


Massimo Gallucci
Silvia Capoccia · Alessia Catalucci

Radiographic Atlas of Skull and Brain Anatomy



Massimo Gallucci · Silvia Capoccia · Alessia Catalucci

Radiographic Atlas of Skull and Brain Anatomy

With 794 Figures

 Springer

MASSIMO GALLUCCI

MD, Professor and Chairman, Department of Neuroradiology, University of L'Aquila, Italy

SILVIA CAPOCCIA

MD, Senior Staff Radiologist at the S. Maria della Stella Hospital, Orvieto, Italy

ALESSIA CATALUCCI

MD, Senior Staff Radiologist at the S. Salvatore Hospital, L'Aquila, Italy

This edition of **Radiographic Atlas of Skull and Brain Anatomy** by Gallucci – Capoccia – Catalucci is published by arrangement with Idelson-Gnocchi srl, Naples, Italy

© 2005 CASA EDITRICE IDELSON-GNOCCHI Srl-Editori dal 1908

ISBN-10 3-540-34190-0 Springer-Verlag, Berlin Heidelberg New York

ISBN-13 978-3-540-34190-1

Library of Congress Control Number: 2006926503

This work is subject to copyright. All rights are reserved, whether the whole or part of the material is concerned, specifically the rights of translation, reprinting, reuse of illustrations, recitation, broadcasting, reproduction on microfilm or in any other way, and storage in data banks. Duplication of this publication or parts thereof is permitted only under the provisions of the German Copyright Law of September 9, 1965, in its current version, and permission for use must always be obtained from Springer-Verlag. Violations are liable for prosecution under the German Copyright Law.

Springer is a part of Springer Science+Business Media

<http://www.springer.com>

© Springer-Verlag Berlin Heidelberg 2007

Printed in Germany

The use of general descriptive names, registered names, trademarks, etc. in this publication does not imply, even in the absence of a specific statement, that such names are exempt from the relevant protective laws and regulations and therefore free for general use.

Product liability: The publishers cannot guarantee the accuracy of any information about the application of operative techniques and medications contained in this book. In every individual case the user must check such information by consulting the relevant literature.

Editor: Dr. Ute Heilmann

Desk Editor: Meike Stoeck

Production Editor: Joachim W. Schmidt

Cover design: Frido Steinen-Broo, eStudio Calamar, Spain

Typesetting: FotoSatz Pfeifer GmbH, D-82166 Gräfelfing

Printed on acid-free paper – 24/3150 – 5 4 3 2 1 0

Preface

The English Edition contains a few differences from the first Italian Edition, which require an explanation. Firstly, some images, especially some 3D reconstructions, have been modified in order to make them clearer. Secondly, in agreement with the Publisher, we have disowned one of our statements in the preface to the Italian Edition. Namely, we have now added a brief introductory text for each section, by way of explanation to the anatomical and physiological notes. This should make it easier for the reader to understand and refer to this Atlas.

These differences derive from our experience with the previous edition and are meant to be an improvement thereof. Hopefully, there will be more editions to follow, so that we may further improve our work and keep ourselves busy on lonesome evenings.

Finally, the improvements in this edition are a reminder to the reader that one should never purchase the first edition of a work.

L'Aquila, January 2006

The Authors

Preface to the Italian Edition

I have been meaning to publish an atlas of neuroradiologic cranio-encephalic anatomy for at least the last decade. Normal anatomy has always been of great and charming interest to me. Over the years, while preparing lectures for my students, I have always enjoyed lingering on anatomical details that today are rendered with astonishing realism by routine diagnostic imaging.

To the allure of the images we should add the necessary teamwork with our colleagues and associates, and as I finally found a go-ahead and open-minded publisher in Guido Gnocchi, I decided to pursue this idea.

The project was fulfilled thanks to the constant, friendly willingness of Silvia Capoccia and Alessia Catalucci, without whom the idea would have remained an idea, Mr Gnocchi, whom I had alerted about the idea of an anatomical atlas at least four years ago, would have been disappointed, the atlas would have been shelved, and I would have been credited with something I did not do.

I am, therefore, grateful to Alessia and Silvia (in inverse alphabetical order of surname on the front cover) for carrying out much of the work. I am equally grateful to Massimo Caulo for providing a number of the images of functional studies, and to architect and graphic wizard Mauro Trappolino for solving problems we had with the more complex images.

To myself, besides my own share of this work, remained the most difficult and challenging part: writing the preface and the dedication.

The preface: the following pages contain images but no text, as is fitting for an atlas. We specifically chose not to focus on technical notes or physiological explanations because we believe that the atlas can be referred to for comparison, checking, or for the location of pathologies, and not for an understanding of their functional meaning or clinical expression. This atlas, therefore, is not intended for those who are already experienced in navigating the anatomy and physiopathology of the nervous system. Rather, it is hoped the less experienced will benefit from it. Should this not be the case, we will not return their money, which in any case will be donated to health projects in the Third World.

The dedication: you may have noticed that, in recent years, medical books have appeared without a bibliography, index, or even whole chapters, and yet one element is always present: a dedication. I gather it represents a crucial element and, thus, I must do my best to provide one. Upon perusing available dedications, I noticed that they nearly always involve family members or professional masters. To whom, then, should I dedicate this work? To a great master of mine, Professor Agnoli, who passed away over a decade ago, I have already dedicated a previous work. As for my family, I am not sure that a dedication would be appropriate. They, too, were the recipients of a previous dedication and, to be honest, this kind of gift might not seem totally unselfish: it is less an authentic dedication than an attempt to quench feelings of guilt for depriving one's family of quality time in order to achieve a "higher" goal. Yet at other times, when the goal is not that high, a dedication is an awkward attempt to involve the neglected family in a form of narcissistic care which, as such, does not leave any room for others.

Therefore, if my daughters should someday ask me: "Why on earth did you dedicate to us a book on skulls?" I would be hard-pressed to find an answer. The best reply would be "because I never wrote a book of poetry". That is why, in the hope of succeeding in writing a book of poetry within the next half century to dedicate to my dearest ones, I do not think it is out of place if I dedicate this work to the job of artisans like myself, Alessia, Silvia, and most of those who will consult it.

Tibetans do not eat meat. Only rarely do they do so, when forced by famine. Folco Maraini wrote (Segreto Tibet, Leonardo da Vinci Publisher, Bari, 1951) that in this case, before they kill the animal, they explain to it the necessity of its sacrifice, and that this will benefit its soul. The animal is also told that the body of its killer will in turn become a meal for other creatures, after its death.

*C'è qualcuno sulla cui pelle ho imparato
C'è qualcuno per la cui pelle non ho dormito.
A questo gioco inevitabile di dare e avere
Che caratterizza il nostro mestiere
E la nostra vita*

*(There are some on whose skin I learnt
There are some for whose skin I did not sleep.
To this unavoidable game of give and take
That characterizes our job
And our lives)*

M. G.

Contents

1 - Surface Anatomy	1
A Skull: Plain Film	3
B Skull: Three-Dimensional Computed Tomography	11
C Brain: Three-Dimensional Magnetic Resonance	25
2 - Sectional Anatomy of the Telencephalon	29
A Sagittal Sections	31
B Coronal Sections	45
C Axial Sections	63
3 - Brainstem and Cerebellum	85
A Sagittal Sections	87
B Coronal Sections	93
C Axial Sections	101
4 - Cranial Nerves and Related Systems	113
A Olfactory Nerve (I) and Olfactory System	115
B Optic Nerve (II), Visual Pathway and Orbit	
I Optic Nerve (II), Visual Pathway	119
II Orbit	127
C Oculomotor Nerve (III), Trochlear Nerve (IV), Abducens Nerve (VI)	141
D Trigeminal Nerve (V)	147
E Facial Nerve (VII) and Vestibulo-Cochlear Nerve (VIII), Acoustic and Vestibular Systems, Petrous Pyramid	
I Facial Nerve (VII) and Vestibulo-Cochlear Nerve (VIII), Acoustic and Vestibular Systems.....	157
II Petrous Pyramid: Computed Tomography.....	171
F Glossopharyngeal Nerve (IX), Vagus Nerve (X), Accessory Nerve (XI), Hypoglossal Nerve (XII)	199
5 - Functional Systems	203
A Motor Systems	
I Pyramidal System	205
II Extrapyrarnidal System: Basal Ganglia; Thalamus	
A Sagittal Sections	217
B Coronal Sections	225
C Axial Sections	235

B Sensory Systems	
I Somatosensory System	243
II Gustatory System	249
C Speech System	253
D Brainstem Pathways and Nuclei	257
E Limbic System and Hippocampus	263
F Commissural and Associative Pathways	275
G Neuroendocrine System	277
H Cerebrospinal Fluid System	289
6 - Vascular Anatomy	297
A Intracranial Arteries	299
B Arterial Vascular Territories	319
C Intracranial Veins	341
<i>Bibliography</i>	353
<i>Subject Index</i>	355

1 Surface Anatomy

Surface Anatomy

The Skull

The skull can be divided into two portions: neural and facial. The neural skull is made up of 6 bones: frontal, parietal, temporal, occipital, sphenoid and ethmoid. The facial skull comprises 8 different bones. In this chapter, they will be briefly described. Synthetic descriptions of sutures between them and of the skull base foramina will follow.

I. Skull Bones

- **frontal bone**

The frontal bone resembles a cockleshell, and consists of two portions: a vertical portion, the squama, corresponding to the forehead region; and an orbital or horizontal portion, which extends to form the roofs of the orbital and nasal cavities.

- **parietal bone**

The parietal bones form the sides and roof of the cranium. Each bone is irregularly quadrilateral in form.

- **temporal bone**

The temporal bones are situated at the base of the skull. Each consists of five parts: squama, petrous, mastoid, and tympanic parts, and styloid process.

- **occipital bone**

The occipital bone is trapezoid-shaped and situated at the back and lower part of the cranium. It contains a large oval aperture, the foramen magnum, through which the cranial cavity communicates with the vertebral canal. The curved, expanded plate behind the foramen magnum is termed the squama, while the thick part in front of the foramen is called the basilar part.

- **sphenoid bone**

The sphenoid bone is a bone situated at the base of the skull in front of the temporal and basilar parts of the occipital bone. It resembles a bat with open wings. It is divided into a median portion or body, two greater and two lesser wings extending outwards from the sides of the body, and two pterygoid processes which project from it downwards.

- **ethmoid bone**

The ethmoid bone is located at the roof of the nose and separates the nasal cavity from the brain. It is lightweight due to a spongy construction. The ethmoid bone consists of four parts:

- the horizontal “cribriform” plate (lamina cribrosa), part of the cranial base
- the vertical “perpendicular” plate (lamina perpendicularis), which is part of the nasal septum
- the two lateral masses (labyrinths)

- **mandible**

The mandible forms the lower jaw (inferior maxillary bone). It is the largest bone of the face. The mandible consists of a curved, horizontal portion, the body, and two perpendicular portions, the rami, connected with the ends of the body at almost right angles.

- **maxilla**

The maxillae join together to form the whole of the upper jaw. They hold the upper teeth, and are connected to the zygomatic bones on the left and right. They assist in forming the roof of the mouth, the floor and lateral wall of the nose, and the floor of the orbit. They contribute to the formation of two fossae, the infratemporal and pterygopalatine, and two fissures, the inferior orbital and pterygomaxillary. Each bone consists of a body and four processes - zygomatic, frontal, alveolar, and palatine.

- **palatine bone**

The palatine bone is situated at the back part of the nasal cavity between the maxilla and the pterygoid process of the sphenoid bone. It contributes to the walls of three cavities: the floor and lateral wall of the nasal cavity, the roof of the mouth, and the floor of the orbit; it contributes to the formation of the pterygopalatine and pterygoid fossae, and the inferior orbital fissure. The palatine bone consists of a horizontal and a vertical part.

- **zygomatic bone**

The zygomatic bone (zygoma; malar bone) is a paired bone articulated with the maxilla, the temporal bone, and the sphenoid bone. It presents a malar and a temporal surface; four processes, the frontosphenoidal, orbital, maxillary, and temporal; and four borders.

- **nasal bone**

The nasal bones are two small oblong bones, varying in size and form; they are placed side by side at the middle and upper part of the face, and join to form the nose.

- **lacrimal bone**

The smallest and most fragile bone of the face, the lacrimal bone is situated at the front part of the medial wall of the orbit.

- **vomer bone**

The vomer bone is located in the midsagittal line, forms the hind and lower part of the nasal septum, and touches the sphenoid, the ethmoid, the left and right palatine bones, and the left and right maxillary bones.

- **inferior nasal concha**

The inferior nasal concha is a lamina of spongy bone (concha nasalis inferior; inferior turbinated bone) that extends horizontally along the lateral wall of the nasal cavity.

II. Sutures

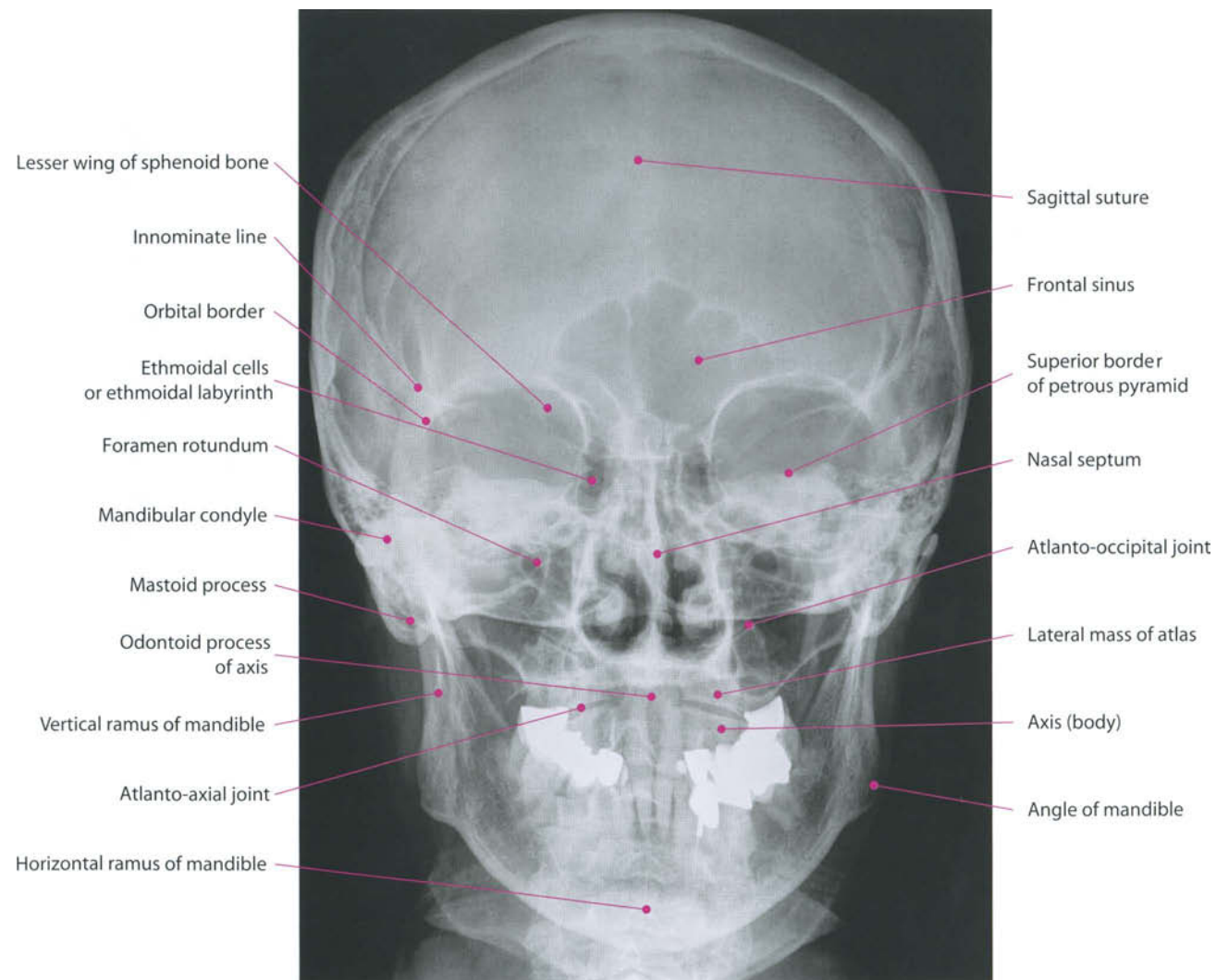
- Sagittal - along the midline, between parietal bones
- Coronal - between the frontal and parietal bones
- Lambdoid - between the parietal and occipital bones
- Squamosal - between the parietal and temporal bones
- Metopic - between the two frontal bones, prior to the fusion of the two into a single bone

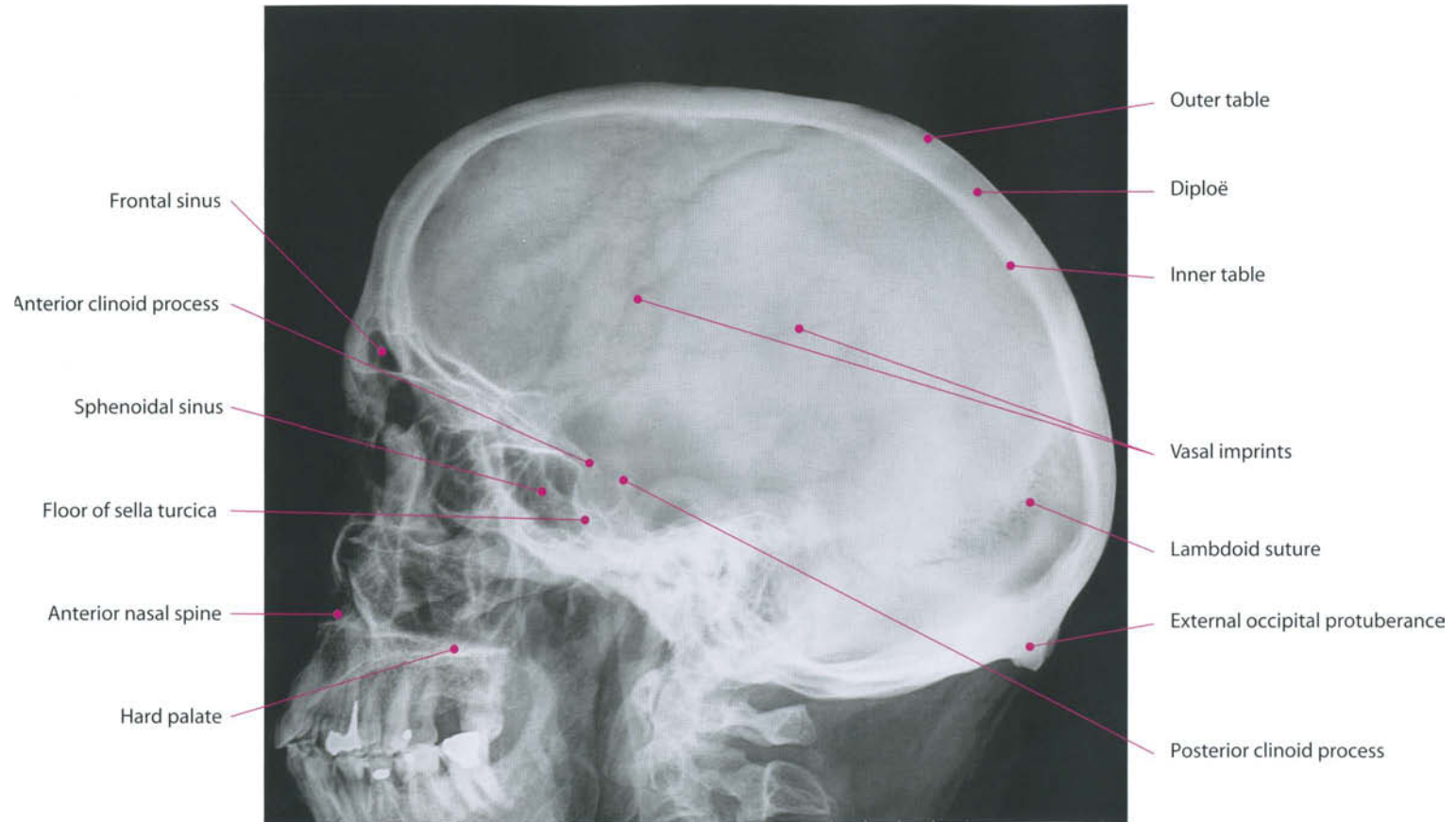
III. Skull Base Foramina

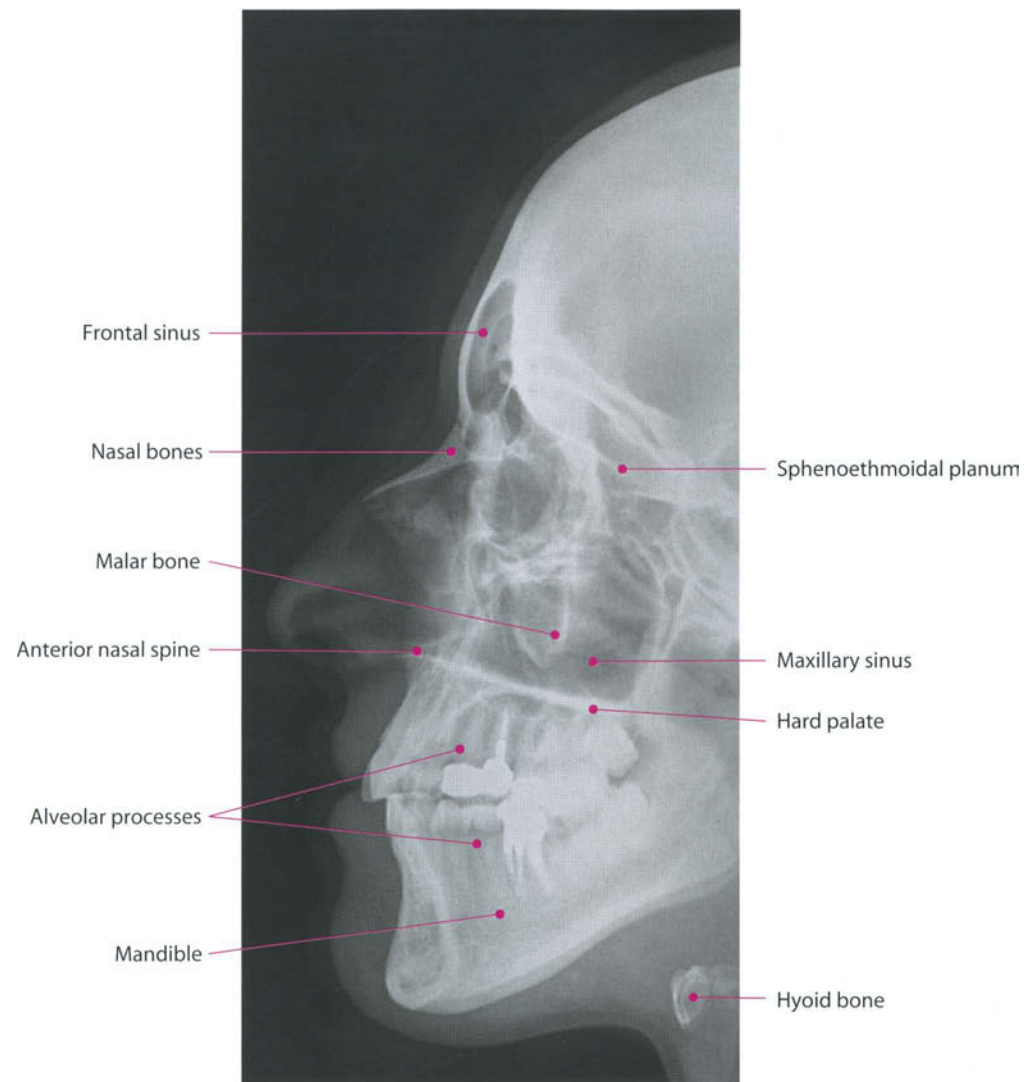
The skull base is crossed by several foramina. The following is a list of them and their contents:

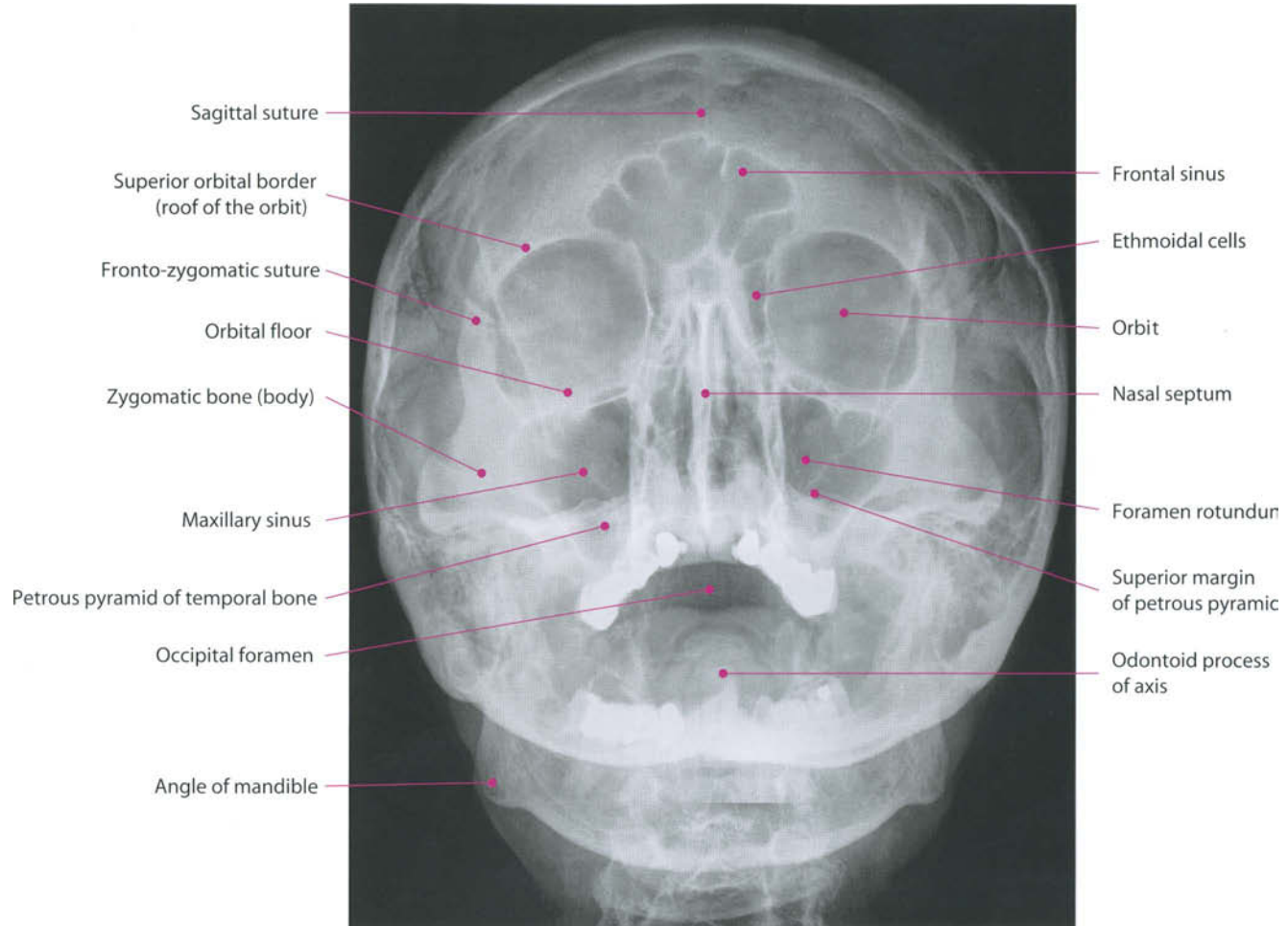
- foramen caecum: emissary vein to superior sagittal sinus
- foramina of cribriform plate: olfactory nerve bundles
- posterior ethmoidal foramen: posterior ethmoidal artery, vein and nerve
- optic canal: optic nerve [II], ophthalmic artery
- superior orbital fissure: oculomotor nerve [III] trochlear nerve [IV] lacrimal, frontal and nasociliary branches of ophthalmic nerve [V1]

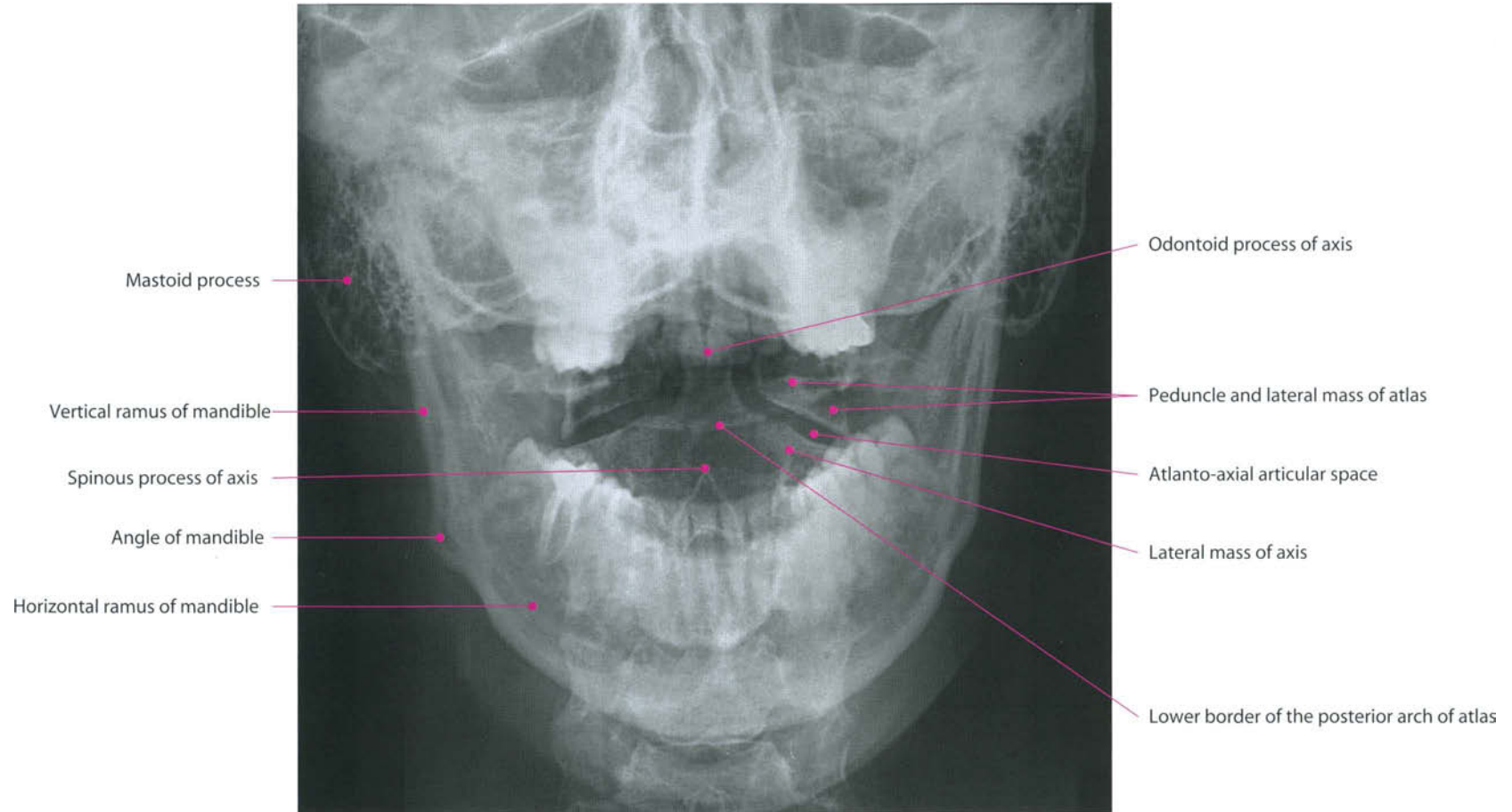
- abducens nerve [VI]
- superior ophthalmic vein
- foramen rotundum: maxillary nerve [V2]
- foramen ovale:
 - mandibular nerve [V3]
 - accessory meningeal artery
 - lesser petrosal nerve (occasionally)
- foramen spinosum:
 - middle meningeal artery and vein
 - meningeal branch of mandibular nerve
- foramen lacerum:
 - internal carotid artery
 - internal carotid nerve plexus
- canal of lesser petrosal nerve
- canal of greater petrosal nerve
- internal acoustic canal:
 - facial nerve [VII]
 - vestibulocochlear nerve [VIII]
 - labyrinthine artery
- jugular foramen:
 - inferior petrosal sinus
 - glossopharyngeal nerve [IX]
 - vagus nerve [X]
 - accessory nerve [XI]
 - sigmoid sinus
 - posterior meningeal artery
 - internal jugular vein
- hypoglossal canal: hypoglossal nerve [XII]
- foramen magnum:
 - medulla oblongata
 - vertebral arteries
 - meningeal branches of vertebral arteries
 - spinal roots of accessory nerves.

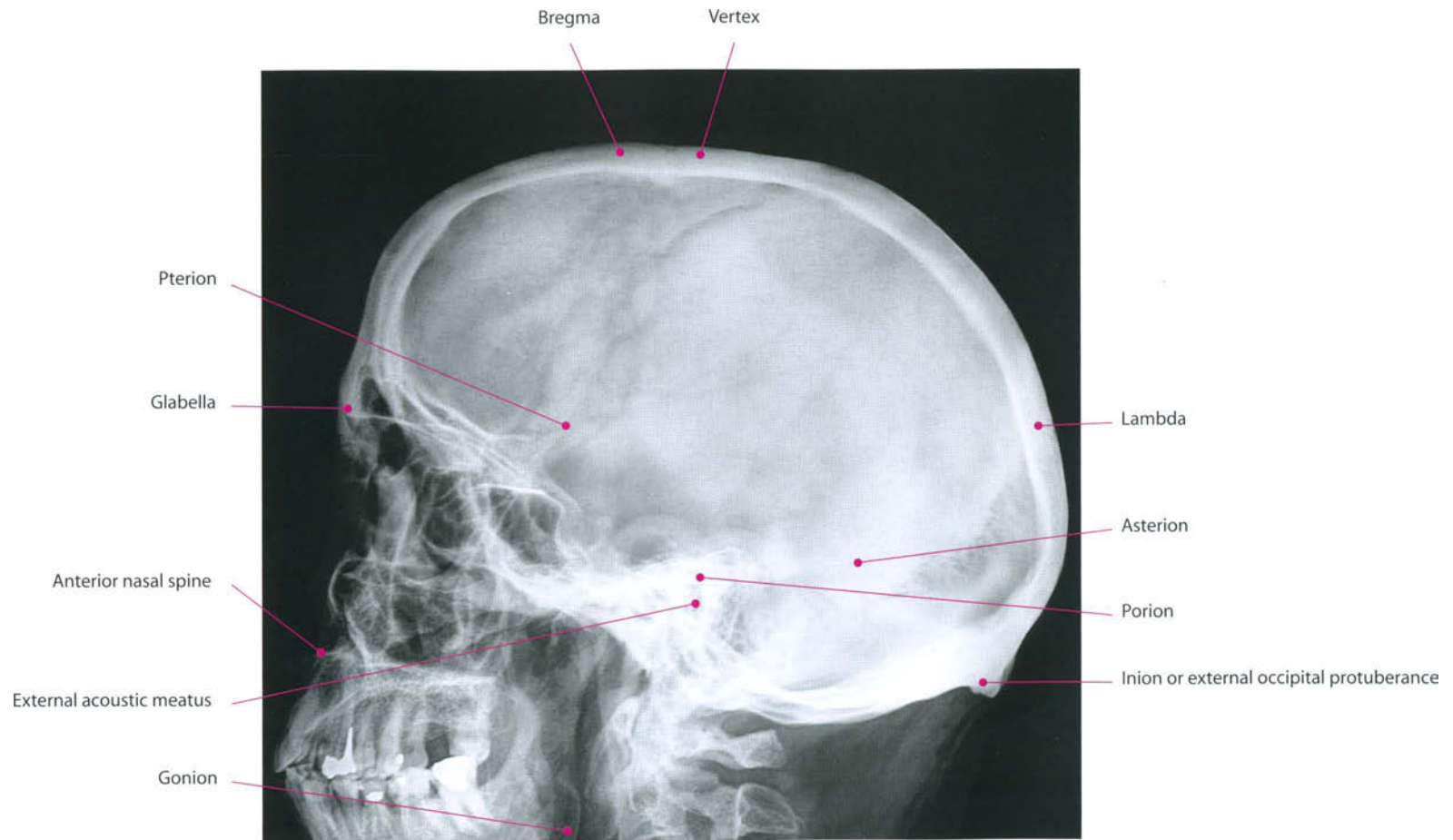


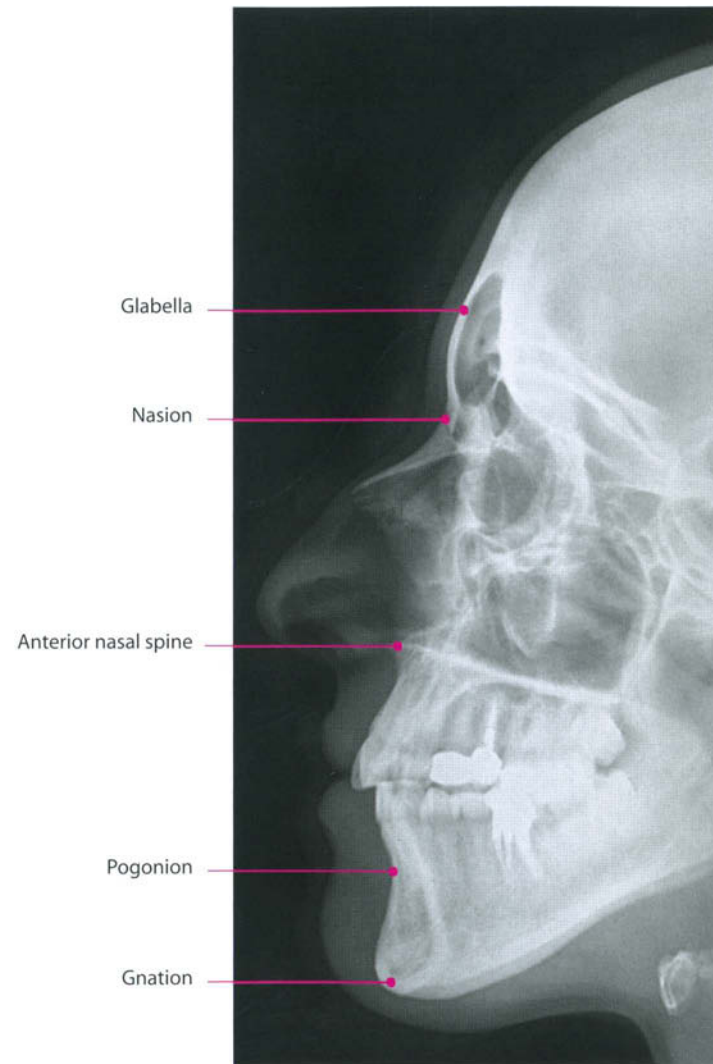


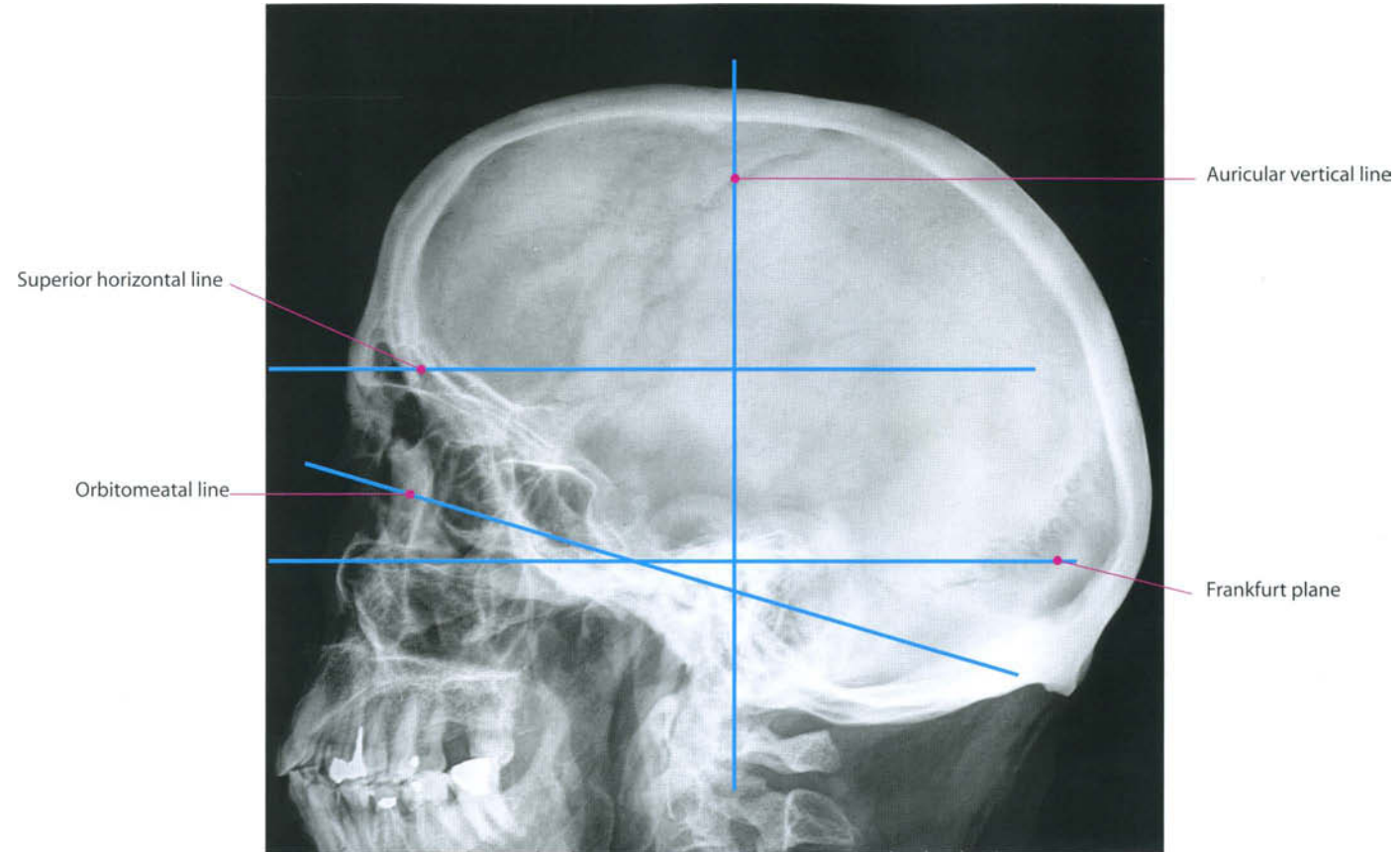


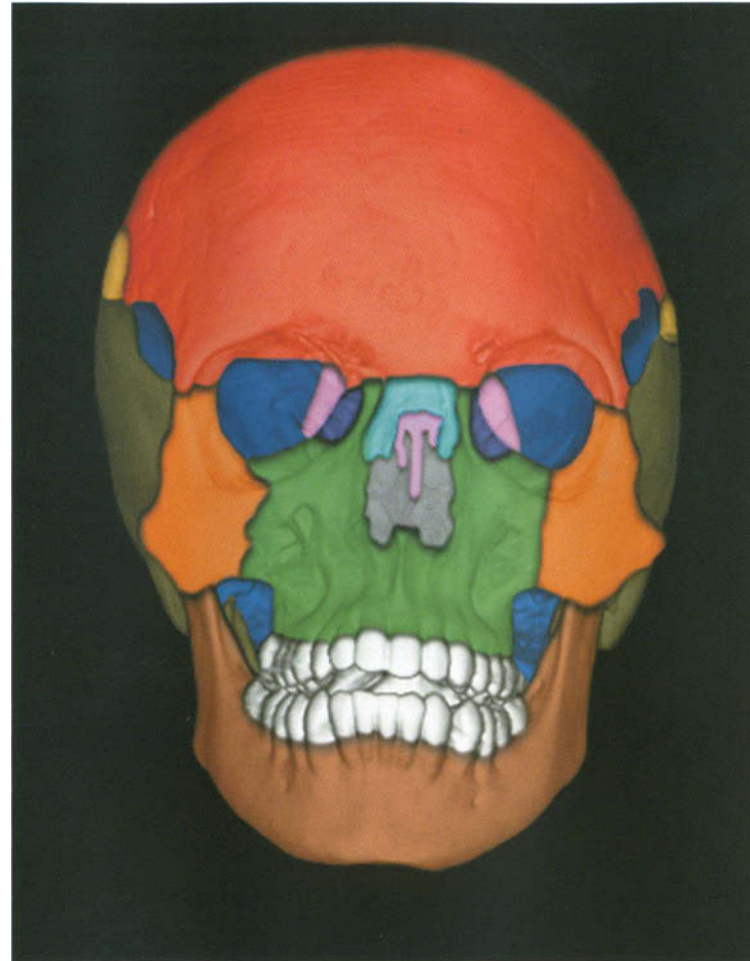




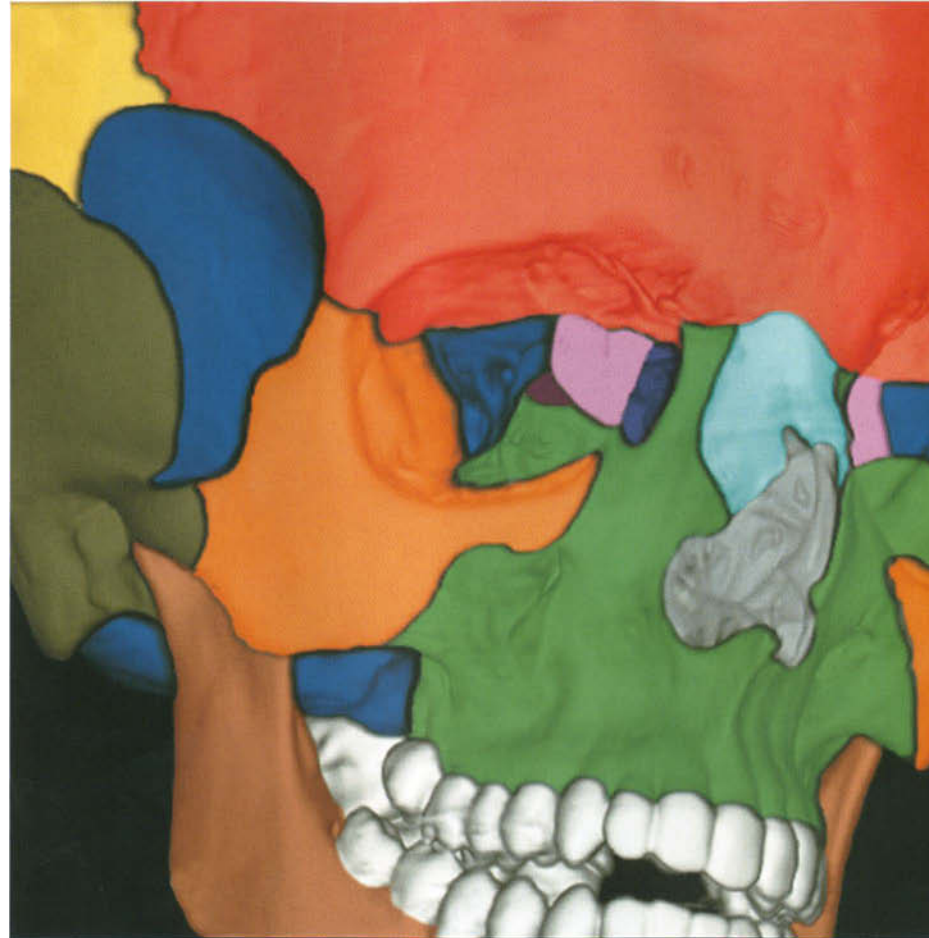



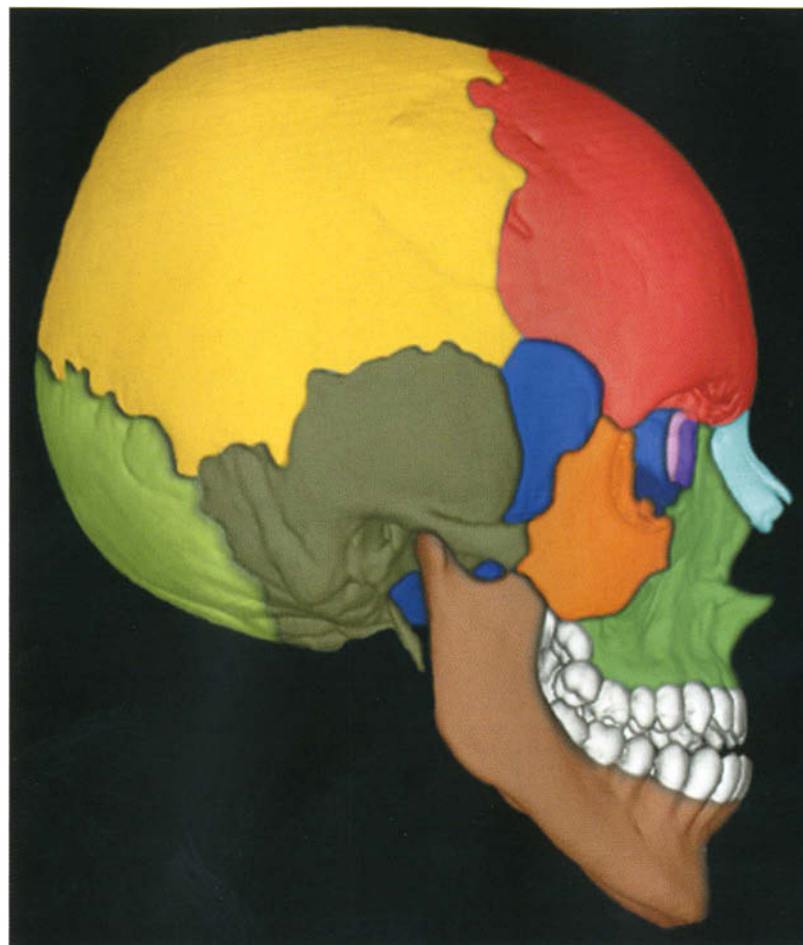





- Frontal bone
- Sphenoid bone
- Parietal bone
- Lacrimal bone
- Ethmoid bone
- Nasal bones
- Temporal bone
- Zygomatic bone
- Maxillary bone
- Mandible



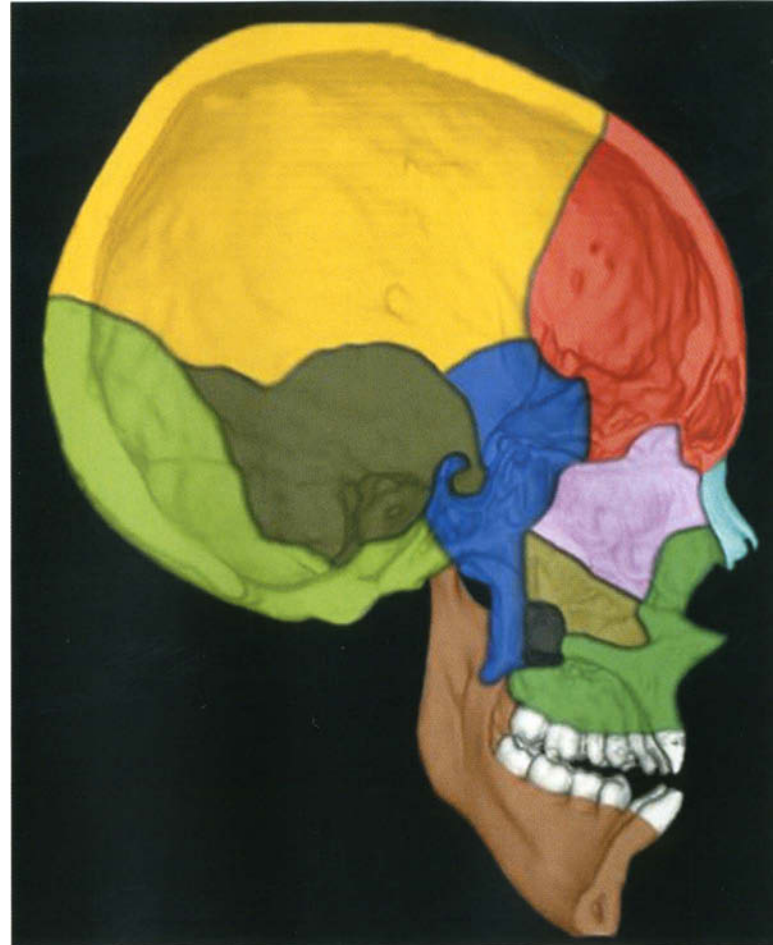
- Orbital process of the palatine bone
- Frontal bone
- Sphenoid bone
- Parietal bone
- Lacrimal bone
- Ethmoid bone
- Nasal bones
- Temporal bone
- Zygomatic bone
- Maxillary bone
- Mandible



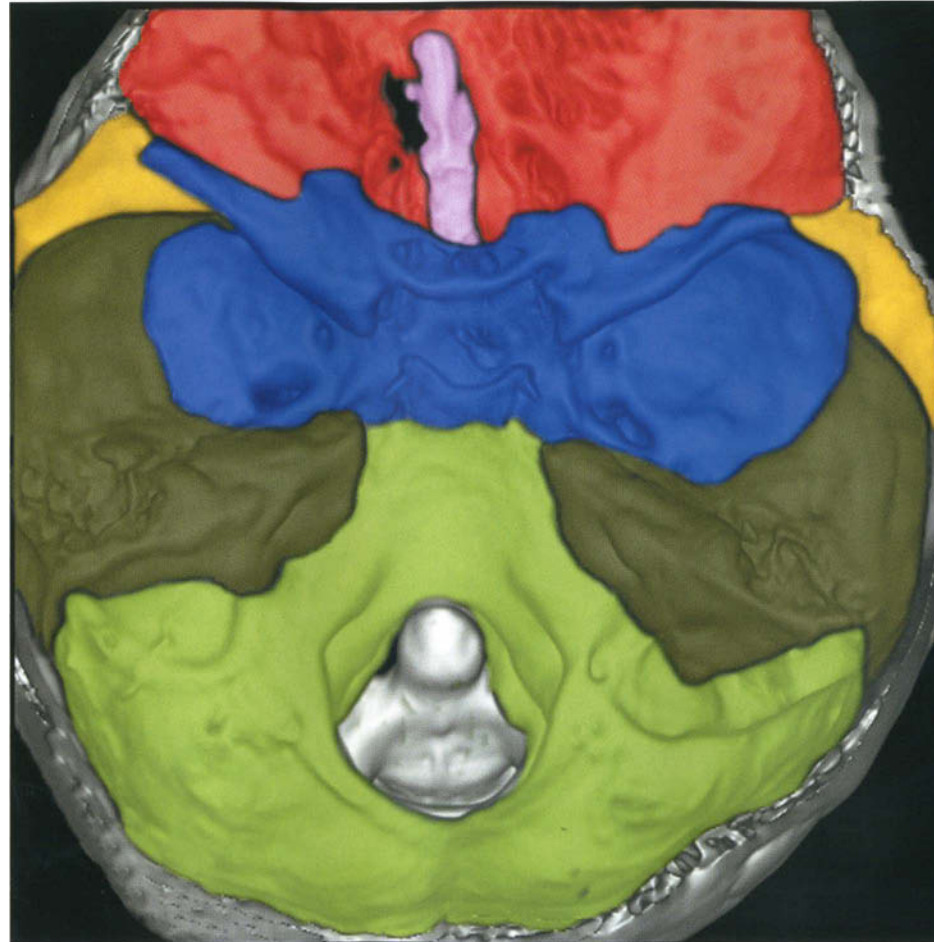
- Frontal bone
- Sphenoid bone
- Parietal bone
- Lacrimal bone
- Ethmoid bone
- Occipital bone
- Nasal bones
- Temporal bone
- Zygomatic bone
- Maxillary bone
- Mandible



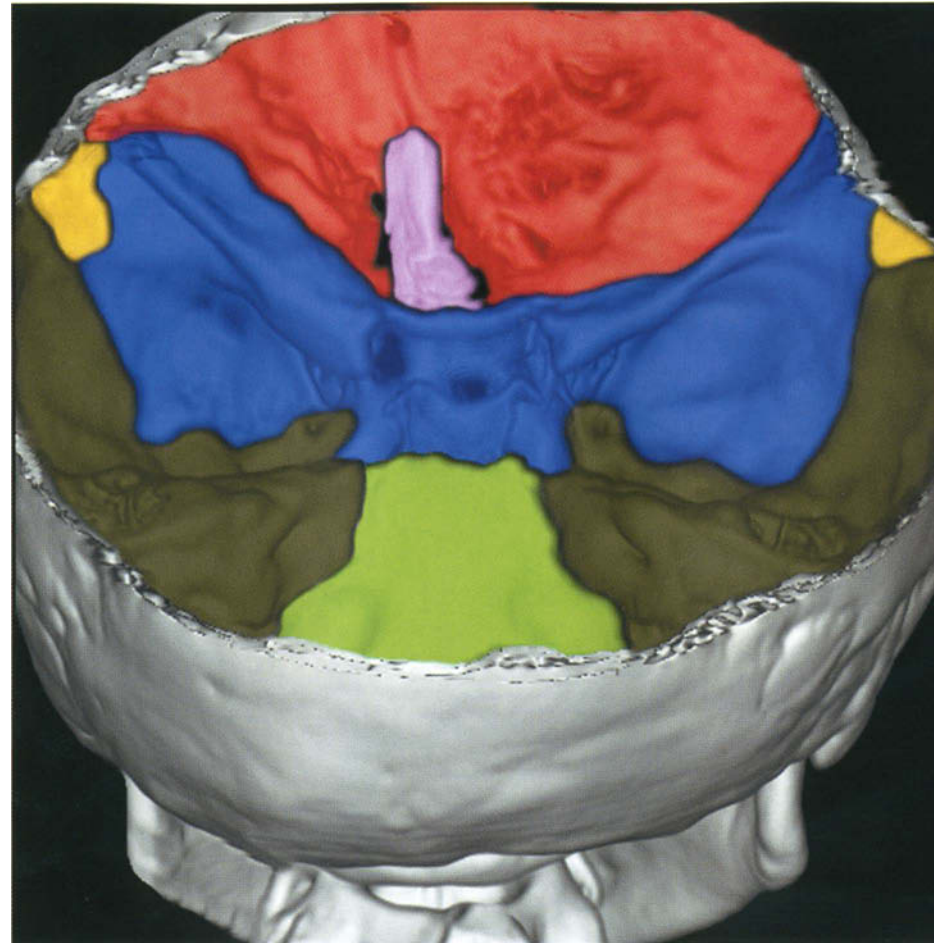
- Parietal bone
- Temporal bone
- Zygomatic bone
- Occipital bone
- Mandible



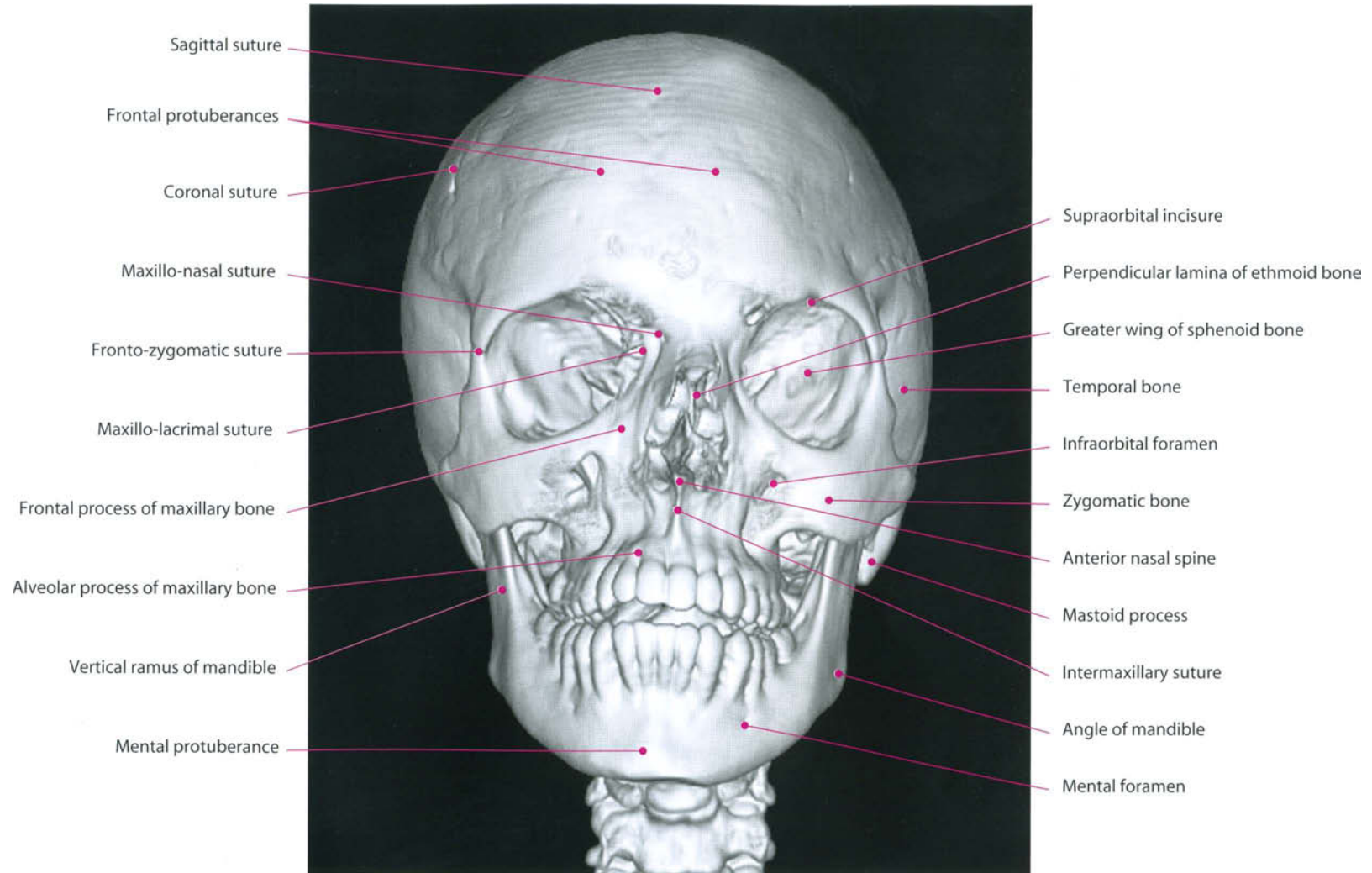
- Frontal bone
- Sphenoid bone
- Parietal bone
- Palatine bone
- Ethmoid bone
- Nasal bones
- Vomer bone
- Occipital bone
- Maxillary bone
- Mandible
- Temporal bone

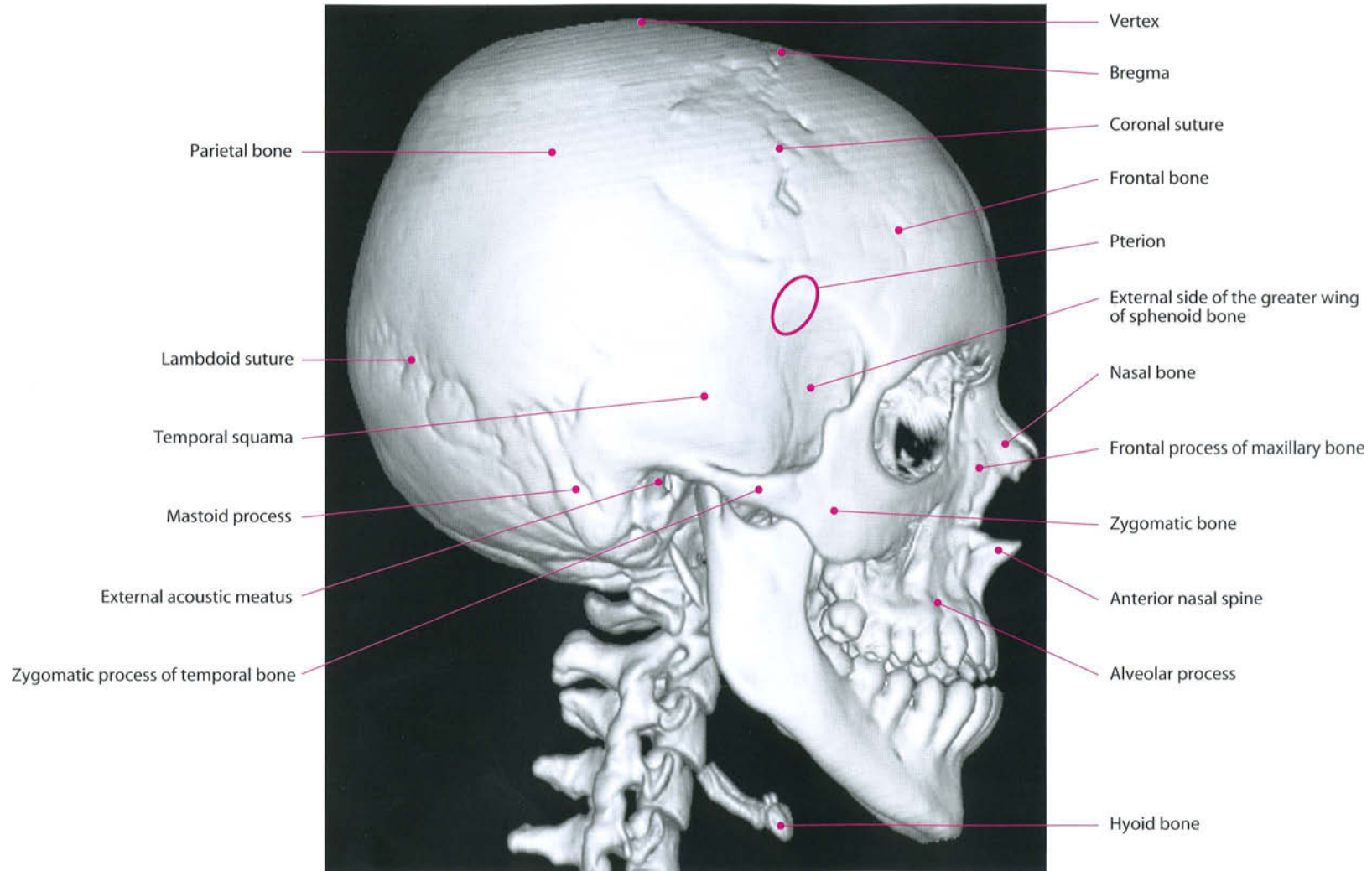


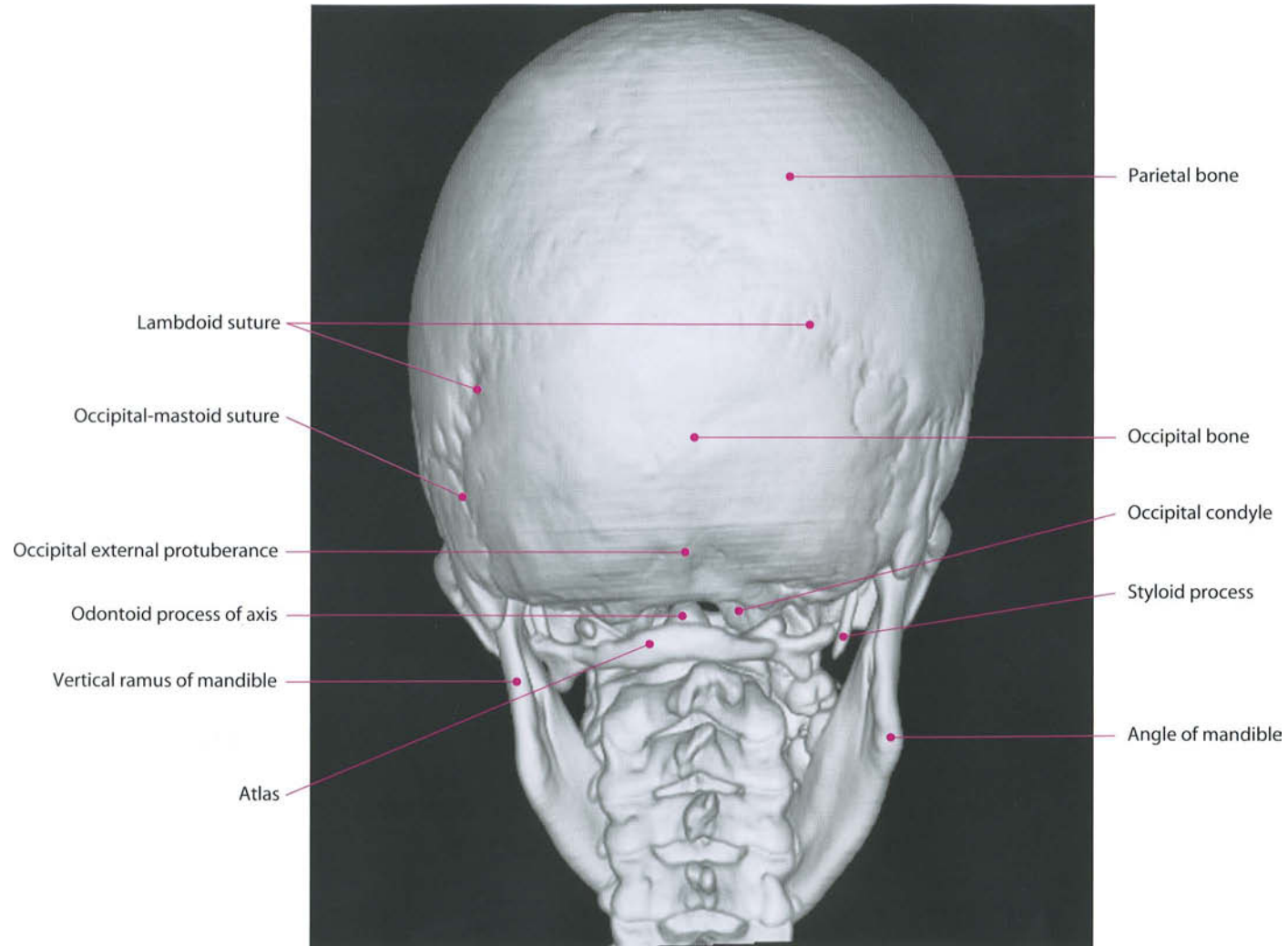
- Frontal bone
- Sphenoid bone
- Parietal bone
- Ethmoid bone
- Temporal bone
- Occipital bone

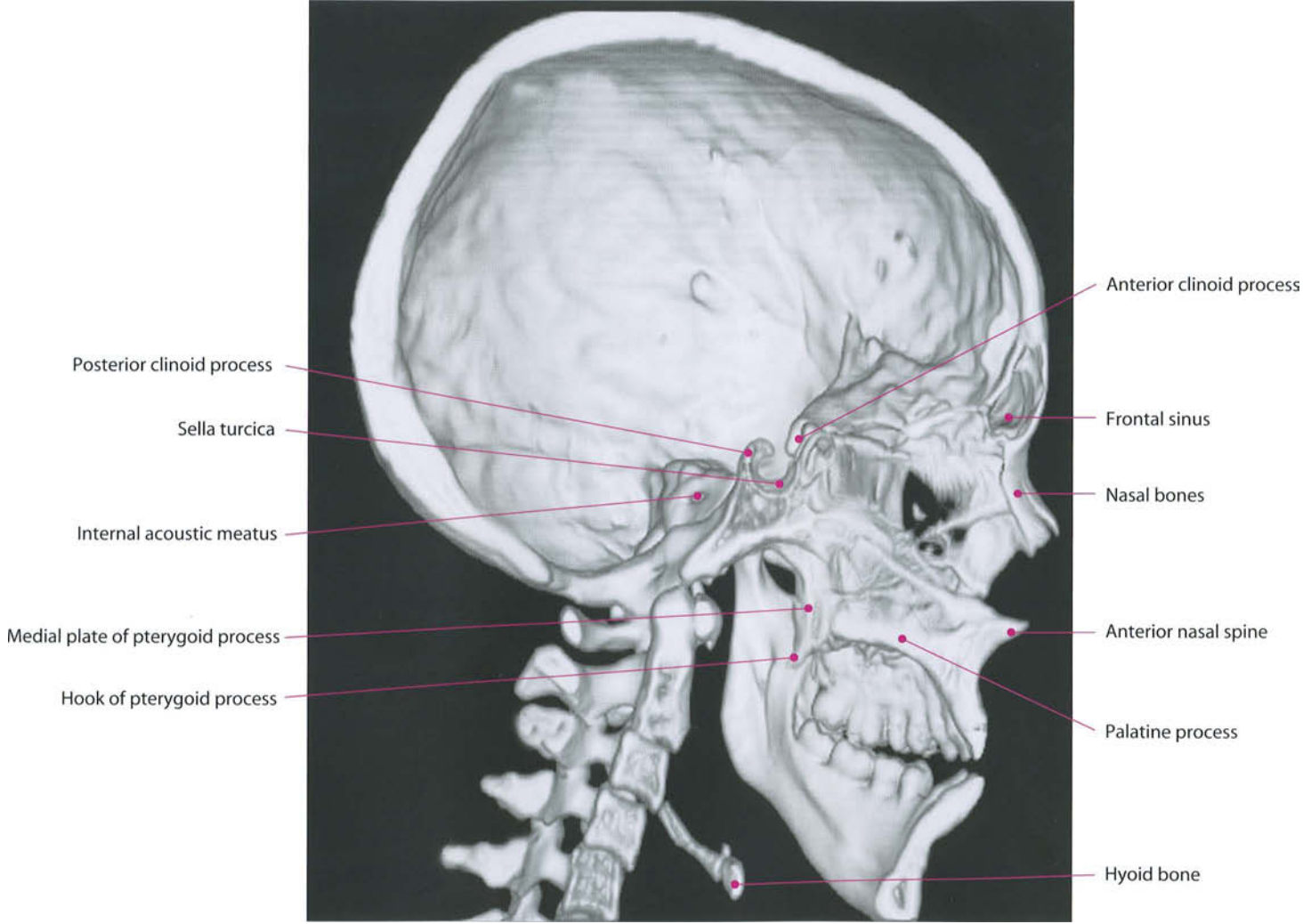


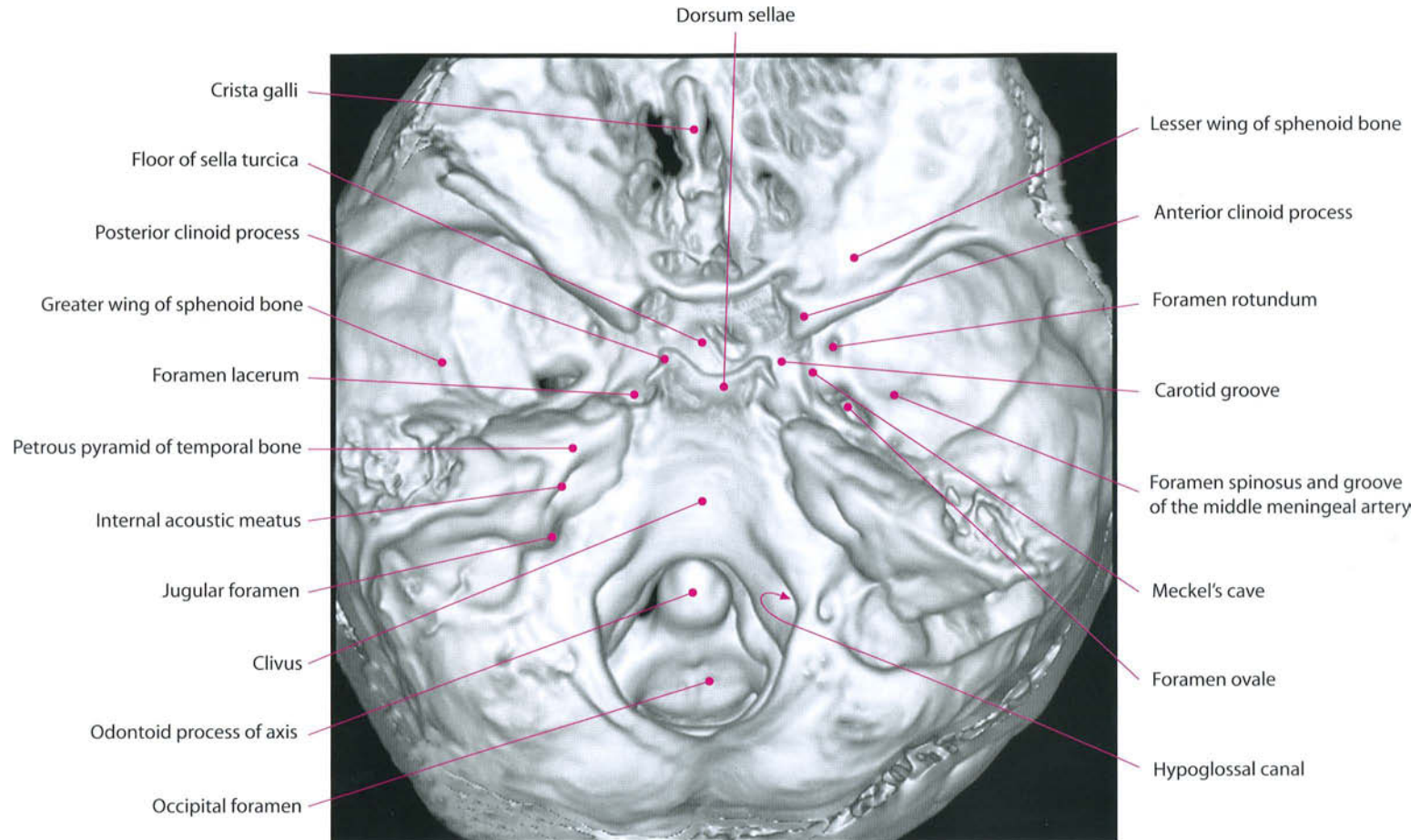
- Frontal bone
- Sphenoid bone
- Parietal bone
- Ethmoid bone
- Temporal bone
- Occipital bone

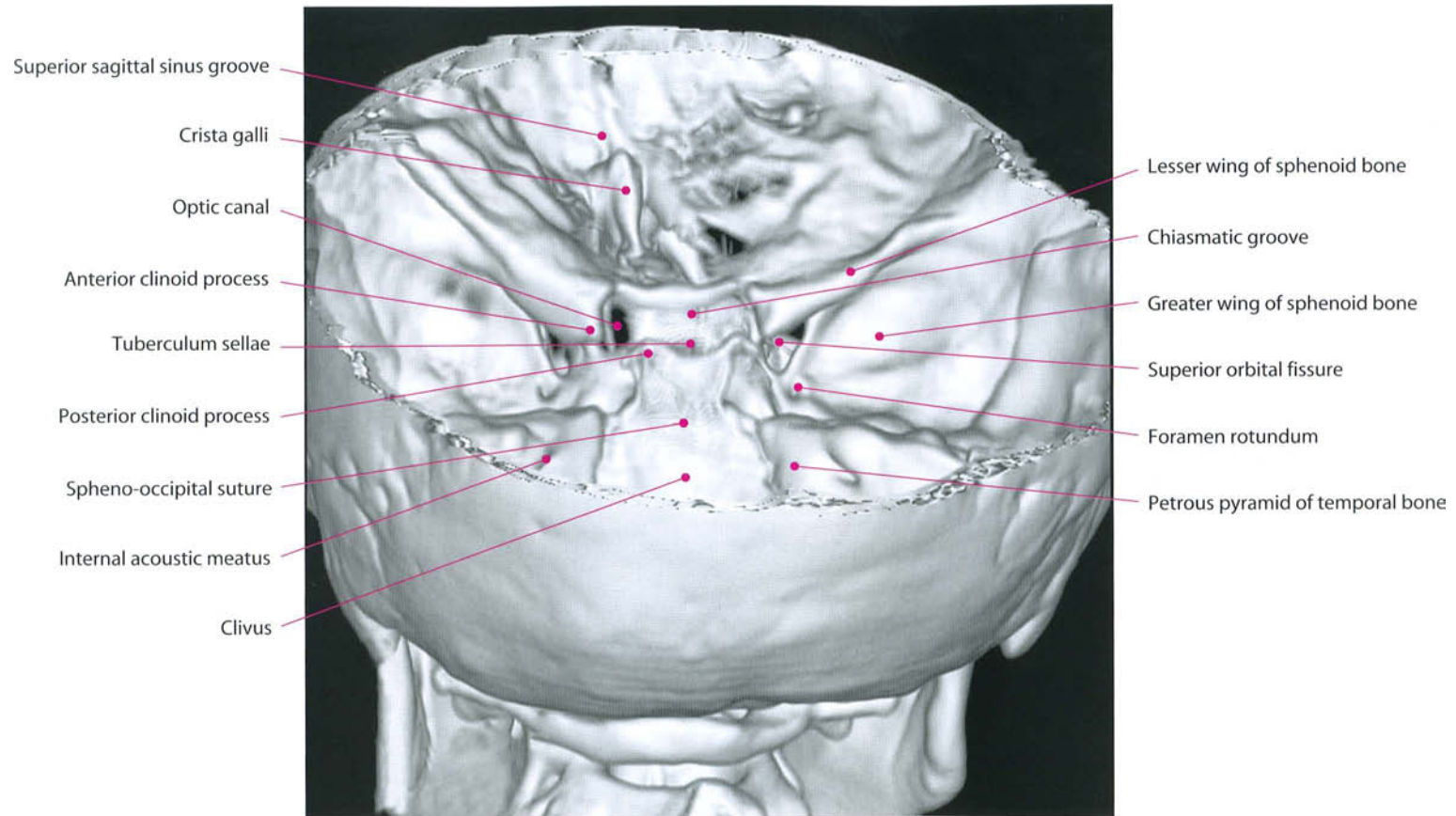












The Brain

The brain or encephalon is the cranial part of the neuraxis, distinguished from the spinal cord (medulla spinalis).

The average weight of the brain is about 1380 g in the adult male and about 1250 g in the adult female. The brain increases rapidly during the first four years of life and reaches its maximum weight by about the twentieth year. As age advances, the brain decreases slowly in weight.

It is composed of a rostral portion, the forebrain (prosencephalon), and the truncus cerebri (brainstem). The prosencephalon is formed by two hemispheres (telencephalon) and an impar and median structure. The latter has an anterior part named telencephalon impar, and a posterior part consisting of the diencephalon.

The brainstem is formed by the mesencephalon (midbrain) and the rhombencephalon. The latter is divided into metencephalon (pons and cerebellum) and myelencephalon (medulla oblongata).

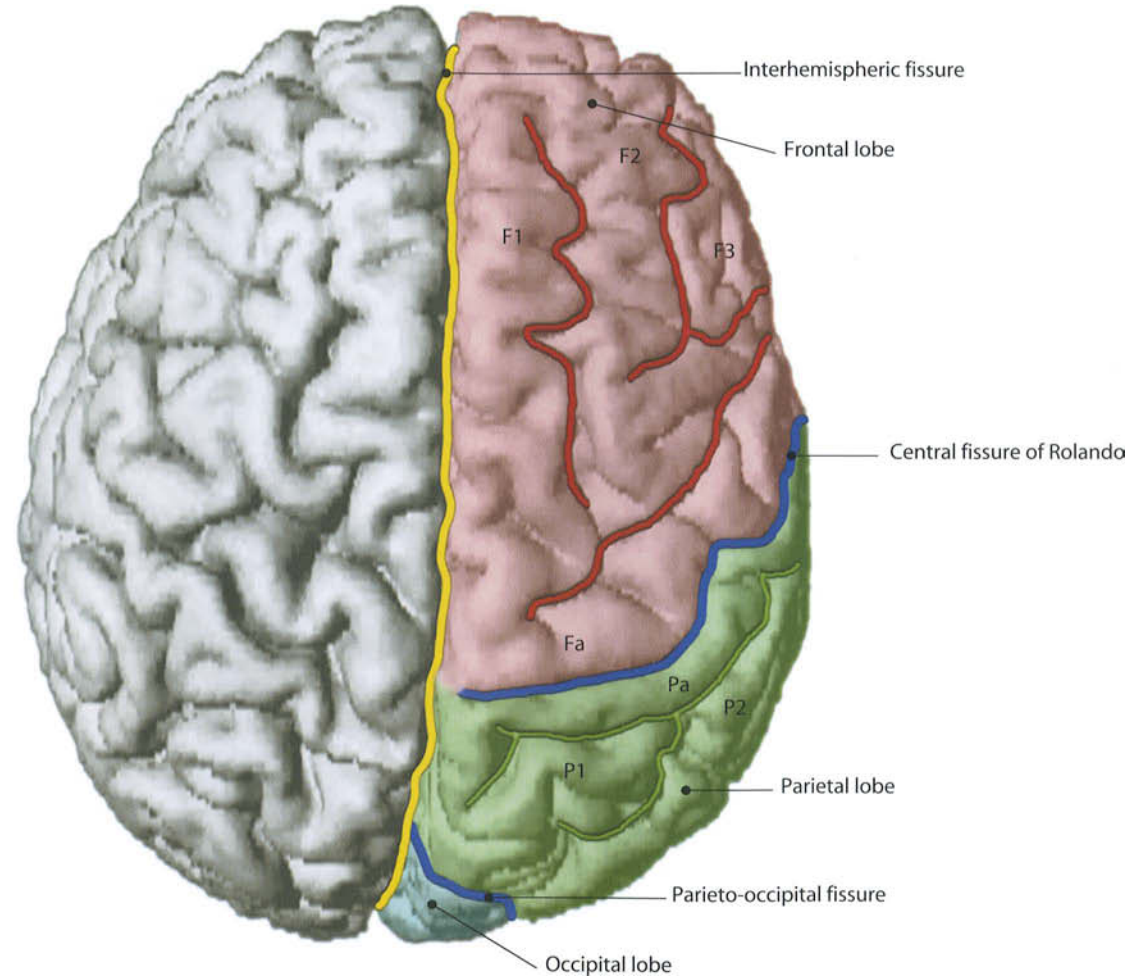
The surface of the cerebral hemisphere is characterized by the presence of furrows of two different types: fissures, more prominent and relatively constant in their relationships, and sulci, less deep and more subject to individual variations.

The interhemispheric fissure separates the two hemispheres and hosts the great cerebral falx, a thick meningeal membrane. The sylvian or lateral fissure, quite deep, divides the frontal and parietal lobes from the temporal one. The rolandic or central fissure separates the frontal and parietal lobes. On the medial surface the parieto-occipital fissure divides the precuneus (parietal) from the cuneus (occipital). It extends on the outer aspect of the hemisphere. The border between occipital and temporal lobes on the lateral surface of the brain is less sharp and the division is somewhat arbitrary, passing through the parieto-occipital fissure and the preoccipital notch, in the inferior aspect of the temporal lobe. The preoccipital notch is difficult to identify and it is conventionally located 4 cm frontal to the occipital pole.

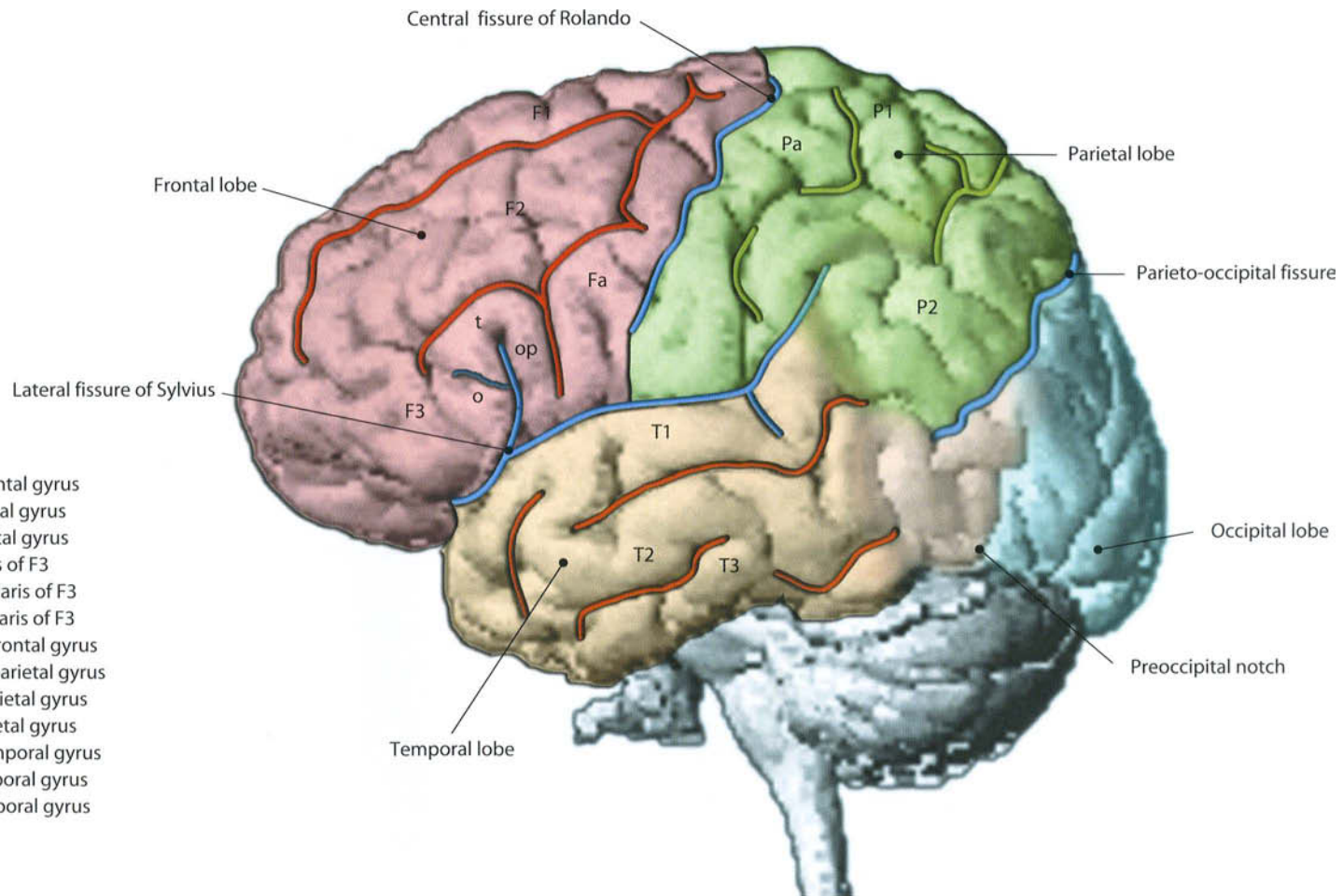
The insula is hidden inside the sylvian fissure. In order to see it, the frontal and temporal opercula must be opened.

The most relevant feature in the medial aspect of the brain hemisphere is the corpus callosum (see also p. 275). This is the most important interhemispheric commissure, made of 5 parts: the most anterior and inferior one is the ro-

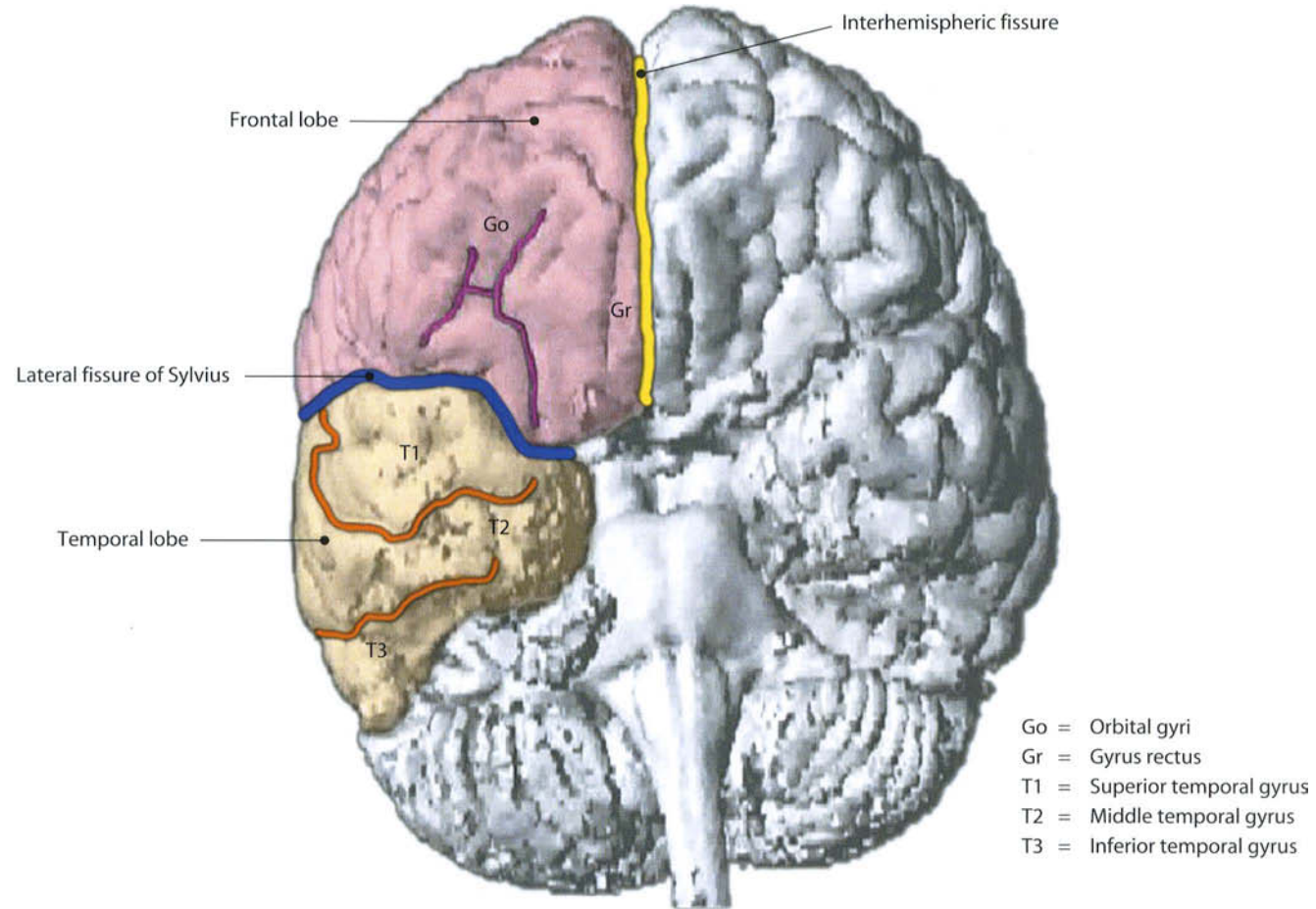
trum, immediately dorsal to the anterior commissure (connects portions of middle and inferior temporal gyri): above the rostrum, the genu continues posteriorly with the body of the corpus callosum, which ends in correspondence with the frontal lobe, followed by a notch, the isthmus, and finally the splenium. The corpus callosum is cranially covered by the cingulate gyrus, separated from it by the callosal sulcus. Immediately below its posterior aspect, the fornix is found. This peculiar structure is an interhemispheric commissure (hypothalamic commissure) comprising two columns that originate from the mammillary bodies. They extend forwards and upwards, toward the center of the corpus callosum, where the columns travel together to form the body of the fornix, while maintaining their fibers separate. Afterwards, they become separate by the commissure of the fornix, and continue backward and then down and forward, towards the anterior commissure and hippocampus, ending in the region of the uncus. The parieto-occipital fissure separates the precuneus and cuneus. The medial aspect of the temporal lobe offers the clear distinction of the uncus of the hippocampus, followed posteriorly by the parahippocampal and the fusiform gyri.



- F1 = Superior frontal gyrus
- F2 = Middle frontal gyrus
- F3 = Inferior frontal gyrus
- Fa = Ascending frontal gyrus
- Pa = Ascending parietal gyrus
- P1 = Superior parietal gyrus
- P2 = Inferior parietal gyrus



- F1 = Superior frontal gyrus
- F2 = Middle frontal gyrus
- F3 = Inferior frontal gyrus
- o = Pars orbitalis of F3
- t = Pars triangularis of F3
- op = Pars opercularis of F3
- Fa = Ascending frontal gyrus
- Pa = Ascending parietal gyrus
- P1 = Superior parietal gyrus
- P2 = Inferior parietal gyrus
- T1 = Superior temporal gyrus
- T2 = Middle temporal gyrus
- T3 = Inferior temporal gyrus



2 Sectional Anatomy of the Telencephalon

Sectional Anatomy of the Telencephalon

The cross-sectional anatomy of the telencephalon is shown on the following pages. As in almost all other sections of this book, MRI cuts are taken following conventional planes.

Axial cuts are parallel to Talairach's bicommissural plane (a plane passing through the anterior and posterior commissures, as identified on the midsagittal plane). Coronal cuts are taken perpendicular to the axial ones; sagittal cuts are parallel to the interhemispheric fissure.

On each page the anatomical cut obtained with a T1-w inversion recovery sequence is fully described. In addition, the same anatomical cut obtained with a T2-w FSE sequence is printed. At the bottom of the page, reference images on the other two planes of the space are shown, with the aim of giving spatial information that can aid in mentally identifying and locating the plane studied.

Cross-sectional anatomy needs no special comments as the anatomical structures are better described in the chapters relative to their functions.

Some comments concern the white matter macroscopic morphology. It consists of fibers, varying in size and arranged in bundles, and may be divided into three distinct systems.

- Projection fibers connect the hemisphere with the lower parts of the brain and the spinal cord.
- Transverse or commissural fibers unite the two hemispheres.
- Association fibers connect different structures in the same hemisphere; in many cases, these are collateral branches of the projection fibers, but others are axons of independent cells.

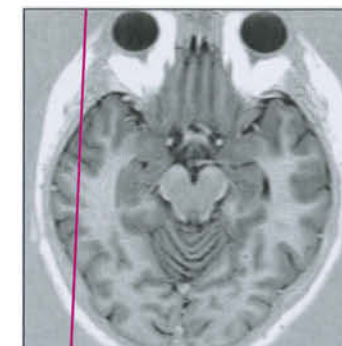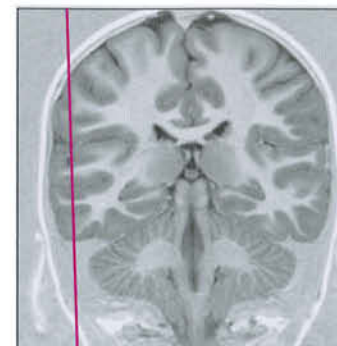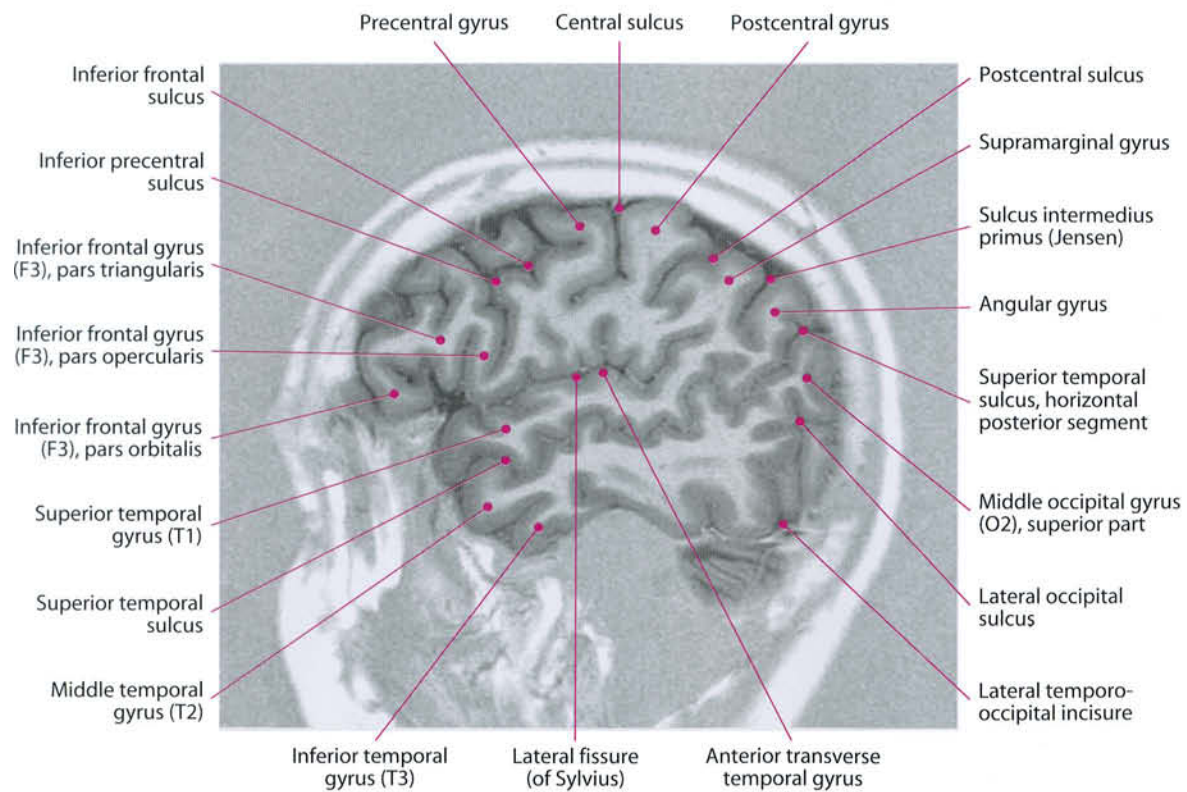
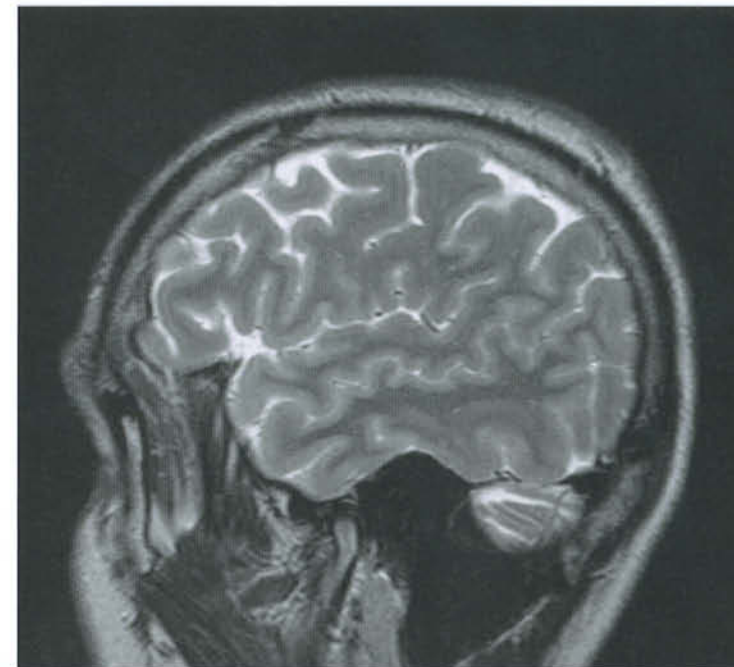
Axial cross-sections of the brain, when taken above the corpus callosum, show a mass of white matter on each hemisphere referred to as "centrum semiovale". Below it, projection fibers arising from the cortex and directed towards the internal capsule, together with fibers ascending from below towards the cortex, form the "corona radiata". The former occupy a narrow space on each side of the bodies of the lateral ventricles.

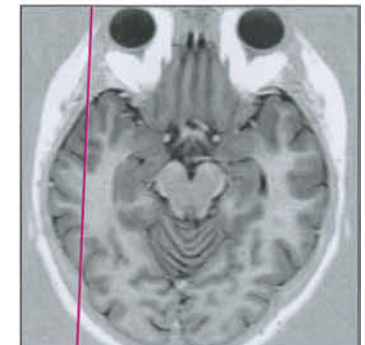
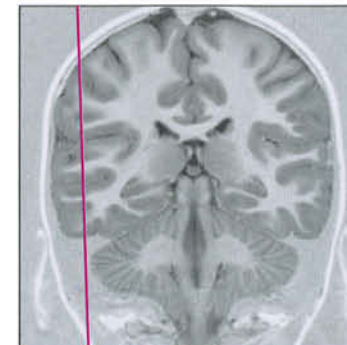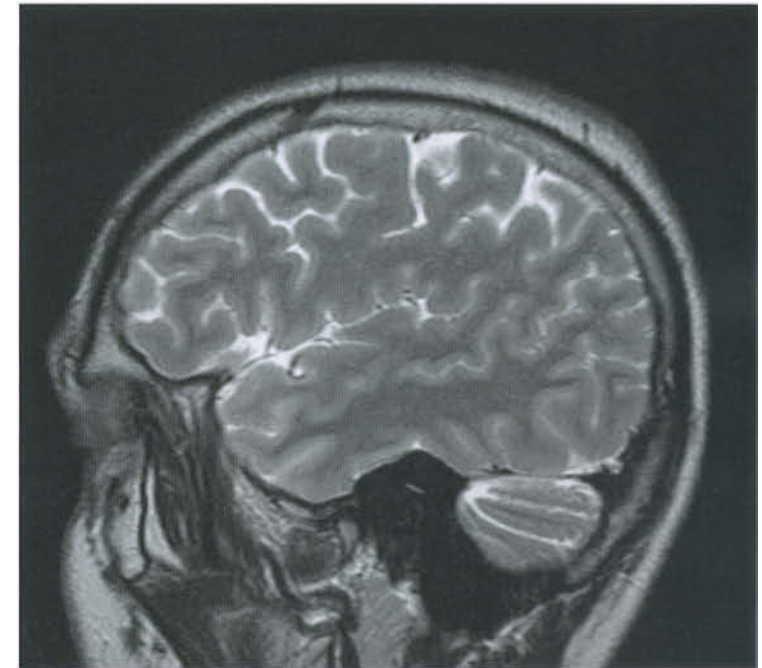
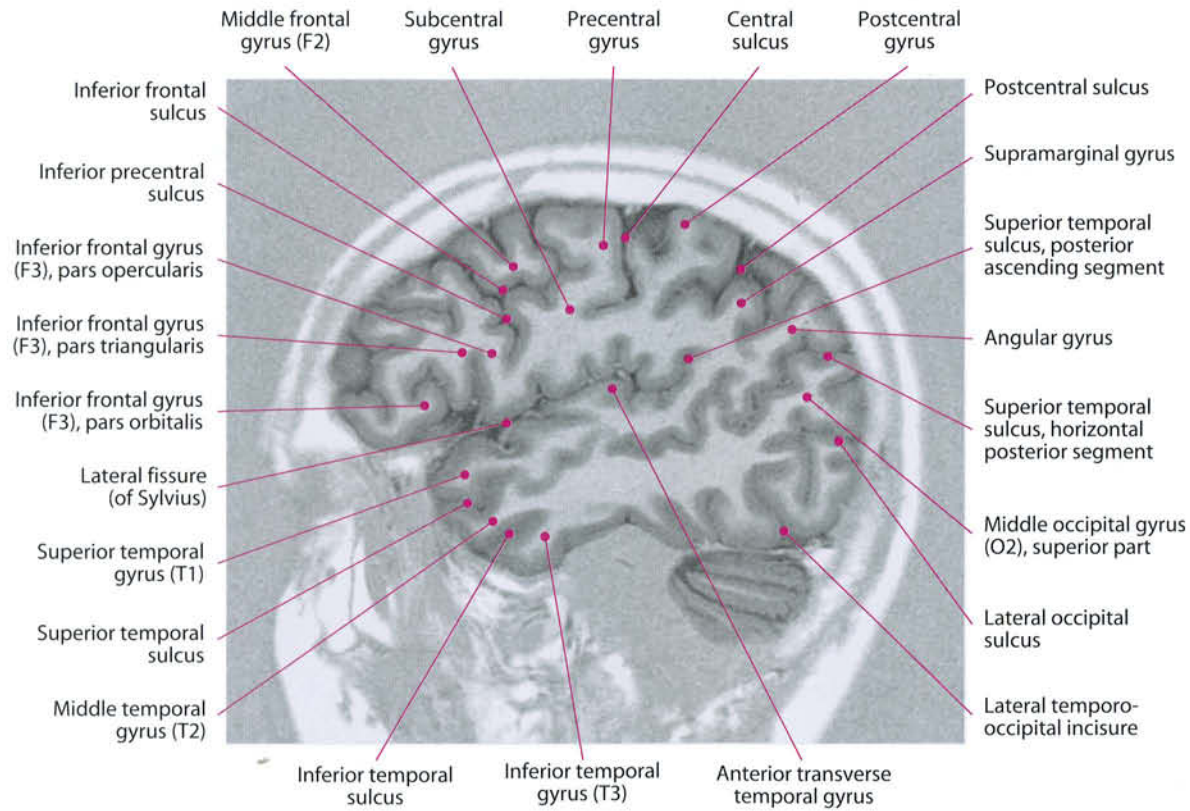
Similarly, a special contingent of fibers comes from the lateral geniculate body and reaches the occipital cortex, passing laterally to the occipital horn of the lateral ventricles, be-

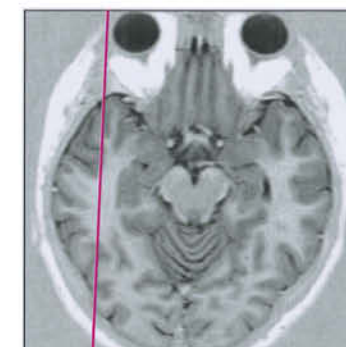
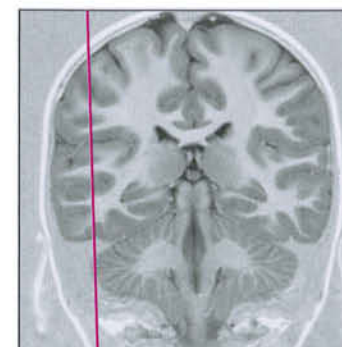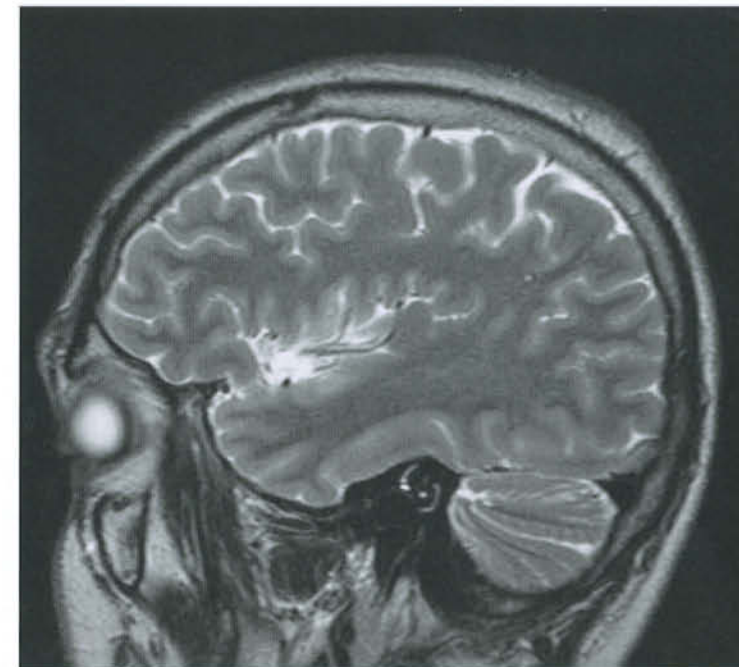
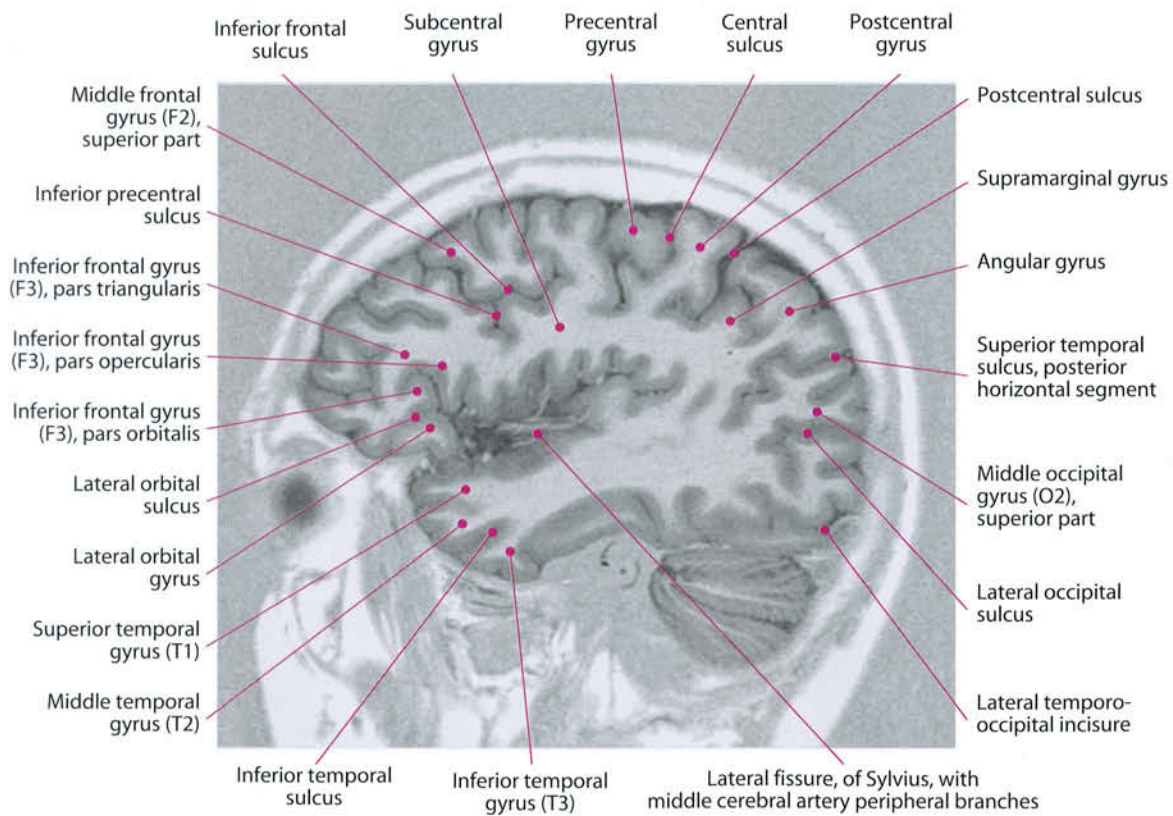
ing more horizontally oriented. They are the optic radiations, i.e. the final part of the visual pathway.

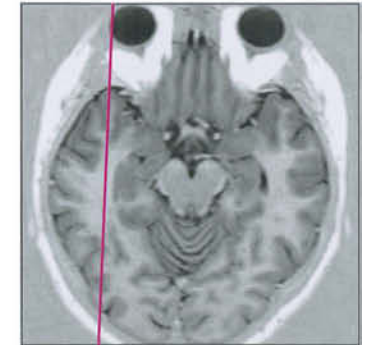
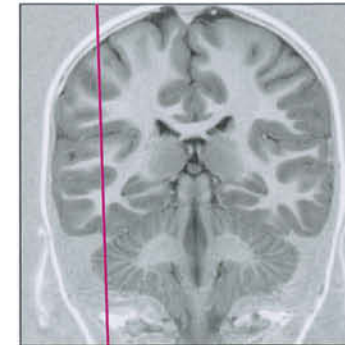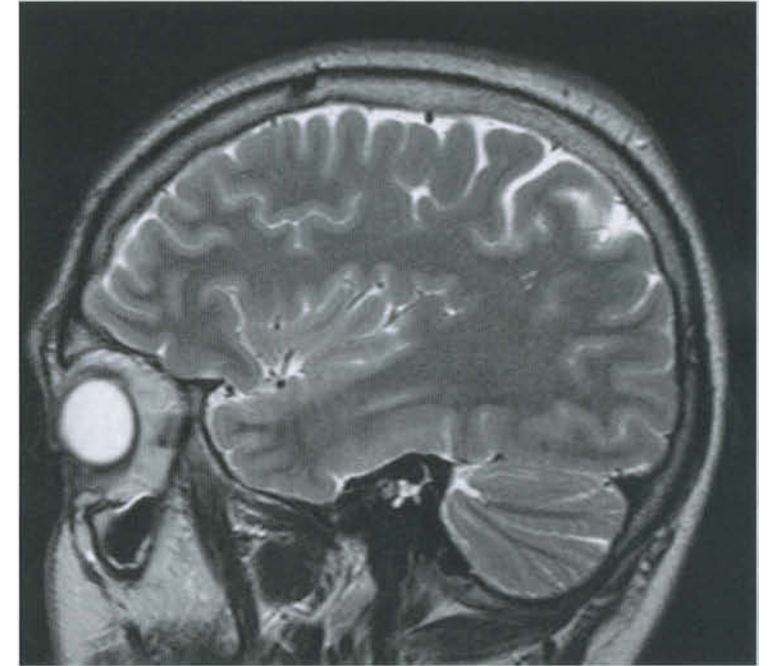
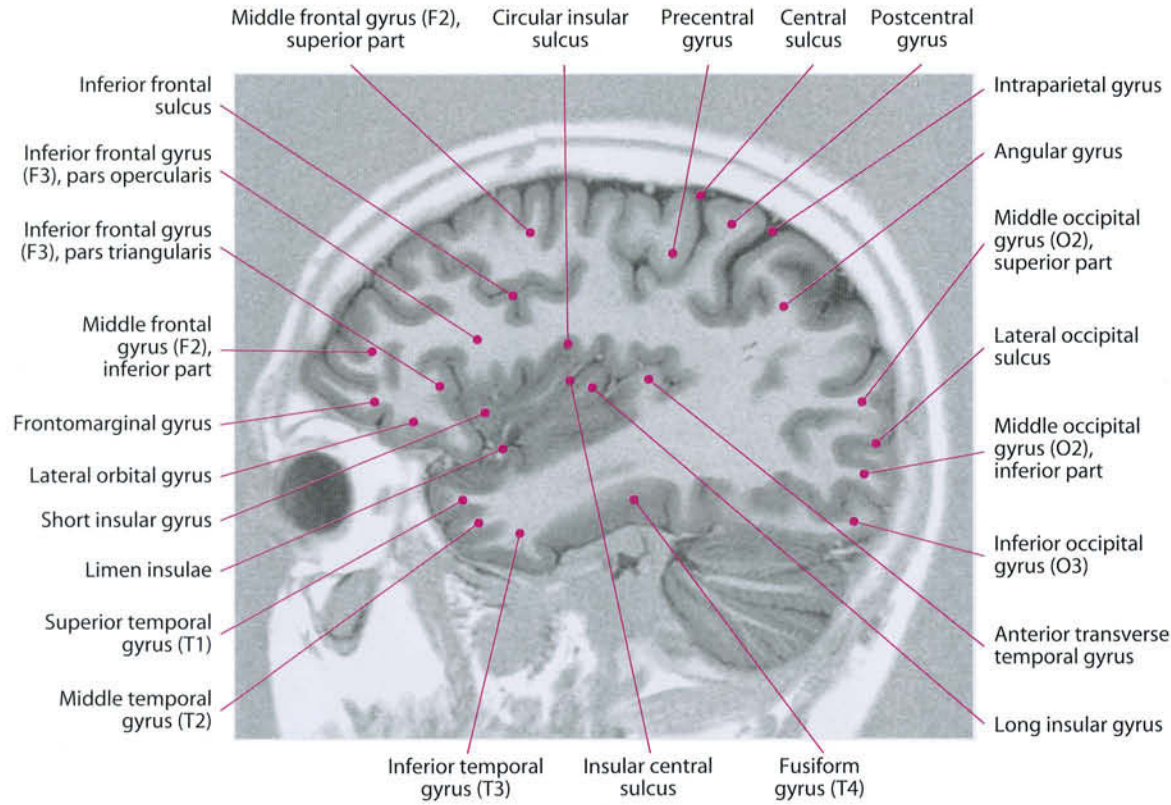
Finally, in the axial cuts a mild asymmetry between the hemispheres can be observed.

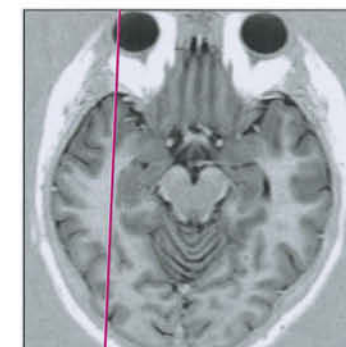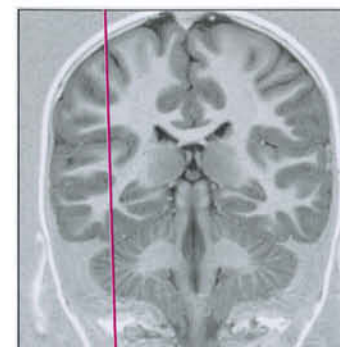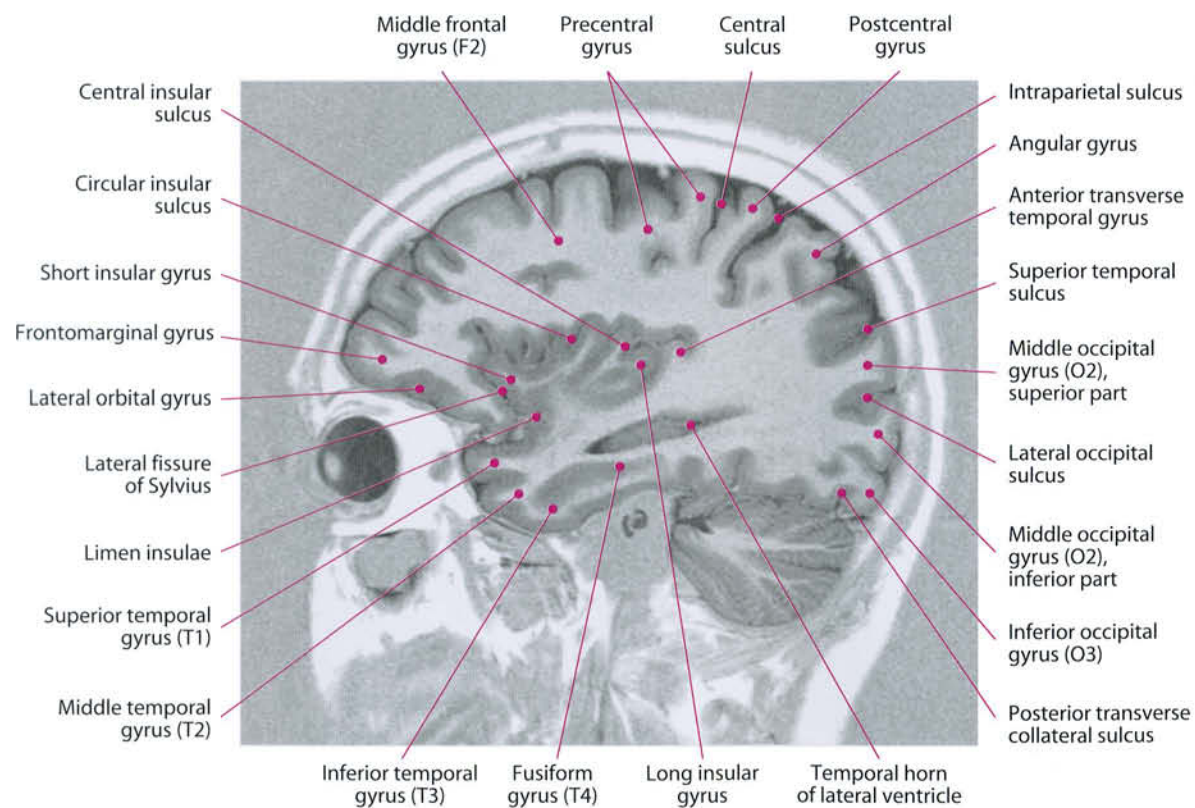
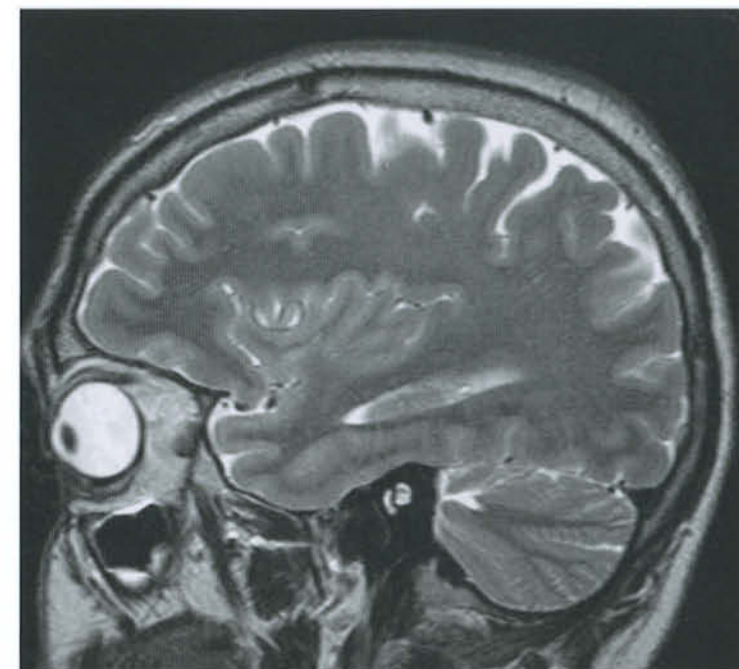
This asymmetry is due to the hemispheric dominance. It is commonly known that 95% of right-handed people have hemispheric dominance on the left, while in 50 to 75% of left-handed individuals the dominant hemisphere is the left one. The dominance is anatomically expressed by a mild hemispheric hypertrophy that is at its most in the occipital region: the left occipital lobe, in such cases, extends slightly farther back than the right one, sometimes scalloping the occipital bone, sometimes bulging on the midline. The left occipital horn is usually longer than the contralateral, and the left transverse venous sinus is lower and smaller than the right one in about 50% of individuals.

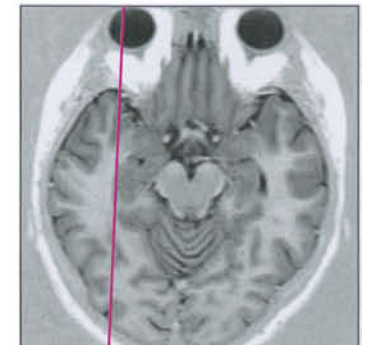
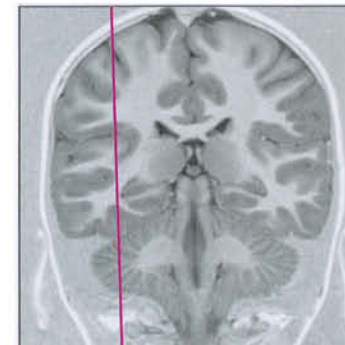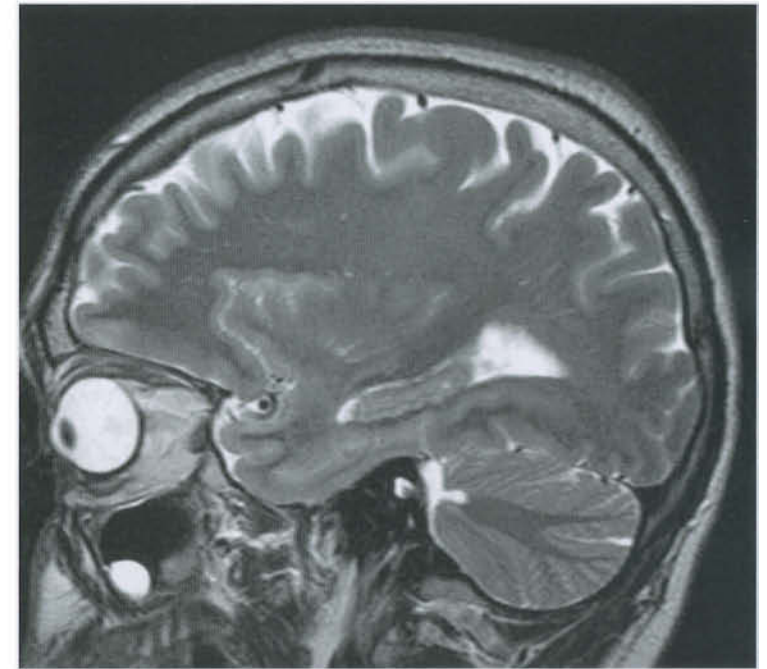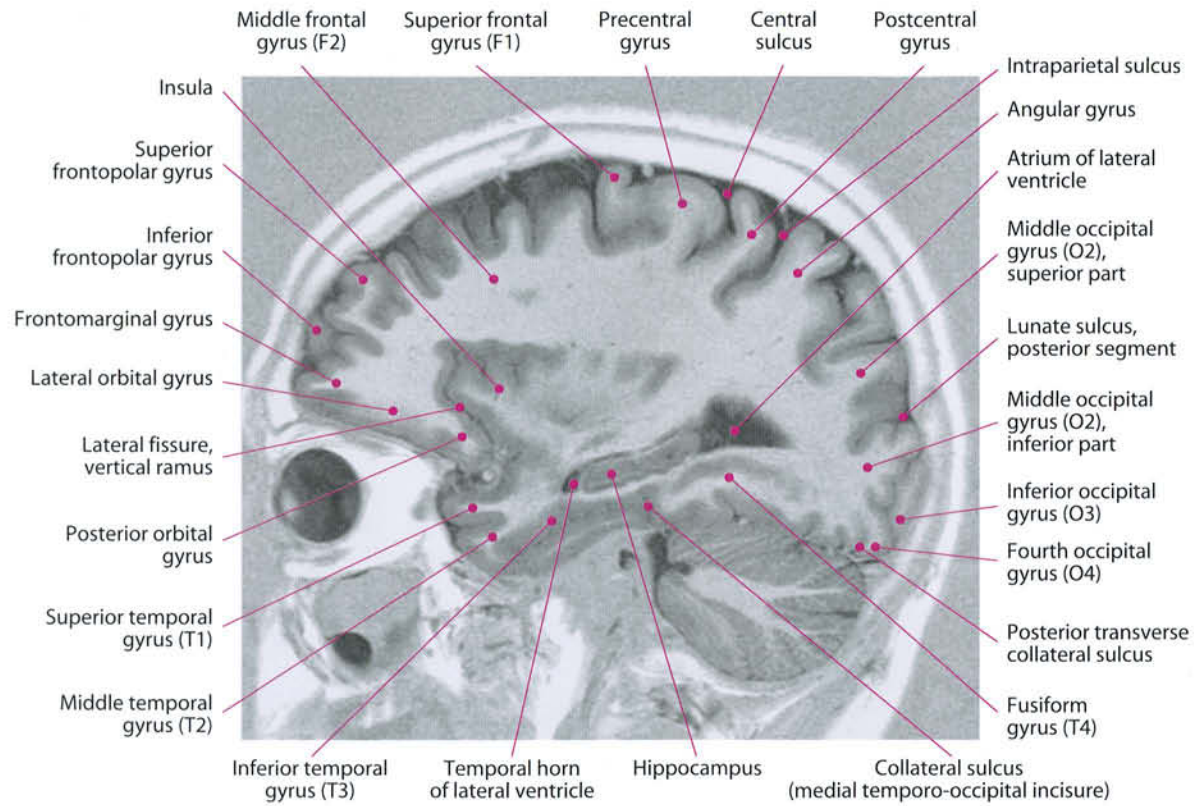


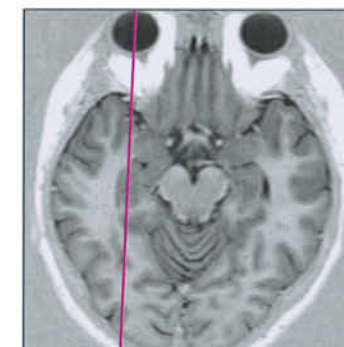
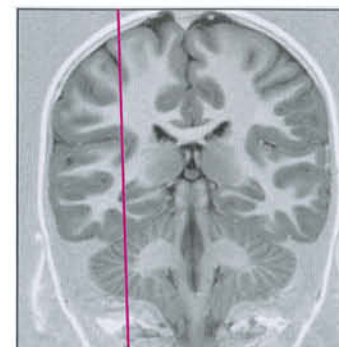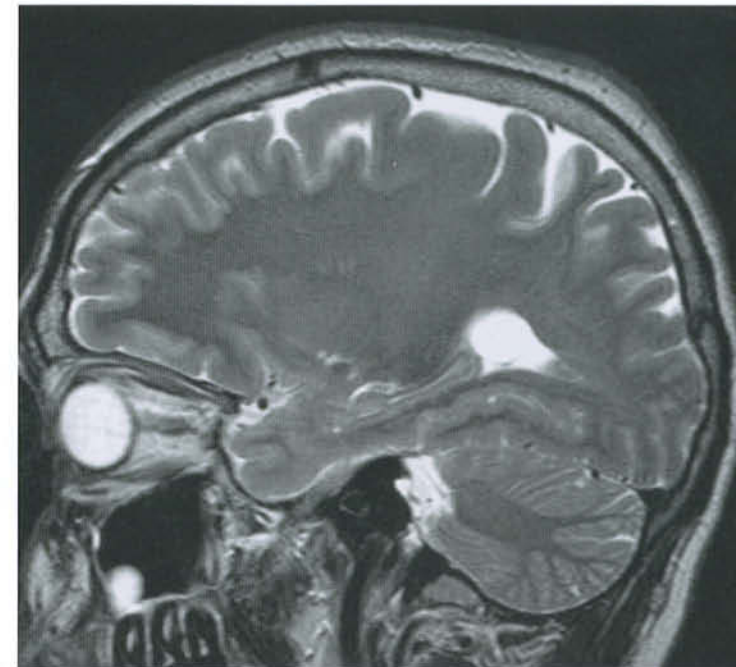
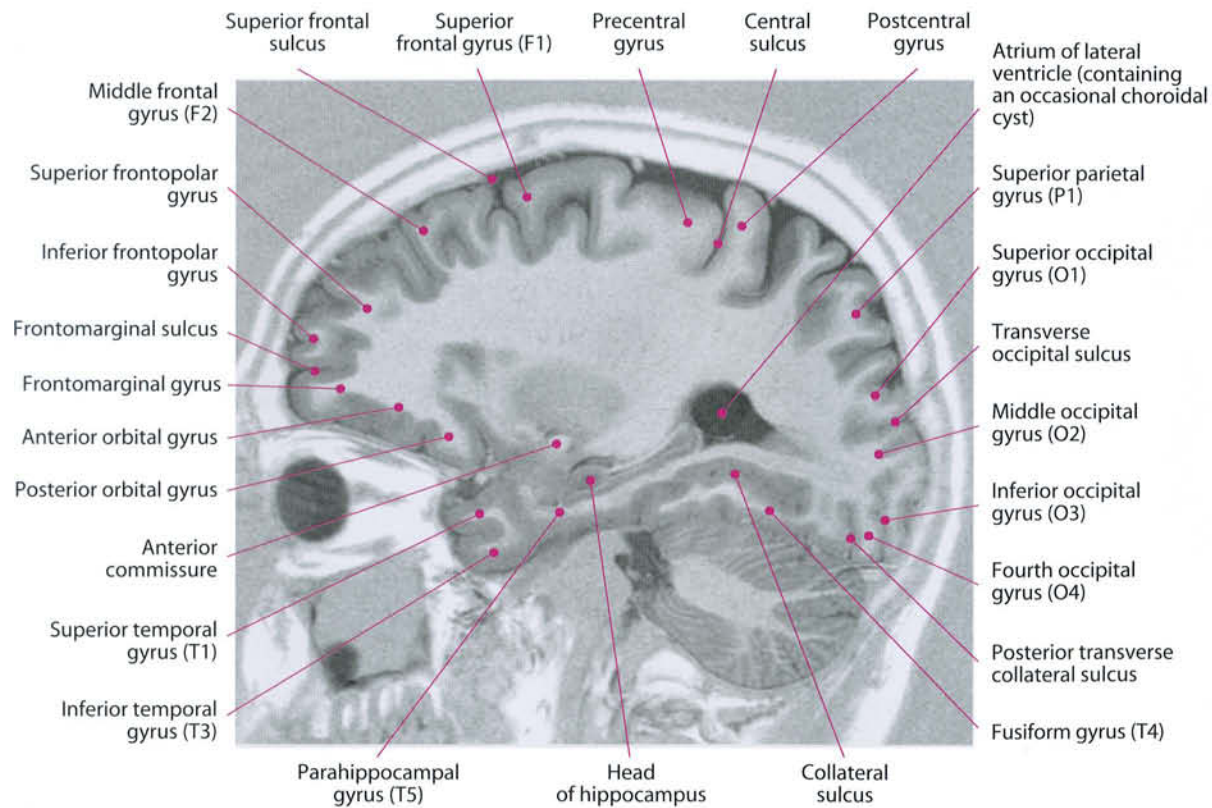


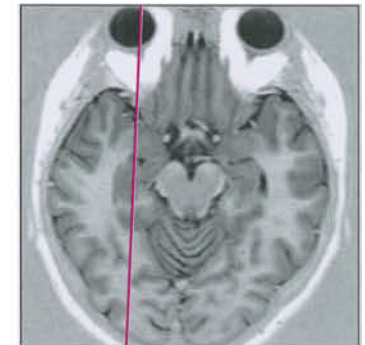
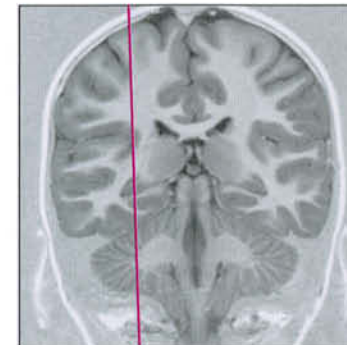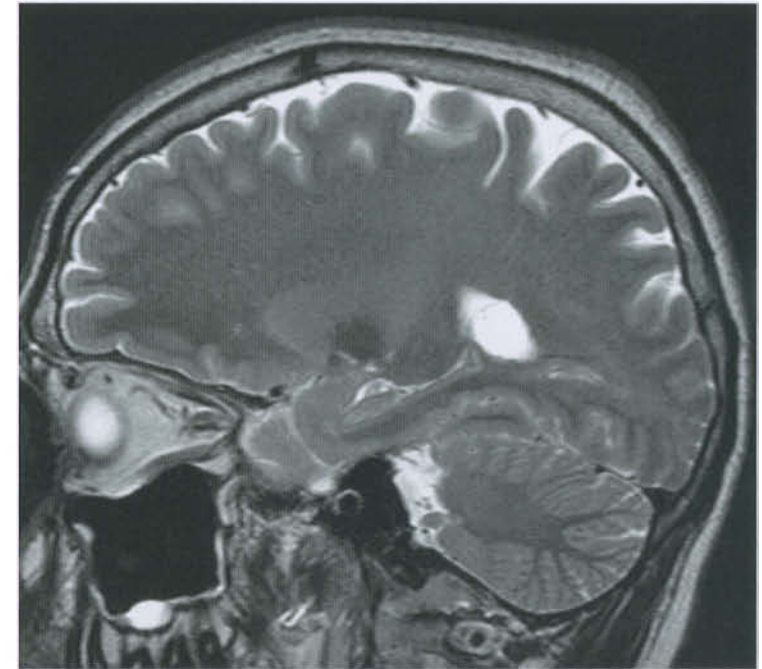
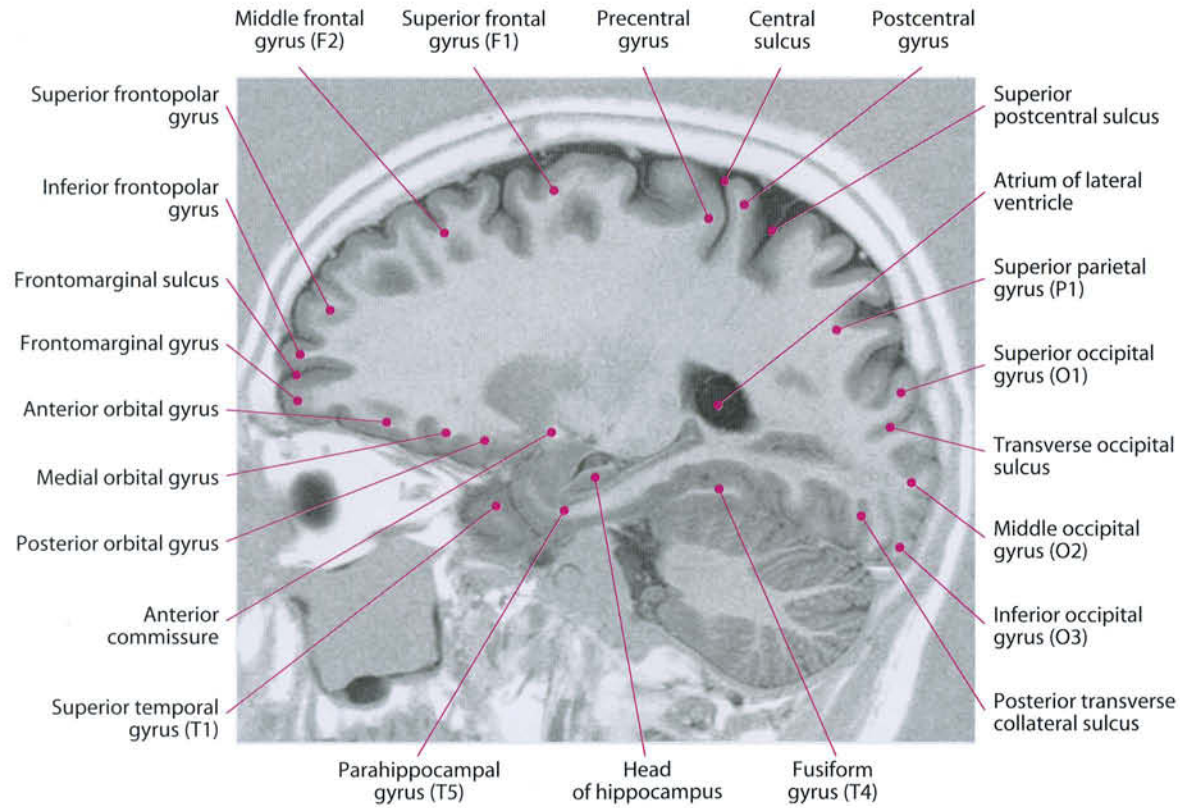


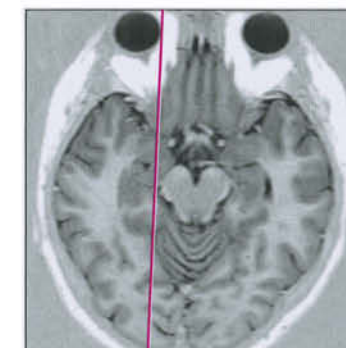
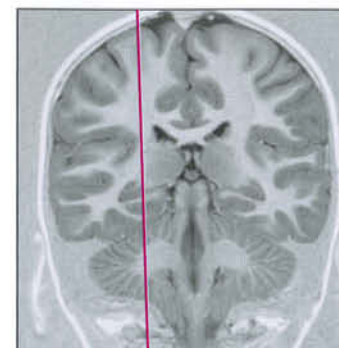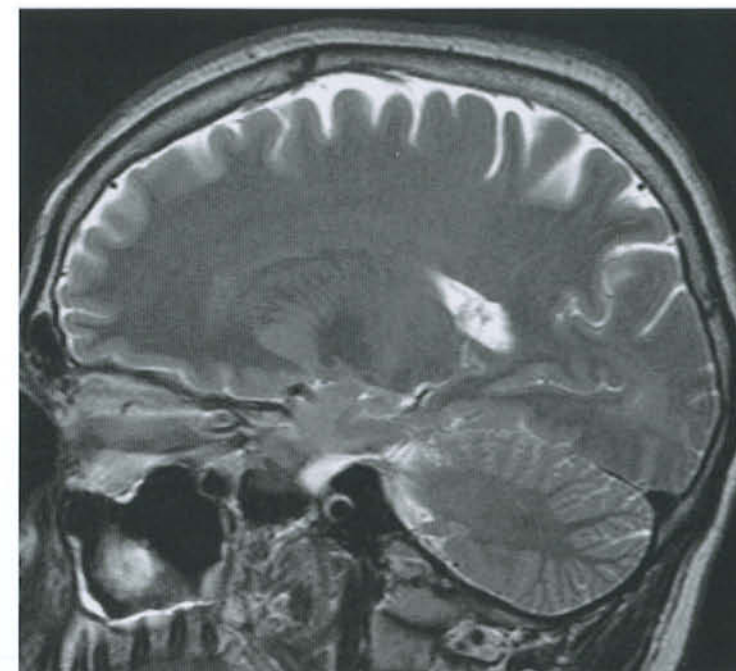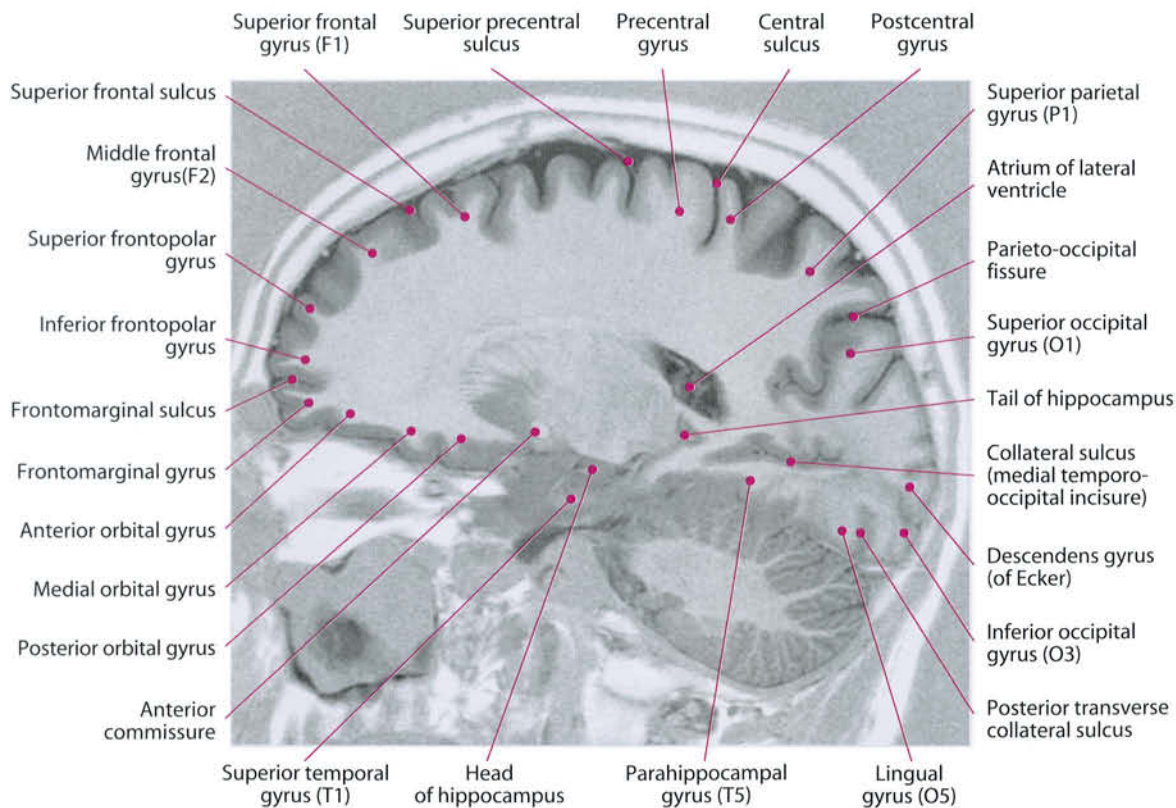


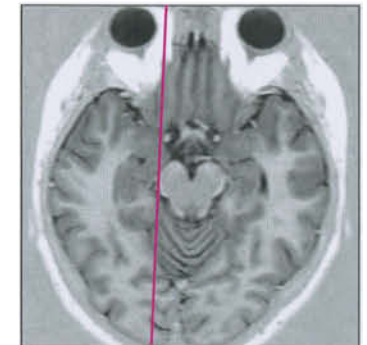
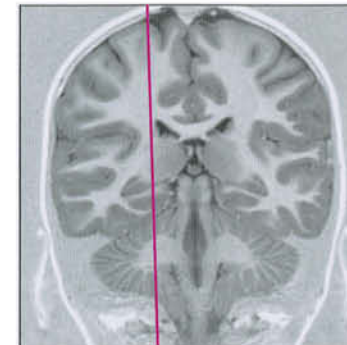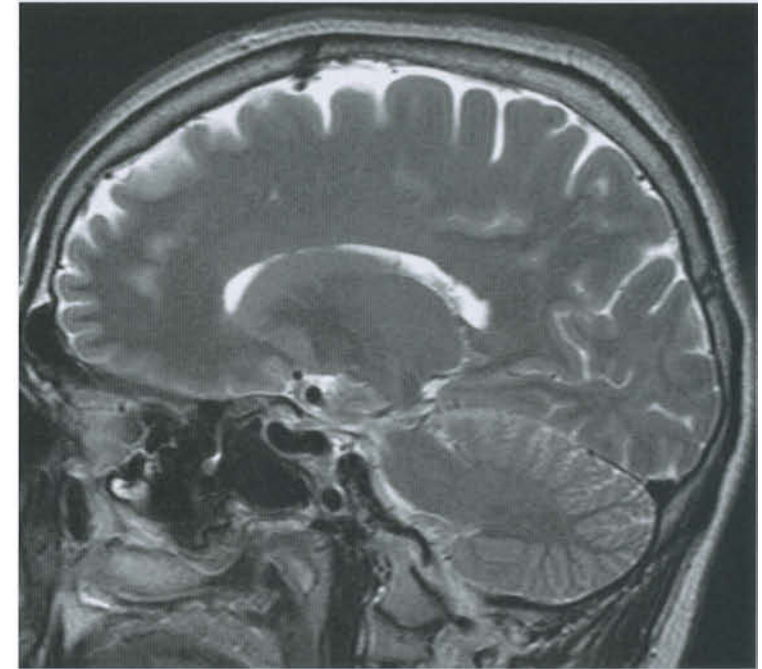
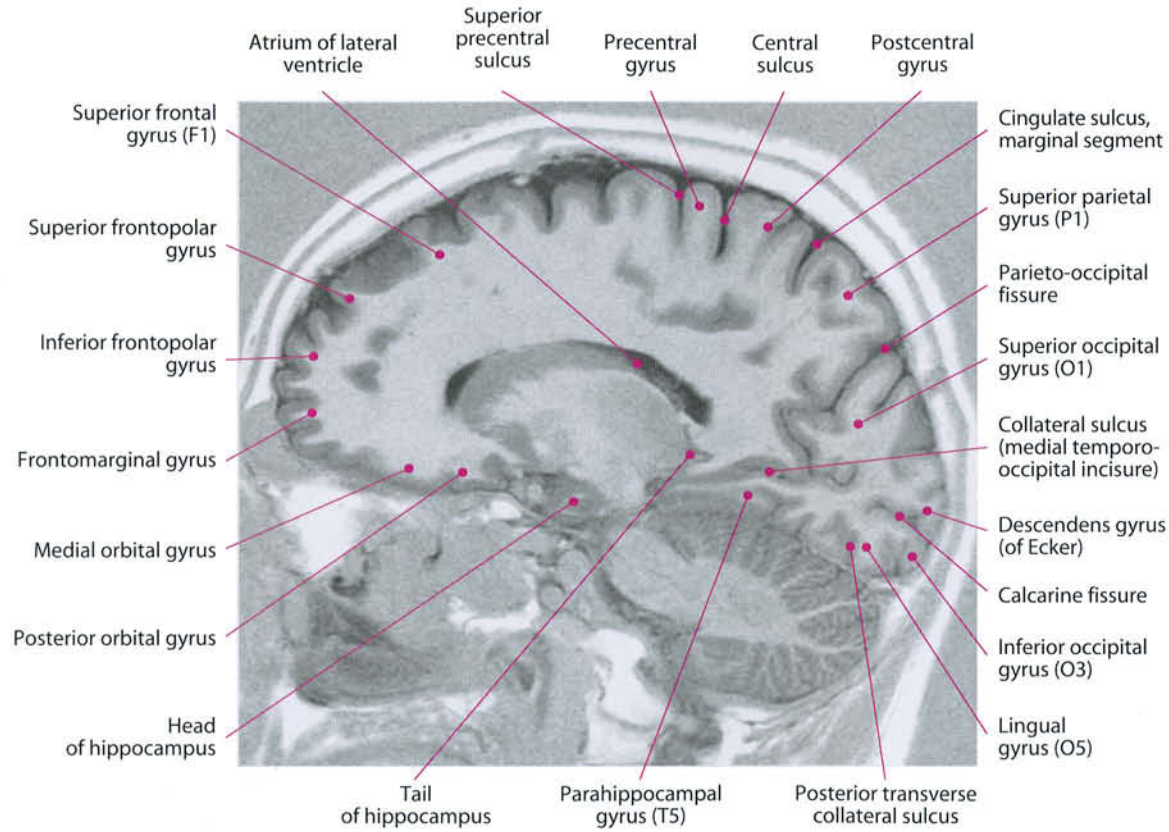


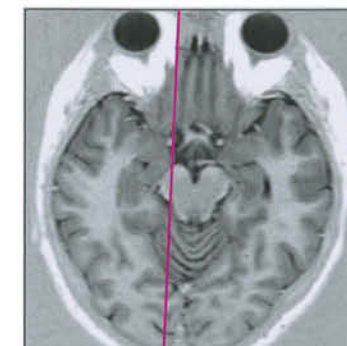
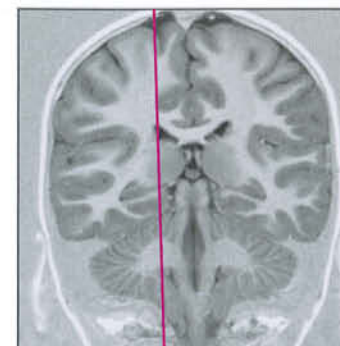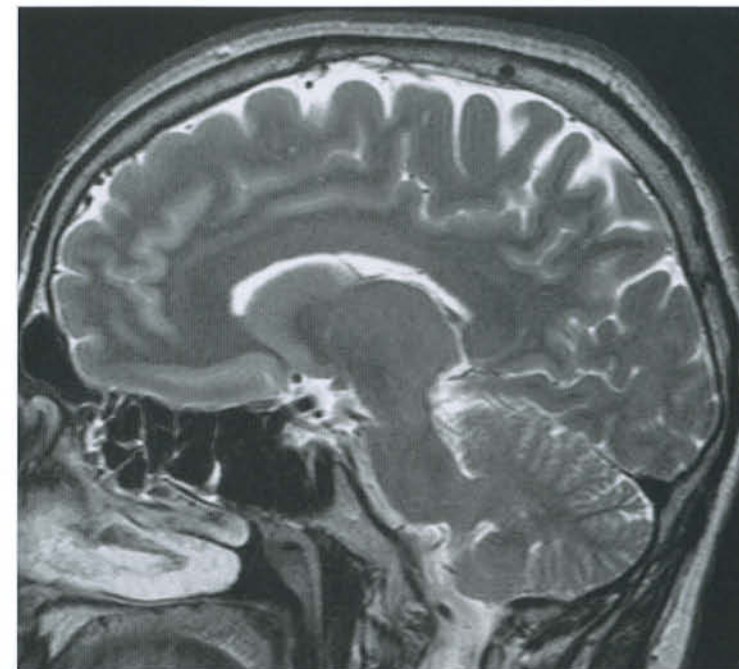
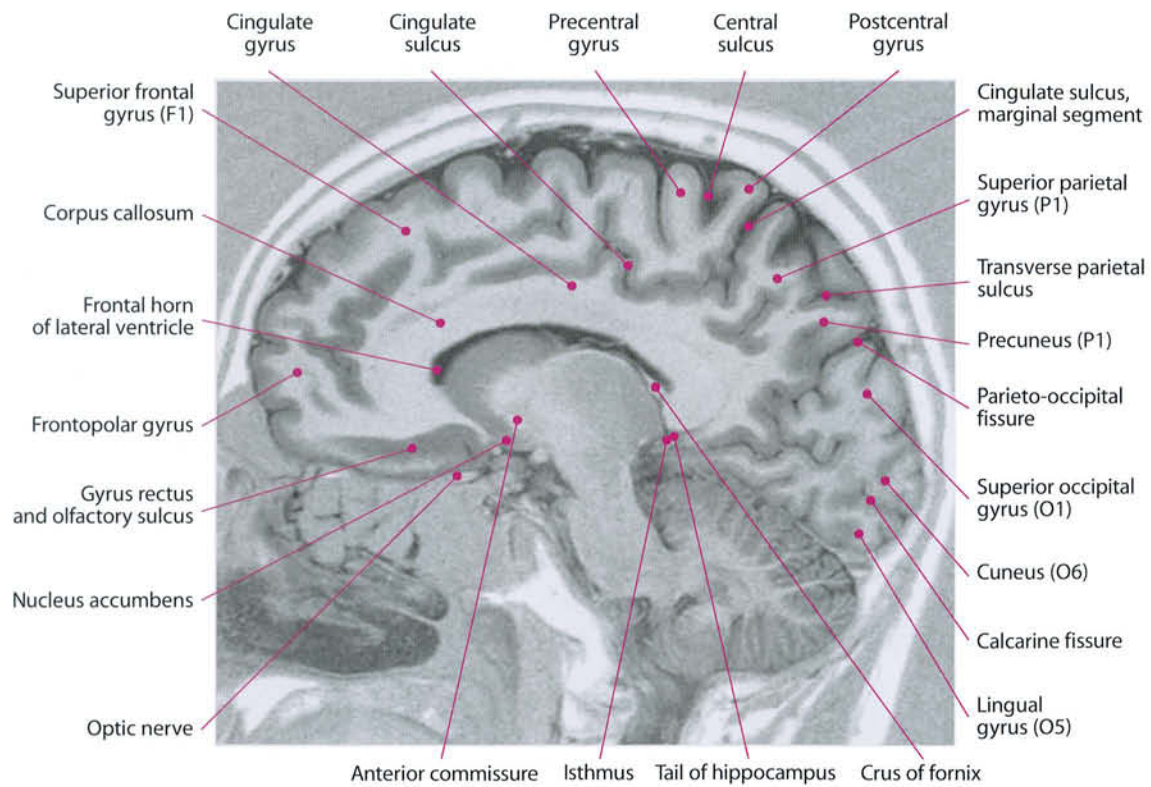


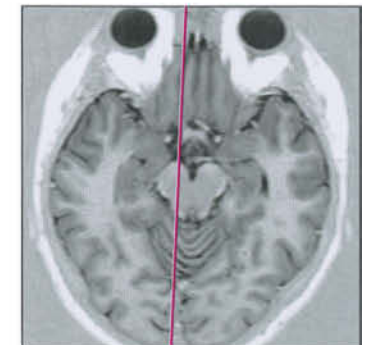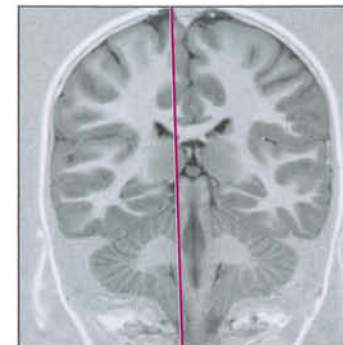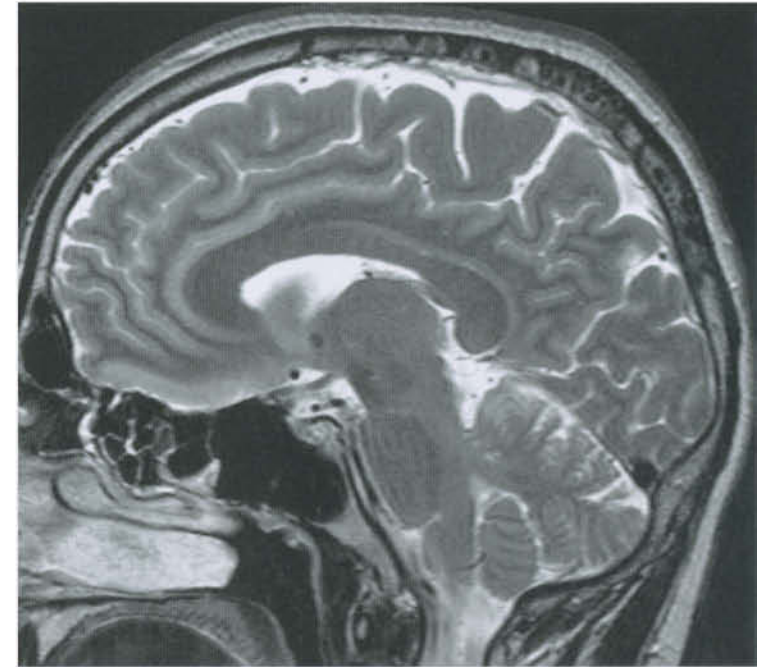
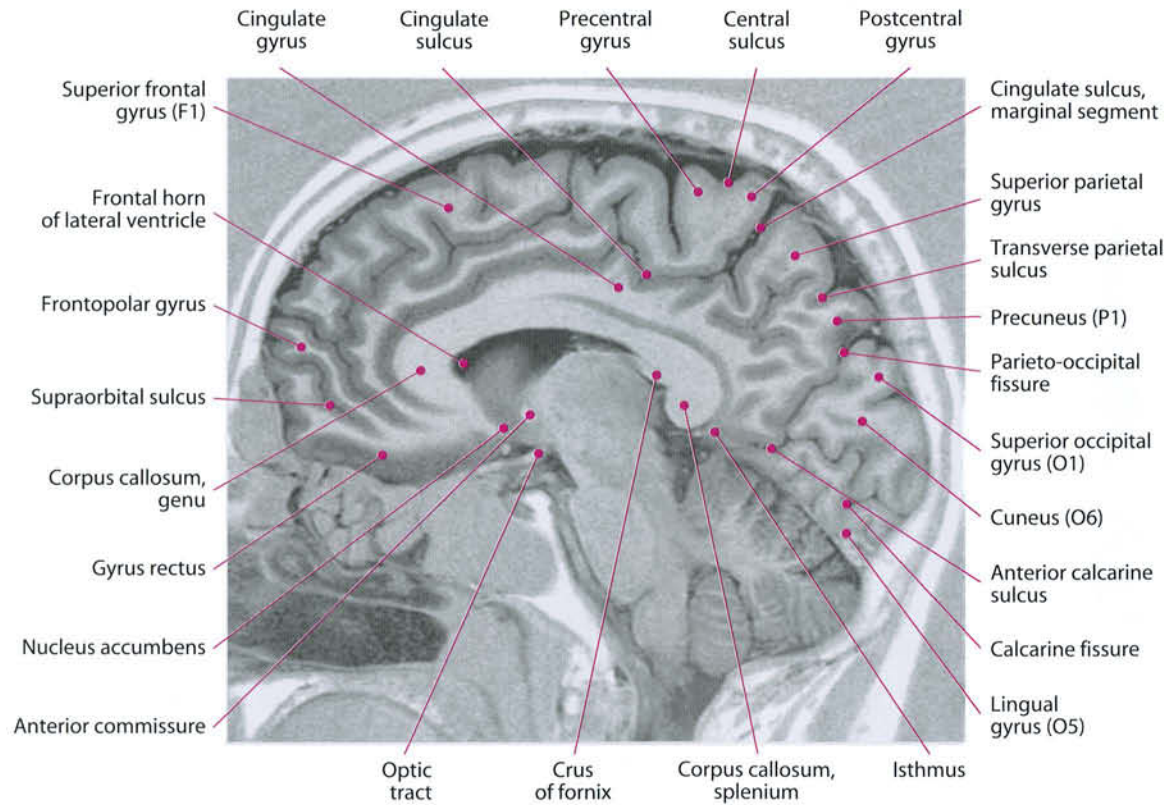


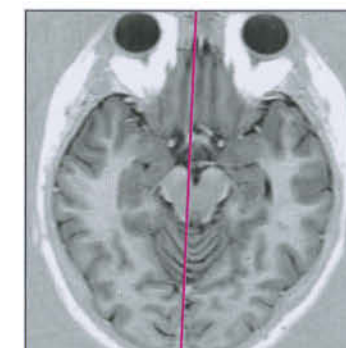
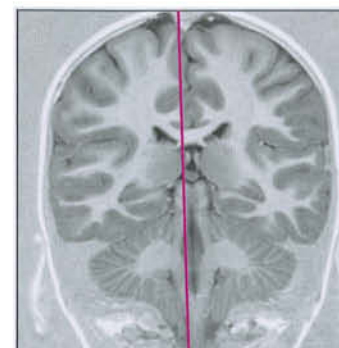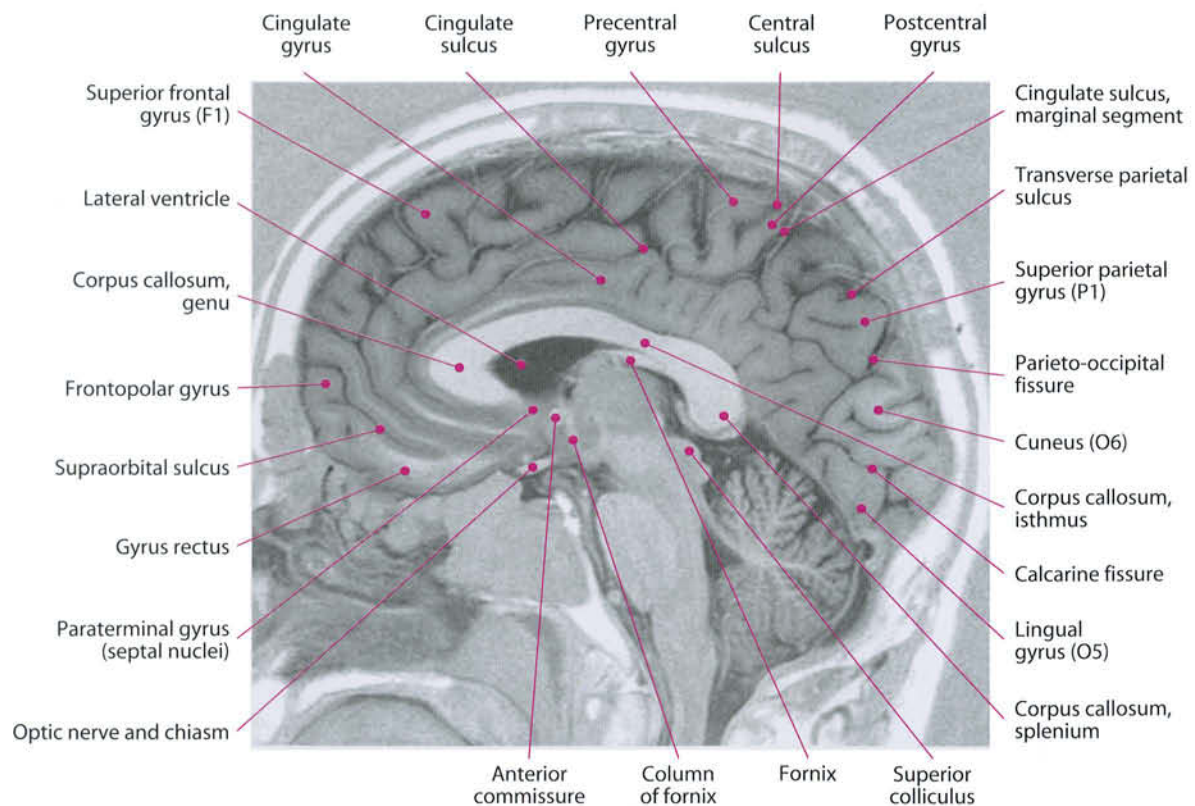
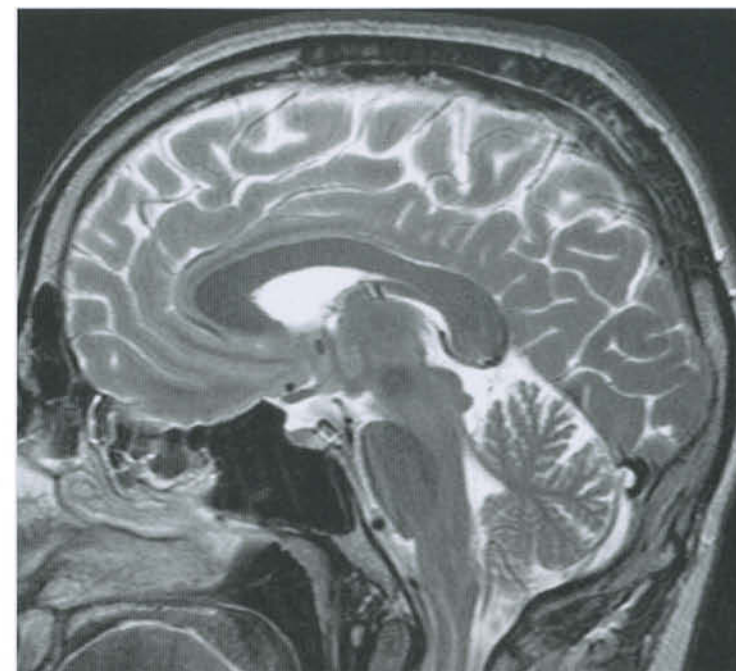


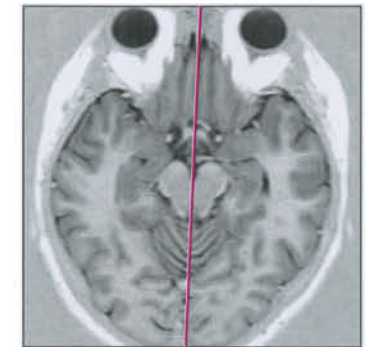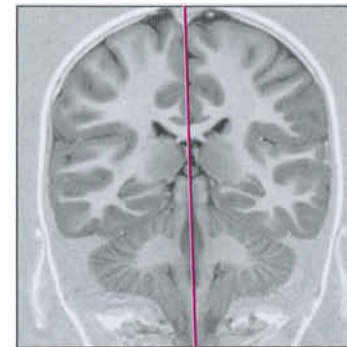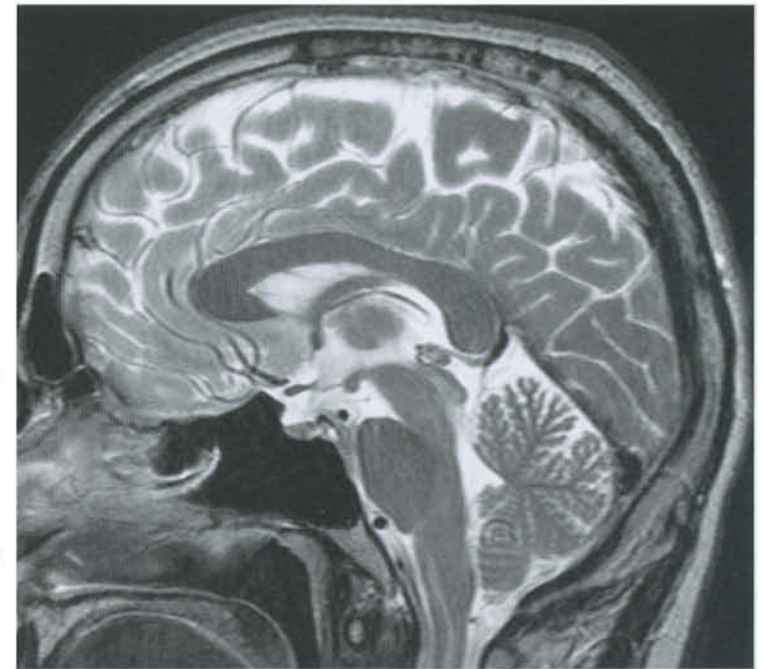
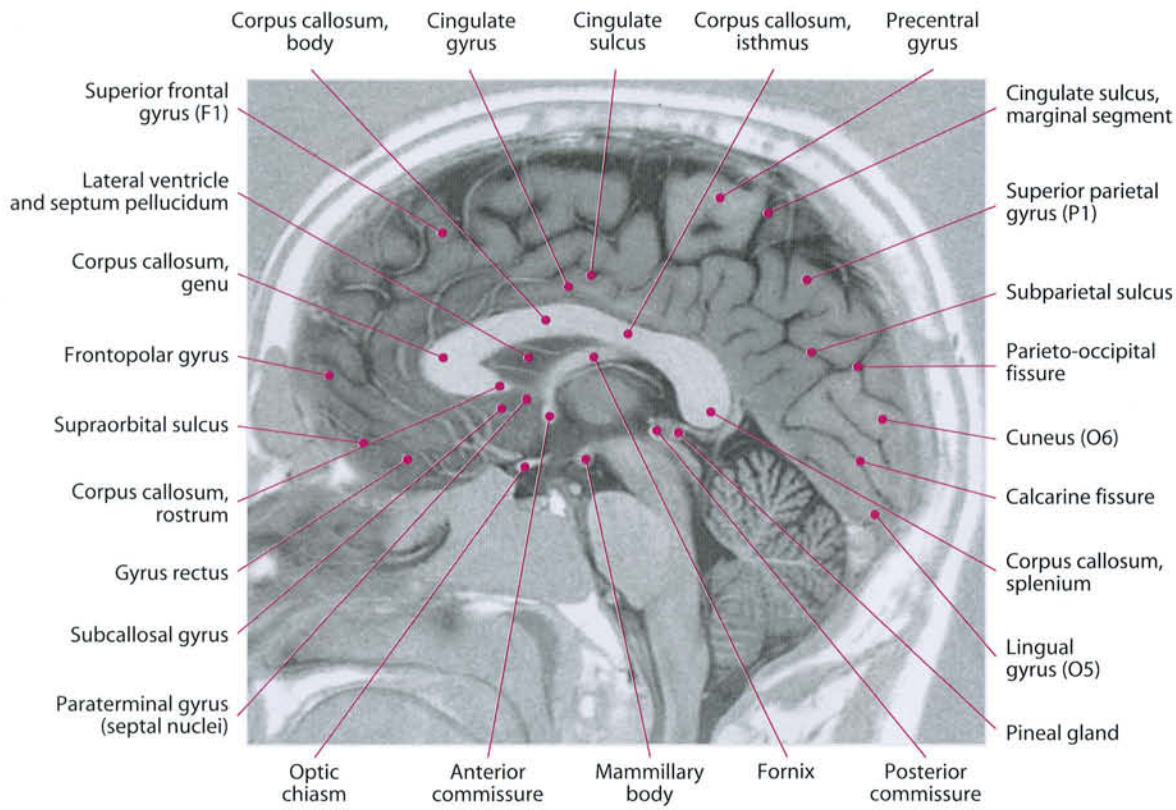


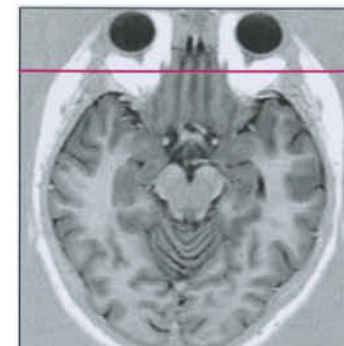
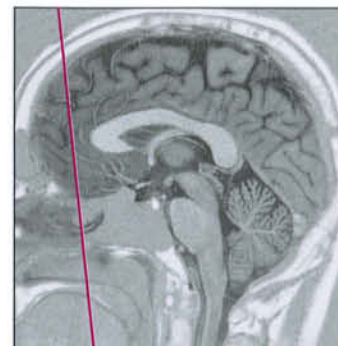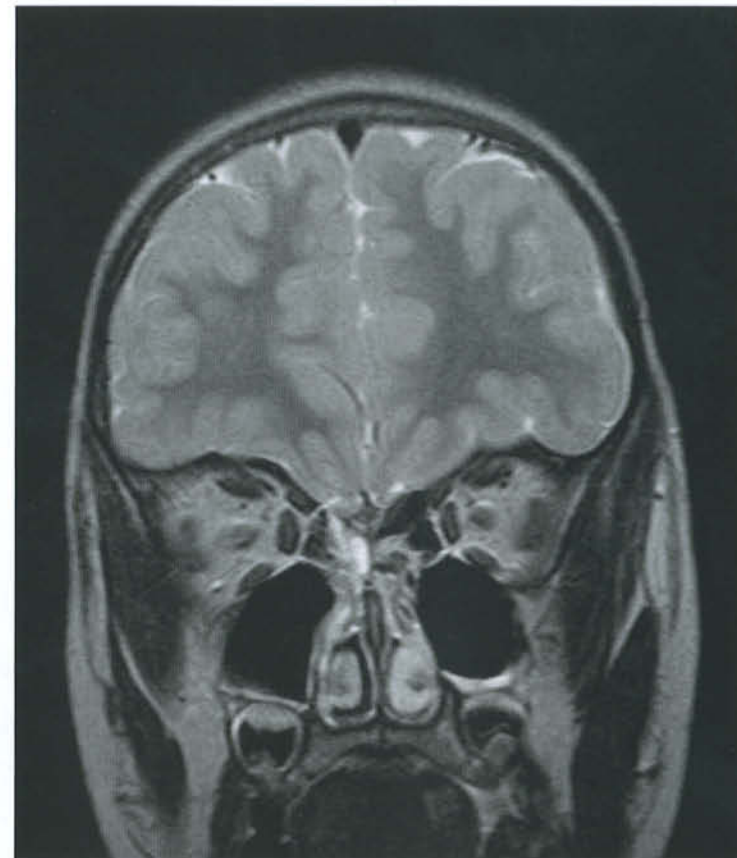
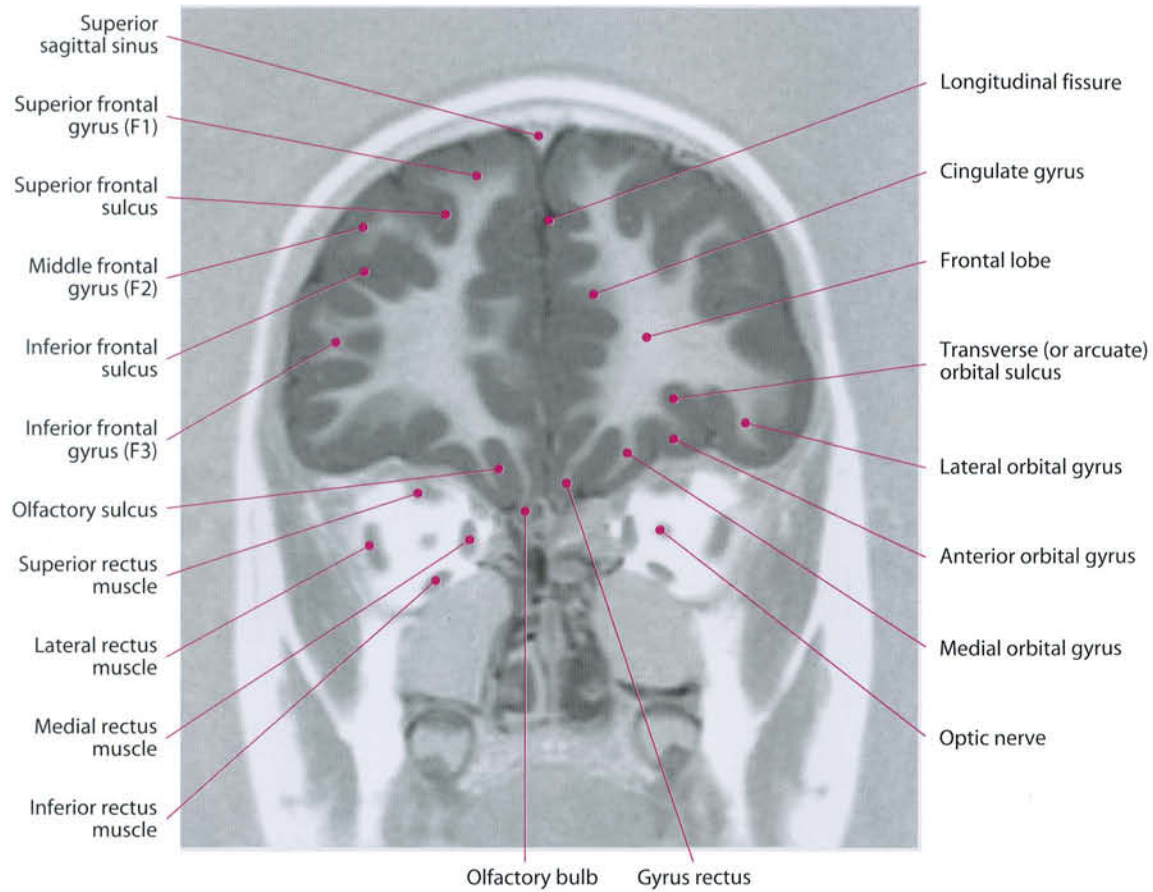


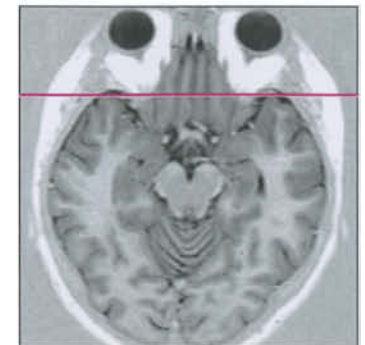
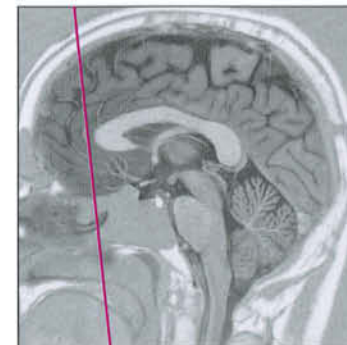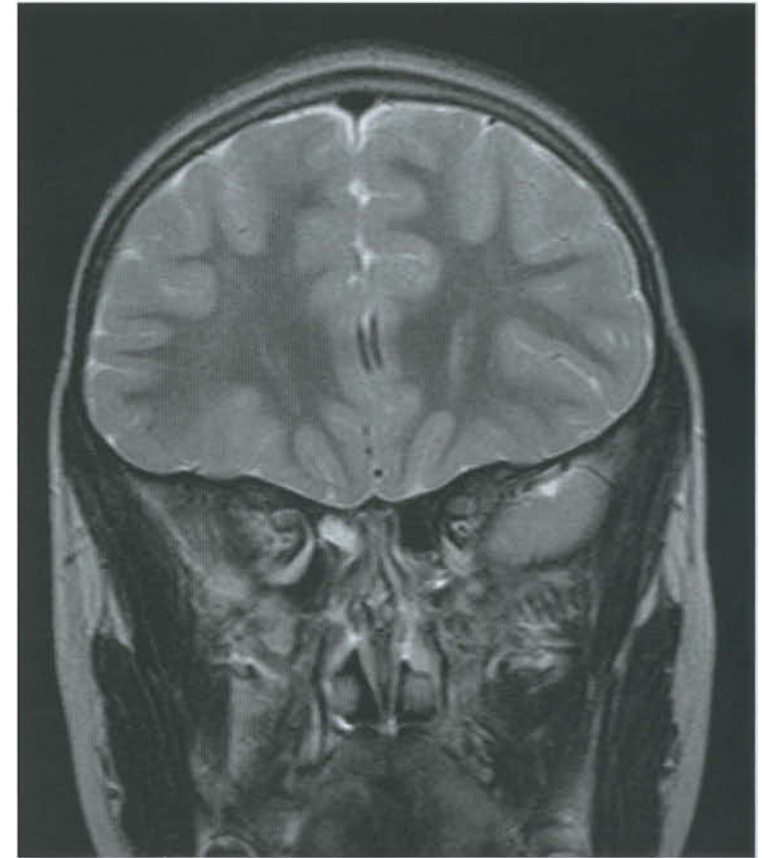
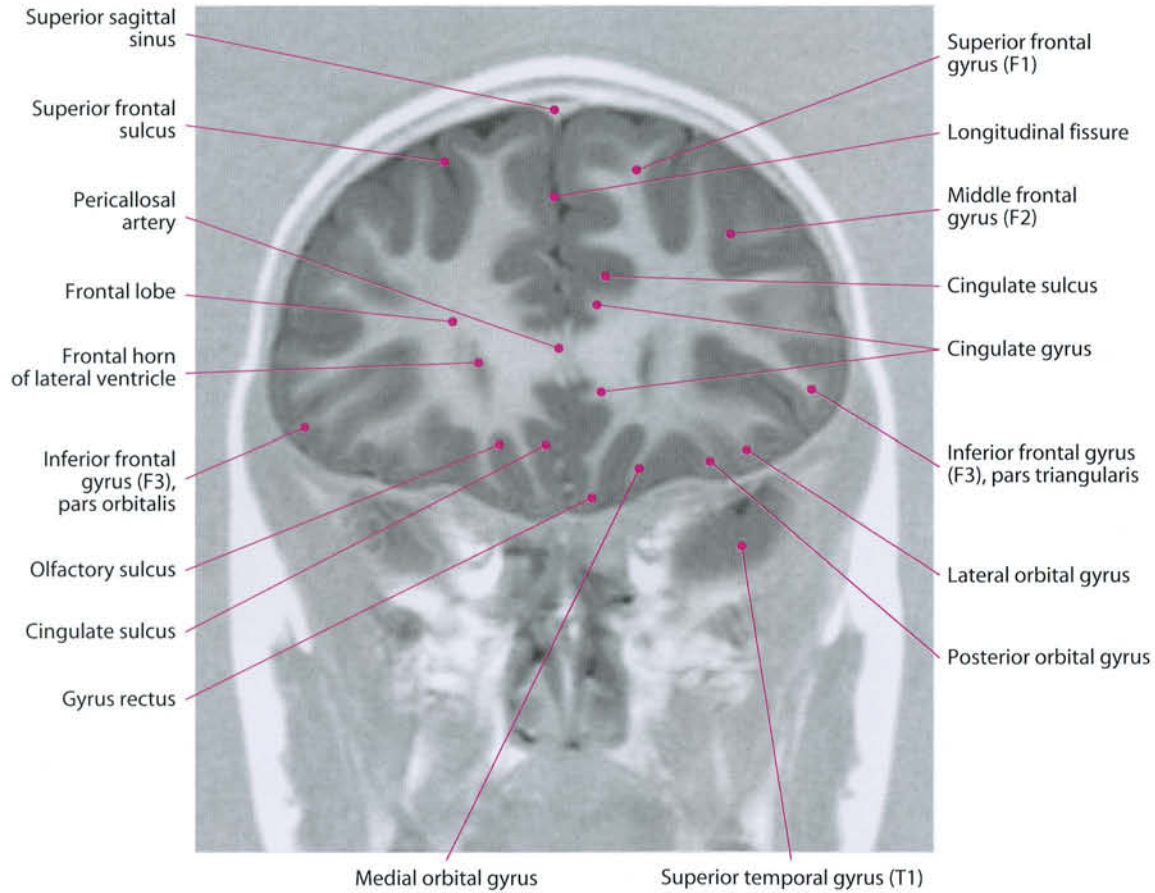


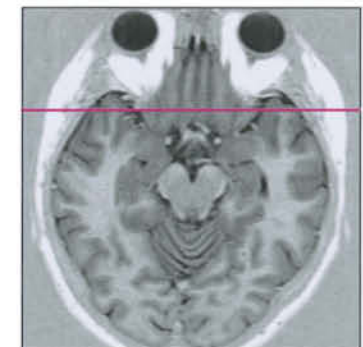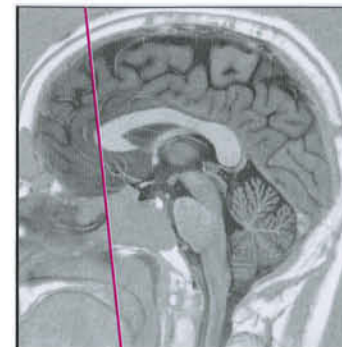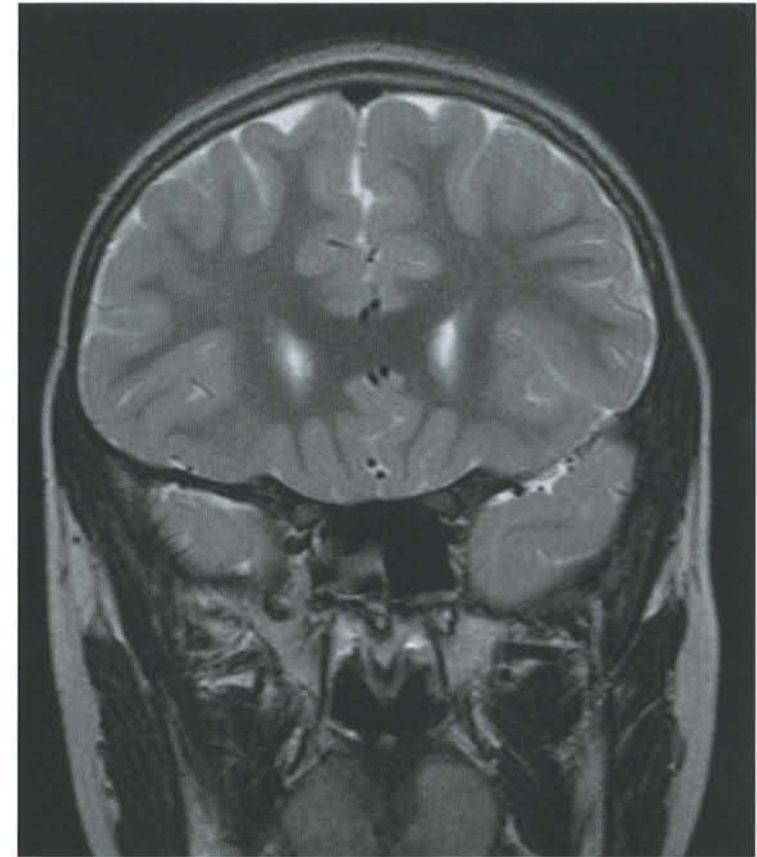
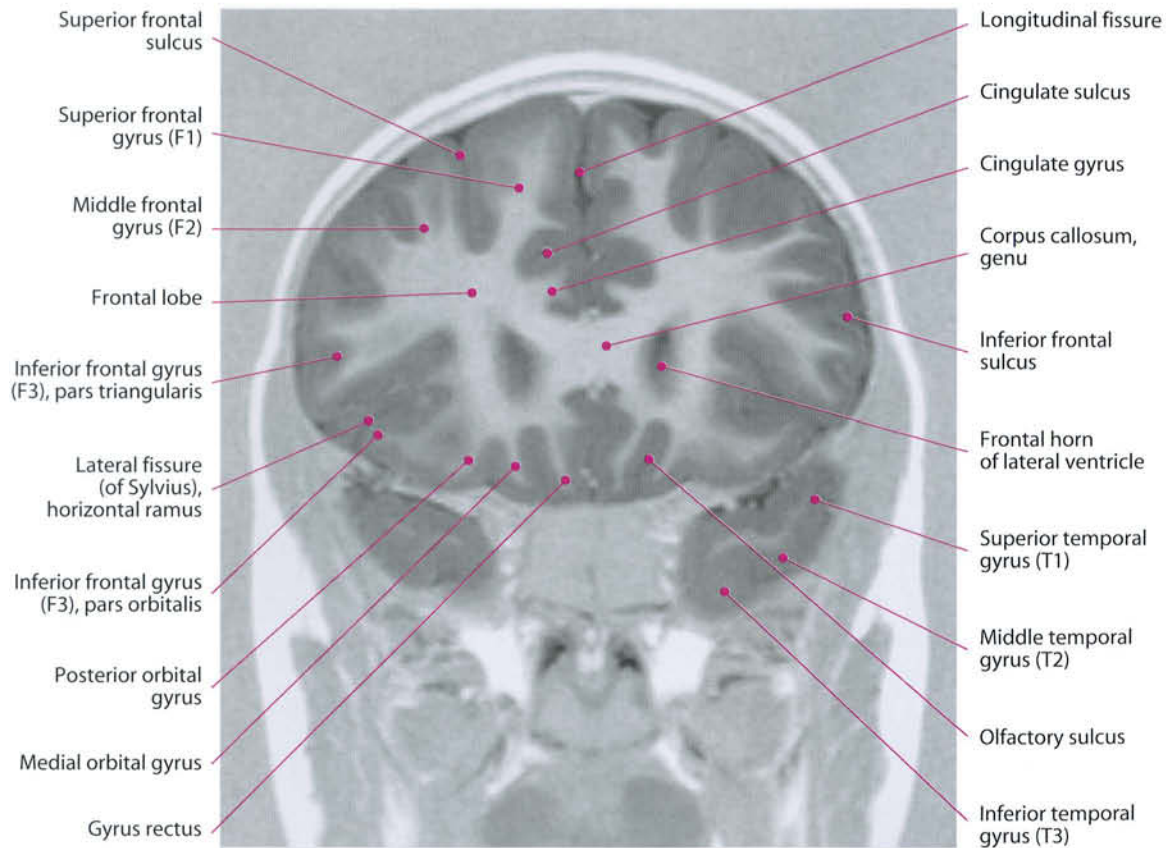


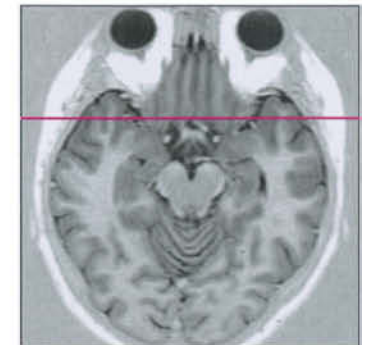
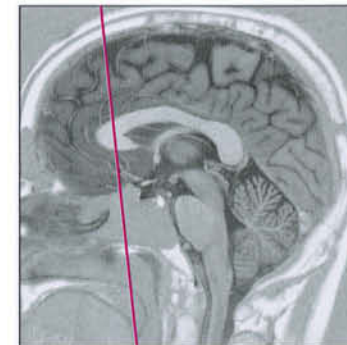
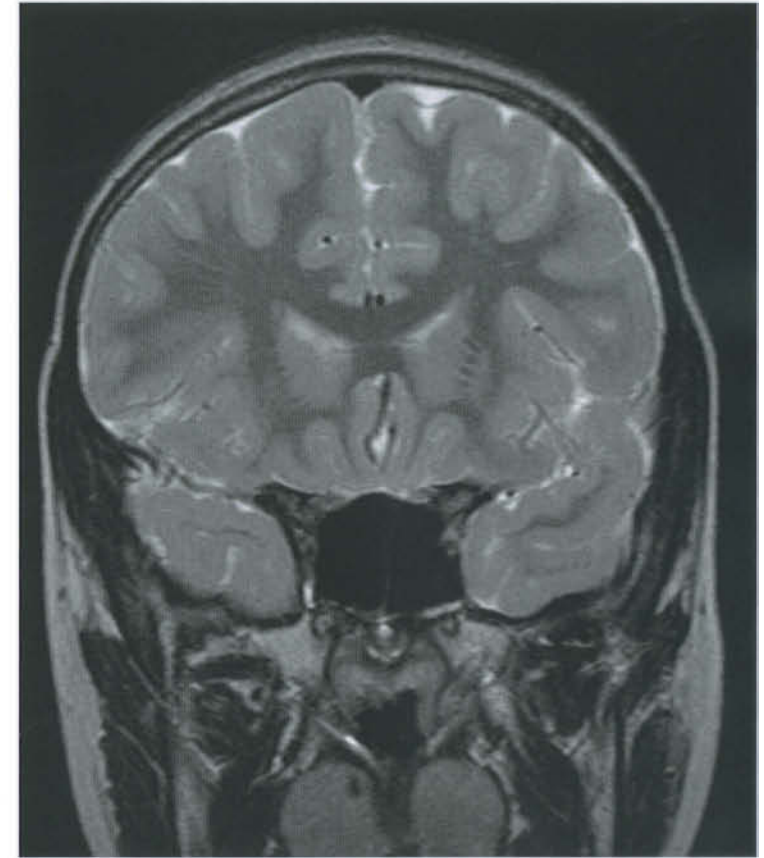
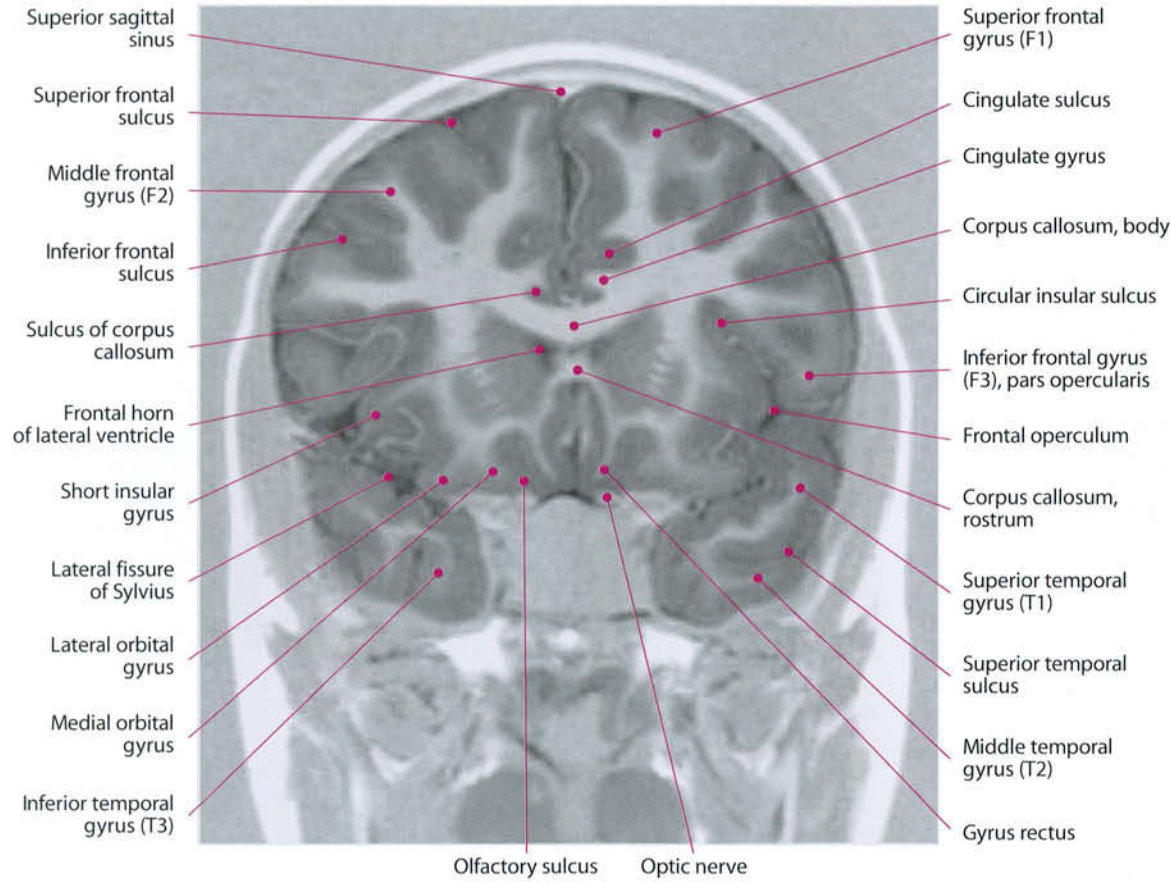


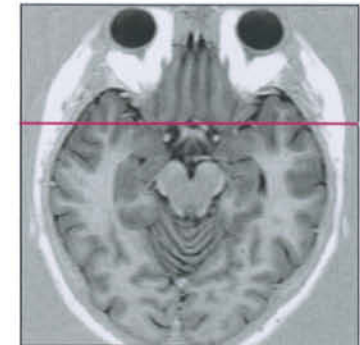
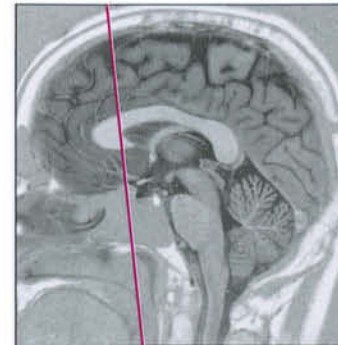
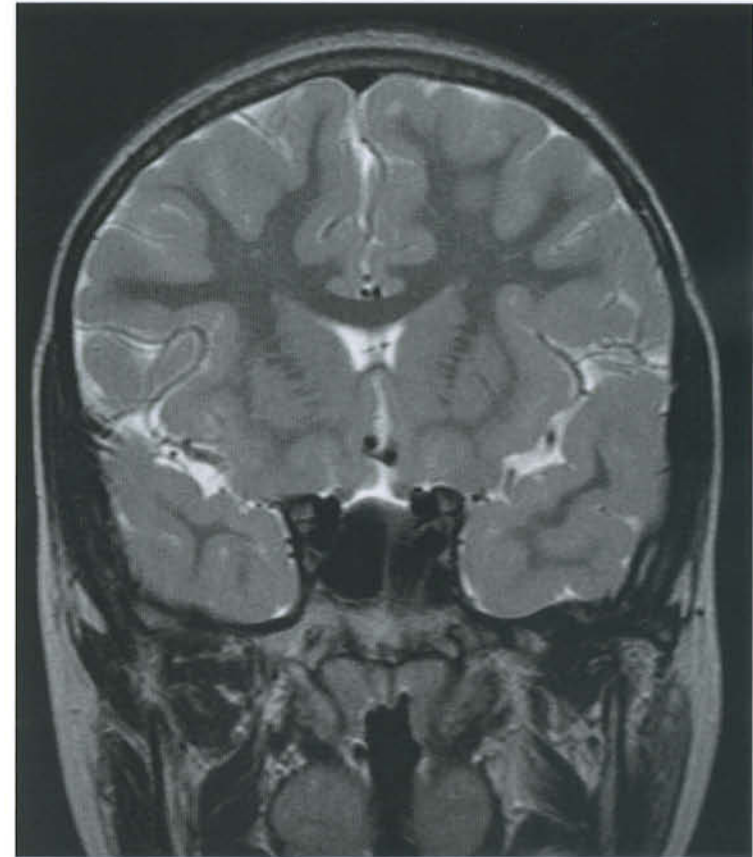
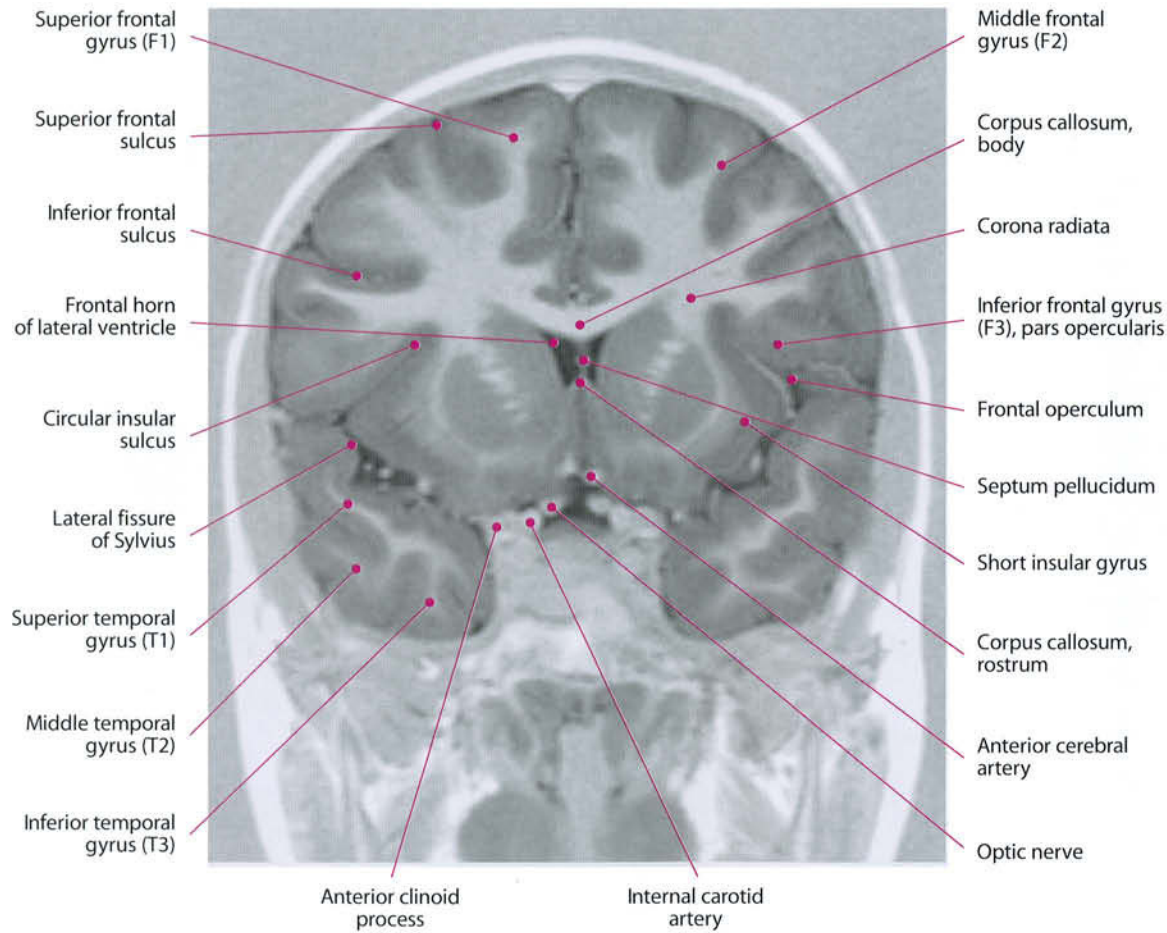


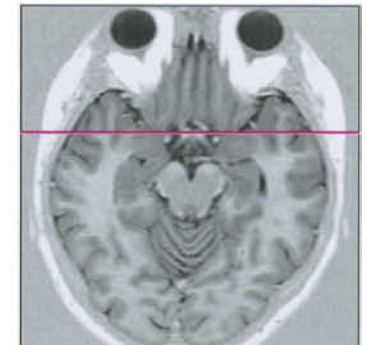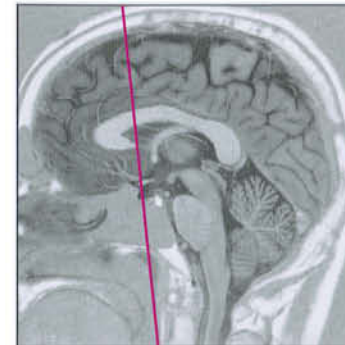
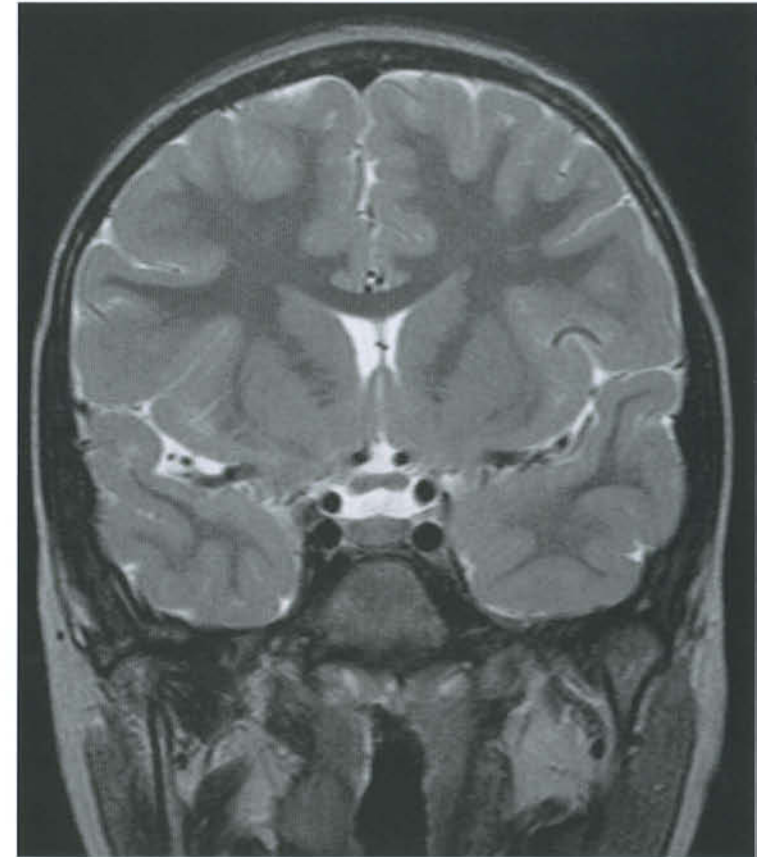
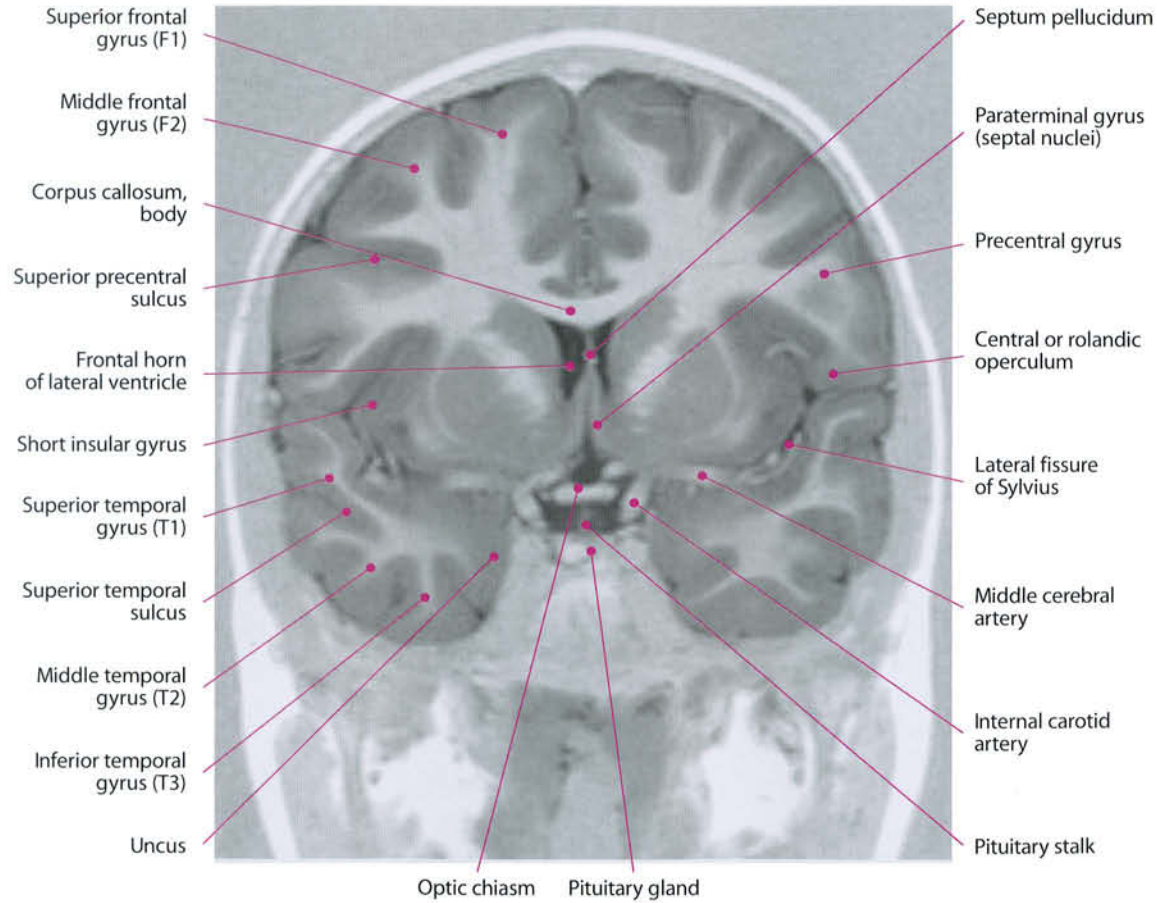


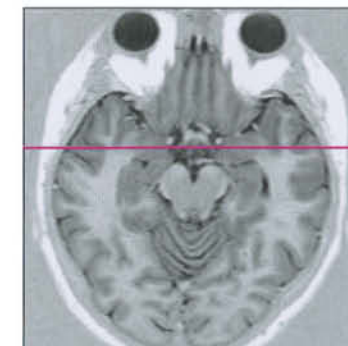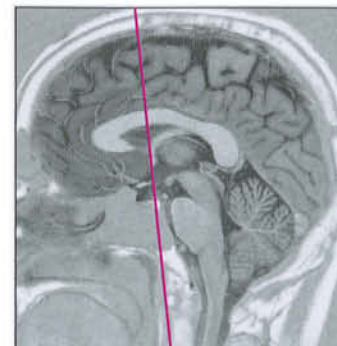
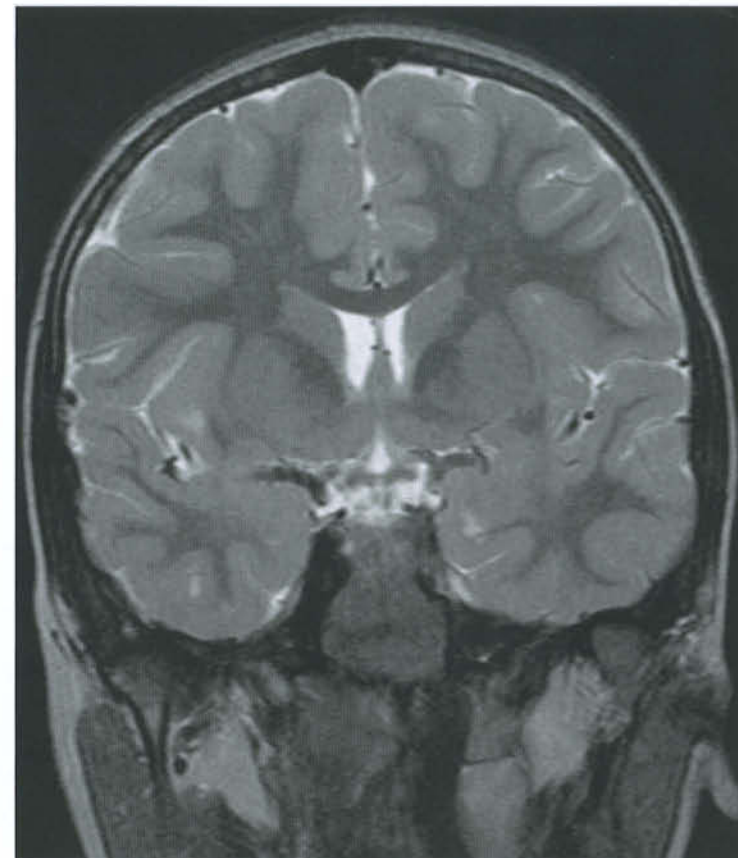
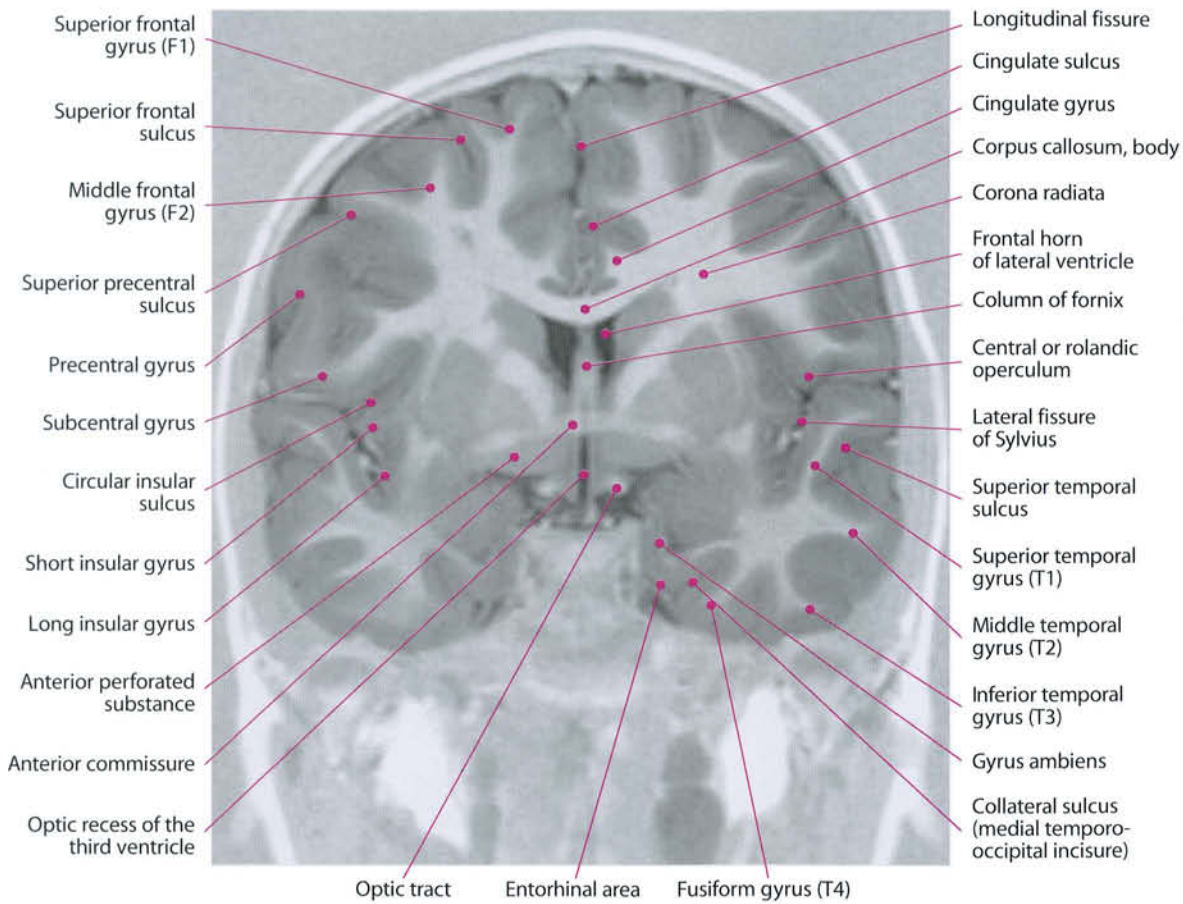


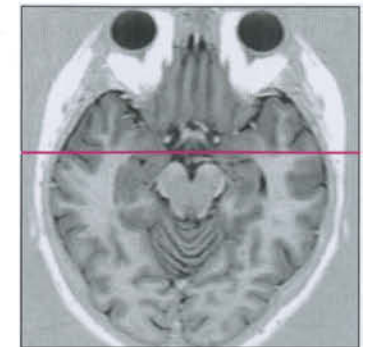
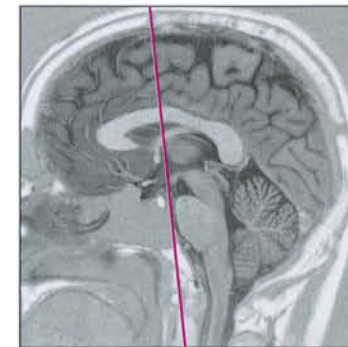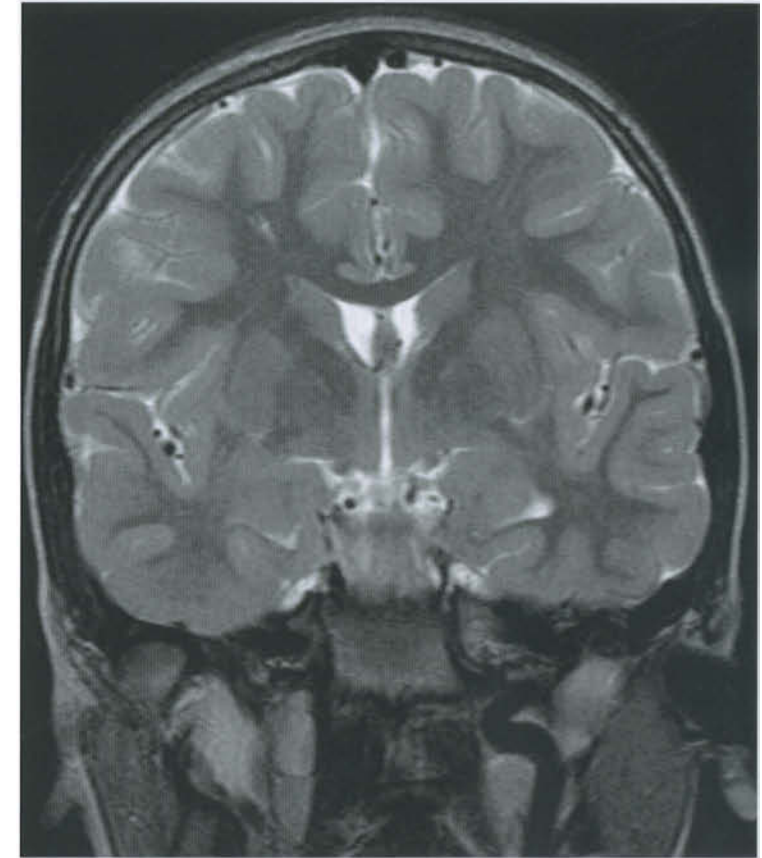
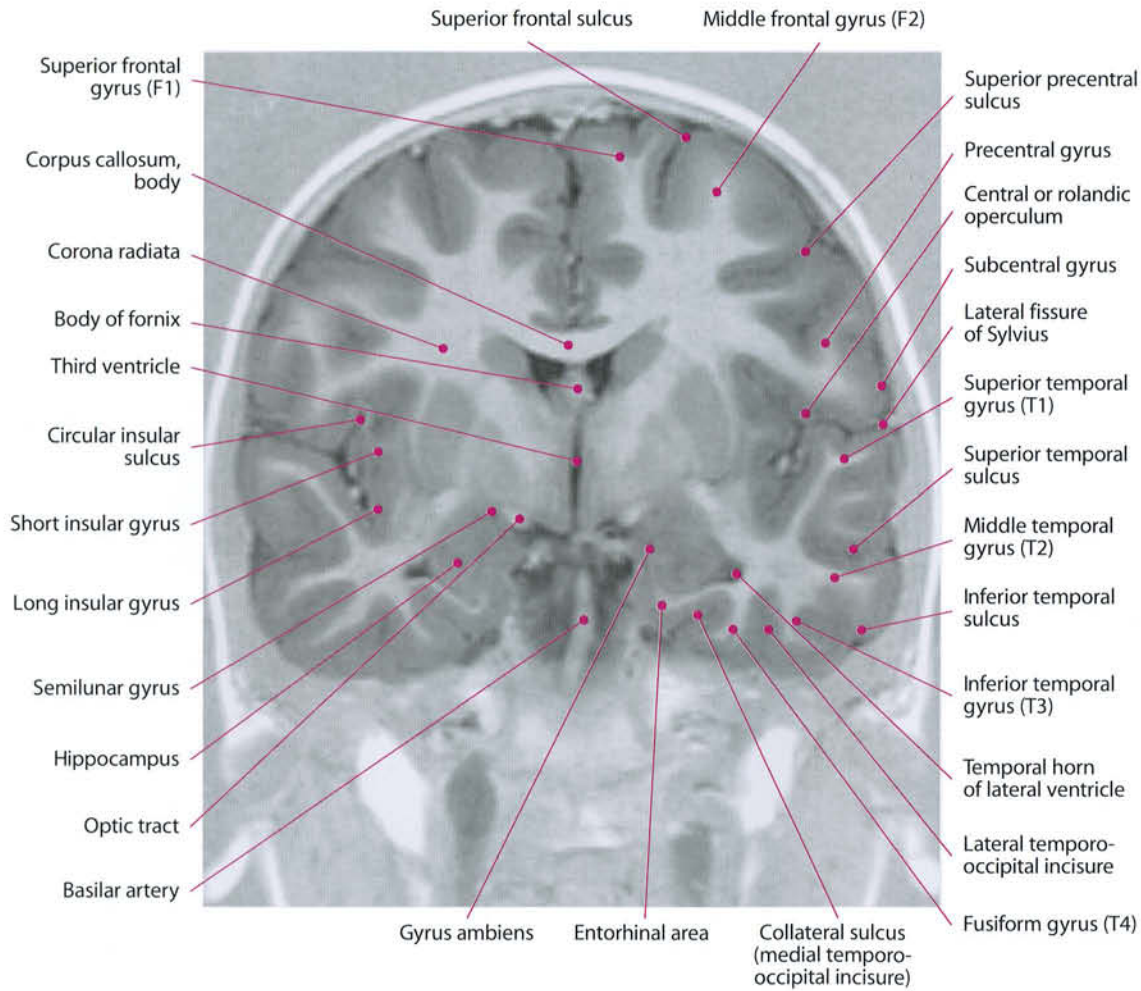


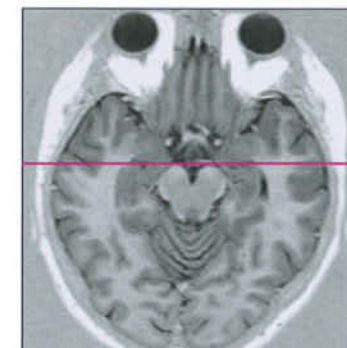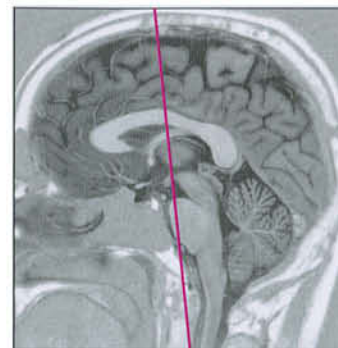
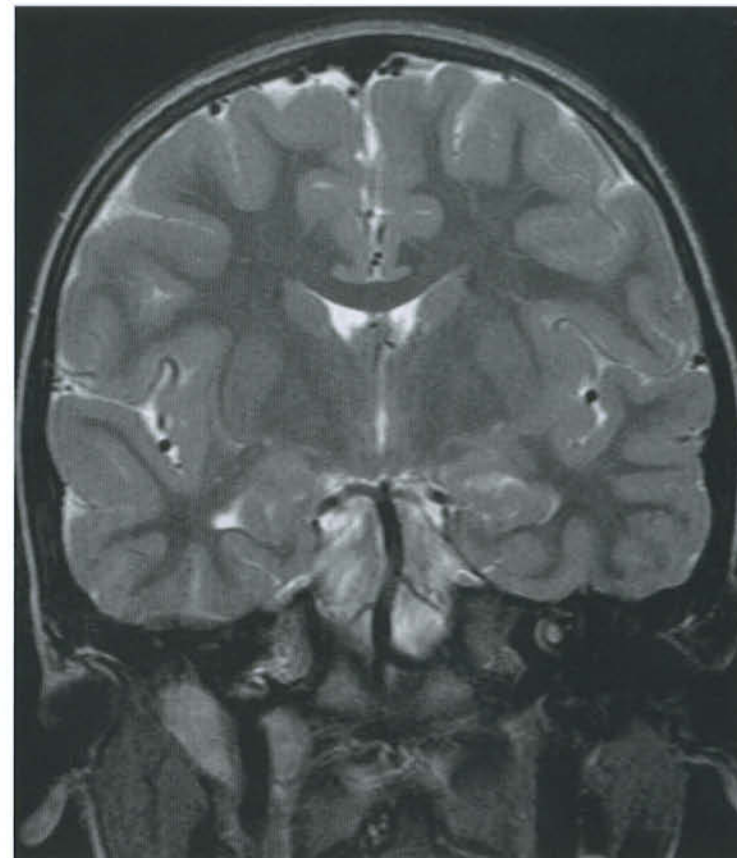
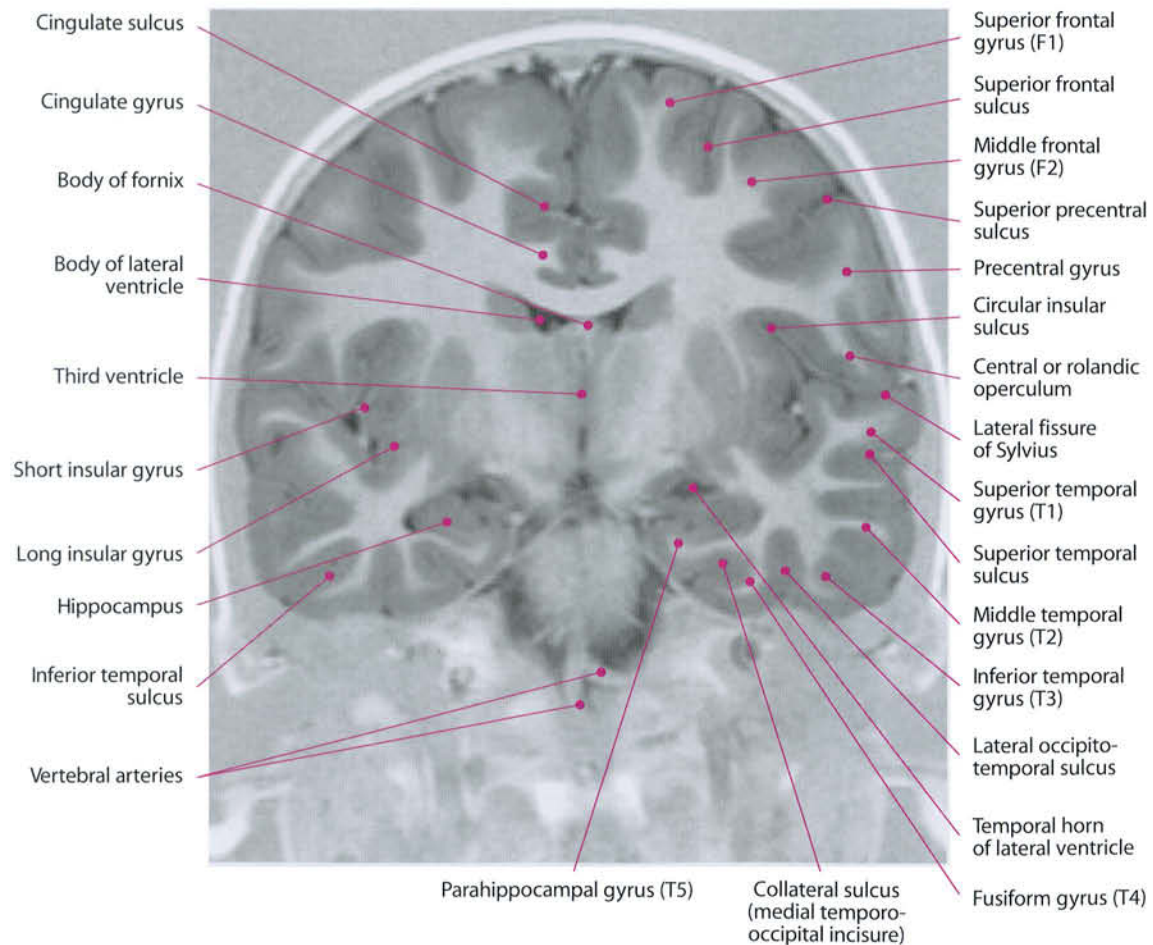


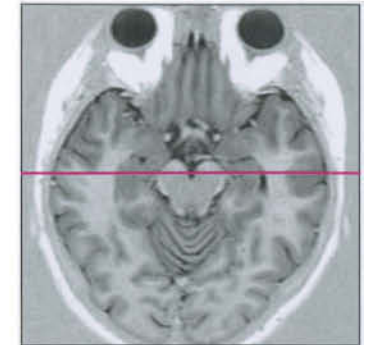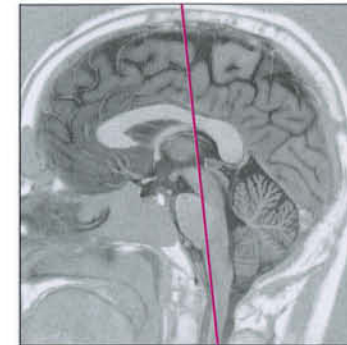
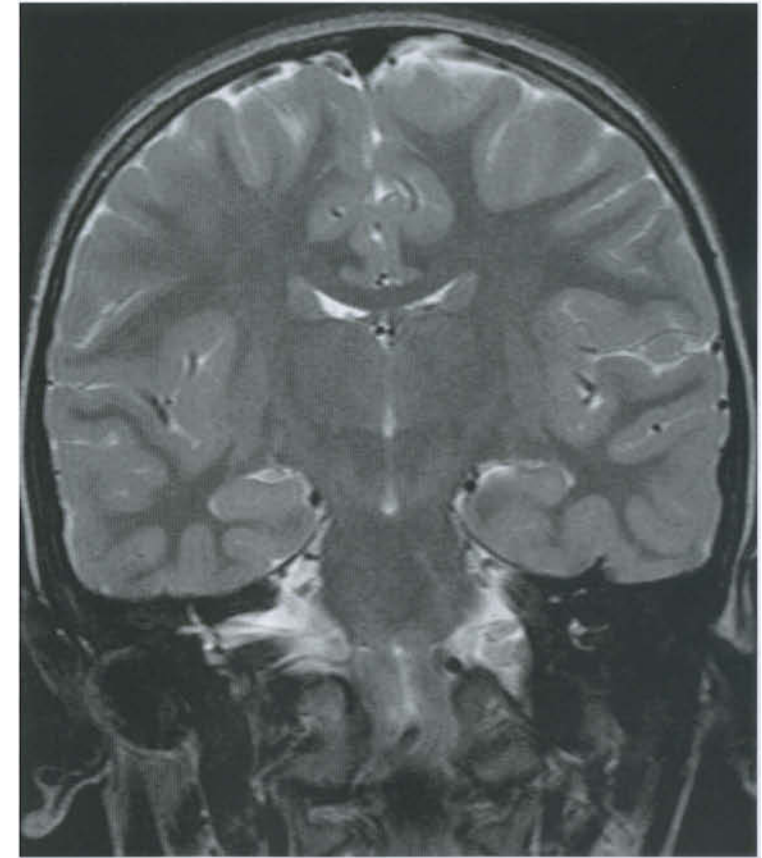
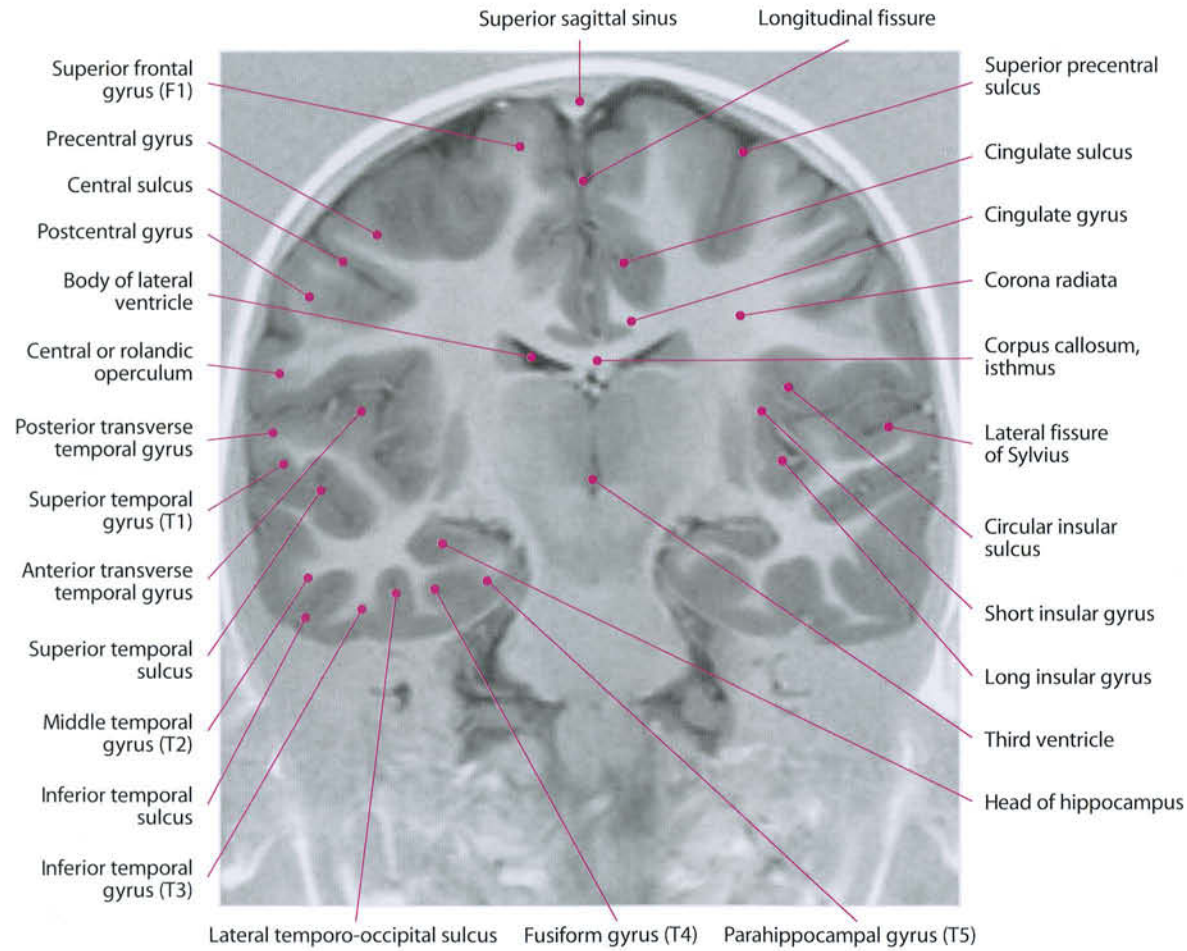


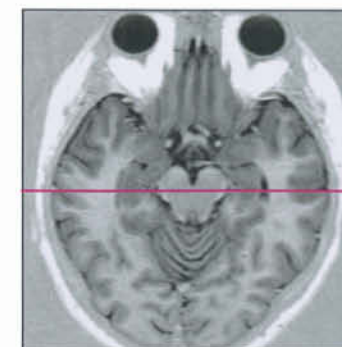
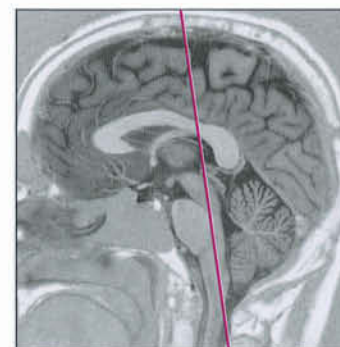
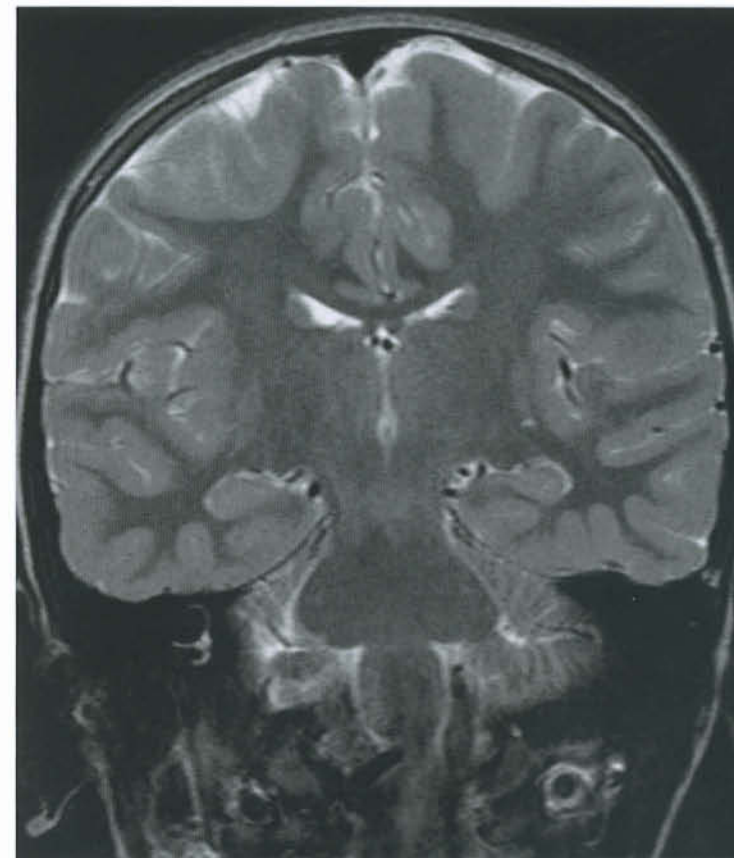
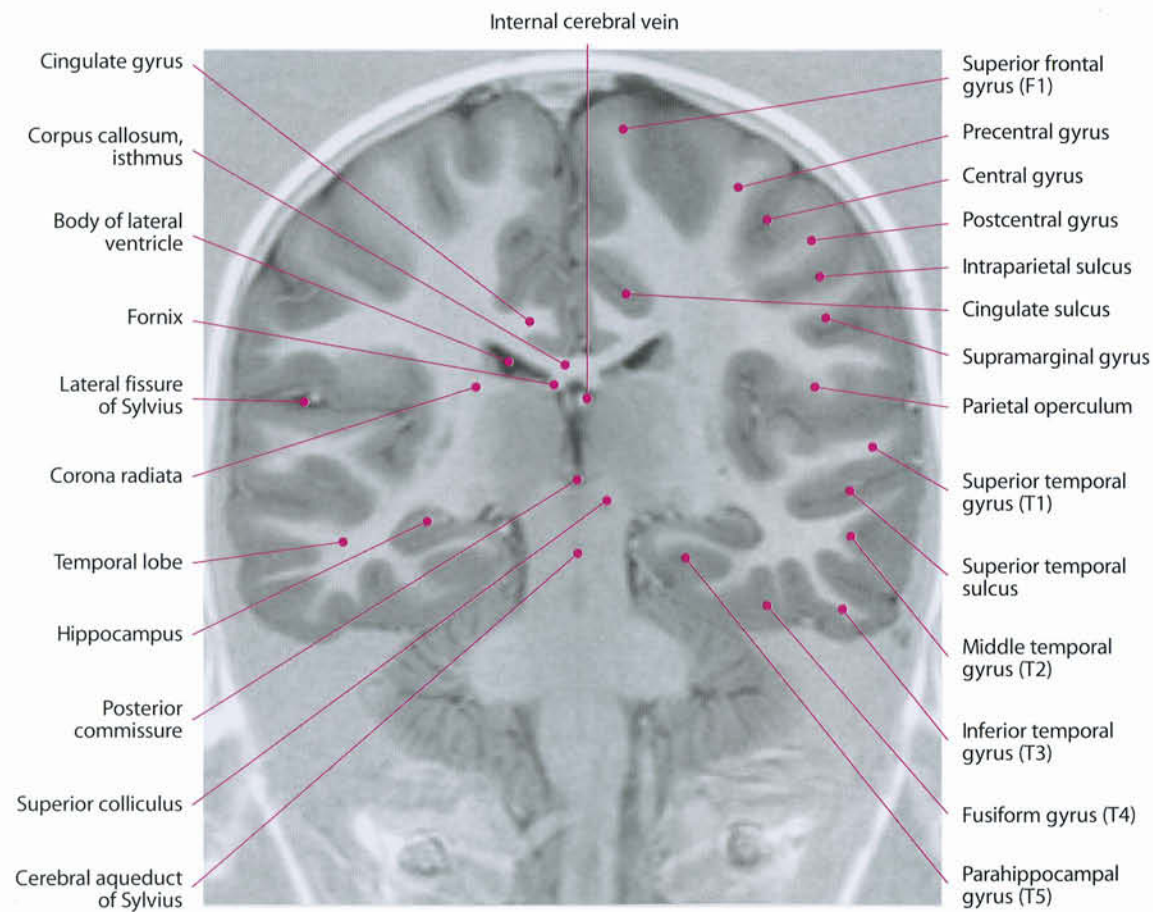


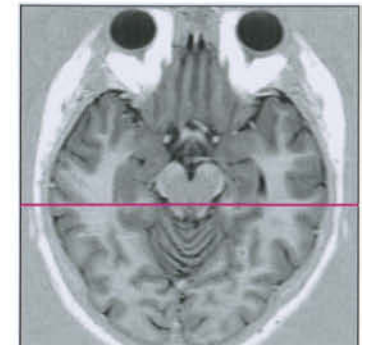
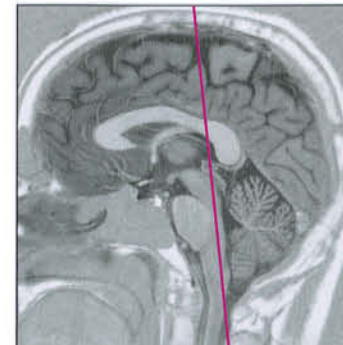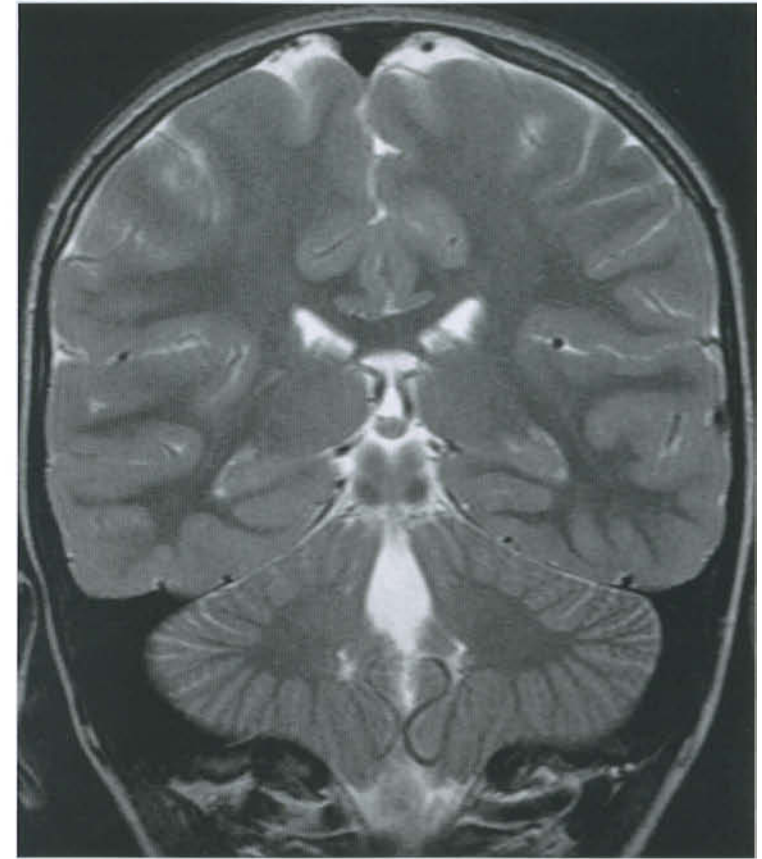
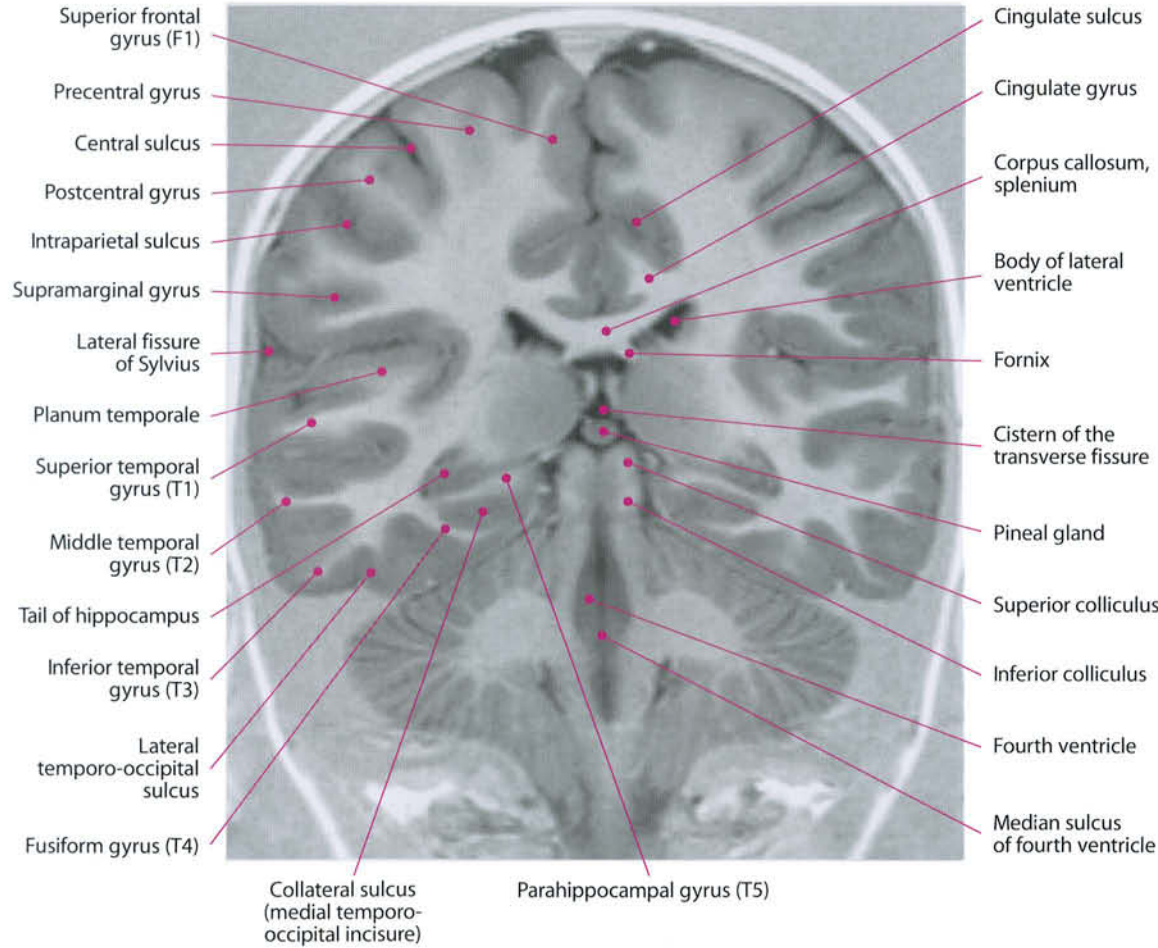


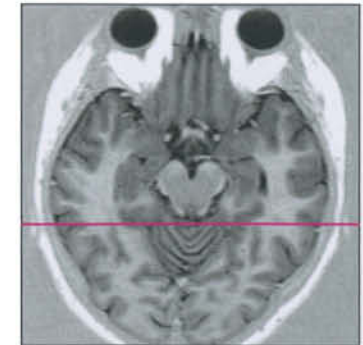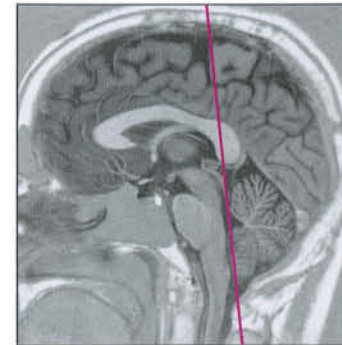
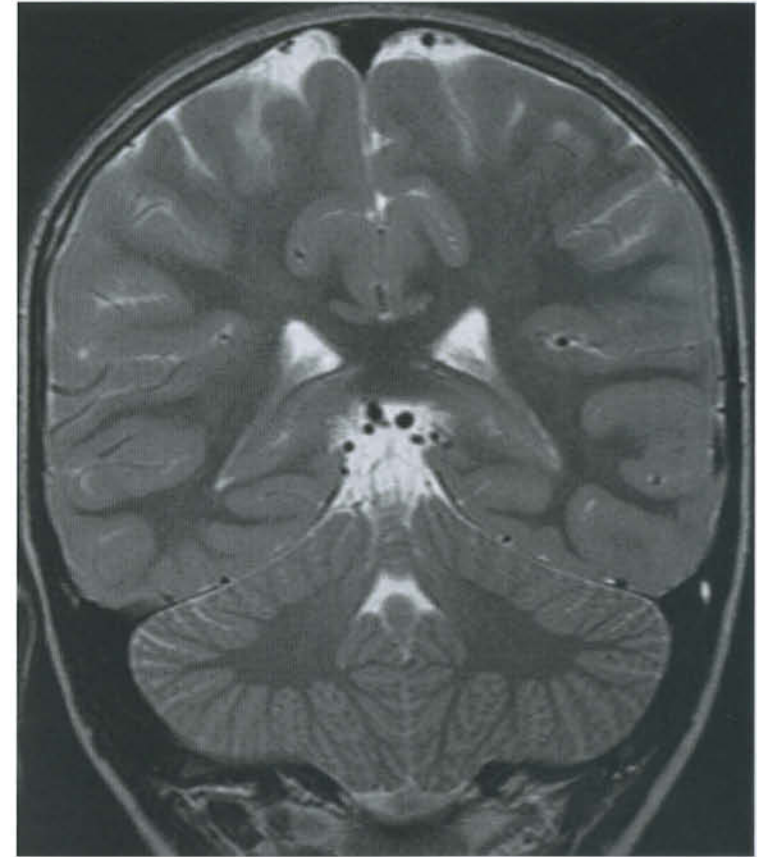
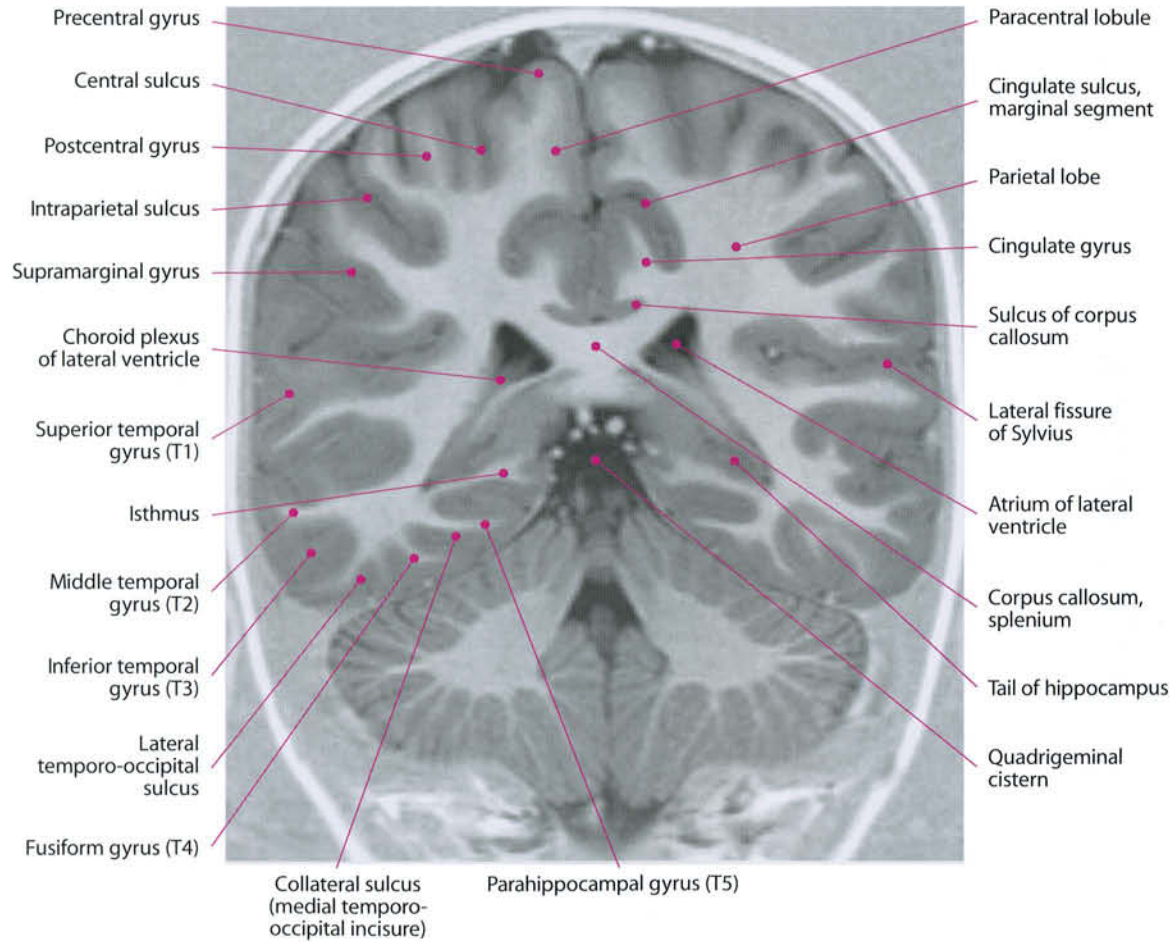


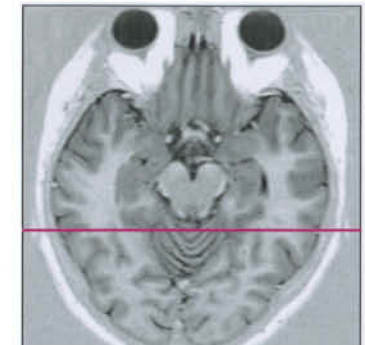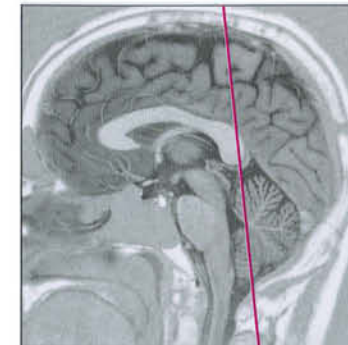
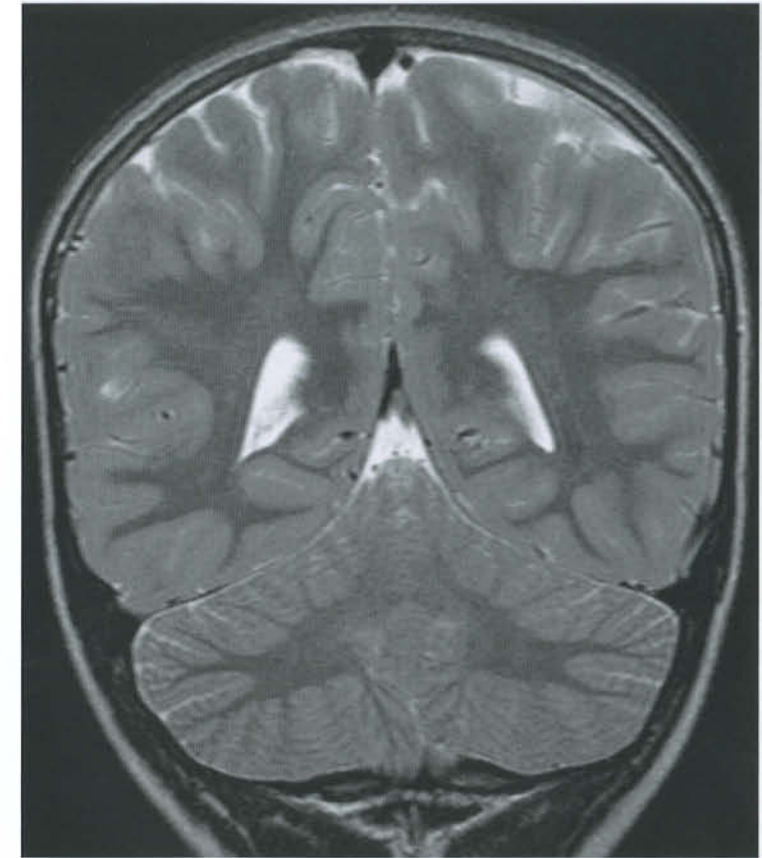
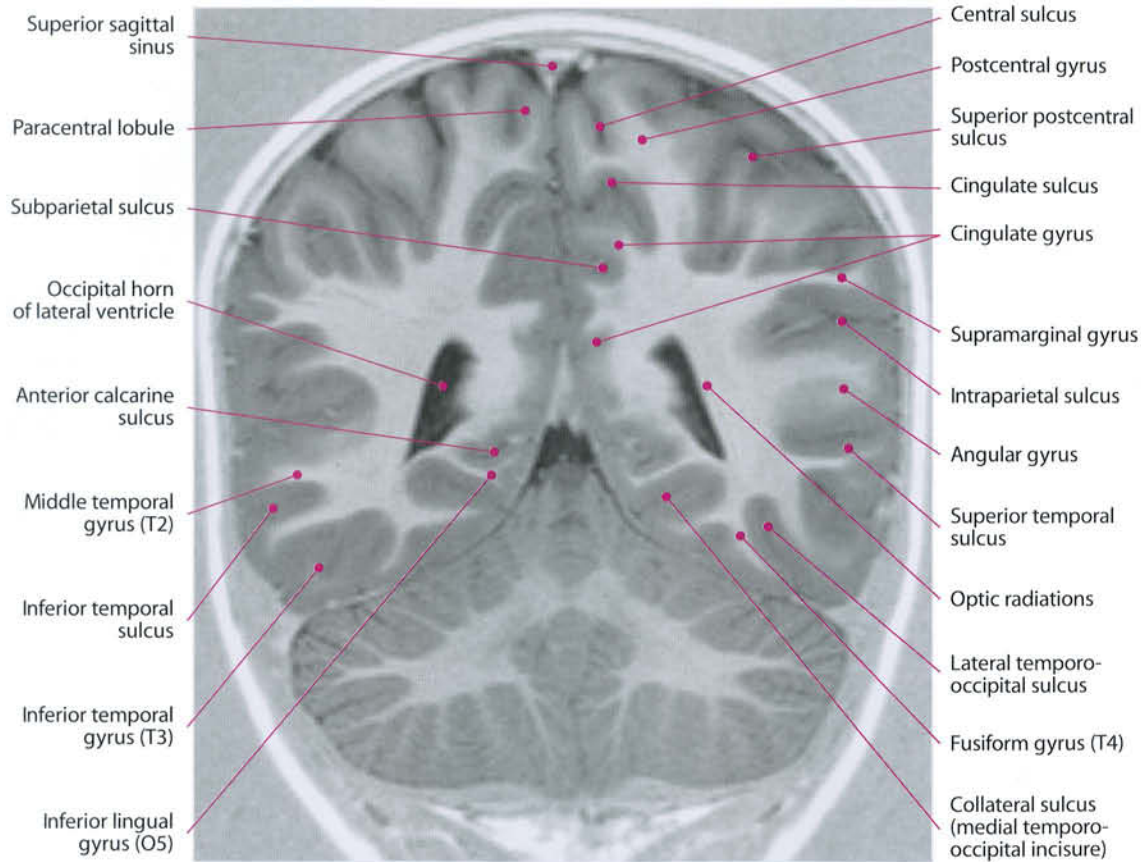


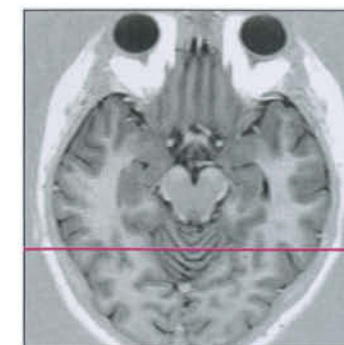
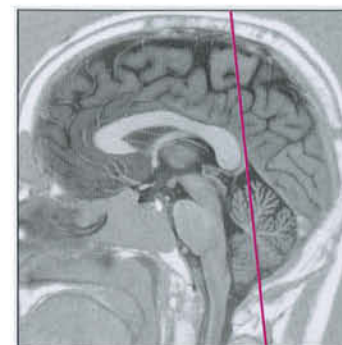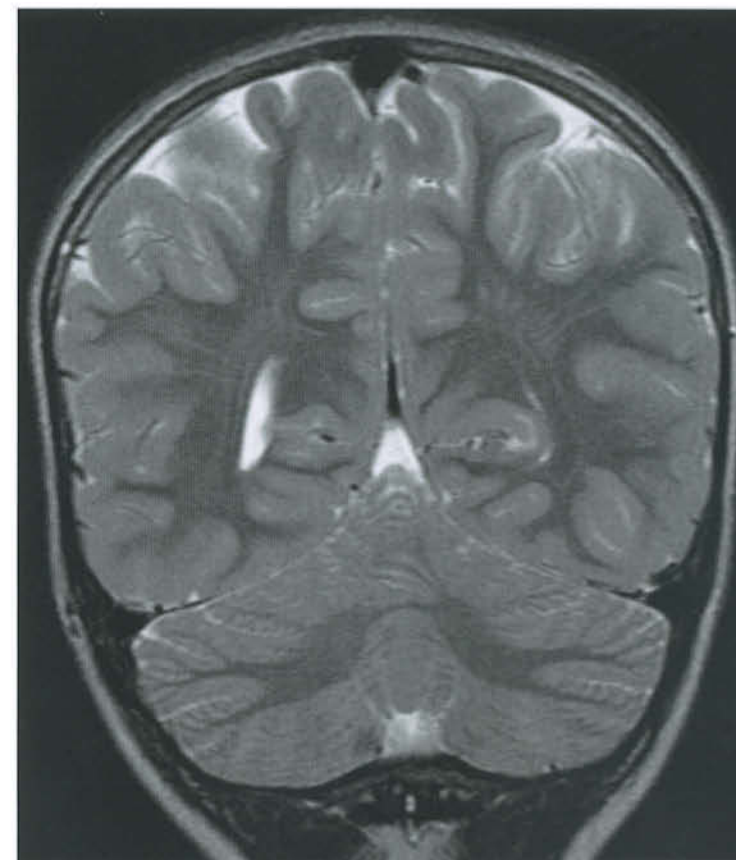
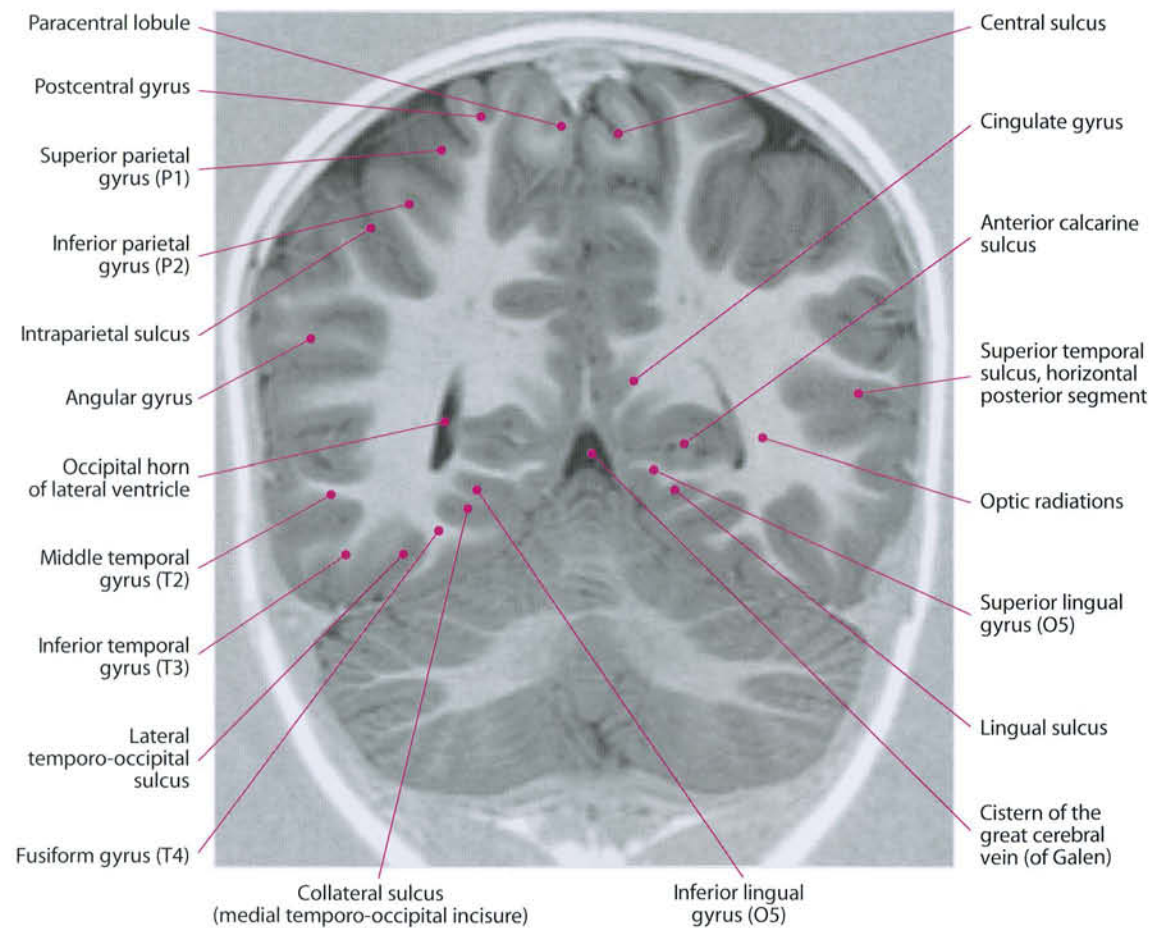


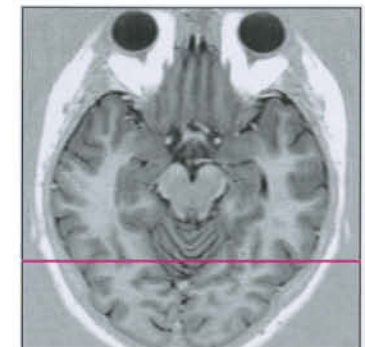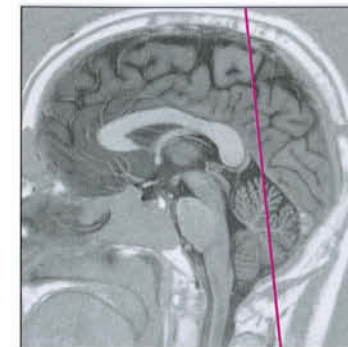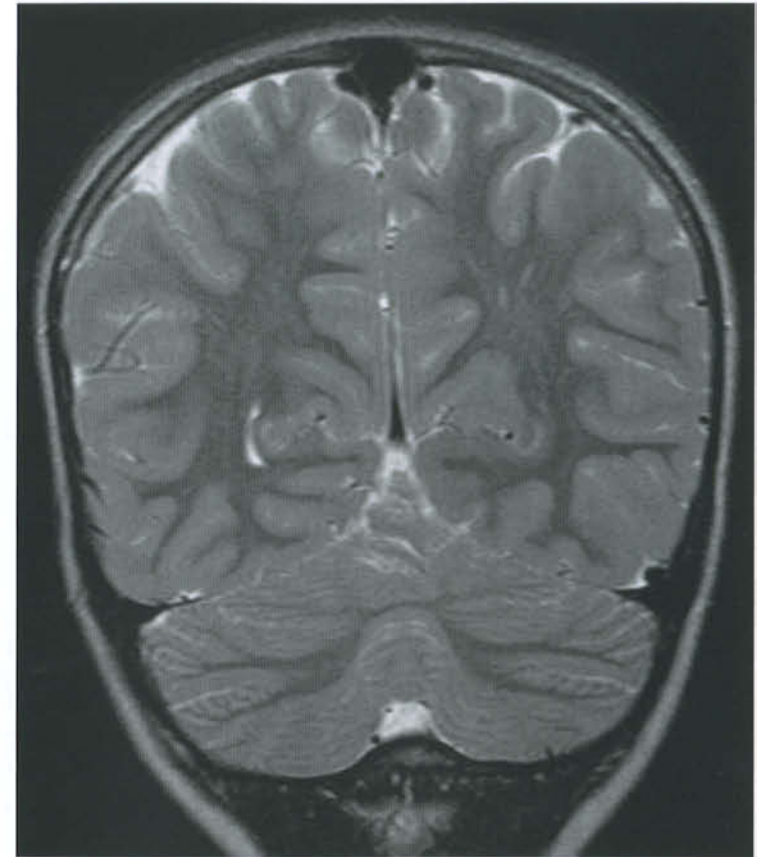
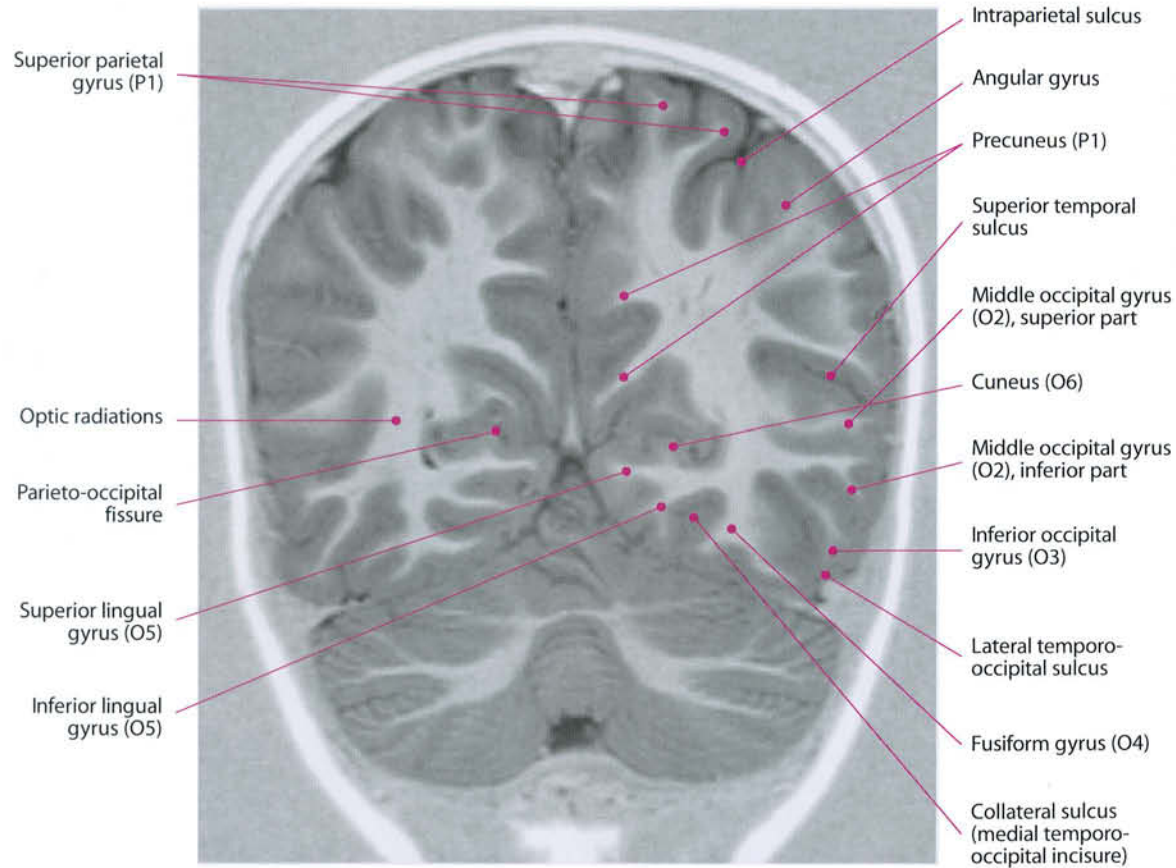


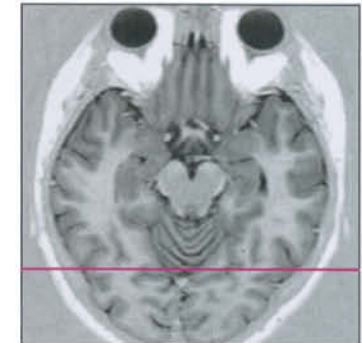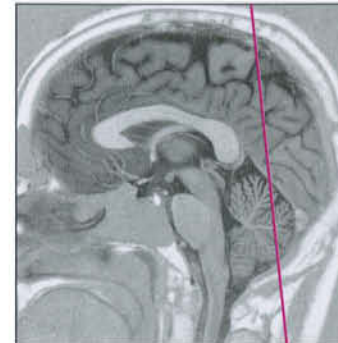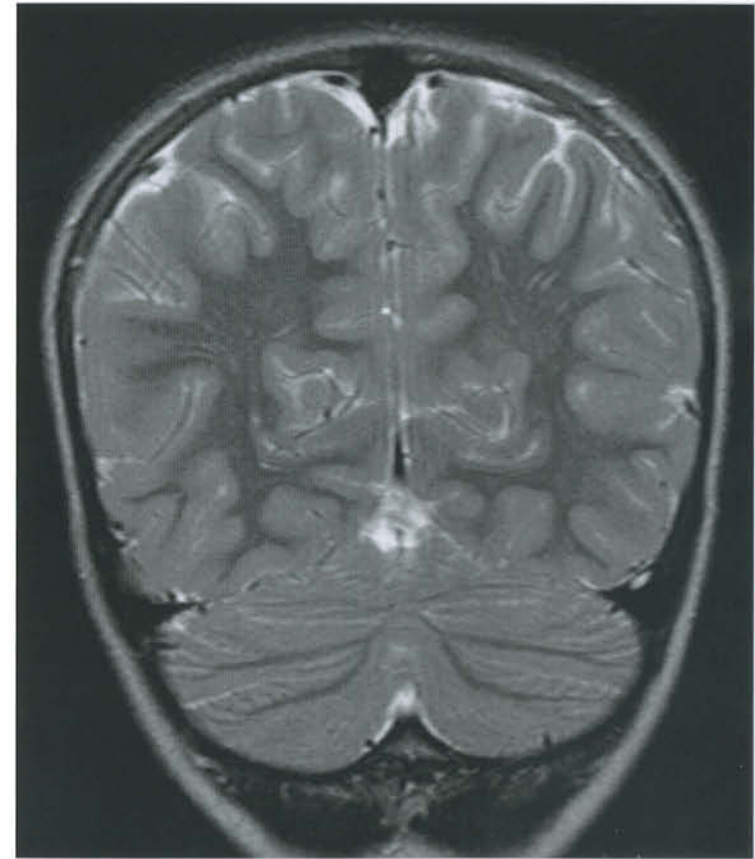
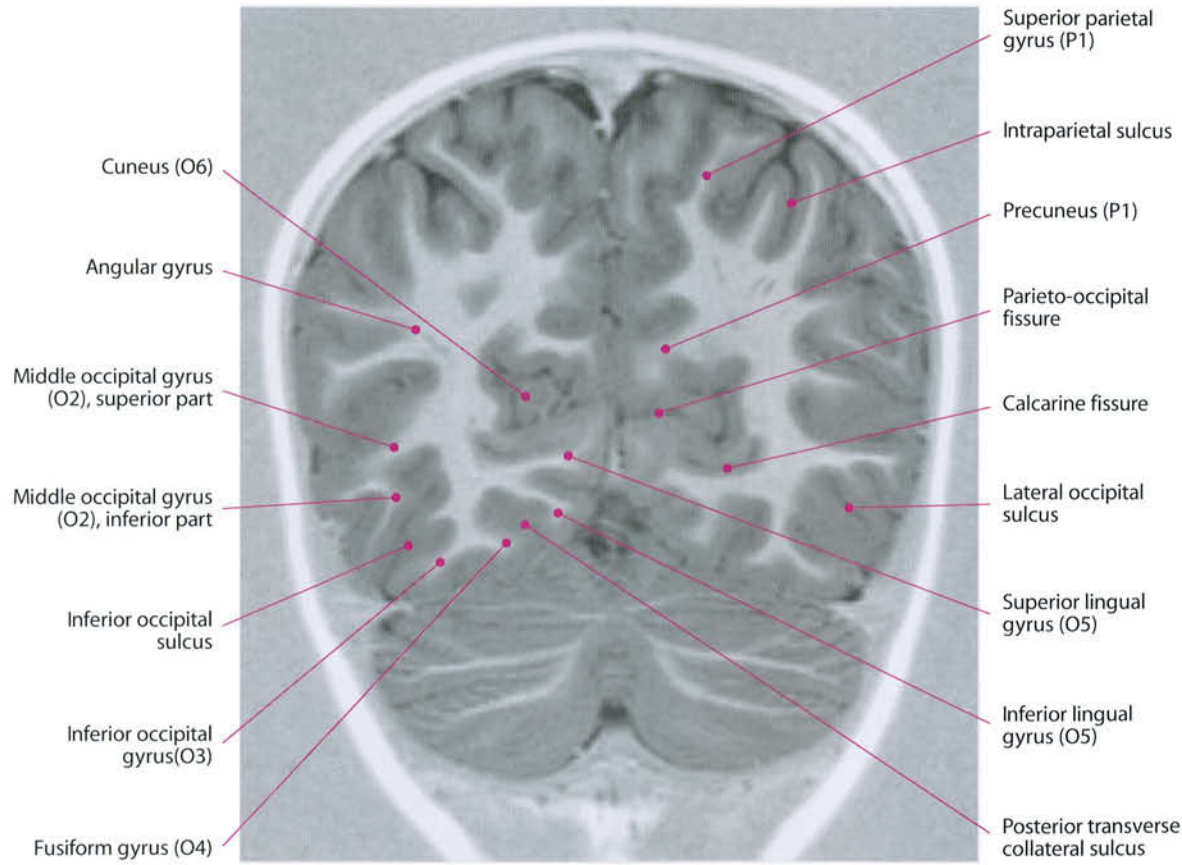


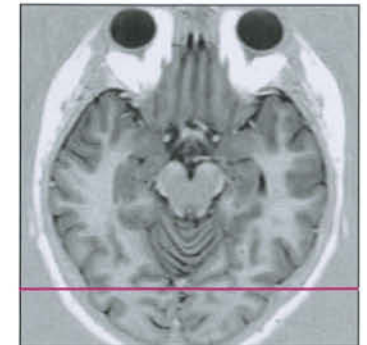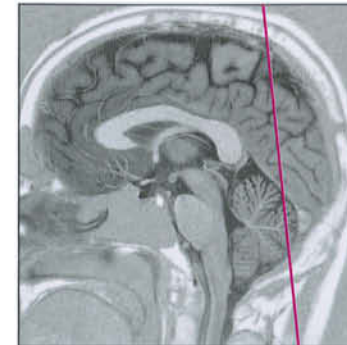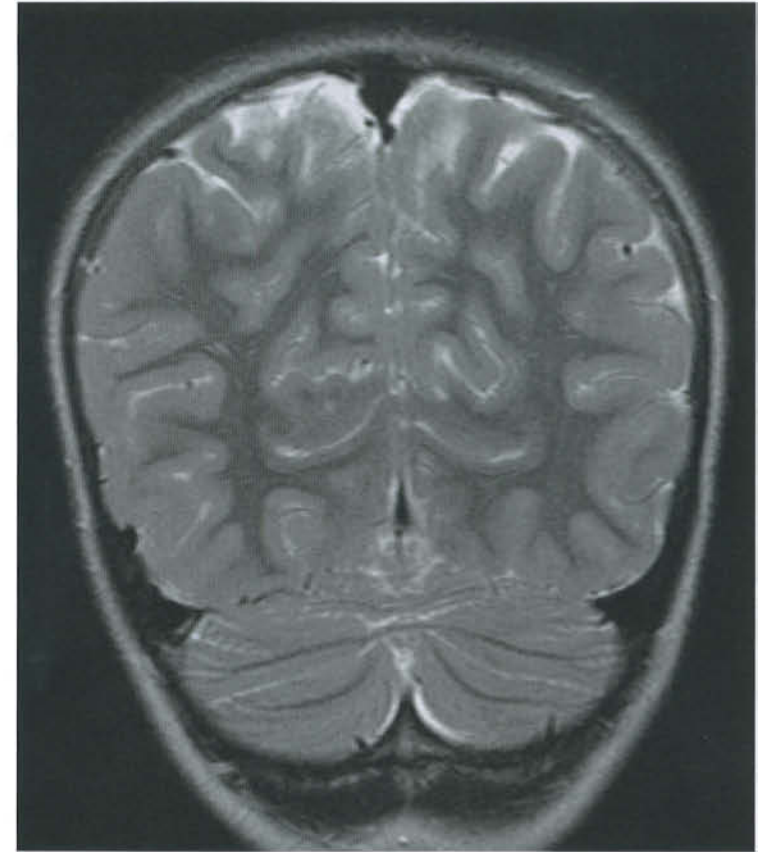
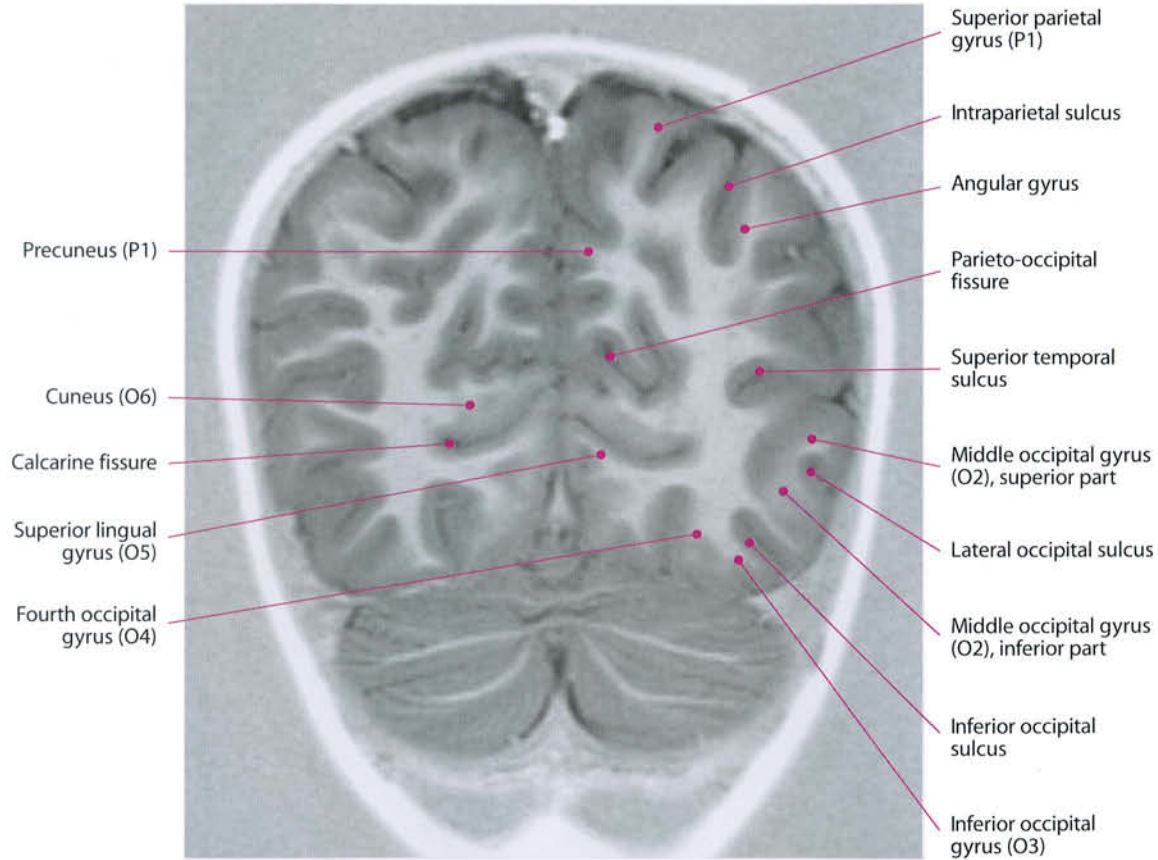


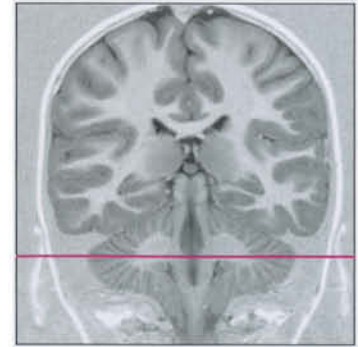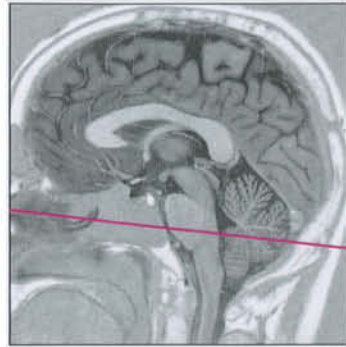
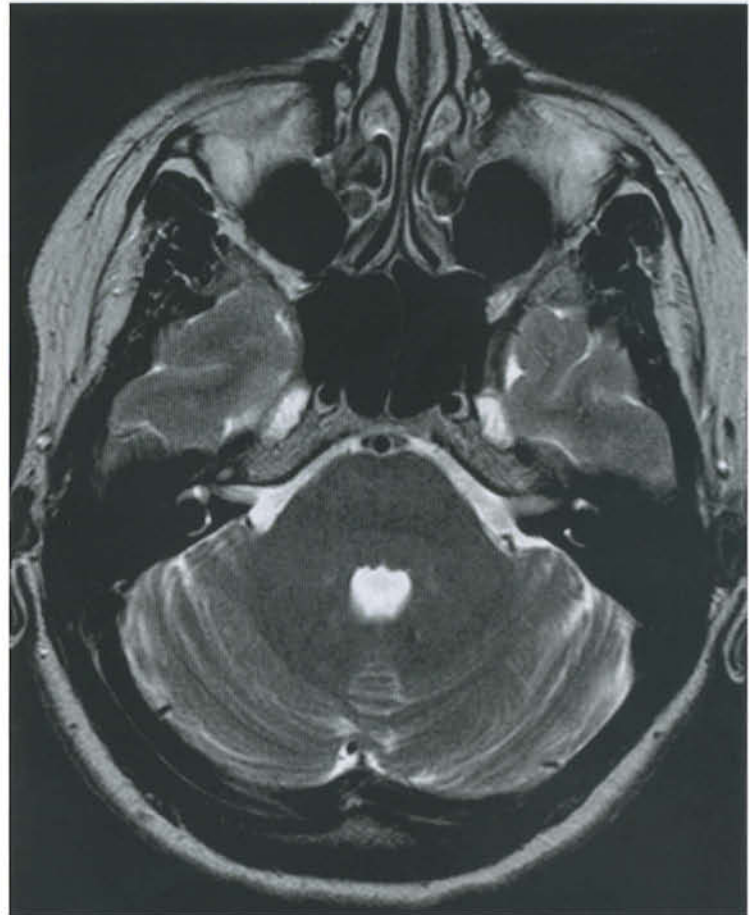
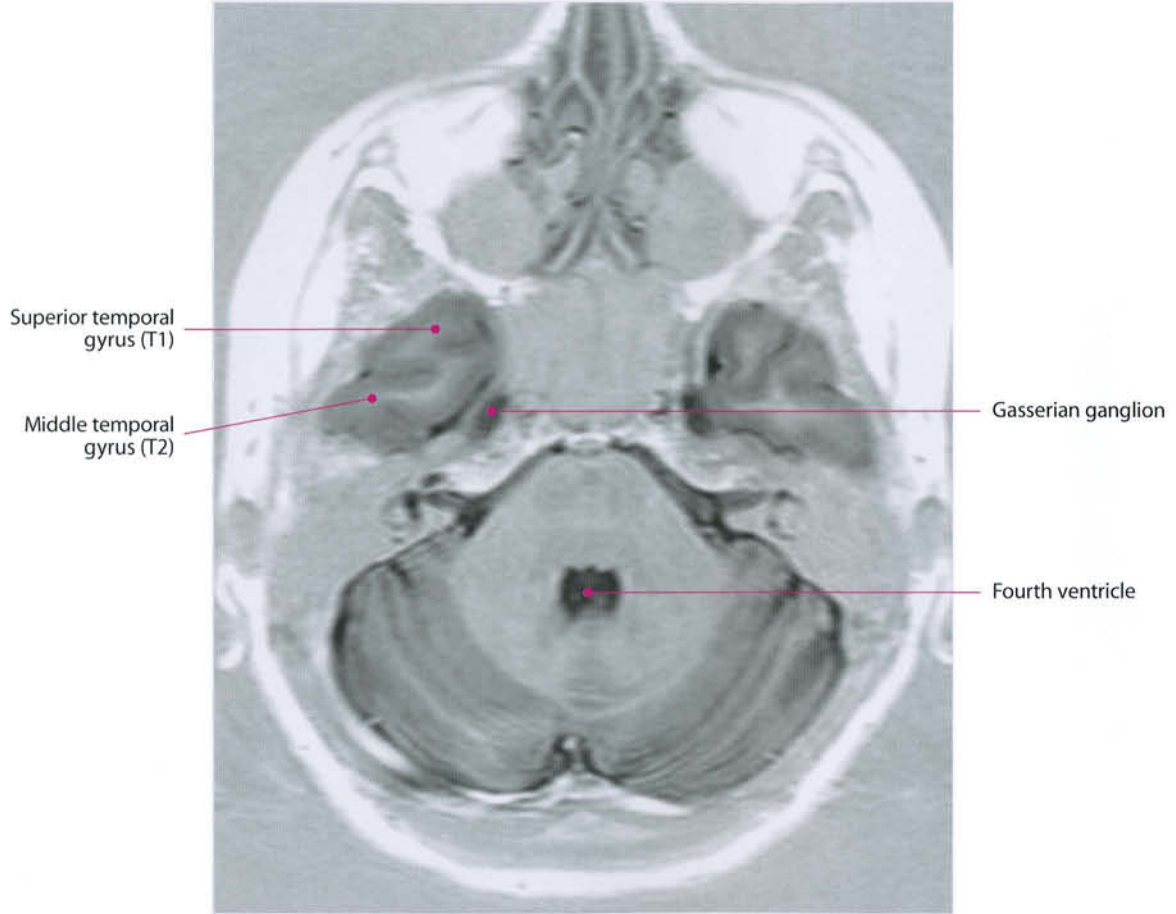


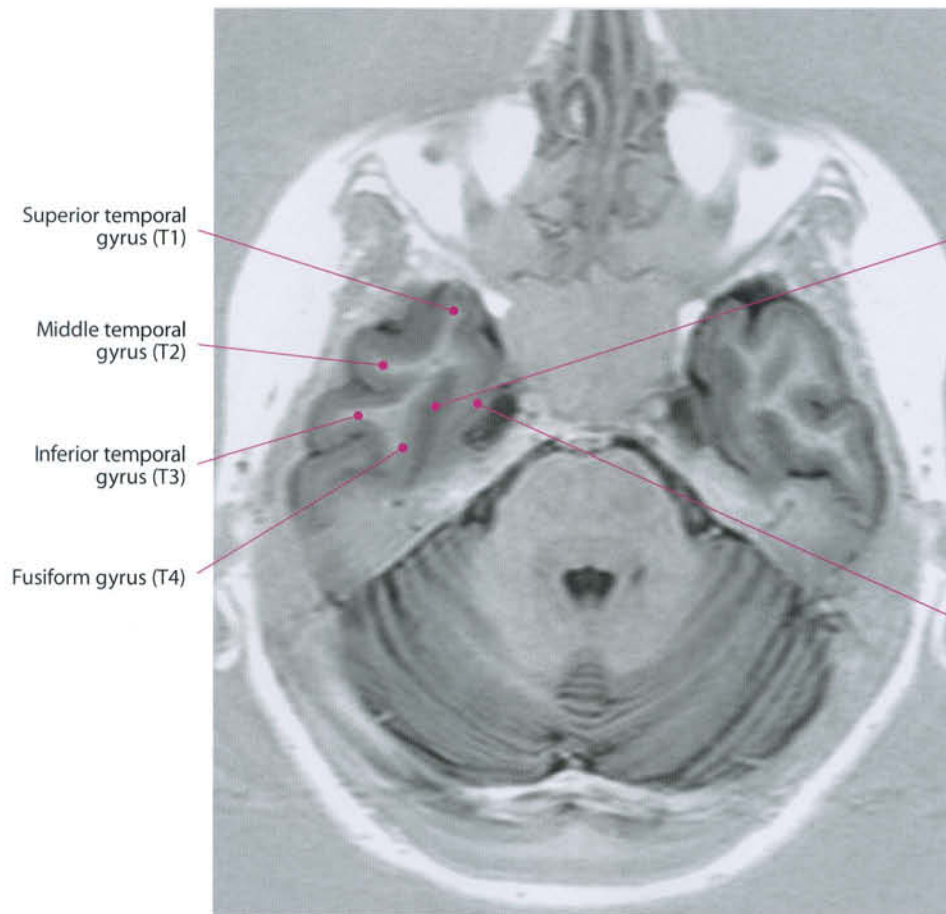






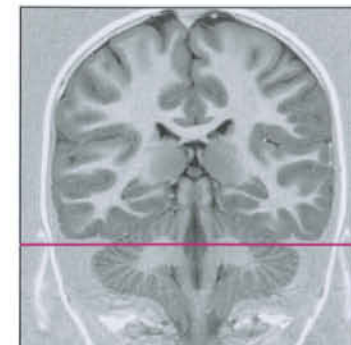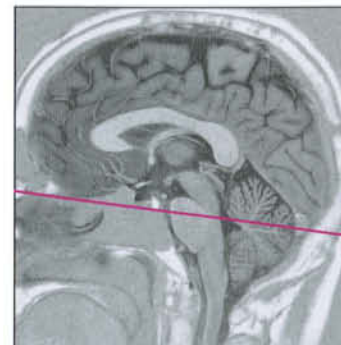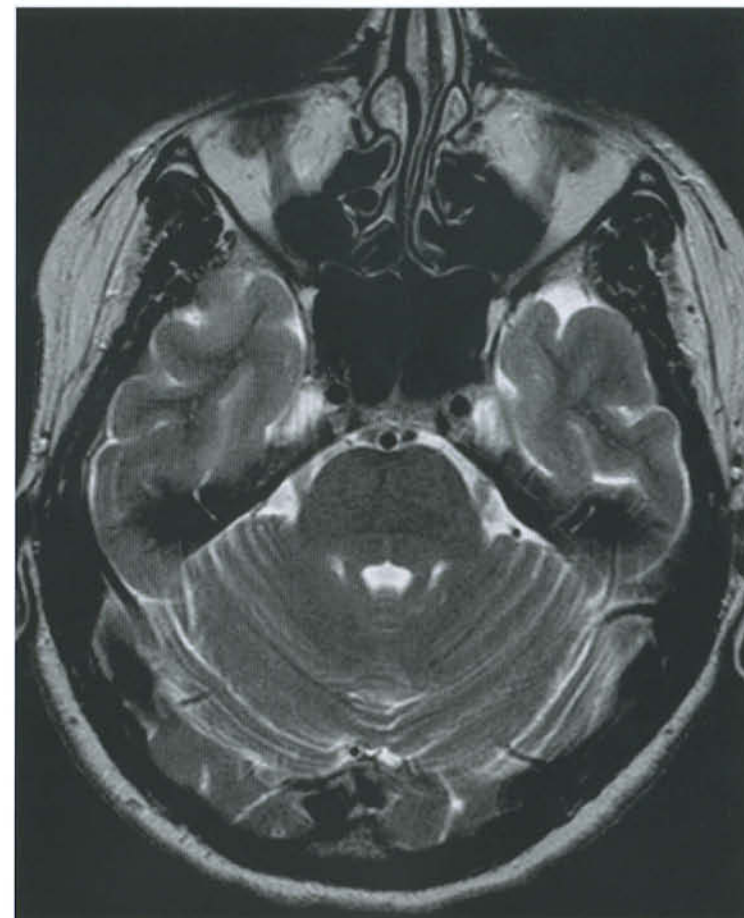


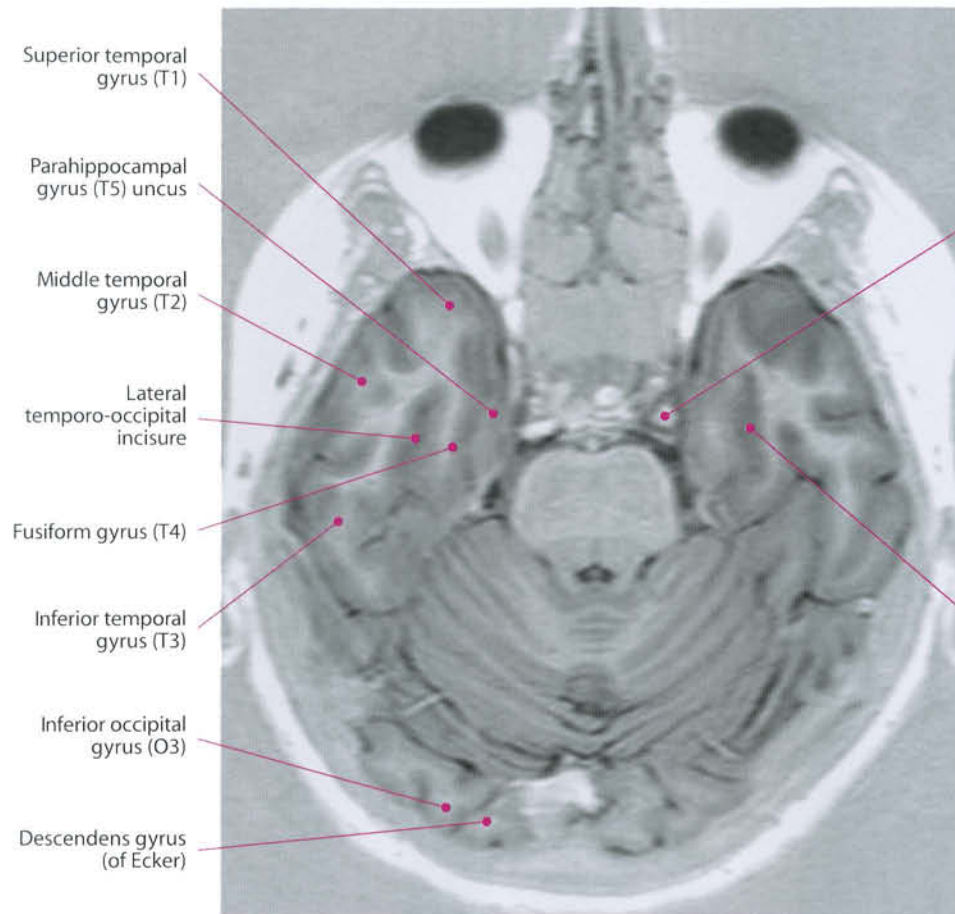




Collateral sulcus
(medial occipito-temporal sulcus)

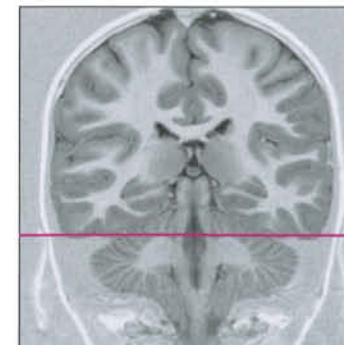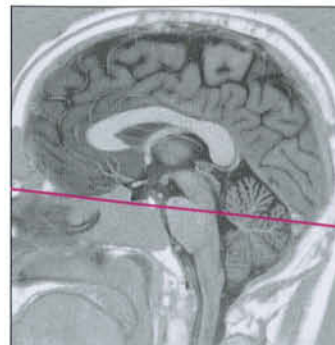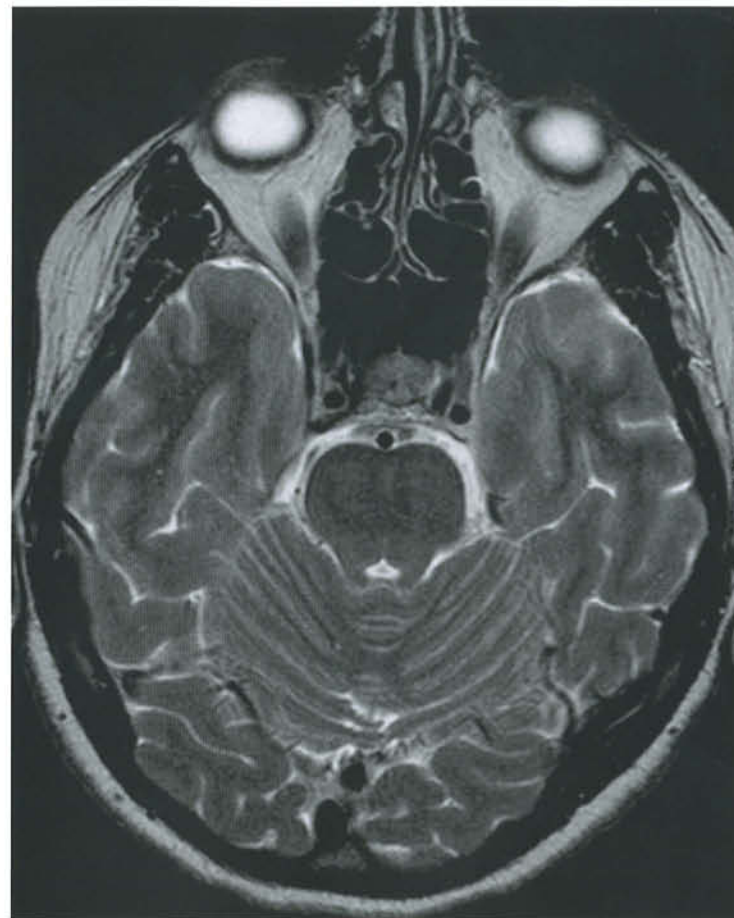Parahippocampal
gyrus (T5); piriform
lobe, entorhinal area

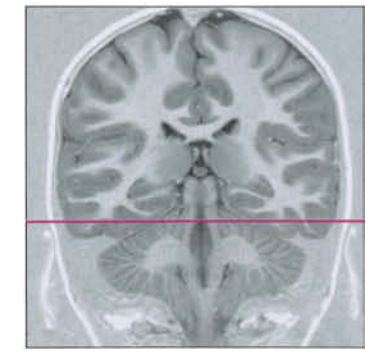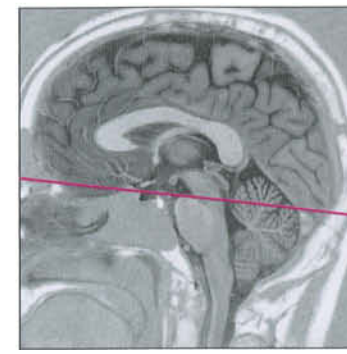
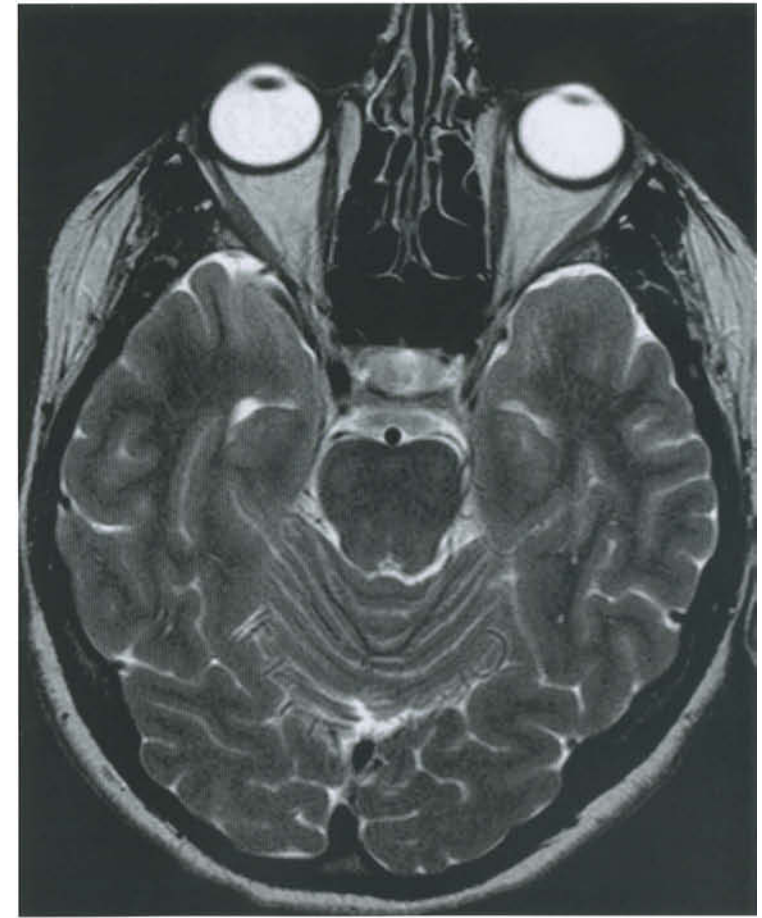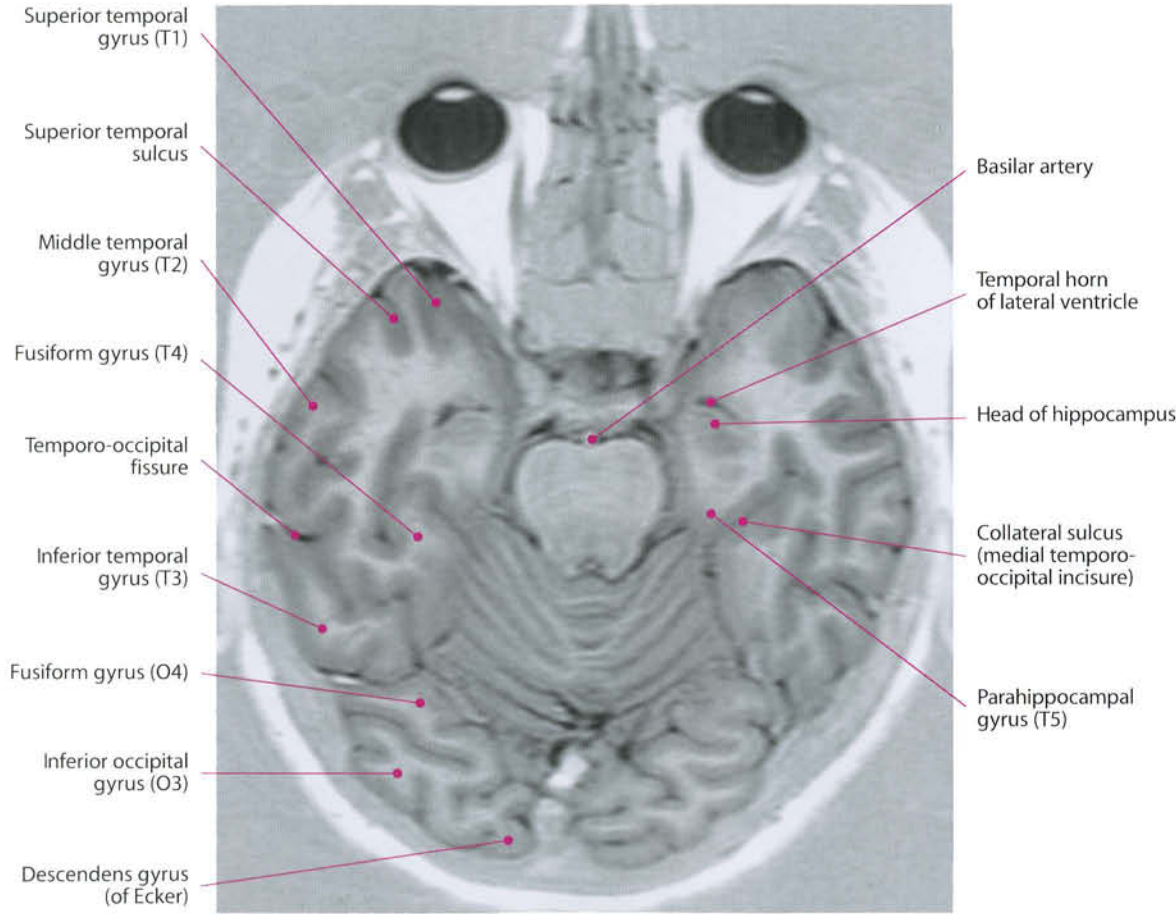


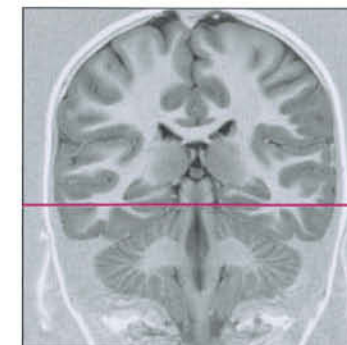
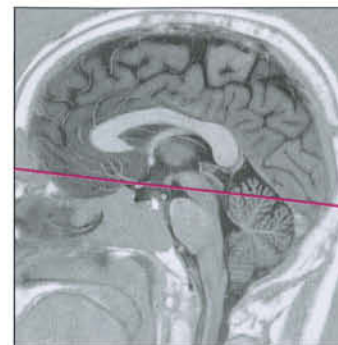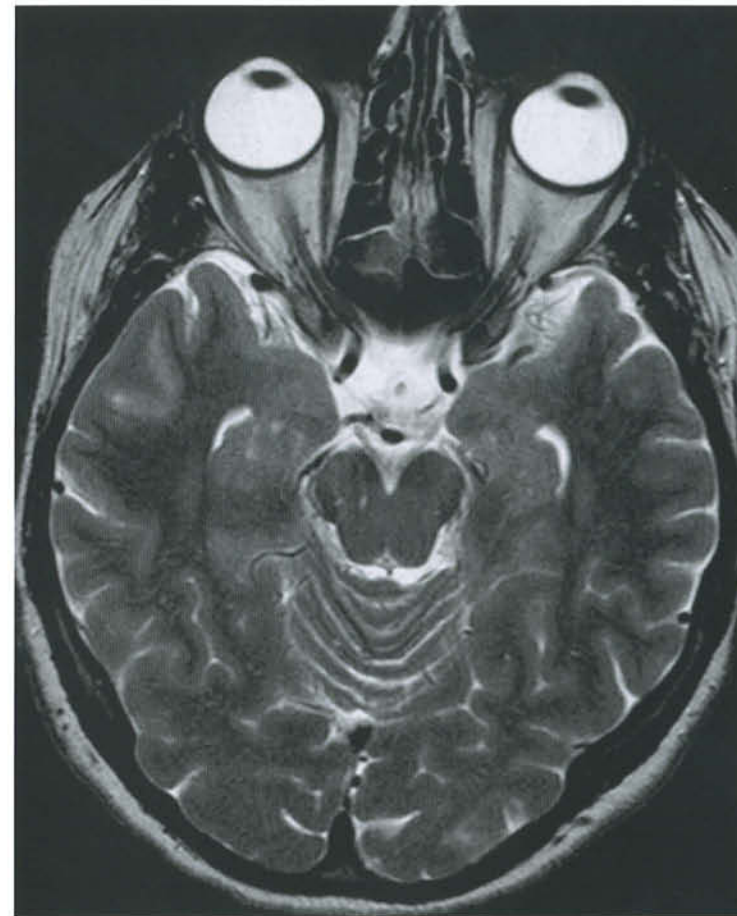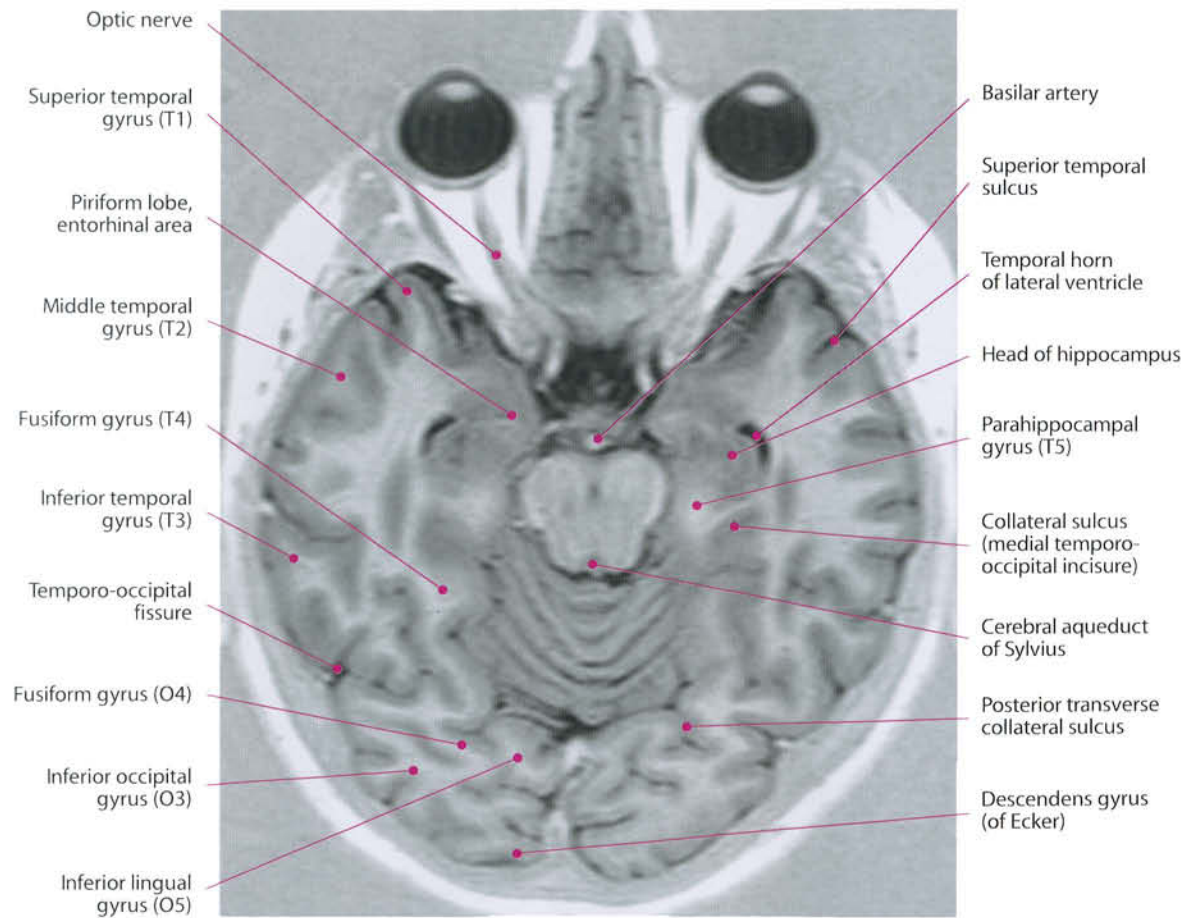


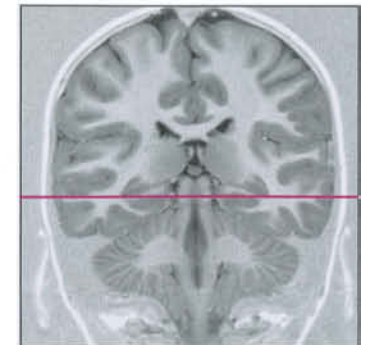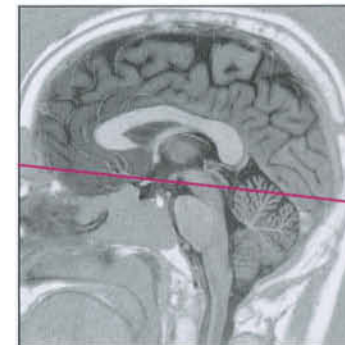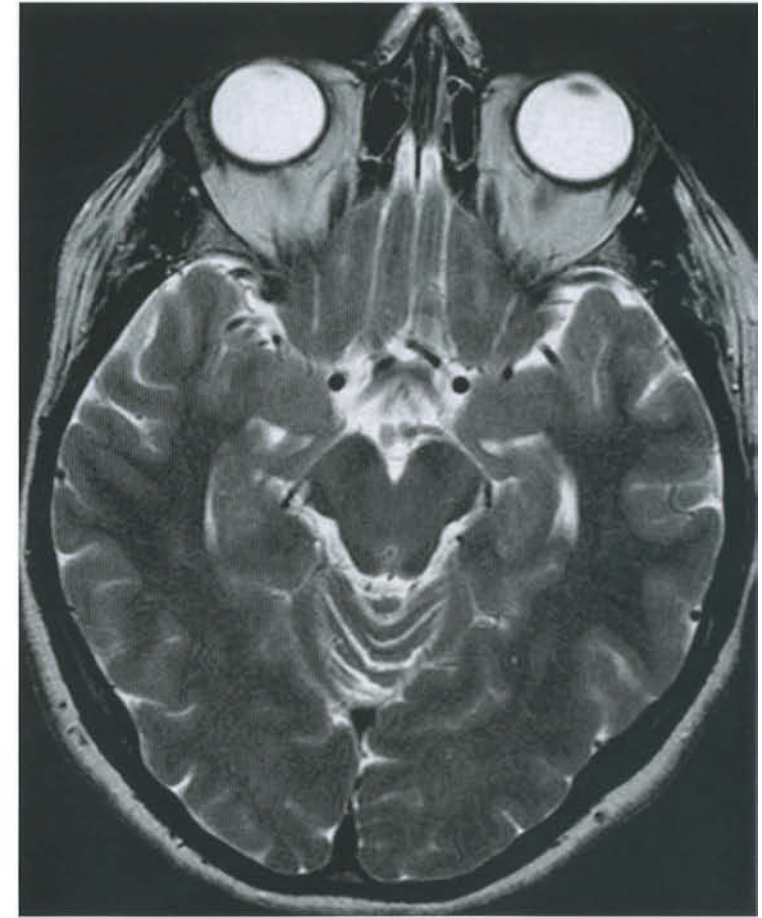
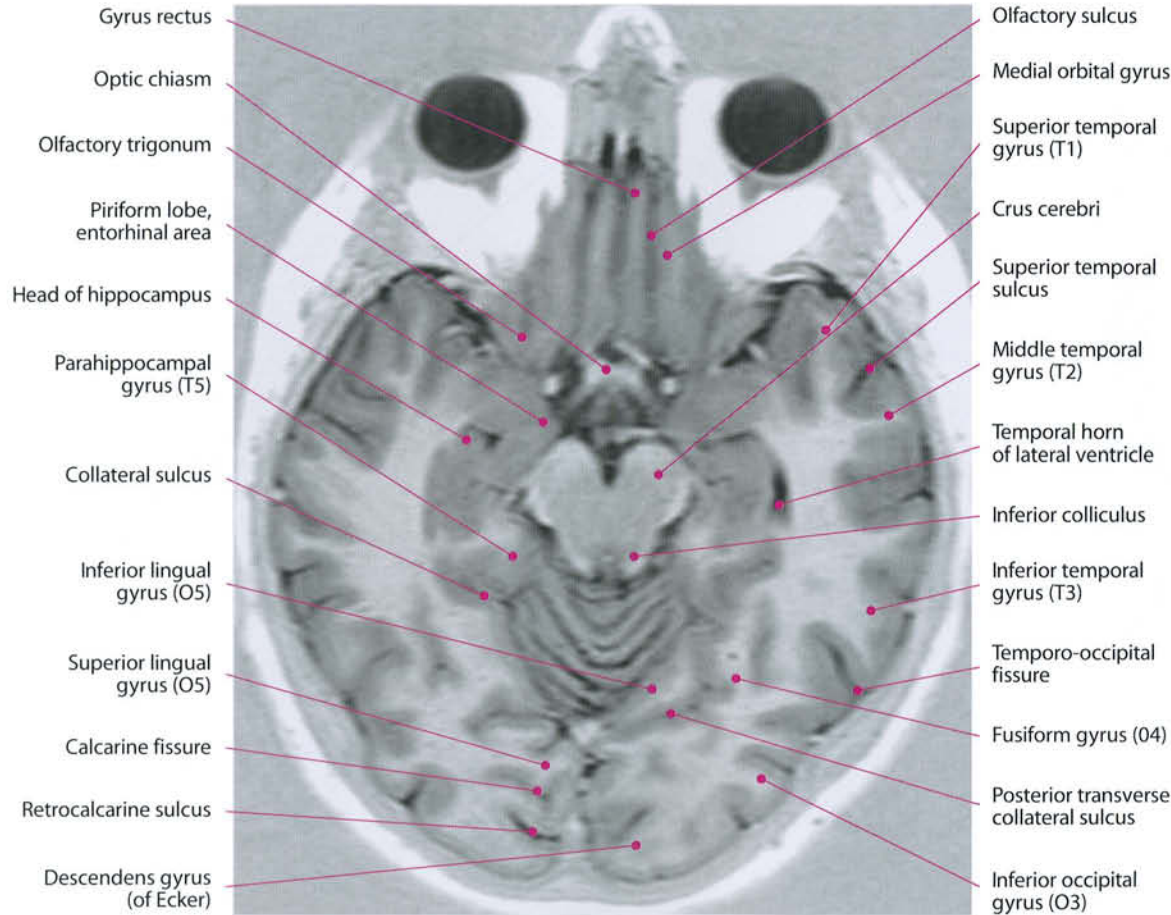
Internal carotid artery

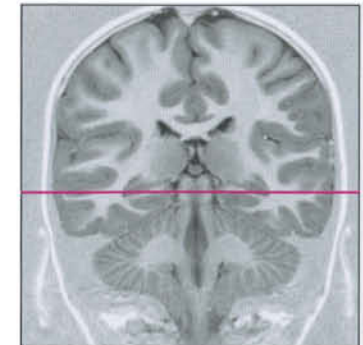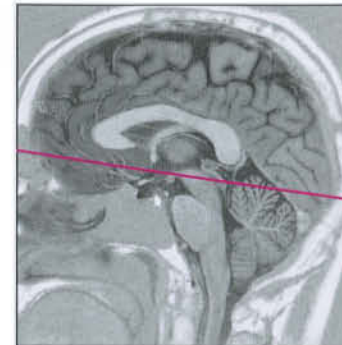
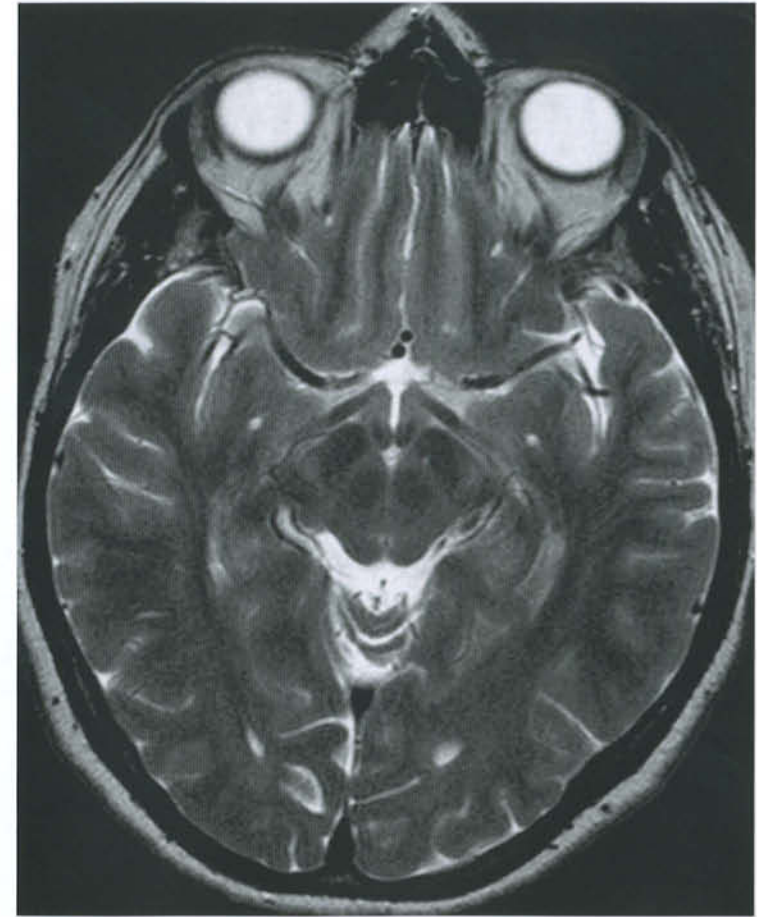
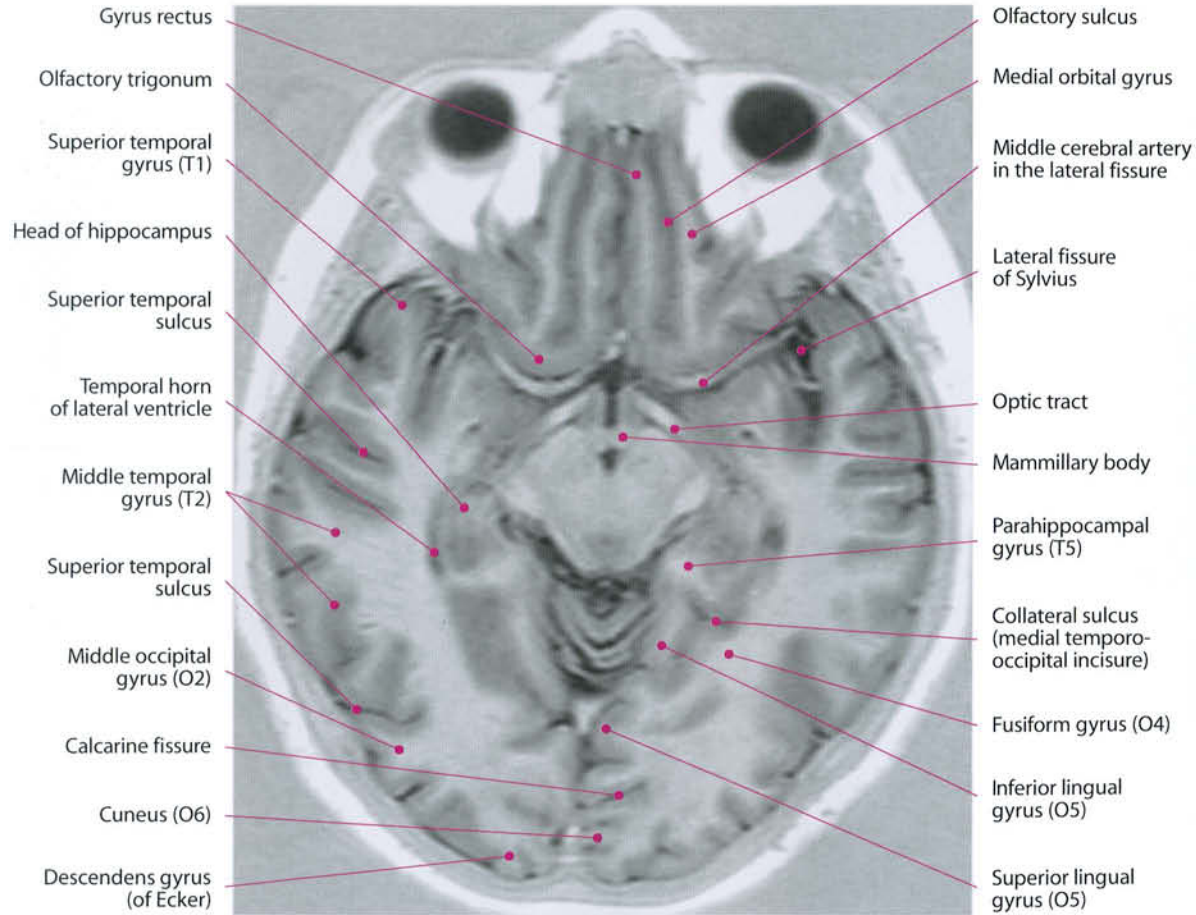
Collateral sulcus (medial temporo-occipital incisure)

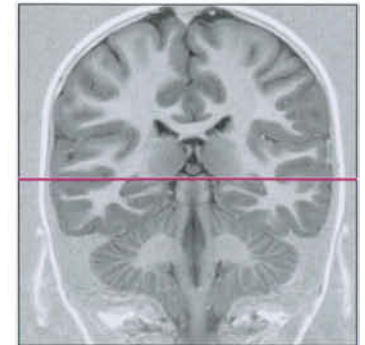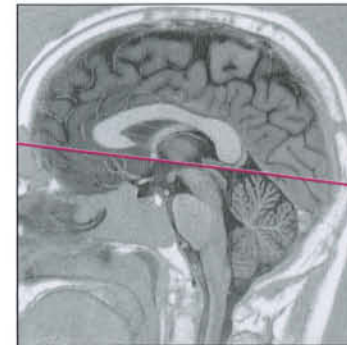
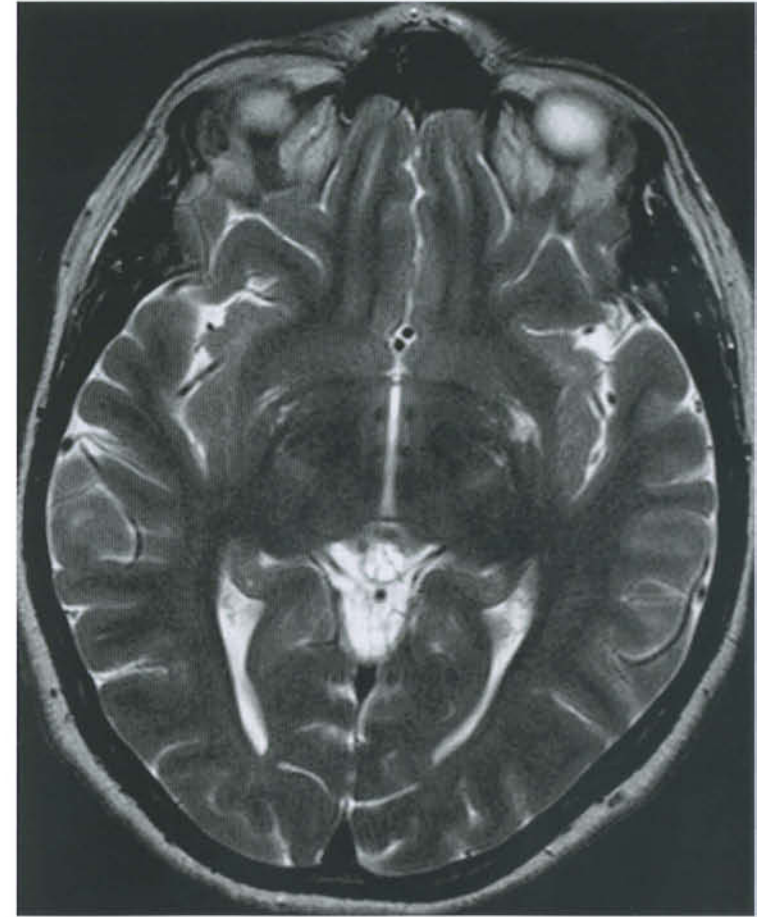
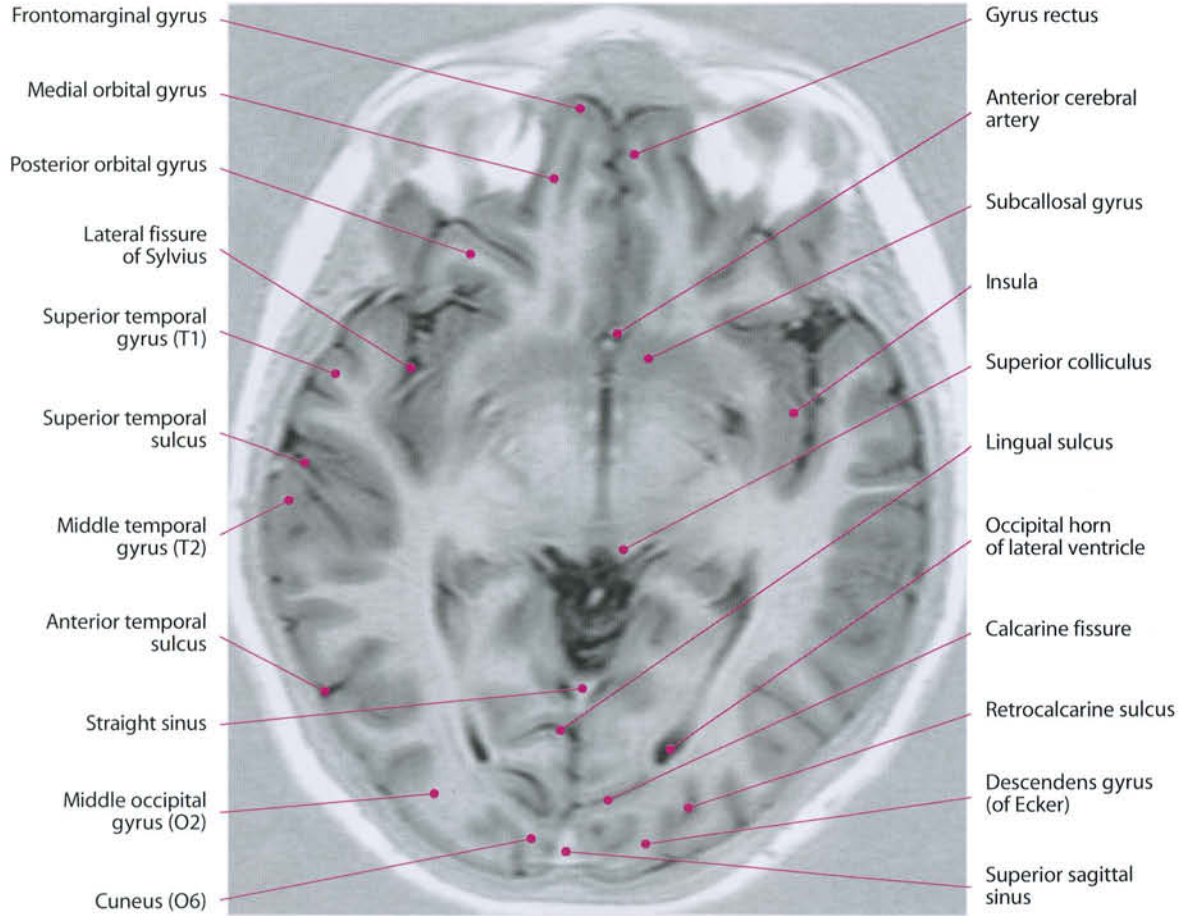


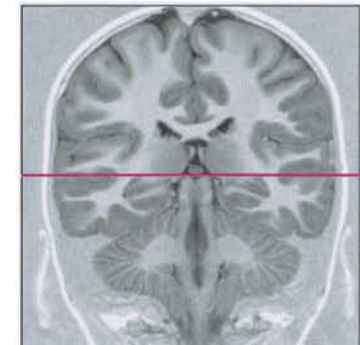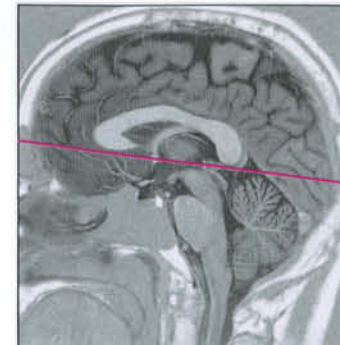
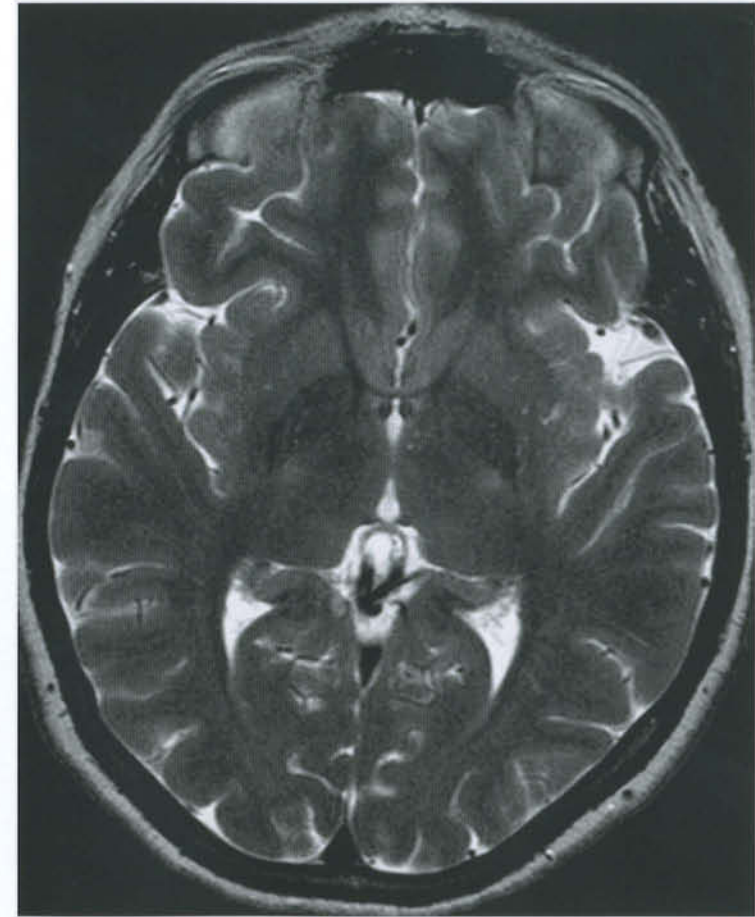
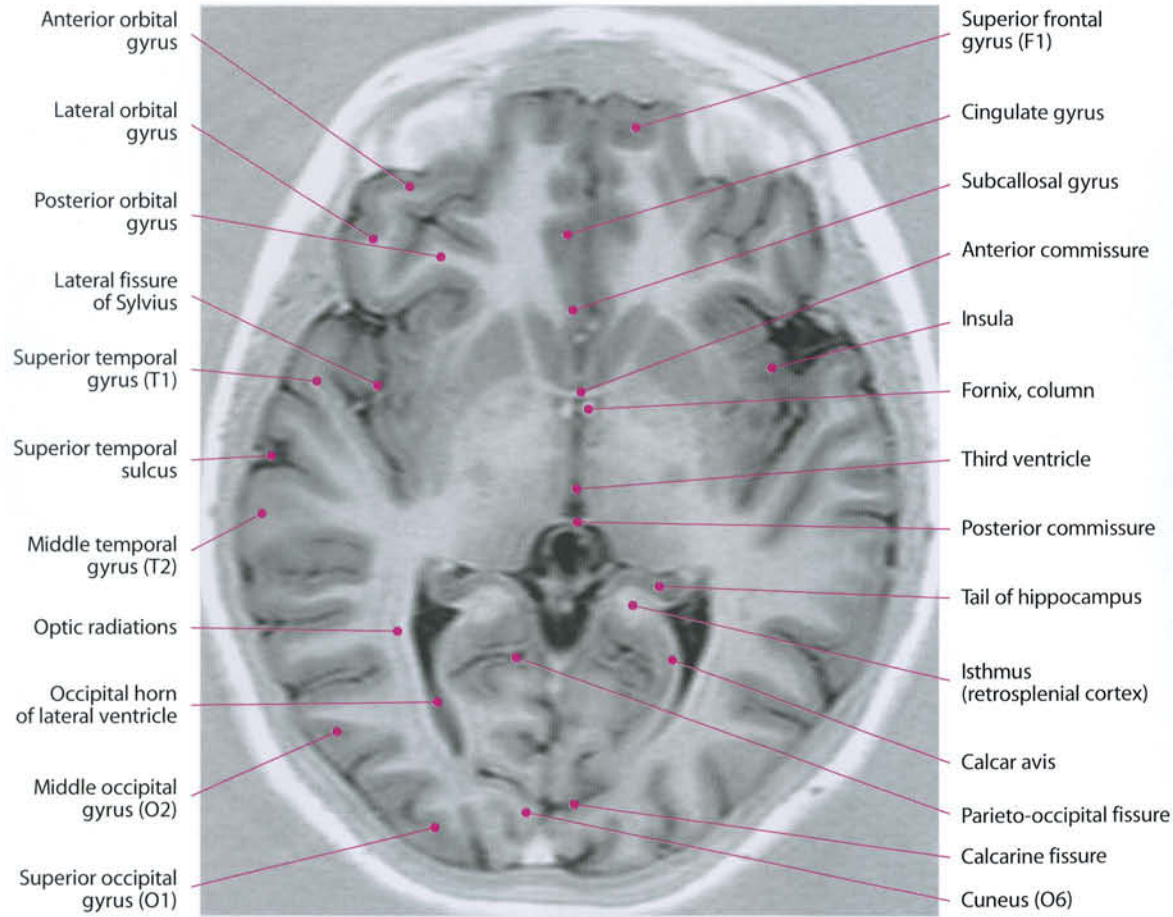


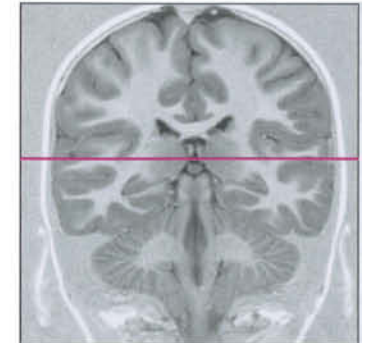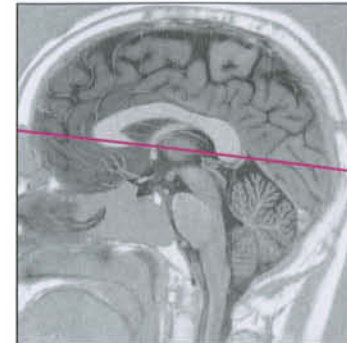
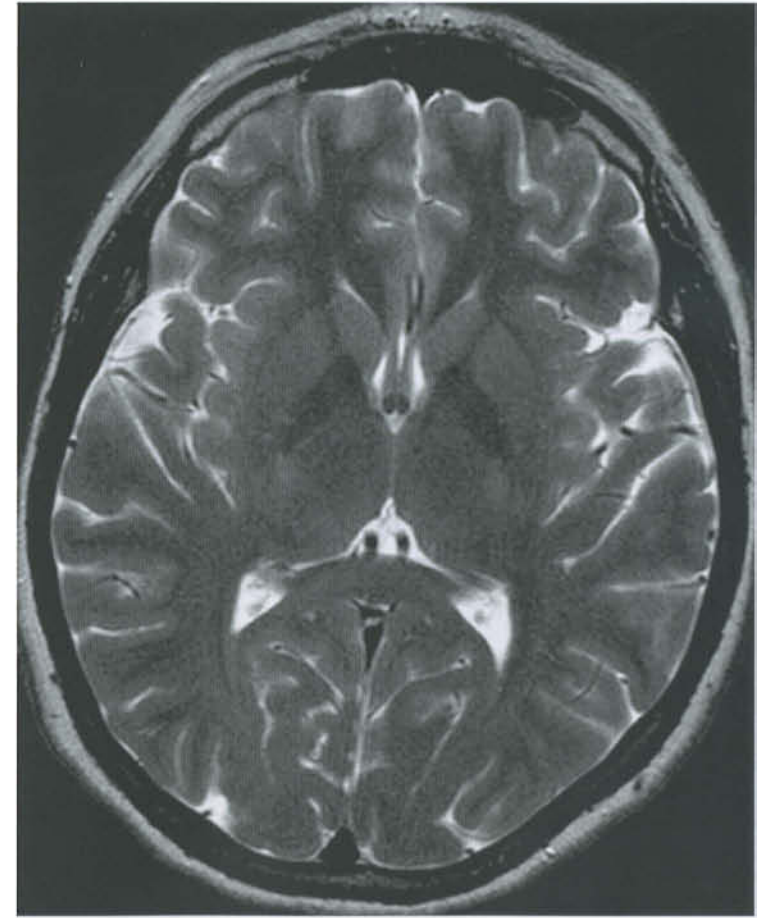
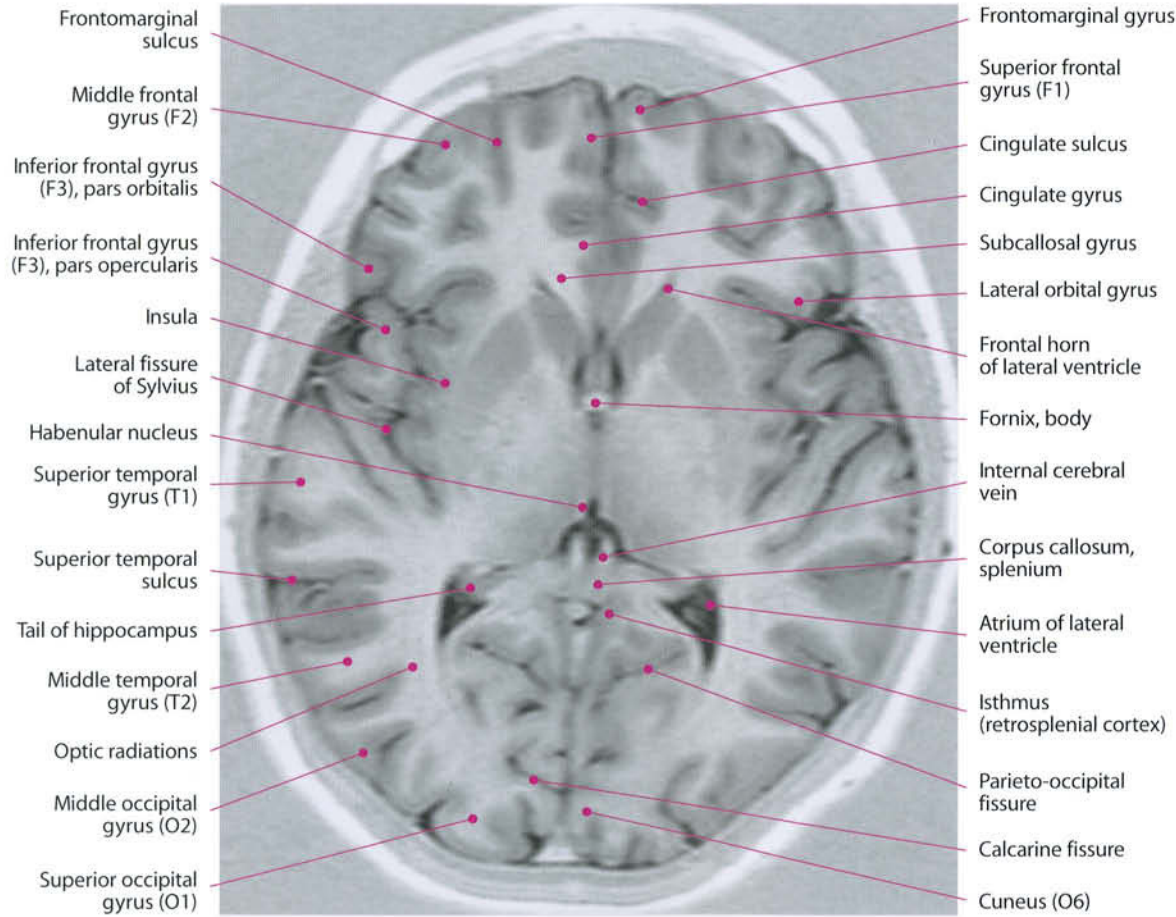


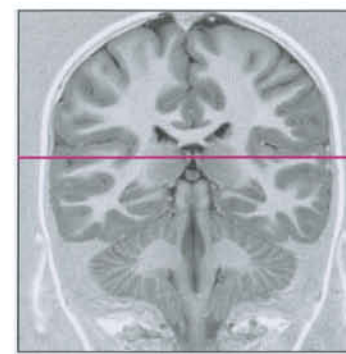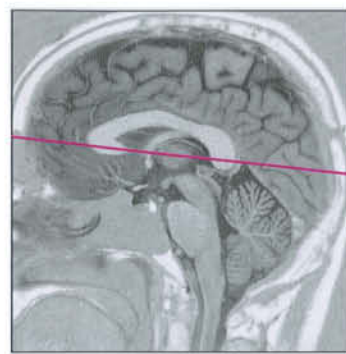
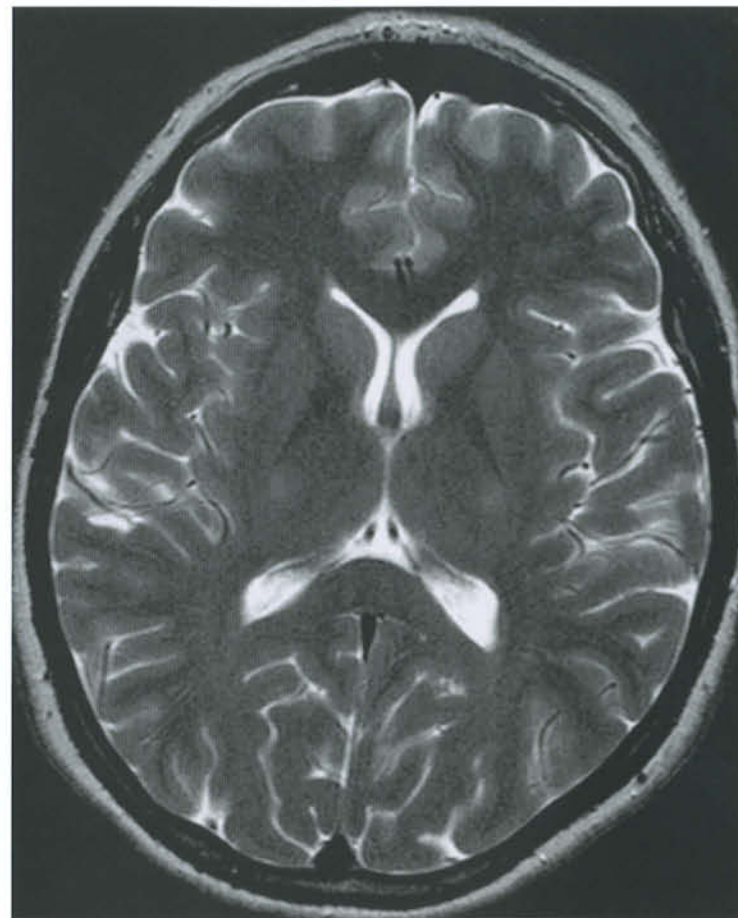
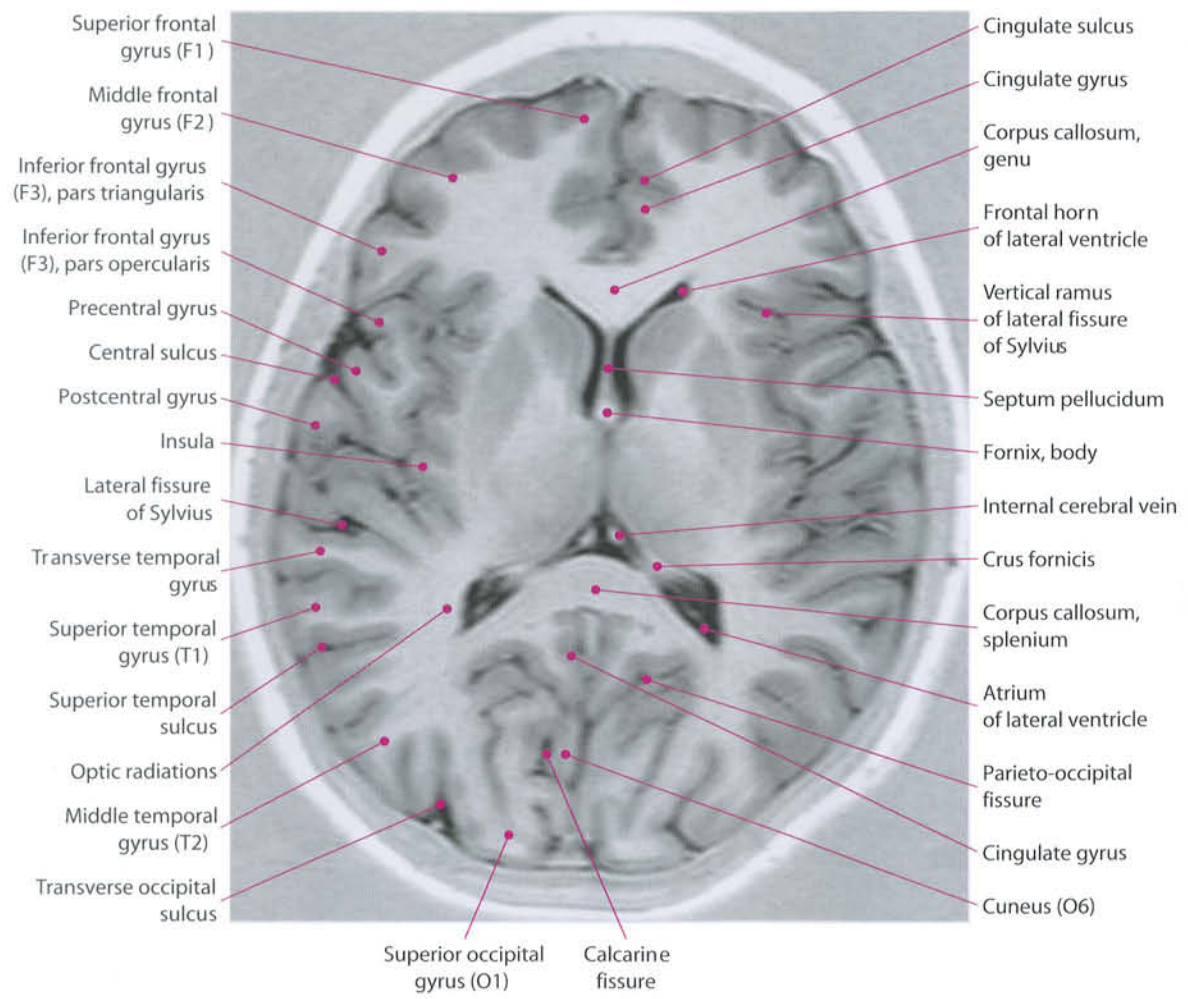


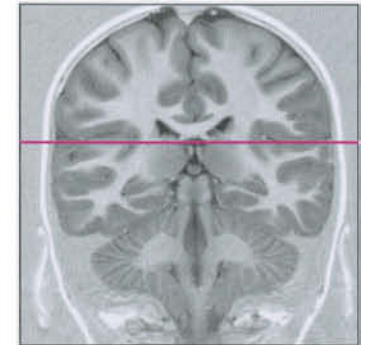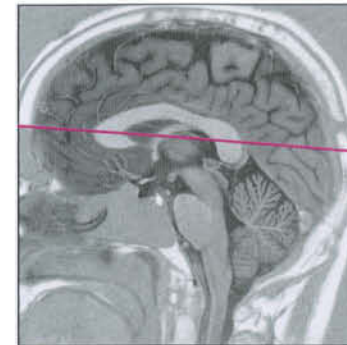
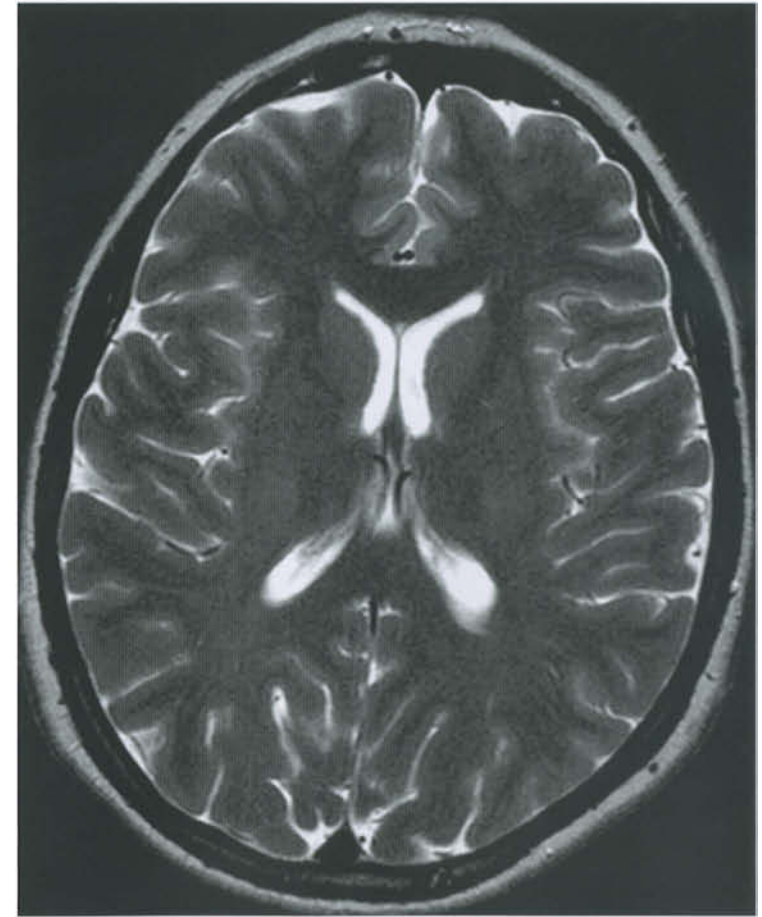
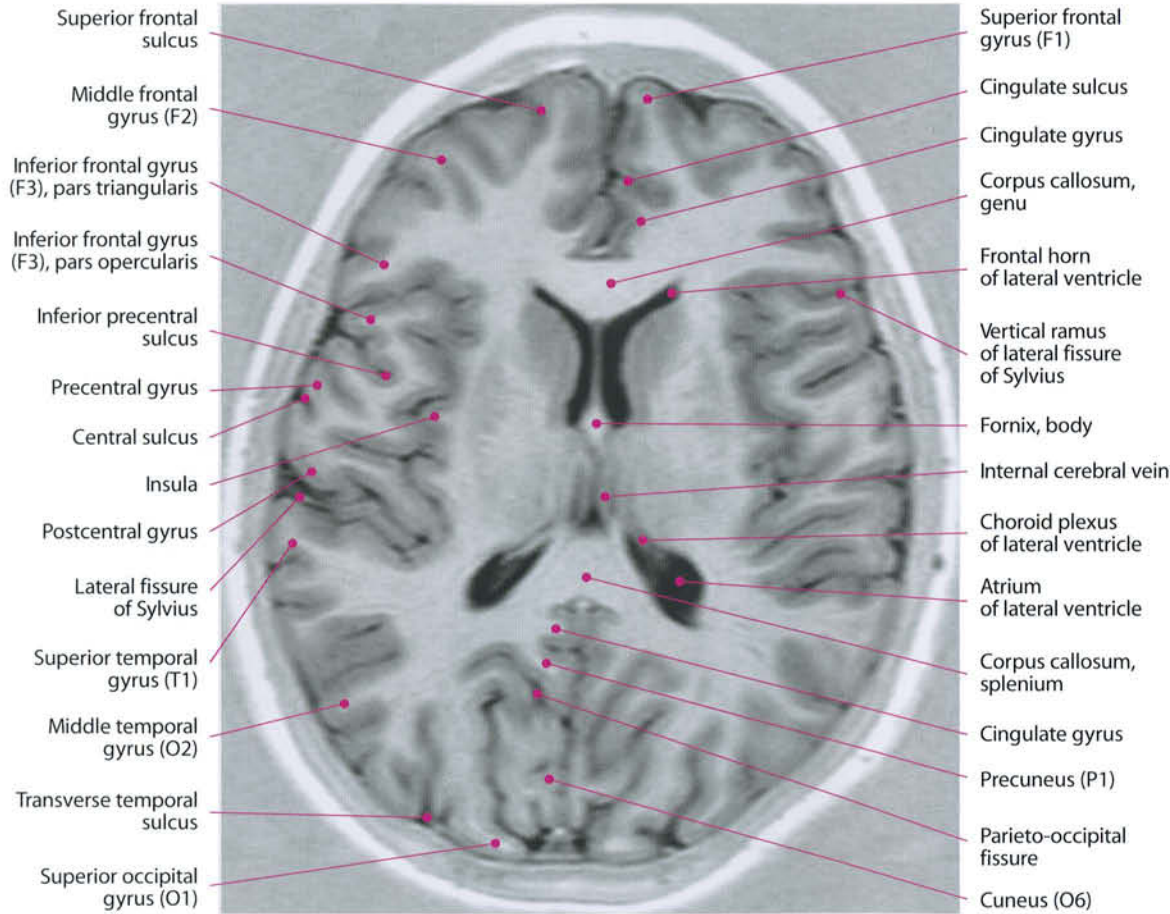


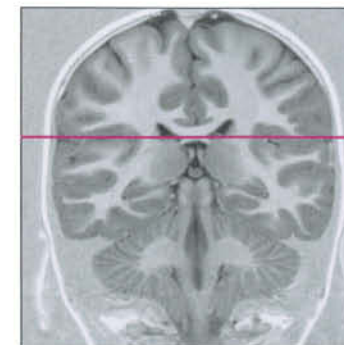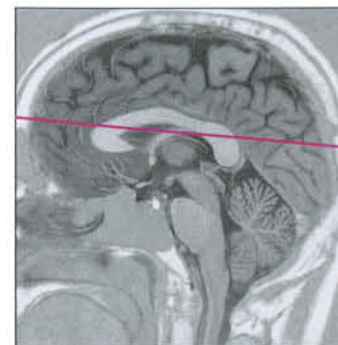
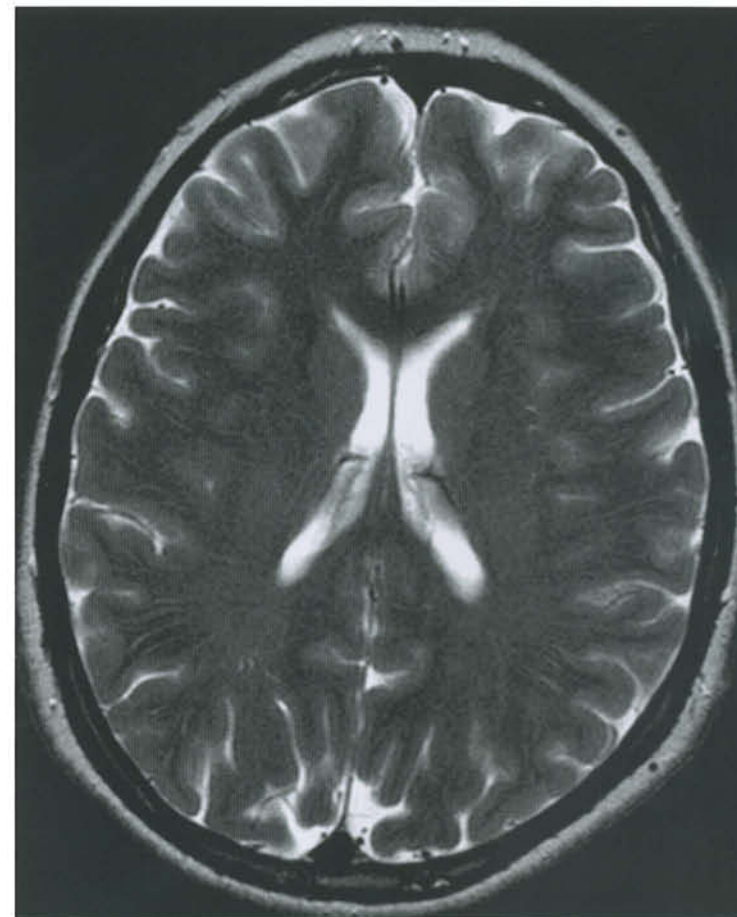
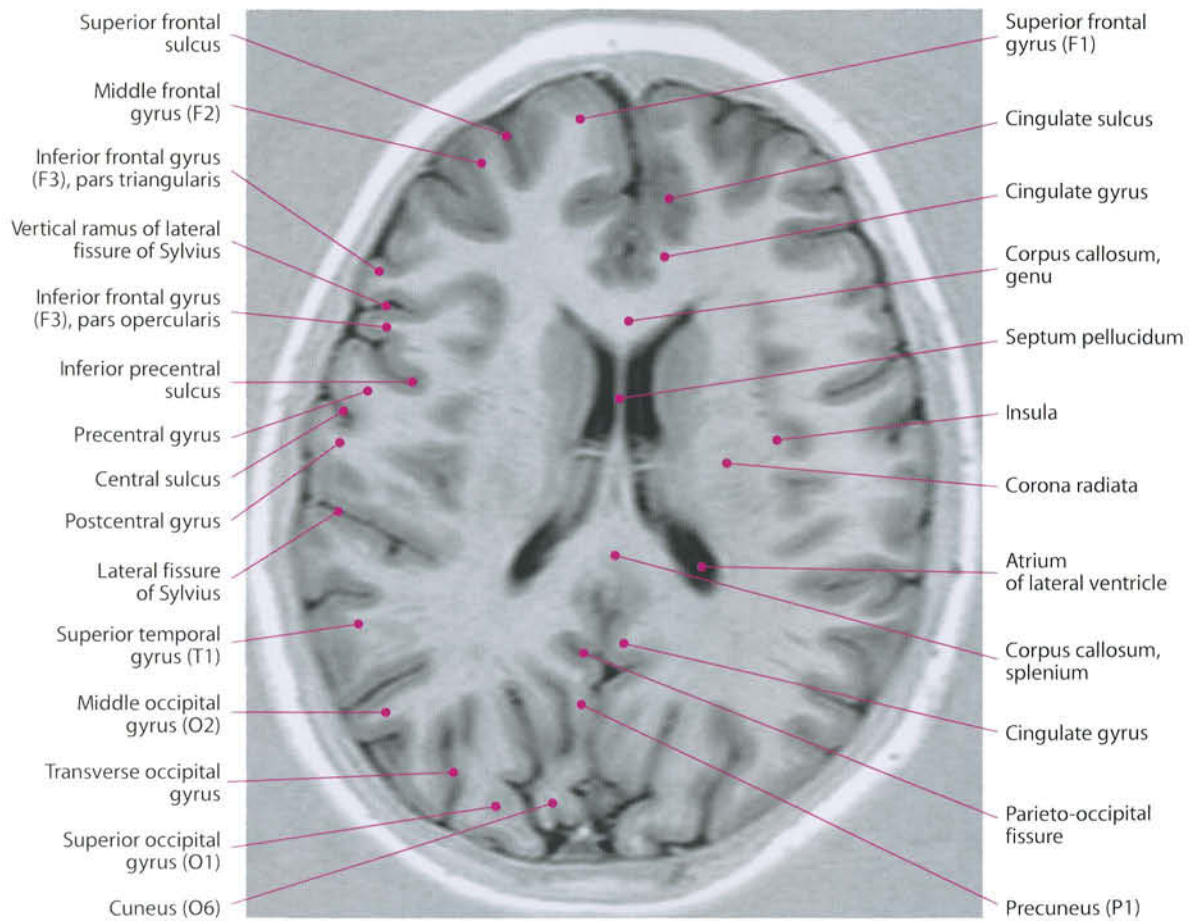


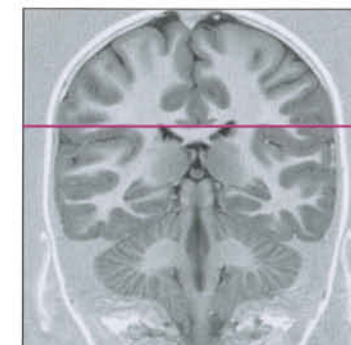
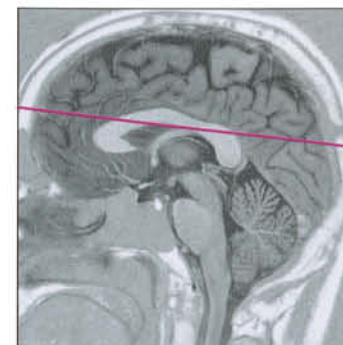
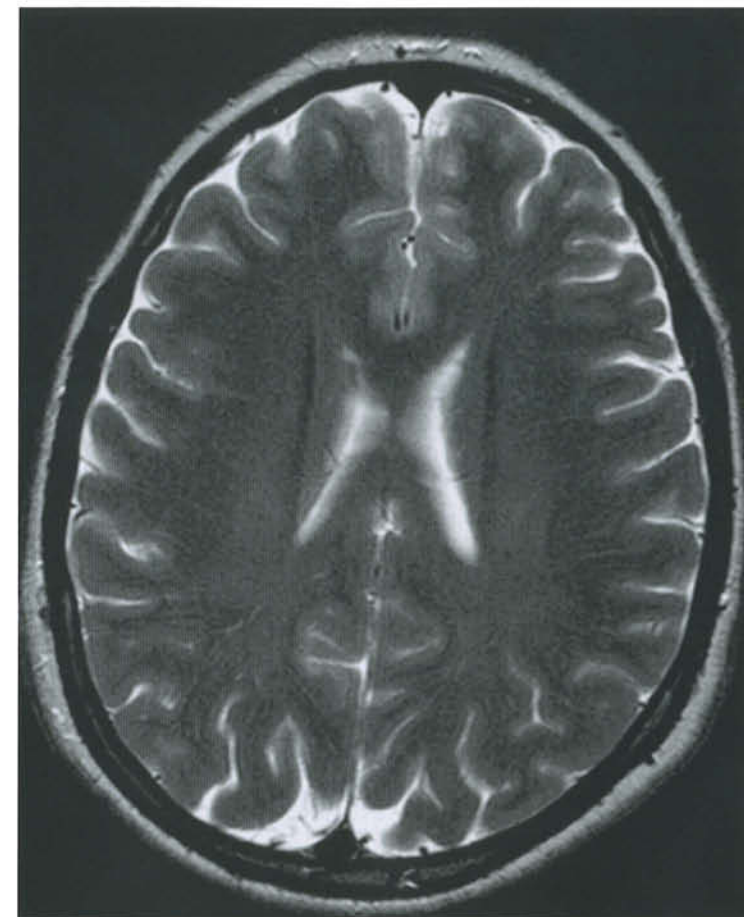
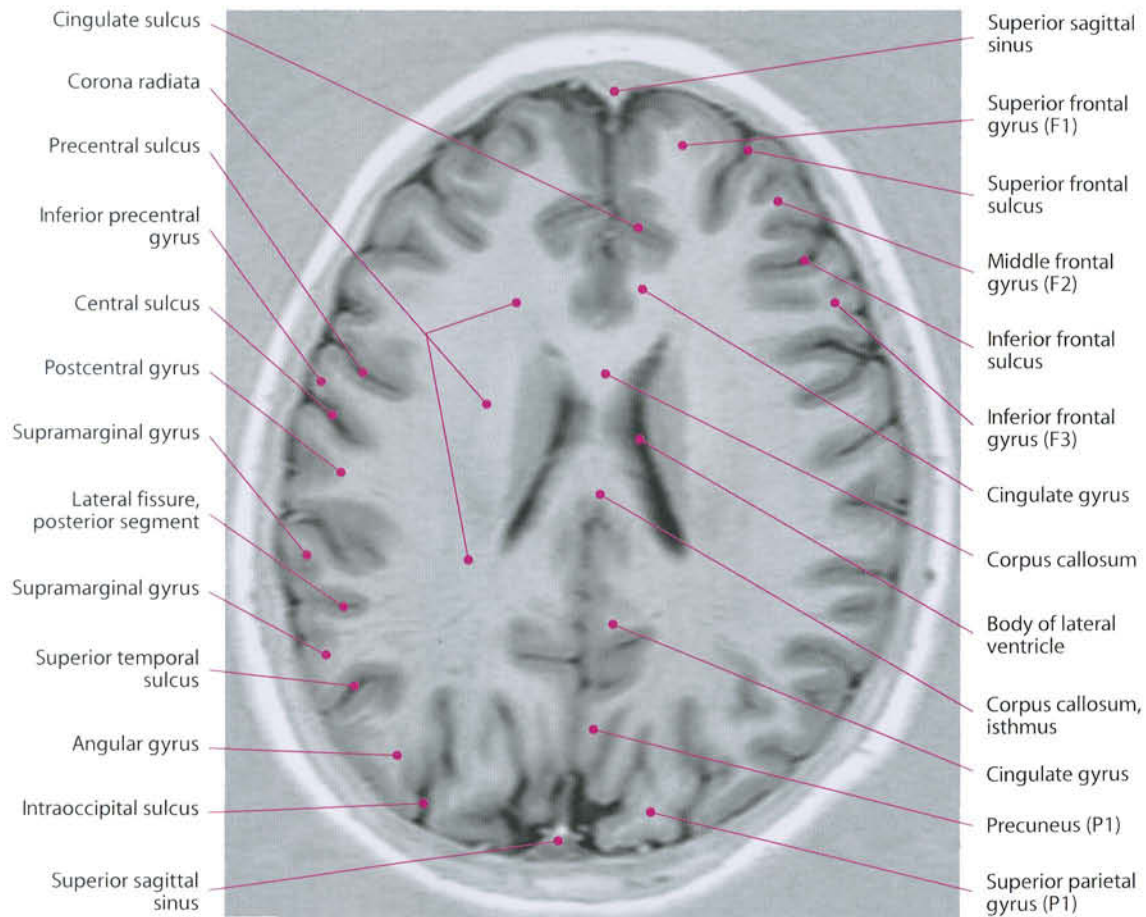


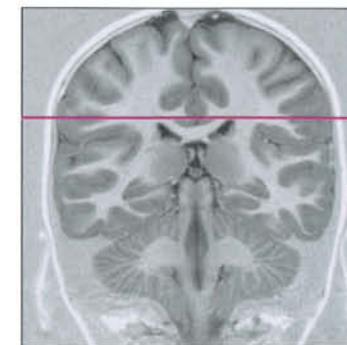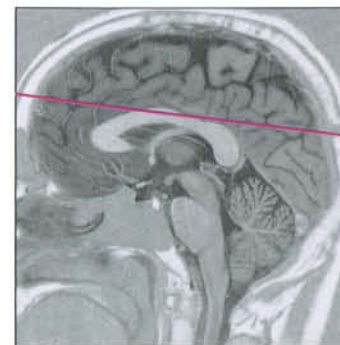
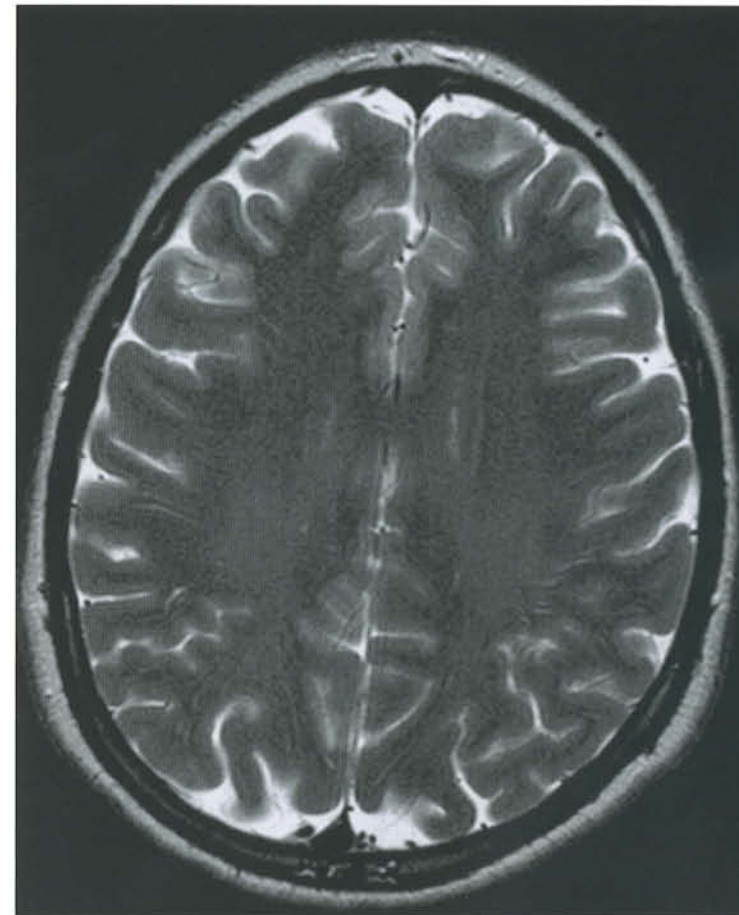
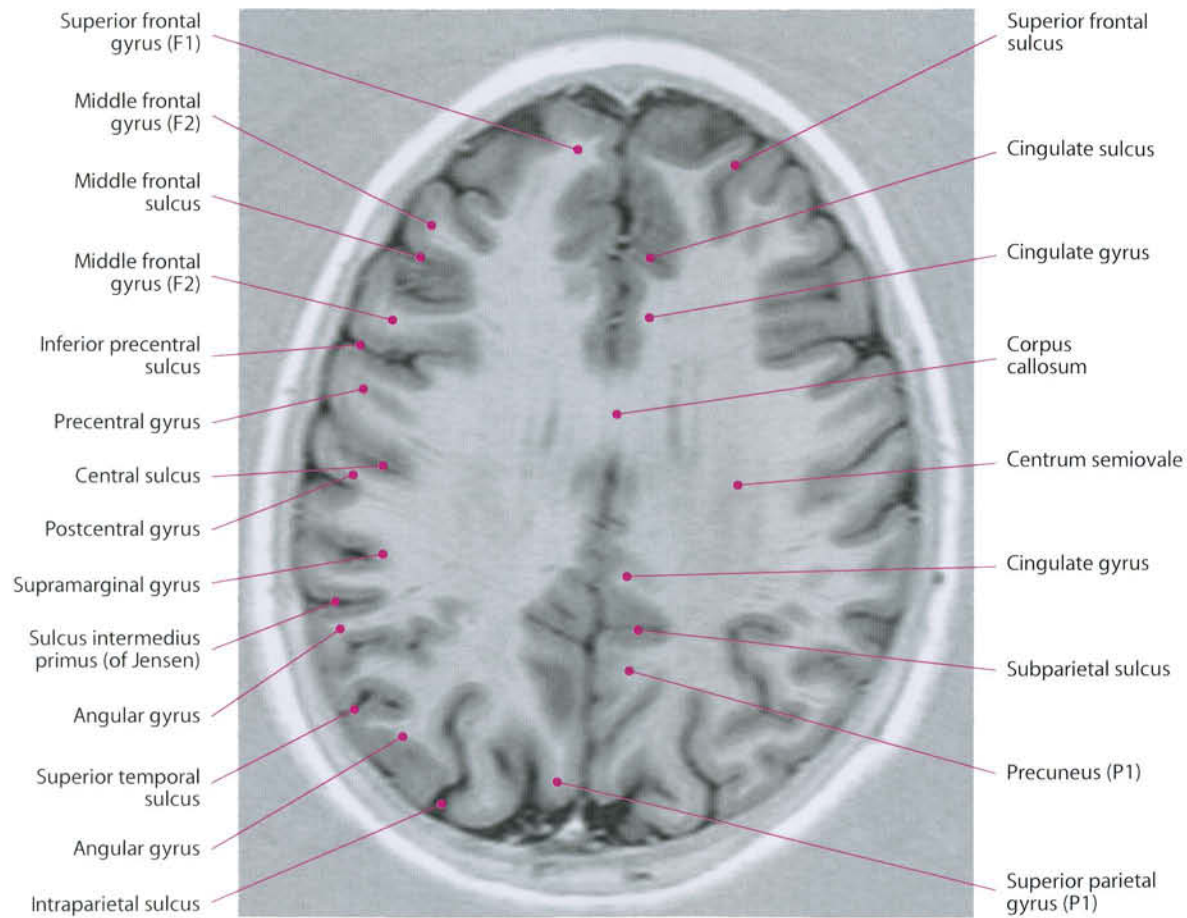


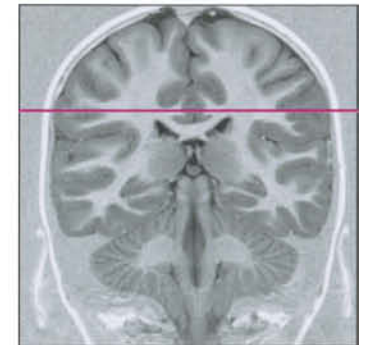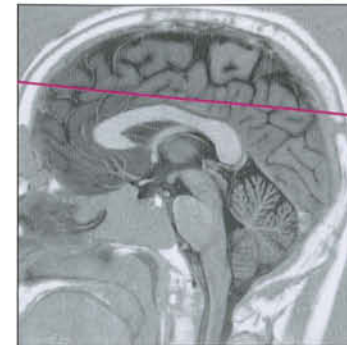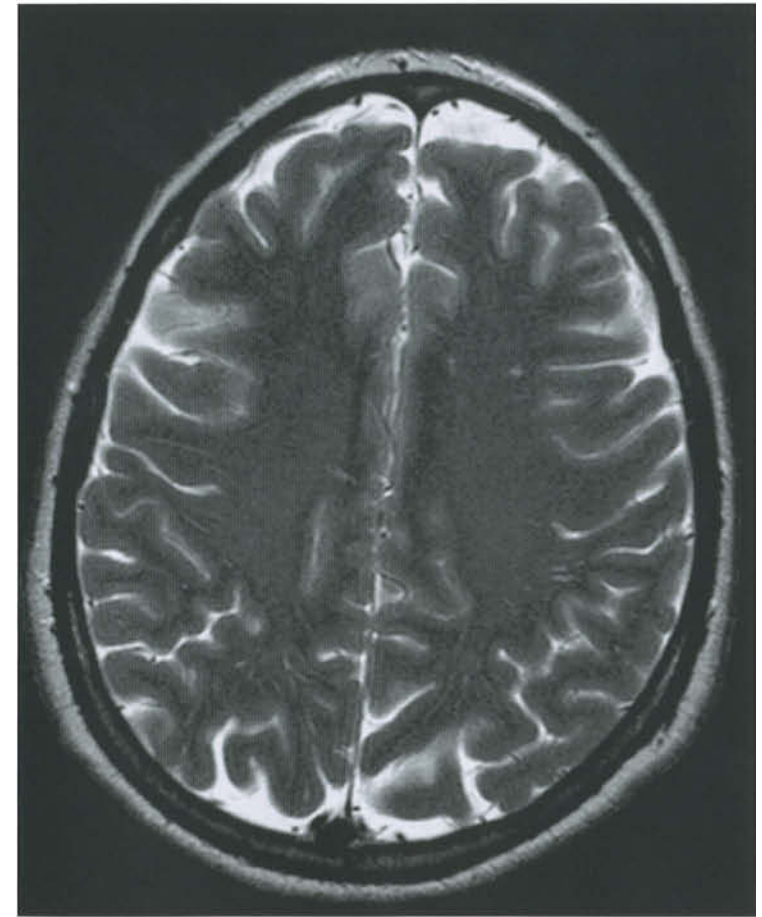
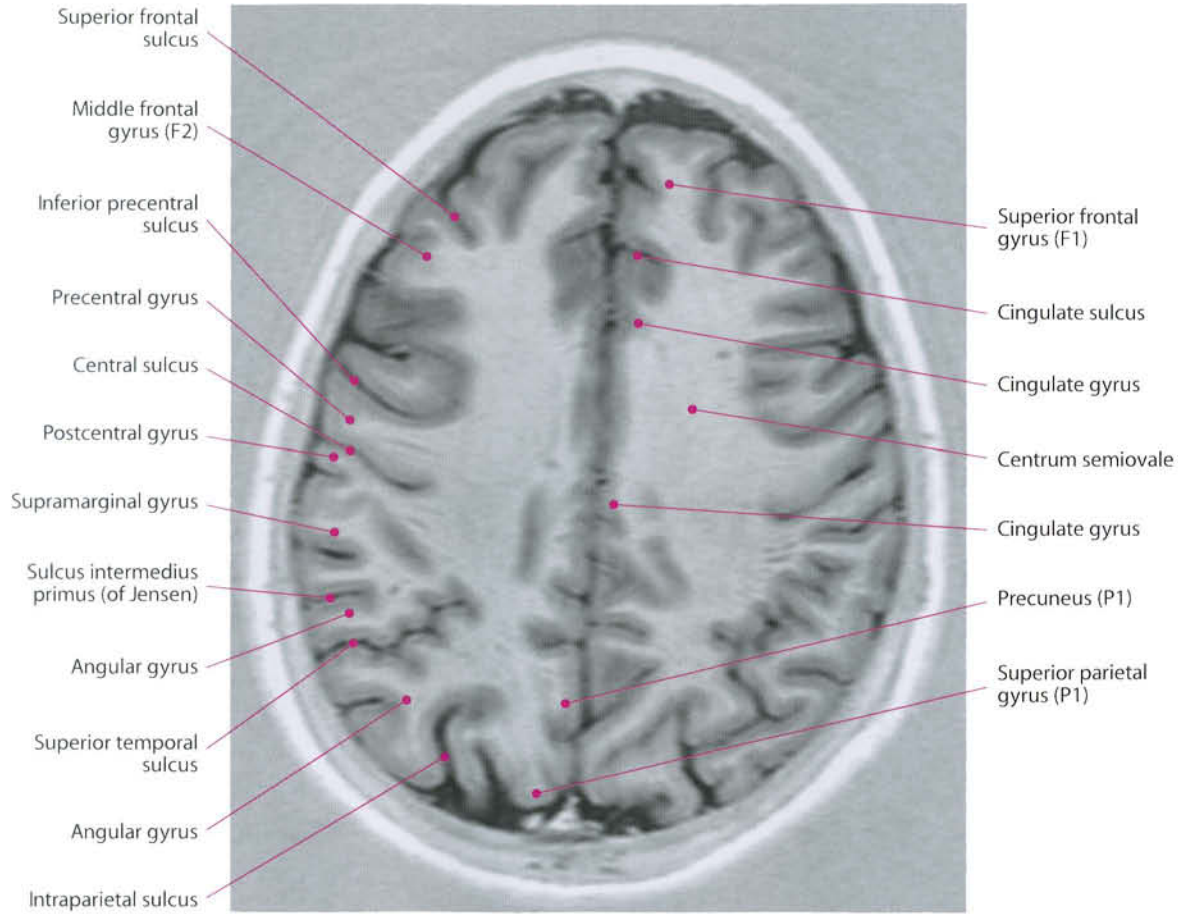


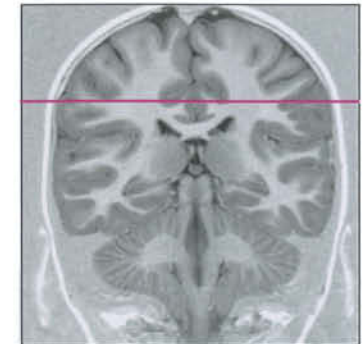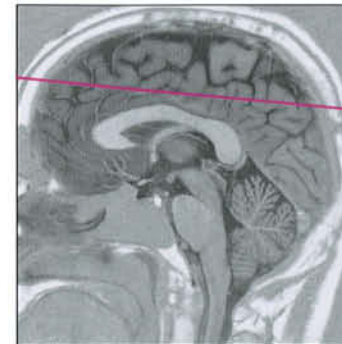
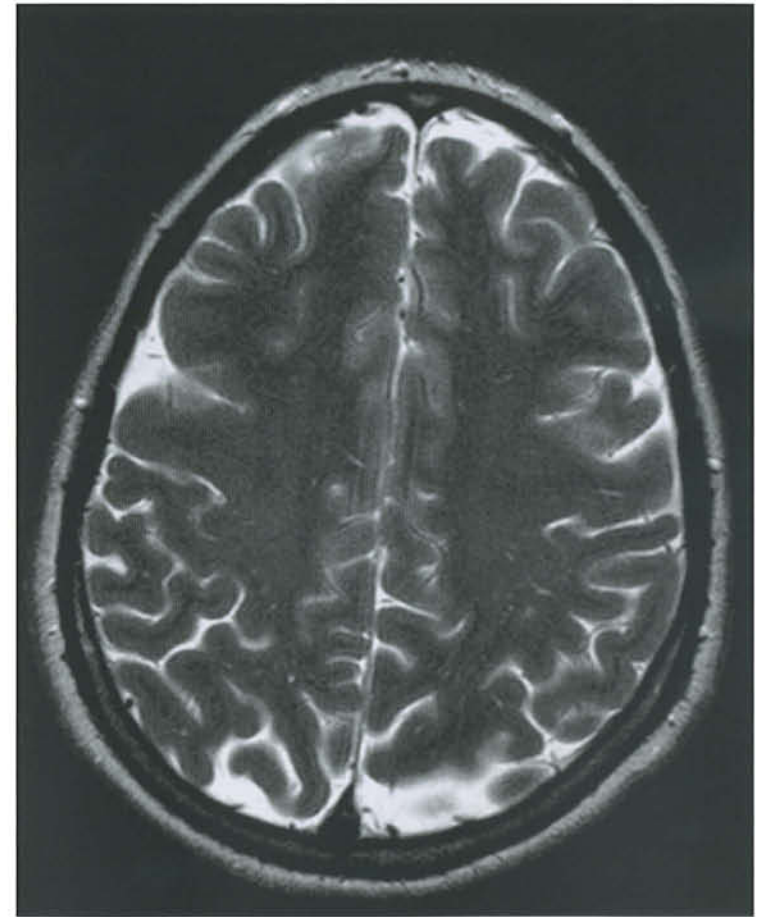
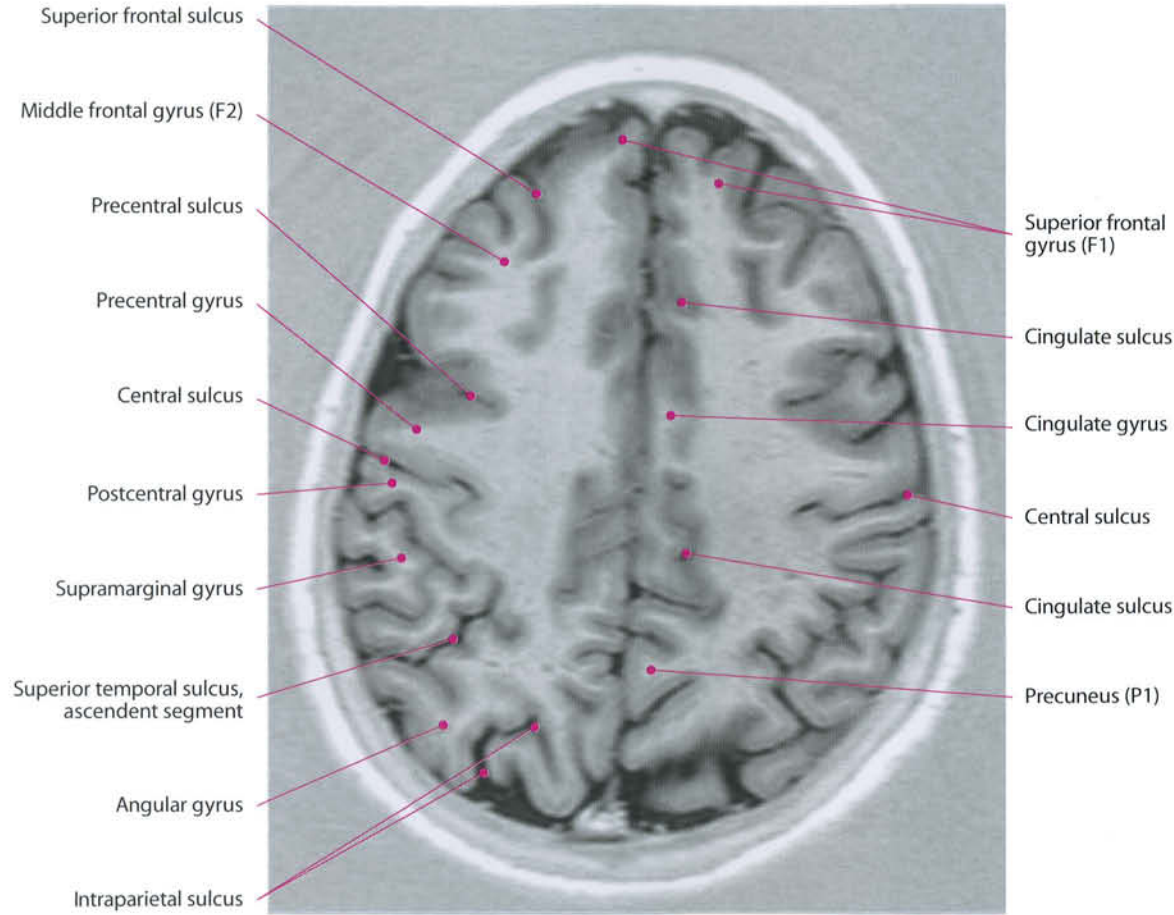


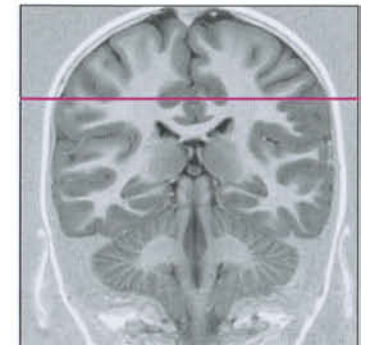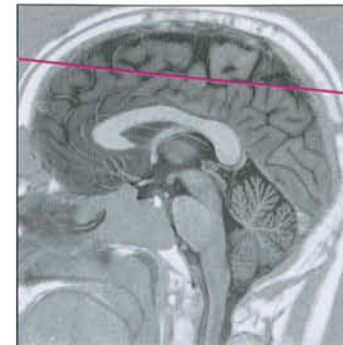
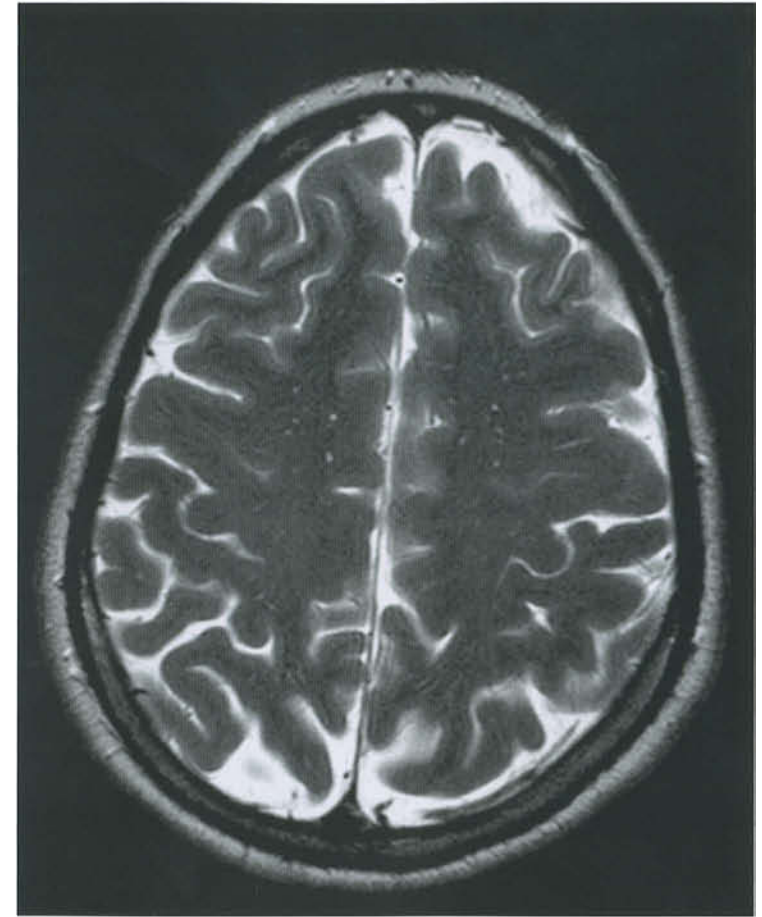
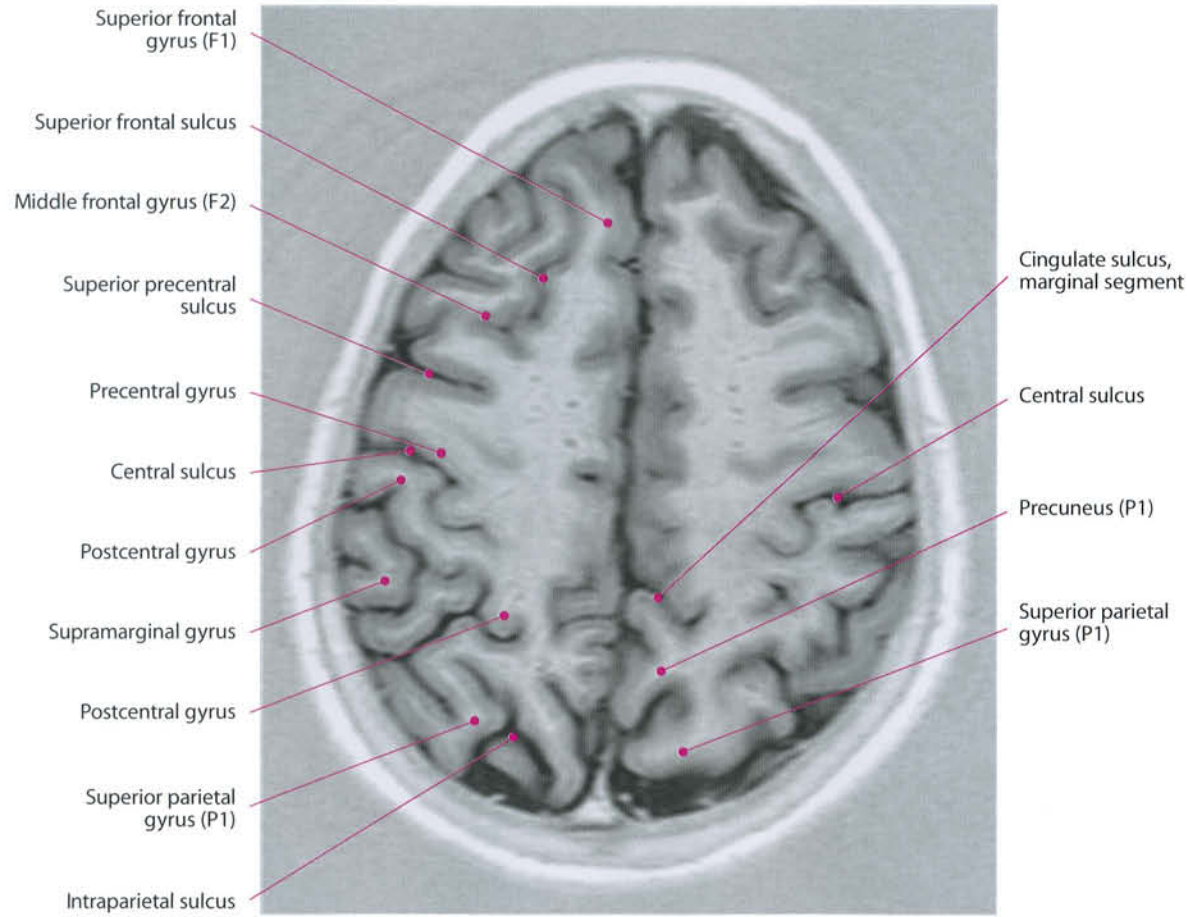


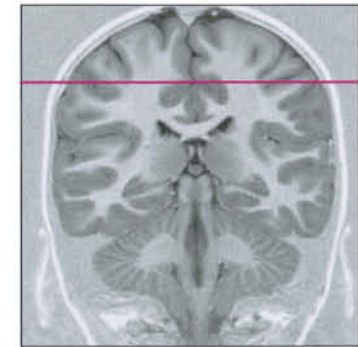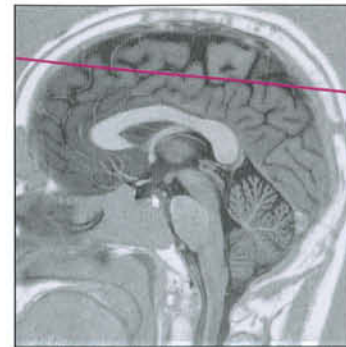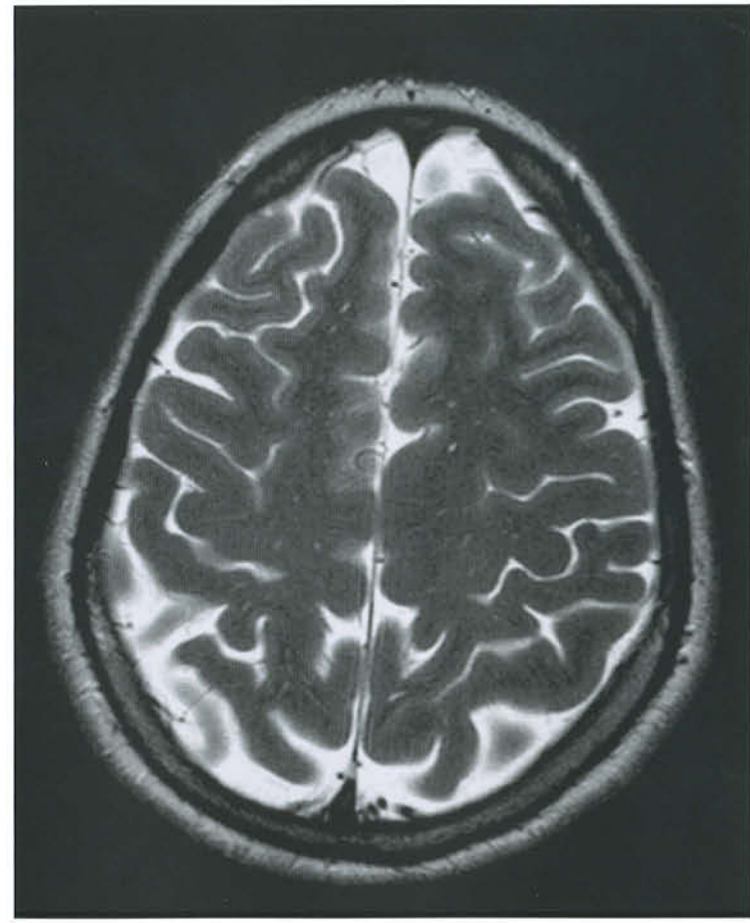
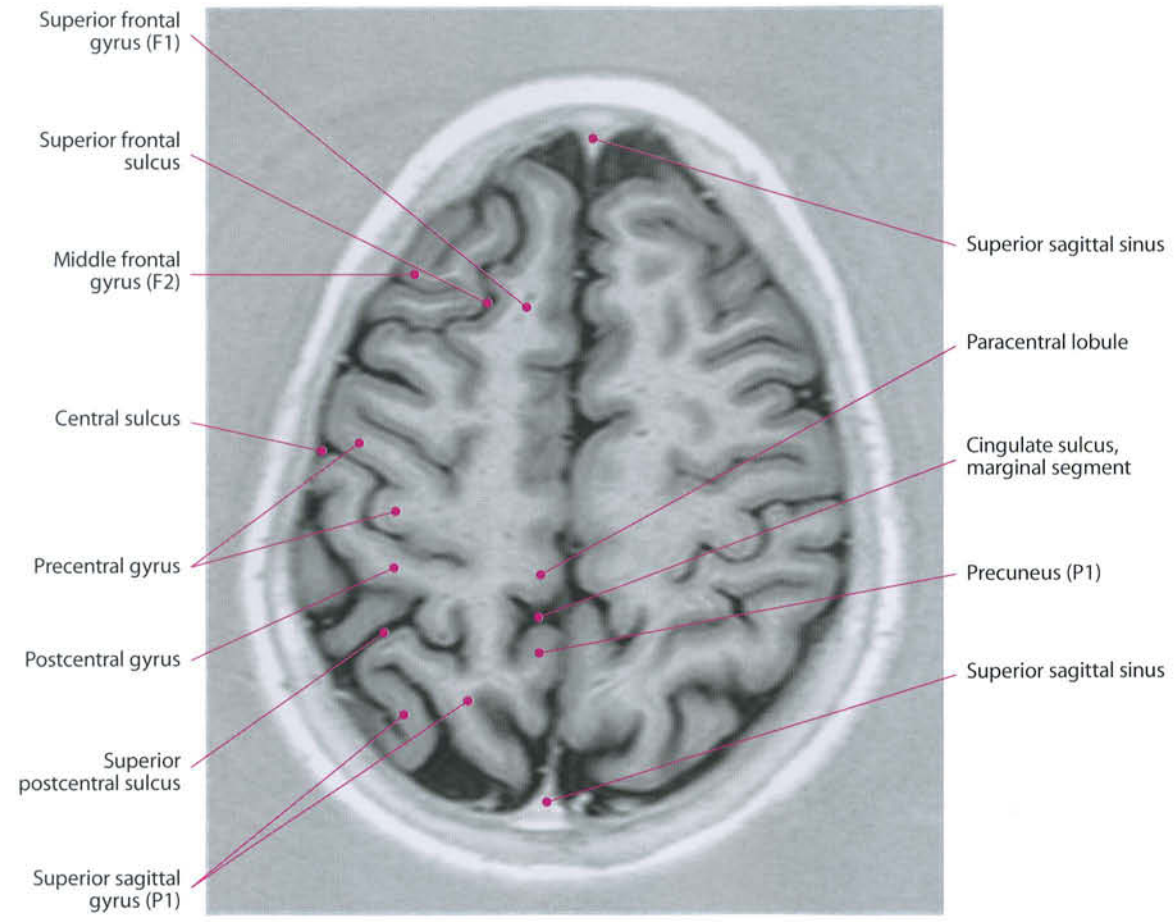


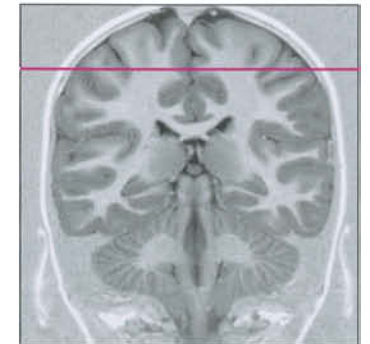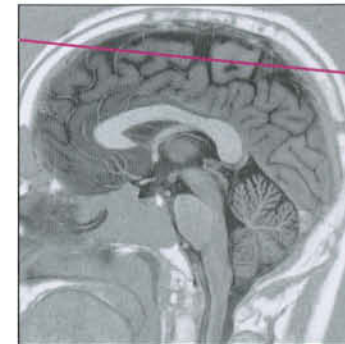
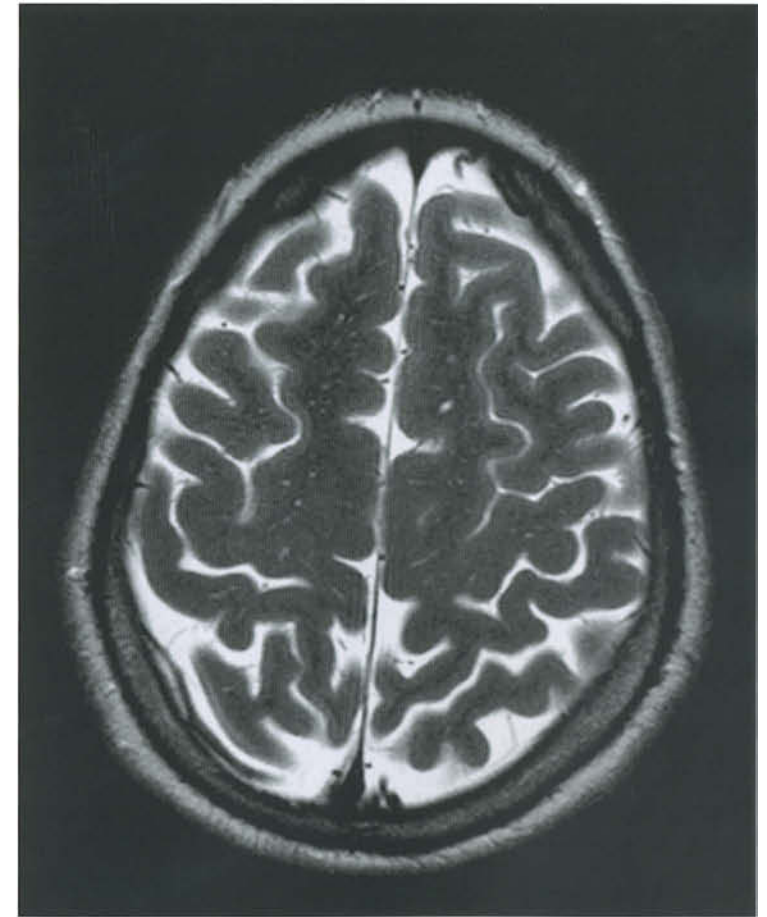
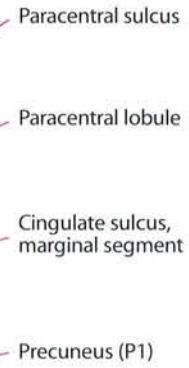
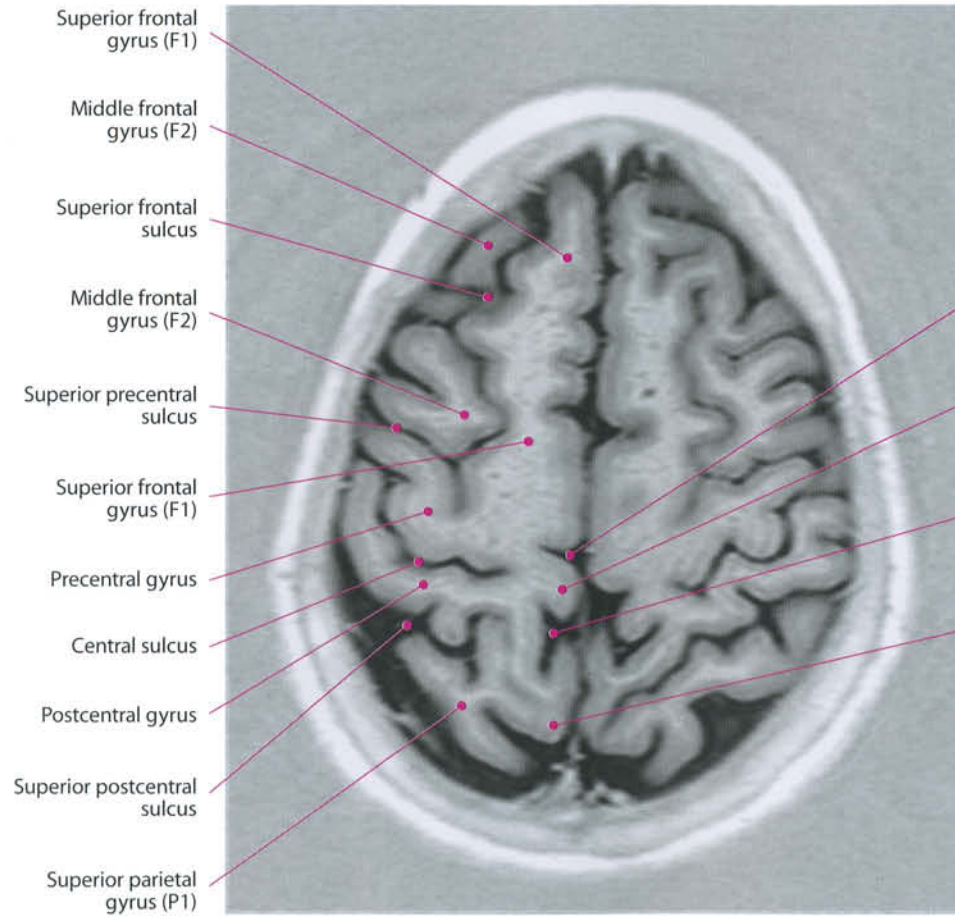


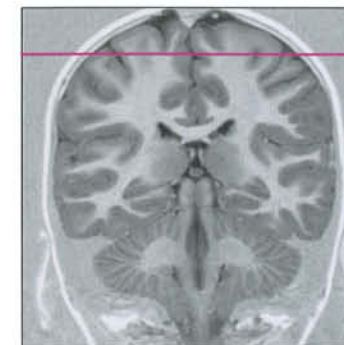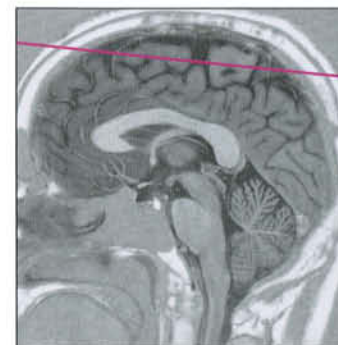
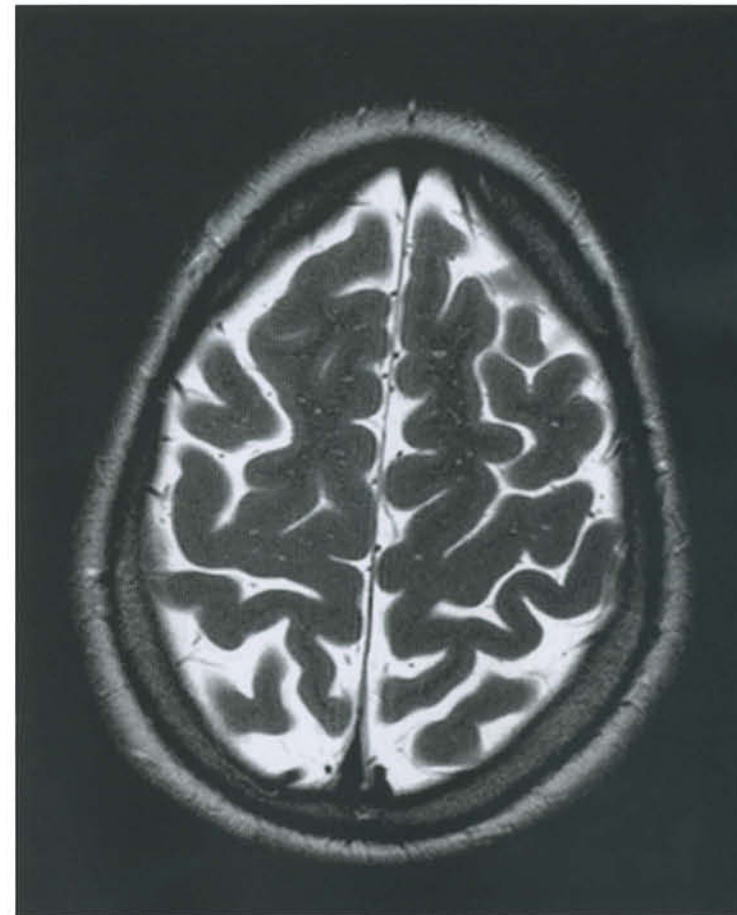
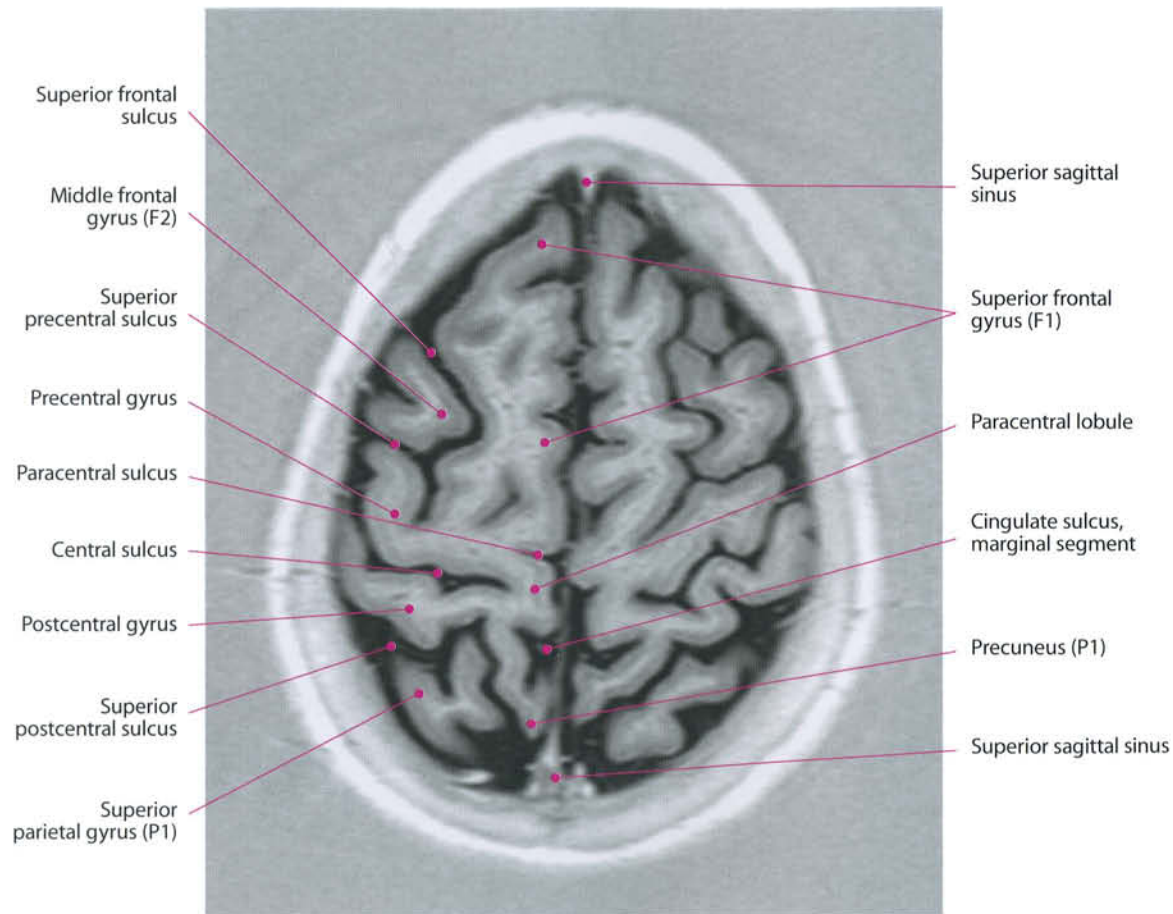


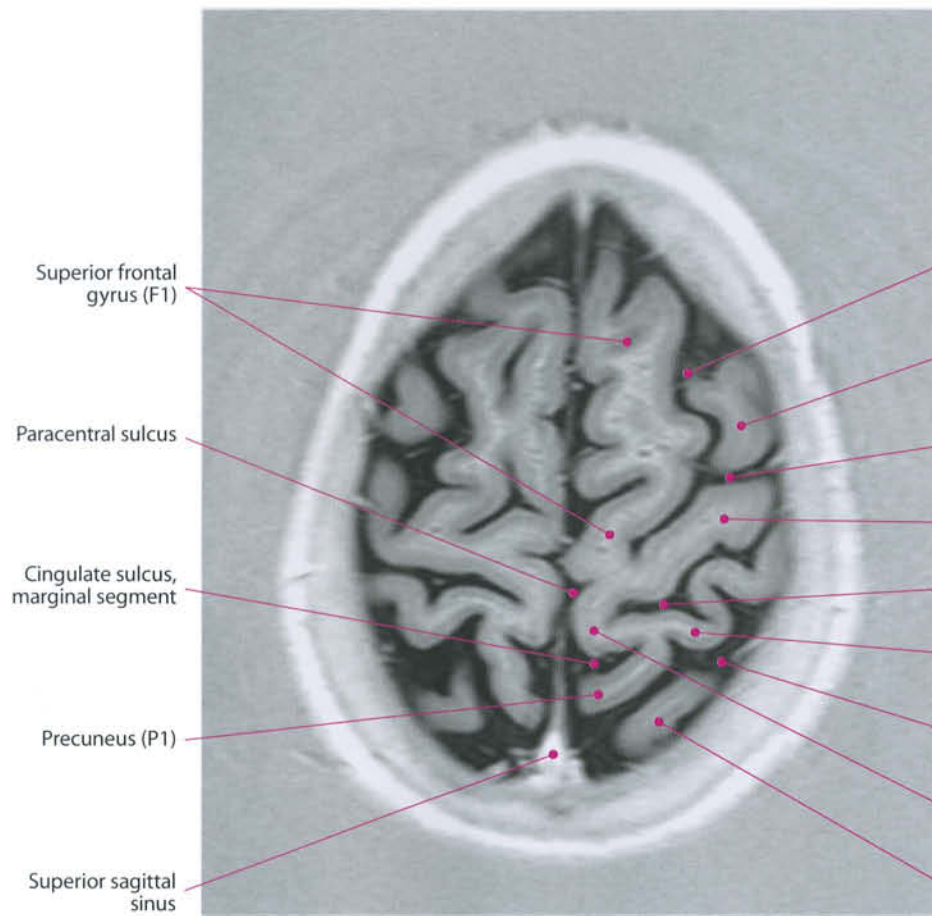




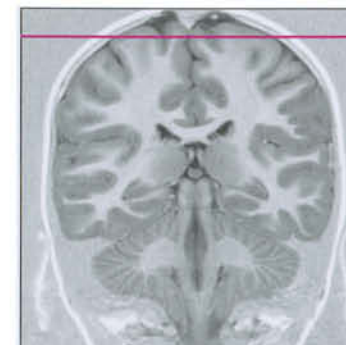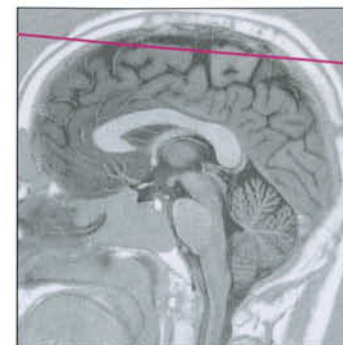
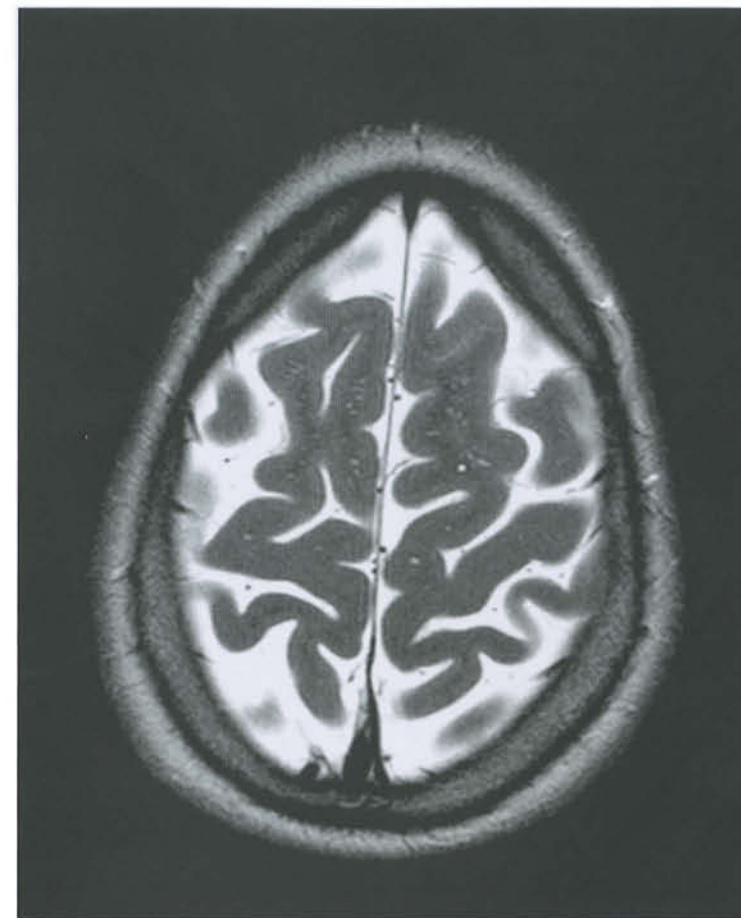








- Superior frontal sulcus
- Middle frontal gyrus (F2)
- Superior precentral sulcus
- Precentral gyrus
- Central sulcus
- Postcentral gyrus
- Superior postcentral sulcus
- Paracentral lobule
- Superior parietal gyrus (P1)



3 Brainstem and Cerebellum

Brainstem and Cerebellum

Brainstem and cerebellum are the contents of the posterior fossa, delimited superiorly by the tentorium cerebelli.

The brainstem comprises the midbrain, pons and medulla oblongata. It is directly connected with the diencephalon, composed by thalamus, pineal body, posterior commissure, habenula, and stria medullaris. From anterior to posterior it can be divided into pes, tegmentum and tectum. The tectum of the brainstem is represented by the quadrigeminal plate, while the tectum of the pons and medulla is the cerebellum. The main pathways and nuclei of the brainstem are described in chapters 4 and 5.

I. Midbrain

The midbrain is about 2 cm in length. The posterior part is represented by the tectum, or quadrigeminal plate. This contains two pairs of tubercles (superior and inferior), also termed collicles. They are separated from the tegmentum by a virtual plane passing through the cerebral aqueduct of Sylvius. In front of the tegmentum, the pes of the brainstem is constituted of the cerebral peduncles, also called crura, two thick bundles of fibers diverging upward from below, rostrally limited by the substantia nigra. Between them, the interpeduncular fossa is found. Anteriorly, it is limited by the two mammillary bodies (part of the hypothalamus), while in its depth is the posterior perforated substance through which perforating arteries pass.

II. Pons

The pons is the thicker portion of the brainstem of about 25-30 mm in length. It bulges from midbrain and medulla and is separated from them by the superior and inferior pontine sulci. It is posteriorly covered by the cerebellum, united to it by means of the middle cerebellar peduncles (brachia pontis).

III. Medulla Oblongata

The medulla is the lowest part of the brainstem. It continues caudally with the spinal cord. The cord's sulci are present even in the medulla, where they are more prominent.

These are:

the median (anterior) sulcus, which disappears at the level of the pyramidal decussation, and the anterolateral (preolivary) sulcus, through which the hypoglossal nerve emerges. The eminence between the median and anterolateral sulcus is called the pyramid and hosts the motor fibers of the pyramidal tract. Lateral to the anterolateral sulcus is the olive. Posterior to the olive, the fossetta lateralis is found. This region is supplied by the lateral medullar arteries, most of which come from the postero-inferior cerebellar artery. Infarct of this area is responsible for the Wallenberg syndrome. Posterior to this area, the inferior cerebellar peduncle (corpus restiforme – restiform body) is found.

IV. Cerebellum

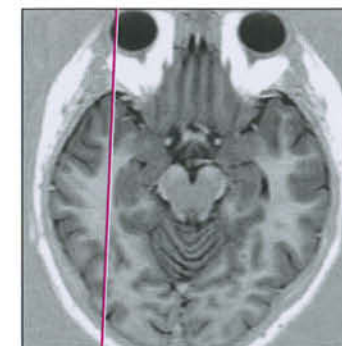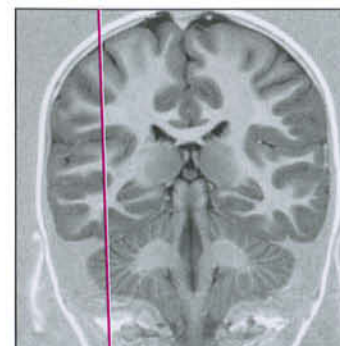
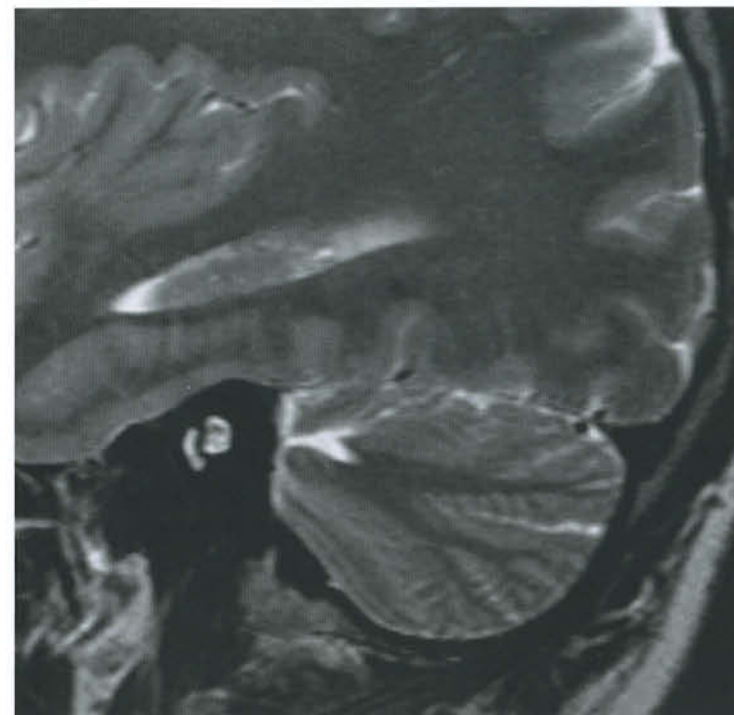
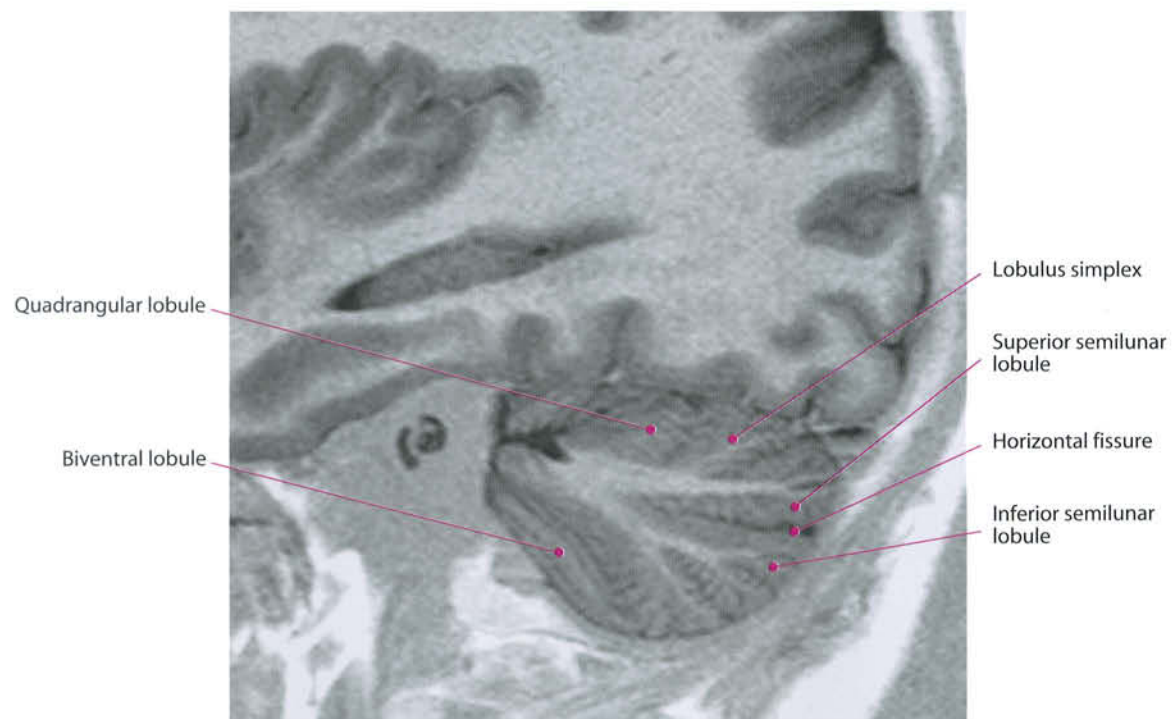
The cerebellum consists of two hemispheres and a median structure: the vermis. On the superior surface, there is no clear separation between the hemispheres. In the sagittal cuts, nine segments and two sulci are recognizable. The first segment, lingual, is adjacent to the superior medullary velum (Vieussens's valve), a membrane that delimites superiorly the fourth ventricle. The nodulus is against the inferior medullary velum, which delimites the ventricle inferiorly.

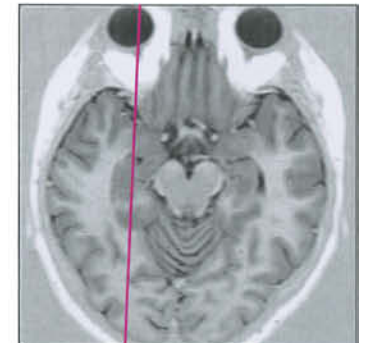
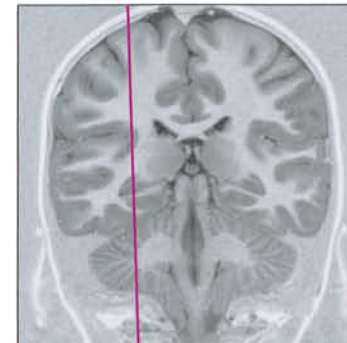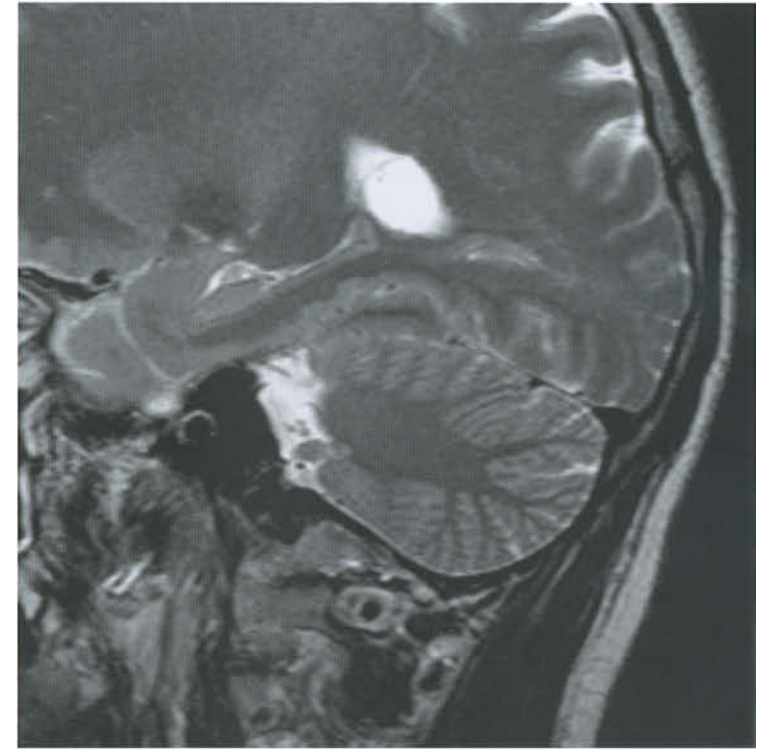
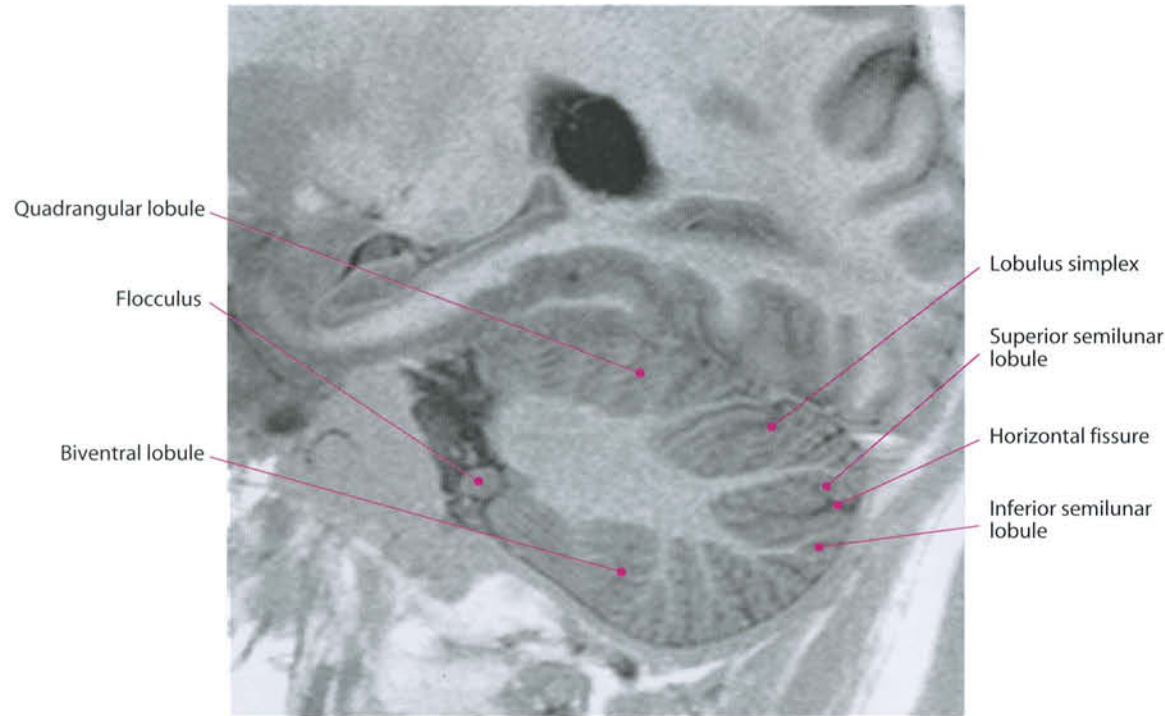
The cerebellar hemispheres are made up of a thick core of white matter (corpus medullaris) covered by the cerebellar cortex. This presents some fissures, of which the most important is the horizontal one that divides the cerebellar hemispheres into two lobes: anterior and posterior. Other fissures subdivide the lobes into lobules, and these into folia.

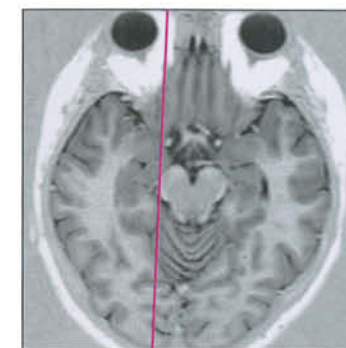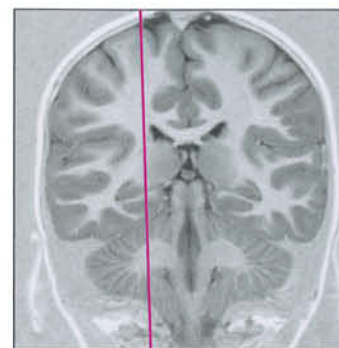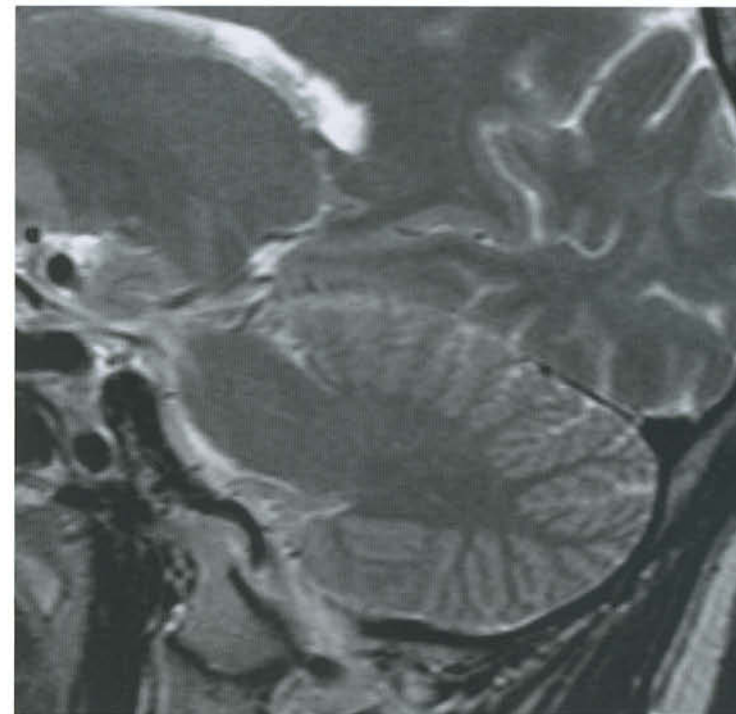
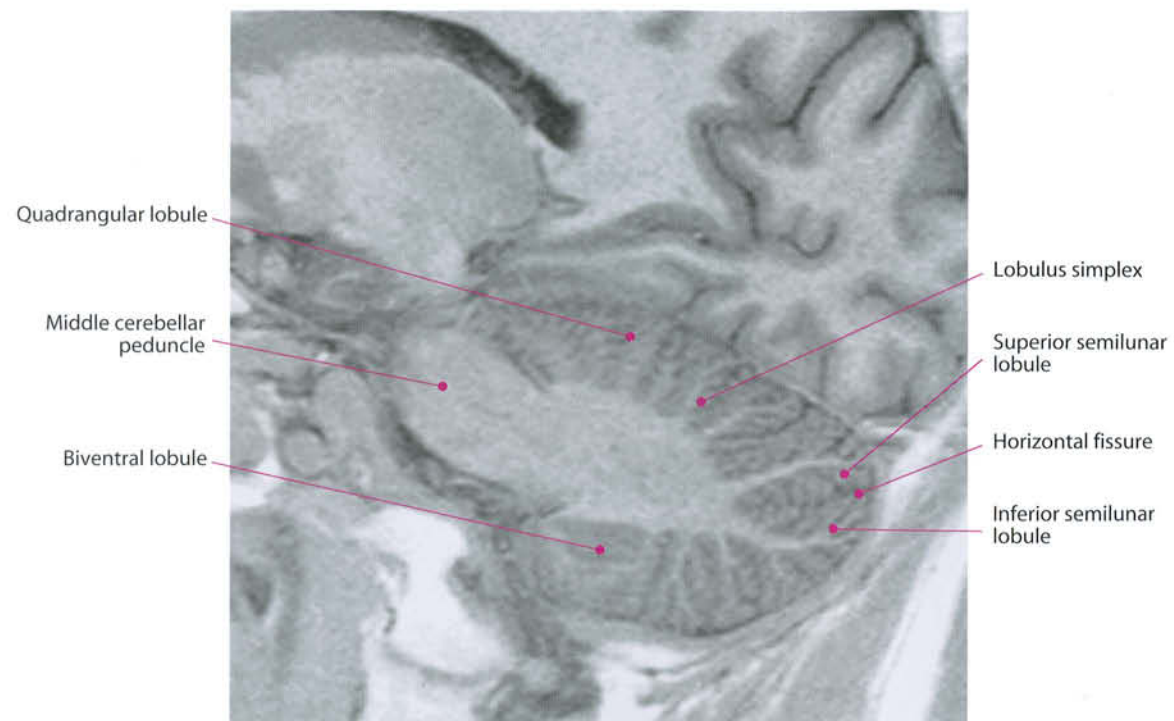
Within the white matter of the cerebellum, four gray nuclei are recognized, around and close to the posterior aspect of the fourth ventricle: fastigial, dentate, globose and emboliform nuclei.

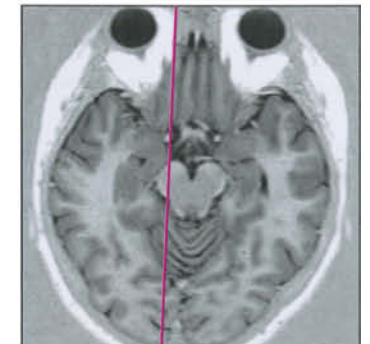
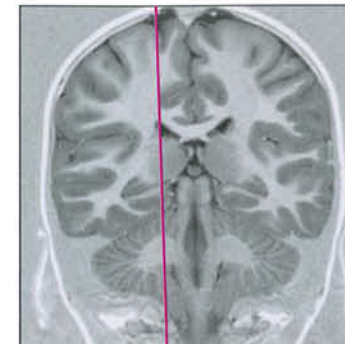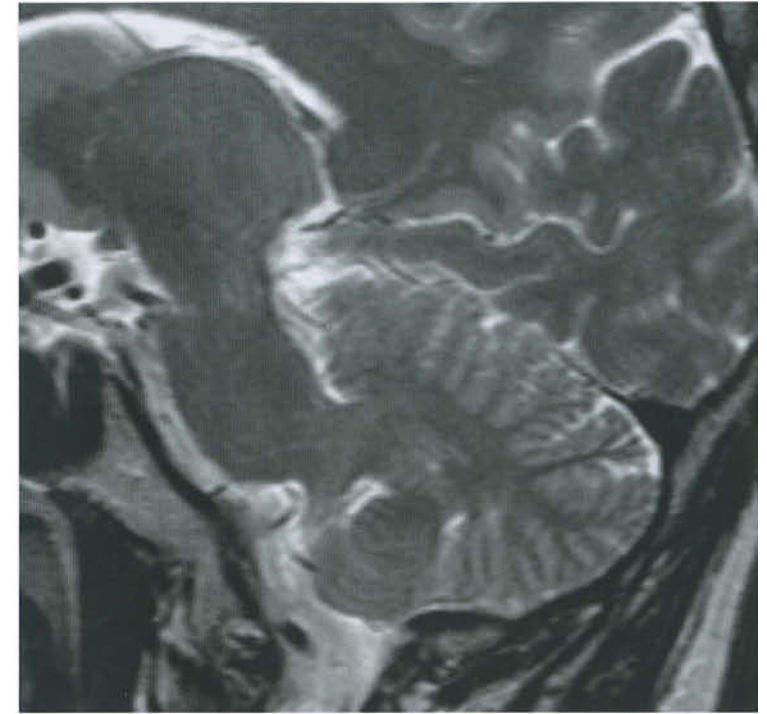
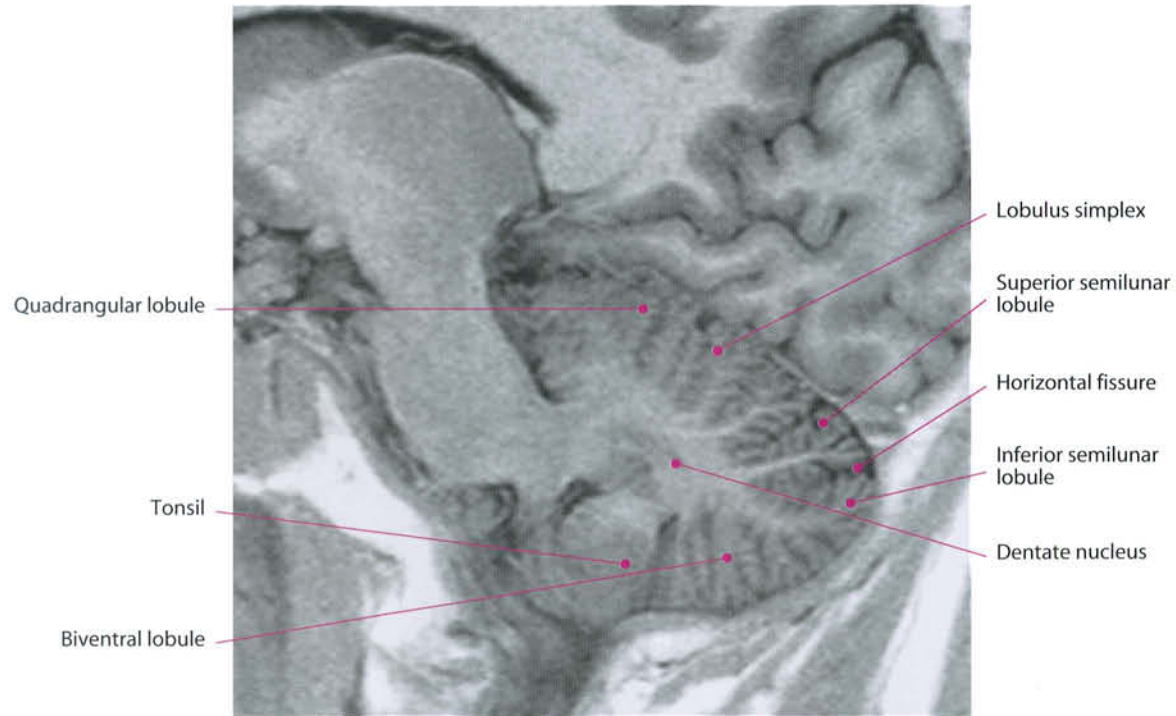
The cerebellum is attached to the brainstem by three bridges: the superior, middle and inferior cerebellar peduncles. The superior cerebellar peduncle (brachium conjunctivum) is thin, oblique, vertically and mid-laterally oriented, starting immediately below the inferior colliculum. It follows the velum medullaris superior. The fibers of the superior cerebellar peduncles decussate in the midbrain, and most of them end at the opposite red nucleus. The middle cerebellar peduncle is the biggest cerebellar bridge, and most of the pathways from and to the cerebellum pass through it.

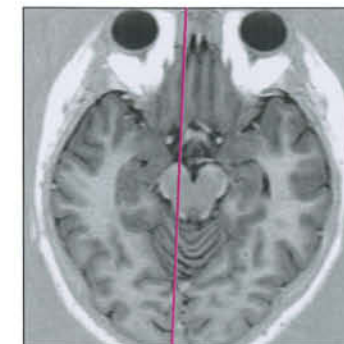
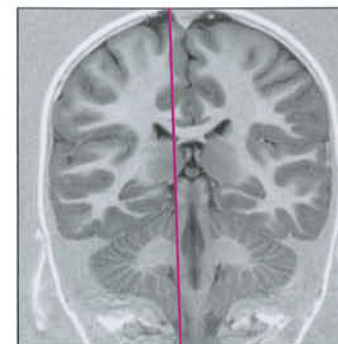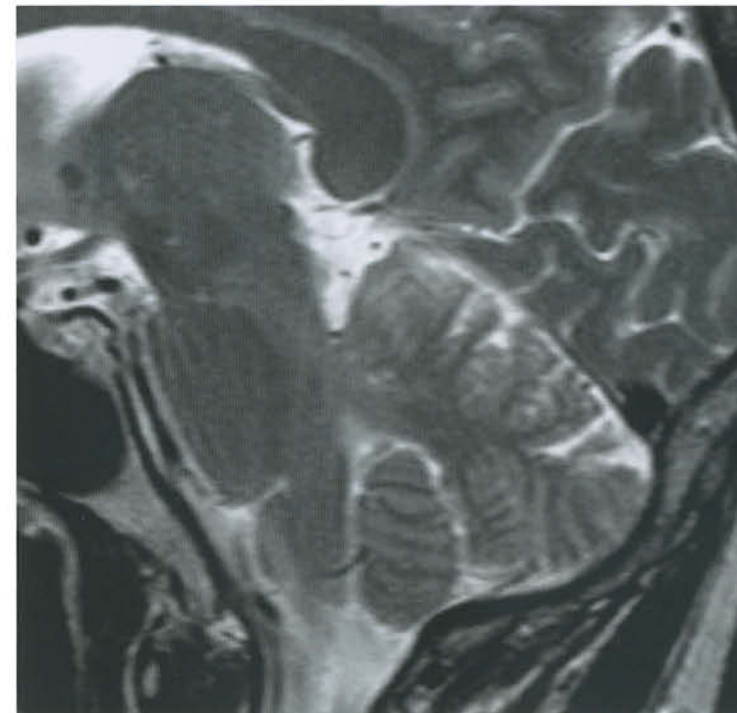
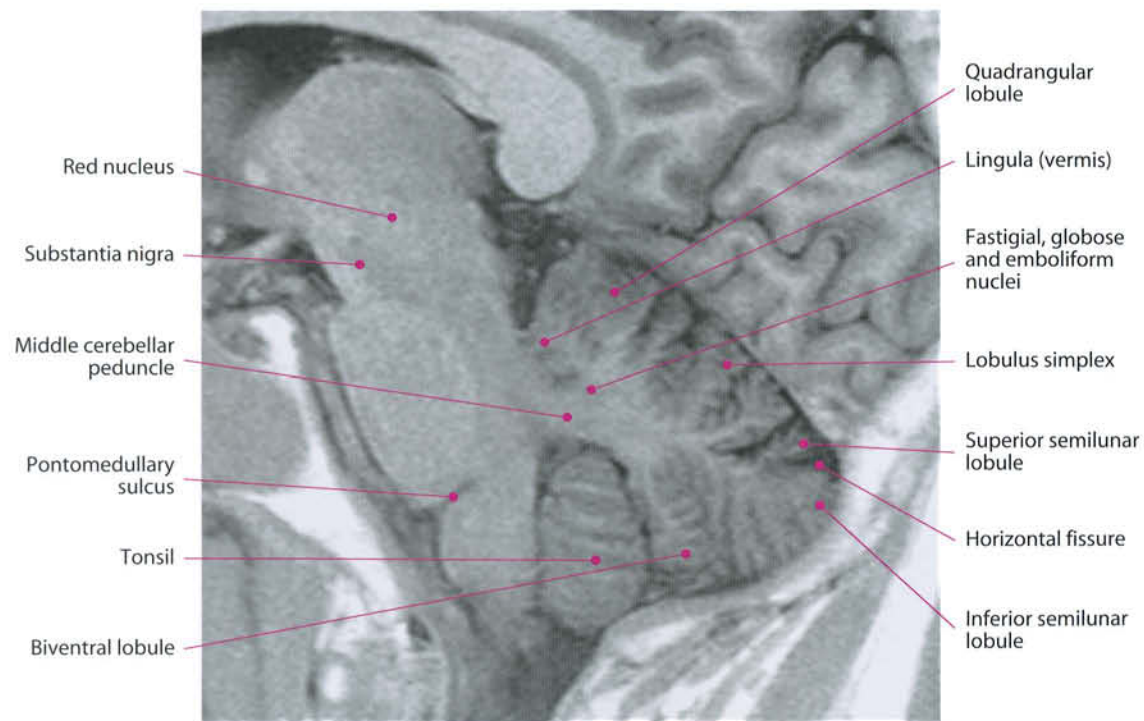The inferior cerebellar peduncle (restiform body) contains fibers from the medulla and spinal cord. It is thin, originates from the dorsolateral aspect of the upper medulla oblongata, ascends and diverges before entering the cerebellum. Phylogenetically, the cerebellum is divided into three portions: archi, paleo, and neo-cerebellum. The archicerebellum, constituted by flocculus and nodulus, is mostly devoted to the maintenance of orthostatic equilibrium. The paleocerebellum (amygdala, pyramis, uvula and anterior lobe) governs proprioceptive stimuli coming from muscles and articulations. The neocerebellum includes most of the cerebellar hemisphere and the intermediate portion of the vermis; it seems mostly devoted to the finest regulation of motoricity in both voluntary and involuntary movements.

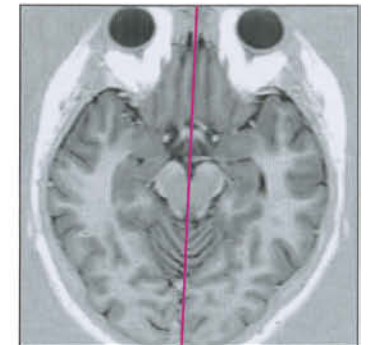
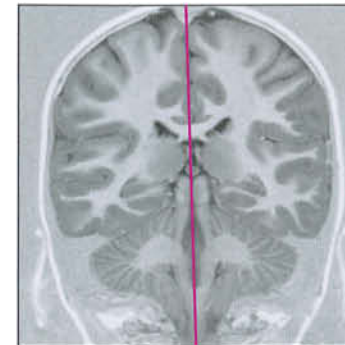
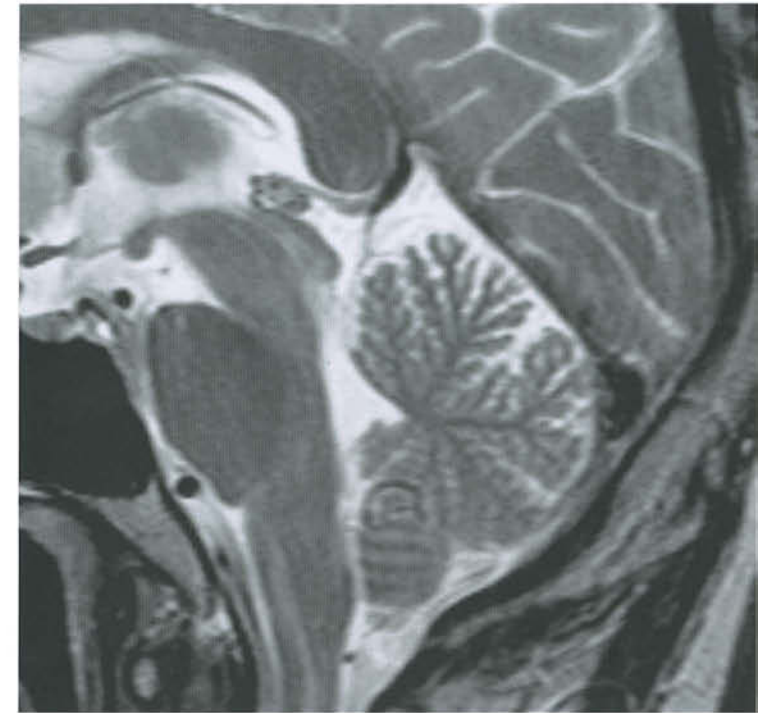
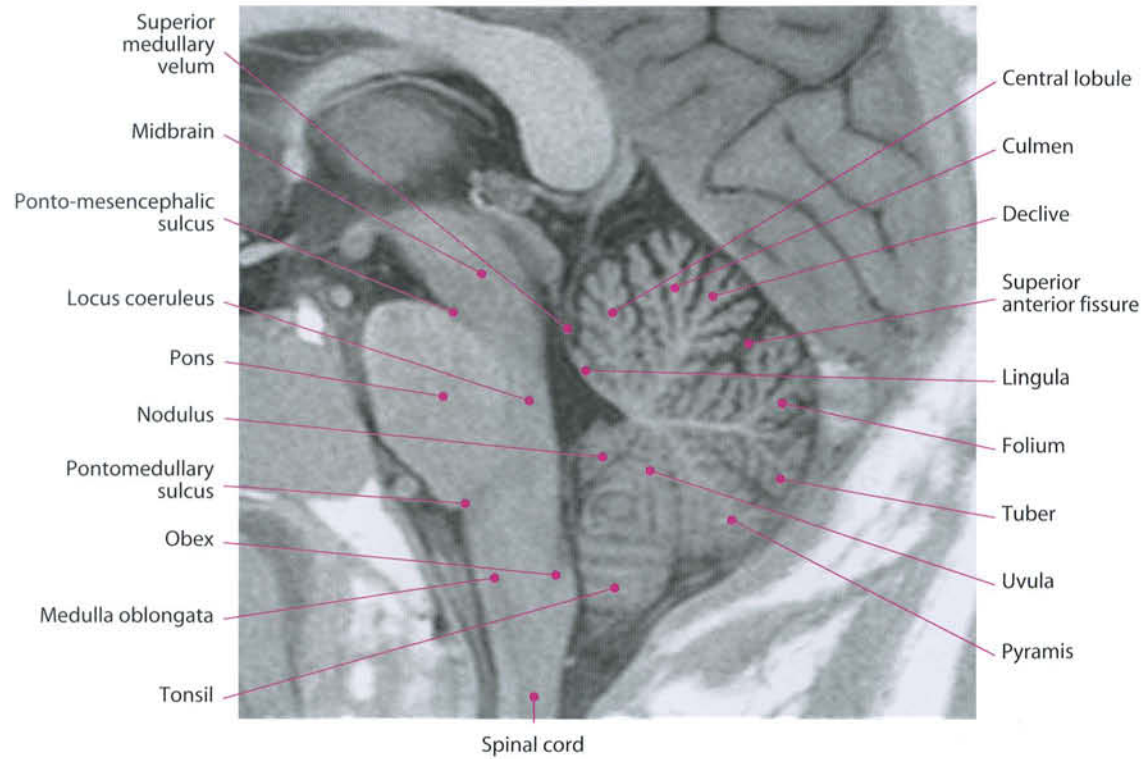


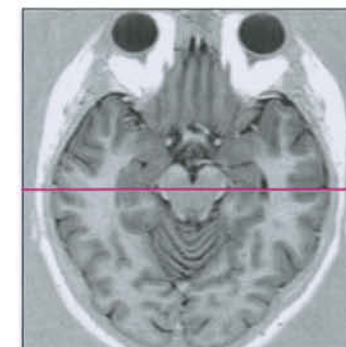
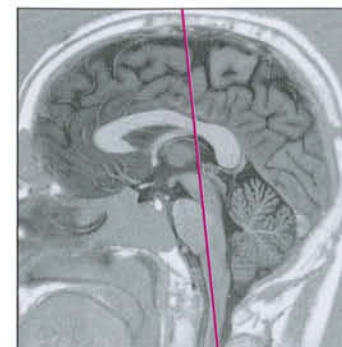
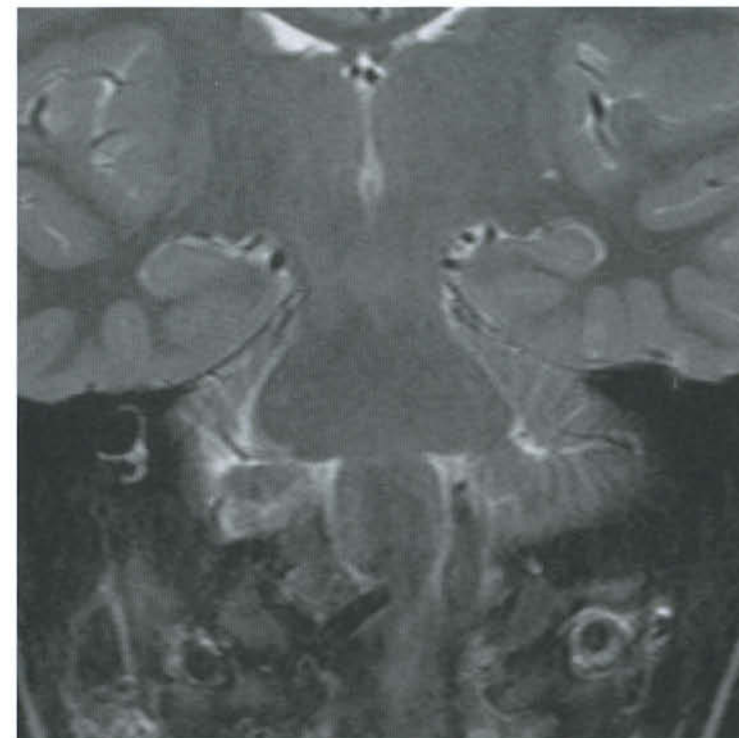
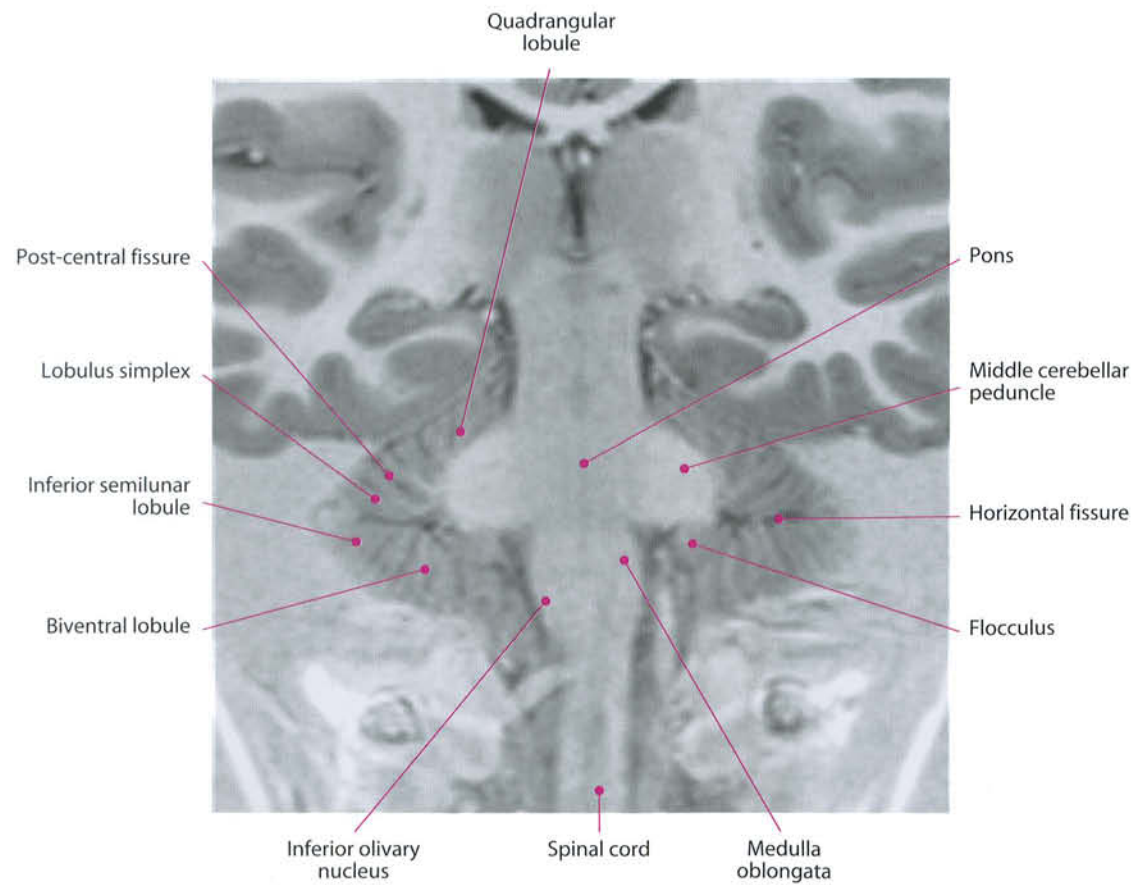


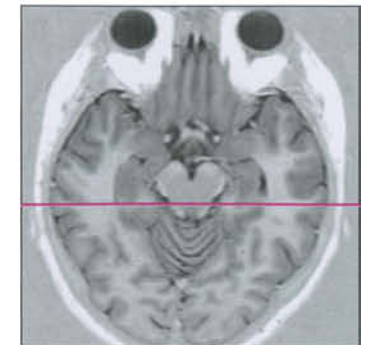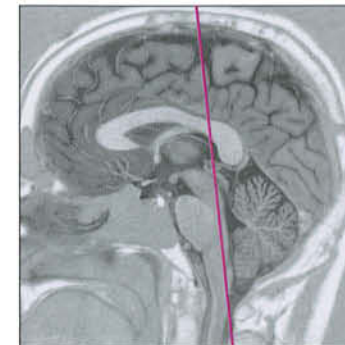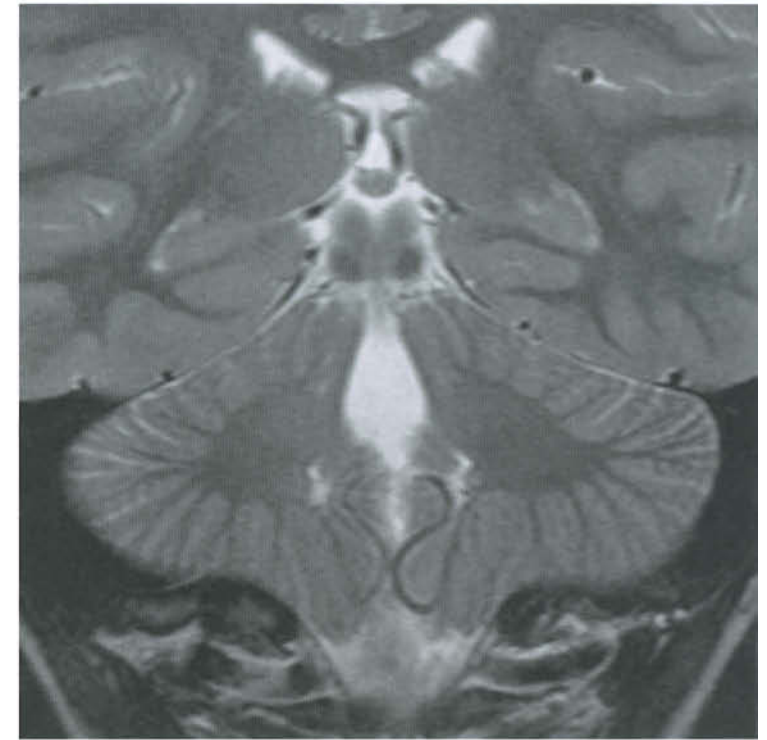
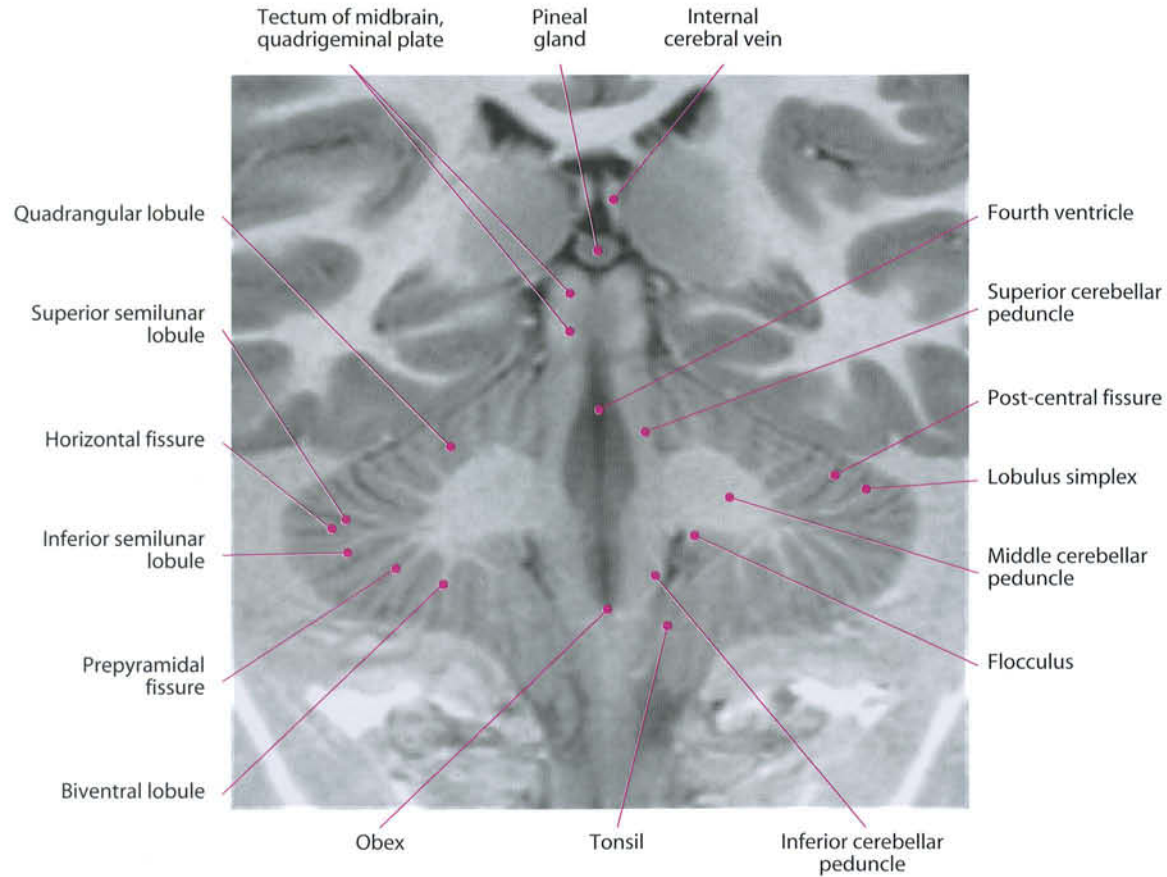


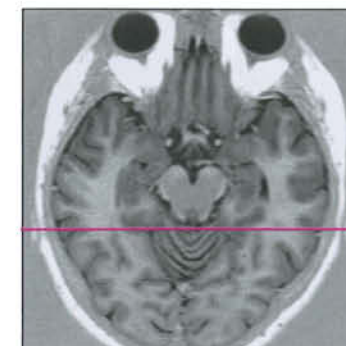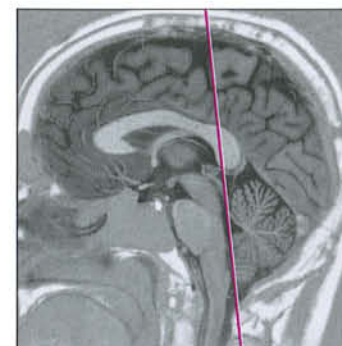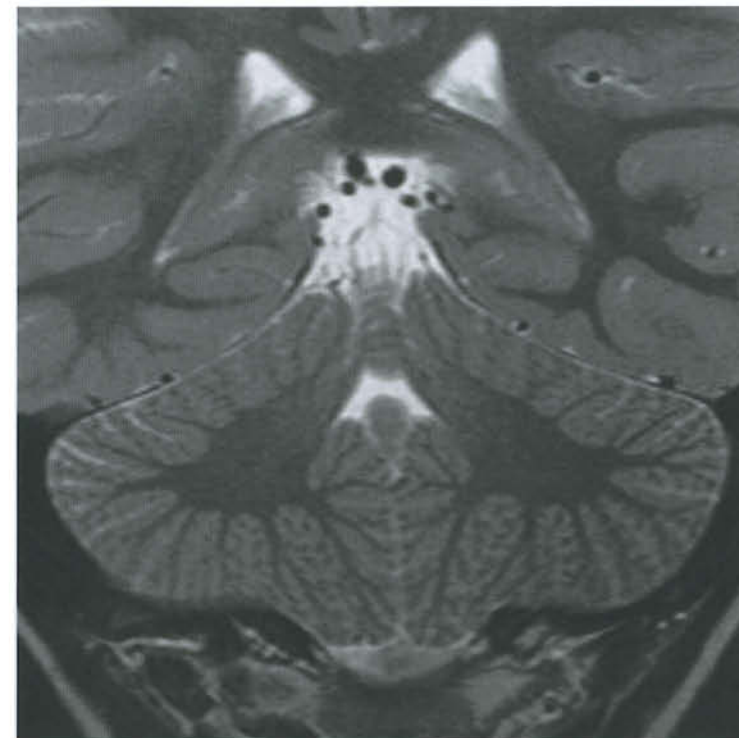
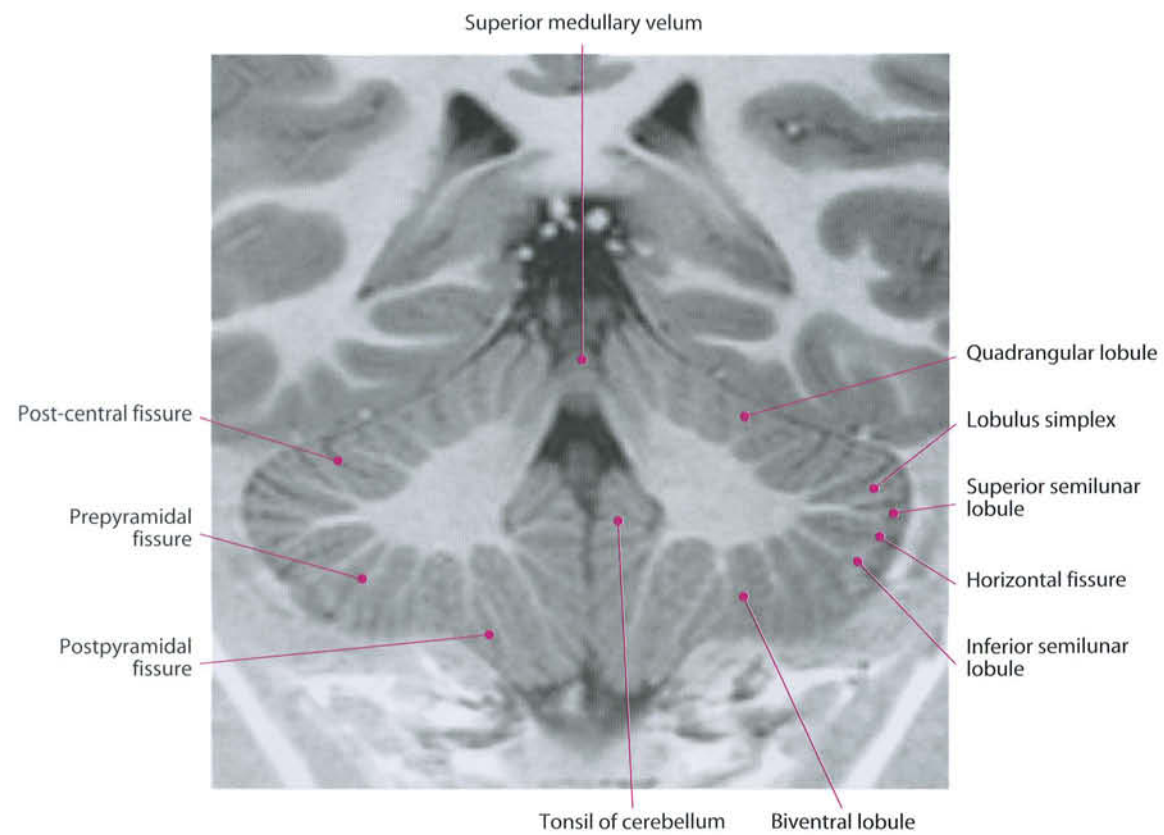


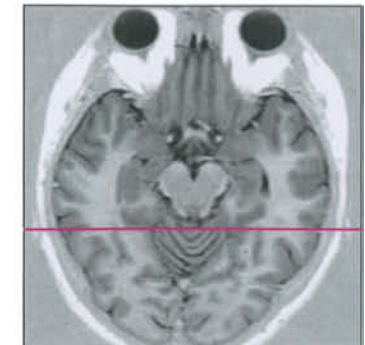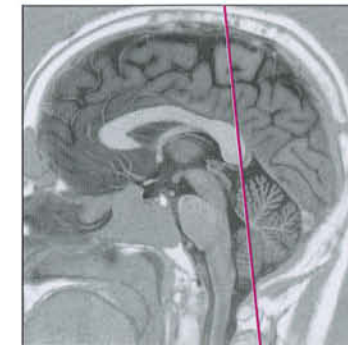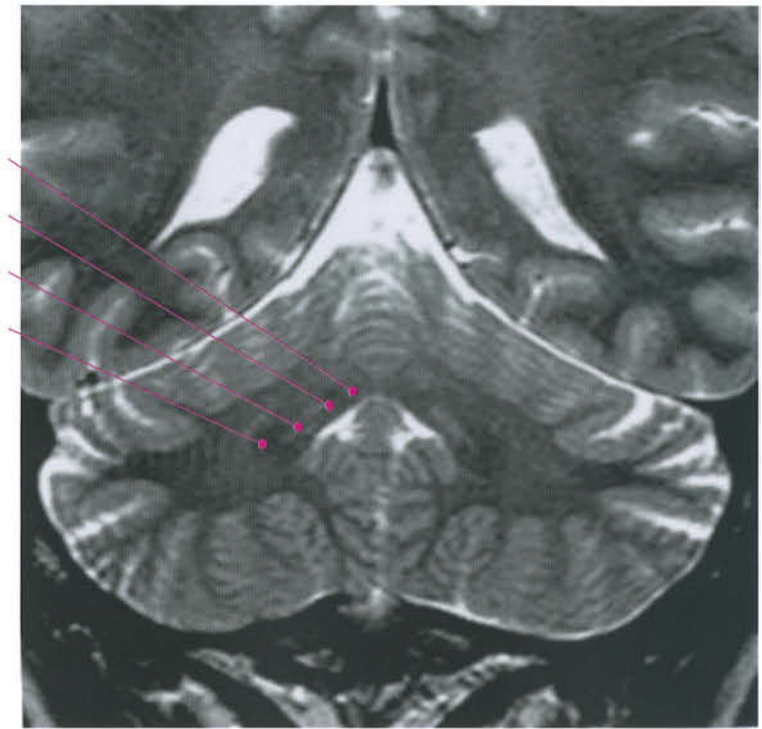
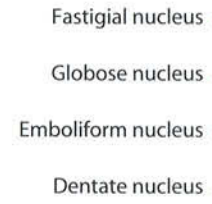
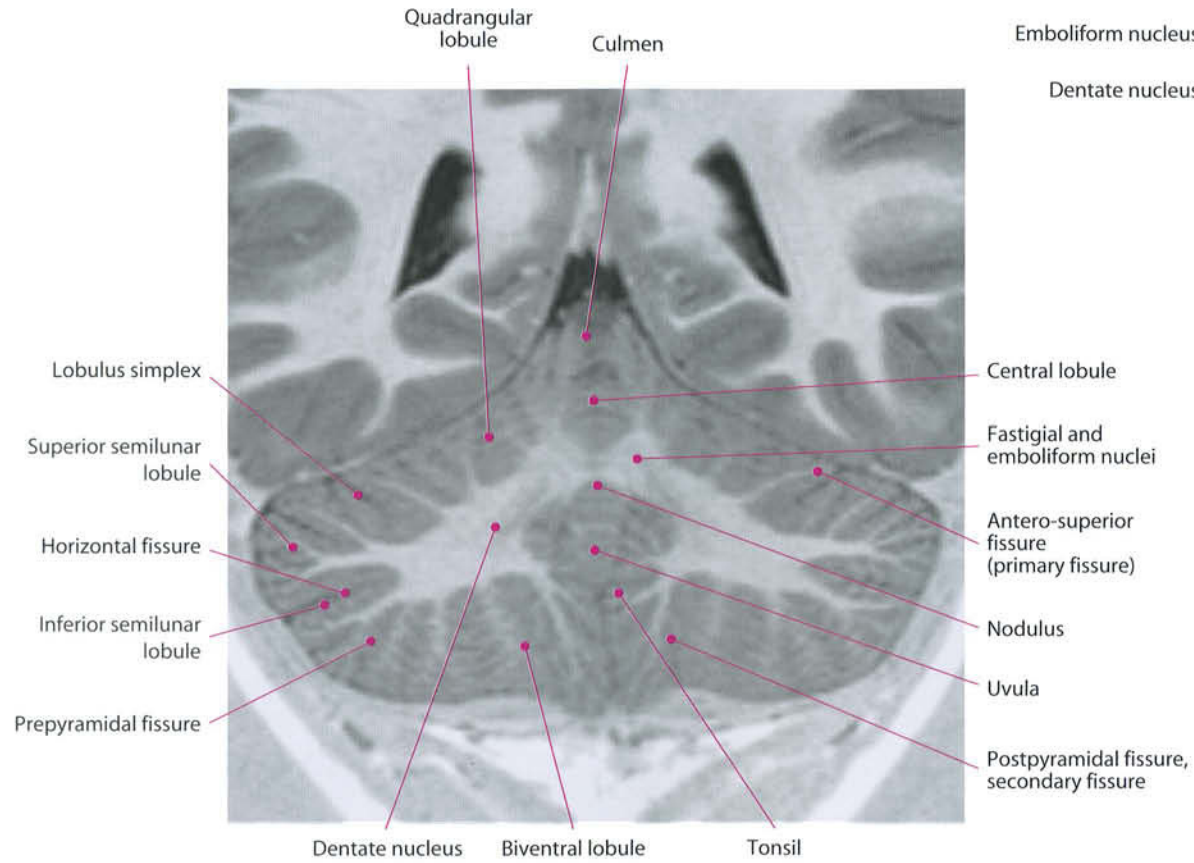


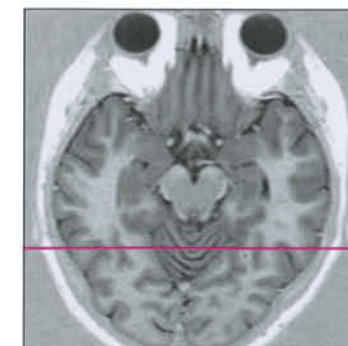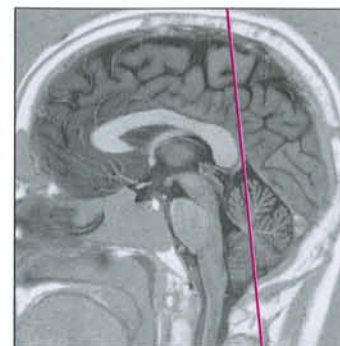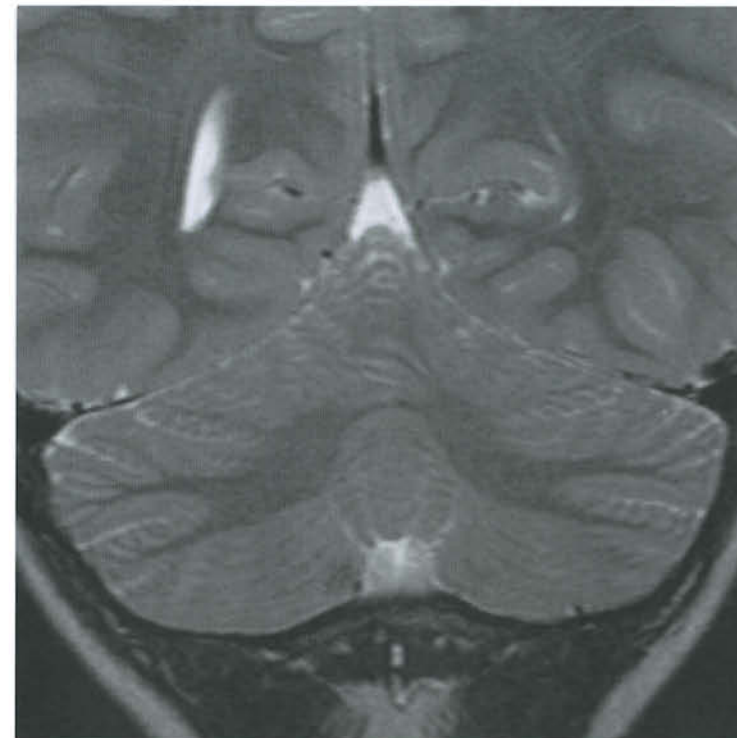
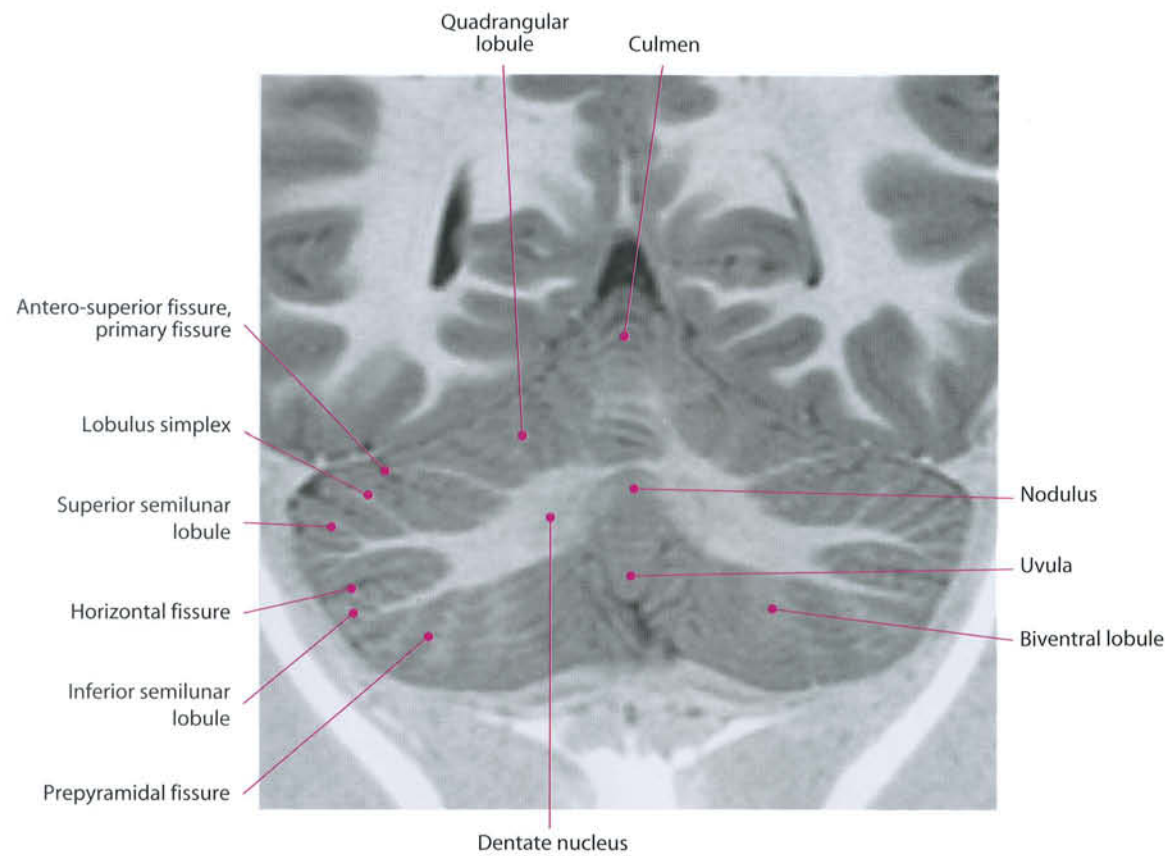


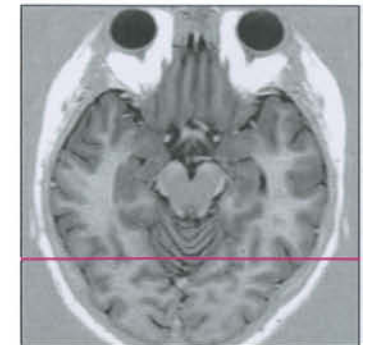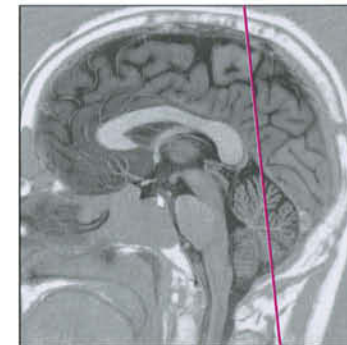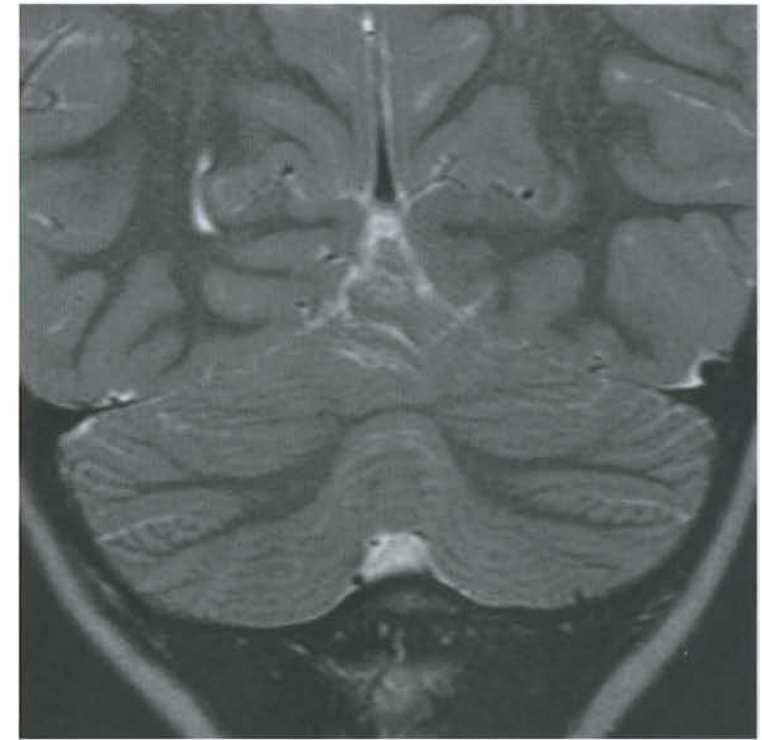
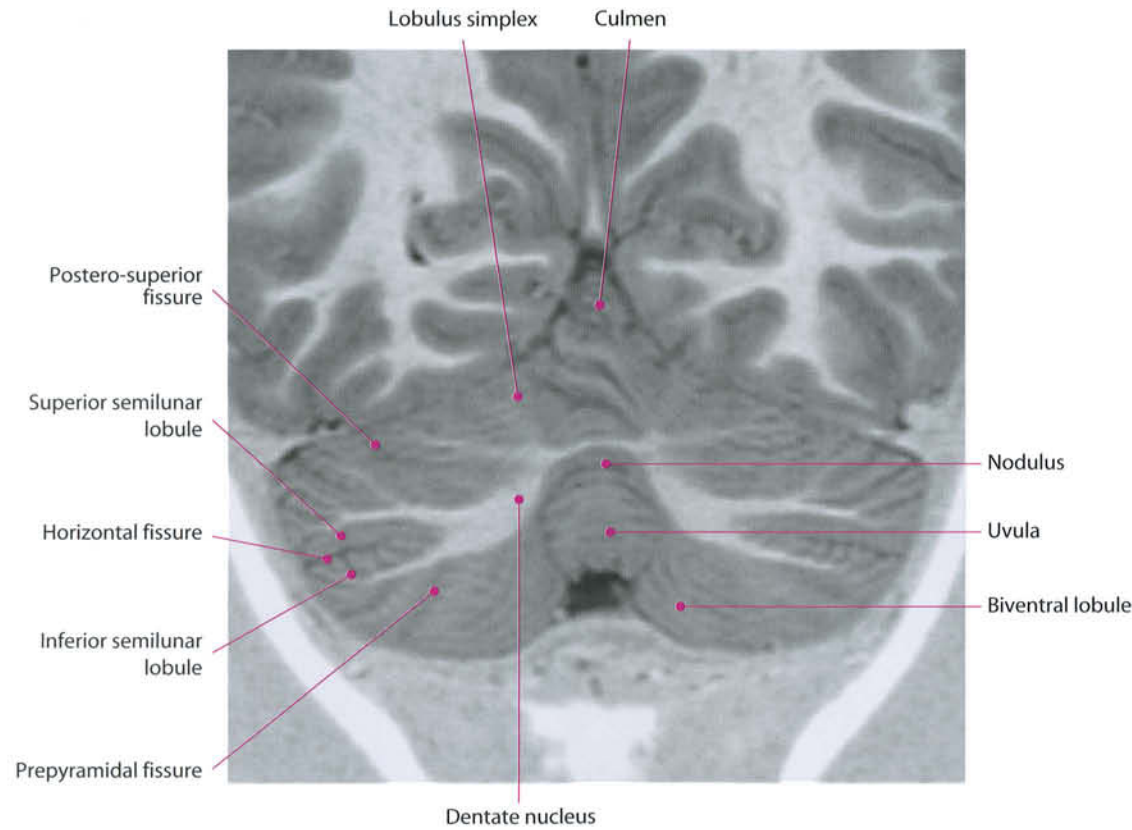


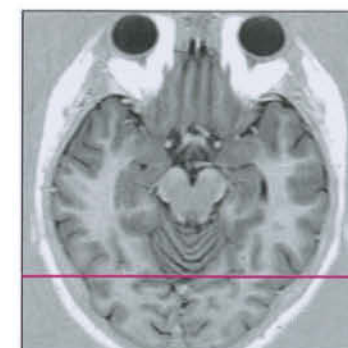
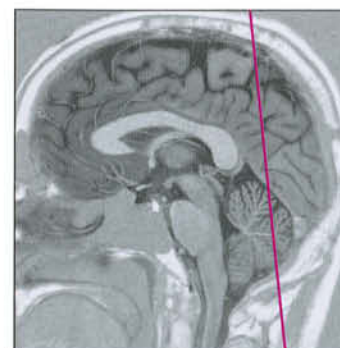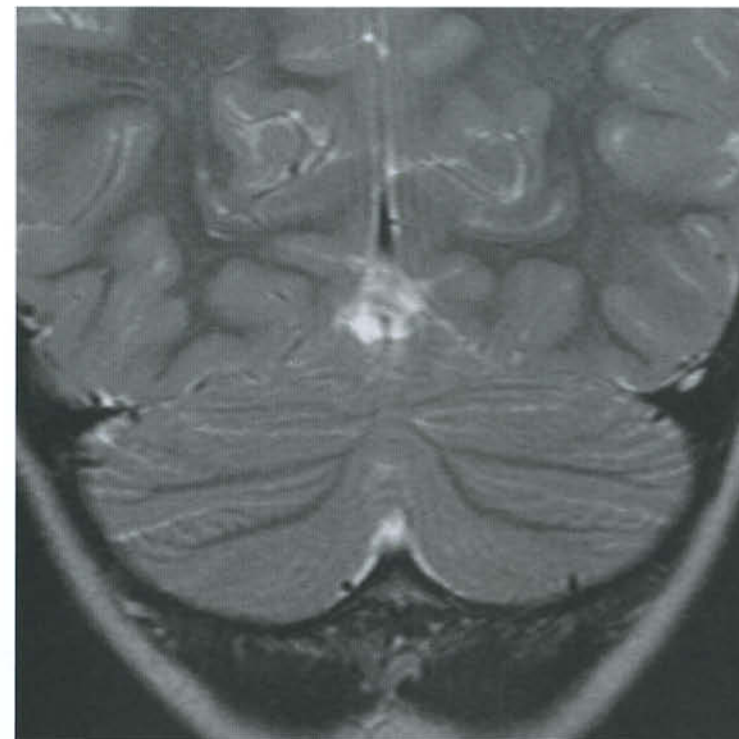
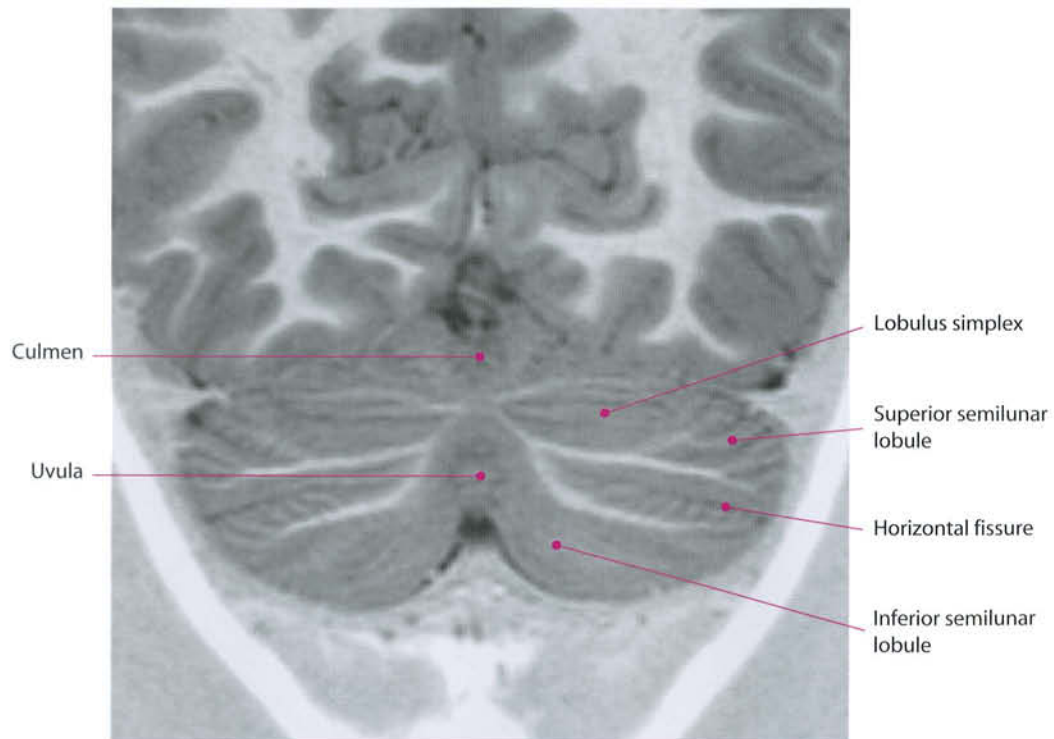


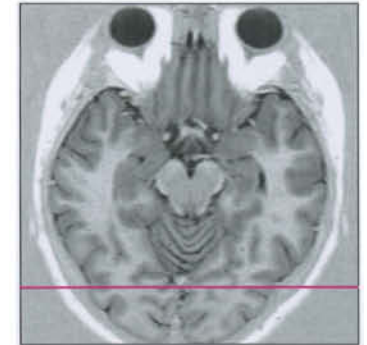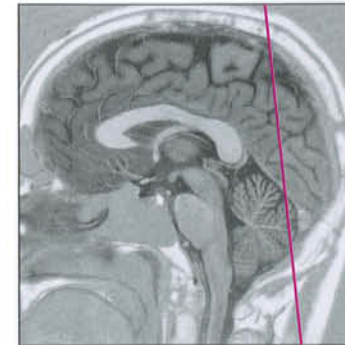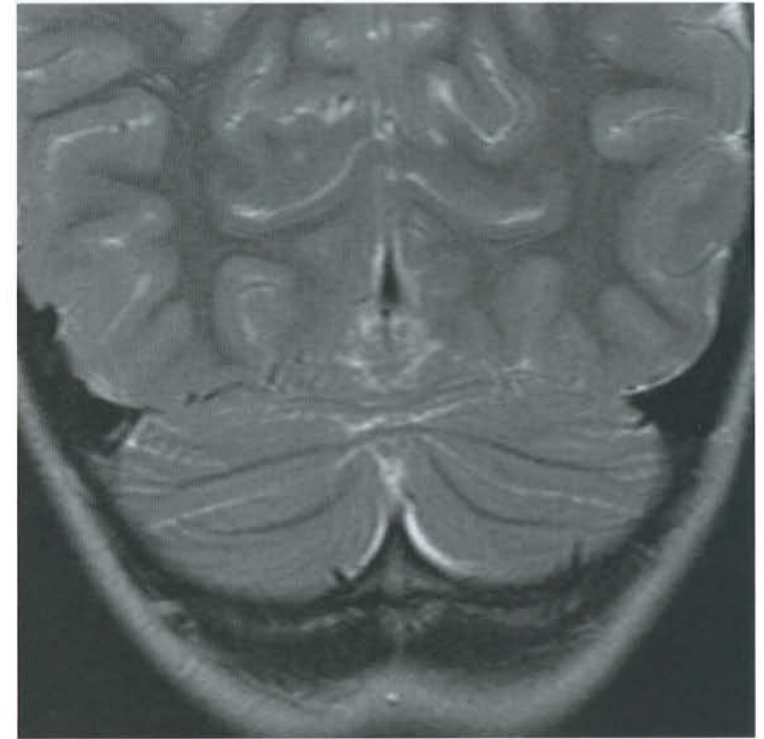
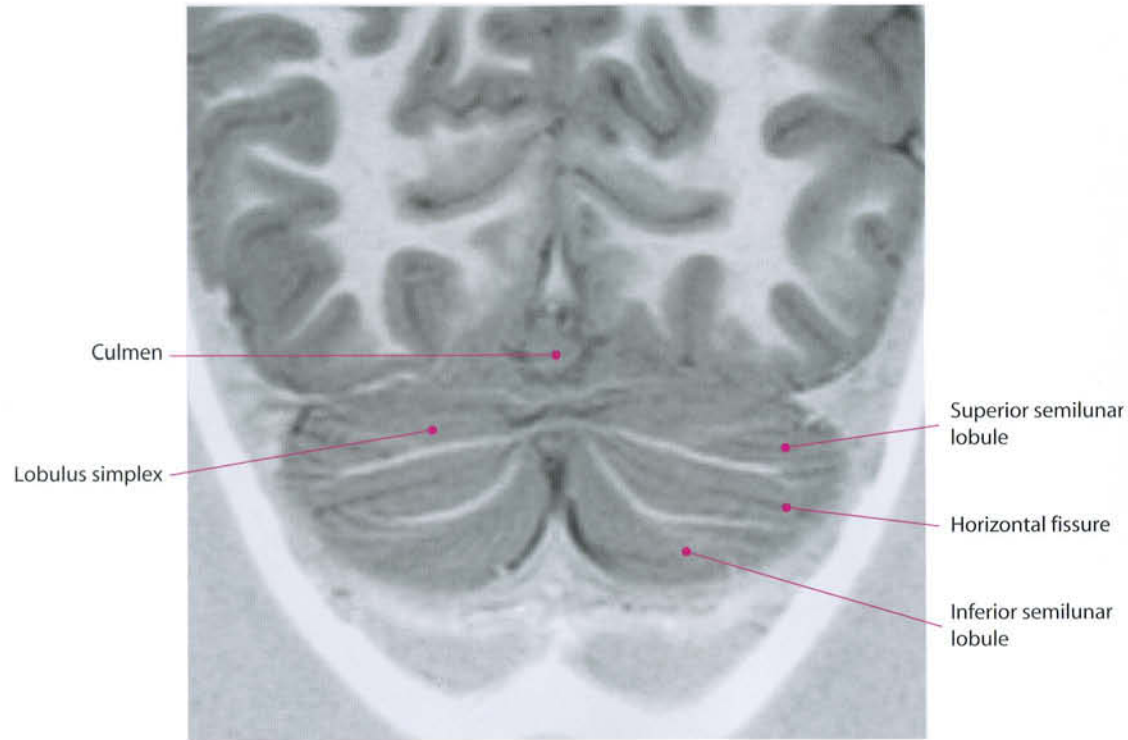


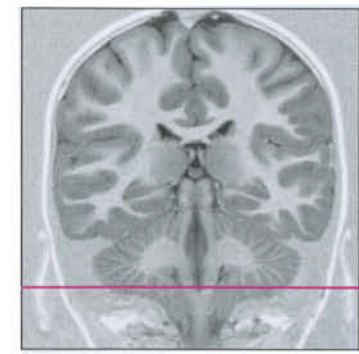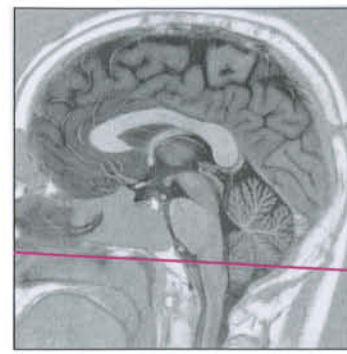
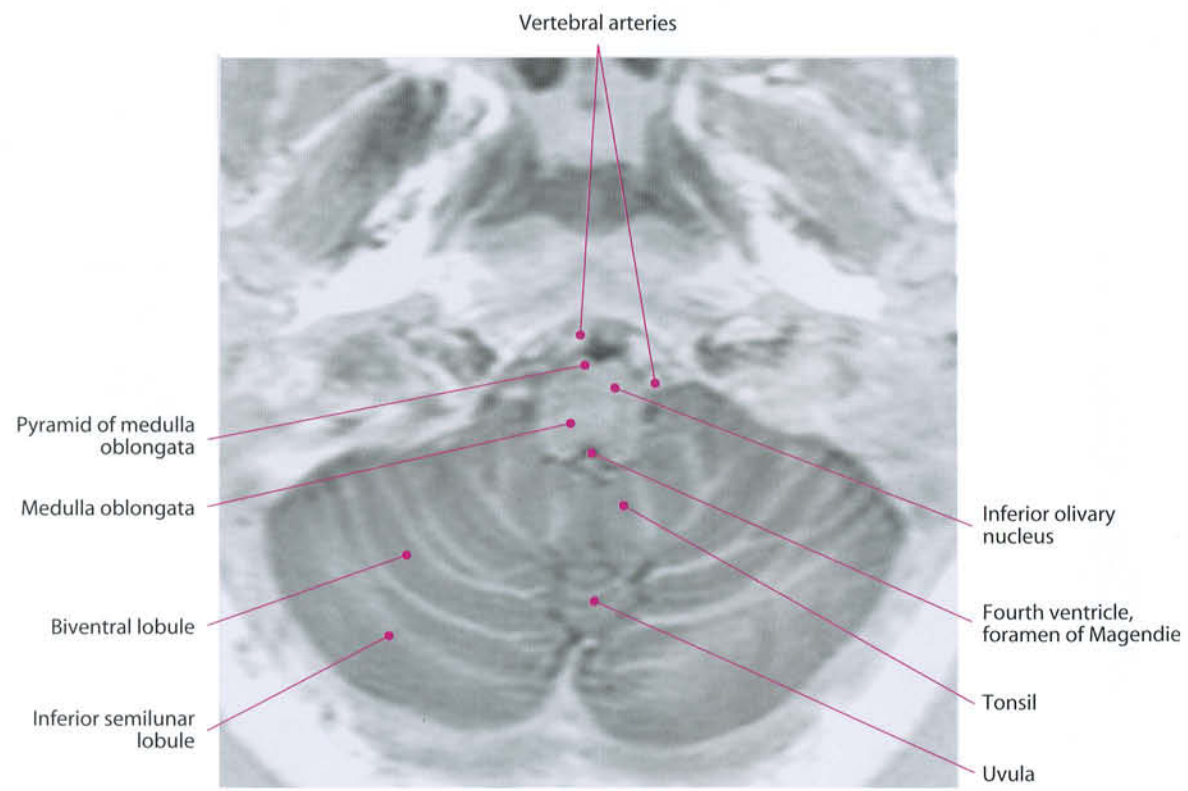
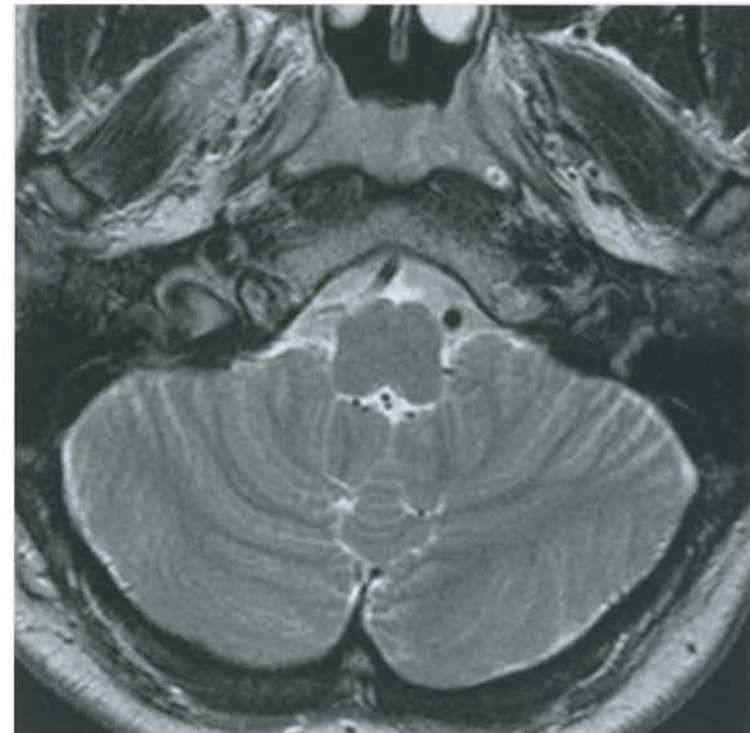


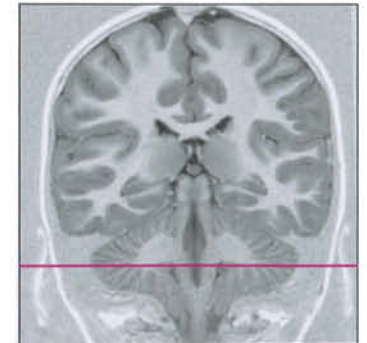
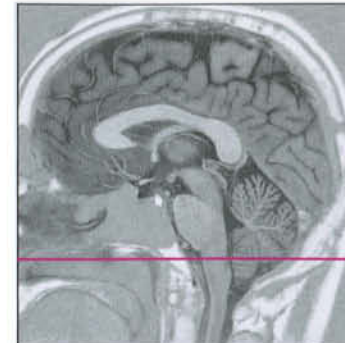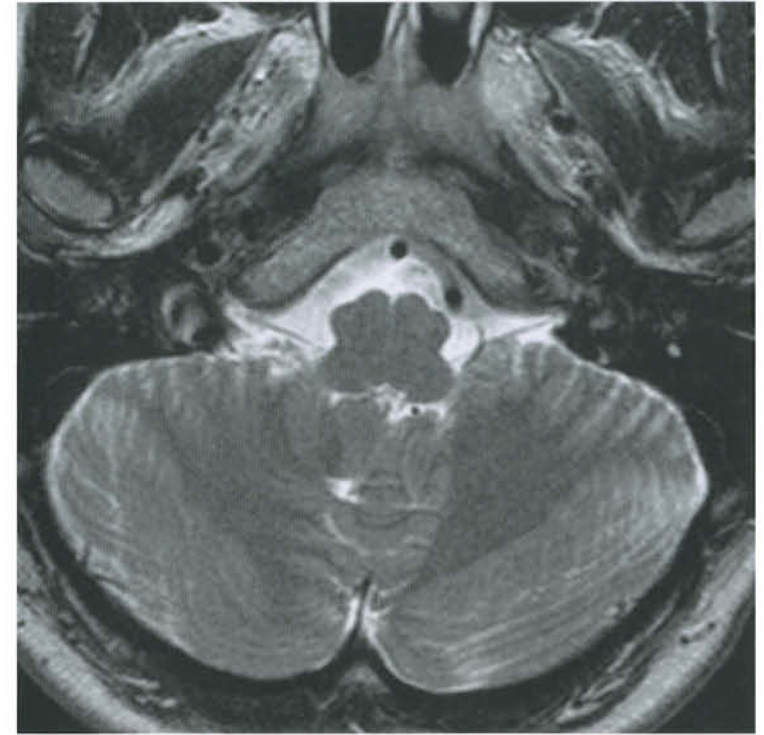
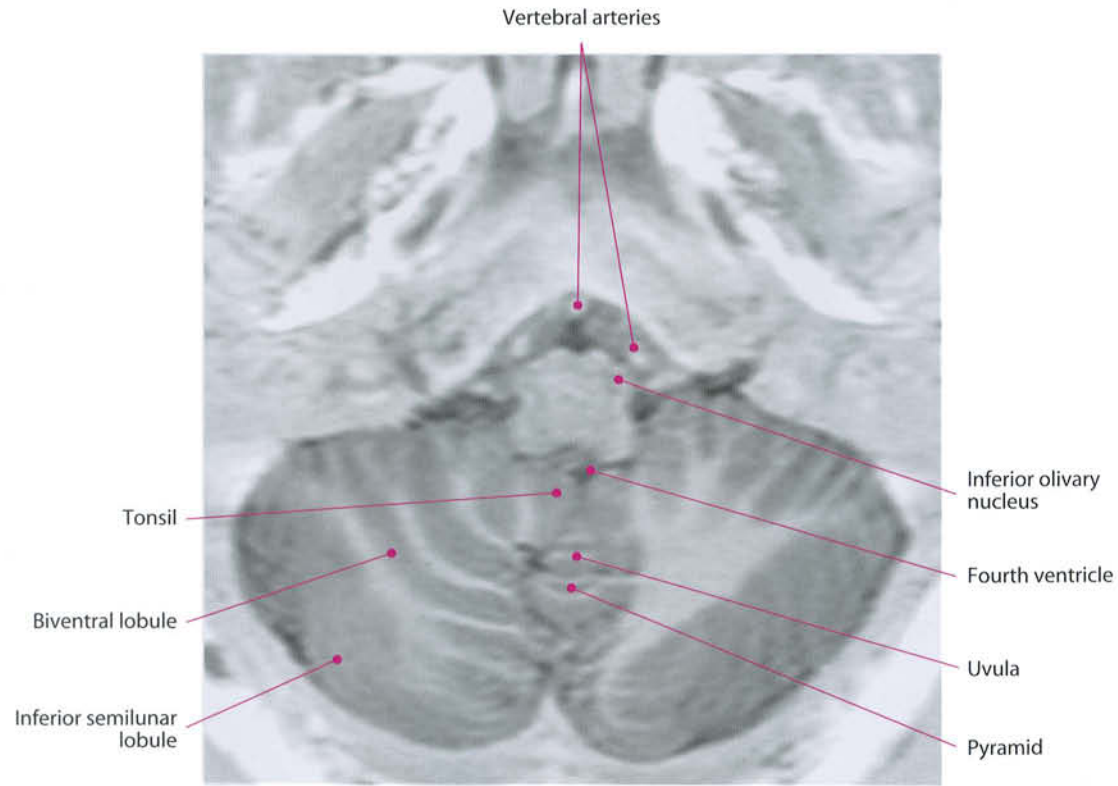


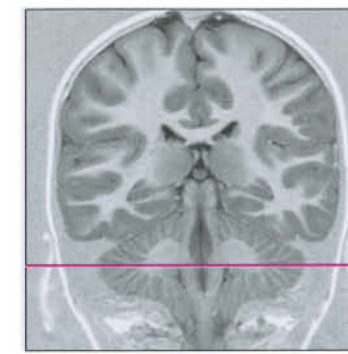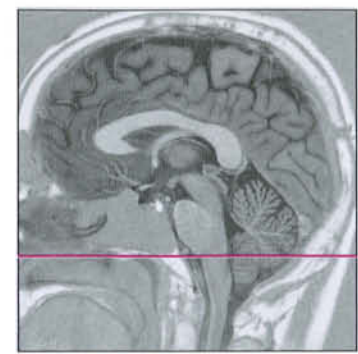
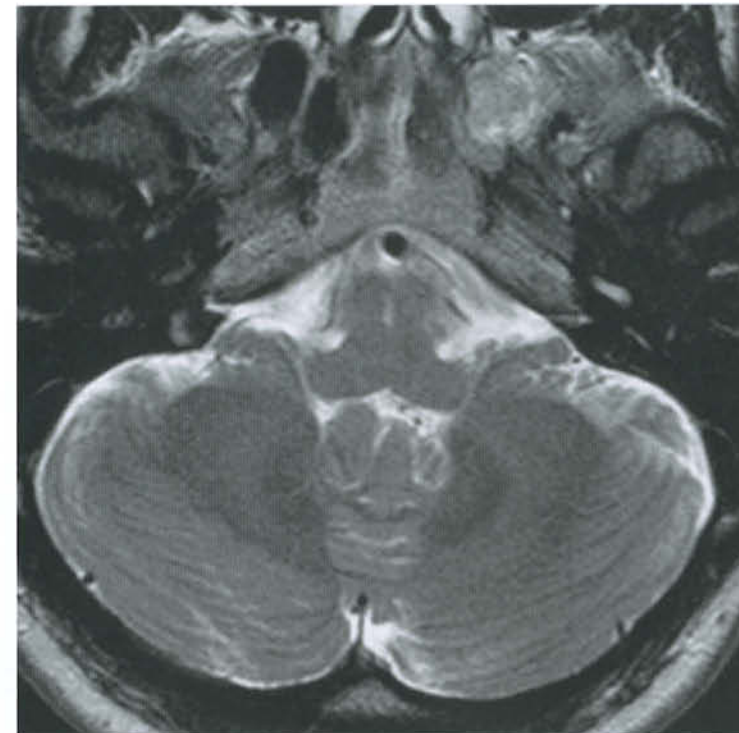
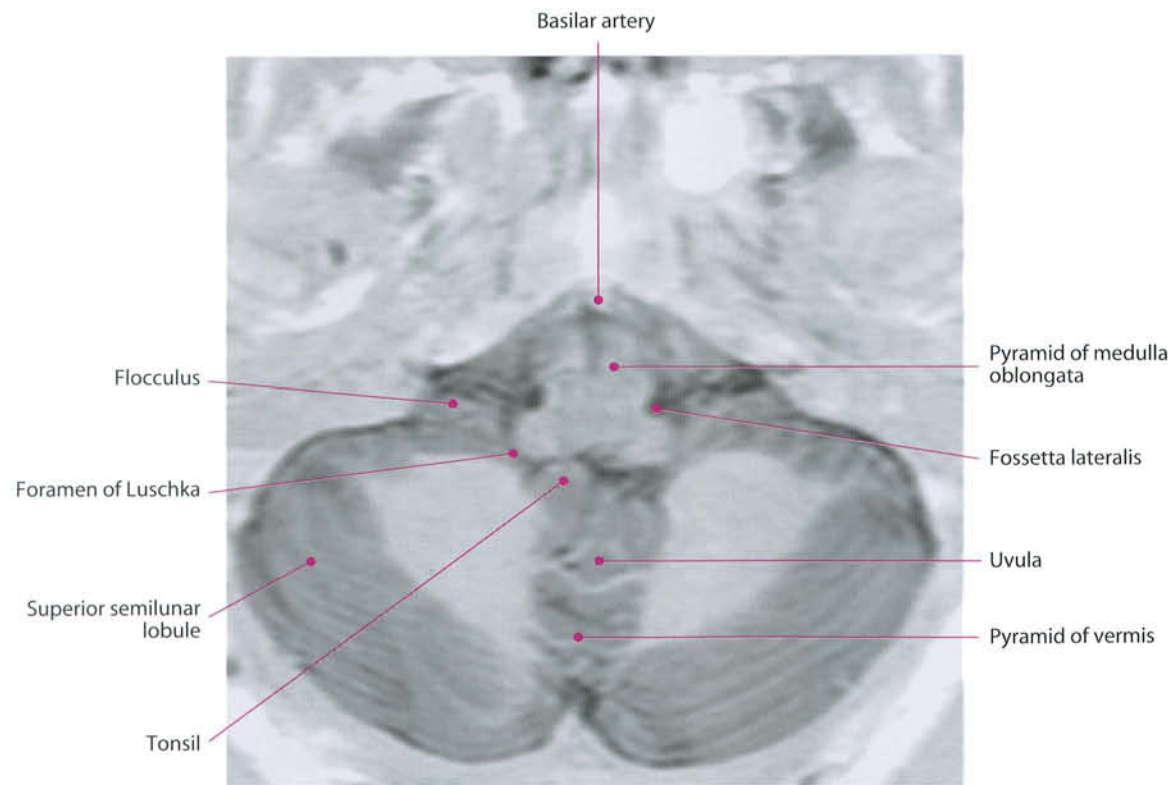


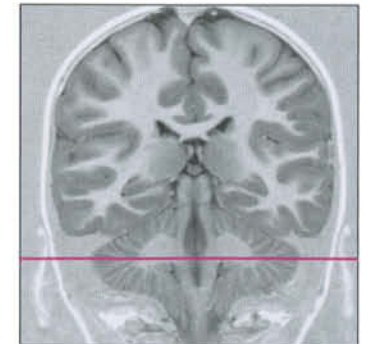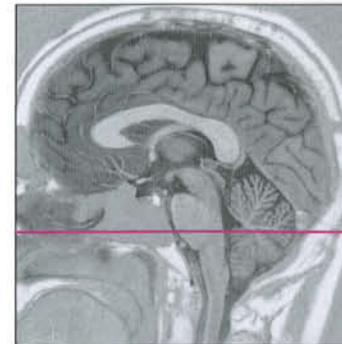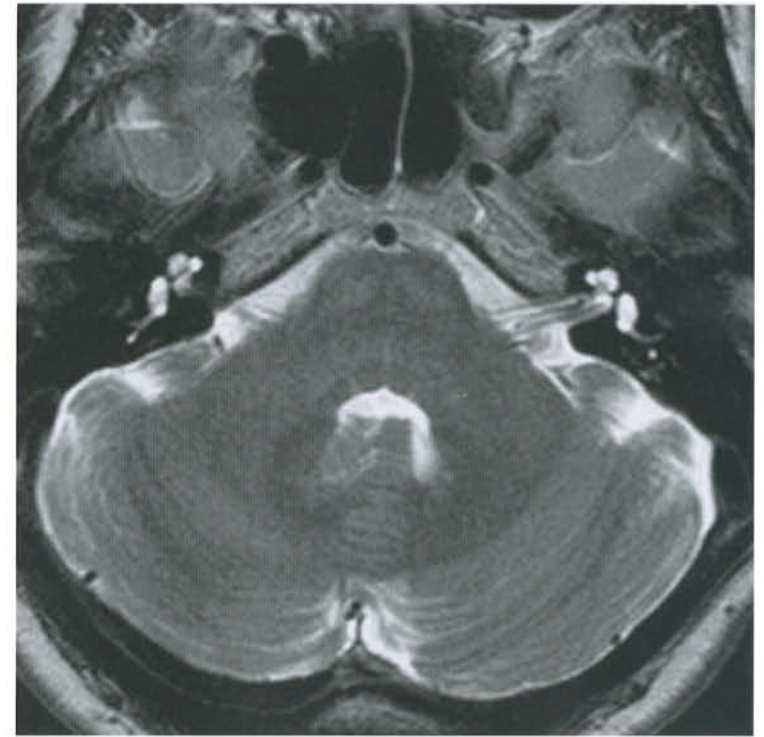
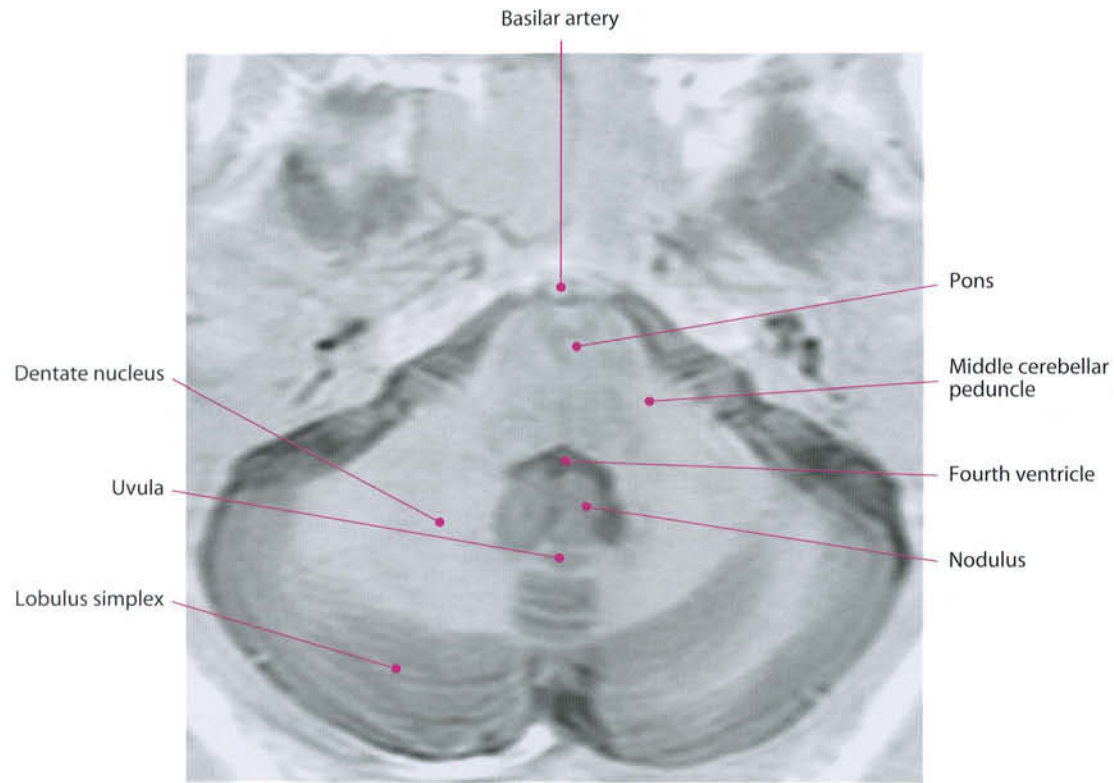


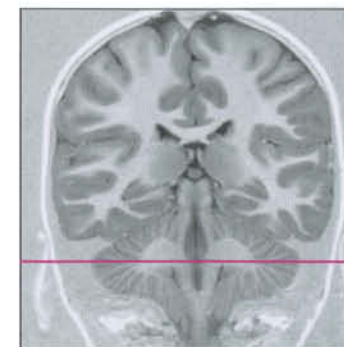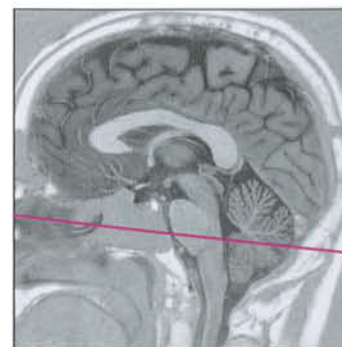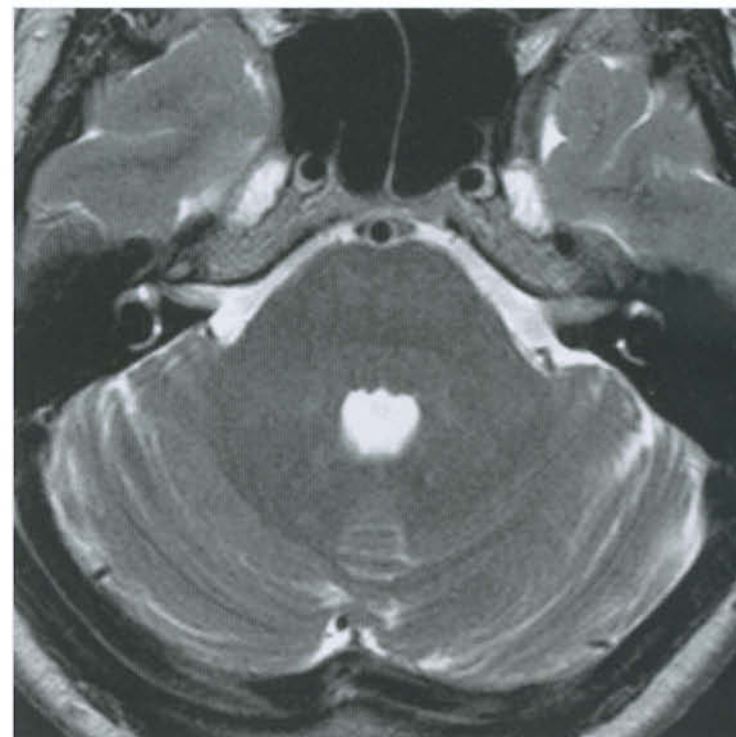
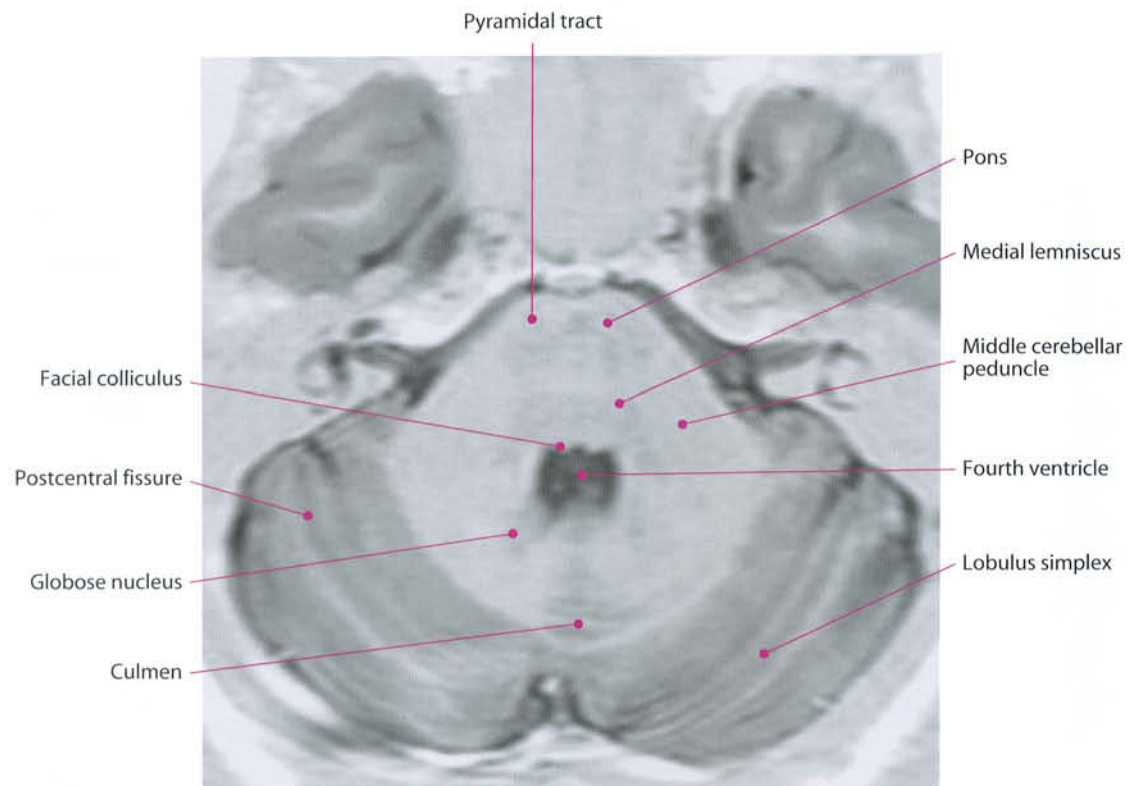


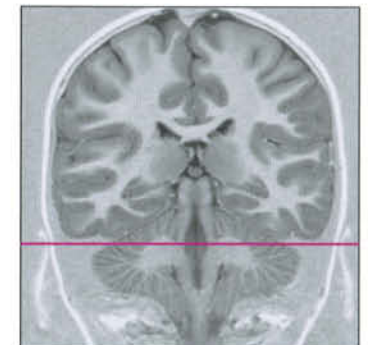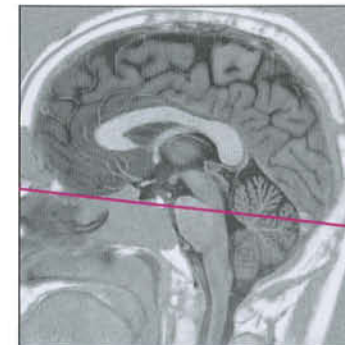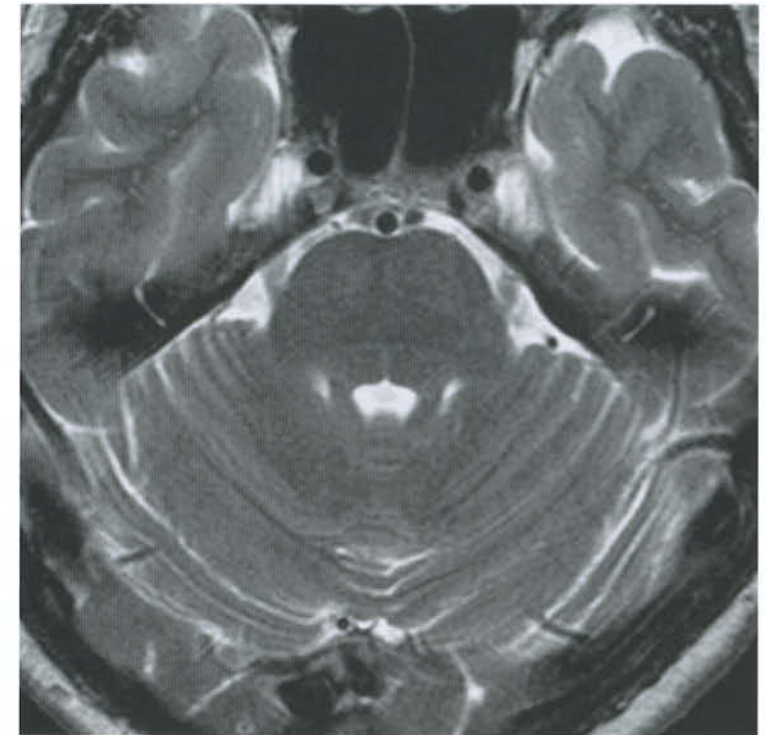
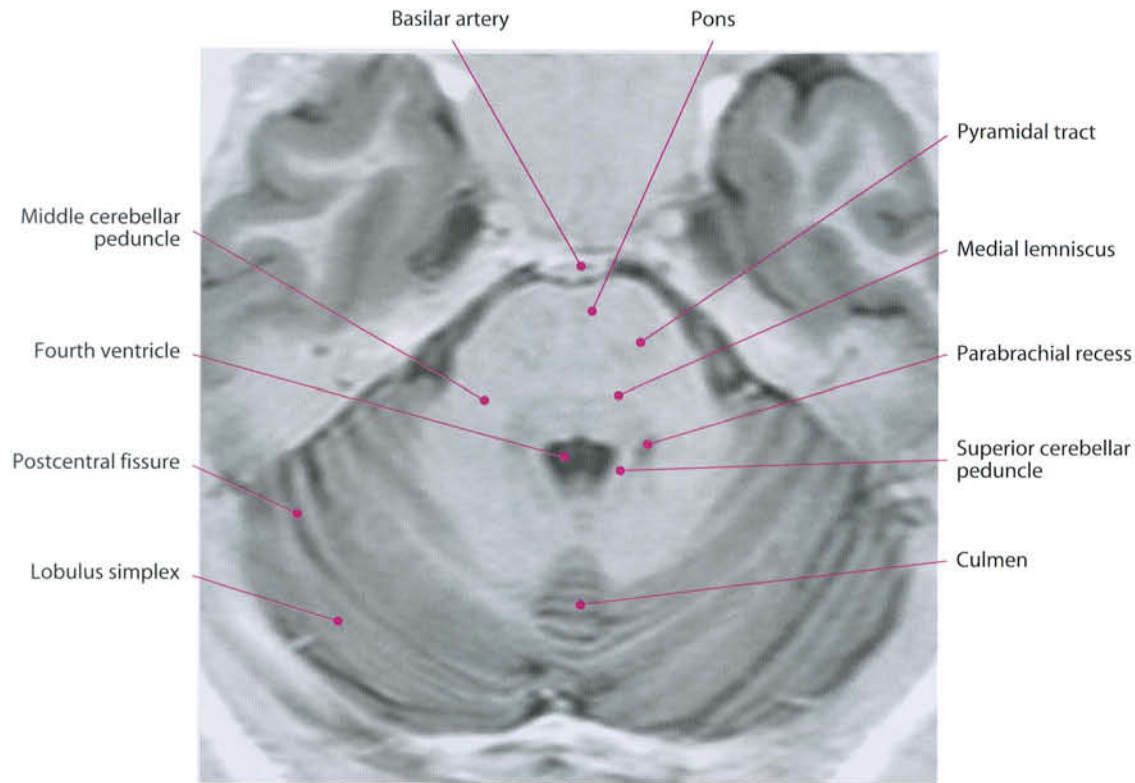


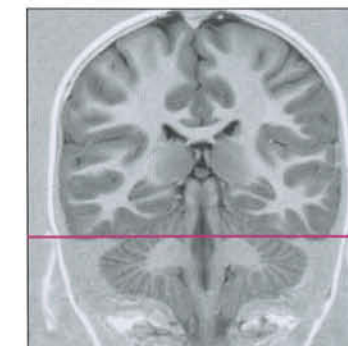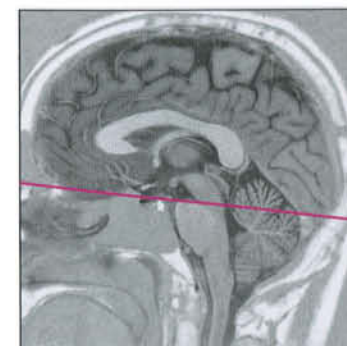
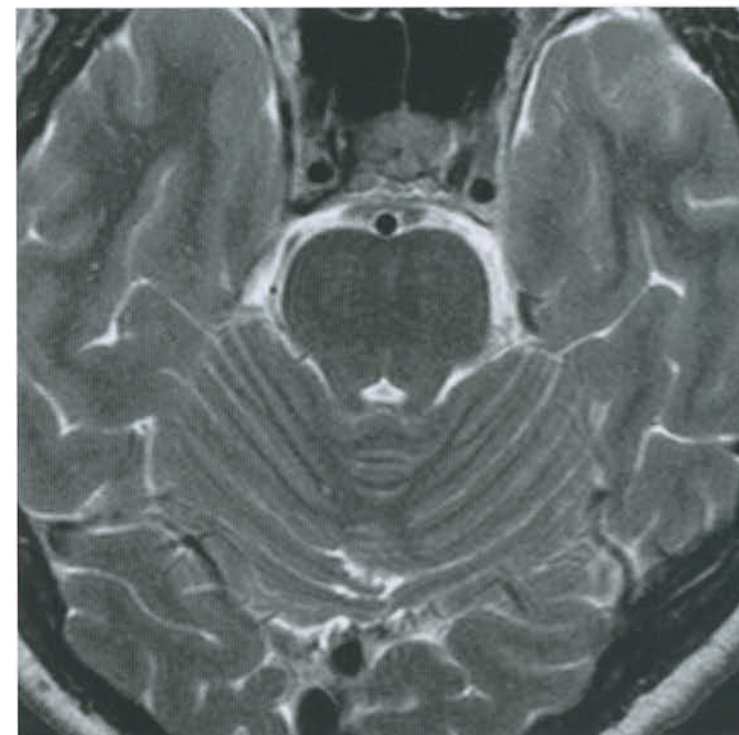
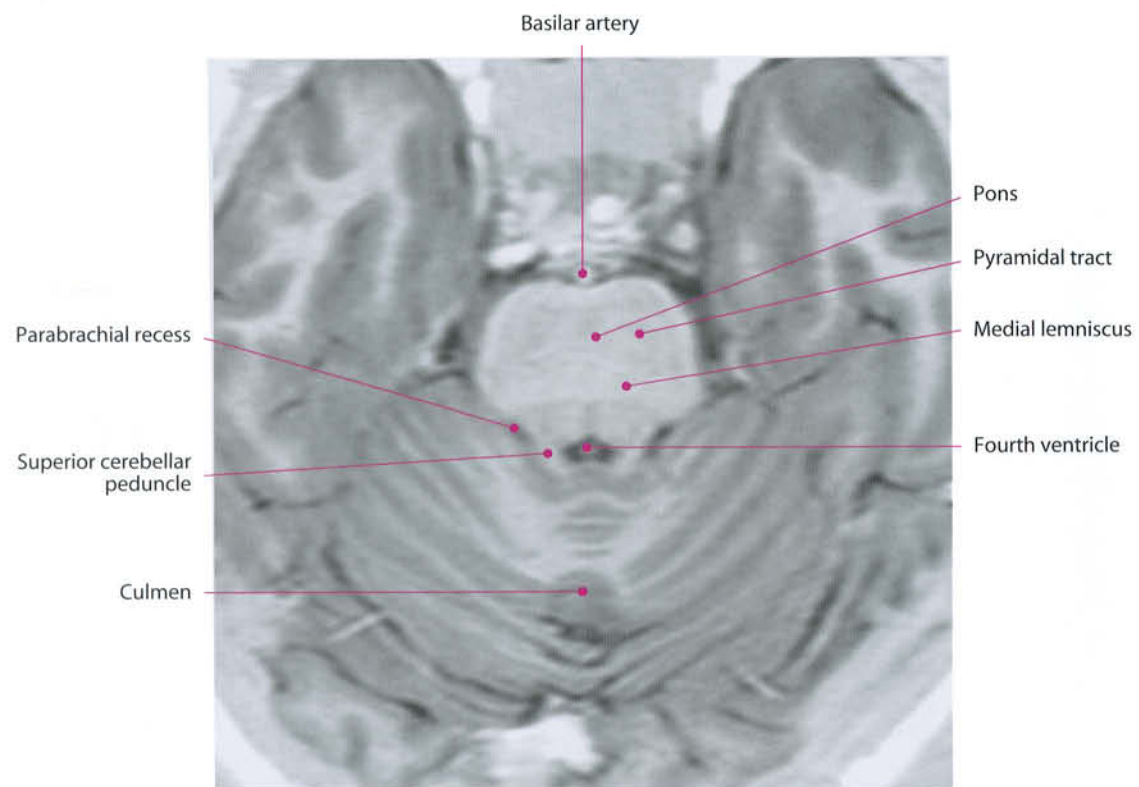


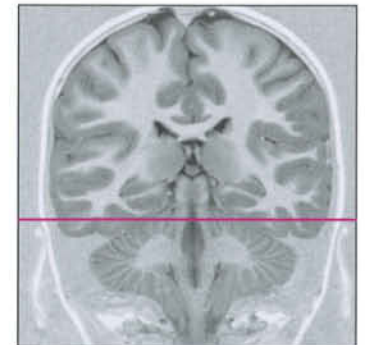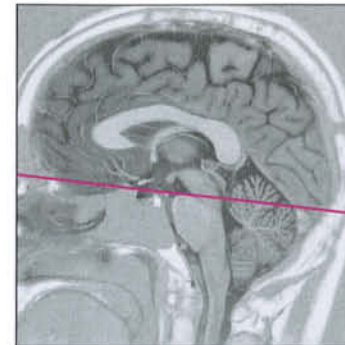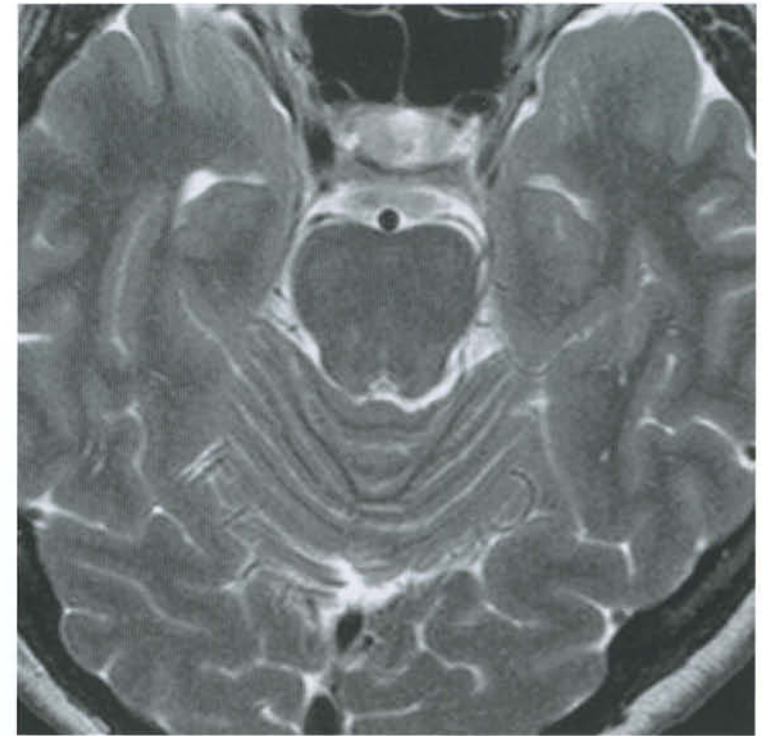
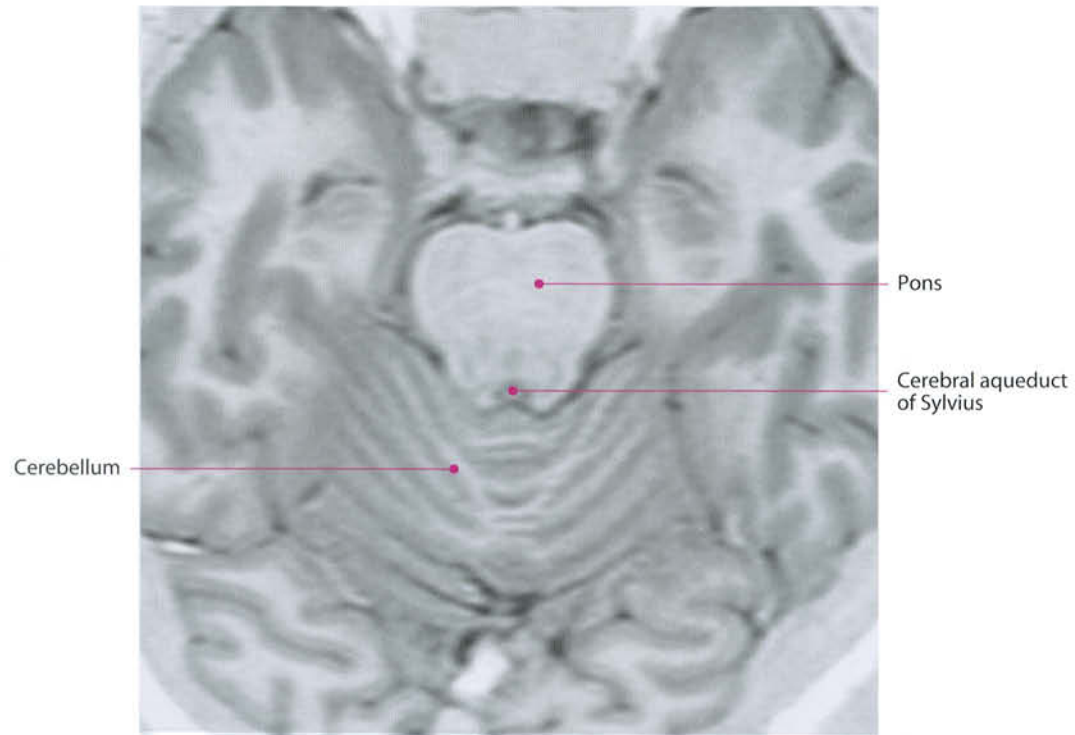


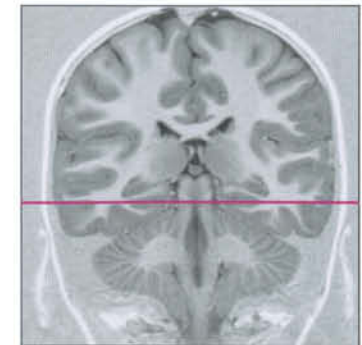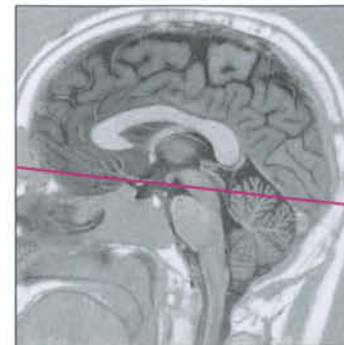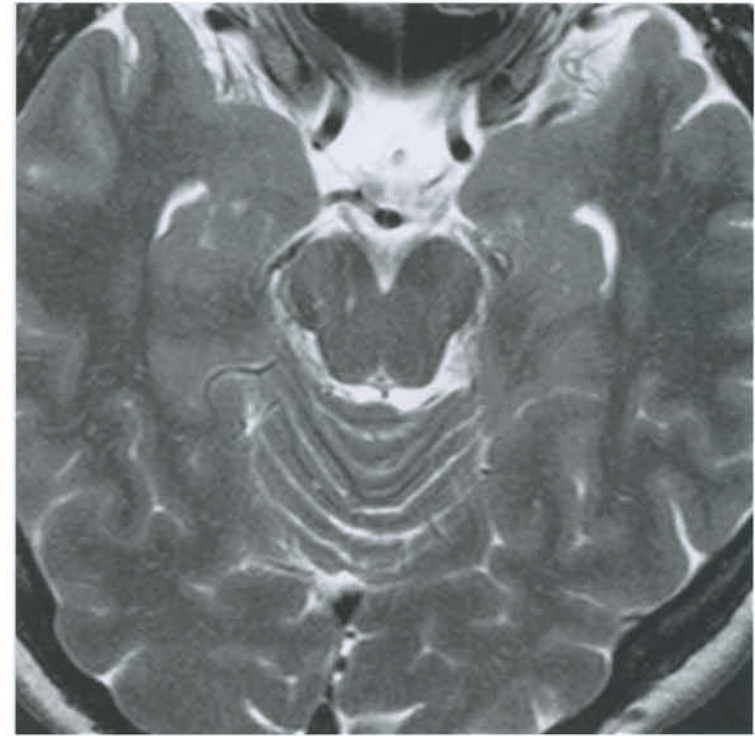
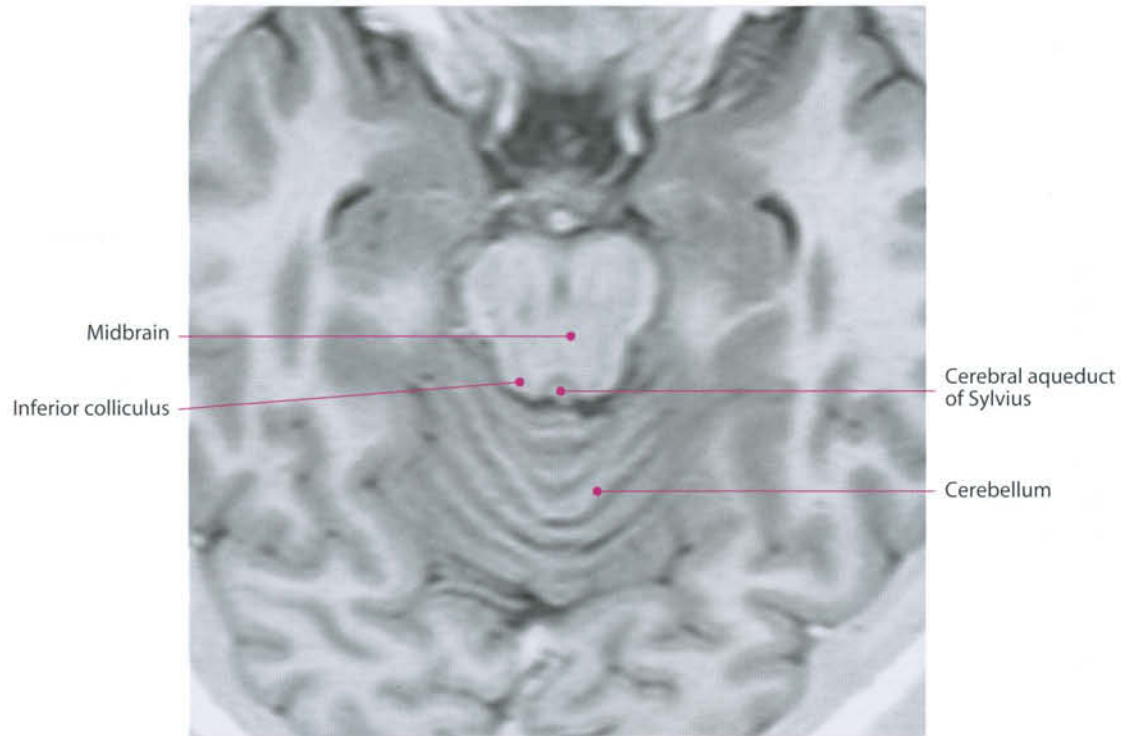


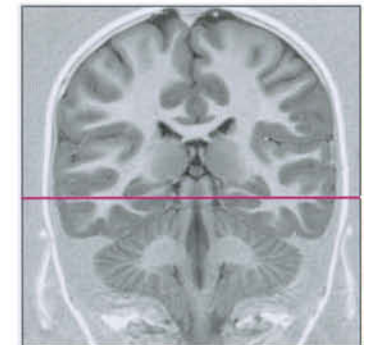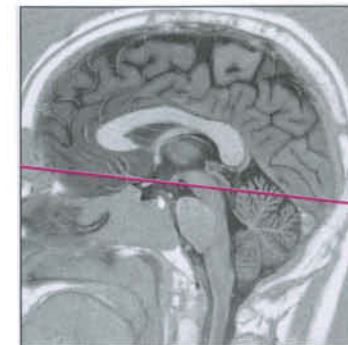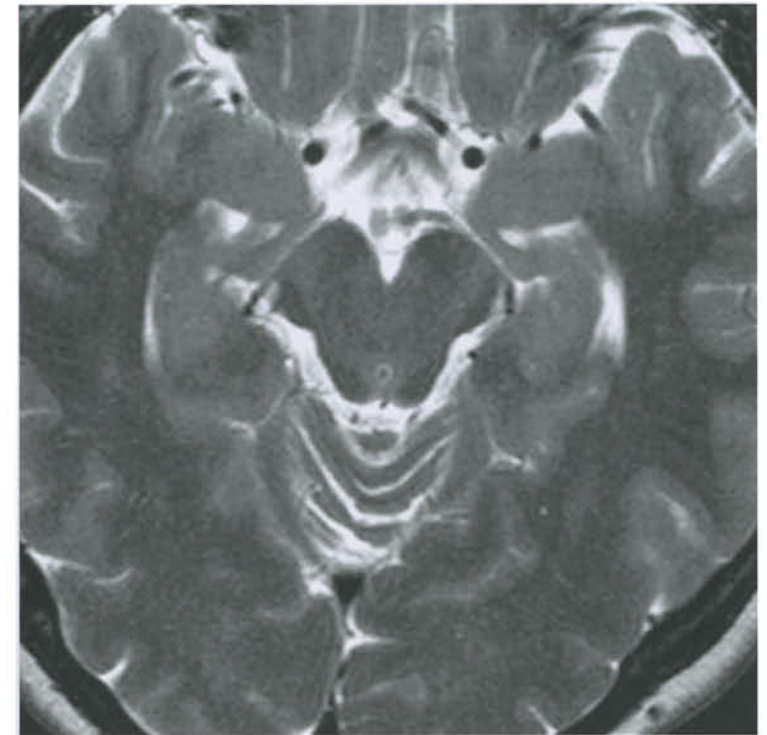
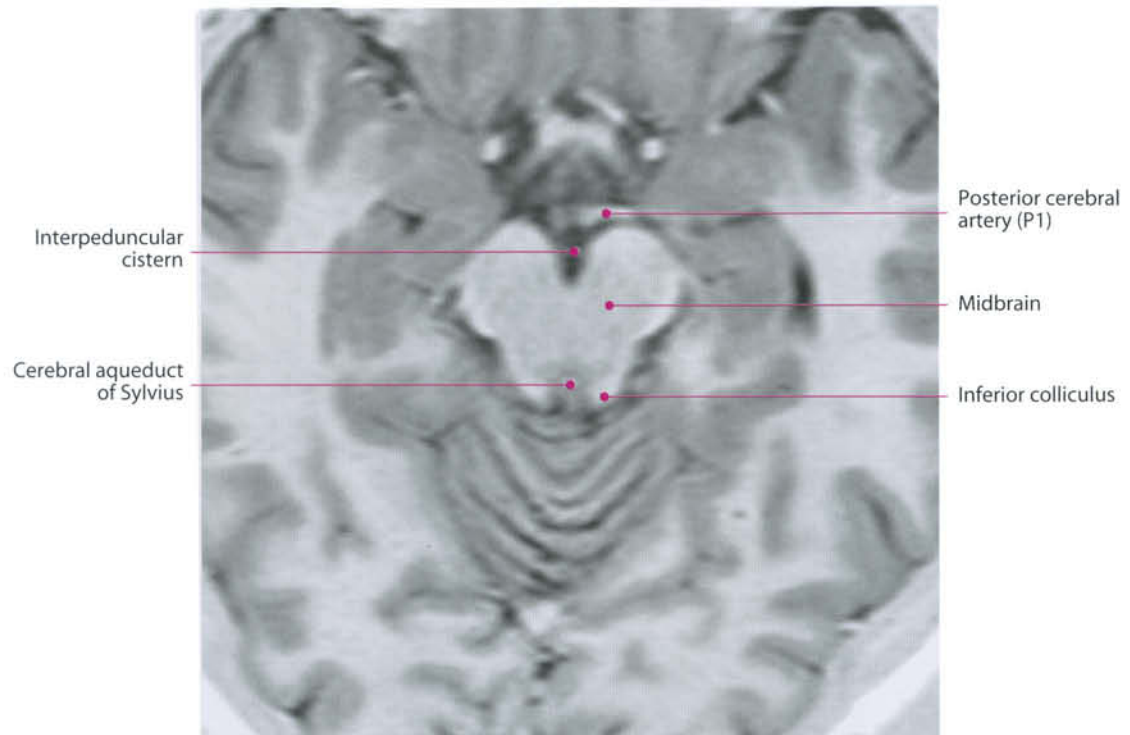


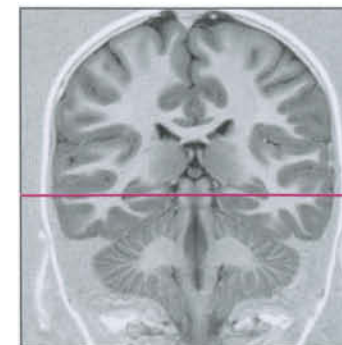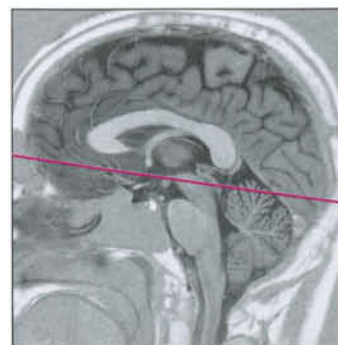
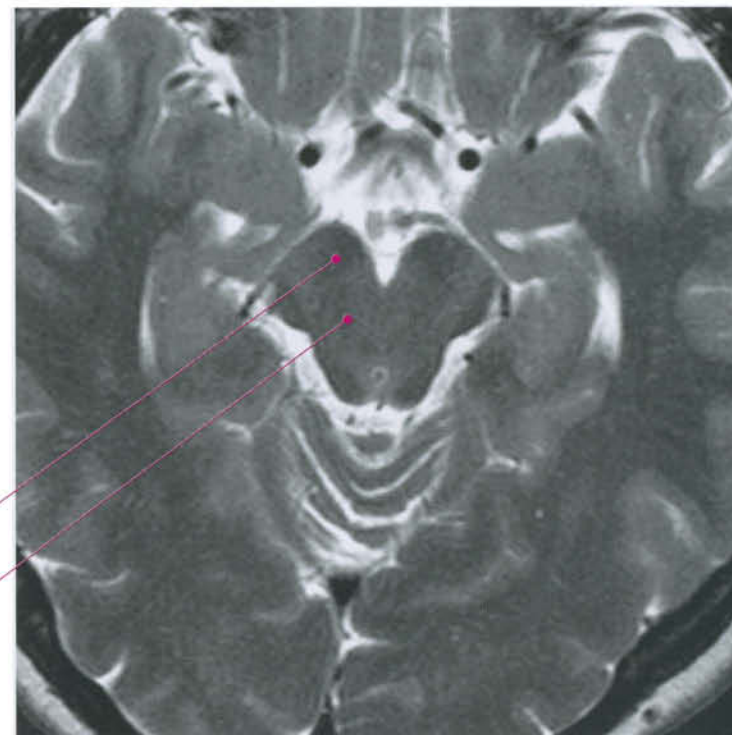
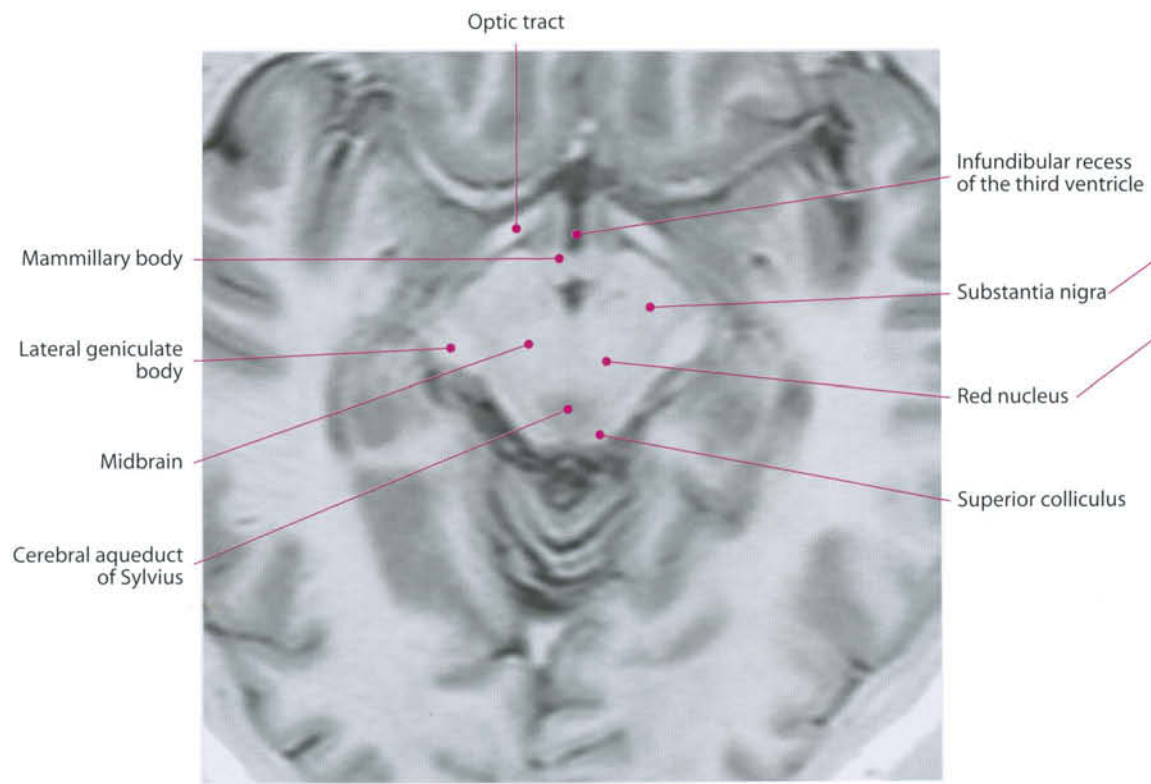












4 Cranial Nerves and Related Systems

Olfactory Nerve and System

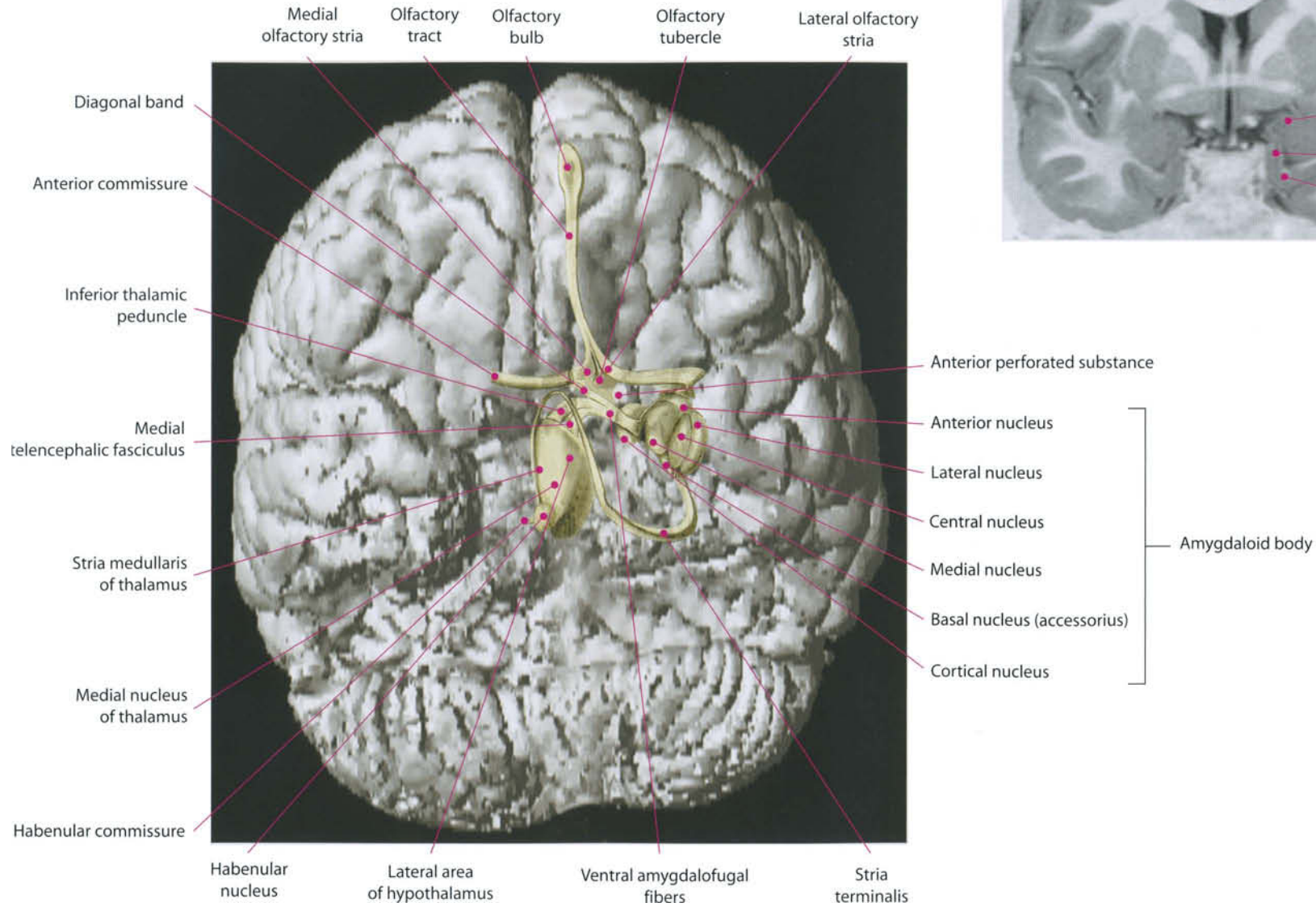
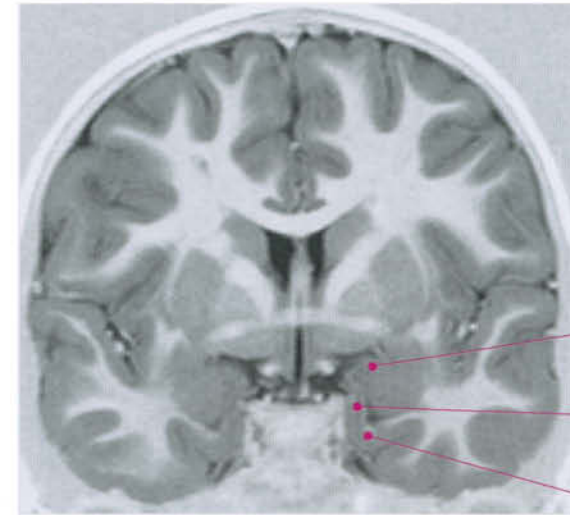
The olfactory epithelium is located in the mucosa of the superior nasal concha, and takes up about 2.5 cm². Inside the olfactory mucosa, olfactory cells are located. They are the peripheral receptors that transmit pulses to the olfactory neurons. The latter are about 6,000,000 bipolar cells (Schulze's cells) distributed inside the epithelium. Their dendrites group together in several filaments which constitute the true olfactory nerves; they cross the cribriform plate of the ethmoid bone and reach the olfactory bulb. The olfactory bulb is a gray matter mass, an evagination of the telencephalon, located between the gyrus rectus and the cribriform plate, containing neurons termed "mitral cells". Their dendrites continue in the olfactory tract, which terminates with the olfactory trigone and tuberculum, in correspondence with the anterior perforated substance. Here, a group of dendrites cross the midline through the anterior commissure and join the contralateral fibers. Before ending, two striae diverge: the lateral olfactory stria, connected with the lateral olfactory nucleus and directed to the amygdaloid body, and the medial olfactory stria, directed to the septal nuclei and hypothalamus. Cortical projections of the olfactory function are identified mostly in the prepiriform and entorhinal cortex.

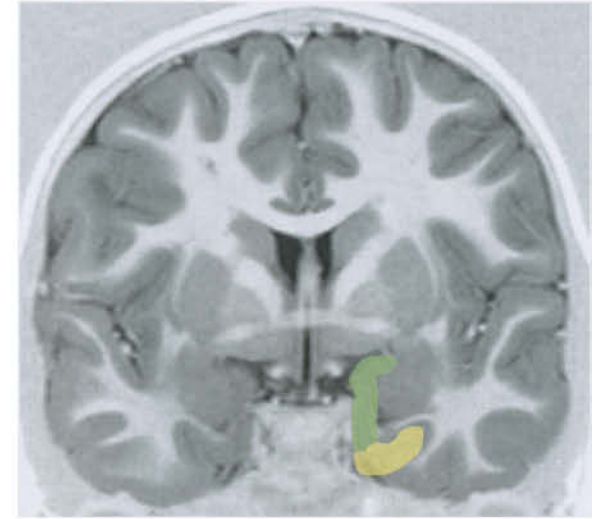
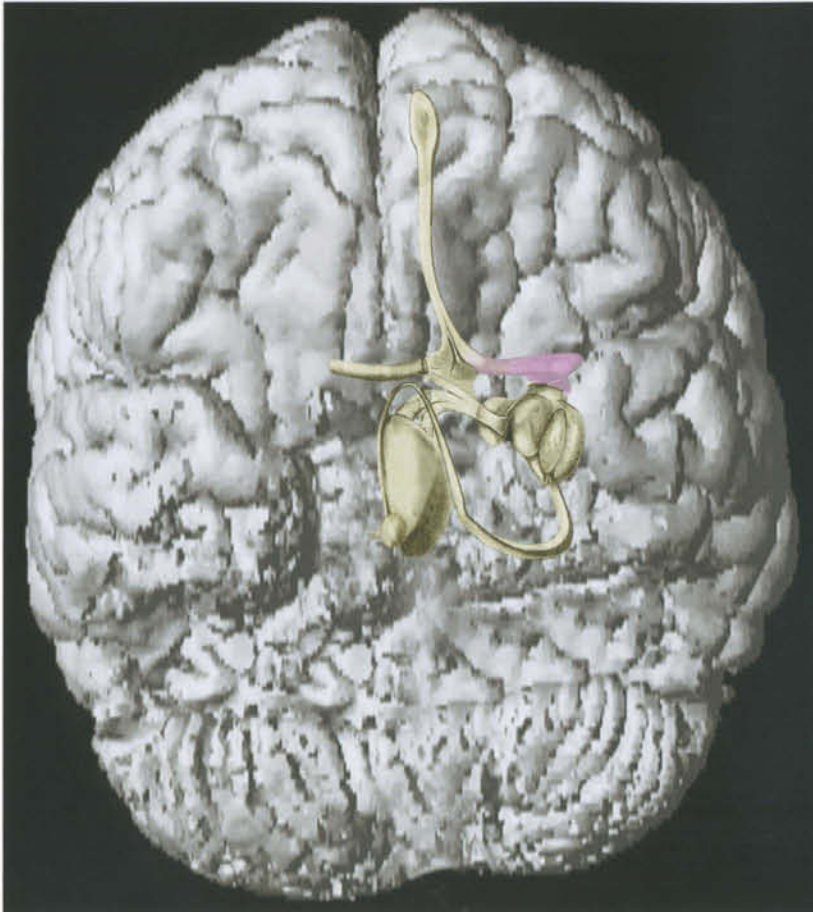
Optic Nerve, Visual Pathway and Orbit




I. Optic Nerve and Visual Pathway

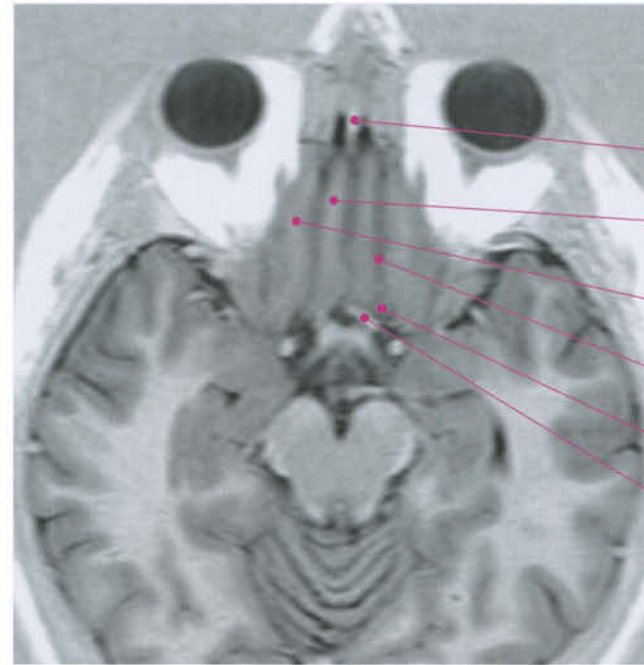
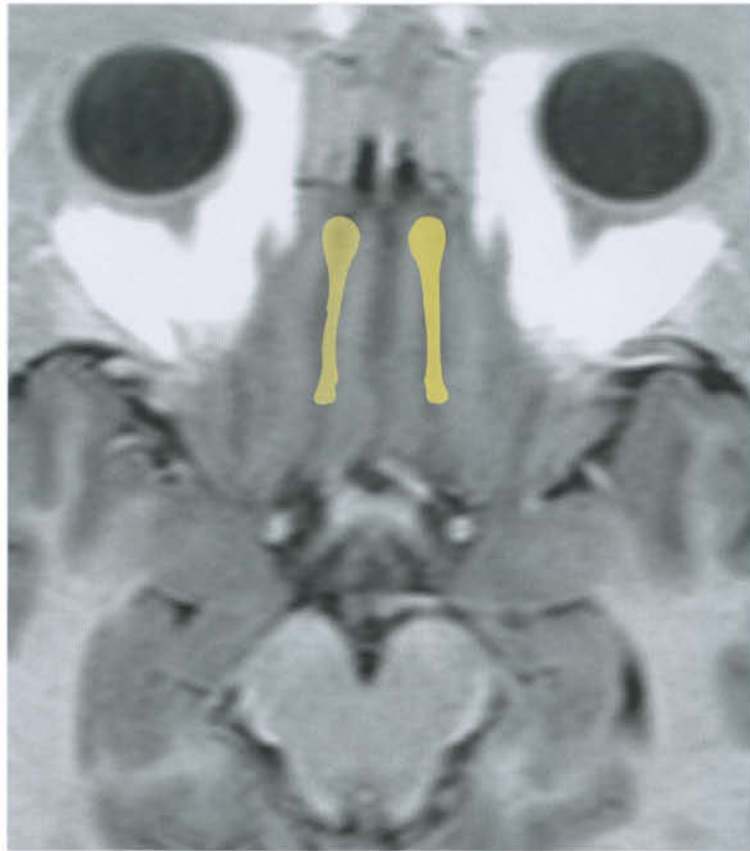
Similarly to the olfactory system, the optic nerve is not a peripheral nerve, as it is mostly an evagination of the telencephalon. Retinic photoreceptors, cones and rods, relay the signal for further processing to other retinic neurons: bipolar cells, horizontal cells, amacrine cells, retinal ganglion cells, and interplexiform cells. Axons from the ganglion cells form the optic nerve. The potentials generated are transmitted via the optic nerve to the lateral geniculate nucleus (visual information), superior colliculus (somatic reflexes), and pretectal areas (autonomic reflexes). In mammals, visual information is relayed to the thalamic lateral geniculate body, from which optic information is directed to the primary visual cortex through the geniculostriate projection, or optic radiation. In humans, the cortical area surrounds both walls

of the calcarine fissure, extending to the adjacent cortex (area 17). Visual information is topographically oriented. The right visual field, for instance, activates neurons of the left retina (medial in the left eye, lateral in the right one). The pulse is then transmitted to the left geniculate body and the left occipital cortex. The upper portions of the visual field are laterally projected in the geniculate body and become inferior in optic radiation and pericalcarine cortex.

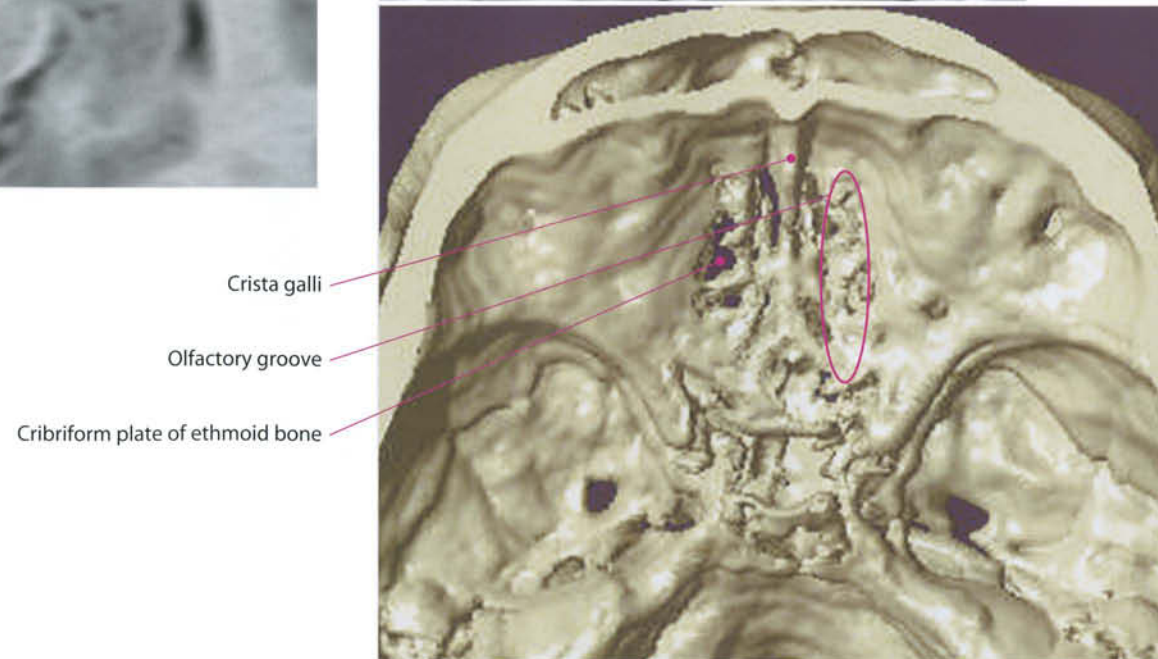




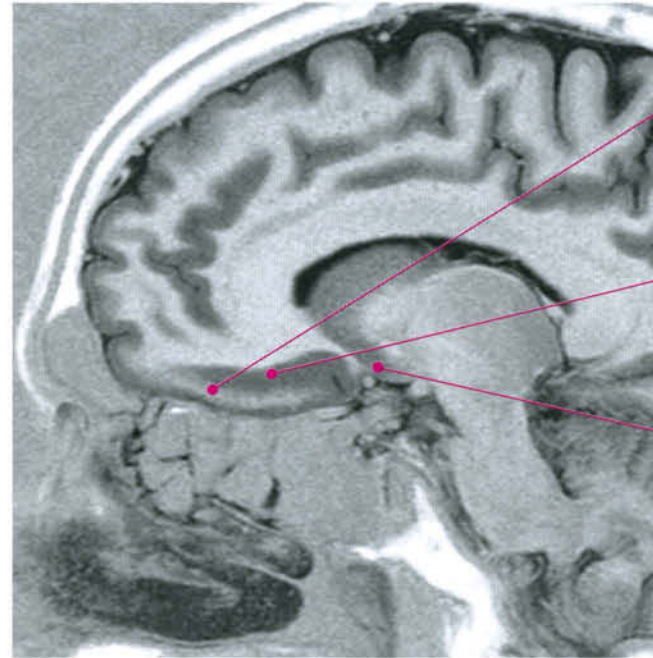
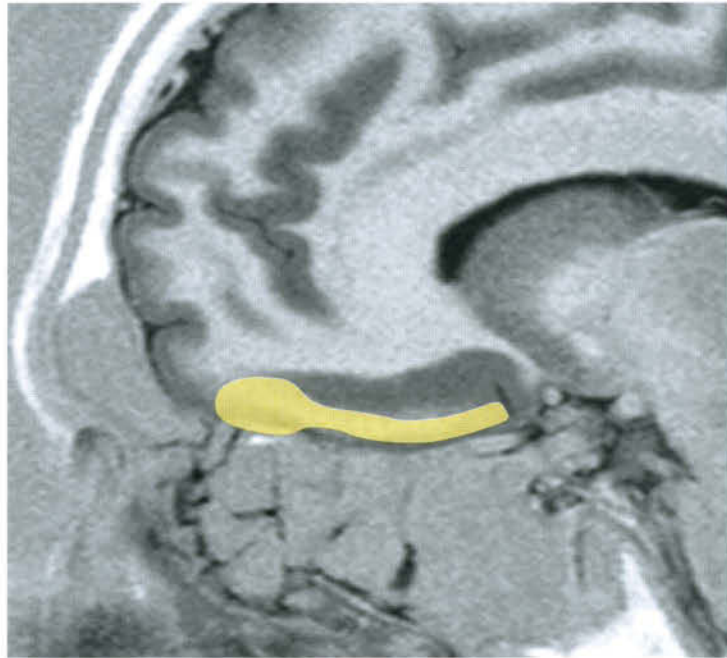
-  Lateral olfactory tract
-  Primary olfactory area
-  Secondary olfactory area



- Crista galli
- Gyrus rectus
- Medial orbital gyrus
- Olfactory sulcus
- Olfactory trigone
- Anterior cerebral artery



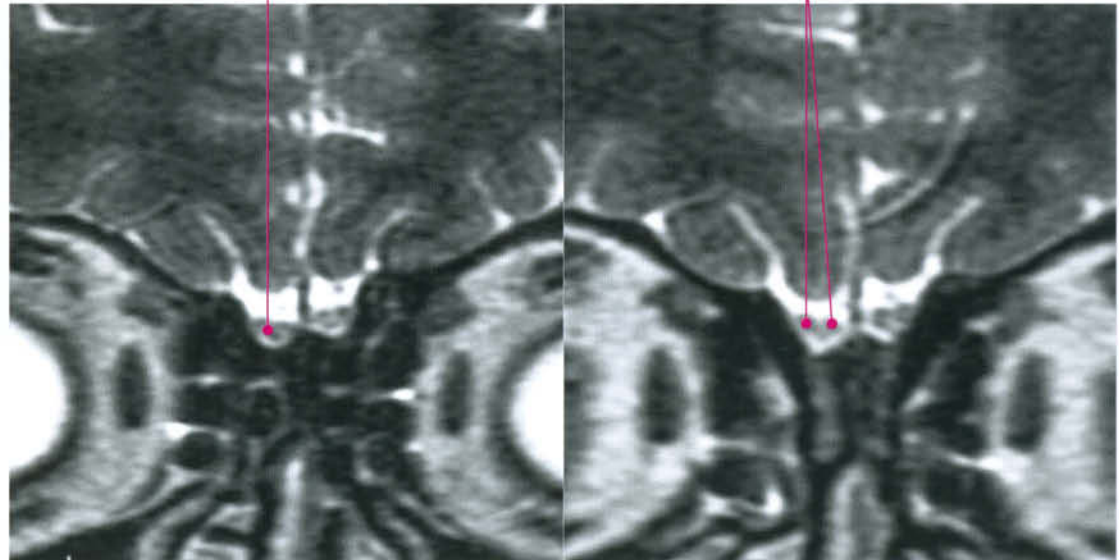
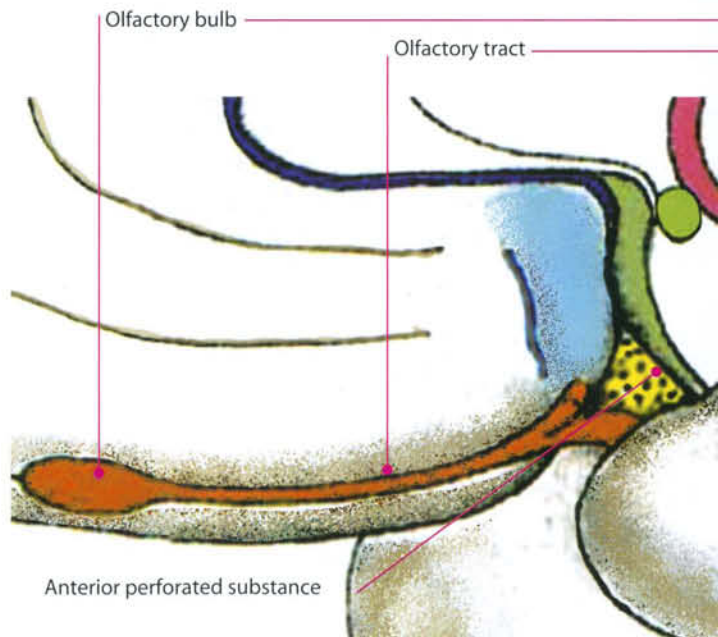
- Crista galli
- Olfactory groove
- Cribriform plate of ethmoid bone

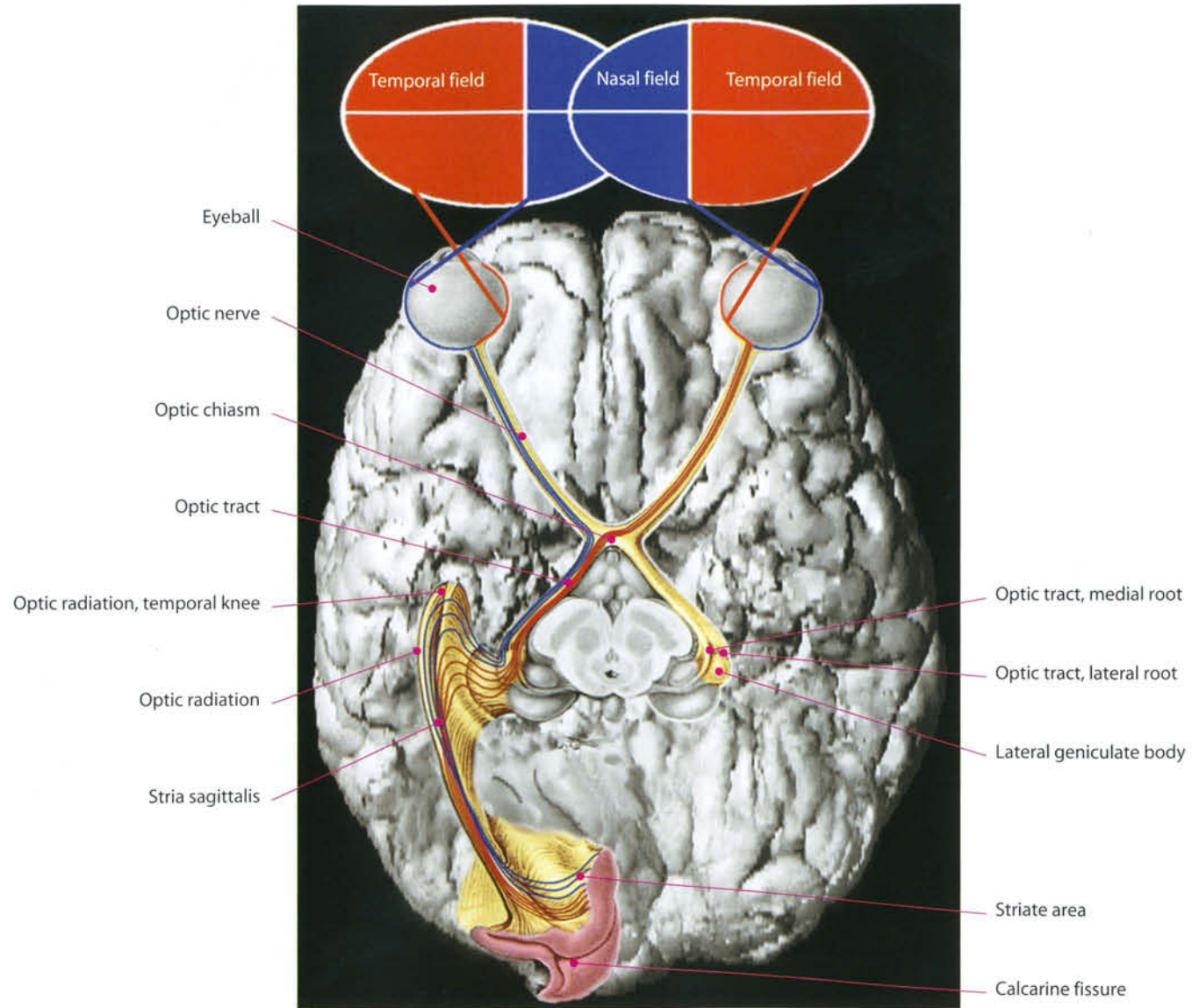


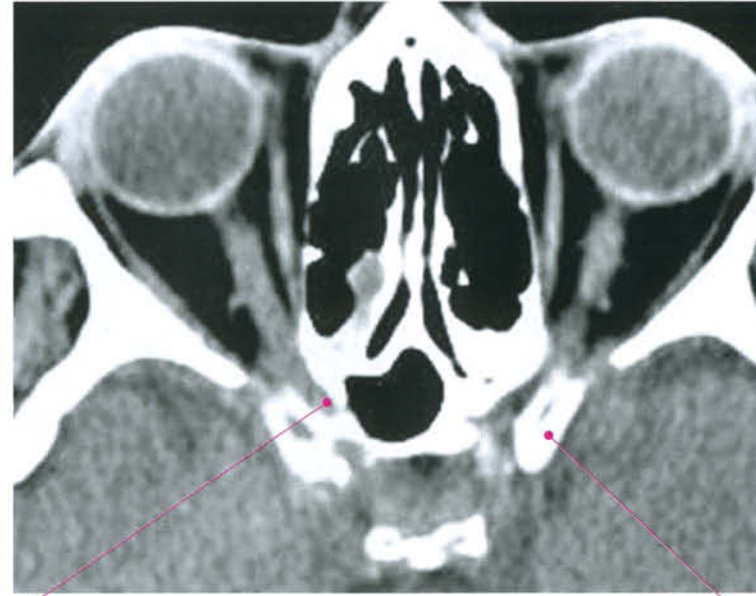
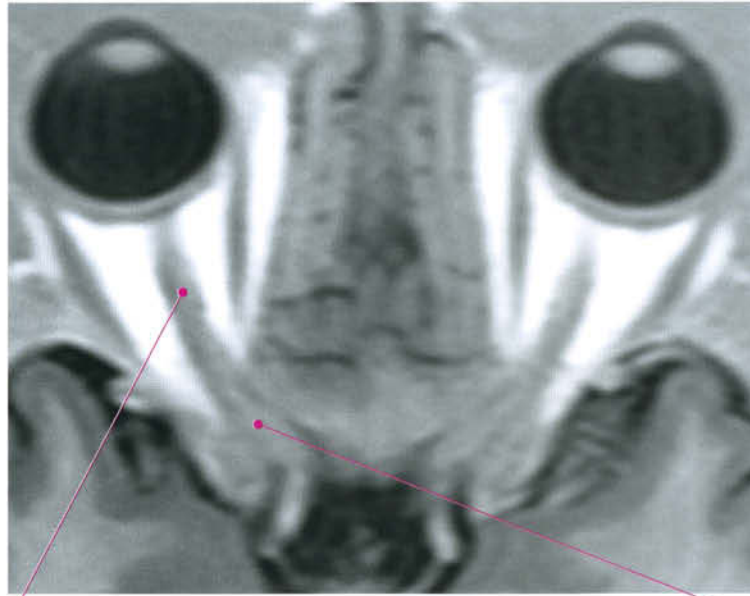
Gyrus rectus

Olfactory sulcus

Anterior perforated substance



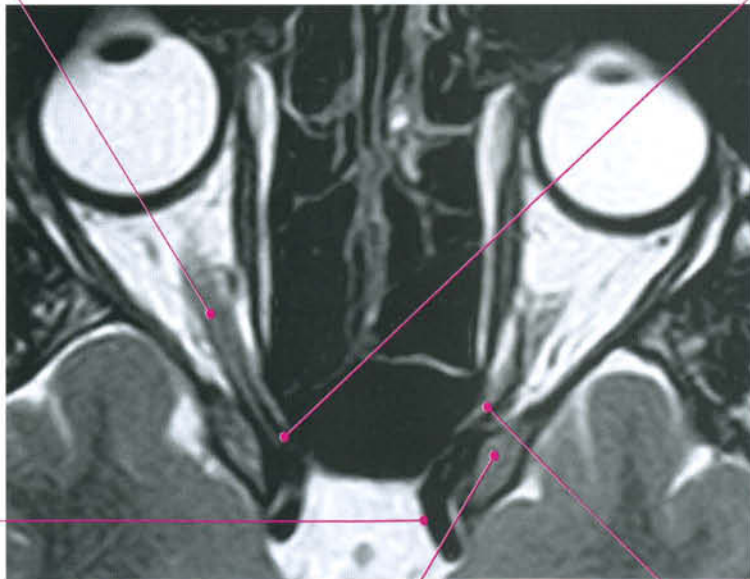



Optic nerve

Optic canal

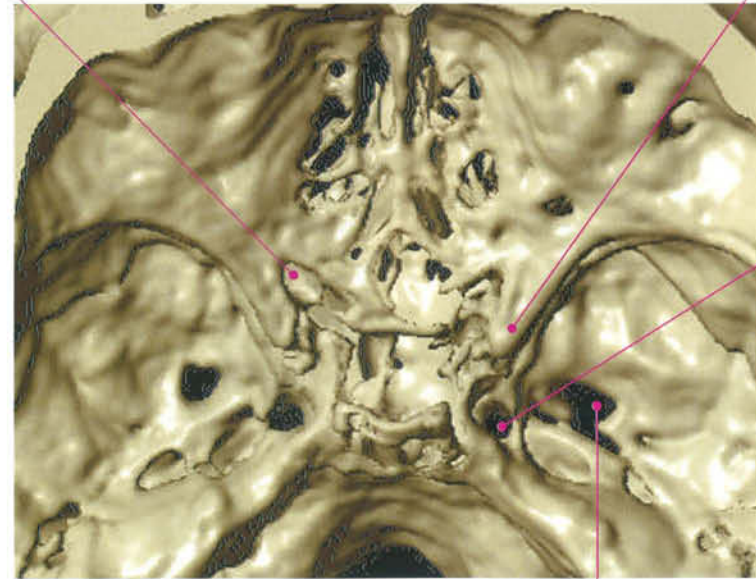
Anterior clinoid process



Internal carotid artery

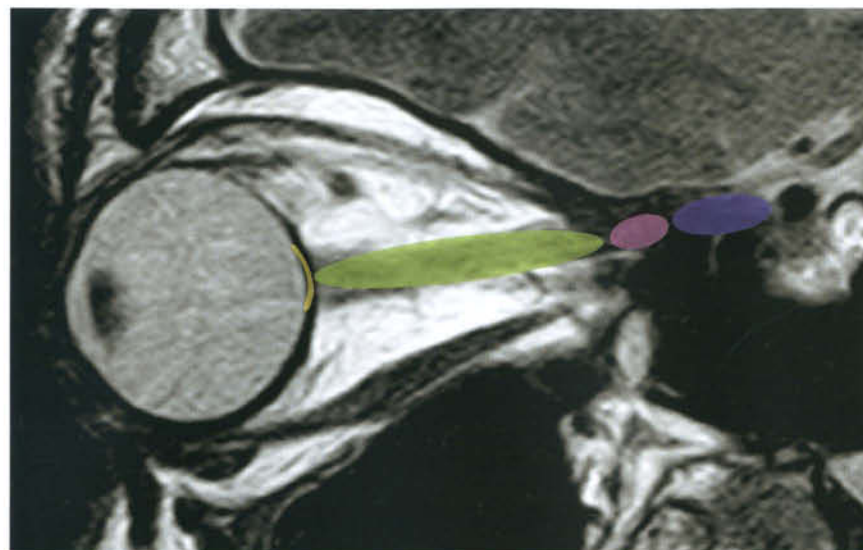
Anterior clinoid process





Ophthalmic artery

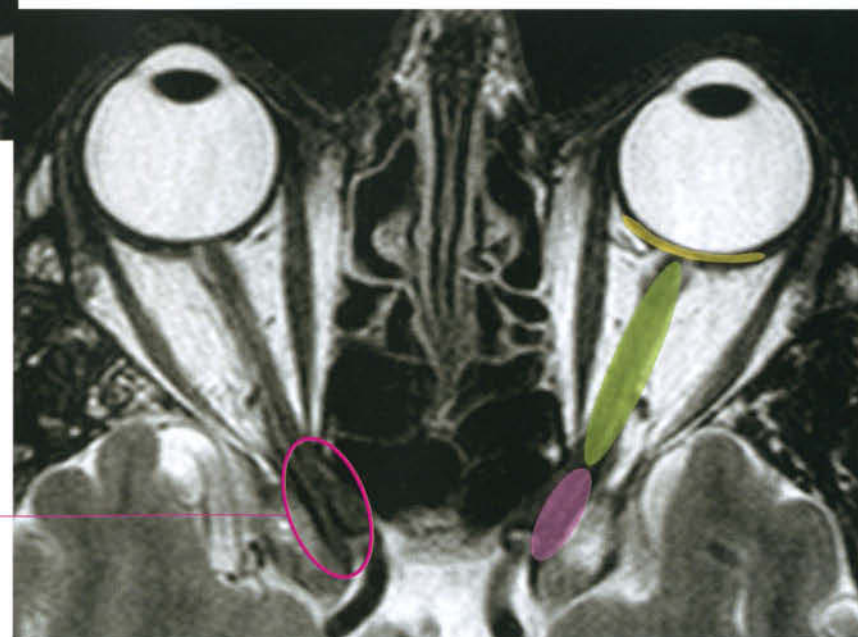


Carotid canal

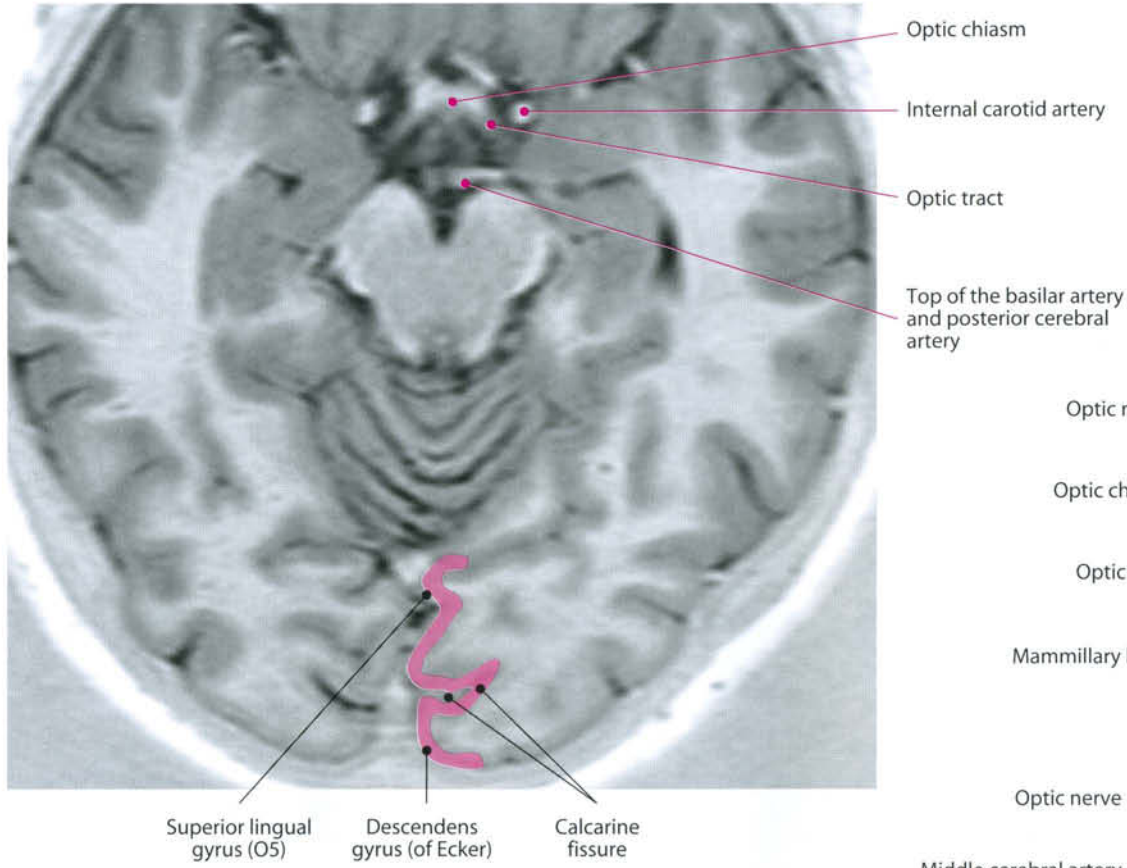
Foramen ovale



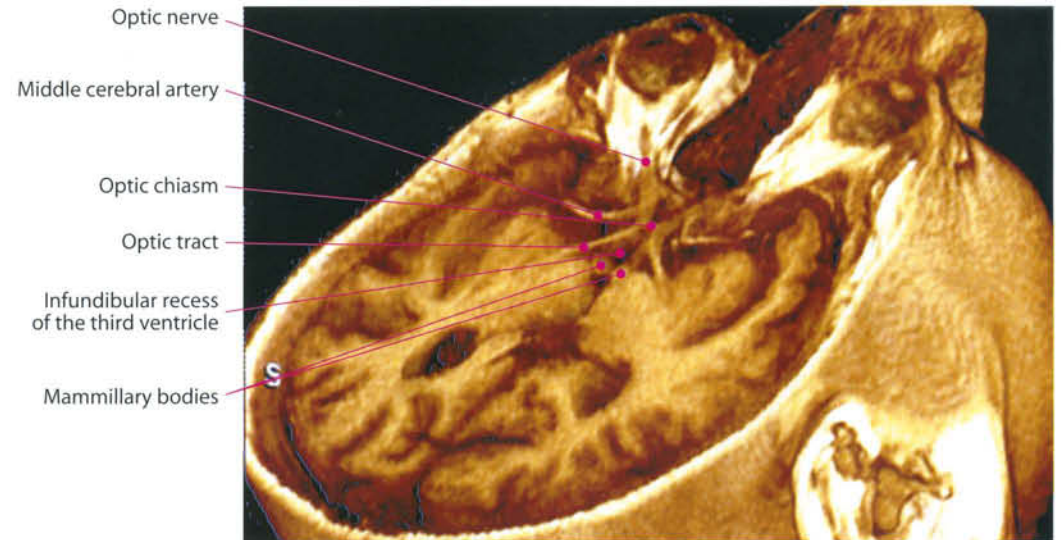
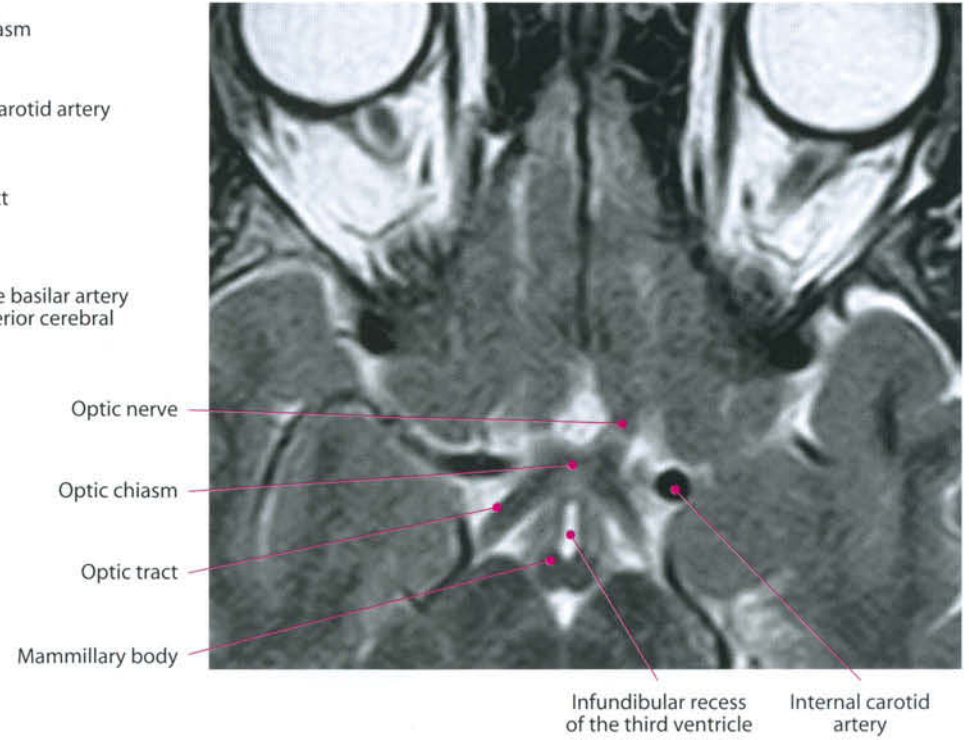
-  Retinal ganglion cells
-  Intraorbital portion
-  Foraminal portion
-  Prechiasmatic portion

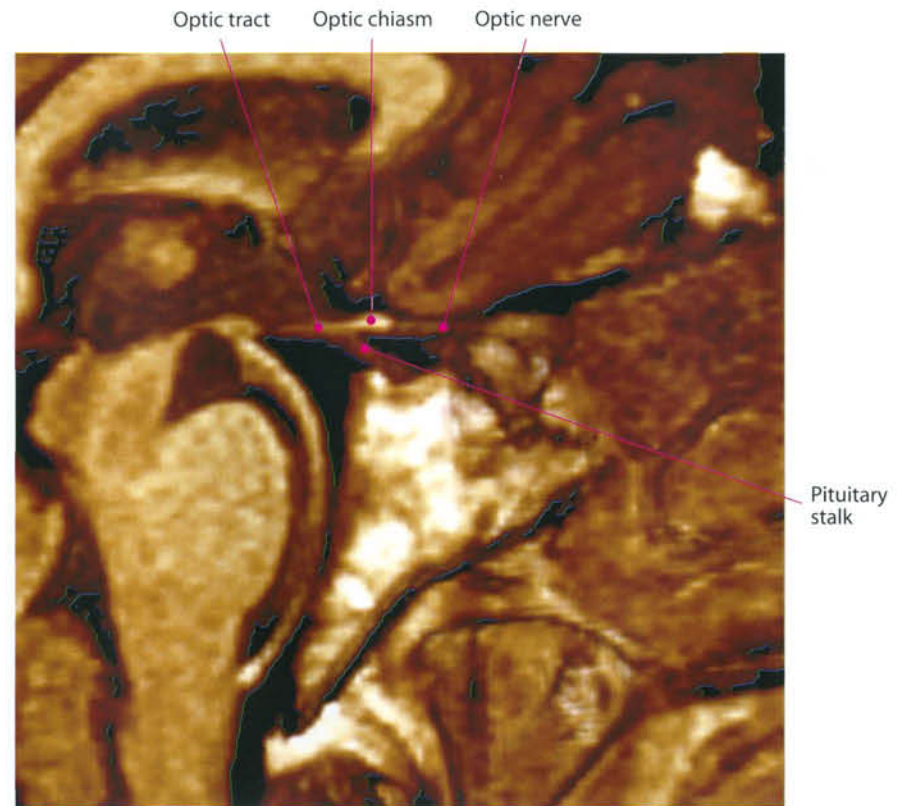
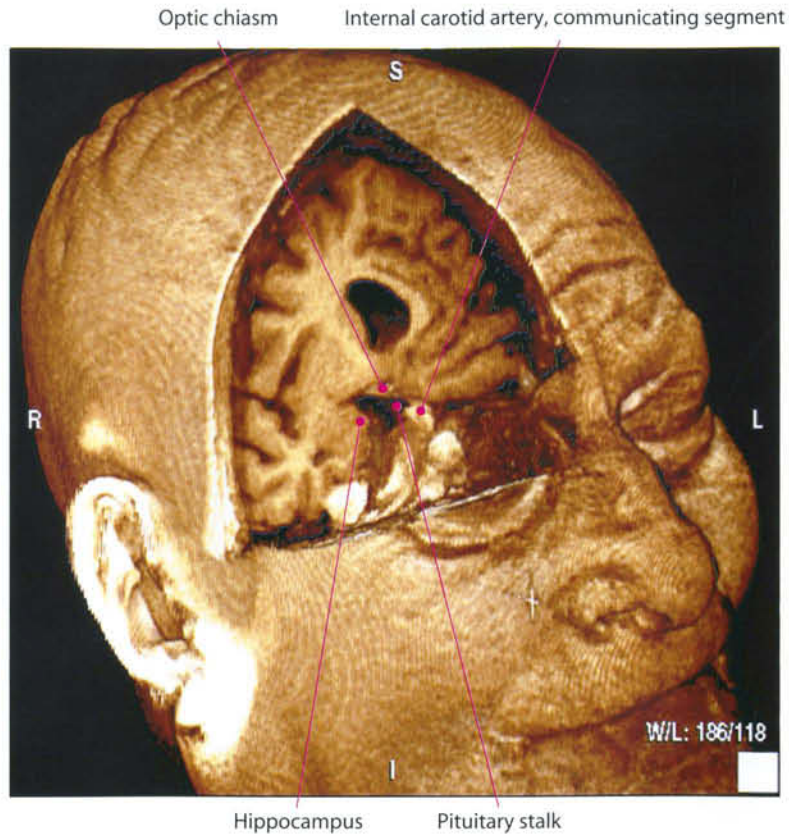


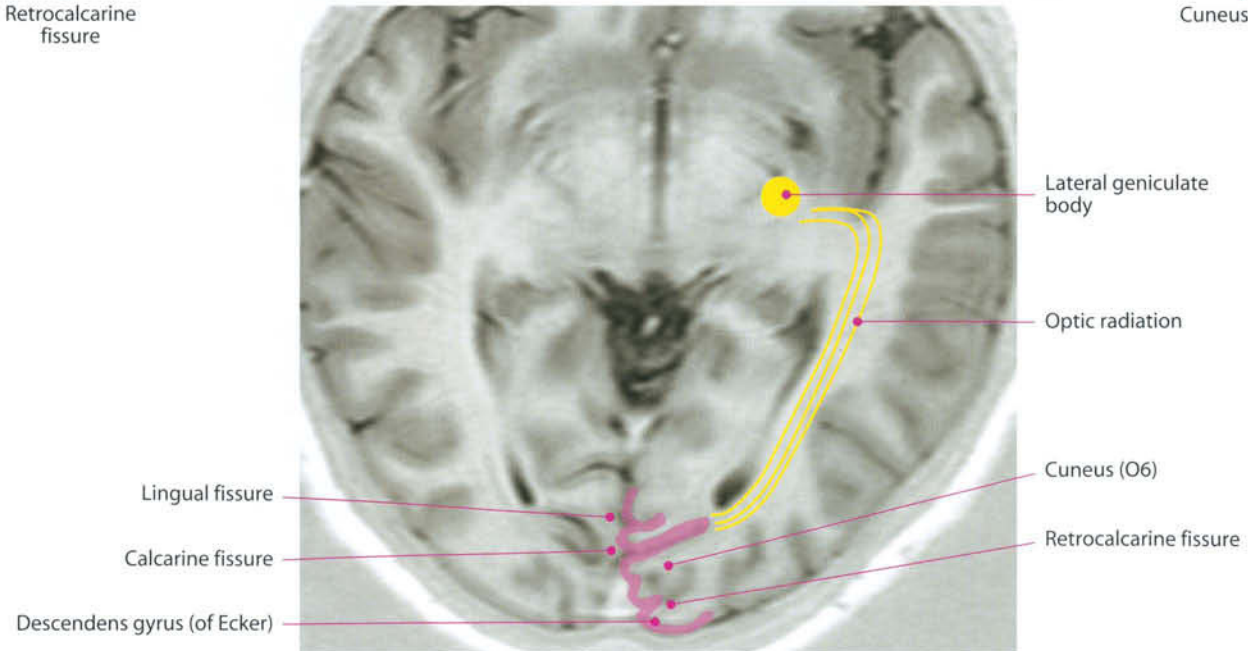
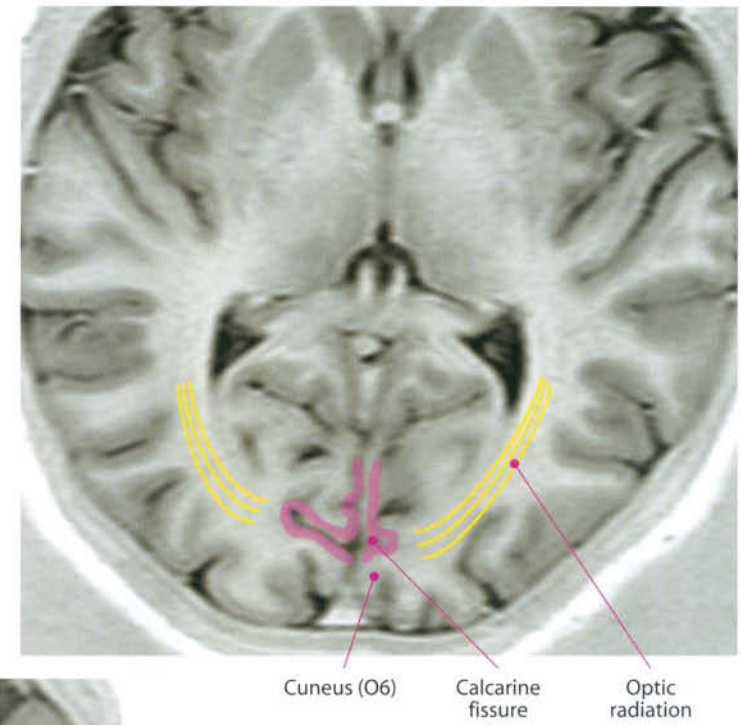
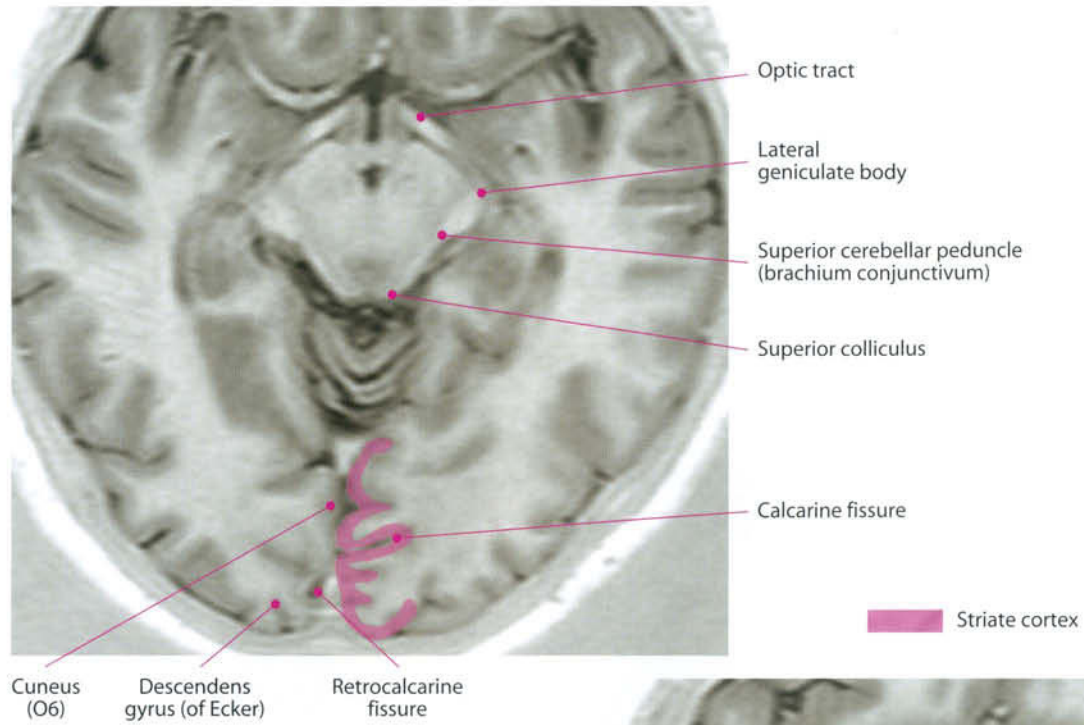
Optic canal

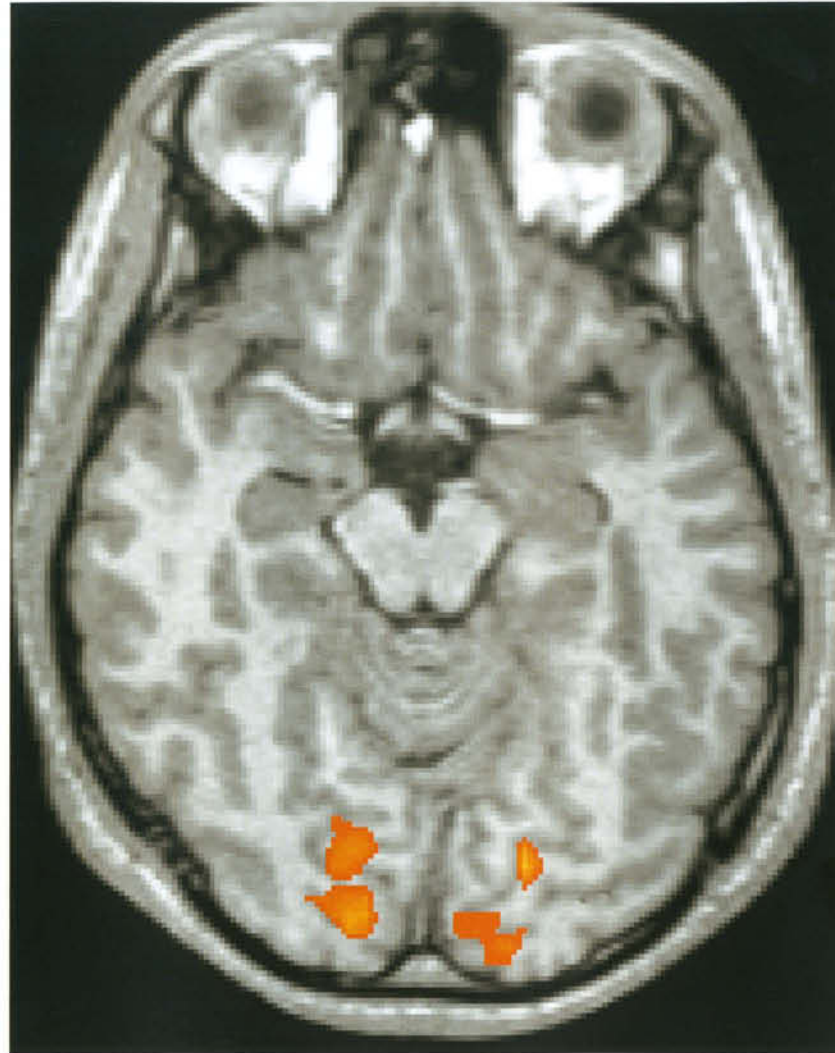


Striate cortex









Region of activation obtained during visual stimulation white black and white drawings.
(Courtesy of Massimo Caulo, MD, PhD, ITAB, Chieti, Italy)

II. Orbit and Contents

In this chapter the anatomy of the orbit will be divided as follows: Bony anatomy; extrinsic eye muscles; eyeball; lacrimal gland and system; vessels.

II. 1. Bony Anatomy

The orbit consists of 7 bones

- **Roof:** orbital plate of frontal bone, lesser wing of sphenoid bone;
- **Floor:** orbital plate of maxilla bone, orbital surface of zygomatic bone, orbital process of palatine bone
- **Lateral wall:** zygomatic bone, greater wing of sphenoid bone
- **Medial wall:** frontal process of maxillary bone, lacrimal bone, orbital plate of ethmoid bone, body of sphenoid bone

The **frontal bone** forms the orbital plate and the roof of the orbit. Here, the superior orbital margin contains a supraorbital notch or foramen for the supraorbital neurovascular bundle.

The **ethmoid bone** gives rise to the inner part of the medial wall, the orbital plate (lamina papyracea).

The **lacrimal bone** forms the remaining part of the medial wall of the orbit; it articulates: anteriorly with the frontal process of the maxilla; superiorly with the frontal bone; posteriorly with the ethmoid bone; inferiorly with the orbital process of the maxilla.

The **sphenoid bone** articulates anteriorly with the zygomatic bone, superiorly with the frontal bone, medially with the orbital process of the palatine bone. It forms the optic canal for the optic nerve and ophthalmic artery; the superior orbital fissure, between the lesser and greater wings of the sphenoid bone for the oculomotor, trochlear, and abducens nerves, branches of the ophthalmic division of the trigeminal nerve, superior ophthalmic vein, lymphatics.

Maxillary bone: the frontal process forms part of the medial orbital wall and margin; the orbital process forms the floor of the orbit and contains the infraorbital groove and canal for the infraorbital neurovascular bundle. The infraorbital foramen represents the anterior opening of the infraorbital canal.

The **palatine bone** orbital process forms a small part of the floor of the orbit posteriorly.

The **zygomatic bone** forms the greater part of the lateral wall of the orbit and the lateral part of the inferior orbital margin.

II. 2. Extrinsic Eye Muscles

The orbit contains the following muscles:

Orbicularis oculi: closes the eyelids, originates in the medial orbital margin and palpebral ligament.

Levator palpebrae superioris: elevates the upper eyelid. It is inserted on the apex of the orbit above the optic canal and to the skin and fascia of the upper eyelid and superior tarsal plate.

Superior rectus: elevates and adducts the eyeball. It originates from the common tendinous ring at the apex of the orbit and ends on the sclera on the superior surface of the eyeball.

Inferior rectus: depresses and adducts the eyeball. It is inserted on the common tendinous ring at the apex of the orbit and the sclera on the inferior surface of the eyeball.

Medial rectus: adducts the eyeball. It goes from the common tendinous ring at the apex of the orbit to the sclera on the medial surface of the eyeball.

Lateral rectus: adducts the eyeball. It is inserted on the common tendinous ring at the apex of the orbit and the sclera on the lateral surface of the eyeball.

Oblique superior: depresses and adducts the eyeball. It is inserted on the apex of the orbit above the optic canal, passes through a fibrocartilagenous pulley known as the *trochlea* and reaches the sclera, on the superior surface of the eyeball.

Oblique inferior: elevates and adducts the eyeball. It is inserted on the floor of the orbit lateral to the lacrimal groove and on the sclera on the inferior surface of the eyeball, beneath the lateral rectus muscle.

II. 3. The Eyeball

The eye is the visual system receptor organ. Photoreceptor cells in the retina (rods and cones) transform the light signals into electrical signals that are further processed by other retinal neurons: bipolar cells, horizontal cells, amacrine cells, retinal ganglion cells, and interplexiform cells, and transmit the potentials to the optic nerve.

The eye is located in the anterior part of the orbit. It contains two segments: a small transparent anterior seg-

ment, the aqueous humor, and a large posterior opaque one, the vitreous body. These are separated by the lens, which is held in place by the suspensor ligaments. The aqueous humor is further divided into anterior and posterior chambers by the iris. The aqueous flows from the posterior chamber, around the iris, and into the anterior chamber, where it drains into the canal of Schlemm. The eyeball is composed of three layers: the outermost (sclera), which continues with the transparent cornea anteriorly; the intermediate (choroid), which continues with the ciliary body and iris anteriorly; and the innermost (retina).

II. 4. The Lacrimal Gland

The lacrimal gland is the organ responsible for tear production (Latin: lacrima = tear). It is located in the orbit beneath the orbital plate of the frontal bone. It is innervated by postganglionic parasympathetic fibers from the pterygopalatine ganglion via communicating branches to the lacrimal nerve. Tears are collected by lacrimal papillae, located medially on the edge of the upper and lower eyelids. They contain two openings called lacrimal puncta that drain the tears into lacrimal canaliculi. The lacrimal sac is located at the medial wall of the orbit, receives lacrimal canaliculi and drains to the nasolacrimal duct.

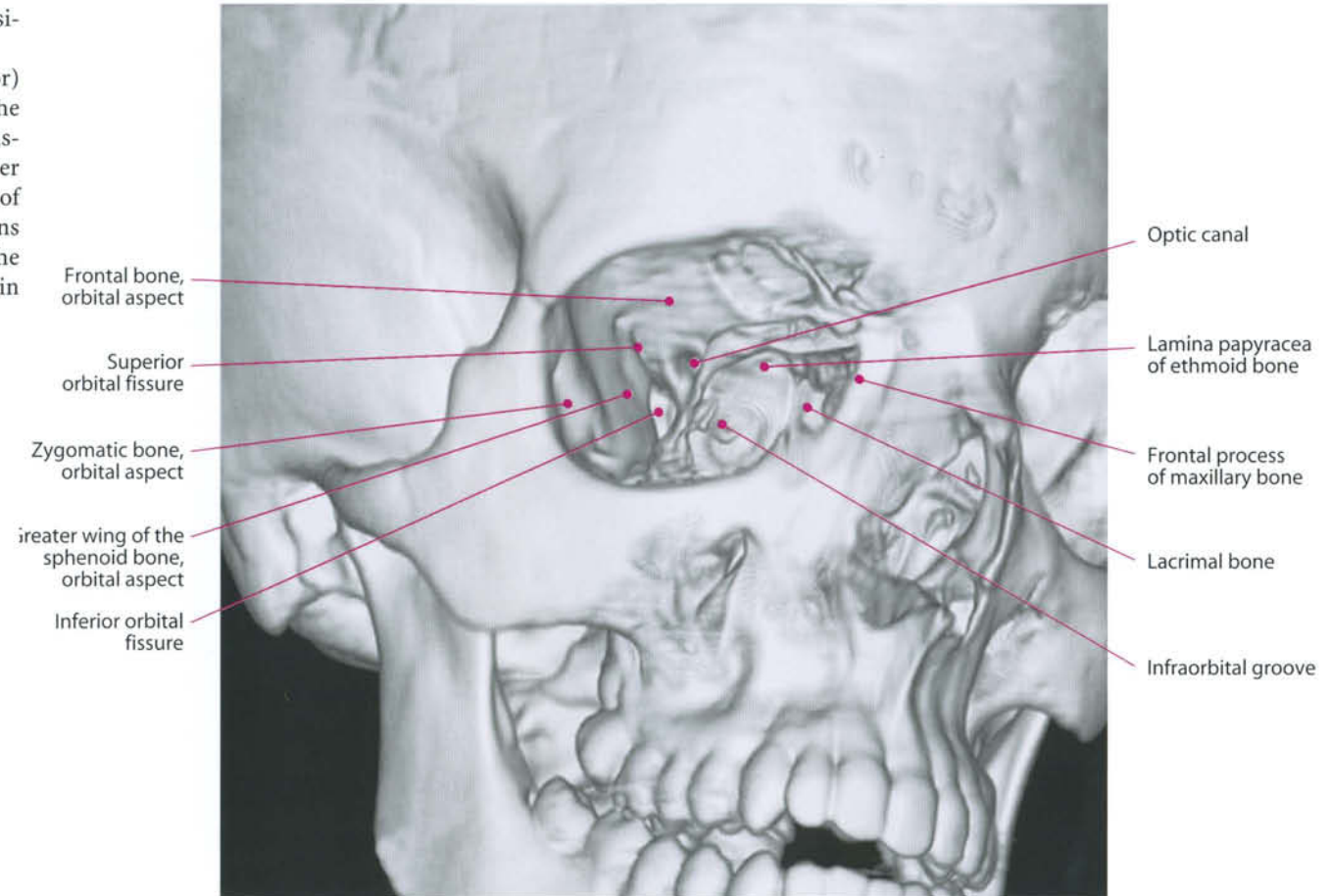
II. 5. Vessels

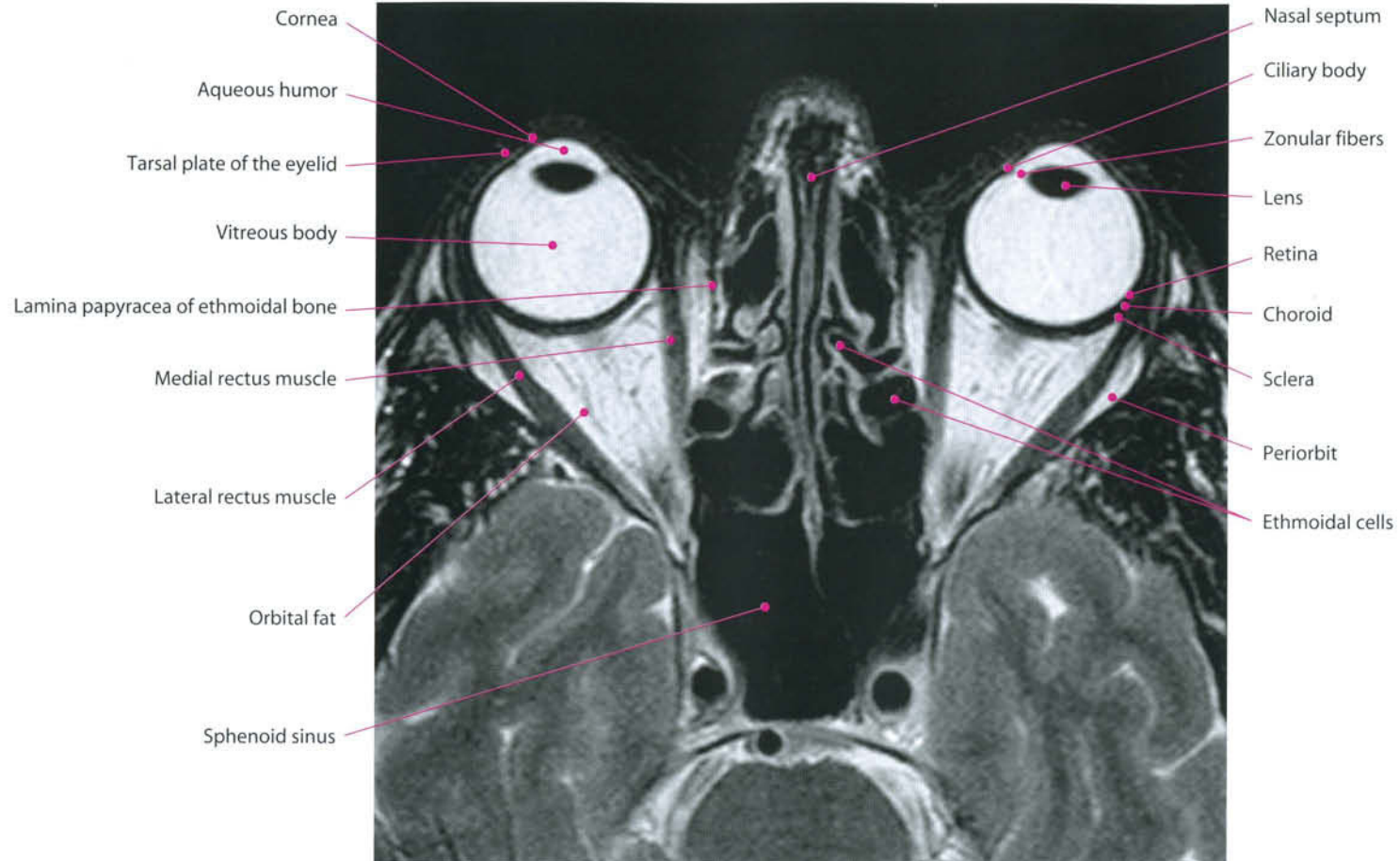
The main artery which supplies the eye and orbit is the **ophthalmic a.** It originates from the internal carotid and courses anteriorly, following the optic nerve on its lateral aspect into the optic canal. After crossing it, the artery gives rise to a lateral branch, the lacrimal artery, directed to the gland and the lateral rectus muscle, and a medial branch, the central retinal artery, the only artery to the retina. Afterwards, the artery curves medially, crossing the nerve on its upper surface and gives rise to its terminal branches:

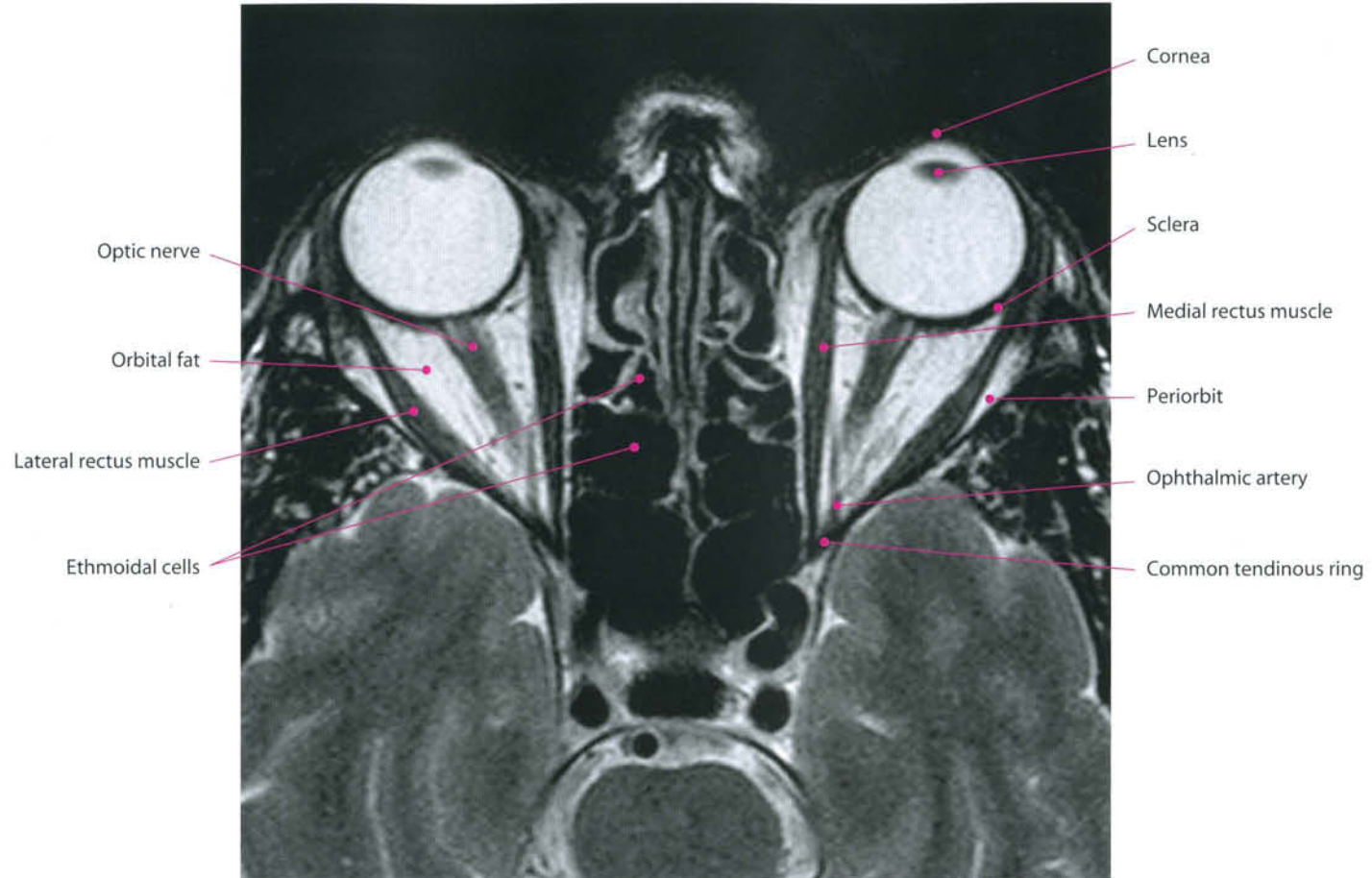
muscular, anterior and posterior ethmoids, medial palpebral, supraorbital, supratrochlear, dorsal nasal.

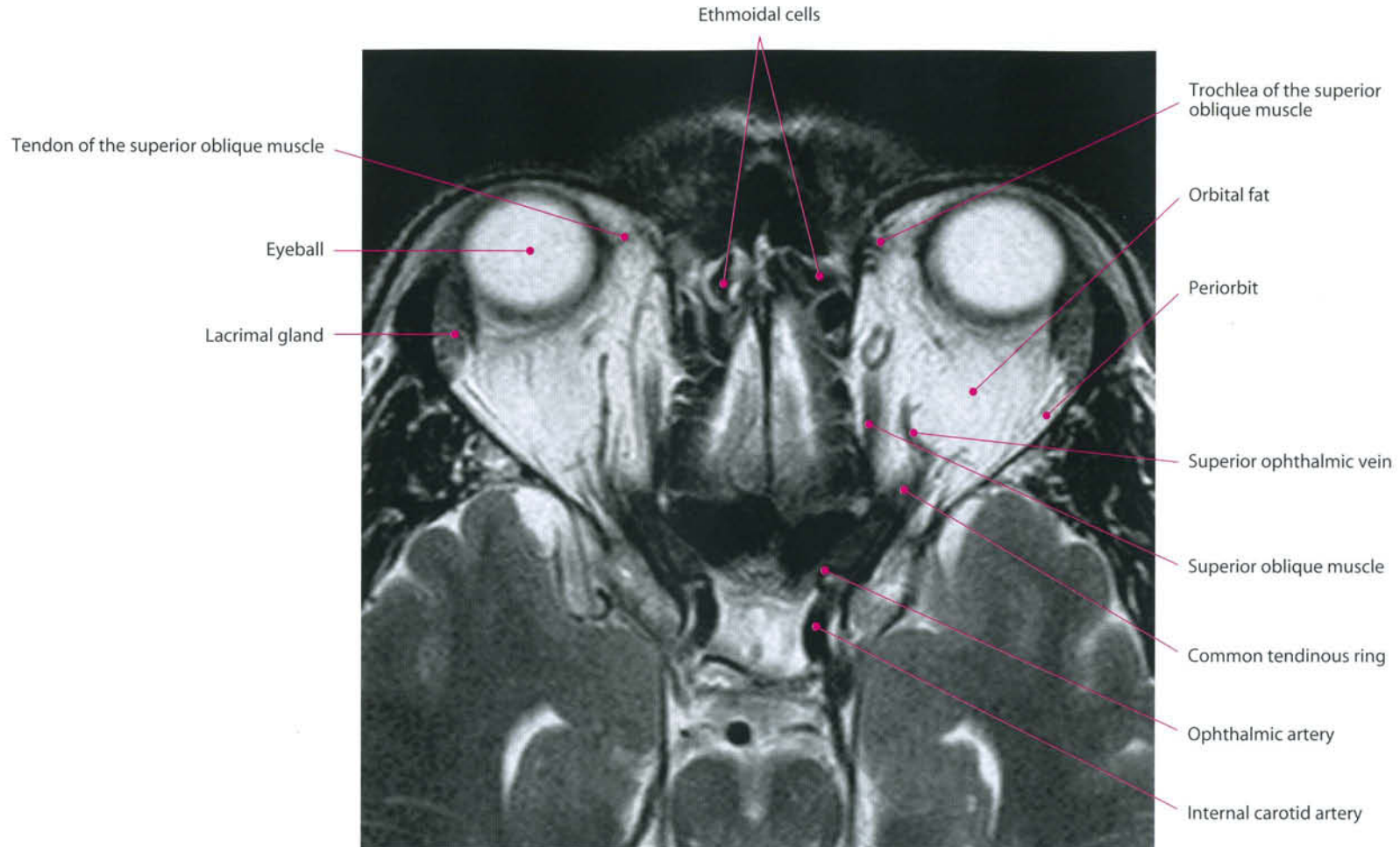
There are two ophthalmic veins: superior and inferior, devoid of valves

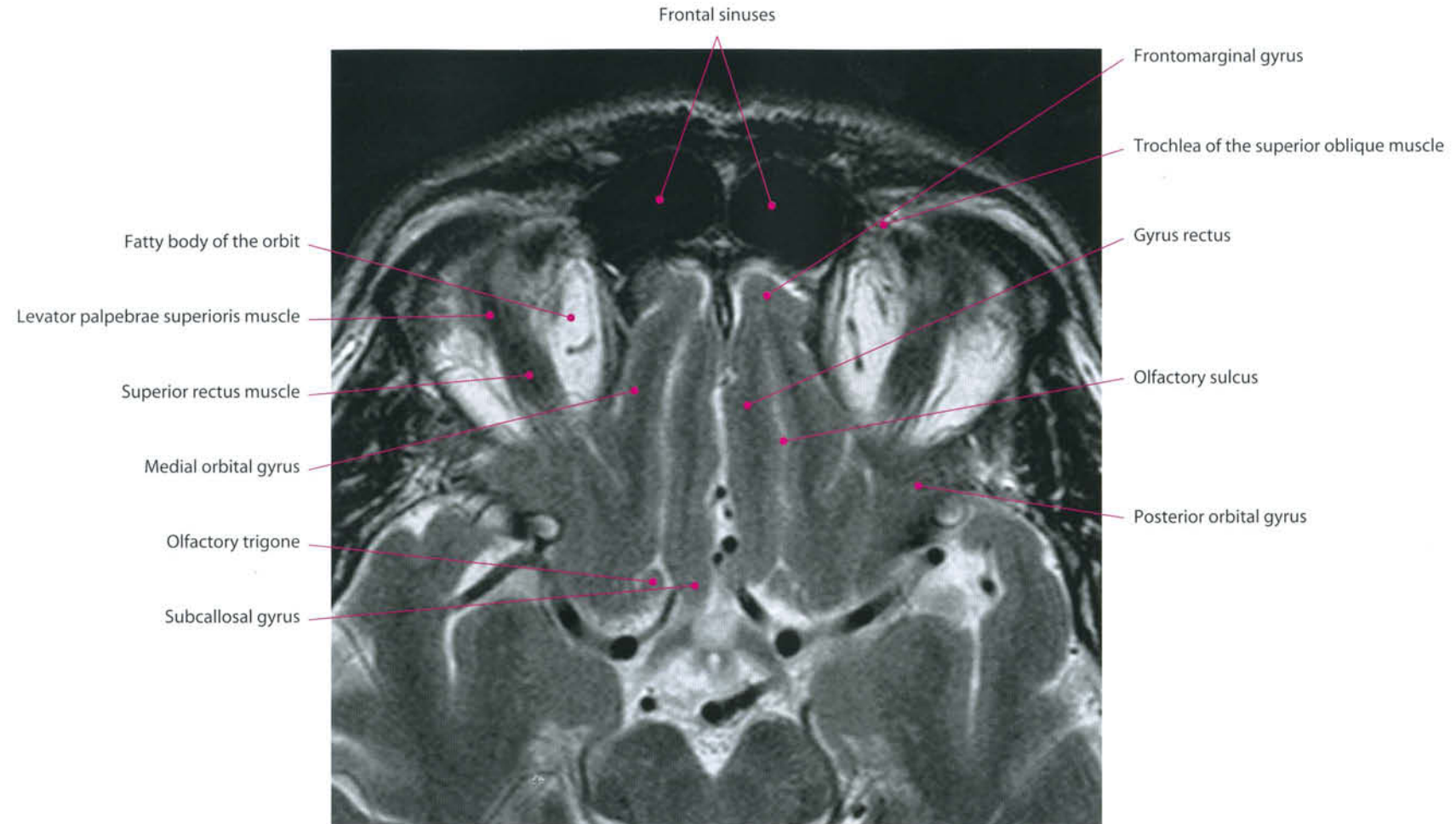
1. *The superior ophthalmic vein* (v. ophthalmica superior) begins at the inner angle of the orbit from the nasofrontal vein which communicates anteriorly with the angular vein; it pursues the same course as the ophthalmic artery, and receives tributaries corresponding to the branches of that vessel. It passes between the two heads of the lateral rectus and through the medial part of the superior orbital fissure, and ends in the cavernous sinus.
2. *The inferior ophthalmic vein* (v. ophthalmica inferior) begins from a venous network located anteriorly on the floor and medial wall of the orbit; it receives some muscular and lacrimal veins, runs backward into the lower part of the orbit and divides into two branches. One of these passes through the inferior orbital fissure and joins the pterygoid venous plexus, while the other enters the cranium through the superior orbital fissure and ends in the cavernous sinus.

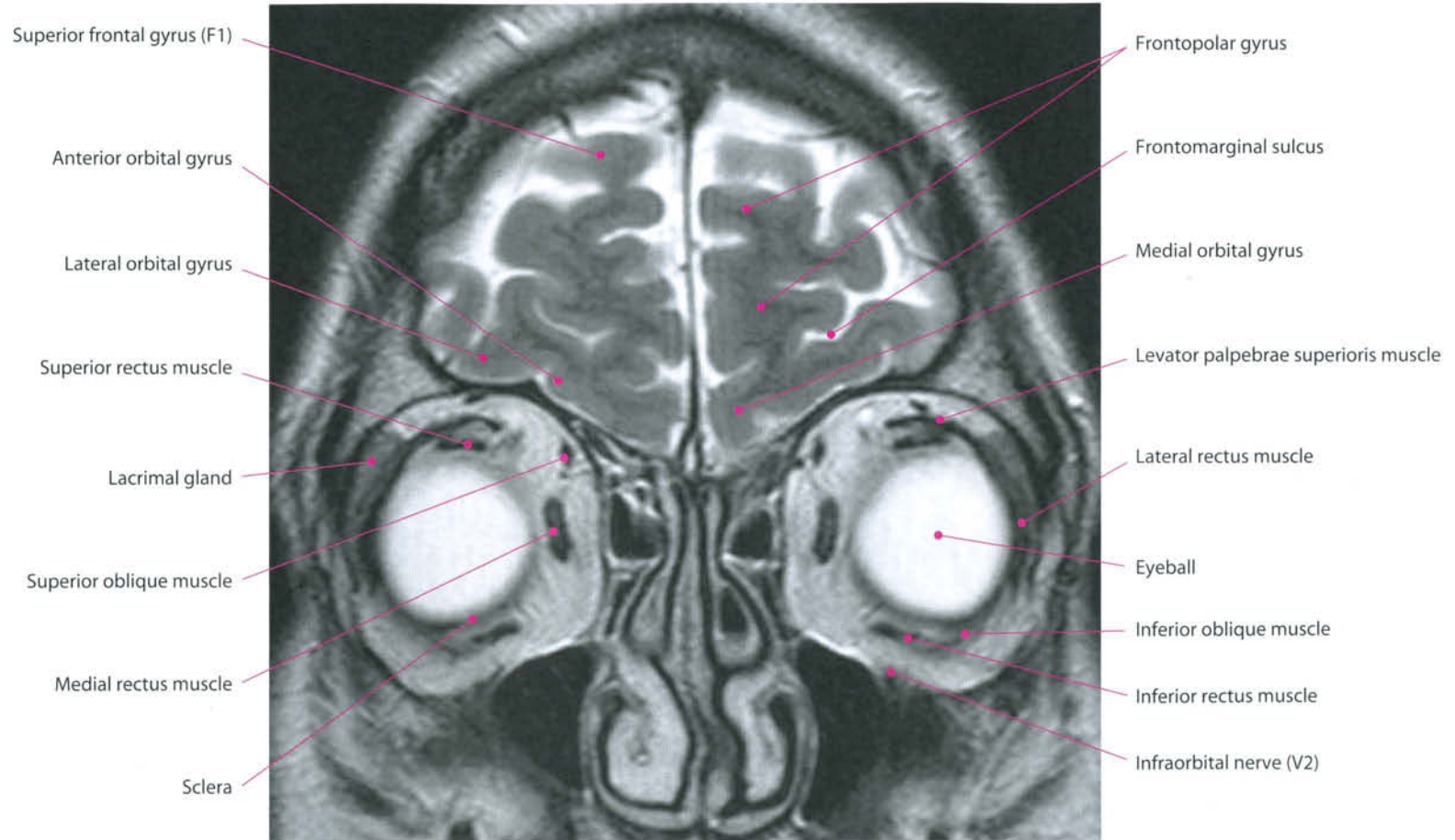


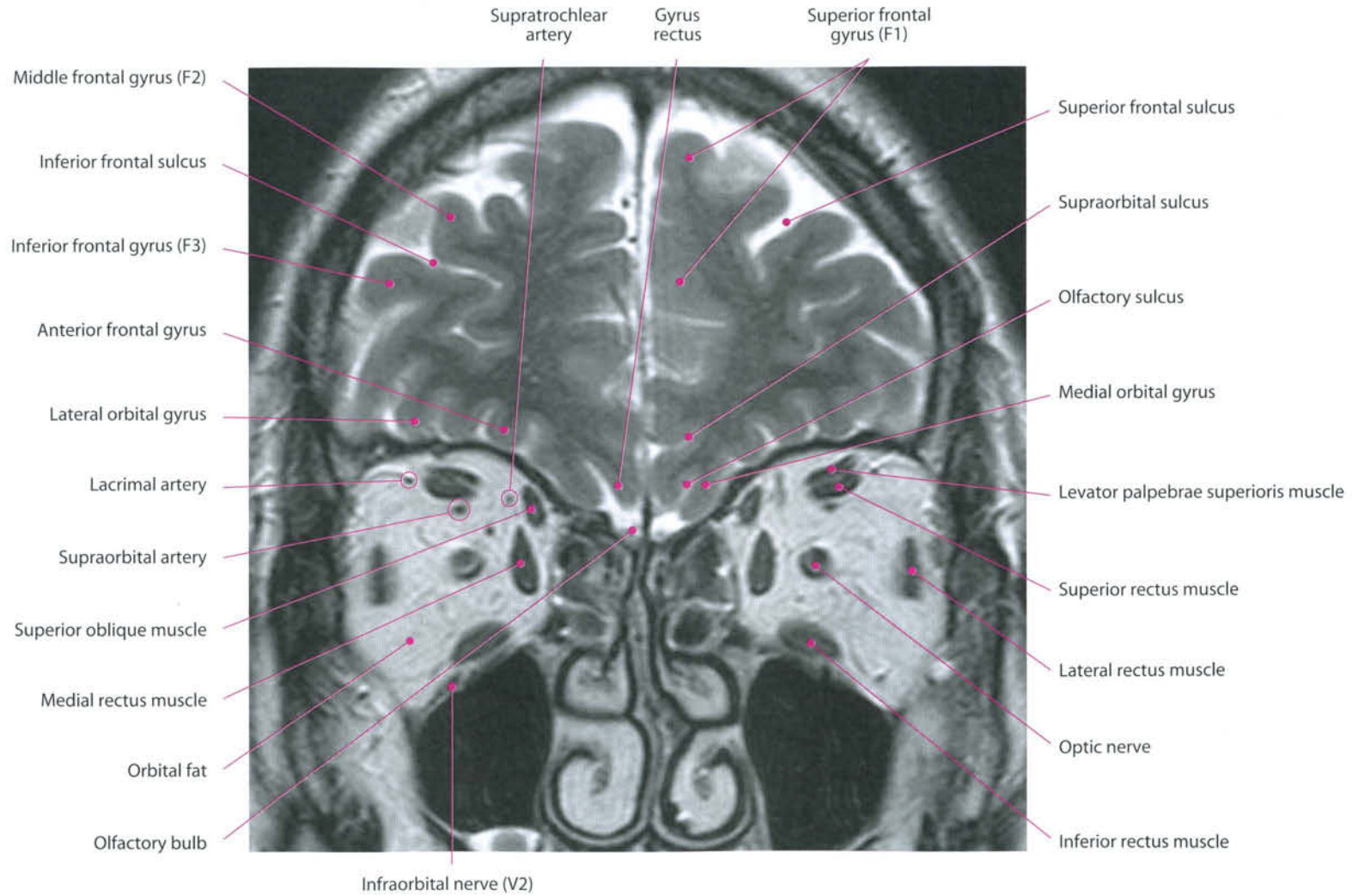


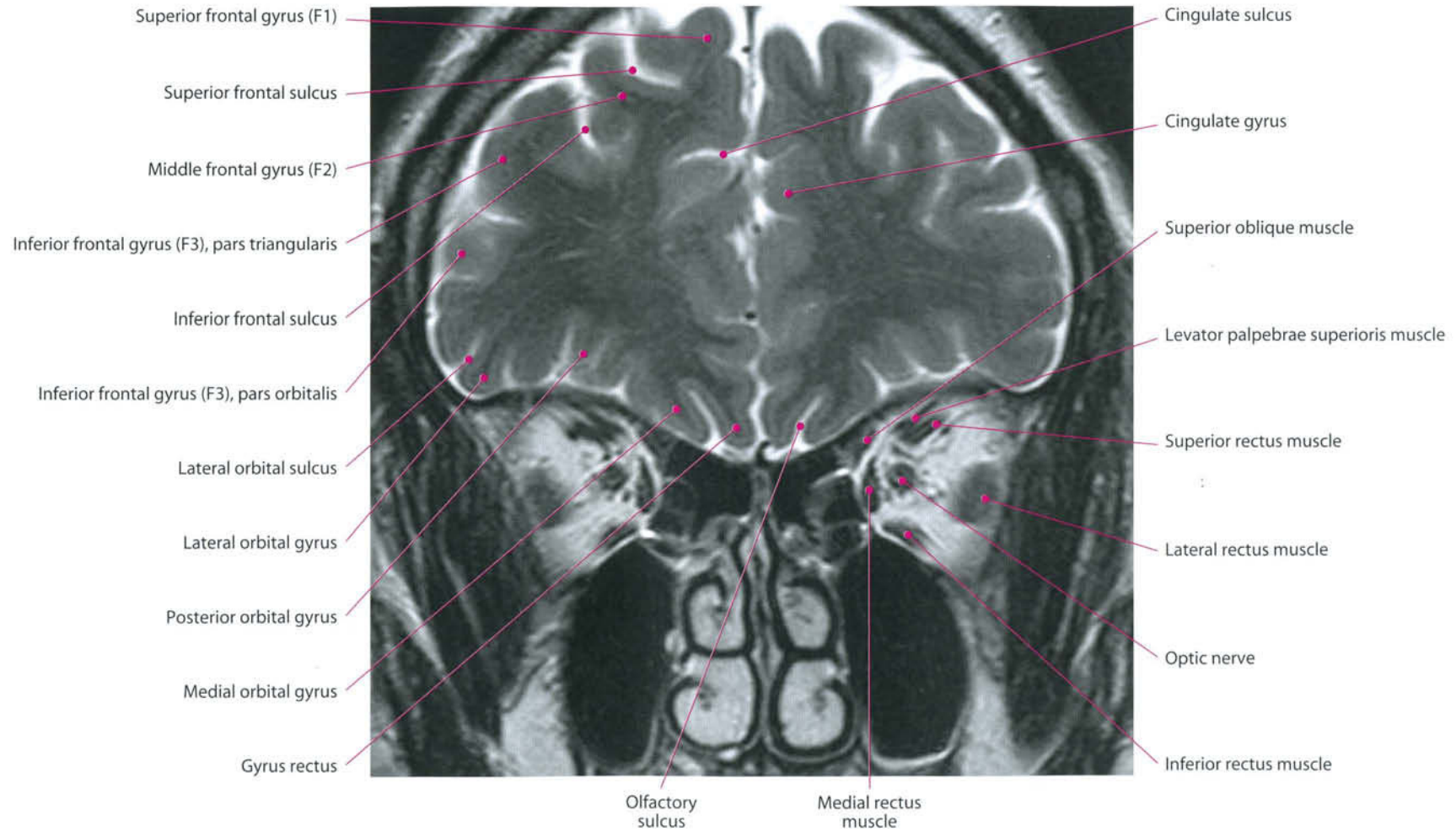


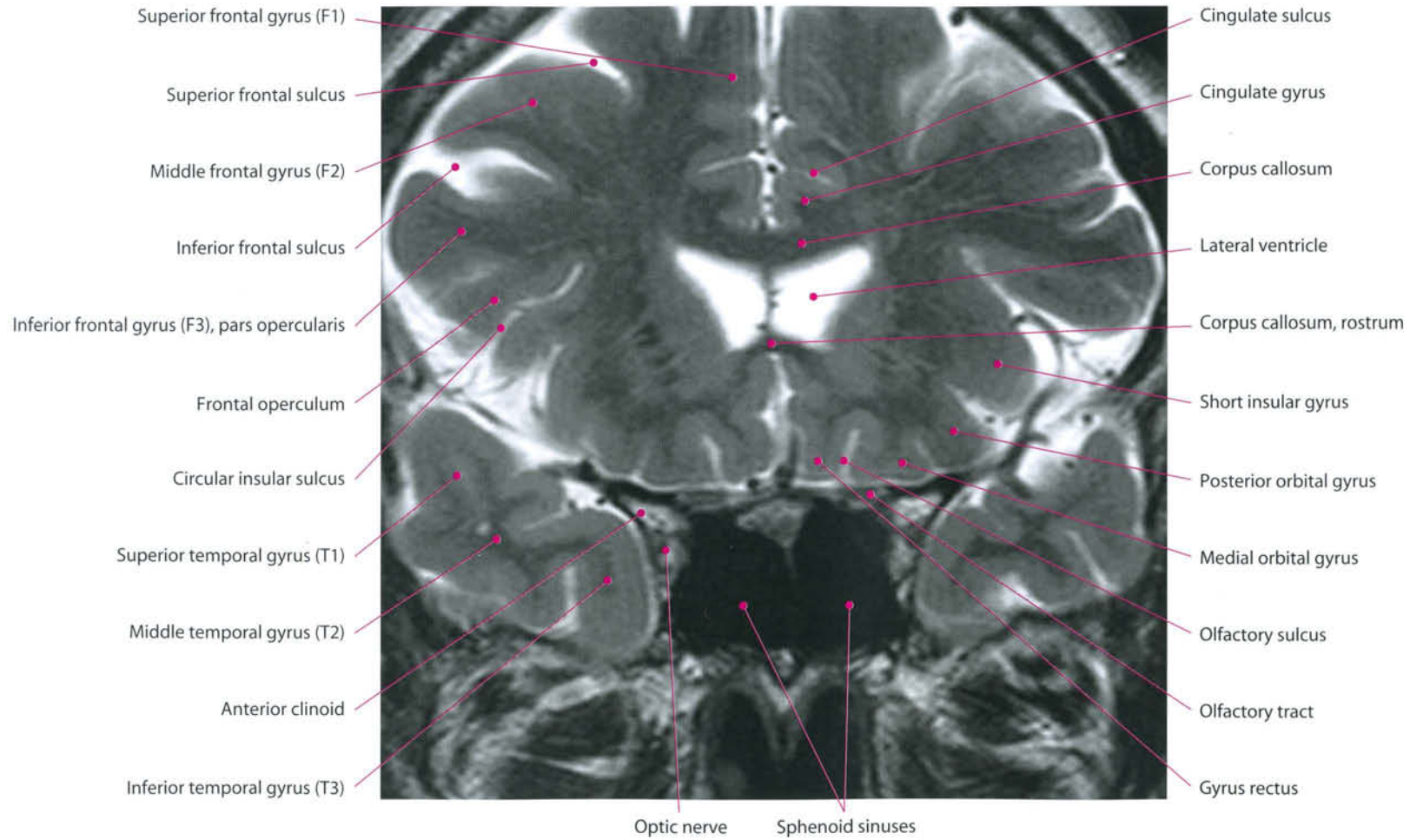


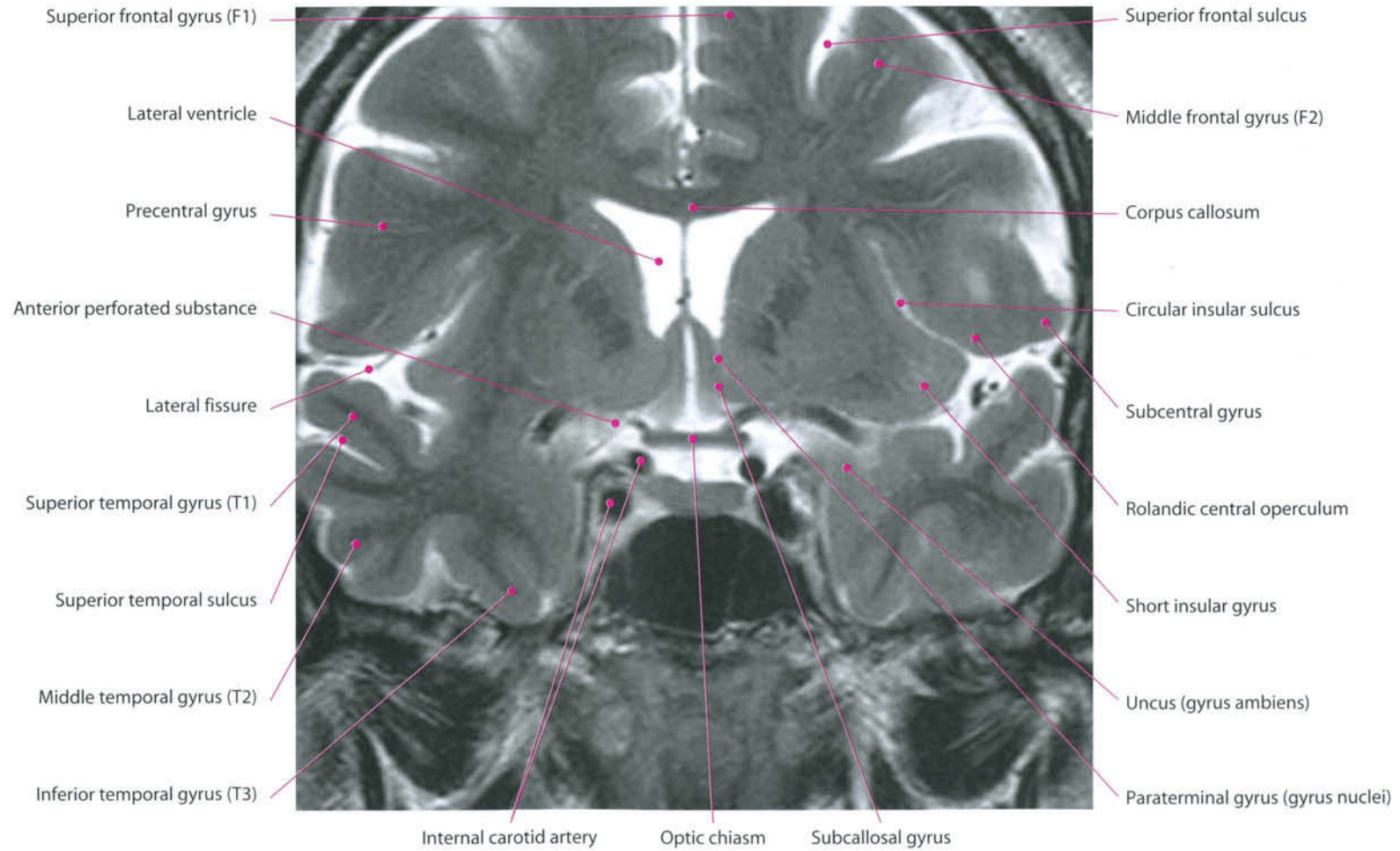

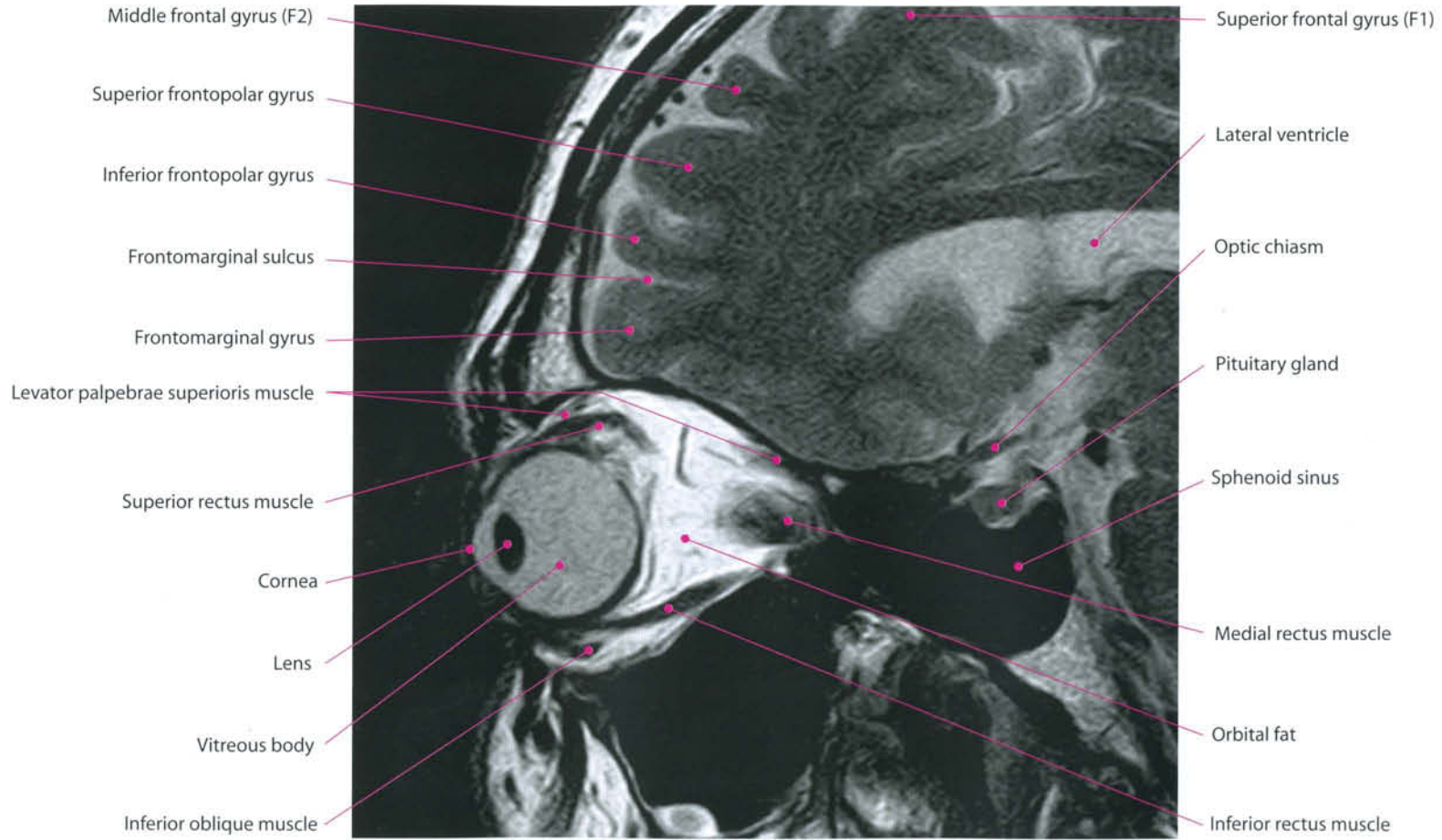


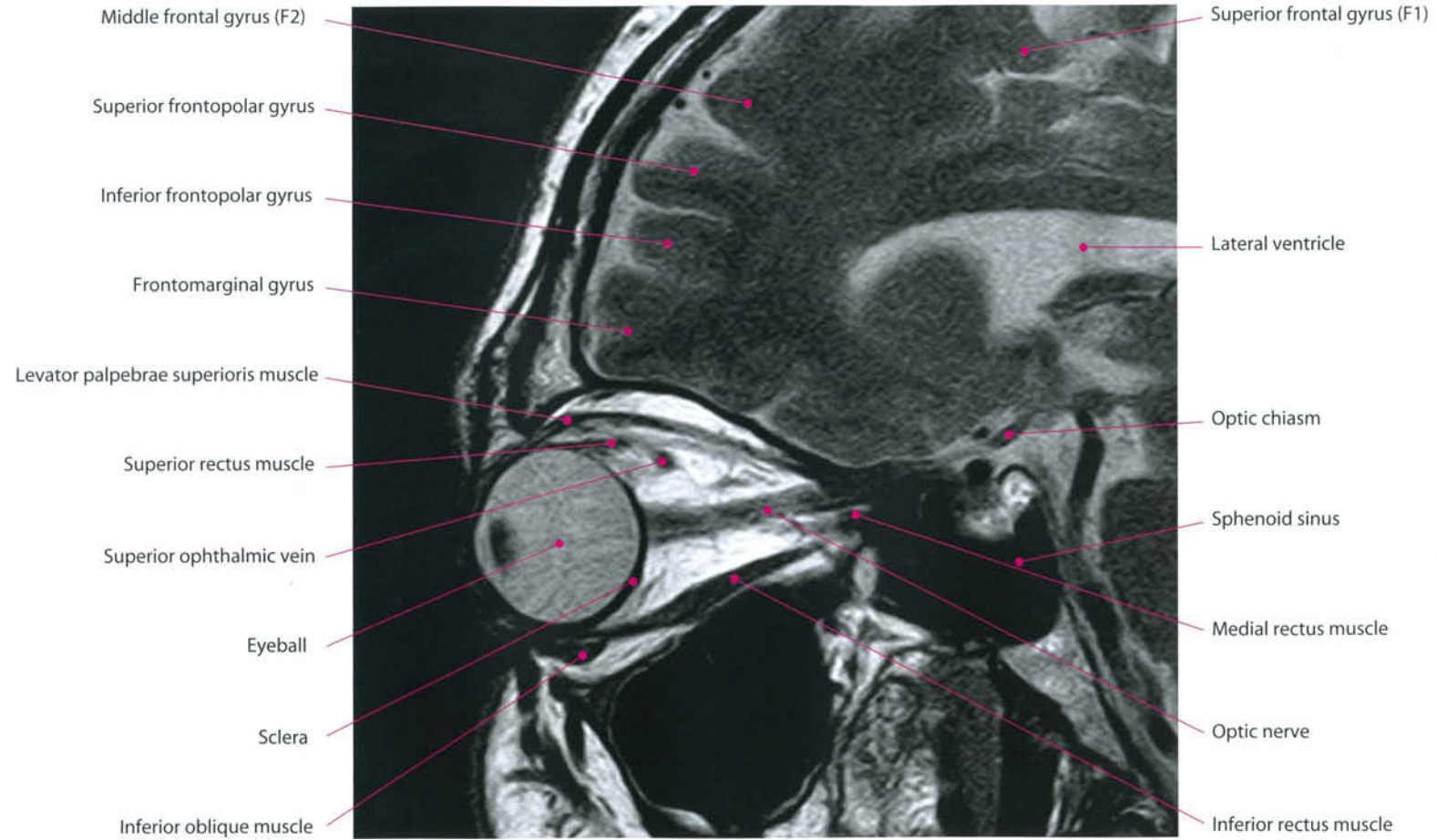


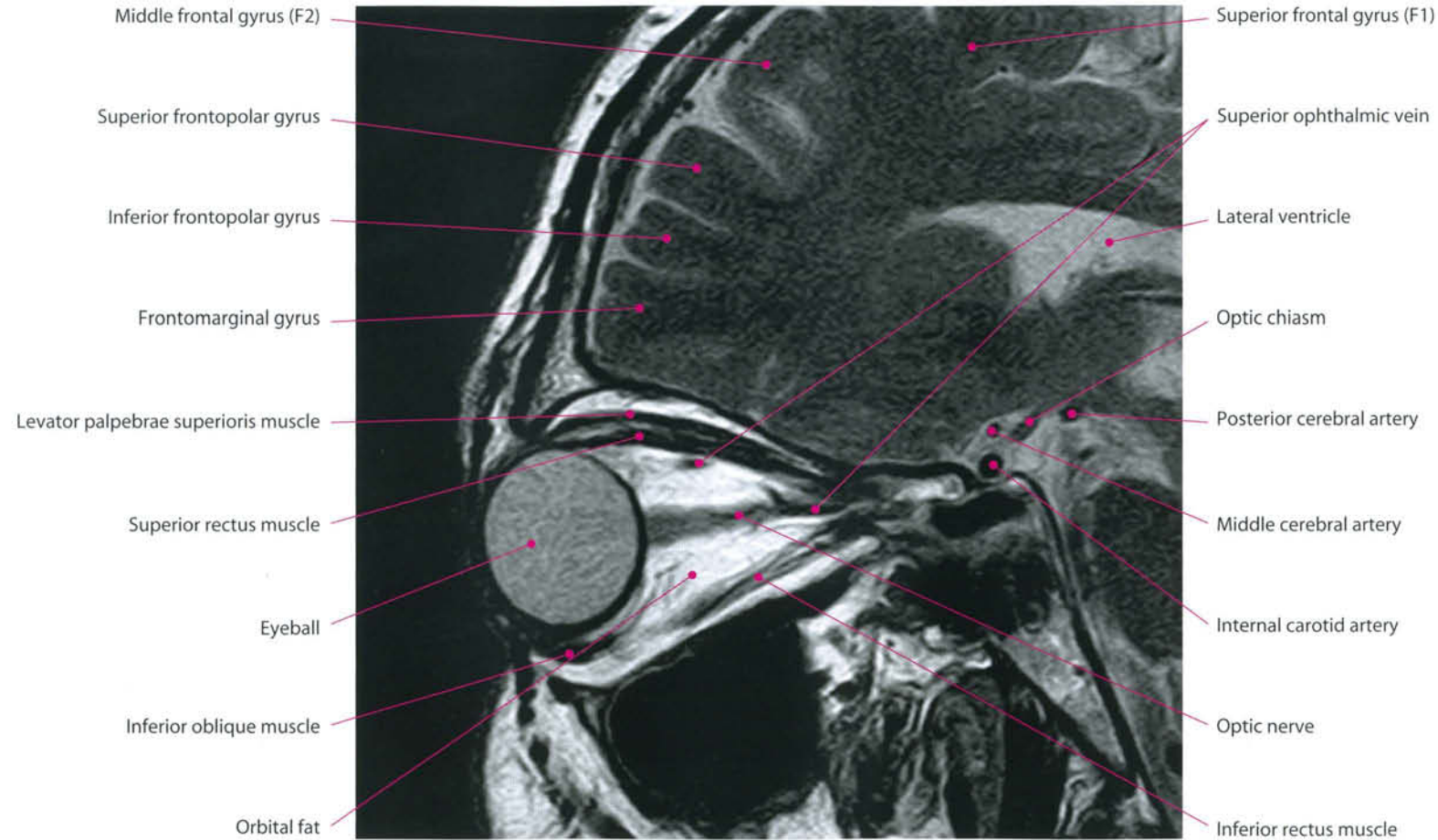












Oculomotor (III), Trochlear (IV) and Abducent (VI) Nerves

I. Oculomotor Nerve (III Cranial Nerve)

The nucleus of the oculomotor nerve is on the upper end of the midbrain, ventrally to the sylvian aqueduct, on the median line, in a V-shaped zone formed by the diverging fibers of the medial longitudinal fasciculus.

The complex consists of lateral columns with a general somatic efferent (GSE), which works for the innervation of the eye's extrinsic muscles (rectus inferior, inferior oblique, rectus medialis, rectus superior), and the nucleus caudalis centralis, which innervates the levator palpebrae superioris muscle. The Westphal nucleus and the anterior median nucleus form the parasympathetic general visceral efferent (GVE) component of the nuclear complex. Their fibers innervate the ciliary muscles and the sphincter pupillae, and travel together with the GSE fibers, remaining located at the periphery of the nerve. For this reason, they are usually the first to be affected by extrinsic compressions (neurovascular conflicts, aneurysms, etc.).

The direct and crossed radicular fibers pass ventrally through the red nucleus and emerge in the interpeduncular fossa, in correspondence with the medial aspect of the cerebral peduncle, immediately below the posterior cerebral and posterior communicating arteries. The nerve enters the cavernous sinus, remaining within its dural lateral wall, in the upper portion, and enters the orbit through the upper lateral aspect of the superior orbital fissure.

Associated with the nuclear complex of the oculomotor nerve, there are three accessory nuclei:

- Cajal's interstitial nucleus: placed on the rostral mesencephalon and formed by neurons mixed with the medial longitudinal fasciculus fibers. The fibers cross at the level of the posterior commissure and head for all the somatic components of the oculomotor nuclear complex, except for the ventral column, the bilaterally trochlear nuclei, the homolateral medial vestibular nucleus, and the spinal cord, as an interstitial spinal tract;
- Darkshevich's nucleus: it is placed in the substantia grisea centralis, in the ventrolateral position and dorsolaterally to the somatic columns of the oculomotor nuclear complex. Its fibers insert into the posterior

commissure but not into the oculomotor nuclear complex.

- Posterior commissure's nucleus: it is placed in the substantia grisea centralis at the dorsolateral level; its cells are strictly connected to the fibers of the posterior commissure.

The nuclear complex of the oculomotor nerve receives impulses from the cerebral cortex, through corticoreticular fibers, from the cerebellum (nucleus dentatus), the nuclei vestibulares (in particular, they reach the lateral somatic cell columns), the colliculus superior (not through a direct connection, but Cajal's nucleus and the mesencephalic reticular formation), the reticular formation, and Cajal's interstitial nucleus.

II. Trochlear Nerve (IV Cranial Nerve)

The trochlear nerve nucleus is on the midbrain's lower position, at the level of the colliculus inferior, ventrolaterally to the sylvian aqueduct. It is considered an appendix of the oculomotor nuclear complex, dorsal and caudal to the medial longitudinal fasciculus.

The GSE fibers move posteriorly and caudally, surround the sylvian aqueduct and penetrate the velum medullaris anterior, or valve of Vieussens, where they cross and emerge on the brainstem's dorsal surface, under the inferior colliculi. They surround the brainstem, penetrate the dural lateral wall of the cavernous sinus below the oculomotor nerve, and enter the orbit through the superior orbital fissure. The IV cranial nerve innervates the superior oblique muscle.

It receives fibers from the medial longitudinal fasciculus, which connects it to the vestibular nuclei.

III. Abducent Nerve (VI Cranial Nerve)

The nucleus of the abducent nerve is located in the pons, near the tegmen of the fourth ventricle, surrounded by the genu of the facial nerves' radicular fibers (colliculus facialis). Its GSE fibers cross the tegmentum rhombencephali moving ventrolaterally, and emerge at the end between pons and medulla, at the level of the pontomedullary sulcus to the foramen cecum's sides, superiorly to the bulbar pyramids. The nerve ascends in the prepontine cistern and penetrates inside the cavernous sinus through the canal of Dorello. It innervates the lateral rectus muscle.

The nucleus of the abducent nerve receives direct and crossed fibers coming from the vestibular nuclei (inferior, medial and lateral) and pulses deriving from the cerebral cortex, through corticoreticular fibers and intercalated neurons in the reticular formation.

Trigeminal Nerve (V Cranial Nerve)

The trigeminal nerve is mixed, mainly sensitive, and containing general somatic afferent (GSA) and motor special visceral efferent (SVE) fibers. It derives from the reunion of three branches: ophthalmic (V1), maxillary (V2) and mandibular (V3). The ophthalmic nerve derives from the conjunction of three main branches: lacrimal, frontal and nasociliary. It carries sensitivity from the upper face and the eye, penetrates the skull through the superior orbital fissure and forms the V1 nerve. This passes through the cavernous sinus and reaches Meckel's cave, where the trigeminal ganglion (or Gasser's or semilunar ganglion) is located. The sensitivity of the maxillary region and the upper teeth is carried by the maxillary nerve. It passes through the foramen rotundum, enters the cavernous sinus and reaches the Gasserian ganglion. The mixed component is represented by the 3rd branch, the mandibular nerve. It carries sensitivity from the mandibular region of the face and the lower teeth and receives the meningeal branch through the foramen spinosum. Moreover, it carries motor fibers mostly directed to masticator muscles (temporal, masseter and pterygoid) and the tensor veli palatini and tensor tympani muscles. The three branches join together in Gasserian ganglion. This is a plexiform structure, located in a proper cistern inside Meckel's cave. The preponderance of CSF makes the MR signal of the ganglion CSF-like in T2-w sequences. The GSA component of the trigeminal nerve, with a voluminous root, penetrates the pons' lateral part, at the edge toward the middle cerebellar peduncle, crosses the tegmentum, and ends in the sensory nuclei of the pons and bulb: mesencephalic nucleus, main sensory nucleus and nucleus spinalis, where a definite topographic organization exists: ophthalmic fibers are more ventral; mandibular dorsal and maxillary ones are intermediate.

The nerve's special visceral efferent (SVE) component originates from the motor nucleus at the level of the pons, and exits medially at the access of the sensory root.

The mesencephalic nucleus of the trigeminal nerve is near the lateral edge of the gray matter of the fourth ventricle's and sylvian aqueduct's upper parts. Here, proprioceptive impulses (of pressure and kinaesthesia) arrive from teeth, periodontium, hard palate, and capsulae articulares.

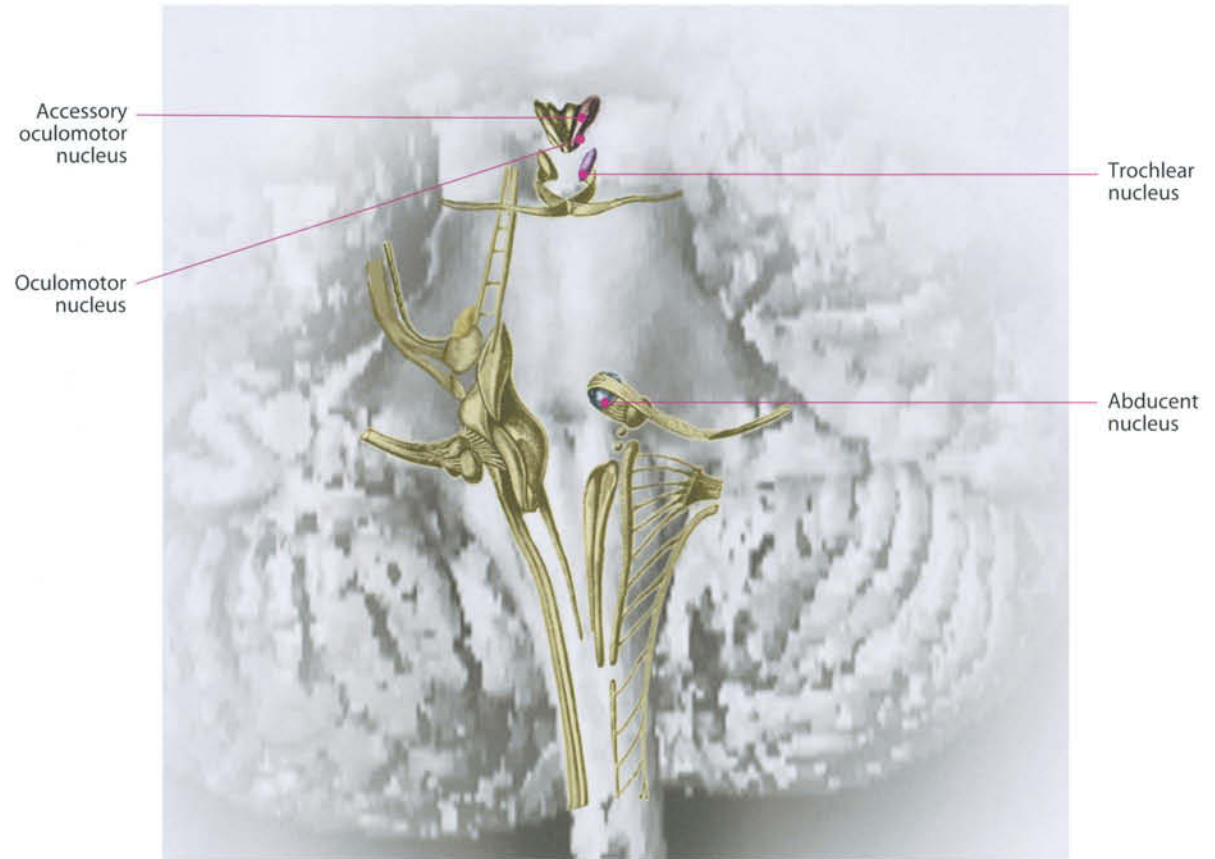
The main sensory nucleus is placed laterally at the access of the trigeminal nerve's radicular fibers in the upper part of the pons and receives general somatic afferent (GSA) fibers, transporting impulses for touch and pressure.

The spinal tract extends from the level of the trigeminal nerve's root in the pons to upper cervical spinal segments. It receives impulses from the internal structures of nose and mouth, from the cutaneous facial regions, forehead, cheeks and jawbone, and contains small groups of fibers with GSA components coming from the VII, IX and X nerves.

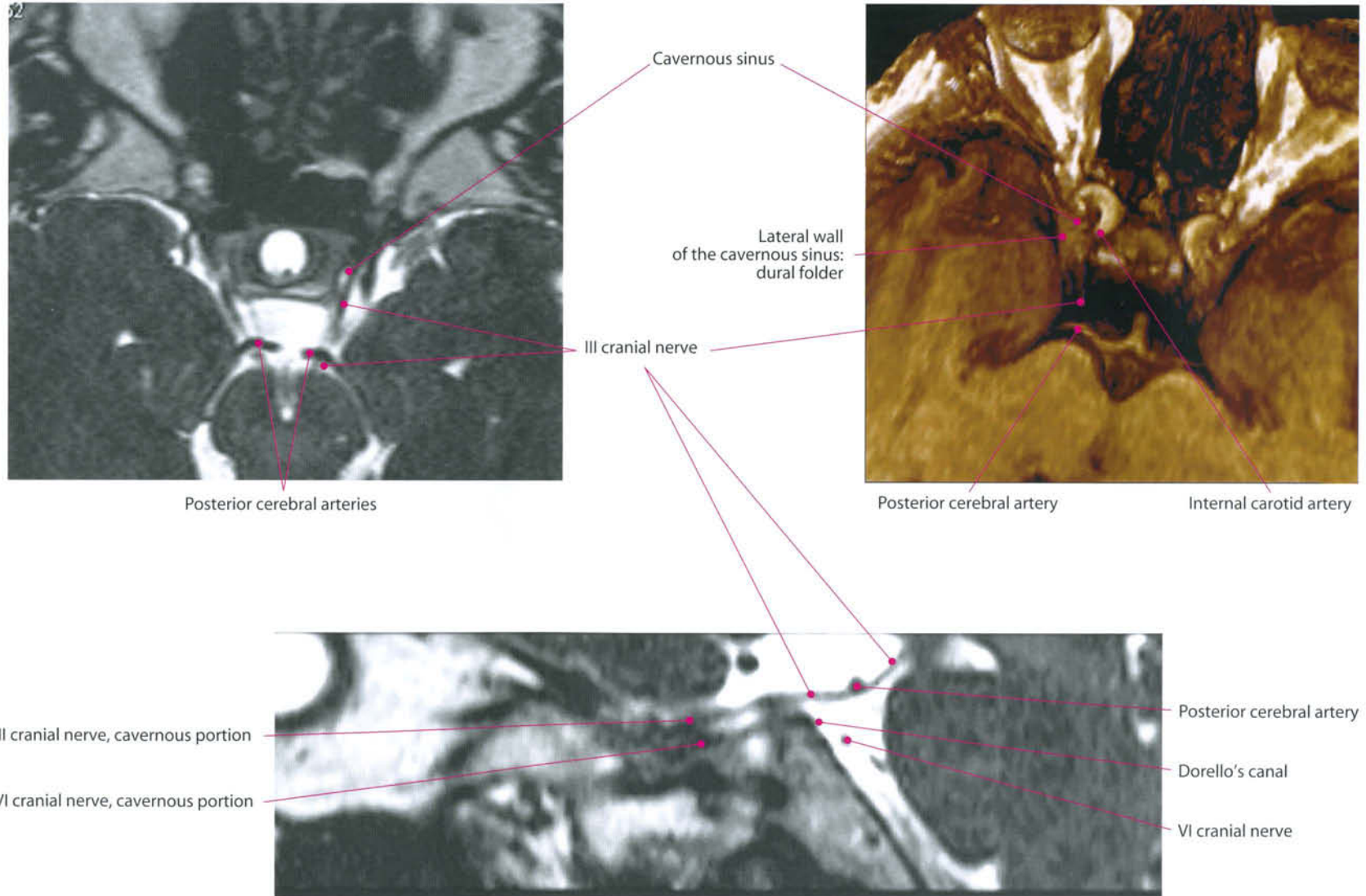
The motor nucleus (masticator nucleus) is placed medially between the motor root and the main sensory nucleus. It receives collaterals from the mesencephalic and main sensory nuclei and from the nucleus of the VIII nerve.

The sensory nuclei of the trigeminal nerve (principal and spinal) show connections to the reticular formation of the bulb, to the cerebellum (through the inferior cerebral peduncle), and to the nucleus ventralis posteromedialis thalami of the opposite side (ventral thalamic trigeminal tract) and of the same side (dorsal trigeminal tract).

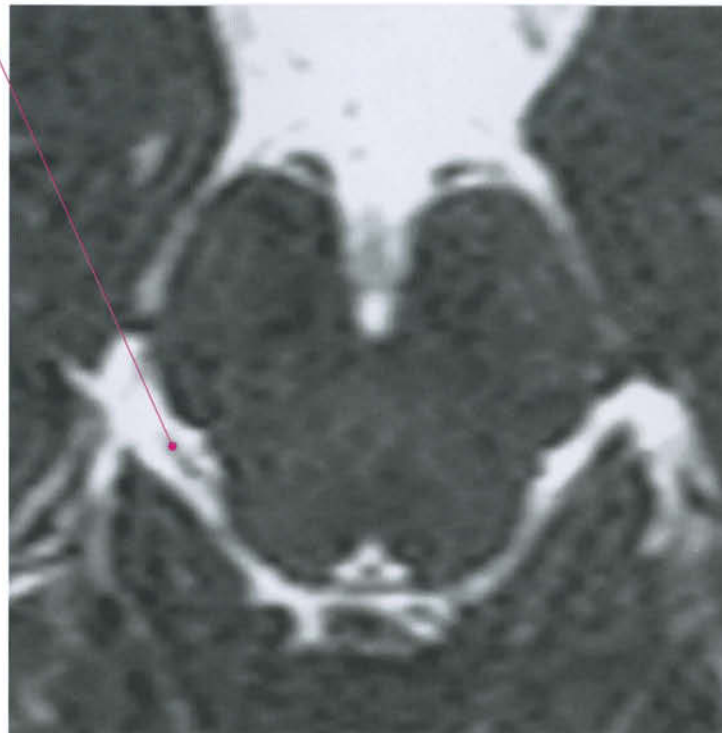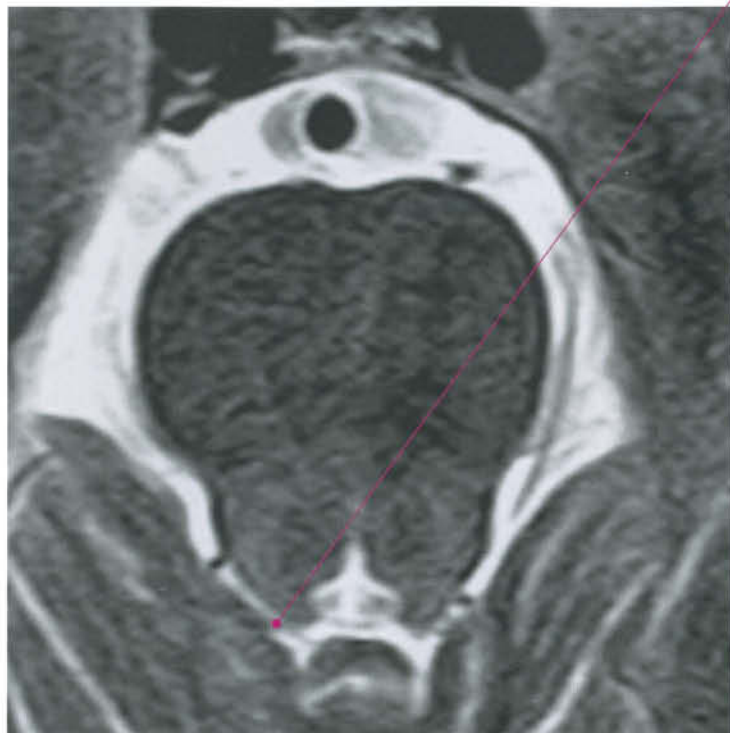The mesencephalic nucleus projects to the cerebellum. It is also connected to the nuclei of XII, XI, X, IX, VII and V nerves for corneal, lacrimal, sneezing, vomiting, salivary and oculo-cardiac reflexes.



III Cranial Nerve: Oculomotor Nerve

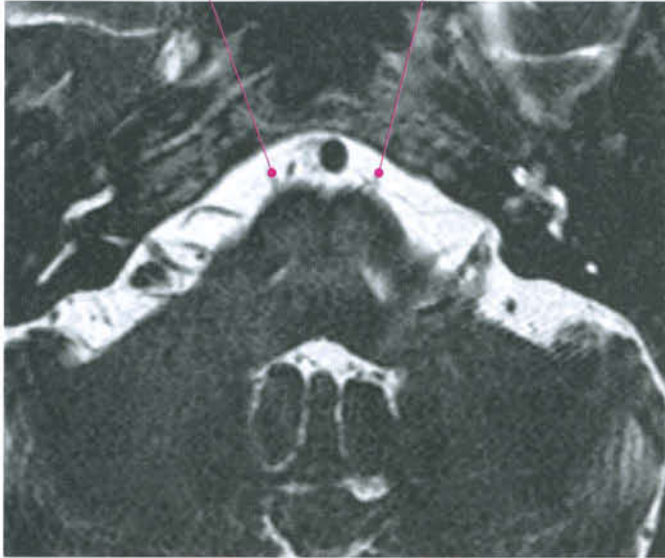


IV Cranial Nerve: Trochlear Nerve

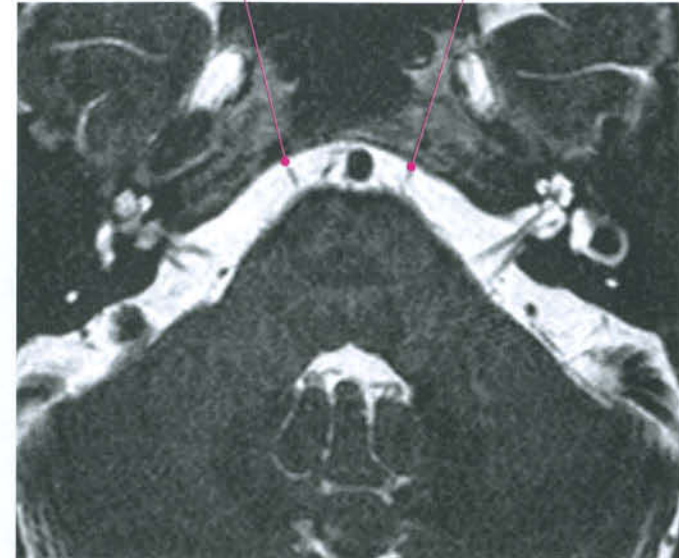


VI Cranial Nerve: Abducent Nerve

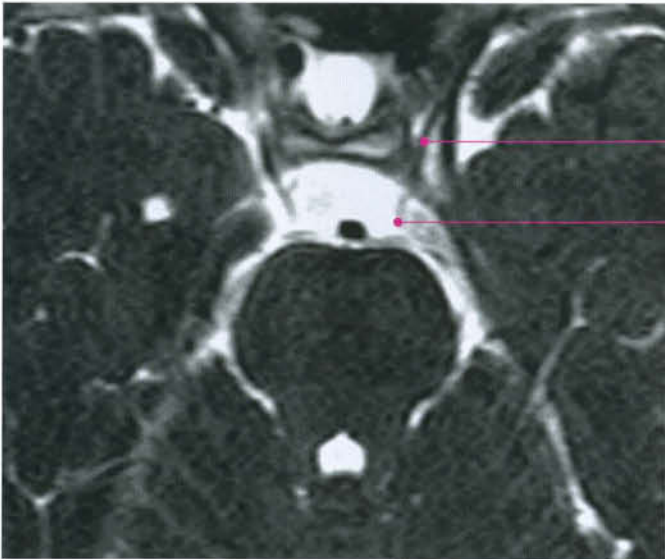
Emergence at the pontomedullary sulcus



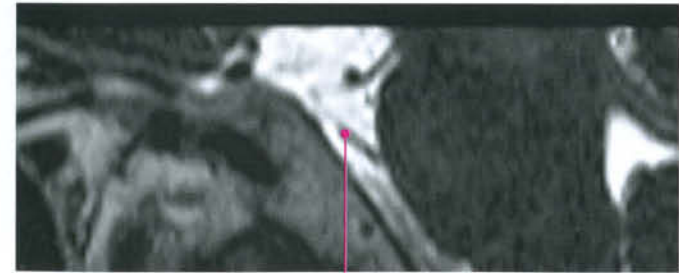
Cisternal portion at the mid-level of the pons

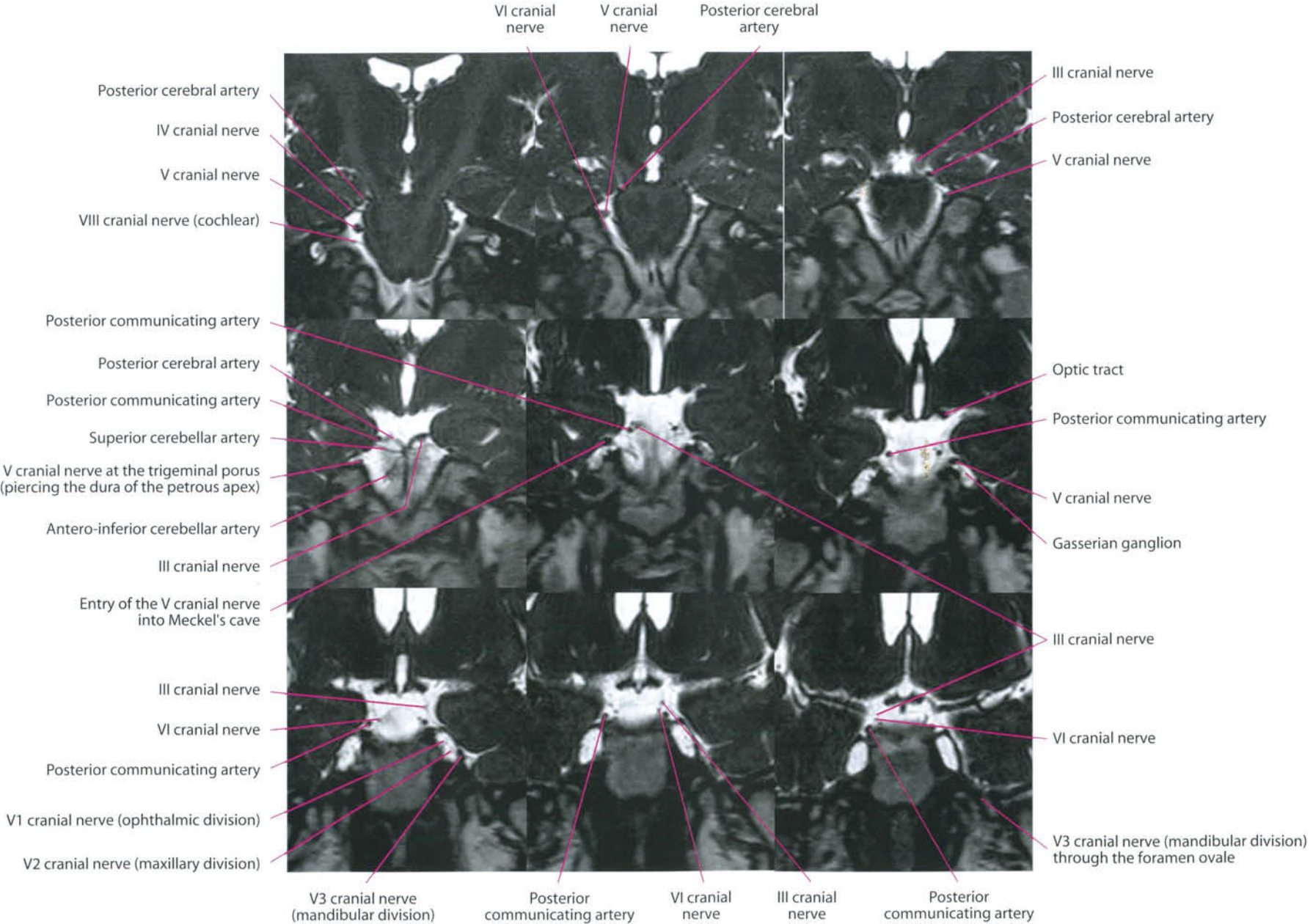


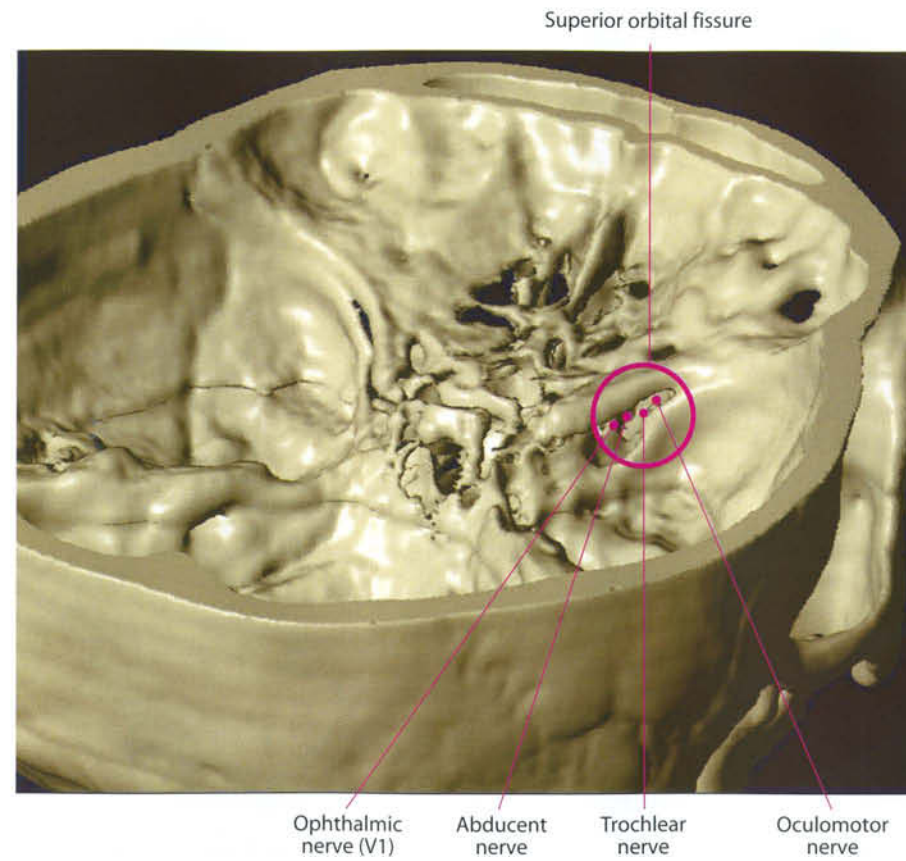
Entry into the cavernous sinus through Dorello's canal



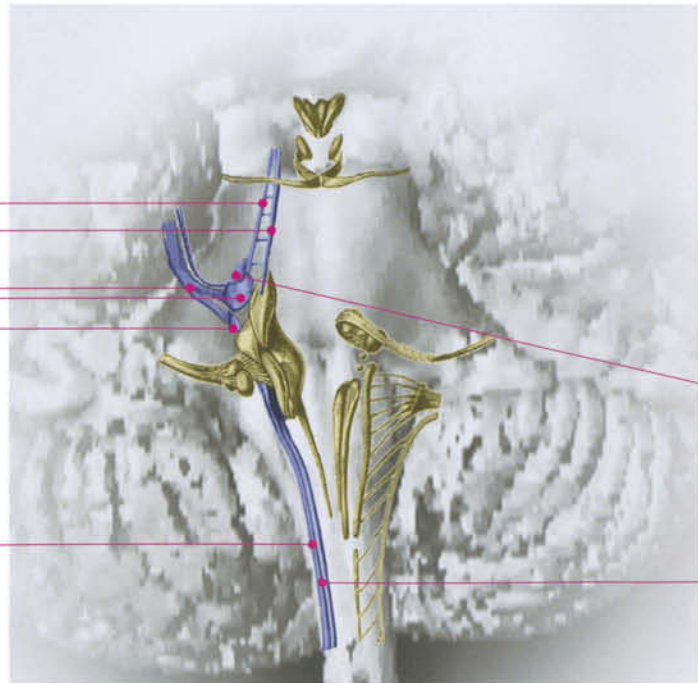
Cisternal portion





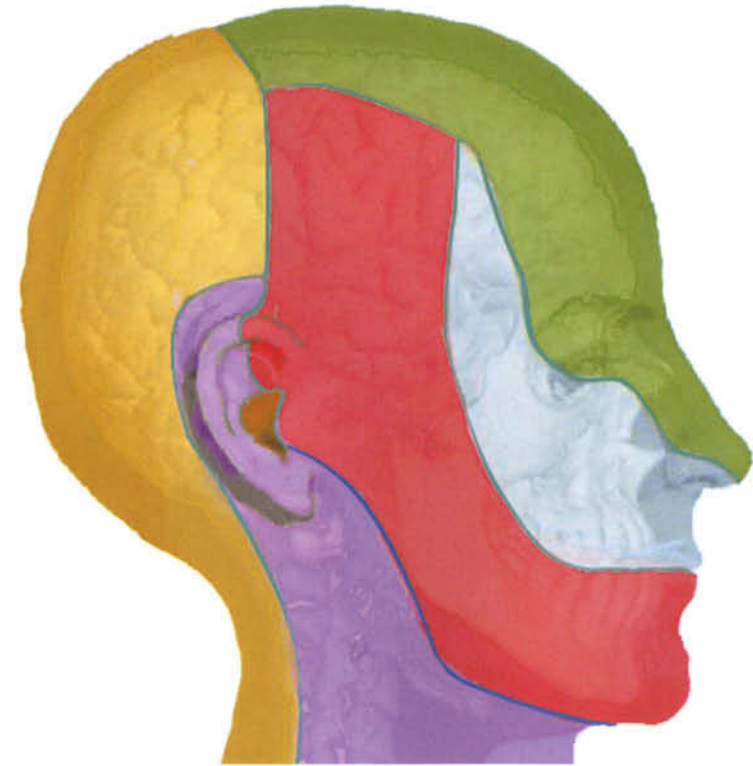

- Spinal tract of trigeminal nerve
- Spinal nucleus of trigeminal nerve
- Sensory nucleus of trigeminal nerve
- Sensory root of trigeminal nerve
- Mesencephalic nucleus of trigeminal nerve
- Mesencephalic tract of trigeminal nerve

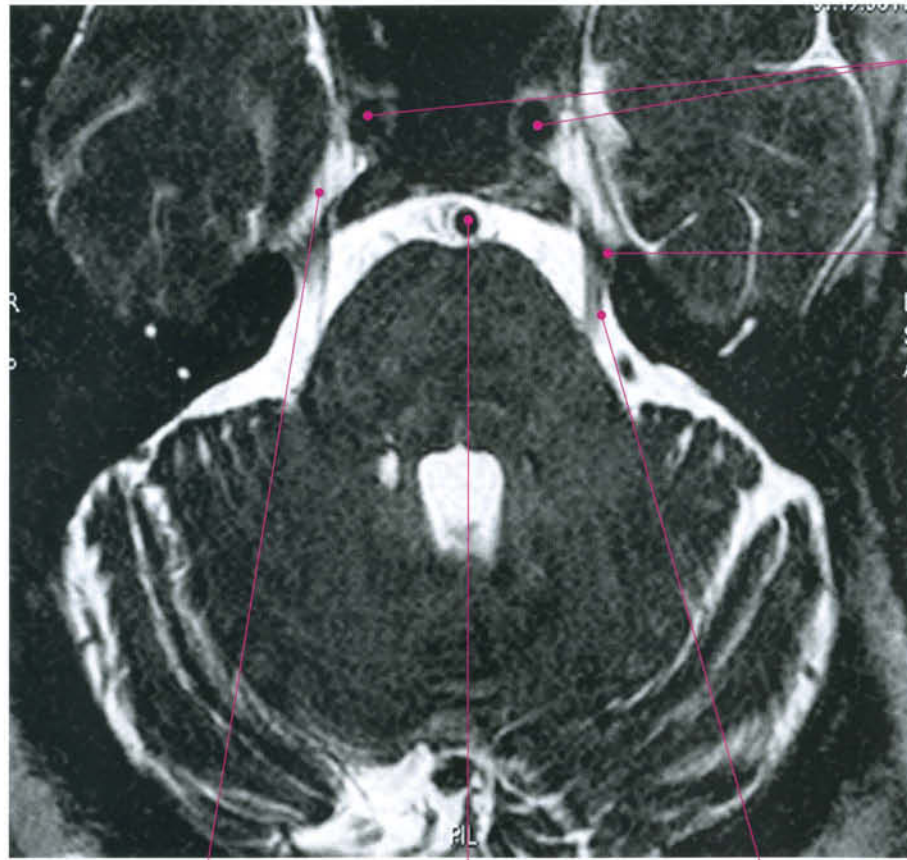


Motor nucleus of trigeminal nerve

Spinal nucleus of trigeminal nerve



- Ophthalmic nerve (V1), branch of trigeminal nerve
- Maxillary nerve (V2), branch of trigeminal nerve
- Mandibular nerve (V3), branch of trigeminal nerve
- Branches from cervical plexus
- Dorsal rami of cervical spinal nerves
- Auricular branches of vagus nerve



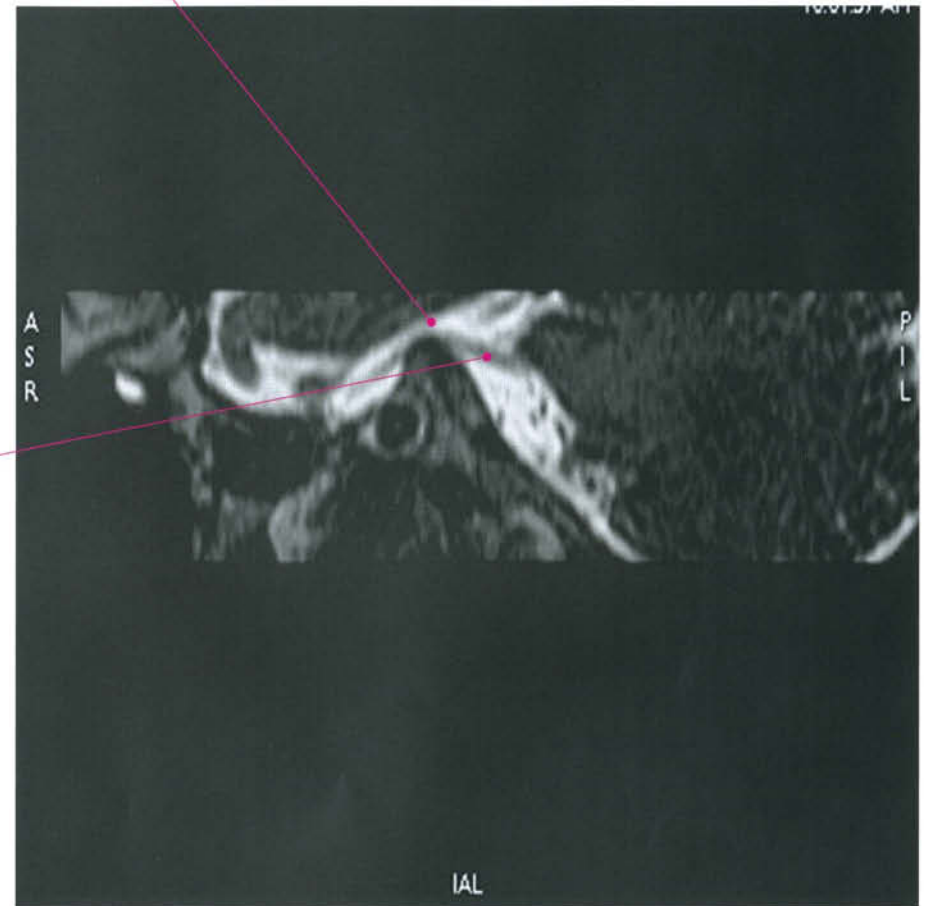
Internal carotid artery

Dural pass through the trigeminal porus at the petrous apex, toward Meckel's cave

Plexiform appearance of the gasserian ganglion

Basilar artery

Cisternal portion of the trigeminal nerve

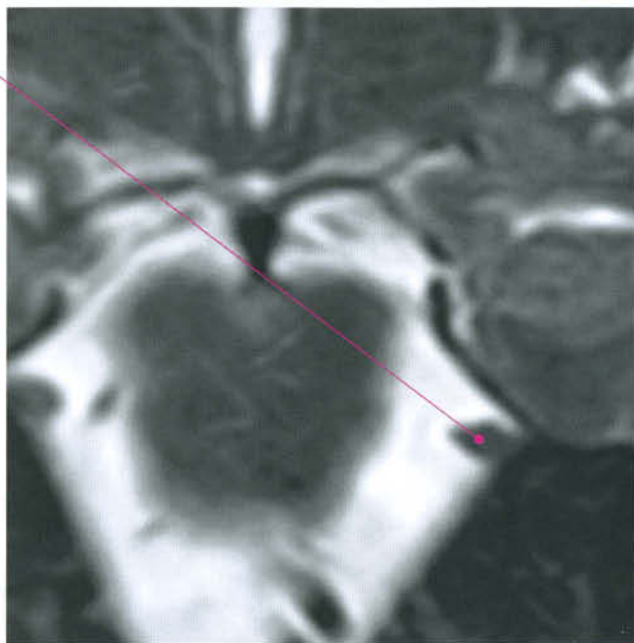
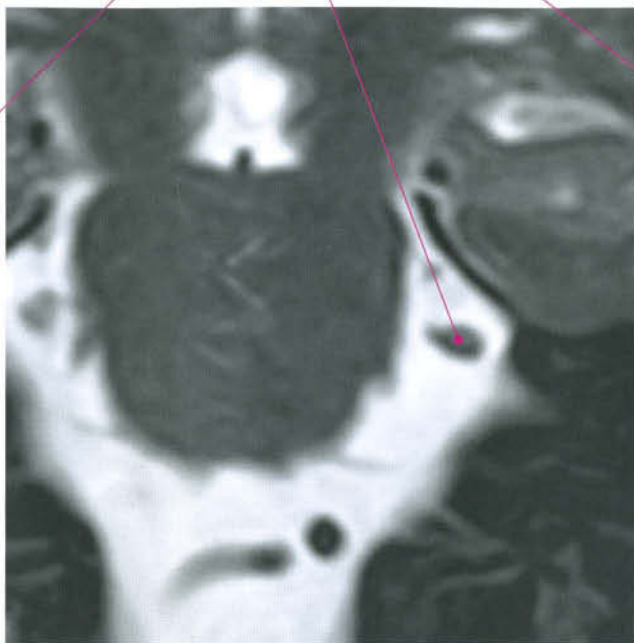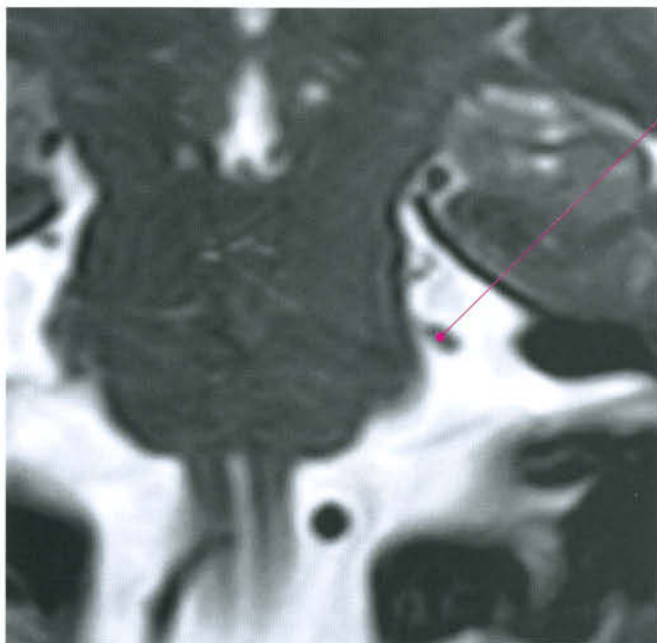


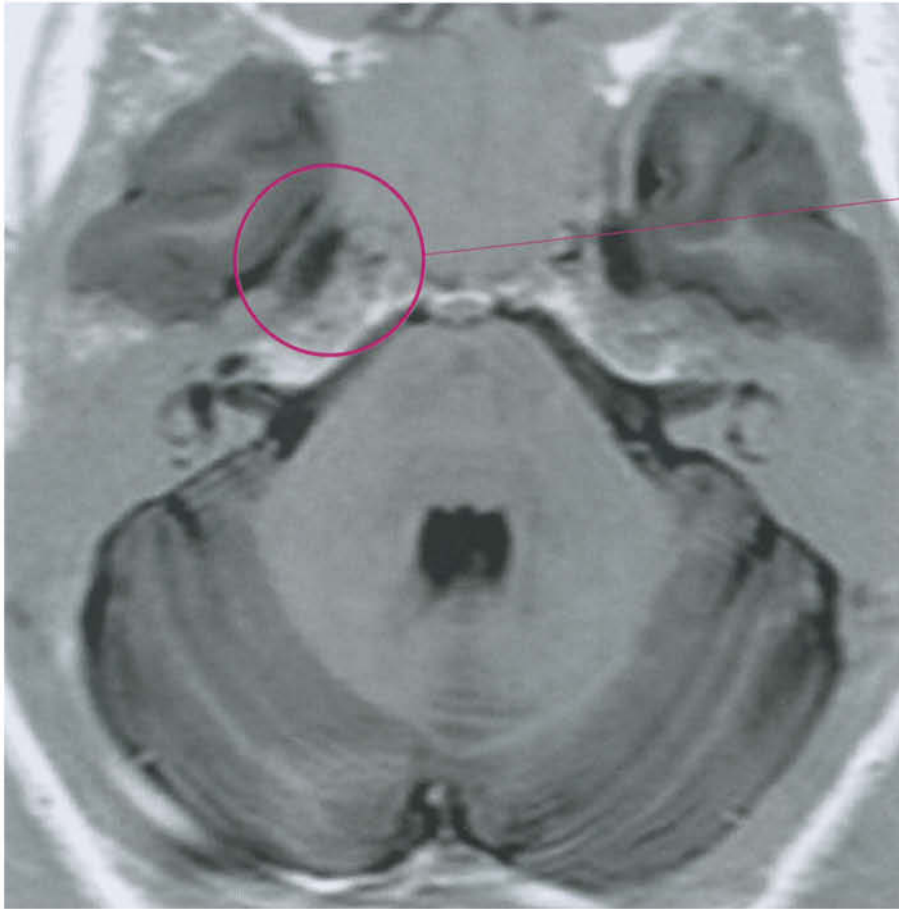
A
S
R

P
I
L

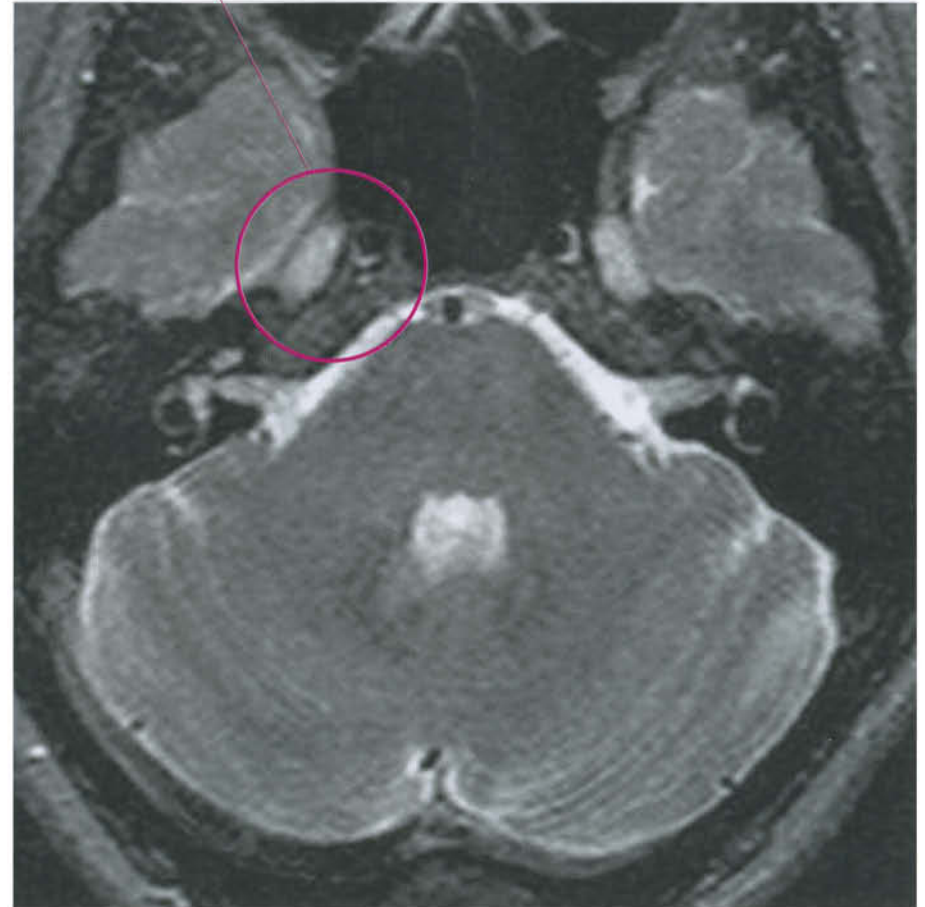
IAL

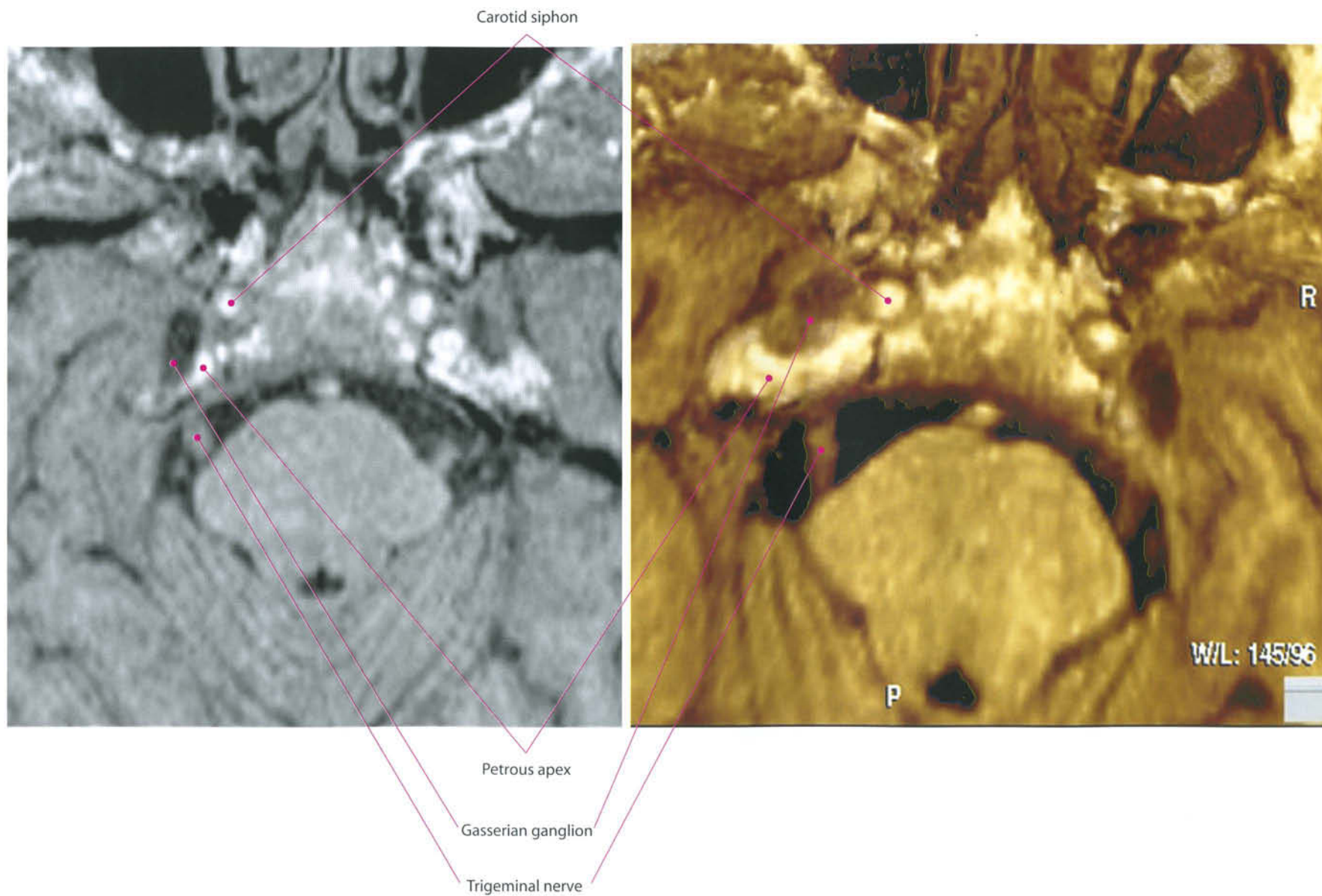
Trigeminal nerve, cisternal portion

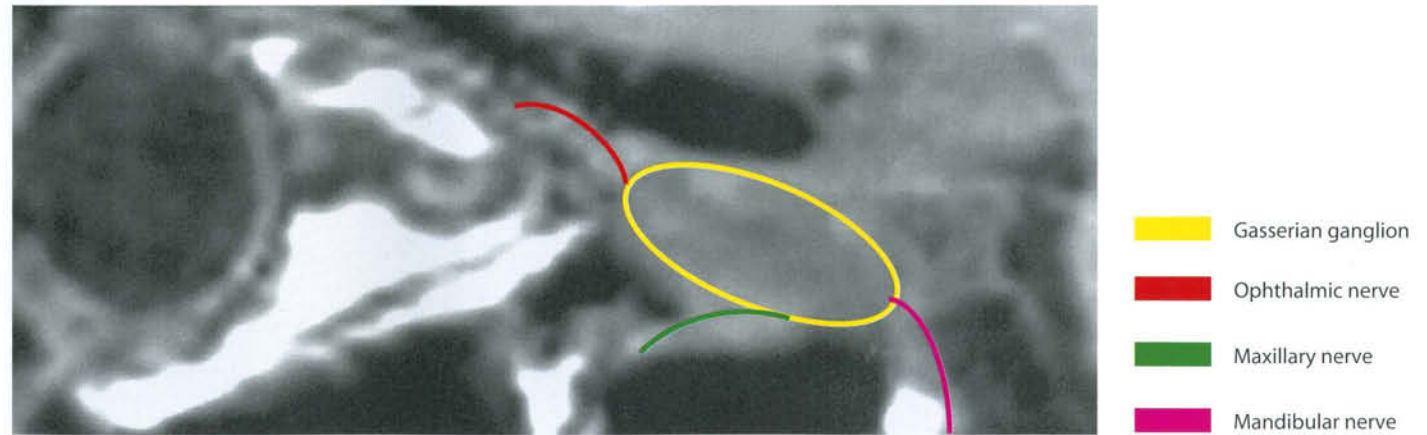
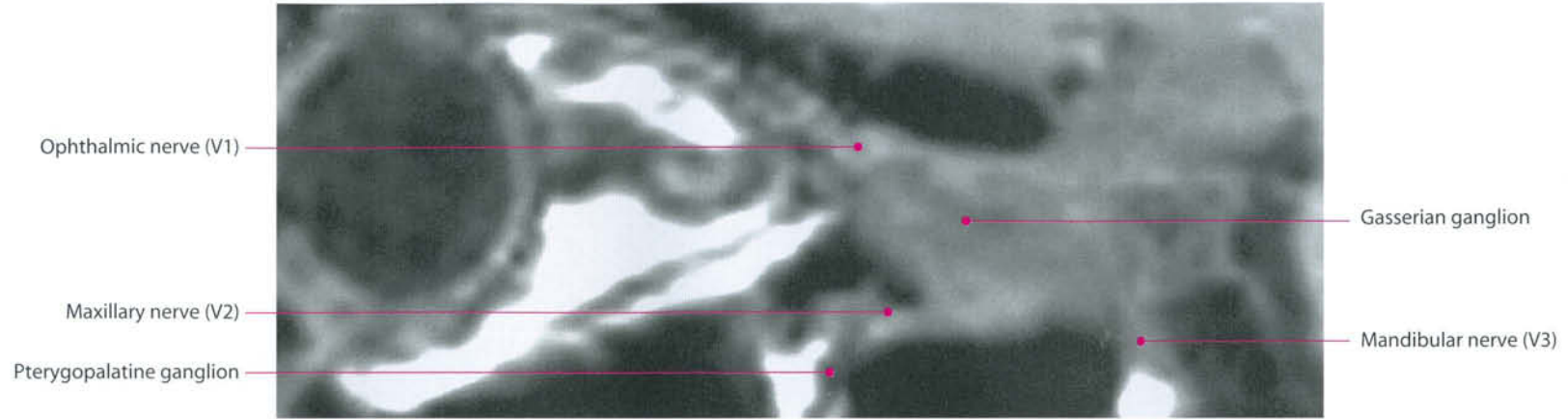


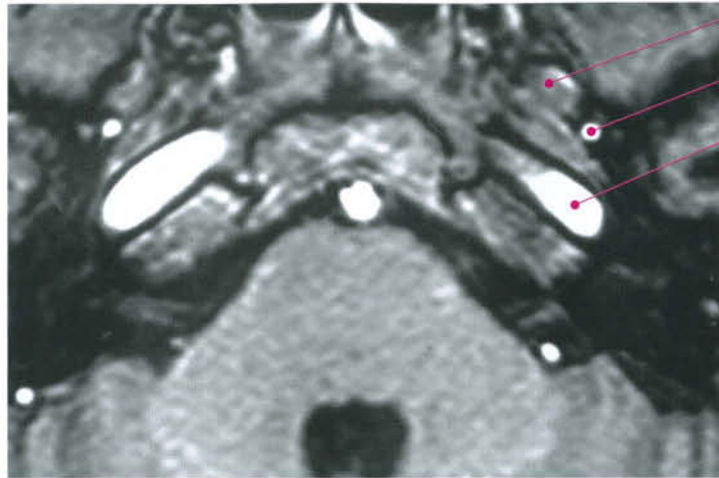


Gasserian ganglion

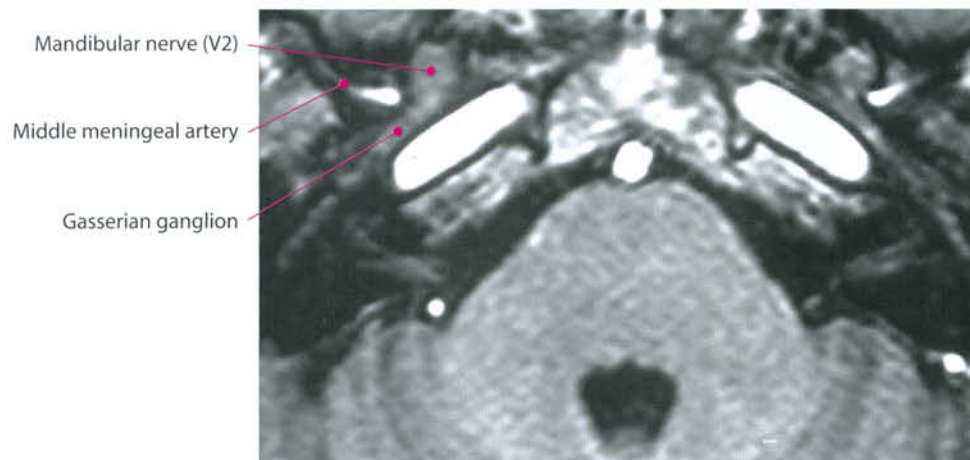




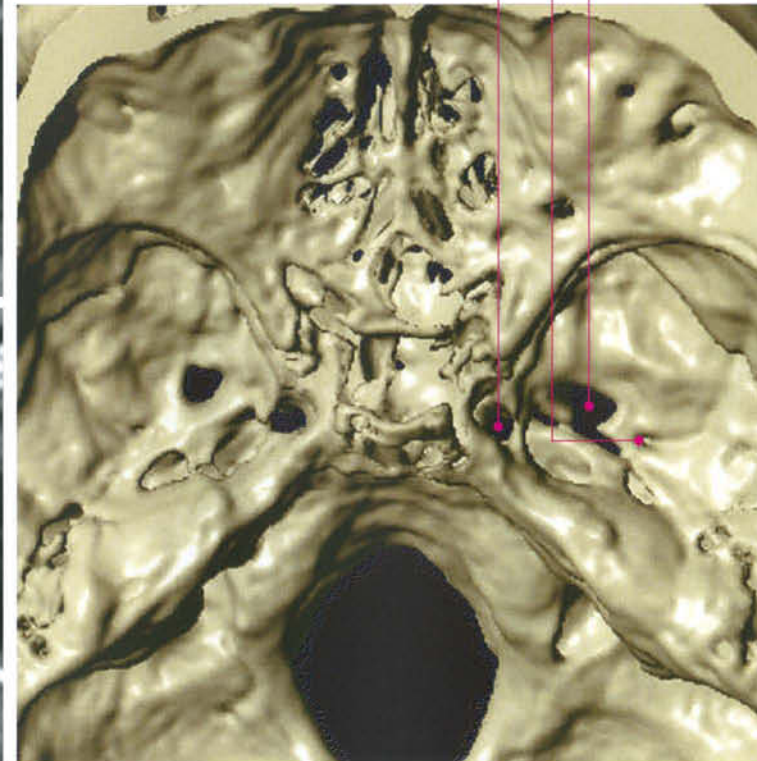


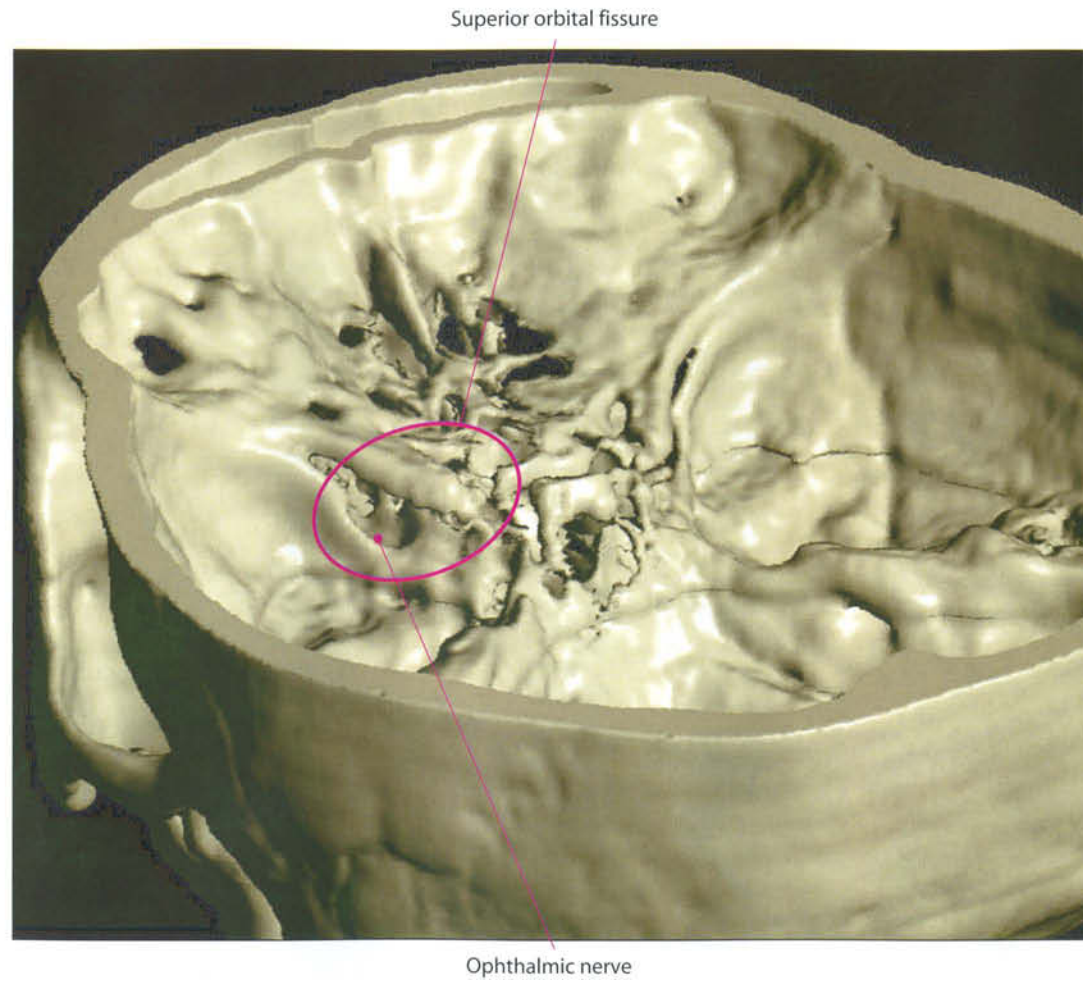


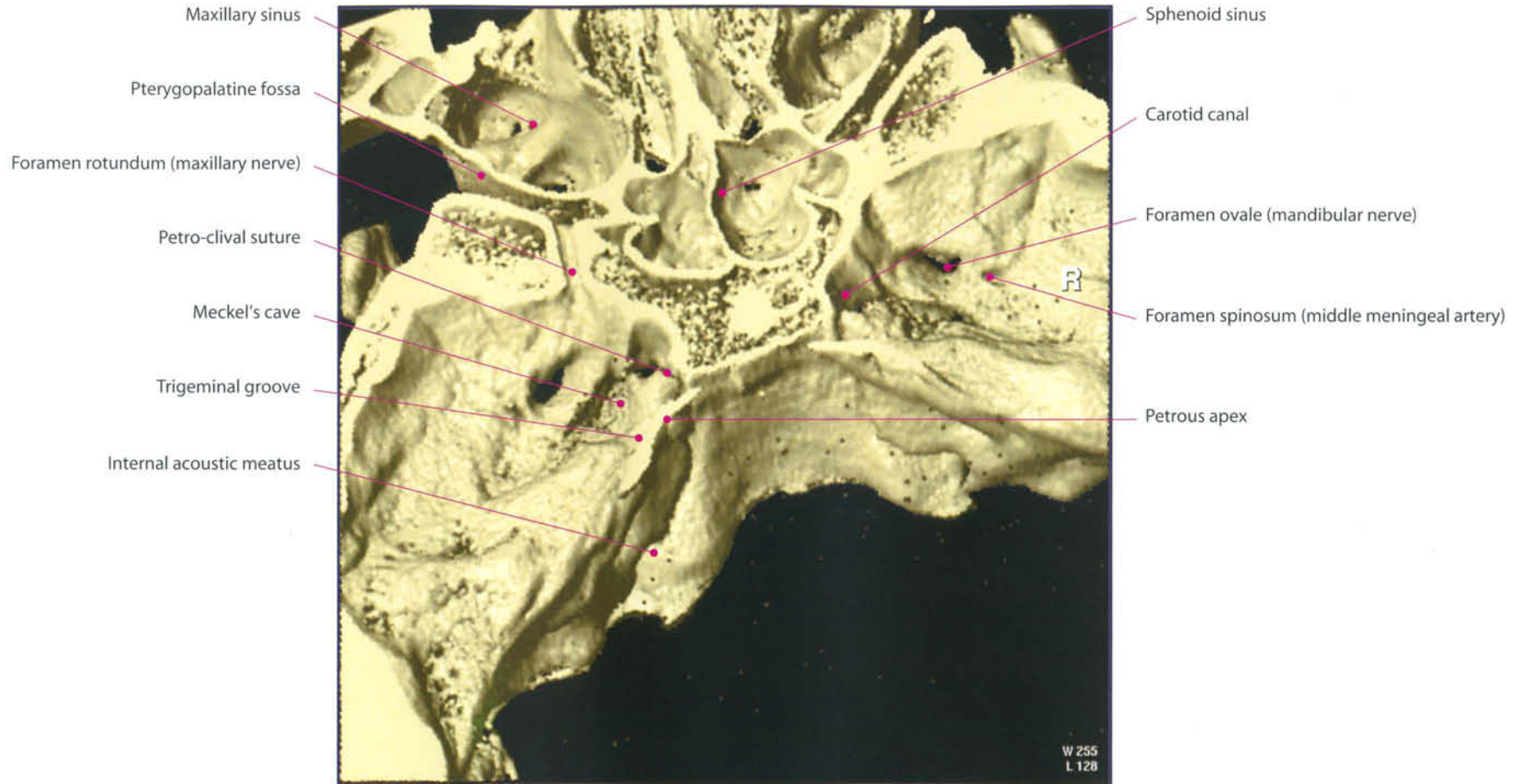
- Mandibular nerve (foramen ovale)
- Middle meningeal artery (foramen spinosum)
- Carotid artery, petrous segment (foramen lacerum)



- Mandibular nerve (V2)
- Middle meningeal artery
- Gasserian ganglion







Facial (VII Cranial Nerve), Cochlear (VIII Cranial Nerve, pars Cochlearis), Vestibular (VIII Cranial Nerve, pars Vestibularis) Nerves, Related Systems and Petrous Bone

I. Facial Nerve (VII Cranial Nerve) and Its System

The motor nucleus of the facial nerve is placed in the tegmen of the pons, dorsally to the nucleus olivaris superior and ventromedially to the nucleus spinalis of the trigeminal nerve. The special visceral efferent (SVE) fibers emerging from the dorsal side of the nucleus are dorsomedially projected on the tegmen of the fourth ventricle. These fibers go up longitudinally, medially to the nucleus of the abducent nerve, and dorsally to the medial longitudinal fasciculus; near the rostral pole of the abducent's nucleus, they curve ventrolaterally and emerge from the brainstem into the bulbopontine sulcus, in correspondence with the supraolivary fossa, and medially to the nervus intermedius. They innervate the facial mimetic muscles, the posterior belly of digastric muscle, the stylohyoideus, styloglossus, platysma, buccinator, stapedius muscles, and some muscles of the velum palati.

This nucleus exhibits connections with the sensory nuclei of the V, VIII (cochlear), IX and X cc.nn.

The general somatic afferent (GSA) fibers carry cutaneous sensory impulses from the external auditory meatus and the region behind the ear; centrally, these fibers enter the dorsal portion of the spinal tract of the trigeminal nerve.

The preganglionic parasympathetic general visceral efferent (GVE) radicular component of the nervus intermedius, or Wrisberg's nerve, originates from two nuclei, the lacrimo-mucosal nucleus and the superior salivatory nucleus, located in the pons, rostrally to the inferior salivatory nucleus, and emerges from the bulbopontine sulcus, between the motor root of the facial nerve and the vestibular nerve.

The bundle of fibers originating from the lacrimo-mucosal nucleus emerges in the bulbopontine sulcus with the motor root of the facial nerve, and innervates the lacrimal gland, the nasal and buccal mucosa. The small radicular component originating from the superior salivatory nucleus spreads to the submandibular and sublingual glands.

These two nuclei are connected with the gustatory nucleus (VII, IX, and X cc.nn.) and the main sensory nucleus of the trigeminal nerve.

The special visceral afferent fibers (SVA) of the nervus intermedius reach the rostral portion of the nucleus of the tractus solitarius (gustatory nucleus), and carry the gustatory sensitivity of the front two-thirds of the tongue, whereas the general somatic afferent (GSA) fibers belong to the dorsal part of the spinal tract of the trigeminal nerve and carry cutaneous sensory impulses from the external auditory meatus and the region behind the ear.

The nerve crosses the ponto-cerebellar angle's cistern together with the VIII cranial nerve, enters the internal acoustic canal and penetrates its bottom. This is separated by a horizontal bony lamina (crista falciformis) into two compartments. The superior one is divided in two by a vertical fibrous wall. The complex facial-Wrisberg's intermediate nerve penetrates the upper-anterior compartment, and reaches the geniculate fovea in the petrous bone, where the geniculate ganglion is located. Here, fibers of the intermediate nerve separate and course anteriorly into the greater petrosal superficial nerve, toward the pterygopalatine ganglion and the lacrimal gland. The remaining fibers of the facial nerve curve backward and remain horizontal, then go downward reaching the foramen stylomastoideum, where they exit to join the parotid gland. Two main branches originate during this course: nervi stapedium and chorda tympani.

II. Cochlear Nerve, Vestibular Nerve (VIII Cranial Nerves) and Their Systems

II. 1. Acoustic System

Acoustic stimuli are generated by the tympanic membrane and are transmitted to the manubrium of the malleus, then to the incus and the stapes. The stapes base articulates with the oval window, which transmits the acoustic wave to the perilympha of the cochlea. The cochlea is a spiral structure composed of two and a half turns around a central bony structure, the modiolus. Each cochlear turn is divided by an osseous spiral lamina and a membranous one (basilar membrane), which contains the endolymphatic receptor system. Fibers originate from the basilar membrane, reach the spiral (Corti's) ganglion and cross the cribriform infero-anterior part of the internal wall of the internal acoustic canal (iac). Here, they form the cochlear nerve that joins the superior and inferior vestibular nerves and the posterior ampullary nerve, forming the VIII cranial nerve, and traveling together

with the facial one through the ponto-cerebellar cistern. The cochlear component of the vestibulocochlear nerve reaches the ventral and dorsal cochlear nuclei on the lateral side of the inferior cerebellar peduncle in the bulbopontine area, entering the brainstem at the supraolivary fossa level and branching off. These nuclei present a tonotopic localization which is also maintained in the following tracts of the pathway: the fibers coming from the apical turn of the cochlea, where low-pitched tones are located, reach the nucleus cochlearis ventralis and the ventral part of the dorsal nucleus; the fibers coming from the basal turn of the cochlea, where high-pitched tones are located, terminate in the dorsal portion of the dorsal nucleus.

The cochlear nuclei form the central cochlear pathway that is made up of acoustic striae of ventral type (originated from the ventral nucleus), of dorsal type (originated from the dorsal nucleus) and of intermediate type (originated from the dorsal portion of the ventral nucleus). These provide fibers to the reticular formation and the nucleus olivaris superior of the corpus trapezoideum, of the lateral lemniscus and to the superior quadrigeminal body. They go on to cross the median raphe and, like the lateral lemniscus, reach the medial geniculate bodies and the telencephalic cortex (gyrus temporalis superior).

The motor nucleus of the V, VI and VII cc.nn. exhibits connections with these nuclei that are inserted along the central acoustic pathway.

II. 2. Vestibular System

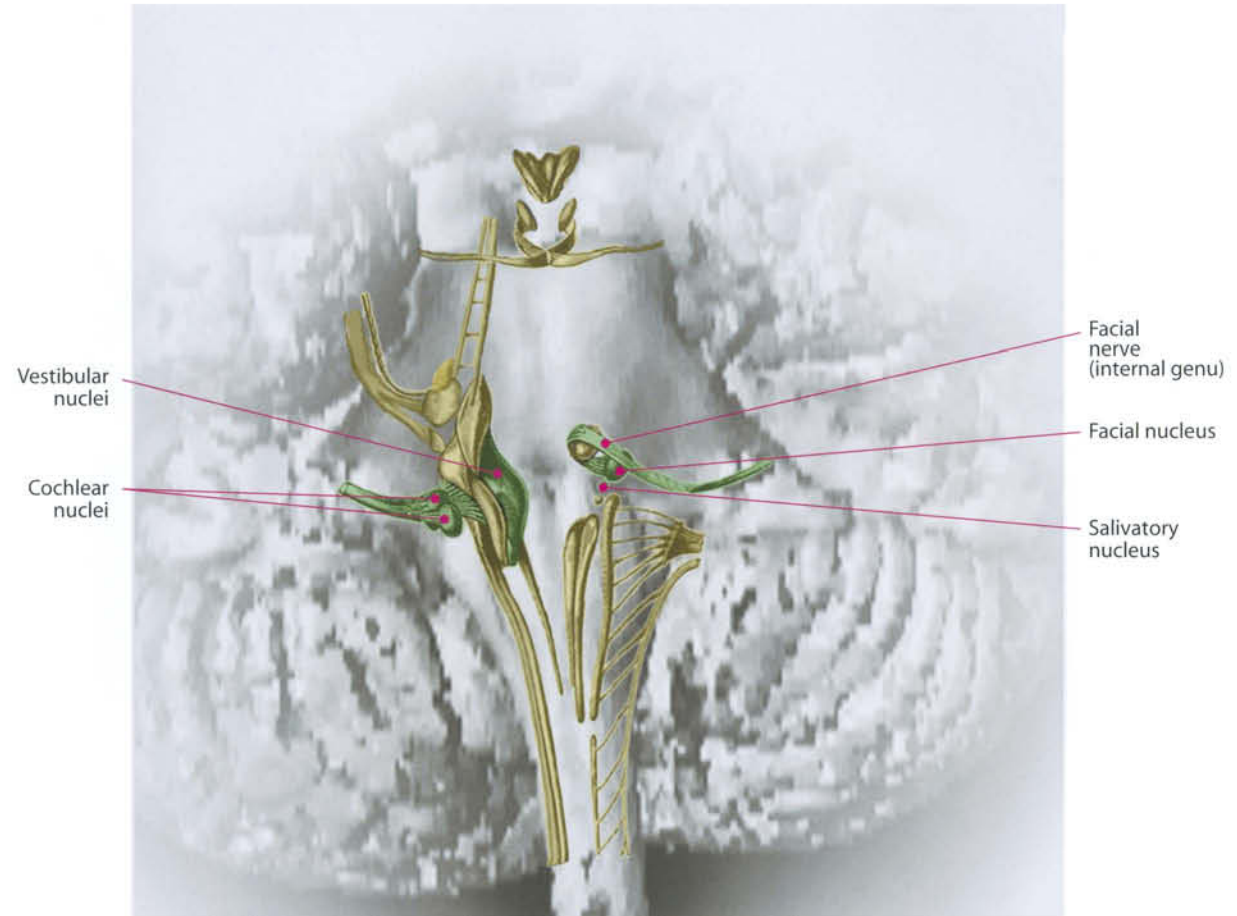
The vestibular stimuli come from fibers collected together in three main branches: inferior and superior vestibular nerves and posterior ampullary nerve. The superior vestibular nerve receives fibers coming from utricle, and superior and lateral semicircular canals; the inferior vestibular nerve is formed by fibers from the saccule; fibers of the posterior semicircular canal are collected in the posterior ampullary nerve. The superior vestibular nerve crosses the posterior wall of the iac in the postero-superior space, while the postero-inferior is occupied by inferior vestibular and posterior ampullary nerves. After crossing the iac's posterior wall, the three nerves form Scarpa's ganglion. From this point on, the vestibular nerve joins the acoustic and fuses with it. Vestibular nuclei are located on the tegmen of the fourth ventricle, rostrally to the hypoglossal nucleus, and extend well beyond

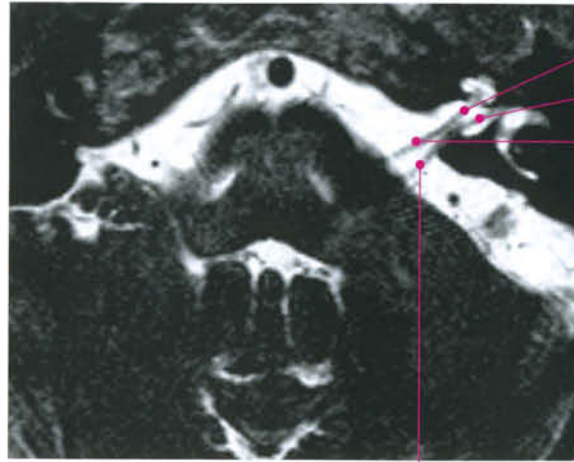
the nucleus of the abducent nerve. They are reached by the fibers of the vestibular nerve which enter the brainstem in correspondence with the retroolivary fossa, at the bulbo-pontine sulcus level. Once they have entered the vestibular complex, they branch off and spread in various ways to the nuclei of the same and opposite side, and to the interstitial nucleus of the vestibular nerve which is located between the vestibular fibers near the point where the nerve enters the brainstem, and then move towards the cerebellar cortex (nodule, uvula and flocculus of the same side). They carry the stimuli of gravity and acceleration.

The nuclei are placed in two longitudinal columns: the lateral column includes the descending (Deiters' nucleus), lateral and superior vestibular nuclei; the medial column is made up of the medial vestibular nucleus.

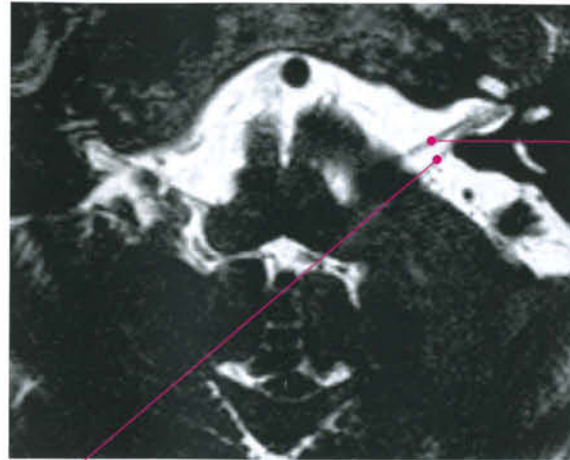
The descending vestibular nucleus is located in the bulb medially to the accessory cuneate nucleus. It then spreads rostrally inside the inferior cerebellar peduncle as far as the site where the vestibular nerve enters the brainstem. Distinctive projections from the macula utriculi and the macula sacculi (dorsolateral portion of the descending vestibular nucleus) reach this point.

The vestibular nuclei present connections with the cortex (ascending frontal gyrus), the bone marrow (vestibular-spinal and spinal-vestibular tracts), the cerebellum (vestibulo-cerebellar and cerebellovestibular tracts), the reticular formation, the nuclei of the III, IV, VI, and XI cc.nn. through the medial longitudinal fasciculus, and with the motor nucleus of the V c.n.



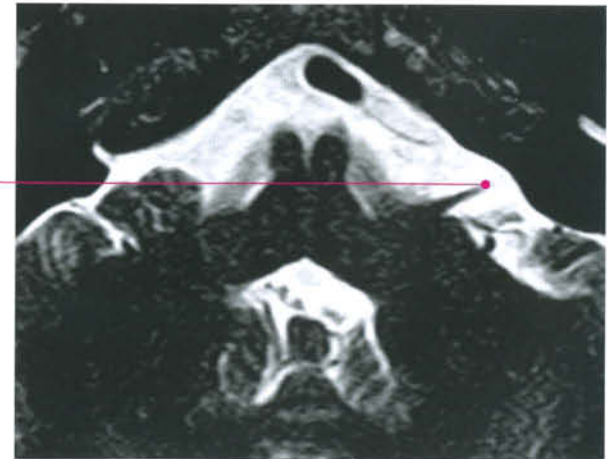


Cochlear nerve
Vestibular nerve
Facial nerve

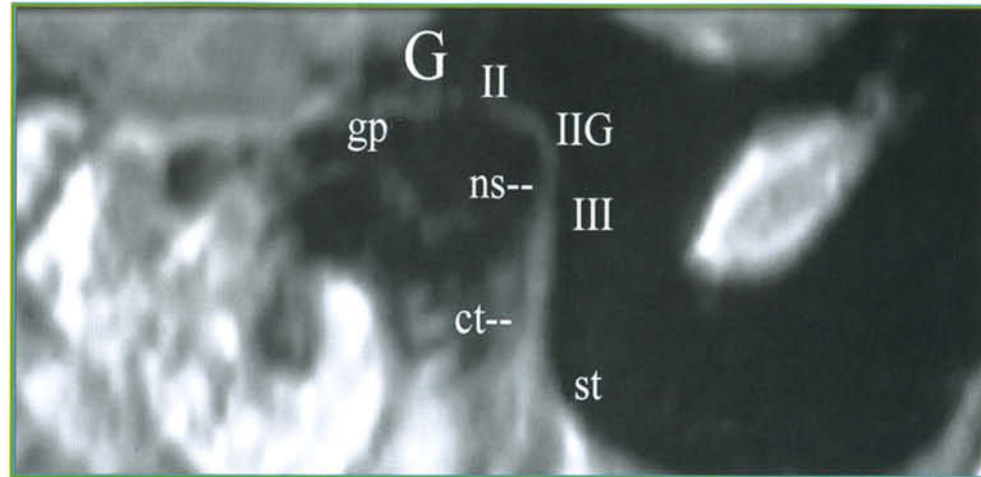
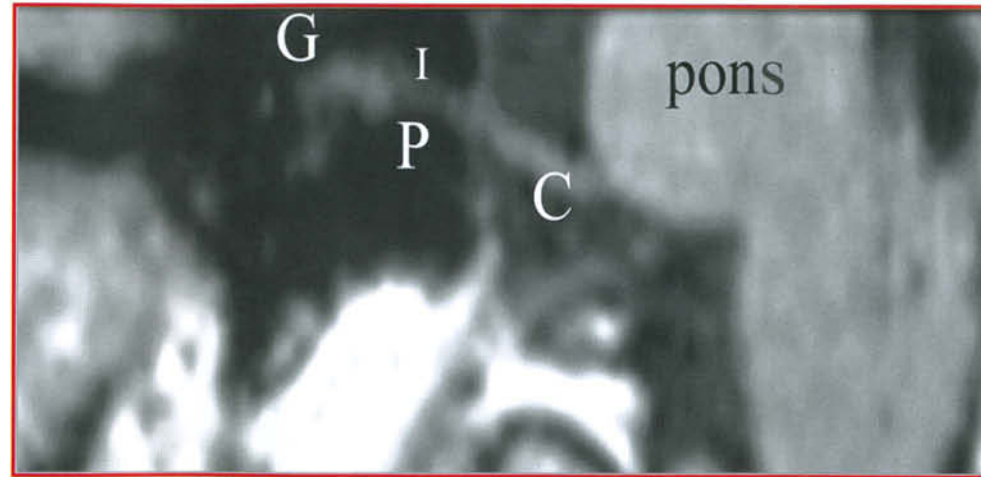
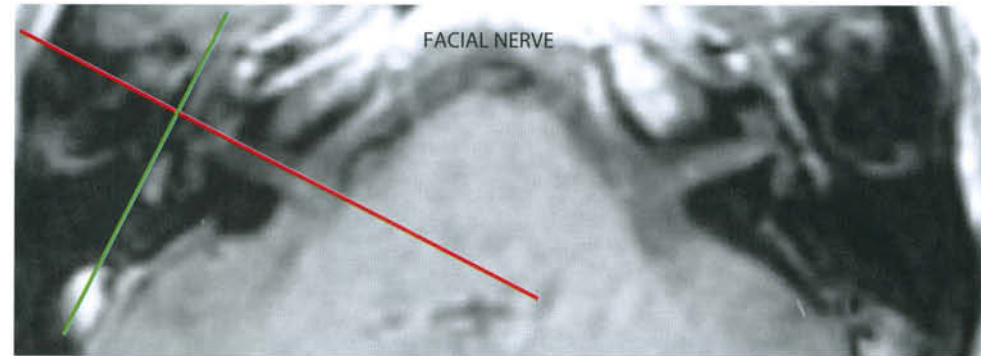
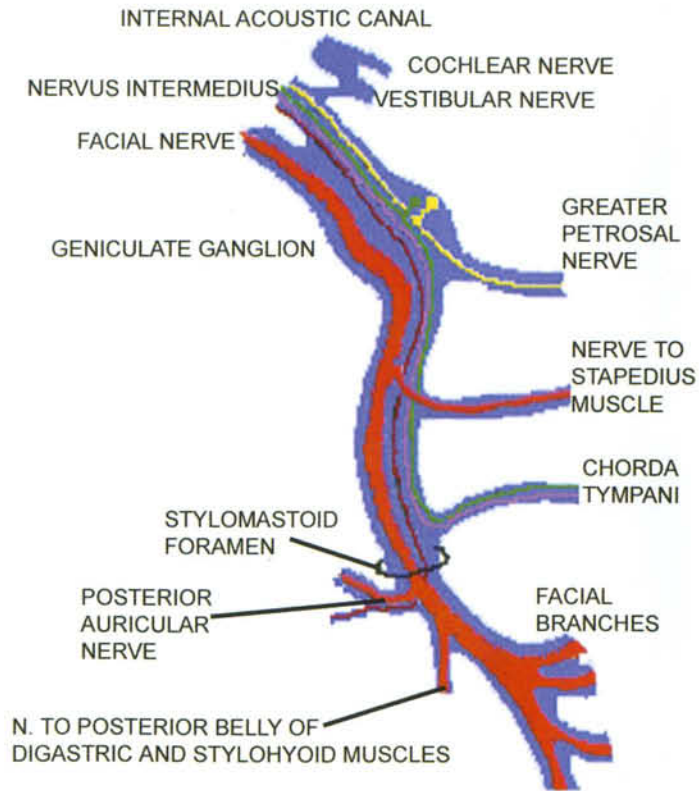


Facial nerve

Vestibulocochlear nerve

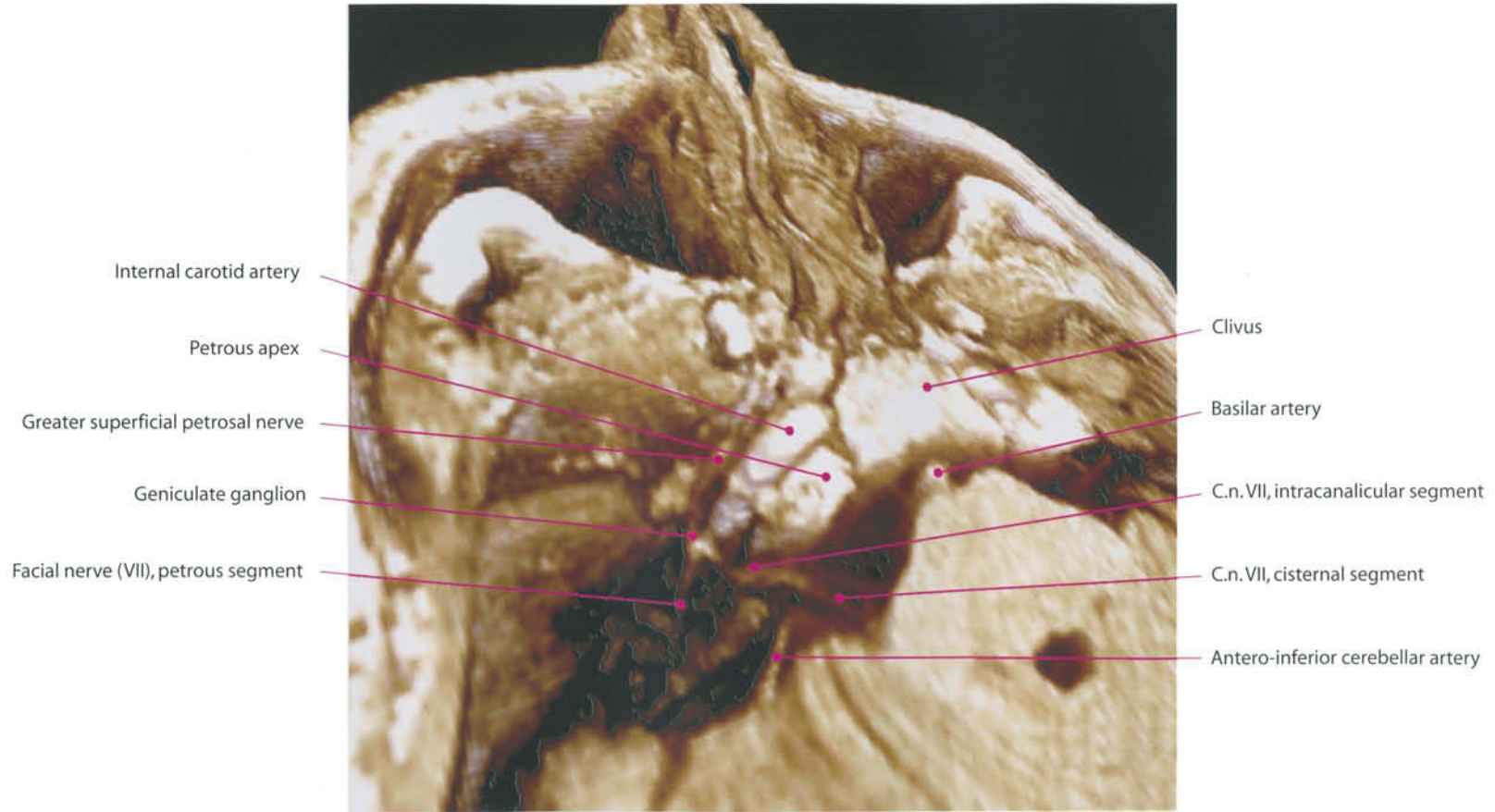


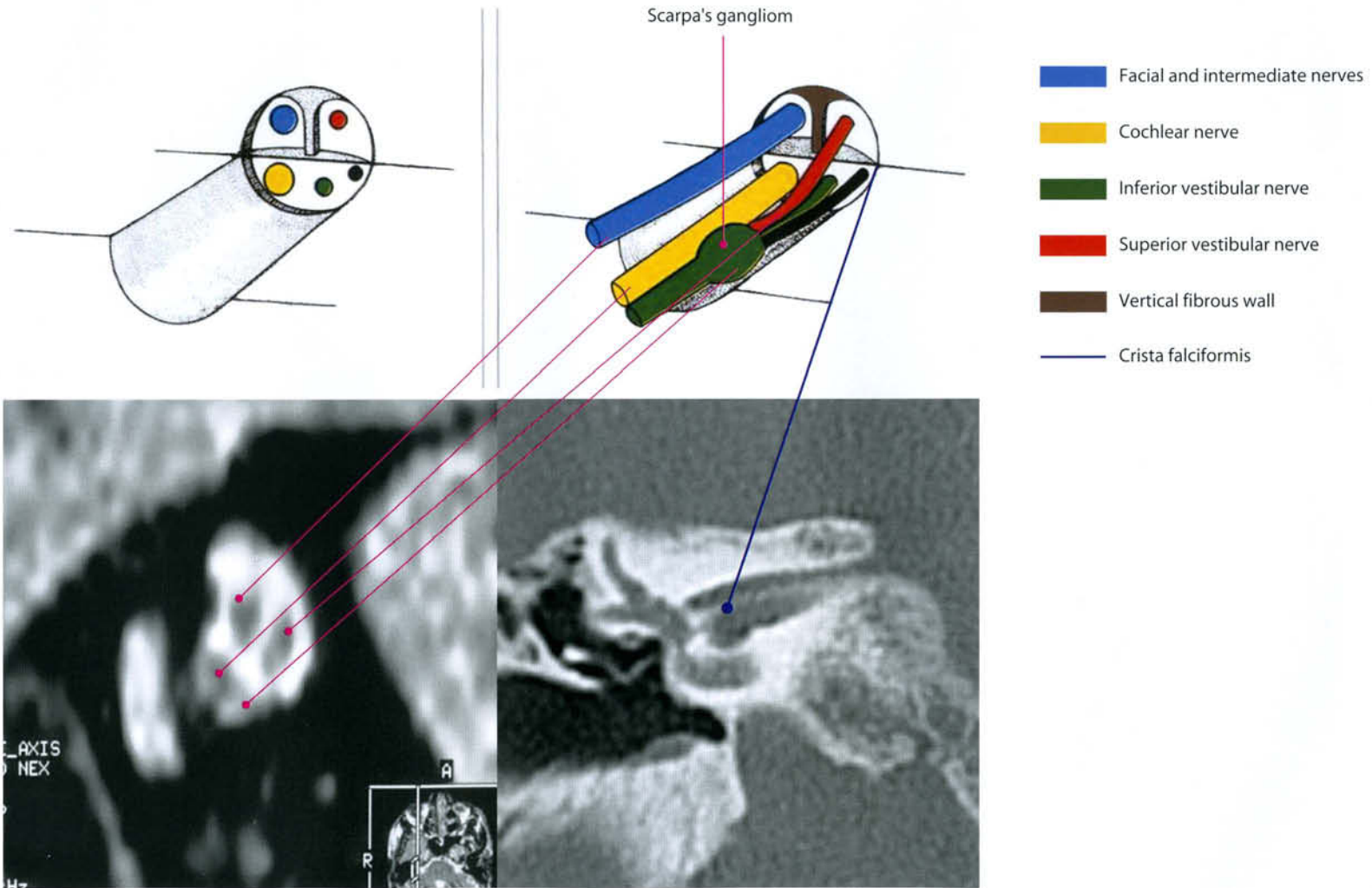
- MOTOR FIBERS
- ● GLAND SECRETORY FIBERS
- TASTE
- SENSORY FIBERS



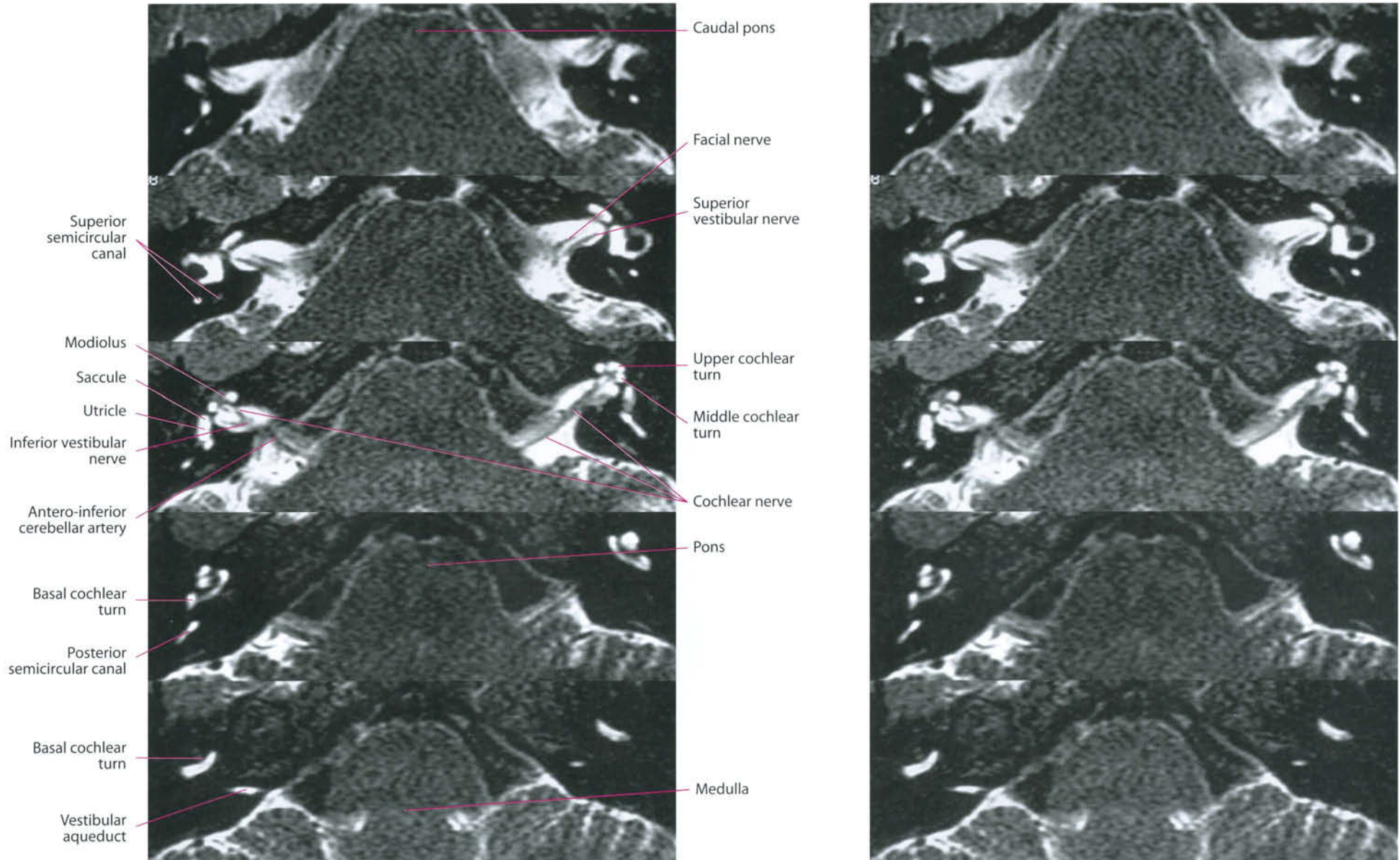
- | | |
|--|-----------------------------------|
| I = first segment (horizontal) of facial nerve | C = pontocerebellar angle cistern |
| II = second segment (horizontal) of facial nerve | gp = greater petrosal nerve |
| III = third segment (vertical) of facial nerve | ns = n. to stapedius muscle |
| IIG = second knee (geniculum) of facial nerve | ct = chorda tympani |
| G = geniculate ganglion | st = stylomastoid foramen |
| P = petrous pyramid | |

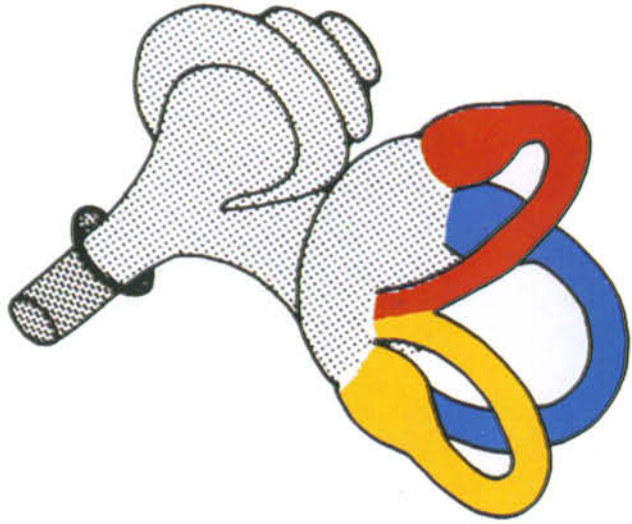
Facial and Intermediate (Wrisberg) Nerves



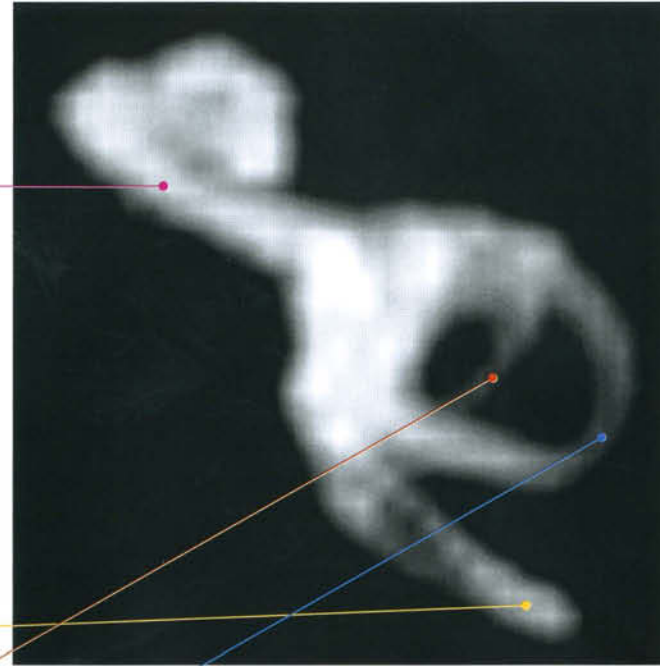

Membranous Labyrinth





Cochlea

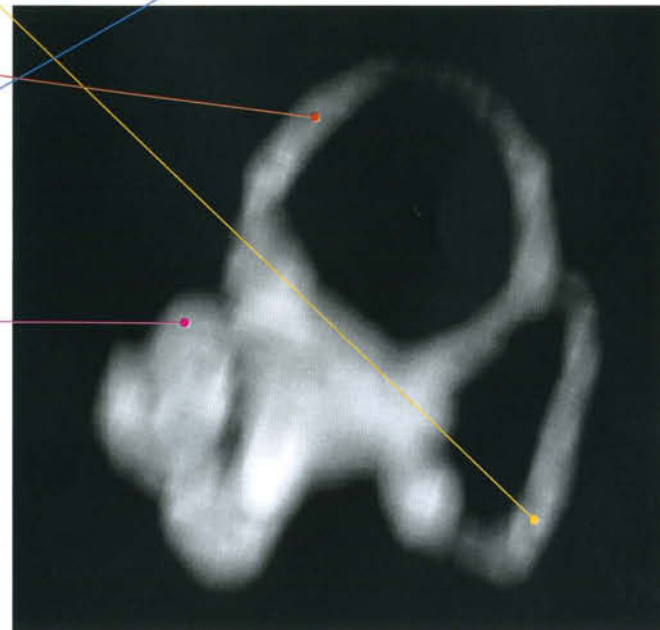
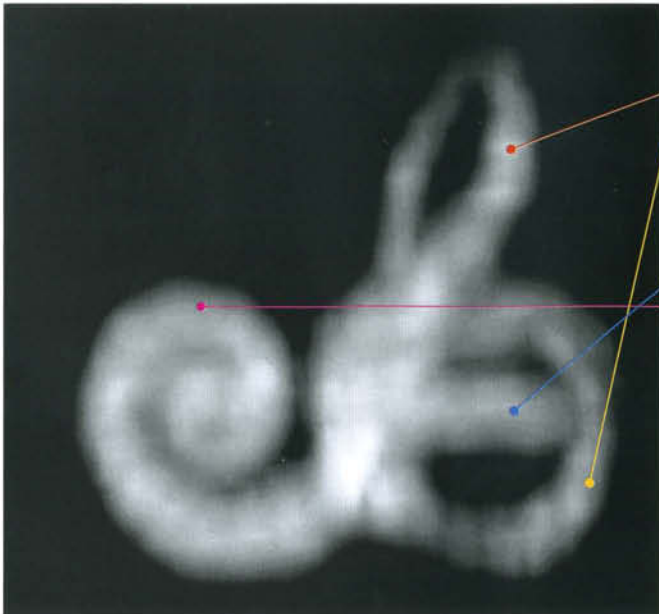


Posterior
s.c.

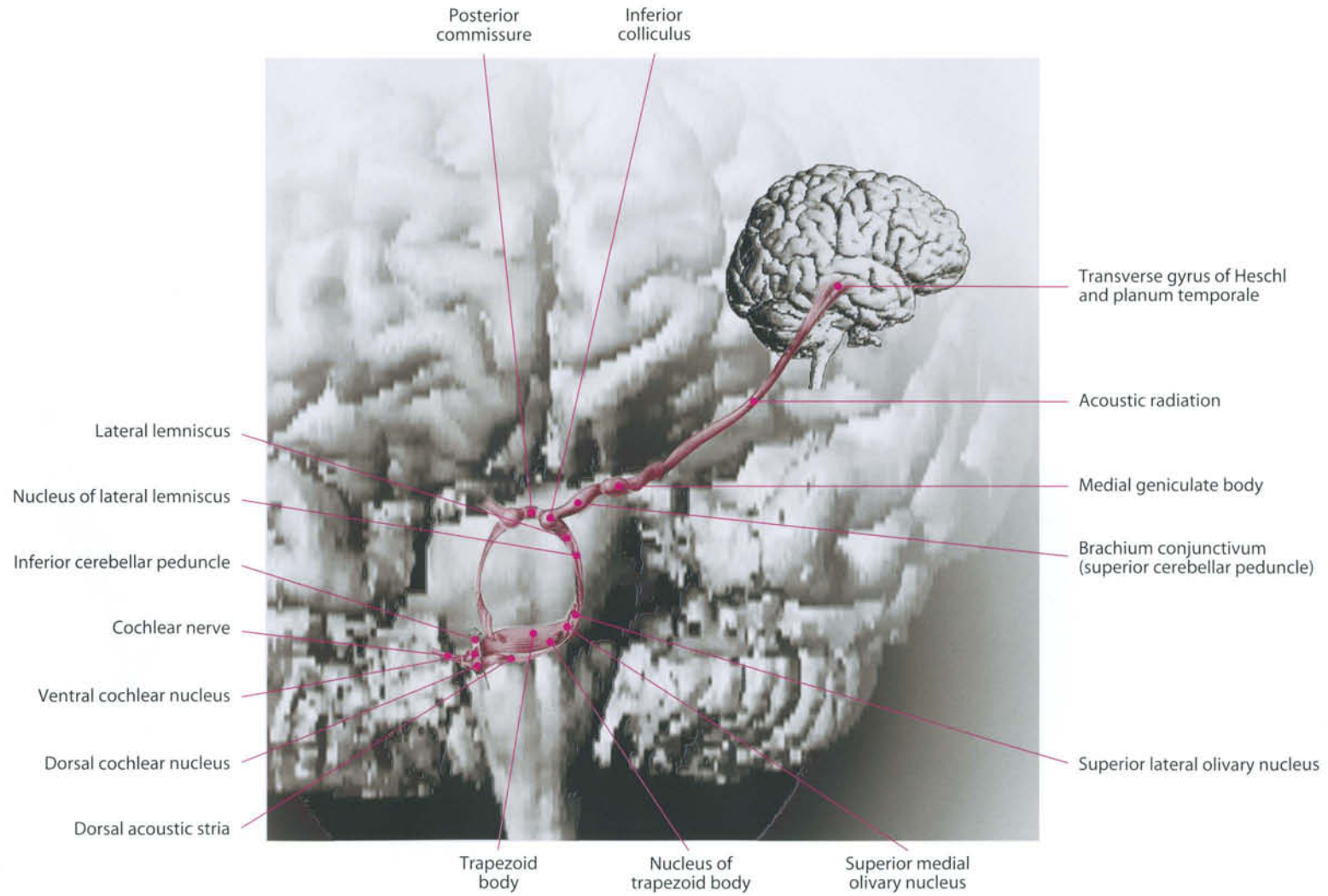
Superior
s.c.

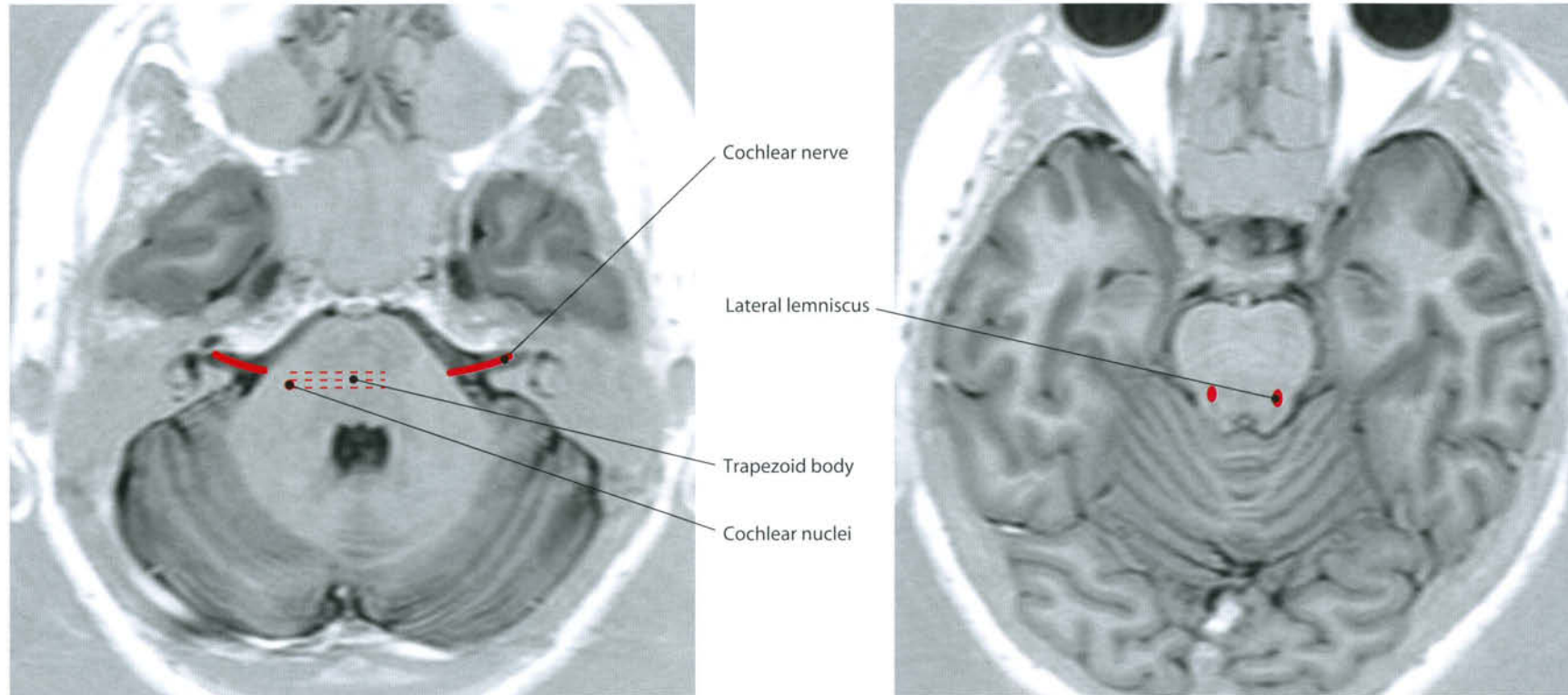
Lateral
s.c.

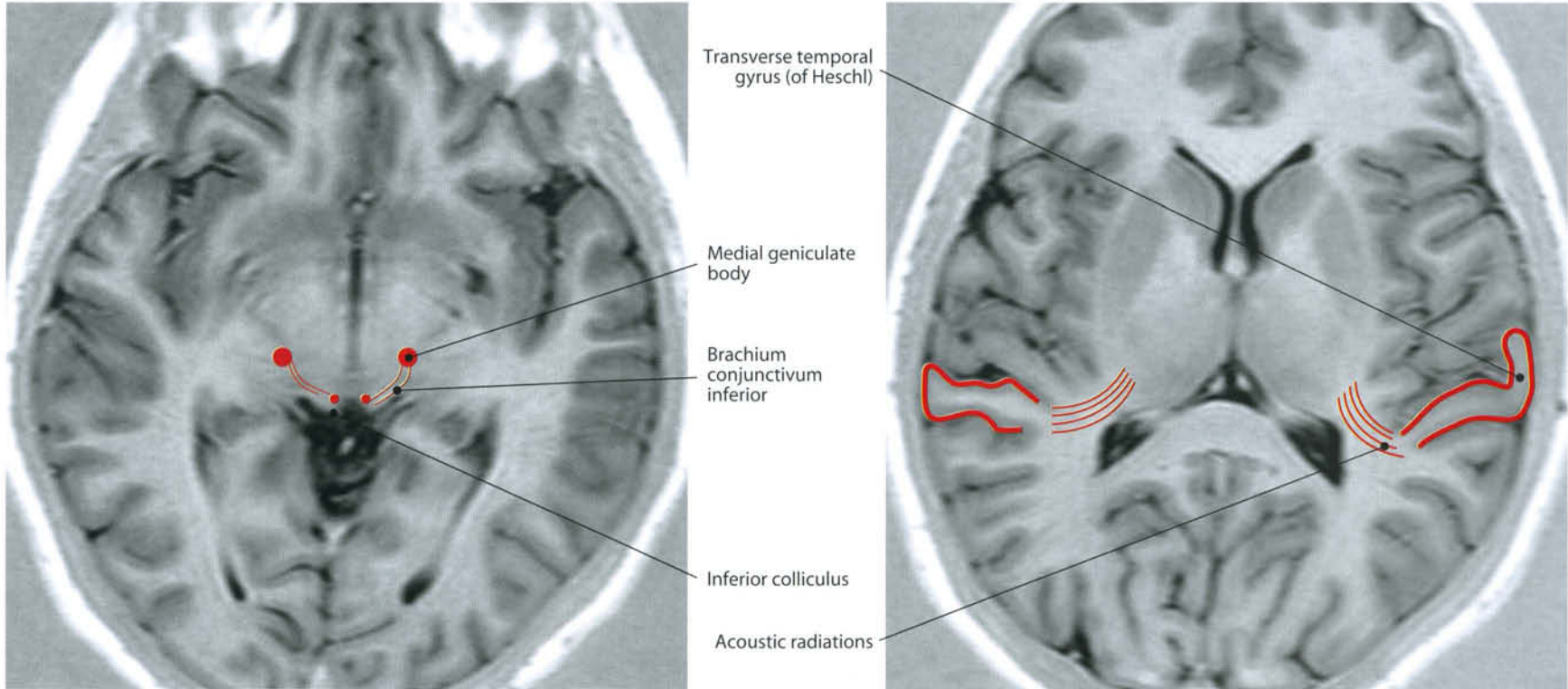
Cochlea

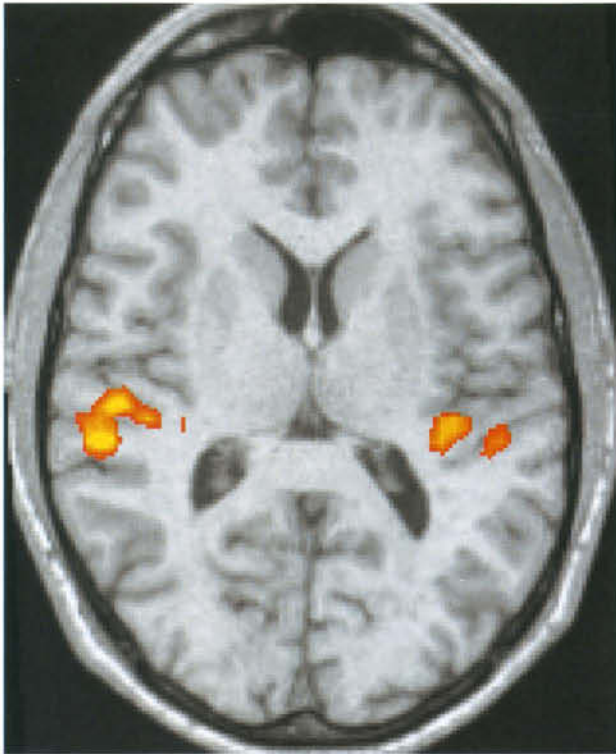


Acoustic System

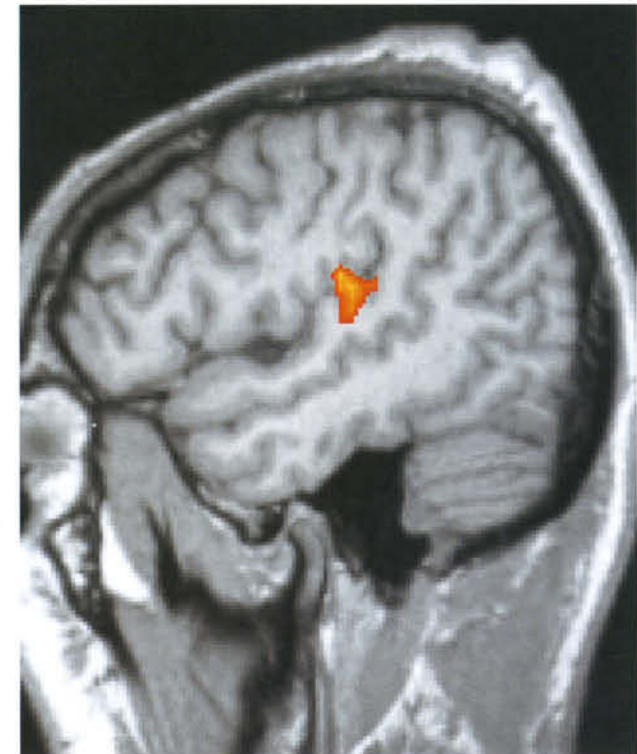
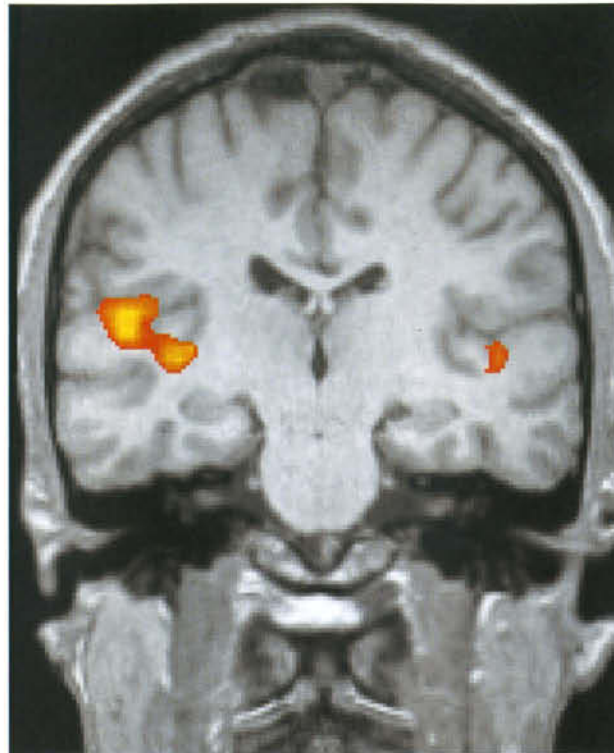




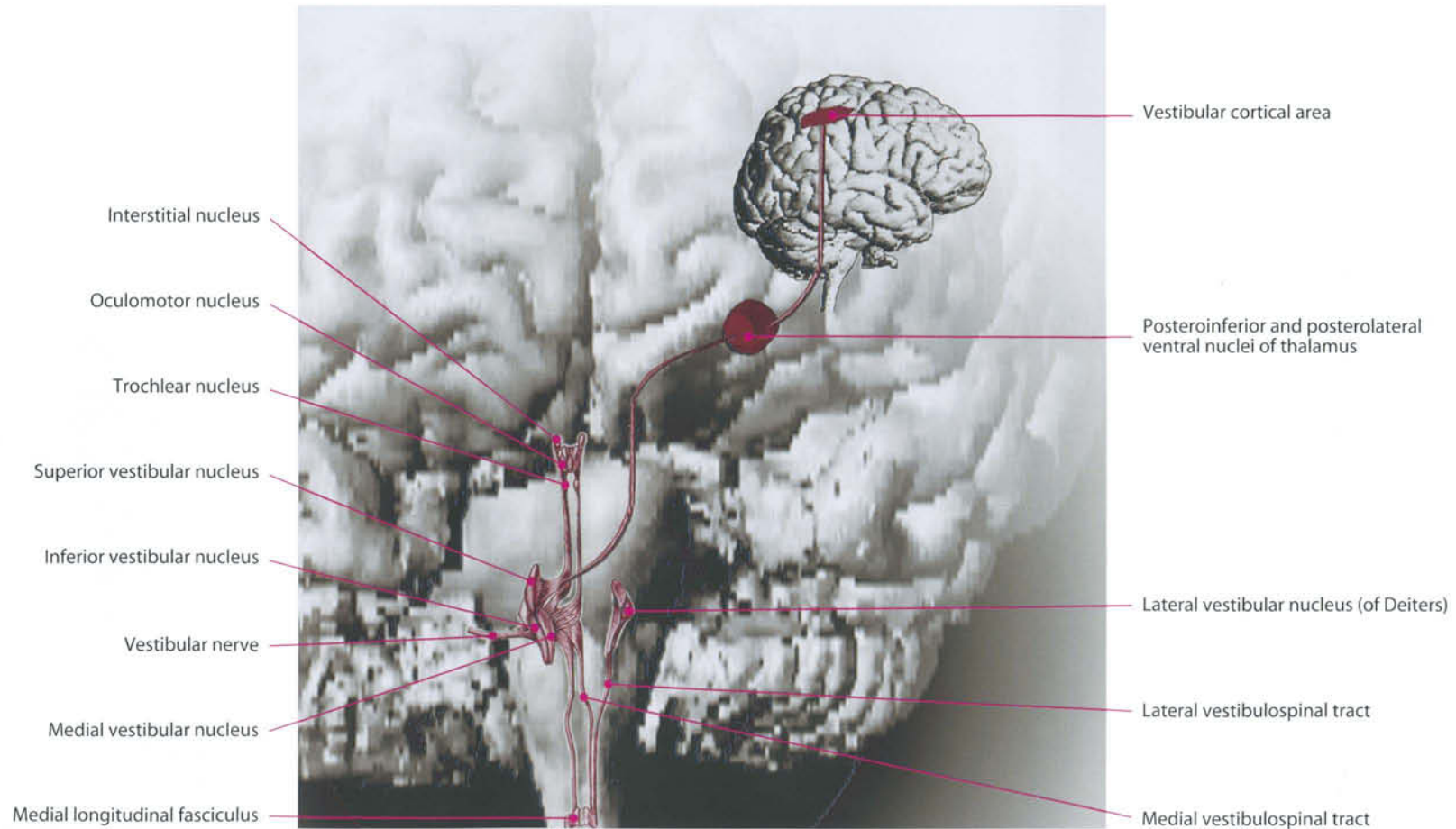


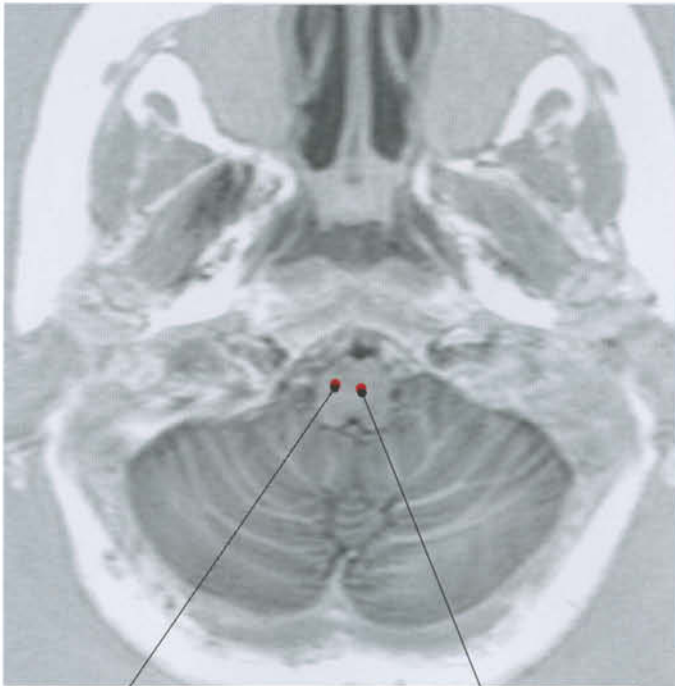

Regions of activation obtained during acoustic stimulation with pure tones at 800-1000 Hz frequency.
Courtesy of Massimo Caulo, MD, PhD, ITAB, Chieti, Italy



Vestibular System

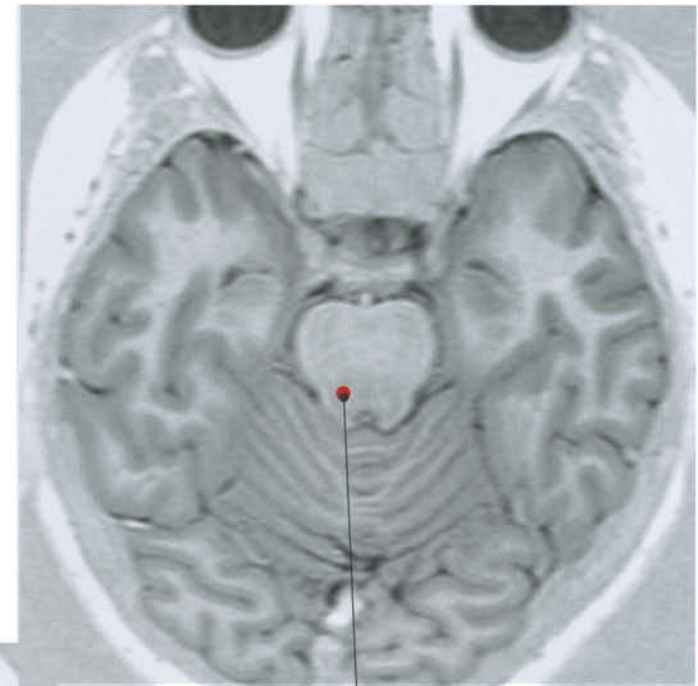




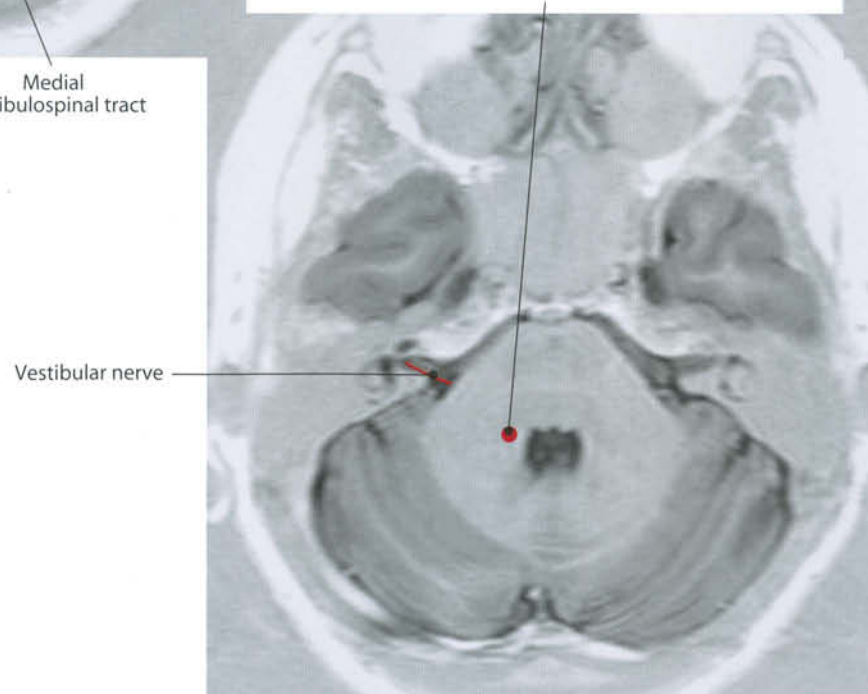
Lateral vestibulospinal tract

Medial vestibulospinal tract

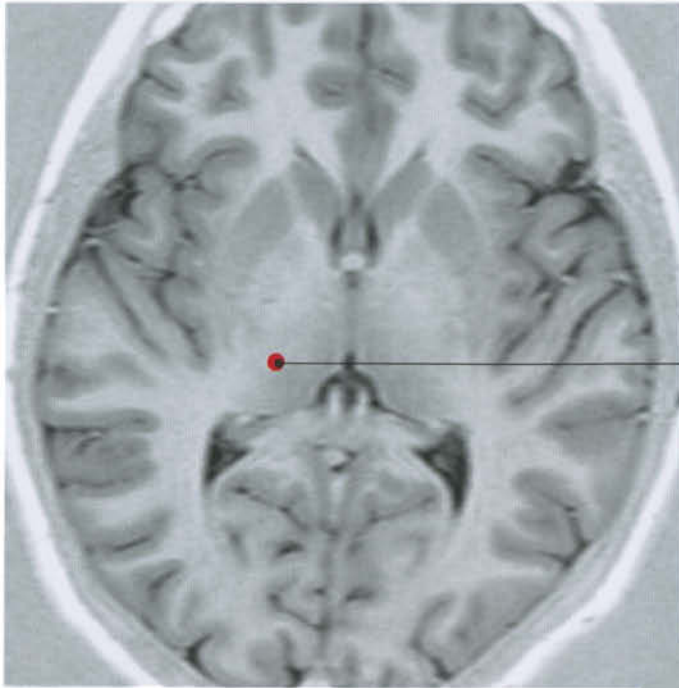
Lateral vestibular nucleus (Deiters)



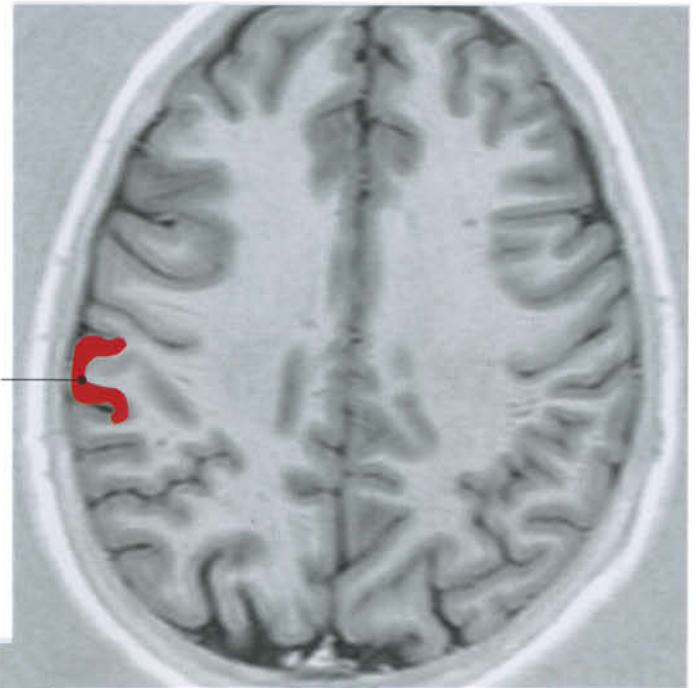Vestibulothalamic tract



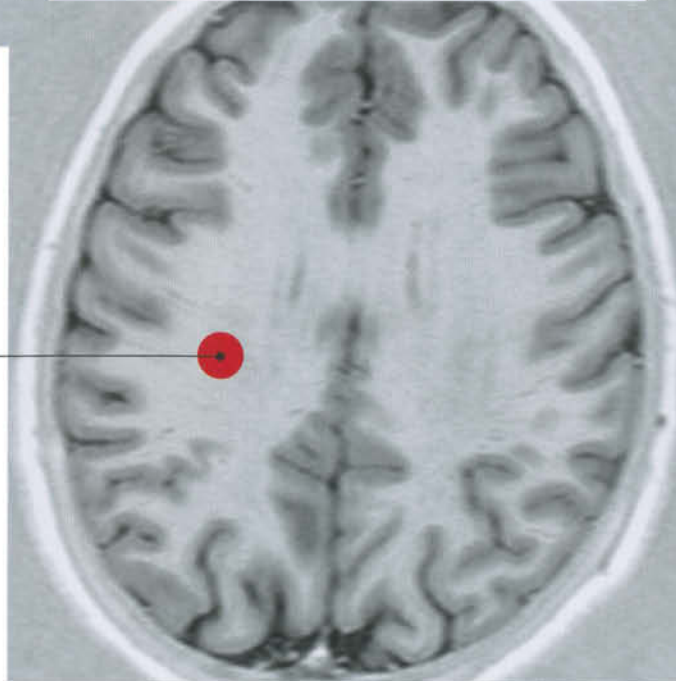Vestibular nerve



Ventral intermediate thalamic nucleus

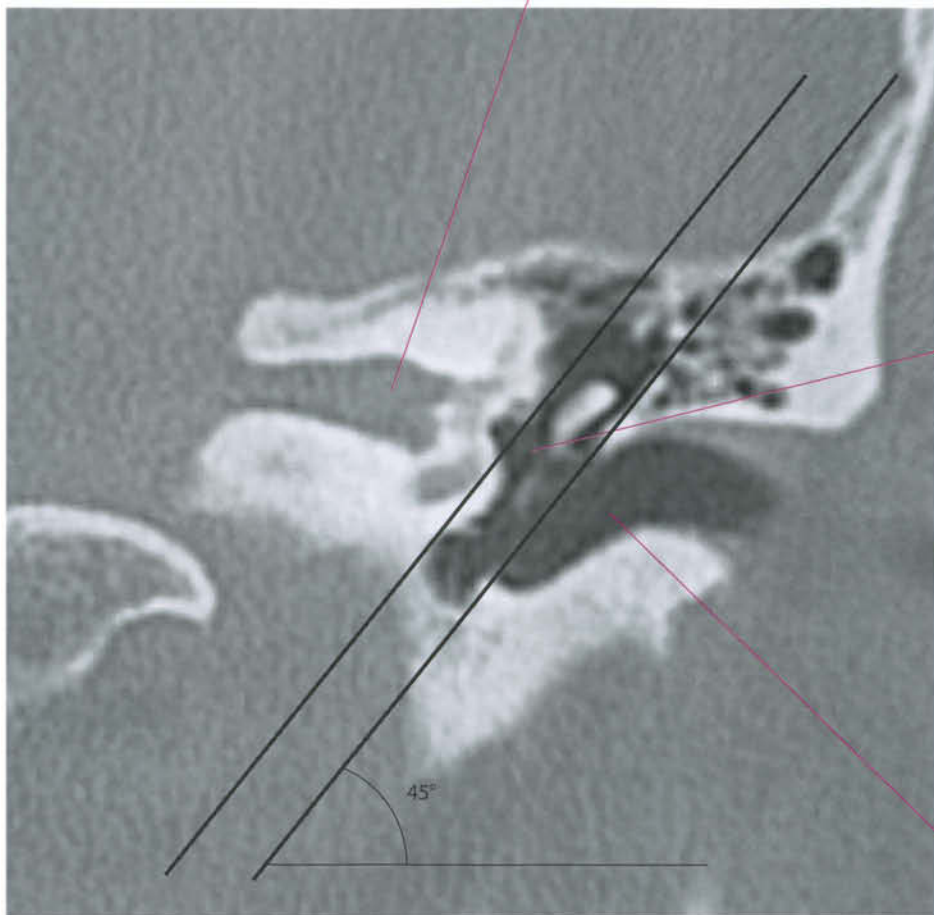


Vestibular cortical area



Vestibular fibers in the centrum semiovale

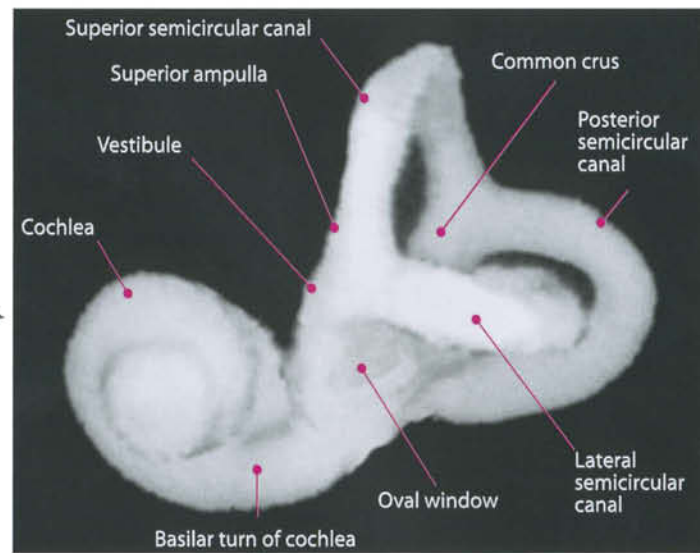
CT Coronal Section



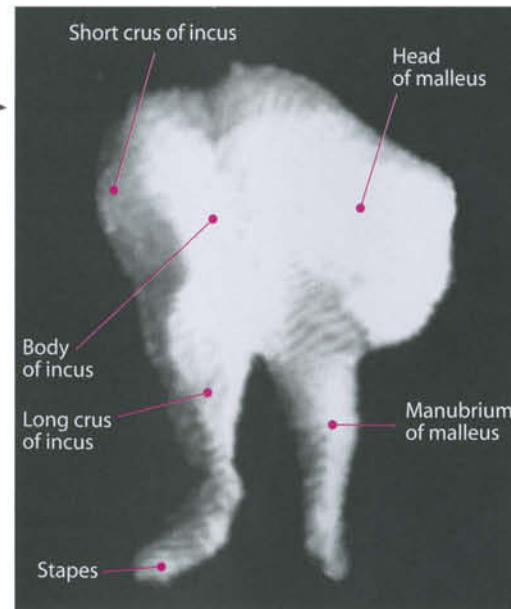
Inner Ear {
Internal auditory canal (IAC)
Labyrinth

Middle Ear {
Mastoid air cells
Tympanic cavity
Ossicular chain

External Ear: External auditory canal (EAC)

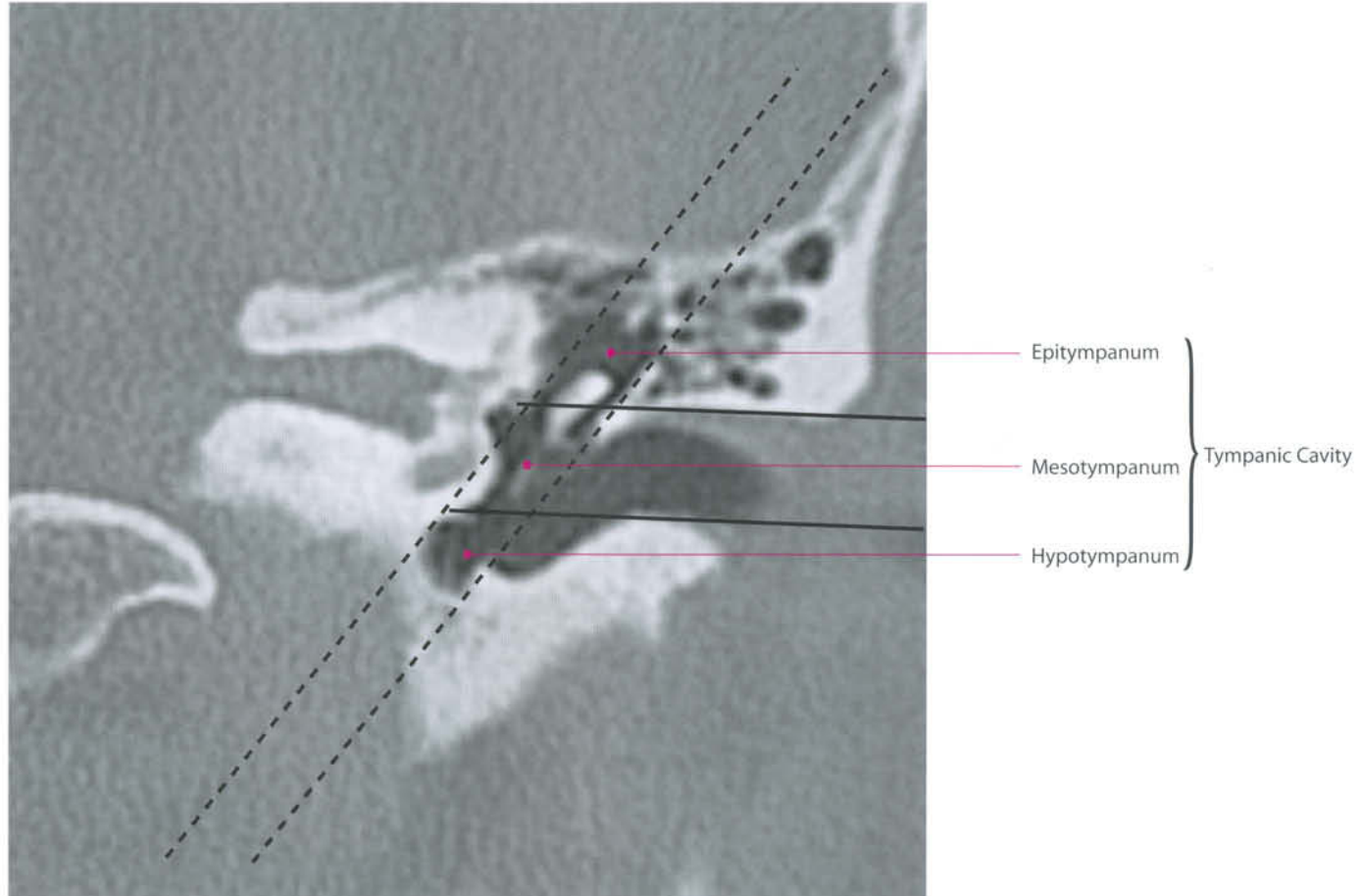


Bony labyrinth: 3D CT reconstruction

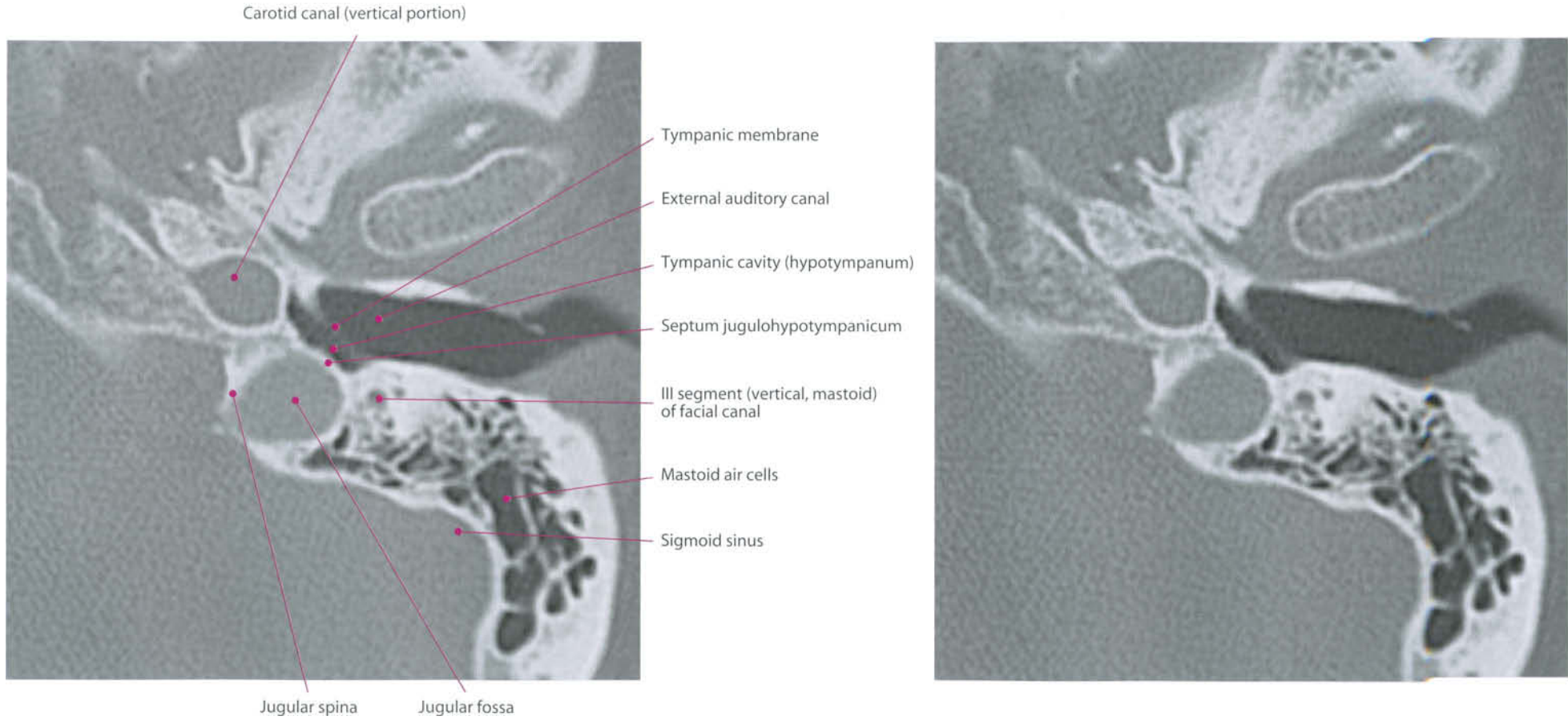


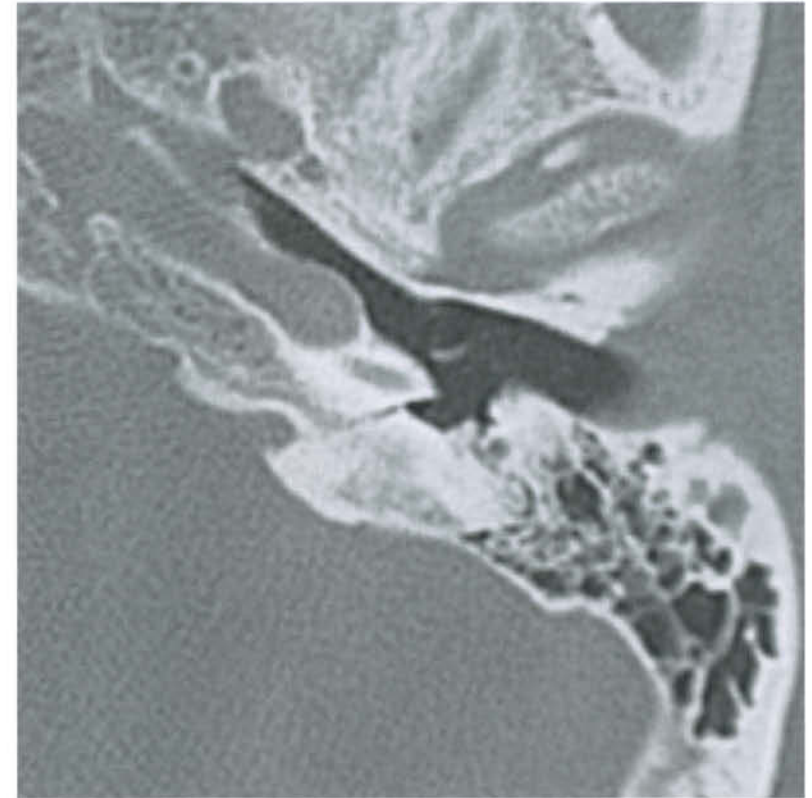
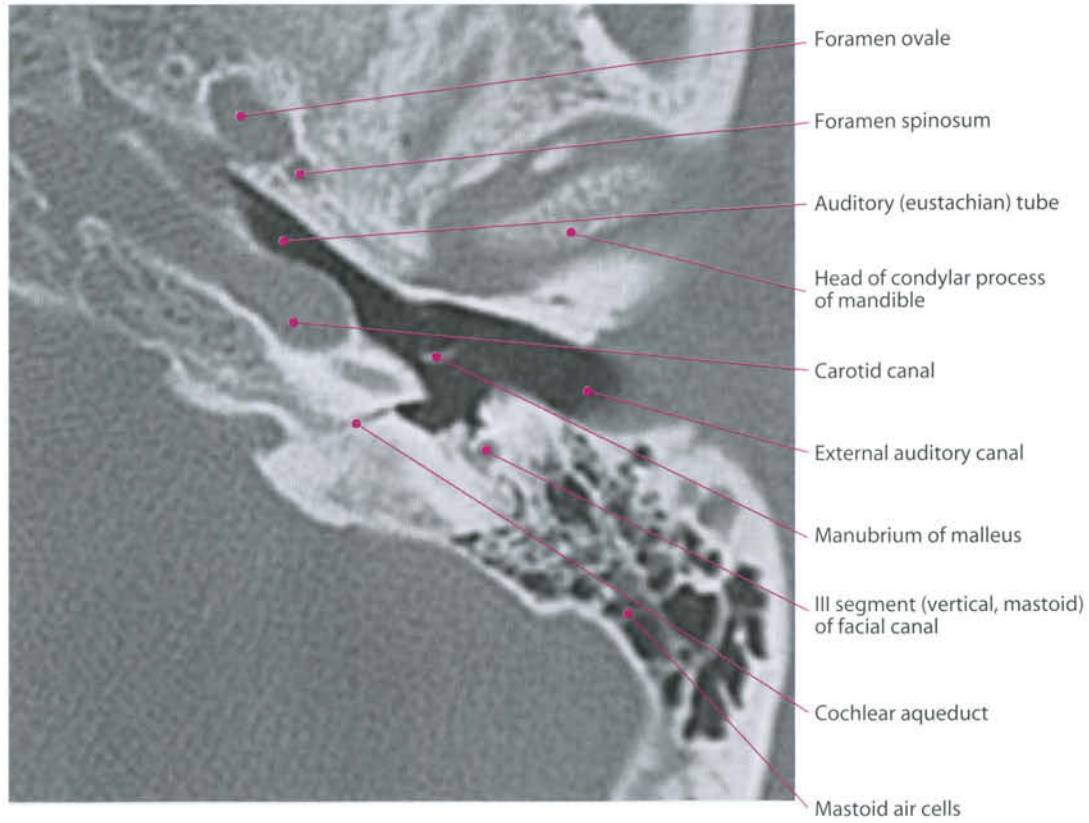
Ossicular chain: 3D CT reconstruction

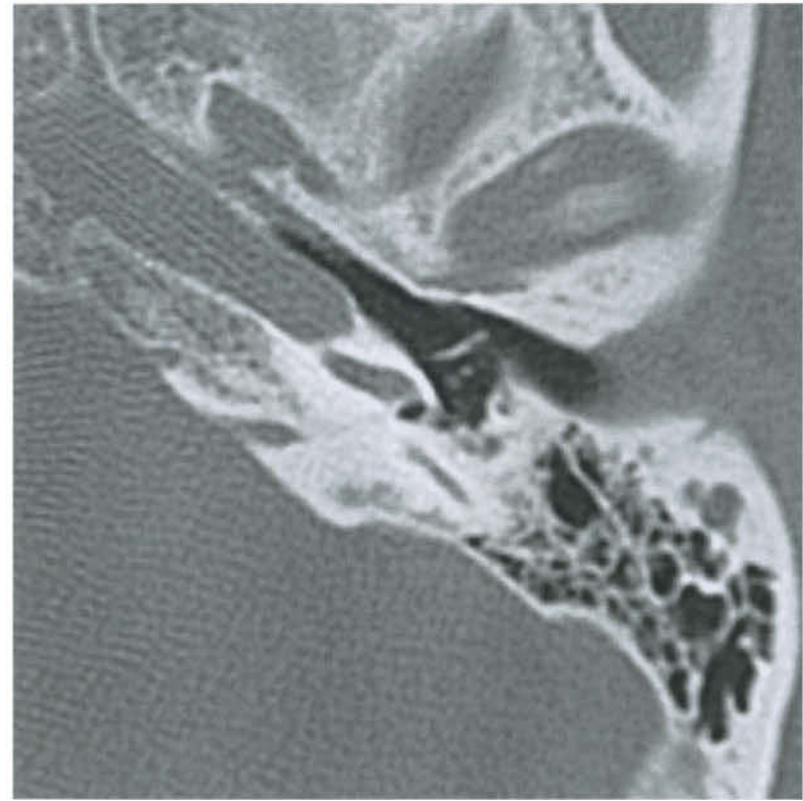
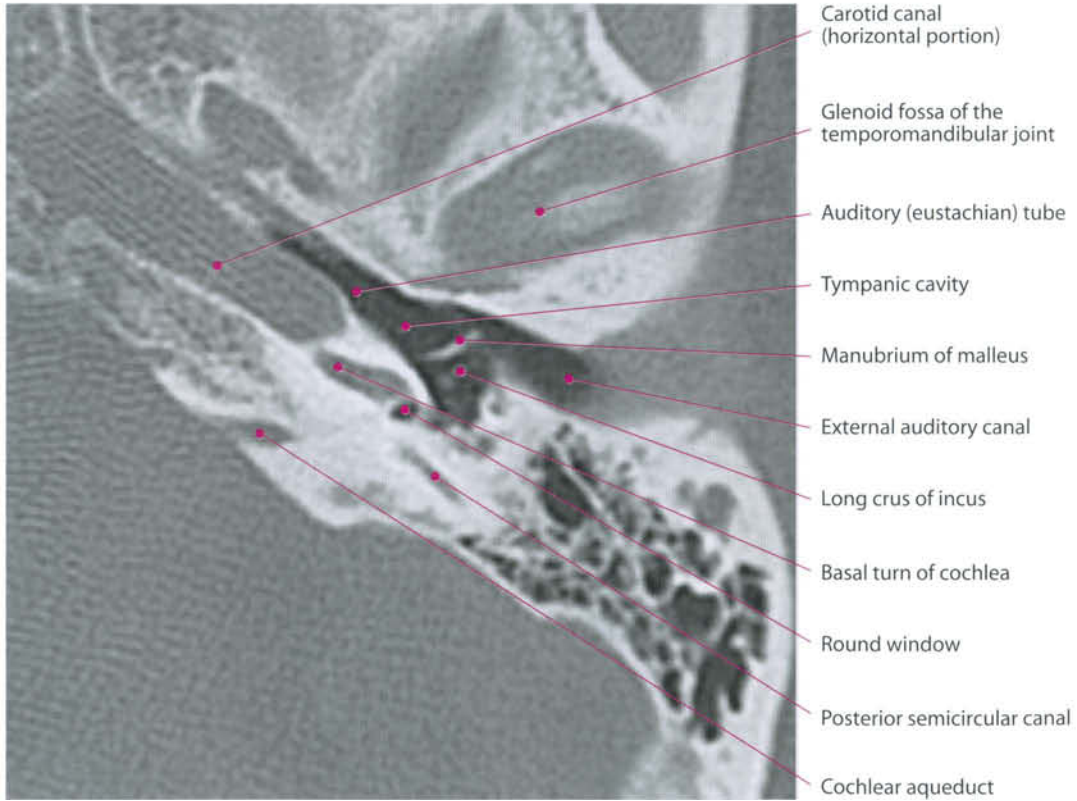
CT Coronal Section

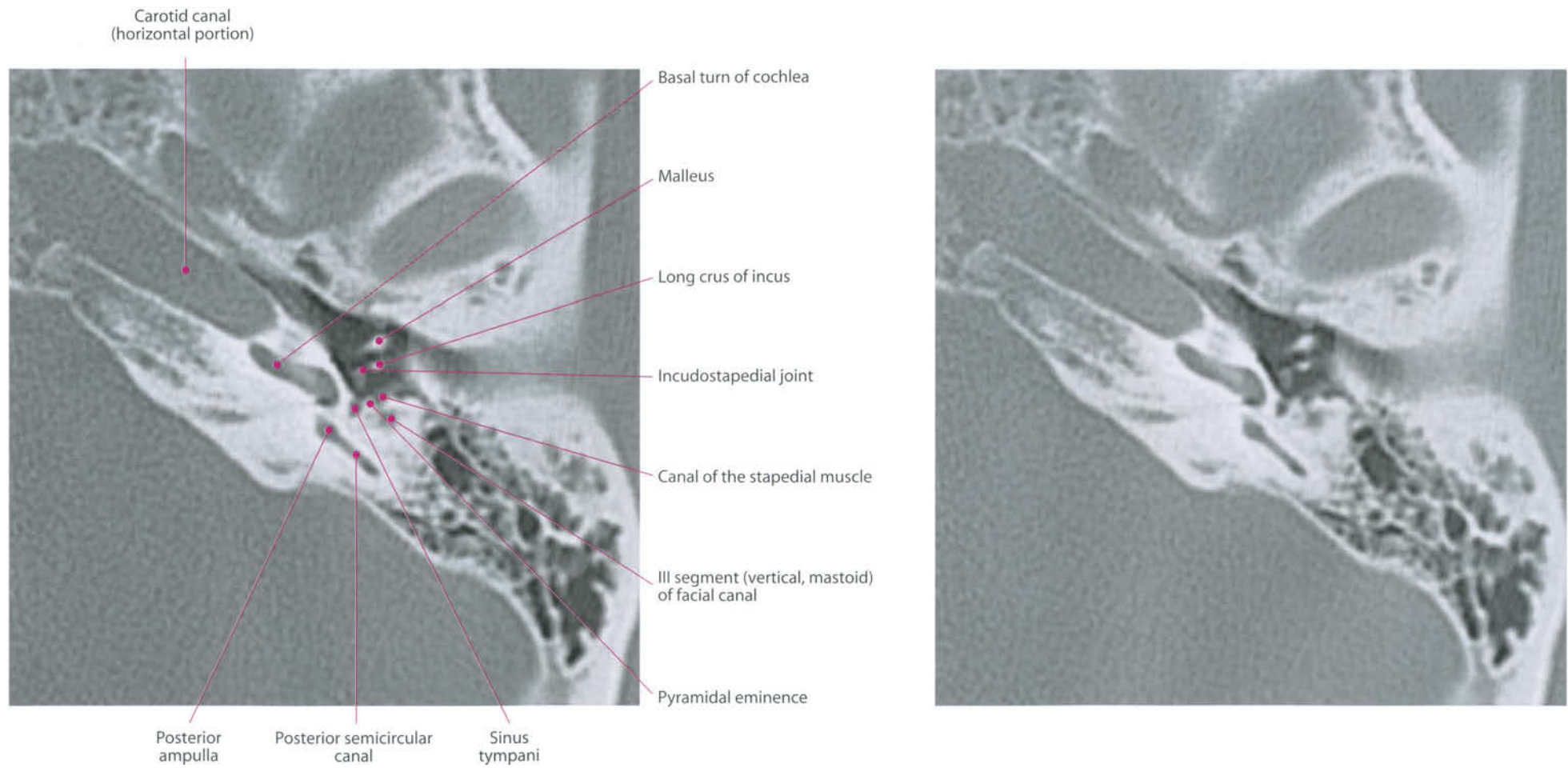


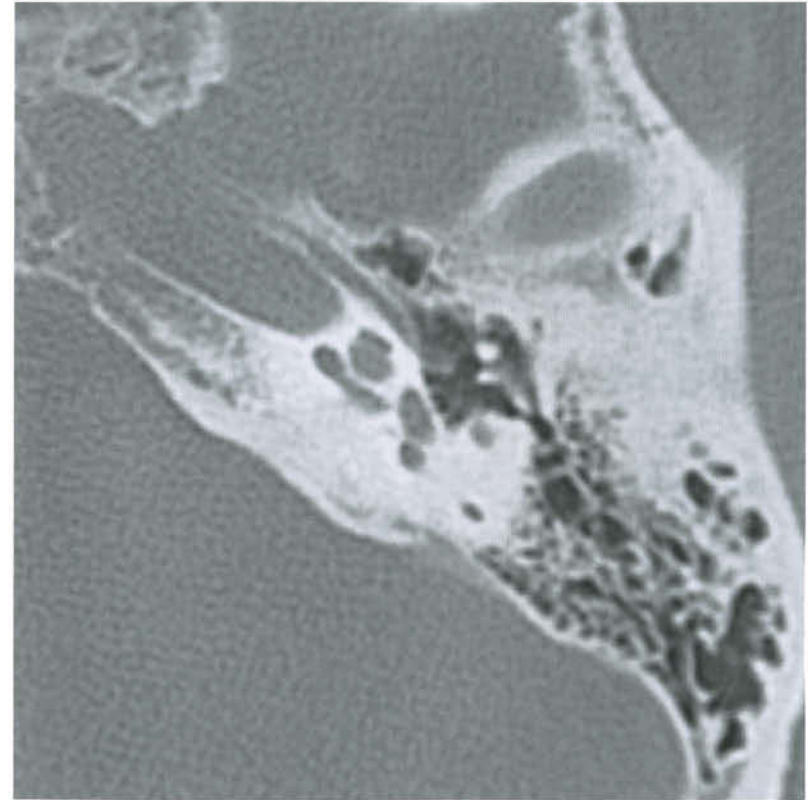
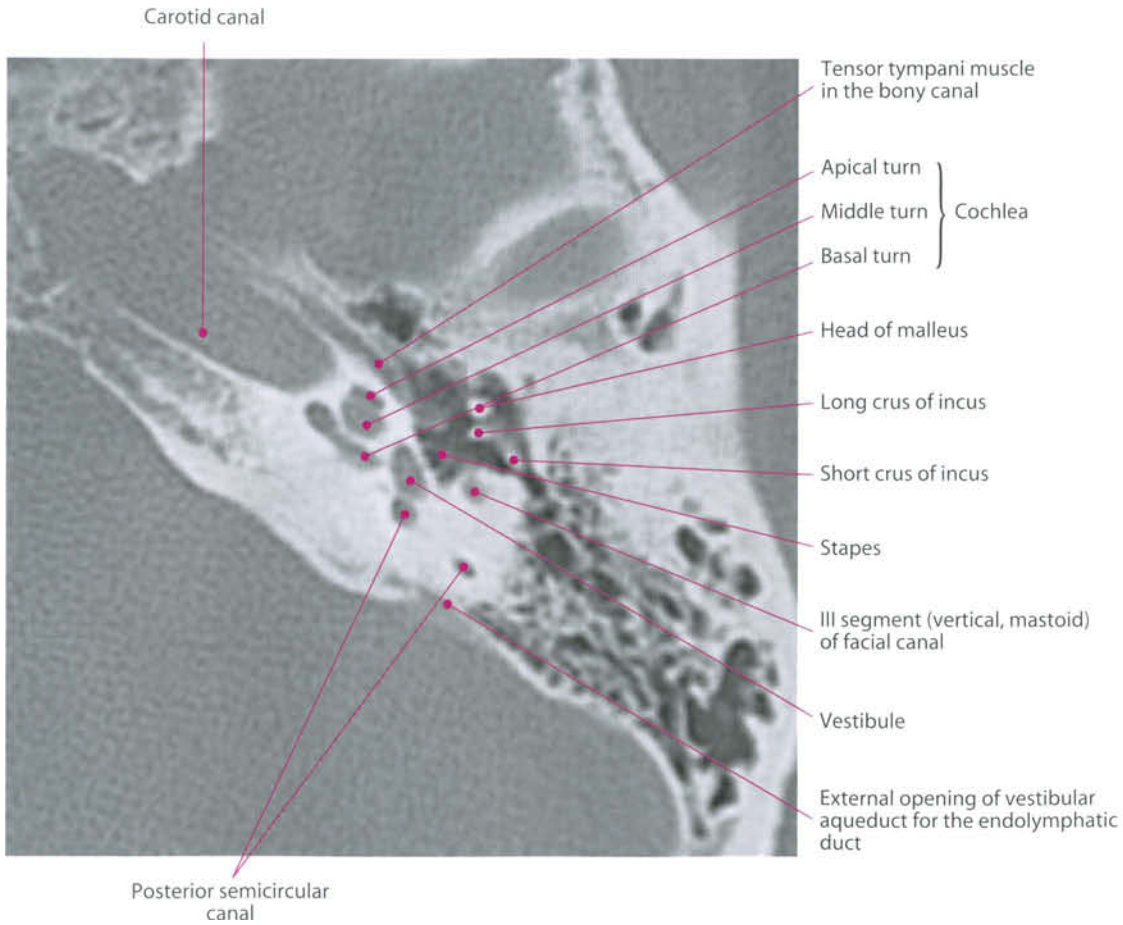
Axial Sections

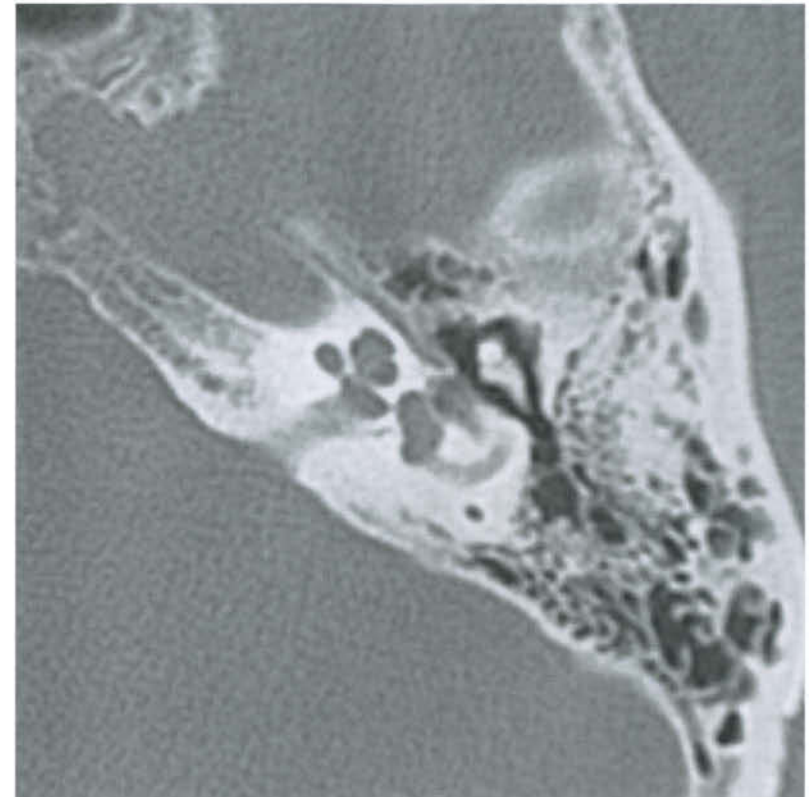
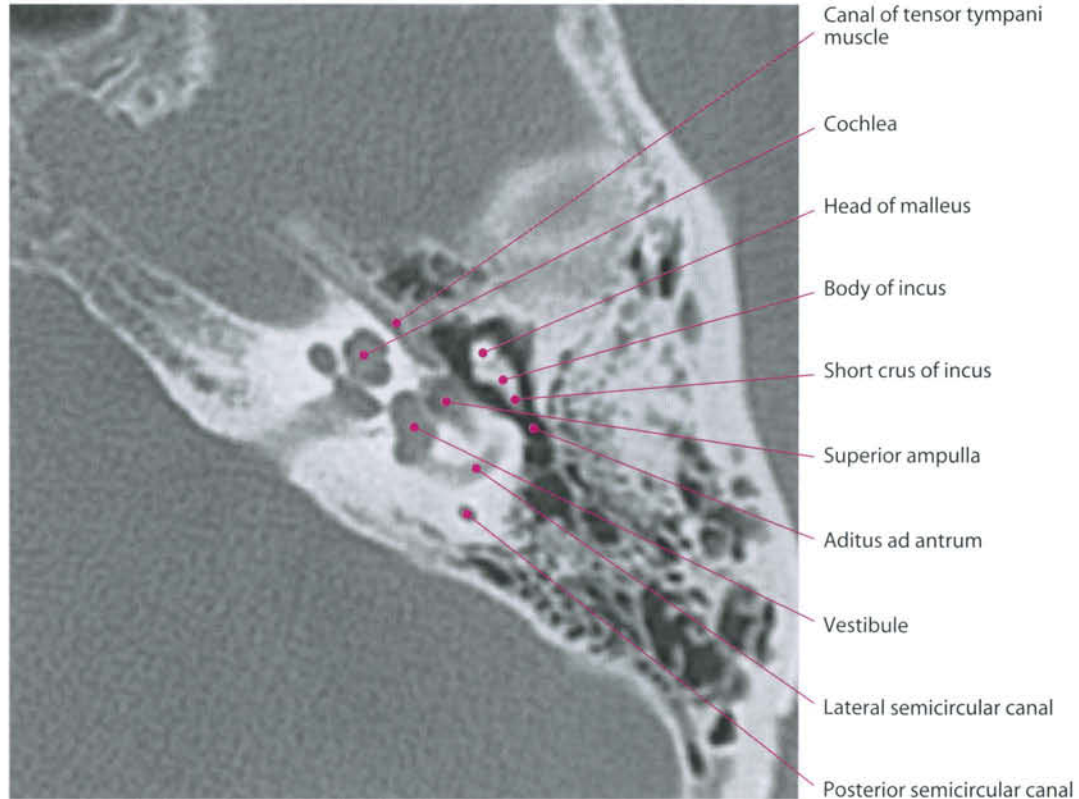


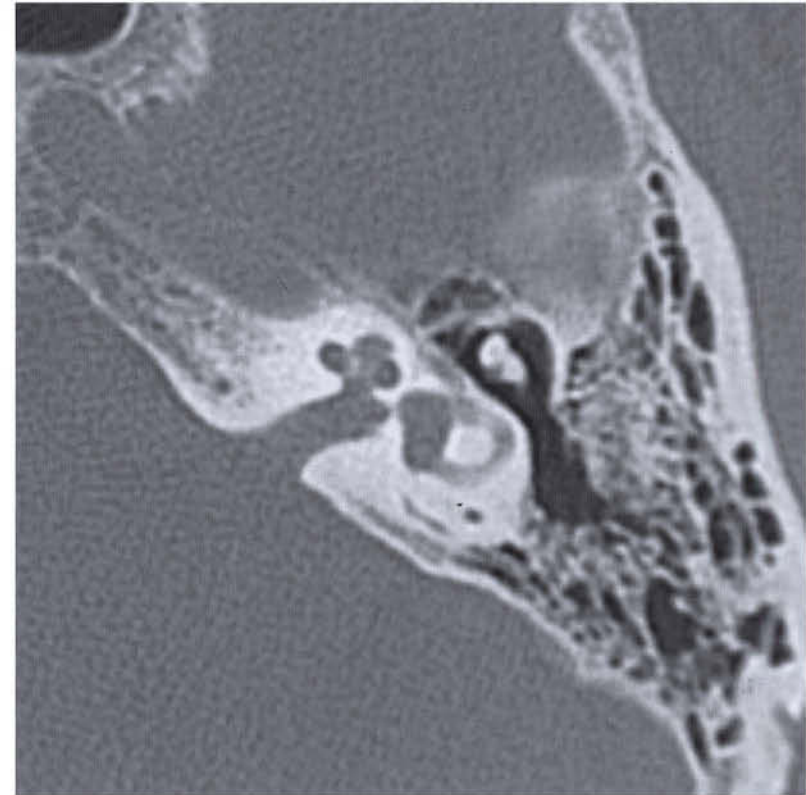
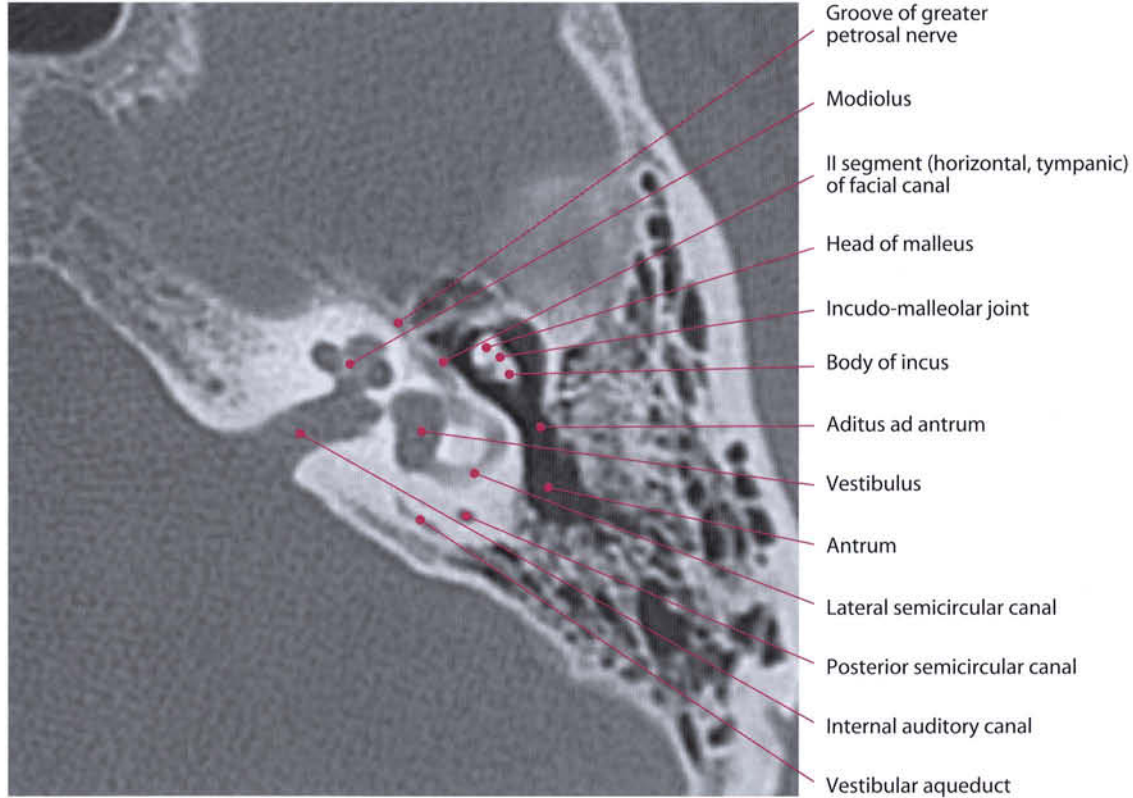


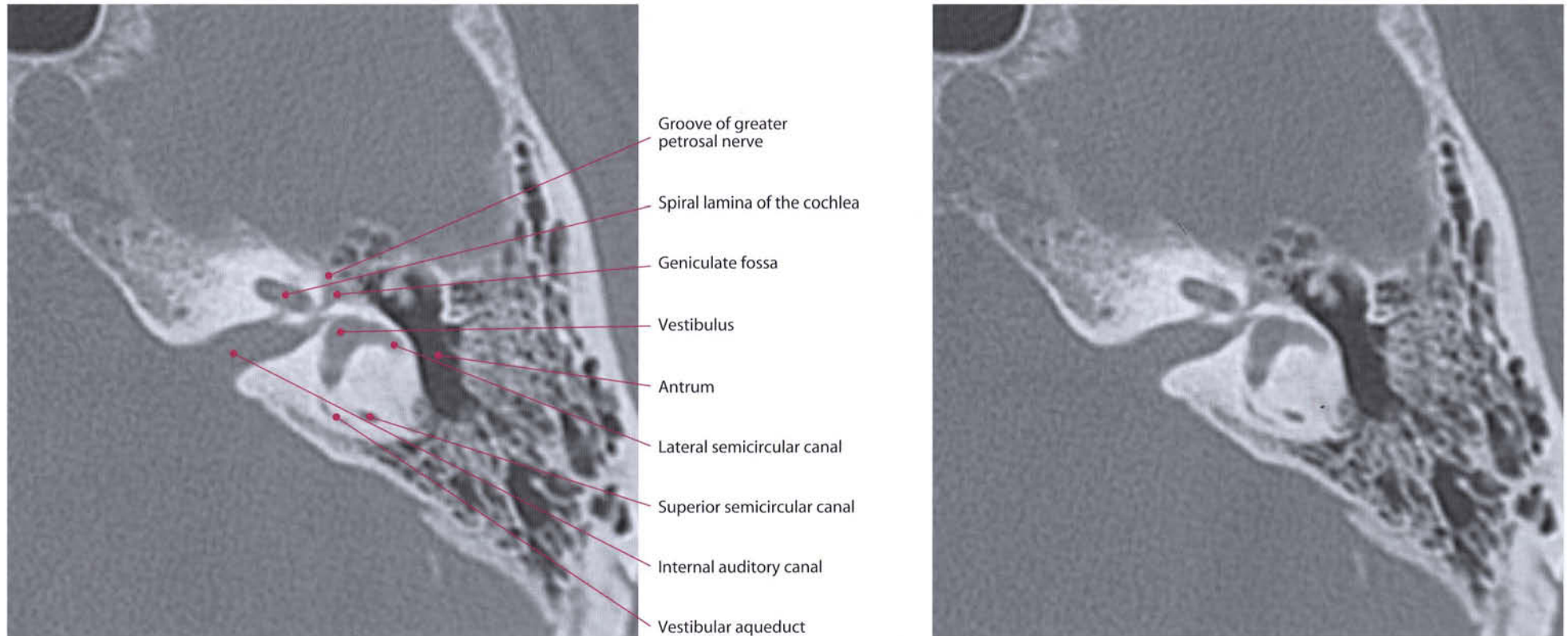


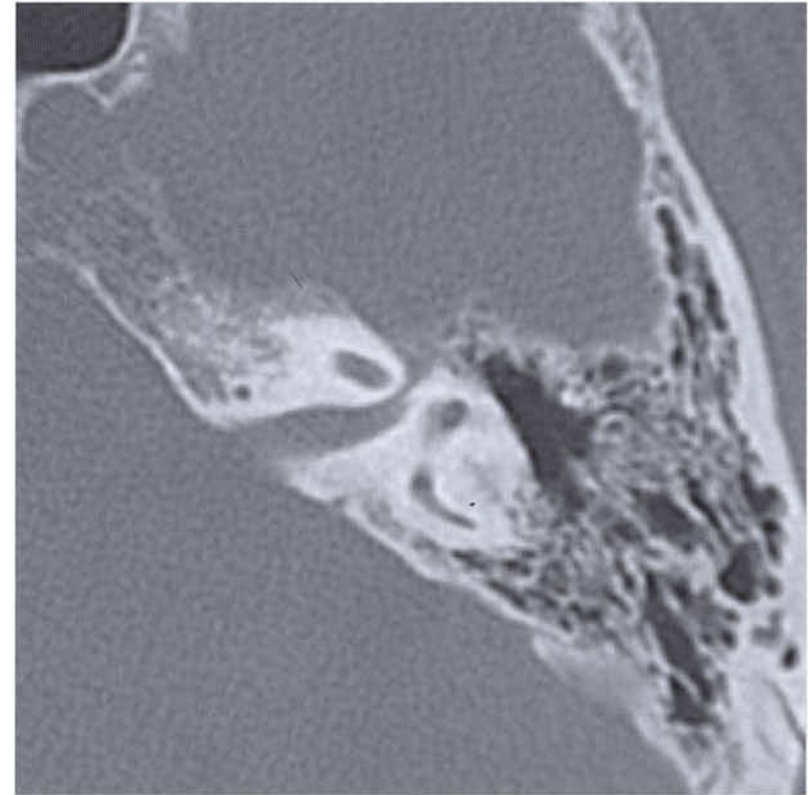
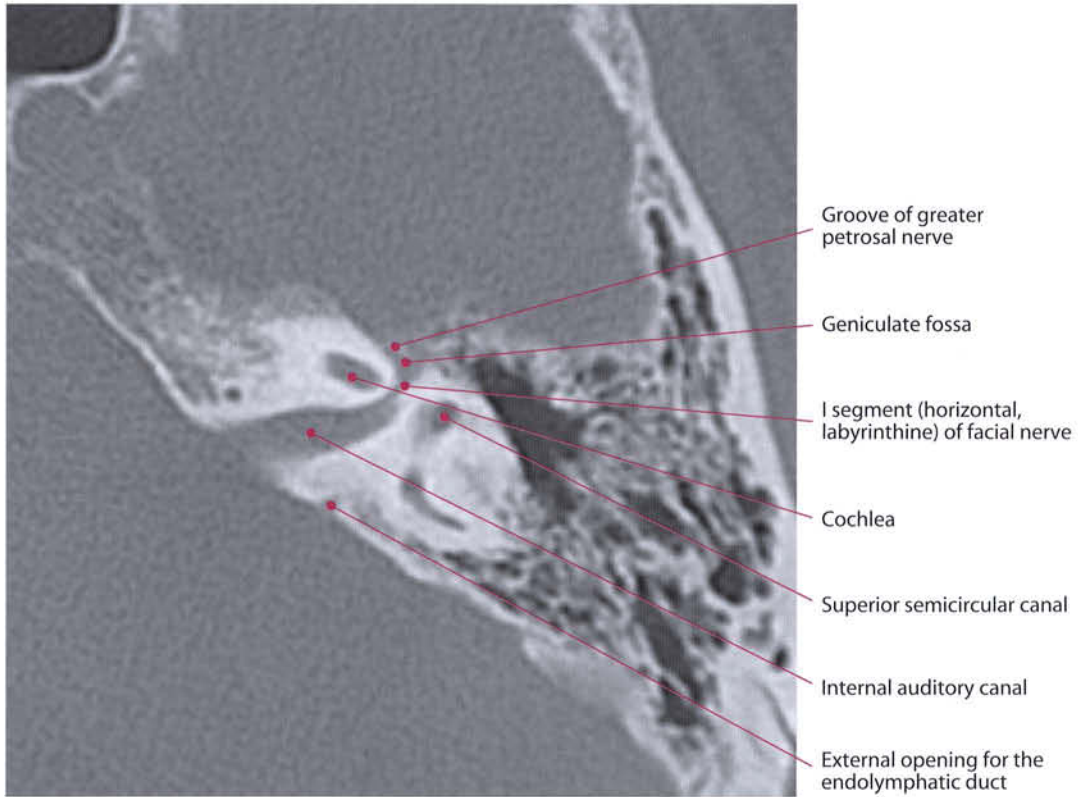


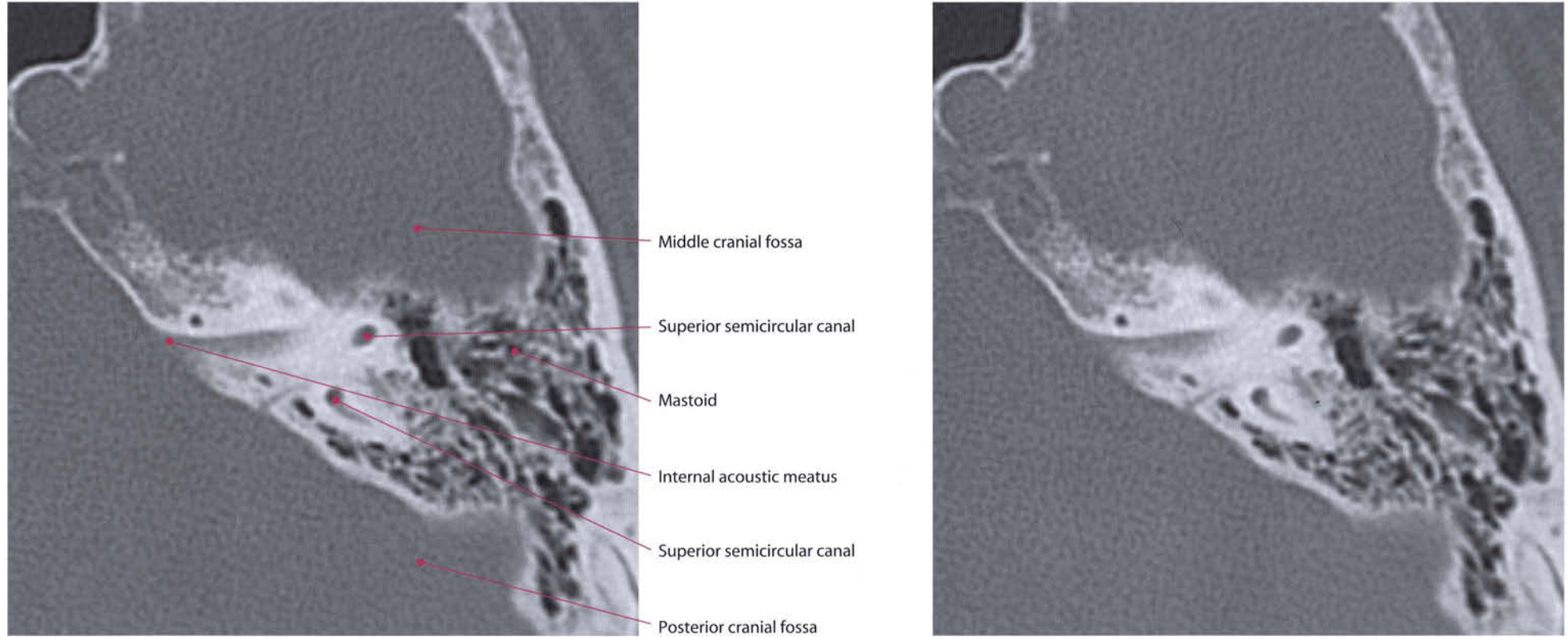


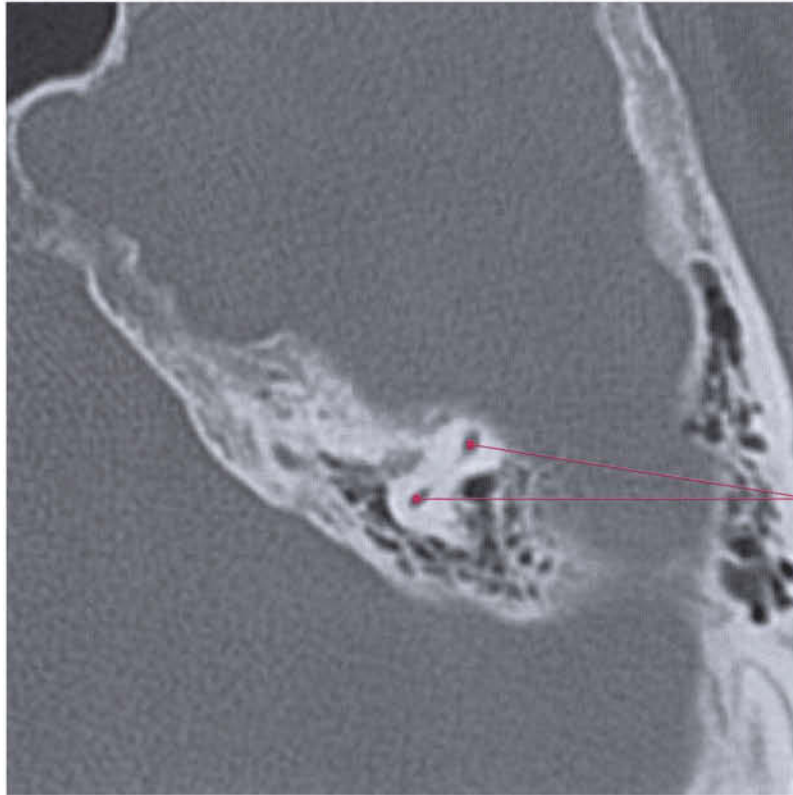




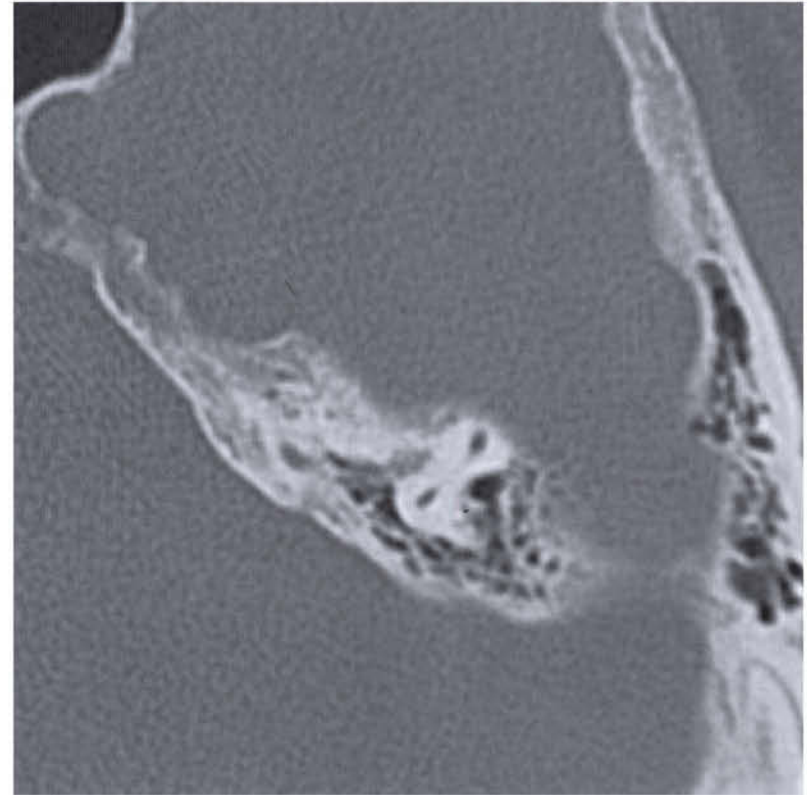




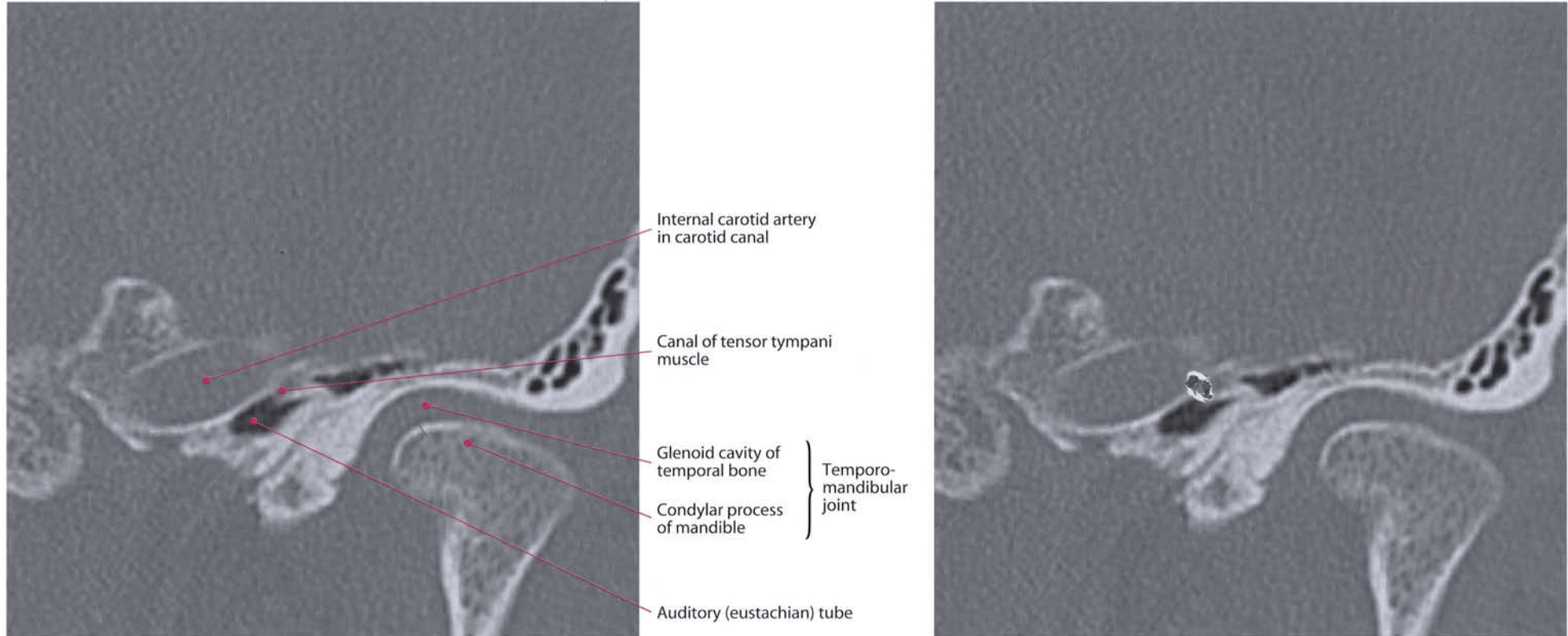


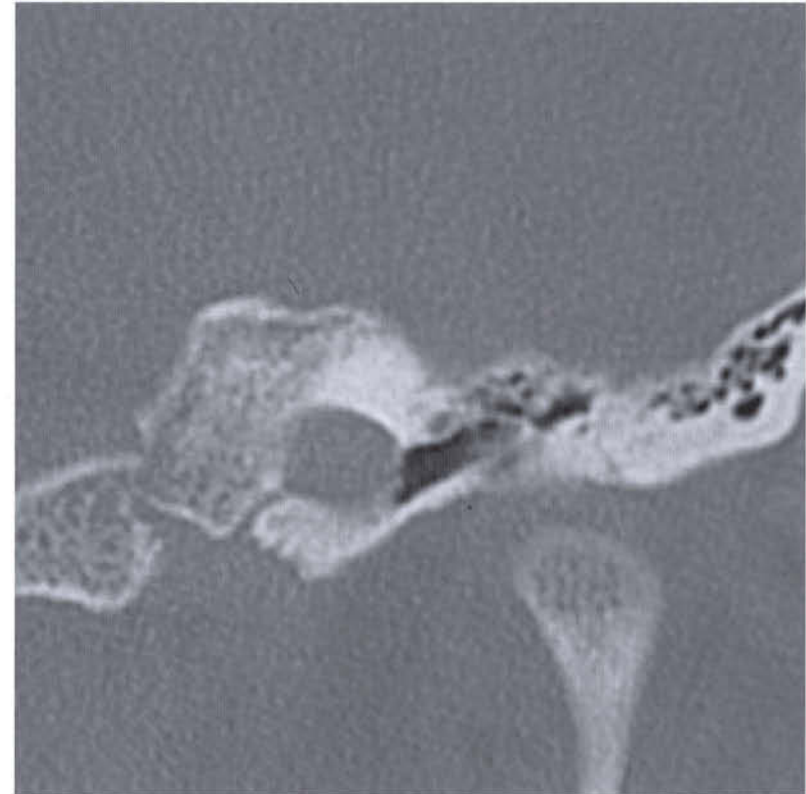
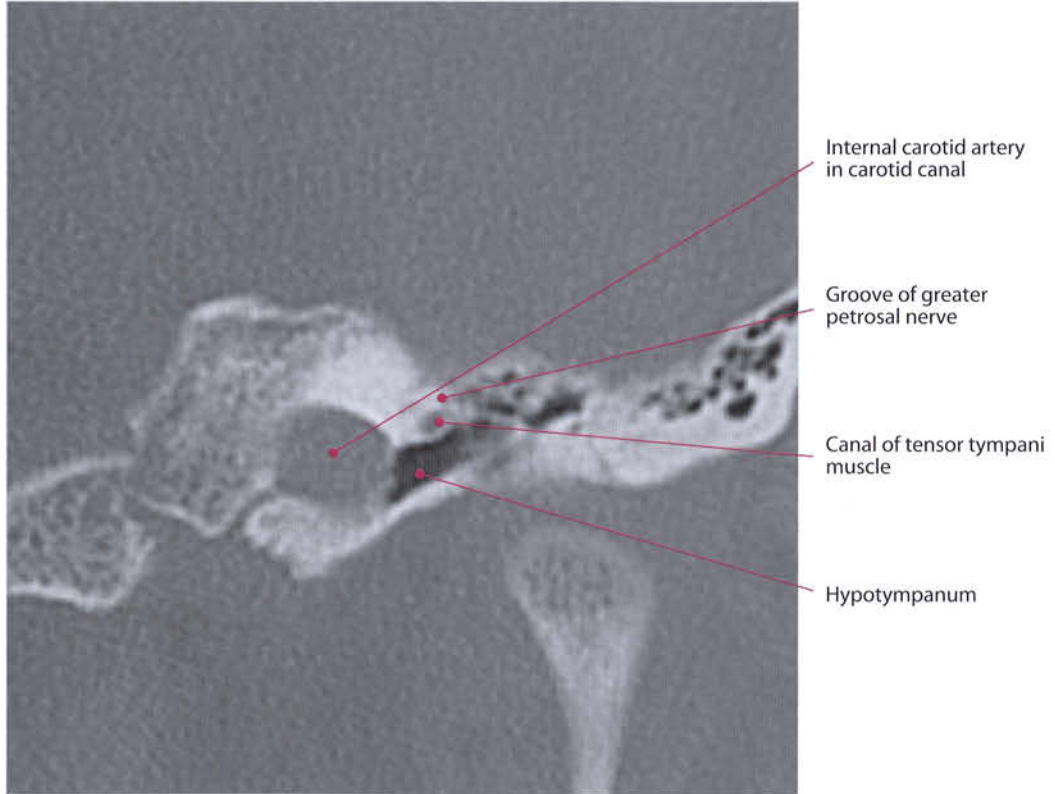


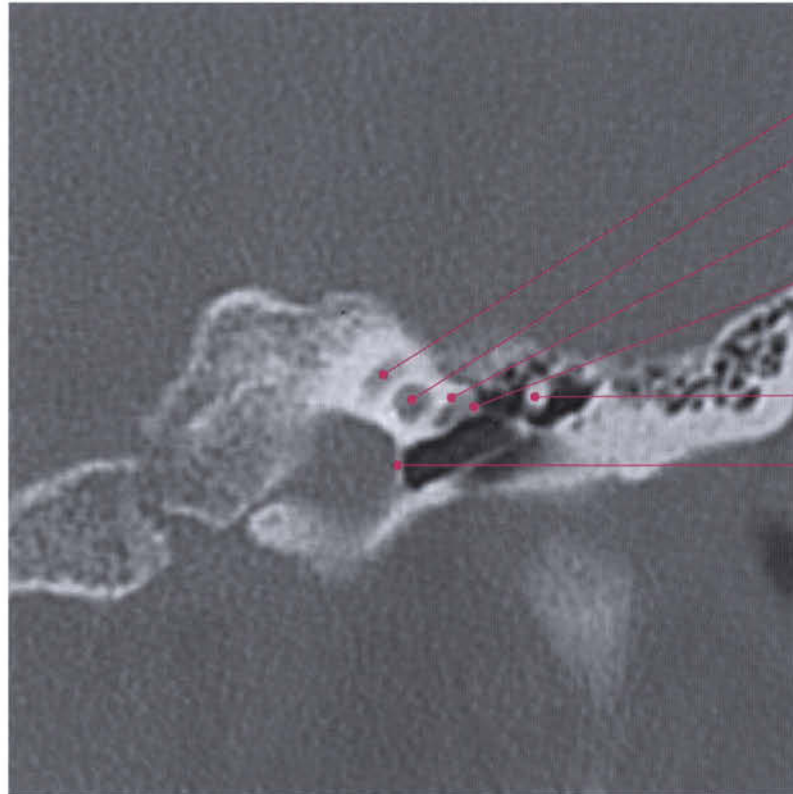
Superior semicircular canal



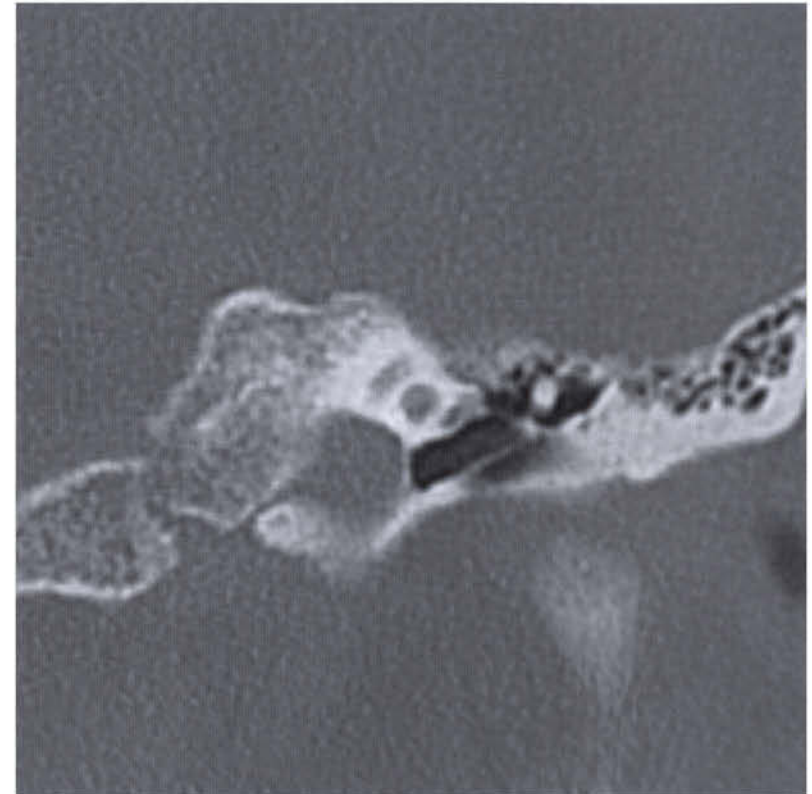
Coronal Sections

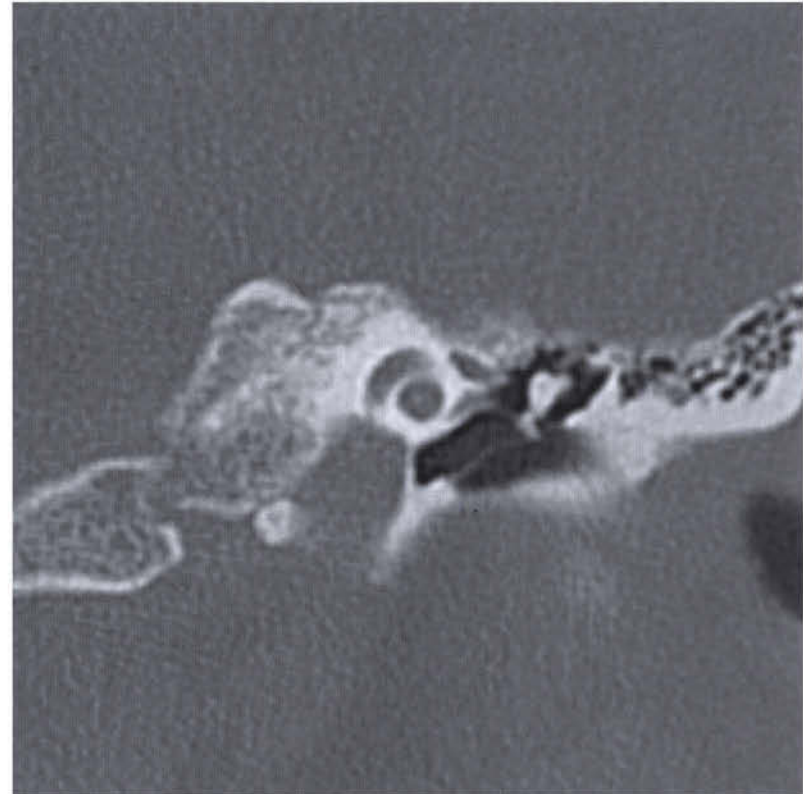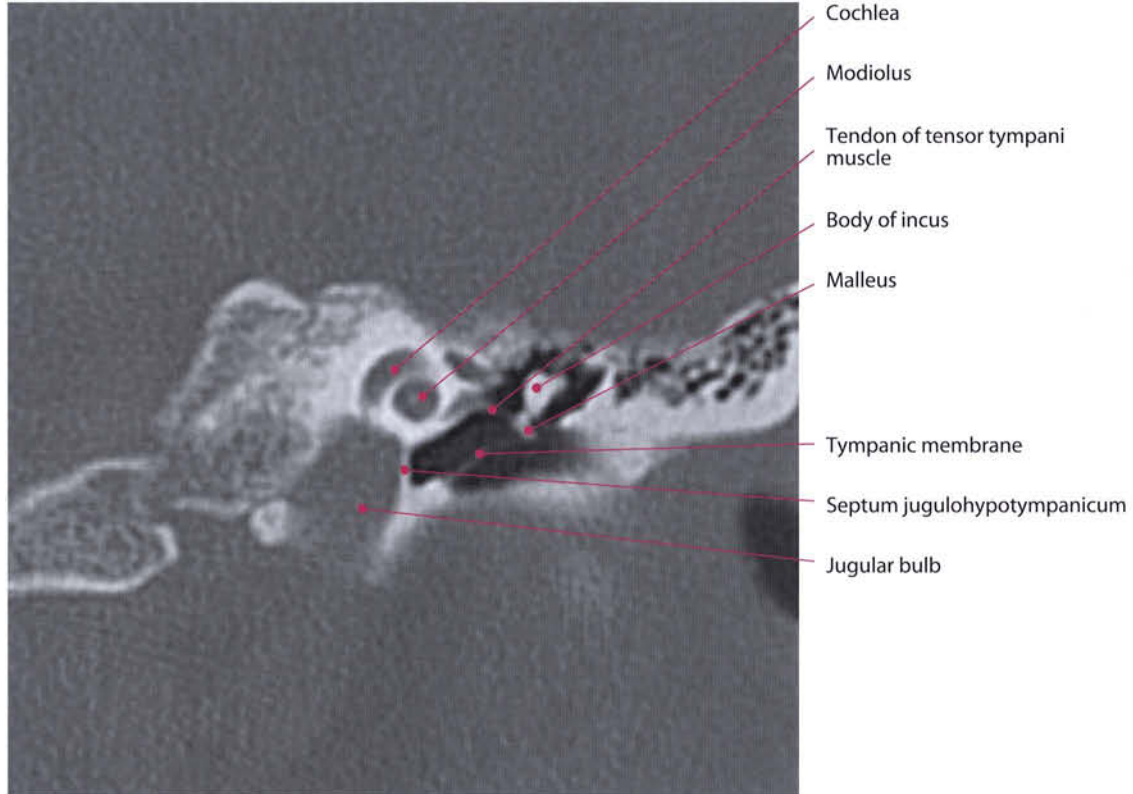


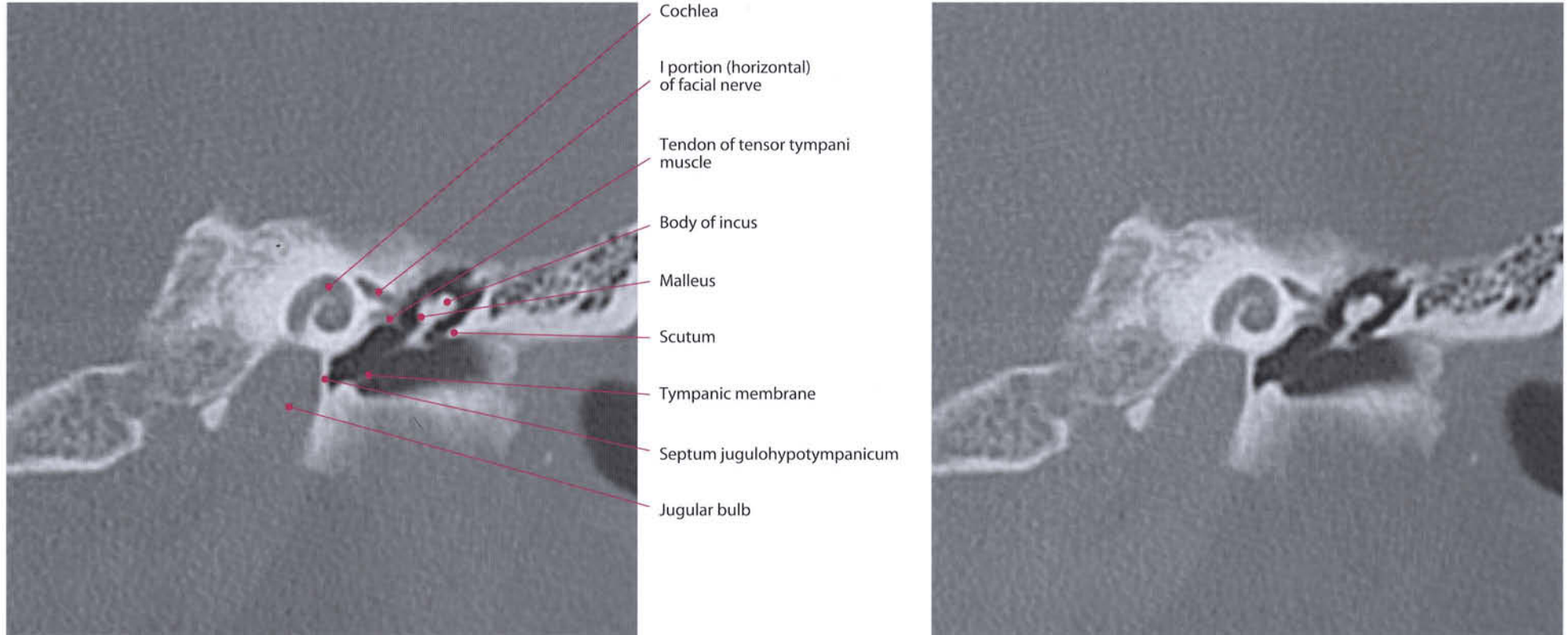


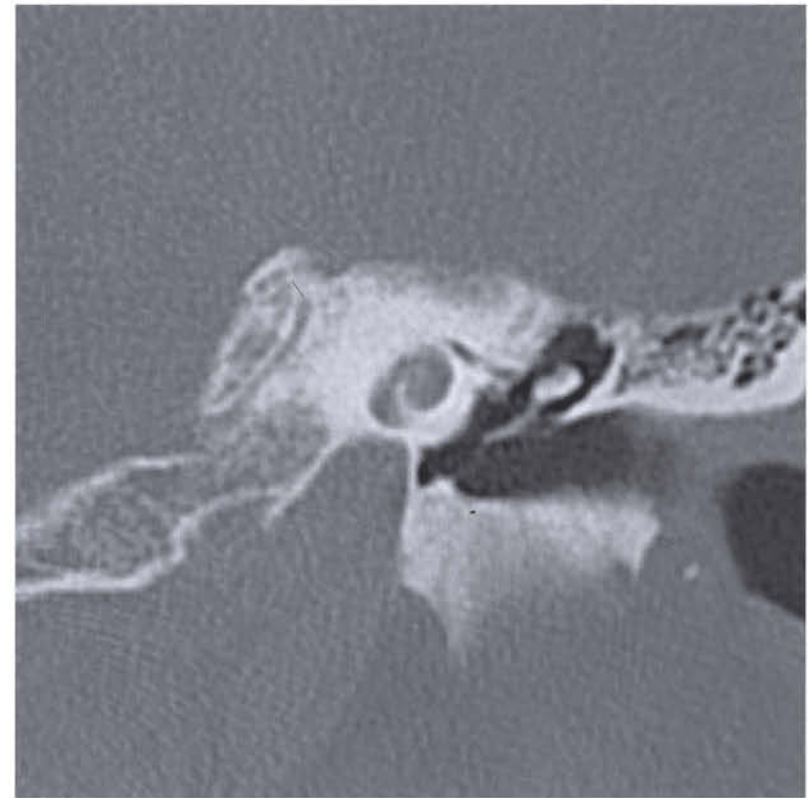
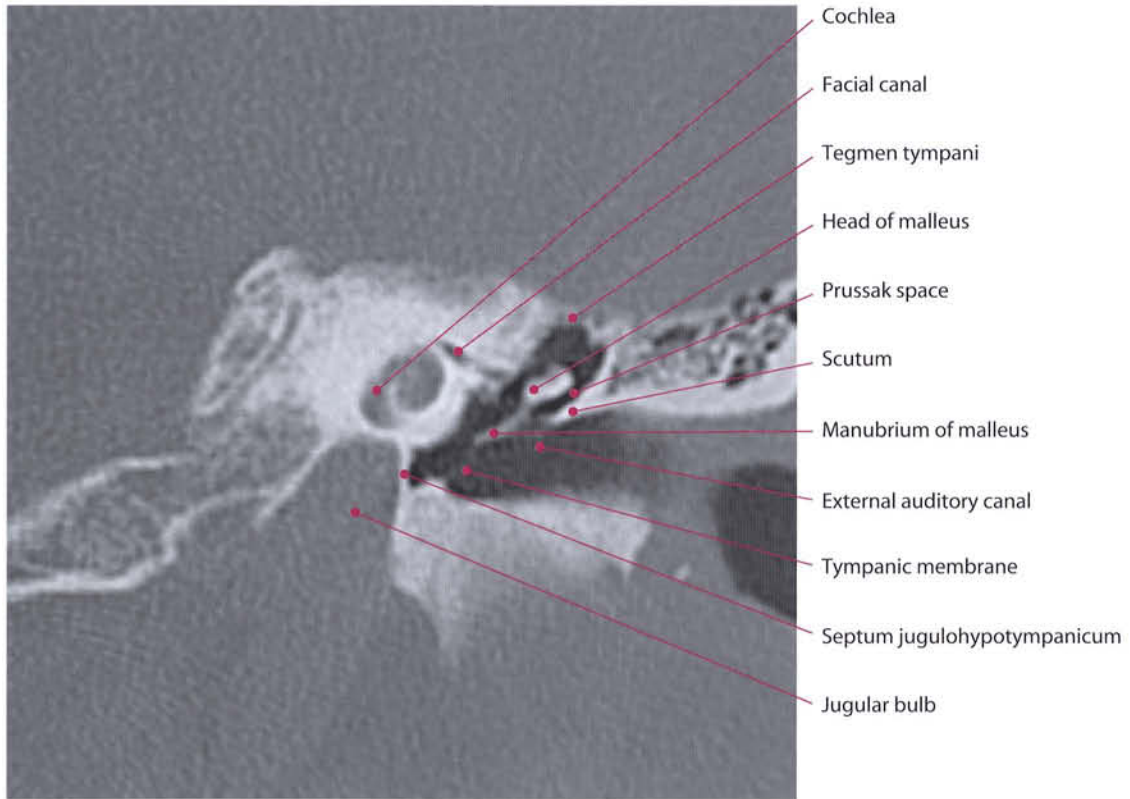


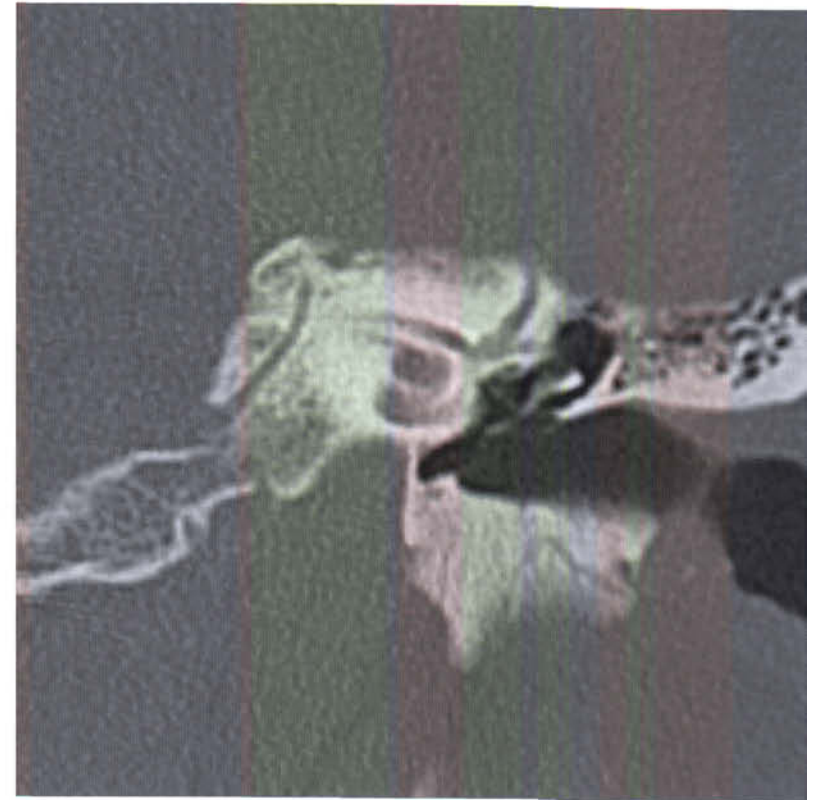
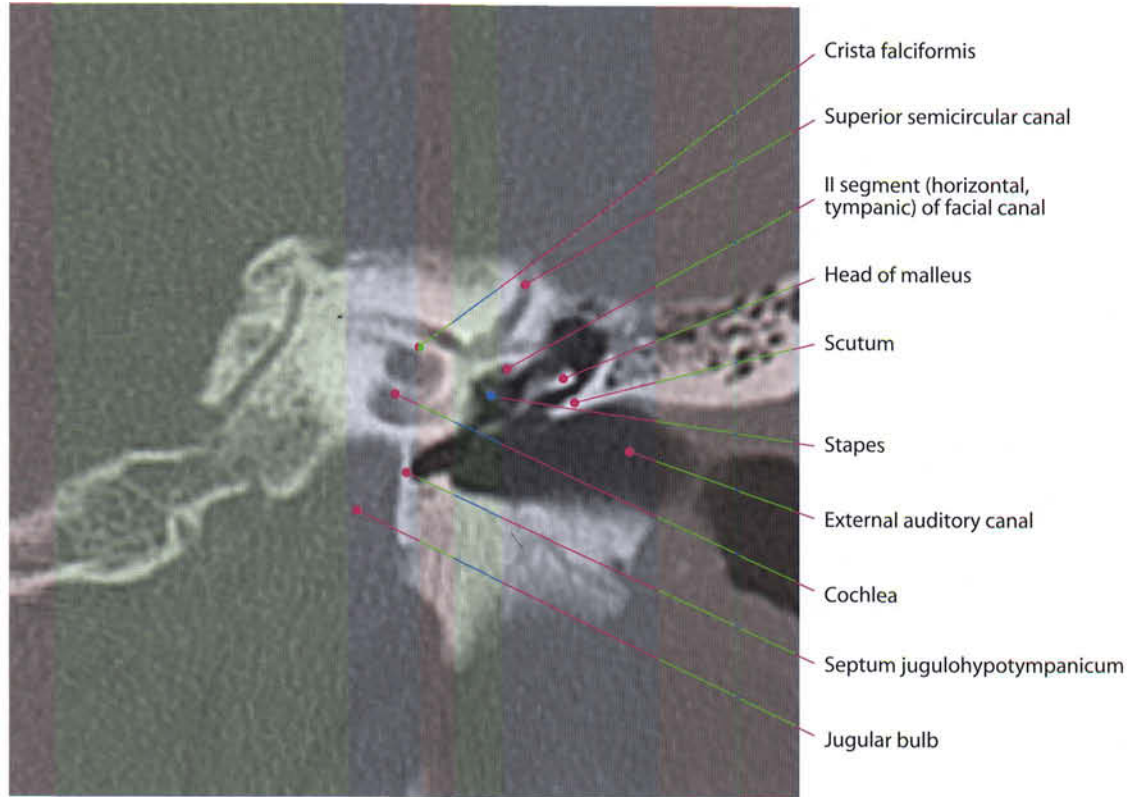
- Middle turn } Cochlea
- Upper turn }
- Geniculum of facial nerve
- Tensor tympani muscle
- Head of malleus
- Septum jugulohypotympanicum

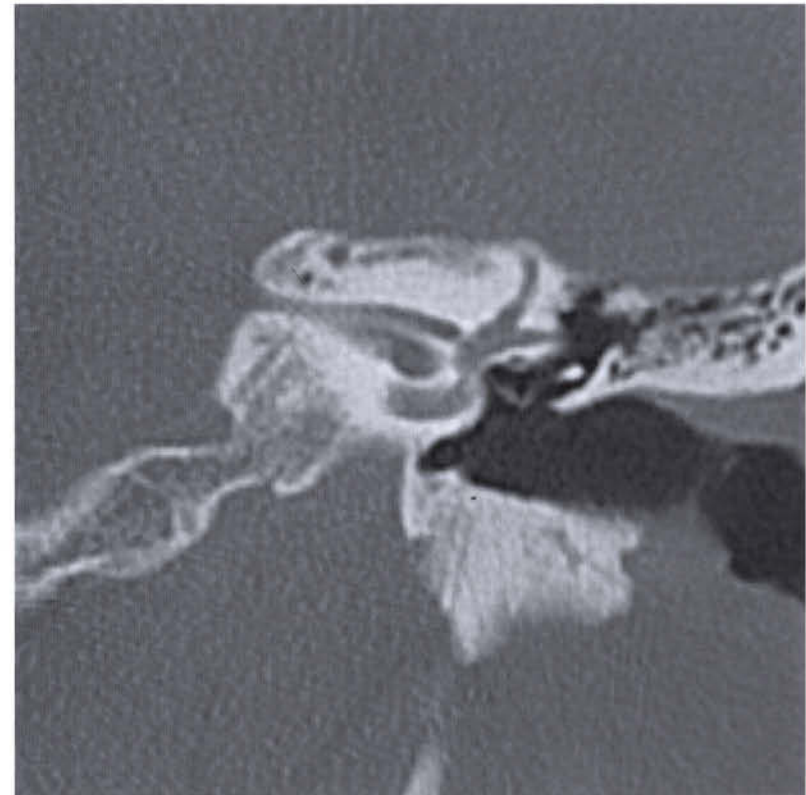
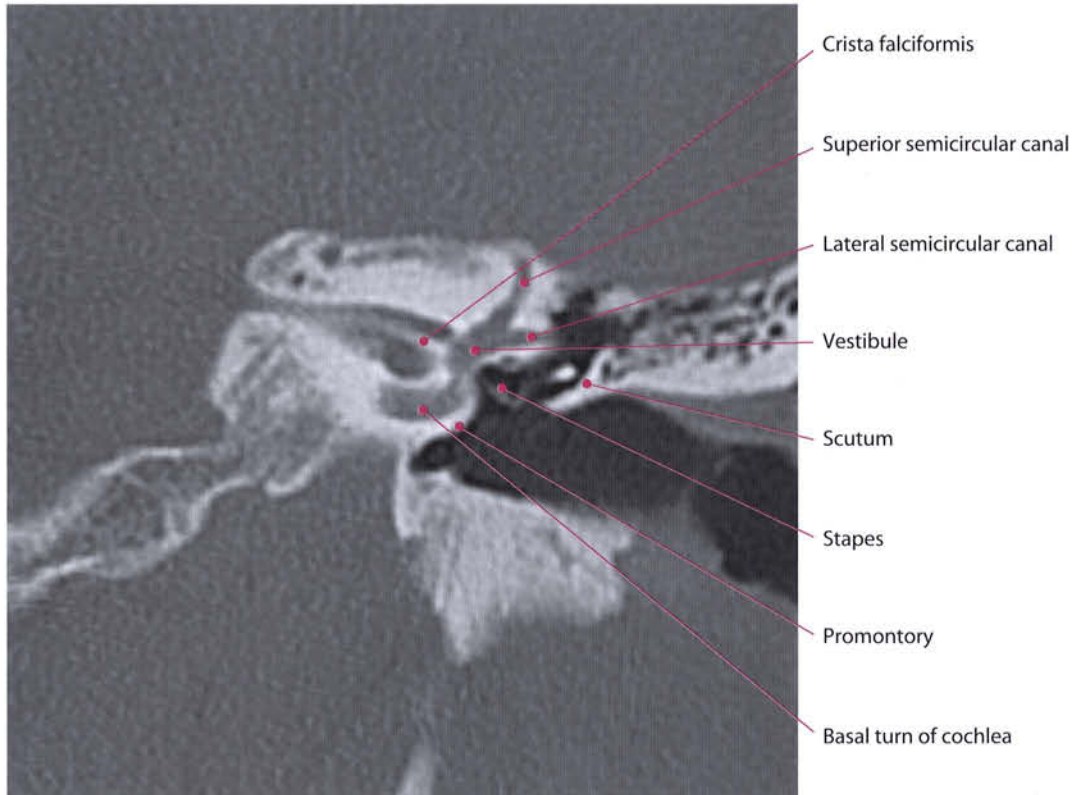


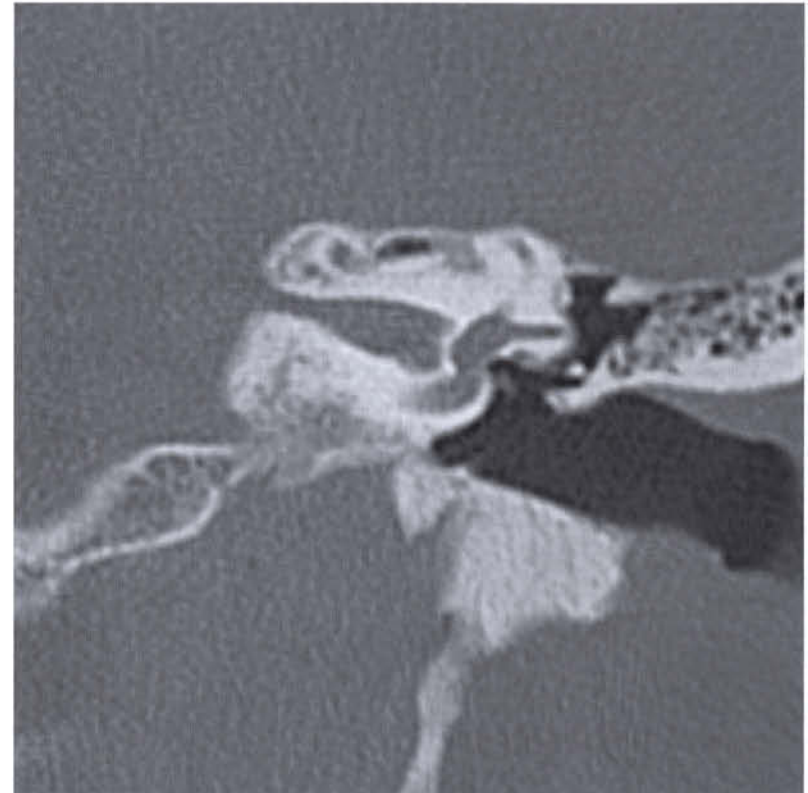
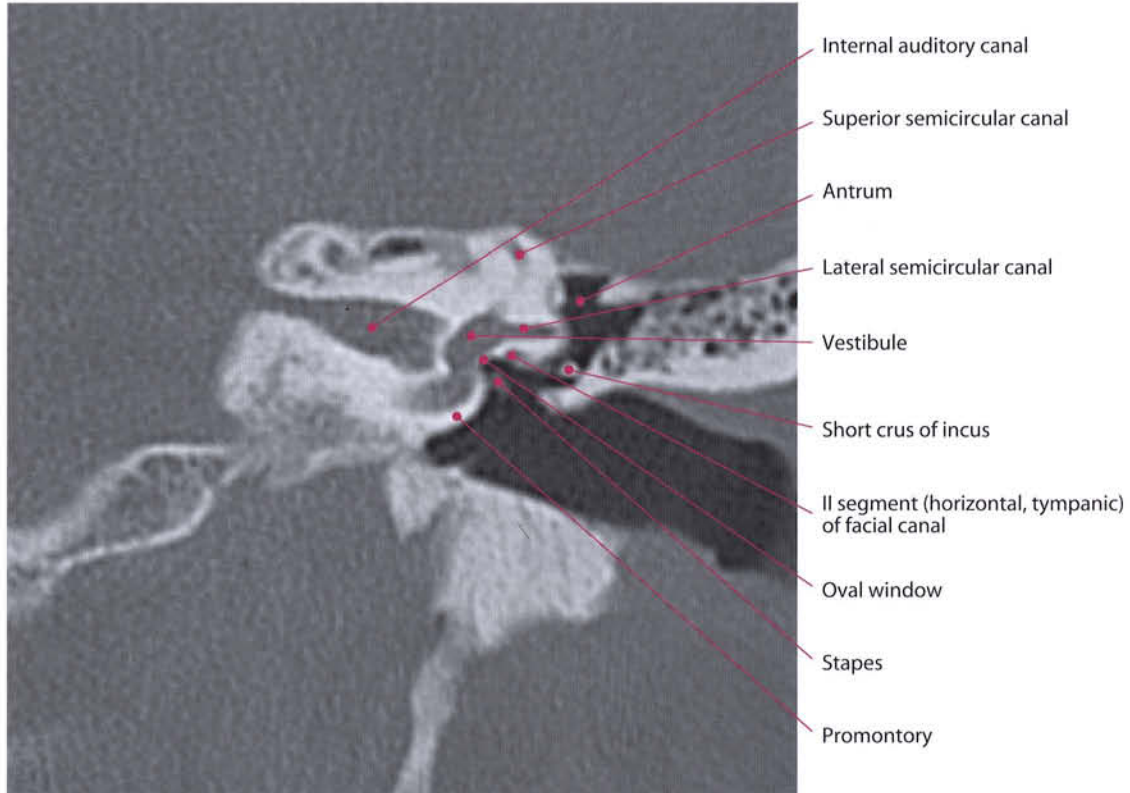


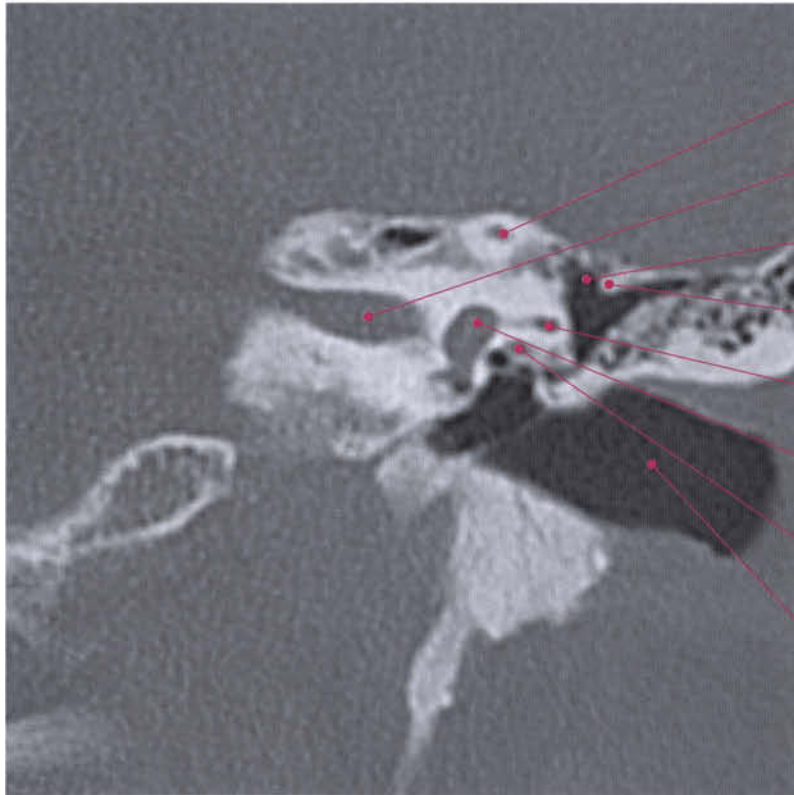




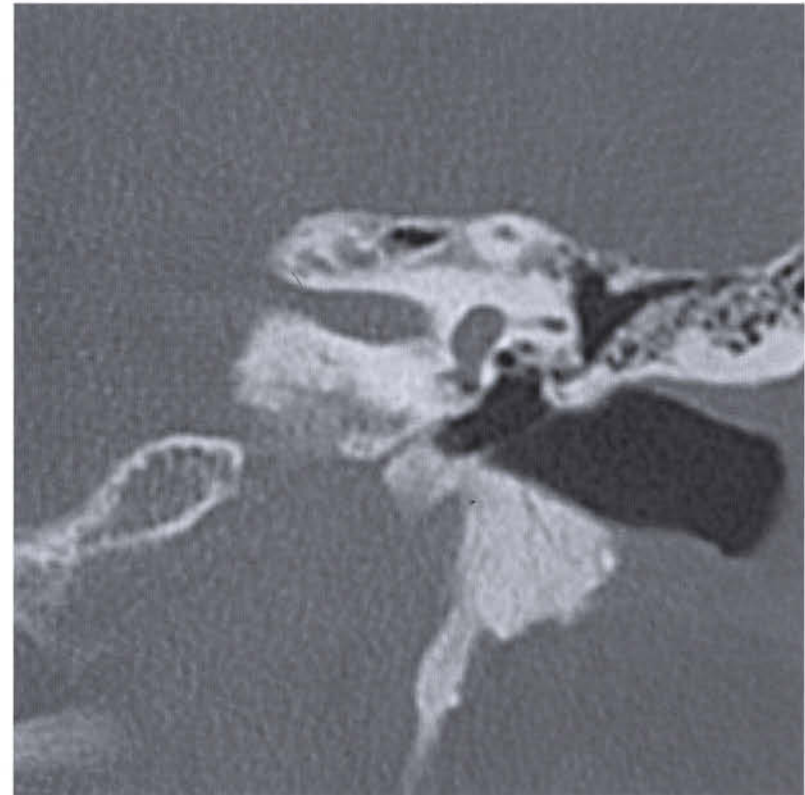


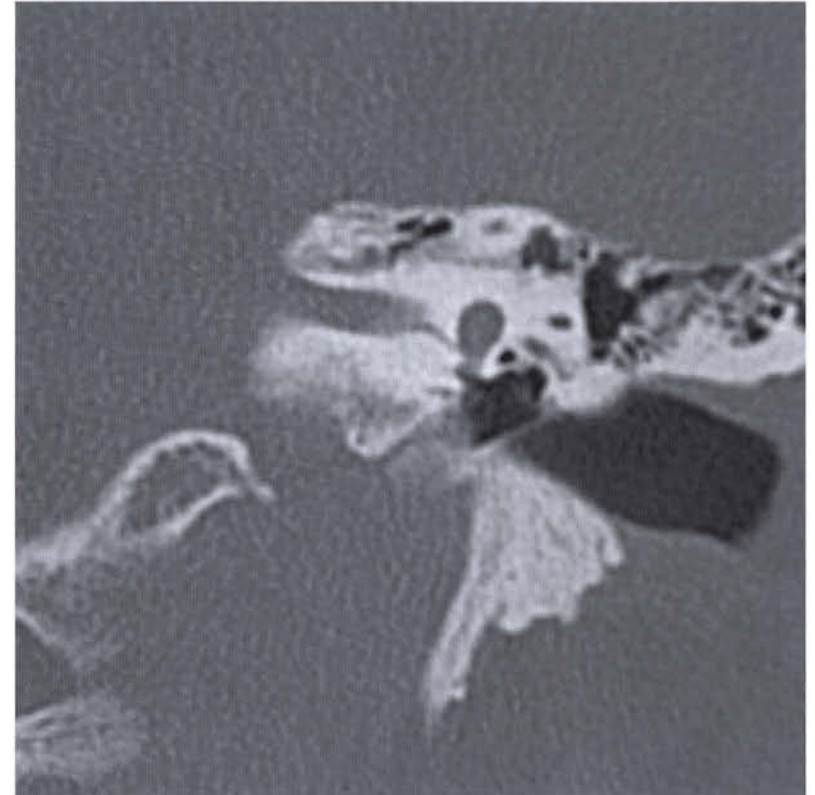
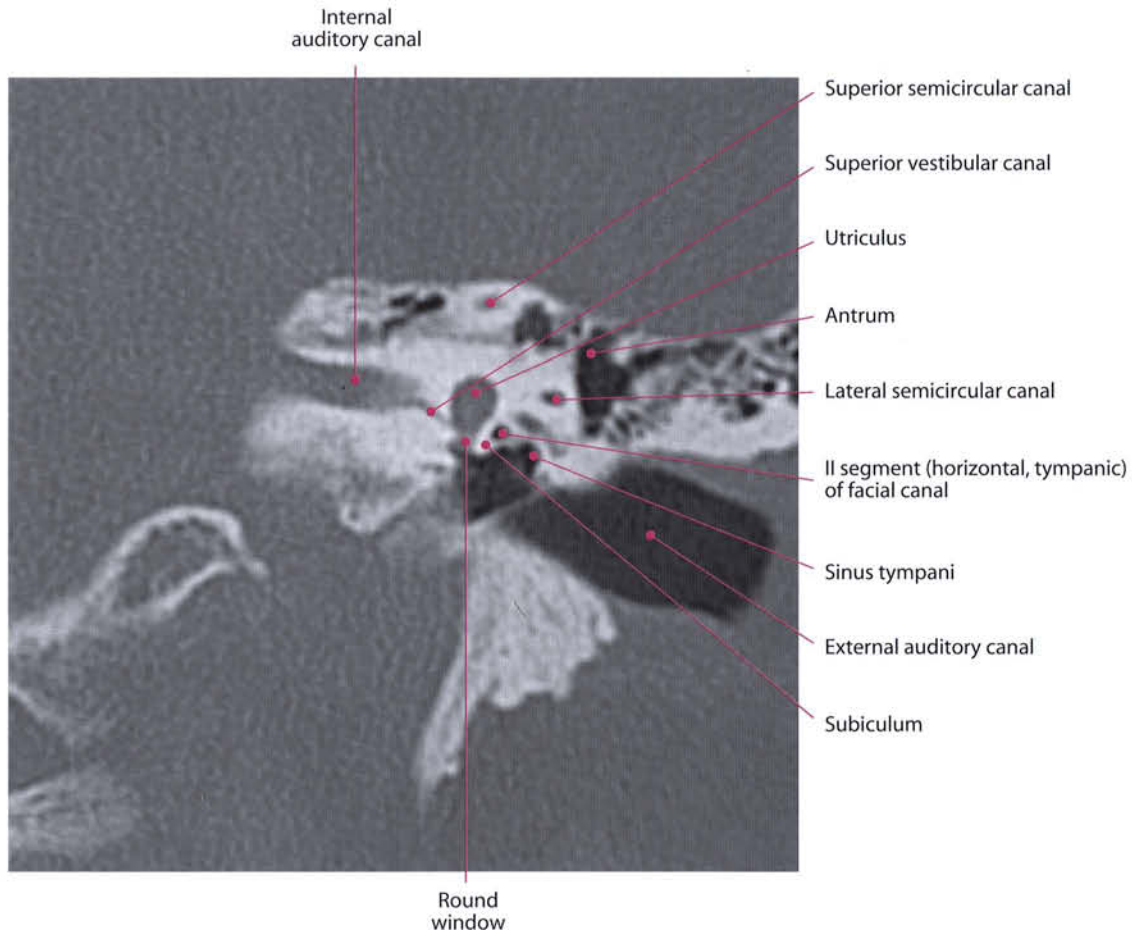


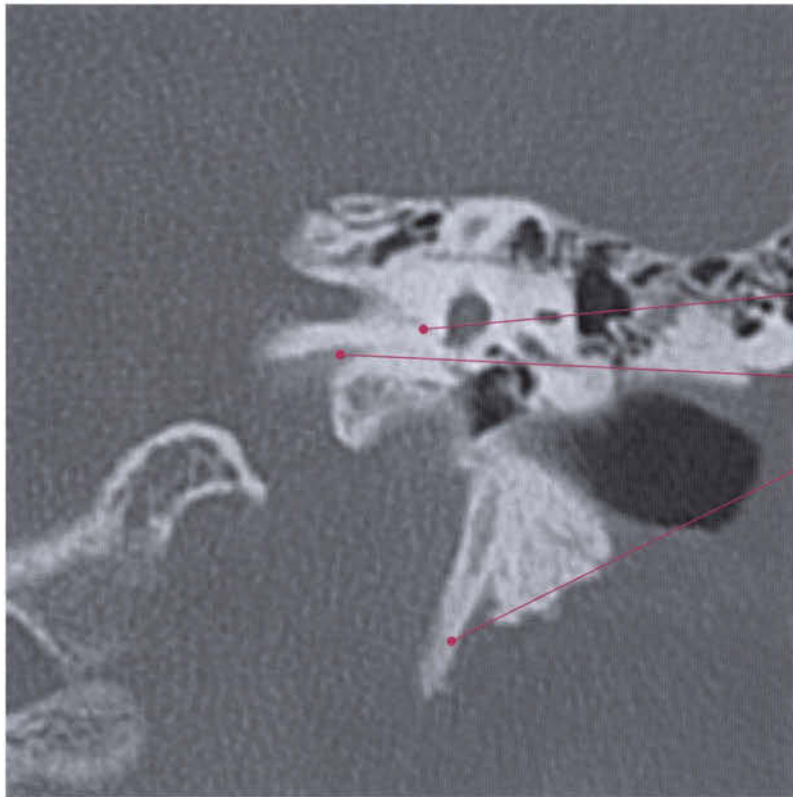




- Superior semicircular canal
- Internal auditory canal
- Antrum
- Korner's septum
- Lateral semicircular canal
- Vestibule
- II segment (horizontal, tympanic) of facial canal
- External auditory canal



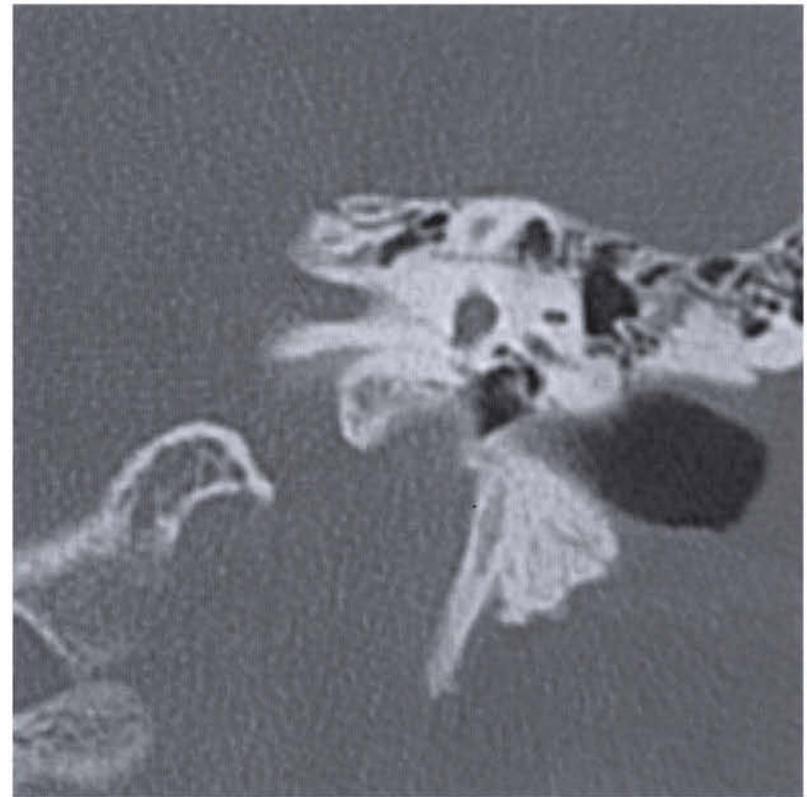


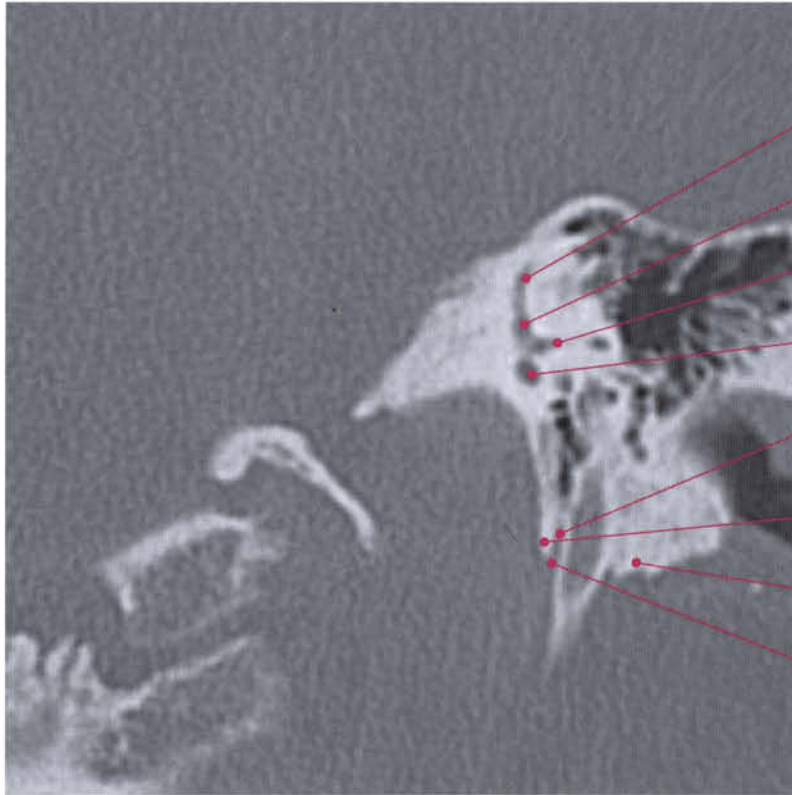


Inferior vestibular canal

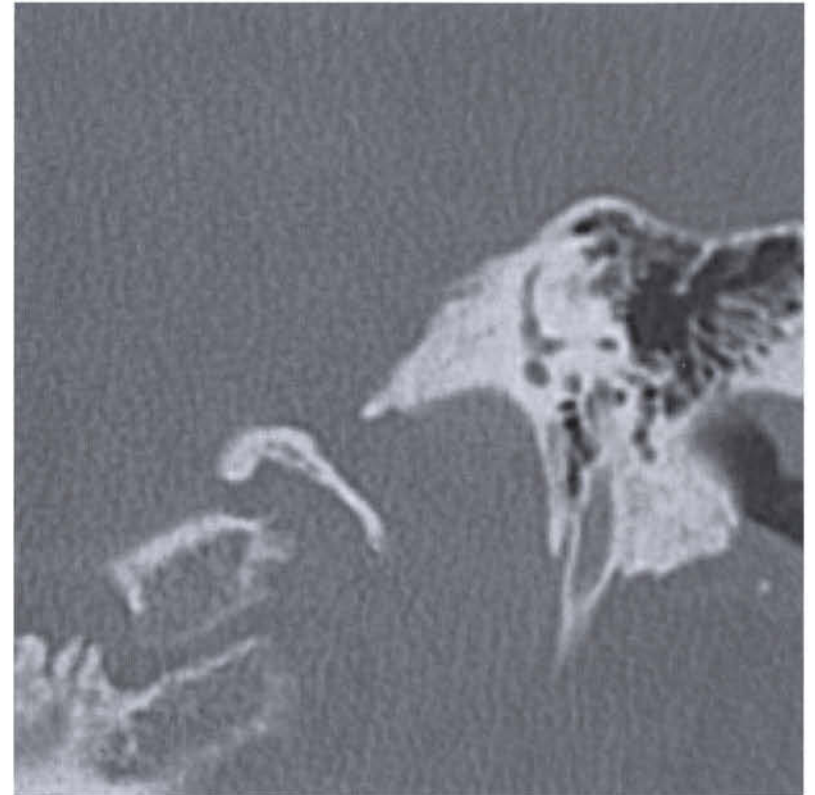Vestibular aqueduct

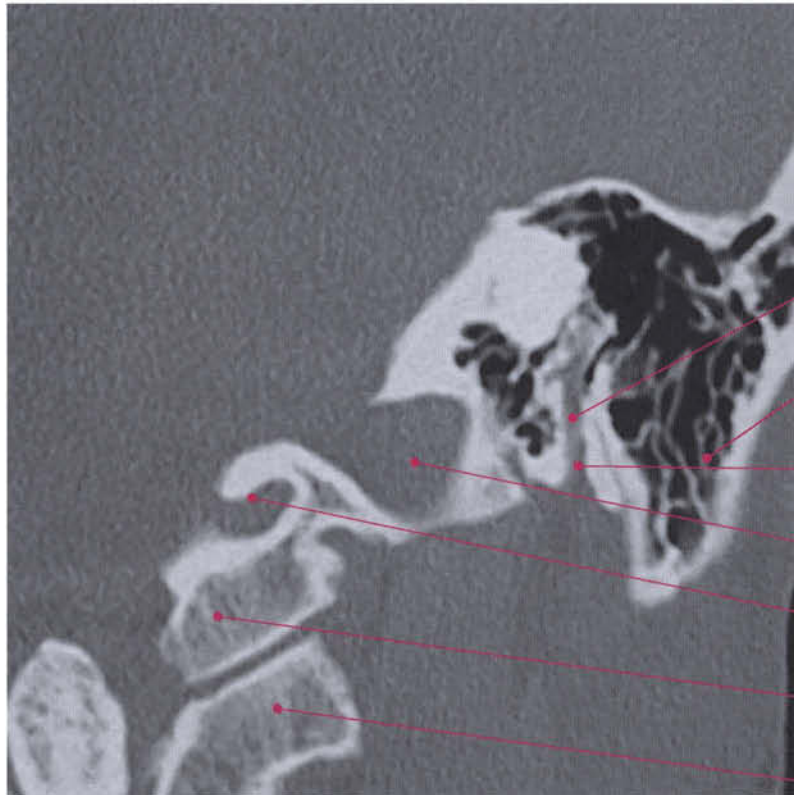
Styloid process





- Superior semicircular canal
- Superior ampulla
- Lateral semicircular canal
- Posterior ampulla
- III segment (vertical, mastoid) of facial canal
- Styloid process
- Mastoid
- Stylomastoid foramen





III segment (vertical, mastoid)
of facial canal

Mastoid

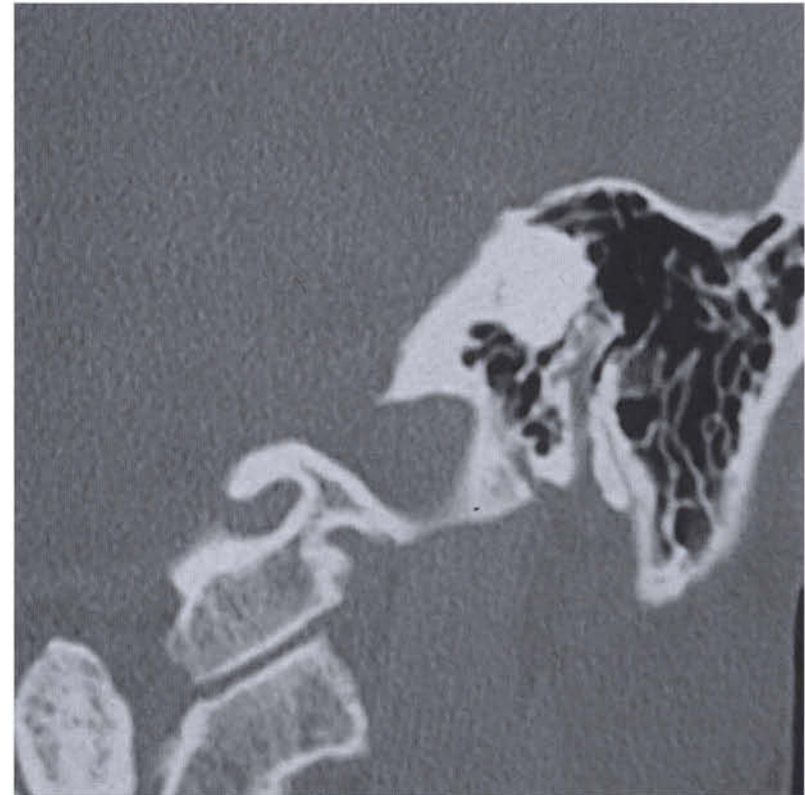Stylomastoid foramen

Sigmoid sinus

Condylar canal

Occipital condyle

Lateral mass of atlas



Glossopharyngeal (IX Cranial Nerve), Vagus (X Cranial Nerve), Accessory (XI Cranial Nerve), Hypoglossal (XII Cranial Nerve) Nerves

The ninth (glossopharyngeal) and tenth (vagus) nerves arise from the upper part of the medulla, lateral to the olive. The eleventh (accessory) emerges behind or lateral to the olive, with several fibers extended along most of the medulla length. The twelfth (hypoglossal) nerve emerges from the anterolateral (preolivary) sulcus at the lower part of the medulla.

The IX, X and XI cranial nerves reach the pars nervosa of the jugular foramen, while the XII cranial nerve exits the skull through the hypoglossal canal.

I. Glossopharyngeal Nerve (IX Cranial Nerve)

At the bulbar level, the glossopharyngeal nerve comes from a group of cells located in the rostral portion of the nucleus ambiguus. This originates a small bundle of special visceral efferent (SVE) fibers which emerges cranially to the fibers of the X c.n., at the level of the posterior lateral sulcus of the bulb (sulcus of mixed nerves), and innervates the stylopharyngeus and the cephalopharyngeus muscles.

The inferior salivatory nucleus (cranial part of the dorsal motor nucleus) originates the preganglionic general visceral efferent (GVE) fibers, which immediately emerge in the sulcus of mixed nerves above the roots of the vagus and innervate the parotid gland. The inferior salivatory nucleus is reached by fibers from the hypothalamus which present numerous connections with the neurons of the reticular formation. Moreover, fibers from the nucleus of the tractus solitarius (VII, IX and X cc.nn.) and from the main sensory nucleus of the trigeminal nerve reach this point.

The spinal tract and the spinal nucleus of the trigeminal nerve are reached by a small contingent of GSA fibers carrying general somatic sensitivity from cutaneous areas around the ear.

The special visceral afferent (SVA) fibers carrying gustatory sensations from the posterior third part of the tongue enter the posterolateral part of the bulb, in the sulcus of mixed nerves, together with the roots of the vagus, and spread to the rostral portions of the bulbar component of the nucleus of the tractus solitarius (gustatory nucleus).

The general visceral afferent (GVA) fibers that carry impulses regarding the sense of touch, the thermal sense and pain from the mucous membranes of the posterior third of the tongue, the tonsils, the back wall of the upper pharynx and the eustachian tube, terminate in the caudal portion of the nucleus of the tractus solitarius, together with the GVA component of the X c.n.

The GVA fibers carrying impulses from the carotid sinus (carotid sinus reflex) belong to the dorsal motor nucleus of the vagus.

II. Vagus Nerve (X Cranial Nerve)

The ambiguous nucleus is located in the reticular formation at the bulbar level. The SVE fibers move diagonally in a dorso-medial direction like an arch, and join the preganglionic general visceral efferent fibers coming from the dorsal motor nucleus of the vagus to eventually emerge caudally to those of the glossopharyngeal nerve, at the level of the posterior lateral sulcus (sulcus of mixed nerves).

The rostral portion of this nucleus gives origin to the special visceral efferent fibers of the IX c.n., whereas the caudal portion is represented by the cranial part of the spinal accessory nerve and originates the special visceral efferent fibers of the XI c.n. which, joining the fibers of the X c.n., innervate the pharynx and larynx muscles.

The ambiguous nucleus receives rami from the visceral afferent nuclei of the vagus itself, from the IX c.n. and the main sensory nucleus of the V c.n.

The dorsal motor nucleus of the vagus is located in the bulb, posterolaterally to the hypoglossal nucleus, at the level of the ala cinerea in the tegmen of the fourth ventricle.

Preganglionic GVE fibers, originating from the most caudal portion of the nucleus, cross the spinal tract and the spinal nucleus of the trigeminal nerve, emerge in correspondence with the mixed nerves, and spread to the heart (SA, AV nodes, striated muscle in the carotid sinus reflex), the respiratory tract and abdominal viscera.

The dorsal motor nucleus receives fibers mainly from the hypothalamus, from the nucleus of the tractus solitarius and the main sensory nucleus of the V c.n.

The nucleus of the tractus solitarius receives the vagal afferent fibers which enter the inferior cerebellar peduncle ventrally near the lateral side of the bulb, crossing the spinal

tract and the spinal nucleus of the trigeminal nerve.

A small contingent of GSA fibers coming from the cutaneous areas behind the ear and the external auditory meatus enters the dorsal portion of the spinal tract of the trigeminal nerve.

A larger group of general and specific afferent fibers moves dorsomedially and enters the solitary fasciculus together with the fibers of the glossopharyngeal nerve and the nervus intermedius.

The special visceral afferent fibers of the glossopharyngeal nerve and nervus intermedius and the vagus coming from the gustatory buds in the epiglottis region terminate in the rostral part of the nucleus of the tractus solitarius (gustatory nucleus).

III. Accessory Nerve (XI Cranial Nerve)

The SVE component of the spinal accessory nerve originates from a group of bulbar cells, placed ventrally to the nucleus of the IX c.n. This is the cranial or supraspinal component of the spinal accessory nerve and corresponds to the most caudal portion of the nucleus ambiguus.

The fibers emerge from the lateral surface of the bulb, caudally to the vagal filaments, innervating the intrinsic tongue muscles together with those of the nervus laryngeus inferior (recurrent).

The spinal part of the GSE accessory nerve originates from a cell column located in the anterior horn of the first five or six cervical segments in the lateral position. The radicular fibers originating from these cells curve posterolaterally and emerge from the lateral side of the cervical cord between the dorsal and ventral roots of the spinal nerves. They innervate the sternocleidomastoid muscle of the same side and the upper portions of the trapezius.

The spinal component of the accessory nerve receives fibers through the medial longitudinal fasciculus for the coordination of head and eye rotation movements (cephalo- and oculogyric movements).

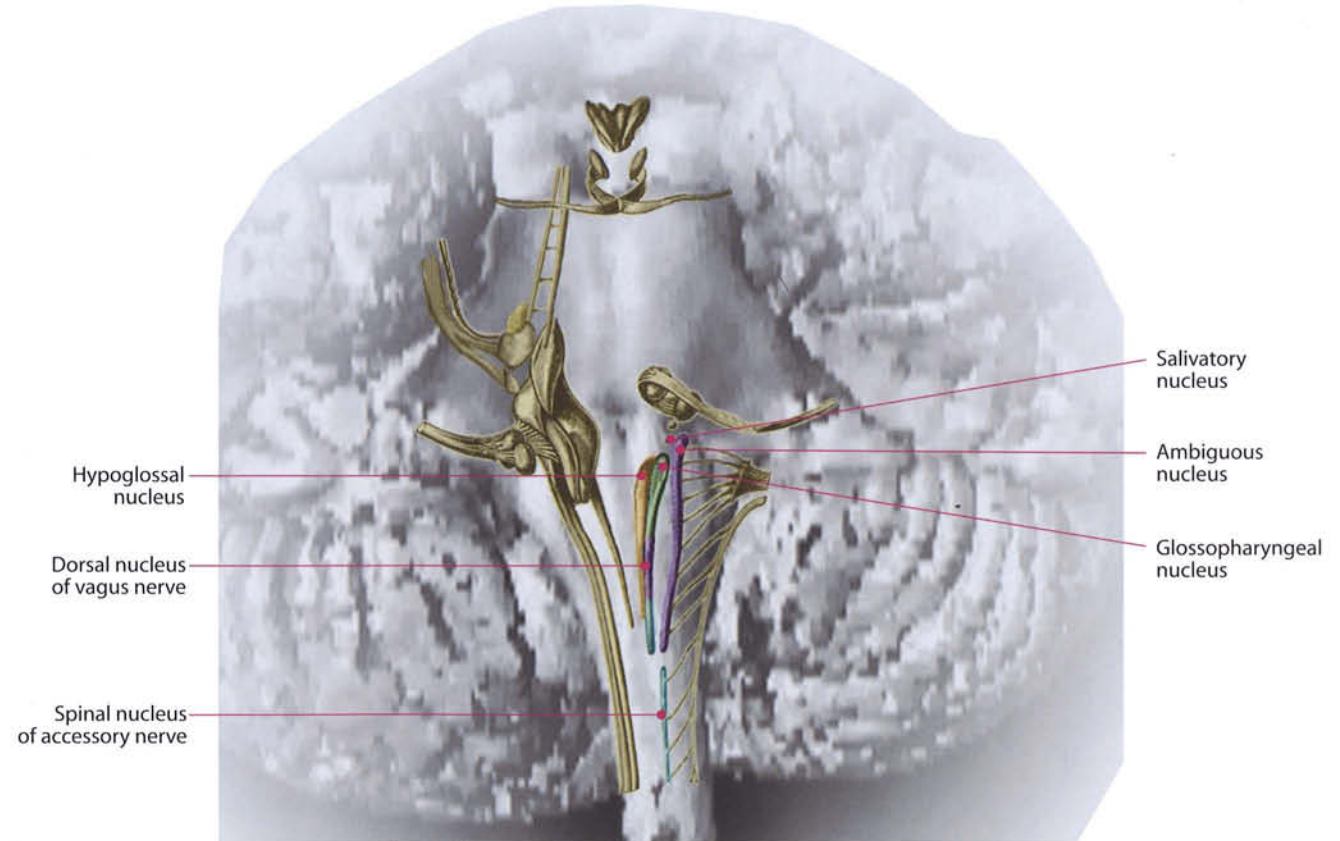
IV. Hypoglossal Nerve (XII Cranial Nerve)

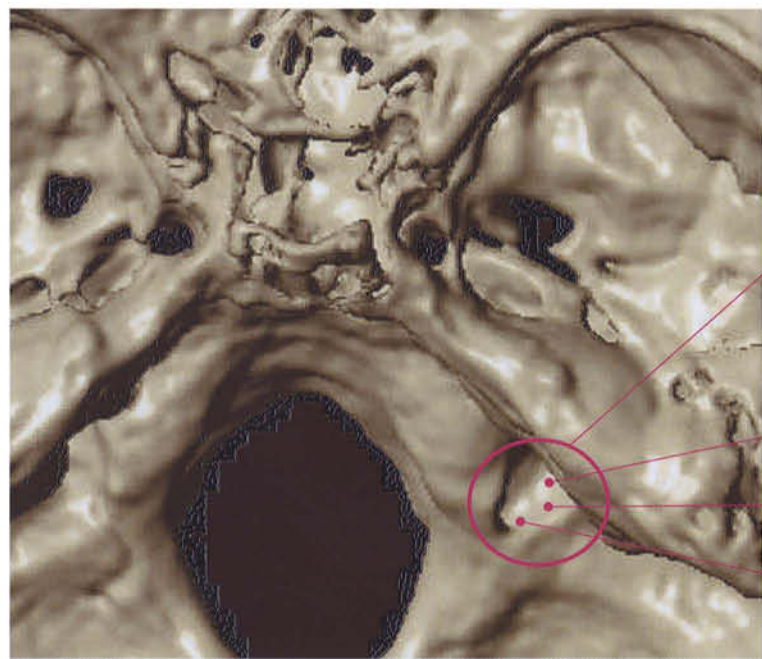
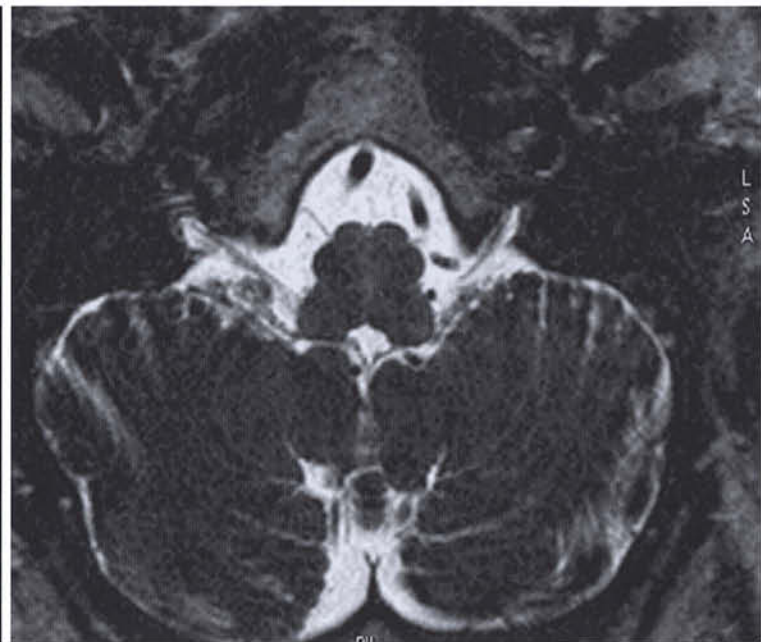
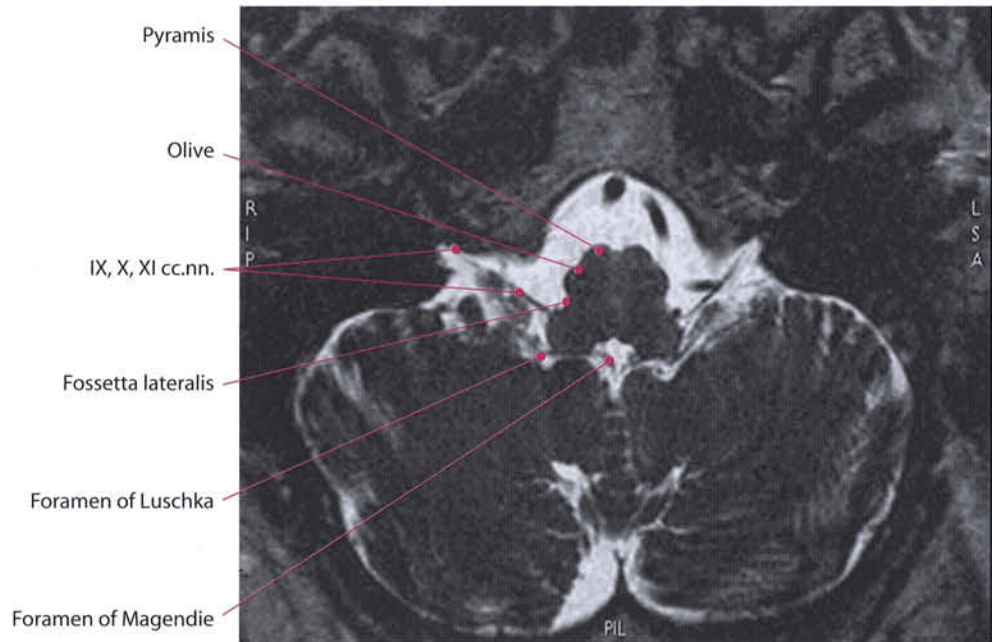
The nucleus of the hypoglossal nerve is located in the dorsal region of the medulla, from the lower edge up to half the tegmen of the fourth ventricle.

The general somatic efferent (GSE) roots emerge from the nucleus ventrally, move forward and outside, and along the lateral margin of the medial longitudinal fasciculus and the medial lemniscus and cross the medial parts of the inferior olive complex. They eventually exit at the level of the anterolateral sulcus of the bulb (preolivary sulcus), between the pyramid and the bulbar olive.

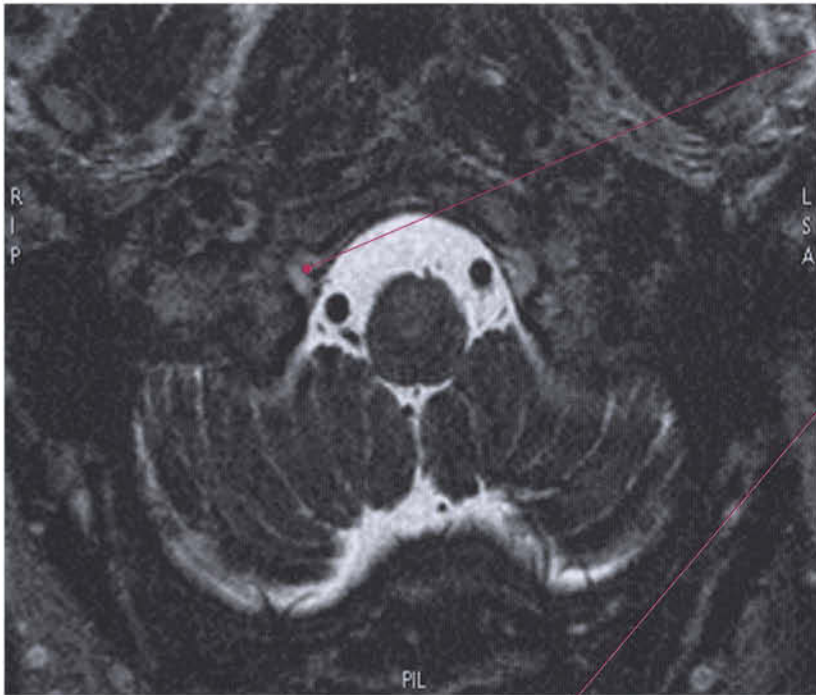
They innervate the intrinsic tongue muscles, the genioglossus, hyoglossus and styloglossus muscles.

The nucleus of the hypoglossal nerve receives collaterals from the descending root of the trigeminal nerve.



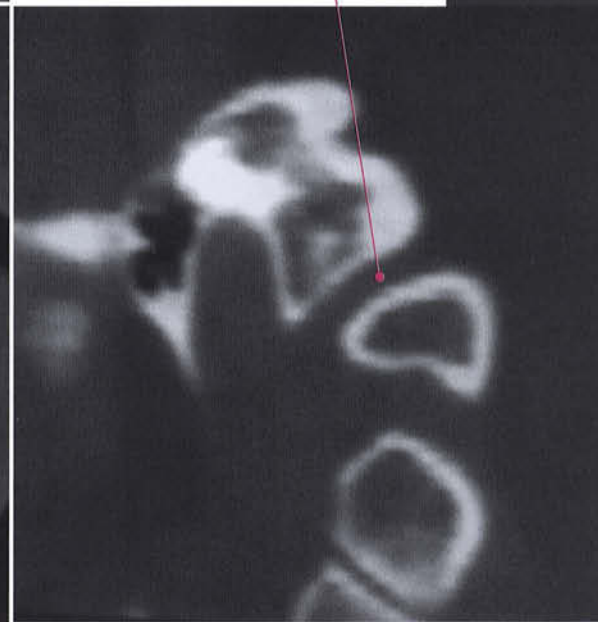
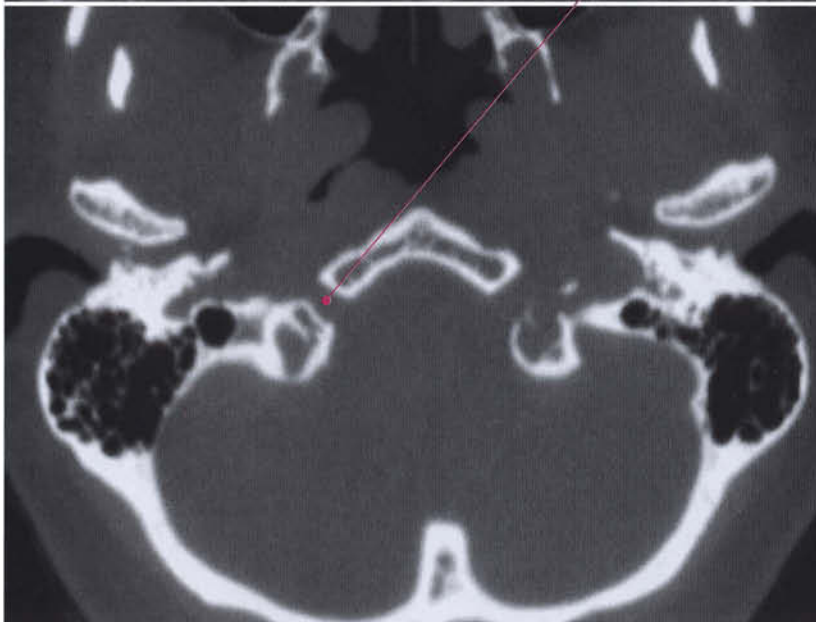
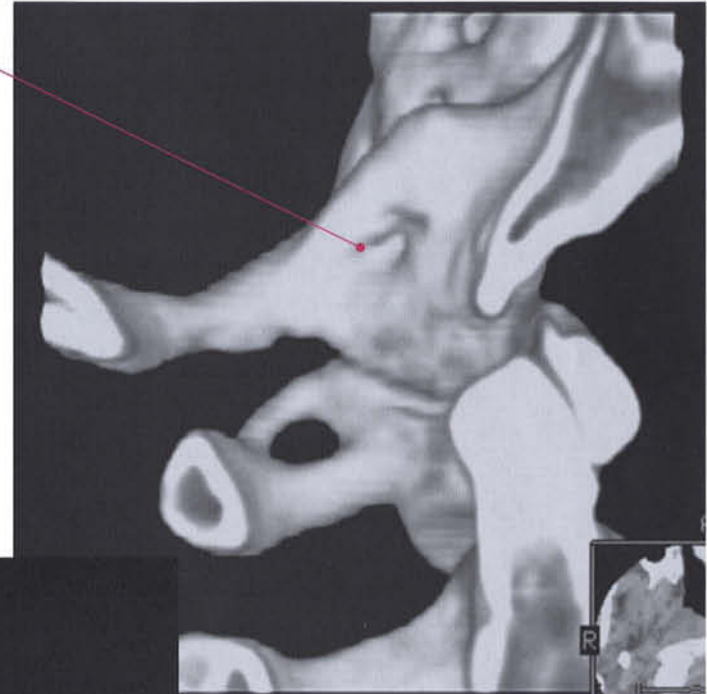


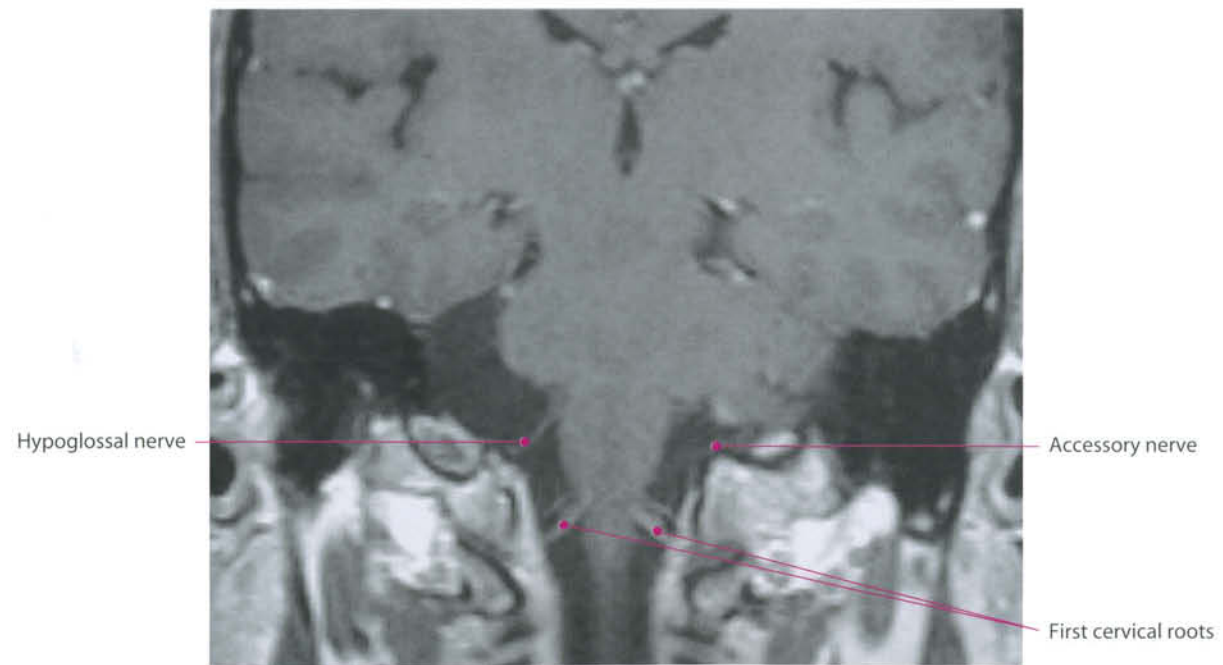
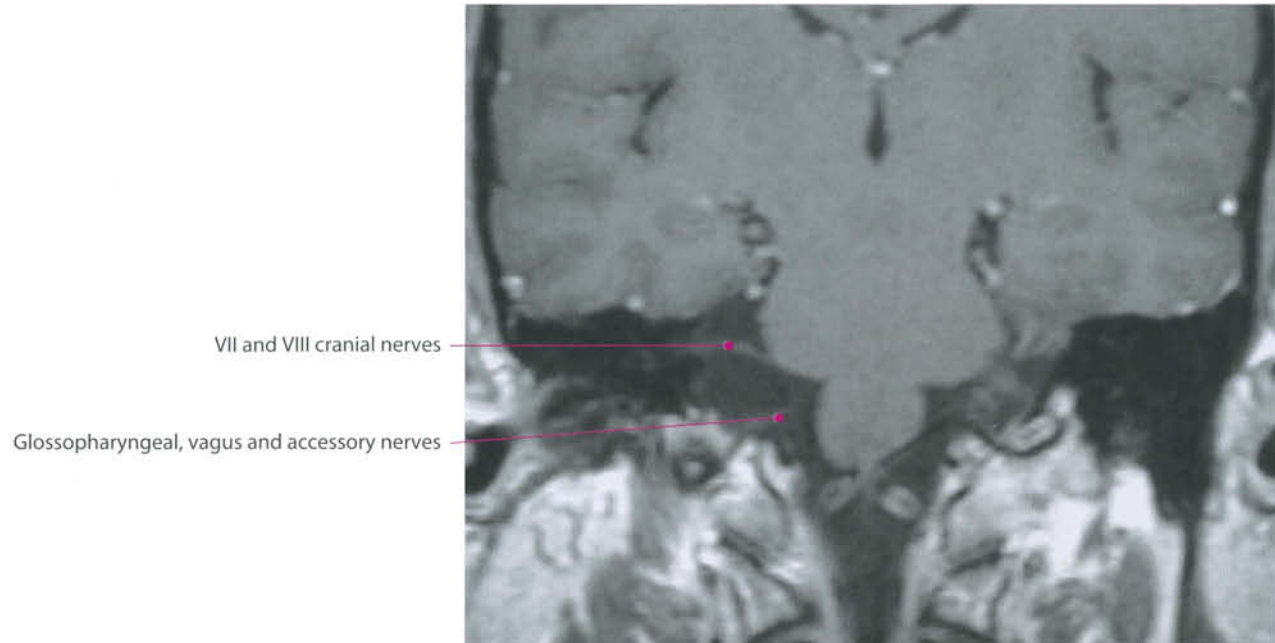
- Jugular Foramen
- Accessory nerve
- Vagus nerve
- Glossopharyngeal nerve



Hypoglossal nerve (XII c.n.) and hypoglossal canal

Hypoglossal Canal





5 Functional Systems

Functional Systems

In this chapter, some of the main CNS structures are grouped together with particular respect to their functional activity. The classification is somewhat arbitrary and covers only a practical aspect: to allow easy identification of a possible lesion location based on symptoms and signs. The main systems are considered on the following pages, while other systems are dealt with together with their cranial nerves. Several other complex cerebral functions not routinely visible through neuroradiological studies are not considered in this chapter.

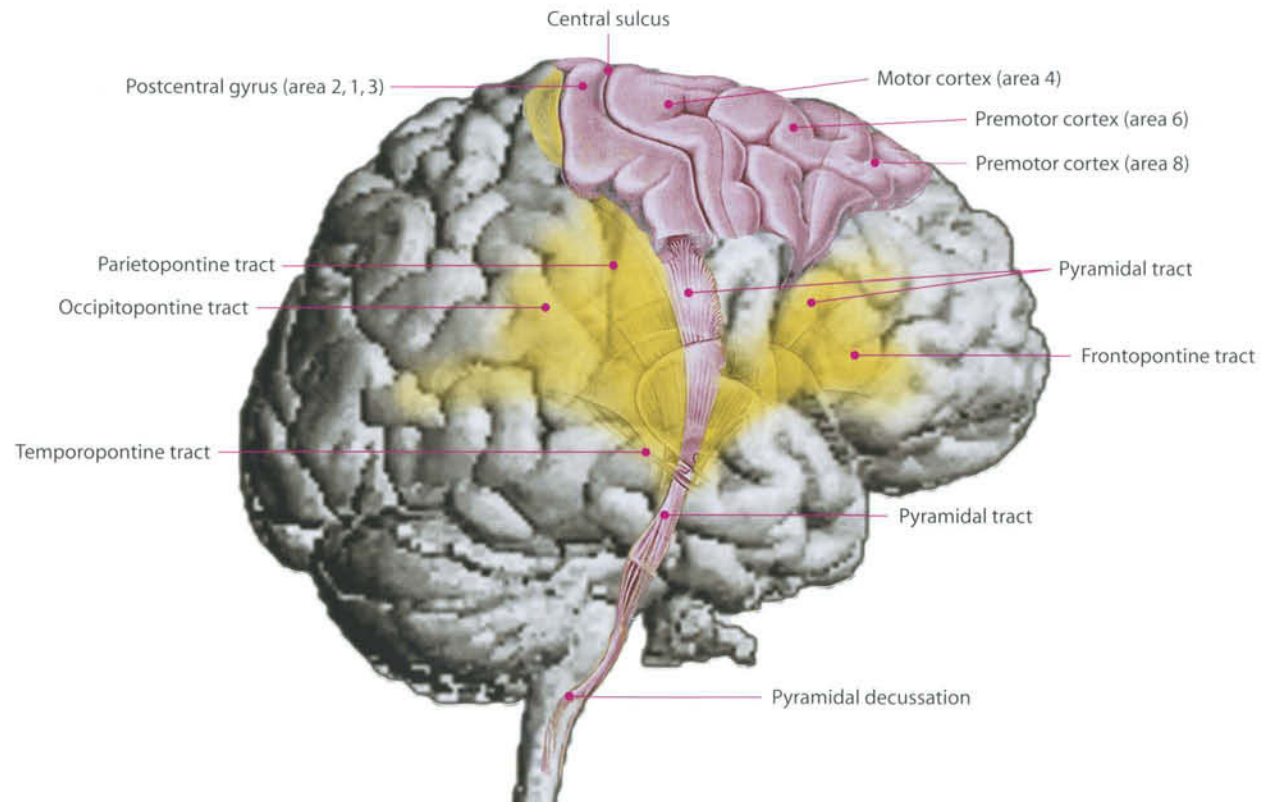
Motor Systems: I

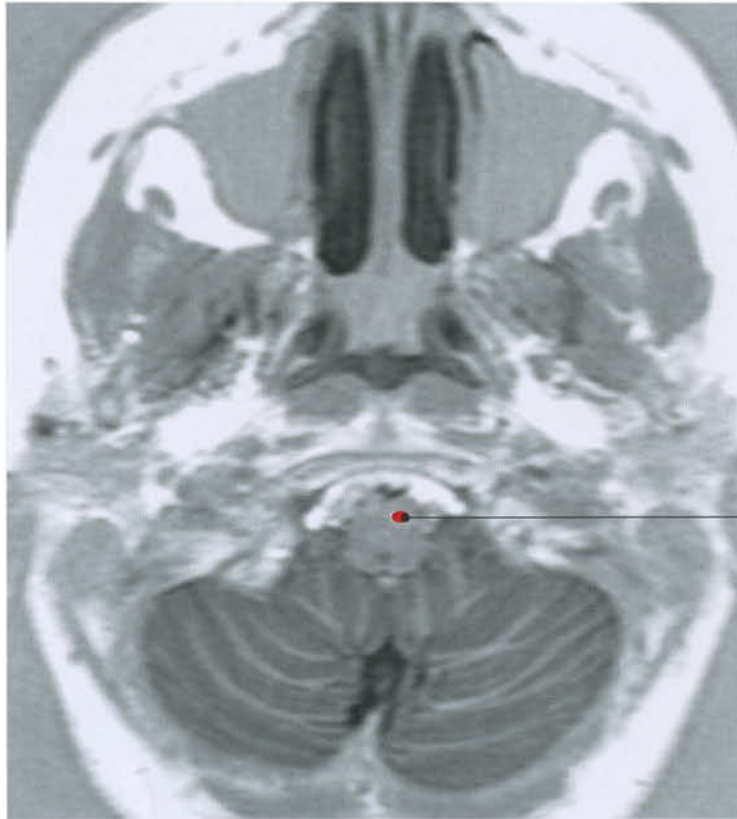
Pyramidal (Primary) Motor System

The motor function is mainly supported by the corticospinal (or pyramidal) tract. The majority of fibers of the pyramidal tract take origin from the precentral gyrus (primary motor area – area 4), and caudal premotor cortex (area 6). The largest amount comes from the axons of the giant pyramidal (or Betz's) neurons located in the V and VI layers of the posterior fifth of the motor cortex. The motor cortex is somatotopically organized, and movements of the hind limb are located in the medial motor cortex (lobulus paracentralis, with the foot located caudally, and the hip at the vertex). The trunk is in the upper part of the prerolandic gyrus, followed by the forelimb and the hand. The motor area for the contralateral hand is thicker than the rest of the primary motor cortex and folded; therefore it is well recognizable ("omega" or "epsilon" sign). Movements of the face are located successively, closer to the sylvian fissure. During their course, the axons pass through the centrum semiovale, the corona radiata, the genu and posterior limb of the internal capsule, the cerebral peduncle, the pons and the medulla. Here, approximately at the foramen magnum level, 80–90% of fibers cross the midline (pyramidal decussation) continuing their course in the anterolateral spinal column (tractus pyramidalis lateralis). The remaining fibers, whose role is still controversial, remain homolateral (tractus pyramidalis anterior). The fibers are somatotopically organized in their entire course: in the internal capsule, head and neck fibers

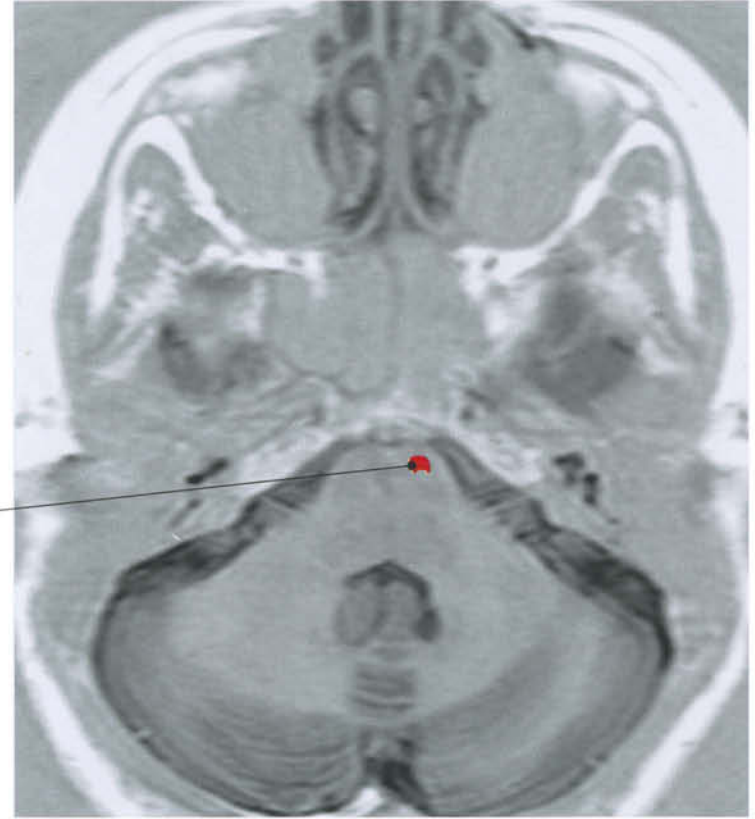
are located in the genu, while in the spinal cord the more distal fibers are the more peripheral. The main terminations of the corticofugal system are: thalamus, striatum, brainstem and spinal cord. In the brainstem, the most important terminations are the tectum, the basal pontine nuclei, and the reticular formation; in the spinal cord, fibers terminate in the anterior horn, in correspondence with the motor nuclei.

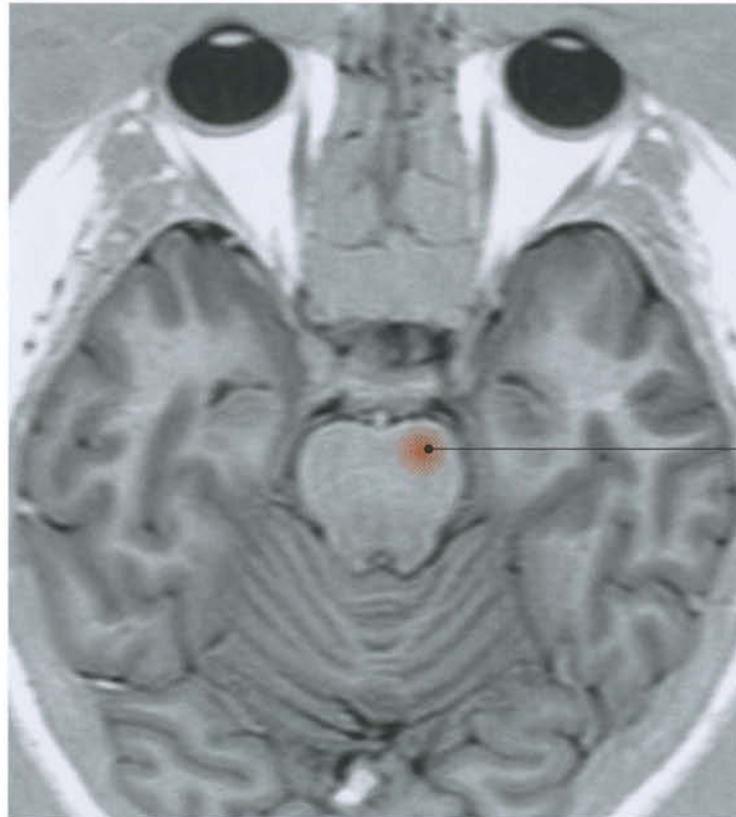Motor Systems - (I) Pyramidal System



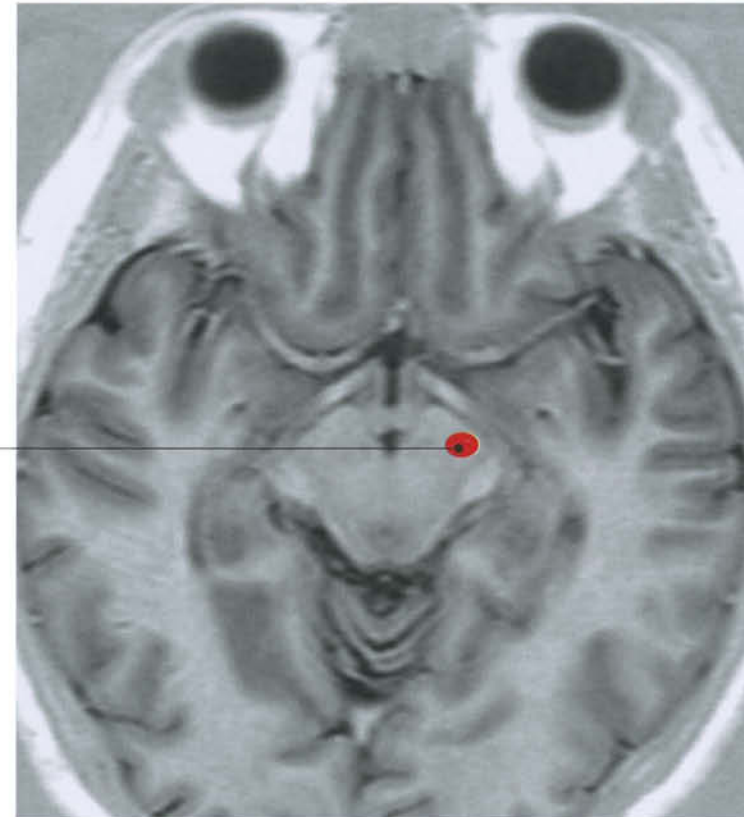


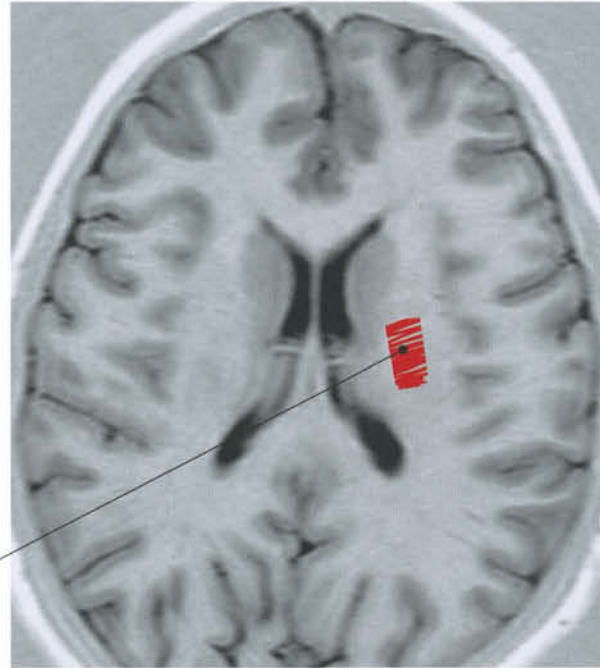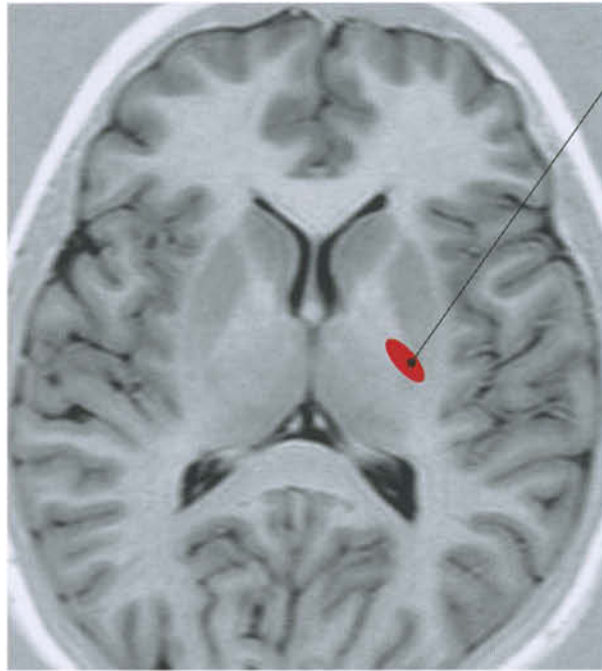
Corticospinal tract



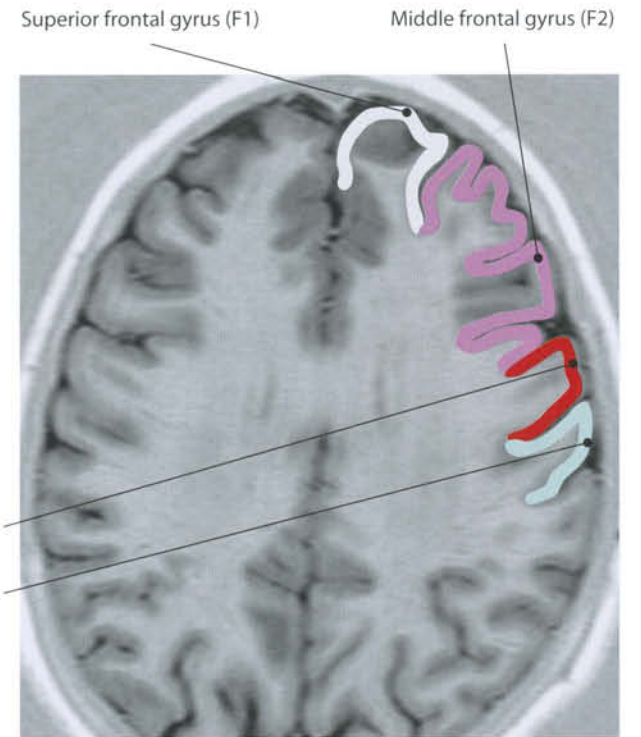

Corticospinal tract

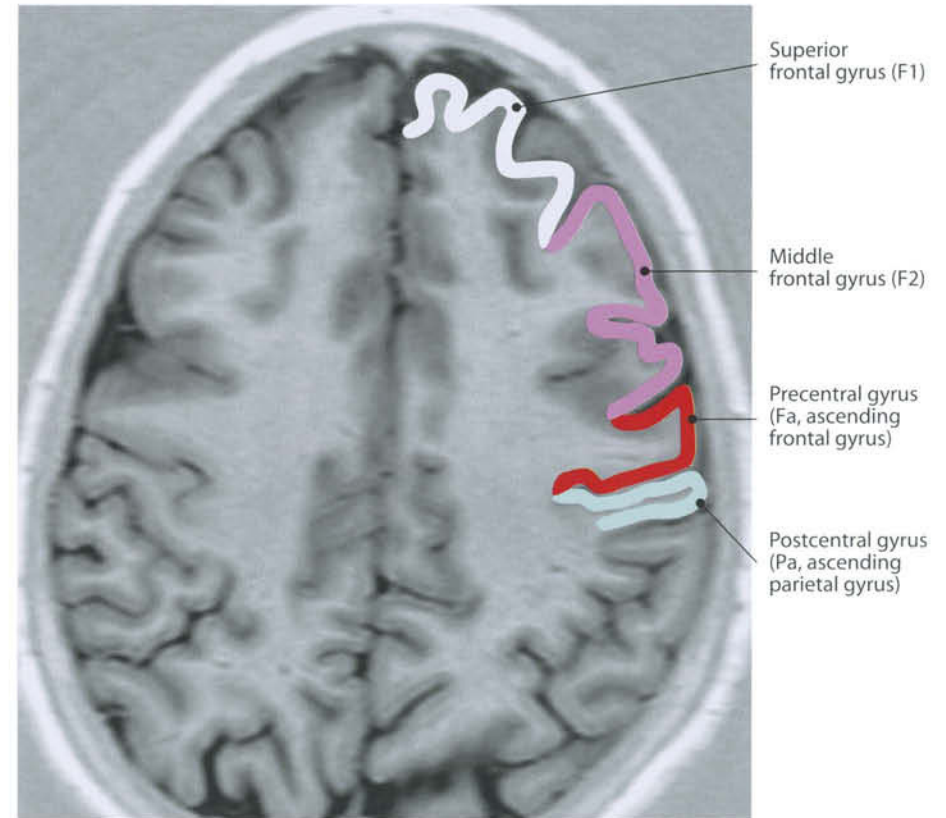
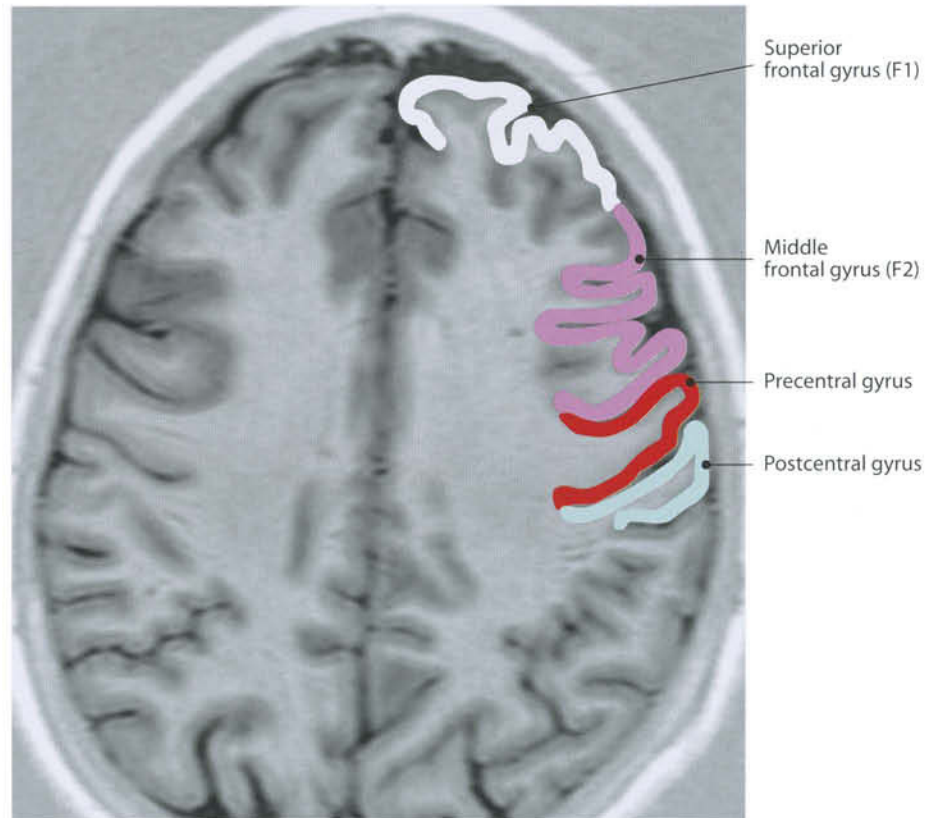




- Primary motor cortex (area 4)
- Areas 2, 1, 3
- Premotor area 8
- Premotor area 6

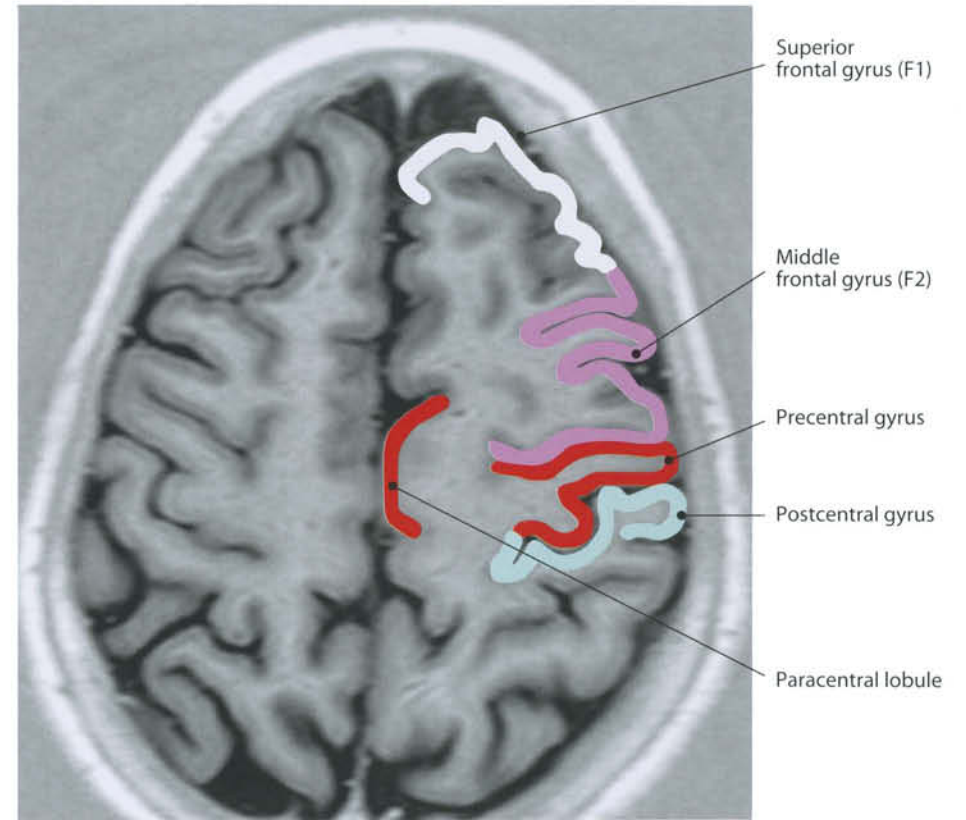
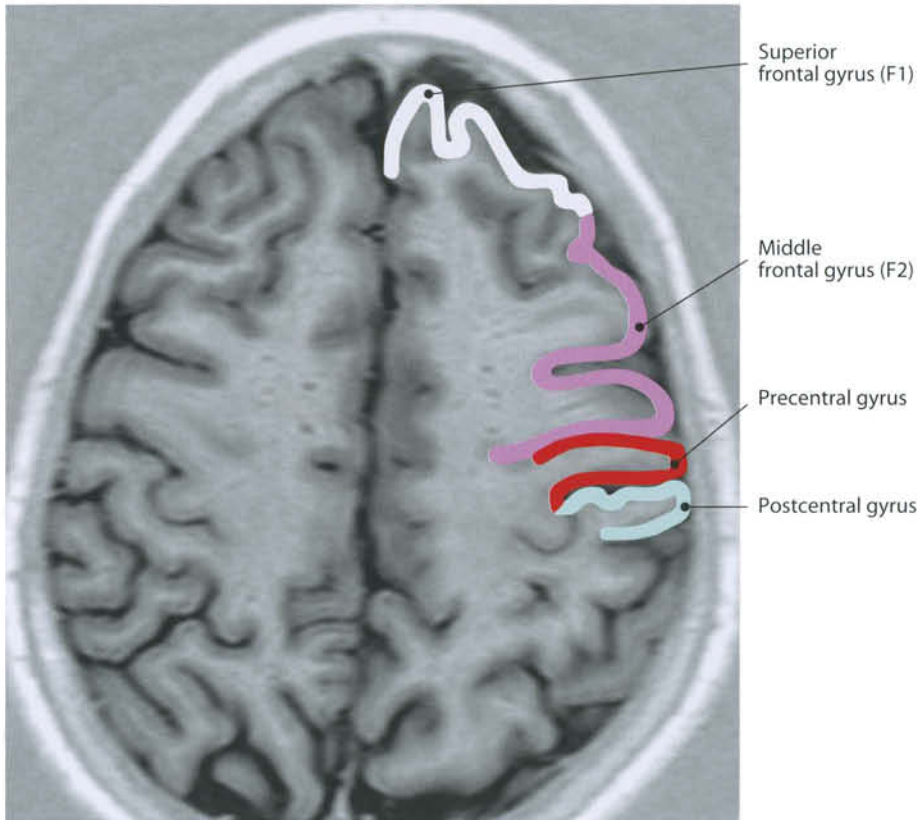


- Primary motor cortex (area 4)
- Areas 2, 1, 3
- Premotor area 8
- Premotor area 6

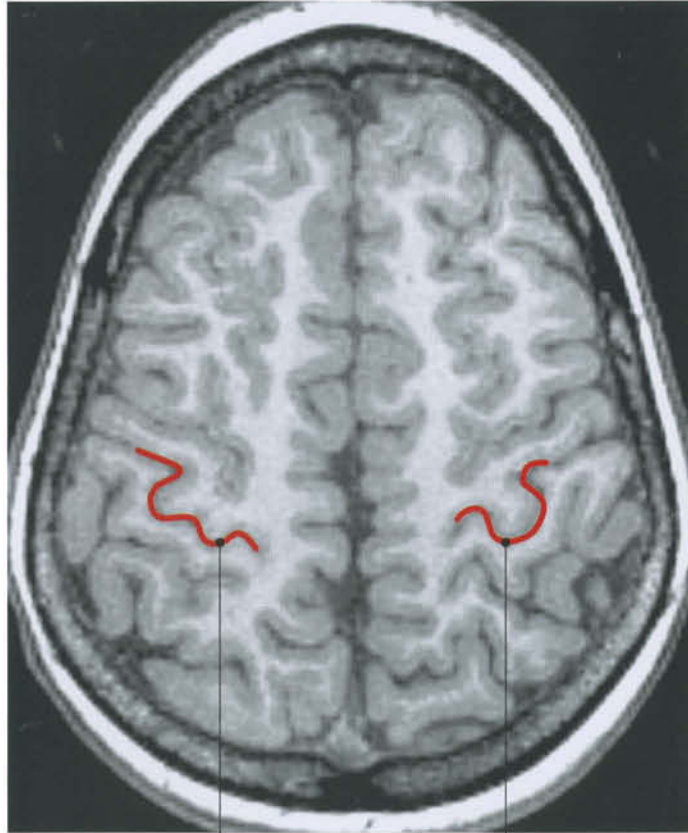

Primary motor cortex (area 4)
Areas 2, 1, 3

Premotor area 8
Premotor area 6

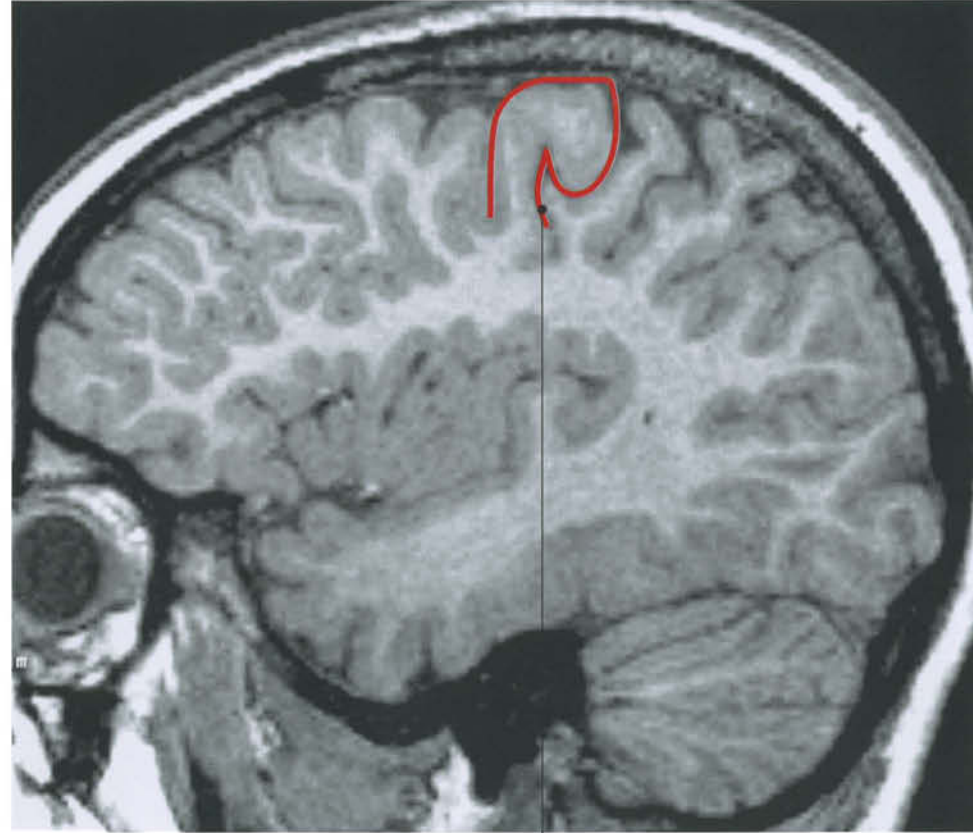


Hand motor area: middle genu of precentral gyrus (preCG) (deep portion)

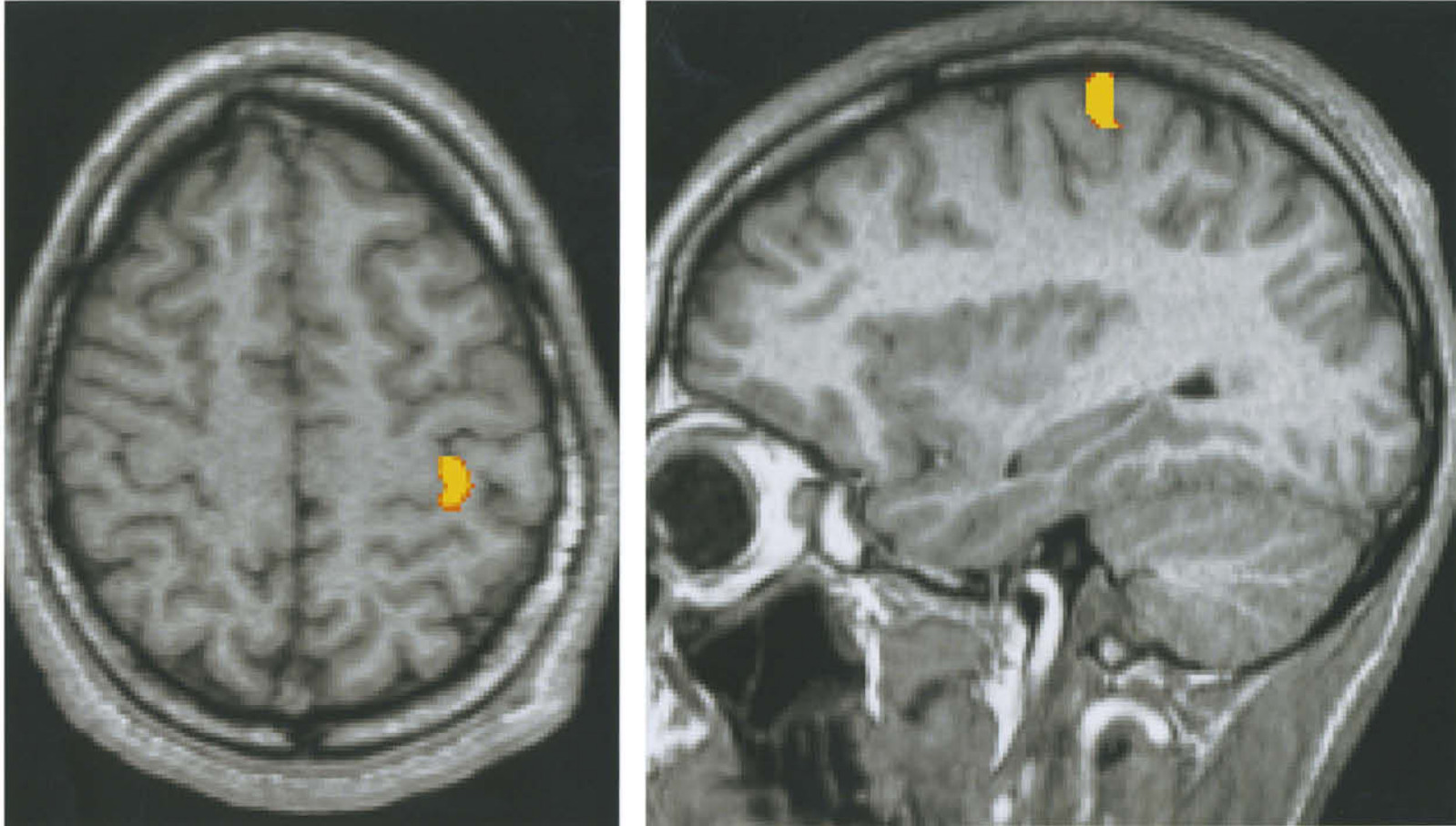


"Epsilon" sign

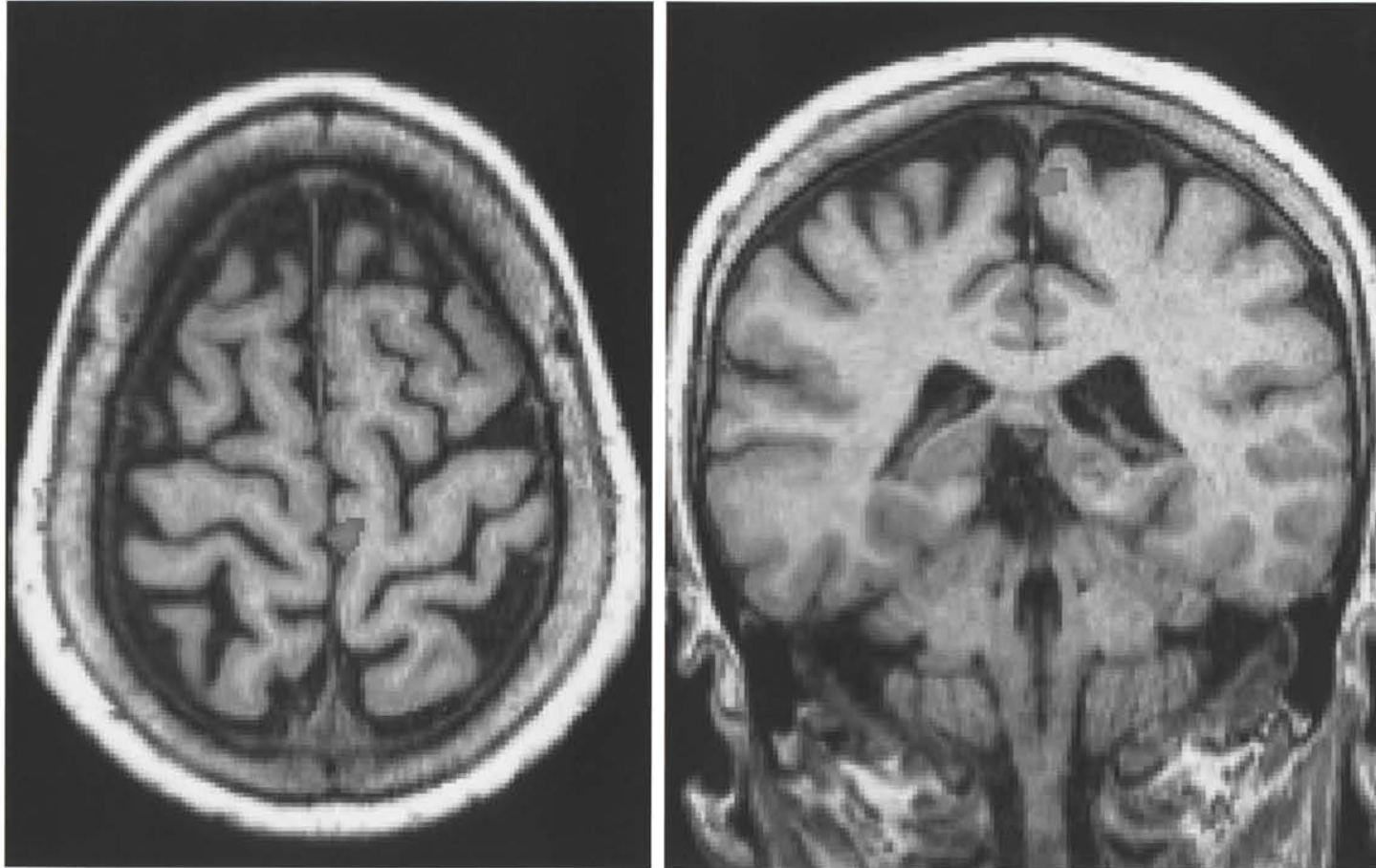
"Omega" sign



"Hook" sign

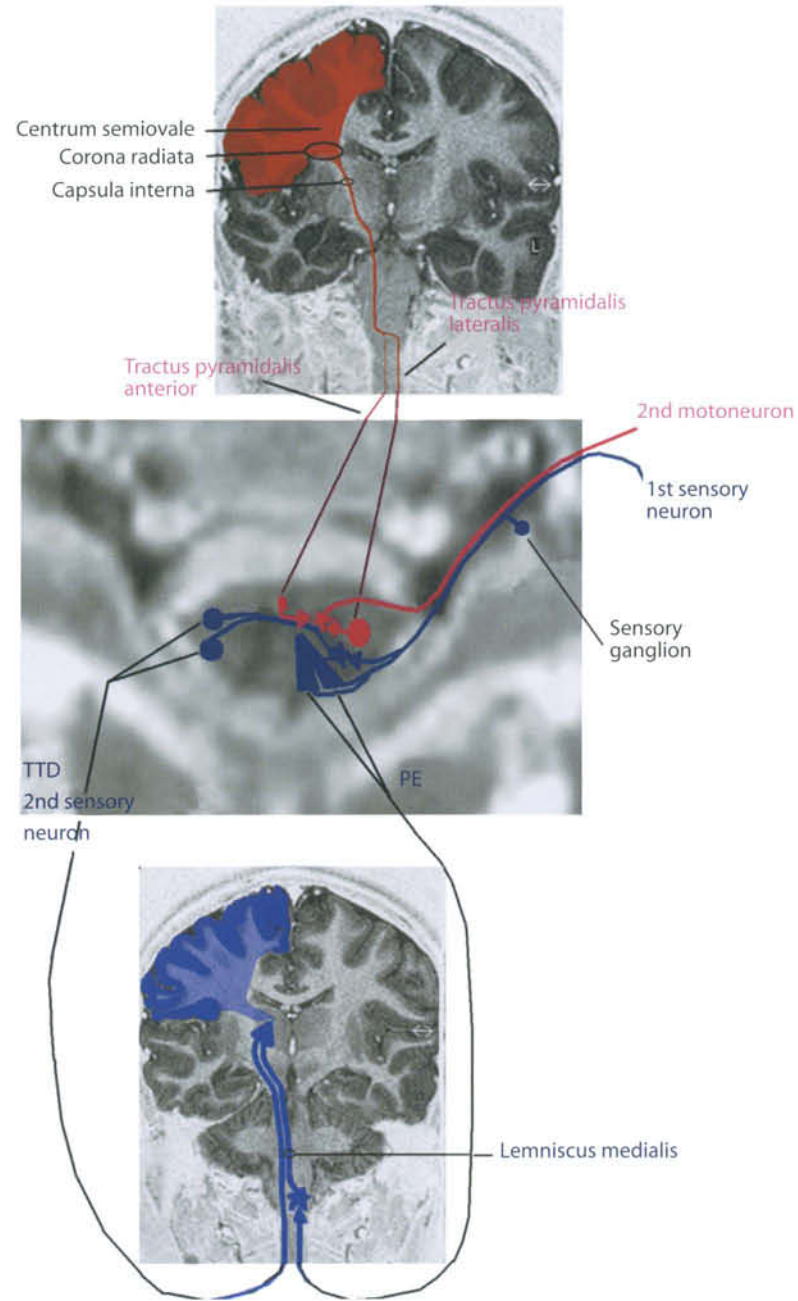


Region of activation obtained during a right finger tapping task. The hand motor area: middle genu of precentral gyrus (preCC).
Courtesy of Massimo Caulo, MD, PhD, ITAB, Chieti, Italy



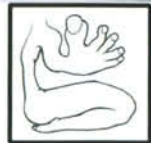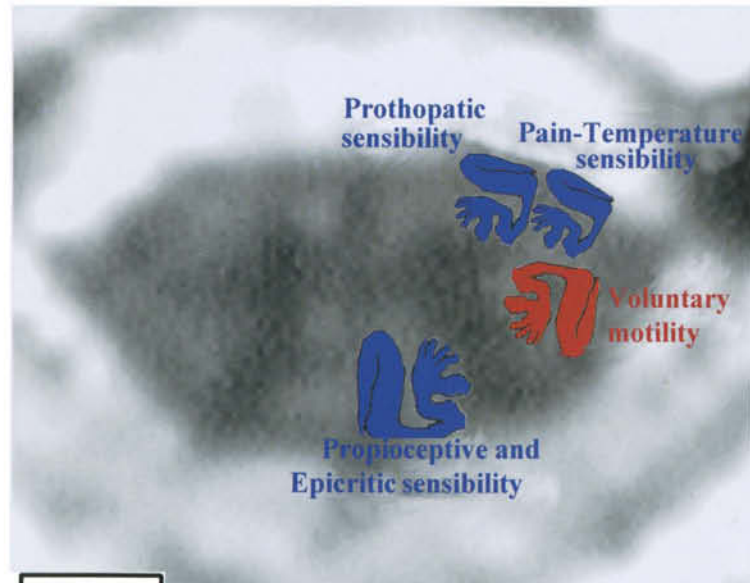
Region of activation obtained during right toe flexion task.
Courtesy of Massimo Caulo, MD, PhD, ITAB, Chieti, Italy

Scheme: Sensory and Motor Pathways

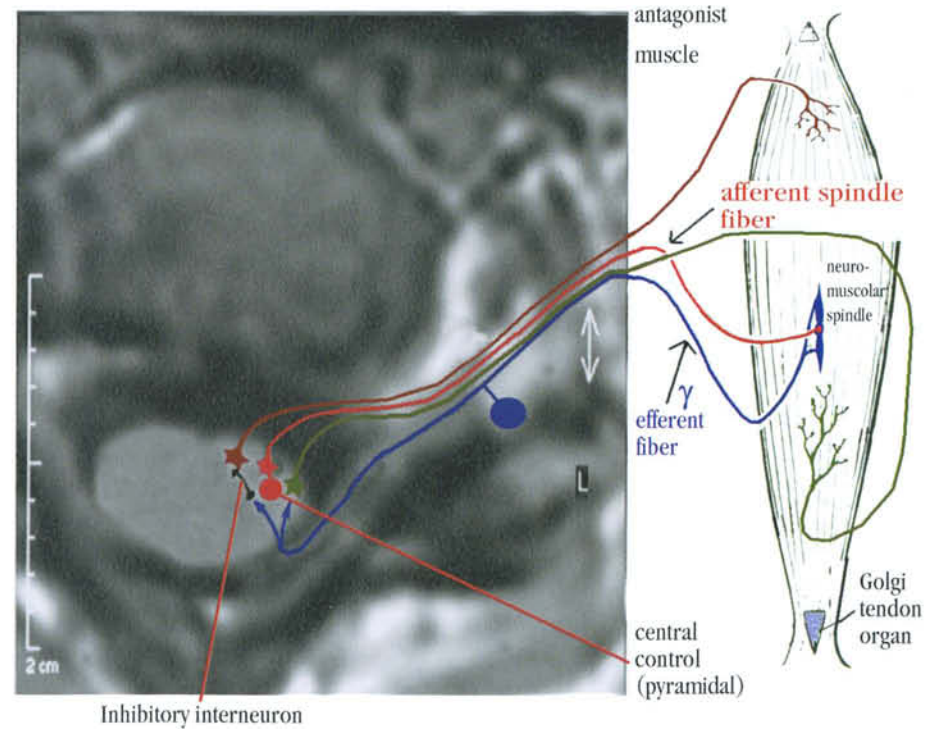


TTD = Touch temperature pain sensibility
 PE = Proprioceptive and epicritic sensibility

Anterior



Somatotopic distribution of intramedullary fibers



Motor Systems: II

Extrapyramidal Motor System And Thalamus

The definition “extrapyramidal system” dates back to the first decades of the last century, when two main, independent motor systems were defined: the pyramidal and the other one, called extrapyramidal. However, this definition has become inadequate by now, and no longer represents the complexity of motor system regulation. Yet, the term extrapyramidal is still used to define motor neurons and pathways relating to the basal ganglia. The basal ganglia comprise the caudate nucleus, the putamen, the globus pallidus, the claustrum, the nucleus accumbens, the subthalamic nucleus, the substantia nigra, the red nucleus, and the periaqueductal gray matter. Other smaller nuclei are also attributed to the extrapyramidal system. The ventral basal thalamus is also considered part of the extrapyramidal system. Because of limits due to imaging cuts, illustrations in this chapter also include thalamic nuclei. Therefore, thalamic anatomy has been improperly included, and will be briefly discussed in the following pages.

I. Basal Ganglia

The striatum is made up of caudate nucleus and putamen. Its volume is approximately 10 cc. The caudate nucleus and the putamen are connected to each other anteriorly, where the head of the former continues with the latter. Posteriorly, they are separated by the anterior limb of the internal capsule, while the posterior limb separates the putamen from the thalamus. The pallidus lies medially to the putamen. Putamen plus pallidus form the lentiform nucleus. The globus pallidus can be divided into an external and an internal segment, separated by the medial medullary lamina. The claustrum is a thin lamina of gray matter lying between the insular cortex and the striatum, separated from the former by the extreme capsule, and from the latter by the external capsule. The nucleus accumbens lies adjacent to the rostromedial part of the striatum. The subthalamic nucleus is situated in the most caudal part of the diencephalon, dorsomedial to the posterior limb of the internal capsule, overlying the rostral part of the substantia nigra. The substantia nigra is the largest cell mass of the mesencephalon. It separates the tegmentum from the cerebral

peduncle. It is divided into a dorsal cellular portion (pars compacta) and a ventral, less cellular pars (pars reticulata). The pars compacta synthesizes Dopamine.

II. Main Extrapyramidal Circuits

The following paragraph briefly describes the main circuits involved in several pathological processes.

- *The principal striatal circuit: cortex - striatum - pallidus - thalamus - cortex.*
The whole of neocortex sends fibers to caudates and putamina. However, most cortical areas project only on the ipsilateral striatum, while the premotor (6,8), motor (4) and somatosensory (3,1,2) cortex distributes fibers bilaterally. Particular meaning is nowadays given to the supplementary motor area, considered an active part of the extrapyramidal system. This belongs to the supplementary motor area (area 6) and is located on the medial aspect of the superior frontal gyrus, in front of the paracentral lobule.
- *The first accessory striatal circuit: striatum - pallidus - thalamus - striatum*
These fibers form the striopallidal and pallidal efferent circuit, which involves the fasciculus thalamicus and terminates in the centromedian and parafascicular nuclei of the thalamus.
- *The second accessory striatal circuit: pallidus - nucleus subthalamicum - pallidus*
The pallidosubthalamic and the subthalamopallidal projections are GABA mediated and involved in several pathological and pathophysiological conditions. The lesion of these can be responsible for ballism in normal subjects, and seems to inhibit parkinsonian symptoms in affected subjects.
- *The third accessory striatal circuit: striatum - substantia nigra - striatum*
The striato-nigral fibers terminate mostly, but not exclusively, in the reticular part of the S.N., and contain large numbers of GABA-, substance P- and dynorphin-positive fibers. The ascending fibers (nigrostriatal system) originate mostly from the dopaminergic cells of the pars compacta of the S.N. These fibers also have a presynaptic glutamatergic connection.

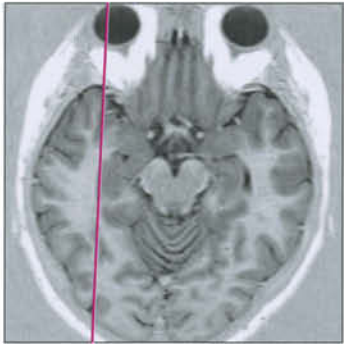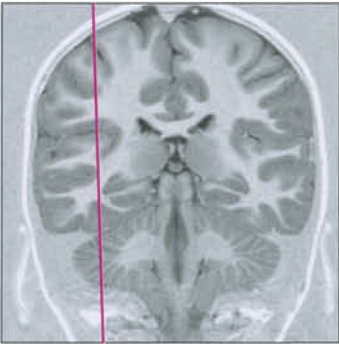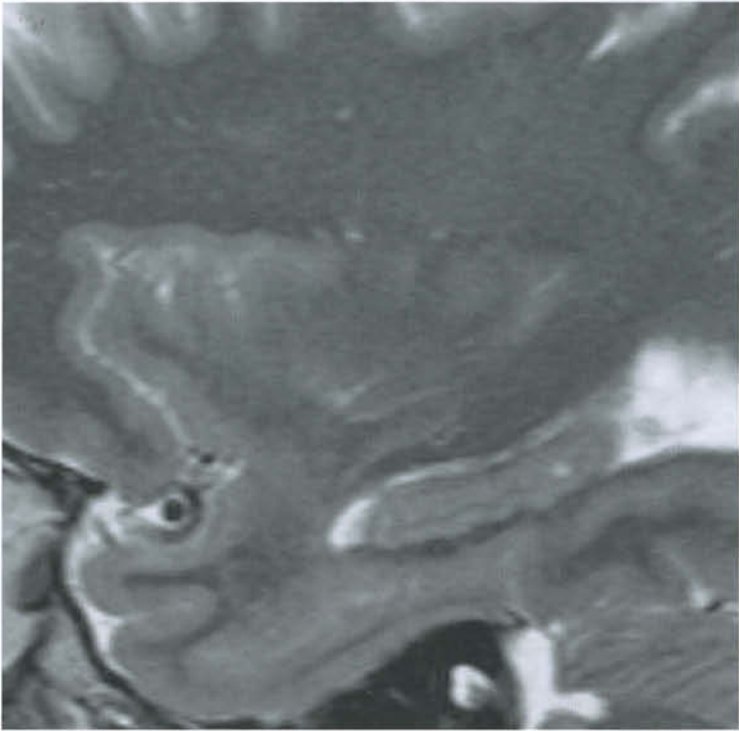
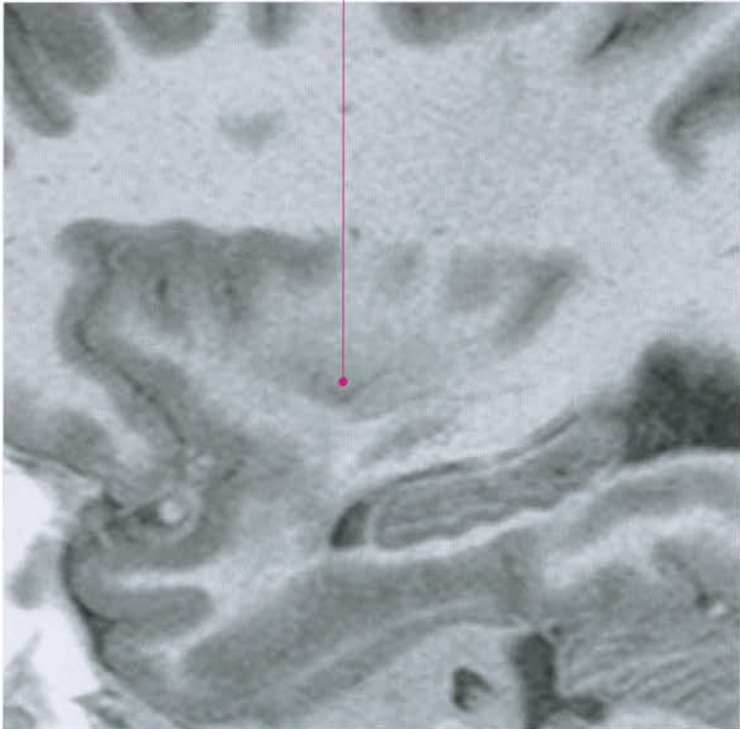
- *The fourth accessory striatal circuit: cortex - striatum - substantia nigra - thalamus - cortex*

III. Thalamus

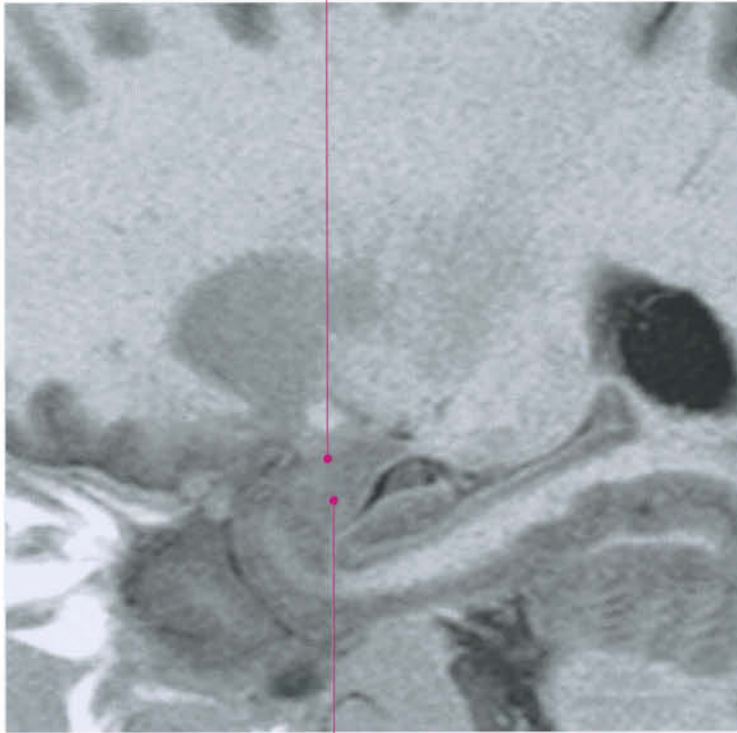
The thalamus is a gray cell mass about 4 cm long, lying on each side of the third ventricle, fused together with the contralateral through a thin junction, the interthalamic mass. The thalamus reaches the third ventricle caudally below and the foramen of Monro anteriorly. The posterior part is broader (pulvinar) and overhangs the quadrigeminal plate. Below the thalamus is the lateral geniculate body; infero-medially the medial geniculate body is separated from it by the brachium of the superior colliculus. Below the thalamus laterally is the subthalamic nucleus, and medially the red nucleus. Superiorly, the thalamus is covered by a layer of white matter and separated from the caudate nucleus by the stria terminalis and the thalamostriate vein. The lateral aspect of the superior surface forms part of the floor of the lateral ventricle, and is covered by the tela choroidea, which separates the thalamus from the fornix.

The thalamus is mainly composed of gray matter and many nuclei have been described inside it. The spatial distribution of these nuclei is rather complex, and only the gross structure is reported in this chapter. They are subdivided into three main groups: anterior nuclear group, medial nuclear group, and lateral nuclear group. The posterior part of the thalamus is the pulvinar. The three groups are separated by the internal medullary lamina, which has a “Y” shape.

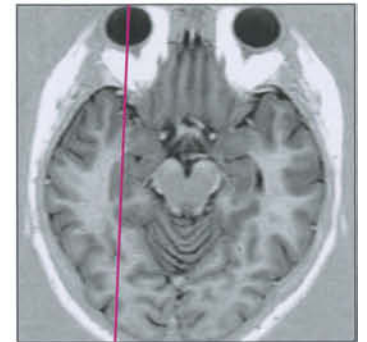
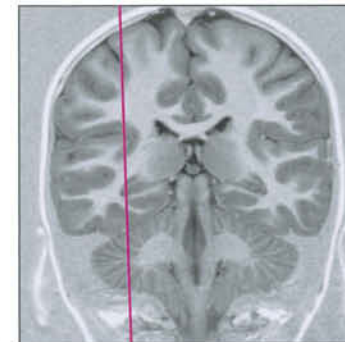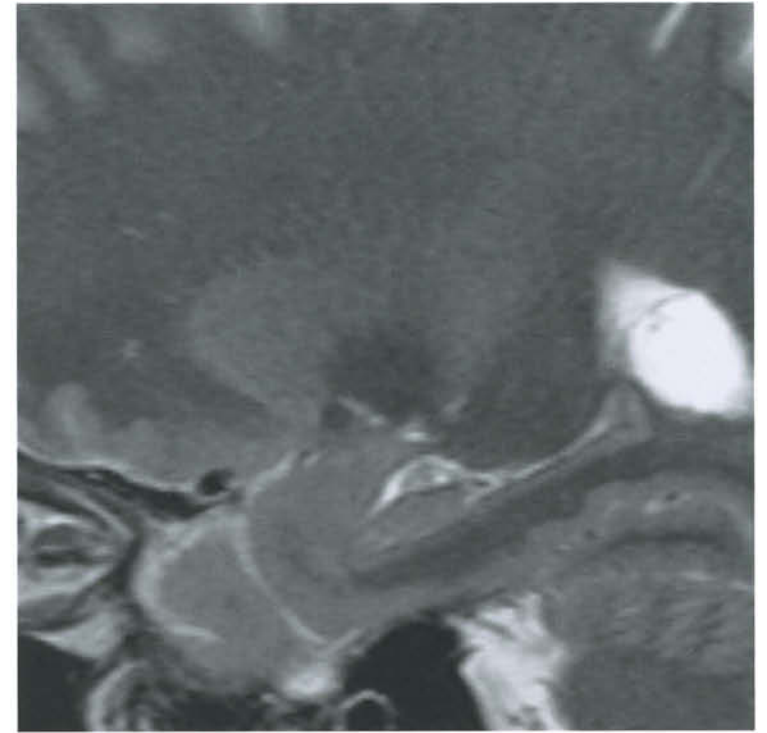
Clastrum

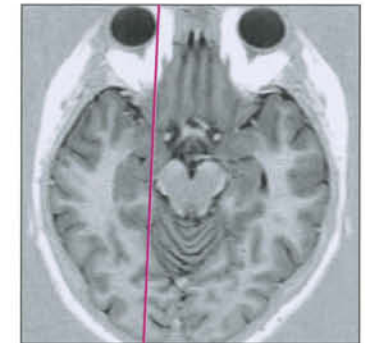
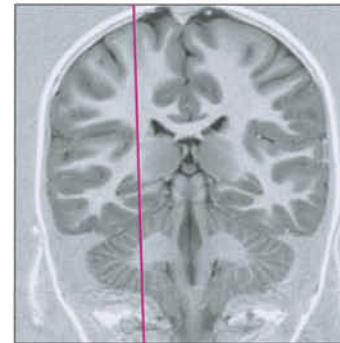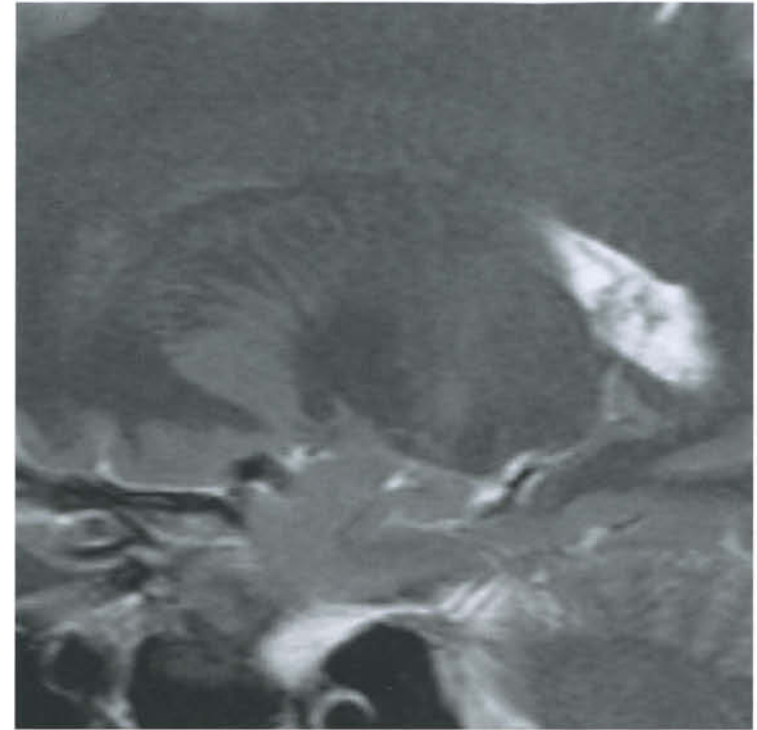
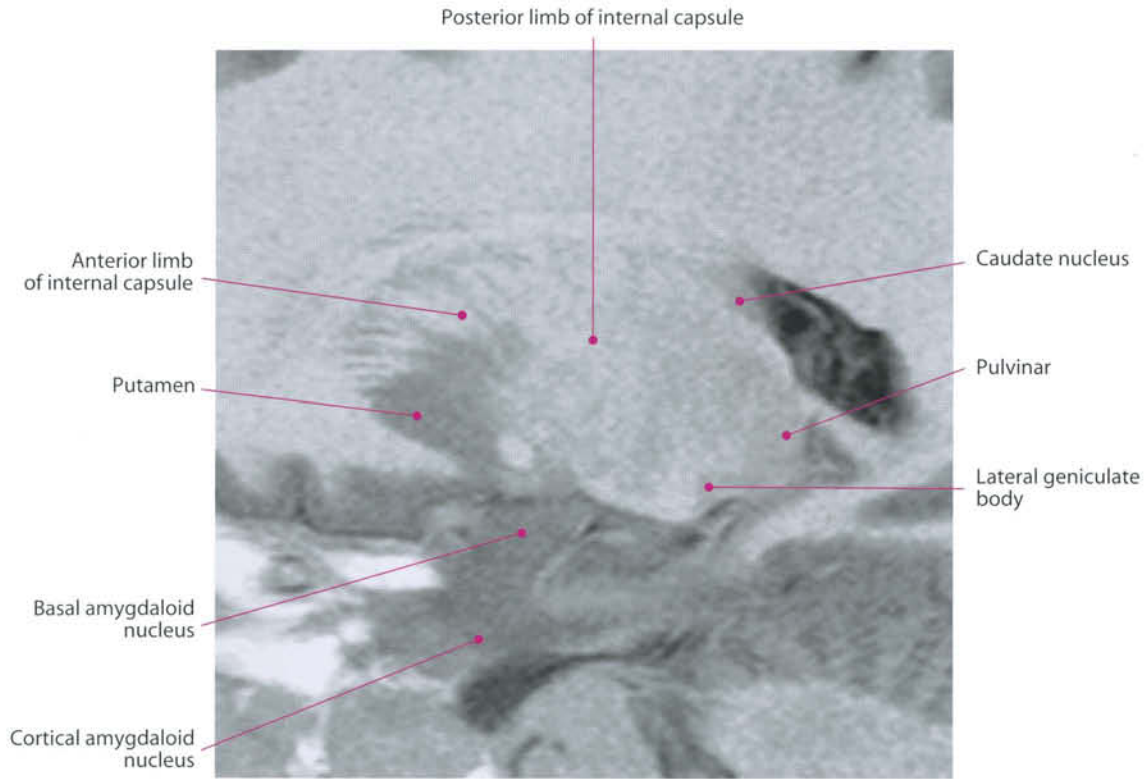


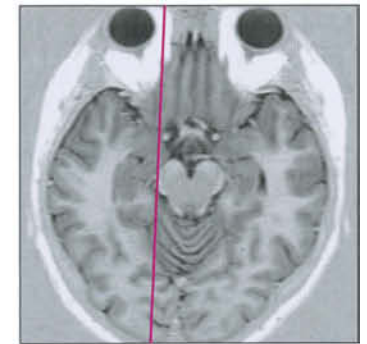
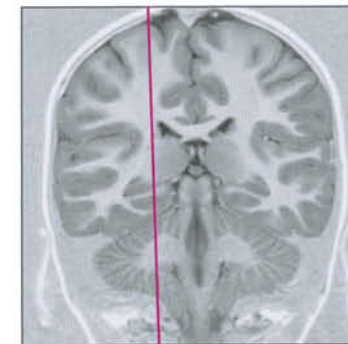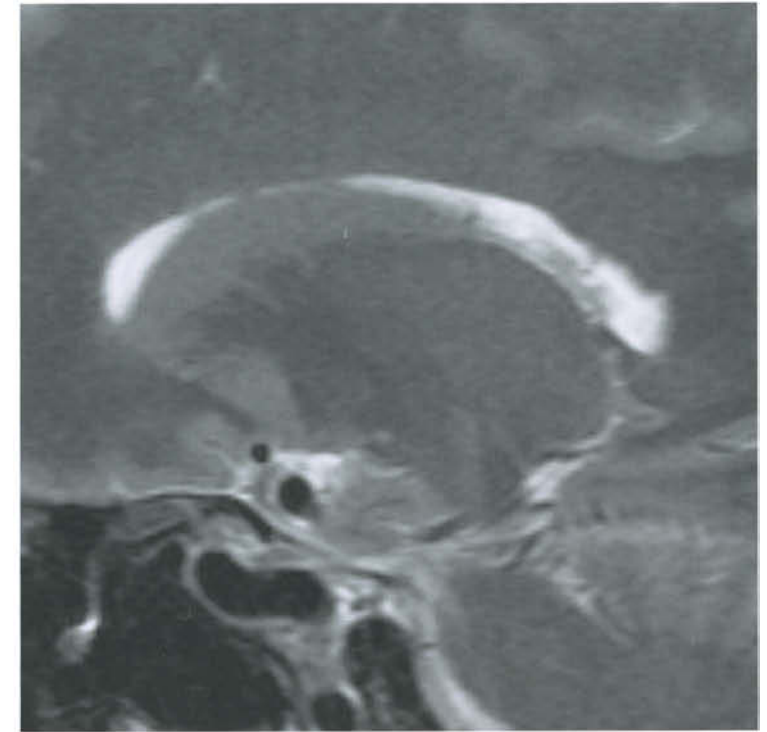
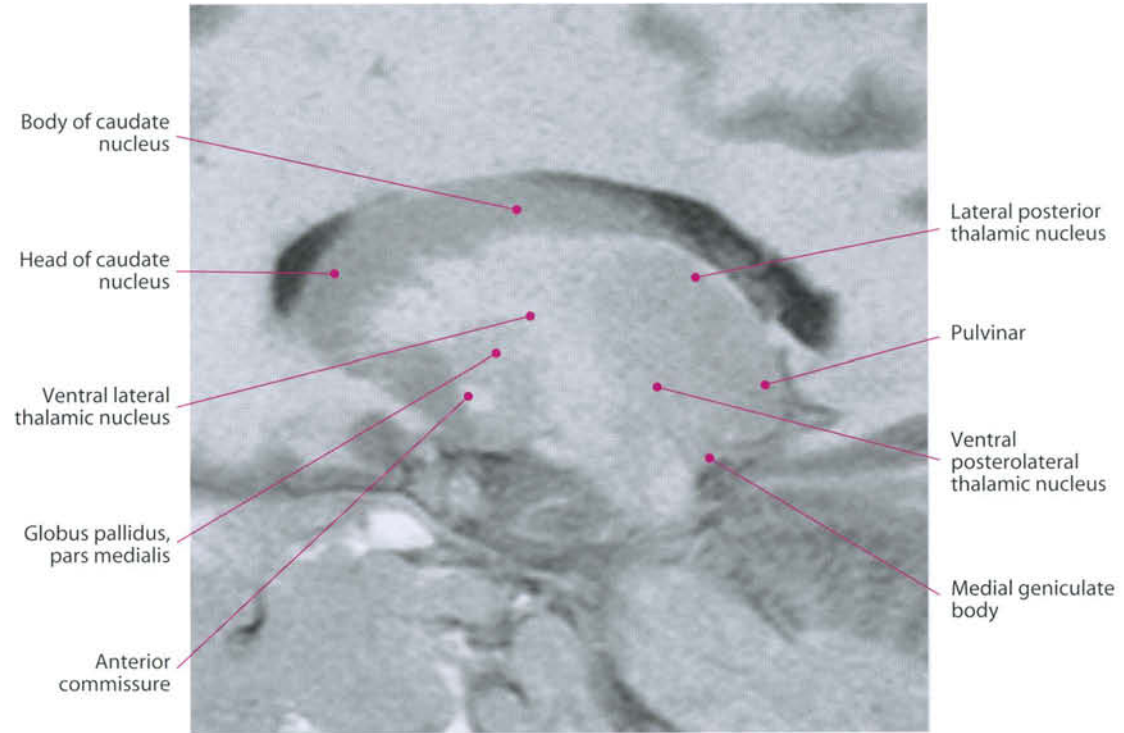
Basal amygdaloid nucleus

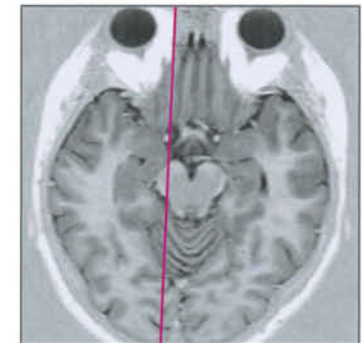
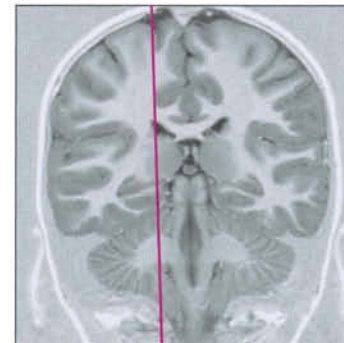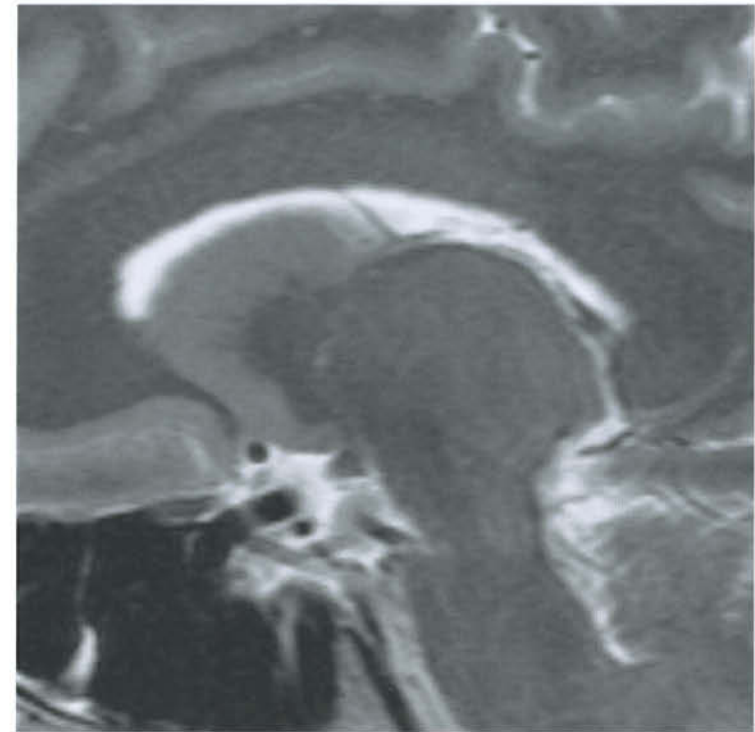
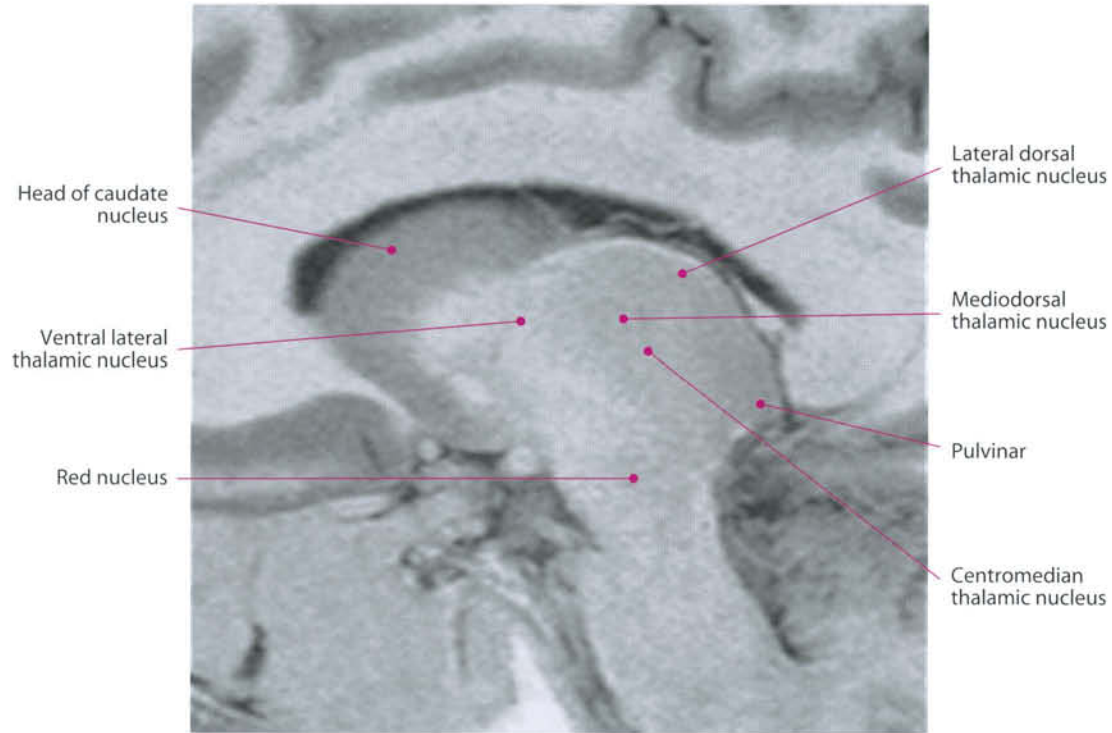


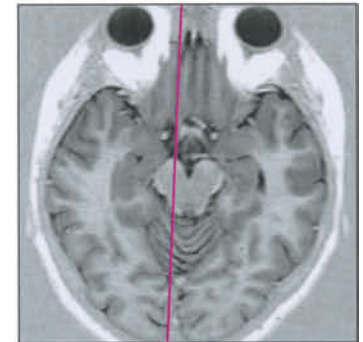
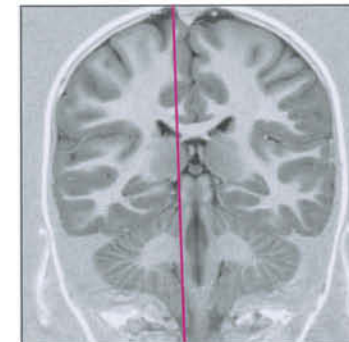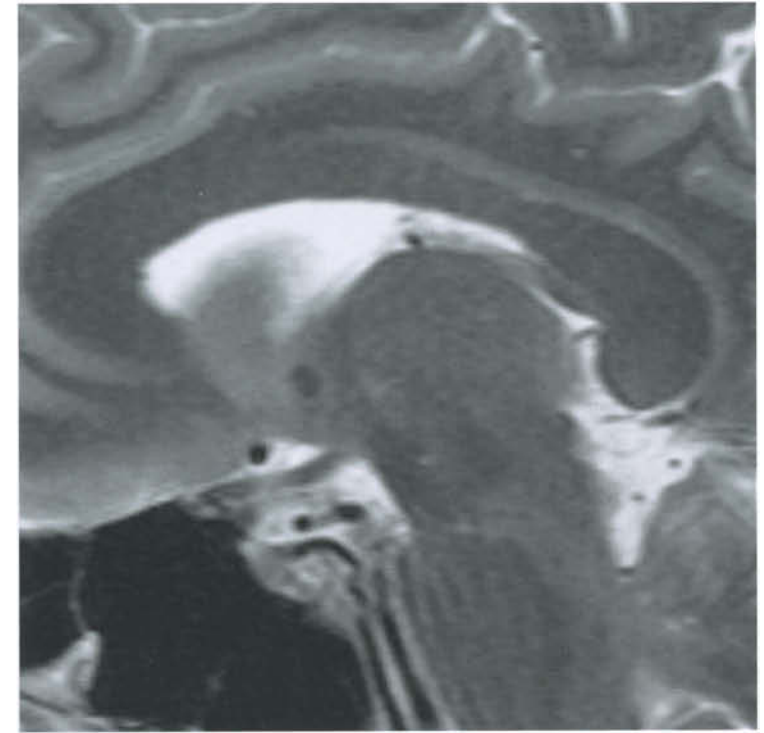
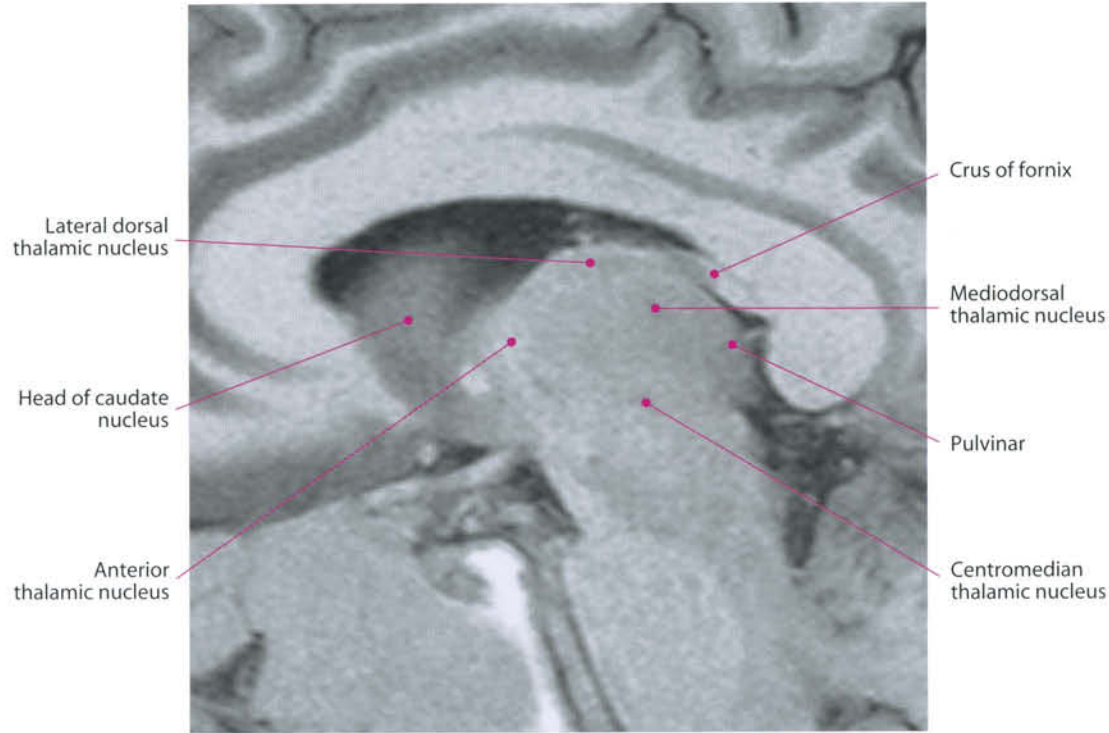
Lateral amygdaloid nucleus

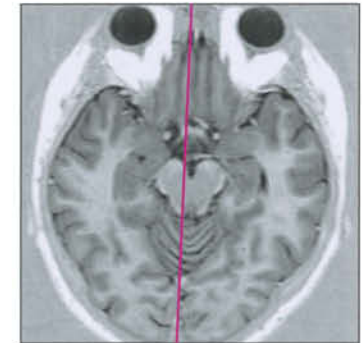
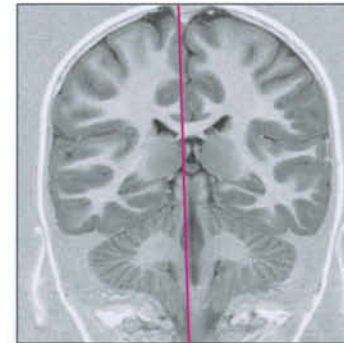
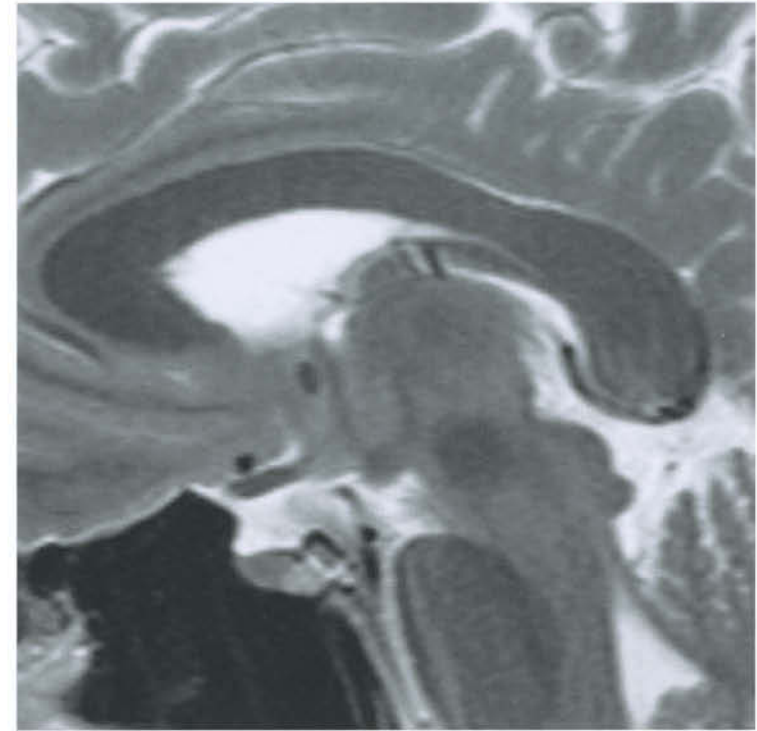
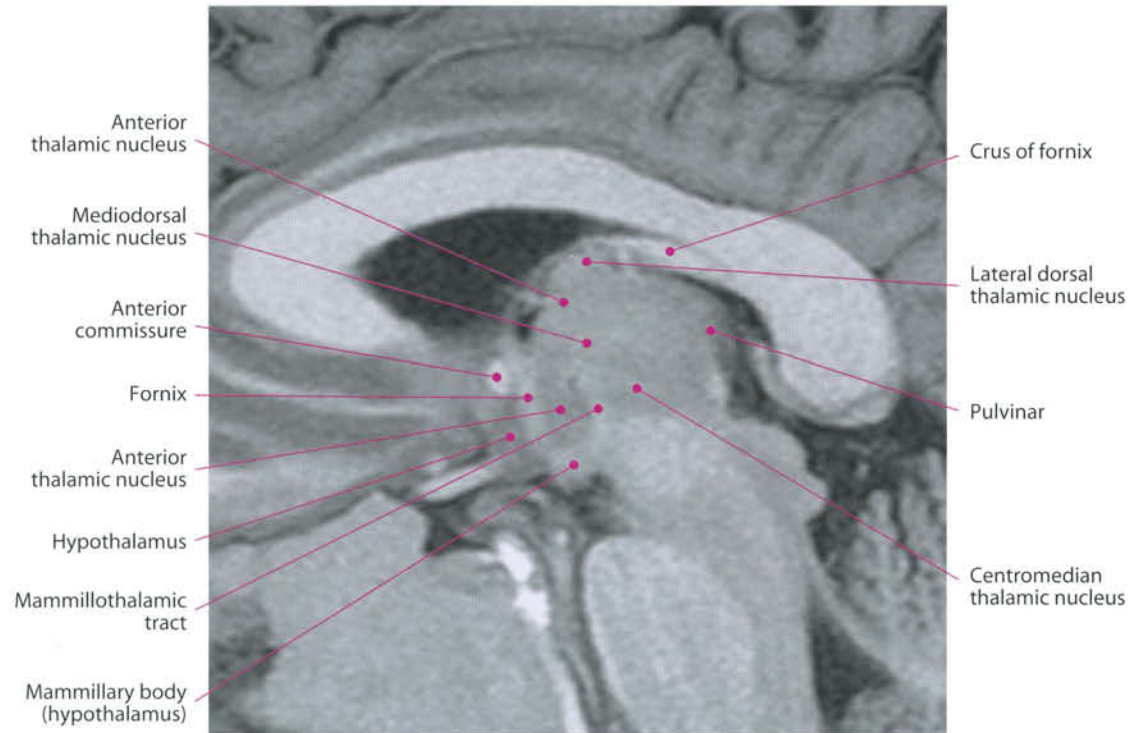


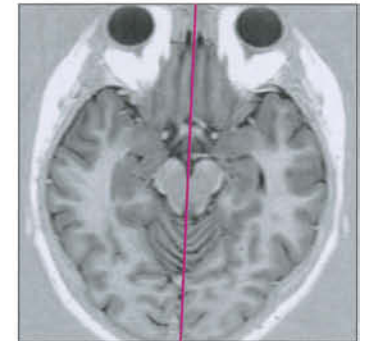
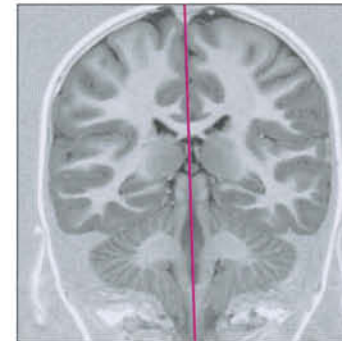
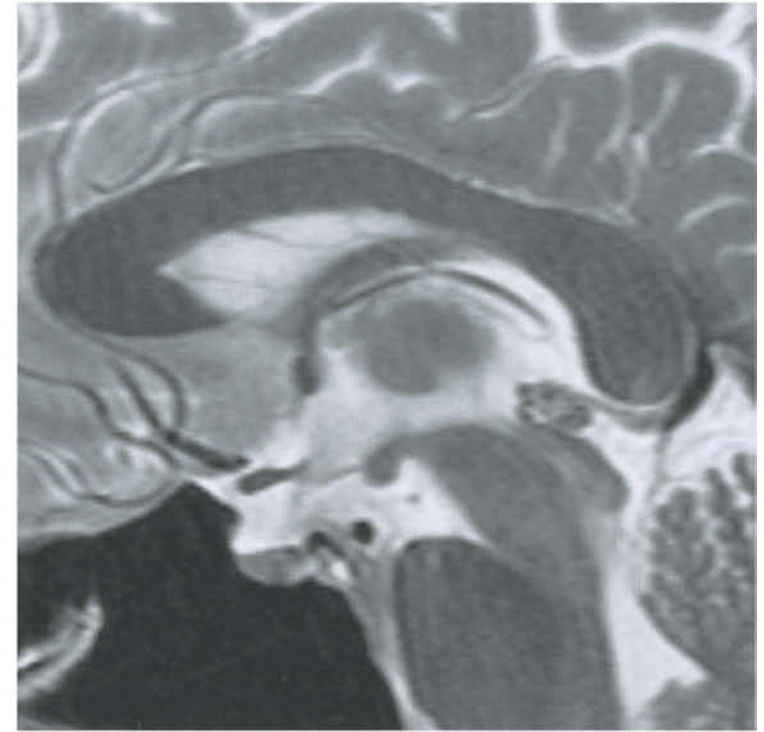
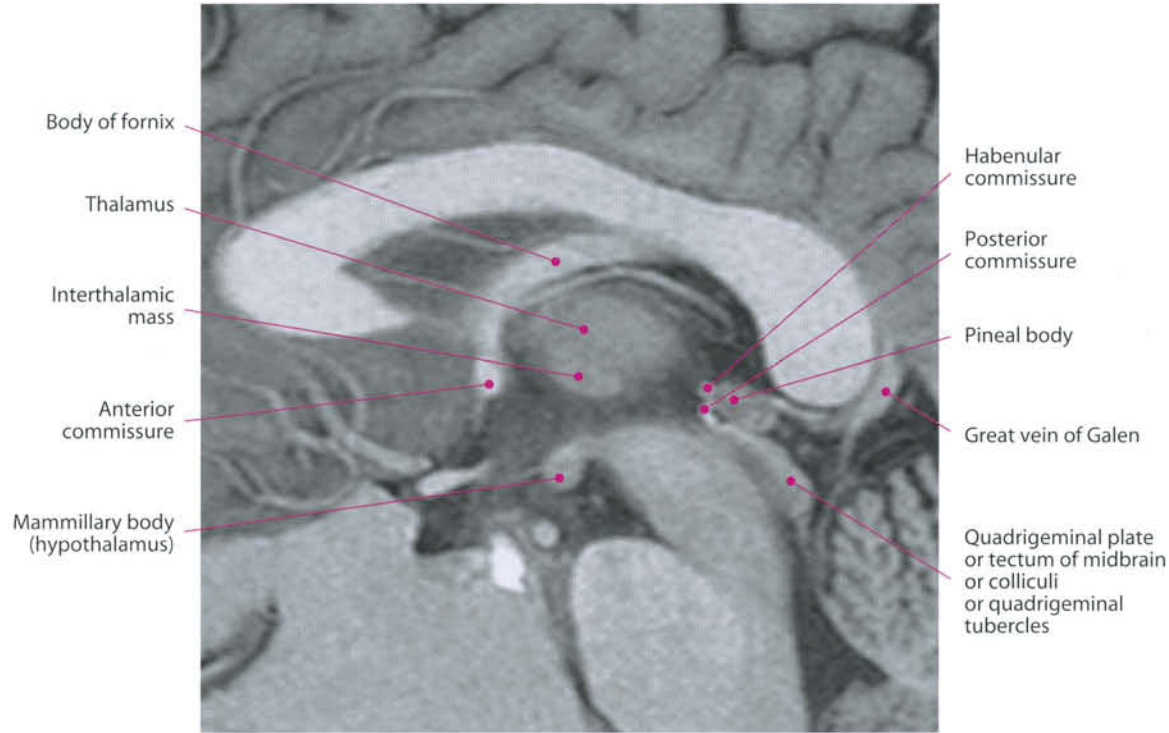
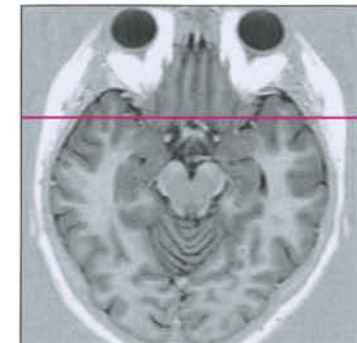
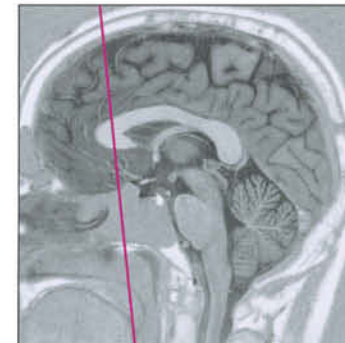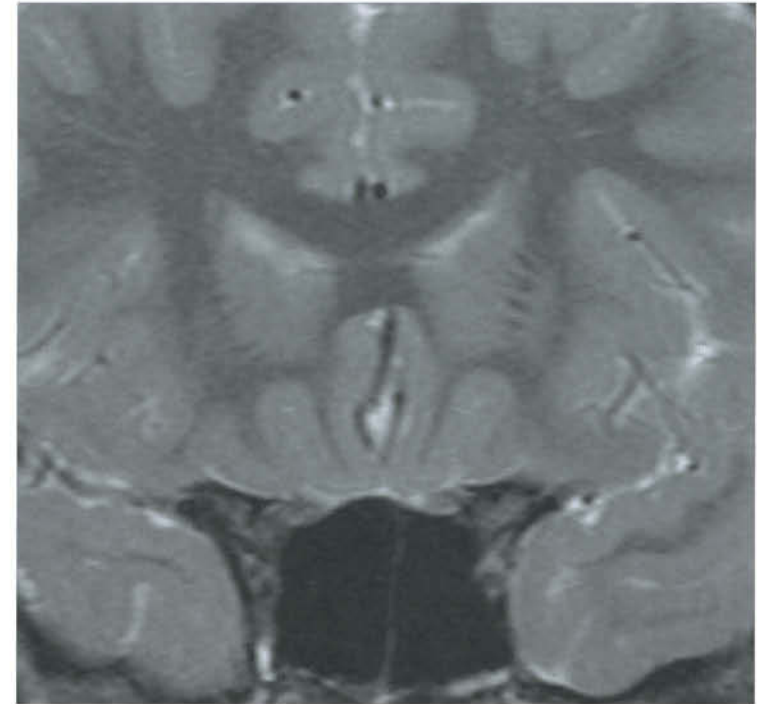
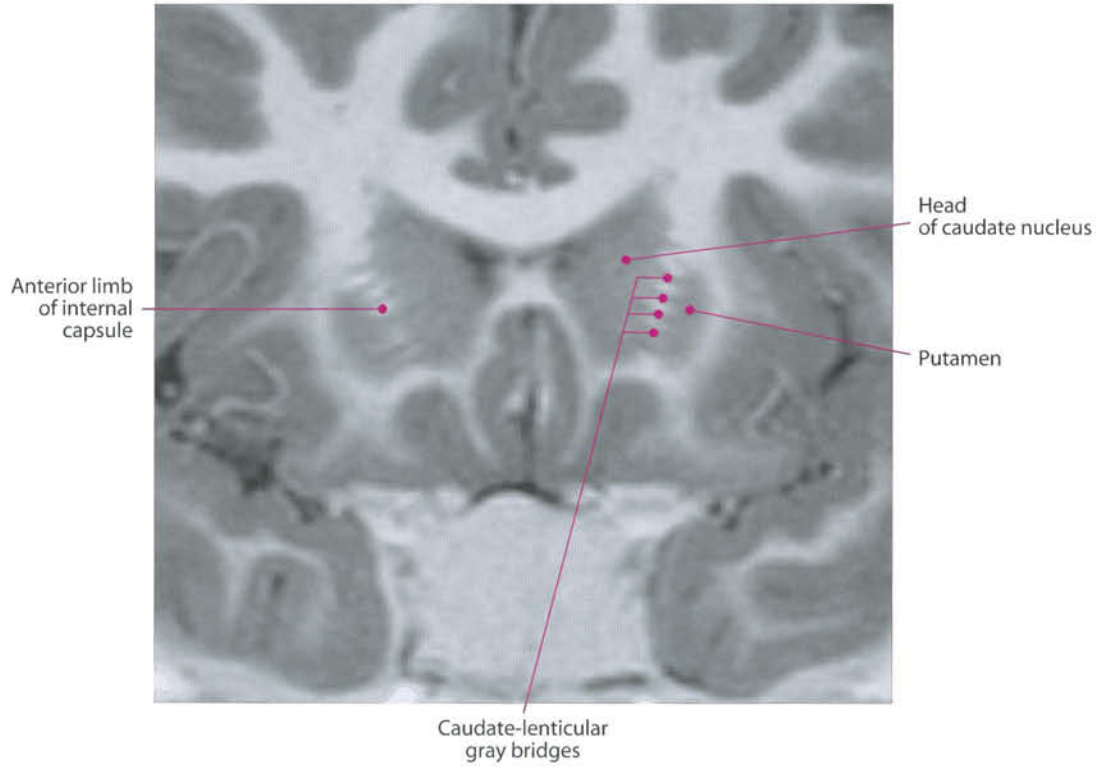


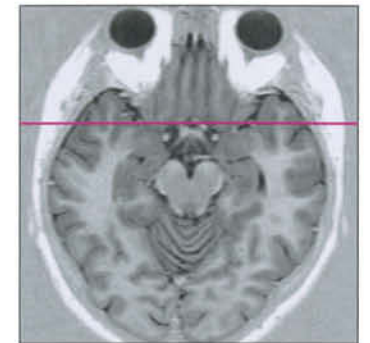
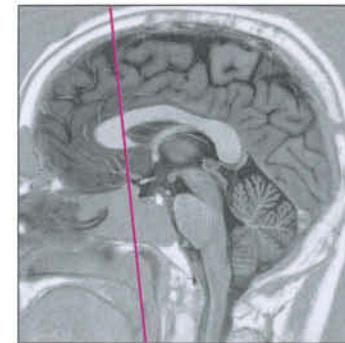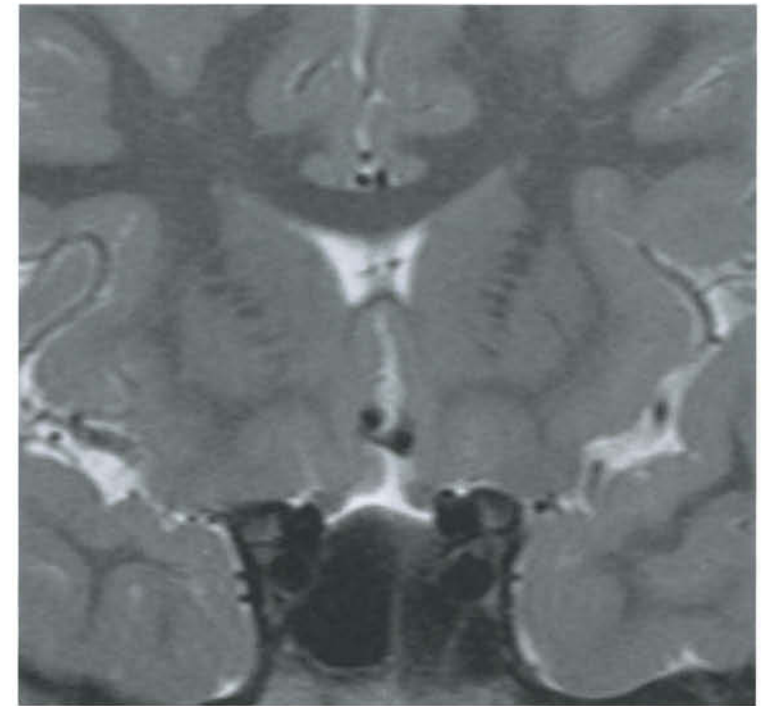
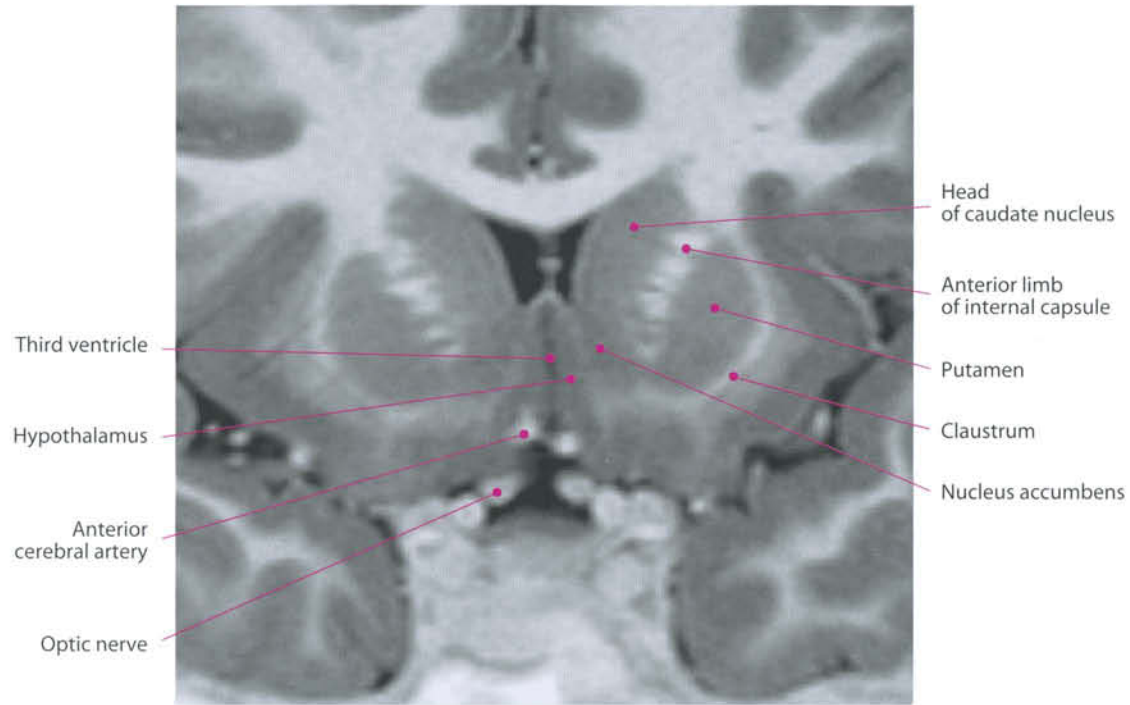


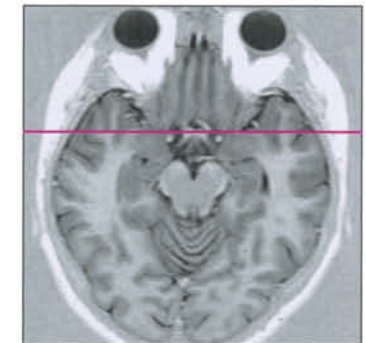
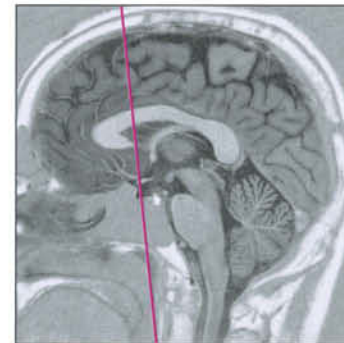
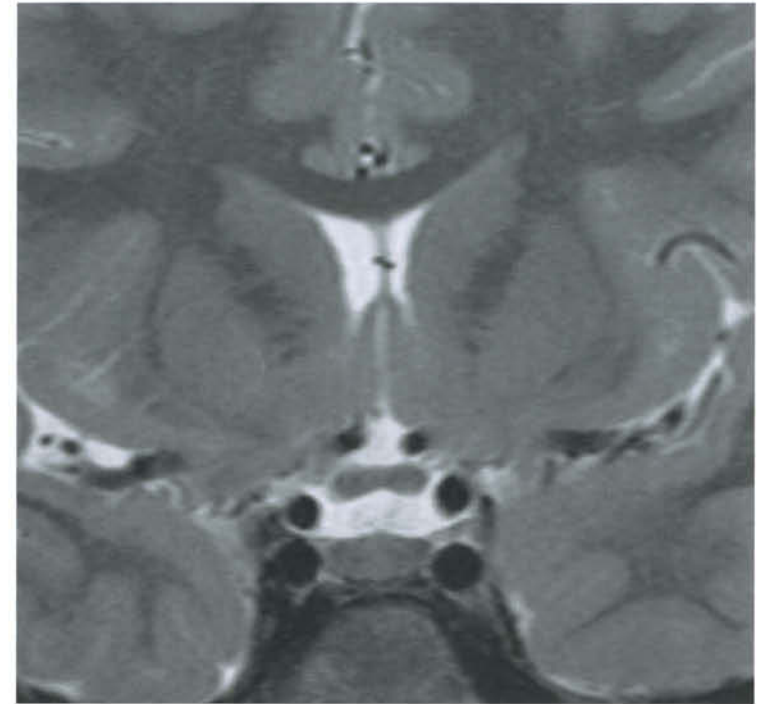
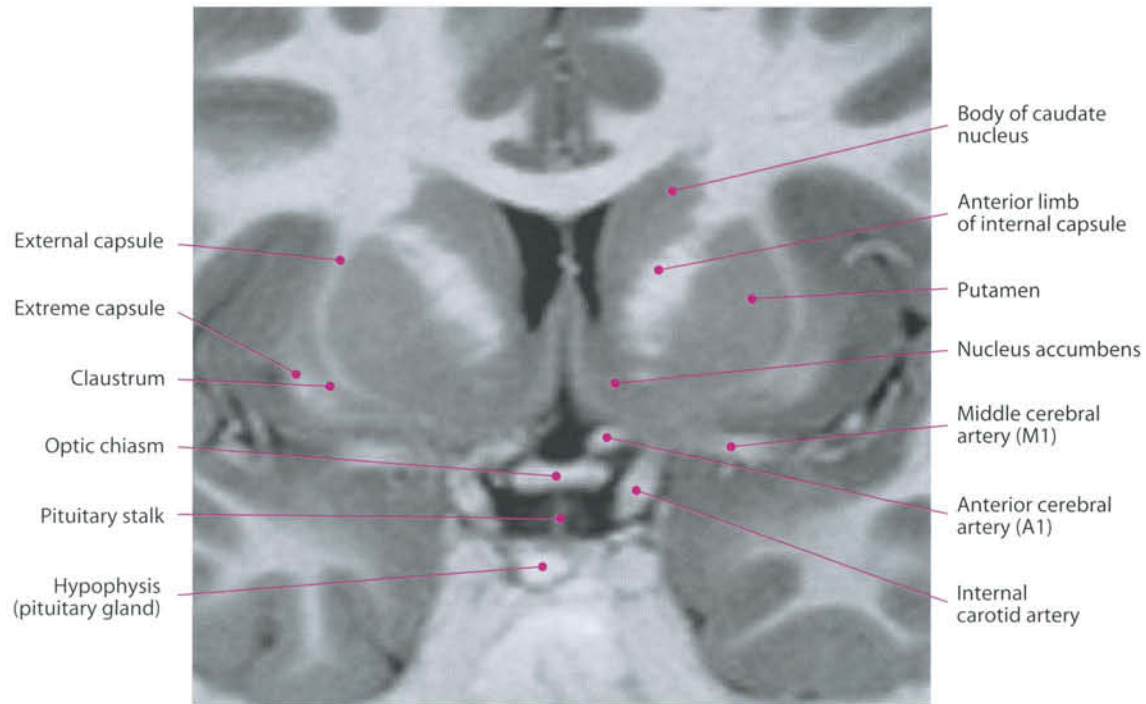


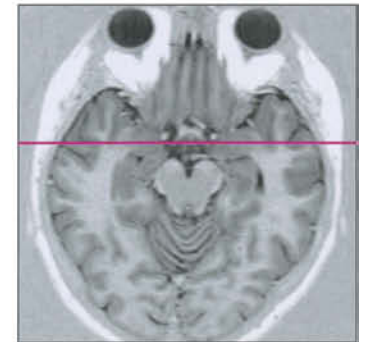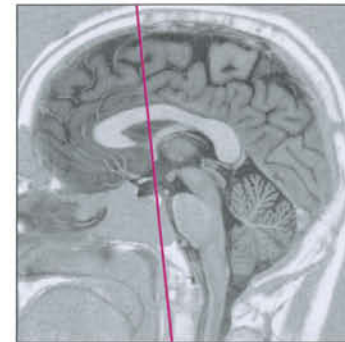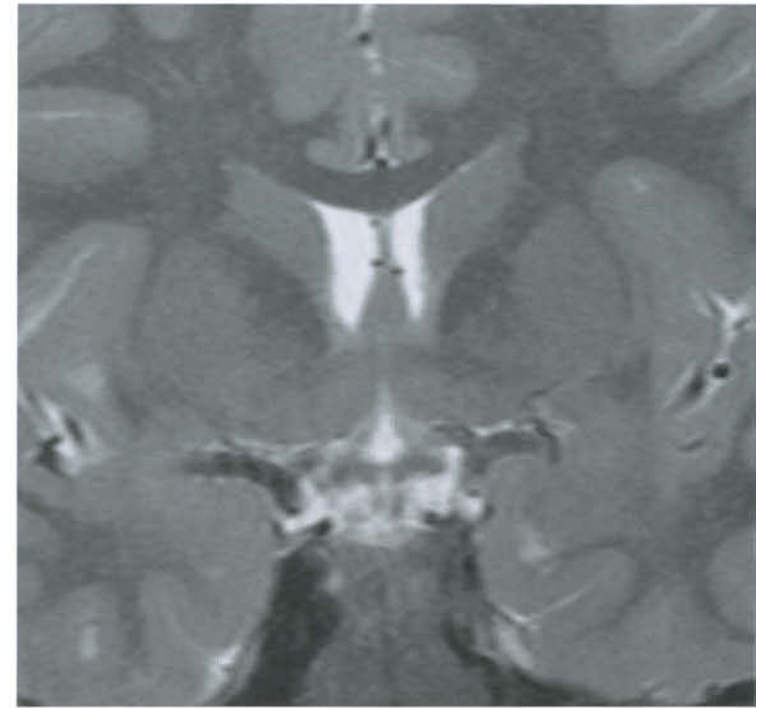
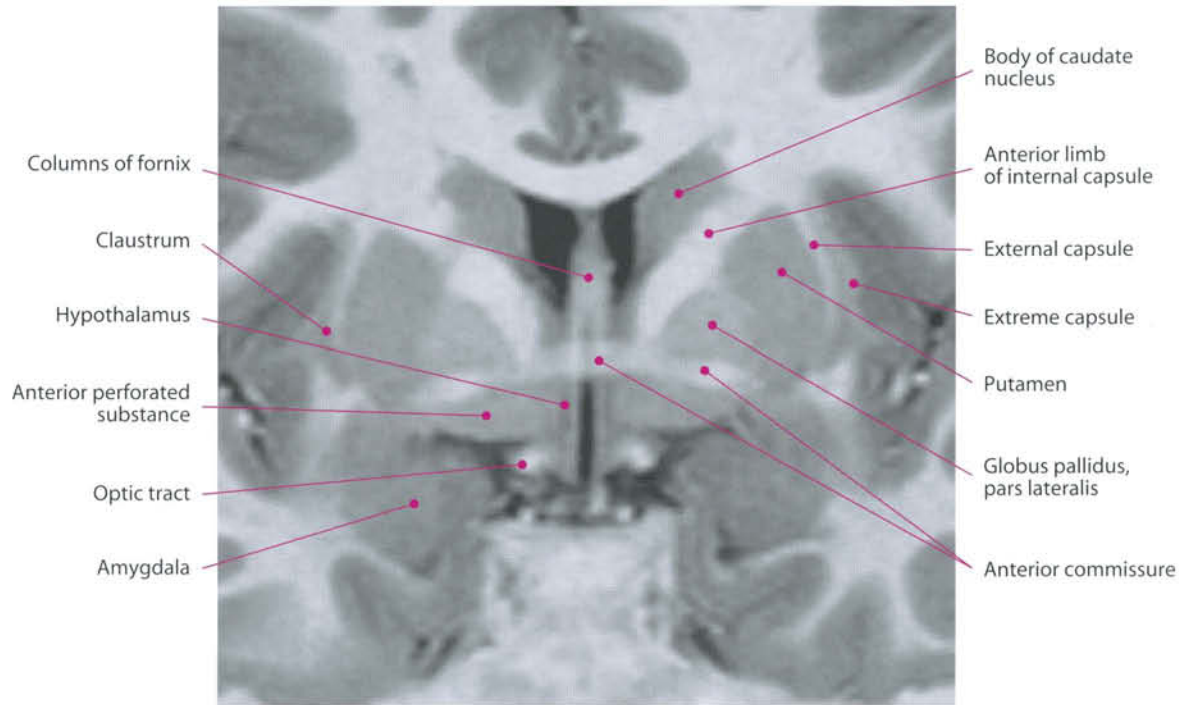


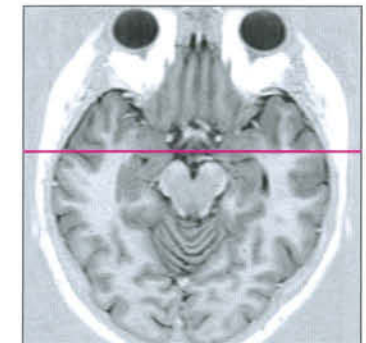
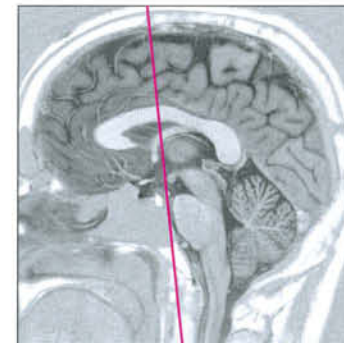
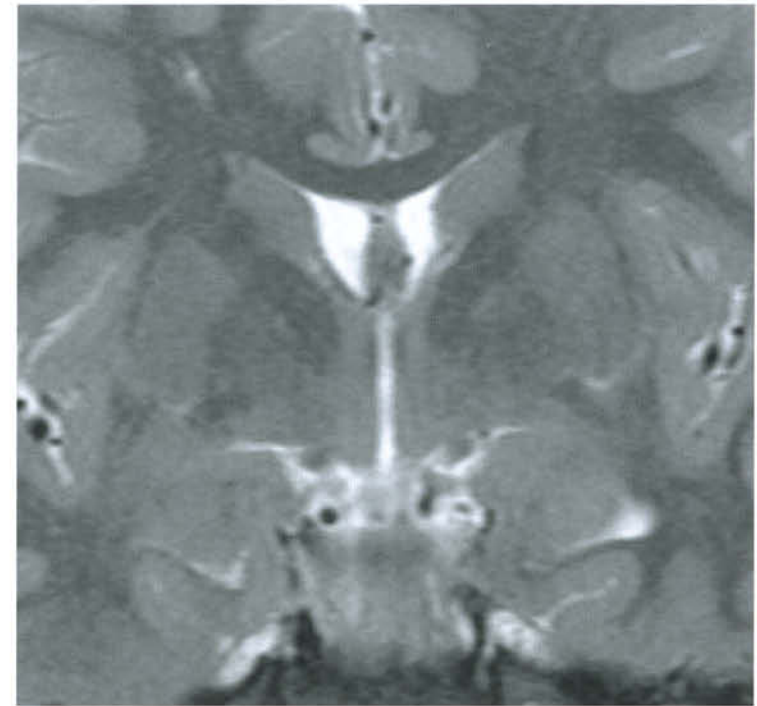
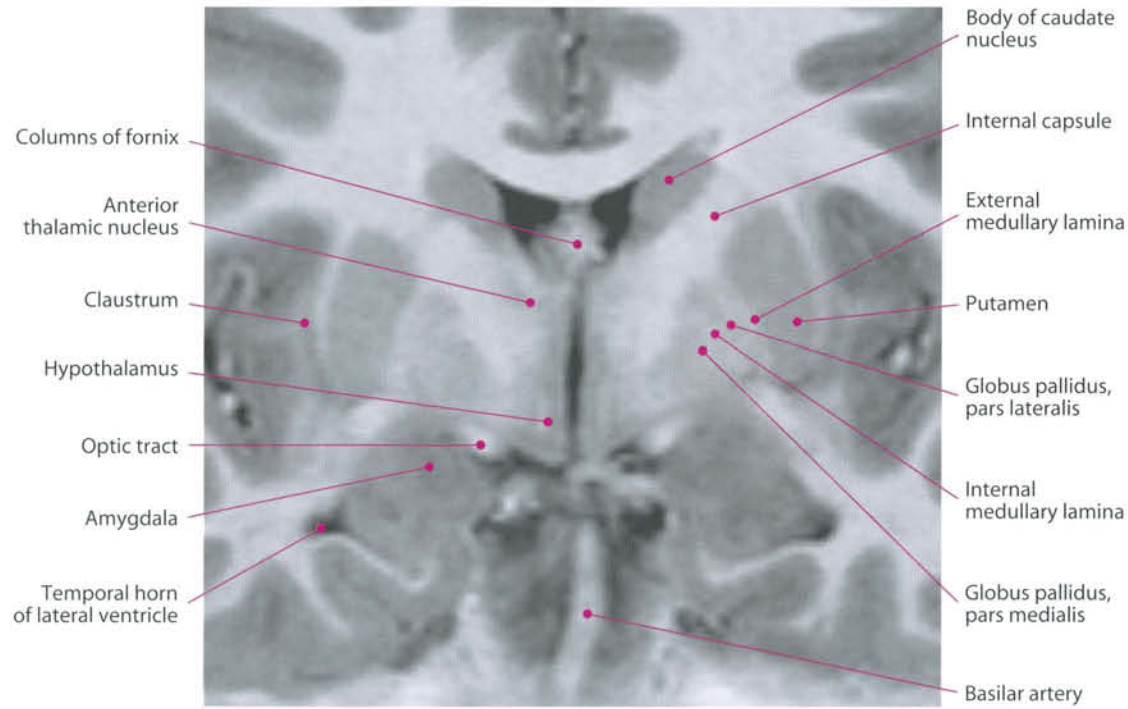


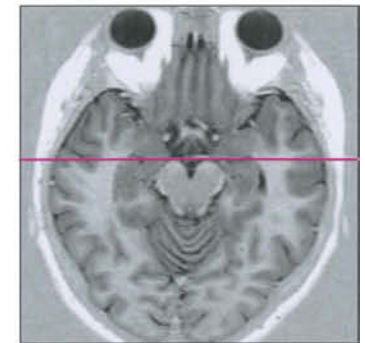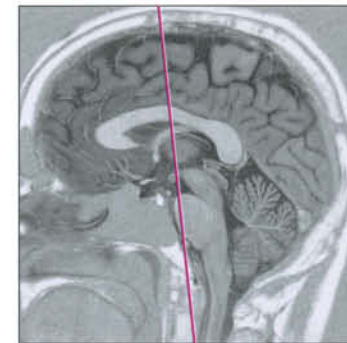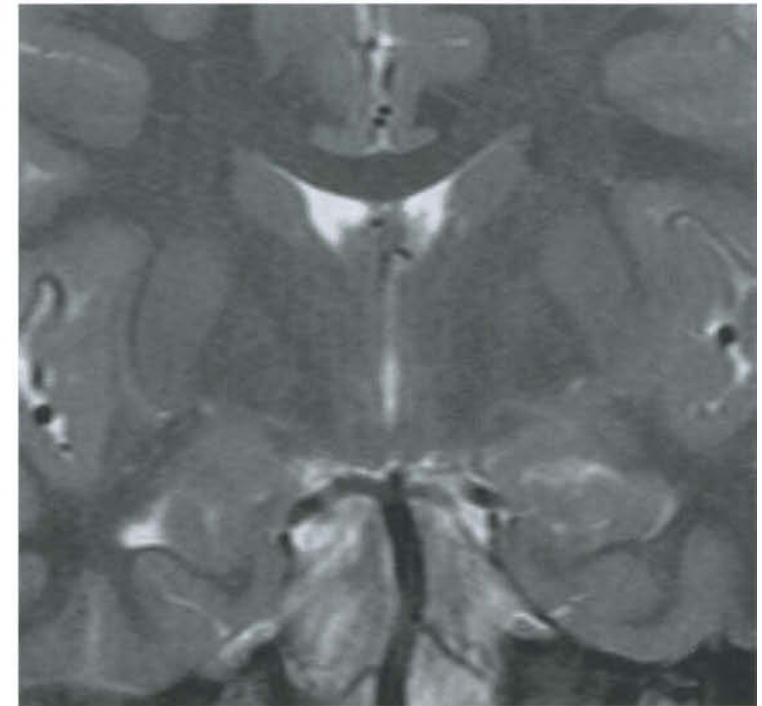
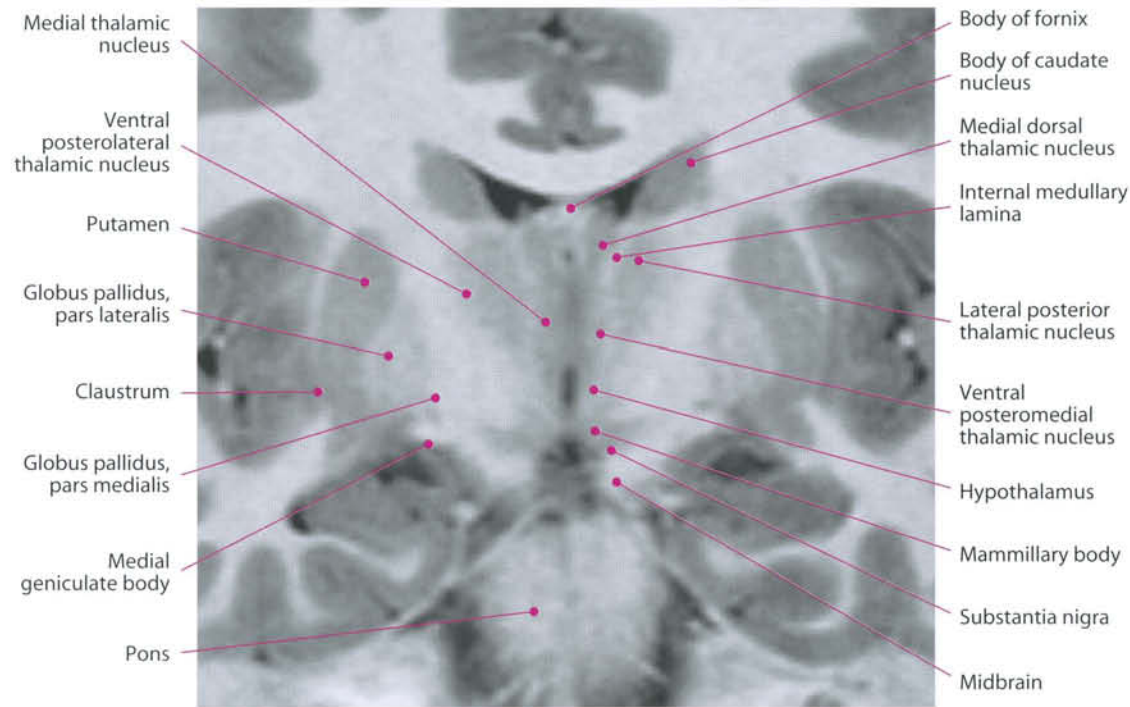


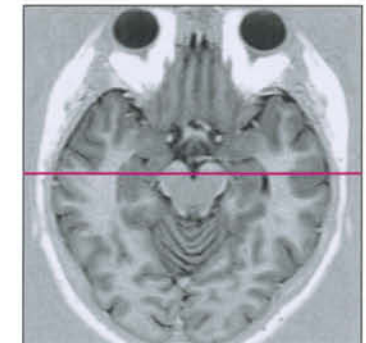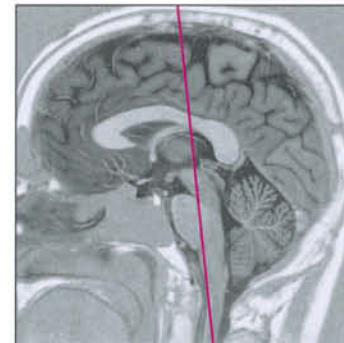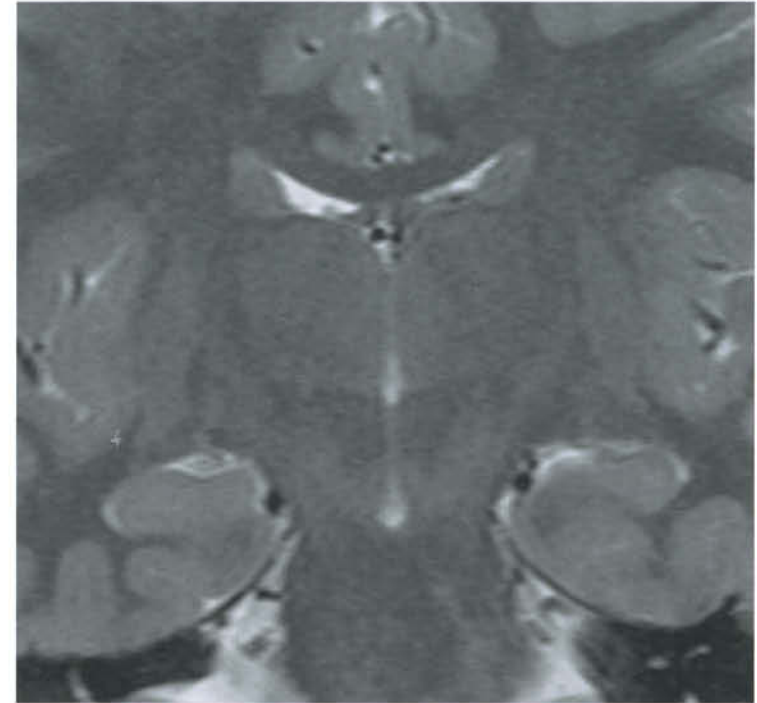
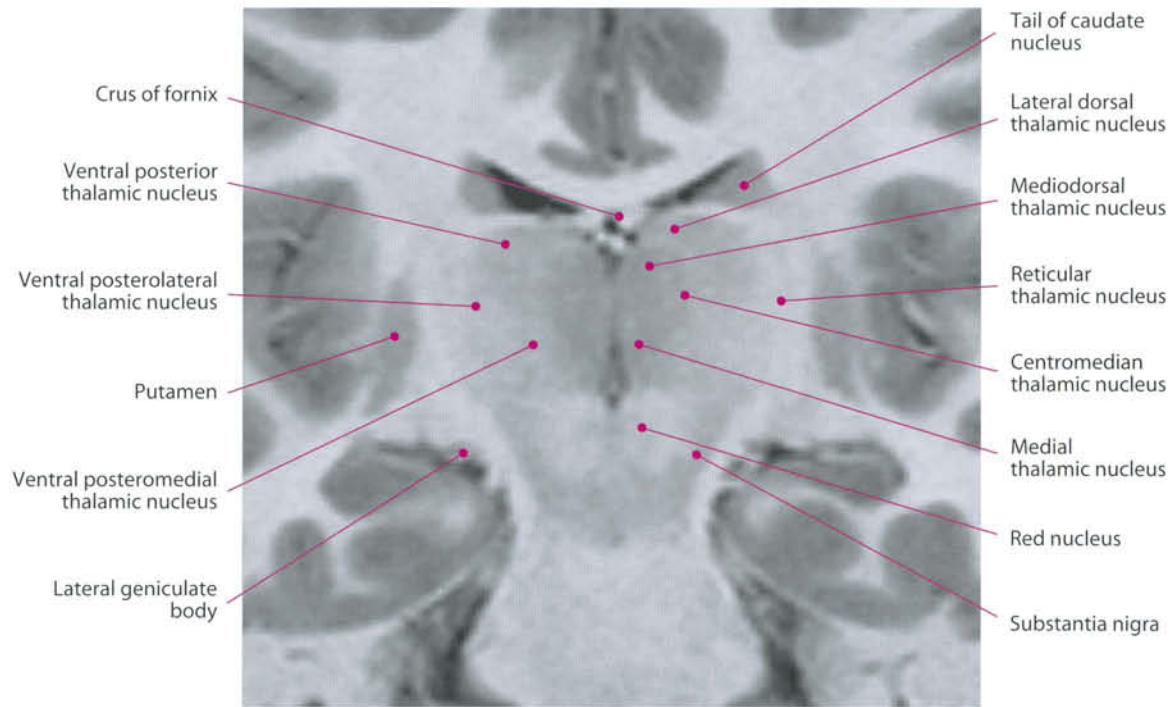


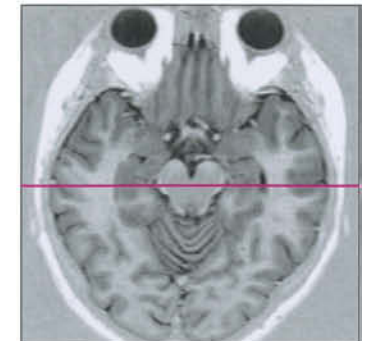
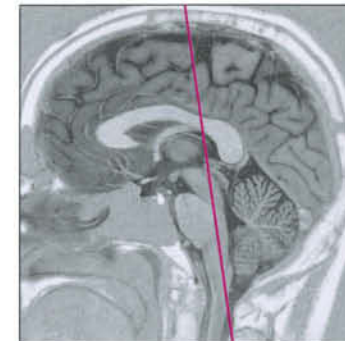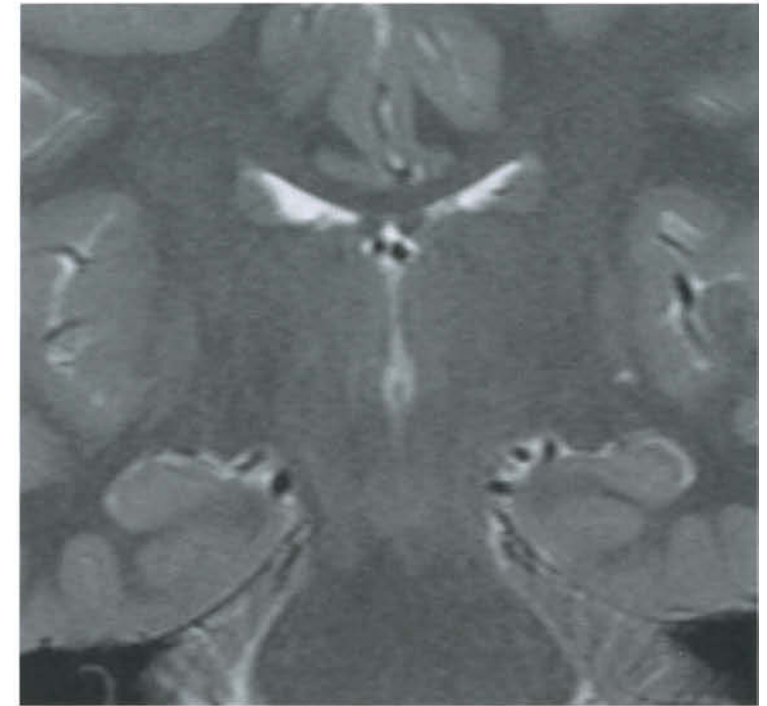
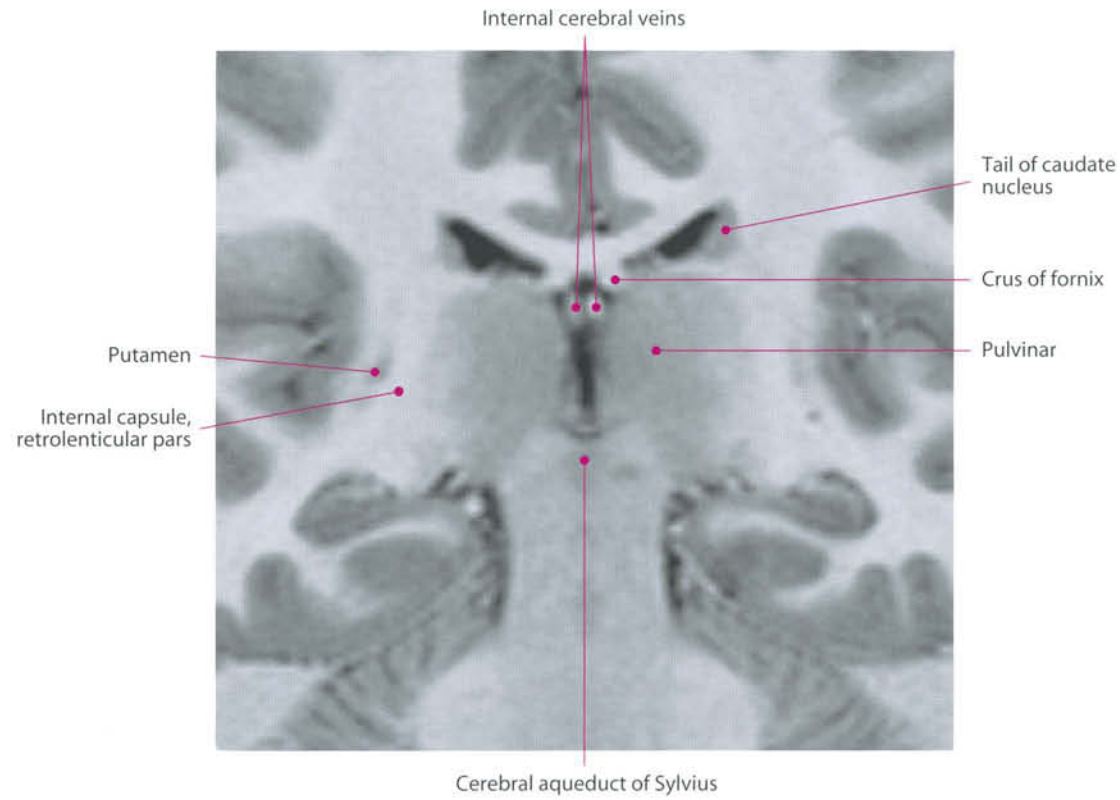


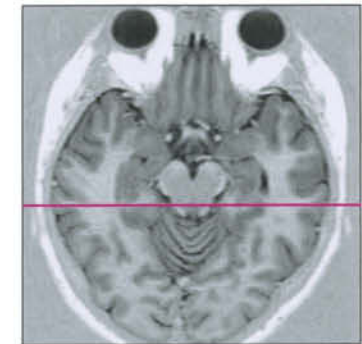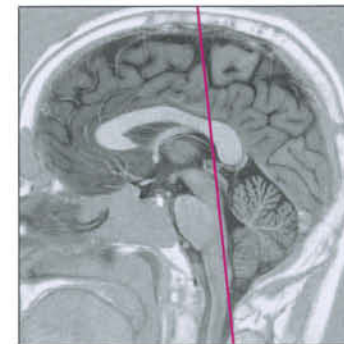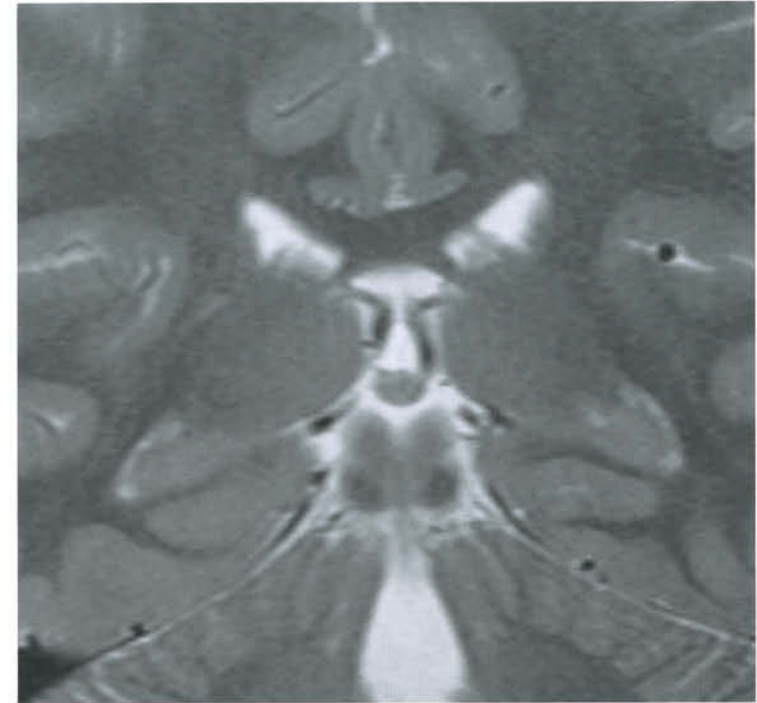
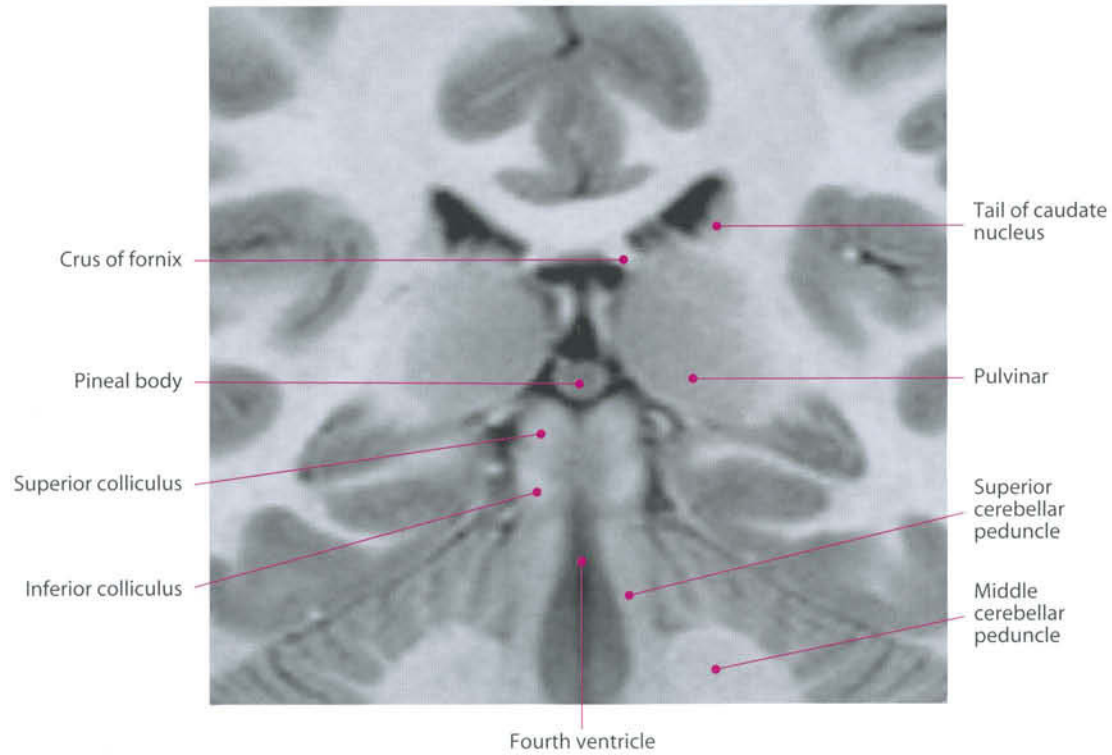




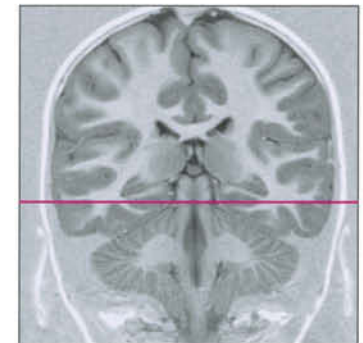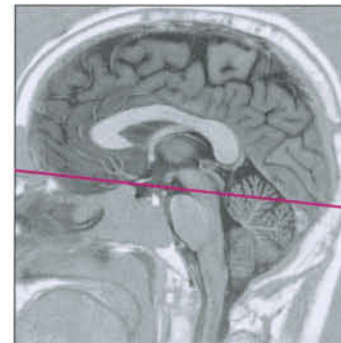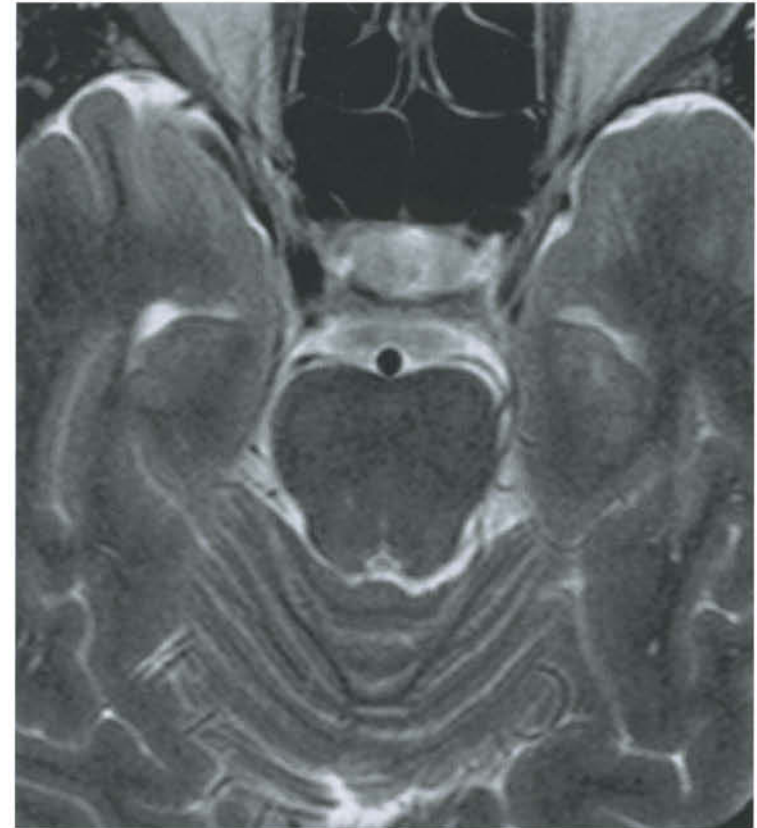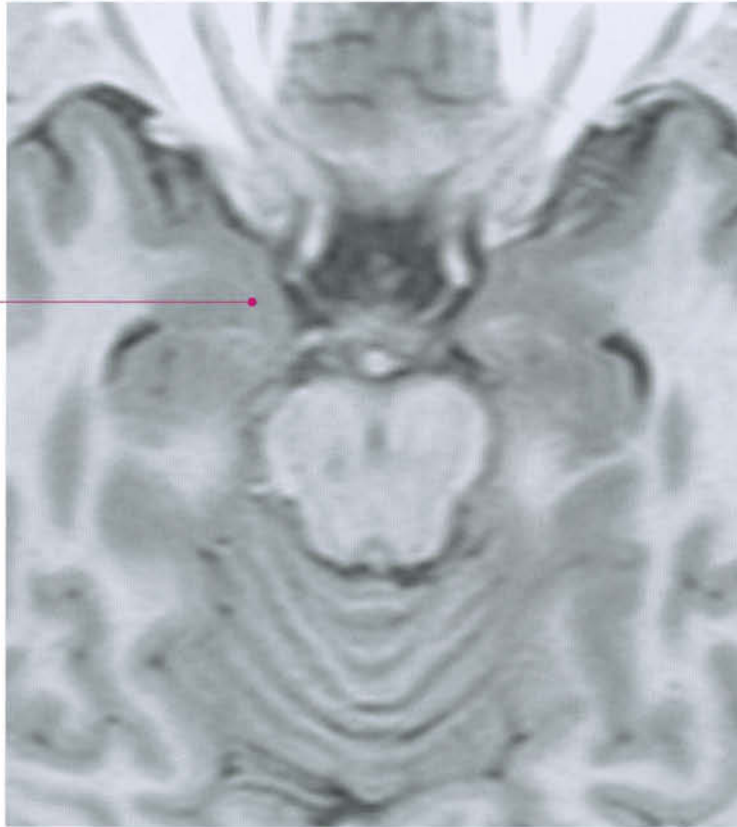




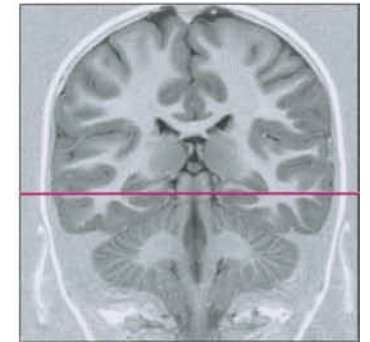
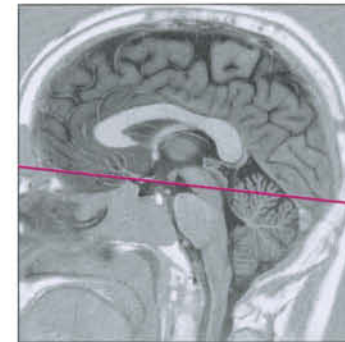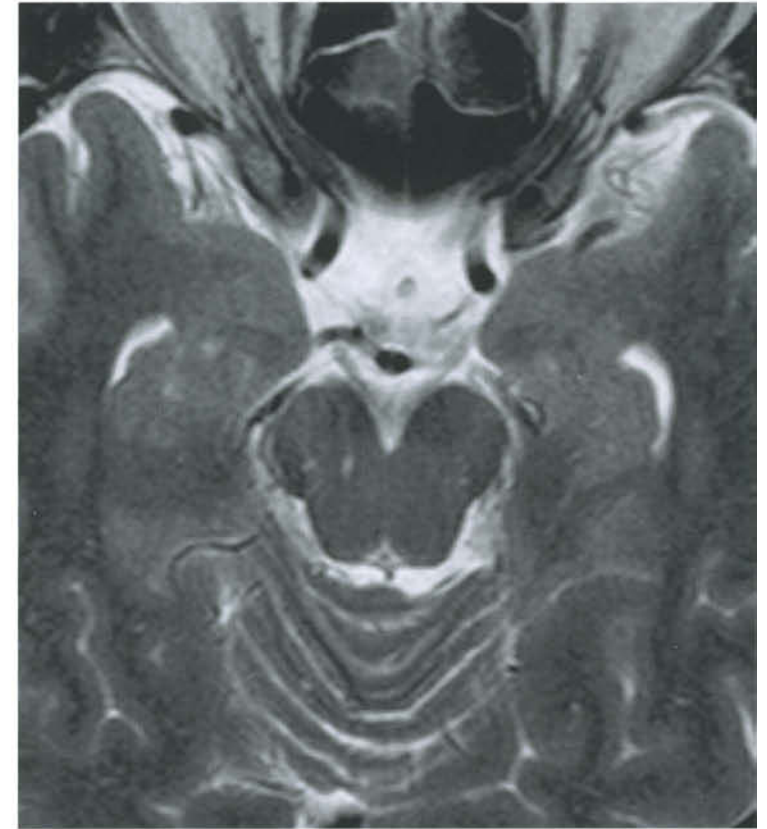
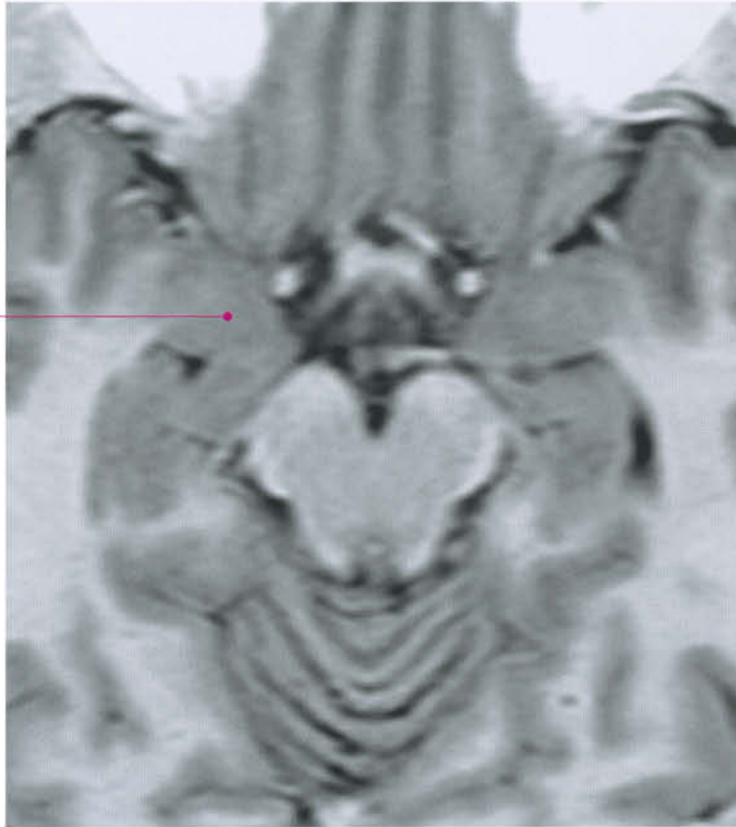


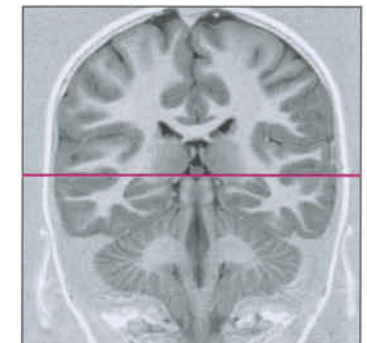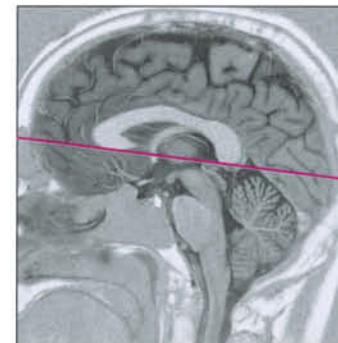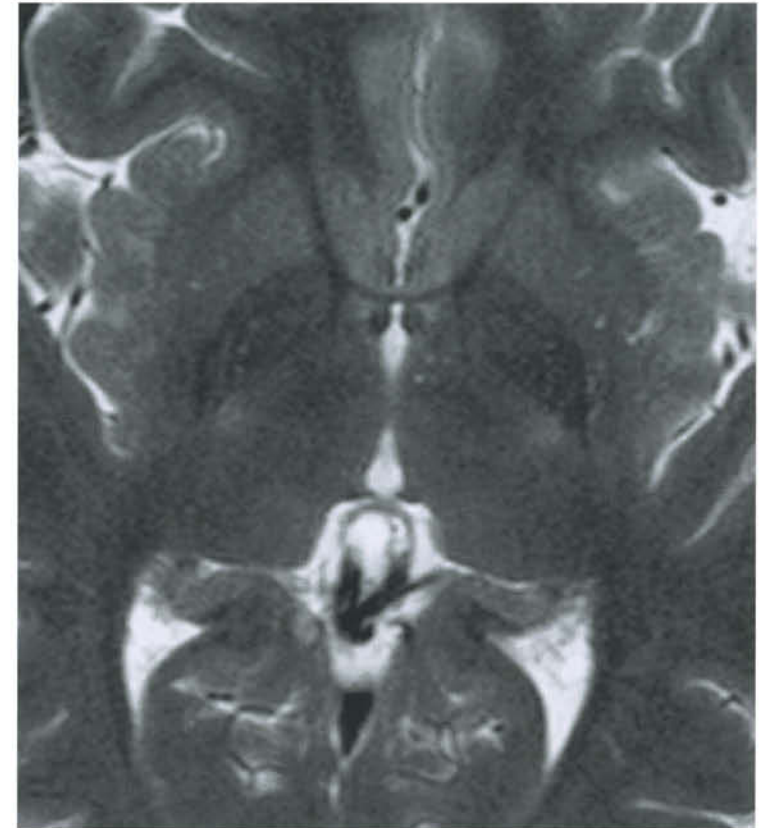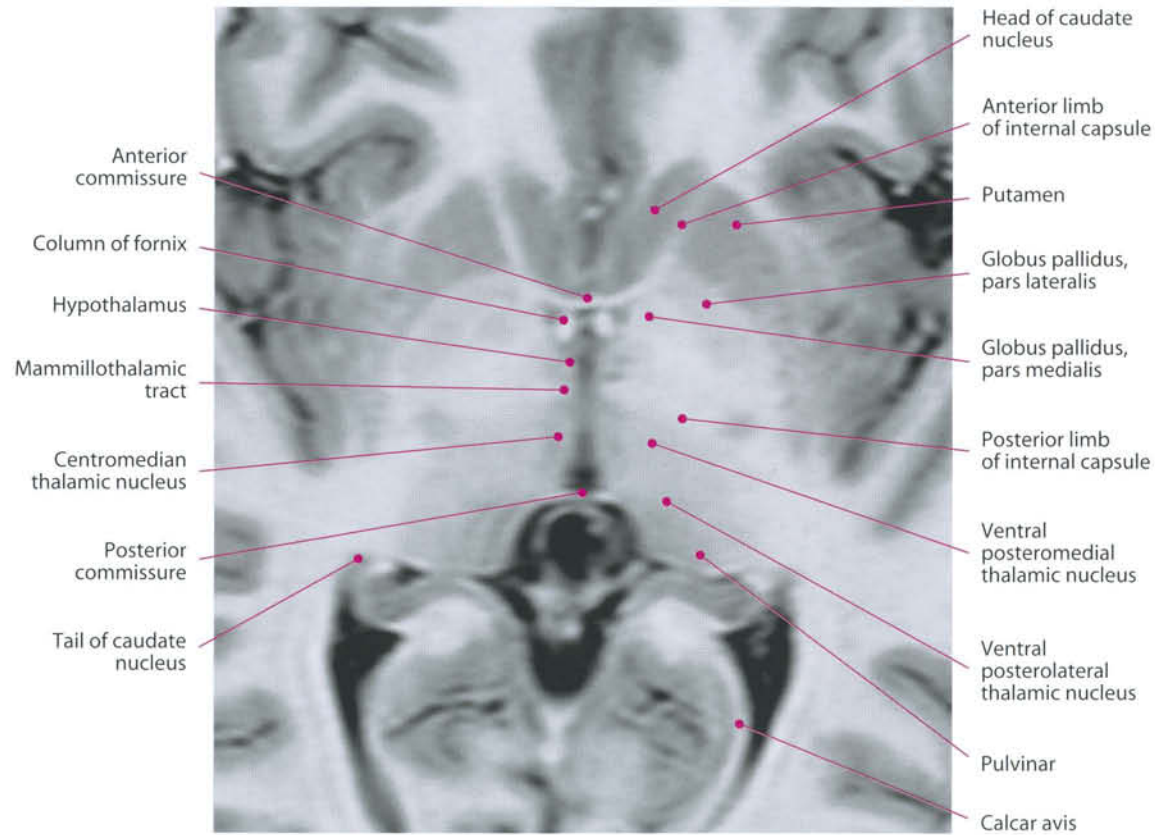


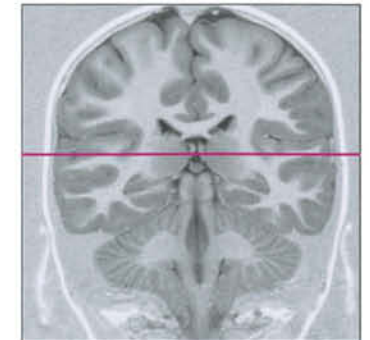
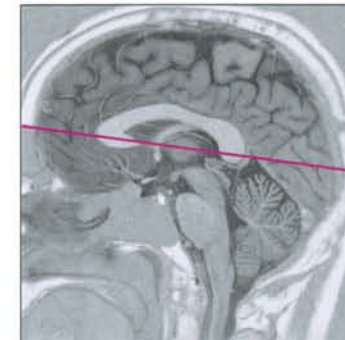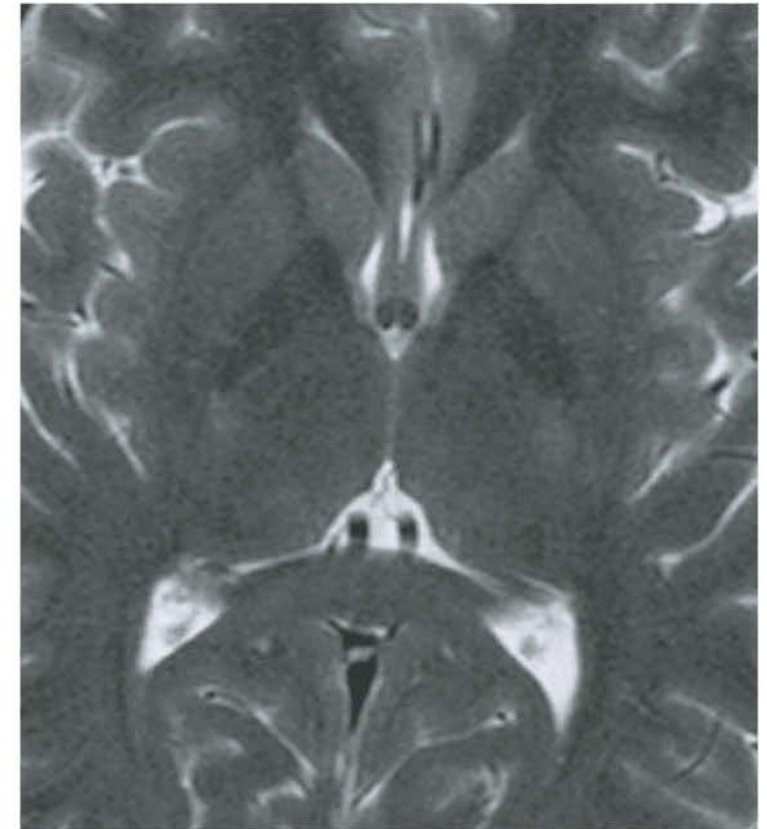
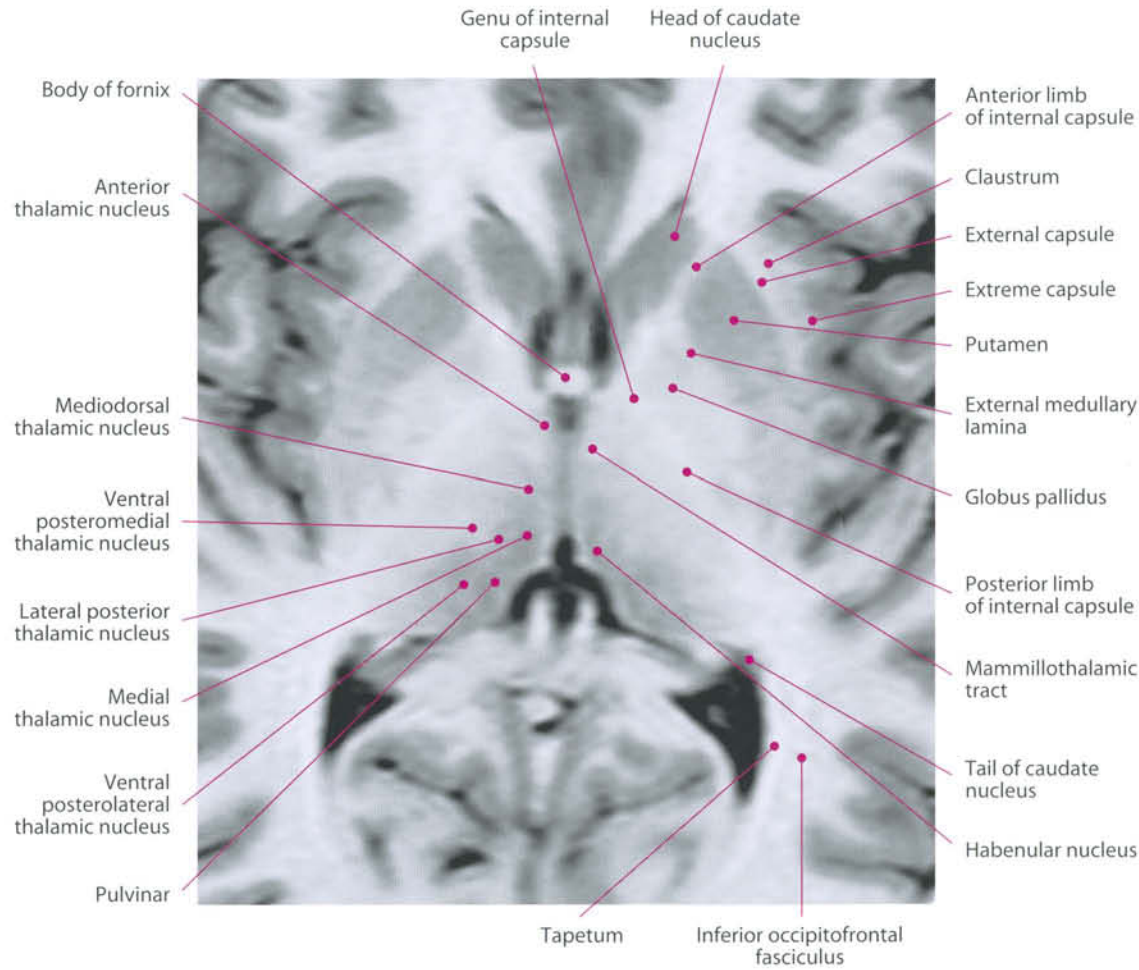
Amygdala

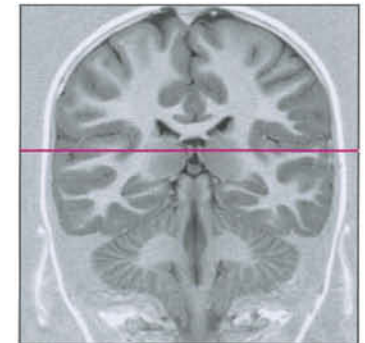
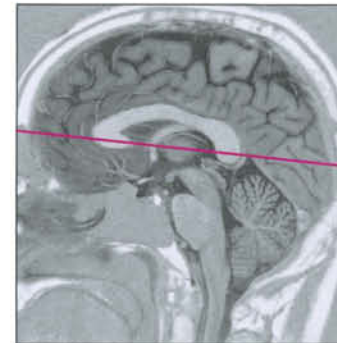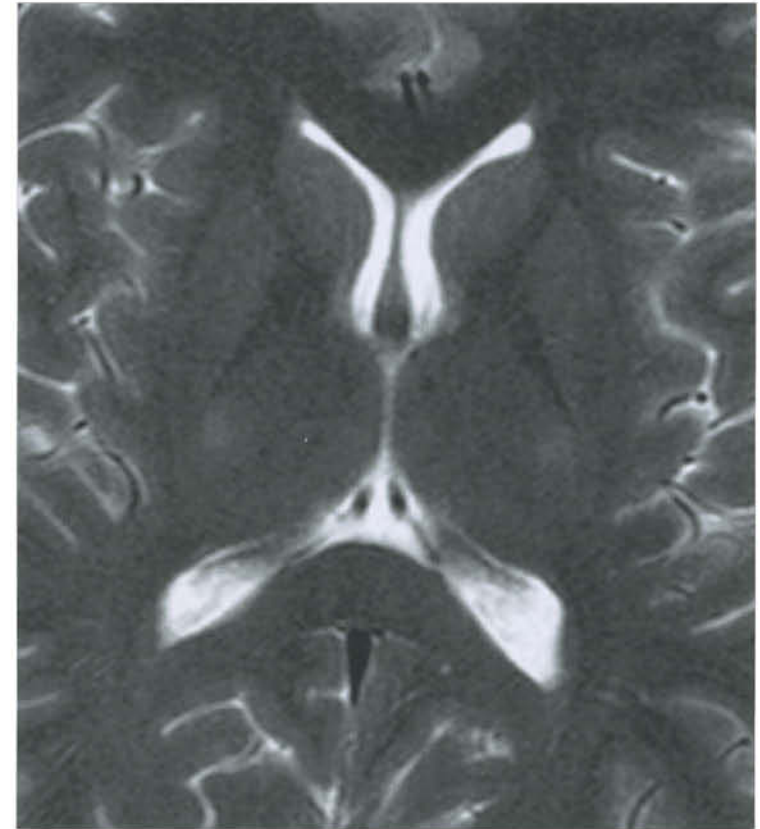
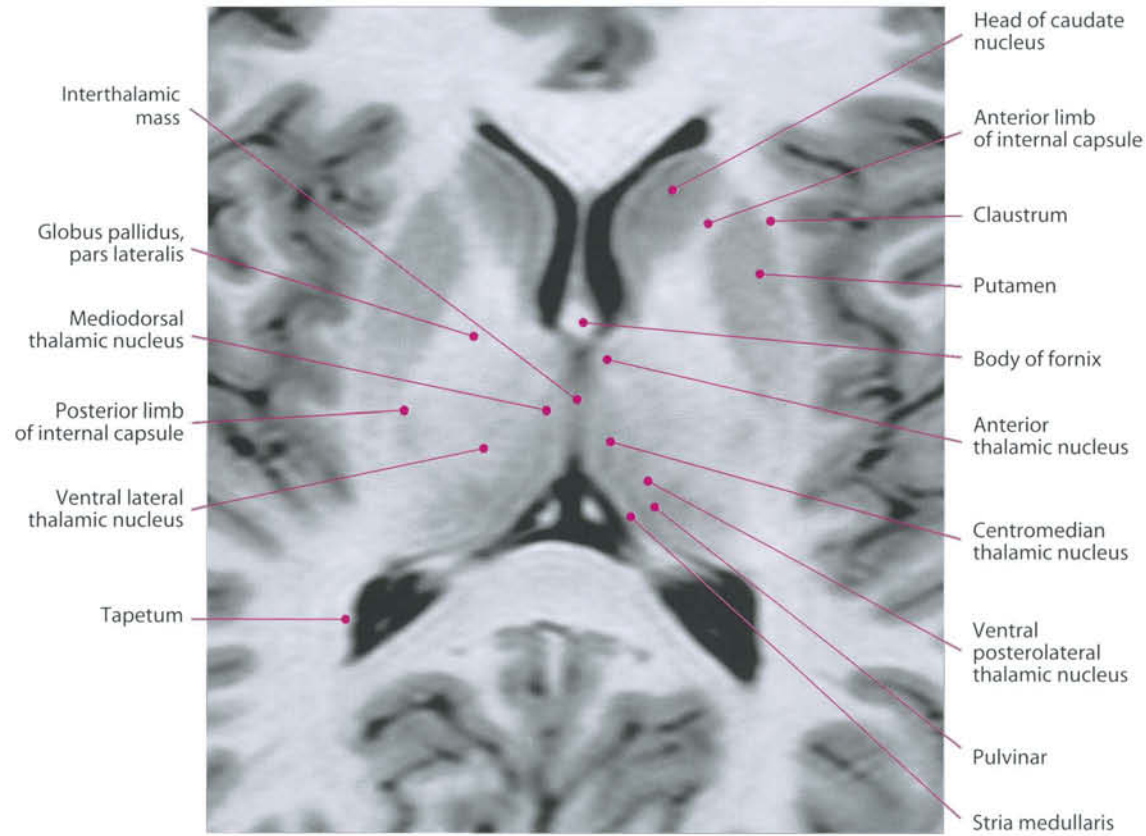


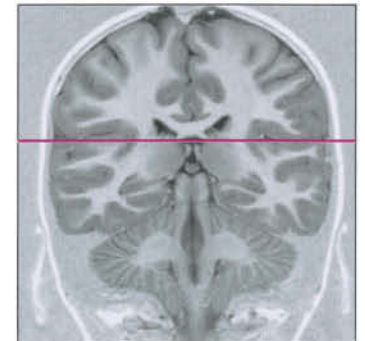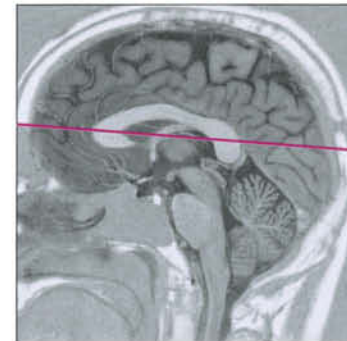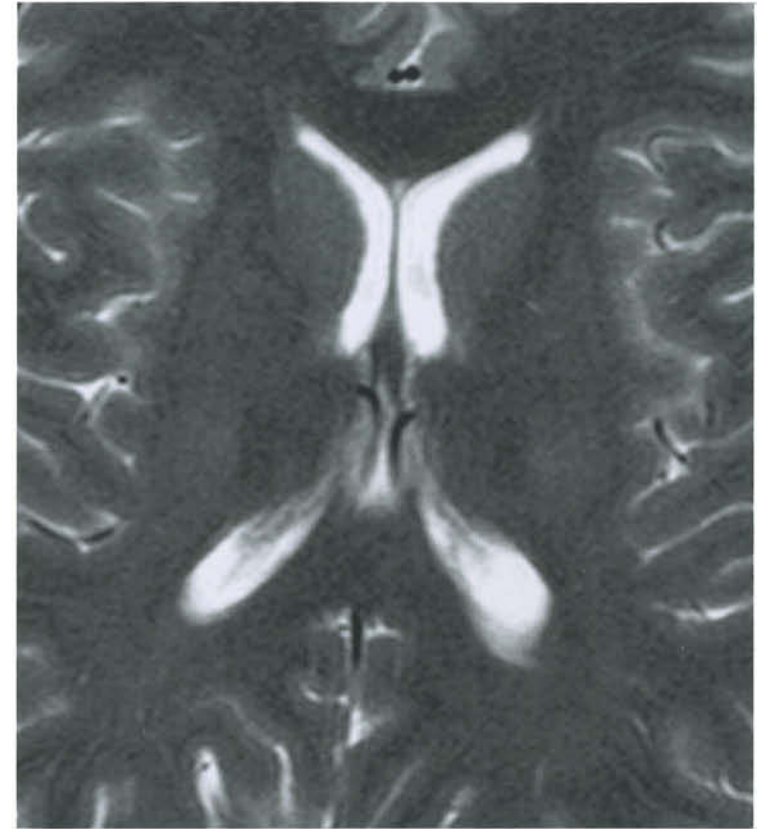
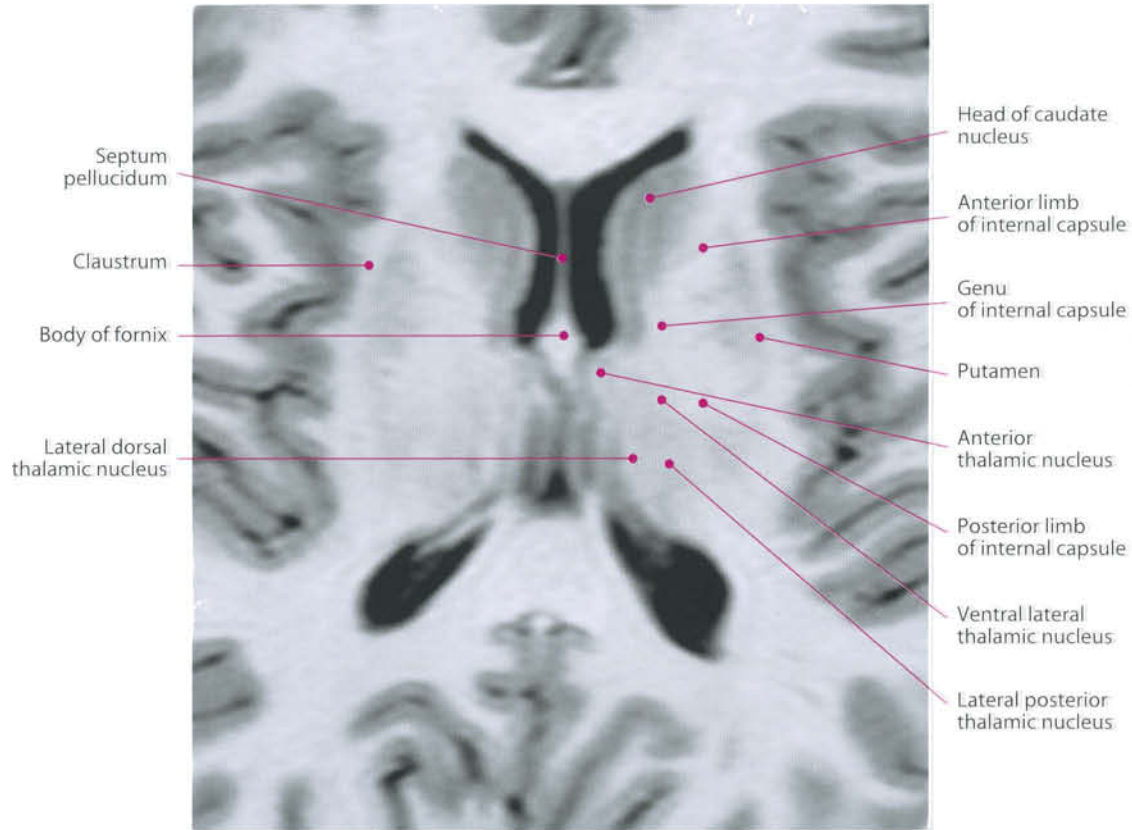
Amygdala

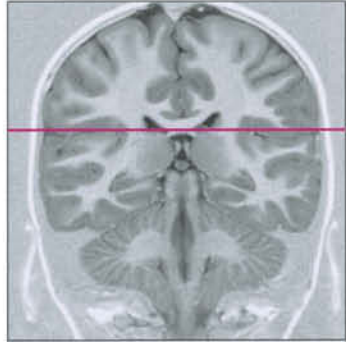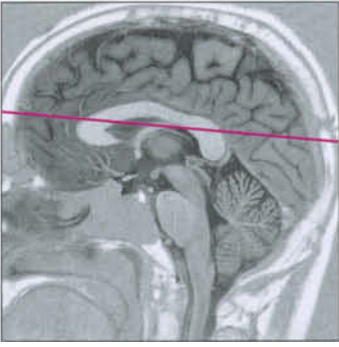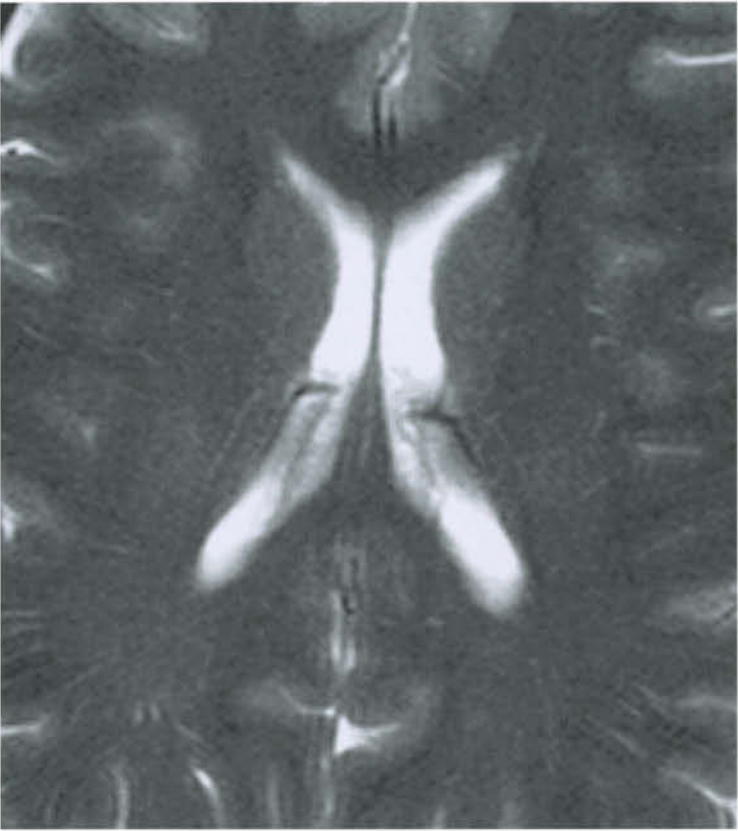
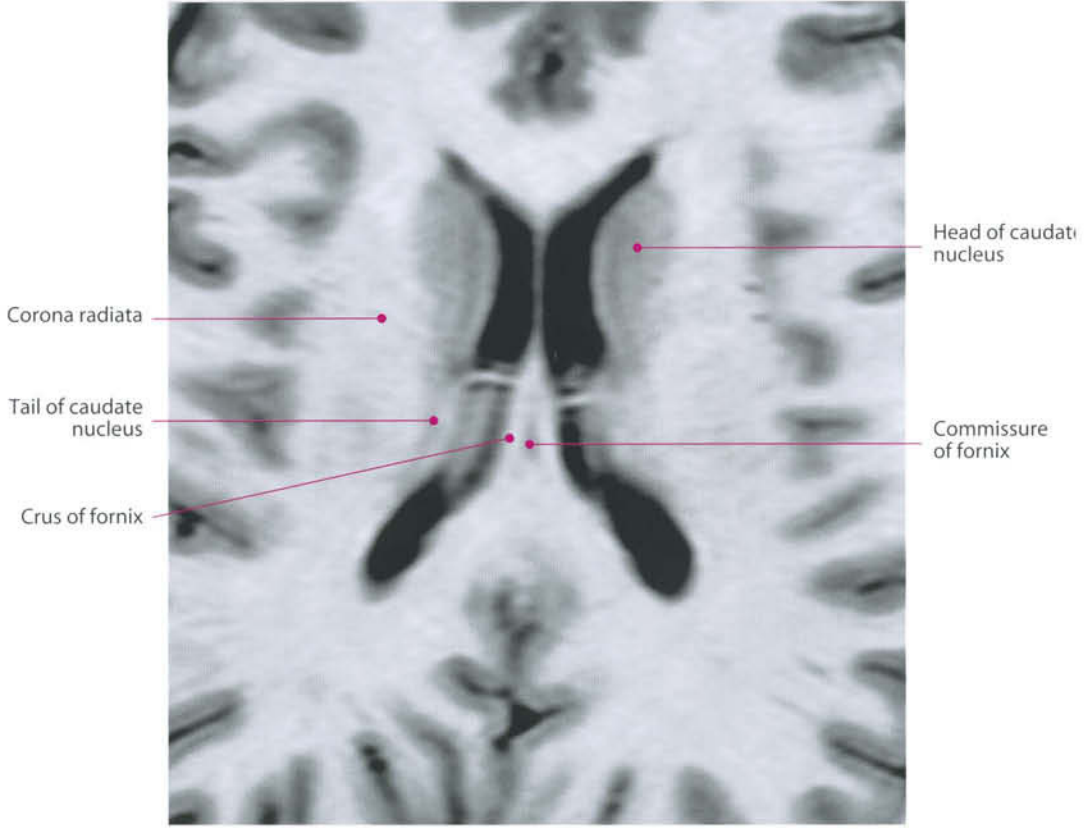






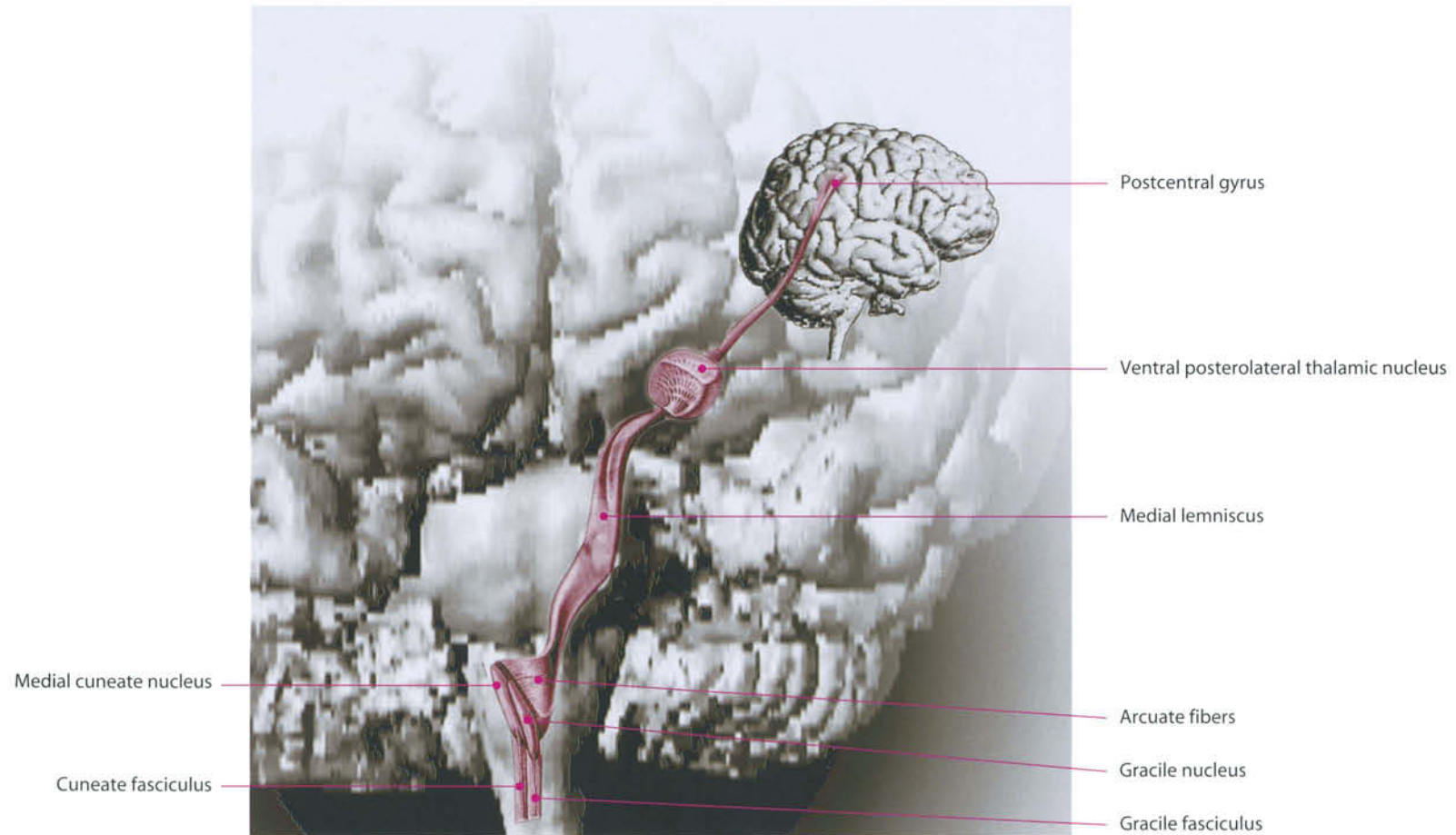




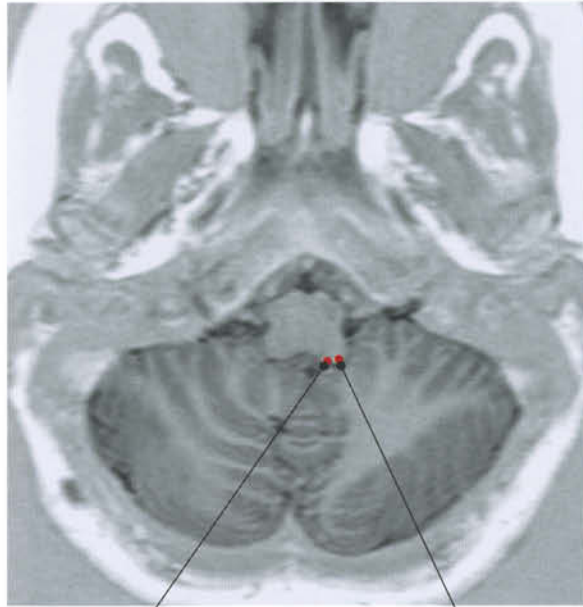

Somatosensory System

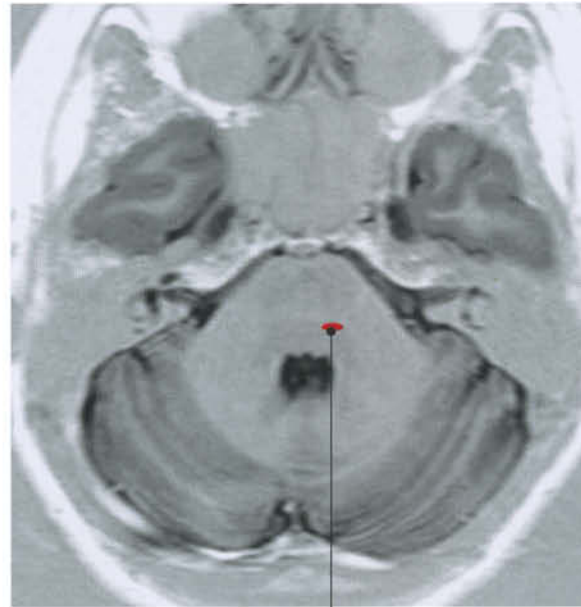Epicritic and deep sensitivity from trunk and limbs is carried by the posterior fasciculus-medial lemniscus pathway. The fibers travel within the spinal cord contralaterally to their origin, in the gracile and cuneatus fascicles, ending in the corresponding dorsal column nuclei, in the posterior aspect of the caudal end of the medulla oblongata. Thereafter, the medial lemniscus originates, and it immediately crosses the midline ascending to the ventral posterior nucleus of the thalamus. The protopathic pathways arise from the dorsal horn of the spinal gray matter. The fibers, which relay pain and temperature sensations, decussate within the cord at the level of their origin, and ascend in the anterolateral funiculus (spinothalamic tract) to the thalamus, traveling together with the medial lemniscus in the brain. Projections from the thalamus reach the somatic sensory area, mainly located in the postcentral (parietal ascending) gyrus. Sensory fibers and terminations are somatotopically organized.



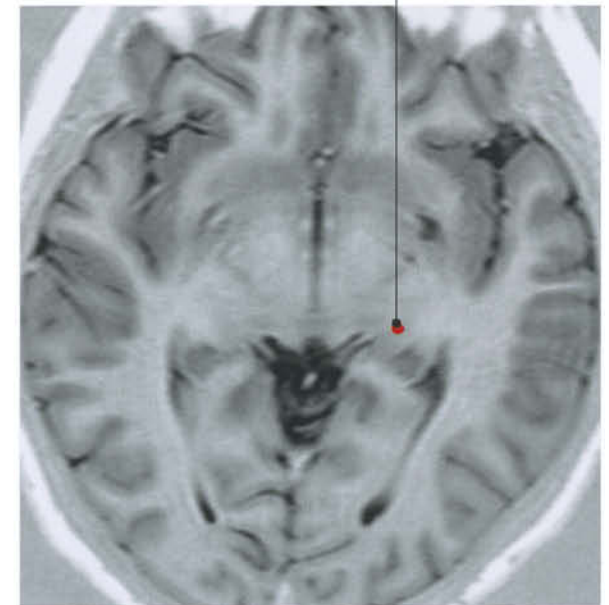


Burdach's
cuneate nucleus

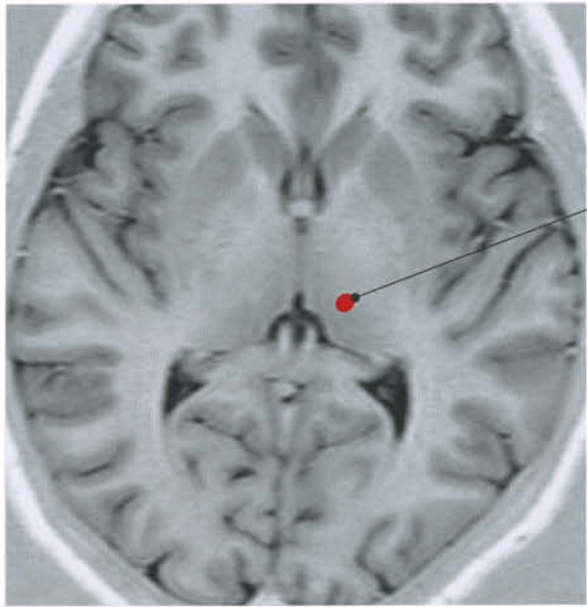
Goll's
gracile nucleus



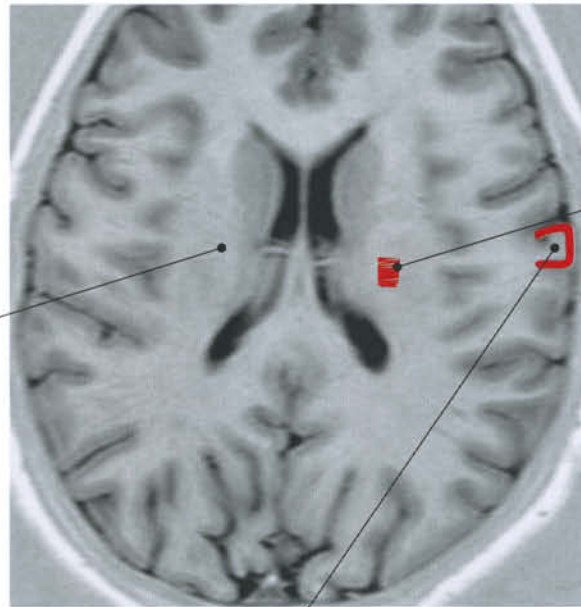
Medial lemniscus



Medial lemniscus



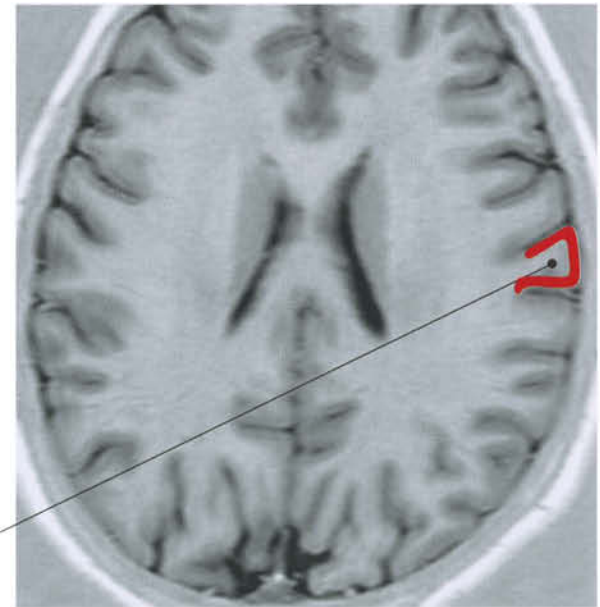Posterolateral nucleus of thalamus



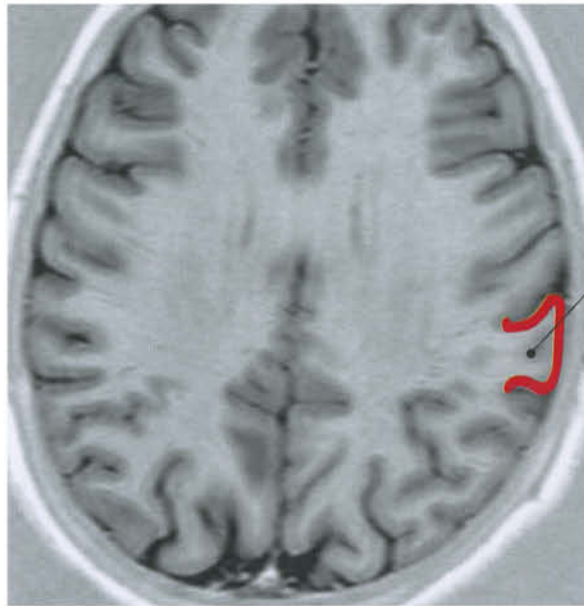Thalamocortical fibers

Corona radiata

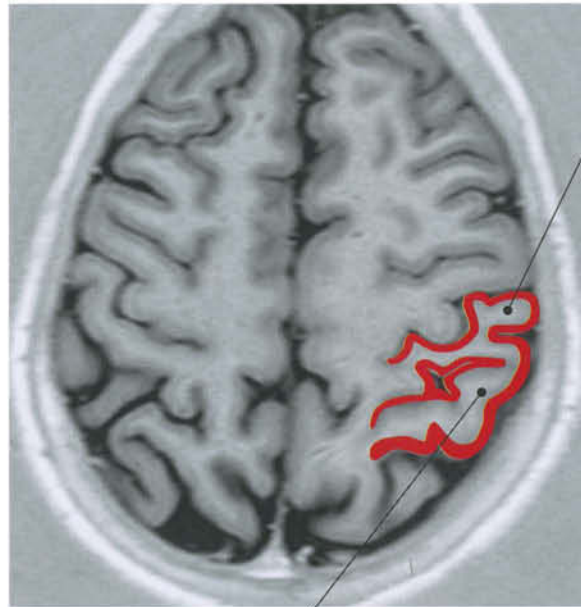Postcentral gyrus (foot) (secondary sensory area)



Postcentral gyrus (primary sensory area)

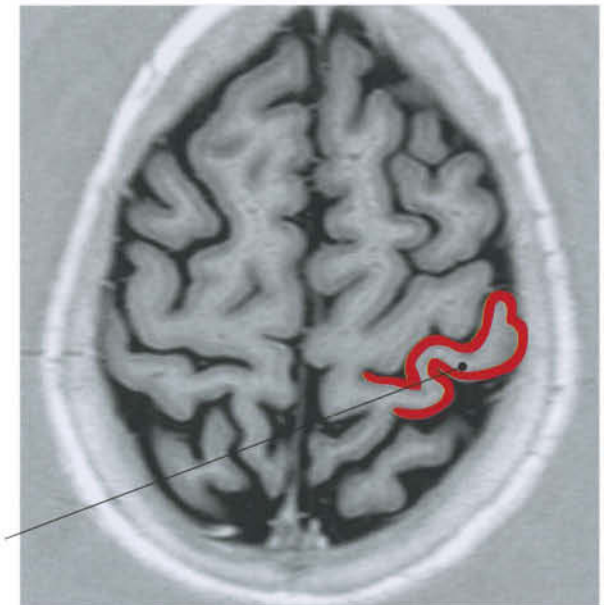


Postcentral gyrus

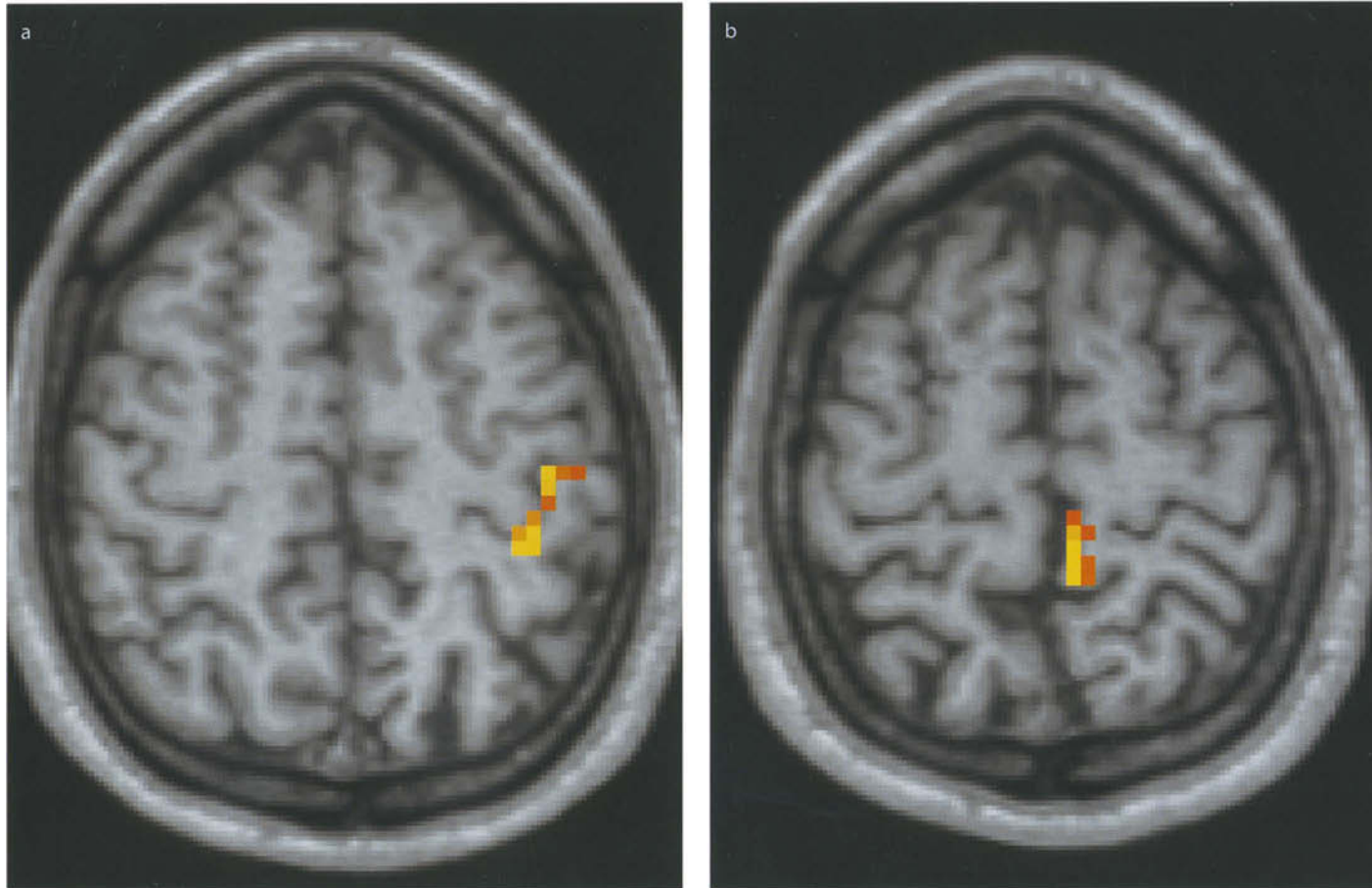


Postcentral gyrus
(projection of ventral posterior nucleus of thalamus)

Superior parietal gyrus (P1)
(projection of lateral posterior nucleus of thalamus)



Postcentral gyrus



Region of activation obtained during electrical stimulation of the right median nerve (a) and of the tibialis nerve (b).
Courtesy of M. Caulo, MD, PhD, ITAB, Chieti, Italy

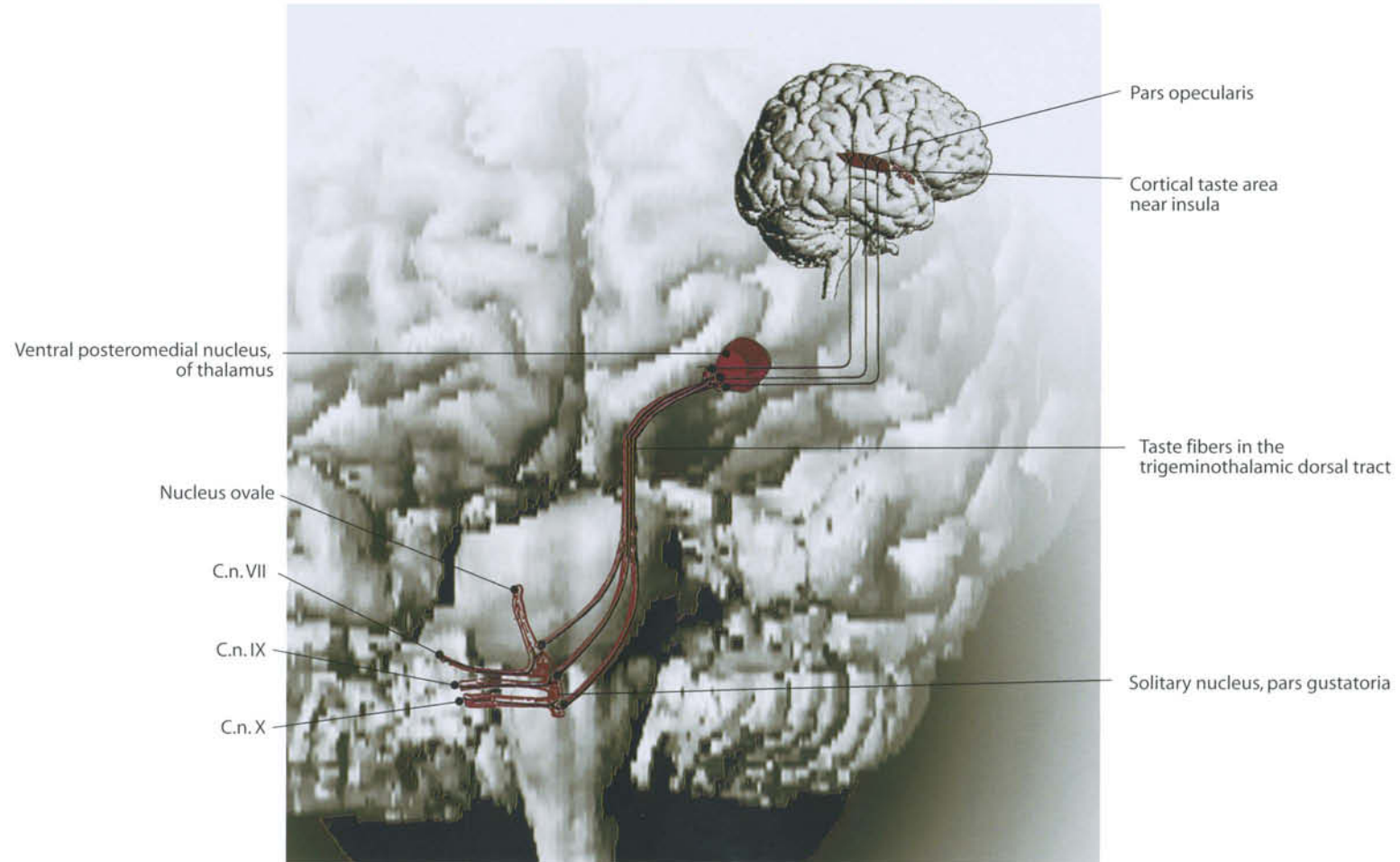
Gustatory System

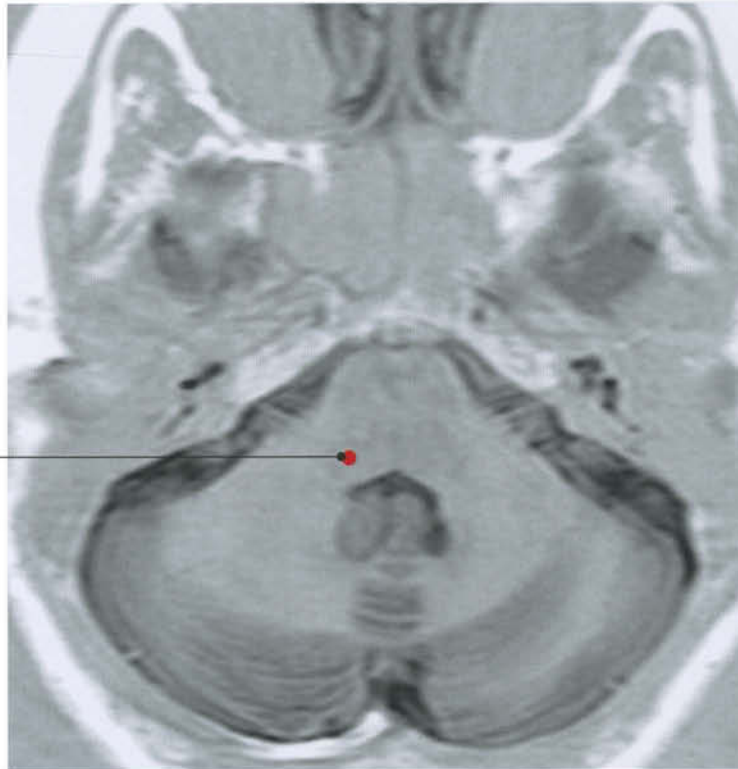
Taste receptors or papillae can be seen on the tongue as little red dots, or raised bumps, particularly at the front of the tongue. They do not have an axon. Information is relayed on to terminals of sensory fibers by transmitter. These fibers derive from the ganglion cells of the cranial nerves VII and IX. The facial nerve (VII c.n.) carries taste sensations from the anterior two thirds of the tongue. Fibers come from the lingual nerve (branch of the trigeminal nerve), reach the chorda tympani and, through it, the facial nerve. The posterior third of the tongue is innervated by the glossopharyngeal nerve (IX c.n.). Cellular bodies are in the plexiform ganglion. Nervous fibers from both nerves terminate at the gustative nucleus (or Nageotte's, or solitary tract nucleus), located in the dorsolateral part of the medulla oblongata.

From there, information is projected to the somatosensory cortex for conscious perception of taste and to the hypothalamus, amygdala and insula, giving the so-called "affective" component of taste, for behavioral response, (e.g. aversion, gastric secretion, feeding behavior).

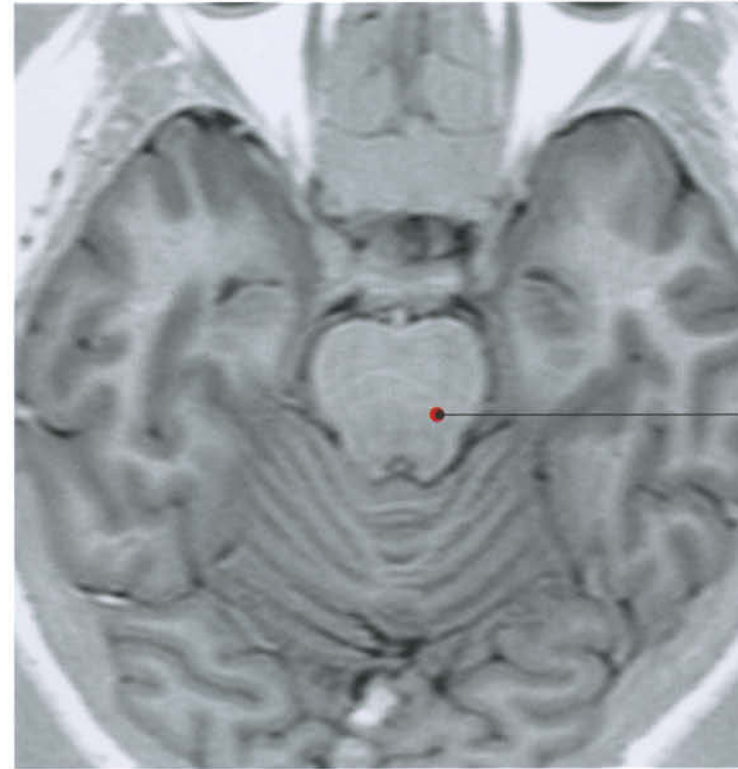
The functional meaning of the gustative cortex is not yet fully understood. More than a simple terminal station for consciousness of taste, it seems to represent part of a more complex circuit which governs the alimentary behavior.

The main cortical area of taste is the opercular cortex (able to de-codify four groups of stimuli: sweet, salt, sour, and bitter). From there, projections start to the orbitofrontal and prepiriform cortex.

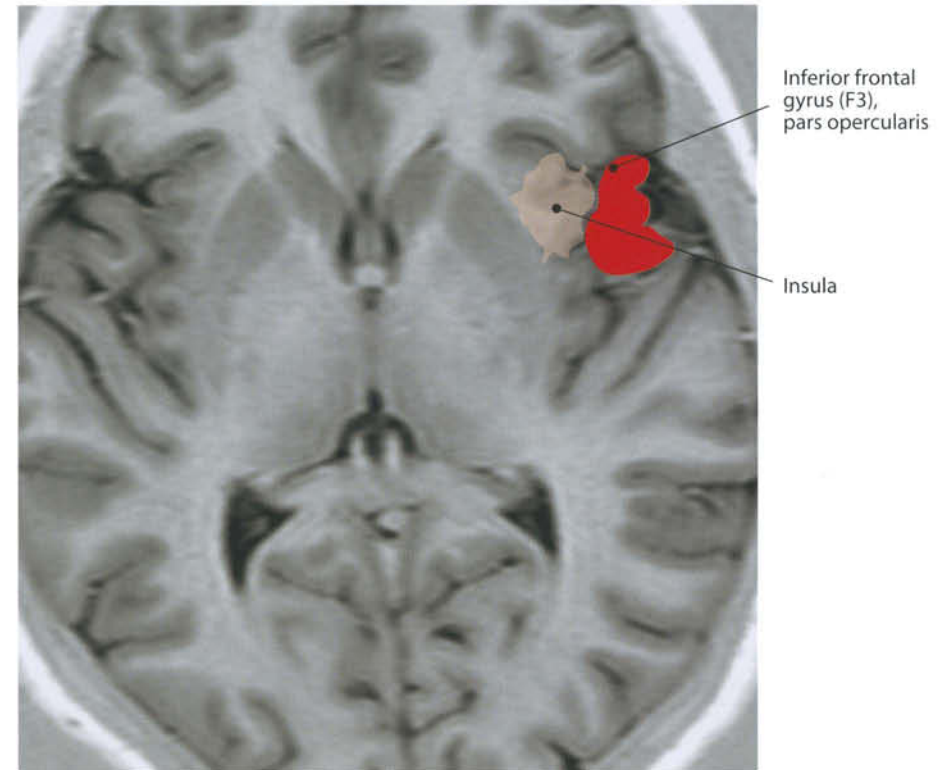
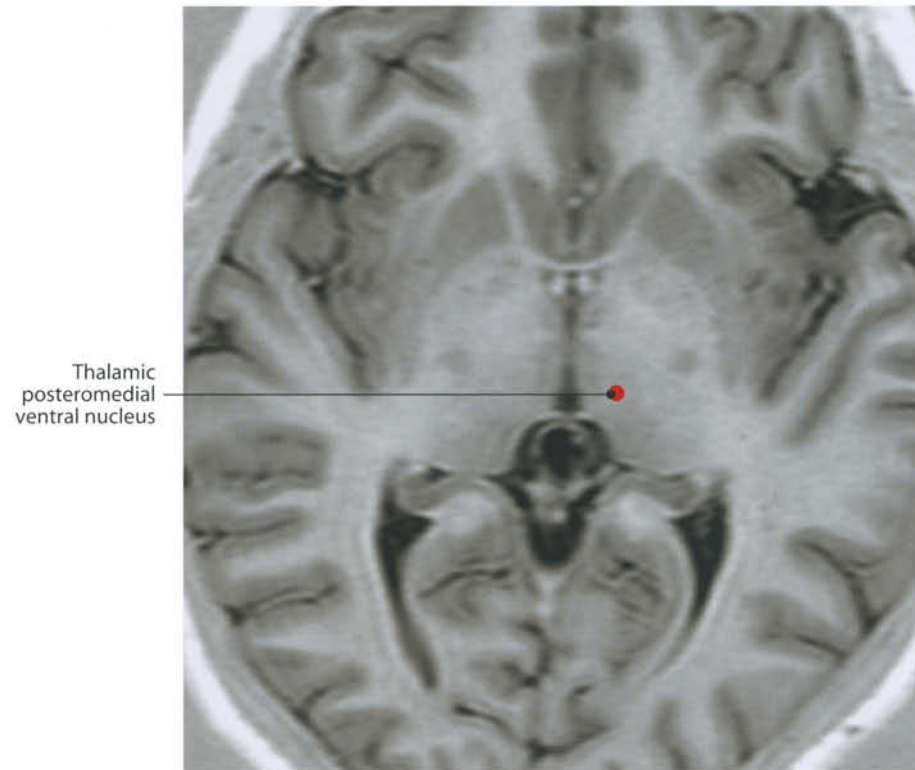




Solitary nucleus



Gustative fibers
in the dorsal
trigeminothalamic tract



Speech System

This is a complex functional system which includes sensorial, cognitive, and motor aspects. In a very elementary interpretation, a frontal (motor) area and a temporal (sensitive) area can be clearly distinguished and recognized in fMRI exams. The speech system is lateralized, being located in the left hemisphere of right-handed and of 70% of left-handed people.

The motor component, which, when impaired, is responsible for the so-called non-fluent aphasia, includes Brodmann's area 44, in the opercular part of the inferior orbital gyrus (termed Broca's speech area). Other authors consider area 45 as part of the Broca's area and area 46 as a marginal area compromise in non-fluent aphasia. In fluent aphasia the compromise includes temporal lobe. In the typical Wernicke's form, the lesion involves the posterior region of the left superior temporal gyrus or the first gyrus of the temporal lobe (areas 21 and 22). The damage often extends into the parietal lobe (angular gyrus, area 39). As Wernicke's area is adjacent to primary auditory cortex (Brodmann's areas 41 and 42), it can be considered an auditory association area. Conduction aphasia results from damage to the arcuate fasciculus, a bundle of nerve fibers that lies below the supramarginal gyrus in the temporal lobe and connects Broca's and Wernicke's areas. Both Broca's and Wernicke's areas are left intact. Affected areas may include superior temporal gyrus, insula, primary auditory cortex, auditory association areas (Brodmann's 21 and 22), and the supramarginal gyrus (area 40). Transcortical sensory aphasia is an extremely rare form of fluent aphasia that occurs when Broca's area, Wernicke's area and the arcuate fasciculus are safe but disconnected from the rest of the brain, as a consequence of lesions in Brodmann's areas 37, 22, and 39. Lesions in area 37 are known to cause anomia.

Brainstem Pathways and Nuclei

This chapter does not describe a single functional entity, seeing as the brainstem is a station in which several different and complex systems meet or run freely. However, from the viewpoint of topographic and radiological anatomy, the knowledge of circuits, pathways and nuclei in the brainstem needs special consideration. For this reason this topic has been inserted in the chapter "Functional Systems". MRI cuts have been com-

pleted with drawings able to reveal the finest structures that are not visible with routine radiological exams and that start to be disclosed with modern imaging technology like MR tractography. These structures do not need additional description, and the reader is advised to look up single functional systems for any further details: brainstem nuclei are covered together with the related cranial nerves (see Chapter 4), the main ascending and descending pathways are covered in the specific functional system (see Chapter 5, pp. 204, 242), while general morphology of the brainstem and its connections with the cerebellum are covered in Chapter 3.

Limbic System and Hippocampus

Based on Broca's classical definition (1878), this system includes subcallosal, cingulate, parahippocampal, and hippocampal gyri. Under a more modern interpretation, the dentate gyrus, amygdaloid nucleus, olfactory nerve, bulb and striae, septal area, anterior perforated substance, septum pellucidum, fornix, anterior commissure, and other smaller structures are included. The limbic system is mainly involved in memory mechanisms and emotional states.

The hippocampus has a particular role: the term means "sea horse" and is due to its peculiar shape when seen in coronal cuts. The parahippocampal gyrus is situated inferiorly and forms the border between the inferior and medial surface of the hemisphere. Superiorly, it continues in the subiculum, toward the hippocampal fissure that delimitates the hippocampus. The hippocampal fissure is bordered above by the dentate gyrus and the fimbria, which is the inferior aspect of the fornix. Immediately above, the choroidal fissure is found, through which enters the choroidal plexus of the temporal horn of the lateral ventricle. Anteriorly, the hippocampus bends up and back to form an uncinat process, the "uncus". Fibers from the hippocampus go immediately below the ventricular ependyma. Beneath them there is a white layer, the alveus. Fibers from the alveus converge to form the fimbria of the fornix.

Commissural and Associative Pathways

Transverse or commissural fibers unite the two hemispheres; association fibers connect different structures in the same

hemisphere. Most commissural and associative pathways are well visible on cross-sectional MRI cuts. In this chapter, the main pathways are drawn on 3D MRI reformatted images. MR tractography can nowadays directly identify many of them.

- **Corpus Callosum (see also p. 24)**

The corpus callosum is the biggest interhemispheric commissure, containing fibers that reach all aspects of the cerebral cortex. It has a central portion, the body or trunk, an anterior part, the genu, and a posterior one, the splenium. The genu bends dorsally and downward to form the rostrum. This becomes progressively thinner and goes toward the anterior commissure. This thinner part is called the "lamina terminalis". The genu's fibers curve forward and lateral to the frontal horns. This structure is called the "forceps minor". The passage between the body and the splenium is often narrow. This portion is also known as "isthmus". The corpus callosum delimitates the roof of the lateral ventricles. The splenium's fibers cover the lateral ventricles posteriorly and extend laterally to cover the lateral aspect of the temporal horn. They are termed the "tapetum", while the most posterior fibers, which curve backwards to the occipital lobes, are called the "forceps major".

- **Anterior Commissure**

The anterior commissure is a bundle of myelinated fibers about 3 mm thick, located above the rostrum of the corpus callosum, anterior to the interventricular foramen of Monro. Its fibers connect the medial aspects of the temporal lobes and course laterally, producing a groove on the anterior inferior part of the lentiform nucleus.

- **Superior Longitudinal Fasciculus**

The superior longitudinal fasciculus, or arcuate fascicle, extends from the frontal to the parietal and occipital lobes. It goes laterally to the corona radiata. Among its fibers, the pathway between the speech areas of Broca and the Wernicke's are included.

- **Fasciculus Occipito-Frontalis**

It extends from the occipital pole to the frontal lobe, passing laterally to the caudate nucleus. Two portions are distinguished: the fasciculus occipito-frontalis superior and the inferior.

- **Inferior Longitudinal Fasciculus**

This fascicle starts from the occipital pole and extends to the temporal lobe passing laterally to the lateral ventricle.

- **Uncinate Fasciculus**

It connects the orbital gyri of the frontal lobe and the speech area with the cortex of the temporal lobe, passing below the claustrum, the external and the extreme capsules.

- **Posterior Commissure**

This structure is located immediately below the pineal gland, on the dorsal aspect of the midbrain, in correspondence with the beginning of the cerebral aqueduct. It is related to the habenular commissure, which is located above, adjacent to the pineal body.

- **Habenular Commissure**

This commissure is specifically devoted to connecting the two habenular nuclei with each other. These nuclei are located on the dorsomedial aspect of the thalami.

- **Fornix**

The fornix is the main hypothalamic commissure. Its morphology is described in Chapter 1 (page 24).

- **Mammillothalamic Tract**

The fibers of the mammillothalamic tract extend from the mammillary body, across the thalamus, to end in the anterior thalamic nuclei. It is adjacent to the third ventricle wall, in the hypothalamus.

- **Short Arcuate Fibers**

These fibers connect adjacent gyri. They are also called “U” Fibers.

Neuroendocrine System

This system is essentially composed of the hypothalamus and the pituitary gland. The system has the particular task of producing hormones. Therefore, a very particular circulation is present.

I. Hypothalamus

The hypothalamus is situated below the thalamus and the basal ganglia, and forms the lateral wall of the lower aspect of the third ventricle, separated from the thalamus by the hypothalamic sulcus. It contains several complex nuclei, the mammillary bodies, anterior to the interpeduncular fossa, the tuber cinereum (a protuberance located behind the infundibulum), the infundibulum, the pituitary stalk, the lamina terminalis and the anterior commissure.

II. Pituitary Gland

The pituitary gland is median, and strongly connected to the hypothalamus by means of the stalk. The gland varies in size and approximately reaches the adult shape and volume by the age of 4. The height of the gland, however, varies over time and in consequence of the hormonal state. In males, it measures about 4 ± 1 mm, in females 4.4 ± 1.4 mm. In females, however, the height is more variable, being more pronounced in fertile life (about 6-7 mm), reaching 10 mm during adolescence and 12 mm during pregnancy.

The gland is composed of two lobes: the anterior, embryologically derived from the I branchial arch (Rathke's pouch), and the posterior, which derives from the hypothalamus. In between is a thin layer, the pars intermedia, that sometimes takes a cystic aspect. It is located inside the sella turcica, covered by the tentorium sellae, a dura mater plica perforated in the middle to leave a passage for the stalk. Laterally, the gland is delimited by the cavernous sinuses. There is no dural wall to delimitate the medial aspect of the cav-

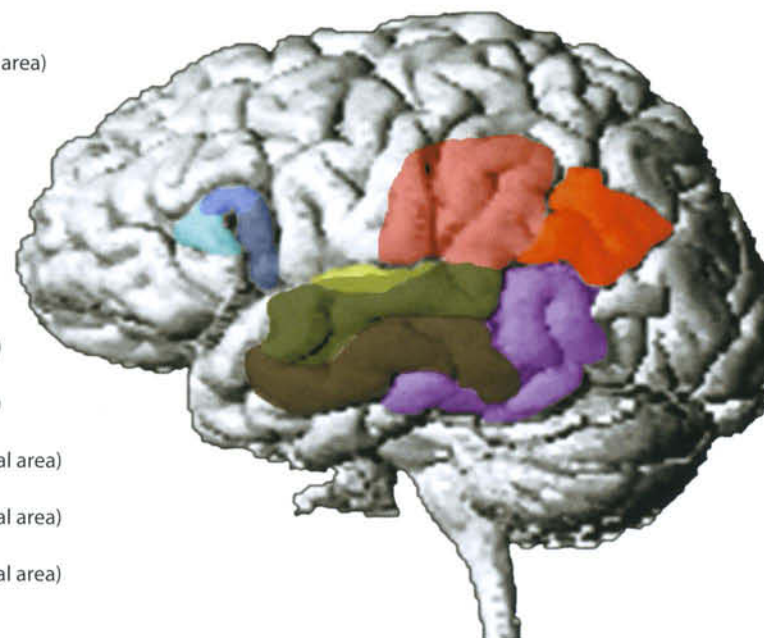
ernous sinus, while the lateral wall is thick, formed by a dural plica. The dura mater of the lateral wall contains the cranial nerves III, IV, V1 and V2. The cranial nerve VI passes inside the sinus.

III. Vascularization

The hypothalamus is richly supplied by several small arteries coming from both carotids and Willis' circle. The anterior lobe of the pituitary gland is supplied by superior pituitary arteries coming from the internal carotid and by posterior communicating arteries. They wrap the upper stalk, where they form an initial capillary network and a group of draining veins. These reach the anterior pituitary lobe, where a second capillary plexus is formed (pituitary portal system). This system receives anterior pituitary hormones. Finally, some principal venous ducts drain the blood toward the cavernous sinus.

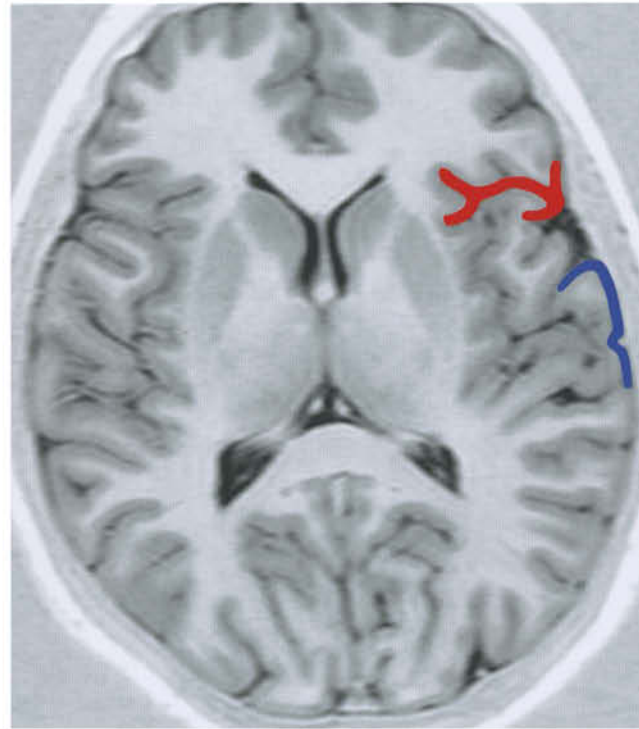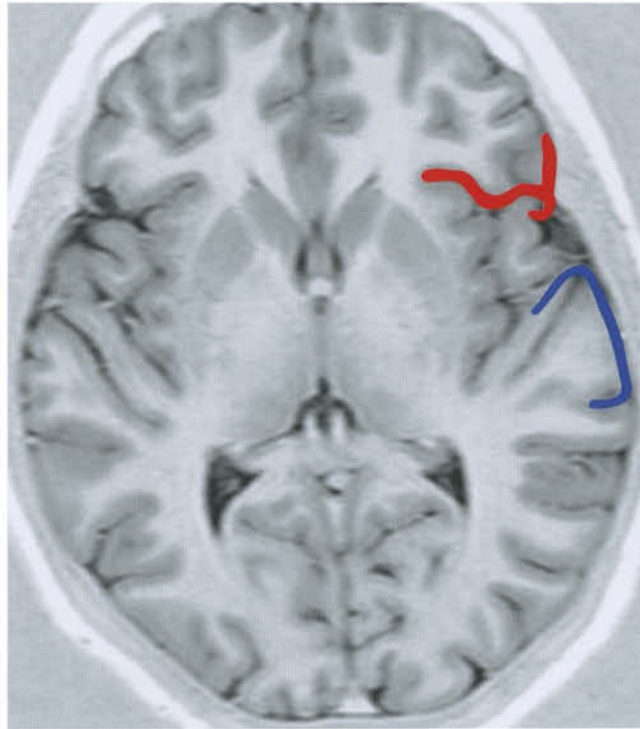
The posterior lobe of the gland receives supply directly from internal carotid arteries, by means of posterior pituitary arteries. The venous drainage is to the cavernous sinus.

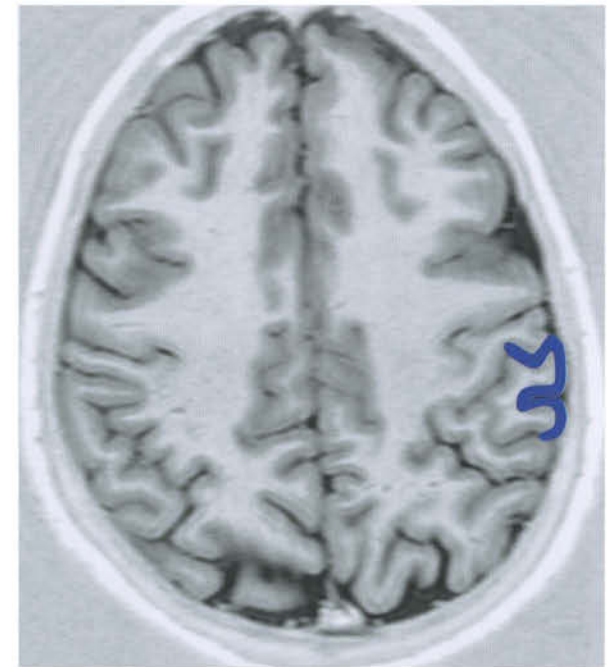
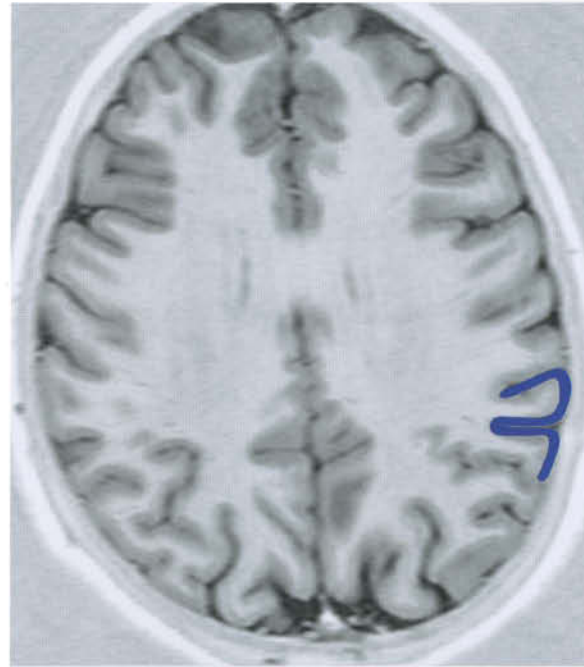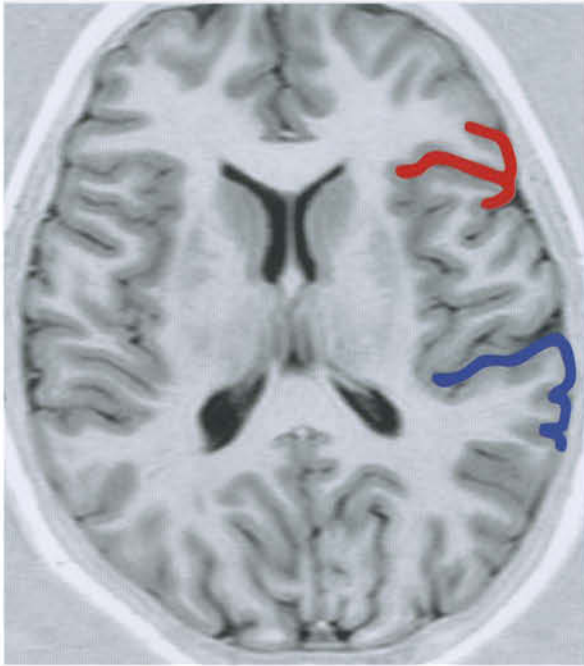
- Area 46 (Motor speech marginal area)
- Area 45 (Broca's speech area)
- Area 44 (Broca's speech area)
- Area 41 (Primary auditory area)
- Area 42 (Primary auditory area)
- Area 22 (Wernicke's speech area)
- Area 21 (Wernicke's speech area)
- Area 37 (Sensory speech marginal area)
- Area 40 (Sensory speech marginal area)
- Area 39 (Sensory speech marginal area)





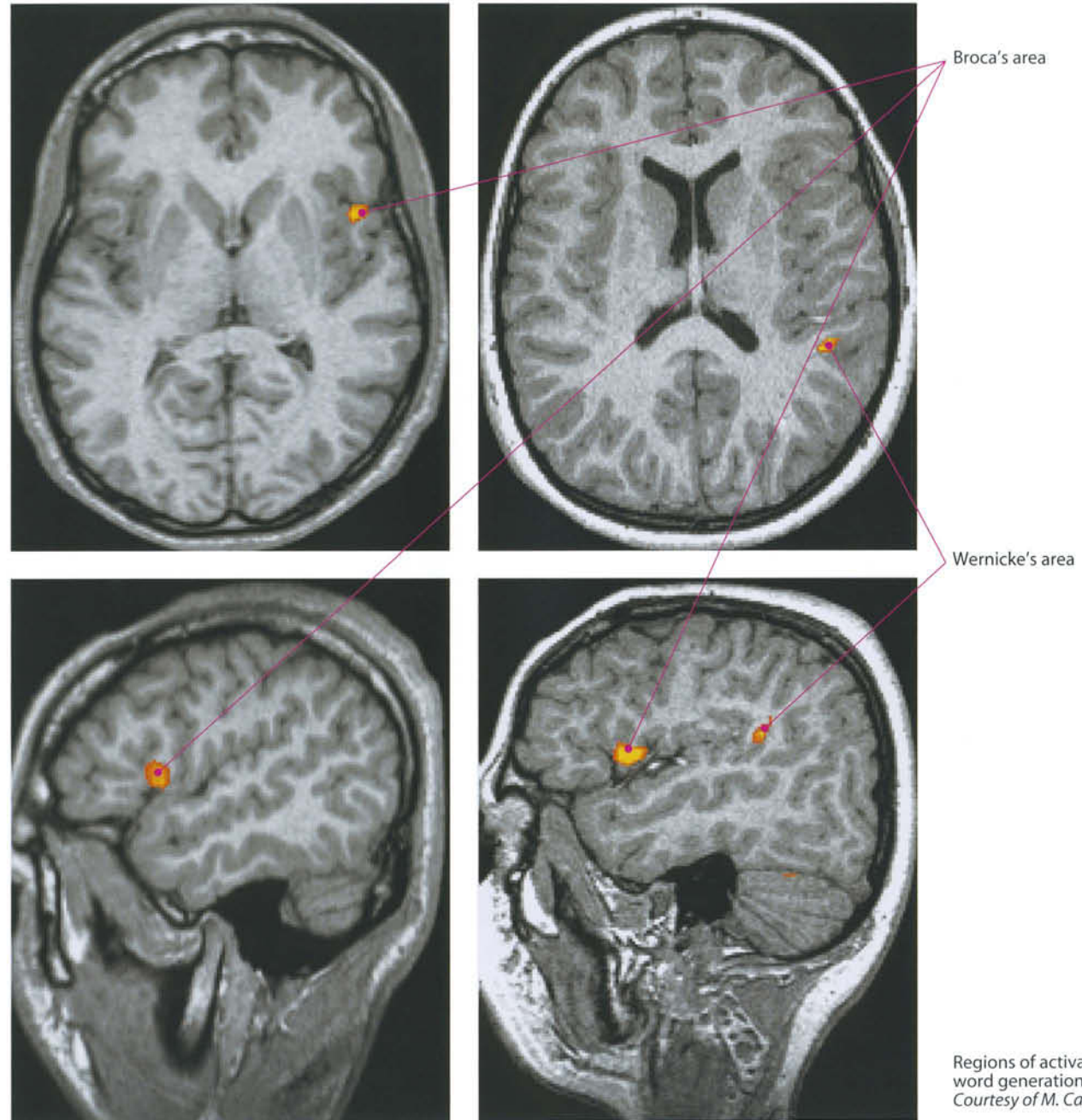
 Speech production area (Broca)

 Speech comprehension area (Wernicke)

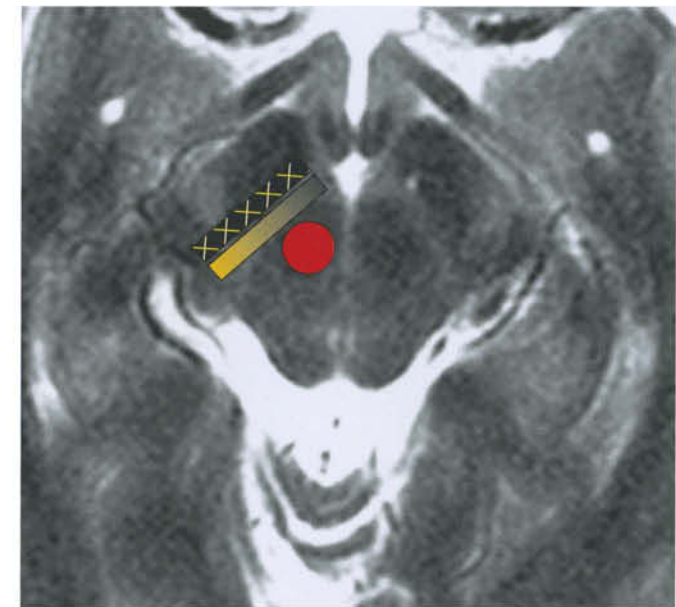
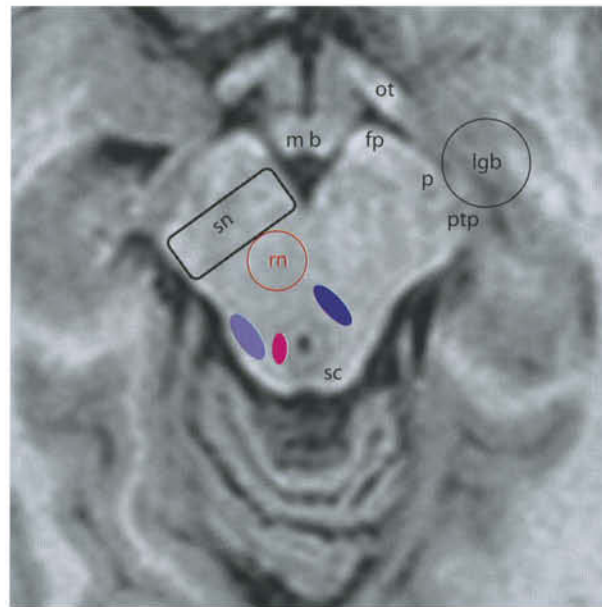
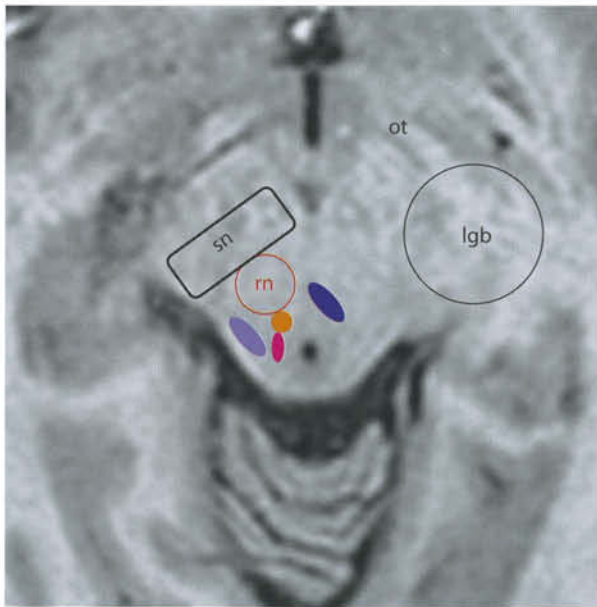




-  Speech production area (Broca)
-  Speech comprehension area (Wernicke)

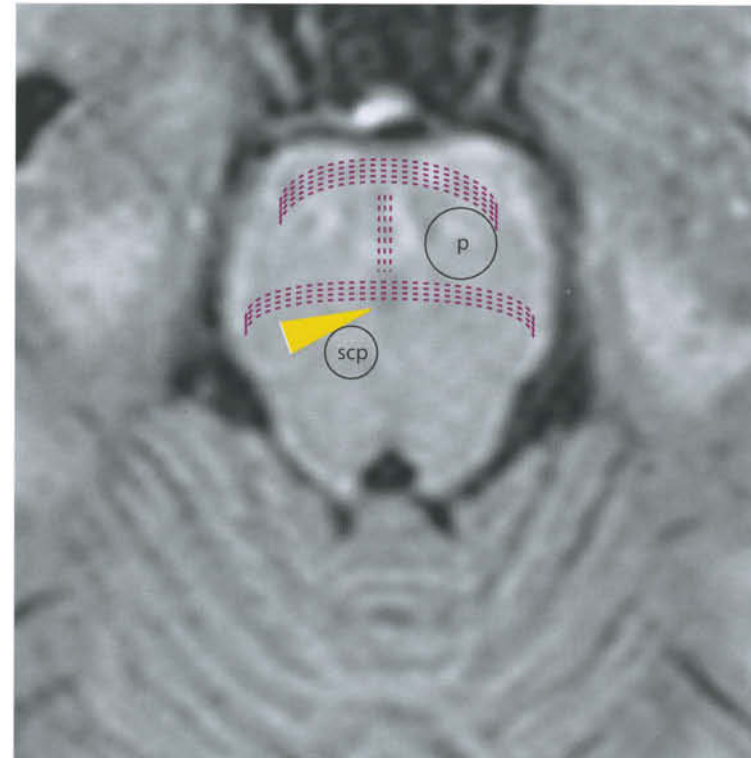
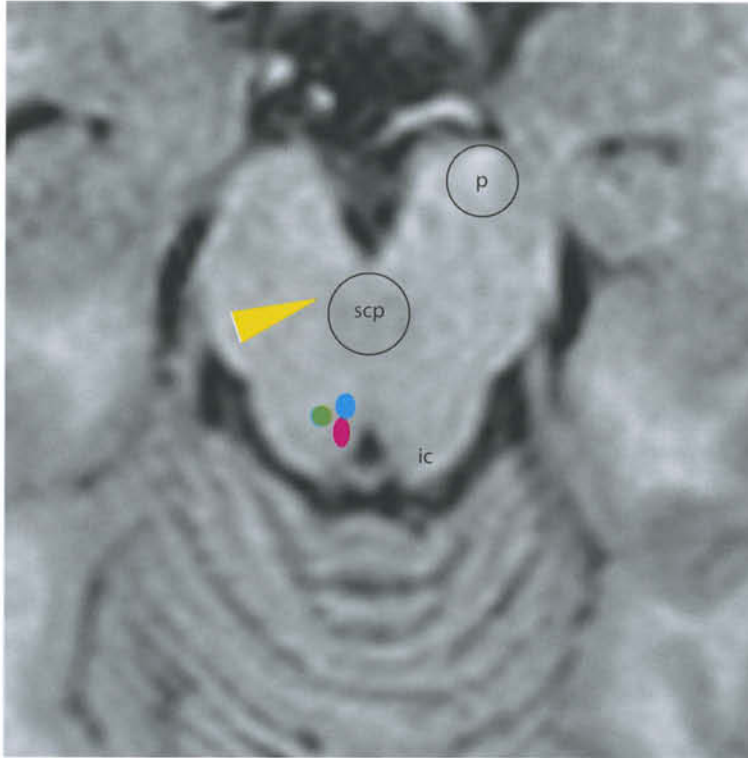

Regions of activation obtained during word generation task.
Courtesy of M. Caulo, MD, PhD, ITAB, Chieti, Italy








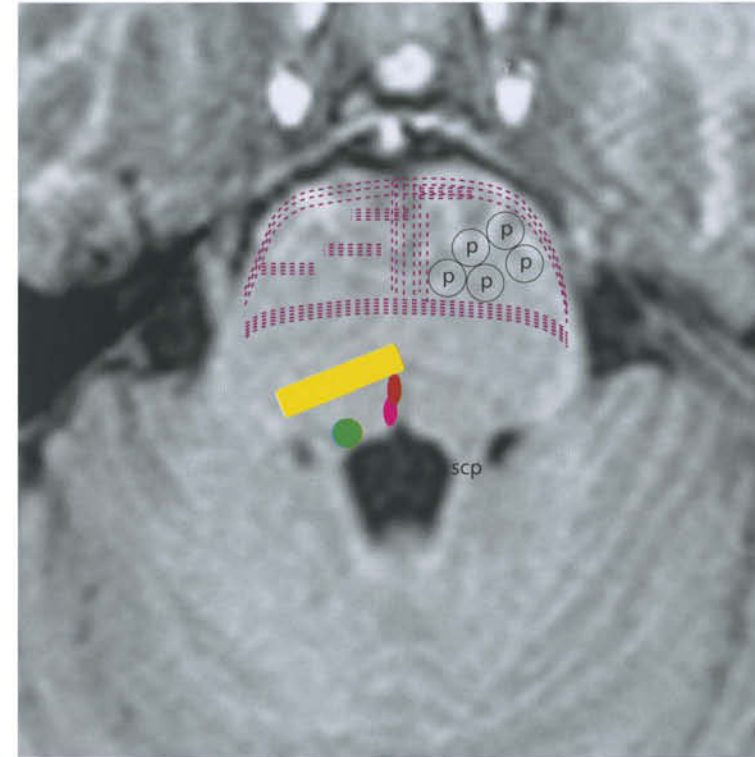
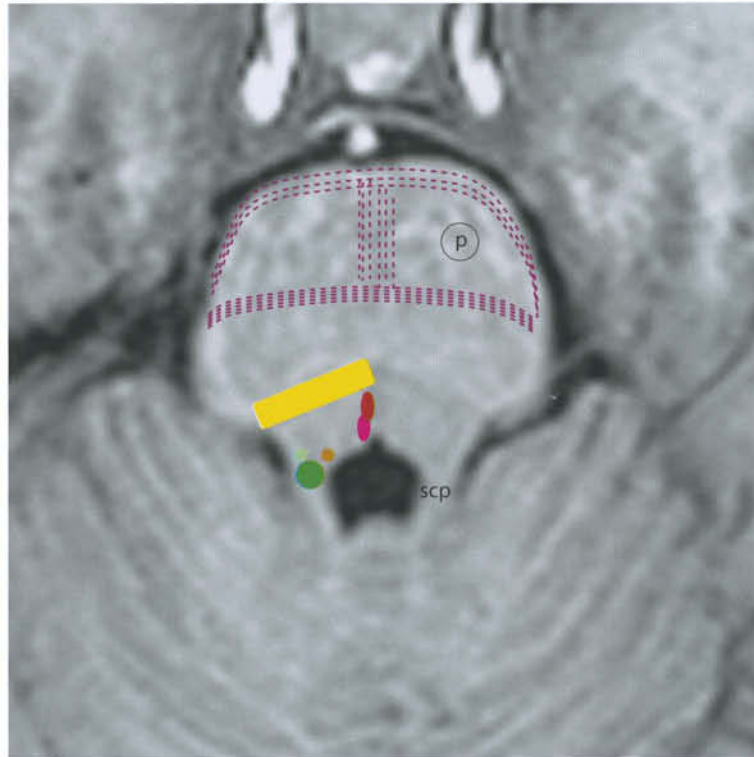
ot = optic tract
 lgb = lateral geniculate body
 rn = red nucleus
 sn = substantia nigra
 mb = mammillary bodies (hypothalamus)
 fp = frontopontine tract
 p = pyramidal tract
 ptp = parietotemporo-pontine tract
 sc = superior colliculus

 Nucleus of oculomotor nerve
 Dorsal longitudinal fasciculus
 Superior cerebellar peduncle
 Spinothalamic tract
 Substantia nigra, pars reticulata
 Substantia nigra, pars compacta
 Red nucleus



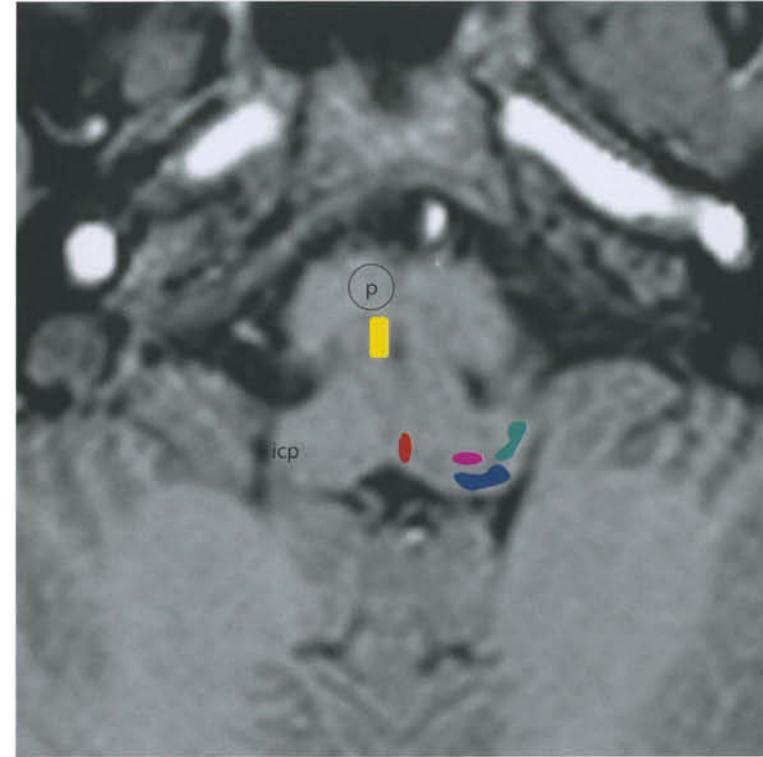
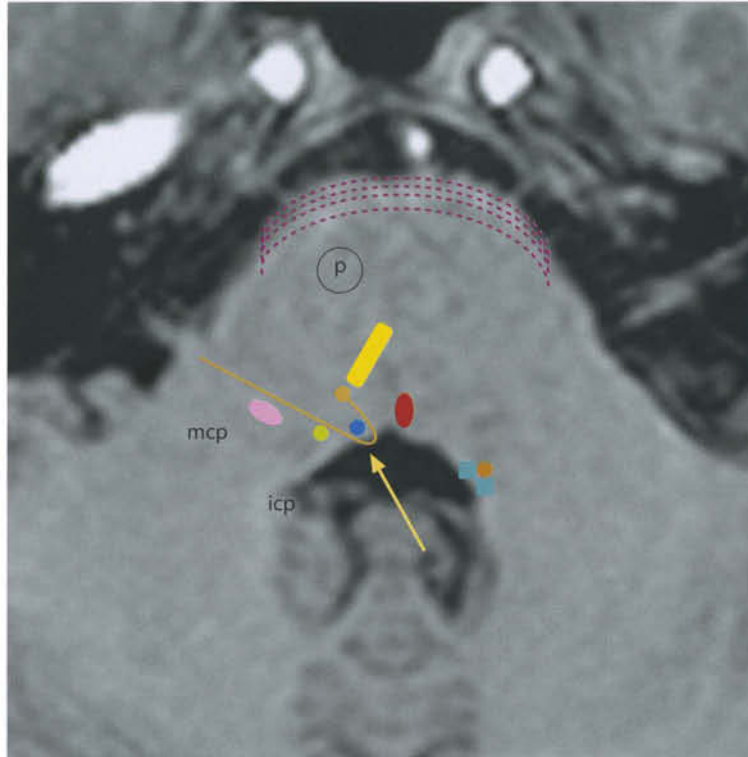
p = pyramidal tract
 scp = superior cerebellar peduncles
 ic = inferior colliculus






 Dorsal longitudinal fasciculus
 Pontocerebellar tract
 Medial lemniscus
 Mesencephalic nucleus of trigeminal nerve
 Nucleus of trochlear nerve



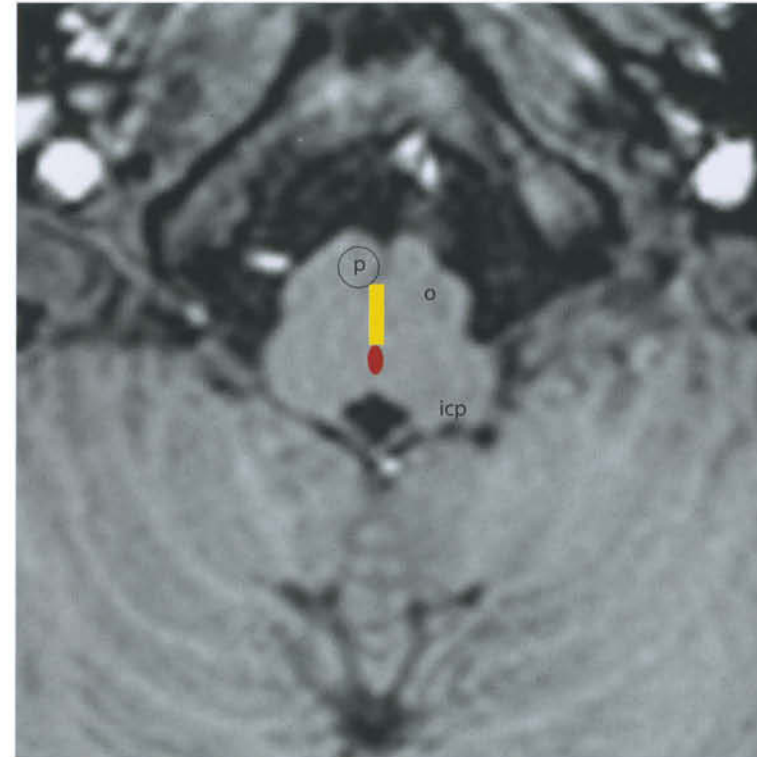
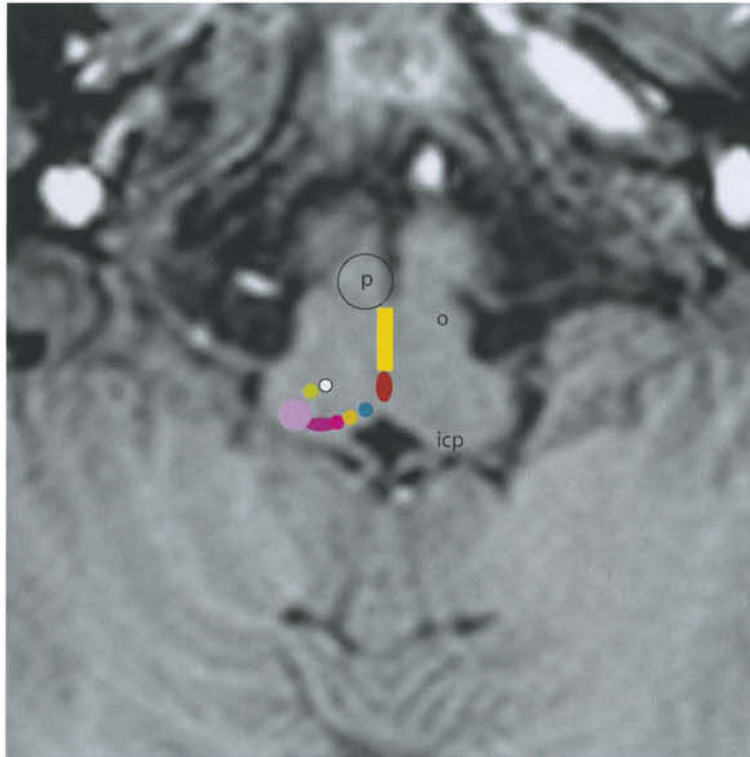
p = pyramidal tract
 scp = superior cerebellar peduncles

- Dorsal longitudinal fasciculus
- Pontocerebellar tract
- Medial lemniscus
- Trigeminal nucleus
- Trigeminal motor nucleus
- Superior vestibular nucleus
- Medial longitudinal fasciculus



- p = pyramidal tract
- mcp = middle cerebellar peduncle
- icp = inferior cerebellar peduncle
-  Pontocerebellar tract
-  Medial lemniscus
-  Abducent nucleus
-  Spinal nucleus of trigeminal nerve
-  Facial nerve and nucleus

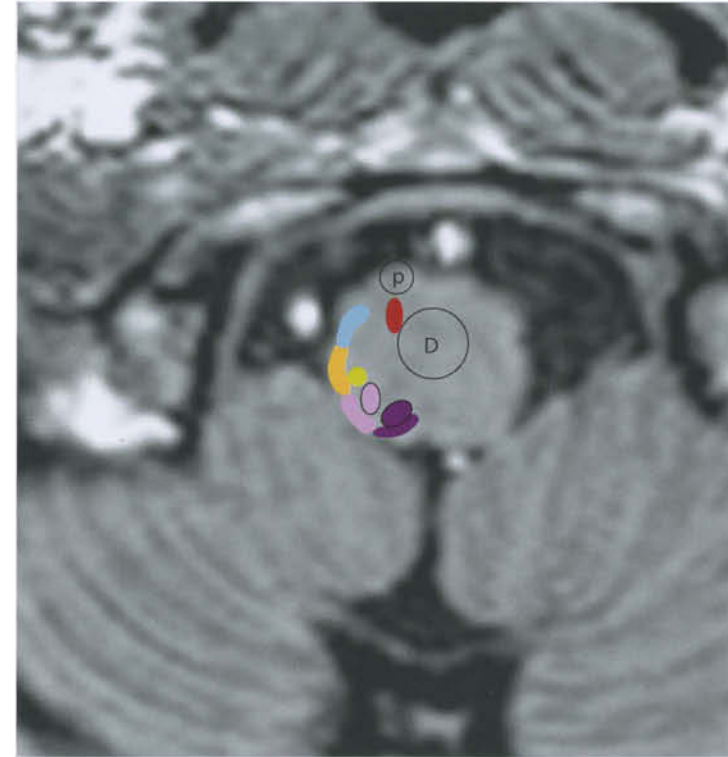
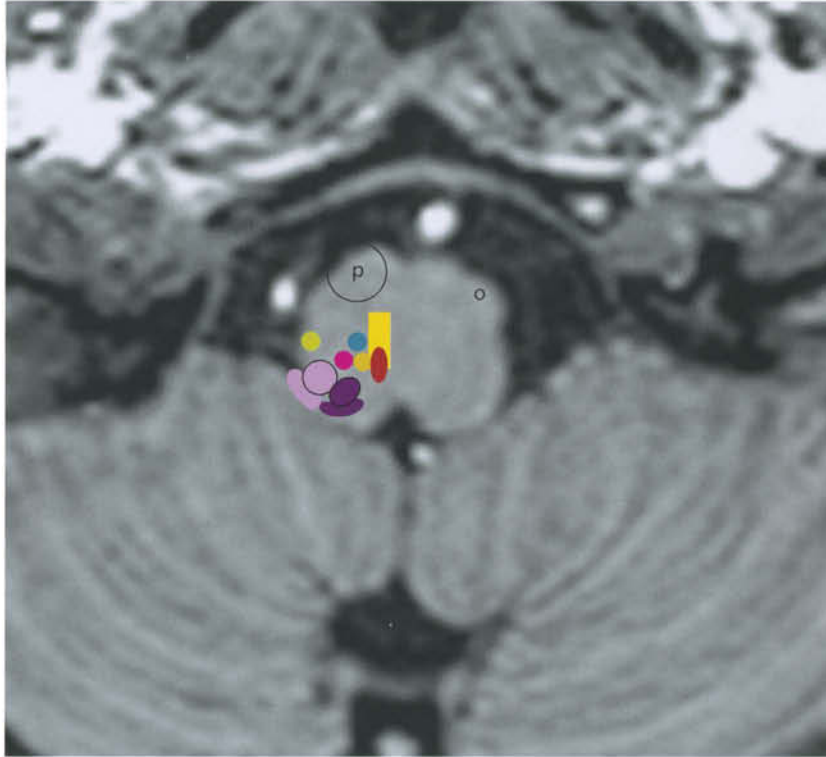
-  Medial longitudinal fasciculus
-  Internal genu of facial nerve (arrow)
-  Medial and lateral vestibular nuclei
-  Superior vestibular nucleus
-  Inferior vestibular nucleus
-  Trapezoid body (acoustic)
-  Ventral cochlear nucleus
-  Dorsal cochlear nucleus



p = pyramidal tract
 o = olive
 icp = inferior cerebellar peduncle

- Medial lemniscus
- Cuneate nucleus
- Spinal nucleus of trigeminal nerve

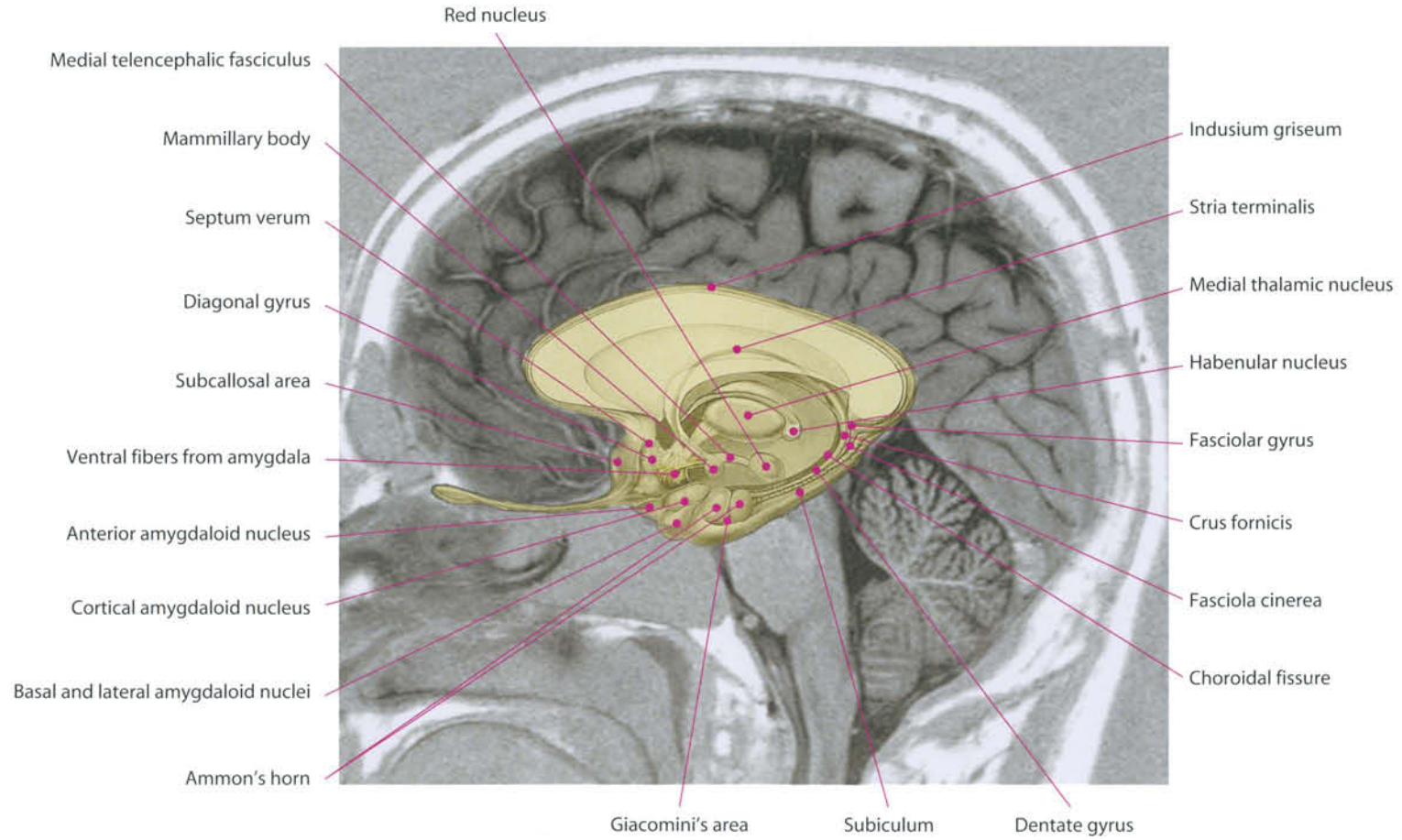
- Solitary nucleus
- Dorsal vagal nucleus
- Hypoglossal nucleus
- Inferior vestibular nucleus
- Medial longitudinal fasciculus
- Nucleus ambiguus



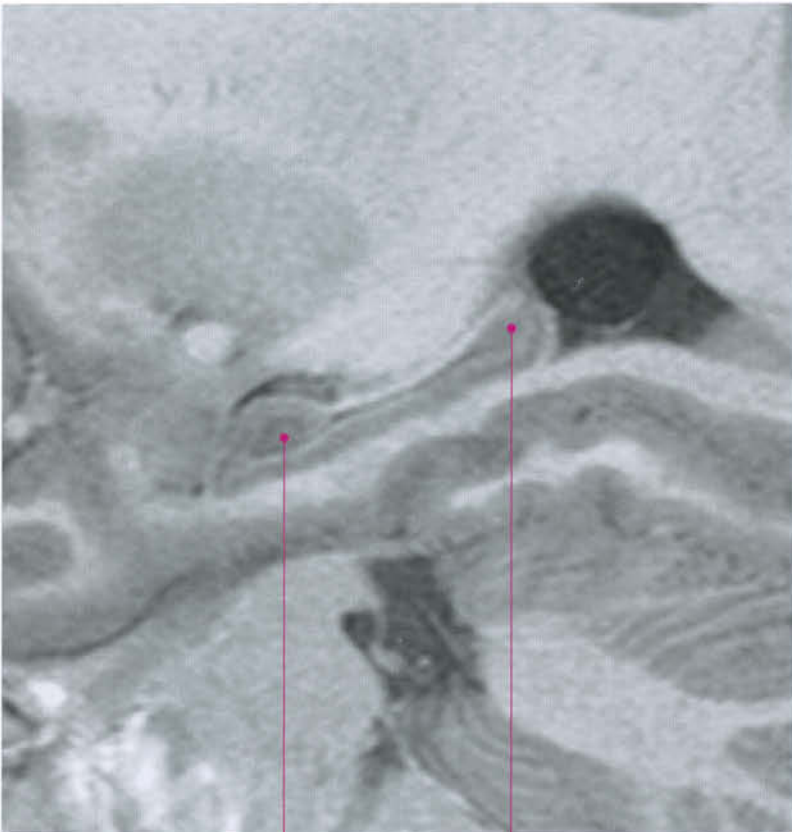
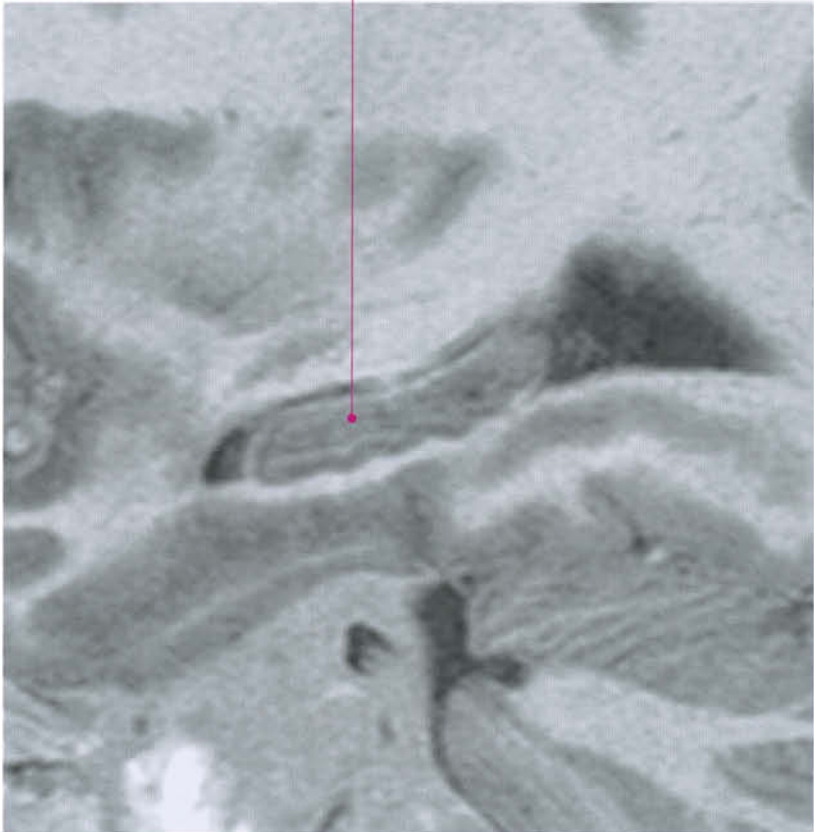
p = pyramidal tract
 o = olive
 D = pyramidal decussation

Cuneate nucleus
 Gracile nucleus
 Medial lemniscus
 Spinal nucleus of trigeminal nerve

Solitary nucleus
 Dorsal vagal nucleus
 Hypoglossal nucleus
 Medial longitudinal fasciculus
 Cuneate fasciculus
 Gracile fasciculus
 Anterior spinocerebellar tract
 Posterior spinocerebellar tract

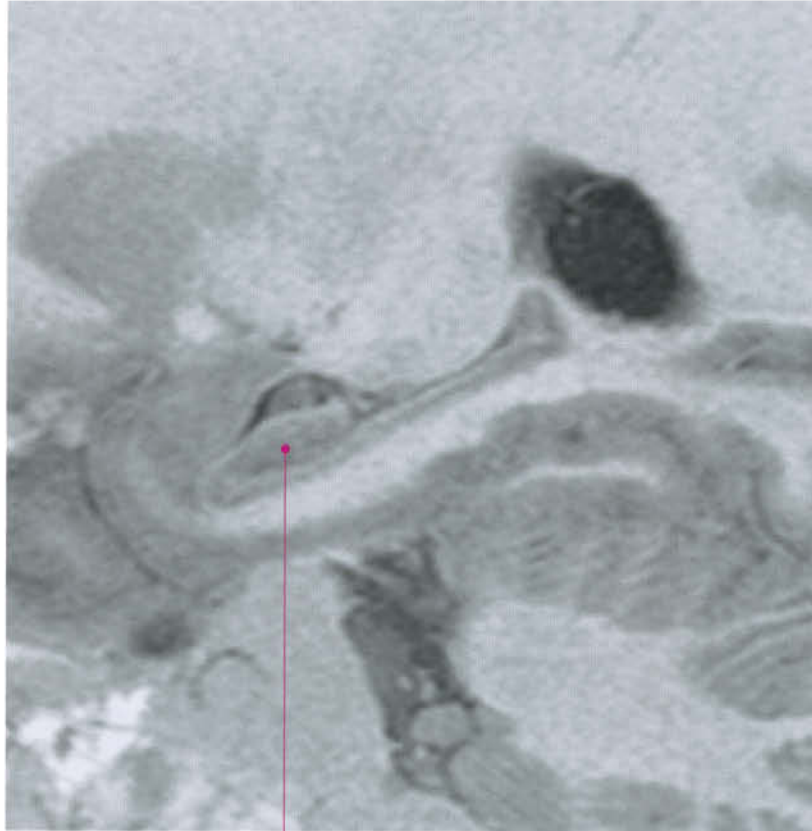


Hippocampus

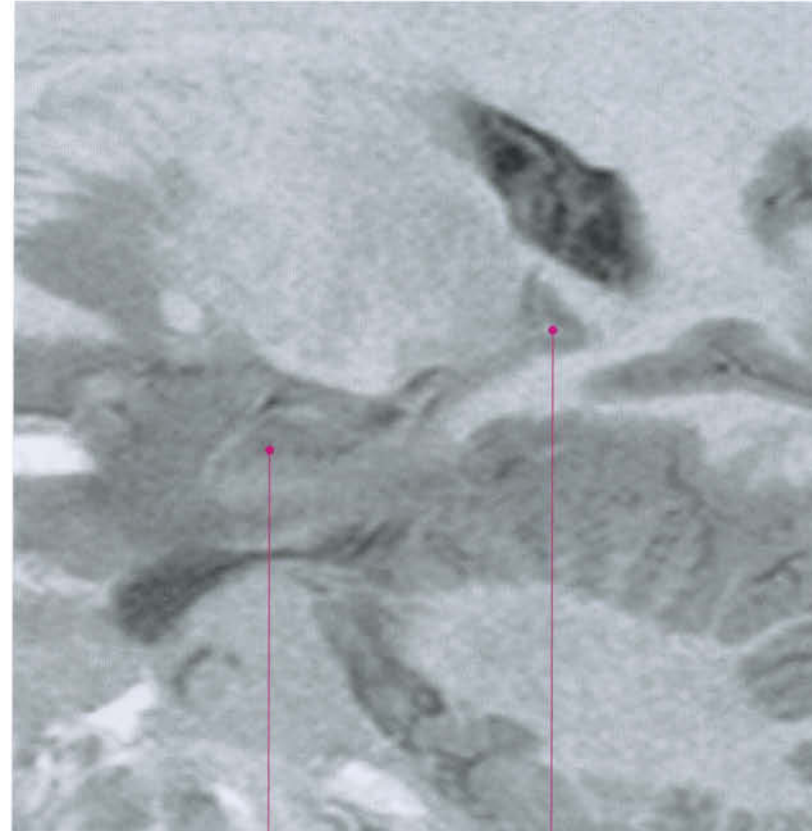


Hippocampus (head)

Hippocampus (body)

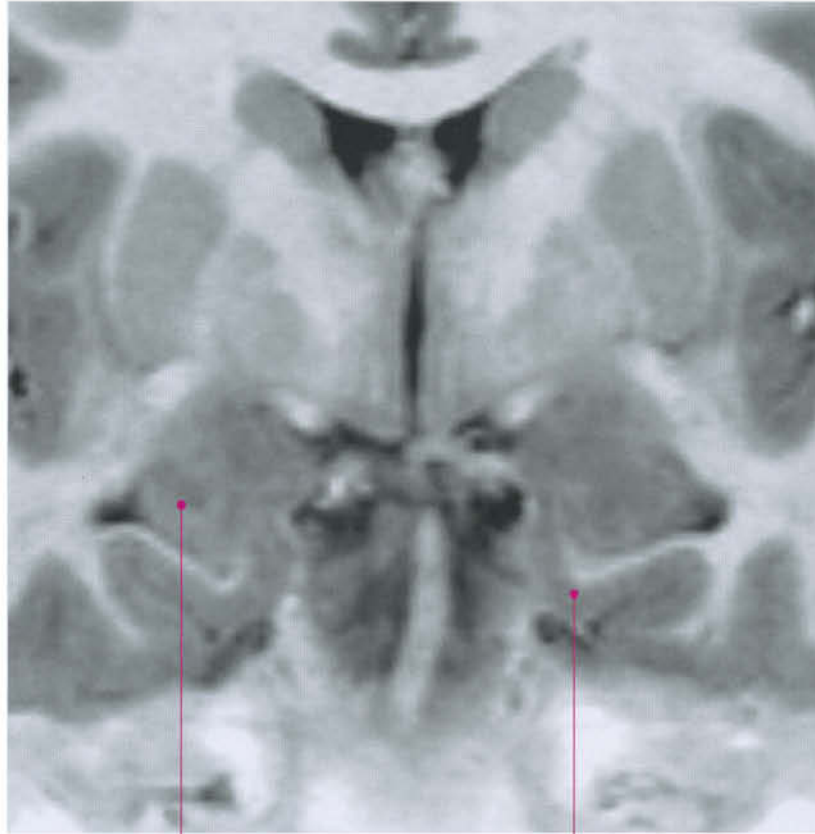


Hippocampus (head)



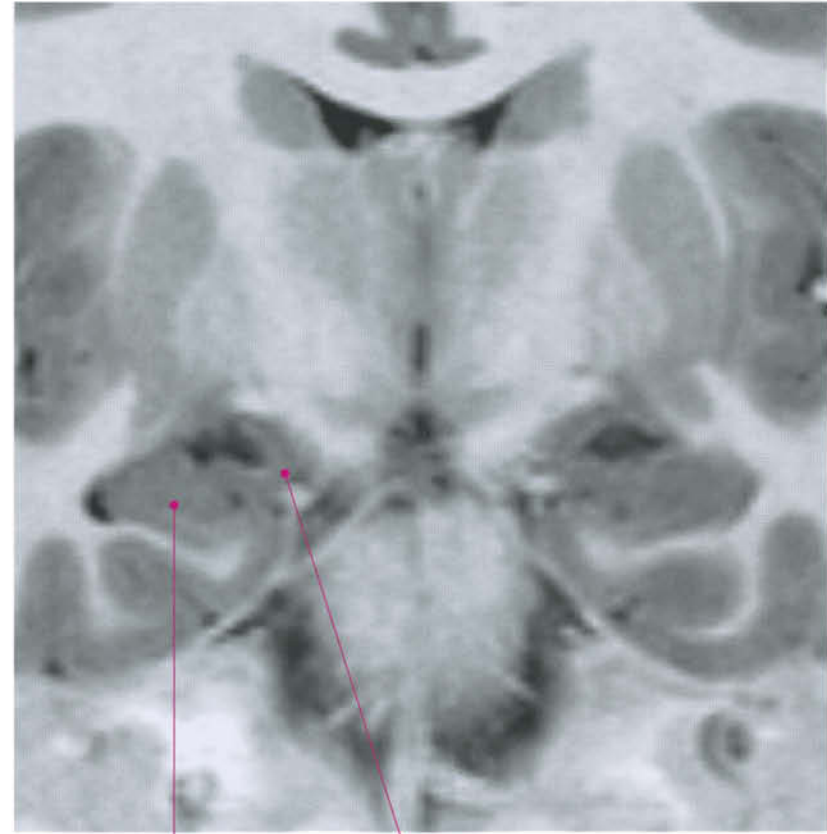
Hippocampus (head)

Hippocampus (tail)



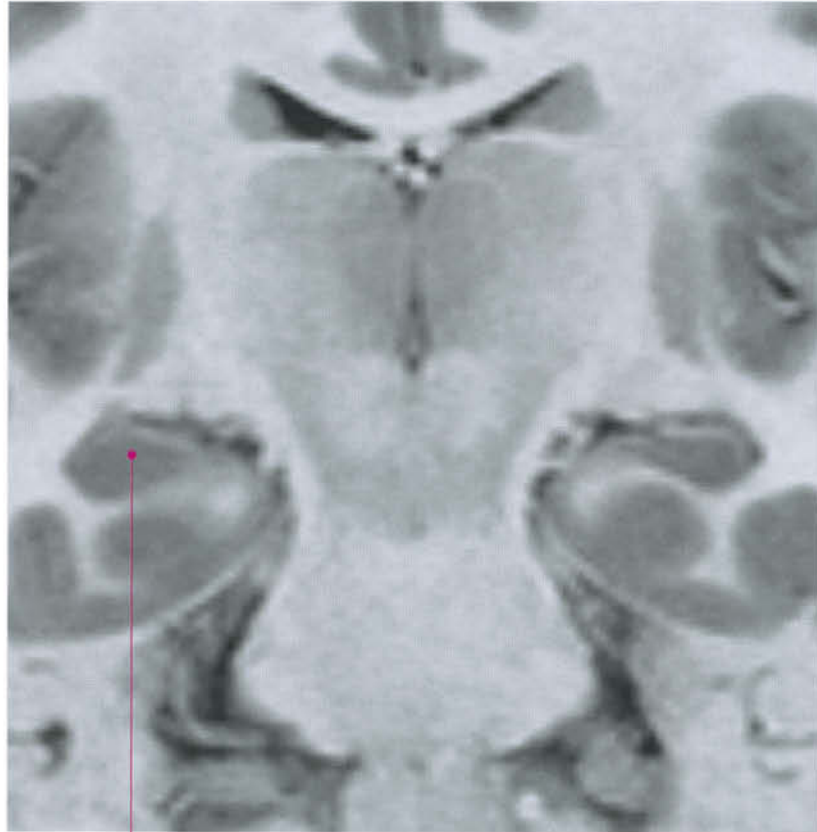Hippocampus

Entorhinal area

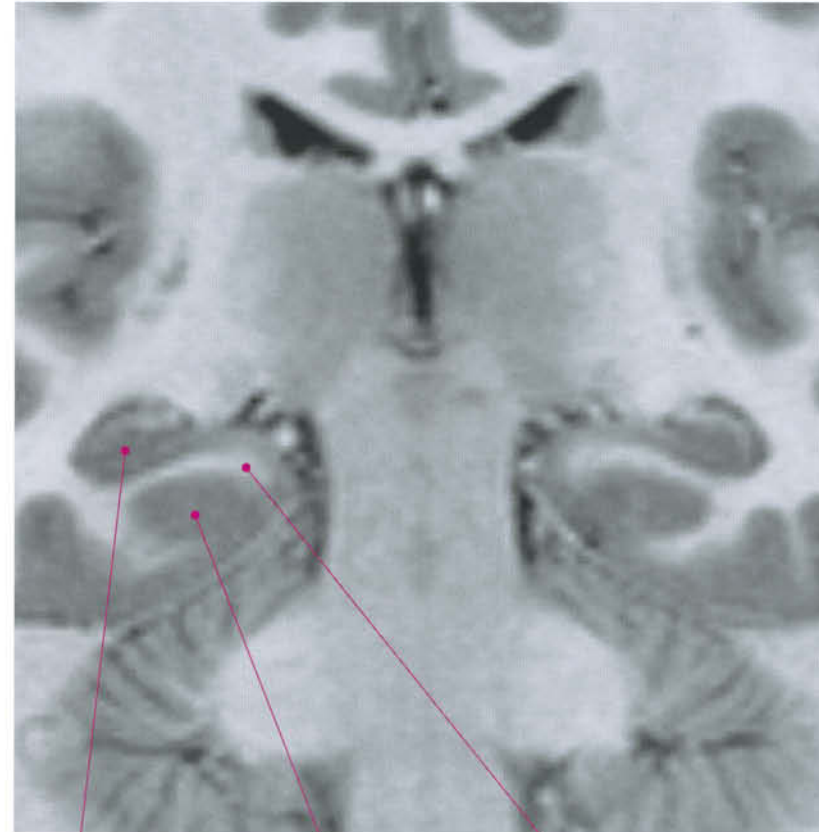


Hippocampus

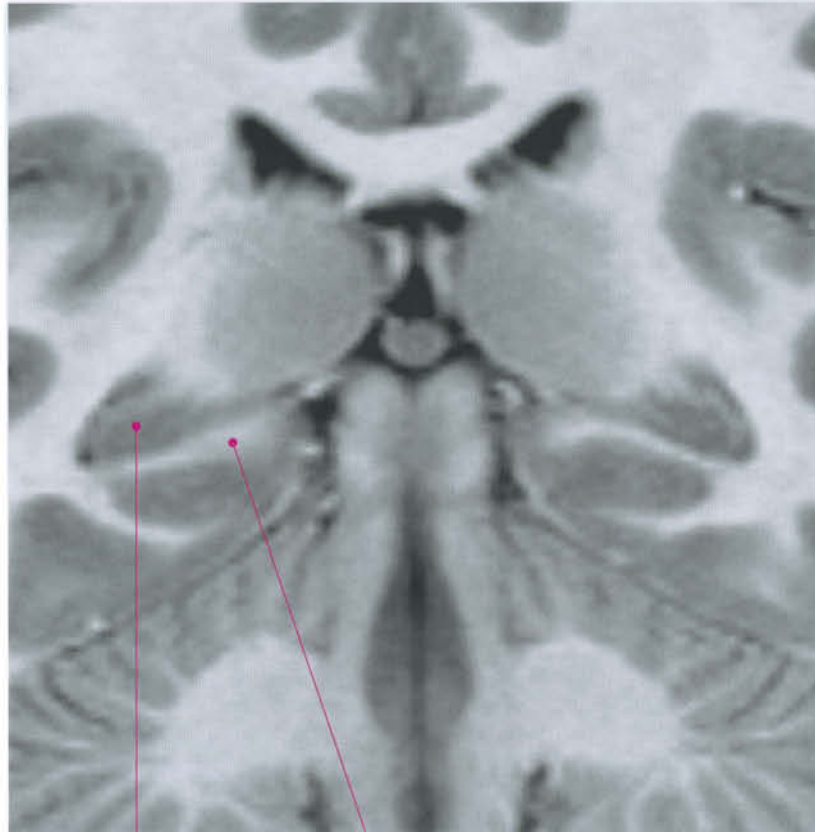
Uncus (apex)



Hippocampus

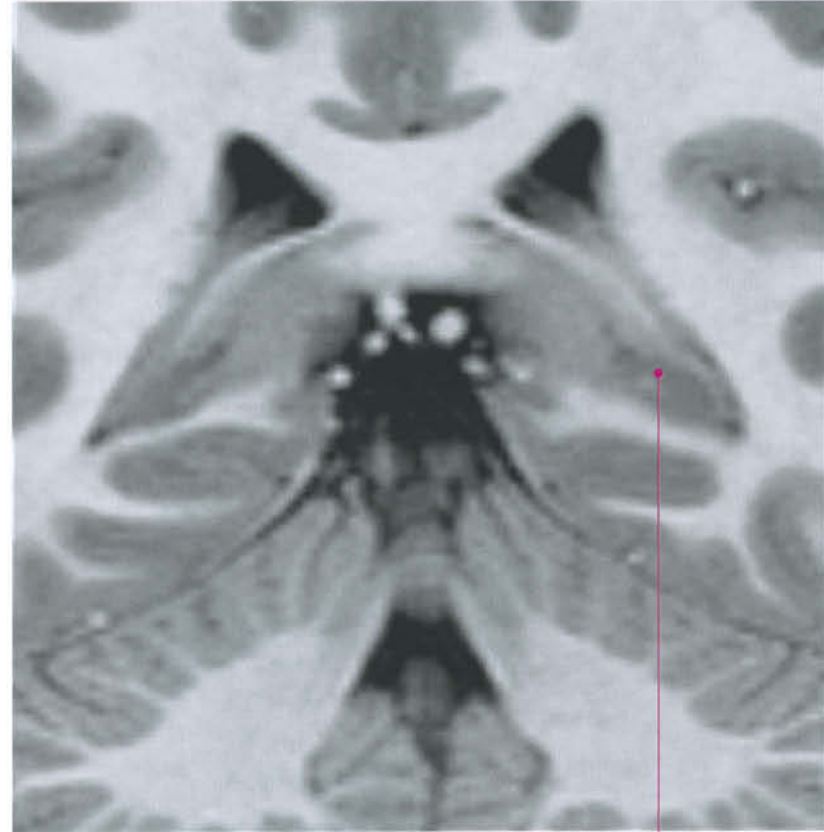

Hippocampus Parahippocampal gyrus (T5) Subiculum

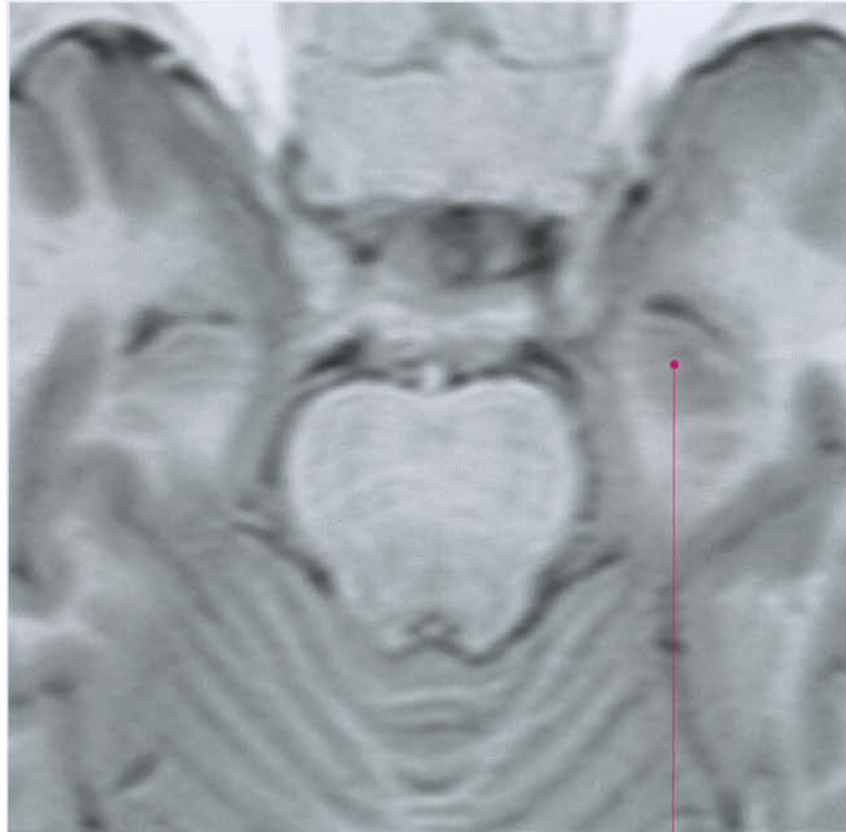


Hippocampus

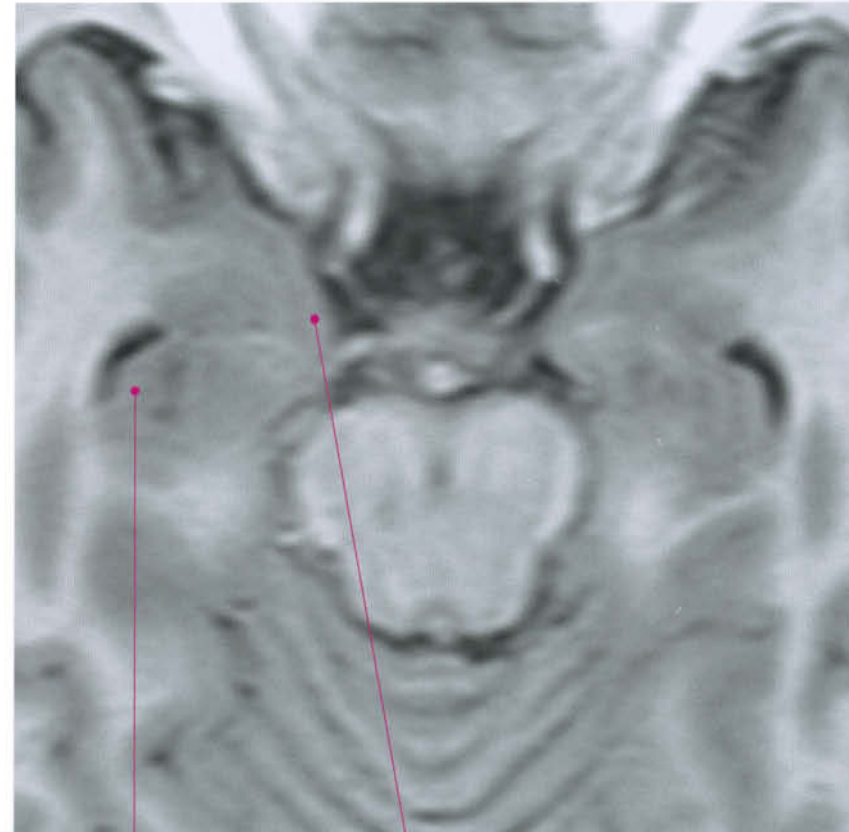
Subiculum



Hippocampus (tail)

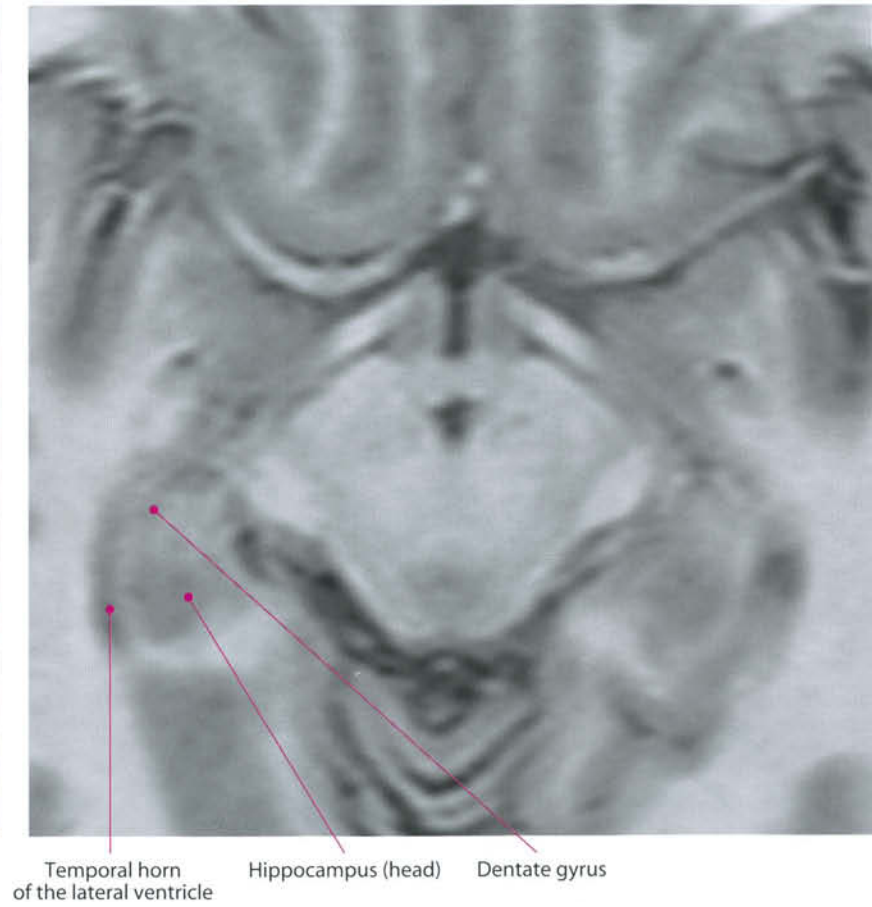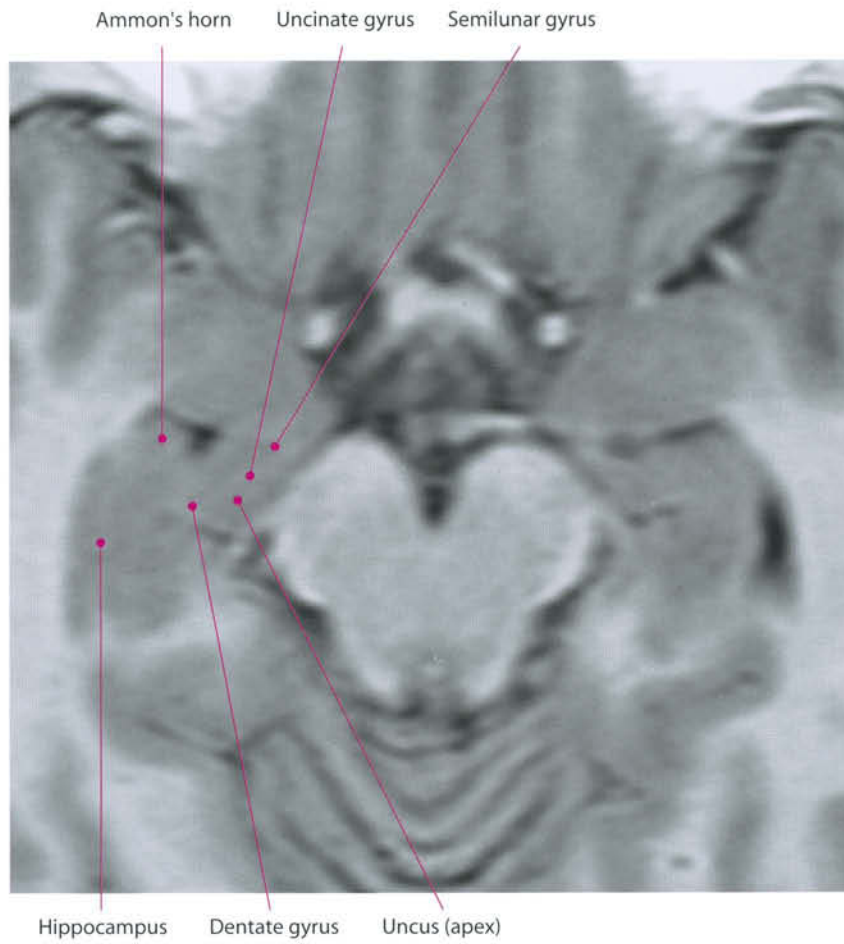


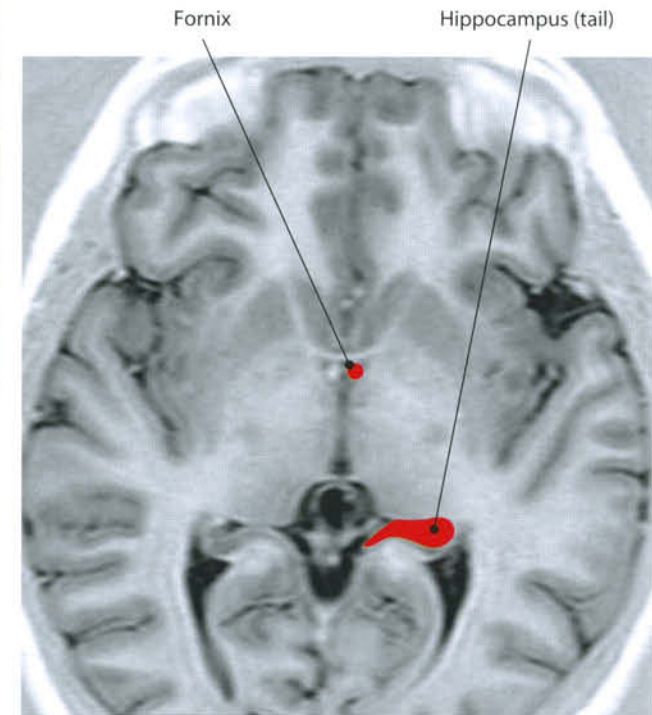
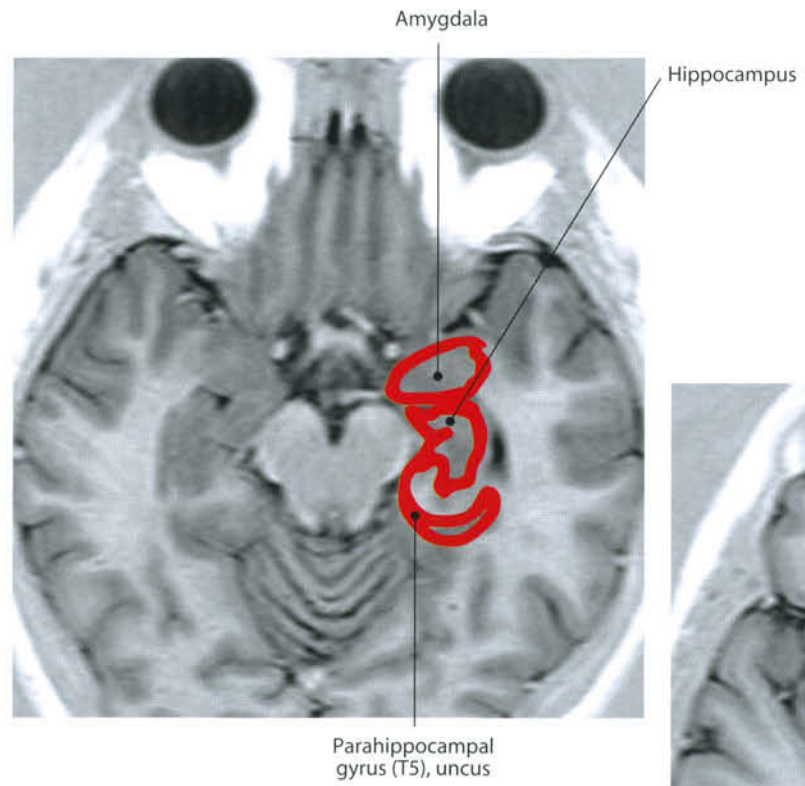
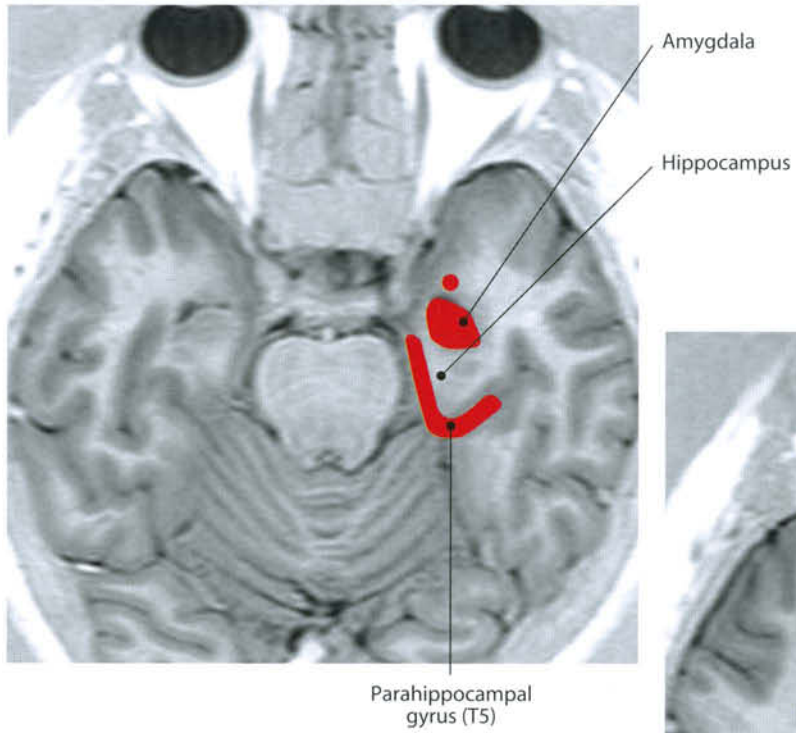
Hippocampus (head)

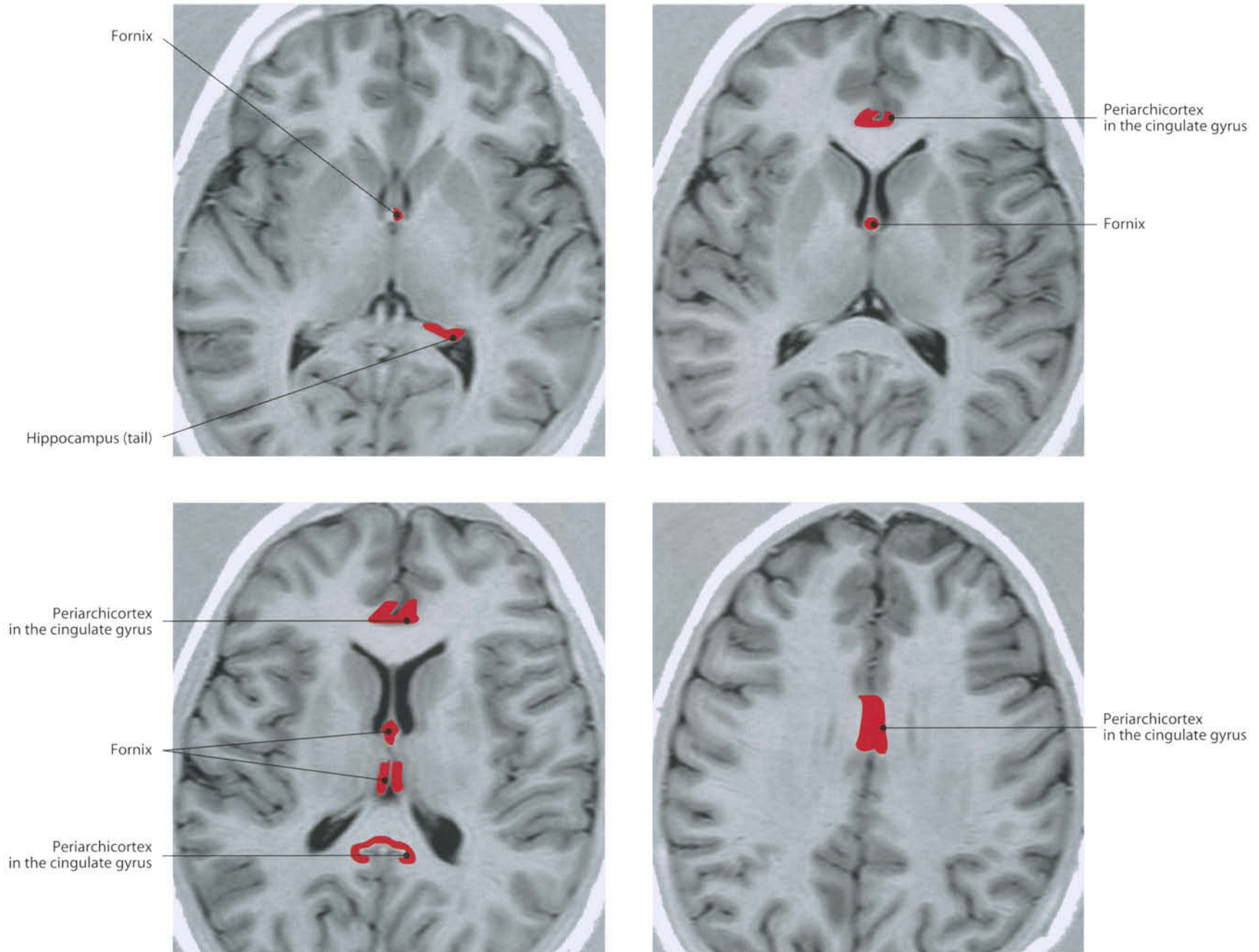


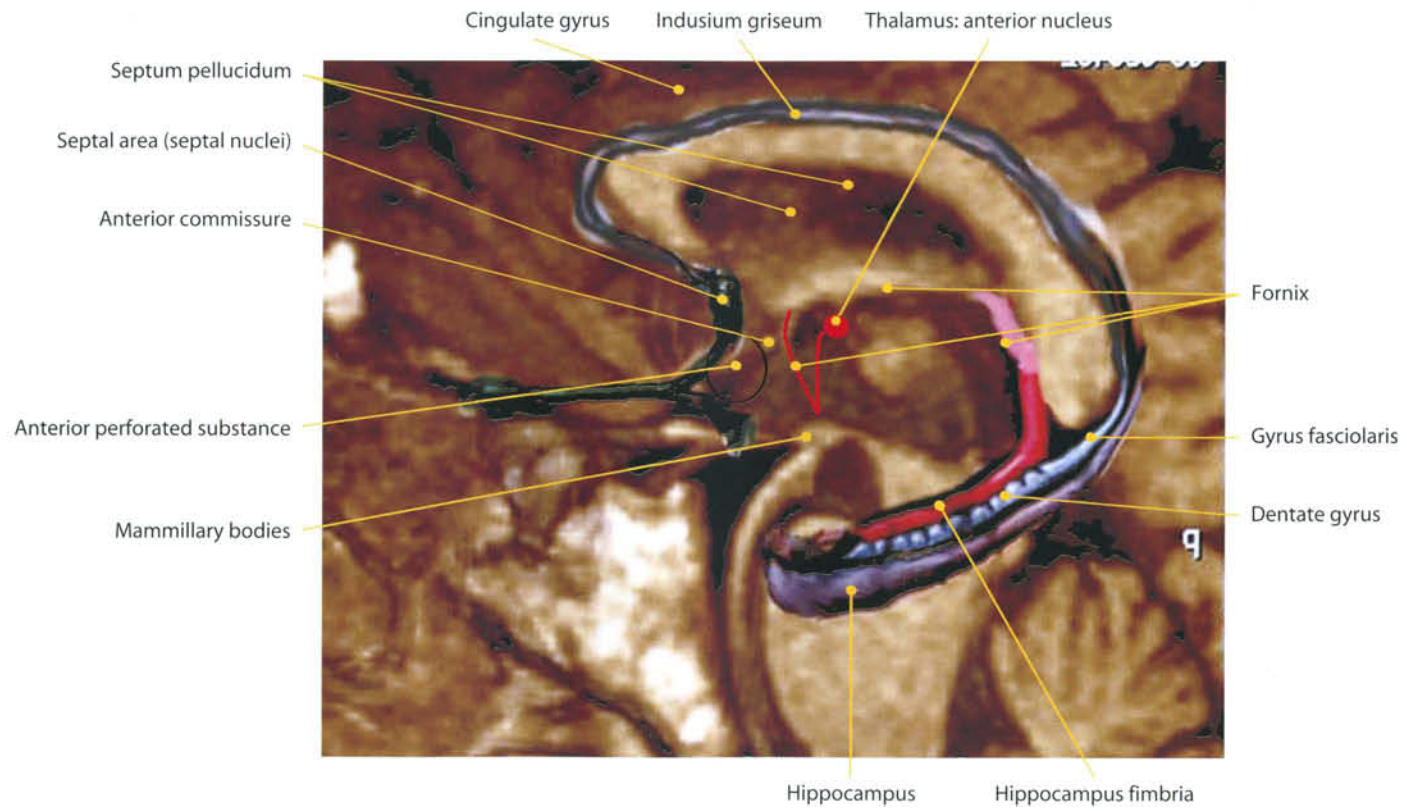
Hippocampus

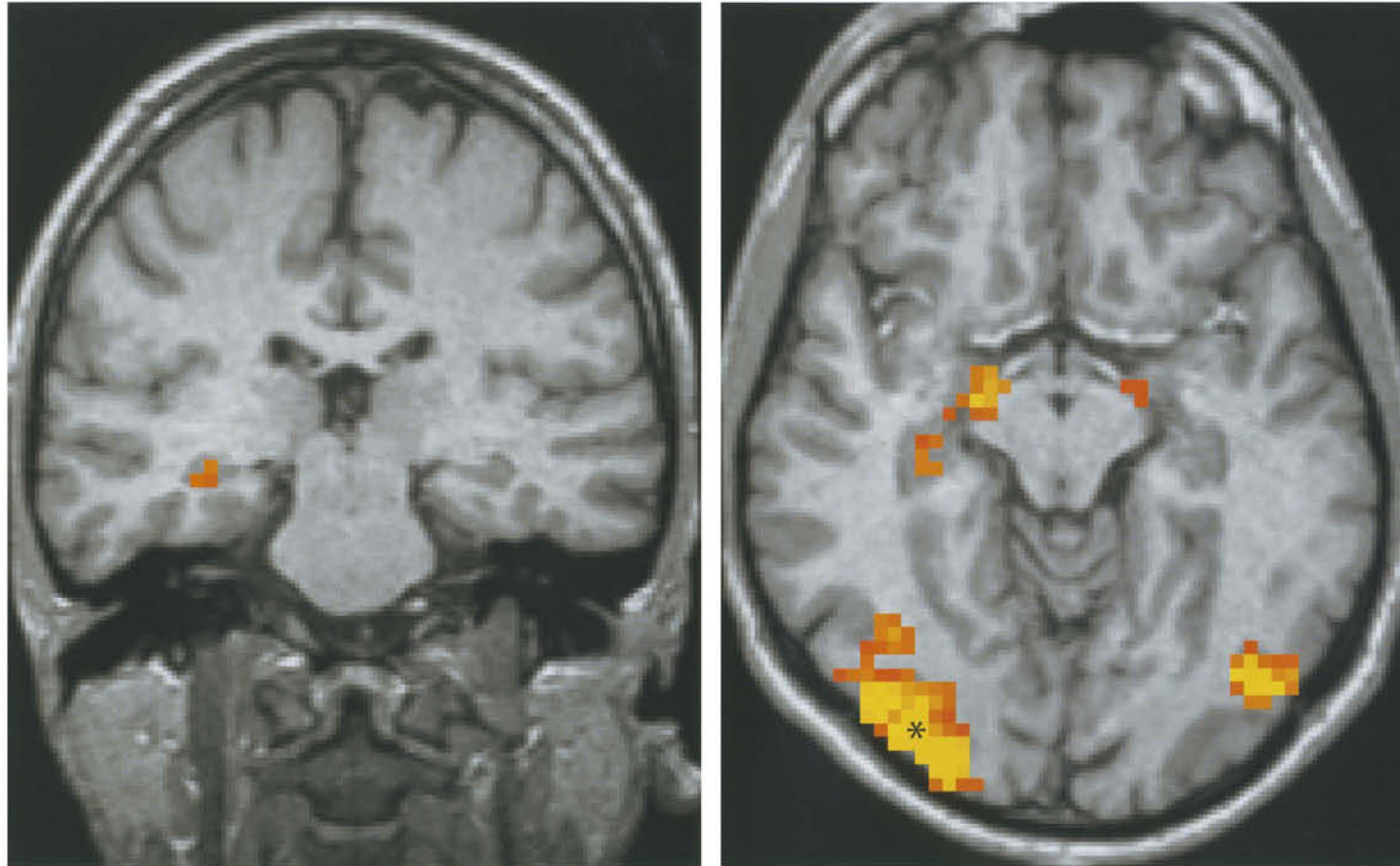
Piriform lobe, entorhinal area



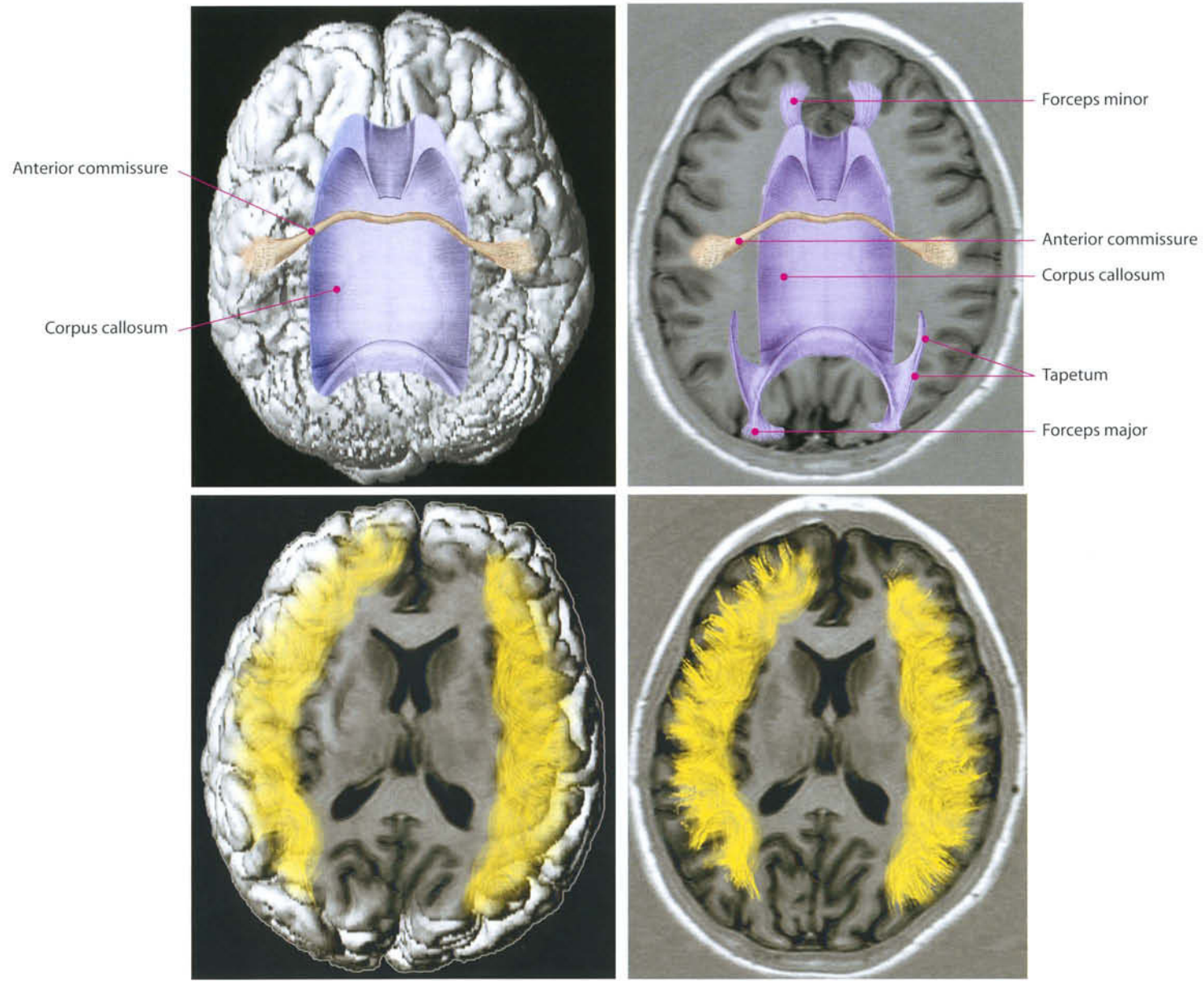




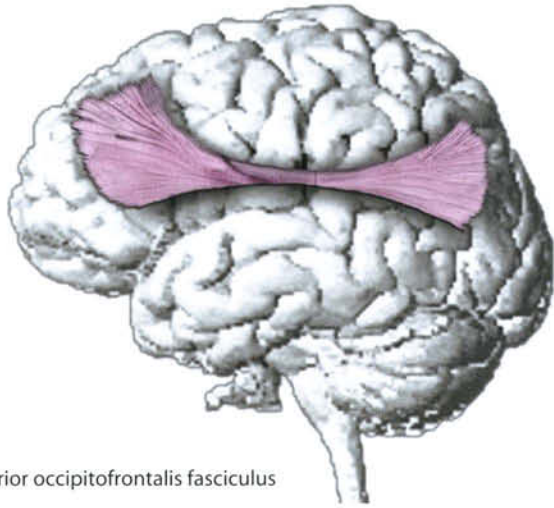




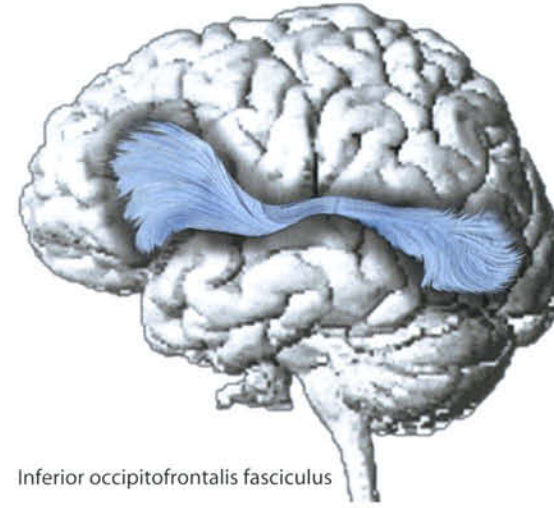
Regions of activation obtained during a "face memory" task. The fusiform gyrus activation seems more directly related to prosopognosic function.
Courtesy of M. Caulo, MD, PhD, ITAB, Chieti



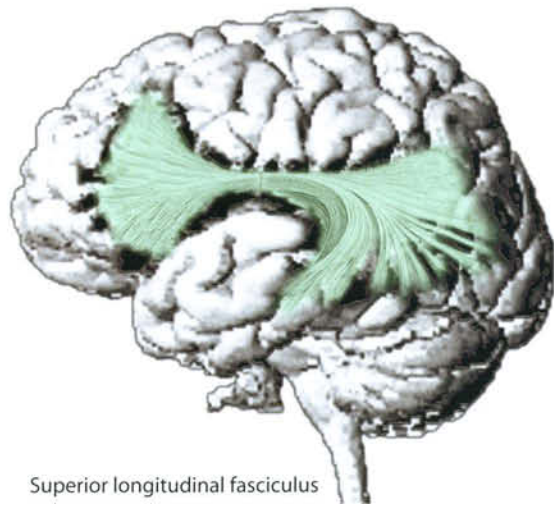
U fibers



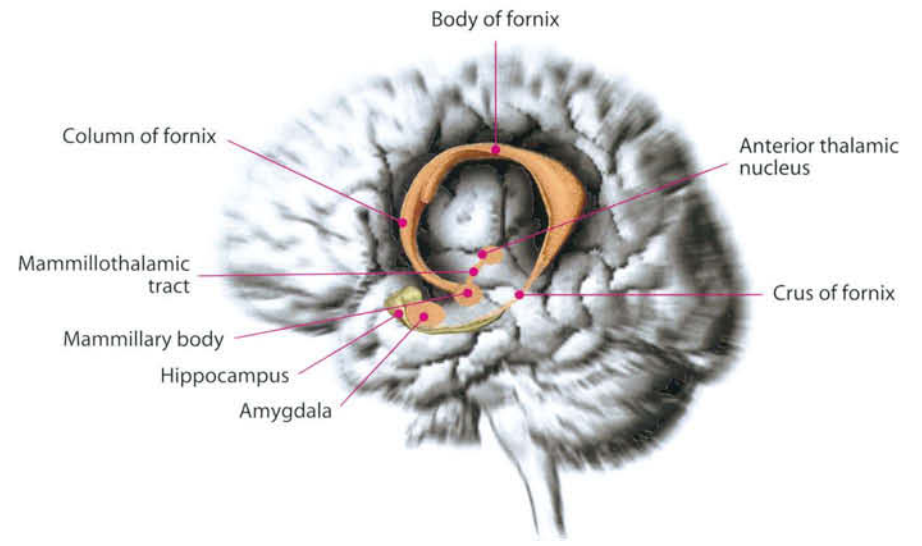
Superior occipitofrontalis fasciculus

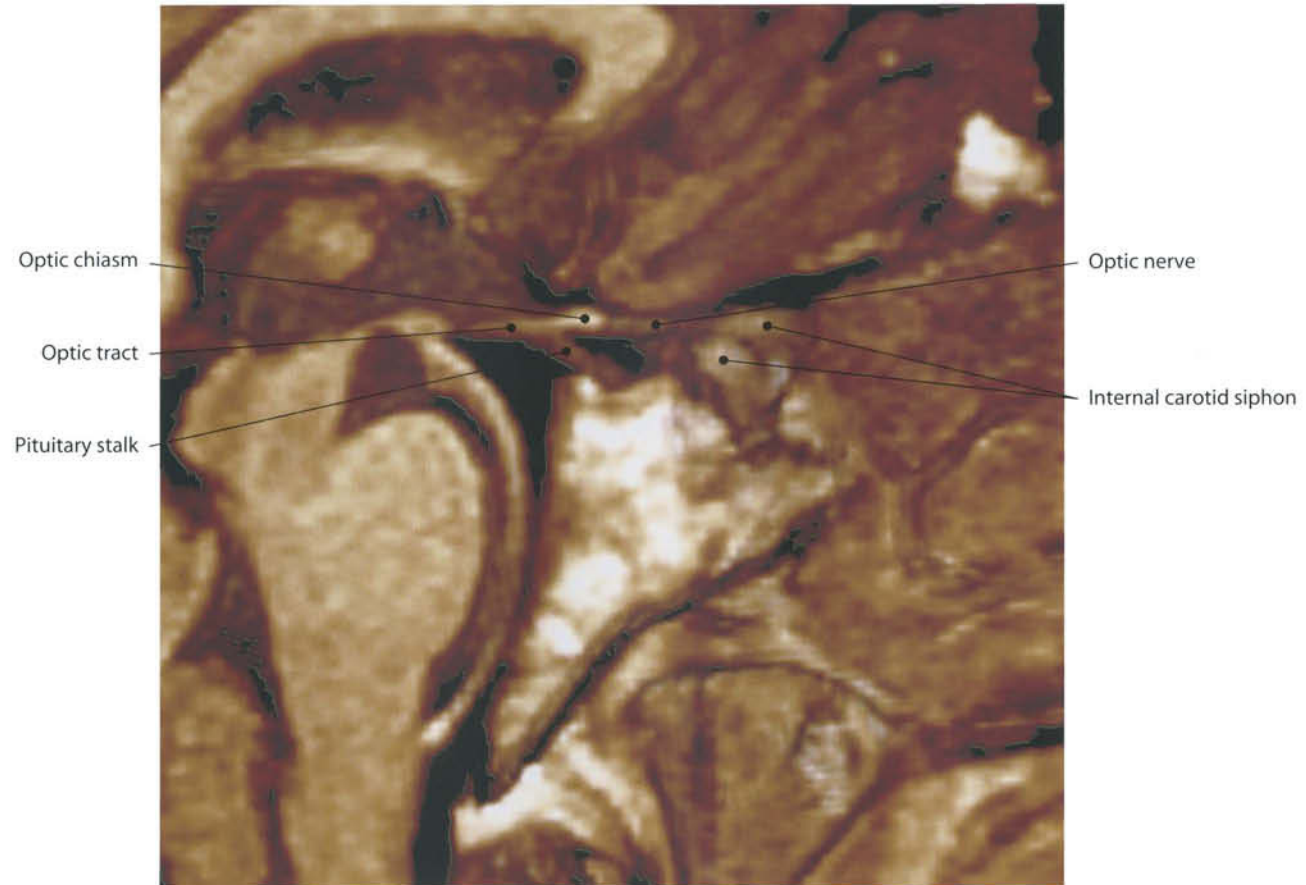


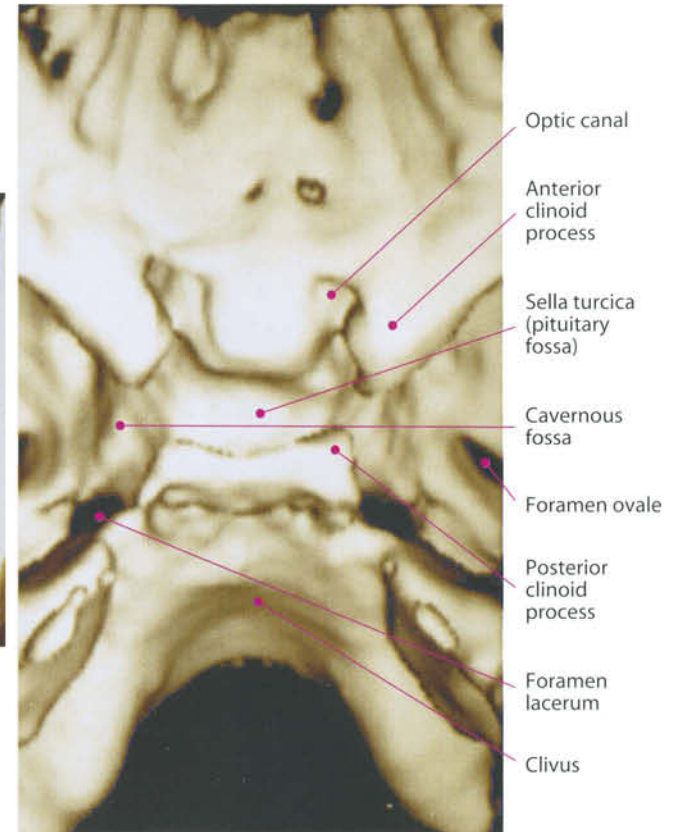
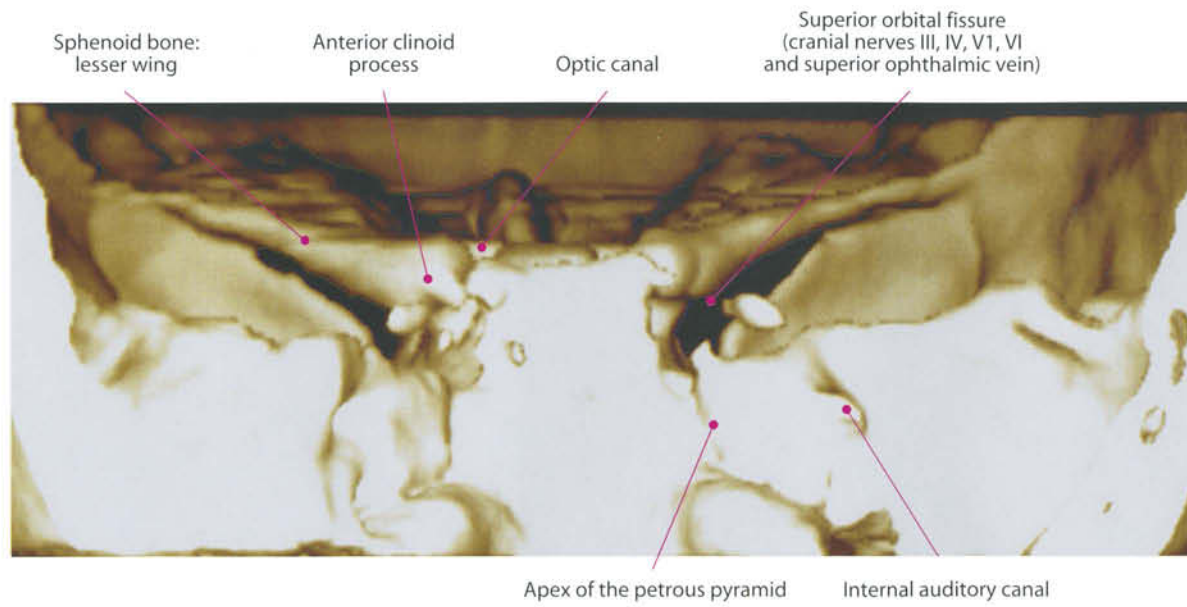
Inferior occipitofrontalis fasciculus

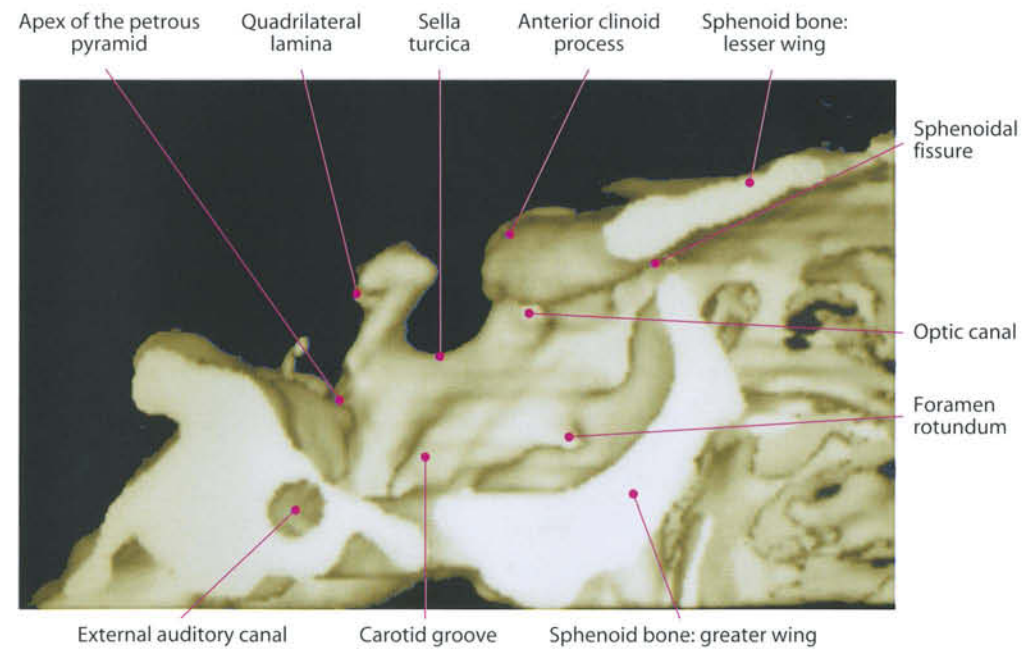
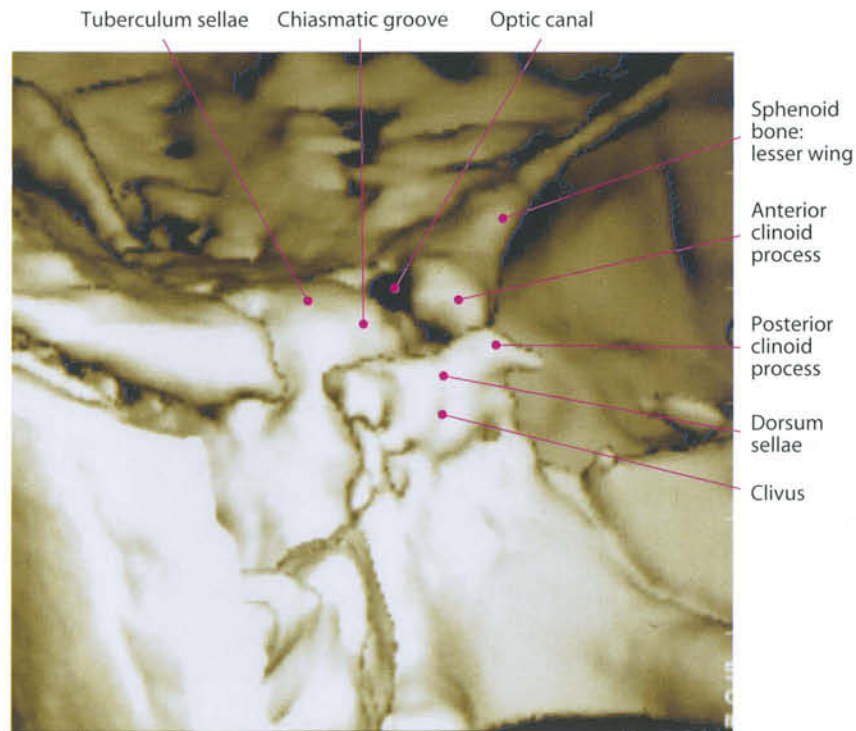


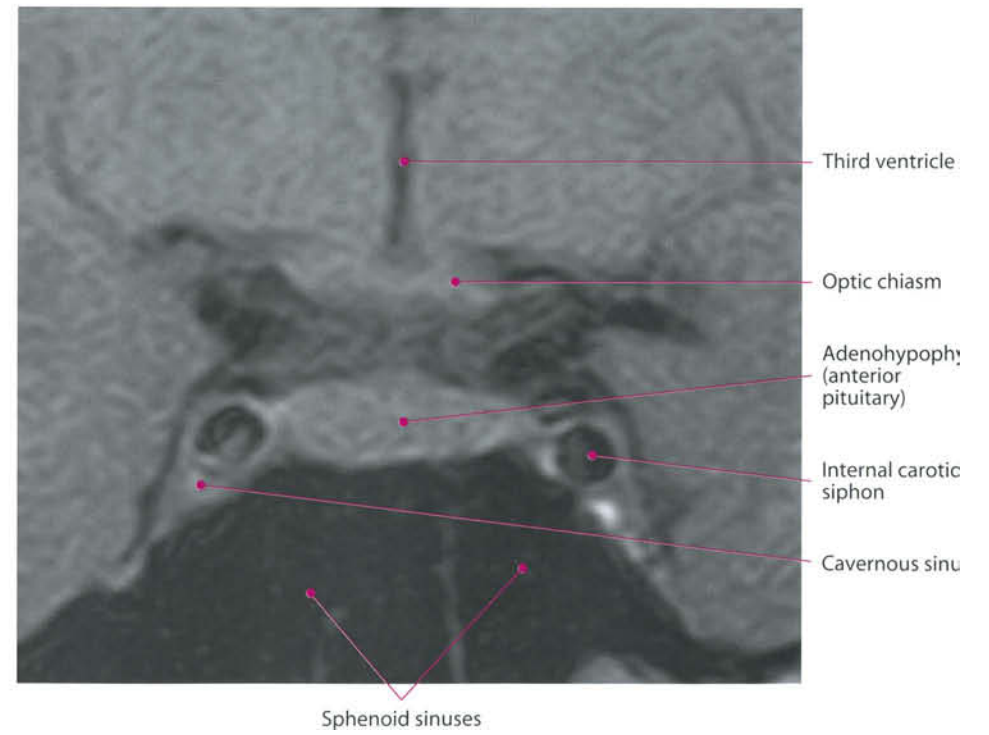
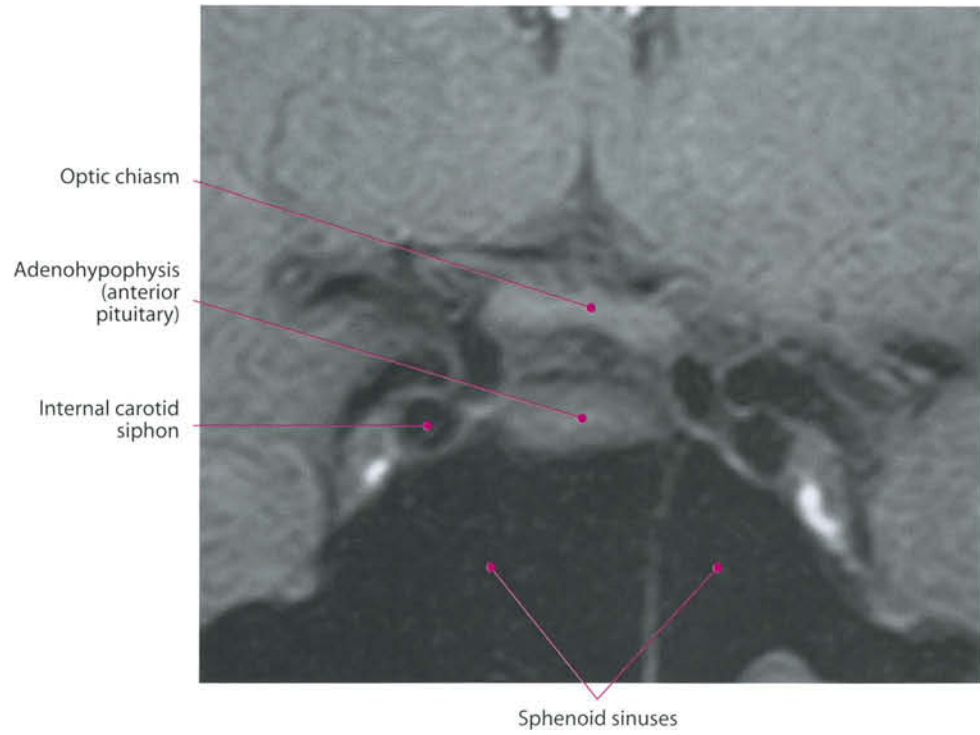
Superior longitudinal fasciculus

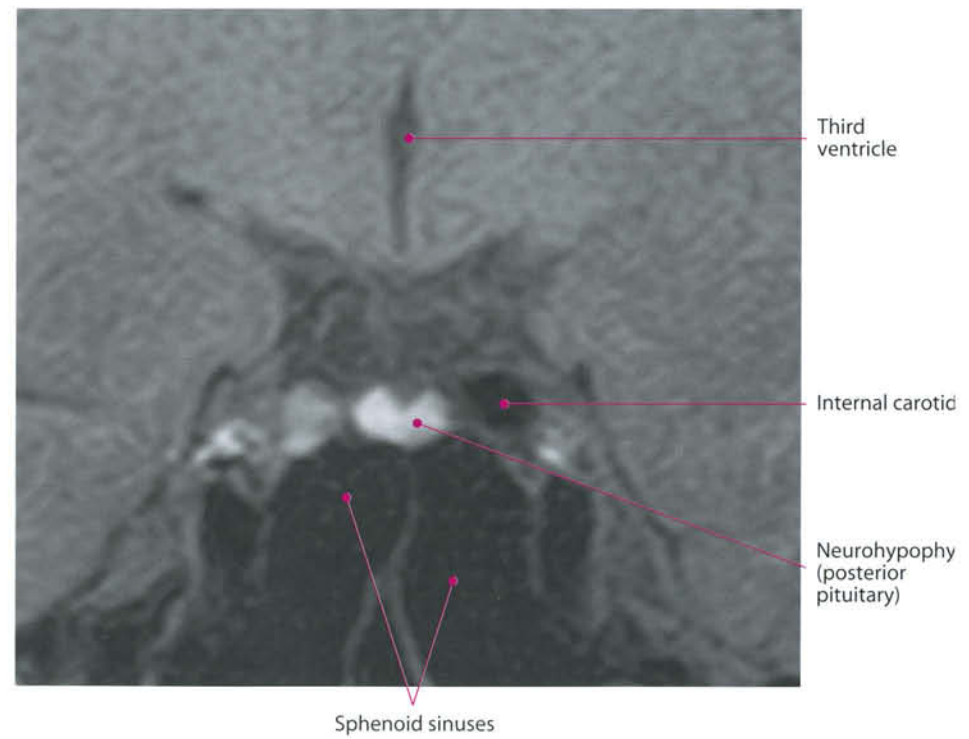
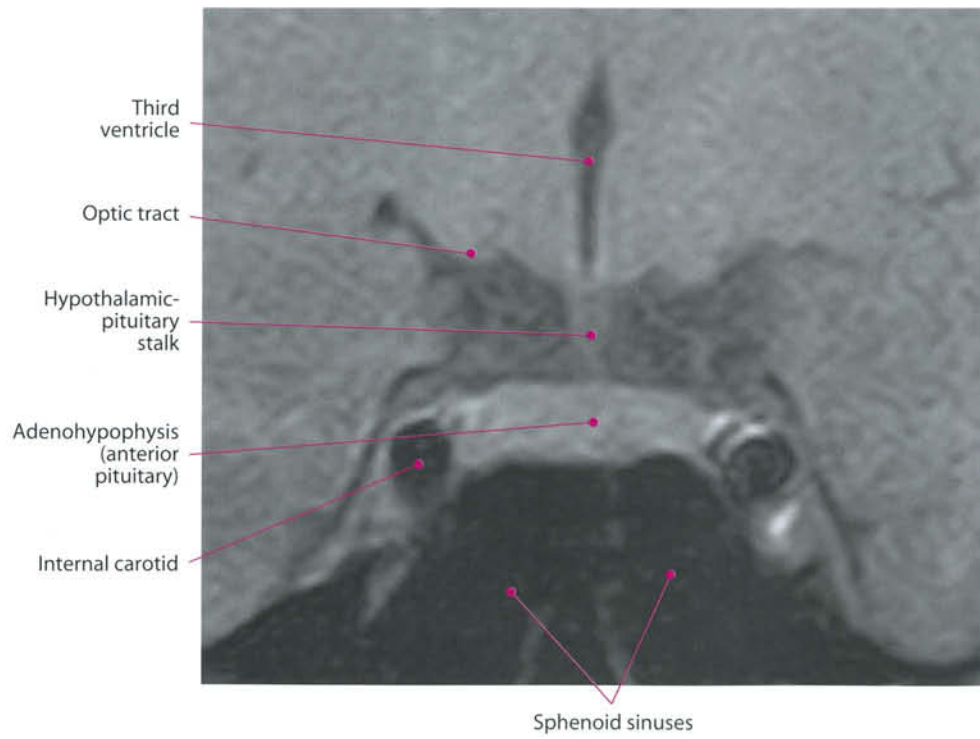


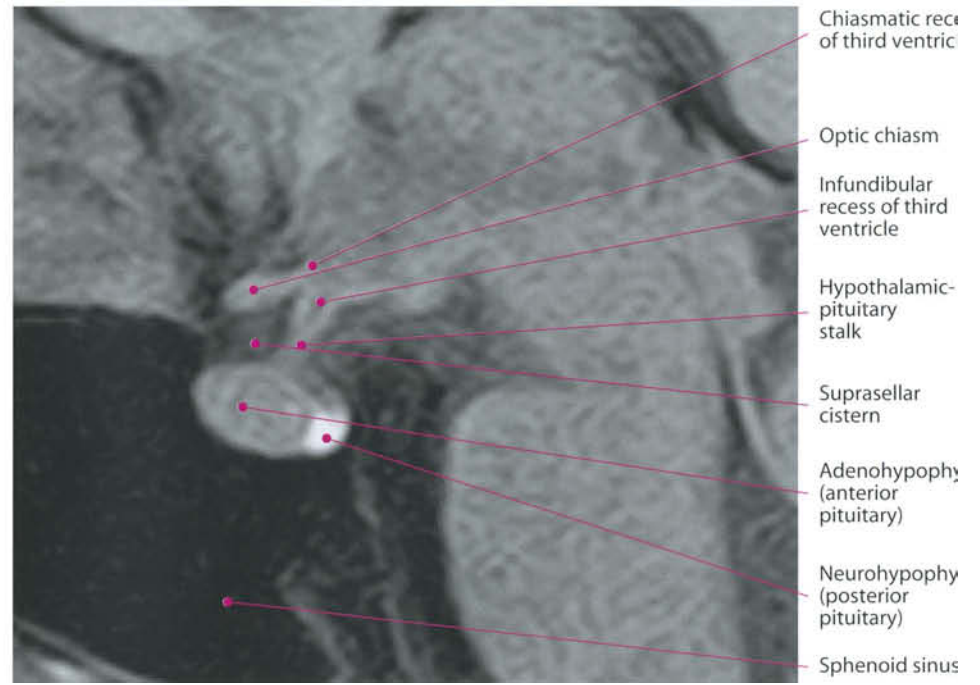
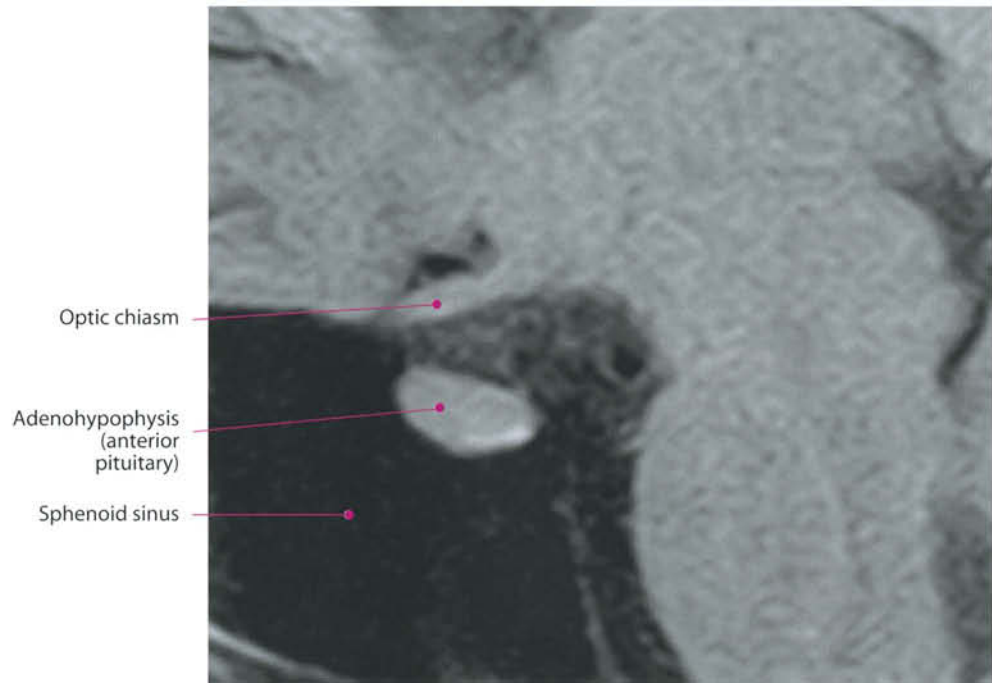


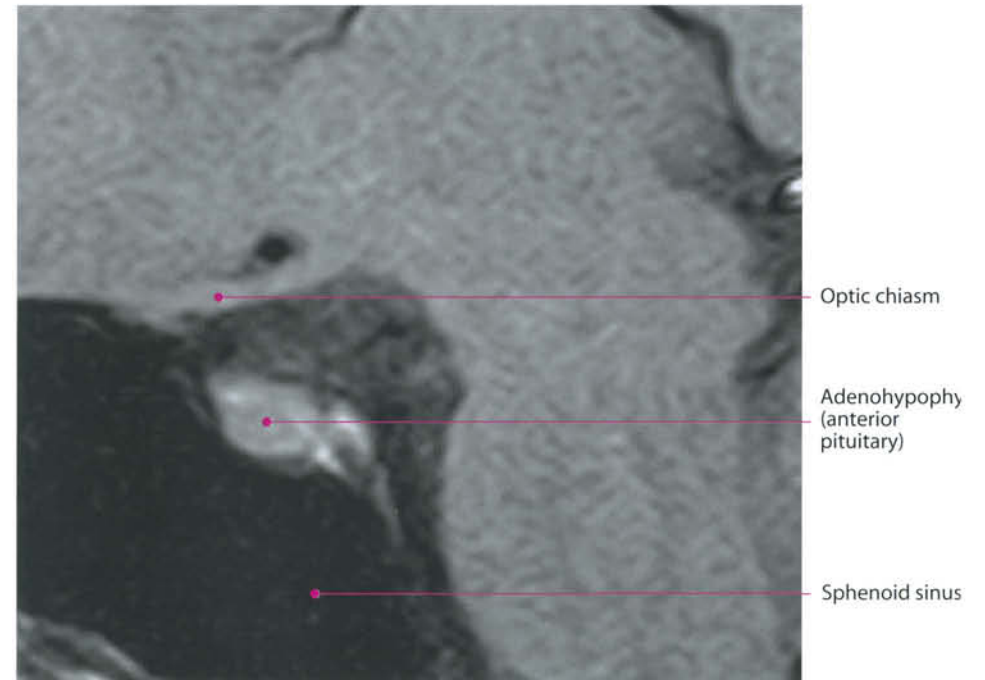
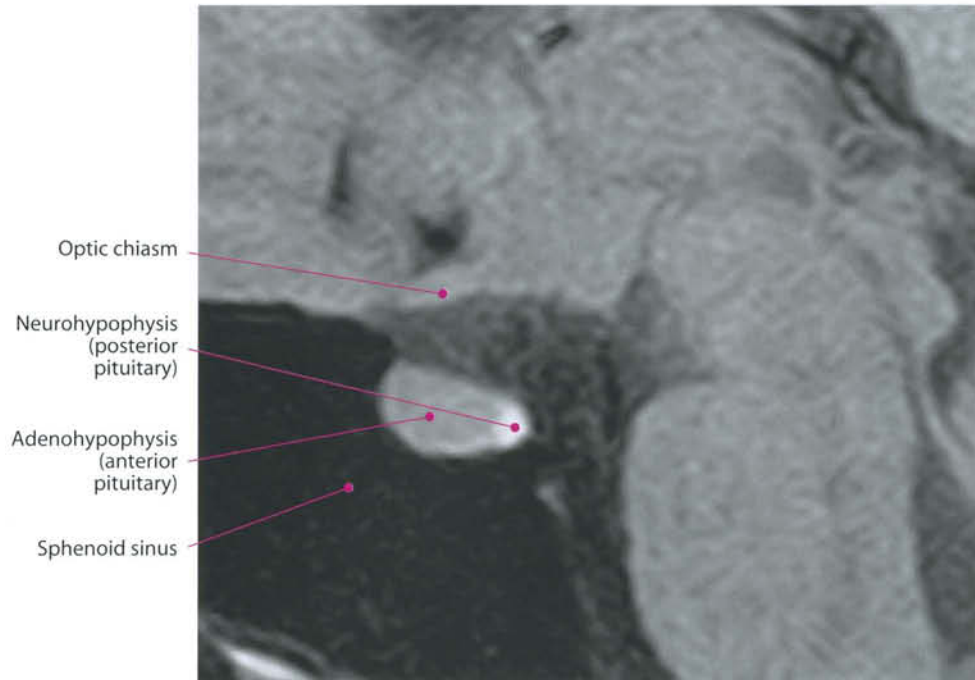




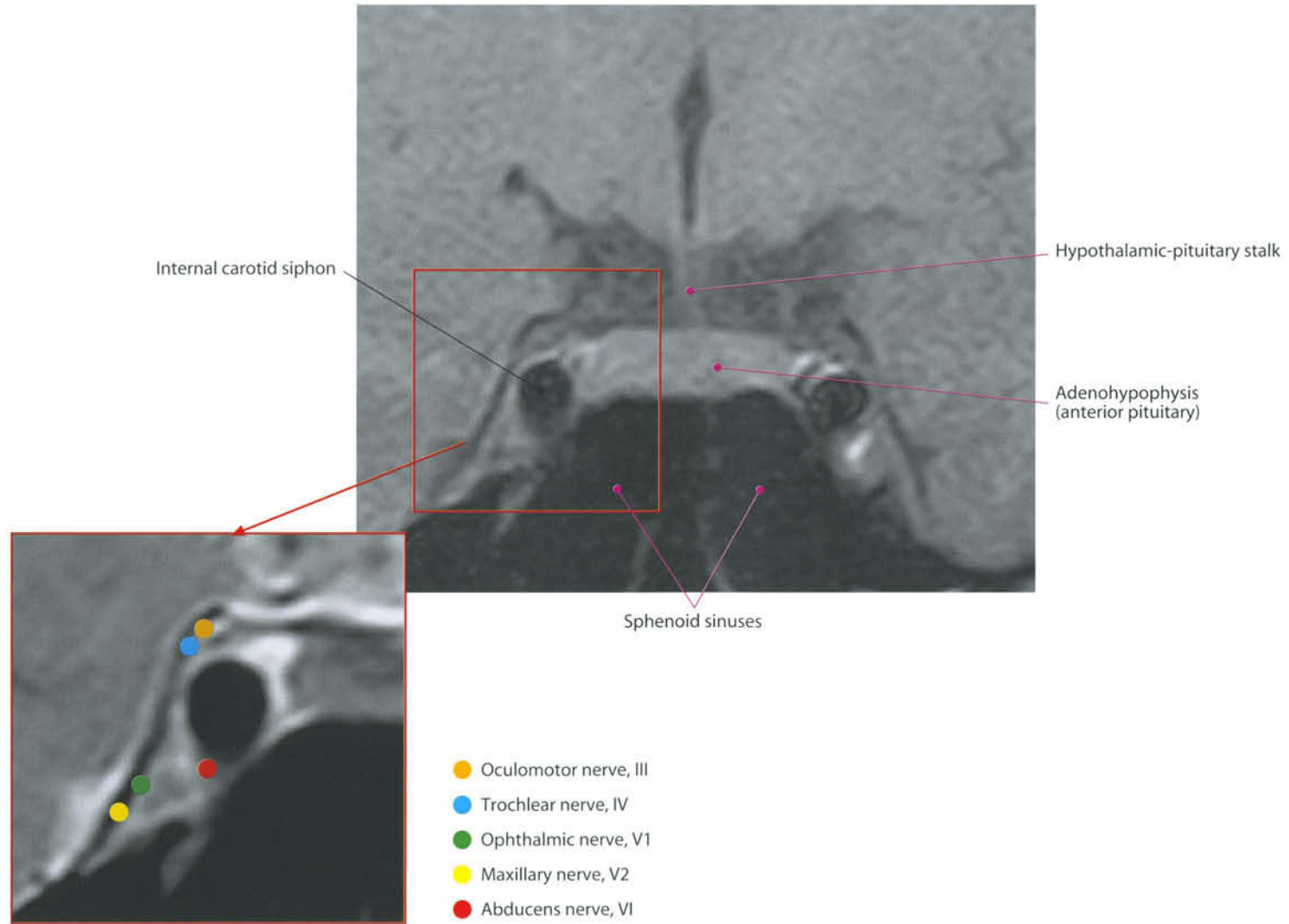


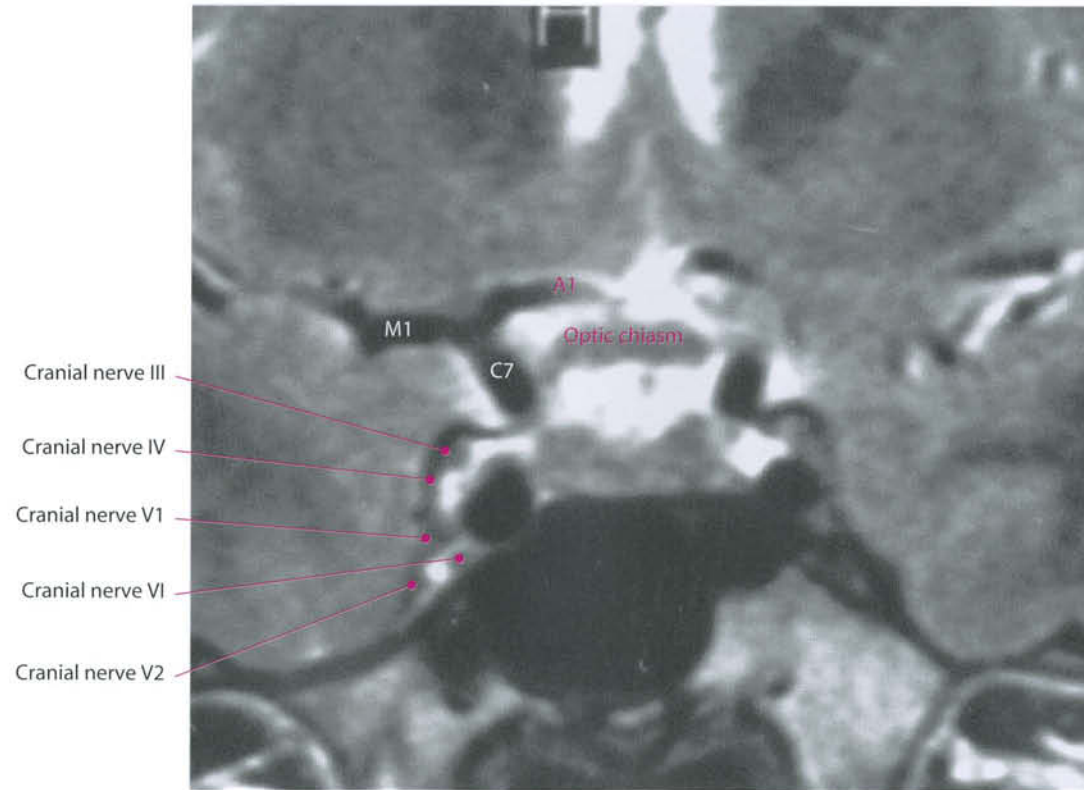




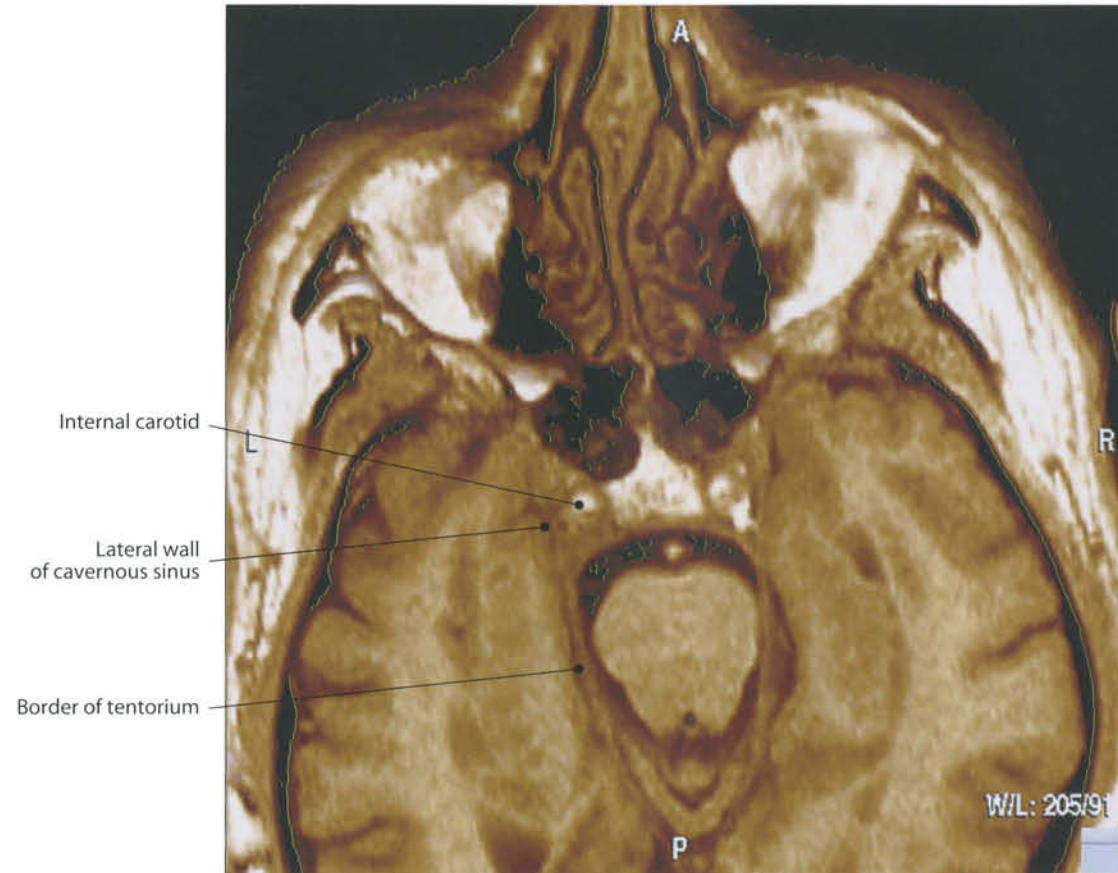


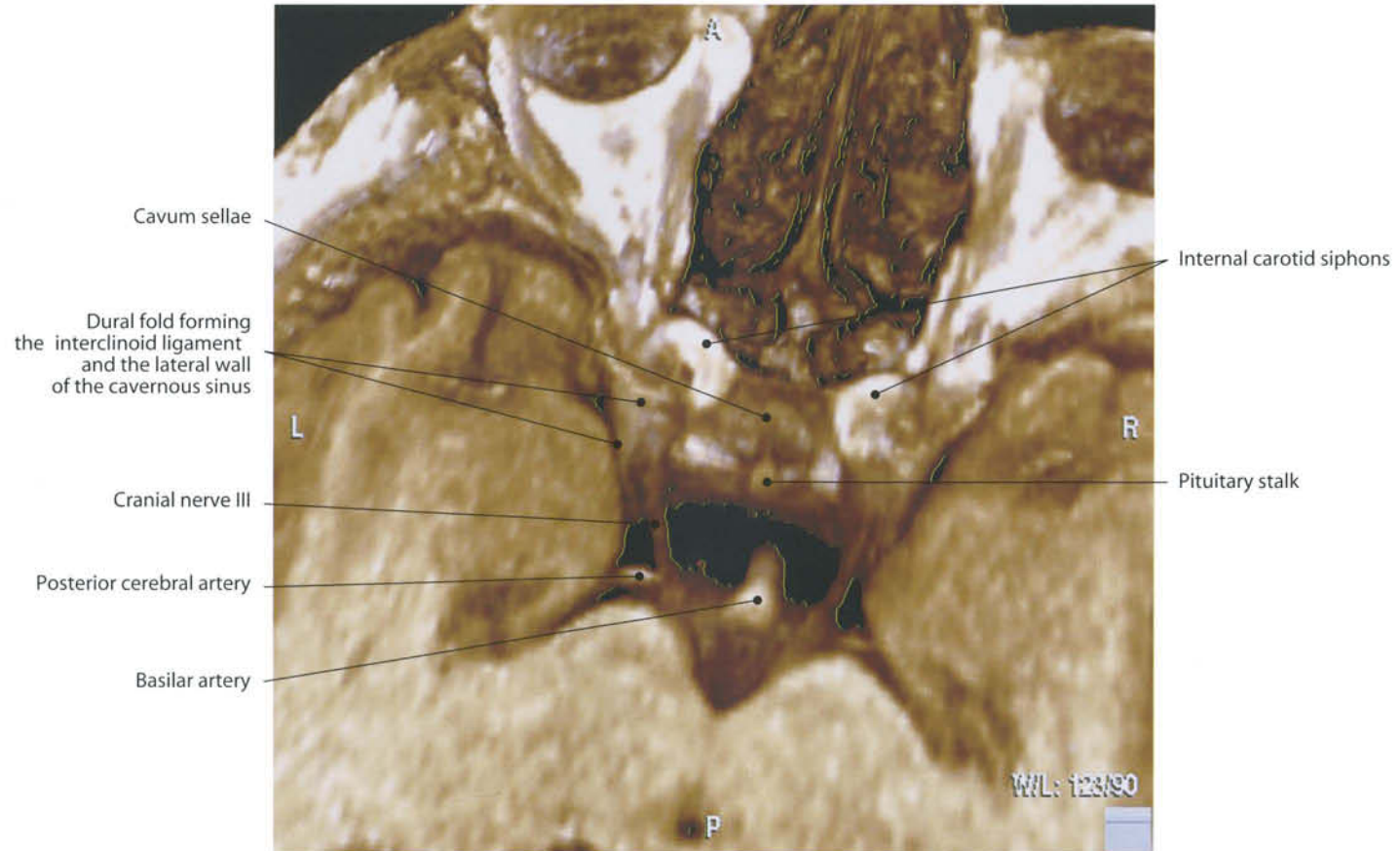
Cavernous Sinus





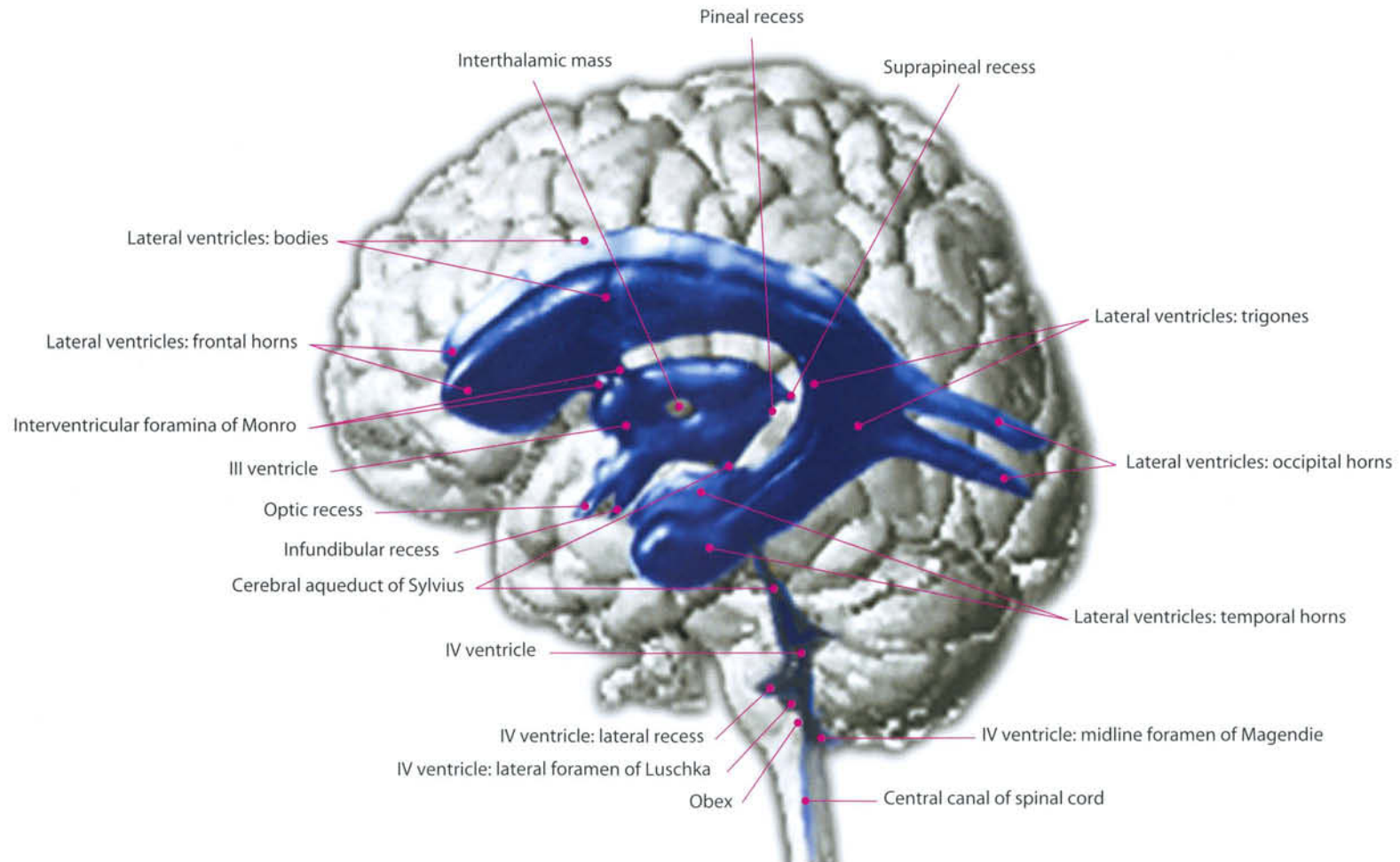
M1 = M1 segment of the middle cerebral artery
A1 = A1 segment of the anterior cerebral artery
C7 = Communicating segment of the internal carotid artery

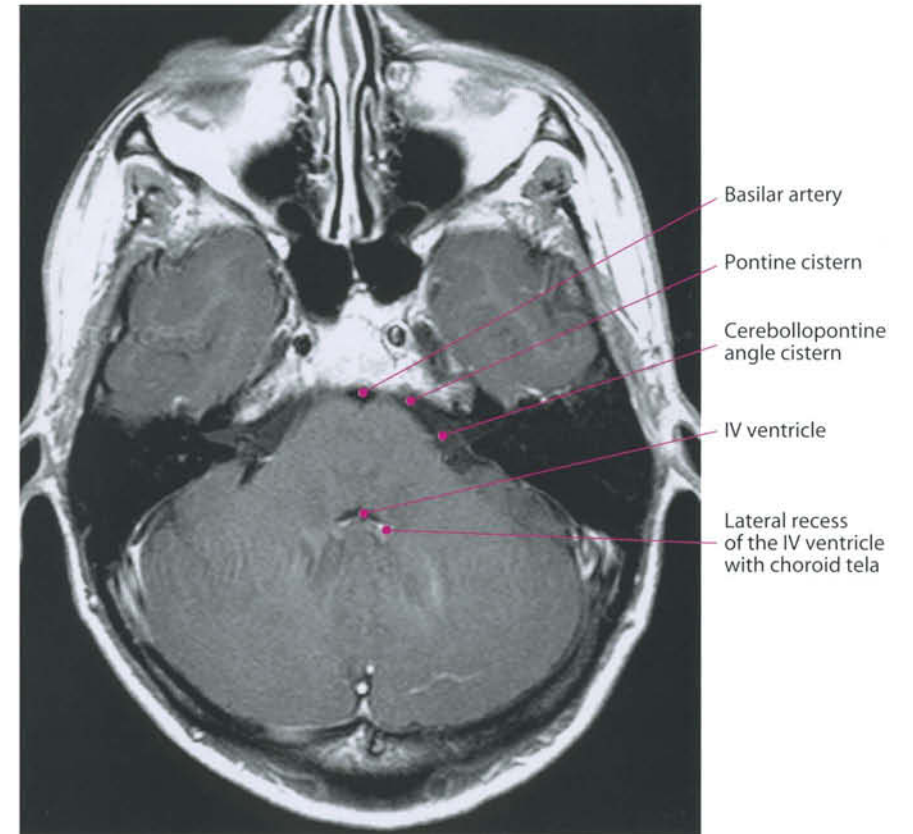
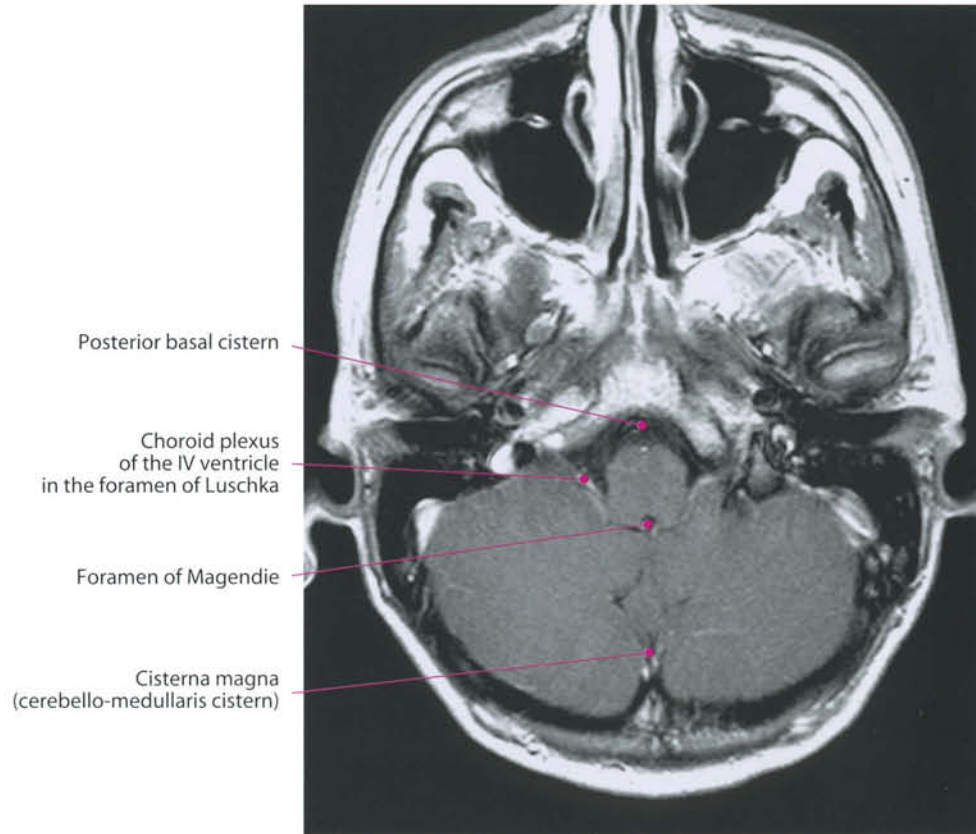


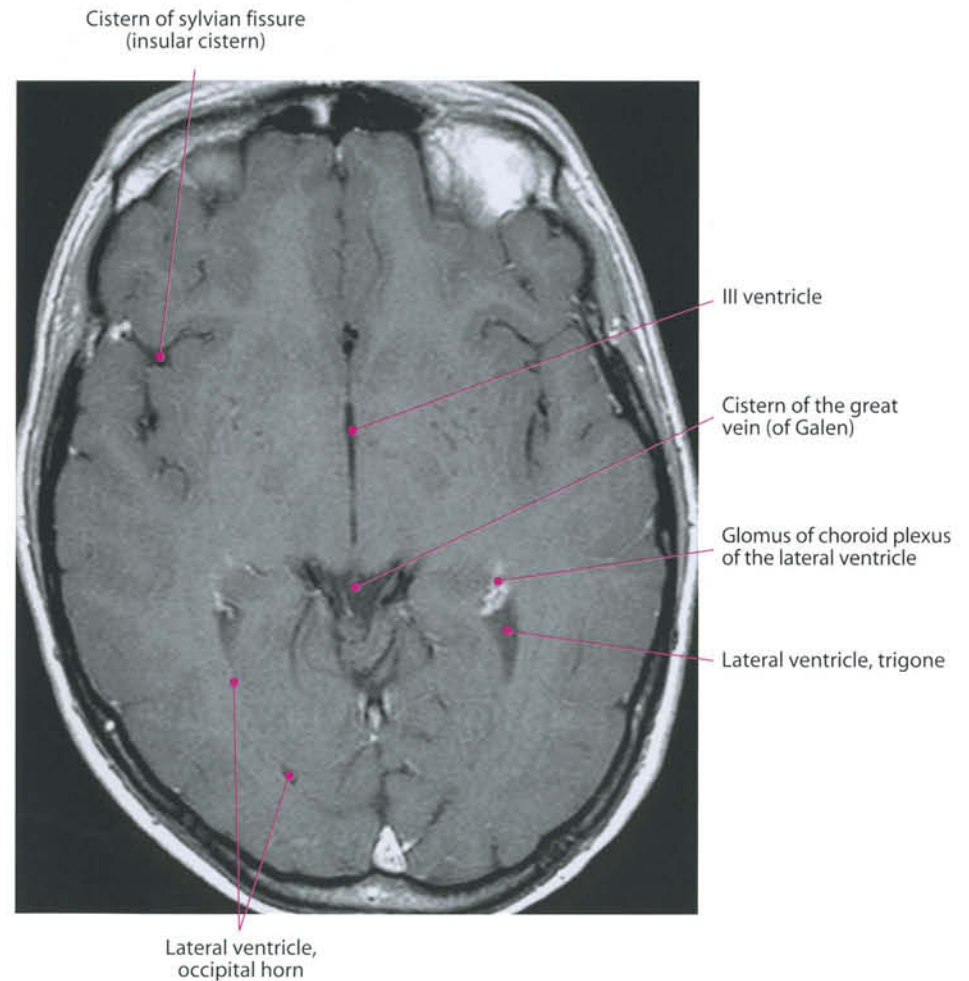
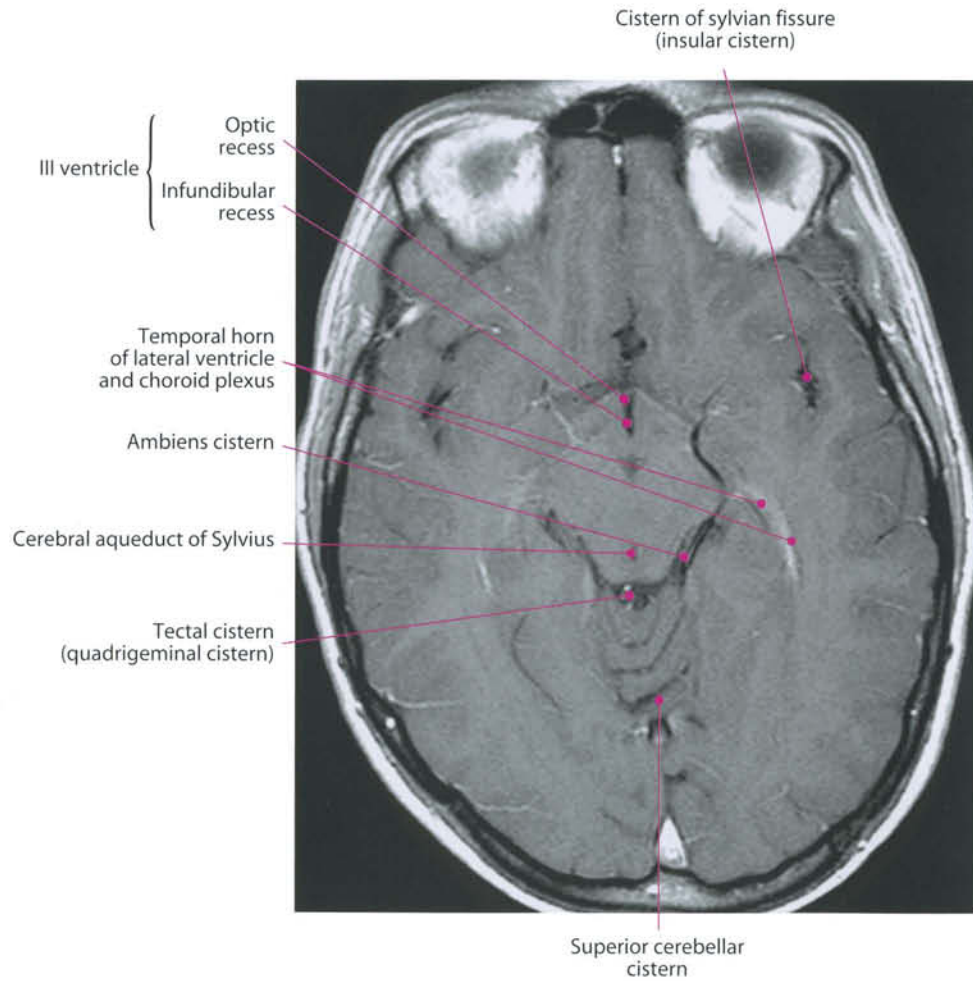


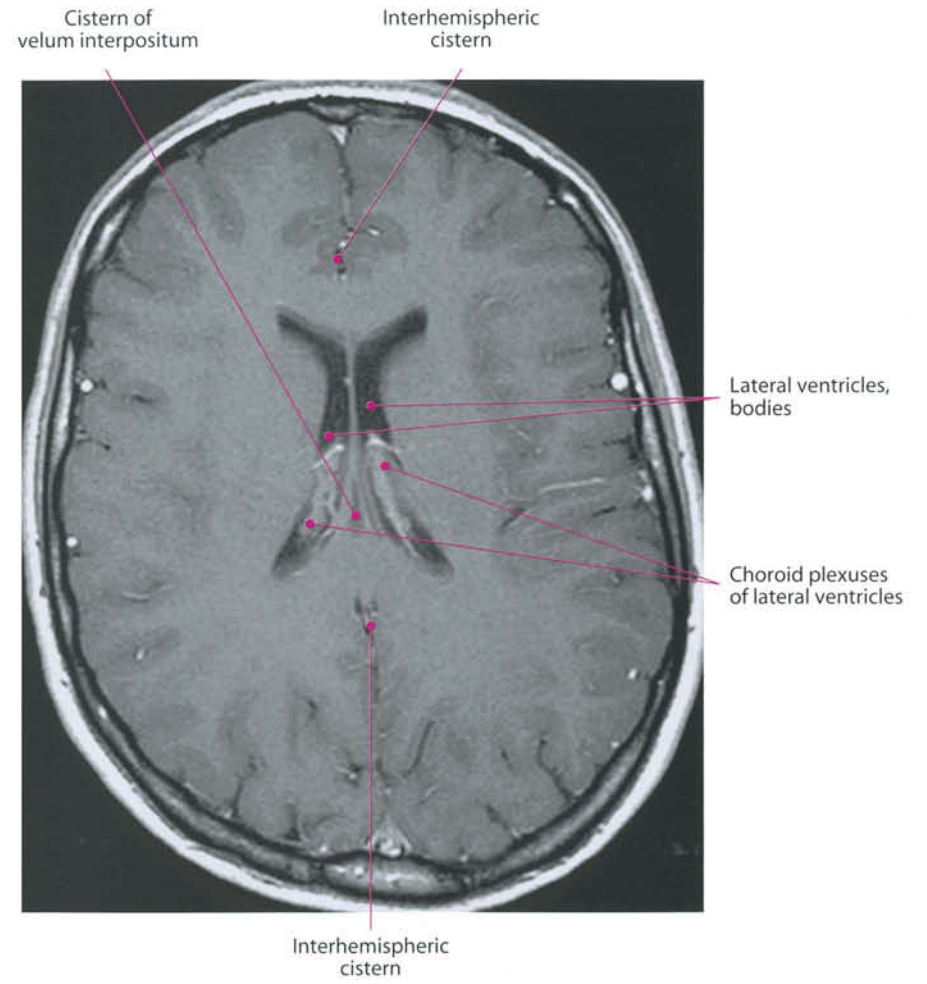
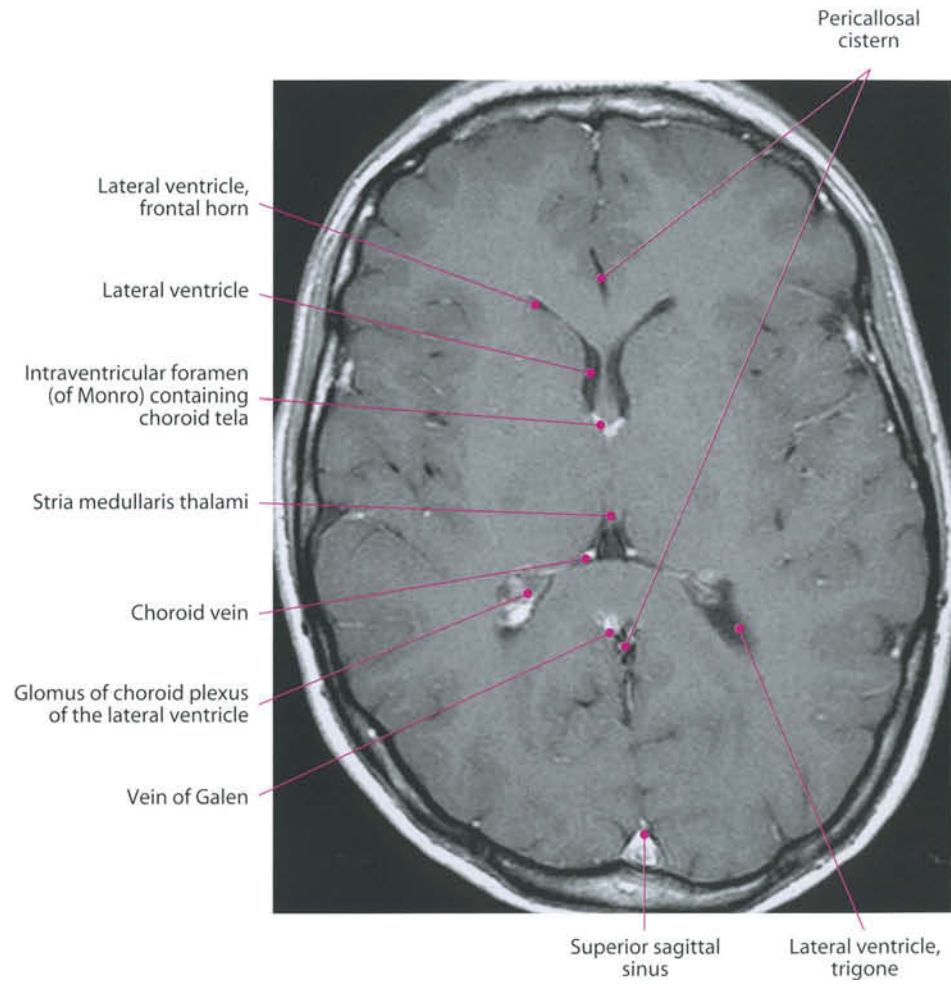
Cerebrospinal Fluid System

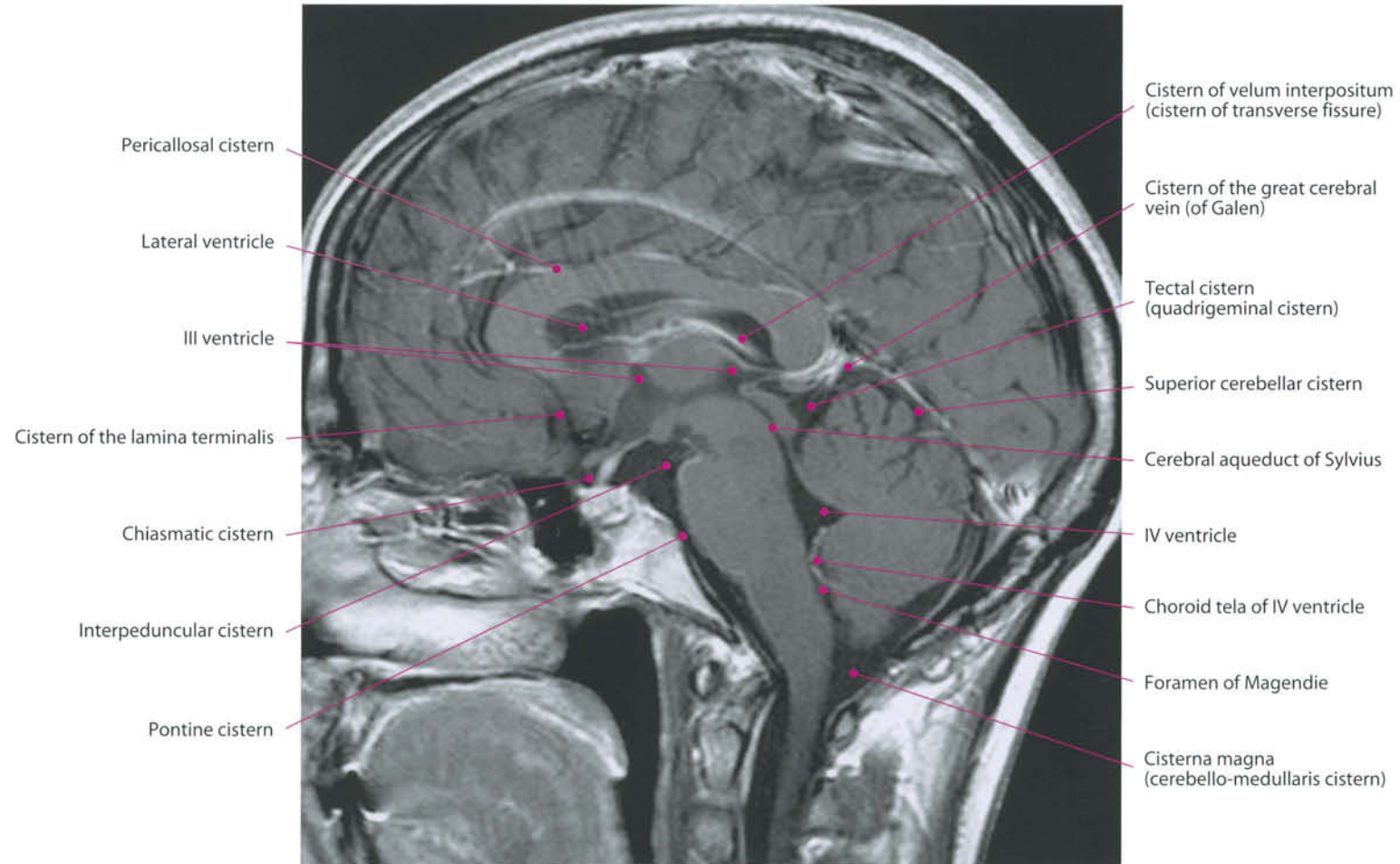
The cerebrospinal fluid (CSF) is located within the ventricles and subarachnoid spaces in the brain and spine. Its composition schematically contains 0-5/ μ l ($0-5 \times 10^6$ /l) cells, 40-80 mg/dl glucose, 15-60 mg/dL protein. The principal source of CSF is represented by the choroid plexi of the lateral, third and fourth ventricles. The total volume is approximately 140-150 ml, 30-40 of which is in the ventricular system, with a production rate of about 20 ml/h and a turnover rate of about 5 h. The CSF moves within the ventricles and subarachnoid spaces under the influence of hydrostatic pressure generated by its production and a complex pushing system dependent on internal carotid pulsation in systole and negative pressure in the superior sagittal sinus during diastole. The CSF cushions the brain, regulates brain extracellular fluid, and allows the distribution of neuroactive substances. The choroid plexi are fringe-like processes of the pia mater which project into the ventricular cavity. They consist of minute and highly vascular villous processes, each with an afferent and an efferent vessel. The arteries of the plexus are the anterior choroidal artery, a branch of the internal carotid that enters the plexus at the end of the temporal horn, and the posterior choroidal arteries, branches of the posterior cerebral artery. The veins of the choroid plexus join the internal cerebral vein. The tela choroidea of the fourth ventricle lies on the roof of the ventricle and adheres to it, reaching the foramen of Magendie. Two lateral thickenings, the choroid plexuses, extend along the lateral foramina of Luschka. Under normal conditions, 90% of CSF is drained by dural venous sinuses. The remaining rate is mostly absorbed by white matter deep veins. The CSF circulates from the lateral and third ventricles toward the fourth ventricle through the cerebral aqueduct, and from here it reaches the cerebral convexity, the granulation of Pacchioni, and the superior sagittal sinus. The flow is pulsatile and synchronized with the heartbeat.

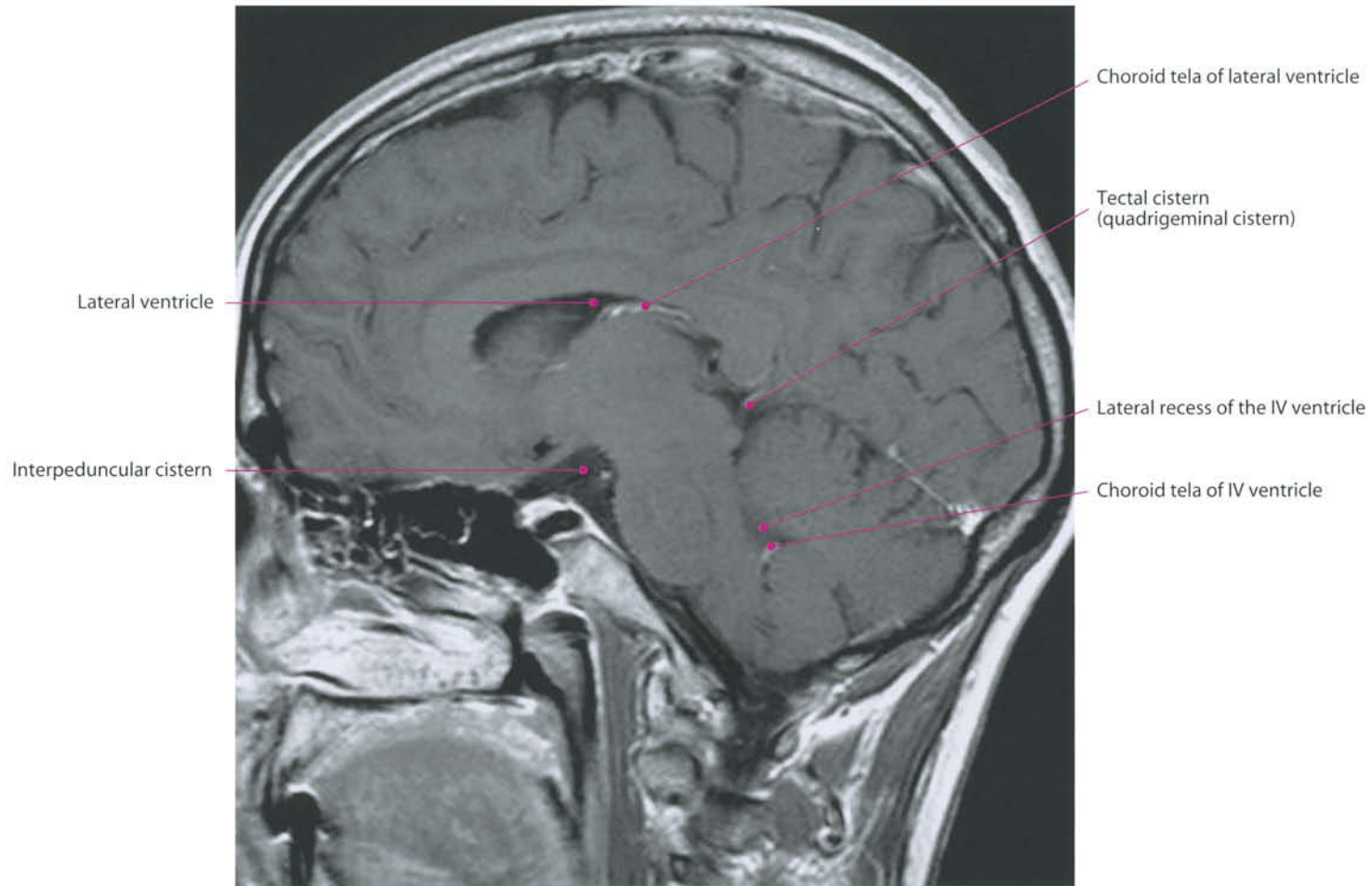


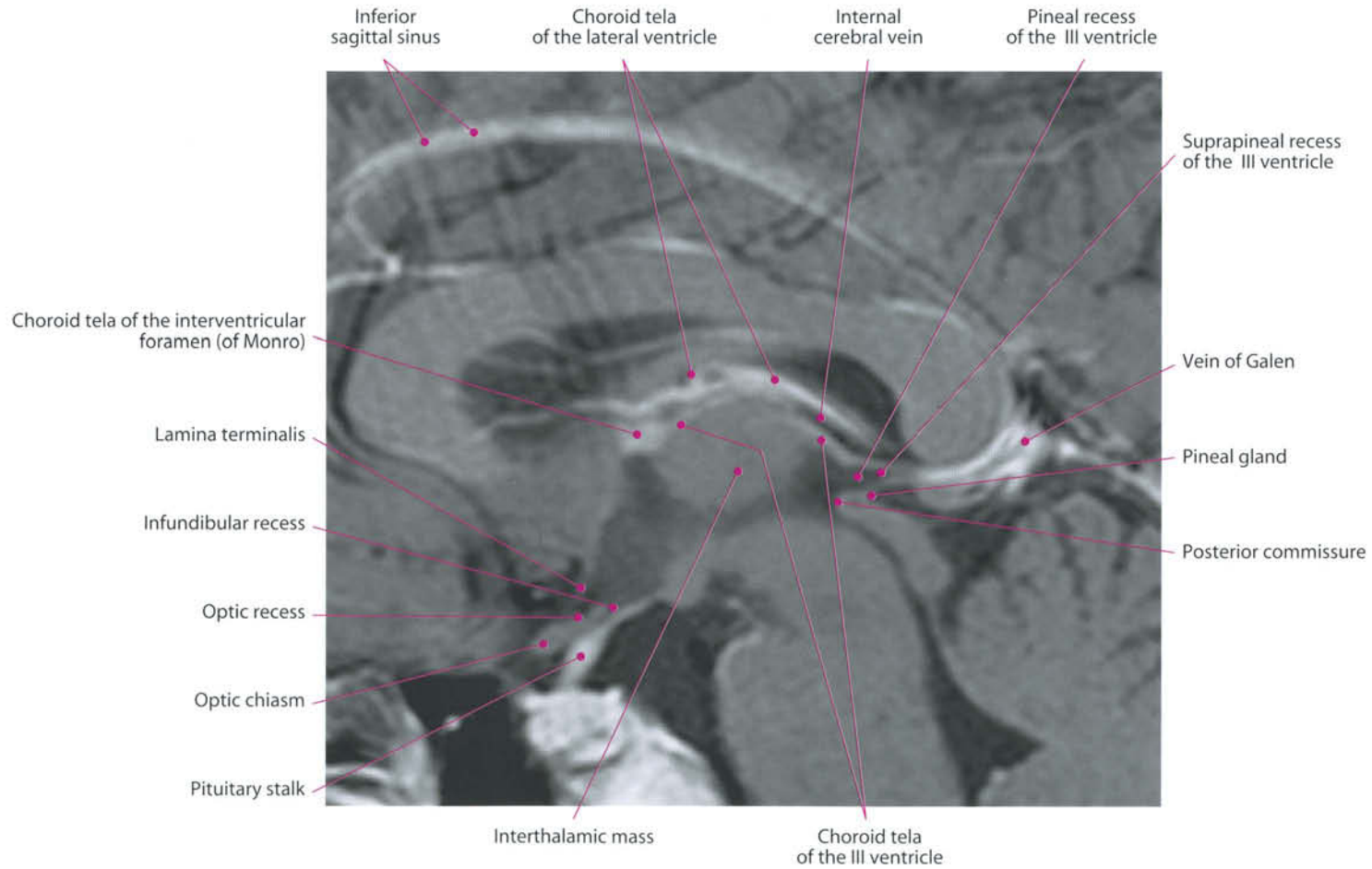


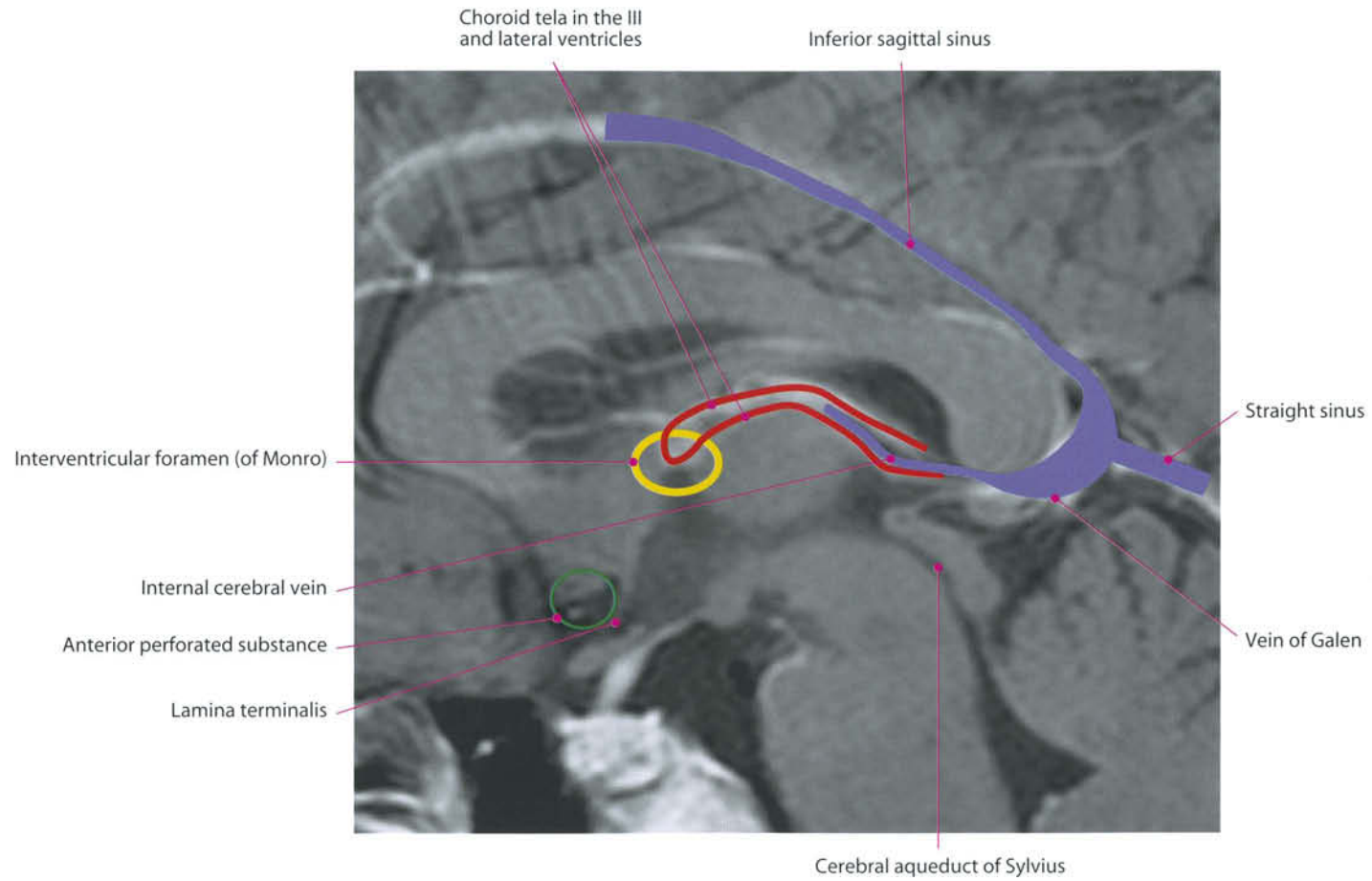












6 Vascular Anatomy

Intracranial Arteries

I. Carotid Artery and Branches

The internal carotid artery supplies the anterior part of the brain and the eye, and sends branches to the forehead and nose. According to the latest classifications, it can be divided into seven segments: cervical, petrous, lacerum, cavernous, clinoid, ophthalmic, and communicating.

- Cervical portion (C1): it begins at the bifurcation of the common carotid, and runs upward to the carotid canal.
- Petrous portion (C2): it corresponds to the petrous portion of the temporal bone. Here, the artery ascends at first (vertical segment), and then curves medialward (horizontal segment), surrounded by the sympathetic carotid plexus.
- Lacerum portion (C3): it extends from the endocranial carotid canal to the petrolineal ligament, and ascends in the carotid sulcus of the basisphenoid. It is separated from the trigeminal ganglion by a thin bony lamina or a fibrous membrane.
- Cavernous portion (C4): it is situated inside the cavernous sinus. It perforates the dura mater forming the roof of the sinus and exits medial to the anterior clinoid process.
- Clinoid Portion (C5): it is the shortest part of the ICA, completely intradural. It comprises only the small superior segment of the anterior ICA genu, between the proximal and distal dural rings.
- Ophthalmic portion (C6): it begins after the distal dural ring, thus representing the first subarachnoid tract. It ends proximal to the posterior communicating artery origin.
- Communicating portion (C7): it starts immediately before the origin of the posterior communicating artery, passes between the optic and oculomotor nerves and reaches the anterior perforated substance at the medial extremity of the lateral cerebral fissure, where it gives off its terminal branches.

The cervical portion of the ICA has no branches. Branches from the other portions are:

1. *The tympanic branch* – a small branch, it enters the tympanic cavity through a minute foramen in the carotid canal, and anastomoses with the anterior tympanic branch of the internal maxillary and with the stylomastoid artery.

2. *The artery of the pterygoid canal (vidian artery)* – small, inconstant.
3. *The cavernous branches* supply the hypophysis, the semilunar ganglion, and the walls of the cavernous and inferior petrosal sinuses. Some of them anastomose with branches of the middle meningeal.
4. *The hypophyseal branches* are one or two in number and supply the pituitary gland.
5. *The anterior meningeal branch* (a. meningea anterior) is a small branch which passes over the small wing of the sphenoid to supply the dura mater of the anterior cranial fossa;
6. *The ophthalmic artery* arises from the internal carotid as the latter emerges from the cavernous sinus and enters the optic canal, below and lateral to the optic nerve. It then passes over the nerve, proceeds anteriorly, and divides into terminal branches (see p. 126);
7. *The anterior cerebral artery (ACA)* (a. cerebri anterior) passes above the optic nerve. In the longitudinal fissure, it is connected by a short trunk (the anterior communicating artery) to the opposite one. This landmark subdivides the artery into segments A1 (or horizontal or precommunicating segment), and A2 (or vertical or postcommunicating segment). Distal and cortical branches are also termed A3. The artery runs in the longitudinal fissure around the corpus callosum until its posterior part, where they end by anastomosing with the posterior cerebral arteries. In its course, the anterior cerebral artery gives off the following main branches: the antero-medial perforating arteries are a group of small arteries which supply the rostrum of the corpus callosum, the septum pellucidum, and the head of the caudate nucleus (recurrent artery of Heubner). The inferior branches supply the olfactory lobe, gyrus rectus, and internal orbital gyrus. The anterior branches supply a part of the superior frontal gyrus, and part of the superior and middle frontal gyri and upper part of the anterior central gyrus. The most prominent is the frontopolar artery. The middle branches supply the corpus callosum, the cingulate gyrus, the medial surface of the superior frontal gyrus, and the upper part of the anterior central gyrus. The posterior branches supply the precuneus and adjacent lateral surface of the hemisphere.
8. *The middle cerebral artery (MCA)* (a. cerebri media) is the largest branch of the internal carotid. It runs at first lateralward in the lateral cerebral or sylvian fissure and then backward and upward on the surface of the insula, where it di-

vides into a number of branches which are distributed to the lateral surface of the cerebral hemisphere. It can be divided into four segments: M1 or horizontal segment, which runs horizontally below the anterior perforated substance, bifurcates or trifurcates in its lateral third and ends at the limen insulae, by turning posterosuperiorly; M2 or insular segments are 6 to 8 in number, lie on the cortical surface of the insula and terminate at the top of the circular gyrus; M3 or opercular segments follow and terminate at the surface of the lateral cerebral fissure; M4 or cortical segments are the distal branches extended over the hemispheric surface. The middle cerebral artery supplies the following main branches: the antero-lateral perforating a., small arteries which supply the inner segments of the lentiform nucleus, the caudate nucleus, the internal capsule, and the thalamus. The inferior lateral frontal a. supplies the inferior frontal gyrus (Broca's convolution) and the lateral part of the orbital surface of the frontal lobe. The ascending frontal a. supplies the anterior central gyrus. The ascending parietal a. is distributed to the posterior central gyrus and the lower part of the superior parietal lobule. The parietotemporal a. supplies the supra-marginal and angular gyri, and the posterior parts of the superior and middle temporal gyri. The temporal branches are distributed to the lateral surface of the temporal lobe.

9. *The posterior communicating artery* (a. communicans posterior) arises from the back side of the internal carotid, and anastomoses with the posterior cerebral artery. From its posterior half some perforating arteries arise, which supply the medial surface of the thalamus and the walls of the third ventricle.
10. *The anterior choroidal artery* (a. choroidea; choroid artery) is a small branch that arises from the internal carotid, close to the posterior communicating artery. It enters the inferior horn of the lateral ventricle through the choroidal fissure and ends in the choroid plexus.

II. Vertebral Artery and Branches

The vertebral artery can be divided into four segments: V1 or extraosseous (from the subclavian artery to C6), V2 or foraminal (from C6 to axis), V3 or extraspinal (from C1 to foramen magnum), V4 or intradural (from foramen magnum to basilar junction).

The artery gives rise to cervical branches destined to spine and muscles; meningeal branches (anterior and posterior

meningeal branches of the V.A.), and intracranial arteries: anterior and posterior spinal arteries; postero-inferior cerebellar artery (PICA).

The anterior spinal artery arises from both distal vertebral arteries from two branches that fuse on the midline. It supplies the anterior surface of the medulla. The posterior spinal artery originates from the distal VA or from the PICA. The PICA has four segments and originates from the distal part of the VA. The first or anterior segment goes lateralward toward the cerebellar olive; the second or lateral continues posteriorly in the cerebello-medullary cistern, forming a caudal loop; the third or posterior medullary segment turns upward behind the posterior medullary velum. The fourth or supratonsillar segment gives the second, cranial loop and courses above the cerebellar tonsil.

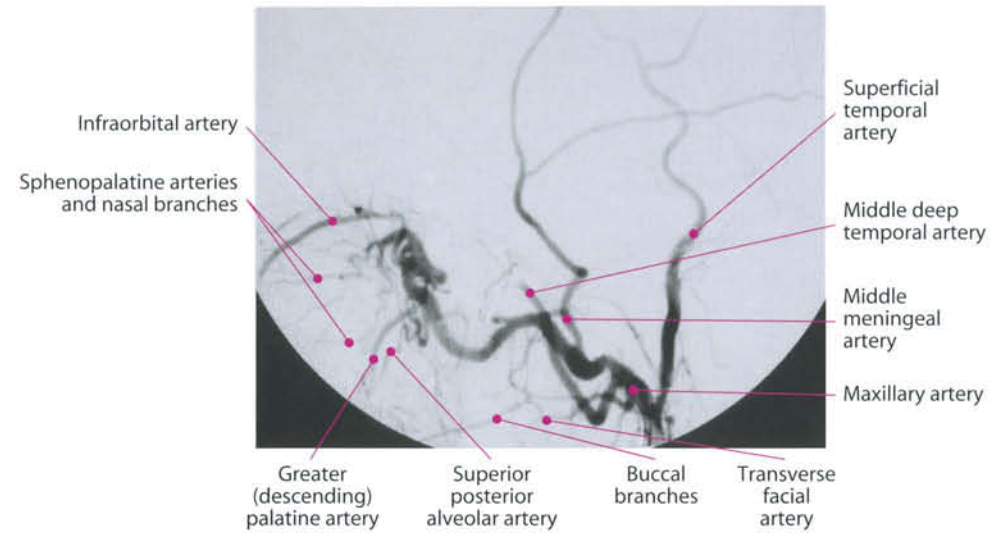
By the fusion on the midline of both vertebral arteries, the basilar artery is formed.

III. Basilar Artery and Branches

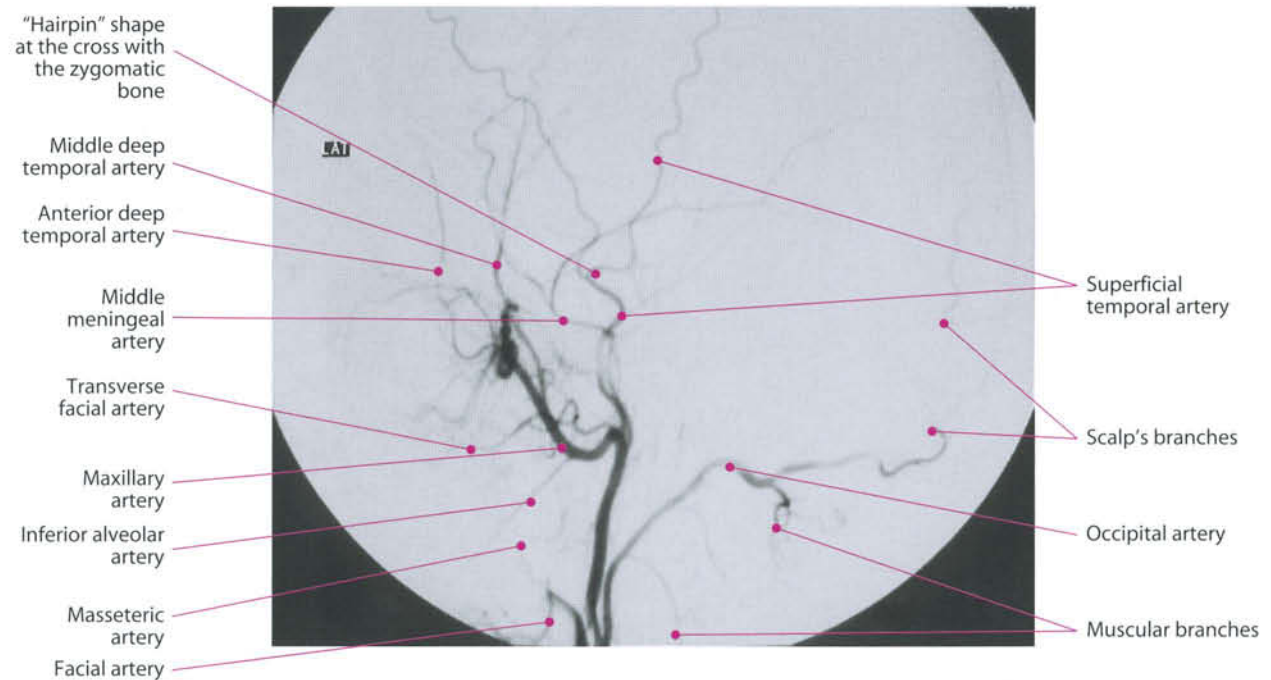The basilar artery (BA) starts from the vertebral artery confluence and ends at its subdivision into the two posterior cerebral arteries. Its main branches are:

1. *Pontine perforating arteries*
They are median, paramedian, and lateral perforating branches destined to supply the midbrain.
2. *Anterior inferior cerebellar artery (AICA)*
It is the smallest of the three cerebellar arteries. It courses posteriorly, ventromedial to the facial and vestibulocochlear nerve, giving rise in 50 % of cases to the
3. *Internal auditory (labyrinthine) artery*. In the remaining cases, this artery can originate directly from the basilar artery or from the PICA. It follows facial and vestibulo-cochlear nerves in the internal acoustic canal. The AICA terminates by coursing over the anterolateral aspect of the cerebellum.
4. *Superior cerebellar artery (SCA)*
It arises immediately before the basilar artery bifurcation. It courses posterolaterally, below the oculomotor nerve, then curves around the midbrain.
5. *Posterior cerebral artery (PCA)*
It is the terminal branch of the BA. During its course it furnishes important collaterals (posterior thalamoperforating, medial posterior choroidal, lateral posterior choroidal and cortical arteries). Anatomically, it is divided into four portions:

Maxillary Artery

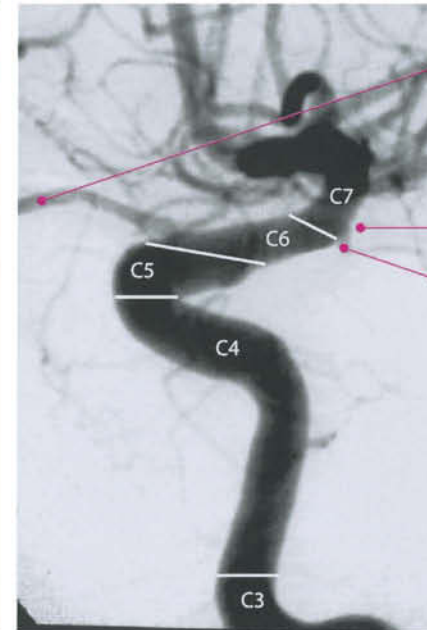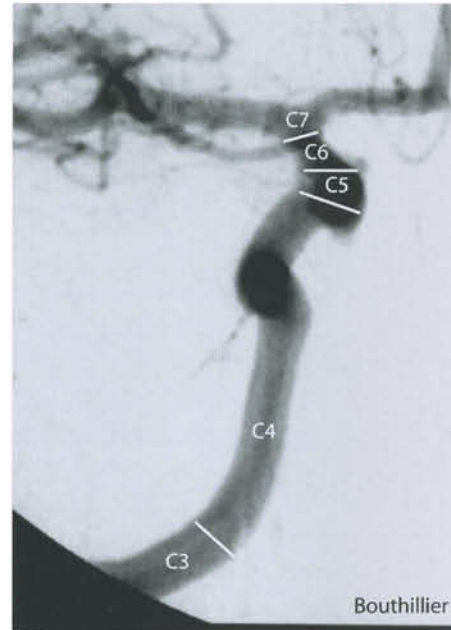


External Carotid Artery

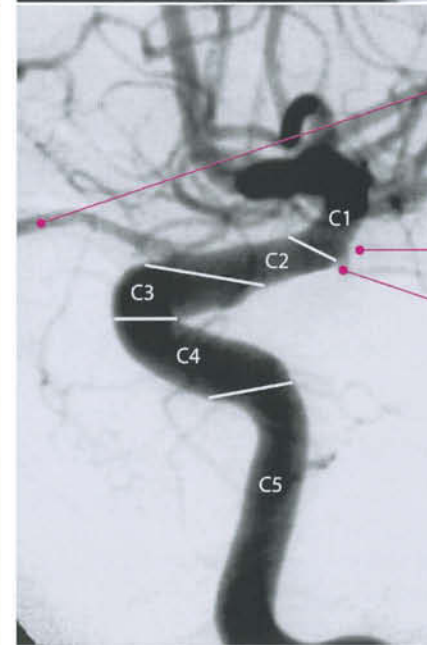
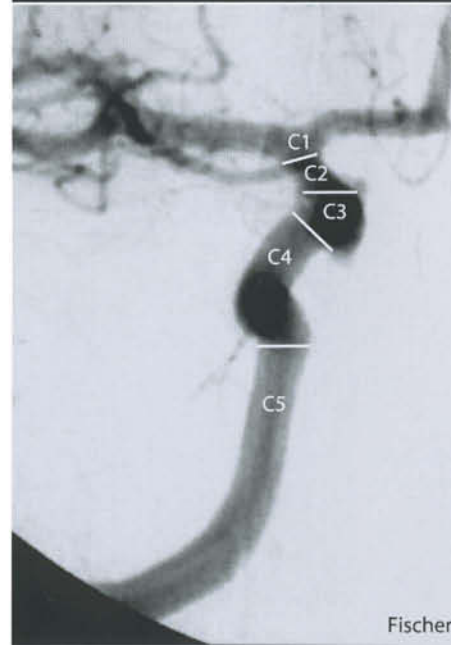


P1 or precommunicating or mesencephalic segment, which lies in the interpeduncular cistern, curving around the midbrain and ending at its junction with the posterior communicating artery. This segment gives off perforating branches destined to the midbrain and thalamus. P2 or ambient segment, which extends to the posterior aspect of the midbrain; P3 or quadrigeminal segment, which goes from the quadrigeminal plate to the calcarine fissure. Sometimes it subdivides into two arteries; P4 or calcarine fissure includes the terminal branches (parieto-occipital and calcarine arteries, cortical branches).

Internal Carotid Artery



Ophthalmic artery
 Anterior choroidal artery
 Posterior communicating artery

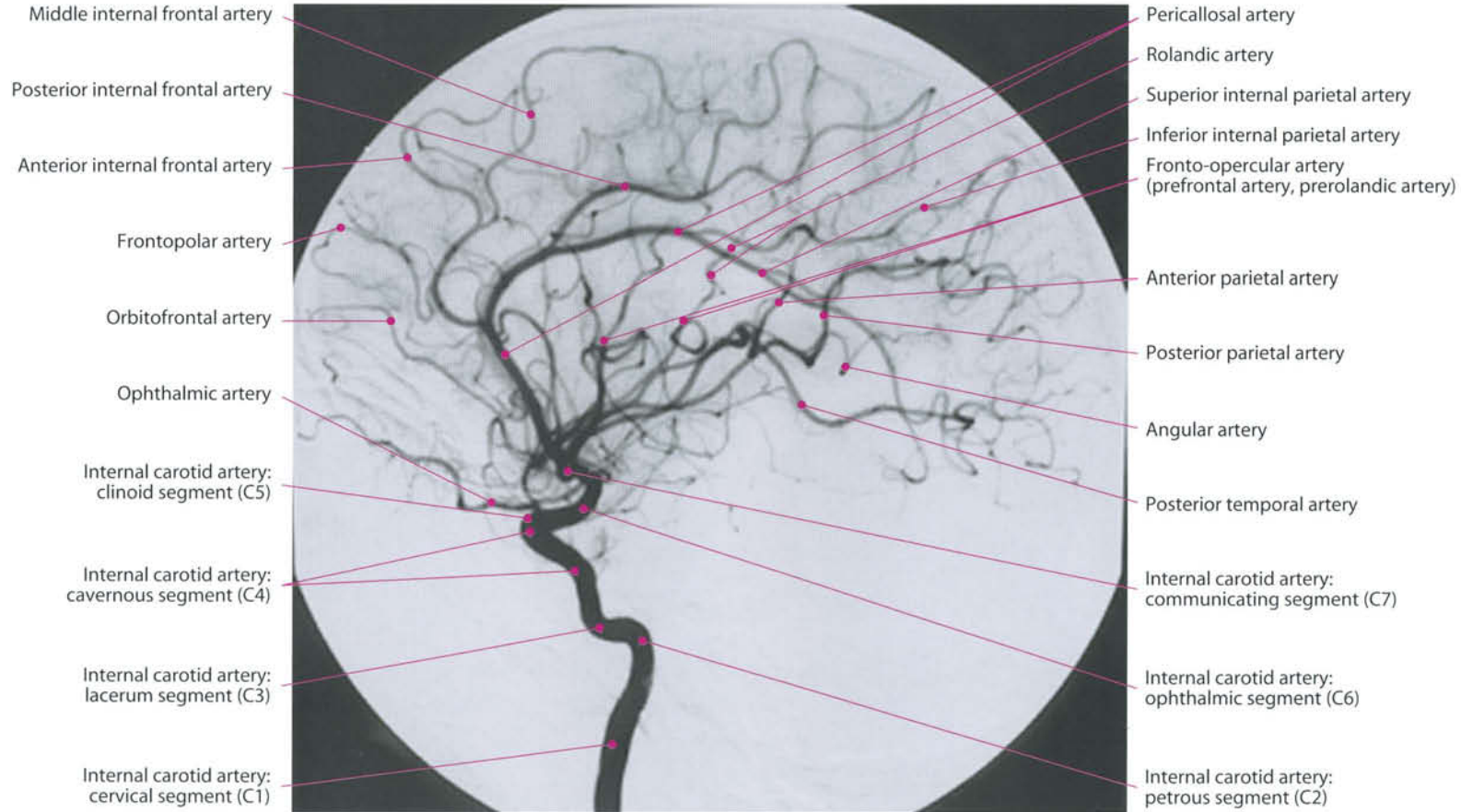


Ophthalmic artery
 Anterior choroidal artery
 Posterior communicating artery

Bouthillier

Fischer

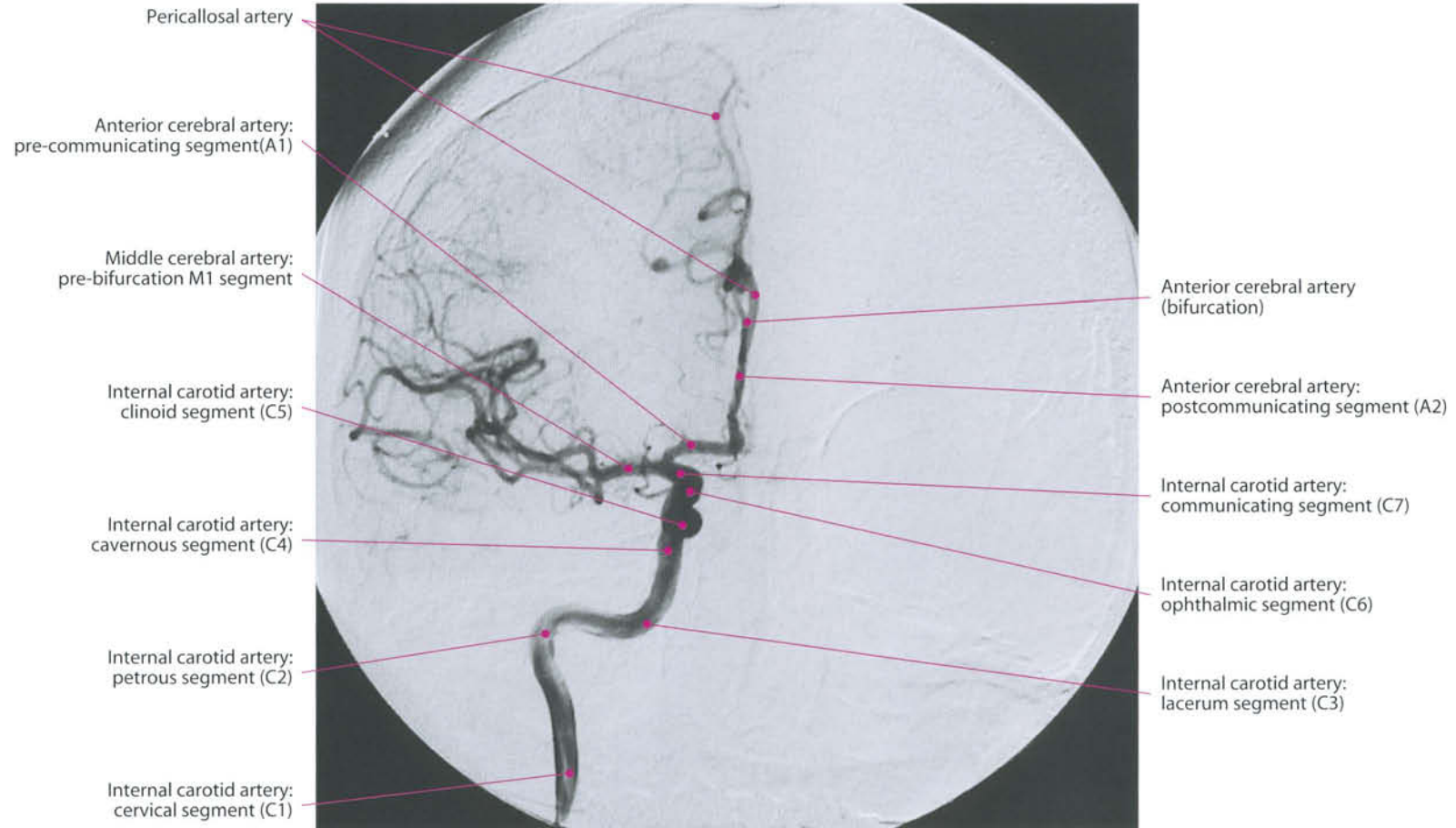Internal Carotid Artery



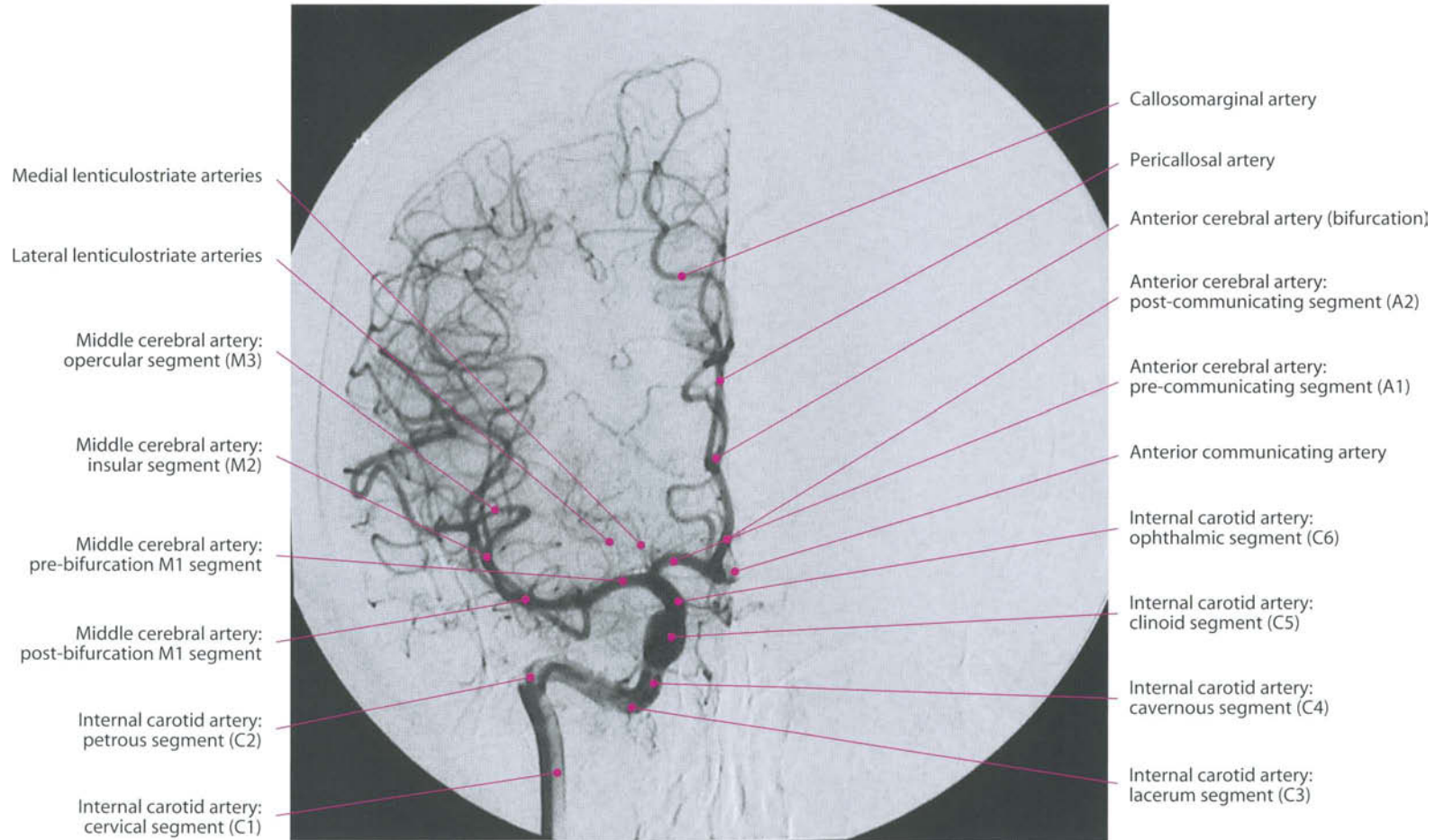
- Middle internal frontal artery
- Posterior internal frontal artery
- Anterior internal frontal artery
- Frontopolar artery
- Orbitofrontal artery
- Ophthalmic artery
- Internal carotid artery: clinoid segment (C5)
- Internal carotid artery: cavernous segment (C4)
- Internal carotid artery: lacerum segment (C3)
- Internal carotid artery: cervical segment (C1)

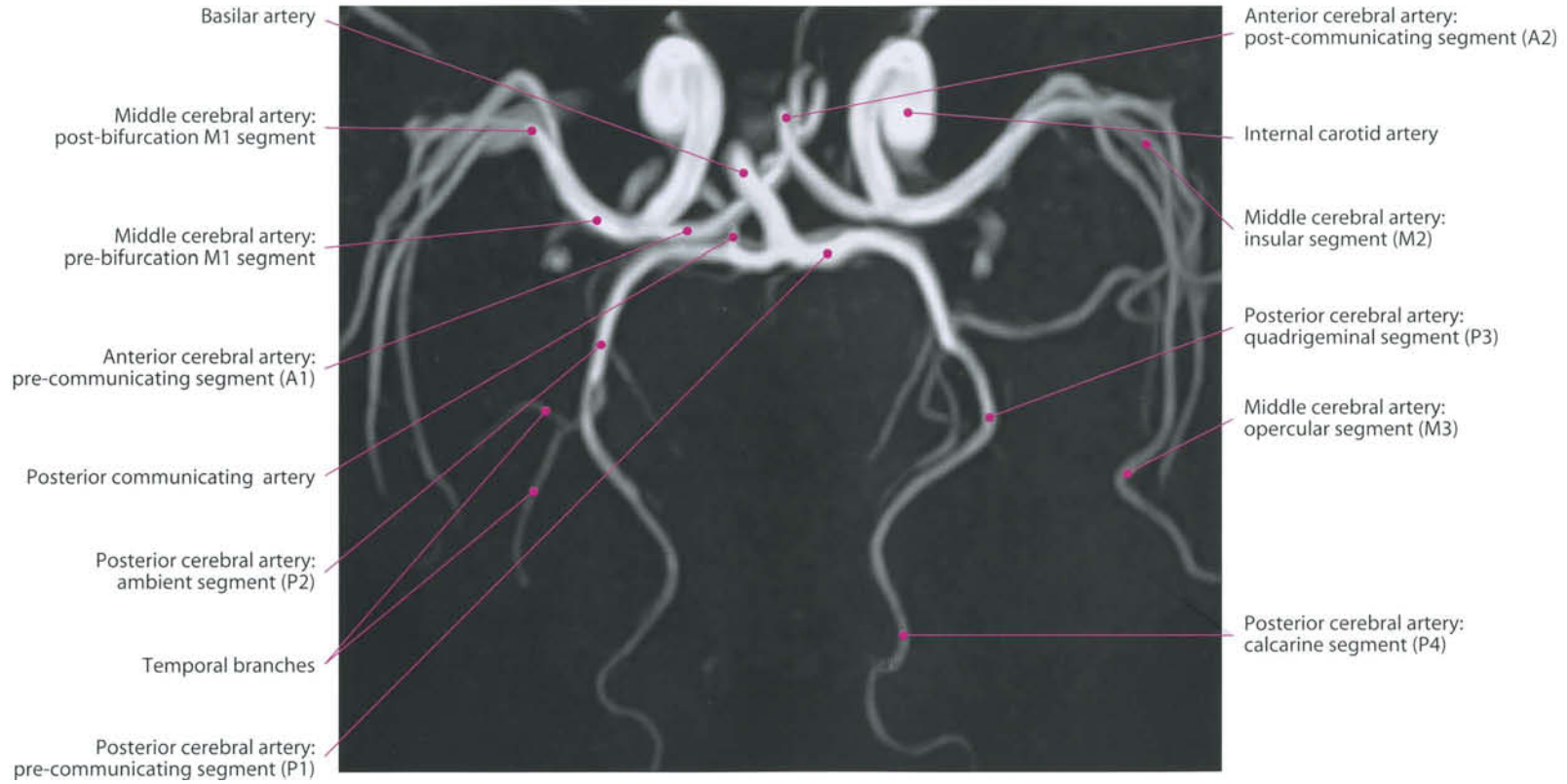
- Pericallosal artery
- Rolandic artery
- Superior internal parietal artery
- Inferior internal parietal artery
- Fronto-opercular artery (prefrontal artery, prerolandic artery)
- Anterior parietal artery
- Posterior parietal artery
- Angular artery
- Posterior temporal artery
- Internal carotid artery: communicating segment (C7)
- Internal carotid artery: ophthalmic segment (C6)
- Internal carotid artery: petrous segment (C2)

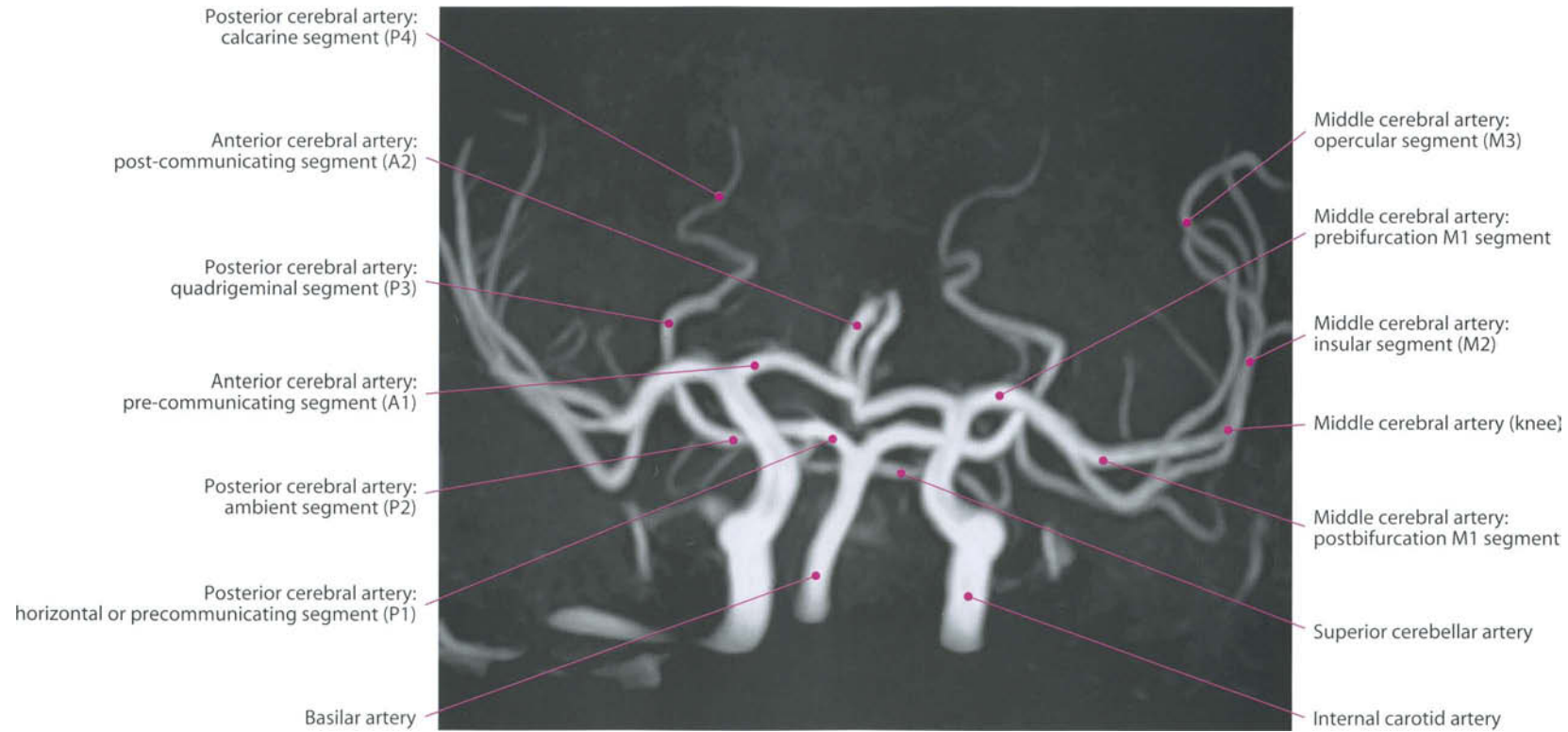
Internal Carotid Artery

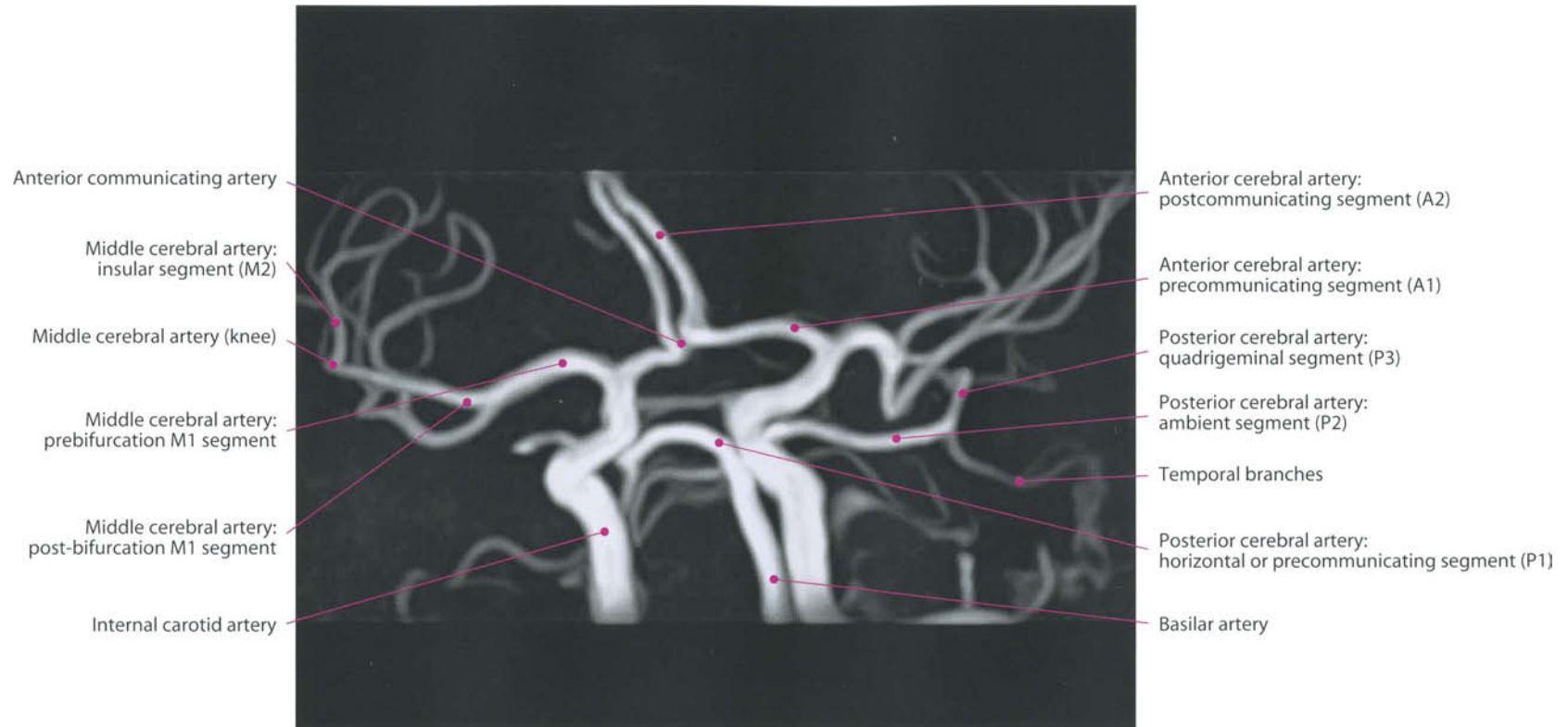

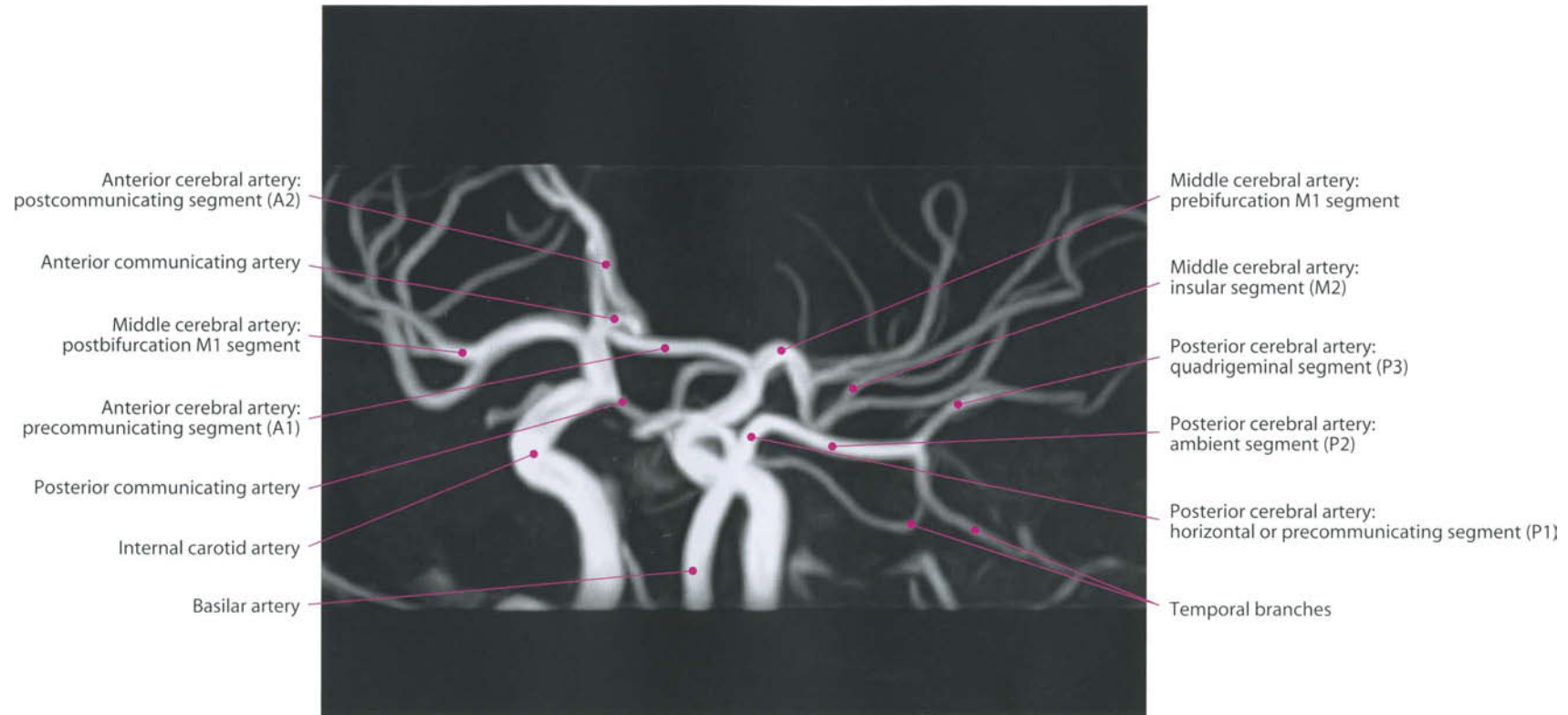
Internal Carotid Artery

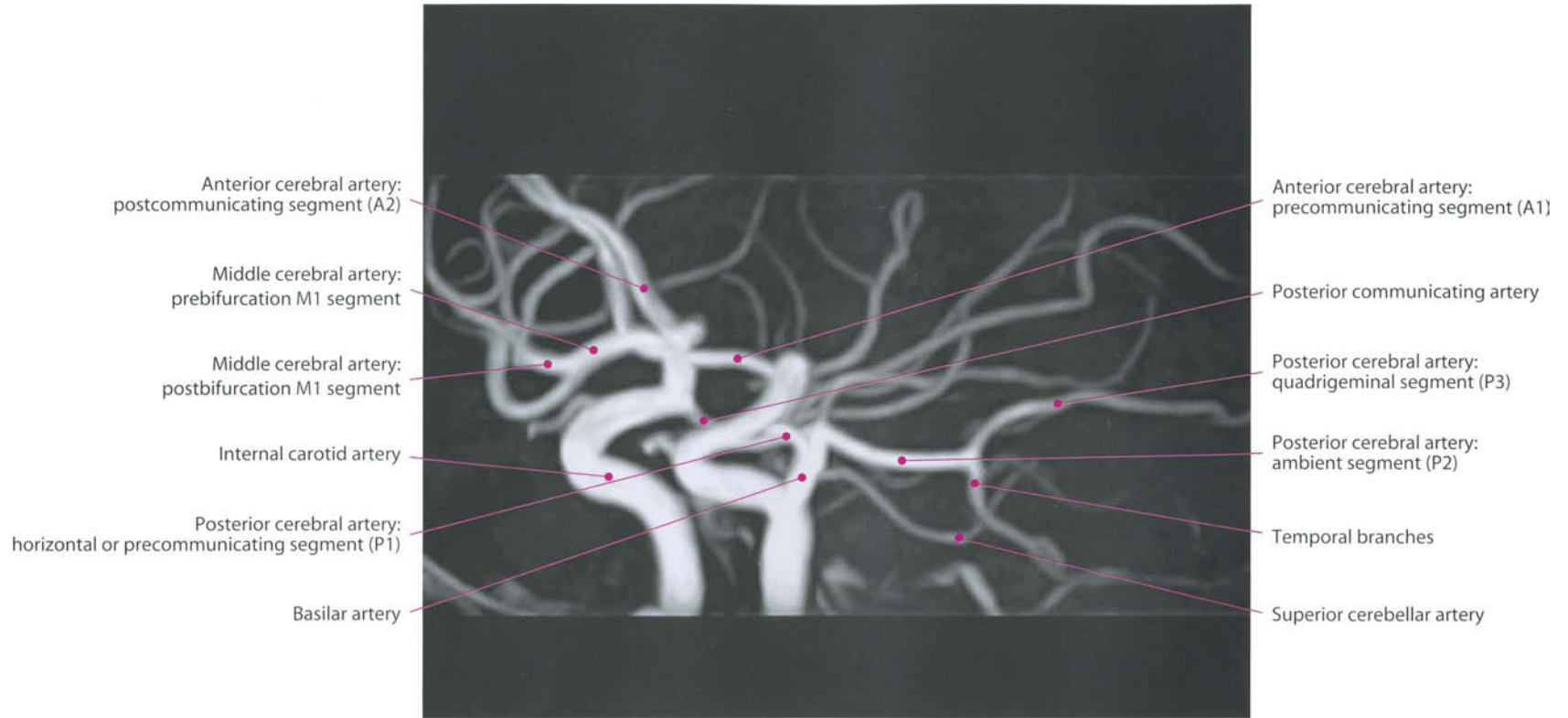


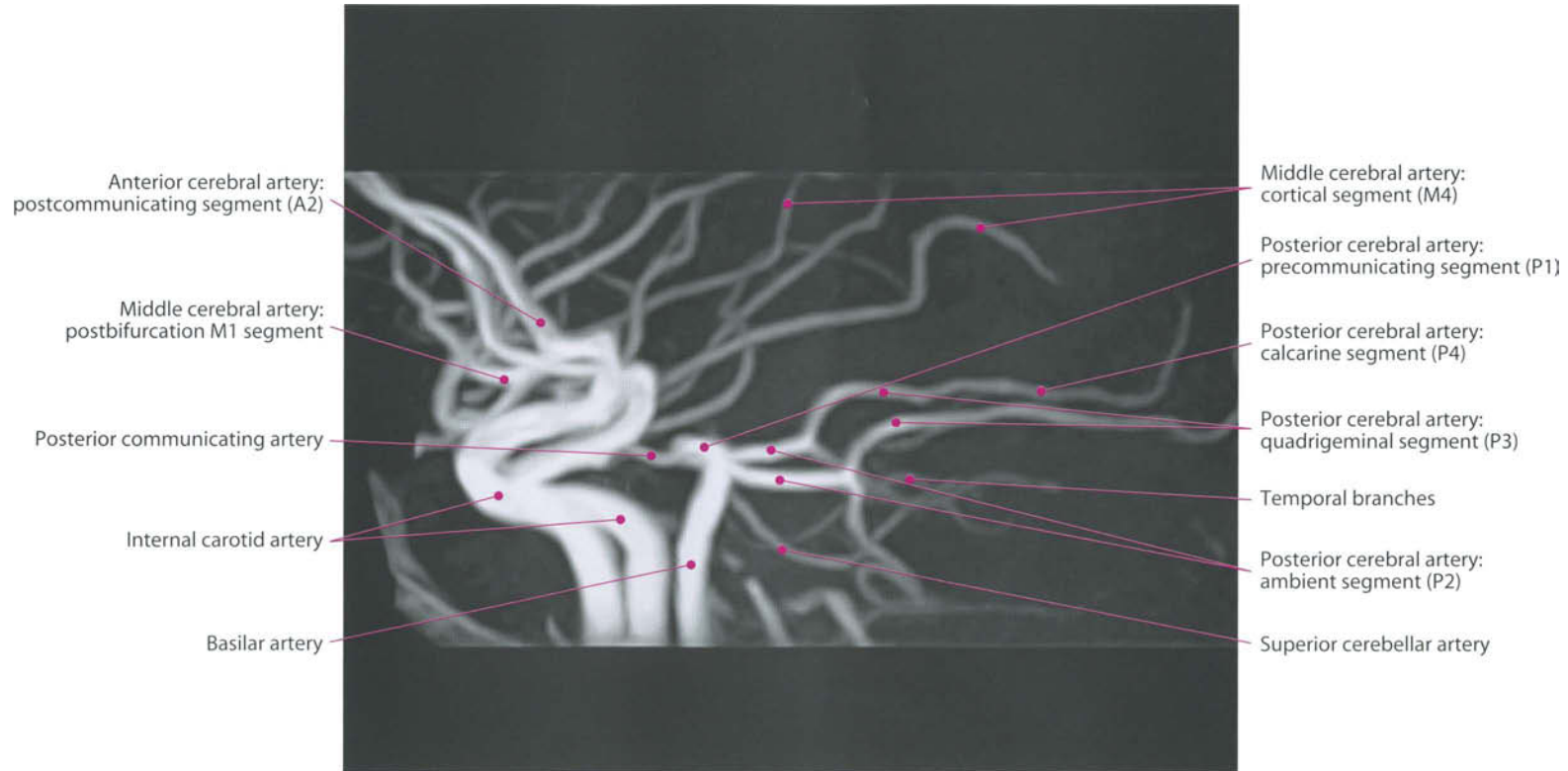


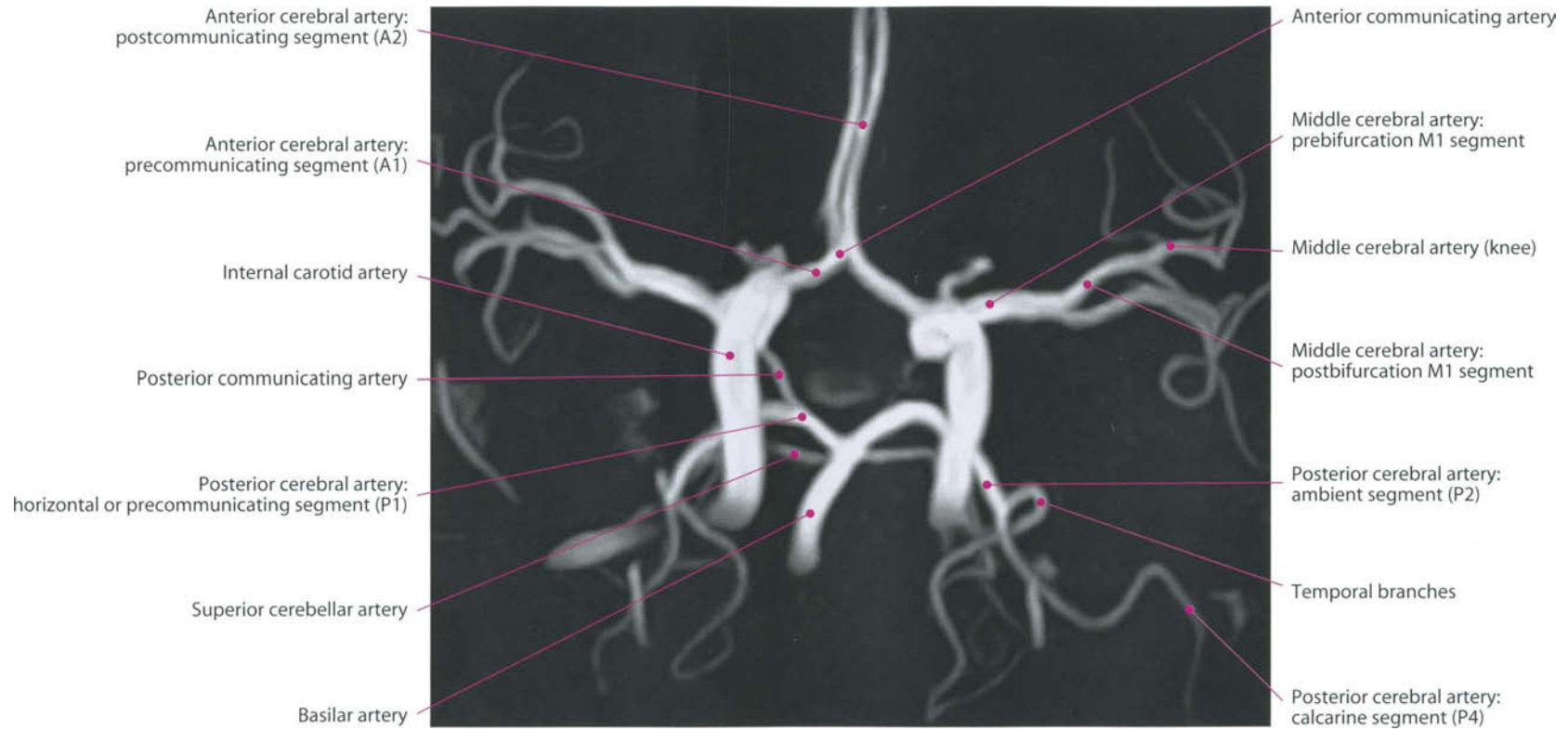


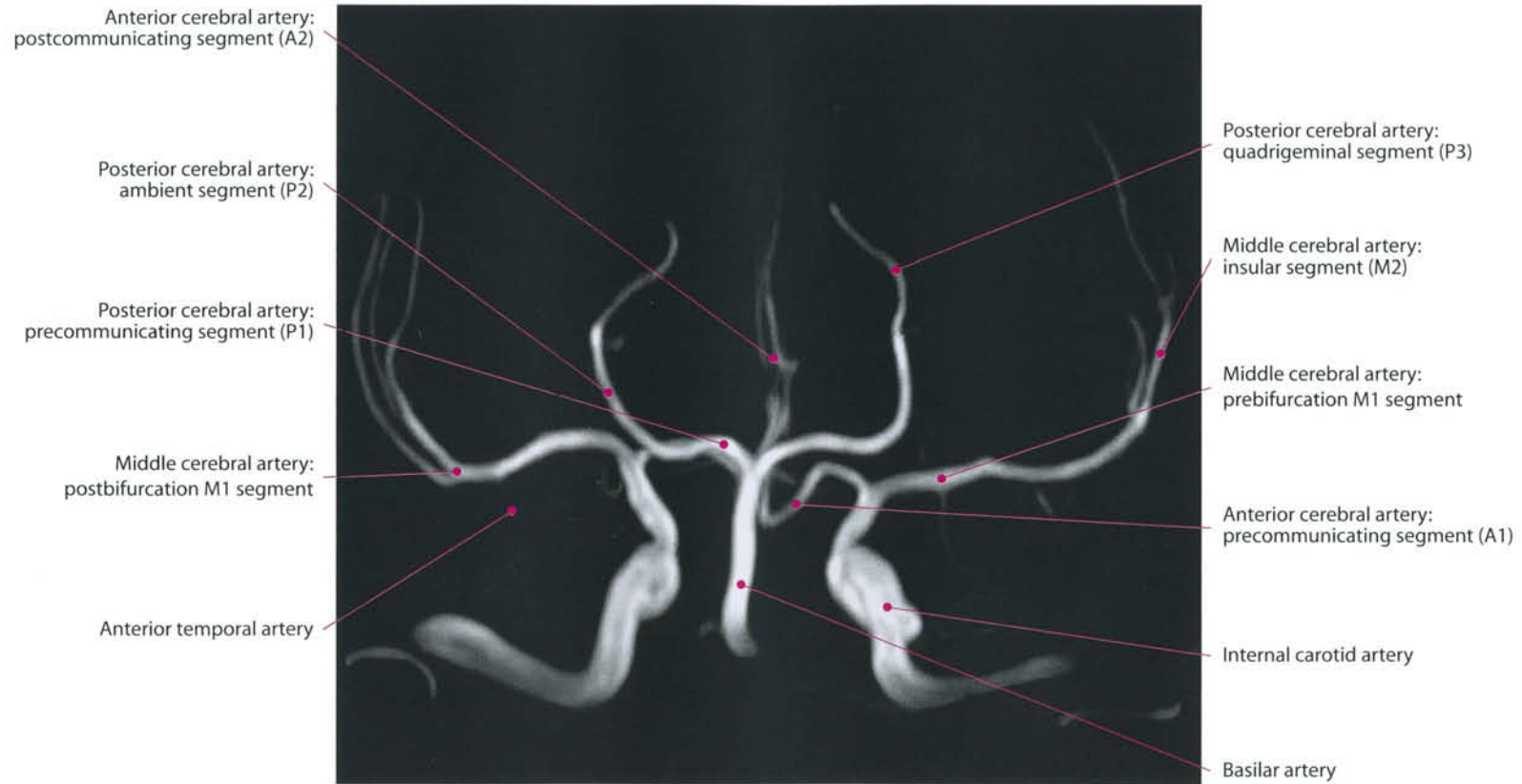


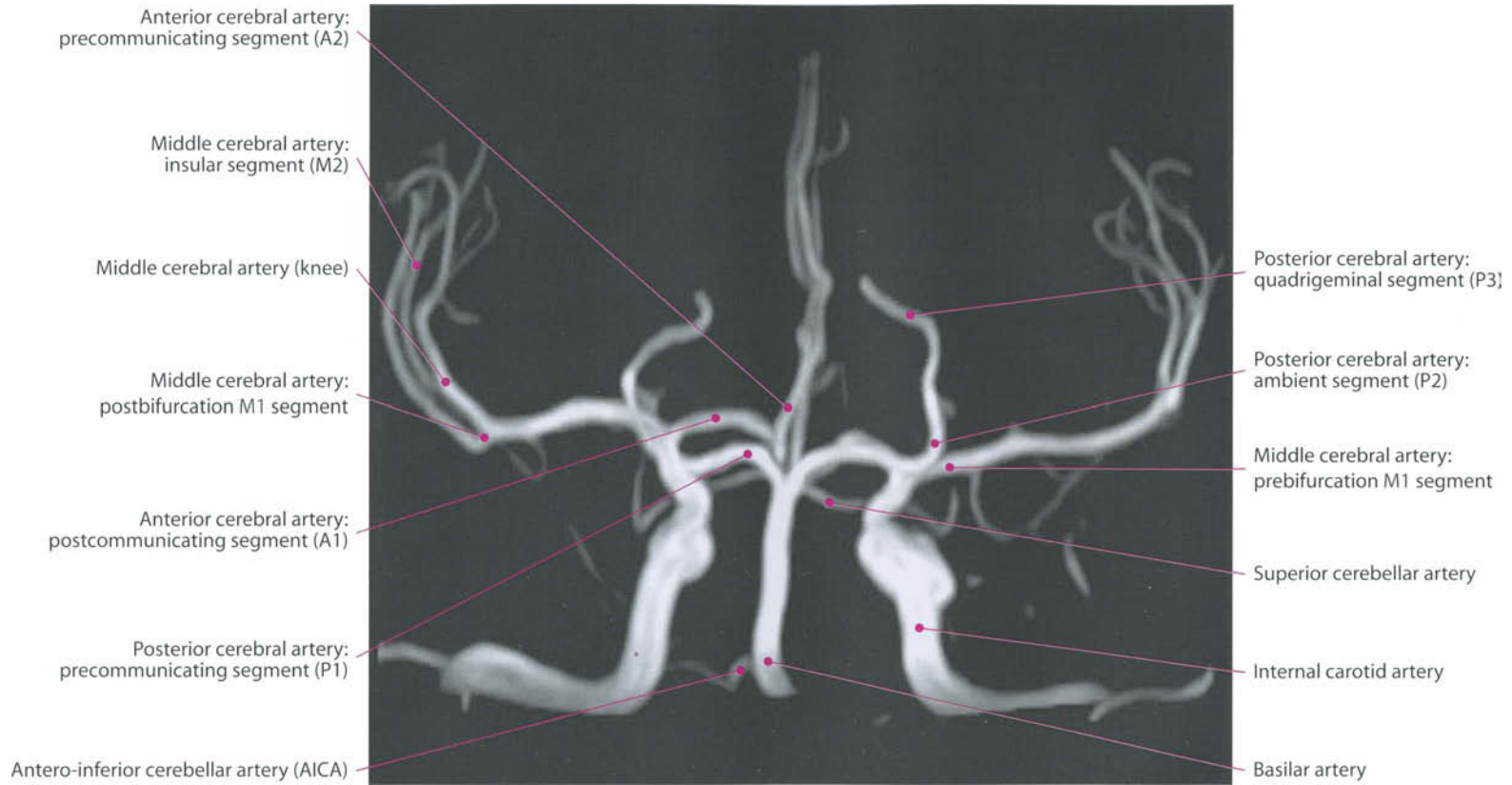


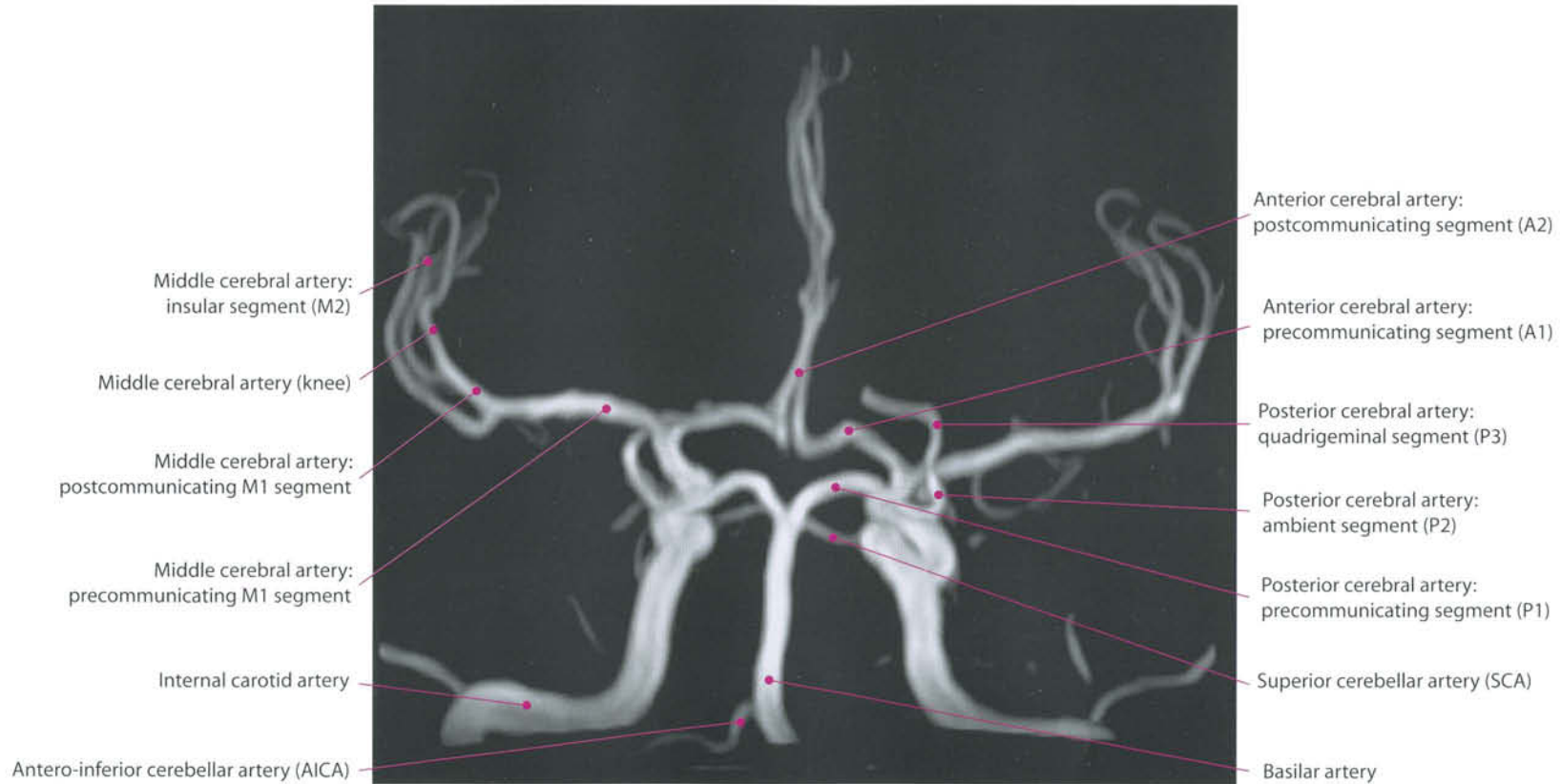


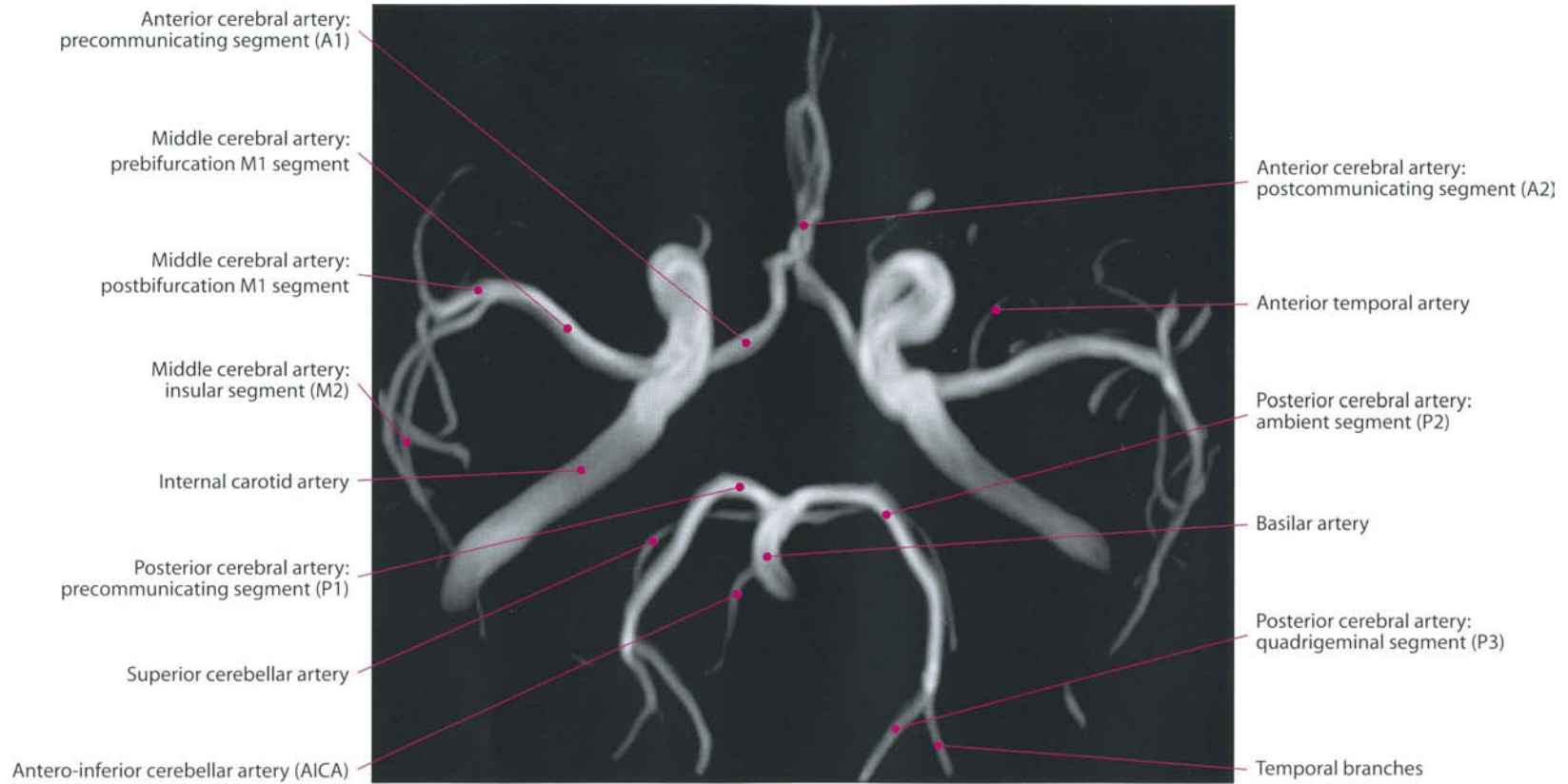




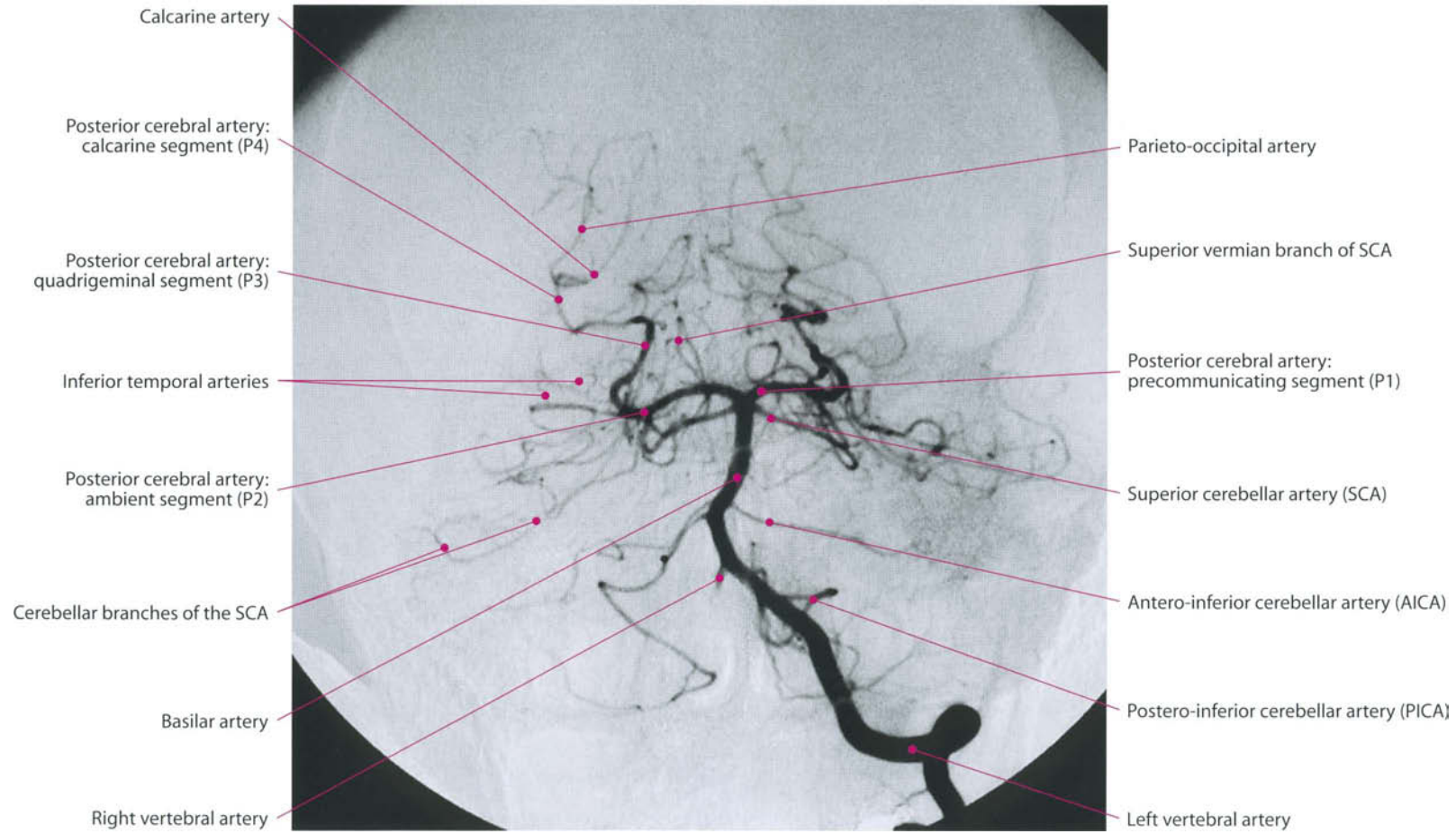




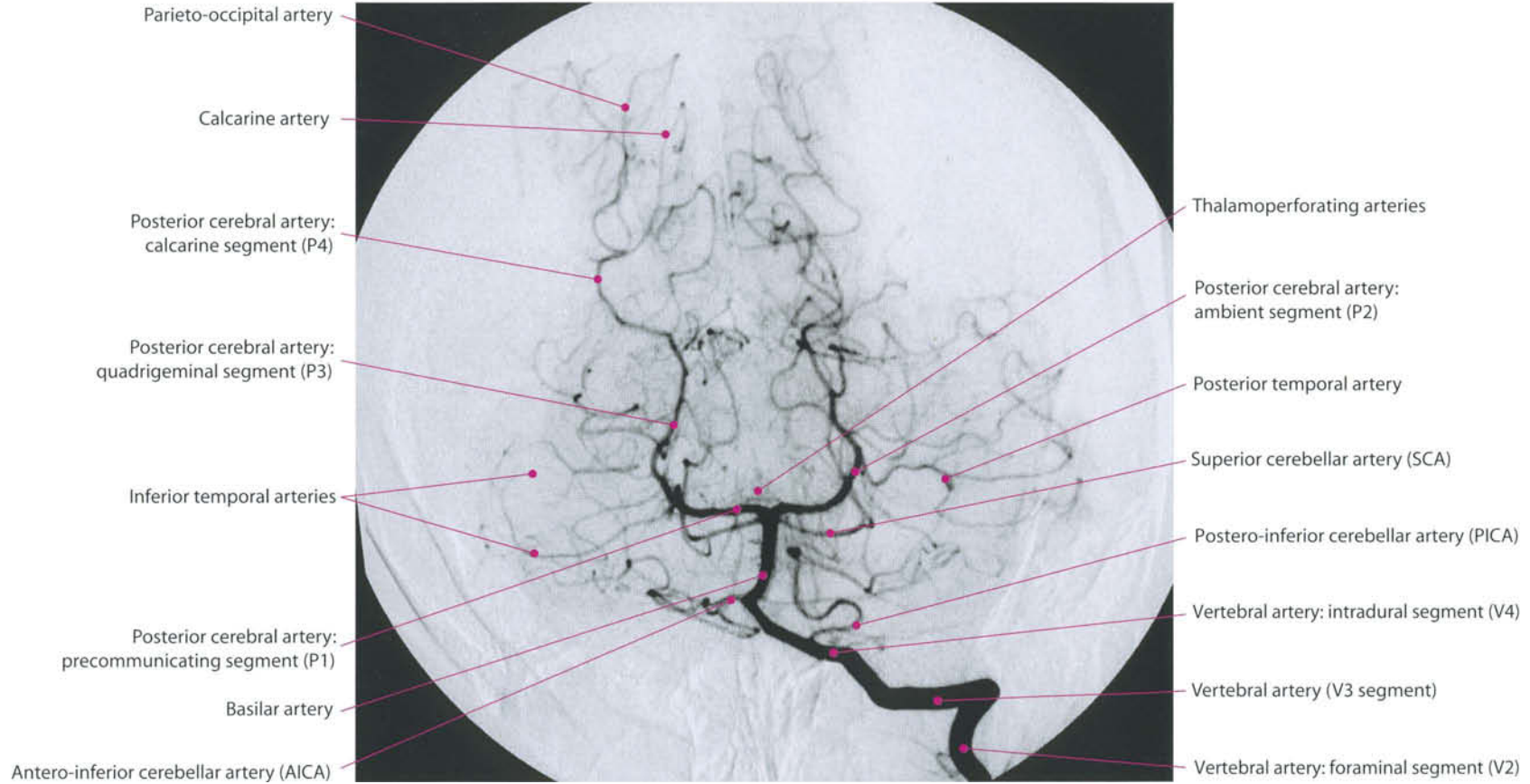




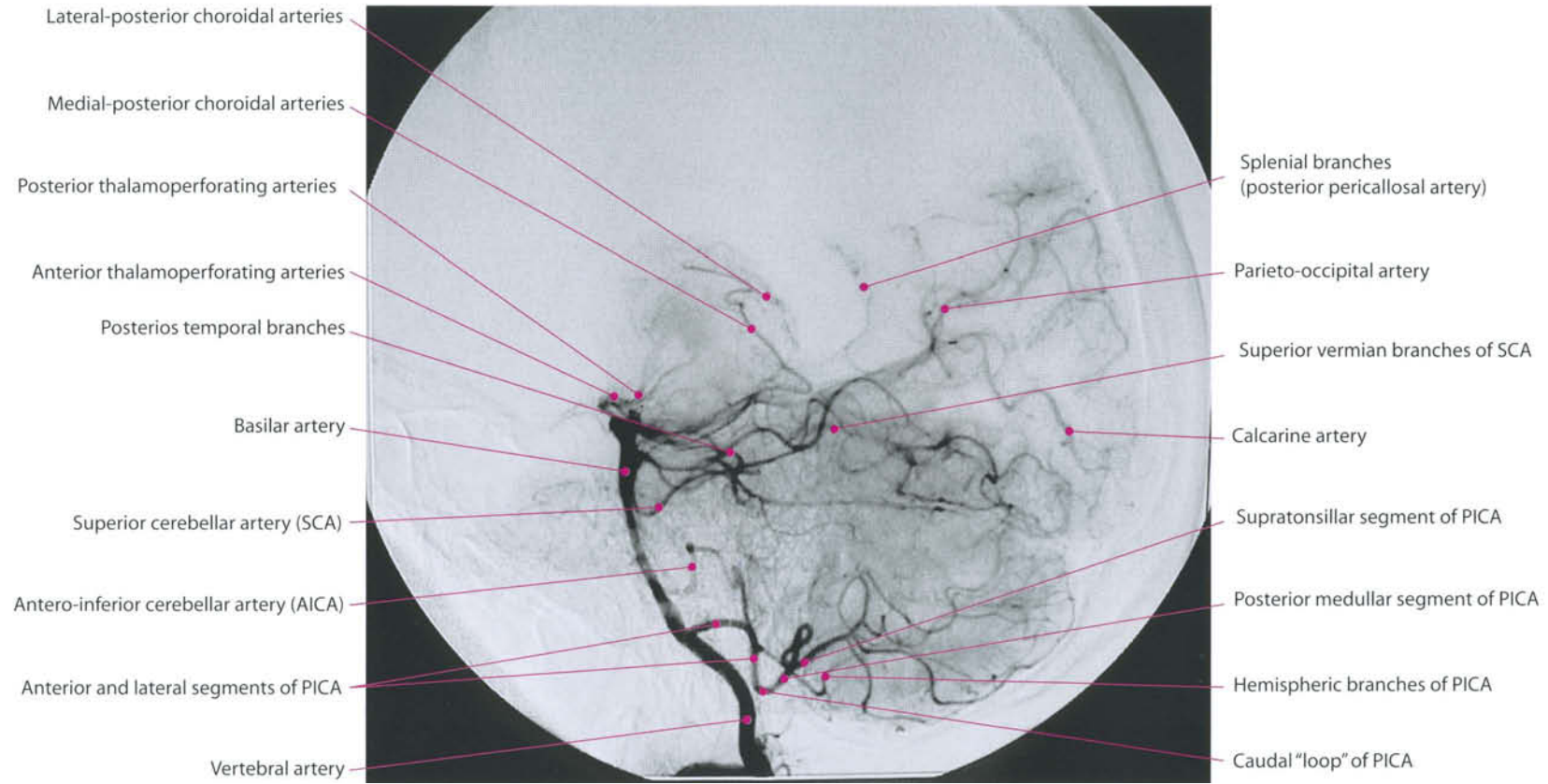
Vertebrobasilar System

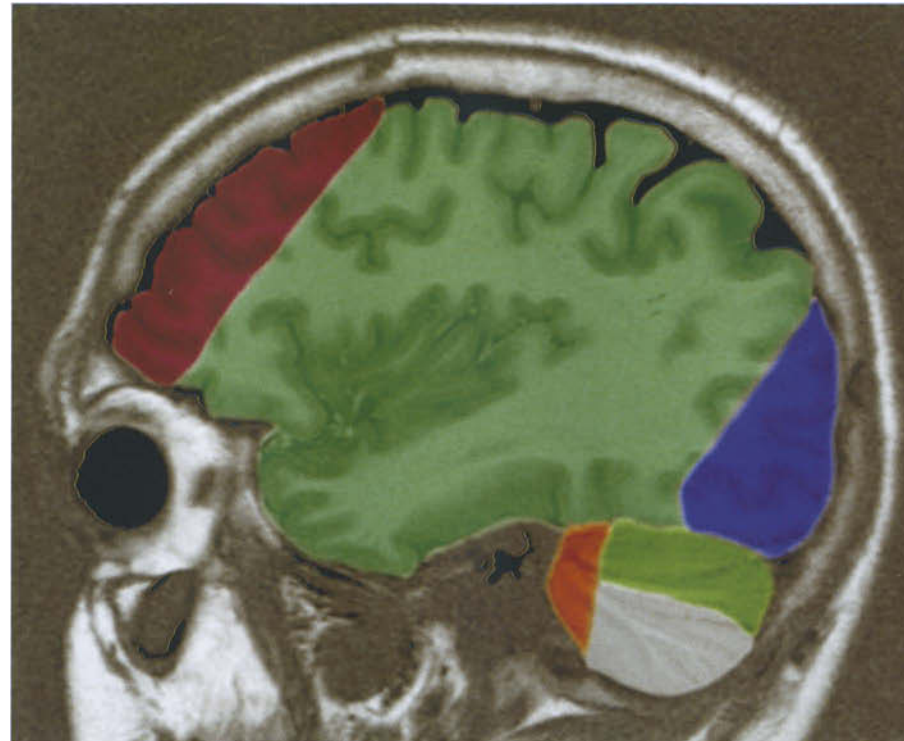


Vertebrobasilar System

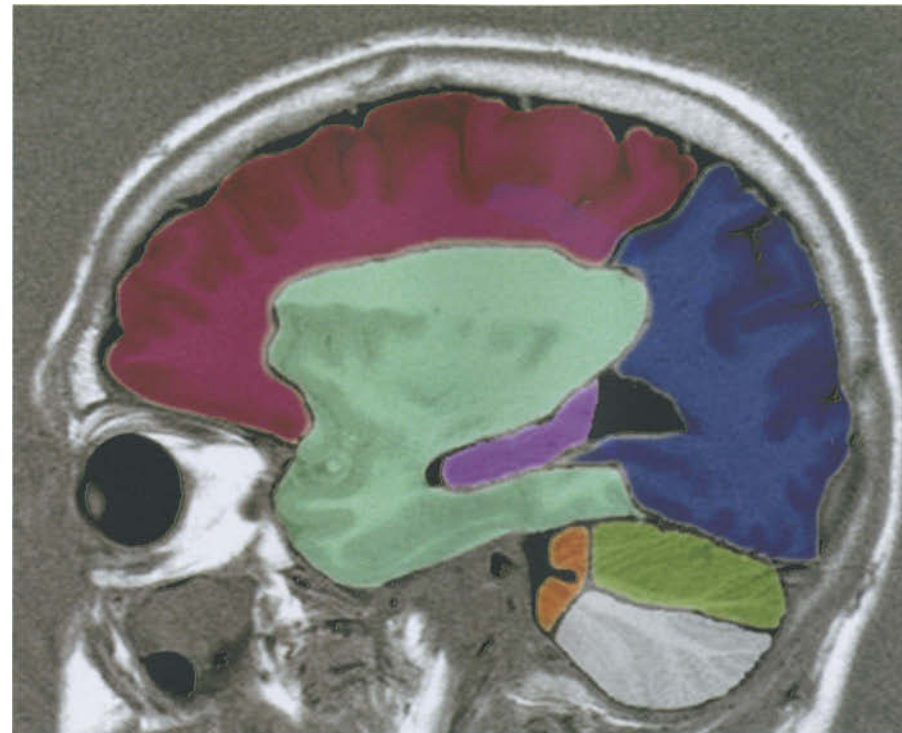


Vertebrobasilar System

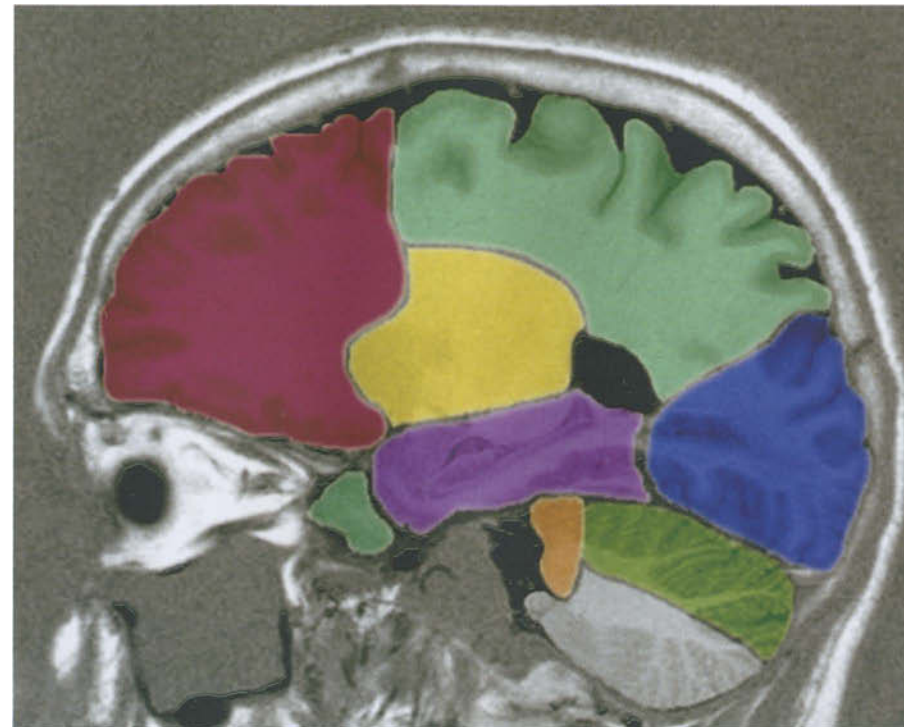




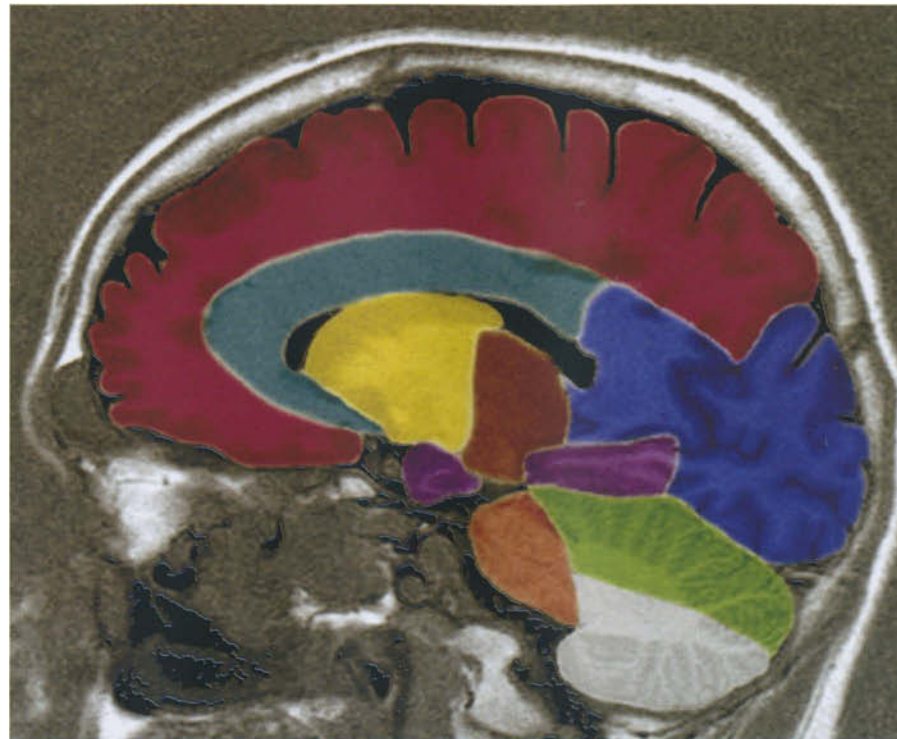
- Anterior cerebral artery
- Middle cerebral artery
- Posterior cerebral artery
- Antero-inferior cerebellar artery
- Postero-inferior cerebellar artery
- Superior cerebellar artery



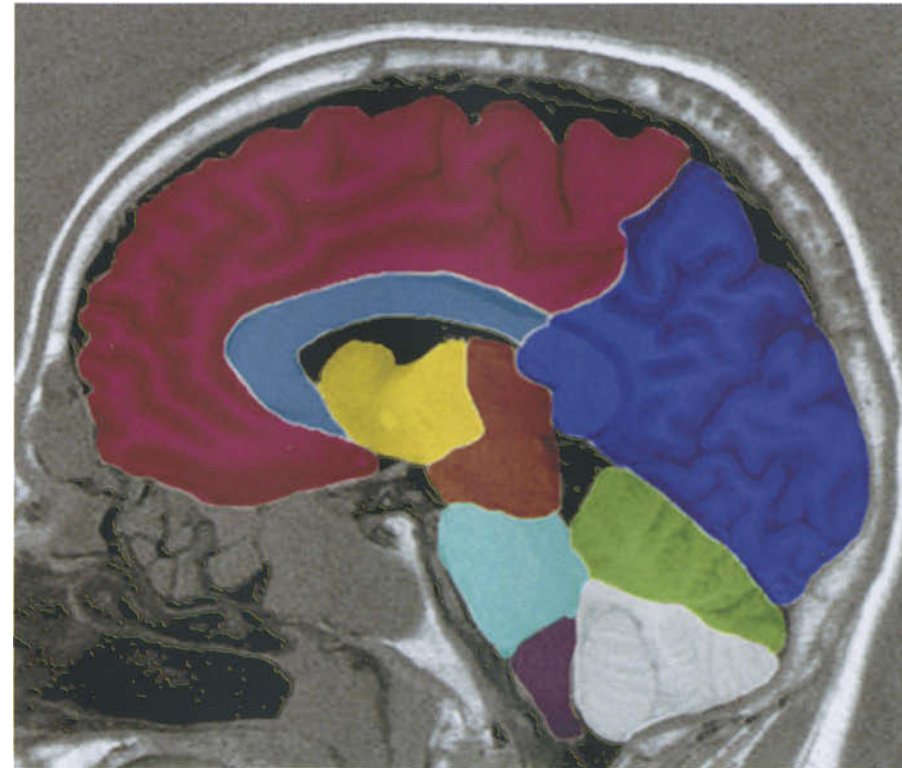
- Anterior cerebral artery
- Middle cerebral artery
- Posterior cerebral artery
- Antero-inferior cerebellar artery
- Postero-inferior cerebellar artery
- Superior cerebellar artery
- Anterior choroidal and anterior thalamoperforating arteries



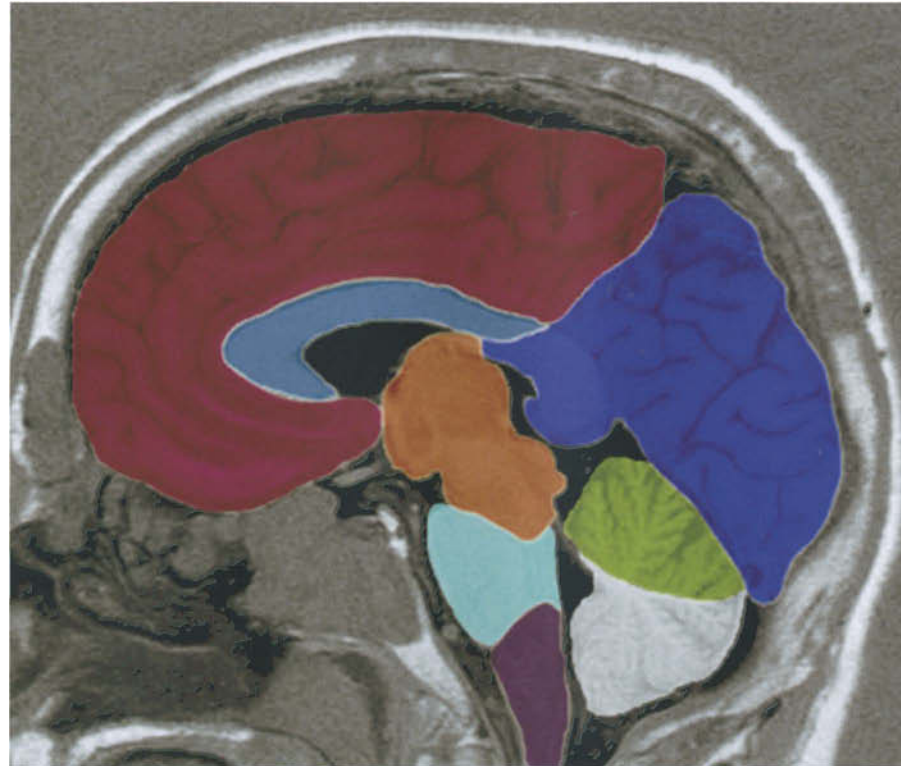
- Anterior cerebral artery
- Middle cerebral artery
- Posterior cerebral artery
- Antero-inferior cerebellar artery
- Postero-inferior cerebellar artery
- Superior cerebellar artery
- Anterior choroidal and anterior thalamoperforating arteries
- Lateral lenticulostriate branches (from middle cerebral artery)



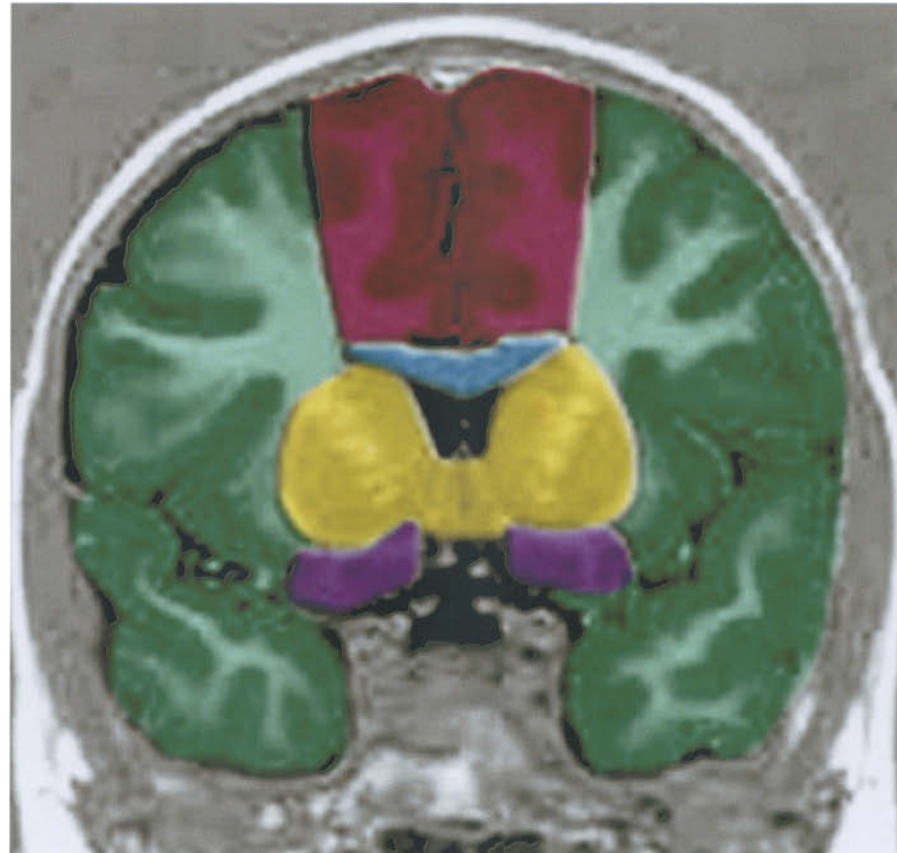
- Anterior cerebral artery
- Posterior cerebral artery
- Antero-inferior cerebellar artery
- Postero-inferior cerebellar artery
- Superior cerebellar artery
- Anterior choroidal and anterior thalamoperforating arteries
- Lenticulostriate branches (from middle cerebral artery)
- Medial lenticulostriate and callosal perforating arteries (from anterior cerebral artery)
- Posterior choroidal and posterior thalamoperforating arteries



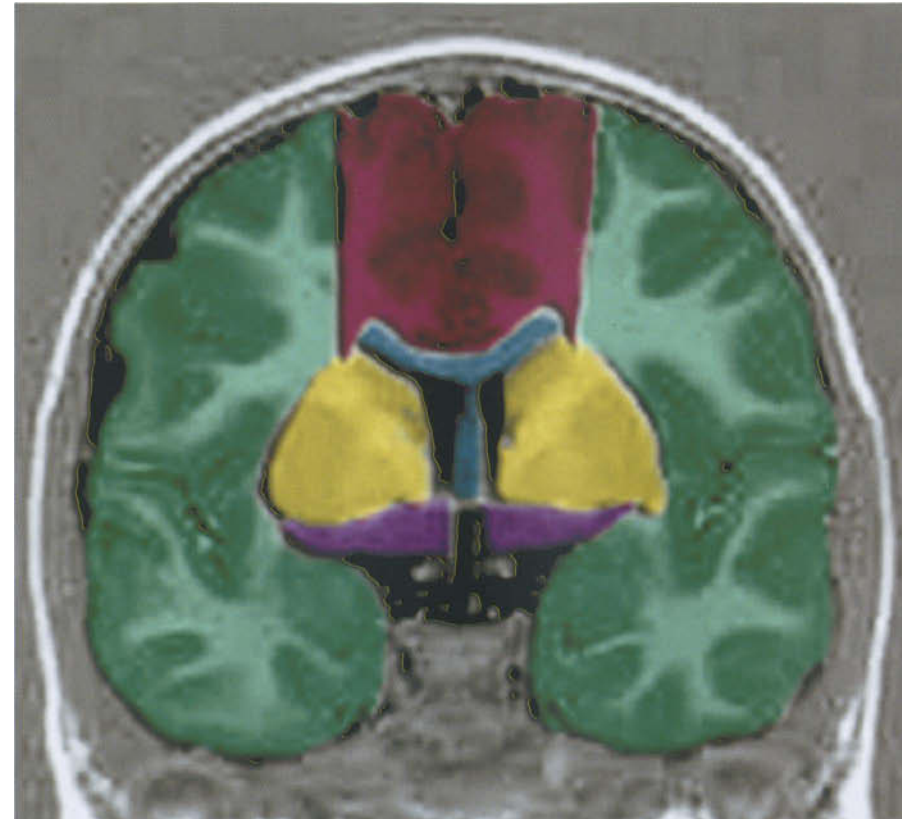- Anterior cerebral artery
- Posterior cerebral artery
- Postero-inferior cerebellar artery
- Superior cerebellar artery
- Lenticulostriate branches (from middle cerebral artery)
- Medial lenticulostriate and callosal perforating arteries (from anterior cerebral artery)
- Posterior choroidal and posterior thalamoperforating arteries
- Perforating branches of basilar artery
- Perforating branches of vertebral artery



- Anterior cerebral artery
- Posterior cerebral artery
- Postero-inferior cerebellar artery
- Superior cerebellar artery
- Medial lenticulostriate and callosal perforating arteries (from anterior cerebral artery)
- Posterior choroidal and posterior thalamoperforating arteries (from posterior cerebral artery)
- Perforating branches of basilar artery
- Perforating branches of vertebral artery



- Anterior cerebral artery
- Middle cerebral artery
- Medial lenticulostriate arteries and callosal perforating arteries (from anterior cerebral artery)
- Lateral lenticulostriate branches (from middle cerebral artery)
- Anterior choroidal and anterior thalamoperforating arteries



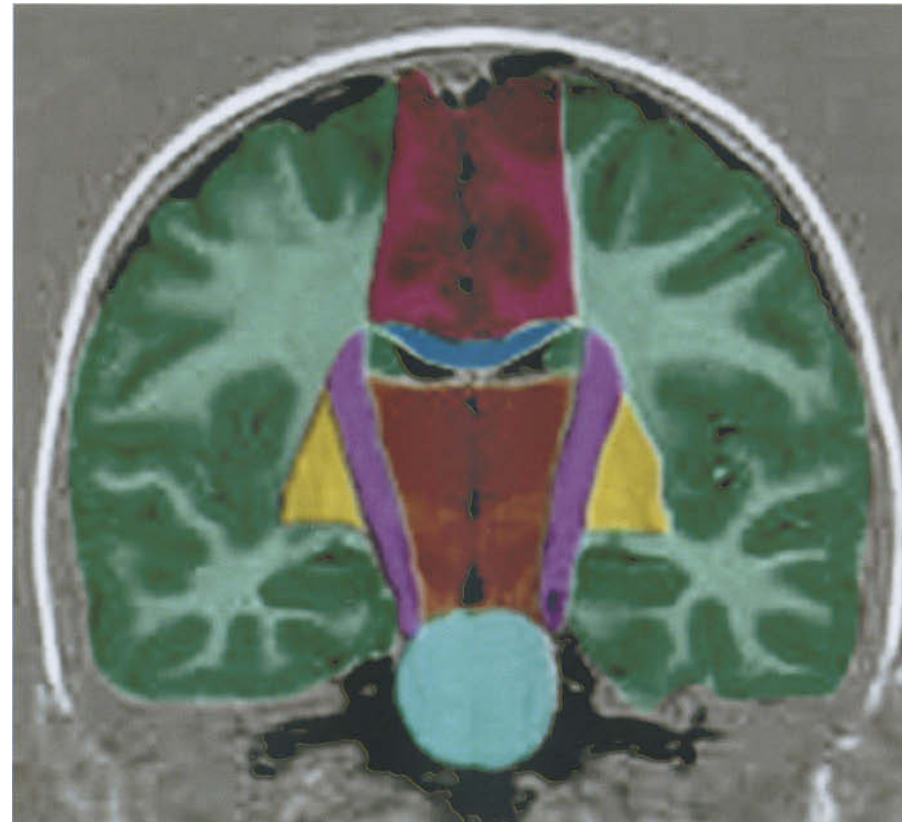● Anterior cerebral artery

● Middle cerebral artery

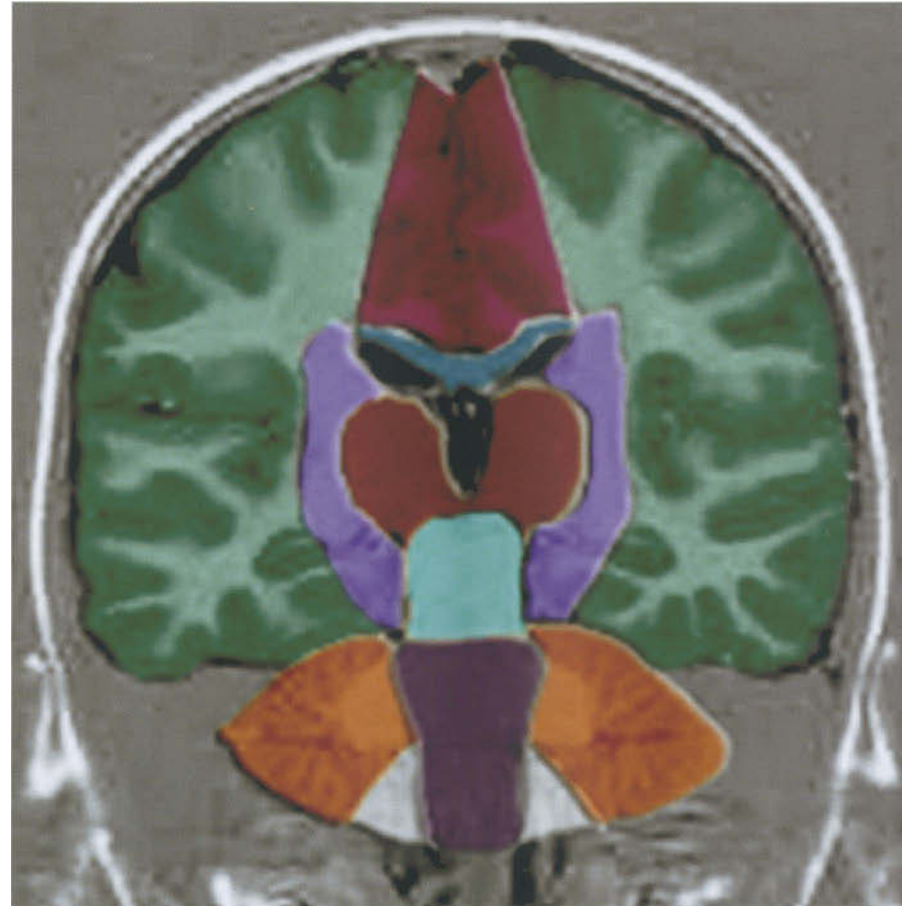
● Medial lenticulostriate arteries
and callosal perforating arteries
(from anterior cerebral artery)

● Lateral lenticulostriate branches
(from middle cerebral artery)

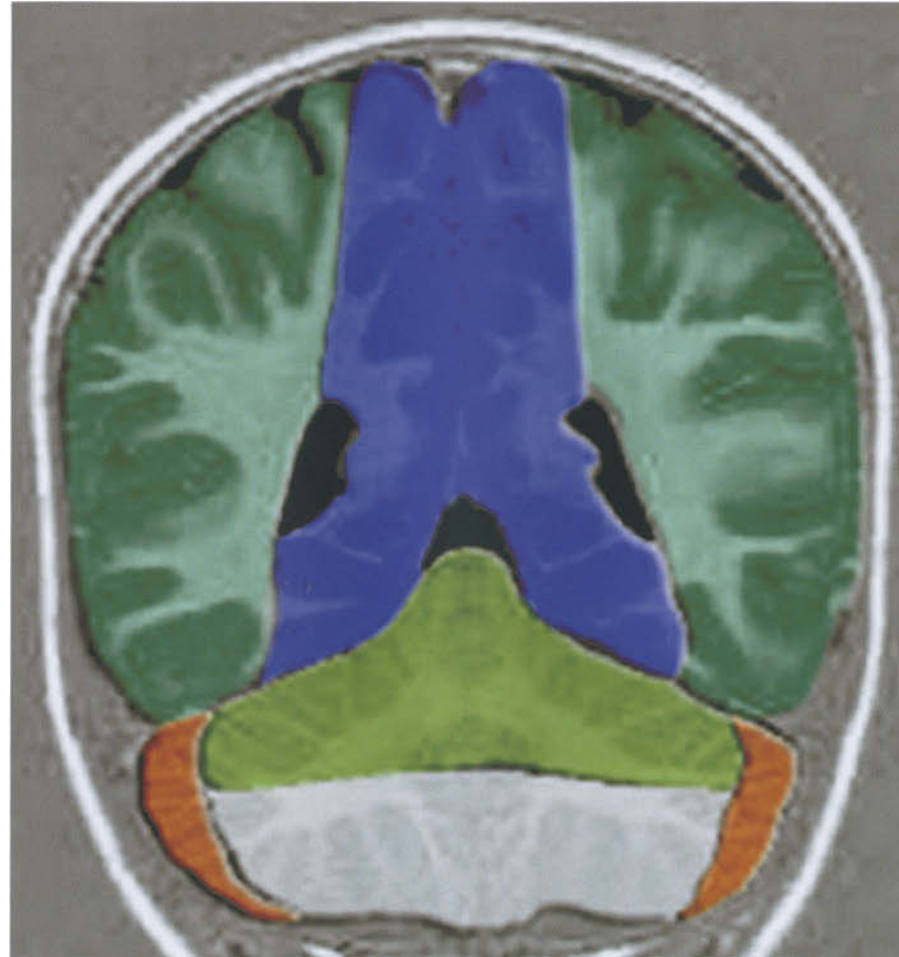
● Anterior choroidal and anterior
thalamoperforating arteries



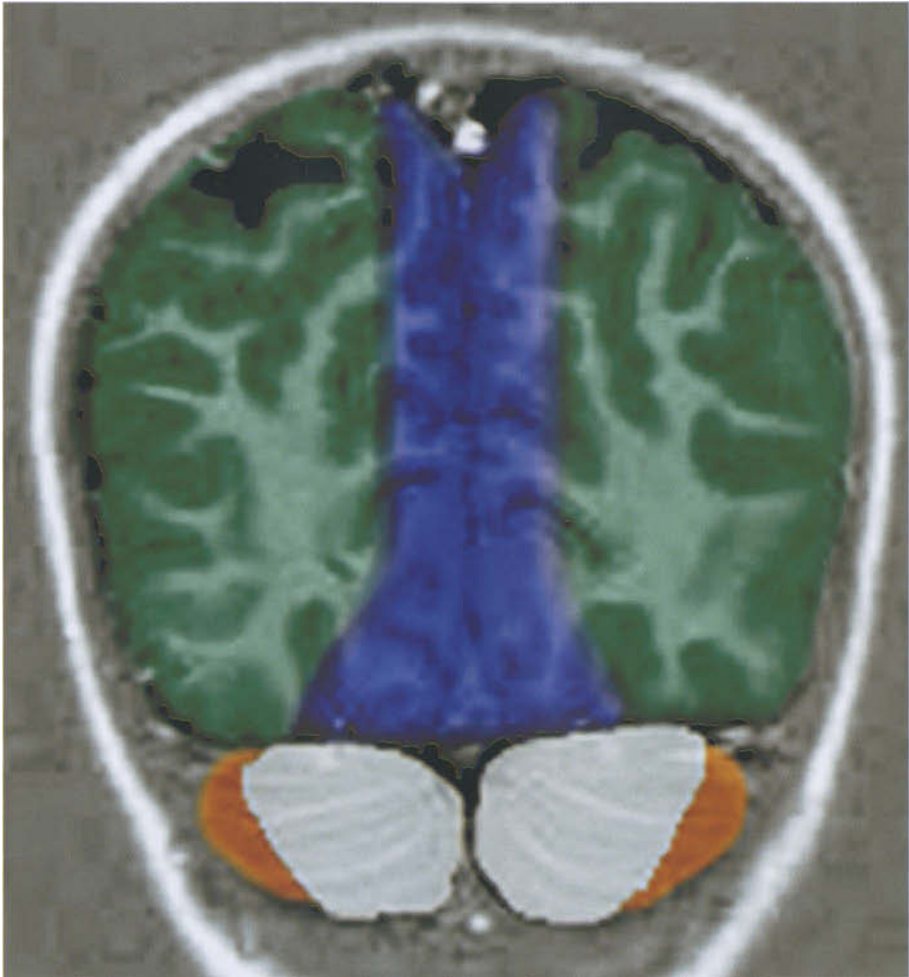- Anterior cerebral artery
- Middle cerebral artery
- Medial lenticulostriate and callosal perforating arteries (from anterior cerebral artery)
- Lateral lenticulostriate branches (from middle cerebral artery)
- Anterior choroidal and anterior thalamoperforating arteries
- Posterior choroidal and posterior thalamoperforating arteries (from posterior cerebral artery)
- Perforating branches of the basilar artery



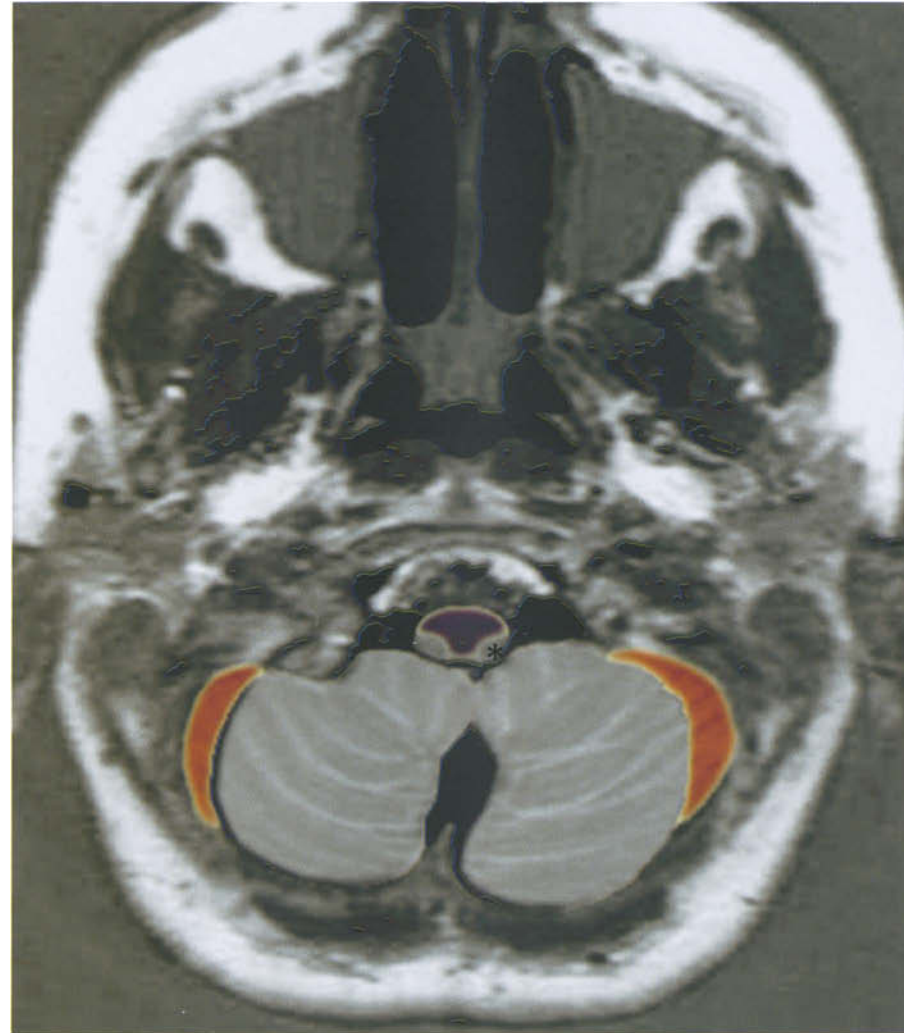
- Anterior cerebral artery
- Middle cerebral artery
- Medial lenticulostriate and callosal perforating arteries (from middle cerebral artery)
- Anterior choroidal and anterior thalamoperforating arteries
- Posterior choroidal and posterior thalamoperforating arteries (from posterior cerebral artery)
- Perforating branches of the basilar artery
- Antero-inferior cerebellar artery
- Postero-inferior cerebellar artery
- Perforating branches of the vertebral artery



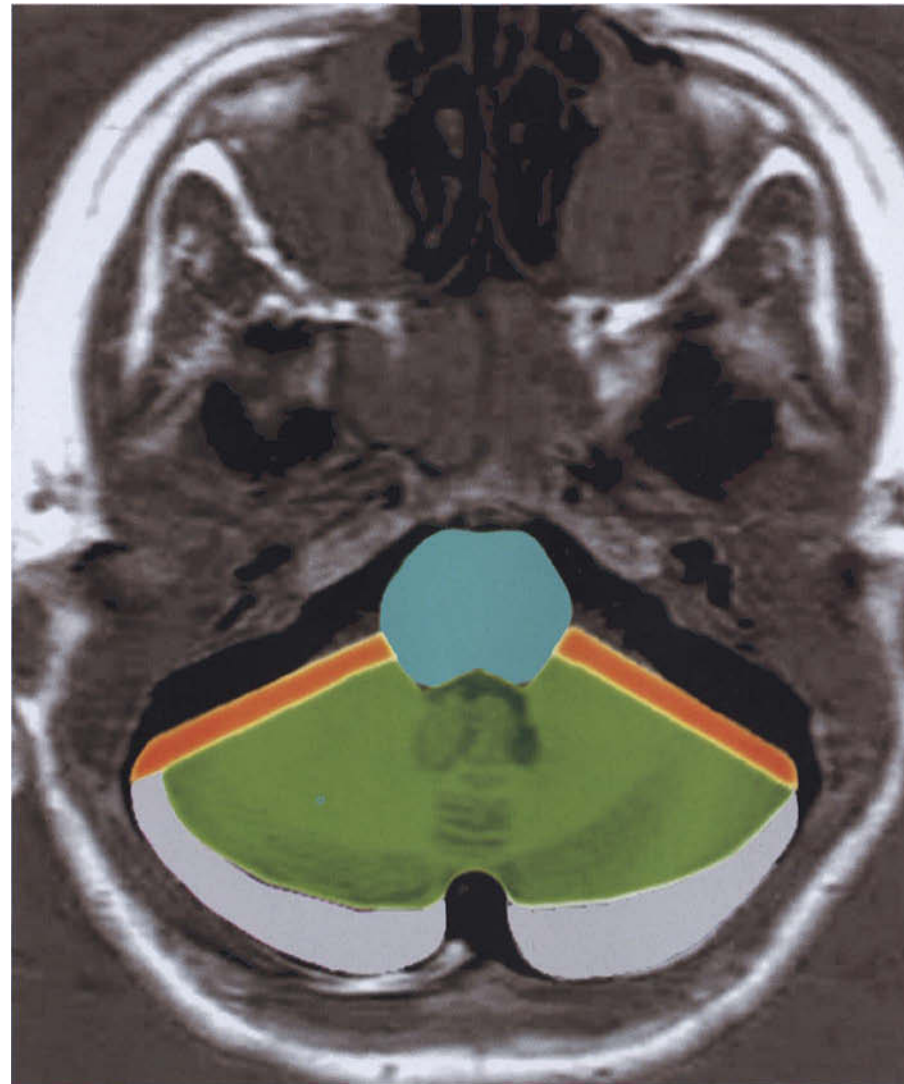
- Middle cerebral artery
- Posterior cerebral artery
- Antero-inferior cerebellar artery
- Postero-inferior cerebellar artery
- Superior cerebellar artery



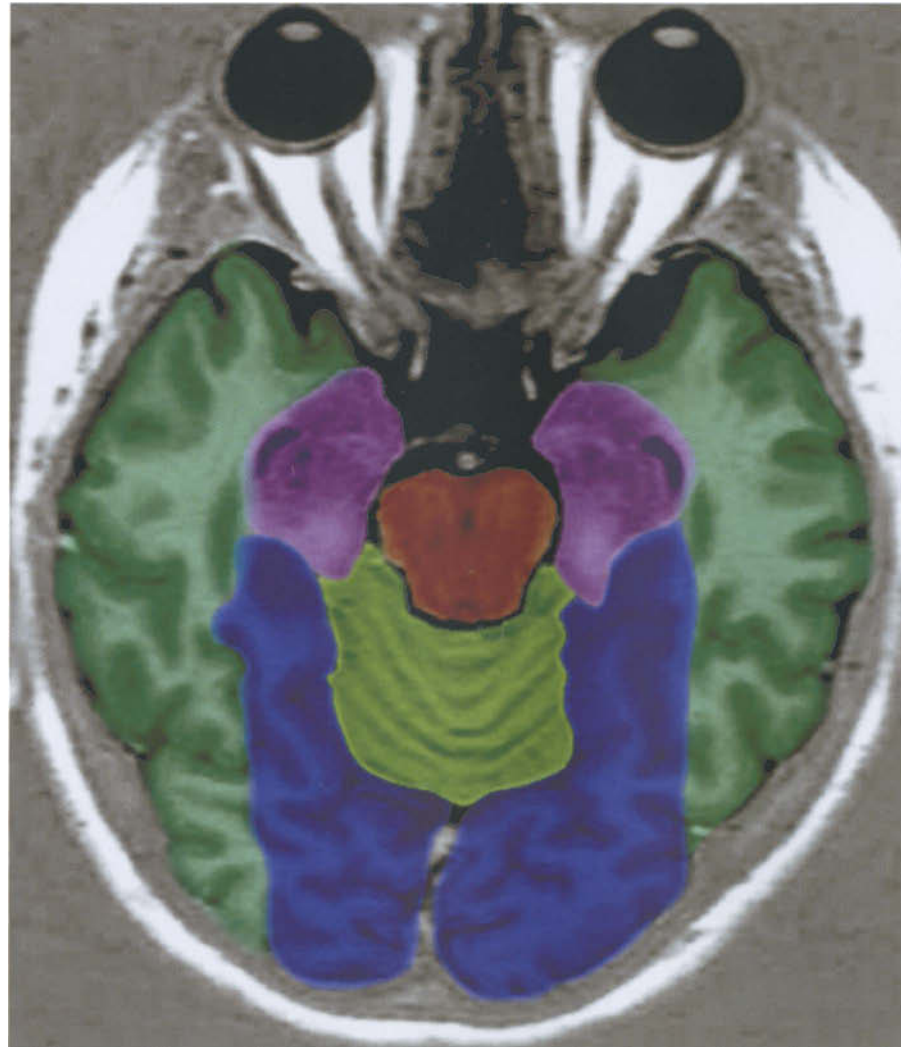- Middle cerebral artery
- Posterior cerebral artery
- Antero-inferior cerebellar artery
- Postero-inferior cerebellar artery



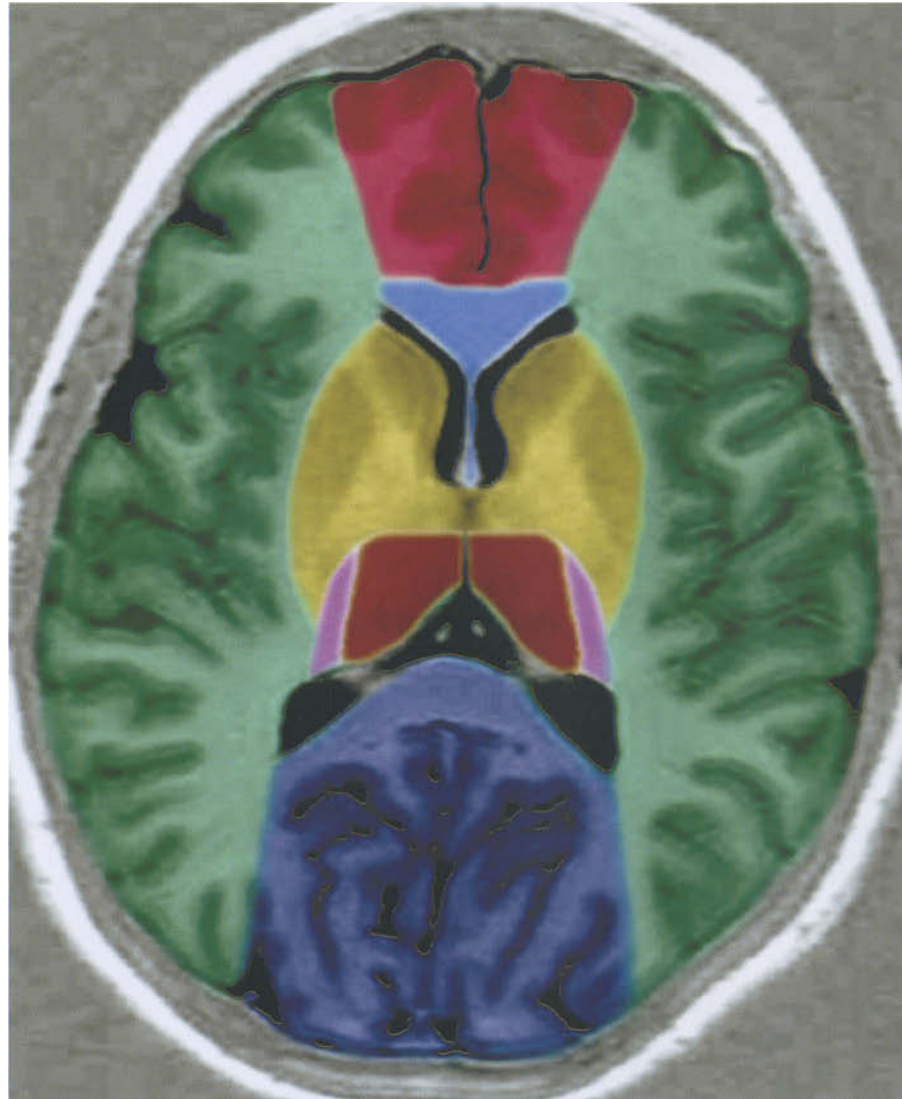- Perforating branches of vertebral artery
- Antero-inferior cerebellar artery
- Postero-inferior cerebellar artery (* lateral medullary segment)



- Postero-inferior cerebellar artery
- Antero-inferior cerebellar artery
- Superior cerebellar artery
- Perforating branches of basilar artery



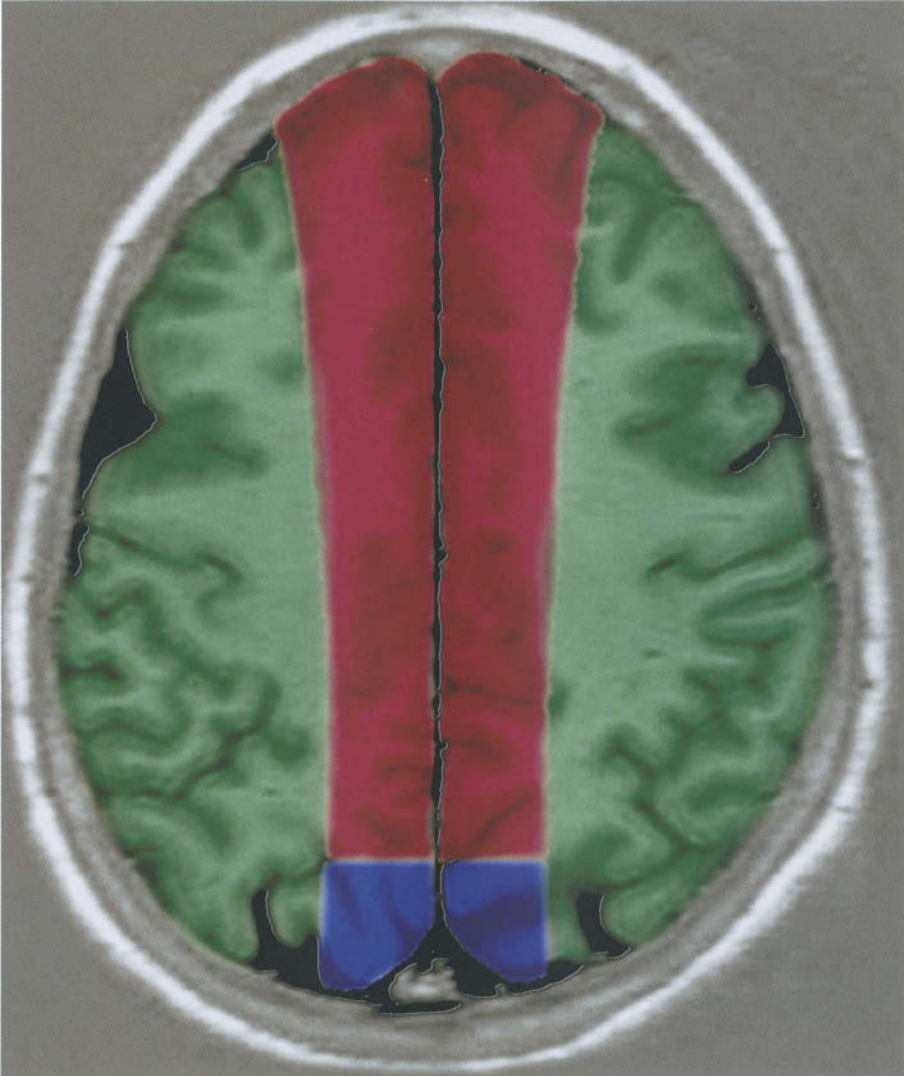
- Superior cerebellar artery
- Posterior cerebral artery
- Anterior choroidal and anterior thalamoperforating arteries
- Posterior choroidal and anterior thalamoperforating arteries
- Middle cerebral artery



- Posterior cerebral artery
- Anterior choroidal and anterior thalamoperforating arteries
- Posterior choroidal and posterior thalamoperforating arteries (from posterior cerebral artery)
- Middle cerebellar artery
- Anterior cerebral artery
- Medial lenticulostriate and callosal perforating arteries (from anterior cerebral artery)
- Lateral lenticulostriate branches (from middle cerebral artery)

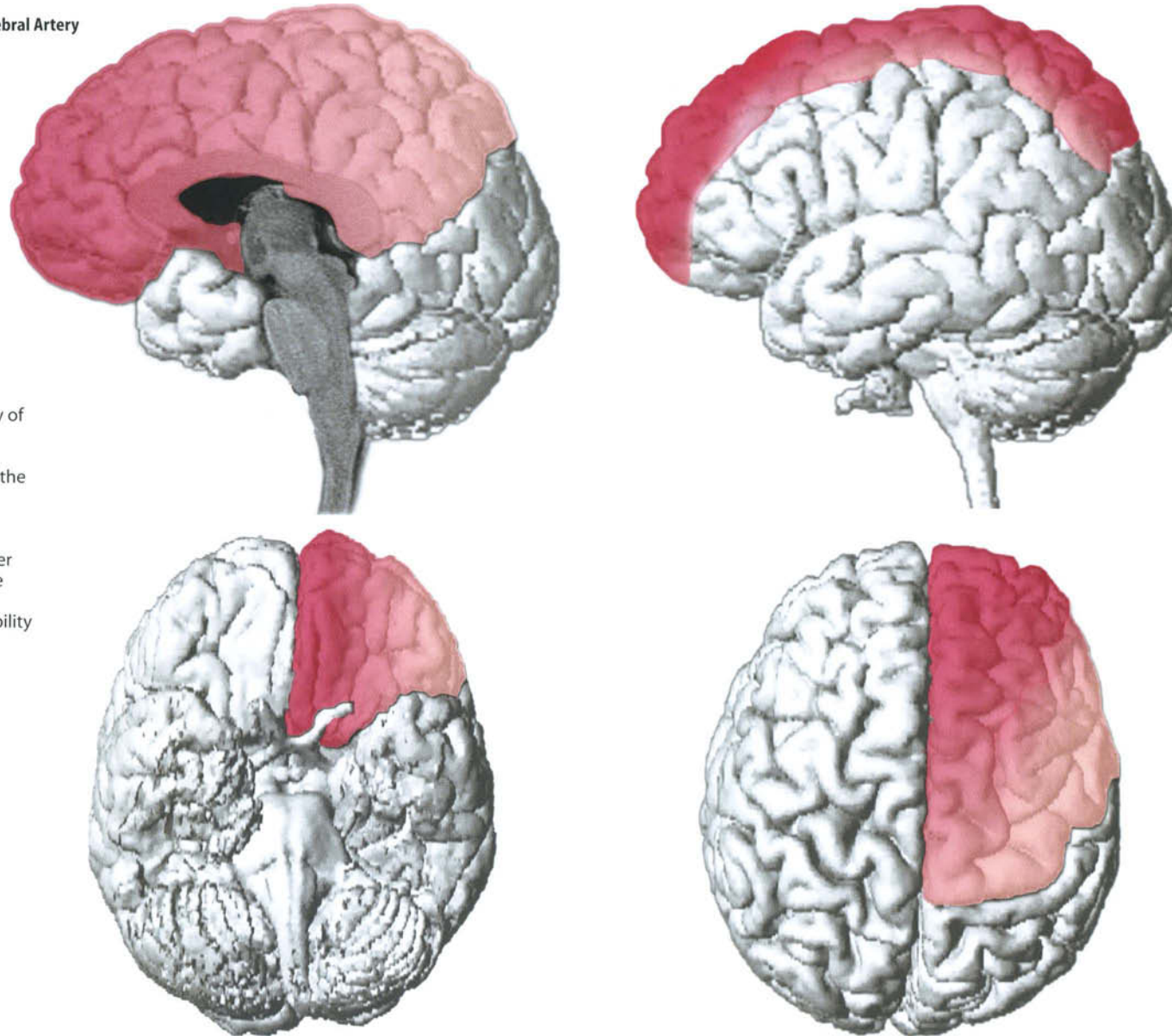


- Posterior cerebral artery
- Anterior choroidal and anterior thalamoperforating arteries
- Middle cerebral artery
- Anterior cerebral artery
- Medial lenticulostriate and callosal perforating branches (from anterior cerebral artery)
- Lateral lenticulostriate branches (from middle cerebral artery)



- Posterior cerebral artery
- Middle cerebral artery
- Anterior cerebral artery

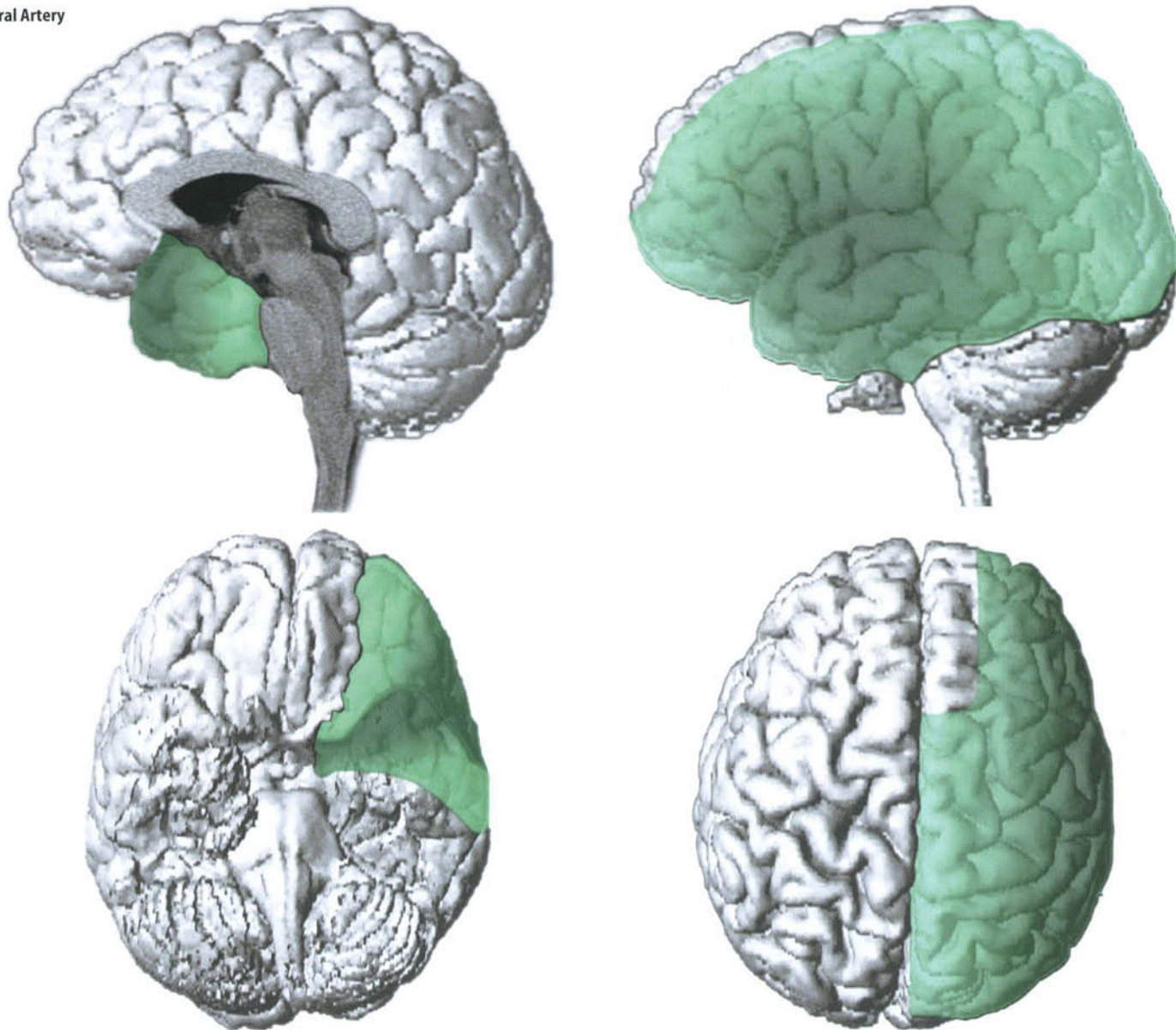
Vascular Territories: Anterior Cerebral Artery



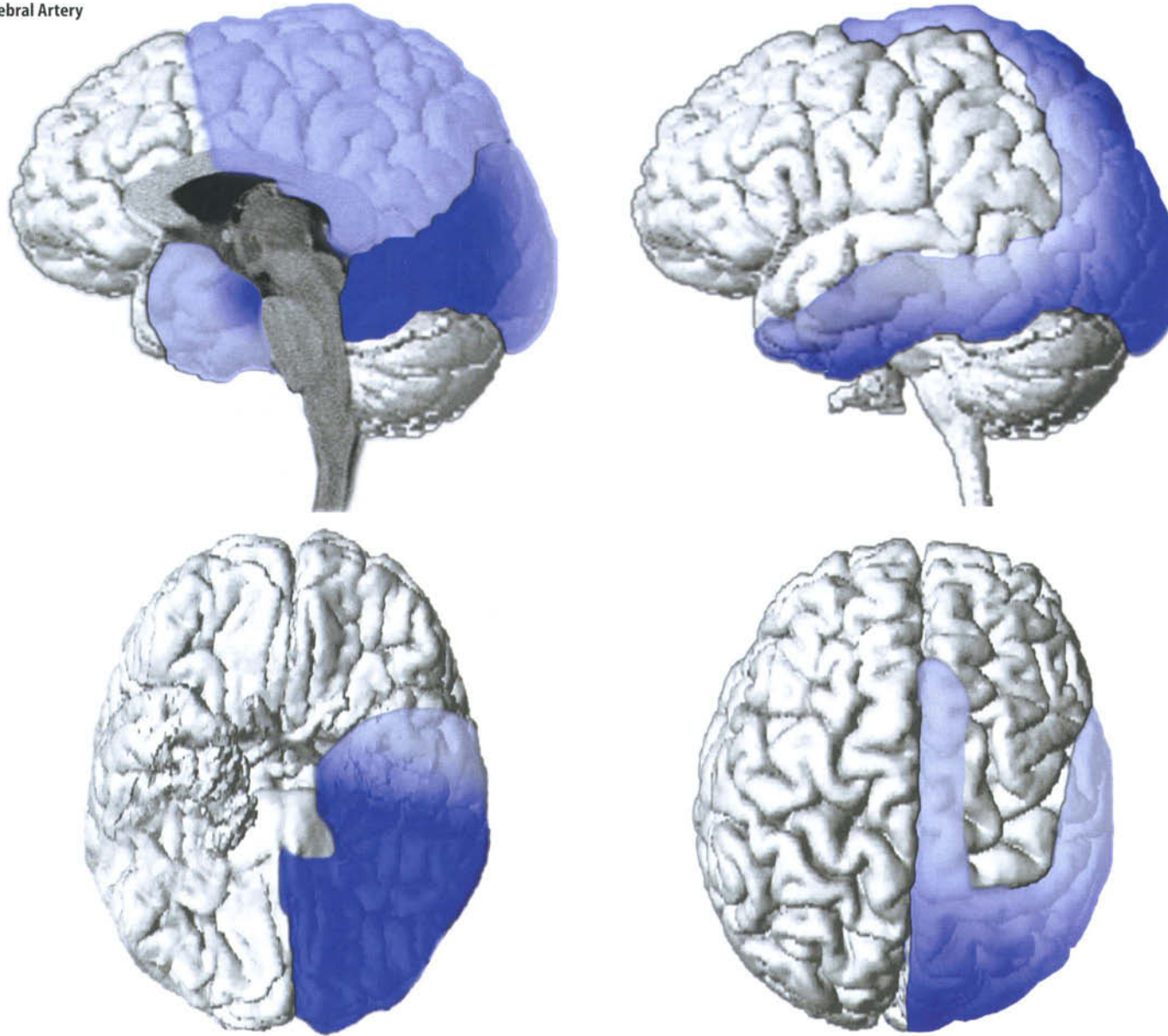
Vascular Territories

The color intensity is directly proportional to the frequency of distribution. For example, in this case, the area in dark red indicates the distribution of the anterior cerebral artery identifiable in 100% of the population. The surrounding area in lighter shades expresses the possible extension of vascularity in relation to individual variability in progressively decreasing percentages.

Vascular Territories: Middle Cerebral Artery



Vascular Territories: Posterior Cerebral Artery



Veins and Dural Sinuses

I. Cerebral Veins

The cerebral veins are divided into two groups: external and internal, depending on whether they drain the outer or inner parts of the brain.

The external veins are the superior, middle and inferior cerebral veins.

The superior cerebral veins (vv. cerebri superiores), eight to twelve in number, drain the superior, lateral, and medial surfaces of the hemispheres. They open into the superior sagittal sinus.

The middle cerebral vein (v. cerebri media; superficial sylvian vein) runs along the lateral cerebral fissure and ends in the cavernous sinus. It is connected with the superior sagittal sinus through the great anastomotic vein of Trolard, which opens into one of the superior cerebral veins; with the transverse sinus through the posterior anastomotic vein of Labbé, which passes over the temporal lobe.

The inferior cerebral veins drain the lower surfaces of the hemispheres. Those on the orbital surface of the frontal lobe join the superior cerebral veins, and the superior sagittal sinus; the temporal ones drain into the middle cerebral and basal veins.

The basal vein is formed at the anterior perforated substance by the union of a small anterior cerebral vein, the deep middle (deep sylvian) cerebral vein, and the inferior striate veins. The basal vein goes around the cerebral peduncle and ends in the internal cerebral vein (vein of Galen); it receives small veins from the interpeduncular fossa, the hippocampal gyrus, and the midbrain.

The internal cerebral vein (vv. cerebri interna) is formed by the choroid vein and the terminal vein (v. terminalis; vena corporis striati). The former originates between the corpus striatum and the thalamus, and drains the deep parts of the hemisphere. Beneath the splenium of the corpus callosum the internal cerebral vein joins the contralateral, and receives the corresponding basal vein, thus forming the great cerebral vein (v. cerebri magna; great vein of Galen).

The cerebellar veins are arranged in two sets: superior and inferior. *The superior cerebellar veins* cross the superior vermian surface, and end in the straight sinus and the inter-

nal cerebral veins. *The inferior cerebellar veins* end in the transverse, superior petrosal, and occipital sinuses.

II. Dural Sinuses

The dural sinuses are blood channels situated between the two layers of the dura mater and covered by endothelium that is continuous with that of the veins. They are:

Superior sagittal, inferior sagittal, straight, transverse, sigmoid, occipital, cavernous, superior petrosal, intercavernous, inferior petrosal, basilar plexus.

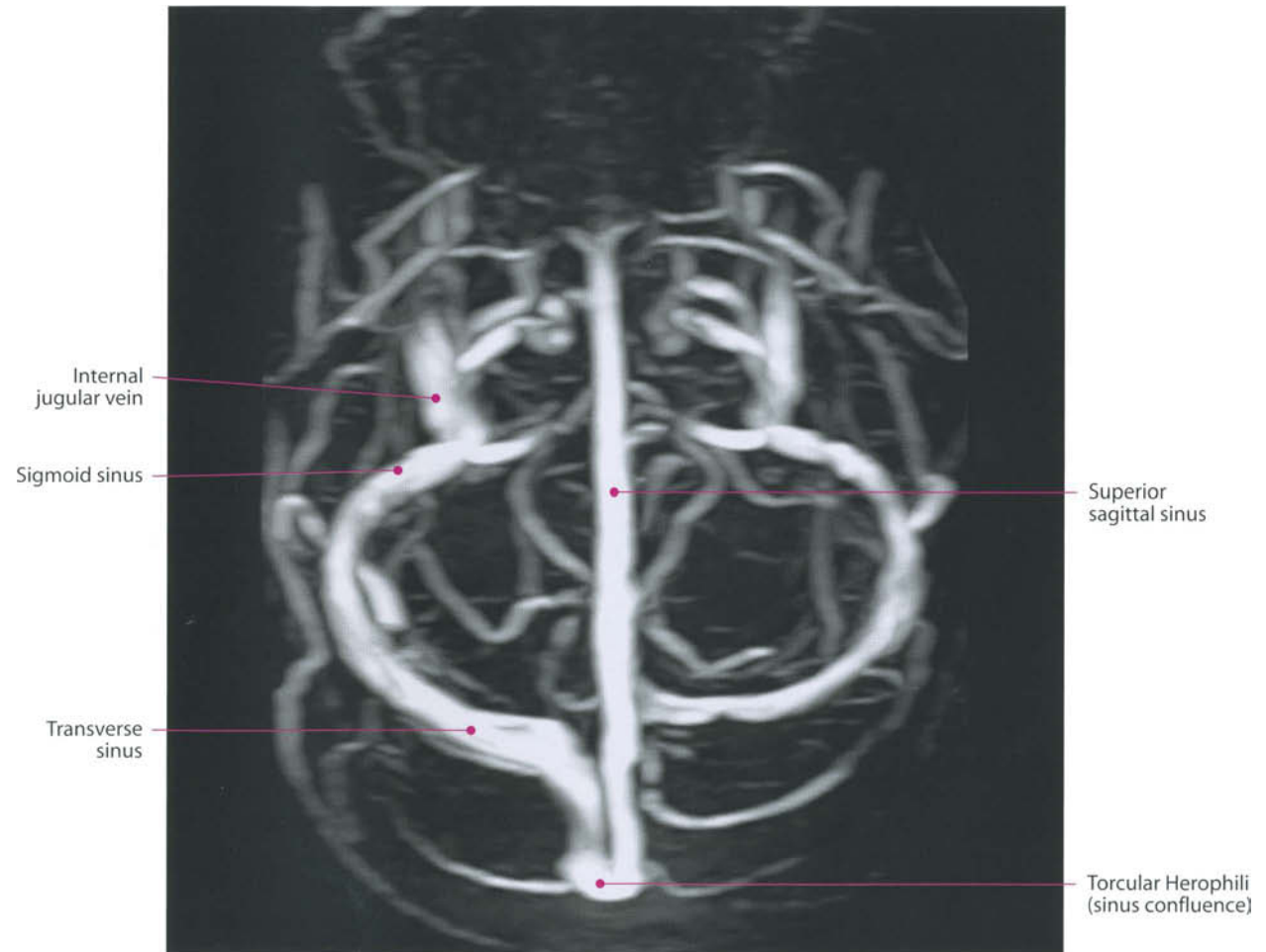
1. *The superior sagittal sinus* occupies the convex margin of the falx. It starts at the foramen cecum, where it receives a vein from the nasal cavity. It runs backwards, lying in midline, in the inner surface of the skull, until the occipital protuberance, where it deviates (usually to the right side), and continues with the corresponding transverse sinus. *The confluence of the sinuses* (confluens sinuum; torcular Herophili) is its dilated extremity, located in correspondence with the internal occipital protuberance. The transverse sinus derives from it. The superior sagittal sinus is triangular in section, narrow in the front, and gradually increases in size as it passes backwards. Small openings communicate with irregular venous spaces (venous lacunae) in the dura mater near the sinus; there are usually three, on either side: a small frontal, a large parietal, and a medium-size occipital. Most cerebral veins and arachnoid granulations (pacchionian bodies) open into these lacunae.
2. *The inferior sagittal sinus* (sinus sagittalis inferior; inferior longitudinal sinus) is in the posterior half or two-thirds of the free margin of the falx cerebri and ends in the straight sinus. It increases in size towards the back, as it receives several veins from the falx cerebri, and some inconstant ones from the medial surfaces of the hemispheres.
3. *The straight sinus* (sinus rectus; tentorial sinus) lies at the line of junction of the falx cerebri with the tentorium cerebelli. It proceeds backwards and runs downward and backwards from the end of the inferior sagittal sinus to the transverse sinus opposite to the one into which the superior sagittal sinus is prolonged, communicating through a cross branch with the confluence of the sinuses. It drains blood from the inferior sagittal sinus, being

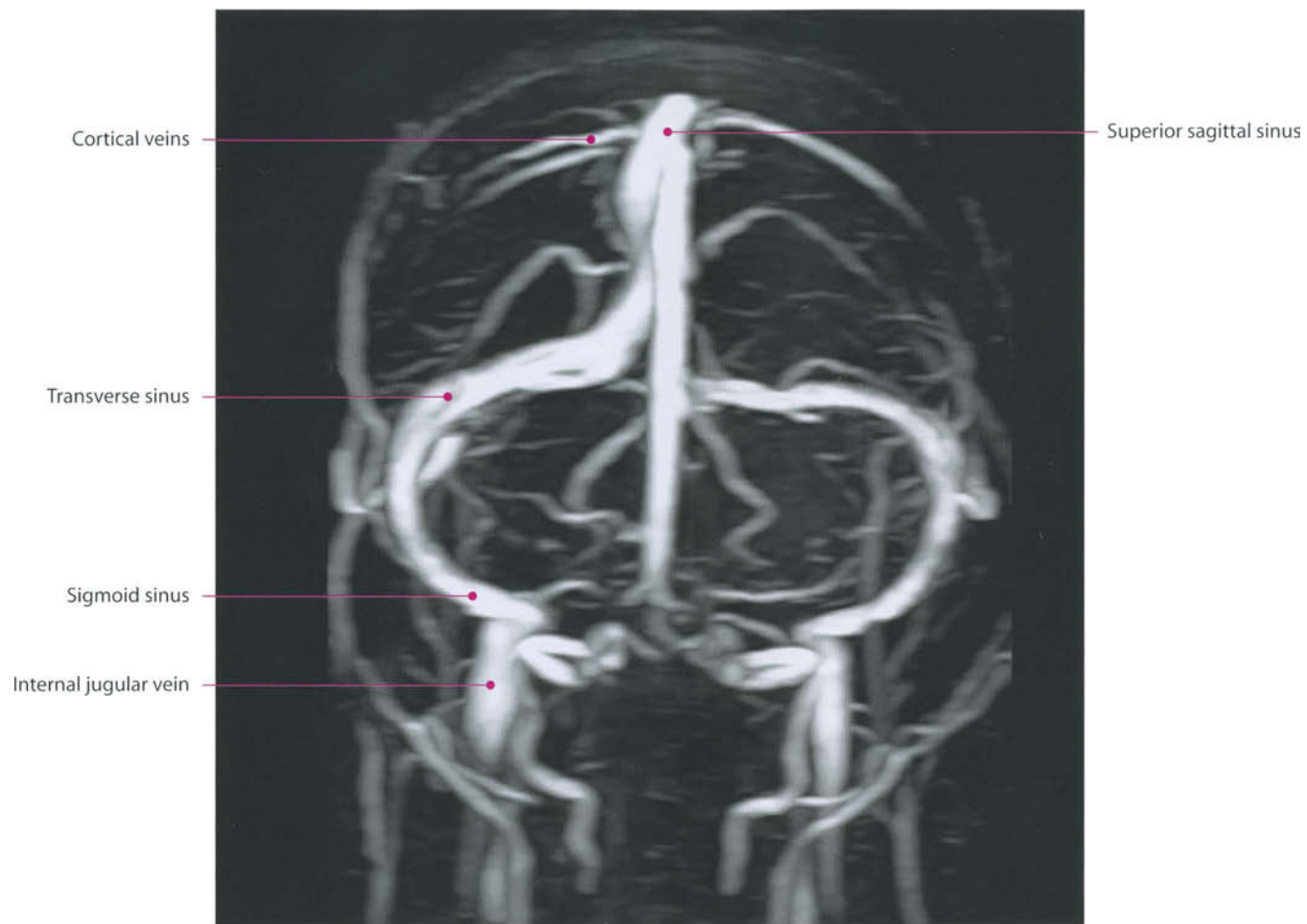
its natural prolongation, the great cerebral vein (great vein of Galen), and the superior cerebellar vein.

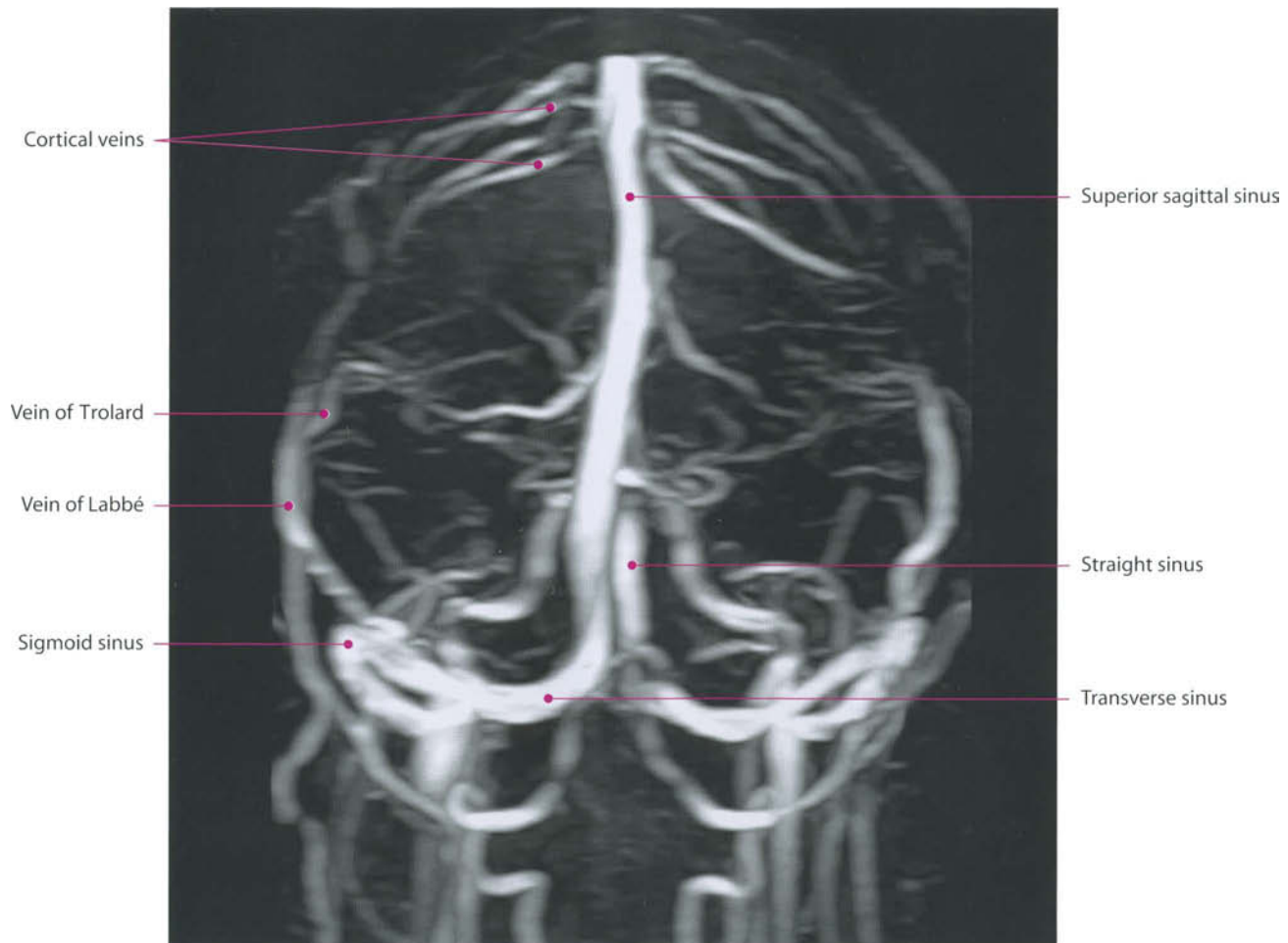
4. *The transverse sinus* (sinus transversus; lateral sinus), is paired in number and large. It begins at the internal occipital protuberance, one (usually the right) being the direct continuation of the superior sagittal sinus, the other, of the straight sinus. Each transverse sinus passes laterally and forward to reach the base of the petrous portion of the temporal bone, and lies in the attached margin of the tentorium cerebelli;
5. *The sigmoid sinus* is the continuation of the transverse one, beginning when it leaves the tentorium and curving downward and medially to reach the jugular foramen. Before it ends in the internal jugular vein, there is an enlargement called the jugular bulb. In its course it rests upon the squama of the occipital, the mastoid angle of the parietal, the mastoid part of the temporal. They receive blood from the superior petrosal sinuses, from the veins of the pericranium by means of the mastoid and condyloid emissary veins, and from the inferior cerebral and inferior cerebellar veins.
6. *The occipital sinus* (sinus occipitalis) is the smallest of the cranial sinuses. It is situated in the attached margin of the falx cerebelli, begins around the margin of the foramen magnum from several small veins, and ends in the confluence of the sinuses.
7. *The cavernous sinus* (sinus cavernosus) is paired and has a reticulated structure due to numerous fibrous filaments that traverse it. It is irregular, placed on either side of the body of the sphenoid bone, from the superior orbital fissure to the apex of the petrous bone. On its medial portion, it contains the internal carotid artery and the abducent nerve; on its lateral wall are the oculomotor, the trochlear, and the ophthalmic and maxillary nerves. The cavernous sinus drains blood from the superior ophthalmic vein through the superior orbital fissure, from some of the cerebral veins, and from the small sphenoparietal sinus, which courses along the lower surface of the small wing of the sphenoid. It communicates with the transverse sinus by means of the superior petrosal sinus; with the internal jugular vein through the inferior petrosal sinus; with the pterygoid venous plexus through the foramen Vesalii, foramen ovale, and foramen lacerum, and with the angular vein through the ophthalmic vein. The two sinuses also communicate with each other

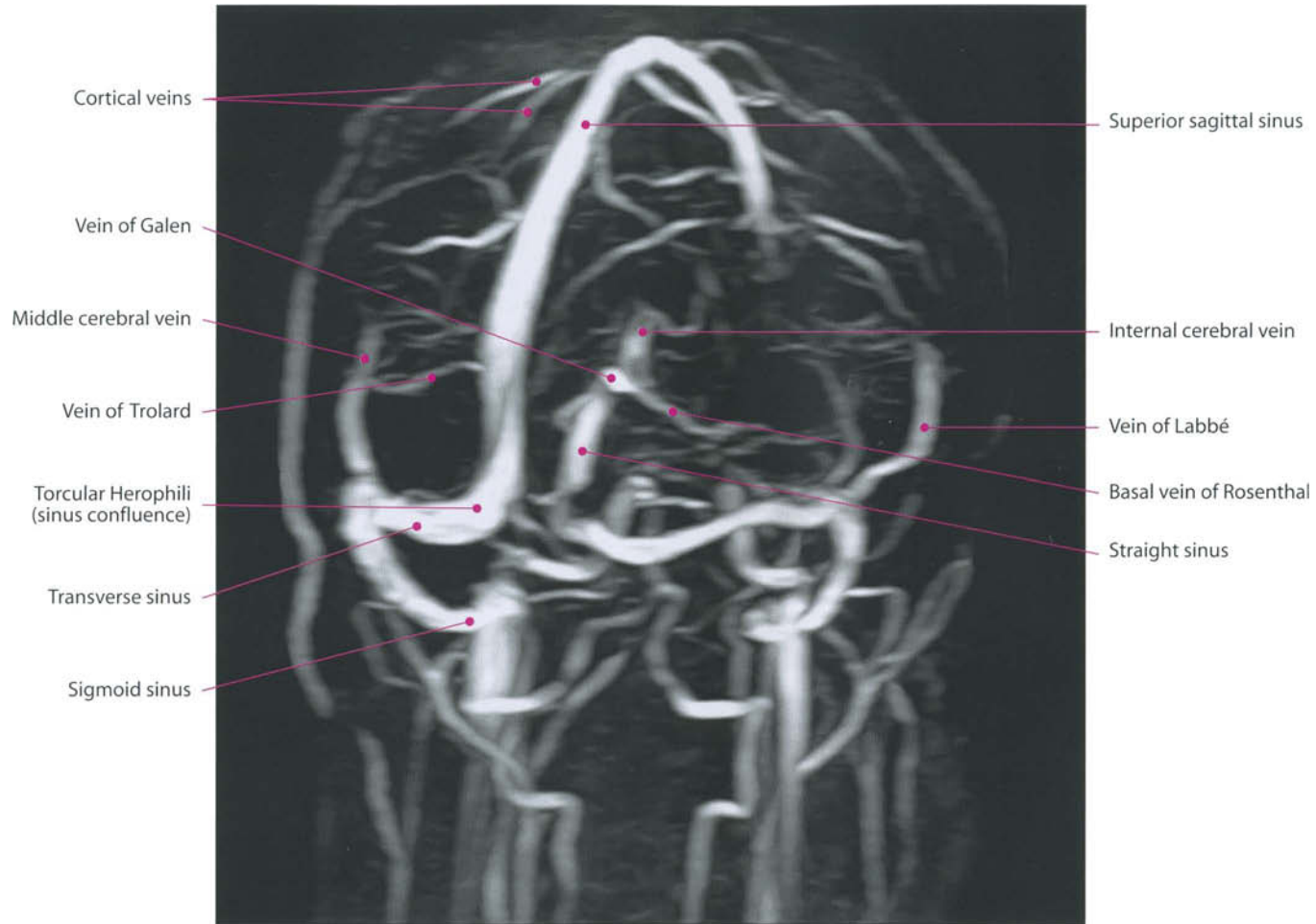by means of the anterior and posterior intercavernous sinuses.

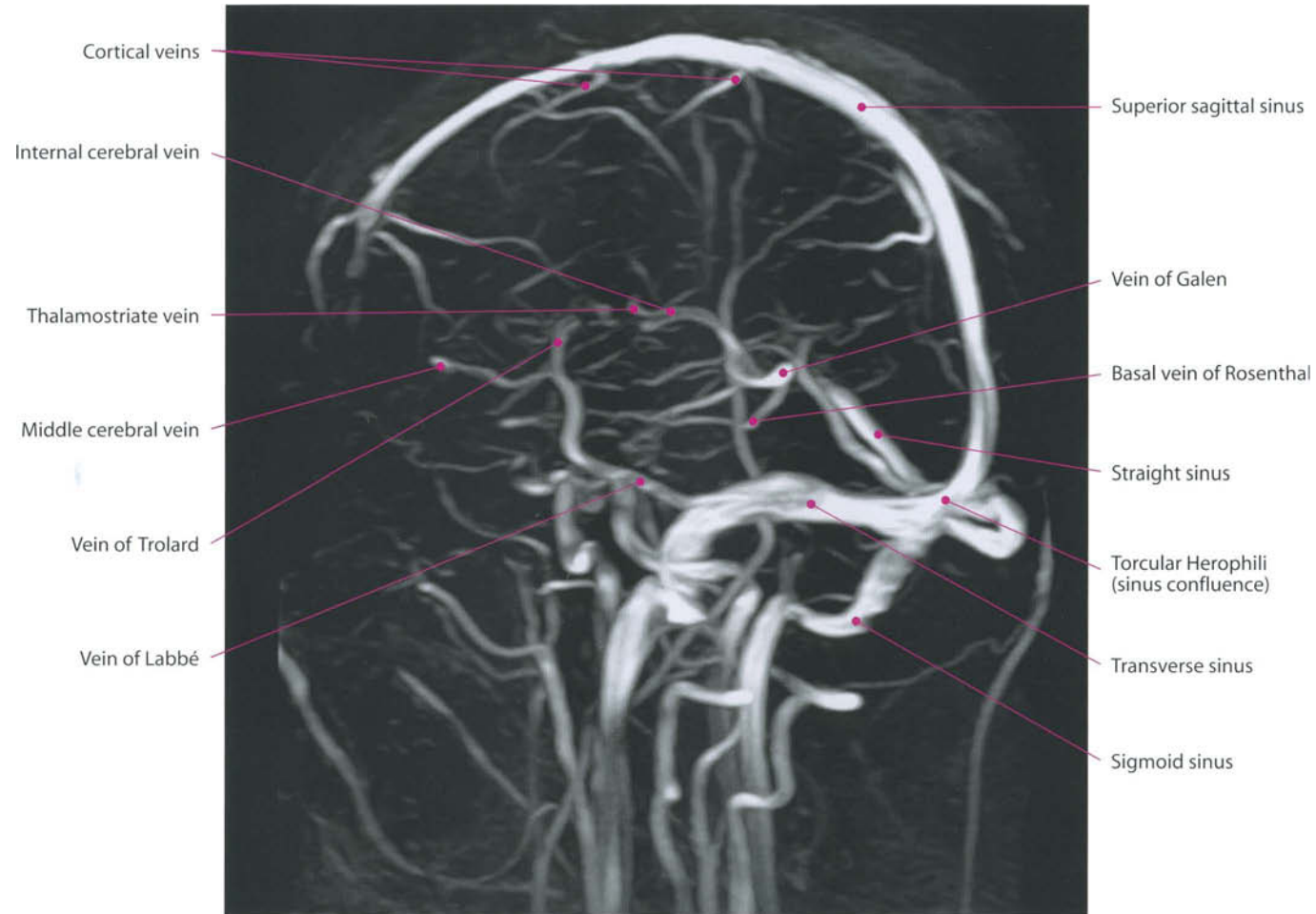
8. *The intercavernous sinuses* (sini intercavernosi) are two, an anterior one and a posterior one, and connect the two cavernous sinuses passing in front of, and behind, the pituitary gland. Together with the cavernous sinuses, they form a venous circle (circular sinus) around the hypophysis.
9. *The superior petrosal sinus* (sinus petrosus superior) is small and narrow, and connects the cavernous with the transverse sinus going lateralward and backward in the attached margin of the tentorium cerebelli and in the superior petrosal sulcus of the temporal bone. It receives some cerebellar and inferior cerebral veins, and veins from the tympanic cavity.
10. *The inferior petrosal sinus* (sinus petrosus inferior) is located in the inferior petrosal sulcus formed by the junction of the petrous bone with the occipital bone. It begins in the cavernous sinus and ends in the superior part of the bulb of the internal jugular vein. The inferior petrosal sinus receives the internal auditory veins and veins from the medulla oblongata, pons, and lower surface of the cerebellum.
11. *The basilar plexus* (plexus basilaris; transverse or basilar sinus) consists of several interlacing venous channels between the layers of the dura mater. It connects the two inferior petrosal sinuses lying over the basi-occipital bone.

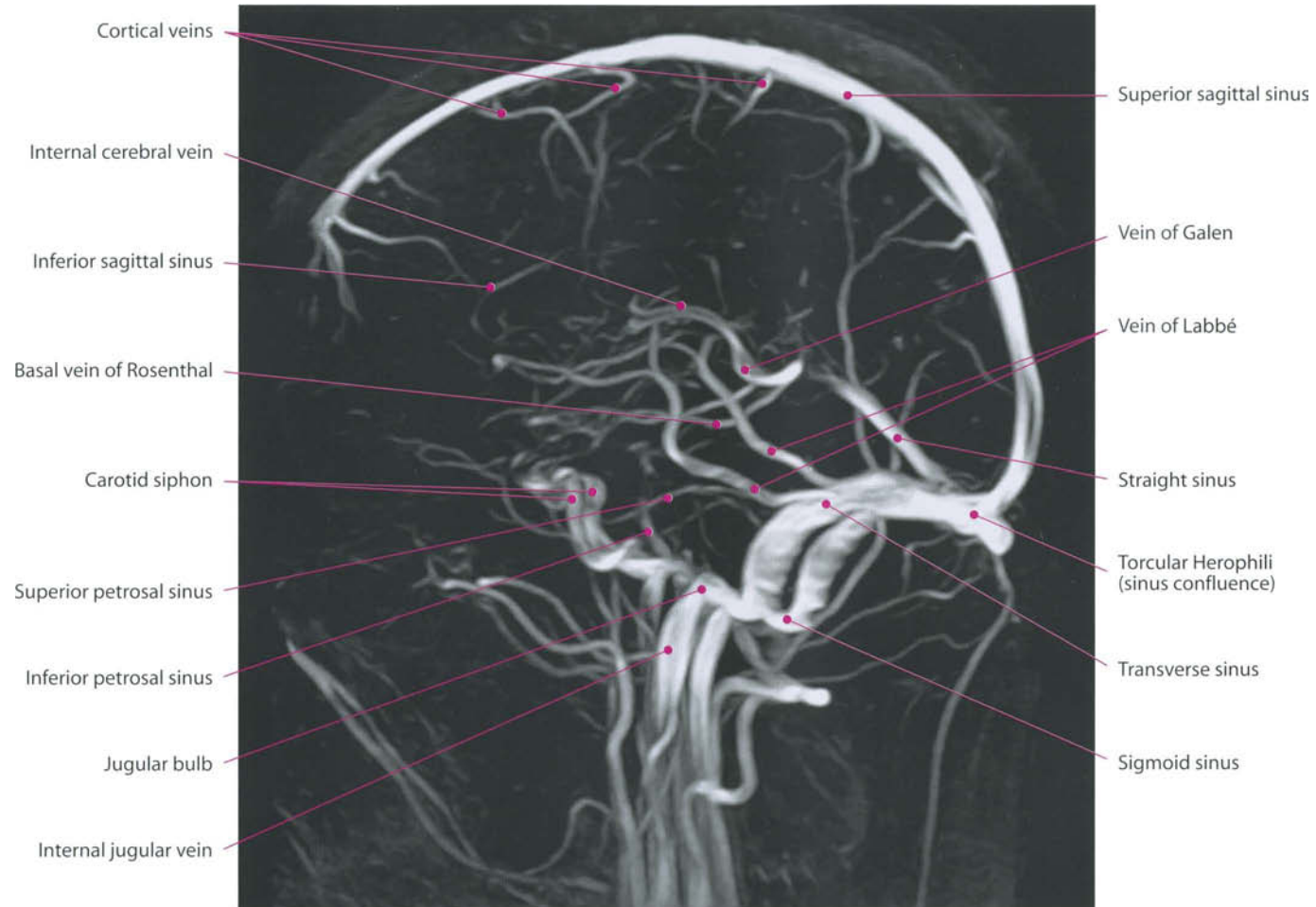


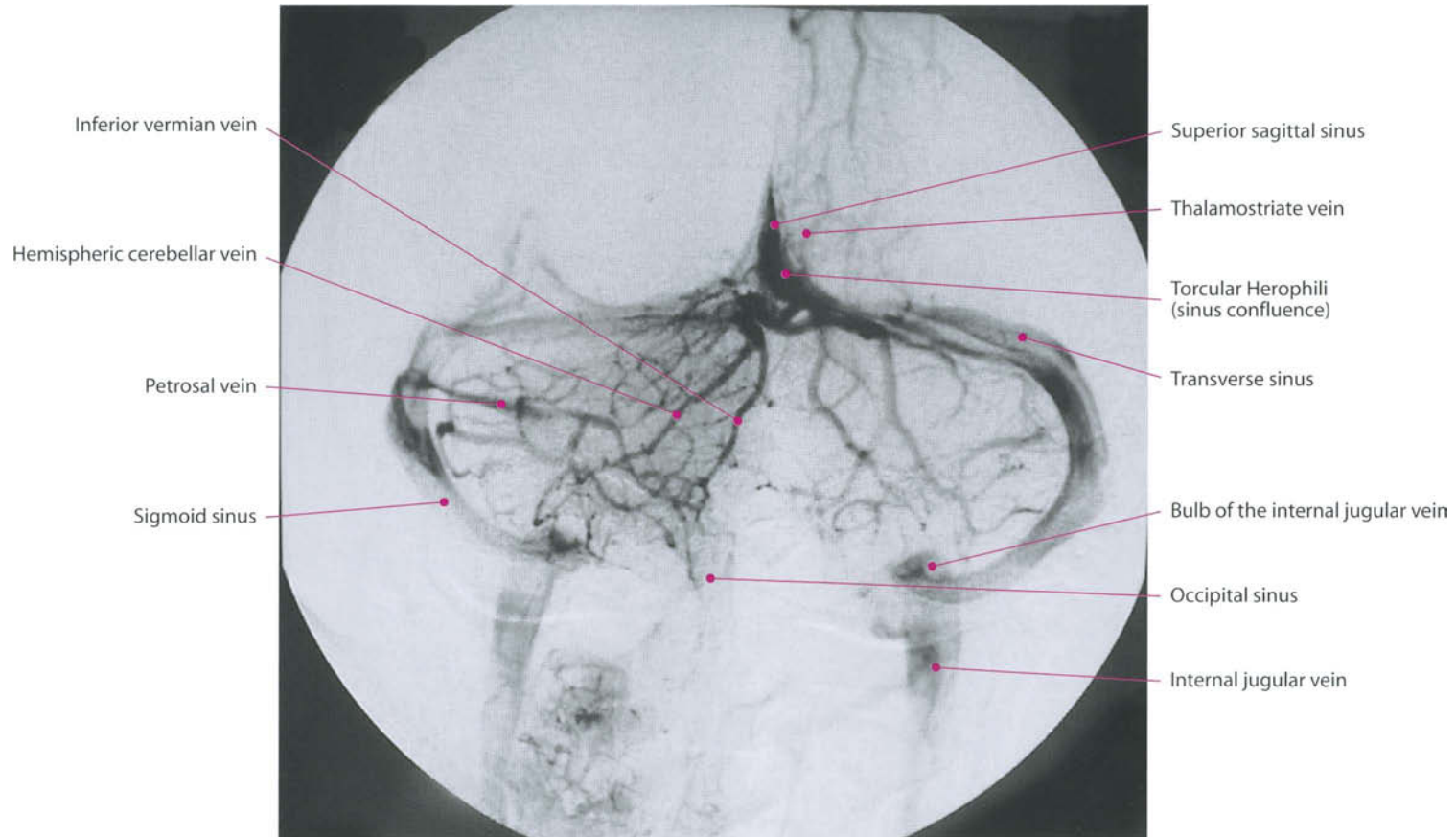


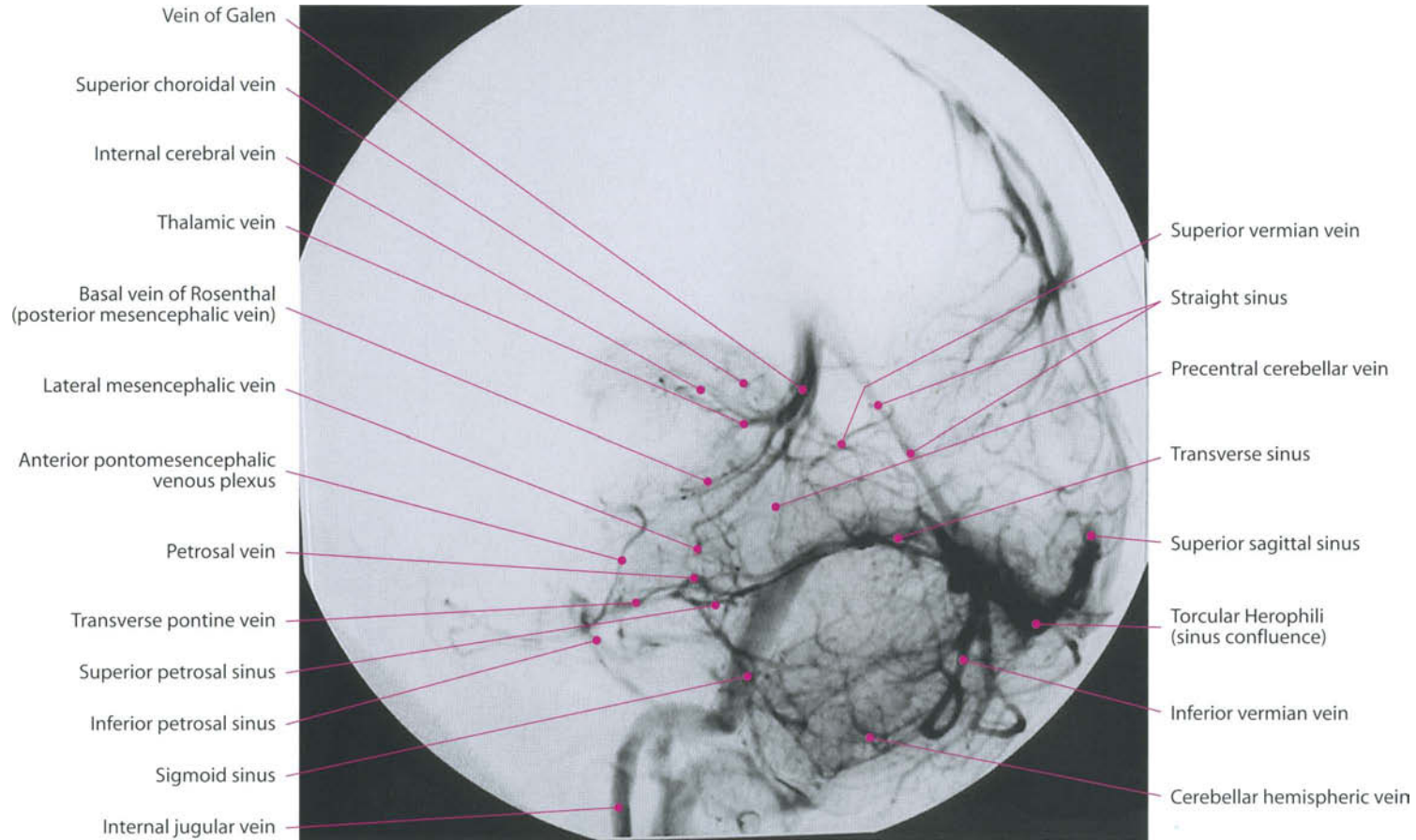


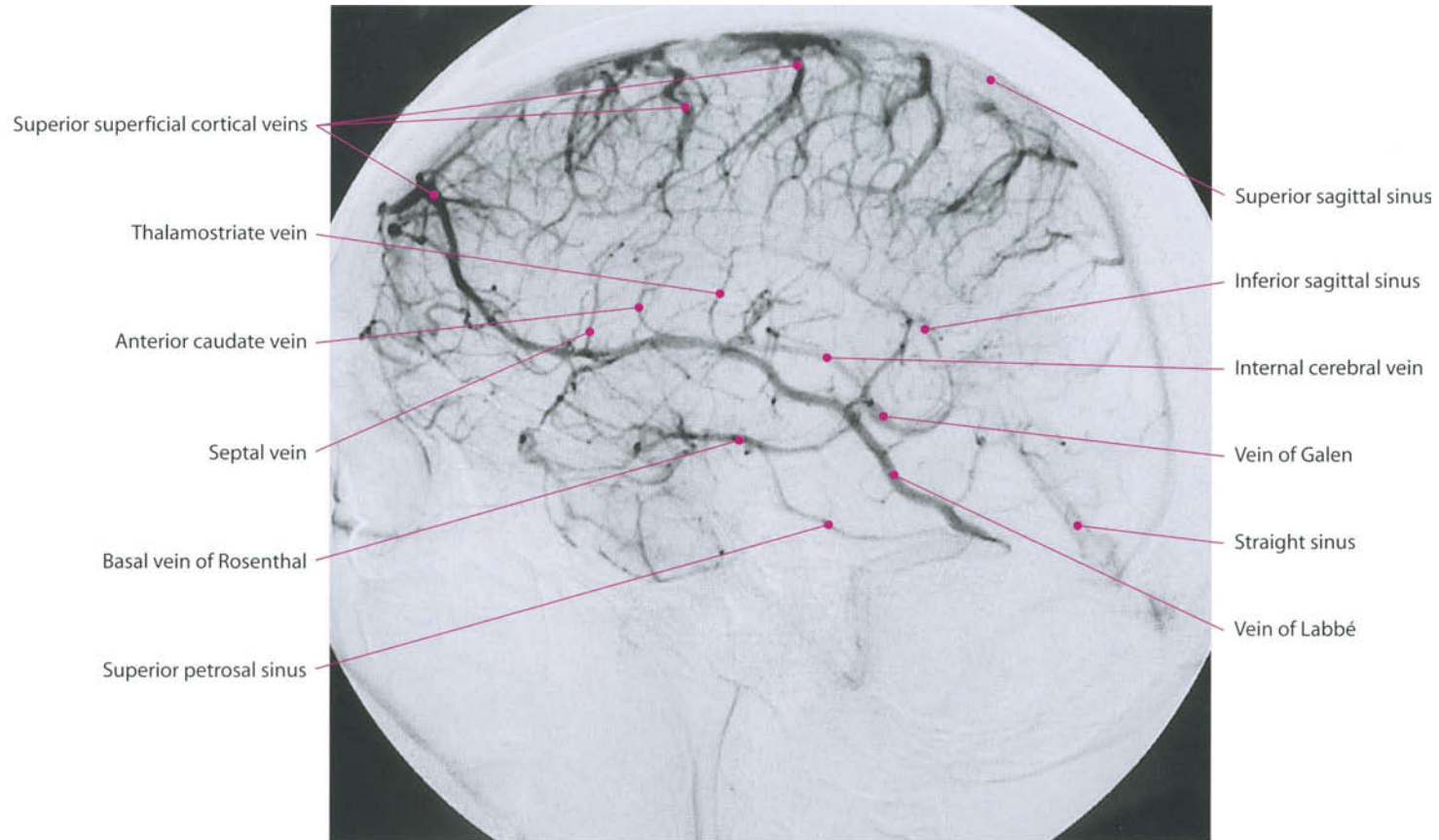


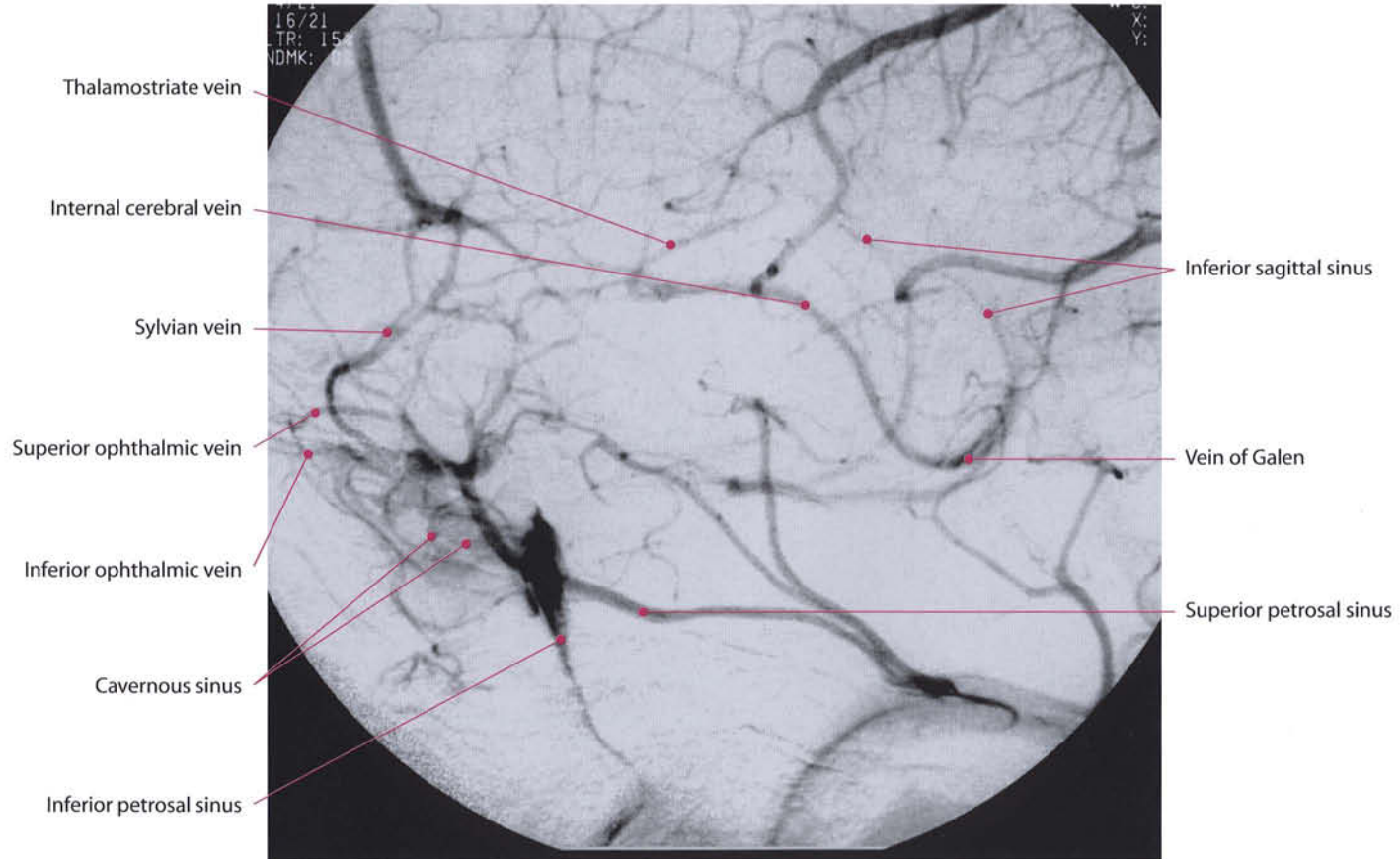


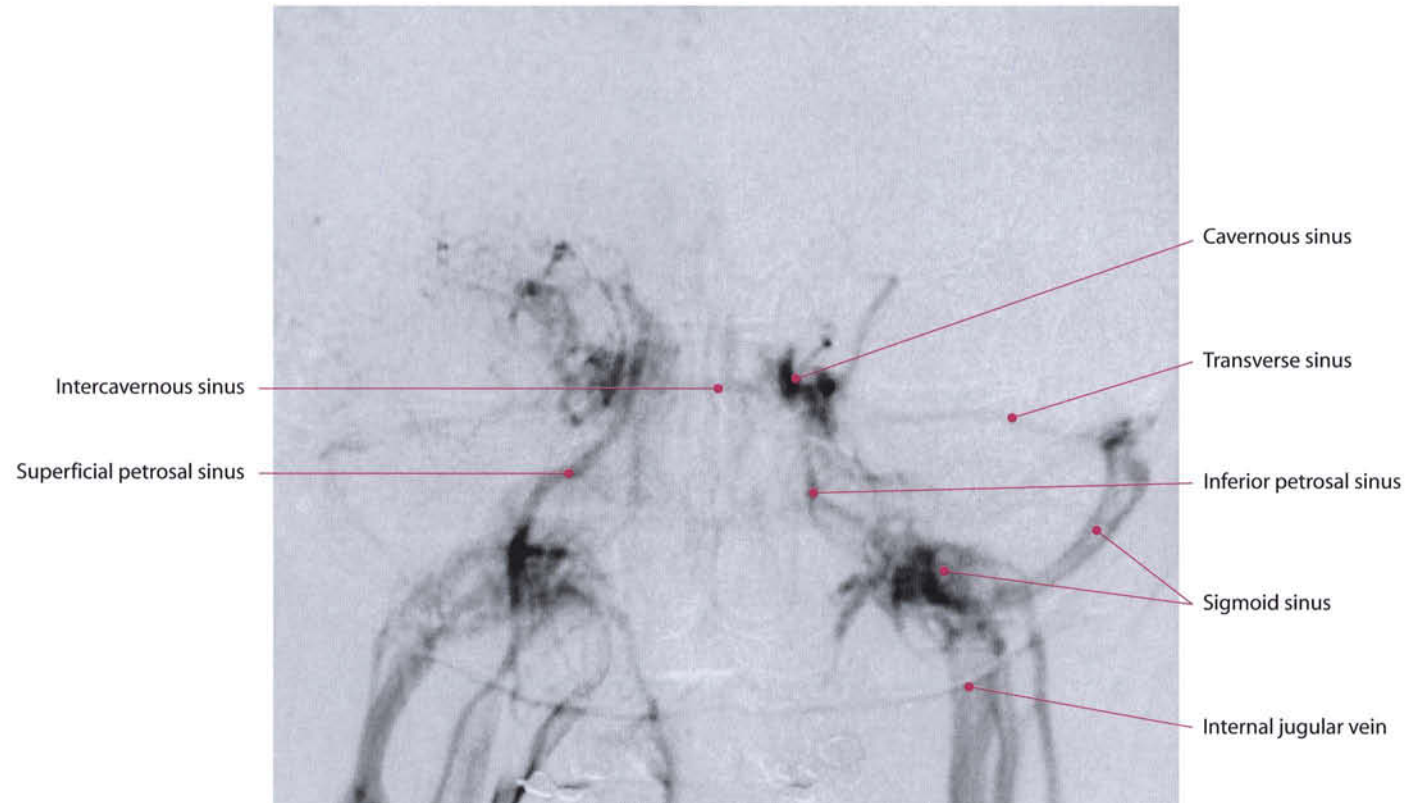


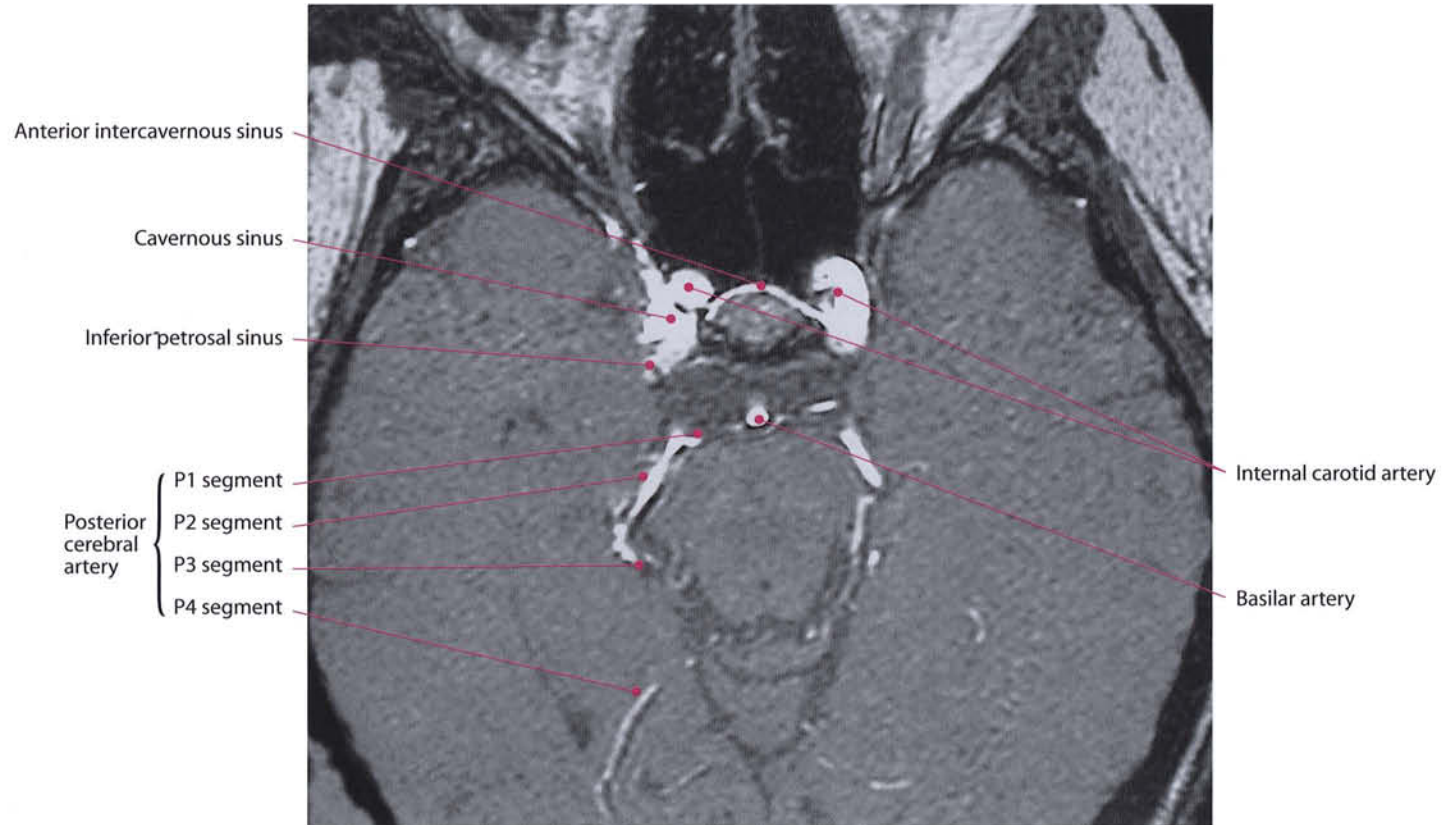












Bibliography

- Bouthillier A., van Loveren H.R., Keller J.T., *Segments of the internal carotid artery: a new classification*. Neurosurgery 38:425-33, 1996.
- Di Salle F., Duvernoy H., Rabischong P., Scarabino T., Salvolini U., *Atlas of Morphology and Functional Anatomy of the Brain*. Springer-Verlag, Berlin, 2005.
- Duvernoy H.M., *The Human Brain: Surface, Blood Supply, and Three Dimensional Sectional Anatomy*, 2nd edition. Springer, Vienna, 1999.
- Duvernoy H.M., *The Human Hippocampus*, 2nd edition. Springer-Verlag, Heidelberg, 1998:
- Gallucci M., Gagliardo O., Splendiani A., De Amicis R., *La loggia cavernosa: anatomia neuroradiologica normale*. Rivista di Neuroradiologia 13:367-73, 2000.
- Gallucci M., Sparvoli L., *Patologia dell'osso temporale*. In: Dal Pozzo G., Compendio di Risonanza Magnetica, Cranio e Rachide. UTET, Torino, 2001:807-836.
- Gallucci M., Splendiani A., Masciocchi C., *Spine and spinal cord: Neuroradiological functional anatomy*. Rivista di Neuroradiologia 11:293-304, 1998.
- Herrero, Barcia C., Navarro J.M., *Functional anatomy of thalamus and basal ganglia*. Child's Nerv. Syst. 18:386-404, 2002.
- Krayenbuhl H., Huber P., Yasargil M.G., *Cerebral angiography*, 2nd completely revised edition. Thieme-Verlag, Stuttgart, 1982.
- Lasjaunias P.L., Berenstein A., *Surgical Neuroangiography: Functional Vascular Anatomy of Brain, Spinal Cord and Spine*. Springer-Verlag, Berlin, 1991.
- Mazzucato F., *Anatomia radiologica tecnica e metodologia. Propedeutiche alla diagnostica mediante immagini*. Ed. Piccin, Torino, 1997.
- Nieuwenhuys R., Voogd J., van Huijzen C., *The human central nervous system*. Springer-Verlag, Berlin, 1988.
- Nolte J., *The Human Brain. An introduction to its functional anatomy*, 4th edition. Mosby, St. Louis, MO, 1999.
- Osborn A.G., *Cerebral Angiography*, 2nd edition. Lippincott Williams and Wilkins, Philadelphia, 1999.
- Osborn A.G., *Diagnostic Neuroradiology*. Mosby-Year Book, St. Louis, MO, 1994.
- Perugini S., Ghirlanda S., Manfrè L., Gallucci M., Castrucci M., *Rocche petrose*, in: Compendio di Tomografia computerizzata e TC spirale. Ed. Dal Pozzo G., 1999:263-285.
- Talairach J., *Co-Planar Stereotactic Atlas of the Human Brain*. Thieme Verlag, Stuttgart, 1988.
- Tamraz J.C., Comair Y.G., *Atlas of Regional Anatomy of the Brain Using MRI with Functional Correlations*. Springer-Verlag, Berlin, 2000.
- Truwitt C.L., Lempert T.E., *High resolution atlas of cranial neuroanatomy*. Lippincott Williams and Wilkins, Baltimore, 1994.

Subject Index

- Adenohypophysis 280, 281, 283, 284
 Aditus ad antrum 178, 179
 Ammon's horn 263, 270
 Ampulla,
 - posterior 176, 196
 - superior 171, 178, 196
 Amygdala 228, 229, 235, 236, 271, 276
 Antrum 179, 180, 192, 193
 Aqueduct,
 - cochlear 174, 175
 - vestibular 162, 177, 180, 195
 Area 1, 2, 3, 208-210
 - Broca's speech (44) 253, 254
 - entorhinal 51, 52, 64, 115, 266, 269
 - hand motor 211, 212
 - marginal 253
 - nasal 119
 - premotor (6, 8) 208-210
 - primary olfactory 116
 - second olfactory 116
 - septal (see also septal nuclei) 273
 - striata 119
 - subcallosal 263
 - temporal 119
 - vestibular cortical 168, 170
 - Wernicke's speech 253, 254
 Artery/ies,
 - angular 301
 - anterior cerebral 49, 70, 226, 227, 319, 326, 334
 - - bifurcation of 302, 303
 - - post-communicating segment, A2 302-304, 313
 - - pre-communicating segment, A1 285, 302-304, 307, 308, 310, 313
 - anterior choroidal 300, 320
 - anterior communicating 303, 306, 310
 - anterior deep temporal 299
 - anterior internal frontal 301
 - anterior parietal 301
 - anterior temporal 314
 - anterior thalamoperforating 317, 320
 - antero-inferior cerebellar 145, 312, 314, 315, 317, 319, 328, 329
 - basilar 52, 66, 67, 103, 106, 107, 122, 287, 290, 304, 306, 311, 315, 327
 - calcarine 315
 - callosomarginal 303
 - descending (greater) palatine 299
 - external carotid 299
 - fronto-opercular 301
 - frontopolar 301
 - inferior internal parietal 301
 - inferior temporal 315, 316
 - infraorbital 299
 - internal carotid 50, 65, 120, 227, 300, 304, 310
 - - cavernous segment, C4 301, 303
 - - cervical segment, C1 301-303
 - - clinoid segment, C5 301-303
 - - communicating segment, C7 285, 301, 302
 - - in carotid canal 184
 - - lacerum segment, C3 301, 303
 - - ophthalmic segment, C6 301, 303
 - - petrous segment, C2 301-303
 - lateral lenticulostriate 303
 - lateral-posterior choroidal 317
 - masseteric 299
 - maxillary 299
 - medial-posterior choroidal 317
 - middle cerebral 50, 69, 139, 227, 319, 326, 334
 - - insular segment, M2 303, 304
 - - opercular segment, M3 303, 304
 - - post-bifurcation M1 segment 303-305, 307, 308
 - - pre-bifurcation M1 segment 285, 302-305, 308
 - middle deep temporal 299
 - middle internal frontal 301
 - middle meningeal 153, 299
 - occipital 299
 - ophthalmic 120, 300, 301
 - orbitofrontal 301
 - parieto-occipital 315-317
 - pericallosal 301-303
 - posterior cerebral 139, 142, 287, 305, 319, 329, 334
 - - ambiens segment, P2 304, 307, 314, 315
 - - calcarine segment, P4 305, 310, 315
 - - horizontal or pre-communicating segment, P1 304, 306
 - - pre-communicating segment, P1 110, 315
 - - quadrigeminal segment, P3 304, 307, 311, 315
 - posterior communicating 145, 300, 304, 308-310
 - posterior internal frontal 301
 - posterior parietal 301
 - posterior temporal 301, 311
 - postero-inferior cerebellar 315, 319, 328, 329
 - prefrontal 301
 - prerolandic 301
 - rolandic 301
 - spheno-palatine 299
 - superficial temporal 299
 - superior cerebellar 305, 308-310, 312, 315, 317, 319, 329
 - superior internal parietal 301
 - superior posterior alveolar 299
 - thalamoperforating 316
 - transverse facial 299
 - vertebral 101, 102, 316, 328
 Asterion 8
 Atlanto-axial,
 - articular space 7
 Atlas 20
 - lateral mass of 3, 7, 197
 - peduncle of 7
 Axis,
 - lateral mass of 7
 - odontoid process of 7, 20, 22
 - spinous process of 7
 Body
 - ciliary 128
 - amygdaloid 115
 - lateral geniculate 111, 119, 257

- mammillary 44, 69, 111, 257, 263
- medial geniculate 164, 166, 220
- trapezoid 164, 165, 260
- Bone,
 - ethmoid 11, 15, 17
 - - cribriform plate of 117
 - - lamina papyracea of 127
 - - perpendicular lamina of 18
 - frontal 11, 15, 17, 19
 - - orbital aspect 127
 - hyoid 5, 19, 21
 - lacrimal 11, 12
 - malar 5
 - maxillary 11, 13, 15
 - - frontal process of 18, 127
 - nasal 5, 11, 13, 15, 19, 21
 - occipital 14, 16, 20
 - palatine 15
 - - orbital process of 12
 - parietal 13-15, 17, 19
 - petrous
 - - superior border of 6
 - sphenoid 12, 13, 15, 16
 - - greater wing of 18, 19, 23, 127
 - - lesser wing of 3, 22, 278, 279
 - temporal 13, 15-18
 - - petrous pyramid of 6, 22, 23
 - vomer 15
 - zygomatic 6, 11, 12, 18, 19, 127
- Brachium,
 - conjunctivum inferior 164, 166
 - conjunctivum superior 124
- Bregma 8
- Bulb
 - olfactory 45, 115, 118, 133
 - jugular 190, 346, 347
- Calcar avis 71
- Canal
 - carotid 120, 174
 - carotid (horizontal portion) 175, 176
 - carotid (vertical portion) 173
 - Dorello's 142
 - external auditory 171, 173, 174, 189, 193, 279
 - facial 189
 - - first segment (horizontal, labyrinthine) of 181, 188
 - - second segment (horizontal, tympanic) of 190, 192
 - - third segment (vertical, mastoid) of 173, 174, 176, 196, 197
 - hypoglossal 201
 - inferior vestibular 195
 - internal auditory 171, 179, 180, 182, 193, 278
 - lateral semicircular 163, 171, 178, 180, 191
 - of stapedial muscle 176
 - of tensor tympani muscle 178, 184, 185
 - optic 23, 120
 - posterior semicircular 163, 171, 175, 176, 178, 180
 - superior semicircular 163, 171, 183, 190, 191
 - superior vestibular 194
 - vertical semicircular 162
- Capsule
 - extreme 227
 - external 227
 - internal
 - - anterior limb of 219, 225, 226
 - - posterior limb of 208, 219
- Cave, Meckel's 22
- Centrum semiovale 78
- Cerebellum 108
- Cerebral aqueduct of Sylvius 55, 67, 108, 232, 291, 293, 296
- Chorda tympani 159
- Choroid 128
- Cistern
 - ambiens 291
 - cerebello-medullaris (see also cisterna magna) 290, 293
 - chiasmatic 293
 - insular (see also cistern of sylvian fissure) 291
 - interpeduncular 110, 293, 294
 - interhemispheric 292
 - of sylvian fissure (see also insular cistern) 291
 - of the cerebello-pontine angle 290
 - of the great cerebral vein (of Galen) 59, 291-293
 - of the lamina terminalis 293
 - of transverse fissure (see also cistern of velum interpositum) 56, 293
 - of velum interpositum (see also cistern of transverse fissure) 293
 - pericallosal 293
 - pontine 290, 293
 - posterior basal 290
 - quadrigeminal (see also tectal cistern) 291-294
 - superior cerebellar 291, 293
 - suprasellar 282
 - tectal (see also quadrigeminal cistern) 291, 293, 294
- Cisterna,
 - magna (see also cerebello-medullaris cistern) 290, 293
- Clastrum 217, 230, 238-240
- Clivus 278, 279
- Cochlea 163, 178, 189, 190
 - apical turn 177
 - basal turn 162, 171, 175, 177, 191
 - middle turn 162, 177, 186
 - spiral lamina of the 180
 - upper turn 162, 186
- Colliculi (see also quadrigeminal tubercle or quadrigeminal plate or tectum of midbrain) 224
- Colliculus,
 - facial 105
 - inferior 56, 68, 109, 166, 233, 258
 - superior 43, 55, 56, 70, 111, 233, 257
- Commissure,
 - anterior 38, 42, 44, 71, 115, 223, 224, 228, 237, 273, 275
 - habenular 115
 - posterior 44, 55, 71, 224, 237
- Condyle, occipital 197
- Cornea 128, 137
- Corona radiata 208, 214, 241
- Corpus callosum 41, 275
 - body of 44, 48
 - genu of 42, 43, 47, 73, 75
 - isthmus of 43, 54
 - radiation of 119
 - rostrum of 44
 - splenium of 42, 43, 56, 57, 72, 75
 - sulcus of 48, 57
- Cortex
 - premotor (area 6) 205
 - premotor (area 8) 205
 - primary motor (area 4) 205, 208, 210
 - retrosplenial 71

- Crista galli 22, 117
 Culmen 92, 96, 99, 106, 107
 Cuneus (O6) 41, 42, 60, 69
- Declive 92
 Diploë 4
 Dorsum sellae 22
 Duct, endolymphatic 181
- Ear,
 – external 171
 – inner 171
 – middle 171
- Falciform crest 161, 190, 191
 Fasciculus,
 – dorsal longitudinal 257, 259
 – gracile 243, 262
 – inferior occipitofrontalis 276
 – medial longitudinal 168, 259, 260, 262
 – medial telencephalic 115, 263
 – superior longitudinal 276
 – superior occipitofrontalis 276
 Fasciola cinerea 263
 Fibers,
 – arcuate 243
 – thalamo-cortical 245
 – zonular 128
 Fissure,
 – antero-superior (primary fissure) 96
 – calcarine 40, 61, 62, 68, 119, 122, 124
 – cavernous 278
 – central of Rolando 25, 26
 – choroidal 263
 – horizontal 87, 90, 93, 97
 – inferior orbital 127
 – interhemispheric 25
 – lateral of Sylvius 26, 31-33, 35, 47, 48, 69, 73, 75
 – longitudinal 45
 – parieto-occipital 26, 39, 40, 42, 60
 – post-central 93, 95, 105, 106
 – postero-superior 98
 – postpyramidal (secondary fissure) 95, 96
 – prepyramidal 94, 97
 – sphenoidal 279
 – superior anterior 92
 – superior orbital 23, 127, 146, 278
 – temporo-occipital 68
 Flocculus 88, 93
 Folium 92
 Foramen
 – infraorbital 18
 – interventricular (of Monro) 289, 292, 296
 – – choroid tela of the 295
 – jugular 22, 200
 – lacerum 278
 – mental 18
 – occipital 6, 22
 – of Luschka 103, 200
 – of Magendie 101, 200, 290, 293
 – ovale 120, 155, 174, 278
 – rotundum 3, 6, 22, 23, 155, 279
 – spinosum 22, 155, 174
 – stylomastoid 159, 196, 197
 Fornix 43, 223, 231, 237, 240, 271, 272
 – body 52, 72, 74, 276
 – column 43, 51, 69, 71, 228, 229, 276
 – crus 41, 42, 73, 263
 Fossa,
 – geniculate 180, 181
 – jugular 173
 – middle cranial 182
 – posterior cranial 182
 – pterygopalatine 155
 Fourth ventricle 63, 94, 101, 289
 – choroid plexus 290
 – choroid tela of 293, 294
 – lateral foramen of Luschka 289
 – lateral recess 289, 290, 294
 – median sulcus of 56
 – midline foramen of Magendie 289
- Ganglion,
 – gasserian 63, 145, 150, 152
 – sensory 214
 Glabella 9
- Gland,
 – lacrimal 129, 132
 – pineal 44, 56, 94, 295
 – pituitary 50
 Globus pallidus,
 – pars lateralis 219, 230, 237-239
 – pars medialis 219, 230, 237, 238
 Gnathion 9
 Gonion 8
 Gray bridges, caudate-lenticular 232
 Groove,
 – carotid 22, 279
 – chiasmatic 23, 279
 – infraorbital 127
 – of greater petrosal nerve 179, 185
 – olfactory 117
 – superior sagittal sinus 23
 Gyrus/i,
 – ambiens (see also uncus) 51, 52, 115, 136
 – angular 31, 34, 35, 59, 62, 78
 – anterior orbital 38, 39, 45, 71
 – anterior transverse temporal 32, 54
 – ascending frontal (Fa) 25
 – ascending parietal (Pa) 25
 – central 35
 – cingulate 41, 42, 46, 51, 56, 71, 72, 273
 – dentatum 263, 270, 273
 – descendens (Ecker) 39, 40, 65, 67, 122
 – diagonal 263
 – fasciolar 263, 273
 – fourth occipital (O4) 36, 62
 – frontomarginal 34, 35, 39, 70, 72, 137
 – frontopolar 42
 – fusiform (O4) 60, 66
 – fusiform (T4) 35, 51, 52, 64
 – inferior frontal (F3) 25, 26, 47, 133
 – – pars opercularis (op) 26, 31, 48, 49, 72, 73, 251
 – – pars orbitalis (o) 26, 31, 46, 72
 – – pars triangularis (t) 26, 31, 46, 47, 73
 – inferior frontopolar 36, 39, 137
 – inferior lingual (O5) 58, 59
 – inferior occipital (O3) 35, 38, 60, 62, 65, 67
 – inferior parietal (P2) 25, 59

- inferior temporal (T3) 26, 31, 35, 47, 48, 52, 64, 66
 - insular long 34, 35
 - insular short 34, 35
 - intraparietal 34
 - lateral orbital 33-35, 45, 71, 72
 - lingual (O5) 39, 68
 - long insular 51
 - medial orbital 39, 45, 68, 70
 - middle frontal (F2) 25, 33, 34, 46, 47, 53, 73, 75, 133, 208-210
 - middle occipital (O2) 32, 34, 36, 38, 60-62, 69, 75
 - middle orbital 38
 - middle temporal (T2) 26, 31, 35, 47, 49, 52, 64, 66
 - nuclei (see also paraterminal gyrus) 136
 - orbital 27
 - parahippocampal (T5) 37, 39, 53, 64, 66, 67, 267
 - paraterminal (see also gyrus nuclei) 43, 44, 50, 136
 - postcentral (Pa, ascending parietal gyrus) 31, 35, 36, 40, 54, 73, 74, 208, 210, 245, 246
 - posterior orbital 36-39, 47, 70, 71
 - posterior transverse temporal 54
 - precentral (Fa, ascending frontal gyrus) 31, 35, 36, 40, 50-52, 54, 74, 80, 208-210
 - rectus 27, 41, 42, 46, 47, 68, 134
 - semilunar 52, 115
 - short insular 48, 49, 51
 - subcallosal 44, 70-72
 - subcentral 32, 33, 51, 52
 - superior frontal (F1) 25, 36, 37, 40, 46, 47, 53, 71, 73, 79, 208-210
 - superior frontopolar 36, 39, 137
 - superior lingual (O5) 122
 - superior occipital (O1) 37, 38, 71, 73
 - superior parietal (P1) 25, 37, 59, 60, 80, 84, 246
 - superior temporal (T1) 26, 31, 35, 47, 48, 52, 54, 64, 66
 - supramarginal 31, 33, 55, 56, 58, 76
 - transverse temporal (of Heschl) 73, 164, 166
 - temporo-occipital 66
- Hard palate 5
- Hippocampus 36, 271, 273
- body 264
 - fimbria 273
 - head 37, 40, 54, 66, 67, 264
 - queue 265
- tail 39, 40, 57, 71, 72, 56
- Hypoglossal canal 22
- Hypothalamic-pituitary,
- stalk 281, 282, 284
- Hypothalamus 228, 229, 237
- Hypotympanum 172, 173, 185
- Incisure,
- lateral temporo-occipital 31-33
 - medial temporo-occipital (see also collateral sulcus) 36
 - supraorbital 18
- Incus,
- body 171, 178, 187, 188
 - long crus 171, 175, 177
 - short crus 171, 177, 178, 192
- Indusium griseum 263, 273
- Inhibitory interneuron 215
- Inion (see also external occipital protuberance) 8
- Insula 36, 71, 74, 251
- Isthmus 41, 42, 57
- Joint,
- atlanto-axial 3
 - atlanto-occipital 3
 - incudo-malleolar 179
 - incudostapedial 176
 - temporo-mandibular 175, 184
- Labyrinth 171
- Lambda 8
- Lamina,
- quadrilateral 279
 - terminalis 295, 296
- Lateral ventricle 43
- atrium of 36, 37, 40, 57, 72, 73, 75
 - body of 53
 - choroid plexus 57, 74, 291, 292
 - - glomus of 291, 292
 - choroid tela 294, 296
 - frontal horn of 41, 46, 47, 49, 72, 73, 74, 289, 292
 - occipital horn of 58, 59, 70, 289, 291
 - temporal horn of 35, 36, 52, 53, 66, 67, 69, 289, 291
 - trigone 289, 291, 292
- Lemniscus,
- lateral 164, 165
 - medial 105, 243, 244, 258-262
 - medialis 214
- Lens 128, 137
- Limen insulae 34, 35
- Line,
- auricular vertical 10
 - Frankfurt or Wirchow's line 10
 - innominate 3
 - orbito-meatal 10
 - superior horizontal 10
- Lingula (vermis) 91
- Lobe,
- frontal 25, 45
 - occipital 26
 - parietal 26, 57
 - piriform 64, 269
 - temporal 26, 27
- Lobule,
- biventral 87, 89, 93, 97, 101
 - inferior semilunar 87, 93, 94, 100, 102
 - paracentral 57, 81, 82, 84, 210
 - quadrangular 87, 93
 - simplex 87, 88, 93, 100, 104
 - superior semilunar 87, 94, 100
- Locus coeruleus 92
- Malleus 187
- body of 178
 - head of 171, 177, 189, 190
 - manubrium of 171, 174, 175, 189
- Mandible 5, 11, 13, 15
- angle of 6, 20
 - condyle 3
 - horizontal ramus of 7
 - vertical ramus of 7, 18
- Massa intermedia 238
- Mastoid 182, 196, 197
- air cell 171, 173, 174
- Meatus,
- external acoustic 8, 19
 - internal acoustic 21 22

- Medulla oblongata 93, 101
- Membrane
- tympanic 187, 173, 188, 189
- Midbrain
- tectum of 93, 109
- Modiolus 162, 179, 187
- Muscle,
- inferior rectus 45, 133, 134, 139
 - lateral rectus 45, 129, 134
 - levator palpebrae superioris 131, 134, 139
 - medial rectus 45, 129, 134
 - superior oblique 130, 134
 - - trochlea of 130
 - superior rectus 45, 131, 134, 139
 - tensor tympani 186
- Nasal septum 6
- Nasion 9
- Nerve,
- abducens VI 284
 - - cavernous portion 142
 - - nucleus of 141
 - accessory 200, 202
 - cochlear 164
 - facial 260
 - - cisternal segment 160
 - - genu of 157
 - - geniculum of 186
 - - internal genu of 260
 - - intracanalicular segment 160
 - - petrous segment 160
 - glossopharyngeal 200, 202
 - great petrosal 159
 - hypoglossal 201, 202
 - inferior vestibular 160
 - intermedius 159
 - mandibular (V3) 145
 - maxillary (V2) 145, 284
 - oculomotor (III) 146, 284
 - - accessory nucleus of 141
 - - cavernous portion 142
 - - nucleus of 141
 - ophthalmic (V1) 145, 146, 284
 - optic 41, 43, 45, 67, 119, 120, 133, 134
 - - infraorbital portion 121
 - posterior auricular 159
 - superior vestibular 161
 - to stapedius muscle 159
 - trigeminal
 - - cisternal portion of 148, 149
 - - mesencephalic nucleus 147
 - - mesencephalic tract 147
 - - motor nucleus of 147
 - - motor root of 147
 - - sensory nucleus 147
 - - sensory root of 147
 - - spinal nucleus 147
 - - spinal tract 147
 - trigeminal (V) 145
 - trochlear (IV) 146, 284
 - - nucleus of 141
 - vagus (X) 200, 202
 - vestibular 168
- Neurohypophysis 281, 283
- Nodus 92, 96, 104
- Nuclei,
- cochlear 157, 165
 - medial and lateral vestibular 260
 - septal (see also gyrus paraterminal, septal area) 43, 273
 - vestibular 157
- Nucleus,
- abducent 260
 - accessory 115
 - accumbens 41, 42, 226
 - ambiguus 199, 261
 - anterior amygdaloid 115, 263
 - basal amygdaloid 218, 219, 263
 - caudate 219
 - - body of 200, 228, 230
 - - head of 205, 220-222, 225, 237-241
 - - tail of 205, 232, 233, 237, 238, 241
 - cortical amygdaloid 219, 263
 - cuneate 244, 261, 262
 - dentate 90, 96, 97, 104
 - dorsal cochlear 164, 260
 - - dorsal vagal 199, 261, 262
 - - emboliform 91, 96
 - - facial 260
 - - fastigial 91, 96
 - - globose 91
 - - gracile 243, 244, 262
 - - habenular 72, 115, 238, 263
 - - hypoglossal 261, 262
 - - inferior olivary 93, 101
 - - inferior vestibular 168, 260, 261
 - - interstitial 168
 - - lateral amygdaloid 218
 - - lateral of amygdala 263
 - - lateral vestibular (Deiters') 168, 169
 - - medial cuneate 243
 - - medial superior olivary 164
 - - medial vestibular 168
 - - mesencephalic
 - - of trigeminal nerve 258
 - - motor trigeminal 259
 - - of lateral lemniscus 164
 - - of nerve glossopharyngeal 199
 - - of nerve hypoglossal 199
 - - of oculomotor nerve 168, 257
 - - of spinal root of accessory nerve 199
 - - of trapezoid body 164
 - - of trochlear nerve 168, 258
 - - oval 249
 - - red 91, 111, 221 231, 257, 263
 - - salivatory 157, 199
 - - solitary 250, 261, 262
 - - pars gustatoria of 249
 - - spinal
 - - of trigeminal nerve 260-262
 - - superior lateral olivary 164
 - - superior vestibular 168, 259, 260
 - - thalamic
 - - anterior 223, 238-240
 - - centromedian 221-223, 237-239
 - - lateral dorsal 221-223, 240
 - - lateral posterior 220, 238, 240
 - - medial 115
 - - mediodorsal 221-223, 238, 239

- - ventral anterior 222, 223
- - ventral intermediate 170
- - ventral lateral 220, 221, 230, 238, 239, 240
- - ventral posterolateral 220, 237, 238, 239, 243
- - ventral posteromedial 237, 238, 249, 251
- trigeminal 259
- ventral cochlear 164, 260

- Obex 92, 289
- Olive 200, 261, 262
- Operculum,
 - central (see also rolandic operculum) 50
 - frontal 48, 49
 - parietal 55
 - rolandic (see also central operculum) 50, 52
- Optic,
 - bulb 119
 - canal 278, 279
 - chiasm 43, 44, 50, 68, 119, 277, 280, 295
 - nerve 139, 226, 277
 - tract 51, 277
- Orbit 6
- Orbital,
 - fat 128
 - floor 6
- Ossicular chain 171

- Peduncle,
 - inferior cerebellar 94, 164, 260, 261
 - middle cerebellar 89, 93, 104, 105, 106, 260
 - superior cerebellar 94, 106, 257, 258, 259
- Periarcheocortex 272
- Periorbit 128
- Petrous pyramid 6, 22, 23
 - apex of 278
- Pineal, body 224
- Pituitary
 - gland 137
 - stalk 50, 123, 277, 295
- Planum,
 - polare 164
 - sphenoidal-ethmoid 5
 - temporale 56

- Plate,
 - quadrigeminal (see also quadrigeminal tubercle or tectum of midbrain or colliculi) 93, 224
- Plexus venous,
 - anterior ponto-mesencephalic 348
- Pogonion 9
- Pons 93, 104, 107, 161
- Porion 8
- Precuneus (P1) 60, 74, 79
- Process,
 - alveolar 5, 18
 - anterior clinoid 4, 21, 22, 23, 120, 278, 279
 - posterior clinoid 4, 21, 23, 278, 279
 - mastoid 7, 19
 - palatine 21
 - pterygoid
 - - hook of 21
 - - lamina of 21
 - styloid 20, 195, 196
- Promontory 191, 192
- Protuberance,
 - external occipital (see also inion) 4, 8, 20
 - frontal 18
 - mental 18
- Pterion 8
- Pulvinar 219, 221, 238, 239
- Putamen 219, 237, 240
- Pyramid 102
 - of medulla 101, 103
- Pyramidal, decussation 205, 262
- Pyramis 92

- Radiation,
 - acoustic 164, 166
 - optic 71, 124
 - - occipital genu 119
 - - temporal genu 119
- Recess,
 - infundibular 289, 295
 - optic 289
 - parabrachial 106, 107
 - pineal 289
 - suprapineal 289

- Retinic ganglion cells 121
- Saccule 162
- Sclera 128
- Scutum 188, 189, 190
- Sella turcica 21, 278, 279
 - floor 4, 22
- Sensibility,
 - epicritic 215
 - pain and temperature 215
 - protopathic 215
 - proprioceptive 215
- Septum,
 - jugulohypotympanicum 173, 187, 190
 - Korner's 193
 - pellucidum 44, 49, 50, 73, 273
 - verum 263
- Sinus,
 - cavernous 142, 280, 286, 287
 - ethmoidal 6
 - - cells of 3
 - frontal 5, 6
 - inferior petrosal 348, 350
 - inferior sagittal 295, 296, 346, 349, 350
 - intercavernous 351
 - intercavernous anterior 352
 - maxillary 6
 - occipital 347
 - sigmoid 173, 197, 341, 342, 344, 347, 348
 - sphenoid 4, 128, 283, 280, 284
 - straight 70, 297, 343, 348
 - superior petrosal 348, 350
 - superior sagittal 45, 70, 76, 81, 292, 341, 348, 349
 - transverse 341-343, 348, 351
 - tympani 176, 194
- Siphon, internal carotid 151, 277, 280, 284
- Space,
 - Prussak 189
- Spina,
 - jugular 173
- Spinal cord 92, 93
- Spine,
 - anterior nasal 9, 19, 21

- Stapes 171, 177, 190, 192
- Stria,
- dorsal acoustic 164
 - lateral olfactory 115
 - medial olfactory 115
 - medullaris 239
 - sagittal 119
 - terminalis 115, 263
- Subiculum 194, 263, 267
- Substance,
- anterior perforated 51, 115, 118, 228, 273, 296
- Substantia nigra 91, 230, 231
- pars compacta 257
 - pars reticulata 257
- Sulcus,
- anterior calcarine 59
 - anterior temporal 70
 - arcuate (see also transverse orbital sulcus) 45
 - calcarine 73
 - central 31, 33, 36, 40, 54, 73, 74, 77
 - central insular 34, 35
 - cingulate 40, 42, 46, 51, 56, 72, 77, 81
 - circular insular 34, 35, 48, 49, 51, 52
 - collateral (see also medial occipito-temporal incisure or sulcus) 36, 39, 51, 52, 60, 64, 65, 66
 - frontal middle 49
 - frontomarginal 37, 39, 72, 137
 - inferior frontal 33, 45, 47
 - inferior occipital 61, 62
 - inferior precentral 74, 75, 77
 - inferior temporal 32, 52
 - intermedius primus (Jensen) 31, 77
 - intraoccipital 76
 - intraparietal 36, 55, 56, 62, 77
 - lateral occipital 32, 33, 61
 - lateral orbital 33
 - lateral temporo-occipital 52, 54, 58, 60
 - lingual 59, 70
 - lunate 36
 - middle frontal 77
 - olfactory 41, 45, 47, 68
 - orbital 46
 - paracentral 82, 83
 - parieto-occipital 71
 - ponto-medullar 91
 - ponto-mesencephalic 92
 - postcentral 32
 - posterior transverse collateral 35, 61, 67, 68
 - precentral 32
 - retrocalcarine 68, 124
 - subparietal 44, 77
 - superior calcarine 58
 - superior frontal 37, 39, 46, 77
 - superior postcentral 58, 81, 82, 84
 - superior precentral 38, 40
 - superior temporal 32, 48, 52, 58, 59, 62, 66, 67, 70, 77
 - supraorbital 42, 43
 - transverse occipital 37
 - transverse orbital (see also arcuate sulcus) 45
 - transverse parietal 41, 43
- Suture,
- coronal 19
 - fronto-zygomatic 6, 18
 - intermaxillary 18
 - lambdoid 4, 19, 20
 - maxillary-nasal 18
 - maxillo-lacrimal 18
 - occipital-mastoid 20
 - petro-clival 155
 - sagittal 3, 18
 - sphenoccipital 23
- System,
- vertebrobasilar 315
- Table,
- inner 4
 - outer 4
- Tarsal plate, of the eyelid 128
- Tectum,
- of midbrain (see also quadrigeminal tubercle or quadrigeminal plate or colliculi) 224
- Tegmen tympani 189
- Temporal,
- squama 19
- Tendon,
- of tensor tympani muscle 187, 188
- Tentorium,
- border of 286
- Territories,
- vascular 319
- Thalamus 224
- Third ventricle 53, 71, 280, 293
- chiasmatic recess 282
 - choroid tela of 296
 - infundibular recess of 111, 122, 282, 291
 - optic recess of 291
 - pineal recess of 295
 - suprapineal recess of 295
- Tonsil 101
- of cerebellum 90, 94
- Torcular Herophili (sinus confluence) 341, 347, 348
- Tract,
- anterior spinocerebellar 262
 - corticospinal 206, 208
 - dorsal trigeminus-thalamic 249, 250
 - frontopontine 205, 257
 - lateral olfactory 116
 - lateral vestibulospinal 169
 - mammillothalamic 237, 238, 276
 - medial vestibulospinal 169
 - occitopontine 205
 - olfactory 115, 118
 - optic 42, 69, 111, 257
 - - lateral root 119
 - - medial root 119
 - parietopontine 205
 - parietotemporopontine 257
 - pontocerebellar 258, 260
 - posterior spinocerebellar 262
 - pyramidal 104, 106, 205, 257, 262
 - spino-thalamic 257
 - temporopontine 205
 - vestibulothalamic 169
- Tractus,
- pyramidalis anterior 214
 - pyramidalis lateralis 214
- Trigone, olfactory 68, 69, 131
- Tube, auditory (eustachian) 174, 175, 184
- Tuber 92

- Tubercle,
 - quadrigeminal (see also quadrigeminal plate or tectum of midbrain or colliculi) 224
- Tuberculum sellae 23, 279
- Tympanic cavity, 171, 175
 - epitympanum 172
 - hypotympanum 172
 - mesotympanum 172

- U-fibers 275
- Uncus (see also gyrus ambiens) 50, 136
 - apex 266
- Utricle 162
- Utriculus 194
- Uvula 92, 96, 97, 101

- Vasal imprint 4
- Vein,
 - anterior caudate 349
 - basal of Rosenthal 344, 348
 - cerebellar hemispheric 348
 - choroid 292
 - cortical 342
 - hemispheric cerebellar 347
 - inferior ophthalmic 350
 - inferior vermian 347, 348
 - internal cerebral 55, 73, 74, 292, 295, 296, 344, 348
 - internal jugular 341, 347
 - lateral mesencephalic 348
 - middle cerebral 344, 345
 - of Galen 224, 292, 295, 296, 344, 345, 348
 - of Labbé 343, 344
 - of Trolard 343
 - petrosal 347, 348
 - posterior mesencephalic (see also basal vein of Rosenthal) 348
 - precentral cerebellar 348
 - septal 349
 - superior choroidal 348
 - superior ophthalmic 130, 139, 350
 - thalamic 348
 - thalamostriate 347
 - transverse pontine 348
- Velum, superior medullary 92

- Vertex 8
- Vestibulus 171, 178, 179, 191-193
- Vitreous 137

- Window,
 - oval 171, 192
 - round 175, 194