



Handbook of Nutrition and Ophthalmology

by

Richard D. Semba, MD, MPH

HANDBOOK OF NUTRITION AND OPHTHALMOLOGY



Giuseppe Arcimboldo, Vertemnus (1591), Courtesy of Skoklosters Slott, Balsta, Stockholm.

Vertemnus (or Vortumnus) was an Etruscan god who was responsible for the transformation of plants from flowering to the bearing of fruit.

HANDBOOK OF NUTRITION AND OPHTHALMOLOGY

By

RICHARD D. SEMBA, MD, MPH

*The Wilmer Eye Institute, The Johns Hopkins University
and Hospital, Baltimore, Maryland*



HUMANA PRESS
TOTOWA, NEW JERSEY

© 2007 Humana Press Inc.
999 Riverview Drive, Suite 208
Totowa, New Jersey 07512

www.humanapr.com

All rights reserved. No part of this book may be reproduced, stored in a retrieval system, or transmitted in any form or by any means, electronic, mechanical, photocopying, microfilming, recording, or otherwise without written permission from the Publisher. All papers, comments, opinions, conclusions, or recommendations are those of the author(s), and do not necessarily reflect the views of the publisher.

Due diligence has been taken by the publishers, editors, and authors of this book to assure the accuracy of the information published and to describe generally accepted practices. The contributors herein have carefully checked to ensure that the drug selections and dosages set forth in this text are accurate and in accord with the standards accepted at the time of publication. Notwithstanding, as new research, changes in government regulations, and knowledge from clinical experience relating to drug therapy and drug reactions constantly occurs, the reader is advised to check the product information provided by the manufacturer of each drug for any change in dosages or for additional warnings and contraindications. This is of utmost importance when the recommended drug herein is a new or infrequently used drug. It is the responsibility of the treating physician to determine dosages and treatment strategies for individual patients. Further it is the responsibility of the health care provider to ascertain the Food and Drug Administration status of each drug or device used in their clinical practice. The publisher, editors, and authors are not responsible for errors or omissions or for any consequences from the application of the information presented in this book and make no warranty, express or implied, with respect to the contents in this publication.

Cover design by Nancy K. Fallatt
Production Editor: Christina Thomas

For additional copies, pricing for bulk purchases, and/or information about other Humana titles, contact Humana at the above address or at any of the following numbers: Tel.: 973-256-1699; Fax: 973-256-8341; E-mail: orders@humanapr.com or visit our website at <http://humanapress.com>

This publication is printed on acid-free paper. 
ANSI Z39.48-1984 (American National Standards Institute) Permanence of Paper for Printed Library Materials.

Photocopy Authorization Policy:

Authorization to photocopy items for internal or personal use, or the internal or personal use of specific clients is granted by Humana Press, provided that the base fee of US \$30.00 per copy is paid directly to the Copyright Clearance Center (CCC), 222 Rosewood Dr., Danvers MA 01923. For those organizations that have been granted a photocopy license from the CCC, a separate system of payment has been arranged and is acceptable to the Humana Press. The fee code for users of the Transactional Reporting Service is 978-1-58829-196-7/07 \$30.00.

Printed in the United States of America. 10 9 8 7 6 5 4 3 2 1

eISBN 978-1-59259-979-0

Library of Congress Cataloging-in-Publication Data
Semba, Richard D.

Handbook of nutrition and ophthalmology / by Richard D. Semba.
p. ; cm. -- (Nutrition and health)

Includes bibliographical references and index.

ISBN: 978-1-58829-196-7 (alk. paper)

1. Geriatric ophthalmology--Handbooks, manuals, etc. 2. Vision disorders in old age--Handbooks, manuals, etc. 3. Eye--Aging--Handbooks, manuals, etc. 4. Eye--Diseases--Handbooks, manuals, etc. 5. Diet in disease--Handbooks, manuals, etc. I. Title.

II. Series: Nutrition and health (Totowa, N.J.)

[DNLM: 1. Eye Diseases. 2. Nutrition. 3. Eye Diseases--prevention & control.

4. Nutrition Disorders--complications. WW 140 S4705h 2007]

RE48.2.A5S46 2007

618.9777--dc22

2006023232

To Tom, Lisa, and Amy, for our wonderful friendship and adventures
from Palo Alto to Paris and Puebla

NUTRITION ◇ AND ◇ HEALTH

Adrianne Bendich, Series Editor

- Handbook of Nutrition and Ophthalmology*, by **Richard D. Semba**, 2007
- Adipose Tissue and Adipokines in Health and Disease*, edited by **Giamila Fantuzzi** and **Theodore Mazzone**, 2007
- Nutritional Health: Strategies for Disease Prevention, Second Edition*, edited by **Norman J. Temple, Ted Wilson and David R. Jacobs, Jr.**, 2006
- Nutrients, Stress, and Medical Disorders*, edited by **Shlomo Yehuda and David I. Mostofsky**, 2006
- Calcium in Human Health*, edited by **Connie M. Weaver and Robert P. Heaney**, 2006
- Preventive Nutrition: The Comprehensive Guide for Health Professionals, Third Edition*, edited by **Adrianne Bendich and Richard J. Deckelbaum**, 2005
- The Management of Eating Disorders and Obesity, Second Edition*, edited by **David J. Goldstein**, 2005
- Nutrition and Oral Medicine*, edited by **Riva Touger-Decker, David A. Sirois, and Connie C. Mobley**, 2005
- IGF and Nutrition in Health and Disease*, edited by **M. Sue Houston, Jeffrey M. P. Holly, and Eva L. Feldman**, 2005
- Epilepsy and the Ketogenic Diet*, edited by **Carl E. Stafstrom and Jong M. Rho**, 2004
- Handbook of Drug–Nutrient Interactions*, edited by **Joseph I. Boullata and Vincent T. Armenti**, 2004
- Nutrition and Bone Health*, edited by **Michael F. Holick and Bess Dawson-Hughes**, 2004
- Diet and Human Immune Function*, edited by **David A. Hughes, L. Gail Darlington, and Adrianne Bendich**, 2004
- Beverages in Nutrition and Health*, edited by **Ted Wilson and Norman J. Temple**, 2004
- Handbook of Clinical Nutrition and Aging*, edited by **Connie Watkins Bales and Christine Seel Ritchie**, 2004
- Fatty Acids: Physiological and Behavioral Functions*, edited by **David I. Mostofsky, Shlomo Yehuda, and Norman Salem, Jr.**, 2001
- Nutrition and Health in Developing Countries*, edited by **Richard D. Semba and Martin W. Bloem**, 2001
- Preventive Nutrition: The Comprehensive Guide for Health Professionals, Second Edition*, edited by **Adrianne Bendich and Richard J. Deckelbaum**, 2001
- Nutritional Health: Strategies for Disease Prevention*, edited by **Ted Wilson and Norman J. Temple**, 2001
- Clinical Nutrition of the Essential Trace Elements and Minerals: The Guide for Health Professionals*, edited by **John D. Bogden and Leslie M. Klevey**, 2000
- Primary and Secondary Preventive Nutrition*, edited by **Adrianne Bendich and Richard J. Deckelbaum**, 2000
- The Management of Eating Disorders and Obesity*, edited by **David J. Goldstein**, 1999
- Vitamin D: Physiology, Molecular Biology, and Clinical Applications*, edited by **Michael F. Holick**, 1999
- Preventive Nutrition: The Comprehensive Guide for Health Professionals*, edited by **Adrianne Bendich and Richard J. Deckelbaum**, 1997

Series Editor Introduction

The Nutrition and Health series of books have, as an overriding mission, to provide health professionals with texts that are considered essential because each includes: 1) a synthesis of the state of the science, 2) timely, in-depth reviews by the leading researchers in their respective fields, 3) extensive, up-to-date fully annotated reference lists, 4) a detailed index, 5) relevant tables and figures, 6) identification of paradigm shifts and the consequences, 7) virtually no overlap of information between chapters, but targeted, inter-chapter referrals, 8) suggestions of areas for future research and 9) balanced, data-driven answers to patient/health professionals questions which are based upon the totality of evidence rather than the findings of any single study.

The series volumes are not the outcome of a symposium. Rather, each editor has the potential to examine a chosen area with a broad perspective, both in subject matter as well as in the organization of their volume. The international perspective, especially with regard to public health initiatives, is emphasized where appropriate. The editors, whose trainings are both research and practice oriented, have the opportunity to develop a primary objective for their book; define the scope and focus, and then may invite the leading authorities from around the world to be part of their initiative. The editor/authors are encouraged to provide an overview of the field, discuss their own research and relate the research findings to potential human health consequences. Because each book is developed de novo, the chapters are coordinated so that the resulting volume imparts greater knowledge than the sum of the information contained in the individual chapters.

Of the 22 books currently published in the Series, only two have been given the title of Handbook. These two volumes, 1). *Handbook of Clinical Nutrition and Aging* and 2.) *Handbook of Drug-Nutrient Interactions*, are comprehensive, detailed and include extensive tables and figures, appendices and detailed indices that add greatly to their value for readers. Moreover, Handbook contents cut across a wide array of health professionals' needs as well as medical specialties. The Nutrition and Health Series now will include its third Handbook volume.

"Handbook of Nutrition and Ophthalmology" written entirely by Dr. Richard Semba is a very welcome addition to the Nutrition and Health Series and fully exemplifies the Series' goals. This volume is especially timely since the aging of the population is predictive of a greater potential for age-related eye diseases that can result in blindness and other adverse health outcomes. Dr. Semba, who is Professor of Ophthalmology at the Wilmer Eye Institute at Johns Hopkins University, is a global leader in nutrition research and has published extensively on the role of vitamin A deficiency in childhood blindness. Dr. Semba is also the co-editor of the well-received volume, *"Nutrition and Health in Developing Countries"* in this Series, that he co-edited with Dr. Martin Bloem. In this new text, Dr. Semba has actually given readers three major complimentary volumes in one. The first "volume" includes the expert detailed descriptions of the clinical consequences of single nutrient deficiencies including excellent photo examples of the ocular consequences of these deficiencies. There are separate chapters for vitamin A, B vita-

mins, zinc, vitamin C and essential fatty acids. The second “volume” contains extensive discussions of the nutrient in question, its discovery, a full discussion of the pathologies associated with the deficiency as well as food sources of the nutrient and a global perspective of where each essential nutrient deficiency is still found in this 21st Century. The last “volume” contains in-depth discussions of the major eye diseases including cataract, macular degeneration, diabetic retinopathy, retinal vascular diseases, ocular consequences of inborn errors of metabolism, and nutritional amblyopias. Two additional chapters provide the bridges between the clinical conditions including obesity and the finding of pro-inflammatory states that cut across many of the eye diseases discussed within this comprehensive volume. The inclusion of molecular explanations for the role of the nutrients in the eye helps us to understand the relevance of ocular pathophysiology in the clinical setting to its pertinence for academic researchers. This text is the first to synthesize the knowledge base concerning ophthalmology, immune function and nutrition for the practicing health professional as well as those professionals who have an interest in the latest, up-to-date information on eye function and its implications for human health and disease.

This volume serves a dual purpose of providing in-depth focus on the biological functions of certain essential nutrients as well as examining the current clinical findings associated with the consequences of deficiency diseases and puts these into historic perspective as well as pointing the way to future research opportunities. Dr. Semba, as the editor, is an internationally recognized leader in the field of ophthalmologic research as well as clinical outcomes. He is an excellent communicator and he has worked tirelessly to develop a book that is destined to be the benchmark in the field because of its extensive, in-depth chapters covering the most important aspects of the complex interactions between cellular functions, diet, eye function, and its impact on disease states. As an example, Dr Semba has included explanations of how all of the cells of the immune system, included subsets of T and B lymphocytes, macrophages and Natural killer cells that interact to affect the development of infectious acute and chronic diseases that cause adverse effects on the eye including diarrheal disease, HIV infection, malaria, measles and tuberculosis.

The introductory chapters provide readers with the basics so that the more clinically-related descriptions can be easily understood. The editor has included 12 informative chapters in the volume. Hallmarks of all of the chapters include complete definitions of terms with the abbreviations fully defined for the reader and consistent use of terms between chapters. Key features of this comprehensive volume include the informative introduction at the beginning of each chapter, more than 170 detailed tables and informative figures, an extensive, detailed index and more than 3200 relevant historic and up-to-date references that provide the reader with excellent sources of worthwhile information about diet and eye health. As an example, there are over 1000 references in the first chapter on vitamin A and nutritional blindness that include citations from Hippocrates, papers published in the 1600s as well as papers just recently published on the web. Dr. Semba has examined each of the original references, rather than relying on other authors’ past reviews, a heroic accomplishment.

In conclusion, “*Handbook of Nutrition and Ophthalmology*” written entirely by Dr. Richard Semba provides health professionals in many areas of research and practice with the most up-to-date, well referenced volume on the importance of nutrition in determin-

ing the health of the eye and eyesight and the effects of chronic nutrient deficiencies on related chronic diseases/conditions that can adversely affect human health. This volume will serve the reader as the benchmark in this complex area of interrelationships between ophthalmology, eye diseases associated with nutrient deficiencies in childhood as well as loss of eyesight associated with less than optimal intakes in adulthood and old age. Moreover, students as well as practitioners can better understand the complexities of these interactions because of the extensive discussions of the physiological functions of the nutrients that are associated with eye health. Dr. Semba is applauded for his efforts to develop the most authoritative resource in the field to date and this excellent text is a very welcome addition to the Nutrition and Health Series.

Adrianne Bendich, Ph.D., FACN

Foreword

Even prior to the invention of the ophthalmoscope in 1851, nutritional deficiencies such as xerophthalmia were known as important causes of vision loss. Many of the toxic effects of nutritional deficiencies on the eye had been described in case reports and series by the early part of the 20th century. However, it has only been more recently, beginning in the 1970s, that the interrelationships between nutrition and chronic ocular diseases, e.g., cataract, age-related macular degenerations (AMD) have been examined in large population-based studies (e.g., the Beaver Dam Eye Study, the Blue Mountains Eye Study) and randomized controlled clinical trials (e.g., the Age-Related Eye Disease Study [AREDS]). This has, in part, been made possible by the development of standardized protocols to assess these conditions by grading of fundus and lens photographs, as well as the development of more robust nutritional epidemiologic instruments to describe the intake of dietary nutrients and supplements.

These studies have provided new insights regarding nutritional exposures and the prevalence of chronic eye diseases (e.g., associations of dietary saturated fats and leafy green vegetables with AMD, the associations of dietary intake vitamin E, riboflavin and folate with nuclear sclerotic cataract). Findings of associations between specific nutrients, especially deficiencies and ocular disease are also important in understanding the possible pathogeneses of these chronic ocular conditions.

Application of findings from these studies through dietary supplementation may have an impact on the incidence and progression of AMD and cataract although clinical trials data are necessary before any recommendation in favor of supplement use is made. Confirmation of nutritional epidemiological findings from observational studies by randomized controlled clinical trials is critical because of the potential problem of uncontrolled confounding. That is, the failure to measure and control for other exposures (e.g., healthy lifestyles, physical activity) that may explain, in part, the earlier finding in cohort studies of reduced risk of cardiovascular disease in association with hormone replacement therapy (HRT) and the contrary finding in the large randomized controlled clinical trial, the Women's Health Initiative, showing an increased risk of acute myocardial infarction from such treatment. Confounding by indication, that is, taking a supplement or drug for a specific condition where an effect is ascribed to the treatment although it may be due to the underlying disease for which the treatment is given may also be another problem limiting the interpretation of data from observational studies. For example, zinc supplements were found to be associated with higher risk of incident late AMD in some epidemiological studies. However, the REDS showed that when an anti-oxidant multi-vitamin supplement was given there was a statistically significant 28% reduction in the risk of progression to end stage AMD compared to those taking placebo.

The application of findings from studies on nutrition and chronic eye disease e.g., AMD and cataract have great importance as the population ages and the burden of such conditions increase. At present, the strongest associations found in epidemiological studies of chronic eye diseases have been with non-modifiable factors (e.g., age, genetic

factors, race with AMD). Only a few modifiable risk factors have been found (e.g., smoking with AMD). Finding specific associations of dietary factors with AMD, cataract and other chronic eye diseases are important because diet is modifiable and such modifications may have the potential of reducing the burden associated with these diseases. With this in mind, the new book by Semba will be important to dietitians, ophthalmologists, optometrists, and the lay public interested in role of nutrition in eye disease. It examines the historical and recent evidence concerning the role of dietary changes in preventing both acute and chronic eye disease.

Dr. Semba's text covers the broad field of nutrition and ophthalmology. The content of the 12 chapters covers specific disease entities e.g., AMD and age-related cataract, diabetic retinopathy, and inborn errors of metabolism) and specific nutrients (e.g., vitamins C, E, A, and B-complex, zinc, fatty acids) and their relation to ocular disease. It is a unique text, in that all chapters were written by one author and cover a large area of material ranging from an historical overview, epidemiology, pathology and treatment of the condition. There are three identified themes within the text, the first emphasizing the efficacy of long-term "healthy" diet, the second the importance of historical perspective of diet and eye disease, and the third the importance of two putative pathogenetic mechanisms, oxidative stress and inflammation. The text provides important and new authoritative information on the relation of nutrition to ocular disorders which will reward the reader with a wealth of insightful information.

Ronald Klien, MD, MPH

Preface

In the last three decades, substantial progress has been made in demonstrating the importance of good nutrition to eye health. Nutrition plays a major role from early infant development through childhood and on through older age as a determinant of visual function and eye disease. I have emphasized three broad themes in the *Handbook of Nutrition and Ophthalmology*. The first is that the adoption of a healthy diet as a major life-long habit will likely have an impact on reducing a substantial proportion of visual impairment and blindness. A major problem facing ophthalmology will be the large increase in diabetic retinopathy that is expected to follow the worldwide epidemic of type 2 diabetes and obesity. The second theme is that a historical perspective is essential to understanding current challenges in ophthalmology, medicine, and public health. Many of the eye diseases caused by nutritional deficiencies were well described when malnutrition was more highly prevalent in some parts of the world. In situations of conflict, famine, and natural disasters, the same eye diseases are seen repeatedly—a poignant example is the recent epidemic of nutritional amblyopia in Cuba. Vitamin A deficiency was once a major cause of childhood blindness in developed countries and today still remains the leading cause of blindness among children in developing countries. The third theme in the *Handbook of Nutrition and Ophthalmology* is that many nutrients play a role in oxidative stress and inflammation. This idea has emerged as a major underlying hypothesis in the pathogenesis of eye diseases. Much more work is still needed to examine the possible intermediary steps between healthy diets and aging-related eye diseases, and this area is likely to be a fruitful one for investigation in the future.

As may be apparent, some of the chapters in this book are longer than others, and in many ways this reflects the level of knowledge in different areas. For example, xerophthalmia is an ancient scourge and there is perhaps more known about vitamin A and nutritional blindness than is known collectively about all the other nutritional deficiencies and eye health. Nutritional amblyopia has a long and complex history, and the relationship between the B complex vitamins and nutritional amblyopia is complex. Less is known about the roles of vitamin C in eye health. The role of carotenoids, zinc, and other nutrients in age-related macular degeneration is a story that is still evolving.

ACKNOWLEDGMENTS

I thank Peter McDonnell for his steadfast support and encouragement. I thank my colleagues Martin Bloem, Saskia de Pee, Luigi Ferrucci, Debra Schaumberg, and Linda Fried for their insight and discussions; Douglas Jabs for his advice and guidance; and Arnall Patz for his kindness and inspiration over the years. I thank Alfred Sommer, Keith West, Jr., Gantira Natadisastra, and Muhilal for our collaborations on nutritional blindness in Indonesia. I thank Adrienne Bendich for her enthusiasm in bringing this book to fruition. I am grateful to Satoru Yamamoto for his translations of the older Japanese literature on fundus xerophthalmicus and on kakke (beriberi) and eye disease. My wife,

Rita Costa Gomes, helped in many ways with works from the French, Portuguese, Spanish, and Italian scientific literature. I thank Kelly Barry and Christopher Wild, Anna Berchidskaia, and Michael Stern, respectively, for their translations of papers from the German, Russian, and Dutch scientific literature. Frank Corl provided the original illustrations and figures, and the staff members of Wilmer Ophthalmic Photography were helpful in preparing photographs.

The preparation of the *Handbook of Nutrition and Ophthalmology* was greatly facilitated by the superb assistance and expertise of the staff of the National Library of Medicine, especially Stephen Greenberg, Elizabeth Tunis, Kenneth Niles, Crystal Smith, and Khoi Le. I also thank Mike Piorunski of the Friedenwald-Romano Library, and the staff of the Bibliothèque Nationale de France, the Österreichische Nationalbibliothek, and the Wellcome Library in London. I also thank Dana Totin Moncrief, Barbara Dancheck, Amanda Ray, Margaret Dayhoff-Brannigan, and Caitlin Howard for moving our laboratory work forward with innovative investigations of nutrition, oxidative stress, and inflammation. Finally, this work would not be possible without the support of the National Institute on Aging (R01 AG02712 and the National Institute on Child Health and Human Development (R01 HD30042, R01 HD32247) of the National Institutes of Health and a Lew R. Wasserman Merit Award from Research to prevent blindness.

Richard D. Semba, MD, MPH

Contents

Series Editor Introduction vii

Foreword xi

Preface xiii

1. Nutrition Blindness: *Vitamin A Deficiency Disorders* 1

2. Cataract 121

3. Age-Related Macular Degeneration 163

4. The Obesity Epidemic: *Implications for Eye Health* 219

5. Nutrition and Diabetic Retinopathy 241

6. Retinal Vascular Disease 257

7. Nutritional Amblyopia and B Vitamin Complex Deficiencies 281

8. Zinc and Eye Health 355

9. Vitamin C and Eye Health 371

10. The Age-Related Proinflammatory State and Eye Disease 391

11. Essential Fatty Acids and Visual Development in Infants 415

12. Inborn Errors of Metabolism 443

Index 485

1

Nutritional Blindness (Vitamin A Deficiency Disorders)

1. INTRODUCTION

Nutritional blindness is a term used to describe xerophthalmia (from the Greek *xeros*, dry, and *ophthalmia*, inflamed eye) and keratomalacia, or corneal necrosis, caused by vitamin A deficiency. According to estimates of the World Health Organization (WHO), nutritional blindness remains the leading single cause of blindness among children worldwide (1,2). Xerophthalmia and keratomalacia are only one aspect of a more complex deficiency disease, known as the vitamin A deficiency disorders, that includes anemia, growth retardation, immune suppression, inflammation, and increased morbidity and mortality from infectious diseases. Nutritional blindness is best understood in the context of the larger syndrome of the vitamin A deficiency disorders, as the factors that may precipitate nutritional blindness are intricately tied to the problems of infectious diseases, hygiene, poor nutrition, and poverty. Young children and women of reproductive age are at the highest risk of vitamin A deficiency, and programs are currently focused on reaching these two high risk groups. The elimination of vitamin A deficiency in developing countries is one of the major challenges in public health and ophthalmology, as the blindness, morbidity, and mortality from the vitamin A deficiency disorders are largely preventable.

2. HISTORICAL BACKGROUND

A historical perspective on vitamin A deficiency is emphasized because many of the conditions that existed in developed countries in the 19th century and early 20th century are similar to the conditions that are found in many developing countries today. Much of what was learned about the eradication of vitamin A deficiency in the United States and Europe in the first half of the 20th century has some relevance for research, programs, and policy in developing countries. There was a remarkable growth in knowledge on the vitamin A deficiency disorders that preceded the characterization of vitamin A and was often based on empirical observation. The period of the 1920s and 1930s was especially important in our current understanding of the relationship of vitamin A deficiency to blindness and mortality, and findings from this era had a strong influence that resulted in changes in medical practice, public health, and health policy in regard to vitamin A. Yet much of these earlier accomplishments have gone largely unappreciated or excluded in literature reviews by some investigators today. In the history of vitamin A, many observations have been made repeatedly, and even as early as 1882, Hilário de Gouvêa noted:

From: *Nutrition and Health: Handbook of Nutrition and Ophthalmology*

By: R. D. Semba © Humana Press Inc., Totowa, NJ

“O que ha de muito curioso no historico da xerophthalmia por vicio de nutrição, é que todos ou quasi todos os autores que a observaram e descreveram, presumiram fazel-o pela primeira vez.”

“It is very curious in the history of xerophthalmia due to nutritional disorders that all or nearly all authors who have observed and described it believed themselves to be the first to do so” (3).

This view from the late 19th century should be well considered, as in the last three decades, many so-called “new” findings in the field of vitamin A are rediscoveries or refinements of previous observations that were made in the 19th and early 20th centuries when vitamin A deficiency was a public health problem in Europe and the United States. This recurring theme is emphasized throughout the chapter.

2.1. Early Perspectives on Xerophthalmia

Night blindness, a clinical manifestation of vitamin A deficiency, has been known from antiquity. In the Hippocratic writings, *Epidemics VI*, night blindness was described among children with whooping cough (4). In the first century AD, Celsus noted the ingestion of animal liver (a rich source of vitamin A) as a treatment for night blindness in *De Medicina* (5). During the European era of exploration and colonization, night blindness was found to be indigenous among populations in Africa (6,7), the East Indies (8), Brazil (9), and China (10). Night blindness appeared to be common among some groups of poorly nourished soldiers, sailors, slaves, pregnant women, and children in the 18th and 19th centuries (11–14). In 1816, the French physiologist François Magendie (1783–1855) fed dogs an experimental diet of sugar and water alone and noted that they developed corneal ulcers and died (15). A few years later in France, Félix-Séverin Ratier (1797–1866) observed bilateral corneal ulcers in a poorly nourished 6-mo-old infant who developed diarrhea and died (16). The British physician Joseph Brown (1784–1868) (17) and the French physician Charles Billard (1800–1832) (18) observed corneal ulcers in poorly fed infants. Later, in the 1840s, the British ophthalmologist William Bowman (1816–1892) also described a case of keratomalacia in an infant whose mother stopped breast-feeding when she was sent to the workhouse (19). It is notable that all four physicians drew comparisons with the corneal ulcers in Magendie’s dogs and raised the question whether this was related to faulty nutrition. As noted by Brown: “Compare this case with Magendie’s account of the dogs fed, or rather starved, on sugar” (17).

In 1863, Pierre Bitot (1822–1888), Professor of Anatomy at the School of Medicine in Bordeaux, described “une tache nacréée ou argentée” (“a pearly or silvery patch”) on the conjunctiva among children suffering from night blindness at the Hospice des Enfants Assistés in Bordeaux (20). He observed 29 children, mostly orphans and abandoned children between the ages of 6 and 19 yr, from 1859 through 1861. Bitot provided a detailed description of the location of the patches and the clinical course of the lesions, and described the reappearance of the lesions after the patches were scraped off the conjunctiva. He examined the lesions microscopically and described the findings as “une altération non encore décrite, une production squameuse spéciale de l’épithélium conjonctival” (“a yet undescribed alteration, a specific squamous production of the conjunctival epithelium”) (20). His classic description of the lesions is reproduced under Subheading 3.2.1. Bitot was born in Podensac, a small town southeast of Bordeaux. He finished his

medical studies in Bordeaux and received his doctor of medicine in Paris in 1848. Bitot became physician for the Bureaux de Charité in 1849 and professor of anatomy at the School of Medicine in Bordeaux in 1854. In 1856 he became chief surgeon of the Bordeaux homes, and during his tenure he made his important clinical observations of xerophthalmia. The patches of keratinized, squamous metaplasia that occur on the bulbar conjunctiva are considered pathognomonic for vitamin A deficiency and are now known as Bitot spots.

Bitot's report was followed three weeks later in the same journal by a report by a military physician, Jean-Antoine Villemin (1827–1892), who had made similar observations and noted that the epithelial changes affected the cornea in addition to the conjunctiva (21). Abraham Netter (1818–1904), a physician in the military hospital in Strasbourg, had also observed the conjunctival lesions in adults with night blindness. He proposed that the conjunctival spot was an epiphenomenon, and that it was not the cause of night blindness but was rather related to sunlight exposure (22). In 1866, Robert Blessig (1830–1878), an ophthalmologist from St. Petersburg who had studied at the University of Dorpat, described the entire spectrum of disease, from conjunctival xerosis, to Bitot spots, corneal xerosis, keratomalacia, and formation of a corneal opacity (23). Blessig sometimes observed conjunctival xerosis and Bitot spots among individuals who also had signs of scurvy (23). Other detailed descriptions were made in Brazil by Manuel da Gama Lobo (1832–1883), who termed the condition “ophthalmia brasiliiana” (24). In his report, Gama Lobo noted that four children with cornea ulceration, diarrhea, and malnutrition later died, and “in our view, these children died of inanition as a consequence of nutritionally limited fare which was given in insufficient quantity” (24).

Earlier descriptions exist of pathological changes of the conjunctiva among individuals with night blindness, but none of the descriptions are as complete as those provided by Bitot. For example, in 1855, Mecklenburg, a physician for the Deutsch-Krone (now present-day Walcz, Poland) district prison, described “constant dryness of the eyes” and conjunctival changes among poorly nourished prisoners who had night blindness: “Die Augen hatten etwas Gläsernes, Glänzendes, nie fand sich Röthung der Conjunctiva, sie erschien im Gegentheil glänzend weiss, fast perlmutterartig” (“The eyes had something glassy, shining about them, there was never a redness in the conjunctiva, on the contrary it appeared a shiny white, almost like mother-of-pearl”) (25). “Gegen Abend—eine bestimmte Stunde konnte Niemand angeben—schwand bei Allen das Sehvermögen, bei den meisten in so hohem Grade, dass sie sich führen und sich manchen Schabernack, wie sie sagten, gefallen lassen mussten; ein Theil dieser letzteren konnte weder bei Mond-noch Kerzenlicht sehen” (“Toward evening—no one could indicate a precise hour—vision disappeared in all of the patients, for most to such a high degree that they had to be led about and had to put up with many a practical joke, as they said; a portion of this last group could see neither by moonlight or candlelight”) (25).

Anton Christian August von Huebbenet (1822–1873), Chief Physician of the Russian Army in the Crimea, described his experiences with epidemics of night blindness among laborers and soldiers in Russia to his colleagues of the Medical Society of the Hospitals of Paris in 1860 (26). Von Huebbenet was born in Gute Ulpich, Livland (Baltic region) and studied medicine at the University of Dorpat. He was professor at Vladimir University in Kiev and director of the surgical department of the Hospitalklinik, where he had an interest in eye diseases. Von Huebbenet took part in the Crimean War in Sebastopol

in 1854–1855 and became concerned with the health of soldiers. In Russia, Von Huebbenet noticed “certain changements dans l’aspect du globe oculaire; sa surface présente un certain degré de sécheresse, la conjonctive s’altère et devient le siege d’une desquamation épithéliale. Ce sont de petites écailles qui se dessèchent et dont les cellules sont atteintes de dégénérescence graisseuse, d’atrophie” (“some changes in the appearance of the eyeball, its surface presents a certain degree of dryness, the conjunctiva changes and is the site of epithelial destruction. These are little scales that become dessicated; their cells have experienced fatty degeneration and atrophy”) (26). Von Huebbenet observed that night blindness and eye changes usually appeared during the Lenten fasts and disappeared after the fast was broken (26).

In Portugal, a year before Bitot published his report of conjunctival lesions associated with night blindness, the military ophthalmologist João Clemente Mendes (b. 1819) clearly described the association between xerophthalmia and night blindness (27). He detailed an outbreak of night blindness that affected 16 boys and 6 girls in an orphanage that housed 93 boys and 109 girls aged 7 to 15 yr. Mendes reported: “Uma doença, a xerophthalmia, que não vimos mencionada por ninguém como acompanhando a cegueira crepuscular, foi observada entre nós no asylo dos orphãos da febre amarella em novembro de 1860” (“An illness, xerophthalmia, that we have not heard mentioned before as accompanying night blindness, was observed by us in an asylum among orphans with yellow fever in November of 1860”). “Em todos os casos se manifestou a alteração da conjunctiva em maior ou menor grau, sendo para notar que algumas creanças tiveram a xerophthalmia sem hemeralopia” (“In all cases there was an alteration of the conjunctiva of greater or lesser degree, being notable that some children had xerophthalmia without night blindness”) (27).

2.2. Characterization of Vitamin A

The existence of vitamin A was shown through a long process that spanned a period of over 130 yr. More than 60 yr after Magendie’s experiments with dogs, Nicolai Lunin (1853–1937) and Carl Socin at the University of Dorpat showed that mice could not survive on purified protein, fat, carbohydrate, and mineral salts alone, but were able to survive if supplemented with milk or egg yolk (28,29). Cornelis Pekelharing (1848–1922) and Frederick Hopkins (1861–1947) both conducted studies that also suggested there was something essential in milk that supported life (30,31). Wilhelm Stepp (1882–1964) extracted lipids from milk with alcohol-ether that contained the active substance (32,33), and Elmer McCollum (1879–1967) and Marguerite Davis, working at the University of Wisconsin, used ether to extract these lipids from cod-liver oil (34). At Yale University, Thomas Osborne (1859–1929) and Lafayette Mendel (1872–1935) made the seminal observation that infectious diseases in vitamin A-deficient animals were quickly alleviated by introduction of butter fat or cod-liver oil in the diet (35,36). In 1916, this growth-promoting and anti-infectious substance was termed “fat-soluble A” (37). The search for vitamin A in other foods revealed that certain plant foods, such as spinach and cabbage (38), carrots (39), and alfalfa and clover (40) had the same properties as “fat-soluble A” in experimental animal studies. In 1929, Thomas Moore (1900–1999) demonstrated that β -carotene could be converted to vitamin A (41). The structure of vitamin A was deduced in 1931 by Paul Karrer (1889–1971) (42,43), and vitamin A was crystallized in 1937 (44). The synthesis of pure vitamin A was not achieved until 1947 (45,46). The role of vitamin

A as a precursor for the visual pigment, rhodopsin, was elucidated by George Wald (1906–1997). The investigations by Wald helped to complete a long line of investigation that began with early observations relating night blindness with lack of vitamin A (47).

2.3. Vitamin A Deficiency and Increased Mortality in Children: Lessons From Denmark

From 1909 to 1920, the Danish ophthalmologist Olaf Blegvad (1888–1961) documented cases of xerophthalmia, or clinical vitamin A deficiency, among children in Denmark (48). From 1911 to 1917, there was a strong, gradual increase in the number of cases of keratomalacia, the most severe eye lesion of vitamin A deficiency, followed by a decline in 1918 and 1919 and then an increase in 1920. During the same period in neighboring Sweden, there was no epidemic of xerophthalmia. Blegvad showed that the export of butter and cheese from Denmark and increased consumption of margarine within the country were linked with the increase in vitamin A deficiency. The manufacture of margarine ceased in 1917 after a German submarine blockade halted importation of raw materials, and butter, which was produced in Denmark at an expensive price, was then rationed at a more affordable cost for the poor after December 21, 1917. On May 1, 1919, butter rationing ceased (Fig. 1) (48). The mortality rate observed among 434 children with xerophthalmia was about 21%, with the highest mortality noted among younger infants. The high mortality of children was attributed to infections and the lack of vitamin A, and it resembled the infections and mortality found in animals experimentally raised on a vitamin A-deficient diet (48). Blegvad concluded that efficacious treatment with whole milk or cod-liver oil containing vitamin A reduced the mortality of children with xerophthalmia (49).

Carl Bloch (1872–1952), a pediatrician in Copenhagen, also dealt with the epidemic of xerophthalmia and provided important descriptions of the epidemiology and treatment of vitamin A deficiency (50). Bloch observed that the number of cases of children admitted with xerophthalmia at the State Hospital in Copenhagen rose from 1912 to 1917 and then dropped dramatically in 1918 (Fig. 2) (51). The abrupt decline in cases of xerophthalmia in 1918 coincides with butter rationing for the poor in 1918 (Fig. 1). Bloch noted that xerophthalmia was associated with lack of milk and green vegetables in the diet and that children with xerophthalmia had retarded growth. He concluded that vitamin A deficiency was characterized by a decline in immunity, increased severity of infections, and a higher risk of death. Child mortality was reduced by providing foods containing vitamin A. Bloch advocated the provision of milk, cream, butter, and cod-liver oil to treat eye disease, promote growth and development, and to reduce infectious diseases of children (50,52). Bloch noted that “the death rate among children is considerable after recovery from xerophthalmia; hardly two thirds of these children reach the age of 8 years” (52).

The concerns about vitamin A deficiency clearly extended beyond children who had xerophthalmia, or clinical vitamin A deficiency. The concept of subclinical vitamin A deficiency was widely discussed in major medical journals in the 1920s. Based on the observations in Denmark and animal studies, Erik Widmark (1889–1945), Professor of Medical and Physiological Chemistry at the University of Lund, concluded in *The Lancet* “...there must be in a population in which xerophthalmia occurs a much larger number of cases in which the deficiency in vitamin A, without producing the eye disease, is the




Fig. 1. Relative amount of butter used each year (oblique lines), substitutes made from animal fats (white spaces), and vegetable fat substitutes (black spaces). From December 1917 to May 1919 butter was rationed so that even the poor could afford it. (Reprinted from ref. 48, with permission from Elsevier.)

cause of a diminished resistance to infections, of general debility, and of malnutrition” (54). A state of subclinical vitamin A deficiency was acknowledged as “the borderline between health and disease” where a child would appear healthy, but in the face of an infection would do less well because of an underlying vitamin deficiency (55). The emphasis shifted from targeting children with xerophthalmia to ensuring adequate vitamin A status of children in populations.

2.4. Ellison’s Landmark Trial and Other Therapeutic Trials of Vitamin A, the “Anti-Infective” Vitamin, 1920–1940

Vitamin A became known as the “anti-infective” vitamin, and from 1920 through 1940, this vitamin underwent considerable evaluation in at least 30 therapeutic trials, from dental caries to pneumonia to measles. These studies were conducted during a period when there was an increased awareness of the problem of infant and child mortality in Europe

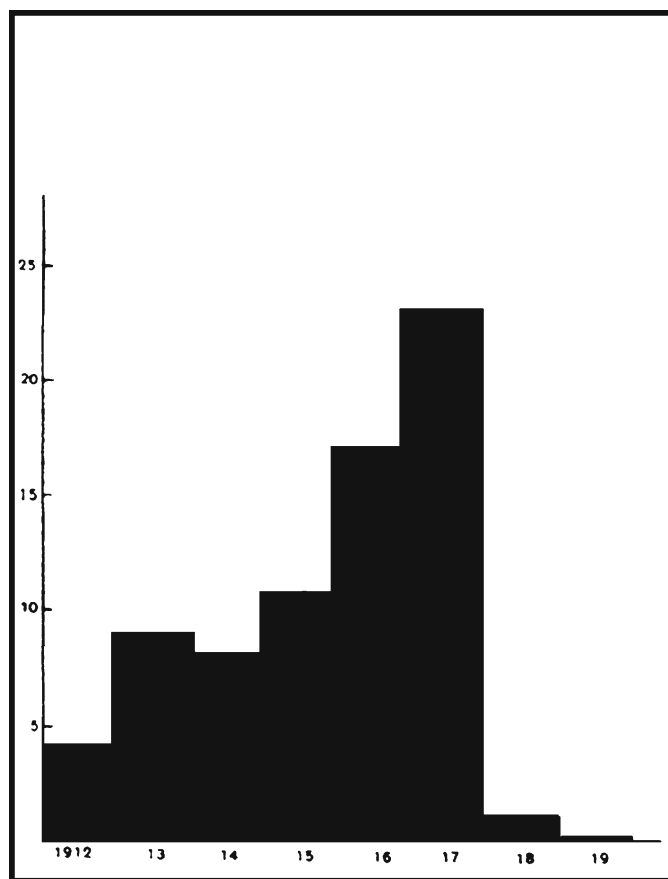


Fig. 2. Frequency distribution of 72 children admitted to the Rigshospital, Copenhagen for xerophthalmia from 1912 to 1919. (Reprinted from ref. 48.)

and the United States (56). It should be emphasized that these trials were not conducted in populations with clinical vitamin A deficiency, i.e., xerophthalmia, was widespread; it was thought that vitamin A would reduce morbidity and mortality from infections in children and adults with subclinical vitamin A deficiency. Among the important discoveries during these trials was that vitamin A supplementation reduced mortality from measles in children (57,58) and reduced the morbidity of puerperal sepsis in women (59,60).

In 1932, Joseph Ellison (b. 1898), a physician in London, discovered that providing vitamin A to children with measles could reduce their mortality by 58% (57). During the 1931–1932 measles epidemic in London, Ellison assigned 600 children with measles at the Grove Fever Hospital (Fig. 3) to one of two groups of 300 children each. One group received vitamin A and the other group did not receive vitamin A. Overall mortality rates in the vitamin A and control groups were 3.7% and 8.7%, respectively, representing a 58% reduction in mortality with vitamin A treatment. Ellison's study, published in the *British Medical Journal* in 1932, was the first trial to show that vitamin A supplementation reduces mortality in young children with vitamin A deficiency. With the introduction of antibiotics in the mid-1930s, greater attention was paid to sulfa antibiotics and later penicillin, and there was an accompanying decline in the number of vitamin A trials.



Fig. 3. Grove Fever Hospital in Tooting, London, site of Ellison's landmark trial in 1932 that showed that vitamin A treatment reduced mortality in young children with measles. (Photo courtesy of the St. George's Medical School Library.)

Vitamin A became a mainstream preventive measure: cod-liver oil was part of the morning routine for millions of children—a practice promoted by physicians and popularized by the pharmaceutical industry (56). The production and importation of cod-liver oil in the United States totaled 4,909,622 lbs in 1929 (61). In the early 1930s in England, the annual consumption of cod-liver oil was 500,000 gallons per year (62). Much of the world's supply of cod-liver oil, and hence, vitamins A and D, came from the commercial fisheries of New England, Norway, and Newfoundland. As noted in the *British Medical Journal*, "cod-liver oil was in use in almost every working-class household, and local authorities spent considerable sums in purchasing bulk supplies for hospitals and sanatoriums" (63). In England, a proposal to tax cod-liver oil in the Ottawa Agreements Bill in the House of Commons in 1932 raised protests, as there was concern that child mortality would increase if the price of cod-liver oil increased and it became less accessible to poor people. As reported in both *The Lancet* and the *British Medical Journal*, one legislator who supported an amendment to exempt cod-liver oil from the proposed taxation noted that many a child in the north of England "owed its life to being able to obtain cod-liver oil" (62,64). Two British physicians also supported the amendment in letters published in *The Lancet* (62). One expert from the Lister Institute of Preventive Medicine noted: "It is evident that any steps which may raise the price and lower the consumption of cod-liver oil, especially in the winter, would have deleterious effect on the health of the population, involving particularly the well-being of the children of the poorer classes"

(62). The concerns of physicians and legislators alike that children receive sufficient vitamin A to protect against the well-known morbidity and mortality of vitamin A deficiency were clearly expressed.

2.5. Public Health Measures to Improve Vitamin A Status in the United States and Europe

By the 1940s, it was widely recognized and accepted that adequate vitamin A nutriture was necessary for resistance to infectious diseases (65). Increased morbidity from infections was clearly ascribed to a deficiency of a single nutrient—vitamin A. As summarized in 1941, “It has been thoroughly established, during the last decade, that a deficiency of vitamin A in the diet, not only leads to interference with normal growth and well being, but lowers the natural resistance of the individuals to infection” (66). The widespread acceptance of this thesis is shown by the practices of the medical profession and public health organization that focused on the eradication of vitamin A deficiency. Major health organizations, including the League of Nations Health Committee, the Women’s Foundation for Health, the Council of British Societies for Relief Abroad, and the Medical Research Council of Great Britain, emphasized the importance of ensuring adequate vitamin A intake in populations in order to increase resistance to infectious diseases (67–70). These concerns were also echoed in nutrition textbooks and research monographs at the time by such influential nutritionists, physicians, and public health leaders such as Robert McCarrison (71), Jack Drummond (72), and Edward Mellanby (73) in England, Georges Mouriquand (74) in France, Giambattista Bietti (75) in Italy, Robert Ammon (76) in Germany, and Henry Sherman (77), Mary Swartz Rose (78), and Wilson Smillie (79) in the United States. Public health measures that were taken to improve vitamin A status of children were institution of school milk programs, fortification of milk and margarine with vitamin A, and the promotion of home gardening (80,81).

In the United States, the Council on Foods and Nutrition of the American Medical Association recommended in 1939 that margarine be fortified with vitamin A (82). In the early 1950s, skimmed milk, which lacked vitamin A, was fortified with 2000 IU of vitamin A per quart, and in 1961, the Food and Nutrition Board of the US National Nutrition Council and the Council on Foods and Nutrition of the American Medical Association reaffirmed their endorsement that margarine, fluid skim milk, and dry nonfat milk should be fortified with vitamin A (84). Federal assistance for providing milk for school children began in 1940 in Chicago and New York. The Special Milk Program was authorized in 1954 and was implemented in order to encourage fluid milk consumption by serving milk at the lowest possible price or at no cost for eligible students. The Special Milk Program became part of the Child Nutrition Act of 1966. Milk consumption in the schools increased more than 10-fold in the period between 1946–1947 and 1969–1970, from 228 million half pints of milk served to 2.7 billion half pints served under the Special Milk Program of the Child Nutrition Act (84).

2.6. Vitamin A Deficiency, Infection, and Mortality in Developing Countries—A Recurring Theme

With improvements in nutrition, hygiene, and living standards, vitamin A deficiency gradually disappeared from Europe and the United States. The Joint Food and Agricultural Organization (FAO)/WHO Expert Committee on Nutrition focused on vitamin A

deficiency as a public health problem in developing countries in the 1950s. The FAO/WHO Expert Committee on Nutrition recognized that dried skimmed milk production had increased greatly after World War II, and that it was a “surplus” food being considered for distribution in developing countries in the form of food aid. The expert committee recommended that dried skimmed milk be fortified with vitamin A (85).

In 1948, Vulimiri Ramalingaswami (1921–2001) drew attention to the important association between diarrheal disease and vitamin A deficiency among young children seen at the Nutrition Clinic of the Nutrition Research Laboratories in Coonor, India (86). He noted that diarrheal disease and altered gastrointestinal pathology were consistent features of vitamin A deficiency, both in humans and in experimental animal models, and that the diarrheal disease resolved with administration of vitamin A (48,50,87–91). In a small therapeutic trial involving children with xerophthalmia and diarrheal disease, Ramalingaswami divided children into three groups: (1) children with keratomalacia and Bitot spots who received daily high doses of vitamin A, (2) children with Bitot spots who were treated with standard bowel-binding substances such as kaolin and bismuth carbonate, and (3) children with Bitot spots and diarrhea who were treated with sulfa antibiotics. In the first group, keratomalacia and Bitot spots improved and diarrhea resolved with vitamin A treatment. In the latter two groups, diarrhea continued until the children were switched to treatment with vitamin A, after which the diarrhea resolved (86). Ramalingaswami concluded: “From these observations and from a consideration of the literature, it is concluded that a deficiency in vitamin A, diarrhea occurs which responds specifically to vitamin A” (86).

In 1958, the National Institutes of Health organized a conference on beriberi, iodine deficiency, and vitamin A deficiency (92). At the conference, H.A.P.C. Oomen (1902–1986), who had spent many years working in the field, reported that children with xerophthalmia in Indonesia often had intestinal and respiratory disease, and made an impassioned plea:

“Xerophthalmia has been the most bitter pill for me to swallow during 18 years of doctor’s work in Indonesia. The over and over repeated experience of discovering a child, recently blinded, in the arms of the mother; having to tell her that I now could nothing more to save its eyesight; remembering that I could have done so with a few spoonful of cod-liver oil some days ago; these things still enter my nightmares. They belong to the most vivid examples of what disprivileged people in underdeveloped regions sometimes miss... More printing space nowadays is devoted to a few cases of hypervitaminosis A, induced by an irresponsible vitamin racket, than to the thousands of small children who die or get blind every year due to the lack of a handful of vitamin A units. What on earth is nutritional science good for, if, even in the atom age, it is not capable to counteract one of the foulest consequences of bad nutrition?”

In 1962 a world-wide assessment of xerophthalmia was organized by WHO and showed that vitamin A deficiency was a major health problem in many parts of the world, especially in south Asia, southeast Asia, sub-Saharan Africa, and Central America (93). The investigators concluded: “There appears to be a universal relation between infectious disease and xerophthalmia.” “Not only may deficiency of vitamin A itself play an important role in lowering the resistance to infection...but infectious diseases themselves predispose to and actually precipitate xerophthalmia” (93). The “survey,” a collection of existing

data, showed that some 43 countries had significant vitamin A deficiency among pre-school children, and this study formed the original basis for WHO's current database for vitamin A deficiency, which is periodically updated as new data become available (94).

Further attention was given to vitamin A deficiency at an international conference held in 1963 in Bellagio, Lake Como, Italy on "How to Reach the Pre-School Child." It was noted that the mortality rates for preschool children in developing countries was sometimes forty times greater than in affluent countries. The participants concluded that there was a real need for emergency action, for a "crash program" to make the world aware of the serious extent of the problem of child mortality and address nutritional needs of children (95). The following year, an international conference on "Prevention of Malnutrition in the Pre-School Child" was held by the National Academy of Sciences in Washington, D.C. Among the conclusions of the conference were that "the mortality rate among malnourished children with xerophthalmia is very high" and "present evidence enforces the ominous conclusion that the incidence of xerophthalmia is increasing" (96). Included in the discussion were pilot schemes for giving large doses of vitamin A to children at risk in countries where xerophthalmia is common (97). Paul György (1893–1976) reported the results of an intervention trial in Indonesia in which a teaspoon of red palm oil was given daily to preschool children in pilot villages, regardless of whether they had xerophthalmia or not. After 2 mo, the prevalence of xerophthalmia dropped from 6.5% to 0.6% (95,98). György was enthusiastic about the results but cautioned: "As stated in the recommendation of the Como Conference, any 'crash action program' for the pre-school child should dovetail with long-term projects already in progress, such as maternal and child health centers, agricultural extension, community development and nutrition education."

In 1965, the Western Hemisphere Nutrition Congress was organized by the American Medical Association, and W. Henry Sebrell (1901–1992), the former director of the National Institutes of Health, noted "vitamin A deficiency... is becoming increasingly recognized as a serious condition which is widespread in some parts of this hemisphere. Vitamin A deficiency accounts for widespread blindness or impaired vision and to a large extent contributes to high mortality" (99). The Interdepartmental Committee on Nutrition for National Defense of the US National Institutes of Health conducted surveys in which data on vitamin A deficiency were collected. Vitamin A deficiency was considered a major health problem in many countries, including Jordan (100), Ethiopia (101), Vietnam (102), Thailand (103), Lebanon (104), and East Pakistan (105). These surveys defined vitamin A deficiency as a public health problem if more than 5% of the population had plasma or serum vitamin A concentration $<0.35 \mu\text{mol/L}$ or more than 15% had concentrations $<0.70 \mu\text{mol/L}$ (106). A high prevalence of Bitot spots was described among children in Lebanon (104), East Pakistan (now Bangladesh) (105), and Ethiopia (101). In 1966, photographs of the stages of vitamin A deficiency, including conjunctival xerosis, Bitot spots, corneal xerosis, corneal ulceration, keratomalacia, corneal staphyloma, and scarring were published in the *Bulletin of the World Health Organization* (107).

From 1959 to 1965, the Interdepartmental Committee on Nutrition for National Defense conducted dietary surveys in eight South American countries and the West Indies. The Office of International Research (formerly the Interdepartmental Committee on Nutrition for National Defense), in collaboration with the Institute of Nutrition of Central America and Panama, made similar studies in the six Central American countries from 1965 to 1967. A technical group meeting was held at the Pan American Health Organization in

1968 in which it was stated: “From experiments in animals... it can be assumed that prolonged low intake of vitamin A and its precursors may have serious effects on growth and development and on resistance to infectious diseases.” “The regular occurrence of xerophthalmia cases in an area is indicative of a very serious preschool public health nutrition problem. The high case fatality rate of at least 25 per cent contributes to underestimation of its magnitude. The severity of the eye lesions and the fatality are inversely related to age, and are greater in males than females” (108). At this meeting in 1968, the technical group at the Pan American Health Organization made comprehensive recommendations for the control of vitamin A deficiency, including the administration of oral high-dose vitamin A one to four times per year to infants and preschool children where vitamin A deficiency is a public health problem, oral high-dose vitamin A to lactating women immediately after delivery, fortification of foods such as dried skim milk with vitamin A, and promotion of nutrition education, increased agricultural production of vitamin A-rich food sources, and greater professional training in regard to vitamin A deficiency (108).

With the growing interest in the relationship between nutrition and infection, in 1965, an expert committee at WHO recommended a systematic review of the literature, and this resulted in an influential work, *Interactions of Nutrition and Infection*, published in 1968 (109). Nevin Scrimshaw, Carl Taylor, and John Gordon reviewed the large body of clinical and experimental evidence that had accumulated and concluded: “One of the first recognized features of avitaminosis A, increased susceptibility to infection, has had strong confirmation” (109). As shown in this section, the scientific conferences, expert committee meetings, and reviews conducted during the 1950s and 1960s indicate that most scientists had little doubt that vitamin A deficiency played an important role in blindness, increased morbidity from infectious diseases, and death.

Indonesia appeared to be one of the countries with the highest prevalence of vitamin A deficiency in the world (107). Early work by Dutch and Indonesian investigators such as C. D. Ouwehand, Johannes Tijssen (1881–1948), Sie Boen Lian, and others showed that xerophthalmia and keratomalacia were common in the Netherland East Indies (110–113). In the 1950s, H.A.P.C. Oomen provided detailed descriptions of xerophthalmia in Indonesia (114), and during the late 1960s, Johanna ten Doesschate (1912–1989) conducted epidemiological investigations in Indonesia that identified risk factors for xerophthalmia, including inadequate dietary intake of vitamin A and carotenoids, *Ascaris* infection, diarrheal disease, tuberculosis, measles, artificial feeding, prematurity, and lower socioeconomic status (115). The main cause of blindness among infants and young children in Indonesia was vitamin A deficiency, and follow-up of small children who had become blind showed that about 30% had subsequently died (115).

2.7. Initiation of National Programs of Vitamin A Supplementation in the Early 1970s

Community-based high-dose vitamin A supplementation was advocated by several scientists (116–118). A 4-yr field study conducted in India in the late 1960s showed that an annual dose of 300,000 IU of vitamin A to children aged 1 to 5 yr reduced the prevalence of Bitot spots and keratomalacia (119). In 1971, a national program to distribute high-dose vitamin A capsules, 200,000 IU every 6 mo, to all children between the ages of 1 and 5 yr was initiated in India (120,121). The distribution of vitamin A was carried

out by the personnel of the primary health centers, maternal and child health centers, and family-planning centers (121). From 1973 to 1975, the government of Indonesia conducted a pilot program of high-dose vitamin A capsules every 6 mo to every preschool child in 20 selected subdistricts in the island of Java (122). In 1972, the Ten-Year Health Plan approved by the Third Special Meeting of Ministers of Health of the countries of the Americas adopted the formal goal to reduce the prevalence of vitamin A deficiency by about one-third and to promote legislation to enforce the fortification of foods with vitamin A (123). Vitamin A fortification of sugar was implemented in Guatemala in 1974 with the underlying rationale of improving growth and increasing resistance to infectious diseases in children (124). In the late 1970s, the Indonesian government also began to consider vitamin A fortification of wheat flour, sugar, or monosodium glutamate (MSG) (125). After further deliberation, of the three, only MSG was considered a suitable carrier. Indonesian government officials were concerned that fortification of MSG would appear to be government endorsement of a commercial product. An analysis by Carl Fritz at Helen Keller International in 1982 showed that fortification of MSG with vitamin A, even if only 10% effective, would be cost-effective in reducing mortality of an estimated 20,000 Indonesian children each year (125).

The “Xerophthalmia Club” and *Xerophthalmia Club Bulletin* were founded in Jerusalem in 1971 at the Conference on the Prevention of Blindness, and H.A.P.C. Oomen was elected its first president. The bulletin was produced three times a year and was meant to provide an interdisciplinary tool to inform and coordinate efforts to eradicate vitamin A deficiency. In 1974, an expert group met in Jakarta, Indonesia under the auspices of WHO and the US Agency for International Development. A standardized classification of xerophthalmia, criteria for defining vitamin A deficiency as a public health problem, and dosage schedules for vitamin A were adapted (126).

The International Vitamin A Consultative Group (IVACG) was established in 1975 with support from the US Agency for International Development (127).

2.8. Further Investigations of the Relationship Between Vitamin A Deficiency and Child Mortality

In longitudinal studies conducted in Indonesia in the late 1970s, Alfred Sommer (b. 1942) and colleagues noted that children with Bitot spots and night blindness had a higher risk of mortality (128), and this observation led to further vitamin A clinical trials in the 1980s and 1990s (129,130). The larger trials were conducted in developing countries such as Indonesia, India, Nepal, Sudan, Ghana, Bangladesh, and Brazil, and these studies showed that vitamin A supplementation or fortification could reduce child mortality from diarrheal disease but not lower respiratory disease (130–132). There have been at least 70 clinical trials conducted in the last 15 yr that have evaluated the potential effect of improving vitamin A status on morbidity and mortality from infectious diseases such as measles, diarrheal disease, acute lower respiratory infection, respiratory syncytial virus infection, malaria, tuberculosis, HIV infection, maternal mortality, infant mortality, and infections in older adults. The contemporary trials revisit many of the same issues that were addressed in vitamin A trials conducted in the 1920s and 1930s (56). The types of interventions with vitamin A include community-based high-dose supplementation, disease-targeted high-dose supplementation, low-dose daily supplementation, weekly supplementation, and fortification of MSG (130,132).

WHO currently recommends high-dose vitamin A supplementation for children with xerophthalmia, acute measles, and diarrheal disease in developing countries where vitamin A deficiency is a public health problem (133). Some developing countries have adopted programs of intermittent, high-dose vitamin A capsule distribution for infants and children, a measure that may reduce diarrheal morbidity and mortality and is largely considered a temporary solution until other remedies can be found (132). The contemporary distribution of vitamin A capsules to children in the community in developing countries resembles the widespread home use of cod-liver oil by the teaspoon or capsule for children in the early half of the 20th century in Europe and the United States. Currently, a return to cod-liver oil is no longer a viable option: the cod fisheries have nearly been depleted in the North Atlantic, and synthetic vitamin A is a relatively inexpensive source for supplements or fortification. Milestones in the history of vitamin A are highlighted in Table 1.

3. BIOCHEMISTRY AND METABOLISM OF VITAMIN A

3.1. *Structure and Characteristics of Vitamin A*

Vitamin A is a generic term that is used to describe compounds that have the biological activity of retinol, such as all-*trans* retinol, retinyl palmitate, retinyl oleate, and retinyl stearate, and provitamin A carotenoids such as α -carotene, β -carotene, and β -cryptoxanthin (Fig. 4). The term “retinoid” refers to both naturally occurring forms of vitamin A and synthetic analogs of retinol, with or without biological activity. All-*trans* retinol has a molecular weight of 286 and consists of a substituted cyclohexenyl (β -ionone) ring, a tetraene side chain, and a primary hydroxyl group at position C-15. The hydroxyl group can be esterified with long-chain fatty acids to form compounds such as retinyl palmitate and retinyl stearate, which are common forms of vitamin A in animal tissues and products. Active metabolites of retinol include all-*trans* retinoic acid and 9-*cis* retinoic acid, probably found in all nucleated cells, and 11-*cis* retinal is found in the retina, where it plays a role in the visual cycle.

3.2. *Dietary Sources and Metabolism of Vitamin A*

3.2.1. FOOD SOURCES OF VITAMIN A

Vitamin A is available in dietary sources as either preformed vitamin A or as provitamin A carotenoids. Rich dietary sources of preformed vitamin A include egg yolk, liver, butter, cheese, whole milk, and cod-liver oil. In animal foods, vitamin A is mostly in the form of retinyl esters, such as retinyl palmitate. In many developing countries, the consumption of foods containing preformed vitamin A is limited, and provitamin A carotenoids often comprise the major dietary source of vitamin A (134). The major provitamin A carotenoids consist of α -carotene and β -carotene, found in such foods as dark green leafy vegetables, carrots, sweet potatoes, mangoes, and papayas, and β -cryptoxanthin, found in foods such as oranges, tangerines, and kiwi fruit. Recent studies show that the bioavailability of provitamin A carotenoids is probably lower than previously believed (135,136). Many factors can affect the absorption and utilization of carotenoids, including the digestibility of the food matrix, food particle size, fat level, presence of vitamin E, amount of carotenoids in the meal, and the presence of deficiencies of iron, zinc, and vitamin A (137).

Table 1
Highlights in the History of Vitamin A

Antiquity	Night blindness described in Hippocratic writings, <i>Epidemics VI</i> (4), and ingestion of liver described as treatment by Celsus in <i>De Medicina</i> (5)
17–18th century	Night blindness encountered in indigenous populations worldwide (6,8–10)
1816	Magendie shows that dogs fed sugar and water developed corneal ulcers and died (15)
1824–1849	Corneal ulcers described in poorly fed infants (16–19)
1855–1863	Conjunctival alterations described by Mecklenburg (25), von Huebbenet 26), Mendes (27), and Bitot (20)
1881	Lunin shows substance in milk is necessary for survival in mice (28)
1911	Stepp extracts lipids from milk with alcohol ether that support life (32,33)
1912	Hopkins shows “accessory factors” in milk are essential for life (31)
1913	McCollum and Davis extract lipids from cod-liver oil with ether that support life (34); Osborne and Mendel show butter-fat contains something essential for life (35)
1911–1920	Bloch and Blegvad describe epidemic of xerophthalmia with high mortality among Danish children during period when butter unavailable to the poor (48–52)
1920–1940	More than 30 trials conducted of vitamin A as prophylaxis or treatment to reduce morbidity and mortality of measles, puerperal sepsis, and other conditions (56)
1931	Karrer describes structure of vitamin A (42,43)
1932	Ellison discovers that vitamin A supplementation reduces mortality in children with measles (57)
1930–1950	High consumption of cod-liver oil in households in Europe and the United States
1932	Outcry in British House of Commons over bill to tax cod-liver oil over fear it would make cod-liver oil too expensive for the poor and increase morbidity and mortality among British children (62–64)
1937	Vitamin A crystallized (44)
1939	Fortification of margarine with vitamin A recommended in the United States (82)
1947	Synthesis of vitamin A (45,46)
1948	Ramalingaswami shows vitamin A therapy reduces severity of diarrhea (86)
1951	Role of vitamin A in visual cycle shown by Wald (47)
1960s	Interdepartmental Committee on Nutrition for National Defense surveys show vitamin A deficiency highly prevalent in some developing countries
1963	International conference in Bellagio, Italy on “How to Reach the Pre-School Child” concludes that mortality among children with xerophthalmia is high (96)
1965	Western Hemisphere Nutrition Congress concludes vitamin A deficiency accounts for substantial blindness and mortality among children (99)
1966	Special Milk Program authorized
1968	Relationship between vitamin A deficiency and infection recognized by Scrimshaw, Taylor, and Gordon (109)
1970s	India and Indonesia commence national programs to distribute high-dose vitamin A capsules to preschool children (120–122)
1974	International Vitamin A Consultative Group organized
1983	Sommer reports Bitot spots and night blindness are associated with increased mortality (128)
1980–1990s	Clinical trials show that vitamin A supplementation reduces morbidity and mortality of preschool children from diarrheal disease (130)

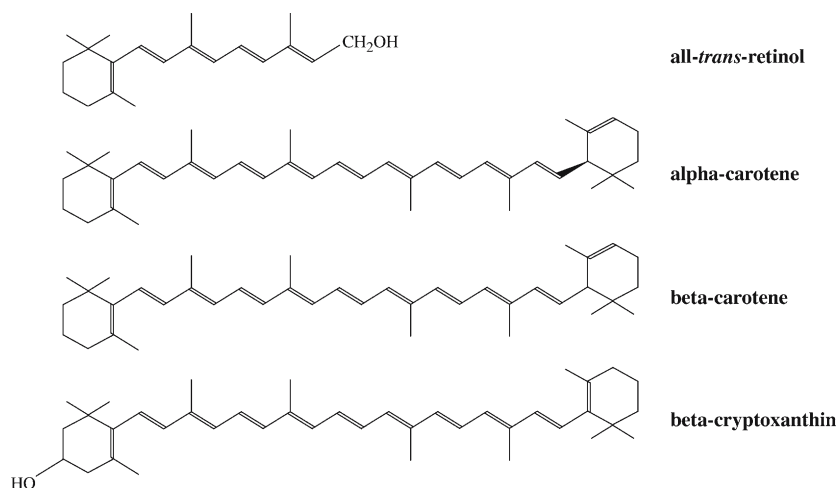


Fig. 4. Structure of carotenoids and vitamin A.

3.2.2. DIGESTION AND ABSORPTION OF VITAMIN A IN FOODS

In the stomach, foods containing vitamin A and carotenoids undergo proteolysis and are released from protein. The presence of fat in the small intestine stimulates the secretion of cholecystokinin, which stimulates the secretion of bile from the gall bladder and the secretion of pancreatic enzymes. Retinyl esters and carotenoids are insoluble in water and within the small intestine are solubilized within bile acid micelles. The presence of fat in the small intestine improves the absorption of retinol and carotenoids by increasing the size and stability of the micelles. In the gut lumen, dietary retinyl esters are hydrolyzed to retinol (138) and then undergo reesterification during absorption (139). The pancreatic enzyme, pancreatic triglyceride lipase, plays an important role in hydrolysis of retinyl esters (140). The brush border membrane in the gut also has hydrolytic activity (141,142) that has been attributed to intestinal phospholipase B (143). Carboxylester lipase was usually considered to be involved in hydrolysis of retinyl esters, but recent work in the carboxylester lipase knockout mouse shows that dietary retinyl ester digestion is not affected by absence of this pancreatic enzyme (144).

Retinol is absorbed in the intestine by both a saturable, carrier-mediated process and a nonsaturable, simple passive diffusion process (145–147). It has been hypothesized that a retinol transporter, not yet characterized, exists on the luminal side of the enterocyte (148). In the cytoplasm of the enterocyte, free retinol appears to be sequestered by cellular retinol-binding protein (CRBP) II, a 16-kDa polypeptide with a single retinoid binding site (149). CRBP II will bind all-*trans*-retinol, 13-*cis*-retinol, and all-*trans*-retinal, but not other *cis* isomers of retinol (150). CRBP II is found in high concentrations in the small intestine (151,152), and upregulation of CRBP II mRNA occurs during pregnancy and lactation (153) and during retinoid deficiency in the rat model (154). CRBP I is also present in enterocytes, but at a much lower concentration than CRBP II (155).

The uptake of β -carotene by enterocytes appears to occur by simple passive diffusion (156), and a saturable, carrier-mediated process has also been proposed (150). Within the enterocyte, β -carotene is either absorbed intact and passes into the portal circulation, undergoes enzymatic cleavage by β -carotene 15,15'-dioxygenase to retinal (157–160), or

is converted to retinoic acid (*161,162*). β -carotene can be cleaved centrally via β -carotene 15,15'-dioxygenase or may undergo excentric cleavage in which β -apocarotenals are produced (*163–165*). In the rat model, central cleavage appears to be the dominant form of oxidation of β -carotene, although small amounts of β -apocarotenals (8', 10', 12', and 14') were detected (*166*). In the presence of oxidative stress, β -carotene 15,15'-dioxygenase may be downregulated with more formation of excentric cleavage products (*167,168*). Retinal is reduced to retinol by retinal reductase activity that is present in microsomes (*169*).

The two sources of retinol in the enterocyte (retinol that is absorbed directly by the enterocyte and retinol generated through cleavage of β -carotene and subsequent reduction of retinal to retinol) have the same metabolic pathway of esterification with long-chain fatty acids and release into the lymphatic circulation. In the enterocytes, lecithin-retinol acyltransferase (LRAT) and acyl-CoA-retinol acyltransferase (ARAT) are thought to be involved in the esterification of retinol, with retinyl esters formed by LRAT targeted for secretion in chylomicrons and retinyl esters formed by ARAT targeted for storage (*148*). The four main retinyl esters are produced in a proportion of about 8:4:2:1 for retinyl palmitate, retinyl stearate, retinyl oleate, and retinyl linoleate (*170,171*). The amount and type of fatty acids ingested with preformed vitamin A in the diet can modulate the pattern of retinyl esters that are secreted in chylomicrons (*172*). Chylomicrons are spherical lipoprotein particles of 75–450 nm in diameter that are composed of triacylglycerols, unesterified and esterified cholesterol, phospholipids, apolipoproteins, unesterified and esterified retinol, carotenoids, and other fat-soluble vitamins. The assembly of chylomicrons occurs in the endoplasmic reticulum and requires apoB48, microsomal triglyceride transfer protein, phospholipids, and triglycerides (*173,174*). The secretion of retinyl esters is dependent on the secretion of chylomicrons and is one of the last steps in the molecular assembly of chylomicrons (*175*). Intraluminal factors such as pH, bile, and fatty acids modulate the secretion of retinyl esters into the lymphatic and portal circulation (*176*). Chylomicrons are secreted by exocytosis from the basolateral surface of the enterocyte into the mesenteric and then thoracic duct lymphatic circulation and on into the general circulation.

3.2.3. UPTAKE AND STORAGE OF VITAMIN A IN THE LIVER AND OTHER TISSUES

In the general circulation, chylomicrons are converted to chylomicron remnants in a process that involves both the hydrolysis of the chylomicron triacylglycerols by lipoprotein lipase, an enzyme located on the luminal surface of capillary endothelial cells (*177*), and the transfer of apolipoproteins, phospholipids, and carotenoids to other lipoproteins or cell membranes. Most of the retinyl esters contained in the chylomicrons do not transfer to other lipoproteins and are largely cleared by the liver (*178,179*). Other tissues take up retinyl esters, such as the mammary gland during lactation (*180–182*), muscle, adipose tissue, and kidneys (*183*), lung (*184*), and blood leukocytes (*185*). Chylomicron remnants are rapidly removed from the circulation by the liver. In normal healthy humans, it is generally thought that the liver contains about 90% of the body stores of vitamin A; however, the distribution of vitamin A stores during deficiency and disease states is unclear (*186*). The liver absorbs most of the retinyl esters in chylomicrons (*187,188*). Chylomicron remnants are removed by the liver between the endothelial cells and hepatocytes within the space of Disse (*189*). The chylomicron remnants bind to receptors on the hepa-

tocytes such as low-density lipoprotein (LDL) receptor and apo E (190), or chylomicron remnant receptor (189).

Retinyl esters are hydrolyzed by retinyl ester hydrolase (191), and within the hepatocyte, retinol is found within endosomes (192). Retinol is transferred to the endoplasmic reticulum, where it binds to retinol-binding protein (RBP). The retinol and RBP complex is translocated to the Golgi complex and then secreted from the hepatocyte (186). Retinol is transferred from hepatocytes to stellate cells (193), and most of the vitamin A stored within the liver is found in stellate cells (194–196), where it is stored as retinyl esters in lipid droplets (186). Some retinol bound to RBP is not taken up by stellate cells and enters the blood (186). Circulating retinol may leave and enter the liver many times in a process known as retinol recycling (197). Two enzymes, LRAT and CRAT, can esterify retinol in stellate cells, of which LRAT is considered the more important enzyme for retinol esterification (198). In vitamin A-deficient rats, LRAT activity is low in the liver but is rapidly upregulated after an oral dose of retinol, suggesting that low LRAT activity may be a mechanism by which retinol is made available for secretion to plasma and delivery to target tissues during a state of vitamin A deficiency (198,199).

Carotenoids are also delivered to tissues via chylomicrons, and carotenoids accumulate in high concentrations in adipose tissue. Higher doses of β -carotene were associated with higher serum concentrations of all-*trans* retinoic acid in rabbits (200). β -carotene can be converted to all-*trans* retinoic acid in the intestine, testes, lung, and kidney without retinol as an obligatory intermediate (162,201). The processing of carotenoids from chylomicron remnants by the liver has not been well characterized.

3.2.4. VITAMIN A IN THE CIRCULATION

The major form of circulating retinol in the blood is as retinol bound to RBP (202), and about 95% of plasma RBP is associated with transthyretin (TTR) in a one-to-one molar ratio. RBP is a single-polypeptide chain with a molecular weight of about 21,000 and a binding site for one molecular of all-*trans* retinol (203). In addition to retinol, other forms of retinoids found in plasma include all-*trans* retinoic acid (204), 13-*cis*-retinoic acid, 13-*cis*-4-oxoretinoic acid (205,206), all-*trans* retinyl β -glucuronide, and all-*trans* retinoyl β -glucuronide (207). The relative concentrations of various retinoids in human plasma are retinol (1–2.5 $\mu\text{mol/L}$), retinyl esters (0.03–0.3 $\mu\text{mol/L}$), retinoic acid (0.003–0.03 $\mu\text{mol/L}$) and retinyl β -glucuronide (0.002–0.01 $\mu\text{mol/L}$) (207,208). Other retinoids such as 9-*cis*-retinoic acid, 9,13-di-*cis*-retinoic acid, and 14-hydroxy-4,14-retro-retinol have been described in human plasma after consumption of liver (209). Retinoic acid also circulates bound to albumin (210). Some insight into the importance of RBP transport of retinol has come from a study of two siblings who had two point mutations in the RBP gene, and normal growth and development but extremely low concentrations of plasma retinol, plasma RBP, and night blindness (211). These observations suggest that retinyl esters in chylomicrons, retinoic acid bound to albumin, and other circulating forms of vitamin A may provide a sufficient supply of vitamin A to most tissues except the retina (211).

Retinol is released from the liver into the circulation in the form of holo-RBP (all-*trans* retinol bound with RBP in a 1:1 molecular complex). Under normal circumstances, plasma retinol concentrations are usually maintained at what is considered a normal homeostatic level, or “set-point” for individuals (212). This level may vary from individual to individual, but is usually in a concentration of about 1–3 $\mu\text{mol/L}$ in healthy adults. Plasma retinol

concentrations will decrease when hepatic retinol stores become inadequate, and this usually occurs when there is insufficient dietary intake of vitamin A for a prolonged period. Plasma retinol concentrations will increase to high levels above the normal range when vitamin A intake is excessive. Various disease states can decrease plasma retinol concentrations, including protein-energy malnutrition (213,214), hypothyroidism (215), zinc status (216), and inflammation and infection (217), or increase plasma retinol concentrations, such as renal disease (218).

Retinol is recycled between the liver and peripheral tissues, as shown by kinetic studies (219). In rats, about 90% of retinol that left the circulation was recycled and not irreversibly metabolized (219). The recycling of retinol appears to be tightly regulated and dependent on the amount of hepatic vitamin A, and extrahepatic tissues contribute a large proportion to the retinol that circulates in plasma (219,220). The half-life of holo-RBP is about 12 h (221). As noted earlier, a large portion of dietary carotenoids pass into the circulation intact within chylomicrons. It is estimated that there are more than 40 dietary carotenoids that may be absorbed, metabolized, and/or utilized by the human body (222). The main dietary carotenoids found in human plasma include α -carotene, β -carotene, β -cryptoxanthin, lutein, zeaxanthin, and lycopene, but other carotenoids and their oxidation products have been identified in human plasma (223). Most carotenoids in the plasma are transported by LDLs, and carotenoids can be delivered to peripheral cells that express the LDL receptor (224).

3.2.5. VITAMIN A UPTAKE BY TISSUES

Retinol is taken up by peripheral tissues in a process that has not been well characterized. Some cells, such as retinal pigment epithelial cells and parenchymal and stellate cells of the liver, have specific surface receptors for RBP (225). Circulating all-*trans* retinoic acid is taken up by cells, as it is able to move through cell membranes in an uncharged state and enter cells. In steady-state tracer studies in rats, the percentage of all-*trans* retinoic acid derived from the plasma was high for the liver and brain, but lower for the spleen and eyes (226). All-*trans* retinoic acid may act on cells through retinoylation, or the acylation of all-*trans* retinoic acid by protein (227–229). All-*trans* retinoic acid may be incorporated into proteins of cells through posttranslation modification in which a retinoyl-CoA intermediate is formed and is followed by the transfer and covalent binding of the retinoyl moiety to protein (230).

3.3. Retinoic Acid Receptors and Gene Regulation

Vitamin A exerts its effects via retinoic acid and retinoid receptors, which are found in the nucleus of the cell. Retinol is converted to all-*trans*-retinoic acid and 9-*cis* retinoic acid in the cytoplasm. Retinoic acid influences gene activation through specific receptors which belong to the superfamily of thyroid and steroid receptors (231). Retinoic acid receptors (RARs) act as transcriptional activators for many specific target genes. The RAR is expressed as isoforms, referred to as RAR α , β , and γ , and retinoid-x receptor (RXR) is also expressed as isoforms, referred to as RXR α , β , and γ (232). All-*trans* retinoic acid is a ligand for RARs, whereas 9-*cis* retinoic acid is a ligand for both RARs and RXRs. 9-*cis*-retinoic acid is functionally distinct from all-*trans*-retinoic acid, and inter-conversion may exist between the two isomers. Each RAR and RXR has a specific DNA-binding domain by which these nuclear receptors may effect transcriptional activity.

The DNA sequences which interact with RAR and RXR are known as retinoic acid response elements (RAREs). RAR and RXR receptors form heterodimers, which bind to DNA and control gene expression. In addition, RXR receptors also can form heterodimers with the thyroid hormone receptor, vitamin D₃ receptor, peroxisome proliferator-activated receptors, and a number of “orphan receptors.” Most RAREs seem to occur in the regulatory region of genes. In the presence of 9-*cis* retinoic acid, RXR/RXR homodimers may form and recognize a subset of RAREs or inhibit the formation of certain heterodimers. Orphan receptors such as chicken ovalbumin up-stream promoter transcription factor (COUP-TF) (233), ARP-1, TAK1 (234), RVR (235), RZR (236), and thymus orphan receptor (TOR) (237) may repress or modulate the induction of genes by retinoic acid. The three-dimensional structures of several different DNA-binding complexes of RXR have been elucidated (238–240). RARs and RXRs may interact with multiple transcriptional mediators and/or corepressors, adding an enormous level of complexity to regulation of retinoic acid responses. Other vitamin A metabolites in the retinoid family may support biological functions via a pathway that is distinct from the retinoic acid pathway. 14-hydroxy-4,14-*retro* retinol supports whereas anhydroretinol inhibits cell growth (241,242). In addition, the oxoretinoids may play a role as RAR ligands (243).

Recently described nuclear receptor-associated proteins, such as SMRT/N-CoR, Sin3, and histone deacetylases (HDACs)-1 and -2 and histone acetylases (CBP/p300 and P/CAF), appear to function as corepressors and coactivators of transcription. A binary paradigm has emerged as an attempt to explain how these proteins work. Unligated receptors bind to response elements of target genes and repress transcription through recruitment of a repressor complex containing corepressors, and transcription is repressed (244,245). Under these conditions, DNA is compact and packaged into chromatin. Ligand binding causes the dissociation of corepressor proteins and promotes the association of coactivators with liganded receptors. Coactivators associated with complexes displaying histone acetyltransferases (HAT), methyltransferase, and kinase or ATP-dependent remodeling (SWI/SNF) activities lead to changes that reduces the compact nature of chromatin (245). The corepressors then disassociate, and a mediator complex known as the Srb and mediator protein-containing complex (SMCC) assembles. SMCC mediates the entry of the transcriptional machinery to the promoter, with resulting initiation of transcription (245).

3.4. Dietary Requirements for Vitamin A

The Food and Nutrition Board of the Institute of Medicine has made new recommendations of vitamin A intake by life stage and gender group (Table 2) (246). These Dietary Reference Intakes (DRIs) are reference values that are quantitative estimates of nutrient intakes to be used for planning and assessing diets in apparently healthy people and include Recommended Dietary Allowances (RDAs), Estimated Average Requirement (EAR), and Adequate Intake (AI) (246). The RDA is defined as “the dietary intake level that is sufficient to meet the nutrient requirement of nearly all (97 to 98 percent) healthy individuals in a particular life stage and gender group.” The EAR is defined as “a nutrient intake that is estimated to meet the requirement of half of the healthy individuals in a life stage and gender group.” AI is defined as “a recommended intake value based on observed or experimentally determined approximations or estimates of nutrient intake by a group (or groups) of healthy people that are assumed to be adequate—used when an RDA cannot be determined” (246).

Table 2
Dietary Reference Intakes for Vitamin A (μg RAE/d)

<i>Age and gender category</i>	<i>AI</i>	<i>EAR</i>	<i>RDA</i>
Infants, 0–6 mo	400	–	–
Infants, 7–12 mo	500	–	–
Children, 1–3 yr	–	210	300
Children, 4–8 yr	–	275	400
Boys, 9–13 yr	–	445	600
Girls, 9–13 yr	–	420	600
Boys, 14–18 yr	–	630	900
Girls, 14–18 yr	–	485	700
Adult men ≥ 19 yr	–	625	900
Adult women ≥ 19 yr	–	500	700
Pregnant women, 14–18 yr	–	530	750
Pregnant women ≥ 19 yr	–	550	770
Lactating women, 14–18 yr	–	885	1200
Lactating women ≥ 19 yr	–	900	1300

AI, Adequate Intake; EAR, Estimated Average Requirement; RDA, Recommended Dietary Allowance. Data from ref. 246.

Table 3
World Health Organization Classification of Xerophthalmia

XN	Night blindness
X1A	Conjunctival xerosis
X1B	Bitot spot
X2	Corneal xerosis
X3A	Corneal ulceration/keratomalacia involving less than one-third of corneal surface
X3B	Corneal ulceration/keratomalacia involving one-third or more of corneal surface
XS	Corneal scar
XF	Xerophthalmic fundus

4. CLINICAL FEATURES

Vitamin A is required for normal immunity, maintenance of mucosal surfaces, growth, reproduction, vision, and hematopoiesis. The vitamin A deficiency disorders consist of a syndrome that includes night blindness, pathological changes of the conjunctiva, cornea, and retina, and blindness, immune suppression and increased inflammation, increased morbidity and mortality from some infectious diseases, growth failure, and anemia.

4.1. Xerophthalmia and Keratomalacia

The WHO classification of xerophthalmia is shown in Table 3. This classification was first adopted in 1976 (126), with minor modification in 1982 (247). The ocular signs are

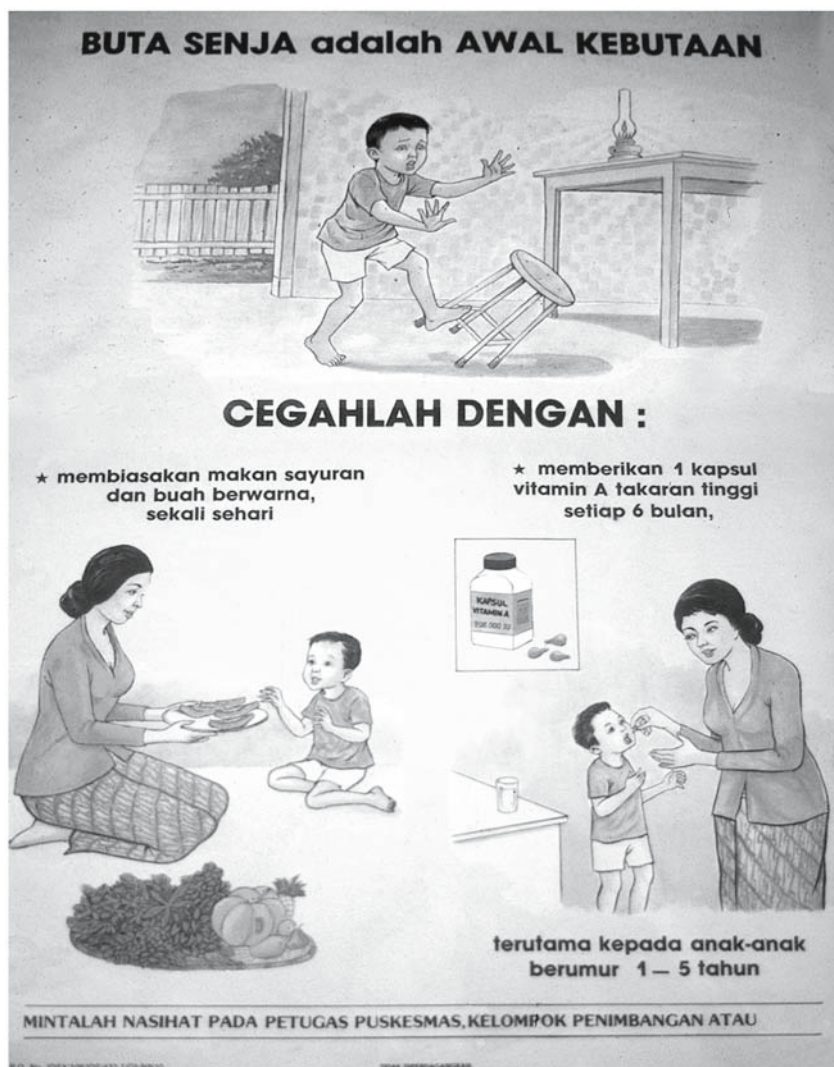

Fig. 5. Night blindness in a public health poster from Indonesia.

classified in order of severity from night blindness (XN) to corneal ulceration and keratomalacia that involves one-third of the cornea or greater (X3B). A corneal scar (XS) is not a sign of active vitamin A deficiency. Xerophthalmic fundus (XS) is usually considered to be a rare condition.

4.1.1. NIGHT BLINDNESS

Vitamin A is the biochemical precursor to rhodopsin, which is essential to the visual cycle in rod photoreceptors and night vision. The earliest clinical manifestation of vitamin A deficiency is often night blindness. Vision is normal during the day, but the vitamin A-deficient individual may have difficulty distinguishing objects at night. A typical history may involve a child who bumps into furniture or objects at night and is afraid to come to the mother when called. In areas where vitamin A deficiency is endemic, it is not uncommon that the condition is well recognized by local people and has a specific name,

such as *kwak moin* “chicken blindness” in Cambodia, or *buta ayam* “chicken eyes” in Indonesia (chickens lack rod photoreceptors and have poor night vision). This phenomenon is shown in a public health poster from Indonesia (Fig. 5).

4.1.2. CONJUNCTIVAL XEROSIS

Vitamin A is essential for the maintenance of normal mucosal epithelia, including the conjunctiva. The normal conjunctiva consists of nonkeratinized columnar epithelium with mucin-secreting goblet cells. During vitamin A deficiency, there is loss of mucin and goblet cells, increased keratinization, and a transition to stratified squamous epithelium. The bulbar conjunctiva may appear dry and roughened, and on oblique illumination may have a pebble-like or bubbly appearance (Fig. 6). The surface of the epithelium may not easily be wetted by tears. Conjunctival xerosis is often associated with night blindness, an observation that was made as early as 1855 (25). Conjunctival xerosis is not considered a good diagnostic indicator of vitamin A deficiency, as it is often overdiagnosed in nutrition surveys. Bitot spots are a more well demarcated area of conjunctival xerosis and are considered separately under Subheading 4.1.3.

The pathological changes in the conjunctiva are related to the role that vitamin A plays in the regulation of mucin and keratin expression. In rats, membrane-spanning mucin ASGP (rMuc4) and secretory mucin rMuc5AC were downregulated during vitamin A deficiency (248). The alterations in mucin gene expression occurred in goblet cells and stratified epithelium of the cornea and conjunctiva, and once severe keratinization occurred, mRNA for rMuc5AC and ASGP were no longer detectable (248). In the rabbit model, vitamin A deficiency is associated with keratinization of the conjunctiva, with up-regulation of AE1 (56.5 kd), AE3 (65–67 kd), and AE2 (56.5 and 65–67 kd) keratins (249). Following treatment with vitamin A, the conjunctiva changes from keratinized, stratified squamous epithelium without goblet cells to normal columnar epithelium with goblet cells (250,251). The loss of keratinization following vitamin A therapy appears to precede the restoration of goblet cells, which appear more slowly in response to treatment (251).

Around the beginning of the nineteenth century, the terms “xerosis,” “xerophthalmia,” and “xerophthalmos” were often used to describe dryness and associated changes of the eye that were considered to be related to conditions such as exposure, scrofula, syphilis, trachoma, and dryness of the eyes in older adults (252–256). The term “xerophthalmia” was applied in relationship to night blindness, corneal ulceration, and keratomalacia after further clinical observations and the development of ideas in the 1860s (20,27).

4.1.3. BITOT SPOT

A well demarcated patch of keratinized, squamous metaplasia of the bulbar conjunctiva, known as a Bitot spot, is considered pathognomonic for vitamin A deficiency. Pierre Bitot’s original description from 1863 (20) is worth repeating:

“La forme de cette tache diffère non-seulement selon les sujets, mais encore aux deux yeux d’un même individu. En général, elle est triangulaire, à sommet externe; la base, voisine de la cornée, est un peu concave. Dans quelques cas, elle était circulaire ou ovalaire; dans d’autres, simplement linéaire. Le plus souvent, les particules qui la composent sont agglomérées de façon à constituer une surface ponctuée, chagrinée; d’autres fois ces particules se disposent en séries ou lignes flexueuse, parallèles, qui donnent à la tache l’aspect d’une surface ondulée ou ridée.”

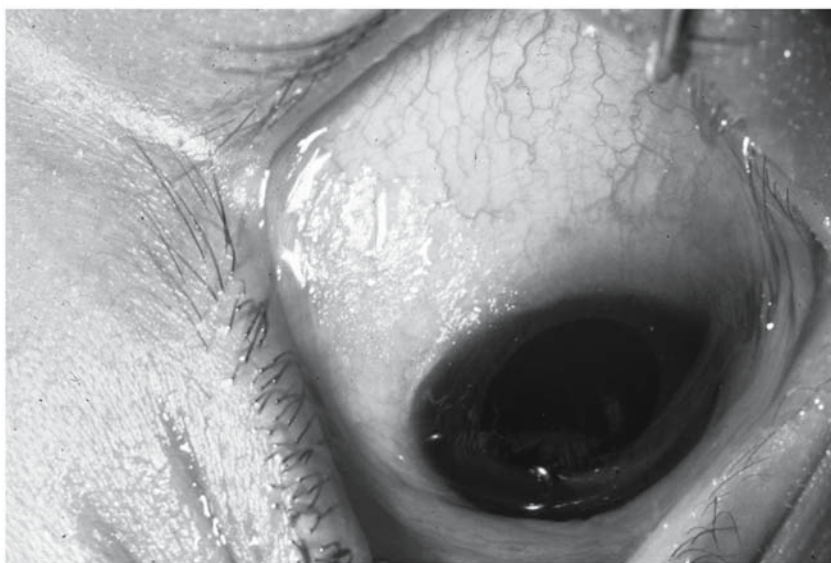


Fig. 6. Conjunctival xerosis. (Courtesy of Task Force Sight and Life.)

“The shape of this patch differs not only from subject to subject, but also differs from eye to eye in the same individual. In general, it is triangular [à sommet externe], the base, which is near the cornea, is slightly concave. In some cases, it was circular or oval; in others, simply linear. Most frequently, the particles that compose it are grouped in such a way as to make up a stippled, distressed surface; in other cases these particles are arranged in a series or in flexible parallel lines that give the patch the appearance of a wavy or wrinkled surface.”

Bitot spots are usually located on the temporal bulbar conjunctiva in the interpalpebral zone of one or both eyes. The spots may have a foamy, “cheesy,” “greasy,” or granular appearance (Fig. 7). If vitamin A deficiency is more severe or longstanding, Bitot spots may also be found on the nasal bulbar conjunctiva on one or both eyes. Thus, any combination of one to four Bitot spots may be found in one individual. The number of Bitot spots generally correlates with the severity of vitamin A deficiency and low serum retinol concentrations (257). It appears that if the Bitot spots are longstanding, there may be a point beyond which the keratinizing squamous metaplasia is irreversible even with vitamin A supplementation. Bitot spots that do not respond to vitamin A therapy have been termed “nonresponsive Bitot spots,” and this phenomenon gave rise to earlier observations of Bitot spots in individuals with normal serum retinol concentrations (258,259). If the spots are rubbed or scraped off the bulbar conjunctiva, they usually reappear after a few days if the patient has not received substantial improvement in vitamin A intake through diet or supplementation.

The histopathology of Bitot spots has been studied extensively and described repeatedly in the scientific literature (20,260–276). The lesion consists of keratinized squamous epithelium with keratohyalin granules in the granular layer. The surface of the lesion may contain desquamated epithelial cells, amorphous debris, and bacteria and/or fungi. Goblet cells are absent. No differences in histopathology have been noted between

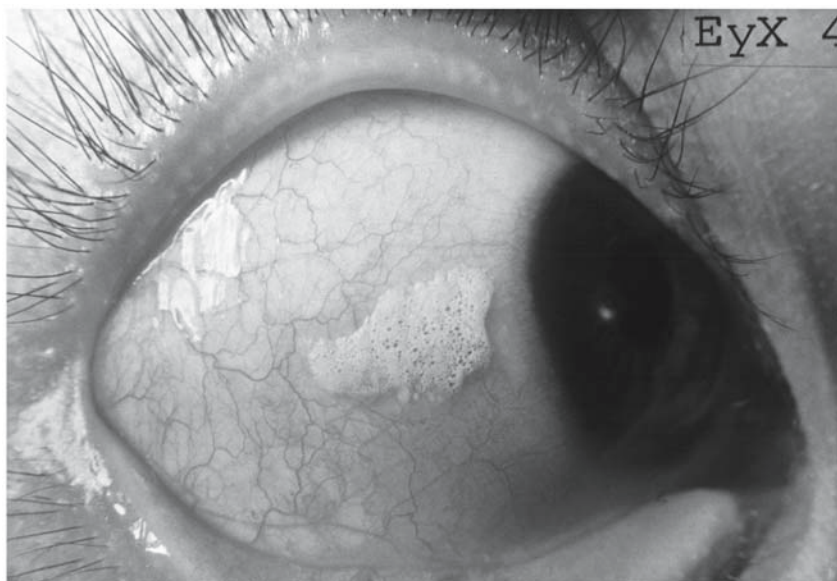


Fig. 7. Bitot spot. (Courtesy of Task Force Sight and Life.)

Bitot spots that are responsive or nonresponsive to vitamin A treatment; however, in the latter, the conjunctiva surrounding the Bitot spot is relatively normal (275). Many investigators have described the presence of a Gram-positive bacillus, *Corynebacterium xerosis*, in Bitot spots. The organism, also known as *Bacillus xerosis*, *Bacterium xerosis* and *Bacterium colomatti*, and *Corynebacterium conjunctivae*, received its present designation from Karl Lehmann (1858–1940) and Rudolf Neumann (1868–1952) in 1899 (277). The bacteria appears to be a commensal organism that does not normally produce eye pathology. P. Colomiatti described an organism from Bitot spots taken from young boys in a correctional institution (278). John Elmer Weeks (1853–1949) obtained pure cultures of the “double bacillus” and inoculated a rabbit cornea using a Graefe knife that had been dipped in the bacterial culture. The cornea healed without suppuration. Other experiments were conducted in with inoculations in the conjunctival sac, and the rabbit developed no reaction (261). Studies conducted by Eugen Fraenkel (1853–1925) and Ernst Franke (1857–1925) at the Allgemeinen Krankenhause in Hamburg, showed that xerosis bacillis were nonpathogenic (279). In 1898, Stephenson attempted to induce xerosis in another human subject by inoculation of the conjunctiva with the frothy material from the conjunctiva and by injecting the conjunctiva of another subject with pure cultures of the xerosis bacilli; this inoculation produced no resulting pathology (280).

4.1.3. CORNEAL XEROSIS

With more severe vitamin A deficiency, the cornea may also undergo squamous metaplasia with keratinization, and the cornea appears hazy and rough instead of smooth and transparent (Fig. 8). The earliest change in corneal xerosis is a punctate keratitis characterized by fine pin-point lesions in the corneal epithelium (281–284). The punctate keratitis is more visible with fluorescein staining, and the intensity of the punctate keratitis is

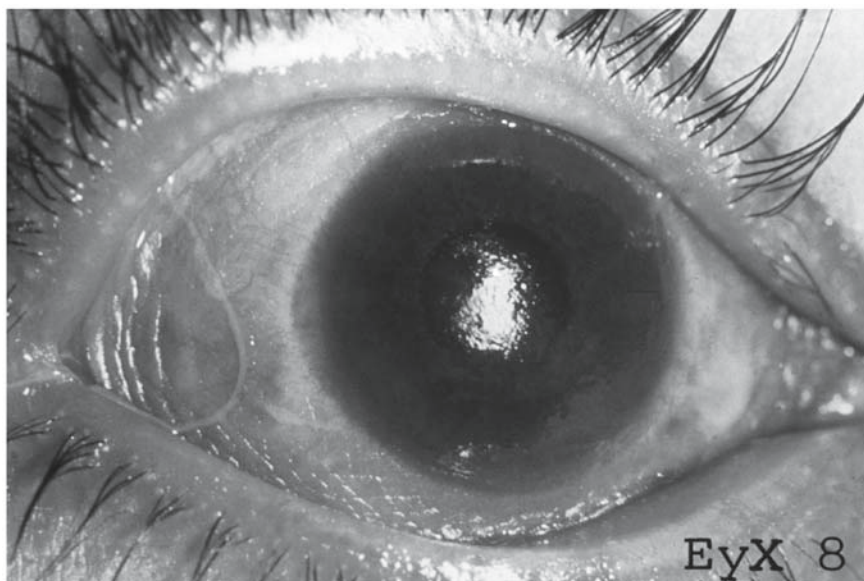


Fig. 8. Corneal xerosis. (Courtesy of Task Force Sight and Life.)

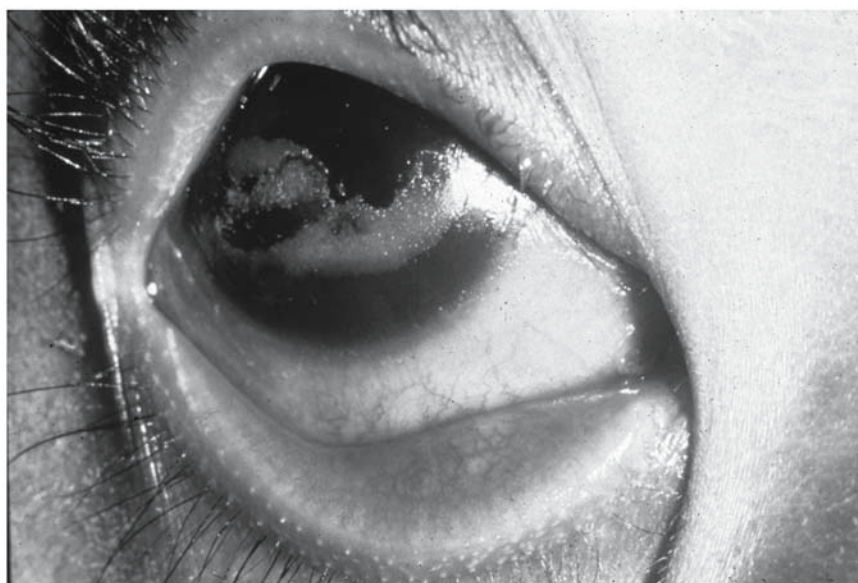


Fig. 9. Corneal xerosis with desquamated epithelium. (Courtesy of Task Force Sight and Life.)

greatest in the inferonasal part of the cornea (283). Corneal xerosis may be more apparent in the inferior portion of the cornea, and there may be underlying stromal edema that is detectable on slit lamp examination (285). In more severe disease, the cornea has a *peau d'orange* appearance, and there may be accumulations desquamated, cornified epithelium that may slough off or form large xerotic plaques on the cornea (285) (Fig. 9). Foreign body sensation, photophobia, and irritation have been described in patients with corneal xerosis (285).

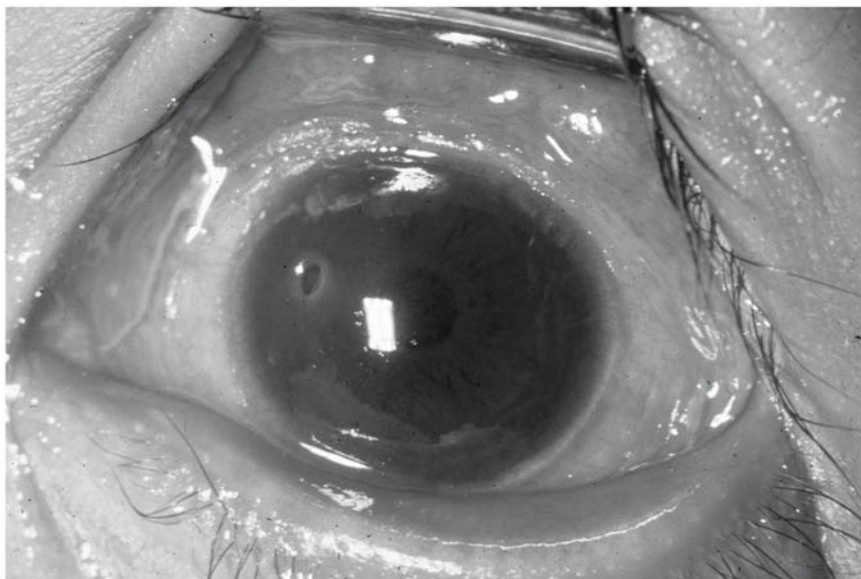


Fig. 10. Corneal ulcer. (Courtesy of Task Force Sight and Life.)

In the vitamin A-deficient rat, keratinization occurs in the corneal epithelium with thickening of the stroma (286). The changes occur without any evidence of a preinflammatory lesion or bacterial infection (286). Pathological changes in the cornea of vitamin A-deficient mice included keratinizing epithelium with loosened outer layers and keratohyalin granules in cells of the intermediate and superficial regions, variegated, invaginated nuclei and mitochondria of the basal cells, and occasional free and phagocytized bacteria on the loosened outer layers of the keratinized epithelium (287). In vitamin A-deficient guinea pigs, punctate corneal irregularities were common, and scanning electron microscopy showed extensive areas of surface epithelial cells lifting off the cornea and large, mound-like irregular projections distributed sparsely over the plasmalemma, in comparison to primary microvilli and no evidence of plasmalemmal disruption in vitamin A-sufficient control animals (273). Studies in vitamin A-deficient rabbits showed multiple punctate epithelial erosions that progressed with a *peau d'orange* appearance and later with development of polycystic microbullae in the central region of the cornea with underlying stromal edema (288). In more severe deficiency, necrotizing stromal infiltrates developed beneath keratinized plaques, with eventually ulceration of the corneal stroma (288). Vitamin A deficiency also affects glycoprotein synthesis in the rat corneal epithelium (289).

4.1.5. CORNEAL ULCER

Corneal ulceration may follow corneal xerosis, and the typical corneal ulcer associated with vitamin A deficiency is round or oval with a relatively clean, punched-out appearance, as if the cornea had been altered with a small trephine (Fig. 10). With full-thickness ulceration, the iris may prolapse through the ulcer. Secondary infection may occur. In a large series of 100 patients with vitamin A deficiency and xerophthalmia in the Philippines, among those with corneal ulceration or perforation, the most common isolates were *Pseudomonas aeruginosa*, *Streptococcus pneumoniae*, and *Moraxella spp.*,

with *P. aeruginosa* cultured from 35% of cases that had a corneal perforation (290). Most of the subjects had concurrent infections such as gastroenteritis, bronchopneumonia, and upper respiratory infection, and about one-third had severe malnutrition.

Experimental animal studies show that the healing process is impaired after various traumatic injuries to the cornea in vitamin A deficiency. After epithelial abrasions of the cornea, vitamin A-deficient rats progressed to extensive epithelial defects and stromal ulceration, often with an intense inflammatory reaction and bacterial infection (291). Impaired wound healing was also observed in vitamin A-deficient rabbits (292). Recovery from thermal burns to the cornea was slower in vitamin A-deficient compared with control rats (293), and polymorphonuclear leukocytes appear to play a role in the worsening of ulcerative lesions (294). Vitamin A deficiency appears to be associated with impaired epithelial migration and impaired production of fibronectin, a glycoprotein that plays a role in adhesion, chemotaxis, and tissue repair (295). The plasminogen activator-plasmin system has been implicated in corneal ulceration (296), but lack of tissue plasminogen activator has been found in the center of induced corneal wounds in vitamin A-deficient rats (297). After mechanical abrasion of the cornea in vitamin A-deficient rats, infiltrates of polymorphonuclear leukocytes were observed, but reepithelialization occurred without severe stromal degradation (298). In contrast, stromal incision in vitamin A-deficient rats resulted in marked stromal degradation, which suggested that stromal injury was more important than polymorphonuclear leukocytes in the pathogenesis of corneal ulceration in vitamin A deficiency (298). Vitamin A-deficient rabbits in the late stages of xerophthalmia were more susceptible to experimental infection with *P. aeruginosa* than animals in the early stages of xerophthalmia or control animals (299). Following induced trauma, *P. aeruginosa* infection and ulceration were worse in vitamin A-deficient compared with control rats (300). The production of collagen in rabbit corneal keratocytes is modulated by retinoids, which suggests an additional mechanism for vitamin A in the maintenance of cornea integrity (301).

Matrix metalloproteinases, collectively known as matrixins, are proteinases that are involved in degradation of the extracellular matrix, and these include collagenases, gelatinases, stromelysins, and matrilysins (302). Corneal ulceration in vitamin A deficiency is influenced by the production of proteinases, which can be produced by the cornea (303–308), inflammatory cells (309), and bacteria (310). The expression of different proteinases in the cornea may vary during vitamin A deficiency and might explain conditions that occur with differences in proteolysis. Under conditions of vitamin A deficiency, with decreased proteolysis, epithelial cells may not exfoliate properly, and with increased proteolysis, superficial punctate keratopathy and increased corneal keratocyte loss may occur (311). Cathepsin D, an aspartic proteinase, was increased threefold in the corneas of vitamin A-deficient rabbits compared with pair-fed control rabbits (311). The production of collagenase in the cornea is increased in vitamin A-deficient rats compared with control rats (293,305).

Retinoids modulate the expression of numerous proteins such as matrix metalloproteinases and plasminogen activator through alteration of gene transcription and through interaction of retinoic acid receptors with transcription factors such as c-Jun and c-Fos at the activator protein (AP)-1 site (312). The promoter region of the collagenase gene contains an AP-1 responsive element that is repressed by retinoic acid (313). RARs do not appear to bind directly to the AP-1 site but appear to bind with c-Jun to form an inactive

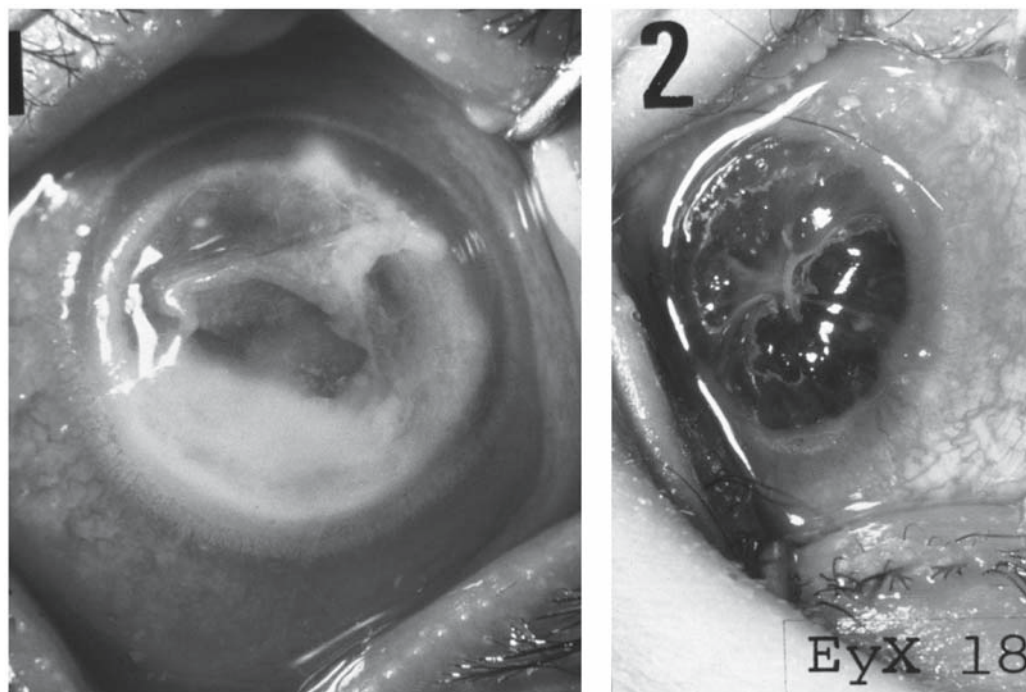


Fig. 11. Keratomalacia. (Courtesy of Task Force Sight and Life.)

complex that does not upregulate collagenase expression (313–315). Interleukin (IL)-1, a potent mediator of inflammation, shows increased activity in the cornea of vitamin A-deficient rats after mechanical injury in comparison to corneas of control rats (316). IL-1 stimulates and retinoic acid inhibits collagenase transcription through inhibition of c-Fos (317). The combination of increased IL-1 activity and deficiency in retinoic acid may both potentially contribute to the increased expression of collagenase in corneal ulceration and keratomalacia associated with vitamin A deficiency.

4.1.6. KERATOMALACIA

Keratomalacia is characterized by melting of the cornea (Fig. 11). In the late 19th century, keratomalacia was not uncommon in Europe and was noted primarily among young infants. Albrecht von Graefe (1828–1870) noted: “although the illness concerned here is not exactly a frequent one, hardly a semester passes when I do not see an incidence of it, and at times I have seen three or four cases within a month. The general picture offered, with some variation of details, is uniform to such an extent that I always held to the idea that a constant general affection must be present in the organism” (318). Von Graefe found that the illness usually occurred within a few weeks of birth, especially among infants with pale appearance, loss of tone, poor nutrition, decline in appetite, and diarrhea (318). Von Graefe recognized that the condition began with a lesion of the bulbar conjunctiva that was “dull, dry, covered with fine scales and raised in appearance with perpendicular wrinkles” and “depleted of its natural moisture,” and that this “acute xerosis” was connected to the corneal destruction that followed. Von Graefe attributed the corneal ulceration to encephalitis, since autopsy findings had suggested brain inflammation among

infants who had died with keratomalacia. Julius Hirschberg (1843-1925), a disciple of Von Graefe, described how apparently healthy infants developed anorexia, diarrhea, marasmus, and then rapidly progressed with xerophthalmia in both eyes (319). Intestinal helminthiasis increases the risk of keratomalacia in children (320,321). Keratomalacia was described in a child with familial hypo-retinol-binding proteinemia (322) and also has been described in acrodermatitis enteropathica (323).

Keratomalacia has also been described among adults, usually in association with severe diarrheal disease (324–326), and sometimes in association with unusual dietary practices, alcoholism, and severe cachexia (*see* Subheading 5.3.10.). The ocular pathology of keratomalacia has been described in a few reports (327,328), including a 27-yr-old woman who followed a “cult” vegetable and grain diet, developed night blindness, keratomalacia, and died (328). Bilateral corneal melting was noted with minimal inflammatory reaction, despite a large corneal perforation. Keratomalacia has been produced in vitamin A-deficient animals (329). A discussion of the biological mechanisms that have been implicated in the pathogenesis of corneal ulceration and keratomalacia was discussed under Subheading 4.1.5. Secondary infection may play a role in keratomalacia (330) but does not appear to be the initiating event (331). Some investigators believe that protein malnutrition is an important contributing factor to keratomalacia because of keratomalacia is more common among individuals with protein energy malnutrition (332,333).

4.1.7. XEROPHTHALMIC FUNDUS

Xerophthalmic fundus (fundus xerophthalmicus) is a condition characterized by fine white, cream-colored, or greyish dot-like, oval, or linear opacities in the retina. It usually occurs among individuals with night blindness, conjunctival xerosis and/or Bitot spots. In 1894 in Freiburg, Karl Baas (1866–1944) described a 15-yr-old field hand with night blindness, conjunctival xerosis, and a large amount of small white dots located in the retina (334). The condition was associated with liver disease and called “ophthalmia hepatica.” Otmar Purtscher (1852–1927) described more cases of “ophthalmia hepatica” in Klagenfurt, Austria in 1900 (335). In 1915, Sanroku (or Saroku) Mikamo described a 12-yr-old boy from Fukuoka, Japan who had night blindness (336). The boy worked for a rice dealer and was known to have been healthy all his life. He began to bump into furniture at night and had dropped a rice bowl, and even after scolding, he continued to have difficulty making his way around when it became dark. One evening he was pouring water into a tub to take a bath, and his friends were astonished to see him pouring the water onto the ground, as he could not see well and had missed the tub completely. The following day he was taken to the eye hospital, where it was noted that he had Bitot spots and small white dots in the equatorial zone of the fundus of both eyes. The fundus findings were depicted (Fig. 12) (336). The patient was noted to have a narrowed visual field, and laboratory investigations revealed that the boy had hookworm infection. During treatment with cod-liver oil, the night blindness and Bitot spots disappeared after a few days, but it took several weeks for all the white dots in the fundus to disappear (336).

In 1922, Robert E. Wright described “a mid-peripheral belt of discreet white spots” in the fundus of patients with night blindness and keratomalacia in Madras, India (337). Misao Uyemura reported two cases of xerophthalmic fundus in 1928 seen at the eye clinic of Keio University in Tokyo (338), and the condition became known later as Uyemura’s syndrome (339). Adalbert Fuchs (1887–1973) described another case while he was a

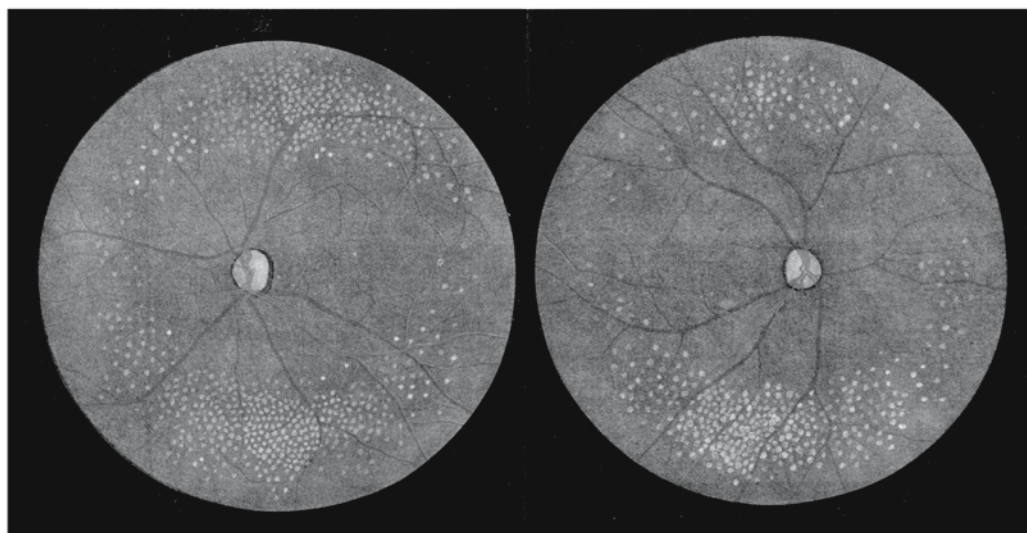


Fig. 12. Fundus xerophthalmicus. (From ref. 336.)

visiting professor at Peking Union Medical College (340), and additional cases were described in Japan (339,341,342), China (343,344), Italy (345,346), and Germany (347). The retinal lesions are located most commonly in the peripheral retina and are usually found in both eyes. As noted by Teng Khoen Hing: “It is striking that in the flourishing cases, where it looks as if they have been scattered lavishly over the surface of the fundus, the granules are glaringly white like sugared caraway seeds. In these cases, we see many ‘sugared caraway seeds’ grow together to ramify like a clover-leaf, or we see them in a row along the vessels, so that the vessels look as if they get a shell in their course in some places” (348). The whitish lesions are located deeper in the retina than the retinal blood vessels. In 1933, Yatsutake described bilateral visual field constriction in a patient with xerophthalmic fundus (342).

Although xerophthalmic fundus is often described as a rare condition, most individuals who are encountered in the field with Bitot spots and/or night blindness do not generally receive a dilated fundus examination and the condition may be overlooked. In the largest published cases series, Teng Khoen Hing examined hundreds of outpatients seen at the Cicendo Eye Hospital in Bandung, Indonesia who had xerophthalmia in a period from about 1956 to 1961 (349). Of 190 subjects with night blindness, 23.7% had xerophthalmic fundus, and of 600 subjects with conjunctival xerosis, Bitot spots, corneal xerosis, or keratomalacia, 35% had xerophthalmic fundus. The highest prevalence of xerophthalmic fundus was found among children aged 5–14 yr. Of 321 cases of xerophthalmic fundus that were reported, 93% had night blindness, conjunctival xerosis, or both (349, 350). An additional case of xerophthalmic fundus was described from Cicendo Eye Hospital in 1978 (351). The severity of xerophthalmic fundus appears to correlate with more longstanding vitamin A deficiency and lower serum vitamin A concentrations (352,353). The highest risk group for xerophthalmic fundus appears to be those in the age group from 5 to 14 yr (350). Xerophthalmic fundus can usually be differentiated from other fundus conditions with white dots, such as retinitis punctata albescens and fundus albipunctatus,




Fig. 13. Rat model, changes in outer segments after vitamin A-deficient diet for 23 wk. (Reprinted from ref. 360, with permission of *Investigative Ophthalmology and Visual Science*.)

because xerophthalmic fundus is often associated with other signs of vitamin A deficiency (conjunctival xerosis, Bitot spots, corneal xerosis, and so on), and the white lesions resolve after treatment with vitamin A (350).

Vitamin A deficiency has been shown to induce histopathological changes in the rod photoreceptors of the retina in experimental animal models (354–360). These changes consist of degeneration of rod outer segments, the external limiting membrane, the retinal pigment epithelium, the outer molecular layer and the inner nuclear layer (356,357). The pathological changes in rod outer segments with prolonged vitamin A deficiency in the rat model includes distention or dispersion of disc into vesicles, and the appearance of vesicles in the pigment epithelium and between processes of the pigment epithelium (Fig. 13). In contrast, normal rod outer segments show regular organization of outer

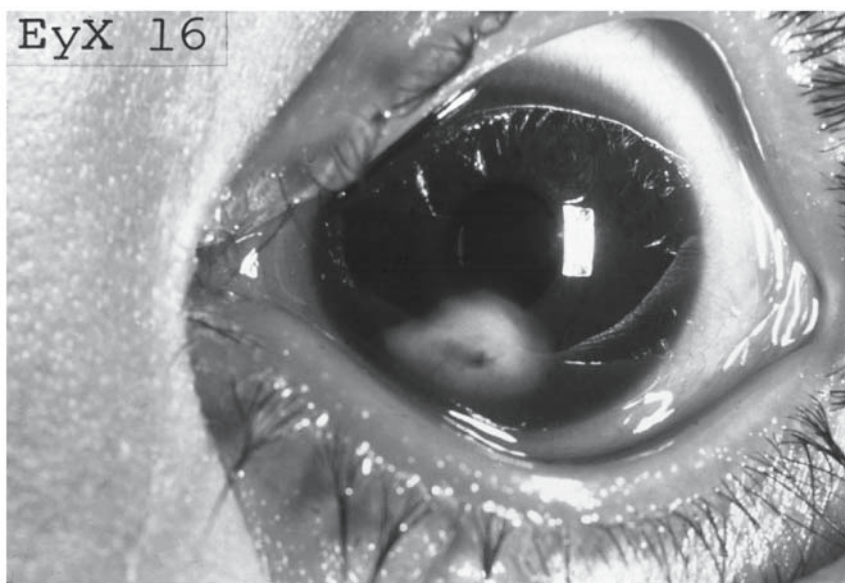


Fig. 14. Corneal scar. (Courtesy of Task Force Sight and Life.)

segment discs and close contact with processes of the pigment epithelium (360). Autoradiographic studies show that the rate of rod outer segment renewal and removal is impaired by vitamin A deficiency (361). Vitamin A-deficient rats with degeneration of the rod photoreceptors may recover to almost normal appearance after refeeding with vitamin A over 10 to 18 wk (357). Refeeding of deficient animals is associated with an increase in rod outer-segment density (362).

Xerophthalmic fundus has been described in a 20-yr-old man who stopped consuming food sources of vitamin A for about 5.5 yr because he thought it would reduce his epileptic seizures (363,364). His serum retinol concentrations were as low as $0.14 \mu\text{mol/L}$ when he was seen as an outpatient (363). The patient refused any treatment with vitamin A and later developed bilateral corneal xerosis. He was eventually admitted on an emergency basis to the hospital with fever, anorexia, abdominal pain, and corneal ulceration. After treatment with daily vitamin A therapy for 3 mo, the yellowish dots in the fundus decreased in size and disappeared (365). A hereditary defect in the gene for serum RBP, a heterozygous missense mutation Ile41Asn and Gly75Asp, is associated with xerophthalmic fundus (366). Fundus examination of two siblings with the condition showed small dots representing focal loss of retinal pigment epithelium (366). The white dots characteristic of xerophthalmic fundus appear as window defects in the retinal pigment epithelium in fluorescein angiograms (351).

4.1.8. CORNEAL SCAR

The sequelae to corneal ulcer and keratomalacia include the formation of a corneal scar or leucoma (Fig. 14). Corneal scarring can arise from causes other than vitamin A deficiency, such as following trauma and infectious keratitis unrelated to vitamin A, thus, the interpretation of corneal scarring must be made with caution in surveys. The corneal scarring that occurs with measles and vitamin A deficiency cannot be distinguished from corneal scarring from vitamin A deficiency without measles. Many surveys of the causes

Table 4
Vitamin A and Immune Function

<i>Function</i>	<i>Effect of vitamin A deficiency</i>
Maintenance of mucosal surfaces	Loss of cilia in respiratory tract Loss of microvilli in gastrointestinal tract Loss of goblet cells and mucin in respiratory, gastrointestinal, and genitourinary tracts Squamous metaplasia of conjunctiva, cornea with loss of goblet cells and mucus and keratinization of ocular surfaces
Function of immune effector cells	Impaired neutrophil, natural killer cell, monocyte/macrophage, and lymphocyte function Altered cytokine production Impaired T- and B-cell activation
Antibody production	Impaired antibody responses to T-cell-dependent antigens and T-cell-independent type 2 antigens
Lymphopoiesis	Altered T-cell subsets

of blindness in schools for the blind may simply classify the corneal scarring as due to “vitamin A deficiency/measles.” The prevalence of vitamin A deficiency as ascertained by institutional surveys should be considered extremely conservative estimates, since corneal ulceration and keratomalacia are associated with high mortality rates. In Hyderabad, India, a longitudinal study of 32 children who had been hospitalized for keratomalacia revealed that nearly one-third died within 3 to 4 mo after discharge from the hospital (367).

4.1.9. OTHER

Widely dilated pupils have been described since at least the seventeenth century among individuals with night blindness, and often the pupils constrict weakly or not at all when a light source such as candlelight is used to illuminate the eyes. Pupillary dilation has formed the basis for a test of vitamin A deficiency (*see* Subheading 6.2.6.).

4.2. Immune Suppression and Inflammation

Vitamin A modulates many different aspects of immune function, both nonspecific (innate) immunity (i.e., maintenance of mucosal surfaces, natural killer (NK) cell activity, and phagocytosis) and specific (adaptive) immunity (i.e., generation of antibody responses). Some aspects of immunity are not affected by vitamin A deficiency. Much of our knowledge of vitamin A and immune function is based on experimental animal studies involving mice, rats, and chickens, and from *in vitro* studies involving modulation of specific cell lines with retinoids. The effects of vitamin A deficiency on immune function are summarized in Table 4.

4.2.1. MUCOSAL IMMUNITY

The mucosal surfaces of the body include the respiratory, gastrointestinal, and genitourinary tracts as well as the cornea and conjunctiva. There are at least seven known mechanisms by which vitamin A deficiency impairs mucosal immunity: (1) loss of cilia in the

respiratory tract, (2) loss of microvilli in the gastrointestinal tract, (3) loss of mucin and goblet cells in the respiratory, gastrointestinal, and genitourinary tracts, (4) squamous metaplasia with abnormal keratinization in the respiratory tract, (5) alterations in antigen-specific secretory immunoglobulin (Ig)A concentrations, (6) impairment of alveolar monocyte/macrophage function, and (7) decreased integrity of the gut. In early studies of vitamin A deficiency in autopsy studies of humans and experimental animals, the findings included widespread pathological alterations in the respiratory, gastrointestinal, and genitourinary tracts (87,368,369). During vitamin A deficiency, there is loss of mucin and goblet cells from the conjunctiva and squamous metaplasia of the conjunctiva and cornea (285,370) and impaired wound healing (298). Vitamin A is involved in the expression of both mucins (248,371) and keratins (249,372,373). Lactoferrin, an iron-binding glycoprotein involved in immunity to bacteria, viruses, and fungi, appears to be modulated in the tear film of children by vitamin A supplementation (374). Loss of mucin and alterations in keratins in vitamin A deficiency may increase susceptibility to experimental ocular infection with pathogens such as *Herpes simplex* virus (375) and *Pseudomonas* (299,300). Other corneal alterations in experimental vitamin A deficiency include structural abnormalities of the epithelial basement membrane complex (376).

In the respiratory tract, pathogens are constantly trapped and removed by the mucociliary elevator in the normal tracheobronchial tree. Vitamin A-deficient animals show loss of ciliated epithelial cells and mucus and replacement by stratified, keratinized epithelium (377–379). The terminal differentiation of keratins is modulated by vitamin A (380,381) and mucin gene expression is regulated by all-*trans* retinoic acid (382,383). Such broad pathological changes in the tracheobronchial tree may be reflected in the observation that vitamin A-deficient mice are more susceptible to ozone-induced lung inflammation (384).

Vitamin A deficiency is associated with morphological and function alterations in the gut that may predispose individuals to more severe diarrheal disease. Vitamin A deficiency in rats is associated with a large reduction in goblet cells in duodenal crypts (385) and impaired biliary secretion of total secretory IgA (386). Reduced villus height was observed in the jejunum of vitamin A-deficient rats that were not challenged with any gastrointestinal pathogens (387). Vitamin A-deficient mice were more susceptible to the destruction of duodenal villi following experimental challenge with rotavirus (388). The genitourinary tract is also adversely affected by vitamin A deficiency, with replacement of normal transitional epithelium with stratified squamous epithelium and expression of distinct types of keratins (389). Changes in the genitourinary epithelia may contribute to increased urinary tract infections in vitamin A-deficient children (390).

Vitamin A deficiency may affect both the concentrations of secretory IgA on mucosal surfaces and specific IgA responses in the gut. In vitamin A-deficient chickens, the concentrations of total IgA were lower in the gut than in control animals (391). Vitamin A-deficient BALB/c mice that were challenged with influenza A had a lower influenza-specific IgA response than control mice (392). Vitamin A-deficient mice had significantly lower serum antibody responses against epizootic diarrhea of infant mice (EDIM) rotavirus infection compared with pair-fed control mice (393). An impaired ability to respond with IgA antibodies to oral cholera vaccine was demonstrated in vitamin A-deficient rats (394). Vitamin A treatment prevented the decline in IgA in the intestinal mucosa of protein-malnourished mice (395). Recent studies in IL-5 receptor-knockout mice suggest

that IL-5 may play an important role in vitamin A-induced modulation of mucosal IgA (396). In vitro studies with HT-29 cells, a human intestinal epithelial cell line, indicate that vitamin A may be involved in the regulation of polymeric immunoglobulin receptor by IL-4 and interferon- γ (397). These data suggest that vitamin A is involved in regulation of IgA transport in response to mucosal infections. Human and animal studies suggest that vitamin A status may also influence gut integrity and healing. Using the urinary lactulose/mannitol excretion test, increased gut permeability was found in infants, and the gut integrity improved following vitamin A supplementation (398). Vitamin A-deficient rats had impaired healing of surgically-induced anastomoses of the colon compared with control rats (399).

4.2.2. NATURAL KILLER CELLS

NK cells play a role in antiviral and antitumor immunity that is not major histocompatibility complex (MHC)-restricted, and NK cells are involved in the regulation of immune responses. Vitamin A deficiency appears to reduce both the number and activity of NK cells. In experimental animal models, vitamin A deficiency reduced the number of NK cells in the spleen (400,401) and peripheral blood (402). The cytolytic activity of NK cells is reduced by vitamin A deficiency (401,402). In aging Lewis rats, marginal vitamin A status reduced the number of NK cells in peripheral blood and the cytolytic activity of NK cells (403). There have been few studies of vitamin A status and NK cells in humans. Children with AIDS who received two doses of oral vitamin A, 60 mg retinol equivalents (200,000 IU), had large increases in circulating NK cells compared with children who received placebo (404).

4.2.3. NEUTROPHILS

Neutrophils play an important role in nonspecific immunity because they phagocytize and kill bacteria, parasites, virus-infected cells, and tumor cells. The function of neutrophils appears to be impaired during vitamin A deficiency. Retinoic acid plays an important role in the normal maturation of neutrophils (405). Experimental animal studies show widespread defects in neutrophil function, including impaired chemotaxis, adhesion, phagocytosis, and ability to generate active oxidant molecules during vitamin A deficiency (406,407). In rats challenged with *Staphylococcus aureus*, impaired phagocytosis and decreased complement lysis activity were found in vitamin A-deficient rats compared with controls rats (408). Vitamin A treatment was shown to increase superoxide production by neutrophils from Holstein calves (409). During vitamin A deficiency, an increase in circulating neutrophils has been observed in some experimental animal studies (410), and this has been attributed in part to impaired apoptosis of myeloid cells (411). Vitamin A inhibited neutrophilic infiltration in rats undergoing induced lung granuloma formation, and histological evidence suggested that vitamin A suppressed the expression of nuclear factor- κ B (412).

4.2.4. HEMATOPOIESIS

Vitamin A deficiency appears to impair hematopoiesis of some lineages, such as CD4⁺ lymphocytes, NK cells, and erythrocytes. In humans, clinical vitamin A deficiency has been characterized by lower total lymphocyte counts and decreased CD4⁺ lymphocytes in peripheral blood, and CD4⁺ lymphocyte counts or percentage increased after vitamin A supplementation (404,413). Vitamin A supplementation does not appear to have any

long term effect on CD4⁺ or CD8⁺ lymphocyte subsets among infants without clinical vitamin A deficiency (414). In the vitamin A-deficient rat, lower NK cell, B-cell, and CD4⁺ lymphocyte counts were found in peripheral blood, and these counts responded to retinoic acid supplementation (411). Retinoids have been implicated in the maturation of pluripotent stem cells to cell lineages that produce different hematopoietic cell lines such as lymphocytes, granulocytes, and megakaryocytes. Retinoids also appear to play a role in the maturation of differentiation of pluripotent stem cells into multipotent (colony-forming unit granulocyte erythroid macrophage mixed [CFU-GEMM]) cells, and differentiation and commitment of CFU-GEMM into erythroid burst-forming units (BFU-E) and then into erythroid colony-forming units (CFU-E) (415–417).

4.2.5. MONOCYTES/MACROPHAGES

Macrophages are involved in the inflammatory response and in the phagocytosis of viruses, bacteria, protozoa, fungi, and tumor cells. Macrophages secrete a wide variety of cytokines, including tumor necrosis factor (TNF)- α , IL-1 β , IL-6, and IL-12. The effect of retinoids on monocyte differentiation has been studied in leukemic myelomonocytic cell lines such as HL-60, U-937, and THP-1 (418–420). Retinoids appear to influence both the number and activity of macrophages (421,422). Vitamin A-deficient animals may have increased numbers of macrophages in lymphoid tissues (423). In vitro studies suggest that all-*trans* retinoic acid decreases TNF- α production in a murine macrophage cell line (424) and regulates IL-1 β expression by human monocytes (425) and human alveolar macrophages (425). All-*trans* retinoic acid inhibited IL-12 production in activated murine macrophages (427) and caused a twofold increase in phagocytosis in murine macrophages (428). Expression of IL-1 may be modified by retinoids in murine macrophages (428,429). In the rat model, vitamin A deficiency was associated with reduced phagocytic function of macrophages (408). In experimental *Salmonella* infection in the rat, vitamin A supplementation improved phagocytosis by macrophages (430).

4.2.6. LANGERHANS CELLS

Langerhan cells serve as antigen-presenting cells in the skin. Dietary vitamin A increases contact sensitivity to a variety of chemical agents in the murine model, and this observation may be related to vitamin A-related modulation of the numbers and function of Langerhans cells (431,432). Retinoic acid treatment in vivo increases the ability of human Langerhans cells to present alloantigens to T-lymphocytes and is associated with increases in surface expression of HLA-DR and CD11c, two molecules involved in antigen presentation (433).

4.2.7. T-LYMPHOCYTES

Vitamin A deficiency may influence T-lymphocyte-related immunocompetence through such mechanisms as a decrease in numbers or distribution, changes in phenotype, alterations in cytokine production, or decreased expression or function of cell surface molecules involved in T-cell signaling (434). There is some evidence that each of these mechanisms may play a role in the immunosuppression associated with vitamin A deficiency. The effects of vitamin A deficiency on lymphopoiesis were discussed previously in “Hematopoiesis.” In preschool children with clinical and subclinical vitamin A deficiency in Indonesia, high-dose vitamin A supplementation was associated with an increase in the proportion of circulating CD4⁺CD45RA⁺, or “naïve” CD4⁺ lymphocytes,

suggesting that vitamin A influences lymphopoiesis (413). Activation of T-lymphocytes requires retinol (435). In human peripheral mononuclear cells, retinol is a cofactor in CD3-induced T-lymphocyte activation (436). All-*trans* retinoic acid has been shown to increase antigen-specific T-lymphocyte proliferation (437) and expression of IL-2 receptors (438). In a trial in Bangladesh, vitamin A supplementation improved responses to delayed type hypersensitivity skin testing among infants who were supplemented to higher vitamin A levels (439).

Vitamin A appears to modulate the balance between T-helper type 1-like responses and T-helper type 2-like responses in experimental animal studies, and this has been the prevailing paradigm for the last decade, as reviewed in detail elsewhere (440). According to this model, vitamin A deficiency causes a shift toward T-helper 1-like responses, whereas vitamin A supplementation causes a shift toward T-helper 2-like responses. There is little evidence to support this model for human vitamin A deficiency, and in fact, clinical observations are not consistent with this model. Vitamin A supplementation enhances immunity to a wide variety of infections such as tuberculosis, measles, malaria, HIV infection, and diarrheal diseases, in which the specific immune-protective immune responses have been characterized as either T-helper 1-like or T-helper 2-like responses.

In mice, *Trichinella spiralis* infection usually stimulates a strong T-helper type 2-like responses, characterized by strong parasite-specific IgG responses and a cytokine profile dominated by IL-4, IL-5, and IL-10 production. However, in vitamin A-deficient mice, infection by *T. spiralis* results in low production of parasite-specific IgG and a cytokine profile dominated by interferon (IFN)- γ and IL-12 production (441–443). Lymphocyte stimulation to concanavalin A or β -lactoglobulin was higher and production of IL-2 and IFN- γ was higher in lymphocyte supernatants from vitamin A-deficient rats compared with control rats, suggesting that vitamin A deficiency modulates a shift toward T-helper type 1-like responses in rats (444). Vitamin A appears to inhibit IFN- γ , IL-2, and granulocyte/macrophage colony-stimulating factor (GM-CSF) by type 1 lymphocytes in vitro (445). The effect of high-level dietary vitamin A on the shift to T-helper type 2-like responses in BALB/c mice has been used to explain the apparent lack of benefit of vitamin A supplementation for acute lower respiratory infections in humans (446). The enhancement of T-helper type 2-like responses by vitamin A may be modulated via 9-*cis* retinoic acid and RXRs (447). Vitamin A-deficient mice show overproduction of IFN- γ (448) and both retinol and retinoic acid appear to downregulate expression and transcription of IFN- γ (449,450). In a mouse model, vitamin A deficiency at the time of antigen exposure was associated with diminished development of T-helper 1 memory cells and increased development of IL-10-producing T-helper 2 cells (451).

4.2.8. B-LYMPHOCYTES

Vitamin A deficiency impairs the growth, activation, and function of B-lymphocytes. Activated B-lymphocytes depend on retinol but not retinoic acid (452–454). B-lymphocytes have been shown to utilize a metabolite of retinol, 14-hydroxy-4,14-*retro*-retinol, instead of retinoic acid, as mediator for growth (241). The effects of retinol and all-*trans* retinoic acid on immunoglobulin synthesis B-lymphocytes has been examined in human cord blood and adult peripheral mononuclear cells (455–458). A T-cell-dependent antigen was used to induce differentiation of human B-lymphocytes into immunoglobulin-secreting cells, and all-*trans* retinoic acid increased the synthesis of IgM and IgG by these

cells. Highly purified T-lymphocytes incubated with retinoic acid enhanced IgM synthesis by cord blood B-lymphocytes, suggesting that retinoic acid modulates T-cell help through cytokine production (458). Apoptosis in B-lymphocytes appears to be mediated via RAR (459). In common variable immunodeficiency, a B-cell deficiency syndrome characterized by defective antibody production, T-cell and monocyte dysfunction, and recurrent infections, vitamin A supplementation was associated with enhanced anti-CD40-stimulated IgG production, serum IgA concentrations, and lymphocyte proliferation to phytohemagglutinin (460).

4.2.9. ANTIBODY RESPONSES

The hallmark of vitamin A deficiency is an impaired capacity to generate an antibody response to T-cell-dependent antigens (444,461), including tetanus toxoid (462,463) and diphtheria antigens in humans (464), tetanus toxoid and other antigens in animal models (465–467), and T-cell-independent type 2 antigens such as pneumococcal polysaccharide (468). Antibody responses are involved in protective immunity to many types of infections and are the main basis for immunological protection for many vaccines. Depressed antibody responses to tetanus toxoid have been observed in vitamin A-deficient children (462) and in vitamin A-deficient animals (469,470). Vitamin A deficiency appears to impair the generation of primary antibody responses to tetanus toxoid, but if animals are repleted with vitamin A prior to a second immunization, the secondary antibody responses to tetanus toxoid are comparable to control animals (466). These findings suggest that formation of immunological memory and class switching are intact during vitamin A deficiency, despite an impaired IgM and IgG response to primary immunization. Human peripheral blood lymphocytes from subjects previously immunized against tetanus toxoid were used to reconstitute control and vitamin A-deficient mice with severe combined immunodeficiency. After challenge with tetanus toxoid, vitamin A-deficient severe combined immunodeficient (SCID) mice had a 2.9-fold increase in human anti-tetanus toxoid antibody compared with a 74-fold increase in control SCID mice (471). In healthy children without vitamin A deficiency, vitamin A supplementation did not enhance antibody responses to tetanus toxoid (472). These findings suggest that vitamin A supplementation is unlikely to enhance antibody responses in subjects who are not vitamin A-deficient. Other evidence that vitamin A is needed for the generation of antibody responses has been noted in retinol-binding protein knockout mice, where serum vitamin A concentrations are extremely low and associated with circulating Ig concentrations (473).

4.3. Increased Infectious Disease Morbidity and Mortality

Vitamin A deficiency increases susceptibility to some types of infections, and there is currently an extensive literature regarding vitamin A deficiency and infection in experimental animal models, as can be found in reviews elsewhere (440,474–477).

4.3.1. DIARRHEAL DISEASES

Vitamin A supplementation or fortification has been shown to reduce the morbidity and mortality of diarrheal diseases among preschool children in developing countries. The reduction in diarrheal disease mortality appears to account for most of the reduction in overall mortality when vitamin A is given through fortification or supplementation on a community level. The main causes of diarrheal diseases among children in developing

countries are rotavirus, *Escherichia coli*, and *Shigella*, *Vibrio cholerae*, *Salmonella*, and *Entamoeba histolytica*. The epidemiology, clinical features, immunology, and pathogenesis of diarrhea may differ according to characteristics of the pathogen, such as production of toxins, tissue invasion, fluid and electrolyte loss, and location of infection. In general, host defenses in the gut include gastric acidity, the presence of normal microflora, gut motility, mucus production, integrity of microvilli, local secretion of antibody, and cell-mediated immunity, and vitamin A deficiency may impair some of these host defenses.

Large community-based clinical trials of vitamin A supplementation in Tamil Nadu, Nepal, and Ghana show that vitamin A supplementation reduced mortality from diarrheal disease but not pneumonia in preschool children (478,479). Vitamin A may reduce the morbidity of diarrheal disease through restoration of gut integrity (480) and enhancement of immune function (440,477). Urinary losses of vitamin A during diarrhea may be substantial in some children (481,482), and persistent diarrhea may reduce the bioavailability of vitamin A (483). Vitamin A supplementation (60 mg retinol equivalent [RE]) reduced morbidity in children with acute shigellosis (484) but the effects of vitamin A supplementation on other specific diarrheal pathogens has not been completely clarified.

4.3.2. MALARIA

Vitamin A supplementation may reduce the morbidity of *Plasmodium falciparum* malaria. *P. falciparum* causes an estimated 1–2 million deaths worldwide each year. A recent randomized, placebo-controlled clinical trial was conducted in Papua New Guinea to examine the effects of vitamin A supplementation, 60 mg RE every 3 mo, on malarial morbidity in preschool children (485). Children between 6 and 60 mo of age were randomly allocated to receive vitamin A or placebo every 3 mo. A weekly morbidity surveillance and clinic-based surveillance were established for monitoring acute malaria, and children were followed for 1 yr. Vitamin A significantly reduced the incidence of malaria attacks by about 20–50% for all except extremely high levels of parasitemia. Similarly, vitamin A supplementation reduced clinic-based malaria attacks, which consisted of self-solicited visits to the clinic by mothers who thought that their children should be seen because of fever. Vitamin A supplementation had little impact in children under age 12 mo and greatest effect from 13 to 36 mo of age.

4.3.3. HIV INFECTION

Vitamin A supplementation may have some benefit for HIV-infected children and pregnant women in developing countries. Low plasma or serum concentrations of vitamin A or intake of vitamin A has been associated with increased disease progression, mortality, and higher mother-to-child transmission of HIV (486). Periodic high-dose vitamin A supplementation seems to reduce morbidity among children born to HIV-infected mothers (487) and diarrheal disease morbidity in HIV-infected children after discharge from the hospital for acute lower respiratory infection (488). A recent controlled clinical trial in Uganda shows that periodic high-dose vitamin A supplementation, 30 RE every 3 mo, reduces morbidity and mortality of HIV-infected children (489). A study in Malawi, which used vitamin A supplementation, 10,000 IU/day, found no increased risk of mother-to-child transmission of HIV, and in fact, the results were suggestive that vitamin A was protective against late mother-to-child transmission of HIV through breastfeeding (490). Vitamin A supplementation does not appear to influence HIV load in the blood (491).

4.3.4. TUBERCULOSIS

Although malnutrition and vitamin A deficiency seem to be major risk factors for the progression of tuberculosis, clinical management usually involves chemoprophylaxis and chemotherapy alone. Cod-liver oil, a rich source of vitamins A and D, has been a standard treatment for tuberculosis in the past. The role of nutrition and tuberculosis remains a major area of neglect, despite the promise that micronutrients have shown as therapy for other types of infections and the long record of the use of vitamins A and D for treatment of pulmonary and miliary tuberculosis in both Europe and the United States. High-dose vitamin A supplementation may reduce the morbidity of tuberculosis in children (492). A recent placebo-controlled trial from Indonesia suggests that daily supplements of vitamin A and zinc given to adults with pulmonary tuberculosis improves the lesion area observed on chest radiograph after 2 mo of tuberculosis chemotherapy, but not at 6 mo follow-up (493). Vitamin A and zinc were associated with earlier clearance of tubercle bacilli from sputum, but no effects were observed on the number of cavities, the surface area of cavities, hemoglobin concentrations, or different anthropometric indicators of nutritional status (493). Studies have not been conducted which address the use of multivitamins and minerals or vitamins A plus D as adjunct therapy for tuberculosis.

4.3.5. INFECTIONS IN PREGNANT AND LACTATING WOMEN

Weekly vitamin A or beta carotene supplementation appeared to reduce the risk of infectious disease morbidity and mortality among pregnant women in Nepal, suggesting that vitamin A status may be important in pregnancy-related morbidity and mortality (494,495). Vitamin A or β -carotene reduced all-cause mortality, and further work is needed to both replicate these findings and to determine the types of infections that might be reduced through improving vitamin A status during pregnancy. The recent trial in Nepal is consistent with two earlier trials from England that showed vitamin A supplementation reduced the morbidity of puerperal sepsis (496,497).

4.4. Growth Retardation

Growth retardation is common among children in developing countries and is considered the best global indicator of physical well-being in children (498). It has long been known that vitamin A-deficient animals exhibit growth failure. Retinoic acid is known to regulate growth hormone gene expression (499). In Indonesia, children with xerophthalmia had reduced linear and ponderal growth (500). Clinical trials show that vitamin A supplementation has an impact on growth, but these effects are strongest in children with more severe vitamin A deficiency (501). In a trial from Aceh, Indonesia, periodic high-dose vitamin A supplementation was associated with greater ponderal growth among boys but not girls (502). In West Java, Indonesia, children in program villages that received vitamin A-fortified MSG had greater linear growth than children from villages without the fortified product (503). Another trial from central Java showed that vitamin A supplementation improved linear growth among preschool children (504). Vitamin A supplementation did not have a significant effect on growth among preschool children with mild to moderate vitamin A deficiency in South India (505). Vitamin A supplementation appeared to have greatest effect on weight gain in children during the season in which intake of vitamin A-rich foods was lowest and infectious disease morbidity was the highest (506). In Tanzania, vitamin A supplementation improved linear and ponderal growth among

infants with HIV infection and malaria, respectively, and reduced the risk of stunting associated with persistent diarrhea (507). It should be noted that in most clinical trials of vitamin A supplementation, children with night blindness and/or Bitot spots were excluded from participation and treated with vitamin A. Some trials also excluded children with severely malnourished children. Thus, analyses of the effect of vitamin A supplementation on child growth from large clinical trials have been limited to children with less severe vitamin A deficiency.

4.5. Anemia

Anemia is commonly associated with vitamin A deficiency and its pathogenesis appears to be multifactorial, related to both the anemia of infection and impairment of iron metabolism.

4.5.1. HISTORICAL BACKGROUND

In the 19th century, it was recognized that anemia often occurred in individuals with night blindness, and this observation led some clinicians to conclude that anemia was among the underlying causes of night blindness (508–511). The administration of cod-liver oil, a potent source of vitamin A, was widely used to treat anemia in the 19th century (512–514). Animal and human studies in the early 20th century suggested that vitamin A deficiency was related to abnormalities of hematopoiesis and iron metabolism. Vitamin A-deficient rats developed areas of gelatinous degeneration in the bone marrow (515) or a reduction in hematopoietic cells in bone marrow (87). Hemosiderosis of the liver and spleen were described in autopsy studies of vitamin A-deficient infants (368), thus linking vitamin A deficiency to abnormalities of iron metabolism. The association between vitamin A deficiency and anemia was often described (280,516–518), and it was observed that vitamin A therapy increased hemoglobin concentrations in humans (519–520).

In 1940, Karl-Heinz Wagner (b. 1915) at the University of Leipzig noted that adults who were given an experimental vitamin A-deficient diet for 6 mo developed low hemoglobin and hematocrit (521). In England, 16 conscientious objectors were given a vitamin A-free diet of varying duration from 11 to 24 mo (522). Although no data were presented, the authors report no apparent abnormalities in hemoglobin, and it is notable that subjects on the vitamin A-free diet received red meat, a rich source of heme iron, throughout the study. Vitamin A deficiency in the rat (523,524) and dog (525) was associated with anemia. The provision of vitamin A to deficient rats resulted in a rapid rise in hemoglobin, leading one group of investigators to conclude: “blood regeneration cannot take place without the presence of vitamin A” (526). Vitamin A-deficient pony fillies developed decreased hematocrit and red blood count compared to control animals (527), and vitamin A-deficient rhesus monkeys developed moderate to severe anemia that was correctable with vitamin A treatment (528). Lower hemoglobin concentrations were found in chicks fed a vitamin A-deficient diet compared with controls (529). Experimental vitamin A deficiency was also associated with an increase in hemoglobin and hematocrit (523,530–532), a contrasting effect attributed to hemoconcentration and abnormalities of water metabolism during the later stages of vitamin A deficiency (532,533).

In 1978, Hodges and colleagues reported the impact of vitamin A deficiency on hematopoiesis in humans (534). Eight middle-aged men were given vitamin A-deficient diets of either (1) a liquid casein formula virtually devoid of vitamin A, (2) a solid diet of soy

protein, selected vegetables, bread, and desserts, all low in vitamin, and (3) a diet composed of regular foods low in vitamin A. The vitamin A depletion time ranged from 359 to 771 d, with a slow decrease in plasma retinol noted over the depletion period. All men received 18–19 mg of iron daily, but mild anemia occurred which was associated with the drop in plasma retinol. Plasma retinol concentrations of >1.05 , 0.70 – 1.05 , and <0.70 $\mu\text{mol/L}$ were associated with mean hemoglobin concentrations of 156 ± 5 , 129 ± 10 , and 118 ± 7 g/L, respectively ($p < 0.01$). Repletion of vitamin A-deficient subjects with either β -carotene or vitamin A was associated with a rise in hemoglobin concentrations. This study provided an important demonstration of the effect of vitamin A deficiency on anemia in humans and provided much stimulus for the laboratory and epidemiological investigation of anemia and vitamin A deficiency of the last two decades.

4.5.2. EPIDEMIOLOGY OF THE ANEMIA OF VITAMIN A DEFICIENCY

A close association between vitamin A deficiency and anemia has been shown in many nutritional surveys from around the world, and perhaps this is not surprising, given the widespread prevalence of nutritional anemia and vitamin A deficiency in developing countries (535). Most of these epidemiological surveys did not identify the underlying causes of anemia, and often the proportion of subjects with concurrent vitamin A deficiency and anemia are not stated. The surveys generally demonstrate that there is often a high prevalence of vitamin A deficiency and anemia in the same population. The food sources that protect against respective nutritional anemia and vitamin A deficiency overlap somewhat, i.e., some green vegetables, liver, but in general do not coincide a great deal, thus, it is reasonable to expect that populations at risk of these two nutritional problems would differ.

From 1954 to 1968, more than 30 nutritional and medical surveys were conducted around the world using methods developed by the Interdepartmental Committee on Nutrition for National Defense (ICNND) (106,534). In the nutrition survey from Paraguay, hemoglobin and plasma retinol concentrations were highly correlated, with a correlation coefficient of 0.90 (536). Pooled data from surveys conducted in Vietnam, Chile, Brazil, Uruguay, Ecuador, Venezuela, Guatemala, and Ethiopia showed a high correlation ($r = 0.77$, $p < 0.0001$) between hemoglobin and plasma retinol concentrations (534). A correlation between hemoglobin and plasma or serum retinol concentrations has been described in many studies, including studies of preschool children from Pakistan ($r = 0.38$, $p < 0.0001$) (537), school-aged children in Central America ($r = 0.21$, $p < 0.05$) (538), school-aged children from Bangladesh ($r = 0.31$, $p < 0.001$) (539), children in India ($r = 0.52$, $p < 0.001$) (540), adolescent girls in Malawi ($r = 0.16$, $p = 0.08$) (541), and older adults in Vienna ($r = 0.56$, $p < 0.001$) (542). During the second trimester of pregnancy, pregnant women in Malawi had a correlation between plasma vitamin A and hemoglobin concentrations ($r = 0.26$, $p < 0.0001$) (Semba et al., unpublished data). In Honduras, 15.5% of children in a national survey had both vitamin A deficiency and anemia (543).

Several clinical trials or intervention studies have been conducted that assessed the impact of improved vitamin A status on hemoglobin and anemia. The impact of improving vitamin A status through fortification was addressed in a community-based trial in Indonesia by Muhilal and colleagues (503). Villages were randomly allocated to receive either unfortified MSG or vitamin A-fortified MSG for 5 mo. In the villages receiving fortified and unfortified MSG, mean hemoglobin concentrations of preschool children changed by $+10$ g/L and -2 g/L, respectively. In a controlled trial of iron, vitamin A, or vitamin A

plus iron administration to anemic children aged 1–8 yr, vitamin A supplementation significantly increased hemoglobin, hematocrit, serum iron, and percent transferrin saturation, but had no apparent effect on total iron binding capacity or serum ferritin (544).

In northeast Thailand, children who received high-dose vitamin A, 60 mg RE, had higher serum iron and percent transferrin saturation compared with control children at 2 mo postsupplementation, but these differences disappeared by 4 mo postsupplementation (545). Further investigation involving school children with conjunctival xerosis showed that children who received 60 mg RE vitamin A had a significant increase in hemoglobin, hematocrit, serum iron, and percent transferrin saturation at 2 wk following supplementation, whereas no changes in these indicators occurred in the control group (546). In a controlled, clinical trial involving preschool children in Indonesia with clinical and subclinical vitamin A deficiency, vitamin A supplementation, 60 mg RE, was associated with a significant increase of 21 g/L hemoglobin and a significant increase in plasma ferritin among those children who were anemic at enrollment (547). A recent study among anemic school children in Tanzania showed that daily vitamin A supplementation was associated with an increase in hemoglobin of 13.5 g/L at 3 mo following enrollment, and a larger increase of 22.1 g/L was observed in children who received both vitamin A and iron (548).

In a study conducted in Bangladesh, women of childbearing age were randomly allocated to receive iron, vitamin A plus iron, or vitamin A plus iron and zinc (549). Significant increases in hemoglobin were observed only among women who received vitamin A, iron, and zinc. The lack of an effect of vitamin A alone on hemoglobin was attributed to the relative lack of vitamin A deficiency among women in this population. In two parallel clinical trials involving 120 HIV-infected and 120 HIV-negative adult, injection drug users in Baltimore, Maryland, two consecutive doses of vitamin A, 60 mg RE, had no impact on hemoglobin concentrations (Deloria-Knoll et al., unpublished data). In this population, HIV-positive and HIV-negative subjects had a low prevalence of anemia and vitamin A deficiency, and the lack of an effect might also be attributed to the relative lack of anemia and vitamin A deficiency in this population.

Studies conducted among pregnant women suggest that vitamin A supplementation alone during pregnancy can increase hemoglobin concentrations (550). In West Java, Indonesia, 251 anemic pregnant women were randomly allocated to receive iron, 60 mg/d, vitamin A, 2.4 mg RE/d, iron, 60 mg/d plus vitamin A, 2.4 mg RE/d, or placebo for 8 wk. After supplementation, the proportion of women who were not anemic in the iron, vitamin A, vitamin A plus iron, and placebo groups was 68%, 35%, 97%, and 16%, respectively. Other studies have also explored the use of vitamin A combined with iron and or folate (551,552). In a population with a high prevalence of iron deficiency anemia, weekly vitamin A supplementation reduced anemia by 9% during pregnancy and postpartum compared with controls. A study conducted in Tanzania suggests that daily multivitamins, but not 30 mg of β -carotene per day, increased hemoglobin concentrations among HIV-positive pregnant women (553). In Indonesia, pregnant women who received weekly vitamin A and iron supplementation had a greater increase in hemoglobin than women who received weekly iron or daily iron (554). There was an accompanying decrease in serum ferritin among women who received vitamin A and iron, suggesting to the investigators that vitamin A supplementation increased the utilization of iron for hematopoiesis.

4.5.3. PATHOPHYSIOLOGY

There are many potential biological mechanisms by which vitamin A deficiency could cause anemia. These mechanisms fall into three general categories: (1) modulation of erythropoiesis, (2) modulation of immunity to infectious diseases and the anemia of infection, and (3) modulation of iron metabolism. There is probably some overlap between these mechanisms, as erythropoiesis and iron metabolism are modulated by infection.

Erythropoiesis. The process of red blood cell formation involves the differentiation of pluripotent stem cells into multipotent (CFU-GEMM) cells, and differentiation and commitment of CFU-GEMM into BFU-E and then into CFU-E (555). Development of BFU-E into erythroblasts requires stem cell factor (SCF), GM-CSF, or IL-3 and erythropoietin. Development of CFU-E into proerythroblasts requires erythropoietin alone (556). Proerythroblasts mature through several stages to orthochromatic erythroblasts, at which stage the nucleus undergoes pyknotic degeneration, and after the nucleus is extruded, the cell is known as a reticulocyte. Hemoglobin synthesis occurs during the differentiation of CFU-E into erythrocyte precursors (557) and continues until the reticulocyte matures into a mature erythrocyte (558). Reticulocytes are released from the bone marrow about 18 to 36 h prior to final maturation into erythrocytes. Control of erythropoiesis is regulated by erythropoietin, a 34-kDa glycoprotein that is produced by the renal cortical cells in response to hypoxia, and erythropoietin induces erythroid progenitor cells to differentiate into proerythroblasts (559). In the erythrocyte lineage, CFU-E have the highest density of erythropoietin receptors on their surface and depend on erythropoietin for their survival (560).

Retinoids and erythropoiesis. The effects of retinoids on erythroid progenitors has been studied in CD34⁺ hematopoietic progenitor cells, which consist of a heterogeneous population of CFU-GEMM, BFU-E, and CFU-E, and in CD36⁺ cells, which consist of intermediate and late erythroid progenitors (late BFU-E and CFU-E) in purified erythrocyte systems (561,562). All-*trans* retinoic acid was shown to stimulate human BFU-E colony formation, suggesting that retinoids were involved in erythropoiesis (563). All-*trans* retinol did not enhance growth of erythroid progenitors in this in vitro culture system that involved fetal calf serum, a rich source of vitamin A (563). Subsequent studies using progenitor cells from human peripheral mononuclear cells in serum free media showed that both retinyl acetate and all-*trans* retinoic acid stimulated d16 (early) erythroid colonies, and a synergism was noted between retinoids, erythropoietin, and insulin-like growth factor (IGF)-I (564). The impact of retinoids on erythropoiesis is complex and depends on the stage of erythrocyte development (565).

Retinoids appear to regulate apoptosis, or programmed cell death, in erythropoietic progenitor cells, but the nature of this interaction may be bidirectional (566). All-*trans* retinoic acid appear to stimulate the survival of purified CD34⁺ cells obtained from mid-trimester fetal blood (567). In CD34⁺ hematopoietic progenitor cells isolated from normal adult human bone marrow, all-*trans* retinoic acid induced apoptosis of CD34⁺ cells and CD34⁺CD71⁺ cells stimulated with erythropoietin (568). By using selective ligand agonists, it was noted that both RARs and RXRs were involved in retinoic acid-mediated apoptosis of erythroid progenitor cells. The effects of retinoids on hematopoiesis are complex and depend on culture conditions, maturation stage of the cells, and cytokines used for stimulation. Whether vitamin A status in humans has any influence on apoptosis

of erythropoietic progenitor cells has not been determined. Many studies have shown that vitamin A supplementation increases hemoglobin concentrations. Whether retinol, all-*trans* retinoic acid, and related retinoids mediate their effects in vivo on erythroid progenitor cells is not known.

Modulation of erythropoietin production by retinoids. The 3'-enhancer region for the erythropoietin gene contains a sequence homologous to DR-2, a steroid-responsive element that appears to be regulated by retinoic acid (569). In vitamin A-depleted rats, intragastric administration of all-*trans* retinoic acid was associated with an increase in serum erythropoietin concentrations within 4 h of dosing, but within 24 h, serum erythropoietin concentrations returned to original levels (569). Vitamin A, but not vitamin E or vitamin C, was shown to have a dose-related effect on the production of erythropoietin in human hepatoma cell lines HepG2 and Hep3B (570). Experimental observations of the modulation of erythropoietin by vitamin A have currently been limited because a renal cell culture model has not been established, and current in vitro models utilize human hepatoma cell lines. Alternatively, modulation of erythropoietin production by vitamin A has been studied in isolated, perfused rat kidneys, and perfusion with vitamin A or the antioxidant desferrioxamine was shown to increase renal erythropoietin synthesis (571). Regulation of erythropoietin gene expression appears to involve both hypoxia and reactive oxygen species (572). Studies in embryonal carcinoma cells suggest that retinoic acid stimulates erythropoietin gene transcription in an oxygen-dependent manner (573).

Recently, a clinical trial was conducted to determine whether vitamin A supplementation would modulate plasma erythropoietin concentrations in pregnant women in Malawi (574). Two hundred three women in the second trimester of pregnancy were randomly allocated to receive daily vitamin A (3 mg RE), iron (30 mg), and folate (400 µg) vs iron (30 mg) and folate (400 µg) (control). At enrollment, 50% of the women were anemic (hemoglobin <110 g/L). Mean (SD) change in hemoglobin from enrollment to 38 wk was 5 <12 g/L ($p = 0.003$) and 7 <16 g/L ($p = 0.003$) in the vitamin A and control groups, respectively. There were no significant differences between vitamin A and control groups in the slope of the regression line between \log_{10} erythropoietin and hemoglobin at enrollment or 38 wk, and between enrollment and follow-up within either group. We concluded from this trial that vitamin A supplementation did not influence erythropoietin production and is not a biological mechanism by which vitamin A modulates anemia.

The anemia of infection. The anemia of infection refers to the anemia observed in individuals in the setting of chronic infection, and it is considered a syndrome within the broader category of the "anemia of chronic disease" (575) or "anemia of inflammation." The anemia of infection is a hypoproliferative anemia in which hypoferrremia is found despite adequate reticuloendothelial iron stores, and the anemia is usually normocytic and normochromic. HIV infection (576) and tuberculosis (577) are two well-known causes of the anemia of infection. Anemia is also common in children with acute infections (578). Inflammatory cytokines, such as TNF- α , IL-1, and IFN- γ have been implicated in the anemia of infection, as they appear to interfere with erythropoiesis (579). TNF- α and IFN- γ also appear to induce hypoferrremia and increase ferritin production (580). Human recombinant TNF- α inhibited CFU-E from bone marrow mononuclear cells but not CFU-E generated from human peripheral mononuclear cells, suggesting that TNF- α inhibited CFU-E through an accessory cell in bone marrow, and marrow fractionation studies suggested that a bone marrow stromal cell was responsible for the inhibitory effects of TNF- α on

CFU-E (581). Hepcidin, the recently discovered iron regulatory hormone, plays a role in the anemia of inflammation (582), and its relationship to the anemia of vitamin A deficiency has not been elucidated.

Other biological mechanisms that may contribute to the anemia of infection include shortened red cell survival, impaired erythropoietin production in response to anemia, inhibited response of erythroid progenitors to erythropoietin, and increased apoptosis of erythroid progenitors (575). Iron mobilization from reticuloendothelial iron stores is reduced during the anemia of infection, and decreased serum iron in the setting of infection is well known and implicated in the host response against infection (583). As described later, decreased mobilization of iron from the liver and spleen also occurs during vitamin A deficiency, and it is not entirely clear whether the same phenomenon during the anemia of infection is related (535). Although it has been hypothesized that vitamin A may modulate the acute phase response, and thus, RBP and transferrin, a controlled clinical trial in Indonesia did not show any effect of vitamin A supplementation, 60 mg RE, on acute phase proteins (α_1 -acid glycoprotein and C-reactive protein) when given to preschool children with clinical and subclinical vitamin A deficiency (584).

Vitamin A and iron metabolism. There are several lines of evidence to show that vitamin A modulates iron metabolism (585). In experimental animal models, vitamin A deficiency increased iron concentrations in the liver (529,533,586–588), spleen (533,589), and femur (587). During vitamin A deficiency, iron absorption appeared to be enhanced (588,589) and bone marrow uptake of iron impaired (588). In vitamin A-deficient rats, the incorporation of ^{59}Fe in erythrocytes was reduced by 40–50% compared with control animals, suggesting that during vitamin A deficiency, iron is trapped in the liver and spleen and not effectively released for erythropoiesis by bone marrow (533,590). Vitamin A repletion in deficient rats stimulated the utilization of iron stores in spleen and bone (591). Vitamin A deficiency did not affect the osmotic fragility of erythrocytes in vitamin A-deficient rats, providing some evidence against increased hemolysis as a mechanism for anemia during vitamin A deficiency (590), and recent studies show that erythropoiesis and erythrocyte turnover were not affected by mild vitamin A deficiency in rats (592).

Poor vitamin A status has been associated with low iron binding capacity and percent transferrin saturation (545,593) but not low circulating transferrin concentrations (593). Iron metabolism was examined in a large study of preschool children, aged 1–5 yr, before and after a program of vitamin A-fortified sugar (594). Two years after vitamin A fortification, indicators of iron status, such as serum iron, percent transferrin saturation, and ferritin concentrations increased. A recent study suggests that gut integrity in infants, as measured by urinary lactulose:mannitol excretion test, is influenced by vitamin A supplementation (595), and these findings suggest another mechanism by which vitamin A status could affect the absorption of nutrients involved in erythropoiesis. In studies using cereal-based diets with labelled ^{59}Fe or ^{55}Fe , both vitamin A and β -carotene enhanced the absorption of nonheme iron in human adults (596).

4.6. Other

Skin lesions and renal calculi were once considered to be a clinical manifestation of vitamin A deficiency, but no causal association has been demonstrated between vitamin A deficiency and these two conditions.

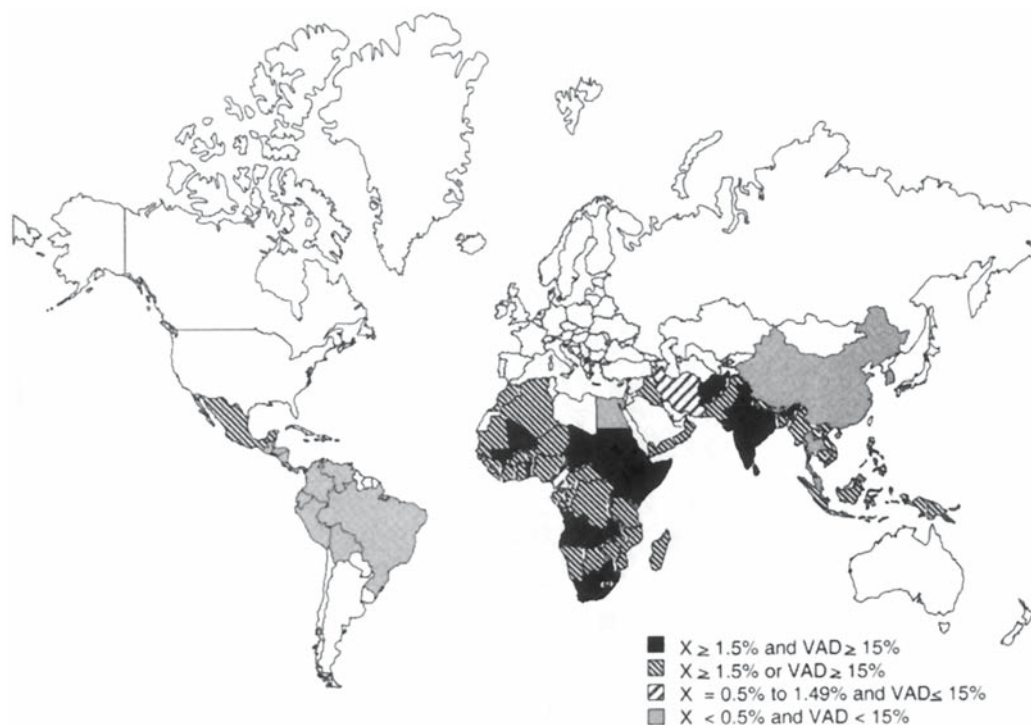


Fig. 15. Geographic distribution of vitamin A deficiency worldwide (World Health Organization). (Reprinted from ref. 601, with permission of the American Society for Nutritional Sciences.)

5. EPIDEMIOLOGY

5.1. Prevalence and Incidence

Worldwide, there are an estimated 140 million preschool children and 7.2 million pregnant women who have vitamin A deficiency (597). In low-income countries worldwide, there are an estimated 453,000 children with blindness or severe visual impairment, and 200,000 have corneal scarring attributed mostly to measles and vitamin A deficiency (2). There is a close synergism between measles and vitamin A deficiency that can result in blindness, and of an estimated 30 million children who develop measles each year, there are an estimated 15,000–60,000 children who become blind (598). Others have suggested that there may be about 350,000 children who go blind from vitamin A deficiency annually (599).

5.2. Global Distribution

The prevalence of vitamin A deficiency is higher in developing countries in southeast Asia, south Asia, east Asia and the Pacific region, sub-Saharan Africa, the Middle East, northern Africa, and Central and South America (Fig. 15) (600,601). Vitamin A deficiency is considered a public health problem in about 78 countries worldwide, and the geographical distribution of vitamin A deficiency follows the same general pattern as for poverty, malnutrition, and greater burden of infectious diseases such as diarrheal disease and malaria. Vitamin A deficiency is often defined as a public health problem based on any of the following criteria among children aged less than 6 yr: (1) prevalence of night

blindness >1.0%, (2) prevalence of Bitot spots >0.5%, (3) prevalence of corneal xerosis and/or ulceration >0.01%, (4) prevalence of xerophthalmia-related corneal scars >0.05% (600). Supportive biochemical evidence of deficiency is a prevalence of serum retinol <0.35 $\mu\text{mol/L}$ in >5% (600).

In the following section, the prevalence of vitamin A deficiency is described in studies from selected countries where there is sufficient data in the published scientific literature. Many surveys of vitamin A deficiency have appeared as internal or local government reports and not in the scientific literature, and many reports up to 1995 have been summarized by WHO (600). The quality of survey design ranges from rigorous population-based cluster sampling to convenience samples. For some countries, there has been little published in the scientific literature within the last decade, and in some cases, prevalence data are available before and after the implementation of vitamin A programs. The existence of programs to improve vitamin A status, especially through high-dose vitamin A capsule distribution, is also described in this section where data are available, as vitamin A programs have generally had a demonstrable impact on the prevalence of vitamin A deficiency in many countries. Although some developing countries have officially adopted a national policy of vitamin A capsule distribution, the extent of implementation and coverage can vary considerably.

5.2.1. SOUTHEAST ASIA

Cambodia. The first national survey to assess the prevalence of vitamin A deficiency in Cambodia was conducted in 2000 by Helen Keller International (602,603). The prevalence of xerophthalmia among children aged 18–60 mo was 0.7% (602), and the prevalence of xerophthalmia among nonpregnant women was 2% (603). The survey revealed that high-dose vitamin A supplementation was reaching 10–55% of children aged 6–59 mo and 1–13% of postpartum women. The government of Cambodia integrated high-dose vitamin A capsule distribution into national immunization days for polio in 1996 (694).

Vietnam. The prevalence of xerophthalmia has declined in Vietnam since the mid-1980s. In a survey in 1985 of 14,238 preschool children in the Hanoi region and the provinces of Vinh Phú, Hà Nam Ninh, Hà Sơn Bình, and Hải Phòng, the overall prevalence of xerophthalmia was 0.78%. Active corneal xerophthalmia was found in 0.08%, and 0.13% of children had corneal scarring from xerophthalmia (605). In 1984, a study of 2207 preschool children in Hoang Thi Luy, Ngo Nhu, and Phan Ke Ton and the vicinity of Ho Chi Minh City showed that 0.24% had night blindness, 0.13% had Bitot spots, 0.13% had corneal xerosis, and 0.27% had corneal scarring (606). In the Vietnam National Blindness Survey conducted 1985–1988, of 34,214 preschool children, 0.37% had night blindness, 0.16% had Bitot spots, 0.07% had corneal xerosis, and 0.12% had corneal scarring (607). A program of high-dose vitamin A capsule distribution commenced in Vietnam in 1988 (607). The program started in seven pilot districts and expanded to all communes of the country by 1993 (607). By 1994, when the National Vitamin A Deficiency survey was conducted in 25 provinces, of 37,920 preschool children, 0.05% had night blindness, 0.045% had Bitot spots, 0.005% had corneal xerosis, and 0.048% had corneal scarring (607). The 1994 survey was conducted 2 mo following the July 1994 round of universal high-dose vitamin A capsule distribution to preschool children, and the coverage of preschool children was nearly 94% (607). Surveys conducted since the 1980s show a clear reduction in the prevalence of clinical vitamin A deficiency among

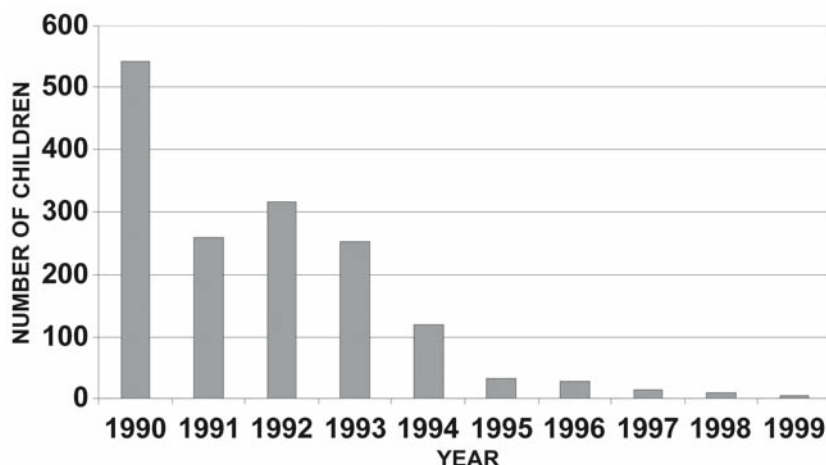


Fig. 16. Temporal decrease of admissions for xerophthalmia in Vietnam. (Adapted from ref. 608.)

preschool children. The number of children with xerophthalmia who were admitted to the main hospitals in Vietnam has decreased greatly from 1990 to 1999 (Fig. 16) (608).

Laos. A survey conducted in 1995 of 3376 children aged 0–71 mo and 680 mothers in 17 provinces showed that night blindness occurred in 0.7% of children aged 24–71 mo and in 5.4% of lactating women (609). Night blindness was found in 11.5% of pregnant women (609).

Thailand. A survey conducted in northeastern Thailand in 1985 showed a prevalence of night blindness of 1.3% and of Bitot spots of 0.4% among preschool children (610). An estimated 20% of preschool children had subclinical vitamin A deficiency in north and northeast Thailand in a survey that used conjunctival impression cytology and relative dose response (RDR) to measure vitamin A deficiency (611). Screening indicators have been used to identify areas at risk for vitamin A deficiency in Thailand (611). A survey of 178 preschool children from three rural villages in Chiang Mai province showed that 14% had serum retinol concentrations $<0.70 \mu\text{mol/L}$ (613). A study of 262 lactating women in rural Chiang Mai province in 1999 showed that 73.6% had breast milk retinol concentrations $<1.05 \mu\text{mol/L}$ (614).

Malaysia. There have been reports of xerophthalmia in Malaysia since the 1920s, but the prevalence of clinical vitamin A deficiency declined by the 1970s (615). A survey among more than 200 aborigine children under age 15 yr in Perak, Malaysia showed that night blindness occurred in 16% and Bitot spots in 2.8% (616). A recent survey by the government and UNICEF suggested that less than 5% of 400 children under age 5 yr had serum retinol levels $<0.70 \mu\text{mol/L}$ (615).

Singapore. Vitamin A deficiency is not a public health problem in Singapore, which is among the countries with the highest standards of living in the world. It is notable that keratomalacia was once present and showed a steady decrease in incidence since World War II (617).

Myanmar. The government of Myanmar began a program of high-dose vitamin A capsule distribution in 1996 (618).

Indonesia. As noted previously, vitamin A deficiency has been recognized as a serious problem in Indonesia since the 1900s (110–115,619). High-dose vitamin A capsule dis-

tribution was introduced in Indonesia in 1971, and an evaluation of capsule distribution by the Indonesian government in 1972–1973 showed that the prevalence of Bitot spots was reduced in children that received capsules (620). The Ministry of Health began more expanded distribution of high-dose vitamin A capsules to preschool children in 1973, and the number of children who received capsules increased from about 74,000 in 1973–1974 to nearly 1 million in 1982–1983. A national survey for vitamin A deficiency was conducted in 1977–1978 (285). The prevalence of Bitot spots was as high as 2.4% in Aceh and 2.0% in Ambon, and overall, the prevalence of Bitot spots was 1% (621). A national survey in 1992 showed that the prevalence of active xerophthalmia declined by 75% and active corneal disease declined by 95% since the 1977–1978 survey (622). Similarly, admissions for xerophthalmia at Cicendo Eye Hospital in Bandung showed a large decline from 1981 to 1992 (623).

5.2.2. SOUTH ASIA

Pakistan. A survey of 532 children, aged 6–60 mo, from the slums of Karachi showed that inadequate dietary intake of vitamin A and subclinical vitamin A deficiency were common (624).

Surveillance for xerophthalmia in hospitals of northwest Pakistan revealed 76 children with blinding xerophthalmia in 12-mo period between 1996 and 1997 (625). Serum vitamin A concentrations have been described in preschool children in Pakistan (626).

India. A survey of vitamin A deficiency was conducted among 164,512 children less than 6 yr old in 16 districts of 11 states in India from 1997 to 2000 and showed the highest prevalence of night blindness and Bitot spots of 5.17% and 4.71%, respectively, in Gaya district (627). In Dibrugarh district, 19.62% of pregnant women reported having night blindness (627). The prevalence of Bitot spots was 1.8%, 0.7%, and 0.7% based on pooled data from seven states from surveys conducted in 1975–1979, 1988–1990, and 1996–1997 (628). A study of 308 children under age 6 yr showed that 35.7% had abnormal impression cytology that was suggestive of subclinical vitamin A deficiency (629).

Bangladesh. Xerophthalmia was recognized in the early 1970s to be the leading cause of blindness among children (630). Vitamin A capsule distribution was initiated in 1973, with periodic dosing given through the Bangladesh Programme for the Prevention of Blindness. A national survey conducted in 1982–1983 showed that vitamin A deficiency was a major public health problem in areas of Bangladesh (630). In 1991, vitamin A capsules were distributed to infants at the time of childhood immunization contacts and also on national immunization days (631). A national survey conducted in 1997–1998 showed that the prevalence of night blindness among preschool children decreased from 3.76% in 1982–1983 to 0.66% (631).

Nepal. Xerophthalmia is a major cause of childhood blindness in Nepal (632). In 1989–1991, at baseline in an intervention trial in Sarlahi, an area in lowland Nepal, 2.8% of 4318 preschool children had xerophthalmia (633). Xerophthalmia has been described in 3–13.2% of preschool children in various parts of Nepal in the early 1990s (600).

Bhutan. Nutritional surveys conducted in the 1980s showed on the basis of prevalence of xerophthalmia and serum retinol levels that vitamin A deficiency was a significant public health problem (600).

Sri Lanka. The average prevalence of Bitot spots in a national survey in 1987 was 0.3%, with some districts showing a higher prevalence (600).

5.2.3. EAST ASIA AND PACIFIC

Mongolia. A survey in 1992 showed that of 1679 children, 0.8% had Bitot spots (634). Of 576 children, aged 7–72 mo, seen in Ulaanbaatar and nine aimags (provinces) in 1998, night blindness was found in 0.16% and 19.8% had serum retinol concentrations <0.70 $\mu\text{mol/L}$ (634).

Philippines. A survey in Quezon, Northern Samar, and Zamboanga del Sur provinces of 11,378 children, aged 6–83 mo, showed that 1.6–4.4% had night blindness and 0.6–2.7% had Bitot spots (635). In Mindanao, a survey of 248 preschool children in a rural area near Davao City showed that 29% had serum retinol <0.70 $\mu\text{mol/L}$ (636). In 1993, a national nutrition survey showed that vitamin A deficiency was a public health problem among children and pregnant and lactating women (637). Country-wide distribution of high-dose vitamin A capsules to children aged 12–59 mo began in 1993 and continued semiannually for 6 yr (638). A national nutrition survey conducted in 1998 showed that low plasma retinol concentrations were common among preschool children and pregnant and lactating women, despite the presence of high-dose vitamin A capsule distribution programs (637). In 1999, vitamin A capsule distribution was integrated with health care services for children aged 0–59 mo that included immunization, deworming, dental hygiene, and other child health issues (638).

Solomon Islands. A survey conducted in 1991 in Guadalcanal, Western Province, and Malaita of children aged 6–72 mo showed that 0.52% had night blindness and 1.42% had Bitot spots (639). Vitamin A initiatives are currently be conducted through the Solmon Islands Development Trust.

Kiribati. Vitamin A deficiency was common in Kiribati (640). In 1989, a survey of 4617 children, aged 6–72 mo, showed that 8.16% had nightblindness and 11.12% had Bitot spots (639,641). Since the time of the survey, a national vitamin A capsule distribution program, nutrition education, and home gardening projects were implemented (641).

Cook Islands. A survey conducted in 1992 of 338 children, aged 6–72 mo, showed that night blindness occurred in 0.59%. No Bitot spots were found (639).

Tuvalu. A survey of 1053 children, aged 6–72 mo, conducted in 1991 showed that 0.19% had night blindness and 0.09% had Bitot spots (639).

Vanuatu. In 1991, a survey of 1785 children, aged 6–72 mo, showed that nightblindness and Bitot spots occurred among 0.06% and 0.06%, respectively (639).

Republic of the Marshall Islands. A survey conducted among 919 preschool children, aged 1–5 yr, in 1994 showed that 59.9% had serum retinol concentrations <0.70 $\mu\text{mol/L}$ (642). A nationwide vitamin A capsule distribution program has been adopted, but sporadic cases of xerophthalmia are still found (Neal Palafox, personal communication, 2005).

Micronesia. An outpatient clinic-based study showed that nightblindness and Bitot spots were relatively common among preschool children in Moen, Truk (644). Vitamin A supplementation was begun in Chuuk and Pohnpei in 1993 and 1998, respectively (645). A survey conducted in Kosrae and Yap in 1999 showed that 63.3% and 33.8% had serum vitamin A levels ≤ 0.70 $\mu\text{mol/L}$, respectively (644).

5.2.4. SUB-SAHARAN AFRICA

Sudan. In a survey of 3461 children under age 5 yr in the eastern Sudan in 1983, the prevalence of Bitot spots was 9.5% (645). The prevalence of Bitot spots was 3.7% among children in a displaced community around Omdurman during a drought in 1986 (646).

A survey in five districts of northern Darfur in 1988 showed a prevalence of night blindness and Bitot spots of 0.52% and 0.1% among children under 6 yr of age (646). Xerophthalmia was found in 2.9% of children aged 6 to 72 mo of age in five rural areas of Khartoum and Gezira provinces in northern Sudan (647).

Ethiopia. Xerophthalmia has been recognized as a major public health problem in Ethiopia (648–651). In a national survey, conducted in 1980–1981, of 6636 children aged 6 mo to 6 yr, 1% had Bitot spots, and a prevalence of 1.6% was noted in the pastoral zone (652). A survey conducted among 14,740 school children in the Shoa region of central Ethiopia showed that 0.91% had Bitot spots (652). In Agaro in southwest Ethiopia, of 432 children, aged 6–59 mo, 4.2% had night blindness and 2.1% had Bitot spots (654). Night blindness and Bitot spots were found in 17% and 26.5% of children aged 6 mo to 6 yr in the Dodota district in central Ethiopia (655). In a survey conducted among 15,087 children, aged 6–71 mo, in Harari, Tigray, Southern National Nationalities and People Region, and Oromiya, night blindness and Bitot spots were found in 0.97% and 3.6%, respectively (656). In Jimma, southwest Ethiopia, of 628 children, aged 6–59 mo, 0.48% had Bitot spots and 0.16% had corneal scarring (657). Dietary intake of vitamin A among children was extremely low (657). In Arssi zone of Dodotana sire district, 188 preschool children and 214 school-aged children were examined for the presence of xerophthalmia. Night blindness and Bitot spots were found among 7.2% and 2.2% of the children (658).

Eritrea. In a national survey conducted in 2002, of 2131 children, aged 6–59 mo, the prevalence of night blindness and Bitot spots was 0.6% and 6.2%, respectively (659). The prevalence of corneal xerosis was 4.1% (659).

Kenya. Vitamin A deficiency was observed in Kenya as earlier as the 1920s (660) and has been periodically recognized in rural areas (661) and prisons (662). In southwestern Kenya, high household income was associated with a greater household level of dietary vitamin A consumption but not increased dietary vitamin A intake by preschool children (663). In a survey of 6435 children, aged 6–72 mo, in 14 districts of eight provinces in Kenya conducted in 1994, 1% had Bitot spots (664). Vitamin A deficiency as assessed by conjunctival impression cytology was highly prevalent among children aged 4 to 7 yr in two high-risk areas of Kenya (665). A high prevalence of vitamin A deficiency was recently described among lactating women in Kenya based on low breast milk retinol concentration (666).

Uganda. The magnitude and distribution of vitamin A deficiency have not been determined on a national level in Uganda (667). A study conducted in the 1960s suggested that serum vitamin A concentrations were low among adults attending an outpatient clinic of Mulago Hospital in Kampala (668). Xerophthalmia was a major cause of blindness among Sudanese refugees seen in Uganda (669). The Ministry of Health of Uganda adopted a policy of vitamin A capsule distribution in 2001.

Tanzania. A survey was conducted among 12,880 children in Mbeya, Iringa, and Kagera regions in Tanzania from 1983 to 1985 (670). Xerophthalmia tended to cluster in certain villages (670). Inadequate consumption of vitamin A-rich foods was noted among children with Bitot spots in rural Tanzania (670).

Congo. A survey of 415 preschool children in South Kivu province showed that 0.7% had night blindness and 19.7% had serum retinol $<0.35 \mu\text{mol/L}$ (672).

Malawi. Vitamin A deficiency was shown to be a problem of importance in the lower Shire Valley, with xerophthalmia found among 3.9% of children under the age of 6 yr

(673). In a study of 650 children aged 2–6 yr in Salima and Dedza in 1988, night blindness was found in 1.4% and Bitot spots in 0.2% (674). A national household and school-based micronutrient survey was conducted in 2001 that showed low serum retinol concentrations consistent with vitamin A deficiency among nearly 60% of young children and almost 90% of nonpregnant women (675). Vitamin A deficiency is common among lactating women in Malawi (676,677).

Zimbabwe. A survey of 207 lactating women and their infants in the Makhaza area showed that 40% of the women had serum retinol $<0.70 \mu\text{mol/L}$ and 76% had low liver stores of vitamin A (678). Vitamin A deficiency was described as a public health problem in 1991 in some districts (600).

Zambia. A study of lactating women who were bringing their children to the under five clinic in a shanty town outside of Ndola showed that 38% had serum retinol $<1.05 \mu\text{mol/L}$ (679). A study of 381 preschool and 814 school-aged children in Ndola district showed that serum retinol $<0.35 \mu\text{mol/L}$ was uncommon except in a shanty town where 22% of children had serum retinol $<0.35 \mu\text{mol/L}$ (680). Vitamin A deficiency was also common among randomly selected children, aged 7–19 mo, attending a pediatric clinic (681). A national survey showed the 65.7% of children under five and 21.5% of women had serum vitamin A levels $<0.70 \mu\text{mol/L}$, and the rates of night blindness were 6.2% and 11.6%, respectively (682).

Angola. A survey conducted in eight provinces showed that subclinical vitamin A deficiency was common among children under the age of 5 yr (683). High-dose vitamin A capsule distribution was integrated with childhood immunization days in 1999. A hospital-based record review showed that xerophthalmia remained a major cause of blindness among children in Luanda in the early 1990s (684).

Mozambique. In Mozambique, an estimated 2.3 million children under the age of 5 yr are vitamin A-deficient (685). Vitamin A deficiency was identified as a major public health in a survey of four provinces in 1998 (686). The Ministry of Health began vitamin A capsule distribution for preschool children and infants aged 6–12 mo in 1999 initially through national immunization days and through maternal and child health campaigns (687). Vitamin A capsule distribution is now integrated with routine child health services but coverage is about 45% (685).

Botswana. A national survey of micronutrient deficiencies in children and women was conducted in 1994 and showed that 35% of children aged 0–71 mo had serum retinol $<0.70 \mu\text{mol/L}$ (688).

South Africa. A national survey conducted in 1994 showed that vitamin A deficiency is an important public health problem in eight provinces (689). The national policy includes high-dose vitamin A supplementation to children aged 6–60 mo and to all mothers 6–8 wk post delivery and targeted supplementation for children with severe undernutrition, persistent diarrhea, measles, or xerophthalmia (690).

Senegal. A survey conducted among preschool children in the groundnut belt of Senegal in 1991 showed that 0.2% had Bitot spots and 11.4% had abnormal conjunctival impression cytology consistent with vitamin A deficiency (691). A high prevalence of subclinical vitamin A deficiency was described among children aged 24–48 mo in the Louga region (692).

Mali. In 1991, a survey of 207 children, aged 4–7 yr, in western Mali showed that 2% had night blindness but none had Bitot spots (693). A survey of 3032 children aged 1–4 yr

in the Djenne and Yelimane districts in 1999 showed that 0.8% and 3.2% had night blindness, respectively, and a high proportion of children had low serum retinol concentrations (694). Since 1998, vitamin A supplementation has been integrated with national immunization days, and additional coverage is provided through regional micronutrient days (695). Two cross-sectional surveys conducted in the Mopti region in 1997 (696) prior to implementation of vitamin A capsule distribution and in 1999, 4 mo after vitamin A capsule distribution, showed that the prevalence of xerophthalmia was lower in 1999 than in 1997 (697).

Mauritania. Vitamin A deficiency has been a public health problem in Mauritania (698), especially after drought seasons (699). Vitamin A deficiency was detected among children attending community health centers using conjunctival impression cytology (700).

Chad. Surveys conducted after a drought in 1984 and after a normal crop in 1985 showed that xerophthalmia was a public health problem (701).

Burkina Faso. Xerophthalmia has been described in Burkina Faso (702,703). Vitamin A deficiency was found to be a public health problem among children aged 6–14 yr in Boulgou province (704).

Niger. Serum vitamin A concentrations were low among children and pregnant and breast-feeding women from refugee camps and nearby villages in the Sahel region (705). A national survey conducted in 1988 showed that 2% of children aged 6–72 mo had night blindness. The prevalence of night blindness was high in Tera, Tillabéri, and Ouallam Provinces (600). High-dose vitamin A capsule distribution was integrated with national immunization days in 1997 (706).

Ghana. A national program of vitamin A supplementation originally distributed vitamin A capsules on National Immunization Days, and the program was expanded in 2000 to provide at least two capsules a year to preschool children (707).

Benin. A small hospital-based study showed that a high proportion of malnourished children had abnormal impression cytology consistent with vitamin A deficiency (708). Vitamin A deficiency is considered to be more prevalent in areas in the northern part of the country (600).

Cameroon. Among 135 children, aged 3–15 yr, in northern Cameroon, mean serum retinol concentrations were 0.47 $\mu\text{mol/L}$ (709). In the Central Province (forested zone) of Cameroon, 85% of 231 children, aged 6–15 yr, had serum retinol concentrations $<0.70 \mu\text{mol/L}$ (710).

5.2.5. NORTH AFRICA

Algeria. Plasma vitamin A concentrations in volunteers from schools, blood donor centers, and among hospital staff in Algeria were lower than values reported in Europe (711).

Morocco. A national survey for vitamin A deficiency in 1996 showed a low prevalence of xerophthalmia but a high proportion of children with low serum retinol concentrations (712). A study of 1453 children and 1004 women from different areas of Morocco showed that subclinical vitamin A deficiency was widespread (713). In a survey from northwest Morocco, a large proportion of children aged 6–59 mo had an inadequate intake of vitamin A (714).

Tunisia. Early case reports suggested that vitamin A deficiency was present in Tunisia (715), but vitamin A deficiency has not recently been identified as a public health problem in this country.

Egypt. Early investigations of vitamin A deficiency in Egypt were focused on serum retinol concentrations in infants with marasmus (716) and intestinal parasites (717).

A national nutrition survey conducted in 1978 showed 4 of nearly 10,000 preschool children had Bitot spots (718). In 1995, a national survey involving 1629 children, aged 6–71 mo, in 5 of the 26 governates of Egypt showed that 11.3% of the children had plasma retinol concentrations 0.35–0.70 $\mu\text{mol/L}$ and 0.6% had plasma retinol $<0.35 \mu\text{mol/L}$ (718). The prevalence of xerophthalmia was assessed among 10,664 children in the Beheira governate in 1996. The prevalence of Bitot spots ranged from 0.09% to 0.21% among children under 72 mo of age (718). In Atries, a traditional rural village north of Giza, 94% of 47 preschool children had serum retinol $<0.70 \mu\text{mol/L}$ and 65.9% had serum retinol $<0.35 \mu\text{mol/L}$ (719). Periodic high-dose vitamin A supplementation was evaluated as early as 1982 among school-aged children in Cairo (720). Consumption of vitamin A-rich plant foods was also found to increase serum retinol concentrations (721).

5.2.6. MIDDLE EAST

Jordan. Early investigations showed that blinding xerophthalmia was a major problem in Jordan in the 1960s (722), and the prevalence of xerophthalmia decreased by 1975 (600). Surveys in poor areas of Jordan show that vitamin A deficiency is still a public health problem. A high prevalence of vitamin A deficiency was described among urbanized, Bedouin children (723).

Iran. A survey conducted in four provinces in Iran among preschool and school-aged children showed that Bitot spots occurred among children in Beshagard, a remote, impoverished area (724). A survey of 1173 children, aged 24–72 mo, in Sistan and Baloochestan provinces in southeast Iran showed that inadequate dietary intake of vitamin A was common and that 0.6% of children had night blindness (725).

Yemen. A survey conducted in 1992 among 2438 children, aged 1–5 yr, in western Yemen showed that night blindness was present in 0.5%, Bitot spots in 1.7%, corneal ulceration in 0.04%, and corneal scarring in 0.04% (726).

Djibouti. A countrywide survey of the prevalence of vitamin A deficiency was conducted in 1988 (727). The prevalence of night blindness and Bitot spots among children under 6 yr of age in rural areas was 0.26% and 1.04%, respectively (727).

5.2.7. CENTRAL AND SOUTH AMERICA

Mexico. A survey conducted in 1993 of 489 preschool children showed that 4.8% of urban and 29.5% of rural children had serum retinol concentrations $<0.70 \mu\text{mol/L}$ (728).

Guatemala. A national survey conducted in 1995 of 1517 children, aged 12–59 mo, showed that 15.8% had serum retinol concentrations $<0.70 \mu\text{mol/L}$ (728). In a survey conducted in five rural hamlets in the region of Alta Verapaz, serum retinol concentrations were measured in 502 children aged 6–78 mo. Twenty-two percent of boys and 18% of girls had serum retinol $<0.7 \mu\text{mol/L}$ (729).

El Salvador. In a country-wide prevalence survey conducted in 1973, of 9508 children aged 1–6 yr, the prevalence of Bitot spots was 0.053% (730). A survey in 1988 of 720 children under the age of 5 yr showed that 36.0% had serum retinol concentrations $<0.70 \mu\text{mol/L}$ (728).

Honduras. In a national survey conducted in 1996 of 1572 children, aged 12–59 mo, 13.6% had serum retinol $<0.70 \mu\text{mol/L}$ (728).

Nicaragua. A national micronutrient survey in 1993 showed that 31.3% of children aged 12–59 mo had serum retinol $<0.70 \mu\text{mol/L}$ (731). The Nicaraguan government began high-dose vitamin A capsule distribution in 1994 through national immunization days.

Panama. A survey conducted in Panama in 1992 of 1566 preschool children showed that 6.1% had serum retinol concentrations $<0.70 \mu\text{mol/L}$ (728).

Colombia. The 1977–1980 National Health Survey in Colombia showed that among children under 5 yr of age, 24.1% had serum retinol $<0.70 \mu\text{mol/L}$ (732). In a national survey conducted in 1995, of 2187 children aged 12–59 mo, 13.6% had serum retinol $<0.70 \mu\text{mol/L}$ (728).

Venezuela. A survey conducted in urban and rural slums in and around Maracaibo showed that more than one-fifth of children aged 24–85 mo had serum retinol $<0.70 \mu\text{mol/L}$ (733), and some clustering was noted between vitamin A deficiency and anemia (734). A survey of children aged 2–14 yr in a low-income community of Valencia showed that 0.7% had serum retinol concentrations $<0.70 \mu\text{mol/L}$ and 0.6% were at high risk of vitamin A deficiency by dietary assessment (735).

Ecuador. In the 1985 National Nutrition and Health Survey in Ecuador, 13.9% of children in rural areas and 11.9% of children in urban areas had serum retinol $<0.70 \mu\text{mol/L}$ (736). In 1993, a survey conducted by the Health Research Institute of the Ministry of Public Health of Ecuador in five provinces showed that of 1232 children, aged 12–59 mo, 18% and 2% had serum retinol concentrations <0.70 and $0.35 \mu\text{mol/L}$, respectively (736). The prevalence of low serum retinol concentrations was higher in the 1993 survey compared to the 1985 survey, however, the most recent survey was designed to assess vitamin A deficiency in the more impoverished provinces of Ecuador.

Peru. A survey of 362 preschool children in Piura and 220 preschool children in Puno showed that 32.8% and 14.1% had serum retinol concentrations $<0.70 \mu\text{mol/L}$, respectively (728).

Bolivia. In the Andean Subregion, of 891 children, aged 12–71 mo, 11.3% had serum retinol $<0.70 \mu\text{mol/L}$ (728). A high prevalence of subclinical vitamin A deficiency has been reported among young children and women of childbearing age in Bolivia (737).

Brazil. Clinical vitamin A deficiency has been most commonly described in northeast Brazil, the poorest and least developed region of the country. As noted in the historical section of this chapter, many important early observations on xerophthalmia were made in Brazil in the 19th century (3,24). In the Sertão region of northeast Brazil in 1981–1982, 1.9% of preschool children had Bitot spots in the period between harvests (738). In the Jequitinhonha valley in Minas Gerais in the early 1980s, 8.9% of preschool children had serum retinol $<0.35 \mu\text{mol/L}$ (739). A survey was conducted in 1998 in Sergipe State in northeastern Brazil involving 607 children aged 6–60 mo, and 9.6% had serum vitamin A levels $<0.35 \mu\text{mol/L}$ (740).

5.3. Risk Factors for Vitamin A Deficiency

Vitamin A deficiency is more common among poor families in developing countries, and along with poverty are many associated risk factors such as low maternal and paternal education, lack of land, crowding, poor hygiene, increased infectious disease morbidity, geographic isolation, lack of a home garden, and inadequate intake of vitamin A. Infants, preschool, and primary school-aged children are at higher risk for vitamin A deficiency,

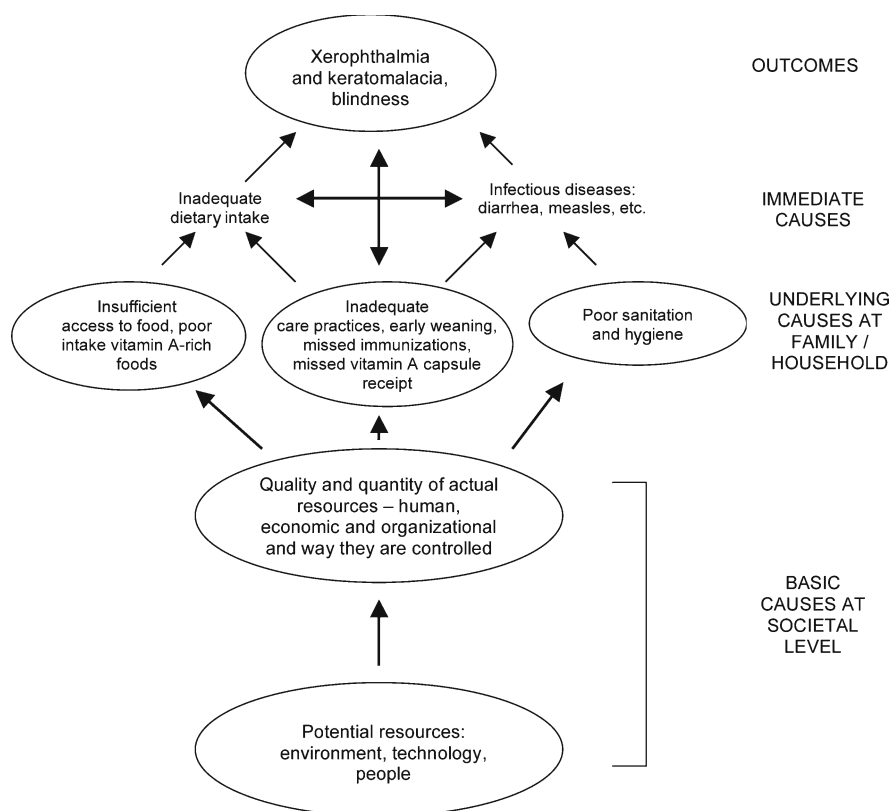


Fig. 17. Risk factors for vitamin A deficiency.

and boys are affected more often than girls. Breast-feeding practices such as no breast-feeding, early weaning, or rapid weaning are associated with an increased risk of vitamin A deficiency. Pregnant women and nonpregnant women of childbearing age are at higher risk of vitamin A deficiency. Vitamin A deficiency tends to cluster in households and in villages, with higher risk of xerophthalmia among children within the same family, and within mothers and their children. The relationships of risk factors for vitamin A deficiency are shown in Fig. 17.

5.3.1. POVERTY

In developing countries, low socioeconomic status is a strong risk factor for vitamin A deficiency, as many families living in poverty cannot afford vitamin A-rich sources of animal foods such as eggs and meat and may have lower consumption of plant sources of vitamin A. However, the effects of poverty extend beyond food availability and quality of the diet. Poverty is also associated with lower quality of housing, lack of running water, poor sanitation, crowding, and an increased burden of infectious diseases. A poor level of education (*see* Subheading 5.3.2.), lower income, lack of land, and no home garden (*see* Subheading 5.3.9.) are part of the general complex of poverty. These factors together may increase the burden of infectious diseases and its associated morbidity, and infectious diseases such as diarrheal disease and measles are well known risk factors that may precipitate xerophthalmia (*see* Subheading 5.3.6.).

Early studies in Copenhagen showed that xerophthalmia was more common in children who came from poor families (49). Investigations in Indonesia conducted in the 1930s and later have shown an association between poverty and xerophthalmia (115,741). Vitamin A intake and dark adaptation testing were worse among the poorest families in a study of families in Pennsylvania conducted in the late 1930s (742). In a country-wide survey in Indonesia in the late 1970s, principal bathing facility and principal occupation of the head of the household were associated with an increased risk of xerophthalmia (285). In the 1982–1983 Bangladesh nutrition survey of vitamin A deficiency that involved 11,618 rural households and 18,660 preschool children, the risk of xerophthalmia was associated with several indicators of low socioeconomic status, including not having a garden or a tin roof on the house (743). Households without a wristwatch, radio, or bicycle had a 1.5–3.2 greater risk of having a child with xerophthalmia. Nearly 80% of blind children came from landless households (743). In Malawi, xerophthalmia was more common in families where the head of the household was a farmer or fisherman compared with a tradesman or merchant (673). Low socioeconomic status, as reflected by an unprotected water source, no private latrine, and bamboo walls of the house, was associated with xerophthalmia among households in Indonesia (744).

In a study of 29,615 children, aged 6–72 mo, in northern Sudan, lack of water piped into the compound and relative poverty (as determined by the household dwelling, family possessions, and personal appearance of family members) were associated with an increased risk of xerophthalmia (647). In a case-control study from Nepal, the risk of xerophthalmia in children was inversely associated with household socioeconomic conditions (745). A thatched roof (odds ratio [OR] 3.25, 95% confidence interval [CI] 2.00–5.29), lack of an upper story of the house (OR 5.92, 95% CI 2.97–11.81), and lesser ownership of a radio (OR 2.52, 95% CI 1.34–4.75), a watch (OR 1.75, 95% CI 1.02–3.01), cattle (OR 2.12, 95% CI 1.35–3.32), or goats (OR 1.59, 95% CI 1.06–2.36) was associated with xerophthalmia (745). In a population-based study of 5352 children, aged 0–5 yr, in Cameroon, risk factors for xerophthalmia included a roof made of leaf or straw (OR 3.97, 95% CI 2.00–7.88), an indicator of low economic status (746).

Xerophthalmia has been associated with larger household size in Indonesia (285) and larger family size in urban Bangladesh (747), but no relationship was found between xerophthalmia and household size in Malawi (673). In Bangladesh, a family size of three or more children compared to one or two children was associated with an increased risk of xerophthalmia (OR 3.2, 95% CI 1.61–6.50) (748). Larger overall fluctuations in poverty may account for changes in the incidence of xerophthalmia over time. In Egypt between 1912 and 1931, the incidence of xerophthalmia in government ophthalmic hospitals peaked in 1913 and in 1918–1919, the former peak coinciding with economic crisis in Egypt and the latter peak coincided with poor conditions in the country at the end of World War I (749).

5.3.2. EDUCATION

A low level of education for the mother, father, or both, appears to be a strong risk factor for xerophthalmia among children. In Bangladesh, maternal education was an independent risk factor for xerophthalmia in her child, after adjusting for occupation of the head of the household, landholding, and other potential confounders (743). The relative risk for a child to have xerophthalmia if the mother had no schooling compared to at least 6 yr of schooling was about three (743). In Malawi, the risk of a household having a child with

xerophthalmia was higher if the head of the household had no formal schooling compared with any formal education (OR 1.38, 95% CI 1.05–1.82) (673). A maternal education level of less than 6 yr was associated with xerophthalmia among households in Indonesia (744). In northern Sudan, literacy of the mother, father, or both was protective against xerophthalmia (647). A level of maternal education less than 9 yr was associated with vitamin A deficiency in rural Mindanao in the Philippines (636). Maternal literacy was associated with lower risk of xerophthalmia in her child (OR 0.10, 95% CI 0.01–0.76) in Nepal (745).

5.3.3. GEOGRAPHIC LOCATION

Xerophthalmia has been described in more isolated, difficult-to-reach villages and households in developing countries. It is more common in rural than urban settings, although xerophthalmia may be found in some slum areas of large cities. A large distance from the house to the nearest road of >20 kilometers was a risk factor for xerophthalmia (OR 2.64, 95% CI 1.06–6.57) among preschool children in Cameroon (746). Among nonpregnant women of childbearing age in Cambodia, the prevalence of night blindness was higher in the more isolated rural provinces of Rattanakiri and Otar Meanchey (603).

5.3.4. AGE

Infants, preschool children, and women of childbearing age are at the highest risk of vitamin A deficiency. Risk factors for vitamin A deficiency among women are discussed separated in sections 3.1.13. and 3.1.14. The reported age distribution of xerophthalmia among infants and children varies, depending on whether the study population is community-based or based on case reports from hospitals or clinics. In general, community-based surveys suggest that the peak age for xerophthalmia among children is about 4–6 yr of age. For example, among preschool children in Jordan, the prevalence of xerophthalmia was highest between 50 and 60 mo of age for girls and 40 and 70 mo of age for boys (750). In a survey of 1715 children, aged 1–16 yr, in Cebu, Philippines, the overall prevalence of xerophthalmia was 2.7%, and of children aged 1–3, 4–6, 7–9, 10–13, and 14–16 yr, the prevalence of xerophthalmia was 1.4, 4.7, 3.3, 1.8, and 3.4%, respectively (751). In a country-wide survey of 13,450 preschool children in Sri Lanka, the prevalence of Bitot spots among children aged 6–11, 12–23, 24–35, 36–47, 48–59, and 60–71 mo was 0.1, 0.2, 0.8, 1.4, 1.4, and 2.1%, respectively (752). In the lower Shire Valley of Malawi, the highest rates of active xerophthalmia (night blindness, Bitot spots, corneal xerosis, corneal ulceration) were found in children aged 3–5 yr (673). The prevalence of xerophthalmia among children aged 6–72 mo in northern Sudan was highest among children aged 4–6 yr (647). In a survey of 11,378 preschool children in three underserved provinces of the Philippines, the prevalence of xerophthalmia was twice as high for children 6 yr of age compared with children under 2 yr of age (635). In western Yemen, children aged 4–5 yr were at greater risk of xerophthalmia than children younger than 4 yr of age (OR 2.9, 95% CI 1.6–5.4) (726).

In hospital and clinic-based reports, the risk of xerophthalmia is higher among younger children and infants. Younger children are more prone to severe eye disease and are more likely to be brought to the hospital or clinic by their mothers. Studies in the early 20th century provide some insight into the age distribution in severe eye disease. Among 430 cases of keratomalacia seen in Copenhagen from 1909 to 1920, the median age was about

8 mo (48). In a consecutive series of 1149 children seen in a 2-yr period in the mid-1960s in an outpatient clinic in Surabaya, Indonesia, xerophthalmia was most common among children who were 2–4 yr of age (115). Of 162 children with corneal xerosis, corneal ulceration, or keratomalacia seen at Cicendo Eye Hospital, Bandung, Indonesia, between 1977 and 1978, 33% of children admitted were 2 yr of age (285). Of 117 children admitted to the same hospital for xerophthalmia between 1981 and 1992, the peak age category of hospitalization was 2–3 yr of age (623).

The presence of vitamin A deficiency among primary school-aged children has not been well characterized, as most surveys of vitamin A deficiency have focused on infants and preschool children. Given the higher prevalence of night blindness and Bitot spots among children aged 4–6 yr in community-based studies, this suggests that the risk of vitamin A deficiency may extend to primary school-aged children. In a survey of 4991 children, aged 0–12 yr, in the Sertão, an arid region of northeast Brazil, the prevalence of Bitot spots was 1% in school-aged children and 0.3% in preschool children ($p < .005$) (738). A higher prevalence of xerophthalmia has been reported among school-aged children compared with preschool children in Ethiopia (753). Xerophthalmia was reported among individuals up to 19 yr of age in a survey of 149 villages in Bangladesh in 1981 (754). In a study of 1325 children displaced by famine in Ethiopia, the prevalence of Bitot spots was 3.35% among children aged 7–14 yr compared with 0.93% among children aged 0–6 yr (755). Inadequate vitamin A intake and low serum retinol concentrations have also been reported in school-aged children (756,757) and in adolescent girls (758). In some cases, the presence of Bitot spots may not necessarily reflect active vitamin A deficiency, especially among older children. With prolonged vitamin A deficiency, the squamous metaplasia of the conjunctiva may become irreversible, even if the individual has returned to a state of replete vitamin A status.

5.3.5. GENDER

Among preschool children, boys have often been reported to be at higher risk of xerophthalmia than girls (115,635,639,641,726,747,751,759,760). Boys were at higher risk than girls of having xerophthalmia in northern Sudan (OR 1.70, 95% CI 1.48–1.95) (647), in the Republic of Kiribati (OR 1.32, 95% CI 1.05–1.67) (641), and in western Yemen (OR 2.1, 95% CI 1.2–4.0) (726).

5.3.6. BREASTFEEDING

Early reports have often linked corneal ulceration and keratomalacia with lack of breastfeeding. Masamichi Mori (1806–1932), in his detailed description of 1511 children with “hikan,” or xerophthalmia and keratomalacia in Japan, noted that the condition rarely occurred in children under age 12 mo unless the infant received total or partial artificial feeding instead of breast milk (761). In 1906, Adalbert Czerny (1863–1941) and Arthur Keller (1868–1934) described xerophthalmia among children in Breslau who were fed flour-based preparations as a substitute for milk or breast-feeding, and xerophthalmia was part of a syndrome they termed “Mehlnährschaden” that included wasting, poor weight gain, depressed immunity, and increased infections (762). In the late 1930s, hundreds of cases of xerophthalmia were reported among infants and young children in Java who received sweetened condensed milk or skimmed milk instead of breast milk by Maria van Stockum (Ottens-van Stockum) (1885–1940) (763) and by J.H. de Haas (764).

In the 1940s, keratomalacia was described among infants in Singapore who were fed sweetened condensed milk, a poor source of vitamin A (765).

Lack of breastfeeding, early cessation of breastfeeding, introduction of vitamin A-poor complementary foods, and rapid weaning are associated with vitamin A deficiency (115,285,747,766–770). In a country-wide survey in Indonesia, breast-feeding was less common among 358 children with Bitot spots compared with matched controls or other normal children (767). In a case-control study of breast-feeding and weaning patterns in Malawi, xerophthalmia was associated with weaning onto porridge, a shorter weaning interval, and early cessation of breast-feeding (769). Another case-control study at a diarrhea treatment center in Dhaka, Bangladesh showed that breastfeeding was protective against xerophthalmia (OR 0.26, 95% CI 0.14–0.49) (770). The frequency of breast-feeding was highly protective against xerophthalmia in Nepal (745). In a case-control study of 666 children with xerophthalmia and 816 children without xerophthalmia in the Republic of Kiribati, current breastfeeding was protective against xerophthalmia (OR 0.30, 95% CI 0.19–0.46) (641).

5.3.7. INFECTIOUS DISEASES

Vitamin A deficiency is characterized by impaired immune function and increased susceptibility to some infectious diseases. In general, the morbidity of infectious diseases is more severe among individuals with vitamin A deficiency. Diarrheal disease, tuberculosis, measles, whooping cough, pneumonia, *Ascaris* infection, and human immunodeficiency virus infection are associated with vitamin A deficiency, and in many situations, an episode of disease will precede a case of xerophthalmia.

Diarrheal disease. A history of diarrheal disease is common among children with xerophthalmia (115,285,369,647,722,743,745,747,754,761,771–775). In 1833, the British ophthalmologist Richard Middlemore (1804–1896) observed individuals with cholera around Birmingham who “consequent to an attack of cholera” developed “ulceration or sloughing of the cornea—and suppuration of the eyeball.” He noted: “In nearly every instance the disease of the eye occurred as the symptoms of cholera were subsiding” and “sometimes the cornea appeared to ulcerate or slough, without having been preceded by any appreciable amount of inflammation” (776). In Bangladesh, all children with multiple corneal ulcers or keratomalacia had a history of diarrhea in the preceding 4 wk (743). In northern Sudan, a history of diarrhea (three or more loose watery stools within 24 h) in the previous 7 d was associated with xerophthalmia (OR 1.22, 95% CI 0.98–1.53) (647). In lowland Nepal, children were at higher risk of xerophthalmia if they had dysentery for 1 to 6 d in the previous 7 d (OR 2.13, 95% CI 1.02–4.46) or dysentery for ≥ 7 d (OR 5.81, 95% CI 1.11–30.58) (745). Previous diarrhea or dysentery was also associated with xerophthalmia in Bangladesh (754). In Ethiopia, the prevalence of diarrhea was twice as high in children with xerophthalmia than among children without xerophthalmia (655). In a random sample of 700 children, aged 0–6 yr, at Saddam Paediatric Hospital in Iraq, xerophthalmia was found in 29% and was associated with diarrheal disease (774). In a study of 400 children, aged 6–59 mo, with acute diarrhea in rural Bangladesh, 7.8% had night blindness and 2.7% had Bitot spots (775). In the Republic of Kiribati, recent diarrhea was associated with xerophthalmia (OR 1.45 95% CI 1.10–1.89 (641).

Measles. The association between measles and vitamin A deficiency has been extensively documented and reviewed in detail elsewhere (598). In 1874, Friedrich Bezold

(1842–1908), a physician in Munich, described keratomalacia in a 5-mo-old infant following an attack of measles (777). Other detailed descriptions were made by the Greek ophthalmologist, Alexios Trantas (1867–1961), in Constantinople at the turn of the century (778,779). These are early examples of many reports of corneal ulceration and keratomalacia associated with acute complicated measles (722,768,780–795). In Bangladesh, nearly 10% of children with active corneal lesions (X2/X3) had a history of measles within the preceding 4 wk (743). In the Republic of Kiribati, a recent history of measles was associated with corneal xerophthalmia (OR 7.73, 95% CI 1.78–33.65) (641).

Respiratory disease. A history of respiratory disease has often been reported in children with xerophthalmia (115,285,673,750) and autopsy series of infants who died with keratomalacia often show evidence of bronchopneumonia (368,369). In longitudinal studies in Indonesia, a previous episode of respiratory disease increased the risk of a child having xerophthalmia (796), and an episode of xerophthalmia increased the risk of subsequently having an episode of respiratory disease (797). Acute measles complicated by lower respiratory infection are associated with xerophthalmia (795). Maternal night blindness has been associated with increased risk in their infants of nasopharyngeal colonization with *S. pneumoniae* (798).

Tuberculosis. Xerophthalmia is associated with tuberculosis in infants and children, and most of these cases typically consist of infants with marasmus or kwashiorkor who had corneal ulceration or keratomalacia (115,369,751,786,799,800). Sydney Stephenson (1862–1923) described tuberculosis in nearly 20% of the children he saw with keratomalacia in London at the turn of the century (799). There were 3 cases of tuberculosis among 17 autopsies of infants and children with keratomalacia that were conducted by Lewis Sweet (1902–1950) and his colleague H. J. K'ang at Peiping Union Medical College (369). Tuberculosis may be underestimated in its association with vitamin A deficiency among infants and children, given the difficulty of confirming the diagnosis of tuberculosis in this age group.

Other infections. Otitis media has been associated with xerophthalmia in many studies (49,115,368,369,643). Kenneth Blackfan (1883–1941) and S. Burt Wolbach (1880–1954) described cases of otitis media in their autopsy series of infants who had died with keratomalacia in Boston (368). Whooping cough has occasionally been reported in association with xerophthalmia (751,780). Intestinal helminth infections such as ascariasis have been associated with vitamin A deficiency and malabsorption of vitamin A (115,801–804), and keratomalacia has been described in association with giardiasis (805). In 1823, the German ophthalmologist Theodor Heinrich Wilhelm Lercche (1791–1847) described an association between intestinal worm infections and night blindness among the general population in St. Petersburg (806). Lercche received his medical degree at the University of Dorpat in 1812 and moved to St. Petersburg, where he noted diarrheal illnesses, helminthiasis, and night blindness, especially around the time of the great fasts (806). Small-pox, which has been eradicated worldwide, was once associated with xerophthalmia (807).

5.3.8. DIET

Xerophthalmia is commonly associated with an inadequate intake of dietary vitamin A (49–52,115,285,636,647,744,746–748,751,767,775,808–811). A lower intake of vitamin A from plant sources was associated with a higher risk of night blindness among children in Bogor, Indonesia (808). The intake of vitamin A per head in families was

adequate, but there was an unequal distribution of vitamin A-containing foods among members of the household (808). In a case-control study of 466 children, under age 6 yr, with Bitot spots and/or corneal xerophthalmia and matched controls in Aceh, Indonesia, the risk of xerophthalmia increased with less frequent consumption of dark green leafy vegetables (OR 6.4, 95% CI 3.4–12.2), yellow fruits or vegetables (OR 4.6, 95% CI 2.7–7.7), egg (OR 2.2, 95% CI 1.5–3.3), or meat and fish (OR 2.4, 95% CI 1.5–3.8) (744). Children with xerophthalmia who were younger than 3 yr of age appeared to be a higher risk of dietary imbalance than were older children (744). In northern Bangladesh among children under the age of 9 yr, no consumption of fish, meat, milk, or eggs (OR 4.90, 95% CI 2.03–11.81), yellow fruits (OR 3.90, 95% CI 1.57–9.85), or dark green leafy vegetables (OR 2.50, 95% CI 0.95–6.47) was associated with an increased risk of night blindness (748).

5.3.9. HOME GARDENS

In many rural areas in developing countries, home gardens are an important source of plant sources of vitamin A and may provide protection against vitamin A deficiency. In Bangladesh, the relative risk of having a child with active corneal lesions (X2/X3) was more than three times greater for households with no garden (743). In the Republic of Kiribati, the presence of a fruit and vegetable garden project was associated with a decreased risk of xerophthalmia (OR 0.70, 95% CI 0.52–0.93) (641).

5.3.10. MALNUTRITION

It has long been recognized that corneal ulceration and keratomalacia are more common among infants with severe malnutrition, as reflected in numerous case reports and case series from around the world (3,16–18,23,24,49,51,52,113,115,261,285,318,337,368,369,750,761,762,764,780,784,786,799,800,805,812–884). Community-based studies also show that xerophthalmia is associated with malnutrition (641,745,760). Among 100 malnourished children up to 8 yr of age seen in New Delhi, India, the prevalence of xerophthalmia increased with the severity of malnutrition (885). Keratomalacia has been described in association with pellagra (868), rickets (835), and scurvy (886). Nearly one-third of adults with beriberi in the Philippines had marked impairment of dark adaptation (887). Corneal ulceration was described in an adult with ulcerative colitis who purposely eliminated all fresh fruits and vegetables from her diet (888). A 39-yr-old man presented with bilateral keratomalacia after he had been on a “healthy diet” of brown rice, pulses, and alfalfa sprouts for 7 yr, with no animal or dairy products (889). In 1890, the German ophthalmologist Wilhelm Uhthoff (1853–1927) described a large series of adults with alcoholism, poor nutrition, and xerophthalmia (890). Keratomalacia was described in a 57-yr-old German man with alcoholism, wasting, and acute pancreatitis (891). In India, infants fed on soy milk for 10 to 12 wk developed xerophthalmia and keratomalacia (892). At the time, the soy milk product was not fortified with any vitamins (893).

In a study of 213 malnourished children, aged 4–60 mo, in Sudan, 29% had xerophthalmia (894). Among children aged 6–35 mo attending a diarrheal treatment center in Dhaka, Bangladesh, the risk of vitamin A deficiency was higher if the child was <60% of the National Center for Health Statistics median of weight-for-age (OR 3.8, 95% CI 1.8–8.0) (770). The association between xerophthalmia and malnutrition has been observed among preschool children in an urban slum in India (811). In Bangladesh, night blindness was associated with protein energy malnutrition, as assessed by mid-upper arm circum-

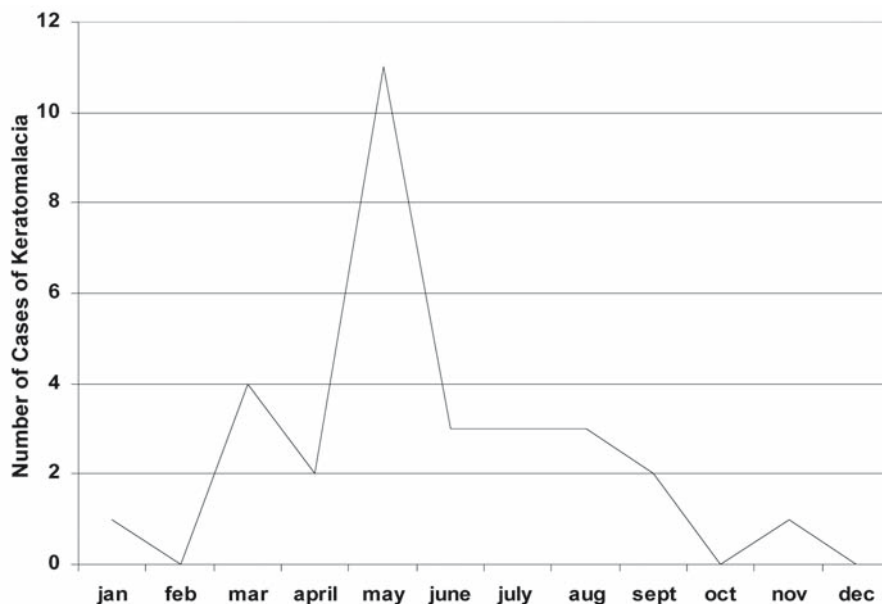


Fig. 18. Seasonality of keratomalacia in Germany, 1922. This historical example from Europe is typical of seasonality described in developing countries today. (Reprinted from ref. 831.)

ference (895). A higher prevalence of both wasting and stunting were described among children with xerophthalmia compared to children without xerophthalmia in a community-based survey of Bangladesh (760). In Nepal, xerophthalmia was also associated with stunting and wasting (745). Subclinical vitamin A deficiency was associated with protein energy malnutrition among preschool children in Zaire (896). In the Republic of Kiribati, xerophthalmia was associated with mild wasting (OR 3.07, 95% CI 2.33–4.04), moderate wasting (OR 3.55, 95% CI 2.04–6.18), and severe wasting (OR 3.82, 95% CI 2.73–5.35), where wasting categories were defined as mid-upper arm circumference ≥ 10 to <25 th percentile, ≥ 5 percentile to <10 th percentile, and <5 th percentile, respectively (641). Lower serum retinol concentrations have been associated with stunting and wasting in studies from Ethiopia (655,656).

5.3.11. SEASON

The incidence of xerophthalmia can have a seasonal pattern in some parts of the world, and these fluctuations are related to the availability of vitamin A-rich foods and patterns of morbidity related to seasonal infections. In the late nineteenth century when malnutrition and diarrhea were more common in London, the peak of cases of keratomalacia coincided with the peak in the diarrhea cases in July–August (799). The examples of seasonality of xerophthalmia are most dramatic from the past in places where xerophthalmia was widespread. In Germany in 1922, the peak incidence among 30 cases of keratomalacia was in May (831) (Fig. 18). In Tianjin, China, a single peak of xerophthalmia was reported from December through April (897) (Fig. 19), however, in nearby Beijing, the incidence of xerophthalmia was highest in January through March and again in July, with the first peak was attributed to scarcity of green vegetables during the winter, and the second peak was attributed to the appearance of diarrhea and dysentery in the summer

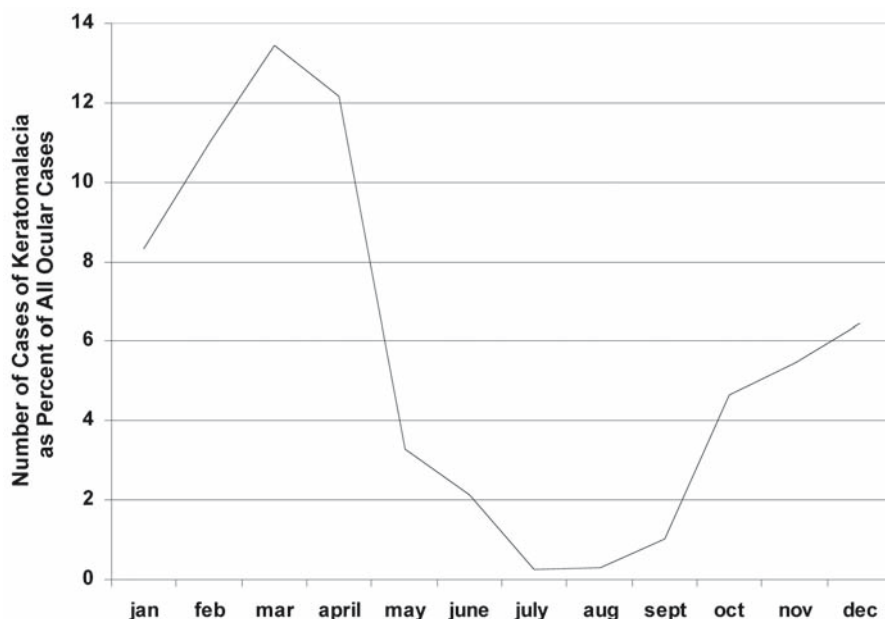


Fig. 19. Seasonality of xerophthalmia in Tianjin, China. (Reprinted from ref. 897.)

(369). In Tunisia, cases of xerophthalmia were also reportedly more common at the end of the hot summer and were associated with chronic diarrhea (872). The seasonal incidence of more than 15,000 cases of xerophthalmia among children was examined in four ophthalmic hospitals in India, Indonesia, and Vietnam (898). In Bangalore, India, there were more cases of xerophthalmia seen from April to June, and this coincided with a relative scarcity of green vegetables and milk and with a higher prevalence of summer diarrhea. In Surabaya and Bandung, Indonesia, the incidence of xerophthalmia was highest from about March to September. In Hanoi, Vietnam, there were two periods in which xerophthalmia was highest, from April to June and from October to December (898). In a longitudinal study of 312 children, aged 0–4 yr, in rural West Bengal, the incidence of night blindness and/or Bitot spots had a small peak in November–December and in a larger peak in May–June (899). The prevalence of Bitot spots was highest in the pre-monsoon season in West Bengal (899). In longitudinal field studies in Indonesia, the number of children with corneal involvement in xerophthalmia was highest in March through August (285). Among children admitted to Cicendo Eye Hospital in Bandung, Indonesia, the peak month of admissions was in March, which corresponds to the dry season (623). The periodicity of xerophthalmia in some populations needs to be taken in account when conducting epidemiological surveys of vitamin A deficiency. Xerophthalmia was also reported to increase after crop failure in Russia (900).

5.3.12. MALABSORPTION

Cystic fibrosis. Cystic fibrosis is an autosomal recessive disease that affects primarily Caucasian populations and is characterized by exocrine pancreatic insufficiency, altered pulmonary mucosal immunity, and other abnormalities affecting the liver, sweat glands, and genitourinary tract (901). Exocrine pancreatic insufficiency causes malabsorption of

fat and fat-soluble vitamins such as vitamin A, and problems such as steatorrhea and poor weight gain. Cystic fibrosis is caused by a mutation in the FES1 gene that encodes the cystic fibrosis transmembrane conductance regulator. Individuals with cystic fibrosis are at a high risk of developing vitamin A deficiency because of malabsorption of vitamin A (902). One study of 36 infants less than 2 mo of age in Colorado showed that vitamin A deficiency was present among 21% of those diagnosed with cystic fibrosis by newborn screening (903). There have been many case reports of xerophthalmia associated with cystic fibrosis (904–913). Low plasma vitamin A concentrations and impaired dark adaptation appear to occur frequently in cystic fibrosis, even among clinically stable, eutrophic, and retinol-supplemented adolescents (914). Night blindness and conjunctival xerosis may still occur despite vitamin A-supplementation among adolescents with cystic fibrosis, especially if they have liver disease (909).

Pulmonary exacerbations of cystic fibrosis are associated with an increase in inflammation and a decrease in plasma retinol concentrations (915). Xerophthalmic fundus has been reported in an 18-yr-old girl with cystic fibrosis who developed night blindness (908). Regular monitoring of serum retinol concentrations in individuals with cystic fibrosis has been recommended because vitamin A deficiency may still occur despite vitamin A supplementation (902). Low serum retinol concentrations were reported to have no correlation with pancreatic sufficiency in cystic fibrosis (916). Regular monitoring of serum retinol concentrations and adherence to vitamin A supplementation may help patients with cystic fibrosis avoid problems with night blindness (917,918). A study of vitamin A concentrations in the liver among fifteen patients with cystic fibrosis from 8 to 34 yr of age show that hepatic retinol concentrations decrease with age (919). These findings are suggestive that long-term vitamin A supplementation is unlikely to increase the risk of hypervitaminosis A in patients with cystic fibrosis (919). A transient increase in intracranial pressure, as manifested by a bulging anterior fontanelle, was reported in two 9-mo-old infants with cystic fibrosis and xerophthalmia after receiving high-dose vitamin A (913).

Celiac sprue. Celiac sprue, also known as celiac disease and gluten-sensitive enteropathy, is a condition of the proximal small intestine that is characterized by malabsorption (920,921). The condition is associated with injury to the small intestine after the ingestion of wheat gluten or related rye and barley proteins and improves on treatment with a gluten-free diet. The condition has a genetic predisposition and may occur in one of every 120–300 persons in both Europe and the United States (921). It mostly occurs in Caucasians but has been reported occasionally in other ethnic groups. Abnormal T-cell mediated immune responses against ingested gluten may occur in those that are genetically predisposed together the disease (921). Common clinical manifestations include diarrhea, failure to thrive, and abdominal distention in children, and diarrhea and iron deficiency anemia in adults. Children and adults with celiac disease may have abnormal absorption of oral vitamin A (922). During active sprue, vitamin A absorption is severely impaired, but during remission of disease, the absorption of vitamin A may be satisfactory (923). Plasma retinol concentrations are reduced in patients with sprue compared with normal individuals (924). Keratomalacia was reported in a 64-yr-old man with a history of celiac sprue after he developed persistent diarrhea in spite of adherence to a gluten-free diet (925).

Other conditions. Night blindness associated with vitamin A deficiency has been reported with intestinal bypass surgery for morbid obesity (926–930). In addition to night

blindness, conjunctival xerosis (926) and Bitot spots (927) have also been reported after intestinal bypass surgery. Xerophthalmia and keratomalacia have been described in an infant with obstructive biliary cirrhosis (931). Night blindness has been associated with alcoholic liver disease (932–934). Severe protein energy malnutrition is associated with impaired intestinal absorption of vitamin A (935).

5.3.13. PREGNANCY

Night blindness has long been recognized among pregnant women, with hundreds of cases reported in the literature (936–961). The requirement for vitamin A increases during pregnancy, and many women may not have adequate intake of vitamin A and subsequently develop night blindness. In general, night blindness is more common in pregnant women from poor families and in association with complications of pregnancy such as hyperemesis, anorexia, diarrhea, and other concomitant infections. In a study conducted in 1889–1892 in Nishne Tagilsk in the Urals, O. Walter noted that night blindness among pregnant women seemed to peak in February through April, and a large proportion indicated that they had repeatedly been night blind during pregnancy (941). At a time when vitamin A deficiency was prevalent in Europe, Theodor Birnbacher and Emanuel Klasten noted that night blindness was more common among pregnant women than nonpregnant women of childbearing age (944), and Birnbacher attributed the night blindness to lack of vitamin A (946). Carsten Edmund (b. 1897) and Svend Clemmesen (b. 1901) in Copenhagen concluded that night blindness in pregnant women was due to vitamin A deficiency because the night blindness was promptly cured after treatment with parenteral vitamin A (947). After margarine was fortified with vitamin A in 1936–1937 in Denmark, they noted a decrease in the number of cases of pregnant women with night blindness (947). Parul Christian has recently brought attention to night blindness during pregnancy as an indicator of vitamin A deficiency (962).

5.3.14. NONPREGNANT WOMEN OF CHILDBEARING AGE

Night blindness has also been reported among nonpregnant women of childbearing age in India (963), Bangladesh (964), Nepal (965), and Cambodia (603). In the 1930s, Adalbert Fuchs reported that night blindness and keratomalacia occurred among lactating women in Mysore, India (966). A strong risk factor for night blindness among women of childbearing age is night blindness during the most recent pregnancy (603). However, it does not appear that vitamin A deficiency during the last pregnancy alone is the main determinant of night blindness, as one might expect that the point prevalence of night blindness would be highest immediately following pregnancy. Instead, the risk of night blindness appears to be consistently high and steady for many months following delivery (Fig. 20), which suggests that there are women who have greater risk overall of night blindness because of poor intake of vitamin A-rich foods (603). Among nonpregnant women in Cambodia, in a final multivariate analysis, risk factors for night blindness included materials of the wall of the house (OR 1.4, 95% CI 0.9–2.0), land ownership ≥ 0.5 hectares (OR 1.4, 95% CI 1.0–1.9), night blindness in the last pregnancy (OR 44.5, 95% CI 29.2–67.8), parity >3 (OR 1.5, 95% CI 1.0–2.1), diarrhea within the last 2 wk (OR 1.9, 95% CI 1.3–2.8), maternal body mass index (OR 1.8, 95% CI 1.2–2.7), and lack of consumption of vitamin A-rich animal foods in the last 24 h (1–60 REs, OR 1.1, 95% CI 0.7–1.6, ≥ 60 retinol equivalents, OR 0.7, 95% CI 0.4–1.0) (603).

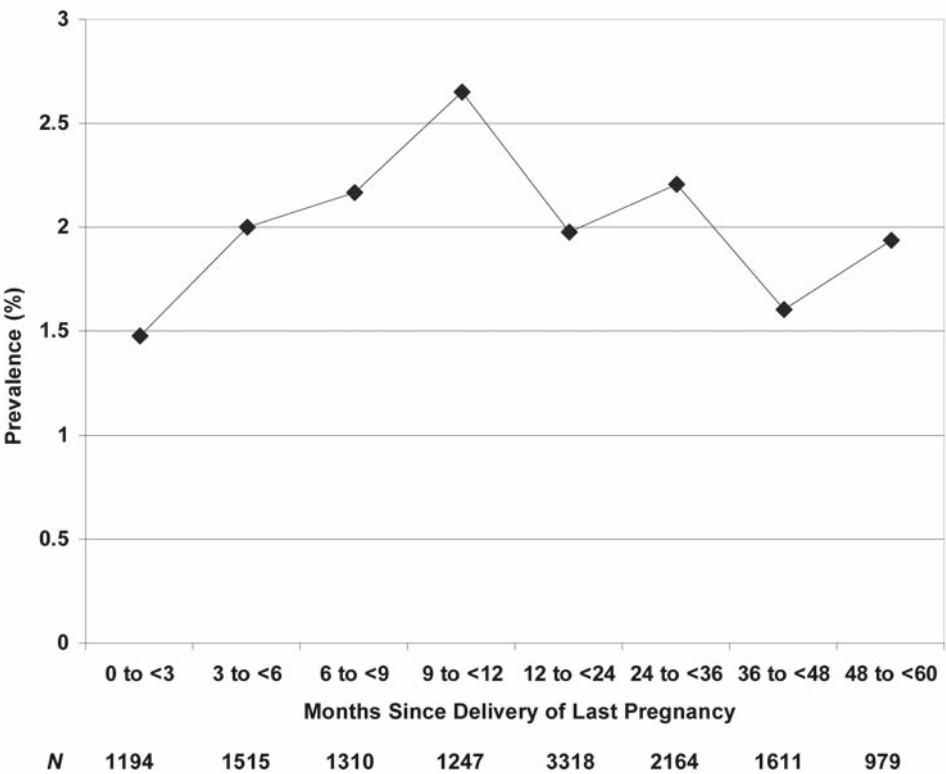


Fig. 20. Point prevalence of night blindness after delivery among women in Cambodia. (Reprinted from ref. 603.)

5.1.15. INSTITUTIONALIZATION

Xerophthalmia has been reported in mental hospitals, prisons, and orphanages where the diet may be inadequate in vitamin A (967–970). In Calcutta, corneal ulceration occurred among prisoners recovering from cholera and was thought to be the result of malnutrition (971). Bitot spots and corneal leucomas were described among inmates of a mental hospital in Mathari, Kenya (969). In Kampala and Luzira Prisons in Uganda in the 1920s, corneal ulceration was observed among inmates who were fed a diet poor in vitamin A (970). No cases of xerophthalmia and corneal ulceration were reported from Mengo Prison, where the inmates were fed four pounds of sweet potato (a rich plant source of vitamin A) each day (970). Xerophthalmia was noted to be common in local prisons in Malawi in the 1980s (Moses Chirambo, personal communication). Medical staff and aid workers who deal with prisoners in developing countries should be aware that the presence of night blindness, Bitot spots, or corneal xerosis among inmates indicate a poor quality diet that is low or devoid of vitamin A-rich foods.

6. DIAGNOSIS OF VITAMIN A DEFICIENCY

6.1. Clinical Diagnosis

Vitamin A deficiency can be diagnosed on the basis of clinical signs and symptoms as described under Subheading 3. The most commonly used clinical indicators of vitamin

A deficiency are night blindness and Bitot spots. Although the earlier literature may refer to night blindness and Bitot spots as “mild” vitamin A deficiency, the presence of clinical vitamin A deficiency actually represents a later, more severe state of vitamin A deficiency. A simple history of night blindness can be used as a diagnostic indicator for vitamin A deficiency (972) and is especially useful in areas where vitamin A deficiency is endemic. As noted previously, Bitot spots are considered pathognomonic for vitamin A deficiency. Individuals who have had longstanding clinical vitamin A deficiency may develop irreversible squamous metaplasia of the conjunctiva, and Bitot spots in these individuals may not respond to vitamin A therapy. Thus, Bitot spots may not necessarily represent active vitamin A deficiency, especially among school-aged children. Infants or children with corneal xerosis, corneal ulceration, or keratomalacia are at an extremely high risk of dying, and great attention must be paid to treatment of vitamin A deficiency and supportive measures (*see* Subheading 7). Corneal scarring is sometimes used as a indicator of past vitamin A deficiency, however, other conditions such as trauma and bacterial ulceration can also leave a corneal scar after the corneal has healed, thus, corneal scarring may be relatively nonspecific. A history of measles associated with corneal scarring may improve the specificity of the diagnosis of vitamin A deficiency.

6.2. Assessment of Vitamin A Status

A wide variety of methods are available to assess vitamin A status, and the more commonly utilized techniques include serum retinol concentrations, breast milk retinol concentrations, conjunctival impression cytology, dark adaptometry, RDR test, and modified relative dose response (MRDR) test (973,974). Liver retinol concentrations are often considered the “gold standard” for vitamin A status, but liver biopsy is highly invasive and rarely used *s*. The methods for the assessment of “vitamin A status” are sometimes not directly comparable, as the endpoints of these measures are quite different, i.e., (1) intake of vitamin A (dietary assessment), (2) hepatic reserves of vitamin A (RDR, MRDR), (3) circulating vitamin A (serum retinol), (4) effect of vitamin A on function (dark adaptometry, pupillary threshold, conjunctival impression cytology), and (5) total body vitamin A stores (deuterated retinol dilution technique). To give some examples, a child could have adequate intake of vitamin A, as demonstrated by dietary assessment, but show impaired dark adaptometry because of malabsorption of vitamin A as a result of intestinal parasites. A lactating woman could have high breast milk retinol concentrations but low serum levels of retinol because of inflammation.

6.2.1. SERUM RETINOL CONCENTRATIONS

Serum or plasma retinol concentrations are widely used to assess the vitamin A status of populations (*see* Subheading 4), but are considered less reliable for assessment of vitamin A status in individuals (973,974). Serum retinol can be measured using high performance liquid chromatography (973), and unless measurements are made immediately, serum or plasma samples should be stored at -70°C or less prior to analysis. In large surveys, the frequency distribution of serum retinol concentrations can provide useful information about the general vitamin A status in a population. The proportion of people with serum retinol concentration $<0.70\text{ }\mu\text{mol/L}$ is used by WHO to determine whether vitamin A deficiency is a public health problem (975). Mild, moderate, and severe vitamin

A deficiency as a public health problem in a population is thought to be reflected by a prevalence of ≥ 2 to $<10\%$, ≥ 10 to $<20\%$, and $\geq 20\%$, respectively (975).

Although serum retinol concentrations are widely used as an indicator of vitamin A status, this assessment method may have some limitations. In the 1940s, longitudinal studies of vitamin A status in adults showed that upper respiratory infections and episodes of fever were associated with a depression in blood retinol concentrations (976). Decreased plasma vitamin A concentrations were observed during infections such as pneumonia (977), and autopsy studies showed normal hepatic vitamin A stores among children who had decreased plasma vitamin A concentrations prior to death (978).

RBP is a negative acute phase protein, and in the presence of inflammation or infection, retinol-binding protein and retinol concentrations may decrease (217,979).

In order to avoid overestimating the prevalence of vitamin A deficiency in populations with a high prevalence of infections, it has been proposed that individuals with elevated acute phase proteins be excluded or that serum retinol concentrations be “adjusted” (980). However, the approach to exclude individuals with infection or depend on “adjusted” retinol values may result in selection bias, as the remaining individuals without infection may be healthier and no longer representative of the population that is being surveyed (981). Because vitamin A deficiency is a syndrome characterized by immune suppression, increased susceptibility to infections, and elevated acute phase proteins (584,676,982), the exclusion of individuals with low plasma retinol concentrations and elevated acute phase proteins may also lead to an underestimation of the prevalence of vitamin A deficiency in some populations (981). Serum retinol concentrations could theoretically be affected by iron deficiency (983,984). Because serum retinol levels are thought to be under homeostatic regulation in the individual, some studies have not shown any response of serum retinol concentrations to vitamin A supplementation (974).

6.2.2. BREAST MILK RETINOL CONCENTRATIONS

Breast milk retinol concentrations are considered a good indicator of vitamin A deficiency among lactating women (985), and procurement of a milk sample is less invasive than taking a venous blood sample. Milk retinol concentrations can be measured using high-performance liquid chromatography (974). WHO utilizes a cut-off of breast milk retinol of $\leq 1.05 \mu\text{mol/L}$ (or $\leq 8 \mu\text{g/g}$ milk fat) to define the prevalence of vitamin A deficiency (975). Mild, moderate, and severe vitamin A deficiency as a public health problem in a population is thought to be reflected by a prevalence of $<10\%$, ≥ 10 to $<25\%$, and $\geq 25\%$, respectively (975). Breast milk retinol concentrations generally increase following vitamin A supplementation (985).

Unlike serum retinol concentrations, breast milk retinol concentrations do not appear to be affected by systemic inflammation (986). The two major sources of vitamin A in the circulation that are available for uptake by the mammary gland for secretion in breast milk are retinol carried by retinol-binding protein and retinyl esters carried by chylomicrons. Studies in animals suggest that chylomicrons provide at least one-third to one-half of vitamin A to mammary gland tissue during lactation for secretion into milk (181), and that in rats, milk retinol can vary with dietary vitamin A intake even when plasma retinol concentrations are relatively unaffected (182). Animal studies show that there may be a homeostatic mechanism by which the transfer of retinol from the circulation to breast

milk is protected within a fairly large range of liver vitamin A stores and serum retinol concentrations (180). In the rat, moderate restrictions of dietary fat or protein had little effect on transfer of vitamin A from dam to pup, but more severe dietary restrictions had a negative impact on milk volume (180). All of these observations suggest that breast milk retinol is shielded from changes in plasma retinol because the mammary gland utilizes a large proportion of retinyl esters that have entered the circulation after absorption in the gastrointestinal tract. A recent study of breast milk concentrations among women with a high prevalence of inflammation shows if defined by milk retinol concentrations, vitamin A deficiency would be a moderate public health problem in the study population (986). However, if serum retinol concentrations were used as the indicator of vitamin A status, and those with inflammation were excluded as advocated by Thurnham and colleagues (980), it would lead to the erroneous conclusion that vitamin A deficiency were not a public health problem in this study population (986).

The concentration of retinol can be expressed per gram of fat in milk if a creamatocrit is obtained, or can be expressed as concentration of retinol per volume of milk. In casual breast milk samples, the measurement of breast milk retinol per gram of fat was found to be the most accurate indicator of response to vitamin A supplementation (987), but another study found that breast milk vitamin A was most sensitive to changes in vitamin A status when expressed as retinol per volume of breast milk (988). Breast milk retinol concentrations decline over time following delivery (989), thus it may be necessary to adjust for time postpartum in comparing breast milk concentration between groups of women.

6.2.3. CONJUNCTIVAL IMPRESSION CYTOLOGY

Conjunctival impression cytology (CIC) is a method in which cells taken from the bulbar conjunctival surface are stained and examined microscopically (973). The basis for this technique dates to the early twentieth century, when scientists noted that keratinization and loss of goblet cells and mucus in the conjunctival epithelium occurred in experimental animals and in humans with vitamin A deficiency. The degree of keratinization in conjunctival smears was used as a method to diagnose vitamin A deficiency by Sweet and K'ang in the 1930s (369). John Youmans (1893–1979) and colleagues examined conjunctival smears that were stained with hematoxylin and eosin, and they noted keratinization of the conjunctival epithelium in adults suspected of having vitamin A deficiency (990). The investigators concluded that conjunctival smear cytology was inadequate for the assessment of vitamin A deficiency because of the great variability in keratinized cells and the lack of response after treatment with vitamin A (990). In another study of conjunctival smear cytology, histological changes were validated against another index of vitamin A status, and the percentage of keratinized cells had poor correlation with plasma retinol concentrations (991). In conjunctival smear cytology, the loss of goblet cells and mucus and loss of nuclei in epithelial cells were considered important indicators of xerosis due to vitamin A deficiency (992).

In CIC, cells are sampled by applying cellulose acetate filter paper to the bulbar conjunctiva, and then the sample is stained using periodic acid-Schiff (PAS) to stain the mucin of goblet cells and hematoxylin to stain the nuclei of epithelial cells (993,994). Another variation of this method is to transfer the cells onto a glass slide before staining (995). The CIC technique is relatively inexpensive, does not require cold storage of samples, and requires a microscope and stains, but difficulties with CIC include problems with interpre-

tation of cytologic changes, confounding by conjunctivitis, and poor correlation of CIC with other measures of vitamin A status such as serum retinol levels and RDR testing (996, 997). Trachoma and conjunctivitis, which may be common in many populations, interferes with the interpretation of CIC (998).

The abnormal cytologic changes seen in CIC should theoretically return to normal following vitamin A supplementation. In a placebo-controlled clinical trial in Indonesia involving 236 preschool children with and without xerophthalmia, the abnormalities seen in CIC at the baseline exam (994) did not respond by five weeks following high-dose vitamin A supplementation (Semba, unpublished data). In the same children, most Bitot spots disappeared five weeks after vitamin A supplementation (257). In another study, abnormal CIC did not respond to vitamin A supplementation until 70–110 d after high-dose vitamin A supplementation (999). It is unclear why large lesions such as Bitot spots would dramatically disappear within five weeks after high-dose vitamin A supplementation, but microscopic lesions of keratinization and goblet cell loss should require months to return to normal.

6.2.4. DARK ADAPTOMETRY

Dark adaptation is a process in which the rod photoreceptors fully regenerate rhodopsin in darkness after exposure to a bright light. The process takes approx 30–35 min. In vitamin A deficiency, rhodopsin levels in the retina decline, and dark adaptation is impaired. The relationship between impaired dark adaptation and vitamin A deficiency was investigated extensively in the 1930s and 1940s (1000, 1001). The threshold for light perception progressively decreases during dark adaptation. A transient plateau is reached at 1–5 min in normal, vitamin A-sufficient people, and after several minutes, there is a transition from cones to rods, with a progressive decrease in threshold until about 30–35 min when the final rod threshold is reached. In vitamin A-deficient individuals, the threshold for dark adaptation is higher. Clinical dark adaptometers can be used to assess dark adaptation, but these instruments tend to be less suitable for field use and for use among children, who may not cooperate with the conditions of testing. Portable dark adaptometry has been used in the field for measuring the time it takes for children to identify letters illuminated by a dim light after the eye has been exposed to bright light (1002). Another procedure, termed rapid dark adaptation time, involves measuring the time it takes for a subject to sort white, blue, and red disks into three piles under lighting conditions consistent with rod illumination after the eyes have been exposed to bright light (1003).

6.2.5. RELATIVE DOSE RESPONSE AND MODIFIED RELATIVE DOSE RESPONSE

The RDR and MRDR tests are used to assess liver reserves of vitamin A. These tests rely on the principle that during vitamin A deficiency, *apo*-retinol-binding protein (unbound to retinol) accumulates in the liver. After a small oral dose of vitamin A is delivered, *holo*-retinol-binding protein (bound to retinol) is released by the liver into the circulation. The RDR test involves taking a blood sample, giving a standard oral dose of vitamin A, and then drawing a second blood sample 5 h after administration of the vitamin A dose. The response is measured as a percentage: $RDR = (A_5 - A_0)/A_5$, where A_5 = serum retinol concentration 5 h after dosing, and A_0 = serum retinol concentration before dosing (1004). An RDR of $\geq 20\%$ is considered to indicate inadequate liver vitamin A reserves. Although the RDR test has been used successfully in some clinical and field studies, the obvious

drawback is the need to draw two successive blood samples on subjects and to have them wait for five hours between the two blood drawings. The RDR test may not be reliable among subjects who have infections and an acute phase response (1005). The MRDR test involves giving a single oral dose of 3,4-didehydroretinol, which will also combine with *apo*-retinol-binding protein in the liver to form *holo*-retinol-binding protein released into the circulation. A blood sample is drawn 4–6 h after dosing, and the molar ratio of 3,4-didehydroretinol/retinol (DR/R) is measured in the serum. A DR/R ratio of ≥ 0.06 is considered to be consistent with inadequate vitamin A status (1006).

6.2.6. PUPILLARY THRESHOLD

Pupillary threshold is a measure of pupil diameter in subjects that are exposed to low illumination. In people with vitamin A deficiency, the pupil does not constrict normally to light because the amount of rhodopsin in the retina is reduced. Measurement of pupil diameter during dark adaptation was proposed as an objective test for vitamin A deficiency as early as the 1930s, but initial testing in vitamin A-deficient rabbits was negative (1007). In the pupillary threshold test, a battery-powered, hand-held illuminator is placed over the eyes, with one eye exposed to a yellow-green, light-emitting diode (LED) that has 12 intensity settings and the contralateral eye illuminated obliquely with a red LED. The subject has both eyes exposed to a bright light and then undergoes dark adaptation for 10 min in a dark tent. Pupillary threshold is measured by having the right eye fix on a non-accommodative target at two meters (to prevent pupillary constriction with accommodation) under conditions of increasing stimulus intensity. The left eye is observed using the red LED and a 2.5 \times loupe until a pupillary response is clearly visible (1008). Pupillary threshold has been tested among young children in Indonesia (1008) and India (1009), and among pregnant women in Nepal (1010). Pupillary threshold correlates with serum retinol concentrations and responds well following vitamin A supplementation (1009).

6.2.7. DIETARY ASSESSMENT

A simplified dietary assessment questionnaire was developed by the International Vitamin A Consultative Group to identify populations at risk for vitamin A deficiency (1011). The questionnaire is adapted for use in different populations, based on locally available sources of vitamin A-rich foods. Food composition tables are used to categorize local foods into high, moderate, and low, depending on vitamin A content of the food and usual portion sizes. Local workers administer the questionnaire to determine the intake and portion size in the last 24 h, and then the usual frequency of intake on a daily, weekly, and monthly basis (1011). A food frequency questionnaire has also been developed by Helen Keller International and uses 24-h recall (602).

6.2.8. OTHER TESTS

Serum –RBP. Serum RBP has been advocated as a surrogate measure for serum retinol (1012–1014). Serum RBP and retinol are highly correlated, and RBP can be measured using simple immunodiffusion assays (1012) or by enzyme-linked immunosorbent assay; however, as an indicator of vitamin A status, serum RBP has the same limitations of serum retinol under conditions of inflammation or infection.

RBP/TTR ratio. The ratio of RBP to TTR has been advocated as a method to measure vitamin A status in the presence of inflammation (1015). During the acute phase response, serum RBP and retinol decrease, but TTR may not decrease, thus, it is thought that a low

Table 5
Treatment Schedule and Vitamin A Dose
for All Age Groups Except Women of Reproductive Age

<i>Timing</i>	<i>Vitamin A dose</i>
Immediately on diagnosis	
<6 mo of age	50,000 IU
6–12 mo of age	100,000 IU
>12 mo of age	200,000 IU
Next day	Same age-specific dose
At least 2 wk later	Same age-specific dose

molar ratio of RBP/TTR can identify people with vitamin A deficiency in the presence of infection (1015). Despite these theoretical considerations, the RBP/TTR ratio has shown poor sensitivity and specificity as an indicator of vitamin A status when applied in studies among hospitalized children in Africa (1016) and among children with inflammation (1017).

Retinoyl β -glucuronide (RAG) hydrolysis test. The RAG hydrolysis test is based on the measurement of retinoic acid in serum (1018). After oral administration of RAG in vitamin A-sufficient animals, RAG is slowly hydrolyzed to retinoic acid, but in vitamin A-deficient animals, the hydrolysis of RAG to retinoic acid is more rapid, and higher retinoic acid concentrations are found in serum (1019). The RAG hydrolysis test is currently undergoing evaluation among children in India (A. Barua, personal communication).

Isotope dilution technique. An isotope dilution technique using deuterated retinol has been used to quantitatively estimate total body reserves of vitamin A in humans (1020, 1021). The technique can detect changes in total body stores of vitamin A in response to different daily vitamin A supplements (1022). The deuterated-retinol-dilution technique has been used to show that consumption of vitamin A-rich plant foods can improve total-body vitamin A stores among men in Bangladesh (1023).

7. TREATMENT OF VITAMIN A DEFICIENCY

7.1. Vitamin A Capsules

High-dose vitamin A supplementation is recommended for immediate treatment of infants, children, and adults (except women of reproductive age) with xerophthalmia according to the treatment schedule shown in Table 5. Women of reproductive age who have night blindness or Bitot spots should be treated with $\leq 10,000$ IU/day or weekly doses of $\leq 25,000$ IU. If women of reproductive age have acute corneal lesions (corneal xerosis, corneal ulceration, keratomalacia), they should be treated as in Table 5. Retinyl palmitate in oily solution, as contained in capsules, is recommended to be taken by mouth. The oral route of administration should be used in almost all cases, and for infants and young children, the capsule can be cut with scissors and the oily solution squeezed into the mouth. Children with corneal xerosis, corneal ulceration, or keratomalacia are usually admitted to the hospital, and this also helps facilitate adjunct support and administration of the vitamin A dose on the following day. For children with night blindness and/or Bitot spots, the subsequent doses of vitamin A can be given to the parent or guardian for administration in the home. Parenteral therapy should be avoided unless the child cannot swallow

or has severe repeated vomiting, and if parenteral therapy is used, water-miscible preparations of vitamin A should be used. Intramuscular injections of oil-miscible preparations of vitamin A are not well absorbed (285,1024).

7.2. Adjunct Treatments

Active xerophthalmia is often accompanied by diarrheal disease, measles, and intestinal helminthiasis, and it can also be associated with protein energy malnutrition. Secondary infections of the eye may also be present. All efforts should be made to treat the underlying conditions with appropriate hydration, supportive care, and antibiotics if indicated (598).

8. PREVENTION OF VITAMIN A DEFICIENCY

8.1. Dietary Modification

Increased consumption of vitamin A-rich foods is an ideal goal in populations that are at high risk for vitamin A deficiency, and strategies to increase consumption include nutrition education and promoting homestead food production. These approaches usually involve efforts to increase the intake of preformed vitamin A from animal sources (eggs, milk, fish liver oils, dairy products) and provitamin A carotenoids (dark green leafy vegetables, carrots, mango, papaya, red palm oil), and the groups that are initially targeted are infants, preschool children, and pregnant or lactating women. Fruits and vegetables are a major source of vitamin A among women of childbearing age in Bangladesh (1025). In Tanzania, nutrition and horticultural education improved knowledge and practices in regard to vitamin A intake in children (1026). Consumption of dark green leafy vegetables and eggs increased in Indonesia after initiation of a social marketing campaign to increase consumption of these foods (1027). In rural South Africa, vitamin A intake was higher among children from household with a home garden compared to those without a home garden (1028). Serum retinol levels were higher among preschool children in a village where home gardens and nutrition education were implemented compared to a control village (1028). In Burkina Faso, both vitamin A intake and serum retinol increased among mothers and children after implementation of a project promoting consumption of red palm oil (1030).

8.2. Food Fortification

Fortification of foods such as sugar, margarine, and noodles with vitamin A has been used to improve vitamin A status in populations (1031). As previously noted, vitamin A fortification of margarine and milk were recommended by the American Medical Association and practiced in the United States since the mid-20th century. The basic principles concerning food fortification are that the fortified food is (1) regularly consumed by the target population, (2) produced in a centralized fashion, (3) not noticeably different in taste, smell, or appearance to the nonfortified food, and (4) retains stability and bioavailability by the time it reaches the level of household consumption (1031). Thus, in rice-producing countries, rice would be a poor vehicle for fortification, because it is produced by many households and lacks a centralized point where the rice could be fortified. Fortification of sugar has been used in Central America since the 1970s (*see* Subheading 2.7.) (124). In households in Guatemala and El Salvador, sugar contains about 9 mg of vitamin A per kilogram and contributes 45–180% of the RDI for people older than 3 yr of age

(1031). Among poor urban toddlers in Guatemala, fortified foods (mostly fortified sugar, margarine, and Incaparina) contribute about one half of the RDI (1032). Fortification of MSG was used in pilot programs in Indonesia and the Philippines in the 1970s and 1980s (503,1033), but the color instability of the vitamin A in MSG and cost were some barriers to implementation of fortified MSG on a wider scale. Vitamin A-fortified margarine improved serum retinol levels and protected against xerophthalmia in Filipino preschool children (1034). Ideally, vitamin A-fortified foods should reach the most remote and impoverished families, as these constitute a higher-risk group for vitamin A deficiency. In remote Indonesia, salt and monosodium glutamate were widely consumed in most households, whereas instant noodles were consumed less in poorer families (1035).

8.3. Control of Infectious Diseases

Given the close relationship between some infectious diseases and vitamin A deficiency, the control of diseases such as measles (598) and diarrheal diseases would likely reduce the risk of xerophthalmia among infants and preschool children. Thus, programs aimed at more effective measles vaccines, prevention of diarrheal diseases, and malaria control would likely have an effect on reducing xerophthalmia. Treatment of intestinal parasites such as *Ascaris lumbricoides* may help to improve the vitamin A status of children who consume a diet high in provitamin A carotenoids (1036,1037).

8.4. Breastfeeding Practices

As noted previously, breastfeeding is protective against xerophthalmia because breast milk provides a major source of vitamin A for infants. Breast milk also provides other essential nutrients and immunological factors that help protect infants against infectious diseases. Maternal education and promotion of breastfeeding is a strategy that helps to reduce the risk of vitamin A deficiency among infants and young children.

8.5. Plant Breeding

Plant breeding has the potential to increase the provitamin A content of several staple foods crops such as rice and cassava (1038). The β -carotene synthetic pathway from the daffodil (*Narcissus pseudonarcissus*) has been introduced into the endosperm of rice (*Oryza sativa*) (1039). The resulting prototype line is known as “Golden Rice” (1040), but this genetically engineered rice has not yet seen widespread use. Transgenic tomato plants have been produced that have higher β -carotene content compared with the regular tomato (1041). Potential hurdles to the use of genetically engineered sources of vitamin A include special interest groups that are opposed to any form of genetically engineered crops.

8.6. Vitamin A Capsule Distribution

As noted under Subheading 2.7., as early as the 1970s, periodic high-dose vitamin A supplementation was implemented in various programs in different developing countries (1042–1044). Periodic high-dose vitamin A supplementation has now been adopted by many countries for the prevention of vitamin A deficiency among preschool children, such as Bangladesh, Indonesia, Vietnam, Nepal, the Philippines, and Thailand (1045–1047). In developing countries where vitamin A deficiency is endemic, the dosage of vitamin A given for prophylaxis is 200,000 IU orally every 4–6 mo for children >12 mo of age and 100,000 IU orally every 4–6 mo for infants 6–12 mo of age (133). It is also

recommended that mothers receive 200,000 IU orally within 8 wk of delivery. Although many countries have policy recommendations regarding postpartum vitamin A supplementation to mothers, the coverage of these programs has been generally low. Vitamin A supplementation has been integrated with national immunization days in some countries (1048). Vitamin A capsule distribution was originally considered to be a short term measure to prevent vitamin A deficiency among preschool children while other measures, such as dietary interventions and food fortification were implemented, but many countries have had vitamin A control programs involving vitamin A capsule distribution for two decades or longer.

9. CONCLUSIONS

Vitamin A deficiency remains a leading cause of morbidity, mortality, and blindness among preschool children in developing countries worldwide. The consequences of vitamin A deficiency include impaired immune function, growth retardation, anemia, xerophthalmia, and blindness. Diverse long-term strategies, including nutrition education, food fortification, and homestead food production are needed to prevent vitamin A deficiency in developing countries. Ultimately, family-based approaches are required to address vitamin A deficiency, because pregnant women and women of childbearing age are at high risk of vitamin A deficiency in many countries and are not reached by vertical programs such as vitamin A capsule distribution. Xerophthalmia and blindness tend to occur among children who are not reached by programs aimed at improving vitamin A status through capsule distribution, fortification, and nutritional interventions. Further work is needed to characterize these households in order to formulate strategies to reach the remaining “out-of-reach” children.

REFERENCES

1. Thylefors B, Negrel AD, Pararajasegeram R, Dadzie KY. Global data on blindness. *Bull World Health Organ* 1995;73:115–121.
2. Gilbert C, Foster A. Childhood blindness in the context of VISION 2020—the right to sight. *Bull World Health Organ* 2001;79:227–232.
3. de Gouvêa H. Contribuição para o estudo da hemeralopia e a xerophthalmia por vicio de nutrição. *Gazeta Medica Brasileira* 1882;1:13–16, 67–72, 92–97, 139–145, 212–222.
4. Hippocrates. *Epidemics*. Book 2, 4–7. Edited and translated by Wesley D. Smith. Cambridge, MA, Harvard University Press: 1994; p. 269.
5. Celsus C. *De Medicina*, Vol II, Book VI. London, Heinemann: 1989; p. 225.
6. Santos J dos. *Ethiopia Oriental, e varia historia de covsa, notaveis do Oriente*. Evora, Manoel de Lira:, 1609.
7. Jackson JG. *An Account of the Empire of Marocco, and the Districts of Suse and Tafielt: Compiled from Miscellaneous Observations Made during a Long Residence in, and Various Journeys through, these Countries*. 2nd edition. London, W. Bulmer, 1811.
8. Bondt J de. *De Medicina Indorum*, lib. IV. Amsterdam, Lugduni Batav, 1642.
9. Pisonis G. *Historia Naturalis Brasiliae. De Medicina Brasiliae. Libri Quator*: I. De aëre, aquis, & locis. II. De morbis endemiis. III. De venenatis & antidotes. IV. De facultatibus simplicium. Amsterdam, L. Batavorum, 1648.
10. Entrecolles FX. *Lettre du Pere d’Entrecolles, Missionnaire de la Compagnie de Jesus, au Pere Duhalde, de la Même Compagnie*. Peking, 8 October 1736. Jesuits. *Lettre Édifiantes et Curieuses, Écrites des Missions Étrangères*. Nouvelle Édition, vol 22. Paris, J. G. Merigot: 1781; pp. 183–245.

11. Hillary W. Observations on the Changes of the Air and the Concomitant Epidemical Disease, in the Island of Barbados. To which is Added a Treatise on the Putrid Bilious Fever, Commonly Called the Yellow Fever; and Such Other Diseases as are Indigenous or Endemical, in the West India Islands, or the Torrid Zone. London, C. Hitch and L. Hawes, 1759.
12. Richard de Hautesierck, FMC. Recueil d'observations de médecine des hôpitaux militaires. Tome II. Paris, Imprimerie Royale, 1772.
13. Caspar. Hemeralopie in epidemischer Form. Wochenschrift für die gesammte Heilkunde 1833;1:73–77.
14. Blane G. Observations on the diseases incident to seamen. London, Joseph Cooper: 1785; pp. 502.
15. Magendie F. Mémoire sur les propriétés nutritives des substances qui ne contiennent pas d'azote. Bulletin des Sciences par la Société philomatique de Paris 1816;4:137–138.
16. Ratier. Note sur un cas d'ulcération de la cornée transparente. Archives Générales de Médecine 1824; 2 ser. 4:255–257.
17. Brown J. Case of ulcerated cornea, from inanition. Edinb J Med Sci 1827;3:218.
18. Billard C. Traité des maladies des enfans nouveaux-nés et a la mamelle, fondé sur de nouvelles observations cliniques et d'anatomie pathologique, faites a l'Hôpital des Enfants-trouvés de Paris, dans le service de M. Baron. Paris, J.B. Baillière, 1828.
19. Bowman W. Lectures on the Parts Concerned in the Operations of the Eye, and on the Structure of the Retina, Delivered at the Royal London Ophthalmic Hospital, Moorfields, June, 1847. To Which Are Added, a Paper on the Vitreous Humor; and also a Few Cases of Ophthalmic Disease. London, Longman, Brown, Green, and Longmans, 1849.
20. Bitot [P]. Mémoire sur une lesion conjonctivale non encore décrite, coïncidant avec l'héméralopie. Gaz Hebd Méd Chir 1863;10:284–288.
21. Villemain JA. De l'altération épithéliale de la conjunctive oculaire dans l'héméralopie. Gaz Hebd Méd Chir 1863;10:332–335.
22. Netter A. Mémoire sur les taches blanches des sclérotiques dans l'héméralopie. Gaz méd Paris 1863;34: 505–507.
23. Blessig [RB]. Ueber Xerose des Bindehautepithels und deren Beziehung zur Hemeralopie. St Petersburg Medicinische Zeitschrift 1866;11:343–354.
24. Ullersperger B [Account by Gama Lobo reported by Ullersperger and translated to German]. Brasilianische Augenentzündung (Ophthalmia braziliana). Klin Monatsbl Augenheilk 1866;4:65–75. Also: Gazeta Medica de Lisboa 1865;No. 16, 28 August 1865, p. 430, and No. 17, 13 September 1865; p. 466.
25. Mecklenburg. Hemeralopia epidemica im Gefängniss des Deutsch-Croner Kreisgerichts. Allgemeine Medicinische Central-Zeitung 1855;24:73–75.
26. de Hubbenet [von Huebbenet, Anton Christian August]. Procès-Verbal de la Séance du 26 Septembre 1860 de la Société Médicale des Hôpitaux de Paris. Observations sur l'héméralopie. Bulletins et Mémoires de la Société Médicale des Hôpitaux de Paris 1860;4:559–561.
27. Mendes JC. Estudo sobre a hemeralopia a proposito dos casos observados na guarnição de Lisboa. O Escholiaste Medico 1862;13:22–24, 39–42, 55–58, 70–72, 85–88, 106–110.
28. Lunin N. Über die Bedeutung der anorganischen Salze für die Ernährung des Thieres. Zeitschr physiol Chem 1881;5:31–39.
29. Socin CA. In welcher Form wird das Eisen resorbirt? Zeitschr Physiol Chem 1891;15:93–139.
30. Pekelharing CA. Over onze kennis van de waarde der voedingsmiddelen uit chemische fabrieken. Nederl Tijdschr Geneesk 1905;41:111–124.
31. Hopkins FG. Feeding experiments illustrating the importance of accessory factors in normal dietaries. J Physiol 1912;44:425–460.
32. Stepp W. Experimentelle Untersuchungen über die Bedeutung der Lipide für die Ernährung. Zeitschr Biol 1911;57:136–170.
33. Wolf G, Carpenter KJ. Early research into the vitamins: the work of Wilhelm Stepp. J Nutr 1997;127: 1255–1259.
34. McCollum EV, Davis M. The necessity of certain lipins in the diet during growth. J Biol Chem 1913; 15:167–175.
35. Osborne TB, Mendel LB. The relationship of growth to the chemical constituents of the diet. J Biol Chem 1913;15:311–326.

36. Osborne TB, Mendel LB. The influence of cod liver oil and some other fats on growth. *J Biol Chem* 1914;17:401–408.
37. McCollum EV, Kennedy C. The dietary factors operating in the production of polyneuritis. *J Biol Chem* 1916;24:491–502.
38. Osborne TB, Mendel LB. The vitamins in green foods. *J Biol Chem* 1919;37:187–200.
39. Steenbock H, Gross EG. Fat-soluble vitamins. II. The fat-soluble vitamin content of roots, together with some observations on their water-soluble vitamin content. *J Biol Chem* 1919;40:501–531.
40. Steenbock H, Gross EG. Fat-soluble vitamins. IV. The fat-soluble vitamin content of green plant tissues together with some observations on their water-soluble vitamin content. *J Biol Chem* 1920;41:149–162.
41. Moore T. The relation of carotin to vitamin A. *Lancet* 1929;2:380–381.
42. Karrer P, Morf R, Schöpp K. Zur Kenntnis des Vitamins-A aus Fischtranen. *Helv Chim Acta* 1931;14:1036–1040.
43. Karrer P, Morf R, Schöpp K. Zur Kenntnis des Vitamins-A aus Fischtranen II. *Helv Chim Acta* 1931;14:1431–1436.
44. Holmes HN, Corbet RE. The isolation of crystalline vitamin A. *J Am Chem Soc* 1937;59:2042–2047.
45. Arens JF, van Dorp DA. Synthesis of vitamin A aldehyde. *Nature (London)* 1947;160:189.
46. Isler O, Huber W, Ronco A, Kofler M. Synthese des Vitamin A. *Helv Chim Acta* 1947;30:1911–1921.
47. Wald G. The photoreceptor process in vision. *Am J Ophthalmol* 1955;40:18–41.
48. Blegvad O. Xerophthalmia, keratomalacia and xerosis conjunctivae. *Am J Ophthalmol* 1924;7:89–117.
49. Blegvad O. Om xerophthalmien og dens forekomst i Danmark i aarene 1909–1920. København, Gyldendalske Boghandel, 1923.
50. Bloch CE. Blindness and other diseases in children arising from deficient nutrition (lack of fat-soluble A factor). *Am J Dis Child* 1924;27:139–148.
51. Bloch CE. Clinical investigation of xerophthalmia and dystrophy in infants and young children (*xerophthalmia et dystrophia alipogenetica*). *J Hygiene* 1921;19:283–303.
52. Bloch CE. Further clinical investigations into the diseases arising in consequence of a deficiency in the fat-soluble A factor. *Am J Dis Child* 1924b;28:659–667.
53. Bloch CE. Effects of deficiency in vitamins in infancy. Caries of the teeth and vitamins. *Am J Dis Child* 1931;42:263–278.
54. Widmark E. Vitamin-A deficiency in Denmark and its results. *Lancet* 1924;1:1206–1209.
55. Cramer W. An address on vitamins and the borderland between health and disease. *Lancet* 1924;1:633–640.
56. Semba RD. Vitamin A as “anti-infective” therapy, 1920–1940. *J Nutr* 1999;129:783–791.
57. Ellison JB. Intensive vitamin therapy in measles. *Br Med J* 1932;2:708–711.
58. Semba RD. On Joseph Bramhall Ellison’s discovery that vitamin A reduces measles mortality. *Nutrition* 2003;19:390–394.
59. Green HN, Pindar D, Davis G, Mellanby E. Diet as a prophylactic agent against puerperal sepsis. *Br Med J* 1931;2:595–598.
60. Cameron SJ. An aid in the prevention of puerperal sepsis. *Trans Edinburgh Obstet Soc* 1931;52:93–103.
61. Prescott SC, Proctor BE. Food technology. New York, McGraw-Hill Book Company, Inc., 1937.
62. Lancet. Parliamentary Intelligence. Ottawa and cod-liver oil. *Lancet* 1932;2:978–979.
63. British Medical Journal. Medical Notes in Parliament. Ottawa Agreements: cod-liver oil. *Br Med J* 1932a;2:661.
64. British Medical Journal. Medical Notes in Parliament. Ottawa Agreements: cod-liver oil. *Br Med J* 1932;2:819.
65. Heilbron IM, Jones WE, Bacharach AL. The chemistry and physiology of vitamin A. *Vit Horm* 1944;2:155–213.
66. Perla D, Marmorston J. Natural Resistance and Clinical Medicine. Boston, Little, Brown and Company, 1941.
67. Mixed Committee of the League of Nations. The Relation of Nutrition to Health, Agriculture and Economic Policy. Document A.13.1937.II.A. Geneva, League of Nations, 1937.
68. Rose MS. Choosing food for health. In: Handbook on Positive Health. [no editor] Revised edition. New York, Women’s Foundation for Health: 1928; pp. 114–132.

69. Council of British Societies for Relief Abroad. Nutrition and Relief Work: Handbook for the Guidance of Relief Workers. London, Oxford University Press, 1945.
70. Medical Research Council. Vitamins: a Survey of Present Knowledge. Special Report Series, No. 167. London, His Majesty's Stationery Office, 1932.
71. McCarrison R. Studies in Deficiency Disease. London, Henry Frowde and Hodder & Stroughton, 1921.
72. Drummond JC, Hilditch TP. The Relative Values of Cod Liver Oils from Various Sources. London, His Majesty's Stationery Office, 1930.
73. Mellanby E. Nutrition and Disease: the Interaction of Clinical and Experimental Work. Edinburgh, Oliver and Boyd, 1934.
74. Mouriquand G. Vitamines et carences alimentaires. Paris, Albin Michel, 1942.
75. Bietti G. Le Vitamine in Oftalmologia. Bologna, Licinio Cappelli, 1940.
76. Ammon R, Dirscherl W. Fermente Hormone Vitamine und die Beziehungen dieser Wirkstoffe zueinander. Leipzig, Georg Thieme, 1938.
77. Sherman HC. The Science of Nutrition. New York, Columbia University Press, 1943.
78. Rose MS. The Foundations of Nutrition. New York, Macmillan, 1927.
79. Smillie WG. Public Health Administration in the United States. Second edition. New York, Macmillan, 1940.
80. Newman G. The Building of a Nation's Health. London, Macmillan, 1939.
81. Tucker DM. Kitchen Gardening in America: a History. Ames, Iowa State University Press, 1993.
82. Council on Foods and Nutrition, American Medical Association. Fortification of foods with vitamins and minerals. J Am Med Assoc 1939;113:681.
83. Bauernfeind JC, Arroyave G. Control of vitamin A deficiency by the nutrification of food approach. In: Bauernfeind JC (ed). Vitamin A deficiency and its control. New York, Academic: 1986; pp. 359–388.
84. Gunderson GW. National School Lunch Program background and development. Food and Nutrition Service-63. Washington, D.C., Food and Nutrition Service, U.S. Department of Agriculture, 1971.
85. World Health Organization. Joint FAO/WHO Expert Committee on Nutrition. Geneva, 26 Octoberâ 2 November 1954. Document WHO/NUT/53. Geneva, World Health Organization, 1954.
86. Ramalingaswami V. Nutritional diarrhoea due to vitamin A deficiency. Indian J Med Sci 1948;2: 665–674.
87. Wolbach SB, Howe PR. Tissue changes following deprivation of fat soluble A vitamin. J Exp Med 1925;42:753–777.
88. Richards MB. The role of vitamin A in nutrition. Br Med J 1935;1:99–102.
89. Tilden EB, Miller EG Jr. The response of monkey (*Macacus rhesus*) to withdrawal of vitamin A from the diet. J Nutr 1930;3:121–140.
90. Pillat A. Does keratomalacia exist in adults? Arch Ophthalmol 1929;2:256–287, 399–415.
91. Rit P. Treatment of infantile diarrhoea with vitamin 'A'. Calcutta Med J 1937;32:454–457.
92. Kinney TD, Follis RH Jr (eds). Nutritional Disease: Proceedings of a Conference on Beriberi, Endemic Goiter and Hypovitaminosis A, held at Princeton, N.J., June 1–5, 1958. Fed Proc 1958;17(suppl 2): i–viii, 1–162.
93. Oomen HAPC, McLaren DS, Escapini H. Epidemiology and public health aspects of hypovitaminosis A. Trop Geogr Med 1964;4:271–315.
94. West KP Jr, McLaren D. The epidemiology of vitamin A deficiency disorders (VADD). In: Johnson GJ, Minassian DC, Weale RA, West SK (eds). The Epidemiology of Eye Disease. Second edition. London, Arnold: 2003; pp. 240–259.
95. György P, Burgess A (eds). Protecting the Pre-school Child: Programmes in Practice. Report on an International Symposium held at The Rockefeller Villa Serbelloni, Lake Como, 3–8 August 1963. London, Tavistock, 1965.
96. National Academy of Sciences. Pre-School Child Malnutrition: Primary Deterrent to Human Progress. An International Conference on Prevention of Malnutrition in the Pre-School Child, Washington, D.C., December 7–11, 1964. National Academy of Sciences—National Research Council Publication 1282. Washington, D.C., National Academy of Sciences, 1966.
97. McLaren DS. The prevention of xerophthalmia. In: Pre-School Child Malnutrition: Primary Deterrent to Human Progress. An International Conference on Prevention of Malnutrition in the Pre-School

- Child, Washington, D.C., December 7–11, 1964. National Academy of Sciences—National Research Council Publication 1282. Washington, D.C., National Academy of Sciences: 1966; pp. 96–101.
98. György P. Programs for combating malnutrition in the pre-school child in Indonesia. In: Pre-School Child Malnutrition: Primary Deterrent to Human Progress. An International Conference on Prevention of Malnutrition in the Pre-School Child, Washington, D.C., December 7–11, 1964. National Academy of Sciences—National Research Council Publication 1282. Washington, D.C., National Academy of Sciences: 1966; pp. 105–111.
 99. Sebrell WH Jr. Population and food supply—implications in this hemisphere. Proceedings Western Hemisphere Nutrition Congress Organized by the Council on Foods and Nutrition, American Medical Association, November 8–11, 1965, Chicago, Illinois. Chicago, American Medical Association, 1966, pp. 7–13.
 100. Interdepartmental Committee on Nutrition for National Defense. The Hashemite Kingdom of Jordan Nutrition Survey on Infants and Preschool Children in Jordan, November 1962–October 1963. National Institutes of Health, Bethesda, 1964.
 101. Interdepartmental Committee on Nutrition for National Defense. Ethiopia Nutrition Survey. Bethesda, National Institutes of Health, 1959.
 102. Interdepartmental Committee on Nutrition for National Defense. Republic of Vietnam Nutrition Survey, October–December 1959. Bethesda, National Institutes of Health, 1960.
 103. Interdepartmental Committee on Nutrition for National Defense. The Kingdom of Thailand Nutrition Survey, October–December 1960. Bethesda, National Institutes of Health, 1962.
 104. Interdepartmental Committee on Nutrition for National Defense. Republic of Lebanon Nutrition Survey, February–April 1961. Bethesda, National Institutes of Health, 1962.
 105. Interdepartmental Committee on Nutrition for National Defense. Pakistan: Nutrition Survey of East Pakistan, March 1962–January 1964. Bethesda, National Institutes of Health, 1966.
 106. Interdepartmental Committee on Nutrition for National Defense. Manual for Nutrition Surveys. Second edition. Bethesda, National Institutes of Health, 1963.
 107. McLaren DS, Oomen HAPC, Escapini H. Ocular manifestations of vitamin-A deficiency in man. *Bull World Health Organ* 1966;34:357–361.
 108. Pan American Health Organization. Hypovitaminosis A in the Americas: Report of a PAHO Technical Group Meeting (Washington, D.C., 28–30 November 1968). Scientific Publication No. 198. Washington, D.C., Pan American Health Organization, 1970.
 109. Scrimshaw NS, Taylor CE, Gordon JE. Interactions of Nutrition and Infection. Geneva, World Health Organization, 1968.
 110. Ouwehand CD. Over “rondar manok.” *Geneesk Tijdschr Nederl Indië* 1900;40:227–229.
 111. Tijssen J. Oorzaken van blindheid in Atjeh. *Geneesk Tijdschr Nederl Indië* 1927;67:99–101.
 112. Lian SB. Avitaminose A bij inlandsche zuigelingen. *Geneesk Tijdschr Nederl Indië* 1929;69:1097–1103.
 113. de Haas JH. On keratomalacia in Java and Sumatra (in particular on the Karo-Plateau) and in Holland. *Mededeel Dienst Volksgezond Nederl Indië* 1931;20:1–11.
 114. Oomen HAPC. Infant malnutrition in Indonesia. *Bull World Health Organ* 1953;9:371–384.
 115. Doesschate J ten. Causes of Blindness in and around Surabaja, East Java, Indonesia. Doctoral thesis. University of Jakarta, Jakarta, Indonesia, 1968.
 116. McLaren DS. Xerophthalmia: a neglected problem. *Nutr Rev* 1964;22:89–91.
 117. Chopra JG, Kevany J. Hypovitaminosis A in the Americas. *Am J Clin Nutr* 1970;23:231–241.
 118. Olson JA. The prevention of childhood blindness by the administration of massive doses of vitamin A. *Israel J Med Sci* 1972;8:1199–1206.
 119. Van Veen AG, Van Veen MS. Some present-day aspects of vitamin A problems in less developed countries. *Ecol Food Nutr* 1974;3:35–54.
 120. Vijayaraghavan K, Naidu AN, Rao NP, Srikantia SG. A simple method to evaluate the massive dose vitamin A prophylaxis program in preschool children. *Am J Clin Nutr* 1975;28:1189–1193.
 121. Kamel WW. A Global Survey of Mass Vitamin A Programs. Office of Nutrition, Technical Assistance Bureau, Agency for International Development, U.S. Department of State, July 1973.
 122. Fritz C. Combating Nutritional Blindness in Children: A Case Study of Technical Assistance in Indonesia. Pergamon Policy Studies on Socio-Economic Development. New York, Pergamon Press, 1980.

123. Pan American Health Organization. Ten-Year Health Plan for the Americas. Final Report of the III Special Meeting of the Ministers of Health of the Americas (Santiago, Chile, 2–9 October 1972). PAHO Official Document 118, Washington, D.C., 1973.
124. Arroyave G. The program of fortification of sugar with vitamin A in Guatemala. Some factors bearing on its implementation and maintenance. In: Scrimshaw NS, Wallerstein MB (eds). *Nutrition Policy Implementation: Issues and Experience*. New York, Plenum: 1982; pp. 75–88.
125. Gershoff SN. Food fortification. In: Scrimshaw NS, Wallerstein MB (eds). *Nutrition Policy Implementation: Issues and Experience*. New York, Plenum: 1982; pp. 61–71.
126. World Health Organization. Vitamin A Deficiency and Xerophthalmia. Report of a Joint WHO/USAID Meeting. Geneva, World Health Organization, 1976.
127. McLaren DS. A Decade of Achievement: the International Vitamin A Consultative Group (IVACG), 1975–1985. Washington, D.C., International Life Sciences Institute—Nutrition Foundation, 1987.
128. Sommer A, Tarwotjo I, Hussaini G, Susanto D. Increased mortality in children with mild vitamin A deficiency. *Lancet* 1983;2:585–588.
129. Sommer A, Tarwotjo I, Djunaedi E, et al. Impact of vitamin A supplementation on childhood mortality: a randomized controlled community trial. *Lancet* 1986;1:1169–1173.
130. Beaton GH, Martorell R, L'Abbe KA, et al. Effectiveness of Vitamin A Supplementation in the Control of Young Child Morbidity and Mortality in Developing Countries. ACC/SCN State-of-the-Art Nutrition Policy Discussion Paper No. 13, United Nations, New York, 1993.
131. The Vitamin A and Pneumonia Working Group. Potential interventions for the prevention of childhood pneumonia in developing countries: a meta-analysis of data from field trials to assess the impact of vitamin A supplementation on pneumonia morbidity and mortality. *Bull WHO* 1995;73: 609–619.
132. Villamor E, Fawzi WW. Vitamin A supplementation: implications for morbidity and mortality in children. *J Inf Dis* 2000;182(suppl 2):S122–S133.
133. WHO/UNICEF/IVACG Task Force. Vitamin A Supplements. A Guide to Their Use in the Treatment of Prevention of Vitamin A Deficiency and Xerophthalmia. 2nd edition. Geneva, World Health Organization, 1997.
134. Bloem MW, Huq N, Gorstein J, et al. Production of fruits and vegetables at the homestead is an important source of vitamin A among women in rural Bangladesh. *Eur J Clin Nutr* 1996;50:S62–S67.
135. de Pee S, West CE, Muhilal, Karyadi D, Hautvast JG. Lack of improvement in vitamin A status with increased consumption of dark-green leafy vegetables. *Lancet* 1995;346:75–81.
136. West CE. Meeting requirements for vitamin A. *Nutr Rev* 2000;58:341–345.
137. Erdman JW Jr, Bierer TL, Gugger ET. Absorption and transport of carotenoids. *Ann NY Acad Sci* 1993;691:76–85.
138. Gray EL, Morgareidge K, Cawley JD. Intestinal absorption of vitamin A in the normal rat. *J Nutr* 1940;20:67–74.
139. Eden E, Sellers KC. Hydrolysis and esterification of vitamin A during absorption. *Biochem J* 1950; 46:261–266.
140. van Bennekum AM, Fisher EA, Blaner WS, Harrison EH. Hydrolysis of retinyl esters by pancreatic triglyceride lipase. *Biochemistry* 2000;39:4900–4906.
141. Rigtrup KM, Ong DE. A retinyl ester hydrolase activity intrinsic to the brush border membrane of rat small intestine. *Biochemistry* 1992;31:2920–2926.
142. Rigtrup KM, McEwen LR, Said HM, Ong DE. Retinyl ester hydrolytic activity associated with human intestinal brush border membranes. *Am J Clin Nutr* 1994;60:111–116.
143. Rigtrup KM, Kakkad B, Ong DE. Purification and partial characterization of retinyl ester hydrolase from the brush border of rat small intestine mucosa: probable identity with brush border phospholipase B. *Biochemistry* 1994;33:2662–2666.
144. Weng W, Li L, van Bennekum AM, Potter SH, et al. Intestinal absorption of dietary cholesteryl ester is decreased but retinyl ester absorption is normal in carboxyl ester lipase knockout mice. *Biochemistry* 1999;38:4143–4149.
145. Hollander D, Muralidhara KS. Vitamin A₁ intestinal absorption in vivo: influence of luminal factors on transport. *Am J Physiol* 1977;232:E471–E477.
146. Hollander D. Intestinal absorption of vitamins A, E, D, and K. *J Lab Clin Med* 1981;97:449–462.

147. Quick TC, Ong DE. Vitamin A metabolism in the human intestinal Caco-2 cell line. *Biochemistry* 1990;29:11116–11123.
148. Harrison EH, Hussain MM. Mechanisms involved in the intestinal digestion and absorption of dietary vitamin A. *J Nutr* 2001;131:1405–1408.
149. Li E, Norris AW. Structure/function of cytoplasmic vitamin A-binding proteins. *Annu Rev Nutr* 1996;16:205–234.
150. Ong DE. Absorption of vitamin A. In: Blomhoff R (ed). *Vitamin A in Health and Disease*. New York, Marcel Dekker: 1994; pp. 37–72.
151. Ong DE, Page DL. Cellular retinol-binding protein (type two) is abundant in human small intestine. *J Lipid Res* 1987;28:739–745.
152. Inagami S, Ong DE. Purification and partial characterization of cellular retinol-binding protein, type two, from human small intestine. *J Nutr* 1992;122:450–456.
153. Quick TC, Ong DE. Levels of cellular retinol-binding proteins in the small intestine of rats during pregnancy and lactation. *J Lipid Res* 1989;30:1049–1054.
154. Rajan N, Blaner WS, Soprano DR, Suhara A, Goodman DS. Cellular retinol-binding protein messenger RNA levels in normal and retinoid-deficient rats. *J Lipid Res* 1990;31:821–829.
155. Ong DE. A novel retinol-binding protein from rat: purification and partial characterization. *J Biol Chem* 1984;259:1476–1482.
156. Hollander D, Ruble PE Jr. β -carotene intestinal absorption: bile, fatty acid, pH and flow rate effects on transport. *Am J Physiol* 1978;233:E686–E692.
157. Olson JA, Hayaishi O. The enzymatic cleavage of β -carotene into vitamin A by soluble enzymes of rat liver and intestine. *Proc Natl Acad Sci USA* 1965;54:1364–1369.
158. Goodman DS, Huang HS. Biosynthesis of vitamin A with rat intestinal enzymes. *Science* 1965;149:879–880.
159. Goodman DS, Huang HS, Shiratori T. Mechanism of biosynthesis of vitamin A from β -carotene. *J Biol Chem* 1966;242:1929–1932.
160. Goodman DS, Huang HS, Kanai M, Shiratori T. The enzymatic conversion of all-trans β -carotene into retinal. *J Biol Chem* 1967;242:3543–3554.
161. Crain FD, Lotspeich FJ, Krause RF. Biosynthesis of retinoic acid by intestinal enzymes of the rat. *J Lipid Res* 1967;8:249–254.
162. Napoli JL, Race KR. Biogenesis of retinoic acid from β -carotene. Differences between the metabolism of β -carotene and retinal. *J Biol Chem* 1988;263:17372–17377.
163. Wang XD, Tang GW, Fox JG, Krinsky NI, Russell RM. Enzymatic conversion of β -carotene into β -apocarotenals and retinoids by human, monkey, ferret, and rat tissues. *Arch Biochem Biophys* 1991;285:8–16.
164. Tang GW, Wang XD, Russell RM, Krinsky NI. Characterization of β -apo-13-carotenone and β -apo-14'-carotenal as enzymatic products of the excentric cleavage of β -carotene. *Biochemistry* 1991;30:9829–9834.
165. Wang XD, Krinsky NI. The bioconversion of β -carotene into retinoids. *Subcell Biochem* 1998;30:159–180.
166. Barua AB, Olson JA. β -carotene is converted primarily to retinoids in rats in vivo. *J Nutr* 2000;130:1886–2001.
167. Yeum KJ, Lee-Kim YC, Yoon S, et al. Similar metabolites formed from beta-carotene by human gastric mucosal homogenates, lipoxygenase, and linoleic acid hydroperoxide. *Arch Biochem Biophys* 1995;321:167–174.
168. Gomboeva SB, Gessler NN, Shumaev KG, Khomich TI, Moiseenok AG, Bykhovskii VY. Some natural and synthetic antioxidants as stabilizers of beta-carotene conversion into vitamin A. *Biochemistry (Moscow)* 1998;63:185–190.
169. Kakkad B, Ong DE. Reduction of retinaldehyde bound to cellular retinol-binding protein (type II) by microsomes from rat small intestine. *J Biol Chem* 1988;263:12916–12919.
170. Huang HS, Goodman DS. Vitamin A and carotenoids. I. Intestinal absorption and metabolism of ^{14}C -labeled vitamin A alcohol and β -carotene in the rat. *J Biol Chem* 1965;240:2839–2844.
171. Goodman DS, Blomstrand R, Werner B, Huang HS, Shiratori T. The intestinal absorption and metabolism of vitamin A and β -carotene in man. *J Clin Invest* 1966;45:1615–1623.

172. Sauvant P, Mekki N, Charbonnier M, Portugal H, Lairon D, Borel P. Amounts and types of fatty acids in meals affect the pattern of retinoids secreted in human chylomicrons after a high-dose preformed vitamin A intake. *Metabolism* 2003;52:514–519.
173. Hussain MM, Kancha RK, Zhou Z, Luchoomun J, Zu H, Bakillah A. Chylomicron assembly and catabolism: role of apolipoproteins and receptors. *Biochim Biophys Acta* 1996;1300:151–170.
174. Bakillah A, Hussain MM. Binding of microsomal triglyceride transfer protein to lipids results in increased affinity for apolipoprotein B. Evidence for stable microsomal MTP-lipid complexes. *J Biol Chem* 2001;276:31466–31473.
175. Nayak N, Harrison EH, Hussain MM. Retinyl ester secretion by intestinal cells: a specific and regulated process dependent on assembly and secretion of chylomicrons. *J Lipid Res* 2001;42:272–280.
176. Hollander D. Retinol lymphatic and portal transport: influence of pH, bile, and fatty acids. *Am J Physiol* 1980;239:G210–G214.
177. Mead JR, Irvine SA, Ramji DP. Lipoprotein lipase: structure, function, regulation, and role in disease. *J Mol Med* 2002;80:753–769.
178. Wilson DE, Chan IF, Ball M. Plasma lipoprotein retinoids after vitamin A feeding in normal man: minimal appearance of retinyl esters among low-density lipoproteins. *Metabolism* 1983;32:514–517.
179. Berr F, Kern F Jr. Plasma clearance of chylomicrons labeled with retinyl palmitate in healthy human subjects. *J Lipid Res* 1984;25:805–812.
180. Pasatiempo AMG, Ross AC. Effects of food or nutrient restriction on milk vitamin A transfer to neonatal vitamin A stores in the rat. *Br J Nutr* 1990;63:351–362.
181. Green MH, Green JB, Akohoue SA, Kelley SK. Vitamin A intake affects the contribution of chylomicrons vs. retinol-binding protein to milk vitamin A in lactating rats. *J Nutr* 2001;131:1279–1282.
182. Ross AC, Pasatiempo AM, Green MH. Chylomicron margination, lipolysis, and vitamin A update in the lactating rat mammary gland: implications for milk retinoid content. *Exp Biol Med* 2004;229:46–55.
183. Blomhoff R, Helgerud P, Rasmussen M, Berg T, Norum KR. In vivo uptake of chylomicron [³H]retinyl ester by rat liver: evidence for retinol transfer from parenchymal to nonparenchymal cells. *Proc Natl Acad Sci USA* 1982;79:7326–7330.
184. Haq R, Chytil F. Retinoic acid rapidly induces lung cellular retinol-binding protein mRNA levels in retinol deficient rats. *Biochem Biophys Res Commun* 1988;156:712–716.
185. Skrede R, Blomhoff R, Maeldandsmo GM, Ose L, Myklebost O, Norum KR. Uptake of chylomicron remnant retinyl esters in human leukocytes in vivo. *Eur J Clin Invest* 1992;22:229–234.
186. Blomhoff R, Green MH, Green JB, Berg T, Norum KR. Vitamin A metabolism: new perspectives on absorption, transport, and storage. *Physiol Rev* 1991;71:951–990.
187. Goodman DS, Huang HS, Shiratori T. Tissue distribution and metabolism of newly absorbed vitamin A in the rat. *J Lipid Res* 1965;6:390–396.
188. Melchior GW, Mahley RW, Buckhold DK. Chylomicron metabolism during dietary-induced hypercholesterolemia in dogs. *J Lipid Res* 1981;22:598–609.
189. Cooper AD. Hepatic uptake of chylomicron remnants. *J Lipid Res* 1997;38:2173–2192.
190. Hamilton RL, Wong JS, Guo LSS, Krisans S, Havel RJ. Apolipoprotein E localization in rat hepatocytes by immunogold labeling of cryothin sections. *J Lipid Res* 1990;31:1589–1603.
191. Harrison EH, Gad MZ. Hydrolysis of retinyl palmitate by enzymes of rat pancreas and liver. Differentiation of bile salt-dependent and bile salt-independent, neutral retinyl ester hydrolases in rat liver. *J Biol Chem* 1989;264:17142–17147.
192. Blomhoff R, Eskild W, Kindberg GM, Prydz K, Berg T. Intracellular transport of endocytosed chylomicron [³H]retinyl ester in rat liver parenchymal cells. Evidence for translocation of a [³H]retinoid from endosomes to endoplasmic reticulum. *J Biol Chem* 1985;260:13566–13570.
193. Hirose K, Yamada E. The localization of the vitamin A in mouse liver as revealed by electron microscope radioautography. *J Electron Microsc (Tokyo)* 1973;22:337–346.
194. Batres RO, Olson JA. Relative amount and ester composition of vitamin A in rat hepatocytes as a function of the method of cell preparation and of total liver stores. *J Nutr* 1987;117:77–82.
195. Lakshman MR, Sundaresan PR, Chambers LL, Shoff PK. Cellular retinyl esters and retinol among parenchymal and stellate cells in normal rat liver. *Lipids* 1988;23:144–147.
196. Green MH, Green JB, Berg T, Norum KR, Blomhoff R. Changes in hepatic parenchymal and nonparenchymal cell vitamin A content during vitamin A depletion in the rat. *J Nutr* 1988;118:1331–1335.

197. Green MH, Green JB. Quantitative and conceptual contributions of mathematical modeling to current views on vitamin A metabolism, biochemistry, and nutrition. *Adv Food Nutr Res* 1996;40:3–24.
198. Ross AC, Zolfaghari R. Regulation of hepatic retinol metabolism: perspectives from studies on vitamin A status. *J Nutr* 2004;134:269S–275S.
199. Ross AC, Zolfaghari R, Weisz J. Vitamin A: recent advances in the biotransformation, transport, and metabolism of retinoids. *Curr Opin Gastroenterol* 2001;17:184–192.
200. Folman Y, Russell RM, Tang GW, Wolf G. Rabbits fed on β -carotene have higher serum levels of all-*trans* retinoic acid than those receiving no β -carotene. *Br J Nutr* 1989;62:195–201.
201. Napoli JL. Retinoic acid synthesis from β -carotene *in vitro*. *Methods Enzymol* 1993;214:193–202.
202. Kanai M, Raz A, Goodman DS. Retinol-binding protein: the transport protein for vitamin A in human plasma. *J Clin Invest* 1968;47:2025–2044.
203. Blaner WS. Retinol-binding protein: the serum transport protein for vitamin A. *Endocrine Rev* 1989;10:308–316.
204. de Leenheer AP, Lambert WE, Claeys I. All-*trans*-retinoic acid: measurement of reference values in human serum by high performance liquid chromatography. *J Lipid Res* 1982;23:1362–1367.
205. Eckhoff C, Nau H. Identification and quantitation of all-*trans*- and 13-*cis*-retinoic acid and 13-*cis*-4-oxoretinoic acid in human plasma. *J Lipid Res* 1990;31:1445–1454.
206. Eckhoff C, Collins MD, Nau H. Human plasma all-*trans*, 13-*cis*- and 13-*cis*-4-oxoretinoic acid profiles during subchronic vitamin A supplementation: comparison to retinol and retinyl ester plasma levels. *J Nutr* 1991;121:1016–1025.
207. Barua AB, Batres RO, Olson JA. Characterization of retinyl β -glucuronide in human blood. *Am J Clin Nutr* 1989;50:370–374.
208. Sani BP, Barua AB, Hill DL, Shih TW, Olson JA. Retinoyl β -glucuronide: lack of binding to receptor proteins of retinoic acid as related to biological activity. *Biochem Pharmacol* 1992;43:919–922.
209. Arnhold T, Tzimas G, Wittfoht W, Plonait S, Nau H. Identification of 9-*cis*-retinoic acid and 9,13-di-*cis*-retinoic acid, and 14-hydroxy-4,14-*retro*-retinol in human plasma after liver consumption. *Life Sci* 1996;59:PL169–PL177.
210. Noy N. The ionization behavior of retinoic acid in aqueous environments and bound to serum albumin. *Biochim Biophys Acta* 1992;1106:152–158.
211. Bielsalski HK, Frank J, Beck SC, et al. Biochemical but not clinical vitamin A deficiency results from mutations in the gene for retinol binding protein. *Am J Clin Nutr* 1999;69:931–936.
212. Green MH, Green JB. Dynamics and control of plasma retinol. In: Blomhoff R (ed). *Vitamin A in Health and Disease*. New York, Marcel Dekker: 1994; pp. 119–133.
213. Smith FR, Goodman DS, Zaklama MS, Gabr MK, El Maraghy S, Patwardhan VN. Serum vitamin A, retinol-binding protein, and prealbumin concentrations in protein-calorie malnutrition. I. A functional defect in hepatic retinol release. *Am J Clin Nutr* 1973;26:973–981.
214. Ingenbleek Y, van den Schrieck HG, de Nayer P, de Visscher M. The role of retinol-binding protein in protein-calorie malnutrition. *Metabolism* 1975;24:633–641.
215. Centanni M, Maiani G, Vermiglio F, et al. Combined impairment of nutritional parameters and thyroid homeostasis in mildly iodine-deficient children. *Thyroid* 1998;8:155–159.
216. Christian P, West KP Jr. Interactions between zinc and vitamin A: an update. *Am J Clin Nutr* 1998;68:435S–441S.
217. Arroyave G, Calcagno M. Descenso de los niveles sericos de retinol y su proteina de enlace (RBP) durante las infecciones. *Arch Latinoam Nutr* 1979;29:233–260.
218. Gerlach TH, Zile MH. Upregulation of serum retinol in experimental acute renal failure. *FASEB J* 1990;4:2511–2517.
219. Green MH, Green JB, Lewis KC. Variation in retinol utilization rate with the vitamin A status in the rat. *J Nutr* 1987;117:694–703.
220. Lewis KC, Green MH, Green JB, Zech LA. Retinol metabolism in rats with low vitamin A status: a compartmental model. *J Lipid Res* 1990;31:1535–1548.
221. Vahlquist A, Peterson PA, Wibell L. Metabolism of the vitamin A-transporting protein complex. I. Turn-over studies in normal persons and in patients with chronic renal failure. *Eur J Clin Invest* 1973;3:352–362.

222. Khachik F, Beecher GR, Goli MB, Lusby WR. Separation, identification, and quantification of carotenoids in fruits, vegetables, and human plasma by high performance liquid chromatography. *Pure Appl Chem* 1991;63:71–80.
223. Khachik F, Beecher GR, Goli MB. Separation and identification of carotenoids and their oxidation products in the extracts of human plasma. *Anal Chem* 1992;64:2111–2122.
224. Willnow TE, Nykjaer A, Herz J. Lipoprotein receptors: new roles for ancient proteins. *Nat Cell Biol* 1999;1:E157–E162.
225. Bavik CO, Busch C, Eriksson U. Characterization of a plasma retinol-binding protein membrane receptor expressed in the retinal pigment epithelium. *J Biol Chem* 1992;267:23035–23042.
226. Kurlandsky SB, Gamble MV, Ramakrishnan R, Blaner WS. Plasma delivery of retinoic acid to tissues in the rat. *J Biol Chem* 1995;270:17850–17857.
227. Takahashi N, Breitman TR. Retinoylation of proteins in mammalian cells. In: Blomhoff R (ed). *Vitamin A in Health and Disease*. New York, Marcel Dekker: 1994; pp. 257–273.
228. Myhre AM, Takahashi N, Blomhoff R, Breitman TR, Norum KR. Retinoylation of proteins in rat liver, kidney, and lung in vivo. *J Lipid Res* 1996;37:1971–1977.
229. Genchi G, Olson JA. Retinoylation of proteins in cell-free fractions of rat tissues in vitro. *Biochim Biophys Acta* 2001;1530:146–154.
230. Renstrom B, DeLuca HF. Incorporation of retinoic acid into proteins via retinoyl-CoA. *Biochim Biophys Acta* 1989;998:69–74.
231. Chambon P. A decade of molecular biology of retinoic acid receptors. *FASEB J* 1996;10:940–954.
232. Kliewer SA, Umesono K, Mangelsdorf DJ, Evans RM. Retinoid X receptor interacts with nuclear receptors in retinoic acid, thyroid hormone and vitamin D₃ signalling. *Nature* 1992;355:446–449.
233. Tran P, Zhang XK, Salbert G, Hermann T, Lehmann JM, Pfahl M. COUP orphan receptors are negative regulators of retinoic acid response pathways. *Mol Cell Biol* 1992;12:4666–4676.
234. Hirose T, Apfel R, Pfahl M, Jetten AM. The orphan receptor TAK1 acts as a repressor of RAR-, RXR- and T₃R-mediated signaling pathways. *Biochem Biophys Res Commun* 1995;211:83–91.
235. Retnakaran R., Flock G, Giguère V. Identification of RVR, a novel orphan nuclear receptor that acts as a negative transcriptional regulator. *Mol Endocrinol* 1994;8:1234–1244.
236. Carlberg C, van Huijsduijnen RH, Staple JK, DeLamarter JF, Becker-André M. RZR_s, a new family of retinoid-related orphan receptors that function as both monomers and homodimers. *Mol Endocrinol* 1994;8:757–770.
237. Ortiz MA, Piedrafitra FJ, Pfahl M, Maki R. TOR: a new orphan receptor expressed in the thymus that can modulate retinoid and thyroid hormone signals. *Mol Endocrinol* 1995;9:1679–1691.
238. Zhao Q, Chasse SA, Devarakonda S, Sierk ML, Ahvazi B, Rastinejad F. Structural basis of RXR-DNA interactions. *J Mol Biol* 2000;296:509–520.
239. Rastinejad F, Wagner T, Zhao Q, Khorasanizadeh S. Structure of the RXR-RAR DNA-binding complex on the retinoic acid response element DR1. *EMBO J* 2000;19:1045–1054.
240. Rastinejad F. Retinoid X receptor and its partners in the nuclear receptor family. *Curr Opin Structural Biol* 2001;11:33–38.
241. Buck J, Derguini F, Levi E, Nakanishi K, Hämmerling U. Intracellular signaling by 14-hydroxy-4,14-*retro* retinol. *Science* 1991;254:1654–1655.
242. Buck J, Grün F, Kimura S, Noy N, Derguini F, Hämmerling U. Anhydroretinol: a naturally occurring inhibitor of lymphocyte physiology. *J Exp Med* 1993;178:675.
243. Blumberg B, Bolado J Jr, Derguini F, et al. Novel retinoic acid receptor ligands in *Xenopus* embryos. *Proc Natl Acad Sci USA* 1996;93:4873–4878.
244. Nagy L, Thomazy VA, Heyman RA, Davies PJA. Retinoid-induced apoptosis in normal and neoplastic tissues. *Cell Death Dif* 1998;5:11–19.
245. Bastien J, Rochette-Egly C. Nuclear retinoid receptors and the transcription of retinoid-target genes. *Gene* 2004;328:1–16.
246. Food and Nutrition Board, Institute of Medicine. Dietary Reference Intakes for Vitamin A, Vitamin K, Arsenic, Boron, Chromium, Copper, Iodine, Iron, Manganese, Molybdenum, Nickel, Silicon, Vanadium, and Zinc: A Report of the Panel on Micronutrients. Washington, D.C., National Academy Press, 2001.

247. World Health Organization. Control of Vitamin A Deficiency and Xerophthalmia: Report of Joint WHO/UNICEF/USAID/Helen Keller International/IVACG Meeting. World Health Organization Technical Report Series No. 672. Geneva: World Health Organization, 1982.
248. Tei M, Spurr-Michaud SJ, Tisdale AS, Gipson IK. Vitamin A deficiency alters the expression of mucin genes by the rat ocular surface epithelium. *Invest Ophthalmol Vis Sci* 2000;41:82–88.
249. Tseng SCG, Hatchell D, Tierney N, Huang AJW, Sun TT. Expression of specific keratin markers by rabbit corneal, conjunctival, and esophageal epithelia during vitamin A deficiency. *J Cell Biol* 1984;99:2279–2286.
250. Sullivan WR, McCulley JP, Dohlman CH. Return of goblet cells after vitamin A therapy in xerosis of the conjunctiva. *Am J Ophthalmol* 1973;75:720–725.
251. Sommer A, Green WR. Goblet cell response to vitamin A treatment for corneal xerophthalmia. *Am J Ophthalmol* 1982;94:213–215.
252. Ammon FA von. Beobachtungen, Ansichten und Zweifel über die Entstehung der Xerosis conjunctivae. *Zeitschrift für die Ophthalmologie in Verein mit vielen Aerzten* 1830–1831;1:65–79.
253. Marchetti L. Intorno la xerosis o xerosis della congiuntiva dell'occhio. *Effermeridi delle Scienze Mediche* 1836;2:50–56.
254. Dupré JMV. Essai sur le xérosis de la conjonctive. Thèse, Faculté de Médecine de Paris, No. 21. Paris, Didot, 1836.
255. Taylor R. Cases of xerophthalmia, with remarks. *Edinb Med Surg J* 1854;81:21–34.
256. Frugier H. De la xérophthalmie. Thèse, Faculté de Médecine de Paris, No. 242. Paris, Alphonse Derenne, 1880.
257. Semba RD, Wirasasmita S, Natadisastra G, Muhilal, Sommer A. Response of Bitot's spots in pre-school children to vitamin A treatment. *Am J Ophthalmol* 1990;110:416–420.
258. Sie Boen Lian. Over vlekken van Bitôt, niet behoorend tot het ziektebeeld der xerophthalmie. *Geneesk Tijdschr Nederl Indië* 1938;78:665–671.
259. Sie-Boen-Lian. Über Bitotsche Flecke, die nicht zu dem Krankheitsbild der Xerophthalmie gehören. *Albrecht von Graefe's Archiv für Ophthalmologie* 1938;139:17–21.
260. Leber T. Ueber die Xerosis der Bindehaut und die infantile Hornhautverschwörung nebst Bemerkungen über die Entstehung des Xerophthalmus. *Albrecht von Graefe's Archiv für Ophthalmologie* 1883;29:225–290.
261. Weeks JE. Xerosis of the conjunctiva in infants and children. *Arch Ophthalmol* 1886;15:332–342.
262. Braunschweig P. Zur Kenntniss der infantilen Xerosis conjunctivae. *Fortschritte der Medicin* 1890;8:889–900.
263. Basso D. Un'epidemia di emeralopia con xerosi epiteliale della congiuntiva. *Annali di Ottalmologia* 1897;26:275–305.
264. Mayou MS. The pathological anatomy of the plaques in epithelial xerosis. *Trans Ophthalmol Soc UK* 1904;24:9–16.
265. Kreiker A. Zur Klinik und Histologie der epithelialen Bindehautxerose. *Albrecht von Graefe's Archiv für Ophthalmologie* 1930;124:191–205.
266. Caocci G. Sulla xerosis epiteliale della congiuntiva (contributo clinico e isto-patologico). *Arch Ottal* 1931;38:528–544.
267. El-Tobgy AF. Histopathology, bacteriology and treatment of Bitot spots. *Bull Ophthalmol Soc Egypt* 1935;28:79–81.
268. Lijó Pavía J, Irigoyen L, Tartari RA. Xerosis conjuntival. Contribución anatómopatológica. *Semana Médica* 1938;2:271–277.
269. Argaud R, Berges R. Considérations anatomo-pathologiques sur le xérosis conjonctival (Taches de Bitot). *Arch d'Ophthalmol* 1938;2:97–107.
270. Damiean-Gillet M. Conjunctival lesions in avitaminosis A. A histopathological study. *Trop Geogr Med* 1958;10:233–238.
271. Rodger FC, Saiduzzafar H, Grover AD, Fazal A. A reappraisal of the ocular lesion known as Bitot's spot. *Br J Nutr* 1963;17:475–485.
272. Reddy PS. Bitot spots and vitamin A deficiencies. *Trans Ophthalmol Soc N Zealand* 1965;17:90–93.
273. Pfister RR, Renner ME. The corneal and conjunctival surface in vitamin A deficiency: a scanning electron microscope study. *Invest Ophthalmol Vis Sci* 1978;17:874–883.

274. Ganley JP, Payne CM. Clinical and electron microscopic observations of the conjunctiva of adult patients with Bitot's spots. *Invest Ophthalmol Vis Sci* 1981;20:632–643.
275. Sommer A, Green WR, Kenyon KR. Bitot's spots responsive and nonresponsive to vitamin A. Clinico-pathologic correlation. *Arch Ophthalmol* 1981;99:2014–2027.
276. Meyer E, Miller B, Zonis S. Electron microscope study of Bitot's spots. *Metab Pediatr System Ophthalmol* 1987;10:42–44.
277. Lehmann KB, Neumann R. *Lehmann's Medizin, Handatanten X. Atlas und Grundriss der Bakteriologie und Lehrbuch der speziellen bakteriologischen Diagnostik*. 2. Auflage, 1899;2:1–497.
278. Colomiatti P. Notes pour servir à l'étude des ophtalmies parasitaires. Congrès périodique international d'ophtalmologie, Comptes-rendu. Premier Congrès de Milan, 1, 2, 3, et 4 Septembre 1880. Milan, Philippe Poncelletti, 1881, pp. 48–50.
279. Fraenkel E, Franke E. Ueber den Xerosisbacillus und seine ätiologische Bedeutung. *Arch Augenheilk* 1887;17:176–192.
280. Stephenson S. On epithelial xerosis of the conjunctiva. *Trans Ophthalmol Soc UK* 1898;18:55–102.
281. Owen HB. The ocular manifestations of vitamin A deficiency. *E Afr Med J* 1933;10:53–58.
282. Stocker F. Keratitis superficialis und Vitamin A. *Schweiz Med Wochenschr* 1936;66:335–337.
283. Sommer A, Emran N, Tamba T. Vitamin A-responsive punctate keratopathy in xerophthalmia. *Am J Ophthalmol* 1979;87:330–333.
284. Newman NJ, Capone A, Leeper HF, et al. Clinical and subclinical ophthalmic findings with retinol deficiency. *Ophthalmology* 1994;101:1077–1083.
285. Sommer A. *Nutritional Blindness: Xerophthalmia and Keratomalacia*. New York: Oxford University Press, 1982.
286. Wason IM. Ophthalmia associated with a dietary deficiency in fat soluble vitamin (A). A study of the pathology. *J Am Med Assoc* 1921;76:908–912.
287. Sheldon H, Zetterqvist H. An electron microscope study of the corneal epithelium in the vitamin A deficient mouse. *Bull Johns Hopkins Hosp* 1956;98:372–405.
288. Van Horn DL, Schutten WH, Hyndiuk RA, Kurz P. Xerophthalmia in vitamin A-deficient rabbits: clinical and ultrastructural alterations in the cornea. *Invest Ophthalmol Vis Sci* 1980;19:1067–1079.
289. Kim YCL, Wolf G. Vitamin A deficiency and the glycoproteins of rat corneal epithelium. *J Nutr* 1974;104:710–718.
290. Valenton MJ, Tan RV. Secondary ocular bacterial infection in hypovitaminosis A xerophthalmia. *Am J Ophthalmol* 1975;80:673–677.
291. Sendele DD, Kenyon KR, Wolf G, Hanninen LA. Epithelial abrasion precipitates stromal ulceration in the vitamin A-deficient rat cornea. *Invest Ophthalmol Vis Sci* 1982;23:64–72.
292. El-Ghorab M, Capone A Jr, Underwood BA, Hatchell D, Friend J, Thoft RA. Response of ocular surface epithelium to corneal wounding in retinol-deficient rabbits. *Invest Ophthalmol Vis Sci* 1988;29:1671–1676.
293. Seng WL, Glogowski JA, Wolf G, Berman MB, Kenyon KR, Kiorpes TC. The effect of thermal burns on the release of collagenase from corneas of vitamin A-deficient and control rats. *Invest Ophthalmol Vis Sci* 1980;19:1461–1470.
294. Seng WL, Kenyon KR, Wolf G. Studies on the source and release of collagenase in thermally burned corneas of vitamin A-deficient and control rats. *Invest Ophthalmol Vis Sci* 1982;22:62–72.
295. Frangieh GT, Hayashi K, Teekhasaene C, et al. Fibronectin and corneal epithelial wound healing in the vitamin A-deficient rat. *Arch Ophthalmol* 1989;107:567–571.
296. Berman M, Leary R, Gage J. Evidence for a role of the plasminogen activator-plasmin system in corneal ulceration. *Invest Ophthalmol Vis Sci* 1980;19:1204–1221.
297. Hayashi K, Frangieh G, Kenyon KR, Berman M, Wolf G. Plasminogen activator activity in vitamin A-deficient rat corneas. *Invest Ophthalmol Vis Sci* 1988;29:1810–1819.
298. Hayashi K, Frangieh G, Hanninen LA, Wolf G, Kenyon KR. Stromal degradation in vitamin A-deficient rat cornea. Comparison of epithelial abrasion and stromal incision. *Cornea* 1990;9:254–265.
299. DeCarlo JD, Van Horn DL, Hyndiuk RA, Davis SD. Increased susceptibility to infection in experimental xerophthalmia. *Arch Ophthalmol* 1981;99:1614–1617.
300. Twining SS, Zhou X, Schulte DP, Wilson PM, Fish B, Moulder J. Effect of vitamin A deficiency on the early response to experimental *Pseudomonas* keratitis. *Invest Ophthalmol Vis Sci* 1996;37:511–522.

301. Kenney MC, Shih LM, Labermeir U, Satterfield D. Modulation of rabbit keratocyte production of collagen, sulfated glycosaminoglycans and fibronectin by retinol and retinoic acid. *Biochim Biophys Acta* 1986;889:156–162.
302. Visse R, Nagase H. Matrix metalloproteinases and tissue inhibitors of metalloproteinases: structure, function, and biochemistry. *Circ Res* 2003;92:827–839.
303. Slansky HH, Freeman MI, Itoi M. Collagenolytic activity in bovine corneal epithelium. *Arch Ophthalmol* 1968;80:496–498.
304. Itoi M, Gnädinger MC, Slansky HH, Freeman MI, Dohlman CH. Collagenases in the cornea. *Exp Eye Res* 1969;8:369–373.
305. Pirie A, Werb Z, Burleigh MC. Collagenase and other proteinases in the cornea of the retinol-deficient rat. *Br J Nutr* 1975;34:297–309.
306. Gordon JM, Bauer EA, Eisen AZ. Collagenase in human cornea. Immunologic localization. *Arch Ophthalmol* 1980;98:341–345.
307. Twining SS, Schulte DP, Zhou X, Wilson PM, Fish BL, Moulder JE. Changes in rat corneal matrix metalloproteinases and serine proteinases under vitamin A deficiency. *Curr Eye Res* 1997;16:158–165.
308. Fini ME, Cook JR, Mohan R. Proteolytic mechanisms in corneal ulceration and repair. *Arch Dermatol Res* 1998;290(suppl):S12–S23.
309. Robertson RB, Ryel RB, Taylor RE, Shyu KW, Fullmer HM. Collagenase: localization in polymorphonuclear leukocyte granules in the rabbit. *Science* 1972;177:64–65.
310. Aliante LG, Cannon BM, White CD, Caballero AR, O'Callaghan RJ, Hobden JA. *Pseudomonas aeruginosa* LasA protease and corneal infections. *Curr Eye Res* 2001;22:266–271.
311. Twining SS, Hatchell DL, Hyndiuk RA, Nassif KF. Acid proteases and histologic correlations in experimental ulceration in vitamin A deficient rabbit corneas. *Invest Ophthalmol Vis Sci* 1985;26:31–44.
312. Pan L, Eckhoff C, Brinckerhoff CE. Suppression of collagenase gene expression by all-trans and 9-cis retinoic acid is ligand dependent and requires both RARs and RXRs. *J Cell Biochem* 1995;57:575–589.
313. Schüle R, Rangarajan P, Yang N, et al. Retinoic acid is a negative regulator of AP-1-responsive genes. *Proc Natl Acad Sci USA* 1991;88:6092–6096.
314. Wolf G. The molecular basis of the inhibition of collagenase by vitamin A. *Nutr Rev* 1992;50:292–294.
315. Schroen DJ, Brinckerhoff CE. Inhibition of rabbit collagenase (matrix metalloproteinase-1; MMP-1) transcription by retinoid receptors: evidence for binding of RARs/RXRs to the -77 AP-1 site through interactions with c-Jun. *J Cell Physiol* 1996;169:320–332.
316. Shams NBK, Reddy CV, Watanabe K, Elgebaly SA, Hanninen LA, Kenyon KR. Increased interleukin-1 activity in the injured vitamin A-deficient cornea. *Cornea* 1994;13:156–166.
317. Lafyatis R, Kim SJ, Angel P, et al. Interleukin-1 stimulates and all-trans-retinoic acid inhibits collagenase gene expression through its 5' activator protein-1-binding site. *Mol Endocrinol* 1990;4:973–980.
318. von Graefe A. Hornhautverschwörung bei infantiler Encephalitis. *Albrecht von Graefe's Archiv für Ophthalmologie* 1866;12:250–256.
319. Hirschberg J. Ueber die durch Encephalitis bedingte Hornhautverschwörung bei kleinen Kindern. *Berlin Klin Wochenschr* 1868;5:324–326.
320. Tiwary R. Intestinal infections and ocular lesions with particular reference to keratomalacia. *J All India Ophthalmol Soc* 1966;14:87–88.
321. Mukherjee SK, Barat DR. Keratomalacia and intestinal helminthiasis. *Indian J Pediatr* 1972;39:194–198.
322. Matsuo T, Matsuo N, Shiraga F, Koide N. Keratomalacia in a child with familial hypo-retinol-binding proteinemia. *Jpn J Ophthalmol* 1988;32:249–254.
323. Feldberg R, Yassur Y, Ben-Sira I, Varsano I, Zelikovitz I. Keratomalacia in acrodermatitis enteropathica (AE). *Metab Pediatr Ophthalmol* 1981;5:207–211.
324. Hildreth JS. Anästhesie der Cornea mit gleichzeitig verminderter Wirkung des Atropins auf die Iris, und deren Einfluss auf ulcerative Hornhautentzündung. *Arch Augenheilk Ohrenheilk* 1870;200–202.
325. Elschnig A. Keratomalacie bei Bindehautxerose. *Wien Med Wochenschr* 1899;49:841–848.
326. Pillat A. Does keratomalacia exist in adults? *Arch Ophthalmol* 1929;2:256–287, 399–415.
327. Schimmelpfennig W. Über einen Fall von infantiler Conjunctivalxerose mit Keratomalacie. *Medicinisches Facultät zu Jena, Dissertation. Leipzig, W. Engelmann, 1896.*
328. Smith RS, Farrell T, Bailey T. Keratomalacia. *Surv Ophthalmol* 1975;20:213–219.

329. Goldschmidt M. Experimenteller Beitrag zur Ätiologie der Keratomalacie. Albrecht von Graefe's Archiv für Ophthalmol 1915;90:354–366.
330. Valenton MJ. Corneal xerophthalmia and keratomalacia. Arch Ophthalmol 1982;100:1974.
331. Sommer A. Corneal xerophthalmia and keratomalacia—reply. Arch Ophthalmol 1982;100:1974.
332. Yap-Kie-Tiong Y. Protein deficiency in keratomalacia. Br J Ophthalmol 1956;40:502–503.
333. Kuming BS. The evolution of keratomalacia. Tran Ophthalmol Soc UK 1967;87:305–315.
334. Baas KL. Ueber eine Ophthalmia hepatica. Nebst Beiträgen zur Kenntniss der Xerosis conjunctivae under zur Pathologie der Augenmuskelerkrankungen. Graefe's Arch Ophthalmol 1894;40:212–246.
335. Purtscher. Beitrag zur Kenntnis der Ophthalmia hepatica (hepatica-Baas). Albrecht von Graefe's Archiv für Ophthalmologie 1900;50:83–122.
336. Mikamo S. [An interesting fundus disease with multiple white dots.] Nippon Ganka Gakkai Zasshi 1915;19:1170–1173.
337. Wright RE. Keratomalacia in southern India. Br J Ophthalmol 1922;6:164–175.
338. Uyemura M. Ueber eine merkwürdige Augenhintergrundveränderung bei zwei Fällen von idiopathischer Hemeralopie. Klin Monatsbl Augenheilk 1928;81:471–473.
339. Fuchs A. White spots of the fundus combined with night blindness and xerosis (Uyemura's syndrome). Am J Ophthalmol 1959;48:101–103.
340. Fuchs A. Ein Fall von weisspunktiertem Fundus bei Hemeralopie mit Xerose. Klin Monatsbl Augenheilk 1928;81:849–850.
341. Shindo S. Ein seltener Fall der idiopathischen Hemeralopie mit speziellem Hintergrundsbefund. Nippon Ganka Gakkai Zasshi 1930;34:153–154, 1487–1491.
342. Yasutake K. Über einen Fall von Fundus oculi mit zahlreichen gelblichenweissen Punkten bei idiopathischer Hemeralopie. Nippon Ganka Gakkai Zasshi 1933;37:45–46, 540–547.
343. Pillat A. Über einige Augenhintergrundsbefunde bei Nachtblindheit, Präxerose und Xerose. Zeitschr Augenheilk 1933;80:189–192.
344. Pillat A. Die klassischen Symptome des Vitamin A-Mangels und der Vitamin A-Mangel als Gesamterkrankung des Körpers. Wien Klin Wochenschr 1940;53:779–783.
345. Scullica F. Avitaminosi e syndrome xeroftalmica. Ann Ottal 1935;63:721–772.
346. Ruata V. Oftalmologia dei paesi caldi. Milano, Ulrico Hoepli, 1938.
347. Hollwich. Hemeralopie mit Augenhintergrundsbefund. Klin Monatsbl Augenheilk 1937;98:389–390.
348. Teng-Khoen-Hing. Fundus changes in hypovitaminosis A. Ophthalmologica 1959;137:81–85.
349. Teng Khoen Hing. Fundus xerophthalmicus. Paediatrica Indonesiana 1965a;5:802–811.
350. Teng Khoen Hing. Further contributions to the fundus xerophthalmicus. Ophthalmologica 1965b;150:219–238.
351. Sommer A, Tjakrasudjatma S, Djunaedi E, Green WR. Vitamin A-responsive panocular xerophthalmia in a healthy adult. Arch Ophthalmol 1978;96:1630–1634.
352. Teng Khoen Hing. Serum vitamin and protein levels in fundus xerophthalmicus. Trop Geogr Med 1965c;17:273–281.
353. Oomen HAPC. Fundus xerophthalmicus. Voeding 1965;26:51–54.
354. Tansley K. Factors affecting the development and regeneration of visual purple in the mammalian retina. Proc Roy Soc Lond B 1933;114:79–103.
355. Tansley K. The effect of vitamin A deficiency on the development of the retina and on the first appearance of visual purple. Biochem J 1936;30:839–844.
356. Johnson ML. The effect of vitamin A deficiency upon the retina of the rat. J Exp Zool 1939;81:67–89.
357. Johnson ML. Degeneration and repair of the rat retina in avitaminosis A. Arch Ophthalmol 1943;29:793–810.
358. Ramalingaswami V, Leach EH, Sriramachari S. Ocular structure in vitamin A deficiency in the monkey. Q J Exp Physiol 1955;40:337–347.
359. Hayes KC. Retinal degeneration in monkeys induced by deficiencies of vitamin E or A. Invest Ophthalmol 1974;13:499–510.
360. Carter-Dawson L, Kuwabara T, O'Brien PJ, Bieri JG. Structural and biochemical changes in vitamin A-deficient rat retinas. Invest Ophthalmol Vis Sci 1979;18:437–446.
361. Herron WL Jr, Riegel BW. Production rate and removal of rod outer segment material in vitamin A deficiency. Invest Ophthalmol Vis Sci 1974a;13:46–53.

362. Herron WL Jr, Riegel BW. Vitamin A deficiency-induced "rod thinning" to permanently decrease the production of rod outer segment material. *Invest Ophthalmol Vis Sci* 1974b;13:54–59.
363. Sharman IM. An unusual case of self-imposed vitamin A deficiency. *Am J Clin Nutr* 1969;22:1134.
364. Fells P, Bors F. Ocular complications of self-induced vitamin A deficiency. *Trans Ophthalmol Soc UK* 1969;89:221–228.
365. Bors F, Fells P. Reversal of the complications of self-induced vitamin A deficiency. *Br J Ophthalmol* 1971;55:210–214.
366. Seeliger MW, Biesalski HK, Wissinger B, et al. Phenotype in retinol deficiency due to a hereditary defect in retinol binding protein synthesis. *Invest Ophthalmol Vis Sci* 1999;40:3–11.
367. Menon K, Vijayaraghavan K. Sequelae of severe xerophthalmia—a follow up study. *Am J Clin Nutr* 1979;33:218–220.
368. Blackfan KD, Wolbach SB. Vitamin A deficiency in infants. A clinical and pathological study. *J Pediatr* 1933;3:679–706.
369. Sweet LK, K'ang HJ. Clinical and anatomic study of avitaminosis A among the Chinese. *Am J Dis Child* 1935;50:699–734.
370. McLaren DS. *Malnutrition and the Eye*. New York, Academic Press, 1963.
371. Koo JS, Jetten AM, Belloni P, et al. Role of retinoid receptors in the regulation of mucin gene expression by retinoic acid in human tracheobronchial epithelial cells. *Biochem J* 1999;338:351–357.
372. Gijbels MJJ, van der Harn F, van Bennekum AM, Hendriks HF, Roholl RJ. Alterations in cytokeratin expression precede histological changes in epithelia of vitamin A-deficient rats. *Cell Tissue Res* 1992;268:197–203.
373. Darwiche N, Celli G, Sly L, Lancillotti F, DeLuca LM. Retinoid status controls the appearance of reserve cells and keratin expression in mouse cervical epithelium. *Cancer Res* 1993;53(suppl 20):2287–2299.
374. Van Agtmaal EJ. *Vitamin A and Protein in Tear Fluid: A Nutritional Field Survey on Preschool Children in Northeast Thailand* [thesis]. Amsterdam, University of Amsterdam, 1989.
375. Nauss KM, Anderson CA, Conner MW, Newberne PM. Ocular infection with herpes simplex virus (HSV-1) in vitamin A-deficient and control rats. *J Nutr* 1985;115:1300–1315.
376. Shams NB, Hanninen LA, Chaves HV, et al. Effect of vitamin A deficiency on the adhesion of rat corneal epithelium and the basement membrane complex. *Invest Ophthalmol Vis Sci* 1993;34:2646–2654.
377. Wilhelm DL. Regeneration of the tracheal epithelium in the vitamin-A-deficient rat. *J Pathol Bact* 1954;67:361–365.
378. Wong YC, Buck RC. An electron microscopic study of metaplasia of the rat tracheal epithelium in vitamin A deficiency. *Lab Invest* 1971;24:55–66.
379. McDowell EM, Keenan KP, Huang M. Effects of vitamin A-deprivation on hamster tracheal epithelium: a quantitative morphologic study. *Virchows Arch B* 1984;45:197–219.
380. Fuchs E, Green H. Regulation of terminal differentiation of cultured human keratinocytes by vitamin A. *Cell* 1981;25:617–625.
381. Eckert RI, Green H. Cloning of cDNAs specifying vitamin A-responsive human keratins. *Proc Natl Acad Sci USA* 1984;81:4321–4325.
382. Manna B, Lund M, Ashbaugh P, Kaufman B, Bhattacharyya SN. Effect of retinoic acid on mucin gene expression in rat airways in vitro. *Biochem J* 1994;297:309–313.
383. Manna B, Ashbaugh P, Bhattacharyya SN. Retinoic-acid regulated cellular differentiation and mucin gene expression in isolated rabbit tracheal epithelial cells in culture. *Inflammation* 1995;19:489–502.
384. Paquette NC, Zhang LY, Ellis WA, Scott AL, Kleeberger SR. Vitamin A deficiency enhances ozone-induced lung injury. *Am J Physiol* 1996;270:L475–L482.
385. Rojanapo W, Lamb AJ, Olson JA. The prevalence, metabolism and migration of goblet cells in rat intestine following the induction of rapid, synchronous vitamin A deficiency. *J Nutr* 1980;110:178–180.
386. Puengtomwatanakul S, Sirisinha S. Impaired biliary secretion of immunoglobulin A in vitamin A-deficient rats. *Proc Soc Exp Biol Med* 1986;182:437–442.
387. Warden RA, Strazzari MJ, Dunkley PR, O'Loughlin EV. Vitamin A-deficient rats have only mild changes in jejunal structure and function. *J Nutr* 1996;126:1817–1826.

388. Ahmed F, Jones DB, Jackson AA. The interaction of vitamin A deficiency and rotavirus infection in the mouse. *Br J Nutr* 1990;63:363–373.
389. Molloy CL, Laskin JD. Effect of retinoid deficiency on keratin expression in mouse bladder. *Exp Mol Pathol* 1988;49:128–140.
390. Brown KH, Gaffar A, Alamgir SM. Xerophthalmia, protein-calorie malnutrition, and infections in children. *J Pediatr* 1979;95:651–656.
391. Rombout JH, Sijtsma SR, West CE, et al. Effect of vitamin A deficiency and Newcastle disease virus infection on IgA and IgM secretion in chickens. *Br J Nutr* 1992;68:753–763.
392. Gangopadhyay NN, Moldoveanu Z, Stephensen CB. Vitamin A deficiency has different effects on immunoglobulin A production and transport during influenza A infection in BALB/c mice. *J Nutr* 1996;126:2960–2967.
393. Ahmed F, Jones DB, Jackson AA. Effect of vitamin A deficiency on the immune response to epizootic diarrhoea of infant mice (EDIM) rotavirus infection in mice. *Br J Nutr* 1991;65:475–485.
394. Wiedermann U, Hanson LÅ, Holmgren J, Kahu H, Dahlgren UI. Impaired mucosal antibody response to cholera toxin in vitamin A-deficient rats immunized with oral cholera vaccine. *Infect Immun* 1993;61:3952–3957.
395. Nikawa T, Odahara K, Koizumi H, et al. Vitamin A prevents the decline in immunoglobulin A and Th2 cytokine levels in small intestinal mucosa of protein-malnourished mice. *J Nutr* 1999;129:934–941.
396. Nikawa T, Ikemoto M, Kano M, et al. Impaired vitamin A-mediated mucosal IgA response in IL-5 receptor-knockout mice. *Biochem Biophys Res Commun* 2001;285:546–549.
397. Sarkar J, Gangopadhyay NN, Moldoveanu Z, Mestecky J, Stephensen CB. Vitamin A is required for regulation of polymeric immunoglobulin receptor (pIgR) expression by interleukin-4 and interferon- γ in a human intestinal epithelial cell line. *J Nutr* 1998;128:1063–1069.
398. Thurnham DI, Northrup-Clewes CA, McCullough FS, Das BS, Lunn PG. Innate immunity, gut integrity, and vitamin A in Gambian and Indian infants. *J Infect Dis* 2000;182(suppl 1):S23–S28.
399. Okada M, Bothin C, Blomhoff R, Kanazawa K, Midtvedt T. Vitamin A deficiency impairs colonic healing but not adhesion formation in germ-free and conventional rats. *J Invest Surg* 1999;12:319–325.
400. Nauss KM, Newberne PM. Local and regional immune function of vitamin A-deficient rats with ocular herpes simplex virus (HSV) infections. *J Nutr* 1985;115:1316–1324.
401. Bowman TA, Goonewardene IM, Pasatiempo AMG, Ross AC. Vitamin A deficiency decreases natural killer cell activity and interferon production in rats. *J Nutr* 1990;120:1264–1273.
402. Zhao Z, Murasko DM, Ross AC. The role of vitamin A in natural killer cell cytotoxicity, number and activation in the rat. *Natural Immunity* 1994;13:29–41.
403. Dawson HD, Li NQ, DeCicco KL, Nibert JA, Ross AC. Chronic marginal vitamin A status reduces natural killer cell number and function in aging Lewis rats. *J Nutr* 1999;129:1510–1517.
404. Hussey G, Hughes J, Potgieter S, et al. Vitamin A status and supplementation and its effects on immunity in children with AIDS. XVII International Vitamin A Consultative Group Meeting. Virtual Elimination of Vitamin A Deficiency: Obstacles and Solutions for the Year 2000, 18–22 March 1996, Guatemala [abstracts]. International Life Sciences Institute, Washington, D.C., 1996, p. 6.
405. Lawson ND, Berliner N. Neutrophil maturation and the role of retinoic acid. *Exp Hematol* 1999;27:1355–1367.
406. Ongsakul M, Sirisinha S, Lamb A. Impaired blood clearance of bacteria and phagocytic activity in vitamin A-deficient rats. *Proc Soc Exp Biol Med* 1985;178:204–208.
407. Twining SS, Schulte DP, Wilson PM, Fish BL, Moulder JE. Vitamin A deficiency alters rat neutrophil function. *J Nutr* 1996;127:558–565.
408. Wiedermann U, Tarkowski A, Bremell T, Hanson LÅ, Kahu H, Dahlgren UI. Vitamin A deficiency predisposes to *Staphylococcus aureus* infection. *Infect Immun* 1996;64:209–214.
409. Higuchi H, Nagahata H. Effects of vitamins A and E on superoxide production and intracellular signaling of neutrophils in Holstein calves. *Can J Vet Res* 2000;64:69–75.
410. Zhao Z, Ross AC. Retinoic acid repletion restores the number of leukocytes and their subsets and stimulates natural cytotoxicity in vitamin A-deficient rats. *J Nutr* 1995;125:2064–2073.
411. Kuwata T, Wang IM, Tamura T, et al. Vitamin A deficiency in mice causes a systemic expansion of myeloid cells. *Blood* 2000;95:3349–3356.

412. Torii A, Miyake M, Morishita M, Ito K, Torii S, Sakamoto T. Vitamin A reduces lung granulomatous inflammation with eosinophilic and neutrophilic infiltration in Sephadex-treated rats. *Eur J Pharmacol* 2004;487:335–342.
413. Semba RD, Muhilal, Ward BJ, et al. Abnormal T-cell subset proportions in vitamin A-deficient children. *Lancet* 1993;341:5–8.
414. Benn CS, Lisse IM, Bale C, et al. No strong long-term effect of vitamin A supplementation in infancy on CD4 and CD8 T-cell subsets. A community study from Guinea-Bissau, West Africa. *Ann Trop Paediatr* 2000;20:259–264.
415. Van Schravendijk MR, Handunnetti SM, Barnwell JW, Howard RJ. Normal human erythrocytes express CD36, an adhesion molecule of monocytes, platelets, and endothelial cells. *Blood* 1992;80:2105–2114.
416. Perrin MC, Blanchet JP, Mouchiroud G. Modulation of human and mouse erythropoiesis by thyroid hormone and retinoic acid: evidence for specific effects at different steps of the erythroid pathway. *Hematol Cell Therapy* 1997;39:19–26.
417. Zermati Y, Fichelson S, Valensi F, et al. Transforming growth factor inhibits erythropoiesis by blocking proliferation of accelerating differentiation of erythroid progenitors. *Exp Hematol* 2000;28:885–894.
418. Breitman TR, Selonick SE, Collins SJ. Induction of differentiation of the human promyelocytic leukemia cell line (HL-60) by retinoic acid. *Proc Natl Acad Sci USA* 1980;77:2936–2940.
419. Öberg F, Botling J, Nilsson K. Functional antagonism between vitamin D₃ and retinoic acid in the regulation of CD14 and CD23 expression during monocytic differentiation of U-937 cells. *J Immunol* 1993;150:3487–3495.
420. Hemmi H, Breitman TR. Induction of functional differentiation of human monocytic leukemia cell line (THP-1) by retinoic acid and cholera toxin. *Jpn J Canc Res* 1985;76:345–351.
421. Katz DR, Drzymala M, Turton JA, et al. Regulation of accessory cell function by retinoids in murine immune responses. *Brit J Exp Pathol* 1987;68:343–350.
422. Katz DR, Mukherjee S, Malsey J, et al. Vitamin A acetate as a regulator of accessory cell function in delayed-type hypersensitivity responses. *Int Arch Allergy Appl Immunol* 1987;82:53–56.
423. Smith SM, Levy NS, Hayes CE. Impaired immunity in vitamin A-deficient mice. *J Nutr* 1987;117:857–865.
424. Mathew JS, Sharma RP. Effect of all-*trans*-retinoic acid on cytokine production in a murine macrophage cell line. *Int J Immunopharm* 2000;22:693–706.
425. Matikainen S, Serkkola E, Hurme M. Retinoic acid enhances IL-1 β expression in myeloid leukemia cells and in human monocytes. *J Immunol* 1991;147:162–167.
426. Hashimoto S, Hayashi S, Yoshida S, et al. Retinoic acid differentially regulates interleukin-1 β and interleukin-1 receptor antagonist production by human alveolar macrophages. *Leukemia Res* 1998;22:1057–1061.
427. Na SY, Kang BY, Chung SW, et al. Retinoids inhibit interleukin-12 production in macrophages through physical associations of retinoid X receptor and NF κ B. *J Biol Chem* 1999;274:7674–7680.
428. Dillehay DL, Walla AS, Lamon EW. Effects of retinoids on macrophage function and IL-1 activity. *J Leuk Biol* 1988;44:353–360.
429. Trechsel U, Evêquoz V, Fleisch H. Stimulation of interleukin 1 and 3 production by retinoid acid in vitro. *Biochem J* 1985;230:339–344.
430. Hatchigian EA, Santos JI, Broitman SA, Vitale JJ. Vitamin A supplementation improves macrophage function and bacterial clearance during experimental *Salmonella* infection. *Proc Soc Exp Biol Med* 1989;191:47–54.
431. Maisey J, Miller K. Assessment of the ability of mice fed on vitamin A supplemented diet to respond to a variety of potential contact sensitizers. *Contact Dermatitis* 1986;15:17–23.
432. Sailstad DM, Krishnan SD, Tepper JS, Doerfler DL, Selgrade MK. Dietary vitamin A enhances sensitivity of the local lymph node assay. *Toxicology* 1995;96:157–163.
433. Meunier L, Bohjanen K, Voorhees JJ, et al. Retinoic acid upregulates human Langerhans cell antigen presentation and surface expression of HLA-DR and CD11c, a β 2 integrin integrally involved in T-cell activation. *J Invest Dermatol* 1994;103:775–779.
434. Göttgens B, Green AR. Retinoic acid and the differentiation of lymphohaemopoietic stem cells. *Bio-Assays* 1995;17:187–189.

435. Garbe A, Buck J, Hämmerling U. Retinoids are important cofactors in T cell activation. *J Exp Med* 1992;176:109–117.
436. Allende LM, Corell A, Madrono A, et al. Retinol (vitamin A) is a cofactor in CD3-induced human T-lymphocyte activation. *Immunology* 1997;90:388–396.
437. Friedman A, Halevy O, Schrift M, et al. Retinoic acid promotes proliferation and induces expression of retinoic acid receptor- α gene in murine T lymphocytes. *Cell Immunol* 1993;152:240–248.
438. Sidell N, Chang B, Bhatti L. Upregulation by retinoic acid of interleukin-2-receptor mRNA in human T lymphocytes. *Cell Immunol* 1993;146:28–37.
439. Rahman MM, Mahalanabis D, Alvarez JO, et al. Effect of early vitamin A supplementation on cell-mediated immunity in infants younger than 6 mo. *Am J Clin Nutr* 1997;65:144–148.
440. Stephensen CB. Vitamin A, infection, and immune function. *Annu Rev Nutr* 2001;21:167–192.
441. Carman JA, Pond L, Nashold F, Wassom DL, Hayes CE. Immunity to *Trichinella spiralis* infection in vitamin A-deficient mice. *J Exp Med* 1992;175:111–120.
442. Cantorna MT, Nashold FE, Hayes CE. In vitamin A deficiency multiple mechanisms establish a regulatory T helper cell imbalance with excess Th1 and insufficient Th2 function. *J Immunol* 1994;152:1515–1522.
443. Cantorna MT, Nashold FE, Hayes CE. Vitamin A deficiency results in a priming environment conducive for Th1 cell development. *Eur J Immunol* 1995;25:1673–1679.
444. Wiedermann U, Hanson LA, Kahu H, Dahlgren UI. Aberrant T-cell function in vitro and impaired T-cell dependent antibody response in vivo in vitamin A-deficient rats. *Immunology* 1993;80:581–586.
445. Frankenburg S, Wang X, Milner Y. Vitamin A inhibits cytokines produced by type 1 lymphocytes *in vitro*. *Cell Immunol* 1998;185:75–81.
446. Cui D, Moldoveanu Z, Stephensen CB. High-level dietary vitamin A enhances T-helper type 2 cytokine production and secretory immunoglobulin A response to influenza A virus infection in BALB/c mice. *J Nutr* 2000;130:1322–1329.
447. Stephensen CB, Rasoly R, Jiang X, et al. Vitamin A enhances in vitro Th2 development via retinoid X receptor pathway. *J Immunol* 2002;168:4495–4503.
448. Carman JA, Hayes CE. Abnormal regulation of IFN- γ secretion in vitamin A deficiency. *J Immunol* 1991;147:1247–1252.
449. Cantorna MT, Nashold FE, Chun TY, Hayes CE. Vitamin A down-regulation of IFN- γ synthesis in cloned mouse Th1 lymphocytes depends on the CD28 costimulatory pathway. *J Immunol* 1996;156:2674–2679.
450. Cippitelli M, Ye J, Viggiano V, et al. Retinoic acid-induced transcriptional modulation of the human interferon-gamma promoter. *J Biol Chem* 1996;271:26783–26793.
451. Stephensen CB, Jiang X, Freytag T. Vitamin A deficiency increases the in vivo development of IL-10 positive Th2 cells and decreases development of Th1 cells in mice. *J Nutr* 2004;134:2660–2666.
452. Buck J, Ritter G, Dannecker L, et al. Retinol is essential for growth of activated human B cells. *J Exp Med* 1990;171:1613–1624.
453. Blomhoff HK, Smeland EB, Erikstein B, et al. Vitamin A is a key regulator for cell growth, cytokine production, and differentiation in normal B cells. *J Biol Chem* 1992;267:23988–23992.
454. Buck J, Myc A, Garbe A, Cathomas G. Differences in the action and metabolism between retinol and retinoic acid in B lymphocytes. *J Cell Biol* 1991;115:851–859.
455. Israel H, Odziemiec C, Ballow M. The effects of retinoic acid on immunoglobulin synthesis by human cord blood mononuclear cells. *Clin Immunol Immunopathol* 1991;59:417–425.
456. Wang W, Ballow M. The effects of retinoic acid on in vitro immunoglobulin synthesis by cord blood and adult peripheral blood mononuclear cells. *Cell Immunol* 1993;148:291–300.
457. Wang W, Napoli JL, Ballow M. The effects of retinol on in vitro immunoglobulin synthesis by cord blood and adult peripheral blood mononuclear cells. *Clin Exp Immunol* 1993;92:164–168.
458. Ballow M, Wang W, Xiang S. Modulation of B-cell immunoglobulin synthesis by retinoic acid. *Clin Immunol Immunopathol* 1996;80:S73–S81.
459. Lømo J, Smeland EB, Ulven S, et al. RAR-, not RXR, ligands inhibit cell activation and prevent apoptosis in B-lymphocytes. *J Cell Physiol* 1998;175:68–77.

460. Aukrust P, Müller F, Ueland T, Svardal AM, Berge RK, Frøland SS. Decreased vitamin A levels in common variable immunodeficiency: vitamin A supplementation *in vivo* enhances immunoglobulin production and downregulates inflammatory responses. *Eur J Clin Invest* 2000;30:252–259.
461. Smith SM, Hayes CE. Contrasting impairments in IgM and IgG responses of vitamin A-deficient mice. *Proc Natl Acad Sci USA* 1987;84:5878–5882.
462. Semba RD, Muhilal, Scott AL, et al. Depressed immune response to tetanus in children with vitamin A deficiency. *J Nutr* 1992;122:101–107.
463. Semba RD, Muhilal, Scott AL, Natadisastra G, West KP Jr, Sommer A. Effect of vitamin A supplementation on IgG subclass responses to tetanus toxoid in children. *Clin Diag Lab Immunol* 1994;1:172–175.
464. Rahman MM, Mahalanabis D, Hossain S, et al. Simultaneous vitamin A administration at routine immunization contact enhances antibody response to diphtheria vaccine in infants younger than six months. *J Nutr* 1999;129:2192–2195.
465. Friedman A, Sklan D. Antigen-specific immune response impairment in the chick as influenced by dietary vitamin A. *J Nutr* 1989;119:790–795.
466. Kinoshita M, Pasatiempo AMG, Taylor CE, Ross AC. Immunological memory to tetanus toxoid is established and maintained in the vitamin A-depleted rat. *FASEB J* 1991;5:2473–2481.
467. Arora D, Ross AC. Antibody response against tetanus toxoid is enhanced by lipopolysaccharide or tumor necrosis factor-alpha in vitamin A-sufficient and deficient rats. *Am J Clin Nutr* 1994;59:922–928.
468. Pasatiempo AMG, Bowman TA, Taylor CE, Ross AC. Vitamin A depletion and repletion: effects on antibody response to the capsular polysaccharide of *Streptococcus pneumoniae*, type III (SSS-III). *Am J Clin Nutr* 1989;49:501–510.
469. Lavasa S, Kumar L, Chakravarti RN, Kumar M. Early humoral immune response in vitamin A deficiency—an experimental study. *Indian J Exp Biol* 1988;26:431–435.
470. Pasatiempo AMG, Kinoshita M, Taylor CE, Ross AC. Antibody production in vitamin A-depleted rats is impaired after immunization with bacterial polysaccharide or protein antigens. *FASEB J* 1990;4:2518–2527.
471. Molrine DC, Polk DB, Ciamarra A, Phillips N, Ambrosino DM. Impaired human responses to tetanus toxoid in vitamin A-deficient SCID mice reconstituted with human peripheral blood lymphocytes. *Infect Immun* 1995;63:2867–2872.
472. Kutukculer N, Akil T, Egemen A, et al. Adequate immune response to tetanus toxoid and failure of vitamin A and E supplementation to enhance antibody response in healthy children. *Vaccine* 2000;18:2979–2984.
473. Quadro L, Gamble MV, Vogel S, et al. Retinol and retinol-binding protein: Gut integrity and circulating immunoglobulins. *J Infect Dis* 2000;182(suppl):S97–S102.
474. Scrimshaw NS, Taylor CE, Gordon JE. Interactions of Nutrition and Infection. World Health Organization, Geneva, 1968.
475. Beisel WR. Single nutrients and immunity. *Am J Clin Nutr* 1982;35(2 suppl):417–468.
476. Nauss KM. Influence of vitamin A status on the immune system. In: Bauernfeind JC (ed). *Vitamin A Deficiency and Its Control*. Orlando, FL, Academic: 1986; pp. 207–243.
477. Semba RD. Vitamin A, immunity, and infection. *Clin Infect Dis* 1994;19:489–499.
478. Beaton GH, Martorell R, L'Abbe KA, et al. Effectiveness of Vitamin A Supplementation in the Control of Young Child Morbidity and Mortality in Developing Countries. ACC/SCN State-of-the-Art Nutrition Policy Discussion Paper No. 13, United Nations, 1993.
479. The Vitamin A and Pneumonia Working Group. Potential interventions for the prevention of childhood pneumonia in developing countries: a meta-analysis of data from field trials to assess the impact of vitamin A supplementation on pneumonia morbidity and mortality. *Bull World Health Organ* 1995;73:609–619.
480. Filteau SM, Rollins NC, Coutoudis A, Sullivan KR, Willumsen JF, Tomkins AM. The effect of antenatal vitamin A and beta-carotene supplementation on gut integrity of infants of HIV-infected South African women. *J Pediatr Gastroenterol Nutr* 2001;32:464–470.
481. Alvarez JO, Salazar-Lindo E, Kohatsu J, Miranda P, Stephensen CB. Urinary excretion of retinol in children with acute diarrhea. *Am J Clin Nutr* 1995;61:1273–1276.

482. Mitra AK, Alvarez JO, Guay-Woodford L, et al. Urinary retinol excretion and kidney function in children with shigellosis. *Am J Clin Nutr* 1998;68:1095–1103.
483. Kelly P, Musuku J, Kafwenbe E, et al. Impaired bioavailability of vitamin A in adults and children with persistent diarrhoea in Zambia. *Aliment Pharmacol Ther* 2001;15:973–979.
484. Hossain S, Biswas R, Kabir I, et al. Single dose vitamin A treatment in acute shigellosis in Bangladeshi children: randomised double blind controlled trial. *Brit Med J* 1998;316:422–426.
485. Shankar AH, Genton B, Semba RD, et al. Effect of vitamin A supplementation on morbidity due to *Plasmodium falciparum* in young children in Papua New Guinea: a randomised trial. *Lancet* 1999;354:203–209.
486. Kennedy CM, Kuhn L, Stein Z. Vitamin A and HIV infection: disease progression, mortality, and transmission. *Nutr Rev* 2000;58:291–303.
487. Coutoudis A, Bobat RA, Coovadia HM, Kuhn L, Tsai WY, Stein ZA. The effects of vitamin A supplementation on the morbidity of children born to HIV-infected women. *Am J Pub Health* 1995;85:1076–1081.
488. Fawzi WW, Mbise RL, Hertzmark E, et al. A randomized trial of vitamin A supplements in relation to mortality among human immunodeficiency virus-infected and uninfected children in Tanzania. *Pediatr Infect Dis J* 1999;18:127–133.
489. Semba RD, Ndugwa C, Perry RT, et al. Effect of periodic vitamin A supplementation on mortality and morbidity of human immunodeficiency virus-infected children in Uganda: a controlled clinical trial. *Nutrition* 2005;21:25–31.
490. Kumwenda N, Mioti PG, Taha TE, et al. Antenatal vitamin A supplementation increases birthweight and decreases anemia, but does not prevent HIV transmission or decrease mortality in infants born to HIV-infected women in Malawi. *Clin Infect Dis* 2002;35:618–624.
491. Semba RD, Lyles CM, Margolick JB, et al. Vitamin A supplementation and human immunodeficiency virus load in injection drug users. *J Infect Dis* 1998;177:611–616.
492. Hanekom WA, Potgieter S, Hughes EJ, Malan H, Kessow G, Hussey GD. Vitamin A status and therapy in childhood pulmonary tuberculosis. *J Pediatr* 1997;131:925–927.
493. Karyadi E, West CE, Schultink W, et al. A double-blind, placebo-controlled study of vitamin A and zinc supplementation in persons with tuberculosis in Indonesia: effects on clinical response and nutritional status. *Am J Clin Nutr* 2002;75:720–727.
494. Christian P, West KP Jr, Khatry SK, et al. Vitamin A or beta-carotene supplementation reduces symptoms of illness in pregnant or lactating Nepali women. *J Nutr* 2000;130:2675–2682.
495. West KP Jr, Katz J, Khatry SK, et al. Double blind, cluster randomised trial of low dose supplementation with vitamin A or beta carotene on mortality related to pregnancy in Nepal. *Brit Med J* 1999;318:570–575.
496. Green HN, Pindar D, Davis G, Mellanby E. Diet as a prophylactic agent against puerperal sepsis. *Brit Med J* 1931;2:595–598.
497. Cameron SJ. An aid in the prevention of puerperal sepsis. *Trans Edinburgh Obstet Soc* 1931;52:93–103.
498. de Onis M. Child growth and development. In: Semba RD, Bloem MW (eds). *Nutrition and Health in Developing Countries*. Totowa, NJ, Humana: 2001; pp. 71–91.
499. Bedo G, Santisteban P, Aranda A. Retinoic acid regulates growth hormone gene expression. *Nature* 1989;339:231–234.
500. Tarwotjo I, Katz J, West KP Jr, Tielsch JM, Sommer A. Xerophthalmia and growth in preschool Indonesian children. *Am J Clin Nutr* 1992;55:1142–1146.
501. Rivera JA, Hotz C, González-Cossío, Neufeld L, García-Guerra A. The effect of micronutrient deficiencies on child growth: a review of results from community-based supplementation trials. *J Nutr* 2003;133:4010S–4020S.
502. West KP Jr, Djunaedi E, Pandji A, et al. Vitamin A supplementation and growth: a randomized community trial. *Am J Clin Nutr* 1988;48:1257–1264.
503. Muhilal, Permeisih D, Idjradinata YR, Muherdiyantiningsih, Karyadi D. Vitamin A-fortified monosodium glutamate and health, growth, and survival of children: a controlled clinical trial. *Am J Clin Nutr* 1988;48:1271–1276.

504. Hadi H, Stoltzfus RJ, Dibley MJ, et al. Vitamin A supplementation selectively improves the linear growth of Indonesian preschool children: results from a randomized controlled trial. *Am J Clin Nutr* 2000;71:507–513.
505. Ramakrishnan U, Latham MC, Abel R. Vitamin A supplementation does not improve growth of preschool children: a randomized, double-blind field trial in South India. *J Nutr* 1995;125:202–211.
506. Bahl R, Bhandari N, Taneja S, Bhan MK. The impact of vitamin A supplementation on physical growth of children is dependent on season. *Eur J Clin Nutr* 1997;51:26–29.
507. Villamor E, Mbise R, Spiegelman D, et al. Vitamin A supplements ameliorate the adverse effect of HIV-1, malaria, and diarrheal infections on child growth. *Pediatrics* 2002;109:1–10.
508. Nozeran A. De l'héméralopie des pays chauds. Thèse. No. 61. Montpellier, Gras, 1865.
509. Parinaud. De l'héméralopie dans les affections du foie et de la nature de la cécité nocturne. *Arch Gén Méd* 1881;1:403–414.
510. Saltini G. Sull'impiego del bisolfato di chinino nella cura dell'Emeralopia idiopatica. *Ann Ottalmol* 1881;10:44–49.
511. Lecoeuvre EC. De l'héméralopia sur une épidémie d'héméralopia avec xérosis épithélial (étude séméiotique). Faculté de Médecine de Paris, Thesis 493, 1896. Paris, Henri Jouve.
512. Thompson T. Effects of cod-liver oil on the blood. *Med Chron Montreal Monthly J Med Surg* 1855;2:111.
513. Greene WA. Cod liver oil. *Nashville J Med Surg* 1877;20:116–118.
514. McArdle TE. Cod-liver oil—a food and a medicine. *J Pract Med* 1896;6:279–282.
515. Findlay GM, Mackenzie RD. The bone marrow in deficiency diseases. *J Pathol Bacteriol* 1922;25:402–403.
516. Mainzer F, Joel W. Vitamin-A-Mangel als Entstehungsfaktor der alimentären Anämie des Kleinkindes. *Acta Med Scand* 1938;96:535–570.
517. Ezickson WJ. Anemia. Its occurrence in renal lithiasis and relationship to vitamin A deficiency. A clinical study of 75 patients. *Urol Cut Rev* 1938;42:820–824.
518. Gamalero PC. Influenza della vitamina A sull'emopoiesi del bambino. *Minerva Pediatrica* 1955;7:583–588.
519. Berglund H, Keefer CS, Yang CS. Deficiency anemia in Chinese, responding to cod liver oil. *Proc Soc Exp Biol Med* 1929;26:418–421.
520. Abbott OD, Ahmann CF, Overstreet MR. Effect of avitaminosis A on the human blood picture. *Am J Physiol* 1939;126:254–260.
521. Wagner KH. Die experimentelle Avitaminose A beim Menschen. *Zeitschr Physiol Chem* 1940;264:153–189.
522. Hume EM, Krebs HA. Vitamin A Requirement of Human Adults: An Experimental Study of Vitamin A Deprivation in Man. A Report of the Vitamin A Sub-Committee of the Accessory Food Factors Committee. Medical Research Council Special Report Series 264, 1949.
523. Sure B, Kik MC, Walker DJ. The effect of avitaminosis on hematopoietic function. I. Vitamin A deficiency. *J Biol Chem* 1929;83:375–385.
524. Frank M. Beitrag zur Hämatologie der A-Avitaminose. *Monatsschr Kinderheilk* 1934;60:350–355.
525. Crimm PD, Short DM. Vitamin A deficiency in the dog. *Am J Physiol* 1937;118:477–482.
526. Koessler KK, Maurer S, Loughlin R. The relation of anemia, primary and secondary, to vitamin A deficiency. *J Am Med Assoc* 1926;87:476–482.
527. Donaghue S, Kronfeld DS, Berkowitz SJ, Copp RL. Vitamin A nutrition of the equine: growth, serum biochemistry and hematology. *J Nutr* 1981;111:365–374.
528. O'Toole BA, Fradkin R, Warkany J, Wilson JG, Mann GV. Vitamin A deficiency and reproduction in rhesus monkeys. *J Nutr* 1974;104:1513–1524.
529. Sklan D, Halevy O, Donaghue S. The effect of different dietary levels of vitamin A on metabolism of copper iron and zinc in the chick. *Int J Vit Nutr Res* 1987;57:11–18.
530. McLaren DS, Tchalian M, Ajans ZA. Biochemical and hematologic changes in the vitamin A-deficient rat. *Am J Clin Nutr* 1965;17:131–138.
531. Nockels CF, Kienholz EW. Influence of vitamin A deficiency on testes, bursa fabricius, adrenal and hematocrit in cockerels. *J Nutr* 1967;92:384–388.

532. Corey JE, Hayes KC. Cerebrospinal fluid pressure, growth, and hematology in relation to retinol status of the rat in acute vitamin A deficiency. *J Nutr* 1972;102:1585–1594.
533. Mejia LA, Hodges RE, Rucker RB. Clinical signs of anemia in vitamin A-deficient rats. *Am J Clin Nutr* 1979;32:1439–1444.
534. Hodges RE, Sauberlich HE, Canham JE, et al. Hematopoietic studies in vitamin A deficiency. *Am J Clin Nutr* 1978;31:876–885.
535. Bloem MW. Interdependence of vitamin A and iron: an important association for programmes of anaemia control. *Proc Nutr Soc* 1995;54:501–508.
536. Interdepartmental Committee on Nutrition for National Defense. Nutrition Survey of Paraguay, May–August 1965. Nutrition Program, National Center for Chronic Disease Control. U.S. Department of Health, Education, and Welfare. Washington, D.C., U.S. Government Printing Office, 1967.
537. Molla A, Badruddin SH, Khurshid M, et al. Vitamin A status of children in the urban slums of Karachi, Pakistan, assessed by clinical, dietary, and biochemical methods. *Am J Trop Med Hyg* 1993;48:89–96.
538. Mejía LA [Majía, sic], Hodges RE, Arroyave G, Viteri F, Torún B. Vitamin A deficiency and anemia in Central American children. *Am J Clin Nutr* 1977;30:1175–1184.
539. Ahmed F, Barua S, Mohiduzzaman M, et al. Interactions between growth and nutrient status in school-age children of urban Bangladesh. *Am J Clin Nutr* 1993;58:334–338.
540. Mohanram M, Kulkarni KA, Reddy V. Hematological studies in vitamin A deficient children. *Int J Vit Nutr Res* 1977;47:389–393.
541. Fazio-Tirrozzo G, Brabin L, Brabin B, Agbaje O, Harper G, Broadhead R. A community based study of vitamin A and vitamin E status of adolescent girls living in the Shire valley, Southern Malawi. *Eur J Clin Nutr* 1998;52:637–642.
542. Wenger R, Ziegler B, Kruspl W, Syré B, Brubacher G, Pillat B. Beziehungen zwischen dem Vitaminstatus (Vitamin A, B₁, B₂, B₆, und C), klinischen Befunden und den Ernährungsgewohnheiten in einer Gruppe von alten Leuten in Wien. *Wien Klin Wochenschr* 1979;91:557–562.
543. Albalak R, Ramakrishnan U, Stein AD, et al. Co-occurrence of nutrition problems in Honduran children. *J Nutr* 2000;130:2271–2273.
544. Mejía LA, Chew F. Hematological effect of supplementing anemic children with vitamin A alone and in combination with iron. *Am J Clin Nutr* 1988;48:595–600.
545. Bloem MW, Wedel M, Egger RJ, et al. Iron metabolism and vitamin A deficiency in children in North-east Thailand. *Am J Clin Nutr* 1989;50:332–338.
546. Bloem MW, Wedel M, van Agtmaal EJ, Speek AJ, Saowakontha S, Schreurs WHP. Vitamin A intervention: short-term effects of a single, oral, massive dose on iron metabolism. *Am J Clin Nutr* 1990;51:76–79.
547. Semba RD, Muhilal, West KP Jr, et al. Impact of vitamin A supplementation on hematological indicators of iron metabolism and protein status in children. *Nutr Res* 1992;12:469–478.
548. Mwanri L, Worsley A, Ryan P, Masika J. Supplemental vitamin A improves anemia and growth in anemic school children in Tanzania. *J Nutr* 2000;130:2691–2696.
549. Kolsteren P, Rahman SR, Hilderbrand K, Diniz A. Treatment for iron deficiency anaemia with a combined supplementation of iron, vitamin A and zinc in women of Dinajpur, Bangladesh. *Eur J Clin Nutr* 1999;53:102–106.
550. Suharno D, West CE, Muhilal, Karyadi D, Hautvast GAJ. Supplementation with vitamin A and iron for nutritional anaemia in pregnant women in West Java, Indonesia. *Lancet* 1993;342:1325–1328.
551. Panth M, Shatrugna V, Yasodhara P, Sivakumar B. Effect of vitamin A supplementation on haemoglobin and vitamin A levels during pregnancy. *Br J Nutr* 1990;64:351–358.
552. Chawla PK, Puri R. Impact of nutritional supplements on hematological profile of pregnant women. *Indian Pediatr* 1995;32:876–880.
553. Fawzi WW, Msamanga GI, Spiegelman D, et al. Randomised trial of effects of vitamin supplements on pregnancy outcomes and T cell counts in HIV-1-infected women in Tanzania. *Lancet* 1998;351:1477–1482.
554. Muslimatun S, Schmidt MK, Schultink W, et al. Weekly supplementation with iron and vitamin A during pregnancy increases hemoglobin concentration but decreases serum ferritin concentration in Indonesian pregnant women. *J Nutr* 2001;131:85–90.

555. Gregory CJ, Eaves AC. Three stages of erythropoietic progenitor cell differentiation distinguished by a number of physical and biologic properties. *Blood* 1978;51:527–537.
556. Migliaccio G, Migliaccio AR, Visser JWM. Synergism between erythropoietin and interleukin-3 in the induction of hematopoietic stem cell proliferation and erythroid burst colony formation. *Blood* 1998;72:944–951.
557. Bondurant MC, Lind RN, Koury MJ, Ferguson ME. Control of globin gene transcription by erythropoietin in erythroblasts from Friend virus-infected mice. *Mol Cell Biol* 1985;5:675–683.
558. Izak G, Karsai A, Eylon I, Herschko C. Ribonucleic acid production and breakdown in synchronized erythroid cohorts from actinomycin-treated animals. *J Lab Clin Med* 1971;77:923–930.
559. Erslev AJ. Erythropoietin. *N Engl J Med* 1991;324:1339–1344.
560. Daniels G, Green C. Expression of red cell surface antigens during erythropoiesis. *Vox Sang* 2000;78 (suppl 2):149–153.
561. Van Schravendijk MR, Handunnetti SM, Barnwell JW, Howard RJ. Normal human erythrocytes express CD36, an adhesion molecule of monocytes, platelets, and endothelial cells. *Blood* 1992;80:2105–2114.
562. Zermati Y, Fichelson S, Valensi F, et al. Transforming growth factor inhibits erythropoiesis by blocking proliferation of accelerating differentiation of erythroid progenitors. *Exp Hematol* 2000;28:885–894.
563. Douer D, Koeffler HP. Retinoic acid enhances growth of human early erythroid progenitor cells in vitro. *J Clin Invest* 1982;69:1039–1041.
564. Correa PN, Axelrad AA. Retinyl acetate and all-trans-retinoic acid enhance erythroid colony formation in vitro by circulating human progenitors in an improved serum-free medium. *Int J Cell Cloning* 1992;10:286–291.
565. Perrin MC, Blanchet JP, Mouchiroud G. Modulation of human and mouse erythropoiesis by thyroid hormone and retinoic acid: evidence for specific effects at different steps of the erythroid pathway. *Hematol Cell Ther* 1997;39:19–26.
566. Rusten LS, Dybedal I, Blomhoff HK, Blomhoff R, Smeland EB, Jacobsen SE. The RAR-RXR as well as the RXR-RXR pathway is involved in signaling growth inhibition of CD34⁺ erythroid progenitor cells. *Blood* 1996;87:1728–1736.
567. Zauli G, Visani G, Vitale M, Gibellini D, Bertolaso L, Capitani S. All-trans retinoic acid shows multiple effects on the survival, proliferation and differentiation of human fetal CD34⁺ haemopoietic progenitor cells. *Br J Haematol* 1995;90:274–282.
568. Josefsen D, Blomhoff HK, Lømo J, Blystad AK, Smeland EB. Retinoic acid induces apoptosis of human CD34⁺ hematopoietic progenitor cells: Involvement of retinoic acid receptors and retinoid X receptors depends on lineage commitment of the hematopoietic progenitor cells. *Exp Hematol* 1999;27:642–653.
569. Okano M, Masuda S, Narita H, et al. Retinoic acid up-regulates erythropoietin production in hepatoma cells and in vitamin A-depleted rats. *FEBS Lett* 1994;349:229–233.
570. Jelkmann W, Pagel H, Hellwig T, Fandrey J. Effects of antioxidant vitamins on renal and hepatic erythropoietin production. *Kidney Int* 1997;51:497–501.
571. Neumcke I, Schneider B, Fandrey J, Pagel H. Effects of pro- and antioxidative compounds on renal production of erythropoietin. *Endocrinology* 1999;140:641–645.
572. Dahgman NA, Elder GE, Savage GA, Winter PC, Maxwell AP, Lappin TR. Erythropoietin production: evidence for multiple oxygen sensing pathways. *Ann Hematol* 1999;78:275–278.
573. Kambe T, Tada-Kambe J, Kuge Y, Yamaguchi-Iwai Y, Nagao M, Sasaki R. Retinoic acid stimulates erythropoietin gene transcription in embryonal carcinoma cells through the direct repeat of a steroid/thyroid hormone receptor response element half-site in the hypoxia-response enhancer. *Blood* 2000;96:3265–3271.
574. Semba RD, Kumwenda N, Taha TE, et al. Impact of vitamin A supplementation on anaemia and plasma erythropoietin concentrations in pregnant women: a controlled clinical trial. *Eur J Haematol* 2001;66:389–395.
575. Means RT Jr. The anaemia of infection. *Ballière's Clin Hematol* 2000;13:151–162.
576. Semba RD, Gray GE. The pathogenesis of anemia during human immunodeficiency virus infection. *J Investig Med* 2001;49:225–239.

577. Morris CDW, Bird AR, Nell H. The haematological and biochemical changes in severe pulmonary tuberculosis. *Q J Med* 1989;73:1151–1159.
578. Jansson LT, Kling S, Dallman PR. Anemia in children with acute infections seen in a primary care pediatric outpatient clinic. *Pediatr Inf Dis* 1986;5:424–427.
579. Murphy M, Perussia B, Trinchieri G. Effects of recombinant tumor necrosis factor, lymphotoxin, and immune interferon on proliferation and differentiation of enriched hematopoietic precursor cells. *Exp Hematol* 1988;16:131–138.
580. Feelders RA, Vreugdenhil G, Eggermont AMM, Kuiper-Kramer PA, van Eijk HG, Swaak AJG. Regulation of iron metabolism in the acute-phase response: interferon γ and tumour necrosis factor α induce hypoferraemia, ferritin production and a decrease in circulating transferrin receptors in cancer patients. *Eur J Clin Invest* 1998;28:520–527.
581. Means RT, Dessypris EN, Krantz SB. Inhibition of human colony-forming units erythroid by tumor necrosis factor requires accessory cells. *J Clin Invest* 1990;86:538–541.
582. Ganz T. Hpcidin—a regulator of intestinal iron absorption and iron recycling by macrophages. *Best Pract Res Clin Haematol* 2005;18:171–182.
583. Kluger MJ, Rothenburg BA. Fever and reduced iron: their interactions as a host defense response to bacterial infection. *Science* 1979;203:374–376.
584. Semba RD, Muhilal, West KP Jr, et al. Hyporetinolemia and acute phase proteins in children with and without xerophthalmia. *Am J Clin Nutr* 2000;72:146–153.
585. West CE, Roodenburg AJC. Role of vitamin A in iron metabolism. *Voeding* 1992;53:201–205.
586. Staab DB, Hodges RE, Metcalf WK, Smith JL. Relationship between vitamin A and iron in the liver. *J Nutr* 1984;114, 840–844.
587. Beynen AC, Sijtsma KW, van den Berg GJ, Lemmens AG, West CE. Iron status in rats fed a purified diet without vitamin A. *Biol Trace Elem Res* 1992;35:81–84.
588. Sijtsma KW, van den Berg GJ, Lemmens AG, West CE, Beynen AC. Iron status in rats fed on diets containing marginal amounts of vitamin A. *Br J Nutr* 1993;70:777–785.
589. Roodenburg AJC, West CE, Yu S, Beynen AC. Comparison between time-dependent changes in iron metabolism of rats as induced by marginal deficiency of either vitamin A or iron. *Br J Nutr* 1994;71: 687–699.
590. Gardner R, Hodges R, Rucker R. Fate of erythrocyte iron in vitamin A deficient rats. *Fed Proc* 1979; 38:762.
591. Roodenburg AJC, West CE, Hovenier R, Beynen AC. Supplemental vitamin A enhances the recovery from iron deficiency in rats with chronic vitamin A deficiency. *Br J Nutr* 1996;75:623–636.
592. Roodenburg AJC, West CE, van Dijk JE, van Eijk HG, Marx JJM, Beynen AC. Indicators of erythrocyte formation and degradation in rats with either vitamin A or iron deficiency. *J Nutr Biochem* 2000;11:223–230.
593. Mejía LA, Arroyave G. Lack of direct association between serum transferrin and serum biochemical indicators of vitamin A nutriture. *Acta Vitaminol Enzymol* 1983;5:179–184.
594. Mejía LA, Arroyave G. The effect of vitamin A fortification of sugar on iron metabolism in preschool children in Guatemala. *Am J Clin Nutr* 1982;36:87–93.
595. Thurnham DI, Northrup-Clewes CA, McCullough FS, Das BS, Lunn PG. Innate immunity, gut integrity, and vitamin A in Gambian and Indian infants. *J Infect Dis* 2000;182(suppl 1):S23–S28.
596. García-Casal MN, Layrisse M, Solano L, et al. Vitamin A and β -carotene can improve nonheme iron absorption from rice, wheat and corn by humans. *J Nutr* 1998;128:646–650.
597. Sommer A, Davidson FR. Assessment and control of vitamin A deficiency: the Annecy Accords. *J Nutr* 2002;132(suppl 9):2845S–2850S.
598. Semba RD, Bloem MW. Measles blindness. *Surv Ophthalmol* 2004;49:243–255.
599. Whitcher JP, Srinivasan M, Upadhyay MP. Corneal blindness: a global perspective. *Bull World Health Organ* 2001;79:214–221.
600. World Health Organization. Global Prevalence of Vitamin A Deficiency. Micronutrient Deficiency Information System Working Paper #2. Geneva, World Health Organization, 1995.
601. West KP Jr. Extent of vitamin A deficiency among preschool children and women of reproductive age. *J Nutr* 2002;132:2857S–2866S.

602. Semba RD, de Pee S, Panagides D, Poly O, Bloem MW. Risk factors for xerophthalmia among mothers and their children and for mother-child pairs with xerophthalmia in Cambodia. *Arch Ophthalmol* 2004;122:517–523.
603. Semba RD, De Pee S, Panagides D, Poly O, Bloem MW. Risk factors for nightblindness among women of childbearing age in Cambodia. *Eur J Clin Nutr* 2003;57:1627–1632.
604. Panagides D, Eilander A, de Pee S, et al. Review of Cambodia's national vitamin A capsule distribution program. XXIVACG Meeting: 25 Years of Progress in Controlling Vitamin A Deficiency: Looking to the Future. Hanoi, Vietnam, February 12–15, 2001 [abstracts]. Washington, D.C., ILSI Research Foundation, 2001, p. 35.
605. Giay T, Nhân NT, Khoi HH. Control of xerophthalmia and vitamin A deficiency in Vietnam. Seminar on Vitamin A Deficiency and Xerophthalmia. National Institute of Nutrition, October 28–29, 1986. Hanoi, Viện Dinh Dưỡng, 1986, pp. 2–10.
606. Verin P, Comte P. La xérophthalmie. Enquête en 1986 au Vietnam. *Ophthalmol* 1988;2:127–128.
607. Bloem MW, Gorstein J. Vietnam: Xerophthalmia Free. 1994 National Vitamin A Deficiency and Protein-Energy Malnutrition Prevalence Survey. Consultancy Report, March 5–17, 1995. Jakarta, Helen Keller International, 1995.
608. Khoi HH, Khan NC, Giay T, et al. Progress of vitamin A deficiency control program in Vietnam. In: Khoi HH, Ninh NX, Khan NC, Lam NT (eds). 20 Years of Prevention and Control of Micronutrient Deficiencies in Vietnam: Research and Development 1980–2000. Hanoi, Medical Publishing House: 2001; pp. 4–22.
609. Malyavin A, Boupahy V, Arouny A, Cohen N. National vitamin A survey in Lao PDR. XVII IVACG Meeting. Virtual Elimination of Vitamin A Deficiency: Obstacles and Solutions for the Year 2000, 18–22 March 1996, Guatemala [abstracts]. Washington, D.C., The Nutrition Foundation, 1996, p. 15.
610. Bloem MW, Wedel M, Egger RJ, Speek AJ, Chusilp K, Saowakonthat S, Schreurs WH. A prevalence study of vitamin A deficiency and xerophthalmia in northeastern Thailand. *Am J Epidemiol* 1989;129:1095–1103.
611. Wanaratna L, Sinawat S, Vasantavisuthi E, Thaineua V. The prevalence of inadequate vitamin A nutriture in preschool children of north and northeast Thailand. *J Med Assoc Thai* 1997;80:139–146.
612. Maleevong K, Durongdej S, Wasantawisut E, Pradipasen M, Pattaraarchachai J, Sinawat S. Development of screening indicators for ranking areas at risk of vitamin A deficiency in Thailand. *J Med Assoc Thai* 2004;87:150–157.
613. Fuchs GJ, Ausayakhun S, Ruckphaopunt S, Tansuhaj A, Suskind RM. Relationship between vitamin A deficiency, malnutrition, and conjunctival impression cytology. *Am J Clin Nutr* 1994;60:293–298.
614. Panpanich R, Vitsupakorn K, Harper G, Brabin B. Serum and breast-milk vitamin A in women during lactation in rural Chiang Mai, Thailand. *Ann Trop Paediatr* 2002;22:321–324.
615. Khor GL. Micronutrient deficiency and its alleviation: the case of Malaysia. *Asia Pac J Clin Nutr* 2002;11(suppl 1):S377–S381.
616. Ngah NF, Moktar N, Isa NHM, et al. Ocular manifestation of vitamin A deficiency among Orang Asli (aborigine) children in Malaysia. *Asia Pac J Clin Nutr* 2002;11:88–91.
617. Loh RCK. Xerophthalmia (keratomalacia) in Singapore—a study. *Singapore Med J* 1967;8:128–133.
618. Zin MM. Improving routine vitamin A distribution through NIDs in Myanmar. XXIVACG Meeting: 25 Years of Progress in Controlling Vitamin A Deficiency: Looking to the Future. Hanoi, Vietnam, February 12–15, 2001 [abstracts]. Washington, D.C., ILSI Research Foundation, 2001, p. 36.
619. Hadikoesoemo GA. Nogmaals over xerophthalmie. *Geneesk tijdschr Nederlandsch Indië* 1938;78:935–941.
620. Tarwotjo I, Tilden R, Satibi I, Nendrawati H. Vitamin A deficiency control in Indonesia. In: Bauernfeind JC (ed). *Vitamin A Deficiency and Its Control*. Orlando, Academic: 1986; pp. 445–460.
621. Ministry of Health, Indonesia. Nutritional Blindness Prevention Project. Characterization of Vitamin A Deficiency and Xerophthalmia and the Design of Effective Intervention Program. Jakarta, Ministry of Health, 1980.
622. Muhilal, Tarwotjo I, Kodyat B, et al. Changing prevalence of xerophthalmia in Indonesia, 1977–1992. *Eur J Clin Nutr* 1994;48:708–714.
623. Semba RD, Susatio B, Muhilal, Natadisastra G. The decline of admissions for xerophthalmia at Cicendo Eye Hospital, Indonesia, 1981–1992. *Int Ophthalmol* 1995;19:39–42.

624. Molla A, Badruddin SH, Khurshid M, et al. Vitamin A status of children in the urban slums of Karachi, Pakistan, assessed by clinical, dietary, and biochemical methods. *Am J Trop Med Hyg* 1993;48:89–96.
625. Kahn MA, Khan MD. The role of district ophthalmologists in surveillance of blinding xerophthalmia in north west frontier province of Pakistan. XX IVACG Meeting: 25 Years of Progress in Controlling Vitamin A Deficiency: Looking to the Future. Hanoi, Vietnam, February 12–15, 2001 [abstracts]. Washington, D.C., ILSI Research Foundation, 2001, p. 39.
626. Rauf S, Sharif N, Hamid A. Serum vitamin A levels in children under five years old. *J Ayub Med Coll Abbottabad* 2002;14:26–27.
627. Toteja GS, Singh P, Dhillon BS, Saxena BN. Vitamin A deficiency disorders in 16 districts of India. *Indian J Pediatr* 2002;69:603–605.
628. Singh P, Toteja GS. Micronutrient profile of Indian children and women: summary of available data for iron and vitamin A. *Indian Pediatr* 2003;40:477–479.
629. Khandait DW, Vasudeo ND, Zodpey SP, et al. Subclinical vitamin A deficiency in undersix children in Nagpur, India. *South East Asia J Trop Med Public Health* 1998;29:289–292.
630. Cohen N, Rahman H, Sprague J, Jalil MA, Leemhuis de Regt E, Mitra M. Prevalence and determinants of nutritional blindness in Bangladeshi children. *World Health Stat Q* 1985;38:317–330.
631. Begum S, Rashid M, Shahjahan M. Vitamin A supplementation program for children in Bangladesh: Strategic changes in distribution and its experiences. XXI IVACG Meeting: Improving the Vitamin A Status of Populations. Marrakech, Morocco, February 3–5, 2003 [abstracts]. Washington, D.C., ILSI Research Foundation Institute, 2003, p. 27.
632. Brilliant LB, Pokhrel RP, Grasset NC, et al. Epidemiology of blindness in Nepal. *Bull World Health Organ* 1985;63:375–386.
633. Katz J, West KP Jr, Khatry SK, et al. Impact of vitamin A supplementation on prevalence and incidence of xerophthalmia in Nepal. *Invest Ophthalmol Vis Sci* 1995;36:2577–2583.
634. Erdenechimeg E, Burmaa B, Lkhagva L, Batdelger S. Vitamin A status in Mongolia. XX IVACG Meeting: 25 Years of Progress in Controlling Vitamin A Deficiency: Looking to the Future. Hanoi, Vietnam, February 12–15, 2001 [abstracts]. Washington, D.C., ILSI Research Foundation, p. 38.
635. Klemm RDW, Villate EE, Tuason CS, Bayugo G, Mendoza OM. A prevalence study of xerophthalmia in the Philippines: implications for supplementation strategies. *South East Asia J Trop Med Public Health* 1993;24:617–623.
636. Rosen DS, Sloan NL, del Rosario A, de la Paz TC. Risk factors for vitamin A deficiency in rural areas of the Philippines. *J Trop Pediatr* 1994;40:82–87.
637. Madriaga JR, Cheong RL, Cabrera MIZ, et al. Changes in prevalence of vitamin A deficiency after five years of bi-annual high-dose vitamin A supplementation in the Philippines. XX IVACG Meeting: 25 Years of Progress in Controlling Vitamin A Deficiency: Looking to the Future. Hanoi, Vietnam, February 12–15, 2001 [abstracts]. Washington, D.C., ILSI Research Foundation, 2001, p. 37.
638. Paulino LS, Barquilla EG, Ramos AC, et al. Garantisadong Pambata: the Philippine strategy of vitamin A supplementation to eliminate vitamin A deficiency. XX IVACG Meeting: 25 Years of Progress in Controlling Vitamin A Deficiency: Looking to the Future. Hanoi, Vietnam, February 12–15, 2001 [abstracts]. Washington, D.C., ILSI Research Foundation, 2001, p. 36.
639. Schaumberg DA, Linehan M, Hawley G, O'Connor J, Dreyfuss M, Semba RD. Vitamin A deficiency in the South Pacific. *Public Health* 1995;109:311–317.
640. Danks J, Kaufman D, Rait J. A clinical and cytological study of vitamin A deficiency in Kiribati. *Aust N Z J Ophthalmol* 1992;20:215–218.
641. Schaumberg DA, O'Connor J, Semba RD. Risk factors for xerophthalmia in the Republic of Kiribati. *Eur J Clin Nutr* 1996;50:761–764.
642. Palafox NA, Gamble MV, Dancheck B, Ricks MO, Briand K, Semba RD. Vitamin A deficiency, iron deficiency, and anemia among preschool children in the Republic of the Marshall Islands. *Nutrition* 2003;19:405–408.
643. Lloyd-Puryear M, Humphrey JH, West KP Jr, et al. Vitamin A deficiency and anemia among Micronesian children. *Nutr Res* 1989;9:1007–1016.
644. Centers for Disease Control and Prevention (CDC). Vitamin A deficiency among children—Federated States of Micronesia, 2000. *MMWR Morb Mortal Wkly Rep* 2001;50:509–512.

645. El Bushra HE, El Tom AR. Vitamin A deficiency: a public health problem in eastern Sudan. *East Afr Med J* 1987;64:782–789.
646. El Bushra HE. Vitamin A deficiency in the Sudan: a call for a surveillance system. *East Afr Med J* 1992;69:279–281.
647. Nestel P, Herrera MG, El Amin A, Fawzi W, Mohammed KA, Weld L. Risk factors associated with xerophthalmia in northern Sudan. *J Nutr* 1993;123:2115–2121.
648. Demeke T, Gebru H. Xerophthalmia: a review of hospital out-patient records. *Ethiopia Med J* 1982;21:15–19.
649. Lindtjörn B. Xerophthalmia in the Gardula area of south-west Ethiopia. *Ethiopia Med J* 1983;21:169–174.
650. De Sole G, Belay Y, Zegeye B. Vitamin A deficiency in southern Ethiopia. *Am J Clin Nutr* 1987;45:780–784.
651. Zerihun N. Xerophthalmia at a welfare home in Jimma town. *Ethiopian J Health Develop* 1997;11:213–218.
652. Wolde-Gebriel Z, Demeke T, West CE. Xerophthalmia in Ethiopia: a nationwide ophthalmological, biochemical and anthropometric survey. *Eur J Clin Nutr* 1991;45:469–478.
653. Wolde-Gebriel Z, West CE, Gebru H, et al. Interrelationship between vitamin A, iodine and iron status in schoolchildren in Shoa Region, Central Ethiopia. *Br J Nutr* 1993;70:593–607.
654. Lemma F, Mariam AG. Xerophthalmia and malnutrition among pre-school children in Agaro Town South-West Ethiopia. *East Afr Med J* 1996;73:179–181.
655. Tafesse Y, Fisseha T, Umata M, Hidar J, Teka W. Vitamin A deficiency: a serious threat in Dodota district in central Ethiopia. *East Afr Med J* 1996;73:303–307.
656. Haidar J, Demissie T. Malnutrition and xerophthalmia in rural communities of Ethiopia. *East Afr Med J* 1999;76:590–593.
657. Getaneh T, Assefa A, Tadesse Z. Dietary practices and xerophthalmia in under-fives in Jimma Town, southwest Ethiopia. *E Afr Med J* 2000;77:313–315.
658. Asrat YT, Omwega AM, Muita JWG. Prevalence of vitamin A deficiency among pre-school and school-aged children in Arssi Zone, Ethiopia. *E Afr Med J* 2002;79:355–360.
659. Alemu Z, Mohammed S. Vitamin A deficiency disorders in pre-school children of Eritrea. XXII IVACG Meeting: Vitamin A and the Common Agenda for Micronutrients. Lima, Peru, November 15–17, 2004 [abstracts]. Washington, D.C., ILSI Research Foundation Institute, 2004, p. 54.
660. Jansen AAJ, Horelli HT. Vitamin A deficiency in Kenya: past and present. *East Afr Med J* 1982;59:107–112.
661. Sinabulya PM. An assessment of the extent of blindness in Machakos District. *East Afr Med J* 1976;53:64–73.
662. Korte R, Wiersinga A. Deficiency in male prisoners reflecting borderline vitamin A intake in the population of Kenya. *Trop Geog Med* 1972;24:339–343.
663. Kennedy ET, Oniangó R. Household and preschooler vitamin A consumption in southwestern Kenya. *J Nutr* 1993;123:841–846.
664. Ngare DK, Muttunga JN, Njonge E. Vitamin A deficiency in pre-school children in Kenya. *E Afr Med J* 2000;77:421–424.
665. Munene RM, Adala HS, Masinde MS, Rana FS. Vitamin A deficiency among Kenyan children as detected by conjunctival impression cytology [sic]. *E Afr Med J* 2003;80:476–479.
666. Ettyang GA, van Market Lichtenbelt WD, Oloo A, Saris WHM. Serum retinol, iron status and body composition of lactating women in Nandi, Kenya. *Ann Nutr Metab* 2003;47:276–283.
667. Kawuma M. Sugar as a potential vehicle for vitamin A fortification: experience from Kamuli district in Uganda. *Afr Health Sci* 2002;2:11–15.
668. Leonard PJ. Serum and liver levels of vitamin A in Ugandans. *E Afr Med J* 1964;41:133–136.
669. Kawuma M. Eye diseases and blindness in Adjumani refugee settlement camps, Uganda. *East Afr Med J* 2000;77:580–582.
670. Pepping F, Kavishe FP, Hackenitz EA, West CE. Prevalence of xerophthalmia in relation to nutrition and general health in preschool-age children in three regions of Tanzania. *Acta Paediatr Scand* 1988;77:895–906.

671. Pepping F, van der Giezen AM, de Jonge KI, West CE. Food consumption of children with and without xerophthalmia in rural Tanzania. *Trop Geogr Med* 1989;41:14–21.
672. Donnen P, Brasseur D, Dramaix M, et al. Vitamin A deficiency and protein-energy malnutrition in a sample of pre-school age children in the Kivu province in Zaire. *Eur J Clin Nutr* 1996;50:456–461.
673. Tielsch JM, West KP Jr, Katz J, et al. Prevalence and severity of xerophthalmia in southern Malawi. *Am J Epidemiol* 1986;124:561–568.
674. Escoute AJ, Chirambo MC, Luzeau R, Amedée-Manesme O. Assessment of vitamin A deficiency in Republic of Malawi by impression cytology method. *Int J Vitam Nutr Res* 1991;61:10–16.
675. Bobrow EA, Mdebwe HJ, Chimtolo F, et al. Vitamin A situation assessment in Malawi: results from the National Micronutrient Survey. XXI IVACG Meeting: Improving the Vitamin A Status of Populations. Marrakech, Morocco, February 3–5, 2003 [abstracts]. Washington, D.C., ILSI Research Foundation Institute, 2003, p. 37.
676. Semba RD, Kumwenda N, Taha TE, et al. Plasma and breast milk vitamin A as indicators of vitamin A status in pregnant women. *Int J Vitam Nutr Res* 2000;70:271–277.
677. Dancheck B, Nussenblatt V, Ricks MO, et al. Breast milk retinol concentrations are not associated with systemic inflammation among breast-feeding women in Malawi. *J Nutr* 2005;135:223–236.
678. Ncube TN, Malaba L, Greiner T, Gebre-Medhin M. Evidence of grave vitamin A deficiency among lactating women in the semi-arid rural area of Makhaza in Zimbabwe. A population-based study. *Eur J Clin Nutr* 2001;55:229–234.
679. Kafwembe EM. Iron and vitamin A status of breastfeeding mothers in Zambia. *East Afr Med J* 2001;78:454–457.
680. Kafwembe EM, Mwandu D, Sukwa Y. Socio-economic status and serum vitamin A levels in Zambian children. *Cent Afr J Med* 1996;42:70–72.
681. Kafwembe EM, Sukwa T, Manyando C, Mwandu D, Chipipa J, Chipaila P. The vitamin A status of Zambian children attending an under five clinic as evaluated by the modified relative dose response (MRDR) test. *Int J Vitam Nutr Res* 1996;66:190–196.
682. Luo C, Mwela C, Foote D, Kafwembe E, Schultz K. National vitamin A deficiency prevalence survey in Zambia. XIX IVACG Meeting: Vitamin A and Other Micronutrients: Biologic Interactions and Integrated Interventions. Durban, South Africa, March 8–11, 1999 [abstracts]. Washington, D.C., ILSI Research Foundation, 1999, p. 51.
683. dos Santos D, Ambrosio JM, Agostinho N, Ferreira NC, Dinis A. Study of vitamin A and iron deficiency in the Republic of Angola, December 1998 [sic]. XX IVACG Meeting: 25 Years of Progress in Controlling Vitamin A Deficiency: Looking to the Future. Hanoi, Vietnam, February 12–15, 2001 [abstracts]. Washington, D.C., ILSI Research Foundation, 2001, p. 42.
684. Carreras FJ, Rodríguez-Hurtado F, David H. Ophthalmology in Luanda (Angola): a hospital based report. *Br J Ophthalmol* 1995;79:926–933.
685. Aguayo VM, Kahn S, Ismael C, Meershoek S. Vitamin A deficiency and child mortality in Mozambique. *Public Health Nutr* 2005;8:29–31.
686. Hassan C, Fidalgo L, van Stiertegehn V, MacArthur C. Implementing universal vitamin A capsule distribution in Mozambique. XX IVACG Meeting: 25 Years of Progress in Controlling Vitamin A Deficiency: Looking to the Future. Hanoi, Vietnam, February 12–15, 2001 [abstracts]. Washington, D.C., ILSI Research Foundation, 2001, p. 63.
687. Khan S, Ismael C, Van Steirtighem V, Meershoek S. Ensuring vitamin A supplementation through routine health services in Mozambique. XXI IVACG Meeting: Improving the Vitamin A Status of Populations. Marrakech, Morocco, February 3–5, 2003 [abstracts]. Washington, D.C., ILSI Research Foundation Institute, 2003, p. 27.
688. Mduma B, Mazhani P, Mawunde H, Mompoti K, Mokgautsi N, Mugabe M. Interventions to alleviate vitamin A deficiency in Botswana: lessons learned from the completed pilot project in Kweneng District, Botswana. XX IVACG Meeting: 25 Years of Progress in Controlling Vitamin A Deficiency: Looking to the Future. Hanoi, Vietnam, February 12–15, 2001 [abstracts]. Washington, D.C., ILSI Research Foundation, 2001, p. 63.
689. South African Vitamin A Consultative Group. Anthropometric, vitamin A, iron and immunization coverage status in children aged 6–71 months in South Africa, 1994. *S Afr Med J* 1996;86:354–357.

690. de Hoop ME, Goga A, Mazibuko N, Matji, Baker SK, MacArthur C. Implementation of vitamin A supplementation in South Africa. XXI IVACG Meeting: Improving the Vitamin A Status of Populations. Marrakech, Morocco, February 3–5, 2003 [abstracts]. Washington, D.C., ILSI Research Foundation, 2003, p. 35.
691. Carlier C, Moullia-Pelat JP, Ceccon JF, et al. Prevalence of malnutrition and vitamin A deficiency in the Diourbel, Fatick, and Kaolack regions of Senegal: epidemiological study. *Am J Clin Nutr* 1991; 53:70–73.
692. Rankins J, Green NR, Tremper W, Stacewicz-Sapuntzakis M, Bowen P, Ndiaye M. Undernutrition and vitamin A deficiency in the Department of Linguère, Louga Region of Sénégal. *Am J Clin Nutr* 1993;58:91–97.
693. Perkins AL. Evaluation of vitamin A deficiency in the Yelimane circle of Mali, West Africa. *Trop Doctor* 1994;24:70–72.
694. Kagnassy D. Distribution of vitamin A during NIDs: evaluation of the impact on children under-five in two districts in Mali. XX IVACG Meeting: 25 Years of Progress in Controlling Vitamin A Deficiency: Looking to the Future. Hanoi, Vietnam, February 12–15, 2001 [abstracts]. Washington, D.C., ILSI Research Foundation, 2001, p. 62.
695. Cissé A, Koné D, Bore M, et al. Regional micronutrient days in Mali. XXI IVACG Meeting: Improving the Vitamin A Status of Populations. Marrakech, Morocco, February 3–5, 2003 [abstracts]. Washington, D.C., ILSI Research Foundation, 2003, p. 35.
696. Schémann JF, Banou AA, Guindo A, Joret V, Traore L, Malvy D. Prevalence of undernutrition and vitamin A deficiency in the Dogon region, Mali. *J Am Coll Nutr* 2002;21:381–387.
697. Schémann JF, Banou A, Malvy D, Guindo A, Traore L, Momo G. National immunization days and vitamin A distribution in Mali: has the vitamin A status of pre-school children improved? *Public Health Nutr* 2003;6:233–244.
698. Chassot P. Fréquence de la tache de Bitot sans malnutrition protéino-énergétique chez les enfants d'un village Mauritanien (Bareina-Trarza). *Rev Int Trach Pathol Ocul Trop Subtrop Sante Publique* 1985; 62:61–66.
699. Chassot P, Barry AK. Lutte contre l'hypovitaminose A en Mauritanie. *Rev Int Trach Pathol Ocul Trop Subtrop Sante Publique* 1989;66:73–84.
700. Chassot P, Cluzeau C, Luzeau R, el Joud R, Barry K. Test de l'impression oculaire de transfert pour la surveillance du status vitaminique A. *Rev Int Trach Pathol Ocul Trop Subtrop Sante Publique* 1990; 67:263–267.
701. Resnikoff S. Aspects épidémiologiques de la xerophthalmie au Tchad. *Med Trop (Mars)* 1988;48: 27–32.
702. Le Francois P, Chevassus-Agnes S, Benefice E, et al. Vitamin A status of populations in three West African countries. *Int J Vitam Nutr Res* 1980;50:352–363.
703. Bénéfice É, Chevassus-Agnes S, Epelboin A, Carles C, Ndiaye AM. Enquête nutritionnelle en Haute-Volta. I. Importance et formes de la malnutrition. *Bull Soc Pathol Exot Filiales* 1983;76:87–94.
704. Meda N, Chevalier P, Mathieu-Daude C. Manifestations oculaires liées à la carence en vitamine A en zone rurale du Burkina Faso. *Med Trop (Mars)* 2000;60:57–60.
705. Lechat MF, Bouche R, de Ville de Goyet C, Boucquey C. Epidémiologie de l'avitaminose A au Niger. *Ann Soc Belge Méd Trop* 1976;56:333–342.
706. Baker SK, Harouna H, Mamadou Taïbou A, Boukari A. Beyond NIDs: Niger's experience in organizing National Micronutrient Days. XX IVACG Meeting: 25 Years of Progress in Controlling Vitamin A Deficiency: Looking to the Future. Hanoi, Vietnam, February 12–15, 2001 [abstracts]. Washington, D.C., ILSI Research Foundation: 2001; p. 64.
707. Amoahful E, Agble R, Nyaku A. Evaluation of three years of non-NIDS vitamin A supplementation: experiences and lessons from Ghana. XXI IVACG Meeting: Improving the Vitamin A Status of Populations. Marrakech, Morocco, February 3–5, 2003 [abstracts]. Washington, D.C., ILSI Research Foundation: 2003; p. 27.
708. Ayivi B. Enquête et soins de la carence en vitamine A chez les enfants atteints de malnutrition. *Dev Sante* 1995;115:28–30.
709. Gouado I, Mbiapo TF, Moundipa FP, Teugwa MC. Vitamin A and E status of some rural populations in the north of Cameroon. *Int J Vit Nutr Res* 1998;68:21–25.

710. Sibetcheu D, Nankap N, Gimou MM, Kollo B, Haselow N, Bernardi R. Cameroon national survey on vitamin A deficiency. XX IVACG Meeting: 25 Years of Progress in Controlling Vitamin A Deficiency: Looking to the Future. Hanoi, Vietnam, February 12–15, 2001 [abstracts]. Washington, D.C., ILSI Research Foundation, 2001; p. 41.
711. Lachili B, Faure H, Arnaud J, et al. Blood micronutrients in Algeria, relationship with sex and age. *Int J Vitam Nutr Res* 2001;71:111–116.
712. Berraho A, Refass L, Chekli H, et al. Vitamin A deficiency among children living in the Kingdom of Morocco: comparison of ophthalmologic and biochemical assessments [sic]. XXI IVACG Meeting: Improving the Vitamin A Status of Populations. Marrakech, Morocco, February 3–5, 2003. Washington, D.C., ILSI Research Foundation Institute: 2003; p. 29.
713. Nasri I, El Bouhali B, Aguenau H, Mokhtar N. Vitamin A deficiency among Moroccan women and children. *Afr Health Sci* 2004;4:3–8.
714. El Kari K, Borghos L, Benajiba N, et al. Daily vitamin A intake and nutritional disorders in preschool children: case of the northwest area of Morocco. XXII IVACG Meeting: Vitamin A and the Common Agenda for Micronutrients. Lima, Peru, November 15–17, 2004 [abstracts]. Washington, D.C., ILSI Research Foundation: 2004; p. 54.
715. Corcos V, Besnainou R. Complications oculaires de l'avitaminose "A" en Tunisie. *Tunisie médicale* 1955;43:591–601.
716. Abdel-Kader MM, Abdel Salam E, Massoud S, Ishaac S. Blood serum vitamin A and beta-carotene in marasmic Egyptian infants. *Gaz Egypt Paediatr Assoc* 1973;21:77–81.
717. El-Naggar B, Gaafar S, Allam H, Osman N, Hussein L. Study of the absorption of vitamin A oily preparation among school pupils from the rural. *Int J Vitam Nutr Res* 1981;51:3–8.
718. Curtale F, Tammam H, Hammoud ES, Aloï A. Prevalence of xerophthalmia among children in Beheira governorate, Egypt. *Rev Santé Méditerran Orient* 1999;5:984–991.
719. El-Arab AE, Khalil F, Hussein L. Vitamin A deficiency among preschool children in a rural area of Egypt: the results of dietary assessment and biochemical assay. *Int J Food Sci Nutr* 2002;53:465–474.
720. Hamdy BH, Elnokaly F, Gaafar S, Elnaggar B, Hussein L. Effectiveness of periodic oral vitamin A dosage on hypovitaminosis in Egypt. *Int J Vitam Nutr Res* 1982;52:235–240.
721. Hussein L, El-Tohamy M. Effect of supplementation with vitamin A or plant carotenes on plasma retinol levels among young Egyptian males. *Int J Vitam Nutr Res* 1989;59:229–233.
722. McLaren DS, Shirajian E, Tchalian M, Khoury G. Xerophthalmia in Jordan. *Am J Clin Nutr* 1965;17:117–130.
723. Khatib IMD. Vitamin A deficiency (VAD) is endemic among the Jordanian desert Beduin inhabitants: an urbanization irony. XXII IVACG Meeting. Vitamin A and the Common Agenda for Micronutrients. Lima, Peru, 15–17 November 2004 [abstracts]. Washington, D.C., ILSI Research Foundation, 2004; p. 55.
724. Kimiagar M, Yassah M, Keyvani F, Malek F. Vitamin A status in Iran. *Int J Vitam Nutr Res* 1988;58:103–104.
725. Kalantari N, Esmaceli M, Nasser E, Rashidi A, Houshiar-Rad A. Vitamin A deficiency survey in Sistan & Baloochestan, I.R. Iran. XX IVACG Meeting: 25 Years of Progress in Controlling Vitamin A Deficiency: Looking to the Future. Hanoi, Vietnam, February 12–15, 2001 [abstracts]. Washington, D.C. ILSI Research Foundation, 2001; p. 40.
726. Rosen DS, al Sharif Z, Bashir M, al Shabooti A, Pizzarello LD. Vitamin A deficiency and xerophthalmia in western Yemen. *Eur J Clin Nutr* 1996;50:54–57.
727. Resnikoff S, Filliard G, Carlier C, Luzeau R, Amédée-Manesme O. Assessment of vitamin A deficiency in the Republic of Djibouti. *Eur J Clin Nutr* 1992;46:25–30.
728. Mora JO, Gueri M, Mora OL. Vitamin A deficiency in Latin America and the Caribbean: an overview. *Rev Panam Salud Publica* 1998;4:178–186.
729. Romero-Abal ME, Mendoza I, Bulux J, Solomons NW. Blood retinol and β -carotene levels in rural Guatemalan preschool children. *Eur J Epidemiol* 1995;11:133–139.
730. Sommer A, Quesada J, Doty M, Faich G. Xerophthalmia and anterior-segment blindness among pre-school-age children in El Salvador. *Am J Ophthalmol* 1975;80:1066–1072.
731. Bonilla J, Mora J, Navas G, López M, Largaespada A. Seven years of successful vitamin A supplementation through national health campaigns in Nicaragua. XXIVACG Meeting: 25 Years of Progress

- in Controlling Vitamin A Deficiency: Looking to the Future. Hanoi, Vietnam, February 12–15, 2001 [abstracts]. Washington, D.C., ILSI Research Institute, 2001; p. 64.
732. Mora JO. Nutritional status of the Colombian population. Results of the 1977–80 National Health Survey. *Int J Vitam Nutr Res Suppl* 1985;27:19–31.
 733. Amaya-Castellanos D, Vilorio-Castejón H, Ortega P, et al. Deficiencia de vitamina A y estado nutricional antropométrico en niños marginales urbanos y rurales en el Estado Zulia, Venezuela. *Invest Clin* 2002;43:89–105.
 734. Castejon HV, Ortega P, Amaya D, Gomez G, Leal J, Castejon OJ. Co-existence of anemia, vitamin A deficiency and growth retardation among children 24–84 months old in Maracaibo, Venezuela. *Nutr Neurosci* 2004;7:113–119.
 735. Páez Valery MC, Solano L, Del Real S. Indicadores de riesgo para la deficiencia de vitamina A en menores de 15 años de una comunidad marginal de Valencia, Venezuela. *Arch Latinoam Nutr* 2002;52:12–19.
 736. Rodríguez A, Guamán G, Nelson DP. Vitamin A status of children in five Ecuadorian provinces. *Bull Pan Am Health Organ* 1996;30:234–241.
 737. Warnick E, Merida M, Chavez AK, et al. Can social marketing of multivitamin/mineral supplements reach low income women? Lessons from Bolivia. XX IVACG Meeting: 25 Years of Progress in Controlling Vitamin A Deficiency: Looking to the Future. Hanoi, Vietnam, February 12–15, 2001 [abstracts]. Washington, D.C., ILSI Research Foundation, 2001; p. 61.
 738. Santos LMP, Dricot JM, Ascitti LS, Dricot d'Ans C. Xerophthalmia in the state of Paraíba, northeast Brazil: clinical findings. *Am J Clin Nutr* 1983;38:139–144.
 739. Araújo RL, Beatriz M, Araújo DG, Sieiro RO, Machado RDP, Leite BV. Diagnostico da situação da hipovitaminose a e da anemia nutricional na população do vale do Jequitinhonha, Minas Gerais, Brasil. *Arch Latinoam Nutr* 1986;36:642–653.
 740. Martins MC, Santos LMP, Assis AMO. Prevalence of hypovitaminosis A among preschool children from northeastern Brazil. *Rev Saude Publica* 2004;38:537–542.
 741. Van Veen AG. Nutritional deficiencies in Indonesia before the war. *Doc Neerl Indonesia Morb Trop* 1950;2:121–127.
 742. Mack PB, Sander AP. The vitamin A status of families in widely different economic levels. *Am J Med Sci* 1940;199:686–697.
 743. Cohen N, Jalil MA, Rahman H, et al. Landholding, wealth and risk of blinding malnutrition in rural Bangladeshi households. *Soc Sci Med* 1985;21:1269–1272.
 744. Mele L, West KP Jr, Kusdiono, PA, et al. Nutritional and household risk factors for xerophthalmia in Aceh, Indonesia: a case-control study. *Am J Clin Nutr* 1991;53:1460–1465.
 745. Khatry SK, West KP Jr, Katz J, et al. Epidemiology of xerophthalmia in Nepal: a pattern of household poverty, childhood illness, and mortality. *Arch Ophthalmol* 1995;113:425–429.
 746. Wilson MR, Mansour M, Atud AE, et al. A population-based study of xerophthalmia in the extreme North Province of Cameroon, West Africa. *Arch Ophthalmol* 1996;114:464–468.
 747. Stanton BF, Clemens JD, Wojtyniak B, Khair T. Risk factors for developing mild nutritional blindness in urban Bangladesh. *Am J Dis Child* 1986;140:584–588.
 748. Hussain A, Kvåle G, Ali K, Bhuyan AH. Determinants of night blindness in Bangladesh. *Int J Epidemiol* 1993;22:1119–1125.
 749. Tobgy AF, Wilson RP. A contribution to the study of xerophthalmia. *Bull Ophthalmol Soc Egypt* 1933;26:69–84.
 750. Patwardhan VN. Hypovitaminosis and epidemiology of xerophthalmia. *Am J Clin Nutr* 1969;22:1106–1118.
 751. Solon FS, Popkin BM, Fernandez TL, Latham MC. Vitamin A deficiency in the Philippines: a study of xerophthalmia in Cebu. *Am J Clin Nutr* 1978;31:360–368.
 752. Brink EW, Perera WDA, Broske SP, Cash RA, Smith JL, Sauberlich HE, Bashor MM. Vitamin A status of children in Sri Lanka. *Am J Clin Nutr* 1979;32:84–91.
 753. Asrat YT, Omwega AM, Muita JWG. Prevalence of vitamin A deficiency among pre-school and school-aged children in Arssi Zone, Ethiopia. *East Afr Med J* 2002;79:355–359.
 754. Khan MU, Haque E, Khan MR. Nutritional ocular diseases and their association with diarrhoea in Matlab, Bangladesh. *Br J Nutr* 1984;52:1–9.

755. Pizzarello LD. Age specific xerophthalmia rates among displaced Ethiopians. *Arch Dis Child* 1986; 61:1100–1103.
756. Awate RV, Ketkar YA, Somaiya PA. Prevalence of nutritional deficiency disorders among rural primary school children (5–15 years). *J Indian Med Assoc* 1997;95:410–411, 415.
757. van Stuijvenberg ME, Faber M, Dhansay MA, Lombard CJ, Vorster N, Benade AJ. Red palm oil as a source of beta-carotene in a school biscuit used to address vitamin A deficiency in primary school children. *Int J Food Sci Nutr* 2000;51(suppl):S43–S50.
758. Ahmed F, Hasan N, Kabir Y. Vitamin A deficiency among adolescent female garment factory workers in Bangladesh. *Eur J Clin Nutr* 1997;51:698–702.
759. Sommer A, Sugana T. Corneal xerophthalmia and keratomalacia. *Arch Ophthalmol* 1982;100:404–411.
760. Cohen N, Jalil MA, Rahman H, Leemhuis de Regt E, Sprague J, Mitra M. Blinding malnutrition in rural Bangladesh. *J Trop Pediatr* 1986;32:73–78.
761. Mori M. Über den sog. Hikan (xerosis conjunctivae infantum ev. keratomalacie). *Jahrb Kinderheilk Phys Erzieh* 1904;59:175–195.
762. Czerny A, Keller A. Des Kindes Ernährung, Ernährungsstörungen und Ernährungstherapie. Volume II. Leipzig, Franz Deutike, 1906.
763. van Stockum MJ. De voeding van het Inheemsche kind en xerophthalmia. *Geneesk Tijdschr Nederl Indië* 1938;78:856–880.
764. de Haas JH, Posthuma JH, Meulemans O. Xerophthalmie bij kinderen in Batavia. *Geneesk Tijdschr Nederl Indië* 1940;80:928–950.
765. Williamson AD, Leong PC. Keratomalacia in Singapore and its relation to vitamin A in milk. *Med J Malaysia* 1949;4:83–95.
766. Peiper A. Keratomalazie bei Buttermilch-Ernährung. *Dtsch Gesundheitsw* 1951;6:632.
767. Tarwotjo I, Sommer A, Soegiharto T, Susanto D, Muhilal. Dietary practices and xerophthalmia among Indonesian children. *Am J Clin Nutr* 1982;35:574–581.
768. Cohen N, Measham C, Khanum S, Khatun M, Ahmed N. Xerophthalmia in urban Bangladesh: implications for vitamin A deficiency preventive strategies. *Acta Paediatr Scand* 1983;72:531–536.
769. West KP Jr, Chirambo M, Katz J, Sommer A, Malawi Survey Group. Breastfeeding, weaning patterns, and the risk of xerophthalmia in southern Malawi. *Am J Clin Nutr* 1986;44:690–697.
770. Mahalanabis D. Breast feeding and vitamin A deficiency among children attending a diarrhoea treatment centre in Bangladesh: a case-control study. *BMJ* 1991;303:493–496.
771. Ross SG. Nutritional keratomalacia in infants with a report of four cases. *Am J Dis Child* 1921;22: 232–243.
772. Stoll BJ, Banu H, Kabir I, Molla Y. Nightblindness and vitamin A deficiency in children attending a diarrheal disease hospital in Bangladesh. *J Trop Pediatr* 1985;31:36–39.
773. Upadhyay MP, Gurung BJ, Pillai KK, Nepal BP. Xerophthalmia among Nepalese children. *Am J Epidemiol* 1985;121:71–77.
774. Al-Kubaisy W, Al-Rubaiy MG, Nassief HA. Xerophthalmia among hospitalized Iraqi children. *East Mediterr Health J* 2002;8:496–502.
775. Ahmed FU, Rahman ME, Mahmood CB. Vitamin A deficiency in children with acute diarrhoea: a community-based study in Bangladesh. *J Health Popul Nutr* 2000;18:119–122.
776. Middlemore R. On certain forms of diseases of the eye observed in individuals who were suffering from, or had recently been attacked by, cholera. *London Medical Gazette* 1833;12:492–494.
777. Bezold F. Keratomalacia nach Morbillen. *Berliner Klin Wochenschr* 1874;11:408–411.
778. Trantas. Complications oculaires de la rougeole. Kératite ponctuée, héméralopie, keratomalacie. *Gaz Méd Orient* 1900;45:10–12.
779. Trantas. Kératite ponctuée dans la rougeole. *Gaz Méd Orient* 1900;45:312–314.
780. Spicer WTH. Kerato-malacia in young children. *Trans Ophthalmol Soc UK* 1893;13:45–55.
781. Hiro Y, Yamada M. Die Masern und die Ceratomalacie. *Monatschr Kinderheilk* 1936;65:438–445.
782. Netrasiri A, Netrasiri C. Kwashiokor in Bangkok (an analytical study of 54 cases). *J Trop Pediatr* 1955;1:148–155.
783. Blatz G. Hornhauteinschmelzung nach Masern. *Klin Monatsbl Augenheilk* 1956;129:762–772.
784. Cat ND. La keratomalacie infantile au Viet Nam. XVIII Cong Ophthalmol Belgium: 1958; pp. 1127–1135.

785. Decker J. Über Masernkomplikationen in Afrika. *Zeitschr Tropenmed Parasitol* 1965;16:437–444.
786. Voorhoeve HWA. Xerophthalmia in the presence of kwashiorkor in Nigeria. *Trop Geogr Med* 1966;18:15–19.
787. McGlashan ND. Measles, malnutrition and blindness in Luapula Province, Zambia. *Trop Geogr Med* 1969;21:157–162.
788. Oomen JMV. Xerophthalmia in northern Nigeria. *Trop Geogr Med* 1971;23:246–249.
789. Krishnamurthy KA, Anatharaman V. Measles a dangerous disease: a study of 1000 cases in Madurai. *Indian Pediatr* 1974;11:267–271.
790. Franken S. Measles and xerophthalmia in East Africa. *Trop Geogr Med* 1974;26:39–44.
791. Sauter JJM. Xerophthalmia and Measles in Kenya. Groningen, Drukkerij van Denderen, 1976.
792. Animashaun A. Measles and blindness in Nigerian children. *Nigeria J Pediatr* 1977;4:10–13.
793. Sandford-Smith JH, Whittle HC. Corneal ulceration following measles in Nigerian children. *Br J Ophthalmol* 1979;63:720–724.
794. Inua M, Duggan MB, West CE, Whittle HC, Kogbe OI, Sandford-Smith JH, Glover J. Post-measles corneal ulceration in children in northern Nigeria: the role of vitamin A, malnutrition and measles. *Ann Trop Paediatr* 1983;3:181–191.
795. Reddy V, Bhaskaram P, Raghuramulu N, et al. Relationship between measles, malnutrition, and blindness: a prospective study in Indian children. *Am J Clin Nutr* 1986;44:924–930.
796. Sommer A, Tarwotjo I, Katz J. Increased risk of xerophthalmia following diarrhea and respiratory disease. *Am J Clin Nutr* 1987;45:977–980.
797. Sommer A, Katz J, Tarwotjo I. Increased risk of respiratory disease and diarrhea in children with preexisting mild vitamin A deficiency. *Am J Clin Nutr* 1984;40:1090–1095.
798. Coles CL, Kanungo R, Rahmathullah L, et al. Pneumococcal nasopharyngeal colonization in young South Indian infants. *Pediatr Infect Dis J* 2001;20:289–295.
799. Stephenson S. On sloughing corneae in infants: an account based upon the records of thirty-one cases. *Ophthalmoscope* 1910;8:782–818.
800. Oomen HAPC. Xerophthalmia in the presence of kwashiorkor. *Br J Nutr* 1954;8:307–318.
801. Sivakumar B, Reddy V. Absorption of vitamin A in children with ascariasis. *J Trop Med Hyg* 1975;78:114–115.
802. Mahalanabis D, Jalan KN, Maitra TK, Agarwal SK. Vitamin A absorption in ascariasis. *Am J Clin Nutr* 1976;29:1372–1375.
803. Mahalanabis D, Simpson TW, Chakraborty ML, Ganguli C, Bhattacharjee AK, Mukherjee KL. Malabsorption of water miscible vitamin A in children with giardiasis and ascariasis. *J Nutr* 1979;32:313–318.
804. Ahmed F, Mohiduzzaman M, Jackson AA. Vitamin A absorption in children with ascariasis. *Br J Nutr* 1993;69:817–825.
805. Véghelyi PV, Láncoz FJ. Avitaminosis A in giardiasis. *Am J Dis Child* 1949;78:257–259.
806. Lerche W. Zweite Nachricht von dem Augenkranken. *Vermischte Abhandlungen aus dem Gebiete der Heilkunde von einer Gesellschaft practischer Aerzte zu St. Petersburg* 1823;2:184–206.
807. Semba RD. The ocular complications of smallpox and smallpox immunization. *Arch Ophthalmol* 2003;121:715–519.
808. Blankhart DM. Individual intake of food in young children in relation to malnutrition and night blindness. *Trop Geogr Med* 1967;19:144–153.
809. Tandon BN, Ramachandran K, Nath LM, et al. Vitamin A nutritional status of rural community of Khol block in Haryana, North India. *Am J Clin Nutr* 1975;28:1436–1442.
810. Fawzi WW, Herrera MG, Willett WC, et al. Vitamin A supplementation and dietary vitamin A in relation to the risk of xerophthalmia. *Am J Clin Nutr* 1993;58:385–391.
811. Fakhir S, Srivastava I, Ahmad P, Hasan SS. Prevalence of xerophthalmia in pre-school children in an urban slum. *Indian Pediatrics* 1993;30:668–670.
812. Teuscher R. Notiz über eine bei Negerkindern in der Provinz Rio de Janeiro beobachtete Krankheitsform. *Jenaische Zeitschr Med Naturwissenschaft* 1867;3:103–104.
813. Leber T. Ueber die Xerosis der Bindehaut und die infantile Hornhautverschwörung nebst Bemerkungen über die Entstehung des Xerophthalmus. *Albrecht von Graefe's Archiv für Ophthalmologie* 1883;29:225–290.

814. Thalberg J. On corneal gangrene produced by inanition. *Arch Ophthalmol* 1883;12:211–227.
815. Schulz R. Beitrag zur Lehre von der “Xerosis Conjunctivae und der infantilen Hornhautverschwärung.” *Albrecht von Graefe’s Archiv für Ophthalmologie* 1884;30:123–130.
816. Kollock CW. A form of xerosis. *Ophthal Rev* 1890;9:249–251.
817. Schanz F. Bacteriologische Befunde bei zwei Fällen von infantiler Xerosis mit Keratomalacie und bei einem Falle von Xerophthalmus. *Arch Augenheilk, Wiesbaden* 1892;25:110–118.
818. Thompson JT. Kerato-malacia in acute infantile jaundice. *Br Med J* 1894;2:597.
819. Achenbach C. Ein Fall von schwerer Xerosis epithelialis mit nachgewiesener Hemeralopie bei einem 9jährigen Knaben. *Berlin Klin Wochenschr* 1895;32:517–519.
820. Herbert H. Epithelial xerosis in the natives of India. *Trans Ophthalmol Soc UK* 1898;18:103–104.
821. Dötsch A. Anatomische und bakteriologische Untersuchungen über infantile Xerosis und Keratomalacie, sowie Bemerkungen über die Verhornung des Bindehaut- und Hornhautepithels. *Albrecht von Graefe’s Archiv für Ophthalmologie* 1900;49:405–429.
822. Schroen. Ein Fall von Keratomalacie (Keratitis xerotica). *Allgemeine Medicinische Central-Zeitung* 1902;71:205–206.
823. Koun LAMH. De la kératomalacie: affection cornéene chez les enfants athrepsiques. *Bordeaux, Imprimerie du Midi, Paul Cassagnol*, 1903.
824. Uththoff. Ueber Keratomalacie mit Xerose der Conjunctiva und Hemeralopie bei Erwachsenen. *Jahres-Bericht der Schlesischen Gesellschaft für vaterländische Cultur* 1904;82:70–72.
825. Ormond AW. Kerato-malacia. *Trans Ophthalmol Soc UK* 1905;25:62–63.
826. Nobel E. Einen Fall von Keratomalazie und Xerosis. *Wien Med Wochenschr* 1921;71:1502–1503.
827. Genck G. Über die kindliche Xerophthalmie (Xerosis und Keratomalacie). *Monatsschr Kinderheilk* 1922;24:251–256.
828. Stolte K. Ueber Keratomalazie. *Klin Monatsbl Augenheilk* 1922;68:739–743.
829. Hamburger R. Ueber Keratomalazie bei Kindern. *Deutsch Med Wochenschr* 1923;49:1301–1303.
830. Wilson JR, DuBois RO. Report of a fatal case of keratomalacia in an infant, with postmortem examination. *Am J Dis Child* 1923;26:431–446.
831. Gralka R. Über gehäuftes Auftreten von Keratomalacie. *Monatsschr Kinderheilk* 1923;26:217–227.
832. Bell JM. Nutritional disturbance, xerophthalmia: with case report. *South Med J* 1925;18:131–132.
833. Ben-Adamantiadis. Héméralopie épidémique idiopathique et kératomalacie. *Ann Ocul* 1925;162:449–454.
834. Elewaut. A propos de trois cas de kératomalacie. *Clinique Ophthalmologique* 1926;30:69–73.
835. Weech AA. Association of keratomalacia with other deficiency diseases. *Am J Dis Child* 1930;39:1153.
836. Wright RE. The importance of keratomalacia as a cause of blindness in India. *Lancet* 1931;1:800–803.
837. Carrillo A. La xeroftalmía, avitaminosis frecuente en Yucatán. *Rev Médica Yucatán* 1932;16:223–230.
838. Lobel A, Elias H. Un cas de kératomalacie incipiente. *Bull Soc Pédiatr Paris* 1932;30:151–152.
839. Brugsch H. Erfolgreiche Keratomalaziebehandlung beim Menschen durch Karotin und Vogan. *Deutsche Med Wochenschr* 1933;59:325–326.
840. Wille WA. Nieuwe ondervindingen omtrent keratomalacie. *Geneesk Tijdschr Nederl Indië* 1933;73:279–285.
841. Kunz E. Ueber die Wirkung des Vitamin A-Präparates Vogan bei einem Fall von Keratomalazie. *Klin Monatsbl Augenheilk* 1934;92:74–78.
842. Wieland E. A-Vitamin “Vogan” (Merck) bei A-Avitaminose (Keratomalazie) im Säuglingsalter. *Münch Med Wochenschr* 1934;81:777–780.
843. Brugsch H. Weitere Heilungen von Keratomalazie mit Vitamin A-Präparaten und über die Voraussetzungen einer erfolgreichen Anwendung solcher Mittel. *Münch Med Wochenschr* 1934;81:1062–1063.
844. Elizalde P de. Un caso de xeroftalmia. *Arch Argentinos Pediatr* 1934;5:316–324.
845. De Troj A. La vitamina A nella cura di infezioni varie in bambini con e senza avitaminosi A. *Pediatrics* 1934;42:1067–1087.
846. Gow WH. Some clinical observations on cases of keratomalacia in Manchuria. *Chinese Med J* 1934;48:885–889.
847. Siegl J. Vogan bei der Behandlung der Keratomalazie im Säuglingsalter. *Med Klinik* 1935;31:644–645.

848. Kotikas A. Über einen Fall von Keratomalacie bei einem Brustkinde. *Monatsschr Kinderheilk* 1935; 63:108–112.
849. Hoat OD. Het voorkomen van xerophthalmie in eenige desa's van het regentschap Keboemen. *Geneesk Tijdschr Nederl Indië* 1936;76:1101–1110.
850. Popoviciu G, Mihalescu O. Keratomalacie la copil de sân alimentat natural. *Clujul Medical* 1936;17: 14–16.
851. Derkač V. Keratomalazie bei Erwachsenen als Vorbote des Todes. *Klin Monatsbl Augenheilk* 1936; 96:380–381.
852. Aykroyd WR, Wright RE. Red-palm oil in the treatment of human keratomalacia. *Indian J Med Res* 1937;25:7–10.
853. Frontali G. La cheratomalacia nel bambino. *Minerva Med* 1938;1:1–11.
854. Trexler CW. A case of malignant keratomalacia. *Virginia Med Monthly* 1939;66:293–294.
855. Clément R, Delon J. Xérophtalmie et avitaminose A. *Arch Méd Enfants* 1939;42:698–710.
856. Biswas RB. Ocular manifestations due to lack of vitamin 'A' in the system. *Indian Med Gaz* 1941; 76:747–750.
857. Kirwan EO'G, Sen K, Biswas RB. Nutrition and its bearing on preventable blindness and eye diseases in Bengal. Preliminary report. *Indian J Med Res* 1941;29:119–124.
858. Goldberg HK, Schlivek K. Necrosis of the cornea due to vitamin A deficiency. Report of a case. *Arch Ophthalmol* 1941;25:122–127.
859. Goll H. Zur Frage: Vitamin A und Keratomalazie beim Säugling. *Münch Med Wochenschr* 1941;88: 1212–1214.
860. Goll H. Keratomalazie und Vitamin-A-Gehalt der Säuglingsernährung. *Arch Kinderheilk* 1942;125: 144–153.
861. Alix ML. Avitaminose A et xérophtalmie chez l'enfant. Paris, R. Foulon, 1942.
862. Kirwan E O'G, Sen K, Bose N. Nutrition and its bearing on preventable blindness and eye diseases in Bengal. *Indian J Med Res* 1943;31:49–62.
863. Rivera Lugo I. A fatal case of avitaminosis A, with postmortem study. *Bol Asoc Méd Puerto Rico* 1944;36:62–65.
864. Pillat A. Zum Auftreten der Keratomalacie der Erwachsenen in Oesterreich. *Wien Klin Wochenschr* 1946;58:557–560.
865. Tupas A, Pecache LV, Melo A. Xerophthalmia and keratomalacia in children. *J Phil Med Assoc* 1947; 23:137–143.
866. Rizk K. A case of keratomalacia cured by penicillin and vitamin A. *Br J Ophthalmol* 1948;32:416–419.
867. Houet R, Weekers R. Xérophtalmie du nourrisson et insuffisance hépatique. *Archives d'ophtalmologie et revue générale d'ophtalmologie* 1949;9:39–43.
868. Biérent P. Note sur un syndrome de pellagre avec kérautomalacie centrale. *Bull Méd Société Française d'Ophtal* 1951;64:304–312.
869. Habachy S. La keratomalacie du nouveau né. *Bull Ophthalmol Soc Egypt* 1953;46:217–222.
870. Zewi A. Xeroftalmi hos sjuka spädbarn beroende på nedsatt A-vitaminresorption. *Nordisk Medicin* 1953;49:575–576.
871. Bethe JGF. Een geval van keratomalacie, met anaemie en huidafwijkingen. *Nederl Tijdschr Geneesk* 1953;97 (8):511–512.
872. Corcos A, Kortobi M, Zarka-Corcos S. Xerophthalmie et keratomalacie chez les enfants en Tunisie. *Nourrison* 1954;42:19–22.
873. Rohmer A, Michel M, Haarscher A, Lobstein A. Deux cas de xérophtalmie chez des nourrissons atteints de dysfonction hépatique, avec lithiase urinaire chez l'un d'eux; les problèmes de l'avitaminose A. *Pediatric* 1954;9:33–39.
874. Bass MH, Caplan J. Vitamin A deficiency in infancy. *J Pediatrics* 1955;47:690–695.
875. Gutheil H. A-Vitamin-Bilanz bei Keratomalacie von Säuglingen. *Arch Kinderheilk* 1956;152:148–158.
876. Yap-Kie-Tiong. Protein deficiency in keratomalacia. *Br J Ophthalmol* 1956;40:502–503.
877. Scragg J, Rubidge C. Kwashiorkor in African children in Durban. *Br Med J* 1960;2:1759–1766.
878. Pereira SM, Begum A, Dumm ME. Vitamin A deficiency in kwashiorkor. *Am J Clin Nutr* 1966;19: 182–186.

879. Kuming BS, Politzer WM. Xerophthalmia and protein malnutrition in Bantu children. *Br J Ophthalmol* 1967;51:649–666.
880. Williams PH, Tsvetkov VL. Bilateral spontaneous expulsion of the lens in a case of kwashiorkor. *J Trop Med Hyg* 1969;72:47–48.
881. Emiru VP. The cornea in kwashiorkor. *J Trop Pediatr* 1971;17:117–134.
882. Baum JL, Rao G. Keratomalacia in the cachectic hospitalized patient. *Am J Ophthalmol* 1976;82:435–438.
883. Colorado-Domínguez J. Queratomalacia en el niño desnutrido. *Gac Med Mex* 1979;115:325–330.
884. Raghuvver CV, Aurora AL, Puri RK, Mathew P. Role of vitamin A deficiency and protein-calorie malnutrition in keratomalacia and Bitot's spots (a clinicopathologic study). *Indian J Ophthalmol* 1979;27:1–9.
885. Mathew M, Sandhu PS. Correlation of stages of xerophthalmia with grades of malnutrition. *Indian J Ophthalmol* 1981;29:191–193.
886. Caksen H, Odabas D. Keratomalacia and scurvy in a severely malnourished infant. *Pediatr Dermatol* 2002;19:93–95.
887. Ocampo G de, Cruz JN. Dark adaptation in adult beriberi. *Acta Medica Philippina* 1940;2:175–188.
888. Gombos GM, Hornblase A, Vendeland J. Ocular manifestations of vitamin A deficiency. *Ann Ophthalmol* 1970;2:680–684.
889. Olver J. Keratomalacia on a 'healthy diet.' *Br J Ophthalmol* 1986;70:357–360.
890. Uthoff W. Ein Beitrag zur Hemeralopie und zur Xerosis conjunctivae epithelialis. Nach einem Vortrage, gehalten in der Gesellschaft der Charitéärzte zu Berlin. *Berlin Klin Wochenschr* 1890;27:630–636.
891. Nicolai U, Rochels R. Bilateral severe keratomalacia after acute pancreatitis. *Cornea* 1993;12:171–173.
892. Singh RP, Marwaha RK, Sheno A. Keratomalacia in Soyab fed infants. *Indian Pediatr* 1987;24:607–608.
893. Wagh MG, Ghooi RB, Shetty RS. Keratomalacia in Soyab fed infants. *Indian Pediatr* 1987;24:955–996.
894. Hussain MAM, Ahmed SM, El Sheikh EHA. Xerophthalmia in malnourished Sudanese children. *Tropical Doctor* 1991;21:139–141.
895. Hussain A, Lindtjörn B, Kvåle G. Protein energy malnutrition, vitamin A deficiency and night blindness in Bangladeshi children. *Ann Trop Paediatr* 1996;16:319–325.
896. Donnen P, Brasseur D, Dramaix M, Vertongen F, Ngoy B, Zihindula M, Hennart P. Vitamin A deficiency and protein-energy malnutrition in a sample of pre-school children in the Kivu Province in Zaire. *Eur J Clin Nutr* 1996;50:456–461.
897. Lossouarn E. Le xérosis à Tientsin. *La Presse Médicale* 1932;40:745–746.
898. Oomen HAPC, ten Doesschate J. The periodicity of xerophthalmia in south and east Asia. *Ecol Food Nutr* 1973;2:207–217.
899. Sinha DP, Bang FB. Seasonal variation in signs of vitamin-A deficiency in rural West Bengal children. *Lancet* 1973;2:228–231.
900. Ewmenijew. [Ueber den Einfluss der Missernten der Jahre 1891–1892 bei der Bevölkerung des Kreises Ostrogostretzk] *Viestnik Oftalmologii* 1896;13:473–474.
901. Lewis MS, Lewis EH III, Amos JA, Tsongalis GJ. Cystic fibrosis. *Am J Clin Pathol* 2003;120(suppl):S3–S13.
902. Feranchak AP, Sontag MK, Wagener JS, et al. Prospective, long-term study of fat-soluble vitamin status in children with cystic fibrosis identified by newborn screen. *J Pediatr* 1999;135:601–610.
903. Sokol RJ, Reardon MC, Accurso FJ, et al. Fat-soluble vitamins in infants identified by cystic fibrosis newborn screening. *Pediatr Pulmon Suppl* 1991;7:52–55.
904. Andersen DH. Cystic fibrosis of the pancreas, vitamin A deficiency, and bronchiectasis. *J Pediatr* 1939;15:763–771.
905. Gamble GC. Keratomalacia and cystic fibrosis of the pancreas. *Am J Ophthalmol* 1940;23:539–544.
906. Petersen RA, Petersen VS, Robb RM. Vitamin A deficiency with xerophthalmia and night blindness in cystic fibrosis. *Am J Dis Child* 1968;116:662–665.
907. Kulczycki LL. Malabsorption with vitamin A deficiency in a college girl treated for cystic fibrosis. *Acta Paediatr Scand* 1971;60:371–372.

908. O'Donnell M, Talbot JF. Vitamin A deficiency in treated cystic fibrosis: case report. *Br J Ophthalmol* 1987;71:787–790.
909. Rayner RJ, Tyrrell JC, Hiller EJ, et al. Night blindness and conjunctival xerosis caused by vitamin A deficiency in patients with cystic fibrosis. *Arch Dis Child* 1989;64:1151–1156.
910. Lindenmuth KA, Del Monte M, Marino LR. Advanced xerophthalmia as a presenting sign in cystic fibrosis. *Ann Ophthalmol* 1989;21:189–191.
911. Neugebauer MA, Vernon SA, Brimlow G, Tyrrell JC, Hiller EJ, Marenah C. Nyctalopia and conjunctival xerosis indicating vitamin A deficiency in cystic fibrosis. *Eye* 1989;3:360–364.
912. Vernon SA, Neugebauer MAZ, Brimlow G, Tyrrell JC, Hiller EJ. Conjunctival xerosis in cystic fibrosis. *J R Soc Med* 1989;82:46–47.
913. Brooks HL Jr, Driebe WT Jr, Schemmer GG. Xerophthalmia and cystic fibrosis. *Arch Ophthalmol* 1990;108:354–357.
914. Huet F, Semama D, Maingueneau C, Charavel A, Nivelon JL. Vitamin A deficiency and nocturnal vision in teenagers with cystic fibrosis. *Eur J Pediatr* 1997;156:949–951.
915. Duggan C, Colin AA, Agil A, Higgins L, Rifai N. Vitamin A status in acute exacerbations of cystic fibrosis. *Am J Clin Nutr* 1996;64:635–639.
916. Lancellotti L, D'Orazio C, Mastella G, Mazzi G, Lippi U. Deficiency of vitamins E and A in cystic fibrosis is independent of pancreatic function and current enzyme and vitamin supplementation. *Eur J Pediatr* 1996;155:281–285.
917. Morkeberg JC, Edmund C, Prause JU, Lanng S, Koch C, Michaelsen KF. Ocular findings in cystic fibrosis patients receiving vitamin A supplementation. *Graefes Arch Clin Exp Ophthalmol* 1995;233:709–713.
918. Ansari EA, Sahni K, Etherington C, et al. Ocular signs and symptoms and vitamin A status in patients with cystic fibrosis treated with daily vitamin A supplements. *Br J Ophthalmol* 1999;83:688–691.
919. Lindblad A, Diczfalusy U, Hultcrantz R, Thorell A, Strandvik B. Vitamin A concentration in the liver decreases with age in patients with cystic fibrosis. *J Pediatr Gastroenterol Nutr* 1997;24:264–270.
920. Ciclitira PJ. AGA technical review on celiac sprue. *Gastroenterology* 2001;120:1526–1540.
921. Farrell RJ, Kelly CP. Celiac sprue. *N Engl J Med* 2002;346:180–188.
922. Breese BB, McCoord AB. Vitamin A absorption in celiac disease. *J Pediatr* 1939;15:183–196.
923. Adlersberg D, Sobotka H. Fat and vitamin A absorption in sprue and jejunoileitis. *Gastroenterology* 1943;1:357–365.
924. Cayer D, Ruffin JM, Perlzweig WA. Vitamin levels in sprue. *Am J Med Sci* 1945;210:200–207.
925. Alwitry A. Vitamin A deficiency in celiac disease. *Br J Ophthalmol* 2000;84:1075.
926. Partamian LG, Sidrys LA, Tripathi RC. Iatrogenic night blindness and keratoconjunctival xerosis. *N Engl J Med* 1979;301:943–944.
927. Brown GC, Felton SM, Benson WE. Reversible night blindness associated with intestinal bypass surgery. *Am J Ophthalmol* 1980;89:776–779.
928. Rogers EL, Douglass W, Russell RM, Bushman L, Hubbard TB, Iber FL. Deficiency of fat soluble vitamins after jejunoileal bypass surgery for morbid obesity. *Am J Clin Nutr* 1980;33:1208–1214.
929. Perlman I, Barzilai D, Haim T, Schramek A. Night vision in a case of vitamin A deficiency due to malabsorption. *Br J Ophthalmol* 1983;67:37–42.
930. Wachtmeister L, Björkhem I, Diczfalusy U, Emami A. Attempts to define the minimal serum level of vitamin A required for normal visual function in a patient with severe fat malabsorption. *Acta Ophthalmol* 1988;66:341–348.
931. Stone JB, Courtney RH. Xerophthalmia and keratomalacia associated with obstructive biliary cirrhosis. *Virginia Medical Monthly* 1941;68:159–163.
932. Haig C, Hecht S, Patek AJ Jr. Vitamin A and rod-cone dark adaptation in cirrhosis of the liver. *Science* 1938;87:534–536.
933. Patek AJ Jr, Haig C. The occurrence of abnormal dark adaptation and its relation to vitamin A metabolism in patients with cirrhosis of the liver. *J Clin Invest* 1939;18:609–616.
934. Carney EA, Russell RM. Correlation of dark adaptation test results with serum vitamin A levels in diseased adults. *J Nutr* 1980;110:552–527.

935. Arroyave G, Viteri F, Béhar M, Scrimshaw NS. Impairment of intestinal absorption of vitamin A palmitate in severe protein malnutrition (kwashiorkor). *Am J Clin Nutr* 1959;7:185–190.
936. Hecker C von. Klinik der Geburtskunde. Beobachtungen und Untersuchungen aus der Gebäranstalt zu München. Leipzig, Wilhelm Engelmann, 1864.
937. Spengler. Hemeralopie bei einer Schwangeren. *Monatsschrift f. Geburtskunde und Frauenkrankheiten* 1865;25:61–63.
938. Wachs. Hemeralopie; dritte Niederkunft; Nachtblindheit zu Ende der Schwangerschaft bis in die ersten Tage des Wochenbettes. *Monatsschrift f. Geburtskunde und Frauenkrankheiten* 1867;30:24–32.
939. Küstner O. Ein Fall von Hemeralopie in den letzten Wochen der Gravidität und den ersten Tagen des Wochenbettes. *Berlin Klin Wochenschr* 1875;12:583–584.
940. Kubli T. Zur Lehre von der epidemischen Hemeralopie. *Arch Augenheilk* 1887;17:409–411.
941. Walter O. Ein Beitrag zur Lehre von epidemischen Nachtblindheit. *Arch Augenheilk* 1893;28:71–99.
942. Wille. Een leerzaam geval van hemeralopia idiopathica cum xerophthalmia. *Geneesk Tijdschr Nederl Indië* 1919;420–439.
943. Klasten E. Die Hemeralopie der Schwangeren. *Zeitschr Geburtshilfe Gynäkol* 1922;85:485–501.
944. Birnbacher T, Klasten E. Die Hemeralopie der Schwangeren. *Zeitschr Augenheilk* 1923;51:309–324.
945. Birnbacher, Theodor. Die epidemische Mangelhemeralopie (sog. essentielle Hemeralopie). Ein Beitrag zur Lehre von den Avitaminosen. *Abhandlungen aus der Augenheilkunde und ihren Grenzgebieten*, Heft 4. Berlin, S. Karger, 1927.
946. Birnbacher T. Ueber den Frühlingsgipfel der epidemischen Mangelhemeralopie und die pathogenetische Bedeutung des Frühjahrs. *Wiener Klin Wochenschr* 1928;41:698–700.
947. Edmund C, Clemmesen S. On parenteral A vitamin treatment of dysaptatio (nyctalo-hemeralopia) in some pregnant women. *Acta Med Scand* 1936;89:69–92.
948. Edmund C, Clemmesen S. On Deficiency of A Vitamin and Visual Dysaptation II. Copenhagen, Levin & Munksgaard, 1937.
949. Juhász-Schäffer A. Schwangerschaftshemeralopie und A-Vitamin. *Klin Wochenschr* 1938;17:407–409.
950. de Haas JH, Meulemans O. Vitamine A en carotinoiden in bloed. II. Over het vitamine A—en carotinoiden-gehalte in het bloed van zwangere en zoogende Inheemsche en Chineesche vrouwen te Batavia. *Geneesk Tijdschr Nederl Indië* 1938;78:847–855.
951. Pies R, Wendt H. Untersuchungen über Hemeralopie. Ein Beitrag zu der Frage des Vorkommens von Vitamin A-Mangelzuständen. *Klin Wochenschr* 1939;18:429–431.
952. Ricketts WA. Vitamin A deficiencies in pregnancy with case reports on two unusually severe examples. *Am J Obstet Gynecol* 1939;38:484–488.
953. Williams PF, Hark B, Fralin FG. Nutrition study in pregnancy. Correlation between dietary survey of vitamin A content and dark adaptation time. *Am J Obstet Gynecol* 1940;40:1–11.
954. Nylund CE. Om mörkeradaptationen hos gravida och digivande kvinnor samt om bestämningar av A-vitamin och karotinoider i blodserum och modersmjölk. *Nordisk Medicin* 1940;8:2521–2527.
955. Hirst JC, Shoemaker RE. Vitamin A in pregnancy. I. Average capacity according to the Feldman adaptometer. *Am J Obstet Gynecol* 1940;40:12–16.
956. Robecchi E. Ipoavitaminosi A ed emeralopia in gravidanza. *Ginecologia* 1941;7:271–284.
957. Llusá JB, Hernández Araña JM. El problema de la vitamina A en la alimentación de la embarazada. *Rev Clín Esp* 1942;7:203–207.
958. Micale G. Ricerche e considerazioni sul senso luminoso delle gravide studiato durante l'attuale periodo bellico. *Arch Ostet Ginecol* 1942;6:233–247.
959. Nylund CE. Über die Untersuchungstechnik bei der Bestimmung von Nachtblindheit als Symptom von Vitamin-A-Mangel und Untersuchungen über das Vorkommen von Nachtblindheit und über ihre Abhängigkeit von der Vitamin-A-Zufuhr. Helsingfors, Mercators Tryckeri, 1944.
960. Dixit DT. Night-blindness in third trimester of pregnancy. *Indian J Med Res* 1966;54:791–795.
961. Mandal GS, Nanda KN, Bose J. Night blindness in pregnancy. *J Obstet Gynaecol India* 1969;19:453–458.
962. Christian P. Maternal night blindness: a new indicator of vitamin A deficiency. IVACG Statement. Washington, D.C., International Vitamin A Consultative Group, ILSI Research Foundation, 2002.

963. Rao KW, De NK, Rao DS. Investigation of an outbreak of night-blindness in a village near Madras. *Indian J Med Res* 1953;41:349–357.
964. Bloem MW, Matzger H, Huq N. Vitamin A deficiency among women in the reproductive years: an ignored problem. Report of the XVI International Vitamin A Consultative Group Meeting. Two Decades of Progress: Linking Knowledge to Action. 24–28 October 1994, Chiang Rai, Thailand. Washington, D.C., International Life Sciences Research Foundation; 1995; p. 78.
965. Katz J, Khattry SK, West KP, et al. Night blindness is prevalent during pregnancy and lactation in rural Nepal. *J Nutr* 1995;125:2122–2127.
966. Fuchs A. Oogziekten, berustende op Avitaminosen. *Geneesk Tijdschr Nederl Indië* 1936;1853–1856.
967. Hepp. Nachträgliche Bemerkungen zu einem früher mitgetheilten Falle von Nachtblindheit. *Verhandlungen des Vereins Pfälzische Ärzte* 1846;53–55.
968. Truc H, Gaudibert J, Rouveyroles. Contributions a l'étude de l'oeil et de la vision chez les criminals. Examen oculaire et visuel de 362 jeunes détenu de la colonie pénitentiaire d'Aniane. *Annales d'oculistique* 1897;117:241–254.
969. Gordon HL. Xerophthalmia in Mathari Mental Hospital. *E Afr Med J* 1933;10:85–90.
970. Mitchell JP. Observations on health in relation to diet in H.M. Central Prison, Uganda. I. Prison diets and morbidity. *E Afr Med J* 1933;10:38–53.
971. Baillie. On the use of cod liver oil in ulceration of the cornea, occurring during recovery from severe cholera, or low forms of disease. *Indian Med Gaz* 1870;5:35–36.
972. Sommer A, Hussaini G, Muhilal, Tarwotjo I, Susanto D, Saroso JS. History of nightblindness: a simple tool for xerophthalmia screening. *Am J Clin Nutr* 1980;33:887–891.
973. Underwood BA, Olson JA (eds). A Brief Guide to Current Methods of Assessing Vitamin A Status. A Report of the International Vitamin A Consultative Group (IVACG). Washington, D.C., The Nutrition Foundation, 1993.
974. Tanumihardjo SA. Assessing vitamin A status: past, present and future. *J Nutr* 2004;134:290S–293S.
975. World Health Organization. Indicators for Assessing Vitamin A Deficiency and Their Application in Monitoring and Evaluating Intervention Programmes. Report No. WHO/NUT/96. Geneva, World Health Organization, 1996.
976. Brenner S, Roberts LJ. Effects of vitamin A depletion in young adults. *Arch Intern Med* 1943;71:474–482.
977. Popper H, Steigmann F. The clinical significance of the plasma vitamin A level. *J Am Med Assoc* 1943;123:1108–1114.
978. Aron HCS. Plasma vitamin A and its clinical significance. A review. *Am J Dis Child* 1949;77:763–773.
979. Filteau SM, Morris SS, Abbott RA, et al. Influence of morbidity on serum retinol of children in a community-based study in northern Ghana. *Am J Clin Nutr* 1993;58:192–197.
980. Thurnham DI, McCabe GP, Northrop-Clewes CA, Nestel P. Effects of subclinical infection on plasma retinol concentrations and assessment of the prevalence of vitamin A deficiency: meta-analysis. *Lancet* 2003;362:2052–2058.
981. Maqsood M, Dancheck B, Gamble MV, et al. Vitamin A deficiency and inflammatory markers among preschool children in the Republic of the Marshall Islands. *Nutr J* 2004;3:21 [Epub].
982. Christian P, Schulze K, Stoltzfus RJ, West KP Jr. Hyporetinolemia, illness symptoms, and acute phase protein response in pregnant women with and without night blindness. *Am J Clin Nutr* 1998;67:1237–1243.
983. Rosales FJ, Jang JT, Pinero DJ, Erikson KM, Beard JL, Ross AC. Iron deficiency in young rats alters the distribution of vitamin A between plasma and liver and between hepatic retinol and retinyl esters. *J Nutr* 1999;129:1223–1228.
984. Jang JT, Green JB, Beard JL, Green MH. Kinetic analysis shows that iron deficiency decreases liver vitamin A mobilization in rats. *J Nutr* 2000;130:1291–1296.
985. Stoltzfus RJ, Underwood BA. Breast-milk vitamin A as an indicator of the vitamin A status of women and infants. *Bull World Health Organ* 1995;73:703–711.
986. Dancheck B, Nussenblatt V, Ricks MO, et al. Systemic inflammation is associated with lower plasma but not lower breast milk retinol concentrations among breastfeeding women in Malawi. *J Nutr* 2005;135:223–226.

987. Rice AL, Stoltzfus RJ, de Francisco A, Kjolhede CL. Evaluation of serum retinol, the modified-relative-dose-response ratio, and breast-milk vitamin A as indicators of vitamin A status in pregnant women. *Int J Vitam Nutr Res* 2000;70:271–277.
988. de Pee S, Yuniar Y, West CE, Muhilal. Evaluation of biochemical indicators of vitamin A status in breast-feeding and non-breast-feeding Indonesia women. *Am J Clin Nutr* 1997;66:160–167.
989. Chappell JE, Francis T, Clandinin MT. Vitamin A and E content of human milk at early stages of lactation. *Early Hum Dev* 1985;11:157–167.
990. Youmans JB, Corlette MB, Corlette MG, Frank H. Inadequacy of conjunctival smears in the diagnosis of slight vitamin A deficiency in adults. *J Lab Clin Med* 1938;23:663–670.
991. Chieffi M, Kirk E. Vitamin studies in middle-aged and old individuals. II. Correlation between vitamin A plasma content and certain clinical and laboratory findings. *J Nutr* 1949;37:67–79.
992. Agarwal LP, Malhoutra RL. Conjunctival smear cytology in xerosis. *Ophthalmologica* 1955;130:378–386.
993. Natadisastra G, Wittpenn JR, West KP Jr, Muhilal, Sommer A. Impression cytology for detection of vitamin A deficiency. *Arch Ophthalmol* 1987;105:1224–1228.
994. Keenum DG, Semba RD, Wirasmita S, Natadisastra G, Muhilal, West KP Jr, Sommer A. Assessment of vitamin A status by a disk applicator for conjunctival impression cytology. *Arch Ophthalmol* 1990;108:1436–1441.
995. Carlier C, Mourey MS, Luzeau R, Ellrodt A, Lemmoniaer D, Amedee-Manesme O. Assessment of vitamin C status in an elderly French population using impression cytology with transfer. *Int J Vitamin Nutr Res* 1989;59:3–7.
996. Gadomski AM, Kjolhede CL, Wittpenn J, Bulux J, Rosas AR, Forman MR. Conjunctival impression cytology (CIC) to detect subclinical vitamin A deficiency: comparison of CIC with biochemical assessments. *Am J Clin Nutr* 1989;49:495–500.
997. Makdani D, Sowell AL, Nelson JD, et al. Comparison of methods of assessing vitamin A status in children. *J Am Coll Nutr* 1996;15:439–449.
998. Lietman TM, Dhital SP, Dean D. Conjunctival impression cytology for vitamin A deficiency in the presence of infectious trachoma. *Br J Ophthalmol* 1998;82:1139–1142.
999. Chowdhury S, Kumar R, Ganguly NK, Kumar L, Verma M, Walia BN. Dynamics of conjunctival impression cytologic changes after vitamin A supplementation. *Br J Nutr* 1997;77:863–869.
1000. Jayle GE, Ourgaud AG, Benoit PH, Blet G, Berard PV. *La vision nocturne et ses troubles*. Paris, Masson, 1950.
1001. Jayle GE, Ourgaud AG, Baisinger LF, Holmes WJ. *Night Vision*. Springfield, IL, Charles C. Thomas, 1959.
1002. Udomkesmalee E. Vision restoration time. In: Underwood BA, Olson JA (eds). *A Brief Guide to Current Methods of Assessing Vitamin A Status. A Report of the International Vitamin A Consultative Group (IVACG)*. Washington, D.C., The Nutrition Foundation: 1993; pp. 27–28.
1003. Olson JA. Rapid dark adaptation time. In: Underwood BA, Olson JA (eds). *A Brief Guide to Current Methods of Assessing Vitamin A Status. A Report of the International Vitamin A Consultative Group (IVACG)*. Washington, D.C., The Nutrition Foundation: 1993; pp. 29–30.
1004. Tanumihardjo SA. The relative dose-response assay. In: Underwood BA, Olson JA (eds). *A Brief Guide to Current Methods of Assessing Vitamin A Status. A Report of the International Vitamin A Consultative Group (IVACG)*. Washington, D.C., The Nutrition Foundation: 1993; pp. 12–13.
1005. Stephensen CB, Franchi LM, Hernandez H, Campos M, Colarossi A, Gilman RH, Alvarez JO. Assessment of vitamin A status with the relative-dose-response test in Peruvian children recovering from pneumonia. *Am J Clin Nutr* 2002;76:1351–1357.
1006. Tanumihardjo SA. The modified relative dose-response assay. In: Underwood BA, Olson JA (eds). *A Brief Guide to Current Methods of Assessing Vitamin A Status. A Report of the International Vitamin A Consultative Group (IVACG)*. Washington, D.C., The Nutrition Foundation: 1993; pp. 14–15.
1007. Wagman IH, Gullberg JE. Effect of vitamin A deficiency upon rate of pupil dilation during dark adaptation. *Proc Soc Exp Biol Med* 1938;38:613–615.
1008. Congdon N, Sommer A, Severns M, et al. Pupillary and visual thresholds in young children as an index of population vitamin A status. *Am J Clin Nutr* 1995;61:1076–1082.

1009. Sanchez AM, Congdon NG, Sommer A, et al. Pupillary threshold as an index of population vitamin A status among children in India. *Am J Clin Nutr* 1997;65:61–66.
1010. Congdon NG, Dreyfuss ML, Christian P, et al. Responsiveness of dark-adaptation threshold to vitamin A and β -carotene supplementation in pregnant and lactating women in Nepal. *Am J Clin Nutr* 2000;72:1004–1009.
1011. Underwood BA. Semiquantitative dietary assessment of vitamin A intake. In: Underwood BA, Olson JA (eds). *A Brief Guide to Current Methods of Assessing Vitamin A Status. A Report of the International Vitamin A Consultative Group (IVACG)*. Washington, D.C., The Nutrition Foundation: 1993; pp. 4–5.
1012. Almekinder J, Manda W, Soko D, Lan Y, Hoover DR, Semba RD. Evaluation of plasma retinol-binding protein as a surrogate measure for plasma retinol levels. *Scand J Clin Lab Invest* 2000;60:199–204.
1013. Gamble MV, Ramakrishnan R, Palafox NA, Briand K, Bergslund L, Blaner WS. Retinol binding protein as a surrogate measure for serum retinol: studies in vitamin A-deficient children from the Republic of the Marshall Islands. *Am J Clin Nutr* 2001;73:594–601.
1014. Semba RD, Yuniar Y, Gamble MV, Natadisastra G, Muhilal. Assessment of vitamin A status of preschool children in Indonesia using plasma retinol-binding protein. *J Trop Pediatr* 2002;48:84–87.
1015. Rosales FJ, Ross AC. A low molar ratio of retinol binding protein to transthyretin indicates vitamin A deficiency during inflammation: studies in rats and *a posteriori* analysis of vitamin A-supplemented children with measles. *J Nutr* 1998;128:1681–1687.
1016. Donnen P, Dramaix M, Brasseur D, Bitwe R, Bisimwa G, Hennart P. The molar ratio of serum retinol-binding protein (RBP) to transthyretin (TTR) is not useful to assess vitamin A status during infections in hospitalized children. *Eur J Clin Nutr* 2001;55:1043–1047.
1017. Filteau SM, Willumsen JF, Sullivan K, Simmank K, Gamble M. Use of the retinol-binding protein: transthyretin ratio for assessment of vitamin A status during acute-phase response. *Br J Nutr* 2000;83:513–520.
1018. Barua AB, Duitsman PK, Olson JA. The role of vitamin A status in the conversion of all-*trans* retinoyl β -glucuronide to retinoic acid in male Sprague-Dawley rats. *Nutr Biochem* 1998;9:8–16.
1019. Olson JA, Barua AB, Kaul S, Tanumihardjo S. The RAG hydrolysis test: a new method for assessing vitamin A status. XIX IVACG Meeting, Durban, South Africa, 9–11 March, p. 54.
1020. Wasantwisut E. Application of isotope dilution technique in vitamin A nutrition. *Food Nutr Bull* 2002;23(suppl 3):103–106.
1021. Ribaya-Mercado JD, Solon FS, Dallal GE, et al. Quantitative assessment of total body stores of vitamin A in adults with the use of a 3-d deuterated-retinol-dilution procedure. *Am J Clin Nutr* 2003;77:694–699.
1022. Haskell MJ, Mazumder RN, Peerson JM, et al. Use of the deuterated-retinol-dilution technique to assess total-body vitamin A stores of adult volunteers consuming different amounts of vitamin A. *Am J Clin Nutr* 1999;70:874–880.
1023. Haskell MJ, Jamil KM, Hassan F, et al. Daily consumption of Indian spinach (*Basella alba*) or sweet potatoes has a positive effect on total-body vitamin A stores in Bangladeshi men. *Am J Clin Nutr* 2004;80:705–714.
1024. Kramer B, Sobel AE, Gottfried SP. Serum levels of vitamin A in children. A comparison following the oral and intramuscular administration of vitamin A in oil and aqueous mediums. *Am J Dis Child* 1947;73:543–553.
1025. Bloem MW, Huq N, Gorstein J, et al. Production of fruits and vegetables at the homestead is an important source of vitamin A among women in rural Bangladesh. *Eur J Clin Nutr* 1996;50(suppl 3):S62–S67.
1026. Kidala D, Greiner T, Gebre-Medhin M. Five-year follow-up of a food-based vitamin A intervention in Tanzania. *Pub Health Nutr* 2000;3:425–431.
1027. de Pee S, Bloem MW, Satoto YR, et al. Impact of a social marketing campaign promoting dark-green leafy vegetables and eggs in Central Java, Indonesia. *Int J Vit Nutr Res* 1998;68:389–398.
1028. Faber M, Venter SL, Benadé AJS. Increased vitamin A intake in children aged 2–5 years through targeted home-gardens in a rural South African community. *Pub Health Nutr* 2002;5:11–16.

1029. Faber M, Phungula MAS, Venter SL, Dhansay MA, Benadé AJ. Home gardens focusing on the production of yellow and dark-green leafy vegetables increase the serum retinol concentrations of 2–5-yr-old children in South Africa. *Am J Clin Nutr* 2002;76:1048–1054.
1030. Zagré NM, Delpeuch F, Traissac P, Delisle H. Red palm oil as a source of vitamin A for mothers and children: impact of a pilot project in Burkina Faso. *Pub Health Nutr* 2003;6:733–742.
1031. Dary O, Mora JO. Food fortification to reduce vitamin A deficiency: International Vitamin A Consultative Group Recommendations. *J Nutr* 2002;132:2927S–2933S.
1032. Krause VM, Delisle H, Solomons NW. Fortified foods contribute one half of recommended vitamin A intake in poor urban Guatemalan toddlers. *J Nutr* 1998;128:860–864.
1033. Solon FS, Fernandez TL, Matham MC, Popkin BM. Planning, implementation, and evaluation of a fortification program. Control of vitamin A deficiency in the Philippines. *J Am Diet Assoc* 1979;74:112–118.
1034. Solon FS, Solon MS, Mehansho H, et al. Evaluation of the effect of vitamin A-fortified margarine on the vitamin A status of preschool Filipino children. *Eur J Clin Nutr* 1996;50:720–723.
1035. Melse-Boonstra A, de Pee S, Martini E, et al. The potential of various foods to serve as carrier for micronutrient fortification, data from remote areas in Indonesia. *Eur J Clin Nutr* 2000;54:822–827.
1036. Jalal F, Nesheim MC, Agus Z, Sanjur D, Habicht JP. Serum retinol concentrations in children are affected by food sources of beta-carotene, fat intake, and anthelmintic drug treatment. *Am J Clin Nutr* 1998;68:623–629.
1037. Persson V, Ahmed F, Gebre-Medhin M, Greiner T. Increase in serum beta-carotene following dark green leafy vegetable supplementation in mebendazole-treated school children in Bangladesh. *Eur J Clin Nutr* 2001;55:1–9.
1038. Welch RM, Graham RD. Breeding for micronutrients in staple food crops from a human nutrition perspective. *J Exp Biol* 2004;55:353–364.
1039. Ye X, Al-Babili S, Klöti A, Zhang J, Lucca P, Beyer P, Potrykus I. Engineering the provitamin A (β -carotene) biosynthetic pathway into (carotenoid-free) rice endosperm. *Science* 2000;287:303–305.
1040. Beyer P, Al-Babili S, Ye X, Lucca P, Schaub P, Welsch R, Potrykus I. Golden Rice: introducing the β -carotene biosynthesis pathway into rice endosperm by genetic engineering to defeat vitamin A deficiency. *J Nutr* 2002;132:506S–510S.
1041. Römer S, Fraser PD, Kiano JW, Shipton CA, Misawa N, Schuch W, Bramley PM. Elevation of the provitamin A content of transgenic tomato plants. *Nat Biotechnol* 2000;18:666–669.
1042. Swaminathan MC, Susheela TP, Thimmayamma BVS. Field prophylactic trial with a single annual oral massive dose of vitamin A. *Am J Clin Nutr* 1970;23:119–122.
1043. Srikantia SG, Reddy V. Effect of a single massive dose of vitamin A on serum and liver levels of the vitamin. *Am J Clin Nutr* 1970;23:114–118.
1044. Vijayaraghavan K, Naidu AN, Rao NP, Srikantia SG. A simple method to evaluate the massive dose vitamin A prophylaxis program in preschool children. *Am J Clin Nutr* 1975;28:1189–1193.
1045. Pedro MR, Madriaga JR, Barba CV, Habito RC, Gana AE, Deitchler M, Mason JB. The national vitamin A supplementation program and subclinical vitamin A deficiency among preschool children in the Philippines. *Food Nutr Bull* 2004;25:319–329.
1046. Bloem MW, Hye A, Wijnroks M, Ralte A, West KP Jr, Sommer A. The role of universal distribution of vitamin A capsules in combating vitamin A deficiency in Bangladesh. *Am J Epidemiol* 1995;142:843–855.
1047. Gorstein J, Shreshtra RK, Pandey S, Adhikari RK, Pradhan A. Current status of vitamin A deficiency and the national vitamin A control program in Nepal: results of the 1998 National Micronutrient Status Survey. *Asia Pac J Clin Nutr* 2003;12:96–103.
1048. Schemann JF, Banou A, Malvy D, Guindo A, Traore L, Momo G. National immunization days and vitamin A distribution in Mali: has the vitamin A status of pre-school children improved? *Public Health Nutr* 2003;6:233–244.

2

Cataract

1. INTRODUCTION

Age-related cataract is the leading cause of blindness worldwide, accounting for about 42% of all blindness (1). An estimated 25 million individuals worldwide were blind as a result of cataract in 2000 (2). Given a large aging population, by 2020, it is estimated that there will be 54 million blind persons among those 60 yr of age and older, and the vast majority of cases of blindness will be due to cataract (1). Both the incidence and prevalence of cataract are higher in developing countries compared with developed countries. More than 90% of the cases of blindness will be in developing countries, where the “backlog” of individuals with untreated cataract has been steadily increasing because of a shortage of trained personnel and resources. Any potential interventions that could delay the progression of cataracts, such as dietary modification or nutritional supplementation, would have a significant impact on the prevalence of blindness. More than 1 million cataract operations are performed each year in the United States at a cost of about \$3.4 billion to Medicare alone (3).

2. HISTORICAL BACKGROUND

In the 1920s, studies conducted among rats suggested that deficiency of B complex vitamins could result in cataracts (4). Subsequent investigation showed that among the B vitamins, the addition of riboflavin to the diet was effective in preventing lens opacities in rats (5–7). Riboflavin was later shown to be essential in the diet to prevent cataracts in pigs (7), salmon (9,10), and cats (11). The significance of these findings for humans was unclear, but these studies gave early support to the idea that nutritional deficiencies could be associated with the formation of cataracts. By the early 1960s, there was still no conclusive evidence to show that the human lens could be damaged by malnutrition (12). The hypothesis that malnutrition is related to the pathogenesis of cataract has been vigorously pursued in the last several decades, as reviewed in this chapter.

3. EPIDEMIOLOGY

3.1. Definitions

Cataract is a condition where the crystalline lens of the eye is no longer completely transparent. There are three general types of age-related cataract that occur in anatomically distinct areas of the lens: nuclear cataract, cortical cataract, and posterior subcapsular cataract. Nuclear cataract involves the nucleus of the lens. Cortical cataract involves the cortex of the lens and is usually characterized by wedged-shaped spokes from the

From: *Nutrition and Health: Handbook of Nutrition and Ophthalmology*

By: R. D. Semba © Humana Press Inc., Totowa, NJ

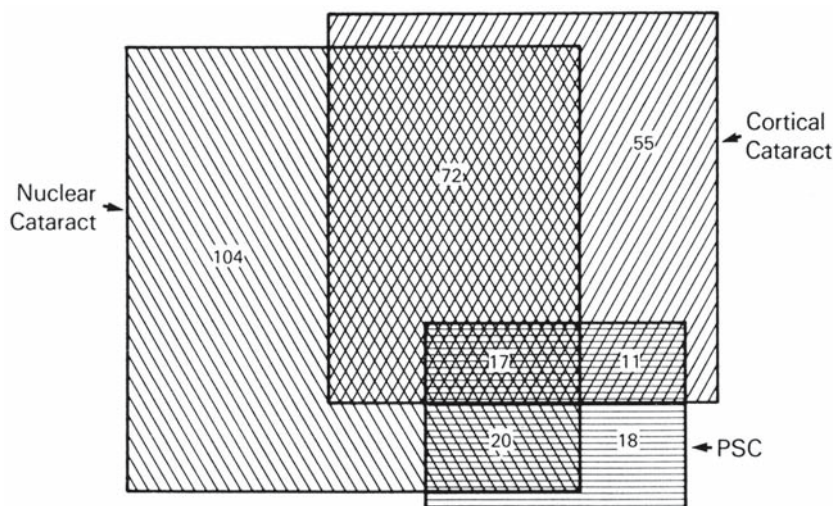


Fig. 1. Venn diagram for 297 subjects with nuclear, cortical, or posterior subcapsular cataract in the 1971–1972 National Health and Nutrition Examination Survey. (Reprinted from ref. 13, with permission of Oxford University Press.)

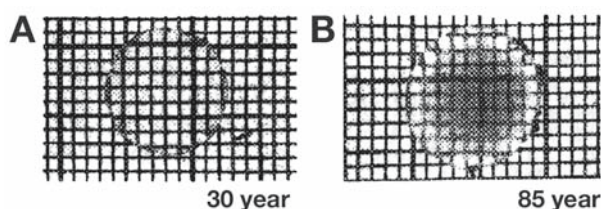


Fig. 2. Lenses of a (A) young and (B) old donor showing the accumulation of brown chromophores in the lens with age. (Reprinted from ref. 14, with permission of Elsevier.)

periphery towards the center. Posterior subcapsular cataract is located just anterior to the posterior lens capsule. These types of opacities may occur alone or in combination with one another (Fig. 1) (13). With age, the lens nucleus begins to change from colorless to yellow, and later in the life the lens nucleus can become brown (Fig. 2) (14).

3.2. Grading of Lens Opacities

Epidemiological studies of cataract have been aided over the last two decades by the development of different systems to classify and grade lens opacities by various research groups (15–29). In these lens classification systems, the clinical appearance of the lens or lens photographs can be compared with a set of standard photographs. The Lens Opacities Classification System has been most commonly adapted by different research groups (30–32), and other major cataract grading systems include the Wilmer (21), Oxford (17), and Wisconsin grading systems (24). Recently, consensus has been reached on a simplified cataract grading system that would allow for easier comparisons across countries for common forms of cataract (33).

3.2. Prevalence and Incidence

Worldwide, an estimated 25 million persons were blind from cataract in 2000 (2). Much of the current knowledge regarding the epidemiology of cataract has been derived from

important large studies conducted over the last two decades that include the Framingham Eye Study in Framingham, Massachusetts, the Beaver Dam Eye Study in Beaver Dam, Wisconsin, the Blue Mountains Eye Study near Sydney, Australia, the Waterman Study of the Chesapeake Bay, Maryland, the Salisbury Eye Evaluation Project in Salisbury, Maryland, the Nurses' Health Study, the Longitudinal Study of Cataract, and the Physicians' Health Study. The definition of cataract has not necessarily been comparable across studies, as studies have often relied on different classification systems for lens opacities. Thus, estimates of prevalence and incidence will vary according to the criteria and grading system used to define cataract.

3.2.1. PREVALENCE

From 1962 to 1970, prevalence and incidence data on blindness due to cataract were collected in the United States, with blindness defined as best corrected acuity of 20/200 or less in the better eye or visual field limited to 20 degrees (34). Among adults aged 45–64, 65–74, 75–84, and ≥ 85 yr, the prevalence of cataract blindness was 23.0, 52.6, 128.4, and 492.2 per 100,000 and the incidence was 3.5, 4.9, 14.0, and 40.8 per 100,000 (34).

The overall prevalence of cataract in the National Health and Nutrition Examination Survey (1971–1972) for white men and women aged 45–64 yr was reported as 5.6% and 2.1%, respectively (35). Among black men and women aged 45–64 yr, the prevalence was 8.3% and 8.5%, respectively (35). For white men and women aged 65–75 yr, the prevalence of cataract among white men and women was 21.6% and 26.8%, respectively, and for black men and women aged 65–76 yr, the prevalence of cataract was 38.3% and 39.1% (35). Among adults aged 45–74 yr, the prevalence rates of nuclear, cortical, and posterior subcapsular cataracts was 10.0%, 7.3%, and 3.1%, respectively (13).

In the Beaver Dam Eye Study, among adults aged 43–84 yr, the prevalence of more severe levels of nuclear cataract (more than level 3 in a 5-step scale) was 17.3% (36). Cortical opacities were found in 16.3% and posterior subcapsular opacities were found in 6.0% of the population (36). Posterior subcapsular opacities occurred 4.5 more often in the presence of cortical opacities, and 5.6 more often in the presence of level three or worse (on a scale of five) nuclear sclerosis (36). The prevalence of visually significant cataract (best corrected acuity of 20/32 or 20/30, depending on the study) in the worse eye among men aged 55–64 yr was 3.9% in the Beaver Dam Eye Study (36). Among male participants, aged 52–85 yr, in the Framingham Eye Study, the prevalence of nuclear, cortical, and posterior subcapsular cataract was 25.2%, 14.1%, and 8.1%, respectively (37).

In the Blue Mountains Eye Study, among individuals aged 49–96 yr, the prevalence of moderate or advanced nuclear opacities was 53.3% in women and 49.7% in men, and the prevalence of moderate cortical cataract was 25.9% in women and 21.1% in men (38). Overall, the prevalence of nuclear, cortical, and posterior subcapsular cataracts among adults ≥ 49 yr of age was 12.4%, 17.5%, and 5.4%, respectively (38). The age-adjusted prevalence of lens opacity, as assessed by Lens Opacities Classification System (LOCS) III, among 1206 Chinese men and women, aged 40 yr or older in Singapore, was 22.6% for nuclear opacity, 23.9% for cortical opacity, and 7.0% for posterior subcapsular opacity (39).

3.2.2. INCIDENCE

Over a 5-yr period in the Beaver Dam Eye Study, among individuals 43–86 yr of age, the cumulative incidence rates of nuclear, cortical, and posterior subcapsular cataract in right eyes only were 12%, 8%, and 3%, respectively (40). Over a 10-yr period in the same

study, among individuals 43–86 yr of age, in right eyes, the crude incidence rates for nuclear, cortical, and subcapsular cataract were 19.4%, 17.4%, and 6.1%, respectively (41). The 10-yr incidence for any type of cataract for either eye was 38.0%. In the Longitudinal Study of Cataract, which involved 764 participants in a clinic-based population with median age 65 yr, the 5-yr incidence rates for new cortical and posterior subcapsular opacities was 7.7% and 4.3%, respectively (42). The 5-yr incidence rates for new nuclear opacities, among those free of nuclear opacities at baseline, was 6% after 2 yr and 8% after 5 yr of follow-up (43). The incidence rates of cataract may vary somewhat between studies, depending on the classification system used to grade lens opacities (42).

3.2.3. DEVELOPING COUNTRIES

Both the prevalence and incidence of cataracts is higher in developing countries compared with developed countries (44–46). The age-adjusted prevalence of cataract in Punjab, India, was almost three times higher than that observed in Framingham (45). In India, the incidence of cataract blindness has been estimated as 0.0581 per person-year for those aged 65 yr and older, with annual cumulative incidences of 5.64% (46). If these rates are extrapolated to all of India, the investigators suggest that there are 3.8 million new cases of cataract blindness each year (46). Greater sunlight exposure and poorer nutritional status in developing countries are among the main risk factors that might explain the higher prevalence and incidence of cataracts in developing countries, as discussed later.

3.3. Nutritional Risk Factors for Cataract

Although many epidemiological studies have shown significant associations between risk of nuclear, cortical, and posterior subcapsular cataract and various nutritional factors, including vitamins, carotenoids, and minerals, observations have not been consistent between studies. There has been greatest interest in the relationship between plasma antioxidants such as the major dietary carotenoids, vitamin E, vitamin C, riboflavin, and selenium and the pathogenesis of cataract. Of the vitamins, trace elements, and other nutrients that have been examined, studies seem to suggest that there is a protective effect for a higher intake or levels of vitamin E, riboflavin, and folate for nuclear cataract. Many of these epidemiological studies utilized lens grading systems for a more precise definition of different types of cataract. Some studies have used a cross-sectional design in which nutritional status, as measured by dietary assessment or plasma/serum concentrations of nutrients, is compared with the presence of cataract. Other studies have assessed nutritional status at baseline and then examined the relationship between nutritional status and incident cataract. The assumption in both these study designs is that nutritional status in general does not change a great deal over time.

3.3.1. MULTIVITAMINS

Most studies suggest that multivitamin supplementation is associated with a decreased risk of nuclear cataract or incident cataract (32,47–52). In the Lens Opacities Case-Control Study, regular use of multivitamins was associated with a decreased risk for all cataract types (odds ratio [OR] 0.63) (32). Lower risk of incident cataract was found among male physicians taking multivitamins in the Physician's Health Study (OR 0.73, 95% confidence interval [CI] 0.54–0.99) compared to nonusers (47). Multivitamin use for greater than ten years was associated with a decreased risk of nuclear cataract (OR 0.6, 95% CI

0.5–0.08) (48) and with a decreased risk of incident nuclear cataract (OR 0.6, 95% CI 0.4–0.9) (50). In Barbados, there was no significant relationship found between multivitamin supplementation for at least one week per month and nuclear cataract (53). Multivitamin supplementation for at least once per week for a year or more was associated with a decreased risk of nuclear cataract in the Longitudinal Study of Cataract (OR 0.69, 95% CI 0.48–0.99) (49). Multivitamin supplementation does not appear to be associated with risk of cortical cataract (48,50,51,53,54) or posterior subcapsular cataract (48,50,51,54).

3.3.2. VITAMIN A

Some studies have suggested that higher plasma vitamin A concentrations or total vitamin A intake is associated with a reduced risk of nuclear cataract (51,55,56), but the overall relationship does not appear to be consistent (48,57). Severe vitamin A deficiency results in xerophthalmia, impaired immunity, growth failure, and higher morbidity and mortality from some infectious diseases, and cataract is not considered as part of the syndrome of severe vitamin A deficiency (*see* Chapter 1). No significant relationship has been found between vitamin A in supplements, vitamin A dietary intake, or plasma vitamin A concentrations and cortical cataract (48,54,56,57) and posterior subcapsular cataract (51,56).

3.3.3. CAROTENOIDS

The seven major dietary carotenoids consist of α -carotene, β -carotene, β -cryptoxanthin, lutein, zeaxanthin, and lycopene. These dietary carotenoids are found in a variety of fruits and vegetables and are strong antioxidants. α -carotene, β -carotene, β -cryptoxanthin, and lutein are found in spinach and other dark green leafy vegetables, and good sources of β -carotene include carrots, papaya, and mango. Oranges and kiwi fruits are good sources of β -cryptoxanthin. Zeaxanthin is found in high concentrations in corn, and good sources of lycopene are tomatoes and tomato products. Epidemiological studies of cataract have used both dietary intake of carotenoids, as derived from food composition tables, and serum or plasma concentrations of carotenoids. Serum or plasma carotenoids are considered to be more accurate than dietary assessment in measuring the dietary intake of carotenoids (58). The biochemistry and functions of carotenoids and the relationship between lutein and zeaxanthin and age-related macular degeneration are presented in more detail in Chapter 4). Although many of the carotenoids have been considered separately in epidemiologic analyses, there may be considerable overlap of carotenoids in some common foods. Studies have not shown a consistent relationship between different dietary carotenoids and nuclear cataract in cross-sectional and prospective studies (52,55,57,59–61). No consistent relationships have been reported between dietary intake or plasma/serum concentrations of α -carotene, β -carotene, β -cryptoxanthin, lutein, zeaxanthin, lycopene, or total carotenoids and nuclear cataract. Likewise, no consistent relationships have been found between dietary intake or plasma/serum concentrations of carotenoids and cortical cataract or posterior subcapsular cataract. Of the major dietary carotenoids, perhaps lutein and zeaxanthin are of the greatest interest in relationship to cataract, because these are the two major carotenoids that have been found in the human lens (62). A recent study suggests that women who consumed fruits, vegetables, and whole grains consistent with healthy eating and the Dietary Guidelines for Americans had lower prevalence of early age-related nuclear lens opacities (63).

3.3.4. VITAMIN D

Vitamin D, which consists of a group of fat soluble seco-sterols, is synthesized in the skin on exposure to ultraviolet B in sunlight, and is also available in a few foods such as fatty fish, fish liver oils, eggs, in vitamin D-fortified foods such as milk and breakfast cereals, and in vitamin supplements that contain vitamin D. Severe vitamin D deficiency results in rickets in children and osteoporosis in adults, and cataract is not known to be part of the syndrome of vitamin D deficiency. Vitamin D intake in supplements has not been associated with risk of nuclear or cortical cataract (48). The relationship between a good laboratory indicator for vitamin D status, such as plasma or serum 25-hydroxyvitamin D, and risk of cataract has not been well characterized.

3.3.5. VITAMIN E

Vitamin E is a term used to describe a group of lipid-soluble tocol and tocotrienol derivatives that are considered to have vitamin E activity. α -Tocopherol appears to be the most biologically relevant form of vitamin E for human health (58). The biochemistry, metabolism, and functions of vitamin E are presented in detail in Chapter 4. The relationship between dietary intake of vitamin E or plasma concentrations of vitamin E and nuclear cataract has been addressed in many studies (49,51,52,55,57,59–61,64–66). In general, assessment of dietary intake of vitamin E may be problematic because a major portion of vitamin E intake may come from cooking oils, and many individuals may not know what types of oils were used in the preparation of foods (58). Various studies suggest that higher dietary intake or plasma concentrations of vitamin E are protective against nuclear cataract (49,52,64), although one study has shown that higher serum α -tocopherol concentrations are associated with a higher risk of nuclear cataract (59). Two studies suggest that there is an association between vitamin E status and cortical cataract (65,66), but among studies there has not been a consistent association between vitamin E status and cortical cataract. No significant relationship has been found between vitamin E intake or plasma/serum concentrations of vitamin E and posterior subcapsular cataract except one study that shows a vitamin E intake of 5–10 mg/d is associated with higher risk of posterior subcapsular cataract (67). In a case-control study from Finland involving 47 cases and 94 controls, low serum concentrations of α -tocopherol were associated with an increased risk of cataract (68).

3.3.6. VITAMIN C

Vitamin C, or ascorbic acid, is a strong antioxidant that is thought to protect the proteins of the crystalline lens from oxidation. The biochemistry, metabolism, and functions of vitamin C are presented in Chapter 9. Severe vitamin C deficiency is characterized by scurvy, and cataract is not considered to be part of the clinical syndrome of scurvy. No consistent relationship has been found between dietary intake or plasma concentrations of vitamin C and nuclear cataract (48,49,51,52,55–57,61). Likewise, there are few data to support the association between vitamin C intake or plasma vitamin C concentrations and risk of cortical cataract or posterior subcapsular cataract. In the guinea pig model, prolonged marginal ascorbic acid deficiency was associated with lower lenticular ascorbic acid concentrations but it did not cause increased cataract formation or increased lipid peroxidation in the lens (69).

3.3.7. THIAMIN

Thiamin is a water-soluble vitamin that plays a role in the metabolism of carbohydrates and branched-chain amino acids. The biochemistry, metabolism, and functions of thiamin are presented in more detail in Chapter 7. Severe thiamin deficiency results in the beriberi, and cataract is not considered to be part of the clinical syndrome of beriberi. Data from the Beaver Dam Eye Survey suggests that the total dietary intake of thiamin is protective against nuclear cataract in men but not women (55). In the Blue Mountains Eye Study, total dietary intake of thiamin was protective against nuclear cataract (56). No significant relationships have been found between thiamin intake or supplementation and cortical cataract (48,51,56), or posterior subcapsular cataract (51,56).

3.3.9. RIBOFLAVIN

Riboflavin is a precursor to the coenzymes FMN and FAD and other covalently bound flavins that are involved in many oxidation-reduction reactions. Riboflavin has strong antioxidant activity through its role in the glutathione redox cycle. The biochemistry, metabolism, and functions of riboflavin are presented in more detail in Chapter 7. Riboflavin deficiency has been associated with cataract in experimental animal models, but the association between riboflavin deficiency and cataract in humans is less clear. Epidemiological studies suggest that a higher dietary intake of riboflavin is associated with lower risk of nuclear cataract (52,55,56). No significant relationship has been found between riboflavin intake or supplementation and cortical cataract or posterior subcapsular cataract. The relationship between laboratory indicators of riboflavin status, such as erythrocyte glutathione reductase, erythrocyte flavin, or urinary flavin and risk of cataract has not been characterized. In a subsample of subjects from the Nurses' Health Study, higher long-term intake of riboflavin and/or thiamin was associated with reduced progression of nuclear lens opacities over 5 yr of follow-up (70).

3.3.10. NIACIN

Niacin is a generic term for nicotinic acid, nicotinamide, and derivatives that have the biological activity of nicotinamide. Niacin is a water soluble vitamin that plays a central role in oxidation and reduction reactions of both catabolic pathways of carbohydrates, lipids, and proteins, and anabolic pathways of fatty acid and cholesterol synthesis. The biochemistry, metabolism, and functions of niacin are presented in more detail in Chapter 7. Severe niacin deficiency results in pellagra, and cataract is not considered to be part of the clinical syndrome of pellagra. Two studies suggest that low dietary intake of niacin is associated with a higher risk of nuclear cataract (55,56). No significant relationship has been described between dietary niacin intake and cortical cataract or posterior subcapsular cataract.

3.3.11. PYRIDOXINE

Vitamin B₆, or pyridoxine and related compounds, plays a role in gluconeogenesis, metabolism of amino acids, hormone modulation, immune function, erythrocyte function, lipid metabolism, and neurotransmitter synthesis. No significant relationship has been found between pyridoxine intake in supplements and nuclear cataracts (48,51) or posterior subcapsular cataract (51). Individuals with the highest pyridoxine intake in

supplements had an increased risk of cortical cataract in the Beaver Dam Eye Study (OR 2.0, 95% CI 1.1–3.7) (48).

3.3.12. FOLATE

Folate is a generic term used to describe a family of compounds with the activity of folic acid, including folylpolyglutamates and folic acid (pteroylglutamic acid) and its derivatives. Folate plays an important role as coenzymes in the synthesis of nucleic acids and amino acids, and folate deficiency has been linked with nutritional amblyopia, as discussed in detail in Chapter 7. Higher folate intake has been associated with lower risk of nuclear cataract among men and women in the Beaver Dam Eye Survey (55) and in the Nurses' Health Study (52). No significant association has been found between folate intake and cortical cataract or posterior subcapsular cataract.

3.3.13. VITAMIN B₁₂

Vitamin B₁₂ is a generic term for corrinoids that have the biological activity of cyanocobalamin. Deficiency of vitamin B₁₂ has been linked with nutritional amblyopia. The biochemistry, metabolism, and functions of vitamin B₁₂ are presented in more detail in Chapter 7. In the Blue Mountains Eye Study, vitamin B₁₂ supplementation of >8.0 µg per day was associated with a decreased risk of nuclear cataract and decreased risk of cortical cataract (51).

3.3.14. ZINC

Zinc is involved in the metabolism of nucleic acids, protein, and lipids, synthesis of hormones, and apoptosis, as presented in more detail in Chapter 8. Dietary zinc intake has not been associated with the risk of nuclear cataract, cortical cataract, or posterior subcapsular cataract (56), but there have been relatively few studies to examine the relationship between zinc status and cataract. The relationships between the various nutrients and the three major types of cataracts in different studies are summarized in Tables 1–3.

3.3.15. PROTEIN

Low consumption of protein foods was associated with a higher risk of concurrent cataract in the Punjab (45). Authors believe that low total protein consumption may account for as much as 40% of the excess prevalence of cataract in the Punjab region compared with that in the United States (45). Low protein intake was also associated with increased risk of nuclear cataract, posterior subcapsular cataract, and mixed cataracts in India (30).

3.3.16. ANTIOXIDANT INDEX

A composite "antioxidant index" based on various combinations of glutathione peroxidase, glucose-6-phosphate dehydrogenase, ascorbic acid, vitamin E, and carotenoids has been utilized to relate antioxidant systems to cataract (30,71). In India, a high antioxidant index (glutathione peroxidase, glucose-6-phosphate dehydrogenase, ascorbic acid, and vitamin E combined) was associated with a decreased risk of posterior subcapsular cataract (OR 0.23, 95% CI 0.06–0.88) and decreased risk of combined nuclear and posterior subcapsular cataract (OR 0.12, 95% CI 0.03–0.56) (30). Another antioxidant index, consisting of high concentrations of at least two or three vitamins or nutrients (vitamin C, vitamin E, carotenoids) were associated with a reduced risk of cataract (71).

Table 1
Nutritional Factors and Risk of Nuclear Cataract

<i>Study^a</i>	<i>Design</i>	<i>n</i>	<i>OR^b</i>	<i>95% CI</i>	<i>Comment^c</i>	<i>Reference</i>
Multivitamin						
Beaver Dam	Cross-sectional	1980	0.9	0.7–1.1	Current supplement use; nondiabetic subjects	48
Beaver Dam	Cross-sectional	172	1.7	0.8–3.8	Current supplement use; diabetic subjects	48
Beaver Dam	Prospective	1980	0.6	0.50.8	Supplement use over 10 yr; nondiabetic subjects	48
Beaver Dam	Prospective	172	1.1	0.4–2.7	Supplement use over 10 yr; diabetic subjects	48
Barbados	Cross-sectional	4314	1.06	0.48–2.32	Daily supplementation for at least 1 wk/mo	53
Longitudinal Cataract	Prospective	744	0.69	0.480.99	Supplementation at least once per week for ≥1 yr	49
Beaver Dam	Prospective	3089	0.6	0.40.9	Supplemented > 10 yr	50
Blue Mountains	Cross-sectional	2873	0.1	0.0–1.0	Supplemented > 10 yr	51
Nurses' Health	Prospective	478	0.57	0.350.93	Supplemented > 10 yr	52
Vitamin A						
Baltimore Longitudinal	Prospective	660	0.93	0.49–1.76	Plasma concentration; highest vs lowest quartile	57
Beaver Dam	Prospective	1980	0.9	0.5–1.7	Intake in supplements; highest vs lowest tertile	48
Beaver Dam	Prospective	859	0.55	0.350.86	Total intake; men; highest vs lowest quintile	55
Beaver Dam	Prospective	1060	0.80	0.54–1.18	Total intake; women; highest vs lowest quintile	55
Blue Mountains	Cross-sectional	2900	0.5	0.30.8	Total intake; highest vs lowest quintile; adjusted age, sex	56
Blue Mountains	Cross-sectional	2873	0.1	0.00.9	Supplemented > 3000 µg/d	51
α-carotene						
Beaver Dam	Prospective	859	0.61	0.390.95	Dietary intake; men; highest vs lowest quintile	55
Beaver Dam	Prospective	1060	0.80	0.55–1.19	Dietary intake; women; highest vs lowest quintile	55
Beaver Dam	Cross-sectional	180	0.30	0.110.84	Dietary intake; men; highest vs lowest quintile	59
Beaver Dam	Cross-sectional	220	2.09	0.87–5.04	Dietary intake; women; highest vs lowest quintile	59
Beaver Dam	Cross-sectional	400	1.14	0.61–2.14	Serum concentration; highest vs lowest quintile	59
Beaver Dam	Prospective	400	0.9	0.4–2.2	Serum concentration; highest vs lowest tertile	60
Nurses' Health	Prospective	478	0.71	0.37–1.35	Dietary intake; highest vs lowest quintile	52
Sheffield	Cross-sectional	372	0.5	0.30.9	Plasma concentration; highest vs lowest tertile	61

(continued)

Table 1 (Continued)

<i>Study^a</i>	<i>Design</i>	<i>n</i>	<i>OR^b</i>	<i>95% CI</i>	<i>Comment^c</i>	<i>Reference</i>
β-carotene						
Baltimore Longitudinal	Prospective	660	1.57	0.84–2.93	Plasma concentration; highest vs lowest quartile	57
Beaver Dam	Prospective	859	0.71	0.46–1.10	Dietary intake; men; highest vs lowest quintile	55
Beaver Dam	Prospective	1060	0.82	0.55–1.22	Dietary intake; women; highest vs lowest quintile	55
Beaver Dam	Cross-sectional	180	0.44	0.44–1.23	Dietary intake; men; highest vs lowest quintile	59
Beaver Dam	Cross-sectional	220	1.31	0.56–3.10	Dietary intake; women; highest vs lowest quintile	59
Beaver Dam	Cross-sectional	400	1.54	0.81–2.91	Serum concentration; highest vs lowest quintile	59
Beaver Dam	Prospective	400	0.9	0.4–2.2	Serum concentration; highest vs lowest tertile	60
Nurses' Health	Prospective	478	0.52	0.280.97	Dietary intake; highest vs lowest quintile	52
Sheffield	Cross-sectional	372	0.7	0.4–1.4	Plasma concentration; highest vs lowest tertile	61
β-cryptoxanthin						
Beaver Dam	Prospective	859	0.87	0.56–1.34	Dietary intake; men; highest vs lowest quintile	55
Beaver Dam	Prospective	1060	1.13	0.76–1.66	Dietary intake; women; highest vs lowest quintile	55
Beaver Dam	Cross-sectional	180	1.07	0.40–2.87	Dietary intake; men; highest vs lowest quintile	59
Beaver Dam	Cross-sectional	220	4.10	1.729.76	Dietary intake; women; highest vs lowest quintile	59
Beaver Dam	Cross-sectional	400	0.84	0.45–1.57	Serum concentration; highest vs lowest quintile	59
Beaver Dam	Prospective	400	0.7	0.3–1.6	Serum concentration; highest vs lowest tertile	60
Nurses' Health	Prospective	478	0.68	0.34–1.35	Dietary intake; highest vs lowest quintile	52
Sheffield	Cross-sectional	372	0.6	0.3–1.1	Plasma concentration; highest vs lowest tertile	61
Lutein						
Beaver Dam	Prospective	859	0.82	0.53–1.26	Dietary intake; men; highest vs lowest quintile	55
Beaver Dam	Prospective	1060	0.73	0.50–1.06	Dietary intake; women; highest vs lowest quintile	55
Beaver Dam	Cross-sectional	180	0.77	0.30–2.01	Dietary intake; men; highest vs lowest quintile	59
Beaver Dam	Cross-sectional	220	1.43	0.61–3.37	Dietary intake; women; highest vs lowest quintile	59
Beaver Dam	Cross-sectional	400	1.45	0.75–2.80	Serum concentration; highest vs lowest quintile	59
Beaver Dam	Prospective	400	0.7	0.3–1.6	Serum concentration; highest vs lowest tertile	60
Sheffield	Cross-sectional	372	0.8	0.4–1.5	Plasma concentration; highest vs lowest tertile	61

Sheffield	Cross-sectional	372	0.7	Zeaxanthin 0.4–1.4	Plasma concentration; highest vs lowest tertile	61
Nurses' Health	Prospective	478	0.52	Lutein/Zeaxanthin 0.290.91	Dietary intake; highest vs lowest quintile	52
Beaver Dam	Prospective	859	1.10	Lycopene 0.71–1.72	Dietary intake; men; highest vs lowest quintile	55
Beaver Dam	Prospective	1060	1.49	1.012.19	Dietary intake; women; highest vs lowest quintile	55
Beaver Dam	Cross-sectional	180	0.62	0.23–1.66	Dietary intake; men; highest vs lowest quintile	59
Beaver Dam	Cross-sectional	220	1.21	0.52–2.79	Dietary intake; women; highest vs lowest quintile	59
Beaver Dam	Cross-sectional	400	1.96	0.98–3.95	Serum concentration; highest vs lowest quintile	59
Beaver Dam	Prospective	400	1.1	0.5–2.6	Serum concentration; highest vs lowest tertile	60
Nurses' Health	Prospective	478	1.16	0.63–2.16	Total intake; highest vs lowest quintile	52
Sheffield	Cross-sectional	372	0.9	0.5–1.8	Plasma concentration; highest vs lowest tertile	61
Beaver Dam	Cross-sectional	220	1.89	Total Carotenoids 0.82–4.35	Dietary intake; women; highest vs lowest quintile	59
Beaver Dam	Cross-sectional	180	0.41	0.15–1.10	Dietary intake; men; highest vs lowest quintile	59
Beaver Dam	Cross-sectional	400	1.90	0.99–3.66	Serum concentration; highest vs lowest quintile	59
Nurses' Health	Prospective	478	0.62	0.34–1.13	Total intake; highest vs lowest quintile; adjusted	52
Nurses' Health	Cross-sectional	478	1.77	0.91–3.43	Plasma concentration; highest vs lowest quintile	52
Beaver Dam	Prospective	1980	1.3	Vitamin D 0.4–4.5	Intake in supplements; highest vs lowest tertile	48
Baltimore Longitudinal	Prospective	660	0.52	Vitamin E 0.26–1.07	Plasma concentration; highest vs lowest quartile	57
Lens Opacities	Case-control	1380	0.44	0.210.90	Plasma α -tocopherol; highest vs lowest quintile	64
Beaver Dam	Prospective	859	0.67	0.43–1.03	Dietary intake; men; highest vs lowest quintile	55
Beaver Dam	Prospective	1060	0.78	0.53–1.14	Total intake; women; highest vs lowest quintile	55
Beaver Dam	Cross-sectional	220	1.89	0.82–4.35	Dietary intake; women; highest vs lowest quintile	59
Beaver Dam	Cross-sectional	180	0.85	0.32–2.25	Dietary intake; men; highest vs lowest quintile	59
Beaver Dam	Cross-sectional	400	2.13	1.054.34	Serum α -tocopherol; highest vs lowest quintile	59
Beaver Dam	Prospective	1980	0.9	0.6–1.5	Intake in supplements; highest vs lowest tertile	48
Kuopio Atherosclerosis	Prospective	410	0.99	0.96–1.03	Plasma vitamin E; highest vs lowest quartile	65

(continued)

Table 1 (Continued)

<i>Study^a</i>	<i>Design</i>	<i>n</i>	<i>OR^b</i>	<i>95% CI</i>	<i>Comment^c</i>	<i>Reference</i>
Vitamin E (continued)						
Longitudinal Cataract	Prospective	744	0.43	0.190.99	Supplementation at least once per week for ≥1 yr	49
Longitudinal Cataract	Prospective	744	0.58	0.360.94	Plasma α-tocopherol; highest vs lowest quintile	49
Beaver Dam	Prospective	400	0.5	0.2–1.1	Serum α-tocopherol; highest vs lowest tertile	60
Vitamin E & Cataract	Cross-sectional	1104	0.89	0.47–1.70	“Ever” vs “never” used supplements, by history	66
Blue Mountains	Cross-sectional	2873	–	–	No significant relationship found with supplements	51
Nurses’ Health	Prospective	478	0.49	0.22–1.09	Supplemented > 10 yr	52
Nurses’ Health	Prospective	478	0.45	0.230.86	Total intake; highest vs lowest quintile	52
Nurses’ Health	Cross-sectional	478	0.48	0.250.95	Plasma concentration; highest vs lowest quintile	52
Sheffield	Cross-sectional	372	0.6	0.3–1.3	Plasma concentration; highest vs lowest tertile	61
Vitamin C						
Baltimore Longitudinal	Prospective	660	1.31	0.65–2.60	Plasma concentration; highest vs lowest quartile	57
Beaver Dam	Prospective	1980	0.7	0.5–1.0	Intake in supplements; highest vs lowest tertile	48
Beaver Dam	Prospective	859	0.62	0.390.97	Total intake; men; highest vs lowest quintile	55
Beaver Dam	Prospective	1060	0.75	0.51–1.11	Total intake; women; highest vs lowest quintile	55
Longitudinal Cataract	Prospective	744	0.80	0.49–1.32	Supplementation at least once per week for ≥1 yr	49
Blue Mountains	Cross-sectional	2900	0.7	0.5–1.1	Total intake; highest vs lowest quintile; adjusted age, sex	56
Blue Mountains	Cross-sectional	2873	–	–	No significant relationship found with supplements	51
Nurses’ Health	Prospective	478	0.36	0.180.72	Supplemented > 10 yr	52
Nurses’ Health	Prospective	478	0.31	0.160.58	Total intake; highest vs lowest quintile	52
Nurses’ Health	Cross-sectional	478	0.54	0.28–1.02	Plasma concentration; highest vs lowest quintile	52
Sheffield	Cross-sectional	372	1.0	0.5–1.9	Plasma concentration; highest vs lowest tertile	61
Thiamin						
Beaver Dam	Prospective	1980	0.7	0.5–1.2	Intake in supplements; highest vs lowest tertile	48
Beaver Dam	Prospective	859	0.58	0.380.91	Total intake; men; highest vs lowest quintile	55
Beaver Dam	Prospective	1060	0.75	0.51–1.10	Total intake; women; highest vs lowest quintile	55
Blue Mountains	Cross-sectional	2900	0.6	0.40.9	Total intake; highest vs lowest quintile; adjusted age, sex	56
Blue Mountains	Cross-sectional	2873	0.6	0.4–1.0	Supplemented > 4.4 mg/d	51

					Riboflavin					
Beaver Dam	Prospective	1980	0.8	0.5–1.3	Intake in supplements; highest vs lowest tertile	48				
Beaver Dam	Prospective	859	0.56	0.360.87	Total intake; men; highest vs lowest quintile	55				
Beaver Dam	Prospective	1060	0.67	0.460.98	Total intake; women; highest vs lowest quintile	55				
Blue Mountains	Cross-sectional	2900	0.6	0.40.9	Total intake; highest vs lowest quintile; adjusted age, sex	56				
Blue Mountains	Cross-sectional	2873	0.6	0.4–1.1	Supplemented > 6.8 mg/d	51				
Nurses' Health	Prospective	478	0.37	0.190.73	Total intake; highest vs lowest quintile	52				
					Niacin					
Beaver Dam	Prospective	1980	0.7	0.4–1.2	Intake in supplements; highest vs lowest tertile	48				
Beaver Dam	Prospective	859	0.56	0.360.86	Total intake; men; highest vs lowest quintile	55				
Beaver Dam	Prospective	1060	0.71	0.49–1.04	Total intake; women; highest vs lowest quintile	55				
Blue Mountains	Cross-sectional	2900	0.6	0.40.9	Total intake; highest vs lowest quintile; adjusted age, sex	56				
Blue Mountains	Cross-sectional	2873	0.4	0.1–1.4	Supplemented > 64 mg/d	51				
					Pyridoxine					
Beaver Dam	Prospective	1980	0.9	0.5–1.4	Intake in supplements; highest vs lowest tertile	48				
Blue Mountains	Cross-sectional	2873	0.6	0.3–1.0	Supplemented > 6.0 mg/d	51				
					Folate					
Beaver Dam	Prospective	1980	0.5	0.2–1.7	Intake in supplements; highest vs lowest tertile	48				
Beaver Dam	Prospective	859	0.50	0.320.79	Total intake; men; highest vs lowest quintile	55				
Beaver Dam	Prospective	1060	0.63	0.430.92	Total intake; women; highest vs lowest quintile	55				
Blue Mountains	Cross-sectional	2873	0.5	0.2–1.2	Supplemented 200 to ≤800 µg/d	51				
Nurses' Health	Prospective	478	0.44	0.240.81	Total intake; highest vs lowest quintile	52				
					Vitamin B₁₂					
Blue Mountains	Cross-sectional	2873	0.3	0.10.7	Supplemented > 8.0 µg/d	51				
					Zinc					
Blue Mountains	Cross-sectional	2900	0.7	0.5–1.1	Total intake; highest vs lowest quintile; adjusted age, sex	56				

^aDetails regarding demographic and other characteristics of the individual studies is found in the main text.

^bAll odds ratios (OR) are from multivariate models adjusting for potential confounders.

^cTotal intake = dietary intake plus intake from supplements

Table 2
Nutritional Factors and Risk of Cortical Cataract

<i>Study</i>	<i>Design</i>	<i>n</i>	<i>OR</i>	<i>(95% CI)</i>	<i>Comment</i>	<i>Reference</i>
Multivitamin						
Beaver Dam	Cross-sectional	1980	1.1	0.8–1.5	Current supplement use; nondiabetic subjects	48
Beaver Dam	Cross-sectional	172	1.0	0.4–2.6	Current supplement use; diabetic subjects	48
Beaver Dam	Prospective	1980	1.6	1.12–1	Supplement use over 10 yr; nondiabetic subjects	48
Beaver Dam	Prospective	172	0.1	00.9	Supplement use over 10 yr; diabetic subjects	48
Barbados	Cross-sectional	4314	0.70	0.47–1.05	Daily supplementation for at least 1 wk per month	53
Beaver Dam	Prospective	3089	0.4	0.2–0.8	Supplemented > 10 yr	50
Blue Mountains	Cross-sectional	2873	0.5	0.3–1.1	Supplemented > 10 yr	51
Nurses' Health	Prospective	492	1.11	0.75–1.63	Supplemented ≥ 10 yr	54
Vitamin A						
Beaver Dam	Prospective	1980	1.8	0.9–3.8	Intake in supplements; highest vs lowest tertile	48
Baltimore Longitudinal	Prospective	600	2.37	1.16–4.83	Plasma concentration; highest vs lowest quartile	57
Blue Mountains	Cross-sectional	2900	0.8	0.6–1.1	Total intake; highest vs lowest quintile; adjusted age, sex	56
Blue Mountains	Cross-sectional	2873	–	–	No significant relationship found	51
α-carotene						
Beaver Dam	Cross-sectional	217	0.87	0.23–3.12	Serum concentration; women; highest vs lowest quintile	59
Beaver Dam	Cross-sectional	179	0.82	0.20–3.44	Serum concentration; men; highest vs lowest quintile	59
Sheffield	Cross-sectional	372	0.9	0.5–1.7	Plasma concentration; highest vs lowest tertile	61
Nurses' Health	Prospective	492	1.03	0.64–1.64	Dietary intake; highest vs lowest quintile	54
β-carotene						
Baltimore Longitudinal	Prospective	600	0.72	0.37–1.42	Plasma concentration; highest vs lowest quartile	57
Beaver Dam	Cross-sectional	217	2.00	0.57–6.98	Serum concentration; women; highest vs lowest quintile	59
Beaver Dam	Cross-sectional	179	0.28	0.06–1.24	Serum concentration; men; highest vs lowest quintile	59
Sheffield	Cross-sectional	372	0.6	0.3–1.1	Plasma concentration; highest vs lowest tertile	61
Nurses' Health	Prospective	492	1.33	0.81–2.19	Dietary intake; highest vs lowest quintile	54
β-cryptoxanthin						
Beaver Dam	Cross-sectional	217	1.45	0.43–4.90	Serum concentration; women; highest vs lowest quintile	59
Beaver Dam	Cross-sectional	179	0.54	0.08–3.78	Serum concentration; men; highest vs lowest quintile	59

Sheffield Nurses' Health	Cross-sectional Prospective	372 492	1.0 1.00	0.5–2.0 0.59–1.71	Plasma concentration; highest vs lowest tertile Dietary intake; highest vs lowest quintile	61 54
Lutein						
Beaver Dam	Cross-sectional	217	1.75	0.49–6.21	Serum concentration; women; highest vs lowest quintile	59
Beaver Dam	Cross-sectional	179	4.84	0.83–28.1	Serum concentration; men; highest vs lowest quintile	59
Sheffield	Cross-sectional	372	1.3	0.7–2.4	Plasma concentration; highest vs lowest tertile	61
Zeaxanthin						
Sheffield	Cross-sectional	372	1.0	0.5–2.0	Plasma concentration; highest vs lowest tertile	61
Lutein/Zeaxanthin						
Nurses' Health	Prospective	492	0.86	0.52–1.44	Dietary intake; highest vs lowest quintile	54
Lycopene						
Beaver Dam	Cross-sectional	217	3.21	0.78–13.2	Serum concentration; women; highest vs lowest quintile	59
Beaver Dam	Cross-sectional	179	0.37	0.06–2.36	Serum concentration; men; highest vs lowest quintile	59
Sheffield	Cross-sectional	372	0.4	0.20.7	Plasma concentration; highest vs lowest tertile	61
Nurses' Health	Prospective	492	1.43	0.87–2.35	Dietary intake; highest vs lowest quintile	54
Total Carotenoids						
Beaver Dam	Cross-sectional	217	3.26	0.92–11.5	Serum concentration; women; highest vs lowest quintile	59
Beaver Dam	Cross-sectional	179	0.62	0.12–3.20	Serum concentration; men; highest vs lowest quintile	59
Nurses' Health	Prospective	492	1.13	0.69–1.86	Dietary intake; highest vs lowest quintile	54
Nurses' Health	Prospective	492	1.08	0.64–1.82	Plasma concentration; highest vs lowest quintile	54
Vitamin D						
Beaver Dam	Prospective	1980	2.0	0.5–7.9	Intake in supplements; highest vs lowest tertile	48
Vitamin E						
Baltimore Longitudinal	Prospective	600	0.96	0.52–1.78	Plasma concentration; highest vs lowest quartile	57
Beaver Dam	Prospective	1980	1.2	0.6–2.3	Intake in supplements; highest vs lowest tertile	48
Lens Opacities	Case-control	1380	0.74	0.43–1.27	Plasma α -tocopherol; highest vs lowest quintile	64
Beaver Dam	Cross-sectional	217	2.11	0.44–10.06	Serum α -tocopherol; women; highest vs lowest quintile	59
Beaver Dam	Cross-sectional	179	3.94	0.59–26.2	Serum α -tocopherol; men; highest vs lowest quintile	59
Kuopio Atherosclerosis	Prospective	410	0.27	0.080.86	Plasma vitamin E; highest vs lowest quartile	65
Vitamin E & Cataract	Cross-sectional	1104	0.44	0.250.77	“Ever” vs “never” used supplements, by history	66
Blue Mountains	Cross-sectional	2873	–	–	No significant relationship found; data not shown	51

(continued)

Table 2 (Continued)

<i>Study</i>	<i>Design</i>	<i>n</i>	<i>OR</i>	<i>(95% CI)</i>	<i>Comment</i>	<i>Reference</i>
Vitamin E (continued)						
Sheffield	Cross-sectional	372	0.6	0.3–1.1	Plasma concentration; highest vs lowest tertile	61
Nurses' Health	Prospective	492	1.21	0.75–1.95	Total intake; highest vs lowest quintile	54
Nurses' Health	Prospective	492	1.17	0.65–2.09	Supplemented ≥ 10 yr	54
Nurses' Health	Prospective	492	1.32	0.81–2.14	Plasma concentration; highest vs lowest quintile	54
Vitamin C						
Baltimore Longitudinal	Prospective	600	1.01	0.45–2.26	Plasma concentration; highest vs lowest quartile	57
Beaver Dam	Prospective	1980	1.8	1.22.9	Intake in supplements; highest vs lowest tertile	48
Blue Mountains	Cross-sectional	2900	1.0	0.7–1.4	Total intake; highest vs lowest quintile; adjusted age, sex	56
Blue Mountains	Cross-sectional	2873	–	–	No significant relationship found; data not shown	51
Sheffield	Cross-sectional	372	1.1	0.6–2.2	Plasma concentration; highest vs lowest tertile	61
Nurses' Health	Prospective	492	0.89	0.55–1.45	Total intake; highest vs lowest quintile	54
Nurses' Health	Prospective	492	0.89	0.55–1.44	Supplemented ≥ 10 yr	54
Nurses' Health	Prospective	492	1.47	0.86–2.52	Plasma concentration; highest vs lowest quintile	54
Thiamin						
Beaver Dam	Prospective	1980	1.7	0.9–3.1	Intake in supplements; highest vs lowest tertile	48
Blue Mountains	Cross-sectional	2900	0.8	0.6–1.1	Total intake; highest vs lowest quintile; adjusted age, sex	56
Blue Mountains	Cross-sectional	2873	0.7	0.5–1.0	For dose > 4.4 mg/d	51
Riboflavin						
Beaver Dam	Prospective	1980	1.7	0.9–3.1	Intake in supplements; highest vs lowest tertile	48
Blue Mountains	Cross-sectional	2900	0.7	0.5–1.0	Total intake; highest vs lowest quintile; adjusted age, sex	56
Blue Mountains	Cross-sectional	2873	0.7	0.5–1.0	For dose > 6.8 mg/d	51
Nurses' Health	Prospective	492	1.49	0.91–2.44	Total intake; highest vs lowest quintile	54
Niacin						
Beaver Dam	Prospective	1980	2.0	1.0–3.8	Intake in supplements; highest vs lowest tertile	48
Blue Mountains	Cross-sectional	2900	0.7	0.5–1.0	Total intake; highest vs lowest quintile; adjusted age, sex	56
Blue Mountains	Cross-sectional	2873	0.6	0.3–1.2	For dose > 64 mg/d	51

Beaver Dam Blue Mountains	Prospective Cross-sectional	1980 2873	2.0 0.7	Pyridoxine		48 51
				1.13.7 0.5–1.1	Intake in supplements; highest vs lowest tertile For dose > 6.0 mg/d	
Beaver Dam Blue Mountains Nurses' Health	Prospective Cross-sectional Prospective	1980 2873 492	4.4 0.6 0.87	Folate		48 51 54
				1.0–18.5	Intake in supplements; highest vs lowest tertile	
				0.3–1.1	For dose 200 to ≤800 µg/d	
Blue Mountains	Cross-sectional	2873	0.6	0.52–1.45	Total intake; highest vs lowest quintile	51 51
				Vitamin B₁₂ 0.39.9	For dose > 8.0 µg/d	
Blue Mountains	Cross-sectional	2900	1.1	Zinc		56 56
				0.8–1.4	Total intake; highest vs lowest quintile; adjusted age, sex	

OR, odds ratio; CI, confidence interval.

Table 3
Nutritional Factors and Risk of Posterior Subcapsular Cataract

<i>Study</i>	<i>Design</i>	<i>n</i>	<i>OR</i>	<i>(95% CI)</i>	<i>Comment</i>	<i>Reference</i>
				Multivitamin		
Beaver Dam	Cross-sectional	1980	0.8	0.5–1.2	Current supplement use; nondiabetic subjects	48
Beaver Dam	Cross-sectional	172	2.4	0.6–9.2	Current supplement use; diabetic subjects	48
Beaver Dam	Prospective	1980	0.8	0.5–1.4	Supplement use over 10 yr; nondiabetic subjects	48
Beaver Dam	Prospective	172	0.6	0.1–5.3	Supplement use over 10 yr; diabetic subjects	48
Beaver Dam	Prospective	3089	0.9	0.5–1.9	Supplemented > 10 yr	50
Blue Mountains	Cross-sectional	2873	0.9	0.5–1.6	Duration of supplementation not specified	51
Nurses' Health	Prospective	492	0.80	0.44–1.45	Supplemented ≥ 10 yr	54
				Vitamin A		
Blue Mountains	Cross-sectional	2900	1.1	0.7–1.9	Total intake; highest vs lowest quintile; adjusted age, sex	56
Blue Mountains	Cross-sectional	2873	–	–	No significant relationship found; data not shown	51
				α-carotene		
Sheffield	Cross-sectional	372	0.7	0.3–1.5	Plasma concentration; highest vs lowest tertile	61
Nurses' Health	Prospective	492	0.59	0.27–1.30	Dietary intake; highest vs lowest quintile	54
				β-carotene		
Sheffield	Cross-sectional	372	0.7	0.3–1.7	Plasma concentration; highest vs lowest tertile	61
Nurses' Health	Prospective	492	0.72	0.35–1.47	Dietary intake; highest vs lowest quintile	54
				β-cryptoxanthin		
Sheffield	Cross-sectional	372	1.2	0.5–2.8	Plasma concentration; highest vs lowest tertile	61
Nurses' Health	Prospective	492	0.74	0.31–1.74	Dietary intake; highest vs lowest quintile	54
				Lutein		
Sheffield	Cross-sectional	372	0.5	0.2–1.0	Plasma concentration; highest vs lowest tertile	61
				Zeaxanthin		
Sheffield	Cross-sectional	372	0.7	0.3–1.7	Plasma concentration; highest vs lowest tertile	61
				Lutein/zeaxanthin		
Nurses' Health	Prospective	492	0.60	0.28–1.30	Dietary intake; highest vs lowest quintile	54
				Lycopene		
Sheffield	Cross-sectional	372	0.5	0.2–1.2	Plasma concentration; highest vs lowest tertile	61
Nurses' Health	Prospective	492	0.78	0.38–1.61	Dietary intake; highest vs lowest quintile	54

Nurses' Health Nurses' Health	Prospective	492	0.54	Total Carotenoids					
	Prospective	492	0.41	0.25–1.13	Dietary intake; highest vs lowest quintile				54
Lens Opacities Visual Impairment Blue Mountains Nurses' Health Nurses' Health Nurses' Health				Vitamin E	Plasma concentration; highest vs lowest quintile				54
	Case-control	1380	0.90	0.35–2.32	Plasma a-tocopherol; highest vs lowest quintile				64
	Cross-sectional	5147	1.47	1.042.09	Vitamin E intake 5–10 mg/d vs <5 mg/d				67
	Cross-sectional	372	0.7	0.3–1.7	Plasma concentration; highest vs lowest tertile				61
	Prospective	492	0.87	0.39–1.92	Total intake; highest vs lowest quintile				54
	Prospective	492	0.66	0.26–1.62	Supplemented \geq 10 yr				54
	Prospective	492	0.95	0.43–2.14	Plasma concentration; highest vs lowest quintile				54
				Vitamin C					
	Cross-sectional	2900	1.0	0.6–1.7	Total intake; highest vs lowest quintile; adjusted age, sex				56
	Cross-sectional	2873	–	–	No significant relationship found; data not shown				51
Blue Mountains Blue Mountains Sheffield Nurses' Health Nurses' Health Nurses' Health	Cross-sectional	372	0.9	0.4–2.1	Plasma concentration; highest vs lowest tertile				61
	Prospective	492	0.64	0.29–1.42	Total intake; highest vs lowest quintile				54
	Prospective	492	0.79	0.38–1.64	Supplemented \geq 10 yr				54
	Prospective	492	0.74	0.32–1.68	Plasma concentration; highest vs lowest quintile				54
				Thiamin					
	Cross-sectional	2900	1.3	0.8–2.2	Total intake; highest vs lowest quintile; adjusted age, sex				56
	Cross-sectional	2873	1.6	1.0–2.6	Dose not specified				51
				Riboflavin					
	Cross-sectional	2900	1.3	0.7–2.2	Total intake; highest vs lowest quintile; adjusted age, sex				56
	Prospective	492	0.73	0.33–1.62	Total intake; highest vs lowest quintile				54
Blue Mountains Blue Mountains Blue Mountains Blue Mountains Nurses' Health Blue Mountains				Niacin					
	Cross-sectional	2900	1.2	0.7–2.1	Total intake; highest vs lowest quintile; adjusted age, sex				56
				Pyridoxine					
	Cross-sectional	2873	1.6	1.0–2.4	Dose not specified				51
				Folate					
	Prospective	492	0.56	0.25–1.25	Total intake; highest vs lowest quintile				54
				Zinc					
	Cross-sectional	2900	1.1	0.6–1.9	Total intake; highest vs lowest quintile; adjusted age, sex				56

OR, odds ratio; CI, confidence interval.

3.3.17. FRUIT AND VEGETABLE INTAKE

In the Women's Health Study, a higher intake of fruits and vegetables was associated with a 10–15% reduced risk of cataract (72). The higher level of intake of fruits and vegetables was considered greater than the lowest quintile, or >3.4 servings of fruits and vegetables per day. In the Nurses' Health Study, of 479 participants aged 52 to 73 yr without previously diagnosed cataract, those who had a higher intake of fruit had a decreased risk of developing nuclear opacities (OR 0.58, 95% CI 0.32–1.05) (63).

3.3.18. FAT INTAKE

There is limited information on the relationship between dietary fat intake and cataract. In the Nurses' Health Study, of 440 women without cataract, cancer, or diabetes, at baseline, intake of total fat and selected fatty acids was calculated based on five food-frequency questionnaires between 1980 and the time of a study eye examination in 1993–1995. Linoleic and linolenic acid intakes were associated with nuclear opacity, but not with cortical or posterior subcapsular opacity (73).

3.3.19. DIETARY GLYCEMIC LOAD

Hyperglycemia may theoretically cause cataracts through disruption of the polyol pathway and increased oxidative stress. A recent large study showed that dietary glycemic load, an indicator of the quality and quantity of carbohydrates in the diet, and glycemic index, a measure of the comparison of the relative plasma glucose response to a specific food compared with a standard source, were not related to the risk of cataract extraction (74).

3.3.20. BODY MASS INDEX

Some studies have suggested an association between high body mass index and risk of cataract (30,75–79), while others have found no association (80). When compared to a body mass index (weight/height² in kg/m²) of <21, women in the Nurses' Health Study with body mass index of 23 to <25, 25 to <29, and ≥29, had a relative risk for cataract extraction of 1.56 (95% CI 1.11–2.18), 1.46 (95% CI 1.05–2.03), and 1.65 (95% CI 1.17–2.32), respectively (75). In a prospective study, men with a body mass index of 22 to <25, 25 to <27.8, and ≥27.8 had a relative risk of incident cataract of 1.54 (95% CI 1.04–2.27), 1.46 (95% CI 0.98–2.20), and 2.10 (95% CI 1.35–3.25), respectively (76). Higher body mass index was associated with an increased risk of nuclear cataract, posterior subcapsular cataract, and cataract extraction (76). In a prospective cohort study involving 714 individuals, aged 52–80 yr, followed for approx 13 yr, a higher body mass index at baseline was associated with an increased risk of cortical opacities (78). An increase in body mass index over time was associated with an increased risk of posterior subcapsular opacities, and no relationship was found between body mass index and nuclear lens opacities (78). A case-control study in northern Italy suggested that both current body mass index and a history of clinically relevant obesity were associated with cataract extraction (77). In addition to high body mass index, abdominal adiposity, as assessed by the waist-to-hip ratio, was an independent risk factor for incident cataract in the Physicians' Health Study (79). In the Blue Mountains Eye Study, obesity, defined as a body mass index ≥30, was associated with an increased risk of cortical cataract (OR 1.6, 95% CI 1.2–2.2) and subcapsular cataract (OR 2.1, 95% CI 1.3–3.5) (81).

The biological mechanism that might explain such an association is not clear, however, potential causal factors that have been associated with obesity include increased serum uric acid concentrations (31,32,64), higher levels of systemic inflammation (82), and glucose intolerance and insulin resistance (83,84). Obesity is associated with elevations in angiotensinogen, transforming growth factor β , tumor necrosis factor α , interleukin 6, C-reactive protein, and other cytokines and inflammatory mediators, thus, the relationship between obesity and cataract is likely to be complex (85). People with high body mass index are at higher risk of endothelial dysfunction, the metabolic syndrome, and other factors that are associated with a low grade proinflammatory state, as discussed in greater detail in Chapters 4 and 10.

3.4. Other Risk Factors for Cataract

Many different epidemiological risk factors have been identified for cataract, and these include race, gender, social and demographic factors, cigarette smoking, infectious and chronic diseases, nutritional status, environmental factors, and drugs, as has been summarized in some reviews (86–88).

3.4.1. AGE

Increasing age is a well known risk factor for cataract (37,45,86,87,89). The overall prevalence of cataract in the Tibet Eye Study and the Beijing Eye Study by age and sex is shown in Fig. 3 (44).

3.4.2. RACE

In the Lens Opacities Case-Control Study, non-whites were at a higher risk of cortical cataract (32). In the 1971–1972 National Health and Nutrition Examination Survey, blacks were at a higher risk of cataract (89). Blacks, when compared with whites, had a higher risk of nuclear or cortical cataract (13). In the Barbados Eye Study, nuclear opacities were most common among whites, whereas cortical opacities were most common among those of African descent (90). In the Salisbury Eye Evaluation project, among blacks, the risk of having cortical opacities was high (OR 4.0, 95% CI 3.3–4.8) and among whites, the risk was higher of having nuclear opacities (OR 2.1, 95% CI 1.7–2.6) and posterior subcapsular opacities (OR 2.5, 95% CI 1.7–2.6) (91).

3.4.3. GENDER

Women appear to be at slightly higher risk of cataract (31,37,89), and the risk may be specifically associated with cortical cataract (13,31,32,92). Data from 1973–1975 in the Framingham Eye Study suggested that among persons aged 52–85, the sex-specific rates of nuclear, cortical, and posterior subcapsular opacities were 27.9%, 17.1%, and 9.7% for women and 22.6%, 10.6%, and 6.4% for men (37). In the Indian subcontinent, a higher prevalence of cataract has been described in young women compared to men (93). In the Beaver Dam Eye Study, the sex-specific prevalence rates for late cataract in the right eye was 18.7% for women and 11.0% for men (36), and age-adjusted rates show that women were at higher risk for incident cataract over a 10-yr period (41). In the Lens Opacities Case-Control Study, women were at higher risk for cortical cataracts only (32). The reasons why women are at higher risk of cataract are not known. In a recent case-control study conducted among women in India, childbearing was associated with an increased

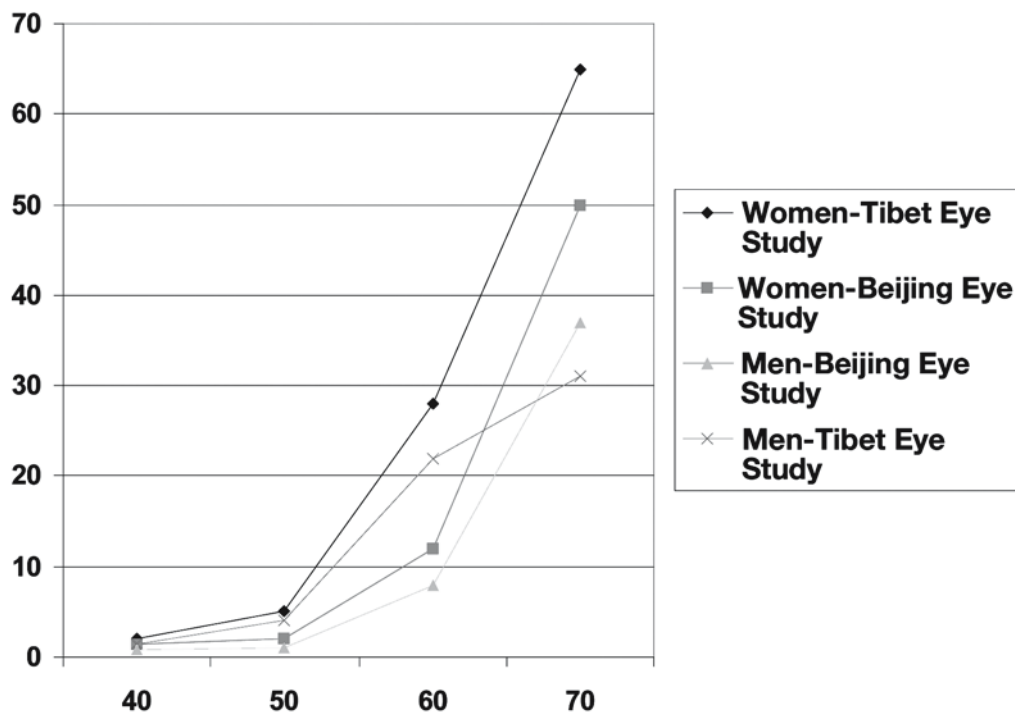


Fig. 3. Prevalence of cataract in the Tibet Eye Study and Beijing Eye Study by age and sex. (Reprinted from ref. 44. Copyright © 1989, American Medical Association. All rights reserved.)

risk of cataract (94). Women with more than three babies had a higher risk of cataract compared to women with one to three babies (OR 2.2, 95% CI 1.3–3.5), and the risk was even higher for women who had 7–11 babies (OR 4.6, 95% CI 2.0–10.6) (94). Multiple pregnancies may put women at higher risk for micronutrient deficiencies, episodes of hyperglycemia, and other factors that could theoretically contribute to the pathogenesis of cataract.

3.4.4. FAMILY HISTORY

In the Italian-American Cataract Study in Parma, Italy, a history of one or more siblings or parent(s) with cataracts was associated with higher risk of cortical, posterior subcapsular, and mixed cataract (31).

3.4.5. CIGARETTE SMOKING

Several studies have shown an association between smoking and increased risk of cataract (32,84,95–100). Smoking generates free radicals and may potentially affect oxidative stress in the lens itself. Cigarette smokers have been shown to have dietary habits that include a lower intake of dietary antioxidants such as vitamin C, vitamin E, and carotenoids. Smokers may have higher general levels of oxidative stress owing to free radicals generated by smoking as well as a lower intake of dietary antioxidants. In the City Eye Study conducted in London, the relative risk for nuclear lens opacity ranged from 1.0 for past light smokers through 2.6 for past heavy smokers to 2.9 for present heavy smokers (96). Cigarette smoking was associated with increased risk of nuclear lens opacities in

a study of 838 watermen of the Chesapeake Bay in Maryland (97). Among women and men in the Beaver Dam Eye Study, 10 pack-years of cigarette smoking was associated with increased risk of nuclear sclerosis (OR 1.09, 95% CI 1.04–1.16 and OR 1.09, 95% CI 1.05–1.14, respectively) and posterior subcapsular cataract (OR 1.06, 95% CI 0.98–1.14, OR 1.05, 95% CI 1.00–1.11, respectively) (99). Smoking was associated with increased risk of both severe nuclear cataract (OR 1.3, 95% CI 1.1–1.6) and posterior subcapsular cataract (OR 1.5, 95% CI 1.5–8.2) in the Blue Mountains Eye Study (100).

3.4.6. DIABETES MELLITUS

Diabetes mellitus has been associated with an increased risk of cataract among adults less than 65 yr old, with relative risks of 4.02 and 2.97 described in the Framingham Eye Study and the Health and Nutrition Examination Survey, respectively (101). Diabetes was associated with increased risk of cortical cataracts, posterior subcapsular cataracts, and mixed cataracts in the Len Opacities Case-Control Study (32). Aldose reductase may play a role in cataract formation in diabetics (102). In diabetic animals, administration of quercitrin, an inhibitor of aldose reductase, reduced the accumulation of sorbitol in the lens and delayed the development of cataract (103). Diabetes was also associated with an increased risk of cataract in the 1971–1972 National Health and Nutrition Examination Survey (89), especially posterior subcapsular cataract (13).

3.4.7. ULTRAVIOLET LIGHT EXPOSURE

Ultraviolet radiation is divided by wavelength into ultraviolet (UV)-A (400–320 nm), UV-B (320–290 nm), and UV-C (<290 nm). Most UV-C is absorbed by the ozone layer (104). Various epidemiological studies have suggested a link between UV-B exposure and cataract (13,89,92,105). In the Nepal Blindness Survey, the prevalence of cataract was higher among residents from villages that received an average of 12 h of sunlight per day compared to those from villages with 7 h of sunlight per day (OR 3.8, $p = 0.001$) (104). In a study conducted among watermen of the Chesapeake Bay, cortical lens opacities were associated with high levels of cumulative UV-B exposure, but no association was found between nuclear cataract and UV-B exposure (105). In a case-control study in Maryland, 168 aphakic cases with a history of posterior subcapsular cataract were matched with 168 controls by age, sex, and referral pattern (106). A history of high exposure to UV-B was associated with an increased risk of posterior subcapsular cataract (106). Increasing UV-B light exposure was also associated with cortical lens opacities among community-dwelling adults, aged 65–84 yr, in Salisbury, Maryland (OR 1.10, 95% CI 1.02–1.20) (107). Individuals who had job locations or leisure activities in the sunlight were at a higher risk of cortical cataract in Italy (31).

3.4.8. DEHYDRATION/DIARRHEA

Severe diarrheal disease and dehydration have been implicated in the pathogenesis of cataract through possible osmotic, metabolic, and nutritional stresses on the lens. Three case-control studies have identified severe dehydrating diarrhea as a risk factor for cataract in India (108–110). In two studies in India, about 40% of cataract in the population was considered to be attributable to severe dehydration or life-threatening diarrheal disease (108,109). Dehydrational crises from severe diarrhea were identified as a major risk factor for cataract in a recent case-control study from Nagpur, India (110). Severe diarrhea was also identified as a risk factor for cataract in Oxfordshire, England (111). In contrast,

no association was found between risk of cataract and lifetime history of severe diarrhea, including cholera, in a case-control study conducted in Tamil Nadu state in India (112). No association was found between a diarrheal disease (an episode confining the individual to bed for 1 d) and cataract (30). Another study from Bangladesh did not find an association between severe diarrhea and risk of cataract (113).

3.4.9. ALCOHOL CONSUMPTION

Alcohol consumption has been associated with an increased risk of cataract (84,95). A two-fold higher risk of cataract was found among individuals who had four or more drinks per day (95). In a case-control study, heavy alcohol use (>91 grams of alcohol per week) was associated with a higher risk of posterior subcapsular cataract (OR 2.70, 95% CI 1.04–6.98) when compared with no alcohol use (114). In the Beaver Dam Eye Study, a history of heavy drinking (four or more drinks per day) was associated with a higher risk of nuclear (OR 1.34, 95% CI 1.12–1.59), cortical (OR 1.36, 95% CI 1.04–1.77), and posterior subcapsular cataract (OR 1.57, 95% CI 1.10–2.25) (115). Current wine consumption was associated with a decreased risk of nuclear cataract (OR 0.84, 95% CI 0.74–0.94). Current alcohol intake was also associated with an increased risk of incident nuclear cataract in the Beaver Dam Eye Study (OR 1.01, 95% CI 1.0–1.02 per 100 g ethanol per week) (40). In the Blue Mountains Eye Study, those who had at least one drink per day had a reduced risk of cortical cataract compared to nondrinkers (OR 0.7, 95% CI 0.6–0.9) (100). Heavy alcohol consumption (four or more drinks per day) was associated with nuclear cataract in current smokers (OR 3.9, 95% CI 0.9–16.6) (100). A “u” shaped-relationship between alcohol consumption and cataract has been suggested, with total abstinence from alcohol and heavy consumption of alcohol being associated with a higher risk of cataract (Fig. 4) (116).

3.4.10. DRUGS

The use of systemic corticosteroids has been associated with an increased risk of posterior subcapsular cataract (32,117). The use of inhaled corticosteroids has been associated with an increased risk of both nuclear and posterior subcapsular cataracts (118) and with an increased risk of undergoing cataract extraction (119). In the Nurses' Health Study, there was no evidence to support the idea that aspirin use was associated with a decreased risk of cataract (75). Other drugs reported to be associated with cataract include allopurinol and phenothiazines, but the epidemiological data are incomplete (87).

3.4.11. LEAD EXPOSURE

Lead exposure is associated with cognitive dysfunction, hypertension, and increased oxidative stress in older adults. Lead exposure has recently been linked with age-related cataract in older men in the Normative Aging Study (120). Among 663 men, aged 60 yr and older, tibial lead concentrations were associated with an increased risk of cataract.

3.4.12. OTHER FACTORS

A low level of education has been associated with cataract in many different studies (30,31,45,89,106). Low level of education was associated with nuclear, posterior subcapsular, and mixed cataract in India (30). The association between low level of education and cataract appears to be an independent association, as other confounding factors such as dietary intake or sunlight exposure do not explain the association (87). Low

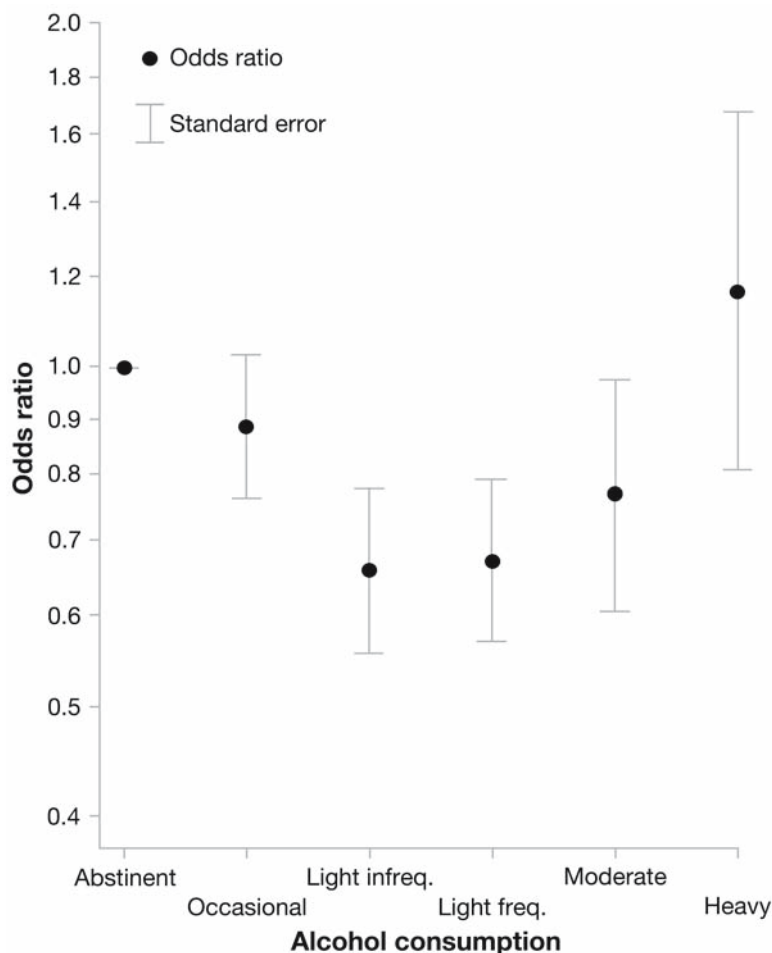


Fig. 4. Relative risk for cataract expressed as odds ratio plotted against six categories of ethanol consumption. (Reprinted from ref. 116, with permission of S. Karger AG, Basel.)

handgrip strength has been associated with higher risk of cataracts (31). The reason for the association between low handgrip strength, an indicator for sarcopenia, and cataract is not clear, but recently, it has been shown that low handgrip, knee, and hip strength in older women is associated with low plasma carotenoid concentrations (121). A recent study from France suggests that low plasma albumin and transthyretin concentrations were associated with an increased risk of cataract (122).

3.5. Cataract and Mortality

Several studies have suggested that lens opacities or a history of cataract surgery is associated with an increased risk of death (123–130), but not all studies have confirmed this association (131). In Boston, survival was compared between 167 patients undergoing cataract surgery and 824 patients undergoing other surgical procedures (123). In cataract patients, the age- and sex-adjusted mortality ratio was 1.78 (95% CI 1.23–2.58), and the increased mortality was not strongly related to diabetes mellitus (123). An analysis

from the Framingham Heart Study suggested that overall, lens opacities were associated with significantly higher mortality, but that age- and sex-adjusted mortality was stronger among individuals with diabetes (death rate ratio 2.62, 95% CI 1.46–4.71) than those without diabetes (death rate ratio 1.17, 95% CI 0.88–1.57) (124). In a study of 473 older, nondiabetic adults in a small English town, those with nuclear cataract at baseline examination had an increased risk of death (adjusted relative hazard for mortality 1.52, 95% CI 1.15–1.99) (125).

Cataract surgery was associated with increased standardised mortality ratio in a study from Sweden, but only in young patients and in patients who had complicating diseases such as diabetes and cardiovascular disease (126). In patients 75 yr of age and older, the standardized mortality ratio was 0.91 ($p = 0.06$), whereas in those 45–74 yr of age, the standardized mortality ratio was 1.33 ($p = 0.05$). In the Blue Mountains Eye Study, of 3654 subjects aged 49 yr and older who were followed from a baseline period of 1992–1994 until 1999, 16.5% of the subjects died. After adjusting for factors associated with mortality, individuals who had any visual impairment at baseline had an increased mortality risk (relative risk [RR] 1.7, 95% CI 1.2–2.3) (127). The presence of nuclear cataract (RR 1.4, 95% CI 1.1–1.8), cortical cataract (RR 1.3, 95% CI 1.0–1.5), and posterior subcapsular cataract (RR 1.4, 95% CI 1.1–1.8) were also associated with an increased risk of death. In Parma, Italy, a study of 1429 individuals showed that mixed type of cataracts with nuclear and posterior subcapsular cataract was significantly associated with an increased risk of death (128). The biological mechanisms that might explain the association between cataract and mortality include systemic processes relating to aging or increased oxidative stress and inflammation (127,130).

4. CLINICAL FEATURES

For clinical features of nuclear cataract, *see* Fig. 5; for clinical features of cortical cataract, *see* Fig. 6; and for clinical features of posterior subcapsular cataract, *see* Fig. 7.

5. PATHOGENESIS OF CATARACT

The pathogenesis of nuclear cataract, cortical cataract, and posterior subcapsular cataract may differ as related to such factors as the anatomic location and the age of the lens fibers. The nucleus consists of lens fibers that were formed during embryonic and fetal life, whereas the cortex consists of lens fibers that were formed later in life. Lens fibers at the surface of the lens are formed recently, within weeks to months. The lens is located in a low oxygen environment due to the lack of a blood supply, and the lens epithelium and fibers primarily derive energy from glycolysis, using glucose from the aqueous humor (132). Nutrients in the aqueous humor need to diffuse the longest distance to reach the lens fibers of the nucleus. In general, the lens is subject to oxidative stress from molecular oxygen and free radicals generated by mitochondria. Superoxide radicals, peroxide, hydroxyl radicals, and single oxygen are major reactive oxygen species that may be produced in the lens (133). Glutathione is the main antioxidant which protects the lens from oxidative damage (133,134). A common feature of many types of cataracts is a reduction in lens glutathione (134). Glutathione has been hypothesized to protect against cataract formation by preventing the formation of high molecular weight protein aggregates responsible for light scattering and lens opacification, by preserving mem-

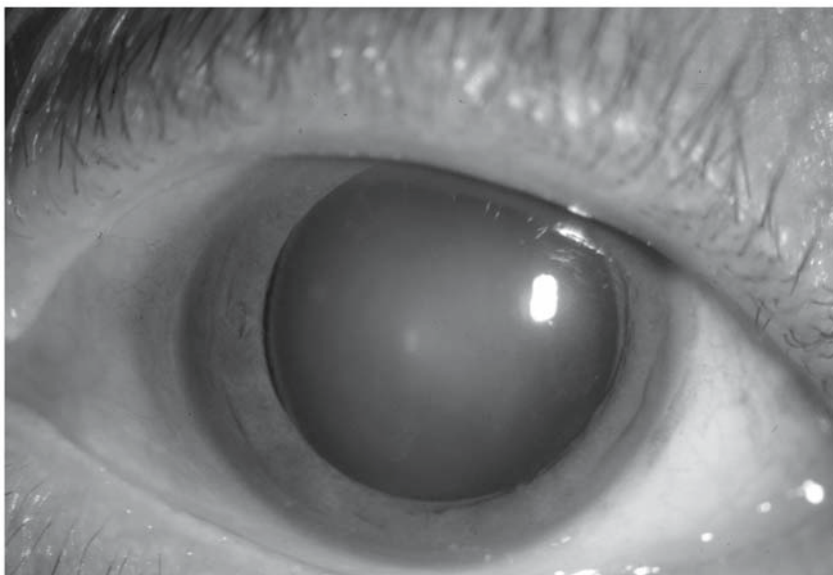


Fig. 5. Nuclear cataract. (Courtesy of Walter Stark.)

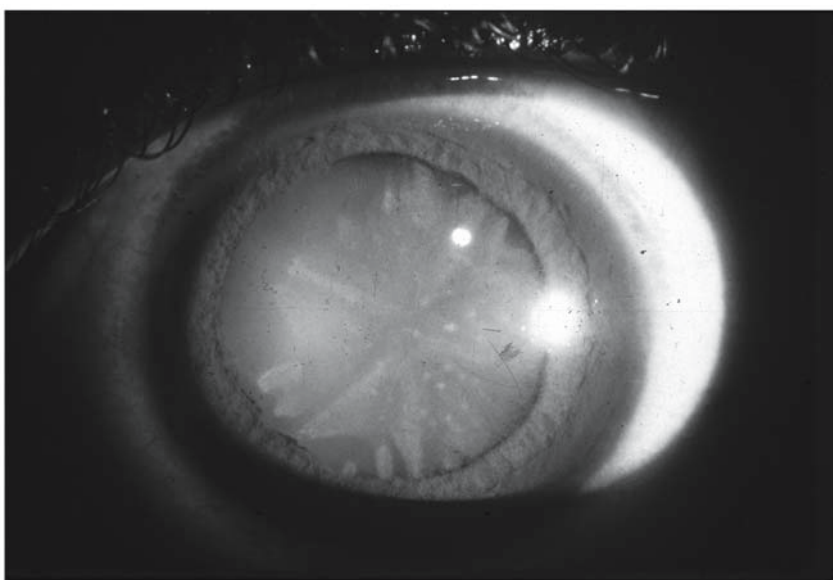


Fig. 6. Cortical cataract. (Courtesy of Walter Stark.)

brane-SH groups involved in cation transport and permeability, and by detoxifying hydrogen peroxide and other free radicals (134).

Another important antioxidant that may protect the lens against oxidative stress is ascorbic acid (135). Ascorbic acid is actively transported from the blood into the aqueous humor, where it is found in high concentrations (135,136). Presumably, ascorbic acid also reacts with free radicals and protects the lens from oxidative damage (135,137). Catalase may also protect the lens against oxidative damage from hydrogen peroxide

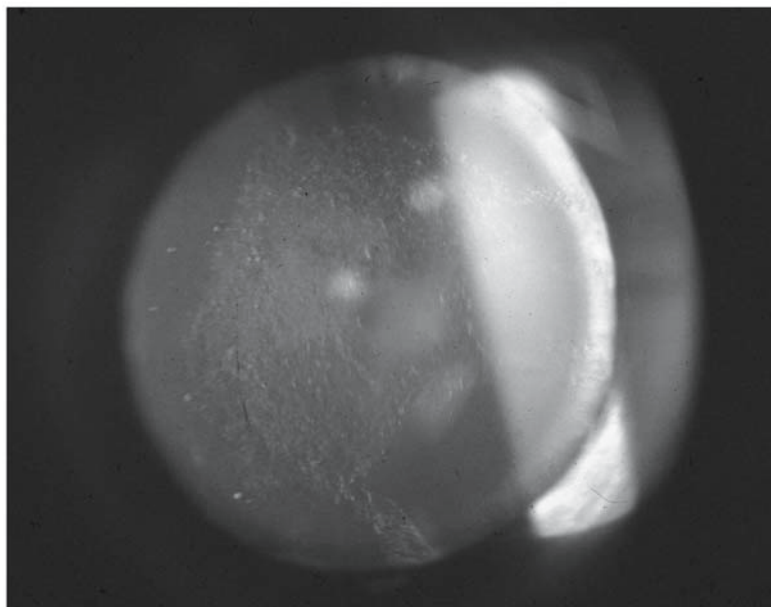


Fig. 7. Subcapsular cataract. (Courtesy of Walter Stark.)

(138), and transferrin in the aqueous humor may bind iron and protect the lens from free radical damage generated by ferrous ions (139). The accumulation of protein aggregates in the lens can increase light scattering (140,141).

5.1. Nuclear Cataract

Oxidative stress in the nucleus can result in damage to lens proteins and lipids, disulfide linking of proteins, protein aggregation, and increased light scattering (133,134,142,143). An increase in lipid peroxidation and protein oxidation has been linked to impairment of glutathione-dependent reduction (134,144–146). The lens contains low molecular weight, fluorescent compounds known as UV filters that absorb UV radiation from 295 nm to 400 nm. The concentrations of UV filters, 3-hydroxykynurenine, kynurenine, and 3-hydroxykynurenine glucoside, decrease linearly with age in the human lens, and oxidized glutathione also decreases in the lens nucleus with age (Fig. 8) (144). A lower concentration of glutathione in the lens with age may allow an increased rate of posttranslational modification of crystallins (134). Impaired diffusion of glutathione in the lens may result in lowered concentration of glutathione in the lens nucleus (145) and possible covalent linking of UV filters to crystallins in the lens (144). A barrier to transport of metabolites within the lens may prevent antioxidants from reaching the lens interior and thus allow oxidation of nuclear components (146). The aggregation of minor lens constituents may contribute to the initiation of lens opacification (147). Nuclear cataract is associated with extensive hydroxylation of protein-bound amino acid residues, which suggests a role for hydroxyl radicals (148). Perhaps the strongest evidence for the role of oxidative stress in the pathogenesis of nuclear cataract comes from a study of 25 patients who were given hyperbaric oxygen therapy (149). All treated patients developed myopic refractive changes with treatment, and seven of fifteen patients with clear lens nuclei

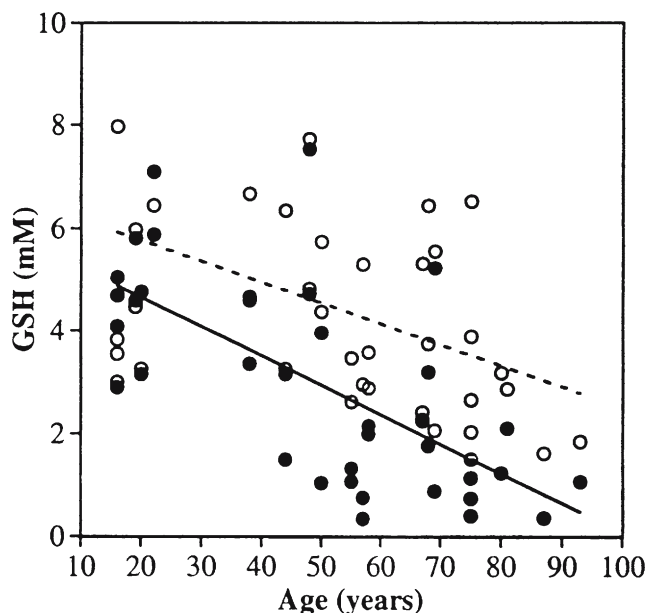


Fig. 8. Concentrations of reduced glutathione in humans lens as a function of age. Linear regression lines shown for nucleus (solid line, solid dots) ($r = -0.47$, $p = 0.002$, $n = 38$) and cortex (dotted line, open dots) ($r = -0.68$, $p < 0.0005$, $n = 38$) of the lens. (Reprinted from ref. 144, with permission of *Investigative Ophthalmology and Visual Science*.)

prior to treatment developed nuclear cataract with reduced visual acuity (149). Oxygen, in excessive amounts, can be toxic to the lens through the generation of reactive oxygen species.

5.2. Cortical Cataract

Cortical cataract is often most pronounced in the inferior nasal quadrant of the lens (92,150,151), the part of the lens most exposed to ultraviolet radiation. Cortical cataract is associated with disruption of the lens fiber cells, formation of vesicles from membrane constituents such as cholesterol and phospholipid, and protein alterations (14,152). Studies of clear human lenses show that ruptured membranes of superficial fibers appear as early as the fourth decade of life (14). Age-related cortical lens changes have been mainly attributed to membrane disorganization induced by increased oxidative stress (14). Ultraviolet-B, or shorter wavelength UV light, appears to be more damaging to the eye than UV-A (105). Other studies suggest that chronic UV-A exposure could also generate free radicals and damage the lens. On exposure to UV light >300 nm, the chromophores in the human lens appeared to initiate photooxidative processes leading to oxidation of endogenous antioxidants glutathione and ascorbate (153). Old human lens proteins absorb more UV-A than UV-B light, which has suggested that UV-A should be considered in the pathogenesis of cortical cataract (154). It is unclear why UV light exposure would cause cataract in the lens fibers that are more shielded by the pigmented iris epithelium from light exposure, especially when the pupil is constricted in bright light. With depletion of stratospheric ozone, UV-B exposure may increase, with higher risk of cortical cataracts (155).

5.3. Posterior Subcapsular Cataract

Posterior subcapsular cataract is characterized by migration of superficial epithelial cells posteriorly from the equator, with enlarged epithelial nuclei and disorganization of postequatorial nuclear rows (156). Posterior subcapsular cataract can be induced by ionizing radiation (157) and by corticosteroids. Oxidative stress can adversely affect the DNA of lenticular epithelial cells, thus giving rise to germinative epithelial cells with aberrant DNA and abnormal development (14).

5. TREATMENT OF CATARACT

Cataract is usually treated by surgical removal of the cloudy lens and implantation of an intraocular lens. The quality of cataract surgery and the quality of outcomes of cataract surgery can vary considerably. The main strategy for reducing the burden of blindness from cataract is to find interventions that can delay the onset of cataract.

6. PREVENTION OF CATARACT

6.1. Evidence From Clinical Trials for Nutritional Interventions

Several clinical trials have been conducted to determine whether nutrients, alone or in combination, can reduce the incidence of lens opacities and the incidence of cataract operations (Table 4) (158–163). These studies generally suggest that micronutrient supplementation in well nourished adults is unlikely to reduce either the incidence of cataract or the incidence of cataract surgery.

6.1.1. LINXIAN CATARACT STUDIES

The Linxian cataract studies consisted of two clinical trials (“dysplasia trial” and “general population trial”) conducted in rural communes of Linxian, China from 1986 to 1991 (158). Linxian is a county in north central China that has a high rate of esophageal cancer and high prevalence of micronutrient deficiencies, and the main objective of the studies was to determine whether vitamin/mineral supplements could reduce the risk of esophageal/gastric cancer (158). Participants also received eye examinations and cataract grading at enrollment and at the end of the trials. In the dysplasia trial, 2141 participants, aged 45 to 74 yr, were randomized to receive multivitamin/mineral supplement or placebo. In a stratified analysis, among individuals aged 65 to 74 yr there was a 36% reduction in the prevalence of nuclear cataract (OR 0.57, 95% CI 0.36–0.90), whereas among individuals aged 45 to 64 yr, there was no significant impact of multivitamin/mineral supplementation. In the dysplasia trial, the micronutrients contained in the supplement included beta carotene, and many of the vitamins and minerals were at levels that exceeded the Recommended Dietary Allowance (RDA) for adults. For example, the study used a daily dose of zinc of 45 mg, when the RDA for men and women is 11 mg and 8 mg, respectively.

In the general population trial, individuals aged 45 to 74 yr were randomly allocated in a factorial design to examine the effects of four different vitamin/mineral combinations (vitamin A/zinc, riboflavin/niacin, vitamin C/molybdenum, and selenium/ α -tocopherol/ β -carotene). The risk of nuclear cataract was reduced among those who received riboflavin/niacin compared to those who did not receive riboflavin/niacin, with the strongest effect

Table 4
Controlled Clinical Trials of Nutritional Interventions to Prevent Cataracts

Study	Design	n	Intervention	Results	Reference
Linxian, China	RCT	2141	Multivitamin/mineral vs placebo	OR (95% CI) Nuclear: 0.80 (0.67–1.12) overall; 1.28 (0.76–2.14) age 45–64 yr; 0.57 (0.360.90) age 6574 yr Cortical: 1.05 (0.88–1.26) overall PSC: 1.41 (0.75–2.67)	158
Linxian, China	RCT factorial design	3249	A: retinol (5000 IU) + zinc (22 mg) B: riboflavin (3 mg) + niacin (40 mg) C: vitamin C (120 mg) + molybdenum (30 µg) D: selenium (50 µg) + α-tocopherol (30 mg) + β-carotene (15 mg) A: α-tocopherol (50 mg) B: β-carotene (20 mg) C: α-tocopherol (50 mg) + β-carotene (20 mg) D: placebo β-carotene (50 mg every other day) vs placebo	Nuclear: 0.77 (0.58–1.02) Cortical: 1.08 (0.92–1.27) PSC: 0.59 (0.31–1.14) Nuclear: 0.59 (0.450.79) Cortical: 1.08 (0.92–1.27) PSC: 2.64 (1.315.35) Nuclear: 0.78 (0.59–1.04) Cortical: 0.92 (0.79–1.09) PSC: 1.25 (0.65–2.38) Nuclear: 1.19 (0.90–1.59) Cortical: 0.96 (0.82–1.13) PSC: 1.56 (0.81–3.00) No significant difference between the four groups in incident cataract extraction	158
ATBC Cancer Prevention Trial Finland	RCT factorial design	28,934			161
Physicians' Health Study, USA	RCT	22,071		More than 12 yr of supplementation, no significant differences in progression in incidence of cataract or rates of cataract extraction between groups	162

Table 4 (Continued)

<i>Study</i>	<i>Design</i>	<i>n</i>	<i>Intervention</i>	<i>Results</i>	<i>Reference</i>
Age-Related Eye Disease Study (AREDS)	RCT		β -carotene (15 mg) + vitamin C (500 mg) + vitamin E (400 IU) vs placebo	In 6.3 yr follow-up, no effect of supplementation on progression of cataract; nearly 70% of participants were taking daily multivitamin and mineral supplement	160
Roché European American Cataract Trial (REACT)	RCT	297	β -carotene (18 mg) + vitamin C (750 mg) + vitamin E (600 mg) vs placebo	In 3 yr follow-up, small decrease in progression to cataract with treatment	162
Vitamin E, Cataract And Age-Related Maculopathy Trial (VECAT)	RCT	1193	Vitamin E (500 IU) vs placebo	4-yr cumulative rate of nuclear, cortical, or posterior subcapsular cataract was not significantly different between treatment groups	163

OR, odds ratio; CI, confidence interval; RCT, randomized, controlled trial; PSC, posterior subcapsular cataract.

found among those aged 65 to 74 yr. There was no significant effect of vitamin/mineral supplements on cortical cataract in either trial. Although the number of subjects with posterior subcapsular cataract in the general population trial was small, the data suggested that riboflavin/niacin might increase the risk of posterior subcapsular cataract. These two trials suggest that in a rural area of China with a high prevalence of micronutrient deficiencies, vitamin/mineral supplements may reduce the risk of nuclear cataracts.

6.1.2. ROCHE EUROPEAN AMERICAN CATARACT TRIAL

The Roche European American Cataract Trial (REACT) study was a randomized, double-masked, placebo-controlled clinical trial of micronutrient supplementation to prevent age-related cataract in 297 adults aged ≥ 40 yr in Boston and in the United Kingdom (159). Patients were recruited in outpatient ophthalmology clinics and were eligible if they had immature age-related cataract in one or both eyes. Patients in the United States were evaluated using LOCS II, and patients in the United Kingdom were evaluated using the Oxford lens grading system. The outcome measure was lens opacification as assessed by a digitized image of the lens, rather than visual function. The study began in 1990 and concluded in 1995, and the results were published in 2002 (159). Patients were randomly allocated to receive a micronutrient supplement (α -tocopherol 200 mg, ascorbic acid 250 mg, β -carotene 6 mg) or placebo. There was a small but significant effect of treatment in lowering the risk of lens opacification among patients at the US site but not the UK site after 2 yr, but after 3 yr, there was a positive effect of treatment in both study sites. The authors noted that the rate of cataract progression is nonlinear, as it tends to be faster in the later than the earlier stages (53,90), thus, long-term progression of cataract, as assessed in this study, is likely to be highly conservative (159). If the treatment effect of 1.6% per 3 yr is extended for a 21-yr period, the authors noted that the difference would be 10.2%. Even a 10% reduction in the rate of cataract progression could potentially reduce the number of cataract operations by 49% (159).

6.1.3. AGE-RELATED EYE DISEASE STUDY

The Age-Related Eye Disease Study (AREDS) was an 11-center, double-masked, clinical trial in which subjects were randomly allocated to receive antioxidants (vitamin C, vitamin E, β -carotene) or no antioxidants (160). Subjects with more than a few small drusen were also randomized to receive tablets with or without zinc and copper as part of a trial in which the outcome was age-related macular degeneration. Of 4629 participants, aged 55–80 yr who had at least one natural lens present, the antioxidant combination had no significant effect on risk of progression of lens opacities or for cataract surgery. Subjects who were using supplements at the time of enrollment were offered a commercial daily multivitamin and mineral supplement at RDA dosages to take throughout the study (Centrum, Whitehall-Robins Healthcare, Madison, NJ). Of the participants, 55% were taking supplements and almost all chose to take the commercial supplement, and an additional 15% of subjects chose to take the commercial supplement. Thus, the study provided daily multivitamin and mineral supplements to nearly 70% of the study participants, in addition to the antioxidants or no antioxidants assigned to each participant. The study showed that use of a high-dose supplement containing vitamin C, vitamin E, and β -carotene had no impact on the development or progression of cataract in a relatively well-nourished cohort of older adults, many of whom were already taking vitamins.

6.1.4. ALPHA-TOCOPHEROL BETA-CAROTENE CANCER PREVENTION TRIAL, FINLAND

In the Alpha-Tocopherol Beta-Carotene (ATBC) trial, 28,934 male smokers, aged 50–69 yr, were randomized to receive α -tocopherol, 50 mg/d, β -carotene, 20 mg/d, both α -tocopherol and β -carotene, or placebo for 5 to 8 yr (161). During follow-up, 425 men had cataract surgery, and the number of cases of cataract surgery in the α -tocopherol, β -carotene, α -tocopherol plus β -carotene, and placebo groups was 112, 112, 96, and 105, respectively. Neither α -tocopherol or β -carotene supplementation affected the incidence of cataract extraction among these male smokers in Finland (161).

6.1.5. PHYSICIANS' HEALTH STUDY, USA

In this trial involving 22,071 male physicians, aged 40–84 yr, participants were randomly assigned to receive β -carotene, 50 mg on alternate days, or placebo, for 12 yr (162). The outcome measures include incident, age-related lens opacity that reduced visual acuity based on self-report confirmed by medical record review, and rate of cataract extraction. Between the β -carotene and placebo groups, the overall incidence of cataract was not significantly different (RR 1.00, 95% CI 0.91–1.09), and the overall rate of cataract extraction was not significantly different (RR 1.00, 95% CI 0.89–1.12) (162).

6.1.6. VITAMIN E, CATARACT AND AGE-RELATED MACULOPATHY TRIAL, AUSTRALIA

In this clinical trial in Melbourne, Australia, 1193 participants, aged 55–80 yr, with early or no cataract were randomized to receive either 500 IU natural vitamin E in soybean oil or placebo for 4 yr (163). The incidence and progression of cataract were assessed with clinical lens opacity grading and computerized analysis of digital lens images. The 4-yr cumulative incidence rates among those who received vitamin E and those who received placebo was 12.9% and 12.1%, respectively, for nuclear cataract ($p = 0.77$), 4.5% and 4.8%, respectively, for cortical cataract ($p = 0.77$), and 1.7% and 3.5% for posterior subcapsular cataract ($p = 0.08$). There was no difference in the rate of cataract extraction between the two groups. This study shows that vitamin E in a daily dose of 500 IU did not reduce the incidence or progression of nuclear, cortical, or posterior subcapsular cataracts (163).

7. CONCLUSIONS

Short-term micronutrient supplementation in well nourished adults appears to have little impact on the incidence or progression of cataract. Although some data suggest that micronutrient supplementation may have an impact on the incidence of cataract in populations with a high prevalence of micronutrient deficiencies, such as Linxian, China, there is little other data to support the idea that micronutrient supplementation will prevent the onset or progression of cataract in other developing world populations. The amount of oxidative damage to the lens during the lifetime of an individual may be cumulative, thus, supplementation with antioxidant micronutrients in later adulthood may have little impact. There is the theoretical problem of “too little, too late” for late onset of micronutrient supplementation, if the actual window for intervention is earlier in life. The cessation of smoking and avoidance of excessive lifetime UV light or sunlight exposure remain the two major strategies to reduce the risk of cataract. Several areas of research have been identified. The relationship between nutritional factors and cataract has gen-

erally been studied in populations where nutritional status is relatively good, i.e., in the United States and Europe. The relationship between nutrient deficiencies and cataract needs to be addressed in populations that actually have a relatively high prevalence of nutritional deficiencies, i.e., low income and middle income countries. Future studies should examine the effect of improving nutritional status early in life, rather than supplementing with micronutrients in middle age or later. Ideally, long-term changes in lifestyle and diet rather than supplementation would be preferred. The relationship between laboratory indicators of riboflavin status, such as erythrocyte glutathione reductase, erythrocyte flavin, or urinary flavin and risk of cataract has not been characterized. Further investigation is needed into the possible relationship between lutein and zeaxanthin and cataract. The most important nutritional intervention for the reduction of cataract may be the prevention of obesity and its associated risk of diabetes mellitus, however, further large epidemiological studies are needed to demonstrate the long-term consequences of preventing obesity and its impact on cataract. Given the relationship between dietary antioxidants and inflammation, it may be possible that the association between dietary antioxidant status and cataract in some epidemiological studies is actually reflecting the level of systemic inflammation. Further studies are needed to address the relationship between antioxidant nutritional status after taking into account the effects of inflammation, as might be reflected by elevations in acute phase proteins and proinflammatory cytokines.

REFERENCES

1. Thylefors B, Négrel AD, Pararajasegaram R, Dadzie KY. Global data on blindness. *Bull World Health Organ* 1995;73:115–121.
2. Johnson GJ, Foster A. Prevalence, incidence and distribution of visual impairment. In: Johnson GJ, Minassian DC, Weale RA, West SK (eds). *The epidemiology of eye disease*. Second edition. London, Arnold: 2003; pp. 3–28.
3. Steinberg EP, Javitt JC, Sharkey PD, et al. The content and cost of cataract surgery. *Arch Ophthalmol* 1993;11:1041–1049.
4. Salmon WD, Hays IM, Guerrant NB. Etiology of dermatitis of experimental pellagra in rats. *J Infect Dis* 1928;43:426–441.
5. Day PL, Darby WJ. The inverse relationship between growth and incidence of cataract in rats given graded amounts of vitamin G-containing foods. *J Nutr* 1936;12:387–394.
6. Day PL, Darby WJ, Cosgrove KW. The arrest of nutritional cataract by the use of riboflavin. *J Nutr* 1938;15:83–90.
7. Day PL, Darby WJ, Langston WC. The identity of flavin with the cataract-preventive factor. *J Nutr* 1937;13:389–399.
8. Miller ER, Johnston RL, Hoefer JA, Luecke RW. The riboflavin requirement of the baby pig. *J Nutr* 1954;52:405–413.
9. Halver JE. Nutrition of salmonoid fishes. III. Water-soluble vitamin requirements of the chinook salmon. *J Nutr* 1957;62:225–243.
10. Poston HA, Riis RC, Rumsey GL, Ketola HG. The effect of supplemental dietary amino acids, minerals and vitamins on salmonids fed cataractogenic diets. *Cornell Vet* 1977;67:473–509.
11. Gershoff SN, Andrus SB, Hegsted DM. The effect of the carbohydrate and fat content of the diet upon the riboflavin requirement of the cat. *J Nutr* 1959;68:75–88.
12. McLaren DL. *Malnutrition and the eye*. New York, Academic, 1963.
13. Hiller R, Sperduto RD, Ederer F. Epidemiologic associations with nuclear, cortical, and posterior subcapsular cataracts. *Am J Epidemiol* 1986;124:916–925.
14. Vrensen GFJM. Aging of the human eye lens—a morphological point of view. *Comp Biochem Physiol A Physiol* 1995;111:519–532.

15. Hockwin O, Lerman S, Laser H, Dragomirescu V. Image analysis of Scheimpflug photos of the lens by multiple linear microdensitometry. *Lens Res* 1985;2:337–350.
16. Brown MAP, Bron AJ, Sparrow JM. Methods for evaluation of lens changes. *Int Ophthalmol* 1988;12:229–235.
17. Brown NAP, Bron AJ, Ayliffe W, Sparrow J, Hill AR. The objective assessment of cataract. *Eye* 1987;1:234–246.
18. Mehra V, Minassian DC. A rapid method of grading cataract in epidemiological studies and eye surveys. *Br J Ophthalmol* 1988;72:801–803.
19. Chylack LT Jr, Leske MC, Sperduto R, Khu P, McCarthy D. Lens opacities classification system. *Arch Ophthalmol* 1988;106:330–334.
20. Sasaki K, Shibata T, Kojima M, Zainuddin D, Sakamoto Y. Experience introducing photographic documentation into epidemiological studies on cataracts. *Lens Res* 1988;5:163–174.
21. West SK, Rosenthal F, Newland HS, Taylor HR. Use of photographic techniques to grade nuclear cataracts. *Invest Ophthalmol Vis Sci* 1988;29:73–77.
22. Chylack LT Jr, Leske MC, McCarthy D, Khu P, Kashiwagi T, Sperduto R. Lens Opacities Classification System II (LOCS II). *Arch Ophthalmol* 1989;107:991–997.
23. Taylor HR, West SK. The clinical grading of lens opacities. *Aust N Z J Ophthalmol* 1989;17:81–86.
24. Klein BEK, Klein R, Linton KLP, Magli YL, Neider MW. Assessment of cataracts from photographs in the Beaver Dam Eye Study. *Ophthalmology* 1990;97:1428–1433.
25. Adamsons I, Taylor KI, Enger C, Taylor HR. A new method for documenting lens opacities. *Am J Ophthalmol* 1991;111:65–70.
26. Bailey IL, Bullimore MA, Raasch TW, Taylor HR. Clinical grading and the effects of scaling. *Invest Ophthalmol Vis Sci* 1991;32:422–432.
27. Sasaki F, Fujisawa K, Sakamoto Y. Quantitative evaluation of nuclear cataract using image analysis. *Ophthalmic Res* 1992;24(suppl 1):26–31.
28. Chylack LT Jr, Wolfe JK, Singer DM, et al. The Lens Opacities Classification System III. *Arch Ophthalmol* 1993;111:831–836.
29. Robman LD, McCarty CA, Garrett SKM, et al. Variability in the assessment of cortical and posterior subcapsular cataract. *Ophthalmic Res* 1999;31:110–118.
30. Mohan M, Sperduto RD, Angra SK, et al. India-US case-control study of age-related cataracts. *Arch Ophthalmol* 1989;107:670–677.
31. The Italian-American Cataract Study Group. Risk factors for age-related cortical, nuclear, and posterior subcapsular cataracts. *Am J Epidemiol* 1991;133:541–553.
32. Leske MC, Chylack LT Jr, Wu SY. The lens opacities case-control study: risk factors for cataract. *Arch Ophthalmol* 1991;109:244–251.
33. Thylefors B, Chylack LT Jr, Konyama K, et al. A simplified cataract grading system. *Ophthalmic Epidemiol* 2002;9:83–95.
34. Kahn HA, Moorhead HB. Statistics on Blindness in the Model Reporting Area, 1969–1970. PHS Publication No. (NIH) 73-427. Washington, D.C., US DHEW, 1973.
35. Klein BE, Klein R. Cataracts and macular degeneration in older Americans. *Arch Ophthalmol* 1982;100:571–573.
36. Klein BEK, Klein R, Linton KLP. Prevalence of age-related lens opacities in a population: the Beaver Dam Eye Study. *Ophthalmology* 1992;99:546–552.
37. Sperduto RD, Hiller R. The prevalence of nuclear, cortical, and posterior subcapsular lens opacities in a general population sample. *Ophthalmology* 1984;91:815–818.
38. Mitchell P, Cumming RG, Attebo K, Panchapakesan J. Prevalence of cataract in Australia: the Blue Mountains Eye Study. *Ophthalmology* 1997;104:581–588.
39. Seah SKL, Wong TY, Foster PJ, Ng TP, Johnson GJ. Prevalence of lens opacity in Chinese residents of Singapore: the Tanjong Pagar Survey. *Ophthalmology* 2002;109:2058–2064.
40. Klein BEK, Klein R, Lee KE. Incident cataract after a five-year interval and lifestyle factors: the Beaver Dam Eye Study. *Ophthalmic Epidemiol* 1999;6:247–255.
41. Klein BEK, Klein R, Lee KE. Incidence of age-related cataract over a 10-year interval. The Beaver Dam Eye Study. *Ophthalmology* 2002;109:2052–2057.

42. Leske MC, Chylack LT Jr, He Q, et al. Incidence and progression of cortical and posterior subcapsular opacities: the Longitudinal Study of Cataract. *Ophthalmology* 1997;104:1987–1993.
43. Leske MC, Chylack LT Jr, Wu SY, et al. Incidence and progression of nuclear opacities in the Longitudinal Study of Cataract. *Ophthalmology* 1996;103:705–712.
44. Hu TS, Zhen Q, Sperduto RD, et al. Age-related cataract in the Tibet Eye Study. *Arch Ophthalmol* 1989;107:666–669.
45. Chatterjee A, Milton RC, Thyle S. Prevalence and aetiology of cataract in Punjab. *Br J Ophthalmol* 1982;66:35–42.
46. Minassian DC, Mehra V. 3.8 million blinded by cataract each year: projections from the first epidemiological study of incidence of cataract blindness in India. *Br J Ophthalmol* 1990;74:341–343.
47. Seddon JM, Christen WG, Manson JE, et al. The use of vitamin supplements and the risk of cataract among US male physicians. *Am J Pub Health* 1994;84:788–792.
48. Mares-Perlman JA, Klein BEK, Klein R, Ritter LL. Relation between lens opacities and vitamin and mineral supplement use. *Ophthalmology* 1994;101:315–325.
49. Leske MC, Chylack LT, He Q, et al. Antioxidant vitamins and nuclear opacities. The Longitudinal Study of Cataract. *Ophthalmology* 1998;105:831–836.
50. Mares-Perlman JA, Lyle BJ, Klein R, et al. Vitamin supplement use and incident cataracts in a population-based study. *Arch Ophthalmol* 2000;118:1556–1563.
51. Kuzniarz M, Mitchell P, Cumming RG, Flood VM. Use of vitamin supplements and cataract: the Blue Mountains Eye Study. *Am J Ophthalmol* 2001;132:19–26.
52. Jacques PF, Chylack LT Jr, Hankinson SE, et al. Long-term nutrient intake and early age-related nuclear lens opacities. *Arch Ophthalmol* 2001;119:1009–1019.
53. Leske MC, Wu SY, Connell AMS, Hyman L, Schachat AP, Barbados Eye Study Group. Lens opacities, demographic factors and nutritional supplements in the Barbados Eye Study. *Int J Epidemiol* 1997;26:1314–1322.
54. Taylor A, Jacques PF, Chylack LT Jr, et al. Long-term intake of vitamins and carotenoids and odds of early age-related cortical and posterior subcapsular lens opacities. *Am J Clin Nutr* 2002;75:540–549.
55. Mares-Perlman J, Brady WE, Klein BEK, et al. Diet and nuclear lens opacities. *Am J Epidemiol* 1995b;141:322–334.
56. Cumming RG, Mitchell P, Smith W. Diet and cataract: the Blue Mountains Eye Study. *Ophthalmology* 2000;107:450–456.
57. Vitale S, West S, Hallfrisch J, et al. Plasma antioxidants and risk of cortical and nuclear cataract. *Ophthalmology* 1993;100:1437–1443.
58. Food and Nutrition Board, Institute of Medicine. Dietary reference intakes for vitamin C, vitamin E, selenium, and carotenoids. Washington, D.C., National Academy Press, 2000.
59. Mares-Perlman JA, Brady WE, Klein BEK, et al. Serum carotenoids and tocopherols and severity of nuclear and cortical opacities. *Invest Ophthalmol Vis Sci* 1995a;36:276–288.
60. Lyle BJ, Mares-Perlman JA, Klein BEK, Klein R, Greger JL. Antioxidant intake and risk of incident age-related nuclear cataracts in the Beaver Dam Eye Study. *Am J Epidemiol* 1999;149:801–809.
61. Gale CR, Hall NF, Phillips DIW, Martyn CN. Plasma antioxidant vitamins and carotenoids and age-related cataracts. *Ophthalmology* 2001;108:1992–1998.
62. Yeum KJ, Taylor A, Tang G, Russell RM. Measurement of carotenoids, retinoids, and tocopherols in human lenses. *Invest Ophthalmol Vis Sci* 1995;36:2756–2761.
63. Moeller SM, Taylor A, Tucker KL, et al. Overall adherence to the *Dietary Guidelines for Americans* is associated with reduced prevalence of early age-related nuclear lens opacities in women. *J Nutr* 2004;134:1812–1819.
64. Leske MC, Wu SY, Hyman L, et al. Biochemical factors in the lens opacities case-control study. *Arch Ophthalmol* 1995;113:1113–1119.
65. Rouhiainen P, Rouhiainen H, Salonen JT. Association between low plasma vitamin E concentration and progression of early cortical opacities. *Am J Epidemiol* 1996;144:496–500.
66. Nadalin G, Robman LD, McCarty CA, Garrett SKM, McNeil JJ, Taylor HR. The role of past intake of vitamin E in early cataract changes. *Ophthalmol Epidemiol* 1999;6:105–112.

67. McCarty CA, Mukesh BN, Fu CL, Taylor HR. The epidemiology of cataract in Australia. *Am J Ophthalmol* 1999;128:446–465.
68. Knekt P, Heliövaara M, Rissanen A, Aromaa A, Aaran RK. Serum antioxidant vitamins and risk of cataract. *BMJ* 1992;305:1392–1394.
69. Ohta Y, Niwa T, Yamasaki T. Effect of prolonged marginal ascorbic acid deficiency on lenticular levels of antioxidants and lipid peroxide in guinea pigs. *Int J Vitam Nutr Res* 2001;71:103–109.
70. Jacques PF, Taylor A, Moeller S, et al. Long-term nutrient intake and 5-year change in nuclear lens opacities. *Arch Ophthalmol* 2005;123:517–526.
71. Jacques PF, Chylack LT Jr, McGandy RB, Hartz SC. Antioxidant status in persons with and without senile cataract. *Arch Ophthalmol* 1988;106:337–340.
72. Christen WG, Liu S, Schaumberg D, Buring JE. Fruit and vegetable intake and the risk of cataract in women. *Am J Clin Nutr* 2005;81:1417–1422.
73. Lu M, Taylor A, Chylack LT Jr, et al. Dietary fat intake and early age-related lens opacities. *Am J Clin Nutr* 2005;81:773–779.
74. Schaumberg DA, Liu S, Seddon JM, Willett WC, Hankinson SE. Dietary glycemic load and risk of age-related cataract. *Am J Clin Nutr* 2004;80:489–495.
75. Hankinson SE, Seddon JM, Colditz GA, et al. A prospective study of aspirin use and cataract extraction in women. *Arch Ophthalmol* 1993;111:503–508.
76. Glynn RJ, Christen WG, Manson JE, Bernheimer J, Hennekens CH. Body mass index: an independent predictor of cataract. *Arch Ophthalmol* 1995;113:1131–1137.
77. Tavani A, Negri E, LaVecchia C. Selected diseases and risk of cataract in women. A case-control study from northern Italy. *Ann Epidemiol* 1995;5:234–238.
78. Hiller R, Podger MJ, Sperduto RD, et al. A longitudinal study of body mass index and lens opacities: the Framingham studies. *Ophthalmology* 1998;105:1244–1250.
79. Schaumberg DA, Glynn RJ, Christen WG, Hankinson SE, Hennekens CH. Relations of body fat distribution and height with cataract in men. *Am J Clin Nutr* 2000;72:1495–1502.
80. Klein BEK, Klein R, Moss SE. Incident cataract surgery: the Beaver Dam Eye Study. *Ophthalmology* 1997;104:573–580.
81. Younan C, Mitchell P, Cumming R, Rochtchina E, Panchapakesan J, Tumuluri K. Cardiovascular disease, vascular risk factors and the incidence of cataract and cataract surgery: the Blue Mountains Eye Study. *Ophthalmic Epidemiol* 2003;10:227–240.
82. Schaumberg DA, Ridker PM, Glynn RJ, Christen WG, Dana MR, Hennekens CH. High levels of plasma C-reactive protein and future risk of age-related cataract. *Ann Epidemiol* 1999;9:166–171.
83. Karasik A, Modan M, Halkin H, Treister G, Fuchs Z, Lusky A. Senile cataract and glucose intolerance: the Israel Study of Glucose Intolerance Obesity and Hypertension (The Israel GOH Study). *Diabetes Care* 1984;7:52–56.
84. Clayton RM, Cuthbert J, Duffy J, et al. Some risk factors associated with cataract in S. E. Scotland: a pilot study. *Trans Ophthalmol Soc UK* 1982;102:331–336.
85. Cottam DR, Mattar SG, Barinas-Mitchell E, et al. The chronic inflammatory hypothesis for the morbidity associated with morbid obesity: implications and effects of weight loss. *Obes Surg* 2004;14:589–600.
86. Leske MC, Sperduto RD. The epidemiology of senile cataracts: a review. *Am J Epidemiol* 1983;118:152–165.
87. West SK, Valmadrid CT. Epidemiology of risk factors for age-related cataract. *Surv Ophthalmol* 1995;39:323–334.
88. Hodge WG, Whitcher JP, Satariano W. Risk factors for age-related cataracts. *Epidemiol Rev* 1995;17:336–345.
89. Hiller R, Sperduto RD, Ederer F. Epidemiologic associations with cataract in the 1971–1972 National Health and Nutrition Examination Survey. *Am J Epidemiol* 1983;118:239–249.
90. Leske MC, Connell AM, Wu SY, Hyman L, Schachat A. Prevalence of lens opacities in the Barbados Eye Study. *Arch Ophthalmol* 1997;115:105–111.
91. West SK, Muñoz B, Schein OD, Duncan DD, Rubin GS. Racial differences in lens opacities: the Salisbury Eye Evaluation (SEE) project. *Am J Epidemiol* 1998;148:1033–1039.
92. Cruickshanks KJ, Klein BEK, Klein R. Ultraviolet light exposure and lens opacities: the Beaver Dam Eye Study. *Am J Pub Health* 1992;82:1658–1647.

93. Burton M, Fergusson E, Hart A, Knight K, Lary D, Liu C. The prevalence of cataract in two villages of northern Pakistan with different levels of ultraviolet radiation. *Eye* 1997;11:95–101.
94. Minassian DC, Mehra V, Reidy A. Childbearing and risk of cataract in young women: an epidemiologic study in central India. *Br J Ophthalmol* 2002;86:548–550.
95. Harding JJ, van Heyningen R. Drugs, including alcohol, that act as risk factors for cataract, and possible protection against cataract by aspirin-like analgesics and cyclopenthiiazide. *Br J Ophthalmol* 1988;72:809–814.
96. Flaye DE, Sullivan KN, Cullinan TR, Silver JH, Whitelocke RAF. Cataracts and cigarette smoking. The City Eye Study. *Eye* 1989;3:379–384.
97. West S, Muñoz B, Emmett EA, Taylor HR. Cigarette smoking and risk of nuclear cataracts. *Arch Ophthalmol* 1989;107:1166–1169.
98. Hankinson SE, Willett WC, Colditz GA, et al. A prospective study of cigarette smoking and risk of cataract surgery in women. *JAMA* 1992;268:994–998.
99. Klein BEK, Klein R, Linton KLP, Franke T. Cigarette smoking and lens opacities: the Beaver Dam Eye Study. *Am J Prev Med* 1993;9:27–30.
100. Cumming RG, Mitchell P. Alcohol, smoking, and cataracts: the Blue Mountains Eye Study. *Arch Ophthalmol* 1997;115:1296–1303.
101. Ederer F, Hiller R, Taylor HR. Senile lens changes and diabetes in two population studies. *Am J Ophthalmol* 1981;91:381–395.
102. Kinoshita JH. A thirty year journey in the polyol pathway. *Exp Eye Res* 1990;50:567–573.
103. Varma SD, Mizuno A, Kinoshita JH. Diabetic cataracts and flavonoids. *Science* 1977;195:205–206.
104. Brilliant LB, Grasset NC, Pokhrel RP, et al. Associations among cataract prevalence, sunlight hours, and altitude in the Himalayas. *Am J Epidemiol* 1983;118:250–264.
105. Taylor HR, West SK, Rosenthal FS, et al. Effect of ultraviolet radiation on cataract formation. *N Engl J Med* 1988;319:1429–1433.
106. Bochow TW, West SK, Azar A, Muñoz B, Sommer A, Taylor HR. Ultraviolet light exposure and risk of posterior subcapsular cataracts. *Arch Ophthalmol* 1989;107:369–372.
107. West SK, Duncan DD, Muñoz B, et al. Sunlight exposure and risk of lens opacities in a population-based study: the Salisbury Eye Evaluation project. *JAMA* 1998;280:714–718.
108. Minassian DC, Mehra V, Jones BR. Dehydration crises from severe diarrhoea or heatstroke and risk of cataract. *Lancet* 1984;1:751–753.
109. Minassian DC, Mehra V, Verry JD. Dehydrational crises: a major risk factor in blinding cataract. *Br J Ophthalmol* 1989;73:100–105.
110. Zodpey SP, Ughade SN, Khanolkar VA, Shrikhande SN. Dehydrational crisis from severe diarrhoea and risk of age-related cataract. *J Indian Med Assoc* 1999;97:13–15, 24.
111. Van Heyningen R, Harding JJ. A case-control study of cataract in Oxfordshire: some risk factors. *Br J Ophthalmol* 1988;72:804–808.
112. Bhatnagar R, West KP Jr, Vitale S, Sommer A, Joshi S, Venkataswamy G. Risk of cataract and history of severe diarrheal disease in southern India. *Arch Ophthalmol* 1991;109:696–699.
113. Kahn MU, Kahn MR, Sheikh AK. Dehydrating diarrhoea & cataract in rural Bangladesh. *Indian J Med Res* 1987;85:311–315.
114. Muñoz B, Tajchman U, Bochow T, West S. Alcohol use and risk of posterior subcapsular opacities. *Arch Ophthalmol* 1993;111:110–112.
115. Ritter LL, Klein BEK, Klein R, Mares-Perlman JA. Alcohol use and lens opacities in the Beaver Dam Eye Study. *Arch Ophthalmol* 1993;111:113–117.
116. Phillips CI, Clayton RM, Cuthbert J, Qian W, Donnelly CA, Prescott RJ. Human cataract risk factors: significance of abstinence from, and high consumption of, ethanol (U-curve) and non-significance of smoking. *Ophthalmic Res* 1996;28:237–247.
117. Black RL, Oglesby RB, von Sallmann L, Bunim JJ. Posterior subcapsular cataracts induced by corticosteroids in patients with rheumatoid arthritis. *JAMA* 1960;174:166–171.
118. Cumming RG, Mitchell P, Leeder SR. Use of inhaled corticosteroids and the risk of cataracts. *N Engl J Med* 1997;337:8–14.
119. Garbe E, Suissa S, LeLorier J. Association of inhaled corticosteroid use with cataract extraction in elderly patients. *JAMA* 1998;280:539–543.

120. Schaumberg DA, Mendes F, Balaram M, Dana MR, Sparrow D, Hu H. Accumulated lead exposure and risk of age-related cataract in men. *JAMA* 2004;292:2750–2754.
121. Semba RD, Blaum C, Guralnik JM, Totin D, Ricks MO, Fried LP. Low carotenoid and vitamin E status are associated with indicators of sarcopenia among older women living in the community. *Aging Clin Exp Res* 2003;15:482–487.
122. Delcourt C, Dupuy AM, Carriere I, Lacroux A, Cristol JP, and POLA Study Group. Albumin and transthyretin as risk factors for cataract: the POLA study. *Arch Ophthalmol* 2005;123:225–232.
123. Hirsch RP, Schwartz B. Increased mortality among elderly patients undergoing cataract extraction. *Arch Ophthalmol* 1983;101:1034–1037.
124. Podgor MJ, Cassel GH, Kannel WB. Lens changes and survival in a population-based study. *N Engl J Med* 1985;313:1438–1444.
125. Thompson JR, Sparrow JM, Gibson JM, Rosenthal AR. Cataract and survival in an elderly nondiabetic population. *Arch Ophthalmol* 1993;111:675–679.
126. Ninn-Pedersen K, Stenevi U. Cataract patients in a defined Swedish population 1986–90: VII Inpatient and outpatient standardised mortality ratios. *Br J Ophthalmol* 1995;79:1115–1119.
127. Wang JJ, Mitchell P, Simpson JM, Cumming RG, Smith W. Visual impairment, age-related cataract, and mortality. *Arch Ophthalmol* 2001;119:1186–1190.
128. Williams SL, Ferrigno L, Mora P, Rosmini F, Maraini G. Baseline cataract type and 10-year mortality in the Italian-American Case-Control Study of age-related cataract. *Am J Epidemiol* 2002;156:127–131.
129. Street DA, Javitt JC. National five-year mortality after inpatient cataract extraction. *Am J Ophthalmol* 1992;113:263–268.
130. Klein R, Klein BEK, Moss SE. Age-related eye disease and survival. The Beaver Dam Eye Study. *Arch Ophthalmol* 1995;113:333–339.
131. Cvetković D, Radovanović Z, Hentova-Senčanić P, Velimirović A. Lebenserwartung nach Altersstaroperation. *Fortschr Ophthalmol* 1985;82:231–234.
132. Winkler BS, Riley MV. Relative contributions of epithelial cells and fibers to rabbit lens ATP content and glycolysis. *Invest Ophthalmol Vis Sci* 1991;32:2593–2598.
133. Spector A. Oxidative stress-induced cataract: mechanism of action. *FASEB J* 1995;9:1173–1182.
134. Reddy VN. Glutathione and its function in the lens—an overview. *Exp Eye Res* 1990;50:771–778.
135. Rose RC, Bode AM. Ocular ascorbate transport and metabolism. *Comp Biochem Physiol* 1991;100A:273–285.
136. Tsukaguchi H, Tokui T, Mackenzie B, et al. A family of mammalian Na⁺-dependent L-ascorbic acid transporters. *Nature* 1999;399:70–75.
137. Varma SD, Kumar S, Richards RD. Light-induced damage to ocular lens cation pump: prevention by vitamin C. *Proc Natl Acad Sci USA* 1979;76:3504–3506.
138. Giblin FJ, Reddan JR, Schrimsher L, Dziedzic DC, Reddy VN. The relative roles of the glutathione redox cycle and catalase in the detoxification of H₂O₂ by cultured rabbit lens epithelial cells. *Exp Eye Res* 1990;50:795–804.
139. McGahan MC, Fleisher LN. Inflammation-induced changes in the iron concentration and total iron-binding capacity of the intraocular fluids of rabbits. *Graefes Arch Clin Exp Ophthalmol* 1988;226:27–30.
140. Delaye M, Tardieu A. Short-range order of crystallin proteins accounts for eye lens transparency. *Nature* 1983;302:415–417.
141. Tanaka T, Benedek GB. Observation of protein diffusivity in intact human and bovine lenses with application to cataract. *Invest Ophthalmol* 1975;14:449–456.
142. Takemoto LJ, Azari P. Isolation and characterization of covalently linked, high molecular weight proteins from human cataractous lens. *Exp Eye Res* 1977;24:63–70.
143. Truscott RJW, Augusteyn RC. Oxidative changes in human lens proteins during senile nuclear cataract formation. *Biochim Biophys Acta* 1977;492:43–52.
144. Bova LM, Sweeney MHJ, Jamie JF, Truscott RJW. Major changes in human ocular UV protection with age. *Invest Ophthalmol Vis Sci* 2001;42:200–205.
145. Sweeney MHJ, Truscott RJW. An impediment to glutathione diffusion in older normal human lenses: a possible precondition for nuclear cataract. *Exp Eye Res* 1998;67:587–595.
146. Truscott RJW. Age-related nuclear cataract: a lens transport problem. *Ophthalmic Res* 2000;32:185–194.

147. Velasco PT, Lukas TJ, Murthy SNP, Duglas-Tabor Y, Garland DL, Lorand L. Hierarchy of lens proteins requiring protection against heat-induced precipitation by the α crystallin chaperone. *Exp Eye Res* 1997;65:497–505.
148. Fu S, Dean R, Southan M, Truscott R. The hydroxyl radical in lens nuclear cataractogenesis. *J Biol Chem* 1998;273:28603–28609.
149. Palmquist BM, Philipson B, Barr PO. Nuclear cataract and myopia during hyperbaric oxygen therapy. *Br J Ophthalmol* 1984;68:113–117.
150. Brown NP, Harris ML, Shun-Shin GA, Vrensen GFJM, Willekens B, Bron AJ. Is cortical spoke cataract due to lens fibre breaks? The relationship between fibre folds, fibre breaks, waterclefts and spoke cataract. *Eye* 1993;7:672–679.
151. Merriam JC. The concentration of light in the human lens. *Trans Am Ophthalmol Soc* 1996;94:803–918.
152. Duindam JJ, Vrensen GFJM, Otto C, Greve J. Cholesterol, phospholipid, and protein changes in focal opacities in the human eye lens. *Invest Ophthalmol Vis Sci* 1998;39:94–103.
153. Dillon J, Ortwerth BJ, Chignell CF, Reszka KJ. Electron paramagnetic resonance and spin trapping investigations of the photoreactivity of human lens proteins. *Photochem Photobiol* 1999;69:259–264.
154. Dillon J, Zheng L, Merriam JC, Gaillard ER. The optical properties of the anterior segment of the eye: implications for cortical cataract. *Exp Eye Res* 1999;68:785–795.
155. McCarty CA, Taylor HR. Recent developments in vision research: light damage in cataract. *Invest Ophthalmol Vis Sci* 1996;37:1720–1723.
156. Streeten BW, Eshaghian J. Human posterior subcapsular cataract: a gross and flat preparation study. *Arch Ophthalmol* 1978;96:1653–1658.
157. Palva M, Palkama A. Ultrastructural changes in x-ray induced cataract of the rat. *Acta Ophthalmol* 1978;56:587–598.
158. Sperduto RD, Hu TS, Milton RC, et al. The Linxian cataract studies. Two nutrition intervention trials. *Arch Ophthalmol* 1993;111:1246–1253.
159. Chylack LT, Brown NP, Bron A, et al. The Roche European American Cataract Trial (REACT): a randomized clinical trial to investigate the efficacy of an oral antioxidant micronutrient mixture to slow progression of age-related cataract. *Ophthalmic Epidemiol* 2002;9:49–80.
160. Age-Related Eye Disease Study Research Group. A randomized, placebo-controlled, clinical trial of high-dose supplementation with vitamins C and E and beta carotene for age-related cataract and vision loss. AREDs Report No. 9. *Arch Ophthalmol* 2001;119:1439–1452.
161. Teikari JM, Rautalahti M, Haukka P, et al. Incidence of cataract operations in Finnish male smokers unaffected by α tocopherol or β carotene supplements. *J Epidemiol Community Health* 1998;52:468–472.
162. Christen WG, Manson JE, Glynn RJ, et al. A randomized trial of beta carotene and age-related cataract in US physicians. *Arch Ophthalmol* 2003;121:372–378.
163. McNeil JJ, Robman L, Tikellis G, Sinclair MI, McCarty CA, Taylor HR. Vitamin E supplementation and cataract: randomized controlled trial. *Ophthalmology* 2004;111:75–84.

3

Age-Related Macular Degeneration

1. INTRODUCTION

Age-related macular degeneration is the leading cause of visual loss among adults aged 65 yr or older in the United States and Europe. With increases in life expectancy and a growing cohort of older adults, the public health impact of age-related macular degeneration on blindness and visual disability is expected to grow even larger in prominence (1). Currently, one in five people over age 65 are living with age-related macular degeneration, and adults with advanced macular degeneration have a markedly reduced quality of life and need for assistance with activities of daily living (1). Although most cases of age-related macular degeneration were once considered largely untreatable, recent data from clinical trials demonstrate that micronutrient supplements may help to prevent the development of more severe disease and visual loss. New research on the relationship between lutein and zeaxanthin may provide further insights towards preventive strategies for age-related macular degeneration.

2. HISTORICAL BACKGROUND

The disciform variant of age-related macular degeneration was described as early as 1875 by Hermann Pagenstecher (1844–1932) and Carl Phillip Genth in Wiesbaden (2). In 1885, the condition was termed senile macular degeneration by Otto Haab (1850–1931) in Zurich (3). Various names have been used to describe age-related macular degeneration (4), including “degeneratio maculae luteae disciformis” by Johann Nepomuk Oeller (1850–1932) in 1905 (5). In 1926, Paul Junius (b. 1871) and Hermann Kuhnt (1850–1925) modified Oeller’s designation to *Die scheibenförmige Entartung der Netzhautmitte* (6), or “disciform degeneration of the macula,” a term that came widely used in ophthalmology. In 1920, Jan van der Hoeve (1878–1952), an ophthalmologist in Leiden, proposed that certain wavelengths of light can produce age-related macular degeneration (7).

The first description of yellow pigment in the macula has been attributed to Francesco Buzzi (1751–1805), an ophthalmologist in Milan (8,9). This finding was independently confirmed by the German physician and anatomist Samuel Thomas von Soemmering (1775–1830), who observed yellow pigment in the macula during dissection of cadaver eyes. At the time, Soemmering believed that there was an actual hole in the center of the macula (10). Further studies were conducted by Everard Home (1756–1832), who dissected the eyes of humans, monkeys, bullocks, and sheep, and concluded that only the human and the monkey eye contained the yellow spot in the macula (11). After the development of the ophthalmoscope in the mid-19th century, controversy evolved regarding the existence of macular yellow pigmentation (9). The variability in observation of yellow

From: *Nutrition and Health: Handbook of Nutrition and Ophthalmology*

By: R. D. Semba © Humana Press Inc., Totowa, NJ

pigmentation in the macula was likely related to the wavelength of light that was used in the ophthalmoscope, as the yellow color was more readily visible with the use of red-free light (9). In 1945, George Wald (1906–1997) observed that the macular pigment in humans had the same absorption spectrum as crystalline leaf xanthophyll. The extra-macular portions of the retina were also noted to contain some xanthophyll, but at a lower concentration per unit area than the macula. Extraction of the yellow pigment from human maculas yielded a hydroxy-carotenoid that Wald believed was lutein or leaf xanthophyll itself, noting “this marks the first appearance of a carotenoid of this type in a mammalian retina” (12).

3. EPIDEMIOLOGY

3.1. Definitions

The epidemiology of age-related macular degeneration has been fairly well characterized among different populations worldwide in the last three decades. Comparisons between studies, especially the earlier studies, has been somewhat limited because of the different definitions of age-related macular degeneration, lack of agreement in grading the disease, and variable use of standardized fundus photographs or examination alone. Consensus on an international classification and grading system was only reached in 1995 (13). The term “age-related maculopathy” refers to a disorder of the macular area of the retina characterized by soft or confluent drusen, areas of increased pigment in the outer retina or choroid associated with drusen, and areas of depigmentation or hypopigmentation of the retinal pigment epithelium. Late stages of age-related maculopathy are called age-related macular degeneration and include dry or geographic atrophy and wet, also known as neovascular, disciform, and exudative age-related macular degeneration (13).

3.2. Incidence and Prevalence

3.2.1. INCIDENCE

The incidence of age-related macular degeneration has been studied in risk groups and population-based studies (14–18). Two hundred patients with macular drusen were followed for an average of 4 yr, and the highest rate of visual loss occurred in those in the seventh decade and beyond (14). Of 71 patients who presented with bilateral macular drusen alone, the 5-yr cumulative risk of developing severe visual loss due to maculopathy was 12.7% (15). In a prospective study of 126 patients with bilateral drusen seen at Moorfields Eye Hospital, the cumulative incidence of new exudative or nonexudative lesions was 23.5% by 3 yr follow-up (16). In the Beaver Dam Eye Study, the incidence and progression of retinal drusen, retinal pigmentary abnormalities, and signs of late age-related maculopathy were studied over 5 yr among 3583 adults, aged 43–86 yr of age (18). The incidence of age-related maculopathy lesions was higher among adults 75 yr of age or older, and after adjusting for age, the incidence was 2.2 times higher among women than men (18). The 5-yr incidence of late age-related maculopathy, defined by the new appearance of either exudative macular degeneration or pure geographic atrophy at follow-up, was 0.9%. In the Chesapeake Bay Waterman Study, a cohort restricted to men of a particular occupation with half the men under 50 yr of age, the 5-yr incidence of late age-related maculopathy was 0.2% (17).

Table 1
Risk Factors for Age-Related Macular Degeneration

Increasing age
Race
Female gender
Family history
Iris color
Hyperopia
Cardiovascular disease
Cigarette smoking
Inflammation
Low grip strength
Low carotenoid status
Obesity
Sunlight exposure

3.2.2. PREVALENCE

The prevalence of age-related macular degeneration increases with age. Among adults <55, 55–64, 65–74, 75–84, and ≥85 yr of age in the Blue Mountains Eye Study in Australia, the prevalence of end-stage age-related macular degeneration (neovascular disease or geographic atrophy) was 0, 0.2, 0.7, 5.4, and 18.5%, respectively (19). Data from the Framingham Eye Study suggest that the prevalence of age-related macular degeneration is 8.8% in one or both eyes in adults over age 52 yr (20). In the Beaver Dam Eye Study involving 4685 adults 42 to 84 yr old, drusen were found in the macula of at least one eye in 95.5% of subjects (21). Late age-related macular degeneration, defined as the presence of exudative disease or geographic atrophy, was found in 0.1, 0.6, 1.4, and 7.1% of individuals aged 43–54, 55–64, 65–74, and ≥75 yr, respectively (21).

3.3. Risk Factors

The epidemiology of age-related maculopathy and age-related macular degeneration has been examined in some large major surveys, including the Framingham Eye Study (20,22), a case-control study in Baltimore (23), the first National Health and Nutrition Examination Survey (NHANES) (24), the Eye Disease Case Control Study (25), and the Blue Mountains Eye Study (19). Some risk factors for age-related macular degeneration are shown in Table 1.

3.3.1. AGE

Increasing age is a strong risk factor for age-related macular degeneration (19,26,27). In the first NHANES, individuals aged 55–64 yr and 65–74 yr had an adjusted prevalence odds ratio (OR) (95% confidence interval [CI]) for age-related macular degeneration of 2.13 (1.67–2.71) and 4.54 (2.80–7.36) compared with individuals aged 45–54 yr (24).

3.3.2. RACE

Age-related macular degeneration appears to be more common and severe among whites than blacks (28). In a study of 3444 black adults, aged 40 to 84 yr, from the Barbados Eye Study, early age-related macular degeneration was found in 23.5% of subjects

(28). Late age-related macular changes, the most visually disabling for of age-related macular degeneration, was found in only 0.6% of black adults, suggesting that the severity of age-related macular degeneration is less among blacks than whites (28). Race was not found to be a significant risk factor for age-related macular degeneration in the first NHANES (24), but the study relied on clinical examination by individuals with varying levels of experience and a standardized diagnosis of age-related macular degeneration was not certain (28). The prevalence of age-related macular degeneration in the non-institutionalized US population ≥ 40 yr of age was 9.2%, based on NHANES III, and the prevalence was higher among non-Hispanic whites (9.3%) compared with non-Hispanic blacks (7.4%) and Mexican Americans (7.1%) (29).

3.3.3. FEMALE GENDER

Most epidemiological studies suggest that women are at higher risk of advanced age-related macular degeneration and visual loss than men (19,25,26). In the Beaver Dam Eye Study, women had a higher risk of developing neovascular age-related macular degeneration than men (18).

3.3.4. FAMILY HISTORY

A family history of macular disease has been identified as a strong risk factor for age-related macular degeneration in a large case-control study in Baltimore (OR 2.9, 95% CI 1.5–5.5) (23). In two case reports, age-related macular degeneration was described in monozygotic twins (30). In nine twin pairs with age-related macular degeneration, the fundus appearance and the incidence of visual impairment were similar (31). Other factors, including diet, geographical background, and medical history, were also essentially the same in the twin pairs (31). In a study of 119 unrelated subjects with age-related macular degeneration in Boston, age-related macular degeneration had a higher prevalence among relatives of subjects, suggesting that age-related macular degeneration has a familial component and that genetic or shared environmental factors may contribute to its development (32).

3.3.5. IRIS COLOR

Blue iris color has been associated with increased risk of age-related macular degeneration (23). In a case-control study involving 102 cases and 103 controls in the United Kingdom, light stromal iris pigmentation was associated with age-related macular degeneration (33). Light-colored irises were identified as one of six major risk factors for age-related macular degeneration in a case-control study involving 1844 cases and 1844 matched controls in France (34). In a study of 650 white patients with age-related macular degeneration and 363 control patients, light-colored irides were found in 76% of patients compared with 40% of controls (35). Light iris pigmentation was associated with more extensive retinal disease in patients who had unilateral neovascular age-related macular degeneration (36).

3.3.6. HYPEROPIA

Hyperopia was identified as a risk factor for age-related macular degeneration in the first NHANES (24) and in a large case-control study in Baltimore, Maryland (23). In the Eye Disease Case Control Study, hyperopes (greater than +1 diopter) had an increased risk of neovascular age-related macular degeneration (25). One potential but rather speculative explanation for the association between hyperopia and age-related macular degeneration may relate to the use of eyeglasses. Myopes, who may wear eyeglasses for most

of their lives, could have possible reduced sunlight exposure compared to hyperopes, who may wear eyeglasses largely after middle age.

3.3.7. CARDIOVASCULAR DISEASE

Cerebrovascular disease was identified as a risk factor for age-related macular degeneration in the first NHANES (24). Individuals with a systolic blood pressure of 130–149, 150–169, and ≥ 170 mmHg had adjusted prevalence odds ratios (95% CI) of 1.15 (1.02–1.29), 1.31 (1.04–1.66), and 1.50 (1.06–2.13), respectively compared with individuals with a systolic blood pressure of <130 mmHg (24). In a case-control study in Baltimore, individuals with low hand grip strength and a positive history of cardiovascular disease had a higher risk of age-related macular degeneration (OR 1.9, 95% CI 1.03–3.34), and a history of cardiovascular diseases was defined as myocardial infarction, angina, other heart problems, arteriosclerosis, hypertension, other circulatory problems, stroke, and/or transient ischemic attacks (23). In a large case-control study in France, arterial hypertension (OR 1.28, 95% CI 1.09–1.50) and coronary artery disease (OR 1.31, 95% CI 1.02–1.68) were associated with age-related macular degeneration (34). In the Rotterdam Study, age-related macular degeneration was associated with plaques in the carotid bifurcation, plaques in the common carotid artery, and lower extremity arterial disease (37). Elevated plasma fibrinogen levels were associated with late age-related macular degeneration in the Blue Mountains Eye Study (38).

Epidemiological studies have not shown a consistent relationship between cardiovascular disease and late age-related macular degeneration (18,20,25,26,39). In the Pathologies Oculaires Liées à l'Age (POLA) Study conducted among 2584 adults aged 60–95 yr in Sète, France, a history of cardiovascular disease was associated with a decreased risk of soft drusen (40). No association was found between cardiovascular disease and late age-related macular degeneration (40). Systemic hypertension was found to be a significant risk factor for choroidal neovascularization in the fellow eye among patients who had known choroidal neovascularization from age-related macular degeneration in one eye (41). Severe hypertension was associated with neovascular age-related macular degeneration in a case-control study involving 182 patients with neovascular disease and 235 control subjects (42).

3.3.8. INFLAMMATION

In the Age-Related Eye Disease Study, elevated C-reactive protein was associated with increased risk of age-related macular degeneration (43). C-reactive protein was measured using a high sensitivity assay in 183 adults without any maculopathy, 200 adults with mild maculopathy, 325 adults with intermediate disease, and 222 with advanced age-related macular degeneration. After adjusting for age, sex, and other variables including smoking and body mass index, C-reactive protein concentrations were associated with increased risk of intermediate and advanced age-related macular degeneration (43). In a prospective study, 251 adults aged 60 yr and older with nonexudative age-related macular degeneration with visual acuity of 20/200 or better in at least one eye were followed for an average of 4.6 yr. Participants in the highest quartile of C-reactive protein had an increased risk of progression of age-related macular degeneration (relative risk [RR] 2.10, 95% CI 1.06–4.18) compared to those in the lowest quartile of C-reactive protein (44). Elevated interleukin-6 was also related to an increased risk of progression of age-related macular degeneration (RR 1.81, 95% CI 0.97–3.36).

3.3.9. CIGARETTE SMOKING

Several studies have identified cigarette smoking as a risk factor for age-related macular degeneration (23,25,39,45,46). In a case-control study conducted in Baltimore, Maryland, cigarette smoking was identified as a significant risk factor for age-related macular degeneration among males only (OR 2.6, 95% CI 1.15–5.75) (23). Current cigarette smoking was associated with increased risk of neovascular age-related macular degeneration in the Eye Disease Case-Control Study (25). In the Copenhagen City Heart Study, smoking was associated with risk of atrophic maculopathy (39). In the Beaver Dam Eye Study, exudative macular degeneration was significantly associated with current smoking among females (OR 2.5, 95% CI 1.01–6.20) and males (OR 3.29, 95% CI 1.03–10.50) compared with ex-smokers or nonsmokers (47). Whether smoking plays a causal role in age-related macular degeneration is not clear, and potential biological mechanisms include increased atherogenesis and increased oxidative stress caused by smoking (48). In the Rotterdam Study, 36 individuals with atrophic age-related macular degeneration and 65 individuals with neovascular age-related macular degeneration were identified among 6174 persons aged 55 yr and older (49). Among subjects younger than 85 yr, current smokers had a 6.6-fold increased risk of neovascular age-related macular degeneration compared to subjects who did not smoke (49). Former smokers also had an increased risk of neovascular age-related macular degeneration compared with nonsmokers (49). Cigarette smoking was an independent risk factor for incident age-related macular degeneration in the Nurses' Health Study (50). Smoking cigarettes for more than 40 yr was a risk factor for age-related macular degeneration in a study from Australia (51).

Lower plasma carotenoids have been described among smokers compared with nonsmokers (52,53), and as described in Chapter 7, it is well known that cigarette smokers have a lower intake of many vitamins compared with comparable nonsmokers (54–59). Smokers are less likely to consume fresh fruits, vegetables, salad, and whole grain cereals compared with nonsmokers, and the consumption of saturated fat, sugar, and alcohol are higher (58). In a case-control study, macular pigment density was compared between 34 smokers and nonsmokers matched by age, sex, dietary patterns, and overall eye, skin, and hair color pigmentation (60). Although cases and controls were matched by dietary intake of carotenoids, nonsmokers had over twice the macular pigment density of smokers (60) (Fig. 1). In a study of healthy adults in Japan, serum concentrations of zeaxanthin were inversely correlated with the number of cigarettes smoked per day (61).

3.3.10. GRIP STRENGTH

Decreased grip strength has been associated with age-related macular degeneration in both the Framingham Eye Study (20) and in a large case-control study in Baltimore (23). Grip strength is an indicator of sarcopenia, or loss of skeletal muscle mass, among older adults (62). Decreased grip strength may be associated with age-related macular degeneration because of oxidative stress may contribute to the pathogenesis of both sarcopenia and age-related macular degeneration. Oxidative stress has been hypothesized to contribute to sarcopenia in older adults because skeletal muscle and nervous tissues do not have the high repair capacities that occur in more mitotically active tissues (63). Changes in skeletal muscle that occur with aging include the accumulation of lipofuscin, which may be formed by the oxidative polymerization of lipids, greater lipid peroxidation, and

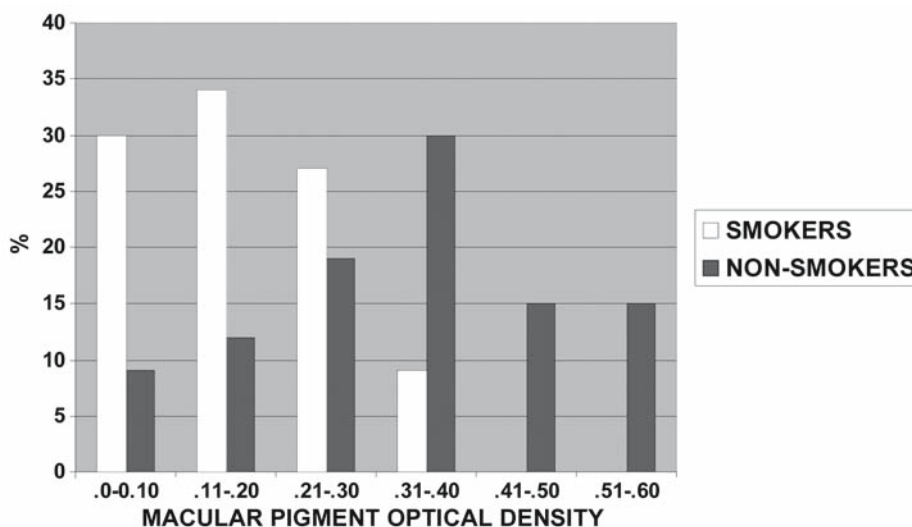


Fig. 1. Frequency distribution of macular pigment optical density for smokers and nonsmoking controls. (Reprinted from ref. 60, with permission of Elsevier.)

an increase in mitochondrial DNA deletions (63). In sarcopenia, most of the loss in strength results from an age-related decrease in muscle mass (62).

3.3.11. NUTRITIONAL FACTORS

Dietary intake. The Beaver Dam Eye Study from Beaver Dam, Wisconsin has provided a wealth of epidemiological data regarding the relationship between nutritional factors and age-related macular degeneration. An inverse association was noted between intakes of provitamin A carotenoids and dietary vitamin E and the incidence of large drusen over 5 yr (64). An inverse association was also found between zinc intake and the incidence of retinal pigmentary abnormalities over 5 yr (64). Adults 43–86 yr of age who were in the highest quintile of dietary intake of zinc from foods had a lower risk of early age-related macular degeneration (OR 0.6, 95% CI 0.4–1.0) compared with subjects in the lowest quintile of dietary intake of zinc from foods (65). Carotenoid intake was not associated with risk of early or late age-related macular degeneration (65). A high intake of saturated fats and cholesterol were associated with a higher risk of early age-related macular degeneration (66). These data support that hypothesis that atherosclerosis and related factors are involved in the pathogenesis of age-related macular degeneration (66).

In the first NHANES, conducted between 1971 and 1972, a high frequency of consumption of fruits and vegetables rich in vitamin A (provitamin A carotenoids and other dietary carotenoids) was associated with a lower risk of age-related macular degeneration (24). The adjusted prevalence odds ratios (95% CI) for age-related macular degeneration among those consuming fruits and vegetables rich in vitamin A one to three, four to six, and seven or more times per week, compared to less than one time per week, were 0.89 (0.80–1.00), 0.71 (0.50–1.00), and 0.59 (0.37–0.99) (24). The relationship between plasma micronutrient concentrations and age-related macular degeneration were examined in the Baltimore Longitudinal Study of Aging (67). In this study, a protective association was found between a high “antioxidant index” consisting of plasma ascorbic acid, α -tocopherol, and β -carotene,

and age-related macular degeneration, adjusting for age, sex, and nuclear opacity (67). No association was found between reported dietary intake of carotene, zinc, vitamin A, or vitamin C and age-related maculopathy in the Blue Mountains Eye Study (68). A high dietary intake of carotenoids was associated with a lower risk of age-related macular degeneration in the Eye Disease Case-Control Study (69). No relationship was found between vitamin E or vitamin C consumption and age-related macular degeneration (69). The assessment of dietary intakes was assessed using a semi-quantitative food frequency questionnaire (70). No association was found between dietary intake of carotenoids, vitamin C, zinc, and the incidence of early age-related macular degeneration in the Blue Mountains Eye Study (71).

In the Nurses' Health Study and Health Professionals Follow-Up Study, 77,562 women and 50,866 men 50 yr of age and older were followed for 18 and 12 yr, respectively (72). There were 464 incident cases of early age-related maculopathy and 316 incident cases of neovascular age-related maculopathy. Men and women who consumed three or more servings per day of fruit had a reduced risk of neovascular age-related maculopathy (RR 0.64, 95% CI 0.44–0.93) compared to those who consumed less than 1.5 servings per day, but a similar relationship was not found for the risk of early age-related maculopathy (RR 0.86, 95% CI 0.64–1.15). Men and women who consumed four or more servings per day of vegetables did not have a reduced risk of early age-related maculopathy (RR 1.50, 95% CI 0.69–1.77) or neovascular age-related maculopathy (RR 1.06, 95% CI 0.73–1.56) compared to those who ate two or less servings of vegetables per day (72). There was no significant relationship found between quintiles of intake of lutein/zeaxanthin and risk of either early age-related maculopathy or neovascular age-related maculopathy.

Intake of dietary fat was associated with an increased risk for age-related macular degeneration. In a prospective study of participants in the Nurses' Health Study and Health Professionals Follow-up Study, those in the highest quintile of total fat intake had an increased risk of developing age-related macular degeneration (RR 1.54, 95% CI 1.17–2.01) compared to those in the lowest quintile of intake. Higher intake of linoleic acid was also associated with an increased risk of developing age-related macular degeneration (73). In a multicenter case-control study of 349 subjects with advanced neovascular age-related macular degeneration and 504 subjects without age-related macular degeneration but with other ocular diseases, higher vegetable fat consumption was associated with an elevated risk of age-related macular degeneration (OR 2.22, 95% CI 1.32–3.74) for those in the highest vs the lowest quintile of intake (74). A higher intake of vegetable, monounsaturated, and polyunsaturated fats and linoleic acid, rather than total fat intake, was associated with a greater risk of advanced age-related macular degeneration, and the diets that were high in omega-3 fatty acids and fish were inversely associated with risk for age-related maculopathy when intake of linoleic acid was low (74). In a prospective cohort study of 261 adults with nonexudative age-related macular degeneration who had mean follow-up of 4.6 yr, higher total fat intake was associated with an increased risk of progression to more advanced age-related macular degeneration (75). Those in the highest quartile of total fat intake had an increased risk of progression (RR 2.90, 95% CI 1.15–7.32) compared to those in the lowest quartile. Intake of animal fats was also associated with an increased risk of progression (RR 2.29, 95% CI 0.91–5.72) in comparing the highest quartile with the lowest quartile. Consumption of nuts was also protective against progression of macular degeneration (75).

In the Rotterdam Study, dietary intake was assessed at baseline (1990–1993) using a semi-quantitative food frequency questionnaire (76). Incident age-related macular degeneration was assessed over follow-up until 2004. Of 4170 people who participated in the follow-up and were at risk of age-related macular degeneration, incident disease occurred in 560 subjects. An above-median intake of β -carotene, vitamin C, vitamin E, and zinc was associated with a 35% reduced risk (hazard ratio [HR] 0.65, 95% CI 0.46–0.92) of developing age-related macular degeneration (76).

Supplement use. In the Physician's Health Study I, during mean 12.5 yr of follow-up of 21,120 men, 279 incident cases of age-related maculopathy were observed (77). Those who used vitamin E supplements had a decreased risk of age-related maculopathy (RR 0.87, 95% CI 0.53–1.43) and users of multivitamin supplements had a reduced risk (RR 0.90, 95% CI 0.68–1.19), but none of the results reached statistical significance. It appeared that those who take certain types of supplements were unlikely to show large reductions in age-related maculopathy (77).

Serum or plasma nutrients. In the Eye Disease Case-Control Study, serum concentrations of carotenoids, vitamin C, vitamin E, and selenium were compared between 421 cases with neovascular age-related macular degeneration and 615 controls (25,78). A reduced risk of age-related macular degeneration was found in the upper two tertiles of carotenoids compared with the lowest tertile (25,78). Of all the case-control studies of its kind, the Eye Disease Case-Control Study had the largest sample size of adults with age-related macular degeneration and therefore the greatest statistical power for discerning differences in different nutrients between cases and controls. No significant association was found between vitamin C, vitamin E, or selenium and age-related macular degeneration (25). No relationship was found between plasma carotenoids, including plasma lutein, α -tocopherol, vitamin A, and age-related maculopathy in a case-control study involving 65 cases and controls seen at Moorfields Eye Hospital (79). In a case-control study from the Beaver Dam Eye Study, serum β -carotene, lutein, zeaxanthin, and α -tocopherol were not associated with age-related macular degeneration (80). The statistical power to examine a relationship between serum lutein/zeaxanthin and age-related maculopathy and age-related macular degeneration may have been more limited because these carotenoids were only measured in a subsample of case-control pairs (80). No inverse relationship was found between lutein and zeaxanthin in the diet or serum and any for of age-related maculopathy in NHANES III (81). In a case-control study of subjects from the Blue Mountains Eye Study, no relationship was found between serum α -tocopherol concentrations and age-related macular degeneration (82). A borderline association was found between plasma α -tocopherol and late age-related macular degeneration in a population-based study of macular degeneration in France (83). In a case-control study involving 46 people with age-related macular degeneration and 46 controls, no relationship was found between total carotenoids, vitamin C, vitamin E, zinc, and age-related macular degeneration (84). The relationships between nutritional status and age-related macular degeneration in some of these studies are highlighted in Table 2.

Macular pigment. Several methods have been used for the in vivo measurement of macular pigment and have been reviewed in detail elsewhere (85). These methods include heterochromatic flicker photometry, in which a subject tries to eliminate the flicker in a visual stimulus that alternates between two different wavelengths, and photographic measurement of macular pigment by comparison of images obtained using blue and green

Table 2

Observational Studies of Nutritional Status in Age-Related Maculopathy (ARM) and Age-Related Macular Degeneration (AMD)

<i>Subjects</i>	<i>Design/methods</i>	<i>Observations</i>	<i>OR (95% CI)</i>	<i>Reference</i>
26 cases (AMD) 23 controls Mean age ~79, ~73 yr respectively	Case-control	No significant differences in mean vitamin A, C, or E, plasma nutrients cholesterol or triglycerides between cases and controls		95
National Health and Nutrition Examination Survey I 178 cases ^a 3082 total Age 45–74 yr	Cross-sectional Dietary intake	Consumption of vitamin-rich foods >7 times/wk vs <1 time/wk Vitamin A Vitamin C	0.59 (0.37–0.99)^b 0.98 (0.79–1.23)	24
Eye Disease Case-Control Study 421 cases (AMD) 615 controls Ages 55–80 yr	Case-control Serum nutrients	Highest vs lowest quintile α-carotene β-carotene β-cryptoxanthin Lutein/zeaxanthin Lycopene Vitamin C Vitamin E Selenium	0.5 (0.3–0.8) 0.3 (0.2–0.5) 0.4 (0.2–0.6) 0.3 (0.2–0.6) 0.8 (0.5–1.3) 0.7 (0.5–1.2) 0.6 (0.4–1.04) 1.3 (0.8–2.1)	78
Moorfields Eye Hospital 65 cases (largely ARM) 65 controls	Case-control Plasma nutrients	Highest vs lowest tertile α-carotene β-carotene β-cryptoxanthin Lutein Lycopene Retinol α-tocopherol Cholesterol Phospholipid 18:2n-6	0.85 (0.48–1.50) 0.5 (0.20–1.20) 1.35 (0.58–3.28) 1.37 (0.57–3.38) 1.00 (0.40–2.57) 1.20 (0.67–2.14) 0.85 (0.48–1.50) 1.00 (0.40–2.48) 0.62 (0.26–1.46)	79

Eye Disease Case-Control Study 356 cases (AMD) 520 controls Age 55–80 yr	Case-control Dietary intake	Phospholipid 22:6n-3	0.82 (0.35–1.93)	69
		Highest vs lowest quintile		
		α-carotene	0.79 (0.5–1.3)	
		β-carotene	0.59 (0.4–0.96)	
		β-cryptoxanthin	0.89 (0.5–1.4)	
		Lutein/zeaxanthin	0.43 (0.2–0.7)	67
		Lycopene	1.16 (0.7–1.8)	
		Lower risk of ARMD in subjects consuming high amounts of spinach or collard greens, winter squash		
		Highest vs lowest quartile		
		β-carotene	0.62 (0.36–1.07)	
		Retinol	1.01 (0.57–1.78)	80
		Vitamin C	0.55 (0.28–1.08)	
		α-tocopherol	0.43 (0.25–0.73)^c	
		Lowest quintile vs all others		
		α-carotene	1.2 (0.7–2.3)	
		β-carotene	0.8 (0.4–1.6)	66
		β-cryptoxanthin	0.6 (0.3–1.1)	
		Lutein/zeaxanthin	0.7 (0.4–1.4) ^d	
		Lycopene	2.2 (1.1–4.8)	
		α-tocopherol	0.8 (0.4–1.5)	
		Highest vs lowest quintile		
		Total fat	0.7 (0.2–2.3) for AMD	
		Total fat	1.3 (0.9–1.9) for ARM	
		Saturated fat	1.5 (0.5–4.5) for AMD	
		Saturated fat	1.8 (1.2–2.7) for ARM	
		Cholesterol	1.4 (0.4–4.8) for AMD	
		Cholesterol	1.6 (1.1–2.4) for ARM	

(continued)

Table 2 (Continued)

<i>Subjects</i>	<i>Design/methods</i>	<i>Observations</i>	<i>OR (95% CI)</i>	<i>Reference</i>
Beaver Dam Eye Study 314 cases (ARM) 30 cases (AMD) 1968 overall Age 43–86 yr	Retrospective cohort Dietary intake	Highest vs lowest quintile α -carotene α -carotene β -carotene β -carotene β -cryptoxanthin β -cryptoxanthin Lutein/zeaxanthin Lutein/zeaxanthin Lycopene Lycopene Vitamin E Vitamin E Vitamin C Vitamin C Zinc Zinc	1.2 (0.3–5.0) for AMD 1.1 (0.8–1.6) for ARM 0.7 (0.2–2.4) for AMD 1.1 (0.8–1.7) for ARM 1.8 (0.3–9.2) for AMD 1.2 (0.8–1.8) for ARM 1.6 (0.5–5.5) for AMD 1.0 (0.7–1.5) for ARM 1.4 (0.4–4.5) for AMD 1.2 (0.8–1.8) for ARM 1.5 (0.5–4.6) for AMD 0.7 (0.5–1.1) for ARM 0.6 (0.2–2.0) for AMD 0.8 (0.5–1.2) for ARM 1.1 (0.3–4.1) for AMD 0.7 (0.5–1.0) for ARM	65
Beaver Dam Eye Study 103 cases (incident ARM) 1279 overall	Retrospective cohort	High vs low quintile Provitamin A carotenoids Vitamin E Zinc Low intake of provitamin A carotenoids and vitamin E associated with incident large drusen; low intake of zinc associated with incident pigmentary abnormalities	1.04 (0.5–2.1) 0.77 (0.4–1.6) 0.71 (0.3–1.4)	64

Blue Mountains Eye Study			68
240 cases (ARM)	Cross-sectional	Highest vs lowest quintile	
72 cases (AMD)	Dietary intake	Carotene	0.73 (0.27–1.99) for AMD
3342 without disease		Carotene	0.66 (0.39–1.10) for ARM
Age ≥49 yr		Zinc	1.04 (0.39–2.75) for AMD
		Zinc	0.79 (0.37–1.32) for ARM
		Vitamin C	1.30 (0.50–3.40) for AMD
		Vitamin C	0.86 (0.52–1.41) for ARM
		Vitamin A	1.22 (0.45–4.43) for AMD
		Vitamin A	1.19 (0.72–1.96) for ARM
		No significant trends across any quintiles; no significant association between intake of foods high in antioxidants and AMD or ARM	

^aAMD defined in this study as: loss of macular reflex pigment dispersion and clumping, and drusen associated with visual acuity of 20/25 or worse believed to be due to this disease, choroidal hemorrhage and connective tissue proliferation between retinal pigment epithelium and Bruch's membrane causing an elevation of the foveal retina (not associated with other conditions), or perimacular accumulation of lipid material within the retina.

^bVitamin A-rich fruits and vegetables, which would be high in provitamin A and other carotenoids.

^cPlasma α -tocopherol not adjusted for total cholesterol or total lipid.

^dPlasma lutein/zeaxanthin measured on subsample of 80 case-control pairs.

OR, odds ratio; CI, confidence interval.

illumination (86). In a case-control study of 56 donor eyes with age-related macular degeneration and 56 control eyes without age-related macular degeneration, the concentrations of lutein and zeaxanthin in concentric regions centered on the fovea was significantly less in eyes with age-related macular degeneration than eyes that did not have the disease (87). An age-related decline in macular pigment optical density has been observed in healthy subjects (88). Subjects with age-related macular degeneration in one eye only had lower macular pigment density in the unaffected eye compared with healthy controls with no history of age-related macular degeneration (88).

Obesity. In the POLA Study, conducted among 2584 residents of Sète, in the south of France, aged 60–95 yr, high body mass index ($>30 \text{ kg/m}^2$) was associated with a twofold increased risk of late age-related macular degeneration (40). A recent prospective study showed that body mass index was associated with the risk of developing age-related maculopathy (89). The relationship between body mass index in four categories (lean, <22.0 ; normal 22.0–24.9; overweight, 25.0–29.9; and obese, ≥ 30) and incident age-related maculopathy was examined in 21,121 men participating in the Physicians' Health Study. After adjusting for age, aspirin and β -carotene treatment, and cigarette smoking, the RR of visually significant dry age-related maculopathy was lowest in men with normal body mass index. Compared with normal men, the RR (95% CI) among men who were lean, overweight, and obese was 1.43 (1.01–2.04), 1.24 (0.93–1.66), and 2.15 (1.35–3.45), respectively, suggesting a J-shaped relationship between body mass index and incidence of dry age-related maculopathy (89). In a prospective cohort study in a hospital-based retinal practice, progression of age-related macular degeneration was associated with higher body mass index, higher waist circumference, and higher waist–hip ratio (90).

3.3.12. SUNLIGHT EXPOSURE

In the Beaver Dam Eye Study, the amount of leisure time spent outdoors during the summer was associated with exudative macular degeneration (OR 2.26, 95% CI 1.06–4.81) but no association was found between estimated ambient ultraviolet (UV)-B exposure and age-related macular degeneration (91). No association was found between age-related macular degeneration and the amount of ocular UV-A and UV-B light exposure among 838 Maryland watermen in the Chesapeake Bay (92), but a history of greater exposure to blue and visible light were associated with a higher risk of disease (93). In a case-control study involving 409 cases and 286 control subjects in Australia, cases with age-related macular degeneration were found to have lower median annual sun exposure than controls (94). In a small study involving 26 cases and 24 controls, the extent of dermal elastosis in sun-protected dermis was associated with age-related macular degeneration, suggesting to the investigators that increased susceptibility of elastic fibers to photic degenerative stimuli was a new risk factor (95).

3.3.13. OTHER FACTORS

Moderate wine consumption was associated with decreased odds of developing age-related macular degeneration in the first NHANES (96). In the Beaver Dam Eye Study, consumption of beer in the past year was related to greater odds of developing increased retinal pigment degeneration (OR 1.13, 95% CI 1.05–1.88), and wine consumption was not related to either early or late age-related macular degeneration (97). In the Blue Mountains Eye Study, no relationship was found between beer or wine intake and early or late age-related macular degeneration, but an increased risk of early age-related macular

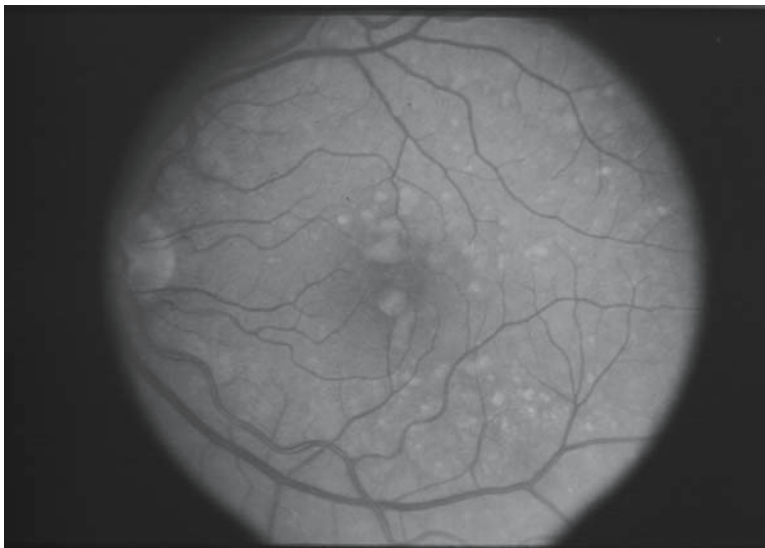


Fig. 2. Age-related macular degeneration with multiple soft drusen. (Courtesy of James P. Dunn.)

degeneration was found among those who drank spirits (98). Alcohol use appears to have little effect on plasma carotenoid concentrations (99).

4. CLINICAL FEATURES

4.1. *Age-Related Maculopathy*

Age-related maculopathy is defined as a disorder of the macular area of the retina characterized by “soft drusen,” discrete whitish-yellow spots external to the neuroretina or retinal pigment epithelium (Fig. 2), areas of increased pigmentation or hyperpigmentation associated with drusen, and areas of depigmentation or hypopigmentation of the retinal pigment epithelium (13). Drusen are localized depositions of hyaline-like material at the level of retinal pigment epithelium and Bruch’s membrane. “Soft drusen” represent localized detachments of the retinal pigment epithelium that occur in a cleavage plane between basal linear deposits and the remainder of Bruch’s membrane. Basal linear deposits consist of vesicular and amorphous material located external to the basement membrane of the retinal pigment epithelium and within the inner aspect of Bruch’s membrane. Basal laminar deposits consist of amorphous or granular eosinophilic material that is located between the plasma membrane of the basement membrane of the retinal pigment epithelium. These relationships are depicted in Fig. 3. Hard drusen, which have distinct borders, are common and not thought to be associated with the development of visual loss from age-related macular degeneration (100). Hard drusen are not considered part of age-related related maculopathy (13).

4.2. *Age-Related Macular Degeneration*

Age-related macular degeneration is considered to be a late state of age-related maculopathy and has been divided into two categories (13).

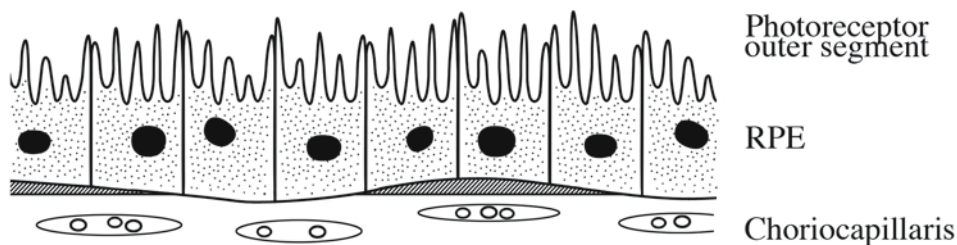


Fig. 3. Diagram of basal laminar deposits.

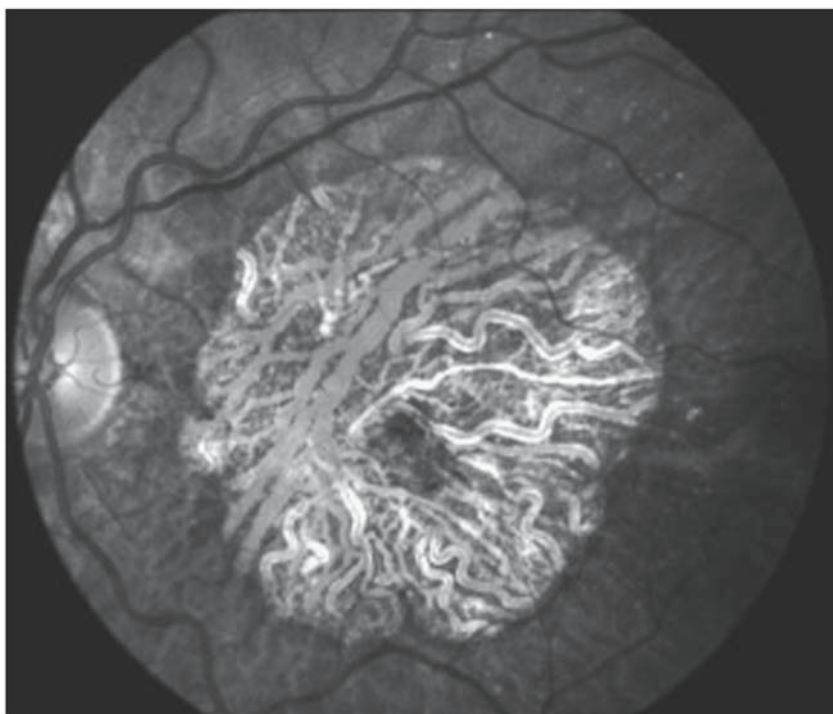


Fig. 4. Geographic atrophy. (Courtesy of Jay M. Haynie.)

4.2.1. DRY AGE-RELATED MACULAR DEGENERATION (GEOGRAPHIC ATROPY)

Dry age-related macular degeneration is characterized by sharply delineated round or oval areas of hypopigmentation or depigmentation in which there is an apparent absence of retinal pigment epithelium and areas in which choroidal vessels are more visible than in surrounding areas (Fig. 4).

4.2.2. WET AGE-RELATED MACULAR DEGENERATION (NEOVASCULAR, EXUDATIVE, OR DISCIFORM)

Wet age-related macular degeneration is characterized by any of the following: sub-retinal or sub-retinal pigment epithelium neovascular membrane(s), detachment(s) of the retinal pigment epithelium, epiretinal, intraretinal, subretinal, or sub-retinal pigment epithelium scar or glial tissue or fibrin-like deposits, subretinal hemorrhages, and hard exudates within the macula and not related to other retinal vascular disease (13) (Fig. 5).

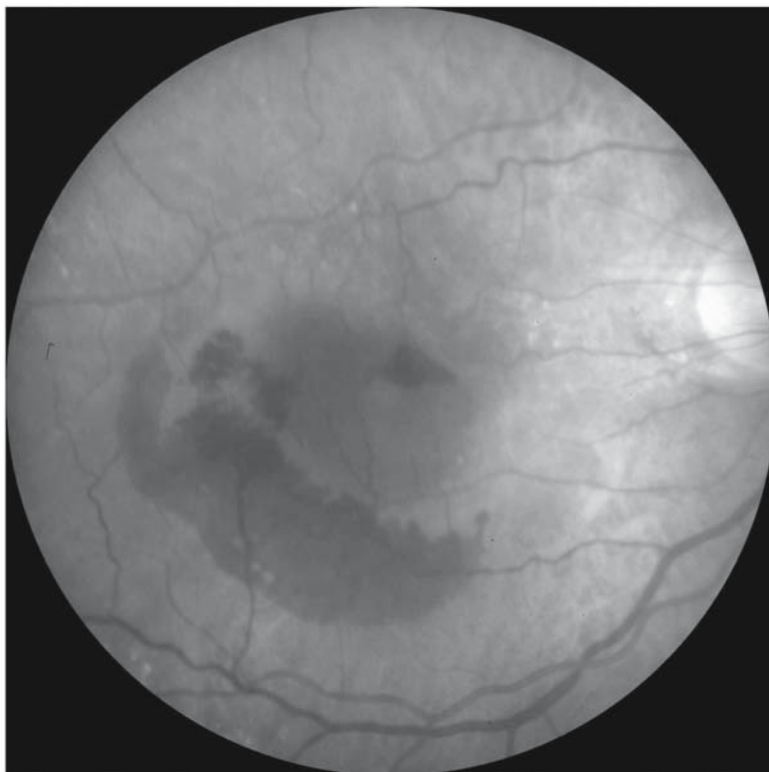


Fig. 5. Neovascular age-related macular degeneration. (Courtesy of Egbert Saavedra.)

5. PATHOPHYSIOLOGY

5.1. Pathological Features of Age-Related Macular Degeneration

Age-related changes in Bruch's membrane include an increase in thickness from childhood to adult life (101,102), and an accumulation of debris on both sides of the elastic layer, a change that begins to occur in the second decade and is common by 20–60 yr of age (103). The main source of the debris appears to be the retinal pigment epithelium (103). Basal laminar deposits are thought to consist of abnormal, undigested material from the retinal pigment epithelium (104). Drusen appear to form by budding or evagination of a portion of retinal pigment epithelium into the subpigment epithelial space, followed by degeneration and disintegration of the basement membrane of the budded portion and deposition of this vesicular, granular, tubular, and linear material in the space external to the retinal pigment epithelium (104) (Fig. 6). Choroidal perfusion on fluorescein angiography also appears to show diffuse thickening of Bruch's membrane (105). With increasing age, there is also an increase in lipofuscin granules in the retinal pigment epithelium (106). Normal aging is also associated with an increase in major histocompatibility complex (MHC) class II immunoreactivity in retinal vascular elements, and a further increase in MHC-II immunoreactivity was associated with incipient age-related macular degeneration (107). A granulomatous reaction to Bruch's membrane has been described in age-related macular degeneration (108). There appears to be a continuum of pathological changes

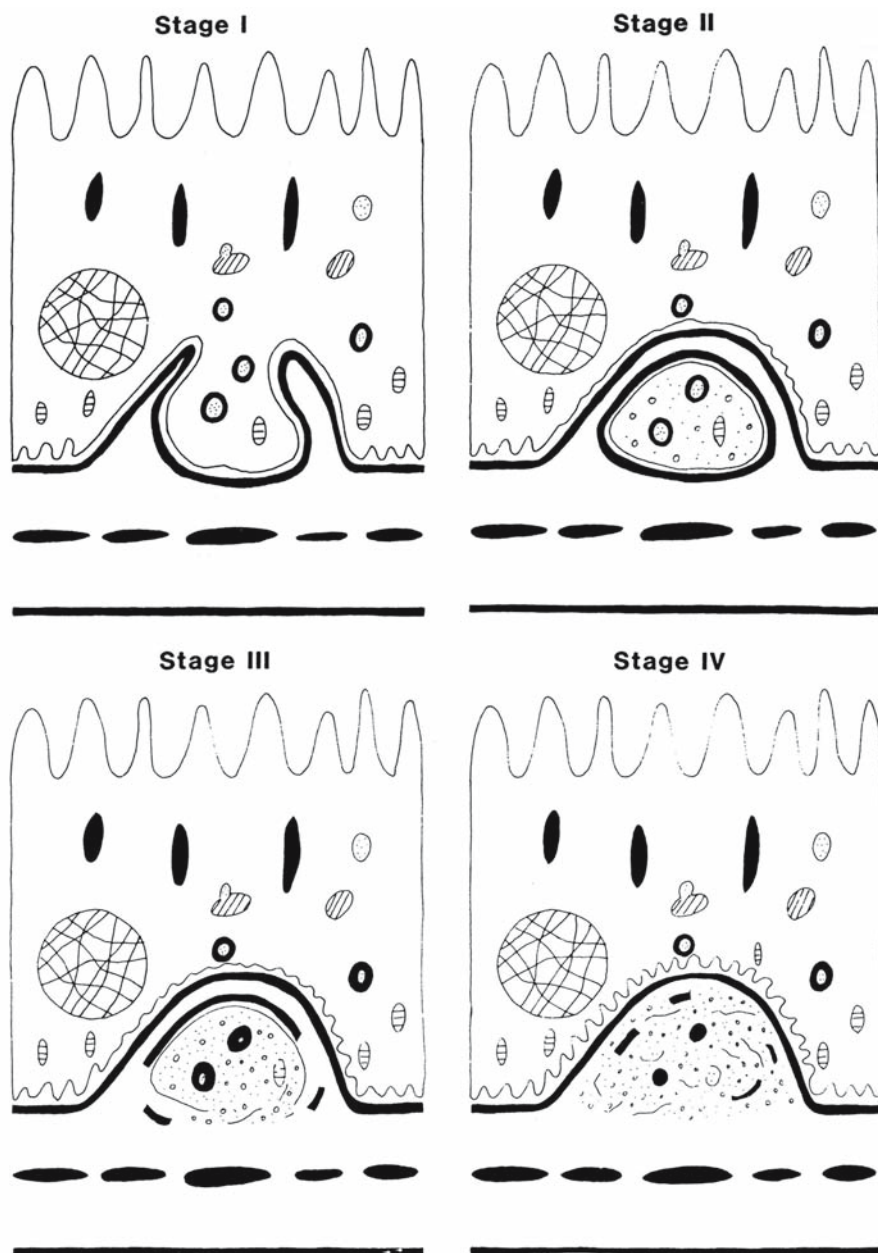


Fig. 6. Formation of drusen (Reprinted from ref. 104, with permission of Elsevier.)

in age-related macular degeneration, and disturbances of retinal pigment epithelium pigmentation, drusen, thickening of Bruch's membrane, and formation of basal laminar deposits are associated with loss of photoreceptor outer segments and atrophy of the choriocapillaris (109). Visual impairment and blindness can follow the loss of photoreceptors from the macula.

5.2. Oxidative Stress

5.2.1. OVERVIEW

The current hypothesis under widespread investigation is that oxidative stress contributes to the pathogenesis of age-related macular degeneration (110–117). Oxygen is required for energy-producing intracellular reactions, but in the process of oxidation, reactive oxygen species can be produced. Antioxidants, such as carotenoids, vitamin C, α -tocopherol, and bilirubin are thought to balance prooxidants such as reactive oxygen species. In addition, cells have enzyme systems with antioxidant activity such as superoxide dismutase, catalase, and glutathione peroxidase. Oxidative stress is used to describe the condition in which there is an imbalance due to a relative deficiency of antioxidants. With oxidative stress, reactive oxygen species can cause damage to DNA, lipids, proteins, and carbohydrates, and cell damage and tissue destruction may result. Reactive oxygen species, such as superoxide anion ($O_2^{\bullet-}$), hydroxyl radical (OH^\bullet), hydrogen peroxide (H_2O_2), and singlet oxygen (1O_2) can be generated through various processes in the retina including mitochondrial respiration, phagocytosis of rod and cone outer segments by the retinal pigment epithelium, reaction of blue light with lipofuscin, reaction of light with endogenous porphyrinic photosensitizers in the choroid, xanthine oxidase, NADPH-dependent oxidase system, auto-oxidation of catecholamines, and prostaglandin H2 synthase (114). There are at least five major reasons why the retina may be subject to an extremely high degree of oxidative stress: (1) the retina is well vascularized and has a greater degree of oxygen consumption than any other tissue, (2) there is a high level of exposure to cumulative irradiation, (3) photoreceptor outer segments are rich in polyunsaturated fatty acids, which can readily be oxidized, (4) the retina contains photosensitizers, and (5) phagocytosis of photoreceptor outer segments by the retinal pigment epithelium produces reactive oxygen intermediates (117). In vitro studies with human retinas suggest that lipid peroxidation is greatest in the macular region and that lipid peroxidation increases in the human retina with age (118). Some antioxidants and antioxidant enzyme systems that are thought to protect the retina from increased oxidative stress are shown in Table 3.

5.2.2. ANTIOXIDANT ENZYME SYSTEMS IN THE RETINA

Enzyme systems in the retina that function in reducing reactive oxygen species include glutathione peroxidase, catalase, and superoxide dismutase. Glutathione acts as an antioxidant by reducing peroxides in a reaction catalyzed by glutathione peroxidase, a selenium-dependent enzyme. Glutathione is found in high concentrations in the retina and retinal pigment epithelium (119). Exogenous glutathione was found to protect culture human retinal pigment epithelial cells from oxidative injury (120). These in vitro studies suggested that glutathione and its amino acid precursors could protect retinal pigment epithelium from oxidative injury. Retinal pigment epithelium appears to synthesize glutathione directly from amino acid precursors (121). Individuals with age-related macular degeneration were found to have significantly lower plasma glutathione concentrations compared with age-matched healthy controls (122). In addition, plasma glutathione concentrations appeared to decrease with increasing age (122).

Catalase is an iron-dependent enzyme that dismutates hydrogen peroxide to water and molecular oxygen, protecting tissues against oxidative damage. The retinal pigment epithelium contains extremely high levels of catalase activity (123), with a level of activity

Table 3

Antioxidants and Antioxidant Enzymes in the Human Retina and Their Putative Functions

<i>Factor</i>	<i>Functions</i>
Glutathione peroxidase	Reduces organic hydroperoxides
Glutathione reductase	Regenerates glutathione
Superoxide dismutase	Catalyzes dismutation of superoxide into oxygen and hydrogen peroxide
Catalase	Scavenges hydrogen peroxide
Metallothionein	Scavenges hydroxyl radicals
Lutein and zeaxanthin	Absorb energy from singlet oxygen
Vitamin E	Protects polyunsaturated fatty acids from auto-oxidation
Vitamin C	Protects against lipid peroxidation
Zinc	Cofactor for copper-zinc superoxide dismutase

that is six times higher than that found in other ocular tissues (124). In a study of donor eyes of adults 50 to 90 yr of age, catalase activity in the retinal pigment epithelium decreased with age and with the presence of macular degeneration (124). In vitro studies demonstrate that zinc can induce catalase expression in cultured fetal human retinal pigment epithelial cells (125), suggesting a potential mechanism by which zinc status might influence catalase activity in vivo. In a primate model of age-related macular degeneration, lower catalase activity and markedly lower zinc concentrations were found in affected retinas compared with control retinas (126).

Two forms of superoxide dismutase are found in human retinal pigment epithelium, a copper-zinc superoxide dismutase and a manganese superoxide dismutase (127). Manganese superoxide dismutase may play a potential role in protecting mitochondria from oxidative damage (127). Two other enzymes that may potentially play a role in the pathogenesis of age-related macular degeneration are heme oxygenase-1 and -2 (128). These enzymes convert heme, a pro-oxidant, to biliverdin. Biliverdin is converted to bilirubin, a strong antioxidant, by biliverdin reductase. In an immunohistochemical study of 21 eyes obtained postmortem from donors aged 42 to 94 yr, copper and zinc superoxide dismutase activity in cytoplasm and lysosomes from macular retinal pigment epithelial cells increased with age, whereas catalase immunoreactivity decreased with age (128). Heme-oxygenase-1 and heme-oxygenase-2 reactivity were significantly higher in macular retinal pigment epithelial cells from eyes with neovascular age-related macular degeneration, suggesting that these two enzymes are upregulated in age-related macular degeneration (128).

Oxidative stress in the retina may ultimately induce apoptosis in retinal pigment epithelial cells. Increased apoptosis was found in cultured human retinal pigment epithelial cells that were exposed to a chemical oxidant, *t*-butylhydroperoxide (129). Mitochondria play an important role in regulating signal transduction in apoptosis, and an early change preceding apoptosis is a decreased in inner transmembrane potential (130). Mitochondrial membrane potential was altered by *t*-butylhydroperoxide in these studies, suggesting that the oxidant induced apoptosis in retinal pigment epithelial cells as a consequence of changes induced in mitochondria (114,129). Antioxidant enzyme activity in red blood cells does not appear to correlate with age-related macular degeneration (131), which

suggests that the disease severity of age-related macular degeneration might relate more closely to localized oxidative stress in the retina, rather than biomarkers of oxidative stress in peripheral blood.

5.2.3. EFFECTS OF PHOTIC IRRADIATION

Photochemical injury to the retina has been described in rats (*132,133*) and primates (*134–136*) exposed to visible light. The retinal pigment epithelium appears to be the most susceptible to light-induced damage (*133*). Blue light of 441 nm wavelength (which does not induce an appreciable temperature rise in the retina), was sufficient to induce retinal damage in the primate after 1000 s of exposure (*136*). The primary lesion occurs in the retinal pigment epithelium and results in hypopigmentation (*135*). Increased lipid hydroperoxide has been found in rod outersegments exposed to light (*137*). Photic injury to the retina was also found in rhesus monkeys that were exposed to the light of an indirect ophthalmoscope (*138*). The damage was more severe in the perifoveal zone compared to the foveal area, which is consistent with the idea that macular pigment protects the foveal region from photic injury (*138*). Carotenoid pigments have been hypothesized to protect the eye against photo-oxidative stress (*139*). The role of carotenoids in the retina is presented under Subheading 5.3.9.

5.2.4. PHOTSENSITIZATION

Photoactive compounds in erythrocytes, such as protoporphyrin IX, a precursor molecule to hemoglobin, have been proposed to play a role in the pathogenesis of age-related macular degeneration (*140*). On exposure to light, protoporphyrin IX generates superoxide anion and singlet oxygen, and these reactive oxygen species could potentially damage vascular endothelium of the choriocapillaris, Bruch's membrane, and the retinal pigment epithelium (*140*). In a mouse model of protoporphyria, exposure to blue light was associated with a time and light-dependent increase in choriocapillary and subretinal pigmental epithelium basal laminar-like deposits (*141*). A model using liposomes has also been used to examine the effect of visible light on photosensitizers (*142*). When carotenoids were incorporated into a model using liposomal membranes, there was less lipid peroxidation and lysosomal lysis (*142*).

5.2.5. LIPOFUSCIN

Lipofuscin, a heterogeneous material composed of lipids, proteins, and different fluorescent compounds, accumulates within the retinal pigment epithelium with aging (*143*). Photoreceptor loss in the human retina has been associated with increasing lipofuscin accumulation (*144*). The age-related increase in lipofuscin may be an important mechanism in the pathogenesis of age-related macular degeneration. Lipofuscin appears as yellow-brown refractile granules, and these "aging pigments" are thought to be due to the accumulation of lysosomal residual bodies containing the end products of photoreceptor outer segment phagocytosis (*145,146*). Some of the fluorophores in retinal pigment epithelium appear to be metabolites of vitamin A (*147–149*). The fluorescence of lipofuscin granules increases with age (*146*). Lipofuscin may act as a sensitizer for the generation of reactive oxygen species, as singlet oxygen, superoxide anion, and hydrogen peroxide, can be produced on exposure to blue light (*150–153*). In an *in vitro* study, cultured human retinal pigment epithelium were fed lipofuscin granules, and on subsequent light exposure, severe damage was seen in these retinal pigment epithelial cells compared to control cells (*154*). Dietary

restriction of vitamin A (147) or caloric restriction (147) has been shown to reduce lipofuscin accumulation in rats.

5.2.6. VASCULAR ENDOTHELIAL GROWTH FACTOR

Vascular endothelial growth factor (VEGF) is an endothelial cell-specific mitogen and an inducer of angiogenesis (156). VEGF has been shown to play a role in retinal neovascularization (157), and the expression of VEGF is upregulated by hypoxia and oxidative stress through hypoxia-inducible factor (HIF)-1 α , which binds to the VEGF-A promoter and induces transcription and through nuclear factor (NF)- κ B, a transcription factor that is induced by redox balance (158).

5.3. Carotenoids

5.3.1. INTRODUCTION

Carotenoids are a group of pigments found in the plant and animal kingdoms that vary across the spectrum from yellow, orange, and red to violet in color. Fruits and vegetables are rich plant sources of carotenoids. There are more than 600 carotenoids found in nature, of which about 50 have been identified in the human diet (159) and 34 have been described in human serum (160). The major dietary carotenoids are α -carotene, β -carotene, β -cryptoxanthin, lycopene, lutein, and zeaxanthin. Of these, α -carotene, β -carotene, and β -cryptoxanthin can be converted into retinol and thus, have been termed provitamin A carotenoids. Lycopene, lutein, and zeaxanthin do not have vitamin A activity and are referred to as nonprovitamin A carotenoids. Recently, there has been a great deal of interest in carotenoids because epidemiological studies have shown associations between high intakes of fruits and vegetables and lower incidence of some cancers, decreased risk of cardiovascular disease, and reduced risk of age-related macular degeneration (161,162).

5.3.2. HISTORICAL BACKGROUND

Some of the major carotenoids were first isolated in the 19th century and early 20th century, and the advent of chromatography helped to accelerate scientific understanding of these substances. In 1831, Heinrich Wilhelm Ferdinand Wackenroder (1798–1854), an analytical chemist at the Pharmaceutical Institute in Jena, discovered *carotin* in the root of the carrot (163). William Christopher Zeise (1789–1847) conducted further investigations on *carotin* in Copenhagen and gave it an empirical formula of C_5H_8 (164). In his studies, August Husemann proposed that *carotin* contained oxygen (165), and in 1861, A. Arnaud established that *carotin* is a hydrocarbon (166). In 1869, Johann Ludwig Wilhelm Thudichum (1829–1901), a chemist at St. Thomas's Hospital in London, found that parts of plants and animals contain a yellow crystallizable substance, which he named "luteine" (167). A dark red pigment, later identified as lycopene, was isolated from *Tamus communis* in 1873 (168) and from tomatoes by the French botanist Pierre-Marie-Alexis Millardet (1838–1902) in 1875 (169). C. A. Schunck showed that the red pigment isolated from tomatoes, which he termed lycopene, has a different absorption spectrum than carotene (170). In 1907, the correct formula $C_{40}H_{56}$ was assigned to carotene by Richard Willstätter (1873–1942), and 3 yr later, Willstätter determined that lycopene, with the formula $C_{40}H_{56}$, is an isomer of carotene. Lutein was isolated from egg yolk in 1912 by Willstätter and Escher (171).

The term *carotenoids* was originally proposed in 1911 by Mikhail Semenovitch Tswett (or Tsvett) (1872–1919), a botanist in Warsaw who pioneered the chromatographic analysis of plant pigments (172,173). By 1922, six carotenoids had been crystallized and analyzed (carotene, lycopene, xanthophyll, lutein, fucoxanthin, and rhodoxanthin) (174). In 1929, a new carotenoid, zeaxanthin, was isolated from maize by Karrer and associates (175,176), and its chemical structure was described in 1931–1932 (177,178). The conversion of β -carotene to vitamin A was demonstrated in 1930 (179). Paul Karrer (1889–1971), a Swiss chemist, elucidated the structures of vitamin A and β -carotene (180,181), two scientific accomplishments for which he received the Nobel Prize in chemistry in 1937.

5.3.3. BIOCHEMISTRY OF THE CAROTENOIDS

Carotenoids are characterized by a polyisoprenoid structure, a long conjugated chain of double bonds known as the polyene chain, and near symmetry around a central double bond (182). In general, well known trivial names based on the source from which the carotenoid was isolated—such as lycopene and zeaxanthin—are used instead of the structural name based on accepted chemical nomenclature (183). The polyene chain consists of a central, long system of alternating double and single bonds, and in this conjugated system, the π -electrons are effectively delocalized over the length of the chain (182). Dietary carotenoids that are the most common in human plasma are either carotenes, 40-carbon hydrocarbons, or xanthophylls (oxocarotenoids), 40-carbon hydroxylated compounds. Carotenes include α -carotene, β -carotene, and lycopene, and xanthophylls include lutein, zeaxanthin, and β -cryptoxanthin (Fig. 7). Carotene consists of polyenes with carbon and hydrogen only, whereas xanthophylls consist of oxygenated polyenes. The all-*trans* isomer is the most common and stable form of carotenoids found in foods, but *cis* isomers exist and may also be produced by heating, as in cooking (159).

Carotenoids are hydrophobic molecules, and thus, carotenoids interact with lipophilic elements of the cell, such as the lipid membrane bilayer. Carotenoids are commonly located within cell membranes, and the location of specific carotenoids within the membrane structure depends on the chemical structure of the carotenoid. The physical properties of carotenoids include the absorption of visible light, the ability to play a role in singlet-singlet energy transfer, and the ability to quench singlet oxygen (184). The long conjugated double bond system of carotenoids allows the carotenoids to absorb light, and the absorption of visible light depends on their specific chemical structure. The absorption of light energy produces a transition $\pi \rightarrow \pi^*$ in which one of bonding π -electrons of the polyene chain is promoted to a previously unoccupied π^* antibonding orbital (182). The π -electrons are delocalized over the polyene chain, and the energy that is needed to produce the transition of $\pi \rightarrow \pi^*$ is small and corresponds to light in the visible spectrum of 400–500 nm (182). Lutein and zeaxanthin are yellow carotenoids that absorb blue light. β -carotene appears orange, and lycopene absorbs light at longer wavelengths and appears red. In photosynthesis, carotenoids act as antenna pigments, absorb light, and transfer this energy to chlorophylls (185).

The carotenoids have distinctive photochemical properties related to having two low-lying electronic excited singlet states (186). The strong absorption of light in the visible region has been attributed to the transition from the ground state S_0 to the second singlet excited state S_2 (182). Carotenoids can also accept excitation energy from highly reactive singlet oxygen, 1O_2 , and this allows carotenoids to protect against damage caused by a

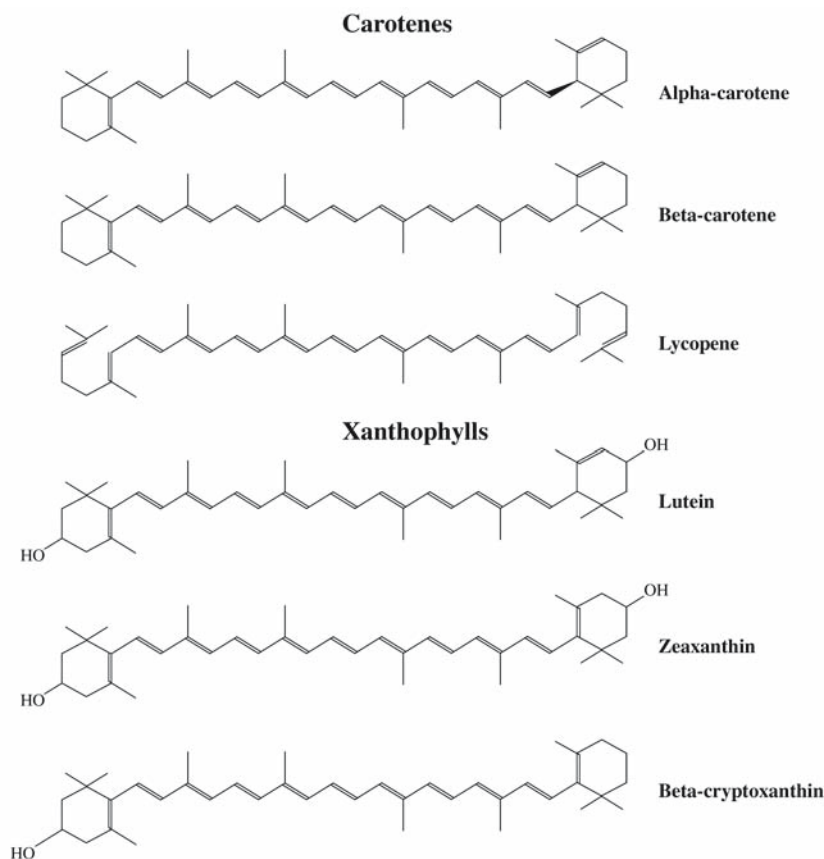
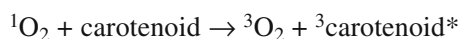
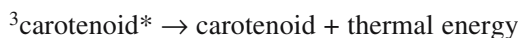

Fig. 7. Structures of major dietary carotenoids.

combination of light and oxygen (187,188). Singlet oxygen is highly reactive and can damage DNA and lipids. The reaction with singlet oxygen generates a triplet excited carotenoid:



The triplet excited carotenoid then dissipates the energy harmlessly through rotational and vibrational interactions to recover the ground state:



Thus, carotenoids can serve to deactivate potentially harmful $^1\text{O}_2$ (188). The ability of carotenoids to protect against photosensitization depends on the number of conjugated double bonds (189). Carotenoids can also quench peroxy radicals (190) and can inhibit lipid peroxidation (191). The carotenoids were the first singlet oxygen quenchers to be characterized and are among the most effective quenchers known (192). Of the major dietary carotenoids in humans, lycopene appears to have the best singlet oxygen quenching ability (193).

5.3.4. DIETARY SOURCES OF CAROTENOIDS

The three major dietary carotenoids in the US diet are β -carotene, lutein, and lycopene (194). Vegetables and fruits such as carrots, spinach, collard greens, apricots, and cantal-

Table 4
Lutein and Zeaxanthin Concentrations in Some Foods (Mole %)

<i>Food</i>	<i>Lutein</i>	<i>Zeaxanthin</i>
Orange pepper	8	37
Egg yolk	54	35
Corn	60	25
Orange juice	15	20
Honeydew melon	17	18
Mango	2	16
Orange	7	15
Red seedless grapes	43	10
Zucchini squash	47	5
Kiwi fruit	54	0
Pumpkin	49	0
Spinach	47	0
Broccoli	22	0

loupe are rich in β -carotene. Tomatos are a rich source of lycopene. Lutein and zeaxanthin, which accumulate in the human macula, are found in high concentrations in food sources such as egg yolk, corn, orange juice, honeydew melon, and orange pepper (195) (Table 4). The carotenoid content of normal US diet is 1.3–3 mg/d of lutein and zeaxanthin combined and about 2.5–3.5 mg/d of β -carotene (194,196). Most studies of the carotenoid composition of foods provide data on lutein and zeaxanthin together or lutein alone (197), as special laboratory techniques are needed to provide separation of lutein and zeaxanthin peaks in high performance liquid chromatography analyses. The human diet is dominated by one stereoisomer of lutein, 3*R*,3'*R*,6'*R*)- β , ϵ -carotene-3,3'-diol, and one stereoisomer of zeaxanthin, the 3*R*,3'*R* stereoisomer (85). The ratio of lutein to zeaxanthin in the human diet ranges from 7:1 to 4:1 (85). Although in the US diet, lutein dominates over zeaxanthin, in some parts of the world where the corn is the main dietary staple, zeaxanthin may potentially dominate over lutein. Fresh spinach and corn meal may contain small amounts of 13-*cis*-lutein and 13-*cis*-zeaxanthin, and these isomers may be found in human plasma (198).

5.3.5. ABSORPTION, STORAGE, AND METABOLISM OF CAROTENOIDS

The absorption of carotenoids depends on several factors, including the matrix within the fruit or vegetable, the physical processing of the foods during cooking and preparation, and the amount of fat consumed with the meal. The amount of carotenoids that is absorbed may vary widely, with greater than 50% absorption of carotenoids in palm oil or pharmacological preparations to as low as 1–2% with raw carrots (199). The bioavailability of carotenoids in foods is increased both by cooking and by decreasing the particle size of the food through slicing, chopping, or blending. Heating is thought to denature the protein in protein-pigment complexes in plant tissues and allow the release of carotenoids (199). More prolonged heating or higher temperatures in cooking may convert many of the carotenoids with all-*trans* configuration to *cis* isomers (200). After foods containing carotenoids are ingested, the carotenoids are incorporated into micelles within

the intestinal lumen. Carotenoids are insoluble in water and must be solubilized within bile acid micelles to facilitate absorption. Micelles with carotenoids are passively absorbed across the brush border of enterocytes. Low levels or absence of dietary fat will greatly reduce the absorption of carotenoids (201,202).

Carotenoids taken in large amounts may interfere with one another's absorption (203,204). β -carotene in large amounts can interfere with the absorption of lutein (203,204). Healthy men who took purified β -carotene in capsules (12 and 30 mg) daily for 6 wk showed significant declines in plasma lutein concentrations, suggesting that pharmacological doses of β -carotene can interfere with lutein absorption or metabolism (205). The absorption and metabolism of carotenoids may also be affected by intake of vitamin E, by alcohol intake, malabsorption, intestinal parasites, thyroid status, and liver disease (199). Vitamin A, iron, and zinc status may affect the carotenoid absorption and metabolism (199). Consumption of alcohol has been reported to increase plasma α -carotene and β -carotene concentrations and decrease lutein/zeaxanthin concentrations in nonsmoking, premenopausal women (206). Plasma carotenoid concentrations appear to respond fairly rapidly to changes in dietary intake of carotenoids. In eleven healthy subjects, plasma carotenoid concentrations fell by about 60% after 2 wk on a low-carotenoid diet (207).

Carotenoids that are taken up by enterocytes may be secreted into lymph unchanged or may be subject to enzymatic cleavage, which may occur centrally or asymmetrically. β -carotene, for example, may be cleaved centrally by β -carotene 15,15'-dioxygenase or by excentric cleavage mechanisms (208,209). Some β -carotene is converted to vitamin A within enterocytes. Excentric cleavage of carotenoids can result in a variety of aldehyde, alcohol, and epoxide metabolites, and the functions, if any, of these derivatives are largely unknown (159). Carotenoids are transported in lymph within chylomicrons to the general circulation. Lipoprotein lipase hydrolyzes much of the triglyceride in the chylomicron, which yields a chylomicron remnant that is taken up largely by hepatocytes (159). Hepatocytes incorporate dietary carotenoids into lipoproteins, and under fasting conditions, up to 75% of hydrocarbon carotenoids in plasma are found in the low-density lipoprotein (LDL) fraction (210). Under fasting conditions, α -carotene, β -carotene, and lycopene are found primarily in the LDL fraction and lutein and zeaxanthin are found in the high-density lipoprotein (HDL) fraction (209). The estimated total body content of carotenoids is 140 mg, of which 84% is found in adipose tissue and 10% is found in the liver (210). The relative concentrations of carotenoids in various tissues in the human body are shown in Table 5 (211–214). The retina contains the highest concentration of carotenoids found in the human body.

Experimental animal studies involving carotenoids are limited because absorption of carotenoids is relatively poor in rodents such as rats, mice, and hamsters (208). In addition, other species such as chicks, rabbits, pigs, and sheep break down β -carotene in the gastrointestinal tract and absorb little β -carotene intact (208). In contrast, humans can absorb a small amount of β -carotene intact and can accumulate relatively large concentrations of carotenoids. The ferret, *Mustela putorius*, appears to absorb carotenoids in a manner similar to humans, and the ferret has been used as a model for β -carotene metabolism (208).

5.3.6. GENERAL FUNCTIONS OF CAROTENOIDS

The carotenoids are perhaps best described as being conditionally essential nutrients, as suboptimal health may result from low intake of particular carotenoids. By definition,

Table 5
Reported Concentrations of Mixed Carotenoids in Human Tissues

<i>Tissue</i>	<i>Carotenoid concentrations</i>	
	<i>(nmol/g)</i>	<i>Reference</i>
Macula ^a	100.7	211
Adrenal gland	33.7	212
	9.4	214
Testes	26.3	212
	7.6	214
Liver	5.0	212
	5.1	214
	5.1	213
Fat	3.3	212
	0.8	214
Ovaries	2.6	212
	0.9	214
Serum	1.1	214
Brain	<0.04	214

^aLutein plus zeaxanthin in perifoveal retina, per g protein.

carotenoids are not essential nutrients, as a low or absent intake of carotenoids, in the presence of an adequate intake of preformed vitamin A, do not result in signs of a deficiency disease and death. Lutein and zeaxanthin might be considered to be conditionally essential nutrients, as strong evidence is accumulating that these two carotenoids are essential for eye health (215). The best-documented function of carotenoids for human health is the role of provitamin A carotenoids as precursors to vitamin A (159). Carotenoids may play a role as antioxidants (216,217), as immune enhancers (218), as mediators of gap junction communication (219), and may influence reproduction. Carotenoids have been described as being both prooxidants and antioxidants (217). β -carotene has been shown to act as a prooxidant, but this may occur under experimental conditions of high oxygen tension or high carotenoid concentrations that might not be relevant to human physiology (217). In humans, in vivo studies suggest that dietary carotenoids may reduce some laboratory biomarkers for oxidative stress, such as plasma malondialdehyde concentrations (considered a marker for lipid peroxidation) and 8-OHdG (considered a marker for DNA damage) (217). Potential roles for carotenoids in the retina are presented in detail under Subheading 5.3.9.

5.3.7. REQUIREMENTS FOR CAROTENOIDS

Currently, there is insufficient evidence to define dietary reference intakes for the major dietary carotenoids, although sufficient data exist to support existing recommendations for increased consumption of fruits and vegetables (220).

5.3.8. ASSESSMENT OF CAROTENOID STATUS

Serum or plasma carotenoid concentrations are considered the best indicator of carotenoid status (220), but this laboratory assay requires analysis by high performance liquid chromatography and storage of plasma or serum samples at -70°C . In NHANES III (1988–

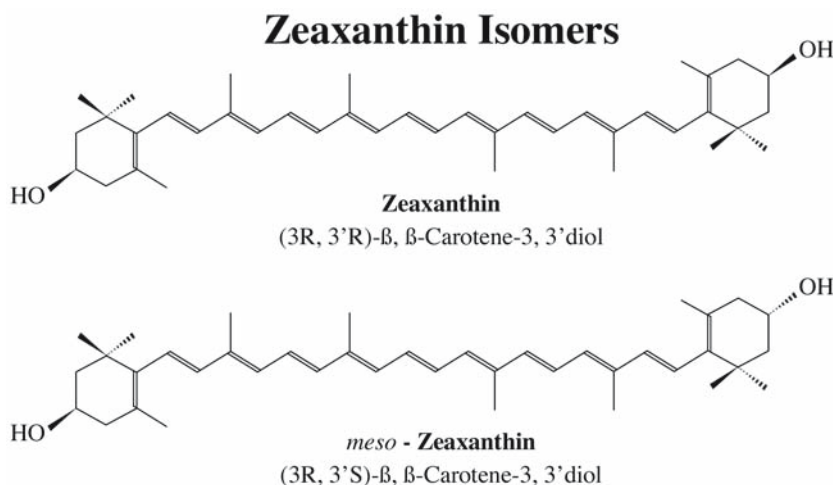


Fig. 8. Zeaxanthin isomers. (After ref. 227.)

1994), the median concentrations of lutein + zeaxanthin (not separated in this laboratory procedure) for 40-yr-old adults was $0.35 \mu\text{mol/L}$ with a 5th and 95th percentile of 0.16 and $0.72 \mu\text{mol/L}$, respectively (159). Food frequency questionnaires can be used to assess dietary intake of carotenoids. In older adults, reasonable correlations have been described between estimated intakes of α -carotene, β -carotene, β -cryptoxanthin, and lycopene and their respective plasma concentrations, but correlations were weak for lutein/zeaxanthin (221). Correlations between plasma carotenoids and dietary intake estimated by food frequency questionnaires may be better among younger than older adults (222).

5.3.9. ROLE OF CAROTENOIDS IN THE RETINA

Macular pigment consists primarily of two carotenoids, lutein and zeaxanthin (223–226). These carotenoids have an intense coloration due to extensive conjugation in the polyene chain (85) and give the macula its yellowish color. Zeaxanthin is found as two isomers, 3R, 3'R-zeaxanthin and *meso*-zeaxanthin (227) (Fig. 8). Zeaxanthin and *meso*-zeaxanthin differ in relation to the stereochemistry of the secondary hydroxyl groups at the 3' position. Lutein, zeaxanthin, and *meso*-zeaxanthin represent about 36%, 18%, and 18% of the total carotenoid content of the retina (85). Several minor carotenoids, consisting of additional isomers of both lutein and zeaxanthin, have also been identified in retinal extracts (228). In the inner macula, the concentration of zeaxanthin is approximately twice that of lutein, but lutein becomes the dominant carotenoid with increasing eccentricity from the fovea (229). Studies in primates show that there is a high degree of symmetry in the lutein and zeaxanthin concentrations in corresponding sections of the retinas between the left and right eyes of individual animals (230). The distribution of macular pigment stereoisomers in the human retina has been mapped. In the adult retina, the concentration of lutein increases and the concentration of *meso*-zeaxanthin decreases with radial distance from the fovea (229). The concentration of macular pigment reaches almost 1 mM within the central macula, which is about three times the concentration of carotenoids in normal human sera (85). In the primate retina, the highest concentrations of macular pigment are located in the inner retinal layers (231,232) (Fig. 9).

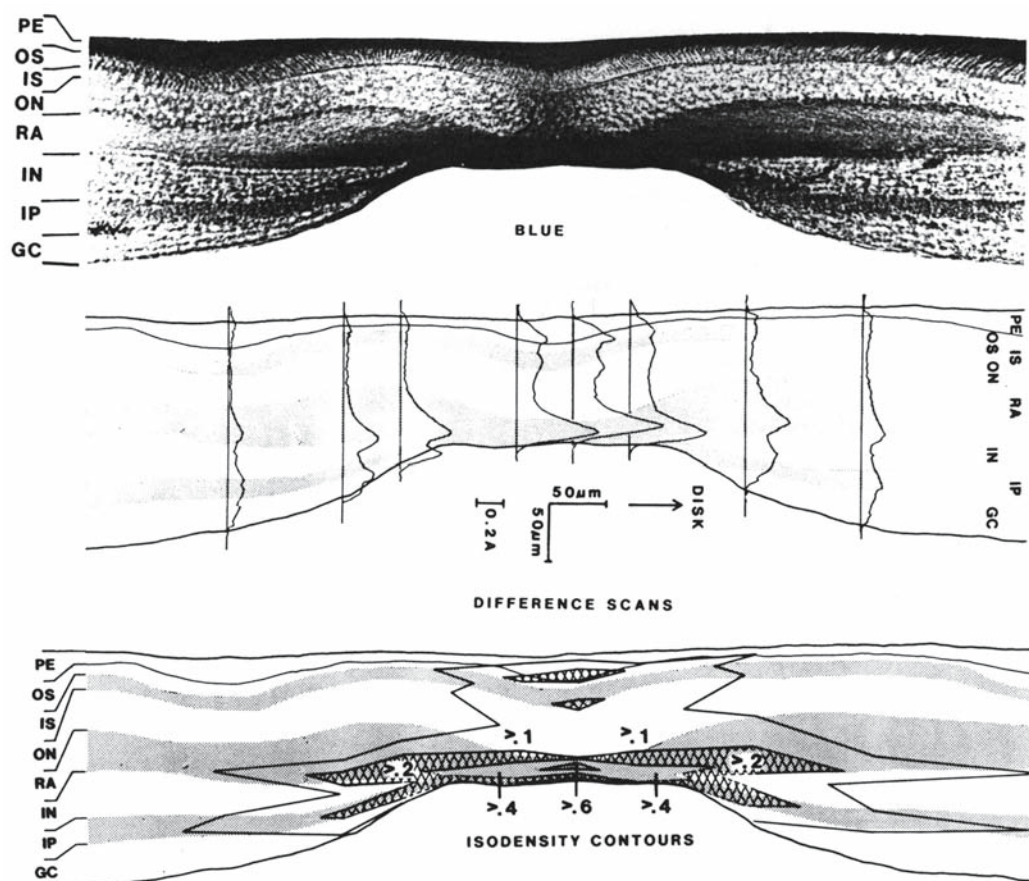


Fig. 9. Cross-sections of a rhesus macaque macula showing the distribution of macular pigment (dark region). Highest concentrations of macular pigment are in the inner retinal layers, lying between incipient light and the photoreceptors. (Reprinted from ref. 252, with permission of *Investigative Ophthalmology & Visual Science*.)

Serum lutein and zeaxanthin concentrations have been positively correlated with macular pigment density in human subjects (233). A high concentration of lutein has been described in subretinal fluid in subjects with rhegmatogenous retinal detachment, which supports the hypothesis that lutein is transported from the blood into the retina (234). The isomer *meso*-zeaxanthin is found in human serum in extremely low concentrations, and it is not clear whether *meso*-zeaxanthin in the plasma is the source for *meso*-zeaxanthin in the retina (85). It has been hypothesized that a yet undescribed isomerase converts lutein to *meso*-zeaxanthin by migration of the 4',5' double bond in lutein to the 5',6' position to form *meso*-zeaxanthin (229). In the human eye, iris, ciliary body, and retinal pigment epithelium and choroid also contain high concentrations of carotenoids, accounting for about one-half of the eye's total carotenoids and about 30% of the total lutein and zeaxanthin found in the eye (235). Carotenoids have been reported to bind to tubulin with the receptor axon layer of the fovea (236), specifically to the paclitaxel-binding site of the β -tubulin subunit of microtubules in the primate retina (237). Other reports show that lutein and zeaxanthin are associated with rod outer segments in the peripheral retina of humans

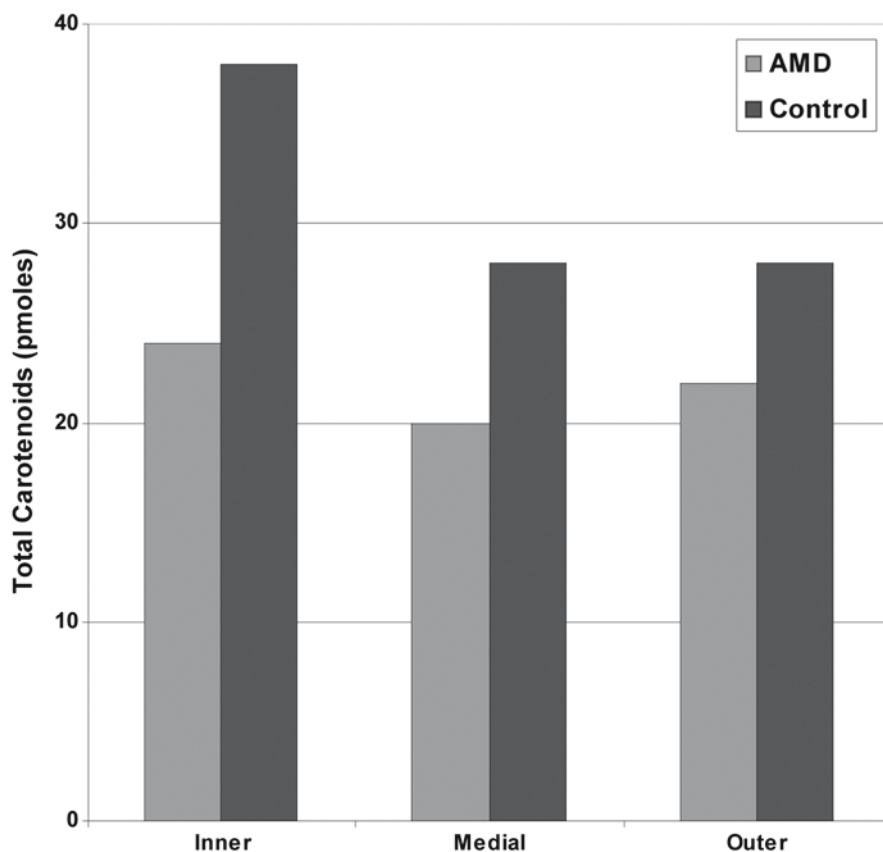


Fig. 10. Comparisons of the mean total concentrations of lutein and zeaxanthin in the inner, medial, and outer regions of the retina in donor eyes with age-related macular degeneration and control eyes. (Reprinted from ref. 239, with permission of *Investigative Ophthalmology & Visual Science*.)

(238), and the concentrations of lutein and zeaxanthin in rod outer segment membranes is 2.7 times more concentrated in the perifoveal compared with the peripheral retinal region (231). The mean total concentrations of lutein and zeaxanthin in the inner, medial, and outer regions of the retina are lower in human eyes with age-related macular degeneration compared with control eyes (239) (Fig. 10).

Macular pigment absorbs and attenuates blue light (240). Currently, the hypothesis that has received the most active investigation is that macular pigment serves to protect the retina from excessive oxidative stress (85). The functions of macular pigment may also include the reduction of chromatic aberration (241), thus, an alternative or perhaps complementary hypothesis is that macular pigment improves visual resolution by absorbing short-wave light (242). Older adults showed a differential loss of sensitivity of short-wavelength-sensitive-cone (S-cone) in the retinal periphery compared with younger adults, suggesting that macular pigment may protect the fovea from light damage (243).

Macular pigment density has been studied in detail in humans using noninvasive psychophysical measurements with tabletop devices that employ light-emitting diodes (244). In a study of 217 subjects, macular pigment density appeared to decline with age, and lower macular pigment density was significantly lower in women than men, was lower

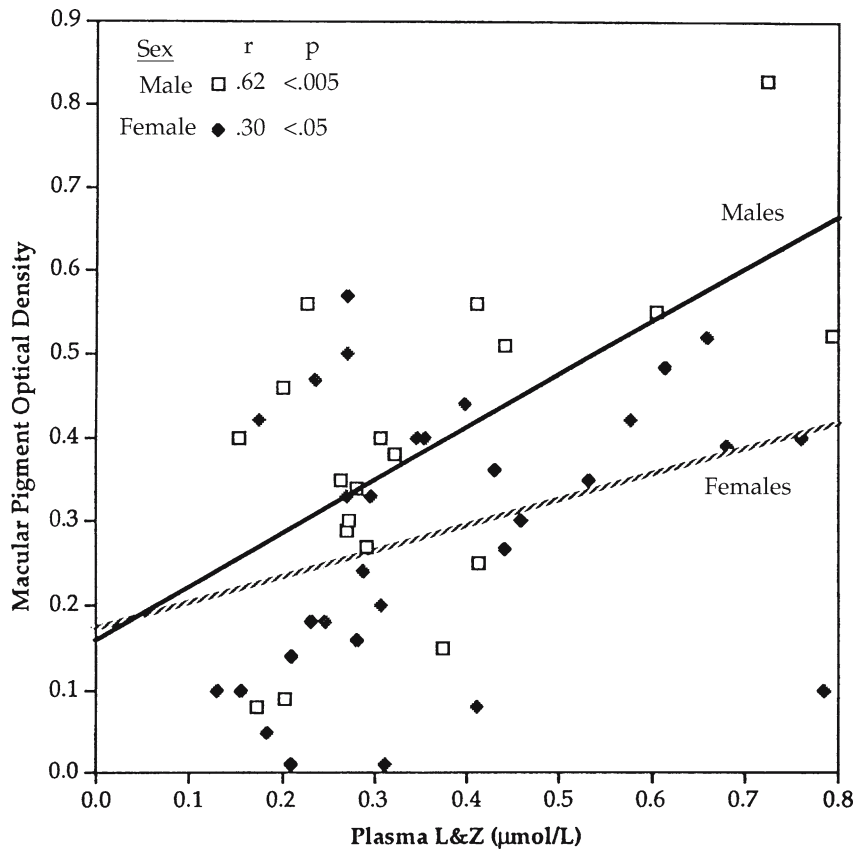


Fig. 11. Relationship of macular pigment optical density to plasma lutein and zeaxanthin concentrations for men ($r=0.62$) and females ($r=0.30$). (Reprinted from ref. 247, with permission of Elsevier.)

in those with light versus dark colored irises, and was low among current smokers who smoked >10 cigarettes per day (245). Macular pigment density appears to be well correlated between the two eyes of the same individual (246). Males have been shown to have higher macular pigment densities than females, despite similar plasma carotenoid concentrations (247). Plasma lutein and zeaxanthin concentrations were positively correlated with macular pigment density among both men and women (247) (Fig. 11). Visual sensitivity appears to be preserved in older adults who have high macular pigment density (248). Among individuals with stable dietary patterns, macular pigment densities appear to change little over time (249). Studies in monozygotic twins suggest that macular pigment density may vary according to dietary intake (250).

There have not been many experimental animal studies of carotenoid deprivation, partly because of the limitations mentioned under Subheading 5.3.5. In one study, monkeys raised on a xanthophyll-free diet showed a total loss of macular pigment that was accompanied by an increase in drusen-like bodies at the level of pigment epithelium (251). Another study showed that no detectable macular pigment and practically no plasma xanthophylls were found in monkeys raised on semipurified diets without carotenoids, and clinical histopathology showed vacuolated retinal pigment epithelial cells that corresponded to window defects in the retinal pigment epithelium (252).

5.3.10. INTERVENTION STUDIES WITH CAROTENOIDS

Some pilot intervention studies have used carotenoids to increase macular pigment or improve vision. Spinach and corn are rich and easily accessible dietary sources of lutein and zeaxanthin. In one trial, 13 subjects received spinach and corn, spinach alone, or corn alone, and increases in macular pigment density were seen in most, but not all, subjects after 4 wk (253). In another study, two subjects consumed lutein esters, equivalent of 30 mg of free lutein per day, for 140 d. Over the first 40 d, serum concentrations of lutein increased 10-fold, and macular pigment density increased by 21% and 39% in the two subjects (254). The investigators estimated that lutein supplementation may have produced a 30–40% reduction in blue light reaching the photoreceptors, Bruch's membrane, and the retinal pigment epithelium (254). In another dietary intervention study, seven subjects consumed spinach and corn daily for 15 wk, and macular pigment density and carotenoid concentrations in serum, buccal mucosal cells, and adipose tissue were measured at baseline, 4, 8, and 15 wk and 2 mo postintervention (255). Daily consumption of spinach and corn resulted in a significant increase in macular pigment density at 4 wk compared to baseline. In a cross-sectional study, lutein concentrations in adipose tissue and macular pigment were compared between 13 women and 8 men. There was a significant positive correlation between lutein concentrations and adipose tissue and macular pigment among men, but a negative correlation among women, suggesting that there may be sex differences in lutein metabolism (255). Lutein supplementation of 20 mg lutein ester/day increased macular pigment optical density in patients with age-related maculopathy (256).

In a small uncontrolled study, 14 male patients with atrophic age-related macular degeneration received 5 oz of spinach, four to seven times per week (257). Short-term improvement in visual function was found in one or both eyes (257). Lutein supplementation was associated with short-term visual improvement among subjects with retinitis pigmentosa and related retinal degenerations who were recruited and followed via the internet (258). In another study of lutein supplementation, 20 mg/d, for 58 patients with retinitis pigmentosa or Usher syndrome, serum lutein concentrations increased significantly by 6 mo, but only about half of the patients showed an increase in macular pigment density (259). Carotenoid extracts from the Gou Zi Qi berry (*Lycium chinense*) contain high concentrations of zeaxanthin, and retinal zeaxanthin increased after supplementation in rhesus monkeys (260). Recently, a clinical trial was conducted with 90 adults at a Veterans Administration hospital who had atrophic age-related degeneration (261). Participants were randomized to receive lutein, 10 mg/d, or lutein 10 mg/d in combination with an antioxidant, multivitamin and mineral supplement, or a placebo for 12 mo. There was a small improvement in Snellen equivalent visual acuity by 5.4 letters in the lutein only group and 3.5 letters in the lutein plus antioxidant, multivitamin, and mineral supplement group compared with placebo (261). Some studies that have attempted to increase macular pigment or improve vision by dietary modification and supplementation are highlighted in Table 6.

5.4. Vitamin E

5.4.1. INTRODUCTION

Vitamin E is a term used to describe a group of lipid soluble tocol and tocotrienol derivatives that are considered to have vitamin E activity. There are eight naturally occurring forms of vitamin E, but α -tocopherol appears to be the most biologically relevant form

Table 6
Interventional Studies of Nutrients and Age-Related Macular Degeneration (ARMD)

<i>Subjects</i>	<i>Observations</i>	<i>Reference</i>
Healthy adults (<i>n</i> = 13)	Subjects received daily spinach and corn (<i>n</i> = 11) or corn only (<i>n</i> = 2), and increases in macular pigment density noted in most but not all subjects after 4 wk; no controls	253
Healthy adults (<i>n</i> = 2)	Lutein supplement, 30 mg/d for 140 d, resulted in 10-fold increase in serum lutein and 21% and 39% increase in macular pigment density in the two subjects; no controls	254
Healthy adults (<i>n</i> = 7)	Daily corn and spinach consumption for 15 wk resulted in increased macular pigment density, increase in serum lutein; no controls	255
Adults with atrophic AMD (<i>n</i> = 14)	Subjects consumed 4–7 portions of spinach, 5 oz, per week; short term improvement found in visual function in one or both eyes; no controls	257
Adults with atrophic AMD (<i>n</i> = 90)	Subjects received either lutein 10 mg, lutein 10 mg plus antioxidants and vitamins and minerals, or placebo for 12 mo. Improvement of Snellen equivalent visual acuity by 5.4 letters in lutein-only group, 3.5 letters in lutein plus other antioxidants, vitamins, and minerals group, vs placebo	261

of vitamin E for human health (220). Vitamin E is thought to function as an antioxidant and appears to protect polyunsaturated fatty acids from oxidative damage. Although vitamin E has been implicated in the pathogenesis of age-related macular degeneration, a recent large clinical trial shows that high-dose vitamin E supplementation alone has no effect on the incidence of age-related macular degeneration (262).

5.4.2. HISTORICAL BACKGROUND

In 1922, Herbert McLean Evans (1882–1971) and Katherine Scott Bishop (1889–1976) demonstrated the existence of a dietary factor that was essential for reproduction in rats (263). This factor became known as the “antisterility vitamin” or “X factor,” and was later named vitamin E by Barnett Sure (1891–1960) in 1924 (264). Following the isolation of pure vitamin E, the name tocopherol was proposed, from the Greek, *tokos* (offspring) and *pherein* (to bear) with the suffix -ol, signifying an alcohol (265). A large international symposium on vitamin E was organized in London in 1939 by the Society of Chemical Industry (266).

5.4.3. BIOCHEMISTRY OF VITAMIN E

The eight naturally occurring forms of vitamin E are α -, β -, γ -, and δ -tocopherol and α -, β -, γ -, and δ -tocotrienol. The tocopherols consist of a chromanol ring with a long saturated (phytyl) side chain, and the tocotrienols consist of chromanol ring with an unsaturated side chain. Because the β -, γ -, and δ -tocopherols and α -, β -, γ -, and δ -tocotrienols are not converted to α -tocopherol by the α -tocopherol transfer protein in the liver, these seven other natural forms of vitamin E are not considered to contribute towards the vitamin E requirement of humans. The liver maintains concentrations of α -tocopherol in plasma, and the only stereoisomers that are maintained are *RRR*- α -tocopherol (2,5,7,8-tetramethyl-2*R*-(4'*R*, 8'*R*, 12' trimethyltridecyl)-6-chromanol), which occurs in foods, and 2*R*-stereoisomeric forms of α -tocopherol that are found in synthetic all racemic- α -tocopherol which include “*d*- α -tocopherol” (220) (Fig. 12). 2*S*-stereoisomers of synthetic, all racemic- α -tocopherol are not maintained in human plasma (267,268) or tissues (220) and do not contribute towards the vitamin E requirements of humans. γ -tocopherol, found in human plasma in low concentrations, is not transported to tissues but is metabolized and excreted.

5.4.4. DIETARY SOURCES OF VITAMIN E

The richest food sources of vitamin E are certain oils, such as wheat germ oil, sunflower oil, and safflower oil, sunflower seeds, almonds, peanut butter, wheat germ and margarine. The vitamin E content of some common foods is shown in Table 7 (269). Beef, chicken, fish, and most fruits and vegetables have little vitamin E. Rich sources of *RRR*- α -tocopherol, the most important source of vitamin E for humans, are wheat germ oil, safflower oil, and sunflower oil, whereas corn and soy oils are richer in γ -tocopherol. Vitamin E supplements are often labeled as “natural vitamin E” or “*d*- α -tocopherol” and consist of *RRR*- α -tocopherol that has been manufactured by methylation of γ -tocopherol found in vegetable oils.

5.4.5. ABSORPTION, STORAGE, AND METABOLISM OF VITAMIN E

The absorption of vitamin E is facilitated by biliary and pancreatic secretions and the formation of micelles in the gastrointestinal lumen (Fig. 13). As with other lipids, vitamin E

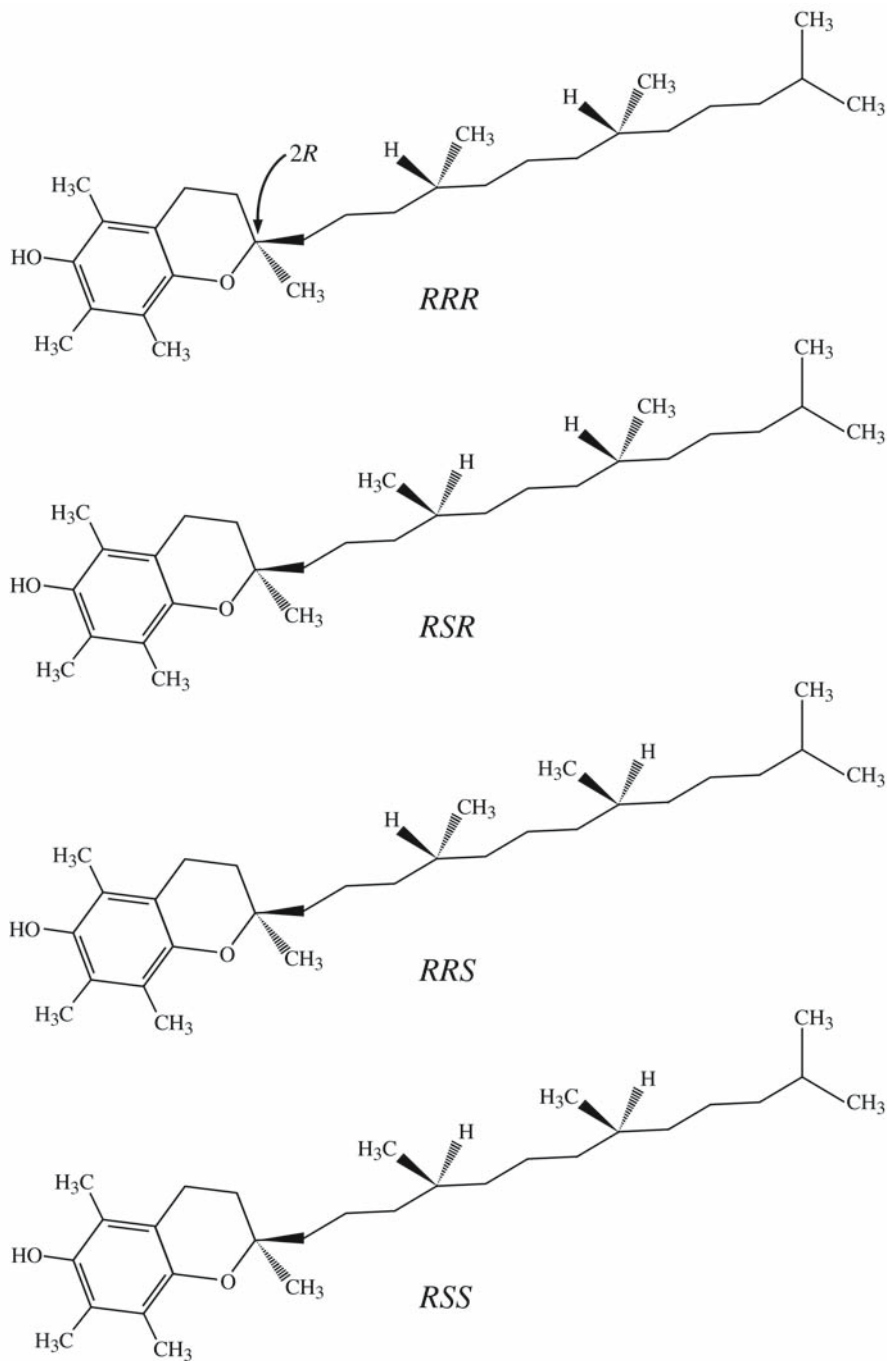


Fig. 12. Isomers of α -tocopherol.

is emulsified in the stomach and small intestine and mixed with bile acids and pancreatic secretions. The vitamin E in supplements is usually manufactured in the form of tocopheryl esters, which require pancreatic esterases for hydrolytic cleavage. Vitamin E is passively absorbed across the brush border of enterocytes in the small intestine. Enterocytes secrete vitamin E to chylomicrons in the lymph, and the enterocytes do not appear

Table 7
Vitamin E Content of Some Foods

<i>Food</i>	<i>Vitamin E (mg/100 g)</i>
Wheat germ oil	150
Sunflower oil, linoleic (less than 60%)	41
Sunflower seeds	39
Almonds	26
Peanut oil	16
Corn oil, salad or cooking	14
Margarine, regular, hard, corn (hydrogenated)	12
Peanut butter, smooth style, no salt	8
Peanuts, all types, raw	8
Spinach, cooked, boiled, drained	2
Butter	2
Whole egg, hard-boiled	1
Ground beef, 10% fat	0.4
Chicken breast, roasted	0.3
Whole wheat bread, commercially prepared	0.3
Apples, raw with skin	0.2

From ref. 269, with some values rounded for clarity.

to discriminate between forms of vitamin E in the packaging of chylomicrons. *RRR*- α -tocopherol appears to be better absorbed than other forms of vitamin E (220). The absorption of vitamin E has been variously reported to range from 15% to 85% (270–272), and the proportion of vitamin E that is absorbed decreases with increasing intake of vitamin E (273,274).

The liver takes up chylomicron remnants which contain vitamin E. Vitamin E is secreted from the liver in very low-density lipoproteins (VLDLs), and α -tocopherol is the only form of vitamin E to be resecreted by the liver (275). Hepatic α -tocopherol transfer protein transfers α -tocopherol between liposomes and microsomes (276). The major lipoprotein in VLDLs is apolipoprotein B-100, which is retained as VLDLs are catabolized by lipoprotein lipase to form LDLs and HDLs. LDLs interact with receptors for apolipoprotein B in peripheral tissues (276). High concentrations of α -tocopherol are found in adipose tissue, the adrenal glands, liver, and skeletal muscle. More than 90% of the vitamin E in the human body is found in fat droplets in adipose tissue (277).

5.4.6. FUNCTION OF VITAMIN E

The main function of vitamin E appears to be as an antioxidant which protects membranes and lipoproteins against excessive lipid peroxidation. No specific, required metabolic function has yet been identified for vitamin E. Vitamin E appears to protect polyunsaturated fatty acids within membrane phospholipids and plasma proteins by scavenging peroxy radicals (276,278). Lipid oxidation can occur during normal aerobic metabolism and during disease processes. Polyunsaturated fatty acids can give up loosely bound hydrogen to highly reactive free radicals, thus becoming fatty acid radicals. Fatty acid radicals take up oxygen and become peroxy radicals, where they can attack further polyun-

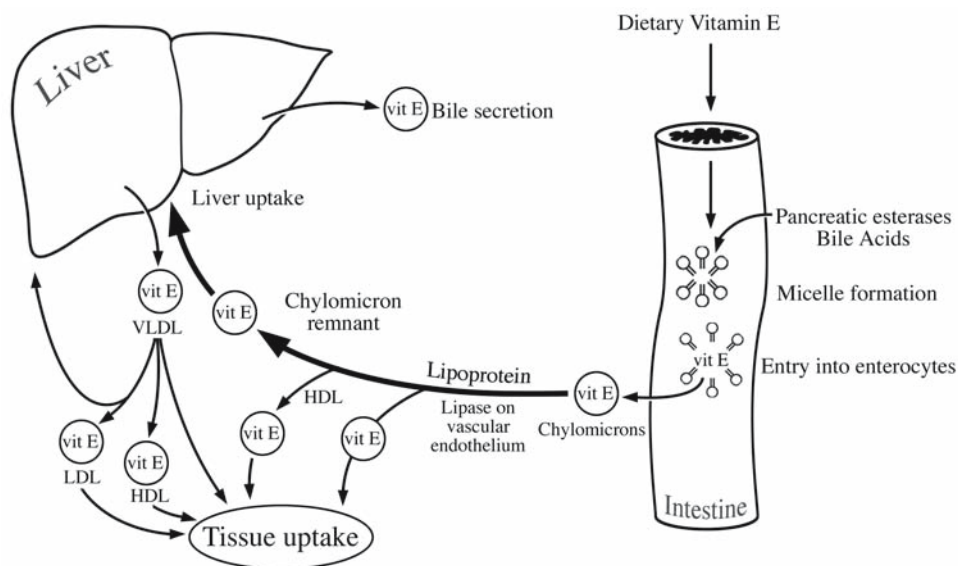
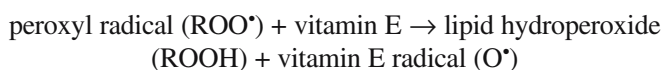
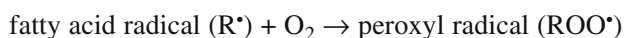
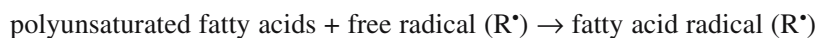
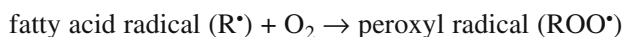
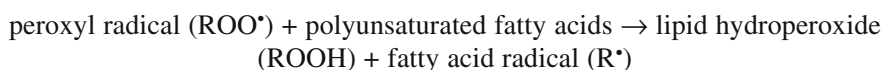


Fig. 13. Absorption, storage and metabolism of α -tocopherol.

saturated fatty acids. Vitamin E protects polyunsaturated fatty acids against autoxidation by breaking this chain by trapping peroxy radicals and yielding a stable lipid hydroperoxide molecule:



In the absence of vitamin E, the chain reaction can continue with autoxidation of polyunsaturated fatty acids:



One tocopherol molecule can protect about 100 molecules of polyunsaturated fatty acids from autoxidative damage, and biological membranes usually contain about 1% as many molecules of vitamin E per molecules of polyunsaturated fatty acids (276). Other activities of vitamin E may include scavenging of singlet oxygen (279).

5.4.7. REQUIREMENTS FOR VITAMIN E

The dietary reference intakes for vitamin E have been determined recently (220) (Table 8). The Adequate Intake (AI) is the recommended level of intake for infants. The Estimated Average Requirement (EAR) is the daily intake value that is estimated to meet the requirement of half of the healthy individuals in a group. The Recommended Dietary Allowance (RDA) is defined as the EAR plus twice the coefficient of variation (CV) to cover 97–98% of individuals in any particular group.

Table 8
Dietary Reference Intakes for Vitamin E (mg/d of α -Tocopherol)

<i>Age and gender category</i>	<i>AI</i>	<i>EAR</i>	<i>RDA</i>
Infants, 0–6 mo	5	–	–
Infants, 7–12 mo	5	–	–
Children, 1–3 yr	–	5	6
Children, 4–8 yr	–	6	7
Boys and girls, 9–13 yr	–	9	11
Boys and girls, 14–18 yr	–	12	15
Adult men ≥ 19 yr	–	12	15
Adult women ≥ 19 yr	–	12	15
Pregnant women	–	12	15
Lactating women	–	16	19

AI, Adequate Intake; EAR, Estimated Average Requirement; RDA, Recommended Dietary Allowance. Based on ref. 220.

5.4.8. EPIDEMIOLOGY OF VITAMIN E DEFICIENCY

Clinical vitamin E deficiency is rare in humans. Premature infants are at higher risk of vitamin E deficiency, which can result in a hemolytic anemia. Among older infants, children, and adults, overt vitamin E deficiency is rare. Individuals who may be at higher risk of vitamin E deficiency are those with malabsorption syndromes, pancreatic insufficiency, short bowel syndrome, and abetalipoproteinemia, an inborn error of metabolism (*see* Chapter 12, Subheading 2). A genetic abnormality in α -tocopherol transport protein has been described (280).

5.4.9. ASSESSMENT OF VITAMIN E STATUS

The most commonly used laboratory test for the assessment of vitamin E status is the measurement of plasma α -tocopherol concentrations by high-performance liquid chromatography (281). Vitamin E deficiency has been defined as a plasma concentration of α -tocopherol $<11.6 \mu\text{mol/L}$ ($<5.0 \mu\text{g/dL}$). The plasma α -tocopherol ($\mu\text{mol/L}$) to plasma cholesterol (mmol/L) ratio has also been advocated for identifying vitamin E deficiency, with a ratio <2.2 indicating risk of vitamin E deficiency (281). Dietary vitamin E intake is difficult to assess from food frequency questionnaires because the source of oil used in food preparation is often unknown, and this uncertainty may add to measurement error for vitamin E status from dietary surveys (282). Smoking does not appear to influence plasma vitamin E concentrations (283).

5.4.10. CLINICAL MANIFESTATIONS OF VITAMIN E DEFICIENCY

Vitamin E deficiency is characterized by a peripheral neuropathy with degeneration of large-caliber axons in the sensory neurons, loss of deep tendon reflexes, skeletal myopathy, and a pigmented retinopathy (284).

5.4.11. ROLE OF VITAMIN E IN THE RETINA

Photoreceptor outer segments are rich in polyunsaturated fatty acids, thus, there has been great interest in the potential role of α -tocopherol as an antioxidant in the retina. α -tocopherol appears to be almost equally distributed between the retina, retinal pigment epithe-

lium, and choroid, and these layers combined contain about 2.9 mg α -tocopherol per 100 g wet weight (285). The adult human eye does not appear to be especially enriched in α -tocopherol compared with other tissues of the body such as adipose tissue, liver, or brain (285). Vitamin E concentrations were examined in a study of 70 eyes from donors aged 9 to 104 yr (286). Higher vitamin E concentrations were found in the retinal pigment epithelium than the retina, and no differences were found in vitamin E concentrations of the retinal pigment epithelium between the macula and peripheral regions (286). The amount of vitamin E in the retina was lower in the macula compared with the peripheral region (286). In contrast, the concentrations of vitamin E were measured from the foveal center to the periphery of the retinas of rhesus monkeys, and the highest concentrations of vitamin E were found in the foveal center with a minimum near the foveal crest (287).

Studies in animal models suggest that retinal pathology results from experimental vitamin E deficiency. In primates fed a vitamin E-deficient diet, a macular degeneration developed after 2 yr (288). The macular degeneration was characterized by degeneration of photoreceptor outer segments and a massive accumulation of lipofuscin in the pigment epithelium (288), a condition similar to that described in vitamin E-deficient dogs (289). The disruption of photoreceptor outer segments was attributed to increased lipid peroxidation (288). Weanling rats that were raised with a diet deficient in vitamins A and E lost 92% of rod nuclei at 35 wk, compared with losses of 34% and 20% among rats raised on diets deficient in vitamin A or E alone, respectively (290). Vitamin E deficiency resulted in the extensive deposition of lipofuscin deposits in the retinal pigment epithelium. Combined antioxidant deficiency produced by diets deficient in vitamin E, selenium, chromium, and sulfur amino acids resulted in loss of photoreceptor cells and pathological changes in the retinal pigment epithelium (291). In rats deprived of dietary vitamin E, the depletion of vitamin E from rod outer segments and retinal pigment epithelium took considerably longer than it did for other ocular tissues or for blood and other organs (292). These findings suggested that vitamin E concentrations are conserved in the retina relative to other tissues and blood (292).

Experimental animal models show that additional dietary vitamin E does not protect the retina against light damage, which is contrary to the idea that vitamin E might protect photoreceptor outer segments from photochemical damage. In albino rats, vitamin E and selenium-supplemented animal showed marked light damage effects compared with vitamin E and selenium-deficient animals (293). Vitamin E supplementation did not protect the retina against damage from cyclic light exposure in rats (244). In adult humans, it is unclear whether vitamin E supplementation can increase vitamin E concentrations in the retina. Premature infants are born with lower concentrations of vitamin E in the retina, but supplementation with vitamin E did not result in much elevation of vitamin E in the retina (295). Recently, a large randomized, double-masked, placebo-controlled clinical trial in Australia showed that daily supplementation with vitamin E had no impact on the incidence of early age-related macular degeneration (262). 1193 healthy participants between 55 and 80 yr of age received vitamin E, 500 IU, or placebo, daily for 4 yr. The incidence of early age-related macular degeneration was 8.6% and 8.1% in the vitamin E and placebo groups, respectively (RR 1.05, 95% CI 0.69–1.61). The incidence of late age-related macular degeneration was 0.8% and 0.6% in the vitamin E and placebo groups, respectively (RR 1.36, 95% CI 0.67–2.77). These findings are consistent with observational studies that have shown that vitamin E status is not associated with age-related

maculopathy or age-related macular degeneration (64,65,78–80,95). In the Alpha-Tocopherol Beta-Carotene Study, there was no beneficial effect of α -tocopherol or β -carotene supplementation on the occurrence of age-related maculopathy (296).

5.5. Zinc

The retina and choroid contain the highest concentrations of zinc of any tissue in the human body. General aspects of zinc and eye health are presented in detail in Chapter 8. As mentioned previously under Subheading 5.2.2., zinc is a cofactor for copper-zinc superoxide dismutase and is involved in the regulation of catalase activity, two important antioxidant enzyme systems in the retina. Two small clinical trials of zinc supplementation for macular degeneration were conducted that had contrasting results (297,298). A randomized, double-masked, placebo-controlled clinical trial involving 151 subjects with drusen or macular degeneration showed that daily zinc supplementation, 100 mg twice per day, decreased visual loss over 12–24 mo of follow-up compared with placebo (297). In addition, subjects who received zinc showed less progression of visible drusen in fundus photographs at the final study visit compared to subjects who received placebo (297). The second randomized, placebo-controlled clinical trial involving 112 subjects with exudative age-related macular degeneration in one eye, showed that oral zinc, 200 mg/d, did not reduce the risk of developing the exudative form of disease in the second eye (298).

6. DIAGNOSIS

The characteristics of age-related maculopathy and age-related macular degeneration have been presented previously under Subheading 4.2. The differential diagnosis of age-related macular degeneration includes basal laminar drusen (cuticular drusen), pattern dystrophy, and central serous chorioretinopathy (100).

7. TREATMENT

A small proportion of patients who develop neovascular age-related macular degeneration may benefit from laser photocoagulation (299,300). Photodynamic therapy using photosensitizing agents in combination with low intensity laser light has been shown to be effective in the treatment of subfoveal choroidal neovascularization (301,302). Another possible treatment is submacular surgery to remove choroidal neovascular membranes (303). Anti-VEGF therapy has been shown to reduce visual loss in neovascular age-related macular degeneration (304). Ranibizumab (Lucentis, Genentech) is a humanized antibody fragment that binds and inhibits VEGF. Recent studies show that ranibizumab is well tolerated and safe (305). A recent phase III clinical trial, Anti-VEGF Antibody for the Treatment of Predominantly Classic Choroidal Neovascularization (ANCHOR), showed that ranibizumab therapy significantly improved vision and gave superior results than photodynamic therapy (306). Most patients with visual loss from age-related macular degeneration do not have choroidal neovascularization, and the potential prevention of visual loss with nutritional supplements is discussed later.

8. PREVENTION

Recently, the Age-Related Eye Disease Study, a double-masked, placebo controlled clinical trial involving 3640 participants aged 55–80 yr, showed that supplementation

with antioxidants (vitamin C 500 mg, vitamin E 400 IU, β -carotene 15 mg) plus zinc (80 mg zinc oxide) and copper (2 mg cupric oxide) could reduce the development of age-related macular degeneration (307). This clinical trial has provided the most definitive evidence to date that antioxidants and zinc may play a role in the pathogenesis of age-related macular degeneration. The clinical trial involved four treatment groups in a 2 H 2 factorial design: antioxidants, zinc, antioxidants + zinc, and placebo. The primary outcome measures of the trial were (1) progression to advanced age-related macular degeneration, and (2) at least a 15-letter decrease in visual acuity score. The mean follow-up in the study was 6.3 yr. There were originally 4757 participants enrolled in the trial, and the participants were divided into four categories at enrollment, based on the severity of their clinical disease: (1) no age-related maculopathy, (2) mild or borderline age-related maculopathy consisting of multiple small drusen, single or nonextensive intermediate drusen, pigment abnormalities, or a combination of these, with visual acuity of 20/32 or better in both eyes, (3) at least one large druse, extensive intermediate drusen, geographic atrophy not involving the center of the macula, or a combination of these, and visual acuity of 20/32 or better in at least one eye, and (4) visual acuity of 20/32 or better and no advanced age-related macular degeneration (geographic atrophy involving the macula or evidence of choroidal neovascularization) in the study eye, and the fellow eye with lesion of advanced age-related macular degeneration or visual acuity less than 20/32 and age-related macular degeneration abnormalities sufficient to explain reduced visual acuity as determined by examination of photographs at the reading center (306). The supplements in the study used nutrients at 5–15 times the RDA.

The results of this large study showed that supplementation with antioxidants plus zinc was protective against the development of advanced age-related macular degeneration (OR 0.72, 99% CI 0.52–0.98). When stratified analyses were restricted to the higher risk subjects, antioxidants plus zinc (OR 0.66, 99% CI 0.47–0.91) or zinc (OR 0.71, 99% CI 0.52–0.99) were associated with reduced odds of developing advanced age-related macular degeneration. Antioxidants with zinc were also associated with a reduced risk of moderate visual loss (OR 0.73, 99% CI 0.54–0.99) (Fig. 14) (306). The investigators conclude that adults over 55 yr of age who have at least one large druse or noncentral geographic atrophy in one or both eyes, or those with advanced age-related macular degeneration in one or both eyes, should consider taking an antioxidant supplement plus zinc such as that used in the study (307). Contraindications to these high-dose supplements include smoking. It has been estimated that 8 million people aged 55 yr or older in the United States have monocular or binocular intermediate or monocular advanced age-related maculopathy (308). In the next 5 yr, an estimated 300,000 people with age-related maculopathy would avoid advanced age-related maculopathy and any associated vision loss if they received antioxidant supplementation (308).

9. CONCLUSIONS

Significant progress has been made in the last two decades in our understanding of the pathogenesis of age-related maculopathy and age-related macular degeneration. Dietary modification and antioxidant nutritional supplementation show promise as approaches to the prevention of visual loss from age-related macular degeneration. The Age-Related Eye Disease Study demonstrated that a supplement high in antioxidants could reduce the

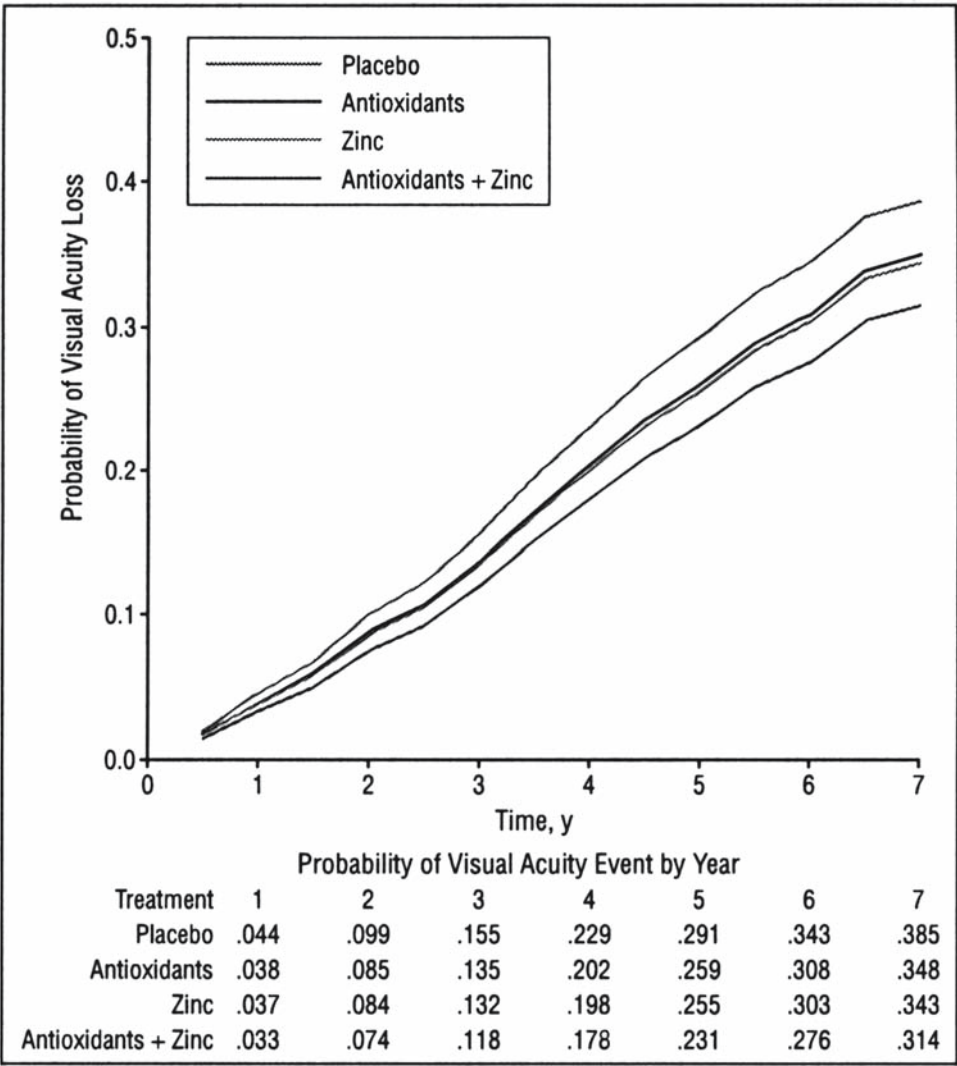


Fig. 14. Probability of visual acuity loss by treatment group in the Age-Related Eye Disease Study. (Reprinted from ref. 306. Copyright © 2001, American Medical Association. All rights reserved.)

progression of age-related macular degeneration. Further research is needed to confirm the various hypothesized roles for macular pigment in the retina, including reduction of oxidative stress and improvement in visual acuity. It is still not known whether dietary modification or antioxidant nutritional supplementation at early stages of age-related macular degeneration will reduce the risk of progression of disease. Such studies would require extremely large sample sizes and long-term follow-up. Binding proteins and transport proteins for macular pigment must be characterized, and the origin of macular pigment needs to be verified. Further work is needed to elucidate the role, if any, of minor carotenoids in the retina. Clinical trials needed to determine whether dietary interventions with xanthophylls can protect against age-related macular degeneration. A new nationwide

study sponsored by the National Institutes of Health, Age-Related Eye Disease Study 2 (AREDS-2) will evaluate lutein and zeaxanthin and omega-3 fatty acids in the reduction of rise to progress to advanced age-related macular degeneration. New methods are needed which can objectively measure macular pigment *in vivo* in the retina without relying on response of subjects. Further studies are needed to determine why women are apparently at higher risk for age-related macular degeneration. Further studies are needed to determine whether lutein and zeaxanthin in the retina can actually inhibit lipid peroxidation. The relationship between antioxidant nutritional status, systemic inflammation, and risk of age-related macular degeneration requires further elucidation.

REFERENCES

1. Williams RA, Brody BL, Thomas RG, Kaplan RM, Brown SI. The psychosocial impact of macular degeneration. *Arch Ophthalmol* 1998;116:514–520.
2. Pagenstecher H, Genth CP. *Atlas der pathologischen Anatomie des Augensapfels*. Wiesbaden, CW Kriedel, 1875.
3. Haab O. Erkrankungen der Macula lutea. *Centralbl prakt Augenheilk* 1885;9:383–384.
4. Verhoeff FH, Grossman HP. Pathogenesis of disciform degeneration of the macula. *Arch Ophthalmol* 1937;18:561–585.
5. Oeller J. *Atlas seltener ophthalmoscopischer Befunde*. Wiesbaden, JF Bergmann, 1905.
6. Junius P, Kuhnt H. Die scheibenförmige Entartung der Netzhautmitte (Degeneratio maculae luteae disciformis). Berlin, S Karger, 1926.
7. Van der Hoeve J. Eye lesions produced by light rich in ultraviolet rays, senile cataract, senile degeneration of the macula. *Am J Ophthalmol* 1920;3:178–194.
8. Buzzi F. Nuove sperienze fatte sull'occhio umano. *Opuscoli Scetti Sulle Scienze e Sulle Arti* 1782;5:87.
9. Nussbaum JJ, Pruett RC, Delori FC. Macular yellow pigment: the first 200 years. *Retina* 1981;1:296–310.
10. Soemmering S. De foramine centrali limbo luteo cincto retinae humanae. *Comment Soc Reg Sci Goetting* 1799;13:3.
11. Home E. An account of the orifice in the retina of the human eye, discovered by Professor Soemmering. To which are added, proofs of this appearance being extended to the eyes of other animals. *Phil Trans Roy Soc London* 1798;part 2:332–345.
12. Wald G. Human vision and the spectrum. *Nature* 1945;101:653–658.
13. Bird AC, Bressler NM, Bressler SB, et al. An international classification and grading system for age-related maculopathy and age-related macular degeneration. The International ARM Epidemiological Study Group. *Surv Ophthalmol* 1995;39:367–374.
14. Gass JDM. Drusen and disciform macular detachment and degeneration. *Arch Ophthalmol* 1973;90:207–217.
15. Smiddy WE, Fine SL. Prognosis of patients with bilateral macular drusen. *Ophthalmology* 1984;91:271–277.
16. Holz FG, Wolfensberger TJ, Piguet B, et al. Bilateral macular drusen in age-related macular degeneration. Prognosis and risk factors. *Ophthalmology* 1994;101:1522–1528.
17. Bressler NM, Muñoz B, Maguire MG, et al. Five-year incidence and disappearance of drusen and retinal pigmental epithelial abnormalities. Waterman Study. *Arch Ophthalmol* 1995;113:301–308.
18. Klein R, Klein BEK, Jensen SC, Meuer SM. The five-year incidence and progression of age-related maculopathy. The Beaver Dam Eye Study. *Ophthalmology* 1997;104:7–21.
19. Mitchell P, Smith W, Attebo K, Wang JJ. Prevalence of age-related maculopathy in Australia: the Blue Mountains Eye Study. *Ophthalmology* 1995;102:1450–1460.
20. Kahn HA, Leibowitz HM, Ganley JP, et al. The Framingham Eye Study. I. Outline and major prevalence findings. *Am J Epidemiol* 1977;106:17–32.
21. Klein R, Klein BEK, Linton KLP. Prevalence of age-related maculopathy. The Beaver Dam Eye Study. *Ophthalmology* 1992;99:933–943.

22. Kahn HA, Leibowitz HM, Ganley JP, et al. The Framingham Eye Study. II. Association of ophthalmic pathology with single variables previously measured in the Framingham Heart Study. *Am J Epidemiol* 1977;106:33–41.
23. Hyman LG, Lilienfeld AM, Ferris FL III, Fine SL. Senile macular degeneration: a case-control study. *Am J Epidemiol* 1983;118:213–227.
24. Goldberg J, Flowerdew G, Smith E, Brody JA, Tso MOM. Factors associated with age-related macular degeneration. An analysis of data from the first National Health and Nutrition Examination Survey. *Am J Epidemiol* 1988;128:700–710.
25. Eye Disease Case-Control Study Group. Risk factors for neovascular age-related macular degeneration. *Arch Ophthalmol* 1992;110:1701–1708.
26. Maltzman BA, Mulvihill MN, Greenbaum A. Senile macular degeneration and risk factors: a case control study. *Ann Ophthalmol* 1979;11:1197–1201.
27. Klein BE, Klein R. Cataracts and macular degeneration in older Americans. *Arch Ophthalmol* 1982;100:571–573.
28. Schachat AP, Hyman L, Leske MC, Connell AMS, Wu SY, Barbados Eye Study Group. Features of age-related macular degeneration in a black population. *Arch Ophthalmol* 1995;113:728–735.
29. Klein R, Rowland ML, Harris MI. Racial/ethnic differences in age-related maculopathy: Third National Health and Nutrition Examination Survey. *Ophthalmology* 1995;102:371–381.
30. Meyers SM, Zachary AA. Monozygotic twins with age-related macular degeneration. *Arch Ophthalmol* 1988;106:651–653.
31. Klein ML, Mauldin WM, Stoumbos VD. Heredity and age-related macular degeneration: observations in monozygotic twins. *Arch Ophthalmol* 1994;112:932–937.
32. Seddon JM, Ajani UA, Mitchell BD. Familial aggregation of age-related maculopathy. *Am J Ophthalmol* 1997;123:199–206.
33. Holz FG, Piguet B, Minassian DC, Bird AC, Weale RA. Decreasing stromal iris pigmentation as a risk factor for age-related macular degeneration. *Am J Ophthalmol* 1994;117:19–23.
34. Chaine G, Hullo A, Sahel J, Soubrane G, et al. Case-control study of the risk factors for age related macular degeneration. *Brit J Ophthalmol* 1998;82:996–1002.
35. Weiter JJ, Delori FC, Wing GL, Fitch KA. Relationship of senile macular degeneration to ocular pigmentation. *Am J Ophthalmol* 1985;99:185–187.
36. Sandberg MA, Gaudio AR, Miller S, Weiner A. Iris pigmentation and extent of disease in patients with neovascular age-related macular degeneration. *Invest Ophthalmol Vis Sci* 1994;35:2734–2740.
37. Vingerling JR, Dielemans I, Bots ML, Hofman A, Grobbee DE, de Jong PT. Age-related macular degeneration is associated with atherosclerosis: the Rotterdam Study. *Am J Epidemiol* 1995;142:404–409.
38. Smith W, Mitchell P, Leeder SR, Wang JJ. Plasma fibrinogen levels, other cardiovascular risk factors, and age-related maculopathy: the Blue Mountains Eye Study. *Arch Ophthalmol* 1998;116:583–587.
39. Vinding T, Appleyard M, Nyboe J, Jensen G. Risk factor analysis for atrophic and exudative age-related macular degeneration. An epidemiological study of 1000 aged individuals. *Acta Ophthalmol Scand* 1992;70:66–72.
40. Delcourt C, Michel F, Colvez A, et al. Associations of cardiovascular disease and its risk factors with age-related macular degeneration: the POLA study. *Ophthalmol Epidemiol* 2001;8:237–249.
41. Macular Photocoagulation Study Group. Risk factors for choroidal neovascularization in the second eye of patients with juxtafoveal or subfoveal choroidal neovascularization secondary to age-related macular degeneration. *Arch Ophthalmol* 1997;115:741–747.
42. Hyman L, Schachat AP, He Q, Leske MC, for the Age-Related Macular Degeneration Risk Factors Study Group. Hypertension, cardiovascular disease, and age-related macular degeneration. *Arch Ophthalmol* 2000;118:351–358.
43. Seddon JM, Gensler G, Milton RC, Klein ML, Rifai N. Association between C-reactive protein and age-related macular degeneration. *JAMA* 2004;291:704–710.
44. Seddon JM, George S, Rosner B, Rifai N. Progression of age-related macular degeneration. Prospective assessment of C-reactive protein, interleukin 6, and other cardiovascular biomarkers. *Arch Ophthalmol* 2005;123:774–782.
45. Paetkau ME, Boyd TAS, Grace M, Bach-Mills J, Winship B. Senile disciform macular degeneration and smoking. *Can J Ophthalmol* 1978;13:67–71.

46. Stryker WS, Kaplan LA, Stein EA, Stampfer MJ, Sober A, Willett WC. The relation of diet, cigarette smoking, and alcohol consumption to plasma beta-carotene and alpha-tocopherol levels. *Am J Epidemiol* 1988;127:283–296.
47. Klein R, Klein BEK, Linton KLP, DeMets DL. The Beaver Dam Eye Study: the relation of age-related maculopathy to smoking. *Am J Epidemiol* 1993;137:190–200.
48. Klein R, Klein BEK. Smoke gets in your eyes too. *JAMA* 1996;276:1178–1179.
49. Vingerling JR, Hofman A, Grobbee DE, de Jong PTVM. Age-related macular degeneration and smoking. The Rotterdam Study. *Arch Ophthalmol* 1996;114:1193–1196.
50. Seddon JM, Willett WC, Speizer FE, Hankinson SE. A prospective study of cigarette smoking and age-related macular degeneration in women. *JAMA* 1996;276:1141–1146.
51. McCarty CA, Mukesh BN, Fu CL, Mitchell P, Wang JJ, Taylor HR. Risk factors for age-related maculopathy. The Visual Impairment Project. *Arch Ophthalmol* 2001;119:1455–1462.
52. Brady WE, Mares-Perlman JA, Bowen P, Stacewicz-Sapuntzakis M. Human serum carotenoid concentrations are related to physiologic and lifestyle factors. *J Nutr* 1996;126:129–137.
53. Ross MA, Crosley LK, Brown KM, et al. Plasma concentrations of carotenoids and antioxidant vitamins in Scottish males: influences of smoking. *Eur J Clin Nutr* 1995;49:861–865.
54. Hebert JR, Kabat GC. Differences in dietary intake associated with smoking status. *Eur J Clin Nutr* 1990;44:185–193.
55. La Vecchia C, Negri E, Franceschi S, Parazzini F, Decarli A. Differences in dietary intake with smoking, alcohol, and education. *Nutr Cancer* 1992;17:297–304.
56. English RM, Najman JM, Bennett SA. Dietary intake of Australian smokers and nonsmokers. *Aust N Z J Public Health* 1997;21:141–146.
57. Brasche S, Winkler G, Heinrich J. Dietary intake and smoking—results from a dietary survey in Erfurt in 1991/92. *Z Ernährungswiss* 1998;37:211–214.
58. Thompson RL, Margetts B, Jackson AA. Smoking: effects on diet and nutritional status. In: Sadler MJ, Strain JJ, Caballero B (eds). *Encyclopedia of Human Nutrition*. San Diego, Academic: 1999; pp. 1759–1764.
59. Phillips EL, Arnett DK, Himes JH, McGovern PG, Blackburn H, Luepker RV. Differences and trends in antioxidant dietary intake in smokers and non-smokers, 1980–1992: The Minnesota Heart Survey. *Ann Epidemiol* 2000;10:417–423.
60. Hammond BR Jr, Wooten BR, Snodderly DM. Cigarette smoking and retinal carotenoids: implications of age-related macular degeneration. *Vision Res* 1996;36:3003–3009.
61. Ito Y, Sasaki R, Suzuki S, Aoki K. Relationship between serum xanthophyll levels and the consumption of cigarettes, alcohol or foods in healthy inhabitants of Japan. *Int J Epidemiol* 1991;20:615–620.
62. Evans WJ. What is sarcopenia? *J Gerontol A* 1995;50A (Special Issue):5–8.
63. Weindruch R. Interventions based on the possibility that oxidative stress contributes to sarcopenia. *J Gerontol A Biol Med Sci* 1995;50:157–161.
64. VandenLangenberg GM, Mares-Perlman JA, Klein R, Klein BEK, Brady WE, Palta M. Associations between antioxidant and zinc intake and the 5-year incidence of early age-related maculopathy in the Beaver Dam Eye Study. *Am J Epidemiol* 1998;148:204–214.
65. Mares-Perlman JA, Klein R, Klein BEK, et al. Association of zinc and antioxidant nutrients with age-related maculopathy. *Arch Ophthalmol* 1996;114:991–997.
66. Mares-Perlman JA, Brady WE, Klein R, VandenLangenberg GM, Klein BEK, Palta M. Dietary fat and age-related maculopathy. *Arch Ophthalmol* 1995;113:743–748.
67. West S, Vitale S, Hallfrisch J, Muñoz B, Muller D, Bressler S, Bressler NM. Are antioxidants or supplements protective for age-related macular degeneration? *Arch Ophthalmol* 1994;112:222–227.
68. Smith W, Mitchell P, Webb K, Leeder SR. Dietary antioxidants and age-related maculopathy: the Blue Mountains Eye Study. *Ophthalmology* 1999;106:761–767.
69. Seddon JM, Ajani UA, Sperduto RD, et al. Dietary carotenoids, vitamins A, C, and E and advanced age-related macular degeneration. *JAMA* 1994;272:1413–1420.
70. Ajani UA, Willett WC, Seddon JM, Eye Disease Case-Control Study Group. Reproducibility of a food frequency questionnaire for use in ocular research. *Invest Ophthalmol Vis Sci* 1994;35:2725–2733.
71. Flood V, Smith W, Wang JJ, Manzi F, Webb K, Mitchell P. Dietary antioxidant intake and incidence of early age-related maculopathy: the Blue Mountains Eye Study. *Ophthalmology* 2002;109:2272–2278.

72. Cho E, Seddon JM, Rosner B, Willett WC, Hankinson SE. Prospective study of intake of fruits, vegetables, vitamins, and carotenoids and risk of age-related maculopathy. *Arch Ophthalmol* 2004;122:883–892.
73. Cho E, Hung S, Willett WC, et al. Prospective study of dietary fat and the risk of age-related macular degeneration. *Am J Clin Nutr* 2001;73:209–216.
74. Seddon JM, Rosner B, Sperduto RD, et al. Dietary fat and risk for advanced age-related macular degeneration. *Arch Ophthalmol* 2001;119:1191–1199.
75. Seddon JM, Cote J, Davis N, Rosner B. Progression of age-related macular degeneration: association with dietary fat intake, transunsaturated fat, nuts, and fish intake. *Arch Ophthalmol* 2003;121:1728–1737.
76. van Leeuwen R, Boekhoorn S, Vingerling JR, et al. Dietary intake of antioxidants and risk of age-related macular degeneration. *JAMA* 2005;294:3101–3107.
77. Christen WG, Ajani UA, Glynn RJ, et al. Prospective cohort study of antioxidant vitamin supplement use and the risk of age-related maculopathy. *Am J Epidemiol* 1999;149:476–484.
78. Eye Disease Case-Control Study Group. Antioxidant status and neovascular age-related macular degeneration. *Arch Ophthalmol* 1993;111:104–109.
79. Sanders TAB, Haines AP, Wormald R, Wright LA, Obeid O. Essential fatty acids, plasma cholesterol, and fat-soluble vitamins in subjects with age-related maculopathy and matched control subjects. *Am J Clin Nutr* 1993;57:428–433.
80. Mares-Perlman JA, Brady WE, Klein R, et al. Serum antioxidants and age-related macular degeneration in a population-based case-control study. *Arch Ophthalmol* 1995;113:1518–1523.
81. Mares-Perlman JA, Fisher AI, Klein R, et al. Lutein and zeaxanthin in the diet and serum and their relation to age-related maculopathy in the Third National Health and Nutrition Examination Survey. *Am J Epidemiol* 2001;153:424–432.
82. Smith W, Mitchell P, Rochester C. Serum beta-carotene, alpha tocopherol, and age-related maculopathy: the Blue Mountains Eye Study. *Am J Ophthalmol* 1997;124:838–840.
83. Delcourt C, Cristol JP, Tessier F, Léger CL, Descomps B, Papoz L, and the POLA Study Group. Age-related macular degeneration and antioxidant status in the POLA study. *Arch Ophthalmol* 1999;117:1384–1390.
84. Simonelli F, Zarrilli F, Mazzeo S, et al. Serum oxidative and antioxidant parameters in a group of Italian patients with age-related maculopathy. *Clin Chim Acta* 2002;320:111–115.
85. Landrum JT, Bone RA. Lutein, zeaxanthin, and the macular pigment. *Arch Biochem Biophys* 2001;385:28–40.
86. Delori FC, Goger DG, Hammond BR, Snodderly DM, Burns SA. Foveal lipofuscin and macular pigment. *Invest Ophthalmol Vis Sci* 1997;38(suppl):S355.
87. Bone RA, Landrum JT, Mayne ST, Gomez CM, Tibor SE, Rwaroska EE. Macular pigment in donor eyes with and without AMD: a case-control study. *Invest Ophthalmol Vis Sci* 2001;42:235–240.
88. Beatty S, Murray IJ, Henson DB, Carden D, Koh HH, Boulton ME. Macular pigment and risk for age-related macular degeneration in subjects from a northern European population. *Invest Ophthalmol Vis Sci* 2001;42:439–446.
89. Schaumberg DA, Christen WG, Hankinson SE, Glynn RJ. Body mass index and the incidence of visually significant age-related maculopathy in men. *Arch Ophthalmol* 2001;119:1259–1265.
90. Seddon JM, Cote J, Davis N, Rosner B. Progression of age-related macular degeneration: association with body mass index, waist circumference, and waist-hip ratio. *Arch Ophthalmol* 2003;121:785–792.
91. Cruickshanks KJ, Klein R, Klein BEK. Sunlight and age-related macular degeneration: The Beaver Dam Eye Study. *Arch Ophthalmol* 1993;111:514–518.
92. West SK, Rosenthal FS, Bressler NM, et al. Exposure to sunlight and other risk factors for age-related macular degeneration. *Arch Ophthalmol* 1989;107:875–879.
93. Taylor HR, Munoz B, West S, Bressler NM, Bressler SB, Rosenthal FS. Visible light and risk of age-related macular degeneration. *Trans Am Ophthalmol Soc* 1990;88:163–173.
94. Darzins P, Mitchell P, Heller RF. Sun exposure and age-related macular degeneration. An Australian case-control study. *Ophthalmology* 1997;104:770–776.
95. Blumenkranz MS, Russell SR, Robey MG, Kott-Blumenkranz R, Penneys N. Risk factors in age-related maculopathy complicated by choroidal neovascularization. *Ophthalmology* 1986;96:552–557.

96. Obisesan TO, Hirsch R, Kosoko O, Carlson L, Parrott M. Moderate wine consumption is associated with decreased odds of developing age-related macular degeneration in NHANES-I. *J Am Geriatr Soc* 1998;46:1–7.
97. Ritter LL, Klein R, Klein BEK, Mares-Perlmann JA, Jensen SC. Alcohol use and age-related maculopathy in the Beaver Dam Eye Study. *Am J Ophthalmol* 1995;120:190–196.
98. Smith W, Mitchell P. Alcohol intake and age-related maculopathy. *Am J Ophthalmol* 1996;122:743–745.
99. Rimm E, Colditz G. Smoking, alcohol, and plasma levels of carotenoids and vitamin E. *Ann NY Acad Sci* 1993;686:323–333.
100. O’Connell SR, Bressler NM. Age-related macular degeneration. In: Regillo CD, Brown GC, Flynn HW Jr (eds). *Vitreoretinal Disease: The Essentials*. New York, Thieme Medical: 1999; pp. 213–240.
101. Hogan MJ, Alvarado J. Studies in the human macula. IV. Aging changes in Bruch’s membrane. *Arch Ophthalmol* 1967;77:410–420.
102. Ramrattan RS, van der Shaft TL, Mooy CM, de Bruijn WC, Mulder PGH, de Jong PTVM. Morphometric analysis of Bruch’s membrane, the choriocapillaris, and the choroid in aging. *Invest Ophthalmol Vis Sci* 1994;35:2857–2864.
103. Feeney-Burns L, Ellersieck MR. Age-related changes in the ultrastructure of Bruch’s membrane. *Am J Ophthalmol* 1985;100:686–697.
104. Ishibashi T, Patterson R, Ohnishi Y, Inomata H, Ryan SJ. Formation of drusen in the human eye. *Am J Ophthalmol* 1986;101:342–353.
105. Pauleikhoff D, Chen JC, Chisholm IH, Bird AC. Choroidal perfusion abnormality with age-related Bruch’s membrane change. *Am J Ophthalmol* 1990;109:211–217.
106. Feeney-Burns L, Hilderbrand ES, Eldridge S. Aging human RPE: morphometric analysis of macular, equatorial, and peripheral cells. *Invest Ophthalmol Vis Sci* 1984;25:195–200.
107. Penfold PL, Liew SCK, Madigan MC, Provis JM. Modulation of major histocompatibility complex class II expression in retinas with age-related macular degeneration. *Invest Ophthalmol Vis Sci* 1997;38:2125–2133.
108. Dastgheib K, Green WR. Granulomatous reaction to Bruch’s membrane in age-related macular degeneration. *Arch Ophthalmol* 1994;112:813–818.
109. Young RW. Pathophysiology of age-related macular degeneration. *Surv Ophthalmol* 1987;31:291–306.
110. Christen WG. Antioxidants and eye disease. *Am J Med* 1994;97(suppl 3A):14S–28S.
111. Anderson RE, Kretzer FL, Rapp LM. Free radicals and ocular disease. In: Armstrong D (ed). *Free Radicals in Diagnostic Medicine*. New York, Plenum: 1994; pp. 73–86.
112. Snodderly DM. Evidence for protection against age-related macular degeneration by carotenoids and antioxidant vitamins. *Am J Clin Nutr* 1995;62(suppl):1448S–1461S.
113. Stahl W, Sies H. Antioxidant defense: vitamins E and C and carotenoids. *Diabetes* 1997;46(suppl 2):S14–S18.
114. Winkler BS, Boulton ME, Gottsch JD, Sternberg P. Oxidative damage and age-related macular degeneration. *Mol Vision* 1999;5:32–41.
115. Christen WG. Antioxidant vitamins and age-related eye disease. *Proc Assoc Am Phys* 1999;11:16–21.
116. Cai J, Nelson KC, Wu M, Sternberg P Jr, Jones DP. Oxidative damage and protection of the RPE. *Prog Retinal Eye Res* 2000;19:205–221.
117. Beatty S, Koh HH, Henson D, Boulton M. The role of oxidative stress in the pathogenesis of age-related macular degeneration. *Surv Ophthalmol* 2000;45:115–134.
118. De la Paz MA, Anderson RE. Region and age-dependent variation in susceptibility of the human retina to lipid peroxidation. *Invest Ophthalmol Vis Sci* 1992;33:3497–3499.
119. Saxena M, Singhal SS, Awasthi YC. A specific, sensitive, and rapid method for the determination of glutathione and its application in ocular tissues. *Exp Eye Res* 1992;55:461–468.
120. Sternberg P Jr, Davidson PC, Jones DP, Hagen TM, Reed RL, Drews-Botsch C. Protection of retinal pigment epithelium from oxidative injury by glutathione and precursors. *Invest Ophthalmol Vis Sci* 1993;34:3661–3668.
121. Davidson PC, Sternberg P Jr, Jones DP, Reed RL. Synthesis and transport of glutathione by cultured human retinal pigment epithelial cells. *Invest Ophthalmol Vis Sci* 1994;35:2843–2849.

122. Samiec PS, Drews-Botsch C, Flagg EW, Kurtz JC, Sternberg P Jr, Reed RL, Jones DP. Glutathione in human plasma: decline in association with aging, age-related macular degeneration, and diabetes. *Free Radic Biol Med* 1998;24:699–704.
123. Atalla F, Fernandez MA, Rao NA. Immunohistochemical localization of catalase in ocular tissue. *Curr Eye Res* 1997;6:1181–1187.
124. Liles MR, Newsome DA, Oliver PD. Antioxidant enzymes in the aging human retinal pigment epithelium. *Arch Ophthalmol* 1991;109:1285–1288.
125. Tate DJ Jr, Miceli MV, Newsome DA. Zinc induces catalase expression in cultured fetal human retinal pigment epithelial cells. *Curr Eye Res* 1997;16:1017–1023.
126. Nicolas MG, Fujiki K, Murayama K, et al. Studies on the mechanism of early onset macular degeneration in cynomolgus monkeys. II. Suppression of metallothionein synthesis in the retina in oxidative stress. *Exp Eye Res* 1996;62:399–408.
127. Oliver PD, Newsome DA. Mitochondrial superoxide dismutase in mature and developing human retinal pigment epithelium. *Invest Ophthalmol Vis Sci* 1992;33:1909–1918.
128. Frank RN, Amin RH, Puklin JE. Antioxidant enzymes in the macular retinal pigment epithelium of eyes with neovascular age-related macular degeneration. *Am J Ophthalmol* 1999;127:694–709.
129. Cai J, Wu M, Nelson KC, Sternberg P Jr, Jones DP. Oxidant-induced apoptosis in cultured human retinal pigment epithelial cells. *Invest Ophthalmol Vis Sci* 1999;40:959–966.
130. Susin AS, Zamzami N, Kroemer G. Mitochondria as regulators of apoptosis: doubt no more. *Biochim Biophys Acta* 1998;1366:151–165.
131. De la Paz MA, Zhang J, Fridovich I. Red blood cell antioxidant enzymes in age-related macular degeneration. *Brit J Ophthalmol* 1996;80:445–450.
132. Noell WK, Walker VS, Kang BS, Berman S. Retinal damage by light in rats. *Invest Ophthalmol* 1966;5:450–473.
133. Hansson HA. A histochemical study of oxidative enzymes in rat retina damaged by visible light. *Exp Eye Res* 1970;9:285–296.
134. Ham WT Jr, Mueller HA, Sliney DH. Retinal sensitivity to damage from short wavelength light. *Nature* 1976;260:153–155.
135. Ham WT Jr, Ruffolo JJ Jr, Mueller HA, Clarke AM, Moon ME. Histologic analysis of photochemical lesions produced in rhesus retina by short-wave-length light. *Invest Ophthalmol Vis Sci* 1978;17:1029–1035.
136. Ham WT Jr, Ruffolo JJ Jr, Mueller HA, Guerry D III. The nature of retinal radiation damage: dependence on wavelength, power level and exposure time. *Vision Res* 1980;20:1105–1111.
137. Kagan VE, Shvedova AA, Novikov KN, Kozlov P. Light-induced free radical oxidation of membrane lipids in photoreceptors of frog retina. *Biochim Biophys Acta* 1973;330:76–79.
138. Borges J, Li ZY, Tso MOM. Effects of repeated photic exposures on the monkey macula. *Arch Ophthalmol* 1990;108:727–733.
139. Kirschfeld K. Carotenoid pigments: their possible role in protecting against photooxidation in eyes and photoreceptors cells. *Proc Roy Soc Lond B* 1982;216:71–85.
140. Gottsch JD, Pou S, Bynoe LA, Rosen GM. Hematogenous photosensitization. A mechanism for the development of age-related macular degeneration. *Invest Ophthalmol Vis Sci* 1990;31:1674–1682.
141. Gottsch JD, Bynoe LA, Harlan JB, Rencs EV, Green WR. Light-induced deposits in Bruch's membrane of protoporphyric mice. *Arch Ophthalmol* 1993;111:126–129.
142. Anderson SM, Krinsky NI. Protective action of carotenoid pigments against photodynamic damage to liposomes. *Photochem Photobiol* 1973;18:403–408.
143. Kennedy CJ, Rakoczy PE, Constable IJ. Lipofuscin of the retinal pigment epithelium: a review. *Eye* 1995;9:763–771.
144. Dorey CK, Wu G, Ebenstein D, Garsd A, Weiter JJ. Cell loss in the aging retina: relationship to lipofuscin accumulation and macular degeneration. *Invest Ophthalmol Vis Sci* 1989;30:1691–1699.
145. Boulton M, McKechnie NM, Breda J, Bayly M, Marshall J. The formation of autofluorescent granules in cultured human RPE. *Invest Ophthalmol Vis Sci* 1989;30:82–89.
146. Boulton M, Docchio F, Dayhaw-Barker P, Ramponi R, Cubeddu R. Age-related changes in the morphology, absorption and fluorescence of melanosomes and lipofuscin granules of the retinal pigment epithelium. *Vision Res* 1990;30:1291–1303.

147. Katz ML, Drea CM, Robison WG Jr. Relationship between dietary retinol and lipofuscin in the retinal pigment epithelium. *Mech Ageing Dev* 1986;35:291–305.
148. Eldred GE, Katz ML. Fluorophores of the human retinal pigment epithelium: separation and spectral characterization. *Exp Eye Res* 1988;47:71–86.
149. Eldred GE, Lasky MR. Retinal age pigments generated by self-assembling lysosomotropic detergents. *Nature* 1993;361:724–726.
150. Boulton M, Dontsov A, Jarvis-Evans J, Ostrovsky M, Svistunenko D. Lipofuscin is a photoinducible free radical generator. *J Photochem Photobiol B* 1993;19:201–204.
151. Gaillard ER, Atherton SJ, Eldred G, Dillon J. Photophysical studies on human retinal lipofuscin. *Photochem Photobiol* 1995;61:448–453.
152. Rózanowska M, Jarvis-Evans J, Korytowski W, Boulton ME, Burke JM, Sarna T. Blue light-induced reactivity of retinal age pigment. *In vitro* generation of oxygen-reactive species. *J Biol Chem* 1995;270:18825–18830.
153. Rózanowska M, Wessels J, Boulton M, et al. Blue light-induced singlet oxygen generation by retinal lipofuscin in non-polar media. *Free Radic Biol Med* 1998;24:1107–1112.
154. Davies S, Mulroy L, McGarvey D, Truscott TG, Boulton M. The phototoxicity of lipofuscin [abstract]. *Invest Ophthalmol Vis Sci* 1998;39:S129.
155. Katz ML, White HA, Gao CL, Roth GS, Knapka JJ, Ingram DK. Dietary restriction slow age pigment accumulation in the retinal pigment epithelium. *Invest Ophthalmol Vis Sci* 1993;34:3297–3302.
156. Ferrara N. Vascular endothelial growth factor: basic science and clinical progress. *Endocrine Rev* 2004;25:581–611.
157. Aiello LP, Avery RL, Arrigg PG, et al. Vascular endothelial growth factor in ocular fluid of patients with diabetic retinopathy and other retinal disorders. *N Engl J Med* 1994;331:1480–1487.
158. Lukiw WJ, Ottlecz A, Lambrou G, et al. Coordinate activation of HIF-1 and NF- κ B DNA binding and COX-2 and VEGF expression in retinal cells by hypoxia. *Invest Ophthalmol Vis Sci* 2003;44:4163–4170.
159. Olson JA. Carotenoids. In: Shils ME, Olson JA, Shike M, Ross AC (eds). *Modern Nutrition in Health and Disease*. Ninth Edition. Baltimore, Williams & Wilkins: 1999; pp. 525–541.
160. Khachik F, Spangler CJ, Smith JC Jr, Canfield LM, Pfander H, Steck A. Identification, quantification, and relative concentrations of carotenoids and their metabolites in human milk and serum. *Anal Chem* 1997;69:1873–1881.
161. Mayne ST. Beta-carotene, carotenoids, and disease prevention in humans. *FASEB J* 1996;10:690–701.
162. Eastwood MA. Interaction of dietary antioxidants *in vivo*: how fruit and vegetables prevent disease? *Q J Med* 1999;92:527–530.
163. Wackenroder H. Ueber das Oleum radices Dauci aetherum, das Carotin, den Carotenzucker und den officinellen succus Dauci; so wie auch über das Mannit, welches in dem Möhrensaft durch eine besondere Art der Gährung gebildet wird. *Magazin für Pharmacie* 1831;33:144–172.
164. Zeise [WC]. Einige Bemerkungen über das Carotin. *J Prakt Chem* 1847;40:297–299.
165. Husemann A. Ueber Carotin und Hydrocarotin. *Annalen der Chemie und Pharmacie* 1861;117:200–229.
166. Arnaud A. Recherches sur la composition de la carotine, sa fonction chimique et sa formule. *Compt Rend Acad Sci* 1886;102:1119–1122.
167. Thudichum JLW. Researches conducted for the Medical Department of the Privy Council, at the Pathological Laboratory of St. Thomas's Hospital. Third series. Results of researches on luteine and the spectra of yellow organic substances contained in animals and plants. *Proc Roy Soc London* 1869;17:253–256.
168. Hartsen [FA]. [no title] *Compt Rend Acad Sci Paris* 1873;76:385.
169. Millardet [PM]A. *Bull Soc Sci Nancy* 1875;2 (I):21.
170. Schunck CA. The xanthophyll group of yellow colouring matters. *Proc Roy Soc London* 1903;72:165–176.
171. Willstätter R, Escher HH. Über das Lutein des Hühnereidotter. *Z physiol Chem* 1912;76:214–225.
172. Tswett M. Physikalisch-chemische Studien über das Chlorophyll. Die Adsorptionen. *Berichte der Deutschen botanischen Gesellschaft* 1906;24:316–323.
173. Tswett M. Über das makro- und mikro-chemischen Nachweis des Carotins. *Berichte der Deutschen botanischen Gesellschaft* 1911;29:630–636.

174. Palmer LS. Carotenoids and related pigments: the chromolipids. New York, The Chemical Catalog Company, 1922.
175. Karrer P, Salomon H, Wehrli H. Pflanzenfarbstoffe XIV. Über einen Carotinoidfarbstoff aus Mais: Zeaxanthin. *Helv Chim Acta* 1929;12:790–792.
176. Karrer P, Wehrli H, Helfenstein H. Pflanzenfarbstoffe XIX. Über Zeaxanthin und Xanthophyll. *Helv Chim Acta* 1930;13:268–273.
177. Karrer P, Helfenstein A, Wehrli H, Pieper B, Morf R. Pflanzenfarbstoffe XXX. Beiträge zur Kenntnis des Carotins, der Xanthophylle, des Fucoxanthins und Capsanthins. *Helv Chim Acta* 1931;14:614–632.
178. Karrer P, Morf R, von Krauss E, Zubrys A. Pflanzenfarbstoffe XXXIX. Vermischte Beobachtungen über Carotinoide (α -Carotin, Zeaxanthin, Carotinoide aus Khaki-früchten). *Helv Chim Acta* 1932;15:490–493.
179. Moore T. The absence of the liver oil vitamin A from carotene. The conversion of carotene to vitamin A *in vivo*. *Biochem J* 1930;24:692–702.
180. Karrer P, Morf R, Schöpp K. Zur Kenntnis des Vitamins-A aus Fischtranen. *Helv Chim Acta* 1931;14:1036–1040.
181. Karrer P, Morf R, Schöpp K. Zur Kenntnis des Vitamins-A aus Fischtranen II. *Helv Chim Acta* 1931;14:1431–1436.
182. Britton G. Structure and properties of carotenoids in relation to function. *FASEB J* 1995;9:1551–1558.
183. IUPAC Commission on the Nomenclature of Organic Chemistry and IUPAC-IUB Commission on Biochemical Nomenclature. Nomenclature of carotenoids (rules approved 1974). *Pure Appl Chem* 1975;41:407–431.
184. Krinsky NI, Rock CL. Carotenoids: chemistry, sources and physiology. In: Sadler MJ, Strain JJ, Caballero B (eds). *Encyclopedia of Human Nutrition*. Volume One. San Diego, Academic: 1999; pp. 304–314.
185. Gust D, Moore TA, Moore AL, Jori G, Reddi E. The photochemistry of carotenoids: some photosynthetic and photomedical aspects. *Ann NY Acad Sci* 1993;691:32–47.
186. Frank HA. Physical and chemical properties of carotenoids. In: Canfield LM, Krinsky NI, Olson JA (eds). *Carotenoids in human health*. *Ann NY Acad Sci* 1993;691:1–9.
187. Foote CS, Denny RW. Chemistry of singlet oxygen. VII. Quenching by β -carotene. *J Am Chem Soc* 1968;90:6233–6235.
188. Stahl W, Sies H. Physical quenching of singlet oxygen and *cis-trans* isomerization of carotenoids. *Ann NY Acad Sci* 1993;691:10–19.
189. Mathews-Roth MM, Wilson T, Fujimori E, Krinsky NI. Carotenoid chromophore length and protection against photosensitization. *Photochem Photobiol* 1974;19:217–222.
190. Burton GW, Ingold KU. Beta-carotene: an unusual type of lipid antioxidant. *Science* 1984;224:569–573.
191. Krinsky NI, Deneke SM. Interaction of oxygen and oxy-radicals with carotenoids. *J Natl Cancer Inst* 1982;69:205–210.
192. Liebler DC. Antioxidant reactions of carotenoids. *Ann NY Acad Sci* 1993;691:20–31.
193. Hirayama O, Nakamura K, Hamada S, Kobayasi Y. Singlet oxygen quenching ability of naturally occurring carotenoids. *Lipids* 1994;29:149–150.
194. Nebeling LC, Forman MR, Graubard BI, Snyder RA. Changes in carotenoid intake in the United States: the 1987 and 1992 National Health Interview Surveys. *J Am Diet Assoc* 1997;97:991–996.
195. Sommerburg O, Keunen JEE, Bird AC, van Kijjk FJGM. Fruits and vegetables that are sources for lutein and zeaxanthin: the macular pigment in human eyes. *Br J Ophthalmol* 1998;82:907–910.
196. Nebeling LC, Forman MR, Graubard BI, Snyder RA. The impact of lifestyle characteristics on carotenoid intake in the United States: the 1987 National Health Interview Survey. *Am J Public Health* 1997;87:268–271.
197. Mangels AR, Holden J, Beecher GR, Forman MR, Lanza E. Carotenoid content of fruits and vegetables: an evaluation of analytic data. *J Am Diet Assoc* 1993;93:284–296.
198. Krinsky NI, Russett MD, Handelman GJ, Snodderly DM. Structural and geometrical isomers of carotenoids in human plasma. *J Nutr* 1990;120:1655–1662.
199. Erdman JW, Bierer TL, Gugger ET. Absorption and transport of carotenoids. *Ann NY Acad Sci* 1993;691:76–85.

200. Chandler LA, Schwartz SJ. HPLC separation of cis-trans carotene isomers in fresh and processed fruits and vegetables. *J Food Sci* 1987;52:669–672.
201. Goodman DWS, Blomstrand R, Werner B, Huang HS, Shiratori T. The intestinal absorption and metabolism of vitamin A and β -carotene in man. *J Clin Invest* 1966;45:1615–1623.
202. Dimitrov NV, Meyer C, Ullrey DE, et al. Bioavailability of β -carotene in humans. *Am J Clin Nutr* 1988; 48:298–304.
203. White WS, Stacewicz-Sapuntzakis M, Erdman JW Jr, Bowen PE. Pharmacokinetics of β -carotene and canthaxanthin after ingestion of individual and combined doses by human subjects. *J Am Coll Nutr* 1994;13:665–671.
204. Kostic D, White WS, Olson JA. Intestinal absorption, serum clearance, and interactions between lutein and β -carotene when administered to human adults in separate or combined oral doses. *Am J Clin Nutr* 1995;62:604–610.
205. Micozzi MS, Brown ED, Edwards BK, Bieri JG, Taylor PR, Khachik F, et al. Plasma carotenoid response to chronic intake of selected foods and β -carotene supplements in man. *Am J Clin Nutr* 1992;55:1120–1125.
206. Forman MR, Beecher GR, Lanza E, et al. Effect of alcohol consumption on plasma carotenoid concentrations in premenopausal women: a controlled dietary study. *Am J Clin Nutr* 1995;62:131–135.
207. Carughi A, Hooper FG. Plasma carotenoid concentrations before and after supplementation with a carotenoid mixture. *Am J Clin Nutr* 1994;59:896–899.
208. Wang XD. Absorption and metabolism of β -carotene. *J Am Coll Nutr* 1994;13:314–325.
209. Parker RS. Absorption, metabolism, and transport of carotenoids. *FASEB J* 1996;10:542–551.
210. Erdman J. The physiologic chemistry of carotenes in man. *Clin Nutr* 1988;7:101–106.
211. Rapp LM, Maple SS, Choi JH. Lutein and zeaxanthin concentrations in rod outer segment membranes from perifoveal and peripheral human retina. *Invest Ophthalmol Vis Sci* 2000;41:1200–1209.
212. Kaplan LA, Lau JM, Stein EA. Carotenoid composition, concentrations, and relationships in various human organs. *Clin Physiol Biochem* 1990;8:1–10.
213. Blankenhorn DH. Carotenoids in man. IV. Carotenoid stores in normal adults. *J Biol Chem* 1957;229: 809–816.
214. Stahl W, Schwartz W, Sundquist AR, Sies H. *Cis-trans* isomers of lycopene and β -carotene in human serum and tissues. *Arch Biochem Biophys* 1992;294:173–177.
215. Semba RD. Are lutein and zeaxanthin conditionally essential nutrients? *Med Hypotheses* 2003;61: 465–472.
216. Edge R, McGarvey DJ, Truscott TG. The carotenoids as anti-oxidants—a review. *J Photochem Photobiol B* 1997;41:189–200.
217. Krinsky NI. Carotenoids as antioxidants. *Nutrition* 2001;17:815–817.
218. Hughes DA. Dietary carotenoids and human immune function. *Nutrition* 2001;17:823–827.
219. Stahl W, Sies H. Effects of carotenoids and retinoids on gap junctional communication. *Biofactors* 2001; 15:95–98.
220. Food and Nutrition Board, Institute of Medicine. Dietary reference intakes for vitamin C, vitamin E, selenium, and carotenoids. Washington, D.C., National Academy Press, 2000.
221. Tucker KL, Chen H, Voge S, Wilson PWF, Schaefer EJ, Lammi-Keefe CJ. Carotenoid intakes, assessed by dietary questionnaire, are associated with plasma carotenoid concentrations in the elderly. *J Nutr* 1999;129:438–445.
222. Carroll YL, Corridan BM, Morrissey PA. Carotenoids in young and elderly healthy humans: dietary intakes, biochemical status, and diet-plasma relationships. *Eur J Clin Nutr* 1999;53:644–653.
223. Bone RA, Landrum JT, Tarsis SL. Preliminary identification of the human macular pigment. *Vision Res* 1985;25:1531–1535.
224. Bone RA, Landrum JT, Fernandez L, Tarsis SL. Analysis of the macular pigment by HPLC: retinal distribution and age study. *Invest Ophthalmol Vis Sci* 1988;29:843–849.
225. Handelman GJ, Dratz EA, Reay CC, van Kuijk FJGM. Carotenoids in the human macula and whole retina. *Invest Ophthalmol Vis Sci* 1988;29:850–855.
226. Bone RA, Landrum JT, Cains A. Optical density spectra of the macular pigment in vivo and in vitro. *Vision Res* 1992;32:105–110.

227. Bone RA, Landrum JT, Hime GW, Cains A, Zamor J. Stereochemistry of the human macular carotenoids. *Invest Ophthalmol Vis Sci* 1993;34:2033–2040.
228. Khachik F, Bernstein PS, Garland DL. Identification of lutein and zeaxanthin oxidation products in human and monkey retinas. *Invest Ophthalmol Vis Sci* 1997;38:1802–1811.
229. Bone RA, Landrum JT, Friedes LM, et al. Distribution of lutein and zeaxanthin stereoisomers in the human retina. *Exp Eye Res* 1997;64:211–218.
230. Handelman GJ, Snodderly DM, Krinsky NI, Russett MD, Adler AJ. Biological control of primate macular pigment. *Invest Ophthalmol Vis Sci* 1991;32:257–267.
231. Snodderly DM, Brown PK, Delori FC, Auran JD. The macular pigment. I. Absorbance spectra, localization, and discrimination from other yellow pigments in primate retinas. *Invest Ophthalmol Vis Sci* 1984;25:660–673.
232. Snodderly DM, Auran JD, Delori FC. The macular pigment. II. Spatial distribution in primate retinas. *Invest Ophthalmol Vis Sci* 1984;25:674–685.
233. Bone RA, Landrum JT, Dixon Z, Chen Y, Llerena CM. Lutein and zeaxanthin in the eyes, serum and diet of human subjects. *Exp Eye Res* 2000;71:239–245.
234. Chan C, Leung I, Lam KW, Tso MOM. The occurrence of retinol and carotenoids in human subretinal fluid. *Curr Eye Res* 1998;17:890–895.
235. Bernstein PS, Khachik F, Carvalho LS, Muir GJ, Zhao EY, Katz NB. Identification and quantitation of carotenoids and their metabolites in the tissues of the human eye. *Exp Eye Res* 2001;72:215–223.
236. Bernstein PS, Balashov NA, Tsong ED, Rando RR. Retinal tubulin binds macular carotenoids. *Invest Ophthalmol Vis Sci* 1997;38:167–175.
237. Crabtree DV, Ojima I, Geng X, Adler AJ. Tubulins in the primate retina: evidence that xanthophylls may be endogenous ligands for the paclitaxel-binding site. *Bioorg Med Chem* 2001;9:1967–1976.
238. Sommerburg OG, Siems WG, Hurst JS, Lewis JW, Kliger DS, van Kuijk FJGM. Lutein and zeaxanthin are associated with photoreceptors in the human retina. *Curr Eye Res* 1999;19:491–495.
239. Bone RA, Landrum JT, Mayne ST, Gomez CM, Tibor SE, Twaroska EE. Macular pigment in donor eyes with and without AMD: a case-control study. *Invest Ophthalmol Vis Sci* 2001;42:235–240.
240. Brown PK, Wald G. Visual pigments in human and monkey retinas. *Nature* 1963;200:37–43.
241. Reading VM, Weale RA. Macular pigment and chromatic aberration. *J Opt Soc Am* 1974;64:231–234.
242. Hammond BR Jr, Wooten BR, Curran-Celentano J. Carotenoids in the retina and lens: possible acute and chronic effects on human visual performance. *Arch Biochem Biophys* 2001;385:41–46.
243. Haegerstrom-Portnoy G. Short-wavelength-sensitive-cone sensitivity loss with aging: a protective role for macular pigment? *J Opt Soc Am A* 1988;5:2140–2144.
244. Wooten BR, Hammond BR Jr, Land RI, Snodderly DM. A practical method for measuring macular pigment optical density. *Invest Ophthalmol Vis Sci* 1999;40:2481–2489.
245. Hammond BR Jr, Caruso-Avery M. Macular pigment optical density in a Southwestern sample. *Invest Ophthalmol Vis Sci* 2000;41:1492–1497.
246. Hammond BR Jr, Fuld K. Interocular differences in macular pigment density. *Invest Ophthalmol Vis Sci* 1992;33:350–355.
247. Hammond BR Jr, Curran-Celentano J, Judd S, et al. Sex differences in macular pigment optical density: relation to plasma carotenoid concentrations and dietary patterns. *Vision Res* 1996;36:2001–2012.
248. Hammond BR Jr, Wooten BR, Snodderly DM. Preservation of visual sensitivity of older subjects: association with macular pigment density. *Invest Ophthalmol Vis Sci* 1998;39:397–406.
249. Hammond BR, Wooten BR, Snodderly DM. Individual variations in the spatial profile of human macular pigment. *J Opt Soc Am A* 1997;14:1187–1196.
250. Hammond BR, Fuld K, Curran-Celentano J. Macular pigment density in monozygotic twins. *Invest Ophthalmol Vis Sci* 1995;36:2531–2541.
251. Malinow MR, Feeney-Burns L, Peterson LH, Klein ML, Neuringer M. Diet-related macular anomalies in monkeys. *Invest Ophthalmol Vis Sci* 1980;19:857–863.
252. Feeney-Burns L, Neuringer M, Gao CL. Macular pathology in monkeys fed semipurified diets. *Prog Clin Biol Res* 1989;314:601–622.
253. Hammond BR, Johnson EL, Russell RM, et al. Dietary modification of human macular pigment density. *Invest Ophthalmol Vis Sci* 1997;38:1795–1801.

254. Landrum JT, Bone RA, Joa H, Kilburn MD, Moore LL, Sprague KE. A one year study of the macular pigment: the effect of 140 days of a lutein supplement. *Exp Eye Res* 1997;65:57–62.
255. Johnson EJ, Hammond BR, Yeum KJ, et al. Relation among serum and tissue concentrations of lutein and zeaxanthin and macular pigment density. *Am J Clin Nutr* 2000;71:1555–1562.
256. Koh HH, Murray IJ, Nolan D, Carden D, Feather J, Beatty S. Plasma and macular responses to lutein supplement in subjects with and without age-related maculopathy: a pilot study. *Exp Eye Res* 2004;79: 21–27.
257. Richer S. Part II. ARMD-pilot (case series) environmental intervention data. *J Am Optom Assoc* 1999; 70:24–36.
258. Dagnelie G, Zorge IS, McDonald TM. Lutein improves visual function in some patients with retinal degeneration: a pilot study via the internet. *Optometry* 2000;71:147–164.
259. Aleman TS, Duncan JL, Bieber ML, et al. Macular pigment and lutein supplementation in retinitis pigmentosa and Usher syndrome. *Invest Ophthalmol Vis Sci* 2001;42:1873–1881.
260. Leung I, Tso M, Li W, Lam T. Absorption and tissue distribution of zeaxanthin and lutein in rhesus monkeys after taking *Fructus lycii* (Gou Qi Zi) extract. *Invest Ophthalmol Vis Sci* 2001;42:466–471.
261. Richer S, Stiles W, Statkute L, et al. Double-masked, placebo-controlled randomized trial of lutein and antioxidant supplementation in the intervention of atrophic age-related macular degeneration: the Veterans LAST study (Lutein Antioxidant Supplementation Trial). *Optometry* 2004;75:216–230.
262. Taylor HR, Tikellis G, Robman LD, McCarty CA, McNeil JJ. Vitamin E supplementation and macular degeneration: randomised controlled trial. *Brit Med J* 2002;325:11.
263. Evans HM, Bishop KS. On the existence of a hitherto unrecognized dietary factor essential for reproduction. *Science* 1922;56:650–651.
264. Sure B. Dietary requirements for reproduction. II. The existence of a specific vitamin for reproduction. *J Biol Chem* 1924;58:693–709.
265. Evans HM, Emerson OH, Emerson GA. The isolation from wheat germ oil of an alcohol, α -tocopherol, having the properties of vitamin E. *J Biol Chem* 1936;113:319–332.
266. Bacharach AL, Drummond JC (eds). *Vitamin E*. New York, Chemical Publishing Co., 1940.
267. Acuff RV, Thedford SS, Hidioglou NN, Papas AM, Odom TA Jr. Relative bioavailability of *RRR*- and *all-rac*- α -tocopheryl acetate in humans: studies using deuterated compounds. *Am J Clin Nutr* 1994; 60:397–402.
268. Kiyose C, Muramatsu R, Kameyama Y, Ueda T, Igarashi O. Biodiscrimination of α -tocopherol stereoisomers in humans after oral administration. *Am J Clin Nutr* 1997;65:785–789.
269. U.S. Department of Agriculture. USDA Nutrient Database for Standard Reference. <http://www.nal.usda.gov/fnic/foodcomp/search/index.html>
270. Blomstrand R, Forsgren L. Labelled tocopherols in man. Intestinal absorption and thoracic-duct lymph transport of *dl*- α -tocopherol-3,4-¹⁴C2 acetate *dl*- α -tocopheramine-3,4-¹⁴C2 *dl*- α -tocopherol-(5-methyl-³H) and *N*-(methyl-³H)-*dl*- γ tocopheramine. *Int Z Vitaminforsch* 1968;38:328–344.
271. MacMahon MT, Neale G. The absorption of α -tocopherol in control subjects and in patients with intestinal malabsorption. *Clin Sci* 1970;38:197–210.
272. Kelleher J, Losowsky MS. The absorption of alpha-tocopherol in man. *Brit J Nutr* 1970;24:1033–1047.
273. Traber MG, Kayden HJ, Green JB, Green MH. Absorption of water-miscible forms of vitamin E in a patient with cholestasis and in thoracic duct-cannulated rats. *Am J Clin Nutr* 1986;44:914–923.
274. Pryor WA. Vitamin E. In: Bowman BA, Russell RM (eds). *Present Knowledge in Nutrition*. Eighth Edition. Washington, D.C., International Life Sciences Institute Press: 2001; pp. 156–163.
275. Traber MG, Burton GW, Ingold KU, Kayden HJ. *RRR*- and *SRR*- α -tocopherols are secreted without discrimination in human chylomicrons, but *RRR*- α -tocopherol is preferentially secreted in very low density lipoproteins. *J Lipid Res* 1990;31:675–685.
276. Traber MG. Vitamin E. In: Shils ME, Olson JA, Shike M, Ross AC (eds). *Modern Nutrition in Health and Disease*. Ninth Edition. Baltimore, Williams and Wilkins: 1999; pp. 347–362.
277. Traber MG, Kayden HJ. Tocopherol distribution and intracellular localization in human adipose tissue. *Am J Clin Nutr* 1987;46:488–495.
278. Niki E, Saito T, Kawakami A, Kamiya Y. Inhibition of oxidation of methyl linoleate in solution by vitamin E and vitamin C. *J Biol Chem* 1984;259:4177–4182.

279. Kaiser S, Di Mascio P, Murphy ME, Sies H. Physical and chemical scavenging of singlet molecular oxygen by tocopherols. *Arch Biochem Biophys* 1990;277:101–109.
280. Cavalier L, Ouahchi K, Kayden HJ, et al. Ataxia with isolated vitamin E deficiency: heterogeneity of mutations and phenotypic variability in a large number of families. *Am J Hum Genet* 1998;62:301–310.
281. Sauberlich HE. *Laboratory Tests for the Assessment of Nutritional Status*. Second Edition. Boca Raton, CRC Press, 1999.
282. Briefel RR, Semplos CT, McDowell MA, Chien S, Alaimo K. Dietary methods research in the Third National Health and Nutrition Examination Survey: underreporting of energy intake. *Am J Clin Nutr* 1997;65:1203S–1209S.
283. Duthie GG, Arthur JR, James WPT. Effects of smoking and vitamin E on blood antioxidant status. *Am J Clin Nutr* 1991;53:1061S–1063S.
284. Sokol RJ. Vitamin E deficiency and neurologic disease. *Annu Rev Nutr* 1988;8:351–373.
285. Alvarez RA, Liou GI, Fong SL, Bridges CDB. Levels of α - and γ -tocopherol in human eyes: evaluation of the possible role of IRBP in intraocular α -tocopherol transport. *Am J Clin Nutr* 1987;46:481–487.
286. Friedrichson T, Kalbach HLV, Buck R, van Kuijk FJGM. Vitamin E in macular and peripheral tissues of the human eye. *Curr Eye Res* 1995;14:693–701.
287. Crabtree DV, Adler AJ, Snodderly DM. Radial distribution of tocopherols in rhesus monkey retina and retinal pigment epithelium-choroid. *Invest Ophthalmol Vis Sci* 1996;37:61–76.
288. Hayes KC. Retinal degeneration in monkeys induced by deficiencies of vitamin E or A. *Invest Ophthalmol* 1974;13:499–510.
289. Hayes KC, Rousseau JE Jr, Hegsted DM. Plasma tocopherol concentrations and vitamin E deficiency in dogs. *J Am Vet Med Assoc* 1970;157:64–71.
290. Robison WG Jr, Kuwabara T, Bieri JG. Deficiencies of vitamins E and A in the rat. Retinal damage and lipofuscin accumulation. *Invest Ophthalmol Vis Sci* 1980;19:1030–1037.
291. Katz ML, Parker KR, Handelman GJ, Bramel TL, Dratz EA. Effects of antioxidant nutrient deficiency on the retina and retinal pigment epithelium of albino rats: a light and electron microscopic study. *Exp Eye Res* 1982;34:339–369.
292. Stephens RJ, Negi DS, Short SM, van Kuijk FJGM, Dratz EA, Thomas DW. Vitamin E distribution in ocular tissues following long-term dietary depletion and supplementation as determined by microdissection and gas chromatography-mass spectrometry. *Exp Eye Res* 1988;47:237–245.
293. Stone WL, Katz ML, Lurie M, Marmor MF, Dratz EA. Effects of dietary vitamin E and selenium on light damage to the rat retina. *Photochem Photobiol* 1979;29:725–730.
294. Katz ML, Eldred GE. Failure of vitamin E to protect the retina against damage resulting from bright cyclic light exposure. *Invest Ophthalmol Vis Sci* 1989;30:29–36.
295. Nielson JC, Naash MI, Anderson RE. The regional distribution of vitamins E and C in mature and premature human retinas. *Invest Ophthalmol Vis Sci* 1988;29:22–26.
296. Teikari JM, Laatikainen L, Virtamo J, et al. Six-year supplementation with alpha-tocopherol and beta-carotene and age-related maculopathy. *Acta Ophthalmol Scand* 1998;76:224–229.
297. Newsome DA, Swartz M, Leone NC, Elston RC, Miller E. Oral zinc in macular degeneration. *Arch Ophthalmol* 1988;106:192–198.
298. Stur M, Tittl M, Reitner A, Meisinger V. Oral zinc and the second eye in age-related macular degeneration. *Invest Ophthalmol Vis Sci* 1996;37:1225–1235.
299. The Macular Photocoagulation Study Group. Argon laser photocoagulation for neovascular maculopathy: five years results from randomized clinical trials. *Arch Ophthalmol* 1991;109:1109–1114.
300. The Macular Photocoagulation Study Group. Laser photocoagulation for juxtafoveal choroidal neovascularization: five year results from randomized clinical trials. *Arch Ophthalmol* 1994;112:500–509.
301. Verteporfin in Photodynamic Therapy Study Group. Verteporfin therapy of subfoveal choroidal neovascularization in age-related macular degeneration: two-year results of a randomized clinical trial including lesions with occult with no classic choroidal neovascularization—Verteporfin in Photodynamic Therapy Report 2. *Am J Ophthalmol* 2001;131:541–560.
302. Verteporfin Roundtable 2000 and 2001 Participants. Guidelines for using verteporfin (visudyne) in photodynamic therapy to treat choroidal neovascularization due to age-related macular degeneration and other causes. *Retina* 2002;22:6–18.

303. [Submacular Surgery Group]. Submacular surgery trials randomized pilot trial of laser photocoagulation versus surgery for recurrent choroidal neovascularization secondary to age-related macular degeneration: I. Ophthalmic outcomes submacular surgery trials pilot study report number 1. *Am J Ophthalmol* 2001;130:387–407.
304. Gragoudas ES, Adamis AP, Cunningham ET Jr, Feinsod M, Guyer DR, VEGF Inhibition Study in Ocular Neovascularization Clinical Trial Group. *N Engl J Med* 2004;351:2805–2816.
305. Rosenfeld PJ, Schwartz SD, Blumenkranz MS, et al. Maximum tolerated dose of a humanized anti-vascular endothelial growth factor antibody fragment for treating neovascular age-related macular degeneration. *Ophthalmology* 2005;112:1048–1053.
306. Brown DM, Kaiser PK, Michels M, et al. Ranibizumab versus verteporfin for neovascular age-related macular degeneration. *N Engl J Med* 2006;355:1432–1444.
307. Age-Related Eye Disease Study Research Group. A randomized, placebo-controlled, clinical trial of high-dose supplementation with vitamins C and E, beta carotene, and zinc for age-related macular degeneration and vision loss. AREDS Report No. 8. *Arch Ophthalmol* 2001;119:1417–1436.
308. Age-Related Eye Disease Study Research Group. Potential public health impact of Age-Related Eye Disease Study results. AREDS Report No. 11. *Arch Ophthalmol* 2003;121:1621–1624.

4

The Obesity Epidemic

Implications for Eye Health

1. INTRODUCTION

The global epidemic of obesity is likely to have long-term and egregious consequences for eye health through different biological pathways and eye diseases. Obesity leads to an increased risk of diabetes, and in turn, diabetes is associated with diabetic retinopathy and an increased risk of cataract. Diabetic retinopathy is becoming the next big “epidemic” of eye disease. Obesity is associated with an increased risk of hypertension and atherosclerosis, and there is likely to be an associated increased risk of retinal vascular disease. Obesity may possibly increase the risk of age-related macular degeneration, as obesity is associated with relatively low plasma lutein and zeaxanthin concentrations and higher levels of inflammation. Obesity is also associated with an increased risk of cataract among individuals without diabetes, although the causal link has not yet been elucidated. As emphasized in this chapter, the long-term prevention of obesity-related eye disease must focus on the childhood period, as childhood obesity is an extremely strong predictor of adult obesity and diabetes.

2. HISTORICAL BACKGROUND

William Banting (1797–1878), an undertaker, was an early writer on obesity in *Letter on Corpulence, Addressed to the Public* (1863) (1). Banting was five feet five inches tall, and at age 66 he weighed 202 pounds. He wrote: “I could not stoop to tie my shoes, so to speak, nor to attend to the little offices humanity requires without considerable pain and difficulty which only the corpulent can understand, I have been compelled to go downstairs slowly backward to save the jar of increased weight on the knee and ankle joints and have been obliged to puff and blow over every slight exertion, particularly that of going upstairs.” Banting was advised to avoid bread, butter, milk, sugar, beer, and potatoes, and in following this regimen, he began to lose about one pound per week. Given the success of losing weight with his new diet, Banting wanted to spread the message to the public. The prevalence of obesity was not well described in Banting’s time, however, the great success of his *Letter*, which went into several editions, seems to indicate that obesity was perhaps not uncommon among some populations in Europe.

Adolphe Quetelet (1796–1874), a Belgian statistician and astronomer, conceived of the body mass index (BMI) with the formula $\text{weight}/\text{height}^2$ in *Physique sociale; ou essai sur le développement de ses facultés de l’homme* (1869) (2). Quetelet’s formula for BMI became widely used and is the current standard for defining obesity in adults. In 1921,

Elliot Joslin (1869–1962), a physician, noted that a large proportion of patients with diabetes were overweight (3). The prevalence of diabetes decreased in countries that experienced food shortages during World War I, as observed by Harold Himsworth (1905–1993), former secretary of the Medical Research Council in England (4). The Metropolitan Life Insurance Company developed actuarial tables based on the relationship of weight and mortality in adults. These “desirable weight” tables were based on height, weight, and type of frame, for men and women aged 25 yr and over (5).

3. Patterns of the Nutrition Transition

The emergence of obesity as a prominent public health problem relates to long-term demographic changes and diet shifts that have been termed the nutrition transition (6). There are five broad patterns of the nutrition transition in human history, and these patterns do not necessarily represent a temporal sequence, as in some locations in the world different patterns may still coexist. In Pattern 1, Collection of Food, the diet was high in carbohydrates and fiber and low in fat. In this hunter-gatherer society, wild animal meat was consumed. In Pattern 2, Famine, agriculture was evolving and the diet was less varied and subject to variation and episodic famines. In Pattern 3, Receding Famine, societies made some progress in reducing famines, and the consumption of fruits and vegetables and animal proteins increased, and starchy staples were less important in the diet. In Pattern 4, Degenerative Disease, a diet high in total fat, cholesterol, sugar and carbohydrate and low in polyunsaturated fats and fiber predominates, and this diet is often accompanied by an increase in sedentary lifestyle, higher obesity, and increased degenerative diseases (6). Pattern 5, Behavioral Change, reflects concern about modifying the diet in order to reduce risk of disease and prolong life. There is an increased intake of fruits and vegetables and carbohydrates, and a reduced intake of processed foods, meat, and dairy products.

4. DEFINITIONS

The World Health Organization (WHO) classifies obesity in adults based on BMI (weight/height²) in metric units (kg/m²). The cut-offs and ranges for the categories of underweight, normal, overweight, pre-obese, and obese are considered to represent the risk of comorbidities (7) (Table 1). In 1997, WHO held an expert consultation on obesity, which indicated a new shift in emphasis by this organization, which had usually focused on issues of breastfeeding and malnutrition. The upper limit of the normal range of a BMI of 24.9 was considered as a compromise to the United States, where higher levels of BMI were considered “normal” (7). Scientists from Asian countries have proposed an alternative classification system for obesity, because comorbidities such as diabetes and hypertension were considered higher among Asians than others in the WHO classification. Under this alternative classification, normal range is 18.5 to 22.9; overweight is ≥ 23 ; at-risk is 23 to 24.9; Obese I is 25 to 29.9; and Obese II is ≥ 30 kg/m² (7).

There is no clear definition of obesity in children, but many studies have used a BMI between the 85th and 95th percentile of the National Health and Nutrition Examination Survey (NHANES) to define overweight, and BMI greater than the 95th percentile to define obese (8). The International Obesity Task Force (IOTF) recently has proposed a new classification system for overweight and obese in children (9). The IOTF analyzed

Table 1
World Health Organization Classification of Obesity

<i>Classification</i>	<i>BMI (kg/m²)</i>	<i>Risk of comorbidities</i>
Underweight	<18.5	Low (but risk of other clinical problems increased)
Normal range	18.5 to 24.9	Average
Overweight	≥25	
Pre-obese	25 to 29.9	Increased
Obese class 1	30.0 to 34.9	Moderate
Obese class 2	35.0 to 39.9	Severe
Obese class 3	≥40	Very severe

From ref. 7.

six large nationally representative cross-sectional growth studies in Brazil, Great Britain, Hong Kong, the Netherlands, Singapore, and the United States. Each study population had more than 10,000 subjects with ages ranging from 6 to 18 yr, and for each population, centile curves were drawn so that at 18 yr, they passed through the adult cut off points of 25 and 30 kg/m² for overweight and obesity. The resulting curves were then averaged to provide age- and sex-specific cut off points from 2 to 18 yr of age. The 85th and 95th centiles of the US BMI reference has been recently proposed as a cut-off point for child overweight and obesity, respectively, but this is far from universally accepted (9).

5. EPIDEMIOLOGY OF THE GLOBAL OBESITY EPIDEMIC

5.1. Prevalence and Incidence in Adults

Worldwide, it is estimated that 250 million people are obese, and that by 2025, there will be 300 million obese individuals (10). Among adults aged 45–59 yr, the regions with the highest prevalence of obesity and overweight are North America, Europe, and northern Africa, and the prevalence is clearly higher among women than men worldwide (7). Most available data show that there is a progressive increase in obesity rates in countries worldwide, but that the rates of increase vary greatly. Obesity prevalence rates have been projected to 2025 in various countries of the world, such as the United States, England and Wales, Mauritius, Australia, and Brazil (11) (Fig. 1). Obesity is increasingly becoming a problem of poor people, a trend that has been attributed to the cheapness of processed, energy-dense foods and time spent watching television (7). Although it was once commonly thought that obesity would be largely restricted to the socioeconomic elite in developing countries, a review of studies conducted in developing countries between 1989 and 2003 shows that obesity is a problem that shifts to lower socioeconomic groups as the gross national product per capita increases in a country, and that women are affected earlier in this shift than men (12).

5.2. Prevalence and Incidence in Children

The global prevalence of overweight among children is 3.3%, as shown by a study of 160 nationally representative, cross-sectional surveys from 94 countries where overweight was defined as weight-for-height >2 standard deviations from the NHANES/WHO

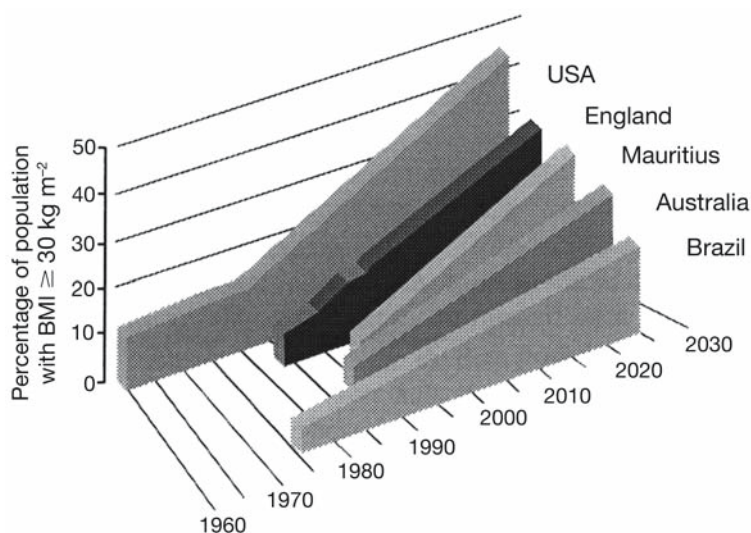


Fig. 1. Historic, current, and projected obesity prevalence rates for the United States, England, and Wales, Mauritius, Australia, and Brazil, 1960–2025. (Reprinted from ref. 11, with permission of Macmillan Publishers Ltd.)

international reference median (13). The countries with the highest prevalence of overweight children are located mainly in the Middle East, North Africa, and Latin America. Of countries with trend data, overweight increased in 16 of 38 countries (13). The global disparities in nutrition and health are apparent when undernutrition is compared with overweight worldwide, as undernutrition still remains a major problem in Africa and Asia, while overweight is more prevalent in other regions (13) (Fig. 2). It is estimated that about 22 million children under 5 yr of age are overweight worldwide (14).

5.3. Regions of the World

5.3.1. UNITED STATES AND CANADA

Currently more than half of the population in the United States is overweight and 20% are obese (10). There has been a large increase in obesity between the first US NHANES in 1960–1961 and the US NHANES III in 1988–1994 (15). In NHANES III, among individuals aged 20–74 yr, 59.3% of men and 49.6% of women were overweight (BMI ≥ 25 kg/m²), and 19.9% of men and 24.9% of women were obese (BMI ≥ 30 kg/m²) (15). A large increase in overweight and obesity has also been observed in Canada (16). The prevalence of overweight increased from 48% to 57% among men and 30% to 35% among women from 1981 to 1996 (16). In the same interval, the prevalence of obesity increased from 9% to 14% among men and 8% to 12% among women (16). The estimated number of deaths per year attributable to obesity among adults in the United States is 280,000 based on hazard ratios from all subjects and 325,000 based on hazard ratios from only nonsmokers and never-smokers (17). In Canada, about 57,000 deaths have been attributed to overweight and obesity from 1985 to 2000 (18).

Childhood obesity is considered the most serious and prevalent nutritional disorder in the United States (19), as 22% of children are overweight and 11% are obese, with girls

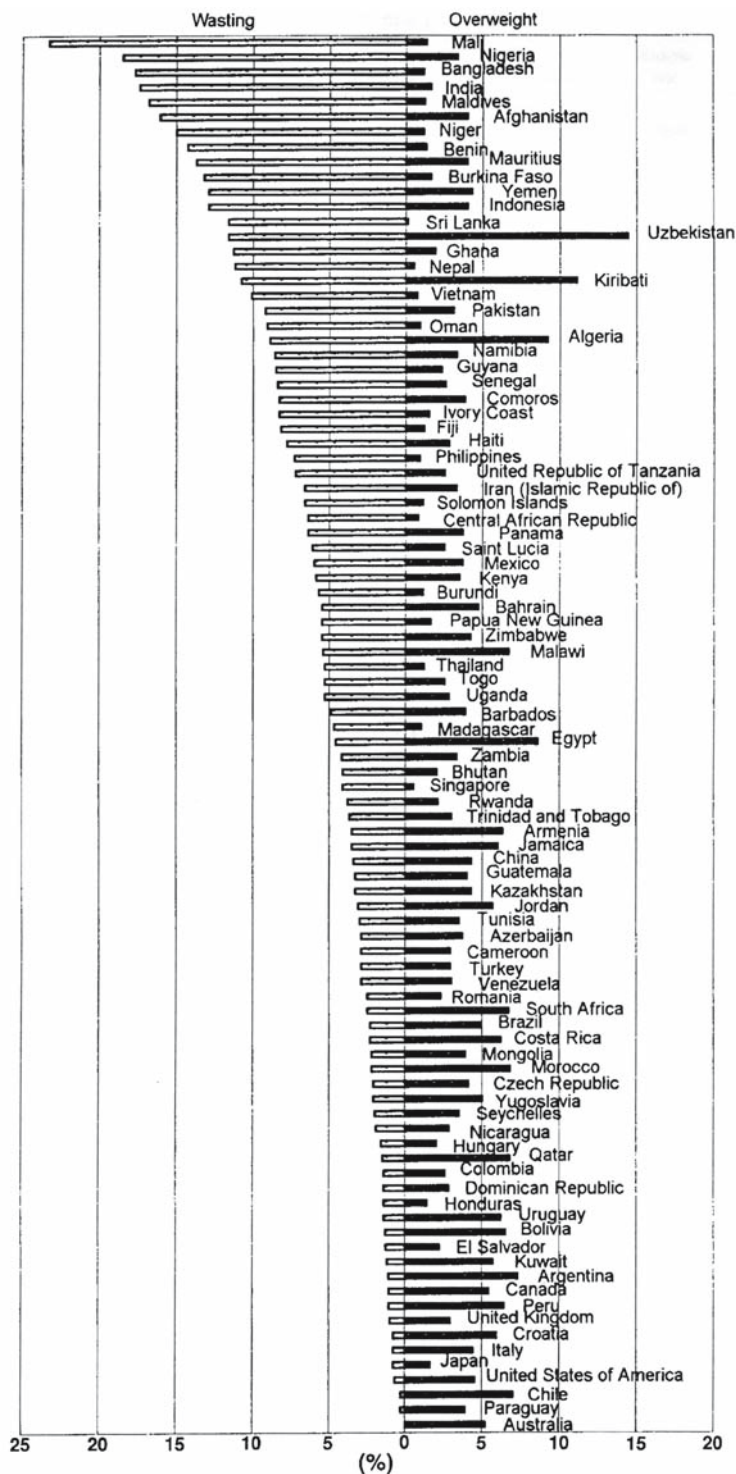


Fig. 2. Weight-for-height distribution of preschool children in 94 countries. (Reproduced from ref. 13, with permission of *The American Journal of Clinical Nutrition*. © Am J Clin Nutr. American Society for Nutrition.)

being more affected than boys (8,20). In a 20-yr period between NHANES I and NHANES II, the prevalence of overweight and obesity increased more than twofold for young girls, but for young boys it increased about 25%. But in children older than 6 yr of age, there has been a doubling of obesity prevalence among boys as well as girls (21). In the Bogalusa Heart Study, the trends in relative weight and obesity were examined among 5- to 24-yr-olds between 1973 and 1994. The prevalence of overweight increased by about twofold between 1973 and 1994, with the largest increases seen in 19- to 24-yr-olds (22). In the United States, the highest prevalence of overweight among boys and girls is among Mexican American children, intermediate among non-Hispanic black children, and lowest in non-Hispanic white children (14). The obesity rates among American Indian children and adolescents are higher than in all other racial groups in the United States (23).

5.3.2. EUROPE

Among adults in Europe, the prevalence of obesity ($\text{BMI} \geq 30 \text{ kg/m}^2$) is about 10–20% among men and 15–25% among women (10), which is less than in the United States. However, the prevalence of overweight ($\text{BMI} 25\text{--}29.9 \text{ kg/m}^2$) is more than 50% in Germany, Finland, and Great Britain. The prevalence of obesity is higher in southern and eastern Europe, especially among women, with higher prevalence of obesity associated with low education, low income, marital status, high parity, cessation of smoking, and low physical activity (24). From 1980 to 1997 in England and Wales, there has been an increase in obesity in adult men from 6% to 17% and in adult women from 8% to 20% (25). In contrast, there have been limited increases in the prevalence of obesity in France. From 1980 to 1991, in two cross-sectional studies involving random sample of households, there were slight increases in the prevalence of obesity and overweight among women but no change among men (26). From 1985 to 1997 in southwestern France, prevalence rates for obesity among men increased from 10% to 13% and in women remained stable at 11% (27). Among adolescents, the prevalence of overweight in 1997–1998 was highest among those in Ireland, Greece, and Portugal, but the prevalence of overweight among adolescents in Europe was less than in the United States (28).

5.3.3. AFRICA

Northern African and sub-Saharan Africa represent different phases of the nutrition transition. Although sub-Saharan Africa has the lowest prevalence of obesity and overweight of any large region in the world, this area has not been spared the general trend toward obesity. The prevalence of obesity and type 2 diabetes mellitus is slowly increasing in some areas of sub-Saharan Africa, and urban areas are more affected than rural areas (29,30). Studies from Mali, Nigeria, and Tanzania show that increases in BMI are accompanied by an increase in the prevalence of diabetes (30). In the Demographic and Health Survey in South Africa in 1998, 29.2% of men and 56.6% of women were overweight ($\text{BMI} \geq 25 \text{ kg/m}^2$) (31). Among preschool children in Africa, undernutrition remains the dominant problem compared with overweight; however, in countries undergoing transition, such as Algeria, South Africa, and Egypt, both wasting and overweight have high prevalence (13).

5.3.4. LATIN AMERICA

Latin America is undergoing rapid demographic change and nutritional transition, with a decline in deaths from infectious diseases and an increase in deaths from noncom-

municable chronic disease (32,33). Obesity has increased from 1974 to 1997 in Brazil (34,35), and in a situation of nutrition transition in Brazil, higher income was a risk factor for obesity, whereas education was protective (35). The prevalence of obesity has approximately doubled in Brazil from 1975 to 1997 (33), and whereas in 1975 the ratio of obesity to underweight was 1:2, the ratio was 2:1 by 1997 (36). In Chile, the prevalence of obesity in large urban populations appears to have increased from 6% to over 15% in men and from 14% to about 23% in women from 1988 to 1997 (33). Obesity and overweight are highly prevalent, especially among women, in Mexico, Costa Rica, and many Caribbean countries (32). In data from 13 countries in Latin America, the prevalence of overweight among children aged 1–5 yr ranged from 6% in Haiti to 24% in Peru (32). The highest prevalence of overweight in children and obesity in women were found in urban areas and households with higher socioeconomic status (32).

5.3.5. RUSSIA AND THE FORMER RUSSIAN STATES

In the Russian Federation, the Russian Longitudinal Monitoring Survey from 1992 to 2000 shows that among men and women aged 19 to 55 yr, the prevalence of overweight ($\text{BMI} \geq 25 \text{ kg/m}^2$) has remained relatively stable at 50% but the prevalence of obesity ($\text{BMI} \geq 30 \text{ kg/m}^2$) increased from 13.3% to 16.0% (37). In Kazakhstan, a survey of over 25,000 individuals over 15 yr of age showed that obesity occurred in 23.7% (38).

5.3.6. SOUTH ASIA AND SOUTHEAST ASIA

The prevalence of central obesity was high in a random sample of adults aged 25–64 yr from a city in Kerala, India (39). A survey conducted in an urban slum area in northern India showed that 15.6% of women and 13.3% of men had $\text{BMI} \geq 25 \text{ kg/m}^2$ (40). In the National Health Survey of Pakistan, 1990–1994, the proportion of adults aged 25–44 yr who had $\text{BMI} \geq 25 \text{ kg/m}^2$ was 9% for men and 14% for women in rural areas and 22% for men and 37% for women in urban areas (41). Increasing urbanization, higher energy dense diets, and reduce physical activity are contributing to the rise of obesity in Pakistan and other parts of south Asia (41). The trend towards obesity has been associated with a rise in the prevalence of diabetes in India. India now has the largest number of people with diabetes of any given country (42). In 1995, there were an estimated 19.4 individuals with diabetes in India, and the number is expected to rise to 57.2 million by 2025 (42).

5.3.7. EAST ASIA AND PACIFIC

In Japan, the National Nutrition Surveys show that the prevalence of overweight and obesity has increased in the 20-yr period from 1976 to 1995 among adults aged 20 yr and older (43). Among men, the prevalence of overweight ($\text{BMI} 25\text{--}29.9 \text{ kg/m}^2$) increased from 14.5% to 20.5%, and the prevalence of obesity ($\text{BMI} \geq 30 \text{ kg/m}^2$) increased from 0.8% to 2.0%. Among women, the prevalence of overweight and obesity decreased slightly during this same period (43). From 1976 to 2000, there was a trend of increased BMI and obesity among boys and girls in Japan (44). In a large study from Kagoshima City, increases in obesity occurred among elementary school children from 1989 to 2001–2002 (45). In China in 1992, the prevalence of overweight ($\text{BMI} 25\text{--}29.9 \text{ kg/m}^2$) and obesity ($\text{BMI} \geq 30 \text{ kg/m}^2$) were 10.7% and 1.6% among men, respectively, and 15.4% and 1.6% among women, respectively (46). Using the same definitions, in South Korea in 1995, the prevalence of overweight and obesity among men was 18.0% and 0.8%, respectively, and among women was 19.9% and 2.2% (48). The prevalence of obesity in some Pacific

Island populations is among the highest reported in the world. The age-standardized prevalence of obesity in Nauru was 64.8% among men and 70.3% among women, and in Western Samoa, 47.7% of men and 70.4% of women were obese (48). Where longitudinal data are available, there have been dramatic increases in obesity over time in the Pacific region (48).

5.3.8. AUSTRALIA AND NEW ZEALAND

In the Australian Diabetes, Obesity and Lifestyle (AusDiab) Study, a cross-sectional study of 11,247 adults aged ≥ 25 yr from 42 randomly selected districts throughout Australia, the prevalence of overweight and obesity among men was 48.2% and 19.3%, respectively, and the prevalence of overweight and obesity among women was 29.9% and 22.6%, respectively (49). The prevalence of obesity increased 2.5-fold compared to data from 1980 (49). Low education level, higher television viewing time, and lower physical activity were each strongly associated with obesity (49). In the 1995 National Nutrition Survey in Australia, 45% of men and 29% of women were overweight, and 18% of men and women were obese (50). There are more than 350,000 individuals who are reported to have diabetes in Australia (51). In the 1997 National Nutrition Survey in New Zealand, 40.4% of males and 30.1% of females were overweight, and a further 14.7% of males and 19.2% of females were obese (52). There has been an increase in overweight and obesity from the 1989 National Nutrition Survey, when 32% were overweight and 11% were obese (52).

6. PATHOGENESIS

6.1. High Fat Intake

High dietary fat intake increases the risk of obesity, as demonstrated by randomized clinical trials and experimental animal studies (53). The energy density of high dietary fat may be a factor in its role in obesity (54). Dietary fat appears to have a weak effect on both satiation and satiety, which may also explain why high fat foods can lead to overconsumption (55).

6.3. Television

The number of hours watching television is a strong predictor of adolescent obesity. Among 4063 children, aged 8–16 yr, in NHANES III, 1988–1994, 26% of the children watched four or more hours of television per day, and 67% watched at least 2 h per day (56). Forty-two percent of black children watched four or more hours of television per day, which was the highest rate of any group. Boys and girls who watched television four or more hours per day had significantly greater body fat and BMI than those who watched television less than 2 h per day. Less vigorous activity was reported for girls and especially non-Hispanic black girls. Children who watched more television were less likely to participate in vigorous activity and tended to have higher BMI (56). A strong dose–response type of relationship was found between hours of television watching and both the prevalence and incidence of overweight (defined as BMI $>$ 85th percentile for age and gender) in a nationally representative cohort of 746 youths aged 10–15 yr (57) (Fig. 3A,B). Television watching may be linked to obesity because of the passiveness of television viewing and the excess of poor nutritional products being advertised (58) (Fig. 4). More

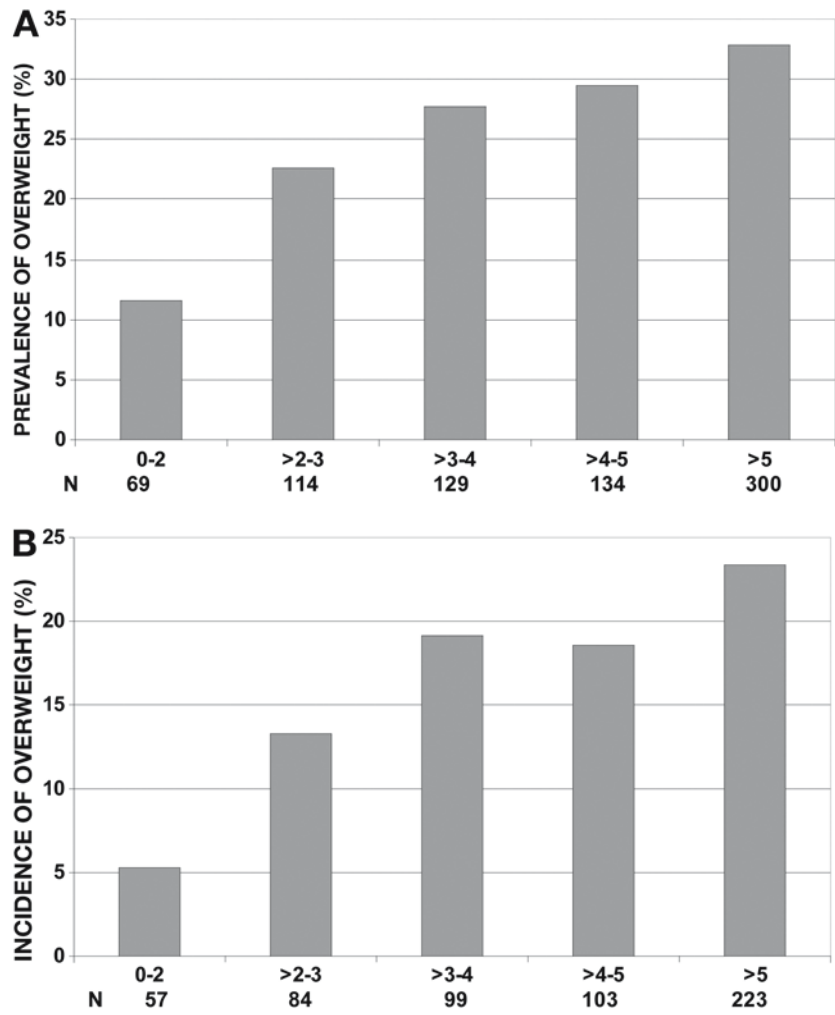


Fig. 3. Estimated prevalence (A) and incidence (B) of overweight children by amount television viewed per day in 1990. All estimated are weighted, and incidence rates are per 4-yr follow-up. (Adapted from ref. 57.)

than half of all youth in the United States have a television set in the room where they sleep (59). The average high school graduate will likely have spent 15,000 to 18,000 h watching television but only 12,000 h in school (58).

6.4. Low Physical Activity

Sedentary lifestyles are associated with a positive energy balance and weight gain. Physical activity accounts for about 15–30% of total energy expenditure (60). Data from studies conducted around the world suggest that if the physical activity level (energy expenditure/basal metabolic rate) is <1.8 , there is about a sevenfold increase of being overweight (61). These figures can be translated into practical terms using some estimates. For example, an adult male aged 30–60 yr who weighs 70 kg and is fairly sedentary (employed in a low-energy occupation such as office work) would have a physical



Fig. 4. Walt Handelsman cartoon: “Bobby darling, did you see this?” Copyright *Times Picayune*. (Reprinted with permission of ©Knight-Ridder Tribune Media Services. All rights reserved.)

activity level of 1.58, placing him at high risk of overweight and obesity (61). To achieve a physical activity level of at least 1.7, this individual would need to expend at least 300 calories per day, which would require 20 min of rapid jogging at a speed of 12 km/h or 1 h of walking at a speed of 4 km/h. If the person has time constraints and is too busy during the week, it would be challenging to transfer this exercise to the weekend, as the same objective of an average activity level of 1.7 would require jogging for 2.5 h or walking 7 h (61). Such considerations suggest that major lifestyle changes may be needed for many individuals in order to reduce the risk of obesity. Despite the increasing prevalence of obesity, evidence suggests that most physicians and health care professionals in the United States do not advise their overweight and obese patients about strategies to lose weight (62).

There has been a steady decline in physical activity among children and adolescents in the United States (63). The 1995 Nationwide Personal Transportation Survey showed that less than one-third of children who lived within a mile of school actually walked to school (59). In the United States in 1991, 42% of high school students were enrolled in daily physical education classes, but by 1997, this rate had fallen to 27% (59).

6.5. Poor Community Design

Urban sprawl, lack of sidewalks, and the propensity to drive instead of walk has an impact on overweight and obesity. In the Behavioral Risk Factor Surveillance System, pooled data from 1998, 1999, and 2000 were used to examine the relationship between obesity and urban sprawl in 206,992 adults (64). The country sprawl index was significantly associated with minutes walked, obesity, BMI, and hypertension, and residents of sprawling counties were less likely to walk during leisure time and more likely to weigh more and to have hypertension compared with those from more compact counties (64). In a travel survey of 10,878 participants in the Atlanta, Georgia region, land-use mix was significantly associated with obesity, with each quartile increase in land-use mix being

associated with a 12.2% reduction in the risk of obesity (65). Each additional hour spent in the car each day was associated with a 6% increase in risk of obesity, whereas each additional kilometer walked per day was associated with a 4.8% decrease in the risk of obesity (65). Obesity was strongly related to daily vehicle miles of travel in a study of data from the California Health Interview Survey 2001 (66).

6.6. Childhood Obesity as a Predictor of Adult Obesity

High birth weight is a predictor of overweight and obesity in adulthood, as demonstrated by data from 71,100 women in the Nurses Health Study I and 92,940 women in the Nurses Health Study II (67). In children, a high BMI is predictive of being overweight at age 30 (68). The risk of obesity in adulthood for both nonobese and obese children is greater if at least one parent is obese (69). A study of health records of 854 subjects in Washington States showed that parental obesity more than doubled the risk of adult obesity in later life among both obese and nonobese children under 10 yr of age (69). Using BMI-for-age growth charts from the Centers for Disease Control for males and females aged 2–20 yr, a child or adolescent with high BMI percentile has a high risk of being overweight or obese at age 35 yr, and the risk increases with age (70). In the Bogalusa Heart Study, of children who were overweight (BMI \geq 95th percentile) at ages 2 to 17 yr, 77% remained obese by ages 18 to 37 yr, (BMI \geq 30) (71).

Childhood obesity is associated with an increased risk of coronary artery disease and diabetes (71). In children, truncal obesity is associated with increased triglycerides and very low-density lipoprotein (VLDL) cholesterol and decreased high-density-lipoprotein (HDL) cholesterol and apolipoprotein A-1 (72). In a sample of 9,167 children from the Bogalusa Heart Study, children with BMI $>$ 95th percentile had higher risk of elevated total cholesterol, triglycerides, fasting insulin, and higher diastolic blood pressure compared with children with BMI less than the 95th percentile (73). Obese adolescents are at higher risk of hypertension and coronary artery disease (74). In an autopsy study of 150 subjects aged 6 to 30 yr who died accidentally, atherosclerotic lesions were already found at an early age and to be correlated with risk factors such as total cholesterol and ponderal index (75). Among adolescents in the United States, the incidence of type 2 diabetes has increased by nearly a factor of 10 (76). The ratio of females to males was 1.7 to 1, and females were more likely to be diagnosed about 1 yr earlier than male patients (76).

7. IMPLICATIONS OF THE OBESITY EPIDEMIC FOR EYE HEALTH

The obesity epidemic has important consequences for general health, including an increased risk of cardiovascular disease, endometrial cancer, osteoarthritis of the knee and hips joints, respiratory disorders, and sleep apnea (10). However, the obesity epidemic may have the greatest implications for diabetes mellitus worldwide.

7.1. The Obesity Epidemic and Diabetes Mellitus

The obesity epidemic has been accompanied by an increase in people with impaired glucose tolerance, the metabolic syndrome, and of diabetes mellitus and its complications. In the Behavioral Risk Factor Surveillance System, a random-digit telephone survey conducted in all states in 2000, BMI, self-reported diabetes, and other information were collected from 184,450 adults aged 18 and over (77). The prevalence of obesity

(BMI ≥ 30 kg/m²) was 19.8% and the prevalence of diabetes was 7.3%. Mississippi had the highest rate of obesity (24.3%) and diabetes (8.8%). Colorado had the lowest rate of obesity (13.8%). Only 24.4% of US adults consumed fruits and vegetables five or more times daily. Self-reported diabetes increased by nearly 50%, from 4.9% in 1990 to 7.3% in 2000 (77). The prevalence of obesity increased by 61% from 1991 to 2000 (77) (Fig. 5). In the survey, 27% of adults reported that they did not engage in any physical activity, and another 28.2% were not regularly active. This study may have underestimated obesity and diabetes, because these diseases are more prevalent among poor people, and poor people are more likely to be without a telephone.

Impaired glucose tolerance, defined as hyperglycemia (with glucose values intermediate between normal and diabetes) following a glucose load, is thought to affect 200 million people worldwide (78). Approximately 40% of people with impaired glucose tolerance will progress to diabetes within 5–10 yr. The metabolic syndrome is defined as at least one of the following three conditions: (1) type 2 diabetes, (2) impaired glucose tolerance, and (3) insulin resistance, plus at least two of following three conditions: (1) hypertension, (2) obesity (BMI ≥ 30 kg/m² or waist–hip ratio >0.90 for men, >0.85 for women), (3) hypertriglyceridemia (triglycerides ≥ 1.7 mmol/L) or low HDL (<0.9 mmol/L for men, <1.0 mmol/L for women), and (4) microalbuminuria (urinary albumin excretion rate ≥ 20 μ g/min or albumin/creatinine ratio ≥ 30 mg/min) (78). The overall prevalence of the metabolic syndrome among US adults ≥ 20 yr of age is estimated to be 23.7%, with a prevalence of 43.5% among those 60–69 yr of age (79). Adults with diabetes have a higher risk of diabetic retinopathy if they have the metabolic syndrome (80).

7.2. The Changing Epidemiology of Diabetic Retinopathy

The prevalence of diabetes mellitus is increasing with the emerging obesity pandemic, and in turn, the prevalence of diabetic retinopathy and related blindness is likely to increase. Currently, it is estimated that there are 150 to 200 million individuals with diabetes worldwide; this figure is project to increase to 221 million by 2010 and 300 million by 2025 (78,81). The prevalence of diabetes increased greatly from 1958 to 2000 in the United States (82) (Fig. 6) and is projected to continue to rise at an accelerated rate (82). The largest projected increases will be in Asia, Africa, and Latin America (78) (Fig. 7). In 1995, the prevalence of diabetes in adults was estimated to be 4.0%, and this figure is predicted to rise to 5.4% by 2025. From 1995 to 2025, in developed countries, there will be a 42% increase, from 51 to 72 million, and in developing countries there will be a 170% increase, from 84 to 228 million (83). Obesity increases the risk of diabetic retinopathy among patients with type 2 diabetes who are already obese (84,85). The risk of retinopathy (at least one microaneurysm, hemorrhage, or hard exudates, or neovascularization with or without fibrous proliferation, or laser coagulation scars) was higher in a subsample of adults with elevated BMI from the Hoorn Study, a population-based study of 2484 adults, aged 50–74 yr (86).

7.3. Economic Impact

In 1997, the direct medical expenditures related to diabetes in 1997 totaled \$44.1 billion (\$7.7 billion for diabetes and acute glycemic care, \$11.8 billion due to excess prevalence of related chronic complications, \$24.6 billion due to excess prevalence of general medical conditions) (87). The total expenditure for people with diabetes was

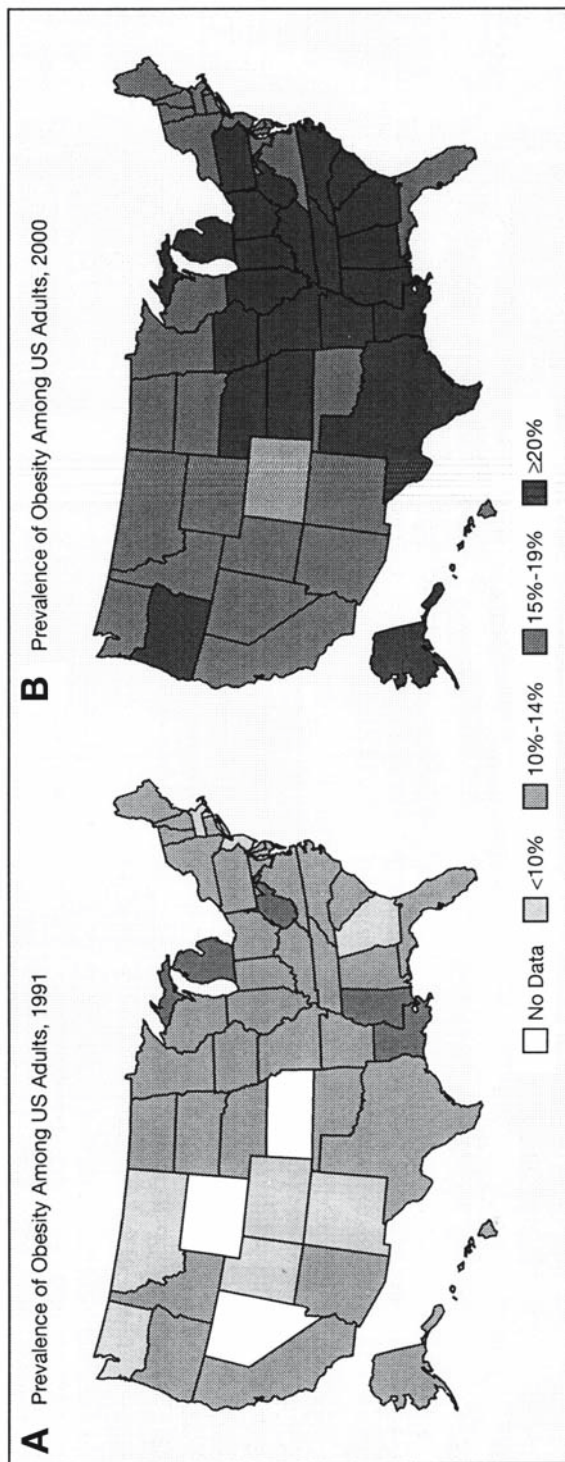


Fig. 5. Increase in the prevalence of obesity in the United States, 1991–2000. (Reprinted from ref. 7. Copyright © 2001, American Medical Association. All rights reserved.)

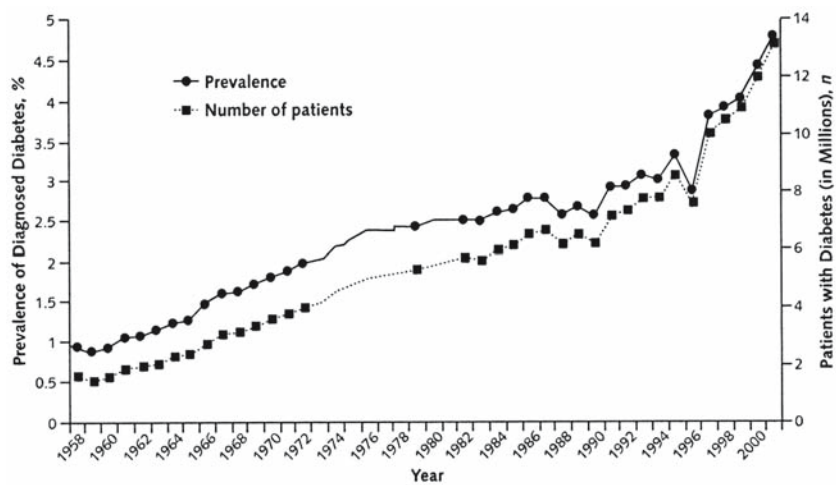


Fig. 6. Prevalence of diagnosed diabetes and the number of people with diabetes in the United States, 1958 to 2000. (Reprinted from ref. 82, with permission of the American College of Physicians.)

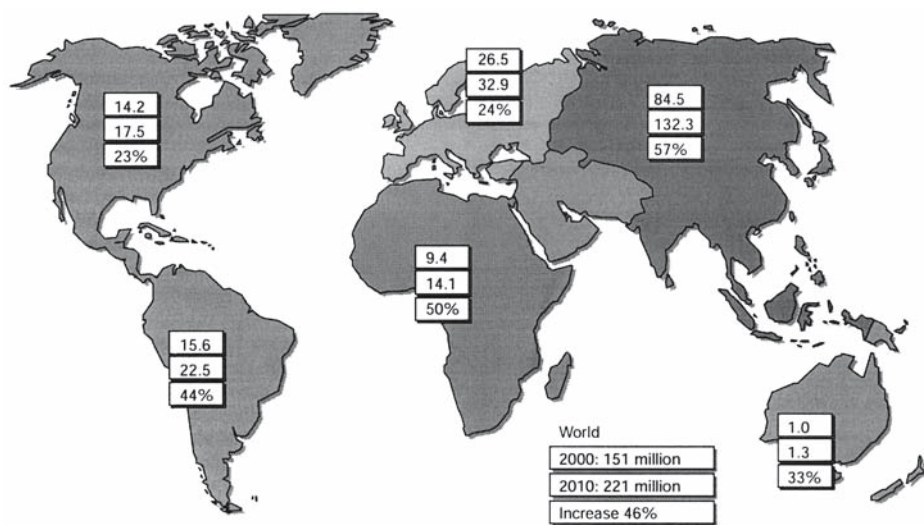


Fig. 7. Number of people with diabetes (in millions) for 2000 and 2010 (top and middle values, respectively), and the percentage increase. (Reprinted from ref. 78, with permission of Macmillan Publishers Ltd.)

\$10,071 per capita, compared with \$2669 for people without diabetes. In 1997, there were 98,224 physician visits and 16,110 emergency room visits related to ophthalmologic problems (87).

7.4. Obesity and Other Eye Conditions

As covered elsewhere in this book, obesity is associated with higher risk of cataract (Chapter 2) and a higher risk of age-related macular degeneration (Chapter 3). A causal relationship between obesity and these two major eye diseases has not been established, thus, it is unclear whether the obesity epidemic will be associated with an increase in cataract and age-related macular degeneration.

8. PREVENTION

There are two main prevention strategies to reduce obesity: primary prevention, which aims to prevent the development of obesity, and secondary prevention, which aims to reverse obesity after the condition has been identified. The treatment of longstanding obesity is sometimes called tertiary prevention but is equivalent to treatment rather than prevention. Prevention strategies must address the entire life span, as there are intergenerational effects of obesity. For the prevention of pediatric obesity, Richard Deckelbaum and Christine Williams have proposed three levels for prevention: (1) primordial prevention, which has the aim of maintaining normal BMI throughout childhood and adolescence, (2) primary prevention, which has the aim of preventing overweight children (BMI in 85th to 95th percentiles) from becoming obese, and (3) secondary prevention, which has aim to treat obese children (BMI >95th percentile) to reduce comorbidity and reverse overweight and obesity (14). Obese children younger than age 10 who have obese parents may benefit most from efforts at prevention (69). Although many different approaches are advocated for the prevention of obesity and make empirical sense, it should be noted that in many areas there is a paucity of data from controlled prevention trials. The American Academy of Pediatrics issued a policy statement in 2003 regarding the prevention of pediatric overweight and obesity, with specific conclusions and recommendations (88) (Table 2).

8.1. Prevention in the Perinatal Period

The risk for type 2 diabetes, hypertension, and coronary artery disease may be related to fetal nutrition, a line of investigation that has been pursued by David Barker and colleagues in Southampton (89). This has become known as the “fetal origins of disease” hypothesis (90). Size at birth has been shown to be a determinant of increased risk of glucose intolerance and obesity in adult life (89). In addition, both low birthweight and high birthweight are associated with an increased risk of death among those who later develop diabetes (91). Maternal nutrition education for pregnant women may help to ensure normal birth weight.

8.2. Promotion of Breastfeeding

The encouragement of breastfeeding is recommended by the American Academy of Pediatrics (88). The promotion of increased breastfeeding and continuous breastfeeding until at least 6 mo of age, with a delay in the introduction of solid foods until after 6 mo of age has been advocated by Deckelbaum and Williams (14).

8.3. Reduction of Sedentary Behavior and Increased Physical Activity

School-based interventions have included modification of school food service, enhanced physical education, health and nutrition education, and reduction of time watching television and videos. In the Child and Adolescent Trial for Cardiovascular Health (CATCH) study, a controlled intervention involving school food service, physical education, and classroom curricula had an impact on reducing energy intake from fat and increasing physical activity, but there was no significant impact on body size, blood pressure, or cholesterol levels (92). A randomized, controlled, school-based trial showed that reduction of television, videotape, and video game use led to decreases in BMI, triceps skinfold

Table 2
American Academy of Pediatrics Policy Statement:
Prevention of Pediatric Overweight and Obesity

Summary/Conclusions

1. Prevalence of overweight and its significant comorbidities in pediatric populations has rapidly increased and reached epidemic proportions.
2. Prevention of overweight is critical, because long-term outcome data for successful treatment approaches are limited.
3. Genetic, environmental, or combinations of risk factors predisposing children to obesity can and should be identified.
4. Early recognition of excessive weight gain relative to linear growth should become routine in pediatric ambulatory settings. Body mass index (BMI) (kg/m^2) should be calculated and plotted periodically.
5. Families should be educated and empowered through anticipatory guidance to recognize the impact they have on their children's development or lifelong habits of physical activity and nutritious eating.
6. Dietary practices should be fostered that encourage moderation rather than overconsumption, emphasizing healthful choices rather than restrictive eating patterns.
7. Regular physical activity should be consciously promoted, prioritized, and protected within families, schools, and communities.
8. Optimal approaches to prevention need to combine dietary and physical activity interventions.
9. Advocacy is needed in the areas of physical activity and food policy for children; research into pathophysiology, risk factors, and early recognition and management of overweight and obesity; and improved insurance coverage and third-party reimbursement for obesity care.

Recommendations

1. Health supervision
 - a. Identify and track patients at risk by virtue of family history, birth weight, or socioeconomic, ethnic, cultural, or environmental factors.
 - b. Calculate and plot BMI once a year in all children and adolescents.
 - c. Use change in BMI to identify rate of excessive weight gain relative to linear growth.
 - d. Encourage, support, and protect breastfeeding.
 - e. Encourage parents and caregivers to promote healthy eating patterns by offering nutritious snacks, such as vegetables and fruits, low-fat dairy foods, and whole grains; encouraging children's autonomy in self-regulation of food intake and setting appropriate limits on choices; and modeling healthy food choices.
 - f. Routinely promote physical activity, including unstructured play at home, in school, in child care settings, and throughout the community.
 - g. Recommend limitation of television and video time to a maximum of 2 h per day.
 - h. Recognize and monitor changes in obesity-associated risk factors for adult chronic disease, such as hypertension, dyslipidemia, hyperinsulinemia, impaired glucose tolerance, and symptoms of obstructive sleep apnea syndrome.
 2. Advocacy
 - a. Help parents, teachers, coaches, and others who influence youth to discuss health habits, not body habitus, as part of their efforts to control overweight and obesity.
 - b. Enlist policy makers from local, state, and national organizations and schools to support a healthful lifestyle for all children, including proper diet and adequate opportunity for regular physical activity.
 - c. Encourage organizations that are responsible for health care and health care financing to provide coverage for effective obesity prevention and treatment strategies.
 - d. Encourage public and private sources to direct funding toward research into effective strategies to prevent overweight and obesity and to maximize limited family and community resources to achieve healthful outcomes for youth.
 - e. Support and advocate for social marketing intended to promote healthful food choices and increased physical activity.
-

thickness, waist circumference, and waist-to-hip ratio (93). In an intervention known as Planet Health, 1295 ethnically diverse students from grades 6 and 7 were randomized to receive curricula related to decreasing television viewing, decreasing consumption of high-fat foods, increasing fruit and vegetable intake, and increasing physical activity (94). The intervention led to decreased obesity among girls but not boys (94). In a childhood obesity clinic, a controlled intervention to reduce sedentary behavior and increase physical activity decreased pediatric obesity (95).

The Centers for Disease Control and Prevention and the American College of Sports Medicine have recommended that every adult should accumulate 30 min or more of moderate-intensity physical activity each day (96). Physical activity alone has been shown to lead to modest reductions in weight among overweight and obese adults (97). The Task Force on Community Prevention Services of the Centers for Disease Control recently reviewed nutrition, physical activity, and a combination of these and other behavioral interventions (98). Based on evidence of effectiveness, the Task Force recommended multi-component interventions that included nutrition and physical activity to control overweight and obesity among adults in the workplace (98). The Task Force showed that there was insufficient evidence to determine the effectiveness of a combination of nutrition and physical activity interventions in the school setting to reduce overweight and obesity (98).

8.4. Diet

Among school-aged children, dietary strategies aimed at improving diet quality include school-based lunch programs, nutrition education, and eating a family dinner every day. In the Baltimore public schools, a classroom intervention known as the Eat Well and Keep Moving Program was implemented among primarily black fourth graders (99). The intervention focused on decreasing consumption of total and saturated fats and increasing fruit and vegetable intake, as well as reducing the amount of time watching television and increasing physical activity. Cross-sectional survey data showed that students in the intervention schools reported less consumption of total energy from fat and saturated fats, higher fruit and vegetable intake, and higher consumption of fiber compared with students from control schools (99). Among 8677 girls and 7525 boys aged 9–14 yr, children who ate a family dinner every day had a higher intake of fruits and vegetables, a higher intake of several nutrients, lower glycemic load, and a lower intake of saturated and trans fat as percent of energy compared with children who ate at a family dinner less frequently (100). In addition, children eating a family dinner every day had less consumption of fried food away from home and soda consumption (100). This study shows that a family dinner is associated with healthful dietary patterns. In obese adolescents, a program of diet and exercise for 20 wk reduced multiple risk factors for coronary heart disease by 41% compared with controls, whereas dietary intervention alone reduced multiple risk factors by about 15% (74).

Most adults who are trying to lose weight do not follow guidelines for reducing caloric intake and increasing physical activity (101). If such recommendations are followed, these are usually of short duration. Popular diets are often tried, and these types of diets have been classified by Marjorie Freedman and colleagues as (1) high-fat, low carbohydrate, high protein diets, the so-called “Atkins” diet, (2) moderate-fat, balanced nutrient reduction diets that are high in carbohydrate and moderate in protein, such as the United

States Department of Agriculture (USDA) diet, DASH diet, and Weight-Watchers diet, and (3) low-fat to very-low-fat, high-carbohydrate, moderate-protein diets, such as the “Ornish” and “Pritkin” diets (101). An evidence-based review of various diets shows that low-fat, low-calorie diets are more successful in maintaining weight loss (101). This diet is high in fruits and vegetables, complex carbohydrates (whole grains and legumes), and low-fat dairy, and rather than be adapted for a short period of “diet,” should form the basis of everyday food choices (101). Randomized trials of low-carbohydrate diets have failed to show that the popular Atkins-style diet was more effective than others (102), with no weight differences between low-carbohydrate and energy restricted diet at 12 mo (103–105).

9. CONCLUSION

The worldwide obesity epidemic is leading to an increase in diabetes mellitus, which in turn will likely be associated with an increase in diabetic retinopathy. Prevention of overweight and obesity will require an integrated approach: improved community design and city planning that encourages walking, reduction of sedentary behaviors and time spent watching television and video games, a lifetime adaptation of healthy eating patterns of a diet high in fruits and vegetables, whole grains, and legumes, and low-fat dairy products. Urgent action is needed to prevent and treat overweight and obesity. The health consequences not only include diabetes and diabetic retinopathy: unless the trend is reversed, it is likely that a decline in life expectancy could occur in the United States in the 21st century (106).

REFERENCES

1. Banting W. A Letter on Corpulence, Addressed to the Public. London, Harrison and Sons, 1863.
2. Quetelet A. *Physique sociale; ou essai sur le développement de facultés de l'homme*. Brussels, C. Muquardt, 1869.
3. Joslin EP. The prevention of diabetes mellitus. *JAMA* 1921;76:79–84.
4. Himsworth HP. Diet and the incidence of diabetes mellitus. *Clin Sci* 1933;2:117–148.
5. New York Metropolitan Life. New weight standards for men and women. *Stat Bull NY Metropolitan Life Ins Co* 1959;40:1–4.
6. Popkin BM. The nutrition transition and its relationship to demographic change. In: Semba RD, Bloem MW (eds). *Nutrition and Health in Developing Countries*. Totowa, NJ, Humana: 2001; pp. 427–445.
7. James PT, Leach R, Kalamara E, Shayeghi M. The worldwide obesity epidemic. *Obes Res* 2001; 9(suppl 4):228S–233S.
8. Goran MI. Metabolic precursors and effects of obesity in children: a decade of progress, 1990–1999. *Am J Clin Nutr* 2001;73:158–171.
9. Cole TJ, Bellizzi MC, Flegal KM, Dietz WH. Establishing a standard definition for child overweight and obesity worldwide: international survey. *BMJ* 2000;320:1240–1243.
10. Visscher TLS, Seidell JC. The public health impact of obesity. *Annu Rev Public Health* 2001;22:355–375.
11. Kopelman PG. Obesity as a medical problem. *Nature* 2000;404:635–643.
12. Monteiro CA, Moura EC, Conde WL, Popkin BM. Socioeconomic status and obesity in adult populations of developing countries: a review. *Bull World Health Organ* 2004;82:940–946.
13. DeOnis M, Blössner M. Prevalence and trends of overweight among preschool children in developing countries. *Am J Clin Nutr* 2000;72:1032–1039.
14. Deckelbaum RJ, Williams CL. Childhood obesity: the health issue. *Obesity Res* 2001;9(suppl 4):239S–243S.
15. Flegal KM, Carroll MD, Kuczmarski RJ, Johnson CL. Overweight and obesity in the United States: prevalence and trends, 1960–1994. *Int J Obesity* 1998;22:39–47.

16. Tremblay MS, Katzmarzyk PT, Willms JD. Temporal trends in overweight and obesity in Canada, 1981–1996. *Int J Obes Relat Metab Disord* 2002;26:538–543.
17. Allison DB, Fontaine KR, Manson JE, Stevens J, VanItallie TB. Annual deaths attributable to obesity in the United States. *JAMA* 1999;282:1530–1538.
18. Katzmarzyk PT, Ardern CI. Overweight and obesity mortality trends in Canada, 1985–2000. *Can J Public Health* 2004;95:16–20.
19. Rocchini AP. Childhood obesity and a diabetes epidemic. *N Engl J Med* 2002;346:854–855.
20. Troiano RP, Flegal KM, Kuczmarski RJ, Campbell SM, Johnson CL. Overweight prevalence and trends for children and adolescents. The National Health and Nutrition Examination Surveys, 1963 to 1991. *Arch Pediatr Adolesc Med* 1995;149:1085–1091.
21. Williams CL. Can childhood obesity be prevented? In: Bendich A, Deckelbaum RJ (eds). *Primary and Secondary Preventive Nutrition*. Totowa, NJ, Humana: 2001; pp. 185–204.
22. Freedman DS, Srinivasan SR, Valdez RA, Williamson DF, Berenson GS. Secular increases in relative weight and adiposity among children over two decades: the Bogalusa Heart Study. *Pediatrics* 1997;99:420–426.
23. Story M, Evans M, Fabsitz RR, Clay TE, Rock BH, Broussard B. The epidemic of obesity in American Indian communities and the need for childhood obesity-prevention programs. *Am J Clin Nutr* 1999;69 (suppl):747S–754S.
24. Seidell JC. Obesity in Europe: scaling an epidemic. *Int J Obesity* 1995;19(suppl 3):S1–S4.
25. Prescott-Clarke P, Primatesta P. *Health Survey for England 1996* (HMSO, London, 1998).
26. Maillard G, Charles MA, Thibult N, Forhan A, Sermet C, Basdevant A, Eschwege E. Trends in the prevalence of obesity in the French adult population between 1980 and 1991. *Int J Obes Relat Metab Disord* 1999;23:389–394.
27. Marques-Vidal P, Ruidavets JB, Cambou JP, Ferrieres J. Trends in overweight and obesity in middle-aged subjects from southwestern France, 1985–1997. *Int J Obes Relat Metab Disord* 2002;26:732–734.
28. Lissau I, Overpeck MD, Ruan WJ, et al. Body mass index and overweight in adolescents in 13 European countries, Israel, and the United States. *Arch Pediatr Adolesc Med* 2004;158:27–33.
29. Osei K, Schuster DP, Amoah AGB, Owusu SK. Pathogenesis of type 1 and type 2 diabetes mellitus in sub-Saharan Africa: implications for transitional populations. *J Cardiovasc Risk* 2003;10:85–96.
30. Motala AA, Omar MAK, Pirie FJ. Epidemiology of type 1 and type 2 diabetes in Africa. *J Cardiovasc Risk* 2003;10:77–83.
31. Puoane T, Steyn K, Bradshaw D, et al. Obesity in South Africa: the South African demographic and health survey. *Obes Res* 2002;10:1038–1048.
32. Martorell R, Khan LK, Hughes ML, Grummer-Strawn LM. Obesity in Latin American women and children. *J Nutr* 1998;128:1464–1473.
33. Uauy R, Albala C, Kain J. Obesity trends in Latin America: transiting from under- to overweight. *J Nutr* 2001;131:893S–899S.
34. Monteiro CA, Mondini L, de Souza ALM, Popkin BM. The nutrition transition in Brazil. *Eur J Clin Nutr* 1995;49:105–113.
35. Monteiro CA, Conde WL, Popkin BM. Independent effects of income and education on the risk of obesity in the Brazilian adult population. *J Nutr* 2001;131:881S–886S.
36. Monteiro CA, Conde WL, Popkin BM. The burden of disease from undernutrition and overnutrition in countries undergoing rapid nutrition transition: a view from Brazil. *Am J Public Health* 2004;94:433–434.
37. Jahns L, Baturin A, Popkin BM. Obesity, diet, and poverty: trends in the Russian transition to market economy. *Eur J Clin Nutr* 2003;57:1295–1302.
38. Kadyrova RKh, Salkhanov BA. [The prevalence of obesity among the adult population of Kazakhstan]. *Vopr Pitan* 1990;(1):30–33.
39. Beegom R, Beegom R, Niaz MA, Singh RB. Diet, central obesity and prevalence of hypertension in the urban population of south India. *Int J Cardiol* 1995;51:183–191.
40. Misra A, Pandey RM, Devi JR, Sharma R, Vikram NK, Khanna N. High prevalence of diabetes, obesity and dyslipidaemia in urban slum population in northern India. *Int J Obes Relat Metab Disord* 2001;25:1722–1729.
41. Nanan DJ. The obesity pandemic—implications for Pakistan. *J Pak Med Assoc* 2002;52:342–436.

42. Pradeepa R, Mohan V. The changing scenario of the diabetes epidemic: implications for India. *Indian J Med Res* 2002;116:121–132.
43. Yoshiike N, Seino F, Tajima S, Arai Y, Kawano M, Furuhashi T, Inoue S. Twenty-year changes in the prevalence of overweight in Japanese adults: the National Nutrition Survey 1976–95. *Obes Rev* 2002;3:183–190.
44. Matsushita Y, Yoshiike N, Kaneda F, Yoshita K, Takimoto H. Trends in childhood obesity in Japan over the last 25 years from the National Nutrition Survey. *Obes Res* 2004;12:205–214.
45. Yoshinaga M, Shimago A, Koriyama C, Nomura Y, Miyata K, Hashiguchi J, Arima K. Rapid increase in the prevalence of obesity in elementary school children. *Int J Obes Relat Metab Disord* 2004;28:494–499.
46. Popkin BM, Doak CM. The obesity epidemic is a worldwide phenomenon. *Nutr Rev* 1998;56:106–114.
47. Kim S, Moon S, Popkin BM. The nutrition transition in South Korea. *Am J Clin Nutr* 2000;71:44–53.
48. Hodge AM, Dowse GK, Zimmet PZ, Collins VR. Prevalence and secular trends in obesity in Pacific and Indian Ocean island populations. *Obesity Res* 1995;3(suppl 2):77S–87S.
49. Cameron AJ, Welborn TA, Zimmet PZ, et al. Overweight and obesity in Australia: the 1999–2000 Australian Diabetes, Obesity, and Lifestyle Study (AusDiab). *Med J Australia* 2003;178:427–432.
50. Australian Bureau of Statistics, Department of Health and Family Services, National Nutrition Survey: selected highlights 1995. Canberra, ABS/DHFS, 1997.
51. Binns CW, Leong JF. Public health nutrition: results and research. *Asia Pac J Public Health* 2000;12(suppl):S18–S20.
52. Wilson BD, Wilson NC, Russell DG. Obesity and body fat distribution in the New Zealand population. *N Z Med J* 2001;114:127–130.
53. Hill JO, Melanson EL, Wyatt HT. Dietary fat intake and regulation of energy balance: implications for obesity. *J Nutr* 2000;130:284S–288S.
54. Poppitt SD, Prentice AM. Energy density and its role in the control of food intake: evidence from metabolic and community studies. *Appetite* 1996;26:153–174.
55. Lawton CL, Burley VJ, Wales JK, Blundell JE. Dietary fat and appetite control in obese subjects: weak effects on satiation and satiety. *Int J Obesity* 1993;17:409–416.
56. Andersen RE, Crespo CJ, Bartlett SJ, Cheskin LJ, Pratt M. Relationship of physical activity and television watching with body weight and level of fatness among children. Results from the Third National Health and Nutrition Examination Survey. *JAMA* 1998;279:938–942.
57. Gortmaker SL, Must A, Sobol AM, Peterson K, Colditz GA, Dietz WH. Television viewing as a cause of increasing obesity among children in the United States, 1986–1990. *Arch Pediatr Adolesc Med* 1996;150:356–362.
58. Strasburger VC. Children, adolescents, and television. *Pediatr Rev* 1992;13:144–151.
59. Dietz WH, Gortmaker SL. Preventing obesity in children and adolescents. *Annu Rev Public Health* 2001;22:337–353.
60. Hoffman DJ, Sawaya AL. Energy balance. In: Sadler MJ, Strain JJ, Caballero B (eds). *Encyclopedia of Human Nutrition*. Volume 2. San Diego, Academic: 1999; pp. 650–658.
61. Ferro-Luzzi A, Martino L. Obesity and physical activity. In: Chadwick GC (ed). *The Origins and Consequences of Obesity*. Ciba Foundation Symposium 201. Wiley, Chichester: 1996; pp. 207–227.
62. Loureiro ML, Nayga RM Jr. Obesity, weight loss, and physician's advice. *Soc Sci Med* 2005;Dec 19 [Epub ahead of print].
63. Schlicker SA, Borra ST, Regan C. The weight and fitness status of United States children. *Nutr Rev* 1994;52:11–17.
64. Ewing R, Schmid T, Killingsworth R, Zlot A, Raudenbush S. Relationship between urban sprawl and physical activity, obesity, and morbidity. *Am J Health Promot* 2003;18:47–57.
65. Frank LD, Andresen MA, Schmid TL. Obesity relationships with community design, physical activity, and time spent in cars. *Am J Prev Med* 2004;27:87–96.
66. Lopez-Zetina J, Lee H, Friis R. The link between obesity and the built environment. Evidence from an ecological analysis of obesity and vehicle miles of travel in California. *Health Place* 2005;Oct 24 [Epub ahead of print].
67. Curhan GC, Chertow GM, Willett WC, et al. Birth weight and adult hypertension and obesity in women. *Circulation* 1996;94:1310–1315.

68. Guo SS, Roche AF, Chumlea WC, Gardner JD, Siervogel RM. The predictive value of childhood body mass index values for overweight at age 35 yr. *Am J Clin Nutr* 1994;59:810–819.
69. Whitaker RC, Wright JA, Pepe MS, Seidel KD, Dietz WH. Predicting obesity in young adulthood from childhood and parental obesity. *N Engl J Med* 1997;337:869–873.
70. Guo SS, Wu W, Chumlea WC, Roche AF. Predicting overweight and obesity in adulthood from body mass index values in childhood and adolescence. *Am J Clin Nutr* 2002;76:653–658.
71. Freedman DS, Khan LK, Dietz WH, Srinivasan SR, Berenson GS. Relationship of childhood obesity to coronary heart disease risk factors in adulthood: the Bogalusa Heart Study. *Pediatrics* 2001;108:712–718.
72. Freedman DS, Srinivasan SR, Harsha DW, Webber LS, Berenson GS. Relation of body fat patterning to lipid and lipoprotein concentrations in children and adolescents: the Bogalusa Heart Study. *Am J Clin Nutr* 1989;50:930–939.
73. Freedman DS, Dietz WH, Srinivasan SR, Berenson GS. The relation of overweight to cardiovascular risk factors among children and adolescents: the Bogalusa Heart Study. *Pediatrics* 1999;103:1175–1182.
74. Becque MD, Katch VL, Rocchini AP, Marks CR, Moorehead C. Coronary risk incidence of obese adolescents: reduction by exercise plus diet intervention. *Pediatrics* 1988;81:605–612.
75. Berenson GS, Wattigney WA, Tracy RE, et al. Atherosclerosis of the aorta and coronary arteries and cardiovascular risk factors in persons aged 6 to 30 years and studied at necropsy (The Bogalusa Heart Study). *Am J Cardiol* 1992;70:851–858.
76. Pinhas-Hamiel O, Dolan LM, Daniels SR, Standiford D, Khoury PR, Zeitler P. Increased incidence of non-insulin-dependent diabetes mellitus among adolescents. *J Pediatr* 1996;128:608–615.
77. Mokdad AH, Bowman BA, Ford ES, Vinicor F, Marska JS, Koplan JP. The continuing epidemics of obesity and diabetes in the United States. *JAMA* 2001;286:1195–1200.
78. Zimmet P, Alberti KGMM, Shaw J. Global and societal implications of the diabetes epidemic. *Nature* 2001;414:782–787.
79. Ford E, Giles W, Dietz W. Prevalence of the metabolic syndrome among US adults. Findings from the Third National Health and Nutrition Examination survey. *JAMA* 2002;287:356–359.
80. Isomaa B, Henricsson M, Almgren P, Tuomi T, Taskinen MR, Groop L. The metabolic syndrome influences the risk of chronic complications in patients with type II diabetes. *Diabetologia* 2001;44:1148–1154.
81. Zimmet PZ. Diabetes epidemiology as a tool to trigger to diabetes research. *Diabetologia* 1999;42:499–518.
82. Engelgau MM, Geiss LS, Saaddine JB, et al. The evolving diabetes burden in the United States. *Ann Intern Med* 2004;140:945–950.
83. King H, Aubert RE, Herman WH. Global burden of diabetes, 1995–2025. Prevalence, numerical estimates, and projections. *Diabetes Care* 1998;21:1414–1431.
84. Manaviat MR, Afkhami M, Shoja MR. Retinopathy and microalbuminuria in type II diabetic patients. *BMC Ophthalmol* 2004;4:9.
85. Henricsson M, Hystrom L, Blohme G, et al. The incidence of retinopathy 10 years after diagnosis in young adult people with diabetes. *Diabetes Care* 2003;26:349–354.
86. Van Leiden HA, Dekker JM, Moll AC, Nijpels G, Heine RJ, Bouter LM, Coen DAS, Polak BCP. Blood pressure, lipids, and obesity are associated with retinopathy. *Diabetes Care* 2002;25:1320–1325.
87. American Diabetes Association. Economic consequences of diabetes mellitus in the U.S. in 1997. *Diabetes Care* 1998;21:296–309.
88. Krebs NF, Baker RD, Greer FR, Heyman MB, Jaksic T, Lifshitz F. American Academy of Pediatrics: policy statement, prevention of pediatric overweight and obesity. *Pediatrics* 2003;112:424–430.
89. Harding JE. The nutritional basis of the fetal origins of adult disease. *Int J Epidemiol* 2001;30:15–23.
90. Ellison PT. Evolutionary perspectives on the fetal origins hypothesis. *Am J Hum Biol* 2005;17:113–118.
91. Leibson CL, Burke JP, Ransom JE, et al. Relative risk of mortality associated with diabetes as a function of birth weight. *Diabetes Care* 2005;28:2839–2843.
92. Luepker RV, Perry CL, McKinlay SM, et al. Outcomes of a field trial to improve children's dietary patterns and physical activity. The Child and Adolescent Trial for Cardiovascular Health. *JAMA* 1996;275:768–776.
93. Robinson TN. Reducing children's television viewing to prevent obesity: a randomized controlled trial. *JAMA* 1999;282:1561–1567.

94. Gortmaker SL, Peterson K, Wiecha J, Sobol AM, Dixit S, Fox MK, Laird N. Reducing obesity via a school-based interdisciplinary intervention among youth: Planet Health. *Arch Pediatr Adol Med* 1999; 153:409–418.
95. Epstein LH, Paluch RA, Gordy CC, Dorn J. Decreasing sedentary behaviors in treating pediatric obesity. *Arch Pediatr Adol Med* 2000;154:220–226.
96. Pate RR, Pratt M, Blair SN, et al. Physical activity and public health. A recommendation from the Centers for Disease Control and Prevention and the American College of Sports Medicine. *JAMA* 1995;273: 402–407.
97. Wing RR. Physical activity in the treatment of adulthood overweight and obesity: current evidence and research issues. *Med Sci Sports Exer* 1999;31(suppl 1):S547–S552.
98. Katz DL, O'Connell M, Yeh MC, et al. Public health strategies for preventing and controlling overweight and obesity in school and worksite settings: a report on recommendations of the Task Force on Community Preventive Services. *MMWR Recomm Rep* 2005;54:1–12.
99. Gortmaker SL, Cheung LWY, Peterson KE, et al. Impact of a school-based interdisciplinary intervention on diet and physical activity among urban primary school children: Eat Well and Keep Moving. *Arch Pediatr Adolesc Med* 1999;153:975–983.
100. Gillman MW, Rifas-Shiman SL, Frazier AL, et al. Family dinner and diet quality among older children and adolescents. *Arch Fam Med* 2000;9:235–240.
101. Freedman MR, King J, Kennedy E. Popular diets: a scientific review. *Obes Res* 2001;9(suppl 1):1S–40S.
102. Astrup A, Larsen TM, Harper A. Atkins and other low-carbohydrate diets: hoax or an effective tool for weight loss? *Lancet* 2004;364:897–899.
103. Foster GD, Wyatt HR, Hill JO, et al. A randomized trial of a low-carbohydrate diet for obesity. *N Engl J Med* 2003;348:2082–2090.
104. Samanha FF, Iqbal N, Seshadri P, et al. A low-carbohydrate as compared with a low-fat diet in severe obesity. *N Engl J Med* 2003;348:2074–2081.
105. Stern L, Iqbal N, Seshadri PK, et al. The effects of low-carbohydrate versus conventional weight loss diets in severely obese adults: one-year follow-up of a randomized trial. *Ann Intern Med* 2004;140: 778–785.
106. Olshansky SJ, Passaro DJ, Hershow RC, et al. A potential decline in life expectancy in the United States in the 21st century. *N Engl J Med* 2005;352:1138–1145.

5

Nutrition and Diabetic Retinopathy

1. INTRODUCTION

Diabetic retinopathy is a microvascular complication of diabetes mellitus that can lead to substantial visual loss and blindness. As noted in Chapter 4, the prevalence of diabetes is projected to increase worldwide as a result of the obesity epidemic, and it is anticipated that there will be an accompanying increase in diabetic retinopathy and related visual impairment and blindness. A large portion of diabetes can be linked to obesity and poor nutrition. The relationships between specific nutrient deficiencies and diabetic retinopathy have not been consistently demonstrated. Current theories of the pathogenesis of diabetic retinopathy include the role of oxidative stress in the upregulation of vascular endothelial growth factor, with subsequent increase in vascular permeability and stimulation of neovascularization. Diabetes can be prevented among high-risk individuals by lifestyle changes that include the adoption of healthy diets combined with moderate exercise. Among those with diabetes, glycemic control and control of hypertension can reduce the risk of diabetic retinopathy.

2. EPIDEMIOLOGY

2.1. Prevalence and Incidence

Diabetic retinopathy is a frequent cause of visual impairment and blindness among middle to older aged adults and is commonly seen in clinical practice. Among adults older than 40 yr in the United States, diabetic retinopathy accounted for 5.4%, 7.3%, and 14.3% of blindness among whites, blacks, and Hispanics, respectively, and accounted for 4.3%, 14.5%, and 13.0% of poor vision among whites, blacks, and Hispanics, respectively (1). Diabetic retinopathy is estimated to result in blindness for more than 10,000 people with diabetes each year in the United States (2). The Wisconsin Epidemiologic Study of Diabetic Retinopathy (WESDR) (1980–1982) showed that among persons with mostly type 1 diabetes, the prevalence of diabetic retinopathy ranged from 17% in those who had diabetes less than 5 yr to 97.5% in those who had diabetes for 15 or more years (3). In the same group, the prevalence of proliferative diabetic retinopathy ranged from 1.2% in persons with diabetes for less than 10 yr to 67% in person with diabetes for more than 35 yr. Among people diagnosed with diabetes at age 30 or older, the prevalence of diabetic retinopathy ranged from 28.8% in those with diabetes for less than 5 yr to 77.8% in those who had diabetes for 15 or more years (4). In this older group, the prevalence of proliferative diabetic retinopathy ranged from 2% in those with diabetes less than 5 yr to 15.5% in those with diabetes for 15 or more years. The incidence of diabetic retinopathy

From: *Nutrition and Health: Handbook of Nutrition and Ophthalmology*

By: R. D. Semba © Humana Press Inc., Totowa, NJ

Table 1
Risk Factors for Diabetic Retinopathy

-
- Longer duration of diabetes
 - Poor glycemic control
 - Hypertension
 - Elevated serum lipid levels
 - Anemia
-

is higher among people with type 1 diabetes compared with type 2 diabetes. In the WESDR, the overall incidence of any diabetic retinopathy was 40.3% over a 4-yr interval. Among people with mostly type 1 diabetes, the incidence was 50.9%, and among people who were diagnosed after age 30, 47.4% of those insulin and 34.4% of those not taking insulin had developed retinopathy by 4 yr of follow-up (5).

2.2. Risk Factors for Diabetic Retinopathy

Several epidemiological risk factors have been identified for diabetic retinopathy (Table 1).

2.2.1. DURATION OF DIABETES

The length of time a person has had diabetes is a major risk factor for the development of diabetic retinopathy, as shown in the WESDR (3,4) and other large cohort studies, such as the Pittsburgh Diabetic Morbidity and Retinopathy Studies (6) and a study of 339 patients in Denmark (7).

2.2.2. GLYCEMIC CONTROL

In the Diabetes Control and Complications Trial, a study of 1441 patients with insulin-dependent diabetes mellitus, aged 13–39 yr, intensive treatment (self-administration of insulin at least three times a day by injection or pump, with doses adjusted based on blood monitoring with the goal of normoglycemia) slowed progression of retinopathy compared with conventional treatment (8). The cumulative 8.5-yr progression of retinopathy was 54.1% with conventional treatment and 11.5% with intensive treatment (8). Participants in this trial were informed of the benefits of intensive therapy. They were then followed by their own physicians, and follow-up showed that the reduction in risk of progression of retinopathy with intensive therapy persisted for at least 4 yr beyond the trial (9,10). In the UK Prospective Diabetes Study of 3867 newly diagnosed patients with type 2 diabetes, intensive blood glucose control with sulphonylureas or insulin significantly reduced the risk of microvascular complications, including need for retinal photocoagulation (11).

2.2.3. HYPERTENSION

In a recent clinical trial involving nineteen hospital-based clinics in the United Kingdom, 758 patients with hypertension and type 2 diabetes mellitus were allocated to a tight blood pressure control program with angiotensin-converting enzyme inhibitor or β -blockers as the main therapy, and 390 were allocated to a less tight blood pressure control program (12). The median follow-up to the end of the trial, death, or the last date at which vital status

was known was 8.4 yr. The tight blood pressure control group showed fewer microaneurysms, hard exudates, and cotton-wool spots at follow-up and were less likely to undergo photocoagulation (12). The cumulative incidence of blindness in one eye was 3.1 per 1000 patient-years in the tight blood pressure control group and 4.1 per 1000 patient-years in the control group (relative risk [RR] 0.76, 95% confidence interval [CI] 0.29–1.99, $p = 0.046$). In the Appropriate Blood Pressure Control in Diabetes (ABCD) Trial, subjects were stratified into hypertensive and normotensive subjects and were randomized to intensive or moderate control of blood pressure. Intensive control of blood pressure did not influence progression of diabetic retinopathy during 5 yr of follow-up in the hypertensive group (13), but in the normotensive group, intensive control of blood pressure retarded the progression of diabetic retinopathy (14). In the Steno-2 Study, eighty patients with microalbuminuria and type 2 diabetes were randomly assigned to receive intensive treatment for control of blood pressure, reduction of serum cholesterol and triglycerides, light-moderate exercise, smoking cessation, and aspirin therapy, and eighty patients were referred to their general practitioner (15). During mean follow-up of 7.8 yr, the patients who received intensive therapy had a lower risk of diabetic retinopathy (hazard ratio [HR], 0.42, 95% CI 0.21–0.86) (15). These three clinical trials suggest that aggressive control of hypertension in patients with type 2 diabetes can reduce progression of diabetic retinopathy.

2.2.4. SERUM LIPID LEVELS

Elevated serum cholesterol levels have been associated with severity of hard retinal exudates in diabetic retinopathy (16,17), and elevated serum triglyceride levels were associated with increased risk for high-risk proliferative diabetic retinopathy (18).

2.2.5. ANEMIA

A low hematocrit was associated with an increased risk of developing high-risk proliferative diabetic retinopathy in the Early Treatment Diabetic Retinopathy Study (ETDRS) (18). In a cohort of 1691 diabetic patients in Finland, anemia, defined as hemoglobin <12 g/dL, was associated with an increased risk of having any retinopathy (odds ratio [OR] 2.0, 95% CI 1.2–3.3) (19). In a stratified analysis involving people with retinopathy who had low hemoglobin levels, there was an increased risk of having severe retinopathy compared to mild retinopathy (OR 5.3, 95% CI 2.3–12.6) (19). The study from Finland did not classify anemia according to the World Health Organization criterion of <12 g/dL for women and <13 g/dL for men. The investigators concluded that diabetics with normocytic anemia had an increased risk of retinopathy, especially more severe retinopathy (19).

Case reports have provided anecdotal evidence that anemia may be related to diabetic retinopathy. Three patients with mild to moderate background diabetic retinopathy developed severe iron deficiency anemia and showed rapid progression to proliferative diabetic retinopathy (20). One patient with diabetic retinopathy showed resolution of microaneurysms after treatment of his iron deficiency anemia with blood transfusions, iron supplements, and B complex vitamin supplements (21). Correction of anemia with erythropoietin therapy has also been associated with improvement in diabetic macular edema (22).

In general, studies linking anemia with diabetic retinopathy have not characterized the type or types of anemia that are associated with retinopathy, and this is an issue that is critical to understanding whether anemia plays a role in the pathogenesis of diabetic retinopathy

or is perhaps more closely related to the inflammation associated with diabetes and its associated morbidity. Among people 65 yr and older in the National Health and Nutrition Examination Survey (NHANES) III, diabetes mellitus is associated with the anemia of chronic inflammation (23). Hepcidin, a recently discovered iron regulatory hormone, is up-regulated by inflammation and leads to the anemia of chronic inflammation by blocking iron absorption in the enterocytes and iron release by macrophages (24). Studies are needed to characterize hepcidin in the anemia associated with diabetes. It is likely that the anemia associated with diabetic retinopathy falls into the category of anemia of chronic inflammation, but further investigations are needed to address this hypothesis.

2.2.6. OBESITY

Obesity and overweight have been linked with diabetic retinopathy, but body mass index is also associated with other risk factors associated with diabetic complications. In a study in Croatia, obesity was associated with a high risk of retinopathy (25). In a study of 592 patients with type 1 diabetes, a higher body mass index was associated with retinopathy, but this relationship was not significant after adjusting for duration of diabetes and hemoglobin A_{1c} (26).

3. NUTRITION AND DIABETIC RETINOPATHY

3.1. Vitamin C

A consistent relationship between vitamin C and diabetic retinopathy has not been demonstrated. Some early studies suggested that vitamin C might play a role in microvascular disease and diabetes, but findings were variable (27–33). In a study from NHANES III (1988–1994) that involved a subsample of 998 people age 40 or older who had diabetes and fundus photographs, no significant relationships were found between serum vitamin C concentrations and risk of diabetic retinopathy (34). Retinopathy in NHANES III was evaluated by nonmydriatic fundus photographs of one randomly chosen eye for all participants. Retinopathy was originally graded as no retinopathy, mild nonproliferative retinopathy, moderate nonproliferative retinopathy, and proliferative retinopathy, but was used in the analysis as any versus no retinopathy, and about 20% of the sample had any retinopathy (34). Although serum ascorbate is used to indicate vitamin C status, its use is limited because large fluctuations in serum ascorbate can occur, and a single measure reflects only recent intake rather than body stores (35). In the San Luis Valley Diabetes Study in southern Colorado, an increased dietary intake of vitamin C was associated with an increased risk of diabetic retinopathy in a cross-sectional study. The study involved 387 participants (82 with background diabetic retinopathy, 39 with preproliferative diabetic retinopathy, and 17 with proliferative diabetic retinopathy, and dietary assessment involved 24-h recall (36). There was no significant relationship between vitamin C intake and diabetic retinopathy in the Atherosclerosis Risk in Communities (ARIC) Study (37).

3.2. Vitamin E

Vitamin E is a chain-breaking antioxidant (reviewed in Chapter 3) that has been hypothesized to play a role in diabetes and diabetic retinopathy. No consistent relationship has been demonstrated between vitamin E and diabetic retinopathy in human studies. In animal studies, vitamin E-deficient rats developed retinal vascular abnormalities such as

increase in retinal capillary basement membrane thickness and accumulation of lipofuscin in capillary walls (38), and abnormal retinal blood flow in diabetic rats was reduced by vitamin E treatment (39). No significant relationship was found between intake of vitamin E and glycosylated hemoglobin among diabetic patients (40). Diabetic retinopathy was not associated with lower plasma vitamin E levels among sixty patients with diabetes (41), and a study of young type 1 diabetic patients showed no differences in serum vitamin E levels between those with retinopathy and other complications and no complications (42). Higher plasma vitamin E levels were found in patients with poor glycemic control and high lipid levels (43). In the San Luis Valley Diabetes Study, higher dietary intake of vitamin E was associated with an increased risk of retinopathy (36). No significant relationships were found between serum α -tocopherol and diabetic retinopathy in NHANES III (34) or between dietary vitamin E intake and diabetic retinopathy in the ARIC study (37).

In small pilot trials, high doses of vitamin E reduced glycosylated proteins after 1–2 mo of supplementation (44), and a modest daily dose of vitamin E reduced glycosylated hemoglobin (45). Vitamin E supplementation reduced lipid peroxidation in type 2 diabetic patients with retinopathy (46). One study showed an apparent increase in retinal blood flow in diabetic patients after high-dose vitamin E treatment (47). In the Heart Outcomes Prevention Evaluation (HOPE) study, the effect of vitamin E on cardiovascular outcomes, including myocardial infarction, stroke, mortality, and secondary outcomes that included laser therapy for diabetic retinopathy, was examined in a 2×2 factorial design involving ramipril, a nonsulfhydryl angiotensin-converting enzyme inhibitor, and vitamin E. Among the 3654 subjects in the study with diabetes, vitamin E did not have any significant effect on the cardiovascular outcomes or on history of laser therapy for diabetic retinopathy (48).

3.3. Zinc

The effects of zinc supplementation on markers of oxidative stress have been studied in two pilot studies in patients with diabetes. In patients with insulin-dependent diabetes with and without retinopathy, zinc supplementation reduced markers of lipid peroxidation (49). In patients with type 2 diabetes who had hemoglobin A_{1c} >7.5%, zinc supplementation, 30 mg/d, for 6 mo decreased plasma thiobarbituric acid reactive substances, a marker for lipid peroxidation, compared with placebo (50).

3.4. Healthy Dietary Pattern

A recent study of 407 men and women with diabetes in Australia suggested that a pattern of dietary intake consistent with a Mediterranean type of diet was protective against diabetic retinopathy (51). The Mediterranean diet is characterized by a high intake of vegetables, legumes, fruits and nuts, cereals, and olive oil, a moderate intake of dairy products, and a low intake of meat and poultry. These data are consistent with a large emerging literature that shows a Mediterranean diet is protective against diabetes (52), peripheral artery disease in diabetics (53), inflammation (54), and mortality (55), as further discussed in Chapter 10 in relation to the age-related proinflammatory state. Another large study suggests that quality of diet is related to diabetic retinopathy. Among 1041 subjects with type 1 diabetes in the Diabetes Control and Complications Trial, a high consumption of total fatty acids and low consumption of dietary fiber were each associated with a higher rate of progression of diabetic retinopathy (56).

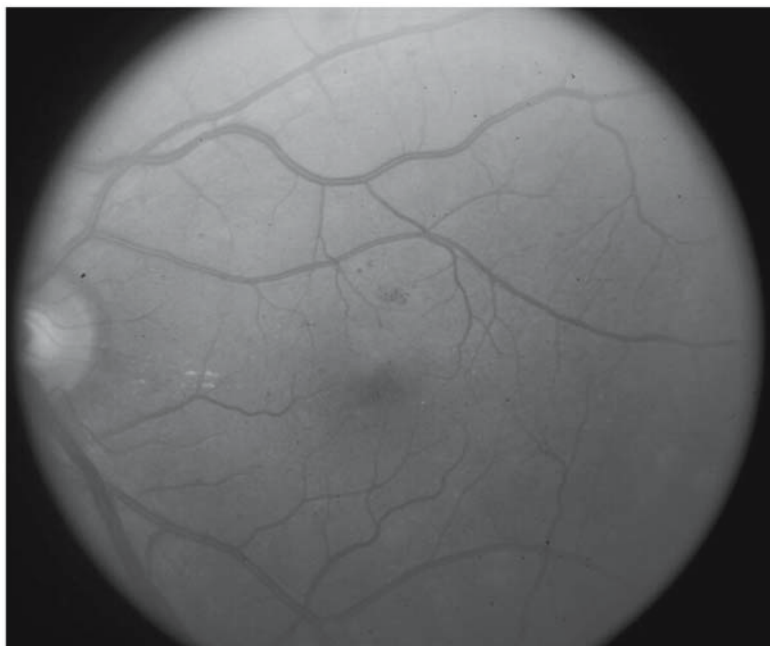


Fig. 1. Background diabetic retinopathy. (Photo courtesy of Neil Bressler.)

4. CLINICAL FEATURES

Diabetic retinopathy is generally classified as (1) nonproliferative retinopathy, characterized by microaneurysms, blot and flame-shaped hemorrhages, and hard exudates (Fig. 1), (2) preproliferative retinopathy, characterized by findings in (1) and in addition, by intraretinal microvascular abnormalities (IRMA), venous beading and loops, and cotton-wool spots, and (3) proliferative diabetic retinopathy, characterized by neovascularization of the retina and/or optic disc, vitreous hemorrhage, preretinal hemorrhage, fibrovascular proliferation, and retinal detachment (Fig. 2). Diabetic macular edema, or diabetic maculopathy, can result from leaking of blood vessels around the macular area. International clinical diabetic retinopathy and diabetic macular edema disease severity scales have been proposed (57). This new classification is based on five stages of severity for diabetic retinopathy (Table 2) and a classification for diabetic macular edema (Table 3). The diagnosis and evaluation of diabetes mellitus have been summarized in detail (2,58).

5. PATHOGENESIS

5.1. Diabetic Retinopathy

Many theories have been proposed for the pathogenesis of diabetic retinopathy, as recently reviewed by Robert Frank (59). The proposed mechanisms include increased production of sorbitol by aldose reductase, inflammation, reactive oxygen species (ROS), advanced glycation products, altered gene expression, increased growth hormone and insulin-like growth factor 1, upregulation of vascular endothelial growth factor (VEGF), and reduction of pigment-epithelium-derived factor (PEDF) (59). Activation of protein kinase C has also been implicated in microvascular changes in diabetes (60). None of these

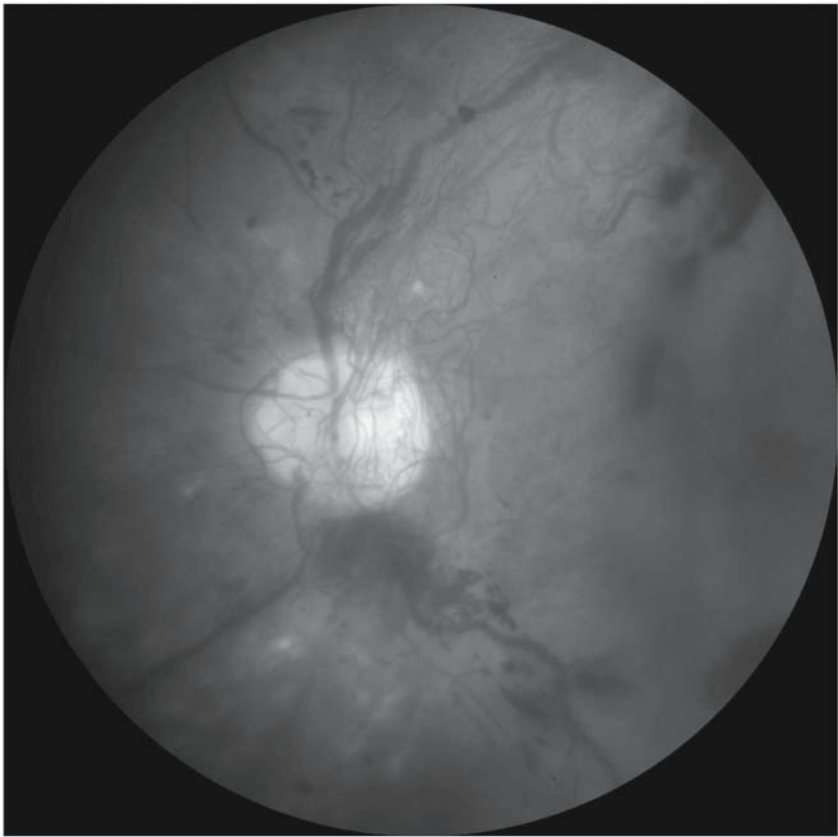


Fig. 2. Proliferative diabetic retinopathy. (Photo courtesy of Neil Bressler.)

Table 2
Diabetic Retinopathy Disease Severity Scale

<i>Proposed disease severity level</i>	<i>Findings observable on dilated ophthalmoscopy</i>
No apparent retinopathy	No abnormalities
Mild nonproliferative diabetic retinopathy	Microaneurysms only
Moderate nonproliferative diabetic retinopathy	More than just microaneurysms but less than severe nonproliferative diabetic retinopathy
Severe nonproliferative diabetic retinopathy	Any of the following: more than 20 intraretinal hemorrhages in each of 4 quadrants; definite venous beading in 2+ quadrants; prominent intraretinal microvascular abnormalities in 1+ quadrants <i>and</i> no sign of proliferative retinopathy
Proliferative diabetic retinopathy	One or more of the following: neovascularization, vitreous/preretinal hemorrhage

Reprinted from ref. 57, with permission of the American Academy of Ophthalmology.

Table 3
Diabetic Macular Edema Disease Severity Scale

<i>Proposed disease severity level</i>	<i>Findings observable on dilated ophthalmoscopy</i>
Diabetic macular edema apparently absent	No apparent retinal thickening or hard exudates in posterior pole
Diabetic macular edema apparently present	Some apparent retinal thickening or hard exudates in posterior pole
If macular edema is present, it can be categorized as:	
Mild diabetic macular edema	Some retinal thickening or hard exudates in posterior pole but distant from the center of the macula
Moderate diabetic macular edema	Retinal thickening or hard exudates approaching the center of the macula but not involving the center
Severe diabetic macular edema	Retinal thickening or hard exudates involving the center of the macula

Reprinted from ref. 57, with permission of the American Academy of Ophthalmology.

mechanisms has been conclusively demonstrated, and therapeutic approaches that include aldose reductase inhibitors, aspirin, antioxidants, aminoguanidine, hypophysectomy, growth hormone-receptor blockers, and other modalities have not been successful. Some of the proposed biological mechanisms overlap, particularly those that involve ROS, inflammation, and the potent angiogenesis factor, VEGF.

The VEGF family of growth factors includes VEGF-A, VEGF-B, VEGF-C, VEGF-D, placenta growth factor, and the viral VEGF homolog VEGF-E (61). VEGF-A, the most well studied of these factors, plays a role in increased vascular permeability and angiogenesis. VEGF-A is secreted by retinal pigment epithelial cells on the side facing the choriocapillaris (62) and by Müller cells (63). Expression of VEGF-A is upregulated by hypoxia and the transcription factor hypoxia-inducible factor (HIF)-1 α , which binds to the VEGF-A promoter and induces transcription (64). Nuclear factor (NF)- κ B, a transcription factor that is induced by redox balance (65), also plays a role in the expression of VEGF (66). Thus, ROS may upregulate VEGF expression by retinal cells such as Müller cells and retinal pigment epithelium, leading to proliferation of new blood vessels in the retina (Fig. 3) (59). PEDF is a potent angiogenic inhibitor and anti-inflammatory factor that appears to have a reciprocal relationship with VEGF (67). Elevated levels of VEGF-A have been described in the ocular fluids of patients with diabetic retinopathy (59,68), as well as higher levels of advanced glycation end products (AGEs), lower total antioxidant status (69), and higher lipid peroxidation (70). AGEs can be generated by the non-enzymatic reaction of glucose and free amino acid reactive groups of proteins (71). Higher levels of markers for oxidative stress have been found in subretinal fluid from patients with diabetic retinopathy (72). NF- κ B is also a key transcriptional factor in the upregulation of interleukin (IL)-6, and VEGF concentrations in aqueous and vitreous humor were significantly correlated with IL-6 levels in the aqueous and vitreous of patients with diabetic retinopathy ($\rho = 0.793$ and $\rho = 0.737$, respectively) (73).

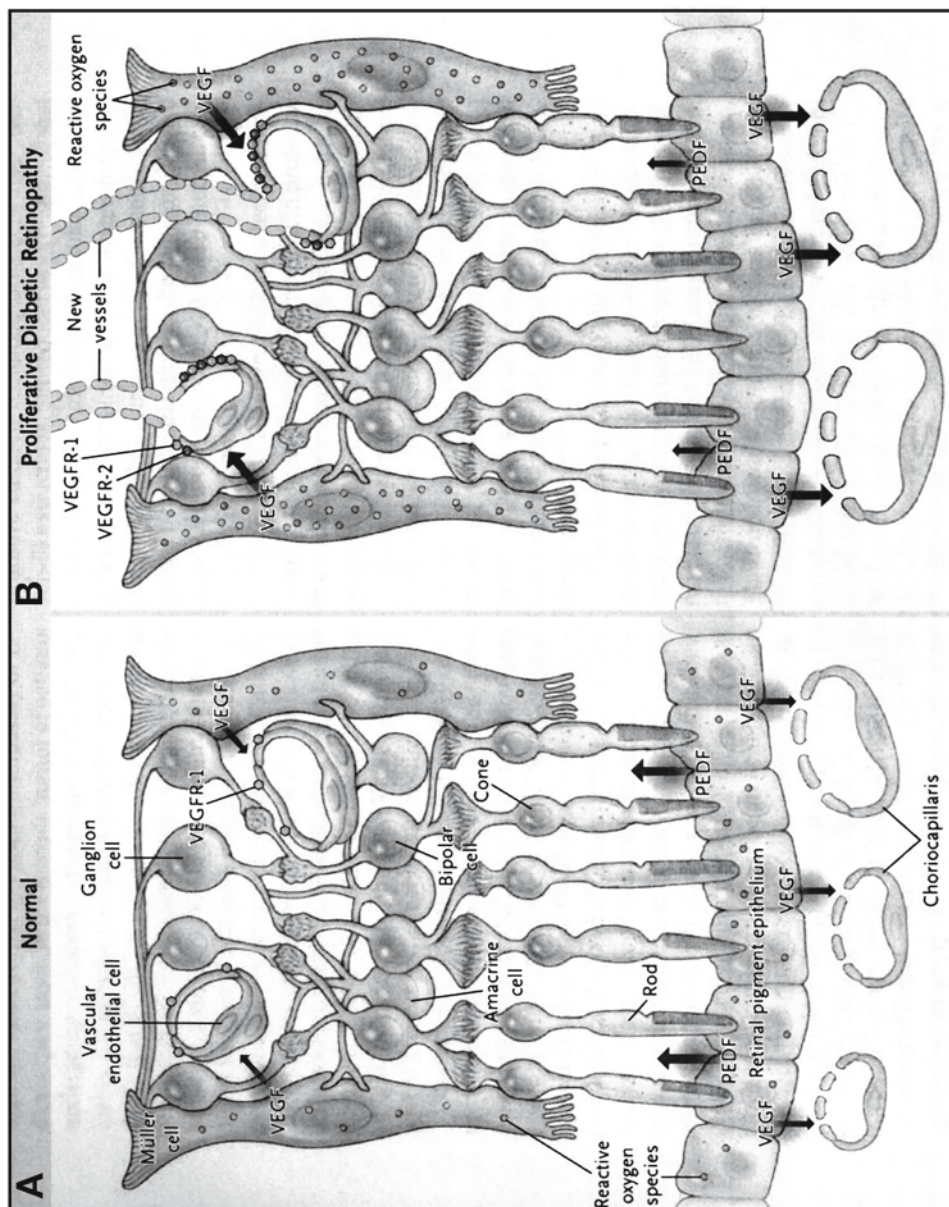


Fig. 3. Mechanism for diabetic retinopathy involving vascular endothelial growth factor and pigment-epithelium-derived factor. (Reprinted from ref. 59. Copyright © 2004, Massachusetts Medical Society. All rights reserved.)

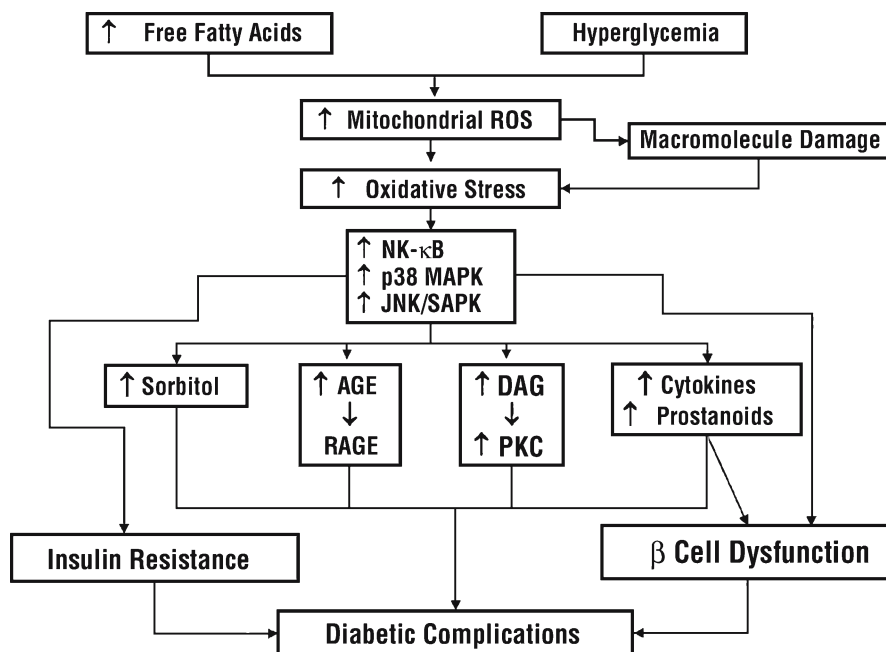


Fig. 4. Proposed general theory for pathophysiology of diabetes involving oxidative stress. (Reprinted from ref. 74. Copyright © 2002, The Endocrine Society.)

5.2. Systemic Diabetes Mellitus

Hyperglycemia is known to result in the generation of reactive oxygen and nitrogen species. Joseph Evans and colleagues have proposed that hyperglycemia and free fatty acid-induced activation of NF- κ B and other oxidative stress-sensitive pathways play a role in the complications of diabetes (Fig. 4) (74). Obesity, a sedentary lifestyle, and a poor quality diet can increase reactive oxygen and nitrogen species, as reviewed in Chapter 10. According to this unifying hypothesis, hyperglycemia can lead to mitochondrial dysfunction, with the increased production of ROS. NF- κ B and other stress-induced signaling pathways, such as p38 mitogen-activated protein kinase (MAPK) and NH₂-terminal Jun kinases (JNKs)/stress-activated protein kinases (SAPKs) are activated by ROS. These transcription factors are involved in the upregulation of inflammatory cytokines and VEGF (74). The sorbitol stress pathway and AGEs also contribute to diabetic complications. Thus, antioxidants are proposed as possible therapeutic interventions to prevent the complications of diabetes (74). The hypothetical model for the pathogenesis of diabetic complications is fairly consistent with the pathogenic mechanisms described under Subheading 5.1. for diabetic retinopathy.

6. TREATMENT

The main modalities for treatment of diabetic retinopathy are retinal laser photocoagulation and vitrectomy (58). Focal laser treatment is used for diabetic retinopathy in the presence of cystoid macular edema. Panretinal photocoagulation is used for high risk proliferative diabetic retinopathy. The use of panretinal photocoagulation is often considered in relation to other factors such as rate of progression, compliance, pregnancy,

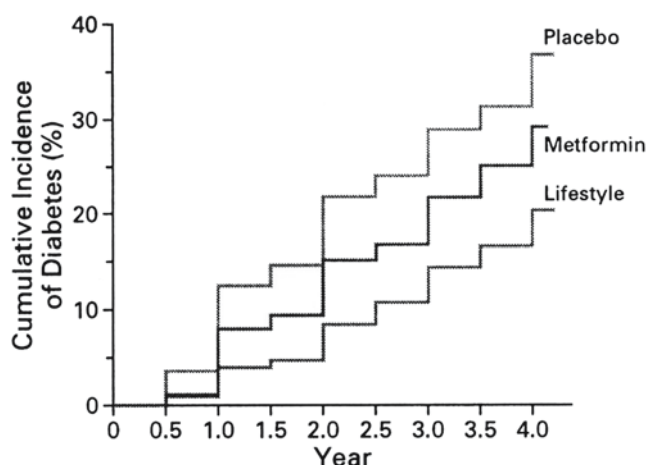


Fig. 5. Cumulative incidence of diabetes by study group in the Diabetes Prevention Program Research Group trial. (Reprinted from ref. 76. Copyright © 2002, Massachusetts Medical Society. All rights reserved.)

impending cataract surgery, and presence of type 1 or type 2 diabetes. Vitrectomy is used for treatment of nonclearing vitreous hemorrhage, traction retinal detachments, and active progressive proliferative diabetic retinopathy, and in some cases, refractory macular edema (2). Experimental therapies undergoing evaluation for diabetic retinopathy include protein kinase C inhibitors, anti-VEGF agents, and corticosteroids (2,75).

7. PREVENTION

7.1. Prevention of Diabetic Retinopathy in Diabetics

An important long-term approach for the prevention of diabetes and visual loss and blindness due to diabetic retinopathy is the permanent adoption of lifestyle and dietary changes that prevent overweight and obesity, as presented and discussed in Chapter 4 or that prevent the development of diabetes among high risk individuals. Many patients who are referred to ophthalmological clinics for management and treatment of diabetic retinopathy have already had longstanding diabetes.

7.2 Prevention of Diabetes in People at High Risk

Major lifestyles changes can reduce the incidence of diabetes in people at high risk. A large, randomized clinical trial involving 3234 nondiabetic persons with elevated fasting and postload plasma glucose concentrations has shown that the incidence of diabetes can be prevented with lifestyle changes (76). The adoption of healthy low-calorie, low-fat diet (following the Food Guide Pyramid [77] and equivalent of a National Cholesterol Education Program Step 1 diet [78]) and moderate exercise can reduce the incidence of type 2 diabetes by nearly 60% (Fig. 5) (76). In a study of 522 middle-aged, overweight subjects (172 men and 350 women) with impaired glucose tolerance, subjects were randomized to individualized counseling aimed at reducing weight, total intake of fat, and intake of saturated fat, accompanied by increasing fiber intake and physical activity (79). At the end of 1 yr, the mean (SD) loss of weight in the intervention and control groups were 4.2 (5.1) kg vs 0.8 (3.7) kg ($p < 0.001$), and at the end of 2 yr the respective loss of

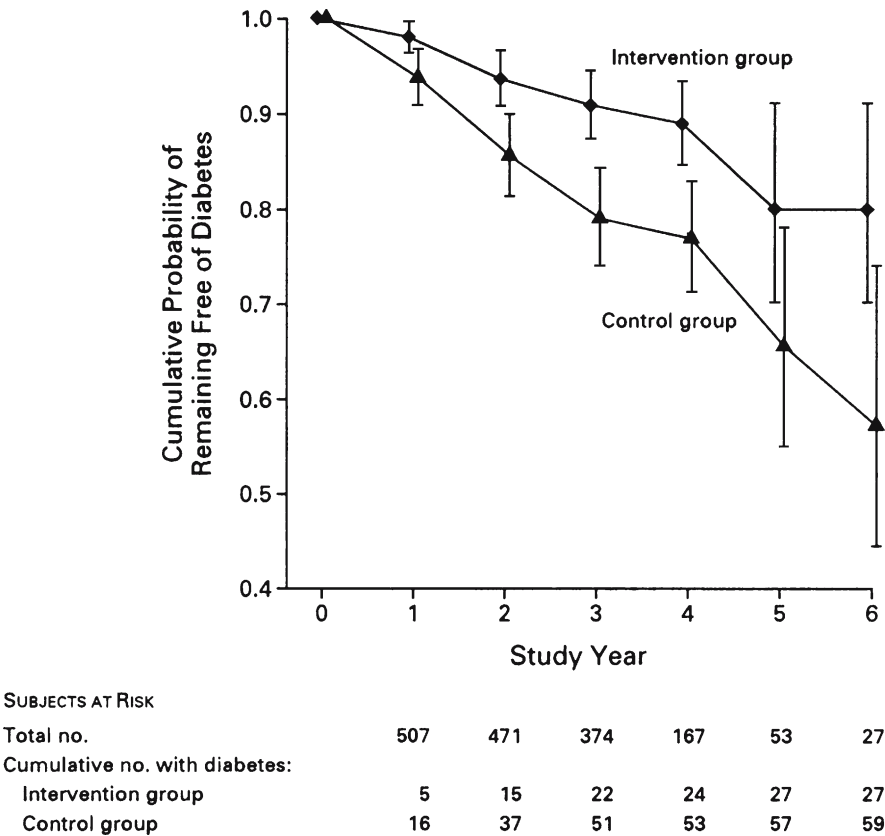


Fig. 6. Proportion of subjects without diabetes during trial. Vertical bars show 95% confidence interval for the cumulative probability of remaining free of diabetes. (Reprinted from ref. 79. Copyright © 2001, Massachusetts Medical Society. All rights reserved.)

weight was 3.5 (5.5) kg vs 0.8 (4.4) kg ($p < 0.001$). The cumulative incidence of diabetes was 11% in the intervention group and 23% in the control group by the end of 4 yr (Fig. 6). Changes in lifestyle reduced the incidence of diabetes by 58% ($p < 0.001$) (79). Among patients with diabetes, the most effective preventive measure is glycemic control, as noted under Subheading 2.2.2. Blood pressure control may help to reduce the risk or progression of diabetic retinopathy, and further trials are being conducted to address this issue (2).

8. CONCLUSIONS

Diabetic retinopathy is a leading cause of visual loss and blindness. A consistent relationship has not been demonstrated between single nutrients and diabetic retinopathy. A healthy dietary pattern characterized by high fruit and vegetable intake appears to be protective against diabetic retinopathy, but causality has not been demonstrated by randomized controlled trials. Certain lifestyle patterns, such as poor dietary quality and lack of physical activity, are factors that contribute to an increased risk of overweight, obesity, and diabetes. Ultimately, the long-term strategy for the prevention of diabetic retinopathy should be aimed at preventing obesity and overweight, and this is one of the major challenges in the area of nutrition and ophthalmology.

REFERENCES

1. Eye Diseases Prevalence Research Group. Causes and prevalence of visual impairment among adults in the United States. *Arch Ophthalmol* 2004;122:477–485.
2. Fong DS, Aiello LP, Ferris FL, Klein R. Diabetic retinopathy. *Diabetes Care* 2004;27:2540–2553.
3. Klein R, Klein BEK, Moss SE, Davis MD, deMets DL. The Wisconsin Epidemiologic Study of Diabetic Retinopathy. II. Prevalence and risk of diabetic retinopathy when age at diagnosis is less than 30 years. *Arch Ophthalmol* 1984;102:520–526.
4. Klein R, Klein BEK, Moss SE, Davis MD, deMets DL. The Wisconsin Epidemiologic Study of Diabetic Retinopathy. III. Prevalence and risk of diabetic retinopathy when age at diagnosis is 30 or more years. *Arch Ophthalmol* 1984;102:527–532.
5. Klein BEK, Klein R. Diabetic retinopathy. In Johnson GJ, Minassian DC, Weale RA, West SK (eds). *The Epidemiology of Eye Disease*. Second Edition. London, Arnold: 2003; pp. 341–355.
6. Kingsley LA, Dorman JS, Doft BH, et al. An epidemiologic approach to the study of retinopathy: the Pittsburgh Diabetic Morbidity and Retinopathy Studies. *Diabetes Res Clin Pract* 1988;4:99–109.
7. Olsen BS, Sjolie A, Hougaard P, et al. A 6-year nationwide cohort study of glycaemic control in young people with type 1 diabetes. Risk markers for the development of retinopathy, nephropathy and neuropathy. *J Diabetes Complications* 2000;14:295–300.
8. The Diabetes Control and Complications Trial. The effect of intensive diabetes treatment on the progression of diabetic retinopathy in insulin-dependent diabetes mellitus. *Arch Ophthalmol* 1995;113:36–51.
9. The Diabetes Control and Complications Trial/Epidemiology of Diabetes Interventions and Complications Research Group. Retinopathy and nephropathy in patients with type 1 diabetes four years after a trial of intensive therapy. *N Engl J Med* 2000;342:381–389.
10. The Writing Team for the Diabetes Control and Complications Trial/Epidemiology of Diabetes Interventions and Complications Research Group. Effect of intensive therapy on the microvascular complications of type 1 diabetes mellitus. *JAMA* 2002;287:2563–2569.
11. UK Prospective Diabetes Study (UKPDS) Group. Intensive blood-glucose control with sulphonylureas or insulin compared with conventional treatment and risk of complications in patients with type 2 diabetes (UKPDS 33). *Lancet* 1998;352:837–853.
12. UK Prospective Diabetes Study (UKPDS) Group. Risks of progression of retinopathy and visual loss related to tight blood pressure control in type 2 diabetes mellitus. *Arch Ophthalmol* 2004;122:1631–1640.
13. Estacio RO, Jeffers BW, Gifford N, Schrier RW. Effect of blood pressure control on diabetic microvascular complications in patients with hypertension and type 2 diabetes. *Diabetes Care* 2000;23(suppl 2): B54–B64.
14. Shrier RW, Estacio RO, Esler A, Mehler P. Effects of aggressive blood pressure control in normotensive type 2 diabetic patients on albuminuria, retinopathy and stroke. *Kidney Int* 2002;61:1086–1097.
15. Gaede P, Vedel P, Larsen N, Jensen GVH, Parving HH, Pedersen O. Multifactorial intervention and cardiovascular disease in patients with type 2 diabetes. *N Engl J Med* 2003;348:383–393.
16. Klein BEK, Moss Se, Klein R, Surawicz TS. The Wisconsin Epidemiologic Study of Diabetic Retinopathy. XIII. Relationship of serum cholesterol to retinopathy and hard exudates. *Ophthalmology* 1991; 98:1261–1265.
17. Chew EY, Kellin ML, Ferris ML, et al. Association of elevated serum lipid levels with retinal hard exudate in diabetic retinopathy. Early Treatment Diabetic Retinopathy Study (ETDRS) Report 22. *Arch Ophthalmol* 1996;114:1079–1084.
18. Davis MD, Fisher MR, Gangnon RE, et al. Risk factors for high-risk proliferative diabetic retinopathy and severe visual loss: Early Treatment Diabetic Retinopathy Study Report #18. *Invest Ophthalmol Vis Sci* 1998;39:233–252.
19. Qiao Q, Keinänen-Kiukaanniemi S, Läärä E. The relationship between hemoglobin levels and diabetic retinopathy. *J Clin Epidemiol* 1997;50:153–158.
20. Shorb SR. Anemia and diabetic retinopathy. *Am J Ophthalmol* 1985;100:434–436.
21. Singh R, Gupta V, Gupta A, Bhansali A. Spontaneous closure of microaneurysms in diabetic retinopathy with treatment of coexisting anaemia. *Br J Ophthalmol* 2005;89:248–249.
22. Friedman EA, Brown CD, Berman DH. Erythropoietin in diabetic macular edema and renal insufficiency. *Am J Kidney Dis* 1995;26:202–208.

23. Guralnik JM, Eisenstaedt RS, Ferrucci L, Klein HG, Woodman RC. Prevalence of anemia in persons 65 years and older in the United States: evidence for a high rate of unexplained anemia. *Blood* 2004;104:2263–2268.
24. Ganz T. Hepcidin—a regulator of intestinal iron absorption and iron recycling by macrophages. *Best Pract Res Clin Haematol* 2005;18:171–182.
25. Katusic D, Tomic M, Jukic T, et al. Obesity—a risk factor for diabetic retinopathy in type 2 diabetes? *Coll Antropol* 2005;29(suppl 1):47–50.
26. de Block CE, de Leeuw IH, van Gaal LF. Impact of overweight on chronic microvascular complications in type 1 diabetic patients. *Diabetes Care* 2005;28:1649–1655.
27. Som S, Basu S, Mukherjee D, et al. Ascorbic acid metabolism in diabetes mellitus. *Metabolism* 1981;30:572–577.
28. Jennings PE, Chirico S, Jones AF, Lunec J, Barnett AH. Vitamin C metabolites and microangiopathy in diabetes mellitus. *Diabetes Res* 1987;6:151–154.
29. Ali SMK, Chakraborty SK. Role of plasma ascorbate in diabetic microangiopathy. *Bangladesh Med Res Counc Bull* 1989;15:47–59.
30. Sinclair AJ, Girling AJ, Gray L, Le Guen C, Lunec J, Barnett AH. Disturbed handling of ascorbic acid in diabetic patients with and without microangiopathy during high dose ascorbate supplementation. *Diabetologica* 1991;34:171–175.
31. Sinclair AJ, Girling AJ, Gray L, Lunec J, Barnett AH. An investigation of the relationship between free radical activity and vitamin C metabolism in elderly diabetic subjects with retinopathy. *Gerontology* 1992;38:268–274.
32. Chakraborty SK. Plasma ascorbate status in newly diagnosed diabetics exhibiting retinopathy—a finding that alarms. *Bangladesh Med Res Counc Bull* 1992;18:30–35.
33. Chakraborty SK. Comparison of plasma ascorbate status between diabetic retinopathy subjects with and without photo-coagulation therapy. *Bangladesh Med Res Counc Bull* 1993;19:39–44.
34. Millen AE, Gruber M, Klein R, Klein BEK, Palta M, Mares JA. Relations of serum ascorbic acid and α -tocopherol to diabetic retinopathy in the Third National Health and Nutrition Examination Survey. *Am J Epidemiol* 2003;158:225–233.
35. Mayne ST. Antioxidant nutrients and chronic disease: use of biomarkers of exposure and oxidative stress status in epidemiologic research. *J Nutr* 2003;133:933S–940S.
36. Mayer-Davis EJ, Bell RA, Reboussin BA, Rushing J, Marshall JA, Hamman RF. Antioxidant nutrient intake and diabetic retinopathy. The San Luis Valley Diabetes Study. *Ophthalmology* 1998;105:2264–2270.
37. Millen AE, Klein R, Folsom AR, Stevens J, Palta M, Mares JA. Relation between intake of vitamins C and E and risk of diabetic retinopathy in the Atherosclerosis Risk in Communities Study. *Am J Clin Nutr* 2004;79:865–873.
38. Robison WG Jr, Jacot JL, Katz ML, Glover JP. Retinal vascular changes induced by the oxidative stress of α -tocopherol deficiency contrasted with diabetic microangiopathy. *J Ocul Pharmacol Therap* 2000;16:109–120.
39. Kunisaki M, Bursell SE, Umeda F, Nawata H, King GL. Prevention of diabetes-induced abnormal retinal blood flow by treatment with d- α -tocopherol. *BioFactors* 1998;7:55–67.
40. Shoff SM, Mares-Perlman JA, Cruickshanks KJ, Klein R, Klein BEK. Glycosylated hemoglobin concentrations and vitamin E, vitamin C, and β -carotene intake in diabetic and nondiabetic older adults. *Am J Clin Nutr* 1993;58:412–416.
41. Martinoli L, Di Felice M, Seghieri G, et al. Plasma retinol and α -tocopherol concentrations in insulin-dependent diabetes mellitus: their relationship to microvascular complications. *Internat J Vit Nutr Res* 1993;63:87–92.
42. Willems D, Dorchy H, Dufrasne D. Serum antioxidant status and oxidized LDL in well-controlled young type 1 diabetic patients with and without subclinical complications. *Atherosclerosis* 1998;137(suppl):S61–S64.
43. Ndahimana J, Dorchy H, Vertongen F. Activité anti-oxydante érythrocytaire et plasmatique dans le diabète de type I. *Presse Méd* 1996;25:188–192.
44. Ceriello A, Giugliano D, Quattraro A, Donzella C, Dipalo G, Lefebvre PJ. Vitamin E reduction of protein glycosylation in diabetes. New prospect for prevention of diabetic complications? *Diabetes Care* 1991;14:68–72.

45. Jain SK, McVie R, Jaramillo JJ, Palmer M, Smith T. Effect of modest vitamin E supplementation on blood glycated hemoglobin and triglyceride levels and red cell indices in type I diabetic patients. *J Am Coll Nutr* 1996;15:458–461.
46. Chung TW, Yu JH, Liu DZ. Reducing lipid peroxidation stress of erythrocyte membrane by α -tocopherol nicotinate plays an important role in improving blood rheological properties in type 2 diabetic patients with retinopathy. *Diabetes Med* 1998;15:380–385.
47. Bursell SE, Clermont AC, Aiello LP, et al. High-dose vitamin E supplementation normalizes retinal blood flow and creatinine clearance in patients with type 1 diabetes. *Diabetes Care* 1999;22:1245–1251.
48. Lonn E, Yusuf S, Hoogwerf B, et al. Effects of vitamin E on cardiovascular and microvascular outcomes in high-risk patients with diabetes. Results of the HOPE Study and MICRO-HOPE Substudy. *Diabetes Care* 2002;25:1919–1927.
49. Faure P, Benhamou PY, Perard A, Halimi S, Roussel AM. Lipid peroxidation in insulin-dependent diabetic patients with early retina degenerative lesions: effects of an oral zinc supplementation. *Eur J Clin Nutr* 1995;49:282–288.
50. Roussel AM, Kerkeni A, Zouari N, Mahjoub S, Matheau JM, Anderson RA. Antioxidant effects of zinc supplementation in Tunisians with type 2 diabetes mellitus. *J Am Coll Nutr* 2003;22:316–321.
51. Brazionis L, Itsiopoulos C, Rowley K, O’dea K. Factor analysis identifies a Mediterranean-style pattern of dietary intake that is protective against diabetic retinopathy. *Asia Pac J Clin Nutr* 2005;14(suppl): S73.
52. Panagiotakos DB, Pitsavos C, Chrysoshoou C, Stefanadis C. The epidemiology of type 2 diabetes mellitus in Greek adults: the ATTICA study. *Diabetes Med* 2005;22:1581–1588.
53. Ciccarone E, di Castelnuovo A, Salcuni M, et al. A high-score Mediterranean dietary pattern is associated with a reduced risk of peripheral arterial disease in Italian patients with type 2 diabetes. *J Thromb Haemost* 2003;1:1744–1752.
54. Esposito K, Marfella R, Ciotola M, Di Palo C, Giugliano G, D’Armiento M, D’Andrea F, Giugliano D. Effect of a Mediterranean-style diet on endothelial dysfunction and markers of vascular inflammation in the metabolic syndrome: a randomized trial. *JAMA* 2004;292:1440–1446.
55. Trichopoulou A, Costacou T, Bamia C, Trichopoulos D. Adherence to a Mediterranean diet and survival in a Greek population. *N Engl J Med* 2003;348:2599–2608.
56. Cundiff DT, Nigg CR. Diet and diabetic retinopathy: insights from the Diabetes Control and Complications Trial (DCCT). *MedGenMed* 2005;7:3.
57. Wilkinson CP, Ferris FL, Klein RE, et al. Proposed international clinical diabetic retinopathy and diabetic macular edema disease severity scales. *Ophthalmology* 2003;110:1677–1682.
58. Aiello LP, Gardner TW, King GL, et al. Diabetic retinopathy. *Diabetes Care* 1998;21:143–156.
59. Frank RN. Diabetic retinopathy. *N Engl J Med* 2004;350:48–58.
60. Ways DK, Sheetz MJ. The role of protein kinase C in the development of the complications of diabetes. *Vitam Horm* 2000;60:149–193.
61. Witmer AN, Vrensen GFJM, van Noorden CJF, Schlingemann RO. Vascular endothelial growth factors and angiogenesis in eye disease. *Prog Ret Eye Res* 2003;22:1–29.
62. Blaauwgeers HGT, Holtkamp GM, Rutten H, et al. Polarized vascular endothelial growth factor secretion by human retinal pigment epithelium and localization of vascular endothelial growth factor receptors on the inner choriocapillaris. Evidence for a trophic paracrine relation. *Am J Pathol* 1999;155:421–428.
63. Hirata C, Nakano K, Nakamura N, et al. Advanced glycation end products induce expression of vascular endothelial growth factor by retinal Müller cells. *Biochem Biophys Res Commun* 1997;236:712–715.
64. Carmeliet P, Dor Y, Herbert JM, et al. Role of HIF-1 α in hypoxia-mediated apoptosis, cell proliferation and tumour angiogenesis. *Nature* 1998;394:485–490.
65. Kabe Y, Ando K, Hirao S, Yoshida M, Handa H. Redox regulation of NF- κ B activation: distinct redox regulation between the cytoplasm and the nucleus. *Antioxid Redox Signal* 2005;7:395–403.
66. Lukiw WJ, Ottlecz A, Lambrou G, et al. Coordinate activation of HIF-1 and NF- κ B DNA binding and COX-2 and VEGF expression in retinal cells by hypoxia. *Invest Ophthalmol Vis Sci* 2003;44:4163–4170.
67. Zhang SX, Wang JJ, Gao G, Shao C, Mott R, Ma JX. Pigment epithelium-derived factor (PEDF) is an endogenous antiinflammatory factor. *FASEB J* 2005;December 20, 2005 [Epub ahead of print].
68. Aiello LP, Avery RL, Arrigg PG, et al. Vascular endothelial growth factor in ocular fluid of patients with diabetic retinopathy and other retinal disorders. *N Engl J Med* 1994;331:1480–1487.

69. Yokoi M, Yamagishi SI, Takeuchi M, et al. Elevations of AGE and vascular endothelial growth factor with decreased total antioxidant status in the vitreous fluid of diabetic patients with retinopathy. *Br J Ophthalmol* 2005;89:673–675.
70. Verdejo C, Marco P, Renau-Piqueras J, Pinazo-Duran MD. Lipid peroxidation in proliferative vitreo-retinopathies. *Eye* 1999;13:183–188.
71. Treins C, Giorgetti-Peraldi S, Murdaca J, Van Obberghen E. Regulation of vascular endothelial growth factor expression by advanced glycation end products. *J Biol Chem* 2001;276:43836–43841.
72. Grattagliano I, Vendemiale G, Boscia F, Micelli-Ferrari T, Cardia L, Altomare E. Oxidative retinal products and ocular damages in diabetic patients. *Free Rad Biol Med* 1998;25:369–372.
73. Funatsu H, Yamashita H, Noma H, et al. Aqueous humor levels of cytokines are related to vitreous levels and progression of diabetic retinopathy in diabetic patients. *Graefes Arch Clin Exp Ophthalmol* 2005;243:3–8.
74. Evans JL, Goldfine ID, Maddux BA, Grodsky GM. Oxidative stress and stress-activated signaling pathways: a unifying hypothesis of type 2 diabetes. *Endocrine Rev* 2002;23:599–622.
75. Bressler NM, Altaweel M, Macugen Diabetic Retinopathy Study Group. Changes in retinal neovascularization after pegaptanib (Macugen) therapy in diabetic individuals. *Ophthalmology* 2005;Dec 9 [Epub ahead of print].
76. Diabetes Prevention Program Research Group. Reduction in the incidence of type 2 diabetes with lifestyle intervention or metformin. *N Engl J Med* 2002;346:393–403.
77. The Food Guide Pyramid. Washington, D.C., Department of Agriculture, Center for Nutrition Policy and Promotion, 1996 (Home and Garden Bulletin no. 252).
78. Step by step: eating to lower your high blood cholesterol. Bethesda, MD: National Heart, Lung, and Blood Institute Information Center, 1987.
79. Tuomilehto J, Lindström J, Eriksson JG, et al. Prevention of type 2 diabetes mellitus by changes in lifestyle among subjects with impaired glucose tolerance. *N Engl J Med* 2001;344:1343–1350.

6

Retinal Vascular Disease

1. INTRODUCTION

Nutritional factors are important risk factors for coronary artery disease, cerebrovascular disease, and peripheral vascular disease, and recently, the role of nutritional factors in the pathogenesis of retinal vascular disease has gained increasing attention. In the last two decades, clinical investigation has established that hyperhomocysteinemia is a major risk factor for vascular disease, including retinal vascular disease. Hyperhomocysteinemia can largely be treated or prevented by improving folate, vitamin B₁₂, and vitamin B₆ intake through dietary modification, fortification, or supplementation. Other nutritional problems, such as disorders of iron metabolism, anorexia nervosa, and lipid abnormalities are also presented in this chapter in relationship to retinal vascular disease and other ocular abnormalities. The relationship of nutritional factors to diabetic retinopathy is covered in Chapter 5, and the association of age-related macular degeneration and cardiovascular disease is discussed separately in Chapter 3.

2. HYPERHOMOCYSTEINEMIA

2.1. Historical Background

In 1969, the pathologist Kilmer McCully observed that a child with elevated plasma homocysteine who died with homocystinuria had vascular lesions that were similar to those found in older adults with arteriosclerosis (1). McCully noted: “the metabolic effects of homocysteine that lead to arterial damage are obscure, and the observations presented in this report suggest a promising area for future research in the pathogenesis of arteriosclerosis” (1). The homocysteine theory of arteriosclerosis was further refined in 1975, when arteriosclerotic plaques were found in the aorta and arteries of rabbits that were administered homocysteine, methionine, or homocysteic acid, both parenterally and in a synthetic diet (2). The distribution and features of the lesions produced by sulfur amino acids were similar to those found in human arteriosclerosis (2). In 1976, patients with coronary artery disease were found to have higher concentrations of homocysteine-cysteine mixed disulfide than controls after a methionine load, providing further support for the idea that elevated homocysteine is related to vascular disease (3). The hypothesis that homocysteine is involved in the pathogenesis of arteriosclerosis has been confirmed in many studies over the last two decades.

2.2. Homocysteine Metabolism

Homocysteine is a sulfur amino acid that is derived from the essential sulfur amino acid, methionine. Methionine is found in dietary proteins, and under normal conditions,

From: *Nutrition and Health: Handbook of Nutrition and Ophthalmology*

By: R. D. Semba © Humana Press Inc., Totowa, NJ

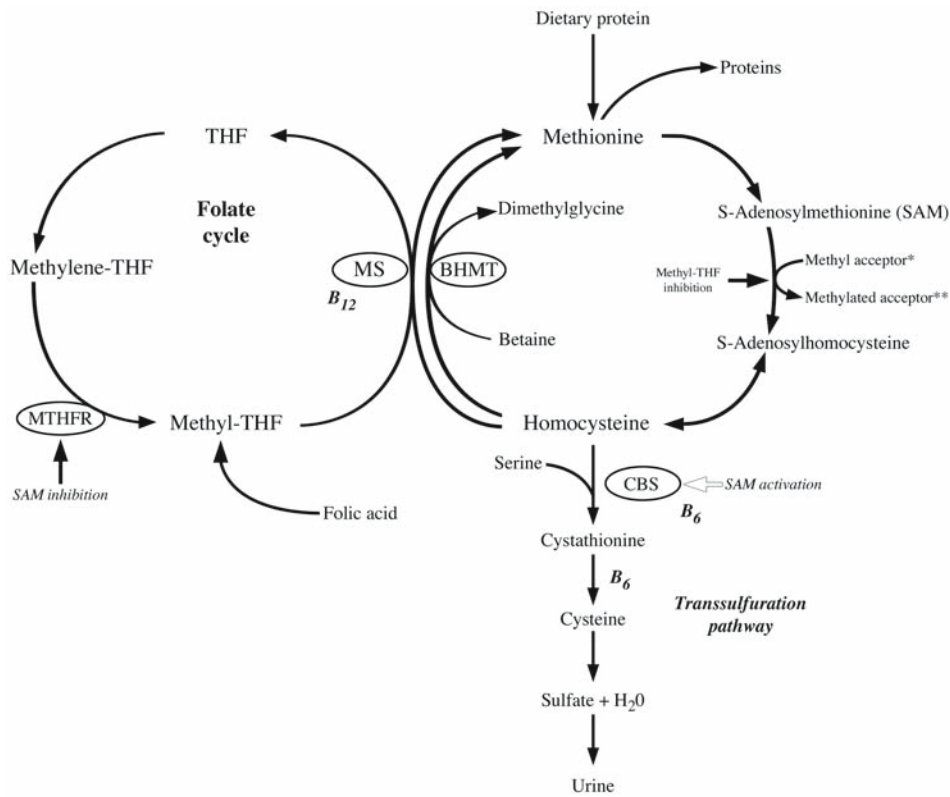


Fig. 1. Relationship between methionine and homocysteine.

methionine is metabolized to homocysteine, and homocysteine may be metabolized via two different pathways back to methionine, or further metabolized to cystathionine and cysteine (Fig. 1). Excess homocysteine is metabolized to homocysteine and excreted in the urine. In the metabolism of homocysteine, folate, vitamin B₆, and vitamin B₁₂, play important roles as coenzymes, thus, a deficiency of any of these B complex vitamins can influence plasma homocysteine concentrations. Vitamin B₆ is a coenzyme in the trans-sulfuration of homocysteine to cysteine. Folate and vitamin B₁₂ are coenzymes for *N*-5-methyltetrahydrofolate: homocysteine methyltransferase in the remethylation of homocysteine to methionine. Homocysteine is also remethylated to methionine via betaine: homocysteine methyltransferase. In the plasma, homocysteine exists in different forms: (1) as homocysteine bound to plasma proteins, primarily albumin (~80%), as homocysteine (two homocysteine molecules linked together) and as cysteine-homocysteine (~15%), and as free reduced homocysteine (~5%). Total homocysteine, sometimes abbreviated as tHcy, refers to the sum of these three forms of homocysteine.

Hyperhomocysteinemia is defined as a sustained elevation above normal of homocysteine and closely related analogs (homocystine, cysteine-homocysteine) in plasma or serum (5). Homocysteine regulation can be disturbed by inadequate status of the three B vitamins that are involved in the balance of homocysteine and methionine. Because of the close relationship between homocysteine metabolism and folate, vitamin B₆, and vitamin B₁₂ status, plasma homocysteine concentrations are also used as markers for deficien-

Table 1
Causes of Hyperhomocysteinemia

A. Inherited defects
1. Enzyme deficiencies
a. Cystathionine β -synthase
b. Methylene tetrahydrofolate reductase
c. Methionine synthase
d. Cobalamin coenzyme synthesis
2. Transport defects
a. Transcobalamin II deficiency
b. Cobalamin lysosomal transporter
B. Acquired defects
1. Nutritional
a. Cobalamin (vitamin B ₁₂) deficiency
b. Folic acid deficiency
c. Pyridoxine (vitamin B ₆) deficiency
2. Metabolic
a. Chronic renal disease
b. Hypothyroidism
3. Drug-induced
a. Methotrexate and other folate antagonists
b. Nitrous oxide and other cobalamin antagonists
c. Azaribine and other pyridoxine antagonists
d. Estrogen antagonists

Reproduced from ref. 4, with permission of Routledge/Taylor & Francis Group, LLC.

cies of these B complex vitamins (5). There are other factors that can alter homocysteine metabolism and cause hyperhomocysteinemia, including inborn errors of metabolism, such as cystathionine β -synthase deficiency, methionine synthase deficiency, transcobalamin II deficiency, chronic renal disease, hypothyroidism, and some drugs (Table 1). Homocystinuria due to cystathionine β -synthase deficiency is presented elsewhere in Chapter 12.

Homocysteine appears to inhibit several different anticoagulant systems, such as the protein C anticoagulant pathway, antithrombin III, human umbilical vein endothelial cells ecto-ADPase, and endothelial cell tissue plasminogen activator (6). Disruption of these vessel wall-related anticoagulant systems by homocysteine may potentially account for the increased thrombosis that occurs with hyperhomocysteinemia.

2.3. Relationship Between Folate Status and Homocysteine

An inverse relationship has generally been found between folate concentrations and total homocysteine concentrations in serum or plasma. An inverse relationship between serum folate and total homocysteine concentrations was described in 1987 by Kang and colleagues (7). Subjects with subnormal serum folate concentrations had more than a 1.65 higher concentration of serum total homocysteine than those with normal serum folate concentrations. An inverse correlation was also found between low serum vitamin B₁₂ concentrations and serum total homocysteine when those with serum folate >18 ng/mL

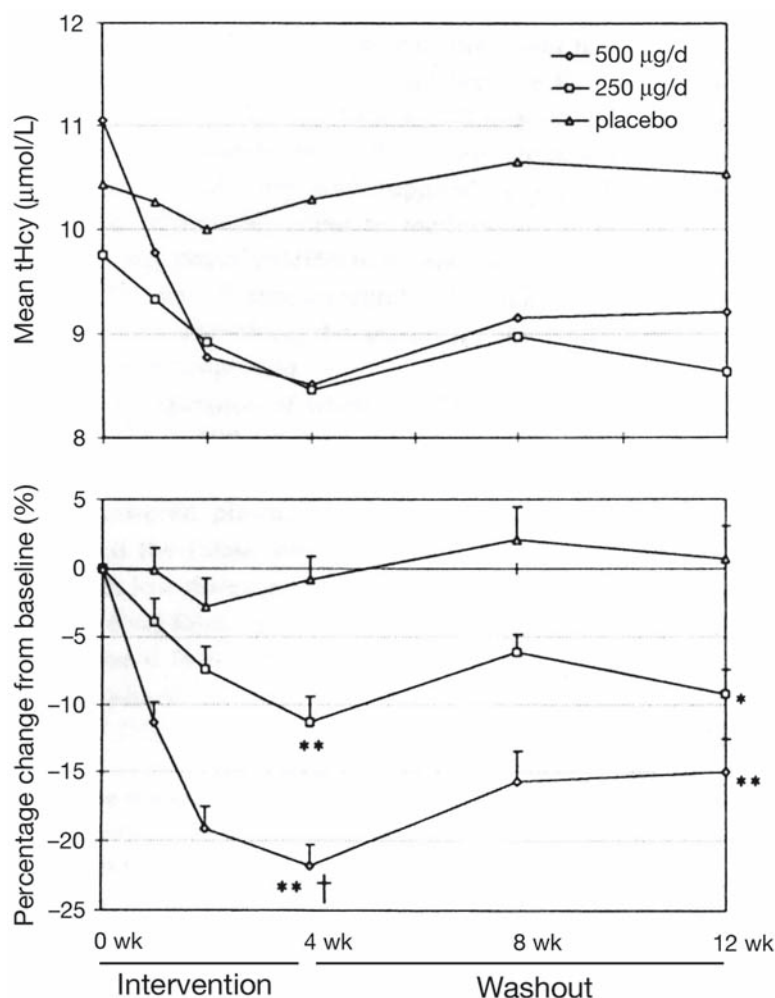


Fig. 2. Impact of folate supplementation on total homocysteine concentrations among women. Mean plasma total homocysteine (tHcy) concentrations during 4 wk of folic acid supplementation and 4 and 8 wk after the end of the intervention period in 144 healthy, nonpregnant women, by intervention group. (Reproduced from ref. 14, with permission of *American Journal of Clinical Nutrition*. Copyright © Am J Clin Nutr. American Society for Nutrition.)

were excluded (7). Elevated serum total homocysteine was described in 18 of 19 patients with folate deficiency (8). A significant inverse relationship was found between plasma folate and plasma homocysteine concentrations among men with and without coronary artery disease (9). Suboptimal folate status was found in 59.1% of men with hyperhomocysteinemia (10). Studies in the Framingham Heart Study cohort also showed that plasma homocysteine was inversely correlated with plasma folate concentrations (11).

Randomized clinical trials have shown that folic acid supplementation will reduce serum or plasma total homocysteine concentrations (12–14). In a randomized controlled clinical trial of folate supplementation, 500 μg per day, 500 μg every other day, or placebo, total homocysteine concentrations decreased among women taking either dose of folate compared with placebo (14) (Fig. 2). Meta-analysis of twelve randomized clinical trials

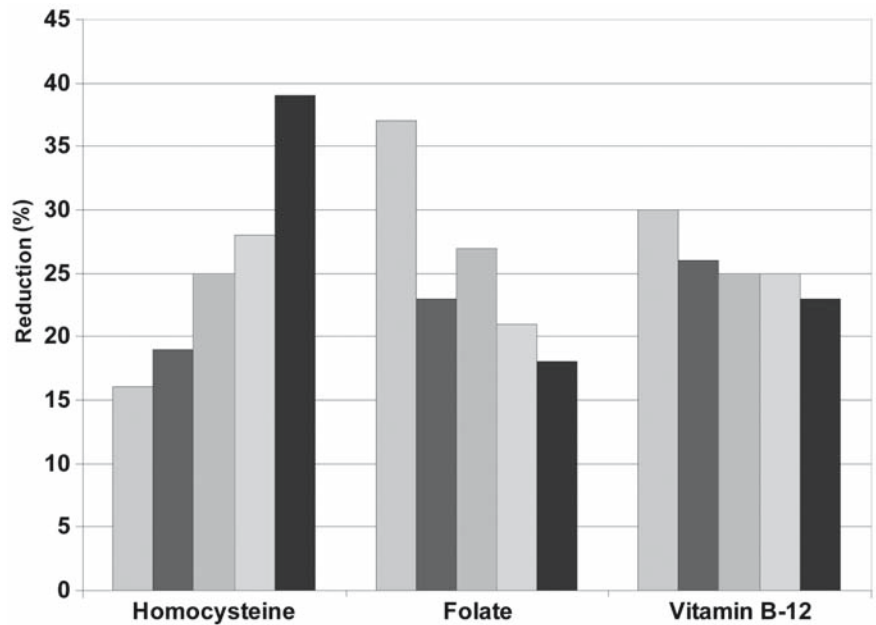


Fig. 3. Reductions in blood homocysteine concentrations with folic acid supplements, stratified by pretreatment blood concentrations of homocysteine, folate, and vitamin B₁₂. (Reproduced from ref. 15, with permission of BMJ Publishing Group.)

of folic acid showed that folic acid supplementation lowered blood homocysteine concentrations, and greater effects of folic acid were noted when subjects started out with lower folate concentrations or higher blood homocysteine concentrations before treatment (15) (Fig. 3). Dietary folic acid reduced blood homocysteine concentrations by 25% (95% confidence interval [CI], 23–28%), and the effect of folic acid was similar for doses from 0.5 to 5 mg per day. In a placebo-controlled, dose ranging study, the effect of low dose folic acid on plasma homocysteine concentrations was examined in 95 patients with documented coronary artery disease (16). The doses consisted of 400 µg, 1 mg, or 5 mg of folate or placebo for 3 mo, in addition to vitamin B₁₂ and vitamin B₆. A similar decrease in homocysteine concentrations was found in all three folate treatment groups, and there was no change in the placebo group (16).

In 1996, the Food and Drug Administration issued a regulation that required all enriched flour, rice, pasta, cereal and other grain products to be fortified with folic acid (140 µg per 100 g) in order to reduce the risk of neural tube defects in newborns. Plasma folate and total homocysteine concentrations were compared in archived samples from the Framingham Offspring Study cohort between subjects who were seen before and after mandatory folic acid fortification went into effect. Between these two periods, among those who did not take vitamin supplements, the prevalence of high homocysteine concentrations (>13 µmol/L) decreased significantly from 18.7 to 9.8%, and prevalence of low plasma folate concentrations significantly decreased from 22.0 to 1.7% (17).

2.4. Relationship Between Vitamin B₆ Status and Homocysteine

Vitamin B₆ serves as a coenzyme in the transsulfuration of homocysteine to cysteine, but clinical studies suggest that the relationship between plasma total homocysteine

concentrations and vitamin B₆ is not as strong as that between plasma total homocysteine and folate or vitamin B₁₂, respectively. Administration of vitamin B₆ (pyridoxine) has been shown to improve the response to the methionine loading test among subjects with vascular disease and elevated total homocysteine concentrations (18).

2.5. Relationship Between Vitamin B₁₂ Status and Homocysteine

Plasma or serum total homocysteine concentrations are usually elevated among patients with vitamin B₁₂ deficiency (19). Asymptomatic vitamin B₁₂-deficient subjects had higher total plasma homocysteine concentrations compared with controls (23.8 vs 11.5 $\mu\text{mol/L}$, respectively $p < 0.0001$) (20). Plasma total homocysteine concentrations returned to normal after administration of hydroxycobalamin to vitamin B₁₂-deficient subjects (20). The relationship between total homocysteine and vitamin B₁₂ deficiency is sufficiently strong that total homocysteine concentrations may be useful in the diagnosis of cobalamin deficiency (21), and elevated serum total homocysteine concentrations may facilitate the diagnosis of cobalamin deficiency among individuals who have cobalamin deficiency with normal serum cobalamin concentrations (22) or cobalamin deficiency without anemia (23).

2.6. Epidemiology of Hyperhomocysteinemia

Plasma homocysteine concentrations are generally higher in men than women, and mean concentrations increase with age (24) (Fig. 4). Among individuals receiving vitamin supplements, the normal frequency distribution and reference range for plasma homocysteine concentrations has been predicted, with a 95% reference range for plasma homocysteine of 4.9 to 11.7 $\mu\text{mol/L}$ (25). In the third National Health and Nutrition Examination Survey (NHANES), age-adjusted geometric mean total homocysteine concentrations among non-Hispanic men and women were 9.6 and 7.9 mmol/L , among non-Hispanic black men and women were 9.8 and 8.2 mmol/L , and among Mexican-American men and women were 9.4 and 7.4 mmol/L (24). The risk for hyperhomocysteinemia may need to be reassessed, since mandatory folate enrichment was implemented in the United States in 1996. Individuals who are carriers or heterozygotes for cystathionine β -synthase deficiency can have slightly elevated plasma total homocysteine concentrations (26), which may put them at higher risk for retinal vascular disease. The frequency of carriers is estimated to be 1 of 200 in the US population. Other inborn errors of metabolism that may cause hyperhomocysteinemia are relatively rare and include vitamin B₁₂ defects (CbC, D, E, F, G) and methylenetetrahydrofolate reductase deficiency (MTHFR). Recently, thermolabile variants of the enzyme MTHFR recently discovered, and 5% to 16% of individuals may be homozygous for the enzyme and up to 50% may be heterozygous (27). MTHFR polymorphism does not seem to be associated with increased risk of vascular disease (28,29). Other factors that may influence plasma total homocysteine concentrations include medications such as fibrates, carbamazepine, phenytoin, methotrexate, and trimethoprim (30).

2.7. Hyperhomocysteinemia and Cardiovascular Disease

Elevated plasma or serum total homocysteine concentrations are associated with an increased risk for cardiovascular disease. The number of studies that examined the relationship between homocysteine and cardiovascular disease has accelerated at a steep

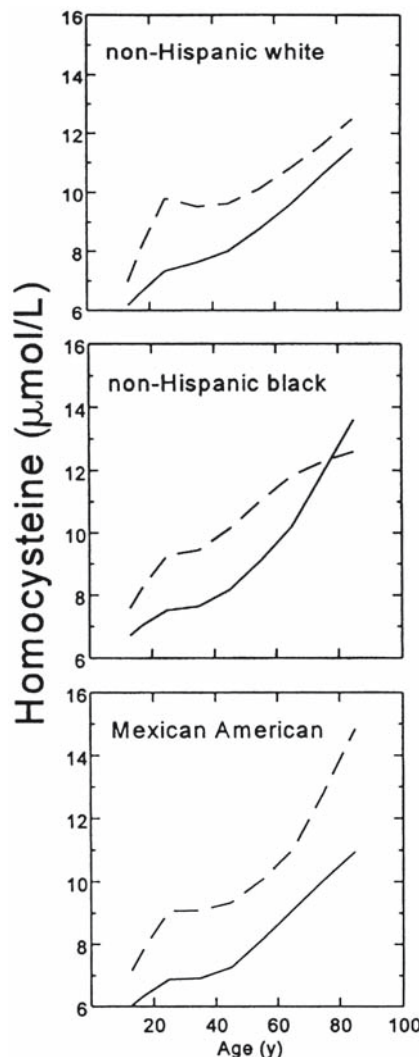


Fig. 4. Smoothed geometric mean serum homocysteine concentration by age group, sex, and race-ethnicity in males (---) and females (—) in the third National Health and Nutrition Examination Survey. (From ref. 24, with permission of the *American Journal of Clinical Nutrition*. Copyright © Am J Clin Nutr. American Society for Nutrition.)

pace over the last two decades (31), and meta-analysis of over two dozen of these studies suggests that 10% of the population risk for coronary artery disease is related to elevated total homocysteine concentrations (32). Another recent meta-analysis suggests that lower blood homocysteine concentrations are associated with a modest 11% lower risk for ischemic heart disease and 19% lower risk of stroke (33).

Subjects with coronary artery disease have been shown to have significantly higher plasma or serum total homocysteine concentrations than controls (9,34). A case-control study from Great Britain showed that subjects who died with ischemic heart disease had higher serum homocysteine levels than controls, 13.1 vs 11.8 μmol/L, respectively (35).

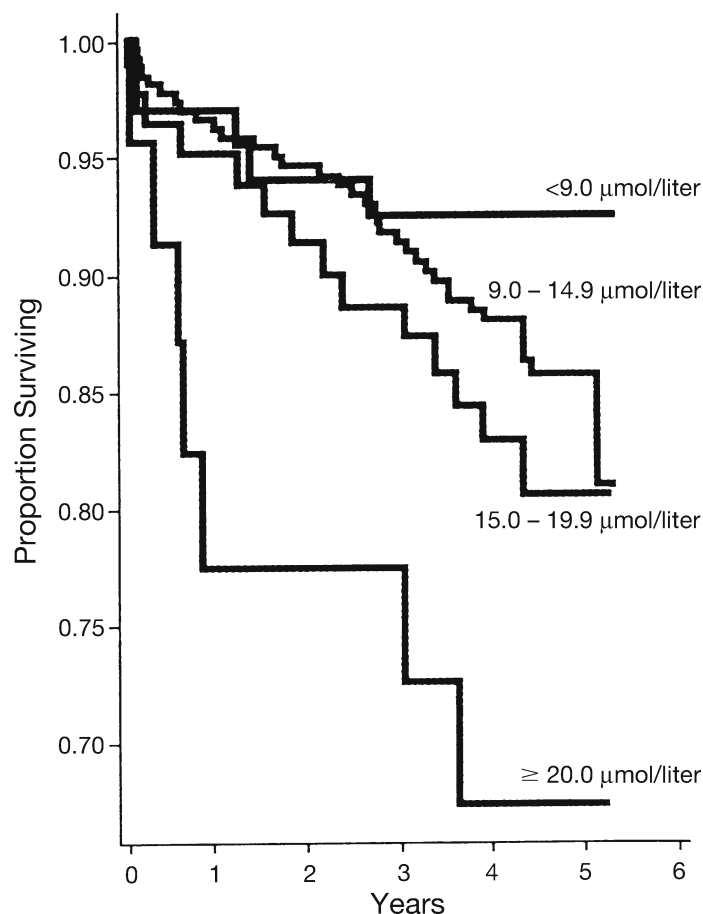


Fig. 5. Estimated survival among patients with coronary artery disease, according to plasma total homocysteine levels. (Reprinted from ref. 37. Copyright © 1997, Massachusetts Medical Society. All rights reserved.)

Higher plasma total homocysteine concentrations are associated with an increased risk of myocardial infarction. In the Physicians' Health Study, 271 of 14,916 male physicians had a myocardial infarction during 5 yr of follow-up (36). A case control study showed that those who had a myocardial infarction had significantly higher plasma homocysteine than matched controls (11.1 ± 4.0 vs $10.5 \pm 2.9 \mu\text{mol/L}$, respectively, $p = 0.03$). Individuals with plasma homocysteine above the 95th percentile of the control distribution had a three-fold increased risk of myocardial infarction (36). A prospective study of 587 patients with angiographically confirmed coronary artery disease showed a graded relationship between plasma homocysteine concentrations and subsequent mortality (Fig. 5), and 3.8% of those with plasma homocysteine $<9 \mu\text{mol/L}$ died vs 24.7% of those with plasma homocysteine $\geq 15 \mu\text{mol/L}$ (37).

Other studies have shown relationships between serum folate concentrations and myocardial infarction or risk of death from heart disease. In a case-control study of 130 patients hospitalized for their first myocardial infarction, mean plasma homocysteine concentrations were higher in cases than controls, and plasma homocysteine was inver-

sely correlated with plasma folate and vitamin B₁₂ concentrations, but not with plasma vitamin B₆ (38). Adults with decreased serum folate concentrations had an increased risk of death from fatal coronary heart disease in the Nutrition Canada Survey (39). In another study from the Physicians' Health Study, risk of acute myocardial infarction or death from coronary artery disease was associated with folate and vitamin B₆ concentrations (40). Men with the lowest 20% of folate levels (<2.0 ng/mL) had a relative risk of 1.4 (95% CI 0.9–2.3) for acute myocardial infarction or death due to coronary artery disease compared with those in the top 80%. For those the lowest 20% compared with top 80% of vitamin B₆, the relative risk was 1.5 (95% CI 1.0–2.2) (40).

2.8. Hyperhomocysteinemia and Peripheral Vascular Disease

Elevated plasma or serum total homocysteine concentrations have been associated with an increased risk for venous and recurrent thrombotic disease in many different studies, as reviewed elsewhere (41). In a case control study of 185 patients with history of recurrent venous thrombosis and 220 controls, homocysteine concentrations were measured after oral methionine loading (42). Hyperhomocysteinemia was defined as >90th percentile of homocysteine concentration post-methionine dose in the controls. Of 185 patients with recurrent thrombosis, 25% had fasting homocysteine concentrations above the 90th percentile of the controls (odds ratio [OR] 3.1, 95% CI 1.8–5.5) (42). In the Leiden Thrombophilia Study, plasma homocysteine concentrations were higher among 269 patients with a first episode of deep venous thrombosis compared with 269 healthy controls matched by age and sex (43). 10% of cases and 4.8% of controls had homocysteine >18.5 µmol/L (OR 2.5, 95% CI 1.2–5.2).

2.9. Hyperhomocysteinemia and Cerebrovascular Disease

Hyperhomocysteinemia is associated with increased carotid artery intimal-medial wall thickening (44) and increased risk of stroke (45). In a study from the United Kingdom, serum was collected from 5661 men, aged 40–59 yr, who were randomly selected from population of one general practice in each of 18 towns. During follow-up, there were 141 incident cases of stroke among those with no history of stroke at screening. Serum total homocysteine was determined in 107 cases and 118 control men. Total homocysteine concentrations were 13.7 vs 11.9 µmol/L ($p = 0.004$) in cases and controls. The relative risk of stroke increased in a dose-response fashion from the 2nd, 3rd, and 4th quartiles of the homocysteine distribution, relative to the first. The relationship between homocysteine and stroke was strong, even after adjusting for other factors such as cigarette smoking, hypertension, and high-density lipoprotein (HDL) cholesterol (45).

Both elevated plasma homocysteine concentrations and low plasma folate or vitamin B₆ concentrations were associated with increased risk of stroke, peripheral vascular disease, and coronary artery disease (46). In a case control study conducted in nine European countries, 750 cases of atherosclerotic vascular disease were matched with 800 controls (47). The relative risk for vascular disease in the top fifth compared with the bottom four fifths of the control fasting total homocysteine distribution was 2.2 (95% CI 1.6–2.9) (47).

2.10. Hyperhomocysteinemia and Retinal Vascular Disease

Hyperhomocysteinemia is associated with retinal vascular disease, including central retinal vein occlusion, branch retinal vein occlusion, and central retinal artery occlusion.

Prior to more widespread recognition of hyperhomocysteinemia as a risk factor for retinal vascular disease, epidemiological studies showed that risk factors for retinal vein occlusion included hypertension, diabetes mellitus, ischemic heart disease, and cerebrovascular disease (48). In a study from the Wilmer Institute, 197 patients with central retinal vein occlusion were compared with National Health Interview Survey patients, and diabetes mellitus and hypertension were risk factors for central retinal vein occlusion (49). The Eye Disease Case-Control Study Group investigated 270 patients with branch retinal vein occlusion and 1142 control patients, and risk factors for branch retinal vein occlusion included a history of hypertension, glaucoma, increased body mass index at 20 yr of age, and higher serum levels of α_2 -globulin (50). Risk factors for hemiretinal vein occlusion included hypertension and diabetes mellitus (51). In the Blue Mountains Eye Study, glaucoma, hypertension, history of stroke, and history of angina were associated with retinal vein occlusion (52). Diabetes mellitus, glaucoma, and hypertension have also been identified as risk factors for retinal vein occlusions in another case-control study (53). Increased blood viscosity has been identified as a risk factor for central retinal vein occlusion (54, 55), and other potential risk factors have been discussed elsewhere (56,57).

An association between homocystinuria and retinal artery occlusions has appeared in case reports. Bilateral central retinal vein occlusions were described in a 6-yr-old child with homocystinuria (58), and early reports of optic atrophy and sclerotic arteries in homocystinuria may have been late findings related to retinal artery occlusion (59,60). In a case report, a 24-yr-old man developed bilateral central retinal vein occlusions, and plasma homocysteine concentrations were found to be 26.2 $\mu\text{mol/L}$ (61). Retinal vein occlusions as reported in series of children and young adults (62,63) may have included cases of unrecognized hyperhomocystinuria. Elevated homocysteine was found in a 33-yr-old man with central retinal vein occlusion who had no vascular risk factors except cigarette smoking (64).

In a study of 19 patients under the age of 50 yr who had retinal vein occlusion or retinal artery occlusion, 4 of 19 patients had elevated homocysteine concentrations after methionine loading test, leading the investigators to conclude that hyperhomocysteinemia was associated with increased risk of premature retinal artery and retinal vein occlusions (65). In a case-control study, 74 patients with central retinal vein occlusion were found to have plasma homocysteine concentrations of 11.58 $\mu\text{mol/L}$ compared with 9.49 $\mu\text{mol/L}$ in controls (66). Plasma homocysteine concentrations were studied in 74 cases with non-arteritic anterior ischemic optic neuropathy, central retinal vein occlusion, and central retinal artery occlusion and 81 controls, and significantly elevated plasma homocysteine concentrations were found among the cases with retinal vascular disease (67). Elevated plasma homocysteine was associated with nonarteritic ischemic optic neuropathy in two younger adults without diabetes (68). In a case-control study, 87 cases of central retinal vein occlusion, hemiretinal vein occlusion, branch retinal vein occlusion, or central retinal artery occlusion were matched with 87 controls (69). Mean plasma homocysteine concentrations were significantly higher in all disease groups compared with controls, and when adjusted for other factors, OR, 2.85, 95% CI 1.43–5.68. Mean plasma homocysteine in cases and controls was 12.9 vs 10.7 $\mu\text{mol/L}$ ($p < 0.0001$) (69). Although the homozygous genotype for the thermolabile methylenetetrahydrofolate reductase enzyme (TT genotype) has been associated with vascular occlusive disease, in a recent case-control study, the TT genotype was not associated with increased risk of retinal vascular disease (70).

In contrast, a study from Israel of 59 patients with retinal vein occlusion showed a significant association between the TT genotype and retinal vein occlusion (71).

2.11. Prevention of Hyperhomocysteinemia

Several studies have shown that serum or plasma total homocysteine concentrations can be reduced to normal following folate supplementation (14,15,72) or a combination of folate and other B vitamin supplements (73). There may be a potential benefit of reducing 13,500 to 50,000 deaths from coronary artery disease annually by increasing the intake of folic acid (32). Clinical trials are currently in progress to examine the effects of B vitamin supplementation on risk of recurrent stroke or death from cardiovascular disease (74–76).

3. DISORDERS OF IRON METABOLISM

Although iron deficiency and iron deficiency anemia are extremely common, there have only been isolated case reports where severe iron deficiency has been associated with retinal vascular disease. Excess iron stores have been implicated in the pathogenesis of the retinopathy of prematurity.

3.1. Iron Deficiency

Iron is essential for oxygen and energy metabolism and is a constituent of hemoglobin, myoglobin, cytochromes, and other iron-containing enzymes. Iron deficiency is the most common micronutrient deficiency worldwide, affecting a large proportion of children and women in both developed and low income countries. Iron deficiency may potentially contribute to retinal vascular disease through anemia and compromised oxygen delivery to the retina, but such a biological mechanism has not been well elucidated.

3.1.1. BIOCHEMISTRY OF IRON

Iron is element 26 in the periodic table and has an atomic weight of 55.85. Iron exists in two oxidation states in aqueous solution, either Fe^{2+} , the ferrous form, or Fe^{3+} , the ferric form. Iron can change between these forms, enabling it to serve as a catalyst in redox reactions by donating or accepting electrons. Iron-containing compounds play key roles in oxygen and energy metabolism. The role of iron in oxidative stress is presented in further detail under Subheading 3.2.1.

3.1.2. DIETARY SOURCES OF IRON

Foods that are rich in iron include liver, beef, veal, fish, eggs, soybeans, broccoli, green beans, and pasta. The absorption of iron depends on factors which include overall iron status, the mixture of foods in the meal, and the presence of vitamin C. From an economic standpoint, animal foods that contain heme iron tend to be more expensive and may be a barrier to obtaining iron-rich sources of food in low income situations.

3.1.3. ABSORPTION, STORAGE, AND METABOLISM OF IRON

Foods that contain iron are absorbed via two different pathways, one for heme iron found in animal products, and the second for absorption of non-heme iron, mostly iron salts, that are found in dairy products and plant foods. The bioavailability of heme iron in foods of animal origin is higher than that for iron from foods of vegetable origin. The absorption of iron in the upper intestine is regulated by the body's need for iron, and the iron content

Table 2
Dietary Reference Intakes for Iron (mg/d)

<i>Age and Gender Category</i>	<i>AI</i>	<i>EAR</i>	<i>RDA</i>
Infants, 0–6 mo	0.27	–	–
Infants, 7–12 mo	6.9	–	11.0
Children, 1–3 yr	–	3.0	7.0
Children, 4–8 yr	–	4.1	10.0
Boys, 9–13 yr	–	5.9	8.0
Girls, 9–13 yr	–	5.7	8.0
Boys, 14–18 yr	–	7.7	11.0
Girls, 14–18 yr	–	7.9	15.0
Adult men ≥19 yr	–	6.0	8.0
Adult women, 19–50 yr	–	8.1	18.0
Adult women >50 yr	–	5.0	8.0
Pregnant women, 14–18 yr	–	23.0	27.0
Pregnant women, 19–50 yr	–	22.0	27.0
Lactating women, 14–18 yr	–	7.0	10.0
Lactating women, 19–50 yr	–	6.5	9.0

AI, Adequate Intake; EAR, Estimated Average Requirement; RDA, Recommended Dietary Allowance. Based on ref. 77.

of the body is highly conserved. Factors that enhance the absorption of dietary iron include vitamin C. Phytates and polyphenols in plant foods can inhibit the absorption of dietary iron. Iron is taken up by duodenal enterocytes and transferred into the plasma in the form of bilirubin and iron transported by transferrin. About two-thirds of the total iron of the human body is found in the form of hemoglobin in circulating erythrocytes, with the remainder in liver stores and in myoglobin in muscle tissue.

3.1.4. FUNCTIONS

Hemoglobin, myoglobin, and cytochromes contain a heme protein, or iron-porphyrin prosthetic group, that bind iron in the center of a porphyrin ring. Hemoglobin combines with oxygen in the pulmonary circulation and becomes largely deoxygenated in the capillary circulation, where it delivers oxygen to tissues. In severe anemia, the hemoglobin content of erythrocytes is reduced, decreasing oxygen delivery to tissues and leading to chronic tissue hypoxia. Myoglobin in muscle transports and stores oxygen needed for muscular contraction. Cytochromes a, b, and c are involved in oxidative phosphorylation and the production of cellular energy. Cytochromes serve as electron carriers in transforming adenosine disphosphate (ADP) to adenosine triphosphate (ATP), the primary energy storage compound. Cytochrome P450 is found in microsomal membranes of liver and intestinal mucosal cells. Other non-heme, iron-containing enzymes include NADH dehydrogenase and succinate dehydrogenase, hydrogen peroxidases, catalase, peroxidase, aconitase, phosphoenolpyruvate carboxykinase, and ribonucleotide reductase.

3.1.5. REQUIREMENTS FOR IRON

The Food and Nutrition Board of the Institute of Medicine has made new recommendations for iron intake by life stage and gender group (77) (Table 2). The Adequate Intake

(AI) is the recommended level of intake for infants. The Estimated Average Requirement (EAR) is the daily intake value that is estimated to meet the requirement of half the healthy individuals in a group. The Recommended Dietary Allowance (RDA) is defined as the EAR plus twice the coefficient of variation (CV) to cover 97–98% of individuals in any particular group.

3.1.6. EPIDEMIOLOGY OF IRON DEFICIENCY

Iron deficiency is the most common nutritional deficiency worldwide, affecting half of children and women and a quarter of men in developing countries (78) and 7–12% of children and women in industrialized countries (79,80). In the United States, iron deficiency remains a major problem of women. Among women aged 20–49 yr in NHANES III (1988–1994), iron deficiency and iron deficiency anemia were found in 11% and 5% of women, respectively (81). These data, which used a conservative estimate for iron deficiency, suggest that at least 7.8 million women of childbearing age have iron deficiency and 3.3 million have iron deficiency anemia in the United States (81). There is a common, erroneous perception that iron deficiency and iron deficiency anemia are no longer important nutritional problems in the United States, but the prevalence rates for iron deficiency and iron deficiency anemia have not changed in the last 30 yr and may actually be increasing (82). Low income and minority women of childbearing age are the highest risk group for iron deficiency in the United States (81).

3.1.7. ASSESSMENT OF IRON STATUS

Iron deficiency is often diagnosed using laboratory indicators such as serum or plasma ferritin, total iron-binding capacity, transferrin saturation, erythrocyte protoporphyrin, serum or plasma transferrin receptor, and red cell indices (5,83). Use of these laboratory indicators have been described in detail elsewhere (5,83) and can be briefly summarized as follows. A serum or plasma ferritin <12 µg/L is considered to be consistent with iron deficiency among individuals >15 yr of age. Ferritin is a positive acute phase reactant, thus, in the presence of inflammation or infection, ferritin concentrations can be elevated in the presence of iron deficiency. Thus, serum or plasma ferritin should be considered as a conservative indicator of iron deficiency. Recent data suggest that a cut-off of 30 µg/L may be more appropriate for defining iron deficiency in adults (84–87). Among adults, a transferrin saturation <16%, total iron-binding capacity >400 µg/dL, erythrocyte protoporphyrin >70 µg/dL, and serum transferrin receptor >8.5 mg/L, have been used, separately or in combination, to define iron deficiency (5). Many of these indicators can also be affected by infection or inflammation. Red cell indices showing a microcytic, hypochromic anemia are consistent with iron deficiency. Iron deficiency anemia is usually defined as anemia in combination with one or more iron status indicators that are consistent with iron deficiency. According to World Health Organization criteria for the diagnosis of anemia, the cut-off points for hemoglobin are as follows: children aged 6 mo–6 yr, <110 g/L; children aged 6–14 yr, <120 g/L; adult males, <130 g/L; adult females, nonpregnant, <120 g/L; and adult females, pregnant, <110 g/L (5).

3.1.8. CLINICAL MANIFESTATIONS OF IRON DEFICIENCY

The main manifestation of iron deficiency is anemia, and anemia may cause fatigue, reduced work capacity, and reduced capacity for thermoregulation in cold environments. Among pregnant women, iron deficiency anemia has been associated with low birth weight,

prematurity, and increased fetal death. Iron deficiency in children is associated with impaired psychomotor and cognitive development and behavioral abnormalities. Nonspecific symptoms and signs of iron deficiency anemia include shortness of breath and pallor. Conjunctival pallor, especially in the cul-de-sacs, is a nonspecific ocular sign of severe iron deficiency.

3.1.9. RETINAL VASCULAR DISEASE ASSOCIATED WITH IRON DEFICIENCY ANEMIA

Severe iron deficiency anemia may compromise oxygen delivery to the retina, and there have been occasional case reports of iron deficiency anemia associated with background retinopathy, venous stasis retinopathy, central retinal artery occlusion, central retinal vein occlusion, and non-arteritic ischemic optic neuropathy. Chronic severe iron deficiency anemia has been associated with retinal hemorrhages and cotton wool spots (88), and there do not appear to be differences in the retinopathy associated with iron deficiency versus the anemia of chronic disease (89). Central retinal vein occlusion was reported in a 44-yr-old woman who presented with blurred vision, dyspnea, and a hemoglobin concentration of 62 g/L (90). Venous stasis retinopathy was described in a 36-yr-old woman who presented with acute onset of blurred vision in one eye, a microcytic, hypochromic anemia, and a hemoglobin concentration of 72 g/L (91). The patient had a 1-yr history of heavy menstrual flow in which she would typically use 20 pads per day for 5 d. The venous stasis retinopathy improved rapidly after blood transfusion, and further investigation showed that her menorrhagia was due to a large leiomyoma (91). A partial central retinal artery occlusion was described in a 13-yr-old girl with iron deficiency anemia (92). Central retinal vein occlusion was reported in a 37-yr-old woman with iron deficiency anemia and hemoglobin concentration of 94 g/L (93). The patient had no history of glaucoma, cardiovascular disease, hyperlipidemia, diabetes mellitus, cigarette smoking, intravenous drug use, oral contraceptive use, or use of any other medication. The patient was treated with oral ferrous sulfate and fibrinolytic therapy. By 2 wk, her vision had improved to 20/20 and had remained stable (93). Nonarteritic ischemic optic neuropathy was reported in a 50-yr-old woman with hypermenorrhea, serum ferritin <5 µg/L, and hemoglobin concentration of 73 g/L (93). Severe iron deficiency anemia may also potentially accelerate the course of diabetic retinopathy (94).

3.1.10. PAPILLEDEMA ASSOCIATED WITH IRON DEFICIENCY ANEMIA

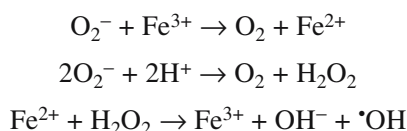
There have been rare case reports of papilledema associated with iron deficiency anemia (95–97). In one case report, a 42-yr-old man developed iron deficiency from bleeding hemorrhoids and presented with iron deficiency anemia, papilledema, and severe thrombocytosis (98). All three findings responded to treatment with oral iron supplementation (98).

3.2. Excess Iron Stores

Excess iron stores, or iron overload, is the opposite end of the spectrum and is less common than iron deficiency. A recent study conducted among exclusively white, older men and women living in the community of Framingham, Massachusetts showed that elevated iron stores were found in 12.9% of the subjects, and iron overload was considered more of a problem than iron deficiency among older white Americans (99). Although iron overload, an excess of total body iron, has been linked with accelerated disease processes (100), including heart disease (101), cancer (102), and diabetes (103), strong evidence showing a definitive causal relationship is lacking.

3.2.1. EXCESS IRON STORES AND RETINOPATHY OF PREMATURITY

Iron has been hypothesized to cause oxygen radical injury and increase the risk of retinopathy of prematurity (104,105). Retinopathy of prematurity is a fibrovascular proliferation of the retina found mainly in very premature infants. Premature infants may lack effective antioxidant systems, which may allow greater damage to tissues from free radicals. Much of the antioxidant activity of plasma is associated with two iron-associated antioxidants, ceruloplasmin and transferrin (105). Ceruloplasmin catalyzes the oxidation of ferrous to ferric iron, and apotransferrin serves as an antioxidant by binding ferric ions. Preterm infants have low plasma concentrations of ceruloplasmin and transferrin and high levels of transferrin saturation (106). Sullivan has hypothesized that retinopathy of prematurity is primarily a disorder of iron-associated antioxidant deficiency, thus, he termed the condition the “oxygen radical disease of prematurity” (105). The capacity of the iron-associated antioxidant system in premature infants may be unable to handle exogenous iron, and oxygen radical injury may increase because of the role of iron in the formation of highly reactive hydroxyl radical ($\cdot\text{OH}$) from superoxide (O_2^-), known as the Haber-Weiss reaction:



Several studies have been conducted to examine the hypothesis that iron status is related to the retinopathy of prematurity. In a study of 184 very low-birthweight infants conducted in two neonatal intensive care units in Liverpool, frequency of blood transfusion and gestational age were independently associated with retinopathy of prematurity (107). Two previous studies had suggested an association between blood transfusion and retinopathy of prematurity in low-birthweight infants (108,109). In a prospective study of 56 very low-birthweight infants, those who developed retinopathy of prematurity had significantly high serum iron (OR, 1.90, 95% CI 1.06–3.90) and transferrin saturation (OR 1.73, 95% CI 1.03–3.27) in the first week of life than those without retinopathy, after controlling for potential confounding variables (110). An observational study involving 114 very low-birthweight infants showed that the relative risk of developing retinopathy of prematurity was 6.4 (95% CI 1.2–33.4) for infants who received 16.45 mL/kg and 12.3 (95% CI 1.6–92.5) for infants who received >45 mL/kg of blood transfusion (111). Infants who developed retinopathy of prematurity had significantly higher serum ferritin concentrations and lower transferrin concentrations than infants without retinopathy of prematurity, but these differences were not significant after adjusting for transfusion volume (111).

In a study of 230 preterm infants who were randomly allocated to receive treatment with recombinant human erythropoietin and iron (1 mg/kg/d intravenously from the second to the fourth week, and then 12 mg/kg/d orally until the seventh week) or no treatment (control), 43.8% of the treated group and 21.7% of the control group developed retinopathy of prematurity ($p = 0.0007$) (112). There was a significant positive correlation between serum ferritin concentrations at the second, fourth, and sixth week of treatment and the severity of the retinopathy of prematurity. The investigators suggested that iron supplementation increased retinal free iron and may have contributed to the oxidative injury to retinal vessels (112).

3.2.2. EXCESS IRON STORES AND MACULAR DEGENERATION

Aceruloplasminemia is a rare autosomal recessive disease that is associated with iron overload. A mutation in the ceruloplasmin gene results in impaired iron export from several tissues and the accumulation of iron in the retina, brain, and pancreas. In a case report from Japan, a 56-yr-old man was found to have a retinal degeneration with yellowish discoloration of the fundus and midperipheral retinal pigment epithelium cell atrophy (113). Multiple subretinal yellowish-white lesions and retinal pigment epithelium cell atrophy was described in a Caucasian man with aceruloplasminemia (114). Biopsy of the conjunctival epithelium revealed Perls' Prussian blue-positive epithelial cells, indicating tissue iron overload.

4. ANOREXIA NERVOSA

Anorexia nervosa, a disorder characterized by self-imposed weight loss, endocrine dysfunction, and an altered view of eating and weight, usually in young women, has rarely been associated with retinal vascular disease and cataracts in case reports. Anorexia nervosa is similar to a state of semistarvation, and accompanying changes include elevated plasma carotenoids, hypercholesterolemia, altered thyroid hormone and catecholamine metabolism, amenorrhea, reduced libido, and constipation. Anorexia nervosa has been associated with central retinal vein occlusion and cataracts. Whether these eye conditions are causally related to anorexia nervosa or are chance associations is not clear. A 21-yr-old woman with anorexia nervosa presented with central retinal vein occlusion and vision of 20/200 (115). In the year after the divorce of her parents, the patient lost 18 kg, and at presentation, her body mass index (weight/height²) was 16.1. She had severe iron deficiency anemia with a hemoglobin concentration of 65 g/L. Following treatment with oral ferrous sulfate and a high calorie and protein rich diet, the vision returned to 20/20 (115). Bilateral subcapsular cataracts have also been described in women with anorexia nervosa (116,117). Anorexia nervosa has not been associated with ocular signs of vitamin A deficiency, despite low levels of vitamin A intake (118).

5. HYPERLIPIDEMIAS AND LIPEMIA RETINALIS

Lipemia retinalis is a rare fundus abnormality that is associated with primary and secondary hyperlipidemia. The condition is characterized by pale, creamy or milky white retinal blood vessels and a salmon-colored fundus due to elevated triglycerides in the retinal and choroidal circulation.

5.1. Hyperlipidemias

Lipemia retinalis has been described in different primary hyperlipidemias: Type I (exogenous hyperlipidemia), Type III (remnant hyperlipidemia), Type IV (endogenous hyperlipidemia), and Type V (mixed hyperlipidemia) and with secondary hyperlipidemias. Primary disorders associated with Type I are familial lipoprotein lipase deficiency and C-II apolipoprotein deficiency. Type III is associated with familial dysbetalipoproteinemia. Type IV is associated with familial hypertriglyceridemia (mild form), familial multiple lipoprotein-type hyperlipidemia, sporadic hypertriglyceridemia, and Tangier disease. Type V is associated with mixed hyperlipidemia are familial hypertriglyceridemia (severe form), familial lipoprotein lipase deficiency, and C-II apolipoprotein deficiency. These disorders

Table 3
Hyperlipidemias Associated With Lipemia Retinalis

<i>Primary disorder</i>	<i>Phenotype</i>	<i>Frequency</i>	<i>Lipid</i>	<i>Features</i>
Familial lipoprotein lipase deficiency	I, V	Very rare	↑ Chylomicrons	Childhood onset; pancreatitis, eruptive xanthomas
Familial C-II deficiency	I, V	Very rare	↑ Chylomicrons	Sometimes protein asymptomatic; pancreatitis, abdominal pain, hepatosplenomegaly
Familial dysbetalipoproteinemia	III	Rare	↑ LDL, VLDL	Cardiovascular disease, diabetes, tuberous xanthomas, striae palmaris
Familial hypertriglyceridemia (mild)	IV	1%	↑ VLDL	Asymptomatic; moderate increase in coronary heart disease risk

LDL, low-density lipoprotein; VLDL, very low-density lipoprotein. Modified from refs. 119,120.

have been reviewed in detail elsewhere (119). The hyperlipidemias that have been associated with lipemia retinalis are summarized in Table 3 (119,120). The most common secondary hyperlipidemia associated with lipemia retinalis is chylomicronemia that results from uncontrolled diabetes mellitus.

5.2. Historical Background

In 1880, the ophthalmologist Albert G. Heyl (1847–1895) presented a case report at the Philadelphia County Medical Society of a 20-yr-old man with diabetes mellitus and wasting who complained of dimness of sight (121). Fundus examination revealed light salmon-colored retinal blood vessels. Heyl noted: “On pricking the finger, a drop of blood would escape, having very much the color of a piece of pink coral, followed by a thick, whitish fluid, of the color and consistence of an oil-emulsion...” Since Heyl’s description, there have been numerous case reports in the literature of lipemia retinalis (122–139). In most of these cases, lipemia retinalis was associated with severe diabetes mellitus.

5.3. Clinical Presentation

Idiopathic hyperlipemia is associated with lipemia retinalis, lid xanthelasmas, and corneal arcus, and is rarely associated with lipid interstitial keratitis (140), iris xanthomas (135), and yellowish lesions in the deep retina that are thought to represent small intra-retinal xanthomas (141). Type III hyperlipoproteinemia has been associated with Schnyder central stromal corneal dystrophy and lipemia of the limbal vessels (142). In a experimental canine model, hyperlipoproteinemia caused deposition of lipid in peripheral cornea but did not any appreciable fundus lesions (143). Lipemia retinalis has been described in rhesus monkeys with thyroid suppression and long-term ingestion of a high-cholesterol diet (144). A grading system was developed for lipemia retinalis, consisting of Grade I

(early) in which the peripheral vessels have a creamy tint, Grade II (moderate) in which there is extension of cream-colored vessels towards the disc, and Grade III (marked) in which all vessels are cream-colored with arteries being indistinguishable from veins, and the fundus has a salmon color (145). Lipemia retinalis generally occurs when plasma or serum triglyceride concentrations reach 28 mmol/L (145). The condition has been described in a 29-d-old infant (146).

In order to study retinal vascular abnormalities associated with hyperlipidemias, fluorescein angiography was conducted in 40 patients with hyperlipidemia, 99 patients with retinal vein occlusion, and 40 patients without retinal vein occlusion (147). Of the 40 patients with hyperlipidemia, there were 8 patients with type IV and V hyperlipidemia who had retinal arterial abnormalities consisting of peripheral vessel closure, leakage of fluorescein from the peripheral vasculature, or evidence of retinal infarction. Of the 99 patients with retinal vein occlusion, there was a significantly higher prevalence of hyperlipidemia in the retinal vein occlusion group compared with the control group (148). In a study comparing 26 patients with hyperlipidemia with 22 controls, there were no differences noted in retinal arterioles between the two groups, suggesting that hyperlipidemia alone is not a risk factor for the development of retinal arteriolar changes (149). Histopathological findings in lipemia retinalis include progressive obstruction of retinal vessels with lipid, deposition of lipid within large and small vessels in the choroid, and lipid deposition within the retina (150).

5.4. Laboratory Findings

Lipemia retinalis is often associated with striking visible changes in venous blood that is drawn for analysis. The blood may appear grossly lipemic, with cloudy or milky plasma (139,142,150). Laboratory studies show elevated cholesterol and triglycerides, and depending on the disorder involved, elevations in low-density lipoproteins and very low-density lipoproteins. Secondary causes of elevated lipoproteins, such as diabetes mellitus, hypothyroidism, kidney disease, excessive alcohol intake, and liver disease need to be excluded.

5.5. Management of Hyperlipidemias

The initial approach to hyperlipidemia is to reduce dietary intake of cholesterol and saturated fats, increase exercise, reduce alcohol intake, and stop smoking, as appropriate. Affected patients should be advised to lower their intake of egg yolks, whole-milk dairy products, and red meat, and substitute fruits, vegetables, and whole-grain food products. Coconut oil, palm oil, and hydrogenated vegetable oils should be replaced in cooking with olive oil or non-hydrogenated vegetable oils. Treatment with niacin or statins may be indicated, and such therapy should be undertaken by the patient's primary care physician. Lipemia retinalis usually improves with a reduction in fat intake and other therapies aimed at reducing triglycerides, although longstanding lipemia retinalis can lead to massive lipid exudation and irreversible vision loss (138).

6. CONCLUSIONS

Nutritional disorders such as inadequate folate, vitamin B₆, vitamin B₁₂ status, severe iron deficiency, excess iron stores, anorexia nervosa, and hyperlipidemias are associated with increased risk of retinal vascular disease. If further work confirms the causal rela-

tionships between nutritional disorders and the retinal vascular diseases discussed in this chapter, this would suggest that a large proportion of retinal vascular disease may be preventable with better nutrition. Studies are needed to determine whether mandatory folic acid fortification of bread flour and other food products since 1996 has had an apparent impact on the incidence of retinal artery or retinal vein occlusion in the United States. It is unclear whether daily folic acid or B complex vitamin supplementation in patients with retinal vein occlusion will reduce the risk of having a subsequent retinal vein occlusion in the opposite eye. Although iron deficiency and iron deficiency anemia could theoretically contribute to retinal hypoxia and progression of diabetic retinopathy, it is unclear whether such a relationship may exist among young women with diabetes mellitus who have iron deficiency or iron deficiency anemia. Further studies are needed to determine whether milder forms of hyperlipidemia are associated with an increased risk of retinal vascular disease. Controlled clinical trials may be needed to confirm the hypothesis that excess iron stores are involved in the pathogenesis of the retinopathy of prematurity.

REFERENCES

1. McCully KS. Vascular pathology of homocysteinemia: implications for the pathogenesis of arteriosclerosis. *Am J Pathol* 1969;56:111–128.
2. McCully KS, Wilson RB. Homocysteine theory of arteriosclerosis. *Atherosclerosis* 1975;22:215–227.
3. Wilcken DEL, Wilcken B. The pathogenesis of coronary artery disease. A possible role for methionine metabolism. *J Clin Invest* 1976;57:1079–1082.
4. Green R, Jacobsen DW. Clinical implications of hyperhomocysteinemia. In: Bailey LB (ed). *Folate in Health and Disease*. New York, Marcel Dekker: 1995; pp. 75–122.
5. Sauberlich HE. *Laboratory Tests for the Assessment of Nutritional Status*. Second Edition. Boca Raton, CRC Press, 1999.
6. Harpel PC, Zhang X, Borth W. Homocystine and hemostasis: pathogenetic mechanisms predisposing to thrombosis. *J Nutr* 1996;126(suppl 4):1285S–1289S.
7. Kang SS, Wong PWK, Norusis M. Homocysteinemia due to folate deficiency. *Metabolism* 1987;36:458–462.
8. Stabler SP, Marcell PD, Podell ER, Allen RH, Savage DG, Lindenbaum J. Elevation of total homocysteine in the serum of patients with cobalamin or folate deficiency detected by capillary gas chromatography-mass spectrometry. *J Clin Invest* 1988;81:466–474.
9. Lewis CA, Pancharuniti N, Sauberlich HE. Plasma folate adequacy as determined by homocysteine level. *Ann NY Acad Sci* 1992;669:360–362.
10. Ubbink JB, Vermaak WJH, Van der Merwe A, Becker PJ. Vitamin B-12, vitamin B-6, and folate nutritional status in men with hyperhomocysteinemia. *Am J Clin Nutr* 1993;57:47–53.
11. Selhub J, Jacques PF, Wilson PWF, Rush D, Rosenberg IH. Vitamin status and intake as primary determinants of homocysteinemia in an elderly population. *J Am Med Assoc* 1993;270:2693–2698.
12. Landgren F, Israelsson B, Lindgren A, Hultberg B, Andersson A, Brattström L. Plasma homocysteine in acute myocardial infarction: homocysteine-lowering effect of folic acid. *J Intern Med* 1995;237:381–388.
13. O'Keefe CA, Bailey LB, Thomas EA, et al. Controlled dietary folate affects folate status in nonpregnant women. *J Nutr* 1995;125:2717–2725.
14. Brouwer IA, Van Dusseldorp M, Thomas CMG, et al. Low-dose folic acid supplementation decreases plasma homocysteine concentrations: a randomized trial. *Am J Clin Nutr* 1999;69:99–104.
15. Homocysteine Lowering Trialists' Collaboration. Lowering blood homocysteine with folic acid based supplements: meta-analysis of randomised trials. *Br Med J* 1998;316:894–898.
16. Lobo A, Naso A, Arheart K, et al. Reduction of homocysteine levels in coronary artery disease by low-dose folic acid combined with vitamins B₆ and B₁₂. *Am J Cardiol* 1999;83:821–825.
17. Jacques PF, Selhub J, Bostom AG, Wilson PWR, Rosenberg IH. The effect of folic acid fortification on plasma folate and total homocysteine concentrations. *N Engl J Med* 1999;340:1449–1454.

18. Brattström L, Israelsson B, Norrving B, et al. Impaired homocysteine metabolism in early-onset cerebral and peripheral occlusive arterial disease. *Atherosclerosis* 1990;81:51–60.
19. Ueland PM, Refsum H, Stabler SP, Malinow MR, Andersson A, Allen RH. Total homocysteine in plasma or serum: methods and clinical applications. *Clin Chem* 1993;39:1764–1779.
20. Brattström L, Israelsson B, Lindgärde F, Hultberg B. Higher total plasma homocysteine in vitamin B₁₂ deficiency than in heterozygosity for homocystinuria due to cystathionine β -synthase deficiency. *Metabolism* 1988;37:175–178.
21. Allen RH, Stabler SP, Savage DG, Lindenbaum J. Diagnosis of cobalamin deficiency. I: Usefulness of serum methylmalonic acid and total homocysteine concentrations. *Am J Hematol* 1990;34:90–98.
22. Lindenbaum J, Savage DG, Stabler SP, Allen RH. Diagnosis of cobalamin deficiency: II. relative sensitivities of serum cobalamin, methylmalonic acid, and total homocysteine concentrations. *Am J Hematol* 1990;34:99–107.
23. Lindenbaum J, Healton EB, Savage DG, et al. Neuropsychiatric disorders caused by cobalamin deficiency in the absence of anemia or macrocytosis. *N Engl J Med* 1988;318:1720–1728.
24. Jacques PF, Rosenberg IH, Rogers G, et al. Serum total homocysteine concentrations in adolescent and adult Americans: results from the third National Health and Nutrition Examination Survey. *Am J Clin Nutr* 1999;69:482–489.
25. Ubbink JB, Becker PJ, Vermaak WJH, Delport R. Results of B-vitamin supplementation study used in a prediction model to define a reference range for plasma homocysteine. *Clin Chem* 1995;41:1033–1037.
26. Dudman NPB, Wilcken DEL, Wang J, Lynch JF, Macey D, Lundberg P. Disordered methionine/homocysteine metabolism in premature vascular disease: its occurrence, cofactor therapy, and enzymology. *Arterioscler Thromb* 1993;13:1253–1260.
27. Kang SS, Zhou J, Wong PWK, Kowalisyn J, Strokosch G. Intermediate homocysteinemia: a thermolabile variant of methylenetetrahydrofolate reductase. *Am J Hum Genet* 1988;43:414–421.
28. Ma J, Stampfer MJ, Hennekens CH, et al. Methylenetetrahydrofolate reductase polymorphism, plasma folate, homocysteine, and risk of myocardial infarction in US physicians. *Circulation* 1996;94:2410–2416.
29. Folsom AR, Nieto FJ, McGovern PG, et al. Prospective study of coronary heart disease incidence in relation to fasting total homocysteine, related genetic polymorphisms, and B vitamins: the Atherosclerosis Risk in Communities (ARIC) study. *Circulation* 1998;98:204–210.
30. Weger M, Stanger O, Haas A. Hyperhomocysteinemia: a risk factor for central retinal vein occlusion. *Am J Ophthalmol* 2001;131:290–291.
31. Refsum H, Ueland PM, Nygård O, Vollset SE. Homocysteine and cardiovascular disease. *Ann Rev Med* 1998;49:31–62.
32. Boushey CJ, Beresford SAA, Omenn GS, Motulsky AG. A quantitative assessment of plasma homocysteine as a risk factor for vascular disease. Probable benefits of increasing folic acid intakes. *JAMA* 1995;274:1049–1057.
33. Homocysteine Studies Collaboration. Homocysteine and risk of ischemic heart disease and stroke. A meta-analysis. *JAMA* 2002;288:2015–2022.
34. Clarke R, Daly L, Robinson K, Naughten E, Cahalane S, Fowler B, Graham I. Hyperhomocysteinemia: an independent risk factor for vascular disease. *N Engl J Med* 1991;324:1149–1155.
35. Wald NJ, Watt HC, Law MR, Weir DG, McPartlin J, Scott JM. Homocysteine and ischemic heart disease: results of a prospective study with implications regarding prevention. *Arch Intern Med* 1998;158:862–867.
36. Stampfer MJ, Malinow MR, Willett WC, Newcomer LM, Upson B, Ullmann D, Tishler PV, Hennekens CH. A prospective study of plasma homocyst(e)ine and risk of myocardial infarction in US physicians. *JAMA* 1992;268:877–881.
37. Nygård O, Nordrehaug JE, Refsum H, Ueland PM, Farstad M, Vollset SE. Plasma homocysteine levels and mortality in patients with coronary artery disease. *N Engl J Med* 1997;337:230–236.
38. Verhoef P, Stampfer MJ, Buring JE, et al. Homocysteine metabolism and risk of myocardial infarction: relation with vitamins B₆, B₁₂, and folate. *Am J Epidemiol* 1996;143:845–859.
39. Morrison HI, Schaubel D, Desmeules M, Wigle DT. Serum folate and risk of fatal coronary heart disease. *JAMA* 1996;275:1893–1896.

40. Chasan-Taber KL, Selhub J, Rosenberg IH, et al. A prospective study of folate and vitamin B₆ and risk of myocardial infarction in US physicians. *J Am Coll Nutr* 1996;15:136–143.
41. D'Angelo A, Selhub J. Homocysteine and thrombotic disease. *Blood* 1997;90:1–11.
42. Den Heijer M, Blom HJ, Gerrits WBJ, et al. Is hyperhomocysteinemia a risk factor for recurrent venous thrombosis? *Lancet* 1995;345:882–885.
43. Den Heijer M, Koster T, Blom HJ, et al. Hyperhomocysteinemia as a risk factor for deep-vein thrombosis. *N Engl J Med* 1996;334:759–762.
44. Malinow MR, Nieto FJ, Szklo M, Chambless LE, Bond G. Carotid artery intimal-medial wall thickening and plasma homocyst(e)ine in asymptomatic adults: the Atherosclerosis Risk in Communities Study. *Circulation* 1993;87:1107–1113.
45. Perry IJ, Refsum H, Morris RW, Ebrahim SB, Ueland PM, Shaper AG. Prospective study of serum total homocysteine concentration and risk of stroke in middle-aged British men. *Lancet* 1995;346:1395–1398.
46. Robinson K, Arheart K, Refsum H, et al. Low circulating folate and vitamin B₆ concentrations: risk factors for stroke, peripheral vascular disease, and coronary artery disease. *Circulation* 1998;97:437–443.
47. Graham IM, Daly LE, Refsum HM, et al. Plasma homocysteine as a risk factor for vascular disease. The European Concerted Action Project. *JAMA* 1997;277:1775–1781.
48. Hayreh SS, Zimmerman B, McCarthy MJ, Podhajsky P. Systemic diseases associated with various types of retinal vein occlusion. *Am J Ophthalmol* 2001;131:61–77.
49. Elman MJ, Bhatt AK, Quinlan PM, Enger C. The risk for systemic vascular diseases and mortality in patients with central retinal vein occlusion. *Ophthalmology* 1990;97:1543–1548.
50. Eye Disease Case-Control Study Group. Risk factors for branch retinal vein occlusion. *Am J Ophthalmol* 1993;116:286–296.
51. Sperduto RD, Hiller R, Chew E, et al. Risk factors for hemiretinal vein occlusion: comparison with risk factors for central and branch retinal vein occlusion. The Eye Disease Case-Control Study. *Ophthalmology* 1998;105:765–771.
52. Mitchell P, Smith W, Chang A. Prevalence and associations of retinal vein occlusion in Australia: the Blue Mountains Eye Study. *Arch Ophthalmol* 1996;114:1243–1247.
53. Rath EZ, Frank RN, Shin DH, Kim C. Risk factors for retinal vein occlusions. A case-control study. *Ophthalmology* 1992;99:509–514.
54. Williamson TH, Rumley A, Lowe GDO. Blood viscosity, coagulation, and activated protein C resistance in central retinal vein occlusion: a population controlled study. *Br J Ophthalmol* 1996;80:203–208.
55. Larson J, Olafsdottir E, Bauer B. Activated protein C resistance in young adults with central retinal vein occlusion. *Br J Ophthalmol* 1996;80:200–202.
56. Williamson TH. Central retinal vein occlusion: what's the story? *Br J Ophthalmol* 1997;81:698–704.
57. Greaves M. Aging and the pathogenesis of retinal vein thrombosis. *Br J Ophthalmol* 1997;81:810–811.
58. Wilson RS, Ruiz RS. Bilateral central retinal artery occlusion in homocystinuria. *Arch Ophthalmol* 1969;82:267–268.
59. Mukuno K, Matsui K, Haraguchi H. Ocular manifestations of homocystinuria, report of two cases. *Acta Soc Ophthalmol Japan* 1967;71:66–73.
60. Schimke RN, McKusick VA, Huang T, Pollack AD. Homocystinuria. Studies of 20 families with 38 affected members. *JAMA* 1965;193:711–719.
61. Bioussé V, Newman NJ, Sternberg P Jr. Retinal vein occlusion and transient monocular visual loss associated with hyperhomocystinemia. *Am J Ophthalmol* 1997;124:257–260.
62. Gupta A, Agarwal A, Bansal RK, Agarwal A, Chugh KS. Ischaemic central retinal vein occlusion in the young. *Eye* 1993;7:138–142.
63. Grevén CM, Slusher MM, Weaver RG. Retinal arterial occlusions in young adults. *Am J Ophthalmol* 1995;120:776–783.
64. Cabezas-León MM, García-Montero MR, Morente-Matas P. Hiperhomocistinemia como un factor de riesgo para la trombosis de la vena central de la retina en un paciente joven. *Rev Neurol* 2003;37:441–443.
65. Wenzler EM, Rademakers JJM, Boers GHJ, Cruysberg JRM, Webers CAB, Deutman AF. Hyperhomocysteinemia in retinal artery and retinal vein occlusion. *Am J Ophthalmol* 1993;115:162–167.

66. Vine AK. Hyperhomocysteinemia: a risk factor for central retinal vein occlusion. *Am J Ophthalmol* 2000;129:640–644.
67. Pianka P, Almog Y, Man O, Goldstein M, Sela BA, Loewenstein A. Hyperhomocystinemia in patients with nonarteritic anterior ischemic optic neuropathy, central retinal artery occlusion, and central retinal vein occlusion. *Ophthalmology* 2000;107:1588–1592.
68. Kawasaki A, Purvin VA, Burgett RA. Hyperhomocysteinaemia in young patients with non-arteritic anterior ischaemic optic neuropathy. *Br J Ophthalmol* 1999;83:1287–1290.
69. Cahill M, Karabatzaki M, Meleady R, et al. Raised plasma homocysteine as a risk factor for retinal vascular occlusive disease. *Br J Ophthalmol* 2000;84:154–157.
70. Cahill M, Karabatzaki M, Donoghue C, et al. Thermolabile MTHFR genotype and retinal vascular occlusive disease. *Br J Ophthalmol* 2001;85:88–90.
71. Loewenstein A, Goldstein M, Winder A, Lazar M, Eldor A. Retinal vein occlusion associated with methylenetetrahydrofolate reductase mutation. *Ophthalmology* 1999;106:1817–1820.
72. Mason JB, Miller JW. The effects of vitamins B₁₂, B₆, and folate on blood homocysteine levels. *Ann NY Acad Sci* 1992;669:197–203.
73. Brönstrup A, Hages M, Pietrzik K. Lowering of homocysteine concentrations in elderly men and women. *Int J Vitam Res* 1999;69:187–193.
74. Ubbink JB. The role of vitamins in the pathogenesis and treatment of hyperhomocyst(e)inemia. *J Inher Metab Dis* 1997;20:316–325.
75. Omenn GS, Beresford SAA, Motulsky AG. Preventing coronary heart disease: B vitamins and homocysteine. *Circulation* 1998;97:421–424.
76. Clarke R, Collins R. Can dietary supplements with folic acid or vitamin B6 reduce cardiovascular risk? Design of clinical trials to test the homocysteine hypothesis of vascular disease. *J Cardiovasc Risk* 1998;5:249–255.
77. Food and Nutrition Board, Institute of Medicine. Dietary Reference Intakes for Vitamin A, Vitamin K, Arsenic, Boron, Chromium, Copper, Iodine, Iron, Manganese, Molybdenum, Nickel, Silicon, Vanadium, and Zinc: A Report of the Panel on Micronutrients. Washington, D.C., National Academy Press: 2001; pp. 290–393.
78. UNICEF/UNU/WHO/MI. Preventing Iron Deficiency in Women and Children: Background and Consensus on Key Technical Issues and Resources for Advocacy, Planning, and Implementing National Programs. Geneva, UNICEF/UNU/WHO/MI Technical Workshop, 1998.
79. Pilch SM, Senti FR. Assessment of the Iron Nutritional Status of the U.S. Population Based on the Data Collected in the Second National Health and Nutrition Examination Survey, 1876–1980. Bethesda, MD, Federation of American Societies for Experimental Biology, 1984.
80. Dallman PR, Yip R, Johnson C. Prevalence and causes of anemia in the United States, 1976–1980. *Am J Clin Nutr* 1984;39:437–445.
81. Looker AC, Dallman PR, Carroll MD, Gunter EW, Johnson CL. Prevalence of iron deficiency in the United States. *JAMA* 1997;277:973–976.
82. Fairbanks VF. Iron in medicine and nutrition. In: Shils ME, Olson JA, Shike M, Ross AC (eds). *Modern Nutrition in Health and Disease*. Ninth Edition. Baltimore, Williams & Wilkins: 1999; pp. 193–221.
83. Lynch S, Green R. Assessment of nutritional anemias. In: Ramakrishnan U (ed). *Nutritional Anemias*. Boca Raton, CRC: 2001; pp. 23–42.
84. Magnusson B, Björn-Rasmussen E, Hallberg L, Rossander L. Iron absorption in relation to iron status. *Scand J Haematol* 1981;27:201–208.
85. Milman N, Pedersen NS, Visfeldt J. Serum ferritin in healthy Danes: relation to marrow haemosiderin iron stores. *Dan Med Bull* 1983;30:115–120.
86. Milman N. Serum ferritin in Danes: studies of iron status from infancy to old age, during blood donation and pregnancy. *Int J Hematol* 1996;63:103–135.
87. Van den Broek NR, Letsky EA, White SA, Shenkin A. Iron status in pregnant women: which measurements are valid? *Br J Haematol* 1998;103:817–824.
88. Holt JM, Gordon-Smith EC. Retinal abnormalities in diseases of the blood. *Br J Ophthalmol* 1969;53:145–160.
89. Rubenstein RA, Yanoff M, Albert DM. Thrombocytopenia, anemia, and retinal hemorrhage. *Am J Ophthalmol* 1968;65:435–439.

90. Kirkham TH, Wrigley PFM, Holt JM. Central retinal vein occlusion complicating iron deficiency anemia. *Br J Ophthalmol* 1971;55:777–780.
91. Kurzel RB, Angerman NS. Venous stasis retinopathy after long-standing menorrhagia. *J Reprod Med* 1978;20:239–242.
92. Matsuoaka Y, Hayasaka S, Yamada K. Incomplete occlusion of central retinal artery in a girl with iron deficiency anemia. *Ophthalmologica* 1996;210:358–360.
93. Kacer B, Hattenbach LO, Hörle S, Scharrer I, Kroll P, Koch F. Central retinal vein occlusion and non-arteritic ischemic optic neuropathy in 2 patients with mild iron deficiency anemia. *Ophthalmologica* 2001;215:128–131.
94. Shorb SR. Anemia and diabetic retinopathy. *Am J Ophthalmol* 1985;100:434–436.
95. Lubeck MJ. Papilledema caused by iron-deficiency anemia. *Trans Am Acad Ophthalmol Oto-Lar* 1959;63:306–310.
96. Beutler E, Fairbanks VF, Fahey JL. *Clinical Disorders of Iron Metabolism*. New York, Grune and Stratton: 1963; pp. 131–132.
97. Capriles L. Intracranial hypertension and iron-deficiency anemia. *Arch Neurol* 1963;9:147–153.
98. Knizley H, Noyes WD. Iron deficiency anemia, papilledema, thrombocytosis, and transient hemiparesis. *Arch Intern Med* 1972;129:483–486.
99. Fleming DJ, Jacques PF, Tucker KL, et al. Iron status of the free-living, elderly Framingham Heart Study cohort: an iron-replete population with a high prevalence of elevated iron stores. *Am J Clin Nutr* 2001;73:638–646.
100. Beard J. Iron status of free-living elderly individuals. *Am J Clin Nutr* 2001;73:503–504.
101. Tuomainen T, Punnonen K, Nyyssonen K, Salonen JT. Association between total body iron stores and risk of acute myocardial infarction in men. *Circulation* 1998;97:1461–1466.
102. Stevens RG, Jones DY, Micoaazi MS, Taylor PR. Body iron stores and the risk of cancer. *N Engl J Med* 1988;319:1047–1052.
103. Salonen JT, Tuomainen TP, Nyyssonen K, Lakka HM, Punnonen K. Relation between iron stores and non-insulin dependent diabetes in men: case-control study. *Br Med J* 1998;317:727.
104. Sullivan JL. Retinopathy of prematurity and iron: a modification of the oxygen hypothesis. *Pediatrics* 1986;78:1171–1172.
105. Sullivan JL. Iron, plasma antioxidants, and the ‘oxygen radical disease of prematurity.’ *Am J Dis Child* 1988;142:1341–1344.
106. Sullivan JL. Retinopathy of prematurity. Low iron binding capacity may contribute. *Br Med J* 1993;307:1353–1354.
107. Cooke RWI, Clark D, Hickey-Dwyer M, Weindling AM. The apparent role of blood transfusions in the development of retinopathy of prematurity. *Eur J Pediatr* 1993;152:833–836.
108. Sacks LM, Schaffer DB, Anday EK, Peckham GJ, Delivoria-Papadopoulos M. Retrolental fibroplasia and blood transfusion in very low-birth-weight infants. *Pediatrics* 1981;68:770–774.
109. Clark C, Gibbs JAH, Maniello R, Outerbridge EW, Aranda JV. Blood transfusion: a possible risk factor in retrolental fibroplasia. *Acta Pediatr Scand* 1981;70:535–539.
110. Inder TE, Clemett RS, Austin NC, Graham P, Darlow BA. High iron status in very low birth weight infants is associated with an increased risk of retinopathy of prematurity. *J Pediatr* 1997;131:541–544.
111. Hesse L, Eberl W, Schlaud M, Poets CF. Blood transfusion: iron load and retinopathy of prematurity. *Eur J Pediatr* 1997;156:465–470.
112. Romagnoli C, Zecca E, Gallini F, Girlando P, Zuppa AA. Do recombinant human erythropoietin and iron supplementation increase the risk of retinopathy of prematurity? *Eur J Pediatr* 2000;159:627–634.
113. Yamaguchi K, Takahashi S, Kawanami T, Kato T, Sasaki H. Retinal degeneration in hereditary ceruloplasmin deficiency. *Ophthalmologica* 1998;212:11–14.
114. Dunaief JL, Richa C, Franks EP, et al. Macular degeneration in a patient with aceruloplasminemia, a disease associated with retinal iron overload. *Ophthalmology* 2005;112:1062–1065.
115. Shibuya Y, Hayasaka S. Central retinal vein occlusion in a patient with anorexia nervosa. *Am J Ophthalmol* 1995;119:109–110.
116. Miller D. A case of anorexia nervosa in a young woman with development of subcapsular cataracts. *Trans Ophthalmol Soc U K* 1958;78:217–222.

117. Stigmar G. Anorexia nervosa associated with cataract (report of a case). *Acta Ophthalmol* 1965;43: 787–789.
118. Abraham SF, Banks CN, Beumont PJV. Eye signs in patients with anorexia nervosa. *Aust J Ophthalmol* 1980;8:55–57.
119. Havel RJ, Kane JP. Introduction: structure and metabolism of plasma lipoproteins. In: Scriver CR, Beaudet AL, Sly WS, Valle D (eds). *The Metabolic & Molecular Bases of Inherited Disease*. Eighth Edition. New York, McGraw-Hill: 2001; pp. 2705–2716.
120. Spaeth GL. Ocular manifestations of lipoprotein disease. *J Cont Educ Ophthalmol* 1979;41:11–24.
121. Heyl AG. Intra-ocular lipemia. *Trans Am Ophthalmol Soc* 1880;3:54–66.
122. Wagener HP. Lipemia retinalis: reports of three cases. *Am J Ophthalmol* 1922;5:521–525.
123. McCann WS. Lipemia retinalis. *Bull Johns Hopkins Hosp* 1923;34:302–304.
124. Chase LA. Diabetic lipaemia retinalis with report of a case. *Canad Med Assoc J* 1927;17:197–204.
125. Parker WR, Culler AC. Lipemia retinalis. *Am J Ophthalmol* 1930;13:573–584.
126. McKee SH, Rabinowitch IM. Lipaemia retinalis. *Canad Med Assoc J* 1931;25:530–534.
127. Marble A, Smith RM. Blood lipids in lipaemia retinalis. *Arch Ophthalmol* 1936;15:86–94.
128. Holt LE Jr, Aylward FX, Timbres HG. Idiopathic familial lipemia. *Bull Johns Hopkins Hosp* 1939;64: 279–314.
129. Goodman M, Shuman H, Goodman S. Idiopathic lipemia with secondary xanthomatosis, hepatosplenomegaly and lipemic retinalis. *J Pediatr* 1940;16:596–606.
130. Falls HF. Lipemia retinalis. Report of a case. *Arch Ophthalmol* 1943;30:358–361.
131. Kauffman ML. Lipaemia retinalis. *Am J Ophthalmol* 1943;26:1205–1208.
132. Lepard CW. Lipemia retinalis in the non-diabetic patient. *Arch Ophthalmol* 1944;32:37–38.
133. Grossmann EE, Hitz JB. Lipemia retinalis associated with essential hyperlipemia. *Arch Ophthalmol* 1948;40:570–573.
134. Lewis N. Intra-ocular involvement in a case of xanthomatous biliary cirrhosis. *Br J Ophthalmol* 1950; 34:506–508.
135. Frank L, Levitt LM. Idiopathic hyperlipemia with secondary xanthomatosis. Report of a case. *Arch Derm Syph* 1951;64:434–436.
136. Everett WG. Nondiabetic lipemia retinalis: report of a case. *Arch Ophthalmol* 1952;48:712–715.
137. Martinez KR, Cibis GW, Tauber JT. Lipemia retinalis. *Arch Ophthalmol* 1992;110:1171.
138. Rayner S, Lee N, Leslie D, Thompson G. Lipaemia retinalis: a question of chylomicrons? *Eye* 1996;10: 603–608.
139. El-Harazi SM, Kellaway J, Arora A. Lipaemia retinalis. *Austr N Z J Ophthalmol* 1998;26:255–257.
140. Dunphy EB. Ocular conditions associated with idiopathic hyperlipemia. *Am J Ophthalmol* 1950;33: 1579–1586.
141. Thomas PK, Smith EB. Ocular manifestations in idiopathic hyperlipaemia and xanthomatosis. *Br J Ophthalmol* 1958;42:501–506.
142. Bron AJ, Williams HP. Lipaemia of the limbal vessels. *Br J Ophthalmol* 1972;56:343–346.
143. Slatter DH, Nelson AW, Stringer JM. Effects of experimental hyperlipoproteinemia on the canine eye. *Exp Eye Res* 1979;29:437–447.
144. Yanko L, Michaelson IC, Rosenmann E, Ivri M, Lutsky I. Effects of experimental hyperlipoproteinaemia on the retina and optic nerve in rhesus monkeys. *Br J Ophthalmol* 1983;67:32–36.
145. Vinger PF, Sachs BA. The ocular manifestations of hyperlipoproteinemia. *Am J Ophthalmol* 1970;70: 563–573.
146. Hayasaka S, Fukuyo T, Kitaoka M, et al. Lipaemia retinalis in a 29-day-old infant with type 1 hyperlipoproteinaemia. *Br J Ophthalmol* 1985;69:280–282.
147. Dodson PM, Galton DJ, Winder AF. Retinal vascular abnormalities in the hyperlipidaemias. *Trans Ophthalmol Soc UK* 1981;101:17–21.
148. Dodson PM, Galton DJ, Hamilton AM, Blach RK. Retinal vein occlusion and the prevalence of lipoprotein abnormalities. *Br J Ophthalmol* 1982;66:161–164.
149. Orlin C, Lee K, Jampol LM, Farber M. Retinal arteriolar changes in patients with hyperlipidemias. *Retina* 1988;8:6–9.
150. Kurz GH, Shakib M, Sohmer KK, Friedman AH. The retina in type V hyperlipoproteinaemia. *Am J Ophthalmol* 1976;82:32–43.

7

Nutritional Amblyopia and B Complex Vitamin Deficiencies

1. INTRODUCTION

Nutritional amblyopia is defined as retrobulbar optic neuropathy with bilateral visual loss, central or cecocentral scotomas, and dyschromatopsia due to dietary deficiency. The condition is generally reversible if treated with proper diet and vitamins within 2 or 3 mo of onset of visual loss, but the prognosis for visual recovery is worse with longstanding disease and atrophy of the papillomacular bundle. Associated findings may include skin, mucosal, neurological, gastrointestinal, and hematological signs and symptoms characteristic of specific or mixed B vitamin deficiencies involving thiamin, niacin, folate, vitamin B₁₂ and/or riboflavin. Riboflavin deficiency has been linked with cataract.

2. PUBLIC HEALTH SIGNIFICANCE

In the early twentieth century, nutritional amblyopia was not uncommon, perhaps accounting for up to 1% of patients seen in ophthalmological practice. With the rise in socioeconomic standards and hygiene, improved knowledge of nutrition, and mandatory fortification of some foods with B vitamins, the incidence of nutritional amblyopia decreased in many industrialized countries. Nutritional amblyopia was the focus of attention during World War II and the Korean War, when a large proportion of prisoners of war developed the disease under the conditions of dietary deprivation during captivity. The largest single epidemic of nutritional amblyopia occurred in Cuba from 1991 to 1994, when over 50,000 individuals developed optic neuropathy and/or peripheral neuritis and other symptoms during a period of food rationing. The recent outbreak in Cuba is a reminder that epidemics of nutritional amblyopia can occur under conditions of widespread dietary deprivation. In the future, the disorder can be anticipated to occur again under conditions of famine, food shortage, war, strife, and captivity where the intake of some B complex vitamins is not adequate.

3. HISTORICAL BACKGROUND

Nutritional amblyopia was described as early as the late 19th century in Jamaica and in Japan. Henry Strachan, a senior medical officer in Jamaica, described a syndrome that was characterized by dimness of sight, numbness and cramps in the hands and feet, a burning sensation in the soles of the feet and palms of the hands, often with absent knee jerks and occasional hearing loss. With more advanced disease, individuals developed muscle

From: *Nutrition and Health: Handbook of Nutrition and Ophthalmology*

By: R. D. Semba © Humana Press Inc., Totowa, NJ

wasting, difficulty walking, and “claw” hand and foot (1,2), findings that were consistent with advanced beriberi (3). Patients developed retrobulbar involvement of the optic nerve, with occasional hyperemia of the optic disc and a well marked scotoma, but optic atrophy was not observed. Dermatological findings included irritation and eczema at the margin of the nostrils and mouth, with redness of the lips and inside of the mouth, and with loss of surface epithelium of the tongue. The disease seemed to occur nearly always among black Jamaicans, and Strachan had the opportunity to observe and treat 510 patients and to make more detailed observations on 121 of these patients.

The treatment adopted by the Public Hospital of Kingston consisted of bed rest, nourishing food, and quinine and strychnine in modest doses combined with iodide of potassium. No patients died. Strachan raised the question whether the condition was caused by “the poison of beri-beri” as beriberi was widely attributed to some type of toxin at the time. Strachan also speculated that a toxin produced by malaria parasites was possibly the cause, however, he concluded that “good food was important” in treatment of the disease (1). At the same time as Strachan’s work in Jamaica, several Japanese physicians began to describe large case series of adults with beriberi who had reduced vision, central or centrocecal scotomas, and temporal optic disc atrophy (4–6). Visual recovery was noted when the patients were put on a diet protective against beriberi (3).

4. EPIDEMIOLOGY

Nutritional amblyopia has usually been described in epidemic or sporadic form, primarily among impoverished individuals, prisoners of war, inmates in jails, poorly fed soldiers, alcoholics, refugees, students in boarding schools where the diet is poor, among people subject to economic or trade embargo, and in populations following natural disasters such as hurricanes, droughts, or crop failures. Nutritional amblyopia has been described nearly worldwide. An estimated 1–7% of British prisoners-of-war who survived captivity in southeast Asia in Japanese prison camps during World War II were affected by nutritional amblyopia (7,8). In the recent epidemic in Cuba, the attack rate of neuropathy was 461.4 per 100,000 (9). The incidence of nutritional amblyopia in many industrialized countries has dropped since the beginning of the 20th century.

5. CLINICAL FEATURES

Nutritional amblyopia typically presents as a gradual decrease in vision, with difficulty reading and recognizing faces. Most patients complain that the decrease in vision has taken place over several days or weeks. A central or cecocentral scotoma is usually present, either as a scotoma to red or green or as an absolute scotoma. The absolute scotoma rarely exceeds five degrees in diameter. At first, there may be no associated ophthalmological findings. Slight hyperemia of the optic disc and occasional retinal hemorrhages may occur in the early stage of the disease, and later, temporal disc pallor and loss of the papillomacular bundle are usually seen. The condition may fluctuate with temporary changes in diet. The condition is generally reversible if treated with proper diet and vitamins within 2 or 3 mo of onset of visual loss, but the chance of visual recovery is decreased with longstanding disease and atrophy of the papillomacular bundle. Associated findings may include skin, mucosal, neurological, gastrointestinal, and hematological signs and symptoms characteristic of specific or mixed B vitamin deficiencies.

6. PATHOGENESIS

Nutritional amblyopia is caused by deficiencies of one or more B complex vitamins, and clinical and experimental evidence suggests that thiamin deficiency, niacin deficiency, vitamin B₁₂ deficiency, and folate deficiency alone or in combination may cause nutritional amblyopia. The clinical presentation of many patients with nutritional amblyopia shows that multiple B vitamin deficiencies may occur simultaneously, and the metabolism of many B vitamins is closely interrelated, with a deficiency in one vitamin affecting the metabolism of another. So-called “tobacco-alcohol amblyopia” and “tobacco amblyopia” should be considered nutritional amblyopia, as these apparent disorders have not stood rigorous scrutiny over the last few decades. The epidemiological and experimental evidence implicating tobacco as the primary etiology in so-called “tobacco amblyopia” is weak. Many of the so-called “tropical amblyopias” occurring in epidemic form are likely due to dietary deficiency. The role of specific micronutrients in the pathogenesis of nutritional amblyopia is presented below.

6.1. Thiamin Deficiency

Thiamin is a water-soluble vitamin that plays a role in the metabolism of carbohydrates and branched-chain amino acids. Thiamin deficiency is the cause of several disorders, most notably beriberi, a syndrome that involves the cardiovascular and nervous systems, Wernicke encephalopathy and Korsakoff psychosis, usually found among chronic alcoholics, and more rare conditions such as congenital lactic acidosis, intermittent ataxia of childhood, and subacute necrotizing encephalomyelopathy (Leigh disease). Thiamin deficiency has been implicated as a cause of nutritional amblyopia, and there are three lines of evidence that support this idea: (1) the association of disorders of thiamin deficiency with nutritional amblyopia, (2) experimental animal models of thiamin deficiency, and (3) reversal of nutritional amblyopia with thiamin treatment in humans.

6.1.1. HISTORICAL BACKGROUND

Beriberi has been known since antiquity in Asia, where it was described in ancient Chinese and Japanese medical texts (10). In the East Indies, Jacob de Bondt (1592–1631) noted that the word “beriberi” was derived from a local word for sheep because of the tottering walk of those affected by the disease (11). Polished rice began to be consumed more widely in Japan during the Tokugawa era (1603–1867), and a large epidemic of *kakké*, or beriberi, occurred in Edo, now present day Tokyo, in 1691. Beriberi became highly prevalent in the Japanese navy, and a physician, Kanehiro Takaki (1849–1920), found that provision of more meat, beans, and milk in the standard diet would virtually eliminate beriberi from the navy (12). In the East Indies, the Dutch physician Christaan Eijkman (1858–1930) produced a disease resembling human beriberi in chickens that were fed polished rice, and rice polishings were found to protect against this type of polyneuritis in chickens (13–15). Human investigations conducted in mental institutions (16,17), in prisons (18,19), and in labor camps (20) showed that those who ate unpolished rice, which still contained the germ of the rice, had a lower risk of developing beriberi compared to those who ate polished rice. In spite of the large reduction of beriberi in the Japanese military with early dietary reforms, the incidence of beriberi reached a peak in the Japanese civilian population in the 1920s. Worldwide, the highest incidence of beriberi has occurred

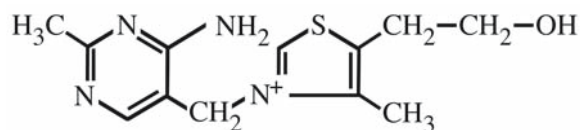


Fig. 1. Structural formulas of thiamin and thiamin pyrophosphate.

in east and southeast Asia, and most reports of nutritional amblyopia associated with beriberi have come from this region and are summarized later in the section.

In 1911, Casimir Funk (1884–1967), working at the Lister Institute in London, claimed to have isolated a substance, “vitamine,” that prevented beriberi (21). Although further work did not verify Funk’s claim, his term “vitamine” endured and was later shortened to “vitamin.” Umetaro Suzuki (1874–1943) and colleagues prepared a crystalline substance from rice bran, named “oryzanin” which protected chickens from polyneuritis (22). In the East Indies, two Dutch chemists, Barend Jansen (1884–1962) and Willem Donath (1889–1957), succeeded in isolating thiamin in 1926 (23). Thiamin was synthesized by Robert Williams (1886–1965) and Joseph Cline (b. 1908) in 1936 (24). Fortification of family flour and baker’s white bread with thiamin, riboflavin, niacin, and iron began in the United States in the early 1940s, with a subsequent marked reduction in cases of beriberi and pellagra seen in urban hospitals serving the poor, such as Bellevue Hospital in New York City (25). Similar action was taken in Great Britain and Canada at this time, but other countries followed much later. The mandatory thiamin enrichment of bread flour in the 1990s was associated with a subsequent reduction in the prevalence of Wernicke-Korsakoff syndrome in Australia (26,27). In the nomenclature of thiamin, obsolete terms for this vitamin include vitamin B₁, oryzamin, torulin, polyneuramin, vitamin F, antineuritic vitamin, and antiberiberi vitamin. General historical accounts of beriberi and thiamin can be found elsewhere (10,28–30).

6.1.2. BIOCHEMISTRY OF THIAMIN

Thiamin has the formula 3-(4-amino-2-methylpyrimidin-5-ylmethyl)-5-(2-hydroxyethyl)-4-methylthiazolium and consists of one pyrimidine ring and one thiazole ring that are linked by a methylene group (Fig. 1). In a normal adult, about 80% of total thiamin is found in the form of thiamin pyrophosphate (TPP), with about 10% as thiamin triphosphate (TTP), and the remainder as thiamin monophosphate (TMP) and thiamin (30a). The four forms of thiamin can be interconverted by tissue enzymes: (1) thiamin pyrophosphokinase (TPK) catalyzes the formation of TPP from thiamin and adenosine triphosphate (ATP), (2) TPP-ATP phosphoryl transferase (P-transferase) catalyzes the formation of TTP from TPP and ATP, (3) thiamin monophosphatase that hydrolyzes TMP to form thiamin, (4) thiamin pyrophosphatase that hydrolyzes TPP to form TMP, and (5) thiamin triphosphatase that hydrolyzes TTP to form TPP. Thiamin hydrochloride, a commercial form of thiamin, is a white crystalline substance that is water-soluble and relatively stable in dry form, but it can be destroyed in soluble form by heat at pH >5.0 and can be cleaved by sulfites that are used in the processing of some foods.

6.1.3. DIETARY SOURCES OF THIAMIN

The richest dietary sources of thiamin are yeast, pork, and legumes. The thiamin content of cereal grains is high in the germ portion but low in the endosperm, thus, removal of the

Table 1
Thiamin Content of Some Selected Foods

<i>Food</i>	<i>Thiamin (mg/100 g)</i>
Rice bran, crude	2.75
Yeast, dry baker's	2.36
Pork, sirloin, broiled	0.95
Bread, French	0.52
Garbanzos or chickpeas, dry	0.48
Bacon, cured and cooked	0.46
White beans, dry, raw	0.44
Bread, pumpernickel	0.33
Dark rye flour	0.32
Bread, pita, unenriched	0.28
Corn, sweet, white, raw	0.20
Barley, pearled	0.19
Spinach, boiled	0.09
Cassava, raw	0.09
Egg, hard boiled	0.07
Chicken breast roast	0.07
Sirloin steak, trimmed, broiled	0.07
Orange, navel, raw	0.07
Carrots, raw	0.07
Rice, long grain, unenriched, cooked	0.07
Baked potato with skin	0.06
Turnip, raw	0.04
Rice, short grain, unenriched, cooked	0.02

Based on US Department of Agriculture National Nutrient Database for Standard Reference (<http://www.nal.usda.gov/fnic/foodcomp/search/>) (31).

germ through food processing, as in highly milled polished rice and white flour, will substantially reduce the thiamin content of cereals. Fruits and vegetables, dairy products, and seafood are not good dietary sources of thiamin. The thiamin content of some selected foods is shown in Table 1 (31). Some types of food processing can destroy thiamin, such as high temperatures during cooking, and the addition of sodium bicarbonate to preserve the green color of vegetables and legumes. After losses following some types of food processing, there is relatively little quantitative data regarding the bioavailability of thiamin, and most evidence suggests that the thiamin in most foods tested is highly available for absorption and utilization by humans (32).

6.1.4. ABSORPTION, STORAGE, AND METABOLISM OF THIAMIN

During digestion, thiamin phosphoesters in food are broken down by phosphatases to yield free thiamin in the intestinal lumen. The jejunum and ileum in the small intestine are the main sites for thiamin absorption, and thiamin is absorbed by both active transport and passive diffusion. At low concentrations in the intestinal lumen, thiamin is mainly absorbed through active transport. At higher concentrations, active transport follows saturation kinetics and some passive diffusion occurs (33). The entry of thiamin into the

enterocyte is reduced by ethanol administration and aging (34). Single large doses of oral thiamin greater than 5 mg are mostly unabsorbed (35–37). In the blood, thiamin is transported mostly within erythrocytes as TPP, and about 20% is bound to proteins in the plasma as free thiamin and TPP. The total thiamin content of the normal adult human body is about 30 mg (0.11 mmol), and the biological half-life of thiamin is about 9–18 d. The highest concentrations of thiamin are found in the liver, heart, kidney, and brain. Skeletal muscle, because of its overall mass, contains about 40–50% of the total thiamin in the human body. Thiamin metabolites are mostly excreted in the urine, and pyrimidine carboxylic acid, thiazole acetic acid, and thiamin acetic acid are the main urinary metabolites of thiamin. In healthy lactating women, human milk thiamin content increases with the progression of lactation, and mature milk contains about 200 µg/L of thiamin (38). The absorption of thiamin may be impaired during folate or protein deficiency (39,40).

6.1.5. FUNCTIONS

Thiamin, in the form of TPP, acts as a coenzyme in the oxidative phosphorylation of α -ketoacids and in transketolase reactions, two processes that are important in carbohydrate and lipid metabolism (Fig. 2). Pyruvate, α -ketoglutarate, and α -ketoacids derived from leucine, isoleucine, and valine (all branched chain amino acids) undergo oxidative decarboxylation through multienzyme complexes that include TPP and are located within the mitochondria. Pyruvate undergoes oxidative decarboxylation by pyruvate dehydrogenase to form acetyl-coenzyme A (CoA), and CoA subsequently enters the tricarboxylic acid (Krebs) cycle. α -ketoglutarate undergoes oxidative decarboxylation by α -ketoglutarate dehydrogenase to succinyl-CoA in the tricarboxylic acid cycle. α -ketoacids derived from branched-chain amino acids undergo decarboxylation by branched-chain dehydrogenase. In the cytoplasm, a TPP-dependent transketolase is involved in the transketolation of ketosugars that contain three to seven carbons. This pathway is important for the production of nicotinamide adenine dinucleotide phosphate (NADPH) for many biosynthetic reactions including fatty acid synthesis, for conversion to pentoses, especially ribose-5-phosphate, a component of many important molecules such as RNA, DNA, ATP, CoA, NAD, and FAD, and for interconversion of ketosugars, some of which can enter the glycolysis pathway (41). Thiamin has been postulated to play a role in nerve conduction. TPP may influence the gating mechanism for Na^+ and K^+ transport via (Na^+-K^+) -ATPase. Thiamin deficiency may potentially affect metabolism of some neurotransmitters, as acetylcholine, γ -aminobutyric acid, glutamate, and aspartate are produced primarily through the metabolism of glucose (41).

6.1.6. REQUIREMENT FOR THIAMIN

The Food and Nutrition Board of the Institute of Medicine has made new recommendations of thiamin intake by life stage and gender group (42) (Table 2). The Adequate Intake (AI) is the recommended level of intake for infants. The Estimated Average Requirement (EAR) is the daily intake value that is estimated to meet the requirement of half the healthy individuals in a group. The Recommended Dietary Allowance (RDA) is defined as the EAR plus twice the coefficient of variation (CV) to cover 97–98% of individuals in any particular group. The requirements for thiamin increased with pregnancy and lactation. Increased catabolism during infection, inflammatory, trauma, or surgery can increase the demand for thiamin. Studies in healthy human volunteers suggest that

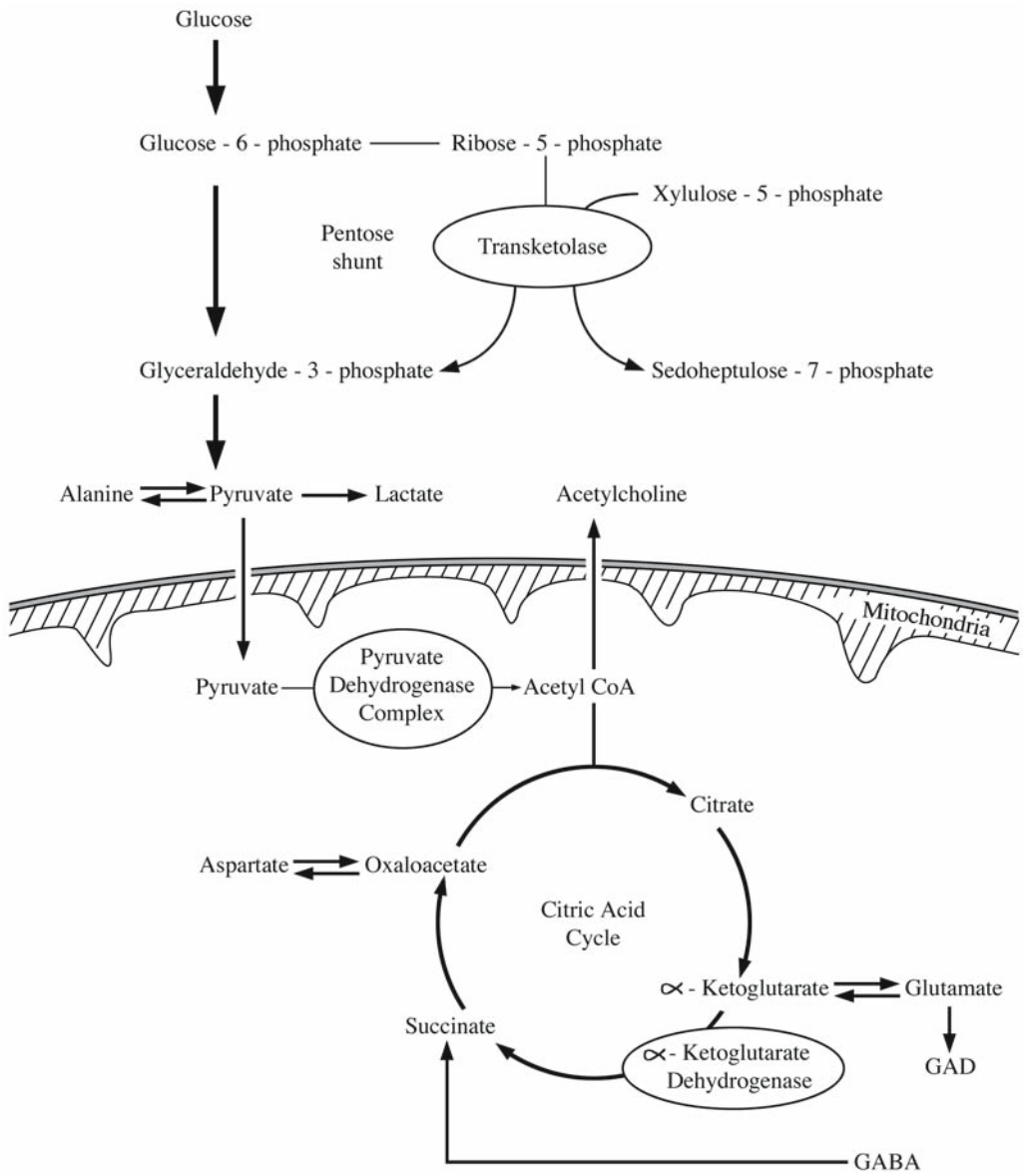


Fig. 2. Thiamin-dependent metabolic pathways.

a higher carbohydrate intake will increase the requirement for thiamin (43). It has been thought that the requirement of thiamin is increased by physical exercise, since thiamin, as thiamin pyrophosphate, plays an important role in energy-producing metabolic pathways, but there is not much data to support this idea (44).

6.1.7. EPIDEMIOLOGY OF THIAMIN DEFICIENCY

Beriberi has been described nearly worldwide, and over the last 200 yr, the highest prevalence of beriberi has been found in Japan, China, southeast Asia, the Malay archipelago, New Guinea, Melanesia, south Asia, parts of Africa, northeast Brazil, the Caribbean region, and Newfoundland. Nutritional amblyopia associated with beriberi has also been

Table 2
Dietary Reference Intakes for Thiamin (mg/d)

Age and gender category	AI	EAR	RDA
Infants, 0–6 mo	0.2	—	—
Infants, 7–12 mo	0.3	—	—
Children, 1–3 yr	—	0.4	0.5
Children, 4–8 yr	—	0.5	0.6
Boys and girls, 9–13 yr	—	0.7	0.9
Boys, 14–18 yr	—	1.0	1.2
Girls, 14–18 yr	—	0.9	1.0
Adult men ≥19 yr	—	1.0	1.2
Adult women ≥19 yr	—	0.9	1.1
Pregnant women	—	1.2	1.4
Lactating women	—	1.2	1.4

AI, Adequate Intake; EAR, Estimated Average Requirement; RDA, Recommended Dietary Allowance. Based on ref. 42.

generally described within this geographical distribution. Heinrich Botho Scheube depicted the known areas for beriberi in *Die Beriberi-Krankheit* in 1894 (45) (Fig. 3), and the map demonstrates how widespread beriberi was at the turn of the century. The main risk factors for beriberi include an inadequate dietary intake of thiamin-containing foods, low socioeconomic class, low educational level, chronic alcoholism, and inadequate parenteral nutrition. Prolonged high consumption of tea or coffee and folate deficiency also increases the risk of thiamin deficiency. Increased excretion of thiamin can occur with diuretics, suggesting that diuretics may be a risk factor for thiamin deficiency (46). Impaired thiamin status occurs among an estimated 5% of the population over 60 yr of age in North America (47) and laboratory evidence of inadequate thiamin status has been found 12–23% of institutionalized and noninstitutionalized older adults (48–50). Adults with human immunodeficiency virus infection may be at higher risk of Wernicke encephalopathy (51).

6.1.8. ASSESSMENT OF THIAMIN STATUS

The three most widely used procedures for the assessment of thiamin status are measurement of erythrocyte transketolase activity, thiamin concentrations in the blood, and urinary excretion of thiamin (52). Transketolase is an enzyme that requires thiamin pyrophosphate, thus, erythrocyte transketolase assay is a functional test of thiamin status. Erythrocyte transketolase activity is measured with and without the addition of thiamin pyrophosphate. In the erythrocyte transketolase thiamin pyrophosphate stimulation assay, the thiamin pyrophosphate effect, or “TPP effect” is interpreted as normal, low, and deficient when values are 0–15%, 16–24%, and >25%, respectively (52). Serum and whole blood thiamin concentrations can be measured using high-performance liquid chromatography. Whole blood thiamin concentrations of 6.96 ± 1.26 µg/dL have been described in normal patients compared with 2.29 ± 1.06 µg/dL in patients with beriberi (53). Urinary excretion of thiamin is commonly used to assess thiamin status and is considered to correspond well with the development of thiamin deficiency. Urinary thiamin reflects more recent dietary intake of thiamin. Random urine samples are usually collected and the thia-

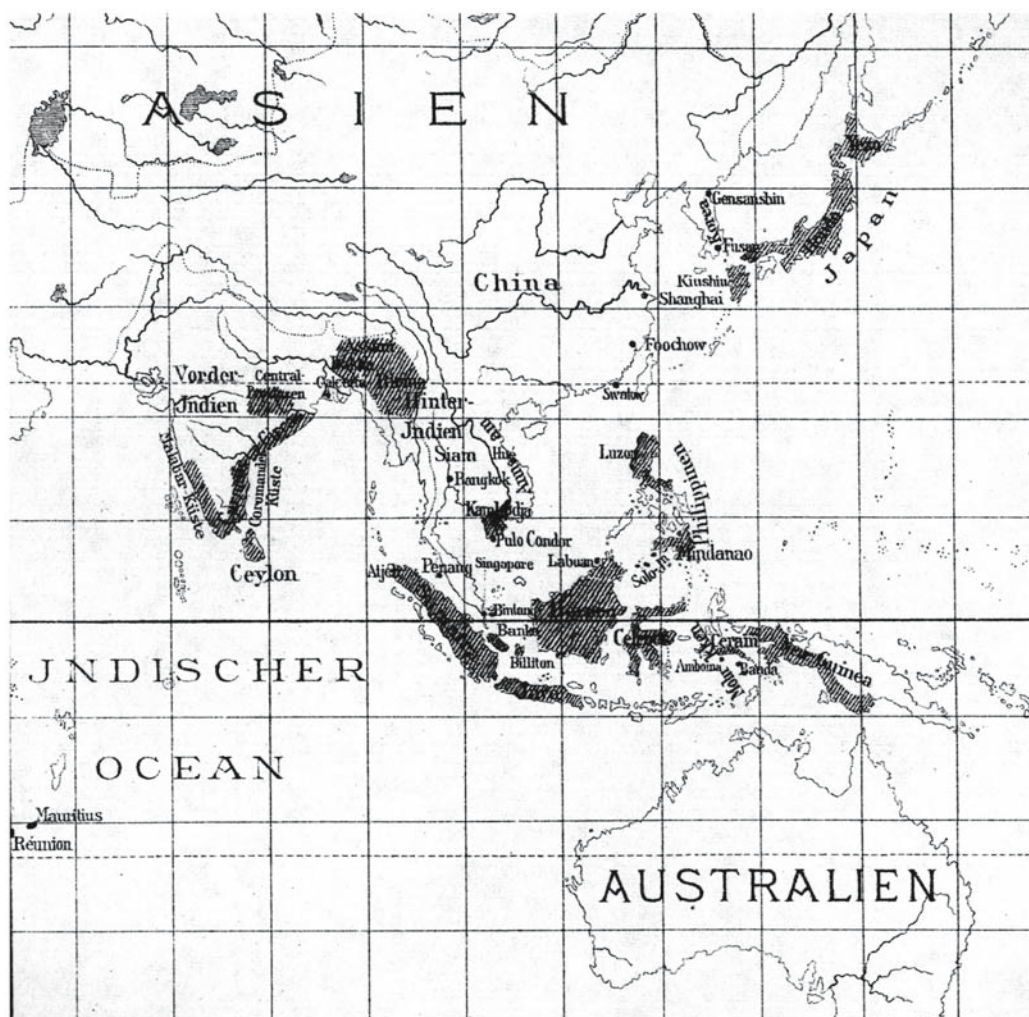

Fig. 3. Historical map showing worldwide distribution of beriberi in 1894. (From ref. 45.)

min concentration is expressed per gram of creatinine. For adults, urinary thiamin is considered deficient, low, and acceptable according to the values of <27 , $27-65$, and ≥ 66 μg thiamin/gram creatinine (52). Guidelines for younger age groups are found elsewhere (52).

6.1.9. CLINICAL MANIFESTATIONS OF THIAMIN DEFICIENCY

Thiamin deficiency may present as beriberi and Wernicke-Korsakoff syndrome, and a deficiency in thiamin-dependent enzymes may result in childhood syndromes such as Leigh syndrome and congenital lactic acidosis. Beriberi among adults usually falls into two principle forms, dry (paralytic or nervous), and wet (cardiac), and the disease among infants is known as infantile beriberi (54). Among adults, the onset of beriberi may be marked by a mild anorexia, mild tachycardia, and malaise. A symmetrical hypesthesia usually occurs, starting in the lower extremities, finger tips, lower abdomen around the umbilicus, and in the perioral region (54) (Fig. 4). Patients often describe a numb or burning sensation

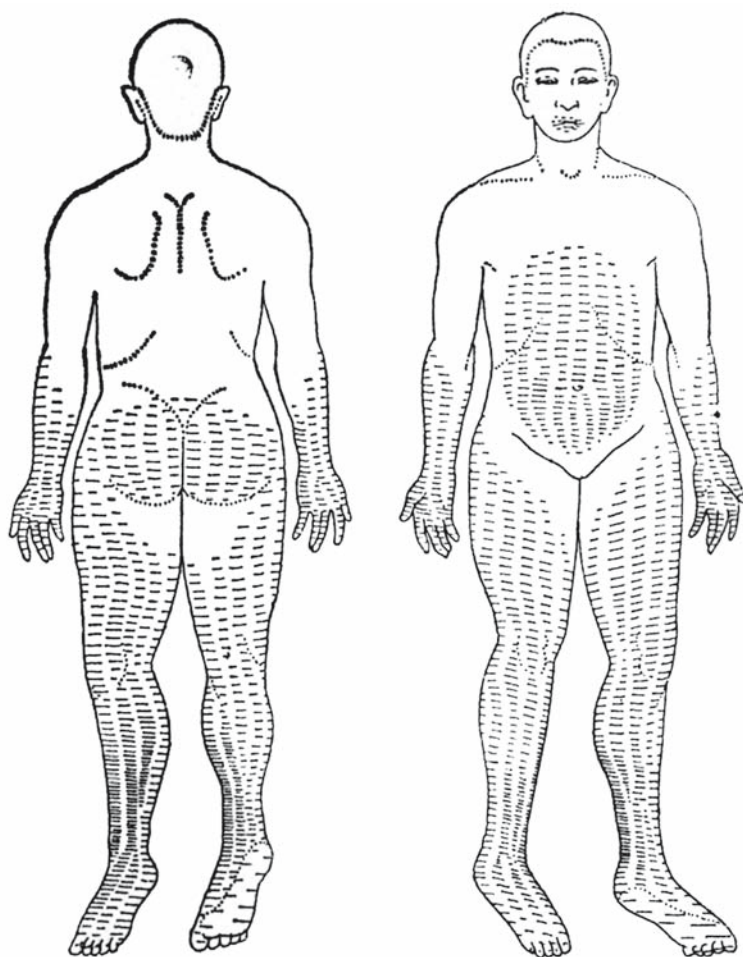


Fig. 4. Hypesthetic areas in a beriberi patient. (From ref. 54.)

in the legs and toes. Early in the disease, there may be a slight pretibial edema, and patients may complain of pain in the extremities, especially calf tenderness. Loss of Achilles tendon and patellar reflexes are common. There are no pathognomonic findings in beriberi, and the disease is often categorized as dry or wet based on the predominance of signs and symptoms.

Dry beriberi is characterized by peripheral neuropathy with a symmetrical impairment of sensory, motor, and reflex functions. Neurological findings include flaccid paralysis of the extensor muscles, with “wrist drop” (3) (Fig. 5) and “foot drop.” Patients have an impaired ability to rise up from a squatting position. Muscular atrophy and tenderness and pain in the muscles make walking and sleeping difficult, and in the advanced stage, patients may become cachectic. Wet beriberi is characterized by palpitations and dyspnea on exertion, with wide pulse pressure, cardiomegaly, and signs of congestive heart failure, such as pitting edema in the extremities. An acute fulminant form of beriberi, “shoshin,” has been described and is characterized by tachycardia, dyspnea, cyanosis, cardiomegaly, circulatory collapse, and high mortality. Infantile beriberi generally occurs among breast-fed infants whose mothers have thiamin deficiency but may occur among milk and formula-



Fig. 5. Wrist drop in a patient with dry beriberi. (From ref. 3.)

fed infants. Clinical findings include aphonia, tachycardia, vomiting, pallor, irritability, cardiomegaly, convulsions, and sudden death.

6.1.10. NUTRITIONAL AMBLYOPIA ASSOCIATED WITH THIAMIN DEFICIENCY

Reduced vision and central scotomas were described among many patients with beriberi in Japan by Hori (4) in 1888. Kono described amblyopia and bilateral central scotomas in six patients with beriberi (5), and the cause of the amblyopia and central scotoma in patients with beriberi was attributed to retrobulbar neuritis (6). Many more cases of nutritional amblyopia were described in Japan at the turn of the century, including the description of temporal disc pallor and the involvement of the papillomacular bundle (6,55,56). In Brazil, a “weakening of the optic nerve” was described in a case of beriberi (57), and reduced vision with beriberi, termed “beriberi amblyopia” was described among patients in the Philippines (58). Outbreaks of retrobulbar optic neuritis were reported among soldiers with beriberi in Nanking, China (59,60) and in adults with beriberi in Peking (61). Other cases were reported from Argentina (62) and also in Newfoundland (63), where beriberi outbreaks were widespread among people who depended on finely milled white flour as the main staple (64,65).

From 1927 to 1930, about 60 patients with retrobulbar neuritis were seen per year at Tokyo Imperial University, and 89.5% of the men and 82.6% of the women had symptoms of beriberi (66). Most of the cases of retrobulbar neuritis had a diet that consisted principally of polished rice. Among the patients with beriberi and retrobulbar neuritis, 31.5% had temporal pallor of the disc, 5.5% had retinal hemorrhages, 14.7% had hyperemia of the papilla, and 16.8% had an abnormal fundus reflex (66). A large proportion in a series of ninety patients presenting with central scotoma in Japan also had beriberi (3). Pathological findings of the eyes of patients with beriberi showed degeneration of the papillomacular bundle with atrophy of the myelin sheaths (67), and the findings were similar to those in so-called “alcohol amblyopia.” By the late 1930s, it was well established that nutritional amblyopia occurred in beriberi (54,68), but with the decline of beriberi worldwide, many of these clinical observations were subsequently forgotten.

6.1.11. OPTIC ATROPHY ASSOCIATED WITH WERNICKE-KORSAKOFF SYNDROME

Reduced vision with bilateral central or cecocentral scotomas has been described among patients with the Wernicke-Korsakoff syndrome, a symptom complex that is found in alco-

6.1.13. EVIDENCE FROM EXPERIMENTAL ANIMAL MODELS

Experimental animal models show that thiamin deficiency results in damage to the retina and optic nerve. Optic nerve degeneration has been described in birds with experimental polyneuritis (81–83), and reduced vision has been described in thiamin-deficient pigeons (84). Rats fed on synthetic diets without vitamin B complex vitamins also developed degeneration of the optic nerve (85). Lesions of the eighth cranial nerve in the region of the vestibular and cochlear nuclei were also found in thiamin-deficient rats (86). Demyelination of the sciatic nerve occurred among Sprague-Dawley rats that were fed a basal diet supplemented with purified B complex vitamins without thiamin, and optic nerve changes in deficient animals consisted of swelling of the retinal ganglion cells that was reversible with thiamin administration (87). In carefully designed studies using pair-fed animals and experimental diets supplemented with purified vitamins, Frederick C. Rodger showed that chronic thiamin deficiency caused degeneration of the optic nerve and retinal ganglion cells in rats (88). Although myelin degeneration has been considered as the central characteristic nervous system lesion of thiamin deficiency (89), it is not clear whether myelin degeneration occurs as the primary or secondary event during thiamin deficiency (90). In careful pair-fed experiments using electron microscopy, thiamin-deficient rats had degeneration of small myelin sheaths of distal and intramuscular nerves and atrophy and degeneration of skeletal muscle (91).

6.1.14. EVIDENCE OF HUMAN STUDIES OF EXPERIMENTAL THIAMIN DEFICIENCY

In experimental studies, beriberi was produced among adults receiving a diet in which polished rice was the main staple (16–19). These studies generally involved neurological assessment and had no mention of any detailed eye examinations. In one study in Bilibid prison in Manila, disturbances in vision were reported by one subject on a diet of polished rice (19). In another study of experimental thiamin deficiency, reduced vision was reported by one subject who developed beriberi (92). In Japan, three patients with reduced vision, bilateral central scotomas, and beriberi were admitted to the hospital and fed a diet rich in vitamin B (93). When the patients were starting to recover their visual acuity, they were then fed a thiamin-deficient diet consisting of 400–500 grams cooked polished rice, three times per day. Their symptoms of beriberi were exacerbated, and their visual acuity, which had been improving, began to decline again. The patients then received oryzanin extract, with subsequent recovery of visual acuity to normal and recovery from beriberi. The author noted that relapse of beriberi and amblyopia could be induced by a thiamin-deficient diet and could subsequently be cured by addition of oryzanin, a rich source of thiamin, in the diet (93). In thiamin deprivation studies involving patients from a psychiatric hospital in Minnesota, no ocular abnormalities were described among four subjects with acute severe deficiency (94), five subjects with mild deficiency (95), and two others with moderate deficiency (96). Although mild neuropathy was present, the classic syndrome of beriberi was not produced among these patients (96).

6.1.15. TREATMENT OF NUTRITIONAL AMBLYOPIA WITH THIAMIN

There have been only a few detailed reports of treatment of nutritional amblyopia with thiamin alone, as most affected individuals have been reportedly treated with B complex vitamins, brewer's yeast, or marmite, a commercial yeast preparation. However, some existing reports suggest that nutritional amblyopia is associated with thiamin deficiency

in the absence of some other B vitamin deficiencies, and that thiamin treatment is associated with improvement in the disease.

Nutritional amblyopia was treated successfully with thiamin in two US servicemen who adopted a high-protein, low-carbohydrate diet in order to lose weight (97). The first patient, a 33-yr-old jet pilot, originally weighed 238 lbs, and on a diet of cheese, meat, eggs, and fish, with occasional green leafy vegetables, his weight dropped to 185 lbs in 5.5 mo. He began to note numbness and tingling in his toes, and 2 wk later, he had difficulty seeing the "meatball," a red light on the aircraft carrier deck that guides the pilot's landing. The eye examination was normal except for reduced visual acuity, dyschromatopsia, and bilateral central scotomas. The patient had a serum transketolase level of 66 $\mu\text{g/dL}$ (consistent with thiamin deficiency), and his serum folate and vitamin B₁₂ concentrations were normal. After treatment with a regular diet and 50 mg thiamine per day, his serum transketolase level rose to 145 $\mu\text{g/dL}$ and his vision recovered.

The second patient was a 36-yr-old aircraft mechanic who weighed 221 lbs. He restricted his diet to cheese, eggs, and red meats, plus vitamin C, 500 mg/d. After 4.5 mo, he developed reduced visual acuity, bilateral central scotomas, and bilateral temporal disc pallor with loss of nerve fibers from the papillomacular bundle. His serum transketolase level was 60 $\mu\text{g/dL}$, and his serum folate and vitamin B₁₂ concentrations were normal. After treatment with a regular diet and 50 mg thiamin per day, his visual acuity returned to normal and the scotoma disappeared from the left eye. Mild temporal disc pallor and a small scotoma remained in the right eye. His serum transketolase level rose to 148 $\mu\text{g/dL}$. Neither smoked tobacco or drank alcohol, and tests for syphilis were negative. The diet of meat and dairy products that was adapted by these two men was insufficient in thiamin but high in folate, niacin, riboflavin, and vitamin B₁₂.

In another report, two children developed nutritional amblyopia while being treated with a ketogenic diet for control of childhood seizures (98). The children were not receiving vitamin supplements as recommended. In both children, the serum transketolase levels were low, and serum folate and vitamin B₁₂ concentrations were normal. Thiamin was given with B complex vitamin supplements, and the vision improved. Parenteral hyperalimentation without vitamins may increase the risk of nutritional amblyopia (99,100). A 22-yr-old male was hospitalized after a motor vehicle accident and developed eye signs of Wernicke syndrome, including nystagmus, abducens palsy, and bilateral optic neuropathy, after 4 wk of parenteral hyperalimentation without vitamins (99). Serum thiamin concentrations were 11 ng/dL (normal 20–50 ng/dL). After receiving an additional 300 mg thiamin for 4 wk, his neurological deficits recovered. A 35-yr-old man with ulcerative colitis developed bilateral optic neuropathy and an oculomotor palsy after receiving parenteral hyperalimentation without thiamin for about 4 wk. He was diagnosed as having Wernicke syndrome, and after treatment with subcutaneous thiamin (25–50 mg), his visual acuity returned to normal but the patient had residual loss of nerve fibers in the papillomacular bundle of both eyes (100).

6.2. Niacin Deficiency

Niacin is a generic term for nicotinic acid, nicotinamide, and derivatives that have the biological activity of nicotinamide. Niacin is a water soluble vitamin that plays a central role in oxidation and reduction reactions of both catabolic pathways of carbohydrates,

lipids, and proteins, and anabolic pathways of fatty acid and cholesterol synthesis. Niacin deficiency results in pellagra, a deficiency disease often characterized by “the four Ds,” dermatitis, diarrhea, dementia, and death. Nutritional amblyopia has been associated with pellagra, and several reports suggest that administration of niacin alone can improve the disease. Less work has been done on the pathogenesis of neurological lesions in niacin-deficient animals.

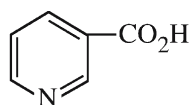
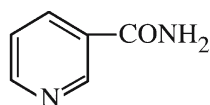
6.2.1. HISTORICAL BACKGROUND

Pellagra was described among the peasants of Spain by Gaspar Roque Francisco Narciso Casal y Julian (1680–1759) in a posthumous work *Historia natural y médica del principado de Asturias* in 1762. Casal practiced medicine in Oviedo, Asturias, and there he encountered a disease known locally as *mal de la rosa*. The disease was heralded by a red discoloration of the skin and was soon accompanied by diarrhea and mental changes. The skin lesions of pellagra, including a pigmented rash around the neck that later became known as “Casal’s necklace,” were illustrated in Casal’s work (101). A French physician, François Thiéry (1718–1792) visited Casal in Madrid, and based on Casal’s observations, published the first description of pellagra in 1755 (102). Théophile Roussel (1816–1903) made more detailed descriptions of pellagra in peasants in France who subsisted on corn (103, 104), and Gaetano Strambio (1752–1831) described pellagra among Italian peasants who ate polenta (105). The term *pellagra* was introduced by Francesco Frapolli (d. ca. 1773) in Italy in 1771, from the Italian words *pelle* (skin) and *agra* (rough) (106).

Although many early observers attributed pellagra to a dietary problem, in was a common belief that pellagra might be caused by an infection or food toxin (107–109). Pellagra became widely prevalent in the South of the United States, and by 1916, for example, it was the second leading cause of death in South Carolina. Outbreaks of pellagra seemed to occur more commonly in asylums, jails, and poorhouses (110). In 1914, Joseph Goldberger (1874–1929), a physician in the US Public Health Service, conducted investigations of pellagra in South Carolina and showed that pellagra could be prevented by supplying milk, butter, and lean meat in the diet (111, 112). Goldberger conducted the famous Rankin Prison Farm Experiment, in which a syndrome thought to be pellagra was produced among prison volunteers by a restricted, mainly cereal diet (113). A diet that resulted in pellagra among humans also produced a disease identical to black tongue in dogs (114), showing that black tongue was canine pellagra. Nicotinic acid was so named because it was found to be an oxidation product of nicotine. Nicotinic acid was first isolated by Casimir Funk in 1911, who originally thought that his isolate from yeast and rice polishings was the factor that prevented beriberi (21) (see Subheading 6.1.1.). Niacin was implicated as the deficient dietary factor involved in the etiology of pellagra in 1937 (115). The history of pellagra has been reviewed elsewhere (116–118).

6.2.2. BIOCHEMISTRY OF NIACIN

Niacin is a term used to describe two different compounds, nicotinic acid and nicotinamide, that have the biological activity of this member of the B group of vitamins. Nicotinic acid is also known as pyridine-3-carboxylic acid, and nicotinamide is also known as niacinamide. The structure of nicotinic acid and nicotinamide are shown in Fig. 7. Nicotinic acid contains a pyridine ring with a carboxylic acid group at position 3, whereas nicotinamide contains a carboxamide moiety at this position. Niacin is a component of the

**Nicotinic acid (niacin)****Nicotinamide (niacinamide)****Fig. 7.** Structure of nicotinic acid and nicotinamide.**Table 3**
Niacin Equivalents in Some Foods

<i>Food</i>	<i>Niacin equivalents (mg/100g)</i>
Liver, beef, braised	23.65
Chicken breast, no skin, roasted	19.71
Peanuts	16.22
Rice, white, unenriched, long-grain, dry	6.96
Fish, white, raw	6.56
Beef, lean, ground, raw	5.56
Cheese, cheddar	5.41
Bread, wheat flours, unenriched	3.31
Peas, green, raw	2.70
Eggs, whole, boiled	2.61
Corn bread, unenriched, dry mix	2.10
Potatoes, whole, raw	1.58
Milk, whole	1.35
Molasses	0.93
Beer	0.51
Red wine	0.22
Lard	0

Based upon US Department of Agriculture National Nutrient Database for Standard Reference (<http://www.nal.usda.gov/fnic/foodcomp/search>) (31), where nicotinic acid equivalents are calculated as available nicotinic acid + tryptophan/60.

coenzymes nicotinamide adenine dinucleotide (NAD) and NADPH. Obsolete names for niacin include vitamin PP, pellagra preventive factor (PP factor), pellagramine, and niamid.

6.2.3. DIETARY SOURCES OF Niacin

Rich dietary sources of niacin include red meat, liver, fish, poultry, legumes, eggs, oil seeds, cereal grains, yeast, and corn. Preformed niacin is found in foods in the form of nicotinamide, nicotinic acid, and related pyridine nucleotide coenzymes, NAD(H₂) and NADP(H₂). L-Tryptophan, the amino acid precursor to nicotinic acid, is found in dietary protein. The content of niacin in food depends on both preformed niacin and tryptophan, thus, the niacin content of foods is expressed as niacin equivalents (NE). NE are defined as niacin content in milligrams plus one one-sixtieth the tryptophan content in milligrams (119). The niacin content of selected foods is shown (Table 3) (31). The bioavailability of preformed niacin in foods is increased by alkaline pH. Although corn is rich in niacin, most of the niacin in corn is biologically unavailable. In North and South America, treatment of corn with alkali, as in the grinding of tortillas with water and calcium hydroxide, released the protein-bound niacin and made it available for absorption (120).

Table 4
Dietary Reference Intakes for Niacin (mg/d Niacin Equivalents)

<i>Age and gender category</i>	<i>AI</i>	<i>EAR</i>	<i>RDA</i>
Infants, 0–6 mo	2 ^a	—	—
Infants, 7–12 mo	4	—	—
Children, 1–3 yr	—	5	6
Children, 4–8 yr	—	6	8
Boys and girls, 9–13 yr	—	9	12
Boys, 14–18 yr	—	12	16
Girls, 14–18 yr	—	11	14
Adult men ≥19 yr	—	12	16
Adult women ≥19 yr	—	11	14
Pregnant women	—	14	18
Lactating women	—	13	17

^aPreformed niacin for infants, 0–6 mo.

AI, Adequate Intake; EAR, Estimated Average Requirement; RDA, Recommended Dietary Allowance. Based on ref. 42.

6.2.4. ABSORPTION, STORAGE, AND METABOLISM OF NIACIN

Nicotinic acid and nicotinamide are rapidly absorbed in the stomach and intestine by both a saturable transport mechanism at low concentrations and through simple diffusion at high concentrations. In the enterocytes, nicotinamide is largely converted to NAD. The primary form of niacin circulating in the blood is nicotinamide, released from NAD by NAD glycohydrolases in the intestinal mucosa. The liver metabolizes nicotinic acid and nicotinamide to NAD, and the liver has some storage capacity for NAD. Tryptophan is converted to NAD in the liver. In a niacin-replete state, niacin is methylated to *N*¹-methylnicotinamide (NMN), and NMN and other related oxidation products are excreted in the urine.

6.2.5. FUNCTIONS OF NIACIN

Niacin, nicotinamide, and tryptophan serve as precursors for NAD and NADP. NAD and NADP play central roles in oxidation and reduction reactions (121). Dehydrogenases use NADP as coenzymes to oxidize or reduce substrates through hydrogen transfer at the C-4 position of the pyridine ring. NAD⁺ is reduced to NADH in glycolysis, the oxidation of acetate in the tricarboxylic acid cycle, β -oxidation of fatty acids, oxidative decarboxylation of pyruvate, and other reactions. The potential free energy stored in carbohydrates, lipids, and proteins is transferred to NADH, which is used to form ATP. NADP dehydrogenases are used in the synthesis of fatty acids and cholesterol. NAD is involved in mono-ADP-ribosylation, in which the ADP-ribose moiety is transferred from NAD to an amino acid residue on proteins. The amino acids modified by mono-ADP-ribosylation include arginine and cysteine.

6.2.6. REQUIREMENT FOR NIACIN

The Food and Nutrition Board of the Institute of Medicine has made new recommendations of niacin intake by life stage and gender group (42) (Table 4). The requirements for niacin may potentially be higher during iron, riboflavin, or vitamin B₆ deficiency, as there are interactions between these respective nutrients and niacin metabolism. Deficiency of these nutrients could decrease the conversion of tryptophan to niacin (42).

6.2.7. EPIDEMIOLOGY OF NIACIN DEFICIENCY

Pellagra was once common in countries such as France, Italy, Spain, Portugal, and the United States in the late 19th and early 20th century, and the disease still appears in parts of Africa, south Asia, and China. In developed countries, pellagra may occur among alcoholics (122). The main cause of niacin deficiency is an inadequate intake of foods that contain bioavailable niacin and tryptophan. Both vitamin B₆ and riboflavin deficiencies may contribute to niacin deficiency because vitamin B₆ and riboflavin are coenzymes for kynureninase and kynurenine hydroxylase, respectively, in the conversion of tryptophan to nicotinic acid. As a result of these interactions, riboflavin deficiency is characterized by some of the same signs and symptoms that are found in pellagra, such as stomatitis, cheilosis, and glossitis. Long-term isoniazid treatment for tuberculosis may increase the risk of niacin deficiency, since isoniazid depletes vitamin B₆. Copper is also required in the conversion of tryptophan to nicotinic acid, and copper deficiency may increase the risk of niacin deficiency. In Hartnup disease, an autosomal recessive disorder, the absorption of tryptophan is impaired, increasing the risk of niacin deficiency. Optic atrophy has also been associated with copper deficiency, vitamin B₆ deficiency, and isoniazid therapy, but the biological mechanisms involved in the pathogenesis of optic atrophy in these cases are unclear. Rare inborn errors of tryptophan metabolism include tryptophanuria, xanthurenic aciduria, and kynureninuria.

6.2.8. ASSESSMENT OF NIACIN STATUS

The most commonly used indicators of niacin status are measurements of nicotinamide metabolites in the urine such as *N*¹-methyl nicotinamide and *N*¹-methyl-2-pyridone-5-carboxylamide (2-pyridone). Both of these metabolites may be reduced in generalized malnutrition. The interpretation of these assays may be more problematic in pregnancy and diabetes mellitus. The preferred assay for niacin status is the ratio of 2-pyridone to *N*¹-methyl nicotinamide in urine (123), with deficient, marginal, and adequate status indicated by a ratio of <1.0, 1.0–1.3, and 1.3–4.0, respectively (124). The ratio of these metabolites can be measured in a casual fasting urine sample.

6.2.9. CLINICAL MANIFESTATIONS OF NIACIN DEFICIENCY

Most patients with pellagra do not present with a classic triad of dermatitis, diarrhea, and dementia (125–127). Pellagra has such protean manifestations that even the most experienced specialists of the past, such as Cesare Lombroso, noted: “We have seen that pellagra varies not only from district to district but also from individual to individual...on this account no suffering or enormous suffering may be admitted, so giving rise to the saying that there are no diseases, only sick people” (118). In a series of 4121 patients with pellagra from an endemic area, the following proportion of patients had specific features: dermatitis (85%), glossitis (61%), edema (51%), diarrhea (50%), stomatitis (45%), neuropathy (40%), and dementia (26%) (128). In a study in Baltimore, 18 adults who were all had the typical skin lesions of pellagra had the following other clinical features: edema (56%), neuropathy (56%), dementia (50%), diarrhea (39%), glossitis (39%), and stomatitis (11%) (122). The skin lesions of pellagra consist of an erythematous, pigmented, exfoliative dermatitis that occurs usually on the face, neck, dorsal surface of the hands and wrists, elbows, and top of the feet and ankles (128) (Figs. 8 and 9). A “weeping,” erythematous pigmented dermatitis may occur on the scrotum or labia majorum in pellagra.

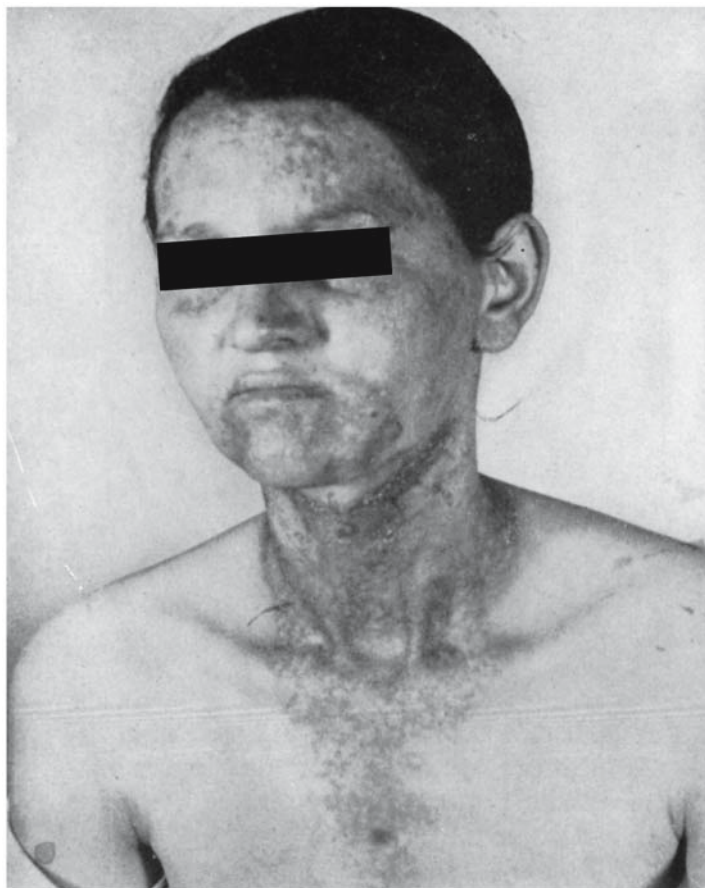


Fig. 8. Pellagrous dermatitis in a young women. (From ref. 128.)

6.2.10. NUTRITIONAL AMBLYOPIA ASSOCIATED WITH PELLAGRA

Nutritional amblyopia has been described in patients with pellagra and in patients who had the signs and symptoms of pellagra combined with beriberi. In Italy in the nineteenth century, there were several reports of reduced vision and optic atrophy among adults with pellagra (129–131). Decreased vision and optic atrophy were described in 55 patients with pellagra (132). In 1917, Phinzy Calhoun described decreased vision, central scotomas, and mild optic atrophy in adults with pellagra in Georgia (133). He later expanded his investigation to the Georgia State Sanitarium in Milledgeville, where the superintendent allowed him to perform eye examinations on many of the several hundred inmates with pellagra. At the time, many pellagra patients with mental alterations and dementia were placed in asylums. Calhoun described ten cases with reduced vision, central or paracentral scotomas, optic atrophy, and loss of the papillomacular bundle (134). He also thought that the visual fields were mildly contracted in some patients (133,134). In a report from Savannah, Georgia, 58 patients with pellagra were examined at the US Marine Hospital, and the patients typically presented with red tongue, diarrhea, and a burning sensation in the feet. One-third of the patients complained of “dimness of vision,” and it is unclear whether the patients had an eye examination (135). In a study of 55 patients at the Illinois State Hospital for the Insane in Bartonsville, Illinois, several patients were found to have

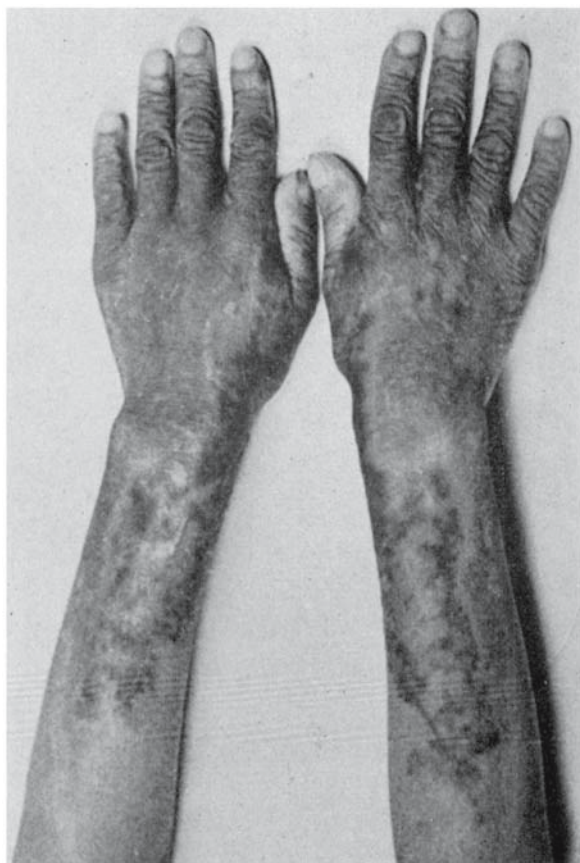

Fig. 9. Symmetrical dermatitis of the hands. (From ref. 128.)

optic atrophy (136). Reduced vision, central scotomas, and retrobulbar neuritis were described in three patients with pellagra, of whom one originally presented with retrobulbar neuritis before the signs of pellagra appeared (137). Other case reports in the literature have described an association between pellagra and optic neuritis or optic atrophy (138–141).

The nutritional amblyopia described among patients with pellagra in Italy and the United States is similar to some of the disorders that have been loosely described as “tropical amblyopia.” In 1917, Henry Harold Scott (1874–1956) observed an outbreak of visual loss among laborers on sugar cane estates in Jamaica. The disorder consisted of decreased vision, glossitis, angular stomatitis, numbness in the lower extremities, burning in the feet, and decreased deep tendon reflexes (142). The epidemic was originally noted in the neighborhood of Spanish Town (St. Jago de la Vega), the old capital of Jamaica, among both men and women cane cutters who were previously in good health. The epidemic began during the cutting and carrying of the crop and ceased after the cane had been cut. Scott noted that the laborers did not generally eat breakfast prior to coming to the fields, preferring to eat sugar cane for breakfast and then throughout the day. Scott remarked that the “central neuritis” of the affected plantation laborers and the disorder described by Strachan (1,2) were similar and thought that those affected in the sugar plantation had signs and symptoms of both pellagra and beriberi (142).

A disorder characterized by dimness of vision, glossitis, angular stomatitis, and parasthesias in the extremities was also described in Sierra Leone (143). The condition was brought to the attention of the medical officer, when he was asked to investigate an outbreak of the disease among students in a girls school that was “notorious for its bad diet.” The condition was treated successfully using cod-liver oil, a rich source of vitamin A, and marmite, a rich source of B complex vitamins. The author believed that the disease was similar to the disorder described in Jamaica by Scott (142), but the condition became known later as the “A and B avitaminosis of Sierra Leone” (144).

From 1929 to 1937, D. G. Fitzgerald Moore, a colonial medical officer, observed more than 5000 cases of nutritional amblyopia associated with pellagra in Nigeria (145). The syndrome was well-known in areas of Nigeria and had a fairly consistent presentation of glossitis, angular stomatitis, scrotal or vulvar dermatitis, and decreased vision. Typically the patient would complain of decreased central vision for both reading and distance, and the first visible ophthalmic finding would be a slight temporal pallor of the optic disc. The problem was originally called to his attention when he found young adolescents with the disease in certain boarding schools (146). In schools with established dietaries there was no disease, but in other schools with no controlled dietary the disease could be rampant with over one-quarter of the students affected (147).

When Moore first encountered cases, he used cod-liver oil with malt and an iron-rich tonic without much effect, but then found that patients would recover quickly when marmite was added to the treatment (147). Moore later realized that the disease in Nigeria was the same as that described by Wright in Sierra Leone (148). In the boarding schools, the syndrome occurred among the “self-feeders” who made their own food every day: “The boys began the day by eating a cabin (dog) biscuit in the early morning, followed at noon by a very badly-prepared mixture, cooked by themselves, of gari (kassava or manioc) soup, with little or no green food; of meat, they had 1 oz. only every three days; there was very little protein of any kind. Their evening meal was little better. In fact, these boys were living on gari (kassava) as their main food, which was almost entirely carbohydrate” (149). The disease would often improve after the school children went home to their parents for the holidays.

Moore thought that the disease was due to a dietary deficiency, but he also thought that the boys were consuming cassava of bad quality (149). In another school in southern Nigeria with 80 pupils, Moore found that all the girls had nutritional amblyopia, but none of the boys were affected (150). The school was located in a remote area and had provisions brought by canoe twice a week, and food was distributed equally to students of each sex. The food in the school was “seriously deficient in proteins.” “Further inquiry showed that the boys augmented their diet daily by the simple expedient of catching and roasting the land crabs that existed in countless numbers in the vicinity. This was not permissible to the girls, who were kept in strict seclusion” (151). The authorities in Nigeria recognized the problem with their boarding schools, and they formed special dietetic committees to make recommendations for approved dietaries in the schools (152). These measures were aimed at terminating the bad feeding practices applying to the “boarding-in” and “self-feeder” type of students in the boarding schools.

A similar condition was described in epidemic form among children following a devastating hurricane and subsequent period of food shortage in Jamaica (153). Affected children presented with “dark eyes,” glossitis, angular stomatitis, abnormal dry, and thickened

skin lesions, and the condition responded well to cod-liver oil and a liberal diet. The disease also occurred in endemic form among children from poor urban families, and in 1945, 74 children were seen with the disease at the School Clinic in Kingston, Jamaica (153). Unless discovered by routine school exam, children did not complain of “dark eyes” until their vision dropped to 6/24, 6/60 or less. “Dark eyes” in local terms meant that the child was not able to see the blackboard, or that the print was running together. Altered color vision was common. In the early stages of the disease, the fundus was normal, but later there was temporal pallor of the disc. Ataxia was found in one child, and 10 of the 74 children developed deafness. Most of the children recovered with a treatment of brewer’s yeast, and impaired vision did not improve unless the glossitis and angular stomatitis were also cured. One visiting ophthalmologist noted the similarity between the condition among children in Jamaica and the clinical presentation of nutritional amblyopia in prisoners-of-war (154).

In the 1930s, Landor and Pallister conducted studies among inmates of Singapore and Johore prisons that suggested niacin could be used to treat nutritional amblyopia (155). Autoclaved yeast could prevent experimental black tongue in dogs but would not prevent polyneuritis (156). Under the high temperature of autoclaving, the niacin in yeast was stable but thiamin was destroyed. A syndrome of nutritional amblyopia, paresthesias, and scrotal dermatitis was found in about 7% and 6.4% of prisoners who had been interned for more than 1 yr in the Singapore and Johore prisons, respectively (155). Prisoners in both prisons received parboiled rice, which has been found to be protective against thiamin deficiency since it contains a relatively large portion of the germ. Yeast, whether autoclaved or fresh, was found to be effective in treatment of this syndrome (155). The heat-stable portion of yeast was later shown by other investigators to contain riboflavin and vitamin B₆, thus adding to the difficulties in attributing the therapeutic effect to niacin alone.

6.2.11. MACULOPATHY ASSOCIATED WITH MEGADOSES OF NIACIN (NIACIN MACULOPATHY)

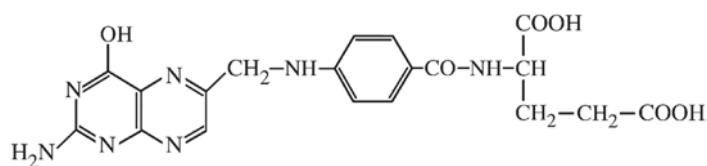
Megadose niacin therapy has been associated with a reversible maculopathy that is characterized by cystoid macular edema (157). High dose niacin therapy is sometimes used in patients with hypercholesterolemia. It has been reported that niacin maculopathy occurs in about 0.67% of patients who are taking high doses of niacin (158). Niacin maculopathy causes cystoid spaces in the inner nuclear and outer plexiform layers, and these abnormalities resolve with discontinuation of niacin (159).

6.3. Folate Deficiency

Folate is a generic term used to describe a family of compounds with the activity of folic acid, including folylpolyglutamates and folic acid (pteroylglutamic acid) and its derivatives. Folate plays an important role as coenzymes in the synthesis of nucleic acids and amino acids, thus, cells that undergo more rapid synthesis such as hematopoietic cells and epithelial cells are affected more early in folate deficiency. Nutritional amblyopia has been associated with folate deficiency, and several reports demonstrate that folate alone can be used to treat the disease.

6.3.1. HISTORICAL BACKGROUND

In the 1930s, Lucy Wills (1888–1964) described megaloblastic anemia among pregnant women in Bombay, India, and the anemia responded to injections of liver or to yeast



Folic acid

Fig. 10. Structure of pteroylglutamic acid.

and marmite taken orally (160–162). This unknown hematopoietic factor became known as “Wills’ factor.” A growth factor in spinach was termed “folic acid” in 1941 (163). The factor that cured megaloblastic anemia was isolated from liver and yeast, and pteroylglutamic acid was synthesized in 1945 (164). Megaloblastic anemia was attributed to folate deficiency alone until subsequent work led to the isolation of vitamin B₁₂, the second major dietary factor that prevented this type of anemia. The fortification of cereal grains with folate became mandatory in the United States after January 1, 1998 (42), and fortification appears to have had an impact on overall improvement of folate status among adults in the United States (165).

6.3.2. BIOCHEMISTRY OF FOLATE

Folates are compounds that contain pteroylglutamic acid, a 2-amino-4-hydroxy-pteridine moiety linked via a methylene group to a p-aminobenzoylglutamate moiety (Fig. 10). This family of compounds differs in the pyrazine ring, which can contain other forms of substitutions, and by the p-aminobenzoylglutamate moiety, which can contain additional glutamates. In foods, the number of glutamates can number from one to nine. Pterylmonoglutamic acid is not common in foods but is the form of folate used in vitamin supplements and in food fortification. Obsolete names for folate include Wills factor, vitamin M, factor U, and vitamin B_c.

6.3.3. DIETARY SOURCES OF FOLATE

The richest natural sources of folate are liver, yeast, dark green leafy vegetables, legumes, and certain fruits. The folate content of certain foods is shown in Table 5 (31). It is currently recognized that the folate content in available food composition databases are generally inaccurate and tend to underestimate the amount of folate contained in foods. The folate yield from foods is higher than contained in most databases, as recent methods have shown that traditional methods did not yield a complete release of folate from the food matrix (42). The bioavailability of naturally occurring folates in mixed diets is about 50% (166).

6.3.4. ABSORPTION, STORAGE, AND METABOLISM OF FOLATE

Most folates in food consist of reduced polyglutamates, and these are hydrolyzed in the gut to monoglutamates. Absorption of folate takes place in the small intestine, primarily in the jejunum. Folates are transported across the intestinal mucosa by a saturable, carrier-mediated system and also by passive diffusion. The metabolism of folate involves the reduction of the pyrazine ring to the active tetrahydro form, the elongation of the glutamate chain by addition of glutamates, and the acquisition and oxidation or reduction of one-carbon units at the N-5 and/or N-10 positions of the 2-amino-4-hydroxy-pteridine moiety (167). In the circulation, folate occurs as free folate in plasma, folate bound to

Table 5
Folate Content of Certain Foods

<i>Food</i>	<i>Folate (μg/100 g)</i>
Bakers yeast, dry	2340
Beef liver, pan fried	260
Chickpeas, boiled	172
Spinach, boiled	146
Peanuts, dry roasted	145
Beans, kidney, boiled	130
Egg, boiled chicken	44
Orange juice	30
Lean ground beef, broiled	10
Beer, 12 fluid ounces	6
Chicken, breast, fried	4
White rice, polished, unenriched, cooked	3

Based on US Department of Agriculture National Nutrient Database for Standard Reference (<http://www.nal.usda.gov/fnic/foodcomp/search>) (31).

albumin and other plasma proteins, and folate within erythrocytes. The normal adult human body contains about 5–10 mg, with about half of the total body folate found in the liver. The enterohepatic recirculation of folate plays an important role in folate balance. About 0.1 mg of biologically active folate is excreted in the bile each day and a large proportion is reabsorbed and reutilized. Excessive alcohol use interferes with the enterohepatic recirculation of folates. Most of the folate that enters the glomerulus is reabsorbed in the proximal renal tubule, thus most secreted folate is reabsorbed (167).

6.3.5. FUNCTIONS OF FOLATE

Folate coenzymes are involved in the transfer of one-carbon units in nucleic acid and amino acid metabolism. These reactions include (1) the *de novo* synthesis of purines, (2) the methylation of deoxyuridylic acid to thymidylic acid in pyrimidine synthesis, (3) the interconversion of serine and glycine, (4) the catabolism of histidine, (5) the conversion of homocysteine to methionine, (6) the generation of formate into the formate pool, and (7) the methylation of transfer RNA in mitochondrial protein synthesis. Both vitamin B₁₂ and folate are required for the synthesis of thymidylic acid. The conversion of 5-methyl-tetrahydrofolate to tetrahydrofolate by methionine synthetase requires vitamin B₁₂ as a cofactor, and vitamin B₁₂ deficiency can result in a megaloblastic anemia that is clinically indistinguishable from the megaloblastic anemia of folate deficiency. The relationship between vitamin B₁₂ and folate has been explained by the methyl trap hypothesis, where non-functional 5-methyl-tetrahydrofolate accumulates and the level of other metabolically active folate coenzymes undergo a concomitant reduction (167).

6.3.6. REQUIREMENT FOR FOLATE

The Food and Nutrition Board of the Institute of Medicine has made new recommendations of folate intake by life stage and gender group (42) (Table 6).

Table 6
Dietary Reference Intakes for Folate ($\mu\text{g/d}$ of Dietary Folate Equivalents)

<i>Age and gender category</i>	<i>AI</i>	<i>EAR</i>	<i>RDA</i>
Infants, 0–6 mo	65	–	–
Infants, 7–12 mo	80	–	–
Children, 1–3 yr	–	120	150
Children, 4–8 yr	–	160	200
Boys and girls, 9–13 yr	–	250	300
Boys and girls, 14–18 yr	–	330	400
Adult men and women ≥ 19 yr	–	320	400
Pregnant women	–	520	600
Lactating women	–	450	500

AI, Adequate Intake; EAR, Estimated Average Requirement; RDA, Recommended Dietary Allowance. Based on ref. 42.

6.3.7. EPIDEMIOLOGY OF FOLATE DEFICIENCY

The risk of folate deficiency is increased with insufficient dietary intake of folates, alcoholism, and malabsorption. The demand of folate is increased under conditions of pregnancy, lactation, and malignancy. Alcohol and certain drugs may play a role in reducing the absorption of folates through inhibition of folate hydrolase in the brush border of the intestine. Some drugs can interfere with absorption or utilization of folates, such as phenytoin, barbiturates, metformin, methotrexate, pentamidine, sulfasalazine, trimethoprim, and triamterene (168,169).

6.3.8. ASSESSMENT OF FOLATE STATUS

Folate status is usually assessed through measurement of plasma folate concentrations, erythrocyte folate concentrations, plasma homocysteine concentrations, hypersegmentation of neutrophils, and the deoxyuridine suppression test (52). The earliest stage of folate deficiency involves a drop in serum folate, followed by a decrease in erythrocyte folate. With further depletion of folate, the deoxyuridine suppression will be abnormal and homocysteine concentrations are elevated. Megaloblastic anemia occurs in the most advanced stage of folate deficiency. The different criteria for folate deficiency are shown for each test (52) Table 7. Plasma folate concentrations are sensitive to acute decreases in folate intake, whereas erythrocyte folate concentrations reflect body folate stores at the time of erythropoiesis.

6.3.9. CLINICAL MANIFESTATIONS OF FOLATE DEFICIENCY

The classic finding in folate deficiency is a megaloblastic anemia that is indistinguishable from the megaloblastic anemia caused by vitamin B₁₂ deficiency. Other clinical manifestations that have been associated with folate deficiency include fatigue, weakness, dyspnea, and anorexia. Angular stomatitis, recurrent aphthous ulcers, and glossitis have been described in folate deficiency. Pallor of the skin and mucous membranes may occur in the presence of anemia.

Table 7
Selected Assays for Folate Deficiency

<i>Assay</i>	<i>Deficient</i>	<i>Low</i>	<i>Acceptable</i>
Serum folate (ng/mL)	<3.0	3.0–5.9	≥6
Serum folate (nmol/L)	<6.8	6.8–13.4	≥13.4
Erythrocyte folate (ng/mL)	<140	140–159	≥160
Erythrocyte folate (nmol/L)	<317	317–355	≥356
Hypersegmentation of neutrophils (%) ^a	–	–	<3.6
Deoxyuridine suppression test	–	–	<10%
Plasma homocysteine (μmol/L)	–	–	<12

^aLobe average.

Based on ref. 52.

6.3.10. NUTRITIONAL AMBLYOPIA ASSOCIATED WITH FOLATE DEFICIENCY

It is reasonable to surmise that many of the patients who were thought to have so-called “tobacco alcohol amblyopia” may actually have had other nutritional problems that included folate deficiency, either isolated or combined with other deficiencies. The effect of chronic alcoholism on folate metabolism is well documented. In a study of 26 patients with nutritional amblyopia and 36 control patients, serum folate and red blood cell folate concentrations were significantly lower in the cases than the controls, whereas vitamin B₁₂ concentrations were not significantly different between the two groups (170). Six patients with bilateral progressive visual loss, poor color vision, and central or ceco-central scotomas, had laboratory evidence of folate deficiency and had normal vitamin B₁₂ levels. Treatment with oral folic acid, 1 mg/d, resulted in visual improvement in all patients (171). All patients consumed tobacco, alcohol, or both, and did not alter their use of these substances during folic acid therapy. Other case reports exist in which patients with nutritional amblyopia and folate deficiency responded to folate treatment (172,173). Folate deficiency has also been associated with a neuropathy (174), but the pathophysiology has not been well elucidated.

6.4. Vitamin B₁₂ Deficiency

Vitamin B₁₂, or cobalamin, is a generic term for corrinoids that have the biological activity of cyanocobalamin. Vitamin B₁₂ is essential for normal formation of the blood and for neurological function. On the molecular level, vitamin B₁₂ plays an important role in amino acid and fatty acid metabolism and in DNA synthesis. Deficiency of vitamin B₁₂, like deficiency of folate, will result in impaired production of tetrahydrofolate necessary for thymidine synthesis, hence, a similar clinical picture of megaloblastic anemia can occur with either deficiency. In addition, vitamin B₁₂ deficiency is characterized by glossitis, papillary atrophy of the tongue, and in advanced deficiency, by neuropathy and spinal cord dysfunction.

6.4.1. HISTORICAL BACKGROUND

Early descriptions of a fatal anemia were made by James Combe (1796–1883) in 1824 (175) and Thomas Addison (1793–1860) in 1849 (176). The anemia became known as pernicious anemia because of its high mortality, and in 1884, subacute combined degenera-

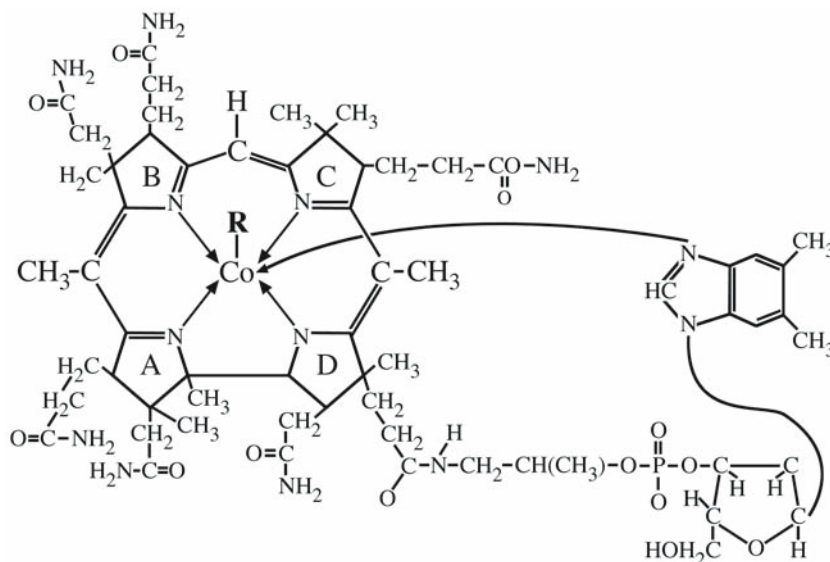


Fig. 11. Structure of cyanocobalamin.

tion of the spinal cord was described in association with pernicious anemia by Otto Leichtenstern (1845–1900) (177). Optic atrophy was noted in a patient with pernicious anemia in 1895 (178). In 1926, George Minot and William Murphy demonstrated that a diet of beef liver would cure pernicious anemia (179). Pernicious anemia was attributed to the absence of an intrinsic factor in gastric juice by William Castle (b. 1897) (180). Cobalamin was crystallized by Edward Rickes and associates in 1948 (181). The history of vitamin B₁₂ has been recounted in detail elsewhere (182).

6.4.2. BIOCHEMISTRY OF VITAMIN B₁₂

The term “vitamin B₁₂” is used by nutritionists to describe cobalamins with the activity of cyanocobalamin, but, strictly speaking, the chemical definition refers to cyanocobalamin, or α -(5,6-dimethyl-benzimidazolyl)-cobamide cyanide (Fig. 11). Cyanocobalamin consists of four reduced pyrroles in a macrocyclic ring termed a corrin, linked to a nucleotide that lies nearly perpendicular to the corrin. Inside the ring is a central cobalt atom. Corrinoids refer to compounds that contain a corrin nucleus with a tetrapyrrolic ring structure. Cyanocobalamin bears some structural relationship with other cyclic tetrapyrroles in nature, such as heme and chlorophyll.

6.4.3. DIETARY SOURCES OF VITAMIN B₁₂

Vitamin B₁₂ is synthesized solely by bacteria. It is not produced by plants and does not occur in vegetables or fruit, unless bacterial or fecal contamination is present in these plant foods. Vitamin B₁₂ is found in animal tissues, and the original source of the vitamin B₁₂ in animal tissues is bacteria. Rich sources of vitamin B₁₂ include liver, beef, lamb, shellfish, fish, egg yolk, and fermented cheeses. The vitamin B₁₂ content of some foods is shown in Table 8 (31).

6.4.4. ABSORPTION, STORAGE, AND METABOLISM OF VITAMIN B₁₂

Vitamin B₁₂ is released from the protein matrix of foods through mastication and pepsin digestion. Cobalamins are then bound by high-affinity glycoproteins, including intrinsic

Table 8
Vitamin B₁₂ Content of Some Foods

<i>Food</i>	<i>Vitamin B₁₂ (μg/100 mg)</i>
Beef liver, fried	83.1
Lamb, trimmed, broiled	2.28
Sirloin steak, trimmed, broiled	1.91
Shrimp, cooked	1.49
Egg, hard boiled	1.11
Cod fish, cooked	1.05
Whole milk	0.44
Chicken breast, stewed	0.27
Carrots	0
Rice	0
Potatoes	0
Any Fruits	0

Based on US Department of Agriculture National Nutrient Database for Standard Reference (<http://www.nal.usda.gov/fnic/foodcomp/search>) (31).

sis factor (IF). IF is secreted chiefly by parietal cells in the stomach and is necessary for the absorption of cobalamin in the ileum. Other glycoproteins, such as haptocorrins (Hc) and transcobalamin (TC) II, bind to cobalamin. In the duodenum, Hc bind mostly to inactive corrinoids and cobalamin analogues and facilitates their excretion in the feces. The IF-cobalamin complex is taken up by specific receptors in ileal mucosal cells, and this uptake is limited to about 1.5–2.0 μg of cobalamin per meal. In the ileal cell, the cobalamin moiety is converted to methyl-cobalamin and adenosyl-cobalamin, and these cobalamins are then released in the blood bound to TC II. Cobalamin is taken up by cells in the body by a receptor specific for TC II. The total body content of vitamin B₁₂ is 3–5 mg, of which half is found in the liver. Vitamin B₁₂ is secreted in the bile and is largely reabsorbed and available for metabolic use. This tight enterohepatic cycle can be interrupted if intrinsic factor is reduced or absent, in which case most or all of the vitamin B₁₂ is lost in the feces.

6.4.5. FUNCTIONS OF VITAMIN B₁₂

Vitamin B₁₂ serves as an essential cofactor for methylmalonyl-CoA mutase and methionine synthetase. Methylmalonyl-CoA mutase requires adenosyl-cobalamin to convert L-methylmalonyl-CoA to succinyl-CoA, a step that occurs in the degradation of amino acids (valine, isoleucine, methionine, and threonine) and odd-numbered fatty acids. Methionine synthetase requires methyl-cobalamin in the folate-dependent methylation of homocysteine to methionine. Thus, vitamin B₁₂ is linked to nucleic acid metabolism with its role in the conversion of methyltetrahydrofolate to tetrahydrofolate. Tetrahydrofolate is involved in the synthesis of thymidylate (*see* Subheading 6.3.5.).

6.4.6. REQUIREMENT FOR VITAMIN B₁₂

The Food and Nutrition Board of the Institute of Medicine has made new recommendations of vitamin B₁₂ intake by life stage and gender group (42) (Table 9). Although the RDA is calculated to meet the requirements of nearly all individuals for the maintenance of hematological status and normal vitamin B₁₂ concentrations, about 10–30% of older

Table 9
Dietary Reference Intakes for Vitamin B₁₂ (μg/d)

<i>Age and gender category</i>	<i>AI</i>	<i>EAR</i>	<i>RDA</i>
Infants, 0–6 mo	0.4	–	–
Infants, 7–12 mo	0.5	–	–
Children, 1–3 yr	–	0.7	0.9
Children, 4–8 yr	–	1.0	1.2
Boys and girls, 9–13 yr	–	1.5	1.8
Boys and girls, 14–18 yr	–	2.0	2.4
Adult men and women ≥19 yr	–	2.0	2.4
Pregnant women	–	2.2	2.6
Lactating women	–	2.4	2.8

AI, Adequate Intake; EAR, Estimated Average Requirement; RDA, Recommended Dietary Allowance. Based on ref. 42.

people may be unable to absorb naturally occurring vitamin B₁₂. The Food and Nutrition Board recommends that adults older than 50 yr of age meet the RDA for vitamin B₁₂ through the consumption of foods that are fortified with vitamin B₁₂ (42).

6.4.7. EPIDEMIOLOGY OF VITAMIN B₁₂ DEFICIENCY

Individuals at higher risk for vitamin B₁₂ deficiency include complete vegetarians (those who consume no animal products, including meats, eggs, and dairy products), and those with atrophic gastritis, a gastrectomy, bacterial overgrowth of the small intestine, fish tapeworm (*Diphyllobothrium latum*) infection, disease or resection of the terminal ileum, and pancreatic insufficiency. Older adults, especially those living in institutions, are at higher risk of malabsorption of cobalamin and subsequent vitamin B₁₂ deficiency. In pernicious anemia, autoantibodies against H⁺K⁺-adenosine triphosphatase in parietal cells lead to loss of gastric parietal cells and eventual deficiency of intrinsic factor needed for vitamin B₁₂ absorption. Recent studies suggest that 2–3% of adults older than 60 yr may have autoantibodies to parietal cells (183,184). Strict vegetarians who are breast-feeding have a higher risk of vitamin B₁₂ deficiency in their infants (185).

Several inherited disorders of vitamin B₁₂ deficiency are known, and these include congenital deficiency of methylene reductase and methionine synthetase, transcobalamin II deficiency, disorders of adenosylcobalamin and methylmalonyl-CoA mutase, and defects in cobalamin synthesis (186). Cobalamin C disease has been associated with bilateral optic atrophy, and early cobalamin treatment did not prevent the development of optic atrophy (187). A pathological study of eyes obtained from a young girl with cobalamin C type vitamin B₁₂ defect revealed partial optic atrophy, macular degeneration, and loss of nerve fibers and ganglion cells between the fovea and optic disc (188). The Imerslund-Grasbeck syndrome occurs in children and is characterized by megaloblastic anemia, proteinuria, and ataxia (189,190).

6.4.8. ASSESSMENT OF VITAMIN B₁₂ STATUS

The most widely used method for the assessment of vitamin B₁₂ status is the measurement of serum cobalamin, and although deficiency is usually defined as a serum vitamin B₁₂ concentration <150 pg/mL, clinical signs of vitamin B₁₂ deficiency has been described

even in the presence of normal or only marginally reduced serum vitamin B₁₂ concentrations. The Schilling test is used to determine whether absorption of vitamin B₁₂ is reduced. A small oral dose of radioactive vitamin B₁₂ is administered during fasting, and after a flushing dose of 1000 µg of intravenous nonradioactive vitamin B₁₂, radioactive vitamin B₁₂ is measured in urine collected over a 48-h period. In patients with pernicious anemia, usually less than 3% of the administered dose is excreted in the urine, whereas in normal healthy individuals, more than 8% is excreted (123). The deoxyuridine suppression test is also used to detect vitamin B₁₂-deficient and/or folate-deficient erythropoiesis.

6.4.9. CLINICAL MANIFESTATIONS OF VITAMIN B₁₂ DEFICIENCY

Vitamin B₁₂ deficiency is characterized by hematopoietic, gastrointestinal, and neurological alterations, including megaloblastic anemia, glossitis, papillary atrophy of the tongue, and in advanced deficiency, by neuropathy and spinal cord dysfunction. The neurological syndrome of vitamin B₁₂ deficiency may begin with symmetrical paresthesias in the hands and the feet, and loss of proprioception and vibratory sense, and later there may be spastic ataxia. Patients may complain of a “pins and needles” or burning sensation in the extremities. Degeneration of the dorsal and lateral columns of the spinal cord is associated with paresthesias and sensory ataxia (191). Impaired bowel function may occur and manifests as constipation. As noted in the following section, nutritional amblyopia can be the presenting sign of vitamin B₁₂ deficiency. The neurological manifestations of vitamin B₁₂ deficiency may precede the development of megaloblastic anemia. Abnormal visual evoked potentials have been documented in untreated patients presenting with pernicious anemia, and these findings suggest that involvement of the visual pathways may occur in advance of any visual complaints during vitamin B₁₂ deficiency (192).

6.4.10. NUTRITIONAL AMBLYOPIA ASSOCIATED WITH VITAMIN B₁₂ DEFICIENCY

Visual loss from vitamin B₁₂ deficiency can occur through nutritional amblyopia and through hemorrhagic complications associated with severe megaloblastic anemia. Optic atrophy (193) and bilateral central scotomas (194) have been described as the presenting sign in pernicious anemia (193), although more typically other findings of vitamin B₁₂ deficiency are present (195,196). A high incidence of pernicious anemia has been found among patients who were originally presumed to have so-called “tobacco alcohol amblyopia” or “tobacco amblyopia,” and nutritional amblyopia in these patients resolved after treatment with vitamin B₁₂ (197). Vitamin B₁₂ absorption, as indicated by Shilling tests, seems to be impaired among individuals who are heavy or active smokers (198,199). Mean serum cobalamin concentrations were lower among 65 subjects with so-called “tobacco amblyopia” compared with healthy pipe smokers and healthy nonsmokers (200). Nutritional amblyopia has been described among vitamin B₁₂-deficient patients infected with *Diphyllobothrium latum* (201). One hundred two fish tapeworm carriers were examined, and four patients had reduced vision, bilateral cecocentral scotomas, and serum vitamin B₁₂ concentrations consistent with deficiency. Deworming was followed by improvement in visual acuity and visual fields. Nutritional amblyopia has also been described in pernicious anemia associated with partial gastrectomy (172) and in vitamin B₁₂ deficiency following resection of the ileum (202).

In a recent case report, a previously healthy 29-yr-old woman with microcytic, hypochromic anemia was found to have a carcinoid tumor in the posterior wall of the stomach

(203). The tumor was excised, and 30 mo after the operation, the patient presented with a history of impaired vision. The patient reduced vision, bilateral optic atrophy, low serum vitamin B₁₂ levels, and an abnormal Shilling test, and administration of intramuscular vitamin B₁₂ restored the serum vitamin B₁₂ levels but her optic atrophy was irreversible.

6.4.11. EVIDENCE FROM EXPERIMENTAL ANIMAL MODELS

Degeneration of the papillo-macular bundle has been found in monkeys on an experimental vitamin B₁₂-deficient diet (204,205). Sixty-four monkeys, of which 61 were rhesus monkeys, *Macaca mulatta*, were divided into three groups (1) a vegetarian diet, (2) a vegetarian diet followed by treatment with vitamin B₁₂, and (3) a B₁₂-supplemented diet for more than 2 yr. Among the monkeys of the three groups, 65.2%, 44.8%, and no animals developed visual degeneration, respectively. Serum vitamin B₁₂ concentrations at the time of death were lower in the vitamin B₁₂-deficient animals compared with the supplemented animals. Degeneration of the papillo-macular bundle found in animals in group 1 and 2 (vitamin B₁₂-deficient monkeys, and resupplemented monkeys) but not in controls, which were normal. The pathological findings consisted of a reduction of the ganglion cells of the central area of the retina and degeneration of the papillo-macular bundle along its entire length. The lesions consisted of patchy, spongiform, sudanophilic areas of degeneration involving the myelin sheaths more than the axons. These lesions were accompanied by astrocytic nuclear hypertrophy and an increase in the number of microglia. A significant correlation was found between the temporal extent of the central area of degeneration and serum vitamin B₁₂ concentration before the time of death. The papillomacular bundle was considered more susceptible to disease because of the higher density of neuroglia in the bundle; astrocytes and oligodendrocytes and their associated need metabolic and energetic support (204,205).

6.4.12. TREATMENT OF NUTRITIONAL AMBLYOPIA WITH VITAMIN B₁₂

The nutritional amblyopia associated with pernicious anemia has been treated successfully with vitamin B₁₂ therapy alone (173,194,206). For example, in a typical case report, a 47-yr-old woman with subacute combined degeneration of the spinal cord and retrobulbar neuritis was diagnosed as having pernicious anemia and was treated with vitamin B₁₂. After a course of 3 mo, her visual acuity improved considerably and her neurological symptoms disappeared by 5 mo. By 12 mo, visual acuity was nearly normal (207). Nutritional amblyopia associated with pernicious anemia usually resolves if the eye condition is treated with vitamin B₁₂ soon after presentation (208), but longstanding cases do not respond to treatment (209). Hydroxycobalamin has been shown to be more effective in the treatment of nutritional amblyopia than cyanocobalamin (173). Patients with megaloblastic anemia and visual findings such as hemorrhagic retinopathy, reduced visual acuity, and dyschromatopsia showed a striking increase weight when they were treated with vitamin B₁₂ (172).

6.5. So-Called “Tobacco-Alcohol Amblyopia”

The disease entity, so-called “tobacco-alcohol amblyopia,” or “tobacco amblyopia,” can be found in the older ophthalmological literature. This term has largely been abandoned in favor of the term nutritional amblyopia. The relationship between tobacco use and/or alcohol use and retrobulbar neuropathy is not directly causal (210–212). In an extensive review of so-called “tobacco amblyopia,” Potts concluded that the relationship between tobacco

use and amblyopia was weak because there is (1) no relationship between the amount of tobacco used and the severity of the disease, (2) no relationship between the amount of nicotine in the tobacco and the severity of disease, (3) no association between duration of use and severity of disease, (4) a variable effect of cessation of tobacco use and therapeutic effect, and (5) an unexplained discrepancy in incidence in the second quarter of the 20th century. In spite of an increase in tobacco use during that period, so-called "tobacco amblyopia" became increasingly rare. From 1913 to 1934, about 1% of ophthalmology patients seen in Edinburgh were diagnosed with so-called "tobacco amblyopia," but for unknown reasons the disease began to decline in the latter part of that period (213,214). The disease was considered to be more common among pipe and cigar smokers, and there has not been an increase in cases of so-called "tobacco amblyopia" with the recent resurgence of cigar smoking. Various toxins in tobacco have been implicated in the pathogenesis of so-called "tobacco amblyopia," including nicotine, cyanide, and some unknown toxins (215–219). Others have argued that poor quality tobacco could cause the disease (220,221).

Smokers are at a higher risk of nutritional amblyopia mainly because of their dietary habits, as many studies have shown that cigarette smokers have a lower intake of many vitamins compared with comparable nonsmokers (222–227). Smokers are less likely to consume fresh fruits, vegetables, salad, and whole grain cereals compared with nonsmokers. The consumption of saturated fat, sugar, and alcohol are higher among smokers (226). It is also well established that alcoholics in general are at higher risk of poor nutrition (228), and there is little evidence to demonstrate that heavy alcohol use itself is toxic to the optic nerve. Alcoholism is the most common cause of folate deficiency in the United States and occurs in up to 80% of chronic alcohol abusers (228). Thiamin deficiency is also common in alcoholics and is associated with Wernicke-Korsakoff syndrome (*see* Subheading 6.1.11.). Other problems with water-soluble vitamins in alcoholics include pyridoxine deficiency and deficiency of vitamin B₁₂.

Although many clinicians had long observed that so-called "tobacco-alcohol amblyopia" was more common among malnourished and impoverished patients, early work by Frank D. Carroll (b. 1907) helped to establish in a more definitive manner that nutritional deficiencies were the underlying etiology of the retrobulbar neuropathy seen in patients with so-called "tobacco-alcohol amblyopia." In 1935, Carroll noted that so-called "tobacco-alcohol amblyopia" accounted for 0.3–0.5% of patients admitted to the eye clinic of the Massachusetts Eye and Ear Infirmary (229). In his initial case series of 55 patients, he noted that about half the patients were unemployed and had increased their use of tobacco and alcohol since they stopped working. He originally advocated abstinence from tobacco and alcohol as a treatment for the disease. The following year, Carroll observed that ten patients with so-called "tobacco-alcohol amblyopia" also had skin lesions typical of pellagra and/or a polyneuritis (230). All the patients had inadequate diets, and he suspected that defective nutrition was the underlying etiology of so-called "tobacco-alcohol amblyopia." Later case reports suggested that patients with so-called "tobacco-alcohol amblyopia" would recover when given thiamin supplements even though they continued heavy alcohol and tobacco use throughout treatment (231). In further investigations, Carroll divided patients with so-called "tobacco-alcohol amblyopia" into four groups consisting of the following treatments: (1) a well balanced diet, (2) a usual diet plus vitamin B complex, (3) an inadequate diet plus vitamin B complex, and (4) an inadequate diet plus thiamin alone (232). During treatment, all the patients were instructed to continue their usual

use of alcohol and tobacco. All 26 patients in the study showed improvement of the disease. These data and further studies suggested that thiamin treatment alone would be effective (232,233). Blood transketolase levels consistent with thiamin deficiency have been described in patients with so-called “tobacco-alcohol amblyopia” (234).

Other studies have shown significantly lower serum vitamin B₁₂ concentrations among patients with so-called “tobacco amblyopia,” and the condition responded to treatment with vitamin B₁₂ (235). Three patients who continued to smoke as heavily as before also improved with vitamin B₁₂ therapy. Other have reported improvement in so-called “tobacco amblyopia” among individuals who continued smoking but improved on vitamin B₁₂ therapy (236). Although some clinicians claim to have identified “pure” cases of so-called “tobacco amblyopia” (237,238), it is notable that the condition responds to vitamin B₁₂ treatment, despite continued smoking and/or drinking (235,238–241). Some have speculated that vitamin B₁₂ deficiency is involved in the pathogenesis of eye disease because of the role of hydroxocobalamin in the metabolism of cyanide (242,243) or methionine metabolism (244).

The syndrome of so-called “tobacco-alcohol amblyopia” was responsive to a well balanced diet or treatment with B complex vitamins (245,246). An autopsy report of a patient with so-called “tobacco-alcohol amblyopia” revealed extensive liver disease, peripheral neuropathy, cerebellar degeneration consistent with chronic malnutrition (246). In the 1960s, Maurice Victor proposed that the term “tobacco-alcohol amblyopia” be abandoned, because the main underlying etiology was nutritional (246). Carroll later also adopted the term “nutritional amblyopia” (247). The incidence of so-called “tobacco-alcohol amblyopia” or “tobacco amblyopia” has decreased greatly during the 20th century (212,248,249), and the decrease is likely due to general improvements in diet as well as mandatory fortification of flour and bread with thiamin, riboflavin, and niacin in the 1940s (*see* Subheading 6.1.1.).

6.6. Nutritional Amblyopia During Times of War

6.6.1. INTRODUCTION

Nutritional amblyopia has appeared in epidemic form among prisoners in concentration camps and civilians subject to severe food shortages during times of war. It has also been described among poorly nourished soldiers in times of peace. Sometimes nutritional amblyopia was an isolated finding, but usually it was associated with other signs and symptoms of dietary deficiencies suggestive of beriberi, pellagra, riboflavin deficiency, and vitamin B₁₂ deficiency. Other synonyms for nutritional amblyopia included “starvation amblyopia,” “camp amblyopia,” “camp eyes,” “kampoogen” in Dutch, “malnutrition amblyopia,” “Inanitionsamblyopie” in German, “avitophthalmia,” “avitaminotic retrobulbar neuritis,” “avitaminosis amblyopia,” “beriberi optic neuritis,” “tropical nutritional amblyopia,” and “amblyopia cum polyneuropathia.”

6.6.2. CLINICAL PRESENTATION

Nutritional amblyopia was often described among previously well nourished, healthy soldiers who were suddenly captured and made prisoners of war. For example, many cases occurred among soldiers who were captured after the surrender of Singapore to the Japanese during World War II. Typically, the onset of visual symptoms in prisoners of

war occurred within 4–12 mo of captivity. A decrease in vision occurred over many days or weeks. The main complaint was usually blurred vision with difficulty reading and recognizing faces because of a decrease in central vision. Bilateral central scotomas were present, and ophthalmic findings sometimes included slight hyperemia of the optic discs early during the disease. With longstanding disease, bilateral temporal disc pallor would be present. There were occasional reports of bilateral constriction of peripheral vision and minute changes in the macula, but most reports noted normal peripheral vision and no macular findings. Often the patients reported that they were more comfortable seeing in dim light rather than bright light. Photophobia, lacrimation, and retrobulbar pain were sometimes present. The most common findings associated with nutritional amblyopia among prisoners of war included a large loss of weight, “burning feet” or paresthesias of the extremities, perioral numbness, glossitis, angular stomatitis, dermatitis consistent with pellagra, and signs and symptoms of beriberi. Nutritional amblyopia often occurred in epidemic form after an outbreak of dysentery in the prison camps.

6.6.3. STUDIES OF AFFECTED PRISONERS OF WAR AND CIVILIANS

Early reports. Nutritional amblyopia was reported as early as 1870 during the siege of Paris by the Germans, during which there was an increase in so-called “tobacco amblyopia” (220), and as recently as the Vietnam War among captured US airmen (170). During World War I, retrobulbar neuritis among soldiers was attributed to nutritional deficiency. Thirty patients with decreased vision and central scotomas were reported by Dinser in 1919 (250). Bad living conditions, unknown toxins, and the heavy strain of war were implicated as the cause of retrobulbar neuritis seen in soldiers and civilians (251–253). Many of these reports came from populations subjected to extreme dietary deprivation, but the majority of the cases were thought to be due to multiple sclerosis, tobacco, alcohol, or to be idiopathic in nature (254–256). During the Spanish Civil War, a series of 98 patients with nutritional deficiencies was described from Madrid (257,258). A large proportion of the patients had retrobulbar neuritis, and other associated neurological problems included paresthesias such as “burning feet” and glossitis. At the end of the Spanish Civil War, physicians in the military hospitals began to see nationalist soldiers with decreased vision, central scotomas, and temporal disc pallor (259). These soldiers had been held prisoners of war by the Marxist army and were fed small portions of rice and lentils during captivity. The vision of the soldiers recovered when they were given a vitamin-rich diet (259).

World War II. Most of the reported cases of nutritional amblyopia during the time of war came from World War II. As noted by the Dutch ophthalmologist Henri Marinus Dekking (1902–1966):

“Nature, that most unscrupulous vivisectionist, has just finished one of her greatest experiments: a war. Of all her vast laboratories, the South East Asia theater of war has yielded some very remarkable results from an ophthalmological standpoint. Hundreds of thousands of men, women and children have been kept in cages for almost four years, and have been subjected to all kinds of deficient diets and to incredible physical and mental strains” (260).

Nutritional amblyopia was observed by physicians who were interned in prison camps, by those practicing among civilians during military occupation, and by many ophthalmologists who examined patients who had been repatriated from prison camps through-

out Asia at the end of World War II. Some of the cases reported in the camps may have also appeared in later case series when the prisoners were examined and processed prior to their return home, and there was also some overlap in the reporting of cases from different internment camps following the war.

The British ophthalmologist, Sir Harold Ridley (1906–2001), examined about 500 prisoners of war who had problems with a deterioration of vision in captivity while imprisoned in Siam (261). Most of these men were forced to work on the Bangkok-Moulmein railway from October 1942 to March 1943, and their diet consisted primarily of polished rice with a vegetable stew comprised of pumpkin, yam, sweet potato, bringal, Chinese radish, and Chinese cabbage. The meat ration was variable and always small, and sometimes it was possible for the prisoners to purchase eggs and bananas. Nutritional amblyopia was accompanied in many cases by skin lesions of pellagra, edema of the lower extremities, beriberi, glossitis, and angular stomatitis. Nerve deafness was often present. Night blindness was a rare complaint. In further work, a total of several hundred prisoners of war from Siam, Malaya, and the Netherlands East Indies were examined, and about 1% of the men were found on release to have impairment of vision of 2–3 yr duration (8). About half the patients with nutritional amblyopia also had beriberi. Ridley noted that among the prisoners, eggs were considered a valuable remedy, and the officers, who had better access to eggs while in captivity, were relatively spared of nutritional amblyopia (8).

The total incidence of nutritional amblyopia among prisoners who were repatriated from the Far East was estimated to be 6.8% (262). Frederick C. Rodger examined 238 prisoners with nutritional amblyopia who were repatriated from Singapore, Hong Kong, Java, Borneo, Ambon, Formosa, and Saigon. From the time of internment, the onset of nutritional amblyopia was reported as 0–4 mo (2.4%), 5–9 mo (28.2%), 10–14 mo (59.3%), 15–19 mo (6.7%), and 20 mo and greater (3.3%). The average time to onset of disease was 11.2 mo. The diet varied between the different prison camps, and the incidence of nutritional amblyopia was higher in some camps than others. In most cases, the onset of visual disturbances was associated with beriberi (262,263). At the end of the war, over 3000 Royal Air Force personnel who were repatriated from Japanese prison camps passed through a reception unit in England and received eye examinations (264,265). Two hundred of the men showed decreased vision and central scotomas, and bilateral temporal disc pallor was common. These men had more longstanding disease and showed little response to treatment. One hundred and thirty six cases were evaluated and examined a second time (265), and 101 of the 163 men had come from Ambon and 42 from Java. The dietary situation in Ambon was considered the worse, as extra food could not be obtained by the prisoners. The most common associated findings were beriberi, pellagra, and “burning feet” (265,266). In one location, over half of the cases of nutritional amblyopia appeared after a dysentery epidemic swept through the camp. The medical officers provided the most severely affected men with badges that said “blind” in order to denote their condition to their captors in the prison camps (266).

Nutritional amblyopia was also found among American soldiers who had been repatriated from Camp Omori, Camp Ofuna, Shinegawa Hospital, and the Kempri (Military Police) Headquarters in Tokyo (267). In captivity, the pilots and personnel from B-29 bombers were singled out for punitive incarceration, and they were placed on half rations of 300 g of rice per day. Most of the patients had been interned for about 6–9 mo and had lost around 44 lbs in weight. In 40 patients, reduced vision, central scotomas, and optic disc

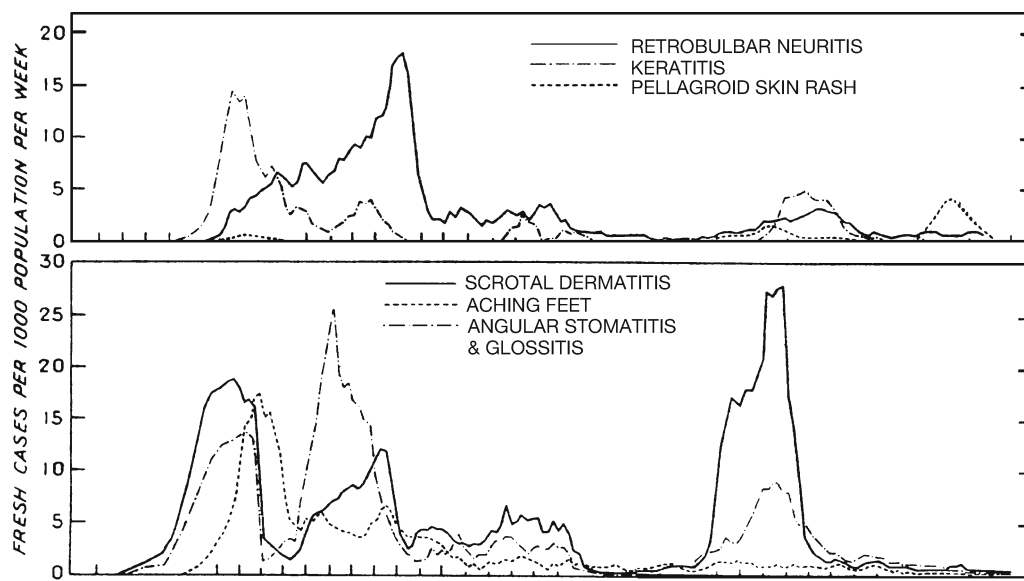


Fig. 12. Incident cases of nutritional amblyopia, Changi prison camp, 1942–1945. (From ref. 269.)

pallor were common, and other associated findings included glossitis and beriberi. One patient died shortly after admission with beriberi heart. In another case series of six American soldiers repatriated from Japanese prison camps after capture on Wake Island, Corregidor, and Bataan, beriberi and pellagra were associated with nutritional amblyopia (268). These soldiers had longstanding disease and developed permanent visual disability.

Singapore. In February 1942, the British surrendered in Singapore after relatively short combat with the Japanese (269), and the plight of these soldiers has been particularly well documented (270,271). The number of cases of nutritional amblyopia that appeared per week was documented in one prison camp (269) (Fig. 12). The large majority of the British soldiers had undergone relatively little hardship and was healthy at the time of capture. A week following capitulation, 52,000 troops were marched sixteen miles to Changi, and some of them were interned locally. In July 1942, about 5.5 mo after capture, there was an epidemic of burning feet in the Changi prison camp. About 500 prisoners of war with burning feet were studied, and 13%, or about 65 cases, had nutritional amblyopia (272). Later in October 1942 to July 1943, nutritional amblyopia reached epidemic proportions in the Changi prison camp, with the number of inpatients exceeding 500 in one period (273). The condition was bilateral, with loss of vision due to involvement of the papillomacular bundle. During the peak of the epidemic of nutritional amblyopia, burning feet affected about 75% of the cases. Other associated findings included stomatitis and glossitis (30–80%). Scrotal dermatitis affected up to 80% of the cases, and about 1% had nerve deafness (273). The treatment for nutritional amblyopia consisted of marmite, and the prognosis was excellent if the history of visual loss was short. For cases that had more than 2 mo without treatment, the prognosis was poor. Most patients responded to treatment within 2–3 wk, with many patients improving from 6/60 or worse to 6/6. Of about 1300 patients treated in the hospital, 95.5% showed improvement, 4% remained stationary, and 0.5% got worse (273).

After the surrender of Singapore, the local population was subjected to dietary deprivation, as the price of meat, eggs, fish, fats, fresh and dried beans rose so high that many people were unable to obtain them. By July 1942, cases of nutritional amblyopia began to appear among civilians in Singapore (274). The condition was usually accompanied by angular stomatitis, glossitis, and sometimes scrotal or labial dermatitis, and many patients also had recent problems with beriberi. Nutritional amblyopia also appeared among civilians in the Changi Jail in December 1942, and about one hundred cases appeared in a 2-mo period in June 1943 (274). During the Japanese occupation of Singapore, many civilians were interned locally for about 3.5 yr. In a civilian interment camp of 3000 men, 5.5% were affected with nutritional amblyopia (7). One hundred and forty-five of these cases were studied more closely, and associated findings included parathesias (27%), altered tendon reflexes (28%), glossitis (15%), and scrotal dermatitis (6%) (7). Other neurological case histories included diplopia and deafness (275).

Hong Kong. The incidence of nutritional amblyopia was higher in Hong Kong than Singapore (270). In the last 6 mo of 1940, with a fall in wages and rise in unemployment, pellagra became common in Hong Kong among civilians (276). Cases of nutritional amblyopia began to appear, and associated findings included parathesias, weakness of the extremities, glossitis, and angular stomatitis. The cases occurred among the poorer classes of Hong Kong. Patients recovered with a treatment of nicotinic acid and better diet (276). About 2 yr later, Hong Kong was occupied by the Japanese, and many civilians from Hong Kong were interned. In one civilian camp that contained about 1300 men, 900 women, and 300 children under age 16, there were 370 cases of nutritional amblyopia (270,277). The diet of the camp provided 1700 calories with 42 g of protein, 23 g of fat, and an estimated daily intake of thiamin, riboflavin, and niacin of 0.38 mg, 0.70 mg, and 8.1 mg, respectively (277), compared with the current RDA of 1.2 mg, 1.3 mg, and 16 mg, respectively, for an adult male (42). Many of the cases had burning feet and peripheral neuropathy.

Nutritional amblyopia was also reported from military internment camps in Hong Kong. In one camp, 174 cases were reported (278). After nearly 4 yr of captivity in Hong Kong and the Japanese islands, an estimated 20% of Winnipeg Grenadiers of Canada developed nutritional amblyopia (279). The Grenadiers left Winnipeg in October 1941 and were captured by the Japanese in December 1941. The caloric intake during captivity dropped to 1700 to 2300 calories per day and then further to 1200 to 1500 calories per day because of spoiled food. In the first few months of internment, most men lost 35–40 lbs of weight. Nutritional amblyopia began in epidemic proportions in August 1942 and reached a peak September and October of 1942. Most of the men developed wet or dry form of beriberi, pellagra, and “hot feet” (279). There was little opportunity for the prisoners of war to trade or purchase food with guards during captivity, and about 60% of the men reported decreased visual acuity at some time during captivity. About 6% of the Canadian prisoners of war were left with permanent visual disability from nutritional amblyopia (280).

Burma and Thailand. The infamous Bangkok-Moulmein railway work camps, popularly known through the film *The Bridge On the River Kwai* (1957), were notable for their extreme degree of dietary deficiencies and nutritional amblyopia (261,281,282). Other reports of nutritional amblyopia came from Nakom Paton (288), Rangoon (284,285). Most of the cases were associated with beriberi (285). After the end of the war, some of the repatriated European and Indian soldiers were examined in Secunderabad, India (286).

Among 3667 sick prisoners of war who were received in India, there were 185 cases of nutritional amblyopia. Burning feet were commonly associated with the eye disease, and a relapse of eye disease was often seen in patients who developed dysentery (286).

Philippines. Many American soldiers who were captured in the Pacific theater during World War II were held prisoner of war by the Japanese in the Philippines. Soldiers who were captured in Bataan and Corregidor in April and May 1942 were placed in prison camps and given a daily diet of about 300 gms polished rice and a thin soup of low grade vegetables and weeds (287). Meat was almost completely lacking for the diet, and rarely a pig would be slaughtered to feed a group of 2500 men. Within the first 4 mo of imprisonment, men developed beriberi, scurvy, pellagra, and ariboflavinosis, and of 6500 men interned in Cabanatuan, 2700 died in the first year. Nutritional amblyopia began to appear in September 1942, about 5–6 mo after capture. After about 2 to 4 wk, retrobulbar pain and burning sensation was reported, with lacrimation and photophobia. The main ocular findings were temporal optic disc pallor and central scotomas. At one point during the internment, the rice polisher broke, and prisoners of war were given unpolished rice for 2 mo. As reported by Bloom: “A definite improvement in the condition of the men resulted during this time. On returning to the diet of polished rice, they suffered a recurrence of former symptoms.” Nutritional amblyopia was noted to be more prevalent among prisoners of war who refused to eat the soup and among those who bartered their food for cigarettes (287).

In a report of eight patients with nutritional amblyopia who were liberated from prison camps in the Philippines, all were noted to have beriberi, seven of the eight had pellagra, and all but one had developed some degree of bilateral nerve deafness (288,289). Bilibid prison in the heart of Manila, once used for a thiamin deprivation study among death row inmates earlier in the century (19), became a prison hospital for American prisoners during World War II. Sick American prisoners of war from prison camps around the Philippines were referred to Bilibid for treatment by staff of the US Navy Medical Corps. At one time, 90% of camp inmates in a total census of about 3000 men had developed some degree of nutritional amblyopia, which they termed “beriberi optic neuritis” (290). During the Japanese occupation of the Philippines, nutritional amblyopia also reached epidemic proportions among the civilian population in December 1942 (291). From 1940 to 1941, 72 cases of retrobulbar neuritis were seen at the Philippine General Hospital in Manila, but from 1942 to 1943, 451 cases were reported (291).

Dutch East Indies (Indonesia). In the Dutch East Indies, nutritional amblyopia was documented in several prison camps. In one extraordinary account from the Bandung (Bandong) camp in West Java, Otto de Raadt, an otorhinolaryngologist, kept detailed medical records of patients with nutritional amblyopia. When the Bandung camp was closed by the Japanese and the prisoners moved, de Raadt buried the notebooks, and after the end of the World War II, the hidden records were dug up and formed the basis for a detailed report (292). One physician noted that ocular complaints were rare among prisoners of war during almost 2 yr of captivity in “Struyswijk” prison in Batavia, where inmates received a diet of unpolished rice, some vegetables, “tempe kedele” made from soy beans, and occasionally beans or peas (293). However, in camps in or near Bandung, where the diet consisted of polished rice and a thin porridge of tapioca, 150 cases of nutritional amblyopia were seen, mostly accompanied by beriberi, and other outbreaks of nutritional amblyopia were

reported in Adek, Log, and Banjoebiroe camps, where polished rice was the main dietary staple (293). In Tjimaji camp, Java, nutritional amblyopia was reported among 7–8% of the internees (260). One physician found that thiamin treatment was effective in treating nutritional amblyopia (294).

Middle East. Nutritional amblyopia was described among 112 German prisoners of war who were held captive in Egypt, and associated findings included ataxia (21%), nerve deafness (11%) and both ataxia and nerve deafness (8%) (295). The cases occurred in a camp of about 10,000 men where diarrhea, dysentery, malnutrition, pellagra, ariboflavinosis, and scurvy were common. Although the recommended diet for the camp was supposed to consist of 3574 calories per day, with sufficient B complex vitamins, the actual conditions were far different because of wartime conditions and shortages (295). Nine cases of nutritional amblyopia were described among German soldiers held prisoners of war by the British in the Mediterranean region (296). Associated findings included burning feet, tinnitus and deafness, hoarseness, weakness in the legs, and dermatitis consistent with pellagra (296).

Europe. Although there were thousands of prisoners of war and civilian prisoners held in different camps in Europe and Russia during World War II, there were only relatively rare reports of nutritional amblyopia compared with southeast Asia and the Middle East. This led some to speculate that the tropical heat or excessive sunlight were a predisposing factor that could explain the high incidence of the disease in the tropics (260). Such climatic and environmental factors do not explain the cases of nutritional amblyopia reported during World War I and the Spanish Civil War (259). After World War II, Berlin became a transit center for Eastern refugees and prisoners of war, and some cases were described among prisoners returning from Russia (297). Other cases were described among the civilian population of Berlin, which was subjected to poor dietary conditions in the latter part of the war (297). Clinical examination of thousands of Poles who were released from Russian concentration camps in 1943 did not reveal any cases of nutritional amblyopia (298). Although the internees received a poor diet, the main staple was black bread, 450–500 g a day, which would provide 1.03–1.15 mg of thiamin per day, close to the current RDA for thiamin.

Korean War. Nutritional amblyopia also affected American servicemen who were held prisoner of war in North Korea (299). A total of 3745 Americans held prisoner of war were repatriated from prison camps in Korea. In spring of 1953, during “Operation Little Switch,” 149 of the most seriously ill prisoners were released. The remaining prisoners were released in August and September 1953 in “Operation Big Switch” after hostilities had ceased. Twenty-two men were found to have nutritional amblyopia, and common associated findings were beriberi, diarrhea, dysentery, peripheral neuropathy, and night blindness. Four of the patients had hearing loss (299).

Vietnam War. In the Repatriated Prisoners of War program, American servicemen were seen after being released from North Vietnam (170). Most of the prisoners of war at that time were aviators who had been shot down and were not ground troops. Of 332 servicemen seen, there were 3 cases of nutritional amblyopia. All three men had been captured in the period from 1963 to 1967, and the diet consisted mostly of turnip soup, potato soup, and no fats. After 1968, vitamins arrived from the Red Cross for the entire population of prisoners in North Vietnam, and no further cases of nutritional amblyopia were seen (170).

6.6.4. ETIOLOGY AND TREATMENT

Nutritional amblyopia among prisoners of war and civilians during times of war is largely consistent with that described in outbreaks of beriberi and pellagra (263,300). In the prison camps, the physicians usually treated the patients with yeast, marmite, B complex vitamins, thiamin alone, niacin alone, thiamin and niacin together, eggs, larger rations, rice polishings, local legumes, and any other vitamins they could find under conditions of extreme scarcity. Good responses to therapy were often described with most of these different treatments. From these reports, it is difficult to evaluate the relative efficacy of the treatments, as these were not controlled studies. In many cases, the physicians ran out of vitamins, and often they did not distinguish between treatment of acute cases, which would be expected to recovery quickly, and longstanding cases, which would not be expected to respond much to treatment. There is an anecdotal report of 70 hospital staff members who took daily thiamin as prophylaxis during a widespread outbreak of nutritional amblyopia in the prison camp and did not develop the disease (278), but there is another report where nutritional amblyopia developed among prisoners on thiamin treatment for beriberi (277).

There can be no doubt that the diets of the prison camps were insufficient in calories, proteins, fats, and most B complex vitamins (301–304). There are well documented outbreaks of beriberi, pellagra, scurvy, ariboflavinosis, and night blindness in many different prison camps (305). Although there were limited rations in the camps, the survival of many prisoners often depended on their ability to purchase extra food on the black market and from local people who came to the camps (306). The provision of vitamins and extra rations from the International Red Cross were also thought to have made a difference in the long-term health of the prisoners (307). The reports of nutritional amblyopia during times of war are summarized in Table 10.

6.7. Case Study: The Cuban Neuropathy Epidemic

6.7.1. INTRODUCTION

In November 1991, several middle-aged men with loss of vision were seen at the Abel Santamaría Hospital in Pinar del Río, the westernmost province of Cuba (308). The men were diagnosed as having retrobulbar optic neuritis. In the ensuing months, about 14 to 36 new cases began to appear each month, and by July 1992, 168 cases had accumulated. In August 1992, 22 inmates from Ariza Prison in Cienfuegos were admitted to Aldereguía Provincial Hospital with edema, painful dysesthesias of the feet and legs, difficulty ambulating, sensory ataxia, and weakness. The patients were thought to have beriberi, and they responded to treatment with a better diet, thiamin, and B complex vitamins. By the end of 1992, there were 472 cases identified, and by March 1993, there were 4461 cases in total (309) (Fig. 13).

A task force was organized to deal with the epidemic on March 20, 1993 (308). The group was chaired by Comandante Fidel Castro Ruz and coordinated by the Civil Defense for Disaster Relief, the Ministry of Public Health, and the Cuban Academy of Sciences (310). The epidemic was distributed across the entire island of Cuba (9) (Fig. 14). An island-wide effort began to identify cases and promote early treatment, using some 18,000 family doctors involved in the primary care system. An increase in reported cases continued, many patients having isolated neuropathies, neuropathies associated with optic neuropathy

Table 10
Reports of Nutritional Amblyopia during Times of War

<i>Location</i>	<i>Observations</i>	<i>Reference</i>
	World War I	
Germany	20 cases	250
Germany	5 cases among soldiers	251
Poland	5 cases	253
Germany	22 cases among soldiers and 15 cases among civilians	254
Austria		255
		256
	Spanish Civil War	
Spain	Many cases among Nationalist soldiers held prisoners-of-war (POWs) by Marxists	259
Spain		257
Spain		258
	World War II	
Southeast Asia	1% of men examined in Rangoon and Singapore were affected; 219 cases identified; 50% of cases had beriberi. Officers had much lower risk of disease and more access to eggs.	8,261
Southeast Asia	238 cases identified; total incidence of nutritional amblyopia among POWs who were repatriated was 6.8%; onset of disease closely associated with beriberi.	262
Southeast Asia	3000 repatriated Royal Air Force personnel seen at reception unit in England; 200 cases identified; many had vascularization at the limbus suggestive of riboflavin deficiency.	265
Southeast Asia	163 cases in Royal Air Force were re-examined; disease associated with beriberi (27%), pellagra (4%), and burning feet (7%).	264
Southeast Asia	Of 1520 POWs repatriated from Camp Omori, Camp Ofuna, Shinegawa Hospital, or Kempri Headquarters in Japan, 40 cases identified; beriberi common among the patients.	266
Southeast Asia	6 cases of America held POW; nearly all had beriberi and/or pellagra.	267
Singapore	British capitulated in Singapore in February 1942. Epidemic of cases from October 1942–July 1943, with over 500 POWs hospitalized with condition in one period. Other findings were scrotal dermatitis (80%), burning feet (75%), stomatitis and glossitis (30–80%), and nerve deafness (1%).	268
Singapore	149 cases in Changi prison camp; recovery after treatment with yeast concentrates was the rule.	271
		270

(continued)

Table 10 (Continued)

<i>Location</i>	<i>Observations</i>	<i>Reference</i>
World War II (continued)		
Singapore	In outbreak of painful feet (burning feet) in Changi prison camp, of 500 cases of painful feet, 13% had nutritional amblyopia.	272
Singapore	After surrender of Singapore to the Japanese, price of meat, eggs, fish, fats, fresh and dried beans rose so high that many local people could not afford them. By July 1942, cases of nutritional amblyopia began to appear in the local population.	274
Singapore	In civilian internment camp, 5.5% of 3000 men developed the disease; 145 cases described in detail; other findings were malnutrition (54%), paresthesias and sensory changes in extremities (27%), altered tendon reflexes (28%), glossitis (15%), scrotal dermatitis (6%).	7
Hong Kong	In last 6 mo of 1940, there was a pellagra outbreak in the local population that coincided with high food prices, low wages, and increased unemployment. 15 cases identified; associated with weakness in extremities, palpitations, giddiness, glossitis, cheilosis.	276
Hong Kong	In civilian internment camp, 370 cases of 2493 internees (14.8%) during two epidemics. Often associated with peripheral neuropathy and burning feet.	277 270
Hong Kong	174 cases in military POW camp; 70 hospital staff took daily thiamin as prophylaxis and none were affected.	278
Hong Kong	Of 375 Winnipeg Grenadiers held as POW, 95 cases identified; 60% of all men reported a decrease in visual acuity at one time or another during captivity.	279 280
Burma	3 cases, including 2 with beriberi.	281
Burma	119 POWs liberated from work camp of Bangkok-Moulmein railway were examined; 17 cases were identified.	282
Burma	277 cases described.	283
Burma	10 cases examined after repatriation of Rangoon.	284
Burma	87 cases examined; 62 had definite history of beriberi	285
Burma	185 cases among 3667 sick repatriated prisoners of war	286
Philippines	33 cases among American captured in Bataan and Corregidor and held POW by Japanese; symptoms improved when rice polisher broke and POWs were given unpolished rice.	287
Philippines	10 cases seen at US Naval Hospital, Philadelphia; 8 had evidence of severe beriberi; 7 had pellagra.	288,289
Philippines	About 90% of prison inmates had optic neuritis during epidemic of nutritional amblyopia.	290
Philippines	28 cases; 71% with angular stomatitis, 50% with paresthesias of fingers or toes, perioral numbness.	291

Indonesia	50 cases in Bandung Camp, Java; associated with scrotal dermatitis, skin changes in nasolabial folds, cheilosis, burning feet, glossitis, and stomatitis.	292
Indonesia	150 cases in Bandung Camp, Java; abnormal sensations in feet and hands were associated with eye disease.	293
Indonesia	7–8% of men in Tjimahi Camp, Java, were affected, and most also had burning feet.	260
Indonesia	5 cases from internment camp in Java; improved after thiamin treatment alone.	294
Middle East	112 cases in German held POW by the British; burning feet were common; other associated symptoms were ataxia (21%), nerve deafness (11%), ataxia and nerve deafness (8%).	295
Egypt	5 cases in Germans held POW by the British; burning and tingling in hands and feet in some;	296
Mediterranean	4 cases in POWs held in Romania, Macedonia, and Tunisia.	
Berlin	Cases observed among POWs returned from Russia and among some civilians in Berlin.	297
	Korean War	
Korea	22 cases in Americans held in prison camps in North Korea; associated with beriberi, diarrhea, and dysentery.	299
	Vietnam War	
Vietnam	3 cases among 332 repatriated Americans held by North Vietnamese; all were captured in 1963–1967 and fed turnip soup, potato soup, no fats. No cases noted after 1968, when vitamins were distributed by Red Cross to all POWs.	170

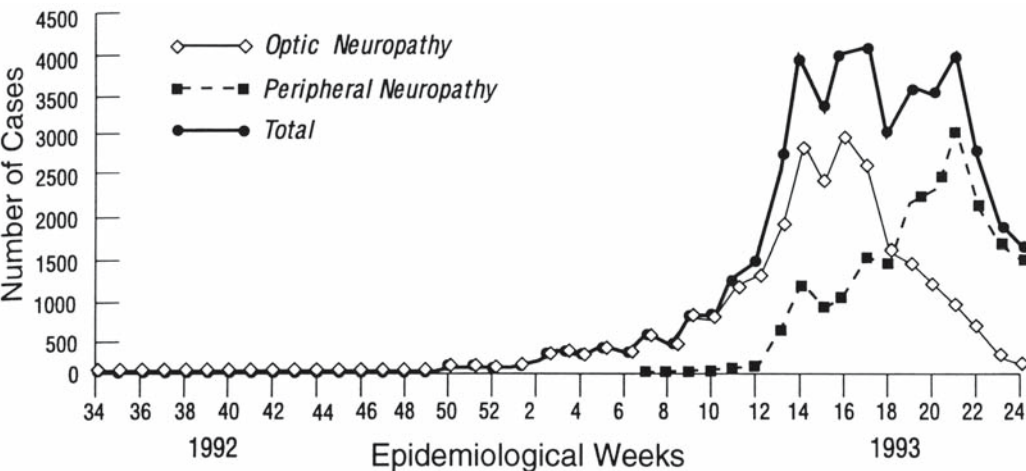


Fig. 13. Profile of the epidemic (the Direction Nacional de Estadísticas, MINSAP, Cuba). (From refs. 308,309.)

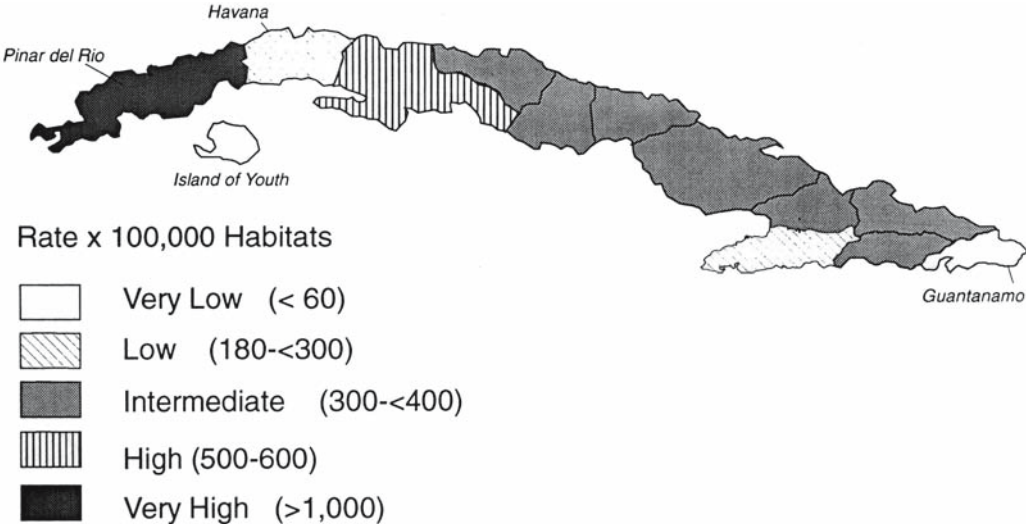


Fig. 14. Incidence rate of neuropathy, by geographic region. (From ref. 9.)

and/or deafness. In early June 1993 there was a large decline in the incidence of cases which coincided with distribution of multivitamin supplements to the entire population of Cuba. Distribution of the vitamins began in May 1993. By January 14, 1994, there was an official tally of 50,862 cases. The history of the epidemic has been summarized elsewhere (308,310,311).

6.7.2. EPIDEMIOLOGY

The cases were classified as having either an optic or peripheral form, although combined forms of the disease were common. Eighty-seven percent of the cases occurred in adults between 25 and 64 yr of age, and the individuals at the lowest risk were children <15 yr, pregnant women, and adults >65 yr old. The national cumulative incidence of all forms of neuropathy, optic and/or peripheral, was 461.4/100,000 persons (9). In total, the

Table 11
Relation of Dietary Intake of Various Nutrients and Cassava to the Risk of Optic Neuropathy

<i>Variable (intake as proportion of total energy)^a</i>	<i>Odds ratio</i>	<i>95% Confidence interval</i>
Energy	0.2	0.1–0.5
Animal protein	0.3	0.1–0.6
Animal fat	0.2	0.1–0.5
Methionine	0.3	0.1–0.6
Cassava	3.0	1.3–6.6
Thiamin	0.5	0.2–1.1
Riboflavin	0.3	0.2–0.7
Niacin	0.5	0.2–1.0
Pyridoxine	0.4	0.2–0.9
Folic acid	0.5	0.2–1.1
Vitamin B ₁₂	0.2	0.1–0.4

^aThe odds ratio is for the highest quartile compared with the lowest quartile. From ref. 312.

Table 12
Relation of Various Types of Behavior and Circumstances to the Risk of Optic Neuropathy

<i>Variable</i>	<i>Odds ratio</i>	<i>95% Confidence interval</i>
Having relatives overseas	0.4	0.2–0.6
Raising chickens at home	0.4	0.2–0.7
Eating lunch <5 times per week	4.4	1.7–11.6
Eating breakfast less than once per week	2.2	1.3–3.7
Going whole days without food	5.9	1.8–15.0
Eating any frozen cassava	0.3	0.1–0.5

Reprinted from ref. 312. Copyright © 1995, Massachusetts Medical Society. All rights reserved.

proportions who were considered to have primarily optic and peripheral forms of the disease were 52% and 48%, respectively (9). The lack of a strict case definition for neuropathy was seen as a limitation in the epidemiological investigations (311).

A case control study was conducted in Pinar del Río in September 1993 order to identify epidemiological risk factors for optic neuropathy (312). One hundred twenty-three patients with severe optic neuropathy were identified and matched to cases by sex, municipality, and age (within 5 yr). The risk of optic neuropathy was lower among in those who had higher intakes of energy, and as a proportion of total energy, animal protein, animal fat, methionine, riboflavin, pyridoxine, and vitamin B₁₂ (312) (Table 11). Although the study did not assess nutritional status of thiamin, niacin, folic acid, vitamin B₁₂, pyridoxine, or riboflavin using biochemical assays, serum measures of vitamin A, major dietary carotenoids, and selenium were assessed. Low serum lycopene, α -carotene, β -carotene, and selenium concentrations were associated with an increased risk of optic neuropathy. Various behavioral and circumstantial factors were also studied (312) (Table 12). Factors that appeared to protect against optic neuropathy were having relatives overseas, raising chickens at home, and eating frozen cassava. Going without lunch or breakfast during the

week or going whole days without food increased the risk of optic neuropathy. Tobacco use, particularly cigar smoking, and high cassava consumption, relative to total energy intake, were both associated with an increased risk of optic neuropathy.

Another case-control study by Mas Bermejo and colleagues (313) showed there was an increased risk of disease with smoking (odds ratio [OR] 4.9, 95% confidence interval [CI] 2.5–9.3), irregular diet or missing meals (OR 4.7, 95% CI 2.5–8.8), combined smoking and drinking history (OR 3.5, 95% CI 1.7–7.4), weight loss (OR 2.8, 95% CI 2.2–3.6), excessive sugar consumption (OR 2.7, 95% CI 2.0–3.7) and heavy drinking (OR 2.3 95% CI 1.0–5.4). Pesticide exposure and household contact were not associated with an increased risk of disease. Another case-control study from the Isle of Youth, Cuba involved 34 cases with bilateral optic neuropathy and 65 healthy controls matched by residential block and age (314). Risk factors that were associated with increased risk of optic neuropathy included weight loss in the last 12 mo and low body mass index. Dietary intake was assessed using a semiquantitative study of intake frequency, and the intake of calories and nutrients was lower and the consumption of alcohol was higher in cases than controls. Intake of all B complex vitamins (thiamin, riboflavin, pyridoxine, niacin, and folic acid) was significantly associated with eye disease. Foods that were protective against disease were tubers and starchy roots (>125 g/d), beans (>120 g/d), oil (>15 g/d), and meat products extended with soybean flour (>15 g/d). Smoking was associated with disease in univariate analysis, but when smoking and alcohol consumption were put in a multivariate analysis with protein, calorie, and nutrient intake, the effect of smoking and alcohol consumption became statistically nonsignificant. This study suggested that foods which contain cyanogenic glucosides, such as yuca (cassava), cabbage, and beans, are not associated with disease, and in fact, some of these were protective against disease.

6.7.3. CLINICAL ASPECTS

The optic neuropathy in the Cuban epidemic was characterized by slowly progressive loss of vision in both eyes, loss of red-green color vision, and sometimes photophobia, burning eyes, lacrimation, and retrobulbar pain (308). Bilateral central or cecocentral scotomas were present and the peripheral visual field was normal. In most cases the optic discs were normal, but 12% had slight hyperemia of optic nerve heads. Loss of nerve fibers in the maculopapillary bundle was a typical finding, and in the context of the Cuban epidemic, was considered pathognomonic (308,315) (Fig. 15). In advanced cases, bilateral temporal optic disc pallor occurred (316) (Fig. 16).

The other neurological findings included a peripheral neuropathy characterized by “burning feet,” tingling, and hyperesthesia of the feet and legs. Bilateral foot drop with a steppage gait and paralysis of hand dorsiflexors were not uncommon and were consistent with beriberi. A dorsolateral myeloneuropathy was evidenced by an increase in urinary frequency, impotence in males, weakness of the legs, and difficulty walking. Gait alterations and frequent falls were often present. Sensorineural deafness, tinnitus, were common. Rarely, there was horseness or dysphagia. In a group of 602 patients with optic neuropathy studied by Santiesteban and colleagues, about one-third presented with skin and mucous membrane lesions consistent with undernutrition, 32% had associated myeloneuropathy, and 21% had hearing deficits on audiometry (317). No fatal cases were reported in the epidemic (9,308). A study of sural nerve biopsies in affected patients showed axonal dystrophy with loss of myelinated nerve fibers, especially large caliber myelinated fibers (318).

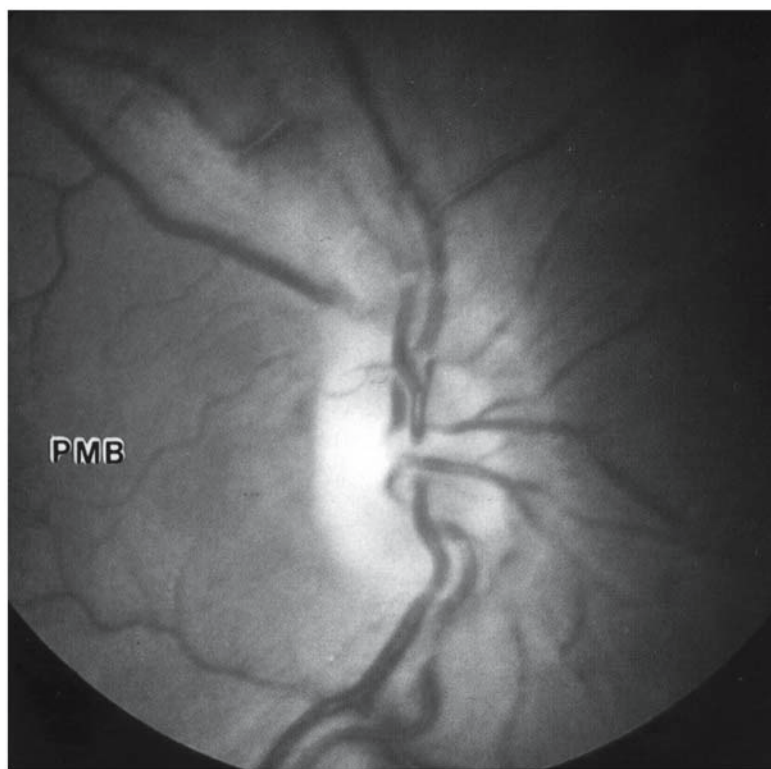


Fig. 15. Loss of papillomacular bundle in a Cuban patient with nutritional amblyopia. (Reprinted from ref. 315. Copyright © 1994, American Medical Association. All rights reserved.)

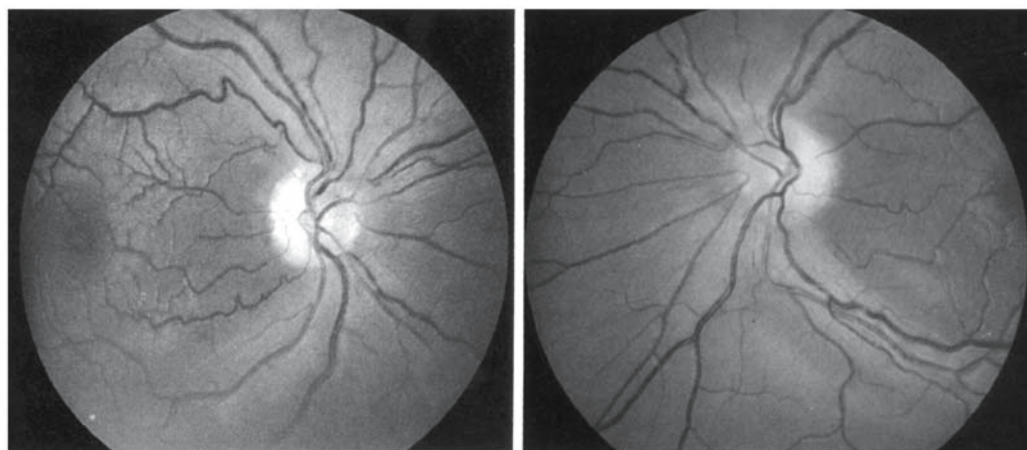


Fig. 16. Bilateral temporal optic disc pallor. (Reprinted from ref. 316. Copyright © 1993, American Medical Association. All rights reserved.)

6.7.4. RESPONSE TO TREATMENT

Confirmed cases were hospitalized and treated with intravenous B-group vitamins and folic acid, and nearly all patients recovered. Less than 0.1% of patients were left with moderate to severe sequelae (308). Oral supplements of B-complex vitamins and vitamin A

were provided by the Cuban government through community-based family physicians to persons in Pinar del Río province in March 1993 and to persons in other provinces starting in May 1993. The incidence of cases decreased during May–June 1993. For patients with optic neuropathy, the vitamin treatment resulted in marked improvement of visual acuity and color vision, except in patients who had a long delay in time of onset of symptoms to vitamin treatment.

6.7.5. INVESTIGATIONS OF OTHER CAUSES OF THE EPIDEMIC

A toxin hypothesis was “vigorously pursued” during initial investigations of the Cuban epidemic (308). Home brewed rum, contaminated tobacco, bush tea, insecticides, dietary cyanogens in cassava, and toxic legumes were among the suspected sources of toxins that could cause the epidemic (308). No toxins were identified, and the epidemiological profile of the outbreak did not fit the toxin theory. It made little sense that home brewed rum, made in thousands of different households with limited distribution, would suddenly appear in epidemic form across the entire island. Many affected individuals did not drink alcohol. Although smokers were at higher risk of optic neuropathy, the disease occurred among non-smokers as well. Other food products, such as bush tea and cassava, were also made produced locally with limited distribution. The only common vehicle for a toxin was edible oil and flour, and these products did not come from a single point source, but rather from many different countries (319). The pattern in an epidemic caused by a toxin in food would show clustering in families and involvement of children, and this did not occur (319). It was even speculated that contaminated poultry feed with antimetabolites such as amprolium could have entered the food supply and caused the outbreak (320). If this were the cause of the epidemic, then the epidemiological pattern would have been the opposite, with children, pregnant women, and adults >65 yr old affected, because individuals in these groups had better access to animal protein such as chicken and eggs during the outbreak.

A genetic hypothesis was also investigated during the Cuban epidemic. The clinical presentation of reduced vision, central or cecocentral scotomas, occasional disc hyperemia, and later, bilateral temporal disc pallor, are also similar to that found in Leber hereditary optic neuropathy. Some affected patients were screened for mitochondrial DNA mutations associated with Leber hereditary optic neuropathy, but these studies did not show any association (321–323). The epidemiological profile of a widespread epidemic in Cuba is not consistent with that expected in a relatively rare genetic condition.

6.7.6. THE SOCIAL AND DIETARY SITUATION

The social and economic situation in Cuba in the period prior and during the epidemic was influenced both by the collapse of the Soviet Union and an economic embargo by the United States (308,324). A recent hurricane had also destroyed the already compromised food crops (325). Food and oil imports were in short supply, and there was a shortage of meat, pork, chicken, fish, eggs, dairy products, and vegetable oil (308). Food rationing was implemented by the Cuban government, but children, pregnant women, and adults >65 yr old received a larger ration of milk and eggs (316).

Nutritional studies conducted during and following the epidemic demonstrate that the Cuban population is highly vulnerable to some dietary deficiencies, such as that for thiamin, riboflavin, niacin, and vitamin B₁₂ (308,312,327–330). Jimenez and colleagues measured vitamin levels in 105 patients with several forms of the disease and asymptomatic

controls. Serum thiamine and TPP effect (TPPE) were normal in only 38% of the patients and 45% of controls, indicating widespread deficiency of thiamin in the population (308). Both patients with neuropathy and unaffected control patients had biochemical evidence of thiamin depletion, and the severity of thiamin deficiency was higher in Pinar del Rio, where the disease was most common, and lower in Havana, where the prevalence of disease was less (326). Two years after the epidemic, vitamin B intake was assessed among 141 healthy middle-aged men in Havana (329). The subjects were seen every 3 mo for 1 yr, and dietary intake and status of thiamin, riboflavin, pyridoxine, folate, and vitamin B₁₂ were measured. Deficient status was noted for all B complex vitamins that were studied except for pyridoxine (329). Further studies also showed that dietary intakes of zinc, vitamin C, and vitamin E were also low in comparison with international reference ranges (329). In another study conducted after the epidemic, smokers were found to have lower concentrations of circulating α -carotene, β -carotene, β -cryptoxanthin, and riboflavin than nonsmokers (330).

The recent epidemic in Cuba is reminiscent of a previous epidemic of amblyopia and peripheral neuropathy that began during the Spanish-American War (331). Domingo L. Madan reported an epidemic increase in cases of amblyopia and peripheral neuropathy characterized by numbness and pain in the toes and feet, accompanied by muscle weakness. The food supply was disrupted during the war, and in May 1898, the United States began a naval blockade of Cuba after declaring war on Spain. This blockade was considered to have contributed to the food shortage and poor quality of food, and the outbreak of eye disease was considered amblyopia due to malnutrition, informally called “amblyopia of the blockade” (331). In 1993, there is no doubt that the social, political, and economic circumstances in 1993 contributed to widespread food shortages, and arguments arose regarding how the collapse of the Soviet Union, the US trade embargo with Cuba, natural disasters, and national government contributed to the epidemic (332–334).

6.7.7. CONCLUSIONS FROM THE CASE STUDY

Nearly one century after Henry Strachan made an early description of nutritional amblyopia in Cuba in 1897 (2), the island was revisited by the largest known epidemic of nutritional amblyopia. Although various etiologies were considered, the circumstances of food rationing, widespread B complex vitamin deficiencies, epidemiological characteristics of the epidemic, clinical presentation of disease, therapeutic response to B complex vitamins, and prevention of further cases with widespread distribution of multivitamin supplements all demonstrate that the underlying etiology of this epidemic was nutritional in nature.

7. DIAGNOSIS OF NUTRITIONAL AMBLYOPIA

The diagnosis of nutritional amblyopia is based on the clinical features of decreased vision, and central or cecocentral scotoma as described under Subheading 5 above. None of the ophthalmological findings are specific for nutritional amblyopia, and the diagnosis should be based on clinical findings, history, and laboratory biochemical evidence of a B vitamin deficiency or combined B complex vitamin deficiencies. Early findings may include slight hyperemia of the optic disc and occasional retinal hemorrhages. Dilation and tortuosity of small retinal vessels with the arcuate areas of the nerve fiber layer have been described as early changes (335). The absolute scotoma rarely exceeds five degrees in diameter. In the late stage of disease, temporal disc pallor and loss of the papillomacular

bundle are usually seen. Associated findings may include skin, mucosal, neurological, gastrointestinal, and hematological signs and symptoms characteristic of specific or mixed B vitamin deficiencies. With associated thiamin deficiency, there may be symmetrical hypesthesia, numb or burning sensation in the legs and toes, loss of Achilles tendon and patellar reflexes, flaccid paralysis of extensor muscles, and other findings as described under Subheading 6.1.9. With associated niacin deficiency, there may be an erythematous, pigmented exfoliative dermatitis, neuropathy, diarrhea, dementia, glossitis, stomatitis, and other findings described under Subheading 6.2.9. Megaloblastic anemia and other clinical manifestations of folate deficiency as described under Subheading 6.3.9. may occur. With associated vitamin B₁₂ deficiency, there may be megaloblastic anemia, glossitis, papillary atrophy of the tongue, and in advanced deficiency, neuropathy and spinal cord dysfunction as described under Subheading 6.4.9. The differential diagnosis of nutritional amblyopia includes Leber hereditary optic neuropathy (336) and toxic optic neuropathies (337). Riboflavin deficiency has also been associated with nutritional amblyopia (*see* Subheading 9.9.6.) and should be considered in the differential diagnosis. Hyperhomocysteinemia has been associated with optic neuropathy and is discussed in Chapter 6.

8. TREATMENT OF NUTRITIONAL AMBLYOPIA

All cases of suspected or confirmed nutritional amblyopia should be treated as soon as possible with daily B complex vitamins or multivitamins that include B complex vitamins, combined with proper diet that includes foods rich in thiamin (e.g., whole grain breads), niacin (e.g., meat, fish, poultry), folate (e.g., beans, green leafy vegetables), and vitamin B₁₂ (e.g., meat, poultry, whole milk). Nutritional amblyopia is generally reversible if treated with proper diet and vitamins within 2 or 3 mo of onset of visual loss, but the chance of visual recovery is decreased with longstanding disease and atrophy of the papillomacular bundle.

9. RIBOFLAVIN DEFICIENCY

Riboflavin is an essential coenzyme for redox reactions in many different metabolic pathways. Riboflavin deficiency, or ariboflavinosis, is of importance in ocular health because it has been associated with corneal vascularization and cataracts. Some of the epidemiological data regarding riboflavin and cataracts are presented in Chapter 3. Cataracts have not been identified as part of the clinical syndrome of riboflavin deficiency in humans, but riboflavin may play a long-term role in the pathogenesis of cataract because of its activity in protecting the crystalline lens against oxidative damage. As with other vitamin B complex deficiencies, such as pellagra and beriberi, riboflavin deficiency was once more common and has declined in prevalence in many developed countries with improvements in socioeconomic standards, better diet, and the fortification of flour, bread, and breakfast cereals with riboflavin. Riboflavin deficiency rarely occurs as an isolated deficiency and is often associated with other vitamin B complex deficiencies.

9.1. Historical Background

Although Alexander Wynter Blyth (1844–1921) described a yellow pigment “lactochrome” in milk in 1879 (338), the significance of this substance as a vitamin was not recognized until many years later. The “water-soluble B” fraction that prevented experimental

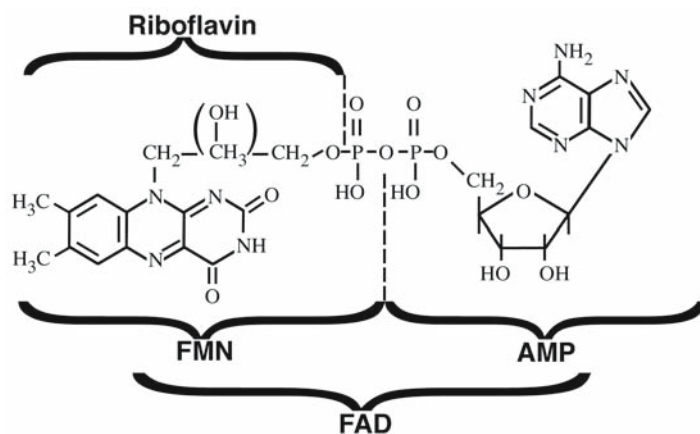


Fig. 17. Structural formulas of riboflavin, flavin mononucleotide (FMN), and flavin adenine dinucleotide (FAD).

beriberi (339) was subsequently separated into a heat-labile portion, vitamin B₁, or thiamin, and a heat-stable portion, vitamin B₂, or the “antipellagra” factor (340,341). It soon became apparent that vitamin B₂ was actually a complex that contained at least three factors: “lactoflavin,” vitamin B₆, and “vitamin PP,” or the “antipellagra” factor niacin. A yellow pigment with green fluorescence was isolated from bottom yeasts in 1932 (342) and was found to be a protein composed of an apoenzyme and a yellow cofactor that served as coenzyme. The following year, this water-soluble pigment “lactoflavin” was isolated in pure form (343,344). The growth-promoting activity of whey was associated with the concentration of yellow pigment that was present (345). Riboflavin was synthesized in 1935 by Richard Kuhn in Heidelberg (346) and Paul Karrer in Zurich (347). Most of the investigations concerned with the corneal vascularization associated with riboflavin deficiency were conducted in the 1940s and 1950s.

9.2. Biochemistry of Riboflavin

Riboflavin, or 7,8-dimethyl-10-(1'-D-ribityl) isoalloxazine, has a basic structure containing an isoalloxazine ring, and the main coenzymes that are derived from riboflavin are flavin mononucleotide (FMN) and flavin adenine dinucleotide (FAD) (Fig. 17). Riboflavin is yellow and has a high degree of natural fluorescence. It is moderately soluble in aqueous solutions, a factor that limits the amount of the vitamin that can be delivered parenterally. Riboflavin is sensitive to degradation by ultraviolet light, a quality that has allowed riboflavin to be used as an experimental agent in photochemical keratodesmos for repair of lamellar corneal incisions (348,349). Obsolete names for riboflavin include vitamin B₂, vitamin G, lactoflavine, lactoflavin, ovoflavin, hepatoflavin, uroflavin, lyochrome, rat growth factor, and cataract-preventive factor.

9.3. Dietary Sources of Riboflavin

Rich dietary sources of riboflavin include milk, meat, liver, dairy products, eggs, and riboflavin-fortified cereals and breads. Vegetables that are higher in riboflavin include broccoli and brussel sprouts.

Table 13
Riboflavin Content of Selected Foods

<i>Food</i>	<i>Riboflavin (mg/100 g)</i>
Yeast extract spread	14.30
Yeast, bakers, dry	5.47
Liver, fried beef	3.43
Kidney, lamb cooked	2.07
Egg, hard-boiled	0.51
Cheese, cheddar	0.38
Beef, ground, lean broiled	0.18
Milk, whole	0.18
Peanuts, raw	0.14
Broccoli, raw	0.12
Potatoes, baked with skin	0.11
Chicken, breast roasted	0.11
Orange	0.05
Apple	0.03
Onion, boiled	0.02
Rice, short-grain, cooked, unenriched	0.01

Based on US Department of Agriculture National Nutrient Database for Standard Reference (<http://www.nal.usda.gov/fnic/foodcomp/search>) (31).

The riboflavin content of some selected foods is shown in Table 13 (31). The extent of riboflavin bioavailability from foods has not been well characterized (350). It is estimated that 95% of food flavin or a maximum of about 27 mg of riboflavin can be absorbed per single meal or dose (351). Most of the riboflavin in foods is found in the form of FAD and FMN.

9.4. Absorption, Storage, and Metabolism of Riboflavin

The upper ileum is the main site for riboflavin absorption. Prior to absorption, FAD and FMN are hydrolyzed in the gut. Absorption of flavins occurs through a saturable, sodium-dependent, active transport system, rather than passive diffusion. Riboflavin is best absorbed in the presence of food (352). In the blood, flavins are transported either tightly bound to immunoglobulins or are more loosely bound to albumin. The metabolism of riboflavin is tightly regulated. There is no body storage of riboflavin, thus, megadoses of riboflavin, as used by some vitamin enthusiasts, are rapidly excreted in the urine.

9.5. Functions of Riboflavin

Riboflavin is a precursor to the coenzymes FMN and FAD and other covalently bound flavins. These flavoenzymes play a role in many oxidation-reduction reactions. FAD is part of the respiratory chain and is involved in energy production. Flavoenzymes are involved in one-electron transfers, dehydrogenase reactions, hydroxylations, oxidative decarboxylations, and dioxygenations. Riboflavin also has strong antioxidant activity through its role in the glutathione redox cycle. Glutathione peroxidase breaks down reactive lipid peroxides, a process that requires reduced glutathione. Reduced glutathione is produced by the FAD-containing enzyme glutathione reductase. Riboflavin deficiency may lower the FAD

Table 14
Dietary Reference Intakes for Riboflavin (mg/d)

<i>Age and gender category</i>	<i>AI</i>	<i>EAR</i>	<i>RDA</i>
Infants, 0–6 mo	0.3	–	–
Infants, 7–12 mo	0.4	–	–
Children, 1–3 yr	–	0.4	0.5
Children, 4–8 yr	–	0.5	0.6
Boys and girls, 9–13 yr	–	0.8	0.9
Boys, 14–18 yr	–	1.1	1.3
Girls, 14–18 yr	–	0.9	1.0
Adult men ≥19 yr	–	1.1	1.3
Adult women ≥19 yr	–	0.9	1.1
Pregnant women	–	1.2	1.4
Lactating women	–	1.3	1.6

AI, Adequate Intake; EAR, Estimated Average Requirement; RDA, Recommended Dietary Allowance. Based on ref. 42.

available for glutathione reductase and inhibit the ability to deal with reactive lipid peroxides and oxidative stress. There are many different flavoenzymes, and these include mitochondrial electron-transfer flavoprotein, mitochondrial NADH dehydrogenase, glutathione reductase, monoamine oxidase, and microsomal FAD-containing mono-oxygenase (353). There are complex interactions between some micronutrients, as niacin requires FAD for the formation of niacin from tryptophan, and FMN is needed for the conversion of vitamin B₆ to pyridoxal 5'-phosphate.

9.6. Requirements for Riboflavin

The Food and Nutrition Board of the Institute of Medicine has made new recommendations of riboflavin intake by life stage and gender group (42) (Table 14). The AI is the recommended level of intake for infants. The EAR is the daily intake value that is estimated to meet the requirement of half the healthy individuals in a group. The RDA is defined as the EAR plus twice the CV to cover 97–98% of individuals in any particular group. The requirements for riboflavin increase with pregnancy and lactation. Physical activity may increase the requirement for riboflavin, but there is still insufficient evidence to change general recommendations for riboflavin intake (Food and Nutrition Board 1998).

9.7. Epidemiology of Riboflavin Deficiency

Inadequate riboflavin status, as defined by laboratory assessment and dietary intake, is highly prevalent in many parts of the world, and specific reports have come from Great Britain (354), Spain (355), Saudi Arabia (356), The Gambia (357), Nigeria (358,359), Zimbabwe (360), China (361), Brazil (362), Mexico (363), and Guatemala (364). Riboflavin deficiency is relatively common in countries that do not require the fortification of foods, such as flour, with riboflavin. Individuals who eat a diet low in dairy products and meat are at more likely to develop riboflavin deficiency, and strict vegetarians who do not take vitamin supplements with riboflavin are at especially higher risk of riboflavin deficiency (365). Diseases such as diabetes mellitus, cancer, and cardiac disease may

increase the risk of riboflavin deficiency (367–369). Phototherapy with ultraviolet light for certain skin disorders and neonatal jaundice may increase the risk of riboflavin deficiency, as riboflavin can be deactivated by ultraviolet light.

9.8. Assessment of Riboflavin Deficiency

Laboratory tests for riboflavin status include urinary excretion of riboflavin and erythrocyte glutathione reductase activity (52). The body does not store riboflavin, thus, riboflavin in excess of requirements is excreted in the urine. Urinary excretion of riboflavin is negligible if the dietary intake of riboflavin is low. Riboflavin status in adults has been defined as deficient, marginal, and acceptable for urine riboflavin of <40, 40–119, and ≥ 120 μg , respectively, per 24-h urine collection (52). If 24-h urine collection cannot be undertaken, riboflavin can be measured in a random urine sample and expressed as μg riboflavin per gram creatinine. Using random urine samples, riboflavin status in adults has been defined as deficient, marginal, and acceptable for urine riboflavin of <27, 27–79, and ≥ 80 μg , respectively, per gram creatinine (52). Urine riboflavin measurements are limited in that they are influenced by sudden withdrawal of riboflavin from the diet, are relatively insensitive to low and moderate intakes of riboflavin, and do not necessarily reflect long term riboflavin status.

The method of choice for assessment of riboflavin status is the erythrocyte glutathione reductase assay. Erythrocyte glutathione reductase is a flavoenzyme that is present within red blood cells, and it requires FAD as a cofactor. Holo-glutathione reductase consists of the enzyme associated with FAD. With long term riboflavin deficiency, there is a progressive loss of FAD from the enzyme, leaving intact apo-glutathione reductase. The assay measures the amount of unsaturated, or apo-glutathione reductase activity, in a blood sample. A fresh blood sample is taken and lysed, and glutathione reductase activity is measured both with and without FAD added to the blood sample. In riboflavin deficiency, the added FAD combines with apo-glutathione reductase and forms functional holo-glutathione reductase, and there is a resulting increase in activity. In the riboflavin-sufficient state, there is mostly holo-glutathione reductase present, thus the added FAD will not cause much change in activity of the enzyme. The result of this test is expressed as the activity coefficient (AC), or the activity with added FAD over the activity without added FAD. For all ages, the activity coefficients that define deficient, marginal, and acceptable riboflavin status are 1.40, 1.20–1.40, and <1.20, respectively (52).

9.9. Clinical Manifestations of Riboflavin Deficiency

9.9.1. GENERAL SIGNS AND SYMPTOMS OF HUMAN RIBOFLAVIN DEFICIENCY

Riboflavin deficiency is characterized by soreness and burning of the lips, mouth, and tongue, cheilosis, angular stomatitis, seborrheic dermatitis, and glossitis (370–372). These findings are not specific for riboflavin deficiency and also occur in pellagra, or niacin deficiency, and folate deficiency. Cheilosis is defined as shallow ulcerations or crusting and chapping of the lips. Angular stomatitis consists of redness and maceration of the angles of the mouth, and this may progress to bleeding fissures, fissures covered with yellow crusts, and scars at the angles of the mouth. The seborrheic dermatitis is found in the nasolabial and nasomalar folds, the alae nasi, the vestibule of the nose, and around the outer and inner canthi of the eyes. The glossitis is characterized by a purplish-red or magenta-

colored tongue with smooth, flattened papillae. Although these oral and facial lesions have been considered by some to be specific for riboflavin deficiency alone (373), there has never been conclusive evidence to separate these lesions from pellagra. Riboflavin deficiency is so widely distributed in small amounts that absolute, total depletion apparently never occurs, and there have been no reports of deaths from riboflavin deficiency (374).

9.9.2. PERIPHERAL CORNEAL VASCULARIZATION IN HUMANS

Riboflavin deficiency has been reportedly associated with peripheral corneal vascularization in humans (375–385), but despite numerous reports, it is uncertain whether this ocular finding can be definitively attributed to riboflavin deficiency. Burning and itching of the eyes, photophobia, and a subepithelial keratitis have also been described in riboflavin deficiency (378,386,387). Angular blepharitis may be present and accompany angular stomatitis (388). Peripheral corneal vascularization is not considered pathognomonic for riboflavin deficiency and has been reported to occur among individuals who are more severely riboflavin-deficient. The corneal vascularity that occurs in riboflavin deficiency has been defined as a condition in which newly formed blood vessels leave the limbic plexus and centripetally enter the subepithelial space of the true cornea (389), and a slit lamp is necessary to see these vessels (376) (Fig. 18). In areas of the world where riboflavin deficiency was more common, there have been large case series of patients with superficial keratitis and corneal vascularization who responded well to riboflavin therapy (390,391).

Initially, there was a great deal of confusion caused by the inappropriate use of the terms “conjunctivitis,” “engorgement of the limbic plexus,” and “circumcorneal injection” to describe corneal lesions associated with riboflavin deficiency (382,392,393). These vague descriptions led to apparent misdiagnosis and overdiagnosis of ocular signs of riboflavin deficiency (394), with some surveys reporting a prevalence of riboflavin deficiency of 50–100% based on the particular interpretation of the vascular abnormality (395–400). One study in The Gambia reported that 37% of 536 Europeans and 5% of 1700 Africans had corneal vascularity, but the prevalence of angular stomatitis, cheilosis, and glossitis was much higher among Africans than Europeans (401). With slit lamp examination and strict criteria for peripheral corneal vascularization, i.e., actual invasion of clear cornea by vessels from the limbus, the prevalence of riboflavin deficiency based on ocular criteria has been much lower in various surveys (382,392,402). Corneal vascularization from riboflavin deficiency was reportedly common in India (403) and China (404). Other corneal conditions, such as previous trauma and trachomatous pannus, have been reported to flare up under conditions of riboflavin deficiency (405,406). Recently, riboflavin deficiency has been linked with the maintenance of the corneal and conjunctival epithelium and goblet cells in riboflavin-deficient rats (407).

The differential diagnosis of peripheral corneal vascularization includes acne rosacea, phlyctenular keratitis, trachoma, chemical burns, and previous infections of the cornea, such as bacterial and viral keratitis. The purported cornea vascularization of riboflavin deficiency has been reported to be accompanied by other signs of riboflavin deficiency, such as angular stomatitis, cheilosis, and glossitis. The purported corneal vascularization seen in riboflavin deficiency reportedly resolves within 3–6 wk with daily oral riboflavin therapy (389). It is not known whether long-standing riboflavin deficiency results in a more refractory state of corneal vascularization to riboflavin therapy. Riboflavin therapy has been attempted for many conditions with corneal vascularity, including acne rosacea,

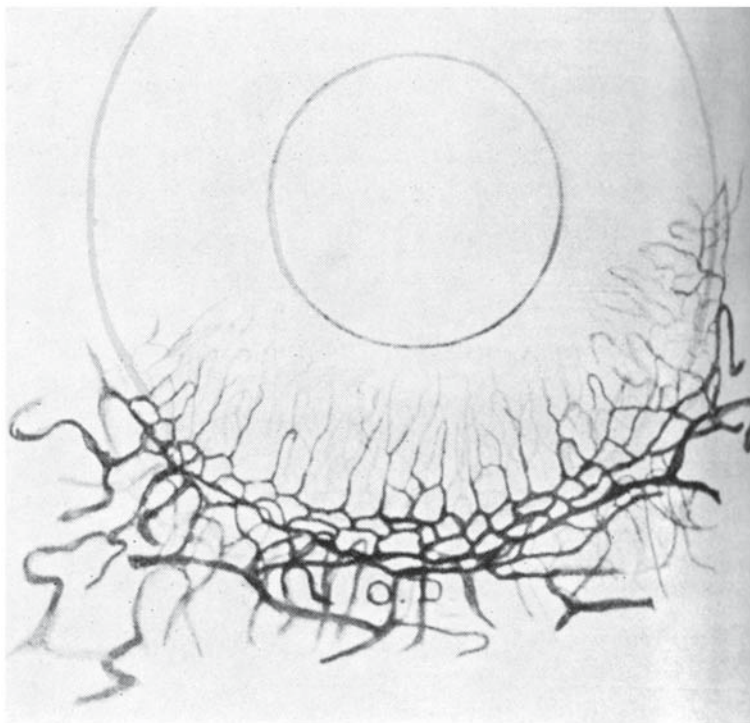


Fig. 18. Corneal vascularization purportedly associated with riboflavin deficiency. (From ref. 376, with permission.)

syphilitic keratitis, phlyctenular keratitis, and herpes zoster keratitis, with mostly negative results (377,408–414). Riboflavin therapy did not reverse the corneal vascularization of patients that were considered to have the signs of riboflavin deficiency, but it appears that most of these patients had corneal vascularization associated with rosacea keratitis (415).

9.9.3. PERIPHERAL CORNEAL VASCULARIZATION IN EXPERIMENTAL DEFICIENCY

Early investigations showed that peripheral corneal vascularization could be produced in riboflavin-deficient rats (Fig. 19) (416–419). Riboflavin deficiency in rats has been used as an experimental model for the study of corneal vascularization (420). After 12 wk on a riboflavin-deficient diet, rats develop a slight polymorphonuclear infiltrate beneath the corneal epithelium, and by 14 wk, the leukocytes extend into the deeper corneal stroma. By the 16th week of deficiency, blood vessels grow into the cornea stroma from the limbus. The leukocytes disappear by 24 wk of riboflavin deficiency, leaving persistent corneal vascularization (420). The presence of keratitis in the experimental animal model is consistent with reports of a subepithelial keratitis in humans with riboflavin deficiency (378) and provides some clues as to the presence of abnormal blood vessels in the cornea. The healing of the cornea in riboflavin deficiency may be exacerbated by ultraviolet light exposure (421).

Attempts have been made to produce riboflavin deficiency experimentally in humans by a low-riboflavin diet (422–425) or by administration of galactoflavin, a riboflavin antagonist (426–428). In four adult subjects kept on a low-riboflavin diet of 0.8–0.9 mg riboflavin/d for 9 mo, no signs of riboflavin deficiency developed, including glossitis,

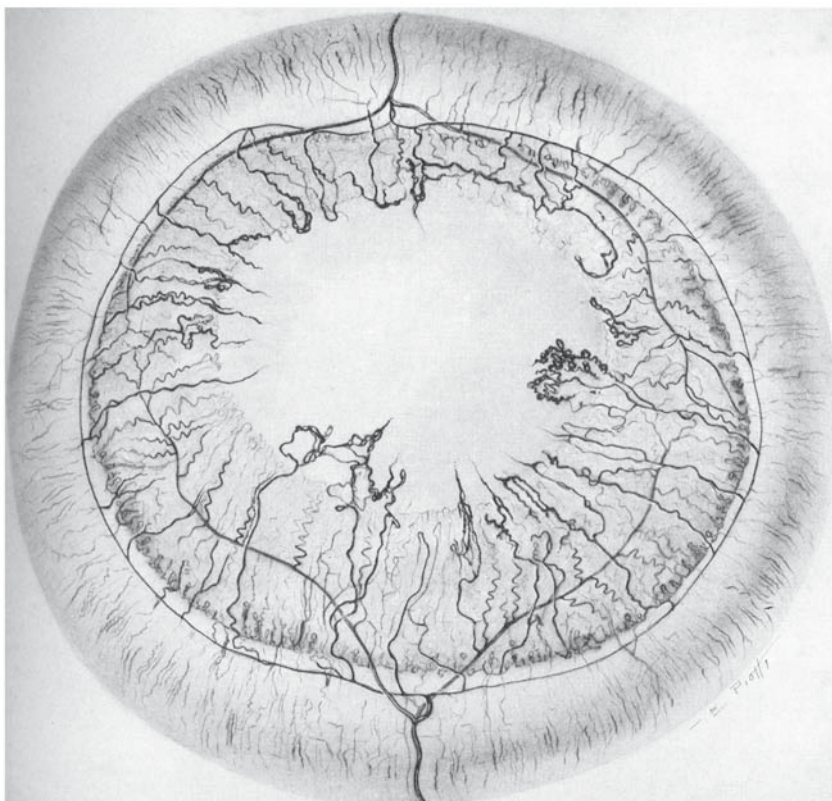


Fig. 19. Drawing of peripheral corneal vascularization in a riboflavin-deficient rat. (From ref. 417, with permission of the Rockefeller University Press.)

angular stomatitis, or corneal vascularization (422). No corneal vascularity was noted in six subjects who received a diet containing 0.9 mg riboflavin per day (423). The daily intake of riboflavin in these studies (422,423) was close to the EAR of riboflavin (0.9 mg/d for women, 1.1 mg/d for men) (42), and perhaps it is not surprising that no signs of riboflavin deficiency occurred in these so-called “deficiency” experiments. Corneal vascularization was not found in three subjects who had a diet of about 0.5 mg riboflavin per day, but the study was terminated after only 5 wk (424). In another study, fifteen male subjects were given 0.6 mg riboflavin per day for over 1 yr, and no subjects developed corneal vascularization (429).

Galactoflavin-induced riboflavin deficiency resulted in a syndrome of sore throat, cheilosis, angular stomatitis, glossitis, seborrheic dermatitis, and anemia, and these changes were reversible with administration of riboflavin (426–428). Some of the patients developed peripheral neuropathy. The signs and symptoms of riboflavin deficiency were induced rapidly after 10–25 d of galactoflavin administration, but peripheral corneal vascularization and cataracts were not found among the 11 study subjects during this short time period (427,428).

9.9.4. RIBOFLAVIN DEFICIENCY AND CATARACTS

Riboflavin was once known as the “cataract-protective factor” after studies demonstrated that riboflavin deficiency would produce cataracts in many different species of

animals, including mice (430), rats (416,432–441), cats (442), dogs (443), and pigs (444). In the early stages of cataract formation, the cataracts are reversible with administration of riboflavin (435). Early efforts were made to apply these findings to humans by treatment of senile cataract with riboflavin therapy (445,446). The flavins FAD and FMN are found in high concentrations in the lens, cornea, and retina (447,448), suggesting an important role for riboflavin in the eye. Riboflavin deficiency has been shown to alter the composition of lens proteins in rats (449) and to lower the glutathione reductase activity of the lens (450–452). Reduced glutathione protects the lens from photo-oxidative stress, and riboflavin is required by glutathione reductase for the regeneration of reduced glutathione. A controlled clinical trial in China suggests that riboflavin/niacin supplements may protect against nuclear cataracts (453). The epidemiological studies regarding nutrition and cataract in humans are discussed in detail in Chapter 3.

9.9.5. RIBOFLAVIN DEFICIENCY AND RETINAL VASCULAR DISEASE

Recent studies suggest that riboflavin could potentially be involved in the pathogenesis of vascular disease, including retinal vascular disease, through its role in the metabolism of homocysteine (455). High plasma concentrations of homocysteine have been associated with diabetic retinopathy (456,457). Animal studies suggest that riboflavin metabolism is altered in diabetes (458,459), and riboflavin deficiency has been described among children with diabetes mellitus (367). The relationships between riboflavin status, homocysteine, and diabetic retinopathy have not been well characterized in humans.

9.9.6. RIBOFLAVIN DEFICIENCY AND NUTRITIONAL AMBLYOPIA

Nutritional amblyopia has been described among children and adults with pellagra. It has been difficult to distinguish pellagra from riboflavin deficiency in these reports, as multiple deficiencies in B complex vitamins were probably present. Some clinicians have classified glossitis and angular stomatitis without dermatitis as *pellagra sine pellagra*, and others have considered that this syndrome actually represents pure riboflavin deficiency. Riboflavin deficiency was also present among prisoners-of-war in South and Southeast Asia during World War II, where a significant proportion of prisoners developed nutritional amblyopia (Subheading 6.6.).

9.10. Treatment of Riboflavin Deficiency

Riboflavin deficiency can be treated with oral riboflavin, 5 mg, two or three times daily. Nutrition education, with emphasis on increasing intake of food sources rich in riboflavin, i.e., meat and dairy products, should be part of an integrated approach to long term prevention of riboflavin deficiency. Riboflavin deficiency can be prevented in strict vegetarians by a daily multivitamin supplement.

10. CONCLUSIONS

Nutritional amblyopia may occur among individuals who have a diet poor in B complex vitamins, and the general settings include alcoholism and malnutrition, dietary deprivation in prisoners, and nutritional deficiencies following natural or man-made disasters such as crop failures and economic hardships. Although some have argued that nutritional amblyopia is due to one specific B deficiency, there are multiple examples from the clinical and experimental literature that suggest that nutritional amblyopia may occur with

thiamin, niacin, folate, or vitamin B₁₂ deficiency, or a combination of these deficiencies. Since B complex vitamins are often found in the same foods, the risk of combined B complex deficiencies is probably higher. Clinical riboflavin deficiency is rare in developed countries where riboflavin fortification of flour and other foods is common. Clinical riboflavin deficiency is purportedly associated with corneal vascularization, and there appears to be an increased risk of cataracts associated with low riboflavin status. Riboflavin appears to be involved as a key antioxidant in the protection of the lens from photo-reactive damage, but further work is needed to elucidate the role of riboflavin in cataract formation.

REFERENCES

1. Strachan H. Malarial multiple peripheral neuritis. *Annu Univ Med Sci* 1888;1:139–141.
2. Strachan H. On a form of multiple neuritis prevalent in the West Indies. *The Practitioner* (London) 1897;51:477–484.
3. Shimazono J. I. B-Avitaminosis und Beriberi. Mit Bemerkungen zur alimentären Anämie, Veränderung der Nervensubstanz durch Aufbrauch und zur zentralen Wirkung der Schilddrüsensubstanz usw. *Ergebnisse der inneren Medizin und Kinderheilkunde* 1931;39:1–68.
4. Hori M. Über Augenerkrankungen bei Kakke. *Tokyo Igakkai Zasshi* 1888;5:4–27.
5. Kono T. Über das Auftreten der centralen Sehschwäche im Verlaufe von Kakke. *Tokyo Igakkai Zasshi* 1896;10:255–262.
6. Komoto J. [On the ophthalmological symptoms in the patient suffering from kakke.] *Tokyo Iji Shinsi* 1898;1030:1–5.
7. Lowther AH. Ocular disturbances associated with malnutrition. General discussion. *Trans Ophthalmol Soc UK* 1946;66:104–107.
8. Ridley H. Ocular disturbances associated with malnutrition. *Trans Ophthalmol Soc UK* 1946;66:45–71.
9. Centers for Disease Control. Epidemic neuropathy—Cuba, 1991–1994. *MMWR Morb Mortal Wkly Rep* 1994;43:183, 189–192.
10. Carpenter KJ. Beriberi, White Rice, and Vitamin B: A Disease, a Cause, and a Cure. Berkeley, University of California Press, 2000.
11. Bondt, J de. *De medicina Indorum. Lugdoni Batavorum, F. Hackium*, 1642.
12. Takaki B. Three lectures on the preservation of health amongst personnel of the Japanese Navy and Army. *Lancet* 1906;1:1369–1374 (lecture 1), 1451–1455 (lecture 2).
13. Eijkman C. Polyneuritis bij hoenders. *Geneesk Tijdschr Nederl Indië* 1890;30:295.
14. Eijkman C. Polyneuritis bij hoenders. *Geneesk Tijdschr Nederl Indië* 1893;32:353.
15. Eijkman C. Polyneuritis bij hoenders. *Geneesk Tijdschr Nederl Indië* 1896;36:214.
16. Fletcher W. Rice and beri-beri: preliminary report on an experiment conducted at the Kuala Lumpur Lunatic Asylum. *Lancet* 1907;1:1776–1779.
17. Fletcher W. Rice and beri-beri. *J Trop Med Hyg* 1909;12:127–135.
18. Vorderman AG. Onderzoek naar het verband tusschen den aard der rijstvoeding in de gevangenissen op Java en Madoera en het voorkomen van beri-beri onder de geïnterneerden. Batavia, Jav. Boekh. & Drukkerij, 1897.
19. Strong RF, Crowell BC. The etiology of beriberi. *Phil J Sci* 1912;7(B):271–411.
20. Fraser H, Stanton AT. An inquiry concerning the etiology of beriberi. *Studies from the Institute for Medical Research*, No. 10, 1909.
21. Funk C. On the chemical nature of the substance which cures polyneuritis in birds induced by a diet of polished rice. *J Physiol* 1911;43:395–400.
22. Suzuki U, Shimamura T, Odake S. Über Oryzanin, ein Bestandteil der Reiskleie und seine physiologische Bedeutung. *Biochemische Zeitschrift* 1912;43:89–153.
23. Jansen BCP, Donath WF. Antineuritische Vitamine. *Chem Weekbl* 1926;23:1387–1409.
24. Williams RR, Cline JK. Synthesis of vitamin B₁. *J Am Chem Soc* 1936;58:1504–1505.
25. Wilder RM, Williams RR. Enrichment of Flour and Bread: A History of the Movement. *Bulletin of the National Research Council* No. 110. Washington, D.C., National Academy of Sciences, 1944.

26. Ma JJ, Truswell AS. Wernicke-Korsakoff syndrome in Sydney hospitals: before and after thiamine enrichment of flour. *Med J Aust* 1995;163:531–534.
27. Harper CG, Sheedy DL, Lara AI, Garrick TM, Hilton JM, Raisanen J. Prevalence of Wernicke-Korsakoff syndrome in Australia: has thiamine fortification made a difference? *Med J Aust* 1998;168:542–545.
28. Vedder EB. *Beriberi*. New York, William Wood and Company, 1913.
29. Williams RR. *Toward the Conquest of Beriberi*. Cambridge, Harvard University Press, 1961.
30. Shimazono N, Katsura E. Review of Japanese Literature on Beriberi and Thiamine. Tokyo, Vitamin B Research Committee of Japan, 1965.
- 30a. Rindi G, de Giuseppe L. The content of thiamine and its mono-, di- and triphosphoric esters in different biological materials. *Int Z Vitamin Forsch* 1961;31:321–326.
31. U.S. Department of Agriculture National Nutrient Database for Standard Reference (<http://www.nal.usda.gov/fnic/foodcomp/search>)
32. Gregory JF III. Bioavailability of thiamin. *Eur J Clin Nutr* 1997;51(suppl 1):S34–S37.
33. Rindi G, Ferrari G. Thiamine transport by human intestine in vitro. *Experientia* 1977;33:211–213.
34. Rindi G, Laforenza U. Thiamine intestinal transport and related issues: recent aspects. *Proc Soc Exp Biol Med* 2000;224:246–255.
35. Friedemann TE, Kmiecik TC, Keegan PK, Sheft BB. The absorption, destruction, and excretion of orally administered thiamin by human subjects. *Gastroenterology* 1948;11:100–114.
36. Morrison AB, Campbell JA. Vitamin absorption studies. I. Factors influencing the excretion of oral test doses of thiamine and riboflavin by human subjects. *J Nutr* 1960;72:435–440.
37. Thomson AD, Leevy CM. Observations on the mechanism of thiamine hydrochloride absorption in man. *Clin Sci* 1972;43:153–163.
38. Picciano MF. Vitamins in milk. A. Water-soluble vitamins in human milk. In: Jensen RG (ed). *Handbook of Milk Composition*. San Diego, Academic: 1995; pp. 675–688.
39. Howard L, Wagner C, Schenker S. Malabsorption of thiamin in folate-deficient rats. *J Nutr* 1974;104:1024–1032.
40. Thomson AD, Baker H, Leevy CM. Patterns of ³⁵S-thiamine hydrochloride absorption in the malnourished alcoholic patient. *J Lab Clin Med* 1970;76:34–45.
41. Tanphaichitr V. Thiamine. In: Rucker RB, Suttie JW, McCormick DB, Machlin LJ (eds). *Handbook of Vitamins*. Third edition. New York and Basel, Marcel Dekker: 2001; pp. 275–316.
42. Food and Nutrition Board, Institute of Medicine. Dietary Reference Intakes for Thiamin, Riboflavin, Niacin, Vitamin B₆, Folate, Vitamin B₁₂, Pantothenic Acid, Biotin, and Choline. A report of the Standing Committee on the Scientific Evaluation of Dietary Reference Intakes and its Panel on Folate, Other B Vitamins, and Choline, and Subcommittee on Upper Reference Levels of Nutrients. Washington, D.C., National Academy Press, 1998.
43. Elmadfa I, Majchrzak D, Rust P, Genser D. The thiamine status of adult humans depends on carbohydrate intake. *Int J Vitam Nutr Res* 2001;71:217–221.
44. Manore MM. Effect of physical activity on thiamine, riboflavin, and vitamin B-6 requirements. *Am J Clin Nutr* 2000;72(suppl):598S–606S.
45. Scheube B. *Die Beriberi-Krankheit: Eine geographisch-medicinische Studie*. Jena, Gustav Fischer, 1894.
46. Suter PM, Vetter W. Diuretics and vitamin B₁: are diuretics a risk factor for thiamin malnutrition? *Nutr Rev* 2000;58:319–323.
47. Iber FL, Blass JP, Brin M, Leevy CM. Thiamin in the elderly—B relation to alcoholism and to neurological degenerative disease. *Am J Clin Nutr* 1982;36:1067–1082.
48. Vir SC, Love AHG. Thiamine status of institutionalised and non-institutionalised aged. *Int J Vitam Nutr Res* 1977;47:325–335.
49. Vir SC, Love AHG. Nutritional status of institutionalized and noninstitutionalized aged in Belfast, Northern Ireland. *Am J Clin Nutr* 1979;32:1934–1847.
50. Hoorn RKJ, Flikweert JP, Westerink D. Vitamin B-1, B-2, and B-6 deficiencies in geriatric patients, measured by coenzyme stimulation of enzyme activities. *Clin Chim Acta* 1975;61:151–162.
51. Boldorini R, Vago L, Lechi A, Tedeschi F, Trabatttoni GR. Wernicke's encephalopathy: occurrence and pathological aspects in a series of 400 AIDS patients. *Acta Biomed Atheneo Parmense* 1992;63:43–49.

52. Sauberlich HE. Laboratory Tests for the Assessment of Nutritional Status. Second edition. Boca Raton, CRC Press, 1999.
53. Kawai C, Wakabayashi A, Matsumura T, Yui Y. Reappearance of beriberi heart disease in Japan. A study of 23 cases. *Am J Med* 1980;69:383–386.
54. Inouye K, Katsura E. Clinical signs and metabolism of beriberi patients. In: Shimazono N, Katsura E. Review of Japanese Literature on Beriberi and Thiamine. Tokyo, Vitamin B Research Committee of Japan: 1965; pp. 29–63.
55. Yamamoto Y. Über Centraskotom bei Kakke. *Ophthalmol Klinik (Stuttgart)* 1903;7:119.
56. Aoki T. Über Centralskotom bei Kakke (Beriberi). *Ophthalmol Klinik (Stuttgart)* 1903;7:118.
57. Tarissan. Le bérubéri au Brésil. *Faculté de Médecine de Paris, Thèse No. 110*. Paris, A. Parent, 1881.
58. Fernando AS. The eye in beri-beri. *Am J Ophthalmol* 1923;6:385–388.
59. P'an C. Retrobulbar neuritis among the Chinese: a preliminary report. *Chin Med J* 1934;48:999–1004.
60. P'an C, Ling WP. Further observations on retrobulbar neuritis in the Chinese. *Chin Med J* 1936;50:1373–1380.
61. Lin CK. Retrobulbar neuritis among the Chinese: report of 53 cases. *Chin Med J* 1936;50:1345–1372.
62. Soriano FJ, Puiggari MI. Neuritis retro bulbar beriberica. *Archivos de Oftalmología de Buenos Aires* 1938;13:244–250.
63. Little JM. Beriberi. *J Am Med Assoc* 1914;63:1287–1290.
64. Little JM. Beriberi caused by fine white flour. *J Am Med Assoc* 1912;58:2029–2030.
65. Aykroyd WR. Beriberi and other food-deficiency diseases in Newfoundland and Labrador. *J Hygiene* 1930;30:357–386.
66. Kagawa S. Studies on the relationship of neuritis axialis to beriberi in Japan (first report). *Jpn J Med Sci* 1938;5:1–16.
67. Kageshima S. [On the anatomical change of eyes, especially of the optic nerves in beriberi.] *Acta Soc Ophthal Jpn* 1918;22:1069.
68. Hagedoorn A. Defizienz-Neuritis. *Klin Monatsbl Augenh* 1939;102:726.
69. Victor M, Adams RD, Collins GH. The Wernicke-Korsakoff syndrome and related neurologic disorders due to alcoholism and malnutrition. Second edition. Philadelphia, F. A. Davis Company, 1989.
70. Victor M, Mancall EL, Dreyfus PM. Deficiency amblyopia in the alcoholic patient. A clinicopathologic study. *Arch Ophthalmol* 1960;64:1–33.
71. Victor M, Dreyfus PM. Tobacco-alcohol amblyopia: further comments on its pathology. *Arch Ophthalmol* 1965;74:649–657.
72. Leigh D. Subacute necrotizing encephalomyelopathy in an infant. *J Neurol Neurosurg Psychiatry* 1951;14:216–221.
73. Kretzschmar HA, DeArmond SJ, Koch TK, et al. Pyruvate dehydrogenase complex deficiency as a cause of subacute necrotizing encephalopathy (Leigh disease). *Pediatrics* 1987;79:370–373.
74. Willems JL, Monnens LAH, Trijbels JMF, et al. Leigh's encephalomyelopathy in a patient with cytochrome *c* oxidase deficiency in muscle tissue. *Pediatrics* 1977;60:850–857.
75. Van Erven PMM, Gabreëls FJM, Ruitenbeek W, Renier WO, Fischer JC. Mitochondrial encephalomyopathy: association with an NADH dehydrogenase deficiency. *Arch Neurol* 1987;44:775–778.
76. Howard RO, Albert DM. Ocular manifestations of subacute necrotizing encephalomyelopathy (Leigh's disease). *Am J Ophthalmol* 1972;74:386–392.
77. Hayashi N, Geraghty MT, Green WR. Ocular histopathologic study of a patient with the T 8993-G point mutation in Leigh's syndrome. *Ophthalmology* 2000;107:1397–1402.
78. Pastoris O, Savasta S, Foppa P, Catapano M, Dossena M. Pyruvate dehydrogenase deficiency in a child responsive to thiamine treatment. *Acta Paediatr* 1996;85:625–628.
79. Di Rocco M, Lamba LD, Minniti G, Caruso U, Naito E. Outcome of thiamine treatment in a child with Leigh disease due to thiamine-responsive pyruvate dehydrogenase deficiency. *Eur J Paediatr Neurol* 2000;4:115–117.
80. Carelli V, Sadun AA. Optic neuropathy in Lhon and Leigh syndrome. *Ophthalmology* 2001;108:1172–1173.
81. Barletta V. Chiasma e nervi ottici nel beri-beri sperimentale del Colombo. (Ricerca isto-patologica). *Rass Ital Ott* 1932;1:210–227.

82. Marchesini E, Papagno M. Contributo clinico ed anatomo-patologico alle manifestazioni oculari nel beri-beri aviario sperimentale. *Ann Ottal Clin Ocul* 1935;63:81–97.
83. Swank RL, Prados M. Avian thiamine deficiency. II. Pathologic changes in the brain and cranial nerves (especially the vestibular) and their relation to the clinical behavior. *Arch Neurol Psychiat* 1942;47:97–131.
84. Chick H, Peters RA, Carter CW, et al. Discussion on avitaminosis (B group) in tropical and temperate countries. *Proc Roy Soc Med* 1933–1934;27:473–487.
85. McDermott W, Webster B, Baker R, Lockhart J, Tompsett R. Nutritional degeneration of the optic nerve in rats: its relation to trypanamide amblyopia. *J Pharmacol* 1943;77:24–39.
86. Prickett CO. The effect of a deficiency of vitamin B₁ upon the central and peripheral nervous systems of the rat. *Am J Physiol* 1934;107:459–470.
87. Leinfelder PJ, Robbie WA. Experimental studies in retrobulbar neuritis. *Am J Ophthalmol* 1947;30:1135–1143.
88. Rodger FC. Experimental thiamin deficiency as a cause of degeneration in the visual pathway of the rat. *Br J Ophthalmol* 1953;37:11–29.
89. Lee J, Sure B. Avitaminosis. XIX. Nerve degeneration in albino rats as studied by the freezing-drying method and polarized light with deficiency of vitamin A or of vitamin B. *Arch Pathol* 1937;24:430–442.
90. Collins GH. The morphology of myelin degeneration in thiamine deficiency. In: Gubler CJ, Fujiwara M, Dreyfus PM (eds). *Thiamine*. New York, John Wiley & Sons: 1976; pp. 261–269.
91. Kark RAP, Brown WJ, Edgerton VR, Reynolds SF, Gibson G. Experimental thiamine deficiency: neuropathic and mitochondrial changes induced in rat muscle. *Arch Neurol* 1975;32:818–825.
92. Tode G. [Experimental B-avitaminosis in man.] *Nisshin Igaku* 1923;13:775, 1267, and *Nisshin Igaku* 1926;16:81.
93. Kagawa S. Studies on the relation of neuritis optica axialis to beriberi in Japan (Third report). *Jpn J Med Sci VIII Int Med Ped Psych* 1938;5:43–60.
94. Williams RD, Mason HL, Wilder RM, Smith BF. Observations on induced thiamine (vitamin B₁) deficiency in man. *Arch Intern Med* 1940;66:783–799.
95. Williams RD, Mason HL, Smith BF, Wilder RM. Induced thiamine (vitamin B₁) deficiency and the thiamine requirement of man: further observations. *Arch Intern Med* 1942;69:721–738.
96. Williams RD, Mason HL, Power MH, Wilder RM. Induced thiamine (vitamin B₁) deficiency in man. Relation of depletion of thiamine to development of biochemical defect and of polyneuropathy. *Arch Intern Med* 1943;71:38–53.
97. Hoyt CS III, Billson FA. Low-carbohydrate diet optic neuropathy. *Med J Aust* 1977;1:65–66.
98. Hoyt CS, Billson FA. Optic neuropathy in ketogenic diet. *Br J Ophthalmol* 1979;63:191–194.
99. Suzuki S, Kumanomido T, Nagata E, Inoue J, Niikawa O. Optic neuropathy from thiamine deficiency. *Intern Med* 1997;36:532.
100. Van Noort BAA, Bos BJM, Kloppe C, Wilms JM. Optic neuropathy from thiamine deficiency in a patient with ulcerative colitis. *Docum Ophthalmol* 1987;67:45–51.
101. Casal G. *Historia natural, y médica del Principado de Asturias*. Obra posthuma. Madrid, M. Martín and F. M. de Mena, 1762.
102. Thiéry [Thiery] F. Description d'une maladie appelée mal de la rose. *J Med Chir Pharm* 1755;2:337–346.
103. Roussel T. *Traité de la Pellagre et des Pseudo-pellagres*. Paris, J. B. Ballière, 1866.
104. Semba RD. Théophile Roussel and the elimination of pellagra from 19th century France. *Nutrition* 2000;16:231–233.
105. Strambio G. *De Pellagra*. Mediolani, 1786–1789.
106. Frapolli F. *Animadversiones in morbum, vulgo pelagram*. Milan, J. Galeatius, 1771.
107. Sambon LW. Progress report on the investigation of pellagra. *J Trop Med Hyg* 1910;13:289–300.
108. Report of the Pellagra Commission of the State of Illinois, November, 1911. Springfield, Illinois, State Journal Company, 1912.
109. Siler JF, Garrison PE, MacNeal WJ. The relation of methods of disposal of sewage to the spread of pellagra. *Arch Intern Med* 1914;14:453–474.
110. Searcy GH. An epidemic of acute pellagra. *Alabama Med J* 1907;20:387–392.

111. Goldberger J, Waring CH, Willets DG. The prevention of pellagra. A test of diet among institutional inmates. *Public Health Reports* 1915;30:3117–3131.
112. Goldberger J, Wheeler GA, Sydenstricker E. A study of the diet of nonpellagrous and of pellagrous households in textile mill communities in South Carolina in 1916. *J Am Med Assoc* 1918;71:944–949.
113. Goldberger J, Wheeler GA. The experimental production of pellagra in human subjects by means of diet. *Hygienic Laboratory Bulletin* 1920;120:7–116.
114. Goldberger J, Wheeler GA. Experimental black tongue of dogs and its relation to pellagra. *Public Health Reports* 1928;43:172–217.
115. Elvehjem CA, Madden RJ, Strong FM, Woolley DW. Relation of nicotinic acid and nicotinic acid amide to canine black tongue. *Am Chem Soc J* 1937;59:1767–1768.
116. Carpenter KJ (ed). *Pellagra. Benchmark Papers in Biochemistry, Volume 2*. Stroudsburg, Hutchinson Ross, 1981.
117. Etheridge EW. *The Butterfly Caste: A Social History of Pellagra in the South*. Westport, CT, Greenwood, 1972.
118. Roe DA. *A Plague of Corn: The Social History of Pellagra*. Ithaca, NY, Cornell University Press, 1973.
119. Paul AA. The calculation of nicotinic acid equivalents and retinol equivalents in the British diet. *Nutrition (London)* 1969;23:131–136.
120. Laguna J, Carpenter KJ. Raw versus processed corn in niacin-deficient diets. *J Nutr* 1951;45:21–28.
121. Jacob RA. Niacin. In: Bowman BA, Russell RM (eds). *Present Knowledge in Nutrition*. Eighth Edition. Washington, D.C., ILSI: 2001; pp. 199–206.
122. Spivak JL, Jackson DL. Pellagra: an analysis of 18 patients and a review of the literature. *J Hopkins Med J* 1977;140:295–309.
123. Gibson RS. *Principles of Nutritional Assessment*. Second Edition. New York, Oxford University Press, 2005.
124. Bender DA. Pellagra. In: Sadler MJ, Strain JJ, Caballero B (eds). *Encyclopedia of Human Nutrition*. San Diego, Academic: 1999; pp. 1297–1302.
125. Stannus HS. Pellagra and pellagra-like conditions in warm climates. Section I. *Trop Dis Bull* 1936;33: 729–741.
126. Stannus HS. Pellagra and pellagra-like conditions in warm climates. Section II. *Trop Dis Bull* 1936;33: 815–825.
127. Stannus HS. Pellagra and pellagra-like conditions in warm climates. Section III. *Trop Dis Bull* 1936;33: 885–901.
128. Gillman J, Gillman T. *Perspectives in Human Malnutrition: A Contribution to the Biology of Disease from a Clinical and Pathological Study of Chronic Malnutrition and Pellagra in the African*. New York, Grune and Stratton, 1951.
129. Calderini CG. Notizie medico-statistiche sulla pellagra, dedotte dallo studio di oltre mille pellagrosi che subirono la cura balnearia nell'Ospitale Maggiore di Milano negli anni 1844, 45 e 46. *Annali Universali di Medicina e Chirurgia* 1847;123:372–432.
130. Rampoldi R. La pellagre e il mal d'occhi. *Ann Ottal* 1885-1886;14:99–112.
131. Roncoroni L. Sul campo visivo, la marcia e l'andatura nei pellagrosi (luglio 1890-febbraio 1891). *Arch Psich Neuropat Antropol Crim Med Leg Torino* 1891;12:114–123.
132. Bietti A. Sulle alterazioni oculari nella pellagra. *Rivista Sperimentale di Frenitria e Medicina Legale delle Alienazioni Mentali* 1901;27:202–204.
133. Calhoun FP. Visual fields in pellagra: a preliminary report. *Ophthal Rec* 1917;26:63–70.
134. Calhoun FP. Alterations in the visual fields associated with pellagra. *Am J Ophthalmol* 1918;1:834–847.
135. Ridlon JR. Pellagra: the value of the dietary treatment of the disease. *Pub Health Rep* 1916;31:1979–1999.
136. Welton CB. Eye symptoms of pellagra: preliminary report of examination of eyes of fifty-five patients. *J Am Med Assoc* 1909;53:1636–1637.
137. Fine M, Lachman GS. Retrobulbar neuritis in pellagra. *Am J Ophthalmol* 1937;20:708–714.
138. Whaley EM. Notes on the eye symptoms of one hundred cases of pellagra—a second report. *Transactions of the National Association for the Study of Pellagra. Second Triennial Meeting at Columbia, South Carolina, October 3 and 4, 1912. Columbia, South Carolina, R. L. Bryan Company: 1914; pp. 343–345.*

139. Krylov T. [Augenerkrankungen bei Pellagra.] *Soviet Vestnek Oftal* 1932;1:388–390.
140. Cronin HJ. Pellagra with ocular disturbance and psychosis. *J Nerv Mental Dis* 1933;78:35–44.
141. Levine J. Pellagra as a cause of optic neuritis: report of a case. *Arch Ophthalmol* 1934;12:902–909.
142. Scott HH. An investigation into an acute outbreak of ‘central neuritis’. *Ann Trop Med Parasitol* 1918; 12:109–196.
143. Wright EJ. Disease due to A and B avitaminosis in Sierra Leone. *West Afr Med J* 1928;2:127–130.
144. Leitch JN. Dietetics in warm climates, including foodstuffs, their analyses and rôle in disease. London, Harrison & Sons, 1930.
145. Moore DF. Retrobulbar neuritis with pellagra in Nigeria. *J Trop Med Hyg* 1939;42:109–114.
146. Moore DGF. Partial loss of central acuity of vision for reading and distance in school children and its possible association with food deficiency. *W Afr Med J* 1930;4:46–48.
147. Moore DGF. Retrobulbar neuritis. *W Afr Med J* 1932;5:28–30.
148. Moore DF. Avitaminosis. *W Afr Med J* 1933;6:65–67.
149. Moore DGF. Retrobulbar neuritis and partial optic atrophy as sequelae of avitaminosis. *Ann Trop Med Parasitol* 1934;28:295–303.
150. Moore DGF. Manioc (kassava) as a native food in Nigeria. *W Afr Med J* 1934;7:97–98.
151. Moore DF. Nutritional retrobulbar neuritis followed by partial optic atrophy. *Lancet* 1937;1:1225–1227.
152. Moore DGF. Retrobulbar neuritis cum avitaminosis. *W Afr Med J* 1934;7:119–120.
153. Whitbourne D. Nutritional retrobulbar neuritis in children in Jamaica. *Am J Ophthalmol* 1947;30:169–171.
154. Carroll FD. Nutritional retrobulbar neuritis. *Am J Ophthalmol* 1947;30:172–176.
155. Landor JV, Pallister RA. Avitaminosis B2. *Trans Roy Soc Trop Med Hyg* 1935;29:121–134.
156. Goldberger J, Lillie RD. A note on an experimental pellagra-like condition in the albino rat. *Public Health Reports* 1926;41:1025–1029.
157. Gass JDM. Nicotinic acid maculopathy. *Am J Ophthalmol* 1973;76:500–510.
158. Millay RH, Klein ML, Illingworth DR. Niacin maculopathy. *Ophthalmology* 1988;95:930–936.
159. Spirm MJ, Warren FA, Guyer DR, Klancnik JM, Spaide RF. Optical coherence tomography findings in nicotinic acid maculopathy. *Am J Ophthalmol* 2003;135:913–914.
160. Wills L, Mehta MM. Studies in ‘pernicious anaemia’ of pregnancy. Part I. Preliminary report. *Indian J Med Res* 1929–1930;17:777–792.
161. Wills L, Talpade SN. Studies in pernicious anemia of pregnancy. Part II. A survey of dietetic and hygienic conditions of women in Bombay. *Indian J Med Res* 1930–1931;18:283–306.
162. Wills L. Treatment of “pernicious anaemia of pregnancy” and “tropical anaemia” with special reference to yeast extract as a curative agent. *Br Med J* 1931;1:1059–1064.
163. Mitchell HK, Snell EE, Williams RJ. The concentration of “folic acid” [letter]. *J Am Chem Soc* 1941; 63:2284.
164. Stokstad ELR. Historical perspective on key advances in the biochemistry and physiology of folates. In: Picciano MF, Stokstad LR, Gregory JF III (eds). *Folic Acid Metabolism in Health and Disease*. New York, Wiley-Liss: 1992; pp. 1–21.
165. Jacques PF, Selhub J, Bostom AG, Wilson PWF, Rosenberg IH. The effect of folic acid fortification on plasma folate and total homocystein concentrations. *N Engl J Med* 1999;340:1449–1454.
166. Gregory JF III. Bioavailability of folate. *Eur J Clin Nutr* 1997;51(suppl 1):S54–S59.
167. Shane B. Folate chemistry and metabolism. In: Bailey LB (ed). *Folate in Health and Disease*. New York, Marcel Dekker: 1995; pp. 1–22.
168. Priest DG, Bunni MA. Folate and folate antagonists in cancer chemotherapy. In: Bailey LB (ed). *Folate in Health and Disease*. New York, Marcel Dekker, Inc.: 1995; pp. 379–403.
169. Morgan SL, Baggott JE. Folate antagonists in nonneoplastic disease: proposed mechanisms of efficacy and toxicity. In: Bailey LB (ed). *Folate in Health and Disease*. New York, Marcel Dekker, Inc.: 1995; pp. 405–433.
170. Knox DL, Chen MF, Guilarte TR, Dang CV, Burnette J. Nutritional amblyopia: folic acid, vitamin B-12, and other vitamins. *Retina* 1982;2:288–292.
171. Golnik KC, Schaible ER. Folate-responsive optic neuropathy. *J Neuro Ophthalmol* 1994;14:163–169.
172. Adams P, Chalmers TM, Foulds WS, Withey JL. Megaloblastic anaemia and vision. *Lancet* 1967;2: 229–231.

173. Chisholm IA. Serum cobalamin and folate in the optic neuropathy associated with tobacco smoking. *Can J Ophthalmol* 1978;13:105–109.
174. Parry TE. Folate-responsive neuropathy. *Presse Med* 1994;23:131–137.
175. Combe JS. History of a case of anaemia. *Trans Med Chir Soc Edinburgh* 1824;1:194–204.
176. Addison T. Anaemia—disease of the supra-renal capsules. *Lond Med Gaz* 1849;43:517–518.
177. Leichtenstern O. Ueber progressive perniciöse Anämie bei Tabeskranken. *Deutsch Med Wochenschr* 1884;10:849–850.
178. Bastianelli G. Le sclerosi combinate del midollo spinale nelle anemie perniciose. *Bullettino della Reale Accademia Medica di Roma* 1895–1896;22:197–244.
179. Minot GR, Murphy WP. Treatment of pernicious anemia by a special diet. *J Am Med Assoc* 1926;87:470–476.
180. Castle WB. Observations on the etiologic relationship of achylia gastrica to pernicious anemia. I. The effect of the administration to patients with pernicious anemia of the contents of the normal human stomach recovered after the ingestion of beef muscle. *Am J Med Sci* 1929;178:748–764.
181. Rickes EL, Brink NG, Koniuszy FR, Wood TR, Folkers K. Crystalline vitamin B₁₂. *Science* 1948;107:396–397.
182. Castle WB. The history of corrinoids. In: Babior BM (ed). *Cobalamin Biochemistry and Pathophysiology*. New York, Wiley Interscience: 1975; p. 1–17.
183. Carmel R. Prevalence of undiagnosed pernicious anemia in the elderly. *Arch Intern Med* 1996;156:1097–1100.
184. Krasinski SD, Russell RM, Samloff IM, et al. Fundic atrophic gastritis in an elderly population: effect on hemoglobin and several serum nutritional indicators. *J Am Geriatr Soc* 1986;34:800–806.
185. Higginbottom MC, Sweetman L, Nyhan WL. A syndrome of methylmalonic aciduria, homocystinuria, megaloblastic anemia and neurologic abnormalities in a vitamin B₁₂-deficient breast-fed infant of a strict vegetarian. *N Engl J Med* 1978;299:317–323.
186. Linnell JC, Bhatt HR. Inborn errors of B₁₂ metabolism and their management. In: Wickramasinghe SN (ed). *Megaloblastic Anaemias, Clinical Haematology*. London, Bailliere Tindall: 1995; pp. 567–601.
187. Patton N, Beatty S, Lloyd IC, Wraith JE. Optic atrophy in association with cobalamin C (cblC) disease. *Ophthalmic Genet* 2000;21:151–154.
188. Traboulsi EI, Silva JC, Geraghty MT, Maumenee IH, Valle D, Green WR. Ocular histopathologic characterization of cobalamin C type vitamin B₁₂ defect with methylmalonic aciduria and homocystinuria. *Am J Ophthalmol* 1992;113:269–280.
189. Salameh MM, Banda RW, Mohdi AA. Reversal of severe neurological abnormalities after vitamin B₁₂ replacement in the Imerslund-Grasbeck syndrome. *J Neurol* 1991;238:349–350.
190. Altay C, Cetin M, Gumruk F, Irken G, Yetgin S, Laleli Y. Familial selective vitamin B₁₂ malabsorption (Imerslund-Grasbeck syndrome) in a pool of Turkish patients. *Pediatr Hematol Oncol* 1995;12:19–28.
191. Metz J. Cobalamin deficiency and the pathogenesis of nervous system disease. *Ann Rev Nutr* 1992;12:59–79.
192. Troncoso J, Mancall EL, Schatz NJ. Visual evoked responses in pernicious anemia. *Arch Neurol* 1979;36:168–169.
193. Cohen H. Optic atrophy as the presenting sign in pernicious anaemia. *Lancet* 1936;2:1202–1203.
194. Lerman S, Feldmahn AL. Centrocecal scotomata as the presenting sign in pernicious anemia. *Arch Ophthalmol* 1961;65:381–385.
195. Hine ML. Subacute combined degeneration of cord in pernicious anaemia with retrobulbar neuritis. *Proc Roy Soc Med* 1936;29:386.
196. Turner JWA. Optic atrophy associated with pernicious anemia. *Brain* 1940;63:225–236.
197. Foulds WS, Chisholm IA, Stewart JB, Watson TM. The optic neuropathy of pernicious anemia. *Arch Ophthalmol* 1969;82:427–432.
198. Foulds WS, Chisholm IA, Brontë-Stewart J, Wilson TM. Vitamin B₁₂ absorption in tobacco amblyopia. *Br J Ophthalmol* 1969;53:393–397.
199. Watson-Williams EJ, Bottomly AC, Ainley RG, Phillips CI. Absorption of vitamin B₁₂ in tobacco amblyopia. *Br J Ophthalmol* 1969;53:549–552.
200. Chisholm IA. Serum cobalamin and folate in the optic neuropathy associated with tobacco smoking. *Can J Ophthalmol* 1978;13:105–109.

201. Björkenheim B. Optic neuropathy caused by vitamin-B₁₂ deficiency in carriers of the fish tapeworm *Diphyllobothrium latum*. *Lancet* 1966;1:688–690.
202. Stambolian D, Behrens M. Optic neuropathy associated with vitamin B₁₂ deficiency. *Am J Ophthalmol* 1977;83:465–468.
203. Lerner AJ. Visual failure caused by vitamin B₁₂ deficiency optic neuropathy. *Int J Clin Pract* 2004;58:977–978.
204. Hind VMD. Degeneration in the peripheral visual pathway of vitamin B₁₂-deficient monkeys. *Trans Ophthalmol Soc UK* 1970;90:839–846.
205. Hind VMD. The histology of vitamin B₁₂ deficiency optic neuropathy in monkeys. In: Cant JS (ed). *The optic nerve*. St. Louis, C. V. Mosby: 1972; pp. 257–269.
206. Enoksson P, Nordén Å. Vitamin B₁₂ deficiency affecting the optic nerve. *Acta Med Scand* 1960;167:199–208.
207. Olivarius BF. Opticusatrofi ved anaemia perniciosa. *Nord Med* 1961;65:157–159.
208. Hamilton HE, Ellis PP, Sheets RF. Visual impairment due to optic neuropathy in pernicious anemia: report of a case and review of the literature. *Blood* 1959;14:387–385.
209. Olivarius BF, Jensen L. Retrobulbar neuritis and optic atrophy in pernicious anemia. *Acta Ophthalmol* 1961;39:190–197.
210. Victor M. Tobacco-alcohol amblyopia: a critique of current concepts of this disorder, with special reference to the role of nutritional deficiency in its causation. *Arch Ophthalmol* 1963;70:313–318.
211. Dunphy EB. Alcohol and tobacco amblyopia: a historical survey. XXXI De Schweinitz Lecture. *Am J Ophthalmol* 1969;68:569–578.
212. Potts AM. Tobacco amblyopia. *Surv Ophthalmol* 1973;17:313–339.
213. Ridley H. Opening paper. Discussion on amblyopia. *Trans Ophthalmol Soc U K* 1931;50:429–454.
214. Traquair HM. Toxic amblyopia, including retrobulbar neuritis. *Trans Ophthalmol Soc UK* 1931;50:351–385.
215. Evans PJ. Tobacco amblyopia. *Trans Ophthalmol Soc UK* 1939;59:241–252.
216. Freeman AG, Heaton JM. The aetiology of retrobulbar neuritis in Addisonian pernicious anaemia. *Lancet* 1961;1:908–911.
217. Chisholm IA, Pettigrew AR. Biochemical observations in toxic optic neuropathy. *Trans Ophthalmol Soc UK* 1970;90:827–837.
218. Lessell S. Experimental cyanide optic neuropathy. *Arch Ophthalmol* 1971;86:194–204.
219. Lessell S. Comment. What is the cause of alcohol and tobacco amblyopia? In: Brockhurst RJ, Boruchoff SA, Hutchinson BT, Lessell S (eds). *Controversy in Ophthalmology*. Philadelphia, WB Saunders: 1977; pp. 873–874.
220. Schepens CL. Is tobacco amblyopia a deficiency disease? *Trans Ophthalmol Soc UK* 1946;66:309–331.
221. Evans PJ. Opening paper. Discussion on amblyopia. *Trans Ophthalmol Soc U K* 1931;50:397–411.
222. Hebert JR, Kabat GC. Differences in dietary intake associated with smoking status. *Eur J Clin Nutr* 1990;44:185–193.
223. La Vecchia C, Negri E, Franceschi S, Parazzini F, Decarli A. Differences in dietary intake with smoking, alcohol, and education. *Nutr Cancer* 1992;17:297–304.
224. English RM, Najman JM, Bennett SA. Dietary intake of Australian smokers and nonsmokers. *Aust N Z J Public Health* 1997;21:141–146.
225. Brasche S, Winkler G, Heinrich J. Dietary intake and smoking—results from a dietary survey in Erfurt in 1991/92. *Z Ernährungswiss* 1998;37:211–214.
226. Thompson RL, Margetts B, Jackson AA. Smoking: effects on diet and nutritional status. In: Sadler MJ, Strain JJ, Caballero B (eds). *Encyclopedia of Human Nutrition*. San Diego, Academic: 1999; pp. 1759–1764.
227. Phillips EL, Arnett DK, Himes JH, McGovern PG, Blackburn H, Luepker RV. Differences and trends in antioxidant dietary intake in smokers and non-smokers, 1980–1992: The Minnesota Heart Survey. *Ann Epidemiol* 2000;10:417–423.
228. Seal CJ, Ford CL, Day CP. Alcoholism: effects on nutritional status. In: Sadler MJ, Strain JJ, Caballero B (eds). *Encyclopedia of Human Nutrition*. San Diego, Academic: 1999; pp. 52–59.
229. Carroll FD. Analysis of fifty-five cases of tobacco-alcohol amblyopia. *Arch Ophthalmol* 1935;14:421–434.

230. Carroll FD. "Alcohol" amblyopia, pellagra, polyneuritis: report of ten cases. *Arch Ophthalmol* 1936;16: 919–926.
231. Johnson LC. Alcohol-tobacco (toxic) amblyopia treated with thiamin chloride. *Arch Ophthalmol* 1939; 21:602–603.
232. Carroll FD. Etiology and treatment of tobacco-alcohol amblyopia. Part I. *Am J Ophthalmol* 1944;27: 713–725.
233. Carroll FD. Etiology and treatment of tobacco-alcohol amblyopia. Part II. *Am J Ophthalmol* 1944;27: 847–863.
234. Dreyfus PM. Blood transketolase levels in tobacco-alcohol amblyopia. *Arch Ophthalmol* 1965;74:617–620.
235. Heaton JM, McCormick AJA, Freeman AG. Tobacco amblyopia: a clinical manifestation of vitamin-B₁₂ deficiency. *Lancet* 1958;2:286–290.
236. Ainsley RG. The Fransworth-Munsell 100 hue test in tobacco amblyopia. *Trans Ophthalmol Soc UK* 1970;90:765–771.
237. Harrington DO. What is the etiology of alcohol and tobacco amblyopia? In: Brockhurst RJ, Boruchoff SA, Hutchinson BT, Lessell S (eds). *Controversy in Ophthalmology*. Philadelphia, WB Saunders: 1977; pp. 866–872.
238. Rizzo JF, Lessell S. Tobacco amblyopia. *Am J Ophthalmol* 1993;116:84–87.
239. Chisholm IA, Bronte-Stewart J, Foulds WS. Hydroxocobalamin versus cyanocobalamin in the treatment of tobacco amblyopia. *Lancet* 1967;2:450–457.
240. Foulds WS, Chisholm IA, Bronte-Stewart J, Reid HCR. The investigation and therapy of the toxic amblyopias. *Trans Ophthalmol Soc UK* 1970;99:739–763.
241. Crews SJ, James B, Marsters JB, West RH. Drug and nutritional factors in optic neuropathy. *Trans Ophthalmol Soc UK* 1970;90:773–794.
242. Wokes F. Tobacco amblyopia. *Lancet* 1958;2:526–527.
243. Smith ABM. Retrobulbar neuritis in Addisonian pernicious anaemia. *Lancet* 1961;1:1001–1002.
244. Dang CV. Tobacco-alcohol amblyopia: a proposed biochemical basis for pathogenesis. *Med Hypotheses* 1981;7:1317–1328.
245. Victor M, Mancall EL, Dreyfus PM. Deficiency amblyopia in the alcoholic patient. A clinicopathologic study. *Arch Ophthalmol* 1960;64:1–33.
246. Victor M, Dreyfus PM. Tobacco-alcohol amblyopia: further comments on its pathology. *Arch Ophthalmol* 1965;74:649–657.
247. Carroll FD. Nutritional amblyopia. *Arch Ophthalmol* 1966;76:406–411.
248. Foulds WS, Pettigrew AR. Tobacco-alcohol amblyopia. In: Brockhurst RJ, Boruchoff SA, Hutchinson BT, Lessell S (eds). *Controversy in Ophthalmology*. Philadelphia, WB Saunders: 1977; pp. 851–865.
249. Samples JR, Younge BR. Tobacco-alcohol amblyopia. *J Clin Neuro Ophthalmol* 1981;1:213–218.
250. Dinser F. Beobachtungen von Neuritis retrobulbaris (Neuritis axialis [Wilbrand und Sanger]) bei Kriegsteilnehmern. *Klin Monatsbl Augenh* 1919;63:701–718.
251. Junius [P]. Zur Frage der tiologisch unklaren Falle von Sehnervenschwund, insbesondere bei Kriegsteilnehmern. *Zeitschrift Augenh* 1919;41:305–323.
252. Kafka. [Diskussion] *Zeitschrift Augenh* 1919;41:286.
253. Szymanowsky K. Zur Frage der retrobulbaren Neuritis bei Kriegsteilnehmern. *Klin Monatsbl Augenh* 1919;62:631–643.
254. Scheffler W. Kriegserfahrungen auf dem Gebiete der retrobulbaren Neuritis. *Klin Monatsbl Augenh* 1919;63:718–728.
255. Bachstez E, Purtscher [O]. ber die Hufung retrobulbarer Neuritiden einschlielich toxischer Amblyopien gegenuber der Zeit vor dem Kriege. *Zeitschrift Augenh* 1920;44:38–44.
256. Jendralski F. Die Intoxikationsamblyopie (Tabak, Alkohol) vor, in und nach dem Kriege. *Deutsche med Wochenschrift* 1922;48:1207–1209.
257. Grande F, Peraita M. Avitaminosis y sistema nervioso. Madrid, Miguel Servet, 1941.
258. Peraita M. Deficiency neuropathies observed in Madrid during the Civil War (1936–9). *Br Med J* 1946; 2:784.
259. Pillat A. Sehnervenschaden durch Vitaminmangel. *Klin Monats Augenh* 1939;103:97–98.
260. Dekking HM. Tropical nutritional amblyopia ("camp eyes"). *Ophthalmologica* 1947;113:65–92.

261. Ridley H. Ocular manifestations of malnutrition in released prisoners of war from Thailand. *Br J Ophthalmol* 1945;29:613–618.
262. Rodger FC. Nutritional amblyopia. A statistical report of the course and progress of two hundred and thirty-eight cases. *Arch Ophthalmol* 1952;47:570–583.
263. Rodger FC, Sinclair HM. Metabolic and Nutritional Eye Diseases. Springfield, Charles C. Thomas, 1969.
264. Livingston PC. Ocular disturbances associated with malnutrition. *Trans Ophthalmol Soc UK* 1946;66:19–44.
265. Hobbs HE. Ocular disturbances associated with malnutrition. General discussion. *Trans Ophthalmol Soc UK* 1946;66:116–122.
266. Hobbs HE, Forbes FA. Visual defects in prisoners-of-war from the Far East. *Lancet* 1946;2:149–153.
267. McDaniel FL, White BV, Thompson CM. Malnutrition in repatriated prisoners of war. *US Naval Med Bull* 1946;46:793–810.
268. Roberts WL, Willcockson TH. Postneuritic optic atrophy in repatriated prisoners of war. *Am J Ophthalmol* 1947;30:165–168.
269. Burgess RC. Deficiency diseases in prisoners-of-war at Changi, Singapore, February 1942, to August, 1945. *Lancet* 1946;2:411–418.
270. Smith DA, Woodruff MFA. Deficiency diseases in Japanese prison camps. Medical Research Council, Special Report Series No. 274. London, Her Majesty's Stationery Office, 1951.
271. Shapland CD. Ocular disturbances associated with malnutrition. General discussion. *Trans Ophthalmol Soc UK* 1946;66:77–95.
272. Cruickshank EK. Painful feet in prisoners-of-war in the Far East: review of 500 cases. *Lancet* 1946;2:369–372.
273. Shapland CD. Ocular disturbances associated with malnutrition. *J Roy Army Med Corp* 1946;87:253–265.
274. Williamson AD. Ocular signs in the prisoner of war from the Far East [letter]. *Br Med J* 1946;1:545–546.
275. Spillane JD. Nutritional Disorders of the Nervous System. Edinburgh, E & S Livingstone, 1947.
276. Wilkinson PB, King A. Amblyopia due to a vitamin deficiency. *Lancet* 1944;1:528–531.
277. Smith DA. Ocular disturbances associated with malnutrition. General discussion. *Trans Ophthalmol Soc UK* 1946;66:111–116.
278. Fraser JD. Ocular disturbances associated with malnutrition. General discussion. *Trans Ophthalmol Soc UK* 1946;66:96–98.
279. Bell PG, O'Neill JC. Optic atrophy in Hong Kong prisoners of war. *Canad Med Assoc J* 1947;56:475–481.
280. Adamson JD, Tisdale PK, Brereton DC, Card LWB. Residual disabilities in Hong Kong repatriates. *Canad Med Assoc J* 1947;56:481–486.
281. Philips AS. Ocular disturbances associated with malnutrition. General discussion. *Trans Ophthalmol Soc UK* 1946;66:99–102.
282. Cross AG. Ocular disturbances associated with malnutrition. General discussion. *Trans Ophthalmol Soc UK* 1946;66:102–104.
283. Hazelton AR. The nature of starvation amblyopia. *J Roy Army Med Corp* 1946;86:171–178.
284. Dansey-Browning GC, Rich WM. Ocular signs in the prisoner of war returned from the Far East. *Br Med J* 1946;1:20–21.
285. Rich WM. Ocular signs in P.O.W.s from the Far East [letter]. *Br Med J* 1946;1:330–331.
286. Denny-Brown D. Neurological conditions resulting from prolonged and severe dietary restriction (case reports in prisoners-of-war, and general review). *Medicine* 1946;26:41–113.
287. Bloom SM, Merz EH, Taylor WW. Nutritional amblyopia in American prisoners of war liberated from the Japanese. *Am J Ophthalmol* 1946;29:1248–1257.
288. Beam AD. Amblyopia due to dietary deficiency: report of eight cases. *Arch Ophthalmol* 1946;36:113–118.
289. Beam AD. Amblyopia due to dietary deficiency. *Am J Ophthalmol* 1947;30:66–72.
290. Pohlman ME, Ritter EF Jr. Observations on vitamin deficiencies: in an eye, ear, nose, and throat clinic of a Japanese prison hospital. *Am J Ophthalmol* 1952;35:228–230.
291. De Ocampo G, Yambao CV, Mañagas PJ, Sevilla CL. Epidemic retrobulbar neuritis in Philippines during the Japanese occupation. *Am J Ophthalmol* 1947;30:698–704.

292. Raadt OLE de. Pellagra in the oto-neurology and rhino-laryngology. Leiden, Universitaire Pers Leiden, 1947.
293. Mulock Houwer AW. Amblyopia cum polyneuropathia caused by starvation. *Ophthalmologica* 1946; 112:177–192.
294. Lian SB. Camp amblyopia. *Ophthalmologica* 1947;113:38–44.
295. Spillane JD, Scott GI. Obscure neuropathy in the Middle East. *Lancet* 1945;2:261–264.
296. Friemann W, Magun R. Ernährungsschäden des Nervensystems bei Kriegsgefangenen (unter besonderer Berücksichtigung der Sehstörungen. *Graefes Arch Ophthalmol* 1949;149:437–488.
297. Obal A. Nutritional amblyopia. *Am J Ophthalmol* 1951;34:857–865.
298. Stannus HS. Ocular disturbances associated with malnutrition. General discussion. *Trans Ophthalmol Soc UK* 1946;66:123–131.
299. King JH Jr, Passmore JW. Nutritional amblyopia: a study of American prisoners of war in Korea. *Am J Ophthalmol* 1955;39:173–186.
300. Goldsmith H. Ocular signs in P.O.W.s from the Far East [letter]. *Br Med J* 1946;1:407.
301. Adolph WH, Greaves AV, Lawney JC, Robinson HL. Nutritional disorders in Japanese internment camps. *War Med* 1944;5:349–355.
302. Whitacre FE. American civilians in a Japanese internment camp. *J Am Med Assoc* 1944;124:652–653.
303. Gupta LM. Malnutrition in recovered prisoners of war and internees; Report of 10 cases evacuated from Thailand. *Br Med J* 1946;1:643–646.
304. Reid JA, Wilson T. Report on nutrition, and discussion of the main causes of death, “F” force, Thailand. *J Roy Army Med Corp* 1947;89:149–165.
305. Churchill MH. Dietary deficiency diseases among prisoners of war. *J Roy Army Med Corp* 1945;85: 294–298.
306. Dunlop EE. Medical experiences in Japanese captivity. *Brit Med J* 1946;2:481–486.
307. Durrant J. Ocular signs in the prisoner of war from the Far East [letter]. *Brit Med J* 1946;1:626–627.
308. Román GC. An epidemic in Cuba of optic neuropathy, sensorineural deafness, peripheral sensory neuropathy and dorsolateral myeloneuropathy. *J Neuro Sci* 1994;127:11–28.
309. Figure from Dirección Nacional de Estadísticas, Ministerio de Salud Pública, Cuba.
310. Román G. Misión a Cuba: La verdadera historia de la epidemia que cambió el derrotero de la isla de Cuba. Barcelona, Prous Science, 2000.
311. Hedges TR, Hirano M, Tucker K, Caballero B. Epidemic optic and peripheral neuropathy in Cuba: a unique geopolitical public health problem. *Surv Ophthalmol* 1997;41:341–353.
312. The Cuba Neuropathy Field Investigation Team. Epidemic optic neuropathy in Cuba—clinical characterization and risk factors. *N Engl J Med* 1995;333:1176–1182.
313. Mas Bermejo P, Rodriguez R, Barcelo C, et al. Neuropatía epidémica en Cuba: un análisis epidemiológico. Ministerio de Salud Pública, La Habana: 1993; pp. 1–14.
314. Gay J, Porrata C, Hernández M, et al. Dietary factors in epidemic neuropathy on the Isle of Youth, Cuba. *Bull PAHO* 1995;29:25–36.
315. Sadun AA, Martone JF, Muci-Mendoza R, et al. Epidemic optic neuropathy in Cuba: eye findings. *Arch Ophthalmol* 1994;112:691–699.
316. Lincoff NS, Odel JG, Hirano M. Letter from Havana: ‘Outbreak’ of optic and peripheral neuropathy in Cuba? *JAMA* 1993;270:511–518.
317. Santiesteban R, Luis S, Marquez M, et al. Aspectos neuro-oftalmológicos de la neuropatía epidémica en Cuba: Estudio de 602 pacientes. Instituto de Neurología y Neurocirugía, La Habana: 1993; pp. 1–22.
318. Borrajo I, Pérez JL, Domínguez C, et al. Epidemic neuropathy in Cuba: morphological characterization of peripheral nerve lesions in sural nerve biopsies. *J Neurol Sci* 1994;127:68–76.
319. Bates C, Macias-Matos C, Rodríguez-Ojea A, Chi N, Jiménez S, Zulueta D. Reply to A Ascherio [letter]. *Am J Clin Nutr* 1997;65:1093.
320. Ascherio A. Antimetabolites and an optic neuropathy epidemic in Cuba [letter]. *Am J Clin Nutr* 1997; 65:1092.
321. Johns DR, Neufeld MJ, Hedges TR III. Mitochondrial DNA mutations in Cuban optic and peripheral neuropathy. *J Neuro-Ophthalmol* 1994;14:135–140.
322. Johns DR, Sadun AA. Cuban epidemic optic neuropathy: mitochondrial DNA analysis. *J Neuro-Ophthalmol* 1994;14:130–134.

323. Newman NJ, Torroni A, Brown MD, et al. Epidemic neuropathy in Cuba not associated with mitochondrial DNA mutations found in Leber's hereditary optic neuropathy patients. *Am J Ophthalmol* 1994; 118:158–168.
324. Román GC. On politics and health: an epidemic of neurologic disease in Cuba. *Ann Intern Med* 1995; 122:530–533.
325. Bates CJ. Intake and status in healthy Havana men, 2 years after the Cuban epidemic neuropathy. *Br J Nutr* 2001;85:641–642.
326. Macias-Matos C, Rodriguez-Ojea A, Chi N, Jimenez S, Zulueta D, Bates CJ. Biochemical evidence of thiamine depletion during the Cuban neuropathy epidemic, 1992–1993. *Am J Clin Nutr* 1996;64: 347–353.
327. Bowman BA, Bern C, Philen RM. Nothing's simple about malnutrition: complexities raised by epidemic neuropathy in Cuba. *Am J Clin Nutr* 1996;64:383–384.
328. Arnaud J, Fleites-Mestre P, Chassagne M, et al. Vitamin B intake and status in healthy Havanan men, 2 years after the Cuban neuropathy epidemic. *Br J Nutr* 2001;85:741–748.
329. Arnaud J, Fleites P, Chassagne M, et al. Seasonal variations of antioxidant imbalance in Cuban healthy men. *Eur J Clin Nutr* 2001;55:29–38.
330. Barnouin J, Cristiá RP, Chassagne M, et al. Vitamin and nutritional status in Cuban smokers and non-smokers in the context of an emerging epidemic neuropathy. *Int J Vitam Nutr Res* 2000;70:126–138.
331. Ordúñez-García PO, Nieto FJ, Espinosa-Brito AD, Caballero B. Cuban epidemic optic neuropathy, 1991 to 1994: history repeats itself a century after the "Amblyopia of the Blockade." *Am J Pub Health* 1996;86:738–743.
332. Perez-Stable E. Epidemic neuropathy in Cuba [letter]. *Ann Intern Med* 1995;123:734.
333. De Long DM. Epidemic neuropathy in Cuba [letter]. *Ann Intern Med* 1995;123:734.
334. Román GC. Epidemic neuropathy in Cuba: reply [letter]. *Ann Intern Med* 1995;123:734.
335. Frisén L. Fundus changes in acute malnutritional optic neuropathy. *Arch Ophthalmol* 1983;101:577–579.
336. Cullom ME, Heher KL, Miller NR, Savino PJ, Johns DR. Leber's hereditary optic neuropathy masquerading as tobacco-alcohol amblyopia. *Arch Ophthalmol* 1993;111:1482–1485.
337. Kerrison JB. Optic neuropathies caused by toxins and adverse drug reactions. *Ophthalmol Clin North Am* 2004;17:481–488.
338. Blyth AW. The composition of cows' milk in health and disease. *J Chem Soc* 1879;35:530–539.
339. McCollum EV, Kennedy C. The dietary factors operating in the production of polyneuritis. *J Biol Chem* 1916;24:491–502.
340. Emmett AD, Luros GO. Water soluble vitamins. I. Are the antineuritic and the growth-promoting water-soluble B vitamins the same? *J Biol Chem* 1920;43:265–287.
341. Smith MI, Hedrick EG. Some nutrition experiments with brewers' yeast with especial reference to its value in supplementing certain deficiencies in experimental rations. *US Public Health Rep* 1926;41: 201–207.
342. Warburg O, Christian W. Über ein neues Oxydationsferment und sein Absorptionsspektrum. *Biochem Zeitschr* 1932;254:438–458.
343. Kuhn R, György P, Wagner-Jauregg T. Über eine neue Klasse von Naturfarbstoffen (Vorläufige Mitteilung). *Berichte der Deutschen Chemischen Gesellschaft* 1933;66:317–320.
344. Kuhn R, György P, Wagner-Jauregg T. Über Ovoflavin, den Farbstoff des Eiklars. *Berichte der Deutschen Chemischen Gesellschaft* 1933;66:576–580.
345. Booher LE. The concentration and probable chemical nature of vitamin G. *J Biol Chem* 1933;102: 39–46.
346. Kuhn R, Reinemund K, Kaltschmitt H, Ströbele R, Trischmann H. Synthetisches 6,7-Dimethyl-9-d-riboflavin. *Naturwissenschaften* 1935;23:260.
347. Karrer P, Schöpp K, Benz F. Synthesen von Flavinen IV. *Helv Chim Acta* 1935;18:426–429.
348. Spoerl E, Huhle M, Seiler T. Induction of cross-links in corneal tissue. *Exp Eye Res* 1998;66:97–103.
349. Mulroy L, Kim J, Wu I, et al. Photochemical keratodesmos for repair of lamellar corneal incisions. *Invest Ophthalmol Vis Sci* 2000;41:3335–3340.
350. Bates CJ. Bioavailability of riboflavin. *Eur J Clin Nutr* 1997;51(suppl 1):S38–S42.
351. Zemleni J, Galloway JR, McCormick DB. Pharmacokinetics of orally and intravenously administered riboflavin in healthy humans. *Am J Clin Nutr* 1996;63:54–66.

352. Jusko WJ, Levy G. Absorption, protein binding and elimination of riboflavin. In: Rivlin RS (ed). Riboflavin. New York, Plenum: 1975; pp. 99–152.
353. Merrill AH Jr, Lambeth JD, Edmondson DE, McCormick DB. Formation and mode of action of flavo-proteins. *Annu Rev Nutr* 1981;1:281–317.
354. Jamieson CP, Obeid OA, Powell-Tuck J. The thiamin, riboflavin and pyridoxine status of patients on emergency admission to hospital. *Clin Nutr* 1999;18:87–91.
355. Faci Vega M, Ortega RM, Requejo AM, et al. Situación dietética y bioquímica en riboflavina de un colectivo de jóvenes de la Comunidad de Madrid. *Nutr Hosp* 2001;16:92–96.
356. El-Hazmi MA, Warsy AS. Riboflavin status in Saudi Arabia—a comparative study in different regions. *Trop Geogr Med* 1989;41:22–25.
357. Bates CJ, Prentice AM, Watkinson M, et al. Efficacy of a food supplement in correcting riboflavin deficiency in pregnant Gambian women. *Hum Nutr Clin Nutr* 1984;38C:363–374.
358. Ajayi OA. Biochemical ariboflavinosis among Nigerian rural school children. *Hum Nutr Clin Nutr* 1984;38:383–389.
359. Ajayi OA, James OA. Effect of riboflavin supplementation on riboflavin nutriture of a secondary school population in Nigeria. *Am J Clin Nutr* 1984;39:787–791.
360. Wacker J, Fruhauf J, Schulz M, Chiwora FM, Volz J, Becker K. Riboflavin deficiency and preeclampsia. *Obstet Gynecol* 2000;96:38–44.
361. Lo CS. Riboflavin status of adolescents in southern China: average intake of riboflavin and clinical findings. *Med J Aust* 1984;141:635–637.
362. Cunha DF, Cunha SF, Unamuno MR, Vannucchi H. Serum levels assessment of vitamin A, E, C, B2 and carotenoids in malnourished and non-malnourished hospitalized elderly patients. *Clin Nutr* 2001;20:167–170.
363. Rosado JL, Bourges H, Saint-Martin B. Deficiencia de vitaminas y minerales en México. Una revisión crítica del estado de la información: II. Deficiencia de vitaminas. *Salud Publica Mex* 1995;37:452–461.
364. Boisvert WA, Castañeda C, Mendoza I, et al. Prevalence of riboflavin deficiency among Guatemalan elderly people and its relationship to milk intake. *Am J Clin Nutr* 1993;58:85–90.
365. Vudhivai N, Ali A, Pongpaew P, et al. Vitamin B1, B2, and B6 status of vegetarians. *J Med Assoc Thai* 1991;74:465–470.
367. Cole HS, Lopez R, Cooperman JM. Riboflavin deficiency in children with diabetes mellitus. *Acta Diabetol Lat* 1976;13:25–29.
368. Rivlin RS. Riboflavin and cancer. In: Rivlin RS (ed). Riboflavin. New York, Plenum: 1975; pp. 369–391.
369. Steier M, Lopez R, Cooperman JM. Riboflavin deficiency in infants and children with heart disease. *Am Heart J* 1976;92:139–143.
370. Goldsmith GA. Riboflavin deficiency. In: Rivlin RS (ed). Riboflavin. New York, Plenum: 1975; pp. 221–244.
371. Sebrell WH, Butler RE. Riboflavin deficiency in man. A preliminary note. *Publ Health Rep* 1938;53:2282–2284.
372. Powell SR, Schwab IR. Nutritional disorders affecting the peripheral cornea. *Int Ophthalmol Clin* 1986;26:137–146.
373. Sydenstricker VP. Clinical manifestations of ariboflavinosis. *Am J Pub Health* 1941;31:344–350.
374. Sebrell WH. Identification of riboflavin deficiency in human subjects. *Fed Proc* 1979;38:2694–2495.
375. Zilstorff-Pedersen K. To tilfælde af ariboflavinosis. Helbredt ved behandling med store doser riboflavin. *Ugesk Laeger* 1927;114:393–395.
376. Sydenstricker VP, Sebrell WH, Cleckley HM, Kruse HD. The ocular manifestations of ariboflavinosis: a progress note. *J Am Med Assoc* 1940;114:2437–2445.
377. Kruse HD, Sydenstricker VP, Sebrell WH, Cleckley HM. Ocular manifestations of ariboflavinosis. *Pub Health Rep* 1940;55:157–169.
378. Sydenstricker VP, Kelly AR, Weaver JW. Ariboflavinosis, with special reference to the ocular manifestations. *South Med J* 1941;34:165–170.
379. Rof Carballo J, Grande Covián F. Ariboflavinosis e invasión capilar de la córnea. Invasión capilar y su relación con el contenido en riboflavina de la dieta. *Rev Clin Espan* 1944;13:315–321.
380. Rof Carballo J, Grande Covean F. Ariboflavinosis e invasión capilar de la córnea. Pruebas terapéuticas. *Rev Clin Espan* 1944;13:380–387.

381. Bassi G, Jona S. Sulle manifestazioni oculari dell'alattoflavinosi umana. *Boll d'Ocul* 1945;24:3–18.
382. Stern HJ. Acute ocular manifestations of ariboflavinosi. *Ophthalmologica* 1947;114:103–106.
383. Jackson CRS. Riboflavin deficiency with ocular signs: report of a case. *Br J Ophthalmol* 1950;34:259–260.
384. Bellomio S. Contributo clinico alla conoscenza della alattoflavinosi oculare. *Boll Ocul* 1955;34:157–170.
385. Raymond LF. Reversible chronic recurrent keratitis with vascularization due to ariboflavinosi. *J Med Soc New Jersey* 1955;52:315–316.
386. Lundh B, Frandsen H. Riboflavin and ariboflavinosi, with special reference to eye changes. *Acta Ophthalmol* 1941;19:331–345.
387. Spies TD, Perry DJ, Cogswell RC, Frommeyer WB. Ocular disturbances in riboflavin deficiency. *J Lab Clin Med* 1945;30:751–765.
388. Chen TT. Angular blepharitis in ariboflavinosi—a not well known clinical manifestation of riboflavin deficiency. *Chinese Med J* 1948;66:1–4.
389. Stern JJ. The ocular manifestations of riboflavin deficiency. *Am J Ophthalmol* 1950;33:1127–1136.
390. Aykroyd WR, Verma OP. Superficial keratitis due to riboflavin deficiency. *Indian Med Gaz* 1942;77:1–5.
391. Verma OP. Further experience in the treatment of superficial keratitis with riboflavin. *Indian Med Gaz* 1942;77:471–472.
392. Gregory MK. The ocular criteria of deficiency of riboflavin. *Br Med J* 1943;2:134–135.
393. Vail D, Ascher KW. Corneal-vascularization problems. *Am J Ophthalmol* 1943;26:1025–1044.
394. Mann I. Ariboflavinosi. *Am J Ophthalmol* 1945;28:243–247.
395. Scarborough H. Circumcorneal injection as a sign of riboflavin deficiency in man, with an account of three cases of ariboflavinosi. *Br Med J* 1942;2:601–604.
396. Sandstead HR. Superficial vascularization of the cornea. The result of riboflavin therapy. *Pub Health Rep* 1942;57:1821–1825.
397. Youmans JB, Patton EW, Robinson WD, Kern R. An analysis of corneal vascularization as found in a survey of nutrition. *Tran Assoc Am Physicians* 1942;57:49–54.
398. Tisdall FF, McCreary JF, Pearce H. The effect of riboflavin on corneal vascularization and symptoms of eye fatigue in R.C.A.F. personnel. *Canad Med Assoc J* 1943;49:5–13.
399. Lyle TK, Macrae TF, Gardiner PA. Corneal vascularisation in nutritional deficiency. *Lancet* 1944;1:393–395.
400. Borsook H, Alpert E, Keighley GL. Nutritional status of aircraft workers in southern California. II. Clinical and laboratory findings. *Milbank Mem Fund Quart Bull* 1943;21:115–157.
401. Scott JG. Corneal vascularity as a sign of ariboflavinosi. *J Roy Army Med Corps* 1944;82:133–135.
402. Kodicek JH, Yudkin J. Slit-lamp microscope in nutrition surveys. *Lancet* 1942;2:753–756.
403. Venkataswamy G. Ocular manifestations of vitamin B-complex deficiency. *Br J Ophthalmol* 1967;51:749–754.
404. Hou HC. Riboflavin deficiency among Chinese. I. Ocular manifestations. *Chinese Med J* 1940;58:616–628.
405. Stern HJ. Conditioned corneal vascularity in riboflavin deficiency: report of a case. *Arch Ophthalmol* 1949;42:438–442.
406. Landau J, Stern HJ. Flare-up of trachomatous pannus due to ariboflavinosi. *Am J Ophthalmol* 1948;31:952–954.
407. Takami Y, Gong H, Amemiya T. Riboflavin deficiency induces ocular surface damage. *Ophthalmic Res* 2004;36:156–165.
408. Wagener HP. Nutritional diseases and the eye. The rôle of vitamin B. *Am J Med Sci* 1936;192:296–300.
409. Johnson LV, Eckardt RE. Rosacea keratitis and conditions with vascularization of cornea treated with riboflavin. *Arch Ophthalmol* 1940;23:899–907.
410. Cosgrove KW, Day PL. The use of riboflavin in the treatment of corneal diseases. *Am J Ophthalmol* 1942;25:544–551.
411. Fish WM. Acne rosacea keratitis and riboflavine (vitamin B2). *Br J Ophthalmol* 1943;27:107–109.

412. Pirie A. The relation of riboflavin to the eye. A review article. *Br J Ophthalmol* 1943;27:291–301.
413. Stern HJ, Landau J. Eczematous keratitis and ariboflavinosis. *Am J Ophthalmol* 1948;31:1619–1623.
414. Corkey JA. Riboflavin in marginal keratitis. *Trans Ophthalmol Soc UK* 1952;72:291–303.
415. Machella TE, McDonald PR. Studies of the B vitamins in the human subject. VI. Failure of riboflavin therapy in patients with the accepted picture of riboflavin deficiency. *Am J Med Sci* 1943;205:214–223.
416. Day PL, Langston WC, O'Brien CS. Cataract and other ocular changes in vitamin G deficiency: an experimental study on albino rats. *Am J Ophthalmol* 1931;14:1005–1009.
417. Bessey OA, Wolbach SB. Vascularization of the cornea of the rat in riboflavin deficiency, with a note on corneal vascularization in vitamin A deficiency. *J Exp Med* 1939;69:1–12.
418. Cochran W, DeVaughn NM, Allen L. Corneal vascularization in ariboflavinosis. *South Med J* 1942;35:888–889.
419. Wiesinger H, Kaunitz H, Slanetz CA. Hornhautveränderungen bei Ratten im Riboflavinomangel. *Ophthalmologica* 1955;129:389–395.
420. Fromer CH, Klintworth GK. An evaluation of the role of leukocytes in the pathogenesis of experimentally induced corneal vascularization. *Am J Pathol* 1975;79:537–550.
421. Lowry OH, Bessey OA. The effects of light, trauma, riboflavin, and ariboflavinosis on the production of corneal vascularity and on healing of corneal lesions. *J Nutr* 1945;30:285–292.
422. Williams RD, Mason HL, Cusick PL, Wilder RM. Observations on induced riboflavin deficiency and the riboflavin requirement of man. *J Nutr* 1943;25:361–377.
423. Keys A, Henschel A, Taylor HL, Mickelsen O, Brozek J. Experimental studies on man with a restricted intake of the B vitamins. *Am J Physiol* 1945;144:5–45.
424. Boehrer JJ, Stanford CE, Ryan E. Experimental riboflavin deficiency in man. *Am J Med Sci* 1943;205:544–549.
425. Sebrell WH, Butler RE, Wooley JG, Isbell H. Human riboflavin requirement established by urinary excretion of subjects on controlled intake. *Pub Health Report* 1941;56:510–519.
426. Lane M, Mengel CE, Doherty DJ. Rapid induction of isolated riboflavin deficiency in man. *J Clin Invest* 1960;39:1004.
427. Lane M, Alfrey CP, Mengel CE, Doherty MA, Doherty J. The rapid induction of human riboflavin deficiency with galactoflavin. *J Clin Invest* 1964;43:357–373.
428. Lane M, Brindley CO. Laboratory and clinical studies with the riboflavin antagonist, galactoflavin. *Proc Soc Exp Biol Med* 1964;116:57–61.
429. Gordon OE. Riboflavin and the cornea. *Quart Bull Northwestern Univ Med School* 1952;26:120–123.
430. Langston WC, Day PL, Cosgrove KW. Cataract in the albino mouse resulting from a deficiency of vitamin G (B₂). *Arch Ophthalmol* 1933;10:508–514.
431. Day PL, Langston WC. Further experiments with cataract in albino rats resulting from the withdrawal of vitamin G (B₂) from the diet. *J Nutr* 1934;7:97–106.
432. O'Brien CS. Experimental cataract in vitamin G deficiency. *Arch Ophthalmol* 1932;8:880–887.
433. Yudkin AM. Ocular disturbances produced in experimental animals by dietary changes: clinical implications. *J Am Med Assoc* 1933;101:921–926.
434. Langston WC, Day PL. Nutritional cataract in the Norway rat (*Mus norvegicus*). *South Med J* 1933;26:128–129.
435. Langston WC, Day PL. The arrest of nutritional cataract in the albino rat by the use of vitamin G (B₂). *South Med J* 1934;27:170–176.
436. Day PL, Darby WJ, Langston WC. The identity of flavin with the cataract-preventive factor. *J Nutr* 1937;13:389–399.
437. Eckhardt RE, Johnson LV. Nutritional cataract and relation of galactose to the appearance of senile suture line in rats. *Arch Ophthalmol* 1939;21:315–327.
438. Baum HM, Michaelree JF, Brown EB. The quantitative relationship of riboflavin to cataract formation in rats. *Science* 1942;95:24–25.
439. Bowles LL, Allen L, Sydenstricker VP, Hock CW, Hall WK. The development and demonstration of corneal vascularization in rats deficient in vitamin A and in riboflavin. *J Nutr* 1946;32:19–31.
440. Kaunitz H, Wiesinger H, Blodi FC, Johnson RE, Slanetz CA. Relation of protein and fat intake to growth and corneal vascularization in galactoflavin-produced ariboflavinosis. *J Nutr* 1954;52:467–482.

441. Srivastava SK, Beutler E. Increased susceptibility of riboflavin deficient rats to galactose cataract. *Experientia* 1970;26:250.
442. Gershoff SN, Andrus SB, Hegsted DM. The effect of the carbohydrate and fat content of the diet upon the riboflavin requirement of the cat. *J Nutr* 1959;68:75–88.
443. Street HR, Cowgill GR, Zimmerman HM. Further observations of riboflavin deficiency in the dog. *J Nutr* 1941;22:7–24.
444. Wintrobe MM, Buschke W, Follis RH Jr, Humphreys S. Riboflavin deficiency in swine, with special reference to the occurrence of cataracts. *Bull Johns Hopkins Hosp* 1944;75:102–114.
445. Derkač V. Zur medikamentösen Behandlung des Altersstars. *Klin Monatsbl Augenheilk* 1938;100:236–243.
446. Wagner H, Richner H, Karbacher P. Vorläufiges Ergebnis der Therapie des Altersstars mit Vitamin B₂ (Lactoflavin)—Verabreichung: Kontrolle mit Spaltlampenmikroskopie. *Klin Monatsbl Augenheilk* 1938;101:543–557.
447. Batey DW, Eckhert CD. Analysis of flavins in ocular tissues of the rabbit. *Invest Ophthalmol Vis Sci* 1991;32:1981–1975.
448. Batey DW, Daneshgar KK, Eckhert CD. Flavin levels in the rat retina. *Exp Eye Res* 1992;54:605–609.
449. Bhat KS. Alterations in the lenticular proteins of rats on riboflavin deficient diet. *Curr Eye Res* 1982–1983;2:829–834.
450. Srivastava SK, Beutler E. Galactose cataract in riboflavin deficient rats. *Biochem Med* 1972;6:372–379.
451. Dutta P, Rivlin RS, Pinto J. Enhanced depletion of lens reduced glutathione by administration of adriamycin® in riboflavin-deficient rats. *Biochem Pharmacol* 1990;40:1111–1115.
452. Bates CJ. Glutathione and related indices in rats lenses, liver and red cells during riboflavin deficiency and its correction. *Exp Eye Res* 1991;53:123–130.
453. Sperduto RD, Hu TS, Milton RC, et al. The Linxian cataract studies. Two nutrition intervention trials. *Arch Ophthalmol* 1993;111:1246–1253.
454. Jacques PF, Taylor A, Moeller S, et al. Long-term nutrient intake and 5-year change in nuclear lens opacities. *Arch Ophthalmol* 2005;123:517–526.
455. McKinley MC. Nutritional aspects and possible pathological mechanisms of hyperhomocysteinaemia: an independent risk factor for vascular disease. *Proc Nutr Soc* 2000;59:221–237.
456. Hoogeveen EK, Kostense PJ, Eysink PE, et al. Hyperhomocysteinemia is associated with the presence of retinopathy in type 2 diabetes mellitus: the Hoorn study. *Arch Intern Med* 2000;160:2984–2990.
457. Vaccaro O, Perna AF, Mancini FP, et al. Plasma homocysteine and microvascular complications in type 1 diabetes. *Nutr Metab Cardiovasc Dis* 2000;10:297–304.
458. Reddi AS, Frank O, Baker H. Riboflavin excretion in normal and diabetic rats. *Int J Vitam Nutr Res* 1990;60:252–254.
459. Reddi AS, Jyothirmayi GN, DeAngelis B, Frank O, Baker H. Tissue concentrations of water-soluble vitamins in normal and diabetic rats. *Int J Vitam Nutr Res* 1993;63:140–144.

8

Zinc and Eye Health

1. INTRODUCTION

Zinc plays an essential role in growth, neurodevelopment, immunity, reproduction, and a wide range of physiological processes, including metabolism of nucleic acids, protein, and lipids, synthesis of hormones, and apoptosis. Zinc deficiency is common in developing countries worldwide (1), and zinc supplementation studies suggest that zinc deficiency may be widespread in North America among infants, children, and pregnant women (2). Acrodermatitis enteropathica, an inborn error of zinc metabolism, is characterized by compromised immunity and skin and ocular findings. Zinc deficiency can also occur in Crohn disease and among individuals receiving total parenteral nutrition without sufficient zinc. The retina and choroid contain the highest concentrations of zinc of any tissue in the human body. Zinc plays an important role in eye health, and recent investigations have demonstrated a causal link between zinc status and age-related macular degeneration. The role of zinc in age-related maculopathy and age-related macular degeneration are presented in greater detail in Chapter 4, under Subheading 5.4.

2. HISTORICAL BACKGROUND

Zinc was used empirically as both an oral and topical therapeutic agent for a variety of human illnesses in the nineteenth century (3). In 1854, zinc was detected in the ashes of vegetables by the German botanist Alexander Braun (1805–1877) (4). Zinc was first recognized to be an essential factor for plant growth by the French plant physiologist, Jules Raulin (1836–1896). Raulin studied the type of nutrients, especially minerals, that were needed for the growth of *Aspergillus niger*, and concluded that zinc was essential for growth (5). In 1877, zinc was described in human muscle and liver (6) and in plants (7), and subsequent investigations revealed the presence of zinc in a wide variety of plants and animals (8). Birckner, after finding high zinc concentrations in egg yolk and human milk, argued on teleological grounds that this element “exerts an important nutritive function, the nature of which is not at present understood” (9). In the 1920s, efforts were made to establish an essential role for zinc in animal models. Despite problems with producing control diets and low zinc diets, these studies suggested that growth and survival of experimental animals was improved by zinc (10–13). With experimental advances, zinc deficiency was convincingly produced in rats (14,15). Further studies showed that hormone production and alanine metabolism were impaired during zinc deficiency (16,17) and that accompanying pathology included atrophy of the thymus, corneal vascularization, and hyperkeratosis and parakeratosis of the skin and esophagus (18). Enzymes such

as carbonic anhydrase and kidney phosphatase were found to contain zinc, suggesting an important basic role for zinc (19,20).

Although zinc was considered by many to be an essential mineral by the late 1930s (21–23), many thought that zinc deficiency could not be a practical problem in human nutrition because of the widespread occurrence of zinc in nature (24). Variations in the zinc concentrations in blood, colostrum, milk, and tissues of humans were known, but no characteristic manifestations of a suspected zinc deficiency were identified (25). William Eggleston showed that the average amount of zinc ingested in a well balanced diet was about 12 mg per day (26). Low concentrations of blood, hair, and fingernail zinc were described among patients with beriberi and pellagra in China (27,28). Metabolic studies of zinc absorption and excretion were used to establish the daily requirements for zinc (28–30). Zinc deficiency in pigs, or parakeratosis, was described in 1955 (31). Human zinc deficiency was described in the 1960s when a syndrome of dwarfism, delayed sexual maturation, and iron deficiency anemia was found in young men who practiced geophagia and had low dietary intakes of zinc (32). Growth and sexual maturation occurred with zinc supplementation, showing that zinc was a limiting essential nutrient (33,34). Zinc supplementation increased sexual maturation faster than a well-balanced diet (35). In 1974, the Food and Nutrition Board of the National Research Council of the National Academy of Sciences established the recommended dietary allowance for zinc. The history of human zinc deficiency has been summarized elsewhere (36).

3. BIOCHEMISTRY OF ZINC

Zinc, a small ion with atomic number of 30 and atomic weight of 65.37, occurs in a divalent state (Zn^{++}) in living organisms and is a strong Lewis acid, or electron acceptor. Zinc is the most abundant intracellular trace element (37). In biological systems, zinc does not exhibit direct redox chemistry. It has a high affinity for electrons and typically binds to proteins, amino acids, peptides, and nucleotides, with an affinity for thiol groups, hydroxy groups, and electron-rich ligands.

4. DIETARY SOURCES OF ZINC

Animal proteins constitute the richest dietary source of zinc, and foods that are especially rich in zinc include shellfish, red meat, liver, kidney, and chicken (38). Whole grains, pork, eggs, dairy products, nuts, beans, lentils, chickpeas, and peas contain moderate concentrations of zinc. Poor sources of zinc include fish, fruits, vegetables, butter, and fats. White breads contain little zinc, as milling removes the zinc-rich bran and germ portions of grains. Drinking water is a minor source of zinc in most populations. The zinc content of some common foods is shown in Table 1 (38). Dietary intakes of zinc can vary greatly, depending on other factors in the diet which may inhibit or enhance zinc absorption. In many populations in developing countries, the consumption of meat and animal products is low and intake and dietary fiber is high, a principle factor contributing to zinc deficiency.

The absorption and availability of dietary zinc can be greatly reduced by substances in plant foods such as phytates (inositol hexaphosphate), fiber, oxalate, tannin, and lignins (39–41). Zinc forms insoluble complexes with phytate, and these complexes reduces the bioavailability of dietary zinc (42). Phytates and other factors are found in high concentrations in whole grains, legumes, leafy vegetables, soy products and formula (43,44), coffee,

Table 1
Approximate Zinc Content of Selected Foods

<i>Food</i>	<i>Zinc</i> <i>(mg/100 mg)</i>
Oysters, raw	16.40
Beef liver, pan fried	5.45
Beef kidney, simmered	4.22
Sirloin, lean, roasted	3.54
Cheese, cheddar	3.11
Chicken, dark meat, roasted	2.80
Clams, raw	1.35
Chicken, light meat, roasted	1.23
Shrimp, raw	1.09
Salmon, raw	0.58
Spinach, boiled	0.57
Butter	0.01

From ref. 38.

and tea. Zinc absorption studies have shown, for example, that little zinc is absorbed after ingestion of a beef taco because the phytates in the corn tortilla reduce the availability of zinc in the beef (41). Other factors that may interfere with zinc absorption include iron, especially when the iron:zinc ratio exceeds 2:1, and calcium, as found in dairy products. Soaking and fermentation of plant foods can reduce the content of phytic acid (45).

5. ABSORPTION, METABOLISM, AND STORAGE OF ZINC

Zinc is absorbed in the small intestine, primarily the duodenum and jejunum (46). The small intestine plays a central role in zinc metabolism and homeostasis, as the absorption of zinc depends on both zinc status and the dietary intake of zinc. Low zinc intake increases the efficiency of absorption of zinc. Zinc is absorbed by passive diffusion down a concentration gradient and also through an active, energy-dependent carrier-mediated process (47,48). The absorption of dietary zinc can range from 1% to 80%, and zinc absorption is increased during pregnancy and lactation (49). Diarrheal disease may interfere with the absorption of zinc and contribute to accelerated fecal losses of zinc. In the enterocytes, metallothionein and cysteine-rich intestinal protein play a role in transmucosal transport of zinc (50,51). Zinc released into the mesenteric capillaries and the portal circulation is bound to albumin and most is taken up by the liver (52). In the plasma, about 60% of zinc is bound to albumin, about 40% is bound to α_2 -macroglobulin, and a small fraction is bound to amino acids (53,54). Plasma zinc represents about 0.1% of total body zinc. In adults, the total body zinc content is estimated to be about 1.5 g in women and 2.5 g in men. The total body zinc content of adults may be maintained with the absorption of about 5 mg/d of zinc (55).

There is no specific storage organ for zinc in the body. Most of the zinc in the body is found in skeletal muscle and bone and is largely unavailable for other nutritional functions in the body. Zinc is found in high concentrations in the pancreas and gonads. The highest concentrations of zinc in the human body are found in the choroid and the retina

Table 2
Zinc Concentrations in Human Tissues

<i>Tissue</i>	<i>Zinc</i> ($\mu\text{g/g}$ dry weight)
Choroid	472
Retina	464
Ciliary body	227
Optic nerve	170
Hair	150
Pancreas	135
Bone	100
Liver	58
Kidney	55
Skeletal muscle	51
Cornea	41
Skin	32
Heart	23
Lens	21
Plasma	1

Based on refs. 37,54,56.

(Table 2) (56). There appear to be two major zinc pools in the body, one with a short half-life and another with a long half-life. The liver, pancreas, kidney, and spleen have more rapid turnover of zinc than bone, muscle, and central nervous system. Zinc is excreted mostly in the feces from pancreatic, biliary, gastric, and intestinal excretion. Lesser amounts of zinc are excreted in the urine, sweat, and through turnover of skin, hair, nails, and through menstrual blood loss, human milk, and semen. About 2–3 mg of zinc are excreted per day in human milk during the first several weeks postpartum, decreasing to 1 mg/d by 2–3 mo postpartum and declining dramatically beyond this period (57).

6. FUNCTIONS OF ZINC

6.1. General Functions

Zinc is essential for immunity, growth, neurological transmission, and reproduction (58). Zinc is involved in the function of more than 300 zinc metalloenzymes that are involved in a wide range of structural, catalytic, and regulatory processes (59). Zinc is an essential component in at least one enzyme in every class of enzyme (60), including oxidoreductases, hydrolases, lyases, and transferases. Zinc plays an important structural role in zinc fingers, protein complexes which form a tetrahedral complex with zinc and provide structural stability for small polypeptides (61). The region of the protein containing the zinc binding domain is essential for binding to DNA and initiation of transcription. An estimated 1% of the human genome codes for zinc finger proteins (62). Zinc has been hypothesized to play a role in the stability of membranes because of its ability to stabilize thiol groups and phospholipids and to quench free radicals (63). Zinc plays an essential role in the function of polymorphonuclear leukocytes, natural killer cells, T and B lymphocytes, and the generation of antibody responses (64). In biological systems,

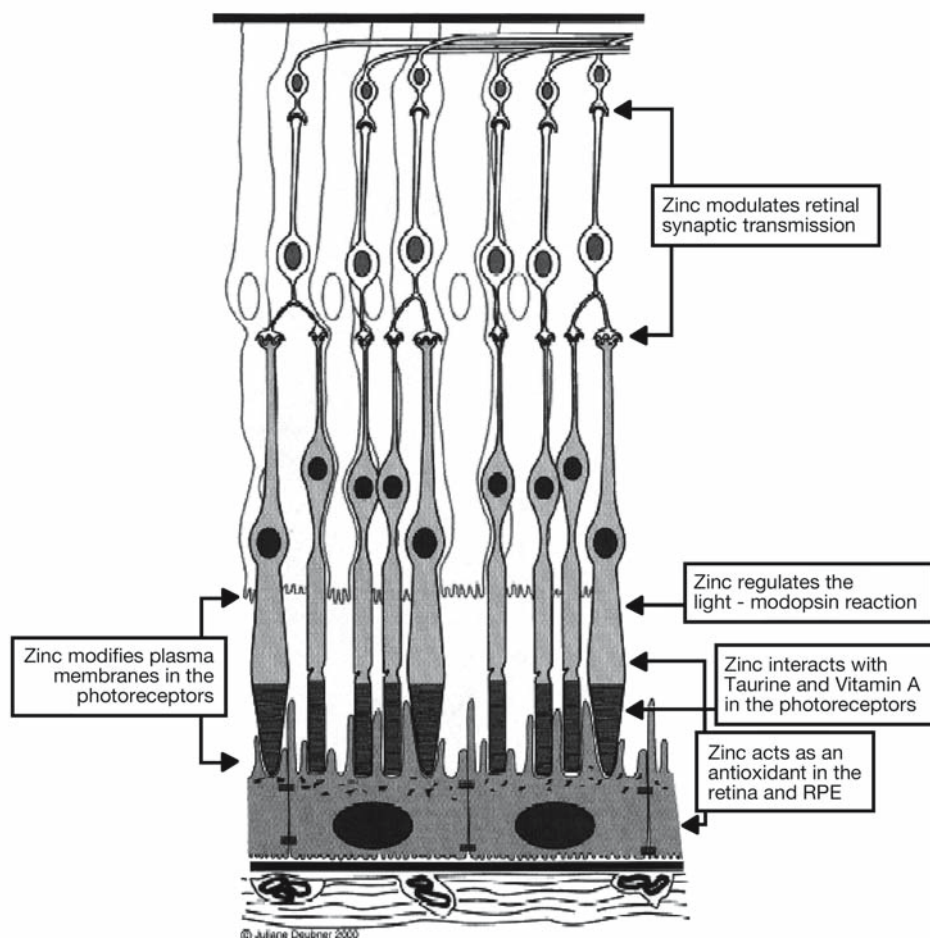


Fig. 1. Functions of zinc in the retina and retinal pigment epithelium. (Reproduced from ref. 68, with permission of the *Journal of the American College of Nutrition*.)

zinc acts as an antioxidant by interacting with sulfhydryl groups of macromolecules and by inducing metallothionein, a strong free-radical scavenger (65). Zinc is a cofactor for Cu-Zn superoxide dismutase, a component of the antioxidant system (66). Zinc plays a role in synaptic transmission, the activity of growth hormone, the polymerization of tubulin, and signal transduction (2,58,62).

6.2. Functions of Zinc in the Eye

It has been hypothesized that zinc has several important functions in the retina and retinal pigment epithelium, such as modification of plasma membranes in photoreceptors, interaction with the light response of photoreceptors, interaction with vitamin A metabolism, antioxidant activity, modulation of synaptic transmission, and involvement in taurine metabolism (67,68) (Fig. 1). Many purported roles for zinc in the retina and retinal pigment epithelium have not been confirmed, and current molecular, physiologic, and histological investigations have recently been reviewed in detail elsewhere (67,68). In general, experimental zinc deficiency does not appear to affect the total zinc content

of the retina (69), and although zinc is involved in many metalloenzymes, only a few zinc metalloenzymes have been shown to have reduced activity during zinc deficiency (68). Zinc is found in the disc membranes of photoreceptor outer segments and may play a role in protein–protein interactions and membrane conformation (70). Zinc may play a role in rhodopsin phosphorylation (71). Retinol dehydrogenase is a zinc metalloenzyme that catalyzes the oxidation of retinol to retinal in the visual cycle, and it has been hypothesized that zinc deficiency will impair the activity of retinol dehydrogenase. However, experimental studies show that the rate of rhodopsin regeneration after extensive bleaching of the retina is not significantly different between zinc-deficient and pair-fed control rats (72). These findings are not consistent with the hypothesis that zinc deficiency interferes with the activity of alcohol dehydrogenase in the retina.

Zinc may be involved in the regulation of the light response, but the precise roles for zinc are unclear. The distribution of zinc appears to shift within the photoreceptor, depending on the light adapted state. During light adaptation, the highest concentrations of histochemically-reactive zinc are found in the inner segment of photoreceptors, whereas during dark adaptation, the highest concentrations of zinc appear to be in the perikarya (67, 73). Zinc may be needed in the inner segments for outer segment membrane synthesis (67). Another potential role for zinc in the retina and retinal pigment epithelium is as an antioxidant (74). Zinc is a cofactor in Cu-Zn superoxide dismutase, an enzyme in the antioxidant system, and is involved in the synthesis of metallothionein, a free radical scavenger. The concentrations of metallothionein in both the retina and retinal pigment epithelium are decreased and indicators of oxidative stress are increased in zinc-deficient rats compared to pair-fed control rats (74). These findings suggest that the retina is vulnerable to greater damage from oxidative stress and are consistent with the general idea that marginal zinc status may contribute to the free radical damage to the eye with aging and macular degeneration (74). The epidemiological data regarding zinc and age-related macular degeneration are presented elsewhere in this book (Chapter 4, Subheading 5.4.). Zinc is found in high concentrations in the terminal synaptic regions of photoreceptors, and it is thought to play a role in synaptic transmission (75,76). The retinal degeneration that occurs in experimental taurine deficiency is exacerbated by zinc deficiency, suggesting an interaction between taurine and zinc (77,78). Morphological changes, such as inclusion bodies in the cytoplasm of the retinal pigment epithelium, have been noted in the retinas of zinc-deficient rats (79).

The lens contains about 21 µg/g of zinc, which is much lower a concentration of zinc than found in the retina, choroid, and optic nerve (Table 2). In contrast to the retina, zinc concentrations in the aqueous humor and lens decrease during experimental zinc deficiency (69). Although zinc deficiency causes cataract in rainbow trout (80), and cataracts have been described in acrodermatitis enteropathica, as described under Subheading 10.2. below, the relationship between zinc status and cataract is still unclear. In human cataractous lenses, the zinc concentrations appear to be increased (81,82). Most of the zinc in the lens is bound in an inexchangeable form, but about 5–8% appears to be part of the exchangeable pool (83). Zinc supplementation has been proposed for prophylaxis of cataracts (84), but definitive evidence for the role of zinc in preventing cataracts is lacking (*see* Chapter 3).

Some corneal collagenases appear to be zinc metalloenzymes (85). Both oral and topical zinc have been shown to have little effect on corneal wound healing, as measured by tensile strength of the wound (86).

Table 3
Dietary Reference Intakes for Zinc (mg/d)

<i>Age and gender category</i>	<i>AI</i>	<i>EAR</i>	<i>RDA</i>
Infants, 0–6 mo	2	—	—
Infants, 7–12 mo	—	2.5	3
Children, 1–3 yr	—	2.5	3
Children, 4–8 yr	—	4	5
Boys and girls, 9–13 yr	—	7	8
Boys, 14–18 yr	—	8.5	11
Girls, 14–18 yr	—	7.3	9
Adult men ≥19 yr	—	9.4	11
Adult women ≥19 yr	—	6.8	8
Pregnant women, 14–18 yr	—	10	12
Pregnant women, 19–50 yr	—	9.5	11
Lactating women, 14–18 yr	—	10.9	13
Lactating women, 19–50 yr	—	10.4	12

AI, Adequate Intake; EAR, Estimated Average Requirement; RDA, Recommended Dietary Allowance. Based on ref. 87.

7. REQUIREMENTS FOR ZINC

The dietary requirements of individuals for zinc have been established by the Food and Nutrition Board (87) (Table 3). The Adequate Intake (AI) is the recommended level of intake for infants. The Estimated Average Requirement (EAR) is the daily intake value that is estimated to meet the requirement of half the healthy individuals in a group. The Recommended Dietary Allowance (RDA) is defined as the EAR plus twice the coefficient of variation (CV) to cover 97–98% of individuals in any particular group.

8. EPIDEMIOLOGY OF ZINC DEFICIENCY

Zinc deficiency is suspected to have a high prevalence worldwide, but the importance of zinc nutriture to human health has only been realized in the last few decades. Consequently, epidemiological data on zinc deficiency has lagged behind that for other more well known vitamin and mineral deficiencies. Zinc intake data from the Third National Health and Nutrition Examination Survey (1988–1994) in the US population suggest that adequate zinc intake was only reached by 55.6% of the population based on the 1989 RDA for zinc (88). Young children aged 1–3 yr, adolescent females aged 12–19 yr, and persons ≥71 yr of age were at the greatest risk of inadequate zinc intakes (88). Zinc supplementation studies in North America also suggest that women of childbearing age and pregnant women are at higher risk of zinc deficiency (89). The risk of zinc deficiency is higher among those with alcoholic liver disease (90) and Crohn disease.

9. ASSESSMENT OF ZINC DEFICIENCY

The most commonly used indicator of zinc status is the measurement of serum or plasma zinc concentration (91). Under the conditions of dietary zinc deficiency, the circulating levels of zinc fall rapidly. Flame or graphite furnace atomic absorption spectrometry is

Table 4
Clinical Manifestations of Zinc Deficiency

Growth retardation
Hypogonadism
Delayed sexual maturation
Immunodeficiency
Increased infections
Diarrhea
Delayed wound healing
Skin lesions
Impaired dark adaptation
Anorexia
Impaired taste (hypogeusia) and smell (hyposmia)

usually used to measure zinc concentration in blood and other biological samples. Serum or plasma zinc concentrations $<0.75 \mu\text{g/mL}$ ($<11.5 \mu\text{mol/L}$) are considered inadequate, $0.75\text{--}0.85 \mu\text{g/mL}$ ($11.5\text{--}13.0 \mu\text{mol/L}$) are considered low or borderline, and $0.85\text{--}1.25 \mu\text{g/mL}$ ($13.0\text{--}19.0 \mu\text{mol/L}$) are considered normal (92). Serum or plasma zinc concentrations can be affected by the acute phase response, exercise, aging, malnutrition, and other factors, and some caution must be taken in the interpretation of this assay. Recent studies suggest that serum or plasma zinc concentrations are acceptable as indicators of zinc status in population-based studies (93–96). The collection of blood for zinc measurements requires the use of trace element-free blood collecting tubes, as zinc values can be artificially increased through zinc contamination in some plastics and rubber stoppers. Hemolyzed samples should not be used for serum or plasma zinc determinations. Other assays that have been used for measuring zinc status include hair and fingernail zinc concentrations, leukocyte zinc, and urinary zinc excretion, but these assays have been more difficult to perform, hard to interpret, and are not considered reliable (92).

10. CLINICAL MANIFESTATIONS OF ZINC DEFICIENCY

10.1. General Clinical Manifestations

The clinical manifestations of zinc deficiency vary widely, and zinc deficiency is not associated with any pathognomonic finding (Table 4). Severe zinc deficiency is characterized by relatively symmetrical skin lesions in the extremities, perioral, and perianal regions, with alopecia and diarrhea. Hypogonadism, delayed sexual maturation, and growth retardation have been described in adolescents with zinc deficiency (32). In older adults, marginal zinc deficiency can be associated with anorexia and impaired taste (hypogeusia). Zinc deficiency during pregnancy has been associated with low birth weight, preterm delivery, and increased complications during delivery (97,98). Maternal and early infant zinc deficiencies may adversely influence infant neurodevelopment (99).

10.2. Ocular Findings in Acrodermatitis Enteropathica

Acrodermatitis enteropathica was described in 1943 by Niels Danbolt (1900–1984) and Karl Closs (b. 1904) in Norway (100). The syndrome was characterized by a fairly symmetrical dermatitis around the mouth, eyes, nares, anus, and protruding parts of the body,

such as the head, trunk, and extremities, hence the term “acrodermatitis.” Other features included total alopecia, photophobia, blepharitis, growth retardation, chronic diarrhea, and steatorrhea. The disease was originally attributed to an unknown defect in the gastrointestinal tract, and initial attempts to treat the disease with vitamins, liver preparations, hormones, and other agents were not successful (100). A description of a syndrome similar to acrodermatitis enteropathica appeared as early as 1902, at which time the disease was called “epidermolysis bullosa hereditaria” (101). Diiodohydroxyquin was used as specific therapy for acrodermatitis enteropathica (102–104), and although some individuals responded well to treatment, cases of optic neuropathy was reported after prolonged treatment (105,106). Diiodohydroxyquin was shown later to augment intestinal zinc absorption, thus providing a basis for its mode of action. In 1973, acrodermatitis enteropathica was associated with zinc deficiency, and zinc therapy was found to reverse the disease (107–109). Acrodermatitis enteropathica was also associated with depressed cellular immunity (110,111), and immune alterations could be corrected with zinc therapy (112). Homozygosity mapping has placed the acrodermatitis enteropathic gene on chromosomal region 8q24.3 (113). The molecular basis for the abnormality of zinc metabolism in acrodermatitis enteropathica is currently unknown and may involve zinc transport proteins (114,115).

The most commonly noted ocular findings in acrodermatitis enteropathic are blepharitis, conjunctivitis, and photophobia. There can be a vesico-bullous dermatitis in the lateral canthal regions, and cilia of the brow and lid margin may be lost (116). Corneal lesions, consisting of a brown, band-like area of intra- and sub-epithelial cornification at the superior limbus with radial fan-like stripes and central opacities, have been described in children (117) and adults (118). Corneal sensation is normal (118). The subepithelial radial lines in the cornea respond to treatment and are not ghost vessels (118). The ocular histopathology of acrodermatitis enteropathica includes thinning of the corneal epithelium, loss of epithelial polarity, anterior corneal scarring and loss of Bowman’s membrane, cataract formation, ciliary body atrophy, retinal degeneration, loss of pigment from the retinal pigment epithelium, and optic atrophy (119). Electron microscopy has shown focal destruction of Bowman’s membrane with replacement by plasma cells and irregularly aligned collagen fibers (120). Other findings that have been described in acrodermatitis enteropathica include punctal stenosis (118), and cataracts (121). Keratomalacia has been described in one child with acrodermatitis enteropathica who was receiving parenteral vitamin A (122). Children with acrodermatitis enteropathica have been reported to show gaze aversion, and this lack of eye-to-eye contact has been thought to represent a reliance on peripheral vision rather than central cone vision (123,124).

10.3. Acquired Zinc Deficiency

A syndrome of acute zinc deficiency has been described in both infants (125) and adults (126–128) receiving total parenteral alimentation without sufficient zinc. The clinical findings resemble acrodermatitis enteropathica and include dermatitis, alopecia, and diarrhea, but it is unclear whether corneal or lenticular changes occur under these circumstances, as detailed slit lamp examinations were not described in these studies (125–127, 129,130). In Crohn disease, zinc absorption is reduced (131), and patients have been reported to have low plasma and hair zinc concentrations and hypogeusia (132). Skin lesions resembling acrodermatitis enteropathica, hypogonadism, and growth retardation have

also been described in Crohn disease (133), but no corneal lesions have been described. Crohn disease has been associated with a subepithelial keratopathy (134), but it is unknown whether zinc deficiency might play a role.

10.3. Zinc Deficiency and Impaired Dark Adaptation

There are at least two potential mechanisms by which zinc status could influence the metabolism of vitamin A. Zinc is required for the synthesis of retinol-binding protein (135,136), and zinc is needed for the function of alcohol dehydrogenase, which reoxidizes rhodopsin to retinaldehyde in the visual cycle (137). Abnormal dark adaptation was reported among six patients with alcoholic cirrhosis, low serum zinc ($<70 \mu\text{g/dL}$), and low serum vitamin A ($15\text{--}37 \mu\text{g/dL}$ or $0.526\text{--}1.29 \mu\text{mol/L}$) concentrations. Improvements in dark adaptation thresholds occurred in 2 wk among three patients given oral zinc sulfate, 220 mg/d. Two patients who received oral vitamin A, 10,000 IU/d for 2–4 wk, did not show a change in threshold until oral zinc was added. A sixth patient treated with both vitamin A and zinc attained a normal threshold within 2 wk (138,139). Liver disease has been associated with vitamin A deficiency and abnormal dark adaptation (140,141), and zinc deficiency and vitamin A deficiency often occur together in chronic alcoholics (142). In a case report, a patient with Crohn disease with impaired dark adaptation responded to zinc supplementation but the dark adaptation curve never returned completely to normal (143). Among pregnant women with night blindness in Nepal, zinc supplementation alone did not restore night vision or improve dark adaptation but may possibly have improved night vision when combined with vitamin A (144). In Thailand, zinc supplementation, 25 mg/d, improved dark adaptation times among children with marginal zinc status (144).

11. TREATMENT AND PREVENTION OF ZINC DEFICIENCY

Zinc deficiency may generally occur due to one or more mechanisms, including inadequate intake of zinc, interference with absorption and bioavailability of dietary zinc, increased losses of zinc, impaired utilization of zinc, and increased requirement for zinc, as during pregnancy, lactation, and periods of rapid growth. Strategies to prevent zinc deficiency generally include dietary diversification, supplementation, fortification, and improving zinc availability in plant sources. Increasing the intake of foods with a high content of zinc such as meat and animal products may be an economic challenge in many settings in developing countries. Other dietary approaches include increasing the intakes of foods which enhance zinc absorption, modifying foods through fermentation, soaking, or other measures to reduce phytic acid content (45). Zinc supplementation is a possible means of preventing zinc deficiency, but it is thought that supplementation must be given often, i.e., daily, and there may be programmatic impediments towards daily supplementation. However, zinc supplementation may have a role in high-risk situations, such as pregnancy, lactation, and early childhood (57,146). A potential complementary strategy to reduce zinc deficiency is that breeding of plants which are low in phytic acid and high in sulfur-containing amino acids which promote zinc absorption (147).

12. CONCLUSIONS

The highest concentrations of zinc in the human body are found in the retina and choroid. Zinc plays a role in the function of photoreceptors and synaptic transmission in the retina.

It also serves as an antioxidant for the retina and retinal pigment epithelium. The precise roles that zinc plays in ocular function are currently under investigation, and recent clinical trials suggest that zinc has an important role in the pathogenesis of age-related macular degeneration. Inadequate dietary intake of zinc is probably more widespread worldwide than previously recognized. Although zinc deficiency has been associated with impaired dark adaptation, these reports have involved extremely small numbers of subjects, and there is little evidence to show that zinc deficiency is the cause of night blindness of any public health magnitude.

REFERENCES

1. Shrimpton R. Zinc deficiency B is it widespread but under-recognized? In: Subcommittee on Nutrition News, vol 9. Geneva, United Nations Administrative Committee on Coordination: 1993; pp. 24–27.
2. Hambidge M. Human zinc deficiency. *J Nutr* 2000;130:1344S–1349S.
3. Trousseau A, Pidoux H. *Traité de Thérapeutique et de Matière Médicale*. Quatrième Édition. Paris, Béchet Jeune: 1851.
4. Braun A. *Philos. Mag* 1854;4th series 8:156.
5. Raulin J. *Études chimiques sur la végétation*. Thèses présentées à la Faculté des Sciences de Paris. Paris, Masson et fils: 1870.
6. Raoult F, Breton H. Sur la présence ordinaire du cuivre et du zinc dans le corps de l'homme. *Comptes rendus hebdomadaires des séances de l'Académie de Sciences* 1877;85:40–42.
7. Lechartier G, Bellamy F. Sur la présence du zinc dans le corps des animaux et dans les végétaux. *Comptes rendus hebdomadaires des séances de l'Académie de Sciences* 1877;84:687–690.
8. Lutz RE. The normal occurrence of zinc in biologic materials: a review of the literature, and a study of the normal distribution of zinc in the rat, cat, and man. *J Ind Hyg* 1926;8:177–207.
9. Birkner V. The zinc content of some food products. *J Biol Chem* 1919;38:191–203.
10. Bertrand G, Benzon B. Sur l'importance du zinc dans l'alimentation des animaux. *Expériences sur la souris*. *Comptes rendus hebdomadaires des séances de l'Académie de Sciences* 1922;175:289–292.
11. McHargue JS. Further evidence that small quantities of copper, manganese and zinc are factors in the metabolism of animals. *Am J Physiol* 1926;77:245–255.
12. Hubbell RB, Mendel LB. Zinc and normal nutrition. *J Biol Chem* 1927;75:567–586.
13. Bertrand G, Benzon B. *Recherches sur l'importance du zinc dans l'alimentation des animaux*. *Expériences sur la souris*. *Bull Soc Chim Biol* 1935;6:203–216.
14. Todd WR, Elvehjem CA, Hart EB. Zinc in the nutrition of the rat. *Am J Physiol* 1934;107:146–156.
15. Stirn FE, Elvehjem CA, Hart EB. The indispensability of zinc in the nutrition of the rat. *J Biol Chem* 1935;109:347–359.
16. Hove E, Elvehjem CA, Hart EB. The physiology of zinc in the nutrition of the rat. *Am J Physiol* 1937;119:768–775.
17. Hove E, Elvehjem CA, Hart EB. Further studies on zinc deficiency in rats. *Am J Physiol* 1938;124:750–758.
18. Follis RH, Day HG, McCollum EV. Histological studies of the tissues of rats fed a diet extremely low in zinc. *J Nutr* 1941;22:223–237.
19. Keilin D, Mann T. Carbonic anhydrase. *Nature* 1939;144:442–443.
20. Cloetens R. Reversible Abspaltung des zweiten Metalles der alkalischen Phosphatase. II. *Biochem Z* 1941;308:37.
21. Mathews AP. *Vitamins, Minerals and Hormones*. Baltimore, William Wood and Company, 1937.
22. Daniel EP. Trace elements. In: United States Department of Agriculture. Food and Life. Yearbook of Agriculture 1939. Washington, D.C., U. S. Government Printing Office: 1939; pp. 213–220.
23. Shohl AT. *Mineral Metabolism*. New York, Reinhold Publishing Corporation, 1939.
24. Darby WJ. Trace elements in human nutrition. In: Herriott RM (ed). *Symposium on Nutrition. The Physiological Role of Certain Vitamins and Trace Elements*. Baltimore, Johns Hopkins Press: 1953; pp. 229–261.

25. Youmans JB. Nutritional Deficiencies: Diagnosis and Treatment. Philadelphia, J. B. Lippincott, 1943.
26. Eggleton WGE. The zinc content of epidermal structures in beriberi. *Biochem J* 1939;33:403–406.
27. Eggleton WGE. The zinc and copper content of blood in beriberi in conditions associated with protein deficiency and in diabetes mellitus. *Chinese J Physiol* 1940;15:33–44.
28. Drinker ER, Fehnel JE, March M. Normal excretion of zinc in the urine and feces of man. *J Biol Chem* 1927;72:375–383.
29. McCance RA, Widdowson EM. The absorption and excretion of zinc. *Biochem J* 1942;36:692–696.
30. Tribble HM, Scouler FI. Zinc metabolism of young college women on self-selected diets. *J Nutr* 1954;52:209–216.
31. Tucker HF, Salmon WD. Parakeratosis or zinc deficiency disease in the pig. *Proc Soc Exp Biol Med* 1955;88:613–616.
32. Prasad AS, Halsted JA, Nadimi M. Syndrome of iron deficiency anemia, hepatosplenomegaly, hypogonadism, dwarfism, and geophagia. *Am J Med* 1961;31:532–546.
33. Prasad AS, Miale A, Farid Z, Schulert AR, Sandstead HH. Zinc metabolism in patients with the syndrome of iron deficiency anemia, hypogonadism, and dwarfism. *J Lab Clin Med* 1963;61:537–549.
34. Sandstead HH, Prasad AS, Schulert AR, Farid Z, Miale A Jr, Bassily S, Darby WJ. Human zinc deficiency, endocrine manifestations, and response to treatment. *Am J Clin Nutr* 1967;20:422–442.
35. Halsted JA, Ronaghy HA, Abadi P, Haghshenass M, Amirhakemi GH, Barakat RM, Reinhold JG. Zinc deficiency in man. The Shiraz experiment. *Am J Med* 1972;53:277–284.
36. Prasad AS. Discovery of human zinc deficiency and studies in an experimental human model. *Am J Clin Nutr* 1991;53:403–412.
37. King JC, Cousins RJ. Zinc. In: Shils ME, Shike M, Ross AC, Cabellero B, Cousins R. *Modern Nutrition in Health and Disease*. Tenth Edition. Philadelphia, Lippincott Williams & Wilkins: 2006; pp. 271–285.
38. Pennington JAT. *Bowes & Church's Food Values of Portions Commonly Used*. Philadelphia, Lippincott Williams & Wilkins, 1998.
39. O'Dell BL, Savage JE. Effect of phytate on zinc availability. *Proc Soc Exp Biol Med* 1960;103:304–309.
40. Turnlund JR, King JC, Keyes WR, Gong B, Michel MC. A stable isotope study of zinc absorption in young men: effects of phytate and α -cellulose. *Am J Clin Nutr* 1984;40:1071–1077.
41. Solomons NW, Jacob RA, Pineda O, Viteri FE. Studies on the bioavailability of zinc in man. II. Absorption of zinc from organic and inorganic sources. *J Lab Clin Med* 1979;94:335–343.
42. Mills CF. Dietary interactions involving trace elements. *Ann Rev Nutr* 1985;5:173–193.
43. Lönnnerdal B, Cederblad Å, Davidsson L, Sandström B. The effect of individual components of soy formula and cows' milk formula on zinc bioavailability. *Am J Clin Nutr* 1984;40:1064–1070.
44. Sandström B, Cederblad Å, Lönnnerdal B. Zinc absorption from human milk, cow's milk, and infant formulas. *Am J Dis Child* 1983;137:726–729.
45. Gibson RS, Yeadall F, Drost N, Mtitimuni B, Cullinan T. Dietary interventions to prevent zinc deficiency. *Am J Clin Nutr* 1998;68(suppl):484S–487S.
46. Weigand E. Absorption of trace elements: zinc. *Int J Vitam Nutr Res* 1983;25(suppl):67–81.
47. Steel L, Cousins RJ. Kinetics of zinc absorption by luminally and vascularly perfused rat intestine. *Am J Physiol* 1985;248:G46–G53.
48. Raffaniello RD, Wapnir RA. Zinc uptake by isolated rat enterocytes: effect of low molecular weight ligands. *Proc Soc Exp Biol Med* 1989;192:219–224.
49. Jackson MJ, Giugliano R, Giugliano LG, Oliveira EF, Shrimpton R, Swainbank IG. Stable isotope metabolic studies of zinc nutrition in slum-dwelling lactating women in the Amazon valley. *Br J Nutr* 1988;59:193–203.
50. Hempe JM, Cousins RJ. Cysteine-rich intestinal protein binds zinc during transmucosal zinc transport. *Proc Natl Acad Sci USA* 1991;88:9671–9674.
51. Cousins RJ, Lee-Ambrose LM. Nuclear zinc uptake and interactions and metallothionein gene expression are influenced by dietary zinc in rats. *J Nutr* 1992;122:56–64.
52. Smith KT, Failla ML, Cousins RJ. Identification of albumin as the plasma carrier for zinc absorption by perfused rat intestine. *Biochem J* 1979;184:627–633.
53. Scott BJ, Bradwell AR. Identification of the serum binding proteins for iron, zinc, cadmium, nickel, and calcium. *Clin Chem* 1983;29:629–633.

54. Mills CF (ed). Zinc in Human Biology. New York, Springer Verlag, 1988.
55. Cousins RJ. Zinc. In: Filer JL, Ziegler E (eds). Present Knowledge in Nutrition, 7th edition. Washington, International Life Sciences Institute Press: 1996; pp. 293–306.
56. Galin MA, Nano HD, Hall T. Ocular zinc concentration. Invest Ophthalmol 1962;1:142–147.
57. Krebs NF, Reidinger CJ, Hartley S, Robertson AD, Hambidge KM. Zinc supplementation during lactation: effects on maternal status and milk concentrations. Am J Clin Nutr 1995;61:1030–1036.
58. Walsh CT, Sandstead HH, Prasad AS, Newberne PM, Fraker PJ. Zinc: health effects and research priorities for the 1990s. Environ Health Perspect 1994;102(suppl 2):5–46.
59. Vallee BL, Auld DS. Zinc coordination, function, and structure of zinc enzymes and other proteins. Biochemistry 1990;29:5647–5659.
60. McCall KA, Huang CC, Fierke CA. Function and mechanism of zinc metalloenzymes. J Nutr 2000;130:1437S–1446S.
61. Berg JM, Shi Y. The galvanization of biology: a growing appreciation for the roles of zinc. Science 1996;271:1081–1085.
62. Frederickson CJ, Suh SW, Silva D, Frederickson CJ, Thompson RB. Importance of zinc in the central nervous system: the zinc-containing neuron. J Nutr 2000;130:1471S–1483S.
63. Bettger WJ, O'Dell BL. Minireview: a critical physiological role of zinc in the structure and function of biomembranes. Life Sci 1981;28:1425–1438.
64. Shankar AH, Prasad AS. Zinc and immune function: the biological basis of altered resistance to infection. Am J Clin Nutr 1998;68(suppl):447S–463S.
65. Sato M, Bremner I. Oxygen free radicals and metallothionein. Free Radic Biol Med 1993;14:325–337.
66. Marklund SL, Westman NG, Lundgren E, Roos G. Copper- and zinc-containing superoxide dismutase, manganese-containing superoxide dismutase, catalase, and glutathione peroxidase in normal and neoplastic human cell lines and normal human tissues. Cancer Res 1982;42:1955–1961.
67. Ugarte M, Osborne NN. Zinc in the retina. Prog Neurobiol 2001;64:219–249.
68. Grahn BH, Paterson PG, Gottschall-Pass KT, Zhang Z. Zinc and the eye. J Am Coll Nutr 2001;20:106–118.
69. Fabe JS, Grahn BH, Paterson PG. Zinc concentration of selected ocular tissues in zinc-deficient rats. Biol Trace Elem Res 2000;75:43–52.
70. Bettger WJ, O'Dell BL. Physiological roles of zinc in the plasma membrane of mammalian cells. J Nutr Biochem 1993;4:194–207.
71. Shuster TA, Martin F, Nagy AK. Zinc causes an apparent increase in rhodopsin phosphorylation. Curr Eye Res 1996;15:1019–1024.
72. Dorea JG, Olson JA. The rate of rhodopsin regeneration in the bleached eyes of zinc-deficient rats in the dark. J Nutr 1986;116:121–127.
73. Ugarte M, Osborne NN. The localization of free zinc varies in rat photoreceptors during light and dark adaptation. Exp Eye Res 1999;69:459–461.
74. Miceli MV, Tate DJ Jr, Alcock NW, Newsome DA. Zinc deficiency and oxidative stress in the retina of pigmented rats. Invest Ophthalmol Vis Sci 1999;40:1238–1244.
75. Wu SM, Qiao X, Noebels JL, Yang XL. Localization and modulatory actions of zinc in vertebrate retina. Vision Res 1993;33:2611–2616.
76. Qian H, Li L, Chappell RL, Ripps H. GABA receptors of bipolar cells from the skate retina: actions of zinc on GABA-mediated membrane currents. J Neurophysiol 1997;78:2402–2412.
77. Gottschall-Pass KT, Grahn BH, Gorecki DKJ, Paterson PG. Oscillatory potentials and light microscopic changes demonstrate an interaction between zinc and taurine in the developing rat retina. J Nutr 1997;127:1206–1213.
78. Gottschall-Pass KT, Grahn BH, Gorecki DKJ, Semple HA, Paterson PG. Depression of the electroretinogram in rats deficient in zinc and taurine during prenatal and postnatal life. J Nutr Biochem 1998;9:621–628.
79. Leure-Dupree AE, Bridges DB. Changes in retinal morphology and vitamin A metabolism as a consequence of decreased zinc availability. Retina 1982;4:294–302.
80. Ketola HG. Influence of dietary zinc on cataracts in rainbow trout (*Salmo gairdneri*). J Nutr 1979;109:965–969.

81. Murata T, Okazawa Y, Hinokuma R. Studies on the trace elements in the crystalline lens. *Folia Ophthalmol (Japan)* 1972;23:648–652.
82. Murata T, Taura Y. Study of trace metallic elements in the lens. *Ophthalmol Res* 1975;7:8–14.
83. Baldwin GF, Bentley PJ. The zinc metabolism of the amphibian lens. *Exp Eye Res* 1980;30:333–343.
84. Heinritz M. Klinisch-biochemische Aspekte einer Prophylaxe und Therapie der senilen Katarakt mit Zinkspartat. *Klin Monatsbl Augenheilk* 1978;172:778–783.
85. Berman MD, Manabe R. Corneal collagenases: evidence for zinc metalloenzymes. *Ann Ophthalmol* 1973;5:1193–1209.
86. Hubbard GB, Herron BE, Andrews JS, Elliott JH. Influence of topical and oral zinc upon corneal wound healing. *Br J Ophthalmol* 1969;53:407–411.
87. Food and Nutrition Board. Dietary Reference Intakes for Vitamin A, Vitamin K, Arsenic, Boron, Chromium, Copper, Iodine, Iron, Manganese, Molybdenum, Nickel, Silicon, Vanadium, and Zinc. Washington, National Academy Press, 2001.
88. Briefel RR, Bialostosky K, Kennedy-Stephenson J, McDowell MA, Ervin RB, Wright JD. Zinc intake of the U.S. population: findings from the Third National Health and Nutrition Examination Survey, 1988–1994. *J Nutr* 2000;130:1367S–1373S.
89. Sandstead HH. Is zinc deficiency a public health problem? *Nutrition* 1995;11:87–92.
90. Vallee BL, Wacker WEC, Bartholomay AF, Robin ED. Zinc metabolism in hepatic dysfunction. I. Serum zinc concentrations in Laínec's cirrhosis and their validation by sequential analysis. *N Engl J Med* 1956;255:403–408.
91. Wood RJ. Assessment of marginal zinc status in humans. *J Nutr* 2000;130:1350S–1354S.
92. Sauberlich HE. Laboratory Tests for the Assessment of Nutritional Status. Second edition. Boca Raton, CRC, 1999.
93. Brown KH, Lanata CF, Yuen ML, Pearson JM, Butron B, Lönnnerdal B. Potential magnitude of the misclassification of a population's trace element status due to infection: example from a survey of young Peruvian children. *Am J Clin Nutr* 1993;58:549–554.
94. Ruz M, Solomons NW, Mejia LA, Chew F. Alterations of circulating micronutrients with overt and occult infections in anaemic Guatemalan preschool children. *Int J Food Sci Nutr* 1995;46:257–265.
95. Friis H, Ndhlovu P, Kaondera K, et al. Serum concentration of micronutrients in relation to schistosomiasis and indicators of infection: a cross-sectional study among rural Zimbabwean school children. *Eur J Clin Nutr* 1996;50:386–391.
96. Brown KH. Effect of infections on plasma zinc concentrations and implications for zinc status assessment in low-income countries. *Am J Clin Nutr* 1998;68(suppl):425S–429S.
97. Caulfield LE, Zavaleta N, Shankar AH, Meriardi M. Potential contribution of maternal zinc supplementation during pregnancy to maternal and child survival. *Am J Clin Nutr* 1998;68:499S–508S.
98. Jameson S. Zinc status in pregnancy: the effect of zinc therapy on perinatal mortality, prematurity, and placental ablation. *Ann NY Acad Sci* 1993;678:178–192.
99. Black MM. Zinc deficiency and child development. *Am J Clin Nutr* 1998;68:464S–469S.
100. Danbolt N, Closs K. Acrodermatitis enteropathica. *Acta Derm Venerol* 1943;23:127–169.
101. Wende GW. Epidermolysis bullosa hereditaria: report of a case presenting unusual features. *J Cut Genito-Urin Dis* 1902;20:537–547.
102. Dillaha CJ, Lorincz AL. Enteropathic acrodermatitis (Danbolt): successful treatment with Diodoquin® (diiodohydroxyquinoline). *Arch Dermatol Syphil* 1953;67:324–326.
103. Lindström B. Familial acrodermatitis enteropathica in an adult. *Acta Derm Venerol* 1963;43:522–527.
104. Tompkins RR, Livingood CS. Acrodermatitis enteropathica persisting into adulthood. *Arch Dermatol* 1969;99:190–195.
105. Van Balen AT. Toxic damage to the optic nerve caused by iodochlorhydroxyquinoline (enterovioform). *Ophthalmologica* 1971;163:8–9.
106. Hache JC, Woillez M, Breuillard F, Desmons F. La névrite optique des iodo-quinoléines. A propos d'un cas d'acrodermatite entéropathique. *Bull Soc Ophtal Fran* 1973;73:501–503.
107. Barnes PM, Moynahan EJ. Zinc deficiency in acrodermatitis enteropathica: multiple dietary intolerance treated with synthetic diet. *Proc Roy Soc Med* 1973;66:327–329.
108. Moynahan EJ. Acrodermatitis enteropathica: a lethal inherited human zinc-deficiency disorder. *Lancet* 1974;2:399–400.

109. Neldner KH, Hambidge KM. Zinc therapy of acrodermatitis enteropathica. *N Engl J Med* 1975;292:879–882.
110. Julius R, Schulkind M, Sprinkle T, Rennert O. Acrodermatitis enteropathica with immune deficiency. *J Pediatr* 1973;83:1007–1011.
111. Endre L, Katona Z, Gyurkovits K. Zinc deficiency and cellular immune deficiency in acrodermatitis enteropathica. *Lancet* 1975;1:1196.
112. Oleske JM, Westphal ML, Shore S, Gorden D, Bogden JD, Nahmias A. Zinc therapy of depressed cellular immunity in acrodermatitis enteropathica: its correction. *Am J Dis Child* 1979;133:915–918.
113. Wang K, Pugh EW, Griffen S, et al. Homozygosity mapping places the acrodermatitis enteropathica gene on chromosomal region 8q24.3. *Am J Hum Genet* 2001;68:1055–1060.
114. Bleck O, Ashton GH, Mallipeddi R, et al. Genomic localization, organization and amplification of the human zinc transporter gene, ZNT4, and exclusion as a candidate gene in different clinical variants of acrodermatitis enteropathica. *Arch Dermatol Res* 2001;293:392–396.
115. Kury S, Devilder MC, Avet-Loiseau H, Dreno B, Moisan JP. Expression pattern, genomic structure and evaluation of the human SLC30A4 gene as a candidate for acrodermatitis enteropathica. *Hum Genet* 2001;109:178–185.
116. López-Linares M, Villar M, Muñoz G. Acrodermatitis enteropatica (Nota sobre un nuevo caso). *Rev Clin Esp* 1962;87:157–160.
117. Wirsching L Jr. Eye symptoms in acrodermatitis enteropathica. A description of a brother and sister, with corneal changes. *Acta Ophthalmol* 1962;40:567–574.
118. Matta CS, Felker GV, Ide CH. Eye manifestations in acrodermatitis enteropathica. *Arch Ophthalmol* 1975;93:140–142.
119. Cameron JD, McClain CJ. Ocular histopathology of acrodermatitis enteropathica. *Br J Ophthalmol* 1986;70:662–667.
120. Warshawsky RS, Hill CW, Doughman DJ, Harris JE. Acrodermatitis enteropathica. Corneal involvement with histochemical and electron micrographic studies. *Arch Ophthalmol* 1975;93:194–197.
121. Racz P, Kovacs B, Varga L, Ujlaki E, Zombai E, Karbuczky S. Bilateral cataracts in acrodermatitis enteropathica. *J Pediatr Ophthalmol Strab* 1979;16:180–182.
122. Feldberg R, Yassur Y, Ben-Sira I, Varsano I, Zelikovitz I. Keratomalacia in acrodermatitis enteropathica (AE). *Metabol Pediatr Ophthalmol* 1981;5:207–211.
123. Moynahan EJ. Zinc deficiency and disturbances of mood and visual behaviour. *Lancet* 1976;1:91.
124. Leopold IH. Zinc deficiency and visual impairment? *Am J Ophthalmol* 1978;85:871–875.
125. Arakawa T, Tamura T, Igarashi Y, Suzuki H, Sandstead HH. Zinc deficiency in two infants during total parenteral alimentation for diarrhea. *Am J Clin Nutr* 1976;29:197–204.
126. Kay RG, Tasman-Jones C, Pybus J, Whiting R, Black H. A syndrome of acute zinc deficiency during total parenteral alimentation in man. *Ann Surg* 1976;183:331–340.
127. Kay RG, Tasman-Jones C. Acute zinc deficiency in man during intravenous alimentation. *Aust N Z J Surg* 1975;45:325–330.
128. Tucker SB, Schroeter AL, Brown PW Jr, McCall JT. Acquired zinc deficiency: cutaneous manifestations typical of acrodermatitis enteropathica. *JAMA* 1976;235:2399–2402.
129. Weismann K, Hjorth N, Fischer A. Zinc depletion syndrome with acrodermatitis during longterm intravenous feeding. *Clin Exp Dermatol* 1976;1:237–242.
130. Weismann K, Fischer A, Hjorth N. Zink-depleteringssyndrom med acrodermatitis under langvarig parenteral ernæring: To tilfælde behandlet med oral og intravenøs zink. *Ugeskr Laeger* 1976;138:1403–1406.
131. Sturniolo GC, Molokhia MM, Shields R, Turnberg LA. Zinc absorption in Crohn's disease. *Gut* 1980;21:387–391.
132. Solomons NW, Rosenberg IH, Sandstead HH, Vo-Khactu KP. Zinc deficiency in Crohn's disease. *Digestion* 1977;16:87–95.
133. McClain C, Soutor C, Zieve L. Zinc deficiency: a complication of Crohn's disease. *Gastroenterology* 1980;78:272–279.
134. Knox DL, Snip RC, Stark WJ. The keratopathy of Crohn's disease. *Am J Ophthalmol* 1980;90:862–865.
135. Smith JC Jr, McDaniel EG, Fan FF, Halsted JA. Zinc: a trace element essential in vitamin A metabolism. *Science* 1973;181:954–955.

136. Christian P, West KP Jr. Interactions between zinc and vitamin A: an update. *Am J Clin Nutr* 1998;68(suppl):435S–441S.
137. Huber AM, Gershoff SN. Effects of zinc deficiency on the oxidation of retinol and ethanol in rats. *J Nutr* 1975;105:1486–1490.
138. Morrison SA, Russell RM, Carney EA, Oaks EV. Failure of cirrhotics with hypovitaminosis A to achieve normal dark adaptation performance on vitamin A replacement [abstract]. *Gastroenterology* 1976;71:922.
139. Morrison SA, Russell RM, Carney EA, Oaks EV. Zinc deficiency: a cause of abnormal dark adaptation in cirrhotics. *Am J Clin Nutr* 1978;31:276–281.
140. Patek AJ Jr, Haig C. The occurrence of abnormal dark adaptation and its relation to vitamin A metabolism in patients with cirrhosis of the liver. *J Clin Invest* 1939;18:609–616.
141. Russell RM, Morrison SA, Smith FR, Oaks EV, Carney EA. Vitamin-A reversal of abnormal dark adaptation in cirrhosis: study of effects on the plasma retinol transport system. *Ann Intern Med* 1978;88:622–626.
142. McClain CJ, Van Thiel DH, Parker S, Badzin LK, Gilbert H. Alterations in zinc, vitamin A, and retinol-binding protein in chronic alcoholics: a possible mechanism for night blindness and hypogonadism. *Alcoholism Clin Exp Res* 1979;3:135–141.
143. McClain CJ, Su LC, Gilbert H, Cameron D. Zinc-deficiency-induced retinal dysfunction in Crohn's disease. *Dig Dis Sci* 1983;28:85–87.
144. Christian P, Khatry SK, Yamini S, et al. Zinc supplementation might potentiate the effect of vitamin A in restoring night vision in pregnant Nepalese women. *Am J Clin Nutr* 2001;73:1045–1051.
145. Udomkesmalee E, Dhanamitta S, Sirisinha S, et al. Effect of vitamin A and zinc supplementation on the nutriture of children in northeast Thailand. *Am J Clin Nutr* 1992;56:50–57.
146. Allen LH. Zinc and micronutrient supplements for children. *Am J Clin Nutr* 1998;68(suppl 2):495S–498S.
147. Ruel MT, Bouis HE. Plant breeding: a long-term strategy for the control of zinc deficiency in vulnerable populations. *Am J Clin Nutr* 1998;68(suppl 2):488S–494S.

9

Vitamin C and Eye Health

1. INTRODUCTION

Vitamin C is a water-soluble vitamin that is essential for the biosynthesis of collagen, carnitine, and catecholamines. It serves as a strong antioxidant and protects proteins, lipids, and DNA from oxidative damage. The eye contains the highest concentrations of vitamin C found in the human body. Vitamin C is important to eye health because of its role in protecting the proteins of the crystalline lens from oxidation, in serving as a free radical scavenger in the retina, and in promoting wound healing in the cornea. Scurvy, the classic syndrome of vitamin C deficiency, includes some findings of ophthalmological importance, including vascular abnormalities of the conjunctiva, dry eyes, and hemorrhages of the conjunctiva, orbit, anterior chamber, and retina. Vitamin C may become increasingly important to ocular health with demographic changes such as increasing life span and a larger aging population, and with the continued depletion of the stratospheric ozone layer (1).

2. HISTORICAL BACKGROUND

Scurvy has been known since antiquity, and it became a more prominent disorder with the expansion of European maritime exploration and trade beginning in the late 15th century. Scurvy accounted for a great deal of morbidity and mortality among seafarers, soldiers, and explorers, and among civilians during times of famine and sieges (2,3). Although there are many early descriptions of the empirical use of citrus fruits and certain plants for the prevention and treatment of scurvy, the idea of scurvy as a nutritional deficiency disorder did not gain stronger ground until the early 20th century. In 1907, Axel Holst (1861–1931) and Theodor Frölich (b. 1870) produced experimental scurvy in the guinea pig (4), a step that facilitated the characterization of the anti-scorbutic factor. The anti-scorbutic factor was isolated in the laboratories of Albert Szent-Györgyi (1893–1986) (5) and Charles Glen King (1896–1988) (6) in 1932. The following year, the structure of ascorbic acid and its synthesis were described by Norman Haworth (1883–1950) and Edmund Langley Hirst (1898–1975) (7). In 1937 Haworth received the Nobel Prize in Chemistry for his work on the chemical structure of vitamin C. The descriptions of vitamin C in the ocular tissues and investigations of vitamin C as a protective factor for the eye began almost immediately after the description and synthesis of ascorbic acid in the 1930s (8–22).

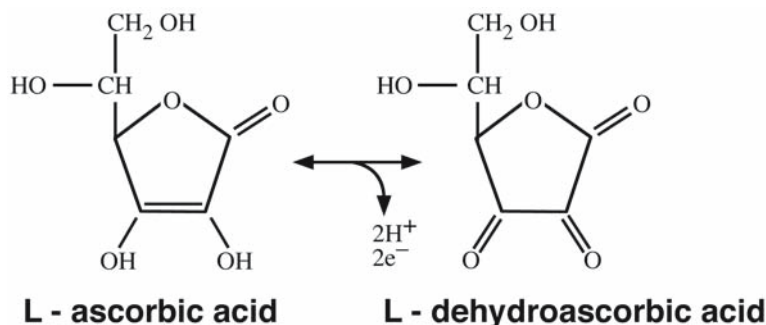


Fig. 1. Structural formulas of L-ascorbic acid and L-dehydroascorbic acid.

3. BIOCHEMISTRY OF VITAMIN C

Vitamin C is a generic term for ascorbic acid, dehydroascorbic acid, and all compounds that have the biological activity of ascorbic acid. Ascorbic acid, or L-ascorbic acid, is chemically defined as 2-oxo-L-theo-hexono-4-lactone-2,3-enediol and consists of a five-member ring with two enolic hydrogens (Fig. 1). The enolic hydrogens are important in the structure of L-ascorbic acid, because they provide electrons for its function as an antioxidant. These electrons can be lost easily, providing strong reducing power for L-ascorbic acid. L-ascorbic acid can be oxidized to L-dehydroascorbic acid via the ascorbyl radical, a relatively stable free radical. L-dehydroascorbic acid can be reduced back to the intermediate free radical and then to L-ascorbic acid. Dehydroascorbic acid can be hydrolyzed irreversibly to diketogulonic acid. Humans, other primates, guinea pigs, and bats are among the few mammals that cannot synthesize ascorbic acid from glucose because of a lack of the enzyme gulonolactone oxidase (23). Obsolete names for vitamin C include hexuronic acid, cevitamic acid, antiskorbutin, and scorbutamin.

4. DIETARY SOURCES OF VITAMIN C

Rich dietary sources of vitamin C include peppers, citrus fruits, broccoli, brussel sprouts, and cauliflower (Table 1) (24,25). Orange juice is rich in vitamin C, and many commercially available fruit drinks that have a small proportion of fruit juice are fortified with vitamin C. Vitamin C is also available in the form of multivitamins and also as megadose supplements. The vitamin C content of vegetables can be reduced by long cooking at high temperature. Ascorbate is the main form of vitamin C in most foods, constituting about 80–90% of the total vitamin C (25).

5. ABSORPTION, STORAGE, AND METABOLISM OF VITAMIN C

Ascorbic acid is absorbed in the intestine through a sodium-dependent, active transport process that is dose dependent and saturable and also by the process of simple diffusion (25). Simple diffusion predominates with high intakes of ascorbic acid. About 70–90% of ascorbic acid is absorbed with the usual dietary intake of ascorbic acid, but the amount absorbed may drop to 50% with higher doses, as with vitamin C supplements of 1 g. Larger megadoses of vitamin C may cause diarrhea and abdominal discomfort because a significant proportion of the unabsorbed ascorbic acid is degraded in the intestinal lumen. Vitamin C circulates as ascorbic acid free in the plasma, bound to albumin, within erythrocytes,

Table 1
Vitamin C Content of Selected Foods

<i>Food</i>	<i>Vitamin C (mg/100 g)</i>
Rose hips	250–800
Chili peppers	200–400
Parsley	200–300
Black currants	150–200
Broccoli	70–163
Brussel sprouts	90–150
Lemons	50–80
Oranges	40–78
Spinach	35–40
Limes	30–40
Potatoes	10–30
Tomatoes	9–30
Chicken	15–20
Apples	5–10
Beef	1–2
Pork	1–2
Cow's milk	0.5–2

Adapted from refs. 24,25.

and concentrated within neutrophils, lymphocytes, and platelets. Dehydroascorbic acid accounts for <2% of total vitamin C concentrations in the blood (25). Dehydroascorbic acid is readily reduced back to ascorbic acid, thus maintaining the total body stores of vitamin C, but some dehydroascorbic acid is hydrolyzed to diketogulonic acid and metabolized to other products that include oxalic acid, threonic acid, L-xylose, and ascorbate-2-sulfate (26). There is little renal excretion of ascorbic acid when the dietary intake of vitamin C is less than about 80 mg/d, but renal excretion of ascorbic acid increases at higher intakes (27). The symptoms of scurvy may occur when the total body pool of ascorbic acid is less than 300 mg (28). The vitamin C content of some human tissues and fluids is shown in Table 2 (26,29). The cornea epithelium and crystalline lens contain some of the highest concentrations of vitamin C in the human body.

6. FUNCTIONS OF VITAMIN C

Vitamin C is known to play a role as electron donor for several important enzymes in humans that are involved variously in collagen biosynthesis, Cq1 complement synthesis, carnitine biosynthesis, cephalosporin synthesis, norepinephrine biosynthesis, pyridine metabolism, tyrosine metabolism, and the activation of peptide hormones (26). L-ascorbic acid functions as a protective antioxidant for reactions that require reduced iron (Fe^{2+}) or copper (Cu^{1+}) metalloenzymes (30). In collagen biosynthesis, the enzyme prolyl hydroxylase requires oxygen, ascorbic acid, iron, and α -ketoglutarate in order to convert peptide-bound proline to hydroxyproline. Ascorbic acid is required as a cofactor for the enzymes 6-N-trimethyl-L-lysine hydroxylase and γ -butyrobetaine hydroxylase in the two-step

Table 2
Vitamin C Content of the Human Eye
and Cornea Related to Other Tissues

<i>Tissue</i>	<i>Vitamin C</i> ($\mu\text{mol}/100\text{ g wet}$)
Corneal epithelium	1100
Leukocytes	40–800
Pituitary gland	227–284
Adrenal glands	170–227
Crystalline lens	142–176
Brain	74–85
Liver	57–91
Heart muscle	28–85
Skeletal muscle	17
Plasma	1.7–8.5

From refs. 26,29.

hydroxylation of 6-*N*-trimethyl lysine to carnitine. In the biosynthesis of norepinephrine, dopamine- β -hydroxylase requires ascorbic acid in the conversion of dopamine to norepinephrine. Some peptide hormones have a terminal amide group which requires α -amidation in order to have biological activity. The enzyme peptidyl glycine hydroxylase requires ascorbic acid as an electron donor in α -amidations of hormones such as thyrotropin-releasing hormone, adrenocorticotrophic hormone, vasopressin, oxytocin, and cholecystokinin (31). Vitamin C is a strong antioxidant and has been shown to protect against lipid peroxidation and DNA damage in a wide variety of studies (26).

7. REQUIREMENT FOR VITAMIN C

The Food and Nutrition Board of the Institute of Medicine has made new recommendations of vitamin C intake by life stage and gender group (Table 3) (32). For definitions of Adequate Intake (AI), Estimated Average Requirement (EAR), and Recommended Dietary Allowance (RDA), *see* Chapter 1, Subheading 3.4. The requirement for vitamin C is an estimated 35 mg/d higher among smokers because of increased oxidative stress and metabolic differences (32).

8. EPIDEMIOLOGY OF VITAMIN C DEFICIENCY

Scurvy is rare in developed countries, but it is occasionally seen among individuals who have odd food habits with little consumption of fruits or vegetables, in situations of alcoholism or drug abuse, in heavy smokers, in patients with cancer, and in elderly men who live alone. In developing countries, scurvy may occur in refugee camps, prisons, and during periods of drought and food shortage. Scurvy has been described in a subject on a Zen macrobiotic diet (33). The clinical presentation of such patients may be unusual, as in hemarthrosis in a patient who shunned fruits and vegetables (34), purpura in an “unrepentant carnivore,” (35), painful gait with bruising in a child with peculiar dietary habits (36), lower extremity rash in a heavy smoker (37), and purpura and gingivitis in older adult patients with cancer (38,39). Scurvy may be increasing among the institution-

Table 3
Dietary Reference Intakes for Vitamin C (mg/d)

<i>Age and gender category</i>	<i>AI</i>	<i>EAR</i>	<i>RDA</i>
Infants, 0–6 mo	40	–	–
Infants, 7–12 mo	50	–	–
Children, 1–3 yr	–	13	15
Children, 4–8 yr	–	22	25
Boys and girls, 9–13 yr	–	39	45
Boys, 14–18 yr	–	63	75
Girls, 14–18 yr	–	56	65
Adult men ≥19 yr	–	75	90
Adult women ≥19 yr	–	60	75
Pregnant women, 14–18 yr	–	66	80
Pregnant women ≥19 yr	–	70	85
Lactating women, 14–18 yr	–	96	115
Lactating women ≥19 yr	–	100	120

AI, Adequate Intake; EAR, Estimated Average Requirement; RDA, Recommended Dietary Allowance. Based on the Food and Nutrition Board (32).

alized elderly and alcoholics in the United States (40). Borderline to deficient vitamin C status is relatively more common among some risk groups in developed countries, such as institutionalized older women (41) and elderly men living alone in the community (42). In the National Health and Nutrition Examination Survey (NHANES) II, 3% of the overall population aged 3–74 yr and 16% of black males aged 55–74 yr had low plasma vitamin C concentrations (43). A higher prevalence of low vitamin C concentrations was also found among cigarette smokers and among those with low incomes (43).

Infantile scurvy is a condition that occurs among infants and young children who do not receive sufficient amounts of vitamin C. The disease was more common in the late 19th century and early 20th century, when infant formula or weaning diet did not contain adequate amounts of vitamin C (44,45). The disease is also known as Barlow disease, after a clinical description made in 1883 by Sir Thomas Barlow (1845–1945) (46). Occasional cases of infantile scurvy still occur in developed countries (47,48), usually among infants who were fed cow's milk and no formula or supplements containing vitamin C.

9. ASSESSMENT OF VITAMIN C STATUS

The laboratory diagnosis of vitamin C deficiency is usually made either by measurement of serum or leukocyte ascorbic acid concentrations. Serum ascorbic acid concentrations usually reflect short term intake of vitamin C, whereas leukocyte ascorbic acid concentrations are considered to reflect more long term vitamin C status (49). In NHANES II, serum ascorbic acid concentrations were classified as deficient, low, and acceptable, based on ranges of <11, 11–23, and >23 $\mu\text{mol/L}$, respectively (50). The preferred method for measurement of ascorbic acid concentrations in serum is by high performance liquid chromatography. Leukocyte ascorbic acid concentrations have been defined as deficient, low, and adequate based on ranges of <57, 57–114, and >114 $\text{nmol}/10^8$ cells (49).

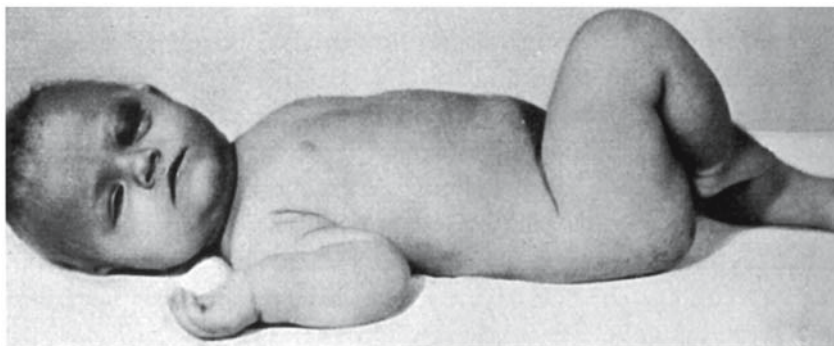


Fig. 2. Marked hematoma of the left eyelid in infantile scurvy. Hematoma is masking the exophthalmos. Note characteristic flexion of the leg, or “frog position” of infantile scurvy. (From ref. 52, with permission of the *Archives of Ophthalmology*.)

10. CLINICAL MANIFESTATIONS OF VITAMIN C DEFICIENCY

10.1. General Systemic Manifestations of Scurvy

Scurvy in adults is characterized by petechiae, ecchymoses, inflamed and bleeding gums, follicular hyperkeratosis, coiled hairs, perifollicular hemorrhages, arthralgias, joint effusions, and impaired wound healing. Old, formerly healed scars and fractures may spontaneously recur (51). Fatigue, dyspnea, gingivitis, and loosening of teeth are often present. Anemia is associated with scurvy. Infantile scurvy is typically characterized by subperiosteal and intramuscular hemorrhages. The gums may be red, swollen, and prone to bleeding. The condition is often described in badly nourished infants with poor weight gain. The infant often lies on his back in the “frog position” with one thigh everted and flexed at the abdomen in order to reduce pressure on a painful, swollen leg (Fig. 2) (52). Petechiae and ecchymoses are less common among infants than adults with scurvy.

10.2. Ophthalmological Findings During Scurvy

Ocular findings during scurvy are rare and are usually related to bleeding complications, as hemorrhages have been described in the eyelids, conjunctiva, orbit, iris, and retina. The most common ocular finding in infantile scurvy is unilateral proptosis, sometimes associated with eyelid ecchymoses. Over the last 125 yr, there have been numerous case reports of proptosis in infantile scurvy since an early clinical description made by Hugo Magnus (1842–1907) in 1878 (52–77). The average age of infants and young children who presented with exophthalmos and scurvy has been 10.5 mo (range 7–24 mo) (52). The subperiosteal regions of long bones and the orbit appear to be prone to hemorrhage because of their rapid physiologic growth. The exophthalmos is firm, nonpulsatile, and occurs spontaneously, usually with no history of trauma. The orbital plate of the frontal bone is the most frequent site of hemorrhage, and for unknown reasons, the left eye seems to be more susceptible (52,60). The exophthalmos will usually resolve within 1–3 wk with vitamin C therapy (Fig. 3) (52,64). Corneal ulceration has been described in one case of severe exophthalmos and exposure (73). Eyelid ecchymoses may also occur without proptosis, causing a “black eye” (60,65).

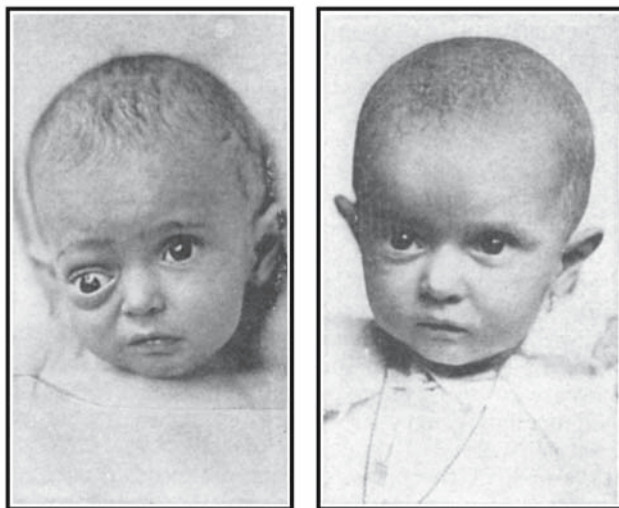


Fig. 3. Spontaneous exophthalmos in an infant with scurvy, before and after treatment. (From ref. 64, with permission of the *Journal of the American Medical Association*.)

In a collective report of infantile scurvy in North American in the late 19th century, a committee of the American Pediatric Society reported “swelling or protrusion of one or both eyes” in 49 of 379 cases, or 12.9% (78). This report and others (68) suggest that orbital hemorrhage with exophthalmos was not uncommon at a time when infantile scurvy was more prevalent. Other ocular findings that have been described in infantile scurvy include retinal hemorrhages (56,79) and hemorrhage into the anterior chamber (62). Orbital hemorrhages rarely may occur in adults with scurvy (66). Bilateral superior subperiosteal orbital hematomas were recently described in a 13-yr-old girl with spontaneous unilateral proptosis and scurvy (Fig. 4) (80). Orbital hemorrhage with proptosis has also been found in monkeys with experimental scurvy (81,82). From a medico-legal point of view, infantile scurvy should be considered in the differential diagnosis of “battered baby” or “shaken baby” syndrome, as eyelid ecchymoses, orbital hemorrhage, hyphema, and retinal hemorrhages can occur in a poorly nourished infant with scurvy in the absence of any physical trauma.

The most common finding among adults with scurvy is subconjunctival hemorrhage (83). Ocular lesions such as conjunctival hemorrhages and small conjunctival varicosities have been described in adults who were experimentally deprived of vitamin C after 74–95 d (83). Retinal hemorrhages have been occasionally described among adults with scurvy (84–92). The fundus appearance is characterized by retinal hemorrhages, exudates, and cotton wool spots (91,92). The retinopathy of scurvy is similar to both background diabetic retinopathy and the retinopathy of HIV infection, and it should be considered in the differential diagnosis in poorly nourished adults and among infants with failure to thrive. In a typical case, a 48-yr-old white, divorced, unemployed man developed painful bruising in the leg muscles (92). He did not have any ocular complaints, but he noted that his gums were bleeding, and one tooth had recently fallen out. For the last 2 yr, the patient had not eaten any fresh fruits or vegetables and had subsisted on tinned foods, meat pies, boiled

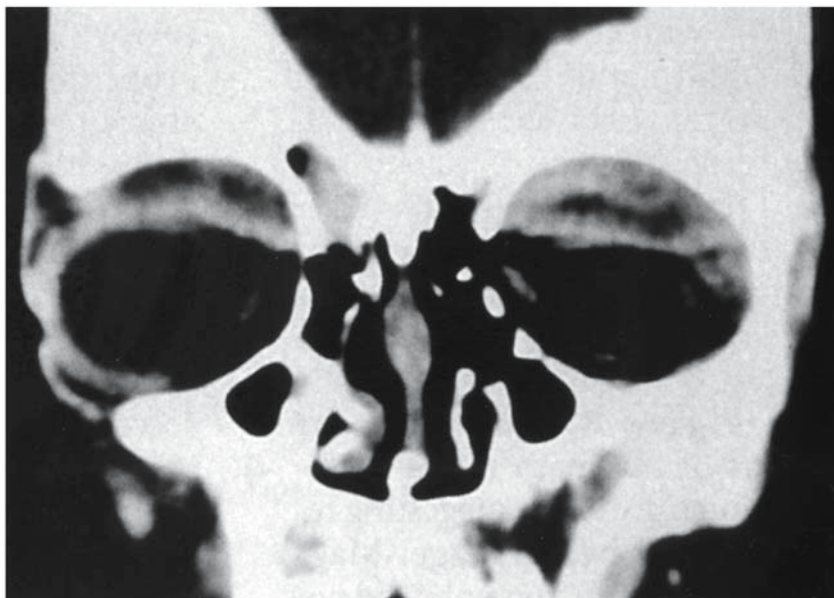


Fig. 4. Coronal computed tomographic scan of a 13-yr-old girl with scurvy reveals bilateral superior subperiosteal orbital hematomas. (From ref. 80, with permission of the *Archives of Ophthalmology*.)

eggs, white bread, and milk. Physical findings included gum hemorrhages, extensive muscle bruising, and petechiae. Ocular examination revealed retinal hemorrhages and exudates (Fig. 5A). The retinal hemorrhages and exudates resolved after 3 wk of vitamin C treatment (Fig. 5B). In one case report, the hemorrhagic diathesis of scurvy was severe enough to complicate cataract surgery (93).

10.3. Vitamin C and Corneal Wound Healing

Vitamin C, through its essential function in collagen synthesis and metabolism, appears to play an important role in corneal wound healing. The corneal epithelium contains the highest concentration of vitamin C found in the human body, 1100 $\mu\text{mol}/100\text{ g}$ wet weight, or about three hundred times the concentration of ascorbic acid found in the plasma (29). High concentrations of ascorbic acid have also been described in the corneal epithelium of many different mammals (94–99). The concentrations of ascorbic acid are lower in the corneal stroma, corneal endothelium, and aqueous humor than in the corneal epithelium (29,99). Ascorbic acid is concentrated through active transport by the ciliary body into the aqueous humor (100–107). The concentrations of ascorbic acid in the aqueous humor are about 20–25 times higher in the aqueous humor than in the plasma. The corneal endothelium takes up L-dehydroascorbic acid from aqueous humor, transports it into the cornea, and reduces it to ascorbic acid (108,109). The physiological mechanisms that account for the extremely high concentrations of vitamin C in the corneal epithelium have not been well characterized. The transport and metabolism of vitamin C in ocular tissues has been reviewed in detail elsewhere (110–112).

The importance of vitamin C to corneal integrity was shown in guinea pigs that developed corneal epithelial edema, disruption of the normal collagen pattern in the stroma,

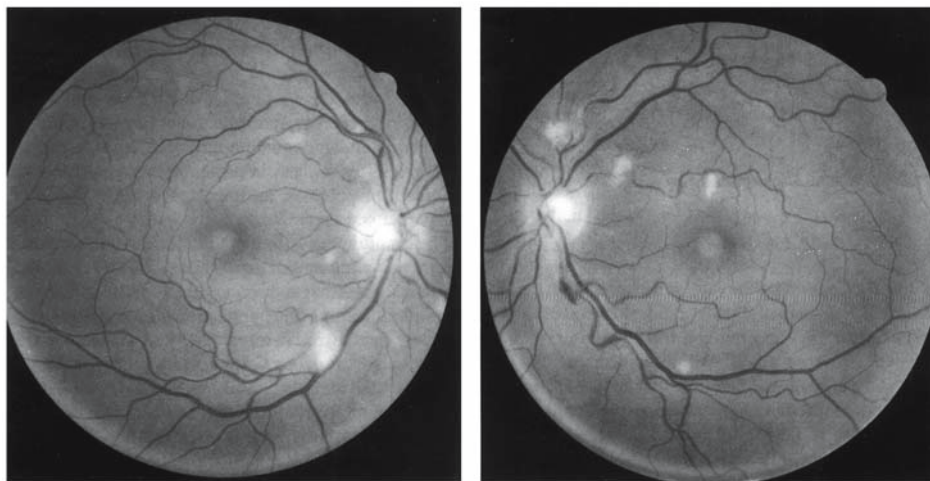


Fig. 5. Retinal hemorrhages and exudates in a 48-yr-old man with scurvy. (From ref. 92, with permission of *Eye*.)

mitochondrial degeneration, extensive alterations in basal cells, and loss of Bowman's membrane (113). After thermal injury to the cornea, scorbutic guinea pigs healed with greater corneal vascularization than normal guinea pigs (114). Roswell Pfister and colleagues have conducted an extensive series of studies of the effects of vitamin C on corneal ulceration in rabbits. Corneal ulceration after alkali injury was prevented by parenteral administration of ascorbic acid (115), and further studies showed that corneal ulceration followed alkali injury in 22% of rabbits treated with subcutaneous ascorbic acid compared with 60% of controls (116). Subcutaneous ascorbic acid treatment also increased the strength of corneal wounds (117). Ascorbic acid, given topically, reduced the incidence of corneal ulceration following alkali injury (118). Following severe alkali burns, the concentrations of ascorbic acid drop to about one-third normal levels in the rabbit eye (119). The ultrastructure of the corneal ulcers resembles the morphological changes noted in experimental scurvy, and corneal ulceration appears to occur when fibroblasts lack sufficient collagen for repair (119). The combination of topical sodium citrate, which inhibits polymorphonuclear leukocytes, and ascorbic acid has been shown to be the most effective in treatment of corneal ulceration following experimental severe alkali injury in rabbits (120–122). In contrast, systemic treatment with ascorbic acid does not appear to affect the healing rate of the corneal epithelium in very mild alkali burns in the rabbit (123). Topical epidermal growth factor appears to increase ascorbic acid concentrations in aqueous humor and corneal wounds in rabbits (124).

Ascorbic acid has been used in the treatment of corneal ulceration for more than 50 yr. In 1950, Boyd and Campbell conducted a placebo-controlled clinical trial of oral vitamin C, 500 mg three times daily, for 51 patients seen at the Glasgow Eye Infirmary with small, acute corneal ulcers (125). Patients who received vitamin C had significantly accelerated healing of deep ulceration compared with those who received placebo (Fig. 6). No significant effect was noted for more shallow ulcers. Ascorbate treatment of corneal ulceration caused by alkaline burns was also reported by others (126). In 1961, Stellamor-Peskir

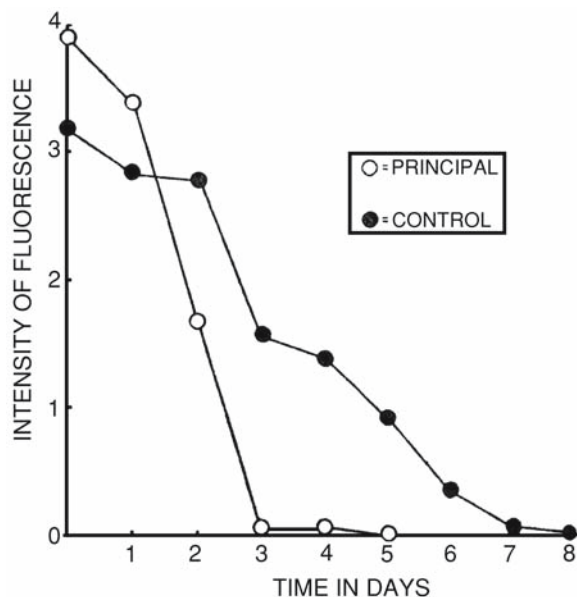


Fig. 6. Mean intensity of fluorescence of deep corneal ulcers among patients treated with oral vitamin C (circles) compared with placebo (solid dot). (Reprinted from ref. 125, with permission of the *British Medical Journal*.)

published a case series of 693 patients with alkali burns who were treated with both local and systemic ascorbic acid (127). Topical and/or oral ascorbate therapy has been used in the treatment of alkali burns of the cornea in some centers (128–131). In an 11-yr retrospective review of 121 cases with alkali burns, a treatment protocol that included topical ascorbic acid 10%, oral ascorbic acid, 500 mg four times per day, and sodium citrate, an inhibitor of neutrophils, appeared to be beneficial for grade 3 but not grade 1 or 2 alkali burns (131).

Wound healing following glaucoma filtration surgery may potentially be influenced by ascorbic acid in the aqueous humor, as reviewed in detail elsewhere (132). Ascorbic acid has been shown to stimulate type I and type III collagen in human Tenon's fibroblasts (133). A recent prospective study of 249 adult patients who underwent trabeculectomy showed no relationship between ascorbic acid concentrations in the aqueous humor and outcome of glaucoma filtering surgery (134).

10.4. Vitamin C and Cataracts

Although cataracts are not associated with scurvy (135), which usually occurs as an acute clinical syndrome, there is some evidence that long term vitamin C status may be related to the pathogenesis of cataracts. Vitamin C appears to play a role in reducing photo-reactive damage to the lens through two mechanisms: first, as a filter for ultraviolet light reaching the cornea and lens, and second, in protecting the lens from oxidative stress. As mentioned previously, the concentration of ascorbic acid in the human corneal epithelium is about 1100 $\mu\text{mol}/100\text{ g}$ wet weight, the highest concentration of vitamin C that has been found in the body (29). The ascorbic acid concentrations in the corneal epithelium (136) and aqueous humor (137) are much higher in diurnal than nocturnal mammals, suggesting that ascorbic acid may play a role in protecting the eye against damage from ultraviolet

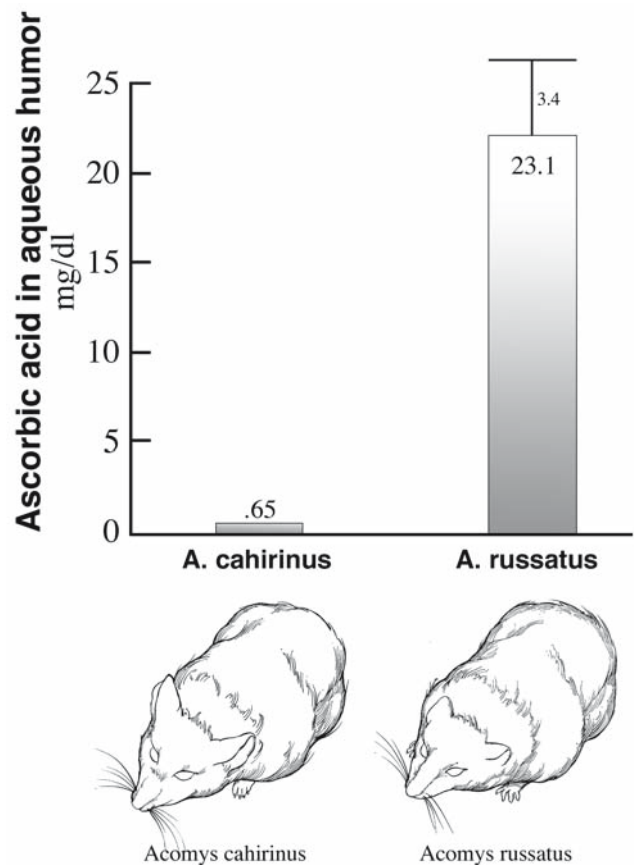


Fig. 7. Concentrations of ascorbic acid in the aqueous humor of two closely related species of spiny mice, *Acomys russatus*, a diurnal species, and *Acomys cahirinus*, a nocturnal species. (Illustration by Frank Corl.)

radiation (138,139). A clue may come from two closely related species of spiny mice, *Acomys russatus*, a diurnal species, and *Acomys cahirinus*, a nocturnal species (Fig. 7). The ascorbic acid concentration in the aqueous humor of the diurnal species was 35 times higher than in the aqueous humor of the nocturnal species (139). These important comparative observations are consistent with the hypothesis that ascorbic acid in the aqueous humor and cornea are adaptations to solar radiation, similar to pigmentation in the skin (136–140).

The vitamin C concentration in the corneal epithelium of reindeer is about 2233 $\mu\text{mol}/100\text{ g}$ wet weight, or about twofold higher than that found in humans (136). Reindeer live usually live at higher elevations (>1000 meters above sea level) in an environment partially covered with snow, and the ultraviolet light exposure is high. In contrast, the lynx, a nocturnal feline, has a vitamin C concentration in the corneal epithelium of 82 $\mu\text{mol}/100\text{ g}$ wet weight (136). What is the potential effect of vitamin C in the human cornea? Given an even distribution of ascorbic acid in the corneal epithelium, ascorbic acid alone would absorb 77% of the incident radiation reaching the basal layer of the epithelium (29). An estimated 99.96% of radiation at 260 nm would be absorbed by ascorbic acid in the epithelium and intervening tissues and fluids before reaching the lens (29). Thus, Brubaker

has proposed that at 260 nm, ocular ascorbic acid would have a Sun Protective Factor (SPF) of 4 for the basal layer of the cornea and SPF 2500 for the lens epithelial layer. In vitro studies show that ascorbic acid in the cornea absorbs a significant amount of ultraviolet (UV) radiation (136,140). The cornea epithelium acts as a UV filter through three mechanisms: (1) absorption of UV-B radiation below 310 nm wavelength, (2) fluorescence-mediated ray transformation to longer wavelengths, and (3) fluorescence reduction (136).

UV light exposure causes lipid peroxidation in the lens epithelium, changes in lenticular proteins, and damage to DNA in the epithelium (141). Free radicals, such as superoxide and hydrogen peroxide, may be balanced by ascorbic acid, glutathione, other antioxidants such as vitamin E and carotenoids, and by enzymes such as superoxide dismutase (142–144). Vitamin C-deficient guinea pigs sustain significantly more damage to the lens epithelium from UV light than normal guinea pigs, an observation consistent with the hypothesis that vitamin C protects the lens against the cataractogenic effect of UV radiation in sunlight (141,145). Dietary ascorbic acid has been shown to protect guinea pigs against heat-induced damage to proteins of the lens (146).

Vitamin C appears to reduce the severity of experimentally induced cataracts (142,147–149). In young rats, selenite increases the peroxidation of lens lipids and can be used to experimentally produce cataracts. Administration of vitamin C can largely prevent cataract formation by selenite (148). In the experimental model of galactose-induced cataract in guinea pigs, ascorbic acid appeared to reduce the development of cataract through pro-oxidant, rather than antioxidant effects (149). In diabetic rats, supplementation with vitamin C was shown to reduce the leakage of gamma-crystallin protein from lenses and a reduction of cataract (150). The vitamin C concentration in the guinea pig lens appears to decrease with age even with the same level of dietary intake of vitamin C (151). Ascorbate was protective against oxidative stress in the mouse lens (152).

Although most evidence suggests that vitamin C is protective against cataracts in experimental animals, others have shown that physiological concentrations ascorbic acid may increase the brunescence of bovine lenses in vitro (153). Ascorbic acid appears to have the potential to cause cross-linking of lens proteins, suggesting a Maillard reaction (154). The metabolism of L-dehydroascorbic acid to diketogulonic acid may play a role in the formation of lens opacities, as diketogulonic acid may be further oxidized to oxalic acid, perhaps explaining the presence of crystalline particles of calcium oxalate in the lens (155). In humans, there is much suggestive epidemiological evidence but little direct evidence to show that vitamin C is protective against senile cataract (144,156). The concentrations of ascorbic acid in the lens and aqueous humor were significantly correlated with concentrations in the plasma in humans (157). The concentrations of ascorbic acid in the lens appear to decrease with severity of cataracts (158,159). The epidemiological studies of vitamin C and cataract are discussed in detail elsewhere in Chapter 3 (Subheading 3.3.6.).

10.5. Vitamin C and the Retina

Ascorbic acid may function to protect the retina from photic damage (160,161). The retina appears to take up ascorbic acid through an energy dependent process (162), and the concentrations of ascorbic acid and dehydroascorbic acid in the retina, subretinal fluid, and pigment epithelium suggest a movement of ascorbate from the vitreous cavity into the subretinal space (163). Concentrations of vitamin C are about twenty times higher

in the retina than in the plasma (161). With intense light exposure, excessive energy must be disposed, otherwise photodynamic reactions may produce free radicals and cause oxidative damage to the retina (161). In guinea pigs, the dominant form of vitamin C is ascorbic acid in the neural retina and dehydroascorbic acid in the retinal pigment epithelium (164). After mild photic damage to the retina, the concentrations of ascorbic acid decrease in the neural retina, and the concentrations of dehydroascorbic acid increase in the retinal pigment epithelium (164,165). Rats supplemented with vitamin C were significantly protected against photic injury in the retina compared with unsupplemented control rats (166). In studies monkeys fed a vitamin C-deficient diet and vitamin C-enriched diet, retinal photic injury in vitamin C-deficient monkeys was characterized by more severe tissue damage, an exaggerated repair response, and more advanced retinal degeneration (161). Ascorbic acid protects rats against retinal light damage (167). Whereas L-ascorbic acid functions as both a coenzyme and antioxidant, D-ascorbic acid, the stereoisomer, is considered to function as an antioxidant only. Both L-ascorbic acid and D-ascorbic acid protected rats against light damage to the retina, suggesting that ascorbic acid plays primarily an antioxidant role in protecting the retina (168).

10.6. Vitamin C in Human Tears

Human tears contain a high concentration of vitamin C in comparison with plasma (169), and the lacrimal gland is capable of uptake, metabolism, and secretion of ascorbic acid in tears (170). The concentration of ascorbic acid in human tears has been found to range from 220–1310 $\mu\text{mol/L}$, with the lower values found with higher tear flow rates (169). Another study described a mean ascorbic acid concentration of 665 $\mu\text{mol/L}$ in basal tear secretions (171). The amount of ascorbic acid that is recovered may vary a great deal depending on the method of tear collection (172).

11. PREVENTION AND TREATMENT OF MARGINAL VITAMIN C STATUS AND DEFICIENCY

Vitamin C deficiency is rare and can be prevented with adequate intake of foods that are rich in vitamin C, such as fruits, vegetables, fruit juices, and vitamin C-fortified cereals and fruit-flavored drinks.

The requirement of vitamin C is higher for smokers. Infantile scurvy has largely disappeared from developed countries with vitamin C-fortified infant formula, better knowledge of nutrition, and improved feeding practices, but sporadic cases of infantile scurvy occur due to lack of knowledge by the parents. In contrast, marginal vitamin C status appears to be more common (43) and consumption of vitamin C-rich foods could be increased. For example, in the United States, only 9% of Americans consume the two fruits and three vegetables recommended by the National Cancer Institute and the National Research Council/National Academy of Science (173). There appears to be little evidence to support the use of megadose vitamin C supplements for eye health, and doses of vitamin C above 2 g per day are associated with increased risk of gastrointestinal disturbances, nephrolithiasis, increased uric acid excretion (32). There is little evidence to support the use for vitamin C eyedrops, except as treatment for severe alkali burns to the cornea, and crystalline deposits of the cornea have been described with the use of vitamin C eye-drops (174).

12. CONCLUSIONS

Vitamin C plays an important role in eye health through several different functions: as a potent antioxidant to protect the lens and retina from oxidative stress, as an absorber of UV radiation in the cornea and aqueous humor, and as a factor involved in the synthesis and metabolism of collagen in the cornea. Scurvy, the clinical deficiency syndrome of advanced vitamin C deficiency, has well known ophthalmological manifestations that are primarily related to hemorrhagic complications, and these findings include hemorrhages of the eyelids, conjunctiva, anterior chamber, iris, retina, and orbit. The long term consequences of marginal vitamin C status on ocular health are not clear, but could include increased risk of cataract and retinal disease. The role of vitamin C status in the pathogenesis of cataracts in humans needs further exploration, especially in populations that are at high risk of marginal and deficient vitamin C status. Further studies are needed to characterize the relationship between vitamin C in tears and potential roles of vitamin C in protecting the cornea and conjunctiva. The relationship between vitamin C in tears and the metabolism of vitamin C in the cornea epithelium has not been characterized. Whether vitamin C concentrations in tears are reduced in certain disease states or among certain risk groups, i.e., smokers and those with low dietary vitamin C intake is unclear. It is not known whether low vitamin C concentration in tears has any adverse effect on ocular health, such as with herpes keratitis or ocular surface abnormalities. Although experimental animal studies and some human observational studies suggest that topical and oral vitamin C is beneficial for alkali burns, conclusive evidence from a rigorously conducted, multicenter clinical trial has not been obtained. The long term consequences of marginal vitamin C status and retinal disease, such as age-related macular degeneration and diabetic retinopathy, are not well understood.

REFERENCES

1. Rose RC, Richer SP, Bode AM. Ocular oxidants and antioxidant protection. *Proc Soc Exp Biol Med* 1998;217:397–407.
2. Carpenter KJ. *The History of Scurvy and Vitamin C*. Cambridge, Cambridge University Press, 1986.
3. Hess AF. *Scurvy Past and Present*. Philadelphia, J. B. Lippincott, 1920.
4. Holst A, Frölich T. Experimental studies relating to ship beri-beri and scurvy. II. On the etiology of scurvy. *J Hygiene* 1907;7:634–671.
5. Svirbely JL, Szent-Györgyi A. The chemical nature of vitamin C. *Biochem J* 1932;26:865–870.
6. King CG, Waugh WA. Isolation and identification of vitamin C. *J Biol Chem* 1932;97:325–331.
7. Haworth WN, Hirst EL. Synthesis of ascorbic acid. *Chemistry and Industry* 1933;52:645–656.
8. Birch TW, Dann WJ. Estimation and distribution of ascorbic acid (vitamin C) and glutathione in animal tissues. *Nature* 1933;131:469–470.
9. Harris LJ. Chemical test for vitamin C, and the reducing substances present in tumour and other tissues. *Nature* 1933;132:27–28.
10. Von Euler H, Martius C. Über den Gehalt der Augenlinsen an Sulfhydrylverbindungen und an Ascorbinsäure. *Hoppe Seylers Z Physiol Chem* 1933;222:65–69.
11. Birch TW, Dann WJ. Ascorbic acid in the eye-lens and aqueous humour of the ox. *Biochem J* 1934;28:638–641.
12. Bietti G, Cartenì A. Ricerche sul contenuto in acido ascorbico (vitamina C) del cristallino di cavie a dieta scorbutigena. *Boll Soc Ital Biol Sper* 1934;9:983–985.
13. Muller MHK. La vitamine C et le problème de la cataracte. *Bull Soc Belge Opht* 1934;69:65–70.
14. Müller HK, Buschke W. Vitamin C in Linse, Kammerwasser und Blut bei normalem und pathologischem Linsenstoffwechsel. *Arch Augenheilk* 1934;108:368–390.

15. Müller HK, Buschke W. Linsenatmung und Vitamin C des Kammerwassers. *Arch Augenheilk* 1934; 108:592–596.
16. Fischer FP. Über das C-Vitamin der Linse. *Klin Wochenschr* 1934;13:596–597.
17. Monjukowa NK, Fradkin MJ. Neue experimentelle Befunde über die Pathogenese der Katarakt. *Arch Ophthalmol (Berlin)* 1935;133:328–338.
18. Bietti G. La vitamin C (acido ascorbico) nei liquidi e tessuti oculari: suoi rapporti colla biologia del cristallino. *Boll Oculist* 1935;14:3–33.
19. Nakamura B, Nakamura O. Über das Vitamin C in der Linse und dem Kammerwasser der menschlichen Katarakte. *Arch Ophthal (Berlin)* 1935;134:197–200.
20. Bellows J. Biochemistry of the lens. V. Cevitamic acid content of the blood and urine of subjects with senile cataract. *Arch Ophthalmol* 1936;15:78–83.
21. Bellows J. Biochemistry of the lens. VII. Some studies on vitamin C and the lens. *Arch Ophthalmol* 1936; 16:58–64.
22. Johnson SW. Cataract and ascorbic acid in the guinea-pig eye. *Biochem J* 1936;30:1430–1437.
23. Sato P, Udenfriend S. Scurvy-prone animals, including man, monkey, and guinea pig, do not express the gene for gulonolactone oxidase. *Arch Biochem Biophys* 1978;187:158–162.
24. Pennington JAT. Bowes & Church's Food Values of Portions Commonly Used. Seventeenth Edition. Philadelphia, Lippincott Williams & Wilkins, 1998.
25. USDA National Nutrient Database for Standard Reference, Release 18. USDA Food Composition Data. Agricultural Research Service, Nutrient Data Laboratory (<http://www.nal.usda.gov/fnic/foodcomp/search>)
26. Rumsey SC, Levine M. Absorption, transport, and disposition of ascorbic acid in humans. *J Nutr Biochem* 1998;9:116–130.
27. Jacob RA. Vitamin C. In: Shils ME, Olson JA, Shike M, Ross AC (eds). *Modern Nutrition in Health and Disease*. Ninth edition. Baltimore, Williams & Wilkins: 1999; pp. 467–483.
28. Blanchard J, Tozer TN, Rowland M. Pharmacokinetic perspectives on megadoses of ascorbic acid. *Am J Clin Nutr* 1997;66:1165–1171.
29. Baker EM, Hodges RE, Hood J, Sauberlich HE, March SC, Canham JE. Metabolism of ¹⁴C- and ³H-labeled L-ascorbic acid in human scurvy. *Am J Clin Nutr* 1971;24:444–454.
30. Brubaker RF, Bourne WM, Bachman LA, McLaren JW. Ascorbic acid content of human corneal epithelium. *Invest Ophthalmol Vis Sci* 2000;41:1681–1683.
31. Halliwell B, Whiteman M. Antioxidant and prooxidant properties of vitamin C. In: Packer L, Fuchs J (eds). *Vitamin C in Health and Disease*. New York, Marcel Dekker: 1997; pp. 59–73.
32. Eipper BA, Mains RE. The role of ascorbate in the biosynthesis of neuroendocrine peptides. *Am J Clin Nutr* 1991;54:1153S–1156S.
33. Food and Nutrition Board, Institute of Medicine. Dietary Reference Intakes for Vitamin C, Vitamin E, Selenium, and Carotenoids: A Report of the Panel on Dietary Antioxidants and Related Compounds. Washington, D.C., National Academy Press, 2000.
34. Sherlock P, Rothschild EO. Scurvy produced by a Zen macrobiotic diet. *JAMA* 1967;199:794–798.
35. Pangan AI, Robinson D. Hemarthrosis as initial presentation of scurvy. *J Rheumatol* 2001;28:1923–1925.
36. Levin NA, Greer KE. Scurvy in an unrepentant carnivore. *Cutis* 2000;66:39–44.
37. Tamura Y, Welch DC, Zic JA, Cooper WO, Stein SM, Hummell DS. Scurvy presenting as painful gait with bruising in a young boy. *Arch Pediatr Adolesc Med* 2000;154:732–735.
38. Assi ME, Thomas G, Taub SJ, Thomas H, Thomas JR, Stang RJ. Scurvy in a nonalcoholic person in the United States. *J Am Osteopath Assoc* 1992;92:1529–1931.
39. Statters DJ, Asokan VS, Littlewood SM, Snape J. Carcinoma of the caecum in a scorbutic patient. *Brit J Clin Pract* 1990;44:738–740.
40. Fain O, Mathieu E, Thomas M. Scurvy in patients with cancer. *BMJ* 1998;316:1661–1662.
41. Oeffinger KC. Scurvy: more than historical relevance. *Am Fam Physician* 1993;48:609–613.
42. Lowik MR, Hulshof KF, Schneijder P, Schrijver J, Colen AA, van Houten P. Vitamin C status in elderly women: a comparison between women living in a nursing home and women living independently. *J Am Diet Assoc* 1993;93:167–172.
43. McClean HE, Dodds PM, Stewart AW, Beaven DW, Riley CG. Nutrition of elderly men living alone. Part 2. Vitamin C and thiamine status. *N Z Med J* 1976;84:345–358.

43. Yetley E, Johnson C. Nutritional applications of the Health and Nutrition Examination Surveys (HANES). *Annu Rev Nutr* 1987;7:441–463.
44. Cheadle WB. Clinical lecture on three cases of scurvy supervening on rickets in young children. *Lancet* 1878;2:685–687.
45. Cheadle WB. Osteal or periosteal cachexia and scurvy. *Lancet* 1882;2:48–49.
46. Barlow T. On cases described as “acute rickets” which are probably a combination of scurvy and rickets, the scurvy being an essential, and the rickets a variable, element. *Med Chir Trans* 1883;66:159–219.
47. Mimasaka S, Funayama M, Adachi N, Nata M, Morita M. A fatal case of infantile scurvy. *Int J Legal Med* 2000;114:122–124.
48. Riepe FG, Eichmann D, Oppermann HC, Schmitt HJ, Tunnessen WW Jr. Infantile scurvy. *Arch Pediatr Adolesc Med* 2001;155:607–608.
49. Sauberlich HE. Laboratory Tests for the Assessment of Nutritional Status. Second Edition. Boca Raton, CRC Press, 1999.
50. Schechtman G, Byrd JC, Hoffmann R. Ascorbic acid requirements for smokers: analysis of a population survey. *Am J Clin Nutr* 1991;53:1466–1470.
51. Cohen IK, Keiser HR. Disruption of healed scars in scurvy—the result of a disequilibrium in collagen metabolism. *Plast Reconstr Surg* 1976;57:213–215.
52. Dunnington JH. Exophthalmos in infantile scurvy. *Arch Ophthalmol* 1931;6:731–739.
53. Magnus. Exophthalmus auf skorbutischer Grundlage. *Deutsch Med Wochenschr* 1878;No. 29:365.
54. Spicer WTH. Orbital haemorrhages occurring in young children. *Trans Ophthalmol Soc UK* 1892;12:33–38.
55. Heubner O. Ueber die Barlow'sche Krankheit. *Berl klin Wochenschrift* 1903;40:285–292.
56. Hirschberg J. Ein Fall von Barlow'scher Krankheit. *Centralbl prakt Augenheilk* 1903;27:206–207.
57. Schlesinger E. Zur Symptomatologie der Barlowschen Krankheit. *Munch Med Wochenschr* 1905; (October 24):2073–2075.
58. Meding CB. Two cases of subperiosteal hemorrhage of the orbit from scurvy. *Arch Ophthalmol* 1905;34:611–612.
59. Snow I. Eye symptoms of infantile scurvy. A case of infantile scurvy with extreme protrusion of the right eyeball, shown by autopsy to be due to a large retrobulbar hematoma. *Arch Pediatr* 1905;22:576–580.
60. Still GF. A clinical lecture on infantile scurvy. *Brit Med J* 1906;2:186–190.
61. Dewey JH. The ocular symptoms of infantile scurvy. *Annals Ophthalmol* 1911;20:307–315.
62. Steindorff K. Ueber Barlowsche Krankheit mit besonderer Berücksichtigung der dabei beobachteten Augenerscheinungen. *Zeitschr Augenheilk* 1911;25:180–185.
63. Brandes. Contribution à l'étude des hématomes spontanées de l'orbite. *Recueil d'Ophthalmologie* 1911; (4 ser) 33:176–177.
64. De Buys LR. Exophthalmos in scurvy. *J Am Med Assoc* 1912;59:2040–2043.
65. Stephenson S. The ocular manifestations of infantile scurvy. *Ophthalmoscope* 1915;13:132–135.
66. Thielmann. Über die skorbutischen Augen-Entzündungen. *Graefe-Saemisch Handbuch der gesamten Augen-heilkunde*. Vol. 14. Berlin, Julius Springer: 1915–1918; pp. 197–205.
67. Steele HM. Exophthalmos, due to scorbutus. *Arch Pediatr* 1921;38:52–53.
68. Blake EM. Ocular changes in infantile scurvy. *Am J Ophthalmol* 1921;4:736–738.
69. Eaton PJ. Scorbutus, with exophthalmos. *Trans Am Ped Soc* 1923;35:395–398.
70. Potter PS. Scorbutus with exophthalmos. *Arch Pediatr* 1924;41:355–356.
71. Tallei E. Le manifestazioni oculari dello scorbuto infantile. *Boll Ocul* 1925;4:247–263.
72. Place EC. Unilateral proptosis due to scurvy. *Am J Ophthalmol* 1925;8:955–957.
73. Jost A. Complications oculaires dans la maladie de Barlow. *Bull Soc Ophtal Paris* 1926;714–717.
74. Van Duyse M. Exophthalmie et scorbut infantile. *Bull Soc Belge Ophtal* 1928;57:51–53.
75. Middelhoven CWC. Een ongewone vorm van morbus barlowi. *Nederl Tijd Geneesk* 1941;85 (III): 3536–3538.
76. Richardson OB. Exophthalmos due to infantile scurvy. *Bull Acad Med Toronto*;1948;22:51–52.
77. Suman RL, Dabi DR. Scurvy - an unusual cause of proptosis? *Indian Pediatr* 1998;35:915–916.
78. Griffith JPC, Jennings CG, Morse JL. The American Pediatric Society's collective investigation on infantile scurvy in North America. *Arch Pediatr* 1898;15:481–499.

79. Shapiro E, Hurwitz S. Hemorrhage of the brain and retina in scurvy. *Arch Pediatr* 1938;55:327–333.
80. Sloan B, Kulwin DR, Kersten RC. Scurvy causing bilateral orbital hemorrhage. *Arch Ophthalmol* 1999; 117:842–843.
81. Harden A, Zilva SS. Experimental scurvy in monkeys. *J Pathol Bact* 1919;22:246–251.
82. Zilva SS, Still GF. Orbital haemorrhage with proptosis in experimental scurvy. *Lancet* 1920;1:1008.
83. Hood J, Hodges RE. Ocular lesions in scurvy. *Am J Clin Nutr* 1969;22:559–567.
84. Mackenzie S. Two cases of idiopathic (progressive pernicious) anaemia with retinal haemorrhages; fatal result. *Trans Ophthalmol Soc UK* 1880–1881;1:48–57.
85. Fialkowsky. Die scorbutischen Augenerkrankungen. *Centralblatt prakt Augenheilk* 1880;4:247–252.
86. Seggel. Scorbutische Erkrankung der Augen. *Klin Monatsbl Augenheilk* 1899;37:298–306.
87. Weill G. Ueber skorbutische Augenleiden. *Zeitschr Augenheilk* 1903;9:514–519.
88. Kitamura S. Ein Beitrag zur Kenntnis der Netzhautveränderungen beim Skorbut. *Deutsche Med Wochenschr* 1910;36:403–404.
89. Löwenstein A. Roseolenähnliche Affektion der Regenbogenhaut neben punktförmigen Bindehautblutungen bei hämorrhagischer Diathese. *Klin Monatsbl Augenheilk* 1917;59:583–588.
90. Thilliez. Hémorragies rétinienées déterminées par un régime sans vitamines. *La Clinique Ophtalmologique* 1925;14 (2 ser):594.
91. Bloxham CA, Clough C, Beevers DG. Retinal infarcts and haemorrhages due to scurvy. *Postgrad Med J* 1990;66:687.
92. Adetona N, Kramarenko W, McGavin CR. Retinal changes in scurvy. *Eye* 1994;8:709–710.
93. Taube EL. Cataract extraction in subclinical scurvy. *Am J Ophthalmol* 1938;21:910–911.
94. Schmid AE, Bürki E. Histochemische Untersuchungen zum Nachweis und zur Lokalisation des Vitamin C im Auge. *Ophthalmologica* 1943;105:65–82.
95. Henkes HE. On the distribution of glutathione and vitamin C in the lens and cornea. *Ophthalmologica* 1946;112:113–128.
96. Pirie A. Ascorbic acid content of cornea. *Biochem J* 1946;40:96–100.
97. Reim M, Seidl M, Brucker K. Accumulation of ascorbic acid in the corneal epithelium. *Ophthalmic Res* 1978;10:135–139.
98. Ringvold A, Anderssen E, Kjønniksen I. Ascorbate in the corneal epithelium of diurnal and nocturnal species. *Invest Ophthalmol Vis Sci* 1998;39:2774–2777.
99. Ringvold A, Anderssen E, Kjønniksen I. Distribution of ascorbate in the anterior bovine eye. *Invest Ophthalmol Vis Sci* 2000;41:20–23.
100. Kinsey VE. Transfer of ascorbic acid and related compounds across the blood-aqueous barrier. *Am J Ophthalmol* 1947;30:1262–1266.
101. Kinsey VE. Dehydroascorbic acid-ascorbic acid in the aqueous humor of rabbits. *Am J Ophthalmol* 1950;33:257–268.
102. Linnér E. Ascorbic acid as a test substance for measuring relative changes in the rate of plasma flow through the ciliary processes. I. The effect of unilateral ligation of the common carotid artery in rabbits on the ascorbic acid content of the aqueous humour at varying plasma levels. *Acta Physiol Scand* 1952; 26:57–69.
103. Langham ME. The use of ascorbic acid to measure the rate of flow of plasma through the ciliary processes. *J Physiol* 1955;130:1–8.
104. Becker B. Ascorbate transport in guinea pig eyes. *Invest Ophthalmol* 1967;6:410–415.
105. Linnér E, Nordström K. Transfer of D-isoascorbic acid and L-ascorbic acid into guinea pig eyes. *Doc Ophthalmol* 1969;26:164–170.
106. Kodama T, Kabasawa I, Tamura O, Reddy VN. Dynamics of ascorbate in the aqueous humor and tissues surround ocular chambers. *Ophthalmic Res* 1985;17:331–337.
107. Chu TC, Candia OA. Active transport of ascorbate across the isolated rabbit ciliary epithelium. *Invest Ophthalmol Vis Sci* 1988;29:594–599.
108. Bode AM, Vanderpool SS, Carlson EC, Meyer DA, Rose RC. Ascorbic acid uptake and metabolism by corneal endothelium. *Invest Ophthalmol Vis Sci* 1991;32:2266–2271.
109. DiMattio J. Ascorbic acid entry into cornea of rat and guinea pig. *Cornea* 1992;11:53–65.
110. Rose RC, Bode AM. Ocular ascorbate transport and metabolism. *Comp Biochem Physiol* 1991;100A: 273–285.

111. Garland DL. Ascorbic acid and the eye. *Am J Clin Nutr* 1991;54:S1198–1202.
112. Campbell FW, Ferguson ID. The role of ascorbic acid in corneal vascularization. *Br J Ophthalmol* 1950; 34:329–334.
113. Delamere NA. Ascorbic acid and the eye. *Subcell Biochem* 1996;25:313–329.
114. Sulkin DF, Sulkin NM, Nushan H. Corneal fine structure in experimental scorbutus. *Invest Ophthalmol* 1972;11:633–643.
115. Campbell FW, Ferguson ID. The role of ascorbic acid in corneal vascularization. *Br J Ophthalmol* 1950; 34:329–334.
116. Levinson RA, Paterson CA, Pfister RR. Ascorbic acid prevents corneal ulceration and perforation following experimental alkali burns. *Invest Ophthalmol* 1976;15:986–993.
117. Pfister RR, Paterson CA. Additional clinical and morphological observations on the favorable effect of ascorbate in experimental ocular alkali burns. *Invest Ophthalmol Vis Sci* 1977;16:478–487.
118. Pfister RR, Hayes SA, Paterson CA. The influence of parenteral ascorbate on the strength of corneal wounds. *Invest Ophthalmol Vis Sci* 1981;21:80–86.
119. Pfister RR, Paterson CA, Hayes SA. Topical ascorbate decreases the incidence of corneal ulceration after experimental alkali burns. *Invest Ophthalmol Vis Sci* 1978;17:1019–1024.
120. Pfister RR, Paterson CA. Ascorbic acid in the treatment of alkali burns of the eye. *Ophthalmology* 1980; 87:1050–1057.
121. Pfister RR, Licolaro ML, Paterson CA. Sodium citrate reduces the incidence of corneal ulcerations and perforations in extreme alkali-burned eyes—acetylcysteine and ascorbate have no favorable effect. *Invest Ophthalmol Vis Sci* 1981;21:486–490.
122. Pfister RR, Haddow JL, Lank KM. Citrate or ascorbate/citrate treatment of established corneal ulcers in the alkali-injured rabbit eye. *Invest Ophthalmol Vis Sci* 1988;29:1110–1115.
123. Pfister RR, Haddox JL, Yuille-Barr D. The combined effect of citrate/ascorbate treatment in alkali-injured rabbit eyes. *Cornea* 1991;10:100–104.
124. Reim M, Beil KH, Kammerer G, Krehwinkel S. Influence of systemic ascorbic acid treatment on metabolite levels after regeneration of the corneal epithelium following milk alkali burns. *Graefe's Arch Clin Exp Ophthalmol* 1982;218:99–102.
125. Gönül B, Kaplan B, Bilgihan K, Budak MT. Effects of epidermal growth factor in artificial tear on vitamin C levels of corneal wounded eye tissues. *Eye* 2001;15:213–216.
126. Boyd TAS, Campbell FW. Influence of ascorbic acid on the healing of corneal ulcers in man. *Br Med J* 1950;2:1145–1148.
127. Much V. Zitronensaftbehandlung bei Tintenstiftverätzungen. *Ophthalmologica* 1951;121:43.
128. Stellamor-Peskir H. Zur Therapie der Alkaliverätzungen des Auges. *Klin Monatsbl Augenheilk* 1961; 139:838–841.
129. Ricklefs G, Gossmann K. Bericht über Kalkverätzungen aus den Jahren 1948–1967. *Klin Monatsbl Augenheilk* 1968;153:59–67.
130. Beare JDL. Eye injuries from assault with chemicals. *Br J Ophthalmol* 1990;74:514–518.
131. Saini JS, Sharma A. Ocular chemical burns—clinical and demographic profile. *Burns* 1993;19:67–69.
132. Brodovsky SC, McCarty CA, Snibson G, Loughnan M, Sullivan L, Daniell M, Taylor HR. Management of alkali burns. An 11-year retrospective review. *Ophthalmology* 2000;107:1829–1835.
133. Gross RL. The effect of ascorbate on wound healing. *Int Ophthalmol Clinics* 2000;40:51–57.
134. Wendt MD, Soparkar CN, Louie K, Basinger SF, Gross RL. Ascorbate stimulates type I and type III collagen in human Tenon's fibroblasts. *J Glaucoma* 1997;6:402–407.
135. Jampel HD, Moon JI, Quigley HA, Barron Y, Lam KW. Aqueous humor uric acid and ascorbic acid concentrations and outcome of trabeculectomy. *Arch Ophthalmol* 1998;116:281–285.
136. Heath H. The distribution and possible functions of ascorbic acid in the eye. *Exp Eye Res* 1962;1: 362–367.
137. Ringvold A. Corneal epithelium and UV-protection of the eye. *Acta Ophthalmol Scand* 1998;76: 149–153.
138. Reiss GR, Werness PG, Zollman PE, Brubaker RF. Ascorbic acid levels in the aqueous humor of nocturnal and diurnal mammals. *Arch Ophthalmol* 1986;104:753–755.
139. Ringvold A. Aqueous humour and ultraviolet radiation. *Acta Ophthalmol* 1980;58:69–82.

140. Koskela TK, Reiss GR, Brubaker RF, Ellefson RD. Is the high concentration of ascorbic acid in the eye an adaptation to intense solar radiation? *Invest Ophthalmol Vis Sci* 1989;30:2265–2267.
141. Ringvold A. In vitro evidence for UV-protection of the eye by the corneal epithelium mediated by the cytoplasmic protein, RNA, and ascorbate. *Acta Ophthalmol Scand* 1997;75:496–498.
142. Reddy VN, Glin FJ, Lin LR, Chakrapani B. The effect of aqueous humor ascorbate on ultraviolet-B-induced DNA damage in lens epithelium. *Invest Ophthalmol Vis Sci* 1998;39:344–350.
143. Varma SD, Kumar S, Richards RD. Light-induced damage to ocular lens cation pump: prevention by vitamin C. *Proc Natl Acad Sci USA* 1979;76:3504–3506.
144. Varma SD, Chand D, Sharma YR, Kuck JF Jr, Richards RD. Oxidative stress on lens and cataract formation: role of light and oxygen. *Current Eye Res* 1984;3:35–57.
145. Van der Pols JC. A possible role for vitamin C in age-related cataract. *Proc Nutr Soc* 1999;58:295–301.
146. Blondin J, Baragi V, Schwartz E, Sadowski JA, Taylor A. Delay of UV-induced eye lens protein damage in guinea pigs by dietary ascorbate. *J Free Radic Biol Med* 1986;2:275–281.
147. Tsao CS, Xu LF, Young M. Effect of dietary ascorbic acid on heat-induced eye lens protein damage in guinea pigs. *Ophthalmic Res* 1990;22:106–110.
148. Vinson JA, Possanza CJ, Drack AV. The effect of ascorbic acid on galactose-induced cataracts. *Nutr Rep Int* 1986;33:665–668.
149. Devamanoharan PS, Henein M, Morris S, Ramachandran S, Richards RD, Varma SD. Prevention of selenite cataract by vitamin C. *Exp Eye Res* 1991;52:563–568.
150. Yokoyama T, Sasaki H, Giblin FJ, Reddy VN. A physiological level of ascorbate inhibits galactose cataract in guinea pigs by decreasing polyol accumulation in the lens epithelium: a dehydroascorbate-linked mechanism. *Exp Eye Res* 1994;58:207–218.
151. Linklater HA, Dzialoszynski T, McLeod HL, Sanford SE, Trevithick JR. Modelling cortical cataractogenesis. XI. Vitamin C reduces gamma-crystallin leakage from lenses in diabetic rats. *Exp Eye Res* 1990;51:241–247.
152. Bates CJ, Cowen TD. Effects of age and dietary vitamin C on the contents of ascorbic acid and acid-soluble thiol in lens and aqueous humour of guinea-pigs. *Exp Eye Res* 1988;46:937–945.
153. Hegde KR, Varma SD. Protective effect of ascorbate against oxidative stress in the mouse lens. *Biochim Biophys Acta* 2004;1670:12–18.
154. Bensh KG, Fleming JE, Lohmann W. The role of ascorbic acid in senile cataract. *Proc Natl Acad Sci USA* 1985;82:7193–7196.
155. Ortwerth BJ, Olesen PR. Ascorbic acid-induced crosslinking of lens proteins: evidence supporting a Maillard reaction. *Biochim Biophys Acta* 1988;956:10–22.
156. Bron AJ, Brown NAP. Perinuclear lens retrodots: a role for ascorbate in cataractogenesis. *Br J Ophthalmol* 1987;71:86–95.
157. Bunce GE, Kinoshita J, Horwitz J. Nutritional factors in cataract. *Annu Rev Nutr* 1990;10:233–254.
158. Taylor A, Jacques PF, Nadler D, Morrow F, Sulsky SI, Shepard D. Relationship in humans between ascorbic acid consumption and levels of total and reduced ascorbic acid in lens, aqueous humor, and plasma. *Curr Eye Res* 1991;10:751–759.
159. Chandra DB, Varma R, Ahmad S, Varma SD. Vitamin C in the human aqueous humor and cataracts. *Int J Vit Nutr Res* 1985;56:165–168.
160. Tessier F, Moreaux V, Birlouez-Aragon I, Junes P, Mondon H. Decrease in vitamin C concentration in human lenses during cataract progression. *Int J Vit Nutr Res* 1998;68:309–315.
161. Organisciak DT, Wang HM, Li ZY, Tso MOM. The protective effect of ascorbate in retinal light damage of rats. *Invest Ophthalmol Vis Sci* 1985;26:1580–1588.
162. Tso MOM. Retinal photic injury in normal and scorbutic monkeys. *Trans Am Ophthalmol Soc* 1987;85:498–556.
163. Fiddick R, Heath H. The in vivo uptake of L-[1-¹⁴C] ascorbic acid by the rat retina and adrenal gland. *Exp Eye Res* 1966;5:329–334.
164. Lai YL, Fong D, Lam LW, Wang HM, Tsin AT. Distribution of ascorbate in the retina, subretinal fluid, and pigment epithelium. *Curr Eye Res* 1986;5:933–938.
165. Woodford BJ, Tso MOM, Lam KW. Reduced and oxidized ascorbates in guinea pig retina under normal and light-exposed conditions. *Invest Ophthalmol Vis Sci* 1983;24:862–867.

166. Tso MO, Woodford BJ, Lam KW. Distribution of ascorbate in normal primate retina and after photic injury: a biochemical, morphological correlated study. *Curr Eye Res* 1984;3:181–191.
167. Li ZY, Tso MOM, Wang HM, Organisciak DT. Amelioration of photic injury in rat retina by ascorbic acid: a histopathologic study. *Invest Ophthalmol Vis Sci* 1985;26:1589–1598.
168. Organisciak DT, Jiang YL, Wang HM, Bicknell I. The protective effect of ascorbic acid in retinal light damage of rats exposed to intermittent light. *Invest Ophthalmol Vis Sci* 1990;31:1195–1202.
169. Organisciak DT, Bicknell IR, Darrow RM. The effects of L- and D-ascorbic acid administration on retinal tissue levels and light damage in rats. *Curr Eye Res* 1992;11:231–241.
170. Paterson CA, O'Rourke MC. Vitamin C levels in human tears. *Arch Ophthalmol* 1987;105:376–77.
171. Dreyer R, Rose RC. Lacrimal gland uptake and metabolism of ascorbic acid. *Proc Soc Exp Biol Med* 1993;202:212–216.
172. Gogia R, Richer SP, Rose RC. Tear fluid content of electrochemically active components including water soluble antioxidants. *Curr Eye Res* 1998;17:257–263.
173. Choy CK, Cho P, Chung WY, Benzie IF. Water-soluble antioxidants in human tears: effect of the collection method. *Invest Ophthalmol Vis Sci* 2001;42:3130–3134.
174. Anderson RE, Kretzer FL, Rapp LM. Free radicals and ocular disease. *Adv Exp Med Biol* 1994;366:73–86.
175. Choong YY, Arumugam G. Crystal deposits in cornea from the use of vitamin C eye drops. *Med J Malaysia* 1999;54:526–527.

10

The Age-Related Proinflammatory State and Eye Disease

1. INTRODUCTION

A low-grade inflammatory state is common among older adults and has been linked to a variety of common aging-related processes such as insulin resistance, dyslipidemia, coagulation, lymphocyte activation, and increased catabolism, with increased risk of atherosclerosis, sarcopenia, osteoporosis, frailty, disability, cognitive impairment, and mortality. Inflammation has been associated with some eye diseases such as age-related macular degeneration, cataract, and diabetic retinopathy and is likely part of more widespread dysregulation that involves multiple systems. Nutrition plays an important role in the pathogenesis of the proinflammatory state, as antioxidant nutrients such as the plant polyphenols, carotenoids, tocopherols, ascorbate, tocopherols, selenium and other antioxidants are involved in maintaining redox balance. Both dietary and endogenous advanced glycation end products can increase oxidative stress and inflammation. The underlying triggers for the proinflammatory state include reactive oxygen species (ROS), and ROS can damage biomolecules directly and also activate transcriptional factors that are central in the upregulation of inflammatory cytokines. Although much work has focused on nutrients and eye diseases, further insight is needed to examine the relationship between antioxidant nutrients, oxidative stress, systemic inflammation, and eye diseases.

2. BIOMARKERS IN THE PROINFLAMMATORY STATE

The proinflammatory state is characterized by increased concentrations of cytokines and acute phase proteins (1,2). Tumor necrosis factor (TNF)- α , interleukin (IL)-1 β , IL-6, and IL-18, and C-reactive protein (CRP), fibrinogen are among the cytokines and acute phase proteins that may be elevated in this proinflammatory state (3). Anti-inflammatory cytokines are involved in the control of the proinflammatory cytokine response, and major anti-inflammatory cytokines include transforming growth factor (TGF)- β , IL-1 receptor antagonist (Ra), IL-4, IL-10, IL-11, and IL-13 (4). The relationship between inflammation and chronic diseases has been more intensively studied for chronic diseases and conditions such as endothelial dysfunction, the metabolic syndrome, atherosclerosis, cardiovascular disease, and Alzheimer disease. Recently studies have begun to address the relationship between inflammation and eye diseases, and studies have been mostly limited to TNF- α , IL-6, CRP, and fibrinogen. Some of the more well-studied biomarkers are discussed as follows.

From: *Nutrition and Health: Handbook of Nutrition and Ophthalmology*

By: R. D. Semba © Humana Press Inc., Totowa, NJ

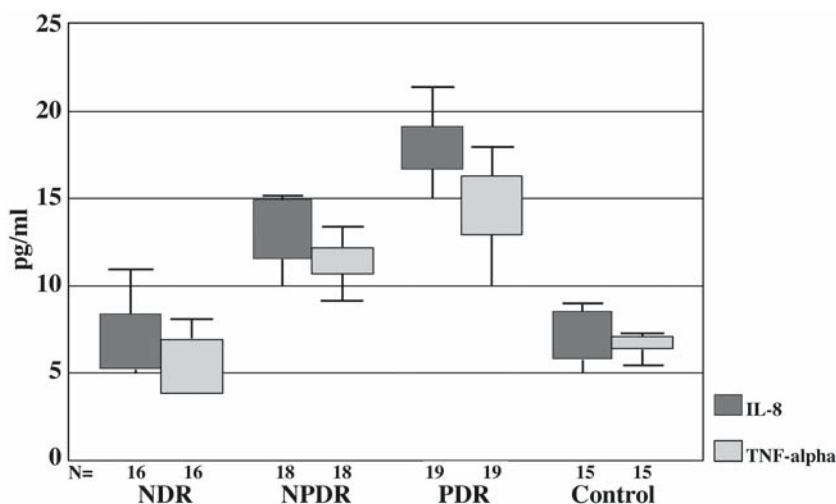


Fig. 1. Mean serum interleukin (IL)-8 and tumor necrosis factor (TNF)- α levels according to stage of diabetic retinopathy (DR): no DR (NDR) ($n = 16$), nonproliferative DR (NPDR) ($n = 18$), proliferative DR (PDR) ($n = 19$), and controls ($n = 15$). Levels of IL-8 and TNF- α were significantly higher in PDR and NPDR patients than controls. (Reprinted from ref. 15, with permission of Macmillan Publishers Ltd.)

2.1. Interleukin-1 β

IL-1 β is a proinflammatory cytokine that is produced by a variety of cells including macrophages, endothelial cells, glia, and neurons (5). IL-1 β is an inducer of TNF- α , IL-2, and cyclooxygenase-2, inducible nitric oxide synthase, and intercellular adhesion molecule (ICAM)-1 (1). Nuclear factor (NF)- κ B is an important regulator of the transcription of IL-1 β (5). Within the central nervous system, overproduction of IL-1 β has been implicated in cognitive decline (6) and Alzheimer's disease (7), but the relationship between elevated circulating IL-1 β and Alzheimer's disease is less clear (6). In the InCHIANTI study of aging, high serum IL-1 β was associated with congestive heart failure and angina (8).

2.2. Tumor Necrosis Factor- α

TNF- α , a member of the TNF cytokine superfamily, is a proinflammatory cytokine produced by a variety of cells, including macrophages and adipocytes (9). TNF- α binds to two cell surface receptors, TNF receptor (TNF-R)I and TNF-RII, and beyond other activities, stimulates the production of other cytokines such as IL-6 (9). The interaction of TNF- α with TNF-RI activates several signal transduction pathways, including NF- κ B (10). TNF-RII signaling appears to play a role in chronic inflammatory disorders (11). TNF- α appears to inhibit erythropoiesis by inhibiting erythroid progenitor cells (12) and negatively regulating the maintenance of cycling human hematopoietic stem cells (13), and elevated TNF- α is associated with defective erythropoietin production (14). Elevated serum TNF- α , soluble IL-2 receptor (IL-2R), and IL-8 levels have been described in patients with proliferative diabetic retinopathy (15) (Fig. 1).

2.3. Interleukin-6

IL-6 is produced by macrophages and T lymphocytes and has both pro- and anti-inflammatory roles. TNF- α and IL-1 β both stimulate the release of IL-6, and IL-6 plays a central

role in inflammation by inducing the production of acute phase proteins, including fibrinogen and CRP, and by contributing to lymphocyte activation, leukocytosis, thrombocytosis, fever, and a general shift toward catabolism in metabolic pathways (16). IL-6 also appears to limit the extent of an inflammatory response by downregulating the release of TNF- α and IL-1 β and promoting the release of IL-1Ra and soluble TNF-RI (17). NF- κ B plays a major role as a transcription factor for IL-6 (16). The receptor complex that mediates the activity of IL-6 consists of an 80-kDa receptor subunit and a 130-kDa signal-transducing element, gp130 (18). Soluble IL-6 receptor (sIL-6R) consists of the 80 kDa subunit, and sIL-6R forms a stimulatory complex with IL-6 that regulates cellular events through direct activation of gp130 in a process known as *trans* signaling (18). Only few cell types have a complete IL-6 receptor on their surface, but because gp130 is ubiquitous, the presence of sIL-6R may make many cell types sensitive to the effects of IL-6. Elevated circulating IL-6 levels were independently associated with the progression of age-related macular degeneration in the Progression of Age-Related Macular Degeneration Study (19). Elevated plasma IL-6 levels were associated with macular edema in a study of 159 patients with diabetic retinopathy (20). No significant differences in serum IL-6 levels were found between 62 patients with less severe vs 31 patients with severe diabetic retinopathy (21). The same study described significant elevations in two chemokines in serum, regulated on activation, normal T-cell expressed and secreted (RANTES) and stromal cell-derived factor (SDF)-1 α , in patients with severe compared with less severe retinopathy (21).

2.4. Interleukin-18

IL-18 is a pleiotropic proinflammatory cytokine that is produced by a variety of cells, including macrophages, adipocytes, lymphocytes, and endothelial cells (22,23). IL-18 regulates T-helper immune responses, induces IFN- γ production, and is considered to be an important mediator of atherosclerosis (23). IL-18 amplifies the inflammatory cascade by inducing the expression of cytokines, chemokines, and adhesion molecules, and both redox balance and TNF- α induce IL-18 through NF- κ B activation (24). Elevated IL-18 levels were associated with elevated serum triglycerides (25), insulin resistance (26), the metabolic syndrome (27), obesity (28), and diabetes (29). Consumption of high-fat meals (30) and hyperglycemia (31) induced elevations in serum IL-18 levels. Elevated IL-18 was an independent predictor of unstable angina and cardiovascular death in adults with coronary artery disease (32) and of coronary events in healthy, middle-aged men (33). Studies of IL-18 gene polymorphisms support the idea that IL-18 plays a causal role in atherosclerosis and related complications (34).

2.5. C-Reactive Protein

CRP is a plasma protein that is largely produced by hepatocytes after an inflammatory stimulus (35). CRP is a pattern recognition molecule that binds to sites that are exposed during cell death or on the surfaces of pathogens and is considered part of the innate immune response (35). The expression of CRP is mostly regulated by IL-6 and IL-1 β (35), but we recently demonstrated that leptin can stimulate the production of C-reactive protein, independent of IL-6 (36). Elevated CRP is associated with an increased risk of coronary heart disease (37–39), stroke and cognitive impairment (40). Elevated levels of plasma CRP were associated with anemia in the InChianti study (41) and in the Valsartan

Heart Failure Trial (42). Elevated circulating CRP levels were independently associated with the progression of age-related macular degeneration in the Progression of Age-Related Macular Degeneration Study (19), but no association between CRP and age-related macular degeneration was found in the Cardiovascular Health Study (43).

2.6. Fibrinogen

Fibrinogen, the major plasma protein coagulation factor, is produced by hepatocytes. Fibrinogen serves as the precursor of fibrin and is an important determinant of platelet aggregation and blood viscosity (44). Fibrinogen is an acute-phase protein, and elevated fibrinogen is a risk factor for cardiovascular disease (45,46) and is an independent predictor of mortality (47–49). Fibrinogen was inversely correlated with hemoglobin among adults with anemia of chronic inflammation (50). In the Diabetes Control and Complications Trial (DCCT), elevated fibrinogen was associated with an increased risk of progression of diabetic retinopathy (51,52). Higher plasma fibrinogen levels have been described in diabetic patients with retinopathy compared with healthy controls (53,54). Fibrinogen was not correlated with the severity of retinopathy in the DCCT/Epidemiology of Diabetes Interventions and Complications (EDIC) study (55). The EURODIAB Prospective Complications Study, among 1215 people with type 1 diabetes, fibrinogen was associated with the incidence of retinopathy over 7.3 yr of follow-up (56). Fibrinogen was no longer associated with incident retinopathy after adjusting for other risk factors such as hemoglobin A_{1c}, fasting triglyceride levels, waist-to-hip ratio, and duration of diabetes (56). In a study of 150 adults with type 2 diabetes, elevated fibrinogen and duration of diabetes were independently associated with diabetic retinopathy in multiple regression analyses (57). In the Blue Mountains Eye Study, elevated fibrinogen was independently associated with risk of age-related macular degeneration (58).

2.7. Transforming Growth Factor- β 1

TGF- β an important regulator of cell proliferation and differentiation, is produced by T-lymphocytes and a variety of other cells (59). TGF- β belongs to a group of structurally related cytokines collectively known as the TGF- β superfamily, and the isoform TGF- β 1 (generally referred to as TGF- β) is the first-described and best-studied member of the group (60). TGF- β inhibits monocyte/macrophage MHC class II expression, suppresses the proliferation and differentiation of T- and B-cells, and limits the synthesis of proinflammatory cytokines such as TNF- α (59). TGF- β has both pro- and anti-inflammatory effects, depending on the cellular context. The effects of TGF- β as an anti-inflammatory cytokine are suggested by TGF- β 1 knockout mice, which show multifocal, severe inflammatory reactions (61). Reduced TGF- β activity is implicated in the pathogenesis of atherosclerosis (59).

2.8. IL-1 Receptor Antagonist

IL-1 Ra is produced by monocyte/macrophages, neutrophils, and other cells, and its main role is to block the proinflammatory activity of IL-1 β by binding to the IL-1 receptor without initiating signal transduction (62). The balance between IL-1 and IL-1Ra may relate to the severity of rheumatoid arthritis, inflammatory bowel disease, and other inflammatory diseases (62). Serum IL-1Ra is elevated in response to inflammation (63), as it is produced by the liver as an acute-phase protein in amounts about 100-fold higher than serum IL-1 (64,65); greater levels of IL-1Ra are needed to functionally inhibit IL-1 in target

cells (62). Thus, IL-1Ra is a strong marker for inflammation. The effects of IL-1Ra as an anti-inflammatory cytokine are suggested by IL-1Ra knockout mice, which can develop an inflammatory arthritis or vasculitis, depending on genetic background (62). The recombinant form of IL-1Ra, anakinra, has been approved for clinical use in the treatment for rheumatoid arthritis (66).

2.9. Interleukin-10

IL-10 is a multifunctional anti-inflammatory cytokine that is produced by a variety of cells, including monocyte/macrophages and lymphocytes. The main function of IL-10 appears to be the limitation and termination of inflammatory responses (67). IL-10 suppresses the synthesis of proinflammatory cytokines such as TNF- α , IL-6, and IL-1 β (67, 68) and reduces the production of chemotactic factors such as IL-8 or CC chemokines (69). Low serum IL-10 is associated with cardiovascular disease, such as unstable angina (70). Among patients with unstable angina, higher serum IL-10 was predictive of a decreased risk of cardiovascular events (71). Elevated serum IL-10 was associated with a more favorable prognosis among patients with acute coronary syndromes and elevated CRP levels (72). Regular physical activity increased serum IL-10 and reduced IL-6 in healthy older men (73) and in patients with coronary heart disease (74).

3. THE CYTOKINE NETWORK IN THE PROINFLAMMATORY STATE

Cytokines function as an integrated network and comprise a series of differentiated responses (1–3). The general dichotomy of pro- and anti-inflammatory mediators is useful conceptually but may oversimplify what is a complex network where the activity of different cytokines and inflammatory mediators probably depend on multiple factors. The inflammatory response is a plastic network composed of redundant signaling among several different mediators, and these mediators have a reciprocal relationship with other biological subsystems, including oxidative/anti-oxidant balance, hormone regulation, and the nervous system (75). Most studies have utilized single markers of inflammation, and much work remains to be done to characterize inflammatory phenotypes based on multiple markers of inflammation.

4. UPREGULATION OF THE PROINFLAMMATORY STATE

4.1. Reactive Oxygen Species

ROS are ubiquitous reactive derivatives of O₂ metabolism that are found in all biological systems. ROS are formed as intermediates in reduction-oxidation (redox) processes that lead from oxygen to water, and ROS participate in cell signaling and regulation (76). The role of ROS and oxidative stress in the proinflammatory state are shown in Fig. 2. It is estimated that 5% of total oxygen metabolism of liver tissues results in the production of ROS (77). Excessive production of ROS that exceeds endogenous defense mechanisms can result in oxidative damage to DNA, protein, and lipids. In the classic definition of Helmut Sies, oxidative stress refers the condition in which the balance between oxidants and antioxidant defenses is upset and excess ROS cause oxidative damage to nucleic acids, proteins, and lipids (78). Among the major ROS are O₂⁻ (superoxide), H₂O₂ (hydrogen peroxide), OH \cdot (hydroxyl radical), R-COO \cdot (fatty acid peroxy radical), nitric oxide (NO), and ONOO⁻ (peroxynitrite). Many ROS have extremely short half-lives and are

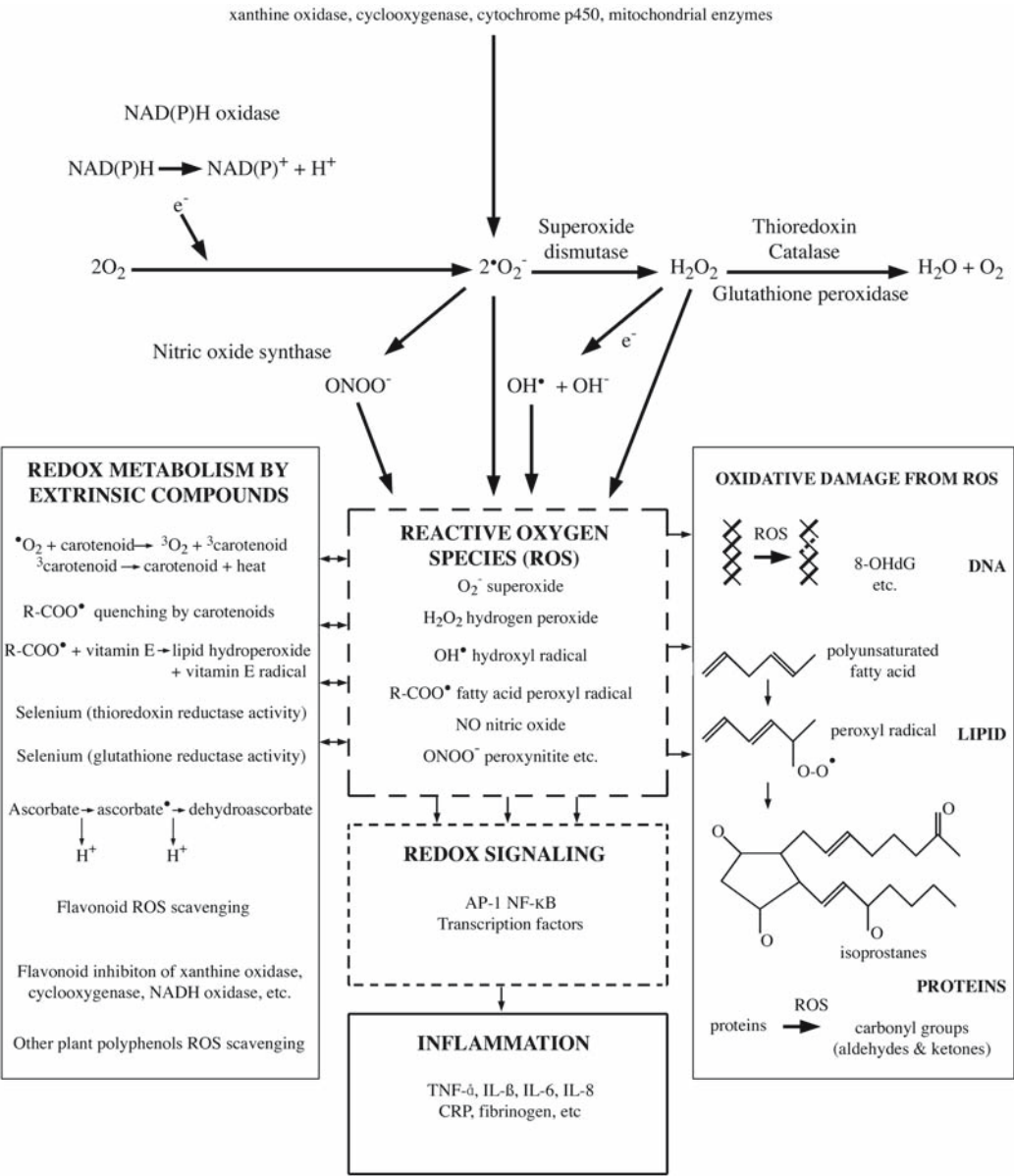


Fig. 2. Reactive oxygen species and upregulation of inflammatory cytokines.

difficult to measure directly in humans, however, the oxidative damage generated by ROS is usually used as a marker for oxidative stress (Subheading 7.2.). Nicotinamide adenine dinucleotide phosphate (NADPH) oxidases, membrane-associated enzymes that catalyze the one electron reduction of oxygen using NADH or NADPH as the electron donor, are major sources of superoxide (79). Superoxide is also produced by xanthine oxidase, an enzyme that catalyzes two terminal steps of purine metabolism (80), by mitochondrial respiratory chain complexes (81), cyclooxygenase, and cytochrome p450 (76). Endothelial nitric oxide synthase (eNOS) is a cytochrome p450 reductase-like enzyme that cata-

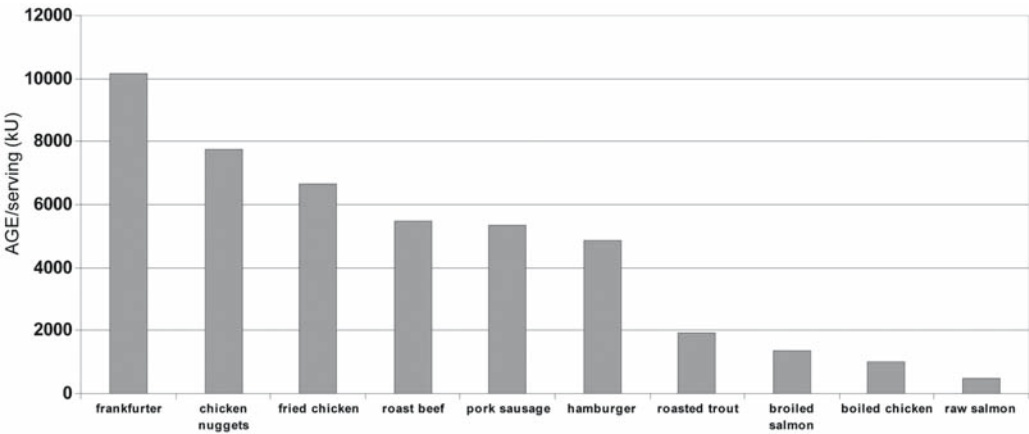


Fig. 3. Advanced glycoxidation end products (AGEs) in selected meat, poultry, and fish, per serving. (Adapted from ref. 87.)

lyzes flavin-mediated electron transport from the electron donor NADPH to a prosthetic heme group (82). In the absence of L-arginine, eNOS can become uncoupled and produce superoxide and hydrogen peroxide (82). NO produced by nitric oxide synthase in combination with superoxide can generate peroxynitrite (83). External sources of ROS include cigarette smoke (84), heavy alcohol use (85), and ultraviolet light exposure (86).

4.2. Advanced Glycation End Products

Advanced glycation end products (AGEs) are a heterogenous group of macromolecules that are formed by the non-enzymatic glycation of proteins, lipids, and nucleic acids (87,88). AGEs can be produced by lipid peroxidation and are also produced by glucose during hyperglycemia (89). AGEs can modify native molecules by cross-linking and by binding to several cellular receptors, including the receptor for advanced glycation end products (RAGE) (88). AGEs have been implicated in some chronic diseases and conditions such as diabetes, inflammation, renal disease, and Alzheimer disease (87). The binding of AGEs to RAGE results in activation of NF- κ B and upregulation of inflammatory cytokines (88). In animal models, dietary AGE restriction resulted in reduced circulating AGEs levels and decreased progression of atherosclerosis (90) and diabetes (91). Proliferative diabetic retinopathy has been recently associated with upregulation of RAGE and its ligands (92).

Commonly consumed foods also contain AGEs in varying amounts, with much higher levels of AGEs found in fatty and fried foods and low levels found in fruits and vegetables (87) (Figs. 3 and 4). The highest AGE levels per serving were found in frankfurters, fried chicken, roast beef, hamburgers, chicken nuggets, French fries, cream cheese, butter, and processed cheese (87). In an intervention study involving a crossover design in 24 diabetic subjects, a diet high in AGEs was associated with increased markers of inflammation (93). A recent pilot study has shown that a meal high in saturated fats (hamburger, French fries) is followed by large elevations in serum IL-6 concentrations (Luigi Ferrucci, personal communication). These studies are consistent with the idea that dietary AGEs can increase systemic inflammation and potentially contribute to chronic diseases. Further work is needed to characterize the relationship between AGEs and eye diseases.

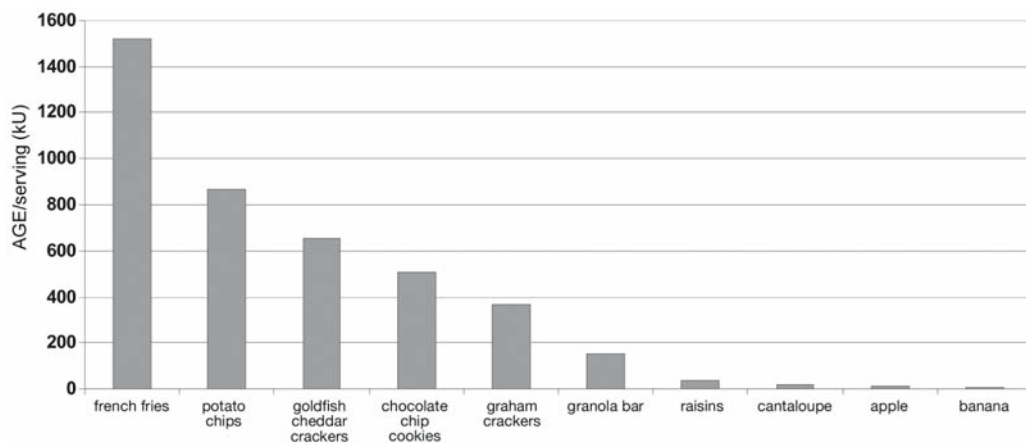


Fig. 4. Advanced glycoxidation end products (AGEs) in snack foods, fruits, and vegetables per serving. (Adapted from ref. 87.)

5. ANTIOXIDANT DEFENSE MECHANISMS

Antioxidant defense mechanisms include antioxidant enzymes such as superoxide dismutase, catalase, thioredoxin, and glutathione peroxidase, and extrinsic compounds such as carotenoids, tocopherols, ascorbate, selenium, and plant polyphenols, including flavonoids.

5.1. Antioxidant Enzymes

Superoxide dismutase (SOD) is an enzyme that catalyzes the breakdown of superoxide into hydrogen peroxide. Several types of SOD are known, including copper- and zinc-containing superoxide dismutase (Cu,ZnSOD), the major intracellular form, and manganese-containing SOD (MnSOD), a form that is located primarily in the mitochondria matrix (94). Extracellular SOD (EC-SOD) is the predominant SOD in plasma, lymph, and the extracellular matrix of tissues (94). Catalase and thioredoxin are enzymes that catalyze the breakdown of hydrogen peroxide to oxygen and water (95). Glutathione peroxidase is a selenoenzyme that plays an important role in the reduction of H_2O_2 and lipid hydrogen peroxides (96).

5.2. Carotenoids

Carotenoids are pigmented compounds found in the flesh of fruits and vegetables, and carotenoids can quench singlet oxygen and reduce peroxy and alkoxyl radicals (97). Major dietary carotenoids include α -carotene, β -carotene, β -cryptoxanthin, lutein, zeaxanthin, and lycopene. The biochemistry, metabolism, and role of carotenoids as antioxidants are presented in detail in Chapter 3 (Subheading 5.4.). In the Women's Health and Aging Study, a population-based study of the causes of disability among older women living in the community in Baltimore, Maryland, low serum carotenoids were a strong independent predictor of subsequent rises in IL-6 (98). Low serum carotenoids were independent predictors of frailty (99), severe walking disability, and all-cause mortality (100). Low selenium was also an independent predictor of all-cause mortality (100). Serum carotenoids are considered the best biological markers for consumption of fruits and vegetables by the Food and Nutrition Board of the Institute of Medicine (101).

Recent large epidemiological studies show that a higher intake of fruits and vegetables is associated with a lower risk of cardiovascular disease (102–104) and all-cause mortality (102–105). A dietary pattern characterized by increased consumption of fruits and vegetables is associated with reduced markers of inflammation and endothelial dysfunction (106). Diets high in fruits and vegetables lower blood pressure (107–109) and reduce markers of oxidative stress induced by acute hyperlipidemia (110). Adherence to the Mediterranean diet, which is characterized by a high intake of fruits, vegetables, and whole grains, and lower consumption of red meat and saturated fats is associated with lower circulating levels of C-reactive protein, IL-6, and fibrinogen (111), and a recent trial showed the Mediterranean diet reduced C-reactive protein and IL-6 in adults (112).

5.3. Vitamin E

Vitamin E acts as a chain-breaking antioxidant that prevents the propagation of lipid peroxidation. The biochemistry, metabolism, and role of vitamin E as an antioxidant is presented in detail in Chapter 3 (Subheading 5.4.).

5.4. Selenium

Selenium is an essential trace element for humans and plays an important role in normal cellular growth and function. Selenium is active as a component of selenoenzymes that include antioxidant enzymes such as glutathione peroxidase, selenoprotein-P, gastrointestinal glutathione peroxidase, and thioredoxin reductase (113). Selenium is widely distributed in human tissues and is found mainly as selenomethionine and selenocysteine. The selenium content in foods can vary widely, depending on the selenium content of soils where foods of plant origin are grown and the selenium content of foods used as animal feed. Clinically apparent selenium deficiency is generally rare and is characterized by an endemic cardiomyopathy known as Keshan disease in China (114). In the United States, over 95% of adults >70 yr of age in the National Health and Nutrition Examination Survey (NHANES) III, 1988–1994, had serum selenium concentrations greater than 100 µg/L (115) that are considered consistent with adequate selenium status (116). Selenium plays a role in redox regulation through selenoenzymes such as glutathione peroxidase and thioredoxin reductase (97). Low selenium intake is associated with low serum selenium and lower activity of selenoenzymes (101).

5.5. Ascorbate

Vitamin C, or ascorbate, is a water-soluble vitamin that is essential for the biosynthesis of collagen, carnitine, and catecholamines. It serves as a strong antioxidant and protects proteins, lipids, and DNA from oxidative damage. Ascorbate acts as an antioxidant via its ability to donate electrons (117). The biochemistry, metabolism, and role of ascorbate as an antioxidant are presented in detail in Chapter 9.

5.6. Plant Polyphenols

Plant polyphenols, found in foods such as fruits, vegetables, wine, tea, and chocolate, are reducing agents that decrease oxidative stress. Polyphenols are the most abundant group of dietary antioxidants, and flavonoids account for about two-thirds of the dietary polyphenols (118). The relationship between polyphenols and risk of cardiovascular disease, cancer, and other chronic diseases is emerging as a fairly recent area of investigation (119,

Table 1
Proposed Mechanisms by Which Polyphenols May Reduce Risk for Cardiovascular Diseases

Oxidative stress
Scavenge reactive oxygen and nitrogen species
Chelate redox-active transition metal ions
Spare and interact with other antioxidants
Inhibition of the reduction oxidization-sensitive transcription factors
Inhibition of pro-oxidant enzymes
Inhibition of antioxidant enzymes
Growth of atherosclerotic plaque
Reduce adhesion molecule expression
Anti-inflammatory
Reduce the capacity of macrophages to oxidatively modify low-density lipoprotein
Platelet function and haemostasis
Inhibit platelet aggregation
Blood pressure and vascular reactivity
Promote nitric oxide-induced endothelial relaxation
Plasma lipids and lipoproteins
Reduce plasma cholesterol and triglycerides

Reprinted from ref. 119, with permission of Lippincott Williams & Wilkins.

120). Polyphenols may reduce the risk for cardiovascular disease through several possible mechanisms, as shown in Table 1 (119). Flavonoids are among the better known polyphenols, and there are over 8000 individual compounds known (121). The basic structure of flavonoids is a flavan nucleus, consisting of 15 carbon atoms arranged in three rings (C₆-C₃-C₆), A, B, and C. The flavonoids are classified into flavones, flavanones, flavonols, flavanolols, isoflavones, and other groups based on level of oxidation and patterns of substitution of the C ring (121). Flavonoids act as antioxidants by inhibiting enzymes that generate superoxide anion and by reducing superoxide, peroxy, alkoxy, and hydroxyl radicals (121). Dietary polyphenols have moderate antiangiogenic functions (Fig. 5) (122) and have also been shown to be vasoprotective (123). Some of the more well-characterized flavonoids are summarized in Table 2 (121, 124). Plant polyphenols can be measured in serum or plasma, but owing to the relatively short half-life, it is not optimal to utilize fasting blood samples. Perhaps this has been one barrier to the study of serum polyphenols in epidemiologic studies, as most study protocols involve the collection of fasting blood samples.

6. ANTIOXIDANT SUPPLEMENTS VS A HEALTHY DIET

The recent investigations of the relationship between inflammation, hypertension, cardiovascular disease, and healthy diets that are rich in fruits, vegetables, and whole grains (102–108) contrast sharply with early research from the 1980–1990s that focused on megadose supplementation with single nutrients such as β -carotene and vitamin E for the prevention of cardiovascular disease and/or cancer, with negative and even harmful results (125, 126). Many of the large clinical trials utilized nonphysiological megadoses of β -carotene that increased serum β -carotene levels 10- to 12-fold above the normal range, and

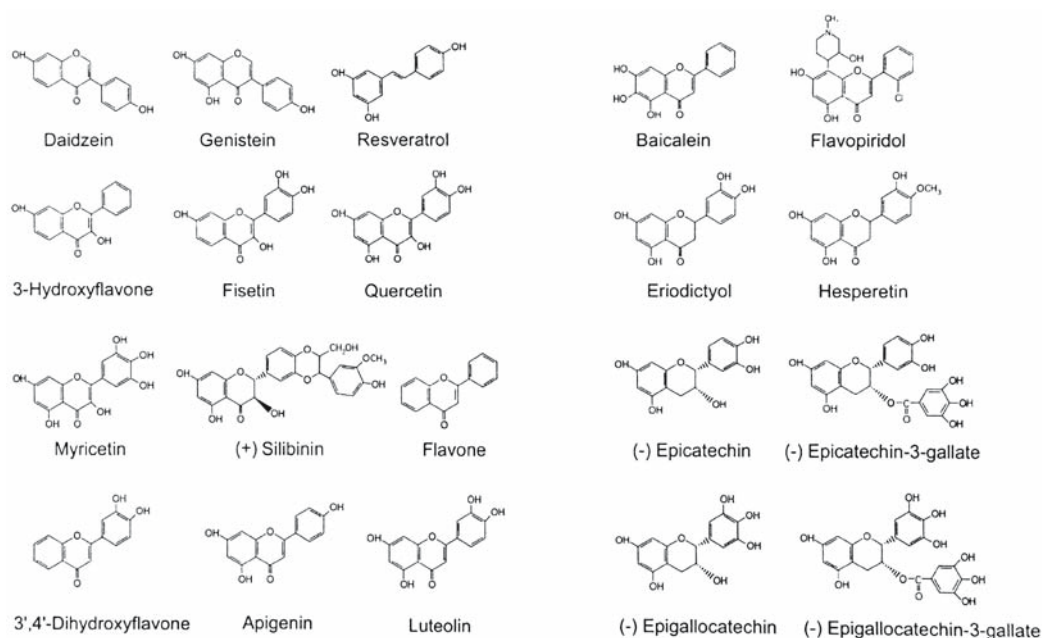


Fig. 5. Chemical structures of antiangiogenic polyphenols. (Reprinted from ref. 122, with permission of Elsevier.)

it is now known that megadose β -carotene supplementation reduces levels of antioxidant enzymes such as SOD and glutathione peroxidase (127) and acts as a prooxidant in high concentrations (128,129). Excentric cleavage products of β -carotene can affect signal transduction (130) and induce oxidative stress by impairing mitochondrial function (131, 132). The negative results of the megadose β -carotene and vitamin E supplementation trials have led to a general perception that antioxidant nutrients do not play a role in cardiovascular disease or cancer. Antioxidants likely function as a highly evolved, related complex, and giving megadoses with one or few elements of this complex may create an imbalance that impairs rather than improves function. Antioxidants in isolation or in high doses may behave differently from mixtures or antioxidants and other polyphenols as found naturally in fruits and vegetables. This may explain why dietary intake of fruits, vegetables, and whole grains (which probably includes many if not all elements of this complex) and not megadose single nutrient supplementation is associated with favorable outcomes.

7. ROLE OF REDOX SIGNALING IN THE EXPRESSION OF INFLAMMATORY CYTOKINES

7.1. Redox Signaling of NF- κ B and AP-1 in the Expression of Inflammatory Cytokines

ROS play a critical role in the activation of the transcription factors NF- κ B (133,134) and AP-1 (135). NF- κ B is a transcriptional regulator that is member of the Rel family pro-

Table 2
Some Common Flavonoids and Their Sources in Food

<i>Class</i>	<i>Flavonoid</i>	<i>Food sources</i>
Flavones	Apigenin	Parsley, celery
	Luteolin	Red pepper
	Chrysin	Fruit skins
	Rutin	Red wine, buckwheat, citrus, tomato skin
Flavanones	Hesperetin	Oranges
	Naringenin	Citrus fruits
	Naringinin	Citrus fruits
	Eriodictyol	Lemons
Flavonols	Quercetin	Onion, lettuce, broccoli, tomato, tea, red wine, berries, olive oil, apple skin
	Kaempferol	Leek, broccoli, endives, grapefruit, black tea
	Myricetin	Cranberries, red wine
Flavanonol	Taxifolin	Citrus fruits
Isoflavones	Genistein	Soybean
	Genistin	Soybean
	Daidzein	Soybean
	Daidzin	Soybean
	Biochanin A	
	Formononetin	
Flavanols	(+)-Catechin	Tea, chocolate
	(-)-Epicatechin	Tea, chocolate
	(-)-Epigallocatechin	Tea
Anthocyanidin	Apigenidin	Colored fruits
	Cyanidin	Cherry, raspberry, strawberry

Based on refs. 121,124.

teins (134). NF- κ B is maintained in the cytoplasm where it is bound to I κ B. ROS enhance the signal transduction pathways for NF- κ B activation in the cytoplasm through serine or tyrosine phosphorylation of I κ B (134), and disruption of the I κ B:NF- κ B interaction is followed by translocation of NF- κ B from the cytoplasm to the nucleus, where NF- κ B regulates the transcription of IL-1 β (5), IL-6 (16), and IL-18 (22). AP-1 is a nuclear transcription factor that is regulated through synthesis of Jun and Fos proteins and their phosphorylation (135,136). Two signaling cascades, c-Jun N-terminal kinases (JNK) and p38 mitogen-activated protein kinase (MAPK), lead to the induction of *jun* and *fos* genes (135). ROS play an important role in the activation of both JNK and MAPK pathways (134,135,137). Selenium is involved in signal transduction of AP-1 (97). Selenomethionine and selenocysteine can attenuate the peroxynitrite-mediated activation of AP-1 and NF- κ B (138). The redox regulation of NF- κ B and AP-1 are involved in the expression of many cytokines that are elevated in the proinflammatory state, such as TNF- α , IL-1 β , IL-6, and IL-18. These cytokines, in turn, are involved in a complex cascade that involves the upregulation of C-reactive protein (35) and feedback loops involving IL-10 and other inflammatory mediators (67).

7.2. Oxidative Damage to DNA, Protein, and Lipids by Reactive Oxygen Species

As noted previously, ROS can be involved in the pathogenesis of disease through two major mechanisms, the first by upregulation of inflammatory cytokines, and the second through direct damage to biomolecules. Most ROS have extremely short half-lives *in vivo* and are difficult to measure directly in humans. Thus, in human studies, oxidative stress is usually assessed by measuring oxidative damage to biomolecules due to ROS (139).

7.2.1. OXIDATIVE DAMAGE TO DNA

One of the most important targets of oxidative damage in cells is DNA, as damage to DNA can readily accumulate in many types of cells (140). ROS-mediated DNA damage occurs in the mitochondria, where most of the ROS are generated, and in the nucleus, both from ROS generated in and outside of mitochondria. DNA damage is thought to generally increase with age (141). DNA damage can consist of single- and double-strand breaks, inter-strand/intrastrand and DNA–protein cross-links, and other oxidation and fragmentation products (142). In animal models, aging is associated with increased nuclear DNA damage in the brain, liver, heart, kidney, and skeletal muscle. In human studies, oxidative damage to DNA is often assessed using urinary 8-hydroxy-2'-deoxyguanosine (8-OHdG), a measure of the specific oxidation of the C-8 of guanine (139,143), or single cell gel electrophoresis using peripheral blood mononuclear cells (PBMCs) (144). An international expert panel on genotoxicity concluded that single cell gel electrophoresis, or the comet assay, using PBMCs is the assay of choice for assessing cellular DNA damage in humans (145).

Elevated urine 8-OHdG occurs in diabetes and cancer patients (146,147), among smokers (148), and among men with low serum β -carotene levels (149). The multicenter Project Generale recently demonstrated that urine 8-OHdG is a strong independent predictor of atherosclerosis (H. Poulsen, personal communication). PBMCs accumulate DNA damage and mutation with increasing age (150–153), and oxidative stress-related factors are associated with DNA damage (141,154–158), including exposure to carcinogens (153,159,160), ionizing radiation (159,161), chemotherapy (162), hypoxia (163), toxic substances (164–166), and cigarette smoking (153,164,167,168). Increased DNA damage in PBMCs has been described in inflammation-related conditions such as coronary artery disease (169,170), diabetes mellitus (171), Alzheimer disease (172,173), and cancer (174,175). The capacity to repair induced DNA damage in lymphocytes may decrease with age (176), but studies to date have been limited. In humans, DNA damage in PBMCs is increased by hyperbaric oxygen treatment (177) and mutagens (178), and decreased by antioxidant supplementation (179), vitamin E supplementation (180), and consumption of antioxidant-rich fruit (181) and carotenoids (182,183). DNA damage in PBMCs decreased after treatment with atorvastatin (184), which has antioxidant properties (185). Although oxidative DNA damage has been studied in many disease states and conditions and oxidative stress within the eye is implicated in ocular disease, the relationships between systemic markers of oxidative DNA damage and eye diseases such as age-related macular degeneration, diabetic retinopathy, and cataract have not been characterized.

7.2.2. OXIDATIVE DAMAGE TO PROTEINS

Protein oxidation is the covalent modification of a protein that is induced either directly by ROS (186), by-products of lipid and free amino acid oxidation (187), and reactive nitro-

gen species (188,189). Oxidation preferentially affects certain protein side chains, especially Pro, Arg, Lys, and Thr residues, and when oxidized, these produce carbonyl groups (aldehydes, ketones) (190). Protein carbonyls are the most studied marker of protein oxidation (188–192). Protein carbonyls lead to loss of structural integrity, cell function (191,193), and increased susceptibility to proteolysis (194,195). Protein carbonyls represent several pathways of oxidative protein damage and are useful in epidemiological studies because they are stable and relatively easy to measure (190). A disadvantage is that protein carbonyls do not reflect any one specific pathway (188). More specific protein oxidation products can be examined but may be limited by problems of low concentrations and need for complex laboratory analyses (196). In model systems, induced oxidative stress increases protein carbonyls in serum and tissues and is associated with skeletal muscle atrophy (196–200). Increased protein carbonyls in tissue are associated with reduced life span in animal models (201–203). Protein carbonyls increase in liver, brain, skeletal muscle, and other tissues with age (189). In humans, elevated oxidized protein levels are found in serum of older compared with younger adults (158,189,204) and among people with cystic fibrosis (205,206) and acute renal failure (207). Elevated protein carbonyls have been described in inflammation-related conditions such as Alzheimer disease (208), atherosclerosis (209), chronic renal disease (210), diabetes mellitus (211–213), and peripheral artery disease (214). Protein carbonyls have been used as an outcome measure in an increasing number of clinical trials (215). Protein carbonyls increase with intravenous iron treatment (a known pro-oxidant) (216) and decrease after vitamin C (217) and grape juice flavonoid intake (218). Oxidative damage to proteins, as reflected by circulating protein carbonyls, appears to be exquisitely sensitive to antioxidant nutrient status. Although protein carbonyls are an important general marker for oxidative protein damage and have been widely applied in epidemiologic studies, the relationship between markers of systemic oxidative protein damage and eye diseases has not been characterized.

7.2.3. OXIDATIVE DAMAGE TO LIPIDS

Oxidative damage to lipids, or lipid peroxidation, occurs when polyunsaturated fatty acids (PUFA) in cell membranes are exposed to ROS, resulting in altered cell membrane structure, impaired function, and cell loss. The initial products of lipid peroxidation are conjugated dienic lipid hydroperoxides, which decompose into alkanes and various aldehydes. Peroxidation of a specific PUFA, arachidonic acid, results in the generation of F_2 isoprostanes (219,220). Isoprostanes generated initially in the cell membrane after reaction with ROS and are chemically stable (221). Isoprostanes are then cleaved, presumably by phospholipases, circulate in the plasma, and are excreted in the urine (221). The most widely used measures of lipid peroxidation are F_2 isoprostanes, hydroperoxides, malondialdehyde, and breath hydrocarbons (222,223). Of these, the measurement of F_2 isoprostanes using mass spectrometry is currently considered the best available biomarker for lipid peroxidation (224). Increased levels of isoprostanes have been described in many conditions that are characterized by increased inflammation, including coronary heart disease (225–228), diabetes (227,228), congestive heart failure (229), and obesity (230). F_2 isoprostanes are also elevated in smokers (231,232). Although lipid peroxidation has been studied in atherosclerosis and cardiovascular disease (224), the relationship between systemic markers of lipid peroxidation and eye diseases has not been well characterized.

8. CONCLUSIONS

Although there is much evidence from animal and cellular studies that redox status is a key factor in the upregulation of proinflammatory cytokines, surprisingly little work has been done to characterize the relationship between oxidative stress, the proinflammatory state, and eye diseases that occur in older adults. An underlying assumption in many of the epidemiologic studies of the relationship between nutritional status and cataract (Chapter 2), age-related macular degeneration (Chapter 3), and diabetic retinopathy (Chapter 5) is that low serum or plasma levels of antioxidant nutrients are consistent with increased oxidative stress. In turn, oxidative stress is a major trigger for the inflammatory state, which is presumably followed by eye disease. Investigations of markers of systemic oxidative damage to DNA, protein, and lipids, and markers of systemic inflammation could add greater insight into the pathogenesis of eye diseases.

REFERENCES

1. Morley JE, Baumgartner RN. Cytokine-related aging process. *J Gerontol A Biol Sci Med Sci* 2004;59:M924–M929.
2. Krabbe KS, Pedersen M, Bruunsgaard H. Inflammatory mediators in the elderly. *Exp Gerontol* 2004;39:687–699.
3. Ferrucci L, Corsi A, Lauretani F, et al. The origins of age-related proinflammatory state. *Blood* 2005;105:2294–2299.
4. Opal SM, DePalo VA. Anti-inflammatory cytokines. *Chest* 2000;117:1162–1172.
5. Watkins LR, Hansen MK, Nguyen KT, Lee JE, Maier SF. Dynamic regulation of the proinflammatory cytokine, interleukin-1 β : molecular biology for non-molecular biologists. *Life Sci* 1999;65:449–481.
6. Wilson CJ, Finch CE, Cohen HJ. Cytokines and cognition—the case for a head-to-toe inflammatory paradigm. *J Am Geriatr Soc* 2002;50:2041–2056.
7. Griffin WST, Mrak RE. Interleukin-1 in the genesis and progression of and risk for development of neuronal degeneration in Alzheimer's disease. *J Leukoc Biol* 2002;72:233–238.
8. Di Iorio A, Ferrucci L, Sparvieri E, et al. Serum IL-1 β levels in health and disease: a population-based study. 'The InCHIANTI study'. *Cytokine* 2003;22:198–205.
9. Hehlhans T, Pfeffer K. The intriguing biology of the tumour necrosis factor/tumour necrosis factor receptor superfamily: players, rules and the games. *Immunology* 2005;115:1–20.
10. Chen G, Goeddel DV. TNF-R1 signaling: a beautiful pathway. *Science* 2002;296:1634–1635.
11. Holtmann MH, Schuchmann M, Zeller G, Galle PR, Neurath MF. The emerging distinct role of TNF-receptor 2 (p80) signaling in chronic inflammatory disorders. *Arch Immunol Ther Exp* 2002;50:279–288.
12. Rusten LS, Jacobsen SEW. Tumor necrosis factor (TNF)- α directly inhibits human erythropoiesis in vitro: role of p55 and p75 TNF receptors. *Blood* 1995;85:989–996.
13. Dybedal I, Bryder D, Fossum A, Rusten LS, Jacobsen SEW. Tumor necrosis factor (TNF)-mediated activation of the p55 TNF receptor negatively regulates maintenance of cycling reconstituting human hematopoietic stem cells. *Blood* 2001;98:1782–1791.
14. Jelkmann W. Proinflammatory cytokines lowering erythropoietin production. *J Interferon Cytokine Res* 1998;18:555–559.
15. Doganay S, Evereklioglu C, Er H, et al. Comparison of serum NO, TNF- α , IL-1 β , sIL-2R, IL-6, and IL-8 levels with grades of retinopathy in patients with diabetic retinopathy. *Eye* 2002;16:163–170.
16. Ershler WB, Keller ET. Age-associated increased interleukin-6 gene expression, late-life diseases, and frailty. *Annu Rev Med* 2000;51:245–270.
17. Hurst SM, Wilkinson TS, McLoughlin RM, et al. IL-6 and its soluble receptor orchestrate a temporal switch in the pattern of leukocyte recruitment seen during acute inflammation. *Immunity* 2001;14:705–714.
18. Jones SA, Horiuchi S, Topley N, Yamamoto N, Fuller GM. The soluble interleukin 6 receptor: mechanisms of production and implications in disease. *FASEB J* 2001;15:43–58.

19. Seddon JM, George S, Rosner B, Rifai N. Progression of age-related macular degeneration. Prospective assessment of C-reactive protein, interleukin 6, and other cardiovascular biomarkers. *Arch Ophthalmol* 2005;123:774–782.
20. Shimizu E, Funatsu H, Yamashita H, Yamashita T, Hori S. Plasma level of interleukin-6 is an indicator for predicting diabetic macular edema. *Jpn J Ophthalmol* 2002;46:78–83.
21. Meleth AD, Agrón E, Chan CC, et al. Serum inflammatory markers in diabetic retinopathy. *Invest Ophthalmol Vis Sci* 2005;46:4295–4301.
22. Reddy P. Interleukin-18: recent advances. *Curr Opin Hematol* 2004;11:405–410.
23. Skurk T, Kolb H, Müller-Schölze S, Röhrig K, Hauner H, Herder C. The proatherogenic cytokine interleukin-18 is secreted by human adipocytes. *Eur J Endocrinol* 2005;152:863–868.
24. Chandrasekar B, Colston JT, de la Rosa SD, Rao PP, Freeman GL. TNF- α and H₂O₂ induce IL-18 and IL-18R β expression in cardiomyocytes via NF- κ B activation. *Biochem Biophys Res Comm* 2003;303:1152–1158.
25. Olusi SO, Al-Awadhi A, Abraham M. Relations of serum interleukin 18 levels to serum lipid and glucose concentrations in an apparently healthy adult population. *Horm Res* 2003;60:29–33.
26. Fischer CP, Perstrup LB, Berntsen A, Eskildsen P, Pedersen BK. Elevated plasma interleukin-18 is a marker of insulin-resistance in type 2 diabetic and non-diabetic humans. *Clin Immunol* 2005;Aug 17 [E-pub ahead of print].
27. Hung J, McQuillan BM, Chapman CML, Thompson PL, Beilby JP. Elevated interleukin-18 levels are associated with the metabolic syndrome independent of obesity and insulin resistance. *Arterioscler Thromb Vasc Biol* 2005;25:1268–1273.
28. Esposito K, Pontillo A, Ciotola M, et al. Weight loss reduces interleukin-18 levels in obese women. *J Clin Endocrinol Metab* 2002;87:3864–3866.
29. Esposito K, Marfella R, Giugliano D. Plasma interleukin-18 concentrations are elevated in type 2 diabetes. *Diabetes Care* 2004;27:272.
30. Esposito K, Nappo F, Giugliano F, et al. Meal modulation of circulating interleukin 18 and adiponectin concentrations in healthy subjects and in patients with type 2 diabetes mellitus. *Am J Clin Nutr* 2003;78:1135–1140.
31. Esposito K, Nappo F, Marfella R, et al. Inflammatory cytokine concentrations are acutely increased by hyperglycemia in humans: role of oxidative stress. *Circulation* 2002;106:2067–2072.
32. Blankenberg S, Tiret L, Bickel C, et al. Interleukin-18 is a strong predictor of cardiovascular death in stable and unstable angina. *Circulation* 2002;106:24–30.
33. Blankenberg S, Luc G, Ducimetière P, et al. Interleukin-18 and the risk of coronary heart disease in European men: the Prospective Epidemiological Study of Myocardial Infarction (PRIME). *Circulation* 2003;108:2453–2459.
34. Tiret L, Godefroy T, Lubos E, et al. Genetic analysis of the interleukin-18 system highlights the role of the interleukin-18 gene in cardiovascular disease. *Circulation* 2005;112:643–650.
35. Black S, Kushner I, Samols D. C-reactive protein. *J Biol Chem* 2004;279:48487–48490.
36. Ble A, Windham BG, Bandinelli S, et al. Relation of plasma leptin to C-reactive protein in older adults (from the InCHIANTI Study). *Am J Cardiol* 2005;96:991–995.
37. Pearson TA, Mensah GA, Alexander RW, et al. Markers of inflammation and cardiovascular disease: application to clinical and public health practice. A statement for healthcare professionals from the Centers for Disease Control and Prevention and the American Heart Association. *Circulation* 2003;107:499–511.
38. Pai JK, Pischon T, Ma J, et al. Inflammatory markers and the risk of coronary heart disease in men and women. *N Engl J Med* 2004;351:2599–2610.
39. Danesh J, Wheeler JG, Hirschfield GM, et al. C-reactive protein and other circulating markers of inflammation in the prediction of coronary artery disease. *N Engl J Med* 2004;350:1387–1397.
40. Kuo HK, Yen CJ, Chang CH, Kuo CK, Chen JH, Sorond F. Relation of C-reactive protein to stroke, cognitive disorders, and depression in the general population: systematic review and meta-analysis. *Lancet Neurol* 2005;4:371–380.
41. Ferrucci L, Guralnik JM, Woodman RC, et al. Proinflammatory state in and circulating erythropoietin in persons with and without anemia. *Am J Med* 2005;118:1288.e11–1228.e19.

42. Anand IS, Kuskowski MA, Rector TS, et al. Anemia and change in hemoglobin over time related to mortality and morbidity in patients with chronic heart failure. Results from the Val-HeFT. *Circulation* 2005;112:1121–1127.
43. McGwin G, Hall TA, Xie A, Owsley C. The relation between C reactive protein and age related macular degeneration in the Cardiovascular Health Study. *Br J Ophthalmol* 2005;89:1166–1170.
44. Lowe GDO, Mackie IJ. Plasma fibrinogen. *Ann Clin Biochem* 2004;41:430–440.
45. Danesh J, Collins R, Appleby P, Peto R. Association of fibrinogen, C-reactive protein, albumin, or leukocyte count with coronary artery disease: meta-analyses of prospective studies. *JAMA* 1998;279:1477–1482.
46. Maresca G, Di Blasio A, Marchioli R, Di Minno G. Measuring plasma fibrinogen to predict stroke and myocardial infarction: an update. *Arterioscler Thromb Vasc Biol* 1999;19:1368–1377.
47. Tracy RP, Arnold AM, Ettinger W, Fried L, Meilahn E, Savage P. The relationship of fibrinogen and factors VII and VIII to incident cardiovascular disease and death in the elderly: results from the Cardiovascular Health Study. *Arterioscler Thromb Vasc Biol* 1999;19:1776–1783.
48. Yano K, Grove JS, Chen R, Rodriguez BL, Curb JD, Tracy RP. Plasma fibrinogen as a predictor of total and cause-specific mortality in elderly Japanese-American men. *Arterioscler Thromb Vasc Biol* 2001;21:1065–1070.
49. Bruno G, Merletti F, Biggeri A, et al. Fibrinogen and AER are major independent predictors of 11-year cardiovascular mortality in type 2 diabetes: the Casale Monferrato Study. *Diabetologia* 2005;48:427–434.
50. Macció A, Madeddu C, Massa D, et al. Hemoglobin levels correlate with interleukin-6 levels in patients with advanced untreated epithelial ovarian cancer: role of inflammation in cancer-related anemia. *Blood* 2005;106:362–367.
51. McMillan DE, Malone JJ, Rand LJ, Steffes M. Hemorheological plasma proteins predict future retinopathy and nephropathy in the DCCT. *Diabetologica* 1986;29:23–29.
52. McMillan DE, Malone JJ, Rand LJ. Progression of diabetic retinopathy is linked to rheologic plasma proteins in the DCCT. *Diabetes* 1995;44:54A.
53. Vekasi J, Marton Z, Kesmarky G, Cser A, Russai R, Horvath B. Hemorheological alterations in patients with diabetic retinopathy. *Clin Hemorheol Microcirc* 2001;24:59–64.
54. Bae SH, Lee J, Roh KH, Kim J. Platelet activation in patients with diabetic retinopathy. *Korean J Ophthalmol* 2003;17:140–144.
55. Klein RL, Hunter SJ, Jenkins AJ, et al. Fibrinogen is a marker for nephropathy and peripheral vascular disease in type 1 diabetes: studies of plasma fibrinogen and fibrinogen gene polymorphism in the DCCT/EDIC cohort. *Diabetes Care* 2003;26:1439–1448.
56. Chaturvedi N, Sjoelie AK, Porta M, et al. Markers of insulin resistance are strong risk factors for retinopathy incidence in type 1 diabetes. The EURODIAB Prospective Complications Study. *Diabetes Care* 2001;24:284–289.
57. Asakawa H, Tokunaga K, Kawakami F. Elevation of fibrinogen and thrombin-antithrombin III complex levels of type 2 diabetes mellitus patients with retinopathy and nephropathy. *J Diabetes Complications* 2000;14:121–126.
58. Smith W, Mitchell P, Leeder SR, Wang JJ. Plasma fibrinogen levels, other cardiovascular risk factors, and age-related maculopathy: the Blue Mountains Eye Study. *Arch Ophthalmol* 1998;116:583–587.
59. Chin D, Boyle GM, Parsons PG, Coman WB. What is transforming growth factor-beta (TGF- β)? *Brit Assoc Plastic Surgeons* 2004;57:215–221.
60. Grainger DJ. Transforming growth factor β and atherosclerosis: so far, so good for the protective cytokine hypothesis. *Arterioscler Thromb Vasc Biol* 2004;24:399–404.
61. Shull MM, Ormsby I, Kier AB, et al. Targeted disruption of the mouse transforming growth factor- β 1 gene results in multifocal inflammatory disease. *Nature* 1992;359:693–699.
62. Arend WP. The balance between IL-1 and IL-1Ra in disease. *Cytokine Growth Factor Rev* 2002;13:323–340.
63. Arend WP, Malyak M, Guthridge CJ, Gabay C. Interleukin-1 receptor antagonist: role in biology. *Annu Rev Immunol* 1998;16:27–55.
64. Granowitz EV, Santos AA, Poutsika DD, et al. Production of interleukin-1 receptor antagonist during experimental endotoxaemia. *Lancet* 1991;338:1423–1424.

65. Gabay C, Gigley J, Sipe J, Arend WP, Fantuzzi G. Production of IL-1 receptor antagonist by hepatocytes is regulated as an acute-phase protein *in vivo*. *Eur J Immunol* 2001;31:490–499.
66. Waugh J, Perry CM. Anakinra: a review of its use in the management of rheumatoid arthritis. *BioDrugs* 2005;19:189–202.
67. Moore KW, de Waal Malefyt R, Coffman RL, O'Garra A. Interleukin-10 and the interleukin-10 receptor. *Annu Rev Immunol* 2001;19:683–765.
68. Pajkrt D, Camoglio L, Tiel-van Buul MCM, et al. Attenuation of proinflammatory response by recombinant human IL-10 in human endotoxemia. Effect of timing of recombinant human IL-10 administration. *J Immunol* 1997;158:3971–3977.
69. Olszyna DP, Pajkrt D, Lauw FN, van Deventer SJH, van der Poll T. Interleukin 10 inhibits the release of CC chemokines during human endotoxemia. *J Infect Dis* 2000;181:613–620.
70. Smith DA, Irving SD, Sheldon J, Cole D, Kaski JC. Serum levels of the anti-inflammatory cytokine interleukin-10 are decreased in patients with unstable angina. *Circulation* 2001;104:746–749.
71. Anguera I, Miranda-Guardiola F, Bosch X, et al. Elevation of serum levels of the anti-inflammatory cytokine interleukin-10 and decreased risk of coronary events in patients with unstable angina. *Am Heart J* 2002;144:811–817.
72. Heeschen C, Dimmeler S, Hamm CW, et al. Serum level of the anti-inflammatory cytokine interleukin-10 is an important prognostic determinant in patients with acute coronary syndromes. *Circulation* 2003;107:2109–2114.
73. Jankord R, Jemiolo B. Influence of physical activity on serum IL-6 and IL-10 levels in healthy older men. *Med Sci Sports Exerc* 2004;36:960–964.
74. Goldhammer E, Tanchilevitch A, Maor I, Beniamini Y, Rosenschein U, Sagiv M. Exercise training modulates cytokines activity in coronary heart disease patients. *Int J Cardiol* 2005;100:93–99.
75. Ferrucci L, Ble A, Bandinelli S, Lauretani F, Suthers K, Guralnik JM. A flame burning within. *Aging Clin Exp Res* 2004;16:240–243.
76. Touyz RM, Schiffrin EL. Reactive oxygen species in vascular biology: implications in hypertension. *Histochem Cell Biol* 2004;122:339–352.
77. Thomas JA. Oxidative stress and oxidant defense. In: Shils ME, Olson JA, Shike M, Ross AC. *Modern Nutrition in Health and Disease*. Ninth edition. Baltimore, Williams & Wilkins: 1999; pp. 751–760.
78. Sies H. Oxidative stress. Introductory remarks. In: Sies H (ed). *Oxidative Stress*. London, Academic: 1985; pp. 1–8.
79. Griendling KK, Sorescu D, Ushio-Fukai M. NAD(P)H oxidase: role in cardiovascular biology and disease. *Circ Res* 2000;86:494–501.
80. Spiekermann S, Landmesser U, Dikalov S, Brecht M, Gamez G, Tatge H, Reepschläger N, Hornig B, Drexler H, Harrison DG. Electron spin resonance characterization of vascular xanthine and NAD(P)H oxidase activity in patients with coronary artery disease: relation to endothelium-dependent vasodilation. *Circulation* 2003;107:1383–1389.
81. Jezek P, Hlavata L. Mitochondria in homeostasis of reactive oxygen species in cell, tissues, and organism. *Int J Biochem Cell Biol* 2005;37:2478–2503.
82. Cai H, Harrison DG. Endothelial dysfunction in cardiovascular diseases: the role of oxidant stress. *Circ Res* 2000;87:840–844.
83. Ghafourifar P, Cadenas E. Mitochondrial nitric oxide synthase. *Trends Pharm Sci* 2005;26:190–195.
84. Alberg AJ. The influence of cigarette smoking on circulating concentrations of antioxidant micronutrients. *Toxicology* 2002;180:121–137.
85. Hoek JB, Pastorino JG. Ethanol, oxidative stress, and cytokine-induced liver cell injury. *Alcohol* 2002;27:63–68.
86. Čejková J, Štípek S, Crkovská J, Ardan T, Pláteník J, Čejka Č, Midelfart A. UV rays, the prooxidant/antioxidant imbalance in the cornea and oxidative eye damage. *Physiol Res* 2004;53:10–19.
87. Goldberg T, Cai W, Peppas M, et al. Advanced glycoxidation end products in commonly consumed foods. *J Am Diet Assoc* 2004;104:1287–1291.
88. Bierhaus A, Humpert PM, Morcos M, et al. Understanding RAGE, the receptor for advanced glycation end products. *J Mol Med* 2005;83:876–886.
89. Jakuš V, Rietbrock N. Advanced glycation end-products and the progress of diabetic vascular complications. *Physiol Res* 2004;53:131–142.

90. Lin RY, Reis ED, Dore AT, et al. Lowering of dietary advanced glycation endproducts (AGE) reduces neointimal formation after arterial injury in genetically hypercholesterolemic mice. *Atherosclerosis* 2002;163:303–311.
91. Hofmann SM, Dong JH, Li Z, et al. Improved insulin sensitivity is associated with restricted intake of dietary glycoxidation products in the db/db mouse. *Diabetes* 2002;51:2082–2089.
92. Pachydaki SI, Tari SR, Lee SE, et al. Upregulation of RAGE and its ligands in proliferative retinal disease. *Exp Eye Res* 2005;[Epub in advance of publication]
93. Vlassara H, Cai W, Crandall J, et al. Inflammatory mediators are induced by dietary glycotoxins, a major risk factor for diabetic angiopathy. *Proc Natl Acad Sci USA* 2002;99:15596–15601.
94. Fattman CL, Schaefer LM, Oury TD. Extracellular superoxide dismutase in biology and medicine. *Free Radic Biol Med* 2003;35:236–256.
95. Arnér ESJ, Holmgren A. Physiological functions of thioredoxin and thioredoxin reductase. *Eur J Biochem* 2000;267:6102–6109.
96. Comhair SAA, Erzurum SC. The regulation and role of extracellular glutathione peroxidase. *Antioxid Redox Signal* 2005;7:72–79.
97. McEligot AJ, Yang S, Meyskens FL Jr. Redox regulation by intrinsic species and extrinsic nutrients in normal and cancer cells. *Annu Rev Nutr* 2005;25:261–295.
98. Walston JD, Xue QL, Semba RD, et al. Serum antioxidants, inflammation, and mortality in older women. *Am J Epidemiol* 2006;163:18–26.
99. Semba RD, Bartali B, Zhou J, Blaum C, Ko CW, Fried LP. Low serum micronutrient concentrations predict frailty among older women living in the community. *J Gerontol A Med Sci Biol Sci* 2006;61: 594–599.
100. Ray AL, Semba RD, Walston J, et al. Low serum selenium and total carotenoids predict mortality among older women living in the community: The Women's Health and Aging Studies. *J Nutr* 2006; 136:172–176.
101. Food and Nutrition Board, Institute of Medicine. Dietary Reference Intakes for Vitamin C, Vitamin E, Selenium, and Carotenoids. National Academy Press, Washington, D.C., 2000.
102. Liu S, Manson JE, Lee IM, et al. Fruit and vegetable intake and risk of cardiovascular disease: the Women's Health Study. *Am J Clin Nutr* 2000;72:922–928.
103. Bazzano LA, He J, Ogden LG, et al. Fruit and vegetable intake and risk of cardiovascular disease in US adults: the first National Health and Nutrition Examination Survey Epidemiologic Follow-up Study. *Am J Clin Nutr* 2002;76:93–99.
104. Steffen LM, Jacobs DR Jr, Stevens J, Shahar E, Carithers T, Folsom AR. Associations of whole-grain, refined-grain, and fruit and vegetable consumption with risks of all-cause mortality and incident coronary artery disease and ischemic stroke: the Atherosclerosis Risk in Communities (ARIC) Study. *Am J Clin Nutr* 2003;78:383–390.
105. Genkinger JM, Platz EA, Hoffman SC, Comstock GW, Helzlsouer KJ. Fruit, vegetable, and antioxidant intake and all-cause, cancer, and cardiovascular disease mortality in a community-dwelling population in Washington County, Maryland. *Am J Epidemiol* 2004;160:1223–1233.
106. Lopez-Garcia E, Schulze MB, Fung TT, et al. Major dietary patterns are related to plasma concentrations of markers of inflammation and endothelial dysfunction. *Am J Clin Nutr* 2004;80:1029–1035.
107. Appel LJ, Moore TJ, Obarzanek E, et al. A clinical trial of the effects of dietary patterns on blood pressure. *N Engl J Med* 1997;336:1117–1124.
108. Sacks FM, Svetkey LP, Vollmer WM, Appel LJ, Bray GA, Harsha D, Obarzanek E, Conlin PR, Miller ER III, Simons-Morton DG, Karanja N, Lin PH, DASH-Sodium Collaborative Research Group. *N Engl J Med* 2001;344:3–10.
109. John JH, Ziebland S, Yudkin P, Roe LS, Neil HAW, Oxford Fruit and Vegetable Study Group. Effects of fruits and vegetable consumption on plasma antioxidant concentrations and blood pressure: a randomised controlled trial. *Lancet* 2002;359:1969–1974.
110. Lopes HF, Martin KL, Nashar K, Morrow JD, Goodfriend TL, Egan BM. DASH diet lowers blood pressure and lipid-induced oxidative stress in obesity. *Hypertension* 2003;41:422–430.
111. Chrysohooou C, Panagiotakos DB, Pitsavos C, Das UN, Stefanadis C. Adherence to the Mediterranean diet attenuates inflammation and coagulation process in healthy adults: the Attica Study. *J Am Coll Cardiol* 2004;44:152–158.

112. Esposito K, Marfella R, Ciotola M, et al. Effect of a Mediterranean-style diet on endothelial dysfunction and markers of vascular inflammation in the metabolic syndrome: a randomized trial. *JAMA* 2004; 292:1440–1446.
113. Klein EA. Selenium: epidemiology and basic science. *J Urol* 2004;171:S50–S53.
114. Chen XS, Yang GL, Chen JO, Chen XC, Wen ZM, Ge KY. On the relations of selenium and Keshan disease. *Biol Tr Elem Res* 1980;2:91–107.
115. Niskar AS, Paschal DC, Kieszak SM, et al. Serum selenium levels in the US population: Third National Health and Nutrition Examination Survey, 1988–1994. *Biol Trace Elem Res* 2003;91:1–10.
116. Sauberlich HE. *Laboratory Tests for the Assessment of Nutritional Status*. Second edition. Boca Raton, CRC Press, 1999.
117. Padayatty SJ, Katz A, Wang Y, et al. Vitamin C as an antioxidant: evaluation of its role in disease prevention. *J Am Coll Nutr* 2003;22:18–35.
118. Scalbert A, Williamson G. Dietary intake and bioavailability of polyphenols. *J Nutr* 2000;130:2073S–2085S.
119. Manach C, Mazur A, Scalbert A. Polyphenols and prevention of cardiovascular diseases. *Curr Opin Lipidol* 2005;16:77–84.
120. Arts ICW, Hollman PCH. Polyphenols and disease risk in epidemiologic studies. *Am J Clin Nutr* 2005; 81(suppl):317S–325S.
121. Pietta PG. Flavonoids as antioxidants. *J Nat Prod* 2000;63:1035–1042.
122. Cao Y, Cao R, Bråkenhielm E. Antiangiogenic mechanisms of diet-derived polyphenols. *J Nutr Biochem* 2002;13:380–390.
123. Stoclet JC, Chataigneau T, Ndiaye M, et al. Vascular protection by dietary polyphenols. *Eur J Pharmacol* 2004;500:299–313.
124. Heim KE, Tagliaferro AR, Bobilya DJ. Flavonoid antioxidants: chemistry, metabolism and structure-activity relationships. *J Nutr Biochem* 2002;13:572–584.
125. Vivekanathan DP, Penn MS, Sapp SK, Hsu A, Topol EJ. Use of antioxidant vitamins for the prevention of cardiovascular disease: meta-analysis of randomized trials. *Lancet* 2003;361:2017–2023.
126. Miller ER III, Pastor-Barriuso R, Dalal D, Riemersma RA, Appel LJ, Guallar E. Meta-analysis: high-dosage vitamin E supplementation may increase all-cause mortality. *Ann Intern Med* 2005;142:37–46.
127. McGill CR, Green NR, Meadows MC, Gropper SS. Beta-carotene supplementation decreases leukocyte superoxide dismutase activity and serum glutathione peroxidase concentration in humans. *J Nutr Biochem* 2003;14:656–662.
128. Palozza P, Serini S, Di Nicuolo F, Piccioni E, Calviello G. Prooxidant effects of β -carotene in cultured cells. *Mol Aspects Med* 2003;24:353–362.
129. Palozza P. Evidence for pro-oxidant effects of carotenoids in vitro and in vivo: implications in health and disease. In: Krinsky NI, Mayne ST, Sies H (eds). *Carotenoids in Health and Disease*. New York, Marcel Dekker: 2004; pp. 127–149.
130. Tibaduiza EC, Fleet JC, Russell RM, Krinsky NI. Excentric cleavage products of β -carotene inhibit estrogen receptor positive and negative breast tumor cell growth in vitro and inhibit activator protein-1-mediated transcriptional activation. *J Nutr* 2002;132:1368–1375.
131. Siems W, Sommerburg O, Schild L, Augustin W, Langhans CD, Wiswedel I. β -carotene cleavage products induce oxidative stress in vitro by impairing mitochondrial respiration. *FASEB J* 2002;16: 1289–1291.
132. Siems W, Wiswedel I, Salerno C, et al. β -carotene breakdown products may impair mitochondrial functions—potential side effects of high dose β -carotene supplementation. *J Nutr Biochem* 2005;16:385–397.
133. Janssen-Heininger YMW, Poynter ME, Baeuerle PA. Recent advances towards understanding redox mechanisms in the activation of nuclear factor κ B. *Free Rad Biol Med* 2000;28:1317–1327.
134. Kabe Y, Ando K, Hirao S, Yoshida M, Handa H. Redox regulation of NF- κ B activation: distinct redox regulation between the cytoplasm and the nucleus. *Antioxid Redox Signal* 2005;7:395–403.
135. Karin M, Takahashi T, Kapahi P, et al. Oxidative stress and gene expression: the AP-1 and NF- κ B connections. *Biofactors* 2001;15:87–89.
136. Shaulian E, Kairn M. AP-1 as a regulator of cell life and death. *Nature Cell Biol* 2002;4:E131–E136.

137. Sumbayev VV, Yasinska IM. Regulation of MAP kinase-dependent apoptotic pathway: implication of reactive oxygen and nitrogen species. *Arch Biochem Biophys* 2005;436:406–412.
138. József L, Filep JG. Selenium-containing compounds attenuate peroxynitrite-mediated NF- κ B and AP-1 activation and interleukin-8 gene and protein expression in human leukocytes. *Free Rad Biol Med* 2003;35:1018–1027.
139. Halliwell B, Whiteman M. Measuring reactive species and oxidative damage *in vivo* and in cell culture: how should you do it and what do the results mean? *Br J Pharmacol* 2004;142:231–255.
140. Kirkwood TBL. Molecular gerontology. *J Inherit Metab Dis* 2002;25:189–196.
141. Von Zglinicki T, Bürkle A, Kirkwood TBL. Stress, DNA damage and ageing—an integrative approach. *Exp Gerontol* 2001;36:1049–1062.
142. Evans MD, Cooke MS. Factors contributing to the outcome of oxidative damage to nucleic acids. *BioEssays* 2004;26:533–542.
143. Wu LL, Chiou CC, Chang PY, Wu JT. Urinary 8-OHdG: a marker of oxidative stress to DNA and a risk factor for cancer, atherosclerosis and diabetes. *Clin Chim Acta* 2004;339:1–9.
144. Collins AR. The comet assay for DNA damage and repair. *Mol Biotechnol* 2004;26:249–261.
145. Tice RR, Agurell E, Anderson D, et al. Single cell gel/comet assay: guidelines for in vitro and in vivo genetic toxicology testing. *Environ Mol Mutag* 2000;35:206–221.
146. Chiou CC, Chang PY, Chan EC, Wu TL, Tsao KC, Wu JT. Urinary 8-hydroxydeoxyguanosine and its analogs as DNA marker of oxidative stress: development of an ELISA and measurement in both bladder and prostate cancers. *Clin Chim Acta* 2003;334:87–94.
147. Nishikawa T, Sasahara T, Kiritoshi S, et al. Evaluation of urinary 8-hydroxydeoxy-guanosine as a novel biomarker of macrovascular complications in type 2 diabetes. *Diabetes Care* 2003;26:1507–1512.
148. Prieme H, Loft S, Klarlund M, Gronbaek K, Tonnesen P, Poulsen HE. Effect of smoking cessation on oxidative DNA modification estimated by 8-oxo-7,8-dihydro-2'-deoxyguanosine excretion. *Carcinogenesis* 1998;19:347–351.
149. Kristenson M, Kucinskienė Z, Schäfer-Elinder L, Leanderson P, Tagesson C. Lower serum levels of β -carotene in Lithuanian men are accompanied by higher urinary excretion of the oxidative DNA adduct, 8-hydroxydeoxyguanosine: the LiVicordia Study. *Nutrition* 2003;19:11–15.
150. Barnett YA, King CM. An investigation of antioxidant status, DNA repair capacity and mutation as a function of age in humans. *Mutat Res* 1995;338:115–128.
151. Betti C, Davini T, Giannessi L, Loprieno N, Barale R. Comparative studies by comet test and SCE analysis in human lymphocytes from 200 healthy subjects. *Mutat Res* 1995;343:201–207.
152. Diem E, Ivancsits S, Rüdiger HW. Basal levels of DNA strand breaks in human leukocytes determined by comet assay. *J Toxicol Environ Health A* 2002;65:641–648.
153. Lam TH, Zhu CQ, Jiang CQ. Lymphocyte DNA damage in elevator manufacturing workers in Guangzhou, China. *Mutat Res* 2002;515:147–157.
154. Barnett YA, Barnett CR. DNA damage and mutation: contributors to the age-related alterations in T cell-mediated immune responses? *Mech Ageing Dev* 1998;102:165–175.
155. Mendoza-Núñez VM, Sánchez-Rodríguez MA, Retana-Ugalde R, Vargas-Guadarrama LA, Altamirano-Lozano MA. Total antioxidant levels, gender, and age as risk factors for DNA damage in lymphocytes of the elderly. *Mech Ageing Dev* 2001;122:835–847.
156. Collins AR, Horváthová E. Oxidative DNA damage, antioxidants and DNA repair: applications of the comet assay. *Biochem Soc Trans* 2001;29:337–341.
157. Møller P, Loft S. Oxidative DNA damage in human white blood cells in dietary antioxidant intervention studies. *Am J Clin Nutr* 2002;76:303–310.
158. Mutlu-Türkoğlu Ü, İlhan E, Öztezcan S, Kuru A, Aykaç-Toker G, Uysal M. Age-related increases in plasma malondialdehyde and protein carbonyl levels and lymphocyte DNA damage in elderly subjects. *Clin Biochem* 2003;36:397–400.
159. Møller P, Knudsen LE, Loft S, Wallin H. The comet assay as a rapid test in biomonitoring occupational exposure to DNA-damaging agents and effect of confounding factors. *Cancer Epidemiol Biomarkers Prev* 2000;9:1005–1015.
160. Sul D, Lee D, Im H, Oh E, Kim J, Lee E. Single strand DNA breaks in T- and B-lymphocytes and granulocytes in workers exposed to benzene. *Toxicol Lett* 2002;134:87–95.

161. Garaj-Vrhovac V, Kopjar N. The alkaline Comet assay as biomarker in assessment of DNA damage in medical personnel occupationally exposed to ionizing radiation. *Mutagenesis* 2003;18:265–271.
162. Kopjar N, Garaj-Vrhovac V, Milas I. Assessment of chemotherapy-induced DNA damage in peripheral blood leukocytes of cancer patients using the alkaline comet assay. *Teratogenesis Carcinog Mutagen* 2002;22:13–30.
163. Møller P, Loft S, Lundby C, Olsen NV. Acute hypoxia and hypoxic exercise induce DNA strand breaks and oxidative DNA damage in humans. *FASEB J* 2001;15:1181–1186.
164. Basaran N, Shubair M, Ündeğer Ü, Kars A. Monitoring of DNA damage in foundry and pottery workers exposed to silica by the alkaline comet assay. *Am J Ind Med* 2003;43:602–610.
165. Gambelunghe A, Piccinini R, Ambrogi M, et al. Primary DNA damage in chrome-plating workers. *Toxicology* 2003;188:187–195.
166. Ündeğer Ü, Basaran N. Assessment of DNA damage in workers occupationally exposed to pesticide mixtures by the alkaline comet assay. *Arch Toxicol* 2002;76:430–436.
167. Frenzilli G, Betti C, Davini T, et al. Evaluation of DNA damage in leukocytes of ex-smokers by single cell gel electrophoresis. *Mutat Res* 1997;375:117–123.
168. Piperakis SM, Visvardis EE, Sagnou M, Tassiou AM. Effects of smoking and aging on oxidative DNA damage of human lymphocytes. *Carcinogenesis* 1998;19:695–698.
169. Botto N, Masetti S, Petrozzi L, et al. Elevated levels of oxidative DNA damage in patients with coronary artery disease. *Coronary Artery Dis* 2002;13:269–274.
170. Demirbag R, Yilmaz R, Kocyigit A. Relationship between DNA damage, total antioxidant capacity and coronary artery disease. *Mutat Res* 2005;570:197–203.
171. Blasiak J, Arabski M, Krupa R, et al. DNA damage and repair in type 2 diabetes mellitus. *Mutat Res* 2004;554:297–304.
172. Mecocci P, Polidori MC, Ingegneri T, et al. Oxidative damage to DNA in lymphocytes from AD patients. *Neurology* 1998;51:1014–1017.
173. Kadioglu E, Sardas S, Aslan S, Isik E, Karakaya AE. Detection of oxidative DNA damage in lymphocytes of patients with Alzheimer's disease. *Biomarkers* 2004;9:203–209.
174. Schabath MB, Spitz MR, Grossman HB, et al. Genetic instability in bladder cancer assessed by the comet assay. *J Natl Cancer Inst* 2003;95:540–547.
175. Smith TR, Miller MS, Lohman KK, Case LD, Hu JJ. DNA damage and breast cancer risk. *Carcinogenesis* 2003;24:883–889.
176. Singh NP, Danner DB, Tice RR, Brant L, Schneider EL. DNA damage and repair with age in individual human lymphocytes. *Mutat Res* 1990;237:123–130.
177. Dennog C, Gedik C, Wood S, Speit G. Analysis of oxidative DNA damage and *HPRT* mutations in humans after hyperbaric oxygen treatment. *Mutat Res* 1999;431:351–359.
178. Menéndez D, Rojas E, Herrera LA, et al. DNA breakage due to metronidazole treatment. *Mutat Res* 2001;478:153–158.
179. Duthie SJ, Ma A, Ross MA, Collins AR. Antioxidant supplementation decreases oxidative DNA damage in human lymphocytes. *Cancer Res* 1996;56:1291–1295.
180. Kan E, Ündeğer Ü, Bali M, Basaran N. Assessment of DNA strand breakage by the alkaline COMET assay in dialysis patients and the role of vitamin E supplementation. *Mutat Res* 2002;520:151–159.
181. Collins AR, Harrington V, Drew J, Melvin R. Nutritional modulation of DNA repair in a human intervention study. *Carcinogenesis* 2003;24:511–515.
182. Porrini M, Riso P. Lymphocyte lycopene concentrations and DNA protection from oxidative damage is increased in women after a short period of tomato consumption. *J Nutr* 2000;130:189–192.
183. Porrini M, Riso P, Brusamolino A, Berti C, Guarnieri S, Visioli F. Daily intake of a formulated tomato drink affects carotenoid plasma and lymphocyte concentrations and improves antioxidant protection. *Br J Nutr* 2005;93:93–99.
184. Harangi M, Seres I, Varga Z, et al. Atorvastatin effect on high-density lipoprotein-associated paraoxonase activity and oxidative DNA damage. *Eur J Clin Pharmacol* 2004;60:685–691.
185. Haendeler J, Hoffmann J, Zeiher AM, Dimmeler S. Antioxidant effects of statins via *S*-nitrosylation and activation of thioredoxin in endothelial cells: a novel vasculoprotective function of statins. *Circulation* 2004;110:856–861.

186. Stadtman ER, Berlett BS. Reactive oxygen-mediated protein oxidation in aging and disease. *Drug Metab Rev* 1998;30:225–243.
187. Traverso N, Menini S, Maineri EP, et al. Malondialdehyde, a lipoperoxidation-derived aldehyde, can bring about secondary oxidative damage to proteins. *J Gerontol Biol Sci* 2004;59A:890–895.
188. Chevion M, Berenshtein E, Stadtman ER. Human studies related to protein oxidation: protein carbonyl content as a marker of damage. *Free Radic Res* 2000;33:S99–S108.
189. Beal MF. Oxidatively modified proteins in aging and disease. *Free Radic Biol Med* 2002;32:797–803.
190. Dalle-Donne I, Rossi R, Giustarini D, Milzani A, Colombo R. Protein carbonyl groups as biomarkers of oxidative stress. *Clin Chim Acta* 2003;329:23–38.
191. Stadtman ER. Metal ion-catalyzed oxidation of proteins: biochemical mechanism and biological consequences. *Free Radic Biol Med* 1990;9:315–325.
192. Berlett BS, Levine RL, Stadtman ER. Carbon dioxide stimulates peroxynitrite-mediated nitration of tyrosine residues and inhibits oxidation of methionine residues of glutamine synthetase: both modifications mimic effects of adenylation. *Proc Natl Acad Sci USA* 1998;95:2784–2789.
193. Davies KJA, Lin SW, Pacifici RE. Protein damage and degradation by oxygen radicals. IV. Degradation of denatured protein. *J Biol Chem* 1987;262:9914–9920.
194. Agarwal S, Sohal RS. Differential oxidative damage to mitochondrial proteins during aging. *Mech Ageing Dev* 1995;85:59–63.
195. Grune T, Shringarpure R, Sitte N, Davies K. Age-related changes in protein oxidation and proteolysis in mammalian cells. *J Gerontol Biol Sci* 2001;56A:B459–B467.
196. Shacter E. Quantification and significance of protein oxidation in biological samples. *Drug Metab Rev* 2000;32:307–326.
197. Mercier S, Breuillé D, Mosoni L, Obled C, Mirand PP. Chronic inflammation alters protein metabolism in several organs of adult rats. *J Nutr* 2002;132:1921–1928.
198. Romero-Ramos M, Venero JL, Garcia-Rodriguez S, Ayala A, Machado A, Cano J. Semichronic inhibition of glutathione reductase promotes oxidative damage to proteins and induces both transcription and translation of tyrosine hydroxylase in the nigrostriatal system. *Free Radic Res* 2003;37:1003–1012.
199. Kannan M, Wang L, Kang YJ. Myocardial oxidative stress and toxicity induced by acute ethanol exposure in mice. *Exp Biol Med* 2004;229:553–559.
200. Łuczaj W, Waszkiewicz E, Skrzydlewska E, Roszkowska-Jakimiec W. Green tea protection against age-dependent ethanol-induced oxidative stress. *J Toxicol Environ Health A* 2004;67:595–606.
201. Sohal RS, Agarwal S, Dubey A, Orr WC. Protein oxidative damage is associated with life expectancy of houseflies. *Proc Natl Acad Sci USA* 1993;90:7255–7259.
202. Ishii N. Oxidative stress and aging in *Caenorhabditis elegans*. *Free Radic Res* 2000;33:857–864.
203. Moskovitz J, Bar-Noy S, Williams WM, Requena J, Berlett BS, Stadtman ER. Methionine sulfoxide reductase (MsrA) is a regulator of antioxidant defense and lifespan in mammals. *Proc Natl Acad Sci USA* 2001;98:12920–12925.
204. Kasapoglu M, Özben T. Alterations of antioxidant enzymes and oxidative stress markers in aging. *Exp Gerontol* 2001;36:209–220.
205. Domínguez C, Gartner S, Liñán S, Cobos N, Moreno A. Enhanced oxidative damage in cystic fibrosis patients. *Biofactors* 1998;8:149–153.
206. Back EI, Frindt C, Nohr D, Frank J, Ziebach R, Stern M, Ranke M, Biesalski HK. Antioxidant deficiency in cystic fibrosis: when is the right time to take action? *Am J Clin Nutr* 2004;80:374–384.
207. Himmelfarb J, McMonagle E, Freedman S, Klenzak J, McMenamin E, Le P, Pupim LB, Ikizler TA, and the PICARD Group. Oxidative stress is increased in critically ill patients with acute renal failure. *J Am Soc Nephrol* 2004;15:2449–2456.
208. Choi J, Malakowsky CA, Talent JM, Conrad CC, Gracy RW. Identification of oxidized plasma proteins in Alzheimer's disease. *Biochem Biophys Res Commun* 2002;293:1566–1570.
209. Miyata T. Alterations of non-enzymatic biochemistry in uremia, diabetes, and atherosclerosis (“carbonyl stress”). *Bull Mem Acad R Med Belg* 2002;157:189–196.
210. Agarwal R. Chronic kidney disease is associated with oxidative stress independent of hypertension. *Clin Nephrol* 2004;61:377–383.

211. Domínguez C, Gussinye M, Ruiz E, Carrascosa A. Oxidative stress at onset and in early stages of type 1 diabetes in children and adolescents. *Diabetes Care* 1998;21:1736–1742.
212. Martín-Gallán P, Carrascosa A, Gussinyá M, Domínguez C. Biomarkers of diabetes-associated oxidative stress and antioxidant status in young diabetic patients with or without subclinical complications. *Free Radic Biol Med* 2003;34:1563–1574.
213. Kalogerakis G, Baker AM, Christov S, et al. Oxidative stress and high-density lipoprotein function in type 1 diabetes and end-stage renal disease. *Clin Sci* 2005;108:497–506.
214. Rutkowska M, Strzyżewski K, Iskra M, Pioruńska-Stolzmann M, Majewski W. Increased protein carbonyl groups in the serum of men with chronic arterial occlusion and the effect of postoperative treatment. *Med Sci Monit* 2005;11:CR79–CR83.
215. Dalle-Donne I, Giustarini D, Colombo R, Rossi R, Milzani A. Protein carbonylation in human diseases. *Trends Mol Med* 2003;9:169–176.
216. Anraku M, Kitamura K, Shinohara A, et al. Intravenous iron administration induces oxidation of serum albumin in hemodialysis patients. *Kidney Int* 2004;66:841–848.
217. Carty JL, Bevan R, Waller H, et al. The effects of vitamin C supplementation on protein oxidation in healthy volunteers. *Biochem Biophys Res Commun* 2000;273:729–735.
218. O'Byrne DJ, Devaraj S, Grundy SM, Jialal I. Comparison of the antioxidant effects of Concord grape juice flavonoids and α -tocopherol on markers of oxidative stress in healthy adults. *Am J Clin Nutr* 2002;76:1367–1374.
219. Roberts LJ, Morrow JD. Measurement of F₂-isoprostanes as an index of oxidative stress in vivo. *Free Radic Biol Med* 2000;28:505–513.
220. Basu S. Isoprostanes: novel bioactive products of lipid peroxidation. *Free Radic Res* 2004;38:105–122.
221. Lawson JA, Rokach J, FitzGerald GA. Isoprostanes: formation, analysis and use as indices of lipid peroxidation *in vivo*. *J Biol Chem* 1999;274:24441–24444.
222. Mayne ST. Antioxidant nutrients and chronic disease: use of biomarkers of exposure and oxidative stress status in epidemiologic research. *J Nutr* 2003;133:933S–940S.
223. Dotan Y, Lichtenberg D, Pinchuk I. Lipid peroxidation cannot be used as a universal criterion of oxidative stress. *Prog Lipid Res* 2004;43:200–227.
224. Morrow JD. Quantification of isoprostanes as indices of oxidant stress and the risk of atherosclerosis in humans. *Arterioscler Thromb Vasc Biol* 2005;25:279–286.
225. Schwedhelm E, Bartling A, Lenzen H, et al. Urinary 8-iso-prostaglandin F_{2 α} as a risk marker in patients with coronary heart disease: a matched case-control study. *Circulation* 2004;109:843–848.
226. Wolfram R, Oguogho A, Palumbo B, Sinzinger H. Enhanced oxidative stress in coronary heart disease and chronic heart failure as indicated by an increased 8-epi-PGF_{2 α} . *Eur J Heart Failure* 2005;7:167–172.
227. Davi G, Ciabattini G, Consoli A, et al. In vivo formation of 8-iso-prostaglandin F_{2 α} and platelet activation in diabetes mellitus. Effects of improved metabolic control and vitamin E supplementation. *Circulation* 1999;99:224–229.
228. Flores L, Rodela S, Abian J, Claria J, Esmatjes E. F₂ isoprostane is already increased at the onset of type 1 diabetes mellitus: effect of glycemic control. *Metabolism* 2004;53:1118–1120.
229. Polidori MC, Pratico D, Savino K, Rokach J, Stahl W, Mecocci P. Increased F₂ isoprostane plasma levels in patients with congestive heart failure are correlated with antioxidant status and disease severity. *J Card Fail* 2004;10:334–338.
230. Keaney JF Jr, Larson MG, Vasan RS, et al. Obesity and systemic oxidative stress. Clinical correlates of oxidative stress in the Framingham Study. *Arterioscler Thromb Vasc Biol* 2003;23:434–439.
231. Morrow JD, Frei B, Longmire AW, et al. Increase in circulating products of lipid peroxidation (F₂-isoprostanes) in smokers: smoking as a cause of oxidative damage. *N Engl J Med* 1995;332:1198–1203.
232. Harman SM, Liang L, Tsitouras PD, et al. Urinary excretion of three nucleic acid oxidation adducts and isoprostane F_{2 α} measured by liquid chromatography-mass spectrometry in smokers, ex-smokers, and nonsmokers. *Free Radic Biol Med* 2004;35:1301–1309.

11

Essential Fatty Acids and Visual Development in Infants

1. INTRODUCTION

The essential fatty acids, linoleic acid and α -linolenic acid, serve as precursors for long-chain polyunsaturated fatty acids (LC-PUFAs) and as precursors for prostaglandins and thromboxanes. The brain, retina, and other neural tissues are especially rich in LC-PUFAs, especially docosahexaenoic acid (DHA) and arachidonic acid (AA). Essential fatty acids cannot be synthesized *de novo* in the human body, and consequently humans must rely on an adequate amount of essential fatty acids in the diet. Essential fatty acids and their long-chain derivatives are available in the fetal period via transport across the placenta and in the neonatal period through breast milk or infant formula. The specific essential fatty acid intake from formula depends on the composition of oils used in the formula. Early infancy may be critical time when visual and brain development of infants are susceptible to the effects of inadequate stores or deficient intake of essential fatty acids. Recent clinical trials suggest that supplemental DHA has a beneficial effect on visual acuity in the first months of life, especially for preterm infants, and a recent effort has been made to reach a consensus about the dietary requirements for DHA for infants and pregnant women (1).

2. PUBLIC HEALTH SIGNIFICANCE

Preterm infants are a high-risk group for a deficiency of essential fatty acids, and preterm births account for a large proportion of births in many countries. According to a recent study of pregnancy outcomes by the World Health Organization, the prevalence of preterm births, as a percent of live births, varies widely among countries, for example: the United Kingdom (4.6%), Argentina (7.2%), Cuba (7.2%), Vietnam (13.6%), Sri Lanka (14.0%), Nepal (15.8%), Indonesia (18.5%), and Myanmar (24.6%) (2). In the United States, the prevalence of preterm deliveries among whites, Hispanics, and blacks is 9.3%, 10.2%, and 16.6%, respectively (2). This survey demonstrates that preterm infants constitute a significant proportion of live births worldwide. Although the long term visual consequences of essential fatty acid deficiency during early infancy have not been completely characterized, the potential consequences could be far reaching as a public health issue given the potentially large numbers of infants at risk worldwide.

As a public health policy issue, efforts are being made to define what should be the recommended concentrations of essential fatty acids and their long-chain derivatives to be contained in formula for optimal infant health. In North America, infant formulas for term

From: *Nutrition and Health: Handbook of Nutrition and Ophthalmology*

By: R. D. Semba © Humana Press Inc., Totowa, NJ

infants usually contained linoleic acid and α -linolenic acid but not arachadonic acid or DHA. Most research has focused on the question whether preterm and term infant formula should be supplemented with arachadonic acid and/or DHA, in addition to linoleic acid and α -linolenic acid. Recent technological advances in chemical and physical separation of fatty acids has allowed the use of concentrated AA and DHA for clinical use, and many preterm and term infant formulas in developed countries now contain AA and/or DHA (3). In 2002 and 2003, infant formulas with added LC-PUFAs became commercially available for term and preterm infants in the United States (4).

3. HISTORICAL BACKGROUND

Early pioneering work on the chemistry of fatty acids was conducted by Michel-Eugène Chevreul (1786–1889), professor of chemistry at the Manufactures Royales des Gobelins, the French national tapestry workshop, and director of the Muséum d'Histoire Naturelle in Paris. Chevreul showed that lard contained a solid and a liquid fat that he named *stearin* and *elain*, respectively. His work on the chemistry of natural fats and oils was reported in his influential monograph *Recherches chimiques sur les corps gras* (1823) (5). In 1822, Edmund Davy (1785–1851) reported that iodine could interact with fats, and this observation eventually led the enumeration of the number of unsaturated bonds in fatty acids by the “iodine number” of fats. The first phospholipid to be described was lecithin, a substance isolated from egg yolk and found to contain both phosphorus and nitrogen by Nicolas Théodore Gobley (1811–1876) in 1846. Further investigations led to the description of kephalin by Johann Ludwig Thudichum (1829–1901) in 1884.

In the late 1920s, Herbert McLean Evans (1882–1971) and George Oswald Burr (b. 1896) described a deficiency disease among rats raised on a diet low in fat (6–8). Lafayette Mendel (1872–1935) and his colleagues found that growth was improved when rats received peanut oil in addition to vitamin A, but the investigators considered it inconclusive whether the difference was due to fat alone (9). In 1929, Burr and his wife, Mildred M. Burr, announced the essentiality of dietary fat in their research with rats. A syndrome consisting of growth failure, scaly skin, kidney lesions, and necrosis of the tail was found when rats were raised on a diet low in fat, and the syndrome was prevented or cured by the addition of 2% fatty acids to the diet (10). Burr and Burr coined the term “essential fatty acids,” and although the idea was initially received with controversy, further work established the essentiality of some fatty acids (11).

In 1933, the pediatrician Arild Edstein Hansen (b. 1899) showed that infantile eczema was associated with alterations in serum lipids, and the condition could be treated successfully with corn oil or other unsaturated fatty acids (12,13). Further clinical investigations helped to establish that deficiency of essential fatty acids could occur among infants (14,15). More definitive evidence for the importance of essential fatty acids came with reports of essential fatty acid deficiency among infants and adults on total parenteral nutrition without fats (16–19). By the mid-1970s, intravenous fat emulsions became generally available, and linoleic acid was considered to be an important component of total parenteral nutrition (20). In 1982, a syndrome of neurological disturbances and blurred vision was described in a young girl who was receiving total parenteral nutrition in which safflower oil was the only source of lipid (21). The patient improved after soybean oil, high in α -linolenic acid, was substituted for safflower oil. A more detailed history of fatty acids can be found elsewhere (22).

4. BIOCHEMISTRY OF FATTY ACIDS

Fatty acids are nonpolar hydrocarbon chains that vary in length from 2 to 30 carbon atoms and have a terminal carboxylic group, with the overall formula: $\text{CH}_3-(\text{CH}_2)_n-\text{COOH}$. Fatty acids can be classified on the basis of chain length (short, 4-6 carbon atoms; medium, 8-12 carbon atoms; long, 14+ carbon atoms), or on the degree of unsaturation. Saturated fatty acids have a chain of carbon atoms in which there are no $\text{C}=\text{C}$ double bonds and each carbon in the chain is bonded to hydrogen atoms except the carbon of the terminal carboxylic group. Monounsaturated fatty acids contain one $\text{C}=\text{C}$ double bond in the chain. Polyunsaturated fatty acids (PUFAs) contain more than one $\text{C}=\text{C}$ double bond. LC-PUFAs are fatty acids of 14 or greater carbon atoms with more than one $\text{C}=\text{C}$ double bond. Most PUFAs exist in the *cis* configuration in which the double bonds are interrupted by a methylene group.

Fatty acids may be described using common or trivial names, systematic chemical names, shorthand notation, or chemical formulae. Shorthand notation, or code, is a useful way to describe fatty acids. The first number indicates the number of carbon atoms, followed by a colon. The number following the colon is the number of unsaturated bonds. The *n* or omega (ω) indicates the position of the first double bond, counting carbon atoms from the methyl end of the fatty acid. The *cis* or *trans* configuration of each double bond can be indicated at the end of the code. Most PUFAs are of the *n*-3, *n*-6, and *n*-9 families, and are known alternatively as omega-3, omega-6, and omega-9 fatty acids. The common names, systematic names, codes, and formulae of some PUFAs covered in this chapter are shown in Table 1.

Linoleic acid and linolenic acid are “parent essential fatty acids” necessary for the synthesis of long-chain fatty acids. LC-PUFAs of the *n*-6 family are synthesized from linoleic acid through a process of desaturation and elongation (Fig. 1). In the *n*-3 family, the same processes are involved, with a terminal step of β -oxidation in the formation of DHA (Fig. 1). The *n*-6 and *n*-3 families of fatty acids compete for the same enzymes involved in desaturation, and there can be relative inhibition of the enzyme system by fatty acid products from either of the *n*-3 or *n*-6 families. Thus, an imbalance in the dietary intake of *n*-6 and *n*-3 precursor fatty acids can influence the resulting amount of LC-PUFAs of each family. The derived essential fatty acids that contain 20 or more carbon atoms and 4 or more double bonds are known as the long-chain polyenes, of which AA (20:4, *n*-6) and DHA (22:6, *n*-3) have received special attention in studies of visual development because of their high concentrations in the retina and brain.

5. ABSORPTION AND METABOLISM OF ESSENTIAL FATTY ACIDS

During fetal development, linoleic acid, α -linolenic acid, and long-chain polyenes, such as AA and DHA, are accreted after placental transfer. Unesterified fatty acids, triacylglycerols of very low-density lipoprotein (VLDL), fatty acids of low-density lipoprotein (LDL), glycerolipids, and sterol esters are the most important sources of fatty acids for placental transfer (23). AA and DHA appear to have different uptake and transport modes from the placenta to the fetus (24). An estimated 31 mg of *n*-6 fatty acids and 15 mg of *n*-3 fatty acids accumulate in fetal brain each week from 26 wk until delivery (25). An accretion of essential fatty acids also occurs in the fetal liver (26). The precise role of the fetal liver and brain in the synthesis of LC-PUFAs is not clear, and during fetal development, the accretion

Table 1
Nomenclature of Some Polyunsaturated Fatty Acids

<i>Common Name</i>	<i>Systematic name</i>	<i>Code</i>	<i>Formula</i>
Linoleic acid	9,12,-Octadecadienoic acid	C18:2, n-6,9 all <i>cis</i>	$\text{CH}_3(\text{CH}_2)_4\text{CH}=\text{CHCH}_2\text{CH}=\text{CH}(\text{CH}_2)_7\text{COOH}$
α -Linolenic acid	9,12,15-Octadecatrienoic acid	C18:3, n-3,6,9 all <i>cis</i>	$\text{CH}_3\text{CH}_2\text{CH}=\text{CHCH}_2\text{CH}=\text{CHCH}_2\text{CH}=\text{CH}(\text{CH}_2)_7\text{COOH}$
Arachidonic acid (AA)	5,8,11,14-Eicosatetraenoic acid	C20:4, n-6,9,12,15, all <i>cis</i>	$\text{CH}_3(\text{CH}_2)_4\text{CH}=\text{CHCH}_2\text{CH}=\text{HCH}_2\text{CH}=\text{CHCH}_2\text{CH}=\text{CHCH}_2\text{CH}=\text{CH}(\text{CH}_2)_3\text{COOH}$
Timnodonic acid	5,8,11,14,17-Eicosapentaenoic acid	C20:5, n-3,6,9,12, 15 all <i>cis</i>	$\text{CH}_3(\text{CH}_2\text{CH}=\text{CH})_5(\text{CH}_2)_3\text{COOH}$
Cervonic acid	4,7,10,13,16,19-Docosahexaenoic acid (DHA)	C22:6, n-3,6,9,12, 15, 18 all <i>cis</i>	$\text{CH}_3(\text{CH}_2\text{CH}=\text{CH})_6(\text{CH}_2)_2\text{COOH}$




Fig. 1. Metabolism of n-6 and n-3 fatty acids.

of AA and DHA in the retina and brain appears to be largely dependent on the maternal supply (27). About 85% of DHA and more than 90% of the AA in the brain accrues between 26 and 40 wk of gestation (25).

In pregnant women, overall maternal essential fatty acid status declines continuously from the first trimester until delivery (28). The absolute plasma concentrations of phospholipid-associated AA and DHA increase by about 20% and 40%, respectively (28). The relative fatty acid concentration of linoleic acid does not change during pregnancy from 10 wk of gestation until delivery, however, the relative concentrations of arachidonic acid and DHA as percent of total fatty acids decrease progressively during pregnancy. At the same time, indicators of a relative essential fatty acid deficiency increase during gestation (28). The plasma phospholipid DHA content of multigravidae is lower than primigravidae (29). During lactation, the mother loses about 70–80 mg of DHA per day in breast milk, but there is little evidence that this loss causes any maternal depletion of DHA (30).

The essential fatty acid status of preterm infants is much lower than that for term infants. Preterm infants have significantly lower levels of PUFAs in umbilical vessel walls than term infants (31). The essential fatty acid composition of umbilical vessel walls is considered to reflect more long-term essential fatty acid status of the fetus (31). The concentrations of n-3 and n-6 LC-PUFAs were lower among preterm compared with term infants (31). Preterm infants also have much lower total body fat content compared with term

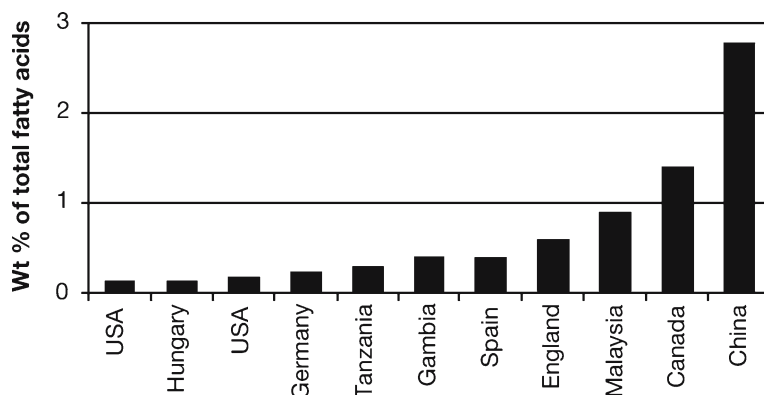


Fig. 2. Docosahexaenoic acid content in human milk samples from different countries. (Reproduced from ref. 41, with permission.)

infants. A preterm infant of 1300-g birthweight has a total body fat content of about 30 g. In comparison, a term infant of 3500-g birthweight has a total body fat content of about 340 g (32). Both preterm and term infants are able to synthesize AA from linoleic acid and to synthesize DHA from α -linolenic acid (33–35). DHA appears to be a better substrate than α -linolenic acid for accretion of DHA in the retina and brain, with an estimated bio-equivalence, or relative efficacy, of about 7:1 (36).

6. DIETARY SOURCES OF ESSENTIAL FATTY ACIDS

6.1. Human Milk

About 200 different fatty acids have been identified in human milk, of which 40 are polyunsaturated (37). Human milk provides the infant with about half of the total energy intake in the form of lipids. In the first 4 to 6 mo of life, the infant accumulates about 1500 to 1600 g of lipids (38). LC-PUFAs are found in human milk throughout lactation (39). During the first 3 mo of lactation, the relative concentrations of linoleic acid and linolenic acid increase while the concentrations of long-chain polyenes decrease (40). The sources of fatty acids include maternal diet, liberation from maternal body stores, and endogenous synthesis from precursor fatty acids, and recent studies suggest that maternal tissue stores supply the major portion of PUFAs in human milk (41). Of the PUFAs, linoleic acid is found in the highest concentration in human milk. Comparison of the fatty acid composition of human milk across different cultures shows a high consistency in long-chain polyene content of milk, except for the n-3 fatty acid content, which appears to reflect maternal intake of sea fish (38). The DHA content in human milk samples varies considerably between countries, with the lowest values being reported from the United States (Fig. 2) (41). Low concentrations of DHA have recently been described in the breast milk of mothers who had malnourished infants (42).

6.2. Food Sources

Most infant formulas usually contain vegetable oils that provide about 10–15 major fatty acids (43). Recently, some commercial manufacturers have added AA and/or DHA to infant formula (1,4). The PUFA content of human milk, vegetable oils, and fish oil is

Table 2
Percent Fatty Acid Composition of Human Milk Compared With Oils Used in Infant Formula

<i>Fatty acid</i>	<i>Human milk</i>	<i>Corn</i>	<i>Soybean</i>	<i>Safflower</i>	<i>Coconut</i>	<i>Marine</i>
Saturated						
8:0	—	—	—	—	6.5	—
10:0	1.2	—	—	—	5.4	—
12:0	5.2	—	—	—	46.7	—
14:0	6.7	—	—	—	18.8	9.5
16:0	22.1	12.6	10.4	6.6	9.8	20.3
18:0	8.2	2.4	4.0	2.6	3.2	3.6
20:0	—	—	0.8	0.1	0.1	0.7
Monounsaturated						
16:1	3.3	0.1	0.1	—	—	13.2
18:1	36.3	25.0	22.3	11.6	7.2	14.4
20:1	0.7	—	—	—	—	1.8
22:1	0.2	—	—	—	—	0.3
Polyunsaturated n-6						
18:2	12.7	58.0	55.1	78.4	2.0	1.2
20:2	0.4	—	—	—	—	0.2
20:4	0.7	—	—	—	—	1.1
22:5	0.2	—	—	—	—	0.3
Polyunsaturated n-3						
18:3	0.6	1.1	7.0	0.3	—	1.0
20:5	0.2	—	—	—	—	18.1
22:5	0.4	—	—	—	—	2.5
22:6	0.4	—	—	—	—	8.7

Reprinted from ref. 23, with permission of Elsevier.

shown in Table 2 (23). Seed oils such as corn oil and safflower oil are rich in linoleic acid and α -linolenic acid. A rich source of AA is egg yolk. Fatty fish is a good source of DHA, especially salmon and mackerel (Table 3) (44,45). For vegetarians, the only source of dietary n-3 fatty acids is linolenic acid, because the long-chain PUFAs of the n-3 family, such as eicosapentaenoic acid and DHA, are found in fish and shellfish.

7. ASSESSMENT OF ESSENTIAL FATTY ACID STATUS

Laboratory methods that can be used for the assessment of essential fatty acid status include measurement of 5,8,11-eicosatrienoic acid, the “Mead” acid (46), measurement of osbond acid (47), use of the triene/tetraene ratio (20:3 n-9 to 20:4 n-6 ratio) (48,49), and use of the essential PUFA index (50). The total amount of essential fatty acids and long-chain polyenes in plasma or red blood cell phospholipids may be a useful indicator of essential fatty acid status of an individual (50). In healthy individuals, 5,8,11-eicosatrienoic acid is only found in trace amounts in plasma, but in the absence of adequate dietary intake of linoleic acid, an increase in plasma 5,8,11-eicosatrienoic acid may occur. In the absence of DHA, the body will synthesize a larger amount of osbond acid, or docosapentaenoic acid (22:5 n-6), and the ratio of DHA to osbond acid can be used as an indicator

Table 3
Linolenic Acid and Docosahexaenoic Acid Content of Selected Foods

<i>Food</i>	<i>Linolenic acid (g/100 g)</i>	<i>Docosahexaenoic acid (g/100 g)</i>
Linseed oil	53.3	0
Canola oil	11.1	0
Soybean oil	6.8	0
Margarine, hard	3.0	0
English walnuts	3.3	0
Soybean sprouts, cooked	2.1	0
Beef fat	0.6	0
Lamb fat	2.3	0
Butter	1.2	0
Surf clam	Trace	0.1
Northern lobster	0	0.1
Atlantic white shrimp	Trace	0.2
Blue crab	Trace	0.2
Atlantic cod	Trace	0.2
Blue mussel	Trace	0.3
Atlantic squid	Trace	0.3
Sardines, canned	0.5	0.6
Pacific herring	0.1	0.7
Coho salmon, farmed	0.1	0.8
European anchovy	0	0.9
Lake trout	0.4	1.1
Atlantic salmon, farmed	0.1	1.2
Bluefin tuna	0	1.2
King mackerel	0	1.2
Atlantic mackerel	0.1	1.6
Herring oil	0.6	4.3
Menhaden oil	1.1	7.9
Cod liver oil	0.7	9.5

Adapted from refs. 44,45.

of DHA status (50). The triene/tetraene ratio has been used to identify essential fatty acid deficiency among patients who are receiving total parenteral nutrition and among children with protein energy malnutrition (51). The PUFA index is the ratio between all essential PUFAs (the sum of all n-3 and n-6 fatty acids) and all of the nonessential unsaturated fatty acids (the sum of all n-7 and n-9 fatty acids). A higher essential PUFA index is thought to reflect better essential PUFA status (50,52).

8. DIETARY REQUIREMENTS FOR ESSENTIAL FATTY ACIDS

A workshop was convened in April 1999 by groups that included the International Society for the Study of Fatty Acids and Lipids (ISSFAL), the US National Institute on Alcohol Abuse and Alcoholism, the US Office of Dietary Supplements at the National Institutes of Health, and the Center for Genetics, Nutrition and Health. The purpose of the

Table 4
Adequate Intake for Infant Formula/Diet

<i>Fatty acid</i>	<i>% Fatty acids</i>
Linoleic acid	10.0
Linolenic acid	1.50
Arachidonic acid	0.50
Docosahexaenoic acid	0.35
Eicosapentaenoic acid	<0.10 (upper limit)

workshop was to reach a consensus regarding the status of dietary essential fatty acids (1). The group endorsed the addition of AA and DHA to all infant formulas, and the Adequate Intake for infants was defined (Table 4). The Adequate Intake is defined as an estimated average requirement that is based on experimentally derived intake levels or approximations of observed mean nutrient intakes by a group (or groups) of health people (1). An upper limit was given for eicosapentaenoic acid because in amounts higher than 0.10% in infant formula, it may antagonize AA and interfere with infant growth. Other recommendations for intakes for adults can be found in the consensus report (1).

9. OVERVIEW OF INFANT VISUAL DEVELOPMENT

The visual system of humans is rudimentary and functional at birth and undergoes rapid development during the first few years of life (53,54). The fovea only reaches adult-like structure by 45 mo of age (55). One week after birth, there is a shallow foveal depression, but thick cones lack outer segments. The outer segments of the cones continue to develop, and a future fovea containing ganglion cells and pure photoreceptor layer of cones can be identified by 22 wk of age. The density of cones in the fovea reaches adult levels by 3 yr of age (55). Myelination of the optic nerve proceeds centrifugally towards the globe, and by 7 mo of age, virtually all fibers near the globe are myelinated (56). Sheath thickness continues to increase during the first 2 yr (56). Myelination of the subcortical pathways is complete by 3 mo (57). The cells of the parvocellular layer of the lateral geniculate nucleus, responsible for color and high acuity, increase rapidly in size during the first 6 to 12 mo of life (58), and cells of the magnocellular layer, involved in low-contrast sensitivity and movement, approach adult size by 2 yr of age (58). The synaptic density of human visual cortex increases rapidly in the first 8 mo of life, followed by a longer period of synapse elimination which continues past 3 yr of age (59). Visual acuity develops rapidly during the first several months of life, and by some tests, can reach 20/20 levels by 6 to 8 mo of age (60). Some of the different tests of visual development that have been used in infants are described in more detail under Subheading 11.11.1.

10. ROLE OF ESSENTIAL FATTY ACIDS IN RETINAL FUNCTION

10.1. Docosahexaenoic Acid in the Retina

DHA is found in very high concentrations in the retina, comprising up to 50% of the phospholipids of human rod outer segment membranes (61). The DHA in the retina is obtained from dietary sources and can also be synthesized from linolenic acid. The retina

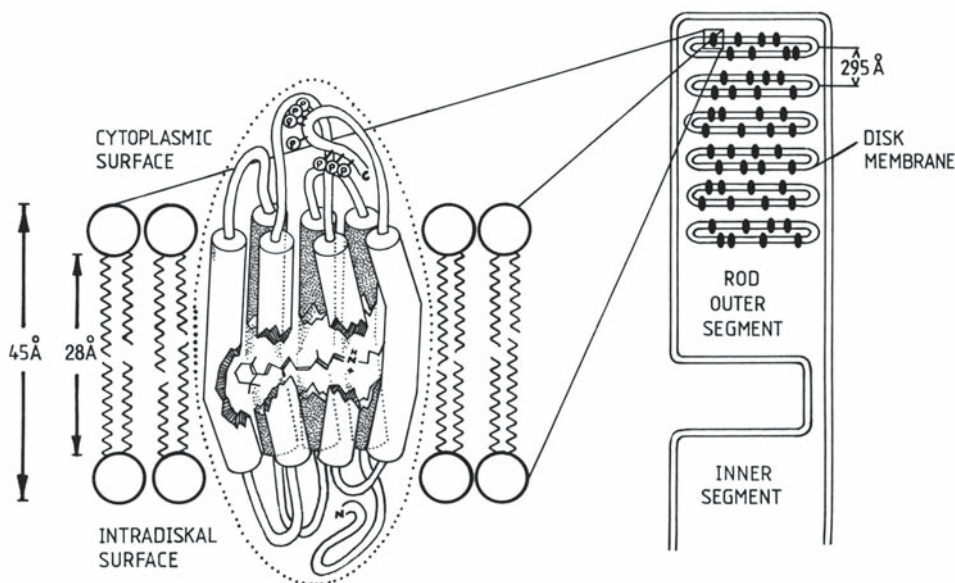


Fig. 3. Relationship of a rhodopsin molecule to disk membranes of the outer segments. The chromophore is 11-*cis* retinal which is bound within the rhodopsin molecule. The rhodopsin molecule is surrounded by membrane phospholipids that are rich in docosahexaenoic acid. (Reproduced from ref. 68, with permission of Elsevier.)

conserves DHA through a tight mechanism of recycling. This mechanism maintains the high concentrations of DHA in the retina, even under conditions of n-3 and n-6 fatty acid deficiency (62–65). The high concentrations and tight recycling of DHA suggests that there must be an important role for this fatty acid (66), and the precise roles of DHA in retinal function are currently being elucidated.

The photoreceptor outer segments are specialized for absorbing photons of light and consist of stacks of membranous discs that are rich in DHA-containing phospholipids. The rod outer segment membranes contain major phospholipids which include phosphatidylcholine, phosphatidylethanolamine, and phosphatidylserine, in addition to smaller amounts of phosphatidylinositol, phosphatidic acid, and sphingomyelin. Phosphatidylethanolamine and phosphatidylserine are particularly rich in DHA. Approximately 60 molecules of DHA-rich phospholipid surround each visual pigment molecule in the disc membranes of rods and cones (67). Rhodopsin comprises seven transmembrane helices and includes an intradiskal domain, a transmembrane domain, and a cytoplasmic domain. The relationship of rhodopsin to the disk membranes of the rod outer segment is shown in Fig. 3 (68).

10.2. Animal Studies of DHA Depletion and Retinal Function

Early animal studies showed that rats raised on a fat-free diet had abnormally low concentrations of DHA in the retina and diminished a-wave amplitudes on the electroretinogram (ERG) (69), an effect that was reversible with n-3 fatty acid supplementation (70). Subsequent studies have shown that retinal function, as assessed by the ERG, also declines in guinea pigs (71) and nonhuman primates (47,72,73) that are deficient in DHA. Infant rhesus monkeys that were deficient in n-3 fatty acids had significantly decreased visual acuity compared with control monkeys (Fig. 4). The a-wave of the ERG originates largely in the

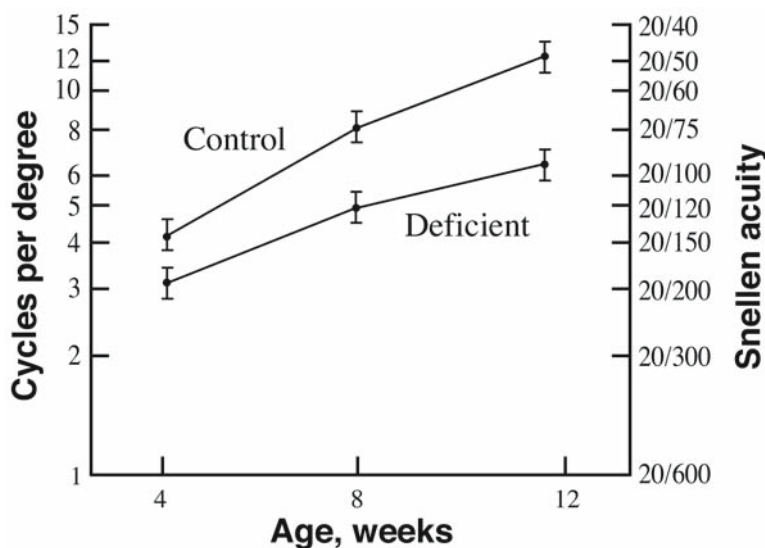


Fig. 4. Visual acuity thresholds (mean \pm standard error of the mean) as determined by the preferential looking method for control and omega-3 fatty acid-deficient infant monkeys. Mean values for the deficient group (black dot) and control group (circles). (Adapted from ref. 47, with permission of the author.)

photoreceptors, thus, DHA deficiency appears to be causing an abnormality in photoreceptor function (67).

10.3. Potential Functions for DHA in the Retina

DHA has been hypothesized to play a role in the regeneration of rhodopsin (66). When the chromophore of rhodopsin, 11-*cis* retinal, is stimulated by light, it undergoes isomerization to all-*trans* retinal and leads to the formation of metarhodopsin II. Metarhodopsin II is deactivated, and some of the all-*trans* retinal is converted to all-*trans* retinol, or vitamin A. In the regeneration of rhodopsin, all-*trans* retinol is transferred to the retinal pigment epithelium, and a new 11-*cis* retinal molecule made within the retinal pigment epithelium is transferred to the rod outer segment. 11-*cis* retinal combines with opsin to form a new rhodopsin molecule. The transfer of 11-*cis* retinal and all-*trans* retinol across the aqueous interphotoreceptor matrix involves interphotoreceptor retinoid-binding proteins (IRBP) (74). DHA has a high affinity for IRBP and is noncovalently bound to IRBP, and DHA is found in high concentrations in rod outer segment and relatively lower concentrations in the retinal pigment epithelium. Thus, a concentration gradient exists for DHA between the rod outer segments and the retinal pigment epithelium.

Chen and colleagues have proposed that DHA modulates the transfer of retinoids between the rod outer segments and retinal pigment epithelium (75). In this model, as IRBP is near the retinal pigment epithelium, it binds a saturated fatty acid, giving a high affinity for binding 11-*cis* retinal. When the IRBP approaches the rod outer segment, DHA displaces the saturated fatty acid, causing a dissociation of 11-*cis* retinal from IRBP and binding with all-*trans* retinol. 11-*cis* retinal then moves into the rod outer segment to combine with opsin and form rhodopsin. When IRBP returns to the retinal pigment epithelium with all-*trans* retinol, saturated fatty acids displace DHA, releasing all-*trans* retinol. IRBP then binds with 11-*cis* retinal to begin the cycle anew.

DHA has been proposed to have other roles in the retina, such as providing the optimal physical environment in the membranes for the activation of rhodopsin in rod outer segments (76–78) and playing a role in the normal phagocytosis of rod outer segments by the retinal pigment epithelium (79,80). DHA may provide the proper mechanical property for rhodopsin function in the lipid bilayer (76). It has been hypothesized that DHA acts as a “molecular spring” in the rod outer segment membrane when rhodopsin absorbs a photon of light and the membrane expands (68). Alternatively, DHA may provide the proper fluid environment in the membranes for the function of rhodopsin (78). In vitro studies suggest that DHA may also protect photoreceptors against apoptosis, or programmed cell death (81).

11. ESSENTIAL FATTY ACIDS IN VISUAL DEVELOPMENT OF INFANTS

11.1. Methods Used for Assessing Visual Development of Infants

The three main tools that have been used for the assessment of visual development among infants have been the ERG, the visual evoked potential (VEP), and preferential looking, a behavioral test (67). The ERG is an electrical potential across the retina that is elicited by light, and it consists of an initial negative component, the a-wave, generated primarily by photoreceptors, followed by a positive component, the b-wave, generated by the inner retina (Fig. 5) (82). The ERG is recorded in a pharmacologically dilated eye using a contact-lens electrode and topical anesthetic. The subject is presented with full field stimulation with flashes of light (83). The rod and cone responses of the ERG can be separated by adjusting the conditions of light and dark adaptation, wavelength of light, flash rate, and stimulus intensity. The measurements from the ERG that are often compared in clinical studies include the amplitude of the wave, the threshold (intensity of light needed to reach a particular amplitude), and peak latency (the time from the flash until the peak of the response), as reviewed in detail elsewhere (67). The ERG does not provide any information regarding visual acuity.

The VEP is a measure of the electrical activity of the brain that is elicited by a change of a visual stimulus and represents the overall processing of visual information from the retina to the visual cortex (84). The VEP is recorded using small disk electrodes applied to the scalp. The subject is usually placed before a video display that shows a checkerboard or grating pattern. When the pattern reverses from dark to light and light to dark, this stimulus elicits a signal that can be recorded. With rapid reversal rates, a steady-state response is obtained, and the waveform resembles a continuous sine wave. The spatial frequency of a pattern can be derived from the amplitude of the VEP using linear regression. The VEP cannot give the locality of any lesion that may be causing decreased visual acuity, but instead provides an overall measurement of visual acuity as perceived by the visual system from the retina to the visual cortex.

Preferential looking methods of visual acuity are based on the natural tendency of infants to look at a patterned target, such as a stripe or checkerboard pattern, rather than a blank target of equal luminance (85). Most studies have relied on the Teller acuity card procedure, a rapid version of the preferential looking method (86). In this test, the infant is held in front of a panel that has two openings for presenting cards. The infant is presented with a card that contains a black and white grating of a particular spatial frequency or a blank gray card that is matched in luminance with the grating card. The observer looks through

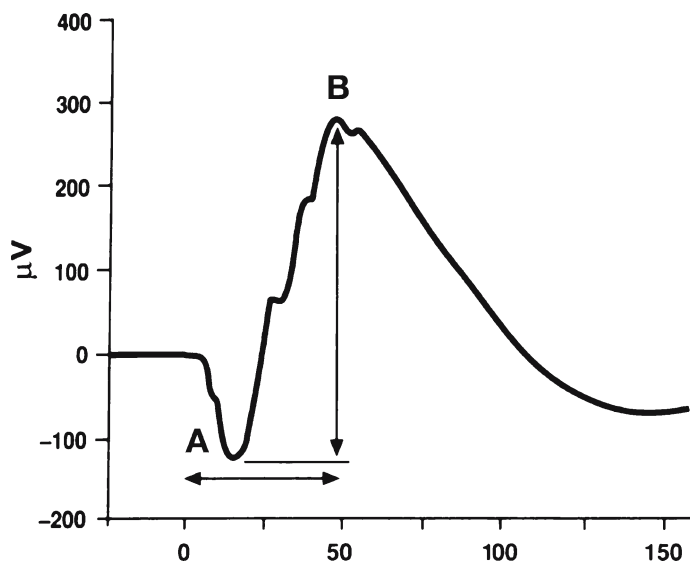


Fig. 5. The electroretinogram response to a relatively bright white flash occurring at time 0 and includes an initial a-wave followed by a larger b-wave. B-wave amplitude is measured from the trough of the a-wave to the peak of the b-wave (vertical arrow). B-wave implicit time is measured from time 0 to the peak of the b-wave (horizontal arrow). (Reprinted from ref. 82, with permission of Elsevier.)

a peephole and judges whether the infant can see the card with the grating (Fig. 6). For spatial frequencies that are well above threshold, the infant shows a correct preference for 80–100% of judgments, but when the spatial frequency is beyond the limit that can be detected by the infant, the correct judgment decreases to about 50%, which is that expected by chance. In usual practice, a correct response level at 75% is customarily used as the end point of the psychometric function (54,67).

The results of visual acuity testing in infants are usually expressed in terms of spatial frequency or cycles per degree. A one octave difference in spatial frequency is equivalent to a halving or doubling of the spatial frequency (54). Thus, there is a one octave difference between 30 and 60 cycles per degree, or between 15 and 30 cycles per degree. The Snellen equivalent of 30, 15, and 7.5 cycles per degree is 20/20, 20/40, and 20/80, respectively. The acuity estimates of behavioral and VEP methods are generally well correlated, but there are differences in the rapidity of visual acuity development between the two methods (67). VEP acuity develops rapidly and attains nearly adult values (about 22 cycles/degree) by 8–12 mo of age, whereas visual acuity as assessed by behavioral methods is about 1 cycle/degree (20/600 Snellen acuity) in the first month postpartum and then increases to 6–11 cycles/degree (about 20/100 Snellen acuity) by 12 mo of age. These differences have been attributed to differences in stimuli, the methods of estimating the threshold, and the rate of maturation of the visual cortex and other neural pathways involved in the behavioral response to the visual stimulus (67).

11.2. Observational Studies

Some observational studies suggested that term infants who were fed formula that did not contain long-chain polyenes had poorer vision than breast-fed infants (Table 5) (87,88).




Fig. 6. Teller acuity card procedure. The infant is held in front of gray screen; shield located at chosen test distance assists in positioning infant and prevents person from holding the infant from seeing the grating. Adult observer holds acuity cards up to opening in screen and watches child through peephole in card. (Reprinted from ref. 86, with permission of *Developmental Medicine and Child Neurology*.)

In a study from Australia, breast-fed term infants had significantly better VEP acuity compared with formula-fed term infants at 22 wk of age (87). In addition, with all infants from the study combined, there was a significant correlation between DHA content of erythrocytes and VEP acuity. The infant formula in the Australian study contained about 6–8% energy as linoleic acid and 0.5–0.8% energy as α -linolenic acid (87). In a longitudinal comparison of term infants in Denmark, the increase in visual acuity as assessed by Teller cards was more rapid in breast-fed compared with formula-fed infants from 1 to 4 mo of age (88).

Most observational studies of term infants have shown no difference in visual acuity of infants who were breast-fed or formula-fed with formula that did not contain LC-PUFAs (Table 5) (89–92). There was no difference in visual acuity assessed by Teller cards between breast-fed and formula-fed term infants at 14 d and 3 mo (89). The investigators concluded that infant formula which contained α -linolenic acid as about 1% of total energy was adequate for normal visual development (89). Further investigators of a larger group of infants who had been breast-fed for various lengths of time or fed formula without AA or DHA had no differences in visual acuity assessed by Teller cards at 9 mo of age (90). A multicenter study of term infants conducted in seven centers in the United States and Canada demonstrated no difference in visual acuity assessed by Teller cards at 3 mo of age between breast-fed infants and infants fed either of two formulas. Formula 1 and 2 had a linoleic acid and α -linolenic acid content of 18.0% and 1.9% vs 34.2% and 4.7%, respectively, and neither formula contained AA or DHA (91). No differences were found between

Table 5
Observational Studies of Essential Fatty Acids and Visual Acuity in Infants

<i>Location</i>	<i>Groups</i>	<i>Findings/comments</i>	<i>Reference</i>
Australia	Formula-fed (<i>n</i> = 8) Breast-fed (<i>n</i> = 8)	Better VEP acuity in breast-fed than formula-fed group at mean age of about 22 wk; no DHA or AA in formula	87
Canada	Breast-fed (<i>n</i> = 17) Formula-fed (<i>n</i> = 18)	No difference in Teller acuity at 14 days and 3 mo between groups; No LC-PUFA in formula	89
Denmark	Breast-fed (<i>n</i> = 17) Formula-fed (<i>n</i> = 16)	Greater increase in Teller acuity from 1 to 4 mo in breast-fed group	88
Canada	Breast-fed for: <1 mo (<i>n</i> = 40) 1–3 mo (<i>n</i> = 51) 4–6 mo (<i>n</i> = 95) 7–8 mo (<i>n</i> = 49) >8 mo (<i>n</i> = 92) Milk/formula (<i>n</i> = 38) Formula only (<i>n</i> = 68)	No difference in Teller acuity at 9 mo between groups; no DHA or AA in formula	90
Australia	Breast-fed, high intake (<i>n</i> = 9) Breast-fed, low intake (<i>n</i> = 7)	Teller acuity and ERG activity not different between groups at 40 wk post-conceptual age; preterm infants	93
USA/Canada	Breast-fed (<i>n</i> = 56) Formula 1-fed (<i>n</i> = 59) Formula 2-fed (<i>n</i> = 57)	No differences in Teller acuity at 3 mo between the groups; no LC-PUFA in formula groups	91
Netherlands	Breast-fed (<i>n</i> = 48) Formula-fed (<i>n</i> = 26)	No differences in Teller acuity at 7 mo	92

VEP, visual evoked potential; DHA, docosahexaenoic acid; AA, arachidonic acid; LC-PUFAs, long-chain polyunsaturated fatty acids, ERG, electroretinogram.

breast-fed and formula-fed term in visual acuity assessed by Teller cards at 7 mo of age (92), and a study of preterm infants in Australia found no difference in ERGs and visual acuity assessed by Teller cards at 40 wk postconceptual age among preterm infants with a high and low intake of human milk (93).

Potential confounding factors in observational studies include tobacco and alcohol use during pregnancy, socioeconomic status, cultural differences among mothers who decide to breast feed or use infant formula, educational differences, and birth weight (92,94). Investigators turned to randomized, controlled clinical trials in order to address the issue whether n-3 fatty acids were essential for visual development in preterm and term infants.

11.3. Clinical Trials in Preterm Infants

A series of controlled clinical trials has recently suggested that n-3 PUFAs improve the visual development of preterm infants (95). At least five clinical trials have evaluated the role of supplemental DHA or DHA plus AA in the visual development of preterm infants (Table 6) (96–108). The characteristics of masking, randomization, assessment methods,

Table 6
Some Clinical Trials of Essential Fatty Acids and Visual Acuity in Preterm Infants

<i>Location</i>	<i>Groups^a</i>	<i>Findings/comments</i>	<i>Reference</i>
United States	Control formula 1 (<i>n</i> = 13) Control formula 2 (<i>n</i> = 16) LC-PUFA (<i>n</i> = 14) Breast-fed (<i>n</i> = 9)	Better VEP acuity at 36 and 57 wk, better Teller acuity at 57 wk in LC-PUFA group than controls; control formula 1 with linoleic acid, formula 2 with linoleic and linolenic acids; lower rod thresholds on ERG in breast-fed and LC-PUFA groups at 36 wk	96–100
United States	Control formula (<i>n</i> = 34) DHA (<i>n</i> = 33)	Better Teller acuity at corrected age of 2 and 4 mo, but no differences at 6.5, 9, and 12 mo	101–104
United States	Control formula (<i>n</i> = 12) DHA (<i>n</i> = 15)	Better visual recognition memory and visual attention by Fagan test in DHA group at 12 mo; feeding until 2 mo past term	105,106
Italy	Control formula (<i>n</i> = 15) LC-PUFA (<i>n</i> = 19) Breast-fed (<i>n</i> = 10)	Flash VEP latency in supplemented and breast-fed groups different from control group at 52 wk postmenstrual age	107
France	Control formula (<i>n</i> = 9) LC-PUFA (<i>n</i> = 13) Breast-fed (<i>n</i> = 11)	No difference in VEP latency between groups after 30 d of treatment	108

^aThe main *n* used in the actual statistical analysis; some *n* may vary at different follow-up visits.

VEP, visual evoked potential; LC-PUFA, long-chain polyunsaturated fatty acids; DHA, docosahexaenoic acid; ERG, electroretinogram.

duration of supplementation, balance of essential fatty acids in formula, and follow-up of these trials has been reviewed in detail elsewhere (95,109).

An early trial, covered in several reports, showed that preterm infants given formula supplemented with LC-PUFAs had better visual acuity as assessed by VEP at 36 wk and VEP and Teller cards at 57 wk (96–100). Two other arms of the study included control formulas that contained linoleic acid and linoleic and linolenic acids, respectively. In addition, rod thresholds of the ERG were lower among the infants who received supplemental LC-PUFAs. In a study from Memphis, preterm infants were randomized to received control formula without DHA and formula with dexamethasone acid (101–104). Visual acuity, as assessed by Teller cards, was significantly better at 2 and 4 mo among infants who received supplemental DHA compared with control formula, but no differences were found at 6.5, 9, and 12 mo (Fig. 7). In a second trial from Memphis, better visual recognition memory and visual attention as assessed by the Fagan test was found among preterm infants supplemented with DHA compared with control formula (105,106).

In a clinical trial conducted in Italy, infants who received supplemental LC-PUFAs had significantly different flash VEP latency at 52 wk postconceptional age compared with

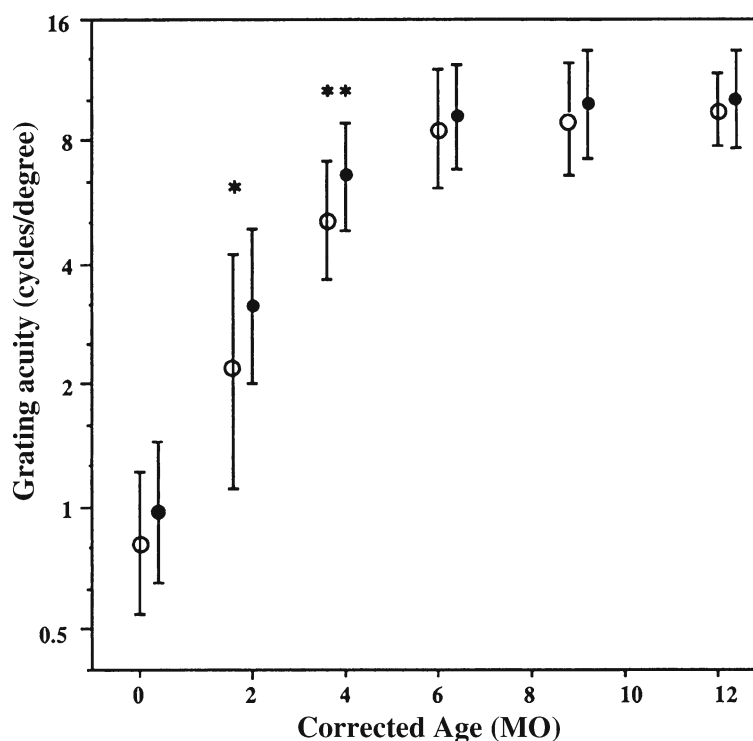


Fig. 7. Visual acuity development in control (circle) and marine-oil-supplemented (solid dot) infants. Control infants differed from supplemented infants: * $p = 0.014$, ** $p = 0.002$. (Reprinted from ref. 102, with permission of the *American Journal of Clinical Nutrition*. © Am J Clin Nutr. American Society for Clinical Nutrition.)

infants who received control formula (107). The investigators believed that the differences in the morphology and latencies of the flash VEP between the groups was due to a slower maturation pattern of VEPs among the preterm infants who received formula without DHA. No differences were found in VEP latency between preterm infants who were randomized to receive formulas with or without LC-PUFAs and those who were breast-fed (108).

Some of the clinical trials included fish oil, a rich source of DHA, and fish oil treatment may have had a negative effect on infant growth (105,106). Supplementation with fish oil may cause a decline in AA, and other studies that have provided both AA and DHA supplementation have not shown any adverse effect on growth (95). A meta-analysis of four of the trials shows that DHA supplementation to infant formula improves visual acuity at 2 and 4 mo of age in preterm infants (Fig. 8) (110). The combined estimates of visual acuity differences (\pm standard error of the mean) at 2 and 4 mo of age were 0.47 ± 0.14 and 0.28 ± 0.08 octaves, respectively (110).

11.4. Clinical Trials in Term Infants

Several randomized clinical trials of supplemental DHA have been conducted among term infants (Table 7) (111–123), and the overall results appear to be mixed. No adverse effects on growth have been reported in these trials involving term infants, despite the

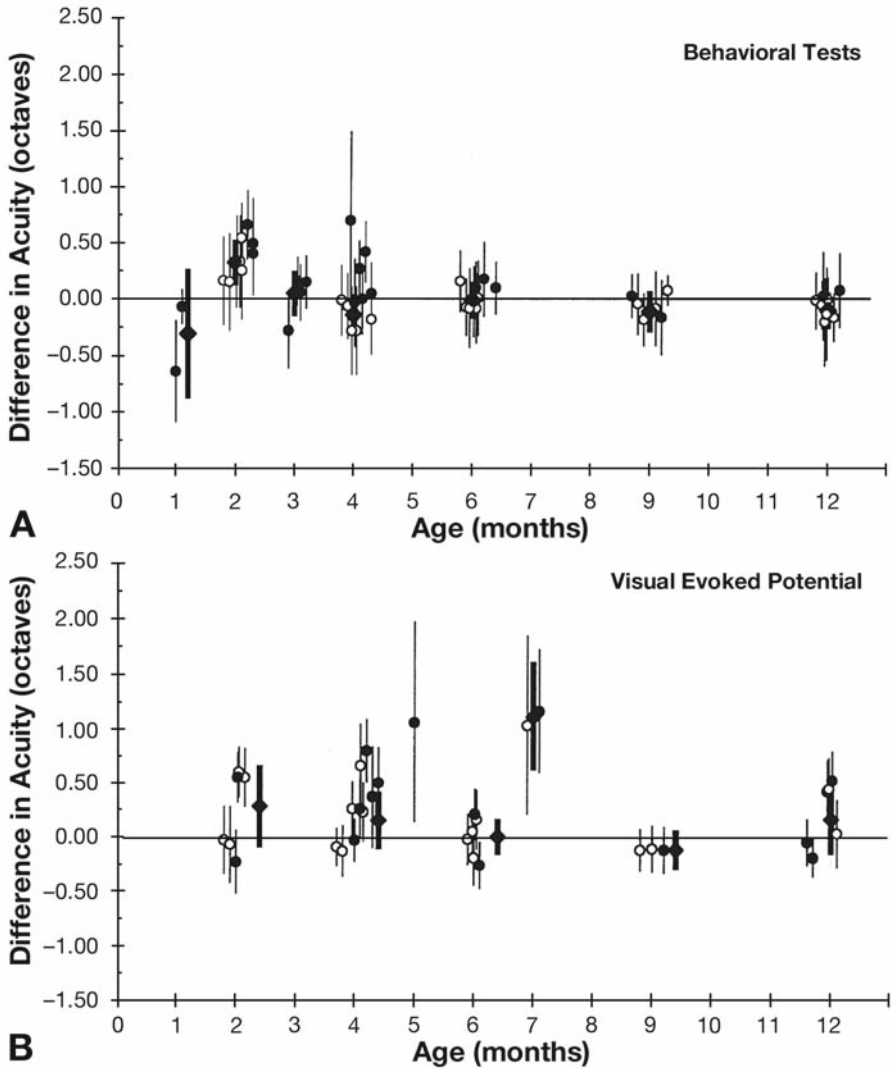


Fig. 8. Meta-analysis of the effect of docosahexaenoic acid on visual acuity of healthy preterm infants, showing differences in visual acuity as assessed by behavioral tests (**A**) and visual evoked potential (**B**). Error bars are 95% confidence intervals. Individual studies are indicated by fine error bars. Large diamonds with bold bars indicate combined visual acuity difference estimates, and bars that do not span zero (horizontal line) indicate significant results. (Reproduced from ref. 110, with permission of the American Academy of Pediatrics.)

fact that four trials utilized formulas with DHA alone (111,113,116,121), which resulted in depletion of AA status of the infants (95).

In a controlled clinical trial in Australia, infants who were randomized to receive formula containing supplemental DHA and eicosapentaenoic acid had better VEP acuity at 16 and 30 wk compared with infants who received control formula (111). There were no significant differences in VEP acuity between breast-fed and supplemented infants. Better sweep VEP acuity was found among term infants at 2 mo who were breast-fed or received formula supplemented with DHA and AA compared with infants randomized

Table 7
Some Clinical Trials of Essential Fatty Acids and Visual Acuity in Term Infants

<i>Location</i>	<i>Groups^a</i>	<i>Findings/comments</i>	<i>Reference</i>
Australia	Control formula (<i>n</i> = 19) EPA + DHA (<i>n</i> = 13) Breast-fed (<i>n</i> = 23) Partial breast-fed (<i>n</i> = 24)	EPA + DHA and breast-fed group had better VEP acuity at 16 and 30 wk compared with other groups	111
United States	Control formula (<i>n</i> = 20) DHA + AA (<i>n</i> = 19) Breast-fed (<i>n</i> = 19)	DHA + AA group and breast-fed groups had better sweep VEP acuity at 2 mo, but no difference at 4, 6, 9, or 12 mo	112
United States	Control formula (<i>n</i> = 45) DHA + AA (<i>n</i> = 46) DHA (<i>n</i> = 43) Breast-fed (<i>n</i> = 63)	No difference in sweep VEP, Teller acuity at 2, 4, 6, 9, and 12 mo between groups; 3 study sites	113
Italy	Control formula (<i>n</i> = 29) LC-PUFA (<i>n</i> = 27) Breast-fed (<i>n</i> = 30)	Brunet-Lézine developmental quotient higher in supplemented and breast-fed group than control at 4 mo but not 24 mo	114,115
Denmark	Control formula (<i>n</i> = 11) DHA + LA (<i>n</i> = 14) DHA (<i>n</i> = 12) Breast-fed (<i>n</i> = 17)	No difference in sweep VEP between different formula groups at 4 mo; better sweep VEP in breast-fed group compared with groups fed formula	116
United States	Control formula (<i>n</i> = 26) DHA + AA (<i>n</i> = 27) DHA (<i>n</i> = 26) Breast-fed (<i>n</i> = 29)	DHA + AA and DHA groups had better sweep VEP acuity than control group at 6, 17, and 52 wk	117
United Kingdom	Control formula (<i>n</i> = 20) DHA + AA (<i>n</i> = 20)	Better means-end problem solving in supplemented group at 10 mo but no difference at 9 mo; two reports have internal inconsistencies	118,119
United Kingdom	Control formula (<i>n</i> = 125) LC-PUFA (<i>n</i> = 125) Breast-fed (<i>n</i> = 104)	No difference in Bayley mental or psychomotor development indices between groups at 9 and 18 mo	120
Australia	Control formula (<i>n</i> = 21) DHA + AA (<i>n</i> = 24) DHA (<i>n</i> = 23) Breast-fed (<i>n</i> = 46)	No differences in VEP acuity at 16 and 34 wk between groups	121,122
United States	Control formula (<i>n</i> = 48) DHA + AA (<i>n</i> = 47)	VEP in DHA + AA group better than control group at 6, 17, 26, 52 wk	123

^aThe main *n* used in the actual statistical analysis; some *n* may vary at different follow-up visits.

EPA, eicosapentaenoic acid; DHA, docosahexaenoic acid; VEP, visual evoked potential; AA, arachidonic acid.

to receive control formula, but these differences were no longer significant at 4, 6, 9, or 12 mo of age (112). In contrast, a multicenter study in the United States found no differences in visual acuity assessed by sweep VEP and Teller cards at 2, 4, 6, 9, and 12 mo between term infants randomized to receive control formula, or formula supplemented

with DHA and/or AA (113). Longer term follow-up at 39 mo also showed no differences in visual motor function or visual acuity between formula or breastfed groups (124). In a study conducted in the United States, term infants who received a formula containing both DHA and AA had better VEP acuity than the control group at 6, 17, 26, and 52 wk of age (123).

Better sweep VEP acuity was found among term infants at 6, 17, and 52 wk among infants randomized to received formula containing DHA or DHA plus AA compared with control formula (117). In contrast, no difference was found in sweep VEP acuity at 4 mo between infants who received supplemental DHA compared with controls in Denmark (116). Another trial in Australia also found no differences in VEP acuity at 16 and 34 wk between term infants who received control formula vs formula supplemented with DHA (121,122).

A clinical trial in Italy showed that infants supplemented with LC-PUFAs had a better Brunet-Lézine developmental quotient, a more global measure of development, at 4 mo of age but not at 24 mo of age (114,115). In two reports from one trial, there were no significant differences in means-end problem solving at 9 mo of age between infants randomized to receive control formula or formula supplemented with AA and DHA, but apparent differences were seen at 10 mo of age (118). In another trial that examined global development, no differences were found in Bayley mental or psychomotor development indices at 9 and 18 mo between infants randomized to receive control formula and formula supplemented with LC-PUFAs (120).

A meta-analysis of some of the randomized trials suggests that visual acuity at 2 mo of age is significantly better among term infants who received supplemental DHA, but there were no significant differences at other ages (Fig. 9) (125). The combined visual acuity difference (\pm standard error of the mean) measured by behavioral methods was 0.32 ± 0.09 octaves at 2 mo of age (125). Another analysis of 14 controlled trials in term infants used “meta-regression” to examine the relationship between visual acuity at 4 mo and the DHA effective dose. The results showed a strong and significant effect of DHA equivalent dose on visual acuity response at 4 mo of age, especially when 10% conversion of α -linoleic acid to DHA was considered (126).

11.5. Implications of the Clinical Trials

The clinical trials of n-3 LC-PUFAs generally show a beneficial effect on visual acuity in preterm infants and perhaps an effect in term infants. Some of the discrepancies among the clinical trials may be related to the use of infant formulas that contain inadequate n-3 fatty acids (<1.5 – 2.0% linolenic acid), differences in the source and composition of the oil used as the source for DHA, and presence or absence of AA and eicosapentaenoic acid (43). The period in which infants are vulnerable to low dietary n-3 fatty acid intakes appears to be short. Although dietary n-3 fatty acids appear to influence the development of visual acuity, the differences as demonstrated in these clinical trials disappear when children are evaluated at a later age. The transient nature of these effects may lead some to conclude that the differences have no lasting importance, but other studies on visual development suggest that early visual experience can be critical to later visual functioning (67). Whether a relative deficiency in DHA early in infancy is related to any subsequent visual problem, such as amblyopia or strabismus, or any later abnormality of cognitive or motor development is unclear.

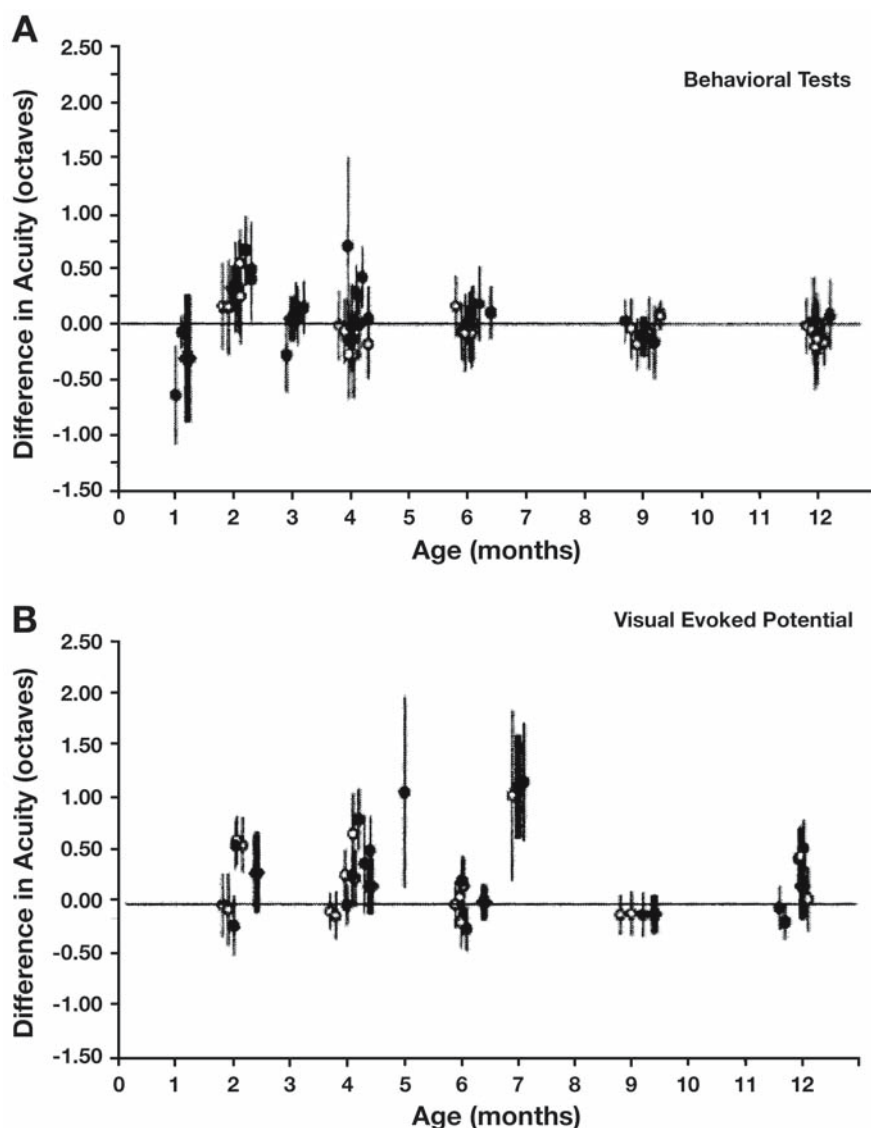


Fig. 9. Visual acuity differences. Open symbols represent randomized comparisons (formula-fed groups with long-chain polyunsaturated fatty acids (LC-PUFAs) vs formula-fed groups with LC-PUFAs). Shaded symbols represent nonrandomized comparisons (human milk vs formula without LCPUFAs). Diamonds represent combined acuity difference estimates of randomized comparisons. (A) Acuity differences measured with behaviorally based tests. (B) Acuity differences measured with visual evoked potentials. (Reproduced from ref. 125, with permission from Elsevier Science.)

Observational studies that have compared breast-fed and formula-fed infants suggest that the expected difference or improvement in cognitive development with supplemental DHA would be about one-third of a standard deviation for the test scores. Using standard sample size and power calculations, about 144 subjects per group or 288 subjects total, would be needed to detect this difference with 80% power and a significant level of 0.05 (127). To date, none of the clinical trials of supplemental LC-PUFAs and neurodevelopment in infants, either preterm or term, have had adequate sample size and

power (127). Studies of infant nutrition require large sample sizes and long follow-up, and therefore can become extremely expensive to conduct (128). With recent recommendations regarding supplemental essential fatty acids (1), the provision of AA and DHA in all infant formulas is likely to become the standard of care, and further clinical trials or observational studies may become difficult to justify.

12. CONCLUSIONS AND RECOMMENDATIONS

The human retina contains an extremely high concentration of DHA, a PUFA of the n-3 (omega-3) family. DHA appears to play an important role in the retina and is necessary for the normal function of rhodopsin. Preterm infants are born with relatively low stores of DHA, and in the past, infant formulas did not contain this n-3 fatty acid. A recent series of clinical trials conducted with both preterm and term infants suggests that the addition of DHA to infant formula will improve the development of visual acuity in the first few months of life, especially among preterm infants. The differences in visual acuity between infants fed formula with and without DHA disappeared after 4 mo of age, and it is unclear whether there are long-term adverse consequences associated with lack of DHA in formula. A recent expert consensus has been reached regarding essential fatty acids for infant health, and it is now recommended that both AA and DHA be added to infant formula, and this recommendation is largely being followed by industry. The addition of LC-PUFAs to infant formula has raised the cost of formula feeding, and the actual long term functional benefits still remain controversial (4).

Several important research issues remain to be addressed. The long-term effects of AA and DHA on eye health are not known and need further characterization. There is a need for adequate sample size and statistical power for clinical trials that assess the effects of essential fatty acids on infant neurodevelopment. The possible effects of *trans* unsaturated fatty acids on essential PUFA status of mothers and infants should be investigated. The use and optimal composition of n-6 and n-3 fatty acids in PUFA supplements for pregnant women is not well known. Finally, the precise role of DHA in rod and cone outer segments must be better characterized.

REFERENCES

1. Simopoulos AP, Leaf A, Salem N Jr. Workshop statement on the essentiality of and recommended dietary intakes for omega-6 and omega-3 fatty acids. *Prostagl Leukotrienes Essential Fatty Acids* 2000; 63:119–121.
2. World Health Organization. Maternal anthropometry and pregnancy outcomes: WHO Collaborative Study. *Bull WHO* 1995;73(suppl):1–98.
3. Uauy E, Hoffman DR. Essential fat requirements of preterm infants. *Am J Clin Nutr* 2000;71:245–250.
4. Koo WWK. Efficacy and safety of docosahexaenoic acid and arachidonic acid addition to infant formulas: can one buy better vision and intelligence? *J Am Coll Nutr* 2003;22:101–107.
5. Chevreul ME. *Recherches chimiques sur les corps gras d'origine animale*. Paris, F. G. Levrault, 1823.
6. Evans HM, Burr GO. A new dietary deficiency with highly purified diets. *Proc Soc Exp Biol Med* 1927; 24:740–743.
7. Evans HM, Burr GO. New dietary deficiency with highly purified diets. II. Supplementary requirement of diet of pure casein, sucrose, and salt. *Proc Soc Exp Biol Med* 1927;25:41–48.
8. Evans HM, Burr GO. A new dietary deficiency with highly purified diets. III. The beneficial effect of fat in the diet. *Proc Soc Exp Biol Med* 1928;25:390–397.

9. McAmis AJ, Anderson WE, Mendel LB. Growth of rats on "fat-free" diets. *J Biol Chem* 1929;82:247–262.
10. Burr GO, Burr MM. A new deficiency disease produced by the rigid exclusion of fat from the diet. *J Biol Chem* 1929;82:345–367.
11. Holman RT, George O. Burr and the discovery of essential fatty acids. *J Nutr* 1988;118:535–540.
12. Hansen AE. Serum lipid changes and therapeutic effect of various oils in infantile eczema. *Proc Soc Exp Biol Med* 1933;31:160–161.
13. Cornbleet T. Use of maize oil (unsaturated fatty acids) in the treatment of eczema. Preliminary report. *Arch Dermat Syphilol* 1935;31:224–226.
14. Wiese HF, Gibbs RH, Hansen AE. Essential fatty acids and human nutrition. I. Serum level for unsaturated fatty acids in healthy children. *J Nutr* 1954;52:355–365.
15. Hansen AE, Wiese HF. Essential fatty acids and human nutrition. II. Serum level for unsaturated fatty acids in poorly-nourished infants and children. *J Nutr* 1954;52:367–374.
16. Hallberg D, Schubert O, Wretling A. Experimental and clinical studies with fat emulsion for intravenous nutrition. *Nutra Dieta Eur Rev Nutr Diet* 1966;8:245–281.
17. Collins FD, Sinclair AJ, Royle JP, Coats DA, Maynard AT, Leonard RF. Plasma lipids in human linoleic acid deficiency. *Nutr Metab* 1971;13:150–167.
18. Paulsrud JR, Pensler L, Whitten CF, Stewart S, Holman RT. Essential fatty acid deficiency in infants induced by fat-free intravenous feeding. *Am J Clin Nutr* 1972;25:897–904.
19. Richardson TJ, Sgoutas D. Essential fatty acid deficiency in four adult patients during total parenteral nutrition. *Am J Clin Nutr* 1975;28:258–263.
20. Wolfram G, Eckart J, Walther B, Zollner N. Factors influencing essential fatty acid requirement in total parenteral nutrition (TPN). *J Parenteral Enteral Nutr* 1978;2:634–639.
21. Holman RT, Johnson SB, Hatch TF. A case of human linolenic acid deficiency involving neurological abnormalities. *Am J Clin Nutr* 1982;35:617–623.
22. Dupont JL. Essential fatty acids. In: Kiple KF, Ornelas KC, (eds). *The Cambridge World History of Food*. Vol. 1. Cambridge, Cambridge University Press: 2000; pp. 876–882.
23. Innis SM. Essential fatty acids in growth and development. *Prog Lipid Res* 1991;30:39–103.
24. Dutta-Roy AK. Transport mechanisms for long-chain polyunsaturated fatty acids in the human placenta. *Am J Clin Nutr* 2000;71(suppl):315S–322S.
25. Clandinin MT, Chappell JE, Leong S, Heim T, Swyer PR, Chance GW. Intrauterine fatty acid accretion rates in human brain: implications for fatty acid requirements. *Early Hum Dev* 1980;4:121–129.
26. Clandinin MT, Chappell JE, Heim T, Swyer PR, Chance GW. Fatty acid accretion in fetal and neonatal liver: implications for fatty acid requirements. *Early Hum Dev* 1981;5:7–14.
27. Greiner RCS, Winter J, Nathanielsz PW, Brenna JT. Brain docosahexaenoate accretion in fetal baboons: bioequivalence of dietary α -linolenic acid and docosahexaenoic acids. *Pediatr Res* 1997;42:826–834.
28. Al MDM, van Houwelingen AC, Kester ADM, Hasaart THM, de Jong AEP, Hornstra G. Maternal essential fatty acid patterns during normal pregnancy and its relationship to the neonatal essential fatty acid status. *Brit J Nutr* 1995;74:55–68.
29. Al MDM, van Houwelingen AC, Hornstra G. Relation between birth order and the maternal and neonatal docosahexaenoic acid status. *Eur J Clin Nutr* 1997;51:548–553.
30. Makrides M, Gibson RA. Long-chain polyunsaturated fatty acid requirements during pregnancy and lactation. *Am J Clin Nutr* 2000;71:307–311.
31. Foreman-Van Drongelen MMHP, Al MDM, van Houwelingen AC, Blanco CE, Hornstra G. Comparison between the essential fatty acid status of preterm and full-term infants, measured in umbilical vessel walls. *Early Hum Dev* 1995;42:241–251.
32. Clandinin MT, Chappell JE, Heim T, Swyer PR, Chance GW. Fatty acid utilization in perinatal de novo synthesis of tissues. *Early Hum Dev* 1981;5:355–366.
33. Carnielli VP, Wattimena DJL, Luijendijk IHT, Boerlage A, Degenhart HJ, Sauer PJJ. The very low birthweight premature infant is capable of synthesizing arachidonic and docosahexaenoic acids from linoleic and linolenic acids. *Pediatr Res* 1996;40:169–174.
34. Salem N Jr, Wegher B, Mena P, Uauy R. Arachidonic and docosahexaenoic acids are biosynthesized from their 18-carbon precursors in human infants. *Proc Natl Acad Sci USA* 1996;93:49–54.

35. Szitanyi P, Koletzko B, Mydlilova A, Demmelmair H. Metabolism of ^{13}C -labelled linoleic acid in newborn infants during the first week of life. *Pediatr Res* 1999;45:669–673.
36. Huang MC, Brenna JT. On the relative efficacy of α -linolenic acid and preformed docosahexaenoic acid as substrates for tissue docosahexaenoate during perinatal development. In: Mostofsky D, Yehuda S, Salem N Jr (eds). *Fatty Acids: Physiological and Behavioral Functions*. Totowa, NJ, Humana: 2001; pp. 99–113.
37. Jensen RG. The lipids in human milk. *Prog Lipid Res* 1996;35:53–92.
38. Koletzko B, Thiel I, Abiodun PO. The fatty acid composition of human milk in Europe and Africa. *J Pediatr* 1992;120:S62–S70.
39. Agostoni C, Marangoni F, Bernardo L, Lammardo AM, Galli C, Riva E. Long-chain polyunsaturated fatty acids in human milk. *Acta Paediatr Suppl* 1999;430:68–71.
40. Xiang M, Lei S, Li T, Zetterström R. Composition of long chain polyunsaturated fatty acids in human milk and growth of young infants in rural areas of northern China. *Acta Paediatr* 1999;88:126–131.
41. Sauerwald TU, Demmelmair H, Koletzko B. Polyunsaturated fatty acid supply with human milk. *Lipids* 2001;36:991–996.
42. Smit EN, Oelen EA, Seerat E, Muskiet FAJ, Boersma ER. Breast milk docosahexaenoic acid (DHA) correlates with DHA status of malnourished infants. *Arch Dis Child* 2000;82:493–494.
43. Innis SM. Essential fatty acids in infant nutrition: lessons and limitations from animal studies in relation to studies on infant fatty acid requirements. *Am J Clin Nutr* 2000;71:238–244.
44. Nettleton JA. Omega-3 fatty acids: comparison of plant and seafood sources in human nutrition. *J Am Diet Assoc* 1991;91:331–337.
45. Hepburn FN, Exler J, Weihrauch JL. Provisional tables on the content of omega-3 fatty acids and other fat components of selected foods. *J Am Diet Assoc* 1986;86:788–793.
46. Fulco AJ, Mead JF. Metabolism of essential fatty acids. VIII. Origins of 5,8,11-eicosatrienoic acid in the fat-deficient rat. *J Biol Chem* 1959;234:1411–1416.
47. Neuringer M, Conner WE, Lin DS, Barstad L, Luck S. Biochemical and functional effects of prenatal and postnatal omega-3 fatty acid deficiency on retina and brain in rhesus monkeys. *Proc Natl Acad Sci USA* 1986;83:4021–4025.
48. Holman RT. Function and biologic activities of essential fatty acids in man. In: Meng HC, Wilmore DW (eds). *Fat Emulsions in Parenteral Nutrition*. American Medical Association, Chicago: 1976; pp. 5–14.
49. Siguel EN, Chee KM, Gong J, Schaefer EJ. Criteria for essential fatty acid deficiency in plasma as assessed by capillary column gas-liquid chromatography. *Clin Chem* 1987;33:1869–1873.
50. Hornstra G. Essential fatty acids in mothers and their neonates. *Am J Clin Nutr* 2000;71:1262S–1269S.
51. Wolff JA, Margolis S, Bujdoso-Wolff K, Matusick E, McLean WC Jr. Plasma and red blood cell fatty acid composition in children with protein-calorie malnutrition. *Pediatr Res* 1984;18:162–167.
52. Lands WEM. Long-term fat intake and biomarkers. *Am J Clin Nutr* 1995;61(suppl):721S–725S.
53. Chandna A. Natural history of the development of visual acuity in infants. *Eye* 1991;5:20–26.
54. Friendly DS. Development of vision in infants and young children. *Pediatr Clin North Am* 1993;40:693–703.
55. Hendrickson AE, Yuodelis C. The morphological development of the human fovea. *Ophthalmology* 1984;91:603–612.
56. Magoon EH, Robb RM. Development of myelin in human optic nerve and tract. A light and electron microscopic study. *Arch Ophthalmol* 1981;99:655–659.
57. Yakovlev PL, Lecours A. The myelogenetic cycles of regional maturation of the brain. In: Minkowski A (ed). *Regional Development of Brain in Early Life*. Oxford, Blackwell: 1967; pp. 3–70.
58. Hickey TL. Postnatal development of the human lateral geniculate nucleus: relationship to a critical period for the visual system. *Science* 1977;198:836–838.
59. Huttenlocher PR, de Courten C, Garey LJ, Van der Loos H. Synaptogenesis in human visual cortex—Evidence for synapse elimination during normal development. *Neurosci Lett* 1982;33:247–252.
60. Fulton AB, Hansen RM, Manning KA. Measuring visual acuity in infants. *Surv Ophthalmol* 1981;25:325–332.
61. Fliesler SJ, Anderson RE. Chemistry and metabolism of lipids in the vertebrate retina. *Prog Lipid Res* 1983;22:79–131.

62. Wiegand RD, Koutz CA, Stinson AM, Anderson RE. Conservation of docosahexaenoic acid in rod outer segments of rat retina during n-3 and n-6 fatty acid deficiency. *J Neurochem* 1991;57:1690–1699.
63. Stinson AM, Wiegand RD, Anderson RE. Recycling of docosahexaenoic acid in rat retinas during n-3 fatty acid deficiency. *J Lipid Res* 1991;32:2009–2017.
64. Anderson RE, O'Brien PJ, Wiegand RD, Koutz CA, Stinson AM. Conservation of docosahexaenoic acid in the retina. *Adv Exp Med Biol* 1992;318:285–294.
65. Bazan NG, Gordon WC, Rodriguez de Turco EB. Docosahexaenoic acid uptake and metabolism in photoreceptors: retinal conservation by an efficient retinal pigmental epithelial cell-mediated recycling process. *Adv Exp Med Biol* 1992;318:295–306.
66. Jeffrey BG, Weisinger HS, Neuringer M, Mitchell DC. The role of docosahexaenoic acid in retinal function. *Lipids* 2001;36:859–871.
67. Neuringer M. Infant vision and retinal function in studies of dietary long-chain polyunsaturated fatty acids: methods, results, and implications. *Am J Clin Nutr* 2000;71:256–267.
68. Dratz EA, Hargrave PA. The structure of rhodopsin and the rod outer segment disk membrane. *Trends Biochem Science* 1983;8:128–131.
69. Benolken RM, Anderson RE, Wheeler TG. Membrane fatty acids associated with the electrical response in visual excitation. *Science* 1973;182:1253–1254.
70. Wheeler TG, Benolken RM, Anderson RE. Visual membranes: specificity of fatty acid precursors for the electrical response to illumination. *Science* 1975;188:1312–1314.
71. Weisinger HS, Vingrys AJ, Sinclair AJ. The effect of docosahexaenoic acid on the ERG of the guinea pig. *Lipids* 1996;31:65–70.
72. Neuringer M, Connor WE, Van Petten C, Barstad L. Dietary omega-3 fatty acid deficiency and visual loss in infant rhesus monkeys. *J Clin Invest* 1984;73:272–276.
73. Anderson GJ, Neuringer M, Lin DS, Connor WE. Can prenatal N-3 fatty acid deficiency be completely reversed after birth? Effects on retinal and brain biochemistry and visual function in rhesus monkeys. *Pediatr Res* 2005;58:865–872.
74. Chen Y, Saari JC, Noy N. Interactions of all-*trans*-retinol and long-chain fatty acids with interphotoreceptor retinoid-binding protein. *Biochemistry* 1993;32:11311–11318.
75. Chen Y, Houghton LA, Brenna JT, Noy N. Docosahexaenoic acid modulates the interactions of the interphotoreceptor retinoid-binding protein with 11-*cis* retinal. *J Biol Chem* 1996;271:20507–20515.
76. Brown MF. Modulation of rhodopsin function by properties of the membrane bilayer. *Chem Phys Lipids* 1994;73:159–180.
77. Dratz EA, Holte LL. The molecular spring model for the function of docosahexaenoic acid (22:6 ω -3) in biological membranes. In: Sinclair A, Gibson R (eds). *The Third International Congress on Essential Fatty Acids and Eicosanoids*, Adelaide, Australia, March 1–5, 1992. Champaign, IL, American Oil Chemists' Society: 1992; pp. 122–127.
78. Litman BJ, Mitchell DC. A role for phospholipid polyunsaturation in modulating membrane protein function. *Lipids* 1996;31:S193–S197.
79. Watanabe I, Aonuma H, Kaneko S, Okuyama H. Effect of a high linoleate and a high α -linolenate diets on size distribution of phagosomes in retinal pigment epithelium. In: Yasugi T, Nakamura H, Soma M (eds). *Advances in Polyunsaturated Fatty Acid Research*. Amsterdam, Excerpta Medica: 1993; pp. 269–272.
80. Bush RA, Malnoe A, Reme CE, et al. Dietary deficiency of n-3 fatty acids alters rhodopsin content and function in the rat retina. *Invest Ophthalmol Vis Sci* 1994;35:91–100.
81. Politi L, Rotstein N, Carri N. Effects of docosahexaenoic acid on retinal development: cellular and molecular aspects. *Lipids* 2001;36:927–935.
82. Neuringer M, Reisbick S, Janowsky J. The role of n-3 fatty acids in visual and cognitive development: current evidence and methods of assessment. *J Pediatr* 1994;125:39–47.
83. Marmor MF, Arden GB, Nilsson SEG, Zrenner E. Standard for clinical electroretinography. *Arch Ophthalmol* 1989;107:816–819.
84. Taylor MJ, McCulloch DL. Visual evoked potentials in infants and children. *J Clin Neurophysiol* 1992;9:357–372.
85. Fielder AR, Dobson V, Moseley MJ, Mayer DL. Preferential looking—clinical lessons. *Ophthalmic Paediatr Genet* 1992;13:101–110.

86. Teller DY, McDonald MA, Preston K, Sebris SL, Dobson V. Assessment of visual acuity in infants and children: the acuity card procedure. *Dev Med Child Neurol* 1986;28:779–789.
87. Makrides M, Simmer K, Goggin M, Gibson RA. Erythrocyte docosahexaenoic acid correlates the with visual response of healthy, term infants. *Pediatr Res* 1993;33:425–427.
88. Jørgensen MH, Hernell O, Lund P, Hølmer G, Michaelsen KF. Visual acuity and erythrocyte docosahexaenoic acid status in breast-fed and formula-fed term infants during the first four months of life. *Lipids* 1996;31:99–105.
89. Innis SM, Nelson CM, Rioux MF, King DJ. Development of visual acuity in relation to plasma and erythrocyte omega-6 and omega-3 fatty acids in healthy term gestation infants. *Am J Clin Nutr* 1994;60:347–352.
90. Innis SM, Nelson CM, Lwanga D, Rioux FM, Waslen P. Feeding formula without arachidonic acid and docosahexaenoic acid has no effect on preferential looking acuity or recognition memory in healthy full-term infants at 9 mo of age. *Am J Clin Nutr* 1996;64:40–46.
91. Innis SM, Akrabawi SS, Diersen-Schade DA, Dobson MV, Guy DG. Visual acuity and blood lipids in term infants fed human milk or formulae. *Lipids* 1997;32:63–72.
92. Bakker EC, van Houwelingen AC, Hornstra G. Early nutrition, essential fatty acid status and visual acuity of term infants at 7 months of age. *Eur J Clin Nutr* 1999;53:872–879.
93. Leaf A, Gosbell A, McKenzie L, Sinclair A, Favilla I. Long chain polyunsaturated fatty acids and visual function in preterm infants. *Early Hum Dev* 1996;45:35–53.
94. Makrides M, Neumann MA, Gibson RA. Perinatal characteristics may influence the outcome of visual acuity. *Lipids* 2001;36:897–900.
95. Gibson RA, Chen W, Makrides M. Randomized trials with polyunsaturated fatty acid interventions in preterm and term infants: functional and clinical outcomes. *Lipids* 2001;36:873–883.
96. Uauy RD, Birch DG, Birch EE, Tyson JE, Hoffman DR. Effect of dietary omega-3 fatty acids on retinal function of very-low-birth-weight neonates. *Pediatr Res* 1990;28:485–492.
97. Birch EE, Birch DG, Hoffman DR, Uauy R. Dietary essential fatty acid supply and visual acuity development. *Invest Ophthalmol Vis Sci* 1992;33:3242–3253.
98. Birch DG, Birch EE, Hoffman DR, Uauy RD. Retinal development in very-low-birth-weight infants fed diets differing in omega-3 fatty acids. *Invest Ophthalmol Vis Sci* 1992;33:2365–2376.
99. Birch E, Birch D, Hoffman D, Hale L, Everett M, Uauy R. Breast feeding and optimal visual development. *J Pediatr Ophthalmol Strabismus* 1993;30:33–38.
100. Uauy R, Hoffman DR, Birch EE, Birch DG, Jameson DM, Tyson J. Safety and efficacy of omega-3 fatty acids in the nutrition of very low birth weight infants: soy oil and marine oil supplementation of formula. *J Pediatr* 1994;124:612–620.
101. Carlson SE, Cooke RJ, Werkman SH, Tolley EA. First year growth of preterm infants fed standard compared to marine oil n-3 supplemented formula. *Lipids* 1992;27:901–907.
102. Carlson SE, Werkman SH, Rhodes PG, Tolley EA. Visual-acuity development in healthy preterm infants: effect of marine-oil supplementation. *Am J Clin Nutr* 1993;58:35–42.
103. Carlson SE, Werkman SH, Peeples JM, Wilson WM. Long-chain fatty acids and early visual and cognitive development of preterm infants. *Eur J Clin Nutr* 1994;48(suppl 2):S27–S30.
104. Werkman SH, Carlson SE. A randomized trial of visual attention of preterm infants fed docosahexaenoic acid until nine months. *Lipids* 1996;31:91–97.
105. Carlson SE, Werkman SH. A randomized trial of visual attention of preterm infants fed docosahexaenoic acid until two months. *Lipids* 1996;31:85–90.
106. Carlson SE, Werkman SH, Tolley EA. Effect of long-chain n-3 fatty acid supplementation on visual acuity and growth of preterm infants with and without bronchopulmonary dysplasia. *Am J Clin Nutr* 1996;63:687–697.
107. Faldella G, Govoni M, Alessandrini R, et al. Visual evoked potentials and dietary long chain polyunsaturated fatty acids in preterm infants. *Arch Dis Child* 1996;75:F108–F112.
108. Bouglé D, Denise P, Vimard F, Nouvelot A, Penneillo MJ, Guillois B. Early neurological and neuropsychological development of the preterm infant and polyunsaturated fatty acids supply. *Clin Neurophysiol* 1999;110:1363–1370.
109. Uauy R, Hoffman DR, Peirano P, Birch DG, Birch EE. Essential fatty acids in visual and brain development. *Lipids* 2001;36:885–895.

110. San Giovanni JP, Parra-Cabrera S, Colditz GA, Berkey CS, Dwyer JT. Meta-analysis of dietary essential fatty acids and long-chain polyunsaturated fatty acids as they relate to visual resolution acuity in healthy preterm infants. *Pediatrics* 2000;105:1292–1298.
111. Makrides M, Neumann M, Simmer K, Pater J, Gibson R. Are long-chain polyunsaturated fatty acids essential nutrients in infancy? *Lancet* 1995;345:1463–1468.
112. Carlson SE, Ford AJ, Werkman SH, Peeples JM, Koo WWK. Visual acuity and fatty acid status of term infants fed human milk and formulas with and without docosahexaenoate and arachidonate from egg yolk lecithin. *Pediatr Res* 1996;39:882–888.
113. Auestad N, Montalto MB, Hall RT, et al. Visual acuity, erythrocyte fatty acid composition, and growth in term infants fed formulas with long chain polyunsaturated fatty acids for one year. *Pediatr Res* 1997;41:1–10.
114. Agostoni C, Trojan S, Bellù R, Riva E, Giovannini M. Neurodevelopmental quotient of healthy term infants at 4 months and feeding practice: the role of long-chain polyunsaturated fatty acids. *Pediatr Res* 1995;38:262–266.
115. Agostoni C, Trojan S, Bellù R, Riva E, Bruzzese MG, Giovannini M. Developmental quotient at 24 months and fatty acid composition of diet in early infancy: a follow up study. *Arch Dis Child* 1997;76:421–424.
116. Jørgensen MH, Hølmer G, Lund P, Hernell O, Michaelsen KF. Effect of formula supplemented with docosahexaenoic acid and γ -linolenic acid on fatty acid status and visual acuity in term infants. *J Pediatr Gastroenterol Nutr* 1998;26:412–421.
117. Birch EE, Hoffman DR, Uauy R, Birch DG, Prestidge C. Visual acuity and the essentiality of docosahexaenoic acid and arachidonic acid in the diet of term infants. *Pediatr Res* 1998;44:201–209.
118. Willatts P, Forsyth JS, DiModugno MK, Varma S, Colvin M. Influence of long-chain polyunsaturated fatty acids on infant cognitive function. *Lipids* 1998;33:973–980.
119. Willatts P, Forsyth JS, DiModugno MK, Varma S, Colvin M. Effect of long-chain polyunsaturated fatty acids in infant formula on problem solving at 10 months of age. *Lancet* 1998;352:688–691.
120. Lucas A, Stafford M, Morley R, et al. Efficacy and safety of long-chain polyunsaturated fatty acid supplementation of infant-formula milk: a randomised trial. *Lancet* 1999;354:1948–1954.
121. Makrides M, Neumann MA, Simmer K, Gibson RA. Dietary long-chain polyunsaturated fatty acids do not influence growth of term infants: a randomized clinical trial. *Pediatrics* 1999;104:468–475.
122. Makrides M, Neumann MA, Simmer K, Gibson RA. A critical appraisal of the role of dietary long-chain polyunsaturated fatty acids on neural indices of term infants: a randomized, controlled trial. *Pediatrics* 2000;105:32–38.
123. Birch EE, Castañeda YS, Wheaton DH, Birch DG, Uauy RD, Hoffman DR. Visual maturation of term infants fed long-chain polyunsaturated fatty-acid supplemented or control formula for 12 mo. *Am J Clin Nutr* 2005;81:871–879.
124. Auestad N, Scott DT, Janowsky JS, et al. Visual, cognitive, and language assessments at 39 months: a follow-up study of children fed formulas containing long-chain polyunsaturated fatty acids to 1 year of age. *Pediatrics* 2003;112:e177–e183.
125. San Giovanni JP, Berkey CS, Dwyer JT, Colditz GA. Dietary essential fatty acids, long-chain polyunsaturated fatty acids, and visual resolution acuity in health fullterm infants: a systematic review. *Early Hum Dev* 2000;57:165–188.
126. Uauy R, Hoffman DR, Mena P, Llanos A, Birch EE. Term infants studies of DHA and AA supplementation on neurodevelopment: results of randomized controlled trials. *J Pediatr* 2003;143:S17–S25.
127. Morley R. Nutrition and cognitive development. *Nutrition* 1998;14:752–754.
128. Gore SM. Statistical considerations in infant nutrition trials. *Lipids* 1999;34:185–197.

12

Inborn Errors of Metabolism

1. INTRODUCTION

Nutritional modification or dietary supplementation can be used as a therapeutic approach for some eye diseases that are due to inborn errors of metabolism. This chapter includes abetalipoproteinemia (Bassen-Kornzweig syndrome), gyrate atrophy, Refsum disease, galactosemia, oculocutaneous tyrosinemia (tyrosinemia type II, Richner-Hanhart syndrome), X-linked adrenoleukodystrophy, homocystinuria (cystathionine β -synthetase deficiency), and Wilson disease. Other inborn errors of metabolism that are relevant to ophthalmology and nutrition have been presented elsewhere in this book, including cystic fibrosis (Chapter 1), Leigh syndrome (Chapter 7), and acrodermatitis enteropathica (Chapter 8). Vitamin A supplementation has been reported to modify the clinical response of two conditions, Sorsby fundus dystrophy and retinitis pigmentosa, and these two disorders are included in this chapter.

2. ABETALIPOPROTEINEMIA (BASSEN-KORNZWEIG SYNDROME)

2.1. *Historical Background*

In 1950, Frank Bassen (b. 1903) and Abraham Kornzweig (b. 1900) described an 18-yr-old Jewish girl, born to first cousins, who had an atypical retinitis pigmentosa, a history of chronic diarrhea, diffuse involvement of the neurological system that resembled Friedrich ataxia, and bizarre, crenated erythrocytes (1). Her younger brother also had the same hematological findings and the beginnings of a pigmentary retinopathy, thus providing further evidence for a hereditary basis to the syndrome. Two years later, Karl Singer and colleagues described a 13-yr-old Jewish boy, born to second cousins, with ataxia, diarrhea, and crenated erythrocytes, which the authors termed “acanthrocytosis” (Greek, *akantha* = thorn). There was no evidence of pigmentary retinopathy found. A puzzling feature of the syndrome in the reported cases was “celiac disease” that started early in life and was associated with malodorous, fatty stools (2). 19 yr of age, the same individual had developed a pigmentary retinopathy and an extremely low serum cholesterol concentration, suggesting that “the entire syndrome is basically an inborn error of fat metabolism...” (3). The syndrome was also described among individuals whose parents were unrelated (4,5). In 1960, H. B. Salt and colleagues described the absence of β -lipoprotein in a young girl with steatorrhea and crenated erythrocytes. They termed the syndrome “ α - β -lipoproteinaemia” and concluded that it was an inborn error of metabolism with an autosomal recessive mode of inheritance (5). The original term “acanthrocytosis” was later replaced by acanthocytosis in the literature (5).

From: *Nutrition and Health: Handbook of Nutrition and Ophthalmology*

By: R. D. Semba © Humana Press Inc., Totowa, NJ




Fig. 1. Montage of photographs of a right eye (above) and left eye (below) of a patient with abetalipoproteinemia. Note clumping of pigment and bone spicules. (From ref. 7, with permission from Elsevier Science.)

2.2. Clinical Features

Abetalipoproteinemia is characterized early in infancy by fat malabsorption and growth failure. In the second decade, neurological abnormalities begin to appear and include the loss of deep tendon reflexes, loss of vibratory sense in the lower extremities, loss of proprioception, progressive ataxia, and spastic gait. Neuropathological findings include spinocerebellar degeneration. In the first decade, visual acuity and visual fields may be normal, but impaired dark adaptation may be present (6). A pigmentary retinopathy usually appears in the second decade with gradual onset of night blindness, reduced color vision, and blindness occurs by the fifth decade. The fundus appearance is characterized by pigmentary abnormalities and bone spicules (Fig. 1) (7). There have been many case reports in the last four decades (8–17). Angioid streaks have been described in abetalipoproteinemia (18,19). The ocular histopathology of abetalipoproteinemia is consistent with that of advanced retinitis pigmentosa and includes loss of photoreceptors, invasion of

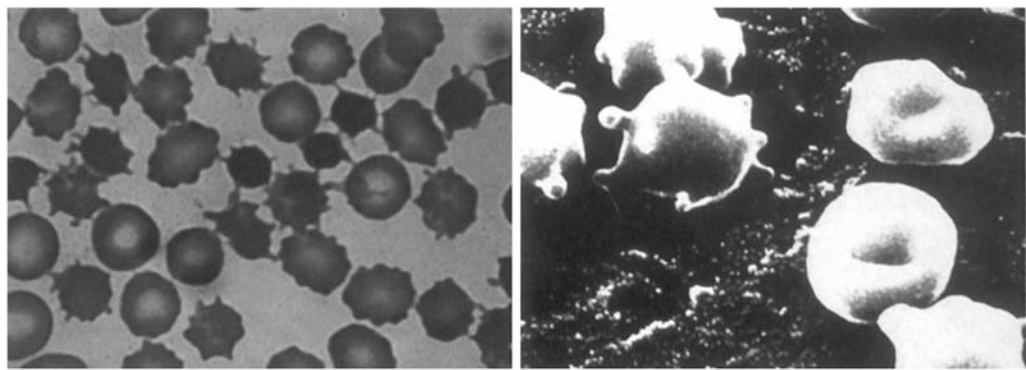


Fig. 2. Blood smear (left) and scanning electron micrograph (right) of red blood cells from a patient with abetalipoproteinemia, demonstrating the typical crenated appearance of acanthocytes. (Reprinted from ref. 22. Copyright © 1993, American Medical Association. All rights reserved.)

Table 1
Clinical and Laboratory Findings in Abetalipoproteinemia

<ul style="list-style-type: none">• Fat malabsorption• Failure to thrive• Loss of deep tendon reflexes• Loss of vibratory sense in lower extremities• Ataxia• Spastic gait• Night blindness• Dyschromatopsia• Pigmentary retinopathy• Anemia with acanthocytes• Abnormal lipid profile
--

pigmented cells into the neuroretina (20,21). Patients with abetalipoproteinemia usually have a mild to moderate anemia with acanthocytes (Fig. 2) (22). Iron deficiency and/or folate deficiency may also occur due to malabsorption (22), and malabsorption of vitamin K may cause an elevated prothrombin time (23). The clinical and laboratory findings of abetalipoproteinemia are summarized in Table 1.

2.3. Metabolic Aspects

Abetalipoproteinemia, a recessive disorder due to mutations of the microsomal triglyceride transfer protein gene, is characterized by an abnormal lipid profile, with total plasma cholesterol concentrations of 0.50–1.30 mmol/L (20–50 mg/dL) and low triglycerides (22). There may be undetectable levels of very low-density lipoproteins (VLDLs), low-density lipoproteins (LDLs), and apolipoprotein B. The fundamental metabolic defect in abetalipoproteinemia is a lack of apolipoprotein B, an essential component of chylomicrons, VLDLs, and LDLs. Although it was originally thought that the defect was in the apolipoprotein B gene itself (22), further studies showed that there was no structural defect in the apolipoprotein B gene (24–26) but rather a defect of the gene encoding the microsomal triglyceride transfer protein (27–30). Microsomal triglyceride transfer protein forms a

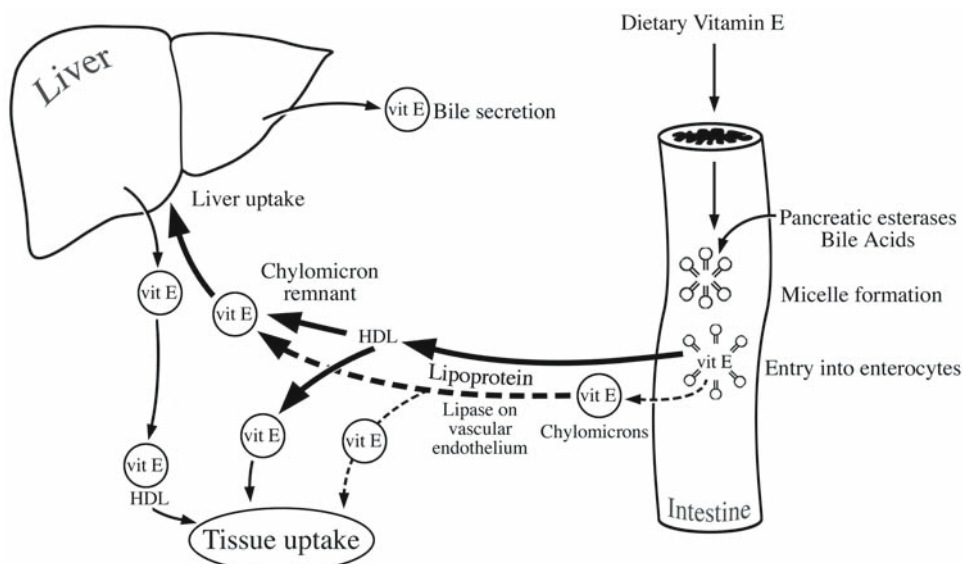


Fig. 3. Vitamin E metabolism in abetalipoproteinemia, showing sites of defective synthesis of microsomal triglyceride transfer protein. (Illustration by Frank Corl.)

heterodimer with protein disulfide isomerase and functions in the loading of apolipoprotein B with lipid (31). In the absence of sufficient lipid, apolipoprotein B is rapidly degraded before secretion (32,33). The gene for microsomal triglyceride transfer protein has been localized to chromosome 4q22-24 (31). A mutation in the α -tocopherol transfer protein gene also causes a syndrome similar to abetalipoproteinemia with progressive ataxia and retinitis pigmentosa (34,35). To summarize, a defect in the production of microsomal triglyceride transfer protein results in the impaired ability to package fat-soluble vitamins A, E, and K, into chylomicrons for transport from the intestine to the liver (Fig. 3). The incorporation of vitamin E into VLDLs by the liver is impaired by the absence of microsomal triglyceride transfer protein, and the overall consequences are extremely low concentrations of chylomicrons, VLDLs, LDLs, and vitamins E, A and K (Fig. 3). The role of microsomal triglyceride transfer protein in abetalipoproteinemia has been reviewed in detail elsewhere (36).

2.4. Nutritional Approaches to the Treatment of Abetalipoproteinemia

In 1961, Angelo DiGeorge and colleagues demonstrated that provision of intravenous lipids in the form of a cottonseed oil emulsion, a rich source of vitamin E, could reverse the acanthocytosis in a patient with abetalipoproteinemia (32). Subsequent studies showed that the abnormalities of the electroretinogram could be reversed in part by high-dose oral vitamin A supplementation (38,39). An 11-yr-old girl with abetalipoproteinemia was treated for 2.5 yr with parenteral vitamins A and E plus medium chain triglycerides, and improvement in both neurological and visual deficits was noted (40). Oral supplementation with vitamins A and E appeared to halt any deterioration of visual function in eight patients with abetalipoproteinemia (41), improved scotopic electroretinogram findings in one patient (42), and delayed the progression of neurological and retinal lesions in others

(43,44). Long-term supplementation with massive oral doses of vitamin E for 12–18 yr with dietary modification appeared to prevent retinopathy in six patients with abetalipoproteinemia (45). Patients with abetalipoproteinemia should avoid dietary fat, especially long-chain saturated fatty acids, in order to reduce steatorrhea, and should take fat-soluble vitamins. Oral supplementation with vitamin E, 150–200 mg/kg per day and vitamin A, 25,000 IU per day or every other day, are recommended for patients (22). Monitoring of vitamin E status is difficult because plasma vitamin E concentrations cannot be used to monitor therapy, and alternatively, the measurement of vitamin E in adipose tissue has been employed (46). Long-term follow-up of 10 patients with abetalipoproteinemia and three patients with homozygous hypobetalipoproteinemia showed that despite vitamin A and E treatment, fundus changes and functional retinal changes can occur (47). Patients with abetalipoproteinemia who receive long-term supplementation with vitamins A and E do not seem to have enhanced oxidative stress (48).

2.5. *Familial Hypobetalipoproteinemia*

Familial hypobetalipoproteinemia, a related defect in the assembly and secretion of apo B-containing lipoproteins in the liver and/or intestine, is a mildly symptomatic genetically heterogeneous autosomal trait characterized by plasma total cholesterol, LDL-cholesterol, and apolipoprotein B levels below the fifth percentile (49). Most people with familial hypobetalipoproteinemia are simple heterozygotes who are asymptomatic, and a large proportion of patients may develop nonalcoholic fatty livers. Malabsorption and mild diarrhea may occur in some patients (49). Familial hypobetalipoproteinemia is due to a truncation-specifying mutation of the APOB gene on chromosome 2, or linkage to chromosome 3 (3p21), or absent linkage to both APOB and to 3p21 (49). “*De novo*” mutations of apolipoprotein B (50) and mutations in the microsomal triglyceride transfer protein have also been described in familial hypobetalipoproteinemia (51). Progressive retinal degeneration can occur in homozygous familial hypobetalipoproteinemia as with abetalipoproteinemia (47). A 51-yr-old white woman with familial heterozygous hypobetalipoproteinemia presented with night blindness and bilateral symmetric depigmentation of the posterior pole (52). Pigment clumping and pavingstone degeneration were present in the retinal periphery. By 75 yr of age, at which time the patient died, the vision had declined to hand motions. Ocular pathology revealed loss of photoreceptors and massive deposition of a basal linear deposit containing macrophages and processes of glial cells, with calcification in some segments (52). Familial hypobetalipoproteinemia is also treated with oral supplementation of vitamin A and vitamin E (47).

3. GYRATE ATROPHY

3.1. *Clinical Features*

Gyrate atrophy is a progressive chorioretinal dystrophy that is inherited as an autosomal recessive trait. The disease is characterized by an underlying defect in a pyridoxal phosphate (PLP)- or vitamin B₆-dependent mitochondrial matrix enzyme, ornithine- δ -aminotransferase. Gyrate atrophy presents in childhood with myopia, and by age 10 yr, there is usually impaired peripheral vision and night blindness. Subcapsular cataracts occur in the second decade, and patients often require cataract extraction. The degree of myopia

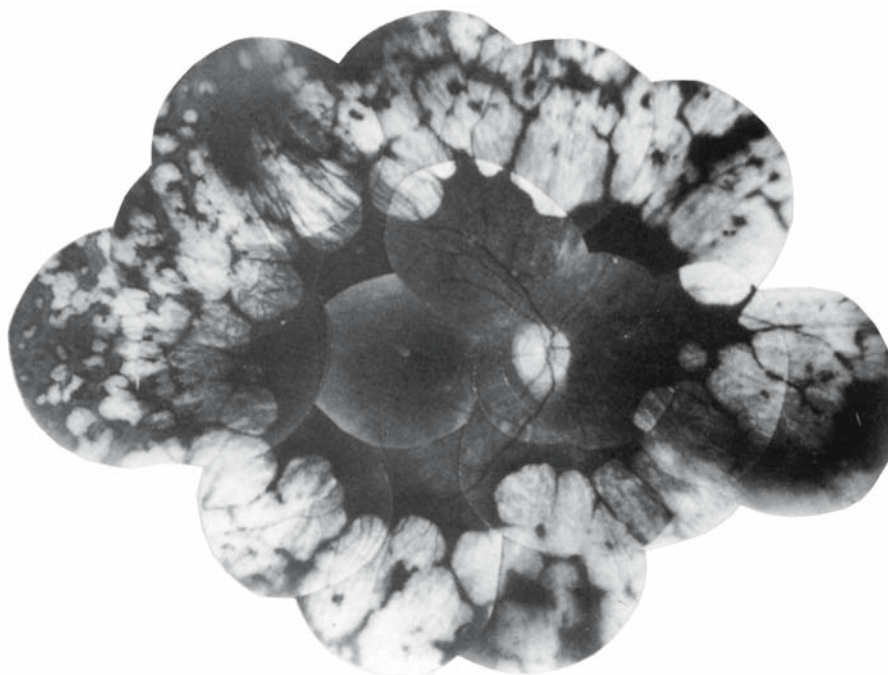


Fig. 4. Fundus appearance in gyrate atrophy. (Reprinted from ref. 57, with permission of Elsevier.)

Table 2

Clinical and Laboratory Findings in Gyrate Atrophy

-
- Progressive myopia
 - Reduced peripheral vision
 - Night blindness
 - Chorioretinal atrophy
 - Other: straight sparse hair, general muscle weakness
 - Elevated plasma ornithine
-

may reach the range of 5–10 diopters. Sharply demarcated areas of chorioretinal atrophy are located initially in the midperiphery of the retina (Fig. 4), and in advanced disease, the areas of chorioretinal atrophy coalesce and encroach on the posterior pole (53). Loss of vision occurs slowly, with blindness occurring in the fourth and fifth decade (53). The ocular histopathology of gyrate atrophy has been described (54). Patients with gyrate atrophy are usually asymptomatic except for ocular problems, and systemic manifestations include fine, straight, and sparse hair and general muscle weakness (55). Recently, degenerative lesions in the white matter have been observed by magnetic resonance imaging in patients with gyrate atrophy (56). The clinical and laboratory findings in gyrate atrophy are summarized in Table 2.

3.2. Metabolic Aspects

Ornithine- δ -aminotransferase is involved in the introconversion of ornithine to pyrroline-5-carboxylate (Fig. 5), and a defect in ornithine- δ -aminotransferase leads to a 10-

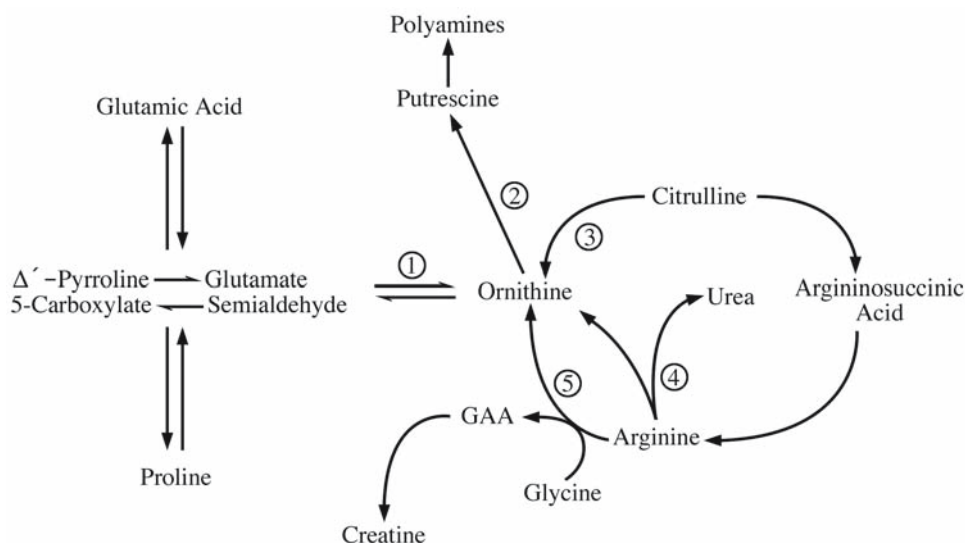


Fig. 5. Pathways of ornithine metabolism.

to 15-fold increase in ornithine in body fluids. Small reductions in plasma glutamate, glutamine, lysine, and creatinine also occur in gyrate atrophy. Ornithine is formed in the body from arginine in the urea cycle. Patients with gyrate atrophy have a great variability in the severity of the disease and their therapeutic response to pyridoxine (vitamin B₆), and this variability is likely related to the amount of residual ornithine- δ -aminotransferase that may be present. Elevated plasma ornithine concentrations were noted in gyrate atrophy patients in 1973 (57) and associated with a defect in ornithine- δ -aminotransferase in 1988 (58). The ornithine- δ -aminotransferase has been cloned and is located on chromosome 10q26. More than 60 different mutations have been identified at the ornithine- δ -aminotransferase locus. Gyrate atrophy has been described worldwide, and some ornithine- δ -aminotransferase gene mutations appear to be unique to certain racial or ethnic groups (59). The V332M mutation (60,61), A226V mutation (62), and E318K mutation (63) have been identified as pyridoxine-responsive. Patients who are responsive to pyridoxine generally have a more slowly progressive disease.

3.3. Experimental Animal Studies

In experimental animal studies, intravitreal injections of L-ornithine in the eyes of rats, rhesus monkeys, and cynomolgus monkeys resulted in degeneration of retinal pigment epithelium and secondary degeneration of adjacent photoreceptor cells (64). No changes were noted after similar intravitreal injections of arginine. An ornithine- δ -aminotransferase-deficient mouse model has been developed by gene targeting (65). Mice in this model develop hyperornithinaemia and a slowly progressive retinal degeneration, with the primary insult appearing the retinal pigment epithelium (66). Restriction of dietary arginine has been shown to reduce ornithine accumulation and completely prevent the retinal degeneration in this mouse model (67). Electron micrographs of the retina from ornithine- δ -aminotransferase-deficient mice on an arginine-restricted diet and standard diet are shown in Fig. 6 (67).

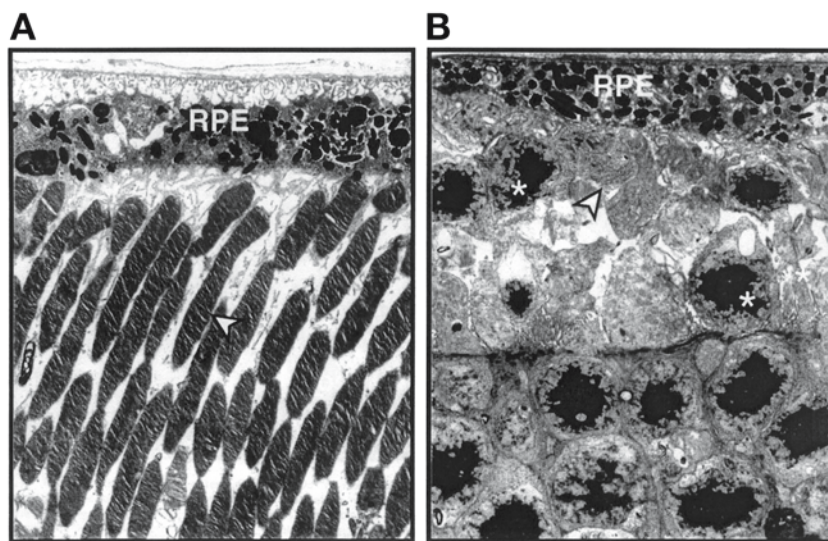


Fig. 6. Electron micrographs of the retinas from ornithine- δ -aminotransferase-deficient mice on an arginine-restricted diet (left) and standard diet (right). (Reprinted from ref. 67. Copyright © 2000, National Academy of Sciences, USA.)

3.4. Nutritional Approaches to the Treatment of Gyrate Atrophy

Two types of nutritional modification may have some therapeutic effect for gyrate atrophy: (1) arginine restriction, and (2) supplementation with vitamin B₆. Given that gyrate atrophy is a rare, slowly progressive disease, the studies evaluating these therapies consist of case studies of treated patients rather than controlled clinical trials (Table 3) (68–75). In order to restrict arginine intake, patients must reduce natural protein intake and take a powdered form of essential amino acids and supplementary vitamins and minerals (76). Arginine restriction can result in large decreases in plasma ornithine (69), but many patients may find it difficult to adhere strictly to this diet. In one case, a woman on an arginine-restricted diet showed some objective improvement in visual measures (70). Studies of sibling pairs suggest that long-term reduction of ornithine may slow the retinal degeneration of gyrate atrophy (71). In a long-term observational study of 27 patients with gyrate atrophy, of whom 17 elected to comply with an arginine-restricted diet and ten were unable to comply, those who adhered to an arginine-restricted diet had slower progression of visual function, as measured by sequential electroretinography and visual field examinations (77).

A small proportion of patients with gyrate atrophy will respond to vitamin B₆ treatment with reductions in plasma ornithine (75,78). Pyridoxal phosphate is the active form of vitamin B₆ and a co-factor for ornithine- δ -aminotransferase. Pyridoxine responders are likely to have ornithine- δ -aminotransferase alleles that have mutations affecting the vitamin B₆ binding site of the enzyme (67). Typical doses of pyridoxine that have been used for adults in these studies are 500–750 mg/d (77). In comparison, the Recommended Dietary Allowance for vitamin B₆ for adult men and women is 1.7 mg/d and 1.5 mg/d, respectively (79). Other attempts to slow the progress of gyrate atrophy with creatinine, lysine, or proline supplementation have suggested a possible slowing of eye disease (68,80–82), but the small numbers of treated patients and lack of controls make it difficult to make

Table 3
Evaluation of Nutritional Interventions for Gyrate Atrophy

<i>Characteristics of patients</i>	<i>Observations</i>	<i>Reference</i>
Creatinine Supplementation		
7 patients	Supplementation for 1 yr; some progression of chorioretinal disease in 3 patients, slight progression in 1 patient	68
Arginine Restriction		
7 females, 2 males, aged 11–46 yr	Mean threefold reduction in plasma ornithine; 4 patients could not continue to follow strict diet; length of follow-up ranged from 4–32 mo; 2 women (ages 37 and 46) had longer follow-up (1 patient had improvement in dark adaptation and visual fields and the other had no change)	69 70
6 pairs of affected siblings	5- to 7-yr reduction of plasma ornithine was associated with slower progression of ocular disease in treated vs untreated sibling comparisons	71
Pyridoxine Supplementation With Low-Protein, Low-Arginine Diet		
5 patients, aged 12–30 yr	Reduction in plasma ornithine of 60% or more within 4–8 wk; 4 of 5 patients showed no improvement in visual acuity, visual fields, dark adaptation, or fundus appearance; the patient with poorest control of plasma ornithine showed progression; none of patients could strictly adhere to restricted diet at home	72
Pyridoxine Supplementation		
7 patients	3 responded to supplementation with >50% reduction in serum ornithine and rise on serum lysine to normal; electroretinogram improved in 1 patient	73 74
Proline Supplementation		
4 patients	Progression of disease in 2 patients; no change in chorioretinal disease in 2 patients; supplementation from 2–5 yr	75

definitive conclusions about these therapies. Lysine supplementation has recently been shown to reduce plasma ornithine concentrations by 21–31% with 1–2 d in pyridoxine unresponsive patients with gyrate atrophy, but the ocular consequences are not clear (83).

4. REFSUM DISEASE

4.1. Clinical Features

In 1946, Sigvald Refsum (1907–1991) described a syndrome characterized by retinitis pigmentosa, chronic polyneuropathy, cerebellar ataxia, and an increase in protein concentrations in the cerebrospinal fluid without an accompanying pleocytosis, and he termed the condition “heredopathia atactica polyneuritiformis” (84). Anosmia, neurogenic impairment of hearing, and cardiomyopathy are usually present, and pupillary abnormalities, lens opacities, skeletal malformations, and skin changes resembling ichthyosis have sometimes been described (85). An accumulation of phytanic acid (3,7,11,15-tetramethyl-

Table 4
Clinical and Laboratory Findings in Refsum Disease

-
- Retinitis pigmentosa
 - Peripheral neuropathy (motor and sensory)
 - Cerebellar findings
 - Cardiac abnormalities
 - Symptoms of cranial nerve involvement
 - Neurogenic hearing loss
 - Anosmia
 - Abnormal pupillary reflex
 - Miosis
 - Skeletal abnormalities
 - Skin changes—ichthyosis
 - Increased cerebrospinal fluid protein without pleocytosis
 - Elevated plasma phytanic acid concentration
-

Reproduced from ref. 97, with permission of The McGraw-Hill Companies.

hexadecanoic acid) was noted in 1963 (86), and patients with the disease were shown to have a defect in the α -oxidation mechanism of β -methyl-substituted fatty acids (87,88). The onset of disease is variable and can occur in the first through third decades. The pigmentary retinopathy in Refsum disease is characterized by fine granular pigmentation, and the bone spicule type of pigmentation is less frequent (89). In advanced disease, waxy-appearing optic discs and attenuated vessels are often present. The ocular pathology of Refsum disease has been described (90). An infantile form of Refsum disease was described in 1982 (91) and is characterized by the appearance during the first year of life by a pigmentary retinopathy, nystagmus, deafness, hypotonia, hepatosplenomegaly, growth retardation, mental retardation, and dysmorphic facial features such as epicanthal folds, a flat nasal bridge, and low-set ears (91,92).

The term “classical Refsum disease” has been applied to patients who have elevated phytanic acid due to a defect in the α -oxidation of phytanic acid and to distinguish them from infantile Refsum disease, in which phytanic acid oxidation is abnormal due to an absence of peroxisomes. Refsum disease is an autosomal recessive disorder (93,94), and heterozygotes usually have normal plasma phytanic acid concentrations and no neurological signs or symptoms. The diagnosis of Refsum disease should be considered in patients who present with retinitis pigmentosa, as it has been suggested that perhaps 1 of 20 patients may have Refsum disease (95). Adult Refsum disease is usually diagnosed by measurement of phytanic acid levels in patients with retinitis pigmentosa and associated polyneuropathy or short metacarpals (96). Smell testing has been advocated as an additional tool for diagnosis of adult Refsum disease (96). The clinical and laboratory findings in Refsum disease are summarized in Table 4 (97). A case of mild pigmentary retinopathy has been described in a patient with Refsum disease who did not present until he was 47 yr old (98).

4.2. Metabolic Aspects

Phytanic acid is a dietary-derived isoprenoid fatty acid that is found in high concentrations in foods such as lamb, beef, liver, canned tuna packed in oil, ham, and dairy

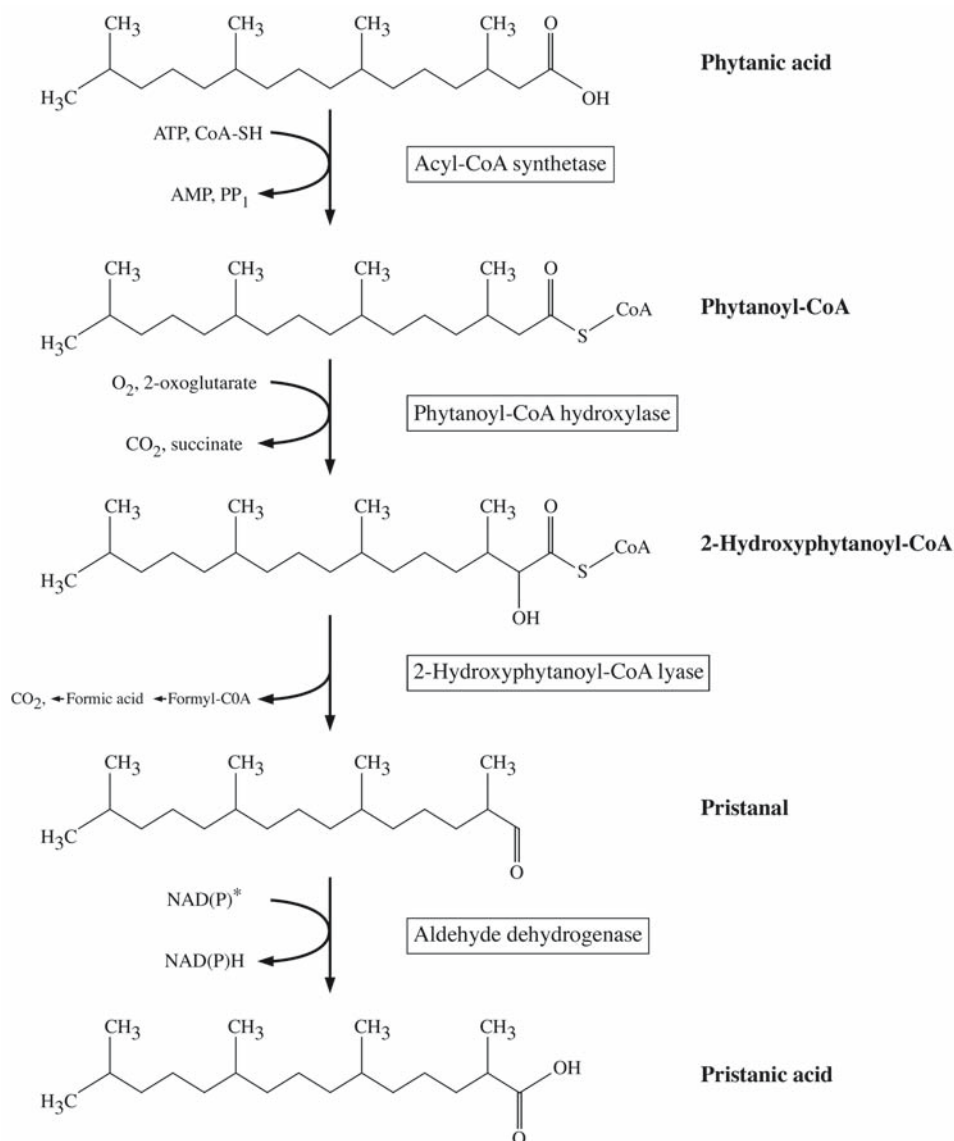


Fig. 7. The α -oxidation pathway of phytanic acid. Refsum disease is caused by a defect in phytanoyl-CoA hydroxylase.

products (99). In classical Refsum disease, the plasma concentrations of phytanic acid are elevated. Patients with Refsum disease have a mutation in the gene that encodes phytanoyl-CoA 2-hydroxylase, a peroxisomal enzyme that allows α -oxidation of phytanic acid to 2-hydroxyphytanoyl-CoA (100–102). 2-hydroxyphytanoyl-CoA is then converted to pristanic acid (103,104) (Fig. 7). Refsum disease can also be caused by mutations in the gene for the peroxisomal targeting signal (PTS)2 gene (105). Histopathological studies have shown that the concentrations of phytanic acid are extremely high in the retina, exceeded only by the concentrations found in the liver and heart (106).

4.3. Nutritional Approaches to the Treatment of Refsum Disease

Dietary treatment for Refsum disease was first attempted when Eldjarn and colleagues showed that a negative phytanic acid balance could be achieved by a diet low in phytanic acid (107). Refsum initiated similar treatment in two affected patients, with a dietary regimen that included removal of butter fat, all visible fat from meat, and avoidance of fruit and vegetables, and these patients had a pronounced reduction in serum phytanic acid concentrations to the normal range (85). Two patients with Refsum disease who were placed on a diet that was low in phytanic acid and phytol showed a slow drop in phytanic acid concentrations in blood and adipose tissue and improvements in ulnar nerve conduction, and an improvement of pain, touch, and proprioception (108). Green vegetables contain phytols and were originally excluded from the diet for patients with Refsum disease. The phytol in green vegetables is largely unabsorbed, and exclusion of green vegetables is now considered unnecessary (97). Available evidence suggests that progression of eye disease and neurological problems can be slowed or halted by dietary treatment (97). The normal Western diet contains about 50 mg of phytanic acid, and the goal of dietary therapy is to reduce the phytanic acid content of the diet to less than 10 mg per day, as described by Masters-Thomas and colleagues (99,109). A combination of plasmapheresis and diet has been used to minimize plasma phytanic acid concentrations (110–112).

5. GALACTOSEMIA

5.1. Clinical Features

In 1908, August Ritter von Reuss (1841–1924) described a breast-fed infant with growth failure and galactose in the urine (113). The infant was given substitutes for milk, and the galactosuria resolved, but the infant died after 3 wk in the hospital. Friedrich Göppert (1870–1927), a professor of pediatrics at Göttingen, reduced the dietary milk and sugar content of a 2-yr-old child with galactosuria, and noted an improvement in the galactosuria (114). Galactosemia was considered to be due to an abnormality in galactose metabolism (115), and cataracts were described in an affected infant (116). Cataracts are the main clinical feature of galactosemia, and they are usually found in the first weeks of life. Severe diarrhea, abdominal distention, vomiting, and failure to thrive are usually present. Galactosemia is a general term for genetic disorders of galactosemia that can be due to inherited defects in three enzymes, and the most common defect is due to a deficiency in galactose-1-phosphate uridylyltransferase, resulting in classical galactosemia. The clinical and laboratory findings in classical galactosemia are shown in Table 5. The second most common defect is in galactokinase, and cataracts are usually present (117–122). Pseudotumor cerebri has also been described in galactokinase deficiency (123–124). Most patients with the third enzyme deficiency, uridine diphosphate galactose 4'-epimerase, are asymptomatic, and this defect is rare. The cataracts that occur in galactosemia may be due to the conversion of accumulated galactose to galactitol via the aldose reductase pathway with resulting increased osmolarity in the crystalline lens (125). Vitreous hemorrhage has been described in infants with untreated galactosemia (126).

5.2. Metabolic Aspects

Galactose is a carbohydrate that is found in milk and milk products in the form of the disaccharide lactose. During digestion, lactose is hydrolyzed by lactase in the brush border

Table 5
Clinical and Laboratory Findings of Classical Galactosemia

-
- Cataracts
 - Vomiting, diarrhea
 - Full fontanelle
 - Lethargy, hypotonia
 - Failure to thrive
 - Jaundice, hepatomegaly
 - Bleeding or excessive bruising
 - Metabolic acidosis
 - Gonadal dysfunction
 - Abnormal Beutler test
 - Abnormal liver function tests
-

The clinical findings in galactokinase deficiency are similar except that liver and kidney abnormalities are not present.

of the intestine to glucose and galactose. Galactose is a major energy source for infants, and to utilize this energy, galactose must be metabolized to glucose. There are three major enzymes involved in the metabolism of galactose: (1) galactokinase, (2) galactose-1-phosphate uridylyltransferase, and (3) uridine diphosphate galactose 4'-epimerase. Galactosemia can result from a deficiency in any of these three enzymes. The main metabolic pathway for galactose metabolism is shown in Fig. 8. Galactokinase activity is highest in the liver and in erythrocytes. Galactokinase phosphorylates galactose to galactose-1-phosphate. The gene for galactokinase has been mapped to chromosome 17p24 (127). Galactose-1-phosphate is catalyzed to glucose-1-phosphate by galactose-1-phosphate uridylyltransferase in a step that involves reaction with UDP-glucose. The gene for galactose-1-phosphate uridylyltransferase has been mapped to chromosome 9p13 (128). UDP-galactose is converted back to UDP-glucose by uridine diphosphate galactose 4'-epimerase (Fig. 8). The gene for uridine diphosphate galactose 4'-epimerase has been mapped to chromosome 1p36 (129). The relative frequencies of mutations for galactokinase, galactose-1-phosphate uridylyltransferase, and uridine diphosphate galactose 4'-epimerase in different populations are presented in great detail elsewhere (130).

Screening for galactosemia can be conducted using a fluorescent spot test (Beutler test) (131), and screening is provided in many countries as part of routine care. In the Republic of Ireland, screening for galactosemia was conducted on 1.2 million infants from 1972 to 1992, and 55 cases of classical galactosemia were detected, giving an estimated frequency of classical galactosemia of 1:23,000 (132). In the United States, most hospital nurseries provide screening for galactosemia (133). Screening may result in earlier diagnosis of galactosemia (134).

5.3. Nutritional Approaches to the Treatment of Galactosemia

The nutritional approach to galactosemia is the discontinuation of breast milk and milk-based formulas. Guidelines for the initial and long-term management of patients with galactosemia have been published elsewhere (135). Milk substitutes that are considered suitable for infants with galactosemia include soy-based formulas such as Isomil®, Pro-

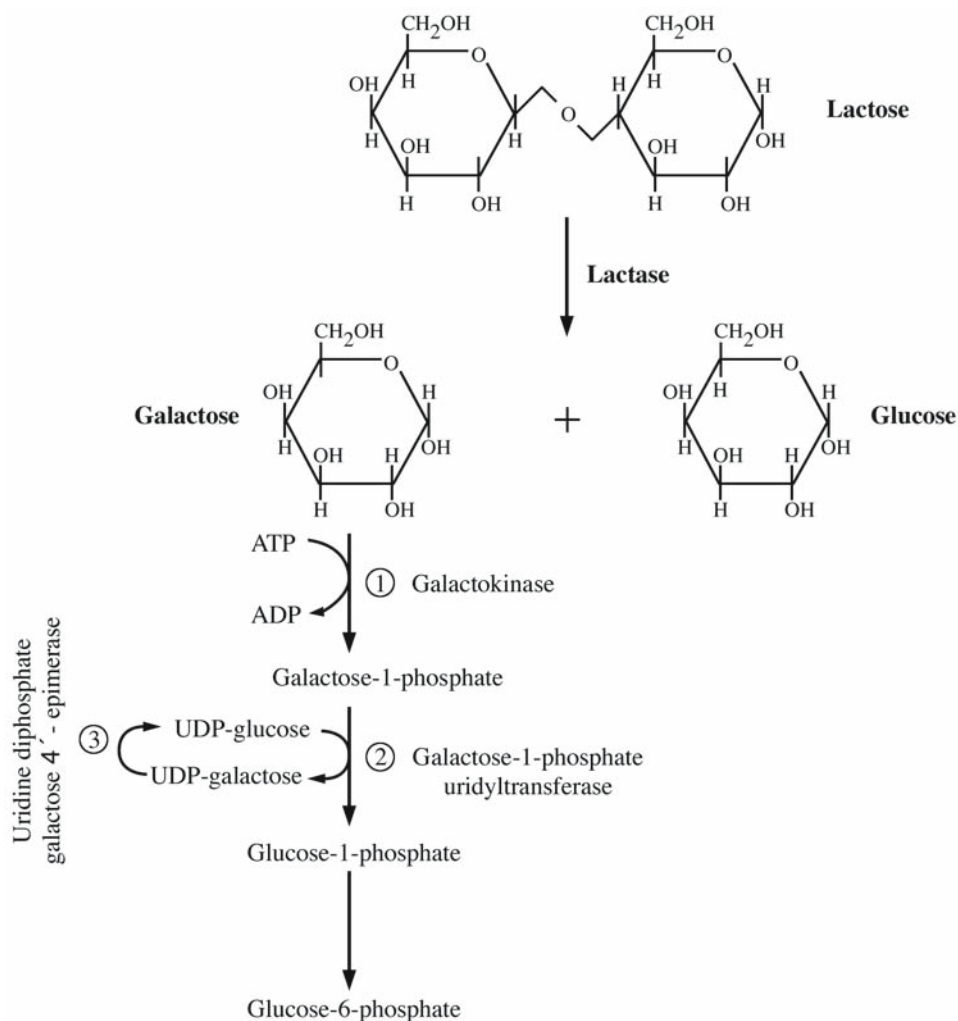


Fig. 8. Metabolism of galactose. Sites of possible enzyme deficiencies are indicated by (*).

sobee®, or Pregestemil®, or Nutramigen® (133,135). Patients must refrain from milk and dairy products throughout life. Galactose is present in small amounts in some fruits, vegetables, and legumes (136), but these appear to be insignificant and not restricted according to current recommendations (135). The cataracts and other systemic abnormalities rapidly respond to dietary restriction of galactose. Slit lamp examinations are recommended for infants at the time of diagnosis and then every 6 mo until 3 yr of age, and then annually. Slit lamp examinations may be helpful in monitoring dietary adherence (125). Dietary restriction does not appear to prevent all the complications of galactosemia, as developmental delays, speech abnormalities, and gonadal failure in women (137,138). Some infants may continue to have elevated erythrocyte galactose 1-phosphate levels despite treatment with a low-galactose (soy) formula, and galactose-free, elemental formula may be needed to decrease erythrocyte galactose 1-phosphate levels to the treatment range (139).

Table 6

Clinical and Laboratory Findings in Oculocutaneous Tyrosinemia

-
- Photophobia, redness, eye pain, lacrimation
 - Dendritiform keratitis
 - Corneal erosions
 - Intraepithelial and deep corneal ulceration
 - Painful hyperkeratotic and erosive lesions of palms and fingertips, plantar surface of feet; sometimes elbows and knees
 - Variable degree of mental retardation
 - Elevated plasma tyrosine concentrations
-

6. OCULOCUTANEOUS TYROSINEMIA

(TYROSINEMIA TYPE II, RICHNER-HANHART SYNDROME)

6.1. Clinical Features

A syndrome consisting of hyperkeratotic lesions of the hands and feet, dendritic corneal lesions, and mental retardation was described by Hermann Richner in 1938 and Ernst Hanhart (1891–1973) in 1947 (140,141). Earlier reports of a similar syndrome were made in the 1920s (142,143). This autosomal recessive disorder is extremely rare and has been described in case reports (144–156). Although the syndrome has been described among many different groups, it appears to be more common among individuals of Italian descent (157). Affected individuals are often born to consanguineous parents, and cutaneous lesions usually appear in the first year of life. Hyperkeratosis occurs on the palmar and plantar surfaces and fingertips, and morphologically the skin appears thickened with fissures, and there may be considerable pain with pressure, as in walking. Some patients may be so severely affected that they have great difficulty ambulating.

The ocular manifestations consist of photophobia, redness, lacrimation, and dendritiform corneal lesions, and these signs and symptoms may appear as early as the first month of life but usually occur within the first decade. The dendritiform lesions sometimes resemble herpetic keratitis, and patients may be treated with antiviral medications before the correct diagnosis is made. The keratitis appears to be due to the crystallization of tyrosine in the cornea, as suggested by experimental animal models (158). The affected human cornea shows vacuolar degeneration with inclusion bodies within the vacuoles and degeneration of collagen fibers (152). The characteristic clinical and laboratory findings of oculocutaneous tyrosinemia are summarized in Table 6. Decreased visual acuity may result from corneal opacities and scarring, and recurrence of corneal deposits in a graft has been described after lamellar keratoplasty in a patient not on dietary therapy (159).

6.2. Metabolic Aspects

The hallmark of oculocutaneous tyrosinemia is the presence of elevated tyrosine concentrations in the blood and urine (160,161) due to an inborn error of metabolism involving a defect in tyrosine aminotransferase, the enzyme that converts tyrosine to *p*-hydroxyphenylpyruvate (162,163). Urinary metabolites of tyrosine, 4-hydroxyphenyllactic acid, 4-hydroxyphenylacetic acid, *N*-acetyltyrosine, and 4-tyramine, are also elevated. Tyrosine is available from exogenous dietary sources and from the metabolism of phenyl-

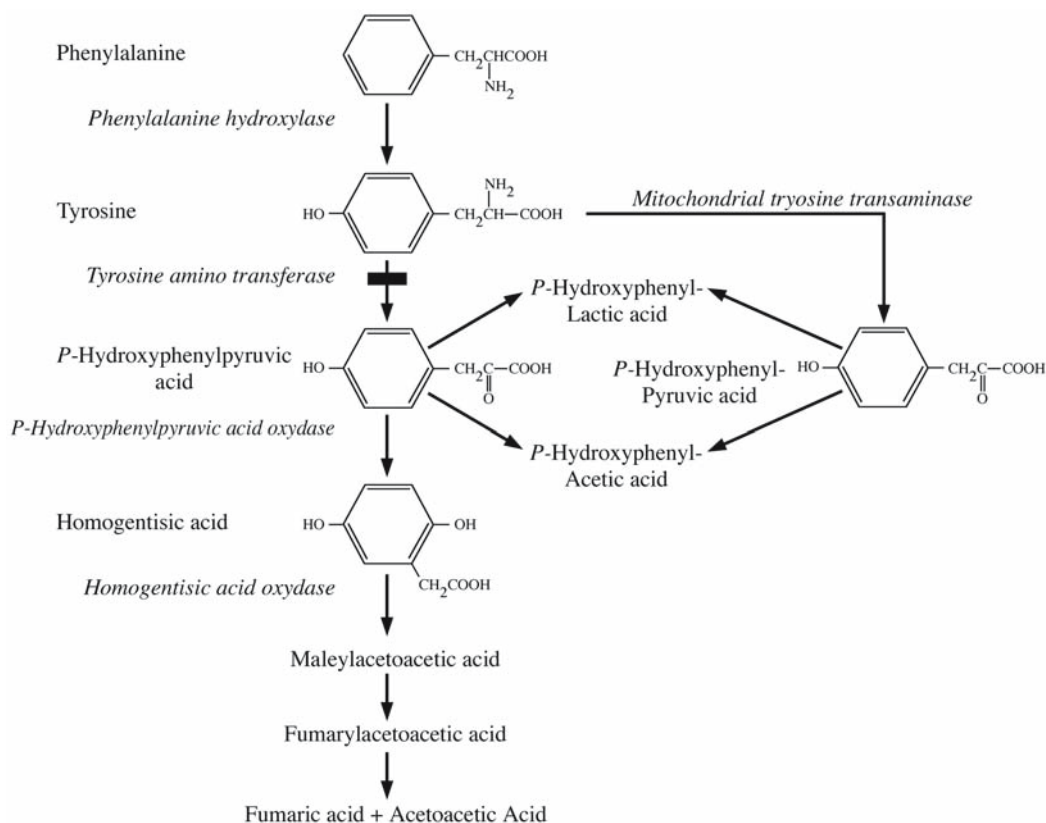


Fig. 9. Tyrosine metabolism.

alanine (Fig. 9). Tyrosine aminotransferase is found in high concentrations in the liver and is also found in mitochondria, except in cells of ectodermal origin, which may explain why there is a particular accumulation of tyrosine in the cornea, hands, and feet (155). Over two dozen different mutations of tyrosine aminotransferase have been described (163, 164). The diagnosis of oculocutaneous tyrosinemia is based on clinical findings as well as hypertyrosinemia and elevated tyrosine and tyrosine metabolites in the urine.

6.3. Nutritional Approaches to the Treatment of Oculocutaneous Tyrosinemia

Dietary restriction of tyrosine and phenylalanine can reduce and prevent the skin and eye lesions, and clinical improvement is usually seen within a few weeks of commencing dietary therapy. Complete resolution of clinical symptoms is possible with adherence to therapy (165). Recurrence of eye and skin lesions can occur if the dietary therapy is stopped (161). Commercial tyrosine- and phenylalanine-free supplements are available.

7. X-LINKED ADRENOLEUKODYSTROPHY

7.1. Clinical Features

In 1923, Ernst Siemerling (1857–1932) and Hans Creutzfeldt (1885–1964) described a boy with bronzed skin, dysphagia, spasticity, and behavioral abnormalities who later

Table 7
Clinical and Laboratory Findings in X-Linked Adrenoleukodystrophy

-
- Childhood cerebral adrenoleukodystrophy
 - Reduced visual acuity
 - Poor school performance
 - Visual field defects, optic atrophy
 - Seizures
 - Rapid neurological progression
 - Adrenomyelopathy
 - Spastic paraparesis
 - Reduced vibratory sense in extremities
 - Difficulty urinating
 - Increased long chain fatty acids in plasma
-

developed tetraplegia, seizures, and died (166). The disease was later known as adrenoleukodystrophy, a disorder that falls within the general category of leukodystrophy, defined as a progressive disease of myelin in which a genetically determined metabolic defect results in the destruction or failed development of central white matter (167). The term adrenoleukodystrophy has been applied to two distinct entities: X-linked adrenoleukodystrophy and neonatal adrenoleukodystrophy, and in this section the term will apply to the X-linked form of the disease. Adrenoleukodystrophy is a rare disorder, and although the exact incidence is not known, in the Netherlands for example, it appears to have a frequency of one in 100,000 male births (168).

Adrenoleukodystrophy can present as several phenotypes such as a childhood cerebral form, an adrenomyelopathy, an Addisonian phenotype with adrenocortical insufficiency, cerebral forms that present in adolescence or adulthood, an asymptomatic form, and with other atypical presentations (168,169). Childhood cerebral adrenoleukodystrophy is the most frequent phenotype, and onset occurs between three and 10 yr of age with poor school performance, deterioration of vision, and reduced auditory discrimination and then rapid progression to seizures, spastic tetraplegia, and dementia (168). The childhood form is an intensely inflammatory cerebral myelinopathy that results in reduced visual acuity, homonymous hemianopia, cortical blindness, and optic atrophy, and loss of ganglion cells from the macula and nonspecific optic atrophy have been described in histopathology (170,171). Adrenomyelopathy is a noninflammatory axonopathy. It is the common form in adults that usually presents in the third and fourth decades with spastic paraparesis, disturbed vibration sense in the lower extremities, and voiding difficulties. Reduced visual acuity and optic disc pallor appear to be due to demyelination in the visual pathways (172). The prevalence of abnormal color vision is higher among patients with adrenomyeloneuropathy than matched controls (173). Patients with cerebral adrenoleukodystrophy often have characteristic findings on magnetic resonance imaging (174). The clinical and laboratory findings of X-linked adrenoleukodystrophy are summarized in Table 7.

7.2. Metabolic Aspects

The main biochemical abnormality of X-linked adrenoleukodystrophy is the accumulation of saturated unbranched very long chain fatty acids such as hexacosanoic acid and

tetracosanoic acid in tissues and body fluids. These fatty acids are normally degraded within peroxisomes, but patients with adrenoleukodystrophy have a defect in β -oxidation of these very long chain fatty acids. Peroxisomes are small intracellular organelles that are found in almost all cells except mature erythrocytes, and their functions include the β -oxidation of very long chain fatty acids, biosynthesis of plasmalogens and bile acids, and glyoxylate detoxification (168). The gene predisposing to adrenoleukodystrophy was mapped to Xq28 (175) and isolated (176). The *ALD* (*ABCD1*) gene encodes the ALD protein, one of four ATP-binding cassette transporters found in the peroxisomal membrane, and over 340 *ALD* mutations have been reported (167). The diagnosis of adrenoleukodystrophy can be based on increased concentrations of very long chain fatty acids in plasma or culture skin fibroblasts or by mutation analysis (167). Gas chromatography/mass spectrometry (177) and electrospray ionization mass spectrometry (178) methods have been developed for detection of very long-chain fatty acids. Very long-chain fatty acids up to 32 carbons have been described in plasma of patients with X-linked adrenoleukodystrophy (179).

7.3. Nutritional Approaches to the Treatment of Adrenoleukodystrophy

Various dietary interventions have been attempted for the treatment of adrenoleukodystrophy, including restriction of dietary hexacosanoic acid (180), restriction of dietary very long chain fatty acids with administration of glyceryl trioleate oil (169), and restriction of dietary very long chain fatty acids with administration of Lorenzo's oil, a highly purified oil mixture containing a 4:1 mix of glyceryl trioleate and glyceryl trierucate (181). The early results of these interventions yielded disappointing results in regard to the clinical course of the disease in patients who were already symptomatic (169). Although Lorenzo's oil has been shown to reduce levels of very long chain fatty acids, functional deterioration continued to occur in treated patients (181). Long-term treatment with Lorenzo's oil did not modify the course of the disease in adult onset adrenoleukodystrophy (182), but early treatment may have slowed the progression of disease somewhat in children with adrenoleukodystrophy (183). A recent multicenter study involving 104 asymptomatic boys who were less than 6 yr old and had a normal magnetic resonance imaging (MRI) showed that treatment with Lorenzo's oil reduced the risk of developing neurological abnormalities and changes in MRI (184). Bone marrow transplantation may provide stabilization of disease in boys or adolescents in the early stages of inflammatory brain disease (185).

8. HOMOCYSTINURIA (CYSTATHIONINE β -SYNTHETASE DEFICIENCY)

8.1. Clinical Features

Patients with elevated homocystine concentrations in urine were described in 1962 (186, 187), and 2 yr later the enzyme defect was identified as a deficiency in cystathionine β -synthetase (188). Homocystinuria is an autosomal recessive disorder characterized by ectopia lentis, myopia, osteoporosis, biconcave vertebrae, scoliosis, thinning and lengthening of long bones (dolichostenomelia) and other skeletal abnormalities, variable degrees of mental retardation, psychiatric disturbances, and vascular occlusions (189). Ectopia lentis is found in about 90% of patients and usually presents in untreated individuals at about 2 yr of age (190). Prior to dislocation, the lens may exhibit phacodonesis, and iridodonesis may be a sign that the lens has dislocated. The lens may dislocate into the anterior chamber

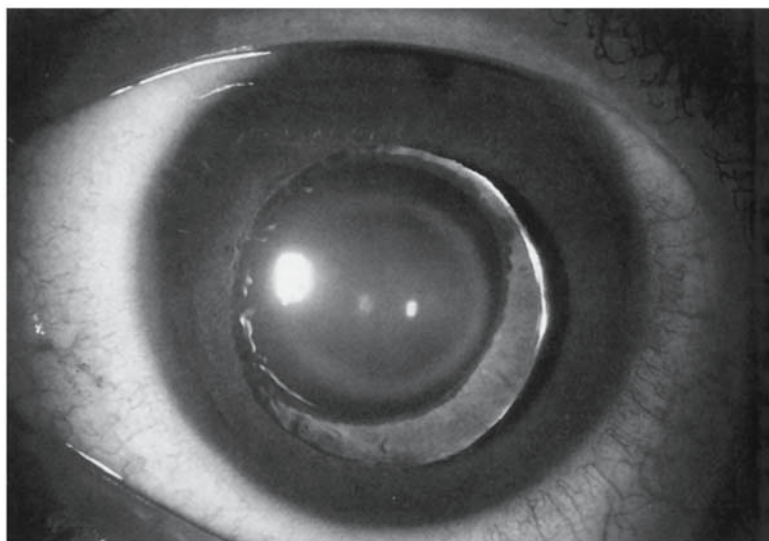


Fig. 10. Patient with homocystinuria who developed lens dislocation into the anterior chamber. (Reprinted from ref. 191, with permission of the American Academy of Ophthalmology.)

Table 8

Clinical and Laboratory Findings in Homocystinuria (Cystathionine β -Synthase Deficiency)

-
- Ectopia lentis
 - Myopia
 - Osteoporosis
 - Thinning and lengthening of long bones (dolichostenomelia)
 - Biconcave vertebrae
 - Scoliosis
 - Other skeletal abnormalities
 - Mental retardation
 - Psychiatric disturbances
 - Vascular occlusions
 - Malar flush (“rosy cheeks”)
 - Elevated fasting plasma homocysteine
 - Elevated fasting plasma methionine
 - Elevated urinary homocysteine and related metabolites
-

(Fig. 10) and may also cause pupillary block glaucoma. Optic atrophy, iris atrophy, anterior staphylomas, lenticular opacities, and corneal opacities may also be common (191). The clinical and laboratory findings in homocystinuria are summarized in Table 8. The diagnosis of homocystinuria is often missed and should be suspected in patients who present to the ophthalmologist or optometrist with high myopia, ectopia lentis, and skeletal, vascular, and/or central nervous system abnormalities (192).

8.2. Metabolic Aspects

Methionine is an essential sulfur amino acid that is found as a component of dietary proteins. In the United States, the average diet contains about 35 mg methionine plus

cysteine per gram of protein (193). Methionine is transported across the intestinal mucosa by neutral amino acid transport systems and circulates free in the plasma until uptake by tissues such as the liver. Methionine is metabolized to homocysteine via the intermediates *S*-adenosylmethionine and *S*-adenosylhomocysteine (Fig. 11). Homocysteine then undergoes transsulfuration to form cysteine or can undergo remethylation to form methionine again. The metabolism of homocysteine to cysteine involves two enzymes, cystathionine β -synthase and cystathionine γ -lyase, both which require pyridoxal 5'-phosphate (vitamin B₆) as cofactors (Fig. 11). The most common cause of homocystinuria is cystathionine β -synthase deficiency, but there are also other genetic defects in the conversion of homocysteine to methionine that may lead to elevated plasma homocysteine concentrations (189). Human cystathionine β -synthase cDNA has been cloned (194), and many cystathionine β -synthase mutations have been described (189). The gene for cystathionine β -synthase has been mapped to chromosome 21q22.3 (195). The zonular fibers contain fibrillin, a 350-kDa glycoprotein that is rich in cysteine residues, suggesting a possible pathogenic mechanism for cystathionine β -synthase deficiency and ectopia lentis (196).

Homocystinuria occurs in 1 of 52,544 births in Ireland (197) and 1 of 60,000 births in New South Wales, Australia (198), but the worldwide frequency may be somewhat lower, between 1:200,000 and 1:335,000 (189). A national newborn screening program in Ireland used a bacterial inhibition assay for initial screening at 3–5 d of life to detect high blood methionine concentrations, and for infants with high blood methionine, further diagnostic studies included analysis for blood concentrations of methionine, free homocysteine, and cysteine (199). Screening programs have used different criteria for detection of homocystinuria, and early screening may miss many cases of patients who are responsive to vitamin B₆ therapy (189). Overall, about 44% of patients with homocystinuria appear to be responsive to vitamin B₆ therapy, but proportion of patients that are responsive to vitamin B₆ therapy as detected in newborn screening programs is about 14% (189). Thus, most patients who are responsive to vitamin B₆ therapy are detected after the newborn period.

8.3. Nutritional Approaches to the Treatment of Homocystinuria

In 1967, G. Winston Barber and George Spaeth reported that three patients with homocystinuria responded to high doses of pyridoxine (vitamin B₆) of 250 to 500 mg/d with a dramatic decrease in plasma and urine homocysteine and decreases of plasma methionine concentrations to the normal range (200). Cystathionine β -synthase requires pyridoxal-5-phosphate, formed from vitamin B₆, as a cofactor (Fig. 11), and the provision of vitamin B₆ may increase the residual enzyme activity in some patients. As mentioned previously, an estimated 44% of patients are responsive to vitamin B₆ therapy. The daily doses of vitamin B₆ used by different groups have ranged from 100–800 mg/d for adults and 150–500 mg/d for infants and children (201). In addition to vitamin B₆ supplementation, current strategies include dietary methionine restriction, supplementing with cystine, giving folate and vitamin B₁₂ in addition to vitamin B₆ and betaine supplementation (201,202). The safety issues of high doses of vitamin B₆ have been reviewed by Adrienne Bendich and Marvin Cohen (203). For adults, doses of 500 mg/d for up to 2 yr appears to be safe (203), but doses of 500 mg/d for infants have been associated with respiratory failure (189).

Detailed guidelines for therapy and monitoring of homocystinuria are presented in detail elsewhere (189). Although most infants detected by newborn screening are not responsive to vitamin B₆, the first step is to determine whether the infant will respond to

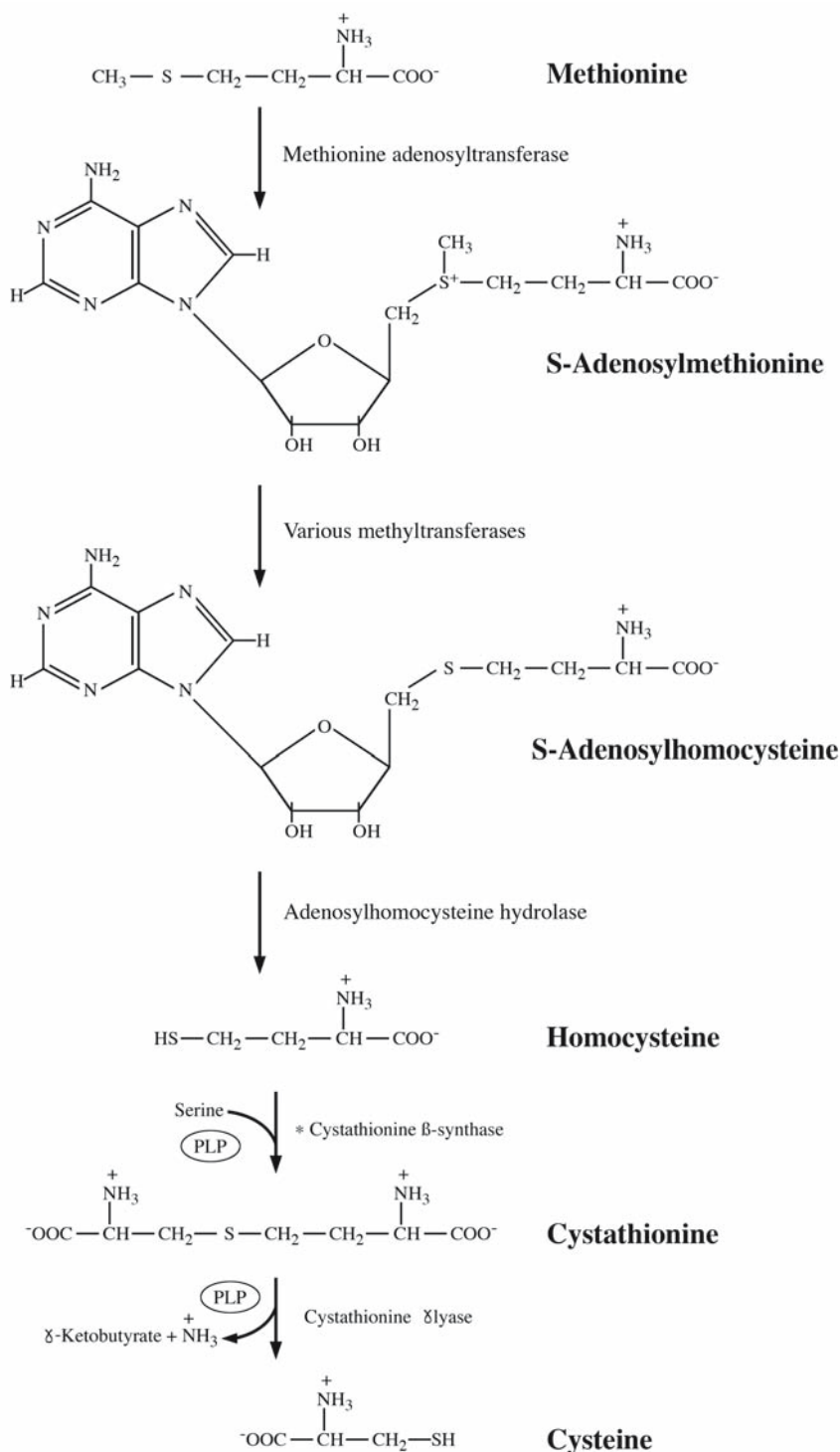


Fig. 11. The metabolism of methionine to homocysteine to cysteine. Homocysteine can also be remethylated back to methionine. The main cause of homocystinuria is β -cystathionine synthase deficiency (*). Both β -cystathionine synthase and cystathionine γ -lyase require pyridoxal 5'-phosphate as cofactors.

vitamin B₆ therapy at an initial dose of 250 mg/d for 4–6 d. Plasma methionine, homocysteine, and/or total homocysteine are monitored daily. Most infants who are responsive to vitamin B₆ will show at least a partial biochemical response to this initial treatment (189). If a response is observed, then the dose of vitamin B₆ is reduced in 50 mg/d decrements to determine the lowest dose that achieves a response. Dietary methionine restriction can be used for infants that are not responsive to vitamin B₆, and methionine-free, cystine-supplemented synthetic mixtures are available (189). In individuals who are diagnosed as having homocystinuria that is not responsive to vitamin B₆ after the newborn period, dietary methionine restriction and/or betaine supplementation can be used, but adherence is often difficult (202). The rationale for betaine supplementation is to utilize an alternative pathway involving the remethylation of homocysteine to methionine by betaine-homocysteine methyltransferase (204).

Early detection and treatment of homocystinuria appears to reduce the risk of lens dislocation and progressive myopia (205,206). In a study of 19 patients with homocystinuria in Ireland, of 14 who had early dietary intervention in the newborn period, none developed ectopia lentis after mean follow-up of 8.2 yr. Of five patients who did not receive treatment until childhood, three had preexisting ectopia lentis, and two without ectopia lentis subsequently developed the condition (197). Patients with late diagnosis of homocystinuria or poor control appear to have worse myopia and problems with ectopia lentis (207). Treatment to lower plasma homocysteine significantly reduces the risk of vascular complications (208) and mental retardation (202,208). Betaine treatment has been shown to reduce the risk of vascular events (209).

9. WILSON DISEASE (HEPATOLENTICULAR DEGENERATION)

9.1. *Clinical Features*

In 1912, Samuel Alexander Kinnier Wilson (1878–1937) described a disorder characterized by progressive degeneration of the lenticular nuclei associated with hepatic cirrhosis (210). This disorder was also described earlier in the nineteenth century by Friedrich Theodor Frerichs (1819–1885) (211). Wilson disease is an inborn error of copper metabolism that is transmitted as an autosomal recessive trait. The main ophthalmological finding is the Kayser-Fleischer ring, which consists of fine granular deposition of copper in the periphery of Descemet's membrane (212). This characteristic ring was described by Bernhard Kayser (1869–1954) and Bruno Fleischer (1874–1965) (213–215). The Kayser-Fleischer ring may be visible only by slit lamp microscopy and appear as a brownish haze in the cornea periphery (Fig. 12). The Kayser-Fleischer ring is usually a golden-brown color but other color variations include green, yellow, blue, ruby red, or a mixture of these colors (212). The ring usually begins in the superior and inferior cornea at the limbus and spreads circumferentially until a complete ring is formed. Unilateral Kayser-Fleischer ring has been described (216). Electron dense deposits consisting of copper are found in Descemet's membrane and the adjacent corneal stroma (Fig. 13) (217). Although the Kayser-Fleischer ring may disappear with penicillamine therapy and low copper diets (218), there is not a close correlation between the Kayser-Fleischer ring and neurological findings (219). Kayser-Fleischer rings are not pathognomonic for Wilson disease and can also occur in other conditions associated with abnormal copper metabolism such as primary biliary cirrhosis, chronic active hepatitis, and other diseases (212,220,221). About 15–20% of

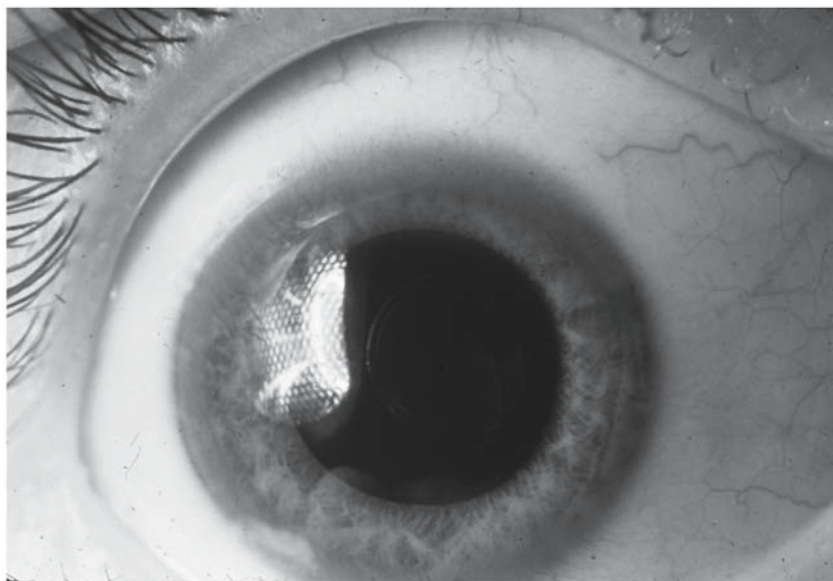


Fig. 12. Kayser-Fleischer ring. (Courtesy of W. Richard Green.)

patients may have a so-called “sunflower” cataract (218,223). The cataract consists of a central disk-shaped opacity of iridescent powdery deposits under the anterior and posterior capsule with spoke-like radiations. Loss of accommodation has been described in two patients with Wilson disease (223).

Patients with Wilson disease typically present with hepatic or neuropsychiatric disease. In children, the most common initial finding is liver dysfunction (224). Liver disease can range from a mild elevation in liver enzymes to chronic active hepatitis to massive liver failure. Liver biopsy may show micronodular cirrhosis with copper deposition. Patients who present with neuropsychiatric disease may present later in life, in the third or fourth decade, and presentation can be highly variable. Neurological signs and symptoms may resemble those found in Parkinson’s disease, with reduced facial expression and dyarthria, and there may be tremor, personality changes, depression, and schizophrenia.

The clinical and laboratory findings of Wilson disease are shown in Table 9.

9.2. Metabolic Aspects

Copper is an essential nutrient that plays a role in copper-containing enzymes involved in a wide variety of processes, including respiration, protection against oxidative stress, hormone metabolism, iron metabolism, and hematopoiesis. Copper is a transition metal that has properties of redox chemistry that lend well to the transfer of electrons, thus, many biological reactions are catalyzed by copper-containing enzymes. Among the copper-containing enzymes important in humans are cytochrome c oxidase, copper/zinc superoxide dismutase, ferroxidase II, monoamine oxidase, tyrosinase, and dopamine β -hydroxylase. The average human adult contains a total of about 110 mg of copper (225). The average dietary copper intake is about 2 mg per day (226), and about 30–75% of dietary copper is usually absorbed, primarily in the duodenum. Foods that are rich in copper include oysters and shellfish, chocolate, nuts, and legumes, and the bran and germ of cereal grains are rich in copper.

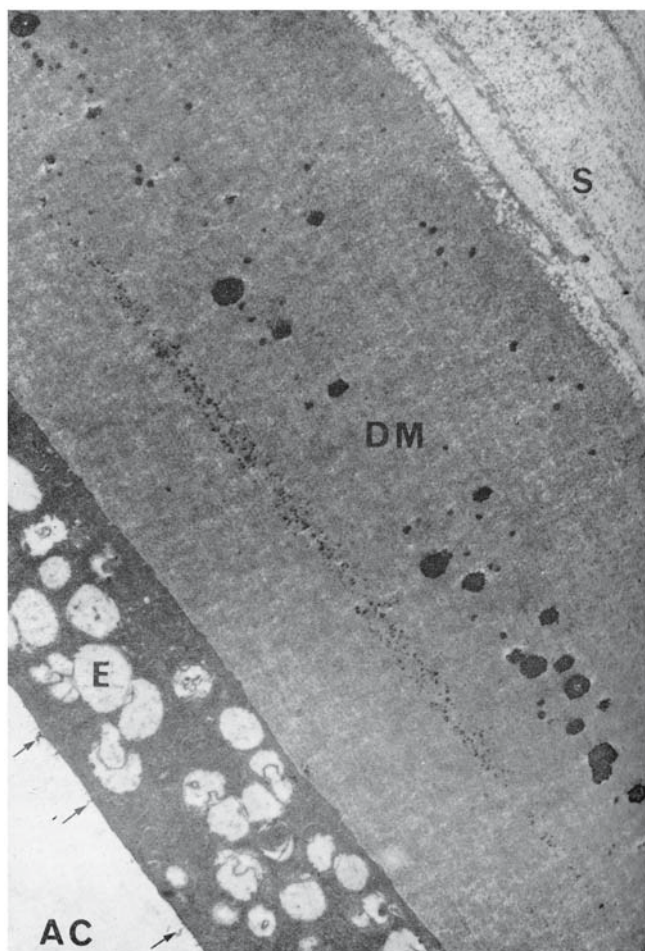


Fig. 13. Electron dense deposits consisting of copper are found in Descemet's membrane and adjacent corneal stroma in Wilson disease. (Reproduced from ref. 217, with permission from BMJ Publishing Group.)

Copper is transported in the circulation bound primarily to albumin, and much of the copper is taken up by the liver, where it is incorporated into ceruloplasmin, a glycoprotein that contains six to seven copper atoms. The liver releases ceruloplasmin, and plasma ceruloplasmin accounts for about 60–65% of plasma copper (227). Copper is taken up by cells that have specific ceruloplasmin receptors on their surface. The main route of copper excretion is through biliary excretion into the gastrointestinal tract and feces, with only minor amounts lost through urine, sweat, hair, and skin.

Wilson disease is due to a defect in copper-transporting adenosine triphosphates (ATPase) in the *trans*-Golgi network of cells (228–230). The Wilson disease gene was localized to chromosome 13 (231), specifically to 13q14.3 (232). The absence or dysfunction of the Wilson ATPase interferes with copper transport and biliary copper secretion. More than 100 different mutations have been identified in patients with Wilson disease worldwide (233). The secretion of ceruloplasmin by the liver is impaired in Wilson disease, and often plasma ceruloplasmin concentrations are below normal values. If fever or inflam-

Table 9
Clinical and Laboratory Findings in Wilson Disease

-
- Kayser-Fleischer rings
 - “Sunflower” cataract
 - Azure lunulae in the fingernails
 - Hepatic disease
 - Chronic active hepatitis
 - Fatty liver
 - Cirrhosis
 - Neuropsychiatric disease
 - Tremor
 - Dysarthria
 - Diminished facial expression
 - Personality changes
 - Depression
 - Schizophrenia
 - Elevated urinary copper concentrations
 - Reduced serum ceruloplasmin
 - Elevated hepatic copper in liver biopsy
-

mation is present, ceruloplasmin concentrations may be elevated by ceruloplasmin is a positive acute phase reactant. Urinary copper concentrations are often elevated (233). The diagnosis of Wilson disease is made on the basis of physical examination, slit lamp examination, and laboratory analyses (233).

9.3. Nutritional Approaches to the Treatment of Wilson Disease

The treatment of Wilson disease consists of chelation therapy with D-penicillamine, combined with other strategies to lower dietary copper or reduce copper absorption. Foods rich in copper, such as shellfish, chocolate, nuts, legumes, and wheat germ must be avoided. Zinc interferes with copper absorption, thus, administration of zinc supplements may help reduce dietary copper absorption. Zinc supplementation has been advocated for asymptomatic patients who had been diagnosed with Wilson disease in childhood but have elevated serum transaminases (234).

10. MENKES DISEASE

Menkes disease is an X-linked disorder characterized by growth failure and unusual kinky hair. The disease was reported by John Menkes in 1962 (235) and was associated with a defect in copper absorption by David Danks and colleagues in 1973 (236). The Menkes gene is located on the long arm of the X chromosome (237). Transport of dietary copper across the gut results in low serum copper concentrations, but copper accumulates in the duodenum, kidney, and pancreas. Copper is required for cytochrome C oxidase, superoxide dismutase, tyrosinase, lysyl oxidase, and other enzymes. Loss of tyrosinase activity results in lack of hair pigmentation. Abnormalities in elastin and collagen production result in weakening of connective tissue, and diverticuli of the bladder, uterus, and other organs. Infants with the classic form of Menkes disease usually present by 2–3 mo of age with growth failure and seizures, an abnormal facies with sagging jowls, and white or grey hair with fine curling like steel wool (pili torti). Skeletal defects such as osteoporosis, rib frac-

tures, and metaphyseal dysplasia occur. Ophthalmic findings may include optic atrophy, ptosis, and iris hypoplasia and hypopigmentation (238). Laboratory studies show serum copper concentrations $<0.75 \mu\text{g/mL}$ ($<11.8 \mu\text{mol/L}$) and low serum ceruloplasmin concentrations. Parenteral administration of copper may correct copper deficiency but does not usually stop the progressive neurological degeneration in infants with Menkes disease (239). Most children with the classic form of Menkes disease die by age three, but those with milder clinical variants may survive for many years.

11. SORSBY FUNDUS DYSTROPHY

11.1. *Clinical Features*

In the 1940s, Arnold Sorsby (1900–1980) and colleagues described an unusual fundus dystrophy characterized by choroidal neovascularization, bilateral central visual loss, and progressive atrophy of the peripheral choroid and retina (240,241). The disorder has an autosomal dominant mode of inheritance, and the condition has also been termed Sorsby pseudoinflammatory macular dystrophy, pseudoinflammatory chorioretinal degeneration of the posterior pole, and hereditary hemorrhagic macular dystrophy. Patients usually present with a central scotoma in one or both eyes in the fifth decade of life with exudation and retinoschisis in the macula with accompanying subretinal hemorrhages and choroidal neovascularization (242–244). The acute lesion heals and is followed by atrophic degeneration of the retina and choroid in the macular region and severe central visual loss (242). Prior to the loss of vision, fundus changes may include pigment epithelial atrophy, small drusen-like lesions or “colloid bodies” in the macula, angioid streaks, and plaque-like subretinal deposits of yellowish material in the macula (245,246). Night blindness may be the earliest symptom of Sorsby fundus dystrophy (247). Onset of visual disturbances may occur as early as the second decade (248). Ocular histopathology shows outer photoreceptor atrophy in the macula, and atrophy of the choriocapillaris, large choroidal vessels, and pigment epithelium in the posterior pole (249). Lipid-rich extracellular deposits accumulate in Bruch’s membrane, and it has been suggested that these deposits interfere with the normal transport of nutrients, such as vitamin A, from the choriocapillaris to the retinal pigment epithelium (250). Sorsby fundus dystrophy can resemble punctate inner choroidopathy (251).

11.2. *Genetic and Metabolic Aspects*

Sorsby fundus dystrophy was genetically linked with chromosome 22q13-1qter (252). The 22q13-1qter region also contains the gene for tissue inhibitor of metalloproteinases (TIMP)-3. The tissue inhibitors of metalloproteinases are a family of small homologous proteins that function in the inhibition and activation of matrix metalloproteins, promotion of cell growth, matrix binding, inhibition of angiogenesis, and induction of apoptosis (253). Patients with Sorsby fundus dystrophy have mutations in the gene for TIMP-3 (254–261). TIMP-3 is a component of Bruch’s membrane (262) and retinal pigment epithelial cells (263). In Sorsby fundus dystrophy, the thick extracellular deposits found in Bruch’s membrane have high concentrations of TIMP-3 (264,265). TIMP-3 may possibly induce retinal pathology by inducing apoptosis in retinal pigment epithelial cells (266) and promoting choroidal neovascularization (267). Deposition of dimerized TIMP-3 has also been hypothesized to play a role in the pathogenesis of the disease (268).

11.3. Treatment of Sorsby Fundus Dystrophy With Vitamin A

Many patients with Sorsby fundus dystrophy have night blindness, and abnormal dark adaptation and altered rhodopsin kinetics suggested that the metabolism of vitamin A might be adversely affected in the retina (250). Oral vitamin A supplementation, 50,000 IU/d, was reversed night blindness in patients with Sorsby fundus dystrophy (269), adding some weight to the hypothesis that the thickened deposits in Bruch's membrane act as a barrier for diffusion of vitamin A from the choriocapillaris to the photoreceptors. The similarities of dark adaptation between vitamin A deficiency and Sorsby fundus dystrophy have been examined (270). Vitamin A supplementation at the dose of 50,000 IU/d should be administered under the supervision of a physician, and this dose is contraindicated in women of childbearing age who are not on reliable contraception and pregnant women (271). In one case report, a woman with Sorby fundus dystrophy and choroidal neovascularization responded to steroid treatment (251).

12. RETINITIS PIGMENTOSA

12.1. Clinical Features

Retinitis pigmentosa is a general term used to describe a heterogeneous set of heritable disorders characterized by retinal degeneration. This group of hereditary photoreceptor degenerations has a worldwide prevalence of about 1 in 4000 (272). The typical clinical findings are night blindness with progressive loss of peripheral visual field and then loss of central vision. Ophthalmoscopic features include attenuated retinal blood vessels, a waxy, pale-appearing optic disc, and intraretinal pigment deposits that sometimes resemble "bone spicules." Cystoid macular edema and cataract are sometimes present. Some forms of retinitis pigmentosa, such as abetalipoproteinemia (Bassen-Korzweig syndrome) and gyrate atrophy, have been presented earlier in this chapter. The ocular histopathology of retinitis pigmentosa has been well characterized. In early disease, there is a loss of the number of rod and cone photoreceptors. The inner nuclear layer undergoes degeneration.

12.2. Metabolic Aspects

Many of the genes for retinitis pigmentosa have not yet been identified. Thaddeus Dryja and colleagues have provided an extensive review of the genes that cause retinitis pigmentosa (273). Some of the genes encode rhodopsin, structural proteins important in the outer segments of photoreceptors, and enzymes involved in the rod phototransduction cascade.

12.3. Nutritional Intervention for Retinitis Pigmentosa

As early as the late 1930s, vitamin A treatment was reported to improve the clinical course of retinitis pigmentosa (274,275). In 1993 it was reported that oral vitamin A supplementation, 15,000 IU/d, slowed the decrease in amplitude of the electroretinogram (ERG) among patients with retinitis pigmentosa (276). These findings showed promise for patients with retinitis pigmentosa (277). Further inquiry showed that vitamin A supplementation was also associated with a slower loss of visual field area among the same patients with retinitis pigmentosa (278), and several studies have shown a correlation between visual field size and ERG amplitude (279). Investigation in two transgenic mouse models for retinitis pigmentosa demonstrate that a high vitamin A diet slowed the course of photoreceptor degeneration in mice with the threonine-17 → methionine (T17M)

mutation but not in mice with the proline-347 → serine (P347S) mutation (280). These results suggested that vitamin A was beneficial for class II rhodopsin mutants, as in the T17M mutation, but not for class I rhodopsin mutants, as in the P347S mutation (280). Oral vitamin A supplementation at the level of 15,000 IU/d appears to be safe for the treatment of retinitis pigmentosa in healthy adult men and nonpregnant women who eat a regular diet without excessive intake of food high in vitamin A (281). Annual monitoring of liver enzymes and triglycerides is recommended for patients on supplementation (281). A recent randomized controlled clinical trial shows that docosahexaenoic acid, in addition to vitamin A supplementation, does not slow the course of disease of patients with retinitis pigmentosa (282). A subgroup analysis suggested that for patients who were commencing vitamin A therapy, the addition of docosahexaenoic acid slowed the course of the disease for 2 yr (283).

13. MAPLE SYRUP URINE DISEASE

Maple syrup urine disease is a rare autosomal recessive disorder characterized by deficiency of branched-chain α -keto acid dehydrogenase with resulting accumulation of branched-chain amino acids leucine, isoleucine, and valine and branched-chain α -keto acids. In 1954, John Menkes and colleagues described four infants with progressive cerebral degeneration and urine that had an odor resembling maple syrup (284). Subsequent investigations showed high concentrations of leucine, isoleucine, and valine (285) and 2,4-dinitrophenylhydrazones in the urine (286). Six loci contribute to the branched-chain α -keto acid dehydrogenase complex. There are five phenotypes of the disease: classic, intermediate, intermittent, thiamine-responsive, and dihydrolipoyl dehydrogenase (E3)-deficient (287). The worldwide frequency of maple syrup urine disease is approximately 1 in 185,000 births, but in the inbred Old Order Mennonite population of Lancaster and Lebanon Counties in Pennsylvania, the frequency has been reported as 1 in 176 newborns (288).

The classic phenotype of maple syrup urine disease is the most common form and includes neonatal onset of poor feeding, weight loss, alternating hypertonia and hypotonia, ketoacidosis, and maple syrup odor to the urine. Ophthalmic findings include optic atrophy, ophthalmoplegia, strabismus, nystagmus, and cortical blindness (289,290). Loss of corneal epithelium has been described in one infant with isoleucine deficiency (291). Treatment of maple syrup urine disease consists of limiting the dietary intake of leucine, isoleucine, and valine. A trial of thiamin therapy is recommended to determine whether the infant may have a thiamin-responsive form of the disease (287). Commercial synthetic formulas are available for maple syrup urine disease, and long-term dietary management can reduce the morbidity and mortality associated with the disease.

14. MOLYBDENUM COFACTOR DEFICIENCY AND ISOLATED SULFITE OXIDASE DEFICIENCY

Molybdenum cofactor deficiency and sulfite oxidase deficiency are two related inborn errors of metabolism that are associated with severe neurological abnormalities, ectopia lentis, and mental retardation. Molybdenum cofactor deficiency is characterized by deficient activity of three enzymes: sulfite oxidase, xanthine dehydrogenase, and aldehyde oxidase, whereas isolated sulfite oxidase deficiency is associated with deficient sulfite

oxidase activity, but normal molybdenum cofactor, xanthine dehydrogenase, and aldehyde oxidase activity. Combined sulfite oxidase deficiency and xanthine oxidase deficiency has also been described (292). Both molybdenum cofactor deficiency and sulfite oxidase deficiency are characterized by seizures, psychomotor retardation, facial dysmorphism, hypertonia and hypotonia, dilated ventricles, and brain atrophy. Spherophakia and ectopia lentis are associated with both molybdenum cofactor deficiency and isolated sulfite oxidase deficiency (293–296). Elevated S-sulfocysteine concentrations may be used for the diagnosis of sulfite oxidase deficiency. Molybdenum cofactor deficiency is not reversible with dietary measures, but there have been reports of some success with limiting the dietary intake of sulfur amino acids in sulfite oxidase deficiency (297).

15. OTHER

Familial hyperlysinemia is an autosomal recessive disease in which there is a defect in lysine degradation due to defective α -amino adipic semialdehyde synthase (298). The clinical manifestations include subluxation of the lens (299). Dietary restriction of proteins may help to reduce plasma lysine concentrations but does not appear to influence long-term development, which may be normal despite high levels of lysine (300).

16. CONCLUSIONS AND RECOMMENDATIONS

Some inborn errors of metabolism show that nutritional modification or intervention can reduce the risk of visual loss and blindness or slow progression of disease. In other conditions, nutritional interventions have had limited effects. The research agenda for these diverse groups of metabolic diseases includes understanding the pathogenic mechanisms involved in Refsum disease, measuring the long-term effects of a phytanic acid-restricted diet on the progression of ocular disease, determining whether a galactose-free, rather than galactose-restricted, diet in the first 6 mo of life will have better long-term outcome. Effective therapies are needed for the treatment of Menkes syndrome.

REFERENCES

1. Bassen FA, Kornzweig AL. Malformation of the erythrocytes in a case of atypical retinitis pigmentosa. *Blood* 1950;5:381–387.
2. Singer K, Fisher B, Perlstein MA. Acanthocytosis: a genetic erythrocytic malformation. *Blood* 1952;7:577–591.
3. Jampel RS, Falls HF. Atypical retinitis pigmentosa, acanthocytosis, and hereditary degenerative neuromuscular disease. *Arch Ophthalmol* 1958;59:818–820.
4. Druet G. Un nouveau cas d'acanthocytose: dysmorphie érythrocytaire congénitale avec rétinite, troubles nerveux et sténoses dégénératives. *Rev Hematol* 1959;14:3–11.
5. Salt HB, Wolff OH, Lloyd JK, Fosbrooke AS, Cameron AH, Hubble DV. On having no beta-lipoprotein: a syndrome comprising a-beta-lipoproteinaemia, acanthocytosis, and steatorrhea. *Lancet* 1960;2:325–329.
6. Wolff OH, Lloyd JK, Tonks EL. A- β -lipoproteinaemia with special reference to the visual defect. *Exp Eye Res* 1964;3:439–442.
7. Yee RD, Herbert PN, Bergsma DR, Biemer JJ. Atypical retinitis pigmentosa in familial hypobetalipoproteinemia. *Am J Ophthalmol* 1976;82:64–71.
8. Druet G, Lamy M, Frézal J, Polonovski J, Rey J. L'acanthocytose. Ses rapports avec l'absence congénitale de bêta-lipoprotéines. *Presse Med* 1961;69:1546–1548.
9. Lamy M, Frézal J, Polonovski J, Druet G, Rey J. Congenital absence of beta-lipoproteins. *Pediatrics* 1963;31:277–289.

10. Schwartz JF, Rowland LP, Eder H, et al. Bassen-Kornzweig syndrome: deficiency of serum β -lipoprotein. *Arch Neurol* 1963;8:438–454.
11. Sobrevilla LA, Goodman ML, Kane CA. Demyelinating central nervous system disease, macular atrophy, and acanthocytosis (Bassen-Kornzweig syndrome). *Am J Med* 1964;37:821–828.
12. Isselbacher KJ, Scheig R, Plotkin GR, Caulfield JB. Congenital β -lipoprotein deficiency: an hereditary disorder involving a defect in the absorption and transport of lipids. *Medicine* 1964;43:347–361.
13. Bach C, Polonovski J, Polonovski C, Leluc R, Jolly G, Moszer M. L'absence congenitale de β -lipoproteines: une nouvelle observation. *Arch Franç Pédiatr* 1967;24:1093–1111.
14. Bohlmann HG, Thiede H, Rosenstiel K, Herdemerten S, Panitz D, Tackmann W. A- β -lipoproteinämie bei drei Geschwistern. *Dtsch Med Wochenschr* 1972;97:892–896.
15. Scanu AM, Aggerbeck LP, Kruski AW, Lim CT, Kayden HJ. A study of the abnormal lipoproteins in abetalipoproteinemia. *J Clin Invest* 1974;53:440–453.
16. Charlin JF, Leluyer B, Brasseur G, Gruber D, Langlois J. Manifestations ophtalmologiques du syndrome de Bassen-Kornzweig. A propos d'un cas. *Bull Soc Ophtal France* 1985;85:11–18.
17. Weber M, Annonier P, Coumaros D, Willemin B, Bronner A. La retinopathie pigmentaire du syndrome de Bassen Kornzweig—B Etude clinique biologique et electrophysiologie de deux cas. *Bull Soc Ophtal France* 1988;88:423–426.
18. Duker JS, Belmont J, Bosley TM. Angioid streaks associated with abetalipoproteinemia. *Arch Ophthalmol* 1987;105:1173–1174.
19. Dieckert JP, White M, Christmann L, Lambert HM. Angioid streaks associated with abetalipoproteinemia. *Ann Ophthalmol* 1989;21:173–175, 179.
20. Sallmann L von, Gelderman AH, Laster L. Ocular histopathologic changes in a case of A-beta-lipoproteinemia (Bassen-Kornzweig syndrome). *Doc Ophthalmol* 1969;26:451–460.
21. Cogan DG, Rodrigues M, Chu FC, Schaefer EJ. Ocular abnormalities in abetalipoproteinemia. A clinicopathologic correlation. *Ophthalmology* 1984;91:991–998.
22. Rader DJ, Brewer HB Jr. Abetalipoproteinemia: new insights into lipoprotein assembly and vitamin E metabolism from a rare genetic disease. *J Am Med Assoc* 1993;270:865–869.
23. Caballero FM, Buchanan GR. Abetalipoproteinemia presenting as severe vitamin K deficiency. *Pediatrics* 1980;65:161–163.
24. Lackner KJ, Monge JC, Gregg RE, et al. Analysis of the apolipoprotein B gene and messenger ribonucleic acid in abetalipoproteinemia. *J Clin Invest* 1986;78:1707–1712.
25. Talmud PJ, Lloyd JK, Muller DPR, Collins DR, Scott J, Humphries S. Genetic evidence from two families that the apolipoprotein B gene is not involved in abetalipoproteinemia. *J Clin Invest* 1988;82:1803–1806.
26. Huang LS, Janne PA, de Graaf J, et al. Exclusion of linkage between the human apolipoprotein B gene and abetalipoproteinemia. *Am J Hum Genet* 1990;46:1141–1148.
27. Wetterau JR, Aggerbeck LP, Bouma ME, et al. Absence of microsomal triglyceride transfer protein in individuals with abetalipoproteinemia. *Science* 1992;258:999–1001.
28. Sharp D, Blinderman L, Combs KA, et al. Cloning and gene defects in microsomal triglyceride transfer protein associated with abetalipoproteinaemia. *Nature* 1993;365:65–69.
29. Shoulders CC, Brett DJ, Bayliss JD, et al. Abetalipoproteinemia is caused by defects of the gene coding the 97 kDA subunit of a microsomal triglyceride transfer protein. *Hum Mol Genet* 1993;2:2109–2116.
30. Ricci B, Sharp D, O'Rourke E, et al. A 30-amino acid truncation of the microsomal triglyceride transfer protein large subunit disrupts its interaction with protein disulfide-isomerase and causes abetalipoproteinemia. *J Biol Chem* 1995;270:14281–14285.
31. Narcisi TME, Shoulders CC, Chester SA, et al. Mutations of the microsomal triglycerida-transfer-protein gene in abetalipoproteinemia. *Am J Hum Genet* 1995;57:1298–1310.
32. Borén J, Wettsten M, Sjöberg A, et al. The assembly and secretion of apoB 100 containing lipoproteins in Hep G2 cells: evidence for different sites for protein synthesis and lipoprotein assembly. *J Biol Chem* 1990;265:10556–10564.
33. Davis RA, Thrift RN, Wu CC, Howell KE. Apolipoprotein B is both integrated into and translocated across the endoplasmic reticulum membrane: evidence for two functionally distinct pools. *J Biol Chem* 1990;265:10005–10011.

34. Yokota T, Shiojiri T, Gotoda T, Arai H. Retinitis pigmentosa and ataxia caused by a mutation in the gene for the α -tocopherol-transfer protein. *N Engl J Med* 1996;335:1770–1771.
35. Yokota T, Shiojiri T, Gotoda T, et al. Friedreich-like ataxia with retinitis pigmentosa caused by the His¹⁰¹ Gln mutation of the α -tocopheral transfer protein gene. *Ann Neurol* 1997;41:826–832.
36. Berriot-Varoqueaux N, Aggerbeck LP, Samson-Bouma M, Wetterau JR. The role of the microsomal triglyceride transfer protein in abetalipoproteinemia. *Annu Rev Nutr* 2000;20:663–697.
37. DiGeorge AM, Mabry CC, Auerbach VH. A specific disorder of lipid transport (acanthrocytosis): treatment with intravenous lipids. *Am J Dis Child* 1961;102:580.
38. Gouras P, Carr RE, Gunkel RD. Retinitis pigmentosa in abetalipoproteinemia: effects of vitamin A. *Invest Ophthalmol* 1971;10:784–793.
39. Sperling MA, Hiles DA, Kennerdell JS. Electroretinographic responses following vitamin A therapy in a-beta-lipoproteinemia. *Am J Ophthalmol* 1972;73:342–351.
40. Azizi E, Zaidman JL, Eshchar J, Szeinberg A. Case report. Abetalipoproteinemia treated with parenteral and oral vitamins A and E, and with medium chain triglycerides. *Acta Paediatr Scand* 1978;67:797–801.
41. Bishara S, Merin S, Cooper M, Azizi E, Delpre G, Deckelbaum RJ. Combined vitamin A and E therapy prevents retinal electrophysiological deterioration in abetalipoproteinaemia. *Br J Ophthalmol* 1982;66:767–770.
42. Judisch GF, Rhead WJ, Miller DK. Abetalipoproteinemia: report of an unusual patient. *Ophthalmologica* 1984;189:73–79.
43. Muller DRP, Harries JT, Lloyd JK. Vitamin E therapy in A- β -lipoproteinaemia. *Arch Dis Child* 1970;45:715.
44. Muller DRP, Lloyd JK, Bird AC. Long-term management of abetalipoproteinaemia: possible role for vitamin E. *Arch Dis Child* 1977;52:209–214.
45. Runge P, Muller DPR, McAllister J, Calver D, Lloyd JK, Taylor D. Oral vitamin E supplements can prevent the retinopathy of abetalipoproteinemia. *Brit J Ophthalmol* 1986;70:166–173.
46. Kayden HJ, Hatam LJ, Traber MG. The measurement of nanograms of tocopherol from needle aspiration biopsies of adipose tissue: normal and abetalipoproteinemic subjects. *J Lipid Res* 1983;24:652–656.
47. Chowers I, Banin E, Merin S, Cooper M, Granot E. Long-term assessment of combined vitamin A and E treatment for the prevention of retinal degeneration in abetalipoproteinemia and hypobetalipoproteinemia patients. *Eye* 2001;15:525–530.
48. Granot E, Kohen R. Oxidative stress in abetalipoproteinemia patients receiving long-term vitamin E and vitamin A supplementation. *Am J Clin Nutr* 2004;79:226–230.
49. Schonfeld G. Familial hypobetalipoproteinemia: a review. *J Lipid Res* 2003;44:878–883.
50. Lancellotti S, Di Leo E, Penacchioni JY, et al. Hypobetalipoproteinemia with an apparently recessive inheritance due to a “de novo” mutation of apolipoprotein B. *Biochim Biophys Acta* 2004;1688:61–67.
51. Di Leo E, Lancellotti S, Penacchioni JY, et al. Mutations in MTP gene in abeta- and hypobeta-lipoproteinemia. *Atherosclerosis* 2005;180:311–318.
52. Brosnahan DM, Kennedy SM, Converse CA, Lee WR, Hammer HM. Pathology of hereditary retinal degeneration associated with hypobetalipoproteinemia. *Ophthalmology* 1994;101:38–45.
53. Takki KK, Milton RC. The natural history of gyrate atrophy of the choroid and retina. *Ophthalmology* 1981;88:292–301.
54. Wilson DJ, Weleber RG, Green WR. Ocular clinicopathologic study of gyrate atrophy. *Am J Ophthalmol* 1991;111:24–33.
55. Kaiser-Kupfer MI, Kuwabara T, Askanas V, et al. Systemic manifestations of gyrate atrophy of the choroid and retina. *Ophthalmology* 1981;88:302–306.
56. Valtonen M, Nanto-Salonen K, Jaaskelainen S, et al. Central nervous system involvement in gyrate atrophy of the choroid and retina with hyperornithinaemia. *J Inher Metab Dis* 1999;22:855–866.
57. Simell O, Takki K. Raised plasma-ornithine and gyrate atrophy of the choroid and retina. *Lancet* 1973;1:1031–1033.
58. Inana G, Hotta Y, Zintz C, et al. Expression defect of ornithine aminotransferase gene in gyrate atrophy. *Invest Ophthalmol Vis Sci* 1988;29:1001–1005.
59. Mashima Y, Shiono T, Tamai M, Inana G. Heterogeneity and uniqueness of ornithine aminotransferase mutations found in Japanese gyrate atrophy patients. *Curr Eye Res* 1996;15:792–796.

60. Ramesh V, McClatchey AI, Ramesh N, et al. Molecular basis of ornithine aminotransferase deficiency in B-6-responsive and -nonresponsive forms of gyrate atrophy. *Proc Natl Acad Sci USA* 1988;85:3777–3780.
61. Dougherty KM, Swanson DA, Brody LC, Valle D. Expression and processing of human ornithine- δ -aminotransferase in *Saccharomyces cerevisiae*. *Hum Mol Genet* 1993;2:1835–1840.
62. Michaud J, Thompson GN, Brody LC, et al. Pyridoxine-response gyrate atrophy of the choroid and retina: clinical and biochemical correlates of the mutation A226V. *Am J Hum Genet* 1995;56:616–622.
63. Mashima Y, Weleber RG, Kennaway NG, Inana G. Genotype-phenotype correlation of a pyridoxine-responsive form of gyrate atrophy. *Ophthalm Genet* 1999;20:219–224.
64. Kuwabara T, Ishikawa Y, Kaiser-Kupfer MI. Experimental model of gyrate atrophy in animals. *Ophthalmology* 1981;88:331–334.
65. Wang T, Lawler AM, Steel G, Sipila I, Milam AH, Valle D. Mice lacking ornithine-delta-aminotransferase have paradoxical neonatal hypoorithinaemia and retinal degeneration. *Nat Genet* 1995;11:185–190.
66. Wang T, Milam AH, Steel G, Valle D. A mouse model of gyrate atrophy of the choroid and retina. Early retinal pigment epithelium damage and progressive retinal degeneration. *J Clin Invest* 1996;97:2753–2762.
67. Wang T, Steel G, Milam AH, Valle D. Correlation of ornithine accumulation prevents retinal degeneration in a mouse model of gyrate atrophy in the cornea and retina. *Proc Natl Acad Sci USA* 2000;97:1224–1229.
68. Sipilä I, Rapola J, Simell O, Vannas A. Supplementary creatinine as a treatment for gyrate atrophy of the choroid and retina. *N Engl J Med* 1981;304:867–870.
69. Valle D, Walser M, Brusilow S, Kaiser-Kupfer MI, Takki K. Gyrate atrophy of the choroid and retina: biochemical considerations and experience with an arginine-restricted diet. *Ophthalmology* 1981;88:325–330.
70. Kaiser-Kupfer MI, de Monasterio F, Valle D, Walser M, Brusilow S. Visual results of a long-term trial of a low-arginine diet in gyrate atrophy of choroid and retina. *Ophthalmology* 1981;88:307–310.
71. Kaiser-Kupfer MI, Caruso RC, Valle D. Gyrate atrophy of the choroid and retina: long-term reduction of ornithine slow retinal degeneration. *Arch Ophthalmol* 1991;109:1539–1548.
72. Berson EL, Shih VE, Sullivan PL. Ocular findings in patients with gyrate atrophy on pyridoxine and low-protein, low-arginine diets. *Ophthalmology* 1981;88:311–315.
73. Weleber RG, Kennaway NG, Buist NRM. Vitamin B₆ in management of gyrate atrophy of choroid and retina. *Lancet* 1978;2:1213.
74. Weleber RG, Kennaway NG. Clinical trial of vitamin B₆ for gyrate atrophy of the choroid and retina. *Ophthalmology* 1981;88:316–324.
75. Hayasaka S, Saito T, Nakajima H, et al. Gyrate atrophy with hyperornithinaemia: different types of responsiveness to vitamin B₆. *Br J Ophthalmol* 1981;65:478–483.
76. Valle D, Walser M, Brusilow SW, Kaiser-Kupfer M. Gyrate atrophy of the choroid and retina: amino acid metabolism and correction of hyperornithinemia with an arginine-deficient diet. *J Clin Invest* 1980;65:371–378.
77. Kaiser-Kupfer M, Caruso RC, Valle D, Reed GF. Use of an arginine-restricted diet to slow progression of visual loss in patients with gyrate atrophy. *Arch Ophthalmol* 2004;122:982–984.
78. Kaiser-Kupfer MI, Valle D, Bron AJ. Clinical and biochemical heterogeneity in gyrate atrophy. *Am J Ophthalmol* 1980;89:219–222.
79. Food and Nutrition Board, Institute of Medicine. Dietary Reference Intakes for Thiamin, Riboflavin, Niacin, Vitamin B₆, Folate, Vitamin B₁₂, Pantothenic Acid, Biotin, and Choline. A Report of the Standing Committee on the Scientific Evaluation of Dietary Reference Intakes and its Panel on Folate, Other B Vitamins, and Choline, and Subcommittee on Upper Reference Levels of Nutrients. Washington, D.C., National Academy Press, 1998.
80. Giordano C, DeSanto NG, Pluvio M, Santinelli R, Stoppoloni G. Lysine in treatment of hyperornithinemia. *Nephron* 1978;22:97–106.
81. Yatziv S, Statter M, Merin S. Metabolic studies in two families with hyperornithinemia and gyrate atrophy of the choroid and retina. *J Lab Clin Med* 1979;93:749–757.
82. Hayasaka S, Saito T, Nakajima H, Takahashi O, Mizuno K, Tada K. Clinical trials of vitamin B₆ and proline supplementation for gyrate atrophy of the choroid and retina. *Br J Ophthalmol* 1985;69:283–290.

83. Elpeleg N, Korman SH. Sustained oral lysine supplementation in ornithine delta-aminotransferase deficiency. *J Inherit Metab Dis* 2001;24:423–424.
84. Refsum S. Heredopathia atactica polyneuritiformis: a familial syndrome not hitherto described. *Acta Psychiatr Neurol Scand (Suppl)* 1946;38:1–303.
85. Refsum S. Heredopathia atactica polyneuritiformis. Phytanic-acid storage disease, Refsum's disease: a biochemically well-defined disease with a specific dietary treatment. *Arch Neurol* 1981;38:605–606.
86. Klenk E, Kahlke W. Über das Vorkommen der 3,7,11,15-tetramethyl-hexadecansäure (Phytansäure) in den Cholesterinestern und anderen Lipoidfraktionen der Organe bei einem Krankheitsfall unbekannter Genese (Verdacht auf Heredopathia atactica polyneuritiformis [Refsum Syndrome]). *Hoppe Seyler's Zeitschr physiol Chem* 1963;333:133–139.
87. Avigan J, Steinberg D, Gutman A, Mize CE, Milne GWA. Alpha-decarboxylation, an important pathway for degradation of phytanic acid in animals. *Biochem Biophys Res Commun* 1966;24:838–844.
88. Eldjarn L, Stokke O, Try K. Alpha-oxidation of branched chain fatty acids in man and its failure in patients with Refsum's disease showing phytanic acid accumulation. *Scand J Clin Lab Invest* 1966;18:694–695.
89. Hansen E, Bachen NI, Flage T. Refsum's disease. Eye manifestations in a patient treated with low phytol low phytanic acid diet. *Acta Ophthalmol* 1979;57:899–913.
90. Toussaint D, Danis P. An ocular pathologic study of Refsum's syndrome. *Am J Ophthalmol* 1971;72:342–347.
91. Scotto JM, Hadchouel M, Odievre M, et al. Infantile phytanic acid storage disease, a possible variant of Refsum's disease: three cases, including ultrastructural studies of the liver. *J Inherit Metab Dis* 1982;5:83–90.
92. Weleber RG, Tongue AC, Kennaway NG, Budden SS, Buist NRM. Ophthalmic manifestations of infantile phytanic acid storage disease. *Arch Ophthalmol* 1984;102:1317–1321.
93. Richterich R, Rosin S, Rossi E. Refsum's disease (heredopathia atactica polyneuritiformis): an inborn error of lipid metabolism with storage of 3, 7, 11, 15 tetramethyl hexadecanoic acid: formal genetics. *Humangenetik* 1965;1:333–336.
94. Herndon JH Jr, Steinberg D, Uhlendorf BW. Refsum's disease: defective oxidation of phytanic acid in tissue cultures derived from homozygotes and heterozygotes. *N Engl J Med* 1969;281:1034–1038.
95. Goldman JM, Clemens ME, Gibberd FB, Billimoria JD. Screening of patients with retinitis pigmentosa for heredopathia atactica polyneuritiformis (Refsum's disease). *Brit Med J* 1985;290:1109–1110.
96. Gibberd FB, Feher MD, Sidey MC, Wierzbicki AS. Smell testing: an additional tool for identification of adult Refsum's disease. *J Neurol Neurosurg Psychiatry* 2004;75:1334–1336.
97. Wanders RJA, Jakobs C, Skjeldal OH. Refsum disease. In: Scriver CR, Beaudet AL, Sly WS, Valle D (eds). *The Metabolic & Molecular Bases of Inherited Disease*. Eighth Edition. New York, McGraw-Hill: 2001; pp. 3303–3321.
98. Yamamoto S, Onozu H, Yamada N, Hayasaka S, Watanabe A. Mild retinal changes in a 47-year-old patient with phytanic acid storage disease. *Ophthalmologica* 1995;209:251–255.
99. Masters-Thomas A, Bailes J, Billimoria JD, Clemens ME, Gibberd FB, Page NGR. Heredopathia atactica polyneuritiformis (Refsum's disease). 2. Estimation of phytanic acid in foods. *J Hum Nutr* 1980;34:251–254.
100. Jansen GA, Ofman R, Ferdinandusse S, et al. Refsum disease is caused by mutations in the phytanoyl-CoA hydroxylase gene. *Nat Genet* 1997;17:190–193.
101. Jansen GA, Wanders RJA, Watkins PA, Mihalik SJ. Phytanoyl-coenzyme A hydroxylase deficiency—the enzyme defect in Refsum's disease. *N Engl J Med* 1997;337:133–134.
102. Jansen GA, Ferdinandusse S, Skjeldal OH, et al. Molecular basis of Refsum's disease: identification of new mutations in the phytanoyl-CoA hydroxylase cDNA. *J Inherit Metab Dis* 1998;21:288–291.
103. Croes K, Casteels M, Asselberghs S, Herdewijn P, Mannaerts GP, Van Veldhoven PP. Formation of a 2-methyl-branched fatty aldehyde during peroxisomal alpha-oxidation. *FEBS Lett* 1997;412:643–645.
104. Verhoeven NM, Schor DSM, ten Brink HJ, Wanders RJA, Jakobs C. Resolution of the phytanic acid α -oxidation pathway: identification of pristanal as product of the decarboxylation of 2-hydroxyphytanoyl CoA. *Biochem Biophys Res Commun* 1997;237:33–36.
105. Jansen GA, Waterham HR, Wanders RJA. Molecular basis of Refsum disease: sequence variations in the phytanoyl-CoA hydroxylase (PHYH) and the PTS2 receptor (PEX7). *Hum Mutation* 2004;23:209–218.

106. Levy IS. Refsum's syndrome. *Trans Ophthalmol Soc UK* 1970;90:181–186.
107. Eldjarn L, Try K, Stokke O, et al. Dietary effects on serum-phytanic-acid levels and on clinical manifestations in hereditary ataxia polyneuritisformis. *Lancet* 1966;1:691–693.
108. Steinberg D, Mize CE, Herndon JH Jr, Fales HM, Engel WK, Vroom FQ. Phytanic acid in patients with Refsum's syndrome and response to dietary treatment. *Arch Intern Med* 1970;125:75–87.
109. Masters-Thomas A, Bailes J, Billimoria JD, Clemens ME, Gibberd FB, Page NG. Hereditary ataxia polyneuritisformis (Refsum's disease). 1. Clinical features and dietary management. *J Hum Nutr* 1980;34:245–250.
110. Lundberg A, Lilja LG, Lundberg PO, Try K. Hereditary ataxia polyneuritisformis (Refsum's disease). Experiences of dietary treatment and plasmapheresis. *Eur Neurol* 1972;8:309–324.
111. Gibberd FB, Billimoria JD, Page NGR, Retsas S. Hereditary ataxia polyneuritisformis (Refsum's disease) treated by diet and plasma-exchange. *Lancet* 1979;1:575–578.
112. Hungerbühler JP, Meier C, Rousselle L, Quadri P, Bogousslavsky J. Refsum's disease: management by diet and plasmapheresis. *Eur Neurol* 1985;24:153–159.
113. Von Reuss A. Zuckerausscheidung im Säuglingsalter. *Wien Med Wochenschr* 1908;58:799.
114. Göppert F. Galaktosuria nach Milchzuckergabe bei angeborenen, familiärem, chronischem Leberleiden. *Berliner klin Wochenschr* 1917;54:473–477.
115. Mason HH, Turner ME. Chronic galactemia: report of case with studies on carbohydrates. *Am J Dis Child* 1935;50:359–374.
116. Bruck E, Rapoport S. Galactosemia in an infant with cataracts: clinical observations and carbohydrate studies. *Am J Dis Child* 1945;70:267–276.
117. Dahlqvist A, Gamstorp I, Madsen H. A patient with hereditary galactokinase deficiency. *Acta Paediatr Scand* 1970;59:669–675.
118. Cook JGH, Don NA, Mann TP. Hereditary galactokinase deficiency. *Arch Dis Child* 1971;46:465–469.
119. Kerr MM, Logan RW, Cant JS, Hutchison JH. Galactokinase deficiency in a newborn infant. *Arch Dis Child* 1971;46:864–866.
120. Oberman AE, Wilson WA, Frasier SD, Donnell GN, Bergren WR. Galactokinase-deficiency cataracts in identical twins. *Am J Ophthalmol* 1972;74:887–892.
121. Levy NS, Krill AE, Beutler E. Galactokinase deficiency and cataracts. *Am J Ophthalmol* 1972;74:41–48.
122. Pickering WR, Howell RR. Galactokinase deficiency: clinical and biochemical findings in a new kindred. *J Pediatr* 1972;81:50–55.
123. Litman N, Kanter AI, Finberg L. Galactokinase deficiency presenting as pseudotumor cerebri. *J Pediatr* 1975;86:410–412.
124. Colin J, Voyer M, Thomas D, Schapira F, Satge P. Cataracte par déficit en galactokinase chez un premature. *Arch Franç Pediatr* 1976;33:77–82.
125. Beigi B, O'Keefe M, Bowell R, Naughten E, Badawi N, Lanigan B. Ophthalmic findings in classical galactosaemia—prospective study. *Brit J Ophthalmol* 1993;77:162–164.
126. Levy HL, Brown AE, Williams SE, de Juan E Jr. Vitreous hemorrhage as an ophthalmic complication of galactosemia. *J Pediatr* 1996;129:922–925.
127. Stambolian D, Ai Y, Sidjanin D, et al. Cloning of the galactokinase cDNA and identification of mutations in two families with cataracts. *Nat Genet* 1995;19:307–312.
128. Shih LY, Suslak L, Rosin I, Searle BM, Desposito F. Gene dosage studies support localization of the structural gene for galactose-1-phosphate uridyl transferase (GALT) to band p13 of chromosome 9. *Am J Med Genet* 1984;19:539–543.
129. Lin MS, Oizumi J, Ng WG, Alfi OS, Donnell GN. Regional mapping of the gene for human UDPGal 4-epimerase on chromosome 1 in mouse-human hybrids. *Cytogenet Cell Genet* 1979;24:217–223.
130. Holton JB, Walter JH, Tyfield LA. Galactosemia. In: Scriver CR, Beaudet AL, Sly WS, Valle D (eds). *The Metabolic & Molecular Bases of Inherited Disease*. Eighth Edition. New York, McGraw-Hill: 2001; pp. 1553–1587.
131. Beutler E, Irwin HR, Blumenfeld CM, Goldenburg EW, Day RW. Field test of galactosaemia screening methods in newborn infants. *J Am Med Assoc* 1976;199:501–503.
132. Badawi N, Cahalane SF, McDonald M, et al. Galactosaemia—a controversial disorder. Screening & Outcome. Ireland 1972–1992. *Irish Med J* 1996;89:16–17.

133. Chung MA. Galactosemia in infancy: diagnosis, management, and prognosis. *Pediatr Nursing* 1997;23:563–575.
134. Waggoner DD, Buist NR, Donnell GN. Long-term prognosis in galactosaemia: results of a survey of 350 cases. *J Inherit Metab Dis* 1990;13:802–818.
135. Walter JH, Collins JE, Leonard JV, and UK Galactosaemia Steering Group. Recommendations for the management of galactosaemia. *Arch Dis Child* 1999;80:93–96.
136. Acosta PB, Gross KC. Hidden sources of galactose in the environment. *Eur J Pediatr* 1995;154(suppl 2):S87–S92.
137. Holton JB. Galactosaemia: pathogenesis and treatment. *J Inher Metab Dis* 1996;19:3–7.
138. Widhalm K, Miranda de Cruz BDO, Koch M. Diet does not ensure normal development in galactosemia. *J Am Coll Nutr* 1997;16:204–208.
139. Zlatunich CO, Packman S. Galactosaemia: early treatment with an elemental formula. *J Inherit Metab Dis* 2005;28:163–168.
140. Richner H. Hornhautaffektion bei Keratoma palmare et plantare hereditarium. *Klin Monatsbl Augenheilk* 1938;100:580–588.
141. Hanhart E. Neue Sonderformen von Keratosis palmo-plantaris, u.a. eine regelmässig-dominante mit systematisierten Lipomen, ferner 2 einfach-rezessive mit Schwachsinn und z. T. mit Hornhautveränderungen des Auges (Ektodermalsyndrom). *Dermatologica* 1947;94:286–308.
142. Spanlang H. Beiträge zur Klinik und Pathologie seltener Hornhauterkrankungen (Dystrophia adiposa corneae, Dyskeratosis corneae congenita). *Zeitschr Augenheilk* 1927;62:21–41.
143. Fuhs H. Über das seltene Syndrom von congenitalen Keratosen an Haut und Kornea. *Dermatol Zeitschr* 1928;53:199–208.
144. Forgacs J, Franceschetti A. Histologic aspect of corneal changes due to hereditary, metabolic, and cutaneous affections. *Am J Ophthalmol* 1959;41:191–202.
145. Ventura G, Biasini G, Petrozzi M. Cheratoma palmoplantare dissipatum associato a lesioni corneali in due fratelli. *Boll Ocul* 1965;44:497–510.
146. Franceschetti AT, Schnyder UW, Felgenhauer WR. Die Cornea beim Richner-Hanhart Syndrom. *Ber Zusammenkunft Dtsch Ophthalmol Ges* 1972;71:109–114.
147. Goldsmith LA, Kang E, Bienfang DC, Jimbow K, Gerald P, Baden HP. Tyrosinemia with plantar and palmar keratosis and keratitis. *J Pediatr* 1973;83:798–805.
148. Biengfang DC, Kuwabara T, Pueschel SM. The Richner-Hanhart syndrome. Report of a case with associated tyrosinemia. *Arch Ophthalmol* 1976;94:1133–1137.
149. Hunziker N. Richner-Hanhart syndrome and tyrosinemia type II. *Dermatologica* 1980;160:180–189.
150. Rehák A, Selim MM, Yada G. Richner-Hanhart syndrome (tyrosinaemia-II) (report of four cases without ocular involvement). *Brit J Dermatol* 1981;104:469–475.
151. Sammartino A, de Crecchio N, Balato G, Lembo A, Federico A, Pallini R. Familial Richner-Hanhart syndrome: genetic, clinical, and metabolic studies. *Ann Ophthalmol* 1984;16:1069–1074.
152. Sayar RB, von Domarus D, Schäfer HJ, Beckenkamp G. Clinical picture and problems of keratoplasty in Richner-Hanhart syndrome (tyrosinemia type II). *Ophthalmologica* 1988;197:1–6.
153. Roussat B, Fournier F, Besson D, Godde-Joly D. A propos de deux cas de tyrosinose de type II (syndrome de Richner-Hanhart). *Bull Soc Opht France* 1988;88:6–7.
154. Foels MO, Dufier JL, Renard G, Gounod N, D’Hermes F, Pouliquen Y. Tyrosinose oculocutane type II ou syndrome de Richner-Hanhart—A propos d’un cas. *Bull Soc Opht France* 1989;89:21–24.
155. Al-Hemidan AI, Al-Hazzaa SAF. Richner-Hanhart syndrome (tyrosinemia type II). Case report and literature review. *Ophthalm Genet* 1995;16:21–26.
156. Tallab TM. Richner-Hanhart syndrome: importance of early diagnosis and early intervention. *J Am Acad Dermatol* 1996;35:857–859.
157. Fois A, Borgogni P, Cioni M, et al. Presentation of the data of the Italian registry for oculocutaneous tyrosinaemia. *J Inherit Metab Dis* 1986;9(suppl):262–S263.
158. Martin GJ, Hueper WC. Biochemical lesions produced by diets high in tyrosine. *Arch Biochem Biophys* 1942;1:435.
159. Bardelli AM, Borgogni P, Farnetani MA, et al. Familial tyrosinaemia with eye and skin lesions: presentation of two cases. *Ophthalmologica* 1977;175:5–9.

160. Goldsmith LA. Molecular biology and molecular pathology of a newly described molecular disease—tyrosinemia II (the Richner-Hanhart syndrome). *Exp Cell Biol* 1978;46:96–113.
161. Zaleski WA, Hill A, Kushniruk W. Skin lesions in tyrosinosis: response to dietary treatment. *Br J Dermatol* 1973;88:335–340.
162. Natt E, Westphal EM, Toth-Fejel SE, et al. Inherited and de novo deletion of the tyrosine aminotransferase gene locus at 16q22.16q22.3 in a patient with tyrosinemia type II. *Hum Genet* 1987;77:352–358.
163. Natt E, Kida K, Odievre M, Di Rocco M, Scherer G. Point mutations in the tyrosine aminotransferase gene in tyrosinemia type II. *Proc Natl Acad Sci USA* 1992;89:9297–9301.
164. Hühn R, Stoermer H, Klingele B, et al. Novel and recurrent tyrosine aminotransferase gene mutations in tyrosinemia type II. *Hum Genet* 1998;102:305–313.
165. Sammartino A, Cerbella R, Cecio A, DeCrecchio G, Federico A, Fronterre A. The effect of diet on the ophthalmological, clinical and biochemical aspects of Richner-Hanhart syndrome: a morphological ultrastructural study of the cornea and the conjunctiva. *Int Ophthalmol* 1987;10:203–212.
166. Siemerling E, Creutzfeldt HG. Bronzekrankheit und sclerosierende Encephalomyelitis (Diffuse Sklerose). *Archiv für Psychiatrie und Nervenkrankheiten* 1923;68:217–244.
167. Berger J, Moser HW, Forss-Petter S. Leukodystrophies: recent developments in genetics, molecular biology, pathogenesis and treatment. *Curr Opin Neurol* 2001;14:305–312.
168. Van Geel BM, Assies J, Wanders RJA, Barth PG. X linked adrenoleukodystrophy: clinical presentation, diagnosis, and therapy. *J Neurol Neurosurg Psychiatry* 1997;63:4–14.
169. Moser HW, Borel J. Dietary management of X-linked adrenoleukodystrophy. *Annu Rev Nutr* 1995;15:379–397.
170. Wray SH, Cogan DG, Kuwabara T, Schaumburg HH, Powers JM. Adrenoleukodystrophy with disease of the eye and optic nerve. *Am J Ophthalmol* 1976;82:480–485.
171. Cohen SM, Green WR, de la Cruz ZC, et al. Ocular histopathologic studies of neonatal and childhood adrenoleukodystrophy. *Am J Ophthalmol* 1983;95:82–96.
172. Kaplan PW, Kruse B, Tusa RJ, Shankroff J, Rignani JE, Moser HW. Visual system abnormalities in adrenomyeloneuropathy. *Ann Neurol* 1995;37:550–552.
173. Sack GH Jr, Raven MB, Moser HW. Color vision defects in adrenomyeloneuropathy. *Am J Hum Genet* 1989;44:794–798.
174. Moser HW, Loes DJ, Melhem ER, et al. X-linked adrenoleukodystrophy: overview and prognosis as a function of age and brain magnetic resonance imaging abnormality. A study involving 372 patients. *Neuropediatrics* 2000;31:227–239.
175. Migeon BR, Moser HW, Moser AB, Axelman J, Sillence D, Norum RA. Adrenoleukodystrophy: evidence for X linkage, inactivation, and selection favouring the mutant allele in heterozygous cells. *Proc Natl Acad Sci USA* 1981;78:5066–5070.
176. Mosser J, Douar AM, Sarde CO, et al. Putative X-linked adrenoleukodystrophy gene shares unexpected homology with ABC transporters. *Nature* 1993;361:726–730.
177. Takemoto Y, Suzuki Y, Horibe R, Shimozaawa N, Wanders RJA, Kondo N. Gas chromatography/mass spectrometry analysis of very long chain fatty acids, docosahexaenoic acid, phytanic acid and plasmalogen for the screening of peroxisomal disorders. *Brain Develop* 2003;27:481–487.
178. Valianpour F, Selhorst JJM, van Lint LEM, van Gennip AH, Wanders RJA, Kemp S. Analysis of very long chain fatty acids using electrospray ionization mass spectrometry. *Mol Genet Metab* 2003;79:189–196.
179. Kemp S, Valianpour F, Denis S, et al. Elongation of very long-chain fatty acids is enhanced in X-linked adrenoleukodystrophy. *Mol Genet Metab* 2005;84:144–151.
180. Brown FR, Van Duyn MAS, Moser AB, et al. Adrenoleukodystrophy: effects of dietary restriction of very long chain fatty acids and of administration of carnitine and clofibrate on clinical status and plasma fatty acids. *John Hopkins Med J* 1982;151:164–172.
181. Aubourg P, Adamsbaum C, Lavallard-Rousseau MC, et al. A two-year trial of oleic and erucic acids ('Lorenzo's oil' as treatment for adrenomyeloneuropathy. *N Engl J Med* 1993;329:745–752.
182. Restuccia D, Di Lazzaro V, Valeriani M, et al. Neurophysiologic follow-up of long-term dietary treatment in adult-onset adrenoleukodystrophy. *Neurology* 1999;52:810–816.
183. Asano JI, Suzuki Y, Yajima S, et al. Effects of erucic acid therapy on Japanese patients with X-linked adrenoleukodystrophy. *Brain Dev* 1994;16:454–458.

184. Moser HW, Raymond GV, Koehler W, et al. Evaluation of the preventive effect of glyceryl trioleate-trierythrate ("Lorenzo's oil") therapy in X-linked adrenoleukodystrophy: results of two concurrent trials. *Adv Exp Med Biol* 2003;544:369–387.
185. Moser H, Dubey P, Fatemi A. Progress in X-linked adrenoleukodystrophy. *Curr Opin Neurol* 2004;17:263–269.
186. Carson NAJ, Neill DW. Metabolic abnormalities detected in a survey of mentally backward individuals in Northern Ireland. *Arch Dis Child* 1962;37:505–513.
187. Gerritsen T, Vaughn JG, Waisman HA. The identification of homocystine in the urine. *Biochem Biophys Res Commun* 1962;9:493–496.
188. Mudd SH, Finkelstein JD, Irreverre F, Laster L. Homocystinuria: an enzymatic defect. *Science* 1964;143:1443–1445.
189. Mudd SH, Levy HL, Kraus JP. Disorders of transsulfuration. In: Scriver CR, Beaudet AL, Sly WS, Valle D (eds). *The Metabolic & Molecular Bases of Inherited Disease*. Eighth Edition. New York, McGraw-Hill: 2001; pp. 2007–2056.
190. Spaeth GL, Barber GW. Homocystinuria—its ocular manifestations. *J Pediatr Ophthalmol Strabismus* 1966;3:42–48.
191. Harrison DA, Mullaney PB, Mesfer SA, Awad AH, Dhindsa H. Management of ophthalmic complications of homocystinuria. *Ophthalmology* 1998;105:1886–1890.
192. Cruysberg JRM, Boers GHJ, Trijbels JMF, Deutman AF. Delay in diagnosis of homocystinuria: retrospective study of consecutive patients. *Br Med J* 1996;313:1037–1040.
193. National Research Council. *Recommended Dietary Allowances*. 10th edition. Washington, D.C., National Academy Press, 1989.
194. Kraus JP, Le K, Swaroop M, et al. Human cystathionine β -synthase cDNA: sequence, alternative splicing and expression in cultured cells. *Hum Mol Genet* 1993;2:1633–1638.
195. Mücke M, Kraus JP, Ohura T, Francke U. The gene for cystathionine β -synthase (*CBS*) maps to the subtelomeric region on human chromosome 21q and to proximal mouse chromosome 17. *Am J Hum Genet* 1988;42:550–559.
196. Sakai LY, Keene DR, Engvall E. Fibrillin, a new 350-kD glycoprotein, is a component of extracellular microfibrils. *J Cell Biol* 1986;103:2499–2509.
197. Burke JP, O'Keefe M, Howell R, Naughton ER. Ocular complications of homocystinuria—early and late treated. *Br J Ophthalmol* 1989;73:427–431.
198. Wilcken B, Hammond J. Homozygous cystathionine β -synthase deficiency (CSD) and homocysteine remethylating disorders: relative incidence in New South Wales [abstract]. *Irish J Med Sci* 1995;164 (suppl 15):23.
199. Yap S, Naughton E. Homocystinuria due to cystathionine β -synthase deficiency in Ireland: 25 years' experience of a newborn screened and treated population with reference to clinical outcome and biochemical control. *J Inher Metab Dis* 1998;21:738–747.
200. Barber GW, Spaeth GL. Pyridoxine therapy in homocystinuria. *Lancet* 1967;1:337.
201. Yap S, Boers HJ, Wilcken B, et al. Vascular outcome in patients with homocystinuria due to cystathionine β -synthase deficiency treated chronically: a multicenter observational study. *Arterioscler Thromb Vasc Biol* 2001;21:2080–2085.
202. Walter JH, Wraith JE, White FJ, Bridge C, Till J. Strategies for the treatment of cystathionine β -synthase deficiency: the experience of the Willink Biochemical Genetics Unit over the past 30 years. *Eur J Pediatr* 1998;157(suppl 2):S71–S76.
203. Bendich A, Cohen M. Vitamin B₆ safety issues. *Ann NY Acad Sci* 1990;585:321–330.
204. Holme E, Kjellman B, Ronge E. Betaine for treatment of homocystinuria caused by methylenetetrahydrofolate reductase deficiency. *Arch Dis Child* 1989;64:1061–1064.
205. Mudd SH, Skovby F, Levy HL, et al. The natural history of homocystinuria due to cystathionine β -synthase deficiency. *Am J Hum Genet* 1985;37:1–31.
206. Taylor RH, Burke J, O'Keefe M, Beighi B, Naughton E. Ophthalmic abnormalities in homocystinuria: the value of screening. *Eye* 1998;12:427–430.
207. Mulvihill A, Yap S, O'Keefe M, Howard PM, Naughton ER. Ocular findings among patients with late-diagnosed or poorly controlled homocystinuria compared with a screened, well-controlled population. *J AAPOS* 2001;5:311–315.

208. Yap S, Rushe H, Howard PM, Naughten ER. The intellectual abilities of early-treated individuals with pyridoxine-nonresponsive homocystinuria due to cystathionine β -synthase deficiency. *J Inher Metab Dis* 2001;24:437–447.
209. Wilcken DEL, Wilcken B. The natural history of vascular disease in homocystinuria and the effects of treatment. *J Inher Metab Dis* 1997;20:295–300.
210. Wilson SAK. Progressive lenticular degeneration, a familial nervous disease associated with cirrhosis of the liver. *Brain* 1912;34:295–509.
211. Frerichs FT. *Klinik der Leberkrankheiten*. Bd. 2. Braunschweig, F. Vieweg u. Sohn, 1861, pp. 62–64.
212. Finelli PF. Kayser-Fleischer ring: hepatolenticular degeneration (Wilson's disease). *Neurology* 1995; 45:1261–1262.
213. Kayser B. Ueber einen Fall von angeborener grünlicher Verfärbung der Cornea. *Klin Monatsbl Augenheilk* 1902;40:22–25.
214. Fleischer B. Die periphere braun-grünliche Hornhautverfärbung, als Symptom einer eigenartigen Allgemeinerkrankung. *Munch Med Wochenschr* 1909;56:1120–1123.
215. Fleischer B. Über eine der "Pseudosklerose" nahestehende bisher unbekannte Krankheit (gekennzeichnet durch Tremor, psychische Störungen, bräunliche Pigmentierung bestimmter Gewebe, insbesondere auch der Hornhautperipherie, Lebercirrhose). *Deutsch Zeitschr Nervenheilk* 1912;44:179–201.
216. Innes JR, Strachan IM, Triger DR. Unilateral Kayser-Fleischer ring. *Br J Ophthalmol* 1986;70:469–470.
217. Harry J, Tripathi R. Kayser-Fleischer ring: a pathological study. *Br J Ophthalmol* 1970;54:794–800.
218. Wiebers DO, Hollenhorst RW, Goldstein NP. The ophthalmologic manifestations of Wilson's disease. *Mayo Clin Proc* 1977;52:409–416.
219. Mitchell AM, Heller GL. Changes in Kayser-Fleischer ring during treatment of hepatolenticular degeneration. *Arch Ophthalmol* 1968;80:622–625.
220. Frommer D, Morris J, Sherlock S, Abrams J, Newman S. Kayser-Fleischer-like rings in patients without Wilson's disease. *Gastroenterology* 1977;72:1331–1335.
221. Rimola A, Bruguera M, Rodés J. Kayser-Fleischer-like ring in a cryptogenic cirrhosis. *Arch Intern Med* 1978;138:1857–1858.
222. Tso MOM, Fine BS, Thorpe HE. Kayser-Fleischer ring and associated cataract in Wilson's disease. *Am J Ophthalmol* 1975;79:479–488.
223. Curran RE, Hedges TR, Boger WP. Loss of accommodation and the near response in Wilson's disease. *J Pediatr Ophthalmol Strab* 1982;19:157–160.
224. Walshe JM. Wilson's disease presenting with features of hepatic dysfunction: a clinical analysis of eighty-seven patients. *Q J Med* 1989;70:253–263.
225. Linder MC. Copper. In: Ziegler EE, Filer LJ, Jr (eds). *Present Knowledge in Nutrition*. Washington, D.C., International Life Sciences Institute Press: 1996; pp. 307–319.
226. Pennington JAT, Wilson DB. Daily intakes of nine nutritional elements: analyzed vs calculated values. *J Am Diet Assoc* 1990;90:375–381.
227. Scott KC, Turnlund JR. Compartment model of copper metabolism in adult men. *J Nutr Biochem* 1994; 5:342–350.
228. Yamaguchi Y, Heiny ME, Gitlin JD. Isolation and characterization of a human liver cDNA as a candidate gene for Wilson disease. *Biochem Biophys Res Commun* 1993;197:271–277.
229. Bull PC, Thomas GR, Rommens JM, Forbes JR, Cox DW. The Wilson disease gene is a putative copper transporting P-type ATPase similar to the Menkes gene. *Nat Genet* 1993;5:327–337.
230. Tanzi RE, Petrukhin K, Chernov I, et al. The Wilson disease gene is a copper transporting ATPase with homology to the Menkes disease gene. *Nat Genet* 1993;5:344–350.
231. Frydman M, Bonne-Tamir B, Farrer LA, et al. Assignment of the gene for Wilson disease to chromosome 13: linkage of the esterase D locus. *Proc Natl Acad Sci USA* 1985;82:1819–1821.
232. Kooy RF, Van der Veen AY, Verlind E, Houwen RHJ, Scheffer H, Buys CHCM. Physical localisation of the chromosomal marker D13S31 places the Wilson disease locus at the junction of bands q14.3 and q21.1 of chromosome 13. *Hum Genet* 1993;91:504–506.
233. Culotta VC, Gitlin JD. Disorders of copper transport. In: Scriver CR, Beaudet AL, Sly WS, Valle D (eds). *The Metabolic & Molecular Bases of Inherited Disease*. Eighth Edition. New York, McGraw-Hill: 2001; pp. 3105–3126.

234. Marcellini M, Di Ciommo V, Callea F, et al. Treatment of Wilson's disease with zinc from the time of diagnosis in pediatric patients: a single-hospital, 10-year follow-up study. *J Lab Clin Med* 2005;1435:139–143.
235. Menkes JH, Alter M, Steigleder GK, Weakley DR, Sung JH. A sex-linked recessive disorder with retardation of growth, peculiar hair, and focal cerebral and cerebellar degeneration. *Pediatrics* 1962;29:764–769.
236. Danks DM, Cartwright E, Stevens BJ, Townley RR. Menkes' kinky hair disease: further definition of the defect in copper transport. *Science* 1973;179:114–1142.
237. Verga V, Hall BK, Wang SR, Johnson S, Higgins JV, Clover TW. Localization of the translocation breakpoint in a female with Menkes syndrome to Xq13.2-q13.3 proximal to PGK-1. *Am J Hum Genet* 1991;48:1133–1138.
238. Lo YS, Jong YJ, Chiang CH, Tsai JL. Menkes' kinky hair disease: report of one case. *Zhonghua Min Guo Xiao Er Ke Yi Xue Hui Za Zhi* 1989;30:196–201.
239. Kaler SG. Diagnosis and therapy of Menkes syndrome, a genetic form of copper deficiency. *Am J Clin Nutr* 1998;67(suppl):1029S–1034S.
240. Sorsby A, Joll-Mason ME. The dystrophies of the macula. *Br J Ophthalmol* 1940;24:469–533.
241. Sorsby A, Joll-Mason ME, Gardener N. A fundus dystrophy with unusual features. *Br J Ophthalmol* 1949;33:67–97.
242. Fraser HB, Wallace DC. Sorsby's familial pseudo-inflammatory macular dystrophy. *Am J Ophthalmol* 1971;71:1216–1220.
243. Holz FG, Haimovici R, Wagner DG, Bird AC. Recurrent choroidal neovascularization after laser photocoagulation in Sorsby's fundus dystrophy. *Retina* 1994;14:329–334.
244. Lafaut BA, De Backer E, Kohno T, De Laey JJ, Meire FM. Indocyanine green angiography in Sorsby's fundus dystrophy. *Graefes Arch Clin Exp Ophthalmol* 2000;238:15–162.
245. Burn RA. Further cases of fundus dystrophy with unusual features. *Br J Ophthalmol* 1950;34:393–403.
246. Hoskin A, Sehmi K, Bird AC. Sorsby's pseudoinflammatory macular dystrophy. *Br J Ophthalmol* 1981;65:859–865.
247. Lip PL, Good PA, Gibson JM. Sorsby's fundus dystrophy: a case report of 24 years follow-up with electrodiagnostic tests and indocyanine green angiography. *Eye* 1999;13:16–25.
248. Forsius HR, Eriksson AW, Suvanto EA, Alanko HI. Pseudoinflammatory fundus dystrophy with autosomal recessive inheritance. *Am J Ophthalmol* 1982;94:634–649.
249. Dreyer RF, Hidayat AA. Pseudoinflammatory macular dystrophy. *Am J Ophthalmol* 1988;106:154–161.
250. Steinmetz RL, Polkinghorne PC, Fitzke FW, Kemp CM, Bird AC. Abnormal dark adaptation and rhodopsin kinetics in Sorsby's fundus dystrophy. *Invest Ophthalmol Vis Sci* 1992;33:1633–1636.
251. Atan D, Gregory Evans CY, Louis D, Downs SM. Sorsby fundus dystrophy presenting with choroidal neovascularisation showing good response to steroid treatment. *Br J Ophthalmol* 2004;88:440–441.
252. Weber BHF, Vogt G, Wolz W, Ives EJ, Ewing CC. Sorsby's fundus dystrophy is genetically linked to chromosome 22q13-qter. *Nat Genet* 1994;7:158–161.
253. Brew K, Dinakarparandian D, Nagase H. Tissue inhibitors of metalloproteinases: evolution, structure and function. *Biochim Biophys Acta* 2000;1477:267–283.
254. Weber BHF, Vogt G, Pruett RC, Störr H, Felbor U. Mutations in the tissue inhibitor of metalloproteinases-3 (TIMP3) in Sorsby's fundus dystrophy. *Nat Genet* 1994;8:352–356.
255. Peters AL, Greenberg J. Sorsby's fundus dystrophy. A South African family with a point mutation on the tissue inhibitor of metalloproteinases-3 gene on chromosome 22. *Retina* 1995;15:480–485.
256. Carrero-Valenzuela RD, Klein ML, Weleber RG, Murphey WH, Litt M. Sorsby fundus dystrophy. A family with the Ser181Cys mutation of the tissue inhibitor of metalloproteinases 3. *Arch Ophthalmol* 1996;114:737–738.
257. Felbor U, Doeprner D, Schneider U, Zrenner E, Weber BHF. Evaluation of the gene encoding the tissue inhibitor of metalloproteinases-3 in various maculopathies. *Invest Ophthalmol Vis Sci* 1997;38:1054–1059.
258. Felbor U, Benkwitz C, Klein ML, Greenberg J, Gregory CY, Weber BHF. Sorsby fundus dystrophy. Reevaluation of variable expressivity in patients carrying a TIMP3 founder mutation. *Arch Ophthalmol* 1997;115:1569–1571.

259. Tabata Y, Isashiki Y, Kamimura K, Nakao K, Ohba N. A novel splice site mutation in the tissue inhibitor of the metalloproteinases-3 gene in Sorsby's fundus dystrophy with unusual clinical features. *Hum Genet* 1998;103:179–182.
260. Isashiki Y, Tabata Y, Kamimura K, Ohba N. Sorsby's fundus dystrophy in two Japanese families with unusual clinical features. *Jpn J Ophthalmol* 1999;43:472–480.
261. Langton KP, McKie N, Curtis A, et al. A novel tissue inhibitor of metalloproteinases-3 mutation reveals a common molecular phenotype in Sorsby's fundus dystrophy. *J Biol Chem* 2000;275:27027–27031.
262. Fariss RN, Apte SS, Olsen BR, Iwata K, Milam AH. Tissue inhibitor of metalloproteinases-3 is a component of Bruch's membrane of the eye. *Am J Pathol* 1997;150:323–328.
263. Della NG, Campochiaro PA, Zack DJ. Localization of TIMP-3 mRNA expression to the retinal pigment epithelium. *Invest Ophthalmol Vis Sci* 1996;37:1921–1924.
264. Fariss RN, Apte SS, Luthert PJ, Bird AC, Milam AH. Accumulation of tissue inhibitor of metalloproteinases-3 in human eyes with Sorsby's fundus dystrophy or retinitis pigmentosa. *Br J Ophthalmol* 1998;82:1329–1334.
265. Chong NHV, Alexander RA, Gin T, Bird AC, Luthert PJ. TIMP-3, collagen, and elastin immunohistochemistry and histopathology of Sorsby's fundus dystrophy. *Invest Ophthalmol Vis Sci* 2000;41:898–902.
266. Majid MA, Smith VA, Easty DL, Baker AH, Newby AC. Adenovirus mediated gene delivery of tissue inhibitor of metalloproteinases-3 induces death in retinal pigment epithelial cells. *Br J Ophthalmol* 2002;86:97–101.
267. Qi JH, Ebrahem Q, Yeow K, Edwards DR, Fox PL, Anand-Apte B. Expression of Sorsby's fundus dystrophy mutations in human retinal pigment epithelial cells reduces matrix metalloproteinase inhibition and may promote angiogenesis. *J Biol Chem* 2002;277:13394–13400.
268. Clarke M, Mitchell KW, Goodship J, et al. Clinical features of a novel TIMP-3 mutation causing Sorsby's fundus dystrophy: implications for disease mechanism. *Br J Ophthalmol* 2001;85:1429–1431.
269. Jacobson SG, Cideciyan AV, Regunath G, et al. Night blindness in Sorsby's fundus dystrophy reversed by vitamin A. *Nat Genet* 1995;11:27–32.
270. Cideciyan AV, Pugh EN Jr, Lamb TD, Huang Y, Jacobson SG. Rod plateaux during dark adaptation in Sorsby's fundus dystrophy and vitamin A deficiency. *Invest Ophthalmol Vis Sci* 1997;38:1786–1794.
271. Weisinger HS, Pesudovs K. Sorsby's fundus dystrophy. *Optometry* 2001;72:435–440.
272. Berson EL. Retinitis pigmentosa: The Friedenwald lecture. *Invest Ophthalmol Vis Sci* 1993;34:1659–1676.
273. Rivolta C, Sharon D, DeAngelis MM, Dryja TP. Retinitis pigmentosa and allied diseases: numerous diseases, genes, and inheritance patterns. *Hum Mol Genet* 2002;11:1219–1227.
274. Filatov VP, Verbitskaia EA. Intramuscular injections of cod liver oil in therapy of pigmented retinitis. *Med Zhur* 1939;9:847–853.
275. Verbitskaia EA. Tratamento da retinite pigmentar pelo retinol. *Arq Brasil Oftal* 1940;3:7–14.
276. Berson EL, Rosner B, Sandberg MA, et al. A randomized trial of vitamin A and vitamin E supplementation for retinitis pigmentosa. *Arch Ophthalmol* 1993;111:761–772.
277. Kupfer C, Berson EL. Information for doctors who follow patients with retinitis pigmentosa. Letter sent to eye care specialists in the United States, June 14, 1993.
278. Berson EL, Rosner B, Sandberg MA, et al. Vitamin A supplementation for retinitis pigmentosa [letter]. *Arch Ophthalmol* 1993;111:1456–1458.
279. Sandberg MA, Weigel-DiFranco C, Rosner B, Berson EL. The relationship between visual field size and electroretinogram amplitude in retinitis pigmentosa. *Invest Ophthalmol Vis Sci* 1996;37:1693–1698.
280. Li T, Sandberg MA, Pawlyk BS, et al. Effect of vitamin A supplementation on rhodopsin mutants threonine-17 → methionine and proline-347 → serine in transgenic mice and in cell cultures. *Proc Natl Acad Sci USA* 1998;95:11933–11938.
281. Semba RD. The safety of daily oral vitamin A supplementation for individuals with retinitis pigmentosa. *Ann Ophthalmol* 2002;34:194–198.
282. Berson EL, Rosner B, Sandberg MA, et al. Clinical trial of docosahexaenoic acid in patients with retinitis pigmentosa receiving vitamin A treatment. *Arch Ophthalmol* 2004;122:1297–1305.
283. Berson EL, Rosner B, Sandberg MA, et al. Further evaluation of docosahexaenoic acid in patients with retinitis pigmentosa receiving vitamin A treatment: subgroup analyses. *Arch Ophthalmol* 2004;122:1306–1314.

284. Menkes JH, Hurst PL, Craig JM. A new syndrome: progressive familial infantile cerebral dysfunction associated with an unusual urinary substance. *Pediatrics* 1954;14:462–467.
285. Westall RG, Dancis J, Miller S. Maple syrup urine disease. *Am J Dis Child* 1957;94:571–572.
286. Menkes JH. Maple syrup urine disease. Isolation and identification of organic acids in the urine. *Pediatrics* 1959;23:348–353.
287. Chuang DT, Shih VE. Maple syrup urine disease (branched-chain ketoaciduria). In: Scriver CR, Beaudet AL, Sly WS, Valle D (eds). *The Metabolic & Molecular Bases of Inherited Disease*. Eighth Edition. New York, McGraw-Hill: 2001; pp. 1971–2005.
288. Marshall L, DiGeorge A. Maple syrup urine disease in the old order Mennonites. *Am J Hum Genet* 1981;33:139A.
289. Zee DS, Freeman JM, Holtzman NA. Ophthalmoplegia in maple syrup urine disease. *J Pediatr* 1974; 84:113–115.
290. Burke JP, O’Keefe M, Howell R, Naughten ER. Ophthalmic findings in maple syrup urine disease. *Metab Pediatr Syst Ophthalmol* 1991;14:12–15.
291. Tornqvist K, Tornqvist H. Corneal deepithelialization caused by acute deficiency of isoleucine during treatment of a patient with maple syrup urine disease. *Acta Ophthalmol Scand Suppl* 1996;(219):48–49.
292. Duran M, Beemer FA, van der Heiden C, et al. Combined deficiency of xanthine oxidase and sulphite oxidase: a defect of molybdenum metabolism or transport? *J Inher Metab Dis* 1978;1:175–178.
293. Irreverre F, Mudd SH, Heizer WD, Lester L. Sulfite oxidase deficiency: studies of a patient with mental retardation, dislocated ocular lenses, and abnormal urinary excretion of S-sulfo-L-cysteine, sulfite and thiosulfite. *Biochem Med* 1967;1:187–199.
294. Lueder GT, Steiner RD. Ophthalmic abnormalities in molybdenum cofactor deficiency and isolated sulfite oxidase deficiency. *J Pediatr Ophthalmol Strabismus* 1995;32:334–337.
295. Parini R, Briscioli V, Caruso U, et al. Spherophakia associated with molybdenum cofactor deficiency. *Am J Med Genet* 1997;73:272–275.
296. Beemer FA, Duran M, Wadman SK, Cats BP. Absence of hepatic molybdenum cofactor. An inborn error of metabolism associated with lens dislocation. *Ophthalmic Paediatr Genet* 1985;5:191–195.
297. Johnson JL, Duran M. Molybdenum cofactor deficiency and isolated sulfite oxidase deficiency. In: Scriver CR, Beaudet AL, Sly WS, Valle D (eds). *The Metabolic & Molecular Bases of Inherited Disease*. Eighth Edition. New York, McGraw-Hill: 2001; pp. 3163–3177.
298. Sacksteder KA, Biery BJ, Morrell JC, et al. Identification of the alpha-aminoadipic semialdehyde synthase gene, which is defective in familial hyperlysinemia. *Am J Hum Genet* 2000;66:1736–1743.
299. Smith TH, Holland MG, Woody NC. Ocular manifestations of familial hyperlysinemia. *Trans Am Acad Ophthalmol Otolaryngol* 1971;75:355–360.
300. Dancis J, Hutzler J, Ampola MG, et al. The prognosis of hyperlysinemia. An interim report. *Am J Hum Genet* 1983;35:438–442.

Index

A

- Abetalipoproteinemia
 - clinical features, 444–445
 - familial form, 447
 - historical background, 443
 - metabolic aspects, 445
 - microsomal triglyceride transfer protein, 446
 - nutritional treatment, 446
 - Addison, Thomas, 306
 - Advanced glycation end products (AGEs)
 - age-related proinflammatory state, 397
 - diabetic retinopathy, 248, 250
 - dietary sources, 397
 - Age-Related Eye Disease Study (AREDS), 152, 153, 167, 202–204
 - Age-related macular degeneration (AMD)
 - See* Age-Related Eye Disease Study (AREDS)
 - carotenoids, 184–194
 - clinical features
 - age-related maculopathy, 177
 - dry AMD (geographic atrophy), 178
 - wet AMD (neovascular), 178
 - definitions, 164
 - diagnosis, 202
 - epidemiology
 - incidence, 164
 - prevalence, 165
 - general risk factors
 - age, 165
 - cardiovascular disease, 167
 - family history, 166
 - gender, 166
 - grip strength, 168–169
 - hyperopia, 166–167
 - inflammation, 167
 - iris color, 166
 - other factors, 176–177
 - race, 165
 - smoking, 168
 - sunlight, 176
 - historical background, 163–164
 - macular pigment, 171, 176
 - nutritional risk factors
 - body mass index, 176
 - carotenoids, 169–175, 203
 - cholesterol, 173
 - fat intake, 170, 173
 - fruit and vegetable intake, 169–170
 - linoleic acid, 170
 - nuts, 170
 - omega-3 fatty acids, 170, 205
 - selenium, 171, 172
 - vitamin A, 170, 172–175
 - vitamin C, 169–171, 203
 - vitamin E, 169, 171–174
 - zinc, 169–170, 174–175, 203
 - pathophysiology
 - catalase, 181–182
 - glutathione peroxidase, 181–182
 - glutathione reductase, 181–182
 - lipofuscin, 183
 - lutein, 182
 - metallothionein, 182
 - oxidative stress, 181–183
 - pathological features, 179–180
 - photic irradiation, 183
 - photosensitization, 183
 - superoxide dismutase, 182
 - vascular endothelial growth factor (VEGF), 184
 - vitamin C, 182
 - vitamin E, 182, 200–201
 - zeaxanthin, 182
 - zinc, 182, 202
 - prevention, 202–203
 - treatment, 202
- Aging
 - age-related macular degeneration (AMD), 165
 - cataract, 141
 - inflammation, 391
- Algeria, 55, 224
- Alpha-tocopherol, *See* Vitamin E
- Alpha-Tocopherol Beta-Carotene Cancer Prevention Trial, 151, 154
- Appropriate Blood Pressure Control in Diabetes Trial, 243
- Angola, 54
- Anorexia nervosa
 - definition, 272
 - cataracts, 272
 - central retinal vein occlusion, 272

Antioxidant defense mechanisms

- antioxidant enzymes, 398
- carotenoids, 398–399
- plant polyphenols, 399–400
- selenium, 399
- vitamin C, 399

Antioxidants

- megadose problems, 401
- supplements versus healthy diet, 400–401

Arachidonic acid (AA), *See* Essential fatty acids

Argentina, 415

Atherosclerosis Risk in Communities (ARIC)

Study, 244, 245

Australia, 154, 176, 221, 222, 226, 245, 284, 428, 429, 433

B

Baas, Karl, 30

Baltimore Longitudinal Study on Aging,
129–136, 169, 173

Bangladesh, 11, 51, 59, 62, 64, 68, 76, 77

Banting, William, 219

Barbados Eye Study, 125, 134, 141, 165

Barker, David, 233

Barlow, Thomas, 375

Bassen, Frank, 443

Bassen-Kornzweig syndrome,
See Abetalipoproteinemia

Beaver Dam Eye Study, 123, 128, 129–139, 141,
143, 144, 164, 165, 166, 169, 171, 173,
174, 176

Beijing Eye Study, 141

Benin, 55

Beriberi, *See* Thiamin deficiency

Bezold, Friedrich, 62

Bhutan, 51

Billard, Charles, 2

Birnbacher, Theodor, 68

Bishop, Katherine Scott, 196

Bitot, Pierre, 2–3, 23–24

Bitot spots, *See* Vitamin A deficiency

Blackfan, Kenneth, 63

Blegvad, Olaf, 5

Blessig, Robert, 3

Bloch, Carl, 5

Blue Mountains Eye Study,
123, 127, 128, 129–139, 140, 146, 165,
167, 170, 175, 176

Blyth, Alexander Wynter, 330

Body mass index

- age-related macular degeneration, 176
- cataract, 140–141

definition, 220

obesity, 219–221

Bolivia, 57

Bondt, Jacob de, 283

Bowman, William, 2

Botswana, 54

Braun, Alexander, 355

Brazil, 3, 57, 61, 221, 222, 225, 287, 333

Breastfeeding, 233

Brown, Joseph, 2

Burkina Faso, 55, 76

Burr, George Oswald, 416

Buzzi, Francesco, 163

C

Calhoun, Phinizy, 299

Cambodia, 49, 60, 68

Cameroon, 55, 59, 60

Canada, 222, 265, 284, 287, 429

Cardiovascular Health Study, 394

Carotenoids

absorption, 187

assessment of status, 189–190

biochemistry

alpha-carotene, 16, 185–186

beta-carotene, 15–16, 185–186

beta-cryptoxanthin, 16

lutein, 185–187

lycopene, 185–186

zeaxanthin, 185–186

cataract, 125, 129–131, 134–135, 138–139

definitions, 184

dietary sources, 186–187

free radical quenchers, 185–186

general functions, 188–189

historical background, 184–185

intervention studies, 194–195

macula, 190–193

metabolism, 188

requirements, 189

role in retina, 190–193

tissue concentrations, 189

vitamin A, 16–18

Carroll, Frank D., 312

Casal y Julian, Gaspar, 295

Castle, William, 307

Cataract

definitions, 121

grading, 122

epidemiology

geographic distribution, 124

incidence, 122–124

prevalence, 123

- general risk factors
 - age, 141
 - alcohol, 144
 - dehydration/diarrhea, 143–144
 - diabetes mellitus, 143
 - drugs, 144
 - family history, 142
 - gender, 141
 - lead exposure, 144
 - other factors, 144–145
 - race, 141
 - smoking, 142
 - ultraviolet light, 143
- historical background, 121
- mortality, 145
- nutritional risk factors
 - body mass index, 140–141
 - carotenoids, 125, 129–131, 134–135, 138–139
 - fat intake, 140
 - folate, 128, 133, 137, 139
 - fruit and vegetable intake, 140
 - glycemic load, 140
 - multivitamins, 124, 129, 134, 138
 - niacin, 127, 133, 136, 139
 - protein, 128
 - pyridoxine, 127, 133, 137, 139
 - riboflavin, 121, 127, 133, 139
 - thiamin, 127, 132, 136, 139
 - vitamin A, 125, 129, 134, 138
 - vitamin B₁₂, 128, 133, 137
 - vitamin C, 126, 132, 136, 139
 - vitamin D, 126, 131, 135
 - vitamin E, 126, 131, 135–136, 139
 - zinc, 128, 133, 137, 139
- pathogenesis, 146–150
- prevention trials, 150–154
- treatment, 150
- types
 - cortical, 149
 - nuclear, 148–149
 - posterior subcapsular, 150
- Celsus, 2
- Chad, 55
- Chevreur, Michel-Eugène, 416
- Clemmesen, Svend, 68
- Child and Adolescent Trial for Cardiovascular Health (CATCH), 233
- Chile, 225
- China, 66, 150, 225, 287, 298, 317, 333, 356, 399
- Cline, Joseph, 284
- Closs, Karl, 362
- City Eye Study (London), 142
- Cobalamin, *See* Vitamin B₁₂
- Colombia, 57
- Combe, James, 306
- Congo, 53
- Cook Islands, 52
- Costa Rica, 225
- Creutzfeldt, Hans, 458
- Cuba, 320–329, 415
- Cuban Neuropathy Epidemic,
See Nutritional Amblyopia
- Cystathione β -synthetase deficiency,
See Homocystinuria
- Cytokines, *See* Inflammation
- Czerny, Adalbert, 61
- D**
 - Danbolt, Niels, 362
 - Davies, Marguerite, 4
 - Davy, Edmund, 416
 - Deckelbaum, Richard, 233
 - Dekking, Henri Marinus, 314
 - Denmark, 5–6, 168, 242, 429, 433
 - Diabetes Control and Complications Trial, 242, 245, 394
 - Diabetes mellitus
 - economic impact, 230
 - epidemic and diabetic retinopathy, 230
 - obesity, 229
 - Diabetic retinopathy
 - clinical features, 246–248
 - disease severity scale, 247
 - epidemiology
 - incidence, 241–242
 - prevalence, 241–242
 - macular edema disease severity scale, 248
 - nutritional risk factors
 - vitamin C, 244
 - vitamin E, 244–245
 - zinc, 245
 - pathogenesis
 - advanced glycation end products (AGEs), 248, 250
 - nuclear factor kappa B (NF- κ B), 248–250
 - oxidative stress, 246, 248–249
 - sorbitol stress pathway, 250
 - vascular endothelial growth factor (VEGF), 246, 248–249
 - prevention
 - diabetics, 251
 - high risk individuals, 251–252
 - risk factors
 - anemia, 243–244

- duration of diabetes, 242
- glycemic control, 242
- hypertension, 242–243
- obesity, 244
- serum lipids, 243
- treatment, 250–251
- DiGeorge, Angelo, 446
- Djibouti, 56
- Docosahexaenoic acid (DHA),
 - See* Essential fatty acids
- Doesschate, Johanna ten, 12
- Donath, Willem, 284

E

Early Treatment Diabetic Retinopathy Study (ETDRS), 243

Eat Well and Keep Moving Program, 235

Ecuador, 57

Edmund, Carsten, 68

Egypt, 56, 59, 224, 319

Eijkman, Christaan, 283

El Salvador, 56, 76

Electroretinogram (ERG), 426

Ellison, Joseph, 7

Eritrea, 53

Essential fatty acids

- assessment of status, 421
- biochemistry
 - linoleic acid, 417
 - linolenic acid, 417
 - monounsaturated fatty acids, 417
 - polyunsaturated fatty acids (PUFA), 417
- composition in formula, 421
- composition in human milk, 421
- definitions, 415
- dietary sources, 420–422
- docosahexaenoic acid (DHA), 423–426
- historical background, 416
- infants, *See* Infant visual development
- metabolism
 - arachadonic acid (AA), 417–419
 - docosahexaenoic acid (DHA), 417–419
 - n-6 fatty acids, 417, 419
 - n-3 fatty acids, 417, 419
- nomenclature, 418
- preterm infants, 419
- public health significance, 415
- requirements, 422–423

Ethiopia, 53

Evans, Herbert McLean, 196, 416

Exercise, 233–235

Eye Disease Case-Control Study, 166, 168, 171, 172, 173, 266

F

Familial hyperlysinemia, 471

Fetal origins hypothesis, 233

Finland, 154, 224, 243

Flavonoids, 399–400, 402

Fleischer, Bruno, 464

Folate

- absorption, 303
- assessment of status, 305
- biochemistry, 303
- dietary sources, 303
- functions, 304
- metabolism, 303–304
- requirements, 304–305
- storage, 303–304

Folate deficiency

- cataract, 128, 133, 137, 139
- clinical manifestations, 305
- epidemiology, 305
- historical background, 302
- hyperhomocysteinemia, 259–261
- nutritional amblyopia, 306

Food and Drug Administration

- folic acid fortification, 261

Food Guide Pyramid, 251

Fraenkel, Eugen, 25

Framingham Eye Study, 123, 141, 143, 165, 168

Framingham Offspring Study, 261

France, 2,–3, 167, 176, 224, 295, 298, 314, 430

Franke, Ernst, 25

Frapolli, Francesco, 295

Frerichs, Friedrich Theodor, 464

Frölich, Theodor, 371

Fruits and vegetables

- age-related macular degeneration (AMD), 169–170
- cataract, 125, 140
- consumption in United States, 230
- inflammation, 399

Fuchs, Adalbert, 30

Funk, Casimir, 284, 295

G

Galactosemia

- clinical features, 454
- laboratory findings, 455
- metabolic aspects, 454–455
- nutritional treatment, 455–456

Gama Lobo, Manuel da, 3

Gambia, 333

Genth, Carl Phillip, 163

Germany, 6, 224, 319

Ghana, 40, 55

Gobley, Nicolas Théodore, 416

Goldberger, Joseph, 295

Göppert, Friedrich, 454

Gordon, John, 12

Greece, 224

Guatemala, 56, 76, 333

György, Paul, 11

Gyrate atrophy

animal studies, 449

clinical features, 447–448

laboratory findings, 448

metabolic aspects, 448–449

nutritional treatment, 450–451

ornithine- δ -aminotransferase, 448

H

Haab, Otto, 163

Haas, J.H. de, 61

Hansen, Arild Edstein, 416

Haiti, 225

Haworth, Norman, 371

Heart Outcomes Prevention Evaluation (HOPE)
study, 245

Hepatolenticular degeneration,
See Wilson disease

Heyl, Albert G., 273

Himsworth, Harold, 220

Hing, Teng Khoen, 31

Hippocratic writings, 2

Hirschberg, Julius, 30

Hirst, Edmund Langley, 371

Holst, Axel, 371

Hopkins, Frederick, 4

Home, Everard, 163

Homocystinuria

clinical features, 460–461

cystathionine β -synthetase, 462

laboratory findings, 461

metabolic aspects, 461–463

nutritional treatment, 462, 464

Honduras, 56

Husemann, August, 184

Hyperhomocysteinemia

causes, 259

cardiovascular disease, 262–265

cerebrovascular disease, 265

epidemiology, 262

folate status, 259–261

historical background, 257

homocysteine

definition, 257

metabolism, 257–259

peripheral vascular disease, 265

prevention, 267

retinal vascular disease, 265–267

vitamin B₁₂ status, 261–262

Hyperlipidemias

classification, 272–273

See Lipemia retinalis

I

India, 10, 12, 30, 40, 43, 51, 64, 68, 124, 128,
143, 144, 225, 302

Indonesia, 10, 12, 13, 22, 31, 41, 43, 44, 50, 51,
59, 60, 61, 63, 64, 66, 77, 315, 318–319, 415

Infant visual development

assessment methods, 426

role of essential fatty acids

clinical trials in preterm infants, 429–421

clinical trials in term infants, 431–434

implications of trials, 434–436

observational studies, 427–429

Infantile scurvy, *See* Vitamin C deficiency

Inflammation

advanced glycation end products (AGEs), 397

age-related macular degeneration, 394

age-related proinflammatory state, 391

biomarkers

C-reactive protein, 393–394

fibrinogen, 394

interleukin-1 β , 392

interleukin-1 receptor antagonist, 394

interleukin-6, 392–393

interleukin-10, 395

interleukin-18, 393

transforming growth factor- β 1, 394

tumor necrosis factor- α , 392

cytokine network, 395

reactive oxygen species, 395–396

redox balance, 398–402

Interdepartmental Committee

on Nutrition for National Defense,
11–12, 15, 43

International Society for the Study

of Fatty Acids and Lipids (ISSFAL), 422

Iran, 56

Ireland, 224

Iron

assessment of status, 269

biochemistry, 267

dietary sources, 267

functions, 268

metabolism, 267–268

requirements, 268

Iron deficiency

clinical manifestations, 269

- epidemiology, 269
- papilledema, 270
- retinal vascular disease, 270
- Iron overload
 - definition, 270
 - macular degeneration, 272
 - retinopathy of prematurity, 271–272
- Italian-American Cataract Study, 142
- Italy, 143, 146, 298, 300, 430, 434
- J**
 - Jamaica, 281–282, 300–301, 302
 - Jansen, Barend, 284
 - Japan, 61, 168, 225, 281, 283, 287, 291, 315
 - Jordan, 11, 56, 60
 - Joslin, Elliot, 220
 - Junius, Paul, 163
- K**
 - Karrer, Paul, 4, 185, 331
 - Kayser, Bernhard, 464
 - Kazakhstan, 225
 - Keller, Arthur, 61
 - Kenya, 53, 69
 - Keratomalacia, *See* Vitamin A deficiency
 - Kiribati, 52, 62–63
 - Klaften, Emanuel, 68
 - Kornzweig, Abraham, 443
 - King, Charles Glen, 371
 - Kuhn, Richard, 331
 - Kuhnt, Hermann, 163
- L**
 - Laos, 50
 - Lebanon, 11
 - Lehmann, Karl, 25
 - Leichtenstern, Otto, 307
 - Lens Opacities Case-Control Study, 124, 141
 - Lerche, Theodor Heinrich Wilhelm, 63
 - Linoleic acid, *See* Essential fatty acids
 - Linolenic acid, *See* Essential fatty acids
 - Linxian Cataract Studies, 150–151, 153
 - Lipemia retinalis
 - clinical features, 273–274
 - historical background, 273
 - laboratory findings, 274
 - management, 274
 - Longitudinal Study of Cataract, 123, 124, 125
 - Lunin, Nicolai, 4
- M**
 - Magendie, François, 2
 - Magnus, Hugo, 376
 - Malawi, 43, 53, 59–60, 62, 69
 - Malaysia, 50, 302
 - Mali, 54, 224
 - Maple syrup urine disease, 470
 - Marshall Islands, 52
 - Mauritania, 55
 - Mauritius, 221, 222
 - McCollum, Elmer, 4
 - McCully, Kilmer, 257
 - Mediterranean-style diet
 - cardiovascular disease, 399
 - diabetic retinopathy, 245
 - inflammation, 399
 - Mendel, Lafayette, 4, 416
 - Mendes, João Clemente, 4
 - Menkes, John, 467
 - Menkes disease, 467–468
 - Metabolic syndrome, 230
 - Mexico, 56, 225, 333
 - Micronesia, 52
 - Mikamo, Sanroku, 30
 - Millardet, Pierre-Marie-Alexis, 184
 - Minot, George, 307
 - Molybdenum cofactor deficiency, 470
 - Mongolia, 52
 - Moore, D. G. Fitzgerald, 301
 - Moore, Thomas, 4
 - Mori, Masamichi, 61
 - Morocco, 55
 - Mozambique, 54
 - Muhilal, 43
 - Multivitamins, 124, 129, 134, 138
 - Murphy, William, 307
 - Myanmar, 50, 317
- N**
 - National Cholesterol Education Program
 - Step 1 Diet, 251
 - National Eye Institute, National Institutes of Health, 205
 - National Health and Nutrition Examination Surveys (NHANES), 123, 143, 165, 166, 167, 169, 171, 172, 176, 189–190, 220, 224, 226, 229, 244, 262, 375, 399
 - Nauru, 226
 - Nepal, 40, 51, 59, 62, 65, 68, 143, 415
 - Netherlands, 167, 221, 429
 - Netter, Abraham, 3
 - Neumann, Rudolf, 25
 - Niacin
 - absorption, 297
 - assessment of status, 298

- biochemistry, 295–296
 - dietary sources, 296
 - functions, 297
 - metabolism, 297
 - requirements, 297
 - storage, 297
 - Niacin deficiency
 - cataract, 127, 133, 136, 139
 - clinical manifestations
 - pellagra, 298
 - nutritional amblyopia, 299–302
 - epidemiology, 298
 - historical background, 295
 - Niacin maculopathy, 302
 - Nicaragua, 57
 - Niger, 55
 - Nigeria, 224, 301, 333
 - Night blindness, *See* Vitamin A deficiency
 - Nurses' Health Study, 123, 127, 128, 129–139, 140, 144, 168, 170
 - Nutritional amblyopia
 - animal models
 - thiamin deficiency, 293
 - vitamin B₁₂ deficiency, 311
 - beriberi, 291
 - clinical features, 282
 - Cuban Neuropathy Epidemic, 320–329
 - definition, 281
 - epidemiology, 282
 - historical background, 281
 - Leigh syndrome, 292
 - pathogenesis
 - See* Folate deficiency
 - See* Niacin deficiency
 - See* Riboflavin deficiency
 - See* Thiamin deficiency
 - See* Vitamin B₁₂ deficiency
 - pellagra, 299–302
 - public health significance, 281
 - treatment
 - B complex vitamins, 330
 - dietary, 330
 - folate, 306
 - thiamin, 293–294
 - vitamin B₁₂, 311
 - wartime outbreaks
 - clinical presentation, 313–314
 - etiology, 320
 - Korean War, 319, 323
 - Spanish Civil War, 314, 321
 - synonyms for nutritional amblyopia, 313
 - treatment, 320
 - Vietnam War, 319, 323
 - World War I, 314, 321
 - World War II, 314–319, 321–323
 - Wernicke-Korsakoff syndrome, 291–292
 - Nutrition Canada Survey, 265
 - Nutrition transition, 220
- ## O
- Obesity
 - American Academy of Pediatrics policy statement, 234
 - body mass index, 220–221
 - childhood, 229
 - definitions, 220
 - economic impact, 230, 232
 - epidemiology
 - incidence, 221–222
 - prevalence, 221–222, 231
 - geographic distribution, 222–226
 - implications for eye health
 - diabetes mellitus, 229–230, 232
 - diabetic retinopathy, 230
 - pathogenesis
 - community design, 228–229
 - diet, 235
 - fat intake, 226
 - physical activity, 227–228
 - television, 226–227
 - prevention
 - breastfeeding, 233
 - diet, 235–236
 - exercise, 233–234
 - perinatal period, 233
 - World Health Organization classification, 221
 - Oculocutaneous tyrosinemia
 - clinical features, 457
 - metabolic aspects, 457–458
 - nutritional treatment, 458
 - tyrosine aminotransferase, 457
 - Omega 3-fatty acids, 170, 205
 - Oomen, H.A.P.C., 10
 - Oeller, Johann Nepomuk, 163
 - Ornithine, *See* Gyrate atrophy
 - Overweight, 220–221
 - Osborne, Thomas, 4
 - Oxidative stress
 - oxidative damage
 - DNA, 403
 - proteins, 403–404
 - lipids, 404
 - redox signaling of inflammation, 401
 - trigger for inflammation, 395–397
 - sarcopenia, 168
 - smoking, 168

P

- Pagenstecher, Hermann, 163
- Papua New Guinea, 40, 287
- Pakistan, 51, 225
- Panama, 57
- Pathologies Oculaires Liées à l'Age (POLA) Study, 167, 176
- Pekelharing, Cornelis, 4
- Pellagra, *See* Niacin deficiency
- Peru, 57, 225
- Philippines, 27, 52, 60, 77, 318
- Physicians' Health Study, 123–124, 151, 154, 171, 176, 264, 265
- Pittsburgh Diabetic Morbidity and Retinopathy Studies, 242
- Phytanic acid, *See* Refsum disease
- Planet Health, 235
- Poland, 3
- Polyunsaturated fatty acids (PUFA),
 See Essential fatty acids
- Portugal, 4, 224, 298
- Purtscher, Otmar, 30
- Pyridoxine (vitamin B₆)
 - cataract, 127, 133, 137, 139
 - treatment for gyrate atrophy, 451
 - treatment for homocystinuria, 462

Q

- Quetelet, Adolphe, 219

R

- Raadt, Otto de, 318
- Ramalingaswami, Vulimiri, 10
- Ratier, Félix Séverin, 2
- Raulin, Jules, 355
- Refsum, Sigvald, 451
- Refsum disease
 - clinical features, 451–452
 - laboratory findings, 452
 - metabolic aspects, 452–453
 - nutritional treatment, 454
 - phytanoyl-CoA hydroxylase, 453
- Retinitis pigmentosa
 - clinical features, 469
 - metabolic aspects, 469
 - nutritional treatments, 469–470
- Retinol, *See* Vitamin A
- Riboflavin
 - absorption, 332
 - assessment of status, 334
 - biochemistry, 331
 - dietary sources, 331–332
 - functions, 332–333

- metabolism, 332
 - requirements, 333
 - storage, 332
- Riboflavin deficiency
 - cataracts, 337
 - clinical manifestations, 334–336
 - epidemiology, 333–334
 - historical background, 330–331
 - nutritional amblyopia, 338
 - retinal vascular disease, 338
 - treatment, 338

- Rickes, Edward, 307
- Richner-Hanhart syndrome, *See* Oculocutaneous tyrosinemia
- Ridley, Harold, 315
- Roche European American Cataract Trial, 152, 153
- Rodger, Frederick C., 315
- Rotterdam Study, 167, 168, 171
- Roussel, Théophile, 295
- Russian Federation, 225

S

- Salisbury Eye Evaluation Project, 123, 143
- San Luis Valley Diabetes Study, 244, 245
- Saudi Arabia, 333
- Scott, Henry Harold, 300
- Scrimshaw, Nevin, 12
- Scurvy, *See* Vitamin C deficiency
- Sebrell, W. Henry, 11
- Selenium
 - age-related macular degeneration (AMD), 171, 172
 - biochemistry, 399
 - deficiency, 399
 - functions, 399
- Senegal, 54
- Siemerling, Ernst, 458
- Singapore, 50, 221, 302, 315, 316
- Singer, Karl, 443
- Smoking
 - age-related macular degeneration, 168
 - cataract, 142–143
 - oxidative stress, 168
- Socin, Carl, 4
- Soemmering, Samuel Thomas von, 163
- Solomon Islands, 52
- Sommer, Alfred, 13
- Sorsby, Arnold, 468
- Sorsby fundus dystrophy
 - clinical features, 468
 - genetic and metabolic aspects, 468
 - nutritional treatment, 469

South Africa, 54, 76, 224

South Korea, 225, 319

Spain, 295, 314, 333

Sri Lanka, 51, 60, 415

Stepp, Wilhelm, 4

Strachan, Henry, 281

Strambio, Gaetano, 295

Sudan, 52–53, 59–60

Sulfite oxidase deficiency, 470

Sure, Barnett, 196

Suzuki, Umetaro, 284

Sweden, 146

Sweet, Lewis, 63

T

Tanzania, 53, 76, 224

Takaki, Kanehiro, 283

Taylor, Carl, 12

Thailand, 11, 50, 77, 315, 317

Thiamin

absorption, 285

assessment of status, 288–289

biochemistry, 284

dietary sources, 284–285

functions, 286

metabolism, 285–287

requirements, 286–288

treatment for nutritional amblyopia,
293–294

Thiamin deficiency

animal models, 293

clinical manifestations

beriberi, 289–291

Wernicke-Korsakoff syndrome, 291

definition, 283

deprivation studies in humans, 293

epidemiology, 287–288

historical background, 283

Leigh syndrome, 292

nutritional amblyopia, 291

optic atrophy, 291–292

Thi  ry, Fran  ois, 295

Thudichum, Johann Ludwig Wilhelm, 184, 416

“Tobacco–Alcohol Amblyopia”

See Nutritional amblyopia, 311–313

Tibet Eye Study, 141, 142

Tjissen, Johannes, 12

Trantas, Alexios, 63

Tswett, Mikhail Semenovitch, 185

Tunisia, 55

Tuvalu, 52

Tyrosinemia type II,

See Oculocutaneous tyrosinemia

U

Uganda, 53, 69

Uhthoff, Wilhelm, 64

UK Prospective Diabetes Study, 242

United Kingdom

age-related macular degeneration (AMD),
171, 172

cataract, 129–136, 146, 153

cod-liver oil use, 7–9

diabetes mellitus, 242

essential fatty acids, 433

hyperhomocysteinemia, 263, 265

obesity, 221, 224

riboflavin deficiency, 333

preterm birth, 415,

vitamin A to reduce child mortality, 6–9

United States,

See National Health and Nutrition

Examination Surveys (NHANES)

cataract, 123

diabetes epidemic, 230–231

essential fatty acids, 429, 430, 433

folate fortification, 303

fortification of flour, 284

infantile scurvy history, 377

obesity, 221, 222, 226–227, 228

pellagra history, 295, 299–300

Uyemura, Misao, 30

V

van der Hoeve, Jan, 163

Van Stockum, Maria, 61

Vanuatu, 52

Vascular endothelial growth factor (VEGF)

age-related macular degeneration (AMD), 184

diabetic retinopathy, 246, 248–249

Venezuela, 57

Vietnam, 11, 43, 49, 77, 314, 315, 319, 415

Villemin, Jean–Antoine, 3

Visual evoked potential (VEP), 426

Vitamin A

absorption and digestion, 16–17

biochemistry

acyl–CoA–retinol acyltransferase (ARAT), 17

beta-carotene, 15–16

beta-carotene 15,15'-dioxygenase, 16

cellular retinol-binding protein (CRBP) II, 16

chemical structure, 14,16

lecithin-retinol acyltransferase (LRAT), 17

relation with carotenoids, 16–18

retinal, 16

retinol-binding protein (RBP), 18

retinoic acid, 17

- food sources, 14
- gene regulation
 - retinoic acid receptors (RAR), 19–20
 - retinoid X receptors, 19–20
 - retinoic acid response elements (RARES), 20
- liver uptake and storage, 17–19
- dietary requirements, 20–21
- tissue uptake, 19
- Vitamin A deficiency, 1–78
 - breastfeeding, 61–62
 - children, 60–61
 - clinical features
 - anemia, 42–47
 - Bitot spot, 23–25
 - conjunctival xerosis, 23
 - corneal ulcer, 27–29
 - corneal scar, 33–34
 - corneal xerosis, 25–27
 - growth retardation, 41–42
 - immune suppression, 34–39
 - pupil dilation, 34
 - keratomalacia, 29–30
 - night blindness, 22–23
 - xerophthalmic fundus, 30–33
 - diagnosis
 - clinical, 69–60
 - conjunctival impression cytology, 72–73
 - dark adaptometry, 73
 - dietary assessment, 74
 - modified relative dose response, 73–74
 - other tests, 74–75
 - pupillary threshold, 74
 - relative dose response, 73–74
 - retinol in breast milk, 71–72
 - retinol in serum, 70–71
 - diet, 63–64
 - education, 59–60
 - epidemiology
 - global distribution, 48–57
 - incidence, 48
 - prevalence, 48
 - risk factors, 57–69
 - gender, 61
 - historical background,
 - early history, 2–4
 - Bellagio meeting, 11
 - characterization of vitamin A, 4–5
 - cod-liver oil, 8–9
 - Denmark in WW I, 5–6
 - diarrhea, 10
 - discovery of mortality reduction, 7–8
 - fortification of margarine, 9
 - fortification of milk, 9
 - historical milestones, 15
 - Indonesia, 12
 - International Vitamin A Consultative Group (IVACG), 13
 - measles treatment, 6–8
 - National Institutes of Health, 10
 - public health measures, 9
 - supplementation programs, 12–13
 - trials for infectious diseases, 13
 - Western Hemisphere Nutrition Congress, 11
 - Xerophthalmia Club, 13
 - home gardens, 64
 - immunity
 - antibody responses, 39
 - B-lymphocytes, 38–39
 - Langerhans cells, 37
 - monocytes/macrophages, 37
 - mucosal immunity, 34
 - natural killer cells, 36
 - neutrophils, 36
 - T-lymphocytes, 37–38
 - infants, 60–61
 - infections
 - diarrheal diseases, 39–40, 62
 - helminthiasis, 63
 - HIV infection, 40
 - malaria, 40
 - measles, 6–8, 62–63
 - otitis media, 63
 - respiratory disease, 63
 - tuberculosis, 41, 63
 - institutionalization, 69
 - malabsorption
 - celiac sprue, 67
 - cystic fibrosis, 66–67
 - malnutrition, 64–65
 - poverty, 58–59
 - pregnancy, 68
 - prevention
 - breastfeeding practices, 77
 - control of infectious diseases, 77
 - dietary modification, 76
 - food fortification, 76–77
 - plant breeding, 77
 - vitamin A capsules, 77–78
 - seasonality, 65–66
 - treatment with vitamin A, 75–76
 - women, 68–69
 - xerophthalmia
 - World Health Organization classification, 21
- Vitamin B₆, *See* Pyridoxine
- Vitamin B₁₂

- absorption, 307–308
 - assessment of status, 309–310
 - biochemistry, 307
 - dietary sources, 307–308
 - functions, 307
 - metabolism, 307
 - requirements, 308–309
 - storage, 307
 - treatment for nutritional amblyopia, 311
- Vitamin B₁₂ deficiency
- animal models, 311
 - clinical features, 310
 - epidemiology, 309
 - historical background, 306–307
 - hyperhomocysteinemia, 261–262
 - nutritional amblyopia, 310–311
- Vitamin C
- absorption, 372
 - assessment of status, 375
 - biochemistry, 372
 - cornea tissue levels, 380
 - dietary sources, 372–373
 - functions, 373–374, 380–382
 - historical background, 371
 - metabolism, 372–373
 - requirements, 374
 - retina, 382–383
 - storage, 372–373
 - tear concentrations, 383
- Vitamin C deficiency
- cataracts, 126, 132, 136, 139, 380
 - clinical features
 - adult scurvy, 376
 - infantile scurvy, 376
 - corneal wound healing, 378
 - diabetic retinopathy, 244
 - epidemiology, 374–375
 - eye findings
 - hemorrhages, 376–378
 - orbital hemorrhage, 376–378
 - proptosis, 376–378
 - retinopathy, 377, 379
 - prevention, 383
 - treatment, 383
- Vitamin E
- absorption, 196–199
 - assessment of status, 200
 - biochemistry, 196–197
 - definitions, 194
 - diabetic retinopathy, 244–245
 - dietary sources, 196, 198
 - function, 198–199
 - historical background, 196
 - metabolism, 196–199
 - requirements, 199–200
 - role in retina, 200–202
 - storage, 198–199
- Vitamin E, Cataract and Age-Related Maculopathy Trial, 152, 154
- Vitamin E deficiency, 200
- Von Graefe, Albrecht, 29
- Von Huebbenet, Anton Christian August, 3
- Von Reuss, August Ritter, 454
- ## W
- Wackenroder, Heinrich Wilhelm Ferdinand, 184
- Wagner, Karl-Heinz, 42
- Wald, George, 5, 164
- Waterman Study, 123, 143, 164, 176
- Weeks, John Elmer, 25
- Western Samoa, 226
- Widmark, Erik, 5
- Williams, Christine, 233
- Williams, Robert, 284
- Wills, Lucy, 302
- Willstätter, Richard, 184
- Wisconsin Epidemiologic Study of Diabetic Retinopathy, 241, 242
- Wilson, Samuel Alexander Kinnier, 464
- Wilson disease
- clinical features, 464, 467
 - Kayser-Fleischer ring, 465
 - laboratory findings, 467
 - metabolic aspects, 465–466
 - nutritional treatment, 467
- Wine
- age-related macular degeneration, 176
 - cataract, 144
- Wolbach, S. Burt, 63
- Women's Health and Aging Study, 398
- Women's Health Study, 140
- World Health Organization, 9–12, 14,
- Wright, Robert E., 30
- ## X
- Xerophthalmia. *See* Vitamin A deficiency
- X-linked adrenoleukodystrophy
- clinical features, 458–459
 - laboratory findings, 459
 - Lorenzo's oil, 460
 - metabolic aspects, 459–460
 - nutritional treatment, 460
- ## Y
- Yemen, 56, 60
- Youmans, John, 72

Z

Zambia, 54

Zeise, William Christopher, 184

Zimbabwe, 54, 333

Zinc

- absorption, 357

- assessment of status, 361–362

- biochemistry, 356

- dietary sources, 356–357

- general functions, 358–359

- functions in eye, 359–360

- historical background, 355–356

- metabolism, 357–358

- requirements, 361

- storage, 357–358

- tissue concentrations, 358

Zinc deficiency

- age-related macular degeneration, 169–170, 174–175, 203

- acrodermatitis enteropathica

 - clinical features, 362–363

 - eye findings, 373

- cataract, 128, 133, 137, 139

- clinical manifestations, 362

- dark adaptation, 364

- diabetic retinopathy, 245

- epidemiology, 361