

# Forensic Pathology of Trauma

*Common Problems for the Pathologist*

---

Michael J. Shkrum, MD  
David A. Ramsay, MB ChB

 HUMANA PRESS



# **Forensic Pathology of Trauma**

# FORENSIC SCIENCE AND MEDICINE

---

**Steven B. Karch, MD, SERIES EDITOR**

HERBAL PRODUCTS: *TOXICOLOGY AND CLINICAL PHARMACOLOGY, SECOND EDITION*,  
edited by **Richard L. Kingston and Timothy S. Tracy**, 2007

CRIMINAL POISONING: *INVESTIGATIONAL GUIDE FOR LAW ENFORCEMENT, TOXICOLOGISTS,  
FORENSIC SCIENTISTS, AND ATTORNEYS, SECOND EDITION*, by **John H. Trestrail, III**, 2007

FORENSIC PATHOLOGY OF TRAUMA: *COMMON PROBLEMS FOR THE PATHOLOGIST*,  
by **Michael J. Shkrum and David A. Ramsay**, 2007

MARIJUANA AND THE CANNABINOIDS, edited by **Mahmoud A. ElSohly**, 2006

SUDDEN DEATHS IN CUSTODY, edited by **Darrell L. Ross and Theodore C. Chan**, 2006

THE FORENSIC LABORATORY HANDBOOK: *PROCEDURES AND PRACTICE*, edited by  
**Ashraf Mozayani and Carla Noziglia**, 2006

DRUGS OF ABUSE: *BODY FLUID TESTING*, edited by **Raphael C. Wong and Harley Y. Tse**, 2005

A PHYSICIAN'S GUIDE TO CLINICAL FORENSIC MEDICINE: *SECOND EDITION*, edited by  
**Margaret M. Stark**, 2005

FORENSIC MEDICINE OF THE LOWER EXTREMITY: *HUMAN IDENTIFICATION AND TRAUMA  
ANALYSIS OF THE THIGH, LEG, AND FOOT*, by **Jeremy Rich, Dorothy E. Dean,  
and Robert H. Powers**, 2005

FORENSIC AND CLINICAL APPLICATIONS OF SOLID PHASE EXTRACTION, by **Michael J. Telepchak,  
Thomas F. August, and Glynn Chaney**, 2004

HANDBOOK OF DRUG INTERACTIONS: *A CLINICAL AND FORENSIC GUIDE*, edited by  
**Ashraf Mozayani and Lionel P. Raymon**, 2004

DIETARY SUPPLEMENTS: *TOXICOLOGY AND CLINICAL PHARMACOLOGY*, edited by  
**Melanie Johns Cupp and Timothy S. Tracy**, 2003

BUPRENOPHINE THERAPY OF OPIATE ADDICTION, edited by **Pascal Kintz and Pierre Marquet**,  
2002

BENZODIAZEPINES AND GHB: *DETECTION AND PHARMACOLOGY*, edited by  
**Salvatore J. Salamone**, 2002

ON-SITE DRUG TESTING, edited by **Amanda J. Jenkins and Bruce A. Goldberger**, 2001

BRAIN IMAGING IN SUBSTANCE ABUSE: *RESEARCH, CLINICAL, AND FORENSIC APPLICATIONS*,  
edited by **Marc J. Kaufman**, 2001

TOXICOLOGY AND CLINICAL PHARMACOLOGY OF HERBAL PRODUCTS, edited by  
**Melanie Johns Cupp**, 2000

CRIMINAL POISONING: *INVESTIGATIONAL GUIDE FOR LAW ENFORCEMENT, TOXICOLOGISTS,  
FORENSIC SCIENTISTS, AND ATTORNEYS*, by **John H. Trestrail, III**, 2000

# FORENSIC PATHOLOGY OF TRAUMA

---

*Common Problems for the Pathologist*

*By*

**Michael J. Shkrum, MD**

*Department of Pathology  
London Health Sciences Centre  
and The University of Western Ontario  
London, Ontario  
Canada*

*and*

**David A. Ramsay, MB ChB**

*Departments of Pathology and Clinical Neurological Sciences  
London Health Sciences Centre  
and The University of Western Ontario  
London, Ontario  
Canada*



**HUMANA PRESS**  
TOTOWA, NEW JERSEY



© 2007 Humana Press Inc.  
999 Riverview Drive, Suite 208  
Totowa, New Jersey 07512

**humanapress.com**

All rights reserved. No part of this book may be reproduced, stored in a retrieval system, or transmitted in any form or by any means, electronic, mechanical, photocopying, microfilming, recording, or otherwise without written permission from the Publisher.

The content and opinions expressed in this book are the sole work of the authors and editors, who have warranted due diligence in the creation and issuance of their work. The publisher, editors, and authors are not responsible for errors or omissions or for any consequences arising from the information or opinions presented in this book and make no warranty, express or implied, with respect to its contents.

Production Editor: Amy Thau

Cover design by Patricia F. Cleary

Due diligence has been taken by the publishers, editors, and authors of this book to ensure the accuracy of the information published and to describe generally accepted practices. The contributors herein have carefully checked to ensure that the drug selections and dosages set forth in this text are accurate in accord with the standards accepted at the time of publication. Notwithstanding, as new research, changes in government regulations, and knowledge from clinical experience relating to drug therapy and drug reactions constantly occurs, the reader is advised to check the product information provided by the manufacturer of each drug for any change in dosages or for additional warnings and contraindications. This is of utmost importance when the recommended drug herein is a new or infrequently used drug. It is the responsibility of the health care provider to ascertain the Food and Drug Administration status of each drug or device used in their clinical practice. The publisher, editors, and authors are not responsible for errors or omissions or for any consequences from the application of the information presented in this book and make no warranty, express or implied, with respect to the contents in this publication.

For additional copies, pricing for bulk purchases, and/or information about other Humana titles, contact Humana at the above address or at any of the following numbers: Tel.: 973-256-1699; Fax: 973-256-8341; E-mail: [orders@humanapr.com](mailto:orders@humanapr.com) or visit our website: <http://humanapress.com>

This publication is printed on acid-free paper. ∞

ANSI Z39.48-1984 (American National Standards Institute) Permanence of Paper for Printed Library Materials.

#### **Photocopy Authorization Policy:**

Authorization to photocopy items for internal or personal use, or the internal or personal use of specific clients, is granted by Humana Press Inc., provided that the base fee of US \$30.00 per copy, is paid directly to the Copyright Clearance Center at 222 Rosewood Drive, Danvers, MA 01923. For those organizations that have been granted a photocopy license from the CCC, a separate system of payment has been arranged and is acceptable to Humana Press Inc. The fee code for users of the Transactional Reporting Service is: [1-58829-458-7/07 \$30.00].

Printed in the United States of America. 10 9 8 7 6 5 4 3 2 1

eISBN: 1-59745-138-X

13-digit ISBN: 978-1-58829-458-6

Library of Congress Cataloging-in-Publication Data

Shkrum, Michael J.

Forensic pathology of trauma : common problems for the pathologist

/ by Michael J. Shkrum and David A. Ramsay.

p. ; cm. -- (Forensic science and medicine)

Includes bibliographical references and index.

ISBN 1-58829-458-7 (alk. paper)

1. Forensic pathology. 2. Wounds and injuries. I. Ramsay, David A. II. Title. III. Series.

[DNLM: 1. Wounds and Injuries--pathology. 2. Autopsy--methods.

3. Forensic Pathology. W 843 S558f 2007]

RA1053.4.S55 2007

614'.1--dc22

2006000940

# *Dedication*

---

*To my parents, who showed me the way, and to Susan, Stephanie, and Paul,  
who kept me on the path.*

*M. J. Shkrum*

*To my parents and other teachers, and to Calum and Mhairi.*

*D. A. Ramsay*

# Preface

---

The practice of forensic pathology includes the collection and analysis of evidence in relation to a corpse in order to establish the cause of death. Knowledge of the cause of death contributes to the determination of the manner of death by medical examiners and coroners, who are occasionally assisted by law enforcement officers. In the process of establishing the cause and manner of death, representatives of various investigative bodies have several responsibilities, including explaining the death to family members, attempting to reduce the risk of similar deaths in the future, and, if applicable, apprehending the individuals who are responsible for the death.

The most well-known and popular role of a forensic pathologist is in the investigation of cases of suspicious death; however, most medicolegal autopsies involve unexpected deaths that are above suspicion, many of which are caused by trauma (trauma being defined as any physical force or agent that causes bodily harm). The purpose of *Forensic Pathology of Trauma: Common Problems for the Pathologist* is to provide practical advice and information about the conduct of the forensic autopsy in cases of trauma, and to offer guidance about the analysis of the autopsy findings in these cases. *Forensic Pathology of Trauma: Common Problems for the Pathologist* will help pathologists—particularly those more accustomed to “hospital” autopsies—avoid common mistakes in medicolegal cases by ensuring that they attend to the fundamental purposes of the forensic autopsy that, in addition to demonstrating the cause of death, addresses such issues as: “(1) the identity of the dead person; (2) the time of death; (3) the circumstances in which the fatal injury was sustained; (4) the type of weapon or agent that was responsible for the injury; (5) factors that may have predisposed the victim to injury, or modified the effects of injury...”(1).

Our approach is to describe common medicolegal “syndromes” or trauma patterns, which are exemplified by the chapter titles, and to provide comprehensive coverage of both the common and uncommon causes of these patterns. Although the book does not cover the autopsy investigation of suspicious death in detail, sufficient information is provided to ensure that a pathologist is aware of the pitfalls in such cases, and that these cases are dealt with appropriately when they do occur.

*Forensic Pathology of Trauma: Common Problems for the Pathologist* is primarily intended for the use of pathologists who perform forensic autopsies as part of a general autopsy service, as opposed to those employed in dedicated forensic autopsy centers; however, we believe the contents will also be of service to anyone who wants to understand the strengths and, more importantly, the limitations of the forensic autopsy.

**Michael J. Shkrum, MD**  
**David A. Ramsay, MB ChB**

## ***Reference***

---

1. Moritz AR. Classical mistakes in forensic pathology. Am J Clin Pathol 26:1382–1397, 1956.

# Acknowledgments

---

We thank the following for their contributions to this undertaking: Lisa Noseworthy and Paula Miller (Department of Pathology, London Health Sciences Centre [LHSC]) for their secretarial assistance; Kris Milne (Department of Pathology, The University of Western Ontario [UWO]) for the preparation of the figures; Kim Walsh, former graduate student in the Department of Pathology, UWO, for assistance in the manuscript preparation; library technicians at the LHSC Library—Linda Crosby and Wendy Tippin—for dealing with our numerous requests for references; Dr. Barry McLellan, the Chief Coroner for Ontario, and Drs. David Legge and Thomas Wilson, Regional Coroners for the Northwestern and Southwestern Ontario regions, respectively, for their support; the coroners and various police agencies in Ontario for their diligent death investigations; Drs. David King and Chitra Rao (Regional Forensic Pathology Unit, Hamilton, Ontario, Canada), and Dr. Michael Pollanen (Provincial Forensic Pathology Unit, Toronto, Ontario, Canada) for their contribution of figures; Dr. Bertha Garcia, the Chief of the Department of Pathology at LHSC for her help and encouragement. We especially thank the pathologists and staff with whom we have worked with over the years in London and southern Ontario for their patience and dedication to the medicolegal autopsy service.—*MJS and DAR*

\* \* \*

I would like to thank the late Dr. Marvin Smout and the late Dr. Douglas Mills, former Chiefs of Pathology in London, Ontario, Canada, for fostering my interest in Forensic Pathology, and Drs. Page Hudson and John Butts, former and current Chief Medical Examiners of North Carolina, respectively, for their mentoring roles. My colleagues at the Multi-disciplinary Accident Research Team (Faculty of Engineering Science, UWO)—Kevin McClafferty, Paul Tiessen, Dr. Robert Green, and Dr. Edwin Nowak—have helped me understand issues related to motor vehicle trauma. Dr. Alan German, Chief, Collision Investigation and Research, Road Safety, and Motor Vehicle Regulation Directorate, has kindly allowed the use of Transport Canada information.—*MJS*

\* \* \*

My colleague, Dr. L. C. Ang, has been a constant and friendly supporter of my involvement in forensic neuropathology, and, with the assistance of Dr. J. Keith, he has provided many thoughtful and helpful comments on the neurological sections in this book. My secretary, Lynn James, has been an invaluable, cheerful, and highly organized assistant for more than a decade and a half. I also wish to acknowledge the influences of Professor J. Z. Young and Dr. M. R. Matthews, who taught me to inquire, think, and persist; of Professor D. I. Graham, who unwittingly swayed me into a career in neuropathology; and of Dr. I. D. Melville, whose humanity inspires me still.—*DAR*



# Table of Contents

---

Dedication ..... v

Preface ..... vii

Acknowledgments ..... ix

Companion CD ..... xiii

*CHAPTER 1*

The “Complete Autopsy”: *The Management of Risk* ..... 1

*CHAPTER 2*

Postmortem Changes: *The “Great Pretenders”* ..... 23

*CHAPTER 3*

Asphyxia ..... 65

*CHAPTER 4*

Thermal Injury ..... 181

*CHAPTER 5*

Bodies Recovered From Water ..... 243

*CHAPTER 6*

Penetrating Trauma: *Close-Range Firearm Wounds* ..... 295

*CHAPTER 7*

Penetrating Trauma: *Sharp Force Injuries* ..... 357

*CHAPTER 8*

Blunt Trauma: *With Reference to Planes, Trains, and Automobiles* ..... 405

*CHAPTER 9*

Craniocerebral Trauma and Vertebrospinal Trauma ..... 519

*CHAPTER 10*

Sudden Neurological Death ..... 607

Index ..... 623

# *Companion CD*

---

All figures appear in both color and black and white on the companion CD.

## Chapter 1

---

# *The “Complete Autopsy”*

## *The Management of Risk*

### **Summary**

Many medicolegal death investigations rely on information derived from autopsies. The success of an autopsy in answering questions (e.g., identification, injury causation) depends on a systematic approach by the pathologist. The “complete autopsy” is a series of necessary steps taken by the pathologist, who receives background information about the deceased, performs an external examination and internal dissection, and collects appropriate bodily samples for supplementary testing. The care exercised by the pathologist in this process is reflected in an accurate autopsy report, which addresses the most important question—the cause of death. The pathologist must be aware of potential pitfalls at every step of the postmortem investigation, any of which can pose a risk to the final resolution of a medicolegal investigation.

**Key Words:** Forensic pathology; autopsy; risk management.

### *1. INTRODUCTION*

A pathologist is a medical specialist who has the unique training and experience to acquire and apply knowledge from an autopsy (1). Death is not the end of a physician–“patient” relationship. A pathologist has an ethical obligation to reliably ensure that the medical observations and conclusions, based on autopsy findings and other information, are valid and do not breach the trust or confidence of family, caregivers, the community, and society (1–5).

A major focus of any autopsy is the determination of the cause of death (i.e., why did the person die?). This allows the certification of an individual’s death (2,6,7). A “hospital” autopsy (i.e., an autopsy done with the consent of a deceased’s family members or a legally authorized representative) has other broader objectives, such as the study of a disease process, an audit of the effectiveness of therapy and accuracy of diagnostic

From: *Forensic Science and Medicine: Forensic Pathology of Trauma:  
Common Problems for the Pathologist*

By: M. J. Shkrum and D. A. Ramsay © Humana Press Inc., Totowa, NJ

procedures, clinicopathological correlation, education of health care professionals, and subject to ethical considerations, research (2,6,8–14). A “forensic” or statutory medicolegal autopsy also addresses these objectives, but a pathologist must be able to answer other questions, that is the five “Ws” (Table 1) (15).

Forensic pathology is the study of how diseases cause sudden and unexpected death and how external agents or forces cause fatal injury (4). Autopsies do improve the accuracy of death certificates and vital statistics (2,12,14,22,26–28). Clinical studies have shown that at least 10% of deaths have a major pathological diagnosis that, if it had been detected during life, might have resulted in survival with appropriate medical treatment (6,14,29–33).

An autopsy is an essential component of many medicolegal death investigations. The pathologist must have the necessary training and/or experience to answer the challenges posed by such investigations (13,34). To maintain a high standard of practice in forensic pathology, a pathologist must participate in peer-review, self-evaluation, and continuing education programs (33). Professional competence is a part of quality assurance—i.e., the structure and systematic actions necessary to provide adequate service with accurate results (1,6,35). In dealing with issues arising from an injury case, pathologists must have a fundamental understanding of trauma pathology (36). Hirsch commented that, “too many pathologists think that the pathology of trauma is simple. Such pathologists fall into one of two groups: those who have not seen traumatic pathology and those who have not thought about what they have seen” (36).

## 2. THE COMPLETE AUTOPSY

A pathologist does not work in isolation. A complete autopsy requires the integration of information from various investigative sources occurring in stepwise progression (Fig. 1) (4). This systematic approach usually reaches successful conclusions regarding the cause of death, the pathophysiological mechanisms or terminal events leading to death, and the manner of death (13,22,37). Communication among the different investigators is essential (13). Deviations from the standards of investigative practice, either by omission or commission, increase the risk of failure of a medicolegal death investigation. The time period of death investigation varies depending on the circumstances. For example, a suspicious death involving unidentified skeletal remains may remain “open” indefinitely.

## 3. THE PSYCHOLOGICAL AUTOPSY

The use of the “psychological” autopsy can assist in the determination of the manner of an unnatural death when the circumstances are equivocal (37–43). This approach is useful in cases of suspected suicide when initial information is limited. Interviews with family, friends, co-workers, physicians, and others by investigators provide insight into the deceased’s state of mind and behavior in the past, and in the period preceding death. This will assist in analysis of an individual’s suicidal intent (see Chapter 3, Heading 14 [44]).

## 4. THE SCENE (“WHERE?”)

### 4.1. “Dead at the Scene”

Not examining a body at the scene has been considered a potential pitfall for the pathologist in a medicolegal death investigation (15,23). Scene visitation is not always

**Table 1**  
**Autopsy Authorization and the Five “Ws”**

	Hospital autopsy	Forensic autopsy
Authorization (13,16–21)	Usually by appropriate family member or legally authorized representative	Mandated by statute. Depending on jurisdiction—coroner, medical examiner, or other legal authority
“Why”?—The cause of death	A major focus	A major focus
“Under what circumstances?”—The manner of death (2,6,8,13,22)	Natural death, i.e., caused by disease and/or age	The cause of death can assist in assigning a manner of death  <b>Natural</b> <ul style="list-style-type: none"> <li>• A sudden and unexpected death from disease</li> <li>• Any disease that could account for death and was unattended by a physician</li> </ul> <b>Accident</b> <ul style="list-style-type: none"> <li>• A death from an unintentional and unpredictable event/act</li> </ul> <b>Suicide</b> <ul style="list-style-type: none"> <li>• A death from a self-intentional act</li> </ul> <b>Homicide</b> <ul style="list-style-type: none"> <li>• A death from the harmful intentions of another</li> </ul> <b>Undetermined</b> <ul style="list-style-type: none"> <li>• A death in which there is insufficient or incomplete information to determine the manner (e.g., conflicting versions of events leading to death, skeletal remains)</li> </ul>
“Where?”—The scene (2,10,23)	Hospital Other health care facilities Home (rarely; chronically ill person under palliative care and no suspicions regarding the circumstances of death)	Anywhere The medicolegal investigation may have to consider more than one scene—where the body was discovered, where the individual was actually injured/died and subsequently moved, where he/she was last seen alive
“Who?”—Identification (2,13,20,24,25)	Usually known Confirmed at autopsy by <ul style="list-style-type: none"> <li>• Hospital bracelets (wrist, ankle)</li> </ul>	Investigation of death in health care institution, identification as for “hospital” autopsy

(Continued)

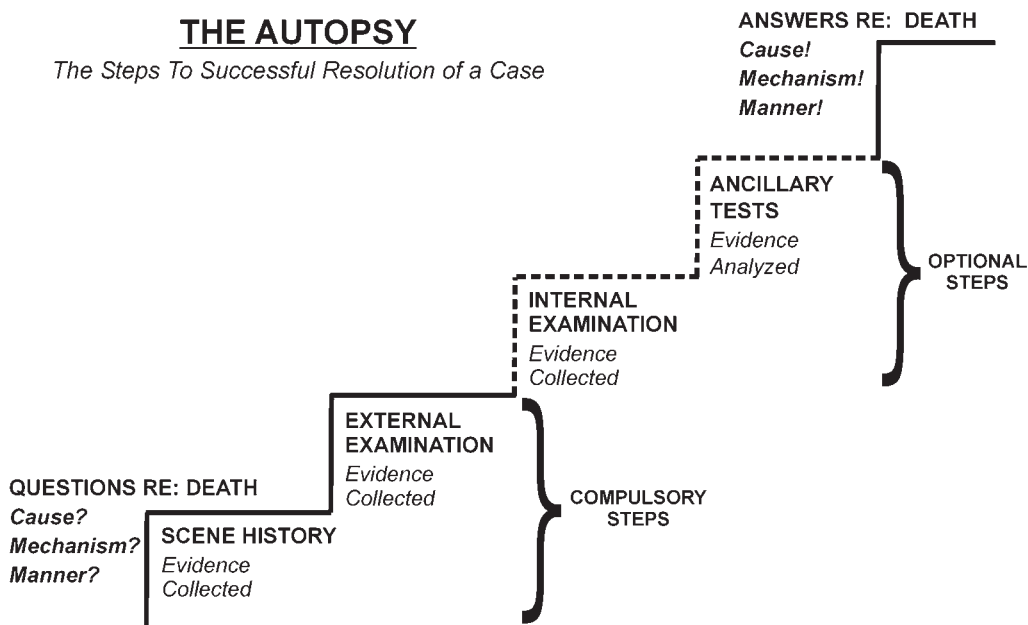


Table 1 (Continued)

	Hospital autopsy	Forensic autopsy
	<ul style="list-style-type: none"> <li>• Tags (body bag, toe)</li> <li>• Review of medical records</li> </ul>	<b>Presumptive</b> <ul style="list-style-type: none"> <li>• Visual identification.</li> <li>• Clothing and personal effects.</li> <li>• Circumstances (e.g., sole occupant of a locked apartment).</li> <li>• General physical features (age, race, sex, height)</li> </ul> <b>Confirmatory</b> —i.e., comparison of unique antemortem/postmortem information <ul style="list-style-type: none"> <li>• Fingerprints</li> <li>• Dental examination</li> <li>• Radiology</li> <li>• Specific physical features (e.g., cutaneous findings such as tattoos, scars, previous surgery, deformity)</li> <li>• DNA</li> </ul>
“When?”—Time of death (see Chapter 2)	Pronouncement of death in medical setting Exact time if witnessed, e.g., during resuscitation	Exact time if reliable witness Unwitnessed death → assessment of certain postmortem changes (rigor mortis, livor mortis, temperature, decomposition) can assist in estimating time of death

necessary or possible for a pathologist conflicted by other duties. Death scene and witness information from different investigators (coroner, medical examiner or investigator, police, fire marshal, etc.) can be communicated to the pathologist by various means (diagrams, photographs, video and digital images) prior to the autopsy (13,23).

If called to the scene, the pathologist needs to document where the death occurred, who was present, and when the scene was attended. At the scene, the pathologist’s focus must be on the deceased and the surroundings relevant to cause of injury and death (e.g., blood stain on a surface, medications, medical paraphernalia, etc.). Investigators can question family and witnesses about medical, psychiatric, family, and occupational history. If an individual had been hospitalized previously, hospital charts must be obtained through a formal medicolegal request. Note is made of any resuscitation efforts that could have created artifactual injuries (see Chapter 3, Subheading 2.6. and Chapter 8, Subheading 6.2.). Information about the deceased’s position and observable postmortem changes needs to be documented (13). The body must not be moved prematurely. Premature or inappropriate removal of a body at the scene compromises the assessment of the relation of certain findings to the surroundings, including postmortem changes used to assess time of death; affects the collection of evidence; raises issues about the presence and integrity of certain personal effects and clothing; and potentially causes



**Fig. 1.** The autopsy. The necessary investigative steps to successfully resolve a medicolegal death investigation.

postmortem artifacts. Any initial manipulation of the body is confined to the recovery of trace evidence (e.g., hair, fibers) that could be lost during transport, a search for means of identification, and an overview of injuries (13,23). Evidence must be preserved by using a sealed body bag if the death is suspicious. Detailed examination is deferred until the actual examination of the body in the autopsy facility.

## 4.2. Rushed to the Hospital

The immediate cause of death (i.e., the fatal condition closest to the time of death in a hospitalized trauma patient) can be from natural causes (e.g., pulmonary thromboembolism; *see* Chapter 8, Subheading 12.3.). The individual is predisposed by the antecedent or “proximate” cause of death—i.e., the underlying factor (e.g., multiple injuries) that initiated an uninterrupted series of pathophysiological events culminating in death (i.e., the “mechanism”—hypercoagulability and venous stasis from immobilization; *see* Heading 11. [20,22]).

In the situation of the delayed death of a hospitalized individual from natural causes owing to trauma, the pathologist must recognize the following:

- These cases require medicolegal investigation, which may not have been apparent to the clinical team, and the coroner or medical examiner must be notified.
- Well-recognized complications leading to death (immediate causes of death) arise during the clinical care of trauma victims and are similar to those arising in the course of a disease (36).

Delayed trauma deaths, particularly in an intensive care setting, can result in voluminous charts requiring time and care when reviewed by a pathologist prior to the autopsy. A cursory perusal jeopardizes the approach required during the postmortem

examination to answer clinical questions and satisfy the needs of a medicolegal investigation. Patience is needed when dealing with disorganized charts, and any missing records need to be found. The pathologist must be able to not only decipher but also appreciate the significance of the “alphabet soup” of complications arising from trauma.

### ***4.3. Some Complications During Intensive Care***

The clinical picture of adult respiratory distress syndrome (ARDS) is characterized by progressive respiratory failure that onsets within a few hours of an abnormal stimulus (45). Hypoxemia requiring intubation, decreased pulmonary compliance, and bilateral chest radiograph abnormalities in the absence of congestive heart failure are typical of ARDS (46). Trauma can either independently cause ARDS by triggering an inflammatory reaction or requires the mediation of other risk factors (e.g., shock).

Diffuse alveolar damage (DAD) is a nonspecific pathological lung reaction occurring in different situations (e.g., pneumonia, aspiration, sepsis, shock, trauma, fat embolism, burns, near-drowning; *see* Chapter 3, Subheading 3.4.; Chapter 4, Subheading 5.2. and Table 1; Chapter 5, Subheading 4.4.; and Chapter 8, Subheading 12.1. [46]). In DAD, inflammatory cell mediators damage alveolar endothelial cells and pneumocytes, resulting in an exudative phase within the first week, characterized by heavy, red edematous lungs at autopsy (45). Microscopic examination reveals precipitation of fibrin membranes (hyaline membranes) in the alveoli, mononuclear cell inflammation in the interstitium, platelet and fibrin microthrombi, and, toward the end of the first week, proliferation of type II pneumocytes. This is followed by an organizing phase during which fibroblasts proliferate in the interstitium and alveolar spaces. There is either eventual resolution or progressive scarring, leading to “honeycomb” lungs.

Systemic inflammatory response syndrome (SIRS) is characterized by hyperthermia or hypothermia, tachycardia, tachypnea, and an elevated or decreased white cell count, mimicking a septic picture (47,48). SIRS results from a systemic activation of an immune response to various infectious and noninfectious processes or diseases associated with tissue hypoperfusion (e.g., infection, trauma, burns). Inflammatory mediators can be demonstrated in the circulation (e.g., C-reactive protein) (49).

Multi-organ failure (MOF)/multiple organ dysfunction syndrome (MODS)/multiple organ failure-syndrome (MOFS) is a possible consequence of SIRS. The typical scenario is that of a multiple trauma patient who is treated for shock but develops MOF days to weeks later (50,51). MOF is implicated in more than 60% of delayed trauma deaths (52). One theory of pathogenesis proposes that release of endogenous gastrointestinal bacteria or their products from an ischemic gut into the circulation results in a septic picture, but positive cultures during the clinical course may be a consequence, not a cause, of organ failure (51,53). Despite the septic picture, no infectious focus is found at autopsy (53). Postmortem blood cultures rarely provide information that was not already known during the clinical course (54). A false-positive blood culture is either the result of contaminants introduced during the obtaining of the specimen at autopsy or agonal bacteremia, particularly if there is an increased postmortem interval (54).

Frank hemorrhage in the background of normal coagulation parameters and platelet count means that the bleeding is potentially corrected by surgery. Disseminated intravascular coagulation (DIC) is the activation of blood clotting owing to endothelial and/or tissue damage from various nontraumatic and traumatic causes (55). There is

consumption of platelets and coagulation factors leading to a bleeding diathesis. Blood oozing from cutaneous puncture sites, incisions, and an operative bed, associated with cutaneous purpura/ecchymoses and patchy visceral hemorrhages (e.g., brain, kidneys, gastrointestinal tract, lungs), suggests a coagulopathy. Concurrent widespread ischemic changes result from platelet–fibrin thrombi in various organs. Fibrinolysis and heparin therapy cause thrombi to disappear so that they are not seen in microscopic sections.

Massive transfusions can lead to coagulopathy (56,57). Packed red blood cells have no functional platelets and decreased levels of certain coagulation factors (V, VIII). Clotting ability is also reduced by hemodilution from a small amount of solution in the transfused-packed red blood cells and platelets. Clotting factors are further diluted by fluid shifts from the interstitium to the intravascular compartment as a result of blood loss. Hypothermia reduces enzyme activity in the coagulation sequence. Decreased body temperature results from emergency transfusion of cold blood and intravenous fluids, diminished heat production by reduced muscular activity, and increased heat loss by immobilization anesthesia. Acidosis caused by tissue hypoperfusion and exacerbated by transfusion of older stored blood decreases platelet function and clotting.

### 5. IDENTIFICATION (“WHO?”)

Accurate identification of an unknown individual or human remains is essential for the following:

- Notification of family to allow for emotional closure, settlement of estates and insurance claims.
- Completion of official records (e.g., death certification, closure of police records).
- Medicolegal investigation to allow questioning of potential witnesses and known associates of the deceased.
- Criminal and civil legal proceedings (6,25).

Misidentification can lead to the following:

- An unauthorized autopsy being done on the wrong body.
- Release of a wrongly identified body to a family and consequent emotional distress and administrative delays.
- Wasted investigative efforts.
- Jeopardized legal proceedings.

Misidentification arises from incomplete, inaccurate, or misleading information. The problem is compounded in a high-volume autopsy facility where the haste to complete cases can lead to the misreading of identifying labels.

Visual recognition by someone who knows the deceased is presumptive but suffices in most cases. Viewing of a body is either at the death scene or in the autopsy facility (6,13). If done at the scene, then information about the identification (e.g., identification bracelet) must be conveyed to the pathologist. Failure to provide this information may require visual identification by the police scene investigator or coroner/medical examiner to the pathologist prior to commencement of the autopsy. Added stress is placed on a family member asked to repeat a viewing. The body removal service sometimes assists in the identification. If a person has been hospitalized, then institutional bracelets identify the deceased.

Depending on the circumstances and nature of the scene, viewing in a morgue may be preferable because of better lighting, ventilation, and security. Viewing in a separate

room outside the main body storage area provides the necessary privacy for the identifier(s) and does not disrupt the normal work flow in a busy facility. Viewing can occur before or after the postmortem. Autopsy personnel prepare the body and make the face “presentable,” i.e., clean off blood and debris (58). Reconstructing a badly injured face may be necessary. Before the face is cleaned or altered, the pathologist must accurately document any findings that could be changed. The pathologist assesses whether the face is not viewable because of decomposition, charring, or massive trauma. If part of the face is not presentable because of trauma, then it can be covered by towels when the body is viewed.

Use of photographic images of the face is an alternative to direct viewing. In such cases, use of a photographic image requires appropriate angling to minimize the adverse emotional effects of an injury (25). The person who identifies the deceased must be accompanied by appropriate personnel. A body-viewing protocol can involve autopsy facility staff, nurses in a hospital, social workers, pastoral care providers, police officers, and coroners/medical examiners. Even when the body of the deceased is preserved, stress sometimes causes the identifier to provide a false-positive or -negative identification. Emotions at the time of viewing cloud perception. Recognition is difficult because the face of the deceased is expressionless. Denial or fatalistic acceptance by the identifier compounds the problem. Rarely, an individual is deliberately misidentified for fraudulent purposes (e.g., concealment of crime, false insurance claim). Viewing of a body for reasons other than identification (e.g., emotional closure, culture, religious practice) is preferable at a funeral home, but use of the autopsy facility may be the only option.

The documentation of clothing and personal effects is another presumptive means of identification. Clothing may be distinctive. An accurate description of the deceased’s clothing provides emotional consistency for a family member who last saw the individual alive. Personal effects can be deliberately switched or planted to mislead identification efforts. Clothing and personal effects may have already been removed or altered at the scene (25). A listing of jewelry items and examination of wallet contents at the scene or in the autopsy facility are necessary steps in the identification process. The pathologist must record clothing and personal effects in the autopsy report. A protocol that outlines items released to police or a funeral home reduces accusations of theft or loss.

Confirmation of identity is required when:

- No one is available to visually identify the deceased.
- Presumptive means of identification (viewing, clothing and personal effects, circumstances) are ambiguous in an otherwise intact body.
- The deceased is not identifiable by presumptive means because of decomposition, charring, skeletonization, or extensive trauma.

Confirmation of identity is by comparison of postmortem findings with antemortem records (Table 1). Various sources of information (e.g., police files including fingerprint records and missing person reports, dental records, medical and other health care files, radiographs, laboratory records and samples, employment and military records) are used.

## *6. EXTERNAL EXAMINATION*

The ability of a pathologist to observe, document, and interpret the significance of external injuries is fundamental to forensic practice (13). The emphasis on the external



examination distinguishes a medicolegal (forensic) autopsy from a family-authorized postmortem (hospital autopsy [13]). Inaccurate or incomplete documentation of external findings is a potential pitfall for the pathologist (15).

A cursory external examination with a focus on the internal dissection to determine cause of death provides little insight into how fatal injuries originated. A cutaneous injury can provide an important clue as to the cause of death. In most instances, skin injuries themselves have no significant pathophysiological effects, but their documentation provides investigative information about what caused those injuries, fatal or nonfatal. If an injured person is hospitalized, then the pathologist must review any medical records, noting resuscitative efforts and any therapeutic and diagnostic procedures that could alter an injury or create external and internal trauma (*see* Chapter 3, Subheading 2.6.; Chapter 8, Subheading 6.2.). Perusal of a hospital chart may provide little solace for a pathologist searching for a detailed description of external injuries. Medical efforts in a clinical setting, particularly when dealing with a severely injured patient, are directed to life-threatening trauma. Relatively little attention is given to cutaneous injuries. Health care personnel usually do not have the expertise to interpret external injuries (e.g., firearm injuries; *see* Chapter 6, Heading 17.). The pathologist must not ignore seemingly trivial injuries that may have medicolegal importance. Failure to note details can undermine the credibility of the pathologist during the investigation and any eventual judicial proceedings.

Various methods of documentation are used to provide an effective record. Narrative descriptions can be too lengthy. If injuries are not described in continuity, then the report is difficult to follow. Word descriptions are enhanced by use of body diagrams (“a picture is worth a thousand words” [59]). A diagram also provides an overall impression of the extent of injuries, emphasizing their severity (20). Diagrams help in the interpretation of photographs. Diagrams can be used as demonstrative evidence in legal proceedings instead of photographic images that may be too graphic for jurors (20,59). Photographic images assist investigators, other experts, and the court in understanding the findings in a case (2,20,59). Although images are not part of the pathologist’s report, they do provide a visual record that assists in the preparation of the report (20,59). Photographic images are not a substitute for a carefully prepared, accurate report. A pathologist must either take or supervise the taking of an adequate number of good-quality images, and be able to state that those images accurately portray the observations made at autopsy (20,59). In a criminally suspicious case, the pathologist must disclose in the autopsy report that photographic images are available, because this information is evidence.

### ***6.1. Photography During External Examination of Cases With Potential for Legal Proceedings or for Education***

- If the administrative and legal framework exists, a pathologist may be requested to examine injuries prior to death (e.g., in an intensive care unit) with the assistance of a police identification officer providing photographic documentation.
- If a hospitalized trauma patient’s death is expected but delayed and the case is under police investigation, then the police, with proper authorization, may take images of evolving external injuries to assist the pathologist.
- The pathologist needs to view images (print, digital, video) taken by police of the scene in certain cases (e.g., “suspicious” deaths, homicides, industrial accidents).

- If the body is sealed, then an identification officer may photograph seals on cooler doors and body bags.
- If images are to be used for educational purposes or other demonstrations, then the face must be masked and genital areas covered.
- Photograph the face, before and after cleaning, for injury documentation and identification (*see* Heading 5.).
- Attempt to crop unwanted details (e.g., pools of blood, gloves, instruments, glare from the autopsy table) from the background of any image.
- Photograph the body overall with clothing.
- Photograph the body overall as various layers of clothing are removed, avoiding cutting or tearing, and noting any defects and foreign material (13).
- Attempt to correlate any defects with observed injuries (13).
- Clothing that is damp from water or blood needs to be examined after it has dried.
- Photograph the unclothed body (front and back) overall, making note of resuscitation and other medical procedures (59).
- Focus on certain findings—foreign material, identifying features, and injuries (59).
- Take photographs of injuries before and after cleaning to ensure that certain features (e.g., bloodstain patterns) are not lost (59).
- “Negative” findings (e.g., lack of injuries on hands) need to be documented (59). Avoid fingerprinting until the hands have been examined.
- Images, particularly close-up views, require a scale with the autopsy accession number (either a straight or L-shaped American Board of Forensic Odontology ruler [59]).
- The scale needs consistent orientation (e.g., scale occupies the more inferior part of the body in the image), particularly in close-up views (59).
- Close-up images can be oriented by including an anatomical landmark. If a landmark is not seen in the close-up, then an overall image is done.
- If separate sets of images are taken by the pathologist and police, review the latter for content and orientation, particularly if legal proceedings are likely.
- The pathologist must realize that a personal collection of autopsy images can be used as evidence.

## **6.2. Autopsy Limited to External Examination Only**

Family objections to dissection may necessitate only an external examination, provided that the medicolegal investigation is not compromised (*see* Heading 7. and refs. 8, 13, 19, and 60–62). An investigating medical examiner or coroner can limit the post-mortem examination to an external examination only, based on adequate background information (63). Certain types of cases (e.g., suicidal hanging, massive trauma) may be suitable for this type of examination. One study showed that the large majority of trauma deaths assessed in emergency departments had unsurvivable injuries. Misdiagnosis at this stage had no bearing on the clinical course (64). A well-documented clinical course (e.g., motor vehicle collision victim), supplemented by diagnostic procedures (laboratory tests, radiology), provides enough information, although internal trauma has been missed in hospitalized patients (14,62,65). Alternatively, an internal examination is essential for a proper medicolegal death investigation, if a cause of death is not apparent (66). Some presumed natural deaths are uncovered as unnatural following an autopsy (67–71). The converse also occurs (63,67,69,70). Studies have compared the accuracy in the determination of cause and manner of death based on initial history and external examinations, which were then supplemented by an autopsy

(63,67,68). The cause of death was accurate in the large majority of unnatural deaths, mostly accidents, in one review (63). In contrast, about one-third of natural deaths had an erroneous assigned cause of death not supported at postmortem (63,68). Another study revealed that certain injuries (e.g., skull fractures) were not appreciated by external examination only (67). The determination that death is a consequence of trauma is very important in criminal investigations, work-related compensation cases, and insurance claims (37,72).

The use of radiology to determine a cause of death, including death in trauma cases, has been described (24,60,73–81). Postmortem radiology is helpful in the detection of injuries (*see* Chapter 5, Subheading 14.8.; Chapter 6, Heading 16.; Chapter 7, Heading 9.). The disadvantages of the use of sophisticated radiological techniques are the cost and the availability of equipment and radiologists to provide opinions.

## 7. INTERNAL EXAMINATION

If there is a death in a clinical setting that does not require medicolegal investigation, then a pathologist, in most jurisdictions, may proceed only with an autopsy that has been authorized by the family or appropriate legal representative (10,18,60,62,82). The request for the autopsy, including internal examination, is initiated by either the family or a physician. Unless there is direct contact with the family, the pathologist relies on a health care professional, usually a physician, to obtain the appropriate informed consent for an autopsy (2,8,10,12,21). The health care professional who interacts with the family members must be aware of their perspective, understand the value of a postmortem examination, and appreciate the institutional process related to the autopsy (2,30). The hospital may provide information pamphlets to next of kin to assist them in understanding the process (2).

The number of hospital autopsies with consent has declined. From 1972 to 1992, the percentage of hospital deaths autopsied with consent decreased to less than 10% in the United States (6). Certain trends or perceived barriers have accounted for the decline. Some of these are:

- A certain percentage of hospital deaths having autopsies is no longer required for institutional accreditation (6,30,83).
- Advances in diagnostic tests lessen the need for autopsies (2,6,30,84).
- Some pathologists are ambivalent about performing postmortems for various reasons (e.g., professionally unrewarding in terms of income, advancement, and educational value; distaste regarding autopsy procedures; fear of infection; perceived lack of sophistication of autopsy pathology; low clinical interest; isolation from other colleagues [1,6,14,30,83]).
- The perception exists that family emotions around the time of death prevent obtaining an autopsy consent (9,14,21,85).
- There may be negative perceptions of the autopsy by the family (the patient has “suffered enough” [14]).
- Other family members may object to the autopsy (83).
- Lack of communication between physicians and family about postmortem results may exist.
- The decreased teaching of pathology to health care undergraduates means that fewer professionals in the future will have the knowledge and training to properly inform families about the nature and benefits of the autopsy (1,2,6,8,9,12,14,21).

Beyond its scientific and educational benefits, the autopsy assists families during bereavement (2,58,85,86). Emotional closure is possible when the cause of death is known. Suspicion and guilt are allayed when reassurance is given that medical care was appropriate (1,9,14,85,87).

During a 20-yr study period, the overall percentage of deaths in the United States having a medicolegal postmortem held steady at about 5% (6). Statutory obligations dictate that certain deaths are investigated, and many of these cases require an autopsy (60,62). During a medicolegal death investigation, the investigator has temporary proprietary rights over the deceased until the body is released to the family (16,21,88). The pathologist acts as a consultant to a coroner or medical examiner if an autopsy is ordered (8,13). The nature of the jurisdiction dictates what percentage of investigations need an autopsy (e.g., increased if there is a high homicide rate). The barriers to the performance of hospital autopsies also exist for medicolegal cases (62). The pathologist relies on the ability of the coroner or medical examiner to explain to a family the nature of and necessity for an autopsy. Although concerns and objections are overridden by statute, a coroner/medical examiner and pathologist still must address them (62). Studies have shown that next of kin are more receptive to the performance of a medicolegal autopsy if the cause of death is unknown or uncertain, there is a suspicion of a crime, ambiguities regarding a life insurance claim are removed, and information about the necessity of an autopsy was communicated (12,58,83).

### **7.1. The Limited Autopsy**

In the clinical setting, family authorization for a complete autopsy allows for examination of all body cavities, dissection of all body organs, retention of tissues and fluid for microscopic examination, and other testing for the determination of pathological diagnoses that point to a cause of death (2,14). The family can ask that the autopsy be restricted to the examination of certain organs and cavities.

In forensic practice, complete autopsies are the ideal, but postmortem examinations can be limited or modified. A high-volume practice and few experienced professional and support staff can limit the completeness of an autopsy (20). Bodies repatriated from other countries may have only body incisions without evidence of further dissection (89). Certain steps are followed to satisfy religious requirements (e.g., *in situ* examination of organs and return of fluids to the body of a deceased of the Orthodox Jewish faith [60]). A medicolegal autopsy may be limited to finding only the cause of death to facilitate timely body release, particularly with pressure from funeral directors, and to allow prompt completion of reports. Limiting the autopsy, however, can cause findings that contribute to the injury causation to be overlooked (e.g., undiagnosed brain tumor contributing to a motor vehicle collision) or fail to answer other questions unrelated to trauma (90).

Endoscopy has been used as an autopsy technique (91,92). Needle insertion (e.g., cisternal tap to rule out subarachnoid hemorrhage) has been done but assumes the bleeding is not artifactual (60).

### **7.2. Organ Harvesting**

For a family of a hospitalized, severely injured patient, the option of organ donation may be offered. This provides emotional closure for the family by reconciling them

to the fact that their loss will do some good (93). A medicolegal investigation, particularly into a criminally suspicious death, takes precedence over organ donation (94). Although pressure by family and the transplantation service may be applied, there must be assurance that harvesting does not compromise the collection of evidence (e.g., toxicology specimens), the documentation and interpretation of injuries, and the determination of the cause of death (95–98). Communication among police, medical examiner/coroner, medical staff, transplant team, and pathologist is essential (94,99). Isolated injuries (e.g., head trauma) allow for both organ donation and a limited autopsy. Radiographic examinations and other testing (e.g., echocardiogram) can rule out other trauma. In addition to conducting the autopsy, the pathologist may be asked to examine the eyes prior to removal of corneas, provide an intraoperative consultation for harvested organs, and examine organs not used for transplantation (95). If the pathologist does not attend the operating room during organ harvesting, then the attending surgeon must confirm that any removed organs did not show injuries (94).

### 7.3. Organ Retention

There are varying amounts of tissue retained from an autopsy. At one end of the spectrum, the final report is based only on the “gross” or external findings (e.g., massive trauma). The sampling of tissues used to prepare microscopic slides and storage of representative tissue in formaldehyde (“stock material”) is not done in these cases. In contrast, whole organs and *en bloc* specimens are kept for review, particularly if legal proceedings are a possibility.

Depending on the jurisdiction, relatives do have proprietary rights over the deceased that allow certain postmortem procedures (e.g., burial) to proceed (16,17,88,93,100–102). In the United Kingdom, parents’ anger, expressed during the Bristol inquiry, about the postmortem retention of their children’s organs prompted the Royal College of Pathologists (RCPATH) to reassess its policies regarding organ retention in hospital-consent and medicolegal autopsies (17,21,101). Similar issues have arisen in Australia (2). There is a varying degree of public and professional awareness of this issue in other jurisdictions.

The RCPATH has proposed guidelines pertaining to tissue retention:

- Retention must be lawful—i.e., it must not contravene statute or breach a common-law tenet (e.g., obscene display).
- The reasons for organ retention must be defensible, open, and justifiable in law and clinical practice (7,8).

A hospital-authorized autopsy requires an informed relative’s agreement and gives a pathologist permission for organ and tissue retention for diagnostic, educational, and research purposes (2,7,18,101). A medicolegal autopsy can override a family’s objections because of the circumstances of the death (2,21). Nevertheless, there are constraints on retention in both types of autopsies (14). The need for retention to establish the cause of death is justified and hopefully accepted by next of kin (7,103). In some cases, the pathologist retains an organ that, in retrospect, does not assist in the determination of the cause of death (e.g., brain, if “no anatomic cause of death” at autopsy [101,104]). Families are more receptive if they are aware of the other benefits of the autopsy (8). The pathologist must be discreet in the use of tissues and images for rounds and other educational purposes (21). Depending on a relative’s perception of research,



there may be no objection to the use of excess tissue normally removed for diagnostic purposes (12,14). Ethical approval is still required (2). In cases in which research is centered on use of tissue beyond what is customarily removed (e.g., spinal column), then special permission from a family member is needed (21). In forensic cases, permission from the head of the medicolegal jurisdiction (chief coroner, chief medical examiner) and family may be required to use any material for education and research, which are outside the scope of the death investigation (7,14,17,18,105).

- Another guideline proposes that, unless the postmortem examination is directed by law, autopsy procedures must be sufficiently flexible to reflect the wishes of relatives while maintaining the standards of diagnostic accuracy (7).

Prohibition of tissue and organ retention may mean an inadequate postmortem examination (7,21). A pathologist, under these circumstances, could decline to do the autopsy (103). There should be latitude to allow organ retention, if there are unexpected findings (7). Adoption of these proposals means an increased administrative burden on already busy autopsy services (21).

- The RCPATH also proposes that, if an autopsy is directed by law, where possible and practicable, the relatives should be fully informed before the examination of what is to be done and its purpose (7).

The pathologist should inform the coroner or medical examiner about retention of an organ (2,7,21,103). This information needs to be conveyed to the family (17). A family may attach symbolic, religious, or cultural significance to certain organs (e.g., brain), but this may not necessarily apply to representative tissue samples for microscopy (2,8–11,14,17,19,21,83,101,106,107). Brain retention is necessary to determine the cause of death in many trauma cases (7,17,103).

Issues regarding the means of tissue disposal (e.g., incineration) and duration of organ retention may arise (7). Relatives may request the return of an organ to the body or a separate burial by the funeral director; however, if legal issues regarding injury and death causation arise pertaining to that organ, then retention is required until the matter is resolved or adjudicated (7,13,94,103).

## 8. TESTS

### 8.1. Microscopy

Study of microscopic sections is the most common test that a pathologist does. Microscopy is an audit of the reliability of the interpretations made during the dissection (7). Not all forensic autopsies require microscopy, but the criteria are vague and rely on the discretion of the pathologist and the nature of the case (6,13,20,35). Selective sectioning, instead of routine sampling of all organs, can decrease the time to report a case (11,14,108). Without microscopy in certain trauma cases, pathological diagnoses bearing on the cause of death cannot be determined (e.g., traumatic axonal injury). Depending on the circumstances of death, unprocessed formalin-fixed tissue is kept for a finite period and then disposed. Glass slides and paraffin blocks are part of the medical record and are archived (7,21). If required in a legal proceeding, slides must be available for review by other pathologists to allow confirmation or revision of the original findings (6,21,103).

## 8.2. Other Specimens

The recognition and collection of evidence is an important part of forensic pathology practice and distinguishes it from a hospital-consent autopsy (6,13,20). Toxicological analysis assists in the determination of the cause of death in certain cases (e.g., suspected medication or illicit drug overdose) when there is “no anatomic cause of death,” i.e., no gross or microscopic cause of death. Toxicology samples—most commonly blood and urine—are collected. To ensure continuity of evidence, sample tubes and containers are sealed. The seal label indicates the name of the deceased, case number, date and time sealed, and the type of specimen, and is signed by the pathologist or police officer attending the autopsy. If an injured individual survives in the hospital for a period of time and then dies, any ethanol or other drugs will have metabolized, rendering postmortem specimens useless for meaningful analysis (109). Admission blood samples, if available, need to be obtained. The laboratory must be informed to hold these samples either by a coroner/medical examiner or designate (pathologist, police officer). In this situation, the hospital needs to have a tracking system to ensure continuity (13,35). If samples do not require analysis, they can be stored.

Pathologists are also responsible for the examination of surgically resected specimens from trauma cases.

## 9. OBSERVERS AT AUTOPSY

One purpose of the hospital-consent autopsy is to educate. A spectrum of health care professionals and trainees are involved. Medicolegal autopsies are also educational, but because of confidentiality, particularly in criminal investigations, attendance at the autopsy is restricted (105).

## 10. COMMUNICATION OF AUTOPSY FINDINGS AND REPORT

Following the completion of a family-authorized autopsy, the pathologist may speak with the attending physician and provide a brief summary of the initial autopsy findings (“provisional anatomical diagnoses”). The clinician conveys these results to the family. After the microscopic examination and other tests have been completed, a final report is issued, usually to the family doctor and attending physicians. A copy of the report is filed in the hospital health records department and becomes available to other clinicians and family, with proper authorization. Following the completion of a medicolegal postmortem, the pathologist reports the findings to a coroner or medical examiner, who interacts with the next of kin. At this stage, any conclusions about the cause of death may be limited and need to await further testing (15,22). The pathologist may discuss the death with the clinical team caring for a hospitalized individual provided the coroner/medical examiner and family have no concerns about the quality of medical care.

A confidential written report is issued to the coroner/medical examiner and other parties by statute. Depending on the jurisdiction, distribution of the report varies (13). Requests by family may be deferred, if there are pending criminal proceedings. A forensic pathologist, functioning as a medical examiner, communicates directly with the family about the autopsy report (110). This report is also viewed by various agencies and

other professionals (110). A release from a coroner/medical examiner may be required before a pathologist's report of a trauma patient is sent to the hospital health records department, where it is available to clinicians. Families appreciate timely release of autopsy reports (110). For hospital deaths, the College of American Pathologists Laboratory Accreditation Program recommends 30 d for completion of routine cases and 90 d for complicated cases (111). The pathologist must expedite a report if there are inquiries from the family and other interested parties. Slow reporting of cases delays not only a family's emotional closure, but also various financial and legal matters (e.g., insurance claims, criminal proceedings).

The format of a report varies, but certain elements are constant (34,111). In addition to the name of the deceased and an accession number, the report records the autopsy pathologist, assistants, and attendees. The name of the coroner or medical examiner who ordered the autopsy is noted. The location of the autopsy and the time and date the case began are given. An external examination, including means of identification and documentation of clothing, follows. Postmortem changes (rigor, livor, decomposition) can be of a greater import than in a hospital case. Signs of recent therapeutic intervention are noted. The internal examination is a listing of findings according to organ systems. A section devoted to external and internal injuries is in the forensic report. Injuries need to be described in continuity rather than being scattered in the narrative to allow for easier reading. Reference to diagrams assists in understanding the trauma observed. Microscopy and other ancillary testing (e.g., toxicology, radiology) are recorded. Any evidence collected and images, particularly of a criminally suspicious death, need to be mentioned. Microscopic sections and photographic images are records that allow an objective review of a case, particularly if it involves a criminal investigation (34).

## *11. CAUSE OF DEATH: THE "BOTTOM LINE"*

An autopsy authorized by next of kin on an individual dying of natural disease yields a number of pathological diagnoses. Although the autopsy report in these cases does not necessarily require a cause of death, a listing of these abnormal findings ("anatomical diagnoses") provides information to the physicians caring for the patient that helps explain to the family why the individual died. In a medicolegal case, the onus is on the pathologist to provide a cause of death, which assists the coroner or medical examiner to accurately certify a death and assign the appropriate manner.

Adelson defined cause of death as "the injury, disease or the combination of the two responsible for initiating the train of physiological disturbances, brief or prolonged, which produced the fatal termination" (112). The cause of death is immediate if the injury or disease kills so quickly that there are no sequelae or complications (112,113). If a complication (e.g., pneumonia) develops during a period of survival, then that sequela becomes the immediate cause of death, and the initiating event is the proximate or antecedent cause, provided a direct relation exists (*see* Subheading 4.2. and refs. 112 and 113). If an individual survives for a period of time, then clinicians may lose sight of the initiating injury that ultimately led to apparent death from natural causes. The pathologist, on perusal of a hospital chart, needs to be aware of this and contact the coroner or medical examiner.

In many trauma cases, the cause of death is well defined (e.g., massive craniocerebral trauma caused by motor vehicle collision [104,113–117]). In other cases of injury with survival, the cause of death can be multifactorial (114). Each of these factors make some contribution to the death of that individual (113,116). Other conditions and diseases could have precipitated the event and influenced the course of the illness but are not directly related to the immediate cause of death. These “significant” factors may or may not contribute to the cause of death (e.g., cause of death: subdural hemorrhage; significant factors: acute ethanol intoxication, diabetes mellitus [113]).

Finding a potential cause of death at autopsy is interpreted in the context of the scene investigation and circumstances of the death (115,116). Historical events provided by the coroner/medical examiner and other investigators are relevant to death by trauma; however, this information may be based on unreliable witness accounts and may evolve (116).

A systematic approach, in most cases, leads to a successful conclusion as to the determination of the cause, mechanism, and manner of death (Fig. 1). In some trauma cases, the cause of death is undetermined (“no anatomic cause of death”). Decomposition renders soft tissue trauma uninterpretable (*see* Chapter 2 and ref. 115). A cause of death may not be determined if there is a lack of investigative information, undue haste, misinterpretation of findings, and an incomplete autopsy (114). In rare instances of trauma, an anatomic cause of death is not found despite a carefully performed postmortem (*see* Chapter 8, Subheading 6.4.3. and ref. 118).

## REFERENCES

1. Pellegrino, E. D. The autopsy. Some ethical reflections on the obligations of pathologists, hospitals, families, and society. *Arch. Pathol. Lab. Med.* 120:739–742, 1996.
2. Royal College of Pathologists of Australasia. Policy Statement: Autopsies and the use of tissue removed from autopsies 1993 (revised 2002). Available at: [www.rcpa.edu.au/applications/DocumentLibraryManager2/upload/Complants%20Handling.pdf](http://www.rcpa.edu.au/applications/DocumentLibraryManager2/upload/Complants%20Handling.pdf). Last accessed: May 15, 2006.
3. Richards, S. J. Confidentiality and the medical report. *Med. Sci. Law* 25:96–102, 1985.
4. Wright, R. K., Tate, L. G. Forensic pathology. Last stronghold of the autopsy. *Am. J. Forensic Med. Pathol.* 1:57–60, 1980.
5. Rose, E. F. Pathology reports and autopsy protocols: confidentiality, privilege, and accessibility. *Am. J. Clin. Pathol.* 57:144–155, 1972.
6. Burton, E. C., McPhee, S. J. Autopsy overview. In: Collins, K. A., Hutchins, G. M., eds. *Autopsy Performance and Reporting*. College of American Pathologists, Northfield, IL, pp. 3–12, 2002.
7. Royal College of Pathologists. Guidelines for the retention of tissues and organs at postmortem examination. 2000.
8. Lynch, M. J. The autopsy: legal and ethical principles. *Pathology* 34:67–70, 2002.
9. Brown, H. G. Perceptions of the autopsy: views from the lay public and program proposals. *Hum. Pathol.* 21:154–158, 1990.
10. Svendsen, E., Hill, R. B. Autopsy legislation and practice in various countries. *Arch. Pathol. Lab. Med.* 111:846–850, 1987.
11. Roberts, W. C. The autopsy: its decline and a suggestion for its revival. *N. Engl. J. Med.* 299:332–338, 1978.
12. Sanner, M. A. In perspective of the declining autopsy rate. Attitudes of the public. *Arch. Pathol. Lab. Med.* 118:878–883, 1994.

13. Randall, B. B., Fierro, M. F., Froede, R. C. Practice guideline for forensic pathology. Members of the Forensic Pathology Committee, College of American Pathologists. *Arch. Pathol. Lab. Med.* 122:1056–1064, 1998.
14. Royal College of Pathologists. The autopsy and audit. 1991. Available at [www.rcpath.org/resources/pdf/AUTOPSYANDAUDIT.pdf](http://www.rcpath.org/resources/pdf/AUTOPSYANDAUDIT.pdf). Last accessed: May 15, 2006.
15. Moritz, A. R. Classical mistakes in forensic pathology (*Am. J. Clin. Pathol.*, 1956). *Am. J. Forensic Med. Pathol.* 2:299–308, 1981.
16. Matthews, P. Whose body? People as property. *Curr. Leg. Probl.* 36:193–239, 1983.
17. Brazier, M. Human tissue retention. *Med. Leg. J.* 72:39–52, 2004.
18. Skegg, P. D. The use of corpses for medical education and research: the legal requirements. *Med. Sci. Law* 31:345–354, 1991.
19. Schmidt, S. Consent for autopsies. *JAMA* 250:1161–1164, 1983.
20. Butts, J. D. Postmortem examination: A statement of principles of the medicolegal autopsy. In: Fierro, M. F., ed. *CAP Handbook for Postmortem Examination of Unidentified Remains. Developing Identification of Well-Preserved, Decomposed, Burned and Skeletal Remains.* College of American Pathologists, Northfield, IL, pp. 11–46, 1998.
21. Royal College of Pathologists. Human bodies, human choices: response from the Royal College of Pathologists. 2002. Available at [www.rcpath.org/resources/pdf/human-bodies.human-choices.college-response.pdf](http://www.rcpath.org/resources/pdf/human-bodies.human-choices.college-response.pdf). Last accessed: May 15, 2006.
22. Hanzlick, R. L. Medical certification of death and cause-of-death statements. In: Froede, R. C., ed. *Handbook of Forensic Pathology.*, College of American Pathologists, Northfield, IL pp. 31–48, 2003.
23. Ernst, M. F. Medicolegal death investigation and forensic procedures. In: Froede, R. C., ed. *Handbook of Forensic Pathology.* College of American Pathologists, Northfield, IL, pp. 1–10, 2003.
24. Schmidt, G., Kallieris, D. Use of radiographs in the forensic autopsy. *Forensic Sci. Int.* 19:263–270, 1982.
25. Fierro, M. F. Identification. In: Froede, R. C., ed. *Handbook of Forensic Pathology.* Northfield, IL, College of American Pathologists, pp. 49–60, 2003.
26. Wagner, B. M. Mortality statistics without autopsies: wonderland revisited. *Hum. Pathol.* 18:875–876, 1987.
27. Cameron, H. M., McGoogan, E. A prospective study of 1152 hospital autopsies: I. Inaccuracies in death certification. *J. Pathol.* 133:273–283, 1981.
28. Kircher, T., Nelson, J., Burdo, H. The autopsy as a measure of accuracy of the death certificate. *N. Engl. J. Med.* 313:1263–1269, 1985.
29. Combes, A., Mokhtari, M., Couvelard, A., et al. Clinical and autopsy diagnoses in the intensive care unit: a prospective study. *Arch. Intern. Med.* 164:389–392, 2004.
30. McPhee, S. J., Bottles, K. Autopsy: moribund art or vital science? *Am. J. Med.* 78:107–113, 1985.
31. Goldman, L. Diagnostic advances v the value of the autopsy. 1912–1980. *Arch. Pathol. Lab. Med.* 108:501–505, 1984.
32. Goldman, L., Sayson, R., Robbins, S., Cohn, L. H., Bettmann, M., Weisberg, M. The value of the autopsy in three medical eras. *N. Engl. J. Med.* 308:1000–1005, 1983.
33. Sens, M. A., Fierro, M. F. Quality assessment and improvement in autopsy pathology. In: Nakhleh, R. E., Fitzgibbons, P. L., eds. *Quality Improvement Manual in Anatomic Pathology.* College of American Pathologists, Northfield, IL, pp. 97–111, 2002.
34. Burke, M. P., Opeskin, K. Audit in forensic pathology. *Am. J. Forensic Med. Pathol.* 21:230–236, 2000.
35. Froede, R. C., Graham, M. A. The medicolegal autopsy: format and quality assurance. In: Froede, R.C., ed. *Handbook of Forensic Pathology.* College of American Pathologists, Northfield, IL, pp. 11–22, 2003.
36. Hirsch, C. S. Forensic pathology and the autopsy. *Arch. Pathol. Lab. Med.* 108:484–489, 1984.



37. Curphey, T. J. Role of the forensic pathologist in the medicolegal certification of modes of death. *J. Forensic. Sci.* 13:163–176, 1968.
38. Weinberger, L. E., Sreenivasan, S., Gross, E. A., Markowitz, E., Gross, B. H. Psychological factors in the determination of suicide in self-inflicted gunshot head wounds. *J. Forensic. Sci.* 45:815–819, 2000.
39. Ritchie, E. C., Gelles, M. G. Psychological autopsies: the current Department of Defense effort to standardize training and quality assurance. *J. Forensic. Sci.* 47:1370–1372, 2002.
40. Diller, J. The psychological autopsy in equivocal deaths. *Perspect. Psychiatr. Care* 17:156–161, 1979.
41. Litman, R. E. 500 psychological autopsies. *J. Forensic. Sci.* 34:638–646, 1989.
42. Jobes, D. A., Berman, A. L., Josselson, A. R. The impact of psychological autopsies on medical examiners' determination of manner of death. *J. Forensic. Sci.* 31:177–189, 1986.
43. Danto, B. L., Streed, T. Death investigation after the destruction of evidence. *J. Forensic. Sci.* 39:863–870, 1994.
44. Jobes, D. A., Casey, J. O., Berman, A. L., Wright, D. G. Empirical criteria for the determination of suicide manner of death. *J. Forensic. Sci.* 36:244–256, 1991.
45. Travis, W. D., Beasley, M. B. The respiratory system. In: Rubin, E., Gorstein, F., Rubin, R., Schwarting, R., Strayer, D., eds. *Rubin's Pathology—Clinicopathologic Foundations of Medicine*. Lippincott; Williams and Wilkins, Baltimore, MD, pp. 583–658, 2005.
46. Garber, B. G., Hebert, P. C., Yelle, J. D., Hodder, R. V., McGowan, J. Adult respiratory distress syndrome: a systemic overview of incidence and risk factors. *Crit. Care Med.* 24:687–695, 1996.
47. Levy, M. M., Fink, M. P., Marshall, J. C., et al. 2001 SCCM/ESICM/ACCP/ATS/SIS International Sepsis Definitions Conference. *Intensive Care Med.* 29:530–538, 2003.
48. Boyd, O., Newman, P. Systemic inflammatory response. In: Webb, A. R., Shapiro, M. J., Singer, M., Suter, P. M., eds. *Oxford Textbook of Critical Care*. Oxford University Press, New York, pp. 918–920, 1999.
49. Foex, B. A. Systemic responses to trauma. *Br. Med. Bull.* 55:726–743, 1999.
50. Johnson, D., Mayers, I. Multiple organ dysfunction syndrome: a narrative review. *Can. J. Anaesth.* 48:502–509, 2001.
51. Bion, J. F. Multiple organ failure—pathophysiology. In: Webb, A. R., Shapiro, M. J., Singer, M., Suter, P. M., eds. *Oxford Textbook of Critical Care*. Oxford University Press, New York, pp. 923–926, 1999.
52. Sauaia, A., Moore, F. A., Moore, E. E., et al. Epidemiology of trauma deaths: a reassessment. *J. Trauma* 38:185–193, 1995.
53. Deitch, E. A. Gut failure: its role in the multiple organ failure syndrome. In: Deitch, E. A., ed. *Multiple Organ Failure—Pathophysiology and Basic Concepts of Therapy*. Thieme Medical Publishers, New York, pp. 40–59, 1990.
54. Wilson, S. J., Wilson, M. L., Reller, L. B. Diagnostic utility of postmortem blood cultures. *Arch. Pathol. Lab. Med.* 117:986–988, 1993.
55. Schwarting, R., Kocher, W. D., McKenzie, S., Alomari, M. Hematopathology. In: Rubin, E., Gorstein, F., Rubin, R., Schwarting, R., Strayer, D., eds. *Rubin's Pathology—Clinicopathologic Foundations of Medicine*. Lippincott; Williams and Wilkins, Baltimore, MD, pp. 1018–1123, 2005.
56. Armand, R., Hess, J. R. Treating coagulopathy in trauma patients. *Transfus. Med. Rev.* 17:223–231, 2003.
57. Phillips, T. F., Soulier, G., Wilson, R. F. Outcome of massive transfusion exceeding two blood volumes in trauma and emergency surgery. *J. Trauma* 27:903–910, 1987.
58. Plattner, T., Scheurer, E., Zollinger, U. The response of relatives to medicolegal investigations and forensic autopsy. *Am. J. Forensic Med. Pathol.* 23:345–348, 2002.
59. Davis, D. Forensic photography. In: Froede, R. C., ed. *Handbook of Forensic Pathology*. College of American Pathologists, Northfield, IL, pp. 459–464, 2003.

60. Mittleman, R. E., Davis, J. H., Kasztl, W., Graves, W. M., Jr. Practical approach to investigative ethics and religious objections to the autopsy. *J. Forensic. Sci.* 37:824–829, 1992.
61. Orlowski, J. P., Vinicky, J. K. Conflicting cultural attitudes about autopsies. *J. Clin. Ethics* 4:195–197, 1993.
62. Rho, Y. M. Medical examiner's authority: challenges to perform autopsies. *N.Y. State J. Med.* 81:1687–1688, 1981.
63. Vanatta, P. R., Petty, C. S. Limitations of the forensic external examination in determining the cause and manner of death. *Hum. Pathol.* 18:170–174, 1987.
64. Seow, E., Lau, G. Who dies at A&E? The role of forensic pathology in the audit of mortality in an emergency medicine department. *Forensic Sci. Int.* 82:201–210, 1996.
65. Albrektsen, S. B., Thomsen, J. L. Detection of injuries in traumatic deaths. The significance of medico-legal autopsy. *Forensic Sci. Int.* 42:135–143, 1989.
66. Clark, M. A. The value of the hospital autopsy. Is it worth the cost? *Am. J. Forensic Med. Pathol.* 2:231–237, 1981.
67. Virkkunen, M., Penttilä, A., Tenhu, M., et al. Comparative study on the underlying cause and mode of death established prior to and after medicolegal autopsy. *Forensic Sci.* 5:73–79, 1975.
68. Nashelsky, M. B., Lawrence, C. H. Accuracy of cause of death determination without forensic autopsy examination. *Am. J. Forensic Med. Pathol.* 24:313–319, 2003.
69. Asnaes, S. Mortality statistics and autopsy: reliability of estimation of the mode of death in Copenhagen and a rural district of Sealand, Denmark. *Forensic Sci. Int.* 14:177–180, 1979.
70. Marshall, T. K. The value of the necropsy in ascertaining the true cause of a non-criminal death. *J. Forensic. Sci.* 15:28–33, 1970.
71. Asnaes, S., Paaske, F. Uncertainty of determining mode of death in medicolegal material without autopsy—a systematic autopsy study. *Forensic Sci. Int.* 15:3–17, 1980.
72. Asnaes, S. The importance of medico-legal autopsies. An analysis of the complex problems regarding damages. *Forensic Sci. Int.* 23:123–127, 1983.
73. Bisset, R. A., Thomas, N. B., Turnbull, I. W., Lee, S. Postmortem examinations using magnetic resonance imaging: four year review of a working service. *BMJ* 324:1423–1424, 2002.
74. Thali, M. J., Yen, K., Plattner, T., et al. Charred body: virtual autopsy with multi-slice computed tomography and magnetic resonance imaging. *J. Forensic. Sci.* 47:1326–1331, 2002.
75. Thali, M. J., Yen, K., Schweitzer, W., et al. Virtopsy, a new imaging horizon in forensic pathology: virtual autopsy by postmortem multislice computed tomography (MSCT) and magnetic resonance imaging (MRI)—a feasibility study. *J. Forensic. Sci.* 48:386–403, 2003.
76. Brookes, J. A., Hall-Craggs, M. A., Sams, V. R., Lees, W. R. Non-invasive perinatal necropsy by magnetic resonance imaging. *Lancet* 348:1139–1141, 1996.
77. Thali, M. J., Schweitzer, W., Yen, K., et al. New horizons in forensic radiology: the 60-second digital autopsy—full-body examination of a gunshot victim by multislice computed tomography. *Am. J. Forensic Med. Pathol.* 24:22–27, 2003.
78. Aghayev, E., Thali, M., Jackowski, C., et al. Virtopsy—fatal motor vehicle accident with head injury. *J. Forensic. Sci.* 49:809–813, 2004.
79. Thali, M. J., Braun, M., Buck, U., et al. Virtopsy—scientific documentation, reconstruction and animation in forensic: individual and real 3D data based geo-metric approach including optical body/object surface and radiological CT/MRI scanning. *J. Forensic. Sci.* 50:428–442, 2005.
80. Yen, K., Vock, P., Tiefenthaler, B., et al. Virtopsy: forensic traumatology of the subcutaneous fatty tissue; multislice computed tomography (MSCT) and magnetic resonance imaging (MRI) as diagnostic tools. *J. Forensic. Sci.* 49:799–806, 2004.

81. Bolliger, S., Thali, M., Jackowski, C., Aghayev, E., Dirnhofer, R., Sonnenschein, M. Postmortem non-invasive virtual autopsy: death by hanging in a car. *J. Forensic. Sci.* 50:455–460, 2005.
82. Skegg, P. D. Criminal liability for the unauthorized use of corpses for medical education and research. *Med. Sci. Law* 32:51–54, 1992.
83. McPhee, S. J., Bottles, K., Lo, B., Saika, G., Crommie, D. To redeem them from death. Reactions of family members to autopsy. *Am. J. Med.* 80:665–671, 1986.
84. Anderson, R. E., Hill, R. B. The current status of the autopsy in academic medical centers in the United States. *Am. J. Clin. Pathol.* 92:S31–S37, 1989.
85. McManus, B. M., Wood, S. M. The autopsy. Simple thoughts about the public needs and how to address them. *Am. J. Clin. Pathol.* 106:S11–S14, 1996.
86. Forrest, G. C., Standish, E., Baum, J. D. Support after perinatal death: a study of support and counselling after perinatal bereavement. *Br. Med. J. (Clin. Res. Ed.)* 285:1475–1479, 1982.
87. Hirsch, C. S. Talking to the family after an autopsy. *Arch. Pathol. Lab. Med.* 108:513–514, 1984.
88. Skegg, P. D. Medical uses of corpses and the “no property” rule. *Med. Sci. Law* 32:311–318, 1992.
89. Lowe, J. W. A post-mortem examination was not done through a large autopsy incision. *Med. Sci. Law* 37:78, 1997.
90. Moar, J. J. Renal adenocarcinoma with tumour thrombi in the inferior vena cava and right atrium in a pedestrian motor vehicle accident fatality: case report and medicolegal implications. *Forensic Sci. Int.* 95:183–192, 1998.
91. Avrahami, R., Watemberg, S., Daniels-Philips, E., Kahana, T., Hiss, J. Endoscopic autopsy. *Am. J. Forensic Med. Pathol.* 16:147–150, 1995.
92. Taff, M. L., Boglioli, L. R. Endoscopy is not autopsy. *Am. J. Forensic Med. Pathol.* 17:86–88, 1996.
93. Perper, J. A. Ethical, religious, and legal considerations to the transplantation of human organs. *J. Forensic. Sci.* 15:1–13, 1970.
94. Davis, J. H., Wright, R. K. Influence of the medical examiner on cadaver organ procurement. *J. Forensic. Sci.* 22:824–826, 1977.
95. Jaynes, C. L., Springer, J. W. Decreasing the organ donor shortage by increasing communication between coroners, medical examiners and organ procurement organizations. *Am. J. Forensic Med. Pathol.* 15:156–159, 1994.
96. Sturmer, W. Q. Can baby organs be donated in all forensic cases? Proposed guidelines for organ donation from infants under medical examiner jurisdiction. *Am. J. Forensic Med. Pathol.* 16:215–218, 1995.
97. Shafer, T. J., Schkade, L. L., Evans, R. W., O’Connor, K. J., Reitsma, W. Vital role of medical examiners and coroners in organ transplantation. *Am. J. Transplant* 4:160–168, 2004.
98. Shafer, T. J., Schkade, L. L., Siminoff, L. A., Mahoney, T. A. Ethical analysis of organ recovery denials by medical examiners, coroners, and justices of the peace. *J. Transpl. Coord.* 9:232–249, 1999.
99. Kramer, J. L. Decreasing the organ donor shortage. *Am. J. Forensic Med. Pathol.* 16:257–260, 1995.
100. Samuels, A. Whose body is it anyway? *Med. Sci. Law* 39:285–286, 1999.
101. Mason, K., Laurie, G. Consent or property? Dealing with the body and its parts in the shadow of Bristol and Alder Hey. *Mod. Law Rev.* 64:710–729, 2001.
102. Hudson, M. Rights of possession in human corpses. *J. Clin. Pathol.* 50:90–91, 1997.
103. Royal College of Pathologists. Guidance for retention of brain and spinal cord following post-mortem examination and where criminal proceedings are in prospect. 2002. Available at [www.rcpath.org/resources/pdf/GUIDELINESBRAIN-ARNedited.pdf](http://www.rcpath.org/resources/pdf/GUIDELINESBRAIN-ARNedited.pdf). Last accessed: May 15, 2006.



104. Patel F. Ancillary autopsy—forensic histopathology and toxicology. *Med. Sci. Law* 35:25–30, 1995.
105. Roberts, L. W., Nolte, K. B., Warner, T. D., McCarty, T., Rosenbaum, L. S., Zumwalt, R. Perceptions of the ethical acceptability of using medical examiner autopsies for research and education: a survey of forensic pathologists. *Arch. Pathol. Lab. Med.* 124:1485–1495, 2000.
106. Boglioli, L. R., Taff, M. L. Religious objection to autopsy. An ethical dilemma for medical examiners. *Am. J. Forensic Med. Pathol.* 11:1–8, 1990.
107. Pellegrino, E. D. Moral and religious concerns about the autopsy. In: Collins, K. A., Hutchins, G. M., eds. *Autopsy performance and reporting*. College of American Pathologists, Northfield, IL, pp. 27–38, 2003.
108. Rosai, J. The posthumous analysis (PHA). An alternative to the conventional autopsy. *Am. J. Clin. Pathol.* 106:S15–S17, 1996.
109. Koskinen, P. J., Nuutinen, H. M., Laaksonen, H., et al. Importance of storing emergency serum samples for uncovering murder with insulin. *Forensic Sci. Int.* 105:61–66, 1999.
110. Adelson, L. The forensic pathologist. “Family physician” to the bereaved. *JAMA* 237:1585–1588, 1977.
111. Hutchins, G. M., Berman, J. J., Moore, G. W., Hanzlick, R. L., Collins, K. A. Autopsy reporting. In: Collins, K. A., Hutchins, G. M., eds. *Autopsy Performance and Reporting*. College of American Pathologists, Northfield, IL, pp. 265–274, 2003.
112. Adelson, L. *The Pathology of Homicide*. Charles C. Thomas, Springfield, IL, 1974.
113. Petty, C. S. Multiple causes of death. The viewpoint of a forensic pathologist. *J. Forensic. Sci.* 10:167–178, 1965.
114. Perper, J. A., Wecht, C. H. Medicolegal problems in determining cause of death in motor vehicle accidents. *Leg. Med. Annu.* 19–25, 1975.
115. Cordner, S. M. Deciding the cause of death after necropsy. *Lancet* 341:1458–1460, 1993.
116. Pollanen, M. S. Deciding the cause of death after autopsy—revisited. *J. Clin. Forensic Med.* 12:113–121, 2005.
117. Gee, D. J. Reaching conclusions in forensic pathology. *Med. Sci. Law* 35:12–16, 1995.
118. Bohrod, M. G. The meaning of “cause of death.” *J. Forensic. Sci.* 8:15–21, 1963.

## Chapter 2

---

# *Postmortem Changes*

## *The “Great Pretenders”*

### **Summary**

After death, natural degradation of a body is manifest as a sequence of changes. Certain postmortem changes, despite being affected by numerous variables, remain rooted as popular methods in the determination of the time of death. A pathologist can also be faced with confounding postmortem changes and artifacts, which either alter real injuries or mimic trauma.

**Key Words:** Postmortem changes; rigor mortis; embalming; entomology.

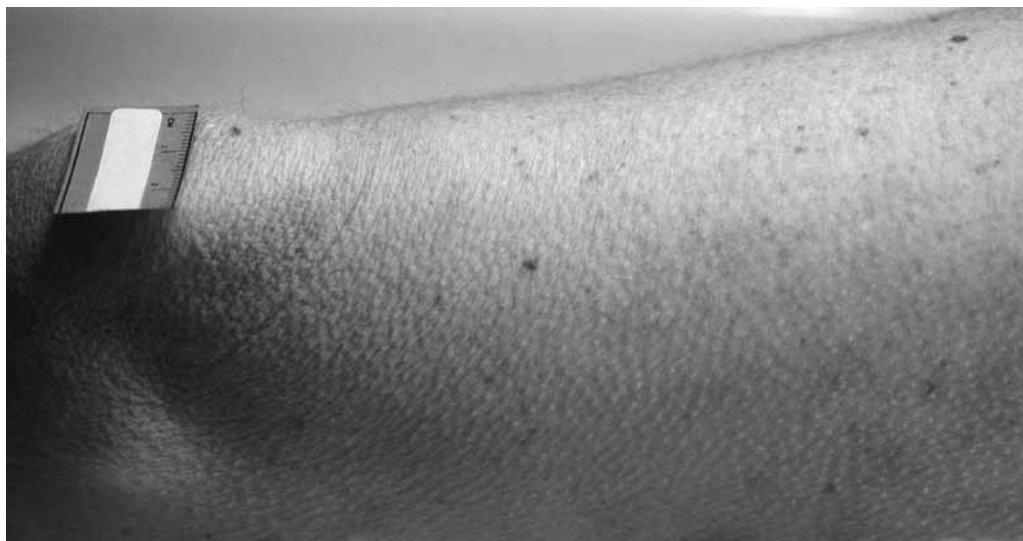### *1. INTRODUCTION*

Deaths under medicolegal investigation are frequently unwitnessed and remain undiscovered for a period of time. As a result, the pathologist encounters postmortem changes that alter and obscure pathological findings, hindering their assessment in the determination of the cause of death. These changes can mean that “no anatomic cause of death” is found. Postmortem changes also mimic injuries, potentially shifting the focus of a medicolegal investigation.

Certain bodily changes are assumed to occur at a constant rate after death (“rate parameters”); therefore, documentation of their extent at a specific time can be extrapolated back to the time of death. A review of standard textbooks of forensic medicine written in the last 50 yr shows that despite the myth fostered by popular literature, television, and movies that the time of death can be determined accurately within a narrow time frame, the reality is that the evolution of various postmortem changes is imprecise, and determination of the time of death is only an estimate (1–8). The pathologist can still be asked during an investigation or in court to determine the time of death; however, the pathologist is at a disadvantage in this determination.

From: *Forensic Science and Medicine: Forensic Pathology of Trauma:  
Common Problems for the Pathologist*

By: M. J. Shkrum and D. A. Ramsay © Humana Press Inc., Totowa, NJ



**Fig. 1.** Cutis anserina (“goose bumps”) caused by cold exposure after death.

Postmortem changes observed during an autopsy are made after the body has been recovered from the scene. Various intervening events (e.g., manipulation of the body, storage in a morgue cooler) mean increased inaccuracy to an already imprecise determination of time of death. Examination at the scene is the best time to record these findings.

Rigor mortis, livor mortis, temperature change, decomposition, and gastric emptying are examples of postmortem changes that progress after death and are within the scope of a pathologist’s observations during autopsy. Other measurable parameters, such as vitreous potassium, are affected by numerous variables (e.g., antemortem concentration, possible concentration differences between eyes, renal function; *see also* refs. 9–17). Various biomarkers used to estimate the postmortem interval are beyond the scope of the usual forensic pathology practice (18). A combination of observations can improve the accuracy of time-of-death estimation (19).

## 2. RIGOR MORTIS

Rigor mortis is defined as postmortem muscle contraction owing to locking of actin–myosin filaments because of decreased ATP synthesis (20).

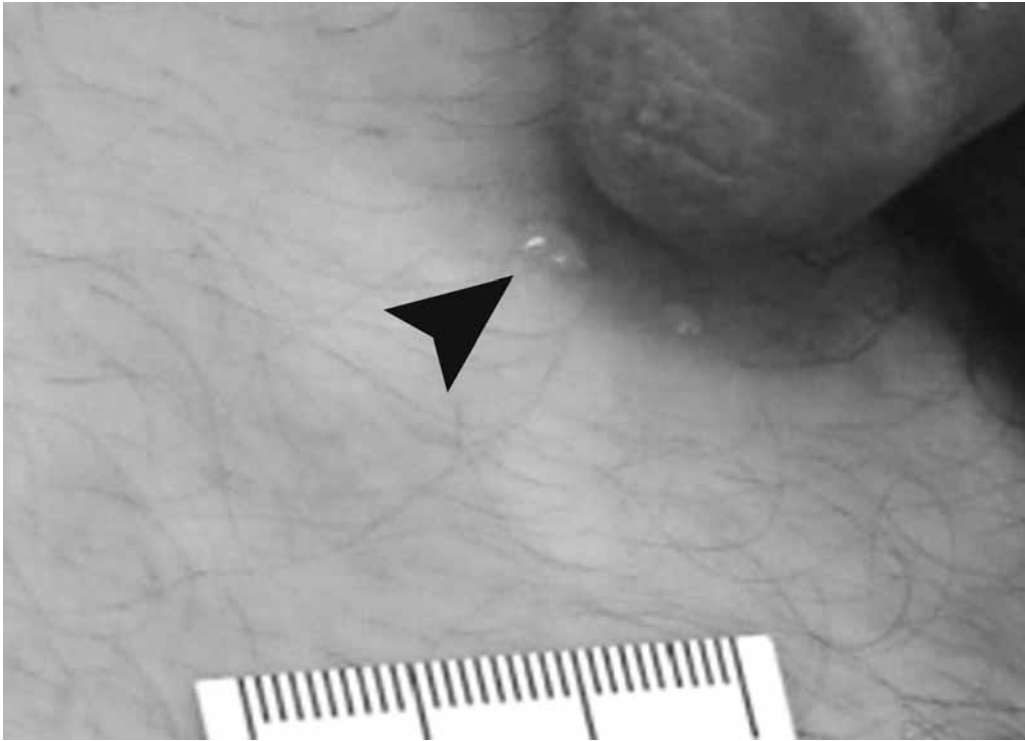
### 2.1. Involvement of Involuntary Muscle

Contraction of arrectores pilorum (smooth muscle of hair follicles) manifests as “goose bumps” (cutis anserina; Fig. 1).

- Significance
  - Exposure to cold postmortem.

Seminal vesicles (smooth muscle) can contract (4).

- Significance
  - Contraction leads to slight expulsion of seminal fluid at tip of penis suggesting sexual activity prior to death (Fig. 2).



**Fig. 2.** Semen deposition (arrowhead) on inner thigh owing to postmortem contraction of seminal vesicles.

Ciliary muscles of the iris, in rigor, alter pupil size. Pupil diameters range from 0.2 to 0.9 cm (average size = 0.4 to 0.5 cm or about 0.25 in.). The pupil outline is not always circular. Pupils can change independently and be of unequal size (Fig. 3).

- Significance
  - Pupil size has no relation to the cause of death; inequality of pupil diameter does not indicate head injury.

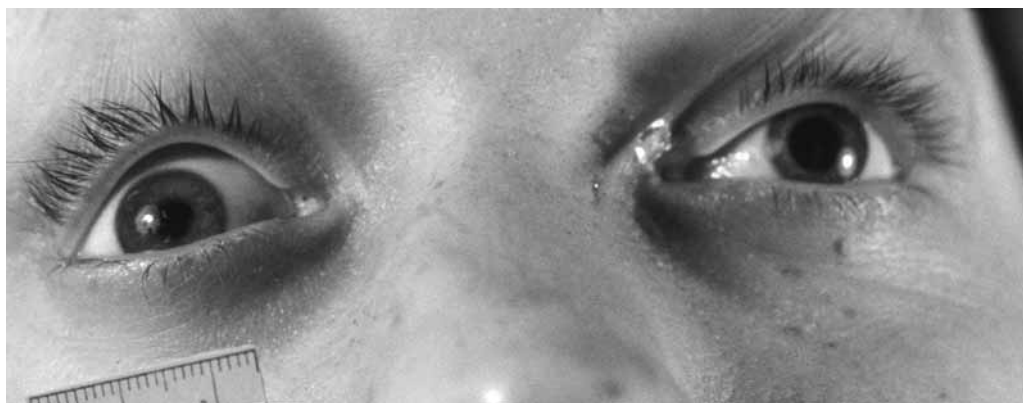If the myocardium of the left ventricle contracts, its wall appears thickened, and the chamber contains a small amount of blood.

- Significance
  - Apparent left ventricular hypertrophy.

## ***2.2. Involvement of Voluntary Muscle (Skeletal Muscle)***

Involvement of skeletal muscle leads to joint stiffening. The following sequence occurs:

- Initial flaccidity (exception: instantaneous rigor):
  - There is sufficient ATP in the immediate postmortem period to allow muscles to remain relaxed and joints limp. This phase ranges from 0.5 to 7 h (mean =  $3 \pm 2$  h [7]).
- Onset and progression:
  - There is simultaneous development of rigor in all muscles, but it is evident sooner in smaller muscle groups (20). The evolution of rigor mortis is not necessarily constant or symmetrical (1,8). Rigor onsets in the jaws, progressing to the upper extremities and then to the lower extremities (Nysten's law; see also refs. 7 and 21). Rigor is



**Fig. 3.** Pupil inequality after death.

assessed as absent, partial, or complete by manipulation of joints during the external examination (i.e., opening of the mouth to assess the temporomandibular joints and flexion/extension of the elbow and knee joints). The time that rigor is fully established in all joints varies from 2 to 20 h (mean =  $8 \pm 1$  h [7]). An individual who dies in the supine position shows slight flexion of the elbows and knees. Rigor persists for 24 to 96 h (mean =  $57 \pm 14$  h [7]).

- Resolution (secondary flaccidity):
  - Rigor lessens and eventually disappears as denaturation of actin–myosin linkages occurs with early decomposition. The disappearance will follow the same pattern as the onset. The time range is 24 to 192 h (mean =  $76 \pm 32$  h [7]).

Various intrinsic and extrinsic factors influence the development of rigor (22,23):

1. Temperature: increased body or environmental temperature decreases the time of onset and resolution (24). The former is likely the result of increased metabolism of ATP, and the latter from rapid denaturation of actin–myosin linkages. Hyperthermia, under various circumstances (e.g., sepsis, cocaine use), enhances the onset. Rigor persists for days under cold conditions (25).
2. Muscle volume and body habitus: increased muscle bulk delays the onset of rigor, but the rigor will be better developed (3,26). Time for resolution may or may not be increased (26). The elderly, cachectic individuals, and infants have a rapid progression of rigor, but it is less developed and disappears more quickly. Rigor can be absent in emaciated and obese individuals (1).

Muscle volume is considered a factor that explains why rigor becomes established in small joints before larger ones (21). Rigor mortis occurs more rapidly in small muscles (e.g., masseter muscle), assuming rigor is a physiochemical process occurring at the same time in all muscles (20,21). Animal experimentation shows a greater decline of ATP in the masseter muscle than larger muscles (20,27). The sequence of rigor could also be explained by the proportion of red and white fibers around the joint being manipulated (21,27). Red muscle undergoes rigor more quickly than does white muscle (21). The muscles of mastication in humans have a high proportional area of red muscle fibers compared with the leg muscles (e.g., gastrocnemius; *see also* ref. 21).

3. Antemortem muscle contraction: increased muscle activity (e.g., exercise, seizure) prior to death hastens rigor (1). Instantaneous rigor (cadaveric spasm, cataleptic rigidity) is characterized by the sudden development of rigor usually localized to muscles that have

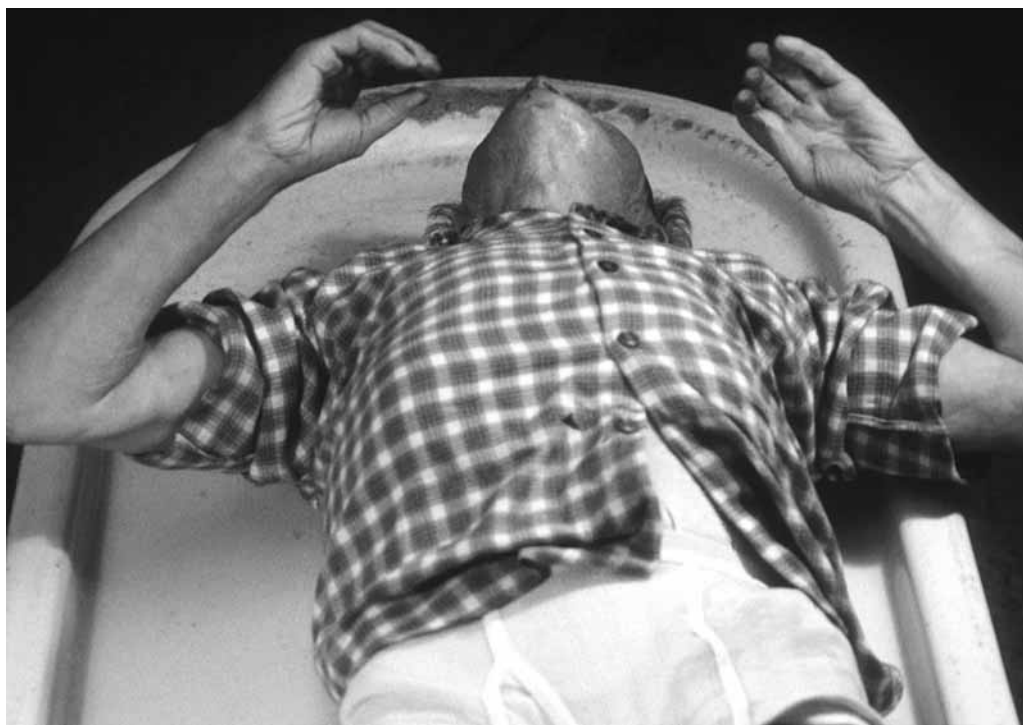

**Fig. 4.** Instantaneous rigor. Hand gripping telephone in a case of sudden death.

forcefully contracted perimortem (Fig. 4; *see also* ref. 1). Generalized instantaneous rigidity has been described in situations of considerable excitement and tension.

- Significance
  - Prior to the onset of rigor mortis, a body can be manipulated to any position.
  - Once rigor is established, it will not conform to a new position (Fig. 5).
  - Because many factors influence the progression of rigor, it is variable as a measure used to determine the time of death. The inaccuracy is enhanced if only one assessment is done (28).
  - Rigor mortis is broken by manipulation of the body. If rigor is maximum, then it does not return. If rigidity is not fully established, then it returns to a lesser degree in a particular joint (range 2–8 h [7]). Forceful manipulation of a stiff joint can tear muscles and fracture a long bone weakened by disease (e.g., osteoporosis, metastasis; *see* Fig. 6). Manipulation of the body occurs at different times prior to the autopsy—i.e., at the scene, during body removal and transportation, and during removal of clothing (e.g., removal of pants from a shirtless individual selectively diminishes rigor in the legs). Rigid upper limbs are deliberately manipulated to allow appropriate autopsy incisions to be made on the torso. Failure to manipulate rigor and expose certain areas of the body results in injuries being missed (e.g., venipuncture in antecubital fossa of an intravenous drug user).
  - Resolution of rigor in the jaws allows the mouth to be examined for injuries, if the mouth could not be opened during the initial examination.
  - Flaccidity following resolution of rigor can relax muscles of the pelvic floor, leading to widening of the vaginal and anal orifices. Suspicion of sexual assault arises (Fig. 7).





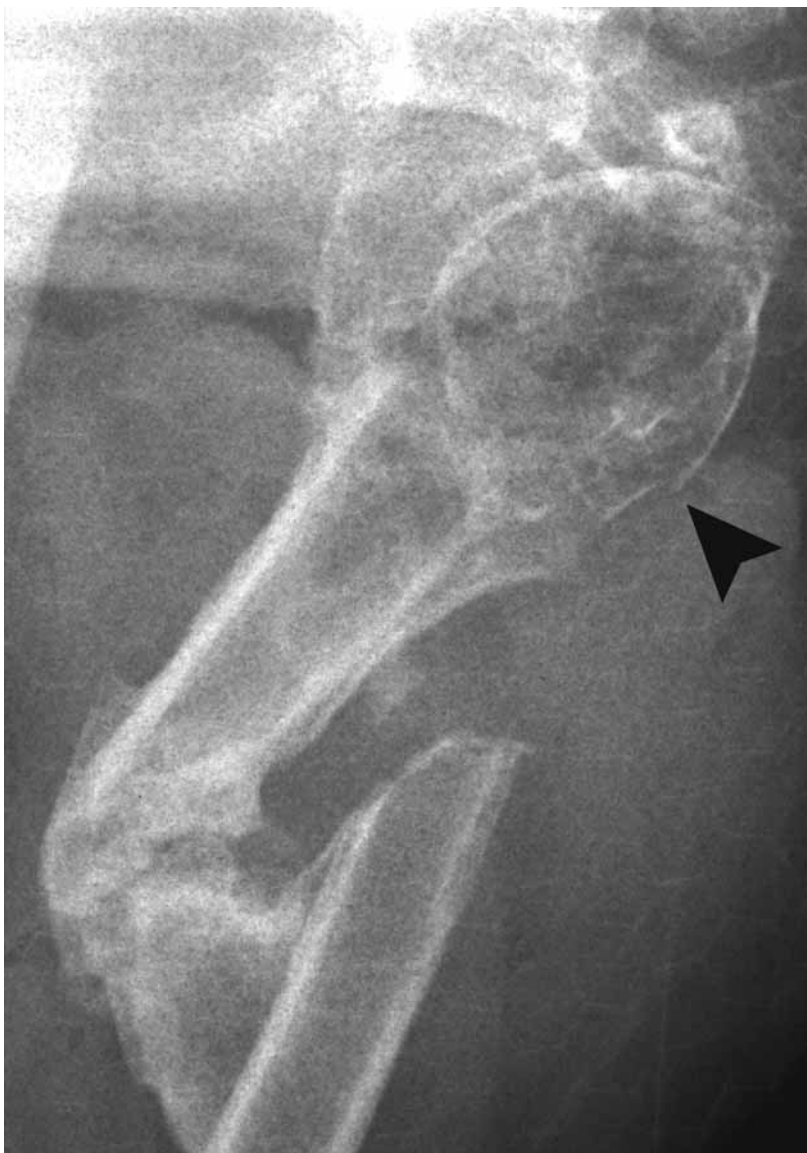**Fig. 5.** Man found dead sitting at kitchen table, slumped forward and resting on arms. Moved from scene to autopsy facility.

- The rapid onset of rigor can be linked to certain causes of death associated with increased or abnormal muscle contraction (e.g., electrocution, strychnine poisoning, myotonic dystrophy; see Fig. 8).
- “Instantaneous” rigor may be consistent with the circumstances of the death.

### *3. LIVOR MORTIS (LIVOR, LIVIDITY, POSTMORTEM HYPOSTASIS, POSTMORTEM SUGGILATION)*

Because of the cessation of blood flow at death, there is gravitational settling of blood that distends capillaries and veins, resulting in discoloration of skin in the non-compressed dependent areas of the body (Fig. 9). Slight hypostasis has been described in living individuals dying from a prolonged illness and terminal circulatory failure (4). Patchy lividity (1- to 3-cm or about 0.5- to 1-in. areas) has been described in nondependent areas of the body and attributed to venous blood being squeezed to the skin surface by muscles undergoing rigor mortis (4). A sequence of changes has been described:

- Onset and progression: lividity first becomes apparent 20 min to 4 h after death (2,7). Discoloration is at maximum intensity from 3 to 16 h (7). At “fixation,” lividity does not shift with a change of body position (time range = 6 to 12 h). Complete shifting occurs from 2 to 6 h and incomplete shifting (i.e., lividity partly persisting in the original location and changing according to a new position) is possible from 4 to 24 h (7). Fixation can

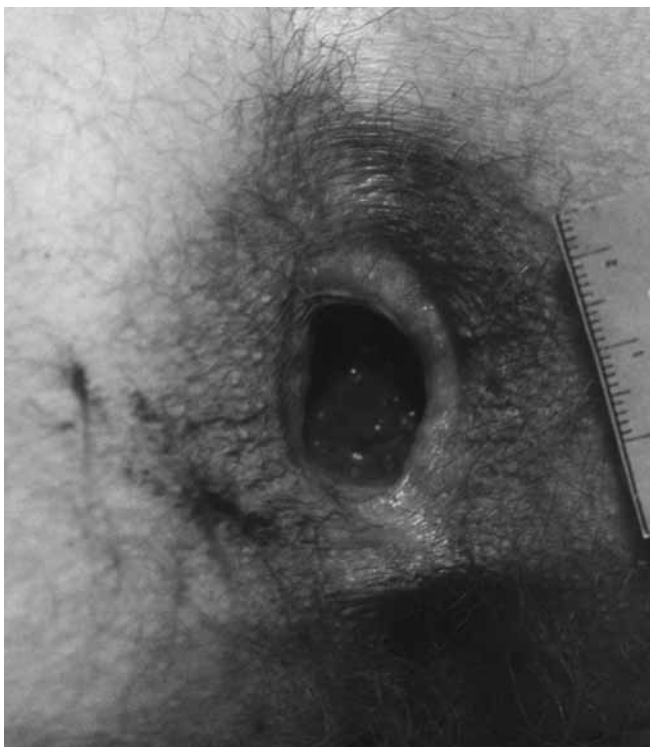


**Fig. 6.** Fracture of humeral head (arrowhead) caused by forceful manipulation of previously fractured arm in rigor mortis at the scene. (Courtesy of Dr. E. Tweedie, London Health Sciences Centre, London, Ontario, Canada.)

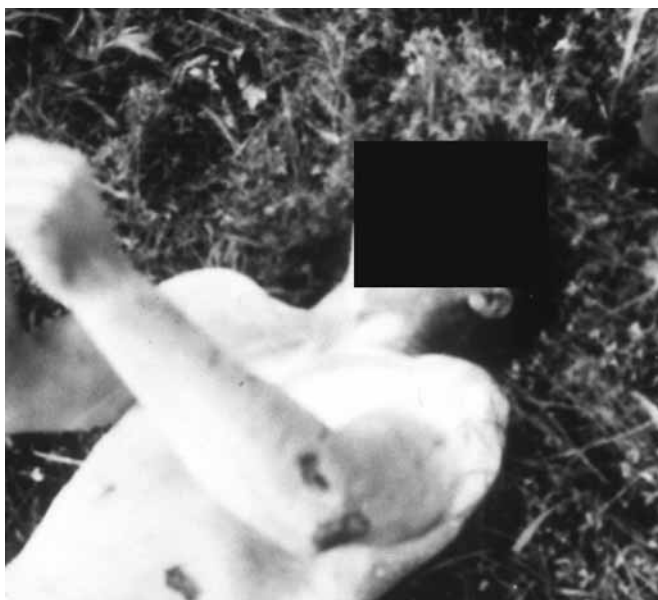occur up to 3 d after death (7,29,30). Blanching of livid areas by thumb pressure occurs from 1 to 20 h (7,31).

Various mechanisms have been proposed to explain fixation. Blood, initially fluid, clots; however, the presence and time of occurrence of postmortem clotting are variable. Alternatively, there is diffuse extravasation of blood into soft tissues owing to vessel leakage, but this is also observed in nonfixed livor. Blood seepage is not consistently present in fixed lividity (1,30). Blood cannot shift from engorged capillaries because adjacent venous pressure is high (4). Another explanation is that unfaded lividity (fixed livor)

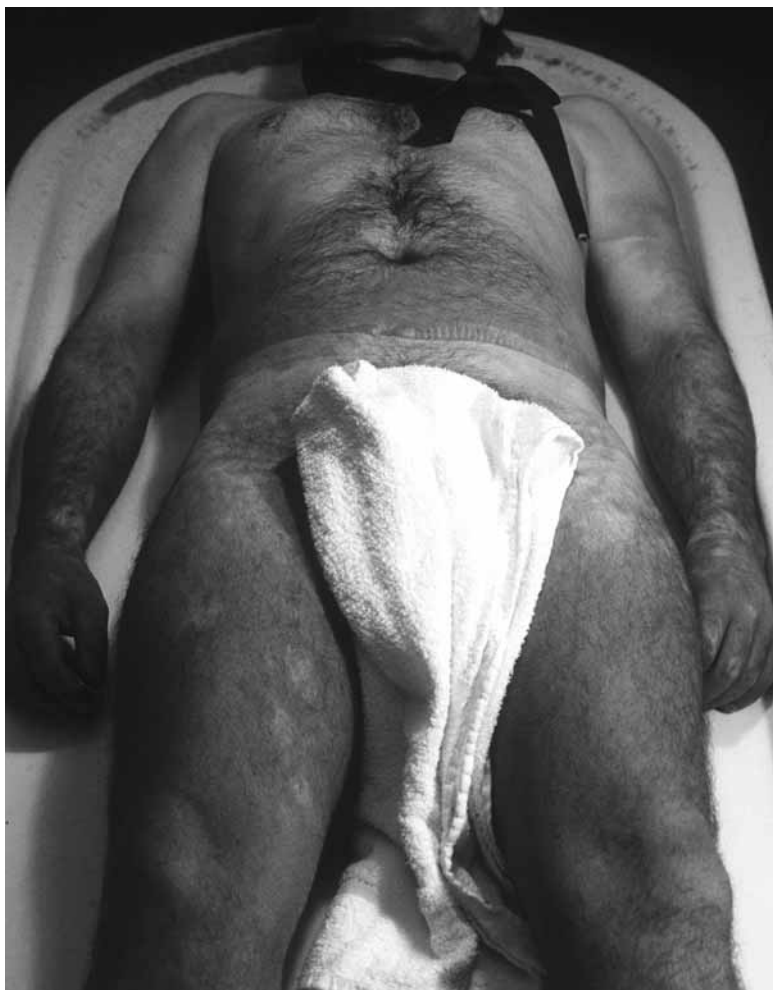



**Fig. 7.** Postmortem muscle flaccidity, following resolution of rigor, leads to widening of anal orifice.



**Fig. 8.** Electrocution. Pronounced flexor muscle contraction of the arms of a man holding an antenna, which contacted a high-voltage line. (Courtesy of Office of the Chief Medical Examiner, Chapel Hill, NC.)



**Fig. 9.** Suicidal hanging. Suspension for unspecified period of time; lividity in dependent areas of arms and legs.

results from progressive hemoconcentration and red blood cell-clumping resulting from transudation of plasma from engorged vessels (30,32).

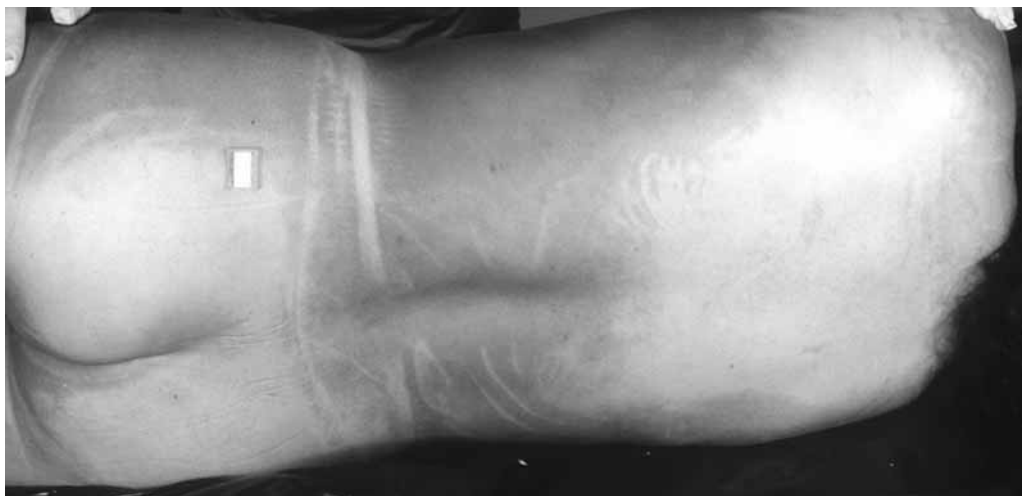- Resolution: livor persists until decomposition occurs.

The significance is as follows:

- The assessment of the degree of lividity can provide only an estimate of the time of death.
- The presence of livor, particularly if fixed, in the nondependent areas of a body at a death scene indicates that the body's position has been changed (1).

### ***3.1. Distribution and “Pressure Points”***

Compressed parts of the body result in areas of normal-colored skin demarcated by lividity. If a deceased individual is supine, “pressure points” are observed on the occipital scalp, midback, buttocks, posterior thighs, calves, and heels (Fig. 10). If prone, pressure is applied to the forehead, nose, cheek (if the head is turned), chin, chest, lower abdomen, and anterior thighs. Pressure points also develop in areas of constriction or



**Fig. 10.** Person found dead in supine position. Livor on back. Pallor on upper back and buttocks corresponds to typical pressure points. Note pale bands at waistline created by constriction of belt and underwear. Refrigeration had turned the lividity partly red. (See Companion CD for color version of this figure.)

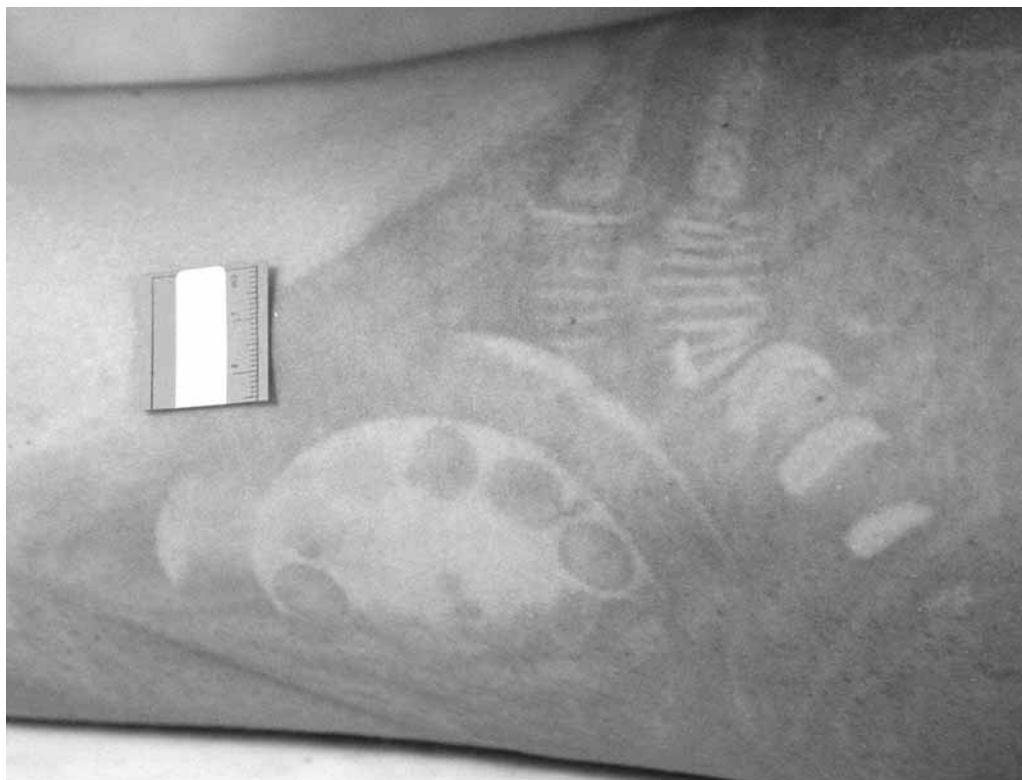
localized compression (e.g., tight clothing; *see* Fig. 10). In a supine individual, the larynx pressing the esophagus against the spine can cause a transverse band of pallor across the cricoid esophagus (4).

- Significance
  - Irregular pale areas in livor on the neck can suggest to an investigator the possibility of manual application of pressure—i.e., strangulation; however, this scenario is not realistic, as pressure would need to be sustained during the time livor is developing.
  - Horizontal pale lines on the skin of the neck suggest ligature compression, assuming a ligature had been present while livor was developing. Taping or binding an endotracheal tube around the cheeks and neck can create this artifact (*see* Chapter 3, Fig. 20). Similarly, prominent skin folds can squeeze an intervening crease (*see* Chapter 3, Fig. 20).
  - If part of the body is resting on a particular surface or object, then its negative image can be reproduced on the livid site. This observation can be linked to the scene and circumstances of the death (Fig. 11).

### 3.2. Discoloration

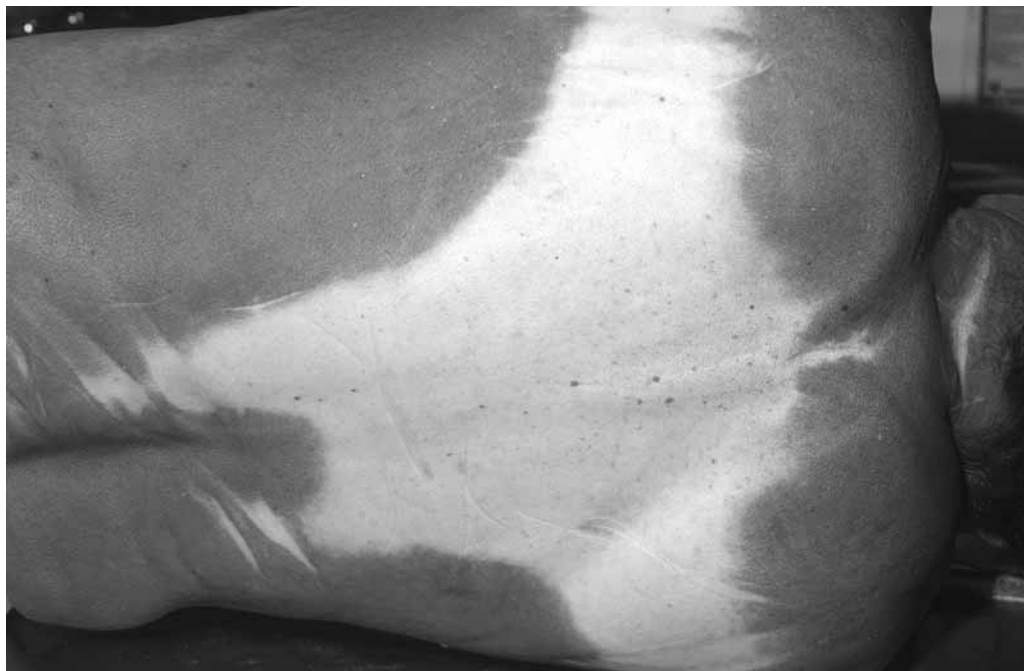Livid skin is either purple/blue or red, depending on the concentration of deoxygenated blood. Red livor is seen if the body is cold (Fig. 10). This is indistinguishable from certain poisoning deaths (e.g., carbon monoxide poisoning [33]). Lividity is difficult to discern in a dark-skinned individual. Decomposition turns livid areas brown or green. Dependent organs and tissues appear “congested” or hemorrhagic (e.g., if supine, posterior lungs and retroperitoneum, including kidneys; if prone, anterior organs such as heart and intestines).

- Significance
  - Lividity is poorly developed in individuals who are anemic, have bled severely, or had organs harvested.

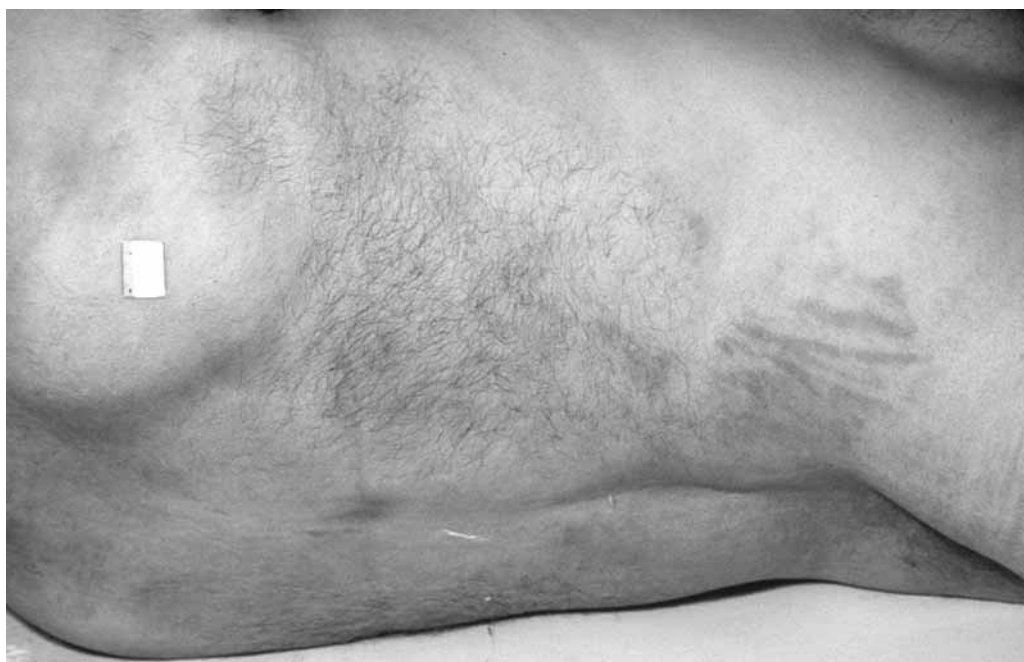

**Fig. 11.** Person found dead with thigh resting on rotary telephone. “Negative” impression of dial and extension cord in livid area.

- Apparent cyanosis of the face could be lividity. The heart of a large individual is at a higher level than the more dependent head.
- Different colors of lividity are associated with certain poisoning deaths (1):
  - Red—carbon monoxide (*see* Chapter 3, Subheading 3.9.; *see also* Fig. 12); fluoroacetate; cyanide.
  - Green—hydrogen sulfide (also generated during decomposition).
  - Brown—methemoglobinemia (e.g., ingestion of nitrates; *see also* Fig. 13).
  - Intense purple—propane (34).
- During the initial external examination, livor can obscure an antemortem contusion (Fig. 14). Body repositioning during the autopsy can shift lividity from an apparent bruise, allowing better visualization. The suspicious area can be examined at the conclusion of the autopsy dissection, when blood has drained from the body and the intensity of lividity has diminished. Re-examination of a refrigerated autopsied body the next day may reveal bright red but diminished livor in contrast to a darker bruise (Fig. 14).
- Antemortem injuries are mimicked by lividity. Patchy red/blue skin discoloration suggests a contusion. If such an area is due to nonfixed lividity, then thumb blanching helps distinguish it from a bruise. Similarly, incision of an area of lividity is more likely to result in oozing of nonclotted blood from vessels in contrast to a true contusion, where blood has seeped into soft tissue.

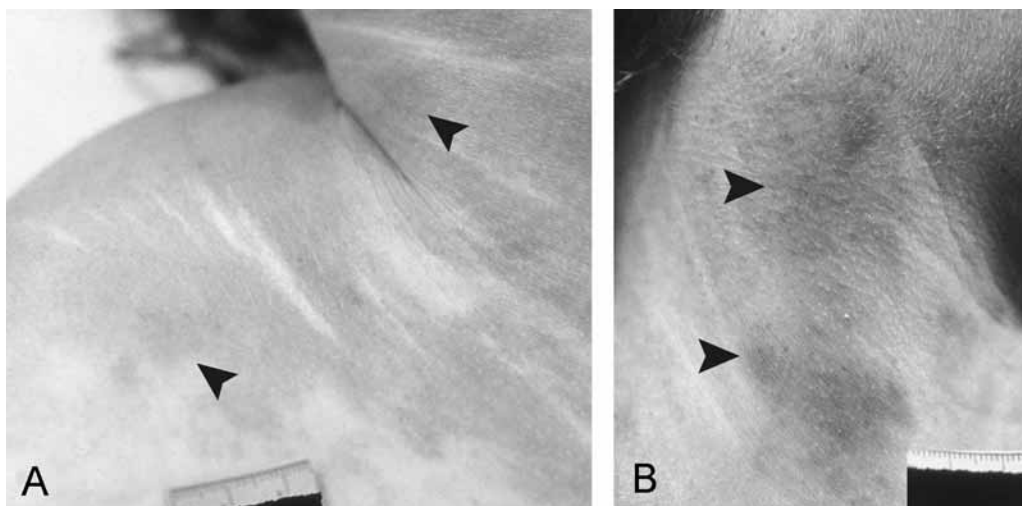


**Fig. 12.** Red livor mortis on back. Carbon monoxide poisoning. (See Companion CD for color version of this figure.)



**Fig. 13.** Brown livor mortis on back. Methemoglobinemia owing to nitrate ingestion. (See Companion CD for color version of this figure.)



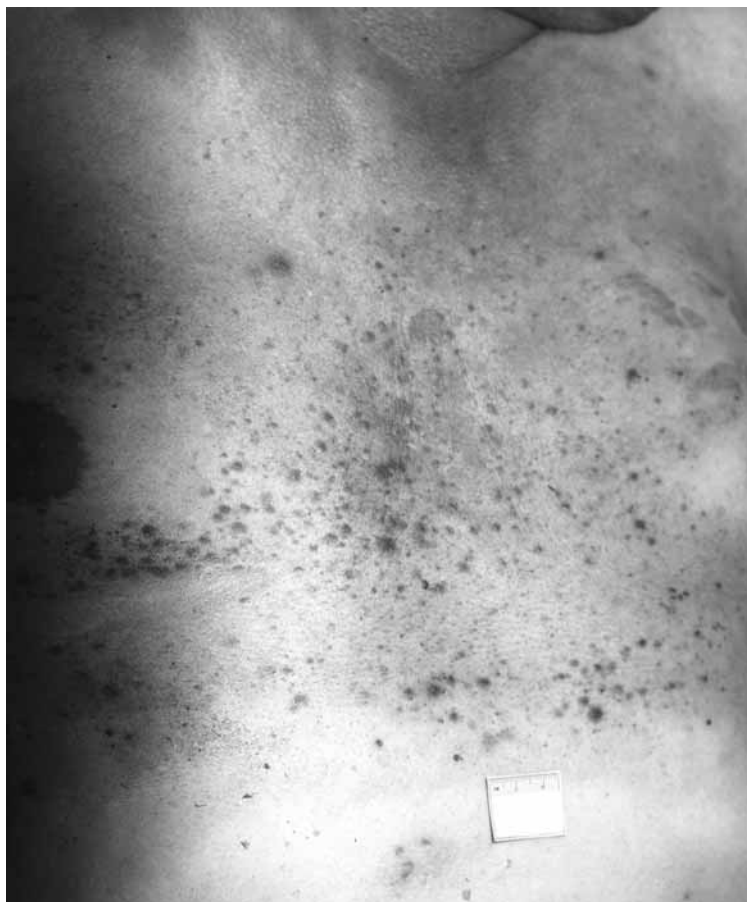

**Fig. 14.** Woman strangled using armhold. (A) Pale linear lines on lateral aspect of neck are caused by neck creases in area of livor mortis. Indistinct bruises (arrowheads) (B) Examination of the deceased next day after autopsy dissection. Lividity diminished allowing visualization of extensive bruising (arrowheads) on lateral neck. (See Companion CD for color version of this figure.)

### 3.3. Postmortem Hemorrhage

Bleeding occurs after death if blood vessels, engorged by blood postmortem, rupture. Contributory factors include increased pressure caused by body position, early decomposition, and trauma. Rupture of capillaries is manifest as petechiae (Tardieu spots). The development of petechiae is a harbinger of decomposition, but they can be seen as early as 2 to 4 h after death, if the body has been suspended (6). Rupture of larger vessels (venules) causes purpura or larger ecchymoses. The distribution of postmortem cutaneous hemorrhage is in areas of livor and is not seen in areas uninvolved by lividity (Fig. 15).

- Significance
  - Postmortem hemorrhage (petechiae, purpura/ecchymoses or “pseudobruises,” external bleeding) mimics true injuries occurring antemortem (see Chapter 8, Subheading 3.1.; see also Fig. 16).
  - Open antemortem wounds in dependent body sites can continue to ooze blood after death. Open postmortem injuries (e.g. abrasions, lacerations) can redden and “bleed” mimicking a vital reaction (35,36).
  - A significant amount of bleeding can occur from major vessels in a dependent part of the body (e.g., aorta, ranging from 100 to 1300 mL [average 450 mL] into the pleural cavity [37]). The presence of a hemothorax from a traumatically ruptured aorta in the context of an instantaneously fatal brainstem injury implies that bleeding likely occurred postmortem (37).
  - Microscopic examination cannot distinguish between the extravasation of blood seen in an early antemortem contusion and postmortem hemorrhage.
  - Loose supporting connective tissue (e.g., face, neck) in a dependent body site can promote the development of external and internal postmortem hemorrhage (see Chapter 5, Fig. 5).

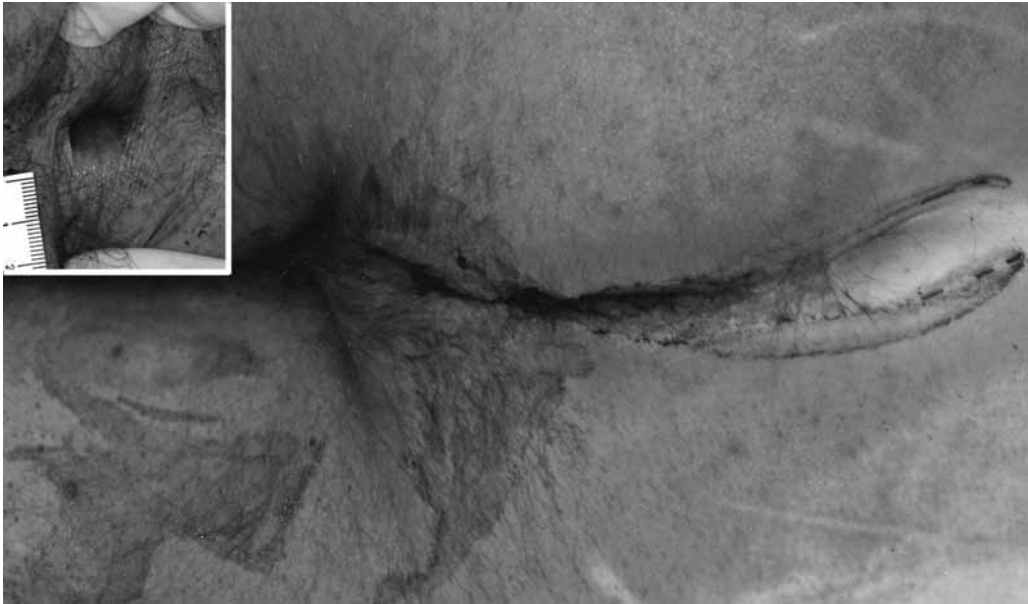

**Fig. 15.** Found prone. Lividity on chest associated with numerous petechiae, which did not involve the nonlivid abdomen.

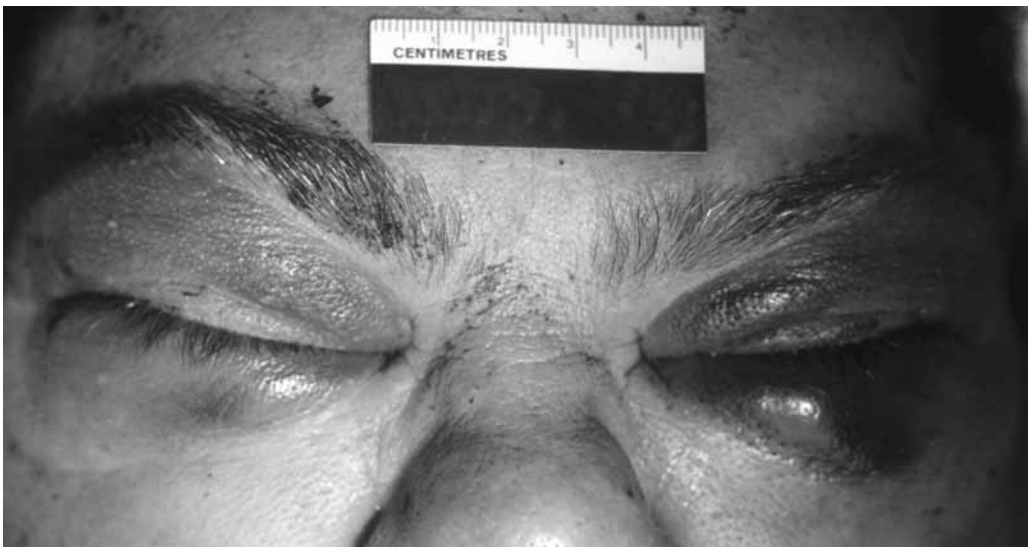Nosebleeds can occur (3). “Pseudobruises” tend to be small; however, pronounced facial bruising has been described in an individual who was in a head-down position and sustained postmortem scalp injuries (38). Periorbital hematomas (“black eyes”) can be caused by direct trauma, tracking of blood from a scalp wound, and hemorrhagic extravasation from an orbital plate fracture (39). Black eyes can occur around the time of infliction of a rapidly fatal injury (39). They can also be observed postmortem (*see* Heading 11.). Removal of eyes for corneal transplantation can cause periorbital hemorrhage (Fig. 17; ref. 39). Postmortem head trauma can result in periorbital hematoma and is enhanced by lividity (39). A small hematoma of a single eyelid, compared with extensive hemorrhage in both eyelids, in the absence of direct trauma is not necessarily an antemortem event (39). The presence of postmortem petechiae and larger confluent hemorrhages in the conjunctiva and sclera raises the suspicion of asphyxia from neck compression (Figs. 18 and 19, and refs. 40–42). Information from investigators about the circumstances of the death and the exclusion of internal neck trauma by careful neck dissection help rule out foul play.

A head-dependent position is associated with temporalis muscle and galeal hemorrhages simulating blunt trauma (*see* Chapter 3, Fig. 2; *see also* ref. 40). The

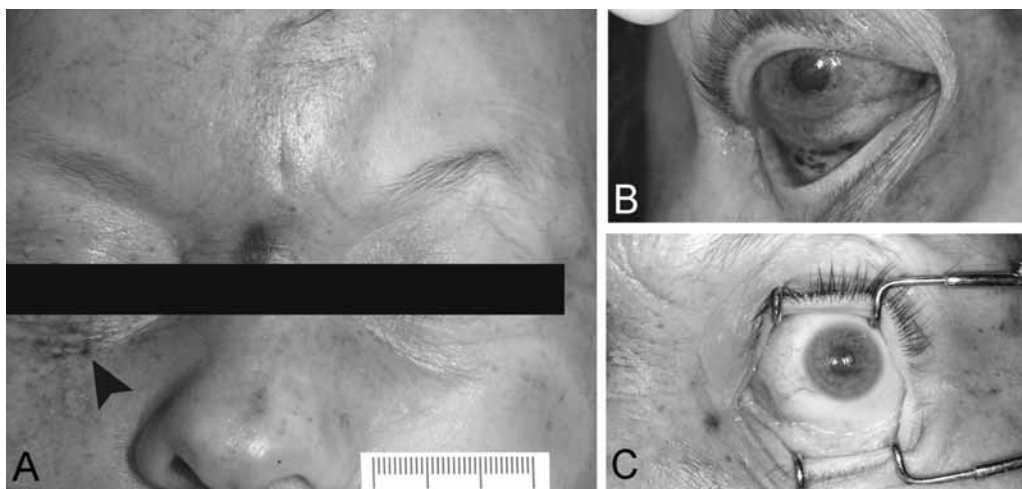




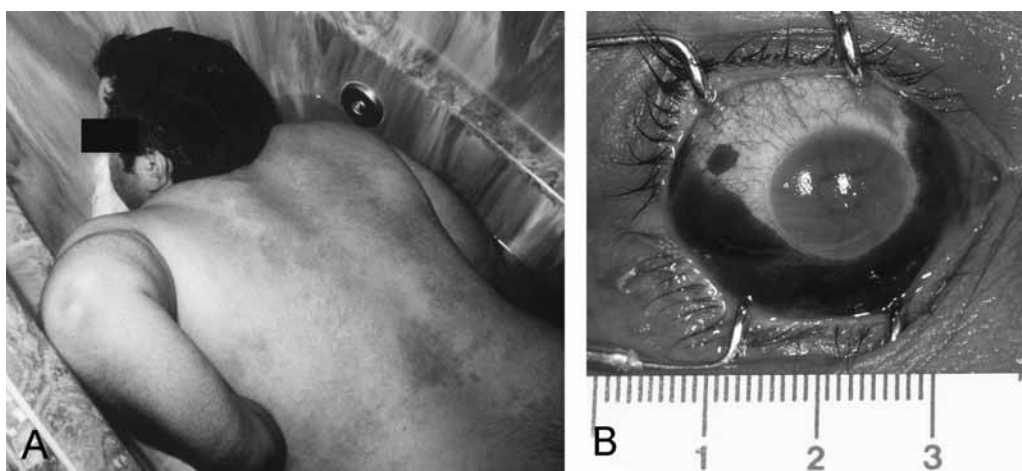
**Fig. 16.** Suicide by hanging. Victim had also bound his flexed legs with electrical cord (see Chapter 3, [Fig. 11](#)). Intense lividity of lower extremities and petechiae noted on posterior legs. Perianal “hemorrhage.” No evidence of anal trauma (inset). Congested mucosal veins were seen.



**Fig. 17.** “Black” eyes. Eyes removed postmortem for the purpose of donation. Sudden death owing to cardiomyopathy in an obese individual. (Courtesy of Dr. D. King, Regional Forensic Pathology Unit, Hamilton, Ontario, Canada.)

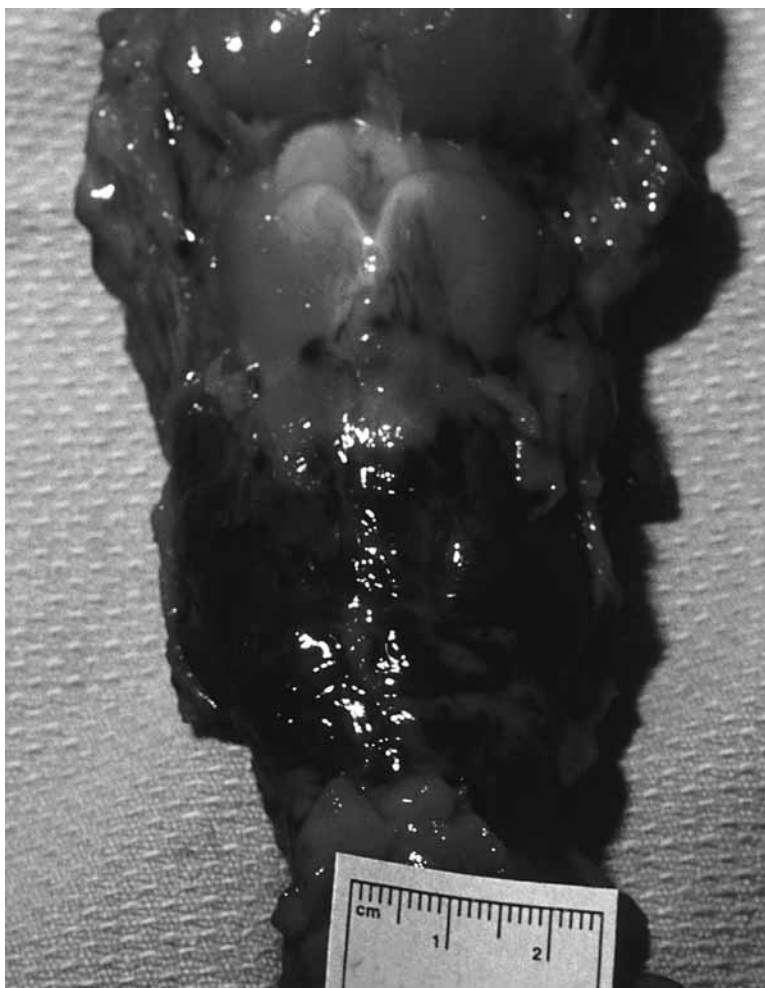

**Fig. 18.** Postmortem orbital petechiae, resulting from the prone head-down position. (A) Lividity of face with sparing of left side which was pressed against the floor. Note petechiae below right eyelid (arrowhead). (B) Right lower eyelid retracted to show conjunctival petechiae. (C) Left eye showed no petechiae.



**Fig. 19.** Postmortem orbital hemorrhage. (A) Found prone in tub. (B) Confluent ocular hemorrhage owing to pronounced facial lividity.

head-down position has been recognized as a predisposing factor for the development of soft-tissue neck hemorrhage in fatal drownings (6). These hemorrhages can be extensive (Fig. 20 and ref. 43). Focal hemorrhages are found in the anterior, middle, and posterior compartments of the neck and are, at least, partly attributable to hypostasis (*see* Chapter 5, Subheading 10.6. [43]). The finding of neck hemorrhage is not exclusive to drowning and is found in any situation in which lividity occurs in a body that is prone or head-down (*see* Chapter 3, Subheading 1.4.; Chapter 5, Heading 12.). The effect of the prone or head-down position is enhanced if the buttocks are elevated.



**Fig. 20.** Extensive soft-tissue hemorrhage in anterior neck in individual found prone. No fractures of the hyoid–larynx were observed.

#### *4. BODY COOLING (ALGOR MORTIS)*

Postmortem heat loss occurs by four mechanisms, depending on the scene and circumstances (4,6,7):

- Evaporation—humidity and precipitation vary the amount of evaporation from skin and clothing.
- Radiation—as a factor, it decreases as the body cools (e.g., sun shining on a body, cooling system in a dwelling).
- Conduction—heat exchange occurs between contact surfaces owing to temperature differences.
- Convection—heat loss is from air exchange from noncontact surfaces.

Loss of body heat postmortem has been described as a sigmoidal decline over time (4,7). The initial plateau phase assumes that the body is a solid cylinder that

loses heat from its surface according to a slowly developing temperature gradient. During this time, body metabolism continues to generate heat. If this phase is not considered, then a calculation based on rectal temperature, used to estimate the time of death, is affected. A linear decrease in rectal temperature follows and is proportional to the temperature difference between the warm body surface and cooler environment. The final plateau phase marks the decreased effect of the temperature gradient.

Various equations, algorithms, and nomograms using rectal temperature have been developed (44). As stated by Henssge et al., “even with the increased complexity of the algorithms, this does not guarantee any greater accuracy of the calculated times” (7). Simple rule-of-thumb formulae are comparable to more complex methods (6,7).

Examples include:

1. Time since death = (Rectal temperature at time of death – measured rectal temperature [°F]) ÷ 1.5
2. Time since death = (Rectal temperature at time of death – measured rectal temperature [°C]) + 3\*

Models developed to determine the postmortem interval based on body temperature rely on assumptions and a number of factors, some incalculable (1,7). The rectal temperature reflects the core body temperature (98.6°F or 37°C). Normal rectal temperature varies in living individuals (in adults, 34.2–37.6°C or 93.6°–99.7°F) depending on many factors (e.g., diurnal variation, exercise [7]). Because of less developed thermoregulatory control, newborns and premature infants can have an elevated rectal temperature. Body temperature increases under certain conditions (e.g., sepsis, use of certain drugs [cocaine, neuroleptics], nonfebrile diseases [hyperthyroidism]). Depending on environmental conditions, rectal temperature can be raised or lowered. Hypothermia increases inaccuracy. A prolonged agonal period may follow injury (6). During this time, body temperature regulation can be affected and cooling may occur before death.

The greater the difference between body and environmental temperature, the faster is the rate of cooling (4). Submersion in cold water cools a body more quickly (4). Uncertainty arises if there have been changes in environmental temperature between the time of death and temperature recording. The investigator must realize that the body recovery site is not necessarily the place of death. Increased body size, body fat, and clothing/coverings decrease the rate of cooling (4,7). A thin unclothed body in a cold environment may not exhibit an initial temperature plateau (4). Body position (extended or crouched) can influence body heat loss (7).

## 5. DECOMPOSITION

Decomposition is the process of progressive postmortem dissolution. Decomposition is the result of autolysis and putrefaction (45). Autolysis is tissue softening and liquefaction caused by the release of intracellular enzymes. Putrefaction is liquid and gaseous transformation of tissues and organs by local and hematogeneous spread of intestinal bacteria and

---

\* Compensatory number to account for possible initial delay in cooling of body.

other microorganisms. Insect and animal predation (anthropophagy) contribute. Putrefaction is enhanced if there are open skin wounds. Decomposition is delayed in newborns because meconium is sterile.

- Significance
  - Decomposition appears after other postmortem changes (rigor mortis, livor mortis, decrease in body temperature) have occurred. As a determinant of the time of death, decomposition is subject to considerable variability.
  - A decomposed body poses an identification challenge.
  - A decomposed body found in a dwelling can reflect social isolation (46). A claim by next of kin for burial may be slow in developing.

### **5.1. Factors Promoting Decomposition**

Factors that promote the onset and progression of decomposition increase autolysis and bacterial growth, enhancing putrefaction (45).

- Heat: a warm environment promotes decomposition (47). An elevated body temperature hastens the onset—e.g., sepsis can accelerate decomposition even in patients who die in the hospital. Extreme heat retards decomposition by enzyme deactivation and reduction in the number of bacteria. Refrigeration does not necessarily delay decomposition. A frozen body can decompose faster when it thaws, as bacteria multiply.
- Environmental medium: the type of environment in which a body is found affects the rate of decomposition. Casper's rule is that 1 wk of open exposure to air is equivalent to 2 wk of water submersion and 8 wk of burial in soil (45). The deeper a body is buried, the better its preservation during an elapsed period of time (48). This is because the body is cooler, slowing decomposition, and is less subject to insect and animal activity (45,48). Corpses are spared this activity when buried at a depth of about 1 m (3 to 4 ft) (45, 47, 48). Bodies buried in peat have been well preserved for centuries (45).

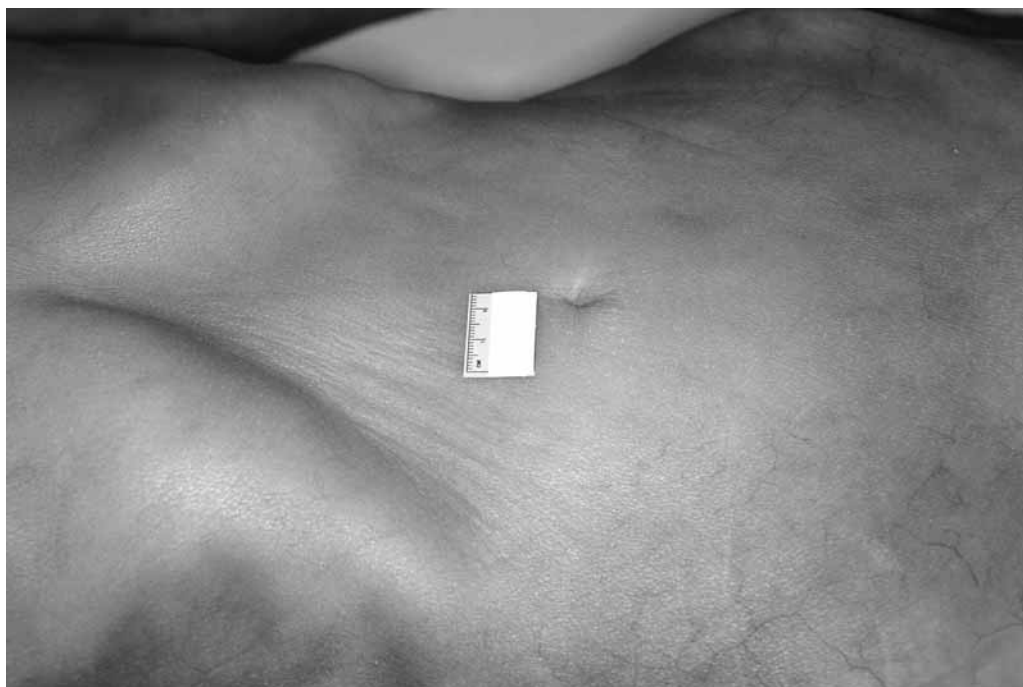
Increased conductive heat loss in a body exposed to a certain medium slows decomposition. For example, a body lying on a conductive (metal) surface can decompose more slowly.

- Body habitus: infants and children cool more quickly, delaying decomposition. The insulative properties of fat decrease heat loss and increase the rate of decomposition in an obese person, although some have not observed this (47).
- Clothing and other coverings: heavy clothing and thick coverings retain body heat and accelerate decomposition, but increased external pressure by tight clothing can delay decomposition by preventing gaseous expansion of tissues and bacterial spread in the bloodstream (3).
- Body position—postmortem congestion: increased intravascular blood volume (congestion) promotes bacterial growth and dissemination. Blood loss decreases putrefaction. Anterior lividity resulting from a prone position congests intestinal vessels, accelerating putrefaction. Decomposition is enhanced in the head, neck, and upper chest in an individual in the head-down position.
- Trauma: injured sites provide an entry site for bacteria and faster decomposition (45,49).

### **5.2. Decomposition Changes (The “Four Ds”)**

The onset and progression of decomposition are variable. In temperate conditions, changes begin 24 to 48 h after death.



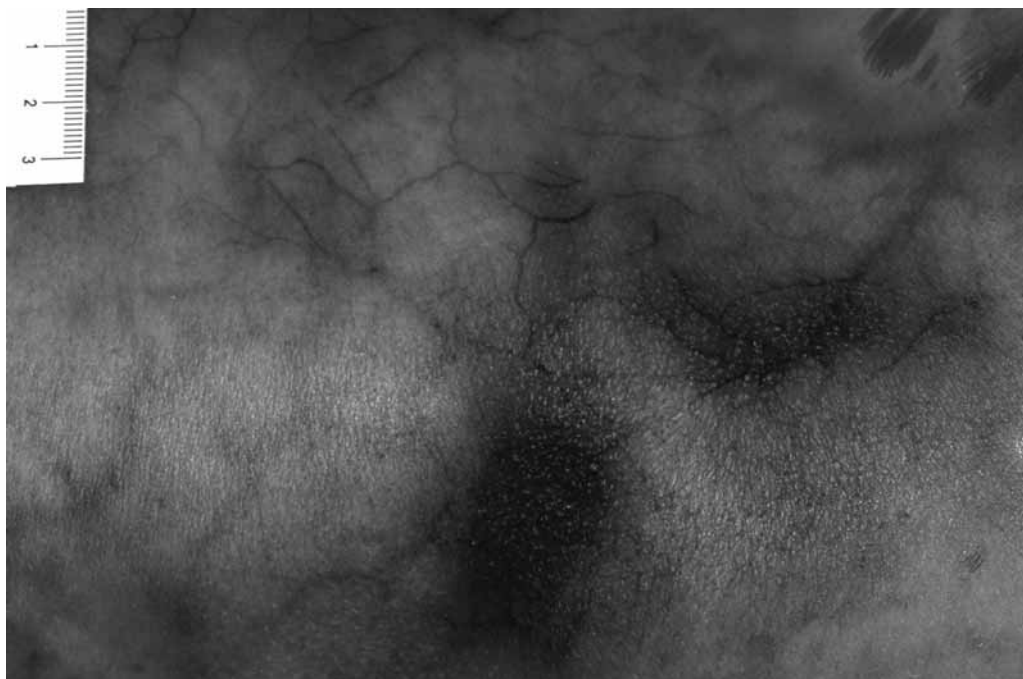


**Fig. 21.** Early decomposition. Green discoloration of abdomen. (See Companion CD for color version of this figure.)

### 5.2.1. Discoloration

Hemolysis and generation of hydrogen sulfide gas from anaerobic bacteria such as *Clostridium welchii* result in the earliest decomposition change, i.e., blue-dark green discoloration in the lower abdominal quadrants (right to left owing to proximity of cecum to skin; see also Fig. 21 and ref. 50). Eventually the entire abdomen becomes discolored, followed by the rest of the body. Seepage of hemoglobin pigments from hemolysed blood and gaseous rupture of blood vessels leads to localized skin discoloration in areas of lividity (green, purple, black), mimicking contusions (Fig. 22). “Marbling” refers to an arboreal pattern of discoloration due to hemolysis following a vascular distribution (Fig. 23).

- Significance
  - Localized cutaneous discoloration from decomposition mimics antemortem bruises (Fig. 22 and ref. 51). One study tried to resolve this problem. Although hemoglobin pigments filter easily through blood vessels, erythrocyte membranes diffuse less readily because of their molecular size (51). Because bruises are caused by actual disruption of blood vessels, they contain a large amount of erythrocyte membrane (51). Immunohistochemical studies of contusions and postmortem discolorations showed that a positive reaction for glycophorin A, a component of red blood cell membrane, indicated an antemortem injury (51). Glycophorin A was not found in postmortem bruises and was present in only a minority of contusions occurring during life.
  - Pre-existent contusions and external hemorrhage are accentuated by hemolysis and diffusion of blood.
  - Diffuse extravasation of blood in deeper soft tissues and organs raises the possibility of disease and injury, e.g., diffuse “hemorrhage” in posterior scalp of a supine



**Fig. 22.** Focal discoloration from decomposition mimics antemortem bruising. Note prominent blood vessels on the livid back. (Courtesy of Dr. M. Moussa, London Health Sciences Centre, London, Ontario, Canada.)

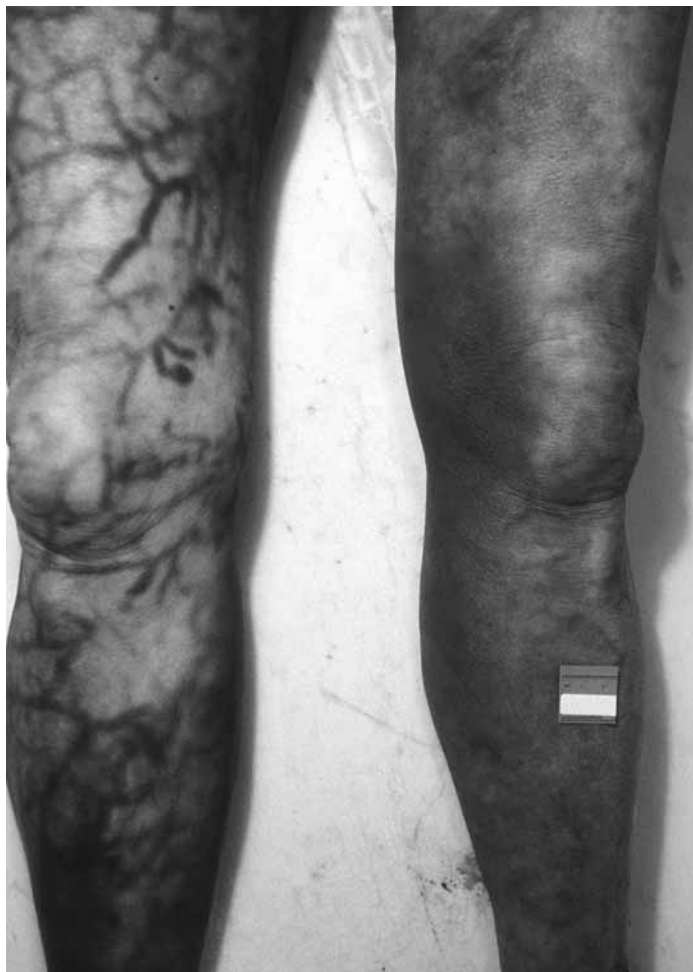individual suggests trauma; “congested” hemorrhagic lungs (microscopy can even show apparent intra-alveolar edema); pancreatic “hemorrhages” simulating pancreatitis.

- Seepage of sanguinous fluid into body spaces and cavities suggests antemortem injury, e.g., “Hemothoraces” of less than a few 100 mL of sanguinous fluid in each chest cavity are consistent with decomposition; markedly “congested” vessels and thin films of blood in the subdural/subarachnoid spaces, particularly in the occipital lobe area in a supine individual, mimic subarachnoid hemorrhage (Fig. 24). Inspection of the vertex of the brain, after the calvarium is removed, is advantageous because softening from decomposition hinders orientation and examination once the brain is removed.
- Pink teeth occur during decomposition and result from hemolysis of extravasated blood in the dentinal tubules (Fig. 25; refs. 52–57). Postmortem production of carboxyhemoglobin is not a factor (55,57). Cephalic congestion, when it results from a head-down position, and a moist environment (e.g., drowning victim) are factors that promote the development of pink teeth (55–57). Fingernails can also be discolored pink (57). Pink discoloration of teeth is independent of the cause of death (53,56,57). This change is observed within 1 to 2 wk following death (54,56).

### 5.2.2. Distension

Various gases are produced (e.g., hydrogen sulfide, methane, ammonia, carbon dioxide) during putrefaction. Gaseous permeation into skin/soft tissue and organs manifests as crepitus and distension. Localized swelling of the genitalia, anus, and face (bulging eyes, tongue protrusion) is seen. The deceased is unrecognizable. Generalized body distension





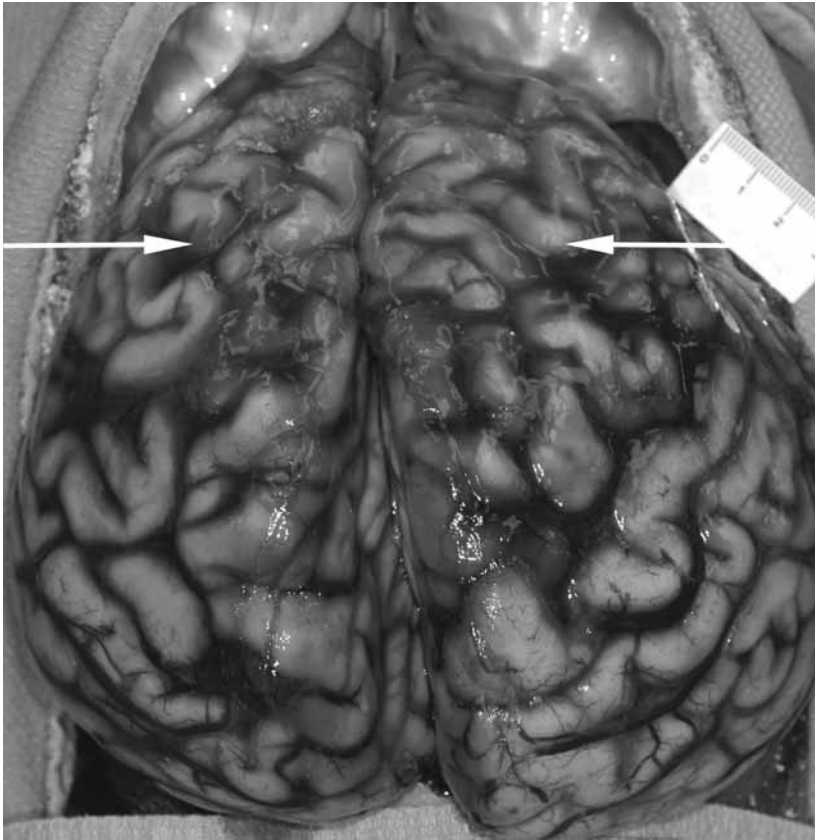
**Fig. 23.** “Marbling” of right leg in contrast to lividity of left leg. The blood vessels have been accentuated by decomposition.

can suggest an apparently large individual. Gas accumulates in body cavities, and their opening is marked by an audible expulsion and visible deflation of the body.

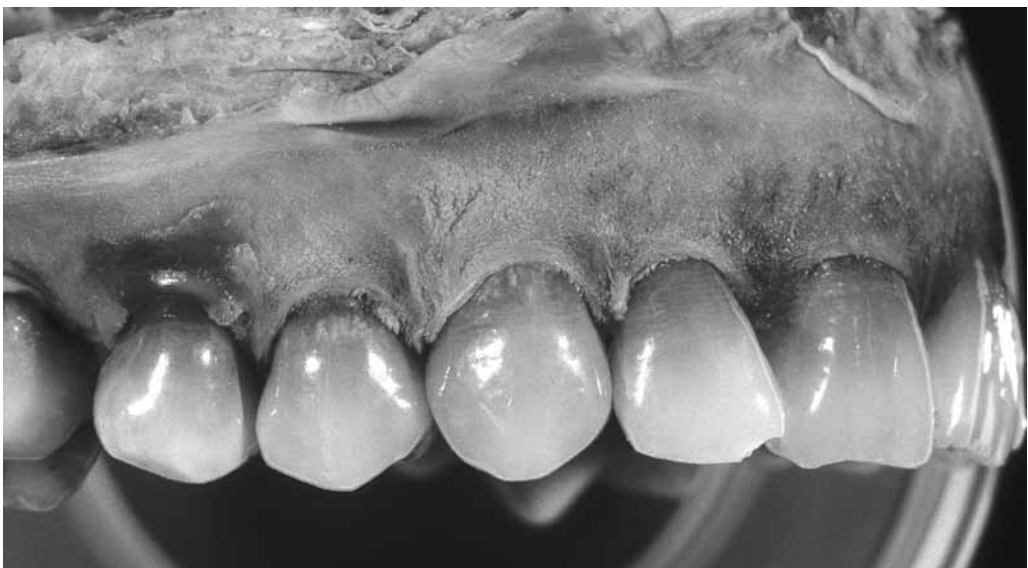- Significance
  - Apparent “epistaxis” caused by rupture of nasal vessels occurs.
  - Gaseous distension of lungs leads to expulsion of sanguinous fluid and gastric content from the mouth and nose (“purge”), simulating a facial injury (Fig. 26). Gas can force feces from the rectum. Postmortem expulsion of a fetus has been described (3).
  - Postmortem surgical wound dehiscence mimics sharp-force injury. A history of prior surgery and the finding of sutures in the wound solve this problem (58,59). Dehiscence occurs even in wounds that are months old (58).

### *5.2.3. Degradation*

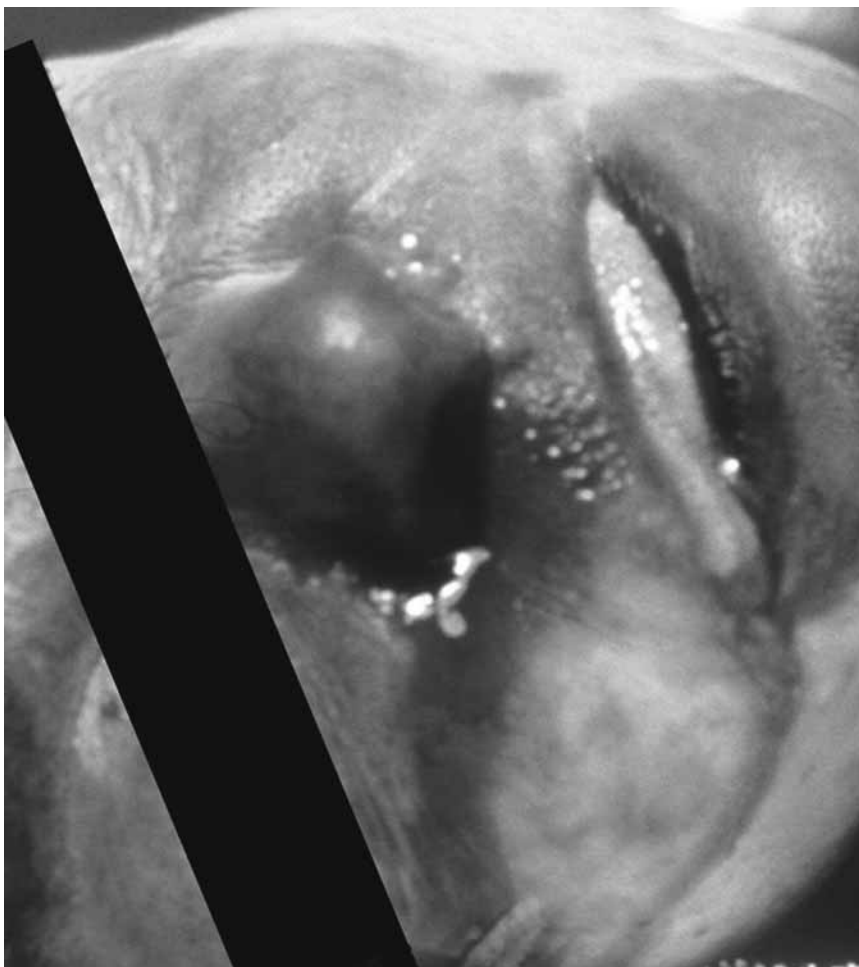
Decomposition causes a loss of anatomic integrity of skin and other tissues. Localized areas of skin peel (“skin slippage”) occur (Fig. 27). Gas- or fluid-filled cutaneous blisters form (Fig. 28). Broken blisters and areas of skin slippage dry out, leaving yellow/brown/red



**Fig. 24.** Decomposed body. Note “congestion” of subarachnoid blood vessels on the posterior aspect of the brain (below level of arrows).



**Fig. 25.** Pink teeth caused by decomposition. (See Companion CD for color version of this figure.)



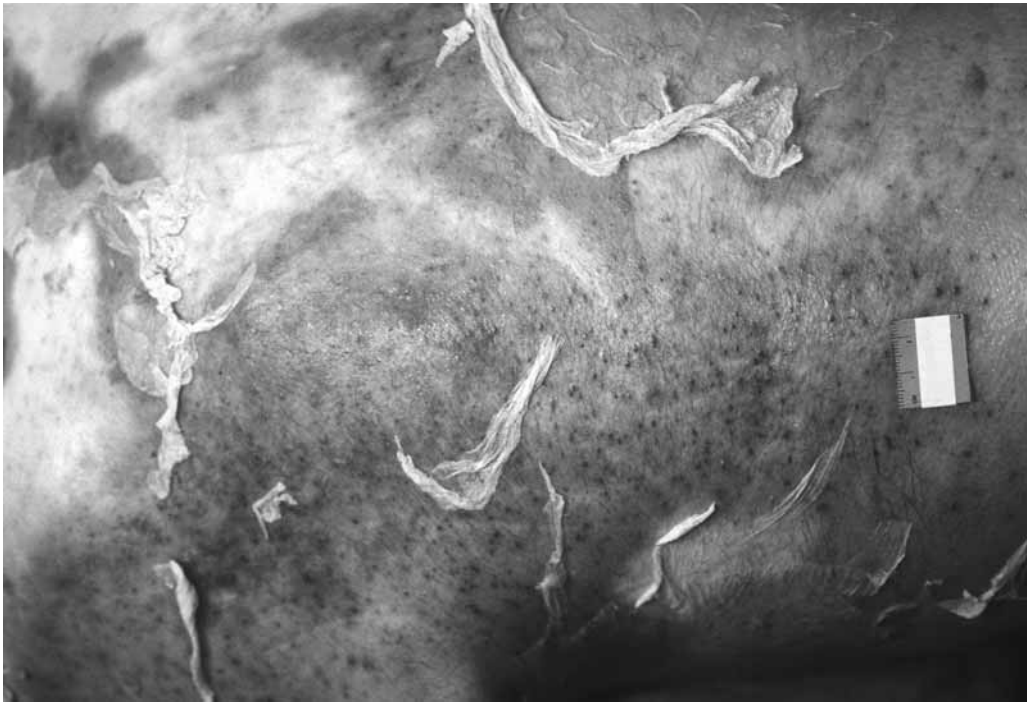
**Fig. 26.** Decomposition. “Purge” of sanguinous fluid from nostrils and mouth.

areas with a parchment-like texture (Fig. 29). The attachment of hair and nails loosens, allowing for their easy removal. Scalp hair remains as a mass in warm weather (47). Loosening of skin of hands and feet leads to “degloving” (Fig. 30). Apparent ruptures of the upper gastrointestinal tract (esophagus, esophagomalacia; stomach, gastromalacia) are observed. If microscopic examination shows an inflammatory reaction, then the rupture is antemortem. Cystic change in the brain (encephalomalacia) mimics infarcts.

- Significance
  - Loss of skin integrity mimics trauma (e.g., abrasion).
  - Blister formation simulates thermal injury.
  - Ocular petechiae can disappear with decomposition, although drying can preserve them (42).

#### 5.2.4. Dissolution

Certain organs and tissues (e.g., pancreas) decompose quickly, and others (e.g., bone, uterus, prostate) are slower to decay. Progressive decomposition leads to disappearance of

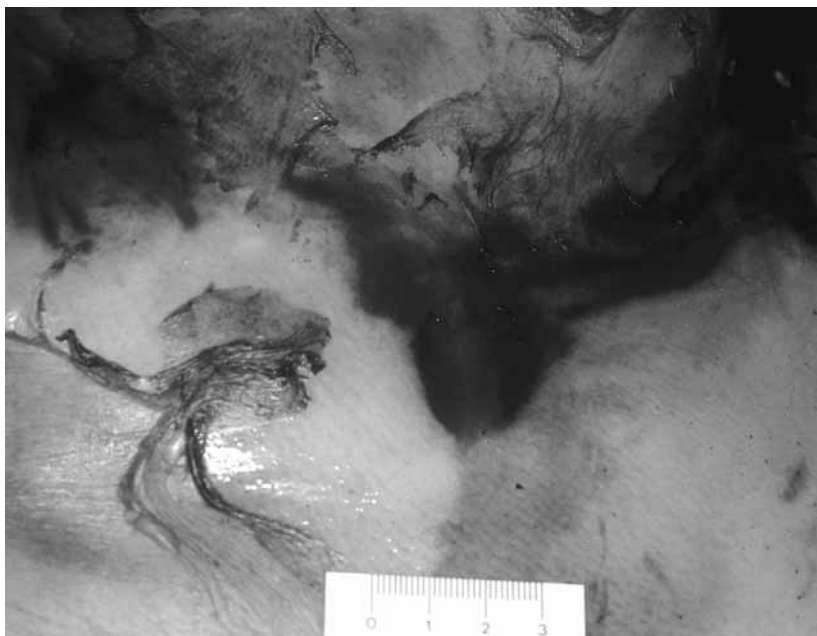


**Fig. 27.** Decomposition. Skin slippage.

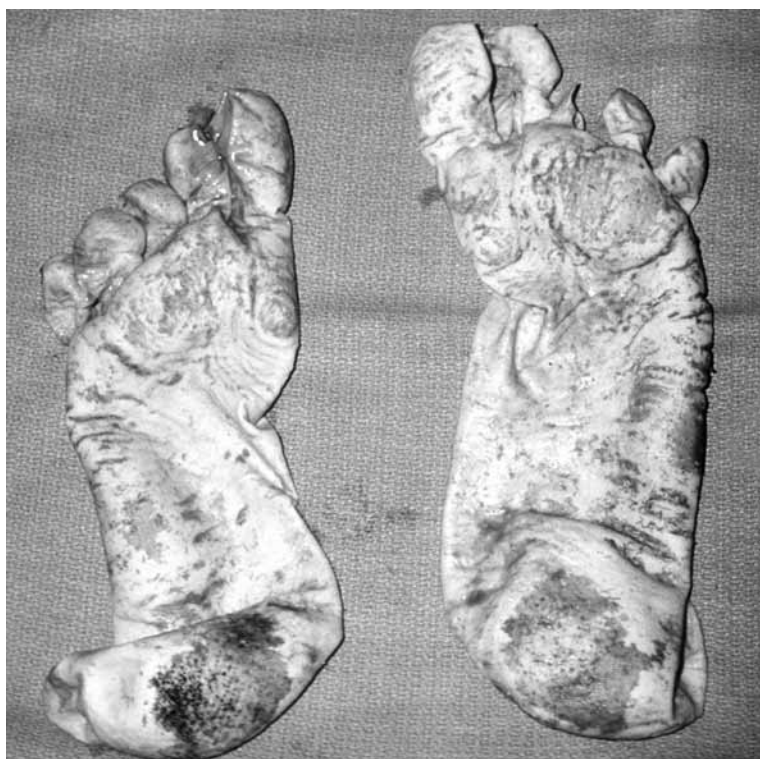


**Fig. 28.** Blisters from decomposition.

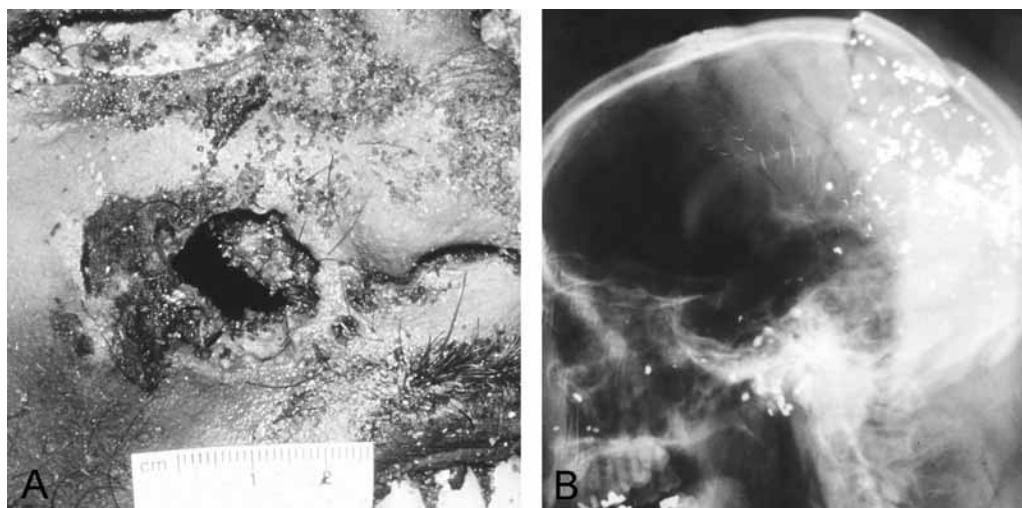




**Fig. 29.** Decomposition. Neck and upper chest show skin slippage. Band of yellow-brown discoloration following distribution of collar.



**Fig. 30.** Decomposition. Degloving of skin of feet. (Courtesy of the Office of the Chief Medical Examiner, Chapel Hill, NC.)



**Fig. 31.** Homicide. Autopsy not done during initial investigation because of severe decomposition. **(A)** Shotgun wound of right cheek. Wound was obscured by maggot infestation. Death was originally attributed to natural causes. **(B)** Radiograph of skull showing shotgun pellets. (Courtesy of the Office of the Chief Medical Examiner, Chapel Hill, NC.)

tissues and organs and eventual skeletonization (2 to 4 wk in warm to hot weather) (47). Disarticulation of skeletal remains eventually occurs (60). Issues may arise as to whether the recovered remains are human (61).

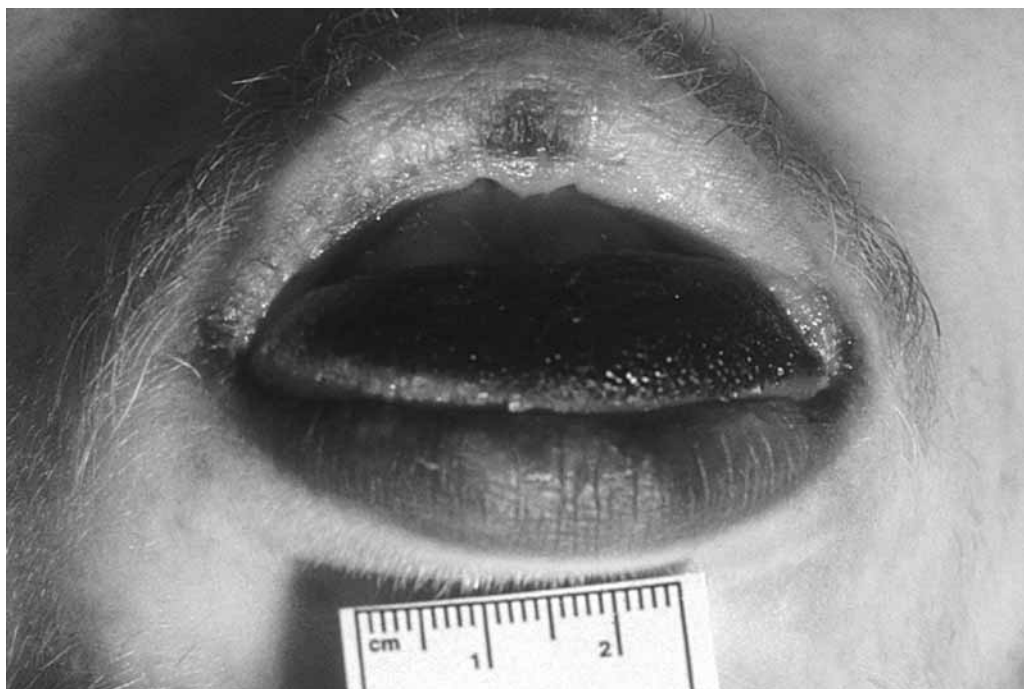#### 5.2.5. “Unfit for Examination”

Discoloration, distension, degradation, and dissolution, as components of decomposition, can disorient a pathologist already reeling from malodorous gases emanating from a body seething with maggots. Failure to approach these cases systematically with a complete autopsy can result in a traumatic cause of death being missed (Fig. 31; ref. 62). The more advanced the decomposition, the greater the likelihood of not finding a cause of death (“no anatomic cause of death,” “undetermined”; see also ref. 62).

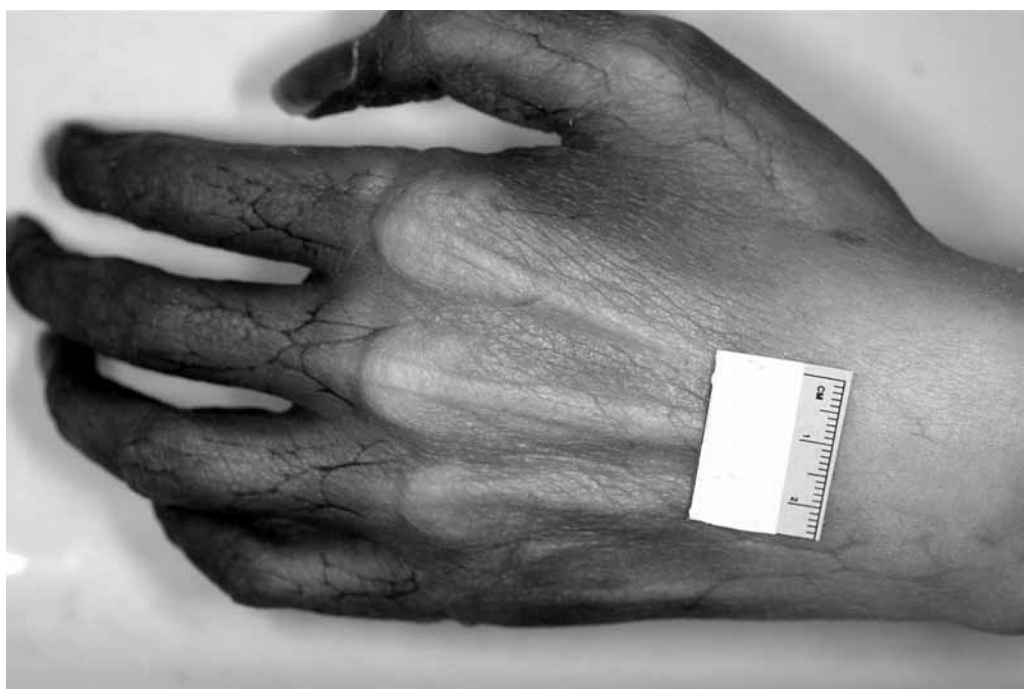### 5.3. Variants of Decomposition

Drying (mummification) is a variant of decomposition. Localized drying can affect the tip of the partly exposed tongue, the lips, the tips of fingers and toes, and the scrotum (Figs. 32–34). If the eyelids are not closed after death, then scleral drying appears as a horizontal brown line (*taches noires sclérotiques*; see Fig. 35). Another eye change is corneal clouding. It occurs 2 to 3 h after death if the eyes are open, and by 24 h if they are shut (6,8). Generalized transformation of skin to a brown-black leathery consistency happens under dry conditions (Fig. 36). An “empty” body—i.e., empty body cavities—is sometimes seen (63). Although the estimated time for generalized mummification in temperate climates is months, the author has observed it 1 mo after death in his locale (southwestern Ontario in the summer). Mummification is possible in the snow (64).

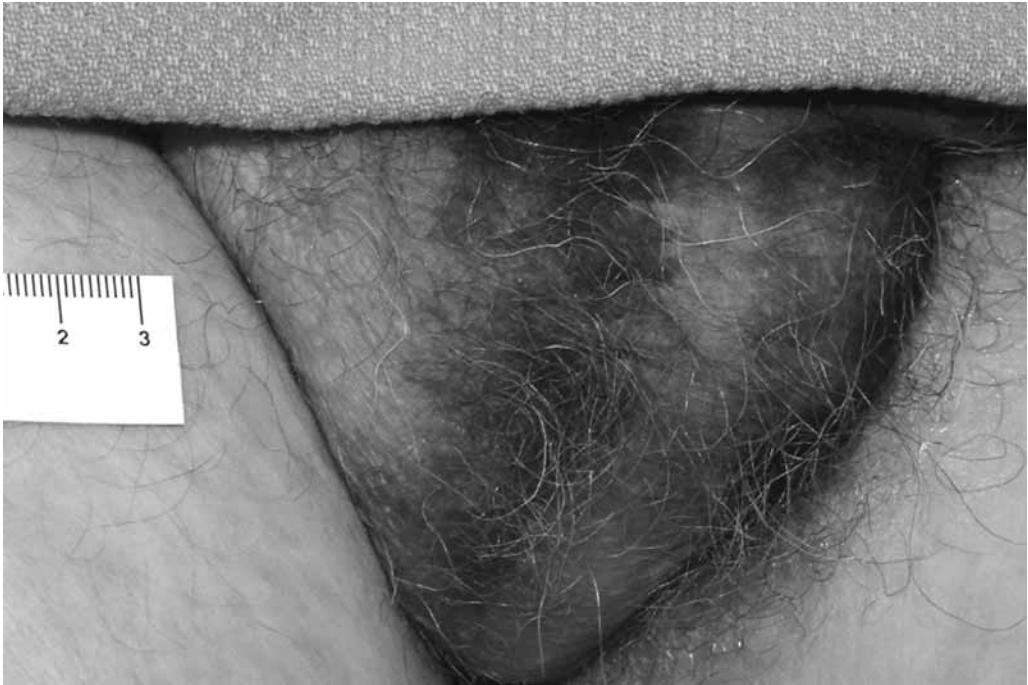



**Fig. 32.** Postmortem drying of tip of exposed tongue and lower lip.



**Fig. 33.** Postmortem drying of fingertips: a challenge for police officers trying to obtain fingerprints.



**Fig. 34.** Postmortem drying of scrotum, mimicking bruising.



**Fig. 35.** "*Taches noires*." Scleral drying artifact.

- Significance
  - Drying of fingertips makes fingerprinting a challenge (Fig. 33; refs. 65 and 66).
  - The localized dark discoloration seen in a dried scrotum or tongue mimics injury (Figs. 32 and 34). Incision into the site reveals no hemorrhage. Examination of the removed testes shows no abnormality.
  - Scleral drying artifact suggests antemortem hemorrhage (Fig. 35). The artifact does not extend elsewhere on the sclera.



**Fig. 36.** Mummification. Leather-like skin in pelvic area of partly skeletonized remains.


Another variant of decomposition is adipocere (*adipo* = fat, *cere* = wax), a dirty yellow, greasy, or clay-like material formed by alteration of subcutaneous fat by endogenous lipases and bacterial enzymes (Fig. 37; refs. 45 and 67). Hydrolysis of triglycerides leads to liquified neutral fats (storage fats), which penetrate adjacent soft tissue (e.g., muscle) and viscera. Bacterial enzymes transform unsaturated fatty acids into saturated forms, mainly palmitic and stearic acid. These fatty acids have higher melting points (palmitic acid = 63°C or 142°F, stearic acid = 81°C or 176°F) than the temperature of a gravesite (3–16°C or 37–59°F). As a result, the fatty acids crystallize, leading to the formation of a firm solid. Adipocere is more likely to form in an obese body or a female because of a higher fat content (45). Numerous other factors have been proposed in the development of adipocere (e.g., moist or water-logged soils) (45). Adipocere is variably distributed on the body surface and encases bones; it has also been noted in a fatty liver. Adipocere can remain unchanged for years (45). The reduced water solubility of adipocere means that a corpse can retain its shape. The estimated time of occurrence of adipocere in temperate climates is several months postmortem (45).

## 6. GASTRIC CONTENTS

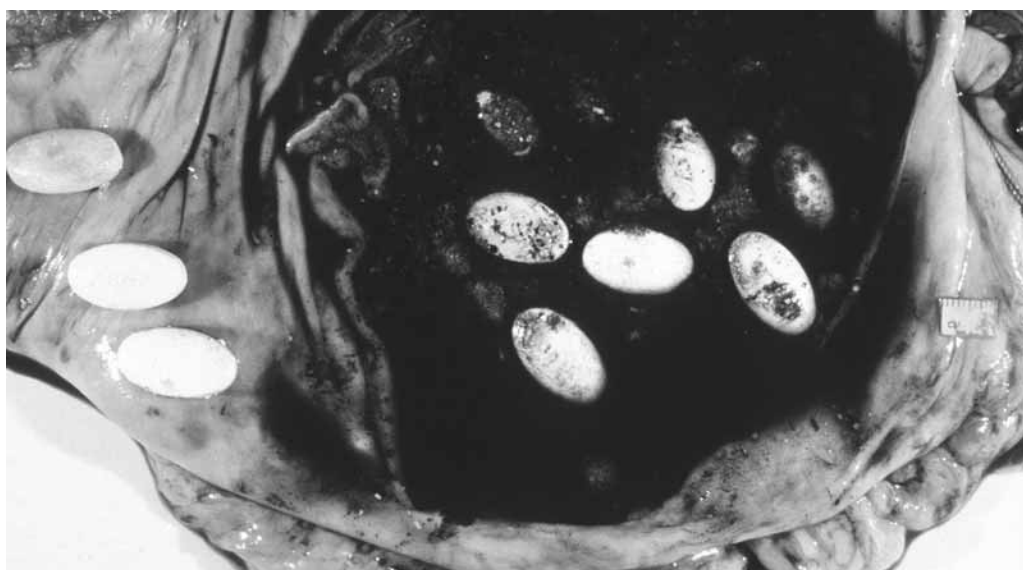The description of stomach contents has been used to estimate the time of death, if the time, volume, and character of the individual's last meal are known (68–70). On occasion, if pills are not digested, stomach contents provide a clue to a toxicological cause of death (Fig. 38; ref. 68). The investigator may request that the pathologist examine the stomach, particularly if other postmortem parameters were not recorded during the initial examination of the body at the scene.

Documentation of the type of food, its volume, and state of digestion is done at autopsy. One assumption is that if the contents are recognizable and distinctive, then a





**Fig. 37.** Adipocere encasing long bone.



**Fig. 38.** Stomach opened at autopsy. In most cases, medications will have dissolved in the stomach by the time of death. The finding of an excess number of pills supports intentional ingestion.

similar meal has not been eaten in the interim. Simultaneously ingested liquid, digestible solid, and nondigestible solid foods are emptied from the stomach at different rates ([69](#)). Liquids are emptied rapidly ([68–70](#)). Another assumption is that digestion and gastric emptying proceed at regular rates. Meals of high volume and caloric content are emptied more slowly (e.g., light meal, 2 h; medium-sized meals, 3–4 h; heavy meals, 4–6 h), but digestion of various foods is variable and continues after death ([5,68,69,71,72](#)). Some

foodstuffs (e.g., fibrous vegetables) are more resistant to digestion and persist in the stomach (72). Larger pieces of less-chewed food are digested more slowly and remain in the stomach longer (71–73). Gastric emptying varies in the same individual and between individuals under similar circumstances eating the same meal (69). Gastric emptying is affected by many factors. Some factors delaying emptying include trauma, shock, disease, increased intracranial pressure owing to head injury, emotional upset, ethanol, and other drugs (e.g., narcotic analgesics; refs. 68,70–72). Severe trauma can delay emptying up to several days (70). Stomach contents are rarely useful in estimating the time of death because of the many variables involved (68,69,71,74).

## 7. EMBALMING ARTIFACTS

Embalming is a funeral home procedure that prepares and preserves a body for an open-casket funeral and attempts to reduce the effects of various postmortem changes (75,76). Embalming leads to drying and hardening of soft tissues (75). Embalmed bodies eventually decay, beginning at pressure points such as the buttocks and legs, the areas least penetrated by embalming fluid (47,77).

After clothing is removed, the hair is shampooed and a man's face is shaved (76). The body is cleaned (76). An incision, usually in the subclavicular area, allows blood to be drained from the venous system and embalming fluid to be perfused, under pressure, into an artery (Fig. 39; refs. 75 and 77). Embalming fluid is a mixture of formaldehyde, anticoagulants, perfumes, surfactants to reduce surface tension and increase permeation of fluid, coloring agents, modifying agents (e.g., moisturizers or dehydrating agents), and solvents (alcohols, water, glycerine compounds) carrying the various embalming chemicals. Femoral and brachial arteries are also used (75,76). More than one access site has been seen (77). The incisions are sutured and absorbent powder or cotton is put into the incision base to prevent leakage (77).

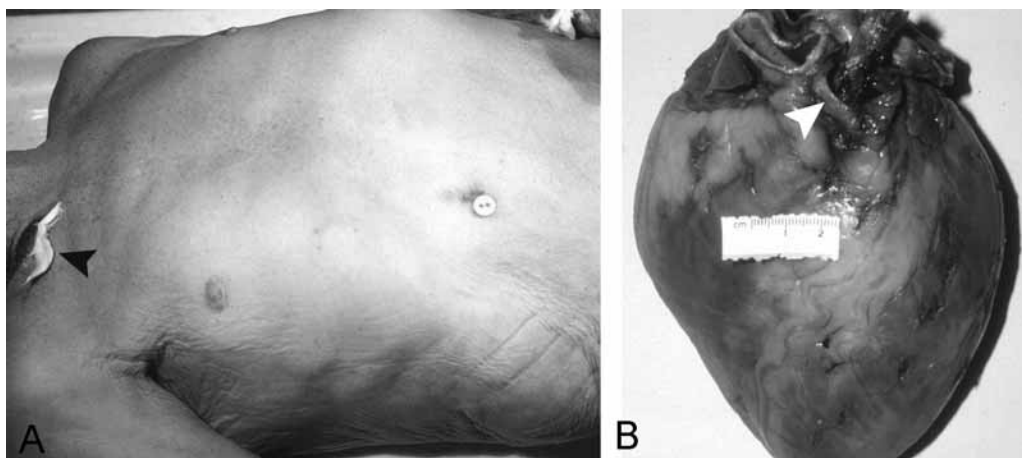
To reduce gaseous distension, the abdomen is punctured near the umbilicus by a trocar that perforates the intestine (77). Other viscera are also punctured (Fig. 39; ref. 76). Injection of the scrotum may be done (77). Trocared hollow organs (e.g., heart, urinary bladder) are aspirated of their contents, and embalming fluid is injected into the body cavities (75–77). The trocar cutaneous wound is plugged with a button or sutured (Fig. 39; ref. 77). Sometimes a trocar is inserted directly into an extremity (77).

Cosmetics are applied to the face. Caps cover the eyes and the jaws are wired or sutured (77). Injection of “tissue builders” into the orbits and face, to lessen a gaunt appearance, may be done (76,77).

The body is reclothed. The backs of garments are cut to allow ease of dressing. Underlying plastic garments may be necessary to prevent leakage (77).

If there has been an autopsy, stabilizing metallic clamps are screwed into the skull and joined by wires (77). Cavities may be filled with material (e.g., cloth, paper towels) soaked in embalming fluid (77). A viscera bag may be present (77). Granular material inside the cavities consists of hardening or dehydrating compounds and embalming powders.

- Significance
  - The blood is unsuitable for toxicological analysis. Vitreous is an alternative (76).
  - Blood coagulates, forming “pseudothrombi,” and mimics pulmonary thromboembolism (Fig. 39; refs. 75 and 77).



**Fig. 39.** Embalmed body. **(A)** Button on abdomen concealing trocar insertion site. Subclavian incision site covered by cotton dressing (arrowhead). **(B)** Embalmed heart showing artifactual trocar wounds. Note clotted blood in main pulmonary artery (arrowhead), mimicking a thromboembolus.

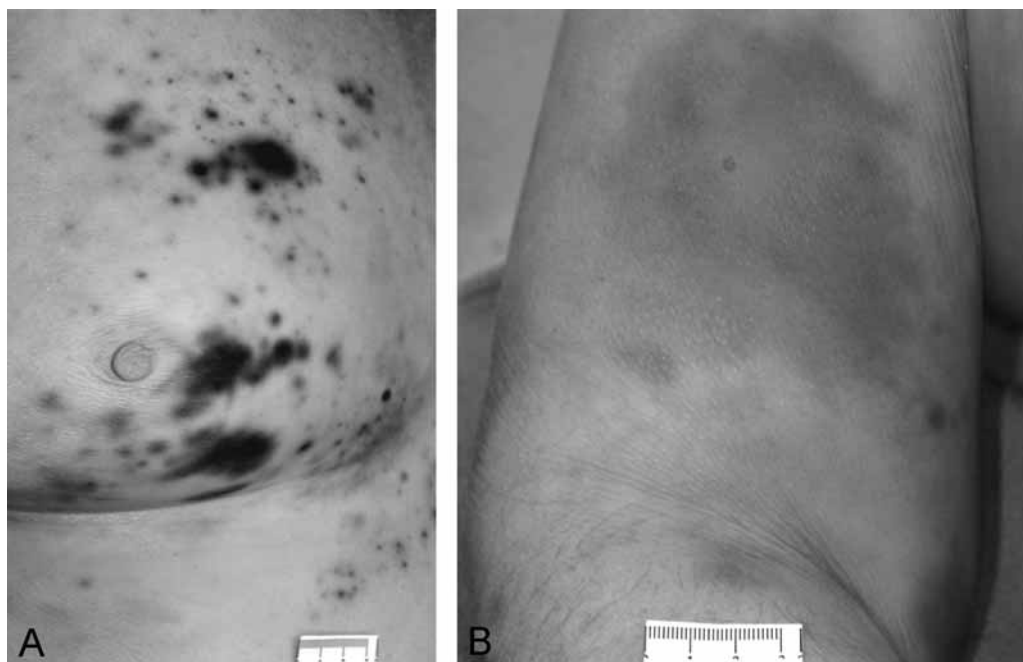
- Injuries are simulated (75,76,78,79).
- Perfusion of embalming fluid can accentuate preexisting contusions or form post-mortem bruises or hematomas (e.g., in the neck area) owing to vessel rupture (Fig. 40; refs. 75–77). The decrease in lividity from drainage of blood further enhances the appearance of real or artifactual bruises, which can be a source of consternation for next of kin and investigators (76).
- Trocar punctures affect not only intra-abdominal organs but also thoracic and pelvic structures (Fig. 39; ref. 75). Cases have been described of antemortem bullet wounds being covered by trocar buttons (75,76).
- Facial makeup can obscure trauma (Fig. 41; refs. 75 and 76).
- Eye caps need to be removed to observe ocular hemorrhage (76).
- Wounds can be altered (i.e., sutured [75,77,79]).
- Shaving can cause neck abrasions, simulating strangulation (76,77).
- Coloring agents impart a bright red appearance, mimicking carbon monoxide poisoning (76).

## 8. FORENSIC ENTOMOLOGY

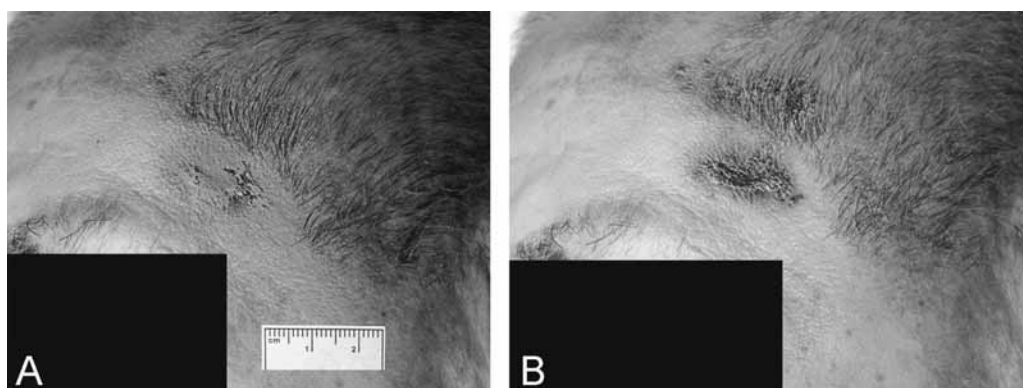
Forensic entomology is defined as the use of insects and other arthropods in medicolegal death investigations (45,80). The pathologist must be aware of the significance of insects on the body and can assist in their collection (49). The pathologist also documents findings relevant to the forensic entomologist (e.g., clothing, apparent injuries).

Flies (order Diptera; Calliphoridae, or blowflies) are among the first colonizers of a deceased individual (45). The maturation of these insects (egg–larva–pupa–adult insect) serves as a biological clock, 1 to 2 wk following death (45,49,80,81). Data regarding fly lifecycles in one area cannot necessarily be used in another region (45,80). The presence of ammonia-rich compounds and hydrogen sulfide are important stimulants for egg deposition (45). Diptera do not oviposit in mummified tissue, favoring moist tissue (45). Development during the larval stages is dependent on the temperature at the death





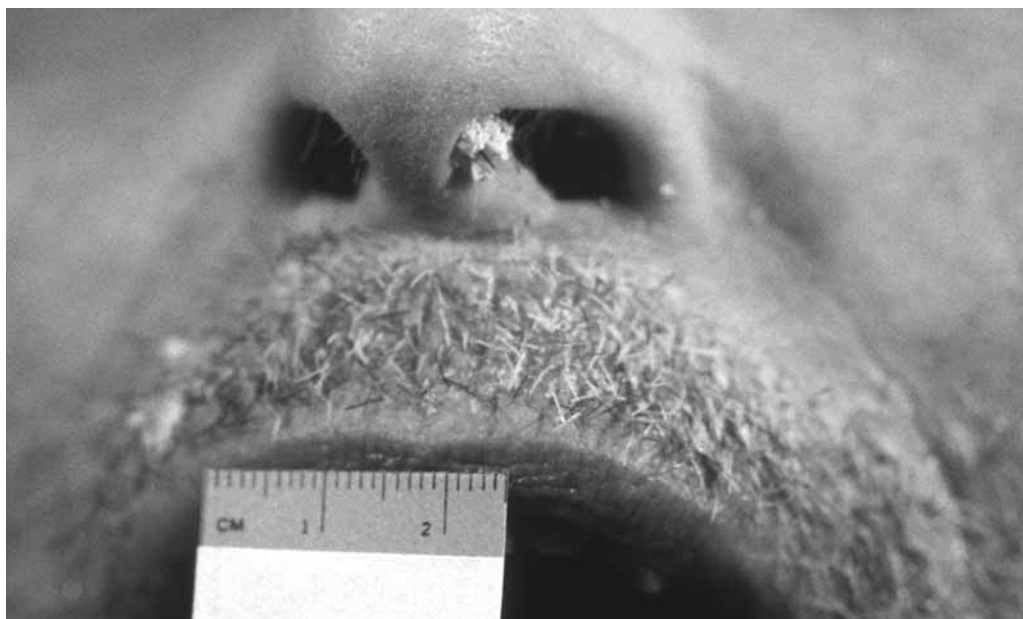
**Fig. 40.** Embalmed body. The deceased was described as “unsteady” on her feet. She was prescribed warfarin because of a previous diagnosis of pulmonary thromboembolism. She needed assistance walking when visiting a doctor a few days prior to her death. No contusions were visible on external examination by the coroner prior to embalming. The embalmer remarked that some bruises started to appear while perfusing the body. **(A)** At autopsy, numerous bruises were visible on the chest. **(B)** Large bruise, inner right arm.



**Fig. 41.** Embalmed body. **(A)** Facial cosmetic had been applied. **(B)** Face wiped to reveal an abrasion on the left temple.

scene before the body was found (45,47,49,80). Eggs are first laid in the orifices or wounds of the corpse within seconds of death (Figs. 31, 42; refs. 45, 47, and 82).

Eggs, larvae, pupae, and adult flies are collected (80). Larvae are preserved in 10% formalin. Eggs and larvae are also placed in a specimen jar with a food source (e.g., liver, muscle from body), covered with gauze, and kept at ambient temperature and humidity.



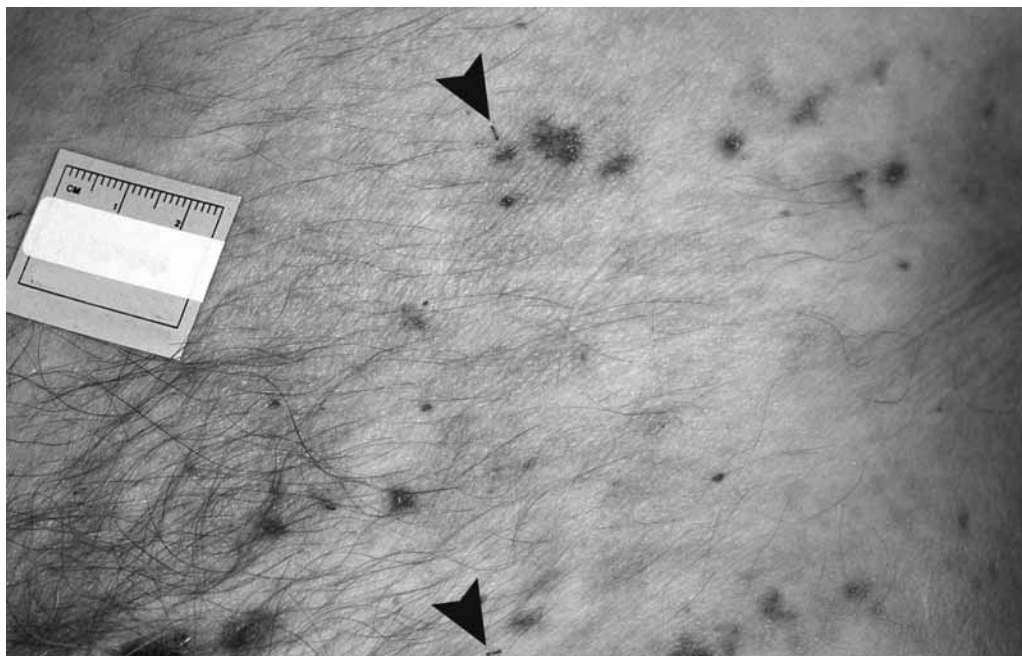
**Fig. 42.** Fly eggs deposited in left nostril.

- Significance
  - Larvae alter wounds (36,49,62). Masses of larvae on the skin can be a clue to a site of bleeding (49,82).
  - Live maggots, in the absence of a dead body at a location, suggest that a corpse was present (49). The finding of human DNA in larvae indicates feeding on a human body (50).
  - Toxicological analysis can be done on fly larvae and reflects use of drugs in the deceased (49,50).
  - Refrigeration does not dampen feeding activity by larvae if maggot masses form (47,82). Temperatures within these masses range from 27 to 35°C (81 to 95°F (50)).
  - Other insects (e.g., ants, cockroaches, beetles) can create artifactual injuries (Fig. 43; refs. 36, 78, 81, 83, and 84).

## 9. POSTMORTEM ANIMAL PREDATION

Postmortem predation creates injuries that arouse suspicions of homicide (35,36,48,85–89). Animal activity alters antemortem injuries (36). The typical case is an individual living alone who dies of natural causes (36,89); a free-roaming house pet (dog or cat) is trapped inside the house, and its usual food is unavailable. A pet can also be motivated by other reasons when food is present (85). A frantic pet may start to lick or nudge an unconscious owner and can become frantic, biting the body (85,89). The confined space of a dwelling can also lead to aggressive behavior toward the owner (89). The postmortem interval for predation is estimated to be less than 1 d (88). One case report, involving a dog, indicated predation within 45 min (89).

Other mammals (e.g., rodents) can gnaw on the body (85,90,91). Rodent excrement or fur at the scene is a clue to the nature of the injuries (85,87). Rodent activity



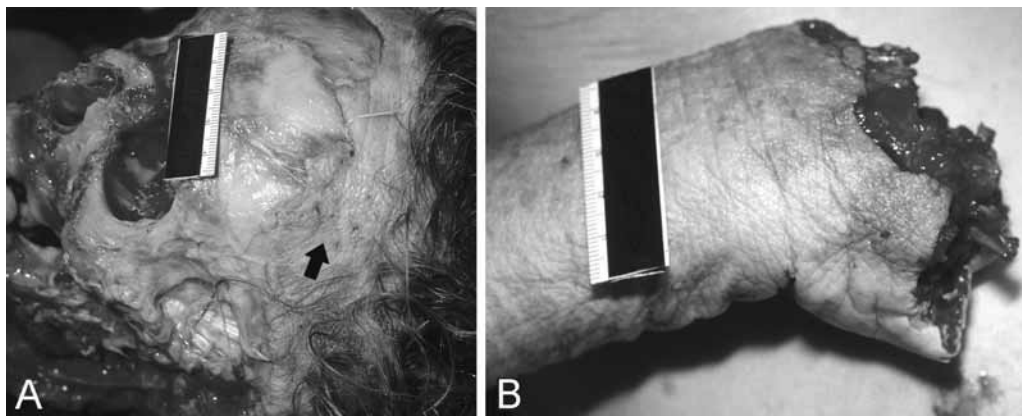
**Fig. 43.** Postmortem predation by ants (arrowheads) causing artifactual “abrasions.”

occurs indoors in low socioeconomic settings and outdoors among homeless people (87). Outdoors, various animals can carry away bones (36,47).

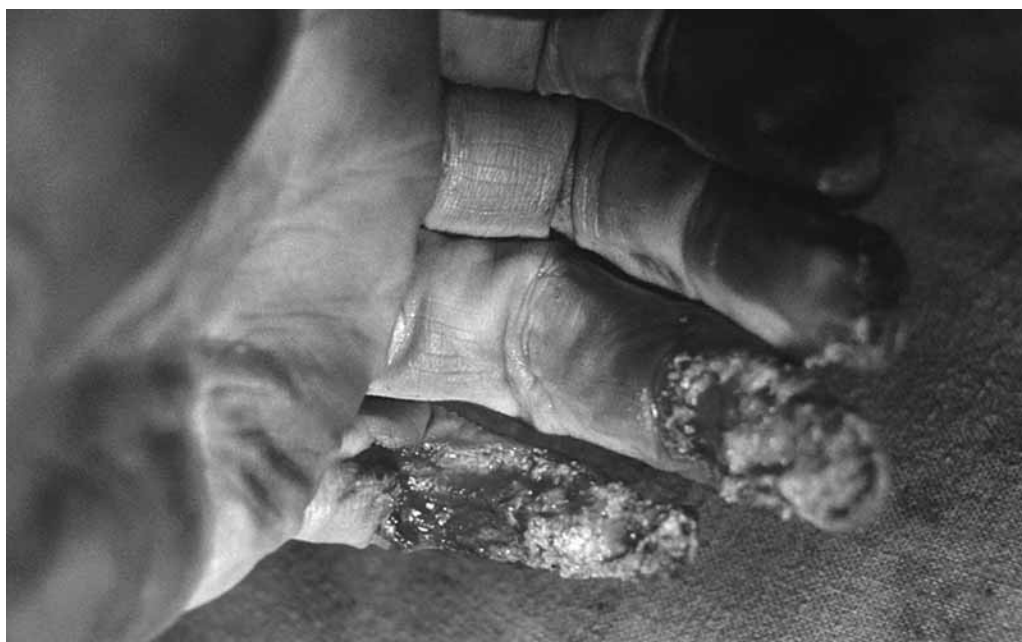### **9.1. Autopsy Examination**

There is a predilection for the exposed soft parts of the body (e.g., mouth and nose [36,87–89]). Large defects on the face, neck, and torso with variable loss of viscera and bony injury are observed following predation by large pets (e.g., dog; *see* Fig. 44 and refs. 36, 85, 86, and 88). Body parts (e.g., ears) can be missing (Fig. 44; ref. 91). Rodents can gnaw on areas of the body covered by clothes (87). The wounds are associated with minimal bleeding or bruising (85–87,89). Animal hair can be found in the wounds (89). No self-defense injuries are evident (85,87). Bite marks caused by canine teeth (dogs and large cats) and claw-induced linear scratch marks may be seen at the edge of the defect (Fig. 44; refs. 85, 88, and 89). Stab wound-like punctures are characteristic of canine dentition of carnivore origin (85). Rodent predation is characterized by layered damage of tissue (90). Rodents continue to gnaw in one area until all skin and soft tissue is chewed, exposing tendons, ligaments, and bone (87). Compared with the large irregular defect edges of canine predation, rodent wounds are smoother, finely serrated, and scalloped (Fig. 45; refs. 36, 85, 87, and 90). Parallel cutaneous lacerations indicative of tooth marks can be seen (36,87). Microscopic examination of the wounds does not show evidence of an inflammatory reaction (85,86).

The stomach of an animal may contain human remains, which can be confirmed by microscopic and DNA analysis (89).



**Fig. 44.** Postmortem predation by a dog. **(A)** Large irregular soft tissue defect of face. Note puncture wounds possibly from canine teeth (arrow). **(B)** Loss of hand owing to predation. (Courtesy of Dr. C. Rao, Regional Forensic Pathology Unit, Hamilton, Ontario, Canada.)




**Fig. 45.** Rodent predation of fingers after death. (Courtesy of Dr. D. King, Regional Forensic Pathology Unit, Hamilton, Ontario, Canada.)

### *10. CONCURRENCE (ASSOCIATION) OBSERVATIONS*

The time of death of an individual can be linked to the scene ([Fig. 46](#)). For example, a person who is found dead in a house and has 3 d worth of newspapers accumulated on the front porch has likely been dead for that period of time.





**Fig. 46.** Kitchen calendar crossed off to the 10th day of the month. The lone occupant was found dead 1 wk later in a decomposed state.

## 11. POSTMORTEM PROCEDURES

Postmortem procedure artifacts can create “injuries.” Some examples include:

- Scleral hemorrhage from needle aspiration of eye to obtain vitreous humor; periorbital hematoma owing to enucleation of eyes for corneal harvesting (*see* Subheading 3.3.; [Fig. 17](#); and refs. [92](#) and [93](#)).
- Basal skull fracture caused by forced removal of the calvarium when the skull has not been completely sawed.

## REFERENCES

1. Burton, J. F. Fallacies in the signs of death. *J. Forensic Sci.* 19:529–534, 1974.
2. Burton, J. F. The estimated time of death. *Leg. Med. Annu.* 1976:31–35, 1977.
3. Gonzales, T. A., Vance, M., Helpert, M., Umberger, C. J. *Legal Medicine, Pathology and Toxicology*. 2nd ed. Appleton Century Crofts, New York, 1954.
4. Camps, F. E. *Legal Medicine*. 2nd ed. John Wright and Sons, Bristol, UK, 1968.
5. Adelson, L. *The Pathology of Homicide*. Charles C. Thomas, Springfield, IL, 1974.
6. DiMaio, V. J., DiMaio, D. *Forensic Pathology*. 2nd ed. CRC Press, New York, 2001.
7. Henssge, C., Knight, B. E., Krompecher, T., Madea, B., Nokes, L. *The Estimation of the Time Since Death in the Early Postmortem Period*. 2nd ed. Arnold, London, 2002.
8. Perper, J. A. Time of death and changes after death—Part 1. Anatomical considerations. In: Spitz, W. V., ed. *Medicolegal Investigation of Death. Guidelines for the Application of Pathology to Crime Investigation*. Charles C. Thomas, Springfield, IL, pp. 14–64, 1993.

9. Bray, M. Chemical estimation of fresh water immersion intervals. *Am. J. Forensic Med. Pathol.* 6:133–139, 1985.
10. Coe, J. I. Vitreous potassium as a measure of the postmortem interval: an historical review and critical evaluation. *Forensic Sci. Int.* 42:201–213, 1989.
11. James, R. A., Hoadley, P. A., Sampson, B. G. Determination of postmortem interval by sampling vitreous humour. *Am. J. Forensic Med. Pathol.* 18:158–162, 1997.
12. Lange, N., Swearer, S., Sturner, W. Q. Human postmortem interval estimation from vitreous potassium: an analysis of original data from six different studies. *Forensic Sci. Int.* 66:159–174, 1994.
13. Madea, B., Henssge, C., Honig, W., Gerbracht, A. References for determining the time of death by potassium in vitreous humor. *Forensic Sci. Int.* 40:231–243, 1989.
14. Mulla, A., Massey, K. L., Kalra, J. Vitreous humor biochemical constituents: evaluation of between-eye differences. *Am. J. Forensic Med. Pathol.* 26:146–149, 2005.
15. Munoz, J. I., Suarez-Penaranda, J. M., Otero, X. L., et al. A new perspective in the estimation of postmortem interval (PMI) based on vitreous. *J. Forensic Sci.* 46:209–214, 2001.
16. Pounder, D. J., Carson, D. O., Johnston, K., Orihara, Y. Electrolyte concentration differences between left and right vitreous humor samples. *J. Forensic Sci.* 43:604–607, 1998.
17. Stephens, R. J., Richards, R. G. Vitreous humor chemistry: the use of potassium concentration for the prediction of the postmortem interval. *J. Forensic Sci.* 32:503–509, 1987.
18. Vass, A. A., Barshick, S. A., Sega, G., et al. Decomposition chemistry of human remains: a new methodology for determining the postmortem interval. *J. Forensic Sci.* 47:542–553, 2002.
19. Henssge, C., Althaus, L., Bolt, J., et al. Experiences with a compound method for estimating the time since death. II. Integration of non-temperature-based methods. *Int. J. Legal Med.* 113:320–331, 2000.
20. Kobayashi, M., Takatori, T., Iwadate, K., Nakajima, M. Reconsideration of the sequence of rigor mortis through postmortem changes in adenosine nucleotides and lactic acid in different rat muscles. *Forensic Sci. Int.* 82:243–253, 1996.
21. Kobayashi, M., Ikegaya, H., Takase, I., Hatanaka, K., Sakurada, K., Iwase, H. Development of rigor mortis is not affected by muscle volume. *Forensic Sci. Int.* 117:213–219, 2001.
22. Krompecher, T., Bergerioux, C., Brandt-Casadevall, C., Gujer, H. R. Experimental evaluation of rigor mortis. VI. Effect of various causes of death on the evolution of rigor mortis. *Forensic Sci. Int.* 22:1–9, 1983.
23. Krompecher, T., Fryc, O. Experimental evaluation of rigor mortis. IV. Change in strength and evolution of rigor mortis in the case of physical exercise preceding death. *Forensic Sci. Int.* 12:103–107, 1978.
24. Krompecher, T. Experimental evaluation of rigor mortis. V. Effect of various temperatures on the evolution of rigor mortis. *Forensic Sci. Int.* 17:19–26, 1981.
25. Varetto, L., Curto, O. Long persistence of rigor mortis at constant low temperature. *Forensic Sci. Int.* 147:31–34, 2005 .
26. Krompecher, T., Fryc, O. Experimental evaluation of rigor mortis. III. Comparative study of the evolution of rigor mortis in different sized muscle groups in rats. *Forensic Sci. Int.* 12:97–102, 1978.
27. Kobayashi, M., Takatori, T., Nakajima, M., et al. Does the sequence of onset of rigor mortis depend on the proportion of muscle fibre types and on intra-muscular glycogen content? *Int. J. Legal Med.* 112:167–171, 1999.
28. Krompecher, T. Experimental evaluation of rigor mortis. VIII. Estimation of time since death by repeated measurements of the intensity of rigor mortis on rats. *Forensic Sci. Int.* 68:149–159, 1994.
29. Suzutani, T., Ishibashi, H., Takatori, T. [Studies on the estimation of the postmortem interval. 2. The postmortem lividity (author's transl.). *Hokkaido Igaku Zasshi* 52:259–267, 1978.
30. Noriko, T. Immunohistochemical studies on postmortem lividity. *Forensic Sci. Int.* 72:179–189, 1995.



31. Inoue, M., Suyama, A., Matuoka, T., Inoue, T., Okada, K., Irizawa, Y. Development of an instrument to measure postmortem lividity and its preliminary application to estimate the time since death. *Forensic Sci. Int.* 65:185–193, 1994.
32. Sannohe S. Change in the postmortem formation of hypostasis in skin preparations 100 micrometers thick. *Am. J. Forensic Med. Pathol.* 23:349–354, 2002.
33. Bohnert, M., Weinmann, W., Pollak, S. Spectrophotometric evaluation of postmortem lividity. *Forensic Sci. Int.* 99:149–158, 1999.
34. Avis SP, Archibald J.T. Asphyxial suicide by propane inhalation and plastic bag suffocation. *J. Forensic Sci.* 39:253–256, 1994.
35. Prahlow, J. A., Linch, C. A. A baby, a virus, and a rat. *Am. J. Forensic Med. Pathol.* 21:127–133, 2000.
36. Byard, R. W., James, R. A., Gilbert, J. D. Diagnostic problems associated with cadaveric trauma from animal activity. *Am. J. Forensic Med. Pathol.* 23:238–244, 2002.
37. Nikolic, S., Atanasijevic, T., Micic, J., Djokic, V., Babic, D. Amount of postmortem bleeding: an experimental autopsy study. *Am. J. Forensic Med. Pathol.* 25:20–22, 2004.
38. Burke, M. P., Olumbe, A. K., Opeskin, K. Postmortem extravasation of blood potentially simulating antemortem bruising. *Am. J. Forensic Med. Pathol.* 19:46–49, 1998.
39. Betz, P., Lignitz, E., Eisenmenger, W. The time-dependent appearance of black eyes. *Int. J. Legal Med.* 108:96–99, 1995.
40. Reh, H., Haarhoff, K. [The significance of the settling of blood into dependent and soft tissues as evidence for death by throttling and choking (author's transl.)]. *Z Rechtsmed* 77:47–60, 1975.
41. Maxeiner, H., Bockholdt, B. Homicidal and suicidal ligature strangulation—a comparison of the post-mortem findings. *Forensic Sci. Int.* 137:60–66, 2003.
42. Betz, P., Penning, R., Keil, W. The detection of petechial haemorrhages of the conjunctivae in dependency on the postmortem interval. *Forensic Sci. Int.* 64:61–67, 1994.
43. Carter, N., Ali, F., Green, M. A. Problems in the interpretation of hemorrhage into neck musculature in cases of drowning. *Am. J. Forensic Med. Pathol.* 19:223–225, 1998.
44. Henssge, C., Madea, B. Estimation of the time since death in the early post-mortem period. *Forensic Sci. Int.* 144:167–175, 2004.
45. Fiedler, S., Graw, M. Decomposition of buried corpses, with special reference to the formation of adipocere. *Naturwissenschaften* 90:291–300, 2003.
46. Honigschnabl, S., Schaden, E., Stichenwirth, M., et al. Discovery of decomposed and mummified corpses in the domestic setting—a marker of social isolation? *J. Forensic Sci.* 47:837–842, 2002.
47. Mann, R. W., Bass, W. M., Meadows, L. Time since death and decomposition of the human body: variables and observations in case and experimental field studies. *J. Forensic Sci.* 35:103–111, 1990.
48. Rodriguez, W. C. III, Bass, W. M. Decomposition of buried bodies and methods that may aid in their location. *J. Forensic Sci.* 30:836–852, 1985.
49. Campobasso, C. P., Introna, F. The forensic entomologist in the context of the forensic pathologist's role. *Forensic Sci. Int.* 120:132–139, 2001.
50. Amendt, J., Krettek, R., Zehner, R. Forensic entomology. *Naturwissenschaften* 91:51–65, 2004.
51. Kibayashi, K., Hamada, K., Honjyo, K., Tsunenari, S. Differentiation between bruises and putrefactive discolorations of the skin by immunological analysis of glycophorin A. *Forensic Sci. Int.* 61:111–117, 1993.
52. Kirkham, W. R., Andrews, E. E., Snow, C. C., Grape, P. M., Snyder, L. Postmortem pink teeth. *J. Forensic Sci.* 22:119–131, 1977.
53. van Wyk, C. W. Postmortem pink teeth. Histochemical identification of the causative pigment. *Am. J. Forensic Med. Pathol.* 10:134–139, 1989.

54. van Wyk, C. W. Postmortem pink teeth: in vitro production. *J. Oral Pathol.* 17:568–572, 1988.
55. Brondum, N., Simonsen, J. Postmortem red coloration of teeth. A retrospective investigation of 26 cases. *Am. J. Forensic Med. Pathol.* 8:127–130, 1987.
56. Borrmann, H., Du, C. A., Brinkmann, B. Medico-legal aspects of postmortem pink teeth. *Int. J. Legal Med.* 106:225–231, 1994.
57. Ortmann, C., DuChesne, A. A partially mummified corpse with pink teeth and pink nails. *Int. J. Legal Med.* 111:35–37, 1998.
58. Biddinger, P. W. Postmortem wound dehiscence. A report of three cases. *Am. J. Forensic Med. Pathol.* 8:120–122, 1987.
59. McGee, M. B., Coe, J. I. Postmortem wound dehiscence: a medicolegal masquerade. *J. Forensic Sci.* 26:216–219, 1981.
60. Haglund, W. D. Disappearance of soft tissue and the disarticulation of human remains from aqueous environments. *J. Forensic Sci.* 38:806–815, 1993.
61. Byard, R. W., James, R. A., Zuccollo, J. Potential confusion arising from materials presenting as possible human remains. *Am. J. Forensic Med. Pathol.* 22:391–394, 2001.
62. Meyersohn, J. Putrefaction: a difficulty in forensic medicine. *J. Forensic Med.* 18:114–117, 1971.
63. Emson, H. E. The case of the empty body. *Am. J. Forensic Med. Pathol.* 12:332–333, 1991.
64. Ambach, E., Tributsch, W., Ambach, W. Is mummification possible in snow? *Forensic Sci. Int.* 54:191–192, 1992.
65. Schmidt, C. W., Nawrocki, S. P., Williamson, M. A., Marlin, D.C. Obtaining fingerprints from mummified fingers: a method for tissue rehydration adapted from the archeological literature. *J. Forensic Sci.* 45:874–875, 2000.
66. Kahana, T., Grande, A., Tancredi, D. M., Penalver, J., Hiss, J. Fingerprinting the deceased: traditional and new techniques. *J. Forensic Sci.* 46:908–912, 2001.
67. Forbes, S. L., Stuart, B. H., Dadour, I. R., Dent, B. B. A preliminary investigation of the stages of adipocere formation. *J. Forensic Sci.* 49:566–574, 2004.
68. Horowitz, M., Pounder, D. J. Is the stomach a useful forensic clock? *Aust. N. Z. J. Med.* 15:273–276, 1985.
69. Horowitz, M., Pounder, D. J. Gastric emptying—forensic implications of current concepts. *Med. Sci. Law* 25:201–214, 1985.
70. Rose, E. F. Factors influencing gastric emptying. *J. Forensic Sci.* 24:200–206, 1979.
71. Jaffe, F. A. Stomach contents and the time of death. Reexamination of a persistent question. *Am. J. Forensic Med. Pathol.* 10:37–41, 1989.
72. Suzuki, S. Experimental studies on the presumption of the time after food intake from stomach contents. *Forensic Sci. Int.* 35:83–117, 1987.
73. Pera, P., Bucca, C., Borro, R., Bernocco, C., De, L. A., Carossa, S. Influence of mastication on gastric emptying. *J. Dent. Res.* 81:179–181, 2002.
74. Murphy, G. K. The trials of Steven Truscott. *Am. J. Forensic Med. Pathol.* 12:344–349, 1991.
75. Oxley, D. W. Examination of the exhumed body and embalming artifacts. *Med. Leg. Bull.* 33:1–7, 1984.
76. Rivers, R. L. Embalming artifacts. *J. Forensic Sci.* 23:531–535, 1978.
77. Hanzlick, R. Embalming, body preparation, burial, and disinterment. An overview for forensic pathologists. *Am. J. Forensic Med. Pathol.* 15:122–131, 1994.
78. Prahlow, J. A., McClain, J. L. Lesions that simulate gunshot wounds. *J. Clin Forensic Med.* 4:121–125, 1997.
79. Opeskin, K. An unusual injury. *Med. Sci. Law* 32:58–60, 1992.
80. Kulshrestha, P., Chandra, H. Time since death. An entomological study on corpses. *Am. J. Forensic Med. Pathol.* 8:233–238, 1987.

81. Benecke, M. A brief history of forensic entomology. *Forensic Sci. Int.* 120:2–14, 2001.
82. Anderson, G. S. The use of insects to determine time of decapitation: a case-study from British Columbia. *J. Forensic Sci.* 42:947–950, 1997.
83. Denic, N., Huyer, D. W., Sinal, S. H., Lantz, P. E., Smith, C. R., Silver, M. M. Cockroach: the omnivorous scavenger. Potential misinterpretation of postmortem injuries. *Am. J. Forensic Med. Pathol.* 18:177–180, 1997.
84. Prahlow, J. A., Barnard, J. J. Fatal anaphylaxis due to fire ant stings. *Am. J. Forensic Med. Pathol.* 19:137–142, 1998.
85. Tsokos, M., Schulz, F. Indoor postmortem animal interference by carnivores and rodents: report of two cases and review of the literature. *Int. J. Legal Med.* 112:115–119, 1999.
86. Tsokos, M., Schulz, F., Puschel, K. Unusual injury pattern in a case of postmortem animal depredation by a domestic German shepherd. *Am. J. Forensic Med. Pathol.* 20:247–250, 1999.
87. Tsokos, M., Matschke, J., Gehl, A., Koops, E., Puschel, K. Skin and soft tissue artifacts due to postmortem damage caused by rodents. *Forensic Sci. Int.* 104:47–57, 1999.
88. Rossi, M. L., Shahrom, A. W., Chapman, R. C., Vanezis, P. Postmortem injuries by indoor pets. *Am. J. Forensic Med. Pathol.* 15:105–109, 1994.
89. Rothschild, M. A., Schneider, V. On the temporal onset of postmortem animal scavenging. “Motivation” of the animal. *Forensic Sci. Int.* 89:57–64, 1997.
90. Haglund, W. D. Contribution of rodents to postmortem artifacts of bone and soft tissue. *J. Forensic Sci.* 37:1459–1465, 1992.
91. Patel, F. Artefact in forensic medicine: postmortem rodent activity. *J. Forensic Sci.* 39:257–260, 1994.
92. Harris, L. S. Subscleral hemorrhage. *Am. J. Forensic Med. Pathol.* 7:177–178, 1986.
93. Di Maio, V. J. Subscleral hemorrhage. *Am. J. Forensic Med. Pathol.* 6:95, 1985.

## Chapter 3

---

# Asphyxia

### Summary

The mechanism of death in asphyxia is impairment of oxygen and carbon dioxide exchange. Mechanical asphyxia (i.e., physical interference with breathing and/or circulation) is frequently encountered in medicolegal death investigations. Although the presence of external and internal petechiae is considered a hallmark of an asphyxial death, this finding is not invariable in different types of mechanical asphyxia. Consequently, debate continues about the relative roles of impaired breathing and circulation in the formation of petechiae. Hanging is a common type of mechanical asphyxia, occurring under various circumstances, some unusual. A range of external and internal postmortem findings is observed. Other types of mechanical asphyxia can have more subtle physical signs stressing the importance of the systematic approach of the “complete autopsy” in these cases. In deaths caused by inhalation of toxic gas (e.g., carbon monoxide), confirmation of the cause of death is only by toxicological testing.

**Key Words:** Asphyxia; petechiae; carbon monoxide.

### 1. INTRODUCTION

#### 1.1. Mechanisms of Asphyxia

The word *asphyxia* is of Greek derivation and means “a stopping of the pulse” (1). Any death is asphyxial in nature, but in a forensic pathology setting, asphyxia means interference with the exchange of oxygen and carbon dioxide in the body (1).

Interference of oxygen and carbon dioxide exchange can be by mechanical means (mechanical asphyxia). Obstruction to airflow can occur at any level from the nose and mouth down to the alveoli (anoxic anoxia [2]). In cases of neck compression, laryngo-tracheal obstruction and occlusion of the posterior pharynx by displacement of the tongue are possible but are not the only reasons for asphyxia (3–5). Ligature placement has been observed above tracheostomy sites of hanged individuals (6,7). Also, vomitus is seen in airways of suicidal hanging cases (3). Compression of the neck causes vascular constriction. Narrowing of the carotid and vertebral arteries decreases flow of oxygenated blood to the brain; compression of the jugular veins diminishes flow of carbon

From: *Forensic Science and Medicine: Forensic Pathology of Trauma:  
Common Problems for the Pathologist*

By: M. J. Shkrum and D. A. Ramsay © Humana Press Inc., Totowa, NJ

dioxide and waste metabolites from the brain (stagnant hypoxia [2]). The amount of force required to compress neck structures has been determined experimentally: jugular vein, 2 kg (4.5 lb); carotid artery, 5 kg (11 lb); trachea, 9 kg (20 lb); and vertebral artery, 30 kg (66 lb [8]). These observations imply that venous flow is decreased before arterial and airway obstruction occur (3). The loss of consciousness due to venous obstruction leads to loss of muscle tone and consequent flaccidity, allowing more pressure on the neck and narrowing of the carotid artery and airway (3). Impairment of breathing by hindering chest wall movement is also a type of mechanical asphyxia.

Abnormalities of inspired air cause asphyxia. Lack of oxygen is another form of anoxic anoxia. Inhalation of noxious gases (chemical asphyxia) leads to either impaired interaction between oxygen and hemoglobin, i.e., anemic anoxia (e.g., as a result of carbon monoxide inhalation) or the inability of tissues to utilize oxygen, i.e., histotoxic anoxia (e.g., caused by cyanide; *see* Subheading 3.9.; Chapter 4, Subheading 4.1., and ref. 2).

## **1.2. Classification of Mechanical Asphyxia**

The following is a classification of mechanical asphyxia based on the level of obstruction:

- Smothering (suffocation)—gagging (mouth and nose).
- Choking (mouth, oropharynx, larynx).
- Strangulation, including hanging (neck including larynx, trachea, and major blood vessels).
- Positional asphyxia (neck).
- Drowning (upper and lower respiratory tract).
- Traumatic asphyxia—overlying (chest).
- Wedging—interposition (chest).

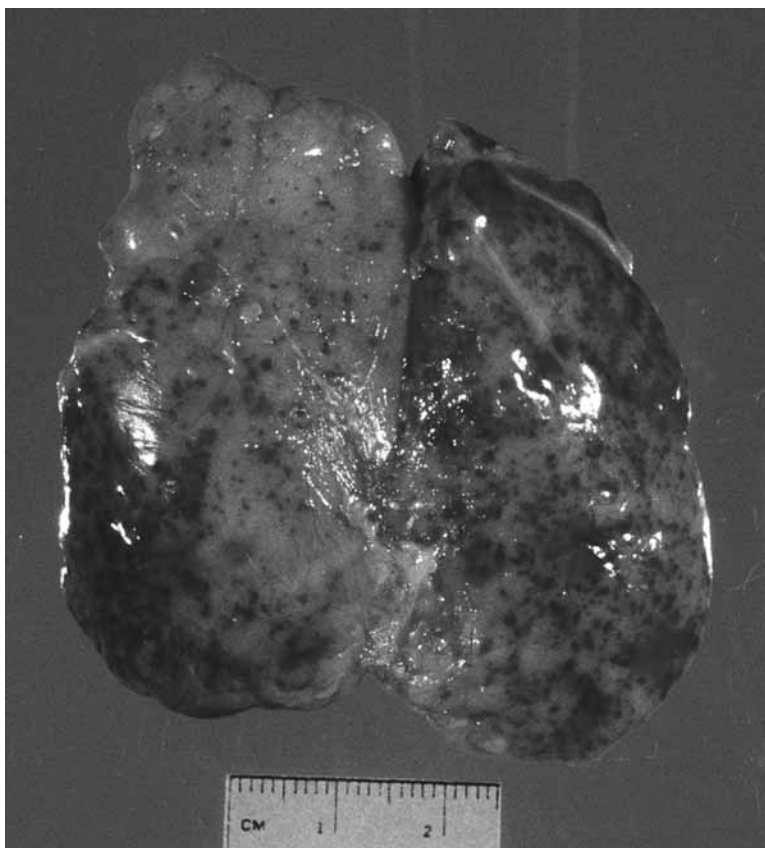
## **1.3. Asphyxial Stigmata**

Certain external and internal postmortem findings have been associated with asphyxia but are nonspecific:

- Cyanosis (purple discoloration of nailbeds and face, including lips and earlobes).
- Fluidity of blood.
- Pulmonary congestion and edema.
- Dilation of right ventricle (*see* Subheading 1.5.).
- Petechiae on serosal surfaces (epicardium, visceral pleura) and certain organs (e.g., thymus; *see* Heading 6 and Fig. 1). Care must be taken in interpretation of apparent petechiae on the pleural surface. Subpleural petechiae may appear or disappear during the course of an autopsy. The latter occurs when the lungs have been removed from the mediastinum. “Pseudopetechiae” can also be misinterpreted. These can be the result of engorged venous channels in the pleura, small areas of thickened pleura, or subpleural collections of carbon pigment (9).

## **1.4. Neck Compression and Petechiae**

A petechia is a pinpoint, nonraised, round purple or red spot (<2 mm or 0.125 in.) that results from capillary rupture (10). Areas of the body lacking relative tissue support are predisposed to petechiae (11). Various nonasphyxial mechanisms can cause petechiae (e.g., widespread cutaneous and visceral petechiae in fulminant infections such as meningococcemia associated with direct capillary damage and consumption coagulopathy [10]).

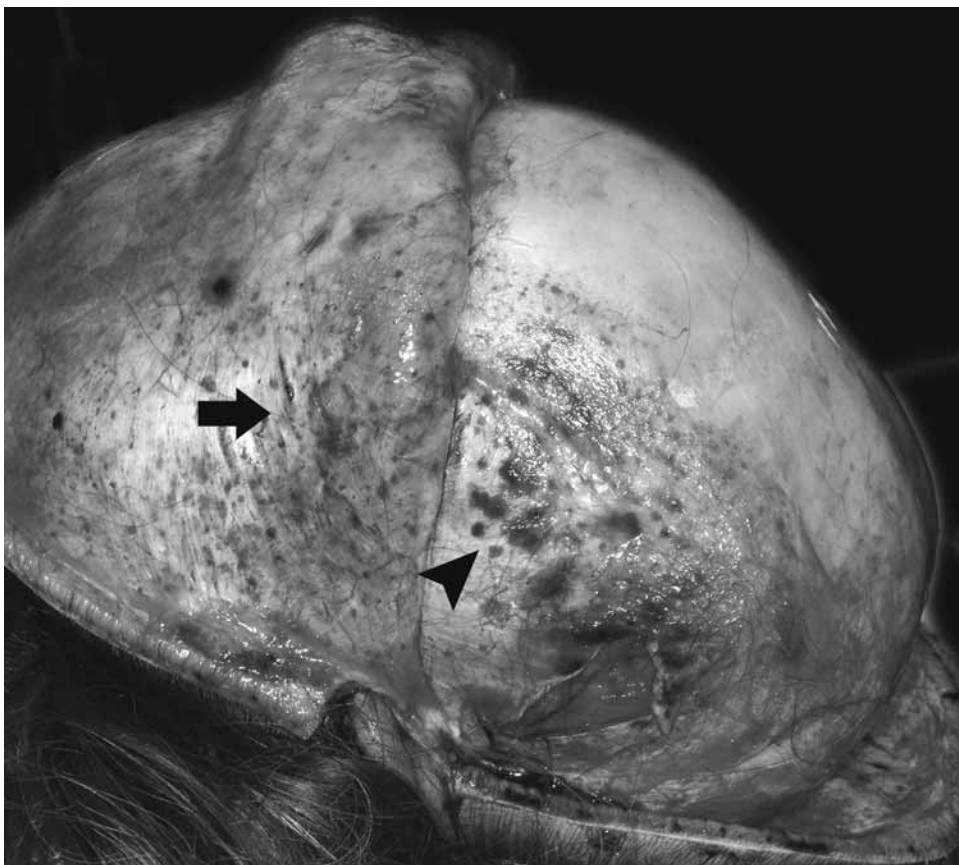


**Fig. 1.** Petechiae of thymus in a case of sudden infant death syndrome. In areas, multiple petechiae have become confluent.

The presence of petechiae has been causally linked with asphyxia. Capillary rupture was thought to be caused by increased intravascular pressure and hypoxia ([12–18](#)). Their distribution in the head and neck arouses suspicion of neck compression; however, petechiae are noted in nonhypoxic individuals and in survivors of strangulation who were not rendered unconscious ([19](#)). Cephalic petechiae are observed in volunteers suspended upside down, resulting in increased intraocular pressure ([20](#)).

Increased cephalic venous pressure alone is the factor responsible for the development of postmortem petechiae in areas of lividity, particularly cephalic petechiae in the head-down position (*see* Chapter 2, Subheading 3.3. and ref. [21](#)). Subgaleal petechiae are considered an artifact of scalp reflection during autopsy; however, in the context of a case, they can indicate increased cephalic venous pressure, either antemortem or postmortem (i.e., face down; *see* [Fig. 2](#) and refs. [1](#), [15](#), [22](#), and [23](#)). In certain types of mechanical asphyxia, cephalic petechiae reflect increased venous pressure with variable arterial blood flow ([10,14,24,25](#)). Cephalic petechiae imply incomplete or intermittent neck compression. Their absence, in the context of neck compression, means complete reduction of arterial and venous blood flow to the head (e.g., “complete” hanging; *see* Subheading 2.1.6.). In rare cases, carotid sinus stimulation by neck compression leads to sudden death from vagal-induced cardiac arrest ([3,5](#)). In this scenario, cephalic petechiae





**Fig. 2.** Reflected anterior scalp exposing calvarium. Scattered petechiae on scalp under-surface (arrow) and temporalis muscle (arrowhead.) Deceased found facedown.

are absent (5,26). Certain types of mechanical asphyxia (e.g., smothering), which do not involve vascular compression, rarely show petechiae, and if observed, they are few.

Conjunctival petechiae do occur in the absence of facial cutaneous petechiae. Although some sources have stated that facial petechiae are not present without ocular petechiae, cases of isolated facial petechiae have been described (e.g., 1-yr-old suspended from crib, overlaying death in child [24,27,28]). Observers have noted that petechiae tend to be less frequent in pediatric asphyxial deaths (17,29).

### ***1.5. Chest Compression and Cephalic Petechiae***

The jugular venous system divides into the more superficial external jugular vein (EJV) and the internal jugular vein (IJV). Not all veins of the head and neck are valveless. The IJV valve is situated 0.5 to 2 cm (up to 0.75 in.) above the union of the subclavian and internal jugular veins (30). The valve normally prevents retrograde blood flow to the brain when there is increased intrathoracic pressure (e.g., coughing [30]). In individuals with a normal central venous pressure (CVP), coughing creates an average transvalvular gradient of 45 to 50 mmHg across a competent valve. Cadaver studies have shown that the IJV valve remains competent up to an average gradient of 75 mmHg.

Unlike the subclavian veins, the IJV is in direct line with regurgitant systolic venous flow from the right side of the heart.

If the competence of the normal IJV valve is exceeded, then increased cephalic pressure leads to capillary rupture and the development of facial and ocular petechiae. This distribution of petechiae can be seen in normal, conscious, nonhypoxic individuals who experience forceful chest wall and abdominal muscle contractions (e.g., labor and delivery, prolonged severe vomiting or coughing [12,21,30]). Glottic closure by a Valsalva maneuver can enhance intrathoracic pressure (12).

The transvalvular gradient is reduced if the IJV valve is damaged. Chronic damage results from long-standing CVP elevation owing to tricuspid valve regurgitation. Acute damage can occur with the insertion of central venous lines.

Cephalic petechiae are observed in natural deaths in which there has been an element of acute right heart failure (i.e., decreased venous flow) but continued left ventricular function (i.e., systemic arterial circulation [12–14]). Complete heart stoppage should not result in petechiae (12). Cardiovascular disease, particularly atherosclerotic heart disease, is the most common disease associated with petechiae, but other conditions (e.g., epilepsy) can also display facial and ocular petechiae. Trauma, other than neck compression (e.g., gunshot wound to head, craniocerebral trauma alone or with other injuries), is associated with cephalic petechiae (13).

Cardiopulmonary resuscitation (CPR) in deaths from disease and injury may play a role in the development of petechiae in the head and neck and appears to enhance the development of conjunctival petechiae (*see* Subheading 2.6.1. and refs. 13 and 14). One report described an extreme case of chest compression and cephalic bleeding. A man developed a subarachnoid hemorrhage following 45 min of CPR (31). In contrast, one study stated that CPR alone did not produce petechiae (30). Few cases of petechiae were seen in individuals dying of lung disease or pulmonary thromboembolism, both conditions associated with right ventricular failure. CPR may enhance petechiae already developing prior to the onset of resuscitation. Studies of intermittent chest compression in resuscitation have shown variable results in terms of IJV valve competence. Mechanical chest compression of 80 to 100 lb at 60 compressions per minute showed an average transvalvular gradient of 19 mmHg and a competent valve even with prolonged times before resuscitation was initiated (30). In contrast, another study, using manual and mechanical CPR at 80 compressions per minute and an estimated force of 70 lb, showed regurgitation during the systolic phase. Many cases of traumatic asphyxia show signs of a marked increase in cephalic venous pressure (*see* Subheadings 3.8.3. and 3.8.4.). Continuous chest compression, usually involving a considerable weight differential, is involved (i.e., >1000 lb or 5–10 times adult weight).

### ***1.6. Intrathoracic Petechiae and Sudden Infant Death Syndrome***

Sudden infant death syndrome (SIDS) was defined by an expert panel convened by the National Institute of Child Health and Human Development as “the sudden death of an infant under one year of age which remains unexplained after a thorough case investigation, including performance of a complete autopsy, examination of the death scene, and review of the clinical history” (*see* Subheading 2.1.5. and ref. 32). Typically, these children are well or have had symptoms of a cold, are put to bed, and are then found dead (33,34). SIDS likely represents a heterogeneous group of disorders (35). Autopsies on these

children show features that overlap with nonspecific signs of asphyxia (*see* Subheading 1.3. and refs. 36–38). Pulmonary congestion and edema result in expulsion of fluid from the nose and mouth (34,37). There is right ventricular dilation (37). Petechiae commonly involve the thymus, visceral pleura, and pericardium (Fig. 1) (32,34,36,37,39). This distribution was thought to arise from changes in intrathoracic pressure caused by forceful respiratory efforts against some type of mechanical occlusion of the airway (*see* Subheading 3.4. and ref. 9). Some cases of SIDS may be caused by smothering, which has similar nonspecific findings (*see* Subheading 3.1. and refs. 34,36, and 37).

### 1.7. Microscopic Indicators of Asphyxia

Attempts to diagnose and discriminate among different types of asphyxia based on microscopic examination of lung tissue have been described. One study showed the following:

- Aspiration—congestion, septal hemorrhage, foreign material (*see* Subheading 3.4.).
- Suffocation—ductal overinsufflation, interstitial edema (*see* Subheading 3.1.).
- Drowning—intra-alveolar edema, dilation of alveolar spaces, with compression of septal capillaries (*see* Chapter 5, Subheading 11.4.).
- Strangulation (including hanging)—alveolar hemorrhagic edema with collapse, interstitial edema, and emphysema or focal emphysema associated with bronchiolar dilation/constriction (40,41).

Pulmonary hemosiderosis has been proposed as an indicator of asphyxia. There did not appear to be a correlation between presence of lung siderophages and deaths classified as “asphyxial” in a study of 206 infant deaths (premature newborns to 49 mo [42]).

Many asphyxial deaths are unwitnessed and often victims are found dead. Some individuals are resuscitated, but develop hypoxic–ischemic encephalopathy and die from secondary pneumonia (7,15).

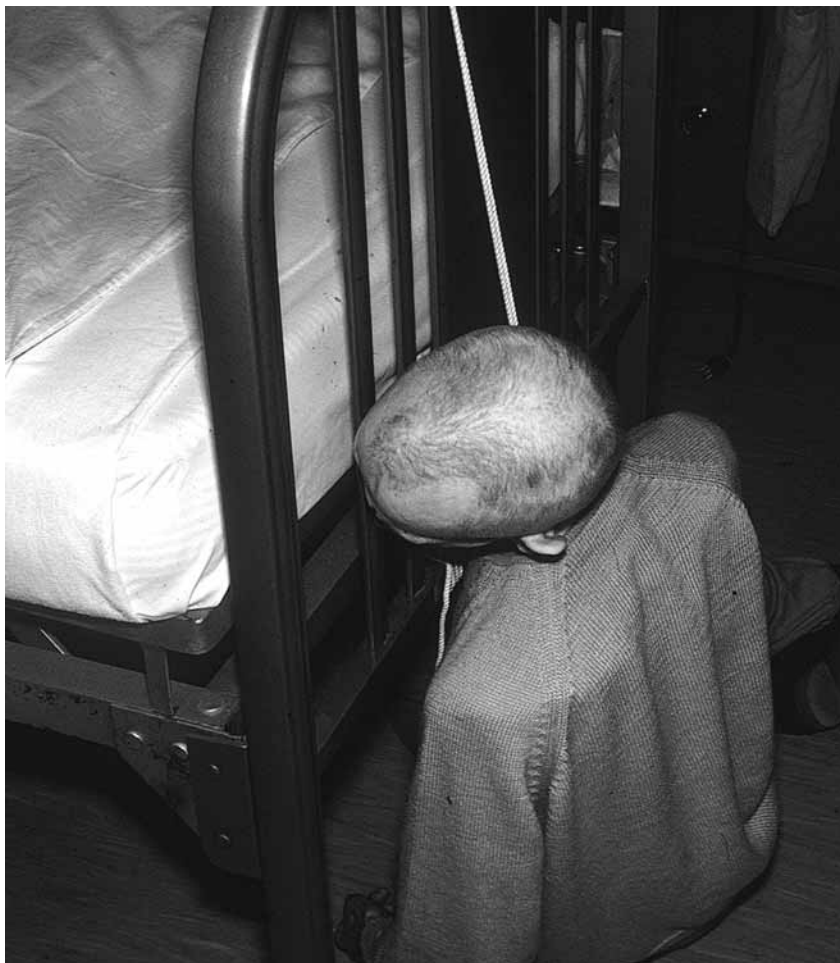## 2. LIGATURE AND SUSPENSION DEATHS

### 2.1. Hanging

Hanging is defined as a constriction of the neck because of force applied as a result of suspension by the weight of at least part of the body (Fig. 3; refs. 3 and 43). The typical hanging death involves tightening of a ligature, but this is not necessary (29,44). Accidental hanging may not involve a ligature (*see* Subheading 2.1.5. and ref. 28). Although hanging is a form of ligature strangulation, the latter implies neck constriction from a ligature not tightened by the body’s weight during suspension. In rare cases, a neck ligature is tightened by a suspended weight applied by a supine individual (45,46). Additional outside force is sometimes applied to tighten the ligature (e.g., motor vehicle, elevator [44,47,48]).

The amount of body weight involved tightening the ligature depends on the position of the body. Khokhlov determined the following (49):

Position	% of Body weight involved stretching ligature
Standing, toes touching floor	98%
Standing, feet flat	>65%
Kneeling, buttocks down	74%
Kneeling, buttocks up	64%



**Fig. 3.** Hanging in sitting position.

Sitting, back inclined down	32%
Sitting, back upright	17.5%
Recumbent, prone	18.3%
Recumbent, supine	9.7%

In studies of hanging deaths in Australia and Northern Ireland, fewer than half of the bodies were completely suspended. About 40% of the Australian victims were standing (16,43). Hanging lying down occurred in 1% of cases. This was also observed in the Northern Ireland series (50). If the point of suspension is high, a means of elevation (e.g., stool, box, or ladder) may be nearby (50).

The following weights have been observed to compress or damage neck structures (8,49):

Jugular vein	2 kg (4.4 lb)
Carotid artery	2.5 to 10 kg (5.5 to 22 lb)
Airway (level of thyrohyoid membrane)	10 kg (22 lb)

Trachea	15 kg (33 lb)
Vertebral artery	8.2 to 30 kg (18 to 66 lb)
Fractures	
Thyroid cartilage lamina	14.3 kg (31.5 lb)
Cricoid cartilage	18.8 kg (41 lb)

Studies of fresh human larynges show that thyroid and cricoid cartilage fractures occur with the application of static forces averaging 15.8 and 20.8 kg (34.8 and 45.8 lb), respectively (51). Dynamic forces (velocities up to 11 mph or 18 km/h) cause fractures at forces averaging 30% more. Imminent structural collapse and severe fatal airway compromise occurred when the force averaged 55 kg (121 lb).

### 2.1.1. Hanging in the General Population

Hanging is a common method of asphyxial suicide in many countries (43,52–56). In various studies, at least 70% were males (24,43,50,57–59). The age range varies from late adolescent to very old (58,59). A history of a previous attempt may be elicited (up to half of deaths in one English study [59]). The same series documented a suicide note in about one-third of cases, consistent with other reviews (43,59). The victim's home is the most frequent site, but hangings also occur in outside locations (5,23,43,50,53,58).

Some suicidal hangings arouse suspicion of homicide (e.g., unusual location, such as a motor vehicle [60]). Conversely, a suicidal hanging can be staged as a homicide (e.g., gag in mouth [61,62]). In these cases, the victim can be motivated by life insurance restrictions, revenge against family and associates, notoriety, and arousal of sympathy and guilt from others. More than one victim can be found at a scene (5,23,63). A hanging can be staged as a suicide to conceal a homicide (e.g., strangulation [64–67]). Unless the victim is an infant or an adult incapacitated by either disease, sleep, an intoxicant, or other life-threatening trauma (e.g., prior strangulation and beating to unconsciousness), homicidal hanging by a single assailant is difficult (8,66,68,69). A single assailant implies a disparity in size between the assailant and victim (7). Homicidal hanging of a normal, conscious adult victim likely involves several assailants (e.g., lynching [66]).

A psychological autopsy to assess suicidal risk factors can assist in determination of the appropriate manner of death (see Chapter 1, Heading 3. and refs. 67 and 70). Scene investigation (e.g., absence of forced entry, no evidence of theft or struggle) is helpful in exclusion of suspicious events leading to the hanging.

Accidental deaths from hanging rarely occur in adults (e.g., suspended by shoulder belt in motor vehicle, suspended in elevator; see refs. 44, 48, and 71 and Fig. 4).

### 2.1.2. Hanging During Incarceration

All manners of death are possible while the victim is in prison (72–78). Inmates of prisons have a higher rate of suicide than the general population (72,74,78–85).

In jail, the risk of suicide is increased because of the transient nature of the population and the fact that jail is a new experience for many of these new inmates (76,78,80). The inmate may be intoxicated when jailed (58,78,80,85,86). Although some studies have shown that jail suicide victims have been incarcerated for nonviolent crimes, others have observed that arrest for crimes against persons (e.g., armed robbery, rape, murder) predominate, and the anticipation of a lengthy prison sentence is a possible





**Fig. 4.** Reclusive woman found slumped on her side suspended from a bent door key (arrow), which was tied to a shoelace worn around the victim's neck. Postmortem toxicology showed ethanol intoxication.

stressor (73,76,80,82,87). This contradiction could be attributed to the type of facility involved (82). Individuals admitted to lockups (police-run short-term detention facilities) are there usually for minor offenses and sometimes are withdrawing from alcohol and drugs (82). Prison inmates typically have been arrested for more serious charges (82). One review revealed that at least 75% of victims had a psychiatric history (87). Most jail suicides occur within 1 to 2 d of incarceration (58,73,78,80,85,87). Self-inflicted sharp force injuries are common, but hanging is more likely to be lethal (83–85). Bed linen is commonly used as a ligature in prisons (83,87).

Long-term prison inmates who commit suicide have a high frequency of psychiatric disorders diagnosed either prior to or during incarceration (72,76,83,88,89). The prospect of lengthy incarceration is a motive for suicide (81,89). In a Texas study, at least half of



imprisoned suicide victims had made a prior suicide attempt, about two-thirds had made at least one attempt during their imprisonment, and about two-thirds had a history of alcohol and substance abuse (88). Other studies have shown a similar high incidence of drug abuse and suicide attempts (76,83). Lack of access to alcohol and drugs may reduce the ability of the inmate to deal with the stresses of prison life (88). The majority (60%) of prisoners in a British study killed themselves within the first 3 mo of incarceration (89). Studies have shown that many hanging suicides tended to happen between midnight and 8:00 AM, when supervision was reduced (80–82,87). Some suicides occur during the day with the expectation by the victim that imminent resuscitation by staff is possible (89). An inmate may stage a hanging to stimulate apparent unconsciousness. Consequent hospitalization can provide a means of escape (78). The majority of victims are male (83,88). Most are younger than 35 yr of age, mirroring the general prison population (76,89). Various means (e.g., overdose, cutting, jumping, strangulation) are used, but hanging is the most frequent (76–78,80,81,85,87–90). In one study, 95% of suicide victims in a maximum security psychiatric institution hanged themselves (79).

Deaths in jails and prisons require careful scene investigation and a thorough autopsy, particularly because of public allegations of homicide against the authorities or criticism of their failure to recognize a potential suicide (74–78,80,90).

### 2.1.3. *Psychiatric Institutions*

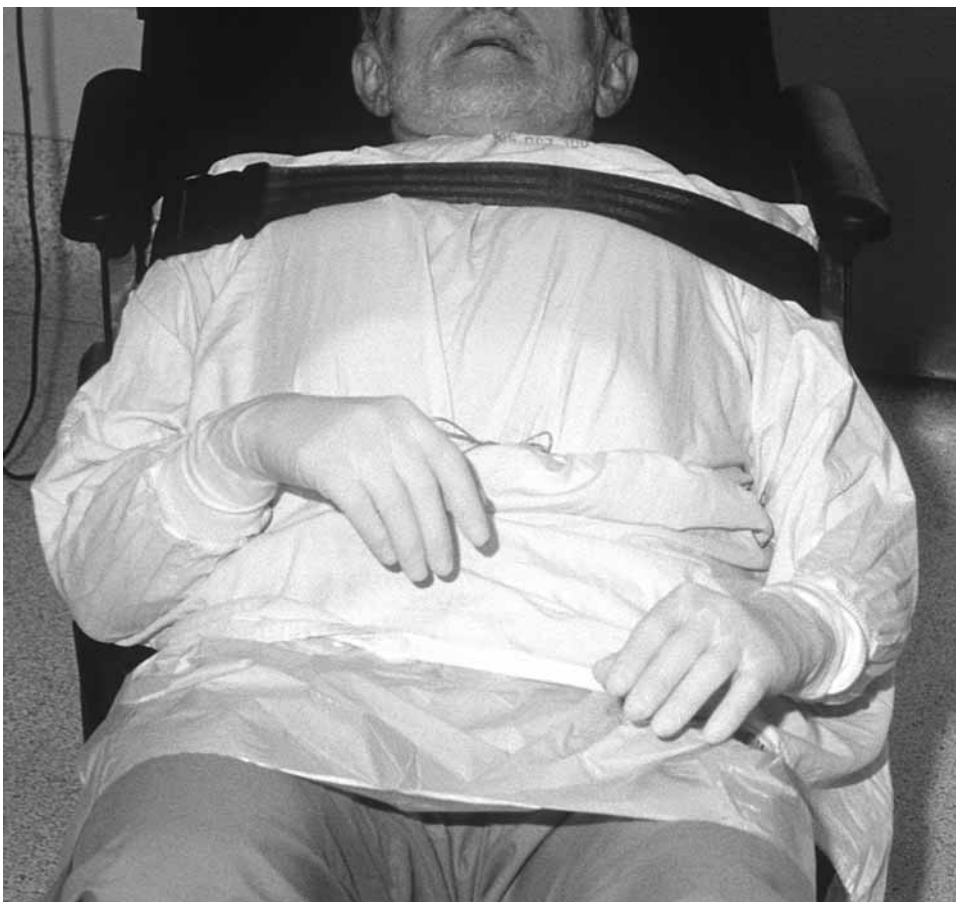Suicide rates in psychiatric institutions, particularly involving schizophrenics, are higher than in the general population (91). Suicides are committed while on approved and unofficial absences from the hospital (91). Violent methods (e.g., jumping in front of a train or off a building, hanging) are the usual means. Suicides are unpredictable in this setting because patients will give little warning, and there may have been apparent clinical improvement (91).

### 2.1.4. *Nursing Homes and Other Chronic Care Facilities*

Residents of nursing homes and other chronic care facilities may be restrained. The following criteria have been proposed for attributing deaths to restraints: no apparent acute illness at the time of death; restraint at the time of death or immediately before; discovery in abnormal restraint position such that the patient would have had great difficulty in self-extrication; and exclusion of postmortem postural changes (92).

Deaths may be unwitnessed (92–95). In a retrospective analysis of physical restraint deaths occurring mostly in nursing homes, victims were found suspended from chairs or beds (92). Detailed analysis of these deaths showed that all were demented, most had impulsive or involuntary movements, and many had recently tried to escape a restraint or been found in an abnormal position while restrained (92). A vest restraint on a seated patient may be improperly positioned initially or subsequently. A bottom strap may be absent. As a result, sliding under the vest occurs with consequent pressure on the neck, leading to asphyxia (Fig. 5; refs. 92,94–96). These patients, because of diminished physical and mental abilities, are unable to extricate themselves (94). A victim's small size is also a contributory factor (92). A wheelchair can flip, entrapping an individual in a vest restraint (see Subheading 3.7. and ref. 97).

Other types of suspension deaths have been described in this setting: neck compression from an electrically raised head of the bed with an improperly positioned



**Fig. 5.** Simulation of sliding under a vest restraint fastened only on the chest. (Courtesy of Dr. J. Walton, Huron Perth Healthcare Alliance, Stratford, Ontario, Canada.)

restraint; slippage between the side bar of a bed and mattress with the neck caught on the side bar; and falling out of bed with the electrical cord of a bedside lamp around the neck (*see* Subheading 3.2. and refs. [48](#),[92](#),[94](#),[98](#), and [99](#)). Chest compression may play a role in victims found hanging from beds (*see* Subheading 3.8. and refs. [92](#),[100](#), and [101](#)).

Resuscitation efforts alter the position of the patient, and eyewitness accounts documented in medical records are important in determining how the individual died ([100](#),[101](#)). The possibility of asphyxiation may be not appreciated, and the physicians certifying the death may not intensively investigate a death in a chronic care facility ([92](#)). Staff may attempt to conceal an unnatural death by scene alteration or by failing to report the incident because of fear of criminal and civil proceedings ([92](#),[96](#),[98](#)).

### *2.1.5. Children and Adolescents*

#### *2.1.5.1. SUICIDES*

Suicide by hanging is rare in children. An Australian study observed that 3.7% of 298 hanging deaths occurred in children 12 yr of age or younger ([28](#)). An 8-yr-old male

victim was documented in an American study (15). Another study noted a 9-yr-old boy (102). A 7-yr-old was observed in a series from Northern Ireland (50). Scottish and Turkish series showed a minimum age of 11 yr and a male predominance (103,104). Various reasons for children committing suicide include anger toward parents, manipulation to gain love, and a desire to join a dead relative (102,105).

Adolescent suicide victims in various American jurisdictions favored the use of firearms, but hanging was the most frequent method in other countries (106–108).

Various studies have noted that psychiatric disorders, including drug and alcohol abuse, history of suicide threats and attempts, antisocial behavior, and disturbed family structure were common (70,106,107). A note was left in up to one-third of cases. Deaths usually occur at home (106). Most deaths are unwitnessed by adults, but other children can be present in some cases (103).

#### 2.1.5.2. ACCIDENTS

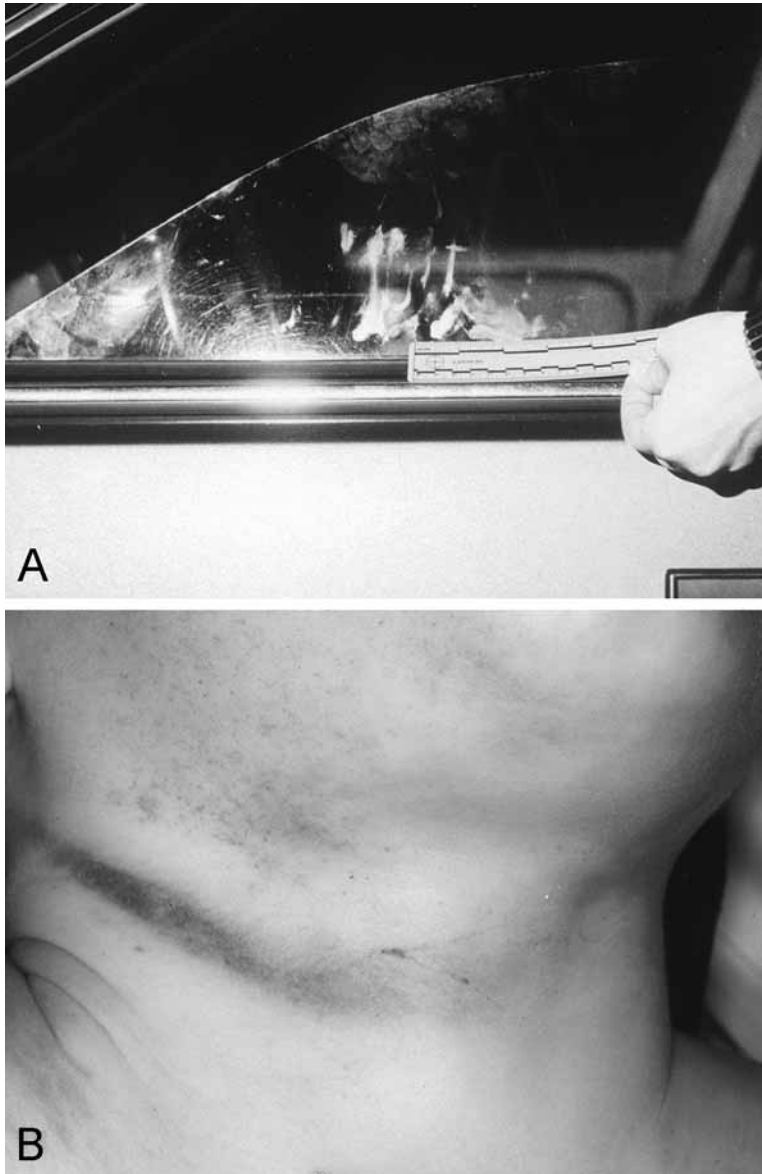
A study from Scotland showed a rate of 0.7 accidental hanging deaths per 100,000 children per year (103). Hanging deaths in children aged 6 yr and younger are usually accidental (15). Hangings involving children between 6 and 12 yr of age can be equivocal in terms of manner of death because, at this age, a child may not have the insight into the nature of death (107).

- Child 1 yr old or younger (unable to stand)
  - Entrapment of head and neck in crib, baby buggy (*see* Subheading 3.2. and refs. 15, 28,50, and 109–112).
  - Entanglement of clothing in crib (4,28).
  - Caught in diaper bag string, elastic strap, pacifier cord, chain (4,43,113–115).
- Child older than 1–3 yr (able to stand [116])
  - Suspension from foot of bed/mattress (29).
  - Suspension from high chair (4).
  - Ligature suspension (e.g., restraining harness or straps in crib or car seat, clothing, pacifier cord, curtain cord, collapsible clothesline, wall light switch strings, looped rope swing [4,15,28,29,48,103,117–121]).
  - Neck compressed by upper edge of car window and body suspended (Fig. 6; refs. 4, 122, and 123).
  - Neck caught between hinged lid and toy box (114).

Crib deaths include SIDS cases (*see* Subheading 1.6. and ref. 4). Scene investigation and interviews of caregivers must exclude the possibility of accidental asphyxia. Inspection of the crib determines whether it is unsafe, defective, or hazardous (4).

- Older children (unsupervised [4])
  - “Play” hanging (e.g., pretending to be a cowboy); “experimental” behavior (4,15,28, 48,50,103,116,124,125).
  - Isolated or repeated acting out for sympathy after punishment or stress (4,125).
  - Jumping or playing on bed and suspended by lanyard key, headband (125,126).
  - Neck caught between window and window sill (4).
  - Suspended from playground equipment (4,48,103,114,127).
  - Physically handicapped child caught in a restraint (*see* Subheading 2.1.4. and ref. 4).
  - Autoerotic asphyxia (*see* Subheading 2.7. and refs. 4,43, and 48).

Because of the lack of adult supervision, all unnatural manners of death must be considered (Fig. 7).



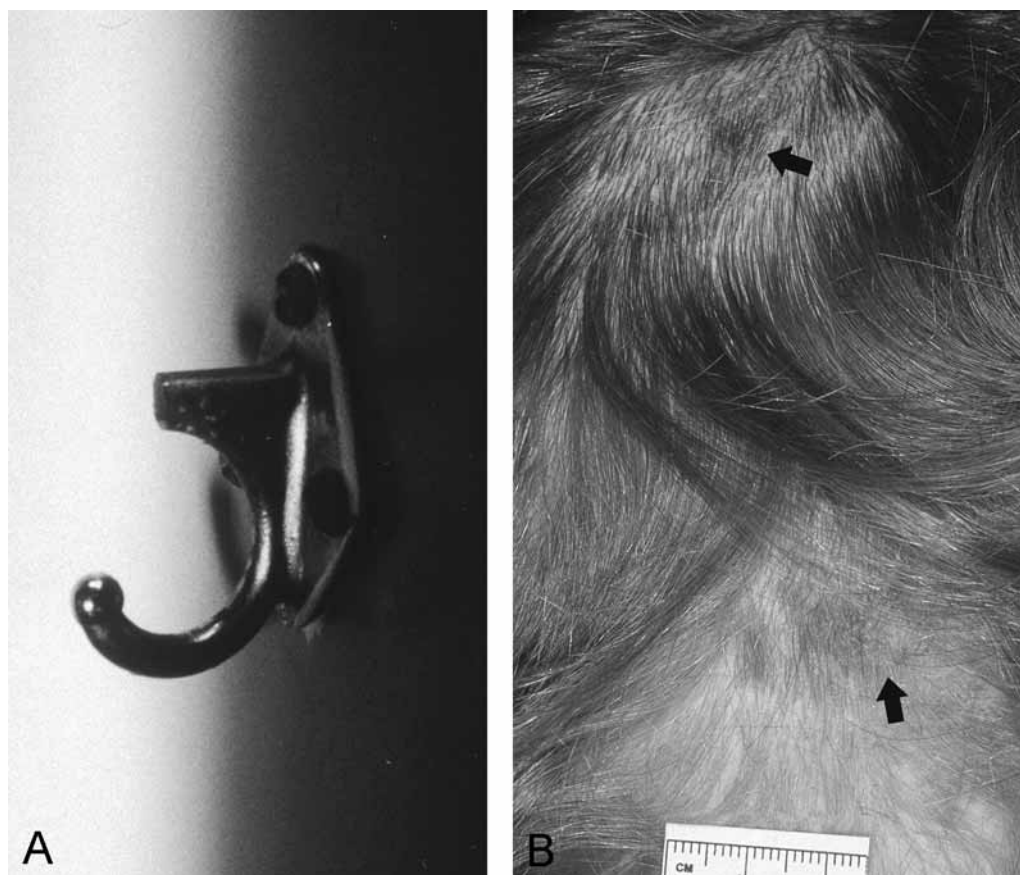
**Fig. 6.** Accidental suspension death. (A) Young girl found suspended on outside of car with her neck wedged between edge of partly open window and A-pillar. Fingerprint smudges on window. (B) Partial neck furrow.

#### 2.1.5.3. *HOMICIDES*

Some examples reported in the literature include:

- 8-yr-old female found hanging in open area (7,28,103).
- 2.5-yr-old male (dyadic death [128]).
- 4-yr-old female suspended from a doorknob (128).

Sexual assault must be considered under these circumstances (7,28,43,103).



**Fig. 7.** Hanging death of undetermined manner. (A) Young boy found suspended, under suspicious circumstances, from a coat hook on the toilet stall door in the washroom at his school. (B). Survival in hospital for several days. Severe hypoxic–ischemic encephalopathy. Abrasions (arrows) on posterior scalp were not from the coat hook but from friction from a cervical collar.

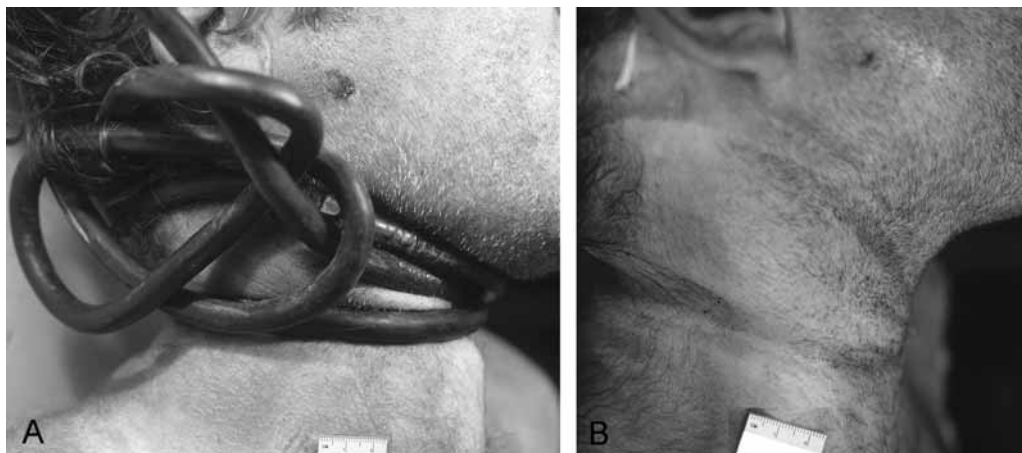
### 2.1.6. External Examination of Hanging Deaths

Dependent livor is observed in the lower arms and legs depending on the duration of suspension (*see* Chapter 2, Fig. 9 and ref. 23).

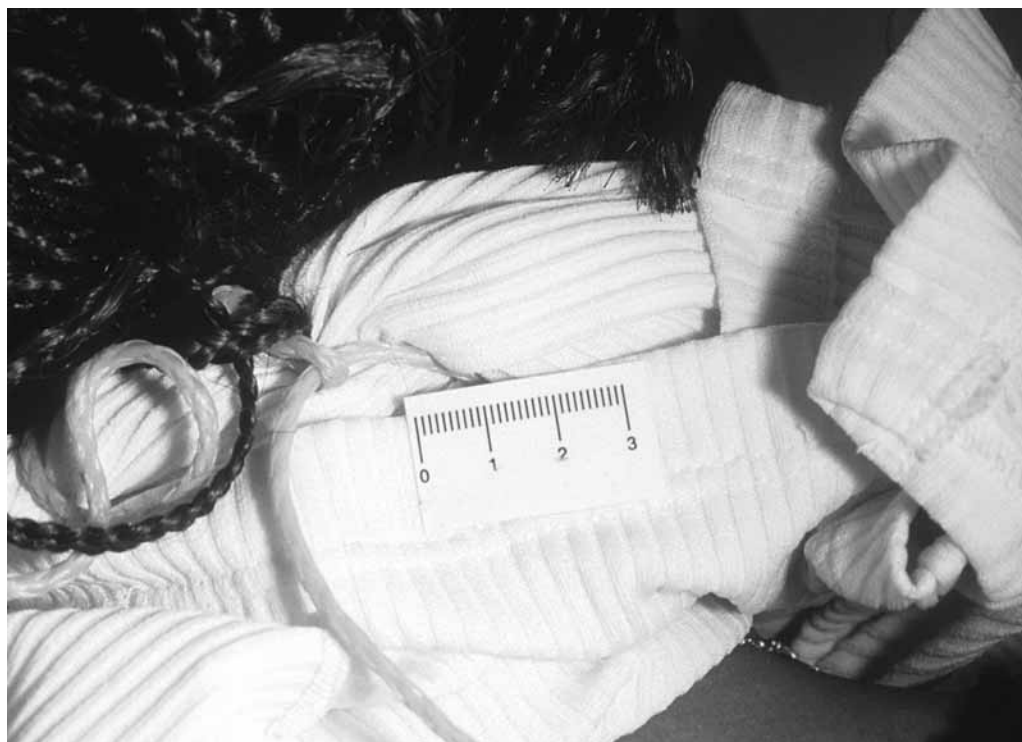#### 2.1.6.1. LIGATURE ON NECK

Ropes, electric cords, and belts are common (23,24,43,50,57,58). The ligature may be altered, i.e., unraveled or cut by next of kin and investigators (16). The ligature can be wound multiple times (Fig. 8; refs. 5, 24, and 62). The ligature can be simply looped around the neck or there can be an elaborate knot (e.g., multiple loops in a hangman's noose [16,46]). An Australian study showed that when a knot was used, it was fixed in 25% of cases and was a slipknot in the rest (16). A series from Northern Ireland showed that 69.5% used a slipknot, 8.6% used a fixed knot, and 10.5% just looped the ligature around the neck (50). Knot analysis can assist in determination of manner of death (1). Hair caught in a knot is suspicious, although hair can be interposed between the noose and skin (65,67).



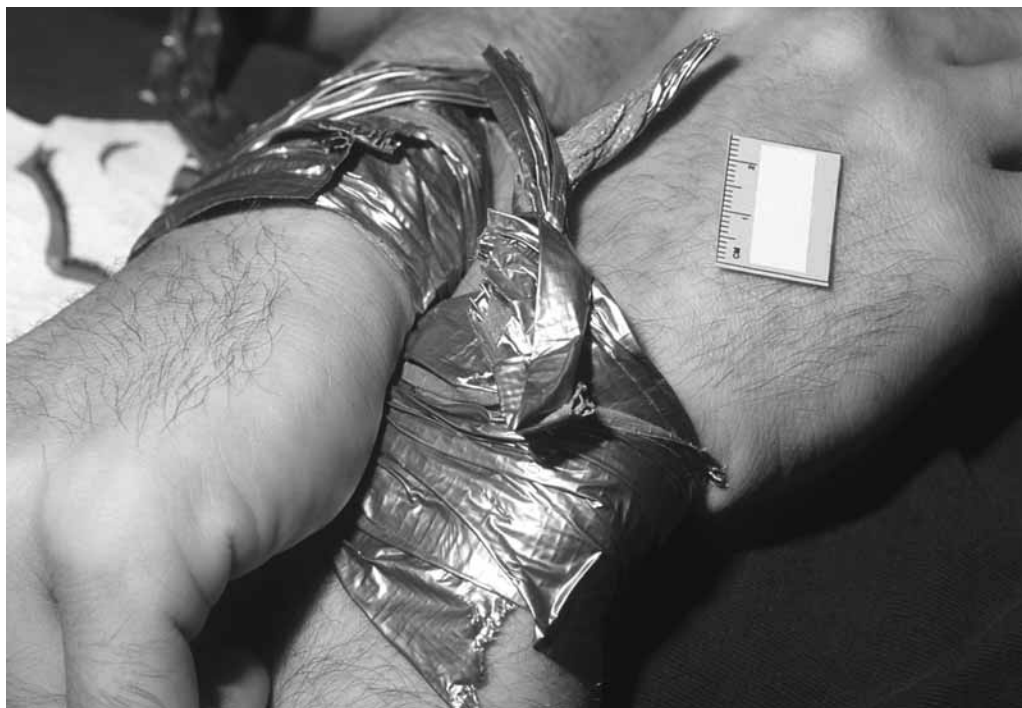

**Fig. 8.** Suicide by hanging. (A) Extension cord wound three times around neck. (B) Resulting furrows on neck.



**Fig. 9.** Suicide by hanging. The female victim placed a sweater between the ligature and her neck.

The neck can be protected by padding in suicides (Fig. 9; see Subheading 2.7.1.3. and refs. 23 and 46). Clothing can be seen under the ligature (62). Tissue (epidermis, fat from ruptured blisters) can be transferred from the compressed site to the ligature or interposed material (129). Usually a single ligature is used, but the original can break on suspension, resulting in a second ligature being employed (128).



**Fig. 10.** Suicide by hanging (ligature—rope). Wrists bound by duct tape.

#### *2.1.6.2. LIGATURES ON OTHER BODY SITES*

Binding of other areas of body is not necessarily indicative of homicide or autoerotic death (*see* Subheading 2.7.1.3. and refs. [5,7,130–132](#)). Extremities can be bound ([Figs. 10 and 11](#)). Wrists can be tied behind the back, and even handcuffs have been used ([131,132](#)). Such bindings are usually loose, have been easily applied or stepped through, and can be easily released ([61,131–133](#)).

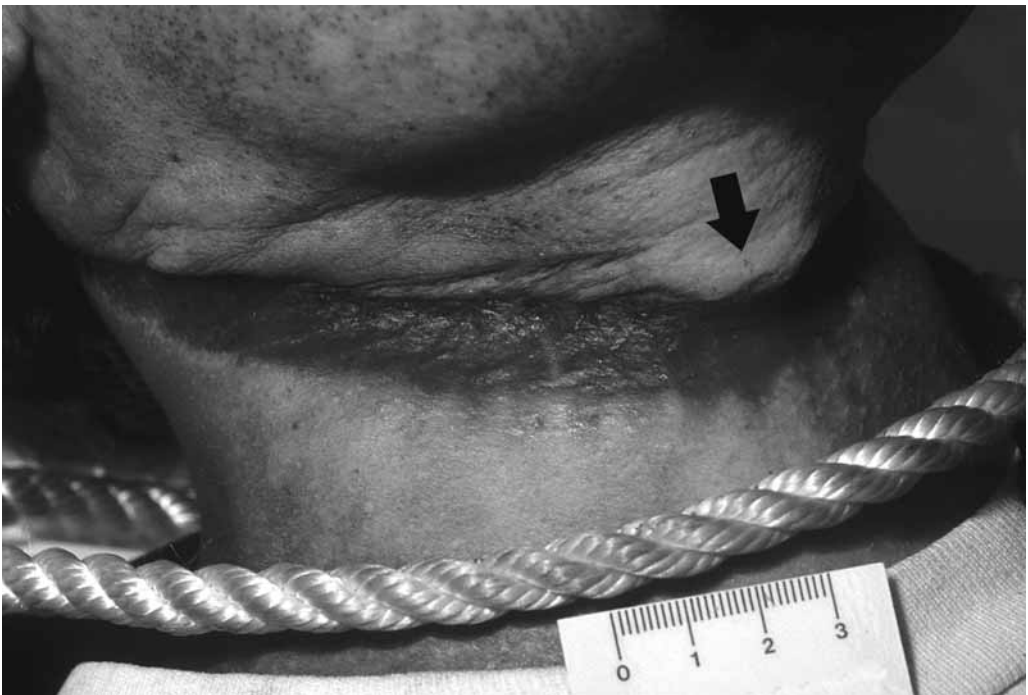#### *2.1.6.3. SIGNS OF COMPRESSION ON NECK AND OTHER BODY SITES*

A neck “furrow,” a result of compression and rubbing, is seen in most cases ([23](#)). A furrow is typically yellow or brown with a parchment-like appearance and can appear soon after suspension (in one case report, 25 min from the time last seen alive; *see* [Fig. 12](#) and refs. [28,29,62](#), and [134](#)). Red or pink neck marks suggest an antemortem hemorrhage, but this may simply be owing to squeezing of blood postmortem ([66,134,135](#)). Abrasions and contusions adjacent to the furrow are suspicious of homicidal ligature strangulation ([6](#)). Postmortem blisters have been observed on skin squeezed adjacent to a furrow ([Fig. 13](#) and ref. [62](#)).

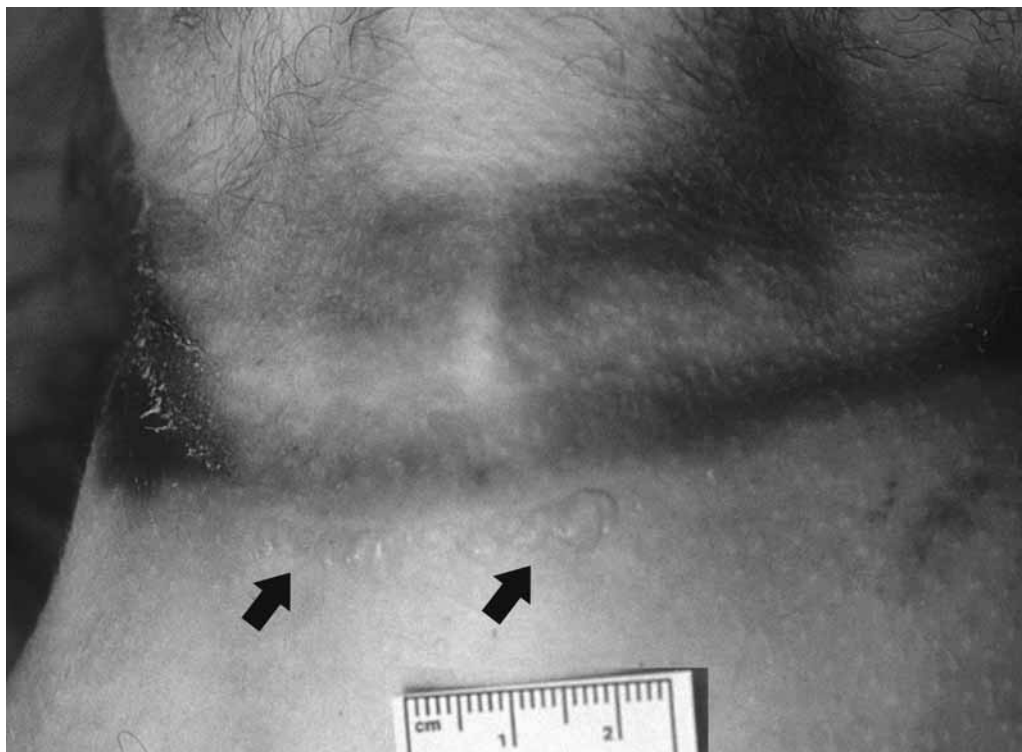
The furrow is typically at or above the thyroid cartilage prominence (notch, Adam’s apple) in contrast to ligature strangulation, in which the furrow is typically on or below the thyroid cartilage (refs. [7, 8, 15, 16](#), and [50](#) and [Fig. 12](#)). Some cases of suicidal hanging, however, do show the furrow at the level of the thyroid cartilage ([134](#)). Furrow location may be dependent on the type of ligature. One study showed that furrows, in cases of complete suspension with a hard plastic clothesline, were above the thyroid cartilage, but deaths involving cotton cloth and incomplete suspension were



**Fig. 11.** Suicidal hanging (ligature—electrical cord). Another electrical cord was used to bind the knees (see Chapter 2, [Fig. 16](#)).



**Fig. 12.** Suicide by hanging. Typical neck furrow passing over prominence of thyroid cartilage (arrow).

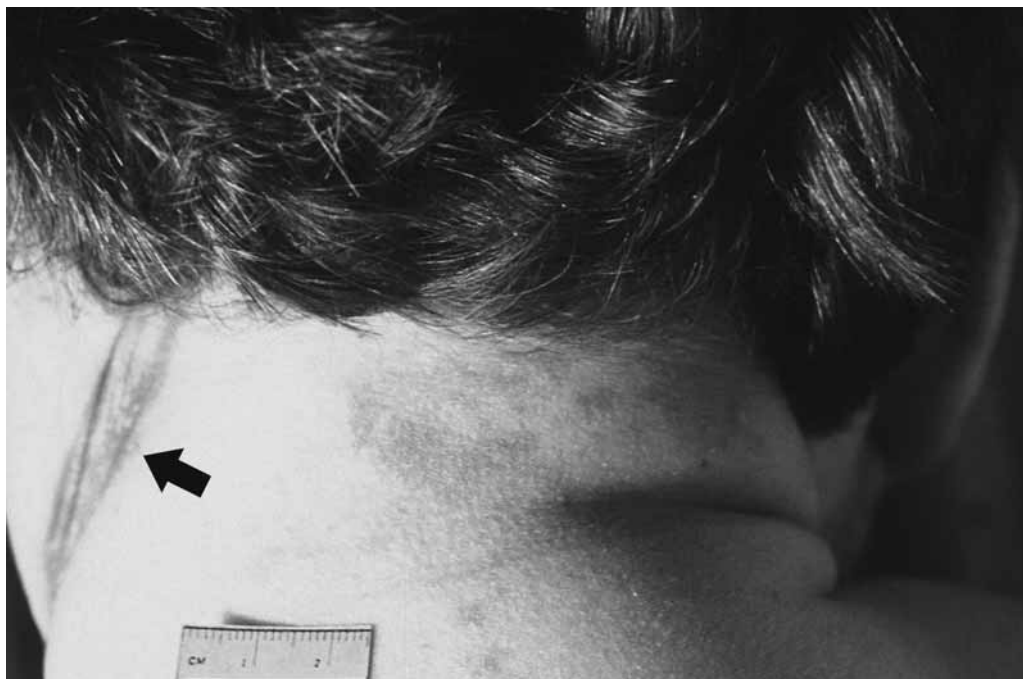

**Fig. 13.** Suicide by hanging. Note blisters (arrows) below inferior neck furrow.

below it (5). In some young children suspended from cribs by clothing, a furrow has been observed at the level of cricoid cartilage (29). An abraded area below a furrow may indicate upward slippage of the ligature, more likely seen when suspension is complete (7,16,24). The furrow is typically angled or canted up to the point of suspension, i.e., the knot (Fig. 14; ref. 28). The point of suspension is usually at the side of the neck, but suspension does occur from the front, which results in a horizontal furrow on the back of the neck (Fig. 15; refs. 5 and 24). A ligature may encircle the neck completely and then looped anteriorly or posteriorly, resulting in a horizontal furrow (Fig. 16). A horizontal furrow arouses suspicions of homicidal strangulation (Fig. 17; ref. 136). Decapitated individuals who jump from heights can have a horizontal furrow, if a tough nonslip ligature was used (137). This has also been described in victims who become horizontal relative to the suspension point (e.g., kneeling forward [50,138]).

The pattern of the ligature can be reproduced in the furrow (Fig. 18) (15,29,128). Its width approximates that of the ligature (28). Ligature fibers can be transferred to the skin of the furrow and be taped from the surface (62). A ligature that is obliquely situated on the neck exerts consistent pressure in the antero- and posterolateral areas (139). The furrow and other compression marks may be incomplete, faint, or absent (28). A furrow is absent if a person is promptly “cut down,” has material interposed between the ligature and skin, survives for a period of time allowing healing to occur, uses soft material, or employs a broad ligature (Fig. 19; refs. 3,5,6,16,23, and 78). Signs of compression are lacking if death is by vagal stimulation





**Fig. 14.** Suicide by hanging. Suspension point posterior. Furrow angled or canted up (arrow) behind the left ear.

(5,90,140). Pressure marks, initially present, may disappear in several hours following ligature removal (134). If there is neck lividity, pallor is localized to areas of compression (93). Care must be taken not to mistake neck creases and resuscitation efforts for furrows (Fig. 20).

Signs of compression can be seen on other areas of the body (e.g., axilla from vest restraints, bound extremities; see Subheading 2.1.4. and ref. 96).

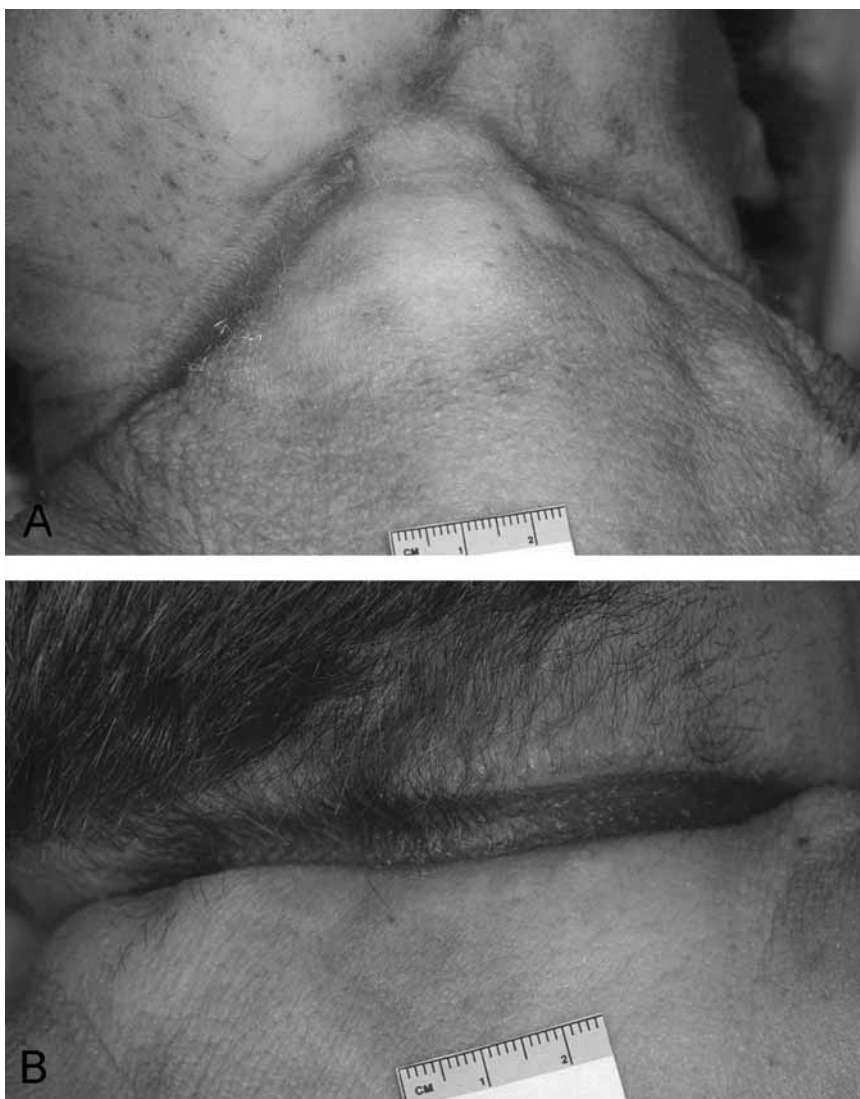
#### 2.1.6.4. FACE

Cyanosis of the face and neck is caused by venous congestion and incomplete carotid artery occlusion (e.g., use of a fixed knot, partial suspension; see refs. 5, 7, 23, 50, and 78). In contrast, facial pallor is noted when there is total arterial blockage (e.g., full suspension; see Fig. 21 and refs. 23, 50, and 78). This is more frequent (50). There can be congestion and edema of the conjunctivae (7). Dried blood-stained mucus may come from nostrils, corner of mouth, and ears (7,78). The tongue can protrude (Fig. 21; refs. 23 and 128).

#### 2.1.6.5. PETECHIAE

Distribution of petechiae is typically on the eyes and on the skin of the face and neck above the ligature site (Fig. 22; ref. 29). Eyelid petechiae were seen in 27% and conjunctival/scleral petechiae in 33% of hangings in one study (16). Both sites were involved in 18%. Petechiae are an indication that a victim was alive when suspension occurred (129). Their presence varies in partial and full suspension of adults and children (5,7,15,24,28,29,61,123,128,141). The evolution of petechiae depends on a number of factors, such as the tightness and the duration of initial application of the ligature before





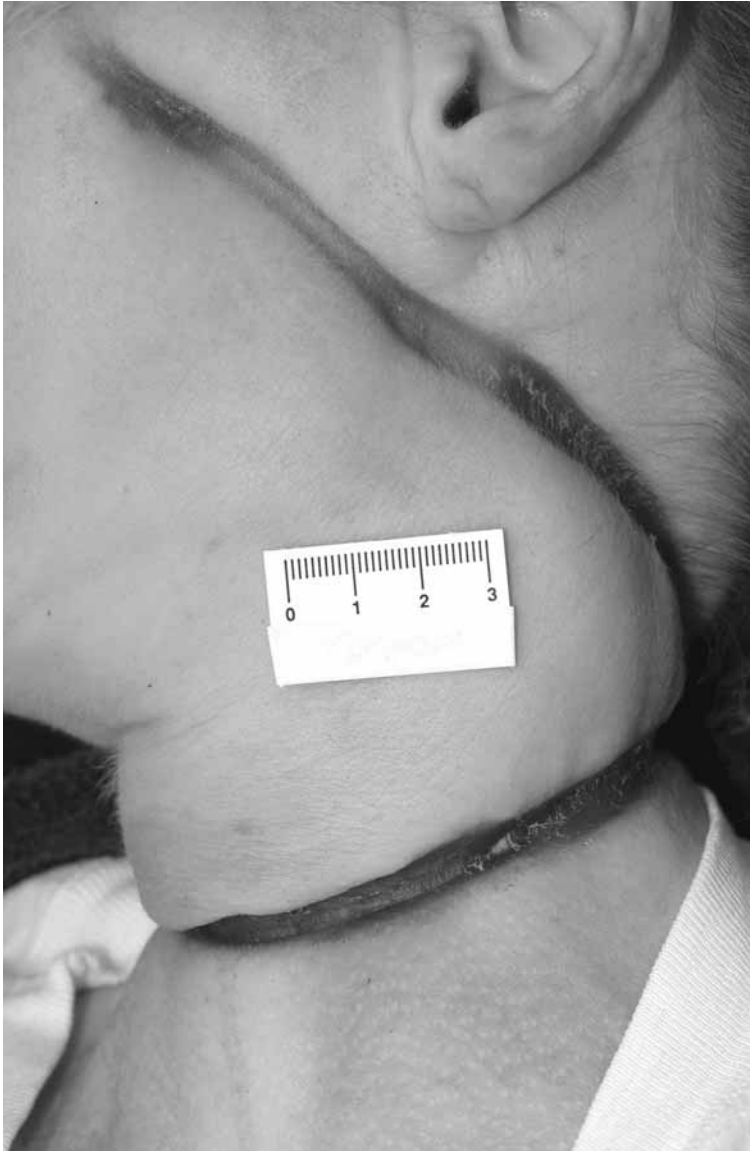**Fig. 15.** Suicidal hanging. (A) Suspension point (knot) above larynx. Anterior furrow angled. (B) Horizontal furrow, posterior neck.

pressure due to the full body weight is exerted and the absence of a slipknot in cases of partial suspension (24). For those completely suspended, angling of the head and neck away from the knot may result in only partial reduction of arterial blood flow (24). Petechiae have been described in sitting individuals asphyxiated by a vest restraint (96).

#### 2.1.6.6. OTHER SIGNS OF TRAUMA

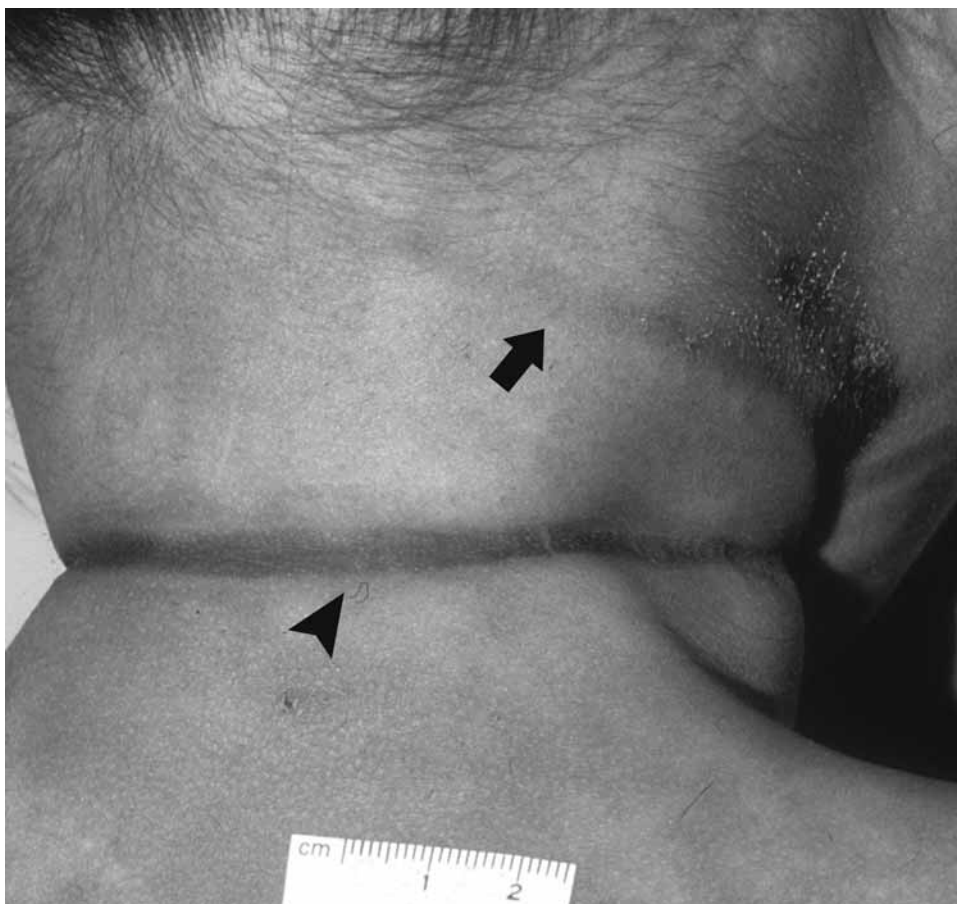
The hands may be near the ligature, but injuries indicating attempted relief of the applied pressure are usually not seen, underscoring the rapid loss of consciousness (Figs. 23 and 24; ref. 57). Fingernail abrasions on the neck are possible (3).

Trauma unrelated to the fatal event may have preceded the suicide and arouses suspicion (16). There may be coexistent acute, healing, or old nonfatal self-inflicted



**Fig. 16.** Ligature looped around neck, crossed posteriorly and extended across cheeks resulting in horizontal neck furrow. (Courtesy of Dr. E. Rowe, St. Thomas-Elgin General Hospital, St. Thomas, Ontario, Canada.)

injuries (e.g., “hesitation” incised wounds; *see* refs. [16](#), [50](#), [61](#), [66](#), and [68](#)). Some injuries are more worrisome (e.g., superficial stab wounds; *see* ref. [128](#)). Self-mutilation (e.g., excision of male genitalia) can be observed in psychotics and transsexuals ([7](#)). Bruises can occur in the axillae and lower legs when a living victim is lifted onto a stretcher ([78](#)). A gag may have been inserted in the mouth ([132](#)). Postmortem trauma results from careless handling of the deceased (e.g., victim cut down striking a hard surface), resuscitation, and animal predation ([Fig. 25](#); refs. [66](#), [68](#), [78](#), and [90](#)).

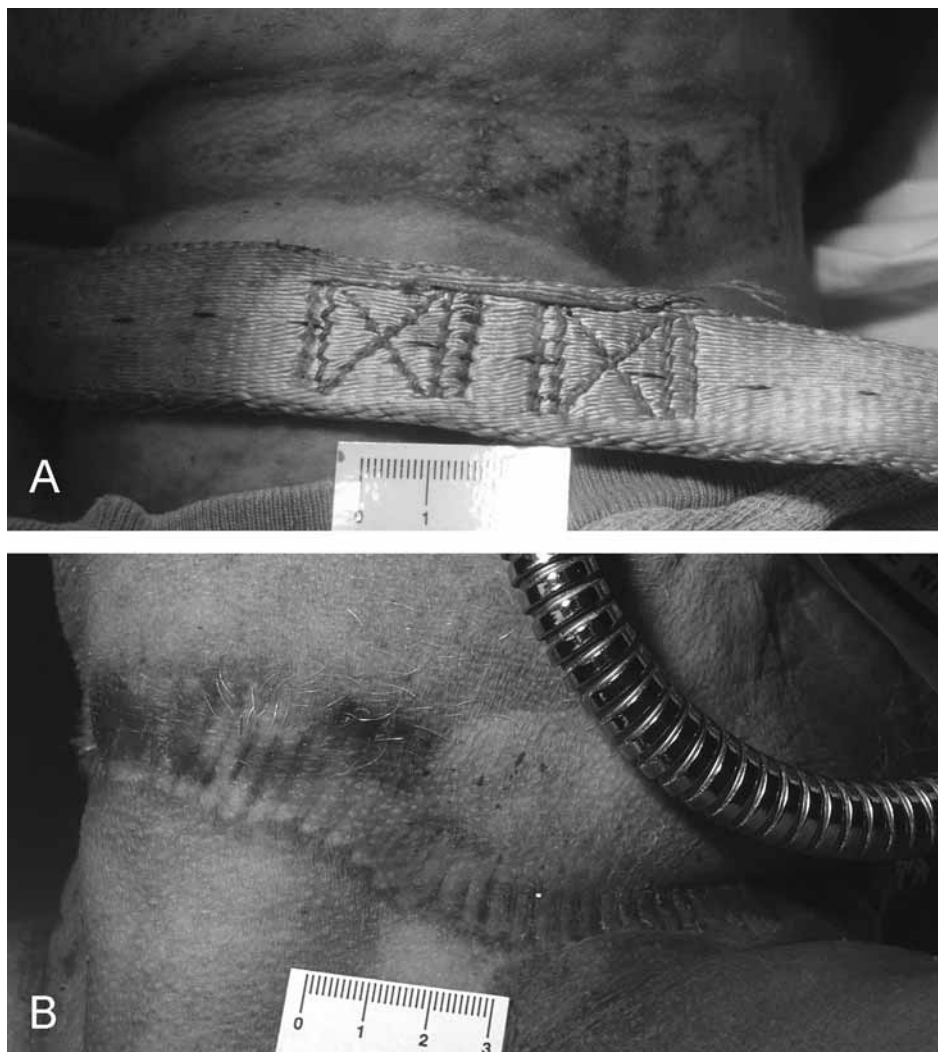


**Fig. 17.** Young girl. Homicidal ligature strangulation masquerading as suicidal hanging. Note two furrows on posterior neck (arrow)—faint hanging furrow canted up; arrow-head—horizontal furrow from strangulation. (Courtesy of the Office of the Chief Medical Examiner, Chapel Hill, NC.)

Injuries occur during hanging (e.g., thrashing; *see* refs. [50](#), [66](#), and [68](#)). In homicidal hangings, other trauma (e.g., facial and scalp bruises) is absent if the victim has been incapacitated ([66,68](#)). Signs of external blunt trauma, strangulation, or sharp force injury may be seen in homicides disguised as suicides ([6,7,28,68](#)).

### *2.1.7. Internal Examination of Hanging Deaths*

Internal injuries are absent in many hangings, even with complete suspension, which underscores that hanging is a “gentle” form of asphyxia, particularly when self-inflicted ([4,7,15,16,23,24,28,50,93,128](#)). Consciousness is lost rapidly, with little time for purposeful activity ([125](#)). Vagal stimulation leading to sudden cardiac arrest could also be a factor ([90](#)). Internal neck injuries were seen in about 60% of hanging deaths in one series ([16](#)). There was a higher frequency of trauma in complete compared with incomplete suspensions (62 to 46%).

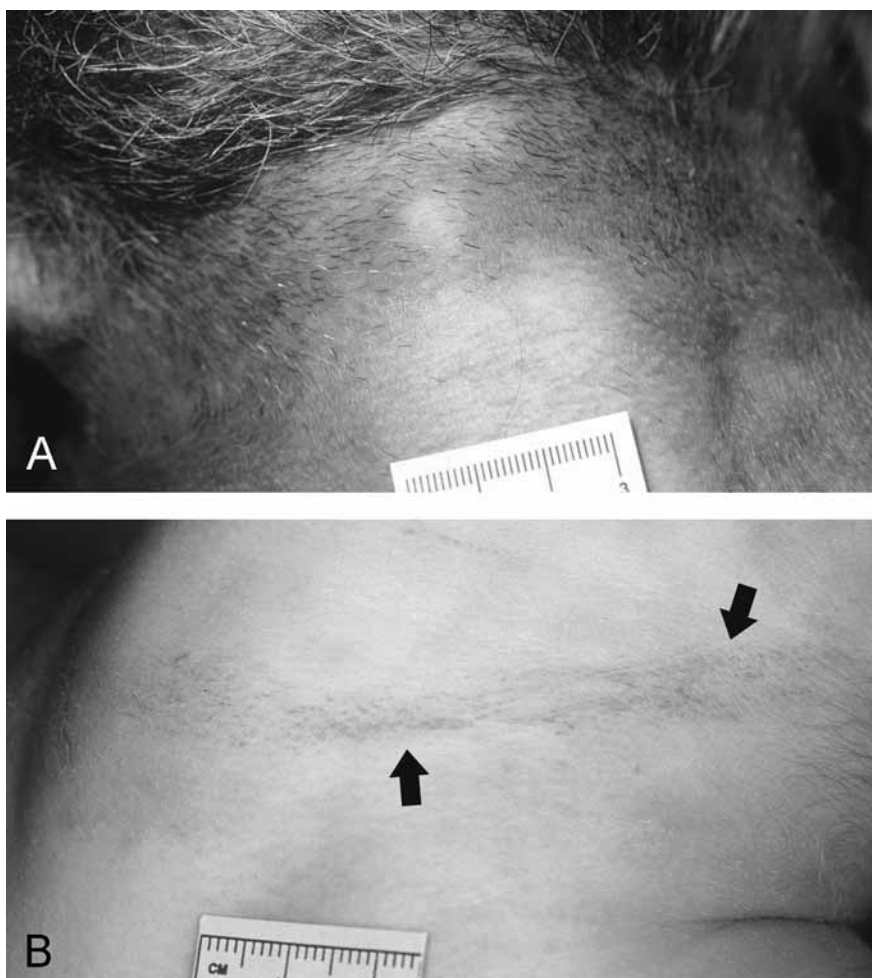


**Fig. 18.** Suicides by hanging. Examples (A,B) of patterned furrows.

#### 2.1.7.1. *SOFT-TISSUE HEMORRHAGE*

Soft-tissue or muscle hemorrhages are seen in a minority of cases. In various series, the range is from about 3% to about one-third (16,23,24,50,57). Soft-tissue hemorrhages in the neck indicate that the individual was alive when the injuries were inflicted (17,18,129). Hemorrhage adjacent to fracture sites supports the supposition that they occurred antemortem. Hemolysis from decomposition decreases visible hemorrhage (142). Alternatively, the postmortem origin of a hemorrhagic focus cannot be entirely excluded, especially when there is decomposition (*see* Chapter 2, Subheading 3.3. and ref. 142). No correlation between the presence of soft-tissue hemorrhages and hyoid/larynx fractures has been noted (24). The amount of hemorrhage is usually insufficient to cause death (*see* Subheading 2.1.7.2.). In certain situations (e.g., following extraction of teeth), extensive hemorrhage in the neck musculature has caused asphyxia (143).





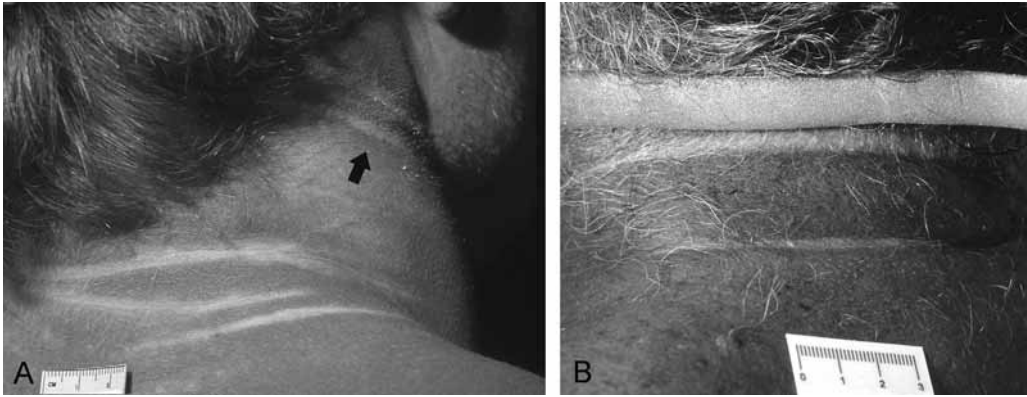
**Fig. 19.** Suicides by hanging. (A) Hanging furrow absent. Suspension less than 20 min. (B) Furrow fading (arrows). Survival several days.

#### 2.1.7.2. SITES OF HEMORRHAGE

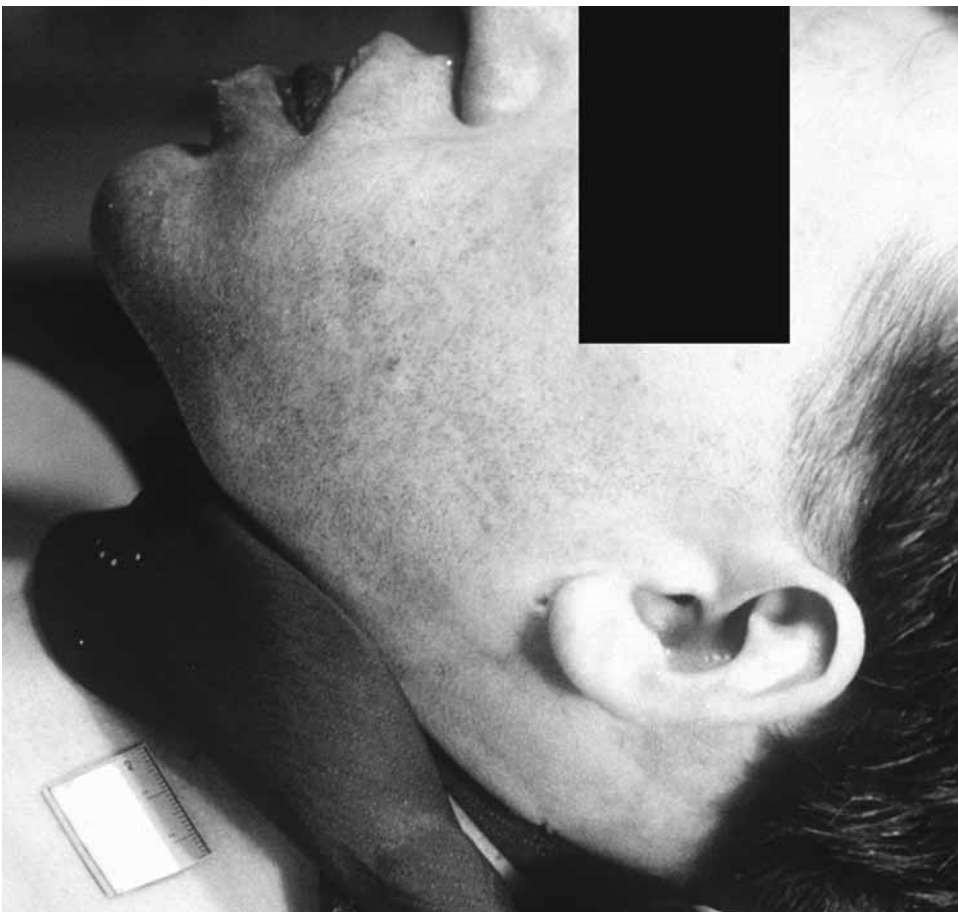Sites of hemorrhage may include the following:

- Sternocleidomastoid muscles underlying compression site (Fig. 26; ref. 28).
- Strap muscles (15).
  - Extensive hemorrhage combined with glottic edema and bleeding can interfere with breathing (144).
- Thyroid membrane.
- Connective and muscle tissue adjacent to thyroid cartilage (Fig. 26; ref. 15).
- Soft tissue adjacent to intact hyoid bone and thyroid cartilage (superior horns [28]).
- Soft tissue adjacent to fracture sites (hemorrhage is absent if site artifactually fractured after death or neck compression totally compromised circulation; see Fig. 26 and ref. 145).
- Periosteum, with or without muscle involvement, at inferior insertion of sternocleidomastoid muscle as a result of neck hyperextension (tendency for hemorrhage to be seen on side of highest ligature mark [107,129,146]).

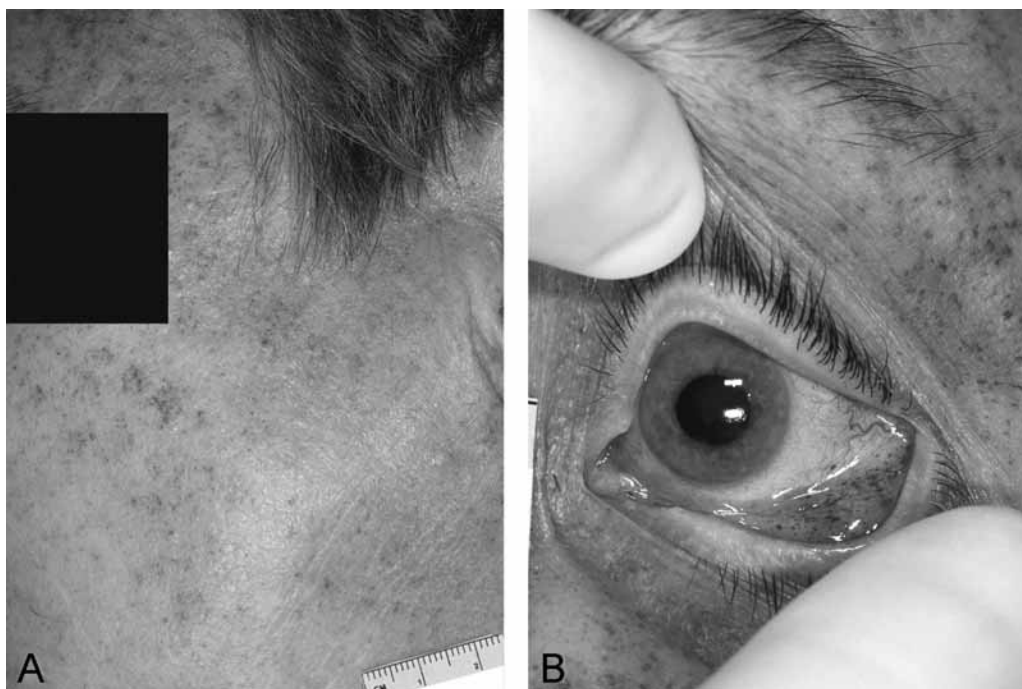



**Fig. 20.** Hanging. (A) Pale furrow (arrow) created by pressure of ligature in area of lividity. Three pale neck creases inferiorly. (B) Pale "furrow" in area of lividity created by soft tie fastened to an endotracheal tube. More inferior linear horizontal pale area is a neck crease.



**Fig. 21.** Hanging. Facial pallor; protruding tongue darkened by drying.



**Fig. 22.** Hanging. (A) Cutaneous petechiae above furrow. (B) Conjunctival and periorbital petechiae.

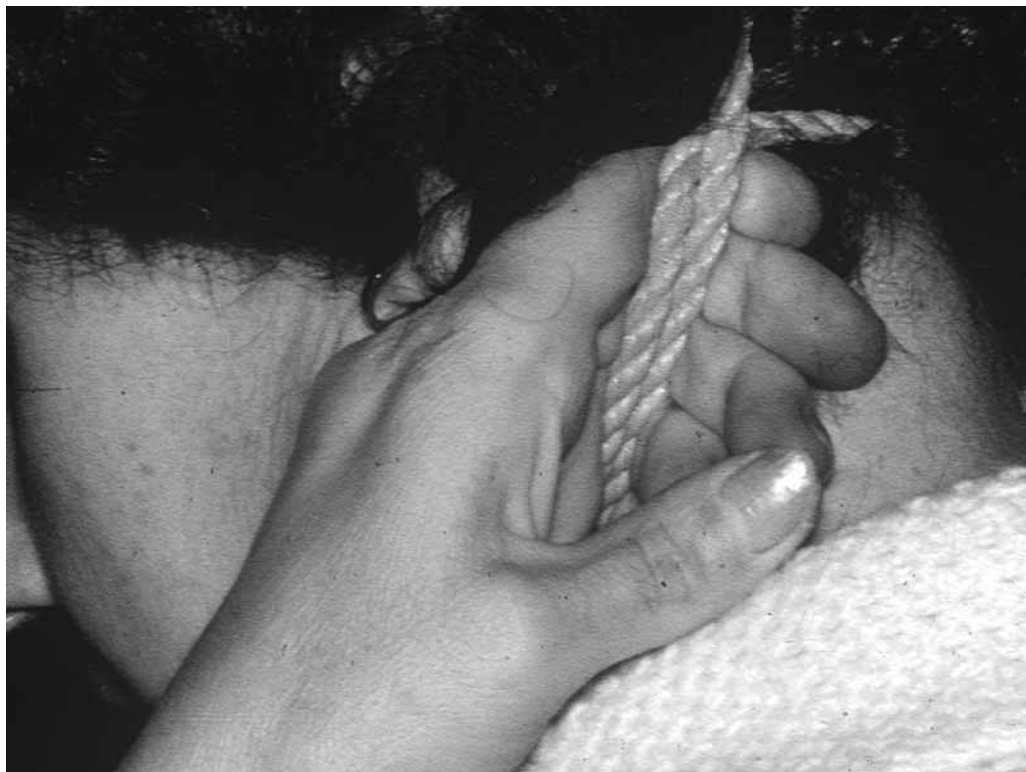- Hemorrhage may not be seen grossly but can be observed with microscopic sections (see Subheading 2.4 and ref. [142](#)).
- Hemorrhage in the posterior cricoarytenoid muscles is a nonspecific finding from various causes ([146–148](#)).

#### 2.1.7.3. PETECHIAE

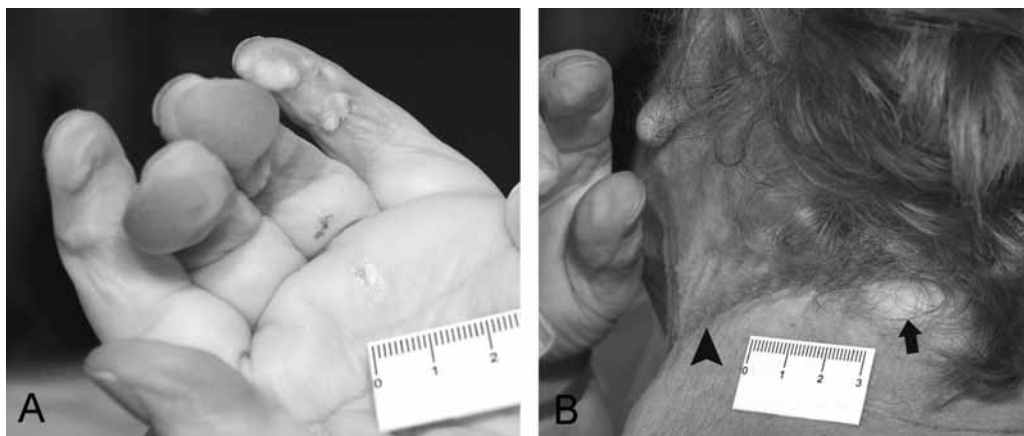
Petechiae have been described on the buccal mucosa, base of tongue, and epiglottis ([15,28](#)). One series noted that epicardial petechiae were seen in 19% of hangings and visceral pleural petechiae in 6% ([16](#)). Both sites were involved in 4%. Internal petechiae were observed in 10% of cases when hanging was complete, 19% when incomplete.

#### 2.1.7.4. FRACTURES

The incidence of anterior neck fractures in hangings increases with age although they do occur at a young age and are absent in older individuals (e.g., 14-yr-old boy with fracture of superior horn of larynx; no fractures in 78-yr-old despite considerable ossification of thyroid cartilage [[24,134,145,152–154](#)]). The frequency of fractures depends on the diligence and dissection method used ([57,134,145,149,154–156](#)). Radiological assessment increases the yield ([145,153,157](#)). Stereomicroscopic examination has documented hyoid and larynx injuries in almost three-fourths of suicidal hangings, a higher yield than those obtained by using the conventional methods of palpation, radiograph imaging, and dissection ([156](#)).

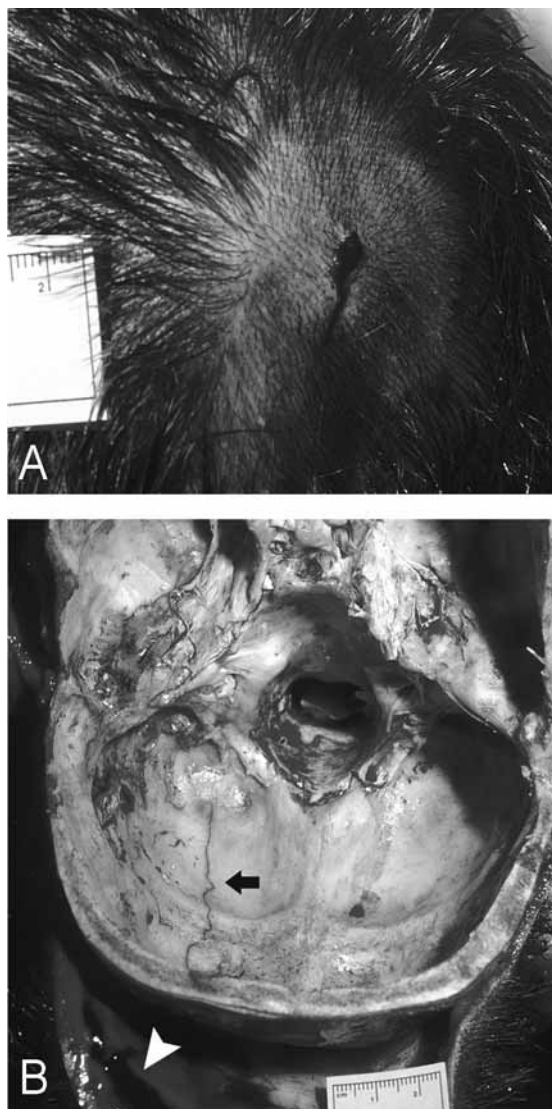


**Fig. 23.** Hand positioned on ligature used in hanging suicide.



**Fig. 24.** Hanging. (A) Swollen and blistered fingertips because of hand placement under constricting ligature. (B) Fingertip impression (arrow) in area of livor mortis and adjacent to furrow (arrowhead).

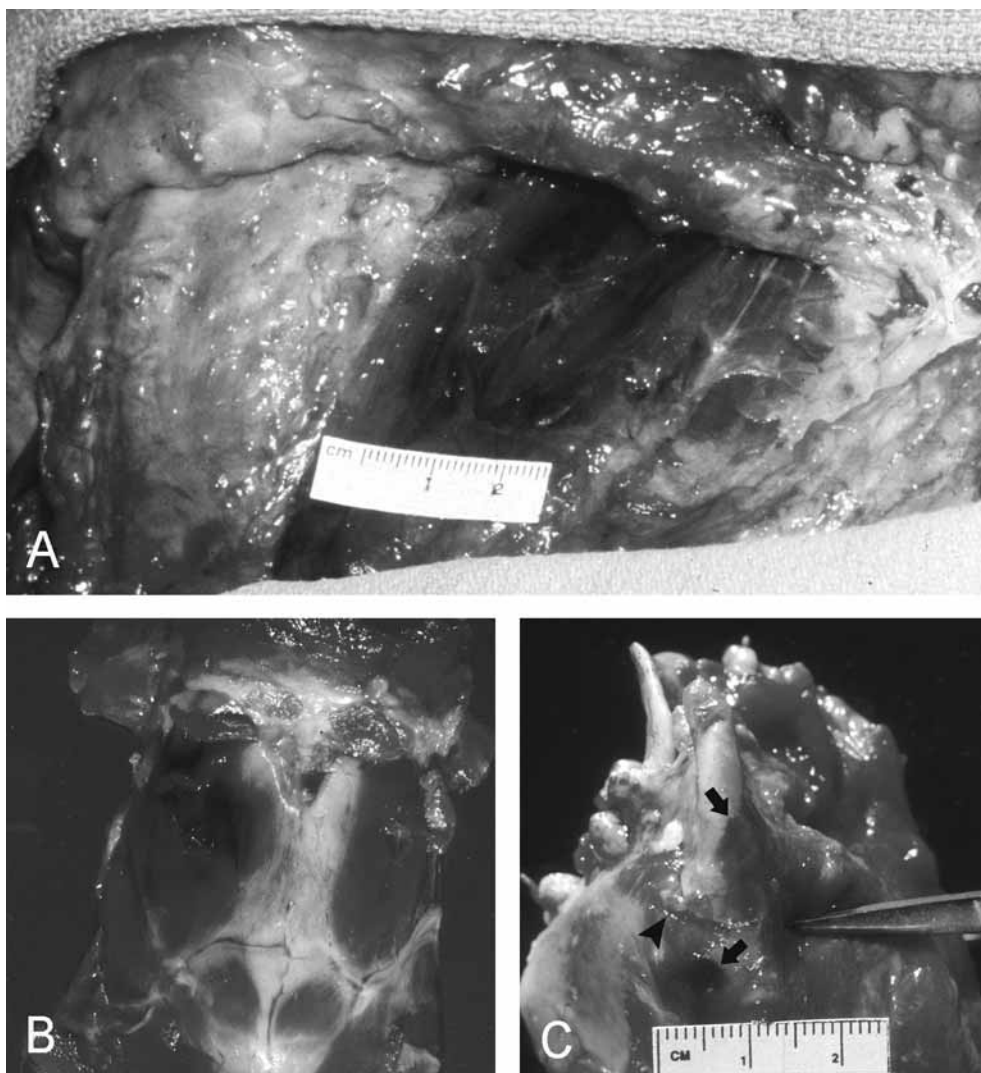
The most common fracture in suicidal hanging involves the superior horn of the larynx (see [Table 1](#); [Fig. 26](#); and ref. [16](#)). Fractures of the laryngeal lamina are uncommon and are associated with either complete suspension or a long drop ([16](#)). Generally, a higher incidence of fractures of the hyoid/larynx is noted in manual and ligature



**Fig. 25.** Deceased hanging victim cut down at scene; head struck concrete floor. (A) Scalp laceration, left occiput exposed by shaving hair. (B) Left occipital bruise (arrow-head) on undersurface of scalp. Removal of dura from base of skull revealed linear fracture (arrow).

strangulation (109). In a review by Betz and Eisenmenger of 109 accidental and suicidal hangings, 37% had two superior horns fractured; 15% had both superior horns and a hyoid cornu (greater horn) broken; 10% had both superior horns and hyoid cornu fractured (including a 28-yr-old [155]). In another series, hyoid fractures were typically associated with thyroid cartilage fractures (16). The pattern of external neck injuries, damage to the hyoid–larynx complex, and associated hemorrhages raises the possibility of homicidal neck compression (68,155,158). Ubelaker’s review of the literature determined the following fracture frequencies in homicidal ligature and manual strangulation:





**Fig. 26.** Soft-tissue hemorrhages in suicidal hanging. (A) Hemorrhage in left sternocleidomastoid muscle. (Courtesy of the Office of the Chief Medical Examiner, Chapel Hill, NC.) (B) Larynx, anterior view. Hemorrhage in muscle adjacent to right thyroid cartilage. (C) Fractured left superior horn of larynx (arrowhead). Foci of hemorrhage (arrows).

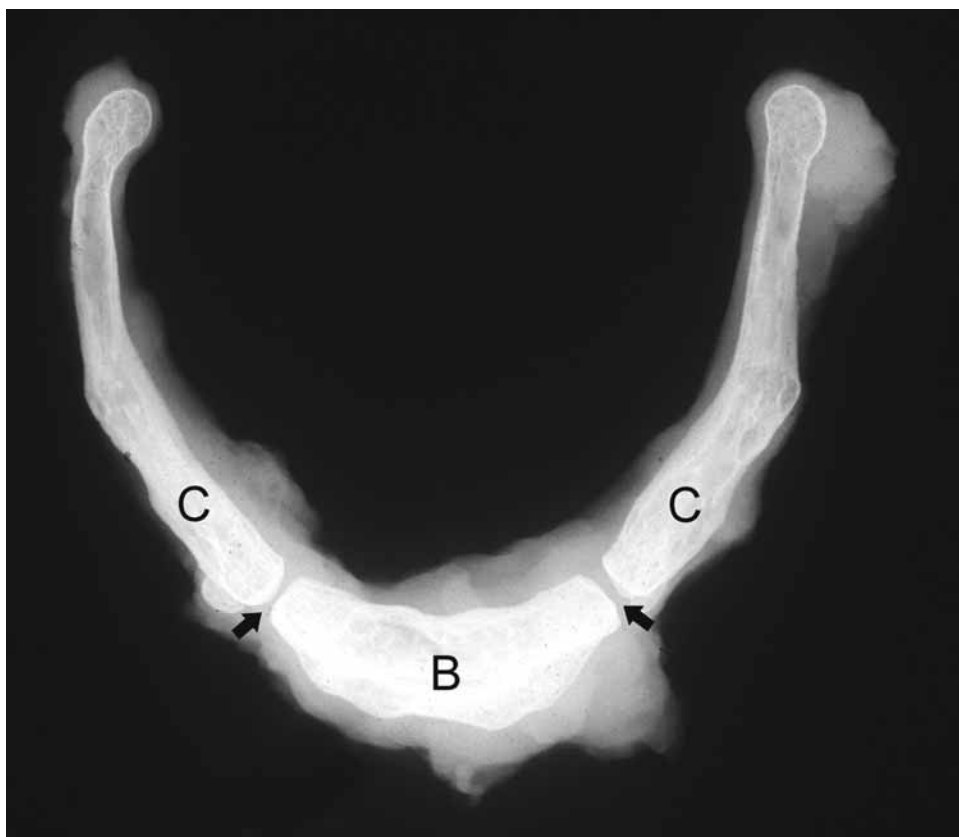
thyroid cartilage, 32% (ligature) and 34% (manual); hyoid, 11% (ligature) and 34% (manual); and cricoid, 9% (ligature) and 1% (manual [149]).

The hyoid bone, a mobile structure, is protected anteriorly by the mandible and soft tissue, and posteriorly by the cervical spine (Fig. 27). Hyoid fracture is uncommon clinically (144,159). A number of factors determine whether a hyoid bone fractures in strangulation and hanging deaths. The shape, i.e., the curvature, of the greater horns means that fractures usually occur in the posterior and middle parts (160). Most hyoid bones are symmetrical (136). Although different dimensions and shapes—i.e., hyperbolic (breadth = length) and parabolic (breadth > length)—have been related to fracture



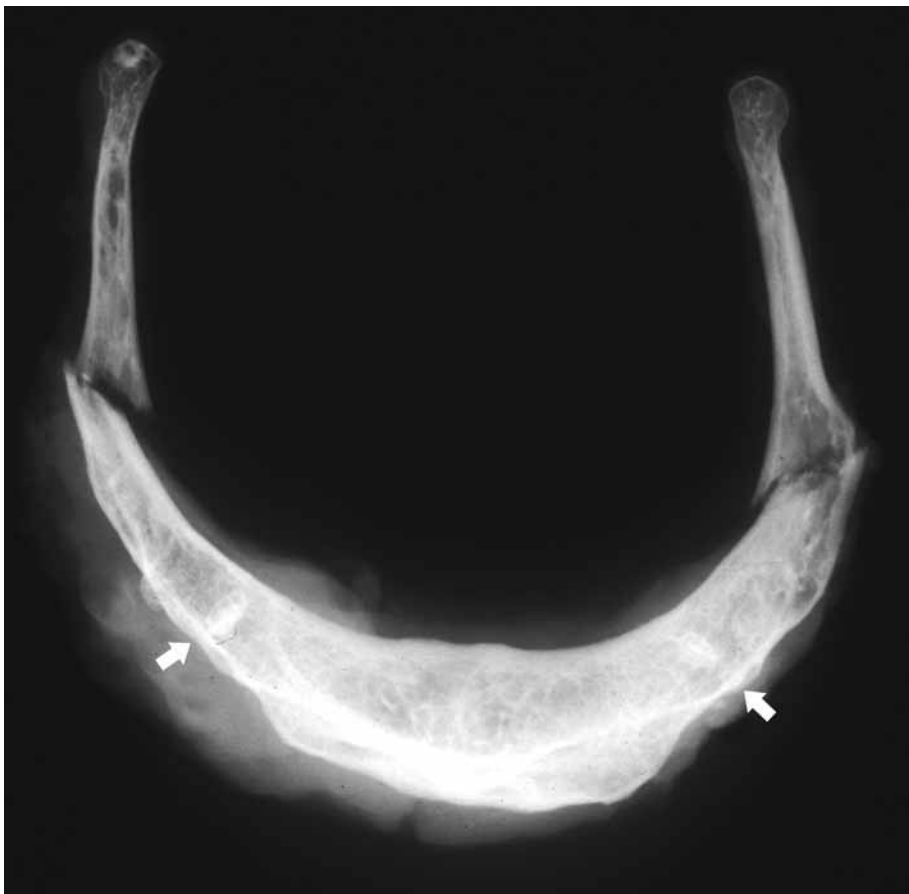
**Table 1**  
**Fractures: Hanging Suicides**

	Ubelaker (149)	Paparo (134)	Simonsen (150)	Luke (24)	DiMaio (151)	Feigin (152)	Samara- sekera (16)	James (57)
Number of cases	Literature review	167	80	61	83	307	233	84
Thyroid cartilage	15%	11%	28%	13%	11%	5%	30%	25%
Hyoid bone	8%	6%	9%	23%	—	3%	7%	17%
Combined thyroid cartilage-hyoid	—	3%	9%	—	—	1%	8%	5%
Cricoid	0.0003%	0.6%	—	—	—	—	1 case	—
Cervical spine	Rare	—	—	—	1%	1%	1 case	—



**Fig. 27.** Radiograph of hyoid bone. Body of hyoid (**B**). Greater horns or cornua (**C**). Synchondroses (“joints”) not fused (arrows).

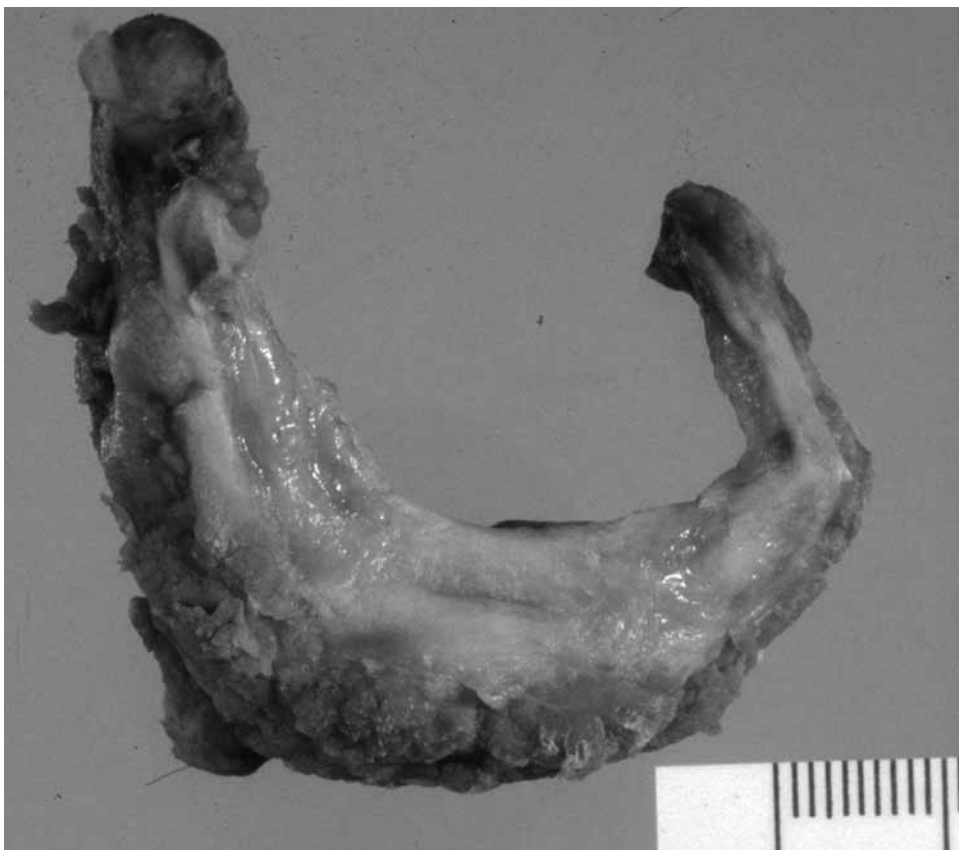patterns, hyoid width/length ratios are distributed across the population and do not fall into discrete categories (136,161). The degree of ossification or fusion of cornual synchondroses or “joints” predisposes to fracture (Fig. 28; ref. 161). Fusion and fracture incidence increases with age (145,153,161). Children have flexible hyoids and fractures of the hyoid–larynx structures are rare (18). Fusion begins in individuals 21 to 30 yr old



**Fig. 28.** Suicidal hanging; prolonged suspension. Radiograph of hyoid bone. Bilateral fractures of greater horns. Note bilateral fusion of body and greater horns (arrows).

(136). Miller et al. observed an overall incidence of 16.7% bilateral fusion in this age group (136). Bilateral fusion plateaus in the sixth decade, such that 60% of female and 70% of male synchondroses are ossified (162). Another study showed there were no sex differences in the rate of fusion (136). Notably, a significant percentage of the elderly still have flexible greater cornua; therefore, neck compression cannot be excluded in an older individual who has an unfractured hyoid bone (162). The relatively increased mobility of a nonfused or incompletely fused hyoid synchondrosis must not be mistaken for fracture (149). A radiograph of a dissected hyoid bone can be used to assess the degree of fusion. One study showed that, of 34 hyoid bones of people aged 21 to 30 yr, 12.5% had unilateral fusion (136). About 30% of individuals greater than 70 yr of age showed unilateral fusion or nonfusion (136).

Other factors playing a role in hyoid fracture are the nature, magnitude, and distribution of force applied to the neck and the time interval between the infliction of neck pressure and death (161,163). Knot placement on the side of the neck was thought to increase the likelihood of fracture (8). A greater tendency for fracture was observed when the highest point of the ligature knot was behind the ear (155). Others have found

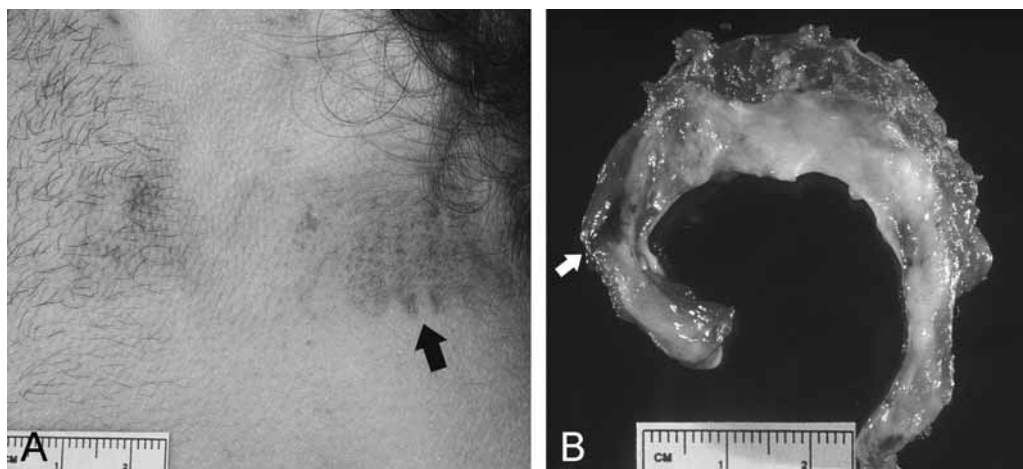


**Fig. 29.** Suicidal hanging. Fracture of left greater horn of hyoid. Ligature knot on right side of neck.

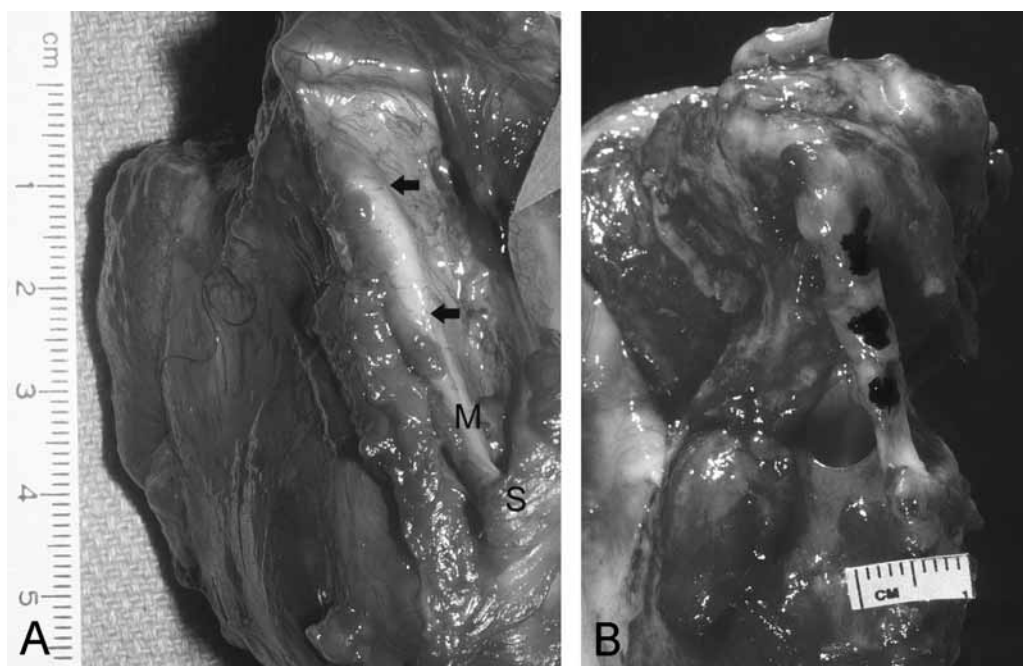
that hyoid bone injuries are not reliable in determining knot location (Fig. 29; ref. 154). Hyoid fractures can occur when suspension is not complete (e.g., a fractured hyoid in an elderly person seated and wearing a vest restraint [49,96,152]). One study showed a higher frequency of fracture in complete suspension compared with incomplete suspension (22 vs 10% [16]).

Hyoid fracture is caused by blunt trauma (e.g., motor vehicle collision) and is usually associated with other fractures (e.g., mandible, thyroid/cricoid cartilage; see Fig. 30 and refs. 144,149,159,164, and 165). Isolated hyoid fractures are possible when there is hyperextension of the neck (159). Chronic alcoholics are predisposed to hyoid fracture (149). Fractures of the hyoid and larynx are found in natural deaths, presumably from intense muscle contractions during the agonal stages of a cardiac arrest or following violent coughing (153,165). A hyoid fracture can be associated with pharyngeal lacerations (159). Even without mucosal injury, laryngeal edema can cause airway compromise (159).

Palpation of the hyoid bone *in situ* may reveal a variably calcified stylohyoid ligament attached to the lesser cornu, which occurs even in children (165). Fractures at this site are rare, and an incompletely ossified ligament should not be confused with a fracture (165).

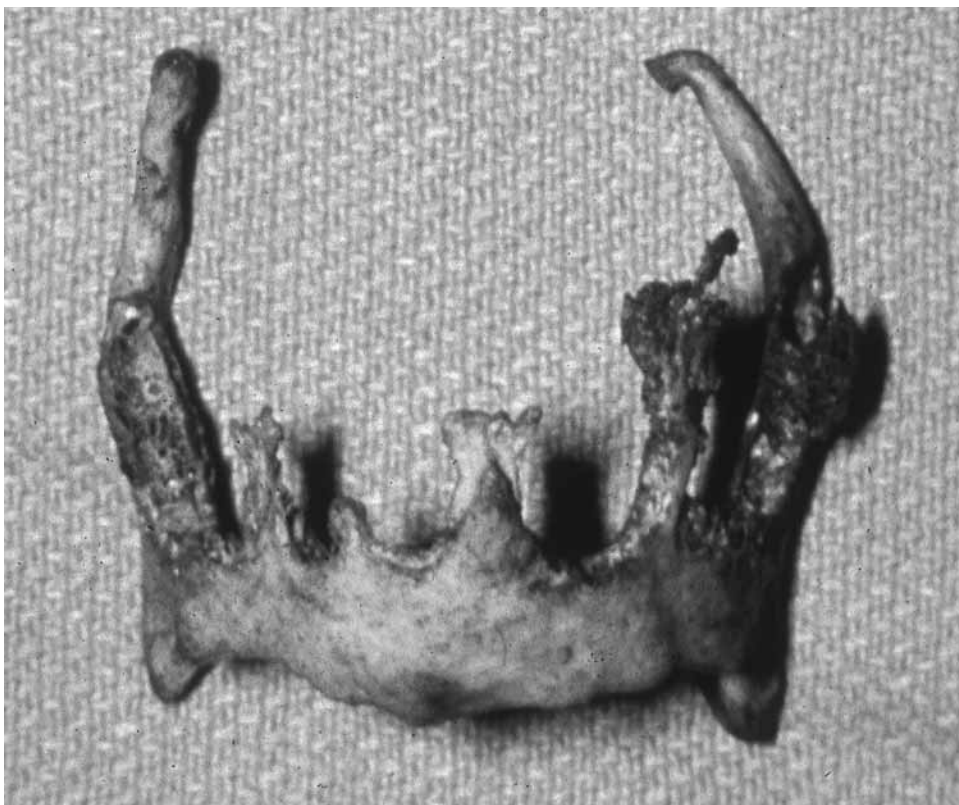


**Fig. 30.** Pedestrian run-over. (A) Abrasion (arrow) on left neck. (B) Fracture of left greater cornu of hyoid (arrow) with associated hemorrhage.



**Fig. 31.** Anatomic variations of superior horn of larynx. (A) The right superior horn is not attached to the superior (S) edge of the thyroid cartilage lamina. A fibrous membrane (M) extends from it to a “floating” superior horn (superior and inferior limits indicated by arrows). (B) Right superior horn of thyroid cartilage composed of three mobile segments (highlighted with ink).

Any examination of the superior horns of the larynx must consider anatomic variations that should not be confused with fractures (Fig. 31; refs. 142,156,157,165, and 166). A common anatomic variant is a mobile, variably calcified cartilaginous nodule (triticeous cartilage) in the thyrohyoid ligament above the superior horn (165).



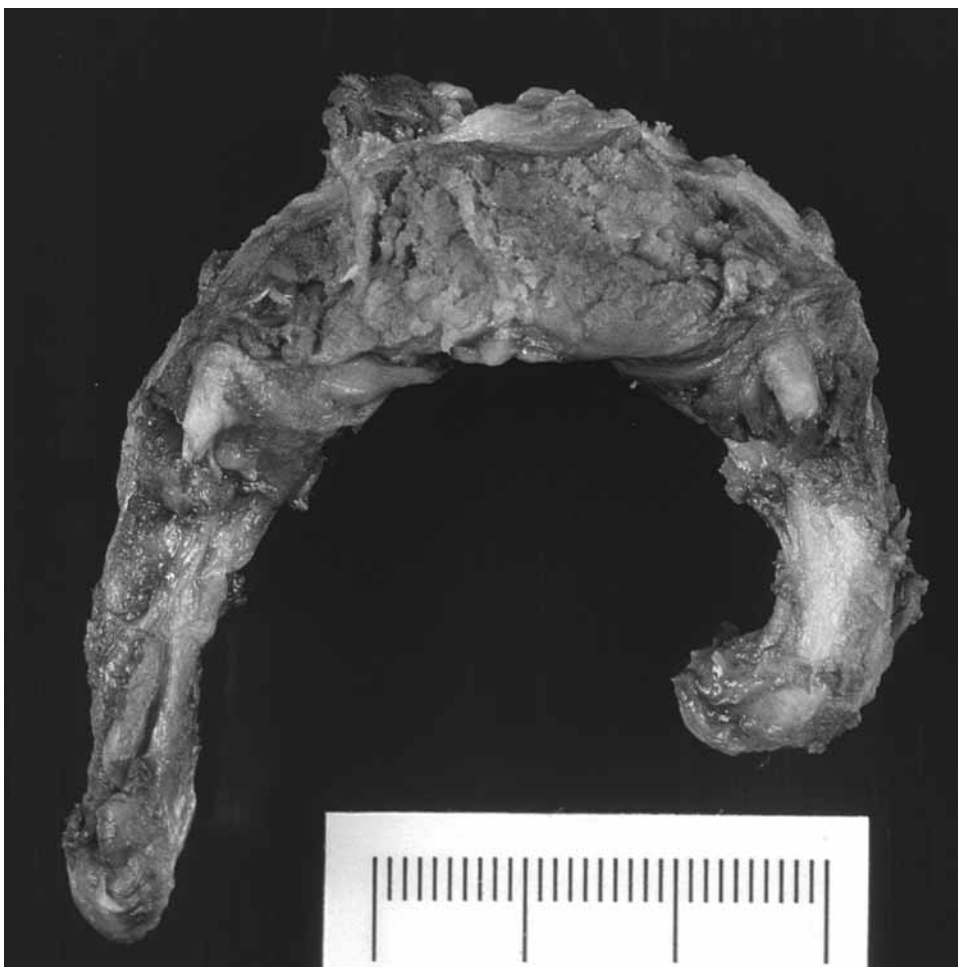**Fig. 32.** Skeletal remains. Irregular ossification of thyroid cartilage lamina. Note prominent superior horns that have completely ossified.

Fracture incidence rises with age as calcification progresses, but this is variable because ossification does not proceed in a constant manner (Fig. 32; refs. 16, 50, 57, 142, 145, 153, and 157). Calcification can be absent in older individuals (64,157). Superior horn fractures are seen with partial suspension (in one study, 50% of complete suspension and 31% of incomplete suspension cases [16,49,152]). Laryngeal fractures do occur opposite knot placement (16,154). Narrow furrows had a higher incidence (62%) of laryngeal fracture than broad marks (15%) in one study (16).

Superior horn fractures are not unique to fatal neck compression. Direct blunt trauma (e.g., motor vehicle impact, falls from heights), resuscitation, and poor autopsy technique can lead to this injury (51,142,167). Fractures of the lamina do occur with blunt trauma (64,168). Healed injuries may be identified in the hyoid bone and larynx (Fig. 33). One study, using skeletonized autopsy specimens, showed previous trauma in 17.3% and involvement of two elements in 3.2% of cases (168). Old fractures were identified in the thyroid cartilage (11.4%), cricoid (7.3%), hyoid (1.6%), and trachea (0.2%).

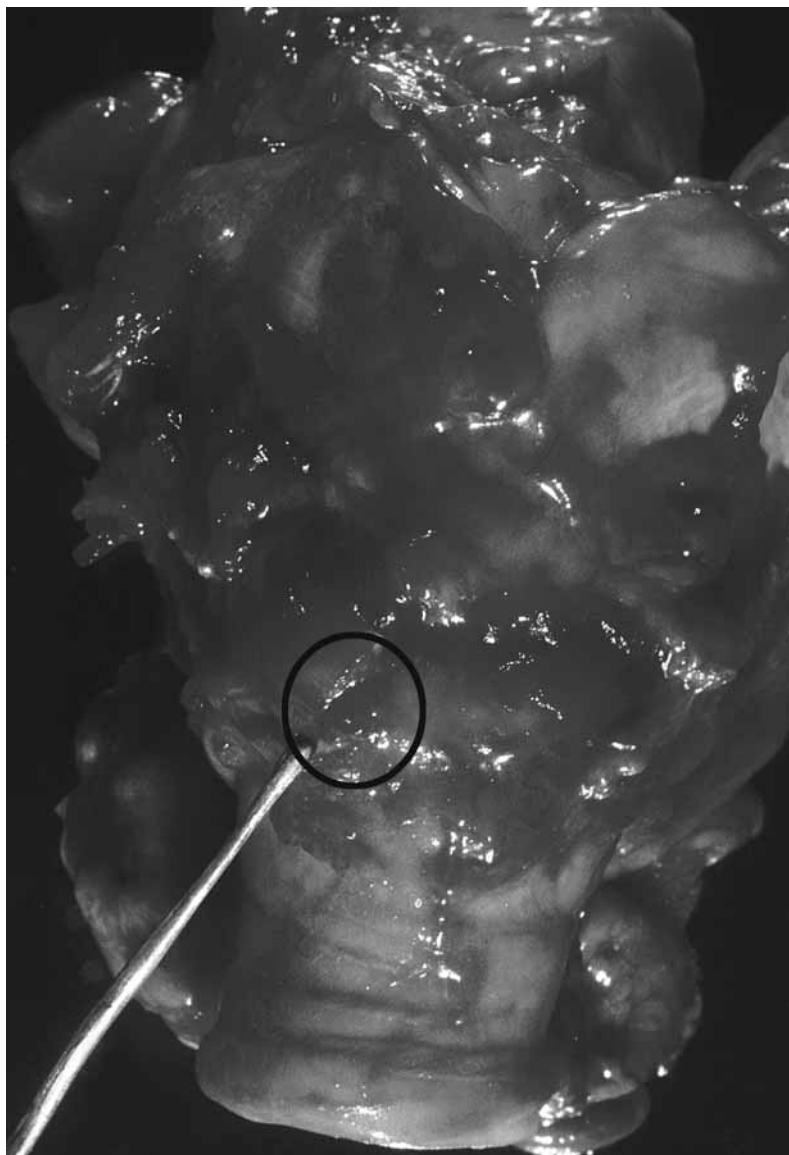Fractures of the thyroid cartilage lamina can result from long-drop hangings (109). Such a fracture in the setting of a “usual” hanging raises suspicions of a homicidal direct neck blow followed by a staged suicide (64). Cricoid fractures from suicidal hanging are rare (Table 1; Fig. 34; ref. 16).





**Fig. 33.** Healed fracture of right greater horn of hyoid. Previous hanging attempt.

Cervical spine fractures are usually associated with “long drops” and hangings in older individuals with osteoporosis; however, one case report described a C-spine fracture (C1–C2) in a 12-yr-old boy who did not drop a long distance ([Fig. 35](#); refs. [7](#), [16](#), [50](#), [152](#), and [154](#)). A 23-yr-old man was suspended 4.6 m (15 ft), and on his waist there was an 11-kg (25-lb) chain ([46](#)). He sustained a C3 vertebral fracture. A 10-yr-old boy was jumping on a bed when he became suspended from a bedpost by a lanyard holding a house key ([126](#)). He had a C1/C2 dislocation. Extensive associated neck trauma can be observed when the cervical spine is fractured ([7](#)). In judicial hangings, the drop length (in the range of 8 ft or 2.44 m) was calculated based on the subject’s weight with the objectives being neck dislocation and a humane instantaneous loss of consciousness ([169](#)). Although a classical “hangman’s fracture”—i.e., fracture–dislocation of C2 through its pedicles—has been described, studies have shown variable damage (i.e., absence of complete fracture, fractures from C1 to C5 including involvement of other bony elements; see [Fig. 36](#) and ref. [169](#)). Basal skull fractures have been observed ([169](#)). Rarely, the classical fracture is seen in a seatbelt user involved in a motor vehicle collision ([71,170](#)).

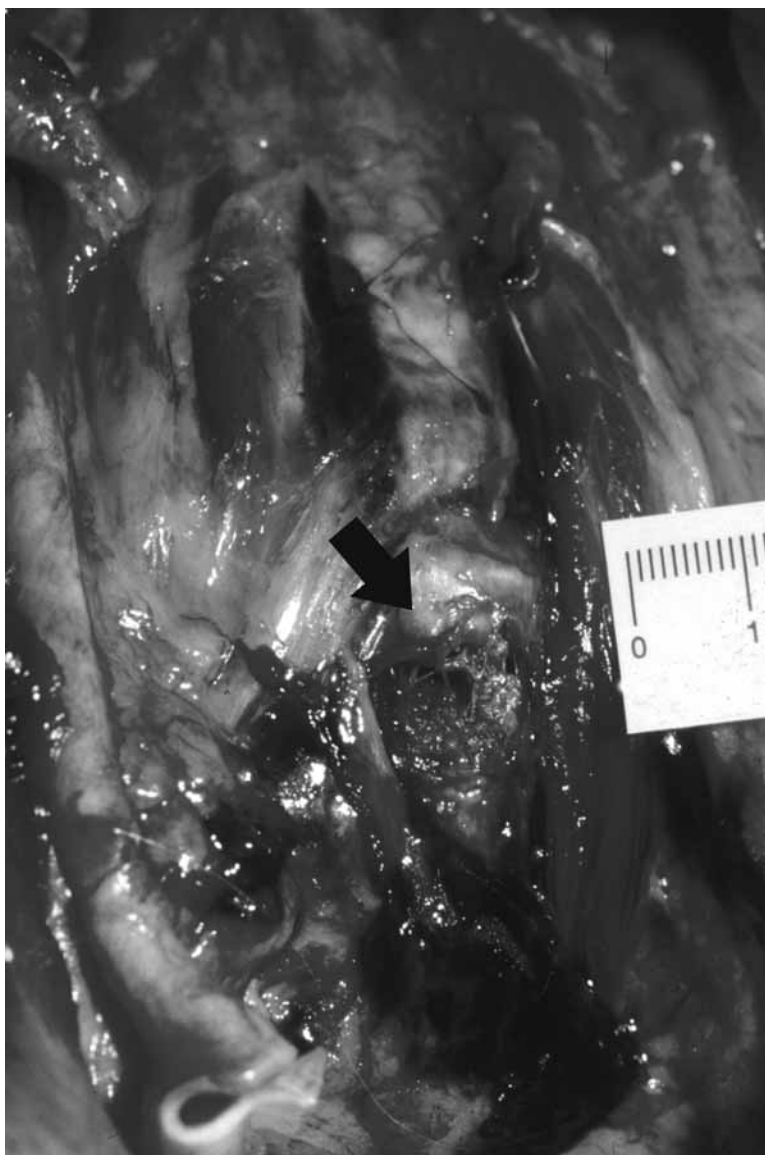


**Fig. 34.** Right cricoid fracture seen in hanging death (circled area adjacent to probe indicates depressed fracture site).

Decapitations are described in large individuals, with application of outside force (e.g., motor vehicle) and in long drops ([129,137,169,171,172](#)).

Rare cases of frontocranial suspension, i.e., the suspension point from the center of forehead and the noose around the back of the neck, have been described ([173](#)).

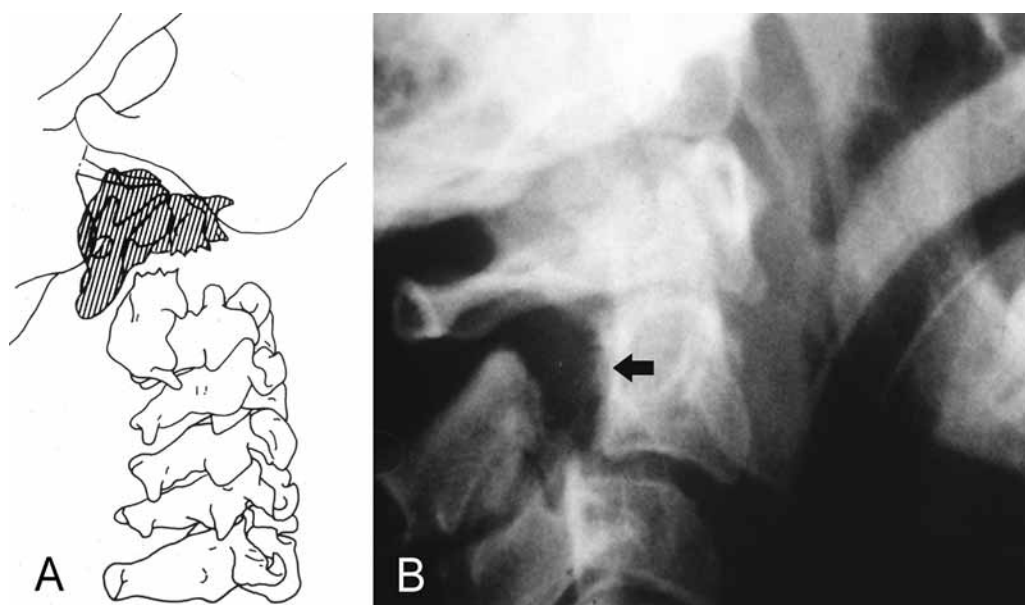
In contrast to disruptive injuries of the larynx–trachea and cervical spine, fractures of the hyoid and superior horns of the larynx are not usually a direct cause of death ([174](#)). They do indicate that significant forces have been applied to the neck, and asphyxial mechanisms are implicated in the death ([174](#)).



**Fig. 35.** Obese man (>100 kg) with psychiatric history. Hanging in stairwell about 20 min. Exposure of anterior cervical spine. Cervical spine (C6–C7 fracture; arrow). Tracking of hemorrhage in soft tissue below fracture site.

#### 2.1.7.5. OTHER TRAUMA AND FINDINGS

Tongue injuries are seen in neck compression ([175](#)). In hangings, tongue protrusion between clenched teeth is a common finding ([Fig. 21](#)). Injuries include bite marks with or without underlying small hemorrhages (“marginal” hemorrhages) and varying degrees of “internal” muscle hemorrhage. In one study of 178 homicidal strangulations, 28% of manual strangulations and 16% of ligature strangulations had bite marks ([175](#)). In contrast, of the 20 suicidal strangulations and 255 hangings, 0 and 1%, respectively, had bite marks ([175](#)). The frequency of deeper tongue hemorrhages was 53, 42, 50, and 4% of homicidal manual,



**Fig. 36.** Classical “hangman’s fracture.” (A) Fracture through pedicle of C2 (axis) by hyper-extension. Dislocation of C1 (atlas) and vertebral body of C2 (lined) leading to spinal cord trauma and death. (Reprinted, with permission, from ref. 170 and the Journal of Forensic Sciences, Vol. 34, No. 2, copyright ASTM International, West Conshohocken, PA). (B) Radiograph of a “hangman’s fracture” (fracture of pedicle of C2—arrow).

homicidal ligature, and suicidal ligature strangulations, and hangings, respectively (175). Hemorrhage was found by either transverse or sagittal incisions of the tongue. “Central” hemorrhages are indicative of severe congestion and are more likely in strangulation deaths (175,176). In one series of hangings, 2% had bleeding restricted to the tip of the tongue (175). Some of the hanging cases that showed tongue bleeding in this series were atypical, i.e., the deceased were either sitting or kneeling. Most of the hangings studied had evidence of cranial congestion, i.e., facial petechiae. Another mechanism leading to tongue hemorrhage is direct pressure of the hyoid on the base of the tongue (175).

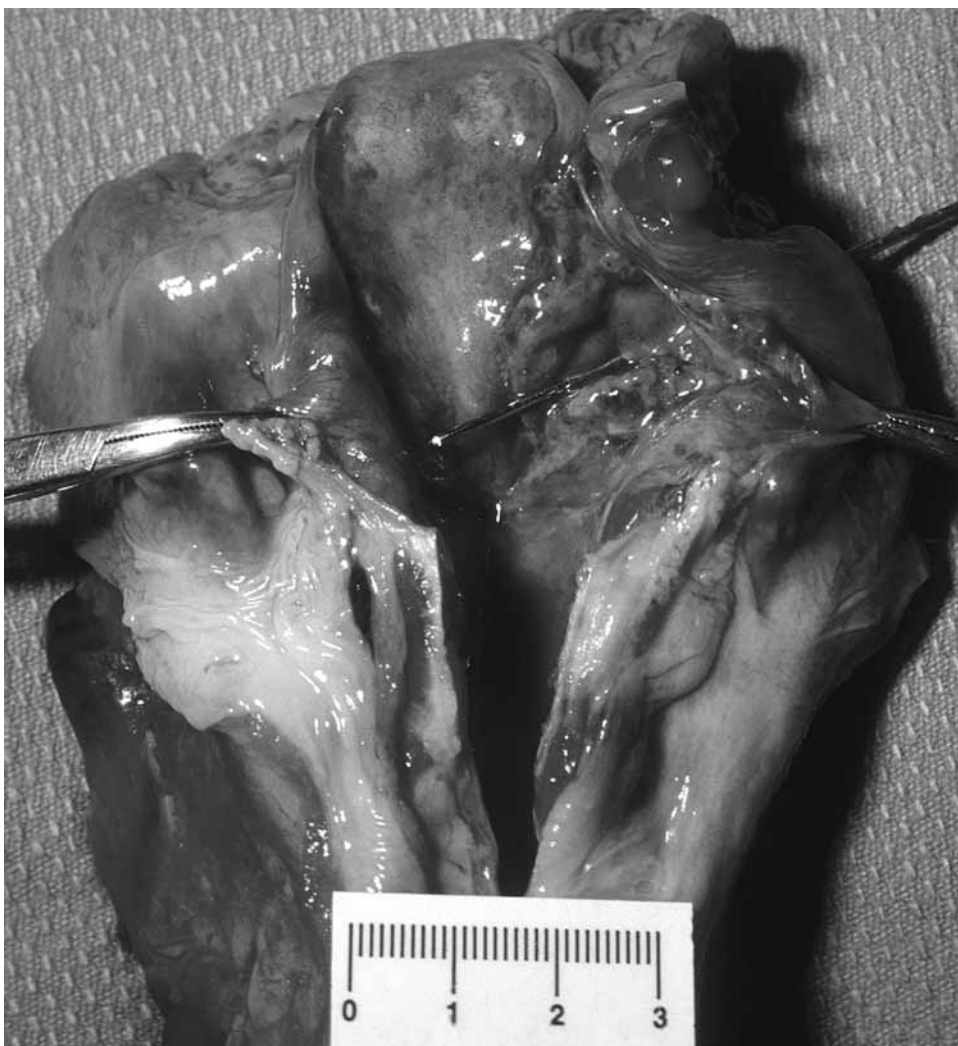Tears in the upper respiratory tract can be observed leading to secondary subcutaneous and mediastinal emphysema (Fig. 37; ref. 174).

Carotid intimal tears have been associated with obese victims, long drops, and posteriorly placed knots (7,129,154). Intimal tears of one or more carotid arteries were more common with complete suspension (12%) than incomplete suspension (2%) in one series (16). Carotid injury is also seen in homicidal strangulation (109).

A study of 36 suicidal hangings showed vertebral artery injuries (rupture, intimal tear, subintimal hemorrhage) in one-fourth of cases (177). Subintimal hemorrhage was most frequent. Longitudinal traction was considered the mechanism, but complete suspension was not a prerequisite. There was an association with cervical spine injury.

Craniocerebral trauma raises the possibility of homicidal hanging; however, injuries arise from careless handling of the body (see Subheading 2.1.6.6., Fig. 25, and refs. 68 and 78).

Any genital injuries may mean a sexual assault homicide (7,28).



**Fig. 37.** Delayed death from hanging. Probe indicates transmural laceration in epiglottic area. (Courtesy of Dr. B. Wehrli, London Health Sciences Centre, London, Ontario, Canada.)

## 2.2. Ligature Strangulation

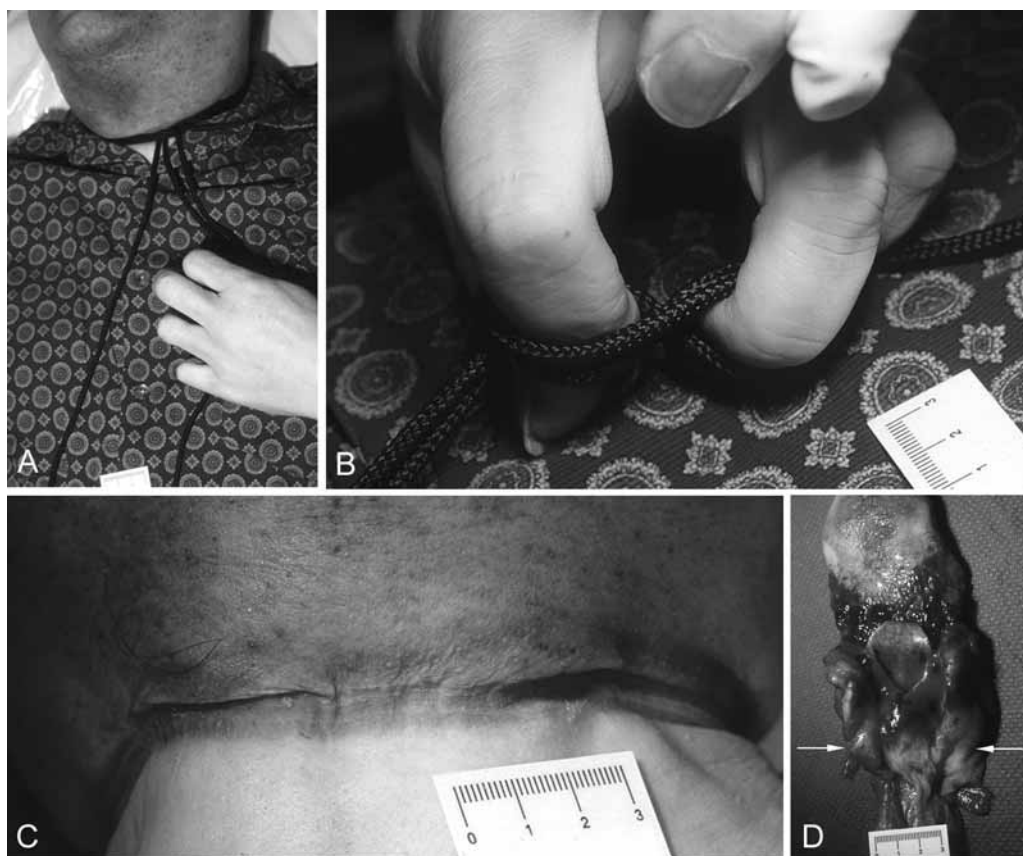
Suicide by ligature strangulation is suspicious for homicide (26). Investigation of the scene usually shows no signs of struggle (26). A suicide note may be found. A past psychiatric history including suicide attempts and ideation may be elicited.

External and internal findings assist in distinguishing suicide from a homicide (Table 2; Fig. 38).

Unusual ligatures have been used (e.g., elastic band, nylon stocking, torn clothing [26,179,184]). The deceased's hands can be close to or involved with tightening the ligature (Fig. 38; ref. 26).

Accidental ligature strangulation occurs in a variety of circumstances (185). The “long-scarf” syndrome refers to an incident in which an article of clothing around the





**Fig. 38.** (A) Suicidal ligature strangulation. (B) Positioning of fingers on shoelace cord progressively tightened it around the neck. (C) Horizontal neck furrow. Note intense cyanosis and cutaneous petechiae above constriction. Ocular petechiae were also present. (D) Dissection of tongue and larynx. Posterior view. Note intense congestion and hemorrhage (petechiae, confluent hemorrhages) above level of constriction (indicated by arrows).

victim's neck becomes entangled, usually in a stationary or moving mechanical device (e.g., ski rope tow, snowmobile engine), and the clothing becomes increasingly constricted owing to the continued action of the machine (Fig. 39; refs. 48, 109, and 186–189). Blunt trauma can also be evident (190). Ligature strangulation deaths are seen in autoerotic asphyxia (*see* Subheading 2.7.1.).

### 2.3. Manual Strangulation

Fatal application of pressure to the neck by use of one or both hands is a homicide. Pressure can also be applied by other parts of the extremities (e.g., choke hold [90,191]). Self-application of manual pressure for the purpose of committing suicide or by accident results in release of the grip once consciousness is lost (3). Cephalic petechiae are observed. External injuries of the neck can be obvious (contusions, abrasions including fingernail scratches) or subtle (Fig. 40; ref. 192). Their presence depends on a number of factors: the magnitude of the compression force; continuous

concentration of force on a small area; the length, shape, and sharpness of the nails; skin elasticity; and the presence of neck-shielding material (e.g., collar [19,193,194]). Fingernail marks may be caused by the victim trying to relieve the pressure (see Subheadings 2.1.6.6. and 2.6.1.).

Manual pressure can be applied to the neck during extrication, resulting in trauma (138).

## **2.4. Microscopic Examination in Cases of Neck Compression**

Microscopy of the furrow reveals abraded or compressed epidermis and dermis (62). Vesicles or blisters filled with serous fluid and fat occur (Fig. 13).

Inflammation associated with hemorrhage is a vital reaction (142). The presence of inflammation is consistent with a period of survival after neck compression with or without resuscitative efforts. An inflammatory reaction has been seen in tongue hemorrhages in cases of strangulation in which the assailant confessed that the victim survived about half an hour (175). The earliest detection of granulocytes has been stated to be 15 min in open and closed skin trauma, and their presence assumes there was no preceding episode of neck trauma (195). Studies of cutaneous or other bodily wounds may not necessarily be applicable to neck compression cases because of variations in perfusion of different tissues (195). Fibrin deposition is an antemortem event, occurring 10 to 30 min after injury (142). Other “vital” reactions, occurring within minutes of compressive and other types of injury, include muscle alterations, such as contraction bands and hyaline change (Zenker’s wavy degeneration [142,196]).

Immunohistochemistry has been applied to the study of tissue injuries in strangulation and blunt neck trauma cases (195,197–202).

Longitudinal sections of the superior horns of the larynx, in cases of neck compression, have shown hemorrhage, retraction, and invagination of ruptured and nonruptured perichondrium (142). Even without obvious laryngeal damage, laryngeal hemorrhages are observed in cases of manual strangulation and blunt trauma (203,204). Parasagittal sections of formalin-fixed larynges in manual strangulation cases show laryngeal hemorrhages within cartilage, muscle, and epithelium, findings that could be applicable to other types of neck compression (158,192,205).

Typically 5 to 8 min of suspension leads to death, but successful resuscitation is possible even after 30 min of suspension (206). Delayed deaths show hypoxic–ischemic encephalopathy and cerebral edema (3,16,90,125,174,207). Rare cases of delayed encephalopathy are described related to necrotic lesions in the basal ganglia (125). Aspiration and pneumonia are delayed complications (3).

## **2.5. Toxicology in Ligature Neck Compression Deaths**

Toxicological analysis is not done in all hanging deaths (107). Ethanol has been present in up to one-fourth to one-half of suicides by hanging (24,43,50,58,59). High levels of ethanol need to be interpreted in the context of whether the deceased was able to perform the necessary steps to commit suicide by hanging (43). The presence of an excess amount of pills in the upper gastrointestinal tract signals an intent to commit suicide (183). Elevated or toxic levels of medications in the blood support self-intent, assuming that medication was not given to incapacitate a murder victim (50).

**Table 2**  
**Ligature Strangulation: Homicide vs Suicide**

	Homicide	Suicide
Nature of victim	Children, women, elderly consistent with size disparity between victim and assailant ( <a href="#">18,65</a> ).	Adults, not children
<b>External findings</b>		
<b>Ligature</b>		
• Absent or inapparent	Yes.	No. Present around neck.
• More than one ligature	Yes	Yes ( <a href="#">26</a> ).
• Wound multiple times	Yes	Yes. More likely in suicide ( <a href="#">26,179–181</a> ).
• Single or multiple knots	Yes	Yes. Knots not required as victim's hands or legs can hold unknotted ligatures in place; stick can be used as a "windlass" device; leaning forward can increase neck pressure ( <a href="#">1,18,109,180–184</a> ).
• Knot position	Posterior > lateral > anterior	Anterior > posterior ( <a href="#">26</a> ).
Furrow	Yes—80%	Yes, 10% ( <a href="#">45,179</a> ). Furrow uncommon. Instead, linear pale area on neck from absent lividity owing to compression. Other case reports have documented a groove with reproduction of the pattern of the ligature ( <a href="#">26</a> ).
<b>Face</b>		
<b>Petechiae</b>		
• Ocular	Yes	Yes
• Facial	Yes	Yes
• Neck	Yes	Yes
	Petechiae can be absent in homicides ( <a href="#">151</a> ).	Ocular and facial petechiae numerous in suicides but can be few or absent. Absence explained by complete carotid artery compression ( <a href="#">26,178,179</a> ).
Facial cyanosis and congestion	Yes Some cases if ligature not removed shortly after application.	Yes ( <a href="#">26,179,180</a> ). One-half cases  Absent if complete arterial compression by strong ligature ( <a href="#">180</a> ).

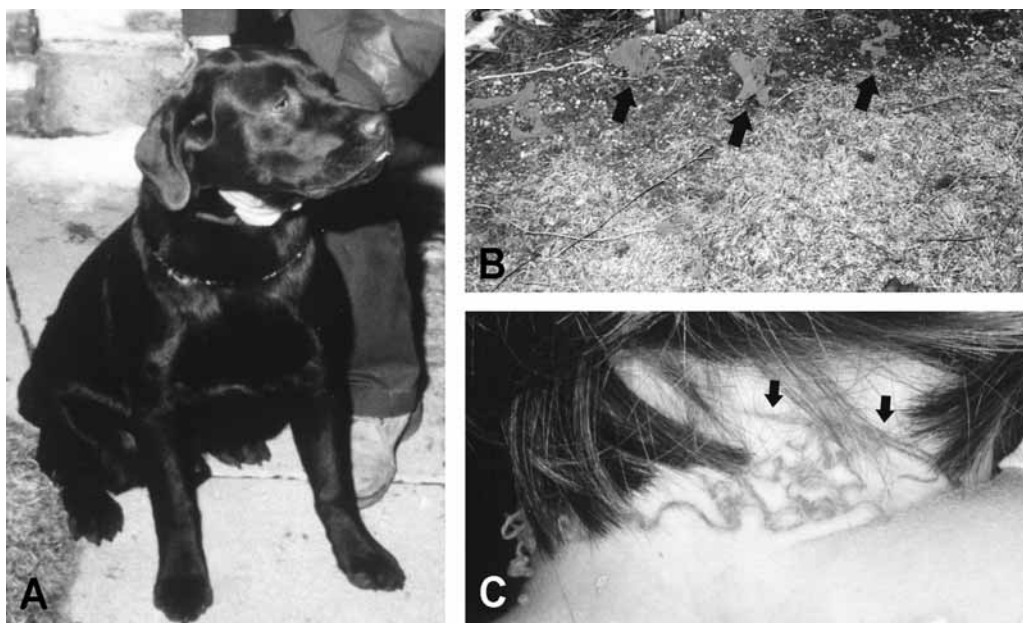
**Table 2** (Continued)

	Homicide	Suicide
Other external injuries	Yes—80%	Yes—20%
Self-inflicted		e.g., wrist incisions
Signs of struggle	Facial trauma—smothering (65). Blunt trauma on chest (assailant kneeling on victim [65]). “Defensive” injuries. Genital injuries (female [65]).	
<b>Internal Findings</b>		
Anterior neck muscle hemorrhage and laryngohyoid fractures	Yes—more than 80% The degree and extent of hemorrhage and fractures greater in homicides (178). Fractures can be multiple and observed in one-third to two-thirds of cases. In one study, presence of neck trauma occurred irrespective of whether hard, narrow vs soft, broad ligature used.	Yes—less than 50% Sternomastoid muscle most affected muscle. Laryngohyoid fractures are rare. If noted, limited to single fracture of superior horn of thyroid cartilage. Multiple fractures are not seen.
Tongue		
Tongue injuries from upward displacement of larynx/hyoid into base of tongue; mucosal injuries can also arise from facial blow		
• Hemorrhages	Yes	Yes—can be extensive (175).
• Bite marks	Yes	No (175).
Laryngeal mucosal hemorrhage	Yes	Yes
Vocal cord hemorrhage	Yes	No
Intrinsic laryngeal muscle hemorrhage	Yes	No
Carotid intimal tears	Yes (109).	Possible

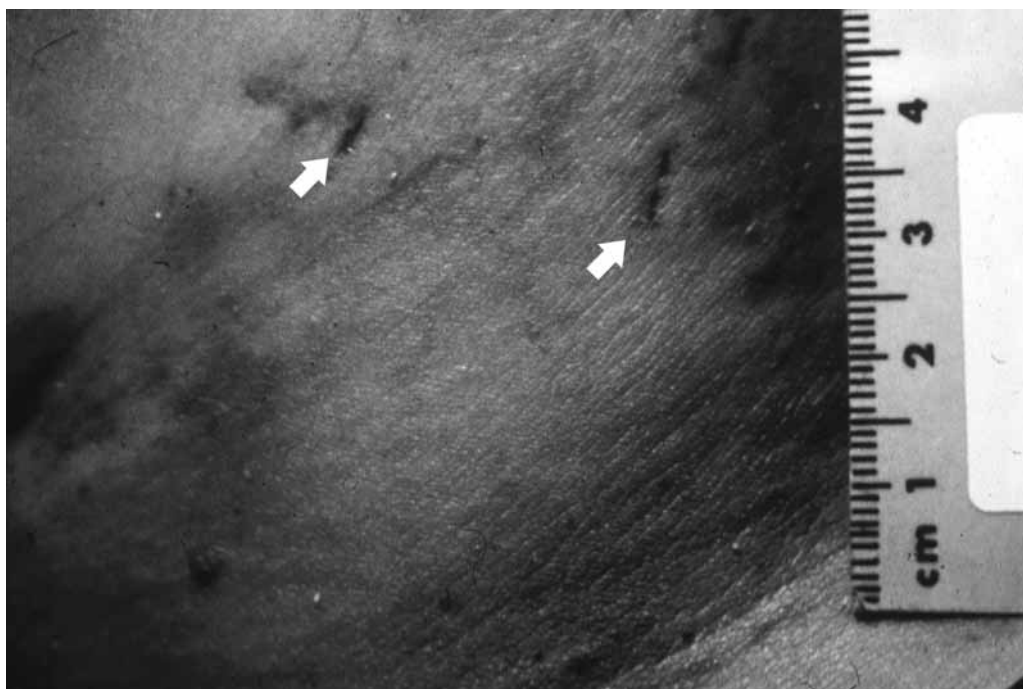
Adapted from ref. 178.

## 2.6. Artfactual Injuries of Face and Neck From Resuscitation

External and internal trauma sustained during resuscitation can mimic findings associated with neck compression and other more subtle types of asphyxia (e.g., smothering). Leaving resuscitative devices in place and having access to any discarded items is essential in determining their role in injury causation (143). Rescuers need to be questioned whether any injuries were apparent to them prior to resuscitation or could have been inflicted by them (143).



**Fig. 39.** Unusual case of accidental ligature strangulation. (A) Child's dog. (B) Dog bit into girl's long scarf and dragged her. Fragments of scarf were strewn around the yard (arrows). (C) Threads from scarf on posterior neck. Note furrow and embedded thread (arrows).



**Fig. 40.** Manual strangulation. Fingernail abrasions (arrows).



### 2.6.1. External Findings (Resuscitation)

In a series of intubated individuals, 16 yr and older, the following was observed within 24 h (208,209):

- Cutaneous abrasions of neck.
- Facial and conjunctival petechiae as consequence of chest compression.
- Oral trauma—abrasions of lips and buccal mucosa; contusions; lacerations (including frenulum).

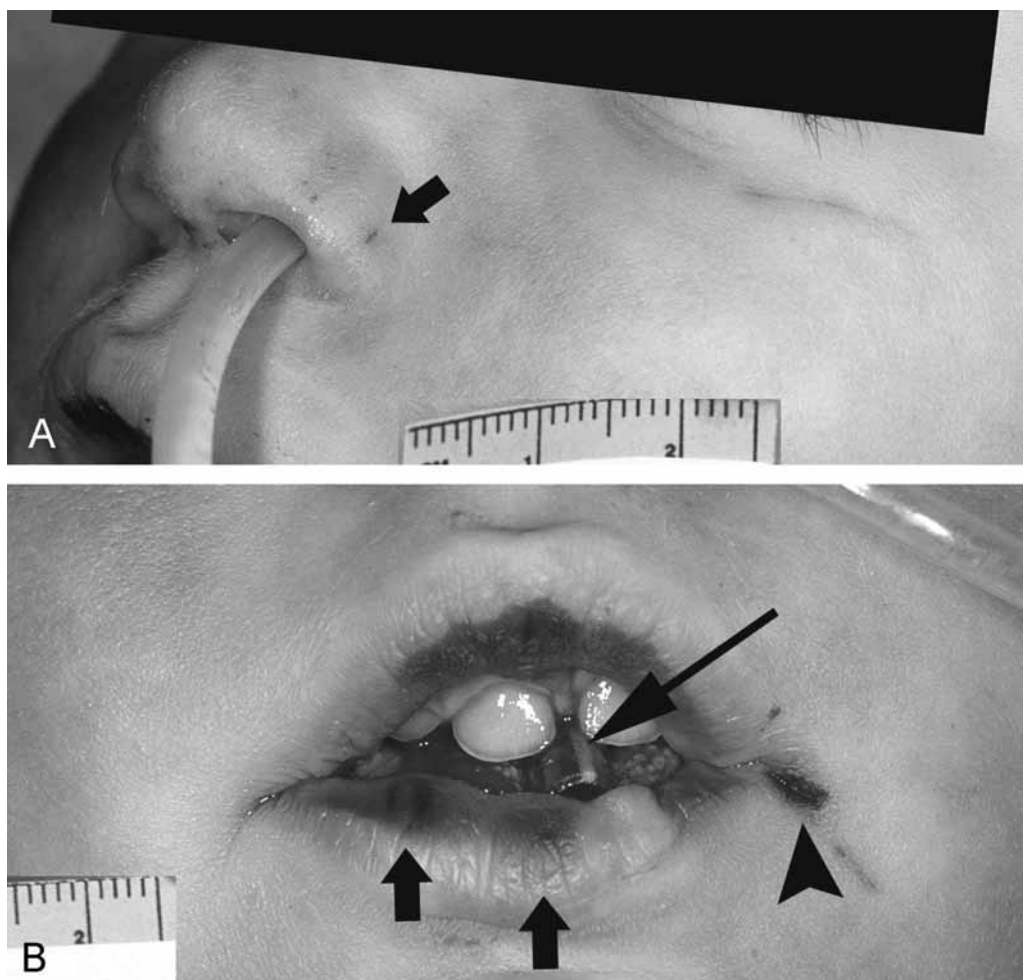
Another study of deceased individuals who had cardiopulmonary resuscitation immediately prior to death showed that about 4% of the cases (21 of 1677 nonselected medicolegal autopsies) had evidence of external or internal injuries of the face and neck (210). The external injuries consisted of contusions and abrasions. They were situated on the tip of the nose and nostrils (mouth-to-mouth ventilation), cheeks (compression with fingertips to remove vomit from victim's mouth), mandibular margins (jaw-thrust), and carotid area (palpation of carotid pulse). In contrast, in manual strangulation cases abrasions were distributed over the whole anterior neck area, particularly the larynx, and were also seen in the lower part of the face and back of neck. Strangulation abrasions tended to be oriented randomly rather than parallel to each other. In this study, there were no petechiae on the face and conjunctiva.

In a pediatric series (<1 yr old), various trauma was seen using either an air-bag-valve mask, mouth-to-mouth resuscitation, or intubation (143). Associated with the mask, abrasions were symmetrically distributed over the nasal bridge, undersurface of nose, lips, cheeks, and anterior chin. Positioning the patient's head and neck to maintain airway patency was associated with fingernail abrasions on various parts of head and face. Mouth-to-mouth resuscitation was usually employed by the first responder. Tightly grouped fingernail abrasions in a tight perinasal distribution were seen (Fig. 41). Scrapes were more loosely distributed on the cheeks, forehead, and chin. Intubation caused lip injury (e.g., contusion–laceration), but it was less common in children because of the lack of teeth (Fig. 41). Attempts to intubate a mouth clenched in rigor increases the probability of injury (Fig. 42).

### 2.6.2. Internal Findings (Intubation)

In the series of intubated individuals, the following injuries were observed: (208,211,212):

- Chipped or loosened teeth.
- Contusions or lacerations of base of tongue, epiglottis, piriform recess.
- Petechiae of epiglottic mucosa.
- Laryngeal mucosal edema, contusions, petechiae (glottic and subglottic [90,213,214]).
- Laceration of epiglottis; other lacerations (glottic, hypopharynx [214–217]).
- Glottic stenosis as a long-term complication owing to ischemic ulceration from pressure; tracheostomy also leads to subglottic stenosis (213).
- Tracheobronchial lacerations or rupture (218–220).
- Esophageal rupture.
- Superficial and deep neck muscle hemorrhages (210).
- Hyoid and thyroid cartilage fractures rare (90,208,221).
- Cricoid hemorrhage (211).



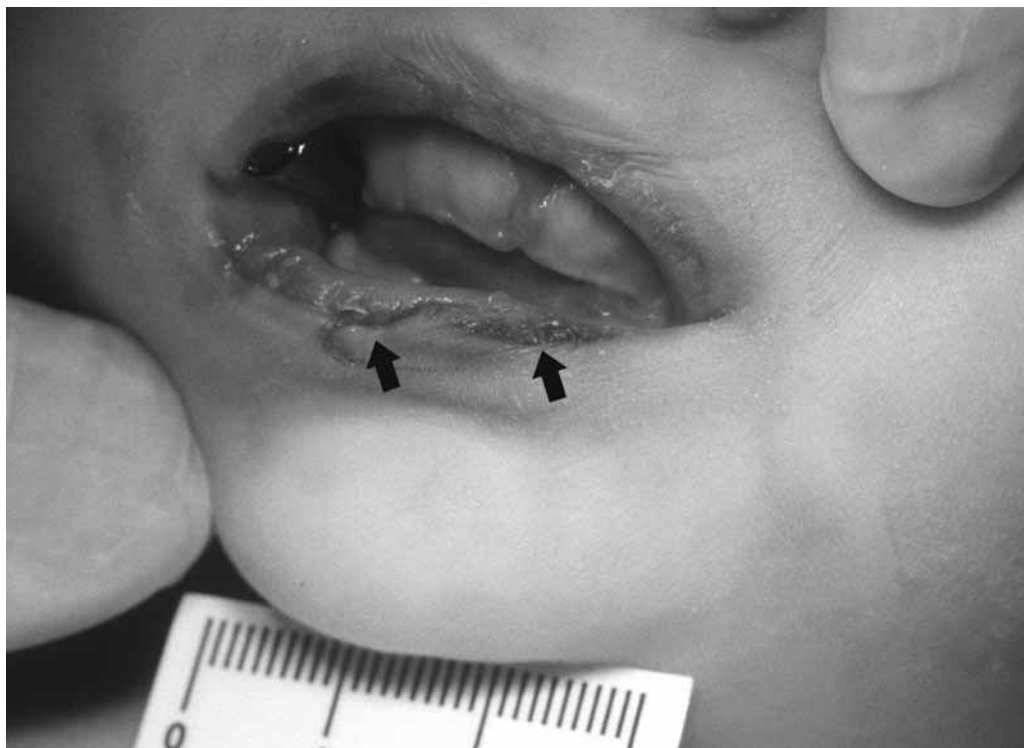
**Fig. 41.** Attempted resuscitation of a child. **(A)** Nasogastric tube in left nostril. Note small abrasions, left nostril (largest indicated by arrow). **(B)** Endotracheal tube (long arrow). Exposed end cut to allow lips to be examined. Lip contusions (arrows). Abrasion near left corner of mouth (arrowhead).

Studies of short-term intubation have shown about a 6% incidence of laryngeal injury. A large majority of these injuries consists of submucosal hematomas. Mucosal laceration is infrequent. The development of these lesions appears related to the degree of patient relaxation, the presence of anatomical difficulties, and the experience of the medical personnel in performing the intubation (214,222).

Misplacement of endotracheal tubes (right mainstem bronchus, piriform sinus, esophagus, brain through a basal skull fracture) has been described (211,212,223).

## 2.7. Autoerotic Deaths

Paraphilia refers to a nonpsychotic mental disorder in which an unusual act or imagery is necessary for sexual gratification (224,225). An autoerotic fatality occurs when the act created by the deceased for the purpose of sexual gratification directly



**Fig. 42.** Apparent sudden infant death syndrome. Jaws in rigor. Attempts to intubate led to lip lacerations (arrows).

causes death (225,226). Hazelwood et al. suggested five criteria for determining death during autoerotic practice: a physiological mechanism for obtaining or enhancing sexual arousal that is dependent on either a self-rescue mechanism or the victim's judgment to discontinue its effect; solo sexual activity; sexual fantasy aids; prior dangerous autoerotic practice; and no apparent suicidal intent (227).

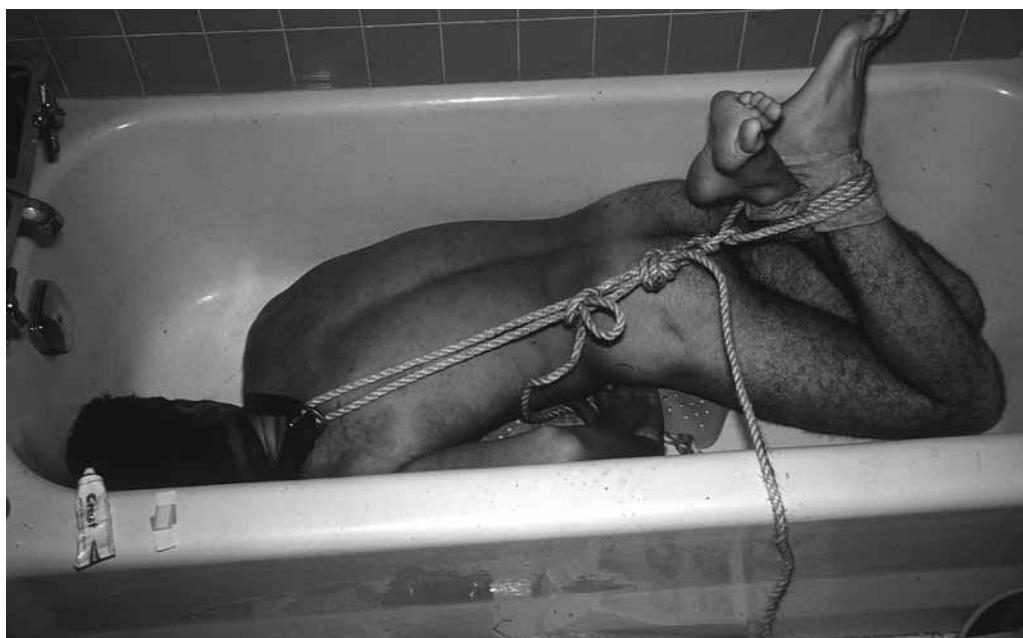#### 2.7.1. Autoerotic Asphyxia (*Sexual Asphyxia, Hypoxyphilia, Asphyxiophilia*)

Autoerotic asphyxia is a paraphilia in which sexual arousal and orgasm depend on self-induced asphyxia up to, but not including, a loss of consciousness (141,228,229).

Hanging is the most common mechanism used (225,228–235). Neck compression leads to decreased cerebral blood flow. Consequently, cognitive inhibition is decreased, and the subjective sensations of lightheadedness and exhilaration associated with hypoxia and hypercapnia enhance the pleasurable effects of masturbation (229, 232–234,236–238). When the victim fails to extricate himself, then the full weight of his body tightens the ligature (234,237,239–241). As in the usual hanging, a rapid loss of consciousness leads to death (6,141,229). Vagal stimulation can also progress to sudden cardiac arrest (227,231,233,236,237).

Other means of autoerotic asphyxial deaths have been described:

- Suffocation by plastic bags/wrap/raincoat/pillow/sack (224,228–232,237,242–247).
- Head wrapped in duct tape and use of airway tube (240).
- Gag (sock) or objects (rubber balls, zucchini) in mouth (141,243,248–251).



**Fig. 43.** Autoerotic asphyxia. Ligature strangulation. Note padding on ankles. Pornographic literature was positioned on bathroom floor.

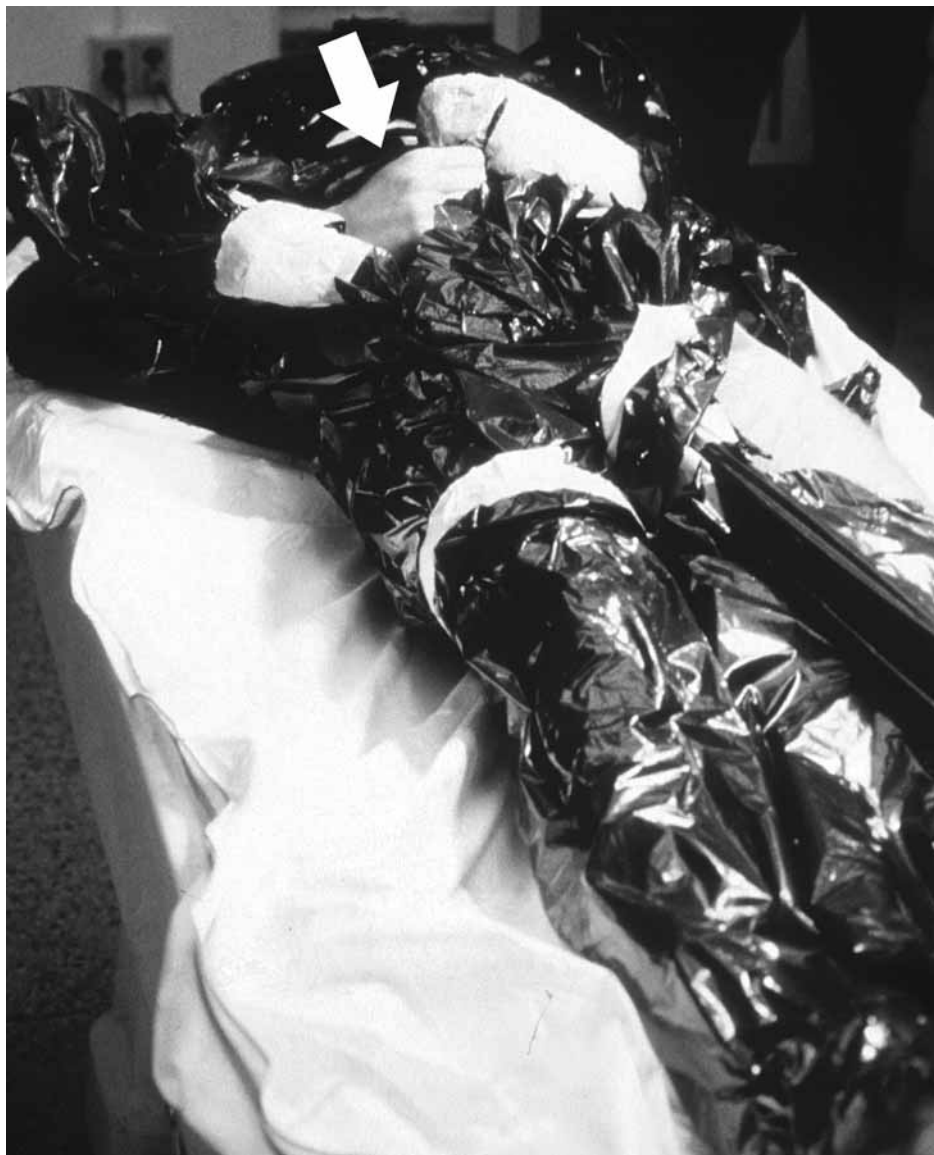- Ligature strangulation (one case report describes woman's hair entangled in a slipknot, preventing release; *see* Fig. 43 and refs. 109, 224, 228, 230, 241, 247, 249, and 252–254).
- Ligature around thorax and abdomen (*see* Subheading 3.7. and refs. 229, 247, and 255).
- Wrapped in plastic (a tube may be used for breathing; *see* Fig. 44 and ref. 256).
- Wet suit (229,257).
- Suspension by power hydraulics (258).
- Inverted suspension (258).
- Wedged in garbage can (chest compression [228]).
- Motor vehicle (chest compression [259]).
- Partial or total submersion (229,260).
- Inhalation of aerosol propellants, chemicals, and gases for euphoric effects used in combination with either a mask, a plastic bag, an item of clothing (e.g., sock), or a soaked rag (224,229,230,234,236,238,257,261).

#### 2.7.1.1. EPIDEMIOLOGY

An estimated 250 to 1000 autoerotic deaths per year occur in the United States (i.e., 1–2/10<sup>6</sup>/yr; in Scandinavia, 0.5/10<sup>6</sup>/yr [228,229,232,238,262]). The most common age group is 12 to 25 yr (228–230,232,233,238). Males predominate and female deaths are rare (estimated male-to-female ratio  $\geq$  25 to 50:1 [227–229,231–233,235,238,239, 241,243,252,262–265]). Typically, there is a solitary victim (229,233,262). The majority are single (228–230,234,238). Most are heterosexual, and the majority are reported as well-adjusted (227–232,234,238,239,262).

#### 2.7.1.2. SCENE FINDINGS AND CIRCUMSTANCES ASSOCIATED WITH AUTOEROTIC ACTIVITY

Initial investigation of an autoerotic hanging suggests suicide (224,231,232, 238,253). An apparent suicide note can be staged (253). Alternatively, the unusual



**Fig. 44.** Autoerotic asphyxia. Wrapped in garbage bags. Right hand exposed (arrow).

nature of the scene may suggest a sadistic/ritualistic homicide. Suspicion of homicide also applies if the victim is female, and the scene findings are subtle ([239,241,252](#)). Further investigation of the scene, the circumstances of the death and background of the deceased, and the external examination of the victim assist in the determination that a rare type of accident has occurred ([141,229,234,237,243,250,253,266](#)). A psychological autopsy may be necessary (*see* Chapter 1, Heading 3. and refs. [227, 236, 253, 255, 265](#), and [266](#)). Autoerotic or masochistic suicides are uncommon ([225,227, 237,249,253,267](#)). A homicide can be disguised as an autoerotic death ([133,229,262](#)). Some fantasy hangings are not done for a sexual purpose (e.g., pretending to be a cowboy [[46](#)]). Next of kin can alter the scene to remove evidence of autoerotic activity



because of the stigma associated with such deaths (228,229,231,232,239,268–270). The scene can also be disrupted by resuscitation attempts.

The location is secure or secluded (e.g., locked room in home, basement or attic, workshop, workplace after hours, motor vehicle, jail cell, motel/hotel rooms, other residences, remote outdoor locations [141,224,227–229,231,232,234,238–240,243,263,271–273]). There are no signs of a struggle or forced entry to suggest homicide. Windows may be covered (227,274).

The victim is in a position that allows self-extrication (229). Commonly, the victim's body is partly supported with the feet touching the ground. Sitting, kneeling, and lying down have been described (225–227,229,231,238,275). In a Danish study, about two-thirds of victims were incompletely suspended, 28% completely suspended, 4% inverted, and 4% had used ligature strangulation (228).

Pornographic material, which can be homosexual or sadomasochistic in nature, may be present and mirror(s) can be positioned to allow viewing of the act (141,225,227,228,231–235,238,239,243,261,263,268,273). One report describes photographs of a woman glued to the victim's body (48). Mirrors are also used in suicide (227,236,239,263). Sexual items are less likely to be present if the victim is female (239,241,252,263). Items that assist in sexual activity can be found on, in, or near the body (273). Some are overtly sexual (e.g., condom, vibrator, fetish and bondage objects [227–232,238,241,243,263]). Others may not appear overtly sexual (e.g., wooden table leg, hairbrush, urinary catheter, vacuum cleaner [225,268,276,277]). More elaborate arrangements have been observed when older men are involved, and the proportion exhibiting bondage, transvestism, or both increases (230,263).

Participants learn of autoerotic behavior by word of mouth, contact with individuals of similar sexual inclinations, sex manuals, medical books, pornographic literature, and detective magazines, information from the news media, movies showing hanging, consensual observation of others, and their own initiative (228,229,232,233,235,239,254,261,266,275,278–280). Literature showing autoerotic methods or videotapes showing personal autoerotic episodes may be present (243). Siblings in the same family have been described (281).

Information about autoerotic activity can be elicited from a spouse or girlfriend, relatives, neighbors, physicians, prostitutes, and others (46,224,225,227,231,233,235,238,241,243,253,273,276). There may be a history of other paraphilias (240). Interviews (e.g., no history of depression) and scene investigation (e.g., no suicide note) indicate that the victim did not want to die (225,226,229,233,241,262). Scene findings can support past autoerotic activities (e.g., suspension point abrasions on a joist from previous hangings; see (Fig. 45 and refs. 46, 227–229, 232–235, 239, 255, 260, 262, 266, and 274). The complexity of the methods and paraphernalia used suggest prior experience (227,229).

### 2.7.1.3. EXTERNAL EXAMINATION

Hanging is the most common method (Fig. 46). Soft material may be interposed between the ligature and skin, but protective padding is not always present (Fig. 46; refs. 141,228,229,231–233,235,238,239,241,252,258,262–264,275, and 282). A neck furrow or mark is still possible with padding (141).

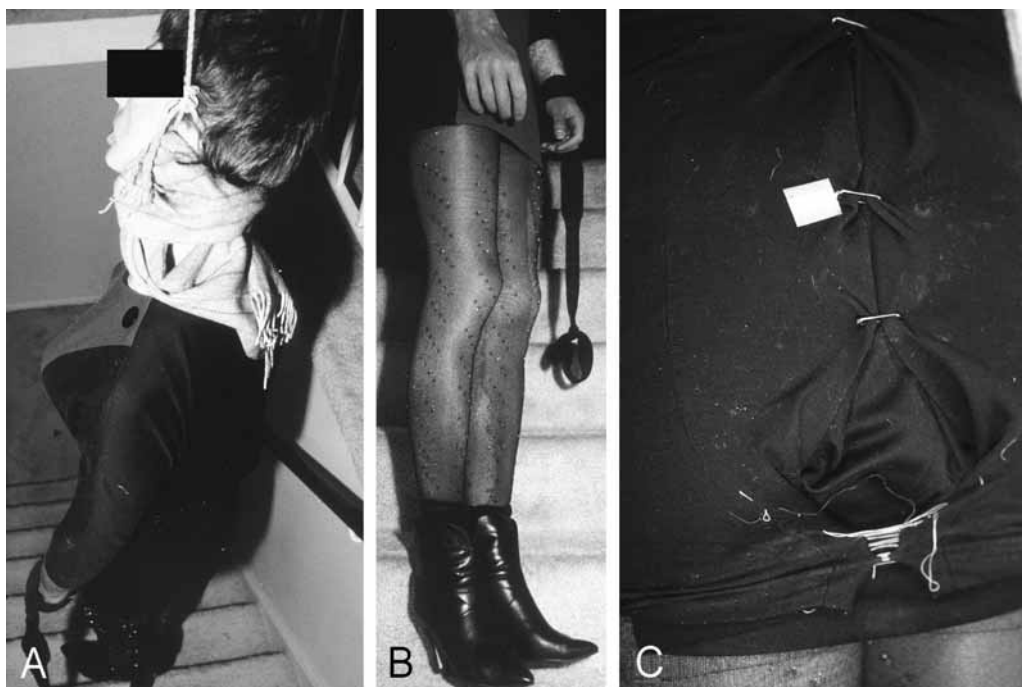
Self-rescue mechanisms are used by the victim (e.g., a knife to cut a ligature [227,229,231,232,238,243,260]). Simply standing relieves neck pressure while hanging



**Fig. 45.** Autoerotic asphyxia by hanging. Indentation on joist consistent with past suspension.

(Fig. 46; refs. 232 and 238). The arrangement or configuration of the bindings on the neck and other body sites allows voluntary compression (233,281). These bindings are usually loose (Fig. 46; refs. 224, 263, and 281).

Evidence of other paraphilias has been observed (229). There may be bondage, i.e., the use of physically restraining materials or devices that have sexual significance for the user (e.g., plastic, rubber, or leather attire [225,227,228,230,233–235,238,249, 253,258,267,282]). A man may be tightly wrapped in women's apparel or other items (Fig. 46; refs. 232 and 240). The extremities and genitals may be bound (Figs. 46 and



**Fig. 46.** Autoerotic asphyxia by hanging. (A) Man dressed in women's clothing found hanging in stairwell. Note scarf interposed between ligature and neck. (B) Shoes almost touching stair. Loose binding around wrists. Ankles bound. (C) Dress folds sewn together.

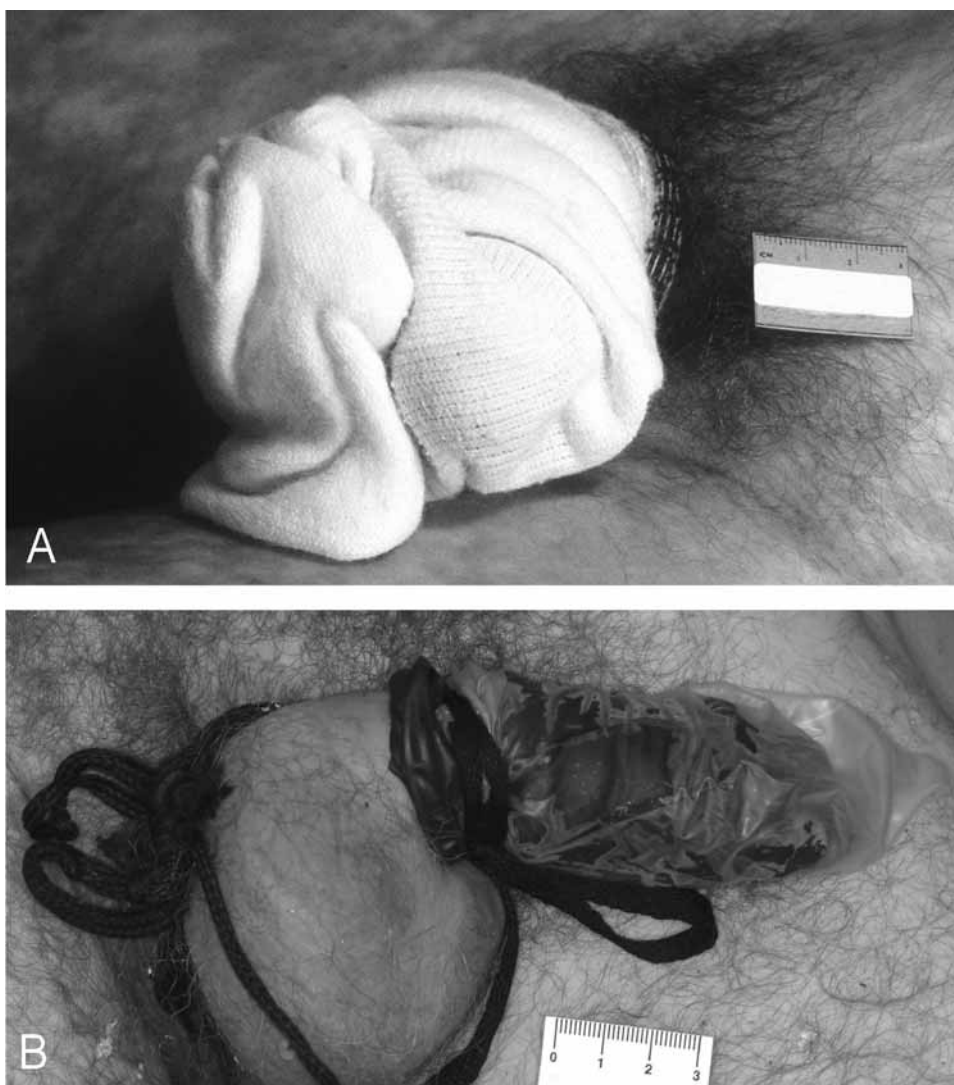
47; refs. 141, 231, 232, 235, 238, and 266). Hyperthermia could occur in a tightly bound individual (283). Bondage has also been described in women (224,241,263,265). Bindings create marks on different parts of the body (Fig. 48; refs. 252 and 281).

Devices and sexual paraphernalia can be found on or in the body. This has been described in women (224). Foreign objects may be present in the rectum, vagina, or urethra. Associated trauma is possible (e.g., peritonitis, hemorrhage; *see* Chapter 7, Subheading 2.4. and refs. 239, 263, 265, 266, and 282–284).

Evidence of recent and healed self-inflicted injury from sexual arousal is noted in some cases. Trauma (e.g., piercings, burns) on the genitals, nipples, and other body sites have been found (225,227,228,234,238,239,253,258,263,264,282). Pubic hair may be shaved (230). Sexual masochism is rare in women (239,241).

Evidence of sexual activity may be seen. The victim's hand may be near the genital area (225,234,241,273,275). The purpose of the autoerotic act is not necessarily masturbation; i.e., the hands are not always used to stimulate the genitals (229,258). Genitalia can be exposed (141,226,227,238,239,262,271). A zipper can be open (268). The presence of semen near the penis and priapism do not necessarily indicate masturbation but may be a postmortem event (*see* Chapter 2, Subheading 2.1, Fig. 2; refs. 28, 78, 90, 225, and 234). The penis may be in a condom or other material (e.g., plastic bag containing tissue paper) that may contain seminal fluid (Fig. 47; refs. 227, 238, and 274). Seminal fluid may be found on clothes or on the thighs (240,243,275).

Frequently, a male dresses in women's clothing (Fig. 46; refs. 225–227,229, 231–234,239,243,258,261,274,276,285). The clothing may belong to the deceased's wife,



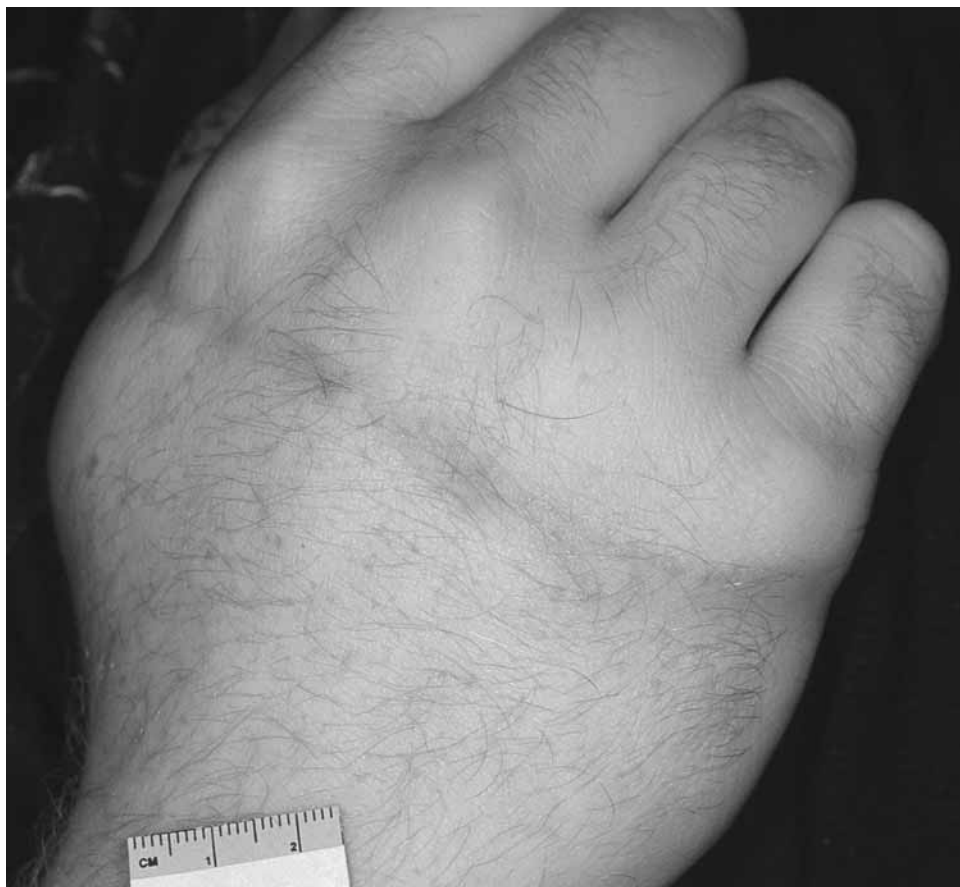**Fig. 47.** Autoerotic asphyxia by hanging (two cases). **(A)** Sock wrapped around penis. **(B)** Condom. Ties around penis and scrotum. (Courtesy of Dr. E. Tweedie, London Health Sciences Centre, London, Ontario, Canada.)

daughter, or girlfriend (229,238). Cisvestism (i.e., obtaining sexual satisfaction from dressing in clothes typical of one's own sex, e.g., a cowboy outfit, biker's "leathers") may be practiced (227,232). Cross-dressing men are more likely to show evidence of anal self-stimulation with various devices, mirror-gazing, and self-photography (230). Women rarely wear unusual attire (239,241,263). Victims can be partly or completely naked (227,229,231,234,241,243,258,268,273,281).

### 2.7.2. "Atypical" Autoerotic Deaths

"Atypical" autoerotic deaths result from sexual stimulation by nonhypoxic mechanisms (about 10% [228,247,250,258,273]). These include:





**Fig. 48.** Faint mark on dorsum of right hand used by victim to secure a ligature during autoerotic hanging.

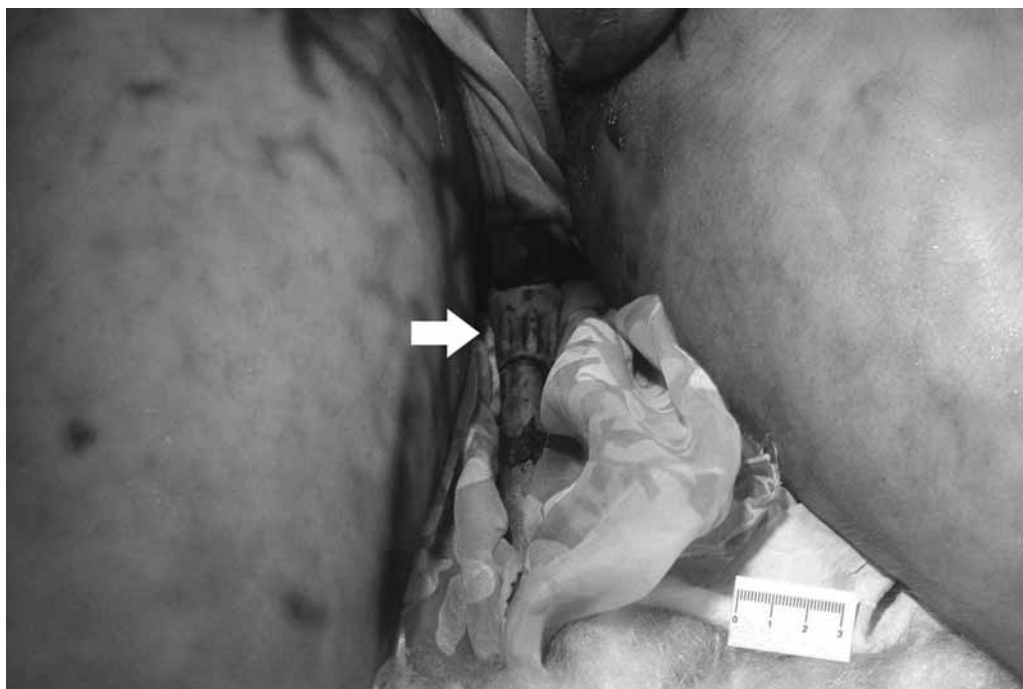
- Electrocution ([228,229,238,247,250,286–289](#)).
- Inhalants.
  - Mechanisms of death can be multifactorial ([273](#)). Hypoxia can result from displacement of oxygen by gas (e.g., nitrous oxide, propane [[247,261,268,273](#)]). Some agents cause arrhythmia (e.g., trichloroethane, fluorocarbons [[273,290](#)]). Nitrates are associated with severe vasodilation ([229,273](#)). Other gases are central nervous system (CNS) depressants (e.g., tetrachloroethylene, gasoline [[229,271](#)]). These various inhalants are also used to commit suicide ([291](#)).
- Delayed death owing to bronchopneumonia secondary to renal failure from a urinary bladder calculus around a self-introduced catheter ([292](#)).
- Intrarectal wound caused by firearm (*see* Chapter 6, Heading 10).

Deaths from natural disease occurs during autoerotic practices ([Fig. 49](#); refs. [226, 228, 243, 244, 250, and 276](#)).

### 2.7.3. Toxicology

Analysis for ethanol, drugs, and other intoxicants that may have been taken to enhance the autoerotic experience may explain the inability of a victim to extricate





**Fig. 49.** Man found dead from ischemic heart disease dressed in woman's clothing. Use of metal rod (arrow) for anal stimulation.

himself ([133,225,243,248,255,261,273](#)). Toxicological tests are not always ordered if the scene and circumstances leave no doubt as to the accidental nature of the act ([107](#)).

#### 2.7.4. Consensual Sexual Activities

Deaths happen during consensual sexual activity and can suggest homicide ([244](#)). The victim can be engaged in either a sadomasochistic practice or a hypoxic scenario intended to prolong orgasm. Some scenarios include the following:

- Bondage and asphyxia (e.g., manual/ligature strangulation, gagging/bags, chokehold [[191,239,244,249,253,254,262,277,279](#)]).
- Suffocation during fellatio and aspiration of semen ([244](#)).
- Air embolism from oral sex during late stage of pregnancy ([244](#)).
- Electrocution ([293,294](#)).
- Genital injuries from foreign body insertion and fisting ([295](#)).
- Natural death ([247,253](#)).
- Nonfatal self-inflicted and genital injuries during intercourse ([244](#)).

## 2.8. Pathologist's Approach to a Hanging Death

### 2.8.1. External Examination

- Clothing and personal effects description.
- Evidence of other trauma; distribution of lividity.
- Is ligature available? *In situ* or removed? If *in situ*, note knot position, number of loops. Photograph ligature. If *in situ*, cut away from knot. Reconstruct circumference by joining cut ends with tape ([Fig. 50](#)). The ligature is evidence.



**Fig. 50.** Suicidal hanging. Ligature was removed from neck by cutting away from knots. Note reconstruction of ligature by tape (arrows).

- Ligature description:
  - Type of material.
  - Circumference of noose.
  - Width.
  - Nature of knot (slipknot, fixed).
- Ocular or facial petechiae.
- Tongue protrusion between clenched teeth.
- Description of furrow or skin “mark” (62):
  - Course (angled or canted up).
  - Width.
  - Neck circumference at level of furrow (to determine degree of neck constriction; noose circumference < neck circumference).
  - Pattern.
  - Transfer of ligature material.
  - Associated skin changes or trauma.
  - Relation to thyroid cartilage.

### 2.8.2. Internal Examination

- Anterior neck structures examined last—i.e., following collection of toxicology samples and removal of other tissues and organs—to allow drainage of blood and reduce the possibility of artifactual hemorrhage.
- Exposure of anterior neck structures either by midline incision from symphysis pubis to chin or Y-shaped chest and abdominal incision. The former is advocated as the best

method but causes difficulties for funeral home preparations. If using a Y-incision, do not initially dissect the upper flap above the clavicles; otherwise, settled blood can collect at the junction of the flap and underlying soft tissue, creating an artifact. If the death is suspicious, the tips of the incision at the shoulders can be extended behind the ears to allow better exposure and ease of removal. In suspicious cases, the pathologist must do this dissection.

- Prior to removal of anterior neck structures, gently palpate the hyoid bone. A variably calcified stylohyoid ligament may be felt. Inspect anterior neck muscles, including sternocleidomastoid muscles (incisions to rule out hemorrhages).
- Remove anterior neck structures (tongue, larynx, and trachea with thyroid gland and attached strap muscles; submandibular glands may be included).
- Inspect the tongue. Cut through the tongue (tip to base) to observe hemorrhage.
- Note whether hemorrhage is present in the submandibular glands.
- Dissect away the strap muscles and note any hemorrhage.
- Remove the thyroid gland, weigh, and section.
- Dissect muscle tissue away from the cricoid. Dissect muscle tissue away from the laminae of the thyroid cartilage and superior horns. Note any hemorrhage or fracture. Beware of anatomic variations of the superior horns.
- Palpate the hyoid bone again and note whether it is rigid or lax. Note any hemorrhages adjacent to the hyoid or thyrohyoid ligament. Dissect away the hyoid (note that the lesser cornua are variably long and may be inadvertently cut).
- If there is a suspicion of fracture, radiographs of the hyoid and larynx can be done.
- Specialized larynx dissection—i.e., longitudinal sections through the larynx to note intracartilaginous hemorrhages—is optional but may be informative in hanging cases.
- Open the esophagus posteriorly.
- Open the larynx–trachea posteriorly. If the larynx is calcified, manual force will be required to open the larynx (a crack may be felt or heard). Observe any submucosal hemorrhage or petechiae, mucosal injuries, and aspiration.
- The pathologist must retain the formalin-fixed specimen if the death was unusual or suspicious in anticipation of later legal proceedings and review by another expert.

### 3. “*SUBTLE*” *ASPHYXIAS*

Deaths resulting from neck compression usually have observable physical findings. Although internal neck trauma may be lacking, a furrow or mark is typically seen on the neck. Other types of asphyxial deaths lack obvious injuries and are “subtle.” Investigation of the scene and circumstances, coupled with the pathologist’s diligence in finding “subtle” clues at autopsy, help determine an asphyxial mode of death. In the case of asphyxiants, toxicological analysis is essential when there is “no anatomic cause of death.”

#### 3.1. *Smothering (Suffocation)*

Deaths from smothering involve impairment of breathing by obstruction of the nose and mouth. Some reserve the term *suffocation* for deaths in confined spaces, but the terms “suffocation” and “smothering” are generally used interchangeably (116). Determination of the cause and manner of death in a suffocation or smothering death hinges on the investigation because of the lack of pathognomonic signs (22). A smothering death can be suspicious for homicide (22,296). Smothering is a method of infanticide.

### 3.1.1. Overlaying

Overlaying is a form of smothering by a larger individual lying on top of a smaller individual, usually an infant (27). Besides airway obstruction, blood flow in the neck and chest excursion are impaired. One series showed an age range of victims from 6 d to 11 mo and in another, 70% were younger than 3 mo (27,117).

SIDS and other means of smothering must be considered (35,297). In various studies of SIDS fatalities, a disproportionate number of cases occurred in children who had shared a bed with a parent or older sibling (38,298). More recent literature has underscored the controversy about the relative benefits and risks associated with bed-sharing (38,299–301). Postulated mechanisms to explain the increased risk of SIDS in bed-sharing infants include hypoxia owing to re-breathing of parental expired air, airway obstruction, and thermal stress. Blair et al. have suggested that “it is not bed-sharing *per se* that is hazardous but rather the particular circumstances in which bed-sharing occurs” (299). An investigation of an overlaying case needs to consider the following:

- The victim shared a bed with an adult, who can be obese, or with older siblings. More than two individuals may be involved (27,113,115,116,302,303).
- Unless there is an admission by the bed-sharer, overlaying is difficult to determine (304).
- Children are usually on an adult bed (waterbeds, single or twin beds) or a sofa and only occasionally in a crib (27,305).
- The clothing of the adult and child, and the bedding requires examination (*see* Subheading 3.1.1.1.).
- Ethanol intoxication or a medical condition, neither freely admitted by the adult, can be a factor depressing an arousal response in the older bed-sharer (27,116,304).

#### 3.1.1.1. EXTERNAL EXAMINATION

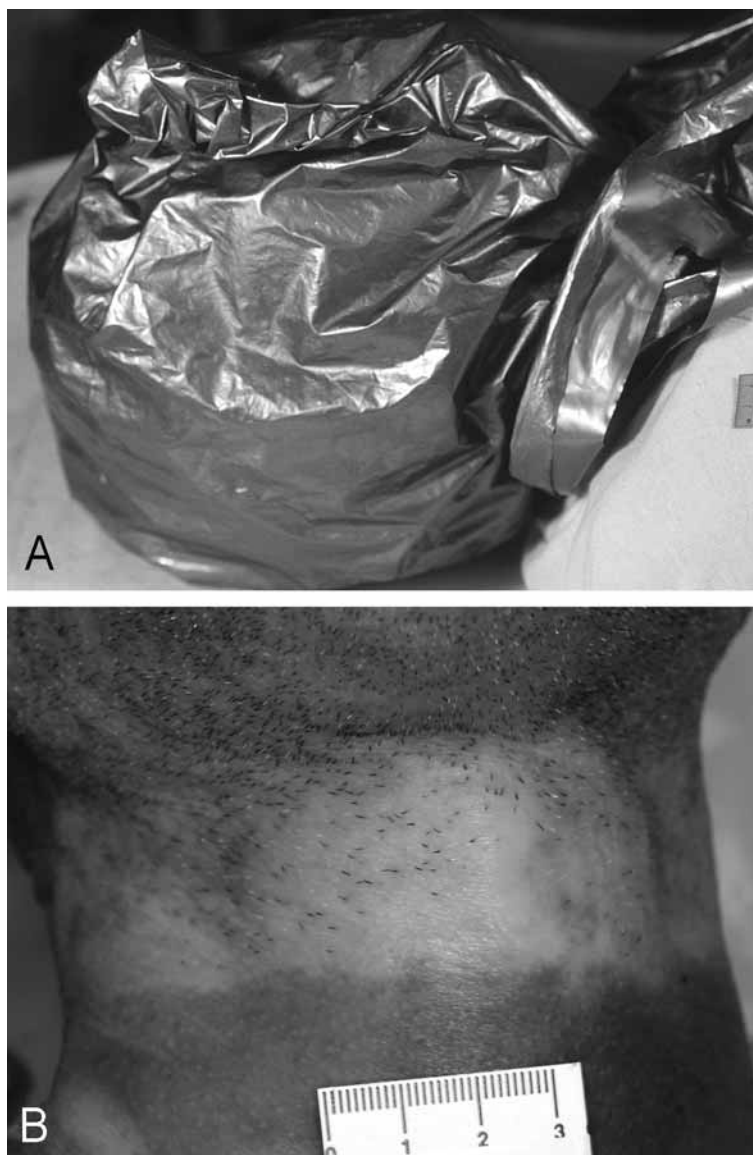
There is a paucity of findings similar to SIDS and smothering cases (27,297). Pressure marks from bedding or clothing (adult’s or child’s) may be seen on the victim, but these also occur postmortem (27). The lividity pattern indicates the position of the child, who may show areas of pressure pallor from the bed-sharer. Some cases show a few contusions on the face and head, and even a few abrasions of the nose and cheek, depending on the firmness of the opposing surface (27). Ocular and facial petechiae are uncommon and relatively few (27). No oral or intraoral injuries are found, particularly if the child lacks dentition (27,113). There can be intraoral petechiae (113). Multiple cutaneous injuries and oral or intraoral injuries raise the possibility of homicidal asphyxia (27).

#### 3.1.1.2. INTERNAL EXAMINATION

The majority of cases show intrathoracic petechiae (27,113). The finding of epidural hemorrhage around the cervical cord was thought to be caused by congestion of the perivertebral venous plexus owing to chest compression; however, it is a nonspecific postmortem feature seen in deceased infants (306).

### 3.1.2. Plastic Bag Asphyxia

Plastic bag asphyxia results from decreased oxygen concentration in the available inspired air and physical obstruction of the mouth and nose (257). The latter mechanism arises when a plastic bag becomes electrically charged and adheres to the face, aided by



**Fig. 51.** Plastic bag asphyxia (suicides). (A) Elderly woman. (B) Neck pallor created by knotting and tying of three plastic bags.

condensation ([242,257](#)). Alternatively, the placement of the plastic bag on the face may stimulate the sympathetic nervous system, resulting in a terminal arrhythmia.

#### 3.1.2.1. SUICIDES

As a method of suicide, plastic bag suffocation is more common among the elderly ([Fig. 51](#); refs. [307–309](#)). This could be because of the availability and easy use of plastic bags ([307,309](#)). Death is relatively painless and would appeal to older and more debilitated individuals ([307,309](#)). Plastic bag asphyxia has been described in *Final Exit: The Practicalities of Self-Deliverance and Assisted Suicide for the Dying*, published by



the Hemlock Society, a right-to-die group (56,307,309,310). In the year after its publication, the number of plastic bag asphyxial suicides in New York increased, but the overall suicide rate did not (310). Similarly, after the book had been translated into Danish, this method of suicide rose in that country (56). Three series of plastic bag suicides are summarized in Table 3.

Asphyxiating gases (propane, ether, helium) have been used, and the gas tank is usually situated beside the body (311–313). A modified bag has been described and was removed by the deceased's helpers in an attempt to mask the death as natural (312). A victim can be assisted by a helper who positions the plastic bag. If propane is used in conjunction with the plastic bag, a prominent odor caused by ethyl mercaptan, which is added to propane, may be detected (311,314). A 13-yr-old committed suicide using a bag containing aerosol deodorant (257).

### 3.1.2.2. ACCIDENTS

The following scenarios have been described:

- Autoerotic asphyxia (*see* Subheading 2.7.1.).
- Drug misadventure—volatile inhalants (e.g., chloroform, propane [257,308,315,316]).
- Inhalation of volatile hydrocarbons (e.g., trichlorethane) or fluorocarbon propellants. If the bag does not cover the head, arrhythmia is the likely mechanism of death (315, 317,318).
- Children (e.g., plastic bag in crib [48,114,115,117]).
- Plastic sheet—institutional deaths (e.g., patient's face covered by plastic sheet placed for bed wetting [48]).

A death scene can be altered to make a suicide or homicide appear to be an accident (257).

### 3.1.2.3. DESCRIPTION OF PLASTIC BAG

In an Ontario series of suicides, the bag was secured in 95% of cases (Fig. 51; ref. 307). A rubber band was most commonly used to secure the bag (22%). A large, clear plastic bag covering the head and secured at the waist has been described (311). Eight cases (7%) studied in Ontario used more than one bag (up to three; *see* Fig. 51). About one-fourth made additional efforts to assist their deaths, e.g., obstructing the nose and mouth with a gag to ensure death, placing a mask over the nose and mouth to prevent the discomfort of the bag sticking to the face, tying the hands and/or feet to restrict movement, inhaling a noxious substance in the bag (e.g., carbon monoxide, propane), or modifying the bag (insertion of a breathing tube with electrical device/timer to simultaneously pull out the tube and shut off the lights). Use of a breathing tube may also be used to prevent panic by allowing the victim to breathe while ingested drugs begin to take effect.

In a Seattle review, the bag was in place in 65% of cases. In about 80%, a single bag was used (309). It was fastened in two-thirds of cases. Condensation was noted in the bag in half the cases. None of the individuals used additional efforts to assist their deaths.

A Scottish series (27 suicides, 3 accidents) showed 19 bags secured (257). In five cases, two or more bags were present, and in six cases, noxious agents were in the bag (e.g., aerosol glue, chloroform).

One case has been described in which a 40-yr-old woman hanged herself with a plastic bag over her head (308).

**Table 3**  
**Plastic Bag Asphyxia (Suicide)**

Series	% Of all suicides	Age range	Male/female	Scene	Suicide note	"Right-to-die" literature	Previous suicide attempt	Debilitating or life-threatening disease
Ontario, Canada 1993–1997 <i>n</i> = 110 (307)	1.91%	16–95 yr (avg. 60.2 yr), more than half >60 yr	57%/43%	Home = 80%; hotel/motel = 10%; chronic care facility or hospital = 9% tent = 1%	1/2	12%	Approximately one-third (2 had used plastic bag previously).	40%
Seattle, WA 1984–1993 <i>n</i> = 53 (309).	2.6%	18–93 yr (avg. 72.5 yr) more than 80% >50 yr	47%/53%	Home = 87% Other — motels/ hotels, chronic care facility, retirement center, hospital	1/2	11%	Approximately one-fourth	38% 15% terminal
Scotland 1984–1998 <i>n</i> = 30 (257)	27/30 suicides 0.2% of all deaths	31–81 yr (avg. = 50 yr); 45 yr (males), 61 yr (females)	67%/33%	Home = 83% Other — hotel, hospital, workplace, countryside	1/3	11%	Approximately one-third	

### 3.1.2.4. EXTERNAL FINDINGS

Like other smothering deaths, there is a paucity of external findings in plastic bag deaths. If the plastic bag is removed at the scene by the victim's associates or investigators, the diagnosis becomes difficult (308). In the Ontario series of suicides, conjunctival or facial petechiae were seen in 7.5% of cases (307). A ligature mark was noted in about one-fourth of the cases (Fig. 51). The Seattle review revealed that petechiae were found in about 10% of deaths when the body was well preserved (309). Petechiae, usually conjunctival, were few (<3 total), but one decedent showed florid facial and conjunctival petechiae following prolonged resuscitation. About 20% showed external marks on the neck corresponding to the securing fastener (half were rubber bands). The Scottish study found external and internal petechiae in 16% (conjunctiva, eyelids, other areas of the face, neck, pleura [257]). Facial congestion occurred in three cases. Four cases (13%) showed neck marks corresponding to the site of fastening.

There may be coexistent injuries indicative of suicide (e.g., wrist incisions [314]).

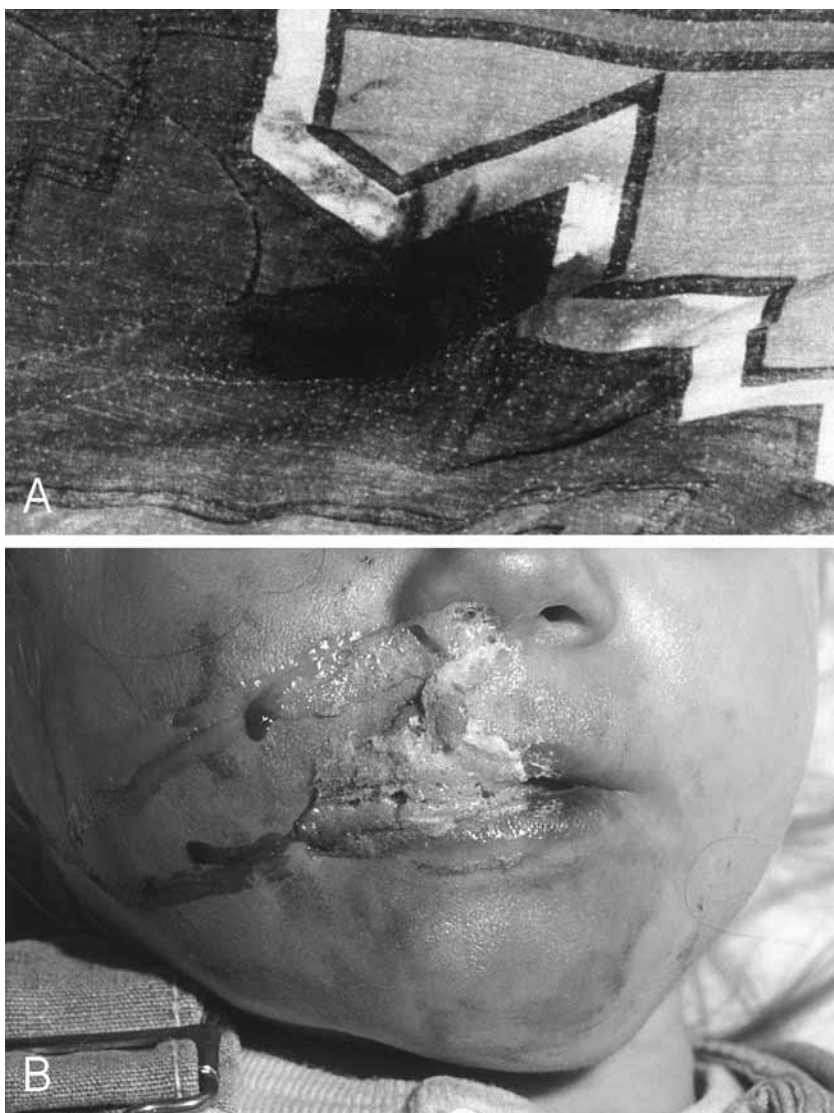### 3.1.2.5. INTERNAL EXAMINATION

Pulmonary edema and congestion have been seen in about half of deaths (307). Visceral petechiae were found in less than 20% of the Ontario cases and in only 4% in the Seattle study (307,309). No internal neck hemorrhage was described in the Ontario series, but one case observed in the Seattle review had focal hemorrhage in the thyroid membrane (307,309). The Scottish series found that 9 of 30 victims had preexisting disease (coronary atherosclerosis, lung disease), which could have altered their response to hypoxia (257). In rare instances, a brain tumor, which may have contributed to depression (e.g., meningioma in frontal lobe area), was found (319).

### 3.1.3. Some Other Means of Suffocation/Smothering (Accident and Suicide)

- Gas mask (320); modified gas mask and anesthetic gas (321); anesthetic face mask and anesthetic gas (*see* Subheading 2.7.1. and ref. 291); air-filter mask and helium (322).
- Motorcycle helmet (visor taped, bath towel encircled neck) combined with asphyxiant (269).
- Duct tape (case report description: tape started on the left side of the mouth, covered the eyes, nose, and mouth, and ended on the lower right cheek [296]).
- Pillow (case report description: 32-yr-old male chronic schizophrenic [22]).
- Children younger than 1 yr of age have been found dead facedown on soft surfaces (e.g., pillow, bean bag, waterbed, sheepskin rug, polystyrene-filled cushions, suspended rocking cradle [32,35,113,117,302,323–325]). The child is unable to extricate itself (113,324). The nose and mouth are obstructed, worsened by mucus and regurgitated milk (Fig. 52; refs. 113 and 323). Rebreathing of carbon dioxide has been demonstrated experimentally (323,326,327). Smothering by this means is uncommon in adults (Fig. 53).

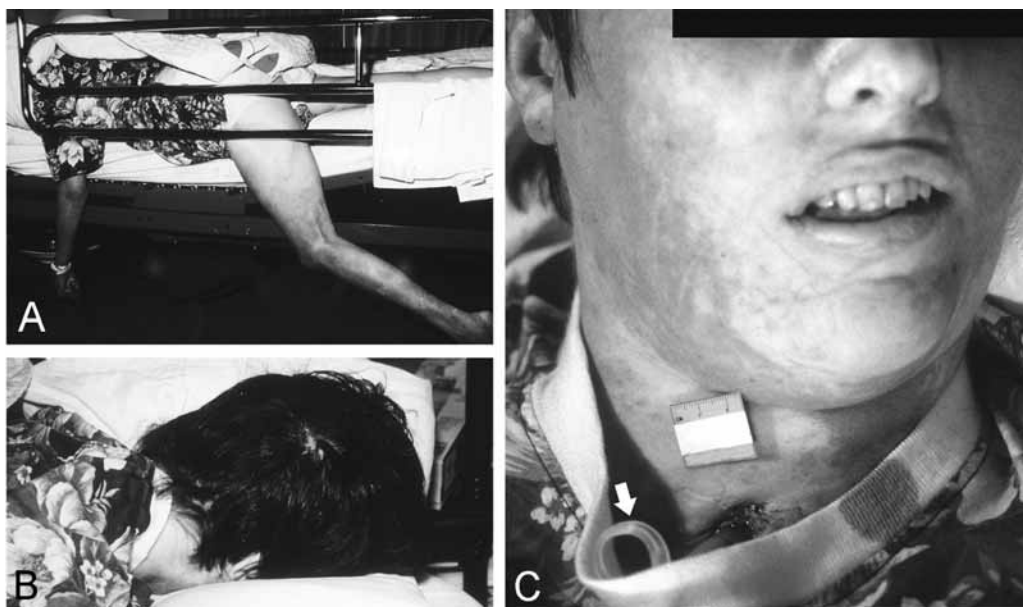Sleeping in the prone position is a risk factor for death from SIDS (38). An abnormal response to increased inspired carbon dioxide concentration has been proposed (327). In a small percentage of infants, nasal obstruction during sleep and a delayed or absent mouth breathing response were considered factors leading to apnea (328). Normally, when a child is aroused under these conditions, it should move away from the potentially lethal environment (327). In the presence of soft bedding, movement of the head from side to side could worsen the situation by creating a deeper pocket, which traps expired air (327). Controlled lifting of the head, while in the prone position, is not



**Fig. 52.** Smothering in a confined space. **(A)** Child found wedged between bed and wall wrapped by thick bed cover. Orange stain where face pressed. **(B)** Regurgitated fluid (milk) coated right nostril and mouth.

attained until 3 mo of age. The ability of infants to turn from lying facedown to the supine position is reached by 6 mo (327). These actions are hindered if the child is tightly covered by bedding (327).

Anatomic characteristics of the infant pharynx and upper respiratory tract have been postulated as factors in airway obstruction (32). When prone, the softer nasal cartilage of infants is compressed. Certain infants could have increased tongue bulk and relatively small jaws, which decrease airflow. During sleep, there may be close approximation of the base of the tongue, soft palate, epiglottis, and pharynx owing to relaxation.



**Fig. 53.** Hemiplegic woman. **(A)** Found face down. Arm and leg wedged by bed rail. **(B)** Face in soft pillow. **(C)** Circumoral pallor. Tracheostomy tube (arrow) was capped.

The baby's head is a major temperature-regulating site. If covered, this could predispose to hyperthermia and hypoventilation (32,35,329,330).

Underlying pulmonary infection may increase the risk of dying, perhaps by contributing to laryngospasm or bronchospasm (34,329,330).

### 3.1.3.1. EXTERNAL EXAMINATION

- Gas mask deaths—conjunctival petechiae and facial congestion (mechanical pressure of mask on the face); indentations on facial skin (320).
- Anesthetic face mask—marks around mouth and nose (291).
- Compression of face in soft material—pallor around pressure points (tip of nose, perioral area, midpart of forehead, cheeks, chin) surrounded by lividity (“circumoral pallor”); tip of nose can be deviated (Fig. 53; refs. 22 and 325). If dentition is present, then abrasions on the lips and buccal mucosa from biting may be seen (Fig. 54).

Other trauma (e.g., blunt force, penetrating trauma) suggests a struggle and possible homicide (22,296). Binding of other body sites can be seen (e.g., ankles [296]).

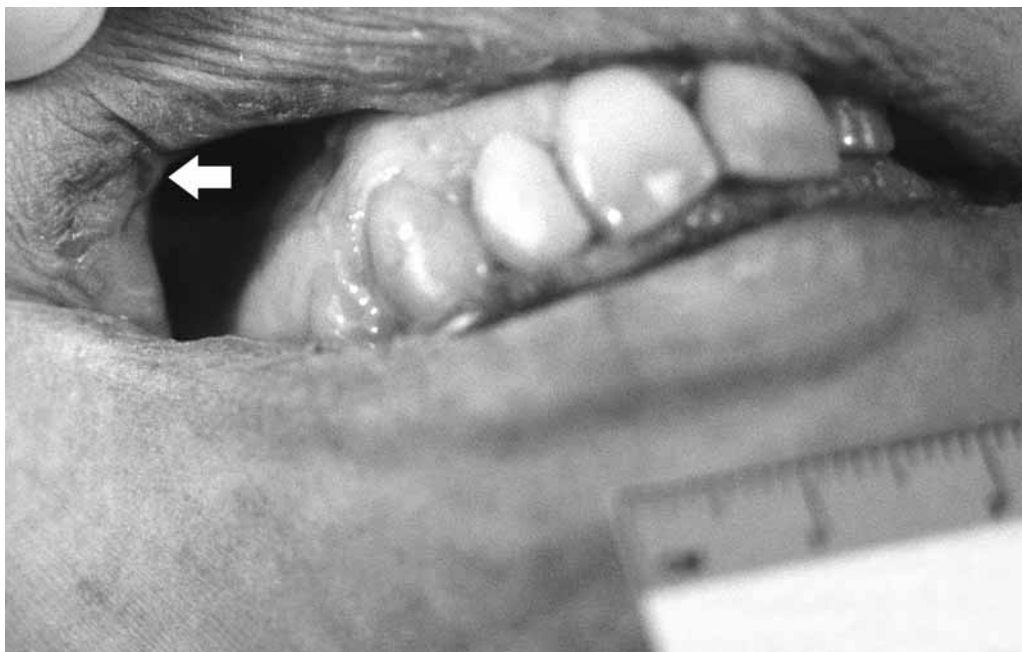### 3.1.3.2. INTERNAL EXAMINATION

Intrathoracic petechiae are absent or seen in variable numbers in children (113). No petechial hemorrhages have been described in suicidal smotherings using duct tape or a pillow (22,296). Nonspecific pulmonary congestion is observed (22). Larger lung intraparenchymal hemorrhages may be resuscitative in origin (113).

### 3.1.4. Toxicology: Suffocation and Smothering

If the circumstances are not suspicious, then toxicological testing may not be done. Toxicology testing in “suspicious” deaths determines whether the victim was incapacitated and vulnerable to a homicidal assault (22,269,296,308).





**Fig. 54.** Smothering (see Fig. 53). Small abrasion on right upper lip (arrow) from lower tooth.

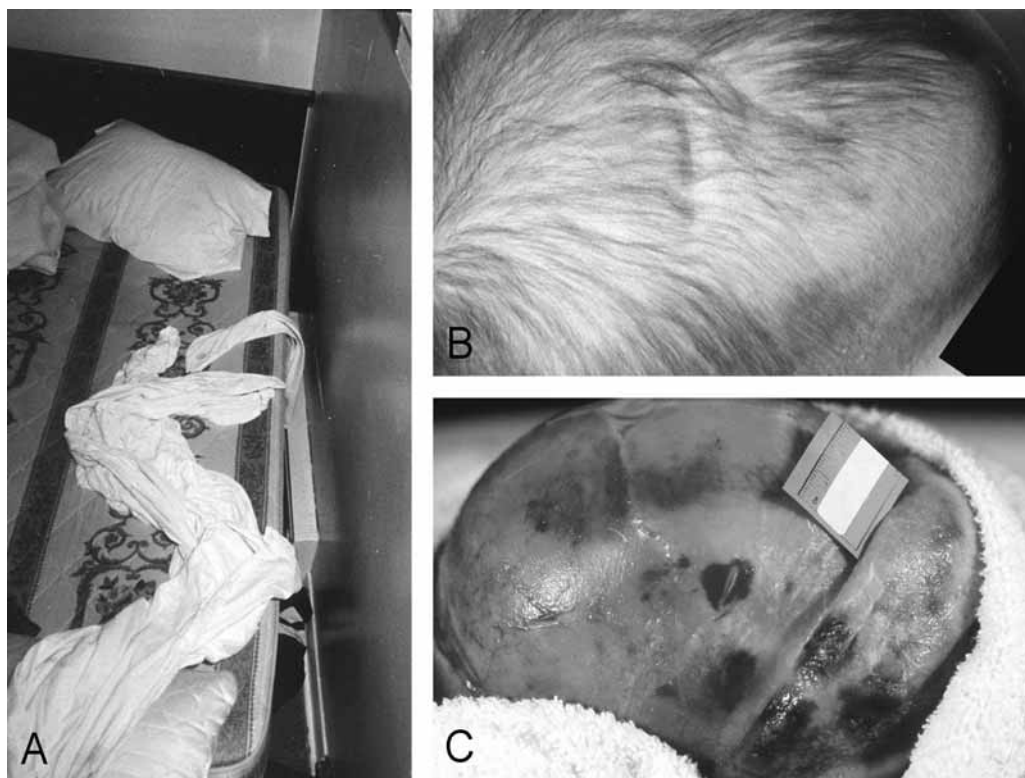
In plastic bag suicides, ethanol is present in about one-fifth to one-third of cases (257,307,309). Certain drugs (benzodiazepines, diphenhydramine, antidepressants) are commonly found (307). Above-therapeutic concentrations and toxic and fatal levels of medications occur (307,309).

Analysis for volatiles in a plastic bag requires retention of postmortem blood preserved with fluoride, sampling of tissue (e.g., lung, liver, brain), and submission of the bag in an airtight can or glass jar, which is refrigerated until testing (257,269,314,316,321,331). Some gases (e.g., helium) cannot be tested, emphasizing the importance of investigation of the scene and circumstances surrounding the death (312).

### **3.2. Wedging (Death by Interposition)**

*Wedging* is a form of mechanical asphyxia in which the face, neck, or thorax is compressed between two firm structures (see Subheadings 3.7. and 3.8. and ref. 27). Adults can become wedged between a bed rail and mattress (see Subheading 2.1.4. and refs. 99 and 332). In a review of 2178 infants younger than 13 mo of age dying of mechanical suffocation in the United States from 1980 to 1997, wedging was the most frequent scenario (40%), followed by oronasal obstruction or smothering (24%), over-laying (8%), entrapment with suspension (7%), and hanging (5% [117]).

Young children, aged 3 mo to 2 yr, are usually found in an adult bed or their own crib/bed (117). One study showed that wedging was seen primarily in 3- to 6-mo-old children (117). At this stage, infants have the capability to move to the corners of beds and cribs, but they do not have the muscle development to be able to extricate themselves out of a wedged position. They become wedged between the mattress and



**Fig. 55.** Wedging. (A) Infant found wedged between the bed and wall. Child also suffered severe burns from malfunctioning electric baseboard heater. (B) Indentation on scalp from edge of bed. (C) Reflected scalp showing associated contusions.

either the wall, bed frame, a piece of furniture, mesh, or another mattress (Fig. 55; refs. 4, 27, 35, 111, 113–117, 302, and 303). Parents may believe that pushing a bed against a wall prevents a child from falling out while sleeping. Heads wedged between crib slats or bedrails is another scenario (27,113–115,302). A defective or malfunctioning cot is a possibility (see Subheading 2.1.5.2. and ref. 117). The mechanism of death in these cases could be aspiration (110).

Few external findings are seen; this emphasizes the importance of scene investigation and interviews. Some cases show facial contusions or abrasions (27). Linear marks and indentations on the scalp and neck are consistent with contact with a firm surface (e.g., edge of bed frame; see Fig. 55 and ref. 27). Facial petechiae are rare, in contrast with adult traumatic asphyxia cases (27). No oral injuries are observed. Finding multiple cutaneous and oral injuries heightens the suspicion of nonaccidental asphyxia (27).

A minority of cases have intrathoracic petechiae; usually only a few are present (27).

### **3.3. Choking (Aspiration of Foreign Body, “Café Coronary,” “Creche Coronary”)**

#### **3.3.1. Scene and Circumstances (Accidental Choking Deaths)**

The phases of acute fatal airway obstruction are:

1. Penetration of the object into the airway.
2. Obstruction of the airway.
3. Failure to expel once the obstruction has occurred (333).

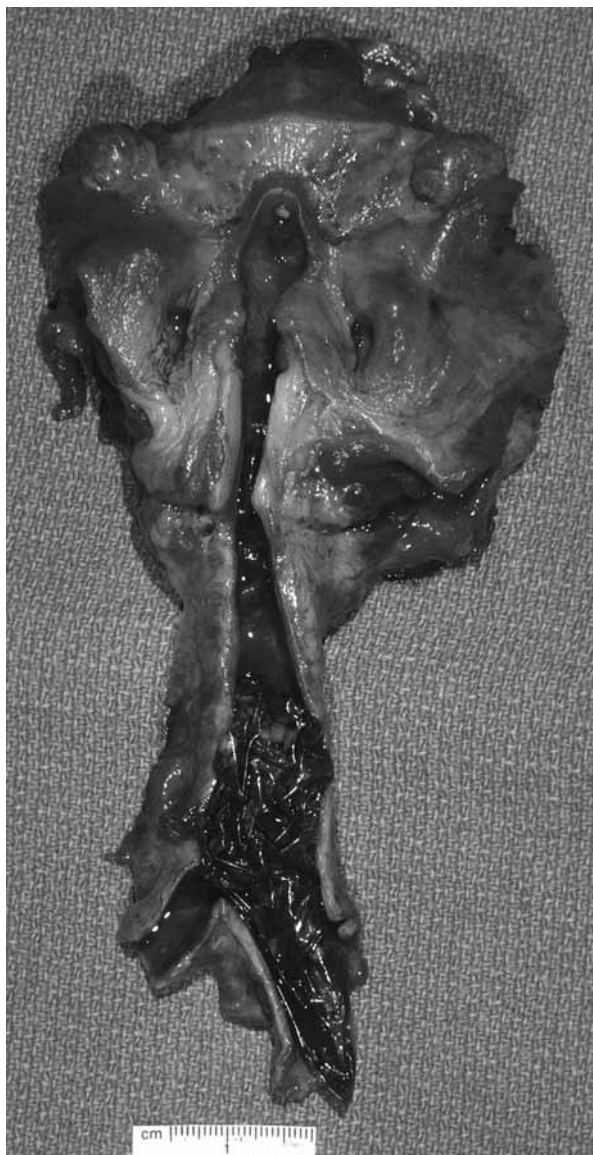Witnesses of a sudden death may describe signs of acute upper airway (glottic) obstruction (stridor, respiratory distress, coughing, choking) and the inability of the victim to speak (334–337). A rapid, deep inhalation frequently follows, causing a foreign object to pass further down the airway (333,338). Laryngospasm occurs (338). At this point, vagal stimulation, leading to arrhythmia and apnea, is a possible mechanism of death (339). An allergic reaction, manifest as laryngeal mucosal edema, happens under some circumstances (e.g., aspiration of pepper [340]). In some cases of foreign body obstruction in the esophagus and lower tracheobronchial tree, there is an asymptomatic period prior to the onset of respiratory symptoms (coughing, wheezing, dyspnea [334,336,341,342]). When hot liquid is aspirated, the onset of symptoms (difficulty speaking, dyspnea) develops following a latent period, up to 8 h (343). Incomplete obstruction eventually becomes complete when respiratory tract mucosal edema, inflammation, hemorrhage and bronchospasm occur (334). Chronic symptoms can develop (*see* Subheading 3.5.).

Choking is a common cause of accidental death in children less than 1 yr of age (116,334,344). Ninety percent of choking deaths happen before the age of 5 yr. Various reviews have shown an age range of 4 mo to 14 yr (344). Older victims tend to be mentally challenged, but normal older children can choke (334). Children aged 1 to 3 yr are vulnerable to choking (“creche coronary”) because of their increased mobility, inability to judge the appropriateness of placing small objects in their mouths and appreciate the size of a piece of food, small airways, inadequate dentition for chewing (i.e., development of incisors before molars allows biting but not proper mastication), and weaker cough reflex (116,333,336,337,342,345–348).

Home is the most common setting for incidents involving children (344). In many instances, the child is given an item by an adult who may not recognize the potential danger (344,349). The choking event is often unwitnessed (334). In one series, there was an adult present in about half the choking incidents, but direct supervision may have been lacking (333,344). Other children can distract supervising adults (e.g., in a day care center [347]).

Choking occurs while eating and playing (e.g., running [347]). Sampling of new foods can lead to choking (347). Pica syndrome is the ingestion of inappropriate material that occurs in children and adults (345). Mentally challenged individuals and people with neurological disorders can devour food ravenously (gluttony; *see* Fig. 56 and refs. 340 and 350). Children younger than 1 yr of age are more likely to aspirate food, whereas older children tend to choke on nonfood items (334,348). In very young children, the possibility of SIDS arises, but choking needs to be considered (334). Choking on a pacifier has been described (Fig. 57; refs. 114 and 351). Pacifier use was less frequent in SIDS cases than in controls in one study (352).

In adult cases, there is either a sudden collapse mimicking an apparent heart attack while eating (“café coronary”) or the death is unwitnessed (334,335,350,353). Predisposing factors include a decreased protective airway reflex resulting from aging, poor dentition with a tendency to swallow food whole, alcohol consumption, and ingestion of other CNS depressants impairing the gag reflex (335,341,342,345,350,354,355). Only a third of fatalities happen in a restaurant (355). Most adult choking deaths occur

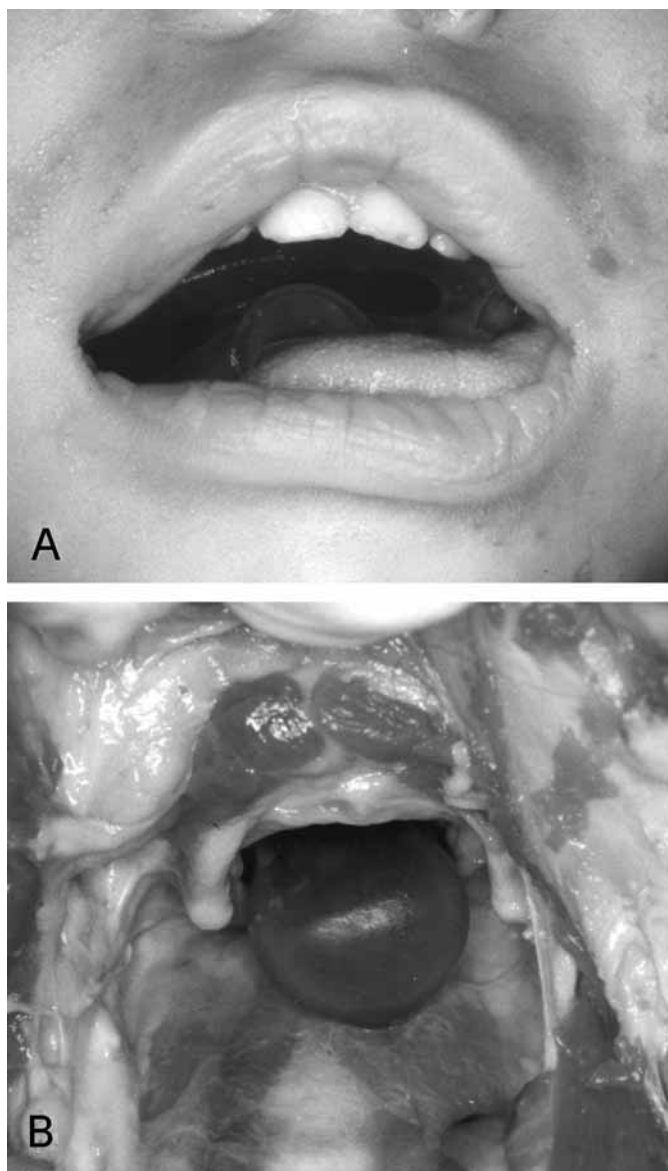


**Fig. 56.** Mentally challenged individual. Pica. Piece of plastic pushed down into carina by endotracheal tube. (Courtesy of the Office of the Chief Medical Examiner, Chapel Hill, NC.)

at home, in a nursing home, or in a psychiatric institution (350,355). Deaths have been described in hospitals (350). Long-term care patients may have an underlying neurological or psychiatric disorder, resulting in a decreased cough reflex or dysphagia (341,345,350,355–358).

Other choking situations have been described. A bulimic individual can aspirate an object used to induce vomiting (e.g., fork [359]). Abnormal positions while eating can result in choking (350). Xerostomia (dry mouth) from salivary gland dysfunction causes swallowing difficulty (350). An emotional outburst can trigger a choking episode (360). A blow to the mouth, a seizure, or a loss of consciousness are other scenarios (360).





**Fig. 57.** Infant. Choking on pacifier. **(A)** Pacifier in mouth. **(B)** Anterior neck (larynx removed). Pacifier protruding through oropharynx.

### *3.3.2. Role of Pepper Spray in “In-Custody Deaths”*

Oleoresin capsicum (OC) is a crude extract of hot peppers (genus *Capsicum*) that, when in contact with respiratory mucous membranes, causes individuals to choke or cough. OC may be used during police apprehension of an individual (*see* Subheading 3.7. and ref. [361](#)). Variable dyspnea caused by bronchoconstriction parallels the intensity of the coughing. Asthmatics and others with pulmonary disease are at risk ([90](#)). Some subjects are unable to speak. A case of laryngeal edema complicated by respiratory arrest has been described in an 11-yr-old boy ([362](#)). To assess the role of OC in the death of an



individual, various factors must be considered: the circumstances of the apprehension, the temporal relationship between OC use and the onset of symptoms, the nature of the symptoms, the activity of the victim following OC use, the presence of natural disease (e.g., ischemic heart disease) that could account for a sudden collapse and unconsciousness, and toxicological analysis to rule out toxic levels of ethanol and other drugs. Swabs of the face, mouth, and upper respiratory tract can detect the presence of pepper spray.

### 3.3.3. Choking and Other Manners of Death

Although most choking deaths are accidental, suicide and homicide are possible (338,363). Suicidal choking is uncommon and usually occurs in psychiatric patients and prisoners (338). Homicidal choking usually involves the aged; individuals debilitated by disease, alcohol, or drugs; and infants. When objects are forced into the mouth, signs of a struggle, if the individual was conscious, may be noted (338). There may be defensive injuries on the victim's hands. Injuries on the upper and lower extremities, as the victim was restrained, may be found. Marks or injuries consistent with victim's head being held may be seen. Perioral, teeth, tongue, and other intraoral injuries can result. The presence of foreign material in the respiratory passages and digestive tract provides supportive evidence that an individual was forcibly choked, particularly if most of the object was removed by the assailant or emergency personnel.

Natural disease can present as upper airway obstruction and sudden death. Coughing or vomiting can displace a tumor into the laryngeal opening. Examples of obstructive tumors described in the literature are:

- Hypopharynx (lipoma [364]).
- Upper esophagus (fibrolipoma, polyp [365–367]).
- Larynx (invasive squamous cell carcinoma, “juvenile” papillomatosis [368]).

Inflammation and reactive processes contributing to upper airway obstruction include:

- Acute epiglottitis.
- Palatine lingual edema of uvula, epiglottis, larynx (anaphylaxis; *see* Chapter 7, Heading 11.)
- Tonsillar enlargement (infectious mononucleosis, streptococcal tonsillitis, diphtheria [369–372]).
- Plasma cell granuloma of glottis (373).

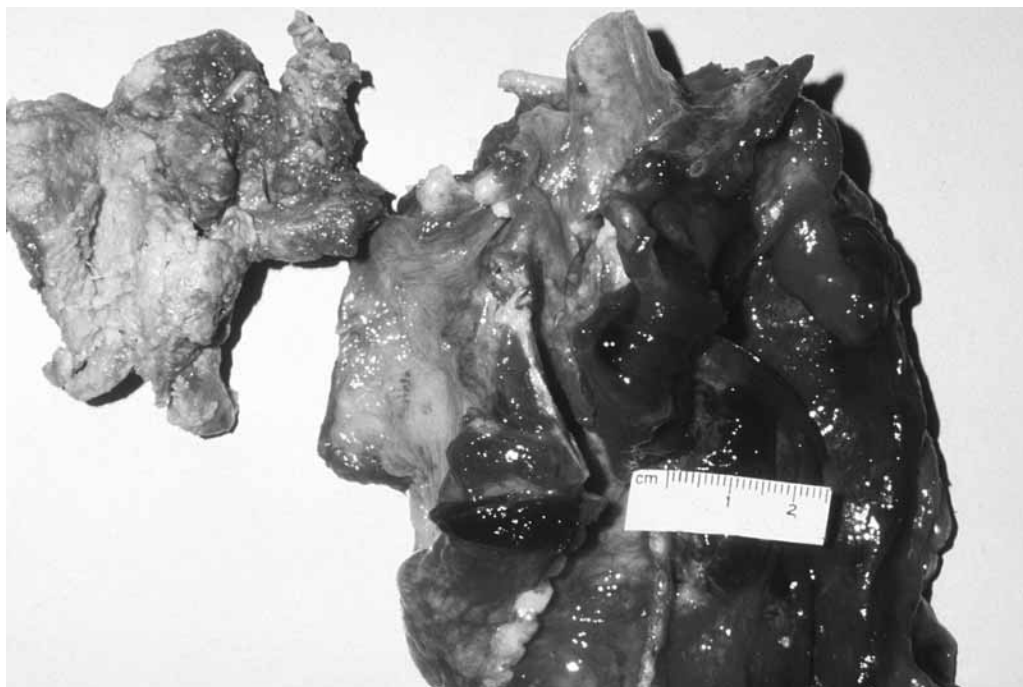Certain conditions (e.g., nasal septal deformity, adenoidal or lingual tonsillar hypertrophy, lingual or laryngeal cysts) predispose to obstructive sleep apnea (sleep apnea syndrome [374]). Ingestion of alcohol can exacerbate this condition (375,376).

### 3.3.4. External Examination: Choking

There are few external findings in choking deaths. Subconjunctival hemorrhages without cutaneous petechiae have been described (334,350). The general state of dentition needs to be assessed.

### 3.3.5. Internal Examination: Choking

There may be no indication of a foreign body in the airway until the autopsy (334,350,377). If a foreign body is found, then inquiries must be made about the circumstances of the death. An “innocent” explanation about the presence of the foreign



**Fig. 58.** Choking. Piece of pork chop removed from larynx at autopsy. (Courtesy of the Office of the Chief Medical Examiner, Chapel Hill, NC.)

body may be elicited (e.g., placement of a coin at time of death as part of a traditional Chinese funeral practice [378]). Alternatively, the obstructing object is visualized during intubation but then is removed and not available for the pathologist to examine (114,355). Inquiry about any resuscitative efforts must be done. If resuscitation occurred and an artificial airway was inserted into the mouth, artifactual dislodgement of foreign material further into the pharynx may result (see Fig. 56 and refs. 355 and 360). Insertion of an endotracheal tube pushes a foreign body deeper into the larynx, trachea, mainstem bronchi, and esophagus. Failure to remove the larynx and inspect the oropharynx at autopsy means missing a cause of sudden death (335,369,379).

The level of obstruction depends on the dimensions of the foreign body and its relation to the age and airway size of the victim (333,334). Some examples of nonfood items described in adults are dental or medical appliances, nasal secretions, talcum powder, hardware, feces, medications, and diagnostic media (e.g., barium [341,345,350,356,357,363,380–382]). The foreign body can be radiopaque (360). Children can choke on various items: balloons, small toys, hardware, coins, and the like (114,334,344,346,383–385). Children choke more commonly on food (336). The food items are usually round and firm, yet pliable to allow molding in the airway (114,333,347,349). Items such as beans can swell (379). Many types of food have caused choking in children (e.g., hot dog, bread, rice, candy, nuts, gum, fruits, vegetables [114,334,337,344,347,383]). In adults, meat and vegetable matter, animal bones, and whole fish have caused choking (Fig. 58; refs. 341,355,356, and 386). Softer foods are seen in institutionalized patients who have choked (355).

Epiglottic congestion, laryngeal mucosal hemorrhage, congestion, and petechiae have been described in choking cases (334,350,360). In children and adults, aspiration of hot liquid leads to epiglottic, laryngeal, and tracheal edema, and mucosal denudation requiring assisted ventilation (343,387,388).

Underlying disease predisposing to choking or aspiration should be assessed (340,389).

Sharp foreign bodies (e.g., bones, toothpicks) can be inadvertently swallowed with food. Deliberate swallowing of foreign bodies leading to airway obstruction does occur in the mentally handicapped, individuals with psychiatric disorders, prisoners, and criminals who are smuggling contraband (e.g., jewelry, drugs [390]). Some swallowed objects can remain in or penetrate the gastrointestinal tract (e.g., open safety pin in esophagus puncturing heart leading to hemopericardium, toothpick through small bowel into common iliac artery, bone penetrating esophagus into aorta or common carotid artery, wood screw in retroperitoneum with septicemia, coin impacted in esophagus compressing adjacent trachea [337,379,391–394]).

The Heimlich maneuver—i.e., the application of abdominal pressure to relieve the obstruction—can be associated with complications (353).

### **3.4. Acute Aspiration**

#### **3.4.1. Pharyngeal and Gastric Contents**

Terminal aspiration of sterile acidic gastric contents and oropharyngeal secretions containing bacteria occurs frequently as an agonal event and is often observed at autopsy (395). Cough and gag reflexes are depressed at death, allowing agonal regurgitation into the airway (396). This is not necessarily a cause of death, but a sign that an individual is obtunded (36,209,333,396). Psychiatric and neurological disorders that lead to choking cause aspiration of vomit (397).

Aspiration of gastric contents is common in individuals with a decreased level of consciousness (drug overdose, anesthesia [395,397,398]). Critically ill patients are at risk (395). The supine position predisposes to gastroesophageal reflux (398). Reflux is enhanced by decreased gastric motility, which leads to retained gastric contents and stomach distension in critically ill individuals (395). The risk of aspiration is high after removal of an endotracheal tube because of the residual effects of sedative drugs, the presence of a nasogastric tube, swallowing dysfunction related to upper airway sensitivity, glottic injury, and laryngeal muscular dysfunction (395). Although a nasogastric tube is present, significant volumes of acid can still accumulate, depending on tube placement (398). The tube also passes through the esophageal sphincters, interfering with their function (398). Gastrostomy-tube and nasogastric-tube feeding offer no protection from aspiration of colonized oral secretions (395). Postoperative patients are more likely to aspirate when swallowing rather than when vomiting or regurgitating, and they are usually seated (397).

Aspiration can present with acute respiratory distress, but in many elderly patients, it is “silent” (395). Coughing can be a sign of acute aspiration (397). Mendelson’s syndrome refers to the acute “autolytic” appearance of the lung as an immediate response to aspiration of acidic (pH <2.5) stomach contents (395,398). Microscopic examination reveals edema and foreign material in distal airways and alveoli (Fig. 59; refs. 350, 363, and 397). Eventual bacterial colonization occurs. If acute inflammation develops in response to

bacteria (aspiration pneumonia), this indicates a survival period. If the pneumonia is extensive, then it is a cause of death (395,397). Inhalation of nonobstructing food particles can lead to a hemorrhagic pneumonia within hours (398). Within a few days, a granulomatous response is observed (see Subheading 3.5. and ref. 398). Diffuse alveolar damage also may follow (398). Inhalation of more basic (pH >2.5) liquid leads to pulmonary edema, which resolves rapidly with little lung damage and inflammation (398). Pulmonary edema occurs several hours after base aspiration, in contrast with acid aspiration (398). Passive transfer of gastric contents to the air passages does occur after death (396,397). Gastric contents were found in the air passages in about one-fourth of adult and pediatric deaths (“sudden infant deaths”) in one study (396). Green discoloration of lung parenchyma may be observed (Fig. 59). At autopsy, green or brown material may be seen in the mainstem (usually right) or intraparenchymal bronchi (Fig. 60; refs. 337, 342, 377 and 389).

Toxicology is important to rule out incapacitation by alcohol and other drugs, particularly if there is no clearly defined cause of death (355).

Gastroesophageal reflux is one theory proposed to explain apnea leading to SIDS (35). The introduction of acid into the esophagus was also thought to cause cardiac arrhythmia (35,399). Studies have shown that most apneic episodes are independent of gastroesophageal reflux (399). Reflux is more likely to occur while the infant is awake rather than when the child is sleeping, the usual scenario in SIDS (399). Gastroesophageal reflux may simply be a manifestation of general developmental delay (35). Reflux is less likely in the prone position, a risk factor for SIDS (ref. 400; see Subheading 3.1.3.).

### 3.4.2. Aspiration of Particulate Material

Aspiration of various types of particulate material causes obstruction in the lower respiratory tract. Examples include:

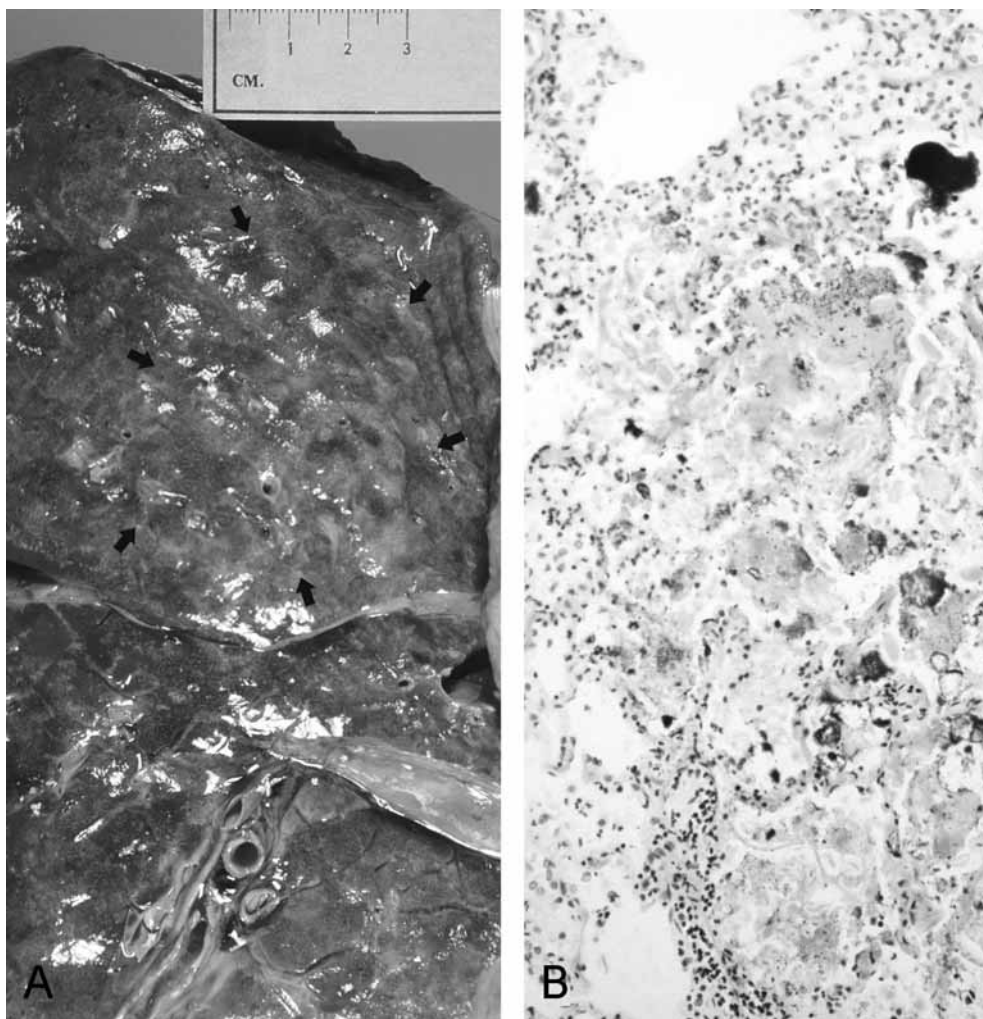
- Sand and/or gravel following burial of a live individual. Initial mouth-to-mouth resuscitation and intubation can further impact material (see Chapter 5, Subheading 10.2. and refs. 401–404).
- Pepper. Most cases described are homicides—i.e., punishment of a child by forcibly putting pepper in its mouth (405–407). Mechanisms of death include mechanical obstruction and mucosal edema due to the irritant effects of pepper.
- Talcum powder (children [408–410]). Talc particles (magnesium silicate) are polarizable, and demonstrated on microscopic examination of the lungs.

## 3.5. Chronic Aspiration

Typically, chronic aspiration of oropharyngeal secretions and food affects the elderly and debilitated (e.g., cancer, neurological disorder) and institutionalized individuals who likely have swallowing difficulties (354,357,389,395,397,398). The elderly frequently have poor oral hygiene, resulting in colonization of their mouths by respiratory tract pathogens (Enterobacteriaceae, *Pseudomonas aeruginosa*, *Staphylococcus aureus* [395]).

Because of the circumstances, a history of aspiration may not be elicited (377, 411,412). This is also applicable to children who may inhale a foreign body but yet are asymptomatic. Aspiration in the debilitated can be repeated, manifesting as recurrent pneumonia, episodic bronchospasm, bronchiectasis, or a lung abscess (336,337, 341,342,377,379,389,412–414). Eventual respiratory arrest can occur.





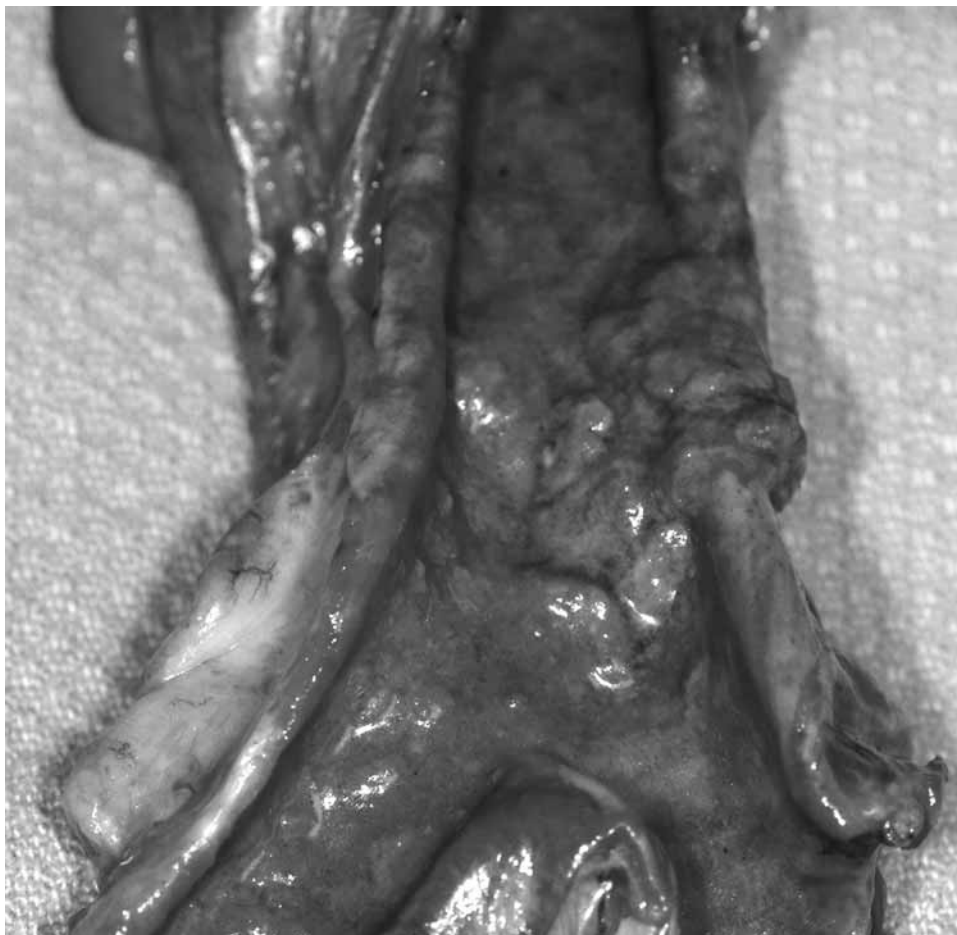**Fig. 59.** Acute aspiration. **(A)** Area of green discoloration of lung parenchyma owing to aspiration of bilious stomach contents (delimited by arrows; see Companion CD for color version of this figure). **(B)** Microscopic section of lung. Aspirated material from pharynx and stomach (H&E, original magnification  $\times 100$ ).

Microscopic examination of the lungs affected by chronic aspiration will reveal associated bronchiolitis, bronchopneumonia, and/or foreign body granulomatous inflammation (Fig. 61; refs. 337, 377, and 389).

### 3.6. Gagging

Gagging combines features of smothering and choking. A gag in a victim's mouth or wrapped around the nose and mouth interferes with the ability to breathe and swallow (338). A foreign object can be inserted into the victim's mouth prior to gagging (338). Although they are usually associated with homicides (e.g., elderly robbery victim, neonaticide), gags have also been used to stifle screams by victims using a painful method of suicide (e.g., self-immolation [415]).





**Fig. 60.** Acute aspiration. Larynx and mainstem bronchi.

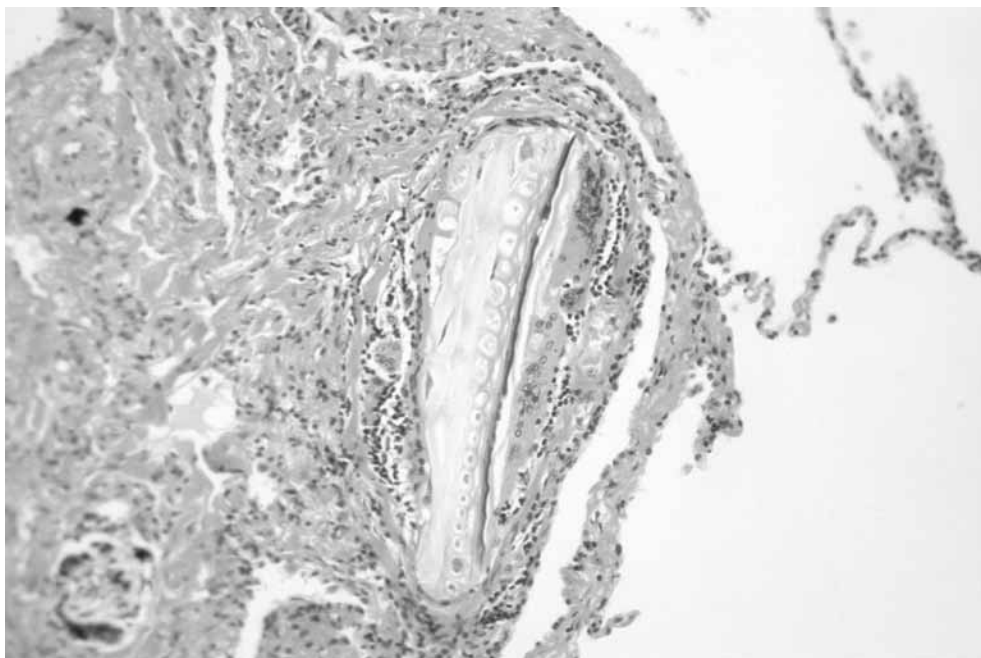
### **3.7. Positional Asphyxia**

Positional asphyxia is a fatal condition owing to the body being oriented in an unusual position, either induced or adopted independently, which mechanically interferes with pulmonary ventilation by airway obstruction and interference of chest wall excursion (Fig. 62; refs. 416 and 417).

Ventilatory pump failure can be the result of decreased central respiratory drive (e.g., depressant drugs), chest wall defects (e.g., flail chest), and respiratory muscle fatigue (418). A victim may not be able to self-extricate from a position because of various factors (e.g., alcohol or other drugs, debilitation, degenerative brain disease [97, 99, 246, 418–420]). Alcohol and other drugs acting as CNS depressants relax muscles, including the tongue, causing airway obstruction (97, 416). Toxic levels of these drugs also depress central respiratory centers. The CNS respiratory drive fails to respond to the increased biochemical demands of the body (417, 419, 421).

Variations of positional asphyxia have been described:

- Head-down position (reverse suspension, “upside-down;” see Fig. 63 and refs. 246, 416, 419, 420, and 422).



**Fig. 61.** Chronic aspiration. Foreign body granulomatous inflammation (vegetable material; H&E, magnification  $\times 200$ ).



**Fig. 62.** Positional asphyxia.

- In contrast to the erect position, where thoracic breathing predominates, a person head-down has limited chest wall excursion ([246,423–426](#)). In cases of complete reverse suspension, the abdominal viscera press on the diaphragm, prolonging the inhalation phase ([427](#)). Initially, respiratory frequency increases to compensate ([427](#)).



**Fig. 63.** Positional asphyxia. Reverse suspension following vehicle rollover. (Courtesy of Dr. C. Rao, Regional Forensic Pathology Unit, Hamilton, Ontario, Canada.)

Eventually, hypoxia ensues because of the decrease in chest wall movement due to respiratory muscle fatigue (421,427). The decreased effectiveness of the respiratory muscles means the ability of intrathoracic pressure to allow effective venous return to the heart is reduced (246,425). Also, blood volume shifts to the head, where venous return to the heart is not as efficient (246). Diminished blood flow further respiratory muscle fatigue and eventually cardiac arrest occurs (425).

- The head-down position leads to death of rabbits in half a day (427). A decreased and often irregular pulse rate is observed in human volunteers (427). Estimates of time until death in humans (e.g., parachutists, occupants in a vehicle rollover) range from several hours to a day (246,419).
- The Trendelenburg position in the clinical setting has effects on cardiac and pulmonary function (419,427).
- Neck or trunk hyperflexion while head-down or sitting upright (e.g., neck hyperflexed occluding tracheostomy site; goiter occluding airway) leads to obstruction of the respiratory tract (416,417).

- Trunk flexed over object (e.g., edge of bathtub) restricting diaphragm and chest movement (48,417).
- Recreational abdominal suspension and compression (e.g., 12-yr-old girl suspended on swing by synthetic webbing [421]).
- Neck or chest compression (e.g., neck flexion from entrapment by bedrail; *see* Subheadings 2.1.4, 3.2., and 3.8. and refs. 99, 332, and 417).
- “Excited Delirium”, “Prone Restraint Asphyxia” and the use of “Tasers.”
  - Deaths during prone restraint (“prone restraint asphyxia”) arise when an individual becomes highly agitated (“excited delirium”), as a result of psychosis or stimulant drug intoxication (e.g. cocaine, hallucinogens, methamphetamine), and is subdued (428–431). These deaths occur in institutions and in the custody of police; therefore, they are problematic and controversial cases. During the delirium, individuals become paranoid, insensitive to pain and agitated (428,429,431,433). They possess “superhuman” strength, and a number of police officers are required to restrain and subdue them (429,431). Typically, these victims, after a period of considerable struggle, become quiet and then go into cardiorespiratory arrest (429,431,433). Various forms of restraint are employed, one variation of which is “hog-tying” or “hobbling” (417), which has been implicated as the primary cause of death.
  - The events and phenomena leading up to deaths associated with prone restraint asphyxia are complicated and it essential that other causes of death, i.e. disease and trauma (e.g. head injury, neck compression, visceral injury) are excluded (430,431, 436). When faced with an apparent case of prone restraint asphyxia, several factors may have contributed to death (418,428–431,433,436–439): pressure may have been exerted on the neck (428,429,431); weight may have been applied to the chest wall (429); exhaustion, hypoxia, acidosis and hyperpyrexia may occur as a consequence of a prolonged struggle; alteration of brain receptor function in individuals who are chronic abusers of cocaine makes them prone to cocaine-induced excited delirium and hyperthermia (431–434); chronic cocaine use can lead to cardiomegaly and myocardial fibrosis, which are risk factors for an arrhythmia, the risk of which is potentiated by the “hyper-adrenaline” state of acute intoxication (418,431–433,435). In addition, it should be remembered that death can occur in unrestrained cases of excited delirium (432,433) or in individuals who are restrained in other than the “hog-tied” position (439a).
  - The complexity of the various pre-mortem phenomena in fatal cases of prone restraint asphyxia prompted a series of experiments on human volunteers to determine the degree to which positioning of normal individuals in the “hog-tied” prone position after exercise interferes with the process of respiration, which relies on three critical processes (418): a patent airway; a “bellows” mechanism by which gases are moved into and out of the airways through the action of the ribs, intercostal muscles, diaphragm, abdominal wall and accessory muscles of respiration; and lungs in which there is a normal flow of gases into and out of the airspaces and across the alveolar walls to and from the pulmonary vasculature. Although the earliest of these studies suggested that the “hog-tied” position increased the recovery times of both heart rate and peripheral oxygen saturation after exercise (439b), these observations were refuted in a subsequent study that used more sophisticated methods for determining blood oxygenation and, in addition, which assessed pulmonary function (439). The latter study demonstrated that ‘hog-tying’ did produce a mild restrictive pulmonary deficit, to no less than 80% of normal predicted values, but this deficiency was not associated with hypoxia, hypercapnia or a delay in the post-exercise restitution of normal heart rate nor were the mild changes in pulmonary function any different from

those occurring in unrestrained individuals who were lying supine or prone (418,439). The placement of up to 50 lbs of weight on the back did not further compromise respiratory function in additional studies on “hog-tied” healthy volunteers (435).

- The observations in healthy volunteers suggest that forcible restraint *per se* is not the sole cause of death in prone restraint asphyxia, leading to a commentary by Reay and Howard (418) that, in such causes, “causes of death are a matter of conjecture and cover the spectrum of catecholamine rush, neuroleptic malignant syndrome, psychogenic death (including exhaustive mania and excited delirium), and exercise induced cardiac arrest” or, in their other words, that “during the investigation [of prone restraint asphyxia] multiple factors emerge, all of which may have played some role in the death and none of which is convincing enough to stand alone as the undisputed cause of death.” In such instances, Howard and Reay recommended that death is certified “by a descriptive statement that encompasses identified factors in the death” (418).
- As well as physical attempts at restraint, subjugation of individuals displaying excited delirium may also involve administration of pepper spray and electric shocks using a “taser”, at times without apparent effect (428,429,431) (see Subheading 3.3.2.).
- A “taser” is a hand-held weapon (“neuromuscular incapacitation device”) that uses a gunpowder charge to project two barbs, which remain tethered to the weapon by electric wires. When the barbs penetrate or lie in clothing close to, the skin, an incapacitating electric shock whose duration is controlled by the operator immobilizes the victim (439c–439f) and allows restraints to be placed. Several models of the taser weapon are, or have been, available, including the “original” Police model, a less powerful “public” model and a more recent advanced M26 model that is more effective at incapacitating individuals (439d).
- Tasers cause primary injuries, in the form of small puncture wounds and burns at the site of lodgement of the barbs or secondary injuries owing to falls caused by the incapacitating electric shock (439g). Rhabdomyolysis may also occur but its cause is uncertain because of the other potentially myotoxic factors that exist in many patients who are subjected by taser (see Chapter 8, Heading 13).
- Most deaths purported to be associated with the use of a taser have occurred minutes to hours after the electric shock and in individuals who are also intoxicated by phencyclidine (phenyl-cyclohexyl-piperidine [PCP]) (439g,439h) and/or cocaine (439g), both of which alone are capable of causing sudden death, or in cases who have pre-existing heart disease (439g). A prospective case study of all patients admitted to an Emergency Department over a five and a half year period who had been shot with a taser recorded 3 deaths in 218 patients; two cases developed a cardiac arrest 5 minutes and 15 minutes after being shot by a taser, and one case showed a respiratory then cardiac arrest 25 minutes after taser electrocution—all of the three cases had high serum and liver levels of PCP (439h). In addition, a case report describes a 16-year-old male who developed, and was resuscitated from, ventricular fibrillation after he had been shot by a taser, providing some evidence of a direct association between a taser electric shock and a potentially fatal cardiac dysrhythmia; however, the interval between the taser shooting and collapse of the patient is not recorded and the report does not state whether or not the victim was intoxicated by PCP, cocaine or other substance (439i). In contrast, analysis of the event record of an implantable defibrillator after a taser hit showed no evidence of ventricular fibrillation (439j).
- Experimental studies in pigs prove that the electrical charge required to induce ventricular fibrillation is directly related to body mass and is 15 to 42 times greater the



charged delivered by the taser (439k). Studies on healthy human volunteers have shown no effect of taser discharges on cardiac activity at the time of, or 24 hours after, the electric shock (439l), in line with earlier observations showing no ECG abnormalities in patients treated in the Emergency Room after being shot by a taser (439h).

- The foregoing observations suggest that a taser strike, which delivers an electrical charge to the body, is, by itself, not a likely cause of death because of the immediacy of fatal collapse observed in typical electrocution deaths (*see* Chapter 4, Subheading 7.1.4.). Nevertheless, it is almost impossible to prove (or refute) the extent to which an electric shock, delivered by a taser to an individual in a state of physiological or toxicological “excited delirium”, is the immediate cause of death, a problem reminiscent of the difficulties in deciding which of the many factors cause death in prone restraint asphyxia, as discussed previously in this section. There is some justification, therefore, for the comment that “...while the use of tasers may be generally safe in healthy adults, preexisting heart disease, psychosis and the use of drugs... may substantially increase the risk of fatality.”(439m)
- SIDS (*see* Subheading 3.1.3.).

### 3.7.1. Postmortem Findings: Positional Asphyxia

A case of positional asphyxia usually has few physical findings (417). Because the deceased has been moved, an accurate description of original position at the scene is crucial in determining the cause of death. Other causes of death need to be excluded (97,418).

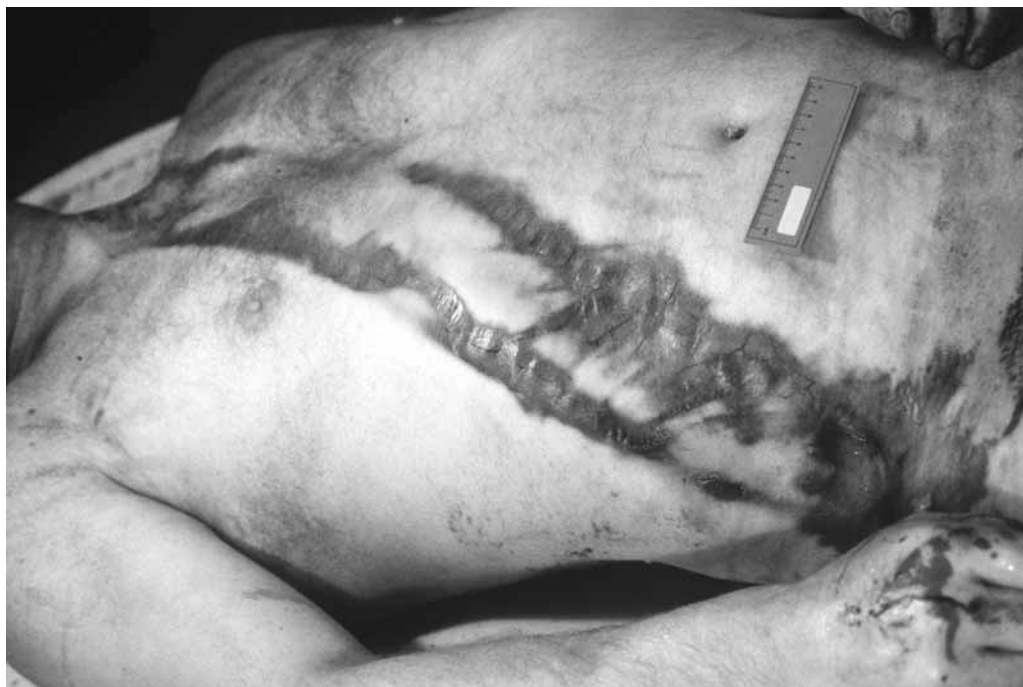If the person was head-down, then lividity is seen in the face, neck, and upper chest. Cephalic congestion and swelling are noted (419). Associated cephalic cutaneous and ocular petechiae occur but can be absent (416,419,440). Blunt trauma cutaneous injuries, indicative of struggling, may be found (416,419). Internally, there can be congestion of the base of tongue, epiglottis, and trachea (416). Congestion of the brain and lungs is also observed. Bruising of the chest wall, diaphragm, peripancreatic area, and spleen is consistent with abdominal suspension (421).

## 3.8. Traumatic Asphyxia

### 3.8.1. Scene and Circumstances

Traumatic asphyxia was first described in 1837 by Ollivier, who saw individuals crushed to death during mob violence (11,441–445). Information about the circumstances of the fatality assist in determining the cause of death, particularly when findings are lacking (443,446). The common theme is chest compression by an object weighing more than the victim. Classification of whether an asphyxial death is positional or traumatic hinges on the situation described (*see* Subheading 3.7. and ref. 416). If chest compression is considerable, then traumatic asphyxia has occurred. If the deceased assumed a particular body position resulting in neck or chest compression, then positional asphyxia is the likely scenario.

- Motor vehicle-related deaths are the most common (445). Various situations have been described:
  - Motor vehicle slipped off jack during repair (443–445).
  - Ejection of motor vehicle occupant and subsequent crushing by rollover (443,446).



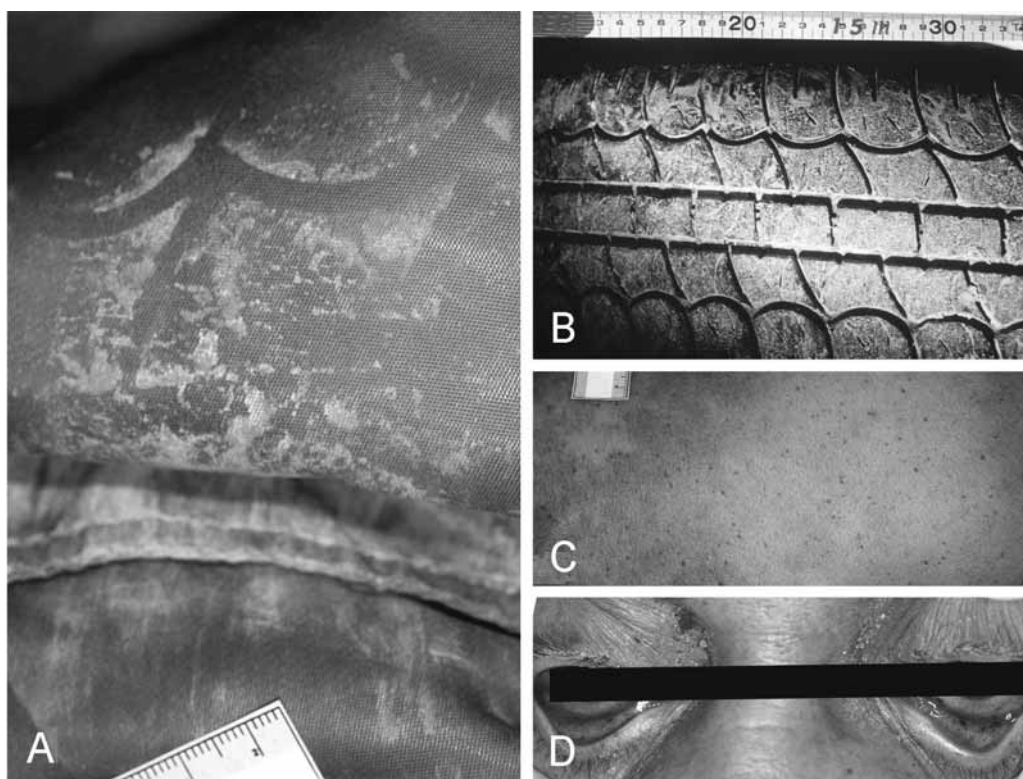
**Fig. 64.** Traumatic asphyxia. Pinned by farm machinery. (Courtesy of Dr. M. E. Kirk, London Health Sciences Centre, London, Ontario, Canada.)

- Front seat occupant pinned between seat and either steering wheel or dashboard (422,443,444).
- Pedestrian run down by slowly moving car (443).
- Garbage truck compaction of homeless/intoxicated individual sleeping, or passed out in dumpster (447).
- Entanglement of clothing in driveshaft of car (448).
- Pinned or crushed by heavy machinery, construction material, falling debris, cave-in (see Subheading 3.10., Fig. 64, and refs. 441, 443–445, and 449).
- Fallen appliances, furniture (particularly children [443,450]). This has been described as a means of homicide.

Homicides resulting from traumatic asphyxia may have evidence of other asphyxial methods (e.g., smothering, strangulation [451]).

### 3.8.2. Mechanisms of Traumatic Asphyxia

Severe compression or crushing of the chest, upper abdomen, and/or back interferes with thoracic respiratory movement (441,450). Rarely, a “jackknife” injury occurs when the victim’s chest is in contact with the thighs and knees, or “accordion” pressure is inflicted on a child (441). Typically, there is a weight disparity between the compressing force and victim (usually > 1000 kg or 500 lb [441,444,445]). The length of compression time before death varies depending on force severity. An individual can die in seconds if there is considerable weight, but usually at least 2 to 5 min elapse before death ensues (441,446).



**Fig. 65.** Subtle signs of traumatic asphyxia. Man run over and pinned under vehicle that contained three occupants and had poor suspension. (A) Victim's jacket. Dirt impression from tire tread. (B) Tire tread. (C) Cutaneous petechiae in nonlivid areas of back. (D) Conjunctival petechiae, lower eyelids (retracted).

Survivors, in one series, were extricated within 15 min, but the decedents were pinned within or under their vehicles from 5 to 15 min (443,446). Victims can be crushed slowly (441). Information regarding the minimum threshold weight to cause death is scarce. The large loads described in the literature imply that at least five times body weight is involved. Experimental work on guinea pigs showed a three times weight differential resulted in death of some subjects in 10 min (452). One case report described a 13-kg child pinned by the legs of a 60-kg adult, who had a 0.7-kg leg cast, for 40 min (weight differential about 1.8 times, if the adult's legs and cast are equivalent to 40% of the perpetrator's body weight, i.e., 24 kg [49,453]).

### 3.8.3. External Findings: Traumatic Asphyxia

Although classical signs have been described, they are not always evident. Only subtle features (e.g., petechiae) may be observed (443,446). *Masque ecchymotique* refers to the classic appearance of blue-red to blue-black discoloration of the face and neck with variable involvement of the upper thorax, back, and arms, and associated petechiae or ecchymoses (Fig. 65; refs. 11, 441, and 443–446). Maximum discoloration may not appear in survivors until several days after the incident (441). The skin is spared discoloration under points of pressure (441,445). Discoloration disappears usually within a few weeks and does not undergo the color changes seen with the healing

of bruises (441,444). The color is not altered by the administration of oxygen (441). Petechiae disappear within days, but subconjunctival ecchymoses can persist for weeks, eventually fading to yellow and disappearing (11,441,444). There is associated facial edema (11,441,444,445). Similar but less pronounced observations are seen as a result of difficult delivery, prolonged vomiting or coughing, seizures and asthmatic episodes (see Subheading 1.5. and refs. 441 and 444). External blunt trauma injuries can be seen on the head, neck, and torso (444–446).

Sudden severe compression of the torso raises intrathoracic pressure, obstructing flow of blood from the superior vena cava into the right heart (see Subheading 1.5. and refs. 11, 441, and 443–445). Venous drainage of the head and neck area is through the IJV and EJV. The EJV drains the superficial soft tissues of the scalp and neck. Although the EJV possesses valves, they are not competent to prevent flow reversal at pressures exceeding 45 mmHg (maximal pressures during resuscitation, 40 mmHg). In contrast, the IJV, which drains the upper airway and brain, is more resistant to a rise in CVP. The rigid skull and the capacitance of the venous sinus system protect the brain from intraparenchymal hemorrhage (454). Compression of the torso may be not enough to raise the venous pressure in the head and neck to produce the classic external findings (444). A “fear response”—i.e., taking a breath and holding it when faced with an impending disaster—results in glottic closure and accentuation of intrathoracic pressure (443,444,450). The lower torso is spared because the Valsalva maneuver compresses the inferior vena cava (455). During severe vomiting and coughing, forceful contraction of the thoracoabdominal muscles against a closed glottis can lead to increased cephalic venous pressure (441). Relative stasis of blood in dilated capillaries causes dark discoloration (441,443, 445). Consequent vessel rupture results in petechiae and ecchymoses. Cutaneous petechiae are absent if chest compression is severe enough to impair left and right heart function (442).

### 3.8.4. Internal Findings: Traumatic Asphyxia

Internal findings may be minimal or absent. The following have been observed:

- Eyes: Purtscher’s retinopathy (retinal hemorrhages [441]).
- Mouth, nose, ears: pharyngeal, sublingual, nasal, and auditory canal petechiae/ecchymoses, which can result in external bleeding; bleeding from the nose and ears mimics a basal skull fracture (11,441).
- Upper respiratory tract: epiglottic, laryngeal, and tracheal petechiae; laryngeal edema (443,446).
- Bones: rib/clavicle fractures; extremity and pelvic fractures also possible (441,443, 445,446,456); skull fractures rare (441,445); bone marrow and fat emboli may or may not be seen (446).
- Lungs: contusions/lacerations; hemo-/pneumothorax; congestion (443–446,456).
- Heart: injuries rare (ruptures, contusion) (445,454,457).
- Abdomen: hepatic/splenic lacerations (443–445).
- CNS: cerebral edema; cerebral petechiae, intracerebral hemorrhage rare; spinal cord ischemia (441,443,444,456).

If there are severe injuries, multiple blunt trauma is the cause of death (441,443,450, 454). Internal injuries, such as rib fractures, may not be fatal but indicate that compression was sustained (443). Pulmonary fat embolism should be considered (see Chapter 8,

Subheading 12.1. and ref. 449). The lack of other fatal injuries supports asphyxia as the mechanism of death (443,446). Impaired venous blood flow to the right heart and decreased cerebral perfusion are other possible mechanisms (443). To exclude the possibility of incapacitation by alcohol and drugs, toxicological analysis is required (443).

### 3.9. Carbon Monoxide

Carbon monoxide (CO) is the leading cause of death resulting from poisoning (458,459). CO is a tasteless, odorless, colorless, and nonirritant gas that is produced by the incomplete combustion of carbon-containing substances (460–468). During combustion, if the availability of oxygen (O<sub>2</sub>) is high and the temperature below 710°C (1310°F), carbon dioxide (CO<sub>2</sub>) production is favored, but in O<sub>2</sub>-deficient environments at higher temperatures, CO formation occurs (see Chapter 4, Heading 2. and ref. 469). Common sources of CO include tobacco smoking, automobile exhaust, industrial processes, unvented or faulty heating units, and fires (460,462,464,466–468,470–472). An uncommon source of CO is dichloromethane (methylene chloride), used in paint remover, aerosol propellants, and degreasers (460–462,465,466,468,469). A combination of formic acid and sulfuric acid produces CO (473).

CO binds reversibly to hemoglobin to form carboxyhemoglobin (COHb; refs. 461 and 474). Because CO affinity for hemoglobin is 200 to 250 times greater than O<sub>2</sub>, blood O<sub>2</sub>-carrying capacity is reduced (461,462,464–466,468,471,474–476). Hypoxic effects are enhanced because CO binding to hemoglobin modifies remaining O<sub>2</sub> binding sites, increasing hemoglobin affinity for O<sub>2</sub> and displacing the O<sub>2</sub> dissociation curve to the left, thereby decreasing O<sub>2</sub> release to cells (461,462,465–468,471,472,475, 477–480). Decreased tissue O<sub>2</sub> delivery stimulates breathing, increasing CO uptake and causing respiratory alkalosis, further shifting the oxyhemoglobin dissociation curve to the left (481). About 10 to 15% of absorbed CO binds reversibly to other heme proteins, myoglobin, and the mitochondrial cytochrome oxidase (cytochrome a3) system essential in the production of ATP (462,466,467,471,475,478,481–485). CO may reduce muscle function (475,481). Other harmful mechanisms of tissue damage (e.g., brain–lipid peroxidation) have been described (461,467,472,475,481).

Endogenous production of CO yields a baseline COHb saturation of 0.4 to 0.7% (461,462,465,479). An abnormal COHb level depends on the atmospheric concentration of CO, duration of CO exposure, and the ventilatory rate and depth (461–463,465–471, 474,480,486).

The normal atmospheric concentration of CO is usually less than 0.001% (10 ppm [461,463,468]). The atmospheric concentration can exceed 0.01% (100 ppm) in heavy urban traffic and during periods of atmospheric stagnation (460,463,466). COHb averages 1 to 2% in urban nonsmokers (461–463,465,468). Heavy smokers can have a COHb saturation approaching 10% and cigar smokers up to 20% (460,462,466,480, 487). An atmospheric CO concentration of 1% (10,000 ppm) can equilibrate to about 95% COHb (462,466).

At rest (pulmonary ventilation about 6 L/min), COHb saturation = 3 × % CO in environment × time of exposure (min). For light activity (ventilation about 9–10 L/min), COHb saturation = 5 × % CO × time of exposure (470). High concentrations of CO (>1% or 10,000 ppm), such as in suicidal inhalation and fire deaths, lead to unconsciousness and death, without prodromal symptoms, within a short time (462,466,



**Table 4**  
**Symptoms Related to COHb Concentrations**

% COHb	Healthy adult	History of heart disease
Up to 10%	Asymptomatic	Less exertion needed to cause chest pain in individuals with angina pectoris.
10–20%	Headache; dyspnea with exertion.	Potentially lethal (arrhythmia).
20–30%	Throbbing headache; nausea; abnormal manual dexterity; fatigue; dimming of vision.	
30–40%	Severe headache; nausea and vomiting; visual disturbance; mental confusion; weakness (35% potentially lethal).	
40–50%	Syncope; tachycardia; tachypnea.	
50–60%	Coma; seizure (life-threatening).	
>60%	Compromised cardiorespiratory function; death.	

Adapted from refs. [462](#), [465](#), [466](#), [471](#), [482](#), [488](#), [491](#), and [498–500](#).

[488–491](#)). An active person, breathing air containing 5% CO, has a COHb level of about 10% in about 10 s, and about 40% in 30 s ([492](#)). Lethal levels of COHb are achieved within 10 min in a closed garage (CO 0.5–1.0%) ([468,470,493](#)). A CO concentration of 0.2 to 0.3% (2000–3000 ppm) can lead to death within 1 to 2 h ([465,469,491,494](#)). CO uptake is enhanced when ventilation is increased by CO<sub>2</sub> emission from automobile exhaust, stimulating the central respiratory control center ([491](#)). Household pets, because of their smaller size and greater metabolic rate, succumb before human occupants in a dwelling ([471,472,481,495](#)).

Because of the fixed oxygen needs of the cardiovascular system and CNS, related symptoms are common with prolonged (subacute) exposure to relatively low CO concentrations (0.02–0.12% [200–1200 ppm]; see [Table 4](#) and refs. [461](#), [467](#), [468](#), [470](#), [477](#), [479](#), [496](#), and [497](#)).

Patients admitted to a burn unit with COHb levels above or equal to 10% have shown electrocardiographic and biochemical evidence of cardiac injury ([501](#)). Low levels of CO worsen myocardial ischemia in physically active individuals with angina ([502](#)). Patients with coronary artery disease cannot increase coronary blood flow when COHb saturation is raised acutely (<10% saturation [[470,485](#)]). Other medical and constitutional factors predispose individuals to the toxic effects of CO ([462,465,466,468,474,481,491,503,504](#)). Infants, individuals with anemia or lung disease, and the elderly are more susceptible. Fetal death has been observed in cases of nonlethal maternal CO poisoning ([463,472](#)). CO binds more avidly to fetal hemoglobin than to maternal hemoglobin (hemoglobin A).

The half-life of COHb in resting adults at sea level is 4 to 5 h. CO is eliminated essentially unchanged from the lungs ([462,465,468,479](#)). Resuscitation decreases COHb. The administration of pure O<sub>2</sub> reduces the half-life to 80 min, and to 24 min when hyperbaric O<sub>2</sub> is used ([460,462,463,465,466](#)). Low levels are also encountered if the clinical presentation is delayed, or there has been a period of survival ([463,464,472,475,480](#)).



**Fig. 66.** Carbon monoxide poisoning. Vehicle's exhaust diverted by hose into office space in garage, where the deceased was found.

### *3.9.1. Scene and Circumstances*

Common scenarios encountered are suicidal inhalation cases, fire victims, and nonfire-related unintentional deaths (*see* Chapter 4, Heading 4. and refs. 458, 463, and 469). In a US study of CO-related deaths from 1979 to 1988, about half of the 56,133 certified deaths were suicides, 28% were fire-related, and 20% were unintentional (458). Intentional and unintentional CO poisoning occurs predominantly in males (458,494,504).

Use of motor vehicle exhaust fumes is a common means of suicide (Fig. 66; refs. 505 and 506). The most frequent method involves connection of the exhaust pipe to the interior of the vehicle using some type of tubing (491,494,507). The tube is inserted through one of the windows and the opening sealed. The vehicle can be in the open or in a garage (Fig. 66; refs. 494 and 507). Vehicle doors may be locked and sealed with tape (507). A suicide note may be present (494). The car motor can be still idling when the victim is found. The ignition may be on, but the motor can stop from either lack of fuel or cessation of gasoline combustion resulting from O<sub>2</sub> depletion in a closed environment (474,490,494,507,508). Unusual settings have been described (e.g., ignition off, automobile in garage and not running, victim with keys in the closed trunk [509]). Victims of suicide have been observed lying in the open or an enclosed area, close to the automobile exhaust with or without a hose connected to the exhaust pipe (Fig. 66; refs. 488 and 510).

Suicide by inhalation of coal gas, supplied to home gas appliances, was observed in the past but has decreased with the conversion to natural gas (methane) (464,471,490,494,505,511–513). “Cleaner” fuels (propane, methane) i.e., those undergoing more complete combustion, can still cause CO poisoning (468). Features described with coal gas suicides include proximity of victim to gas appliance or to a hose attached to a gas fixture (e.g., in kitchen), an airtight room, the smell of gas, or an explosion.

The majority of unintentional nonfire-related deaths in one series was caused by motor vehicle exhaust, mainly from defective stationary vehicles (458,468). CO poisoning accounts for fewer than 1% of all motor vehicle deaths (514). Among the defects described in CO poisoning deaths involving motor vehicles have been design flaws and rust perforation of the exhaust system and holes in the floor of the passenger compartment, fender panels, or trunk (463,468,515). Scenarios include sleeping in a vehicle, couples parking, warming up a car, and fixing a car in an enclosed space (514,515). Windows can be partly open (up to 10 cm or 4 in. [515]). Vehicles can be idling in open garages (477,515). Inspection of the vehicle reveals the ignition, the heater, or air conditioner is on, the gas gauge empty, and the battery dead. Less common accidental CO-related fatalities involving motorized vehicles have been described:

- Car washes (car idling with doors closed because of cold weather); indoor gasoline-powered pressure washer (516,517).
- Gasoline-powered equipment at indoor sporting events, enclosed workspaces (463,465,518,519).
- Working or living quarters adjacent to garages (463,477).
- Car exhaust fumes distributed in dwelling by forced-air furnace (520).
- Muffler submerged in mud with CO seeping through rusted floor boards (515,521).
- Car exhaust pipe plugged with snow (515,522,523).
- Swimmer becoming overcome by fumes emitted at water level by an idling boat engine (521).
- Boats with enclosed cabins (524).
- Children in rear of pickup trucks covered by canopies or tarpaulins (525).

Malfunctioning heating systems (e.g., blocked chimney) using combustible fuels can cause fatal CO poisoning (463,465,475,477,494,504,520,526,527). Inspection of the scene is necessary to determine the CO level in the atmosphere, malfunction of the heating system, and the presence of working CO detectors (463,480,494,504,520). Unintentional deaths typically occur in the winter months (458,477,515,528,529). An Austrian study of CO-related deaths showed that more than half of unintentional cases occurred in people over age 60 (504). The overuse of flueless gas-fueled water heating appliances during the cold months was a major factor. Power outages have been associated with clusters of CO-related deaths as a result of the use of a fuel-burning heating or cooking device as an alternative source of heat in an enclosed space (461,463,465,468,528,530,531). Other appliances (e.g., air-conditioning unit, electrical heater) have been described in CO deaths (463,465,468,469,494).

Because of the varied physical effects of low-level CO exposure, poisoning is not always obvious in nonfire-related deaths (461). The symptoms, signs, and prognosis of acute poisoning, presenting in a clinical setting, only approximate COHb levels (Table 4; refs. 461, 463–465, 467, 471, 472, 475, 483, 498, and 532). Even individuals exposed in the same incident can have varying responses (467). The physiological effects are not as intense if COHb concentration is attained gradually (460,520). Furthermore, the role

of CO in a death can be missed when the scene and circumstances are not suggestive (468,527,533). Symptoms are nonspecific and mimic other conditions—e.g., nausea and vomiting, chest pain, altered consciousness, agitation, and confusion (461,465,471,475,481,495,503,534). Neurological symptoms are caused by occult CO exposure (535). Relative tissue hypoxia results in reflex vasodilation and increased cerebral blood flow, leading to headache (“winter headache” [475,495,536]). In three case series, the most frequent acute symptoms were headache (91%), dizziness (77%), weakness (53%), nausea (47%), and confusion or difficulty concentrating (43%; refs. 465, 468, and 489). Seizures are possible. Because flu and CO poisoning both peak in winter, the chance of misdiagnosis increases (463). Suspicions should be aroused when more than one individual in a particular enclosed site is sick or dead (489,537,538). Failure to diagnose CO poisoning means its source remains undiscovered, increasing the risk of death for not only the victim who returns to that environment but also for others present (461,465,468,495).

Homicidal CO poisoning is rare (e.g., exhaust fumes used to poison an immobilized person [458,490]). A victim of CO poisoning can be placed in a bed to simulate a natural death (490).

### 3.9.2. External Examination


CO causes vasodilation (482,500). Red lividity is enhanced by congestion of superficial cutaneous vessels (ref. 539; see Chapter 2, Subheading 3.2.). Problems discerning and interpreting lividity arise in dark-pigmented, decomposed, and refrigerated bodies (469,490,540). In dark-skinned individuals, fingernail beds can be examined.

“Cherry-red” discoloration is variably observed in the clinical setting, which reflects the observer’s visual acuity and experience, and the fact that lower COHb concentrations are usually encountered (461,471,481,500). Cyanosis is more likely (461,532). Congestion of deeper vessels by COHb causes the skin to appear cyanotic (539). An individual in a cold environment who succumbs to CO vasoconstricts superficial skin vessels, resulting in sequestration of CO-saturated blood in deeper tissues (540). At the scene, failure to examine the entire body and poor lighting means missing the diagnosis (490). The characteristic red lividity of CO poisoning is usually associated with a COHb level greater than 30%; however, some cases with a COHb level up to 80% do not show this finding (17,533,540). One study showed that about 98% of unintentional CO-related deaths had typical lividity (533). Three victims without red livor had COHb levels of 18, 28, and 31%, respectively. Coroners recognized only 61% of deaths at the scenes as CO-related, based on the color of the lividity. The older the victim, the worse the recognition (>80 yr, 59% unrecognized, compared with 19% for individuals aged 21 to 30 yr).

Erythematous lesions and bullae have developed in hospitalized patients either on bony pressure points or in noncompressed areas (465,468,541,542). Microscopic examination shows vesicle formation within and under the epidermis, and sweat gland necrosis (465,468,539,542).

### 3.9.3. Internal Examination

Serosal surfaces, blood, and organs appear “cherry-pink” (Fig. 67; refs. 490 and 540). This is useful if cutaneous lividity cannot be assessed (540). Formalin fixative turns bright red when exposed to tissues in cases of CO asphyxia (Fig. 67) (490,540).



**Fig. 67.** Carbon monoxide poisoning. **(A)** Bright red discoloration of pleural lining in a dark-skinned individual (courtesy of the Office of the Chief Medical Examiner, Chapel Hill, NC). **(B)** Formalin-fixed stock autopsy tissue. Bright red fixative owing to carbon monoxide in jar on left side. (See Companion CD for color version of this figure).

Pathological changes from CO poisoning are seen in hospitalized patients and long-term survivors. Lesions in the heart vary from petechial hemorrhages to myocardial necrosis (496). Rhabdomyolysis from the direct toxic effects of CO and prolonged immobility lead to renal failure (*see* Chapter 8, Heading 13. and refs. 465, 479, and 543–545). Neuronal hypoxic injury is most pronounced in the deep gray matter, usually in a symmetrical distribution, and although not pathognomonic, may be the only indication of previous CO-related brain injury (465,479,490,546,547). Widespread hypoxic neuronal degeneration and cerebral white matter degeneration also occur (546–548). Delayed neurological and psychiatric symptoms can develop following a period of initial improvement (462,463,475,483,500,546,548,549).

### 3.9.4. Toxicology

Whole blood samples, either venous or arterial, collected at autopsy must be preserved with sodium fluoride and refrigerated (460,461). COHb is stable with proper preservation but can be altered by bacterial metabolism during decomposition (460,520,550,551). There is no difference in COHb levels in heart compared with peripheral blood; however, a difference greater than 50% (i.e., heart:peripheral = 1.5:1) could reflect a short survival interval and a lack of equilibration in the circulation (474,552). Spleen specimens have been a substitute for blood if it is unavailable, and high splenic COHb levels do correlate with blood concentrations (553). Liver tissue has been used, and a positive result is possible even if there has been resuscitation (474,552,554).

A range of COHb in certain types of acute CO poisonings has been observed:

- Automobile exhaust fatalities (460,494).
  - COHb range: 48–93% (average 72%); 74% average (in open); 77% average (in garage)
  - Accidental: more than 30% (515).



- Ethanol can be a factor in unintentional CO deaths (515,529). Ethanol can potentiate the effects of CO such that lower levels of COHb are associated with fatality (see Chapter 4, Subheading 4.1. and ref. 520). In a Danish study, the blood alcohol concentration averaged about 190–200 mg/dL in domestic fires, and the mean COHb was about 60% (494). In contrast, suicides by CO from car exhaust fumes had an average COHb of 77% and blood alcohol concentration of 80 mg/dL. CNS depressants can also interfere with mental and physical abilities (516).
- Fire fatalities (see Chapter 4, Subheading 4.1. and refs. 460, 480, 494, and 520).
  - COHb range: 25 to 85% (average 59%); 53% average (charred); 63% average (uncharred); 3 to 94% in another study.
- Confined spaces (see Subheading 3.10. and refs. 494 and 520).
  - COHb range 7 to 77% (13 victims, faulty heating systems); 68% average (103 gas suicides); 72% average (19 victims, malfunctioning gas appliances).
- Open spaces (510).
  - COHb range: 79%, 81%, 58% (3 suicide victims lying in proximity to automobile exhaust).
  - CO has about the same density (0.968) as air and pockets can form (460,475).
- Elderly victims.
  - One study of unintentional CO deaths showed that the older the victim, the lower the COHb concentration (533). In a Danish study, accidental deaths of victims ranging from 64 to 90 yr of age had average COHb of 49% (494).

Most cases of suicide by automobile exhaust inhalation are self-evident, but CO poisoning is not always confirmed by toxicological testing (474,490,551). Exhaust tailpipe CO concentration ranges up to 7% in older vehicles (462,465,507). Catalytic converters reduce CO emission up to 90% (<0.5% CO [491,508,555–557]). Although COHb is low (<10%) when there is a catalytic convertor, asphyxia results from increased CO<sub>2</sub> and decreased O<sub>2</sub> in the confined space of the vehicle (458,491,493,508). Elevated CO levels are possible in vehicles with catalytic convertors if either the engine is started cold or the converter is not functioning well (491). COHb saturation can be low because of a survival period prior to discovery. A suicide victim found in a car with a vacuum cleaner hose connected to the exhaust had a COHb lower than 5% (474). The hose had become detached from the pipe. Hypoxic changes were seen in the brain and had developed over the 2 to 3 d the victim lay in a coma before being discovered. A vehicle engine can run out of gas before causing death. The amount of generated CO can be enough for sublethal hypoxic brain damage.

### 3.10. Confined Space

A *confined space* is an enclosure with limited entry and exit. It has the potential for dangerous atmospheric contamination because of poor ventilation, and is not intended for continuous occupancy (e.g., tank, sewer, silo [558–560]). Such a space may require periodic inspection, maintenance, repair, or cleaning (560). A confined space also can have an open top and be of sufficient depth to restrict ventilation (e.g., pit, trench [558]). The typical scenario is that a worker enters the space, is overcome, and dies. Another worker, who attempts rescue, also collapses (560–562).

Room air typically contains 20.9% O<sub>2</sub>, 79% nitrogen, and 0.1% CO<sub>2</sub>, water vapor, and other inert gases (2,499,563). Contamination of the confined space atmosphere includes, but is not restricted to, any combination of O<sub>2</sub> depletion (asphyxiating), presence



**Fig. 68.** Child trapped in a toolbox. (Courtesy of the Office of the Chief Medical Examiner, Chapel Hill, NC.)

of explosive, flammable substances (flammable), irritant and corrosive chemicals (irritant and corrosive), and adverse concentrations of toxic substances (toxic [558,559,563]). Features of a confined space atmosphere that are immediately dangerous to life have been defined: an  $O_2$  concentration of 16% or less; a minimum flammability level concentration of a combustible gas or vapor that will ignite if an ignition source is present; and a concentration of the toxic substance, immediately dangerous to life (269,559,563–566). Irritant or corrosive substances can affect the respiratory system alone (e.g., ammonia) or have combined respiratory/systemic effects (e.g., benzene [558]). Lack of  $O_2$  is the most common cause of death (560). A level of  $O_2$  less than 5 to 10% is incompatible with life resulting in death within minutes (see Chapter 4, Subheading 4.1.). Breathing gas lacking  $O_2$  causes unconsciousness in seconds (567). Breathing ceases, but cardiac output can continue for a short time (567). If the fall in respired  $O_2$  happens slowly, the victim experiences fatigue and is unable to escape (567).

The lethal level of  $CO_2$  is above 10% (2,493,499,562,564,566,568,569).  $CO_2$  is 1.5 times heavier than air and can “pocket” (2,269).  $CO_2$  not only asphyxiates, but also causes acidosis (2,499).  $CO_2$  is fatal even when atmospheric  $O_2$  is normal (2,570). An atmospheric concentration of 30% causes unconsciousness in seconds to minutes (568). At high levels,  $CO_2$  induces narcosis (568).

Zugibe et al. defined confined space-hypoxia syndrome as a confined space death owing to an oxygen-deficient environment (Fig. 68) (559,564). Decreased atmospheric oxygen can result from consumption by microorganisms, work-related activities (e.g., welding), chemical reactions (e.g., rust), absorption by agents stored in tanks (e.g., activated charcoal), and displacement by another minimally toxic gas (e.g., propane, nitrogen, methane accumulation in a silo or sewer [2,269,558,560,563,564,567,571]). The displacing gas can also be toxic (e.g., CO generation from microbiological breakdown of organic

matter, release of hydrogen sulfide during removal of putrefied organic material and industrial waste [558,561,572,573]). Some gases that displace O<sub>2</sub> (e.g., propane) have CNS depressant effects at high atmospheric concentrations and lead to cardiac arrest (311). Mechanical hazards (e.g., machinery), adverse thermal conditions (hypothermia, hyperthermia), and falling objects pose additional threats in confined spaces (558,563). Workers trapped in cave-ins can be covered and suffocated (*see* Subheading 3.8.1. and ref. 574). Cases of children trapped in refrigerators has been described (48,114,116).

Atmospheric testing for noxious gases and O<sub>2</sub> levels at the death scene and postmortem analysis of blood and other tissues must be done (269,561,562,564,572,575). Scene simulations may be required (2). Airtight metal containers are used to collect lung tissue (311). CO<sub>2</sub> is elevated normally in postmortem blood and cannot be tested.

### REFERENCES

1. Spitz, W. V. Asphyxia. In: Spitz, W. V., ed. *Medicolegal Investigation of Death: Guidelines for the Application of Pathology to Crime Investigation*. Charles C. Thomas, Springfield, IL, pp. 444–497, 1993.
2. Gill, J. R., Ely, S. F., Hua, Z. Environmental gas displacement: three accidental deaths in the workplace. *Am. J. Forensic Med. Pathol.* 23:26–30, 2002.
3. Iserson, K. V. Strangulation: a review of ligature, manual, and postural neck compression injuries. *Ann. Emerg. Med.* 13:179–185, 1984.
4. Feldman, K. W., Simms, R. J. Strangulation in childhood: epidemiology and clinical course. *Pediatrics* 65:1079–1085, 1980.
5. Elfawal, M. A., Awad, O. A. Deaths from hanging in the eastern province of Saudi Arabia. *Med. Sci. Law* 34:307–312, 1994.
6. Davison, A. M. Medico-legal aspects of accidental and non-accidental hanging. *J. R. Nav. Med. Serv.* 75:33–36, 1989.
7. Cooke, C. T., Cadden, G. A., Hilton, J. M. Unusual hanging deaths. *Am. J. Forensic Med. Pathol.* 9:277–282, 1988.
8. Polson, C. J., Gee, D. J. *The Essentials of Forensic Medicine*. 3rd ed. Pergamon Press, New York, 1973.
9. Zaini, M. R., Knight, B. Sub-pleural petechiae and pseudo petechiae. *J. Forensic Sci. Soc.* 22:141–145, 1982.
10. Jaffe, F. A. Petechial hemorrhages. A review of pathogenesis. *Am. J. Forensic Med. Pathol.* 15:203–207, 1994.
11. Lowe, L., Rapini, R. P., Johnson, T. M. Traumatic asphyxia. *J. Am. Acad. Dermatol.* 23: 972–974, 1990.
12. Ely, S. F., Hirsch, C. S. Asphyxial deaths and petechiae: a review. *J. Forensic Sci.* 45:1274–1277, 2000.
13. Rao, V. J., Wetli, C. V. The forensic significance of conjunctival petechiae. *Am. J. Forensic Med. Pathol.* 9:32–34, 1988.
14. Hood, I., Ryan, D., Spitz, W.U. Resuscitation and petechiae. *Am. J. Forensic Med. Pathol.* 9:35–37, 1988.
15. Clark, M. A., Feczko, J. D., Hawley, D. A., Pless, J. E., Tate, L. R., Fardal, P. M. Asphyxial deaths due to hanging in children. *J. Forensic Sci.* 38:344–352, 1993.
16. Samarasekera, A., Cooke, C. The pathology of hanging deaths in Western Australia. *Pathology* 28:334–338, 1996.
17. DiMaio, V. J., DiMaio, D. *Forensic Pathology*. 2nd ed. CRC Press, New York, 2001.
18. Adelson, L. *The Pathology of Homicide*. Charles C. Thomas, Springfield, IL, 1974.
19. Harm, T., Rajs, J. Types of injuries and interrelated conditions of victims and assailants in attempted and homicidal strangulation. *Forensic Sci. Int.* 18:101–123, 1981.

20. Friberg, T. R., Weinreb, R. N. Ocular manifestations of gravity inversion. *JAMA* 253: 1755–1757, 1985.
21. Betz, P., Penning, R., Keil, W. The detection of petechial haemorrhages of the conjunctivae in dependency on the postmortem interval. *Forensic Sci. Int.* 64:61–67, 1994.
22. Hicks, L. J., Scanlon, M. J., Bostwick, T. C., Batten, P. J. Death by smothering and its investigation. *Am. J. Forensic Med. Pathol.* 11:291–293, 1990.
23. Luke, J. L. Asphyxial deaths by hanging in New York City, 1964–1965. *J. Forensic Sci.* 12:359–369, 1967.
24. Luke, J. L., Reay, D. T., Eisele, J. W., Bonnell, H. J. Correlation of circumstances with pathologic findings in asphyxial deaths by hanging: a prospective study of 61 cases from Seattle, WA. *J. Forensic Sci.* 30:1140–1147, 1985.
25. Luke, J. L. Strangulation as a method of homicide. Study 1965–1966. in New York City. *Arch. Pathol.* 83:64–70, 1967.
26. Di Nunno, N., Costantinides, F., Conticchio, G., Mangiatordi, S., Vimercati, L., Di Nunno, C. Self-strangulation: an uncommon but not unprecedented suicide method. *Am. J. Forensic Med. Pathol.* 23:260–263, 2002.
27. Collins, K. A. Death by overlaying and wedging: a 15-year retrospective study. *Am. J. Forensic Med. Pathol.* 22:155–159, 2001.
28. Cooke, C. T., Cadden, G. A., Hilton, J. M. Hanging deaths in children. *Am. J. Forensic Med. Pathol.* 10:98–104, 1989.
29. Moore, L., Byard, R. W. Pathological findings in hanging and wedging deaths in infants and young children. *Am. J. Forensic Med. Pathol.* 14:296–302, 1993.
30. Maxeiner, H. Congestion bleedings of the face and cardiopulmonary resuscitation—an attempt to evaluate their relationship. *Forensic Sci. Int.* 117:191–198, 2001.
31. Gueugniaud, P. Y. Subarachnoid hemorrhage: a complication of CPR? *Crit. Care. Med.* 15:284–285, 1987.
32. Willinger, M., James, L. S., Catz, C. Defining the sudden infant death syndrome SIDS.: deliberations of an expert panel convened by the National Institute of Child Health and Human Development. *Pediatr. Pathol.* 11:677–684, 1991.
33. Leach, C. E., Blair, P. S., Fleming, P. J., et al. Epidemiology of SIDS and explained sudden infant deaths. CESDI SUDI Research Group. *Pediatrics* 104:e43, 1999.
34. Handforth, C. P. Sudden unexpected death in infants. *Can. Med. Assoc. J.* 80:872–873, 1959.
35. Byard, R. W. Possible mechanisms responsible for the sudden infant death syndrome. *J. Paediatr. Child Health* 27:147–157, 1991.
36. Werne, J., Garrow, I. Sudden apparently unexplained death during infancy. I. Pathologic findings in infants found dead. *Am. J. Pathol.* 29:633–675, 1953.
37. Valdes-Dapena, M. The sudden infant death syndrome: pathologic findings. *Clin. Perinatol.* 19:701–716, 1992.
38. Alexander, R. T., Radisch, D. Sudden infant death syndrome risk factors with regards to sleep position, sleep surface, and co-sleeping. *J. Forensic Sci.* 50:147–151, 2005.
39. Krous, H. F. The microscopic distribution of intrathoracic petechiae in sudden infant death syndrome. *Arch. Pathol. Lab. Med.* 108:77–79, 1984.
40. Delmonte, C., Capelozzi, V. L. Morphologic determinants of asphyxia in lungs: a semi-quantitative study in forensic autopsies. *Am. J. Forensic Med. Pathol.* 22:139–149, 2001.
41. Brinkmann, B., Fechner, G., Puschel, K. Identification of mechanical asphyxiation in cases of attempted masking of the homicide. *Forensic Sci. Int.* 26:235–245, 1984.
42. Jackson, C. M., Gilliland, M. G. Frequency of pulmonary hemosiderosis in Eastern North Carolina. *Am. J. Forensic Med. Pathol.* 21:36–38, 2000.
43. Cooke, C. T., Cadden, G. A., Margolius, K. A. Death by hanging in Western Australia. *Pathology* 27:268–272, 1995.
44. Verma, S. K., Agarwal, B. B. Accidental hanging with delayed death in a lift. *Med. Sci. Law* 39:342–344, 1999.

45. McMaster, A. R., Ward, E. W., Dykeman, A., Warman, M. D. Suicidal ligature strangulation: case report and review of the literature. *J. Forensic Sci.* 46:386–388, 2001.
46. Clark, M. A., Kerr, F. C. Unusual hanging deaths. *J. Forensic Sci.* 31:747–755, 1986.
47. Hardwicke, M. B., Taff, M. L., Spitz, W. U. A case of suicidal hanging in an automobile. *Am. J. Forensic Med. Pathol.* 6:362–364, 1985.
48. Flobecker, P., Ottosson, J., Johansson, L., Hietala, M. A., Gezelius, C., Eriksson A. Accidental deaths from asphyxia. A 10-year retrospective study from Sweden. *Am. J. Forensic Med. Pathol.* 14:74–79, 1993.
49. Khokhlov, V. D. Calculation of tension exerted on a ligature in incomplete hanging. *Forensic Sci. Int.* 123:172–177, 2001.
50. Davison, A., Marshall, T. K. Hanging in Northern Ireland—a survey. *Med. Sci. Law* 26:23–28, 1986.
51. Travis, L. W., Olson, N. R., Melvin, J. W., Snyder, R. G. Static and dynamic impact trauma of the human larynx. *Trans. Sect. Otolaryngol. Am. Acad. Ophthalmol. Otolaryngol.* 80:382–390, 1975.
52. Martinez, A. P., Cameron, J. M. Trends in suicide 1983–1987. *Med. Sci. Law* 32:289–295, 1992.
53. Copeland, A. R. Suicide among the elderly—the Metro-Dade County experience, 1981–83. *Med. Sci. Law* 27:32–36, 1987.
54. Bowen, D. A. Hanging—a review. *Forensic Sci. Int.* 20:247–249, 1982.
55. Pounder, D. J. Why are the British hanging themselves? *Am. J. Forensic Med. Pathol.* 14:135–140, 1993.
56. Rogde, S., Hougen, H. P., Poulsen, K. Suicides in two Scandinavian capitals—a comparative study. *Forensic Sci. Int.* 80:211–219, 1996.
57. James, R., Silcocks, P. Suicidal hanging in Cardiff—a 15-year retrospective study. *Forensic Sci. Int.* 56:167–175, 1992.
58. Guarner, J., Hanzlick, R. Suicide by hanging. A review of 56 cases. *Am. J. Forensic Med. Pathol.* 8:23–26, 1987.
59. Cooper, P. N., Milroy, C. M. Violent suicide in South Yorkshire, England. *J. Forensic Sci.* 39:657–667, 1994.
60. Blanco Pampin, J. M., Lopez-Abajo Rodriguez, B. A. Suicidal hanging within an automobile. *Am. J. Forensic Med. Pathol.* 22:367–369, 2001.
61. Adair, T. W., Dobersen, M. J. A case of suicidal hanging staged as homicide. *J. Forensic Sci.* 44:1307–1309, 1999.
62. Bohnert, M., Faller-Marquardt, M., Lutz, S., Amberg, R., Weissner, H. J., Pollak, S. Transfer of biological traces in cases of hanging and ligature strangulation. *Forensic Sci. Int.* 116:107–115, 2001.
63. Avis, S. P., Hutton, C. J. Dyadic suicide. A case study. *Am. J. Forensic Med. Pathol.* 15:18–20, 1994.
64. Camps, F. E. The case of Emmett Dunne. *Med. Leg. J.* 27:156–161, 1959.
65. Srivastava, A. K., Das Gupta, S. M., Tripathi, C. B. A study of fatal strangulation cases in Varanasi India. *Am. J. Forensic Med. Pathol.* 8:220–224, 1987.
66. Leth, P., Vesterby, A. Homicidal hanging masquerading as suicide. *Forensic Sci. Int.* 85:65–71, 1997.
67. Simon, R. I. Murder masquerading as suicide: postmortem assessment of suicide risk factors at the time of death. *J. Forensic Sci.* 43:1119–1123, 1998.
68. Vieira, D. N., Pinto, A. E., Sa, F. O. Homicidal hanging. *Am. J. Forensic Med. Pathol.* 9:287–289, 1988.
69. Puschel, K., Holtz, W., Hildebrand, E., Naeve, W., Brinkmann, B. [Hanging: suicide or homicide?]. *Arch. Kriminol.* 174:141–153, 1984.
70. Shafii, M., Carrigan, S., Whittinghill, J. R., Derrick, A. Psychological autopsy of completed suicide in children and adolescents. *Am. J. Psychiatry* 142:1061–1064, 1985.



71. James, R. A., Byard, R. W. Asphyxiation from shoulder seat belts: an unusual motor vehicle injury. *Am. J. Forensic Med. Pathol.* 22:193–195, 2001.
72. Wobeser, W. L., Datema, J., Bechard, B., Ford, P. Causes of death among people in custody in Ontario, 1990–1999. *CMAJ* 167:1109–1113, 2002.
73. Frost, R., Hanzlick, R. Deaths in custody. Atlanta City Jail and Fulton County Jail, 1974–1985. *Am. J. Forensic Med. Pathol.* 9:207–211, 1988.
74. Smith, R. The state of the prisons. Deaths in prison. *Br. Med. J. (Clin. Res. Ed.)* 288:208–212, 1984.
75. Copeland, A. R. Deaths in custody revisited. *Am. J. Forensic Med. Pathol.* 5:121–124, 1984.
76. Novick, L. F., Remmlinger, E. A study of 128 deaths in New York City correctional facilities 1971–1976.: implications for prisoner health care. *Med. Care* 16:749–756, 1978.
77. Johnson, H. R. Deaths in police custody in England and Wales. *Forensic Sci. Int.* 19:231–236, 1982.
78. Smialek, J. E., Spitz, W. U. Death behind bars. *JAMA* 240:2563–2564, 1978.
79. Perez-Carceles, M. D., Inigo, C., Luna, A., Osuna, E. Mortality in maximum security psychiatric hospital patients. *Forensic Sci. Int.* 119:279–283, 2001.
80. Hayes, L. M. National study of jail suicides: seven years later. *Psychiatr. Q.* 60:7–29, 1989.
81. Tuskan, J. J., Jr., Thase, M. E. Suicides in jails and prisons. *J. Psychosoc. Nurs. Ment. Health Serv.* 21:29–33, 1983.
82. DuRand, C. J., Burtka, G. J., Federman, E. J., Haycox, J. A., Smith, J. W. A quarter century of suicide in a major urban jail: implications for community psychiatry. *Am. J. Psychiatry* 152:1077–1080, 1995.
83. Green, C., Kendall, K., Andre, G., Looman, T., Polvi, N. A study of 133 suicides among Canadian federal prisoners. *Med. Sci. Law* 33:121–127, 1993.
84. Joukamaa, M. Prison suicide in Finland, 1969–1992. *Forensic Sci. Int.* 89:167–174, 1997.
85. McKee, G. R. Lethal vs nonlethal suicide attempts in jail. *Psychol. Rep.* 82:611–614, 1998.
86. Jordan, F. B., Schmeckpeper, K., Strobe, M. Jail suicides by hanging. An epidemiological review and recommendations for prevention. *Am. J. Forensic Med. Pathol.* 8:27–31, 1987.
87. Copeland, A. R. Fatal suicidal hangings among prisoners in jail. *Med. Sci. Law* 29:341–345, 1989.
88. He, X. Y., Felthous, A. R., Holzer, C. E., III, Nathan, P., Veasey, S. Factors in prison suicide: one year study in Texas. *J. Forensic Sci.* 46:896–901, 2001.
89. Topp, D. O. Suicide in prison. *Br. J. Psychiatry* 134:24–27, 1979.
90. Reay, D. T. Death in custody. *Clin. Lab. Med.* 18:1–22, 1998.
91. Shah, A., Ganesvaran, T. Suicide among psychiatric in-patients with schizophrenia in an Australian mental hospital. *Med. Sci. Law* 39:251–259, 1999.
92. Miles, S. A case of death by physical restraint: new lessons from a photograph. *J. Am. Geriatr. Soc.* 44:291–292, 1996.
93. Osculati, A., Fassina, G. Two cases of accidental asphyxia by neck compression between bed bars. *Am. J. Forensic Med. Pathol.* 21:217–219, 2000.
94. Weakley-Jones, B., Wernert, J. Accidental deaths in the aged by protective devices. *J. Ky. Med. Assoc.* 84:397–398, 1986.
95. Dube, A. H., Mitchell, E. K. Accidental strangulation from vest restraints. *JAMA* 256:2725–2726, 1986.
96. Corey, T. S., Weakley-Jones, B., Nichols, G. R., Theuer, H. H. Unnatural deaths in nursing home patients. *J. Forensic Sci.* 37:222–227, 1992.
97. Bell, M. D., Rao, V. J., Wetli, C. V., Rodriguez, R. N. Positional asphyxiation in adults. A series of 30 cases from the Dade and Broward County Florida Medical Examiner Offices from 1982 to 1990. *Am. J. Forensic Med. Pathol.* 13:101–107, 1992.

98. DiMaio, V. J., Dana, S. E., Bux, R. C. Deaths caused by restraint vests. *JAMA* 255:905, 1986.
99. Parker, K., Miles, S. H. Deaths caused by bedrails. *J. Am. Geriatr. Soc.* 45:797–802, 1997.
100. Miles, S. H., Irvine, P. Deaths caused by physical restraints. *Gerontologist* 32:762–766, 1992.
101. Emson, H. E. Death in a restraint jacket from mechanical asphyxia. *CMAJ* 151:985–987, 1994.
102. Copeland, A. R. Childhood suicide: a report of four cases. *J. Forensic Sci.* 30:965–967, 1985.
103. Wyatt, J. P., Wyatt, P. W., Squires, T. J., Busuttil, A. Hanging deaths in children. *Am. J. Forensic Med. Pathol.* 19:343–346, 1998.
104. Goren, S., Gurkan, F., Tirasci, Y., Ozen, S. Suicide in children and adolescents at a province in Turkey. *Am. J. Forensic Med. Pathol.* 24:214–217, 2003.
105. Toolan, J. M. Suicide in children and adolescents. *Am. J. Psychother.* 29:339–344, 1975.
106. Weinberger, L. E., Sreenivasan, S., Sathyavagiswaran, L., Markowitz, E. Child and adolescent suicide in a large, urban area: psychological, demographic, and situational factors. *J. Forensic Sci.* 46:902–907, 2001.
107. Schmidt, P., Muller, R., Dettmeyer, R., Madea, B. Suicide in children, adolescents and young adults. *Forensic Sci. Int.* 127:161–167, 2002.
108. Copeland, A. R. Teenage suicide—the five-year Metro Dade County experience from 1979 until 1983. *Forensic Sci. Int.* 28:27–33, 1985.
109. Green, M. A. Morbid anatomical findings in strangulation. *Forensic Sci.* 2:317–323, 1973.
110. Variend, S., Usher, A. Broken cots and infant fatality. *Med. Sci. Law* 24:111–112, 1984.
111. Bass, M. Asphyxial crib death. *N. Engl. J. Med.* 296:555–556, 1977.
112. Byard RW, Beal SM, Simpson A, Carter RF, Khong TY. Accidental infant death and stroller-prams. *Med. J. Aust.* 165:140–141, 1996.
113. Gilbert-Barness, E., Hegstrand, L., Chandra, S., et al. Hazards of mattresses, beds and bedding in deaths of infants. *Am. J. Forensic Med. Pathol.* 12:27–32, 1991.
114. Baker, S. P., Fisher, R. S. Childhood asphyxiation by choking or suffocation. *JAMA* 244:1343–1346, 1980.
115. Sturner, W. Q., Spruill, F. G., Smith, R. A., Lene, W. J. Accidental asphyxial deaths involving infants and young children. *J. Forensic Sci.* 21:483–487, 1976.
116. Nixon, J. W., Kemp, A. M., Levene, S., Sibert, J. R. Suffocation, choking, and strangulation in childhood in England and Wales: epidemiology and prevention. *Arch. Dis. Child.* 72:6–10, 1995.
117. Drago, D. A., Dannenberg, A. L. Infant mechanical suffocation deaths in the United States, 1980–1997. *Pediatrics* 103:e59, 1999.
118. Robertson, D., Rookwood, K., Rutter, N. Collapsible washing lines: a strangulation hazard. *Br. Med. J. (Clin. Res. Ed.)* 282:1664, 1981.
119. Little, A. S. Drapery cord injury and strangulation in babies. *Am. Fam. Physician* 49:335, 1994.
120. Hord, J. D., Anglin, D. Accidental strangulation of a toddler involving a wall light switch. *Am. J. Dis. Child.* 147:1038–1039, 1993.
121. Rauchschwalbe, R., Mann, N. C. Pediatric window-cord strangulations in the United States, 1981–1995. *JAMA* 277:1696–1698, 1997.
122. Byard, R. W., James, R. A. Car window entrapment and accidental childhood asphyxia. *J. Paediatr. Child Health* 37:201–202, 2001.
123. Calvet, R., Gonzalez-Gil, J., Gonzalez-Azpeitia, C. An unusual fatal case of accidental asphyxia in a child. *J. Forensic Sci.* 37:1697–1701, 1992.
124. Perrot, L. J., Froede R. C., Jones, A. M. Asphyxiation by hanging in two young Hispanic children—homicide, suicide, or accidental deaths? A review of pediatric hangings. *Am. J. Forensic Med. Pathol.* 6:284–288, 1985.

125. Digeronimo, R. J., Mayes, T. C. Near-hanging injury in childhood: a literature review and report of three cases. *Pediatr. Emerg. Care* 10:150–156, 1994.
126. Denton, J. S. Fatal accidental hanging from a lanyard key chain in a 10-year-old boy. *J. Forensic Sci.* 47:1345–1346, 2002.
127. Petruk, J., Shields, E., Cummings, G. E., Francescutti, L. H. Fatal asphyxiations in children involving drawstrings on clothing. *CMAJ* 155:1417–1419, 1996.
128. Lew, E. O. Homicidal hanging in a dyadic death. *Am. J. Forensic Med. Pathol.* 9:283–286, 1988.
129. Rothschild, M. A., Schneider, V. Decapitation as a result of suicidal hanging. *Forensic Sci. Int.* 106:55–62, 1999.
130. el Khafief, H. Unusual cases from Dubai, United Arab Emirates. *Am. J. Forensic Med. Pathol.* 12:187–190, 1991.
131. Goonetilleke, U. K. Two unusual cases of suicide by hanging. *Forensic Sci. Int.* 26:247–253, 1984.
132. Marsh, T. O., Burkhardt, R. P., Swinehart, J. W. Self-inflicted hanging with bound wrists and a gag. *Am. J. Forensic Med. Pathol.* 3:367–369, 1982.
133. Wright, R. K., Davis, J. Homicidal hanging masquerading as sexual asphyxia. *J. Forensic Sci.* 21:387–389, 1976.
134. Paparo, G. P., Siegel, H. Neck markings and fractures in suicidal hangings. *Forensic Sci. Int.* 24:27–35, 1984.
135. Saukko, P., Knight, B. *Knight's Forensic Pathology*. 3rd ed. Arnold, London, 2004.
136. Miller, K. W., Walker, P. L., O'Halloran, R. L. Age and sex-related variation in hyoid bone morphology. *J. Forensic Sci.* 43:1138–1143, 1998.
137. Raja, U., Sivaloganathan, S. Decapitation—a rare complication in hanging. *Med. Sci. Law* 37:81–83, 1997.
138. Hocking, F. D. Hanging and manual strangulation. *Med. Sci. Law* 6:49–51, 1966.
139. Khokhlov, V. D. Pressure on the neck calculated for any point along the ligature. *Forensic Sci. Int.* 123:178–181, 2001.
140. Ruszkiewicz, A. R., Lee, K. A., Landgren, A. J. Homicidal strangulation by victim's own hair presenting as natural death. *Am. J. Forensic Med. Pathol.* 15:340–343, 1994.
141. Garza-Leal, J. A., Landron, F. J. Autoerotic asphyxial death initially misinterpreted as suicide and a review of the literature. *J. Forensic Sci.* 36:1753–1759, 1991.
142. Rajs, J., Thiblin, I. Histologic appearance of fractured thyroid cartilage and surrounding tissues. *Forensic Sci. Int.* 114:155–166, 2000.
143. Kaplan, J. A., Fossum, R. M. Patterns of facial resuscitation injury in infancy. *Am. J. Forensic Med. Pathol.* 15:187–191, 1994.
144. Guernsey, L. H. Fractures of the hyoid bone. *J. Oral Surg. Anesth. Hosp. Dent. Serv.* 12:241–246, 1954.
145. Morild, I. Fractures of neck structures in suicidal hanging. *Med. Sci. Law* 36:80–84, 1996.
146. Keil, W., Forster, A., Meyer, H. J., Peschel, O. Characterization of haemorrhages at the origin of the sternocleidomastoid muscles in hanging. *Int. J. Legal Med.* 108:140–144, 1995.
147. Keil, W., Kondo, T., Beer, G. M. Haemorrhages in the posterior cricoarytenoid muscles—an unspecific autopsy finding. *Forensic Sci. Int.* 95:225–230, 1998.
148. Paparo, G. P., Siegel, H. On the significance of posterior crico-arytenoid muscle hemorrhage. *Forensic Sci.* 7:61–65, 1976.
149. Ubelaker, D. H. Hyoid fracture and strangulation. *J. Forensic Sci.* 37:1216–1222, 1992.
150. Simonsen, J. Patho-anatomic findings in neck structures in asphyxiation due to hanging: a survey of 80 cases. *Forensic Sci. Int.* 38:83–91, 1988.
151. DiMaio, V. J. Homicidal asphyxia. *Am. J. Forensic Med. Pathol.* 21:1–4, 2000.
152. Feigin, G. Frequency of neck organ fractures in hanging. *Am. J. Forensic Med. Pathol.* 20:128–130, 1999.

153. Hansch, C. F. Throat-skeleton fractures by strangulation. *Z. Rechtsmed.* 79:143–147, 1977.
154. Nikolic, S., Micic, J., Atanasijevic, T., Djokic, V., Djonic, D. Analysis of neck injuries in hanging. *Am. J. Forensic Med. Pathol.* 24:179–182, 2003.
155. Betz, P., Eisenmenger, W. Frequency of throat-skeleton fractures in hanging. *Am. J. Forensic Med. Pathol.* 17:191–193, 1996.
156. Khokhlov, V. D. Injuries to the hyoid bone and laryngeal cartilages: effectiveness of different methods of medico-legal investigation. *Forensic Sci. Int.* 88:173–183, 1997.
157. Gordon, I., Shapiro, H. A., Taljaard, J. J., Engelbrecht, H. E. Aspects of the hyoid-larynx complex in forensic pathology. *Forensic Sci.* 7:161–170, 1976.
158. Pollanen, M. S. A triad of laryngeal hemorrhages in strangulation: a report of eight cases. *J. Forensic Sci.* 45:614–618, 2000.
159. Szeremeta, W., Morovati, S. S. Isolated hyoid bone fracture: a case report and review of the literature. *J. Trauma* 31:268–271, 1991.
160. Pollanen, M. S., Bulger, B., Chiasson, D. A. The location of hyoid fractures in strangulation revealed by xeroradiography. *J. Forensic Sci.* 40:303–305, 1995.
161. Pollanen, M. S., Chiasson, D. A. Fracture of the hyoid bone in strangulation: comparison of fractured and unfractured hyoids from victims of strangulation. *J. Forensic Sci.* 41:110–113, 1996.
162. O'Halloran, R. L., Lundy, J. K. Age and ossification of the hyoid bone: forensic implications. *J. Forensic Sci.* 32:1655–1659, 1987.
163. Pollanen, M. S., Ubelaker, D. H. Forensic significance of the polymorphism of hyoid bone shape. *J. Forensic Sci.* 42:890–892, 1997.
164. Whyte, A. M. Fracture of the hyoid bone associated with a mandibular fracture. *J. Oral Maxillofac. Surg.* 43:805–807, 1985.
165. Porraath, S. Roentgenologic considerations of the hyoid apparatus. *Am. J. Roentgenol. Radium Ther. Nucl. Med.* 105:63–73, 1969.
166. Watanabe, H., Kurihara, K., Murai, T. A morphometrical study of laryngeal cartilages. *Med. Sci. Law* 22:255–260, 1982.
167. Mancuso, A. A., Hanafee, W. N. Computed tomography of the injured larynx. *Radiology* 133:139–144, 1979.
168. Khokhlov, V. D. Knitted fractures of the laryngopharynx framework as a medico-legal matter. *Forensic Sci. Int.* 104:147–162, 1999.
169. Spence, M. W., Shkrum, M. J., Ariss, A., Regan, J. Cranio-cervical injuries in judicial hangings: an anthropologic analysis of six cases. *Am. J. Forensic Med. Pathol.* 20:309–322, 1999.
170. Shkrum, M. J., Green, R. N., Nowak, E. S. Upper cervical trauma in motor vehicle collisions. *J. Forensic Sci.* 34:381–390, 1989.
171. Prichard, P. D. A suicide by self-decapitation. *J. Forensic Sci.* 38:981–984, 1993.
172. Tracqui, A., Fonmartin, K., Geraut, A., Pennera, D., Doray, S., Ludes, B. Suicidal hanging resulting in complete decapitation: a case report. *Int. J. Legal Med.* 112:55–57, 1999.
173. Crompton, M. R. Fronto-cranial suspension—an unusual form of hanging. *Med. Sci. Law* 26:203–206, 1986.
174. Line, W. S., Jr., Stanley, R. B., Jr., Choi, J. H. Strangulation: a full spectrum of blunt neck trauma. *Ann. Otol. Rhinol. Laryngol.* 94:542–546, 1985.
175. Bockholdt, B., Maxeiner, H. Hemorrhages of the tongue in the postmortem diagnostics of strangulation. *Forensic Sci. Int.* 126:214–220, 2002.
176. Suyama, H., Nakasono, I., Yoshitake, T., Narita, K., Yoshida, C. Significance of haemorrhages in central parts of the tongue found in the medicolegal autopsy. *Forensic Sci. Int.* 20:265–268, 1982.
177. Saturnus, K. S. Injury of the vertebral artery in suicidal hanging. *Forensic Sci. Int.* 25:265–275, 1984.

178. Maxeiner, H., Bockholdt, B. Homicidal and suicidal ligature strangulation—a comparison of the post-mortem findings. *Forensic Sci. Int.* 137:60–66, 2003.
179. Kogan, Y., Bloom, T. Suicidal ligature strangulation with an elastic band. *Am. J. Forensic Med. Pathol.* 11:329–330, 1990.
180. Claydon, S. M. Suicidal strangulation by ligature: three case reports. *Med. Sci. Law* 30:221–224, 1990.
181. Frazer, M., Rosenberg, S. A case of suicidal ligature strangulation. *Am. J. Forensic Med. Pathol.* 4:351–354, 1983.
182. Gaur, J. R., Verma, R. K., Thakur, G. C. Suicidal strangulation. *Med. Sci. Law* 32:55–56, 1992.
183. Zecevic, D. Suicidal strangulation with a double-knotted noose. *J. Forensic Sci.* 27:963–967, 1982.
184. Kennedy, N. M., Whittington, R. M., White, A. C. Suicide by self-strangulation whilst under observation. *Med. Sci. Law* 35:174–177, 1995.
185. Shepherd, R. T. Accidental self-strangulation in a young child—a case report and review. *Med. Sci. Law* 30:119–123, 1990.
186. Deidiker, R. D. Accidental ligature strangulation due to a roller-type massage device. *Am. J. Forensic Med. Pathol.* 20:354–356, 1999.
187. Habal, M. B., Meguid, M. M., Murray, J. E. The long scarf syndrome—a potentially fatal and preventable hazard. Report of 11 cases. *JAMA* 221:1269–1270, 1972.
188. Kohli, A., Verma, S. K., Agarwal, B. B. Accidental strangulation in a rickshaw. *Forensic Sci. Int.* 78:7–11, 1996.
189. Aggarwal, N. K., Agarwal, B. B. Accidental strangulation in a cycle rickshaw. *Med. Sci. Law* 38:263–265, 1998.
190. Meguid, M. M., Gifford, G. H., Jr. The long free-flowing scarf—a new health hazard to children. *Pediatrics* 49:290–293, 1972.
191. Michalodimitrakis, M., Frangoulis, M., Koutselinis, A. Accidental sexual strangulation. *Am. J. Forensic Med. Pathol.* 7:74–75, 1986.
192. Pollanen, M. S. Subtle fatal manual neck compression. *Med. Sci. Law* 41:135–140, 2001.
193. Shapiro, H. A., Gluckman, J., Gordon, I. The significance of finger nail abrasions of the skin. *J. Forensic Med.* 9:17–19, 1962.
194. Perper, J. A., Sobel, M. N. Identification of fingernail markings in manual strangulation. *Am. J. Forensic Med. Pathol.* 2:45–48, 1981.
195. Fieguth, A., Franz, D., Lessig, R., Kleemann, W. J. Fatal trauma to the neck: immunohistochemical study of local injuries. *Forensic Sci. Int.* 135:218–225, 2003.
196. Tabata, N. Morphological changes in traumatized skeletal muscle: the appearance of “opaque fibers” of cervical muscles as evidence of compression of the neck. *Forensic Sci. Int.* 96:197–214, 1998.
197. Betz, P., Nerlich, A., Wilske, J., et al. Immunohistochemical localization of fibronectin as a tool for the age determination of human skin wounds. *Int. J. Legal Med.* 105:21–26, 1992.
198. Fechner, G., Hauser, R., Sepulchre, M. A., Brinkmann, B. Immunohistochemical investigations to demonstrate vital direct traumatic damage of skeletal muscle. *Int. J. Legal Med.* 104:215–219, 1991.
199. Thomsen, H., Held, H. Susceptibility of C5b-9 m. to postmortem changes. *Int. J. Legal Med.* 106:291–293, 1994.
200. Fechner, G., Bajanowski, T., Brinkmann, B. Immunohistochemical alterations after muscle trauma. *Int. J. Legal Med.* 105:203–207, 1993.
201. Fieguth, A., Kleemann, W. J., von Wasielewski, R., Werner, M., Troger, H. D. Influence of postmortem changes on immunohistochemical reactions in skin. *Int. J. Legal Med.* 110:18–21, 1997.
202. Grellner, W., Dimmeler, S., Madea, B. Immunohistochemical detection of fibronectin in postmortem incised wounds of porcine skin. *Forensic Sci. Int.* 97:109–116, 1998.



203. Maxeiner, H. [Injuries to laryngeal articulations in strangulation and throttling]. *Arch. Kriminol.* 179:38–44, 1987.
204. Maxeiner, H. [Soft tissue hemorrhage within the larynx following strangulation]. *Z. Rechtsmed.* 94:127–135, 1985.
205. Pollanen, M. S., McAuliffe, D. N. Intra-cartilaginous laryngeal haemorrhages and strangulation. *Forensic Sci. Int.* 93:13–20, 1998.
206. Pradeep, K. G., Kanthaswamy, V. Survival in hanging. *Am. J. Forensic Med. Pathol.* 14:80–81, 1993.
207. Aggarwal, N. K., Kishore, U., Agarwal, B. B. Hanging-delayed death a rare phenomenon. *Med. Sci. Law* 40:270–272, 2000.
208. Raven, K. P., Reay, D. T., Harruff, R. C. Artifactual injuries of the larynx produced by resuscitative intubation. *Am. J. Forensic Med. Pathol.* 20:31–36, 1999.
209. Leadbeater, S., Knight, B. Resuscitation artefact. *Med. Sci. Law* 28:200–204, 1988.
210. Harm, T., Rajs, J. Face and neck injuries due to resuscitation versus throttling. *Forensic Sci. Int.* 23:109–116, 1983.
211. Krischer, J. P., Fine, E. G., Davis, J. H., Nagel, E. L. Complications of cardiac resuscitation. *Chest* 92:287–291, 1987.
212. Sommers, M. S. Potential for injury: trauma after cardiopulmonary resuscitation. *Heart Lung* 20:287–293, 1991.
213. Streitz, J. M., Jr., Shapshay, S. M. Airway injury after tracheotomy and endotracheal intubation. *Surg. Clin. North Am.* 71:1211–1230, 1991.
214. Peppard, S. B., Dickens, J. H. Laryngeal injury following short-term intubation. *Ann. Otol. Rhinol. Laryngol.* 92:327–330, 1983.
215. Galvis, A. G., Kelley, C. F. Hypopharynx perforation during infant's resuscitation. *JAMA* 242:1526–1527, 1979.
216. Hawkins, D. B., Seltzer, D. C., Barnett, T. E., Stoneman, G. B. Endotracheal tube perforation of the hypopharynx. *West. J. Med.* 120:282–286, 1974.
217. Lee, T. S., Jordan, J. S. Pyriform sinus perforation secondary to traumatic intubation in a difficult airway patient. *J. Clin. Anesth.* 6:152–155, 1994.
218. Marty-Ane, C. H., Picard, E., Jonquet, O., Mary, H. Membranous tracheal rupture after endotracheal intubation. *Ann. Thorac. Surg.* 60:1367–1371, 1995.
219. Massard, G., Rouge, C., Dabbagh, A., Kessler, R., Hentz, J. G., Roeslin, N. et al. Tracheobronchial lacerations after intubation and tracheostomy. *Ann. Thorac. Surg.* 61:1483–1488, 1996.
220. Kaloud, H., Smolle-Juettner, F. M., Prause, G., List, W. F. Iatrogenic ruptures of the tracheobronchial tree. *Chest* 112:774–778, 1997.
221. Gregersen, M., Vesterby, A. Iatrogenic fractures of the hyoid bone and the thyroid cartilage. A case report. *Forensic Sci. Int.* 17:41–43, 1981.
222. Kambic, V., Radsel, Z. Intubation lesions of the larynx. *Br. J. Anaesth.* 50:587–590, 1978.
223. Nagel, E. L., Fine, E. G., Krischer, J. P., Davis, J. H. Complications of CPR. *Crit. Care Med.* 9:424, 1981.
224. Behrendt, N., Buhl, N., Seidl, S. The lethal paraphiliac syndrome: accidental autoerotic deaths in four women and a review of the literature. *Int. J. Legal Med.* 116:148–152, 2002.
225. Boglioli, L. R., Taff, M. L., Stephens, P. J., Money, J. A case of autoerotic asphyxia associated with multiplex paraphilia. *Am. J. Forensic Med. Pathol.* 12:64–73, 1991.
226. Byard, R. W., Bramwell, N. H. Autoerotic death. A definition. *Am. J. Forensic Med. Pathol.* 12:74–76, 1991.
227. Hazelwood, R. R., Burgess, A. W., Groth, A. N. Death during dangerous autoerotic practice. *Soc. Sci Med [E]* 15:129–133, 1981.
228. Behrendt, N., Modvig, J. The lethal paraphiliac syndrome. Accidental autoerotic deaths in Denmark 1933–1990. *Am. J. Forensic Med. Pathol.* 16:232–237, 1995.

229. Uva, J. L. Review: autoerotic asphyxiation in the United States. *J. Forensic Sci.* 40:574–581, 1995.
230. Blanchard, R., Hucker, S. J. Age, transvestism, bondage, and concurrent paraphilic activities in 117 fatal cases of autoerotic asphyxia. *Br. J. Psychiatry* 159:371–377, 1991.
231. Diamond, M., Innala, S. M., Ernulf, K. E. Asphyxiophilia and autoerotic death. *Hawaii Med. J.* 49:11–16, 24, 1990.
232. Innala, S. M., Ernulf, K. E. Asphyxiophilia in Scandinavia. *Arch. Sex. Behav.* 18:181–189, 1989.
233. Resnik, H. L. Erotized repetitive hangings: a form of self-destructive behavior. *Am. J. Psychother.* 26:4–21, 1972.
234. Tough, S. C., Butt, J. C., Sanders, G. L. Autoerotic asphyxial deaths: analysis of nineteen fatalities in Alberta, 1978 to 1989. *Can. J. Psychiatry* 39:157–160, 1994.
235. Shields, L. B., Hunsaker, D. M., Hunsaker, J. C., III. Autoerotic asphyxia: part I. *Am. J. Forensic Med. Pathol.* 26:45–5, 2005.
236. Sheehan, W., Garfinkel, B. D. Adolescent autoerotic deaths. *J. Am. Acad. Child Adolesc. Psychiatry* 27:367–370, 1988.
237. Knight, B. Fatal masochism—accident or suicide? *Med. Sci. Law* 19:118–120, 1979.
238. Burgess, A. W., Hazelwood, R. R. Autoerotic asphyxial deaths and social network response. *Am. J. Orthopsychiatry* 53:166–170, 1983.
239. Byard, R. W., Hucker, S. J., Hazelwood, R. R. A comparison of typical death scene features in cases of fatal male and autoerotic asphyxia with a review of the literature. *Forensic Sci. Int.* 48:113–121, 1990.
240. Sinn, L. E. The silver bullet. *Am. J. Forensic Med. Pathol.* 14:145–147, 1993.
241. Byard, R. W., Hucker, S. J., Hazelwood, R. R. Fatal and near-fatal autoerotic asphyxial episodes in women. Characteristic features based on a review of nine cases. *Am. J. Forensic Med. Pathol.* 14:70–73, 1993.
242. Johnstone, J. M., Hunt, A. C., Ward, E. M. Plastic-bag asphyxia in adults. *Br. Med. J.* 5214:1714–1715, 1960.
243. Breitmeier, D., Mansouri, F., Albrecht, K., Bohm, U., Troger, H. D., Kleemann, W. J. Accidental autoerotic deaths between 1978 and 1997. Institute of Legal Medicine, Medical School Hannover. *Forensic Sci. Int.* 137:41–44, 2003.
244. Eckert, W. G., Katchis, S., Donovan, W. The pathology and medicolegal aspects of sexual activity. *Am. J. Forensic Med. Pathol.* 12:3–15, 1991.
245. Ikeda, N., Harada, A., Umetsu, K., Suzuki, T. A case of fatal suffocation during an unusual auto-erotic practice. *Med. Sci. Law* 28:131–134, 1988.
246. Madea, B. Death in a head-down position. *Forensic Sci. Int.* 61:119–132, 1993.
247. Shields, L. B., Hunsaker, D. M., Hunsaker, J. C., III, Wetli, C. V., Hutchins, K. D., Holmes, R. M. Atypical autoerotic death: part II. *Am. J. Forensic Med. Pathol.* 26:53–62, 2005.
248. Breitmeier, D., Passie, T., Mansouri, F., Albrecht, K., Kleemann, W. J. Autoerotic accident associated with self-applied ketamine. *Int. J. Legal Med.* 116:113–116, 2002.
249. Litman, R. E., Swearingen, C. Bondage and suicide. *Arch. Gen. Psychiatry* 27:80–85, 1972.
250. Cooke, C. T., Cadden, G. A., Margolius, K. A. Autoerotic deaths: four cases. *Pathology* 26:276–280, 1994.
251. Burgess, A. W., Hazelwood, R. R. Autoerotic asphyxial deaths and social network response. *Am. J. Orthopsychiatry* 53:166–170, 1983.
252. Byard, R. W., Bramwell, N. H. Autoerotic death in females. An underdiagnosed syndrome? *Am. J. Forensic Med. Pathol.* 9:252–254, 1988.
253. Hazelwood, R. R., Dietz, P. E., Burgess, A. W. Sexual fatalities: behavioral reconstruction in equivocal cases. *J. Forensic Sci.* 27:763–773, 1982.
254. Burch, P. M., Case, M. E., Turgeon, R. Sexual asphyxiation: an unusual case involving four male adolescents. *J. Forensic Sci.* 40:490–491, 1995.

255. Thibault, R., Spencer, J. D., Bishop, J. W., Hibler, N. S. An unusual autoerotic death: asphyxia with an abdominal ligature. *J. Forensic Sci.* 29:679–684, 1984.
256. Minyard, F. Wrapped to death. Unusual autoerotic death. *Am. J. Forensic Med. Pathol.* 6:151–152, 1985.
257. Jones, L. S., Wyatt, J. P., Busuttil, A. Plastic bag asphyxia in southeast Scotland. *Am. J. Forensic Med. Pathol.* 21:401–405, 2000.
258. O'Halloran, R. L., Dietz, P. E. Autoerotic fatalities with power hydraulics. *J. Forensic Sci.* 38:359–364, 1993.
259. Rupp, J. C. The love bug. *J. Forensic Sci.* 18:259–262, 1973.
260. Sivaloganathan, S. Aqua-eroticum—a case of auto-erotic drowning. *Med. Sci. Law* 24:300–302, 1984.
261. Leadbeatter, S. Dental anesthetic death. An unusual autoerotic episode. *Am. J. Forensic Med. Pathol.* 9:60–63, 1988.
262. Rosenblum, S., Faber, M. M. The adolescent sexual asphyxia syndrome. *J. Am. Acad. Child Psychiatry* 18:546–558, 1979.
263. Gosink, P. D., Jumbelic, M. I. Autoerotic asphyxiation in a female. *Am. J. Forensic Med. Pathol.* 21:114–118, 2000.
264. Sass, F. A. Sexual asphyxia in the female. *J. Forensic Sci.* 20:181–185, 1975.
265. Danto, B. L. A case of female autoerotic death. *Am. J. Forensic Med. Pathol.* 1:117–121, 1980.
266. Hiss, J., Rosenberg, S. B., Adelson, L. “Swinging in the park”. An investigation of an autoerotic death. *Am. J. Forensic Med. Pathol.* 6:250–255, 1985.
267. Byard, R. W., Botterill, P. Autoerotic asphyxial death—accident or suicide? *Am. J. Forensic Med. Pathol.* 19:377–380, 1998.
268. McLennan, J. J., Sekula-Perlman, A., Lippstone, M. B., Callery, R. T. Propane-associated autoerotic fatalities. *Am. J. Forensic Med. Pathol.* 19:381–386, 1998.
269. Downs, J. C., Conradi, S. E., Nichols, C. A. Suicide by environmental hypoxia (forced depletion of oxygen). *Am. J. Forensic Med. Pathol.* 15:216–223, 1994.
270. Henry, R. I. Suicide by proxy: a case report of juvenile autoerotic sexual asphyxia disguised as suicide. A common occurrence? *J. Clin. Forensic Med.* 3:55–56, 1996.
271. Isenschmid, D. S., Cassin, B. J., Hepler, B. R., Kanlun, S. Tetrachloroethylene intoxication in an autoerotic fatality. *J. Forensic Sci.* 43:231–234, 1998.
272. Emson, H. E. Accidental hanging in autoeroticism. An unusual case occurring outdoors. *Am. J. Forensic Med. Pathol.* 4:337–340, 1983.
273. Gowitt, G. T., Hanzlick, R. L. Atypical autoerotic deaths. *Am. J. Forensic Med. Pathol.* 13:115–119, 1992.
274. Eriksson, A., Gezelius, C., Bring, G. Rolled up to death. An unusual autoerotic fatality. *Am. J. Forensic Med. Pathol.* 8:263–265, 1987.
275. O'Halloran, R. L., Lovell, F. W. Autoerotic asphyxial death following television broadcast. *J. Forensic Sci.* 33:1491–1492, 1988.
276. Imami, R. H., Kemal, M. Vacuum cleaner use in autoerotic death. *Am. J. Forensic Med. Pathol.* 9:246–248, 1988.
277. Baik, S. O., Uku, J. M. Ligature strangulation of a woman during sadomasochistic sexual activity. *Am. J. Forensic Med. Pathol.* 9:249–251, 1988.
278. Dietz, P. E., Harry, B., Hazelwood, R. R. Detective magazines: pornography for the sexual sadist? *J. Forensic Sci.* 31:197–211, 1986.
279. Wesselius, C. L., Bally, R. A male with autoerotic asphyxia syndrome. *Am. J. Forensic Med. Pathol.* 4:341–344, 1983.
280. Dietz, P. E., Evans, B. Pornographic imagery and prevalence of paraphilia. *Am. J. Psychiatry* 139:1493–1495, 1982.
281. Bell, M. D., Tate, L. G., Wright, R. K. Sexual asphyxia in siblings. *Am. J. Forensic Med. Pathol.* 12:77–79, 1991.

282. Tournel, G., Hubert, N., Rouge, C., Hedouin, V., Gosset, D. Complete autoerotic asphyxiation: suicide or accident? *Am. J. Forensic Med. Pathol.* 22:180–183, 2001.
283. Byard, R. W., Eitzen, D. A., James, R. Unusual fatal mechanisms in nonasphyxial autoerotic death. *Am. J. Forensic Med. Pathol.* 21:65–68, 2000.
284. Eckert, W. G., Katchis, S. Anorectal trauma. Medicolegal and forensic aspects. *Am. J. Forensic Med. Pathol.* 10:3–9, 1989.
285. Carr, A. C., Shankel, L. W. Transvestism and hanging episodes in a male adolescent. *Psychiatr. Q.* 30:478–493, 1956.
286. Tan, C. T., Chao, T. C. A case of fatal electrocution during an unusual autoerotic practice. *Med. Sci. Law* 23:92–95, 1983.
287. Cairns, F. J., Rainer, S. P. Death from electrocution during auto-erotic procedures. *N. Z. Med. J.* 94:259–260, 1981.
288. Sivaloganathan, S. Curiosum eroticum—a case of fatal electrocution during auto-erotic practice. *Med. Sci. Law* 21:47–50, 1981.
289. Klintschar, M., Grabuschnigg, P., Beham, A. Death from electrocution during autoerotic practice: case report and review of the literature. *Am. J. Forensic Med. Pathol.* 19:190–193, 1998.
290. Cordner, S. M. An unusual case of sudden death associated with masturbation. *Med. Sci. Law* 23:54–56, 1983.
291. Chadly, A., Marc, B., Barres, D., Durigon, M. Suicide by nitrous oxide poisoning. *Am. J. Forensic Med. Pathol.* 10:330–331, 1989.
292. Sivaloganathan, S. Catheteroticum. Fatal late complication following autoerotic practice. *Am. J. Forensic Med. Pathol.* 6:340–342, 1985.
293. Ditto, E. W., III. Electrocution during sexual activity. *Am. J. Forensic Med. Pathol.* 2:271–272, 1981.
294. Schott, J. C., Davis, G. J., Hunsaker, J. C., III. Accidental electrocution during autoerotism: a shocking case. *Am. J. Forensic Med. Pathol.* 24:92–95, 2003.
295. Shook, L. L., Whittle, R., Rose, E. F. Rectal fist insertion. An unusual form of sexual behavior. *Am. J. Forensic Med. Pathol.* 6:319–324, 1985.
296. Avis, S. P. An unusual suicide. The importance of the scene investigation. *Am. J. Forensic Med. Pathol.* 14:148–150, 1993.
297. Bartholomew, S. E., Macarthur, B. A. The continuing enigma of sudden infant death 1882–91–1977–86. *Scott. Med. J.* 32:131–132, 1987.
298. Luke, J. L. Sleeping arrangements of sudden infant death syndrome victims in the District of Columbia—a preliminary report. *J. Forensic Sci.* 23:379–383, 1978.
299. Blair, P. S., Fleming, P. J., Smith, I. J., et al. Babies sleeping with parents: case-control study of factors influencing the risk of the sudden infant death syndrome. CESDI SUDI research group. *BMJ* 319:1457–1461, 1999.
300. Rosenberg, K. D. Sudden infant death syndrome and co-sleeping. *Arch. Pediatr. Adolesc. Med.* 154:529–530, 2000.
301. McKenna, J. J., Gartner, L. M. Sleep location and suffocation: how good is the evidence? *Pediatrics* 105:917–919, 2000.
302. Nakamura, S., Wind, M., Danello, M. A. Review of hazards associated with children placed in adult beds. *Arch. Pediatr. Adolesc. Med.* 153:1019–1023, 1999.
303. Byard, R. W., Beal, S., Blackbourne, B., Nadeau, J. M., Krous, H. F. Specific dangers associated with infants sleeping on sofas. *J. Paediatr. Child Health* 37:476–478, 2001.
304. Thach, B. T. Sudden infant death syndrome: old causes rediscovered? *N. Engl. J. Med.* 315:126–128, 1986.
305. Norvenius, S. G. Sudden infant death syndrome in Sweden in 1973–1977 and 1979. *Acta Paediatr. Scand. Suppl.* 333:1–138, 1987.
306. Francisco, J. T. Smothering in infancy: its relationship to the “crib death syndrome.” *South. Med. J.* 63:1110–1114, 1970.

307. Bullock, M. J., Diniz, D. Suffocation using plastic bags: a retrospective study of suicides in Ontario, Canada. *J. Forensic Sci.* 45:608–613, 2000.
308. Perez Martinez, A. L., Chui, P., Cameron, J. M. Plastic bag suffocation. *Med. Sci. Law* 33:71–75, 1993.
309. Haddix, T. L., Harruff, R. C., Reay, D. T., Haglund, W. D. Asphyxial suicides using plastic bags. *Am. J. Forensic Med. Pathol.* 17:308–311, 1996.
310. Marzuk, P. M., Tardiff, K., Hirsch, C. S., et al. Increase in suicide by asphyxiation in New York City after the publication of Final Exit. *N. Engl. J. Med.* 329:1508–1510, 1993.
311. Fonseca, C. A., Auerbach, D. S., Suarez, R. V. The forensic investigation of propane gas asphyxiation. *Am. J. Forensic Med. Pathol.* 23:167–169, 2002.
312. Ogden, R. D., Wooten, R. H. Asphyxial suicide with helium and a plastic bag. *Am. J. Forensic Med. Pathol.* 23:234–237, 2002.
313. Winek, C. L., Collom, W. D., Wecht, C. H. Suicide with plastic bag and ethyl ether. *Lancet* 1:365, 1970.
314. Avis, S. P., Archibald, J. T. Asphyxial suicide by propane inhalation and plastic bag suffocation. *J. Forensic Sci.* 39:253–256, 1994.
315. Anderson, H. R., Macnair, R. S., Ramsey, J. D. Deaths from abuse of volatile substances: a national epidemiological study. *Br. Med. J. Clin. Res. Ed.* 290:304–307, 1985.
316. Tsoukali, H., Dimitriou, A., Vassiliades, N. Death during deliberate propane inhalation. *Forensic Sci. Int.* 93:1–4, 1998.
317. Crawford, W. V. Death due to fluorocarbon inhalation. *South. Med. J.* 69:506–507, 1976.
318. King, G. S., Smialek, J. E., Troutman, W. G. Sudden death in adolescents resulting from the inhalation of typewriter correction fluid. *JAMA* 253:1604–1606, 1985.
319. Feigin, G. Suicide and meningioma. *Am. J. Forensic Med. Pathol.* 9:334–335, 1988.
320. Hiss, J., Kahana, T., Arensburg, B. Suicidal asphyxia by gas mask. *Am. J. Forensic Med. Pathol.* 15:213–215, 1994.
321. Howard, J. D. Suffocation from use of modified gas mask. *Am. J. Forensic Med. Pathol.* 16:140–141, 1995.
322. Gallagher, K. E., Smith, D. M., Mellen, P. F. Suicidal asphyxiation by using pure helium gas: case report, review, and discussion of the influence of the internet. *Am. J. Forensic Med. Pathol.* 24:361–363, 2003.
323. Emery, J. L., Thornton, J. A. Effects of obstruction to respiration in infants, with particular reference to mattresses, pillows, and their coverings. *Br. Med. J.* 3:209–213, 1968.
324. Moore, L., Bourne, A. J., Beal, S., Collett, M., Byard, R. W. Unexpected infant death in association with suspended rocking cradles. *Am. J. Forensic Med. Pathol.* 16:177–180, 1995.
325. Gilbert-Barness, E., Emery, J. L. Deaths of infants on polystyrene-filled beanbags. *Am. J. Forensic Med. Pathol.* 17:202–206, 1996.
326. Bolton, D. P., Cross, K. W., McKettrick, A. C. Are babies in carry cots at risk from CO<sub>2</sub> accumulation? *Br. Med. J.* 4:80–81, 1972.
327. Bolton, D. P., Taylor, B. J., Campbell, A. J., Galland, B. C., Cresswell, C. Rebreathing expired gases from bedding: a cause of cot death? *Arch. Dis. Child.* 69:187–190, 1993.
328. Swift, P. G., Emery, J. L. Clinical observations on response to nasal occlusion in infancy. *Arch. Dis. Child.* 48:947–951, 1973.
329. Stanton, A. N. Sudden infant death. Overheating and cot death. *Lancet* 2:1199–1201, 1984.
330. Fleming, P. J., Levine, M. R., Azaz, Y., Wigfield, R., Stewart, A. J. Interactions between thermoregulation and the control of respiration in infants: possible relationship to sudden infant death. *Acta Paediatr. Suppl.* 82 Suppl 389:57–59, 1993.
331. Imami, R. H., Kemal, M. Propane asphyxiation. *Am. J. Forensic Med. Pathol.* 7:76–77, 1986.
332. Di Nunno, N., Vacca, M., Costantinides, F., Di Nunno, C. Death following atypical compression of the neck. *Am. J. Forensic Med. Pathol.* 24:364–368, 2003.



333. Harris, C. S., Baker, S. P., Smith, G. A., Harris, R. M. Childhood asphyxiation by food. A national analysis and overview. *JAMA* 251:2231–2235, 1984.
334. Bhana, B. D., Gunaselvam, J. G., Dada, M. A. Mechanical airway obstruction caused by accidental aspiration of part of a ballpoint pen. *Am. J. Forensic Med. Pathol.* 21:362–365, 2000.
335. Haugen, R. K. The cafe coronary: Sudden deaths in restaurants. *JAMA* 186:142–143, 1963.
336. Blazer, S., Naveh, Y., Friedman, A. Foreign body in the airway. A review of 200 cases. *Am. J. Dis. Child.* 134:68–71, 1980.
337. Aytac, A., Yurdakul, Y., Ikizler, C., Olga, R., Saylam, A. Inhalation of foreign bodies in children. Report of 500 cases. *J. Thorac. Cardiovasc. Surg.* 74:145–151, 1977.
338. Taff, M. L., Boglioli, L. R. Homicidal traumatic asphyxia associated with pebble impaction of the upper airway. *Am. J. Forensic Med. Pathol.* 13:271–274, 1992.
339. Downing, S. E., Lee, J. C. Laryngeal chemosensitivity: a possible mechanism for sudden infant death. *Pediatrics* 55:640–649, 1975.
340. Sheahan, K., Page, D. V., Kemper, T., Suarez, R. Childhood sudden death secondary to accidental aspiration of black pepper. *Am. J. Forensic Med. Pathol.* 9:51–53, 1988.
341. Limper, A. H., Prakash, U. B. Tracheobronchial foreign bodies in adults. *Ann. Intern. Med.* 112:604–609, 1990.
342. McGuirt, W. F., Holmes, K. D., Feehs, R., Browne, J. D. Tracheobronchial foreign bodies. *Laryngoscope* 98:615–618, 1988.
343. Mellen, P. F., Golle, M. F., Jr., Smialek, J. E. Fatal hot coffee scald of the larynx. Case report. *Am. J. Forensic Med. Pathol.* 16:117–119, 1995.
344. Lifschultz, B. D., Donoghue, E. R. Deaths due to foreign body aspiration in children: the continuing hazard of toy balloons. *J. Forensic Sci.* 41:247–251, 1996.
345. Byard, R. W. Coprophagic cafe coronary. *Am. J. Forensic Med. Pathol.* 22:96–99, 2001.
346. Rimell, F. L., Thome, A., Jr., Stool, S., et al. Characteristics of objects that cause choking in children. *JAMA* 274:1763–1766, 1995.
347. Byard, R. W. Unexpected death due to acute airway obstruction in daycare centers. *Pediatrics* 94:113–114, 1994.
348. Altmann, A. E., Ozanne-Smith, J. Non-fatal asphyxiation and foreign body ingestion in children 0–14 years. *Inj. Prev.* 3:176–182, 1997.
349. Mittleman, R. E. Fatal choking in infants and children. *Am. J. Forensic Med. Pathol.* 5:201–210, 1984.
350. Hunsaker, D. M., Hunsaker, J. C., III. Therapy-related cafe coronary deaths: two case reports of rare asphyxial deaths in patients under supervised care. *Am. J. Forensic Med. Pathol.* 23:149–154, 2002.
351. Mihalakis, I. Asphyxia from pacifier. *Md., State Med., J.*, 20:53–54, 1971.
352. Fleming, P. J., Blair, P. S., Pollard, K., et al. Pacifier use and sudden infant death syndrome: results from the CESDI/SUDI case control study. CESDI SUDI Research Team. *Arch. Dis. Child.* 81:112–116, 1999.
353. Heimlich, H. J. The Heimlich maneuver: prevention of death from choking on foreign bodies. *J. Occup. Med.* 19:208–210, 1977.
354. Pontoppidan, H., Beecher, H. K. Progressive loss of protective reflexes in the airway with the advance of age. *JAMA* 174:2209–2213, 1960.
355. Mittleman, R. E., Wetli, C. V. The fatal cafe coronary. Foreign-body airway obstruction. *JAMA* 247:1285–1288, 1982.
356. Jacob, B., Huckenbeck, W., Barz, J., Bonte, W. Death, after swallowing and aspiration of a high number of foreign bodies, in a schizophrenic woman. *Am. J. Forensic Med. Pathol.* 11:331–335, 1990.
357. Leadbeatter, S., Douglas-Jones, A. G. Asphyxiation by glottic impaction of nasal secretions. *Am. J. Forensic Med. Pathol.* 10:235–238, 1989.

358. Gelperin, A. Sudden death in an elderly population from aspiration of food. *J. Am. Geriatr. Soc.* 22:135–136, 1974.
359. Jones, T. M., Luke, L. C. Life threatening airway obstruction: a hazard of concealed eating disorders. *J. Accid. Emerg. Med.* 15:332–333, 1998.
360. Adelman, H. C. Asphyxial deaths as a result of aspiration of dental appliances: a report of three cases. *J. Forensic Sci.* 33:389–395, 1988.
361. Steffee, C. H., Lantz, P. E., Flannagan, L. M., Thompson, R. L., Jason, D. R. Oleoresin capsicum (pepper) spray and “in-custody deaths.” *Am. J. Forensic Med. Pathol.* 16:185–192, 1995.
362. Winograd, H. L. Acute croup in an older child. An unusual toxic origin. *Clin. Pediatr. Phila.* 16:884–887, 1977.
363. Steele, A. A. Suicidal death by aspiration of talcum powder. *Am. J. Forensic Med. Pathol.* 11:316–318, 1990.
364. Fyfe, B., Mittleman, R. E. Hypopharyngeal lipoma as a cause for sudden asphyxial death. *Am. J. Forensic Med. Pathol.* 12:82–84, 1991.
365. Taff, M. L., Schwartz, I. S., Boglioli, L. R. Sudden asphyxial death due to a prolapsed esophageal fibrolipoma. *Am. J. Forensic Med. Pathol.* 12:85–88, 1991.
366. Allen, M. S., Jr., Talbot, W. H. Sudden death due to regurgitation of a pedunculated esophageal lipoma. *J. Thorac. Cardiovasc. Surg.* 54:756–758, 1967.
367. Cochet, B., Hohl, P., Sans, M., Cox, J. N. Asphyxia caused by laryngeal impaction of an esophageal polyp. *Arch. Otolaryngol.* 106:176–178, 1980.
368. Sperry, K. Lethal asphyxiating juvenile laryngeal papillomatosis. A case report with human papillomavirus in situ hybridization analysis. *Am. J. Forensic Med. Pathol.* 15:146–150, 1994.
369. Johnson, C. P., Burns, J. Papillary hyperplasia of the lingual tonsil and sudden death in epilepsy. *Am. J. Forensic Med. Pathol.* 13:335–337, 1992.
370. Guarisco, J. L., Littlewood, S. C., Butcher, R. B., III. Severe upper airway obstruction in children secondary to lingual tonsil hypertrophy. *Ann. Otol. Rhinol. Laryngol.* 99:621–624, 1990.
371. Cohle, S. D., Jones, D. H., Puri, S. Lingual tonsillar hypertrophy causing failed intubation and cerebral anoxia. *Am. J. Forensic Med. Pathol.* 14:158–161, 1993.
372. Boglioli, L. R., Taff, M. L. Sudden asphyxial death complicating infectious mononucleosis. *Am. J. Forensic Med. Pathol.* 19:174–177, 1998.
373. Fonseca, C. A., Suarez, R. V. Plasma cell granuloma of the larynx as a cause of sudden asphyxial death. *Am. J. Forensic Med. Pathol.* 16:243–245, 1995.
374. Olsen, K. D., Suh, K. W., Staats, B. A. Surgically correctable causes of sleep apnea syndrome. *Otolaryngol. Head Neck Surg.* 89:726–731, 1981.
375. Robinson, R. W., White, D. P., Zwillich, C. W. Moderate alcohol ingestion increases upper airway resistance in normal subjects. *Am. Rev. Respir. Dis.* 132:1238–1241, 1985.
376. Krol, R. C., Knuth, S. L., Bartlett, D., Jr. Selective reduction of genioglossal muscle activity by alcohol in normal human subjects. *Am. Rev. Respir. Dis.* 129:247–250, 1984.
377. Pervez, N. K., Aisen, P. S., Bleiweiss, I. J., Brady, B., Winters, S. Occult aspiration of a nut in an elderly patient: a case report. *Am. J. Forensic Med. Pathol.* 9:163–165, 1988.
378. Rogers, C., Chang, B., Shibuya, R. A coin in the airway. *Am. J. Forensic Med. Pathol.* 15:91–92, 1994.
379. Blumberg, J. M., Johnston, E. H. The forensic pathologist and the unsuspected foreign body. *J. Forensic Sci.* 8:231–249, 1963.
380. Tamura, N., Nakajima, T., Matsumoto, S., Ohyama, T., Ohashi, Y. Foreign bodies of dental origin in the air and food passages. *Int. J. Oral Maxillofac. Surg.* 15:739–751, 1986.
381. Sherman, B. M., Karliner, J. S., Kikkawa, Y., Oka, M., Goldin, R. Fatal traumatic ingestion of a radiolucent dental prosthesis. *N. Engl. J. Med.* 279:1275–1276, 1968.
382. Hazelrigg, C. O. Ingestion of mandibular complete denture. *J. Am. Dent. Assoc.* 108:209, 1984.

383. Jumbelic, M. I. Airway obstruction by a ball. *J. Forensic Sci.* 44:1079–1081, 1999.
384. Ryan, C. A., Yacoub, W., Paton, T., Avard, D. Childhood deaths from toy balloons. *Am. J. Dis. Child.* 144:1221–1224, 1990.
385. Anas, N. G., Perkin, R. M. Aspiration of a balloon by a 3-month-old infant. *JAMA* 250:385–386, 1983.
386. Deidiker, R. Return of the killer fish: accidental choking death on a bluegill *Lepomis macrochirus*. *Am. J. Forensic Med. Pathol.* 23:197–198, 2002.
387. Kulick, R. M., Selbst, S. M., Baker, M. D., Woodward, G. A. Thermal epiglottitis after swallowing hot beverages. *Pediatrics* 81:441–444, 1988.
388. Jung, R. C., Gottlieb, L. S. Respiratory tract burns after aspiration of hot coffee. *Chest* 72:125–128, 1977.
389. Inayama, Y., Uda, N., Amano, T., et al. Fatal aspiration of sardine fry in a patient with lung cancer. *J. Forensic Sci.* 45:478–482, 2000.
390. Simson, L. R., Jr. Sudden death while attempting to conceal illegal drugs: laryngeal obstruction by a package of heroin. *J. Forensic Sci.* 21:378–380, 1976.
391. Peeler, M. B., Riley, H. D., Jr. Cardiac tamponade due to swallowed foreign body. *AMA J. Dis. Child.* 93:308–312, 1957.
392. Byard, R. W., Moore, L., Bourne, A. J. Sudden and unexpected death—a late effect of occult intraesophageal foreign body. *Pediatr. Pathol.* 10:837–841, 1990.
393. Russo, S. S., Taff, M. L., Ratanaproeaksa, O., Spitz, W. U. Sudden death resulting from chicken bone perforation of the esophagus. *Am. J. Forensic Med. Pathol.* 7:263–265, 1986.
394. Norman, M. G., Cass, E. Cardiac tamponade resulting from a swallowed safety pin. *Pediatrics* 48:832–833, 1971.
395. Marik, P. E. Aspiration pneumonitis and aspiration pneumonia. *N. Engl. J. Med.* 344:665–671, 2001.
396. Knight, B. H. The significance of the postmortem discovery of gastric contents in the air passages. *Forensic Sci.* 6:229–234, 1975.
397. Gardner, A. M. Aspiration of food and vomit. *Q. J. Med.* 27:227–242, 1958.
398. Wynne, J. W., Modell, J. H. Respiratory aspiration of stomach contents. *Ann. Intern. Med.* 87:466–474, 1977.
399. Gaultier, C. L. Interference between gastroesophageal reflux and sleep in near miss SIDS. *Clin. Rev. Allergy* 8:395–401, 1990.
400. Anonymous. American Academy of Pediatrics AAP Task Force on Infant Positioning and SIDS: Positioning and SIDS. *Pediatrics* 89:1120–1126, 1992.
401. Van Dyke, J. J., Lake, K. B. Survival after asphyxia secondary to gravel aspiration. *Arch. Intern. Med.* 136:471–473, 1976.
402. Avital, A., Springer, C., Mogle, P., Godfrey, S. Successful treatment after ‘drowning’ in sand. *Arch. Dis. Child.* 64:615–616, 1989.
403. Bergeson, P. S., Hinchcliffe, W. A., Crawford, R. F., Sorenson, M. J., Trump, D. S. Asphyxia secondary to massive dirt aspiration. *J. Pediatr.* 92:506–507, 1978.
404. Bender, E. M., Moore, E. E., Kashuk, J. L., Hopeman, A. R. Conservative management of sand aspiration: case report. *Mil. Med.* 149:98–99, 1984.
405. Adelson, L. Homicide by pepper. *J. Forensic Sci.* 88:391–395, 1964.
406. Cohle, S. D., Trestrail, J. D., III, Graham, M. A., Oxley, D. W., Walp, B., Jachimczyk, J. Fatal pepper aspiration. *Am. J. Dis. Child.* 142:633–636, 1988.
407. Flintoff, W. M., Jr., Poushter, D. L. Aspiration of black pepper. A case report. *Arch. Otolaryngol.* 100:375–376, 1974.
408. Molnar, J. J., Nathenson, G., Edberg, S. Fatal aspiration of talcum powder by a child, Report of a case. *N. Engl. J. Med.* 266:36–37, 1962.
409. Brouillette, F., Weber, M. L. Massive aspiration of talcum powder by an infant. *Can. Med. Assoc. J.* 119:354–355, 1978.

410. Mofenson, H. C., Greensher, J., DiTomasso, A., Okun, S. Baby powder—a hazard! *Pediatrics* 68:265–266, 1981.
411. Banerjee, A., Rao, K. S., Khanna, S. K., et al. Laryngo-tracheo-bronchial foreign bodies in children. *J. Laryngol. Otol.* 102:1029–1032, 1988.
412. Gay, B. B., Jr., Atkinson, G. O., Vanderzalm, T., Harmon, J. D., Porubsky, E. S. Subglottic foreign bodies in pediatric patients. *Am. J. Dis. Child.* 140:165–168, 1986.
413. Weissberg, D., Schwartz, I. Foreign bodies in the tracheobronchial tree. *Chest* 91:730–733, 1987.
414. Wolkove, N., Kreisman, H., Cohen, C., Frank, H. Occult foreign-body aspiration in adults. *JAMA* 248:1350–1352, 1982.
415. Shkrum, M. J., Johnston, K. A. Fire and suicide: a three-year study of self-immolation deaths. *J. Forensic Sci.* 37:208–221, 1992.
416. Belviso, M., De Donno, A., Vitale, L., Introna, F., Jr. Positional asphyxia: reflection on 2 cases. *Am. J. Forensic Med. Pathol.* 24:292–297, 2003.
417. Reay, D. T., Fligner, C. L., Stilwell, A. D., Arnold, J. Positional asphyxia during law enforcement transport. *Am. J. Forensic Med. Pathol.* 13:90–97, 1992.
418. Chan, T. C., Vilke, G. M., Neuman, T. Reexamination of custody restraint position and positional asphyxia. *Am. J. Forensic Med. Pathol.* 19:201–205, 1998.
419. Purdue, B. An unusual accidental death from reverse suspension. *Am. J. Forensic Med. Pathol.* 13:108–111, 1992.
420. Marshall, T. K. Inverted suspension. *Med. Sci. Law* 8:49–50, 1968.
421. Busuttil, A., Obafunwa, J. O. Recreational abdominal suspension: a fatal practice. A case report. *Am. J. Forensic Med. Pathol.* 14:141–144, 1993.
422. Vega, R. S., Adams, V. I. Suffocation in motor vehicle crashes. *Am. J. Forensic Med. Pathol.* 25:101–107, 2004.
423. Sharp, J. T., Goldberg, N. B., Druz, W. S., Danon, J. Relative contributions of rib cage and abdomen to breathing in normal subjects. *J. Appl. Physiol.* 39:608–618, 1975.
424. Ward, M., Macklem, P. T. The act of breathing and how it fails. *Chest* 97:36S–39S, 1990.
425. Roussos, C. Function and fatigue of respiratory muscles. *Chest* 88:124S–132S, 1985.
426. Roussos, C., Macklem, P. T. The respiratory muscles. *N. Engl. J. Med.* 307:786–797, 1982.
427. Uchigasaki, S., Takahashi, H., Suzuki, T. An experimental study of death in a reverse suspension. *Am. J. Forensic Med. Pathol.* 20:116–119, 1999.
428. Pollanen, M. S., Chiasson, D. A., Cairns, J. T., Young, J. G. Unexpected death related to restraint for excited delirium: a retrospective study of deaths in police custody and in the community. *CMAJ* 158:1603–1607, 1998.
429. O'Halloran, R. L., Lewman, L. V. Restraint asphyxiation in excited delirium. *Am. J. Forensic Med. Pathol.* 14:289–295, 1993.
430. Glatter, K., Karch, S. B. Positional asphyxia: inadequate oxygen, or inadequate theory? *Forensic Sci. Int.* 141:201–202, 2004.
431. O'Halloran, R. L., Frank, J. G. Asphyxial death during prone restraint revisited: a report of 21 cases. *Am. J. Forensic Med. Pathol.* 21:39–52, 2000.
432. Karch, S. B., Wetli, C. V. Agitated delirium versus positional asphyxia. *Ann. Emerg. Med.* 26:760–761, 1995.
433. Wetli, C. V., Mash, D., Karch, S. B. Cocaine-associated agitated delirium and the neuroleptic malignant syndrome. *Am. J. Emerg. Med.* 14:425–428, 1996.
434. Karch, S. B., Stephens, B. G. Acute excited states and sudden death. Acute excited states are not caused by high blood concentrations of cocaine. *BMJ* 316:1171, 1998.
435. Karch, S. B. Cardiac arrest in cocaine users. *Am. J. Emerg. Med.* 14:79–81, 1996.
436. Reay, D. T., Howard, J. D. Restraint position and positional asphyxia. *Am. J. Forensic Med. Pathol.* 20:300–301, 1999.
437. Chan, T. C., Vilke, G. M., Neuman, T. Restraint position and positional asphyxia. *Am. J. Forensic Med. Pathol.* 21:93, 2000.

- 438. Chan, T. C., Neuman, T., Clausen, J., Eisele, J., Vilke, G. M. Weight force during prone restraint and respiratory function. *Am. J. Forensic Med. Pathol.* 25:185–189, 2004.
- 439. Chan, T. C., Vilke, G. M., Neuman, T., Clausen, J. L. Restraint position and positional asphyxia. *Ann. Emerg. Med.* 30:578–586, 1997.
- 439a. Park, K. S., Korn, C. S., Henderson, S. O. Agitated delirium and sudden death: two case reports. *Prehosp. Emerg. Care* 5:214–216, 2001.
- 439b. Reay, D. T., Howard, J. D., Fligner, C. L., Ward, R. J. Effects of positional restraint on oxygen saturation and heart rate following exercise. *Am. J. Forensic Med. Pathol.* 9:16–18, 1988.
- 439c. Koscove, E. M. The Taser weapon: a new emergency medicine problem. *Ann. Emerg. Med.* 14:1205–1208, 1985.
- 439d. Bleetman, A., Steyn, R., Lee, C. Introduction of the Taser into British policing. Implications for UK emergency departments: an overview of electronic weaponry. *Emerg. Med. J.* 21:136–140, 2004.
- 439e. Jenkinson, E., Neeson, C., Bleetman, A. The relative risk of police use-of-force options: evaluating the potential for deployment of electronic weaponry. *J. Clin. Forensic Med.* 2006 (epub ahead of print).
- 439f. Fish, R. M., Geddes, L. A. Effects of stun guns and tasers. *Lancet* 358:687–688, 2001.
- 439g. Kornblum, R. N., Reddy, S. K. Effects of the Taser in fatalities involving police confrontation. *J. Forensic Sci.* 36:434–438, 1991.
- 439h. Ordog, G. J., Wasserberger, J., Schlater, T., Balasubramaniam, S. Electronic gun (Taser) injuries. *Ann. Emerg. Med.* 16:73–78, 1987.
- 439i. Kim, P. J., Franklin, W. H. Ventricular fibrillation after stun-gun discharge. *N. Engl. J. Med.* 353:958–959, 2005.
- 439j. Haegeli, L. M., Sterns, L. D., Adam, D. C., Leather, R. A. Effect of a Taser shot to the chest of a patient with an implantable defibrillator. *Heart Rhythm.* 3:339–341, 2006.
- 439k. McDaniel, W. C., Stratbucker, R. A., Nerheim, M., Brewer, J. E. Cardiac safety of neuromuscular incapacitating defensive devices. *Pacing Clin. Electrophysiol.* 28:S284–S287, 2005.
- 439l. Ho, J. D., Miner, J. R., Lakireddy, D. R., Bultman, L. L., Heegaard, W. G. Cardiovascular and physiologic effects of conducted electrical weapon discharge in resting adults. *Acad. Emerg. Med.* 2006, in press.
- 439m. Allen, T. B. Discussion of “Effects of the taser in fatalities involving police confrontation.” *J. Forensic Sci.* 37:956–958, 1992.
- 440. Wilkins, R. W., Bradley, S. E., Friedland, C. K. The acute circulatory effects of the head-down position negative G in normal man, with a note on some measures designed to relieve cranial congestion in this position. *J. Clin. Invest.* 29:940–949, 1950.
- 441. Fred, H. L., Chandler, F. W. Traumatic asphyxia. *Am. J. Med.* 29:508–517, 1960.
- 442. Gill, J. R., Landi, K. Traumatic asphyxial deaths due to an uncontrolled crowd. *Am. J. Forensic Med. Pathol.* 25:358–361, 2004.
- 443. Sklar, D. P., Baack, B., McFeeley, P., Osler, T., Marder, E., Demarest, G. Traumatic asphyxia in New Mexico: a five-year experience. *Am. J. Emerg. Med.* 6:219–223, 1988.
- 444. Williams, J. S., Minken, S. L., Adams, J. T. Traumatic asphyxia—reappraised. *Ann. Surg.* 167:384–392, 1968.
- 445. Dunne, J. R., Shaked, G., Golocovsky, M. Traumatic asphyxia: an indicator of potentially severe injury in trauma. *Injury* 27:746–749, 1996.
- 446. Copeland, A. R. Vehicular-related traumatic asphyxial deaths—caveat scrutator. *Z. Rechtsmed.* 96:17–22, 1986.
- 447. Staats, P. N., Jumbelic, M. I., Dignan, C. R. Death by compaction in a garbage truck. *J. Forensic Sci.* 47:1065–1066, 2002.
- 448. Wolodzko, A. A., Taff, M. L., Ratanaproseska, O., Spitz, W. U. An unusual case of compression asphyxia and smothering. *Am. J. Forensic Med. Pathol.* 7:354–355, 1986.



449. Hambeck, W., Pueschel, K. Death by railway accident: incidence of traumatic asphyxia. *J. Trauma* 21:28–31, 1981.
450. Campbell-Hewson, G., Egleston, C. V., Cope, A. R. Traumatic asphyxia in children. *J. Accid. Emerg. Med.* 14:47–49, 1997.
451. Lupascu, C., Lupascu, C., Beldiman, D. Mechanical asphyxia by three different mechanisms. *Leg. Med. (Tokyo)* 5:110–111, 2003.
452. Furuya, Y. Experimental traumatic asphyxia (1)—grades of thoracic compression and mortality. *Igaku Kenkyu* 51:117–119, 1981.
453. Kohr, R. M. Inflicted compressional asphyxia of a child. *J. Forensic Sci.* 48:1148–1150, 2003.
454. Rosato, R. M., Shapiro, M. J., Keegan, M. J., Connors, R. H., Minor, C. B. Cardiac injury complicating traumatic asphyxia. *J. Trauma* 31:1387–1389, 1991.
455. Thompson, A., Jr., Illescas, F. F., Chiu, R. C. Why is the lower torso protected in traumatic asphyxia? A new hypothesis. *Ann. Thorac. Surg.* 47:247–249, 1989.
456. Lee, M. C., Wong, S. S., Chu, J. J., et al. Traumatic asphyxia. *Ann. Thorac. Surg.* 51:86–88, 1991.
457. Schiowitz, M. F., Litchman, J., Rizzo, T. F. Traumatic asphyxia and blunt cardiac injury: case report and selected review. *Am. J. Emerg. Med.* 9:325–327, 1991.
458. Cobb N., Etzel, R. A. Unintentional carbon monoxide-related deaths in the United States, 1979 through 1988. *JAMA* 266:659–663, 1991.
459. Caplan, Y. H., Ottinger, W. E., Park, J., Smith, T. D. Drug and chemical related deaths: incidence in the state of Maryland—1975 to 1980. *J. Forensic Sci.* 30:1012–1021, 1985.
460. Baselt, R. C. *Disposition of Toxic Drugs and Chemicals in Man*. Biomedical Publications, Foster City, CA, 2005.
461. Hawkins, M. Carbon monoxide poisoning. *Eur. J. Anaesthesiol.* 16:585–589, 1999.
462. Stewart, R. D. The effect of carbon monoxide on humans. *Annu. Rev. Pharmacol.* 15:409–423, 1975.
463. Abelsohn, A., Sanborn, M. D., Jessiman, B. J., Weir, E. Identifying and managing adverse environmental health effects: 6. Carbon monoxide poisoning. *CMAJ* 166:1685–1690, 2002.
464. Meredith, T., Vale, A. Carbon monoxide poisoning. *Br. Med. J. (Clin. Res. Ed.)* 296:77–79, 1988.
465. Dolan, M. C. Carbon monoxide poisoning. *CMAJ* 133:392–399, 1985.
466. Stewart, R. D. Proceedings: The effect of carbon monoxide on humans. *J. Occup. Med.* 18:304–309, 1976.
467. Hardy, K. R., Thom, S. R. Pathophysiology and treatment of carbon monoxide poisoning. *J. Toxicol. Clin. Toxicol.* 32:613–629, 1994.
468. Ernst, A., Zibrak, J. D. Carbon monoxide poisoning. *N. Engl. J. Med.* 339:1603–1608, 1998.
469. Morgan, D. R., Poon, P., Titley, J., Jagger, S. F., Ruttly, G. N. Unique case of fatal carbon monoxide poisoning in the absence of a combustible fossil fuel. *Am. J. Forensic Med. Pathol.* 22:220–224, 2001.
470. Turino, G. M. Effect of carbon monoxide on the cardiorespiratory system. Carbon monoxide toxicity: physiology and biochemistry. *Circulation* 63:253A–259A, 1981.
471. Urbanetti, J. S. Carbon monoxide poisoning. *Prog. Clin. Biol. Res.* 51:355–385, 1981.
472. Varon, J., Marik, P. E., Fromm, R. E., Jr., Gueler, A. Carbon monoxide poisoning: a review for clinicians. *J. Emerg. Med.* 17:87–93, 1999.
473. Prahlow, J. A., Doyle, B. W. A suicide using a homemade carbon monoxide “death machine”. *Am. J. Forensic Med. Pathol.* 26:177–180, 2005.
474. Opeksin, K., Drummer, O. H. Delayed death following carbon monoxide poisoning. A case report. *Am. J. Forensic Med. Pathol.* 15:36–39, 1994.
475. Weaver, L. K. Carbon monoxide poisoning. *Crit. Care Clin.* 15:297–317, viii, 1999.

476. Rodkey, F. L., O'Neal, J. D., Collison, H. A., Uddin, D. E. Relative affinity of hemoglobin S and hemoglobin A for carbon monoxide and oxygen. *Clin. Chem.* 20:83–84, 1974.
477. Fisher, J. Carbon monoxide poisoning: a disease of a thousand faces. *Chest* 115:322–323, 1999.
478. Lowry, W. T., Juarez, L., Petty, C. S., Roberts, B. Studies of toxic gas production during actual structural fires in the Dallas area. *J. Forensic Sci.* 30:59–72, 1985.
479. Jaffe, F. A. Pathogenicity of carbon monoxide. *Am. J. Forensic Med. Pathol.* 18:406–410, 1997.
480. Dominguez, A. M. Problems of carbon monoxide in fires. *J. Forensic Sci.* 7:379–392, 1962.
481. Chesney, M. L. Carbon monoxide poisoning in the pediatric population. *Air. Med. J.* 21:10–13, 2002.
482. Goldbaum, L. R., Ramirez, R. G., Absalon, K. B. What is the mechanism of carbon monoxide toxicity? *Aviat. Space Environ. Med.* 46:1289–1291, 1975.
483. Thom, S. R., Keim, L. W. Carbon monoxide poisoning: a review epidemiology, pathophysiology, clinical findings, and treatment options including hyperbaric oxygen therapy. *J. Toxicol. Clin. Toxicol.* 27:141–156, 1989.
484. Somogyi, E., Balogh, I., Rubanyi, G., Sotonyi, P., Szegedi, L. New findings concerning the pathogenesis of acute carbon monoxide (CO) poisoning. *Am. J. Forensic Med. Pathol.* 2:31–39, 1981.
485. Balraj, E. K. Atherosclerotic coronary artery disease and “low” levels of carboxyhemoglobin; report of fatalities and discussion of pathophysiologic mechanisms of death. *J. Forensic Sci.* 29:1150–1159, 1984.
486. Peterson, J. E., Stewart, R. D. Predicting the carboxyhemoglobin levels resulting from carbon monoxide exposures. *J. Appl. Physiol.* 39:633–638, 1975.
487. Stewart, R. D., Baretta, E. D., Platte, L. R., et al. Carboxyhemoglobin levels in American blood donors. *JAMA* 229:1187–1195, 1974.
488. Landers, D. Unsuccessful suicide by carbon monoxide: a secondary benefit of emissions control. *West J Med.* 135:360–363, 1981.
489. Burney, R. E., Wu, S. C., Nemiroff, M. J. Mass carbon monoxide poisoning: clinical effects and results of treatment in 184 victims. *Ann. Emerg. Med.* 11:394–399, 1982.
490. Ruszkiewicz, A., de Boer, B., Robertson, S. Unusual presentation of death due to carbon monoxide poisoning. A report of two cases. *Am. J. Forensic Med. Pathol.* 18:181–184, 1997.
491. Morgen, C., Schramm, J., Kofoed, P., Steensberg, J., Theilade, P. Automobile exhaust as a means of suicide: an experimental study with a proposed model. *J. Forensic Sci.* 43:827–836, 1998.
492. Stewart, R. D., Stewart, R. S., Stamm, W., Seelen, R.P. Rapid estimation of carboxyhemoglobin level in fire fighters. *JAMA* 235:390–392, 1976.
493. Schmunk, G. A., Kaplan, J. A. Asphyxial deaths caused by automobile exhaust inhalation not attributable to carbon monoxide toxicity: study of 2 cases. *Am. J. Forensic Med. Pathol.* 23:123–126, 2002.
494. Theilade, P. Carbon monoxide poisoning. Five years' experience in a defined population. *Am. J. Forensic Med. Pathol.* 11:219–225, 1990.
495. Walker, E., Hay, A. Carbon monoxide poisoning. *BMJ* 319:1082–1083, 1999.
496. Jaffe, N. Cardiac injury and carbon monoxide poisoning. *S. Afr. Med. J.* 39:611–615, 1965.
497. Morris, R. D., Naumova, E. N. Carbon monoxide and hospital admissions for congestive heart failure: evidence of an increased effect at low temperatures. *Environ. Health Perspect.* 106:649–653, 1998.
498. Schulte, J. H. Effects of mild carbon monoxide intoxication. *Arch. Environ. Health* 38:524–530, 1963.

499. Schulte, J. H. Sealed environments in relation to health and disease. *Arch. Environ. Health* 85:438–452, 1964.
500. Winter, P. M., Miller, J. N. Carbon monoxide poisoning. *JAMA* 236:1502, 1976.
501. Williams, J., Lewis, R. W., Kealey, G. P. Carbon monoxide poisoning and myocardial ischemia in patients with burns. *J. Burn. Care. Rehabil.* 13:210–213, 1992.
502. Allred, E. N., Bleecker, E. R., Chaitman, B. R., et al. Effects of carbon monoxide on myocardial ischemia. *Environ. Health Perspect.* 91:89–132, 1991.
503. Gemelli, F., Cattani, R. Carbon monoxide poisoning in childhood. *Br. Med. J. (Clin. Res. Ed.)* 291:1197, 1985.
504. Risser, D., Schneider, B. Carbon monoxide-related deaths from 1984 to 1993 in Vienna, Austria. *J. Forensic Sci.* 40:368–371, 1995.
505. Farmer, R., Rohde, J. Effect of availability and acceptability of lethal instruments on suicide mortality. An analysis of some international data. *Acta Psychiatr. Scand.* 62:436–446, 1980.
506. McClure, G. M. Suicide in children and adolescents in England and Wales 1960–1990. *Br. J. Psychiatry* 165:510–514, 1994.
507. Tsunenari, S., Yonemitsu, K., Kanda, M., Yoshida, S. Suicidal carbon monoxide inhalation of exhaust fumes. Investigation of cases. *Am. J. Forensic Med. Pathol.* 6:233–239, 1985.
508. Atkinson, P., Langlois, N. E., Adam, B. J., Grieve, J. H. Suicide, carbon dioxide, and suffocation. *Lancet* 344:192–193, 1994.
509. McAuley, F., Wigmore, J. D. Case report: An unusual case of carbon monoxide poisoning. *J. Can. Soc. Forensic Sci.* 20:83–86, 1987.
510. DiMaio, V. J., Dana, S. E. Deaths caused by carbon monoxide poisoning in an open environment outdoors. *J. Forensic Sci.* 32:1794–1795, 1987.
511. Pounder, D. J. Changing patterns of male suicide in Scotland. *Forensic Sci. Int.* 51:79–87, 1991.
512. Burvill, P. W. The changing pattern of suicide by gassing in Australia, 1910–1987: the role of natural gas and motor vehicles. *Acta Psychiatr. Scand.* 81:178–184, 1990.
513. Bowen, D. A., Duffy, P., Callear, A., Fitton, J. Carbon monoxide poisoning. *Forensic Sci. Int.* 41:163–168, 1989.
514. Copeland, A. R. Non-intentional motor vehicle-related carbon monoxide deaths-revisited. *Z. Rechtsmed.* 96:145–150, 1986.
515. Baker, S. P., Fisher, R. S., Masemore, W. C., Sopher, I. M. Fatal unintentional carbon monoxide poisoning in motor vehicles. *Am. J. Public Health* 62:1463–1467, 1972.
516. Carson, H. J., Stephens, P. J. Four deaths due to carbon monoxide poisoning in car washes. *Am. J. Forensic Med. Pathol.* 20:274–276, 1999.
517. Centers for Disease Control and Prevention. Unintentional carbon monoxide poisoning from indoor use of pressure washers—Iowa, January 1992–January 1993. *JAMA* 270:2034, 2037, 1993.
518. Centers for Disease Control and Prevention. Leads from MMWR. Carbon monoxide intoxication associated with use of a resurfacing machine at an ice-skating rink. *JAMA* 251:1016, 1984.
519. Ely, E. W., Moorehead, B., Haponik, E. F. Warehouse workers' headache: emergency evaluation and management of 30 patients with carbon monoxide poisoning. *Am. J. Med.* 98:145–155, 1995.
520. Caplan, Y. H., Thompson, B. C., Levine, B., Masemore, W. Accidental poisonings involving carbon monoxide, heating systems, and confined spaces. *J. Forensic Sci.* 31:117–121, 1986.
521. Jumbelic, M. I. Open air carbon monoxide poisoning. *J. Forensic Sci.* 43:228–230, 1998.
522. Centers for Disease Control and Prevention. Carbon monoxide poisonings associated with snow-obstructed vehicle exhaust systems—Philadelphia and New York City, January 1996. *JAMA* 275:426–427, 1996.

523. Rao, R., Touger, M., Gennis, P., Tyrrell, J., Roche, J., Gallagher, E. J. Epidemic of accidental carbon monoxide poisonings caused by snow-obstructed exhaust systems. *Ann. Emerg. Med.* 29:290–292, 1997.
524. Silvers, S. M., Hampson, N. B. Carbon monoxide poisoning among recreational boaters. *JAMA* 274:1614–1616, 1995.
525. Hampson, N. B., Norkool, D. M. Carbon monoxide poisoning in children riding in the back of pickup trucks. *JAMA* 267:538–540, 1992.
526. Abu-al Ragheb, S. Y., Battah, A. H. Carbon monoxide fatalities in medicolegal autopsies. *Med. Sci. Law* 39:243–246, 1999.
527. Bass, M., Kravath, R. E., Glass, L. Death-scene investigation in sudden infant death. *N. Engl. J. Med.* 315:100–105, 1986.
528. Hampson, N. B., Kramer, C. C., Dunford, R. G., Norkool, D. M. Carbon monoxide poisoning from indoor burning of charcoal briquets. *JAMA* 271:52–53, 1994.
529. Yoon, S. S., Macdonald, S. C., Parrish, R. G. Deaths from unintentional carbon monoxide poisoning and potential for prevention with carbon monoxide detectors. *JAMA* 279:685–687, 1998.
530. Wrenn, K., Connors, G. P. Carbon monoxide poisoning during ice storms: a tale of two cities. *J. Emerg. Med.* 15:465–467, 1997.
531. Houck, P. M., Hampson, N. B. Epidemic carbon monoxide poisoning following a winter storm. *J. Emerg. Med.* 15:469–473, 1997.
532. Gorman, D. F., Runciman, W. B. Carbon monoxide poisoning. *Anaesth. Intensive Care* 19:506–511, 1991.
533. Risser, D., Bonsch, A., Schneider, B. Should coroners be able to recognize unintentional carbon monoxide-related deaths immediately at the death scene? *J. Forensic Sci.* 40:596–598, 1995.
534. Barret, L., Danel, V., Faure, J. Carbon monoxide poisoning, a diagnosis frequently overlooked. *J. Toxicol. Clin. Toxicol.* 23:309–313, 1985.
535. Heckerling, P. S., Leikin, J. B., Terzian, C. G., Maturen, A. Occult carbon monoxide poisoning in patients with neurologic illness. *J. Toxicol. Clin. Toxicol.* 28:29–44, 1990.
536. Grace, T. W., Platt, F. W. Subacute carbon monoxide poisoning. Another great imitator. *JAMA* 246:1698–1700, 1981.
537. Sadovnikoff, N., Varon, J., Sternbach, G. L. Carbon monoxide poisoning. An occult epidemic. *Postgrad. Med.* 92:86, 1992.
538. Roy, B., Crawford, R. Pitfalls in diagnosis and management of carbon monoxide poisoning. *J. Accid. Emerg. Med.* 13:62–63, 1996.
539. Findlay, G. H. Carbon monoxide poisoning: optics and histology of skin and blood. *Br. J. Dermatol.* 119:45–51, 1988.
540. Carson, H. J., Esslinger, K. Carbon monoxide poisoning without cherry-red livor. *Am. J. Forensic Med. Pathol.* 22:233–235, 2001.
541. Torne, R., Soyer, H. P., Leb, G., Kerl, H. Skin lesions in carbon monoxide intoxication. *Dermatologica* 183:212–215, 1991.
542. Leavell, U. W., Farley, C. H., McIntyre, J. S. Cutaneous changes in a patient with carbon monoxide poisoning. *Arch. Dermatol.* 99:429–433, 1969.
543. Orizaga, M., Ducharme, F. A., Campbell, J. S., Embree, G. H. Muscle infarction and Volkmann's contracture following carbon monoxide poisoning. *J. Bone Joint Surg. Am.* 49:965–970, 1967.
544. Bessoudo, R., Gray, J. Carbon monoxide poisoning and nonoliguric acute renal failure. *Can. Med. Assoc. J.* 119:41–44, 1978.
545. Finley, J., VanBeek, A., Glover, J. L. Myonecrosis complicating carbon monoxide poisoning. *J. Trauma* 17:536–540, 1977.
546. Dutra, F. R. Cerebral residua of acute carbon monoxide poisoning. *Am. J. Clin. Pathol.* 22:925–935, 1952.

547. Ginsberg, M. D. Delayed neurologic deterioration following hypoxia. *Adv. Neurol.* 26:21–44, 1979.
548. Smith, J. S., Brandon, S. Morbidity from acute carbon monoxide poisoning at three-year follow-up. *Br. Med. J* 1:318–321, 1973.
549. Myers, R. A., Snyder, S. K., Emhoff, T. A. Subacute sequelae of carbon monoxide poisoning. *Ann. Emerg. Med.* 14:1163–1167, 1985.
550. Dominguez, A. M., Halstead, J. R., Domanski, T. J. The effects of postmortem changes on carboxyhemoglobin results. *J. Forensic Sci.* 88:330–341, 1964.
551. Busuttil, A., Moody, G. H., Obafunwa, J. O., Dewar, C., McIntosh, M. The skeletonized body: suicidal inhalation of motorbike exhaust. *Am. J. Forensic Med. Pathol.* 18:50–55, 1997.
552. Levine, B., Moore, K. A., Titus, J. M., Fowler, D. A comparison of carboxyhemoglobin saturation values in postmortem heart blood and peripheral blood specimens. *J. Forensic Sci.* 47:1388–1390, 2002.
553. Wu, S. C., Levine, B., Goodin, J. C., Caplan, Y. H., Smith, M. L. Analysis of spleen specimens for carbon monoxide. *J. Anal. Toxicol.* 16:42–44, 1992.
554. Kojima, T., Okamoto, I., Yashiki, M., et al. Production of carbon monoxide in cadavers. *Forensic Sci. Int.* 32:67–77, 1986.
555. O'Brien, J. T., Tarbuck, A. F. Suicide and vehicle exhaust emissions. *BMJ* 304:1376, 1992.
556. Hays, P., Bornstein, R. A. Failed suicide attempt by emission gas poisoning. *Am. J. Psychiatry* 141:592–593, 1984.
557. Wagg, A. S., Aylwin, S. J. Catalytic converter and suicide risk. *Lancet* 342:1295, 1993.
558. Greenberg, S. R. The confined space. A review of a recently discerned medical entity. *Am. J. Forensic Med. Pathol.* 10:31–36, 1989.
559. Zugibe, F. T., Costello, J. T., Breithaupt, M. K., Zappi, E., Allyn, B. The confined space-hypoxia syndrome. *J. Forensic Sci.* 32:554–560, 1987.
560. Kleinfeld, M., Feiner, B. Health hazards associated with work in confined spaces. *J. Occup. Med.* 8:358–364, 1966.
561. Knight, L. D., Presnell, S. E. Death by sewer gas: case report of a double fatality and review of the literature. *Am. J. Forensic Med. Pathol.* 26:181–185, 2005.
562. Manning, T. J., Ziminski, K., Hyman, A., Figueroa, G., Lukash, L. Methane deaths? Was it the cause? *Am. J. Forensic Med. Pathol.* 2:333–336, 1981.
563. Pettit, T. A. Confined spaces: avoiding the hazards. *Occup. Health Saf.* 52:17–19, 1983.
564. Byard, R. W., Wilson, G. W. Death scene gas analysis in suspected methane asphyxia. *Am. J. Forensic Med. Pathol.* 13:69–71, 1992.
565. Balding, L. E., Jordan, F. B., Choi, C. S., Rohrig, T. P. Gas flames, closed spaces, and hypoxia. *Am. J. Forensic Med. Pathol.* 16:229–231, 1995.
566. Guillemin, M. P., Horisberger, B. Fatal intoxication due to an unexpected presence of carbon dioxide. *Ann. Occup. Hyg.* 38:951–957, 1994.
567. James, P. B., Calder, I. M. Anoxic asphyxia—a cause of industrial fatalities: a review. *J. R. Soc. Med.* 84:493–495, 1991.
568. Williams, H. I. Carbon dioxide poisoning: report of eight cases, with two deaths. *Br. Med. J.* 14:1012–1014, 1958.
569. Wagner, G. N., Clark, M. A., Koenigsberg, E. J., Decata, S. J. Medical evaluation of the victims of the 1986 Lake Nyos disaster. *J. Forensic Sci.* 33:899–909, 1988.
570. Ikeda, N., Takahashi, H., Umetsu, K., Suzuki, T. The course of respiration and circulation in death by carbon dioxide poisoning. *Forensic Sci. Int.* 41:93–99, 1989.
571. Kernbach-Wighton, G., Kijewski, H., Schwanke, P., Saur, P., Sprung, R. Clinical and morphological aspects of death due to liquid nitrogen. *Int. J. Legal Med.* 111:191–195, 1998.



572. Kage, S., Kashimura, S., Ikeda, H., Kudo, K., Ikeda, N. Fatal and nonfatal poisoning by hydrogen sulfide at an industrial waste site. *J. Forensic Sci.* 47:652–655, 2002.
573. Adelson, L., Sunshine, I. Fatal hydrogen sulfide intoxication. Report of three cases occurring in a sewer. *Arch. Pathol.* 81:375–380, 1966.
574. Centers for Disease Control and Prevention. Occupational fatalities during trenching and excavation work—United States, 1992–2001. *MMWR Morb. Mortal. Wkly. Rep.* 53:311–314, 2004.
575. Terazawa, K., Takatori, T., Tomii, S., Nakano, K. Methane asphyxia. Coal mine accident investigation of distribution of gas. *Am. J. Forensic Med. Pathol.* 6:211–214, 1985.

## Chapter 4

---

# Thermal Injury

### Summary

Trauma from fires, electrical sources, and blasts is manifest as thermal injury. Explosions can also indirectly injure the body (“blast effects”). All manners of death are possible in cases of thermal injury. Victims—dead at the scene—can sustain highly destructive trauma (e.g., charring, dismemberment), presenting a daunting challenge to the pathologist in determining identification and cause of death, collecting evidence, and distinguishing antemortem injury from postmortem thermal artifact. Survivors who die in the hospital succumb to a host of complications. These delayed deaths exemplify the concept of “immediate” and “proximate” cause of death.

**Key Words:** Burns; fires; smoke inhalation injury; carbon monoxide; electric injuries; lightning; explosions; blast injuries.

### 1. CIRCUMSTANCES OF FIRE

Flame injury is the most common type of burn faced by a pathologist (1–3). All manners of death are possible. Determination of the cause and manner of death requires integration of scene findings and other information provided by fire investigators and police with postmortem findings and ancillary toxicological and chemical testing (4).

Residential fires accounted for three-fourths of fire deaths in a North Carolina study (5). Two-thirds of the victims were male, and almost half were home alone. Many victims were either younger than 5 yr old or older than 64 yr (5). Accidents involve smoking in bed, using faulty heating equipment, cooking, and playing with fire (2,6,7). Predisposing factors for adult victims include alcoholism, senility, psychiatric disorders, and neurological disease (*see* Chapter 3, Subheading 3.9.; Heading 4., and refs. 5 and 8). Several studies have shown that smoke detectors were either lacking or faulty in a significant number of cases (6,7,9). Although smoke detectors reduce the risk of death, one study showed their lack of efficacy in play-related fires involving children (5,6,10). This could be because of this type of fire originating away from a smoke detector (e.g., bedroom), victims hiding after the fires started, and a lack of adult supervision (6,11,12).

From: *Forensic Science and Medicine: Forensic Pathology of Trauma:  
Common Problems for the Pathologist*

By: M. J. Shkrum and D. A. Ramsay © Humana Press Inc., Totowa, NJ

The majority of work-related burn injuries occur in male victims (13–15). The highest proportion (about one-fourth) of fatal thermal burns in a US study was seen in the transportation and public utilities industries (15). The large majority of transportation deaths were in truck drivers involved in motor vehicle crashes (15). Burn mortality was highest in workers aged 65 yr and over. Deterioration of reaction time and other physical abilities, combined with disease and medication use, makes older workers more susceptible to trauma (15).

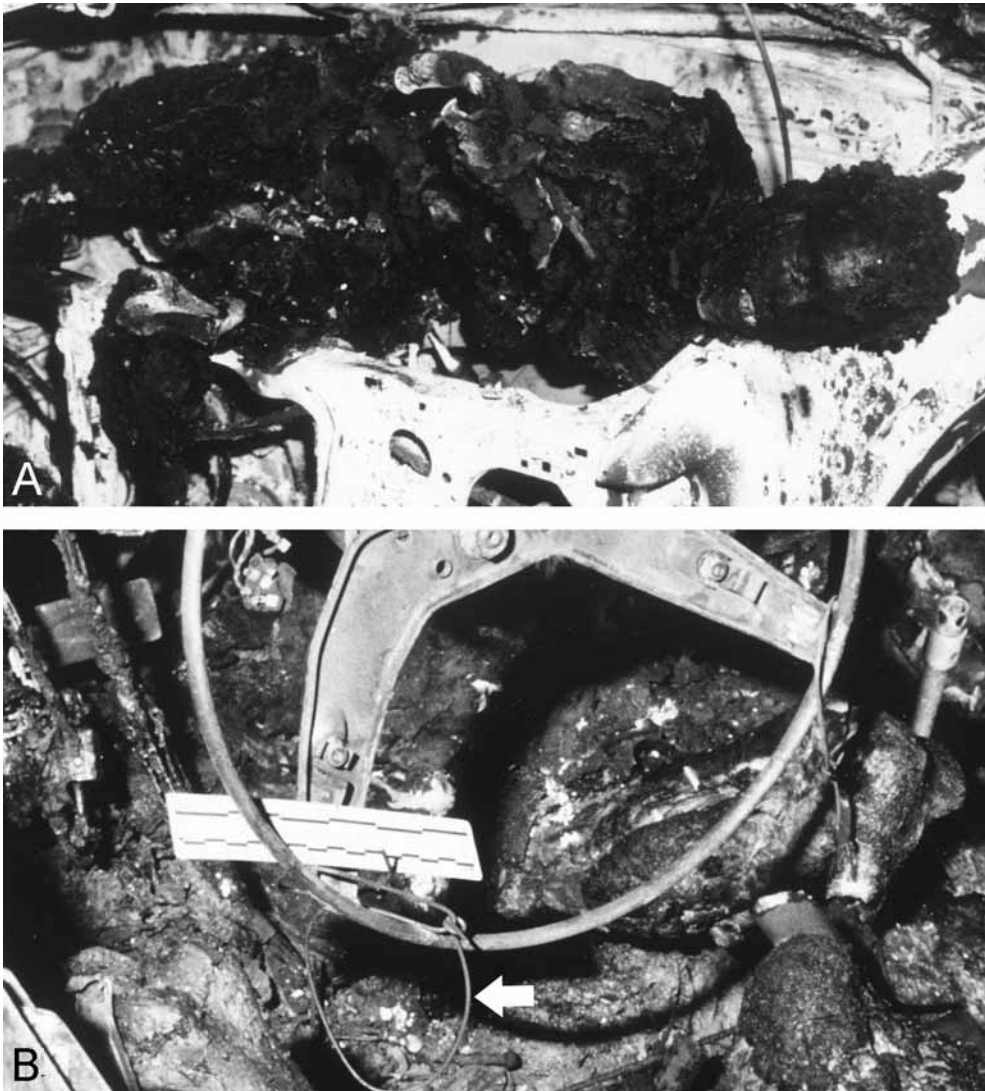
Fire is used as a means of suicide, either by self-immolation or by setting a fire in a dwelling. The scene of self-immolation is usually familiar, but remote locations may be chosen (16–19). The scene can be a public place (17,20). Self-immolation occurs in the setting of motor vehicles (Fig. 1; refs. 17 and 18). A review of clinical and forensic series of self-immolation cases showed a male predominance in most European countries and the Far East, but an increased frequency in women in the Middle East and India (21). In some jurisdictions, self-immolation comprises about 1% of all suicides (17,18). A psychiatric illness is documented in many of victims, but some European and North American studies have shown no history in about half of cases (17,18,21–23). There can be a history of past or recent suicide attempts, including burning (17,18). The motivation is similar to other types of suicide (17,18,21,24). Traditional marriage and hierarchical social structure can compel women in certain countries (e.g., India) to self-immolate (25,26). Religious reasons and political protest are other motivating factors (17,18,21). The latter attracts media attention, leading others to commit suicide by similar means (16,18). For an institutionalized person, access to fire (e.g., matches) may be the only means available for committing suicide (16,18). Concurrent trauma (“complex suicides”) may be observed (e.g., blunt trauma from a fall, gunshot wound to the head, hanging, stab wounds) and arouses suspicion (Fig. 2; refs. 16, 18, 27, and 28). Findings on external examination can be unusual (e.g., rag stuffed in mouth to stifle screams, arms of victim wired to steering wheel to prevent escape; see Fig. 1 and ref. 18). Accelerants are commonly used (see Subheading 4.2. and refs. 18 and 21).

Fires are set deliberately for other reasons (e.g., pyromania, vandalism, revenge, extortion, fraud [4]). Homicides can masquerade as accidental fires (see Fig. 3; refs. 4 and 29; and Subheading 4.1.).

Natural deaths occur prior to or during a fire.

## 2. THE FIRE

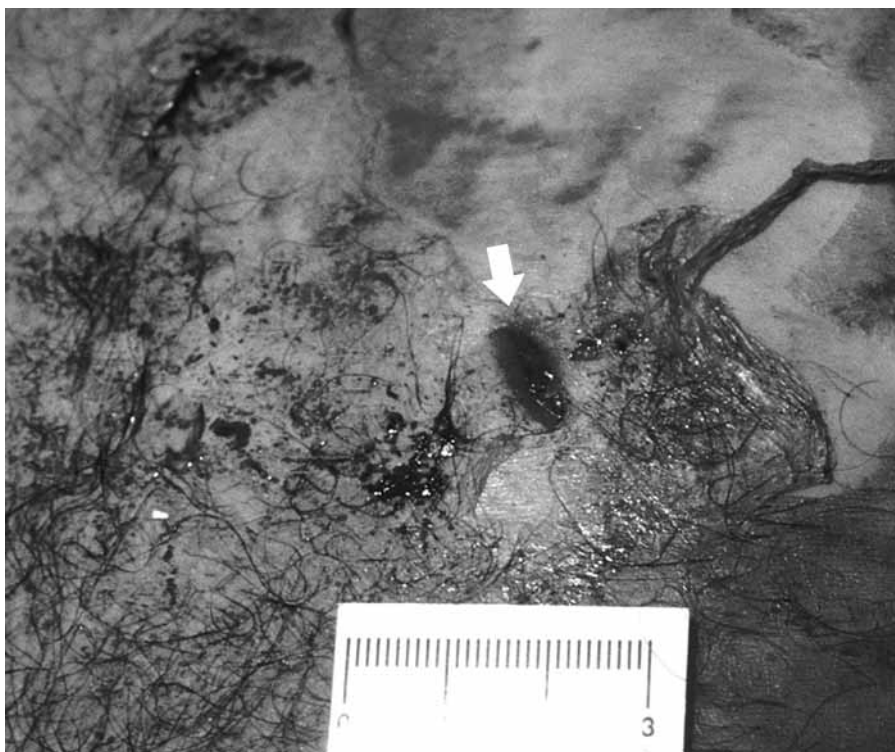
The starting of a fire depends on an ignition source, a sufficient quantity of flammable material near the source, and an adequate oxygen ( $O_2$ ) supply (4,30). Combustion raises the temperature and produces a visible glow or flame (31). Temperatures higher than 150°C (300°F) are reached in building fires within 5 to 10 min (32). In close confines (e.g., an aircraft cabin), a rapidly fatal temperature of about 250°C (480°F) occurs in 5 to 6 min (33). If a door is opened or the integrity of an enclosed structure is breached by heat, then the sudden introduction of  $O_2$  leads to flashover, i.e., a sudden burst of flame as the spontaneous ignition temperature of gases and other combustion products is reached (33). Flashover is likely above 650°C (1200°F [33]). Temperatures higher than 1000°C (1832°F) happen within minutes when an airplane occupant compartment is compromised (33). Temperatures in car fires can be up to 1100°C (1980°F),



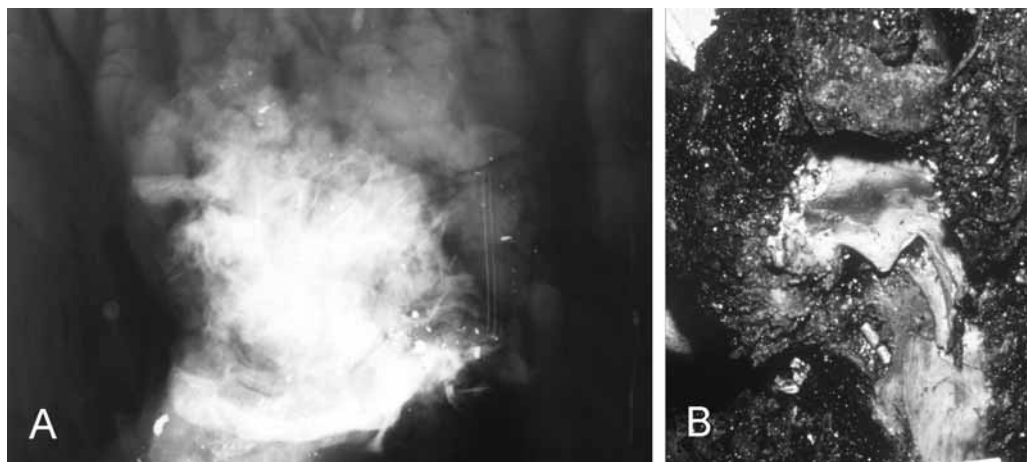
**Fig. 1.** Cases of suicides by fire (self-immolation). Victims alive during fire (smoke inhalation and elevated carboxyhemoglobin). (A) Found under hood of burned vehicle in remote area. (B) Manacled (arrow) to steering wheel. (Reprinted, with permission, from ref. 18 and the Journal of Forensic Sciences, copyright ASTM International, West Conshohocken, PA.)

particularly if fuel is present (34–36). Radiating heat in a high-temperature fire (up to 980°C or 1800°F) in an enclosed space can spontaneously ignite furniture (4).

Initially, carbon-containing materials are oxidized to carbon dioxide, and carbon monoxide (CO) production is low (*see* Chapter 3, Subheading 3.9. and ref. 31). Pyrolysis is the decomposition of a substance under the influence of heat and does not require a normal atmospheric level of O<sub>2</sub> (“incomplete combustion” [31]). Because the O<sub>2</sub> supply is consumed and not readily replenished in a poorly ventilated space, pyrolysis leads to the production of smoke (airborne particles) admixed with toxic gases, such as CO



**Fig. 2.** Fatal house fire. Self-inflicted nonfatal abdominal wound (arrow). Smoke inhalation and elevated carboxyhemoglobin (39%). Extensive burns.



**Fig. 3.** Dead prior to fire. Apparent accidental car fire concealing a homicide. No evidence of smoke and carbon monoxide inhalation. **(A)** Radiograph of skull. Multiple bullet fragments. **(B)** Top of skull burnt and missing. Probe inserted through gunshot hole in base of skull showing track to recovery site of largest bullet fragment (courtesy of the Office of Chief Medical Examiner, Chapel Hill, NC).



(30,31,33,37). If flashover occurs, pyrolysis yields chemically unstable complex compounds, and CO production increases (31,33).

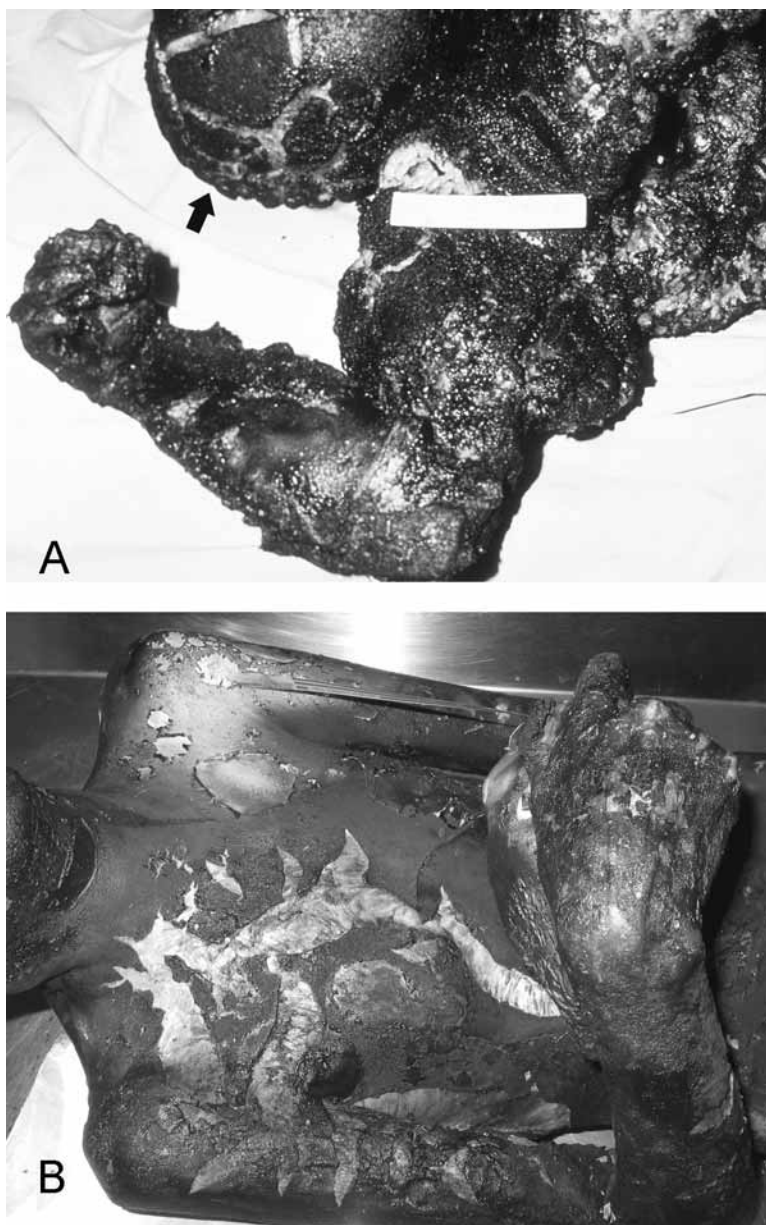
### 3. DEAD AT THE SCENE

#### 3.1. State of the Body

The state of a body found dead at the scene of a fire varies. The body can be relatively undamaged. Areas of the body covered by clothes are relatively protected, and only exposed areas are covered by soot. Burns have been classified as first-degree or superficial partial thickness (reddening or erythema); second-degree or deep partial thickness (i.e., extending deeper into the dermis and characterized by blisters); and third-degree or full thickness (i.e., necrosis of epidermis and entire thickness of dermis, imparting a leathery appearance; see Heading 6. and ref. 38). Extensive charring and disintegration of the body occurs (39). This loss of bodily integrity can be exacerbated by fire department personnel at the scene, particularly if the body is “unrecognizable” and its presence is not appreciated during fire suppression.

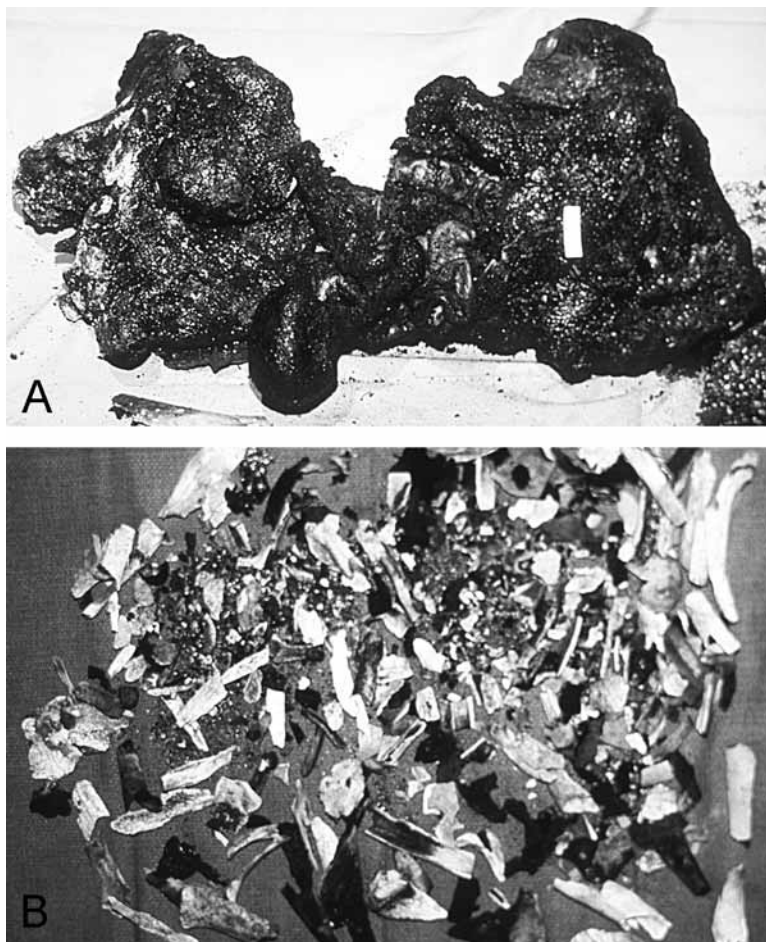
In studies of undissected bodies of elderly individuals cremated at temperatures between 670°C and 810°C (1240°F and 1490°F), the degree of destruction was related to the duration of cremation (35,40,41). After about 10 min, the bodies showed a “pugilistic” posture resulting from heat contraction of the more bulky flexor muscles (Fig. 4). Charring of the face and extremities occurred by about 20 min. After 20 min, fissures appeared on the exposed outer table of the skull. The coronal or sagittal suture separated owing to increased intracranial pressure from steam (34). The skin of the head, torso, and extremities was consumed, resulting in charring of the underlying exposed muscle. Bones of the extremities became visible. The hands were either destroyed or severely burned and connected to the arms only by charred soft tissue. At approx 30 min, fractures had widened in the calvarium and extended to the inner table. In some cases, the outer table had disintegrated into fragments (34,35). At this point, the brain was superficially charred. The thoracic and abdominal cavities were open, with destruction of the sternum and calcination of the anterior rib ends. As a result, internal organs were charred and shrunk. The distal forearms were destroyed, and soft tissue was largely absent from the distal lower extremities. Exposed long bones displayed heat fractures. After 40 min, the calvarium was destroyed and the facial bones fragmented. The lower arms were destroyed and the humeri were exposed. After 50 min, the arms were completely gone and the femoral bones reduced to burned bone stumps. The face had disintegrated, and the base of the skull was exposed. The vertebral bodies were calcined. After 60 min, only central facial bones and skull base remained, and, in some instances, the torso was headless. The internal organs were reduced to ash. The extremities were completely gone. By 1.5 h, the torso had fragmented. Almost complete incineration occurred after 2 to 3 h of cremation (Fig. 5). The body of a child can be reduced to calcined bone within 2 h in a heated stove at a temperature of about 500°C (930°F [36]). Clothes burn when temperatures reach 225°C (440°F [4]).

Temperatures in residential fires can approach those reached in crematory ovens, but complete charring is unusual in outdoor or house fires (35,36). Intervention by firefighting personnel and lack of sufficient fuel to maintain the fire mean that most fires are not of sufficient duration to allow complete consumption of the body (35,36). The implication for the pathologist is that, in most cases, the necessary steps for identification,



**Fig. 4.** Burn artifacts. **(A)** Flexed arm owing to heat effects. Skin splits on scalp (arrow; courtesy of the Office of the Chief Medical Examiner, Chapel Hill, NC). **(B)** Another example of heat flexion of arm and skin splits on chest (courtesy of Dr. E. Tweedie, London Health Sciences Centre, London, Ontario, Canada).

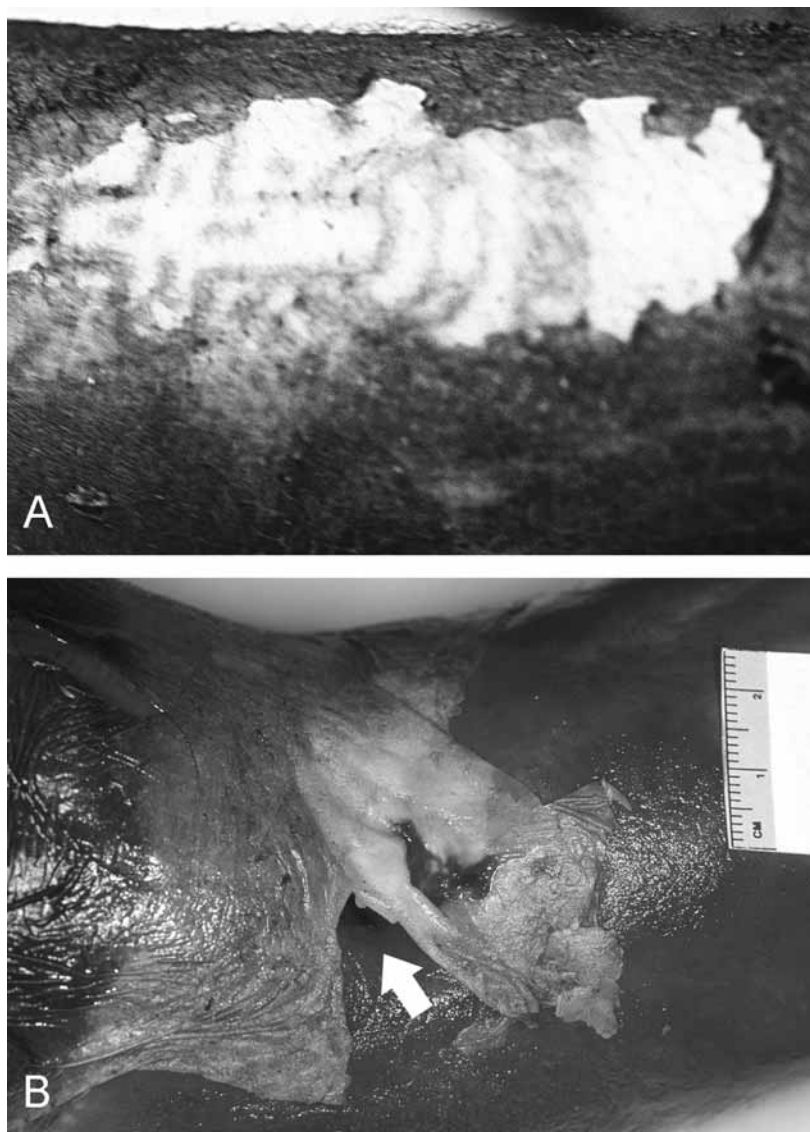
examination of internal organs and tissues to assess the presence of disease and injury, and the collection of body fluids for toxicological analysis are possible (Fig. 5; ref. 40). Unlike a cremation oven, where flame is distributed continuously and evenly on the body under constant conditions, temperatures in a typical fire fluctuate and parts of the body not directly exposed to flame (e.g., pressed against a hard surface), are relatively protected (35,40). In most cases, charring is much less on the side of the body not



**Fig. 5.** Examples of severely charred bodies. **(A)** Charred torso. Despite the extensive burning, internal organs were relatively preserved and toxicology samples obtained (courtesy of the Office of the Chief Medical Examiner, Chapel Hill, NC). **(B)** Calcined remains (courtesy of the Office of the Chief Medical Examiner, Chapel Hill, NC).

exposed to the fire; however, in some cases, complete charring still occurs (40,42). Clothed bodies can be destroyed more quickly than naked ones (43).

In some cases, the pattern of charring reverses, i.e., there is destruction of the torso with relative preservation of the extremities (43,44). Because there is usually minimal fire damage to the surroundings, speculation has arisen about “spontaneous human combustion” (43–45). Typical victims are overweight elderly females (43). These individuals collapse from a disease process, and they are found close to usually obvious external ignition sources (e.g., cigarettes, open fireplaces, candles, stoves, room heaters; see Subheading 4.1. and refs. 43 and 45). If burning of clothing or fabrics near the body (e.g., carpet) occurs for at least 15 min, then splitting of skin allows release of melted subcutaneous fat (44). Fat is the most combustible tissue (43). If the fat is absorbed into porous fabric, which acts like a wick, then flame can persist (44–46). Such fires are unlikely to exhaust  $O_2$  present in a room and do not produce enough heat to ignite adjacent combustible structures by radiant heat (44). Although human fat burns at about



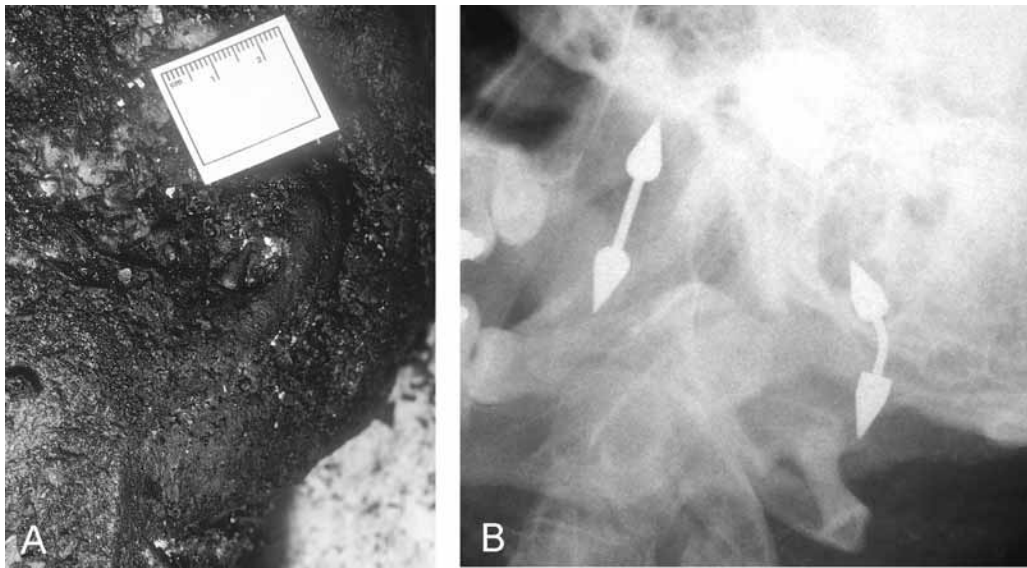
**Fig. 6.** Identification of fire victims. **(A)** Soot-covered skin can be wiped off to reveal distinguishing features (e.g., tattoo). **(B)** Partly burned body. Draining cutaneous sinus (arrow) because of osteomyelitis, a consistency with the medical history.

250°C (480°F), the wick effect allows burning of fat at temperatures as low as 24°C (75°F [45]). The distal limbs, because they contain less fat compared with the obese torso of these victims, do not burn, while the torso smolders (44).

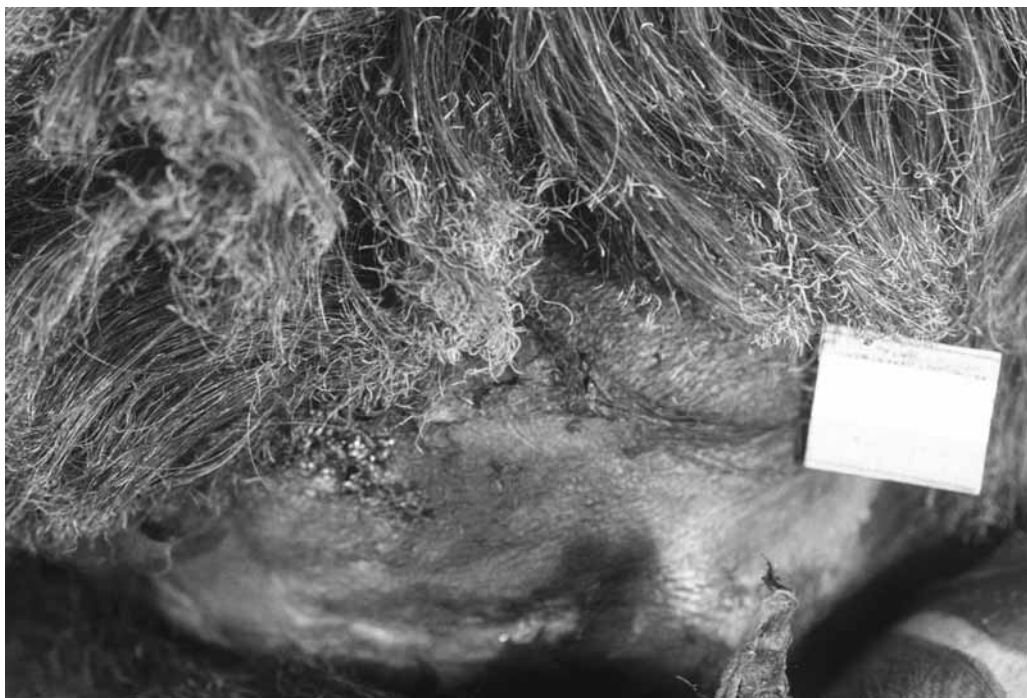
### 3.2. Identification

The circumstances of many fires (e.g., known occupants of a residence) help direct the identification of the victims. If a recovered body is covered by soot and not severely burned, soot can be cleaned to allow visual recognition of the face and other external features (Fig. 6). Clothing and personal effects, if not burned, can assist in identification





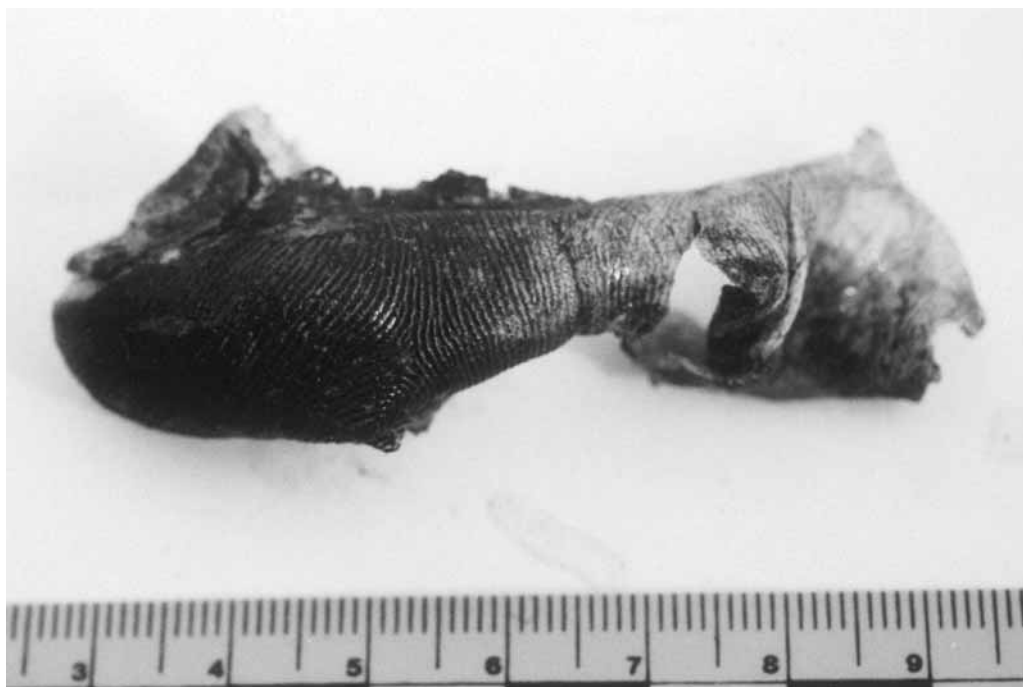**Fig. 7.** Charred body. Motor vehicle collision and fire. Identification by personal effects. **(A)** Left ear. Earring not seen because of charring. **(B)** Radiograph shows distinctive earrings.



**Fig. 8.** Color of hair changed by singeing. (See Companion CD for color version of this figure.)

(Fig. 7). Charring obliterates identifying external features. Height reduction caused by heat contraction means that this feature is inaccurate for identification. Hair color changes also affect identification (Fig. 8). Spitz observed gray hair changing to brassy





**Fig. 9.** Charred body. Finger amputated during autopsy for the purpose of fingerprinting.

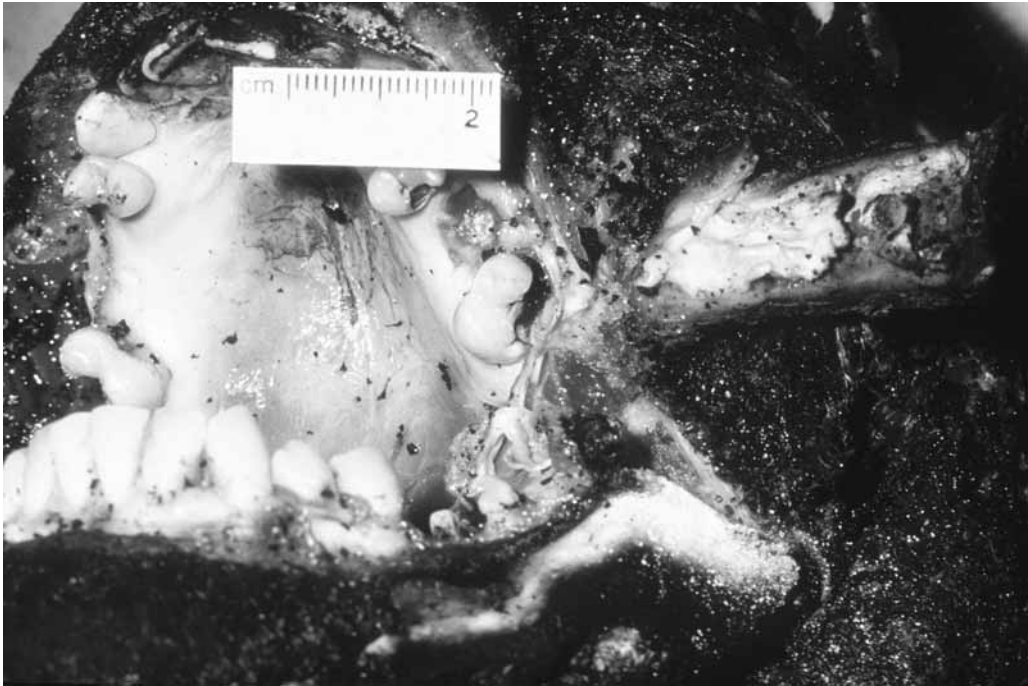blond at about 120°C (250°F [47]). After 10 to 15 min at 205°C (400°F), brown hair acquired a slight reddish hue. Black hair did not change color (47).

Comparative means of identification are used. A clenched hand resulting from heat contracture preserves fingerprints (Fig. 9). If there is tentative identification, any available dental and medical records must be obtained by investigators (Fig. 10). The utility of these records depends on their specificity and accuracy (48). Identification is one role of the radiological examination of a charred body (e.g., evidence of prior surgery, old fracture; (see Subheading 4.3.). If exact matching of antemortem and postmortem information is not possible, then consistencies can still be confirmed by the pathologist and other experts involved (Figs. 6, 11, and 12). If conventional comparison methods are not possible, teeth or bone can be used for DNA analysis (48).

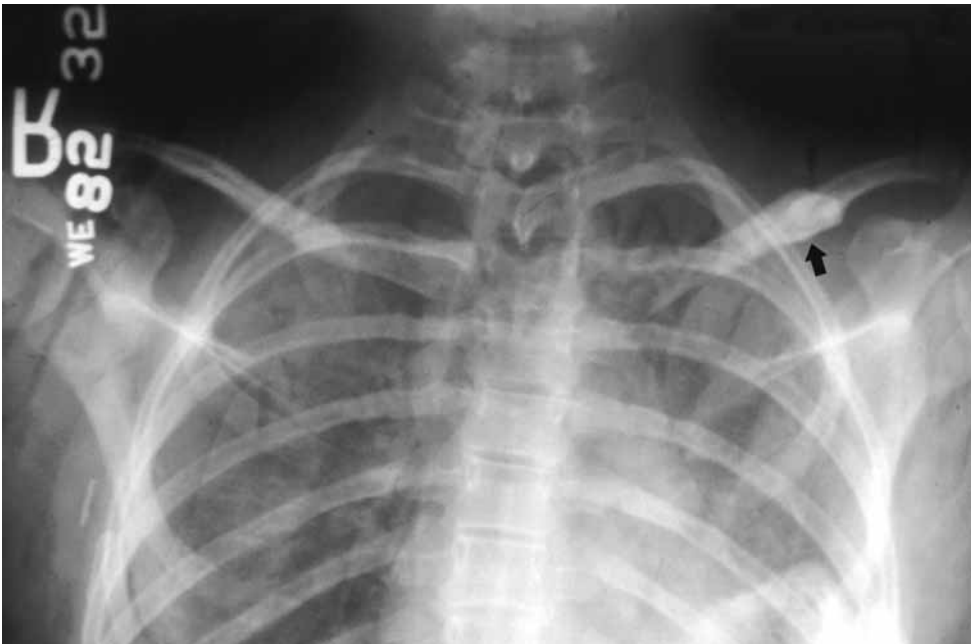### **3.3. Burn Artifacts**

During burning, changes occur that can mimic trauma and hinder identification (see Subheading 3.2.):

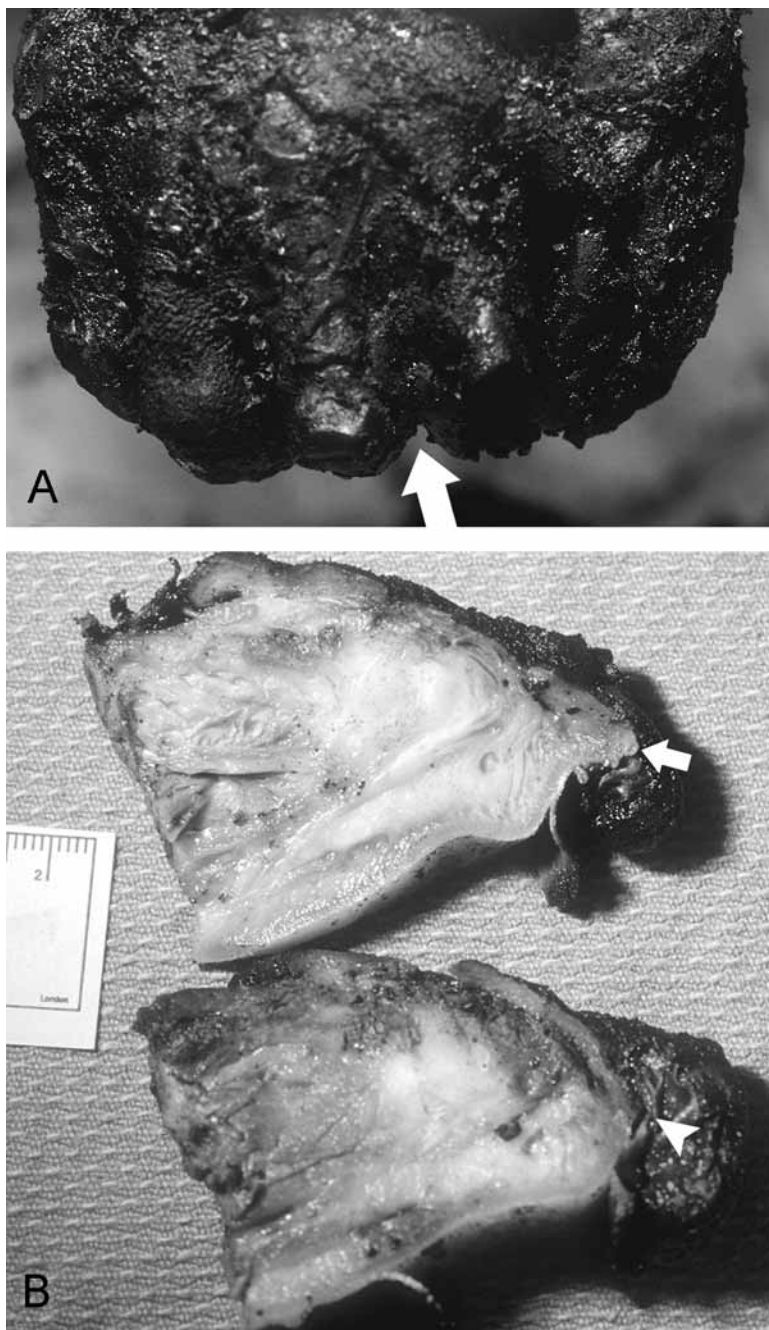
- Remnants of clothing around neck mimic ligature strangulation (Fig. 13).
- “Pugilistic posture” owing to muscle contraction from heat suggests “fight or flight” (Fig. 4).
- Splitting of skin and exposure of subcutaneum suggests incised wounds (see Fig. 4 and ref. 40).
- Heat blisters can form. They are either intact or open. A dried open area turns yellow to dark brown. These blisters are not necessarily a sign of vitality. Accelerants (kerosene, gasoline) can accentuate blister formation and skin slippage (49).



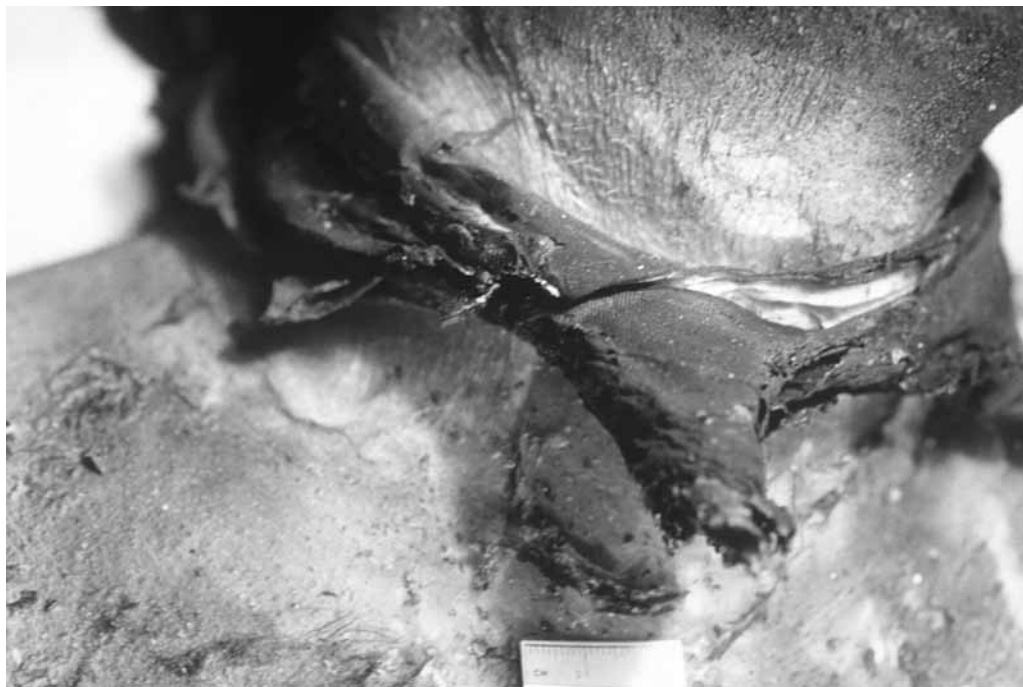
**Fig. 10.** Charred body. Teeth are protected from and more resistant to burning. (Courtesy of the Office of the Chief Medical Examiner, Chapel Hill, NC.)



**Fig. 11.** Charred body. Chest radiograph shows healed clavicle fracture (arrow). If ante-mortem radiographs have been disposed, and are not available for comparison, then a medical history of this injury still provides an identification consistency. (Courtesy of the Office of the Chief Medical Examiner, Chapel Hill, NC.)




**Fig. 12.** Charred body recovered from car fire. The only identifying feature described was a “webbed” toe. **(A)** Right forefoot. Presumed partial syndactyly between second and third toes (arrow). **(B)** Longitudinal autopsy cuts through web spaces. Upper section: fold of skin indicating partial syndactyly (arrow). Lower section: uninvolved web space (arrowhead).



**Fig. 13.** Burned necktie appearing as a ligature.

- A “red line” at the periphery of severely burned or charred skin mimics inflammation and suggests the victim was alive when the burns occurred (Fig. 14). Microscopic examination shows subepidermal blood.
- Heat fractures are not associated with soft tissue hemorrhage (49). Heat amputation of distal extremities is recognized by the presence of charring at the distal ends of the affected bones (Fig. 15). Similarly, charred skull fracture edges are indicative of heat effects. Heat fractures in the extremities are thought to arise from muscle shrinkage (47). Burning of the outer table reduces the strength of the bone. Heat-induced skull fractures are caused either by an increase in intracranial pressure caused by steam (“blow-out” fracture, i.e., fragments displaced outward) or desiccation of the outer table of the cranium (34,50). Heat effects can cause round holes in the skull suggesting a gunshot wound (Fig. 16 [50]). Herniation of cerebral tissue through the fracture defects can be seen (51). Observations regarding heat-induced skull fracture are contradictory. Fracture lines radiating from a skull defect are supposed to indicate a true injury (36). Calvarial heat fractures have been described as elliptical or circular without radiating fracture lines (cited in refs. 34 and 35). In contrast, Spitz observed several fracture lines radiating from a common center in burned skulls (47). A heat fracture of the calvarium is usually located above the temple and sometimes bilateral (47). These fractures are rarely limited to the external table (47). Cranial sutures tend not to burst even in a young individual; however, bursting of the coronal or sagittal suture was observed in a series of cremations (34,47).
- Disintegration of a burned body during extinguishing of fire by either rapid cooling of heated remains or disruption by water under high pressure hinders the assessment of trauma (48).
- Epidural hemorrhage, usually bilateral and associated with charring of the scalp and calvarium, is not the result of trauma (see refs. 42 and 49 and Fig. 17).





**Fig. 14.** “Red” line (arrows) at the edge between burned and unburned skin. (See Companion CD for color version of this figure.)

- Shrunken, firm, yellow or light brown discolored (“cooked”) brain is a heat artifact (47).
- Apparent exsanguination from the nostrils and mouth is observed as heat forces blood from the lungs into the airways (see Subheading 4.1., and ref. 47).
- Introduction of soot into the trachea, either during incision of the charred neck at autopsy or by disintegration from burning, gives the false impression of smoke inhalation (52).
- Treatment artifacts (see Subheading 5.2., Table 1).

#### 4. INCAPACITATION AND LETHALITY DURING A FIRE

##### 4.1. Vitality of the Body (“Was the Victim Dead Prior to or During the Fire?”)

The lethality of fires involves different mechanisms: reduction of environmental  $O_2$ , an increase in CO and other toxic gases, inhalational injury owing to smoke and heat, extreme heat and shock, burns, other types of trauma (e.g., blunt injuries sustained in an attempt at escape), and exacerbation of disease (32,37,52). In rare cases, impairment of breathing by tightening of the thorax or neck owing to heat effects has been proposed (52). Heat and toxic fumes are main causes of death during a fire (49).

Temperatures higher than 150°C (300°F) cause loss of consciousness or death within several minutes (32). Higher temperatures cause immediate death (32). A flashover or explosion can engulf a victim (4,32). Rapid death means that a victim inhales little, if any, combustion and pyrolysis products. Smoke- or heat-induced laryngospasm,





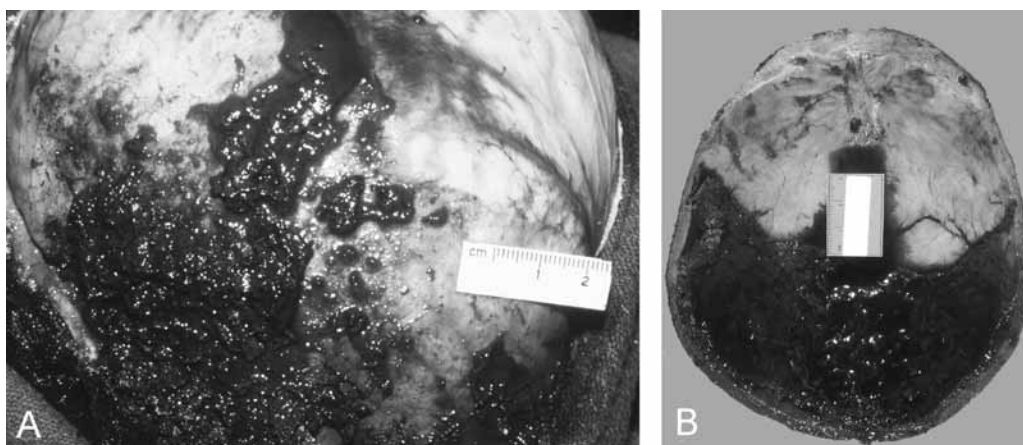
**Fig. 15.** Burn artifact. (A) Charred ends of bones (heat fractures). (B) Amputation of lower extremities due to heat fractures. (Courtesy of Dr. E. Tweedie, London Health Sciences Centre, London, Ontario, Canada.)

respiratory arrest, and/or a vagal reflex-caused cardiac arrest are proposed mechanisms of rapid death during a fire (42,52).

Within a minute, smoke causes incapacitation as a result of coughing, eye irritation, reduced visibility, and disorientation (4,33,37). An unimpaired individual usually attempts to extinguish the fire, warn others, and escape, but this is hindered by the effects of the smoke (4,33,37). Spreading smoke forms a hot layer at ceiling level and then descends rapidly (37). The smoke is relatively low in  $O_2$  and if the  $O_2$  level is below 7%, then incapacitation occurs rapidly (see Chapter 3, Subheading 3.10. and ref. 37). If



**Fig. 16.** Artifactual hole through calvarium of a charred skull. A radiograph showed no projectile. Internal examination did not reveal craniocerebral trauma.



**Fig. 17.** Charred bodies. (A) Epidural “hematoma” seen on removal of the calvarium. (Courtesy of the Office of the Chief Medical Examiner, Chapel Hill, NC.) (B) Bilateral epidural “hematoma” on undersurface of removed calvarium.

the individual crawls along the floor, the effects of smoke are delayed (37). Suffocation is expected when the  $O_2$  concentration falls to 10%, but levels in fires usually are not below 15%. At this point, a fire smolders (49,52). If there is flame evident, there is usually enough  $O_2$  for individuals to breathe (42).

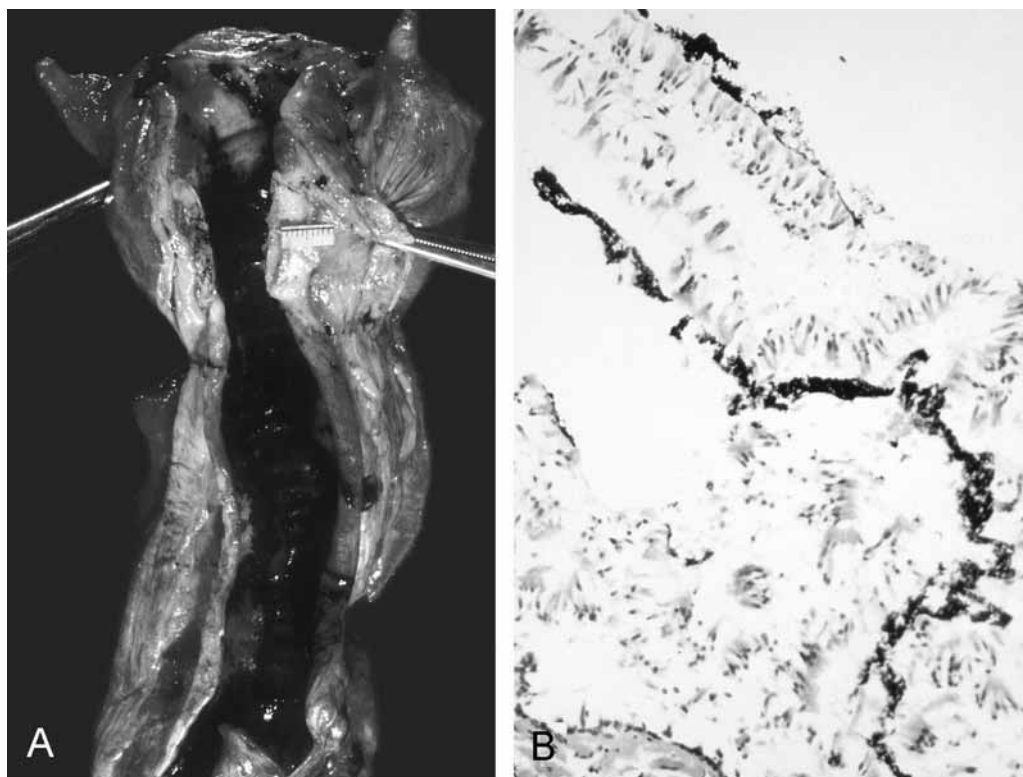
Away from the fire, heat effects and  $O_2$  depletion are less important (37,53). The initial generation of carbon dioxide in a fire stimulates respiration, increasing the inhalation

of other toxic gases (32). Inhalation of these gases, particularly CO, causes death (33,37). The amount of CO produced in a fire is variable, ranging from 0.1 to 10% in the fire atmosphere (*see* Chapter 3, Subheading 3.9.1., and refs 4 and 33). At high concentrations, death occurs quickly (33). At lower concentrations, victims can be active (33). CO can cause strange behavior (e.g., running back into the fire to save an imagined victim; hiding in a closet, under a bed; or in a bathtub [4]). Increased CO is inhaled when respiratory efforts increase during physical exertion (*see* Chapter 3, Subheading 3.9. and ref. 33). The higher O<sub>2</sub> demands created by exertion can cause death at a lower carboxyhemoglobin (COHb) saturation than in subjects at rest (31). Mental and muscular performance deteriorate at a COHb of 30%, and fainting can occur (*see* Chapter 3, Table 4; and ref. 37). Victims can continue to inhale CO even when they are incapacitated (33).

Low levels of CO in victims away from the origin of the fire raises the possibility of inhalation of other toxic gases (37,54). COHb levels are generally higher in nonfire deaths, suggesting that other toxic factors play a role in fires (*see* Chapter 3, Subheading 3.9.4.; and ref. 37). Cyanide (CN) causes more rapid incapacitation than CO (33,37). Its rapid absorption and respiratory depressant effect may limit CO uptake (37). CN is generated from burning materials containing nitrogen compounds (e.g., polyurethane in vinyl, wool, nylon, urea formaldehyde [4,37]). Toxicity results from the inhibition of oxidation of reduced cytochrome a3 in the mitochondrial respiratory chain (55). CN stimulates breathing, which increases inhalation of other toxic gases (30). Various studies have shown no synergistic additive effects of CO and CN (30,37,55–58). In one study, there was no indication that certain cofactors—CO, alcohol, age, and heart disease—affect the level of CN reached in the blood of the victim (57). In many fire deaths, CO is in the fatal range and CN is not at toxic levels, indicating that CO poisoning is the more important cause in most fire deaths (58,59). CN causes incapacitation at blood concentrations in the range of 50 µmol/L (57). In certain situations (e.g., burning of nitrogen-containing plastics), CN in the range of 100 µmol/L is life-threatening and victims have relatively low COHb levels (57,58). Levels of CN ranging from 1 to 3 mmol/L (1000–3000 µmol/L) are lethal (37). If the burning materials contain fluorine, chlorine, or bromine (e.g., polyvinyl chloride, flame retardants), their respective hydrogen gases are released. The corrosive effects of these gases damage the respiratory mucosa and lead to delayed effects (37). Other irritants (formaldehyde, acrolein) are also generated (31). Generation of highly reactive free radicals leads to diffuse alveolar damage (33).

A victim's level of consciousness and ability to escape are affected by drugs and alcohol (4,37). Although intoxication by alcohol or drugs is thought by some to have a synergistic effect with CO, impairment of the ability to escape and to assist others is more likely (*see* Chapter 3, Subheading 3.9.4.; and refs. 4 and 59–62). In one study, victims found dead in bed and, presumably having made no attempt to escape, had a mean blood ethanol level of 268 mg/dL compared with an average of 88 mg/dL in victims found near an exit (59). Studies of fatal fires showed that one-third to one-half of deceased individuals have ingested alcohol (7,62–65).

The observations of increased CO (COHb > 10%) and other noxious gases in the blood, and soot in the mouth, upper respiratory (“smoke inhalation”), and gastrointestinal (GI) tracts are indicators that an individual was alive during the fire (Fig. 18; refs. 4 and 52).

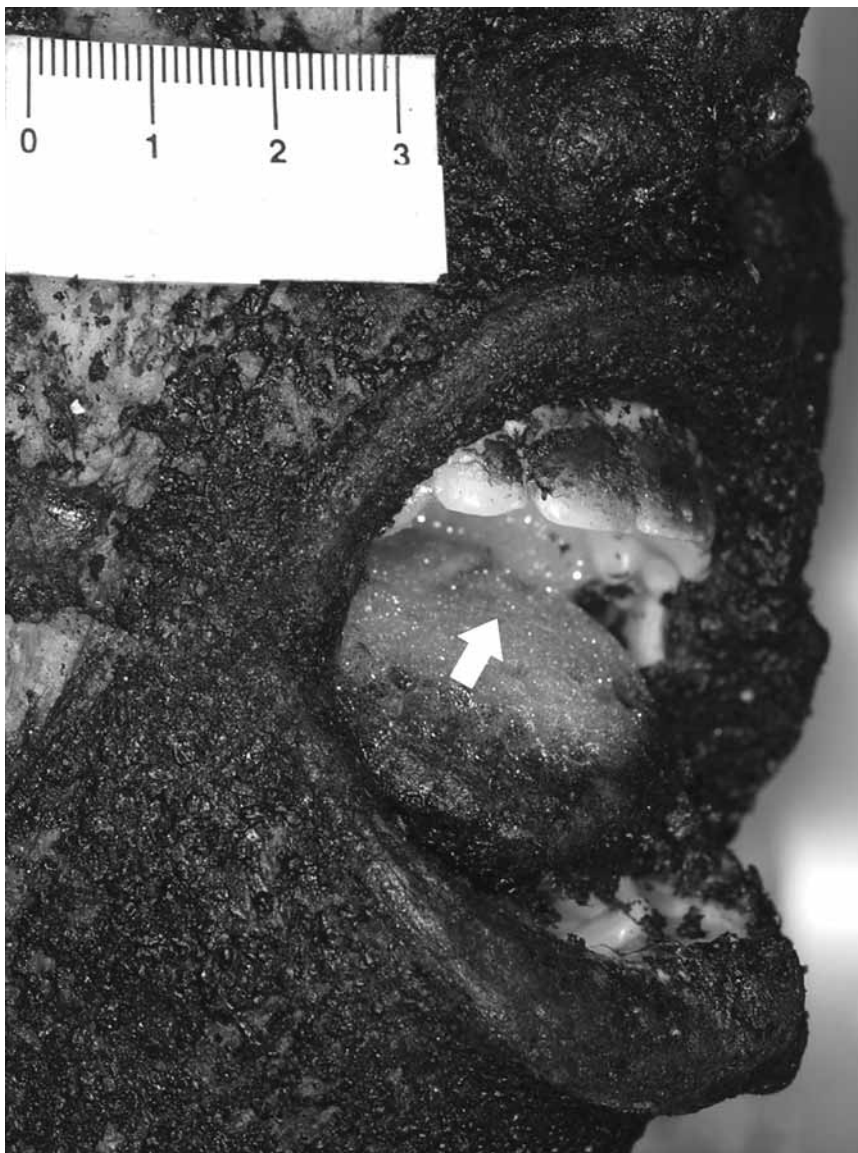


**Fig. 18.** Victim alive during fire. (A) Soot in larynx and trachea (smoke inhalation). (B) Microscopic section, mainstem bronchus. Soot on sloughed respiratory epithelium (H&E, original magnification  $\times 100$ ).

A COHb level of 50% or more is considered a cause of death, but an uncritical, rigid adherence to the requirement that fire victims have high COHb concentrations can be misleading (*see* Chapter 3, Subheading 3.9.4.; and refs. 37 and 66). The majority of fire victims who are dead at the scene show some combination of smoke inhalation, elevated COHb levels ( $>10\%$ ), and swallowing of soot. The latter tends to be less frequent (about one-third of cases in one study [42]). In another study, soot was found in the respiratory tract in about three-fourths of fire victims, in the upper GI tract in about half the cases, and COHb concentrations were above 10% in about two-thirds of deaths (52). Soot in the GI tract occurred in combination with soot aspiration (52). Many victims with elevated COHb also have aspirated soot; however, in some, these findings are not found in combination (42,52,67).

In one study, fire victims had a lethal level of COHb but no respiratory soot (65). Half these deaths were in smoldering fires and, in one, an accelerant had been used (65). Absence of smoke inhalation has been observed in some smoldering fires (42,68). Although soot can be absent and COHb levels low in some suicides by fire, the latter is elevated in most cases. Many are not “flash” fires which are associated with low COHb levels (69). Lower levels of COHb are seen in suicide victims found outdoors (17,18). Individuals found in vehicles tend to have higher COHb saturations (17,18). Soot is seen in cases having slightly elevated COHb (70). This pattern was observed in elderly, helpless individuals whose clothes caught fire (52).



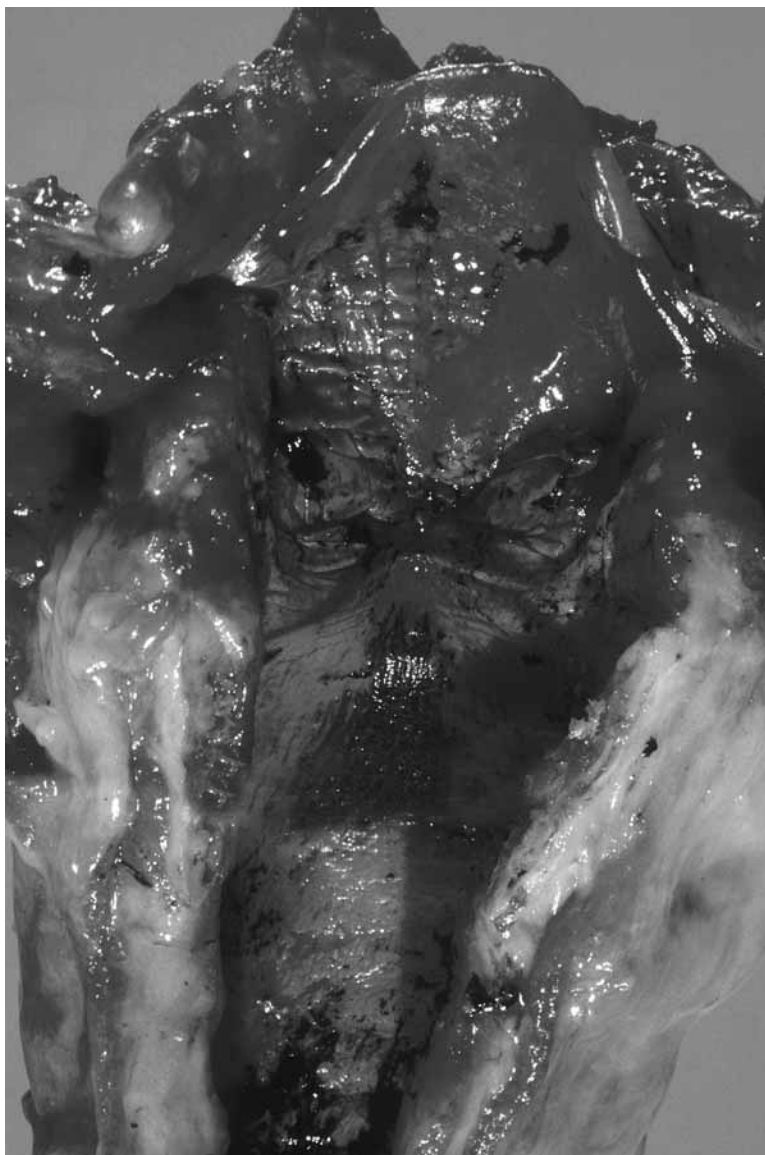


**Fig. 19.** Motor vehicle collision and fire. Froth in mouth (arrow)—a sign of pulmonary edema and an antemortem reaction in this charred body. Cause of death: craniocerebral trauma, carboxyhemoglobin less than 10%.

Charring of the anterior dentition does not imply that the victim's lips were voluntarily open at the time of the fire (71). The presence of copious mucus in the airway indicates vitality during the fire, even in the absence of an increased COHb (49). Pulmonary edema, arising from irritation by smoke, causes foam to be expressed from the nostrils and mouth, indicating that the individual was breathing at the time of the fire (Fig. 19; ref. 47). In some fire deaths, aspiration of fire extinguisher material or foreign material occurs (72).

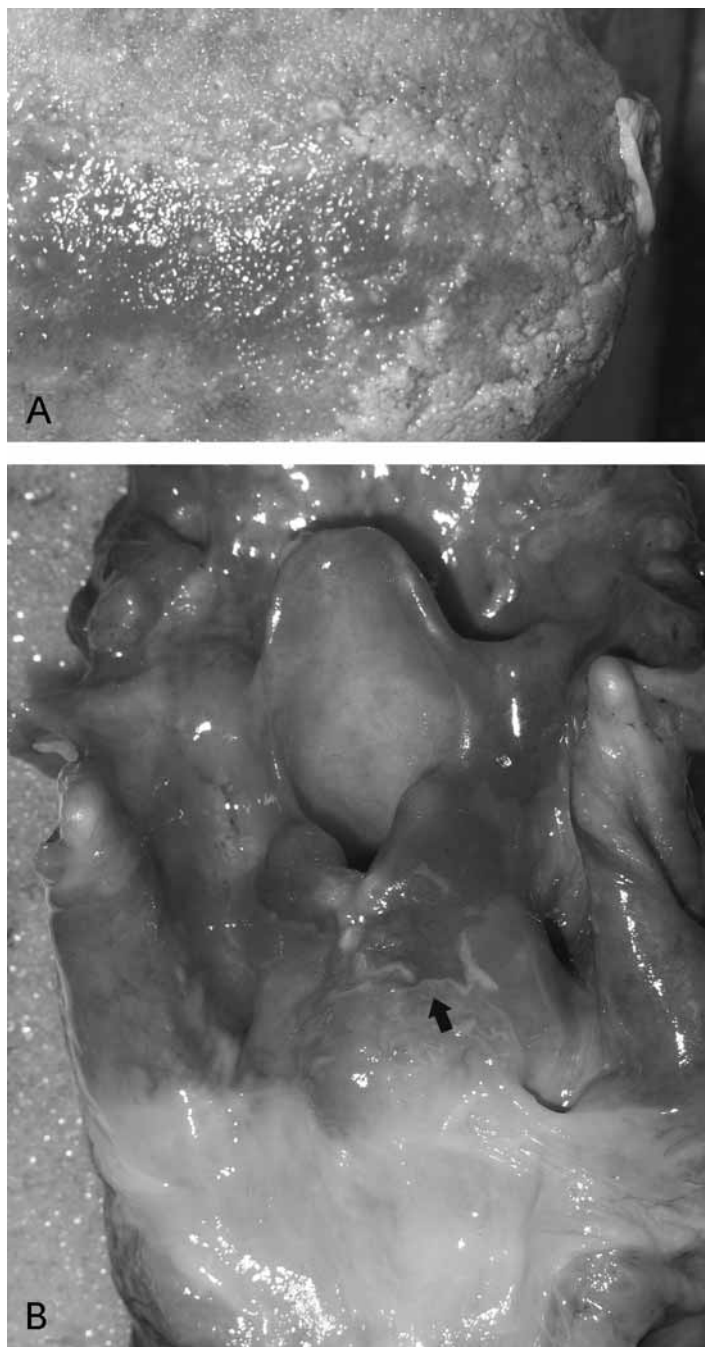
Other possible indicators of vitality during a fire include absence of burns and/or soot deposits in the corners of the eyes ("crow's feet") and incompletely singed eye-





**Fig. 20.** Inhalation injury. Red mucosa of epiglottis caused by congestion. Soot in airway. (See Companion CD for color version of this figure.)

lashes, suggestive of squinting or closing of the eyes owing to smoke irritation; detachment of the mucosa of the tracheobronchial tree, pharynx, epiglottis, or esophagus; and epiglottic swelling (*see* Subheading 4.5. and ref. 52). Air is a poor conductor of heat, and thermal injury is usually limited to the upper airways. Pulmonary damage arises from inhalation of smoke and fumes (49). In one review, heat damage to the upper airway or esophagus was present in about half of cases, some of which had soot deposition (Figs. 20 and 21; ref. 52). Conjunctival and neck muscle hemorrhages have been considered vital reactions in burn victims (73). Hemorrhage in the root of the tongue has been observed in fatal burns, particularly in victims with lower blood CoHb concentrations



**Fig. 21.** Inhalation injury. (A) Tongue erosions. (B) Unopened larynx–trachea. Erosion (arrow) of aryepiglottic folds owing to thermal injury. (Courtesy of Dr. C. Armstrong, London Health Sciences Centre, London, Ontario, Canada.)

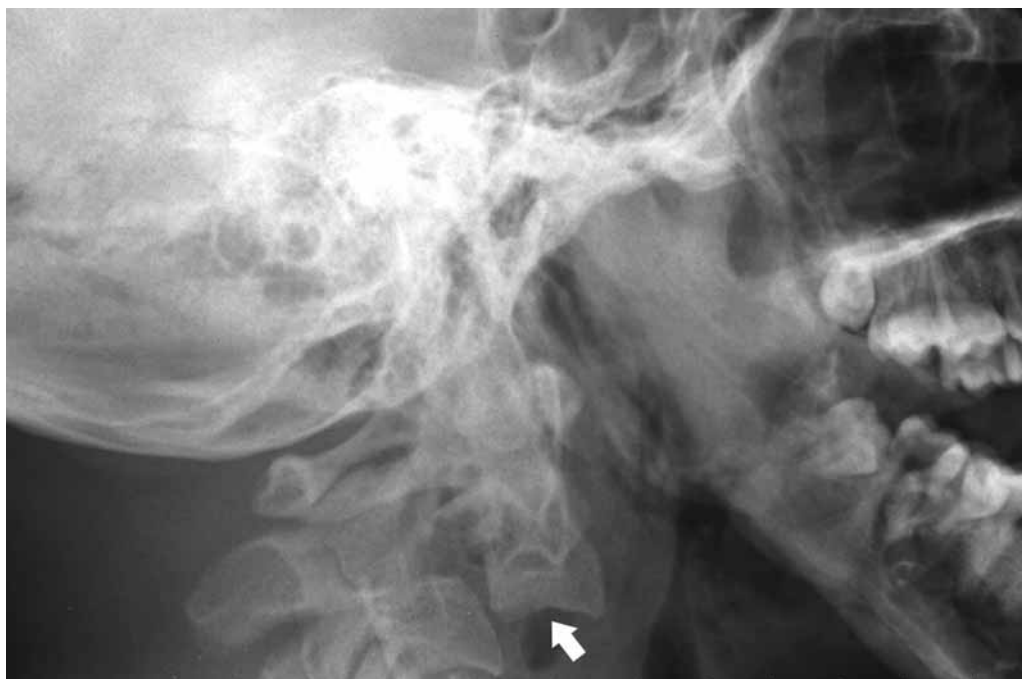(<30%), and the role of cranial congestion from thermal-induced neck or chest pressure has been raised (74). There is no relation between the degree of postmortem tongue protrusion and the amount of soot in the airway (74).



**Fig. 22.** Death prior to fire. No evidence of smoke inhalation and negligible carboxy-hemoglobin. Pinned during dismantling of boxcar. Collapsed boxcar wall lifted from body. Burning due to acetylene torch used by worker. Torn subclavian artery seen at autopsy.

#### ***4.2. Evidentiary Support***

Samples of heart and femoral blood are collected in tubes containing sodium fluoride preservative. Changes in COHb and CN levels have been observed in nonpreserved blood (75–77). Concentrations of COHb and CN have been noted to be elevated in the left ventricle compared with the right (56). A living victim, exposed to fire, inhales toxic gases that are absorbed in the lungs and circulate to the left side of the heart (56,78).



**Fig. 23.** Charred body recovered from car following collision and fire. Radiograph shows C2–C3 dislocation (arrow).

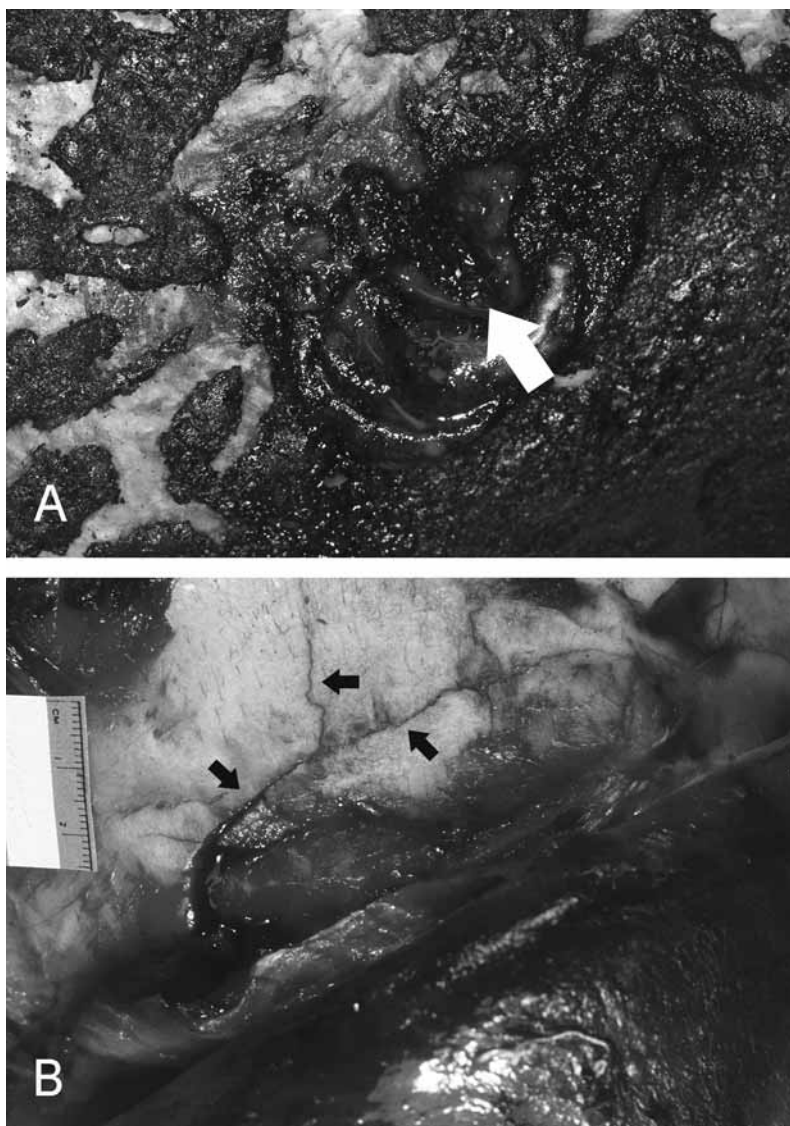
Another study, assessing this “first-pass phenomenon,” did not show differences between the left and right ventricle COHb concentrations in fire victims. This suggests that even though respiration can cease quickly, blood continues to circulate, leading to equalization of the left and right ventricular concentrations (79).

To assess whether accelerant has been used, suspect material is collected at the scene. Accelerants are suspected when there is an odor from the body. A filmy substance can be observed when the body is washed at the time of autopsy (80). Autopsy material (skin and/or soft tissue, burned clothing) is collected as soon as possible because volatiles evaporate (80,81). Accelerant can be ingested by suicide victims and detected in the blood (16,82). In cases of suspected accelerant use, soot may not be detectable in the airways, and COHb is not elevated. Analysis of accelerants in the blood of these cases assists in determining whether the individual was alive. In self-immolation, accelerants are commonly used (19,21,83). Suicide and homicide victims of fire in which accelerants have been used have shown elevated accelerant levels (e.g., gasoline, kerosene) in the left ventricle compared with the right (78,79,84). The proposed explanation for this difference is cessation of the systemic circulation by ventricular fibrillation (79). There are accelerant fire cases in which soot and/or elevated COHb (>10%) have been noted, and no accelerants were detected in the blood.

### 4.3. Other Trauma

Fatal injuries occur prior to a fire (Figs. 22 and 23). Radiographs are necessary prior to dissection, to rule out certain types of injuries (e.g., gunshot wound; see Fig. 3

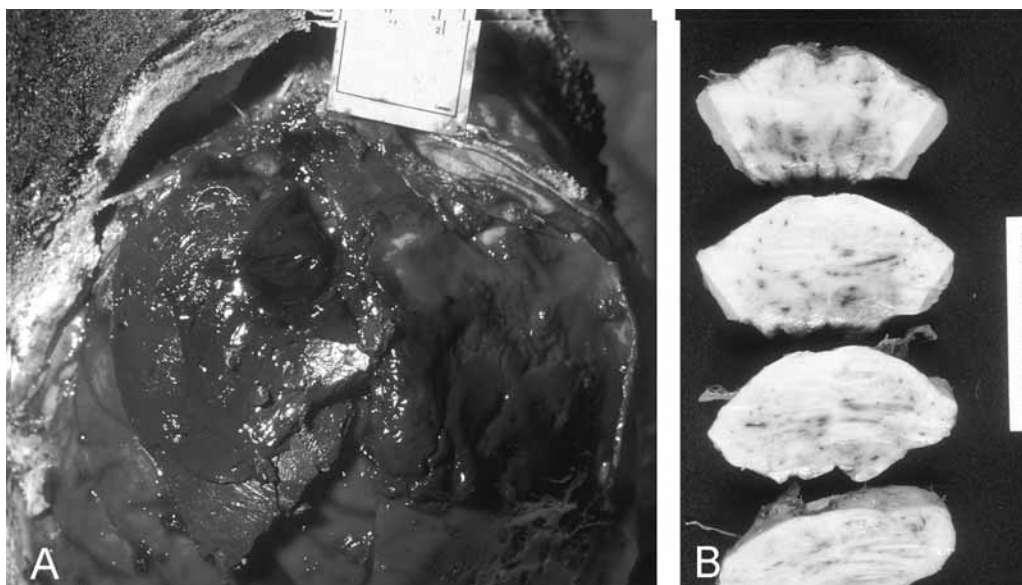




**Fig. 24.** Motor vehicle collisions associated with fires. **(A)** Clotted blood from the ear of a charred victim (arrow). A basal skull fracture was seen. Note skin splits near ear caused by charring. **(B)** Charred body. Scalp reflected to reveal linear skull fracture (arrows) showing no evidence of heat effects, i.e., charring.

and ref. 4). Charring obscures external injuries (Fig. 24; ref. 67). Distinguishing between antemortem and postmortem heat fractures may require assistance of an anthropologist (85). The base of the skull is relatively protected from the direct effect of heat. A fracture of the uncharred skull base indicates antemortem trauma, and this is supported by the presence of hemorrhage in adjacent soft tissues, and subdural and subarachnoid hemorrhage (Fig. 25; refs. 34 and 86). Accumulation of blood in the subdural space is an antemortem event (*see* Subheading 3.3. and refs. 4 and 47). Subdural hemorrhages are typically unilateral (49). Intracerebral injuries can be observed (Fig. 25).





**Fig. 25.** Motor vehicle collisions followed by fires and charring of victims. **(A)** Rollover. Subdural hemorrhage. **(B)** Multiple petechial hemorrhages in brainstem (pons) indicative of diffuse vascular injury.

COHb elevation and soot are absent in cases of fatal trauma (42). Trauma can be sustained during the fire (4). A study of motor vehicle-related fires showed three patterns: smoke inhalation and increased COHb; thermal airway injury; and trauma (67). In this series, levels of COHb greater than 30% strongly suggested inhalation of combustion products as the cause of death (67). A concentration of less than 20% suggested that other causes of death needed to be considered, i.e., trauma and thermal injury sustained during the collision (67). Soot and low COHb levels have been noted in injured occupants of cars that caught fire (52).

#### 4.4. Disease

An apparent fire victim can be dead from disease prior to or during the fire, and may not have an elevated COHb and soot in the airway (Fig. 26; refs. 4, 33, 42, and 52). Individuals compromised by anemia, heart and respiratory disease, or stroke can succumb at lower concentrations of COHb (4). No significant correlation of COHb concentration with age has been observed (56).

#### 4.5. Microscopic Evaluation

Microscopic demonstration of carbon deposits, observed coating the respiratory mucosa at autopsy, confirms smoke inhalation (Fig. 18; ref. 52). Microscopic examination of a burn can assess whether it occurred while the individual was alive. A few polymorphonuclear leukocytes are seen migrating out of blood vessels at about 4 h (52,87). Leukocytic infiltration at the periphery of the burn is evident by 6 h. In most deaths at the scene, burns are postmortem, as the toxic effects of CO and smoke evolve rapidly. Certain histological findings can be caused by autolysis, e.g., mucosal detachment in upper airway



**Fig. 26.** Dead prior to fire. Ischemic heart disease determined during autopsy. No evidence of smoke inhalation and negligible carboxyhemoglobin.

(see Subheading 4.1. and ref. 52). Elongation and palisading of epithelial nuclei in the respiratory tract is a postmortem heat effect (52). Hyperemia and edema of the airway mucosa are a vital but nonspecific reaction (52). The combination of pseudogoblet cells, increased mucus secretion, and vesicular detachment of respiratory epithelium has been considered indicative of antemortem heat effects, even in the absence of soot and increased COHb (52). Examination of lungs from deaths that occurred rapidly shows nonspecific findings (acute congestion, edema [52]). Although indicative of circulation following bony trauma, minor to moderate fat embolism has been seen in the lungs of some fire deaths in which blunt trauma has been excluded (see Chapter 8, Subheading 12.1. and refs. 42, 47, and 52).

## 5. ADMISSION TO HOSPITAL (BURN UNIT PATIENTS)

### 5.1. Epidemiology

Burn victims who present to a hospital and subsequently die have been injured under a variety of circumstances (1,61). Although increasing age, which is associated with declining memory and physical disability, is a risk factor, particularly in accidental fires, some types of fires are typical for certain groups of victims (61). For example, in one study, victims of motor vehicle-related and solvent-use fires were typically in their late teens or early 20s (61). Scalding is a common cause of outpatient visits and admissions to pediatric and adult burn units; however, the majority of severe burns and deaths occur because of fire (1,88–90). Mentally or physically incapacitated individuals (e.g., nursing home residents) who are unable to extricate themselves from hot bathtubs

or showers are typical adult scald victims (2,61,91). Ethanol intoxication can play a role (2). Lack of parental supervision of children while bathing or in the kitchen (e.g., a child reaching for boiling pot on a stove), can result in burns (89,91). The hot water source may be set too high. Reduction of scalding injuries can be achieved by lowering the temperature of the household water heater to below 54.4°C (130°F [92]).

Numerous studies have been done to determine risk factors contributing to the mortality of burn patients. A retrospective review of 1665 acute burn patients, admitted from 1990 to 1994 to Massachusetts General Hospital and the Shriners Burns Institute, determined three risk factors: age greater than 60 yr, more than 40% total body surface area burned, and inhalation injury (93). A mortality formula predicted 0.3, 3, 33, and about 90% mortality, depending, respectively, on whether none, one, two, or three of these risk factors were present. Other prognostic clinical parameters have been described (e.g., the extent of third-degree burns, and underlying chronic respiratory disease [1,94–98]). Pre-existing diseases (e.g., cardiac disease) and other conditions (e.g., alcohol abuse, smoking) may or may not have a bearing on prognosis (1). Patients, including the very young and old, with limited cardiopulmonary reserve are volume-sensitive, i.e., they can develop hypovolemia or hypervolemia during resuscitation (98). Pulmonary edema and congestion are nonspecific findings not necessarily related to volume resuscitation (*see* Subheading 5.2.; Table 1; and ref. 99). Despite the mathematical models developed, the determination of mortality risk factors is not completely definitive because of the complex nature of burn deaths (97). Furthermore, one model may not necessarily be reproducible in another institution (1,97). Prognostic indicators change as mortality decreases with improved treatment (94). Faced with a deceased burn patient who was hospitalized for an extended period of time, the pathologist has the challenge of determining the cause of death based on the information and findings related to a specific case, irrespective of the general prognostic indicators.

## 5.2. Burn Complications

Burn patients develop a host of complications; one or more can contribute to the cause of death (*see* Table 1 and refs. 98, 100, and 101).

Following the development of effective fluid resuscitation for severe burns, sepsis became a leading cause of mortality (1,94,100,101,103). The sources of sepsis are multiple (Table 1). Septicemia can be caused by burn wound infection, pneumonia, urinary tract infection following catheterization, infected intravenous lines, and infection of skin donor sites (101,111).

Infection and burn injury can trigger an unchecked systemic inflammatory response that persists despite the eradication of any infections during the clinical course, leading to multiple organ failure, another common cause of death (*see* Chapter 1, Subheading 4.3. and refs. 1, 88, 103, and 131). Hypovolemic shock can contribute to multiorgan failure (88,103). Patients with multiorgan failure tend to have larger burns and are older, but other studies have not shown this relationship (1,103).

Respiratory failure (inhalation injury, pneumonia, adult respiratory distress syndrome [ARDS]) is also a significant cause of death (1,88,98,100,102,103,110,113,116,131,132).

## 5.3. Injury From Smoke Inhalation

Smoke interferes with normal airway clearance by respiratory epithelium, causes bronchospasm, and affects surfactant-producing pneumocytes (104,108,112). Inhalation

**Table 1**  
**Systemic Complications Post-Burn Significant in the Determination**  
**of the Cause of Death**

---

**Within 3 d**

- Neurological complications from carbon monoxide (CO) poisoning; hypoxic-ischemic encephalopathy (100).
- Inhalation injury (smoke, toxic agents, hot gas, e.g., steam) (94,98,100,102,103).
  - Acute laryngeal edema.
  - Mucosal “burn.”
  - Eventual necrotizing or “pseudomembranous” laryngotracheobronchitis, pneumonia, and respiratory failure (104).
- Shock (extensive burns; refs. 94, 98, 100, 101, and 103).
- Edema—constriction of extremities, torso (“abdominal compartment syndrome”) and neck with potential respiratory compromise requiring escharotomy and fasciotomy<sup>a</sup> (see Chapter 8, Subheading 8.4.; Fig. 27; and refs. 98 and 105–109).
- Myoglobinuria and kidney failure (electrical or crush injury). (See Chapter 8, Heading 13.)
- Paralytic ileus (98).

**Within 7 d**

- Subendocardial hemorrhage, left ventricle (agonal event).<sup>b</sup>
- Pneumonia.
  - Secondary to inhalation injury (airborne; refs. 98–100, 108, 110, and 111).<sup>b</sup>
  - Aspiration ± pneumonia (88).<sup>b</sup>
- Pulmonary hemorrhage, edema, or atelectasis (can be immediate; refs. 98, 99, 101, 102, 108, 112, and 113).<sup>b,c</sup>
- Kidney failure (hypovolemia)—acute tubular necrosis;<sup>b</sup> renal cortical necrosis(100,101).<sup>b,d</sup>
- Burn wound infections (e.g., *Pseudomonas aeruginosa* and other Gram-negative bacteria; *Staphylococcus aureus*; refs. 89, 100, 101, and 111).<sup>b,e</sup>

**After 7 d**

- Acute myocardial infarct (98,103,114,115).<sup>f</sup>
- Infective endocarditis and suppurative thrombophlebitis (vascular line insertion).
- Pneumonia (see Complications within 3 and 7 d).
  - Hematogenous (Gram-negative septicemia, e.g., *P. aeruginosa* owing to burn wound infection, vascular line insertion in a site complicated by suppurative thrombophlebitis, peritonitis owing to occult visceral perforation, urinary tract infection, abscess in a visceral or peripheral vascular injection site [98–100,116]).<sup>g</sup>
- Diffuse alveolar damage (adult respiratory distress syndrome; see Chapter 1, Subheading 4.3.; refs. 99, 116, and 117).
- Thromboembolism.<sup>d,h</sup>
- Gastric and duodenal erosions/ulcers (Curling’s ulcers)<sup>d</sup>; preceding hemorrhagic gastritis (98,100,118).<sup>d</sup>
- Gastric dilatation, complication of sepsis (101).
- Ileus, complication of sepsis (88,98,101).
- Duodenal obstruction owing to superior mesenteric artery syndrome (98,119).<sup>d,i</sup>
- Colon dilatation (pseudo-obstruction) complicated by cecal perforation (120).<sup>d</sup>
- Ischemic (pseudomembranous) enterocolitis (100,101,121).<sup>d</sup>
- Liver failure.<sup>j</sup>
- Acute cholecystitis (calculous, acalculous; refs. 98, 122, and 123).<sup>k</sup>



- Acute hemorrhagic pancreatitis (98).<sup>d</sup>
- Renal failure (see Complications within 3 and 7 d).<sup>d,l</sup>
- Acute pyelonephritis (101)—ascending,<sup>d</sup> hematogenous<sup>d</sup>
- Renal artery thrombosis (cortical infarct [115]).<sup>d</sup>
- Necrotizing prostatitis<sup>d</sup>
- Disseminated intravascular coagulation (DIC) complicating burns, other trauma, sepsis (see Chapter 1, Subheading 4.3. and refs. 98 and 100).<sup>m</sup>
- Acute splenitis, sign of sepsis (100).
- Thymic stress involution in children (100).
- Adrenal hemorrhage (Waterhouse–Friderichsen syndrome [98,100,101,124]).<sup>d,n</sup>
- Pituitary infarct owing to hypovolemia<sup>d</sup>
- Burn wound infection (see Complications within 7 d, less commonly fungi, e.g., *Candida* [111]).
- Visceral abscesses (sign of septicemia).
- Viral infection (cytomegalovirus, herpes simplex, adenovirus [125,126]).<sup>d</sup>

<sup>a</sup>The degree of retraction of skin edges (up to 4–9 cm or 1.5” to 3.5”) of a fasciotomy or escharotomy suggests edema.

<sup>b</sup>Complication also occurs more than 1 wk after burn.

<sup>c</sup>Multiple etiologies of hemorrhage—pulmonary hypertension (e.g., head trauma, congestive heart failure), gastric acid aspiration, fat embolism, DIC, inhalation injury, infarct owing to thromboembolism, septic (e.g., *Pseudomonas*) vascular necrosis. Edema can arise from volume overload and is a sign of cardiac failure.

<sup>d</sup>Uncommon cause of death.

<sup>e</sup>A burn wound can be infected by the hands of hospital personnel, by fomites (e.g., contaminated mattresses), and by fecal contamination from the burn victim. Signs of an invasive burn wound infection include: dark brown to black discoloration of burn, hemorrhagic discoloration of subcutaneous fat underlying the burn, and foci of hemorrhage in soft tissue away from the burned area (98,101). Microscopic assessment may reveal a dense population of microorganisms in the burn (98). Microorganisms are seen invading viable tissue. Vasculitis, necrosis, and hemorrhage can be seen in unburned tissue (98).

<sup>f</sup>Coronary atherosclerosis may be absent. Hypercoagulability (e.g., DIC) complicated by coronary artery thrombosis may be a factor. Thrombi can occur in other vessels (101,115).

<sup>g</sup>Pneumonia of hematogenous origin is characterized by hemorrhagic, subpleural lesions resembling pulmonary infarcts (101,116). Parenchymal necrosis is evident when lung microscopic sections are examined (116). If *Pseudomonas aeruginosa* is involved, numerous Gram-negative bacteria are seen in peribronchial and perivascular spaces (116). Septic thrombi may be observed (116). Early lesions are free of exudate.

<sup>h</sup>One study showed an association between pulmonary thromboembolism and the presence of central venous catheters (127). Although no thrombus was identified in the innominate vein of these cases, the possibility of subclavian thrombosis could not be excluded. The risk of thromboembolus is not related to the size of the burn (101).

<sup>i</sup>Superior mesenteric artery syndrome is characterized by partial or complete duodenal obstruction in patients with more than 30% total body surface area burns (119). The distal duodenum is trapped between anterior (superior mesenteric artery) and posterior structures (spine, aorta). The syndrome is associated with prolonged bed rest and acute weight loss resulting in loss of mesenteric and retroperitoneal fat and a weakening of abdominal muscles. Hyperalimentation has reduced weight loss in burn patients.

<sup>j</sup>Centrilobular hemorrhagic necrosis, intrahepatic cholestasis, and nonspecific hepatitis are signs of sepsis, shock, multiple transfusions, congestive heart failure, and hepatorenal syndrome; cholestatic hepatitis can be the result of medications (98,100,128,129).

<sup>k</sup>Acalculous cholecystitis arises as a result of sepsis, dehydration, multiple surgical procedures, biliary and gastrointestinal stasis, and pancreatitis (98,123).

<sup>l</sup>Septicemia and congestive heart failure are causes. Renal failure is associated with high-voltage electrical injury, crush injury, or delayed resuscitation (98).



of smoke and other combustion products can affect the upper airway only or the entire respiratory tract, including the lung parenchyma (98,99,101,102,104,113).

With the exception of aspiration of boiling water and inhalation of steam and other hot gases (e.g., an explosion involving volatile gases), heated air does not usually cause tracheal injury (99,101,102,113,133). The heat-decreasing capacity of the upper airway allows cooling of inhaled hot gases before they reach the alveoli (*see* ref. 102 and Moritz, cited in refs. 104,133). The presence of facial burns and soot in the airway, a fire in an enclosed space, and unconsciousness during smoke exposure raise the possibility of inhalation injury (102,104,110,116,132,133). Cutaneous burns can be absent (102,104). Clinically, there can be an asymptomatic period of a few days following exposure (98,104,110,113).

The upper airway becomes edematous and inflamed, and respiratory failure follows within 24 h, leading to the requirement for intubation (98,101,102,108,133). Soot usually disappears by the second day of hospitalization (110,113). Inhalation changes involving the trachea can progress to ulceration and eventual widespread severe and extensive mucosal sloughing requiring ventilatory support and possible tracheostomy (98,100,102,113,116). Tracheobronchitis predisposes to pneumonia (98,109,110,113). Intubation and tracheostomy can be complicated by upper airway ulcers and inflammation (99,100,116,134). Glottic and subglottic stenosis is a late complication (134). Severely burned patients are more susceptible to lower respiratory tract infections (116). ARDS is a complication of inhalation injury (*see* Chapter 1, Subheading 4.3. and ref. 104).

## 6. PATHOLOGIST'S ASSESSMENT OF A HOSPITALIZED BURN VICTIM

An autopsy not only helps determine a cause of death, but also uncovers findings unsuspected clinically. In one study at the University of Washington Burn Center from 1989 to 1994, 18% of 88 patients who were subject to an autopsy had clinical diagnostic errors. Premortem detection of the errors in four of these cases might have changed the clinical outcome (135).

The following items should be covered by the pathologist:

1. Review clinical history. Obtain information from other sources (e.g., police, fire investigator), depending on the circumstances of the death.
2. During external examination, record evidence of medical procedures. This includes fasciotomies/escharotomies (Fig. 27).
3. Document extent and appearance of burns (Fig. 28). Is there a pattern that suggests how the burn was caused? For example, scalding victims in hot tub water tend to have burns in the lower part of their bodies (91). Some of these cases show parts of the body spared injury, because of compression against the sides or bottom of a bathtub (136). Photographic documentation is necessary.
4. Rule out other trauma (137).

Table 1 footnote (*Continued*)

<sup>m</sup>Manifest as bleeding from sites of vascular puncture and from mucous membranes, extensive cutaneous ecchymoses, visceral hemorrhage including adrenal glands (130).

<sup>n</sup>Associated with DIC, septicemia, anticoagulant therapy, direct trauma. Also observed in the earlier post-burn period. Rarely, extensive retroperitoneal hemorrhage (124).

(Adapted from ref. 3.)



**Fig. 27.** Burn victim. Escharotomies.

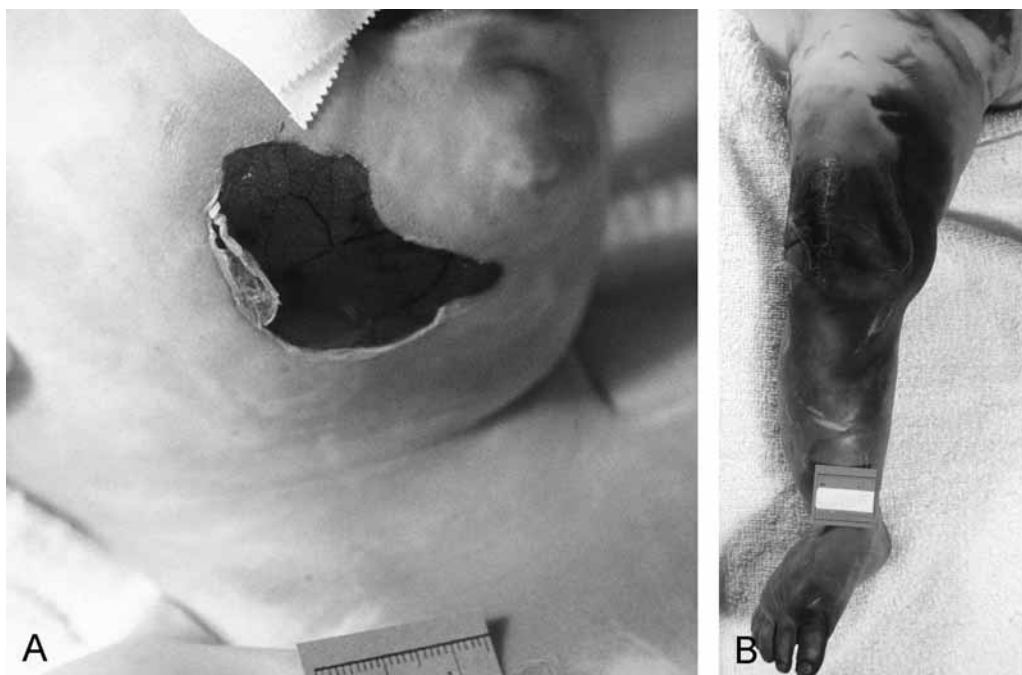
5. A complete autopsy, including microscopic examination of major organs, is required to address the multifactorial reasons for death ([Table 1](#)). Microscopy can include examination of the burns ([Fig. 29](#)).
6. Obtain appropriate samples (e.g., blood, lung, abscess tissue) for culture, if necessary, realizing that burn patients hospitalized for extended periods of time likely have had numerous microbiological studies and received various antibiotics.

## 7. ELECTROCUTION

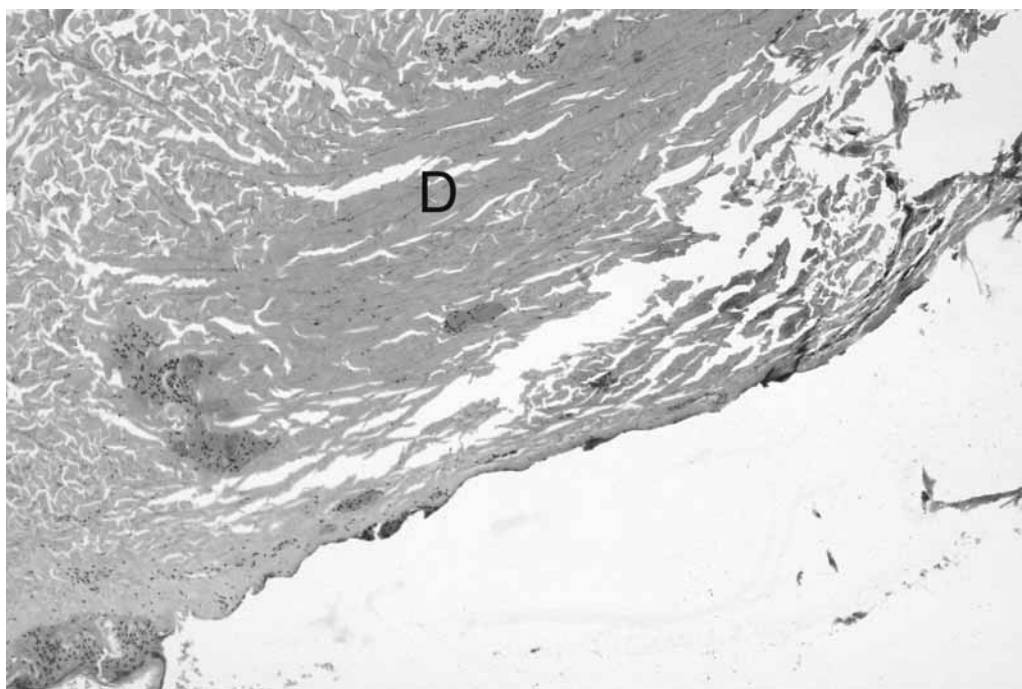
### 7.1. Physics and Pathophysiology of Electrical Injury

The amount of electron flow (current) is proportional to an electron concentration gradient (voltage) and inversely related to the resistance of the connecting medium along the path of flow ([138–140](#)). This is expressed as Ohm's law:  $I = V/R$ , where “ $I$ ” is current (amperes [A]), “ $V$ ” is voltage (volts [V]), and “ $R$ ” is resistance (ohms [ $\Omega$ ]; see refs. [138](#), [139](#), and [141–145](#)).

Electricity exerts two major effects on the body: cellular depolarization of nerves and muscle and heat production, the latter reflecting a longer duration of exposure ([38,140,142,144,146–149](#)). The long axes of most skeletal muscle cells and axons are oriented parallel to the direction of current flow, and transmembrane potentials are affected ([147](#)). Electrical injury of nerve cells and muscle alters membrane permeability by disruption of the lipid bilayer structure of plasma membranes, leading to formation of structural defects or “pores” (electroporation), and by denaturation of membrane proteins ([142,145–147](#)). Temperatures higher than 60°C (140°F)



**Fig. 28.** Burns caused by radiant heat. (A) Blister, broken (second degree). (B) Leathery consistency of lower extremity (third degree).



**Fig. 29.** Partial thickness burn. Epidermis sloughed; dermal alteration (D) (H&E, original magnification  $\times 25$ ).

produce tissue destruction (150). Thermal injury denatures all tissues by coagulation necrosis (38,151).

Various factors determine the relative contribution of these mechanisms and the consequent pattern of electrical injury. They include the type of circuit, duration of contact, resistance of tissues, voltage and amperage of current, pathway of current, and surface area of contact points (i.e., current density inversely related to the area of contact; see refs. 38, 138, 141, 143, and 151–154 and Subheadings 7.3. and 7.4.).

### 7.1.1. Type of Circuit

Alternating current (AC), i.e., an electric field of alternating polarity, has a frequency of 60 Hz in the United States and Canada (50 Hz in Europe [138–140, 142,147,152,155,156]). AC is found in households (low voltage; 15 A in the United States and Canada) and utility lines (high voltage), which are the two most common sites of electrocution deaths (139,145,147,156). AC is the most efficient way to depolarize cells (140). The physiological muscle contraction–relaxation time is 20 to 40 ms (147). Muscle fibers, when continuously stimulated between 40 and 110 times per second (40–110 Hz), go into sustained contraction (tetany [152,157]). Sixty-Hz AC current changes direction 120 times per second (i.e., every 8 ms; [147]). Because tetany occurs at low amperage, AC is more dangerous than direct current (DC; refs. 139, 141, 142, 144, 145, 149, 152, and 158–160). If an AC electrical source is gripped by hand, the stronger flexor muscles of the hand and forearm go into tetanic contraction, which prolongs the grip and increases the duration of exposure to the current and the injury risk (139,141, 142,147,152,157,158). Rigor mortis can occur immediately after death in high-voltage electrocution and be localized to one extremity (Chapter 2, Fig. 8; refs. 140, 147, and 161–163).

In contrast, the electrons flow in one direction in a DC circuit (138,139). DC Tends to cause a single muscle contraction, throwing the victim and resulting in a shorter duration of exposure to the electrical source but increasing the chance of blunt trauma (139,141,142,145,147,152,157). DC occurs in lightning strikes and from contact with certain equipment (e.g., defibrillators [139,140,145,152,164–166]).

### 7.1.2. Resistance

Resistance (R), the inverse of conductivity, is the tendency of tissues to resist the flow of current and is dependent on the moisture content, temperature, and other physical properties of the tissue (142,152). The higher the resistance, the greater the transformation of electrical energy to thermal energy at a given current (38,142,144,145, 151,152,167,168). This is expressed as Joule's law:  $P = I^2 \times R \times T$  ( $I$  = current;  $R$  = resistance;  $T$  = duration of contact).

The human body has a minimal resistance of 500  $\Omega$  (139,159,163). Good tissue conductors include nerves, blood, mucous membranes, and muscle (139–141,152,158). Mucous membranes (mouth, rectum, vagina) have low resistance (range of 100  $\Omega$  [139,141,169,170]). Tendons and fat offer more resistance, and bone is the most resistant (139,141,142,144,152,158,168). Skin has intermediate resistance and is the primary resistor to current flow, resulting in much electrical energy being dissipated at the skin surface contact (138,139,141,142,152,155). Moisture reduces skin resistance (sweating, 2500  $\Omega/\text{cm}^2$ ; immersion in a bathtub, 1200–1500  $\Omega/\text{cm}^2$  [139,141,142,152,171]). Moist



skin does not burn, and increased current will flow into the body (152). In contrast, the heavily callused skin of the palms can have a resistance up to  $2 \times 10^6 \Omega/\text{cm}^2$  (141,147,152,158). As the skin is burned, resistance drops, allowing increased current flow into the body (139,142,145,152).

The amount of heat produced is dependent on current density, which is inversely proportional to the cross-sectional diameter of the body structure, i.e., fingers and toes have more severe burns than an arm or leg (38,141,145,146,148,168). As current flow increases in the body, the current tends to overcome the resistance of less conductive tissues (152). As a result, the entire body becomes a volume conductor, with the exception of bone, and current flows through all tissues, resulting in variable electrical and thermal damage (38,139,147,152,155,168). Skeletal muscle, because it occupies the greatest volume of soft tissue in the extremities, carries the bulk of the current (147). Muscle not only is subjected to the direct thermal effects of current, but also continues to be heated by adjacent bone, which has a higher thermal capacity (38,139,147,148,172).

### 7.1.3. Current

Current is the amount of electrical energy that flows through an object. The amount of current passing through the body is indeterminate because the resistance can only be estimated, particularly at the skin surface (141,147,149). Current passing through the body is responsible for the damage seen (141,149,152,159,171). A sublethal current can startle an individual, causing a fall (159).

### 7.1.4. Pathway

Low-voltage AC kills by either asphyxia (respiratory muscle paralysis) or cardio-respiratory arrest (Table 2).

Current passing through the heart (e.g., hand-to-hand) causes direct myocardial damage and arrhythmia (139,142,144,152,158–160). Ventricular fibrillation is the most common arrhythmia (144,150,159,173). An electrocution victim in ventricular fibrillation can be conscious for about 10 s, and purposeful activity (e.g., turning electrical equipment off) before collapse is possible (140,159–161).

Even though much of the DC passes along the surface of the body in a lightning strike, enough enters the body to cause cardiac arrest, apnea, vascular spasm, and autonomic dysfunction (141,167,174). Lightning and high-voltage electrocution cause ventricular asystole more frequently than fibrillation because of the higher current flow (139,140,143,145,163,165,167). The automaticity of the heart causes normal rhythm to be restored; however, the hypoxia from the respiratory arrest that occurs during asystole can lead to ventricular fibrillation and hypoxic–ischemic encephalopathy (139,141–143,145,152,153,163,166,174,175). About two-thirds of lightning victims survive (142,147,153,164,174,176,177).

Less commonly, respiratory arrest, paralysis, seizures, and direct brain (brainstem) injury result from current passing through the brain (e.g., head to limb [38,141–143,145,152,158–160,164,173,174,178]). Currents in the range of 100 mA, passing from the head to limb, can lead to respiratory arrest (159). A considerable amount of heat is generated by a high-voltage current, leading to irreversible brain death (163). Shocks above 5 A at 60 Hz for 1 s can lead to cessation of breathing even when the respiratory



**Table 2**  
**Effects of AC (60 Hz) Current**

Effects	Amperage (milliampere [mA], ampere [A])
Tingling/pain	1–2 mA
Let-go current (average)	
• Man	7–9 mA
• Woman	6–8 mA
• Child	3–5 mA
Maximum current a person can grasp and let go (50% of men)	16 mA
Tetany (freezing to circuit)	16–20 mA
Respiratory arrest from thoracic muscle tetany	20–50 mA
Ventricular fibrillation	50–100 mA
Ventricular standstill	>2000 mA (>2 A)
Common household circuit breaker	15 A
Maximum intensity of household current (US)	240 A
High voltage	<1000 A
Lightning	>200,000 A

Adapted from refs. [38](#), [140](#), [142](#), [150](#), [157](#), [159](#), and [160](#).

center is not in the path of the current (e.g., hand to foot [[159](#)]). Another mechanism of death is asphyxiation from tetanic contraction of respiratory muscles by current passing from arm to arm or arm to leg(s) ([38](#),[173](#)).

### 7.1.5. Voltage

Voltage (V) is the only known parameter in many cases of electrical injury ([142](#),[143](#),[145](#),[149](#)). Electrical injuries are arbitrarily divided into low- ( $\leq 1000$  V) and high-voltage ([38](#),[141](#),[142](#),[145](#),[147](#),[152](#),[158](#),[163](#)). The greater the voltage, the more extensive the injury, but a 110-V household current still has sufficient current to cause ventricular fibrillation ([144](#),[158](#)). Thermal effects are an important mechanism of injury or death in high-voltage electrocution ([140](#)). Household voltage depends on the locale: 120 V (United States and Canada), 220 V (Europe), or 240 V (Australia, United Kingdom [[139](#),[140](#),[144](#),[147](#),[179](#)]). Workplace tools and machines may be connected to 220- to 440-V power sources ([147](#)). Electrical lines involve thousands of volts. Lightning is associated with a voltage difference of millions of volts between the clouds and ground ([143](#),[164](#),[167](#),[176](#),[180](#)).

## 7.2. Epidemiology and Circumstances

Of 217 accidental electrocutions studied during a 22-yr period in Dade County, Florida, 93 were from high-voltage ( $>1000$  V) and 108 were from low-voltage current ([163](#)). Sixteen deaths were caused by lightning. Another study showed that 39% of electrocution deaths were from low-voltage current (most frequently household voltage [[171](#)]). An Australian study of 104 electrocution deaths showed 88% from low-voltage and 12% owing to high-voltage current ([181](#)). There are about 1000 deaths from electrical injury per year in the United States ([142](#),[147](#), [152](#), [157](#), [159](#),[161](#)). Electrical burns account for 3 to 6.5% of all admissions to American burn

units (142,147,148,152). About half of electrical injury deaths occur at work and the remainder at home (181).

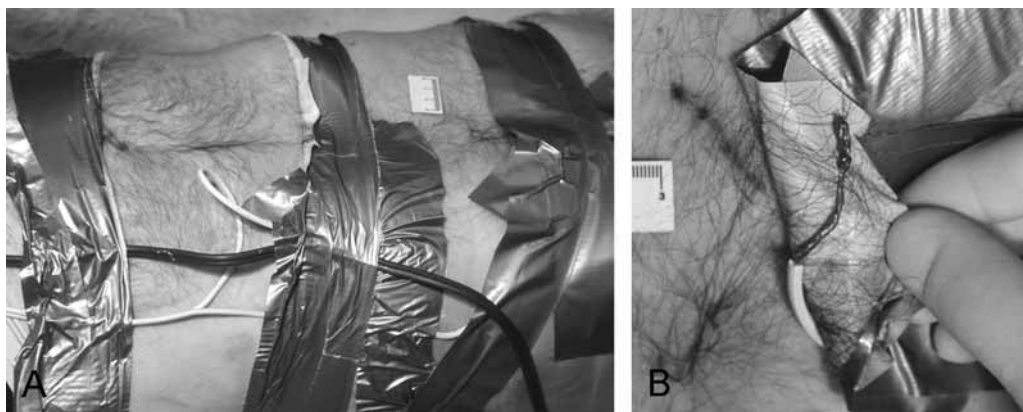
Low-voltage injuries occur under various circumstances (e.g., use of a faulty tool or appliance, repair of electrical equipment, contact with faulty wiring or an energized object [142,163,182,183]). About two-thirds of the fatalities are to individuals between the ages of 15 and 40 yr, and there is a male predominance (174). Failure to ground tools or appliances (i.e., a conducting connection between an electrical circuit or piece of equipment and the earth or its substitute) and using devices near water are risk factors (142,181). The victim may be unqualified to do electrical work (183). High-voltage injuries typically occur in the workplace, predominantly involving men (142,147,158,161). Electrocuted workers tend to be younger than victims in other types of occupational fatalities (148,182,184). The highest number of workplace electrocution deaths happen in the summer owing to increased outdoor activity; decreased use of heavy insulating clothing, including gloves and boots; and decreased skin resistance from sweating (181,184). Various scenarios in the workplace lead to direct contact with a high-voltage electrical source (e.g., a vehicle such as a crane contacting high-tension lines; the raising of metal poles, antennae, or ladders that touch power lines; *see refs. 142, 151, 158, 161, 163, 185, and 186*). The construction and mining industries have the highest death rates (182,187).

Bathtub electrocutions are associated with electrical appliances, typically hair dryers submerged in water. The installation of a ground fault interrupter has reduced this risk (161,188,189). A ground fault interrupter is designed to sense a 5-mA difference between the ground and current wires.

More than 20% of all electrical injuries occur in children (142). Young children are predisposed to low-voltage injury because of their tendency to chew on objects (e.g., electric cords) while crawling and exploring (139,141,142,145,147,152,189,190). Considerable bleeding from an injured labial artery can occur when eschar is removed some days later (139,157,189). Wires may be inadequately protected (183). Young children are also electrocuted by direct (i.e., mouth or finger) or indirect (e.g., fork) contact with electrical outlets (190).

Low-voltage electrocution must be suspected when there is a sudden death while using an electrical appliance, and analysis of the electrical equipment and wiring is required (140,161,163,184). The appliance does not need to be in the on position, as the wiring may have been faulty or the victim may have had time to turn off the appliance (161). The victim may be witnessed collapsing after crying out in pain (140,161,163,181,184). Electrocution does occur during autoerotic activities and consensual sexual activity (*see Chapter 3, Subheading 2.7.2. and refs. 169, 170, 191, and 192*).

Outside the workplace, high-voltage electrocution can occur by direct contact with an intact or downed power line (163). Older children and adolescents can sustain electrical injury through misadventures with high-voltage lines (142,145,151,152,189,190,193). Contact through a conductive device, at home or during recreational activity (antenna, kite), also occurs (163,182,183,194). Electrical burns have resulted while receiving a phone call, because of arcing between a telephone line and high-tension wire that were separated 15 cm (6 in.) (155,195). Continued victim contact with a high- or low-voltage source can electrocute rescuers (139,151,196). Switching and disconnecting energized lines can lead to noncontact “flash” burns (158).



**Fig. 30.** Suicide by electrocution. (A) Elaborate wiring on torso secured by duct tape. (B) Exposed copper wire. Cutaneous burn discolored green. (See Companion CD for color version of this figure.)

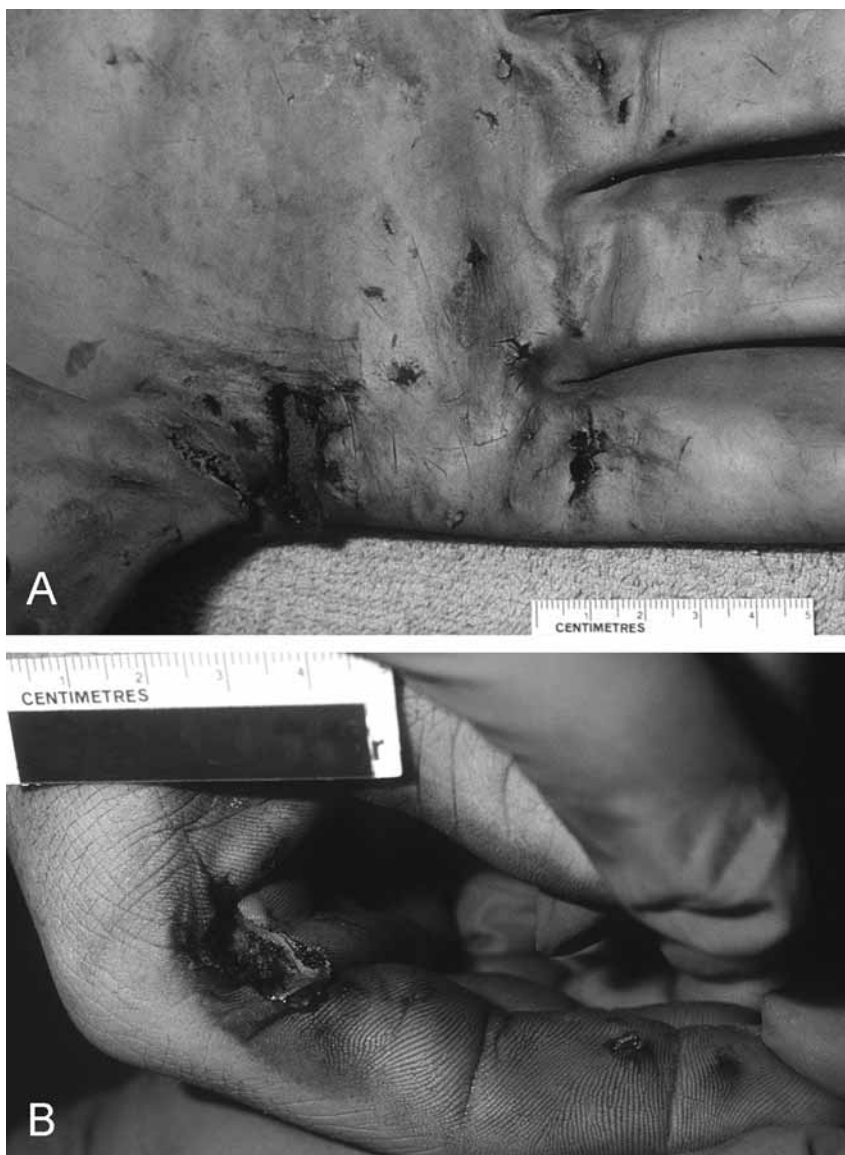All manners of death are possible in electrocution. A study of 220 electrocutions revealed 217 accidents, two suicides, and one homicide (163). Electrocution is an uncommon method of suicide (Fig. 30; refs. 161, 163, 181, 188, and 197–199). A timer can be used (200,201). Wires are connected from an electrical source to the skin surface (161,200). Suicidal electrocution can be staged to mask a homicide by other means (202). Homicide by electrocution is rare (161,163,197,203,204).

Lightning causes 30 to 100 deaths per year in the United States (139,152,159, 174,177). As moist warm air rises within a cold air system, cumulonimbus clouds form (164,174,176,180). Static electricity is created during this movement of particles (144,167,180). A large negative charge results in the bottom of the clouds, and the ground becomes positively charged (144,164,174,176,180). When a potential difference of 30,000 V or more exists, a leader stroke going to the ground meets an upward streamer (pilot stroke) from an object on the ground (e.g., a standing person) within microseconds (164,174,176,205). The most common setting for a lightning strike is in a thunderstorm, but snowstorms, sandstorms, and erupting volcanoes are also associated with lightning (144). Lightning strikes do occur in fair weather conditions, and the thunderstorm can be distant (167,177,206). The majority of lightning strikes are in the summer months (174). Multiple victims are possible (141–143).

Males are at greater risk for being struck by lightning because more men are involved in outdoor work and activities (177,205). Generally, deaths do not occur in well-protected buildings; however, plumbing fixtures, telephones, and other appliances attached to the outside of the house by metal conductors can indirectly injure occupants by means of side flashes (174). Individuals are at risk in open areas and partly sheltered areas (e.g., tents [174,205]). In a study from Singapore, two-thirds of deaths occurred in partly sheltered areas (205). Lightning does not always hit the highest object (174). Lightning victims do not remain electrified (139,174).

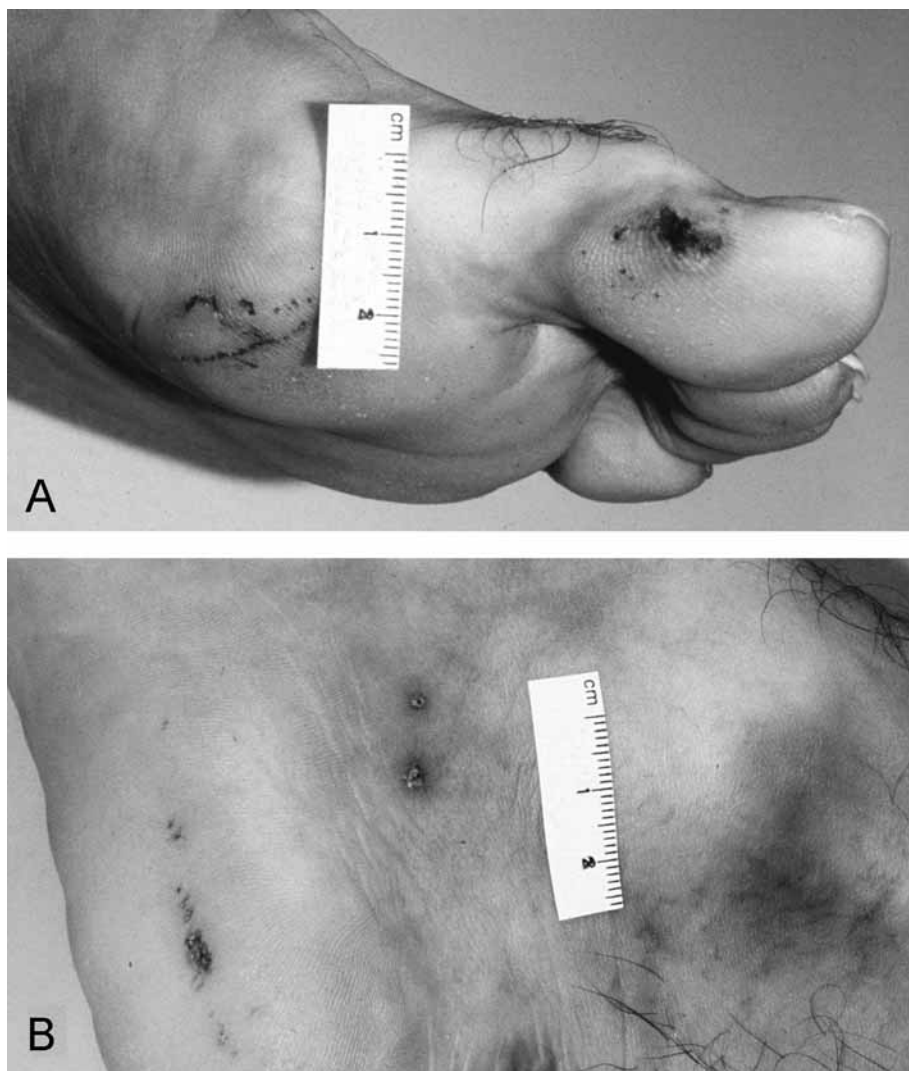
### 7.3. Electrical Burns and Other External Trauma

Direct contact is the most common mechanism of injury (158). The greater the skin resistance, the more likely that burns will result (141). A smaller surface area of



**Fig. 31.** Electrocution burns (contact or entry site). **(A)** Worker's glove. **(B)** Burn on hands. (Courtesy of Dr. D. King, Regional Forensic Pathology Unit, Hamilton, Ontario, Canada.)

contact means a greater current intensity and severity of injury ([158,163](#)). Skin burns can be absent even in high-voltage electrocutions, if the contact area is large and exposure duration short ([140,142,149,163](#)). The most common sites of contact (entry) are the hands ([Fig. 31](#); refs. [141](#), [145](#), and [149](#)). Victims of low-voltage AC electrocution may not have cutaneous burns ([140,147,161,163,181](#)). In an Australian study, about 90% of victims had burns, probably because the domestic voltage in that country is 240 V ([181](#)). The most frequent site of grounding (exit) is the foot ([Fig. 32](#); refs. [141](#), [149](#), [152](#), and [158](#)). A study of low-voltage electrocution deaths showed contact burns—not on the hands, but in areas of thinner skin (chest, neck, face, or arm) likely owing to humid



**Fig. 32.** Electrocutation burns (exit site). **(A)** Death originally attributed to a heart attack. Exit burn on big toe found during external examination at autopsy. (Courtesy of the Office of the Chief Medical Examiner, Chapel Hill, NC.) **(B)** Multiple exit burns below ankle and on heel. (Courtesy of Dr. D. King, Regional Forensic Pathology Unit, Hamilton, Ontario, Canada.)

conditions (184). Multiple entry and exit points are observed when current paths are established through multiple arcs (Fig. 32; refs. 147, 152, and 207).

Exposure to water causes decreased skin resistance and an increased contact area, which reduces current density. The result is no visible skin injury; however, a low-voltage source is still lethal (e.g., moistened skin having a resistance of 1000  $\Omega$  exposed to a 110-V source results in a current of about 0.1 A or 100 mA, the threshold for ventricular fibrillation [138,139,141,145,147,152,208]). Electric burns in bathtubs are possible, if part of the body is grounded to a metal fixture and out of water (188). Unusual water-related electrocutions have been described (e.g., drinking



from a water fountain in contact with an electric current from an underground cable; urinating on an electrified rail line [209]).

Severe burns are more likely with high-voltage contact (141). High-voltage direct contact is associated with deep soft tissue burns and even thermal injury of bone (38). High-voltage victims often have a black metallic coating on the skin surface owing to vaporization of metal contacts (147). Skin burns are sometimes patterned matching the electrical source or an area of the body covered by metal jewelry (161,210).

Entry and exit burns range from pinpoint to large and can be missed (Figs. 31 and 32; refs. 38, 147, and 158). Exit wounds are not necessarily larger than entry wounds (147). They have a central area of charring surrounded by a gray-white zone of necrosis (140,158). A more peripheral red zone can be seen (140,158,161). Surrounding erythema is not necessarily a vital reaction (*see* Subheading 3.3. and ref. 163). Assuming a temperature of at least 90°C (194°F) produces charring, about 30 s of skin contact with a low-voltage electrical source is needed before this occurs (163). A temperature of about 54°C (130°F) for 40 s causes epidermal necrosis (211). Fatal arrhythmia has occurred by the time cutaneous burning is seen, which means that the skin features of electrical burns are likely postmortem (139,163). An AC stimulus lasting from 1 to 10 ms causes ventricular fibrillation, whereas the development of a first-degree or erythematous burn requires 20 s of exposure to a current of more than 20 mA/mm<sup>2</sup> (139,163). In contrast, AC (115 V) applied to a dead pig's skin showed no peripheral hyperemia around the burn site. This was observed only antemortem (212).

Contact is not necessary to cause an electrical burn (38,147,157,207). Arcing is associated with higher voltage (>300 V) electrocution, including lightning (139,140, 147). The forearm of a victim near a 7500 kV power line can draw an arc when 3 to 4 mm away (147). Arcing is possible with larger distances of separation when the fingers are outstretched or pointed objects (e.g., screwdriver) are being held (147,207,209). Electric arc temperatures approach 2500°C to 5000°C (4500°F to 9000°F), causing severe burns (139,141,145,149,150,152,157,161,209). Clothing, particularly shoes and socks, can show arc marks (139–141,149,150,157,161,163,209). Arc burns also extend deep into soft tissue and even bone; however, they can be subtle and missed on external examination (139,141,158,207,209,210). “Kissing” burns occur when electrical current arcs across flexor creases (elbow, axilla, wrist; *see* refs. 144, 145, 147, 152, 158, and 210). Contacts and exits can be difficult to distinguish because arcing is possible at entry and exit points (Figs. 31 and 32; refs. 38 and 151). A victim can be indirectly exposed to the intense heat of electrical current arcing to the ground (139,158).

Lightning injuries can be the result of direct strike, contact, side flash (“splash”), ground current (step voltage), and blunt trauma (*see* Table 3 and refs. 141, 142, 147, 176, and 213).

The duration of the lightning current is brief (100 ms [147]). Lightning striking the head directly can enter skull orifices (eyes, ears, and mouth [152,205]). Such direct-strike victims die immediately (166,224). Contact injury occurs when a person is touching an object (e.g., tent pole) that is part of the current pathway (152). Side flash (splash) refers to lightning jumping or arcing from its primary conductor (e.g., tree) to a lower resistance object (i.e., a nearby individual [152,176]). As lightning hits the ground, current spreads radially. If a person has one foot closer than the other to the strike point, current can pass through the legs and body because of the potential difference between the legs (147,152). Splash and ground currents can involve multiple victims (153). Side flash

**Table 3**  
**Lightning Injuries**

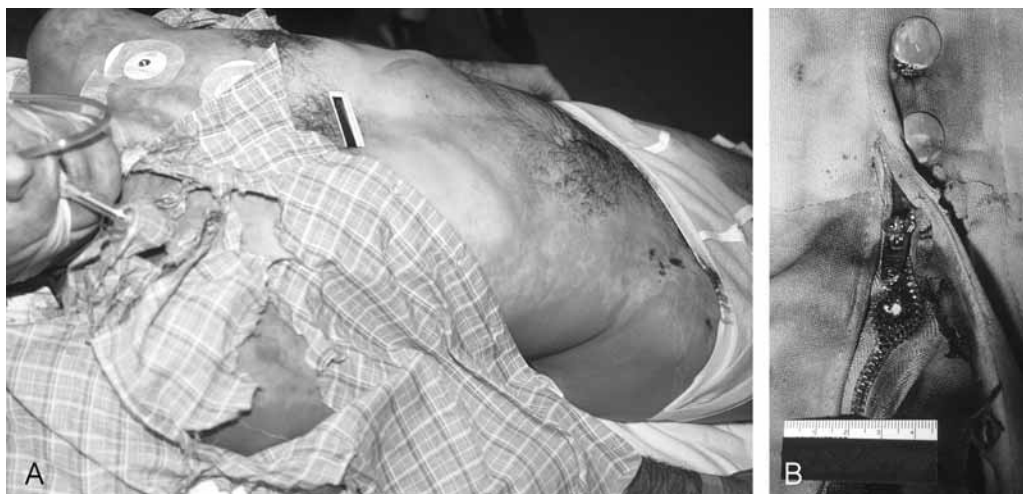---

Cutaneous burns ( <i>139,143,152,153,165,167,174,205</i> )
Absent (discrete entry and exit rare)
Superficial
• Linear (corresponding to accumulation of sweat or water)
• Erythematous burns owing to flashover
• Punctate
Thermal (clothing ignition, melting belt buckles and zippers [ <i>214</i> ])
Singed hair ( <i>205,215</i> )
Lichtenberg figures (ferning, feathering, arborescent “burns,” keraunographic markings [ <i>143,153,174,216</i> ])
Ruptured eardrum (secondary to direct burn, shock waves, basal skull fracture [ <i>143,152,153,165,167,174,217–219</i> ])
Pulmonary contusion (blunt injury, blast effect [ <i>152,153,174,220</i> ])
Myocardial infarct (rare); myocardial contraction bands ( <i>143,153,165–167,174,175,178,221–223</i> )
Muscle necrosis, myoglobinuria, renal failure (rare compared with high-voltage AC electrocution [ <i>143,153,165,180,224</i> ])
Spinal cord damage (direct, secondary to fracture [ <i>167</i> ])
Direct brain injury (associated with cranial burns [ <i>143,164,166,174</i> ])
• Coagulation of parenchyma
• Epidural and subdural hemorrhage (? blunt trauma [ <i>155,166,174,224</i> ])
• Peri- and intraventricular hemorrhage ( <i>155,174</i> )
• Subarachnoid hemorrhage (? blunt trauma [ <i>166,224</i> ])
• Basal ganglia hemorrhage (direct or thermal); brainstem hemorrhages ( <i>166,224,225</i> )
• Skull fracture (blunt trauma [ <i>155</i> ])
Facial fracture (blast effect [ <i>226</i> ])
Postcardiac arrest hypoxic–ischemic encephalopathy ( <i>224</i> )
• Associated cerebral infarction

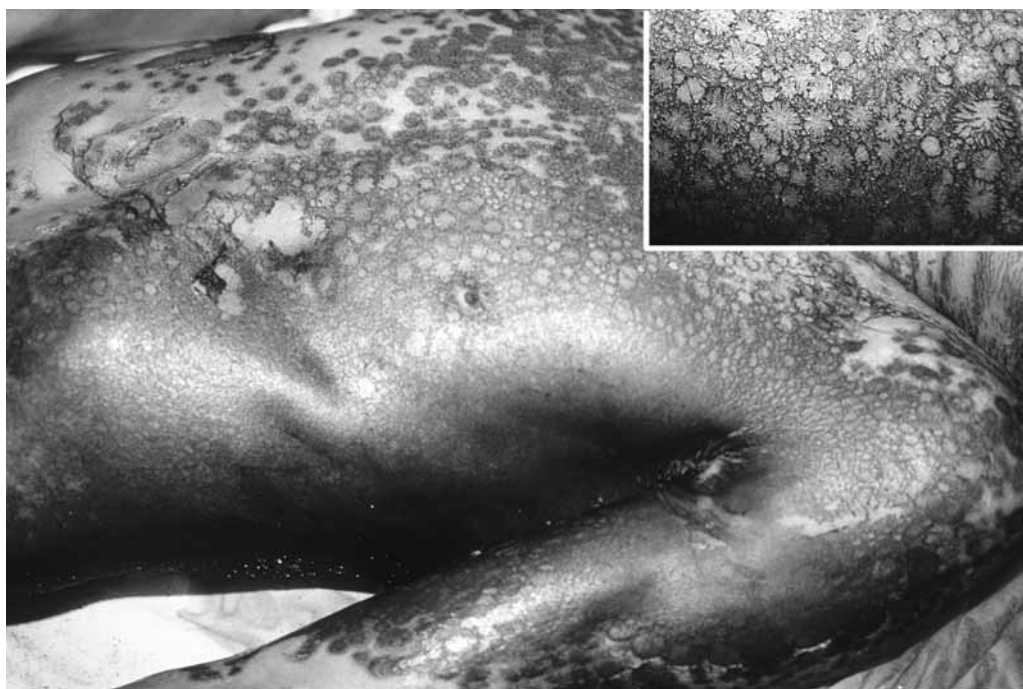---

and ground current tend to spare the head (*166*). Blunt injury results from opisthotonic muscle contraction, from the blast created by the explosive force of air superheated by lightning and then rapidly cooling, and from falls (*147,152,167,174*).

Electrical current normally travels along the outside of a metal conductor (*164,165,174*). Current flowing outside the body covered by wet garments causes vaporization and consequent tearing of clothes (Fig. 33; refs. *139, 141, 143, 144, 147, 150, 153, 174, 178, 205, 215*, and *227*). The latter suggests a sexual assault, particularly when the body is found in the open (*161,174,205*). Temperatures can briefly reach 30,000°C (54,000°F [*153,176*]). Thin metal objects are burned, and black coating may be seen on the victim (Fig. 33; refs. *38, 214*, and *228*). Electric flash burns in high-voltage electrocutions are superficial, red or brown, and typically involve exposed areas of the body (“crocodile skin;” see Fig. 34 and refs. *38, 141, 152, 157, 158, 165*, and *229*). Deep burns are not common in lightning strikes compared with high-voltage electrocution; however, thermal burns do result from ignition of clothing and surroundings (*38,38,139,144,145,147,158,230,231*). In one



**Fig. 33.** Lightning fatality. (A) Clothes torn. (B) Burned zipper. (Courtesy of Dr. D. King, Regional Forensic Pathology Unit, Hamilton, Ontario, Canada.)



**Fig. 34.** Electrocutation (contact with high-voltage line). Cutaneous burns owing to flashover (inset shows “crocodile skin”).

series, 90% of lightning victims suffered burns (two-thirds had burns on the trunk, half had burns on the head), but only 5% had deep burns ([143,153,164,167,174](#)). There is limited internal current flow with a lightning strike, and thermal effects, except for at the site of contact, do not play a major role in organ damage ([139,141,142,147,150,174,180,229](#)).



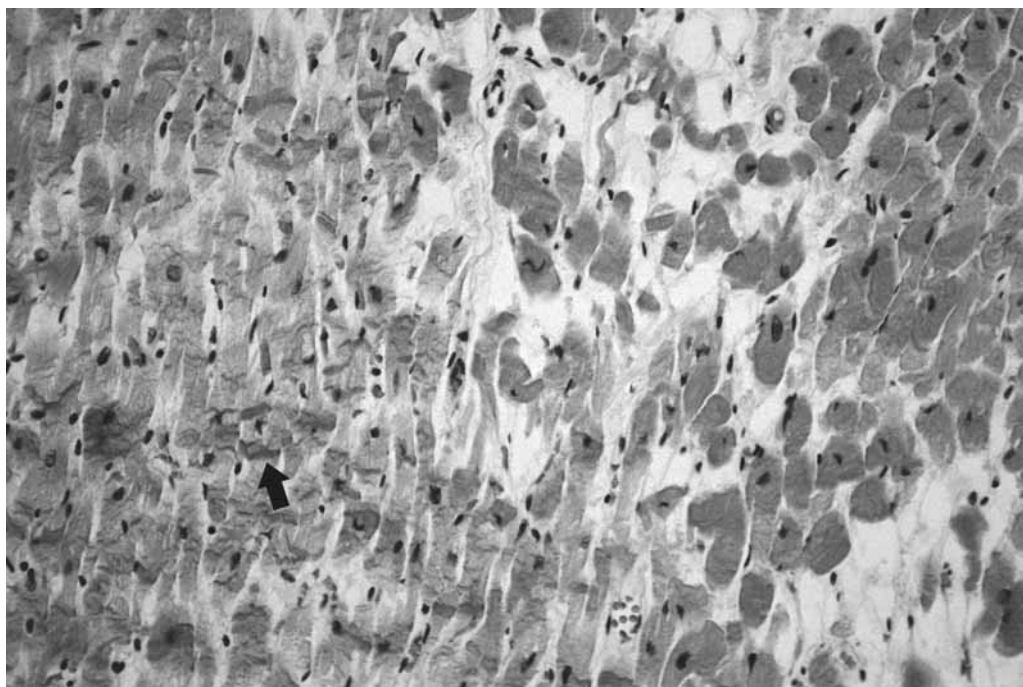
**Fig. 35.** Lightning death. Lichtenberg figures. (Courtesy of Dr. D. King, Regional Forensic Pathology Unit, Hamilton, Ontario, Canada.)

Lichtenberg figures (fern-like figures) describe a physical phenomenon of arborescent red areas on the skin that appear within 1 h of a lightning strike, and usually disappear after 24 to 48 h (Fig. 35; refs. 38, 180, 205, 213, and 216). Lichtenberg figures are not burns. They do not correspond to vessel or nerve distribution. They are related to positive charge caused by a secondary positive flashover from a nearby object in relation to a person hit by negatively charged lightning bolt. The Lichtenberg figure is consistent with fractal behavior, in which a positive discharge attracts electrons from the surrounding skin. (A fractal is a mathematical object that manifests increasing detail with increasing magnification, such that the smaller magnified structure is identical to the larger one [38,213,216]).

#### **7.4. Internal Injuries Owing to Electrocution (Table 3)**

Hospitalized electrocution victims can show evidence of myocardial ischemia and arrhythmias (139,141,145,147,149,152,158). Because of the onset of arrhythmia can be delayed, these patients are monitored for 24 h after admission, particularly when there is a history of heart disease, loss of consciousness at the scene, or apparent current flow through the heart (139,141,142,145,232,233). The heart can be normal at autopsy (181). Petechiae may be found in the myocardium, and larger hemorrhages have been described in the pericardium and endomyocardium (181). Petechiae on eyelids, conjunctiva, visceral pleura, and epicardium are a sign of vitality in an electrocution death (197,234). Their presence does not depend on voltage or current pathway (197). The development of petechiae may be a combination of venous congestion owing to cardiac





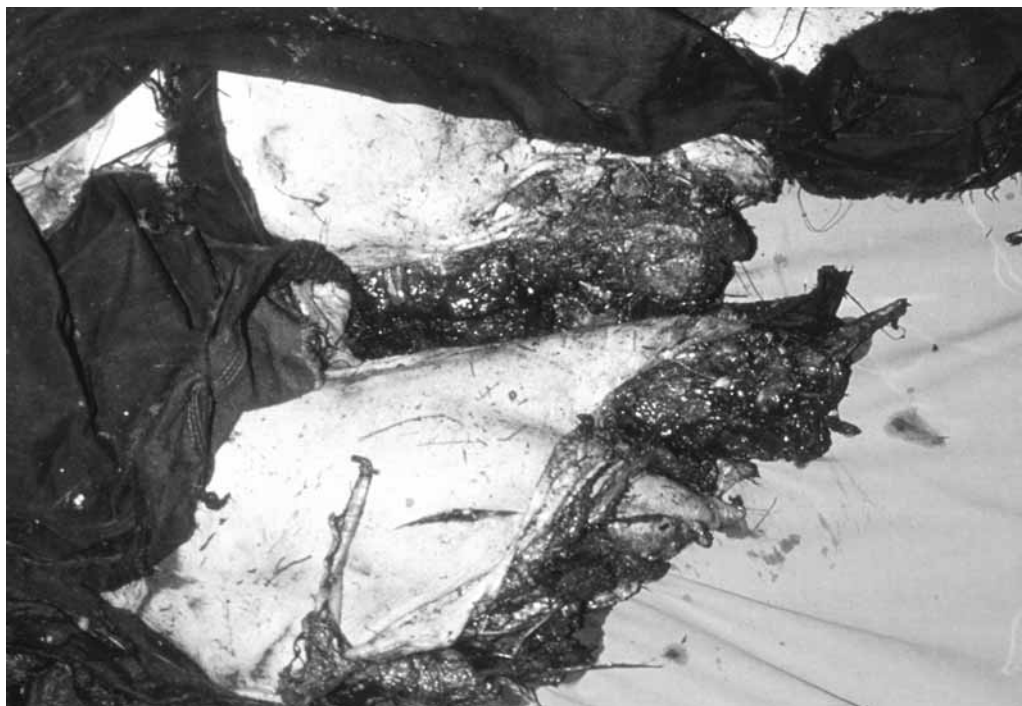**Fig. 36.** Electrocution. Myocardial contraction bands noted particularly on left of image (arrow; H&E, original magnification  $\times 100$ ). (Courtesy of Dr. D. King, Regional Forensic Pathology Unit, Hamilton, Ontario, Canada.)

arrest and elevated blood pressure caused by muscle contractions ([197](#)). Widespread or focal necrosis with variable hemorrhage and acute contraction bands in the myocardium and conduction system are seen, and these changes are responsible for delayed arrhythmias ([Fig. 36](#); refs. [139](#), [142](#), [232](#), [235](#), and [236](#)). Myocardial infarction does occur in the absence of coronary atherosclerosis, and coronary spasm is likely ([236–238](#)). Vascular spasm has also been attributed to lightning ([167](#)). Coronary thrombosis is a rare cause of myocardial infarct in an electrocution victim ([142](#)).

High- and low-voltage electrical current flowing along vessels causes damage to the intima and media (contraction band necrosis), leading to immediate or delayed thrombosis and consequent ischemia ([38,139–142,144,145,147,151,152,157,158,161,235](#)). Major limb arteries are patent because of better heat dissipation because of greater blood flow, but small intramuscular arteries necrose from thermal damage and occlude, even under viable skin ([139,149,154,168,172](#)). Medial damage can lead to aneurysm formation ([149](#)). Elevated blood pressure due to contraction of skeletal muscles and vasoconstriction from electrical current can lead to rupture of pre-existent cerebral aneurysms ([149,234](#)).

Muscle damage is caused by heat, electrical current, ischemia, and trauma ([145](#)). High-voltage current causes considerable muscle, vessel, and nerve damage ([38,150,152](#)). The extent of cutaneous burns in a low-voltage electrocution does not predict the amount of muscle necrosis ([139,141,144,145,147,150,152,157,158,172](#)). Muscle compartment syndromes develop secondary to edema and vascular ischemia ([139,141,147,152](#)). Myoglobinuria leads to renal failure (*see* Chapter 8, Section 13. and refs. [38](#), [141](#), [142](#), [144](#), [145](#), [147](#), [152](#), [157](#), and [158](#)). There is no significant correlation



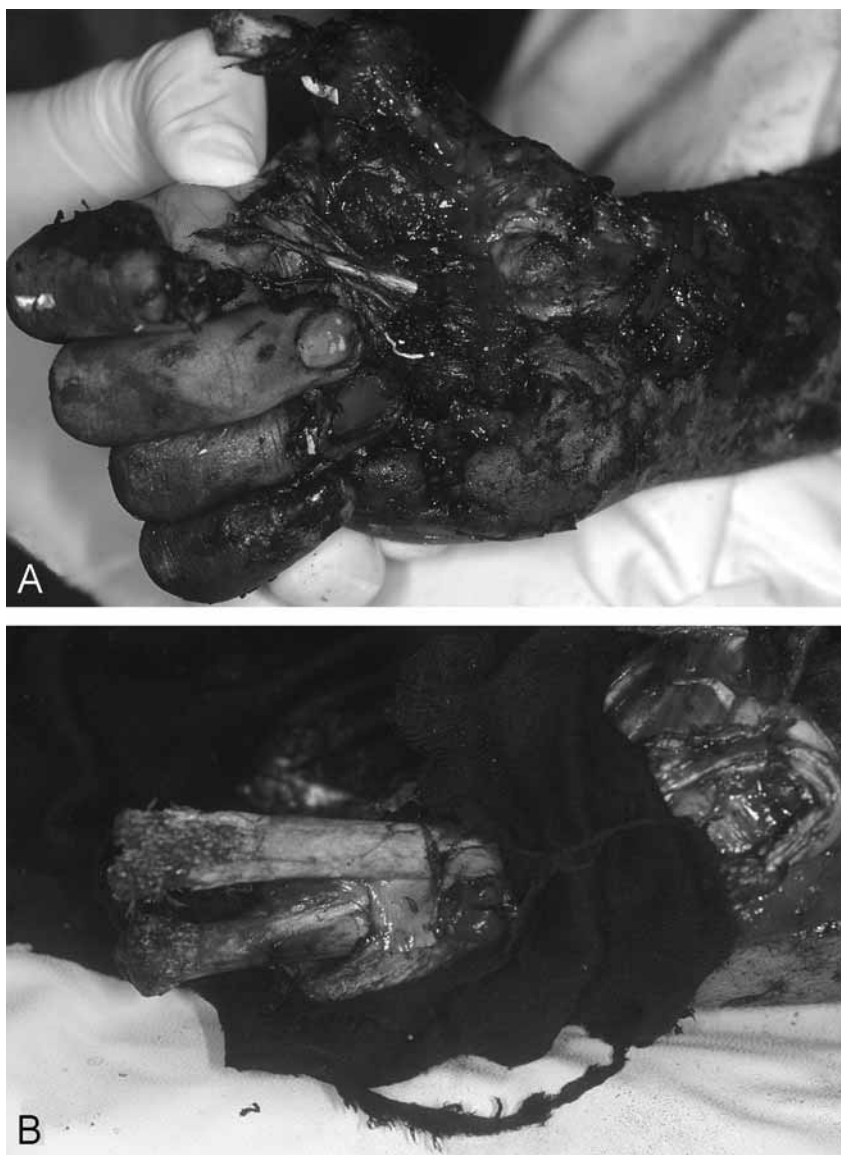

**Fig. 37.** Explosive device in motor vehicle likely under victim's legs. Bilateral traumatic amputations. (Courtesy of the Office of the Chief Medical Examiner, Chapel Hill, NC.)

of postmortem blood myoglobin levels and death by electric current (239,240). Myoglobin increases after death resulting from autolysis (239). Hyperkalemia also occurs (147). Electrical damage of skeletal muscle cell membranes is not immediately apparent as grossly visible necrosis (147,168). Ischemic effects can be delayed (141, 146,150). Electrically injured tissue can be irregular in distribution and be found at sites distant from the visible entry and exit sites (141,146,148). Although the muscle initially appears normal, irreversible electroporation and thermal denaturation changes have already occurred (146). Later discovery of more extensive muscle necrosis indicates progression of these changes (147). Extensive muscle damage from high-voltage burns may require amputation (148,149,189,193,210,230). Gas gangrene has been described (241).

Damage to lungs is rare in electrocution (157). Blunt pulmonary trauma (e.g., contusion) is more common (157,167). ARDS is a sequela (145).

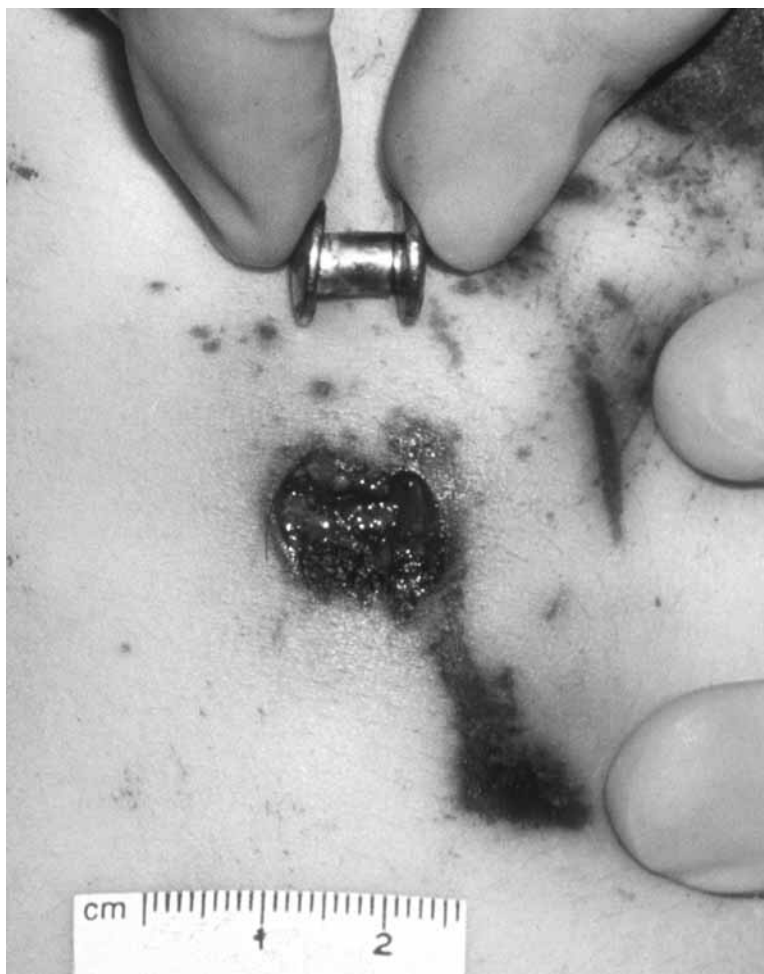Cases of high-voltage and, rarely, low-voltage electrocution causing direct rupture of an abdominal viscus (e.g., stomach, intestine, gallbladder, esophagus) have been observed and likened to blast effects (145,176,242,243). A urinary bladder fistula has been described (244). Coagulation necrosis of small vessels can cause ischemic changes in the bowel (154,242). Paralytic ileus has been observed (154). Solid organ necrosis is usually a consequence of blunt trauma or the direct effects of burns (e.g., liver, pancreas; see refs. 157, 167, 210, 242, and 245). Some cases of solid organ damage have been attributed to electrical current (246).



**Fig. 38.** Damage to hands indicating explosive (grenade) held. **(A)** Severely burned hand and partly amputated fingers. **(B)** Traumatic amputation of hand. Exposed radius-ulna.

DC (e.g., lightning) and high-voltage AC can either throw an individual or result in a fall owing to an intense muscular contraction ([38,141,142,145,147,150,152,157,182](#)). In a lightning strike, there is no prolonged duration of contact from tetanic muscle contractions as seen in AC electrocution ([153,164,165,174](#)). The high temperature of an arc flash rapidly heats air, causing a blast effect that throws the victim ([147,209](#)).

Head injury occurs ([147,166,209,210](#)). Central nervous system sequelae occur irrespective of whether the head was in the apparent pathway of the electric current ([38,147,166,247](#)). Cerebral anoxic injury results from cardiorespiratory arrest ([139,147,152,174](#)). Cerebral vein thrombosis has been observed ([247](#)). Long-term



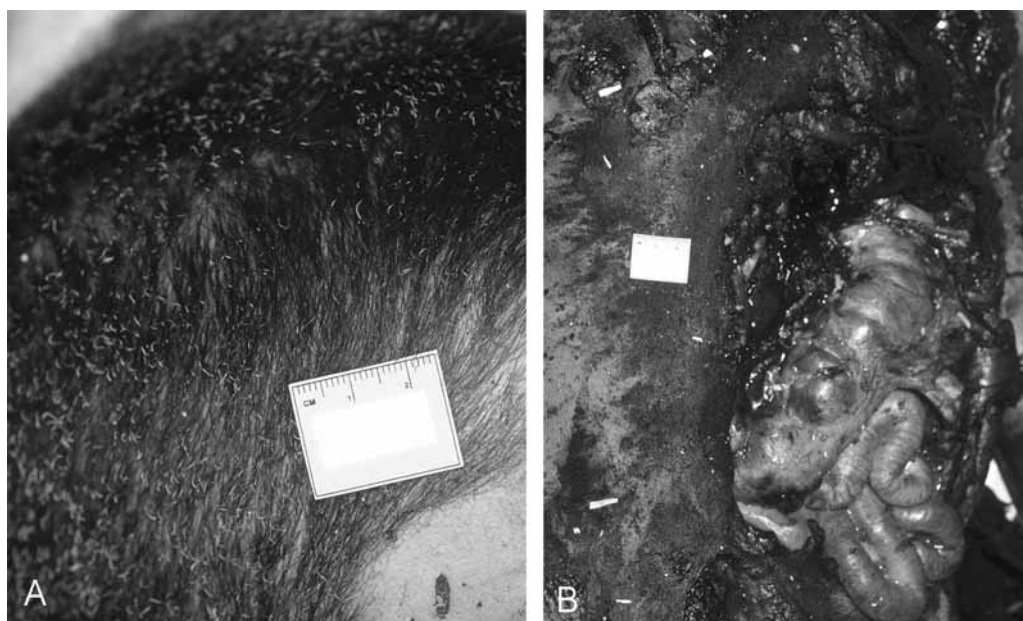
**Fig. 39.** Explosion. Projectile injury. (Courtesy of the Office of the Chief Medical Examiner, Chapel Hill, NC.)

neurological and psychiatric sequelae occur without central nervous system tissue injury (38,147,247). Long-term spinal cord damage has been attributed to low- and high-voltage electrocution (38,178,248). Following a lightning strike, the victim loses consciousness because of cardiorespiratory arrest, which is transient and responds to resuscitation (147). Subsequent behavioral changes and amnesia have been observed (143).

Muscle spasm from AC causes cervical spine and long bone fractures and dislocations (e.g., shoulder [38,144,145,147,152,157,161,210,249,250]). Bony injury also results from falls (152,158).

### **7.5. Microscopy and Trace Evidence**

Microscopy of electrocution contact sites shows vacuolization of epidermis and dermis, subepidermal blistering, elongation of epidermal cells, nuclear streaming, and eosinophilia of dermal collagen (161,170,207,209,251,252). If burned, superimposed charring is evident. Calcium deposition can occur in skin injured by electricity (DC or AC in animals and humans [253–256]). Heterotopic bone formation in soft tissues has



**Fig. 40.** Blast effects. (A) Singed hair. (B) Cutaneous burns; exteriorized bowel.

been described as a consequence of major electrical injury (147). Metal contacts leave ultrastructural and histochemical evidence of metallic deposits (e.g., copper, iron) on a burned or intact area of skin (161,200,234,251,257,258). Elemental analysis can confirm metal deposition (228). The contact source or conductor may show evidence of biological material (i.e., DNA analysis [259]).

## 8. EXPLOSIONS

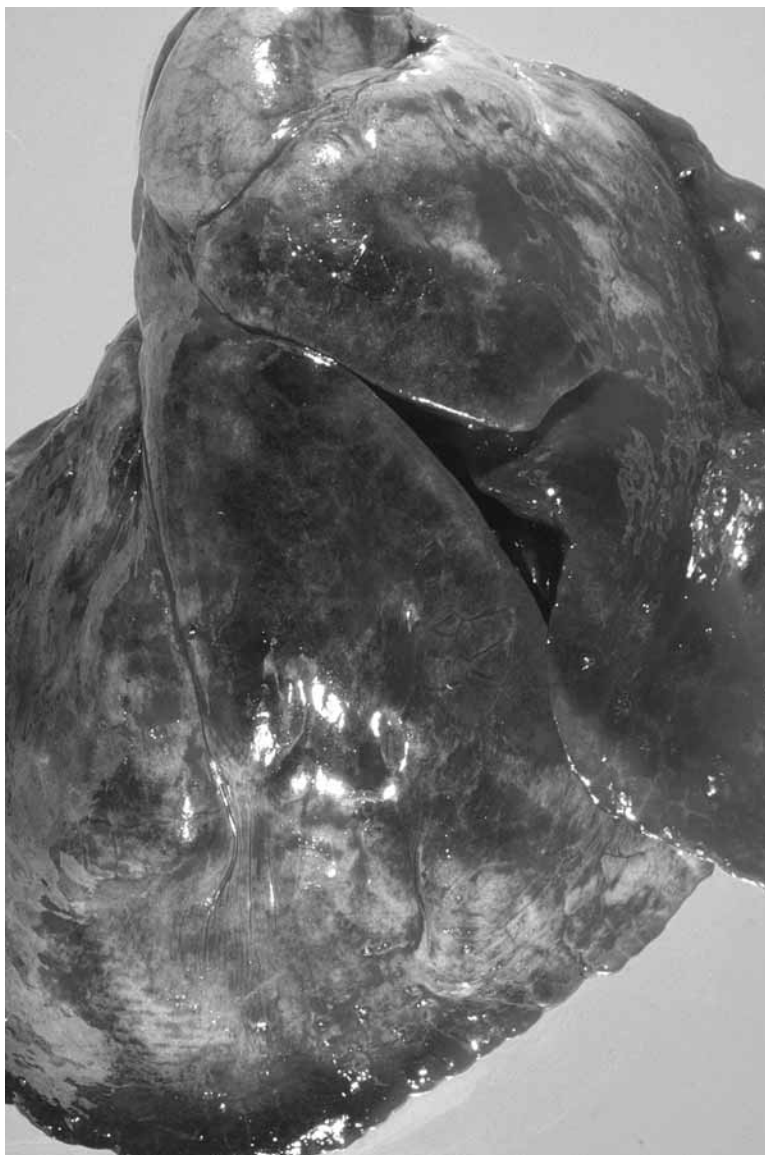
### 8.1. Mechanisms of Injury

“Blast” injury refers to the biophysical events and consequent pathophysiological changes occurring as a result of the effects of detonation and generated shock waves (260). Explosive forces decline rapidly from the blast source (261,262). Chemical explosions involve condensed reactants, which are of either low-order (<16 psi or lb/in.<sup>2</sup>) such as fireworks, or high-order (e.g., dynamite [263,264]). Diffuse reactant explosions involve a mixture of gas and/or particulate material with air (e.g., silo and coal mine explosions [263,265]). An explosion is sparked by either an ignition source (e.g., match), friction, static electricity, or overheating (265,266). All manners of death are possible (267,268).

“Pure” blast injury of internal organs can occur without any signs of external trauma (260). The direct effects are caused by a shock wave (primary blast injury [260,261,265,269–271]). A fraction of this shock wave is absorbed and propagated as a pressure wave in the body (260,272). Pressure greater than 300 psi destroys a human body (263). From the perspective of wave propagation, body tissues are of high viscosity, and as the wave passes through different tissues and organs, it is altered (260).

The most vulnerable parts of the body are air- and gas-containing organs (260,261). Hollow structures are more susceptible because of the bursting effect by stress waves,





**Fig. 41.** Blast effect. Pleural surface of right lung; pulmonary hemorrhage.

which concentrate at the interface between media having large differences in density (260,261). This is enhanced when a pressure wave breaks out of a liquid medium into a gaseous environment (e.g., alveoli, GI tract; refs. 260,273, and 274). Lung injury occurs if the chest wall is depressed at a velocity of at least 20 m/s (46 mph) in less than 0.5 ms (260,261). Blast forces also generate shear waves, which grossly distort or overcome the normal elasticity of tissue and organs by differential motion of adjacent, connected structures (261). Solid organs are susceptible to this type of acceleration–deceleration mechanism (275). An underwater blast exerts its injurious effects over greater distances than an air blast (260).



**Table 4**  
**Blast Injuries**

- 
- External injuries
    - Total body disintegration indicates high-order condensed explosive at close range (260,262,263,274)
    - Mangling of body near explosion with parts of extremities amputated (262,274). Craniofacial injuries, if suicide (267). Lower limb amputations typical of standing or seated individual (Fig. 37; ref. 277). Hand injuries, if explosive device held (Fig. 38; refs. 267, 271, 278, and 279)
    - Projectile injury (263,265,274; Fig. 39)
    - Punctate lacerations (274)
    - Dust tattooing (274). Black soiling from explosive materials (263)
    - Injury from fallen rubble (274)
    - Burns (flash burns and singed hair seen on victims in immediate vicinity; see Fig. 40 and ref. 274)
    - Propulsion of victim into other structures leading to secondary injuries (271)
  - Skull fractures (265)
  - CNS hemorrhages (meninges, brain, nerve roots [260])
  - Retinal hemorrhage (271)
  - Eardrum rupture (a primary blast effect [260,271,272,275,276,280,281])
  - Facial fractures (265)
  - Neck laceration and laryngeal fractures (265)
  - Rib fractures (265)
  - Lung (primary blast effect; see Fig. 41 and ref. 281)
    - Lacerations, hemorrhage (unless respiratory passages are obstructed by blood leading to asphyxia) does not necessarily cause death, survivors can progress to adult respiratory distress syndrome (see Chapter 1, Subheading 4.3. and refs. 260, 261, 265, 271, 276, and 280)
    - Pleural and subpleural hemorrhages (occur at areas of stress concentration—posterior surface of lungs, adjacent to heart, and diaphragm [261])
    - Acute emphysema, subpleural bullae, tension pneumothorax (261)
    - Air embolism (see Chapter 5, Subheading 14.3.; Chapter 7, Subheading 12.1.; Chapter 8, Subheading 12.4.; and ref. 261).
  - Cardiac dysrhythmia (282)
    - Bradycardia (vagal reflex from pulmonary injury [260,283])
    - Commotio cordis (possible when blast victims have no obvious fatal injury; see Chapter 8, Subheading 6.4. and refs. 260 and 261)
  - Myocardial hemorrhage (260)
  - Cardiac laceration (275)
  - Aortic laceration (265)
  - Hepatic laceration (265,275,276)
  - Esophageal, gastric or intestinal perforation (also intramural hemorrhage, transection of fixed parts [260,265,271,276,280])
  - Gallbladder rupture (275)
  - Kidney laceration (265,275)
  - Urinary bladder rupture (271,275)
  - Splenic laceration (265,275)
  - Adrenal laceration (275)

---

Upper and lower extremity fractures, spinal fractures (260,265,271)

CNS, central nervous system.

Other mechanisms of injury include penetrating trauma by secondary missiles that can travel great distances (secondary blast injury), displacement of victim by blast wind (tertiary blast injury), burns from flash or structural fires, exposure to noxious gases, and crush (260,261,263,265–272,276). If there is a fire, the leading edge of the flame travels up to 200 m/s (450 mph) following the blast (266).

Explosions are associated with characteristic injury patterns (Table 4).

## 8.2. Steps in Examination of a Blast Victim

- Recovery of all body parts and clothing (263). Clothing is submitted in either airtight containers (e.g., unused paint can or in bags composed of nylon, polyester, or polypropylene [263,284,285]).
- Note direction of projectile injury (263).
- Examination of hands to determine whether victim's hand was holding explosive (267,271,278,279).
- Collection of explosive residue, burned (black or gray) and unburned (yellow, brown, gray material). Swabs of skin, grossly soiled or without visible residue, and also hands (267). Collection of hair, fingernail scrapings (263,284). Negative control swabs are also submitted (284).
- Collection, from skin surface and within wound tracks, of radiolucent material that may be part of explosive—e.g., paper fragments, wood, plastic (263,267,284). Other foreign material could be part of surroundings (284).
- Full-body photographs.
- Full-body radiographs (267,284). All radiopaque fragments must be collected. These can be components of an explosive device, parts of a body prosthesis, or metallic structures from the surroundings (e.g., car). Radiographs are repeated to ensure that all fragments have been recovered (263,284).
- Toxicological analysis. COHb may be elevated in a CO-rich environment (e.g., coal mine explosion [265,266]).

## REFERENCES

1. Barret, J. P., Gomez, P., Solano, I., Gonzalez-Dorrego, M., Crisol, F. J. Epidemiology and mortality of adult burns in Catalonia. *Burns* 25:325–329, 1999.
2. Crikelair, G. F., Symonds, F. C., Ollstein, R. N., Kirsner, A. I. Burn causation: its many sides. *J. Trauma* 8:572–582, 1968.
3. Panke, T. W., McLeod, C. G. *Pathology of Thermal Injury. A Practical Approach*. Grune and Stratton, Orlando, FL, 1985.
4. Eckert, W. G. The medicolegal and forensic aspects of fires. *Am. J. Forensic Med. Pathol.* 2:347–357, 1981.
5. Marshall, S. W., Runyan, C. W., Bangdiwala, S. I., Linzer, M. A., Sacks, J. J., Butts, J. D. Fatal residential fires: who dies and who survives? *JAMA* 279:1633–1637, 1998.
6. Istre, G. R., McCoy, M. A., Osborn, L., Barnard, J. J., Bolton, A. Deaths and injuries from house fires. *N. Engl. J. Med.* 344:1911–1916, 2001.
7. McGwin, G., Jr., Chapman, V., Rousculp, M., Robison, J., Fine, P. The epidemiology of fire-related deaths in Alabama, 1992–1997. *J. Burn Care Rehabil.* 21:75–83, 2000.
8. MacArthur, J. D., Moore, F. D. Epidemiology of burns. The burn-prone patient. *JAMA* 231:259–263, 1975.
9. Runyan, C. W., Bangdiwala, S. I., Linzer, M. A., Sacks, J. J., Butts, J. Risk factors for fatal residential fires. *N. Engl. J. Med.* 327:859–863, 1992.

10. Mallonee, S., Istre, G. R., Rosenberg, M., et al. Surveillance and prevention of residential-fire injuries. *N. Engl. J. Med.* 335:27–31, 1996.
11. Istre, G. R., McCoy, M., Carlin, D. K., McClain, J. Residential fire related deaths and injuries among children: fireplay, smoke alarms, and prevention. *Inj. Prev.* 8:128–132, 2002.
12. Squires, T., Busuttill, A. Can child fatalities in house fires be prevented? *Inj. Prev.* 2:109–113, 1996.
13. Biddle, E. A., Hartley, D. Fire and flame related events with multiple occupational injury fatalities in the United States, 1980–1995. *Inj Control Saf. Promot.* 9:9–18, 2002.
14. Mandelcorn, E., Gomez, M., Cartotto, R. C. Work-related burn injuries in Ontario, Canada: has anything changed in the last 10 years? *Burns* 29:469–472, 2003.
15. Quinney, B., McGwin, G., Jr., Cross, J. M., Valent, F., Taylor, A. J., Rue, L. W. III. Thermal burn fatalities in the workplace, United States, 1992 to 1999. *J. Burn Care Rehabil.* 23:305–310, 2002.
16. Leth, P., Hart-Madsen, M. Suicide by self-incineration. *Am. J. Forensic Med. Pathol.* 18:113–118, 1997.
17. Rothschild, M. A., Raatschen, H. J., Schneider, V. Suicide by self-immolation in Berlin from 1990 to 2000. *Forensic Sci. Int.* 124:163–166, 2001.
18. Shkrum, M. J., Johnston, K. A. Fire and suicide: a three-year study of self-immolation deaths. *J. Forensic Sci.* 37:208–221, 1992.
19. Sukhai, A., Harris, C., Moorad, R. G., Dada, M. A. Suicide by self-immolation in Durban, South Africa: a five-year retrospective review. *Am. J. Forensic Med. Pathol.* 23:295–298, 2002.
20. Suk, J. H., Han, C. H., Yeon, B. K. Suicide by burning in Korea. *Int. J. Soc. Psychiatry* 37:141–145, 1991.
21. Laloe, V. Patterns of deliberate self-burning in various parts of the world. A review. *Burns* 30:207–215, 2004.
22. Prosser, D. Suicides by burning in England and Wales. *Br. J. Psychiatry* 168:175–182, 1996.
23. Meir, P. B., Sagi, A., Ben Yakar, Y., Rosenberg, L. Suicide attempts by self-immolation—our experience. *Burns* 16:257–258, 1990.
24. Gupta, R. K., Srivastava, A. K. Study of fatal burns cases in Kanpur (India). *Forensic Sci. Int.* 37:81–89, 1988.
25. Mzezewa, S., Jonsson, K., Aberg, M., Salemark, L. A prospective study of suicidal burns admitted to the Harare burns unit. *Burns* 26:460–464, 2000.
26. Kumar, V. Burnt wives—a study of suicides. *Burns* 29:31–35, 2003.
27. Bohnert, M., Rothschild, M. A. Complex suicides by self-incineration. *Forensic Sci. Int.* 131:197–201, 2003.
28. Cingolani, M., Tsakri, D. Planned complex suicide: report of three cases. *Am. J. Forensic Med. Pathol.* 21:255–260, 2000.
29. Suarez-Penaranda, J. M., Munoz, J. I., Lopez, D. A., et al. Concealed homicidal strangulation by burning. *Am. J. Forensic Med. Pathol.* 20:141–144, 1999.
30. Wetherell, H. R. The occurrence of cyanide in the blood of fire victims. *J. Forensic Sci.* 11:167–173, 1966.
31. Hartzell, G. E. Overview of combustion toxicology. *Toxicology* 115:7–23, 1996.
32. Einhorn, I. N. Physiological and toxicological aspects of smoke produced during the combustion of polymeric materials. *Environ. Health Perspect.* 11:163–189, 1975.
33. Hill, I. R. An analysis of factors impeding passenger escape from aircraft fires. *Aviat. Space Environ. Med.* 61:261–265, 1990.
34. Bohnert, M., Rost, T., Faller-Marquardt, M., Ropohl, D., Pollak, S. Fractures of the base of the skull in charred bodies—post-mortem heat injuries or signs of mechanical traumatization? *Forensic Sci. Int.* 87:55–62, 1997.

35. Bohnert, M., Rost, T., Pollak, S. The degree of destruction of human bodies in relation to the duration of the fire. *Forensic Sci. Int.* 95:11–21, 1998.
36. Bohnert, M., Schmidt, U., Perdekamp, M. G., Pollak, S. Diagnosis of a captive-bolt injury in a skull extremely destroyed by fire. *Forensic Sci. Int.* 127:192–197, 2002.
37. Alarie, Y. Toxicity of fire smoke. *Crit. Rev. Toxicol.* 32:259–289, 2002.
38. ten Duis, H. J. Acute electrical burns. *Semin. Neurol.* 15:381–386, 1995.
39. Glassman, D. M., Crow, R. M. Standardization model for describing the extent of burn injury to human remains. *J. Forensic Sci.* 41:152–154, 1996.
40. Eckert, W. G., James, S., Katchis, S. Investigation of cremations and severely burned bodies. *Am. J. Forensic Med. Pathol.* 9:188–200, 1988.
41. Richards, N. F. Fire investigation—destruction of corpses. *Med. Sci. Law.* 17:79–82, 1977.
42. Gerling, I., Meissner, C., Reiter, A., Oehmichen, M. Death from thermal effects and burns. *Forensic Sci. Int.* 115:33–41, 2001.
43. Christensen, A. M. Experiments in the combustibility of the human body. *J. Forensic Sci.* 47:466–470, 2002.
44. DeHaan, J. D., Nurbakhsh, S. Sustained combustion of an animal carcass and its implications for the consumption of human bodies in fires. *J. Forensic Sci.* 46:1076–1081, 2001.
45. Gee, D. J. A case of “spontaneous combustion.” *Med. Sci. Law* 18:37–38, 1965.
46. DeHaan, J. D., Campbell, S. J., Nurbakhsh, S. Combustion of animal fat and its implications for the consumption of human bodies in fires. *Sci. Justice* 39:27–38, 1999.
47. Spitz, W. U. Thermal injuries. In: Spitz, W. U., ed. *Spitz and Fisher’s Medicolegal Investigation of Sudden Death. Guidelines for the Application of Pathology to Crime Investigation.* 3rd ed. Charles C. Thomas, Springfield, IL, pp. 413–443, 1993.
48. Bassed, R. Identification of severely incinerated human remains: the need for a cooperative approach between forensic specialties. A case report. *Med. Sci. Law* 43:356–361, 2003.
49. Hill, I.R. Immediate causes of death in fires. *Med. Sci. Law* 29:287–292, 1989.
50. Hausmann, R., Betz, P. Thermally induced entrance wound-like defect of the skull. *Forensic Sci. Int.* 128:159–161, 2002.
51. Kondo, T., Ohshima, T. Epidural herniation of the cerebral tissue in a burned body: a case report. *Forensic Sci. Int.* 66:197–202, 1994.
52. Bohnert, M., Werner, C. R., Pollak, S. Problems associated with the diagnosis of vitality in burned bodies. *Forensic Sci. Int.* 135:197–205, 2003.
53. Levin, B. C., Rechani, P. R., Gurman, J. L., et al. Analysis of carboxyhemoglobin and cyanide in blood from victims of the Dupont Plaza Hotel fire in Puerto Rico. *J. Forensic Sci.* 35:151–168, 1990.
54. Birky, M., Malek, D., Paabo, M. Study of biological samples obtained from victims of MGM Grand Hotel fire. *J. Anal. Toxicol.* 7:265–271, 1983.
55. Barillo, D. J., Goode, R., Rush, B. F., Jr., Lin, R. L., Freda, A., Anderson, E. J., Jr. Lack of correlation between carboxyhemoglobin and cyanide in smoke inhalation injury. *Curr. Surg.* 43:421–423, 1986.
56. Yoshida, M., Adachi, J., Watabiki, T., Tatsuno, Y., Ishida, N. A study on house fire victims: age, carboxyhemoglobin, hydrogen cyanide and hemolysis. *Forensic Sci. Int.* 52:13–20, 1991.
57. Anderson, R. A., Harland, W. A. Fire deaths in the Glasgow area: III. The role of hydrogen cyanide. *Med. Sci. Law* 22:35–40, 1982.
58. Lundquist, P., Rammer, L., Sorbo, B. The role of hydrogen cyanide and carbon monoxide in fire casualties: a prospective study. *Forensic Sci. Int.* 43:9–14, 1989.
59. Barillo, D. J., Rush, B. F., Jr., Goode, R., Lin, R. L., Freda, A., Anderson, E. J., Jr. Is ethanol the unknown toxin in smoke inhalation injury? *Am. Surg.* 52:641–645, 1986.
60. Levine, B., Moore, K. A., Fowler, D. Interaction between carbon monoxide and ethanol in fire fatalities. *Forensic Sci. Int.* 124:115–116, 2001.

61. Parks, J. G., Noguchi, T. T., Klatt, E. C. The epidemiology of fatal burn injuries. *J. Forensic Sci.* 34:399–406, 1989.
62. Squires, T., Busuttil, A. Alcohol and house fire fatalities in Scotland, 1980–1990. *Med. Sci. Law* 37:321–325, 1997.
63. Gerson, L., Wingard, D. Fire deaths and drinking: data from the Ontario fire reporting system. *Am. J. Drug Alcohol Abuse* 6:125–133, 1979.
64. Gormsen, H., Jeppesen, N., Lund, A. The causes of death in fire victims. *Forensic Sci. Int.* 24:107–111, 1984.
65. Rogde, S., Olving, J. H. Characteristics of fire victims in different sorts of fires. *Forensic Sci. Int.* 77:93–99, 1996.
66. Menchel, S. M., Dunn, W. A. Hydrofluoric acid poisoning. *Am. J. Forensic Med. Pathol.* 5:245–248, 1984.
67. Wirthwein, D. P., Pless, J. E. Carboxyhemoglobin levels in a series of automobile fires. Death due to crash or fire? *Am. J. Forensic Med. Pathol.* 17:117–123, 1996.
68. Walter, J. E., Hirsch, C. S., Zumwalt, R. E. Never say never. Negligible carboxyhemoglobin in the victim of a smoldering mattress fire. *Am. J. Forensic Med. Pathol.* 5:239–244, 1984.
69. Hirsch, C. S., Adelson, L. Absence of carboxyhemoglobin in flash fire victims. *JAMA* 210:2279–2280, 1969.
70. Betz, P., Roeder, G., von Meyer, L., Drasch, G., Eisenmenger, W. Carboxyhemoglobin blood concentrations in suicides by fire. *Med. Sci. Law* 36:313–316, 1996.
71. O'Halloran, R. L., Lundy, J. K. Three fatalities in flash fire with variable dental charring. *Am. J. Forensic Med. Pathol.* 6:248–249, 1985.
72. Suzuki, T., Takahashi, H., Umetsu, K. Unusual aspirations in fire death. *Forensic Sci. Int.* 72:71–76, 1995.
73. Scharschmidt, A., Bratzke, H. [Congestive hemorrhage caused by burns?]. *Arch. Kriminol.* 182:94–100, 1988.
74. Quan, L., Zhu, B. L., Ishida, K., et al. Hemorrhages in the root of the tongue in fire fatalities: the incidence and diagnostic value. *Leg Med (Tokyo)* 5 Suppl. 1:S332–S334, 2003.
75. Fechner, G. G., Gee, D. J. Study on the effects of heat on blood and on the post-mortem estimation of carboxyhaemoglobin and methaemoglobin. *Forensic Sci. Int.* 40:63–67, 1989.
76. Curry, A. S., Price, D. E., Rutter, E. R. The production of cyanide in post mortem material. *Acta Pharmacol. Toxicol. (Copenh.)* 25:339–344, 1967.
77. Ballantyne, B., Bright, J. E., Williams, P. The post-mortem rate of transformation of cyanide. *Forensic Sci.* 3:71–76, 1974.
78. Matsubara, K., Akane, A., Maseda, C., Shiono, H. “First pass phenomenon” of inhaled gas in the fire victims. *Forensic Sci. Int.* 46:203–208, 1990.
79. Miyazaki, T., Kojima, T., Yashiki, M., Chikasue, F., Iwasaki, Y. Interpretation of COHb concentrations in the left and right heart blood of cadavers. *Int. J. Legal Med.* 105:65–68, 1992.
80. Roh, L., Paparo G. Detection of accelerants on a burn victim. *J. Forensic Sci.* 28:292, 1983.
81. Ettling, B. V., Adams, M. F. The study of accelerant residues in fire remains. *J. Forensic Sci.* 13:76–89, 1968.
82. Shiono, H., Matsubara, K., Akane, A., Fukushima, S., Takahashi, S. Immolation after drinking kerosene. *Am. J. Forensic Med. Pathol.* 10:229–231, 1989.
83. Ho, W. S., Ying, S. Y. Suicidal burns in Hong Kong Chinese. *Burns* 27:125–127, 2001.
84. Kojima, T., Yashiki, M., Chikasue, F., Miyazaki, T. Analysis of inflammable substances to determine whether death has occurred before or after burning. *Z. Rechtsmed.* 103:613–619, 1990.
85. Herrmann, N. P., Bennett, J. L. The differentiation of traumatic and heat-related fractures in burned bone. *J. Forensic Sci.* 44:461–469, 1999.
86. Iwase, H., Yamada, Y., Ootani, S., et al. Evidence for an antemortem injury of a burned head dissected from a burned body. *Forensic Sci. Int.* 94:9–14, 1998.



87. Raekallio, J. Histological estimation of the age of injuries. In: Perper, J. A., Wecht, C. H., eds. *Microscopic diagnosis in forensic pathology*. Charles C. Thomas, Springfield, IL, pp. 3–16, 1980.
88. Davies, M. R., Cywes, S., Van der Riet, R. L., Davies, D., Rode, H. A review of deaths in a paediatric burns unit. *S. Afr. Med. J.* 50:1479–1483, 1976.
89. Stitz, R. W. Burns in children. A three-year survey. *Med. J. Aust.* 1:357–361, 1972.
90. Jay, K. M., Bartlett, R. H., Danet, R., Allyn, P. A. Burn epidemiology: a basis for burn prevention. *J. Trauma* 17:943–947, 1977.
91. Cerovac, S., Roberts, A. H. Burns sustained by hot bath and shower water. *Burns* 26:251–259, 2000.
92. Katcher, M. L. Scald burns from hot tap water. *JAMA* 246:1219–1222, 1981.
93. Ryan, C. M., Schoenfeld, D. A., Thorpe, W. P., Sheridan, R. L., Cassem, E. H., Tompkins, R. G. Objective estimates of the probability of death from burn injuries. *N. Engl. J. Med.* 338:362–366, 1998.
94. Curreri, P. W., Luterma, A., Braun, D. W., Jr., Shires, G. T. Burn injury. Analysis of survival and hospitalization time for 937 patients. *Ann. Surg.* 192:472–478, 1980.
95. Feller, I., Flora, J. D., Jr., Bawol, R. Baseline results of therapy for burned patients. *JAMA* 236:1943–1947, 1976.
96. Roi, L. D., Flora, J. D., Jr., Davis, T. M., Wolfe, R. A. Two new burn severity indices. *J. Trauma* 23:1023–1029, 1983.
97. Zawacki, B. E., Azen, S. P., Imbus, S. H., Chang, Y. T. Multifactorial probit analysis of mortality in burned patients. *Ann. Surg.* 189:1–5, 1979.
98. Pruitt, B. A., Jr. Complications of thermal injury. *Clin. Plast. Surg.* 1:667–691, 1974.
99. Pruitt, B. A., Jr., Flemma, R. J., DiVincenti, F. C., Foley, F. D., Mason, A. D., Jr., Young, W. G., Jr. Pulmonary complications in burn patients. A comparative study of 697 patients. *J. Thorac. Cardiovasc. Surg.* 59:7–20, 1970.
100. Linares, H. A. A report of 115 consecutive autopsies in burned children: 1966–80. *Burns Incl. Therm. Inj.* 8:263–270, 1982.
101. Sevvitt, S. A review of the complications of burns, their origin and importance for illness and death. *J. Trauma* 19:358–369, 1979.
102. Heimbach, D. M., Waeckerle, J. F. Inhalation injuries. *Ann. Emerg. Med.* 17:1316–1320, 1988.
103. Marshall, W. G., Jr., Dimick, A. R. The natural history of major burns with multiple sub-system failure. *J. Trauma* 23:102–105, 1983.
104. Hill, I. Inhalational injury in fires. *Med. Sci. Law* 29:91–99, 1989.
105. Hobson, K. G., Young, K. M., Ciraulo, A., Palmieri, T. L., Greenhalgh, D. G. Release of abdominal compartment syndrome improves survival in patients with burn injury. *J. Trauma* 53:1129–1133, 2002.
106. Ivy, M. E., Possenti, P. P., Kepros, J., et al. Abdominal compartment syndrome in patients with burns. *J. Burn Care Rehabil.* 20:351–353, 1999.
107. Quinby, W. C., Jr. Restrictive effects of thoracic burns in children. *J. Trauma* 12: 646–655, 1972.
108. Ruddy, R. M. Smoke inhalation injury. *Pediatr. Clin. North Am.* 41:317–336, 1994.
109. Stone, H. H. Pulmonary burns in children. *J. Pediatr. Surg.* 14:48–52, 1979.
110. DiVincenti, F. C., Pruitt, B. A., Jr., Reckler, J. M. Inhalation injuries. *J. Trauma* 11:109–117, 1971.
111. Santucci, S. G., Gobara, S., Santos, C. R., Fontana, C., Levin, A. S. Infections in a burn intensive care unit: experience of seven years. *J. Hosp. Infect.* 53:6–13, 2003.
112. Nieman, G. F., Clark, W. R., Jr., Wax, S. D., Webb, S. R. The effect of smoke inhalation on pulmonary surfactant. *Ann. Surg.* 191:171–181, 1980.
113. Whitelock-Jones, L., Bass, D. H., Millar, A. J., Rode, H. Inhalation burns in children. *Pediatr. Surg. Int.* 15:50–55, 1999.

114. Meyers, D. G., Hoestje, S. M., Korentager, R. A. Incidence of cardiac events in burned patients. *Burns* 29:367–368, 2003.
115. Sevitt, S. Coronary thrombosis following injury and burns. *Med. Sci. Law* 13:185–191, 1973.
116. Foley, F. D., Moncrief, J. A., Mason, A. D., Jr. Pathology of the lung in fatally burned patients. *Ann. Surg.* 167:251–264, 1968.
117. Paret, G., Ziv, T., Augarten, A., et al. Acute respiratory distress syndrome in children: a 10 year experience. *Isr. Med. Assoc. J.* 1:149–153, 1999.
118. Pruitt, B. A., Jr., Foley, F. D., Moncrief, J. A. Curling's ulcer: a clinical-pathology study of 323 cases. *Ann. Surg.* 172:523–539, 1970.
119. Reckler, J. M., Bruck, H. M., Munster, A. M., Curreri, P. W., Pruitt, B. A., Jr. Superior mesenteric artery syndrome as a consequence of burn injury. *J. Trauma* 12:979–985, 1972.
120. Lescher, T. J., Teegarden, D. K., Pruitt, B. A., Jr. Acute pseudo-obstruction of the colon in thermally injured patients. *Dis. Colon Rectum* 21:618–622, 1978.
121. Desai, M. H., Herndon, D. N., Rutan, R. L., Abston, S., Linares, H. A. Ischemic intestinal complications in patients with burns. *Surg. Gynecol. Obstet.* 172:257–261, 1991.
122. DuPriest, R. W., Jr., Khaneja, S. C., Cowley, R. A. Acute cholecystitis complicating trauma. *Ann. Surg.* 189:84–89, 1979.
123. Munster, A. M., Goodwin, M. N., Pruitt, B. A., Jr. Acalculous cholecystitis in burned patients. *Am. J. Surg.* 122:591–593, 1971.
124. Foley, F. D., Pruitt, B. A., Jr., Moncrief, J. A. Adrenal hemorrhage and necrosis in seriously burned patients. *J. Trauma* 7:863–870, 1967.
125. Linnemann, C. C., Jr., MacMillan, B. G. Viral infections in pediatric burn patients. *Am. J. Dis. Child.* 135:750–753, 1981.
126. Seeman, J., Konigova, R. Cytomegalovirus infection in severely burned patients. *Acta Chir. Plast.* 18:142–151, 1976.
127. Coleman, J. B., Chang, F. C. Pulmonary embolism. An unrecognized event in severely burned patients. *Am. J. Surg.* 130:697–699, 1975.
128. Champion, H. R., Jones, R. T., Trump, B. F., et al. Post-traumatic hepatic dysfunction as a major etiology in post-traumatic jaundice. *J. Trauma* 16:650–657, 1976.
129. Czaja, A. J., Rizzo, T. A., Smith, W. R., Jr., Pruitt, B. A., Jr. Acute liver disease after cutaneous thermal injury. *J. Trauma* 15:887–894, 1975.
130. McManus, W. F., Eurenus, K., Pruitt, B. A., Jr. Disseminated intravascular coagulation in burned patients. *J. Trauma* 13:416–422, 1973.
131. Sheridan, R. L., Ryan, C. M., Yin, L. M., Hurley, J., Tompkins, R. G. Death in the burn unit: sterile multiple organ failure. *Burns* 24:307–311, 1998.
132. Tweed, A., Ross, J. F. A review of the mortality in the burns units at the Victoria General Hospital and the Izaak Walton Killam Hospital, January, 1967, to April, 1977. *Ann. Plast. Surg.* 2:491–498, 1979.
133. Crapo, R. O. Smoke-inhalation injuries. *JAMA* 246:1694–1696, 1981.
134. Moylan, J. A., Jr., West, J. T., Nash, G., Bowen, J. A., Pruitt, B. A., Jr. Tracheostomy in thermally injured patients: a review of five years' experience. *Am. Surg.* 38:119–123, 1972.
135. Fish, J., Hartshorne, N., Reay, D., Heimbach, D. The role of autopsy on patients with burns. *J. Burn Care Rehabil.* 21:339–344, 2000.
136. Balakrishnan, C., Greer, K. A., Tse, K. G., Hardaway, M. Y. Specific pattern burn in a psychiatric patient. *Burns* 19:439–440, 1993.
137. Varghese, T. K., Kim, A. W., Kowal-Vern, A., Latenser, B. A. Frequency of burn-trauma patients in an urban setting. *Arch. Surg.* 138:1292–1296, 2003.
138. Bruner, J. M. Hazards of electrical apparatus. *Anesthesiology* 28:396–425, 1967.
139. Koumbourlis, A. C. Electrical injuries. *Crit. Care Med.* 30:S424–S430, 2002.
140. Wright, R. K. Death or injury caused by electrocution. *Clin. Lab. Med.* 3:343–353, 1983.
141. Cooper, M. A. Electrical and lightning injuries. *Emerg. Med. Clin. North Am.* 2:489–501, 1984.
142. Fontanarosa, P. B. Electrical shock and lightning strike. *Ann. Emerg. Med.* 22:378–387, 1993.

143. Ghezzi, K. T. Lightning injuries. A unique treatment challenge. *Postgrad. Med.* 85:197–198, 201–203, 207–208, 1989.
144. Kobernick, M. Electrical injuries: pathophysiology and emergency management. *Ann. Emerg. Med.* 11:633–638, 1982.
145. Leibovici, D., Shemer, J., Shapira, S. C. Electrical injuries: current concepts. *Injury* 26: 623–627, 1995.
146. DeBono, R. A histological analysis of a high voltage electric current injury to an upper limb. *Burns* 25:541–547, 1999.
147. Lee, R. C. Injury by electrical forces: pathophysiology, manifestations, and therapy. *Curr. Probl. Surg.* 34:677–764, 1997.
148. Luce, E. A., Gottlieb, S. E. “True” high-tension electrical injuries. *Ann. Plast. Surg.* 12:321–326, 1984.
149. Solem, L., Fischer, R. P., Strate, R. G. The natural history of electrical injury. *J. Trauma* 17:487–492, 1977.
150. Sances, A., Jr., Larson, S. J., Myklebust, J., Cusick, J. F. Electrical injuries. *Surg. Gynecol. Obstet.* 149:97–108, 1979.
151. DiVincenti, F. C., Moncrief, J. A., Pruitt, B. A., Jr. Electrical injuries: a review of 65 cases. *J. Trauma* 9:497–507, 1969.
152. Cooper, M. A. Emergent care of lightning and electrical injuries. *Semin. Neurol.* 15: 268–278, 1995.
153. Blount, B. W. Lightning injuries. *Am. Fam. Physician* 42:405–415, 1990.
154. Williams, D. B., Karl, R. C. Intestinal injury associated with low-voltage electrocution. *J. Trauma* 21:246–250, 1981.
155. Morgan, Z. V., Jr., Headley, R. N., Alexander, E. A., Sawyer, C. G. Atrial fibrillation and epidural hematoma associated with lightning stroke; report of a case. *N. Engl. J. Med.* 259:956–959, 1958.
156. Bligh-Glover, W. Z., Miller, F. P., Balraj, E. K. Two cases of suicidal electrocution. *Am. J. Forensic Med. Pathol.* 25:255–258, 2004.
157. Martinez, J. A., Nguyen, T. Electrical injuries. *South. Med. J.* 93:1165–1168, 2000.
158. Butler, E. D., Gant, T. D. Electrical injuries, with special reference to the upper extremities. A review of 182 cases. *Am. J. Surg.* 134:95–101, 1977.
159. Bernstein, T. Effects of electricity and lightning on man and animals. *J. Forensic Sci.* 18:3–11, 1973.
160. Lee, W. R. The mechanisms of death from electric shock. *Med. Sci. Law* 18:23–28, 1965.
161. Jumbelic, M. I. Forensic perspectives of electrical and lightning injuries. *Semin. Neurol.* 15:342–350, 1995.
162. Krompecher, T., Bergerioux, C. Experimental evaluation of rigor mortis. VII. Effect of ante- and post-mortem electrocution on the evolution of rigor mortis. *Forensic Sci. Int.* 38:27–35, 1988.
163. Wright, R. K., Davis, J. H. The investigation of electrical deaths: a report of 220 fatalities. *J. Forensic Sci.* 25:514–521, 1980.
164. Cooper, M. A. Lightning injuries: prognostic signs for death. *Ann. Emerg. Med.* 9:134–138, 1980.
165. Craig, S. R. When lightning strikes. Pathophysiology and treatment of lightning injuries. *Postgrad. Med.* 79:109–112;121–124, 1986.
166. Kleinschmidt-DeMasters, B. K. Neuropathology of lightning-strike injuries. *Semin. Neurol.* 15:323–328, 1995.
167. Whitcomb, D., Martinez, J. A., Daberkow, D. Lightning injuries. *South. Med. J.* 95:1331–1334, 2002.
168. Hunt, J. L., Mason, A. D., Jr., Masterson, T. S., Pruitt, B. A., Jr. The pathophysiology of acute electric injuries. *J. Trauma* 16:335–340, 1976.

169. Ditto, E. W., III. Electrocution during sexual activity. *Am. J. Forensic Med. Pathol.* 2:271–272, 1981.
170. Cooke, C. T., Cadden, G. A., Margolius, K. A. Autoerotic deaths: four cases. *Pathology* 26:276–280, 1994.
171. Bailey, B., Forget, S., Gaudreault, P. Prevalence of potential risk factors in victims of electrocution. *Forensic Sci. Int.* 123:58–62, 2001.
172. Hunt, J. L., McManus, W. F., Haney, W. P., Pruitt, B. A., Jr. Vascular lesions in acute electric injuries. *J. Trauma* 14:461–473, 1974.
173. Levy, L. S. Physiological changes during electrical asphyxiation. *Br. J. Ind. Med.* 28:164–171, 1971.
174. O’Keefe, G. M., Zane, R. D. Lightning injuries. *Emerg. Med. Clin. N. Am.* 22:369–403, 2004.
175. Kleiner, J. P., Wilkin, J. H. Cardiac effects of lightning stroke. *JAMA* 240:2757–2759, 1978.
176. Moran, K. T., Thupari, J. N., Munster, A. M. Lightning injury: physics, pathophysiology and clinical features. *Ir. Med. J.* 79:120–122, 1986.
177. Centers for Disease Control and Prevention. Lightning-associated deaths—United States, 1980–1995. *MMWR Morb. Mortal. Wkly. Rep.* 47:391–394, 1998.
178. Myers, G. J., Colgan, M. T., VanDyke, D. H. Lightning-strike disaster among children. *JAMA* 238:1045–1046, 1977.
179. Mackenzie, E. C. Electrocution in a bath. *Sci. Justice* 35:253–258, 1995.
180. Bartholome, C. W., Jacoby, W. D., Ramchand, S. C. Cutaneous manifestations of lightning injury. *Arch. Dermatol.* 111:1466–1468, 1975.
181. Fatovich, D. M. Electrocution in Western Australia, 1976–1990. *Med. J. Aust.* 157:762–764, 1992.
182. Rossignol, M., Pineault, M. Classification of fatal occupational electrocutions. *Can. J. Public Health* 85:322–325, 1994.
183. Brokenshire, B., Cairns, F. J., Koelmeyer, T. D., Smeeton, W. M., Tie, A. B. Deaths from electricity. *N. Z. Med. J.* 97:139–142, 1984.
184. Zhang, P., Cai, S. Study on electrocution death by low-voltage. *Forensic Sci. Int.* 76:115–119, 1995.
185. Still, J., Orlet, H., Law, E., Wheeler, M., Pickens, H. Electrocution due to contact of industrial equipment with power lines. *Burns* 23:573–575, 1997.
186. Moghtader, J. C., Himel, H. N., Demun, E. M., Bellian, K. T., Edlich, R. F. Electrical burn injuries of workers using portable aluminium ladders near overhead power lines. *Burns* 19:441–443, 1993.
187. Taylor, A. J., McGwin, G., Jr., Valent, F., Rue, L. W., III. Fatal occupational electrocutions in the United States. *Inj. Prev.* 8:306–312, 2002.
188. Lawrence, R. D., Spitz, W. U., Taff, M. L. Suicidal electrocution in a bathtub. *Am. J. Forensic Med. Pathol.* 6:276–278, 1985.
189. Rai, J., Jeschke, M. G., Barrow, R. E., Herndon, D. N. Electrical injuries: a 30-year review. *J. Trauma* 46:933–936, 1999.
190. Nguyen, B. H., MacKay, M., Bailey, B., Klassen, T. P. Epidemiology of electrical and lightning related deaths and injuries among Canadian children and youth. *Inj. Prev.* 10:122–124, 2004.
191. Tan, C. T., Chao, T. C. A case of fatal electrocution during an unusual autoerotic practice. *Med. Sci. Law* 23:92–95, 1983.
192. Cairns, F. J., Rainer, S. P. Death from electrocution during auto-erotic procedures. *N. Z. Med. J.* 94:259–260, 1981.
193. McLoughlin, E., Joseph, M. P., Crawford, J. D. Epidemiology of high-tension electrical injuries in children. *J. Pediatr.* 89:62–65, 1976.

194. McConnell, T. S., Zumwalt, R. E., Wahe, J., Haikal, N. A., McFeeley, P. J. Rare electrocution due to powerline contact in a hot-air balloon: comparison with fatalities from blunt trauma. *J. Forensic Sci.* 37:1393–1400, 1992.
195. Thomas, P. C., Kumar, P. High tension electrical injury from a telephone receiver. *Burns* 27:502–503, 2001.
196. Mitchell, E. K., Davis, J. H. Electrocution by street lighting. *J. Forensic Sci.* 29:836–842, 1984.
197. Karger, B., Suggeler, O., Brinkmann, B. Electrocution—autopsy study with emphasis on “electrical petechiae.” *Forensic Sci. Int.* 126:210–213, 2002.
198. Fernando, R., Liyanage, S. Suicide by electrocution. *Med. Sci. Law* 30:219–220, 1990.
199. Bligh-Glover, W. Z., Miller, F. P., Balraj, E. K. Two cases of suicidal electrocution. *Am. J. Forensic Med. Pathol.* 25:255–258, 2004.
200. Yamazaki, M., Terada, M., Ogura, Y., Wakusugi, C., Mitsukuni, Y. [A suicidal case of electrocution with hypnotic drug poisoning: an autopsy report]. *Nippon Hoigaku Zasshi* 51:95–101, 1997.
201. Risse, M., Weiler, G., Kaiser, H. [Rare suicidal death by electrocution using a timer and vital reaction]. *Arch. Kriminol.* 197:149–154, 1996.
202. Troger, H. D., Urban, R., Weller, J. P. [Homicide simulating electrocution suicide by spinal anesthesia]. *Beitr. Gerichtl. Med.* 50:1–5, 1992.
203. al Alousi, L. M. Homicide by electrocution. *Med. Sci. Law* 30:239–246, 1990.
204. Pfeiffer, H., Karger, B. Attempted homicide by electrocution. *Int. J. Legal Med.* 111:331–333, 1998.
205. Chao, T. C., Pakiam, J. E., Chia, J. A study of lightning deaths in Singapore. *Singapore Med. J.* 22:150–157, 1981.
206. Cherington, M., Krider, E. P., Yarnell, P. R., Breed, D W. A bolt from the blue: lightning strike to the head. *Neurology* 48:683–686, 1997.
207. Chandrasiri, N. Electrocution by dielectric breakdown (arcing) from overhead high tension cables. *Med. Sci. Law* 28:237–240, 1988.
208. Goodson, M. E. Electrically induced deaths involving water immersion. *Am. J. Forensic Med. Pathol.* 14:330–333, 1993.
209. Moar, J. J., Hunt, J. B. Death from electrical arc flash burns. A report of 2 cases. *S. Afr. Med. J.* 71:181–182, 1987.
210. Taylor, P. H., Pugsley, L. Q., Vogel, E. H., Jr. The intriguing electrical burn. A review of thirty-one electrical burn cases. *J. Trauma* 2:309–326, 1962.
211. Danielsen, L., Gniadecka, M., Thomsen, H. K., et al. Skin changes following defibrillation. The effect of high voltage direct current. *Forensic Sci. Int.* 134:134–141, 2003.
212. Dutra, F. R. Electrical burns of the skin. *Medicolegal investigation. Am. J. Forensic Med. Pathol.* 2:309–312, 1981.
213. ten Duis, H. J., Klasen, H. J., Nijsten, M. W., Pietronero, L. Superficial lightning injuries—their “fractal” shape and origin. *Burns Incl. Therm. Inj.* 13:141–146, 1987.
214. Herrero, F., Garcia-Morato, V., Salinas, V., Alonso, S. An unusual case of lightning injury: a melted silver necklace causing a full thickness linear burn. *Burns* 21:308–309, 1995.
215. Blumenthal, R. Lightning fatalities on the South African Highveld: a retrospective descriptive study for the period 1997 to 2000. *Am. J. Forensic Med. Pathol.* 26:66–69, 2005.
216. Cherington, M., Olson, S., Yarnell, P. R. Lightning and Lichtenberg figures. *Injury* 34:367–371, 2003.
217. Weiss, K. S. Otologic lightning bolts. *Am. J. Otolaryngol.* 1:334–337, 1980.
218. Gordon, M. A., Silverstein, H., Willcox, T. O., Rosenberg, S. I. Lightning injury of the tympanic membrane. *Am. J. Otol.* 16:373–376, 1995.
219. Qureshi, N. H. Indirect lightning strike via telephone wire. *Injury* 26:629–630, 1995.
220. Moulson, A. M. Blast injury of the lungs due to lightning. *Br. Med. J. (Clin. Res. Ed.)* 289:1270–1271, 1984.



221. Ekoe, J. M., Cunningham, M., Jaques, O., et al. Disseminated intravascular coagulation and acute myocardial necrosis caused by lightning. *Intensive Care Med.* 11:160–162, 1985.
222. Sinha, A. K. Lightning-induced myocardial injury. A case report with management. *Angiology* 36:327–331, 1985.
223. Zack, F., Hammer, U., Klett, I., Wegener, R. Myocardial injury due to lightning. *Int. J. Legal Med.* 110:326–328, 1997.
224. Cherington, M. Neurologic manifestations of lightning strikes. *Neurology* 60:182–185, 2003.
225. Kint, P. A., Stroy, J. P., Parizel, P. M. Basal ganglia hemorrhage secondary to lightning stroke. *JBR -BTR* 82:113, 1999.
226. Tibesar, R. J., Roy, S., Hom, D. B. Bilateral Le Fort I fracture from a lightning strike injury to the face. *Otolaryngol. Head Neck Surg.* 123:647–649, 2000.
227. Hocking, B., Andrews, C. Fractals and lightning injury. *Med. J. Aust.* 150:409–410, 1989.
228. Jonas, L., Fulda, G., Nizze, H., et al. Detection of gold particles in the neck skin after lightning stroke with evaporation of an ornamental chain. *Ultrastruct. Pathol.* 26:153–159, 2002.
229. Ohashi, M., Kitagawa, N., Ishikawa, T. Lightning injury caused by discharges accompanying flashovers—a clinical and experimental study of death and survival. *Burns Incl. Therm. Inj.* 12:496–501, 1986.
230. Burke, J. F., Quinby, W. C., Jr., Bondoc, C., McLaughlin, E., Trelstad, R. L. Patterns of high tension electrical injury in children and adolescents and their management. *Am. J. Surg.* 133:492–497, 1977.
231. Moran, K. T., Munster, A. M. Low voltage electrical injuries: the hidden morbidity. *J. R. Coll. Surg. Edinb.* 31:227–228, 1986.
232. Jensen, P. J., Thomsen, P. E., Bagger, J. P., Norgaard, A., Baandrup, U. Electrical injury causing ventricular arrhythmias. *Br. Heart J.* 57:279–283, 1987.
233. Bailey, B., Gaudreault, P., Thivierge, R. L., Turgeon, J. P. Cardiac monitoring of children with household electrical injuries. *Ann. Emerg. Med.* 25:612–617, 1995.
234. Sprecher, W., Wenz, W., Haffner, H. T. Rupture of an intracranial aneurysm—unusual complication of an electric shock. *Forensic Sci. Int.* 122:85–88, 2001.
235. James, T. N., Riddick, L., Embry, J. H. Cardiac abnormalities demonstrated postmortem in four cases of accidental electrocution and their potential significance relative to nonfatal electrical injuries of the heart. *Am. Heart J.* 120:143–157, 1990.
236. Xenopoulos, N., Movahed, A., Hudson, P., Reeves, W. C. Myocardial injury in electrocution. *Am. Heart J.* 122:1481–1484, 1991.
237. Walton, A. S., Harper, R. W., Coggins, G. L. Myocardial infarction after electrocution. *Med. J. Aust.* 148:365–367, 1988.
238. Colonna, M., Caruso, G., Nardulli, F., Altamura, B. Myocardial haemorrhagic necrosis in delayed death from electrocution. *Acta Med. Leg. Soc. (Liege)* 39:145–147, 1989.
239. Fieguth, A., Schumann, G., Troger, H. D., Kleemann, W. J. The effect of lethal electrical shock on postmortem serum myoglobin concentrations. *Forensic Sci. Int.* 105:75–82, 1999.
240. Puschel, K., Lockemann, U., Bartel, J. Postmortem investigation of serum myoglobin levels with special reference to electrical fatalities. *Forensic Sci. Int.* 72:171–177, 1995.
241. Poate, W. J., Macafee, A. L. Gas gangrene following electrical burns. A report of two cases. *Br. J. Plast. Surg.* 15:17–19, 1962.
242. Kumar, S., Thomas, S., Lehri, S. Abdominal wall and stomach perforation following accidental electrocution with high tension wire: a unique case. *J. Emerg. Med.* 11:141–145, 1993.
243. Carvajal, H. F., Feinstein, R., Traber, D. L., et al. An objective method for early diagnosis of gram-negative septicemia in burned children. *J. Trauma* 21:221–227, 1981.
244. Chari, P. S., Bapna, B. C., Balakrishnan, C. Electrical burns causing a urinary bladder fistula. Case report. *Plast. Reconstr. Surg.* 61:446–448, 1978.
245. Sinha, J. K., Roy, S. K. Perforation of the caecum caused by an electrical burn. *Br. J. Plast. Surg.* 29:179–181, 1976.

246. Newsome, T. W., Curreri, P. W., Eurenus, K. Visceral injuries: an unusual complication of an electrical burn. *Arch. Surg.* 105:494–497, 1972.
247. Patel, A., Lo, R. Electric injury with cerebral venous thrombosis. Case report and review of the literature. *Stroke* 24:903–905, 1993.
248. Levine, N. S., Atkins, A., McKeel, D. W., Jr., Peck, S. D., Pruitt, B. A., Jr. Spinal cord injury following electrical accidents: case reports. *J. Trauma* 15:459–463, 1975.
249. Kotak, B. P., Haddo, O., Iqbal, M., Chissell, H. Bilateral scapular fractures after electrocution. *J. R. Soc. Med.* 93:143–144, 2000.
250. Brown, R. J. Bilateral dislocation of the shoulders. *Injury* 15:267–273, 1984.
251. Jacobsen, H. Electrically induced deposition of metal on the human skin. *Forensic Sci. Int.* 90:85–92, 1997.
252. Odesanmi, W. O. Things are not always what they seem! Joule burns in electrocution—a report of four cases. *Med. Sci. Law* 27:63–67, 1987.
253. Karlsmark, T., Thomsen, H. K., Danielsen, L., et al. The morphogenesis of electrically and heat-induced dermal changes in pig skin. *Forensic Sci. Int.* 39:175–188, 1988.
254. Karlsmark, T., Thomsen, H. K., Danielsen, L., et al. Tracing the use of electrical torture. *Am. J. Forensic Med. Pathol.* 5:333–337, 1984.
255. Karlsmark, T., Aalund, O., Danielsen, L., et al. The occurrence of calcium salt deposition on dermal collagen fibres following electrical injury to porcine skin. *Forensic Sci. Int.* 39:245–255, 1988.
256. Karlsmark, T., Danielsen, L., Aalund, O., et al. Electrically-induced collagen calcification in pig skin. A histopathologic and histochemical study. *Forensic Sci. Int.* 39:163–174, 1988.
257. Adjutantis, G., Dritsas, C., Iordanidis, P. An unusual occurrence of electric burns in a case of fatal electrocution. *Forensic Sci.* 2:255–257, 1973.
258. Marcinkowski, T., Pankowski, M. Significance of skin metallization in the diagnosis of electrocution. *Forensic Sci. Int.* 16:1–6, 1980.
259. Ortmann, C., Rolf, B., Fechner, G. DNA-typing of cellular material on current conductors. *Int. J. Legal Med.* 111:177–179, 1998.
260. Clemenson, C. J. Blast injury. *Physiol. Rev.* 36:336–354, 1956.
261. Guy, R. J., Glover, M. A., Cripps, N. P. The pathophysiology of primary blast injury and its implications for treatment. Part I: The thorax. *J. R. Nav. Med. Serv.* 84:79–86, 1998.
262. Marshall, T. A pathologist's view of terrorist violence. *Forensic Sci. Int.* 36:57–67, 1988.
263. Wright, R. K. Death or injury caused by explosion. *Clin. Lab. Med.* 3:309–319, 1983.
264. Makitie, I., Paloneva, H., Tikka, S. Explosion injuries in Finland 1991–1995. *Ann. Chir. Gynaecol.* 86:209–213, 1997.
265. Botti, K., Grosleron-Gros, N., Khaldi, N., Oliviera, A., Gromb, S. Postmortem findings in 22 victims due to two grain silo explosions in France. *J. Forensic Sci.* 48:827–831, 2003.
266. Nicholas, E. J. Underground explosions in coal mines. *Med. Sci. Law* 16:240–243, 1976.
267. Shields, L. B., Hunsaker, D. M., Hunsaker, J. C., III, Humbert, K. A. Nonterrorist suicidal deaths involving explosives. *Am. J. Forensic Med. Pathol.* 24:107–113, 2003.
268. Tsokos, M., Turk, E. E., Madea, B., et al. Pathologic features of suicidal deaths caused by explosives. *Am. J. Forensic Med. Pathol.* 24:55–63, 2003.
269. Karmy-Jones, R., Kissinger, D., Golocovsky, M., Jordan, M., Champion, H. R. Bomb-related injuries. *Mil. Med.* 159:536–539, 1994.
270. Mellor, S. G., Cooper, G. J. Analysis of 828 servicemen killed or injured by explosion in Northern Ireland 1970–84: the Hostile Action Casualty System. *Br. J. Surg.* 76:1006–1010, 1989.
271. Clark, M. A. The pathology of terrorism. Acts of violence directed against citizens of the United States while abroad. *Clin. Lab. Med.* 18:99–114, 1998.
272. Cooper, G. J., Maynard, R. L., Cross, N. L., Hill, J. F. Casualties from terrorist bombings. *J. Trauma* 23:955–967, 1983.

273. Andersen, P., Loken, S. Lung damage and lethality by underwater detonations. *Acta Physiol. Scand.* 72:6–14, 1968.
274. Marshall, T. K. Deaths from explosive devices. *Med. Sci. Law* 16:235–239, 1976.
275. Cripps, N. P., Glover, M. A., Guy, R. J. The pathophysiology of primary blast injury and its implications for treatment. Part II: The auditory structures and abdomen. *J. R. Nav. Med. Serv.* 85:13–24, 1999.
276. Saravanapavananthan, N. Injuries caused by home-made explosives. *Forensic Sci. Int.* 12:131–136, 1978.
277. Hull, J. B., Bowyer, G. W., Cooper, G. J., Crane, J. Pattern of injury in those dying from traumatic amputation caused by bomb blast. *Br. J. Surg.* 81:1132–1135, 1994.
278. Varga, M., Csabai, G. A suicidal death by explosives. *Int. J. Legal Med.* 105:35–37, 1992.
279. Karger, B., Zweihoff, R. F., DuChesne, A. Injuries from hand grenades in civilian settings. *Int. J. Legal Med.* 112:372–375, 1999.
280. Katz, E., Ofek, B., Adler, J., Abramowitz, H. B., Krausz, M. M. Primary blast injury after a bomb explosion in a civilian bus. *Ann. Surg.* 209:484–488, 1989.
281. Brismar, B., Bergenwald, L. The terrorist bomb explosion in Bologna, Italy, 1980: an analysis of the effects and injuries sustained. *J. Trauma* 22:216–220, 1982.
282. Guy, R. J., Watkins, P. E., Edmondstone, W. M. Electrocardiographic changes following primary blast injury to the thorax. *J. R. Nav. Med. Serv.* 86:125–133, 2000.
283. Guy, R. J., Kirkman, E., Watkins, P. E., Cooper, G. J. Physiologic responses to primary blast. *J. Trauma* 45:983–987, 1998.
284. Laposata, E. A. Collection of trace evidence from bombing victims at autopsy. *J. Forensic Sci.* 30:789–797, 1985.
285. Yallop, H. J. Loss of clothes in an explosion. *J. Forensic Sci. Soc.* 22:399–400, 1982.

## Chapter 5

---

# *Bodies Recovered From Water*

### Summary

Recovery of a body from water does not mean drowning. Other causes of death, including trauma, are possible. Drowning is a type of asphyxia that involves complex pathophysiological mechanisms, which contribute to death. Premorbid conditions (e.g., ischemic heart disease, epilepsy, ethanol intoxication) increase the risk of drowning. Despite the complexity of the drowning process, associated external and internal findings are few. The lack of specific signs and submersion artifacts can hinder the determination of the cause of death in a presumed drowning. Various drowning “tests” have been used to assist in this assessment. A bathtub death can be particularly challenging because all manners of death occur. A diver’s death, ironically, can be caused by the artificial air supply.

**Key Words:** Asphyxia; drowning; immersion; diatoms; hypothermia; diving.

### 1. INTRODUCTION

Finding a body in water poses a challenge for the pathologist and other investigators determining the cause and manner of death (1–5). All manners of death are possible (6). Drowning is one of the leading causes of death associated with an undetermined manner (7). Information about the circumstances preceding the drowning—i.e., how the victim became submerged—are lacking in many cases, because the events prior to submersion are unwitnessed (1,3,8–10). Witnesses were present in one-half to three-fourths of drownings in some series (11,12). In a review of 1590 bodies found in water, 37.3, 30.8, 12.4, 11.9, and 5.3% of the accidents, homicides, suicides, natural deaths, and undetermined cases, respectively, were witnessed (overall = 25.3% [3]). More than half the witnessed cases had a single uncorroborated witness, which raised issues about the nature of the relationship between the witness and victim. Even multiple witnesses provide contradictory observations. A small percentage (6.9%) of undetermined cases, in one series, were witnessed, but investigators were still uncertain whether entrance into the water was accidental or deliberate (7).

The majority of submerged bodies, including those of undetermined manner, have been classified as drownings (5,7,13). Although the likelihood is that the cause of the

From: *Forensic Science and Medicine: Forensic Pathology of Trauma:  
Common Problems for the Pathologist*

By: M. J. Shkrum and D. A. Ramsay © Humana Press Inc., Totowa, NJ

death in a submerged body is drowning, other potential causes of death (disease, trauma) need to be considered (*see* Headings 5–7. and refs. [1](#), [9](#), [10](#), and [14–16](#)). The postmortem diagnosis of drowning requires exclusion of these other possibilities, with the realization that during the agonal stages of natural and other types of unnatural deaths, aspiration of water does occur ([2,4,7,17–20](#)). An autopsy is essential in the determination of the cause and manner of death ([21,22](#)). Determination that the victim was alive on entering the water and consequently drowned is based on the various nonspecific external and internal findings; however, these observations, coupled with the circumstances of the death, support drowning as a cause of death ([1,3,5–10,19,20,23,24](#)). The determination of drowning is hindered by a prolonged submersion interval, and decomposition alters and obliterates the few pathological findings available ([10,25–27](#)). Pathologists also need to address why the victim was unable to survive in the water ([1](#)). Despite the paucity of postmortem findings, drowning involves complex pathophysiological mechanisms dependent on the various factors related to the victim and the scene.

## *2. EPIDEMIOLOGY AND CIRCUMSTANCES*

### *2.1. Manner of Death*

In a study from Finland of 1590 bodies recovered from water, 56.2% were classified as accidents, 23.8% as suicides, 16.5% as undetermined, 0.8% as homicides, and 2.6% as natural ([3](#)). A 4-yr study of 123 bodies recovered from New York City waterways showed 42% were suicides, 41% undetermined, 13% accidents, and 4% homicides ([5](#)). An interstate study of 1201 submersion cases included 11% of undetermined manner ([13](#)). The manner of death is also dependent on the legal standard of proof, which varies in different jurisdictions ([7](#)).

Various studies have shown that cases considered as drowning (as opposed to bodies recovered from water in which the cause of death is not necessarily drowning) in all age groups are accidental in about 90% of cases ([4,13,18,28–30](#)). Suicides comprise most of the remainder of cases, although some studies outside North America have shown a higher incidence (*see* Heading 3. and refs. [4](#), [9](#), [13](#), [18](#), [24](#), [28](#), and [31–34](#)). Homicides are uncommon ([13,18,28,30,33,35,36](#)). One series found no cases of women younger than 30 yr committing suicide, meaning that accident and homicide needed to be excluded ([37](#)).

### *2.2. Groups at Risk*

Drowning victims are predominantly male (>65% [[11–13,28,30,33,38–48](#)]). A male predominance likely reflects that males are more active and risk-taking in water ([42](#)).

Drownings typically occur in the summer months, more frequently in rivers, lakes, ponds, and creeks ([11–13,32,38,44,45,48](#)). In northern climates, snowmobiles and motor vehicles break through ice ([44](#)). Swimming, diving, and wading are common activities associated with drowning ([12,28,30,44,49,50](#)). Men in their late teens and 20s are at risk ([11,12,30,44,45,47,48,51](#)). Many swimmers who drown are teenagers ([13](#)). Drugs and alcohol are factors, particularly when there is limited adult supervision of teenagers ([29,39,41,45,48,52](#)). Most drowning victims can swim, implying that other factors (e.g., ethanol intoxication) are involved ([13](#)). Other “normal” activities associated



with drowning include fishing, motorboating, and bathing (12,28,33). Drowning of older males occurs more frequently when associated with certain activities (e.g., fishing, motorboating [12,13,47]). Most of these individuals are not wearing life jackets (13,19,44,45,47). Hazardous activities occur in watercraft accidents (overcrowding, speeding, reckless driving [19,45]). Inadvertently entering the water (e.g., motor vehicle crashes, falling into water) also causes drowning (13,30,32,38,44). Ethanol intoxication may be a factor (19,47). These victims are found fully or partly clothed and not wearing a swimsuit (41). Investigators need to exclude the possibility that an individual deliberately entered the water (4,37).

Children are at risk for drowning (28,43,44,47,48,53). Children, particularly those younger than 2 yr old, are vulnerable (54–56). Lacking fully developed motor skills and balance, they cannot extricate themselves from a dangerous situation (55). They are unable to swim, cannot vocalize loudly, and struggle minimally (55). Swimming pool immersion risk is dependent on the prevalence of swimming pools, which is dictated by climate (43,44,57). In cooler climates, drownings tend to occur in natural bodies of fresh water (48).

At home, swimming pools and bathtubs are hazardous settings for infants (*see* Subheading 13.1. and refs. 11, 13, 29, 38–40, 53–56, and 58–60). Children less than 1 yr of age are at risk for bathtub drowning; infants older than 1 yr have a higher risk of drowning in a pool. Children are at higher risk of drowning in inground pools compared with aboveground pools (61). The highest risk in young children is within the first 6 mo after a pool is installed (62). Toddlers may be simply playing near the pool edge rather than wading (12,39,55,57,63). A similar scenario is seen with infants playing near the surf at a beach (46,64). Stepping onto solar pool blankets is a potential hazard for children (48).

Lack of adult supervision around swimming pools, especially those at private residences, has been noted (11–13,19,42,48,57,60,63,65,66). Supervising adults may be intoxicated (48). Although adult supervision around pools was present in 84% of cases in one series, only 18% of the adults witnessed the incident, suggesting a momentary lapse of attention (67). The proximity of adults means that immersion time is usually only minutes, and resuscitation is initiated quickly (39,57). The survival rate for a child losing consciousness in a swimming pool was 65% in one series, compared with 21% in children immersed in a river or creek (40).

Lack of pool barriers is also a factor (13,29,38,39,45,48,56,58–61,63,65,68,69). Fences may be inadequate (e.g., gate lock broken, gate propped open for ease of access [42]). The presence of inadequate fencing gives parents a false sense of security, decreasing their vigilance and delaying the extrication time of the victim (61).

Drowning in public pools usually involves teenagers, even when lifeguards are present (13). A lack of supervision may also be a factor in adult drownings (49). Older children who drown in pools may be unrecognized in a crowd of swimmers (61).

Some studies have noted a high incidence of drowning in 5-gal buckets (38,53,55,56). Toddlers, because of a high center of gravity, are prone to falling into buckets (53,70). The at-risk age is 8 to 15 mo (71). In most cases, the buckets involved have been used for general cleaning or for dirty diapers (53,70). They are filled to at least 10% of capacity, usually with water (53,70). Some contain detergent, cleaner, or bleach (70). Bucket heights range from 34 to 38 cm (14 to 15 in.), and the height of the

victim is 67 to 79 cm (27 to 32 in. [53,55,70]). The buckets may contain items (e.g., toys, clothing) that attract a child's attention (70). The buckets typically are sturdy and do not tip easily even when empty (53,70). Infants have less developed motor control, and, after falling into the bucket, they cannot extricate themselves (53). In some cases, a sleeping infant has rolled into a liquid-filled bucket (70).

### 3. *SUICIDE BY DROWNING*

In various series, the following information has assisted in the determination of suicide: witnesses; a suicide note and suicidal ideation; a history of cancer or terminal illness (known or perceived); recent bizarre behavior or depression; and associated self-inflicted wounds (see Table 1 and ref. 3). A scene finding supportive of suicide is the observation of clothes and personal effects found stacked neatly by the water (4,31). An individual's shoeprints or ski tracks in the snow at the water's edge suggest deliberate entry into cold water (3). There are unusual scene findings that are suspicious (e.g., weights attached to a body, a couple who were tied together at the waist; see Fig. 1 and refs. 4 and 37).

Identification of a submerged body assists in the determination of a suicide (1,5). Once identified, a psychiatric history is helpful (7). Even if there are findings suggestive of suicide (e.g., horizontal wrist scars, toxicological detection of certain medications), without a proper identification, access to additional information is not possible (see Subheading 8.1.). Caution is required in interpreting suicide-like circumstances and past history (e.g., suicide attempts, mental disorder) in assessing the manner of death (7). Suicide is the only manner of death that requires the demonstration of the victim's intent.

## 4. *MECHANISMS OF DEATH FROM WATER SUBMERSION*

### 4.1. *Drowning ("Wet" Drowning, "Classical" Drowning)*

Drowning is defined as the entry or aspiration of fluid through the nose and mouth into the respiratory tract (6,16,47,48,58,73–76). The definition excludes aspiration of vomit, blood, saliva, bile, or meconium (73). "Wet" drowning occurs in about 80 to 90% of cases (see Heading 10. and ref. 75). Complete submersion is not necessary for drowning to occur. An intoxicated, unconscious, epileptic, or very young individual can drown in as little as 5 to 6 cm (2 in.) of water, if fluid covers the mouth and nose (77). The major consequence of drowning is hypoxia (47,48,78–84). The volume and composition of the drowning medium determine the pathophysiological mechanisms leading to hypoxia and eventual cardiac arrest (47,74,78,81,85,86).

The description of the events during drowning are based on witness accounts, human studies, and animal experiments (8). When there is complete submersion without surfacing, a sober victim voluntarily holds his or her breath (58,60,76). This can be enhanced by movements of the respiratory muscles and swallowing against a voluntarily closed glottis (60,87). A large volume of water can be swallowed (58,60,76,87). Vomiting follows, with the risk of gastric content aspiration (58,60,73,88). Concurrent struggling occurs. Children either struggle for 10 to 20 s or sink calmly; adults can struggle up to 60 s (58,73,76). Breath-holding persists until there is an uncontrollable

Table 1  
Suicide by Drowning

Series	<i>n</i>	% Of suicides	% Of drownings	Male: Female	Age range	Site	Psychiatric history	Toxicology	Other comments/ findings
Florida; Copeland (9)	70	4.5% (70/1569)	13.4% (70/521)	41:29	38.6% > 70 yr 1.43% (n = 1) 0–20 yr	Ocean/bay = 31.4% Canal = 21.4% Residence = 21.4% (pool = 10; tub = 5)	Depression—70% Psychiatric history or bizarre behavior—15.7%	<ul style="list-style-type: none"> <li>Of 70 cases, 68 (97.1%) tested for alcohol and 50 (71.4%) for drugs</li> <li>At least 39 (55.7%) negative for ethanol, 17 (24.3%) positive, 12 (17.1%), 100 mg/dL or greater</li> <li>At least 30 (42.8%) negative for drugs, 20 (28.6%) positive (most commonly minor tranquilizers; drugs contributory in three cases)</li> </ul>	Suicide note = 28.6% Verbal equivalent = 25.7% Frequently fully clothed

(Continued)

**Table 1** (*Continued*)

Series	<i>n</i>	% Of suicides	% Of drownings	Male: Female	Age range	Site	Psychiatric history	Toxicology	Other comments/ findings
Florida; Davis (31)	25	2.9% (25/873)	9% (25/267)	14:11	25–91 yr 64% ≥ 65 yr	Residence pool = 28.0% Canal = 24.0% Lake = 20.0% Ocean = 12.0%	Depression—76% Severe mental illness—20%	<ul style="list-style-type: none"> <li>• 6/24 (25%) positive for ethanol (50–350 mg/dL)</li> <li>• 8/25 (32%) tested positive for prescription drugs, three cases beyond therapeutic range (2 in bathtubs, 1 in residential pool)</li> </ul>	<ul style="list-style-type: none"> <li>• About 20% of county inhabitants ≥ 65 yr</li> <li>• Five people drove to location (2 drove into water); 60% in street clothes; 28% partly clothed; 12% nude (<i>see</i> Chapter 5, Heading 13.)</li> </ul>
Texas; Wirthwein et al. (4)	52	0.85% (52/6082)	4% (52/1303)	28:24	21–84 yr 54% males > 40 yr 67% females > 40 yr	Lakes/ponds = 56% Pools = 17%	Psychiatric history and/or alcohol/drug abuse = 50%	<ul style="list-style-type: none"> <li>• Of 52 victims, ethanol positive in 21 but 13 early to mild decomposition</li> <li>• 24 (46%) had other drugs, 4 near or above lethal range</li> </ul>	Two in submerged vehicles

Newfound land, Canada; Avis (72)	22	8.9% (22/ 247)	14:8	77% ≥ 50 yr About one- quarter of all suicides in this age range	Ocean = 86.4% None in bathtubs	• 2/22 (9.1%) tested positive for ethanol (41 mmol/L or 189 mg%, 29.6 mmol/L or 136.5 mg%) • 3/18 (16.7%) tested positive for drugs (trim- ipramine, bro- mazepam, flurazepam), all in therapeutic range	23.5% of women and 6.6% of male chose drowning as means of sui- cide
Adelaide, Australia; Byard et al. (37)	123	76:47	Males: 16–88 yr (avg. 50.5 yr) Females: 34–88 yr (avg. 60.6 yr)	Fresh water = 53.7% Ocean = 46.3%	Mental illness— 43.1%	• Alcohol positive in at least 25 (20.3%) and prescription drugs were seen in 20 cases	Suicide note = 14.6% Health problems = 8.1% Five cases, car driven into water
Finland; Auer (34)	51	17.8% (51/285)	21 to >70 yr 27.5% 21–30 yr 19.6% > 70 yr	Outdoors Tap water (pool, bath) = 5.9%	Psychotic— 15.7%; psychi- atric treatment— 49%; depres- sion—35.3%; suicide attempt— 37.3%		Suicide note = 7.8%





**Fig. 1.** Suicidal drowning. Weight attached to body.

urge to breathe (“break point”), and an involuntary gasp results (60,76,86). During the period of breath-holding, the victim is unable to cry for help (73,88). The mean duration of voluntary breath-holding is about 1.5 min in trained individuals compared with about 1 min in the average person (89). The duration of breath-holding is decreased when the victim is immersed in cold water (*see* Subheading 4.5. and ref. 60).

Following the involuntary gasp, variable laryngospasm occurs when water contacts the glottis (47,58,76,86). More water can also be swallowed at this stage (47). When water is inhaled, a parasympathetic (vagal) reflex causes peripheral airway constriction and increased resistance, resulting in reduced lung compliance (*see* Subheading 4.3. and refs. 58, 60, 76, 90, and 91). Intrapulmonary shunts are created in fresh and salt water submersion by different mechanisms. Inhaled water, contacting the alveolar membrane, affects surfactant (76,78). Experimental studies of dogs showed hyperosmolar, i.e., osmolarity greater than human plasma (e.g., sea water), and iso-osmolar saline solutions dilute or wash out surfactant (58,60,76,81). Fresh water, chlorinated or nonchlorinated, damages the alveolar membrane and decreases surfactant. Impurities in water (dirt, sewage, detergents) are also injurious (*see* Subheading 4.4.). Alveolar collapse (atelectasis) leads to intrapulmonary shunting and ventilation–perfusion mismatch (58,76,78,82,83,85,92). Disturbed pulmonary reflex responses are of prime importance in the clinical setting (73,83). In saltwater drowning, intrapulmonary shunting results when fluid is drawn from the circulation into the alveolar spaces (47,78,83,86,92). Pulmonary edema occurs not only in saltwater drowning but also in freshwater submersion. Although fresh water is absorbed rapidly into the circulation, hypoxia depresses cardiac function. This and altered alveolar capillary permeability

result in an alveolar transudate (84,93,94). The evolution of hypoxia is multifactorial, arising from reduced ventilation owing to laryngospasm, large airway obstruction by froth (edema fluid mixed with water and air), mucus and foreign material, airway constriction, atelectasis, and intra-alveolar edema (60,74,78,90). No difference in survival has been observed in fresh and saltwater drownings; however, rescue services may be better on coastal shores, compared with inland bodies of water, meaning expeditious resuscitation and survival (46,73,88).

Although pulmonary edema is common, changes in blood volume and electrolyte disturbances, as seen in animal experiments (hemoconcentration in saltwater cases; hemolysis, hemodilution, hyponatremia, and hyperkalemia in freshwater aspiration), are usually insignificant in the clinical setting (47,50,58,60,78,80–82,85,88,92,94–97). Generally, the cardiovascular and pulmonary changes associated with the aspiration of water are not dependent on its tonicity (98,99). Changes in intravascular volume in fresh and saltwater drowning are transient in the clinical setting, owing to the body's compensatory mechanisms (47). Electrolyte imbalance can arise from aspiration of large volumes of water. In animal experiments, large volumes (44 mL/kg or 20 mL/lb) of fresh water does cause electrolyte disturbances and hemolysis, but this quantity is unlikely to be aspirated in humans (2,73,100). Research has shown that inhalation of 22 mL/kg (or 10 mL/lb) is associated with normal electrolyte levels (74,78). This was observed in dog experiments, which showed that electrolyte changes were transient and ventricular fibrillation from hyperkalemia did not occur (82,95). One study of drowning victims in fresh and salt water showed that 15% of individuals had inhaled more than 22 mL/kg (10 mL/lb) of water, causing significant changes in chloride levels in the left ventricle (80). Ventricular fibrillation caused by electrolyte disturbance is uncommon in the clinical setting (85,88,95). In animal research, aspiration of 2.2 mL/kg (1 mL/lb) of water causes hypoxia within a few minutes (58,73,76,82,85,92–94). Aspiration of small amounts of water is applicable to near-drowning. There are clinical reports that describe abnormalities resulting from volume and electrolyte changes. For example, significant hemolysis can trigger disseminated intravascular coagulation (DIC [101]). Changes in electrolytes owing to saltwater aspiration are a function of the volume and concentration of the medium (79). Very salty water (e.g., submersion in the Dead Sea) can lead to serum electrolyte changes, but pulmonary pathophysiological complications are still paramount in the clinical management (102).

After the first submerged breath and aspiration of water, secondary apnea follows within seconds (60). There is involuntary gasping under water for several minutes, culminating in respiratory arrest (88). Increasing hypoxia leads to arrhythmias, cardiac arrest, and eventual brain death, if resuscitation is not timely. Unconsciousness from cerebral hypoxia happens within 3 min of involuntary submersion (103). The duration of hypoxia leading to irreversible cerebral damage is age-dependent. Witnessed accounts of immersion time in fatal drownings are estimates at best, and vary depending on age and water temperature (e.g., 3–10 min, if water temperature above 15–20°C [59–68°F]; survival of some children, and even return of normal neurological function, following 5–40 min of immersion in water at 0–15°C [32–59°F]; see Subheading 4.5. and refs. 60, 76, and 103). A study of bathtub immersions showed survival of children who were submerged from 3 to 5 min (median 4 min), and deaths when the immersion time ranged from 3 to 20 min (median 5 min [77]).

## 4.2. Underwater Swimming and Breath-Holding

The “break point”—i.e., the irresistible urge to breathe—is stimulated by a combination of rising arterial carbon dioxide ( $\text{PaCO}_2$ ) and decreasing arterial oxygen ( $\text{PaO}_2$ ) (89,104). The average  $\text{PaCO}_2$  at the break point is 60 mmHg, and the  $\text{PaO}_2$  is about 80 mmHg (58,104). Hyperventilation lowers  $\text{PaCO}_2$  to less than 50 mmHg. If a swimmer hyperventilates and holds his or her breath while doing strenuous activity—i.e., swimming underwater—unconsciousness from hypoxia ( $\text{PaO}_2 < 60$  mmHg) can occur before the break point from increased  $\text{PaCO}_2$  is reached to stimulate breathing (8,58,60,78,105–107). Consequently, drowning occurs. Trained swimmers have a greater tolerance of hypercapnia and, if preoccupied with a goal (e.g., swimming a certain number of laps underwater), can consciously exceed the break point (106,107). Hypercapnia also contributes to arrhythmia (89).

## 4.3. Sudden Death From Submersion (Dry Drowning, Immersion Syndrome)

In about 10 to 20% of cases, the findings of “wet” drowning (pulmonary congestion, froth in respiratory tract) are absent because aspiration of water into the lungs does not occur (6,8,58,74–76,86). Severe glottic spasm was thought to be the mechanism preventing entry of water into the lungs (6,8,47,58,60,74,76,86).

Witnesses have described scenarios in which the victims have been swimming or wading or fall into water and then quickly disappear without a struggle (2,11,15,17–19,78,108). Even with prompt removal from the water, death is immediate. In one study of 34 cases for which information was available, one individual surfaced twice, three surfaced once, and 30 did not surface (11). Apnea can stimulate carotid-body chemoreceptors, contributing to a vagally mediated cardiac arrest (see Subheading 4.1. and ref. 109). The amount of aspirated water may be small, and cardiac arrest precludes further aspiration of water (6,8,58,76,108). Sudden stressful entry into the water could potentiate a vagally mediated cardiac arrest (86). The syndrome particularly affects middle-aged or older men who have ingested nonlethal amounts of ethanol (2,15,18,110). Underlying cardiac disease could increase the risk of sudden collapse (see Heading 7. and ref. 78). Certain individuals may be predisposed to cardiac conduction abnormalities and drown (111).

## 4.4. Near-Drowning

Drowning implies death at the scene (75). Near-drowning is defined as survival for a period of time following resuscitation and treatment (6,32,47,48,56,73,75,87,97). Death is caused by complications (e.g., adult respiratory distress syndrome, pneumonia, sepsis, hypoxic–ischemic encephalopathy, cerebral edema, DIC; see Chapter 1, Subheading 4.3. and refs. 58, 60, 76, 87, and 112). “Secondary drowning” refers to a victim who initially responds well to resuscitation but then suffers respiratory decompensation (46). A proposal to abandon this term has been made (75). Secondary drowning is also applied to a victim drowning after collapsing into water from an illness or an accident (e.g., fall [47,48,73,78]).

Pulmonary complications arise without a loss of consciousness or cessation of breathing (87). Alteration of surfactant can continue after apparently successful resuscitation following aspiration of fresh or salt water (76,87). Fulminant pulmonary edema and alveolar damage develop up to 12 h after a near-drowning incident (76,87,88). The

drowning victim is at risk for aspiration of gastric contents (*see* Subheading 4.1. and refs. [87](#) and [113](#)). Aspiration, inhalation of foreign material, and infection contribute to adult respiratory distress syndrome ([48,59](#)). Hypoxemia leads to multiple organ injury despite mechanical ventilation ([59](#)). Surfactant loss or alteration, atelectasis, increased intrapulmonary shunting, ventilation–perfusion mismatch, and pulmonary edema contribute to hypoxia. About one-third of all near-drowning survivors have been observed to have moderate to severe brain damage ([87](#)). Cold-induced or trauma-associated rhabdomyolysis may result in acute renal failure (*see* Chapter 8, Heading 13. and refs. [87](#) and [97](#)). Hypoxia contributes to the development of acute tubular necrosis ([97](#)).

Favorable prognostic factors in near-drowning cases include young age, relatively short (<10 min) submersion, submersion in cold water (<10°C), absence of aspiration, prompt basic life support, short resuscitation duration (<10 min), rapid return of spontaneous cardiac output, consciousness on admission, presence of pupillary responses, and a core body temperature of less than 33 to 35°C (91–95°F [[59,87,114](#)]). None of these factors is absolutely predictive; therefore, full resuscitation is recommended for all near-drowning victims ([87,115](#)).

Near-drownings are more frequent than drownings ([58,116](#)). In various series of drowning fatalities, immersions have been too long for successful resuscitation to occur. In one study, immersion time was up to 30 min in only 22% of deaths ([30](#)).

## **4.5. Immersion in Cold Water**

### **4.5.1. Cold-Shock Response**

Sudden immersion in cold water can initiate cardiorespiratory reflexes lasting about 2 to 3 min ([87,117](#)).

For a healthy person, the respiratory response represents the greatest threat to survival ([117](#)). A rapid decrease in skin temperature directly stimulates the respiratory drive through afferents from peripheral cold receptors and reaches a maximum in water at about 10°C (50°F [[117,118](#)]). The response can be heightened in a lightly clothed individual ([119](#)). Further reducing the temperature to 0°C (32°F) does not increase the magnitude of the response ([120](#)). In an adult, an initial gasp is followed by uncontrollable hyperventilation ([17,74,87,117,118,121](#)). The resulting reduction in arterial CO<sub>2</sub> tension can lead to ventricular arrhythmia ([117](#)). The reduction of maximum breath-hold times of normally clothed individuals to less than 10 s increases the possibility of water aspiration in turbulent water ([17,87,117](#)). Asynchrony occurs between the action of swimming and breathing, resulting in cold-water swim failure ([87,117](#)). Vigorous movement (e.g., flailing) and consequent vasodilation enhances heat loss ([60](#)).

The initial cardiovascular response reflects sympathetic activation and is characterized by peripheral vasoconstriction, tachycardia, and increased cardiac output ([17,87,117,118,121](#)). Increased heart workload and catecholamine levels can result in arrhythmias, particularly in older victims with cardiovascular disease (*see* Subheading 4.5.3. and refs. [17](#), [96](#), [97](#), and [117](#)). Complete submersion in cold water following breath-holding can increase the frequency of supraventricular arrhythmia ([121](#)).

### **4.5.2. Hypothermia**

Sustained immersion beyond 30 min in cold water leads to hypothermia, defined as a body temperature less than 35°C (95°F [[87,117](#)]). Even in water at 5°C (41°F) for

15 to 30 min, hypothermia is unlikely in a healthy clothed adult immersed head-out (122). Reduction of blood flow to the skin by peripheral vasoconstriction and increased heat production by shivering conserve heat. In laboratory conditions, the core body temperature of an average head-out adult falls to 35°C (95°F) after 1 h in water at 5°C and after 3 to 6 h in water at 15°C (59°F [87]). Historical information suggests that 90 to 120 min is close to the upper limit of survival in water at 0°C (32°F [120]). In real life, heat loss from an unprotected head is enhanced by wind and evaporation (87). Cooling is faster if the head is submerged. Ethanol, despite its vasodilatory effect, does not necessarily increase heat loss, although individuals do feel warm (13,14,17,60,123). Ethanol does reduce shivering during and after submersion (123).

As the core body temperature drops from 34°C to 30°C (93–86°F), the level of consciousness progressively diminishes (87,112,120). As this occurs, water is aspirated unless the victim's head is held above water by a life jacket. Shivering is pronounced until the body temperature reaches 29°C (84°F). Swimming becomes ineffective (87). Ventricular fibrillation occurs when the core temperature reaches below 28°C (82°F), and asystole follows at about 24 to 26°C (75–79°F). Cerebral activity ceases at 22°C (72°F).

“Circumrescue collapse” refers to victims of immersion in cold water who collapse during or shortly after rescue (87,116,124). This has been observed in water up to 18°C (64°F). Immersion compresses peripheral veins of the lower extremities. Blood is redistributed to the upper part of the body (“immersion response” [125]). Increase in central blood volume promotes diuresis and eventual hypovolemia. In cold water, peripheral vasoconstriction exacerbates blood volume redistribution. When an individual is lifted from the buoyant environment of water, the body experiences the full effects of gravity. Pooling of venous blood occurs in the lower extremities, decreasing venous cardiac return. Reflex tachycardia increases demands on the heart and may not be tolerated if cardiac function is compromised by hypothermia and myocardial ischemia, particularly if there is coronary atherosclerosis. In a vertical position, more cardiac effort is required to circulate blood to the brain. The outcome is ventricular fibrillation. Physical exertion by the victim to assist in the rescue increases metabolic demands on the heart. “Rewarming collapse” refers to a drop in arterial pressure when vasoconstriction subsides during rewarming in victims who are hypovolemic because of cold diuresis (124).

In some cases of prolonged submersion in water cooler than 10°C (50°F), the chance of survival is enhanced by hypothermia. This is observed mainly in children and adolescents, although adult survivors have been described (47,48,78,113,116). The rate of hypothermia onset is critical. The normothermic brain suffers irreversible hypoxia if subjected to acute asphyxia longer than 10 min (122). Unlike controlled hypothermia in a medical setting, accidental hypothermia is variable (116,126). For survival to be possible, hypothermia must occur rapidly before severe hypoxia develops from cardiac dysfunction (59,87). Children cool faster because of a greater surface-area-to-mass ratio and a thinner subcutaneum, but reduction of their body core temperature to 24 to 25°C (75–77°F), under controlled conditions (e.g., open heart surgery), still takes about 30 min, too long a period to cool the brain and protect it from drowning-induced hypoxia (59,60,87,126). The degree and rate of body surface cooling, as described, are not enough to be protective (122). Although absorption of aspirated and



swallowed cold water into the circulation is used to explain a more rapid loss of core temperature, absorption of a large amount of water occurs only in a minority of cases (60,87,96,122). A person would need to ingest cold water amounting to 20% of body mass to reach a body temperature of 30°C (122). A diving response may occur in the first 10 min of submersion followed by hypothermia, and in tandem, these physiological processes may allow survival (122).

#### 4.5.3. Mammalian Diving Response

The cold-shock response predominates in most instances of cold water submersion, but about 15% of individuals manifest a diving reflex (see Subheading 4.5.1. and ref. 122). The reflex is more pronounced in children and diminishes with age (28,58,76). The reflex is enhanced as the water becomes colder (122). There is debate as to whether the “mammalian diving response,” either alone or in combination with hypothermia, protects the brain from hypoxia during cold water submersion (48,76,116,122). Immersion of the face in cold water stimulates the ophthalmic division of the trigeminal nerve, and within seconds leads to apnea from reflex inhibition of the respiratory center in the medulla (28,58,76,117,122,127). Facial sensory input and respiratory center inhibition elicit a cardiovascular response, i.e., generalized peripheral vasoconstriction and bradycardia, mediated by sympathetic and vagus nerve stimulation, respectively (122,127). Breath-holding can further enhance bradycardia (122,127,128). The response is also enhanced by fear, but anxiety-induced tachycardia can diminish it (28,122). Autonomic nervous system degeneration (e.g., diabetic neuropathy) and central nervous system depression (e.g., ethanol) blunt the response (122,127). Established bradycardia and shunting of blood from the periphery to the brain and heart occur within 30 s, before consciousness is lost (76,122). Redistribution of blood supply from the periphery to the vital organs and the degree of bradycardia are enough to protect the brain from hypoxia (28,58,117,122). Apnea, as opposed to voluntary breath-holding, prevents aspiration of water. Cold water, approaching 0°C or 32°F, has been associated with a greater incidence of cardiac arrhythmias (28,127).

### 5. OTHER MECHANISMS OF DEATH DURING WATER SUBMERSION

- *Diving*: Of all water-related activities, diving into water causes the most spinal cord injuries, particularly in males aged 20 yr and younger (8,45,47,78). Contributing factors include diving inexperience, unfamiliarity with the area, and ethanol consumption (47).
- *Falls into water*: About one-fourth of drownings in a Maryland study involved activities not normally associated with drowning (fishing at the water's edge, playing, walking near water [11]). Lack of lifelines played a role in deaths of workers.
- *Struck by boat or hit underwater hazard*: Head trauma with unconsciousness is a consequence (11).
- *Entrapment underwater* (e.g., entanglement [47]).
- *Electrocution* (see Subheading 13.6.; Chapter 4, Heading 7.): Electrical burns are absent. The electric shock may be nonlethal but causes muscle paralysis, inhibiting the ability to swim. Death is caused by drowning.
- *Motor vehicle crash into water*: Blunt trauma injuries may contribute to death (30,52). Minor head injuries could cause a transient loss of consciousness (30,52).

- *Suspicious injuries*: Injuries indicative of homicide (e.g., strangulation) or suicide (e.g., self-inflicted incised wounds) may be observed (6,8,9,37).

## 6. EPILEPSY AND DROWNING

Epileptics are at risk for drowning (14,32,38,41,45,47,48,66,112,129–132). Proposed trigger mechanisms include light shimmering on water, hot baths, startle effect during play, and hyperventilation (*see* Subheading 13.1. and refs. 129 and 131). Various studies have shown that 3 to 6% of drowning victims have a history of epilepsy (11,12,30,33,131,132). Drownings occur in natural bodies of water and in domestic settings (132). Individuals can fall out of boats during a seizure and drown if they are not wearing personal flotation devices (132).

In a Canadian study, the duration of the seizure history (9 mo to 39 yr) and the time interval between the last seizure before death (1 wk to 15 yr) were not predictive risk factors for drowning (132). In another study, an 11-yr-old girl drowned after having had her first seizure (14).

Toxicological testing for anticonvulsants usually shows that medications are not detectable or in subtherapeutic amounts (132). Therapeutic levels do not prevent a seizure (14,132).

## 7. OTHER PREEXISTING DISEASE

When deciding the cause of death, the role of disease must be weighed carefully based on the circumstances (1). Underlying disease (e.g., ischemic heart disease) can be coincidental or contributory to drowning (8,11,32,38,49,66). Conduction system abnormalities have been described in drowning victims (133). Review of clinical records and DNA analysis have confirmed a long QT interval in some drowning victims (7). Neurological conditions and other diseases can interfere with mobility (9,32). Disease may be a precipitating factor in suicidal drownings, particularly those involving the elderly (*see* Heading 3. [133]).

## 8. ALCOHOL

Ethanol intoxication impairs judgment, orientation, reflexes, and motor activity, leading to an impaired ability to deal with an unexpected situation (8,12,108,134). Impairment is observed even when the blood alcohol concentration is low (20 mg/dL or 4.3 mmol/L [108]). The risk of accident increases for all persons when the blood alcohol concentration reaches 50 mg/dL (11 mmol/L [108]). Alcohol may enhance certain respiratory tract reflexes (e.g., laryngospasm), triggered by exposure to water, which contribute to “dry drowning” (*see* Subheading 4.3. and refs. 76, 110, and 134). Alcohol consumption without ingestion of food, coupled with strenuous activity, leads to hypoglycemia and impaired thermoregulation (108,135,136). The increase in cutaneous temperature from vasodilation leads to an increased temperature gradient between skin and water and a more pronounced stimulation of cold receptors (17). This may enhance cardiorespiratory reflexes, increasing the possibility of arrhythmia and sudden uncontrollable breathing (*see* Subheading 4.5. and ref. 17).



**Fig. 2.** Woman found drowned in bathtub. Scene investigation revealed empty sleep-aid bottle. Toxicological analysis showed elevated but nonfatal diphenhydramine level.

Various studies of adolescents and adults drowning in different situations have shown that about 40 to 60% have toxicological evidence of ethanol ingestion ([11,12,18,32,33,38,41,108](#)).

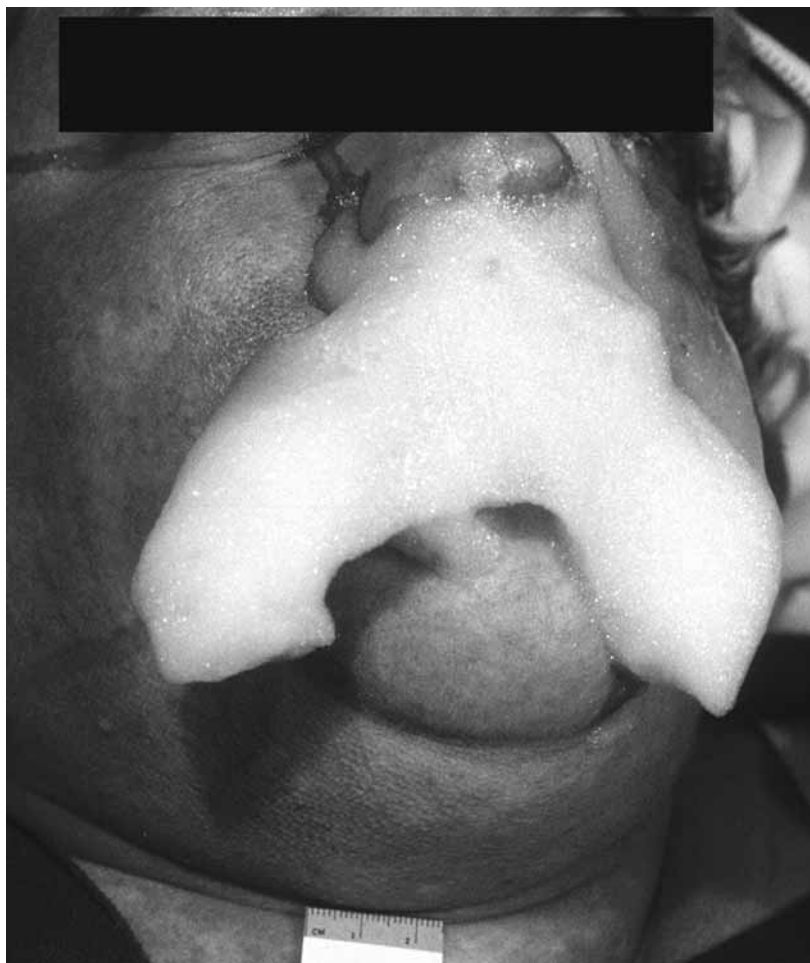
### ***8.1. Alcohol and Drugs in Suicidal Drownings***

The presence of toxic or lethal concentrations of medications can assist in the determination of suicide (*see* [Table 1](#); [Fig. 2](#); and refs. [4](#) and [5](#)). The finding of psychiatric drugs in a deceased person does not necessarily indicate suicide ([5](#)). This observation can verify a history of depression but not suicidal intent ([5](#)). Such medications are used for treatment of other illnesses (e.g., migraine, epilepsy [[5](#)]).

In a New York study, 25% of suicide victims were intoxicated ([5](#)). Ethanol and/or illicit drugs were seen in 41% of suicides. Antihistamines, presumably taken for sleeping problems, were found in 10% of suicides, but none were found in accidental deaths.

## ***9. EXTERNAL EXAMINATION OF A SUBMERGED BODY***

Froth (“meringue-like”) is expressed around the mouth and nostrils in a typical “wet” drowning (*see* [Headings 10. and 12.](#) [Fig. 3](#); and refs. [6](#) and [16](#)). Froth can be washed away by the action of water before body retrieval, disappear after the body has been in the open, or removed before transfer of the body for autopsy ([3](#)). Froth may be not seen by investigators at the scene ([3](#)). In one study, external foam was observed in only 19% of cases ([3](#)).

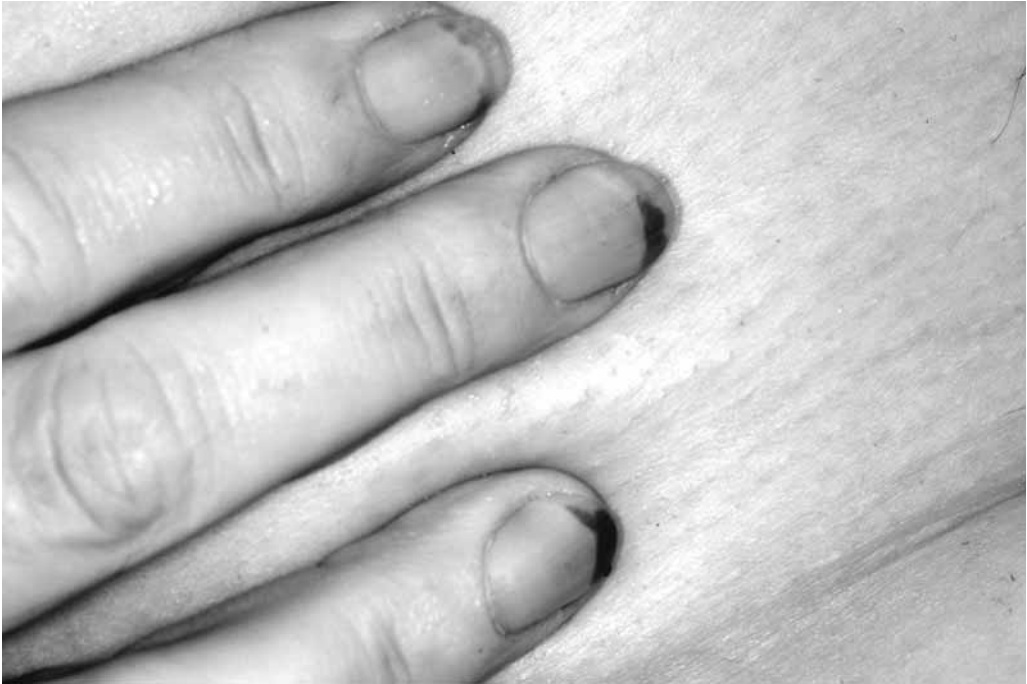

**Fig. 3.** “Wet” drowning. Froth from nose and mouth.

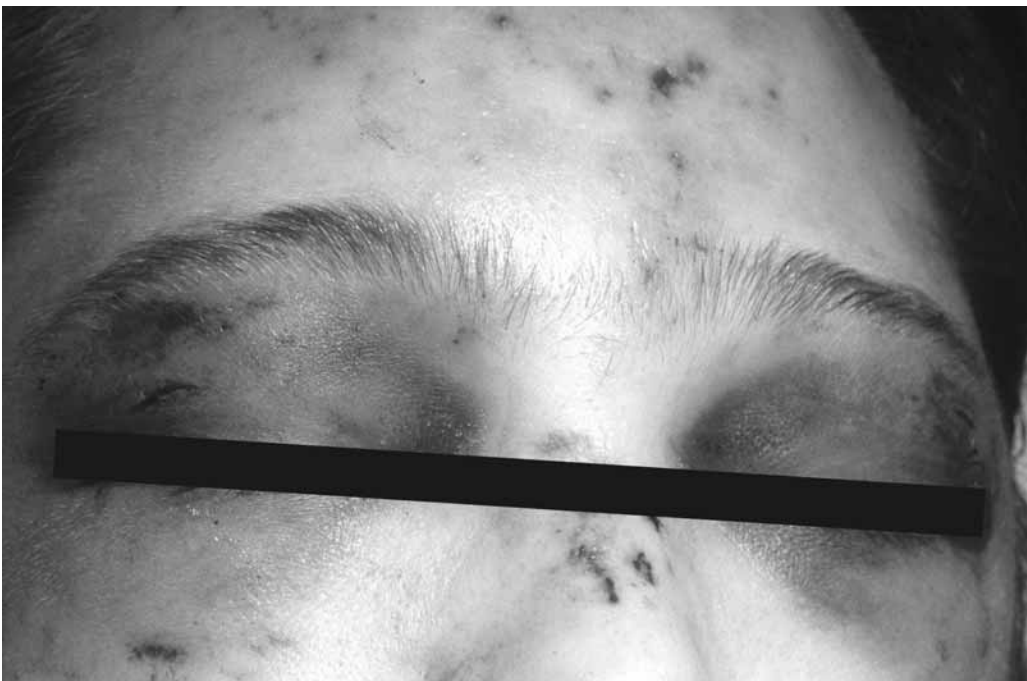Unzipped pants of an inebriated male who slipped into the water is seen uncommonly (1,9). Finding of material (e.g., weeds, sand) clutched in a victim’s hands suggests struggling (6). Dirt under the fingernails could indicate the flailing of hands along a muddy bottom (Fig. 4). Wrist scars or recent self-inflicted sharp force injuries on a drowning victim point toward suicide (see Heading 3. and refs. 9 and 137). Facial or scalp blunt trauma means ruling out underlying cranial and cervical spine trauma; however, cutaneous injuries are possible when the victim assumes a head-down position and scrapes the bottom (see Chapter 2, Subheading 3.3.; Fig. 5; and refs. 11 and 29). The absence of external trauma in an unwitnessed submersion does not mean that drowning is the cause of death (13).

#### *10. INTERNAL EXAMINATION OF A SUBMERGED BODY*

Certain findings, although nonspecific, support aspiration of water (i.e., wet drowning; see Subheading 4.1., Heading 12.).



**Fig. 4.** Dirt under fingernails could suggest the victim's hands were scratching the muddy bed of the creek she entered, but postmortem extrication artifact would need to be excluded.



**Fig. 5.** Facial abrasions and periorbital bruising. Body found floating head-down near rocky shore.




### 10.1. Pleural Effusions

A total of 80 mL or more of pleural fluid (i.e.,  $\geq 40$  mL in each pleural cavity) is found in nondrowning cases (e.g., intoxication, strangulation, smothering, stabbing [138]). The origin of the pleural fluid could result from disease, if the autopsy reveals underlying cardiac abnormality (e.g., myocardial hypertrophy or scarring [138]). A combined weight of the lungs and pleural effusions between 1000 and 2200 g was observed in more than three-fourths of cases having a submersion interval of less than 30 d and assisted the diagnosis of drowning (22). There was no significant difference in the actual amount of fluid seen in fresh and salt water drownings in another study (fresh water,  $521 \pm 340$  mL; salt water,  $768 \pm 536$  mL). About two-thirds of seawater and one-third of freshwater drownings showing no or early decomposition (i.e., skin maceration) had increased pleural fluid (138). In another study, a slightly higher proportion (38%) of seawater drownings had effusions, compared with freshwater cases (33% [24]). There was no correlation found between total lung weights and pleural fluid amount in fresh and saltwater drownings (24,138). Average lung weights, with or without an increase in pleural fluid, were  $1326 \pm 436$  g and  $1310 \pm 358$  g, respectively (138). In drowning and nondrowning cases retrieved from water, the total amount of pleural effusion increases with decomposition owing to passive seepage of the drowning medium into the chest but decreases with advanced decomposition (22,24,138). Levels of more than 250 mL in decomposed bodies may favor drowning (139). The time interval between body recovery and autopsy has no bearing on the amount of pleural effusion (138). Large amounts of pleural fluid can accumulate even after a short submersion interval, but significantly more cases, submerged 8 or more hours, have effusions (67 vs 39% < 8 h [138]). A short submersion interval ( $\leq 20$  min) has been associated with effusions (24). There are no differences in the amounts of pleural fluid based on sex, body weight and length, and heart weight (24). There is no correlation between blood ethanol concentration and amount of pleural fluid (138).

### 10.2. Lungs

Pulmonary edema is not specific to drowning and is seen in natural (e.g., heart disease) and other unnatural deaths (e.g., acute opiate intoxication, epilepsy [4,5,8,14]). Lung findings must be correlated with circumstances (22). Voluminous or overinflated congested lungs are seen in wet drownings (6,16,138). Lungs can bulge from opened thorax, and rib markings are seen on the pleural surface. Dependent congestion suggests a postmortem finding (8). Petechiae may be seen on the visceral pleura (16). Superficial bullae (subpleural emphysema) are sometimes observed (3,16,138). Frothy fluid (edema) is expressed from the cut surface of the lungs (see Fig. 6 and ref. 16). A minimum total lung weight of 1000 g in adults (>18 yr) is significant in distinguishing between drowning and nondrowning cases; however, this cut-off weight may be arbitrary with the realization that variable amounts of water are inhaled (138,140). Other studies have shown:

- Combined weight of lungs = 1411 (avg.)  $\pm$  396.4 g in drowning;  $994 \pm 133.0$  g in 20 controls (age >18 yr; time interval in water <24 h; controls, gunshot wound to head [22]).
- Combined weight of lungs = about 1400 g (avg.); 780 g in 50 controls (age >18 yr; controls, gunshot to head [20]).



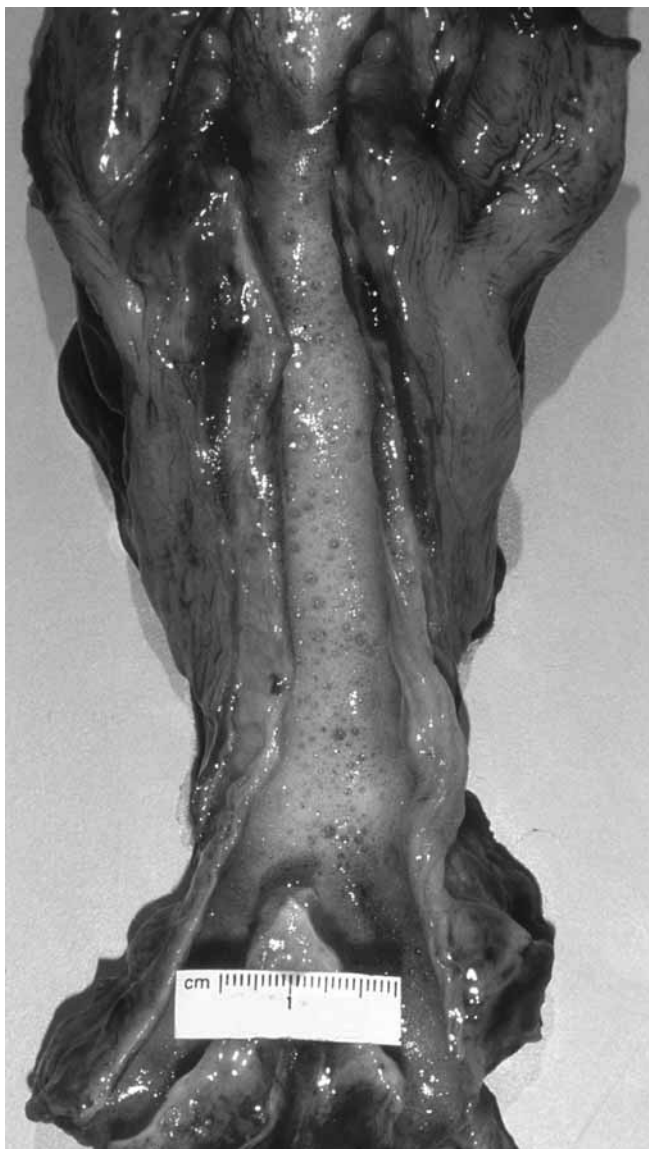**Fig. 6.** Congested lungs from drowning death. Note frothy edema fluid on cut surface of lung (arrows).

No difference in lung weights between fresh and saltwater drownings has been observed (20,22,24,138).

A minority of cases (up to 20% in 2 studies) have lung weights less than 1000 g (20,22,24,138,140). The inference is that these cases could have been dry drowning cases, but the exact circumstances are not always described (3). There is no significant correlation between submersion time and lung weights; however, 13% of witnessed non-putrified cases in a Finnish series had lung and “exudate” weights less than 1000 g compared with 35.6% of witnessed decomposed cases (3,24). Another study of recovered bodies showed a mean combined lung weight of 1439 g (range 720–2740 g) in preserved bodies and an average of 1049 g (range 380–1900 g) in severely decomposed bodies (5). The percentage of “dry” lungs (<1000 g) in nonputrefied compared with decomposed cases was 17% and 51%, respectively. A similar observation—i.e., decreased lung weights following a longer interval in the water—was made in another series (22).

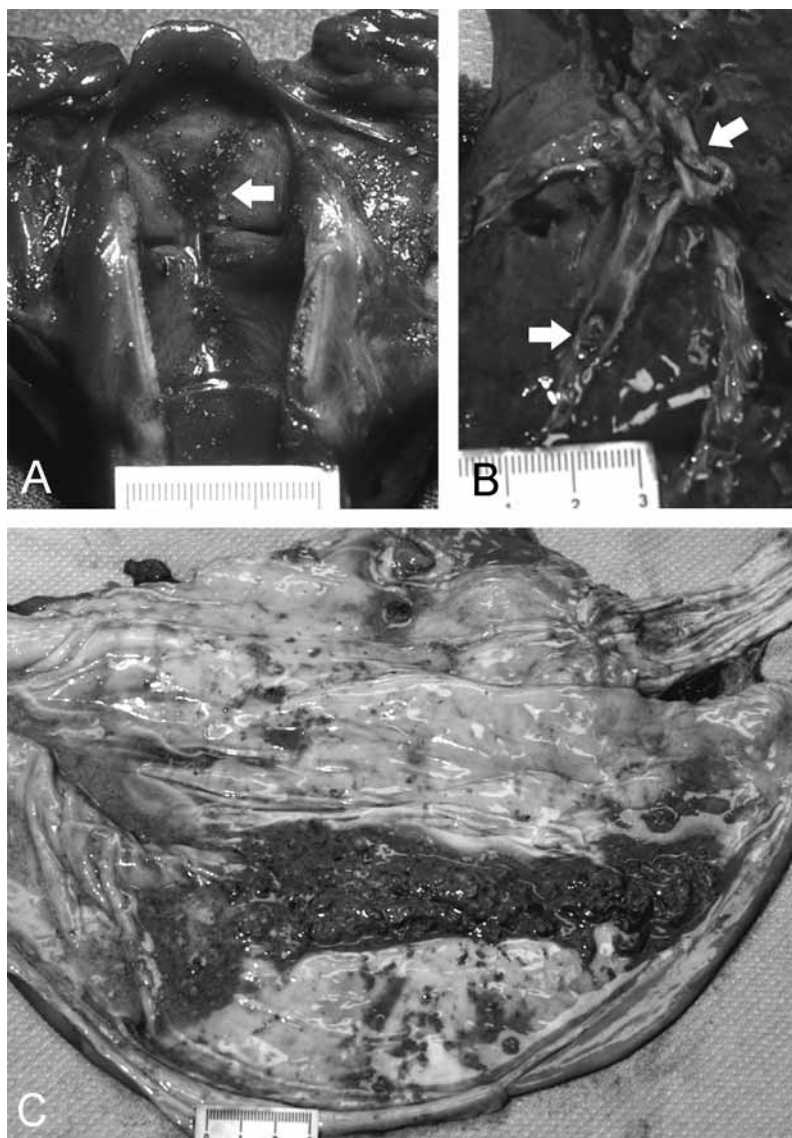
The increase in the average lung weight is greater than expected in drownings compared with other types of asphyxial deaths when body recovery time is short ( $\leq 6$  h); however, distinguishing between drowning and asphyxiation prior to being dumped in the water, based on total lung weight, is not possible unless the lungs are severely congested (e.g., combined weight >2500 g [141]).

Frothy fluid, which can be blood-tinged, is seen in the larynx, trachea, and bronchi (see Heading 9; Fig. 7; and ref. 16). This is an antemortem reaction (22). Froth is an admixture of edema fluid, surfactant, and bronchial secretion (3,90). Edema fluid in freshwater drowning tends to be bloody because the hypotonic medium ruptures red



**Fig. 7.** “Wet” drowning. Froth in upper respiratory tract. (Courtesy of the Office of the Chief Medical Examiner, Chapel Hill, NC.)

blood cells (8). In saltwater drowning, red blood cells tend to retain their integrity (8). The diagnosis of drowning may be more tenuous without the presence of froth (8). Foreign material from the drowning medium may be observed in the upper respiratory tract and lung parenchyma, but finding water or debris in the mouth or upper airway is not sufficient to diagnose drowning (Fig. 8; refs. 2, 16, 21, and 142). Froth can be seen after only a few minutes of immersion (22). Froth disappears as the postmortem interval increases (143). In one study of 1590 submersions, the presence of external foam, froth in the airways, and overlap of the medial edges of the lungs were found, respectively, in 17.3, 46.5, and 42.1% of cases submerged less than 1 d. These findings were still seen in



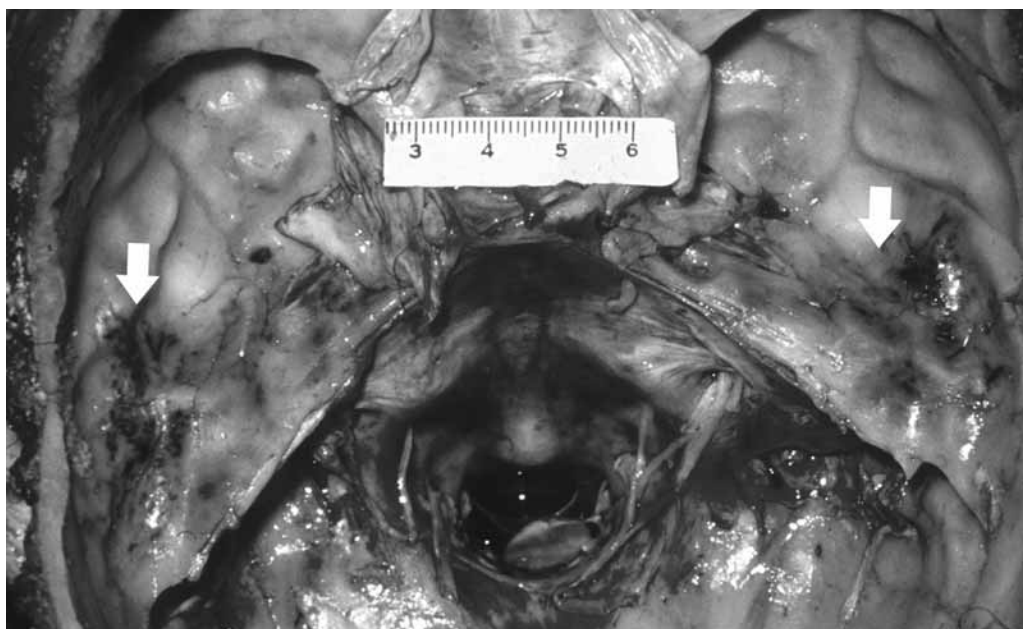**Fig. 8.** Victim drowned after torrent of water entered a drainage tunnel. (A) Dirt in larynx (arrow). (B) Aspirated dirt in bronchi (arrows). (C) Swallowed dirt in stomach.

bodies submerged up to 1 wk, and then began to disappear (3). At 3 mo, these changes were not evident (e.g., only 4% showed overlap of lung tissue in one study [3]). Resuscitation obscures lung findings in drowning (e.g., emphysema, edema [142]).

### 10.3. Other Organ Weights

If the recovery time of a body is short—i.e., within 6 h of death—then certain organ weights may be increased in asphyxiation and drowning cases relative to other types of trauma (141). In one study, the effects of asphyxiation increased the mean organ weights for the lungs, kidneys, liver, and spleen compared with trauma deaths (141). Mean heart





**Fig. 9.** Discoloration of petrous ridges (arrows). “Hemorrhage” in middle ears in a drowning case. (Courtesy of the Office of the Chief Medical Examiner, Chapel Hill, NC.)

and brain weights remained the same in the trauma, asphyxia, and drowning cases. Prolonged submersion can reduce organ weights (141). Small “anemic” spleens have been observed in drownings, but considerable overlap exists in the range of weights when compared with controls (144). Sympathetic stimulation with organ contraction is a proposed mechanism (144). Histological evaluation of the quantity of blood in the splenic sinuses reveals no differences (144). The autopsy finding of a small, anemic spleen in drowning is likely a postmortem change caused by prolonged submersion (141).

#### **10.4. Gastrointestinal Tract**

Fluid and foreign material from medium can be found in the stomach and intestines as a result of swallowing; however, small amounts of water can enter the stomach after death particularly if the pressure of the drowning medium is high (*see* Subheading 4.1.; Fig. 8; refs. 6, 16, and 138).

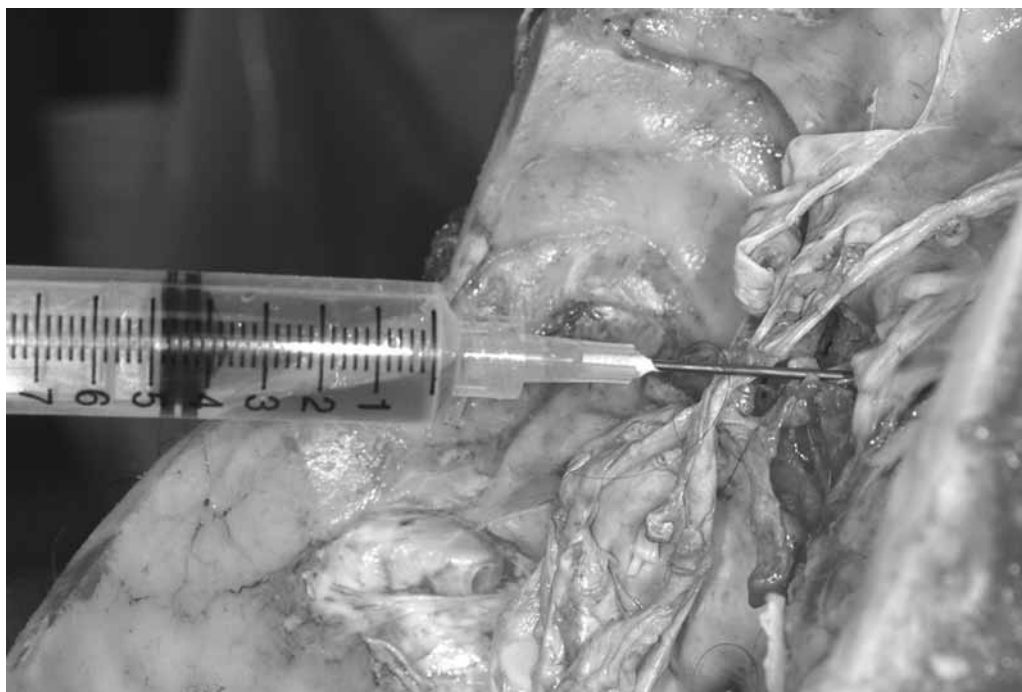#### **10.5. Neck Hemorrhages**

For information on neck hemorrhages, *see* Chapter 2, Subheading 3.3.

#### **10.6. Cranial Findings in Drowning**

Middle ear and mastoid congestion/hemorrhage are manifest as blue discoloration of the petrous bones after stripping the dura (Fig. 9; refs. 6, 25, and 138). This finding is not seen in all cases and occurs at a minimum water depth of about 75 cm (2.5 ft) (25). Middle ear hemorrhage is thought to arise because a pressure differential between the middle ear and the environment caused by blockage of the Eustachian tubes by water (25). Prior scarring from otitis media and a lack of pneumatization of the mastoid air cells are factors that decrease the likelihood of hemorrhage (25). Middle ear





**Fig. 10.** Drowning. Aspiration of fluid from sphenoid sinus.

congestion/hemorrhage may be an indicator that the victim was alive at time of submersion and could explain why experienced swimmers develop difficulties due to disequilibrium (*see* Subheading 14.3. and ref. 6). Alternatively, this finding may be a postmortem change owing to a head-down position (*see* Heading 12; Chapter 2, Subheading 3.3.).

Aspiration of sanguinous watery fluid from the sinuses (e.g., sphenoid sinus) may also be an indicator of drowning (Fig. 10; refs. 8 and 138).

## *11. DROWNING TESTS*

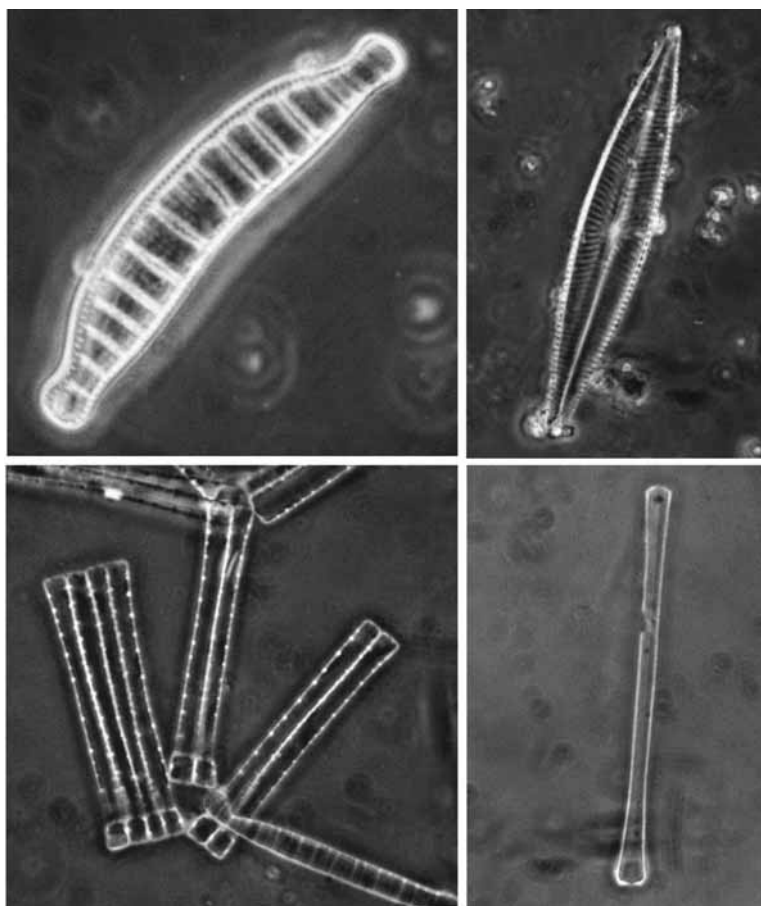
Because of the difficulties diagnosing drowning, various tests have been proposed (1,8). Some are now of historical interest because of the lack of specificity and alteration by decomposition as the submersion interval increases (2,25–27,80,110,145–147).

### *11.1. Plasma Specific Gravity or Osmolarity*

Left atrial blood, diluted by water from the lungs, has a lower specific gravity than the right atrium in freshwater drownings (6,15,148,149). Hemolysis and autolysis of proteins compromise the value of the test (146).

### *11.2. Chloride Test (Gettler Test)*

Chloride and sodium levels in the left heart, compared with the right side or the femoral vein, decrease in freshwater drowning and increase in saltwater drowning (6,8,148). In practice, the results have been equivocal and not useful, because significant electrolyte changes, particularly in freshwater drownings, do not usually occur (80). Studies of other electrolytes have also yielded inconsistent results (150).



**Fig. 11.** Examples of various diatom species viewed with phase-contrast microscopy. Original magnification  $\times 250$ . (Courtesy of Dr. M. Pollanen, Forensic Pathology Unit, Toronto, Canada.)

### ***11.3. Diatom Analysis***

Diatoms are a diverse group of microscopic unicellular algae having cell walls composed of silica; they are widely distributed in fresh and salt water ([Fig. 11](#)) ([146,151–154](#)). More than 100,000 species have been described ([155](#)). Diatom analysis can assist in the diagnosis of drowning in cases of prolonged submersion when the body is decomposed or fragmented ([26,27,151,152](#)).

When water is aspirated into the lungs, diatoms enter the alveolar capillaries and move into the systemic circulation ([153,156](#)). Their concurrent presence in other organs and body sites indicates circulation in an individual who was alive on entering the water ([27,146,151,157](#)). The finding of diatoms in the body depends on their concentration in the body of water and the volume of water inhaled ([27,143,146,152,154](#)). The small amount of water aspirated in so-called dry drownings could be one explanation for negative results ([26,143](#)). Regional and seasonal variation in the type of diatoms, particularly those associated with drowning, can occur in the same body of water and can affect whether diatoms are found in tissue samples ([143,146,152–154,158,159](#)). Extensive

water sampling at the suspected site of drowning at different times and water depths may be required, although experience indicates that a single sample suffices in the majority of cases (143,152,155).

Body tissue samples can be collected from various sites: lungs, heart, brain, liver, kidney, and bone marrow (2,154,155,157). The presence of diatoms in lungs and other organs must be interpreted with caution (154). Contamination by exogenous diatoms means that periodic testing of reagents and equipment is required (6,26,27,151–153,155,157). Diatoms are found in nondrowned individuals owing to inhalation of diatomaceous earth (1,6,146,151,153,157,160–163). Ingestion of diatom-containing food and water is possible (146,151,152,161,162,164). Diatoms can passively enter the lungs and upper respiratory tract during prolonged submersion (2,26,27,143,146,153,154,164). Large quantities of diatoms can be seen in the lungs of presumed drowning victims (143,163). If there is decomposition or trauma, water can contaminate internal organs (2,143,154,157). For this reason, bone (e.g., an intact femur; alternatives—sternum and vertebra), which is less likely to be contaminated, is used (2,152,153,160). The presence of diatoms in the marrow is assumed to have occurred ante-mortem (153). Diatoms found in a deceased individual who regularly swims in the locale where the body was recovered proves exposure to that body of water but not drowning (165).

The femur is sawed along its long axis and about 50 g of marrow removed (153,155). Diatoms or diatom fragments in bone marrow tend to be small ( $<30\ \mu$ ), and the number of species recovered is less than that found in the lungs and water samples (26,151,153,159,164). This suggests that diatoms of limited size embolize to bone (159). Nevertheless, a minimum threshold number of diatoms (quantitative analysis) is recovered in the closed organs of drowning cases, which distinguishes them from nondrowning deaths (26,27,143). The marrow is treated with acid (e.g., nitric acid) (153,155,157). Centrifuging the specimen results in a pellet containing acid-resistant material, i.e., the silica coats of diatoms (146,153,155,166). This residue is placed on glass slides and examined using phase-contrast microscopy (153,155).

Aspirates from nasal sinuses (sphenoid, maxillary), stomach fluid and the suspected drowning medium are also treated the same way (153,155). Diatoms found in stomach contents may represent a contaminant (see Subheading 10.4. and ref. 155).

Analysis for diatoms can assist in certain cases of submersion:

- Confirmation of drowning when the types of diatoms in different organs match those present in the drowning medium (qualitative analysis [6,26,27,143,153–155,166]).

The diatom test can support the diagnosis of drowning when the signs of drowning are equivocal or absent (e.g., decomposition, severed limb [34,155,158]). A disadvantage of the test is its sensitivity. Only 28% of 738 drownings in naturally occurring fresh water and 12% of 33 drownings in water from a domestic source, i.e., water filtered or processed (bathtub, pool, toilet), in one study, gave a positive result (153). In another study, qualitative diatom analysis supported a diagnosis of drowning in one-third of cases (26). Diatoms are unlikely to be seen in bathtub drownings (146,166). Diatom analysis is not as useful in diagnosing drowning when tap water is involved because the diatoms are filtered out by water purification plants (26). Of the four domestic drowning cases in an Ontario study, two had diatoms added to the water (abrasive cleaner, gravel). Swimming pool water can be rich in diatoms if pool filters contain diatomaceous earth (8).

The lack of diatoms does not exclude drowning as a cause of death, and should be interpreted in context of the postmortem findings (27,146,153,157,158). A lack of diatoms can also mean a rapid death, preventing circulation of diatoms to organs. This implies that wet drowning is not the cause of death or that drowning occurred in water lacking diatoms (157,163). The lack of diatoms, based on analysis of femoral marrow, could be explained by the relatively small proportion of blood circulation this bone receives (153).

- Implication of drowning as a cause of death even when the autopsy and circumstances do not suggest drowning (153,155).

This can assist in the investigation of a suspicious death or homicide, particularly when the autopsy does not determine a definitive cause of death (155). Conversely, the autopsy may reveal serious trauma (e.g., strangulation, craniocerebral injury), but the presence of diatoms indicates that the submerged victim was alive, i.e., breathing on entering the water (155).

- Correlation of the types of diatoms recovered from the body and various putative sites of drowning, i.e., the body of water in which the body was immersed at time of recovery.

This can assist in localizing the site of drowning (e.g., bathtub or natural body of water [153,155,157]).

- Diatoms, the only observation that supports the diagnosis of drowning, in decomposed cases (153,163).

The presence of diatoms may not match the putative drowning medium because these bodies can be recovered at sites remote from the drowning location (159).

## 11.4. Microscopic Examination

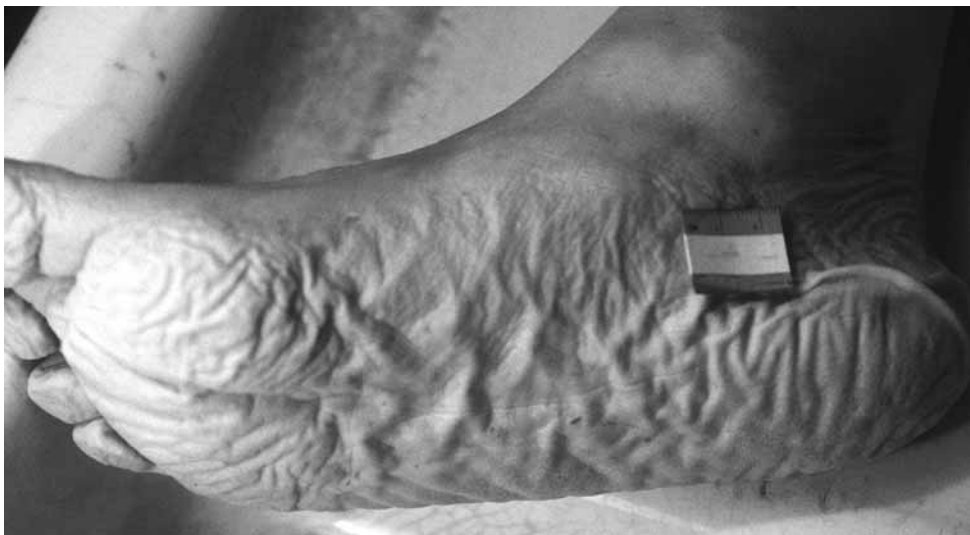Various drowning-related changes have been described using microscopic examination (*see* Chapter 3, Subheading. 1.7. and ref. 145):

- “Emphysema aquosum” refers to dilation of alveoli, thinning of alveolar septae, and compression of alveolar capillaries (2,167).
- Pulmonary congestion, edema, alveolar hemorrhage, alveolar wall disruption (2,145).
- Alveolar macrophages can decrease in nonputrefied drowning cases because of washout by the drowning medium (167); in decomposed bodies, pulmonary macrophage numbers are variable because of “release” from the putrefying alveolar lining and removal by decomposition fluid (145,167).
- Alveolar hemorrhage is significant in drownings, without decomposition, and asphyxial deaths compared with nonasphyxiated individuals (145).

Microscopy is necessary to rule out underlying disease, not visible at autopsy, that caused death or contributed to drowning (145).

## 12. WATER SUBMERSION: POSTMORTEM ARTIFACTS

- Goose skin (“goose bumps,” cutis anserina). This artifact results from spasm of the erector pilae muscles owing to exposure to cold (*see* Chapter 2, Heading 2. and ref. 16).
- Wrinkled hands (“washerwoman’s hands”) and feet (*see* Fig. 12; Chapter 7, Fig. 31; and ref. 16).
- Conjunctival petechiae can disappear after 4 h of fresh water submersion probably due to hemolysis caused by the hypotonic medium (168).
- Decomposition obscures or mimics signs of drowning (*see* Chapter 2, Subheading 5.2. and refs. 6, 15, and 17).



**Fig. 12.** Wrinkling of soles owing to prolonged water submersion (see Chapter 7, Fig. 31).

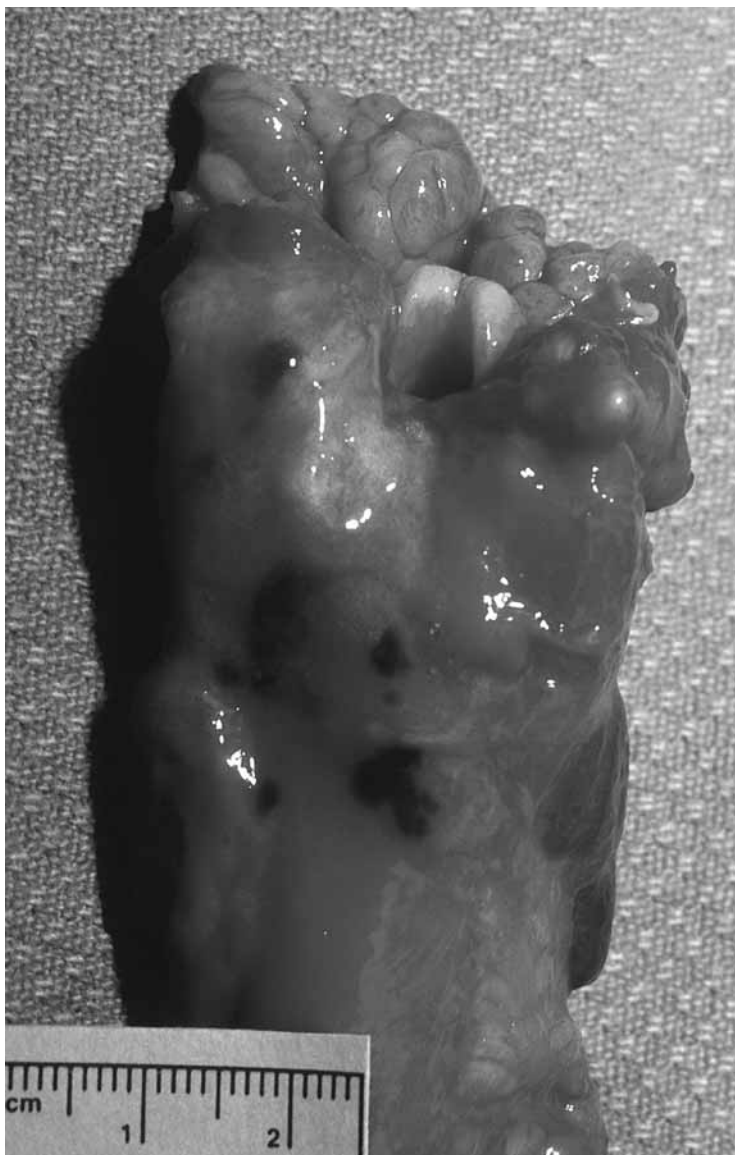- Apparent lung “congestion” (16).
- Extravasation of sanguinous fluid into respiratory tract and pleural cavities (16).
- Gas admixing with decomposition fluid can simulate froth in respiratory tract; sanguinous fluid can be expelled from the nose and mouth (16).
- Dehiscence of incised wounds in varying stages of healing (up to 6 mo) because of bloating (169).
- Signs of drowning disappear (3).
- Head-down position
 

Because the specific gravity of the head is greater than that of the feet, a submerged body floats in a head-down position.

  - Lividity in head and neck area and on anterior surface of body (see Chapter 2, Subheading 3.3. and ref. 6); mastoid/middle ear “hemorrhages” may be a sign of lividity (see Fig. 9; Subheadings 10.6. and 14.3.)
  - Artifactual neck hemorrhages (rule out resuscitation; see Fig. 13).
- Injury (16)
  - Lethal injuries can be difficult to interpret (3).
  - Prolonged submersion can leach blood from open skin wounds.
  - Wildlife, underwater and shore hazards can cause injury (Fig. 14; refs. 2 and 6).
  - In shallow water, the head-down position can lead to certain areas of body (face, outer forearms, knees) scraping the bottom (see Heading 9; Fig. 5; and ref. 170).
  - Abrasions and contusions of the forehead may be caused by removal from water (e.g., side of pool [11]).
  - Resuscitation effects (see Chapter 3, Subheading 2.6. and ref. 2).
- Floating to the surface
 

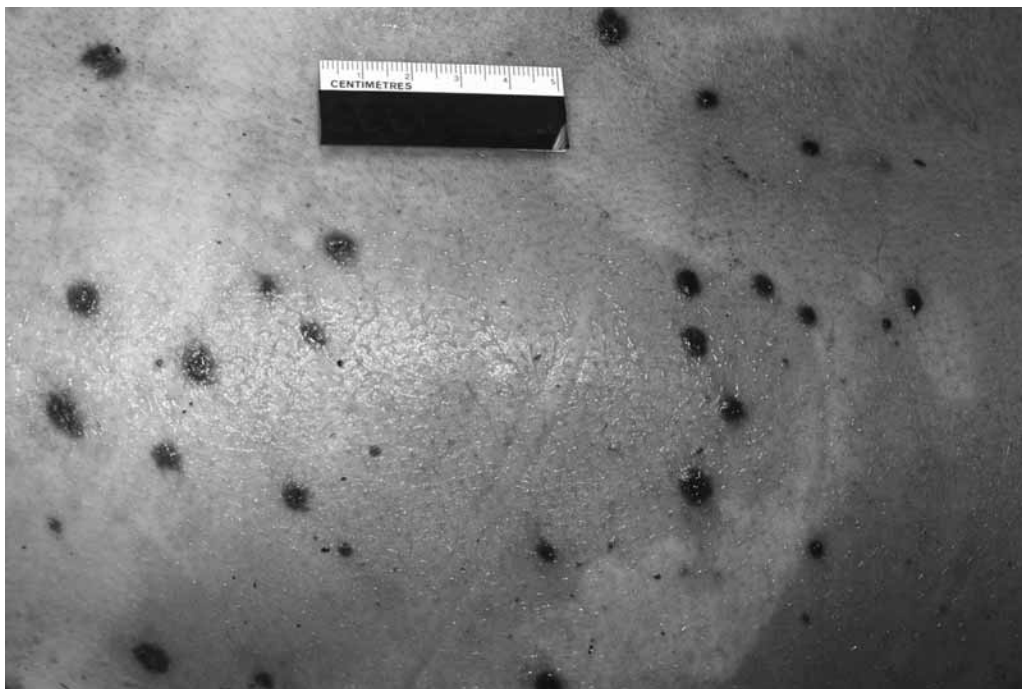
A body does not float until its specific gravity reaches a point of buoyancy from gases generated from decomposition. Interestingly, of 104 bodies recovered floating in New York waterways, 28 were not decomposed (5). If a body’s specific gravity exceeds that of water (fresh water = 1.000; sea water = 1.026), then it sinks (104). The specific gravity of a body is increased by various means (addition of weights, aspiration





**Fig. 13.** Young male drowning victim recovered from a swimming pool. Resuscitation. Posterior larynx. Soft tissue hemorrhages, retroesophageal area.

of water during drowning). Buoyancy is affected by lung volume ([104](#)). One study showed that, at total lung capacity, all subjects floated in fresh and salt water ([171](#)). At functional residual capacity, i.e., a value approximating the lung volume of an unconscious or dead person, 7% of individuals floated in freshwater and 69% in seawater. In fresh water, 5 kg (11 lb) of added weight would sink anyone regardless of lung volume; in sea water, 6.8 kg (15 lb) would suffice. Once a body starts to sink, it will continue sinking because hydrostatic pressure compresses gas in the chest and abdominal organs. Pressure compresses the chest, reducing residual volume and resulting in negative buoyancy ([104](#)).



**Fig. 14.** Submerged body. Injuries caused by leeches. (Courtesy of Dr. C. Rao, Regional Forensic Pathology Unit, Hamilton, Ontario, Canada.)

### *13. BODY IN THE BATH*

The bathroom is potentially the most dangerous room in the house (172). The incidence of bathtubs as a site for drowning varies. In various series, the frequency ranges from about 1 to 8% (11,12,30,31,33,44,173). In the Brisbane drowning study, 8 of 55 (15%) childhood drowning deaths were in bathtubs (54).

All manners of death are possible when a body is found in a bathtub (Table 2).

Series of suicidal drownings have shown that a bathtub scene occurs in up to 10 to 15% of cases (see Table 1 and refs. 4, 9, 22, and 37). Although homicides in this setting are uncommon, any death in a bathtub should be treated as suspicious (177). An investigation must be initiated as soon as possible after the incident (172). Investigators must be aware of possible scene alteration by those discovering the body and by emergency personnel.

#### *13.1. Accidental Deaths: Precipitating Factors*

Precipitating factors for adult accidental drownings include intoxication by ethanol or other drugs, incapacitation by disease (e.g., stroke, seizure, heart disease), invalidism, falls, and lack of supervision of institutionalized individuals and children (see Subheading 2.2., Headings 6–8; and refs. 12, 43, and 176).

Dietz and Baker found that ethanol contributed in 2 of 10 bathtub drownings tested (one individual fell, another had a history of seizures [11]). Of 12 bathing cases involving persons aged 15 and older tested for alcohol in a study by Wintemute et al., only 2 had detectable ( $\geq 1$  mg/dL) ethanol (1 person  $\geq 200$  mg/dL or 34 mmol/L [178]).

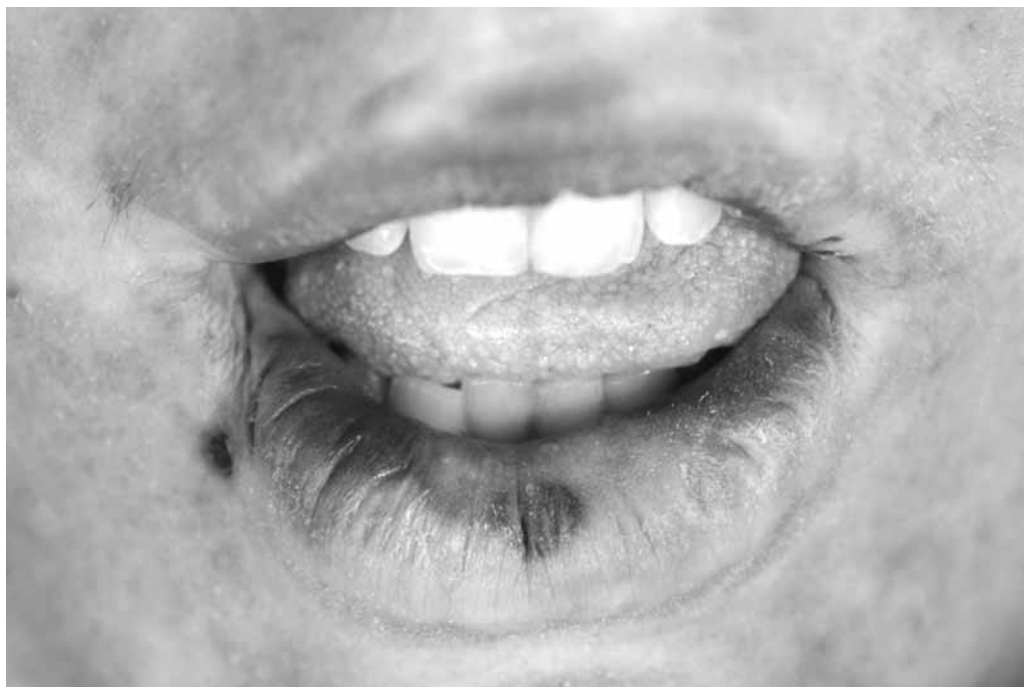Table 2  
Bathhtub Deaths

Series	<i>n</i>	% Of drownings/ submersions	Age range (male: female)	Manner ( <i>n</i> )				Comments
				N	A	S	H	U
Finland, 1976–2000; Lunetta et al. (173)	116	7%		2.6% (3)	30.2% (35)	53.4% (62)	0.9% (1)	12.9% (15)
Denmark and Sweden, 1961–1969; Geertinger, Voigt (174)	51 <sup>a</sup>		22–85 yr (11:31)	9.5% (4)	11.9% (5)	71.4% (30)	2.4% (1)	2 (4.8%) “Suspicious” Suicides included self-inflicted injuries, drug overdose and drowning. Accidents (2 falls, 1 drowning, 1 CO poisoning, 1 epileptic). Natural deaths— cardiac.
Belgium, 1934–1983; Devos et al. (175)	36		6 mo–78 yr (12:24) 9 children	8.3% (3)	63.9% (23)	19.4% (7)	5.6% (2)	19 accidental deaths caused by CO poisoning reflecting nature of heating system. Most of the suicides had toxic levels of alcohol and sedatives. Natural deaths— 2 seizure-related, 1 cardiac disease.

North Carolina, 1982–1983; (67 in bathtub, Shkrum and 2 in whirlpools, Hudson 1 in Jacuzzi) (176)	70	59 adults, 11 children	44% (31)	36% (25)	11% (8)	6% (4)	3% (2)	Manners of death mirrored the overall frequency in the general population investigated under medicolegal jurisdic- tion. Natural — mainly ischemic heart disease. Accident — <i>see</i> Subheading 13.1. Suicide — 4 gunshot, 4 drownings. Homicide — 2 strangled/drowned, 1 child drugged and drowned, 1 child delivered in tub and asphyxiated in plas- tic bag.
---	----	---------------------------	-------------	-------------	------------	-----------	-----------	--

---

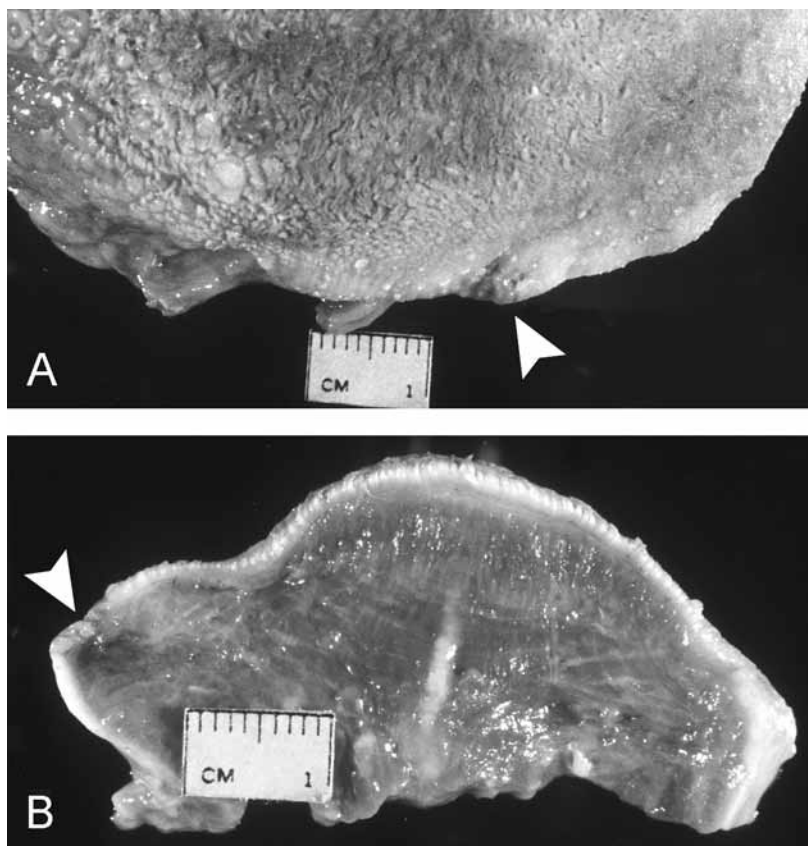
<sup>a</sup>Nine did not have toxicological analysis; 42 assigned accurate manner.  
N, natural; A, accident; S, suicide; H, homicide; U, undetermined.



**Fig. 15.** Drowning in bathtub. Seizure disorder. Lip contusion.

Epileptics are at risk for drowning in bathtubs, particularly when unsupervised ([103,112,131,179](#)). Of eight bathtub drownings in Maryland, six had a seizure history ([11](#)). Seven of 17 epileptics who drowned in the Sacramento County series died in the bathtub ([30](#)). Of five epileptics in a New Zealand series who drowned, one died in the bathtub ([33](#)). Gardner and Devos et al. mention two seizure cases each ([172,175](#)). A Canadian series showed that 60% (15 of 25) of epileptics who drowned were taking an unsupervised bath ([132](#)). An epileptic can be found slumped over the edge of the tub ([131](#)). Although showering reduces the risk, drowning can still occur if the individual collapses and plugs the drain ([132](#)). Other potential injury scenarios include falling and striking the shower enclosure or other fixtures, and inadvertently striking the hot water faucet while having a seizure ([132](#)). Seizures while in the bathtub may not leave signs of a struggle or evidence of splashed water—i.e., seizure activity is not necessarily manifest as involuntary muscle contractions ([112](#)). Biting during a seizure can cause lip injuries. The tongue may be lacerated ([Figs. 15 and 16](#)). An autopsy does not always reveal definitive neuropathological findings (e.g., temporal sclerosis) indicative of epilepsy, but examination of a formalin-fixed brain is better for finding subtle abnormalities in cases without a definitive history of seizures ([Fig. 17](#); refs. [11](#) and [112](#)). The role of epilepsy in a case of bathtub drowning is deduced from the medical history and the toxicological results. Toxicological testing of drowned individuals in bathtubs, who had been prescribed antiepileptic medications, usually show that the drugs were either not detected or present in sub-therapeutic concentrations ([30,132,176](#)). Even individuals with therapeutic levels can drown ([132](#)).





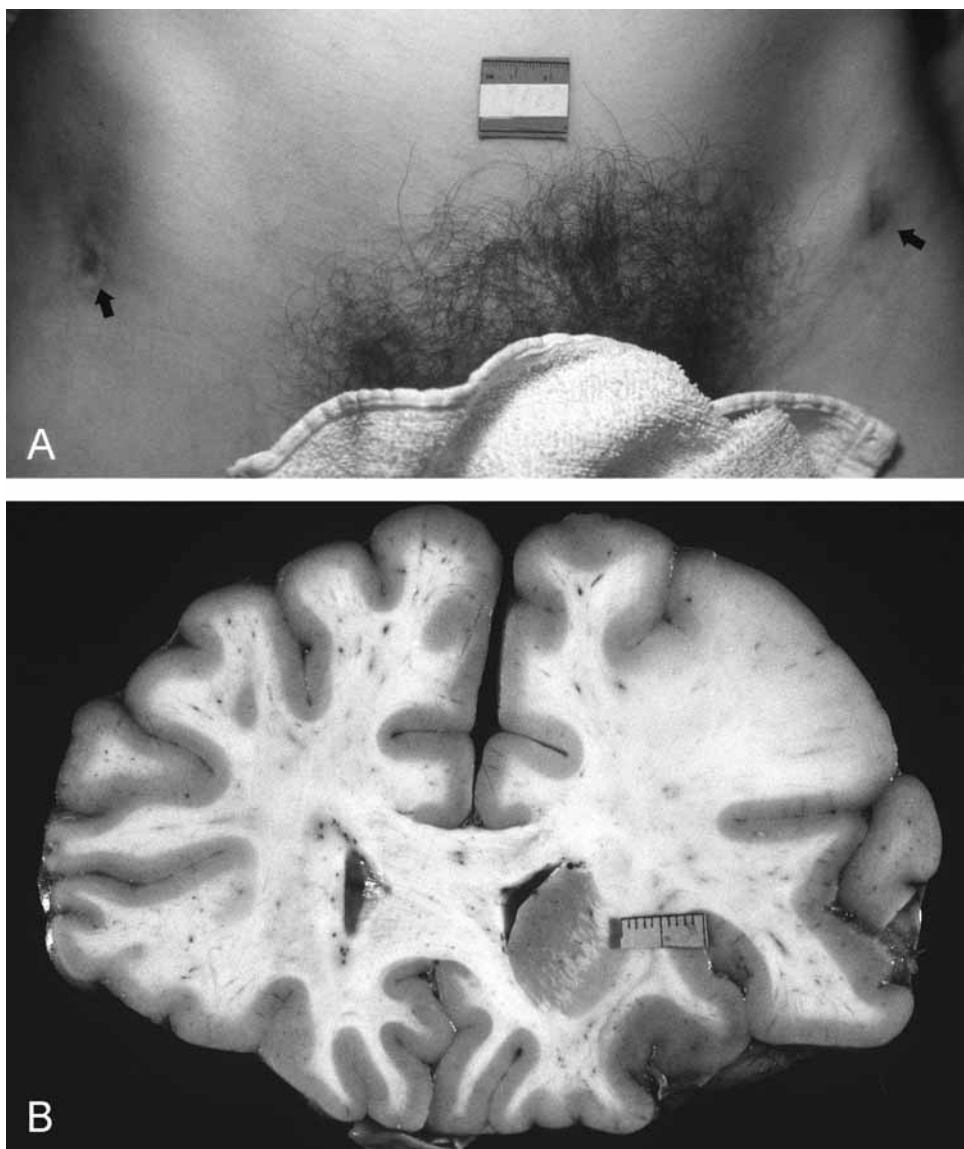
**Fig. 16.** Seizure. **(A)** Laceration (arrowhead), right lateral border of tongue. **(B)** Coronal sections of tongue. Hemorrhage in muscle (arrowhead) corresponding to laceration.

A fall, alone or in combination with ethanol, leading to fatal craniocerebral trauma or positional asphyxia needs to be considered if the victim is found in a dry tub (176).

Most of the children who drowned in a bathtub in a North Carolina series were 6 mo to 2 yr of age (176). Children of this age have been usually left unattended (Fig. 18; refs. 12, 42, 55, 103, 175, 176, and 180). The median depth of water in one series was 20 cm (8 in.), and the range was 5 cm (2 in.) to 35 cm (14 in. [77]). The victims were mostly under 1 yr of age (77). At this age, a child is able to sit and pull up to stand (55). Leaving an infant in the care of an older sibling is an inadequate substitute for adult supervision. These children are also at risk for scalding injuries (103). Issues arise about the role of siblings or playmates in the drowning (55). The family situation can be a risk factor for nonaccidental injury. Immersion is a form of child abuse and is used to commit murder (Fig. 19; refs. 103, 180, and 181).


### 13.2. Suicide

Suicide victims are usually more elderly, and there may be a psychiatric history (see Heading 3. and ref. 182). This method may be chosen by an older person if other methods are not feasible because of illness or immobility (182). Evidence of self-



**Fig. 17.** Woman found slumped over edge of bathtub filled with water. Signs of drowning at autopsy. History of a “fit” about 1 yr prior to death. **(A)** Abrasions of pelvis indicative of pressure from tub edge (arrows). **(B)** Formalin-fixed brain. Expansion of right frontal gyrus. Microscopic examination: astrocytoma. (Courtesy of the Canadian Society of Forensic Science Journal).

inflicted injury may be seen (e.g., wrist slash; *see* Chapter 7, Subheading 2.1. and ref. [182](#)). Some individuals have weighed themselves down by various means (e.g., bowling balls [[182](#)]). A bathroom door locked from the inside is seen only in a minority ([174](#)). Alcohol consumption and sedation by medications have been seen in a number of studies; however, a reduced level of consciousness is not necessary for an individual to deliberately submerge in the bathtub ([182](#)).



**Fig. 18.** Drowning of infant determined to be an accident. Scene findings: mother was in a bathtub with child resting on her torso. She fell asleep and, on awakening, discovered the child submerged. She panicked and sought help. (A) Note the cleanser can on the floor. Cigarette ash was on the floor. The mother did not remember knocking over the ashtray. (B) A frantic call for help.

### ***13.3. Homicide***

Murder can be committed in the bathtub or the murder victim can be deposited in the tub (177). In the latter instance, a tub may be filled with water to ensure death by drowning and to remove trace evidence (177). Drowning and other types of trauma (e.g., strangulation, electrocution) occur alone or in combination (174,177). In cases of strangulation, external signs may be subtle. Most homicide victims are young women, aged 20 to 40 yr (177). If signs of drowning are evident, then the victim was alive when placed in a water-filled bathtub (177). Ethanol intoxication is a factor in incapacitating some victims (177).

### ***13.4. Presence of Water in Tub***

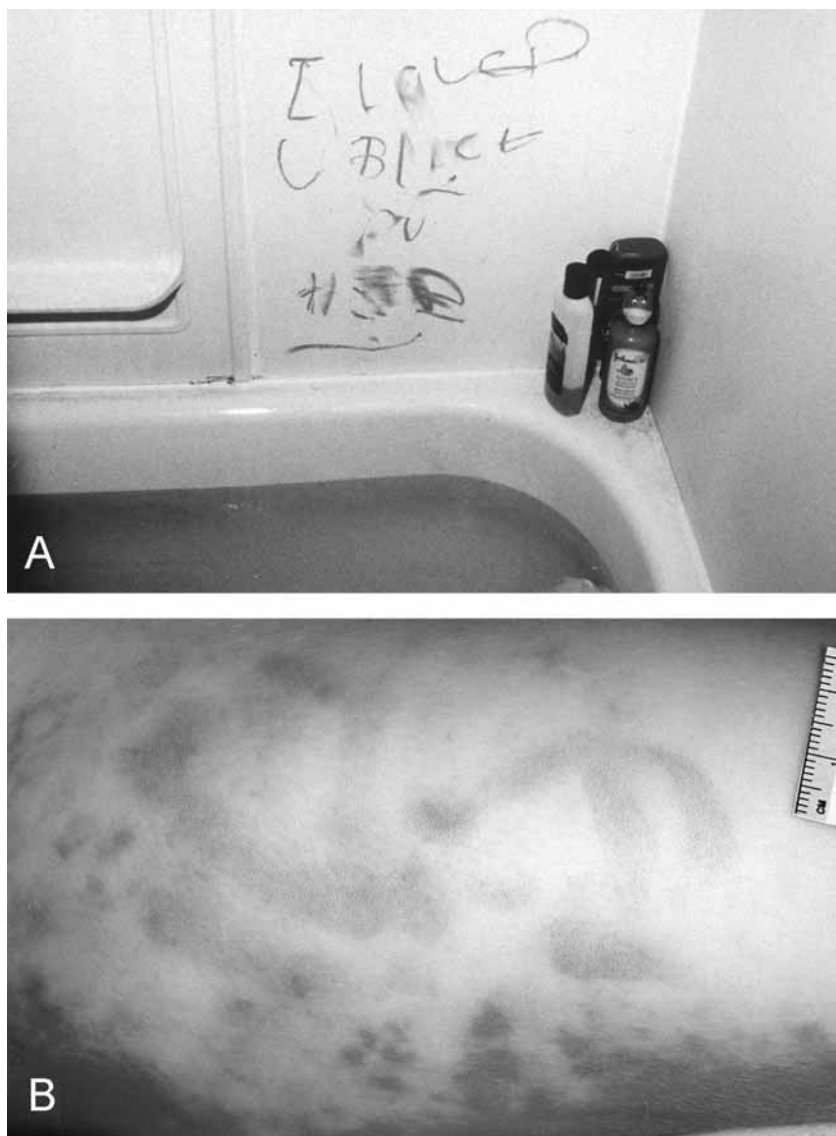
Although water in a tub is expected in a drowning, sometimes a tub will be empty if the water has drained through a loose drain plug (176). Wet hair and clothing are clues that immersion in water has occurred. Submersion of the deceased's face in water does not necessarily mean that drowning is the cause of death (176). Other causes of death need to be excluded. In about half the natural deaths in a North Carolina study, water was observed in the tub (176).

### ***13.5. State of Clothing: Adults***

People who died of disease, accidents, or homicidal trauma are either clothed or unclothed (176,177). Suicide victims can be either fully or partly clothed; however, the observation of an unclothed individual in a bathtub does not rule out suicide (4,31,173,176,182).

### ***13.6. Electrocution***

An electrocution in the bathtub can be either accident, suicide, or homicide (see Heading. 5.; Chapter 4, Heading 7.; and refs. 176, 177, 183, and 184).



**Fig. 19.** Homicidal drowning of infant. Mother had psychiatric history. (A) Lipstick writing on wall of bathroom. (B) Similar writing on child.

#### *14. DIVING-RELATED DEATHS*

Drowning is the main cause of death and occurs during any phase of the dive (185–187). Of 244 drownings in Sacramento County, CA, from 1974 through 1985, 3% occurred while scuba diving (30). Whereas 60% of diving fatalities can be attributed to medical, environmental, or equipment problems, the remainder are unexplained (185). Unexplained deaths occur even if the equipment is functional, an air supply exists in the tank, and there are no signs of physical trauma or apparent medical problems (185). Panic affecting breathing may be a factor (185). Anxious divers of varying experience may remove equipment inappropriately (185).

## 14.1. Types of Diving

### 14.1.1. Recreational

A pathologist is most likely to be involved with recreational diving fatalities (187).

- Breath-hold diving (skin diving)—no breathing apparatus other than snorkel; average person down to 6 to 10 m (20 to 30 ft); spearfishers up to 30 m (100 ft) or more (*see* Subheading 4.2.).
- Self-contained underwater breathing apparatus (scuba) diving—use of ordinary compressed air to depth of 40 m (130 ft); deeper dives require more sophisticated equipment (“technical diving”).

### 14.1.2. Professional/Commercial

- Professional—includes scientific divers conducting research, public safety divers (e.g., police divers), scuba instructors/dive guides.
- Commercial—use of tools for heavy work underwater (e.g., salvage, oil rig maintenance).

Professional and commercial divers at depth use surface-supplied diving—i.e., breathing gas is supplied from the surface via a long hose. Surface-supplied air diving occurs down to 60 m (190 ft) in sea water and is of short duration (<30 min). Surface-supplied mixed-gas diving uses helium, O<sub>2</sub>, and nitrogen (tri-mix) or helium and O<sub>2</sub> to prevent nitrogen narcosis. These dives go down to 90 m (300 ft). Saturation diving involves use of a diving bell and decompression chamber(s) for deep-depth dives for extended periods. After the first 24 h of diving, the diver’s body is completely saturated with inert gas, requiring about 1 d of decompression for every 30 m (100 ft) of depth.

## 14.2. Nitrogen Narcosis and O<sub>2</sub> Toxicity

Nitrogen narcosis and O<sub>2</sub> toxicity are more likely to be seen in professional and commercial diving. Henry’s law states that at constant temperature, the amount of gas dissolved in a liquid (e.g., blood, tissue fluid) is proportional to its partial pressure (104,188–190). At sea level (atmospheric pressure = 1.0 atm), the partial pressures of nitrogen and O<sub>2</sub> are about 0.8 atm (79% concentration in air) and 0.2 atm (21% concentration in air), respectively. Nitrogen narcosis occurs at any depth greater than 30 m (100 ft [188,189,191]). A diver using a compressed air supply at a depth of 40 m or 132 ft (5.0 atm) has a nitrogen partial pressure of 4.0 atm (104). At this depth, a diver is at risk for nitrogen narcosis (“rapture of the deep”), which is similar to the effects of alcohol (188,189,191). Unconsciousness occurs at depths greater than 90 m (300 ft [189]).

At 60 m or 233 ft (8 atm), i.e., beyond the depth of sport divers, the partial pressure of O<sub>2</sub> is 1.6 atm (nitrogen = 6.4 atm). At this depth, there is the risk for O<sub>2</sub> toxicity (i.e., seizure [104,189]).

## 14.3. Extra-Alveolar Air Syndrome

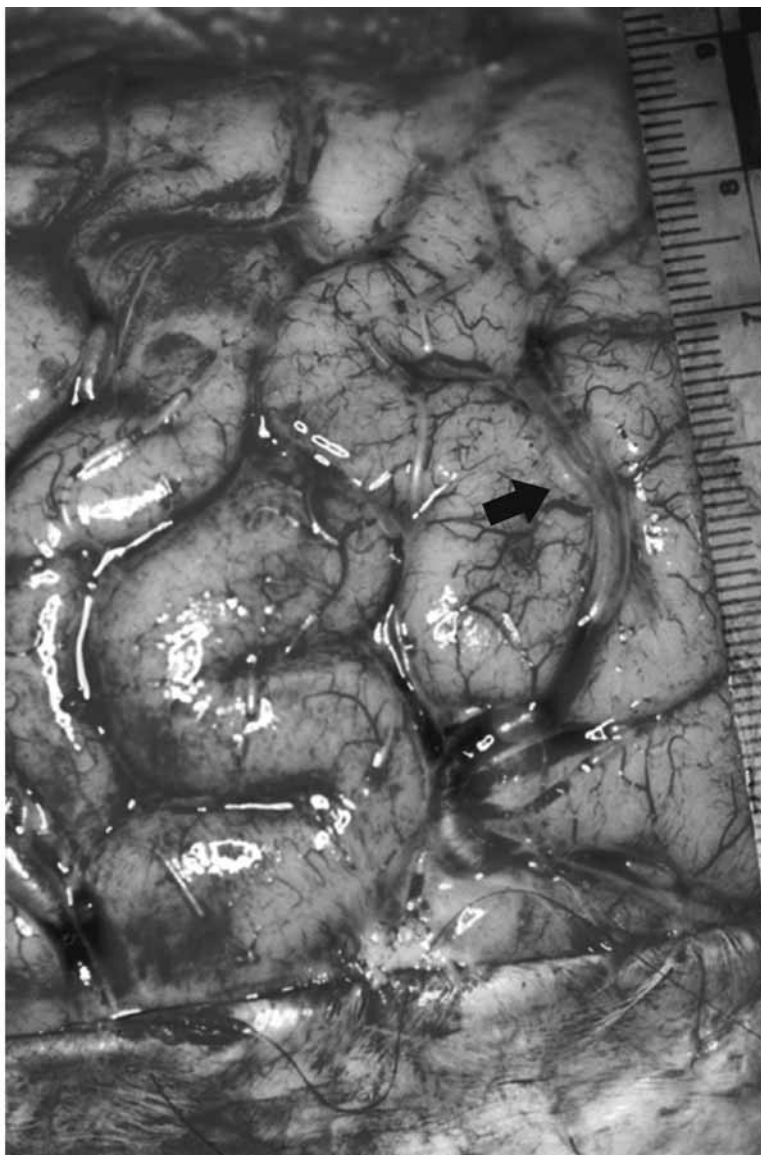
Boyle’s law states that if the temperature of a gas is kept constant, its volume varies inversely with the absolute pressure (i.e., pressure × volume = constant; *see* refs. 104,188–190, and 192). Barotrauma reflects this inverse relationship of pressure and volume (188,189). Barotrauma is caused by a failure of a gas-filled body site to equalize its internal pressure with the changing outside pressure (188,191). It is second only to drowning as the cause of death in diving accidents (186,189).



A diver at depth is subjected to increased pressure. At sea level, 1 atm of pressure (14.7 lb/in<sup>2</sup> or 760 mmHg) is exerted (104,188,191). At a depth of 10 m (33 ft) in sea water (34 ft in fresh water), 2 atm is exerted on an individual (104,187,193). As the diver descends, pressure increases and volume decreases, resulting in a relative vacuum, particularly in rigid bone-encased cavities (e.g., a respiratory tract infection causing blockage of Eustachian tubes and sinuses causes middle ear and sinus hemorrhage, leading to nosebleed [104,188,189,191,194]). Inner ear barotrauma arises from forceful efforts to equalize middle ear pressure, and vertigo results (188,189). Middle and inner ear barotrauma can also be observed on ascent (194). Failure to exhale into a mask means relatively low pressure inside the mask, which causes ocular petechiae and hemorrhage (“mask squeeze” [104]).

The lung volume of a breath-holding diver at the depth of 10 m (33 ft) is halved, but is constant if a regulated compressed air supply (scuba gear) is used (195). Even if this equipment is used, quick ascent, possibly from panic, from a minimum depth of 1.8 to 2.4 m (6 to 8 ft) without exhaling, increases lung volume (104,185,188,189,191,192, 195–197). Exhalation can be impeded by reflex glottic closure or bronchoconstriction if water is aspirated (197). Asthmatics may have bronchospasm because of a cold air supply and irritants in it (198). Overexpansion causes alveolar rupture and tracking of air into the pulmonary interstitium, pleura, and adjacent cavities (104,189). Subcutaneous and mediastinal emphysema, pneumopericardium, and pneumothorax can follow (104,188,189). Even pneumoperitoneum is possible if air passes through the diaphragmatic opening (199–201). Chronic obstructive lung disease (emphysema, asthma) enhances air trapping in the lungs. Pulmonary disease lesions (e.g., emphysematous bullae) are prone to rupture (104,189,196). Entry of air into alveolar capillaries, and eventually the pulmonary veins, leads to air embolism to the coronary and cerebral artery circulation, i.e., arterial gas embolism (AGE; see Fig. 20 and refs. 104, 188, 191, 195, 197, 202, and 203). Air bubbles rise when the head is up (189). Unconsciousness occurs immediately and can happen in a dive lasting only a minute (189,195,196, 202,204). Mechanical blockage in the heart outflow tract can occur (192,195,204). Only a few milliliters of air can be fatal in AGE (192).

The maximum volume of the stomach is about 5 L (193,200). A diver who rapidly ascends from a depth of at least 6 m or 20 ft (typically 43 ± 12 m or 140 ± 40 ft) during a dive of brief duration (8 ± 5 min average) can inflate the stomach, causing injuries ranging from mucosal tearing to rupture (Fig. 21; refs. 193, 199–201, and 205–207). The stomach may be already be distended by a heavy meal and soda (199). The stomach is further expanded if air and water are swallowed while ascending (193,199–201, 206). The lesser curvature is predisposed to tear because it has fewer mucosal folds, is less elastic, and has a single muscle layer (199,200,205). This complication is uncommon because gastric gas usually escapes into the esophagus and duodenum (193). Gastric distension, by increasing angulation, can close the gastroesophageal junction and also cause reflex pylorospasm (199,200,205). Multiple lacerations, involving the mucosa and wall, range from 2 to 15 cm (0.75 to 6 in. [200]). Hematemesis can be a presenting sign. Multiple rupture sites are possible (200). No inflammation is seen. Gastric distension can exacerbate portal hypertension, resulting in variceal bleeding (125). Tears can extend into the gastroesophageal junction (207). Subsequent cardiopulmonary resuscitation can also cause gastric rupture (see Chapter 8, Subheading 6.2. and




**Fig. 20.** Diving accident. Arterial gas embolism in cerebral vessel (arrow). (Courtesy of Dr. B. Sawka, Grey Bruce Health Services, Owen Sound, Ontario, Canada.)

ref. [193](#)). Intestinal rupture is possible ([200](#)). Concurrent signs of extra-alveolar air syndrome are observed ([193](#)).

#### ***14.4. Decompression Sickness***

A scuba diver breathes air that is 79% nitrogen and 21% O<sub>2</sub>. The greater partial pressure of nitrogen means increased nitrogen absorption in a diver at depth for an extended period of time ([104](#)). Nitrogen, an inert gas, is more soluble in fat than in blood ([188](#)). Both can become saturated with nitrogen. The duration of time, not depth, determines the degree of saturation of blood with nitrogen ([104,189,195](#)). The depth of



**Fig. 21.** Diving accident. Quick ascent to surface. Gastric mucosal lacerations. (Courtesy of Dr. K. Newell, Grey Bruce Health Services, Owen Sound, Ontario, Canada.)

the dive determines the total quantity of nitrogen absorbed. Repeated dives increase the risk (188). If there is rapid ascent, then gradual elimination of nitrogen by exhalation cannot keep pace (104,189). Nitrogen bubbles out of solution in the blood and fat, analogous to the bubbles that form when a soda is opened (104,188,189). Entry of nitrogen bubbles into capillaries in adipose tissue lead to venous gas embolism (104,195,196). In dives less than 10 m (33 ft), gradual decompression during ascent is not needed (104). When the depth exceeds 40 m (130 ft), decompression stops are needed. Decompression sickness can still occur with proper pauses on ascent (188,189). Flying after diving can precipitate decompression sickness (189).

Mechanical distension by nitrogen bubbles is a possible cause for pain, which typically affects dense tissue such as ligaments or tendons around joints (the “bends”) ([104,188,189,195](#)). Joint symptoms usually appear within 24 h, but more severe symptoms occur within half an hour ([188,195](#)). Paresis caused by spinal cord involvement occurs when bubbles form in the epidural vein plexus around the spinal cord ([104,188,189,195,202,203](#)). A large volume (80–100 mL) of venous gas in the right heart leads to serious effects (*see* Chapter 7, Subheading 12.1.1. and ref. [192](#)). Numerous bubbles in the pulmonary circulation lead to the “chokes” ([104,188,189,195,208](#)). Paradoxical gas embolism to systemic organs (brain, heart) across a patent foramen ovale can occur ([188,195,208](#)). Seizures are possible. A DIC picture may arise from decompression sickness ([191,195,208](#)). Decompression sickness can occur in combination with air embolism ([188,195,208](#)).

### ***14.5. Pulmonary Edema***

Approximately 1% of divers develop pulmonary edema ([209](#)). It can originate from either cardiogenic causes (increased capillary hydrostatic pressure) or noncardiogenic mechanisms (increased vascular permeability). There may be no obvious precipitating cause, and pulmonary edema can develop after diving in water of any depth and temperature. Various predisposing factors, such as immersion effects (*see* Subheading 4.5.), vigorous attempts to breathe augmenting negative intrathoracic pressure, and tight wet suits, have been described. There may be a history of hypertension.

### ***14.6. Circumstances of Diving-Related Deaths***

The following information is important in the investigation of a diving fatality ([187,190,191](#)).

- Medical history
  - Heart disease, pulmonary disease (chronic obstructive pulmonary disease).
  - Recent respiratory tract infection.
  - Diabetes.
  - Epilepsy.
  - Medications.
  - Alcohol and other drug use.
  - Psychiatric history.
- Prior diving experience.
- Witnesses/dive companion.
  - Diving events.
  - Terminal event?
- Resuscitation efforts.
- Recent meal.
- Underwater hazard leading to blunt trauma or entrapment; failure to follow proper procedures ([186,191,210](#)).
- Surface hazard (boat hull or propellers).
- Environmental conditions.

### ***14.7. Equipment***

Any equipment must be seized and properly stored for later expert inspection ([187](#)). Equipment can fail, be altered, or be used inappropriately ([190,191](#)). The high-pressure

air compressor used to fill the diver's air tank can malfunction (e.g., intake of carbon monoxide from compressor engine [104,190,191]). A diver can run out of air. The inner lining of the tank can be corroded from rust, leading to O<sub>2</sub> depletion (104,190,191,211). Samples of air from the compressor and cylinder need to be taken. The buoyancy compensator controls flotation and can be defective (208). A common finding is the failure of a diver to inflate the compensator in an emergency situation (190). The dive computer is a device used to calculate the amount of time allowable at a depth and assess a diver's decompression status. This computer can provide information about dive depth, duration of various phases of the dive including the ascent, and water temperature (191).

### **14.8. Autopsy Approach to a Diving Death**

Interpretation of postmortem findings requires a multidisciplinary integration of information about the circumstances of the death and an adequate knowledge of diving and its hazards (190,191,212,213).

- Photograph the body with equipment, if not removed.
- Ensure proper identification. Note any identifying features.
- Note the color of the lividity (red-pink discoloration is seen in carbon monoxide poisoning and hypothermia); marbling of skin suggests arterial air embolism (cutis marmorata) in a living individual (195). Lividity in divers tends to be on the back because of the weight of the air tank, in contrast to frontal livor mortis in the usual drowning. Decomposition hinders the assessment of gas in the soft tissues, body cavities, and circulation.
- Observe any signs of trauma.
- Observe for "mask squeeze" on the face. Observe for other signs of barotrauma, e.g., epistaxis. If an otoscope is available, examine the eardrums. Observe for signs of drowning (froth from the nose and mouth).
- If an ophthalmoscope is available, examine the retinal arteries for evidence of air.
- Palpate the skin of the neck and chest to detect crepitation consistent with subcutaneous emphysema.
- Insert a 14- or 16-gage needle attached to a 50-mL syringe, containing a few milliliters of water, through the lateral intercostal spaces bilaterally to assess for pneumothorax. Draw back the syringe plunger to observe air bubbles. Quantitate the pneumothorax. Not performing this step could result in the prosector being greeted with a sudden expulsion of air when the sternum is lifted. Note that resuscitation, i.e., insertion of an endotracheal tube and artificial ventilation, with or without associated rib fractures from cardiopulmonary resuscitation, can cause iatrogenic pneumothorax. Failure to clamp the endotracheal tube while aspirating air from the chest can lead to the mistaken observation of an apparently large pneumothorax.
- Radiographs of the head, neck, and torso assess for presence of intravascular or extravascular air. A decubitus chest film (left side of deceased up) is included. AGE can be associated with large quantities of air (196,214).
- The brain is examined prior to removal of the heart. Prior to removal of the calvarium, a 5-cm<sup>2</sup> piece of bone is cut on either side of the vertex (Sawchuk-Harpur protocol). When the calvarium is removed, the square can be manually compressed while holding the brain and membranes in place. The surface of the brain then is examined for air embolism. Double-clipping the internal carotid and basilar arteries prior to brain removal prevents air from artifactually entering the circulation. Detailed examination of the temporal bone has been described (194).
- A small sternal "window" is made over the heart. The window is filled with water and a syringe inserted into the pericardial sac to assess for pneumopericardium. When the



pericardium is opened, observe whether gas bubbles are present in the coronary vessels. Flood the pericardial sac with water. Taking a 10-mL syringe containing a few milliliters of water, insert the needle below water level into the ventricles. Draw back and note air bubbles (*see* Chapter 7, Fig. 38). The vessels of the visceral pleura can be inspected with the lungs *in situ*. When the sternum is removed, examine the mediastinum for emphysema. The finding of intracardiac and intravascular bubbles is not pathognomonic of AGE or decompression sickness. Nitrogen does come out of solution, even postmortem, when the body is at atmospheric pressure (204,212). Decomposition produces gases. Microbiological cultures may determine whether gas-forming microorganisms are present.

- Consider other traumatic and natural causes of death, particularly in “dry” drowning cases. Examine the heart for evidence of a probe patent foramen ovale. The tongue may be lacerated, indicative of a seizure. Mottled pallor (Leibermeister’s sign) of the tongue may indicate air embolism.
- Resuscitation artifacts create interpretation difficulties (e.g., petechiae, fat/bone marrow embolism).
- The pulmonary hilar and main vessels of the heart can be tied prior to removal of these organs. The lungs can be placed in a sink filled with water, and air is introduced by a syringe into the bronchi to check for potential pleural rupture sites. Examine the lung for blebs and emphysematous bullae. The bronchi and stomach may contain froth and debris, respectively.
- Retention of bone (femur) for diatom studies (if analysis available) may be considered in certain cases depending on the circumstances (*see* Subheading 11.3.).
- Retain brain and spinal cord.
- Perform toxicology (ethanol, drug screen).

## REFERENCES

1. Davis, J. H. Bodies found in the water. An investigative approach. *Am. J. Forensic Med. Pathol.* 7:291–297, 1986.
2. Timperman, J. The diagnosis of drowning. A review. *Forensic Sci.* 1:397–409, 1972.
3. Lunetta, P., Penttila, A., Sajantila, A. Circumstances and macropathologic findings in 1590 consecutive cases of bodies found in water. *Am. J. Forensic Med. Pathol.* 23:371–376, 2002.
4. Wirthwein, D. P., Barnard, J. J., Prahlow, J. A. Suicide by drowning: a 20-year review. *J. Forensic Sci.* 47:131–136, 2002.
5. Lucas, J., Goldfeder, L. B., Gill, J. R. Bodies found in the waterways of New York City. *J. Forensic Sci.* 47:137–141, 2002.
6. Moar, J. J. Drowning—postmortem appearances and forensic significance. A case report. *S. Afr. Med. J.* 64:792–795, 1983.
7. Lunetta, P., Smith, G. S., Penttila, A., Sajantila, A. Undetermined drowning. *Med. Sci. Law* 43:207–214, 2003.
8. Modell, J. H., Bellefleur, M., Davis, J. H. Drowning without aspiration: is this an appropriate diagnosis? *J. Forensic Sci.* 44:1119–1123, 1999.
9. Copeland, A. R. Suicide by drowning. *Am. J. Forensic Med. Pathol.* 8:18–22, 1987.
10. Pachar, J. V., Cameron, J. M. Submersion cases: a retrospective study—1988–1990. *Med. Sci. Law* 32:15–17, 1992.
11. Dietz, P. E., Baker, S. P. Drowning: epidemiology and prevention. *Am. J. Public Health* 64:303–312, 1974.
12. Patetta, M. J., Biddinger, P. W. Characteristics of drowning deaths in North Carolina. *Public Health Rep.* 103:406–411, 1988.

13. Press, E., Walker, J., Crawford, I. An interstate drowning study. *Am. J. Public Health Nations Health* 58:2275–2289, 1968.
14. Smith, N. M., Byard, R. W., Bourne, A. J. Death during immersion in water in childhood. *Am. J. Forensic Med. Pathol.* 12:219–221, 1991.
15. Plueckhahn, V. D. The aetiology of 134 deaths due to “drowning” in Geelong during the years 1957 to 1971. *Med. J. Aust.* 2:1183–1187, 1972.
16. Gordon, I. The anatomical signs in drowning. A critical evaluation. *Forensic Sci.* 1:389–395, 1972.
17. Giertsen, J. C. Drowning while under the influence of alcohol. *Med. Sci. Law* 10:216–219, 1970.
18. Plueckhahn, V. D. Alcohol and accidental drowning. A 25-year study. *Med. J. Aust.* 141:22–25, 1984.
19. Plueckhahn, V. D. Death by drowning? Geelong 1959 to 1974. *Med. J. Aust.* 2:904–906, 1975.
20. Copeland, A. R. An assessment of lung weights in drowning cases. The Metro Dade County experience from 1978 to 1982. *Am. J. Forensic Med. Pathol.* 6:301–304, 1985.
21. Lau, G. Did he drown or was he murdered? *Med. Sci. Law* 42:172–180, 2002.
22. Kringsholm, B., Filskov, A., Kock, K. Autopsied cases of drowning in Denmark 1987–1989. *Forensic Sci. Int.* 52:85–92, 1991.
23. Davis, J. H. Bodies in water. Solving the puzzle. *J. Fla. Med. Assoc.* 79:630–632, 1992.
24. Morild, I. Pleural effusion in drowning. *Am. J. Forensic Med. Pathol.* 16:253–256, 1995.
25. Mueller, W. F. Pathology of temporal bone hemorrhage in drowning. *J. Forensic Sci.* 14:327–336, 1969.
26. Pachar, J. V., Cameron, J. M. The diagnosis of drowning by quantitative and qualitative diatom analysis. *Med. Sci. Law* 33:291–299, 1993.
27. Ludes, B., Quantin, S., Coste, M., Mangin, P. Application of a simple enzymatic digestion method for diatom detection in the diagnosis of drowning in putrified corpses by diatom analysis. *Int. J. Legal Med.* 107:37–41, 1994.
28. Gooden, B. A. Drowning and the diving reflex in man. *Med. J. Aust.* 2:583–587, 1972.
29. Wintemute, G. J., Kraus, J. F., Teret, S. P., Wright, M. Drowning in childhood and adolescence: a population-based study. *Am. J. Public Health* 77:830–832, 1987.
30. Wintemute, G. J., Kraus, J. F., Teret, S. P., Wright, M. A. The epidemiology of drowning in adulthood: implications for prevention. *Am. J. Prev. Med.* 4:343–348, 1988.
31. Davis, L. G. Suicidal drowning in south Florida. *J. Forensic Sci.* 44:902–905, 1999.
32. Bierens, J. J., van der Velde, E. A., van Berkel, M., van Zanten, J. J. Submersion cases in the Netherlands. *Ann. Emerg. Med.* 18:366–373, 1989.
33. Cairns, F. J., Koelmeyer, T. D., Smeeton, W. M. Deaths from drowning. *N. Z. Med. J.* 97:65–67, 1984.
34. Auer, A. Suicide by drowning in Uusimaa province in southern Finland. *Med. Sci. Law* 30:175–179, 1990.
35. Copeland, A. R. Homicidal drowning. *Forensic Sci. Int.* 31:247–252, 1986.
36. Griest, K. J., Zumwalt, R. E. Child abuse by drowning. *Pediatrics* 83:41–46, 1989.
37. Byard, R. W., Houldsworth, G., James, R. A., Gilbert, J. D. Characteristic features of suicidal drownings: a 20-year study. *Am. J. Forensic Med. Pathol.* 22:134–138, 2001.
38. Davis, S., Smith, L. S. The epidemiology of drowning in Cape Town—1980–1983. *S. Afr. Med. J.* 68:739–742, 1985.
39. Wintemute, G. J. Childhood drowning and near-drowning in the United States. *Am. J. Dis. Child.* 144:663–669, 1990.
40. Nixon, J., Pearn, J., Wilkey, I., Corcoran A. Fifteen years of child drowning—a 1967–1981 analysis of all fatal cases from the Brisbane Drowning Study and an 11 year study of consecutive near-drowning cases. *Accid. Anal. Prev.* 18:199–203, 1986.

41. Davis, S., Ledman, J., Kilgore, J. Drownings of children and youth in a desert state. *West. J. Med.* 143:196–201, 1985.
42. Cass, D. T., Ross, F., Lam, L. T. Childhood drowning in New South Wales 1990–1995: a population-based study. *Med. J. Aust.* 165:610–612, 1996.
43. O'Carroll, P. W., Alkon, E., Weiss, B. Drowning mortality in Los Angeles County, 1976 to 1984. *JAMA* 260:380–383, 1988.
44. Hedberg, K., Gunderson, P. D., Vargas, C., Osterholm, M. T., MacDonald, K. L. Drownings in Minnesota, 1980–85: a population-based study. *Am. J. Public Health* 80:1071–1074, 1990.
45. MacLachlan, J. Drownings, other aquatic injuries and young Canadians. *Can. J. Public Health* 75:218–222, 1984.
46. Pearn, J. H., Wong, R. Y., Brown, J., III, Ching, Y. C., Bart, R., Jr., Hammar, S. Drowning and near-drowning involving children: a five-year total population study from the City and County of Honolulu. *Am. J. Public Health* 69:450–454, 1979.
47. Orlowski, J. P. Drowning, near-drowning, and ice-water submersions. *Pediatr. Clin. N. Am.* 34:75–92, 1987.
48. DeNicola, L. K., Falk, J. L., Swanson, M. E., Gayle, M. O., Kissoon, N. Submersion injuries in children and adults. *Crit. Care Clin.* 13:477–502, 1997.
49. Copeland, A. R. Deaths during recreational activity. *Forensic Sci. Int.* 25:117–122, 1984.
50. Wong, L. L., McNamara, J. J. Salt water drowning. *Hawaii Med. J.* 43:208, 210, 1984.
51. O'Shea, J. S. House-fire and drowning deaths among children and young adults. *Am. J. Forensic Med. Pathol.* 12:33–35, 1991.
52. Wintemute, G. J., Kraus, J. F., Teret, S. P., Wright, M. A. Death resulting from motor vehicle immersions: the nature of the injuries, personal and environmental contributing factors, and potential interventions. *Am. J. Public Health* 80:1068–1070, 1990.
53. Jumbelic, M. I., Chambliss, M. Accidental toddler drowning in 5-gallon buckets. *JAMA* 263:1952–1953, 1990.
54. Pearn, J., Nixon, J., Wilkey, I. Freshwater drowning and near-drowning accidents involving children: a five-year total population study. *Med. J. Aust.* 2:942–946, 1976.
55. Byard, R. W., Lipsett, J. Drowning deaths in toddlers and preambulatory children in South Australia. *Am. J. Forensic Med. Pathol.* 20:328–332, 1999.
56. Kibel, S. M., Nagel, F. O., Myers, J., Cywes, S. Childhood near-drowning—a 12-year retrospective review. *S. Afr. Med. J.* 78:418–421, 1990.
57. Wintemute, G. J. Drowning in early childhood. *Pediatr. Ann.* 21:417–421, 1992.
58. Levin, D. L., Morriss, F. C., Toro, L. O., Brink, L. W., Turner, G. R. Drowning and near-drowning. *Pediatr. Clin. N. Am.* 40:321–336, 1993.
59. Kallas, H. J., O'Rourke, P. P. Drowning and immersion injuries in children. *Curr. Opin. Pediatr.* 5:295–302, 1993.
60. Shaw, K. N., Briede, C. A. Submersion injuries: drowning and near-drowning. *Emerg. Med. Clin. N. Am.* 7:355–370, 1989.
61. Pearn, J. H., Nixon, J. Swimming pool immersion accidents: an analysis from the Brisbane Drowning Study. 1977. *Inj. Prev.* 3:307–309, 1997.
62. Wintemute, G. J., Drake, C., Wright, M. Immersion events in residential swimming pools. Evidence for an experience effect. *Am. J. Dis. Child.* 145:1200–1203, 1991.
63. Pearn, J., Nixon, J. Prevention of childhood drowning accidents. *Med. J. Aust.* 1:616–618, 1977.
64. Patrick, M., Bint, M., Pearn, J. Saltwater drowning and near-drowning accidents involving children. A five-year total population study in south-east Queensland. *Med. J. Aust.* 1:61–64, 1979.
65. Pitt, W. R., Balanda, K. P. Childhood drowning and near-drowning in Brisbane: the contribution of domestic pools. *Med. J. Aust.* 154:661–665, 1991.

66. Corbin, D. O., Fraser, H. S. A review of 98 cases of near-drowning at the Queen Elizabeth Hospital, Barbados. *West Indian Med. J.* 30:22–29, 1981.
67. Quan, L., Gore, E. J., Wentz, K., Allen, J., Novack, A. H. Ten-year study of pediatric drownings and near-drownings in King County, Washington: lessons in injury prevention. *Pediatrics* 83:1035–1040, 1989.
68. Fergusson, D. M., Horwood, L. J. Risks of drowning in fenced and unfenced domestic swimming pools. *N. Z. Med. J.* 97:777–779, 1984.
69. Pearn, J. H., Nixon, J. Swimming pool immersion accidents: an analysis from the Brisbane drowning study. *Med. J. Aust.* 1:432–437, 1977.
70. Mann, N. C., Weller, S. C., Rauchschalbe, R. Bucket-related drownings in the United States, 1984 through 1990. *Pediatrics* 89:1068–1071, 1992.
71. Scott, P. H., Eigen H. Immersion accidents involving pails of water in the home. *J. Pediatr.* 96:282–284, 1980.
72. Avis, S. P. Suicidal drowning. *J. Forensic Sci.* 38:1422–1426, 1993.
73. Orłowski, J. P., Szpilman, D. Drowning. Rescue, resuscitation, and reanimation. *Pediatr. Clin. North Am.* 48:627–646, 2001.
74. Ritchie, B. C. The physiology of drowning. *Med. J. Aust.* 2:1187–1189, 1972.
75. Modell, J. H. Drown versus near-drown: a discussion of definitions. *Crit. Care Med.* 9:351–352, 1981.
76. Pearn, J. Pathophysiology of drowning. *Med. J. Aust.* 142:586–588, 1985.
77. Pearn, J., Nixon, J. Bathtub immersion accidents involving children. *Med. J. Aust.* 1:211–213, 1977.
78. Modell, J. H. Drowning. *N. Engl. J. Med.* 328:253–256, 1993.
79. Modell, J. H., Moya, F., Newby, E. J., Ruiz, B. C., Showers, A. V. The effects of fluid volume in seawater drowning. *Ann. Intern. Med.* 67:68–80, 1967.
80. Modell, J. H., Davis, J. H. Electrolyte changes in human drowning victims. *Anesthesiology* 30:414–420, 1969.
81. Giammona, S. T., Modell, J. H. Drowning by total immersion. Effects on pulmonary surfactant of distilled water, isotonic saline, and sea water. *Am. J. Dis. Child.* 114:612–616, 1967.
82. Modell, J. H. Near-drowning. *Int. Anesthesiol. Clin.* 15:107–115, 1977.
83. Modell, J. H. Biology of drowning. *Annu. Rev. Med.* 29:1–8, 1978.
84. Modell, J. H., Kuck, E. J., Ruiz, B. C., Heinitsh, H. Effect of intravenous vs. aspirated distilled water on serum electrolytes and blood gas tensions. *J. Appl. Physiol.* 32:579–584, 1972.
85. Modell, J. H. The pathophysiology and treatment of drowning. *Acta Anaesthesiol. Scand. Suppl.* 29:263–279, 1968.
86. Noble, C. S., Sharpe, N. Drowning: Its mechanism and treatment. *Can. Med. Assoc. J.* 89:402–405, 1963.
87. Golden, F. S., Tipton, M. J., Scott, R. C. Immersion, near-drowning and drowning. *Br. J. Anaesth.* 79:214–225, 1997.
88. Harries, M. G. Drowning in man. *Crit. Care Med.* 9:407–408, 1981.
89. Davis JH. Fatal underwater breath holding in trained swimmers. *J. Forensic Sci.* 1961; 6:301–306.
90. Colebatch, H. J., Halmagyi, D. F. Lung mechanics and resuscitation after fluid aspiration. *J. Appl. Physiol.* 16:684–696, 1961.
91. Colebatch, H. J., Halmagyi, D. F. Effect of vagotomy and vagal stimulation on lung mechanics and circulation. *J. Appl. Physiol.* 18:881–887, 1963.
92. Modell, J. H. Near drowning. *Circulation* 74:IV27–IV28, 1986.
93. Halmagyi, D. F., Colebatch, H. J. Ventilation and circulation after fluid aspiration. *J. Appl. Physiol.* 16:35–40, 1961.
94. Halmagyi, D. F., Colebatch, H. J., Starzecki, B. Inhalation of blood, saliva, and alcohol: consequences, mechanism, and treatment. *Thorax* 17:244–250, 1962.

95. Modell, J. H., Gaub, M., Moya, F., Vestal, B., Swarz, H. Physiologic effects of near drowning with chlorinated fresh water, distilled water and isotonic saline. *Anesthesiology* 27:33–41, 1966.
96. Conn, A. W., Miyasaka, K., Katayama, M., et al. A canine study of cold water drowning in fresh versus salt water. *Crit. Care Med.* 23:2029–2037, 1995.
97. Segarra, F., Redding, R. A. Modern concepts about drowning. *Can. Med. Assoc. J.* 110:1057, 1974.
98. Orlowski, J. P., Abulleil, M. M., Phillips, J. M. The hemodynamic and cardiovascular effects of near-drowning in hypotonic, isotonic, or hypertonic solutions. *Ann. Emerg. Med.* 18:1044–1049, 1989.
99. Orlowski, J. P., Abulleil, M. M., Phillips, J. M. Effects of tonicities of saline solutions on pulmonary injury in drowning. *Crit. Care Med.* 15:126–130, 1987.
100. Modell, J. H., Moya, F. Effects of volume of aspirated fluid during chlorinated fresh water drowning. *Anesthesiology* 27:662–672, 1966.
101. Culpepper, R. M. Letter: Bleeding diathesis in fresh water drowning. *Ann. Intern. Med.* 83:675, 1975.
102. Modell, J. H. Serum electrolyte changes in near-drowning victims. *JAMA* 253:557, 1985.
103. Schmidt, P., Madea, B. Death in the bathtub involving children. *Forensic Sci. Int.* 72:147–155, 1995.
104. Sanford, J. P. Medical aspects of recreational skin and scuba diving. *Annu. Rev. Med.* 25:401–410, 1974.
105. Craig, A. B., Jr. Underwater swimming and drowning. *J. Sports Med. Phys. Fitness* 2:23–26, 1962.
106. Craig, A. B., Jr. Causes of loss of consciousness during underwater swimming. *J. Appl. Physiol.* 16:583–586, 1961.
107. Craig, A. B., Jr. Underwater swimming and loss of consciousness. *JAMA* 176:255–258, 1961.
108. Plueckhahn, V. D. Alcohol consumption and death by drowning in adults; a 24-year epidemiological analysis. *J. Stud. Alcohol.* 43:445–452, 1982.
109. Daly, M. D., Angell-James, J. E., Elsner, R. Role of carotid-body chemoreceptors and their reflex interactions in bradycardia and cardiac arrest. *Lancet* 1:764–767, 1979.
110. Plueckhahn, V. D. Alcohol and accidental submersion from watercraft and surrounds. *Med. Sci. Law* 17:246–250, 1977.
111. Lunetta, P., Levo, A., Laitinen, P. J., Fodstad, H., Kontula, K., Sajantila, A. Molecular screening of selected long QT syndrome (LQTS) mutations in 165 consecutive bodies found in water. *Int. J. Legal Med.* 117:115–117, 2003.
112. Saxena, A., Ang, L. C. Epilepsy and bathtub drowning. Important neuropathological observations. *Am. J. Forensic Med. Pathol.* 14:125–129, 1993.
113. Edwards, N. D., Timmins, A. C., Randalls, B., Morgan, G. A., Simcock, A. D. Survival in adults after cardiac arrest due to drowning. *Intensive Care Med.* 16:336–337, 1990.
114. Modell, J. H., Graves, S. A., Ketover, A. Clinical course of 91 consecutive near-drowning victims. *Chest* 70:231–238, 1976.
115. Waugh, J. H., O'Callaghan, M. J., Pitt, W. R. Prognostic factors and long-term outcomes for children who have nearly drowned. *Med. J. Aust.* 161:594–599, 1994.
116. Orlowski, J. P. Drowning, near-drowning, and ice-water drowning. *JAMA* 260:390–391, 1988.
117. Tipton, M. J. The initial responses to cold-water immersion in man. *Clin. Sci. (Lond.)* 77:581–588, 1989.
118. Tipton, M. J., Golden, F. S., Higenbottam, C., Mekjavic, I. B., Eglin, C. M. Temperature dependence of habituation of the initial responses to cold-water immersion. *Eur. J. Appl. Physiol. Occup. Physiol.* 78:253–257, 1998.
119. Tipton, M. J., Stubbs, D. A., Elliott, D. H. The effect of clothing on the initial responses to cold water immersion in man. *J. R. Nav. Med. Serv.* 76:89–95, 1990.



120. Hayward, J. S., Eckerson, J. D. Physiological responses and survival time prediction for humans in ice-water. *Aviat. Space Environ. Med.* 55:206–211, 1984.
121. Tipton, M. J., Mekjavic, I. B., Eglin, C. M. Permanence of the habituation of the initial responses to cold-water immersion in humans. *Eur. J. Appl. Physiol.* 83:17–21, 2000.
122. Gooden, B. A. Why some people do not drown. Hypothermia versus the diving response. *Med. J. Aust.* 157:629–632, 1992.
123. Graham, T., Baulk, K. Effect of alcohol ingestion on man's thermoregulatory responses during cold water immersion. *Aviat. Space Environ. Med.* 51:155–159, 1980.
124. Golden, F. S., Hervey, G. R., Tipton, M. J. Circum-rescue collapse: collapse, sometimes fatal, associated with rescue of immersion victims. *J. R. Nav. Med. Serv.* 77:139–149, 1991.
125. Nguyen, M. H., Ernsting, K. S., Proctor, D. D. Massive variceal bleeding caused by scuba diving. *Am. J. Gastroenterol.* 95:3677–3678, 2000.
126. Mohri, H., Dillard, D. H., Crawford, E. W., Martin, W. E., Merendino, K. A. Method of surface-induced deep hypothermia for open-heart surgery in infants. *J. Thorac. Cardiovasc. Surg.* 58:262–270, 1969.
127. Gooden, B. A. The diving response in clinical medicine. *Aviat. Space Environ. Med.* 53:273–276, 1982.
128. Campbell, L. B., Gooden, B. A., Horowitz, J. D. Cardiovascular responses to partial and total immersion in man. *J. Physiol.* 202:239–250, 1969.
129. Orłowski, J. P., Rothner, A. D., Lueders, H. Submersion accidents in children with epilepsy. *Am. J. Dis. Child.* 136:777–780, 1982.
130. Pearn, J., Bart, R., Yamaoka, R. Drowning risks to epileptic children: a study from Hawaii. *Br. Med. J.* 2:1284–1285, 1978.
131. Pearn, J. M. Epilepsy and drowning in childhood. *Br. Med. J.* 1:1510–1511, 1977.
132. Ryan, C. A., Dowling, G. Drowning deaths in people with epilepsy. *CMAJ* 148:781–784, 1993.
133. Stumpp, J. W., Schneider, J., Bar, W. Drowning of a girl with anomaly of the bundle of His and the right bundle branch. *Am. J. Forensic Med. Pathol.* 18:208–210, 1997.
134. Pearn, J. Drowning and alcohol. *Med. J. Aust.* 141:6–7, 1984.
135. Mackie, I. Alcohol and aquatic disasters. *Med. J. Aust.* 1:652–653, 1978.
136. Haight, J. S., Keatinge, W. R. Failure of thermoregulation in the cold during hypoglycaemia induced by exercise and ethanol. *J. Physiol.* 229:87–97, 1973.
137. Kurihara, K., Kuroda, N., Murai, T., Matsuo, Y., Yanagida, J., Watanabe, H. A case of suicide by drowning with hesitation marks on the back. *Nippon Hoigaku Zasshi* 43:517–521, 1989.
138. Yorulmaz, C., Arican, N., Afacan, I., Dokgoz, H., Asirdizer, M. Pleural effusion in bodies recovered from water. *Forensic Sci. Int.* 136:16–21, 2003.
139. Terazawa, K., Haga, K. The role of pleural effusion in drowning. *Am. J. Forensic Med. Pathol.* 17:173–174, 1996.
140. Lunetta, P., Modell, J. H., Sajantila, A. What is the incidence and significance of “dry-lungs” in bodies found in water? *Am. J. Forensic Med. Pathol.* 25:291–301, 2004.
141. Hadley, J. A., Fowler, D. R. Organ weight effects of drowning and asphyxiation on the lungs, liver, brain, heart, kidneys, and spleen. *Forensic Sci. Int.* 133:190–196, 2003.
142. Mukaida, M., Kimura, H., Takada, Y. Detection of bathsalts in the lungs of a baby drowned in a bathtub: a case report. *Forensic Sci. Int.* 93:5–11, 1998.
143. Auer, A., Mottonen, M. Diatoms and drowning. *Z. Rechtsmed.* 101:87–98, 1988.
144. Haffner, H. T., Graw, M., Erdelkamp, J. Spleen findings in drowning. *Forensic Sci. Int.* 66:95–104, 1994.
145. Fornes, P., Pepin, G., Heudes, D., Lecomte, D. Diagnosis of drowning by combined computer-assisted histomorphometry of lungs with blood strontium determination. *J. Forensic Sci.* 43:772–776, 1998.

146. Neidhart, D. A., Greendyke, R. M. The significance of diatom demonstration in the diagnosis of death by drowning. *Am. J. Clin. Pathol.* 48:377–382, 1967.
147. Durlacher, S. H., Freimuth, H. C., Swan, H. E., Jr. Blood changes in man following death due to drowning, with comments on tests for drowning. *AMA Arch, Pathol.* 56:454–461, 1953.
148. Foroughi, E. Serum changes in drowning. *J. Forensic Sci.* 16:269–282, 1971.
149. Freimuth, H. C., Swann, H. E., Jr. Plasma specific gravity changes in sudden deaths; observations with specific reference to drowning. *AMA Arch. Pathol.* 59:214–218, 1955.
150. Farmer, J. G., Benomran, F., Watson, A. A., Harland, W. A. Magnesium, potassium, sodium and calcium in post-mortem vitreous humour from humans. *Forensic Sci. Int.* 27:1–13, 1985.
151. Peabody, A. J. Diatoms and drowning—a review. *Med. Sci. Law* 20:254–261, 1980.
152. Hendey, N. I. The diagnostic value of diatoms in cases of drowning. *Med. Sci. Law* 13:23–34, 1973.
153. Pollanen, M. S., Cheung, C., Chiasson, D. A. The diagnostic value of the diatom test for drowning, I. Utility: a retrospective analysis of 771 cases of drowning in Ontario, Canada. *J. Forensic Sci.* 42:281–285, 1997.
154. Ludes, B., Coste, M., Tracqui, A., Mangin, P. Continuous river monitoring of the diatoms in the diagnosis of drowning. *J. Forensic Sci.* 41:425–428, 1996.
155. Pollanen, M. S. Diatoms and homicide. *Forensic Sci. Int.* 91:29–34, 1998.
156. Lunetta, P., Penttilä, A., Hallfors, G. Scanning and transmission electron microscopical evidence of the capacity of diatoms to penetrate the alveolo-capillary barrier in drowning. *Int. J. Legal Med.* 111:229–237, 1998.
157. Krstic, S., Duma, A., Janevska, B., Levkov, Z., Nikolova, K., Noveska, M. Diatoms in forensic expertise of drowning—a Macedonian experience. *Forensic Sci. Int.* 127:198–203, 2002.
158. Gruspier, K. L., Pollanen, M. S. Limbs found in water: investigation using anthropological analysis and the diatom test. *Forensic Sci. Int.* 112:1–9, 2000.
159. Pollanen, M. S. The diagnostic value of the diatom test for drowning, II. Validity: analysis of diatoms in bone marrow and drowning medium. *J. Forensic Sci.* 42:286–290, 1997.
160. Porawski, R. Investigations on the occurrence of diatoms in organs in death from various causes. *J. Forensic Med.* 13:134–137, 1966.
161. Foged, N. Diatoms and drowning—once more. *Forensic Sci. Int.* 21:153–159, 1983.
162. Gylseth, B., Mowe, G. Diatoms in lung tissue. *Lancet* 2:1375, 1979.
163. Auer, A. Qualitative diatom analysis as a tool to diagnose drowning. *Am. J. Forensic Med. Pathol.* 12:213–218, 1991.
164. Spitz, W. U., Schneider, V. The significance of diatoms in the diagnosis of death by drowning. *J. Forensic Sci.* 67:11–18, 1964.
165. Taylor, J. J. Diatoms and drowning—a cautionary case note. *Med. Sci. Law* 34:78–79, 1994.
166. Goonetilleke, U. K. Diatoms in drowning. *Med. Sci. Law* 21:194–195, 1981.
167. Betz, P., Nerlich, A., Penning, R., Eisenmenger, W. Alveolar macrophages and the diagnosis of drowning. *Forensic Sci. Int.* 62:217–224, 1993.
168. Betz, P., Penning, R., Keil, W. The detection of petechial haemorrhages of the conjunctivae in dependency on the postmortem interval. *Forensic Sci. Int.* 64:61–67, 1994.
169. Biddinger, P. W. Postmortem wound dehiscence. A report of three cases. *Am. J. Forensic Med. Pathol.* 8:120–122, 1987.
170. Spitz, W. V. Drowning. In: Spitz, W. V., ed. *Medicolegal Investigation of Death: Guidelines for the Application of Pathology to Crime Investigation*. Charles C. Thomas, Springfield, IL, pp. 498–515, 1993.
171. Donoghue, E. R., Minnigerode, S. C. Human body buoyancy: a study of 98 men. *J. Forensic Sci.* 22:573–579, 1977.

172. Gardner, E. Death in the bathroom. *Med. Leg. Criminologic Rev.* 12:180–195, 1944.
173. Lunetta, P., Levo, A., Mannikko, A., Penttilä, A., Sajantila, A. Death in bathtub revisited with molecular genetics: a victim with suicidal traits and a LQTS gene mutation. *Forensic Sci. Int.* 130:122–124, 2002.
174. Geertinger, P., Voigt, J. Death in the bath. A survey of bathtub deaths in Copenhagen, Denmark, and Gothenburg, Sweden, from 1961 to 1969. *J. Forensic Med.* 17:136–147, 1970.
175. Devos, C., Timperman, J., Piette, M. Deaths in the bath. *Med. Sci. Law* 25:189–200, 1985.
176. Shkrum, M. J., Hudson, P. The body in the bathtub. *Proceedings of 37th Annual Meeting of American Academy of Forensic Sciences.* Las Vegas, NV, 1985.
177. Schmidt, P., Madea, B. Homicide in the bathtub. *Forensic Sci. Int.* 72:135–146, 1995.
178. Wintemute, G. J., Teret, S. P., Kraus, J. F., Wright, M. Alcohol and drowning: an analysis of contributing factors and a discussion of criteria for case selection. *Accid. Anal. Prev.* 22:291–296, 1990.
179. Livingston, S., Pauli, L. L., Pruce, I., Kramer, I. I. Drowning in epilepsy. *Ann. Neurol.* 7:495, 1980.
180. Pearn, J. H., Brown, J., III, Wong, R., Bart, R. Bathtub drownings: report of seven cases. *Pediatrics* 64:68–70, 1979.
181. Pearn, J., Nixon, J. Attempted drowning as a form of non-accidental injury. *Aust. Paediatr. J.* 13:110–113, 1977.
182. Nowers, M. P. Suicide by drowning in the bath. *Med. Sci. Law* 39:349–353, 1999.
183. Budnick, L. D. Bathtub-related electrocutions in the United States, 1979 to 1982. *JAMA* 252:918–920, 1984.
184. Lawrence, R. D., Spitz, W. U., Taff, M. L. Suicidal electrocution in a bathtub. *Am. J. Forensic Med. Pathol.* 6:276–278, 1985.
185. Morgan, W. P. Anxiety and panic in recreational scuba divers. *Sports Med.* 20:398–421, 1995.
186. Nichols, G. R., Davis, G. J., Parola, A. C. Dirty diving. Sudden death of a SCUBA diver in a water treatment facility. *Am. J. Forensic Med. Pathol.* 13:72–75, 1992.
187. Barsky, S., Neuman, T. *Investigating Recreational and Commercial Diving Accidents.* Hammerhead Press, Ventura, CA, 2003.
188. Melamed, Y., Shupak, A., Bitterman, H. Medical problems associated with underwater diving. *N. Engl. J. Med.* 326:30–35, 1992.
189. Neuman, T. S. Diving medicine. *Clin. Sports Med.* 6:647–661, 1987.
190. Obafunwa, J. O., Busuttil, A., Purdue, B. Deaths of amateur scuba divers. *Med. Sci. Law* 34:123–129, 1994.
191. Busuttil, A., Obafunwa, J. A review of the forensic investigation of scuba diving deaths. *Sci. Justice* 35:87–95, 1995.
192. Cooperman, E. M., Hogg, J., Thurlbeck, W. M. Mechanisms of death in shallow-water scuba diving. *Can. Med. Assoc. J.* 99:1128–1131, 1968.
193. Halpern, P., Sorkine, P., Leykin, Y., Geller, E. Rupture of the stomach in a diving accident with attempted resuscitation. A case report. *Br. J. Anaesth.* 58:1059–1061, 1986.
194. Antonelli, P. J., Parell, G. J., Becker, G. D., Paparella, M. M. Temporal bone pathology in scuba diving deaths. *Otolaryngol. Head Neck Surg.* 109:514–521, 1993.
195. Neuman, T. S. Arterial gas embolism and decompression sickness. *News Physiol. Sci.* 17:77–81, 2002.
196. Harker, C. P., Neuman, T. S., Olson, L. K., Jacoby, I., Santos, A. The roentgenographic findings associated with air embolism in sport scuba divers. *J. Emerg. Med.* 11:443–449, 1993.
197. Kanter, A. S., Stewart, B. F., Costello, J. A., Hampson, N. B. Myocardial infarction during scuba diving: a case report and review. *Am. Heart J.* 130:1292–1294, 1995.
198. Weiss, L. D., Van Meter, K. W. Cerebral air embolism in asthmatic scuba divers in a swimming pool. *Chest* 107:1653–1654, 1995.

199. Petri, N. M., Vranjkovic-Petri, L., Aras, N., Druzijanic, N. Gastric rupture in a diver due to rapid ascent. *Croat. Med. J.* 43:42–44, 2002.
200. Molenat, F. A., Boussuges, A. H. Rupture of the stomach complicating diving accidents. *Undersea Hyperb. Med.* 22:87–96, 1995.
201. Titu, L. V., Laden, G., Purdy, G. M., Wedgwood, K. R. Gastric barotrauma in a scuba diver: report of a case. *Surg. Today* 33:299–301, 2003.
202. Warren, L. P., Jr., Djang, W. T., Moon, R. E., et al. Neuroimaging of scuba diving injuries to the CNS. *AJR Am. J. Roentgenol* 151:1003–1008, 1988.
203. Reuter, M., Tetzlaff, K., Hutzelmann, A., et al. MR imaging of the central nervous system in diving-related decompression illness. *Acta Radiol.* 38:940–944, 1997.
204. Neuman, T. S., Jacoby, I., Bove, A. A. Fatal pulmonary barotrauma due to obstruction of the central circulation with air. *J. Emerg. Med.* 16:413–417, 1998.
205. Yeung, P., Crowe, P., Bennett, M. Barogenic rupture of the stomach: a case for non-operative management. *Aust. N. Z. J. Surg.* 68:76–77, 1998.
206. Cramer, F. S., Heimbach, R. D. Stomach rupture as a result of gastrointestinal barotrauma in a SCUBA diver. *J. Trauma* 22:238–240, 1982.
207. Novomesky, F. Gastro-esophageal barotrauma in diving: similarities with Mallory-Weiss syndrome. *Soud. Lek.* 44:21–24, 1999.
208. Strauss, M. B., Borer, R. C., Jr. Diving medicine: contemporary topics and their controversies. *Am. J. Emerg. Med.* 19:232–238, 2001.
209. Slade, J. B., Jr., Hattori, T., Ray, C. S., Bove, A. A., Cianci, P. Pulmonary edema associated with scuba diving: case reports and review. *Chest* 120:1686–1694, 2001.
210. Byrd, J. H., Hamilton, W. F. Underwater cave diving fatalities in Florida: a review and analysis. *J. Forensic Sci.* 42:807–811, 1997.
211. Temple, J. D., Bosshardt, R. T., Davis, J. H. SCUBA tank corrosion as a cause of death. *J. Forensic Sci.* 20:571–575, 1975.
212. Brown, C. D., Kime, W., Sherrer, E. L., Jr. Postmortem intravascular bubbling: a decompression artifact? *J. Forensic Sci.* 23:511–518, 1978.
213. Findley, T. P. An autopsy protocol for skin- and scuba-diving deaths. *Am. J. Clin Pathol.* 67:440–443, 1977.
214. Roobottom, C. A., Hunter, J. D., Bryson, P. J. The diagnosis of fatal gas embolism: detection by plain film radiography. *Clin. Radiol.* 49:805–807, 1994.

## Chapter 6

---

# *Penetrating Trauma*

## *Close-Range Firearm Wounds*

### **Summary**

Firearm deaths are most commonly self-inflicted. The determination of suicide is supported not only by the presence of a close-range wound but also by the scene and historical information. A complete external examination of the victim may also reveal evidence of self-intent on the hand(s), i.e., blood spatter and soot deposition. The head is the most common site for self-inflicted wounds. Cranial injuries can have unique features (e.g., ricochet). Certain factors complicate the assessment of close-range firearm injuries. Medical procedures and interposed clothing can alter wound appearance. Unusually located or multiple wounds arouse suspicion of homicide. Examination of a wound track determines the cause of death. In the case of multiple wound tracks, relative lethality and incapacitation need to be assessed in the determination of manner of death.

**Key Words:** Wounds; gunshot; suicide; head injuries; penetrating.

### *1. DEMOGRAPHY*

The incidence of firearms-related deaths per 100,000 population was 0.14 per 100,000 in England and Wales in 2001 (suicide, 65%; homicide, 7%; undetermined or accidental, 28%), 2.6 in Canada in 2002 (suicide, 80%; homicide, 15%; undetermined or accidental, 5%), and 10.2 in the United States in 2001 (suicide, 67%; homicide, 27%; undetermined or accidental, 6% [[1–3](#)]).

The use of a firearm to commit suicide depends on the availability of firearms ([4–15](#)). In the United States, suicide by firearm is the most common method of committing suicide ([9,16](#)). For example, studies in various southern states show use of a firearm in 65 to 87% of suicides ([17–20](#)). Various European studies have shown that about 4 to 8% of suicides are committed by firearms ([21–23](#)). In US jurisdictions, firearms are used for all victims of murder–suicide in 75 to 96% of cases ([24–29](#)).

Self-inflicted firearm injuries occur in adults of all ages ([21](#)). Various studies have shown that the mean or median age of adult suicides is higher than that of homicide victims ([18,30–37](#)). For example, a New Mexico/South Carolina study of self-inflicted head

From: *Forensic Science and Medicine: Forensic Pathology of Trauma:  
Common Problems for the Pathologist*

By: M. J. Shkrum and D. A. Ramsay © Humana Press Inc., Totowa, NJ



wounds showed that the average age of suicide victims was 39.2 yr, compared with 33.7 yr for murder victims (30). A similar older age distribution is seen in perpetrators of murder–suicide, but if children are murdered, then the average age of the murderer, i.e., the suicide victim, decreases (e.g., in an Australian study, the average was 31 yr [12,28,29,38]).

Gunshot wounds involving children can be of any manner (39,40). Accidents occur when children play with guns (39,41–44). Adolescents may “fool around” with guns, and alcohol intoxication may be a factor in these cases (42). Availability and accessibility to firearms, their resemblance to toy guns, and gun malfunction are factors in accidental firearm deaths (4,41,43). Self-inflicted accidental wounds occur (41). The most common wound site is the head (41,44). Suicidal gunshot wounds are unusual in children and adolescents. A review of 45 shooting deaths of children under 10 yr during a 9-yr period in Cook County, IL, revealed no suicides (45). The minimum age in other studies of self-inflicted firearm injures is relatively consistent: South Carolina, 12 yr; South Carolina–New Mexico, 14 yr; Texas, 11 yr; New York City, 13 yr (6,18,30,32). The firearm can be borrowed or stolen (12,17).

Self-inflicted gunshot wounds show a male predominance, although women are frequent victims in some jurisdictions (9,14,23,33–36,46–49). In foreign countries, fewer than 10% of firearm suicides involve women, whereas in various American jurisdictions the frequency varies from about 5% to 17% (6,18,21,32,37,50,51). The reasons for this sex difference include less access by women to firearms in some countries and the knowledge that a firearm injury is potentially disfiguring, particularly when the entry site is the head (21).

Female victims predominate in murder–suicides (12,52). In various US and international studies, there is a male perpetrator, i.e., suicide victim, in 85 to 100% of cases depending on the age group (12,24–26,28,29,52). If children are murdered, then the percentage of female perpetrators increases (53).

2. SCENE

Whether the investigation involves a single-victim suicide or multiple fatalities in a murder–suicide, the location chosen is usually familiar. In most cases, the deaths occur at home or its vicinity (17,21,24,26,28,34,35,37,46,48–50,54,55). Often the door is secured from the inside (e.g., locked, wedged by chair), which assists the investigation when the circumstances are unusual (e.g., multiple wounds [37,56–60]). Unusual locations (e.g., motor vehicle) have been described (55,61,62).

3. TYPE OF FIREARM

There is a handgun predominance in American and most international studies (20–22,30,32,63–66). In the United States, this reflects the possession of firearms for protection. For example, in one jurisdiction in Texas, the following distribution of firearms was seen in suicide cases (32):

	Handgun <sup>a</sup>	Rifle	Shotgun <sup>b</sup>
Male	76.1%	13.7%	10.2%
Female	87.4%	6.7%	6%

<sup>a</sup>38 special most common.  
<sup>b</sup>12-gauge in more than half of cases.

In other regions (Canada, England, Scandinavia, Australia), there is a predominance of long gun use (rifles and shotguns) because of restrictions on firearm possession

(23,34–37,46–49). Lower caliber weapons (handguns and rifles) are usual in multishot suicides, but higher caliber handguns and shotguns are used (67).

The following is a list of some unusual firearms or projectiles that have been used to cause self-inflicted gunshot wounds:

- Handguns using shotshell (pellets [68]).
- Black powder percussion handgun (69).
- Air gun/rifle (16,70–75).
- “Powerhead” (short nonrifled barrel with cartridge and lead projectile, used for harvesting fish and protection against sharks [16,76]).
- Pen gun (77,78).
- Homemade devices (34,73,79,80).
- Captive bolt pistol (i.e., animal slaughtering gun [16,23,26,34,65,81,82]).
- Pneumatic hammer (83).
- Nail/stud gun (16,84–91).
- Starter’s pistol (73).
- Blank or tear gas cartridges (21,22,92,93).

#### 4. PRESENCE AND POSITION OF FIREARM

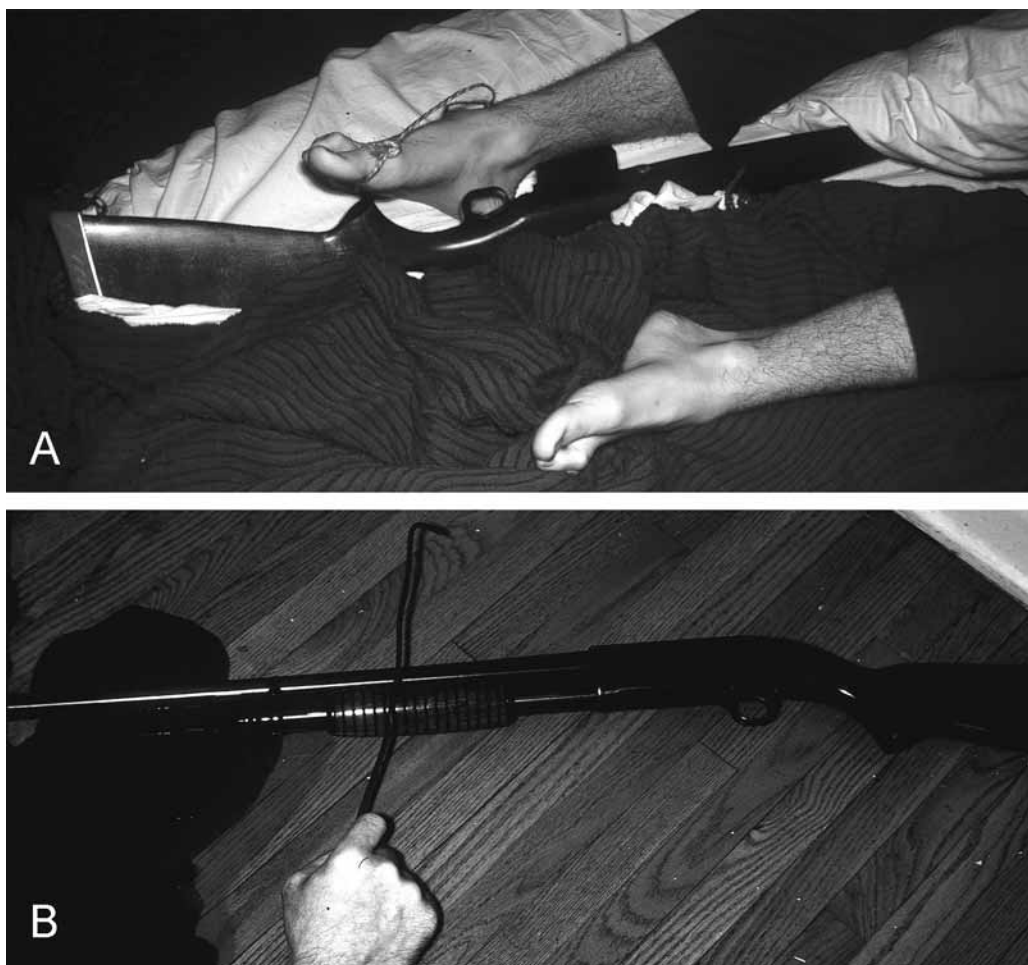
Finding a firearm, particularly in proximity to the deceased, is supportive of suicide (59). In one Texas study, a firearm was found in the hand of a suicide victim, i.e., one finger in the trigger guard or at least one hand loosely gripping the barrel or grip, in 24% of all cases (94). If a handgun was used, it was found in the victim’s hands in 25.7% of the cases. Of those using a long gun (shotgun, rifle), 19.5% had the firearm in their hand, usually the left. Another study showed 20% of victims with a handgun in their hand compared with 11% with long guns (95). A German study revealed that one-third of suicide victims had a firearm in their hands (21). A gun can be positioned in a victim’s hand to conceal a homicide (94).

The Texas study showed the gun on, touching, or within 30 cm (12 in.) of the body in 69% of cases, and more than 30 cm (12 in.) from the body in 7% (4 of 34 the cases involved long guns [94]). There was no correlation found between factors such as gender, location of the entry wound and caliber of the gun, and finding the weapon in the hands of the victim. In multishot suicides, the firearm tends to be in the hands of or near the victim (55,56,96). In rare cases when two firearms are used simultaneously, half the victims have been observed to have firearms in their hands (97).

The victim usually uses the dominant hand to inflict a wound on the same side of the body (i.e., right-handed individual shoots self in right temple), but the opposite (e.g., left temple entry) does occur (16,63,98). In one series, 8% of right-handed individuals shot themselves in the left temple (98). The nondominant hand is also used (99). A weapon can rest on the side of the body opposite to the dominant hand (100).

Other methods of depressing the trigger are used. A toe, a long object, or a string/cord can depress the trigger of a long gun (Fig. 1; ref. 37). A shooting apparatus can be rigged by the victim (46,60). A weapon can be braced or steadied against a firm surface (Fig. 2; refs. 46 and 60).

“Missing” firearms complicate a police investigation of a suicide (16). Firearms are most commonly moved by family and friends, but emergency response personnel and police may also be responsible (94,101). The reasons for moving a firearm by those



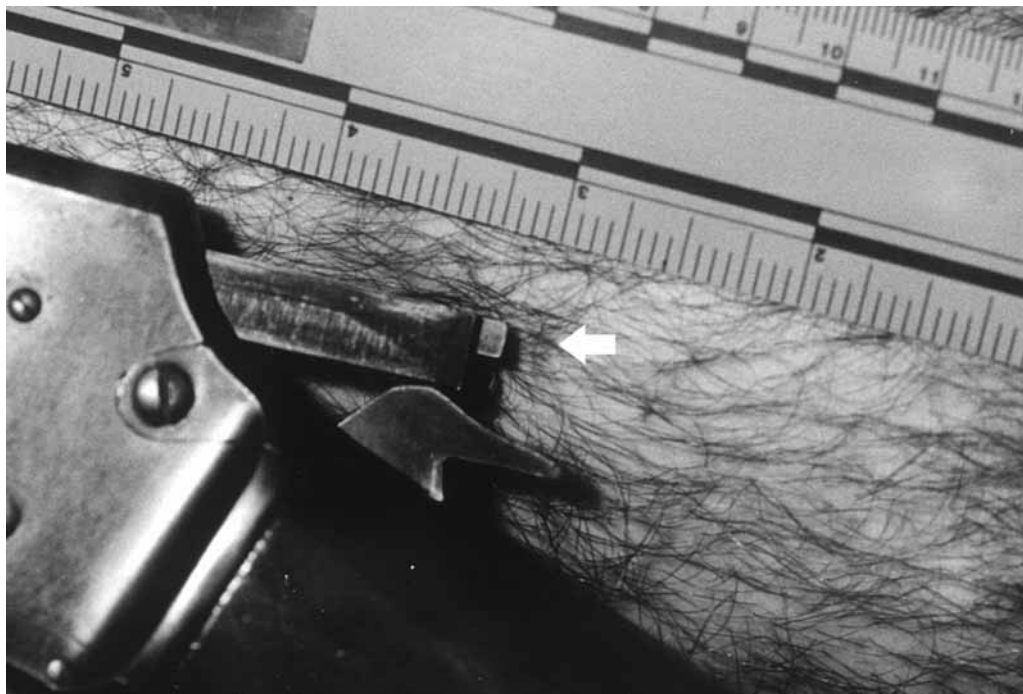
**Fig. 1.** Self-inflicted firearm wounds. Depression of triggers of long guns by: (A) string attached to toe and (B) assist device.

who knew the deceased include a concern about the stigma of suicide, social and religious considerations, anxiety about the adverse effect of a determination of suicide on an insurance claim, and revenge (e.g., simulation of homicide). Similar motives can compel the victim (37,102). Victims have used devices to remove weapons from the scene (e.g., pistol pulled by weight into river after victim shot himself; use of a rubber band [102–104]). The firearm injury may not be immediately fatal or incapacitating, allowing the victim to leave or hide the firearm in another location (22,46,105). The firearm can be stolen by individuals at the scene (94,102). A firearm may be destroyed after the investigation is apparently complete (106).

Firearm alteration or tampering suggests assisted suicide or homicide (107,108).

### 5. OTHER SCENE FINDINGS AND BACKGROUND INFORMATION IN SUICIDE

If self-inflicted wounds are not immediately lethal, then blood can be shed at various sites, indicating purposeful activity prior to death (Fig. 3; refs. 16, 22, 105, and 109). The deceased's footprints can be evident in bloodstains (60).



**Fig. 2.** Suicidal gunshot wound of head. Abrasion (arrow) on leg where breech of rifle contacted the leg steadying the weapon.

A suicide note may be found at the scene. In most American and international studies of self-inflicted firearm injuries, a note is found in about 10 to 40% of cases (6,16–19,21,32,35,46,49,50,110). In one English study, a note was found in 55% of cases (48). Variations include discovery of a will, funeral information, an insurance policy, or other personal papers at the scene (56,110). A note can be incorporated as part of photographic album, video presentation, or on a computer (57,111). Handwriting analysis may be required to verify that the note was written by the victim (111).

Information regarding a previous suicide attempt or threat may be lacking. In various US series of suicidal firearm injuries, prior attempts or threats have ranged from 16 to 38% (18,110). In individuals younger than 19 yr of age, this history was elicited in up to 42% of cases (6,17). Previous methods described in a Texas study included overdose (38%) and use of a gun (9% [32]).

A psychiatric history or disturbance is known in about one-fifth to two-thirds of cases in various series (12,17–19,26,32,46,110). Depression is the most common problem. Psychosis is seen in a small number of victims (e.g., murder–suicides involving filicidal mothers or family annihilator fathers [12]).

Similar factors motivate single victims of suicide and perpetrators of murder–suicide (28). These include relationship problems, financial/economic stresses, poor health or incurable disease, ethanol and drug abuse, legal difficulties including pending incarceration, mental illness, low self-esteem, and a past history of physical and sexual abuse (18,21,24,37,110). Perpetrators of murder–suicide, depending on the situation, are driven by jealousy, retaliation, altruism (“to save the family from the evils of the





**Fig. 3.** Multishot suicide. Nonfatal intraoral wound. Considerable bleeding into pail when this wound was inflicted. Deceased found dead in other room from wound to chest. (Courtesy of Dr. E. Tweedie, London Health Sciences Centre, London, Ontario, Canada.)

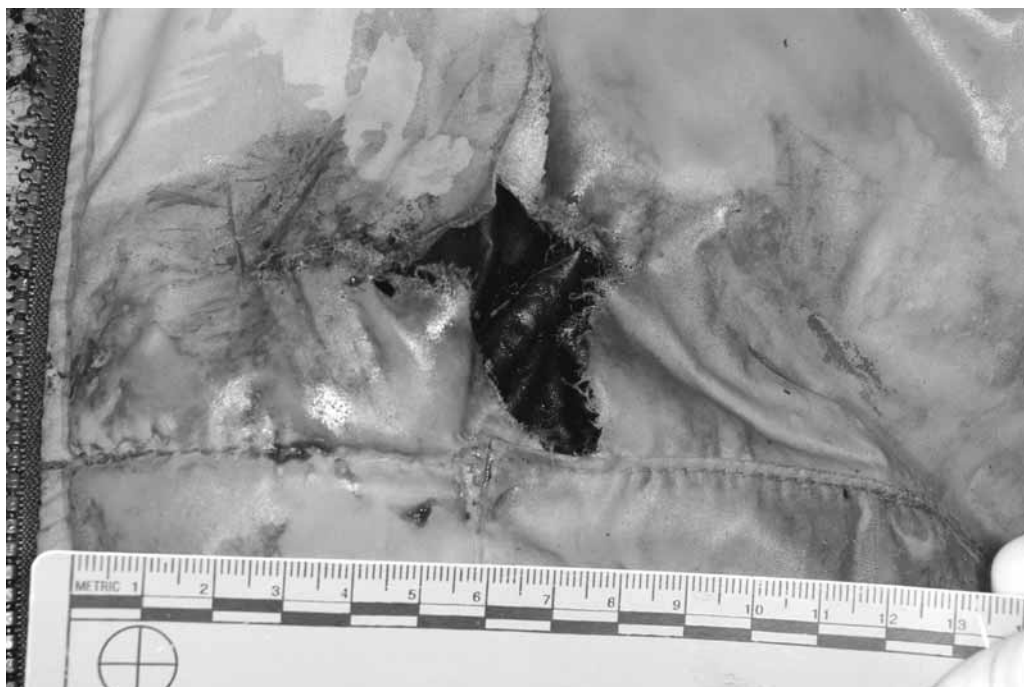
world”) or mercy (e.g., physically ailing spouse [12,24,25,27,28,38,53]). A South Carolina study of self-inflicted firearm fatalities in individuals younger than 18 yr of age showed 42% had a history of risk-taking behavior (e.g., playing with firearms, drug and alcohol abuse [17]). About three-fourths of victims aged 65 yr or more had a high prevalence of cancer and other chronic, debilitating illnesses that had been diagnosed while the victim was alive (18).

Self-inflicted gunshot wounds can be witnessed (16). In an Australian series, 10% of suicides were witnessed (36,46). Self-inflicted firearm wounds can be sustained during the pursuit or apprehension by police (112–114). Perpetrators of murder–suicide were witnessed shooting themselves in 15% of cases in one Texas study and in more than one-half of deaths in a New Hampshire series (26,32).

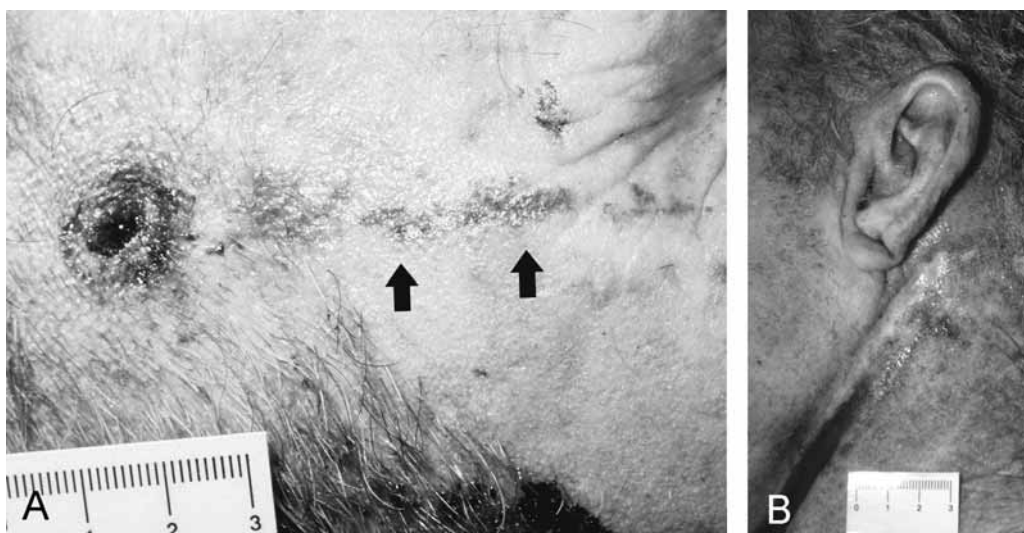
The suicide victim may attempt to create a “gun cleaning” or “hunting” accident (see Heading 21 and refs. 16, 23, and 115). Careful investigation is needed to determine whether discharge of a gun under these circumstances was an accidental death (Fig. 4; ref. 44). Suspicions are aroused when handguns are involved in a hunting incident (42). A shotgun was the most common weapon in accidental deaths, either self-inflicted or inflicted on others (42,115).

Self-inflicted firearm injuries are observed in “complex” suicides, i.e., more than one weapon or means of suicide is used (Fig. 5; refs. 16,77,116–118). These suicides can be “unplanned.” Failure at one attempt (e.g., carbon monoxide poisoning, hanging) leads to use of a firearm even in a different locale (47,119). The suicide can be





**Fig. 4.** Hunting accident. Soot on hunting jacket. Victim was holding his shotgun by the barrel while waving it between two fighting dogs. The weapon accidentally discharged. (Courtesy of Dr. E. Tweedie, London Health Sciences Centre, London, Ontario, Canada.)



**Fig. 5.** Complex suicide. (A) Contact gunshot wound, right frontoparietal area. Note linear bruise (arrows) extending from wound corresponding to radial fracture line. (B) Hanging. Ligature furrow.

“planned.” Concurrent use of different firearms (e.g., air rifle followed by shotgun, simultaneous use of two guns) or a firearm and another mechanism (hanging, poisoning) to lessen the chance of failure of one method have been described ([21,22,36,72,97,116,120](#)).

Classification of murder–suicide is based on the relationship between the perpetrator and victim ([12,24,27,29](#)). Most victims are known to the deceased ([28,29,53](#)). The most common situation is spousal/consortial (40 to 85% [[24–26,29,53,121](#)]). Common motivations in this group include jealousy and illness ([52,121,122](#)). There can be a background of domestic violence ([26,29](#)). Multiple homicide victims are seen in other types of murder–suicide scenarios (e.g., familial or “family” annihilator situation [[28,53,122](#)]).

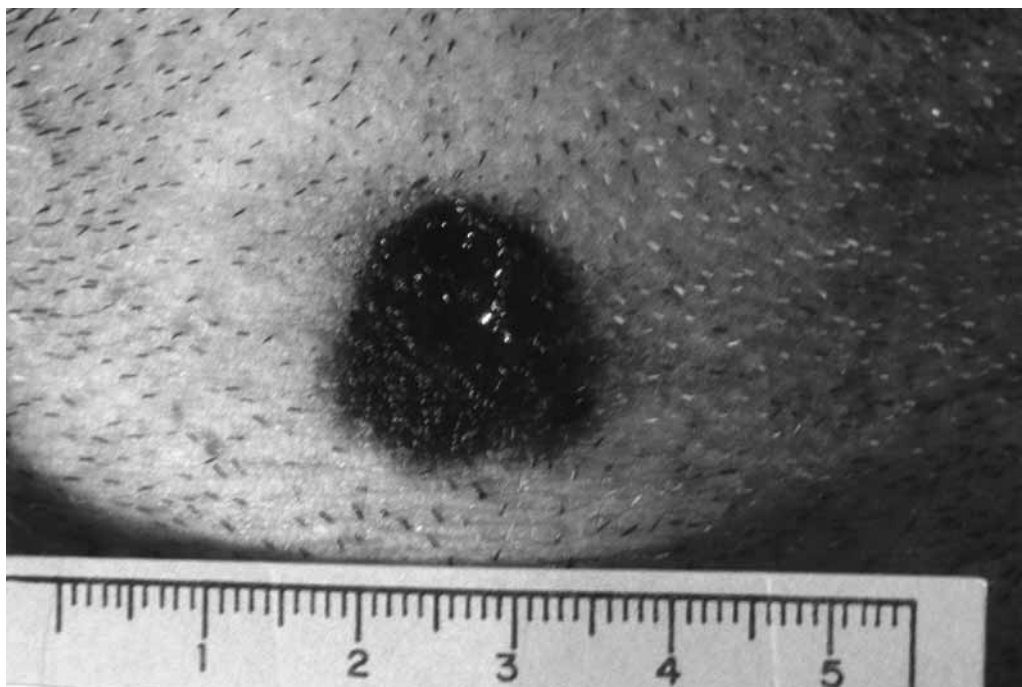
The temporal relationship in a murder–suicide varies. The killing of one or more persons is usually followed very soon after by the suicide of the perpetrator of the homicide (“dyadic” [[123](#)]). Eighty percent of perpetrators killed themselves within 1 h of the murder; however, an older individual may delay suicide for up to 1 mo ([12,28](#)).

## 6. FIREARMS

Rifles and handguns have rifled barrels designed to impart a spin to the bullet and allow a truer trajectory ([16](#)). Most shotgun barrels are smooth, and the usual projectiles are pellets. Rifled shotgun barrels can also fire large slugs ([16](#)). The pellets are either birdshot or larger buckshot, the diameter of the latter generally being greater than 0.25 in. (0.6 cm [[16,124](#)]). If birdshot is used, the pellets can number in the hundreds ([124](#)). Caliber of a handgun or rifle refers to the approximate diameter of the barrel or base of the bullet ([16](#)). The gauge of a shotgun refers to the shotgun barrel diameter ([124](#)). A 12-gauge shotgun has a bore diameter that is equivalent to the diameter (0.729 in.) of 12 equally sized lead balls having a total weight of 1 lb ([124](#)). The exception is a .410-gauge shotgun, which has a bore of 0.410 in. ([16](#)). The only shotgun projectile that equals the bore diameter is a rifled slug ([16](#)).

Depression of the trigger of a handgun/rifle or shotgun causes the firing pin of the weapon to strike primer situated at the end of the cartridge case or shotgun shell. Primer is composed of varying amounts of lead styphnate, barium nitrate, and antimony sulfide. Powder grains, contained in a cartridge case or shotgun shell, are ignited by the flame produced by the crushed primer. The typical powder grain is about 1 mm in diameter ([16](#)). The burning of the powder grains generates a considerable amount of heated gas, which expels a projectile down the barrel of the handgun, rifle, or shotgun. Carbon monoxide is a constituent of the gas ([16](#)). When a bullet or other type of projectile (e.g., pellets, rifled slug from shotgun) emerges from the muzzle end, there is accompanying flame, gas, variably burnt powder grains, smoke (soot), primer residue, and metal from the projectile and cartridge case ([16,124,125](#)). If a revolver is used, this material, with the exception of the projectile, is expelled in a perpendicular direction from the gap (cylinder gap) between the rotating cylinder, which contains the bullets, and the barrel ([16](#)).

The appearance of the wound depends on the distance of the muzzle from the skin. This distance determines the deposition pattern of muzzle discharge in relation to the entry wound.

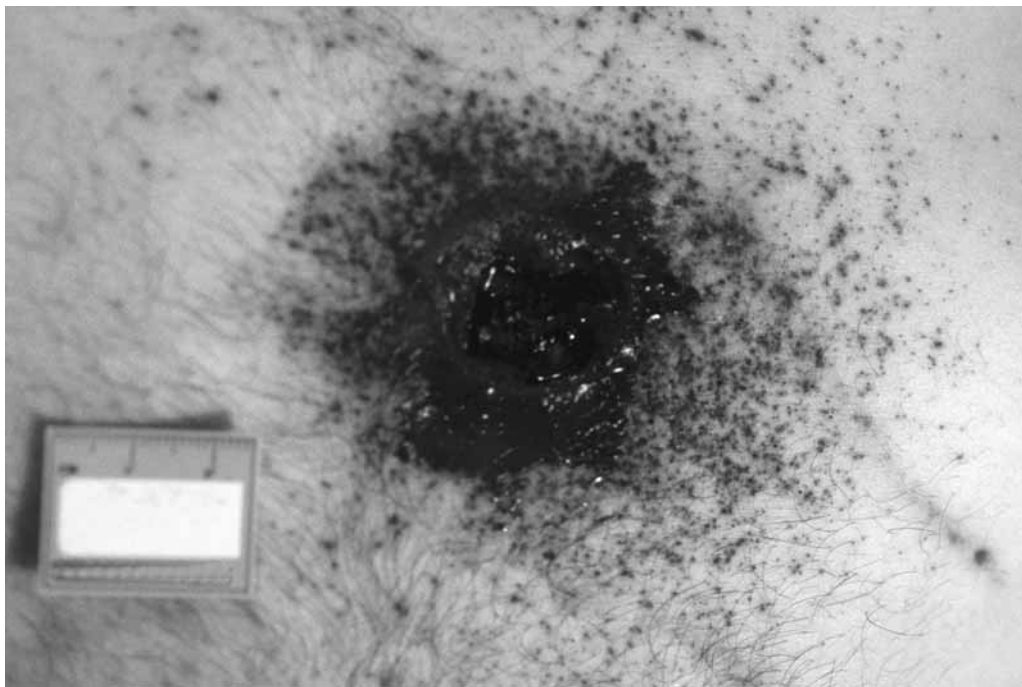


**Fig. 6.** Near or loose contact gunshot wound, chin. Soot has deposited around wound.

## 7. CLASSIFICATION OF ENTRY WOUNDS

Entry wounds can be classified as follows (16):

- *Contact* (see Headings 9. and 12.)
  - At least part of the muzzle is against the skin.
  - Characterized by soot embedded in the seared edges of the wound.
  - Hard contact entries often show little soot on the skin surface.
- *Loose-contact*
  - The muzzle is held lightly against the surface, allowing soot to deposit around the wound (Fig. 6). This wider zone of soot can be inadvertently wiped away.
- *Near-contact*
  - These wounds are similar to loose contact wounds and arise when the muzzle is a short distance from the skin surface.
- *Intermediate*
  - The muzzle is at a distance that allows dispersal of powder grains, resulting in individual impacts on the skin.
  - The resulting numerous red-brown-orange punctate abrasions are referred to as tattooing or stippling (Fig. 7).
  - There can be associated soot deposition around the wound, but because of relatively low density of soot, the amount becomes progressively less as the distance of the muzzle from the skin surface increases.



**Fig. 7.** Intermediate shotgun wound. Stippling.

- *Distant*
  - The muzzle is at a distance (in order of at least a few feet) from the skin surface, which does not allow soot deposition or tattooing to occur.
  - An abrasion ring is noted (Fig. 8).

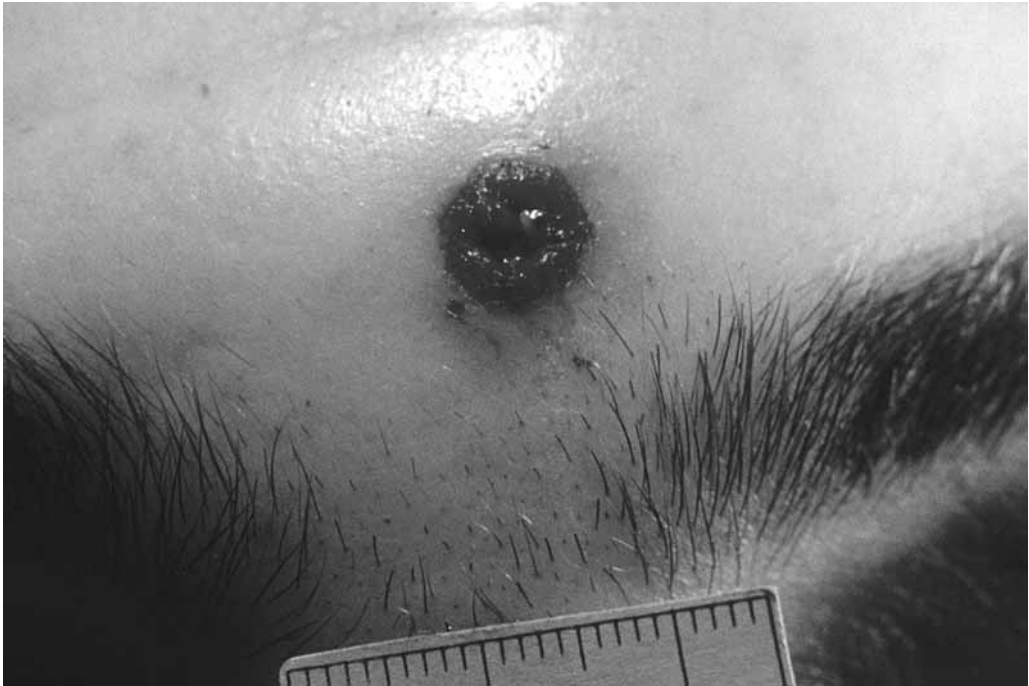Shotgun wounds acquire features owing to pellet separation at intermediate and distant ranges (16,124). Slight pellet separation away from the main shot column leads to “scalloping” around the main hole at intermediate ranges. Wider dispersion of some pellets causes smaller holes around the large main hole where most of the pellets have entered. Complete pellet dispersion occurs at distant ranges. Pellets in the shotgun shell are contained either by felt wadding or in plastic cups (Fig. 9; refs. 16 and 124). The wadding diameter equals the shotgun bore diameter (gauge). Wadding can enter the body at close and intermediate ranges of fire.

Most entrance wounds are surrounded by an abrasion ring (exceptions are bullets from high-velocity rifles and semijacketed handgun bullets) caused by the mechanical trauma of the bullet entering the body (16,125). The size of the entry hole does not correlate with the caliber of the bullet because of skin shrinkage and distortion (125).

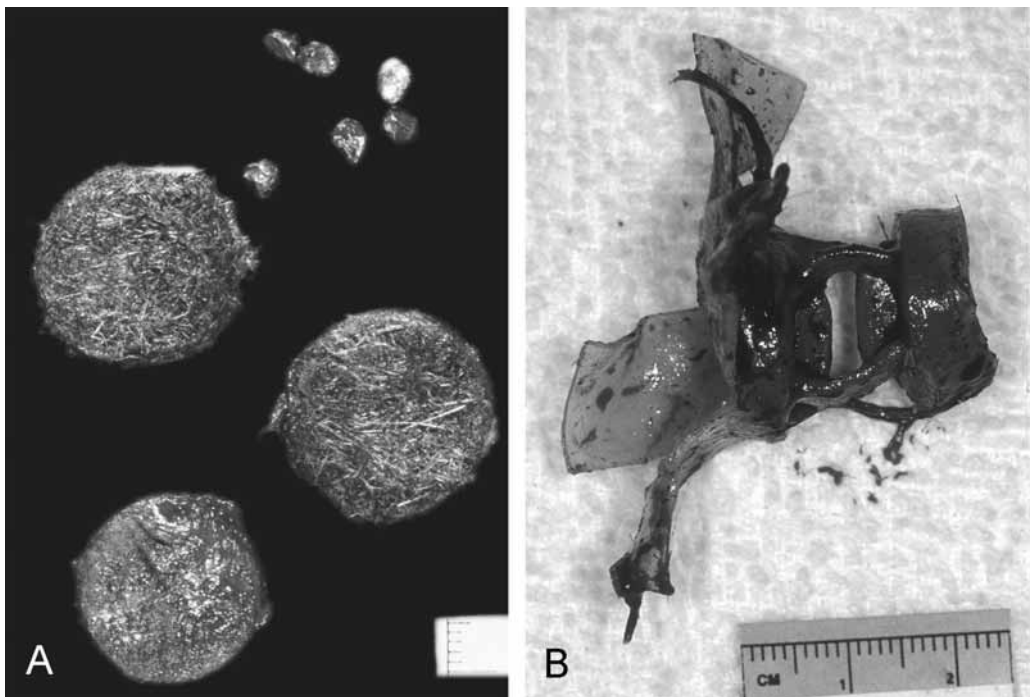
## 8. EXIT WOUNDS

Gunshot exits are typically larger and more irregular than entries, reflecting the larger surface area of the departing bullet caused by a tumbling, deformation, or fragmentation of the projectile (Fig. 10; refs. 16 and 125). Exits, with the exception of shored exits, do not have an abrasion ring. An exit can have an irregular abrasion if the site is shored against a hard surface (e.g., wall, chair; see Fig. 11 and refs. 16, 126, and



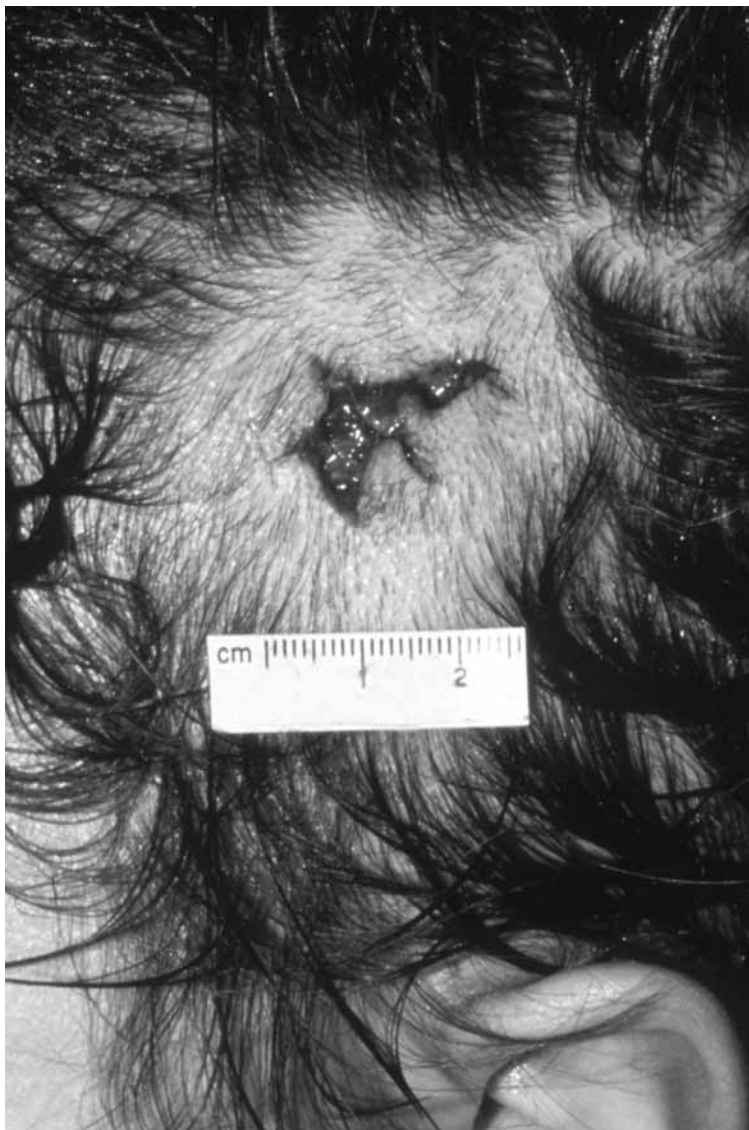

**Fig. 8.** Distant gunshot wound. Concentric abrasion ring indicating bullet entered the body at a perpendicular angle.



**Fig. 9.** Types of shotgun wadding recovered at autopsy. **(A)** Felt wadding and representative pellets. **(B)** Distorted plastic cup.



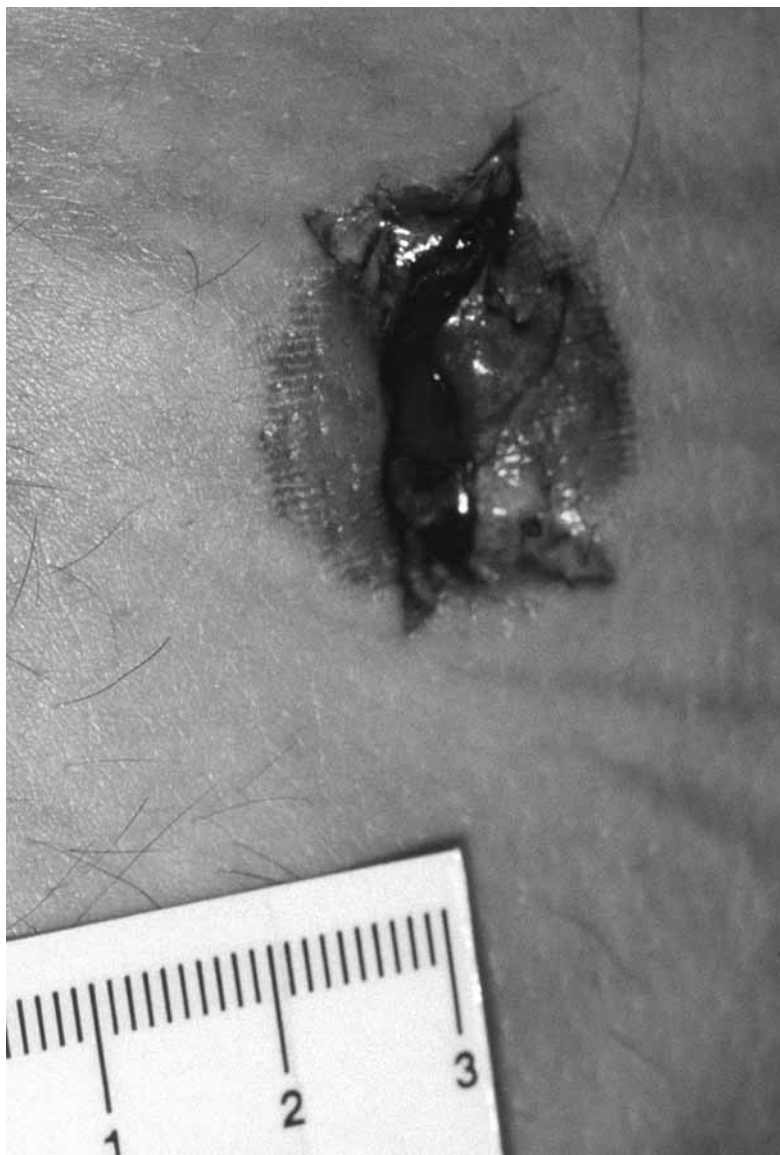

**Fig. 10.** Typical irregular gunshot exit wound, left temporal area (hair shaved around wound).

[127](#)). The everted skin edge of the wound impacts the surface as the bullet exits. Skin elasticity can prevent a projectile from exiting (*see* Heading 16. and Fig. 12). In contact-range shotgun wounds of the head, most pellets tend to exit as opposed to what occurs with torso entries ([124](#)). In a review of suicidal and homicidal gunshot wounds of the head caused by different calibers of weapon, exits occurred in about half of suicides and about 20% of homicides ([16](#)).

### 9. RANGE OF ENTRY WOUNDS IN SUICIDES

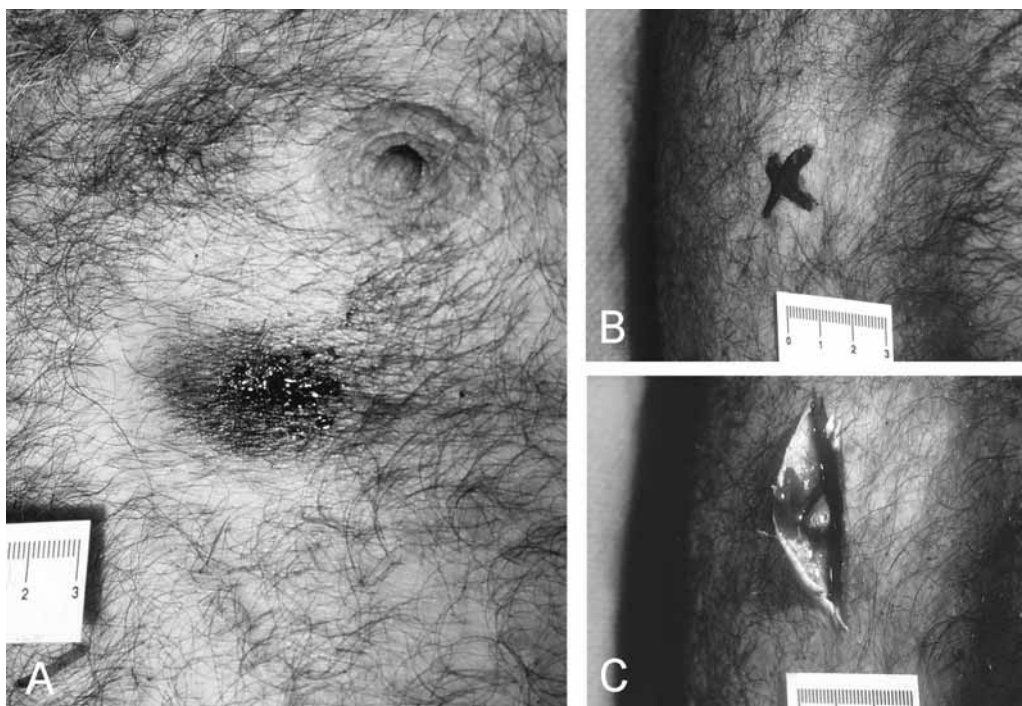
A contact wound favors suicide ([37,49,55,63](#)). Most multiple self-inflicted firearm wounds are contact ([22,51,55,57,67,96,101,109,111,117,120,128,129](#)). Other muzzle-to-



**Fig. 11.** Shored exit on back. Self-inflicted shotgun wound (rifled slug) of chest. Victim's back braced by car seat.

target distances are possible ([16,128,130](#)). In a Dallas, TX, study, all 199 suicides by a single gunshot wound to the head were contact, compared with 11 (9%) of 119 homicides ([63](#)). Only two noncontact wounds were seen in a database of 1200 firearm suicides. In a New Mexico–South Carolina study of 77 suicidal firearm wounds, 97% were contact and 3% were intermediate. Of the homicides, 10% were contact. In the same series, one of four accidents were contact, and the other three were intermediate range ([Fig. 4](#); ref. [30](#)). In a Texas study, 97% of wounds were contact, 2% intermediate, and 1% contact/intermediate ([32](#)).

Contact-range wounds are characterized by soot outside or inside the wound ([16,73,92,93](#)). The amount of soot can be considerable in certain situations: use of a



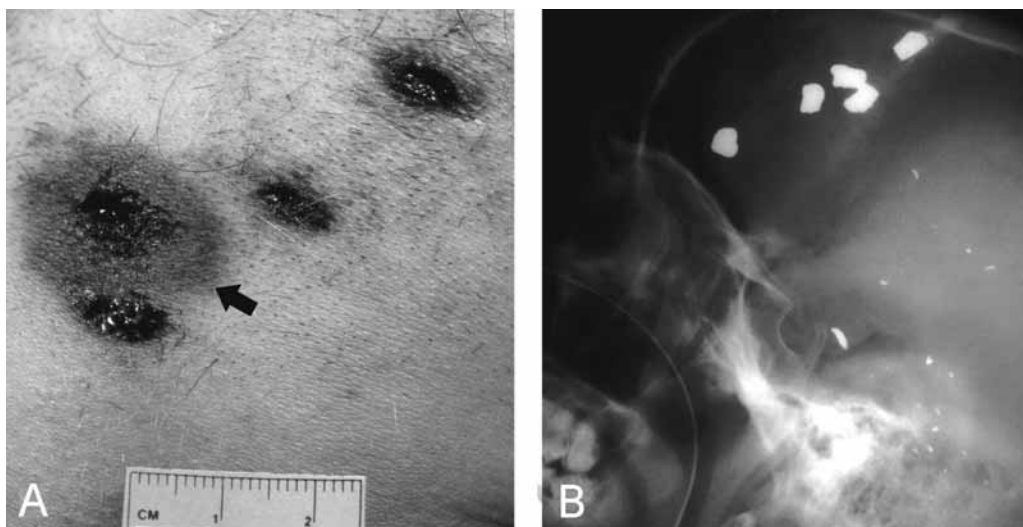
**Fig. 12.** Retention of bullet in body by skin. (A) Contact gunshot wound of chest. (B) Bullet palpable under skin of back (indicated by inked "X"). (C) Incision revealed bullet, which was easily recovered.

percussion handgun in which the combustion of propellant is incomplete; use of a bullet smaller in caliber relative to the weapon, which results in a large amount of unburned ammunition powder being deposited; discharge of weapon more than once through same entry (Fig. 13; refs. 69 and 131).

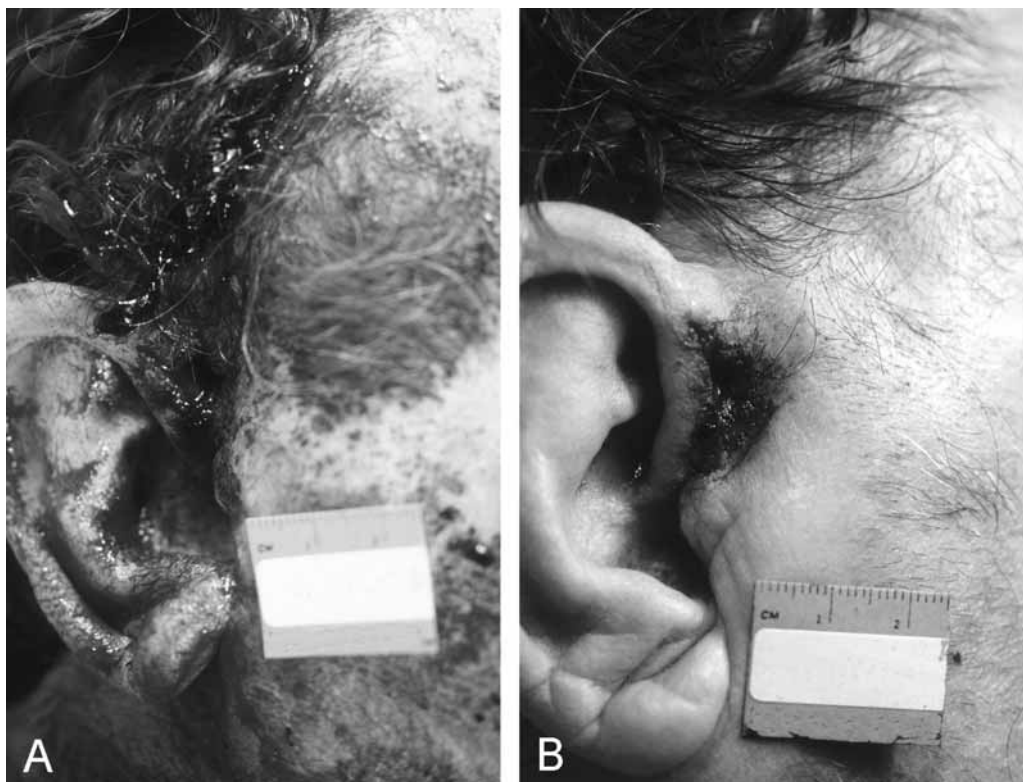Soot is obscured by dried blood, drying of skin, decomposition, and charring (Fig. 14). Subcutaneous hemorrhage can also darken the wound edge. Soot can be absent in a contact wound if a long-barrel .22-caliber rifle is used, because the small powder load burns more completely in the barrel (*see* Heading 24.; Fig. 15; and refs. 16 and 132). In some instances, unusual material is present in the wound (e.g., blue Teflon plug material from a .38 special Glaser Safety slug [119]).

Angled contact and near-contact wounds result in eccentric deposition of soot (16). If the muzzle of the fired weapon is angled and in contact with the skin, then powder is deposited on the part of the entry away from the muzzle. This pattern will indicate the direction of projectile travel (Fig. 16). If the muzzle is angled and not touching the skin, then powder deposits only on the part of the entry close to the muzzle. The powder does not have sufficient density to reach the opposite surface of the entry. This pattern indicates direction from which the projectile originated (Fig. 17). Radiography and wound track documentation assist in differentiating between angled contact and angled near contact wounds (*see* Heading 16.).

In about 50% of contact wounds of the forehead, temple, and neck inflicted by a .22-caliber rimfire rifle, a pencil-like zone of blackened and seared skin extends

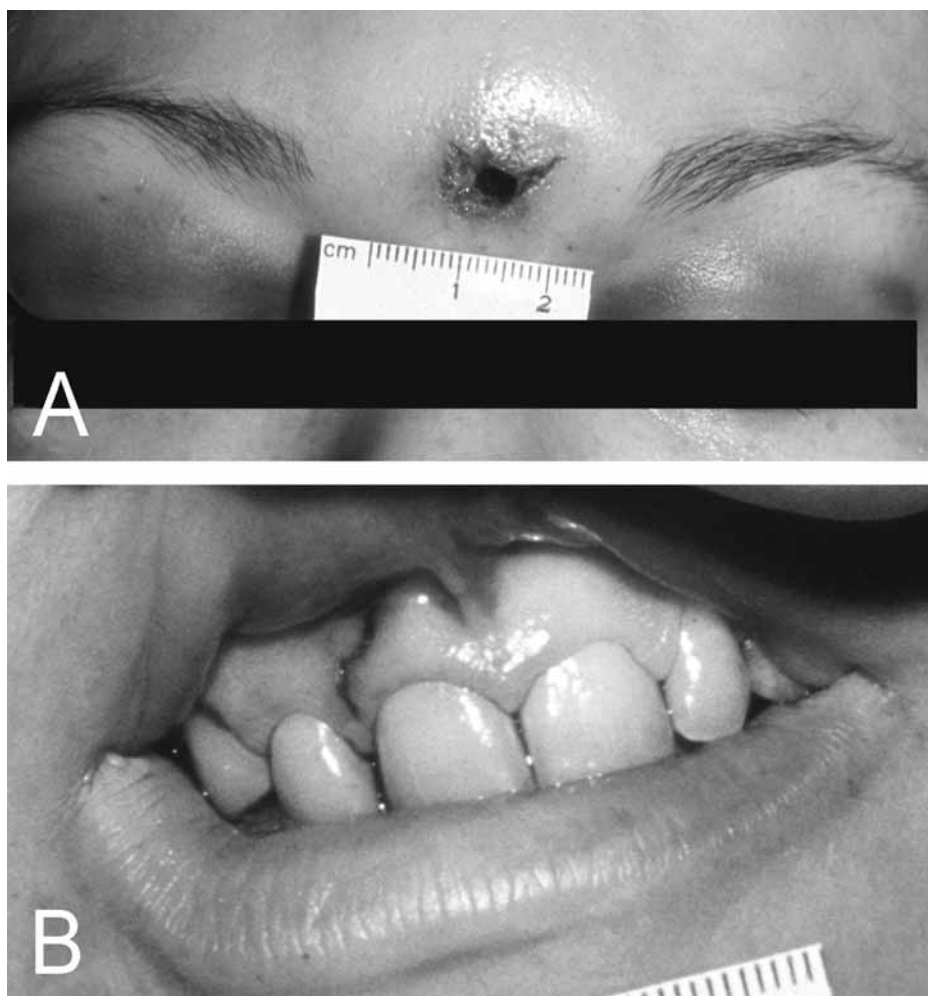


**Fig. 13.** Discharge of handgun more than once through same entry site; homicide. **(A)** Four hard contact gunshot wounds, posterior neck. One entry (arrow) shows more prominent soot deposition and bruising. **(B)** Skull radiograph. Five bullets.



**Fig. 14.** Hard contact gunshot entry anterior to ear. **(A)** Wound is obscured by dried blood. **(B)** Wound area cleaned.





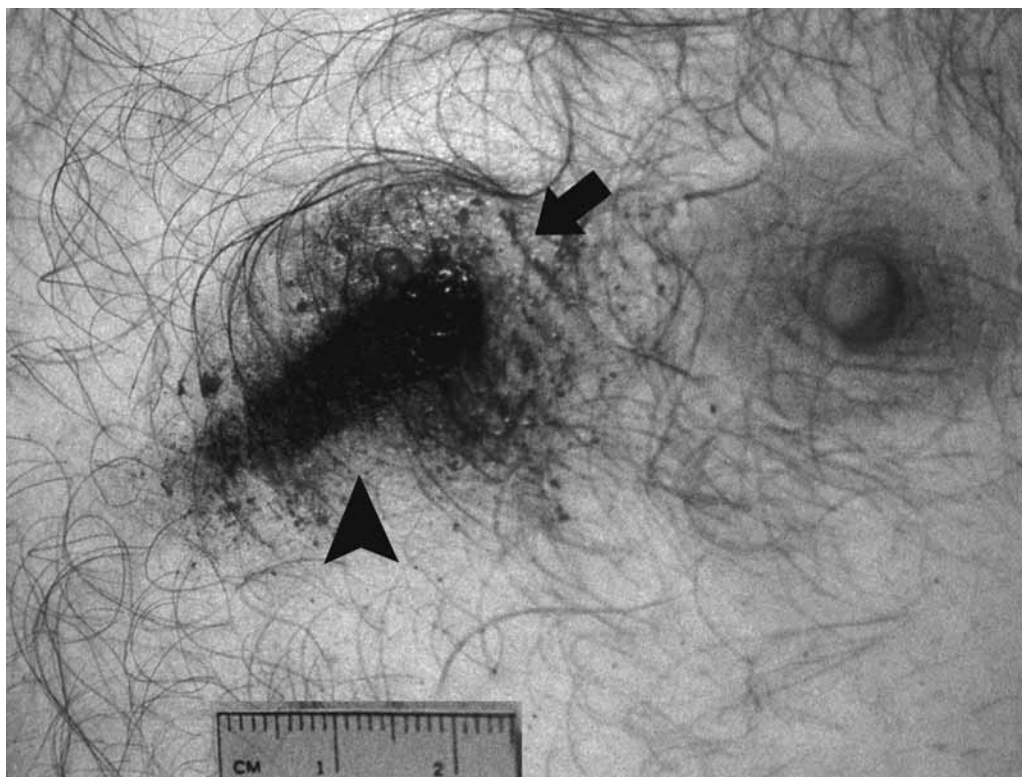
**Fig. 15.** Homicide (.22-caliber rifle). **(A)** Contact range wound, mid-forehead (note slight tearing). Few powder particles were seen in wound. **(B)** Other injuries. Laceration of gingiva, sustained after mouth struck. (Courtesy of the Office of the Chief Medical Examiner, Chapel Hill, NC.)

downward from the entry (Fig. 18). This is caused by a jet of hot gas and soot burning the skin, because either the lower margin of the barrel is not in contact with the skin (“incomplete” contact) or the muzzle slides down because of gravity (16,133,134).

Soot deposition and stippling (cylinder gap effects) can be seen on the skin near the entry (Fig. 19; refs. 16, 119, and 135). Unusual weapons (e.g., stud gun, nail gun) cause gas outlet burns (73). Symmetrical deposition of soot is seen if the pistol has a muzzle brake or vent (86).

Interposition of fabric can create stippling (see Heading 15.; Fig. 20; and refs. 16 and 59). “Pseudostippling” is characterized by separate abrasions caused by lead fragments sheared from a bullet as a result of misalignment of the cylinder and barrel of a handgun (16,58). A bullet can also fragment if objects are interposed between the muzzle and skin (136).



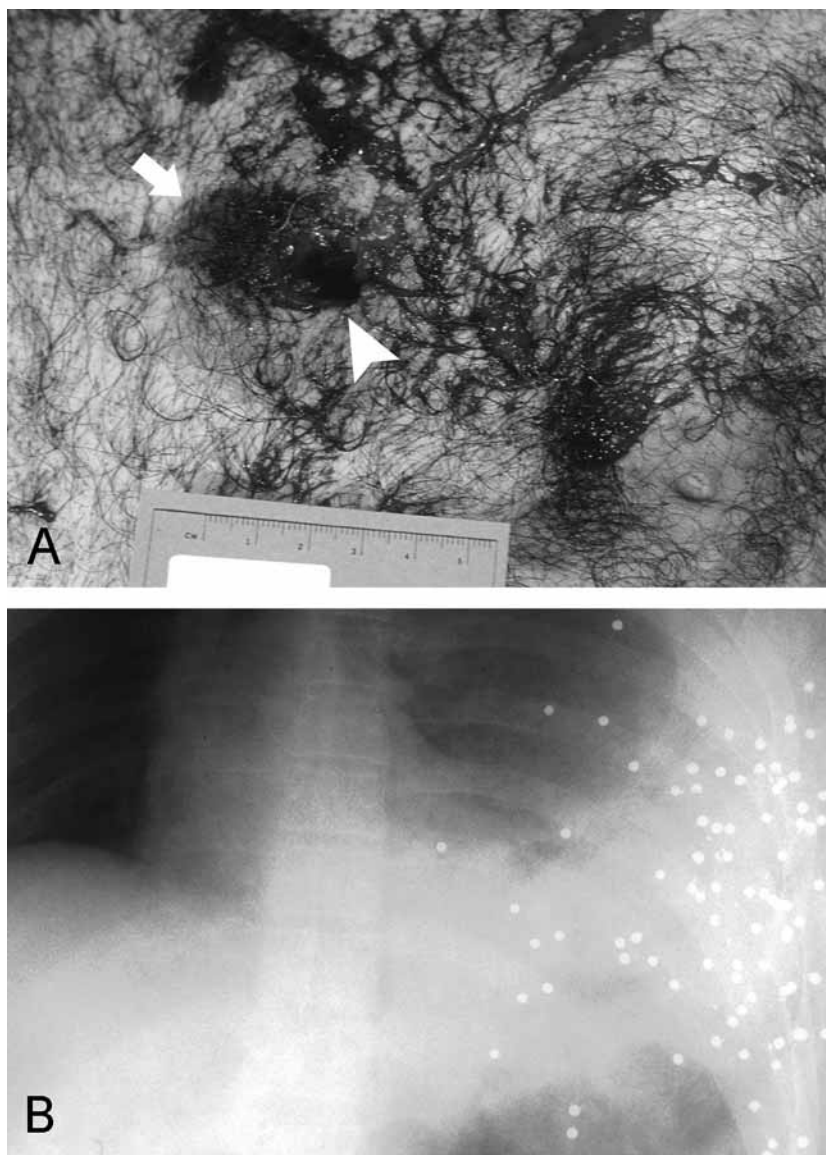


**Fig. 16.** Angled contact gunshot wound of left chest (entry—arrow). Soot (arrowhead) is seen on the inferior-medial aspect of the entry, indicating that the bullet went down and to the right of the deceased (i.e., direction of arrow).

Distant self-inflicted wounds are rare (e.g., weapon held at arm's length, use of an assist device [[16,37,49,124](#)]).

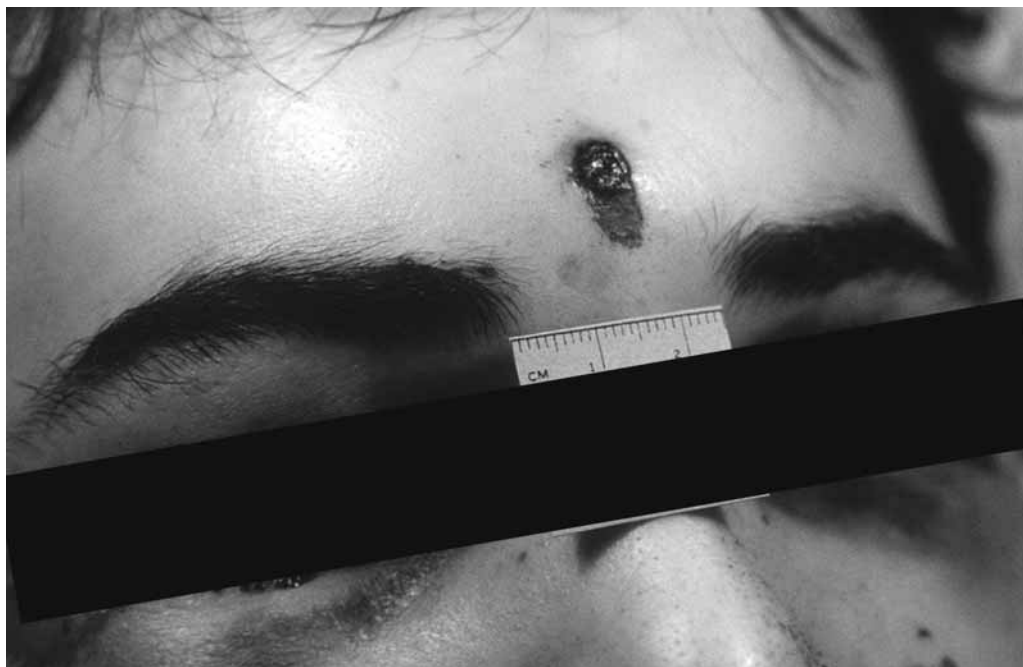### *10. LOCATION OF WOUNDS IN SELF-INFLICTED FIREARM INJURIES*

Certain entry wound sites are characteristic of, but not exclusive to, suicide ([37,59](#)). Various sites of predilection—i.e., those accessible to the victim—have been observed on the head, chest, and abdomen ([20,35,59,102](#)). The head predominates in many studies ([18,19,21,23,33,34,49,59,63,66,95,98,102,117](#)). The temple region (right to left) is the most common site ([21,46,50,51,66,101](#)). For example, in a Texas study, the following distribution was noted: head wounds, 83.7% (right temple, 51.5%; mouth, 20.6%; forehead, 8.7%; left temple, 6.3%; under chin, 4.8%; back of head, 4%; neck, 1.8%; eye, 0.5%; other, 1.8%); chest, 14%; abdomen, 1.9%; and a combination, 0.4% ([32](#)). In a study by Eisele et al., the following distribution was noted: head, 74% (right temporal, 39%; left temporal, 5%; mouth, 9%; midfrontal, 8%; submental, 3%; right parietal, 3%; left head not otherwise specified, 2%; chin, orbit, other frontal, right head not otherwise specified, 1% each; nose, occipital, left parietal, <1% each); neck, 4%; chest, 18%; and abdomen, 4% ([98](#)). Temple wounds favor suicide, but homicide and accident are possible. One study showed that 47% of suicides involved the temple,



**Fig. 17.** Angled near contact shotgun wound of left chest (entry—arrowhead). **(A)** Soot (arrow) is seen on the medial aspect of the wound, which was closer to the angled muzzle. **(B)** Radiograph confirms that the pellets traveled laterally, i.e., to the left of the victim. Note “billiard ball” effect.

compared with 18% of homicides and 25% of accidents (30,37). Some studies show that a mouth entry site is more common if long guns (rifles, shotguns) are used, but a Turkish study showed a handgun predominance (32,34,35,37,49,137,138). Another series showed that the temporoparietal and temple areas were favored when rifles were used (98). A Swedish series revealed neck entries were associated with long guns (37). A series from New Mexico showed long guns favored in facial wounds (cheek, submental area [139]). Chin entry wounds tend to be self-inflicted (30).



**Fig. 18.** Hard contact gunshot entry (.22-caliber rifle). Pencil-like area of searing extending inferiorly from entry.

Self-inflicted intraoral wounds are associated with soot deposition on the lips, teeth, or tongue (Fig. 21). Intraoral wounds can potentially be missed, particularly if rigor makes the mouth difficult to open (Fig. 22; ref. 137). Despite not being seen in some series, an intraoral wound does not exclude the possibility of homicide (30,37,137,140,141). Unlike a homicide, the tongue tends to be involved in suicidal intraoral wounds (Fig. 23; ref. 140).

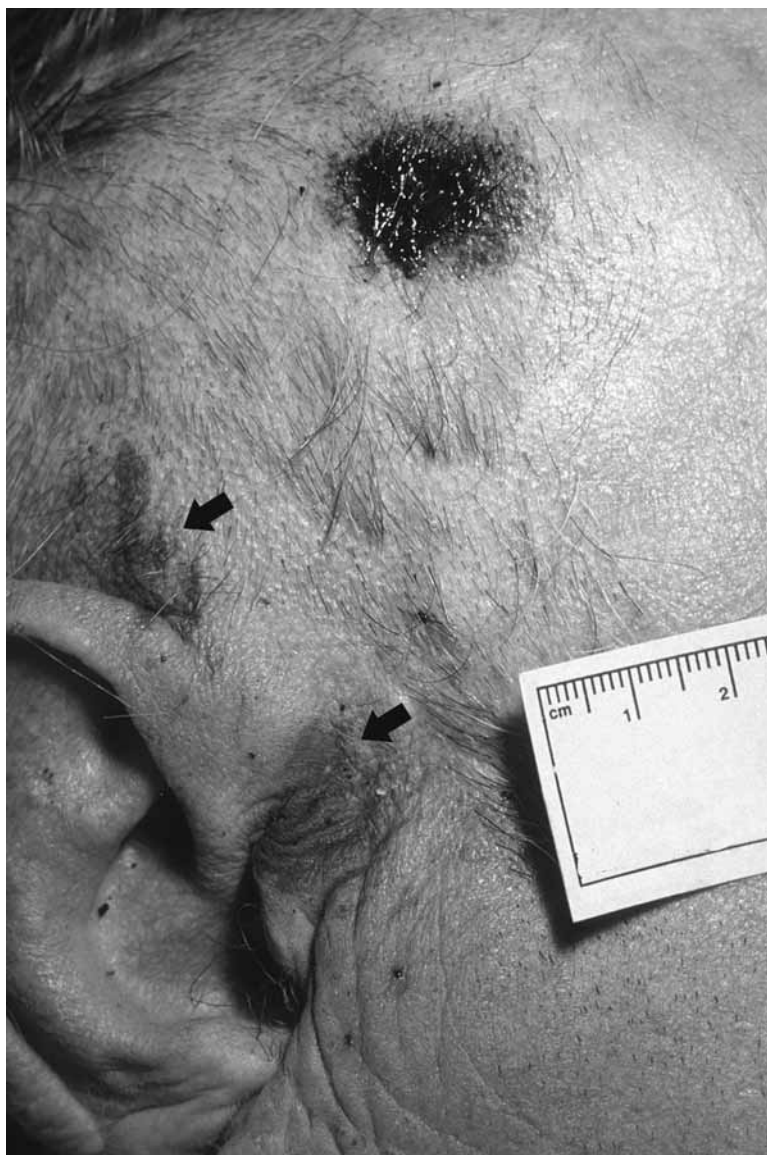Wounds to the back of the head favor homicide and are rarely seen in suicide (16,142). A Texas study showed that, in 10 such cases, 7 involved handguns, 2 used rifles, and 1 had a shotgun (32). Another series revealed that 2.5% of self-inflicted wounds were to the back of the head, compared with 14% of homicides (30). Other unusual entry sites are possible (16). These include the top of the head, nose, ear, eye, umbilicus, and back (37,46,51,57,66,117,143). An intrarectal wound raises the possibility of sexual paraphilia (see Chapter 3, Subheading 2.7.2. and ref. 56).

A self-inflicted chest wound tends to be precordial, whereas a wider distribution is observed in homicides (37,59,102).

Self-inflicted abdominal wounds tend to involve the upper quadrants (144).

### 11. MULTISHOT SUICIDES

A multishot suicide arouses suspicions of homicide, and the autopsy is an essential part of the investigation excluding this possibility (22,55,57,59,60,67,72,109,111,128,129,145). A North Carolina series of 58 multishot suicides showed that they comprised 1.6% of firearm suicides and 0.7% of gunshot wound deaths (67). A Swedish series showed that 3% of firearm suicides were multishot, compared with 57% of

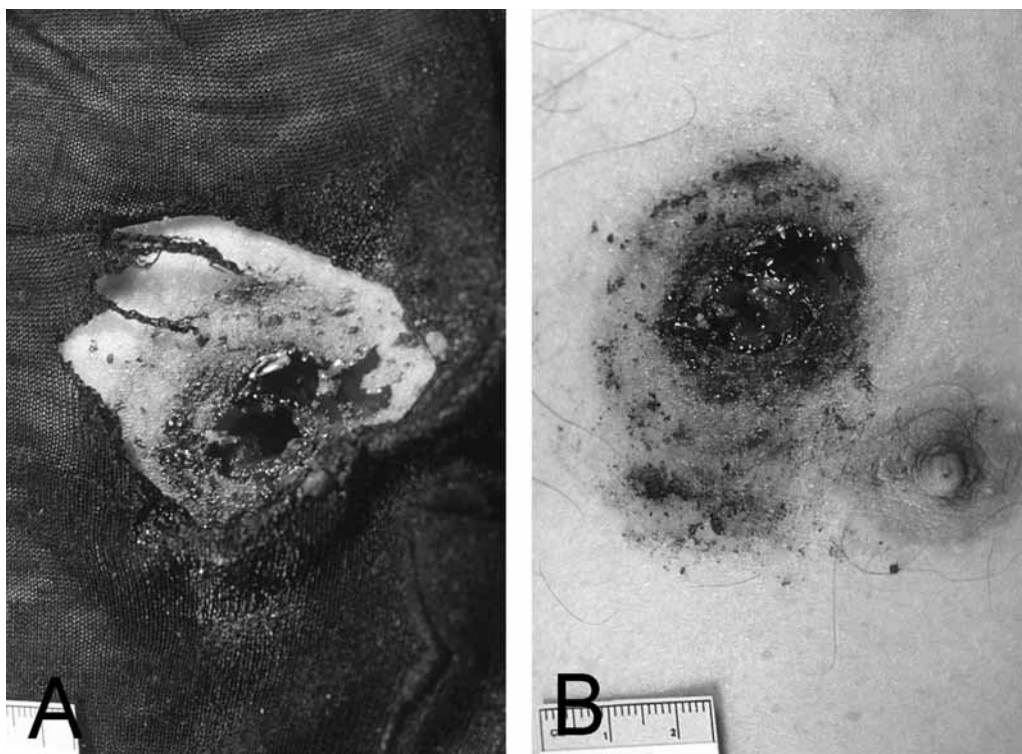


**Fig. 19.** Contact wound, right temple. Note areas of soot (arrows) in front of ear, which were deposited through the cylinder gap of revolver.

homicides (37). A German study showed that more than one gunshot injury was found in 5.6% of suicides, compared with about 54% of homicides (51).

There are various reasons why multiple shots are fired in a suicide: lacking anatomical knowledge, the victim misses vital organs (*see* Heading 14.); the victim's hand flinches when the trigger is pulled; defective, improper, or low-velocity ammunition is used and penetrates the body (e.g., skull) superficially; and certain types of weapons are used (16,22,33,46,55,57,59,67,109,111,117,146). Grazing and superficial perforating wounds are seen (Fig. 24; ref. 16).





**Fig. 20.** Contact gunshot wound of chest. The shirt acted as an “intermediary” target. **(A)** Dark shirt and dried blood obscure soot. **(B)** Shirt removed. Wound cleaned. Apparent stippling pattern.

Multishot suicides commonly involve the precordium, alone or in combination with head and abdominal wounds (55,67,145). Up to 14 entries in the chest have been described (.22-caliber rifle with a clip [60]). The exclusive presence of head wounds in multishot suicides is unusual (see Fig. 25 and refs. 22, 67, 111, 117, 120, and 146). Up to five gunshot entries have been observed (.32-caliber revolver [57]). Eight wounds to the head and neck using blank cartridges have been described (73).

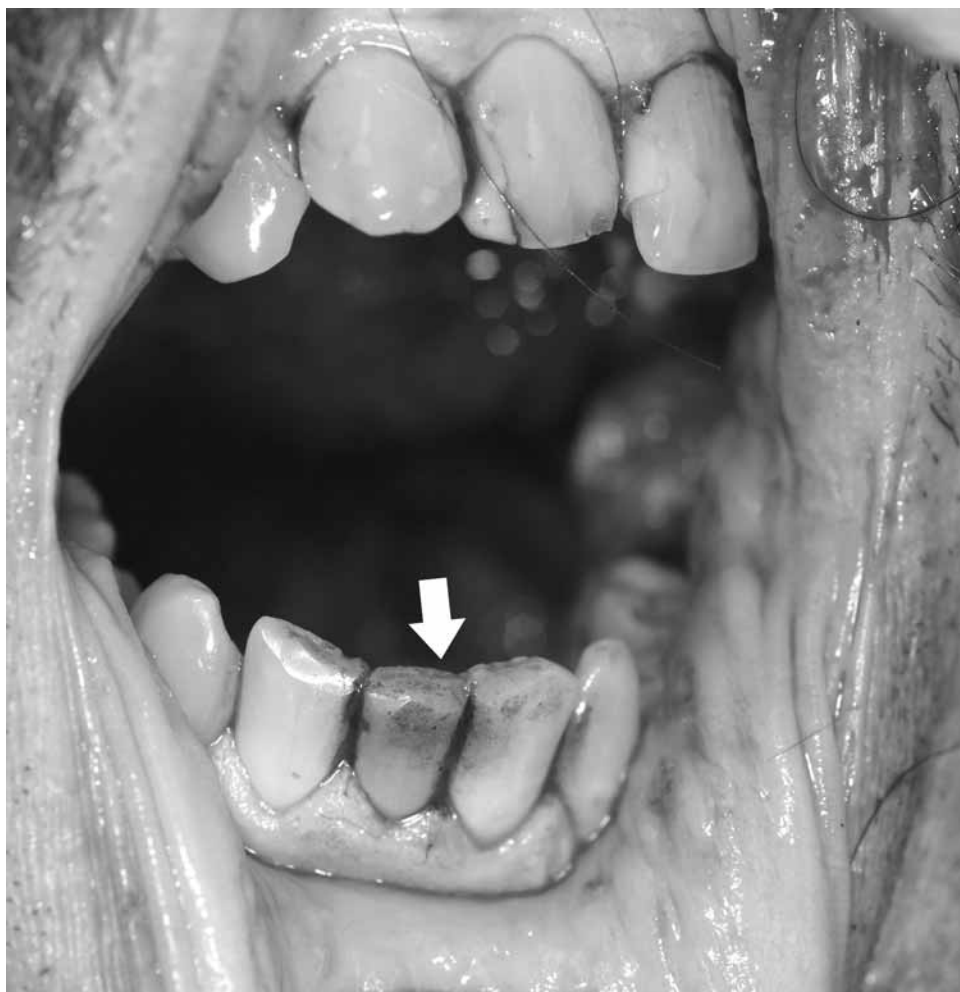
More than one weapon can be used and fired simultaneously (16,55,147,148). Intraoral wounds have been noted in multishot suicides (22).

Tandem bullets fired through one entry are attributed to misfire, i.e., insufficient or defective powder owing to contamination or deterioration (149,150). Other reports have described multiple shots through a single entry (96,145).

## 12. OTHER EXTERNAL FEATURES OF CONTACT ENTRY WOUNDS

Contact range entry wounds can appear stellate where there is relatively thin skin and soft tissue overlying bone (e.g., the head; see Figs. 14, 15, 26, and 27 and ref. 16). This mimics an exit wound. Gas blowback and energy dissipation result in the skin being temporarily lifted from the bony surface and splitting (16). In high-velocity injuries, tissue can be ejected from the entrance, giving the false impression of tissue extruded from an exit (16,151). The tearing can be severe if there is a high volume of gas (e.g., tear gas cartridge, high-velocity rifle, shotgun [16,93]). A high-velocity wound of the mouth can be associated

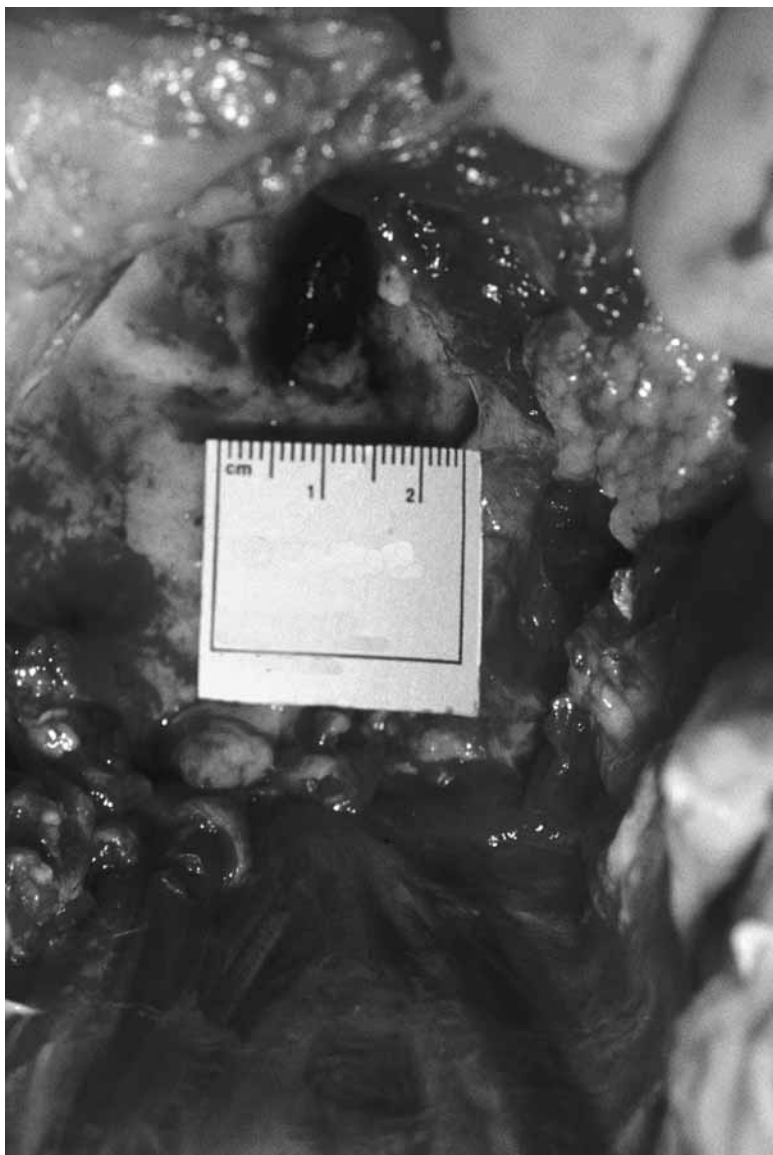




**Fig. 21.** Intraoral self-inflicted gunshot. Soot deposition on lower incisors (arrow).

with extensive fracturing of the skull and tearing around the nose, eyes, and mouth (16). Perioral “stretch” lacerations are limited to mouth entries (Fig. 28; ref. 138). Extensive tearing of the wound requires approximation of the skin edges to determine the entry site (Fig. 29; ref. 16). Distant wounds may be stellate if a projectile enters a bony prominence (e.g., supraorbital ridge, zygoma, mandible [16,132,152]). Tearing is enhanced if the bullet is distorted or tumbles. A bullet entering and exiting the same hole can partly tear the wound edge (e.g., .38-caliber revolver, right temple entry [153]). Certain types of weapons have been described as causing “irregular” entries (119). Falling, after wounding by a firearm, causes cutaneous injuries (e.g., facial abrasion [145]).

Lifting of the skin against the barrel of the handgun, rifle, or shotgun can result in a muzzle imprint (Figs. 26 and 30 and ref. 16). It can be used to correlate a weapon with an injury, particularly if no bullet is recovered; however, the muzzle imprint can be larger than the actual size on the weapon (16,113). The finding of a muzzle imprint also supports the circumstances of a multishot suicide (22,57,59,62). Variations of a muzzle imprint have been seen when a blank cartridge, nail gun, or ejector rod is involved (73,85,92,107).

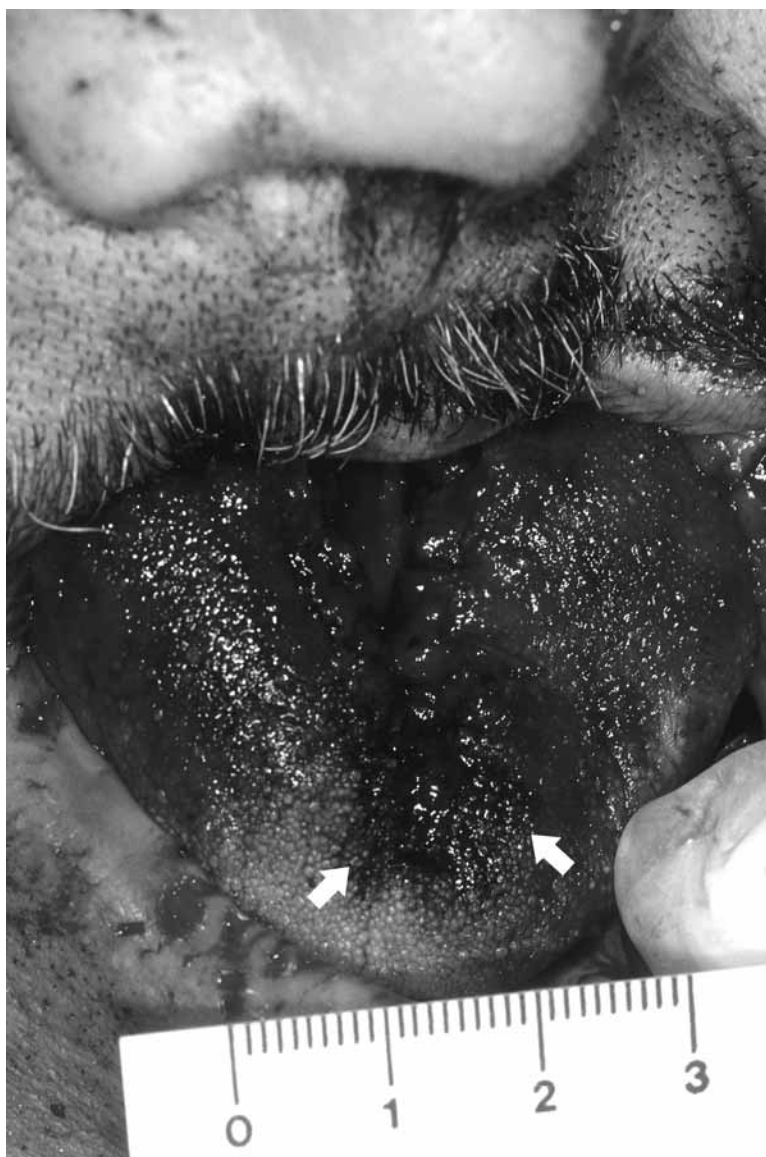

**Fig. 22.** Intraoral (hard palate) contact wound. Jaws were clenched from rigor. Viewed internally from below following removal of tongue and anterior neck structures.

### *13. EXAMINATION OF HANDS IN SUICIDE BY FIREARM*

Certain features on the hands support the circumstances of suicide, particularly in multishot cases (55,154). The hands need to be covered by paper bags to protect evidence, particularly if there are suspicions surrounding the death (Fig. 31; ref. 16). Plastic bags create condensation when the body is refrigerated (16). Fingerprinting and hand washing, as part of body preparation prior to the pathologist's examination, jeopardize the documentation and collection of evidence (Fig. 32; refs. 16 and 154).

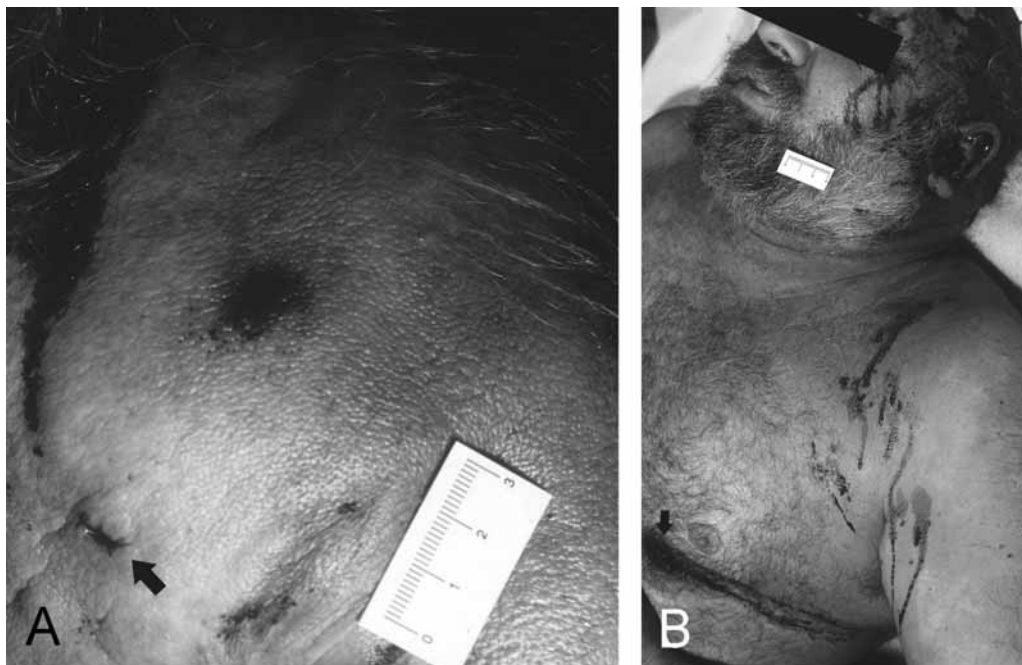
Primer residues, not visible to the naked eye, are deposited on the hands (see Heading 24. and refs. 16 and 155). Blood and/or tissue (e.g., brain matter, if a head



**Fig. 23.** Intraoral gunshot wound. Soot on tongue (arrows). Laceration extending posteriorly.

wound) owing to blowback (“backspatter”) may be found on the dorsum of the hand that fired a pistol/revolver (firing hand) and the hand that steadied the muzzle (nonfiring hand; *see* Heading 23.; [Fig. 33](#); refs. [16](#), [111](#), and [154–157](#)). Radial skin tearing around tight contact wounds is not an invariable finding associated with backspatter ([156](#)).

If the nonfiring hand is used to steady the end of the muzzle of the handgun, rifle, or shotgun, and the muzzle is not tightly apposed to the skin, then soot can be deposited on the thenar aspect of the palm, i.e., the index finger and thumb (“muzzle gap effect;” [Figs. 34–36](#); and refs. [16](#) and [55](#)). If the weapon is a revolver, then soot can be seen on the hypothenar aspect, i.e., little and ring fingers (“cylinder gap effect;” *see* [Fig. 34](#)). Associated injuries (e.g., lacerations) can occur if a higher velocity weapon is used



**Fig. 24.** Multishot suicide (see Fig. 51). **(A)** Contact gunshot wound on left forehead. Track was subcutaneous and the cranium was intact. Exit (arrow). **(B)** Blood stains on face and left shoulder support the observation the victim was upright when the nonfatal head wound was inflicted. He was supine after the fatal chest wound (arrow) as indicated by the tracking of blood from the wound to his back.

(Figs. 34 and 35). Yellow-brown discoloration on the palm of the hand holding the barrel of a weapon is a “rust” stain caused by moisture and perspiration (Fig. 37; ref. 16).

Linear scars on the wrists suggest a previous suicide attempt (73).

#### 14. SIGNIFICANCE OF BLOODSTAINS

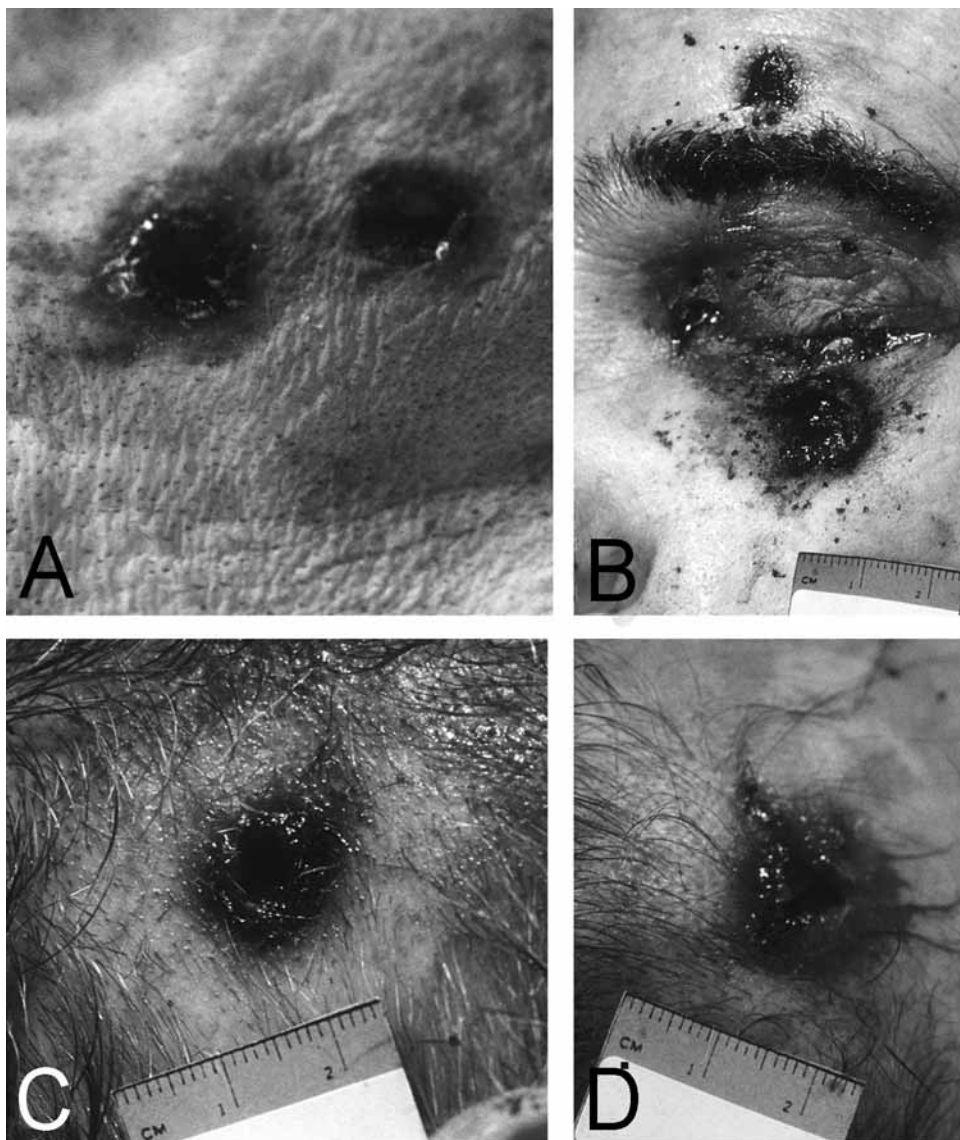
Blood spatter on the hands assists in determining whether a wound was self-inflicted (see Heading 13.).

Vertical blood spatter on the body, clothing, and adjacent surroundings can indicate an upright position (sitting or standing) following infliction of the wound (Fig. 24; refs. 57, 58, 94, and 130). Tracking of blood posteriorly from a wound indicates that the deceased was lying supine (Fig. 24; ref. 106). In multishot suicides, the distribution and extent of bloodstains assist in determining the degree of incapacitation caused by the various wounds. For example, the injurious effects of an intraoral wound, described in one case, appeared more prolonged compared with a temple entry, as indicated by the considerable amount of blood on the front of the body of the deceased and little on the shoulder (22). The finding of blood at different sites of the death scene of a multishot suicide indicates purposeful activity prior to the incapacitating wound (see Heading 18. and Fig. 3).

#### 15. CLOTHING

Individuals with self-inflicted firearm injuries can be nude, bare the entry site by opening their clothes, reclothe themselves after firing, or be clothed (55,59,73,105,



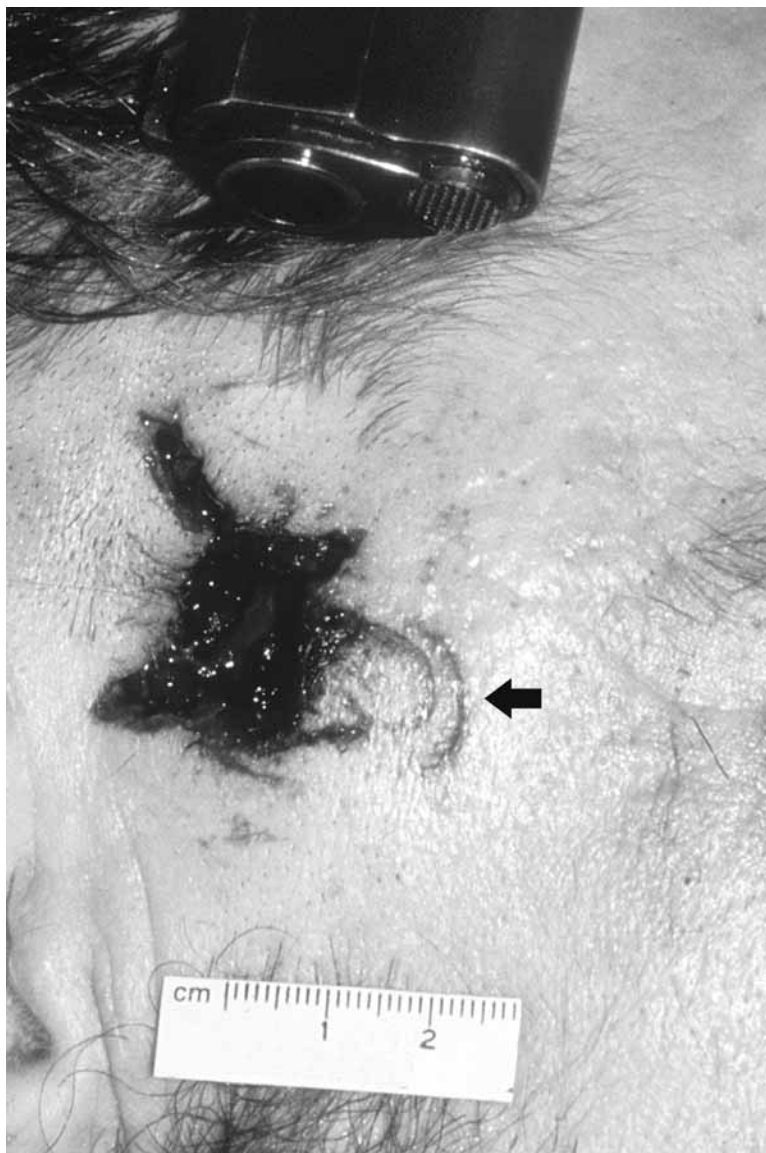


**Fig. 25.** Multishot suicide. Three gunshot wounds of head. (A) Two hard contact wounds under chin. (B) Wound tracks passed through the mouth and mid-facial bones exiting above and below the eye. The cranial cavity was not penetrated. (C) Third hard contact wound above right ear. (D) Wound track passed through the brain and exited from the left scalp. (Courtesy of the Canadian Society of Forensic Science Journal.)

[112,117,158](#)). Shooting through clothing is not an indicator of homicide ([158](#)). Retention of clothing is essential in the police investigation ([16](#)).

Clothing alters the appearance of wounds by acting as an intermediary target (*see* Heading 9.). If clothing or other material is interposed between the muzzle and skin, then soot deposits on the fabric, and other characteristics normally associated with a contact range wound, are altered ([Fig. 20](#); refs. [16](#), [55](#), and [59](#)). Injuries caused by clothing acting as an intermediary target can mimic a contact wound ([Fig. 38](#)). Collection of clothing and any



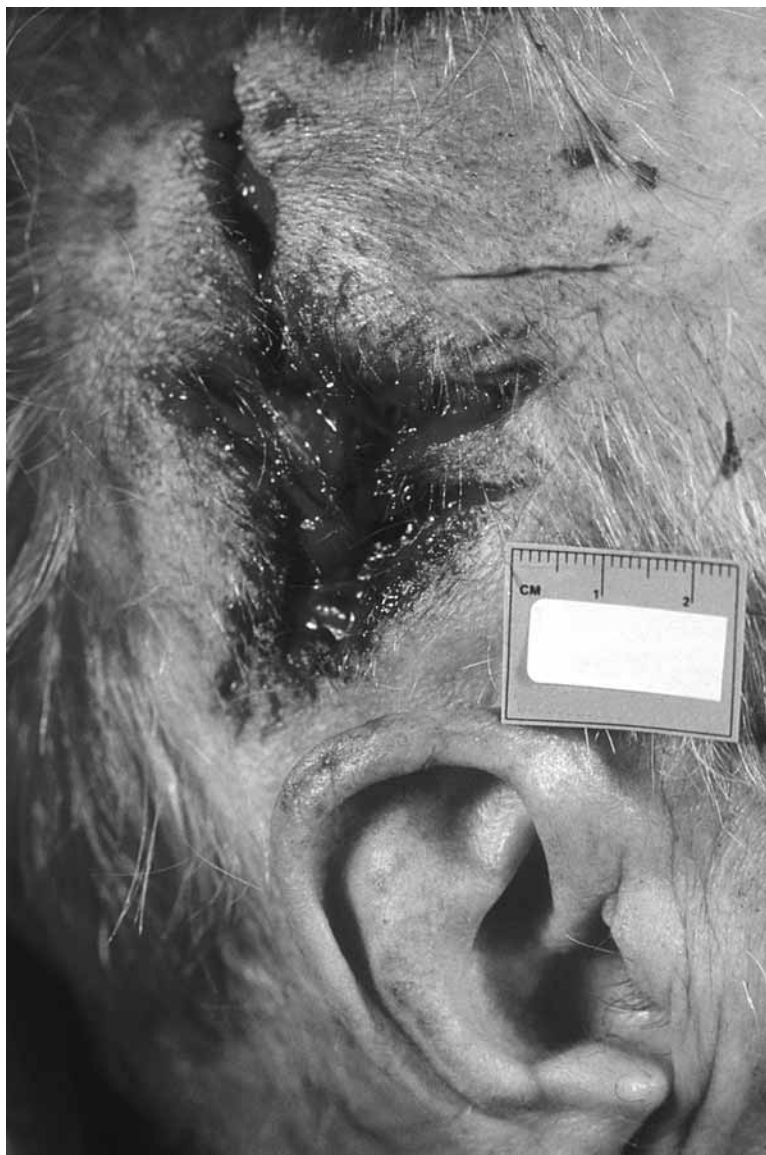

**Fig. 26.** Hard contact gunshot entry, right temple. No soot is seen on the skin surface. The wound edge is stellate. A muzzle imprint (arrow) is evident. (Courtesy of the Office of the Chief Medical Examiner, Chapel Hill, NC.)

other interposed material is essential (159). Soot may be absent on the wound (55). Soot is also obscured by dark clothing and blood (Fig. 20; refs. 103 and 160). Little bleeding around an entry usually involves a small-caliber weapon and an area of the body either under pressure from clothing or elevated. The edge of the material around the entry can be burned (60).

### *16. POSTMORTEM RADIOGRAPHY*

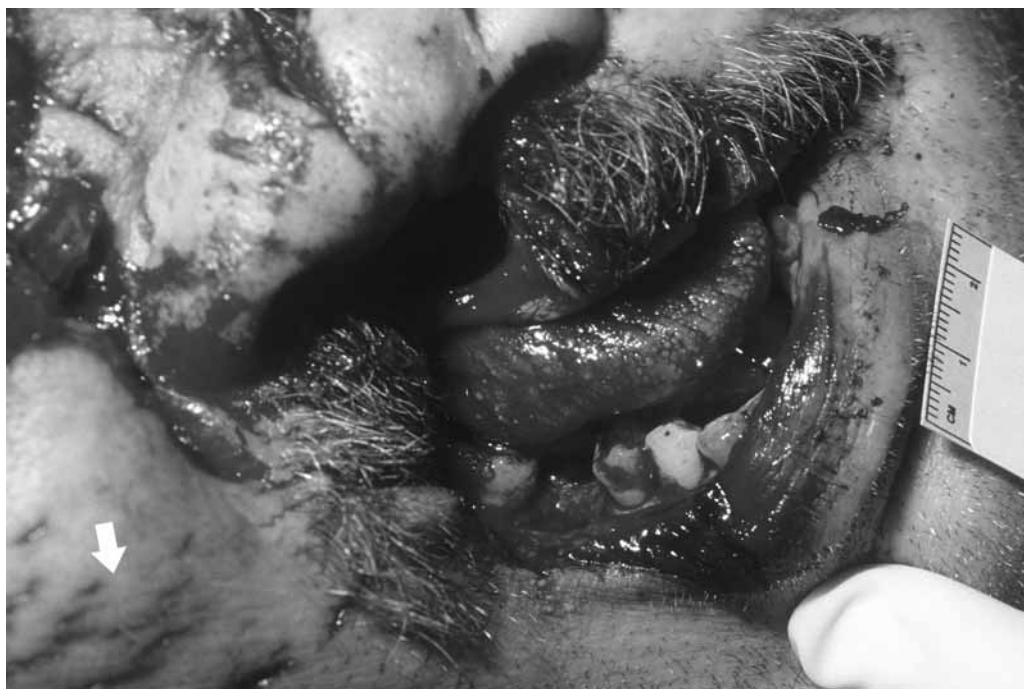Radiography is an essential component of firearm injury examination. Anteroposterior and lateral radiographs assist in determining the location, nature, and



**Fig. 27.** Stellate appearance of large hard contact gunshot entry of right temple mimics an irregular exit wound.

path of projectiles in the body (16). Lateral radiographs are particularly helpful if there is an anterior torso entry and the bullet does not exit from the back. Reliance on only an anteroposterior radiograph leads to a mistaken assumption that a bullet is deep within the body, resulting in a time-consuming search. The posterior location of the projectile, indicated on the lateral radiograph, means that simply palpating and incising the skin on the back allows easy recovery (Fig. 12). More sophisticated radiological techniques (MRI, CT) may play a role in the assessment of firearm injuries (161).

The deposition of radiodense material (lead) from nonjacketed bullets around a contact or near-contact wound assists in distinguishing an entry from an exit wound,



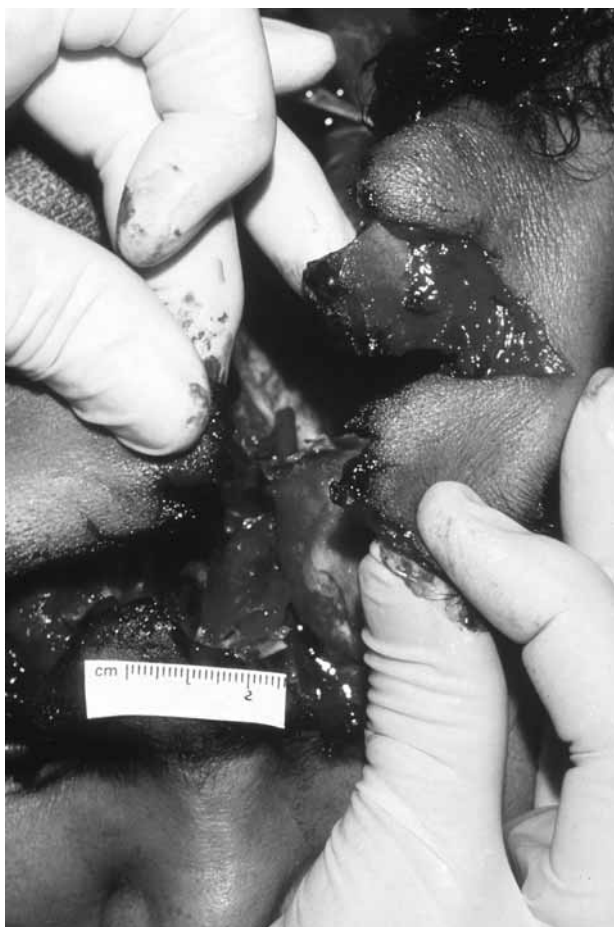**Fig. 28.** Intraoral shotgun wound. Tears around mouth. Perioral stretch lacerations (arrow).

useful when wounds have been obscured by blood, thick hair, skin pigmentation, decomposition, medical alteration, and insect or animal activity ([160,162,163](#)). The presence of lead is confirmed by scanning electron microscopy/energy-dispersive X-ray. Skull wounds owing to gunshots can have lead fragments deposited on the outer table of the cranium ([16](#)). Lead fragments also indicate the path of a wound track. Lead fragments can trace the path of an intracranial ricochet (*see* Subheading 19.4. and ref. [16](#)).

High-velocity ammunition fragments (e.g., from a hunting rifle) create a “snowstorm” pattern ([Fig. 39](#)). Despite the observation that metal fragments from a partly jacketed centerfire weapon are distributed as a cone with its apex oriented toward the entry, one study showed that predicting the direction of travel, based only on lead “snowstorm” seen on a radiograph, was difficult ([162](#)).

Shotgun wadding is not usually radiopaque. An exception occurs when lead is deposited on fiber wads ([16,124](#)). Dispersal of pellets (“billiard ball effect”) in the body is not a sign of a distant shotgun wound and is seen in contact wounds ([Fig. 17](#); refs. [16](#) and [124](#)). Pellets can deform within the body ([164](#)).

Radiographs are also used to document other foreign bodies and injuries ([56](#)). Radiographs demonstrate unique features of certain types of projectile injuries ([119](#)). Tandem projectiles (e.g., .22-caliber bullet and barrel-cleaning brush from a rifle) have been observed ([165](#)). In nailgun suicides, a straight steel nail is found in a self-inflicted wound as opposed to a bent nail in a bystander or user accidentally injured by a ricochet ([85,166–168](#)). A straight nail can be seen in a bystander when the nail has overpenetrated a wall or was fired in midair.

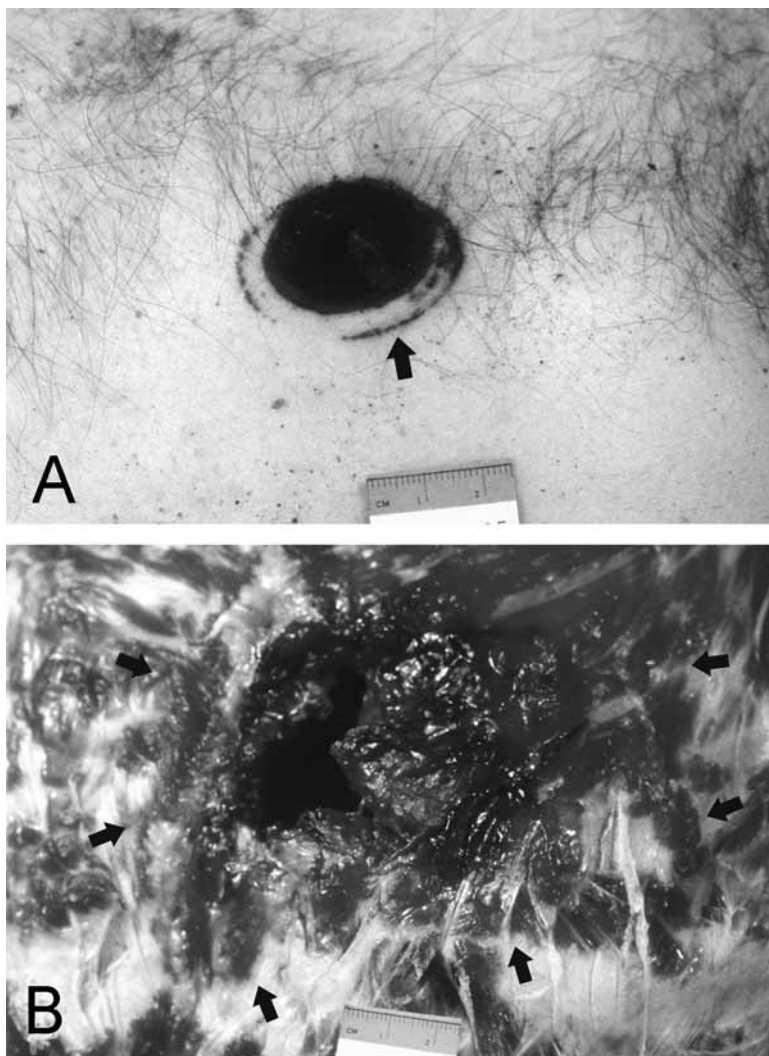


**Fig. 29.** Large-caliber gunshot wound of the forehead. Extensive destruction of cranium. Reconstruction of entry wound. (Courtesy of the Office of the Chief Medical Examiner, Chapel Hill, NC.)

Radiographs must be done in any case where there is an apparent exit. That exit can be created by a partly fragmented bullet or a piece of bone (16). If there is a jacket and core separation of a partly jacketed bullet in the body, radiographs help in the recovery of the jacket, which shows rifling striations (*see* Heading 21; Fig. 40; and ref. 16). Even when there is considerable skull destruction from shotgun pellets, a radiograph confirms the presence of at least a few residual pellets (16). A radiograph can locate small residual fragments of a projectile in a through-and-through gunshot wound. These fragments can be analyzed and compared with ammunition that may have been used (16). If a projectile is not evident in the radiograph despite the lack of a skin exit, then possibilities include an ignored or missed exit, a nonradiopaque projectile (e.g., plastic bullet), projectile embolization (usually shotgun pellets, small-caliber bullets) and discharge of a blank cartridge (16,73,92,93,169,170).

If the bullet and its fragments are not found after the brain is removed, the brain must be X-rayed to confirm that the bullet is still present. Bullets can migrate within the cranium (171,172).



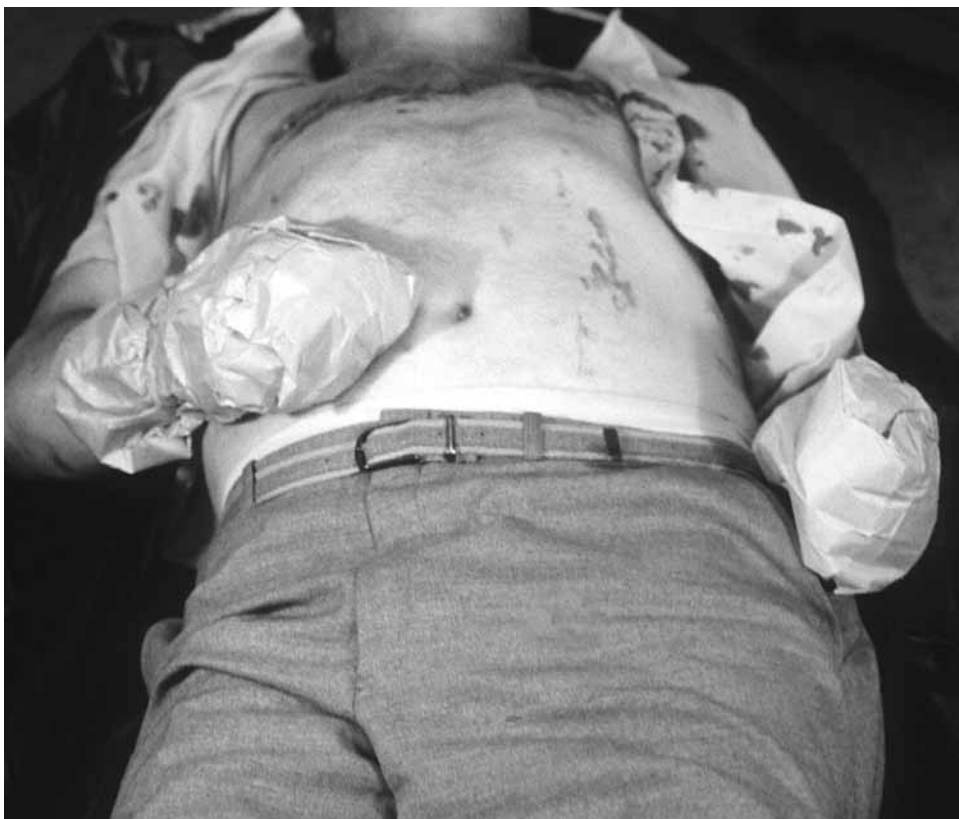

**Fig. 30.** Hard contact shotgun entry, chest. (A) Soot is not visible on the skin. A muzzle imprint (arrow) is observed. (B) Entry, chest wall. Bright red stain (edges indicated by arrows), indicating expulsion of carbon monoxide from muzzle. (See Companion CD for color version of this figure.)

### *17. ENTRY WOUND ALTERED BY MEDICAL CARE*

If an entry wound is altered by medical care, then the pathologist needs further information from hospital personnel regarding what was done (Fig. 41; refs. 16, 66, 99, and 134). The major concern, in an emergency setting, is the care of the patient who has sustained a life-threatening firearm wound. The focus is on internal injuries, but the accurate documentation of external trauma is important for a medicolegal investigation, particularly if the individual survives (173). Medical personnel, inadequately trained to interpret the features of firearm injuries and pressured by the time constraints of resuscitation, miss wounds and misinterpret entry and exit wounds (16,99,132,174). There





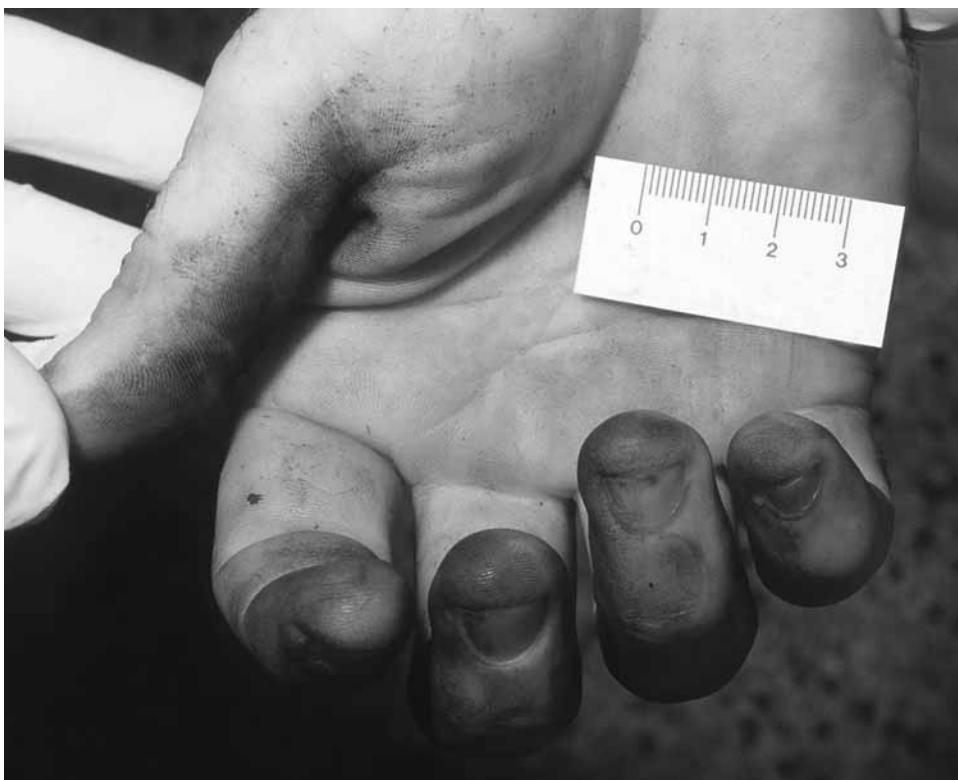**Fig. 31.** Self-inflicted firearm injury. Hands covered by paper bags to preserve evidence.

may be varying descriptions of the wounds in the clinical records, and discrepancies regarding the size and shape, range, location, and direction of fire arise (173,174). A wound in a hospitalized patient is also altered by infection and healing (16). Continuity of evidence issues also can arise in the clinical setting (174).

Specimens from the wound site and track may be resected and submitted for pathological examination (175). The pathology laboratory must have a system to ensure continuity of evidence. The specimen should be examined by a pathologist with forensic experience and documented with photographic images. Inquiries may be made by the police regarding a specimen and any recovered projectiles. Provision of this evidence to the police is only with a patient's consent or under legal warrant and must be recorded.

### *18. INJURY POTENTIAL AND LETHALITY*

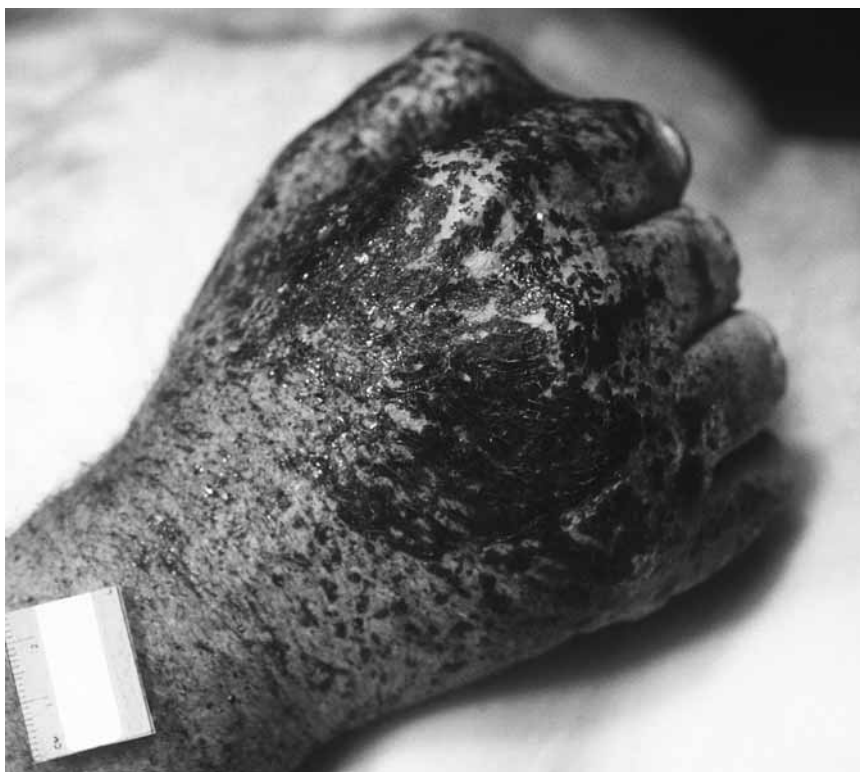The projectile directly crushes tissue (176). As a projectile passes through the body, tissue is temporarily (in the order of 10 ms) accelerated in a radial direction (16,176). The maximum radial extent of the “temporary cavity” is dependent on the amount of energy released from the projectile and the degree of tissue elasticity (16,142,176–178). The energy of a projectile increases exponentially based on its velocity (kinetic energy =  $mv^2/2$  where  $m$  is the projectile's mass and  $v$  is the velocity [16,176–178]). Civilian hunting rifles have velocities ranging from 600 to 1200 m/s (2000–4000 ft/s), civilian handguns less than



**Fig. 32.** Fingerprinting of hands mimics soot deposition.

300 m/s (1000 ft/s), and a .22-caliber rifle 300 to 380 m/s (1000–1250 ft/s [177]). A bullet from a hunting rifle generates a large temporary cavity (Fig. 39; ref. 179). The temporary cavity collapses into a “permanent cavity,” i.e., a grossly visible wound track generally wider than the bullet diameter (Fig. 42; refs. 16 and 177). The size and shape of a permanent cavity is not necessarily dependent on the caliber of the weapon (177). If a low-velocity firearm (e.g., handgun) is involved, tissue elasticity of tissue can cause a wound track to be smaller in diameter than the projectile (16). The size of the temporary and permanent cavities is determined by the nature of the tissue. Less elastic tissue—e.g., brain as compared with muscle and skin—undergoes a larger area of cavitation, resulting in a wider wound track (16,176). Energy dissipation is furthered when the bullet deforms and deviates along its path in the body (16,176). This can cause a track to appear more irregular (177). Bullet fragmentation is enhanced by contact with bone (176). The track may be wider close to the entrance site if the tissue has been lacerated by bone fragments from the entrance fracture or wider closer to the exit site when tumbling of the bullet has occurred (142).

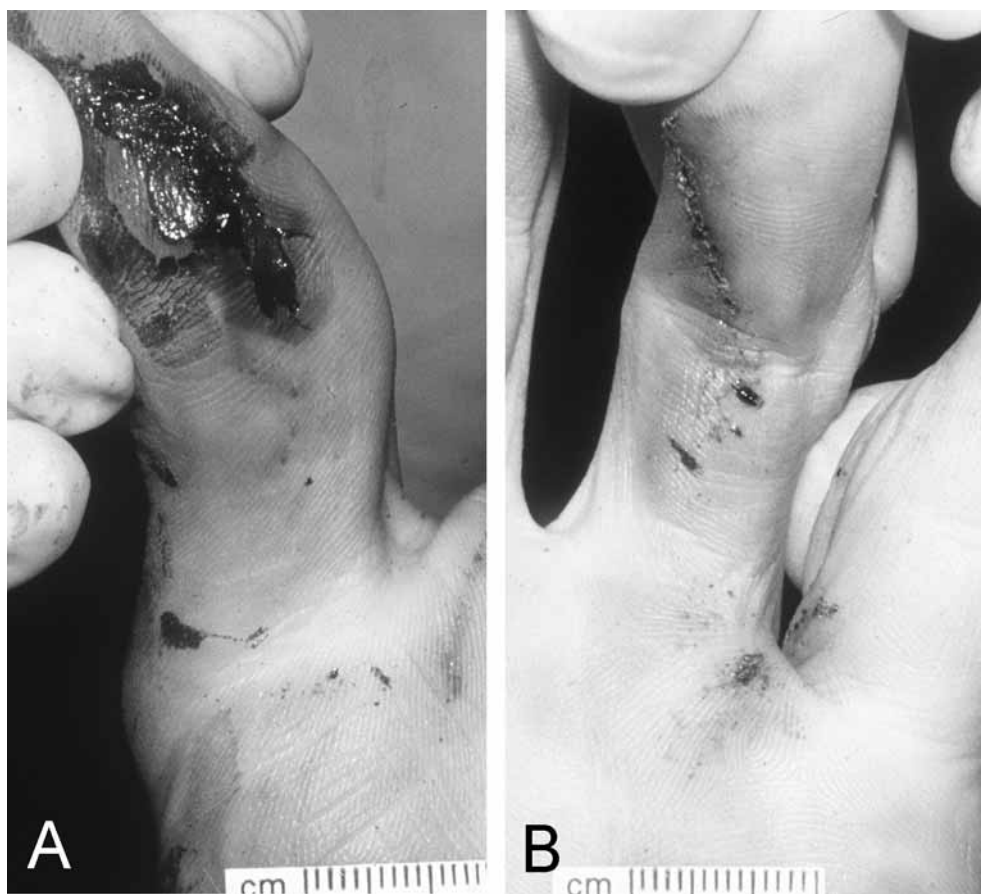
Despite the localized area of tissue destruction, effects are actually more widespread grossly and microscopically, even when low-energy ammunition is involved (16,177, 180,181). For example, in cases of low-velocity fatal gunshot wounds to the head, the usual scenario is respiratory arrest, followed by cardiac arrest, within seconds to minutes (142,180,182). The permanent track in the brain appears as a line of hemorrhage and necrosis, associated with hyperchromatic shrinkage of neurons and loss of glial fibrillary astrocytic protein and  $\beta$ -amyloid precursor protein immunostaining within 2 to 4 mm (about



**Fig. 33.** Suicidal gunshot wound (head). Blood spatter on dorsum of right hand (firing hand).

0.125 in.) of the track ([161,183](#)). The rigid confines of the cranium enhance pressure created by temporary cavity formation ([129,176](#)). During the passage of the projectile in the brain, distant effects outside the visible wound track occur. Pressure marks (grooves) are observed on the uncus gyri and cerebellar tonsils ([177](#)). They are not necessarily caused by cerebral edema, although this has been observed within minutes of wounding ([177](#)). Brain contusions are observed in the vicinity of the entry (coup) and on the opposite side (contrecoup) of the brain, including the exit site ([Fig. 43](#); ref. [177](#)). Contusions may be seen on the base of the frontal, temporal, and occipital lobes, similar to blunt trauma injuries, and the cerebellar tonsils from contact against the base of the skull and falx tentorium, respectively ([Fig. 44](#); ref. [176](#)). Posterior fossa entrance wounds are associated with a laceration of the corpus callosum as it collides with the ventral margin of the falx. Contusions, indirect skull fractures (*see* Subheading 19.3.), and cerebral perivascular hemorrhages (petechiae) are signs of increased intracranial pressure, and the mechanism of death is brainstem dysfunction ([176,177,182](#)). Gross and microscopic examination can show basal ganglionic, brainstem, and cerebellar hemorrhages remote from the wound track ([Fig. 44](#)). Diffuse axonal injury at distant sites has been described ([176,180](#)). If the amount of energy dissipation by the projectile exceeds the elasticity of the organ, bursting occurs ([16,179](#)). Very destructive injuries are apparent. In contrast, the injuring capability of a very low-velocity projectile is simply the result of its penetration of a vital structure ([16,72](#)).

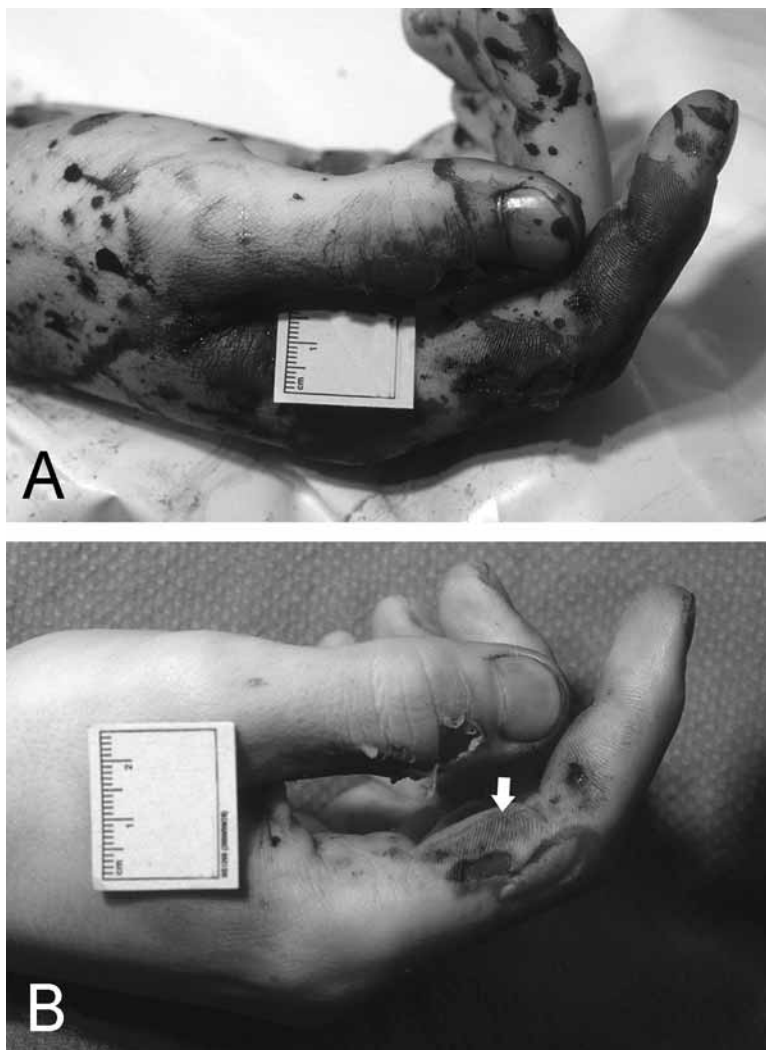
The assessment of firearm injuries includes the determination of how quickly an individual dies. Incapacitation is defined as the inability to perform complex and longer



**Fig. 34.** Contact wound of head from high-caliber handgun. Examination of hand used to steady muzzle (nonfiring hand). (A) Soot around laceration on thumb (muzzle-gap effect). (B) Soot around laceration on ring finger (cylinder-gap effect).

lasting movements because of brain injury or massive blood loss (*see* Heading 14.; refs. 129 and 176). The duration of survival and level of consciousness influence whether purposeful activity was possible after the wound was inflicted (e.g., repeated weapon discharge in a case of multishot suicide; *see* Fig. 3 and refs. 55 and 109). The finding of two instantaneously lethal wounds in an apparent multishot suicide is suspicious of homicide, except when two guns are used (55,129).

The majority of firearm deaths are related to traumatic brain injury; for the period from 1989 to 1998, firearms were the leading cause of fatal traumatic brain injury in the United States (184). Injuries of certain areas of the brain (internal capsule, diencephalon, basal ganglia, cerebellum, brainstem, upper cervical cord) are considered immediately incapacitating and lethal (16,55,57,111,129,182,185). A higher survival rate is seen when brain injuries are limited to a single cerebral lobe compared with tracks crossing the mid-coronal and midsagittal planes (186). The sella turcica and the base of the anterior cranial fossa act as a horizontal bony barrier against radial tissue displacement and overpressure posteriorly from a frontal injury (182). Frontal lobe injury allows survival in some cases (47,67). The frontal lobes are areas of the brain not essential to purpose-

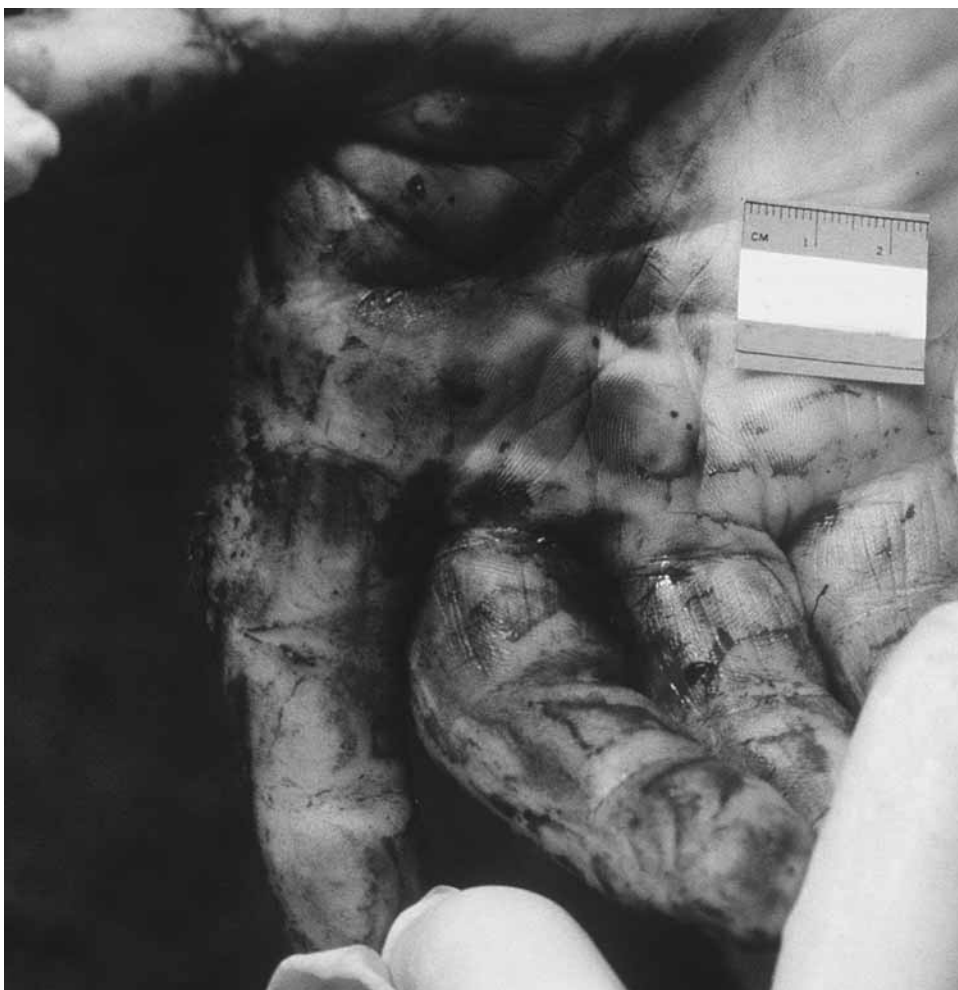

**Fig. 35.** Contact shotgun wound to head. **(A)** Blood spatter on thenar aspect of hand steadying end of muzzle. **(B)** Hand cleaned. Soot (arrow) and lacerations visible (muzzle-gap effect).

ful action or consciousness, but, depending on the caliber of the weapon, wounds at this site can be either instantaneously, rapidly, or not immediately lethal ([111,129,182](#)). Missiles, either crossing the midcoronal and midsagittal planes or present in the posterior cranial fossa, were lethal in all cases in one study ([186](#)). These sequelae occurred regardless of caliber ([186](#)).

Spinal gunshot wounds tend to fracture or shatter the vertebrae through which they pass, but incomplete involvement of the intervertebral ligaments maintains the stability of the vertebral column ([187,188](#)). The spinal cord is injured by the crushing and tearing effect of the primary track, and the effects on the spinal cord of the temporary cavity is less because the spinal cord is less tightly confined by the spinal canal. Vertebral artery injury, including propagation of bilateral vertebral artery thrombi to the basilar artery, can occur ([189](#)).





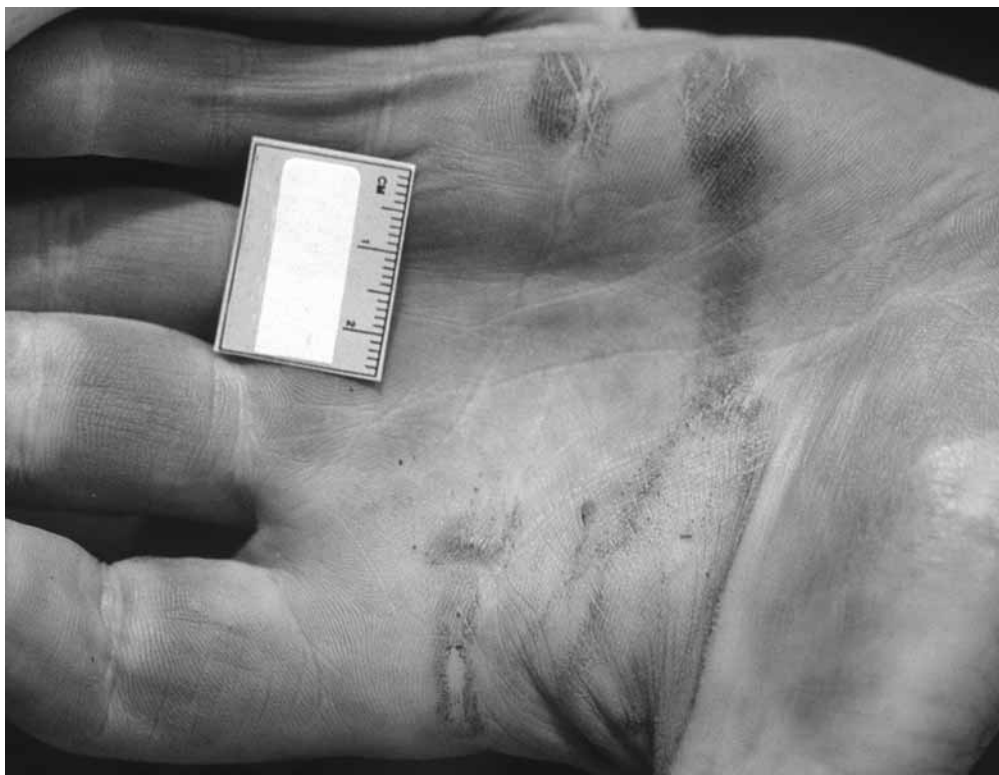**Fig. 36.** Soot on thenar aspect of palm holding the end of a shotgun muzzle (muzzle-gap effect).

Marked secondary ischemic brain injury, brain swelling, and intracerebral hemorrhage, no different from that associated with severe blunt force injury, occurs in cases of gunshot wounds that survive for more than a few hours after the injury (142).

Bleeding from a cerebral venous sinus allows a short period of purposeful activity (182).

Wounds of the heart and aorta are rapidly lethal, allowing some voluntary movement for 10 to 15 s, although more prolonged activity has been observed (16,55,105,129,145,176). When targets of “secondary” importance (e.g., liver, kidney, lung) are injured, bleeding is extensive, but the victim can be conscious and survive for a period of time (minutes) (129).

Nonlethal self-inflicted firearm injuries involving the lower face, mouth (palate), and frontal bone have been observed (16,22,111,182). Delayed morbidity and mortality caused by infection from firearm and air gun wounds have been described (Fig. 45; refs. 66, 70, 139, and 186).



**Fig. 37.** Gunshot suicide. Rust stain on palm of wet hand holding rifle barrel.

## *19. FIREARM INJURIES INVOLVING THE SKULL*

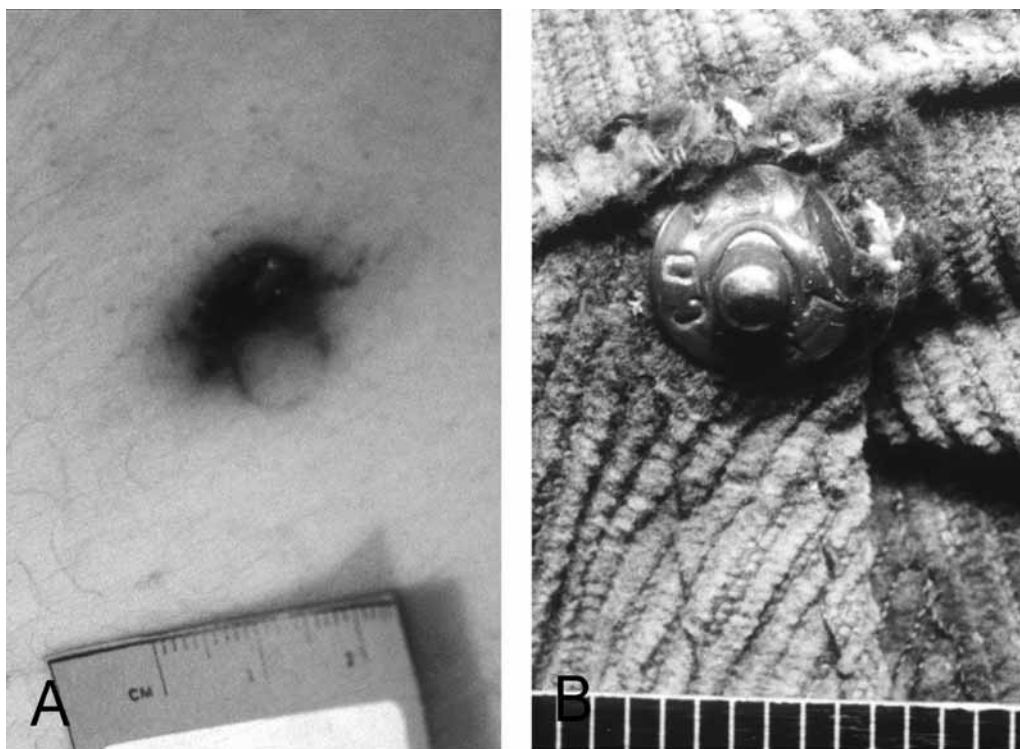
The likelihood of a perforating injury of the skull increases with the caliber and velocity of the bullet, and with the proximity of the weapon to the head at the time of discharge (142,190).

The shapes of entry and exit wounds in the skull are variable, but most entries generally are round or oval (191,192). Exits tend to be irregular and larger because of projectile tumbling and deformation (191,192). Bone fragments do create multiple internal wound tracks in the brain (16,177).

### *19.1. Beveling*

A cratered defect appearing on the inner (“beveled-in”) or outer (“beveled-out”) bony tables is seen in gunshot entry and exit wounds, respectively (16,193). Typically, beveling is observed in the skull but can be seen in other bones (Fig. 46). No association has been found between the size of the entry and the extent of beveling (194). Asymmetric inner beveling does not assist in determining the trajectory of the track (194).

Beveling assists in the determination of the direction of fire—i.e., entry vs exit—particularly if the cutaneous entry has an unusual shape or is not assessable because of fragmentation, decomposition, or surgical intervention (193,194). Beveling can be absent if there is involvement of thin bone (e.g., orbital plates, maxilla) or dense bone (petrous temporal bone [16,191,193]). A beveled-in entry can show outer beveling (16).



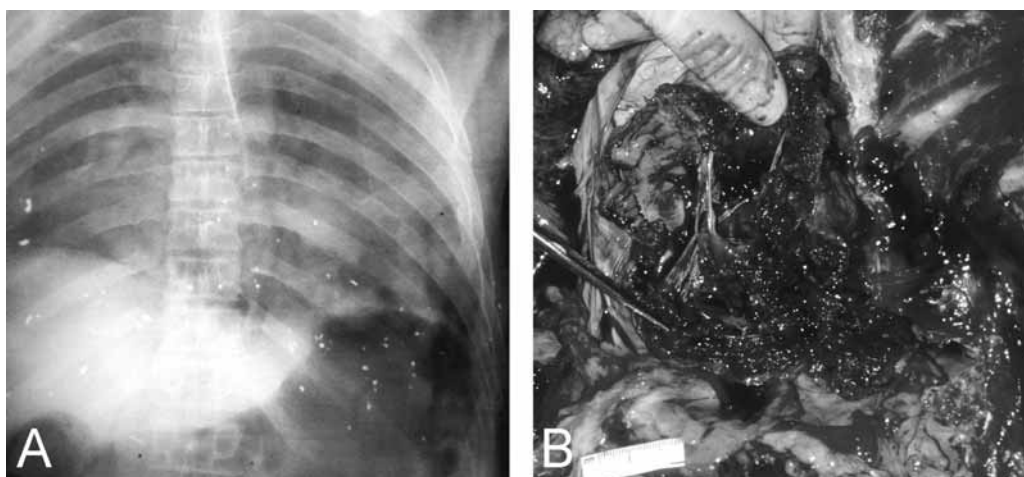
**Fig. 38.** Homicide. Three rifle wounds of torso. **(A)** Entry, left lower abdomen. Semicircular abrasion suggested muzzle imprint and implied the accused “finished off” the deceased at close range after firing two shots at a distance. **(B)** Examination of deceased’s pants showed that a bullet had struck and deformed a circular metal button near the beltline.

Examples include a keyhole defect resulting from tangential shooting, perpendicular contact gunshot wounds, and distant wounds (Fig. 47; refs. 193–196). Bullets can, on rare occasions, exit through an entry, which then shows outer beveling (153). Various mechanisms to explain outer beveling in an entry site have been proposed. They include temporary cavity formation by high-velocity projectiles and blowback of gases in contact-range wounds. The latter is supported by the observation of bone fragments outside the skull (152,191,196). Twisting of the bullet has been dismissed.

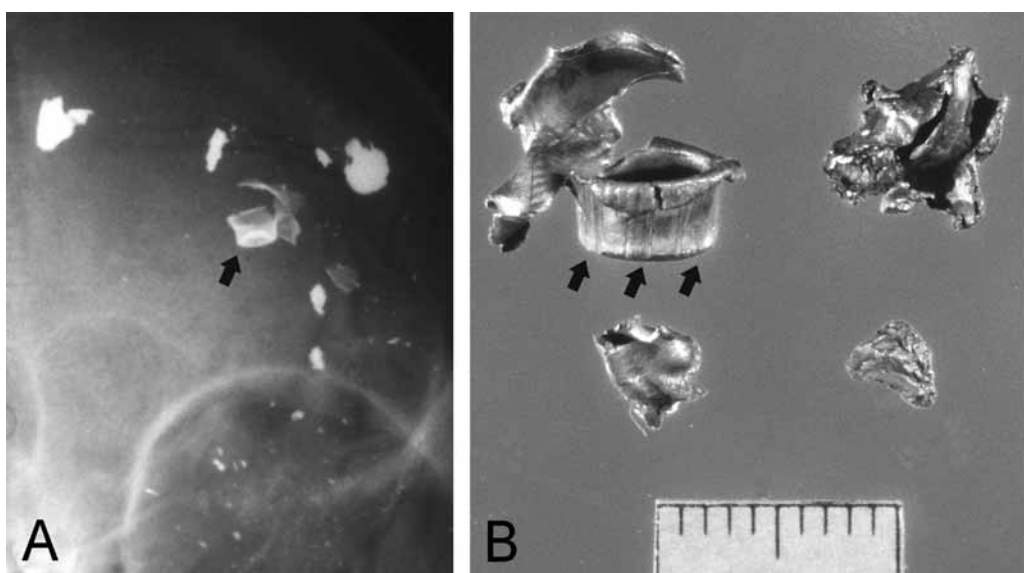
An exit associated with a contact range wound of the head can show inner beveling (191,197). An exit can also show a keyhole defect unrelated to a tangential shot (197,198).

## ***19.2. Fracture Patterns Associated With Entry Site***

If kinetic energy is totally absorbed at the entry site, then fractures are not present (191). Circumferential stresses around the entry and exit lead to radial fractures (Fig. 5; refs. 191 and 199). The radial fractures are not as long at the exit because less energy is available by the time the projectile reaches this site. Intracranial overpressure leads to concentric fractures around entry and exit holes (176,200). These fractures connect with already formed radial fractures, which indicates that they occur after radial fractures have formed (176). The concentric fractures adjacent to exits are less conspicuous than



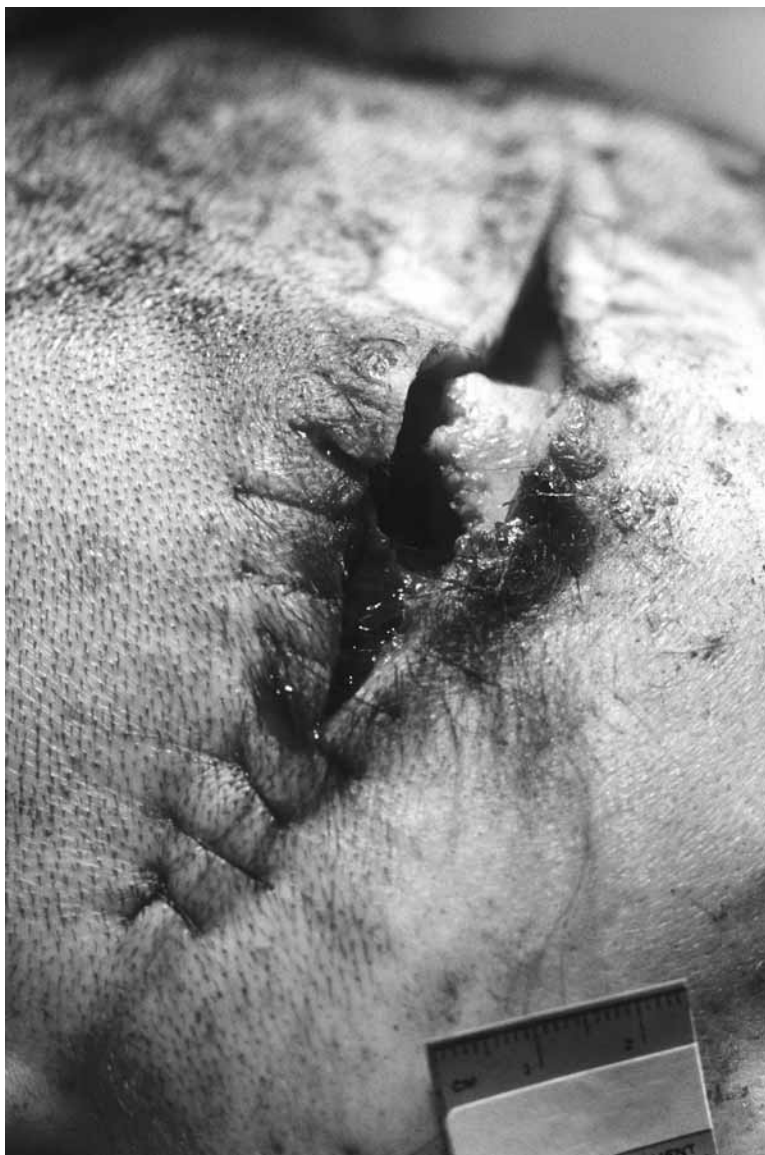**Fig. 39.** High velocity hunting rifle used to commit a homicide. **(A)** Radiograph: “snow-storm” pattern owing to fragmentation of the bullet. **(B)** Considerable destruction of heart in wound path, a reflection of the large temporary cavity created during passage of the projectile. (Courtesy of the office of the Chief Medical Examiner, Chapel Hill, NC.)



**Fig. 40.** Contact head wound. Partial-jacketed bullet. **(A)** Jacket (arrow): core separation, seen in radiograph. **(B)** Removed projectile. The jacket shows visible linear striations (arrows), a general characteristic of the barrel rifling.

those around entries (200). Concentric fractures are not observed without radial fractures (200). Because bone strength is less in tension than in compression, concentric fractures can appear beveled-out (200). Radial fractures are seldom extensively beveled (200). Fracture lines from an exit are arrested by preexistent entry fractures, implying that fractures propagate faster than a bullet travels (191,197,200,201). If multiple entries are present (e.g., multishot suicide), then interrupted fractures can assist in determining





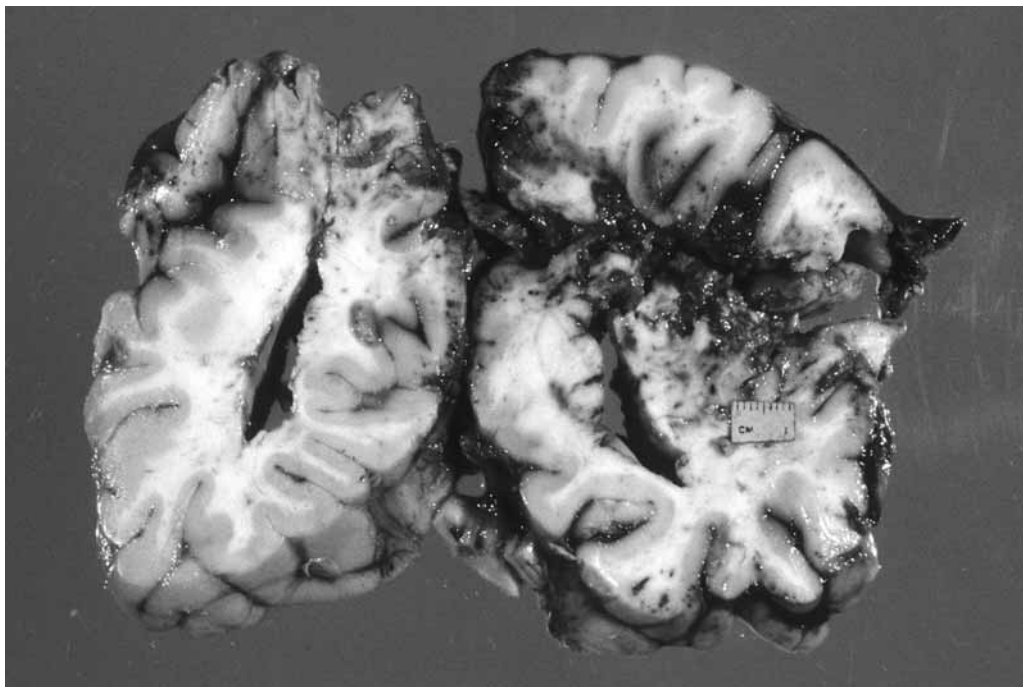
**Fig. 41.** Surgical alteration of a contact gunshot wound of the head.

the sequence of shots (22,201). If cutaneous entry and exit wounds are altered (e.g., decomposition), beveling and intersection of fracture lines are helpful in distinguishing them (201).

### ***19.3. Fractures of Skull Base and Entire Skull***

The base of the skull is predisposed to fracture because of its variable thickness and perforation by nerves and vessels (65). If there is an entry directly involving the base, then a majority of cases show fractures of the middle cranial fossa (65). Temporary cavity formation results in fractures remote from the entry site. Low- and high-energy firearms cause “indirect” fractures of the anterior cranial fossa (e.g., thin orbital and





**Fig. 42.** Self-inflicted gunshot wound. Coronal slice of formalin-fixed brain. Circumscribed wound track caused by low-caliber gun.

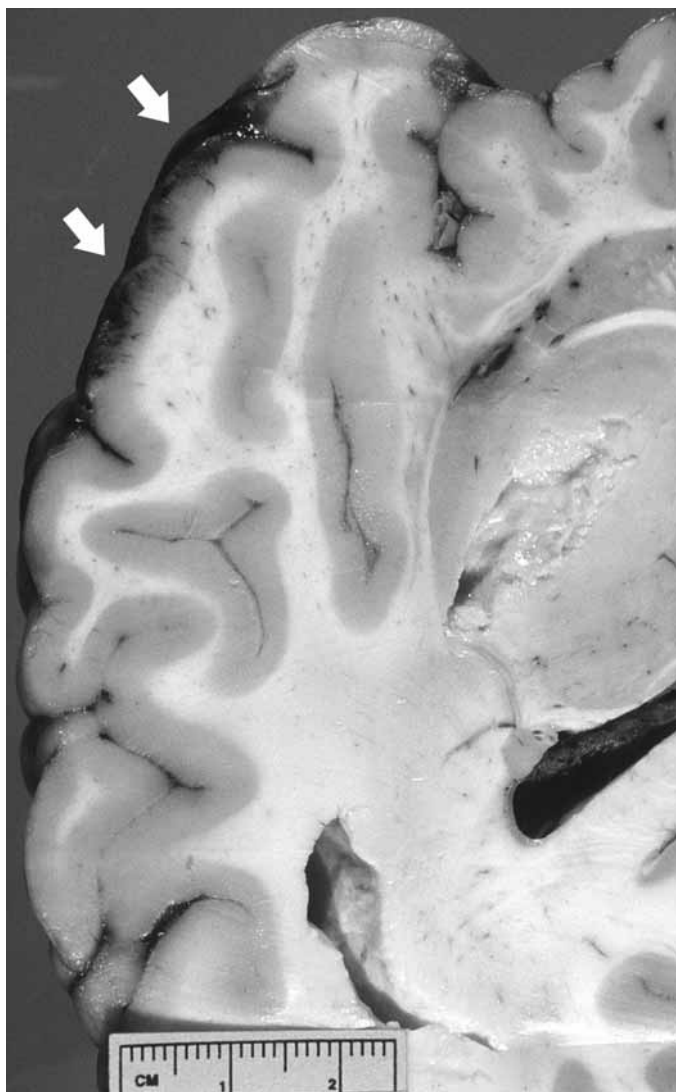
ethmoid plates; *see* Fig. 48 and refs. 65, 176, 177, and 182). Fractures of the middle and posterior cranial fossae tend to be associated with higher velocity weapons (65). “Hinge” fractures, extending across the middle cranial fossa, are associated with high intracranial pressure resulting from shotgun or hunting rifle injuries (65). Gas “blowout” of the anterior head area has been described in contact shotgun wounds of the temple (202). Bullet wounds of the head can cause basal skull fractures and fatal brain contusions without actual penetration of the brain (*see* Subheading 19.5. and ref. 16).

Massive skull destruction is seen typically, but not invariably, in certain contact-range wounds. This depends on the kinetic energy of the projectile and volume of gas generated (Fig. 29; refs 16, 124, 138, 176, and 177). Examples of weapons causing severe destruction include magnum revolvers, hunting/military rifles, and shotguns (59,69,119,120,137,138,203). Contact shotgun entries in the temple, forehead, and scalp generally leave the face intact. Wounds of the mouth and submental area can destroy the face.

Massive brain destruction with ejection of tissue is possible (16,124,176,203,204). Tremendous destruction of the brain does not preclude a neuropathological examination for underlying disease that could have precipitated the fatal incident (205,206).

#### **19.4. Intracranial Ricochet**

Bullets, associated with penetrating injuries, usually come to rest without reaching the contralateral inner skull surface (142). Intracranial ricochets typically involve a small-caliber weapon (16). From the skull entry site, the path of the bullet in the brain parenchyma is straight (Fig. 49; ref. 177). The bullet, after passing through the brain,

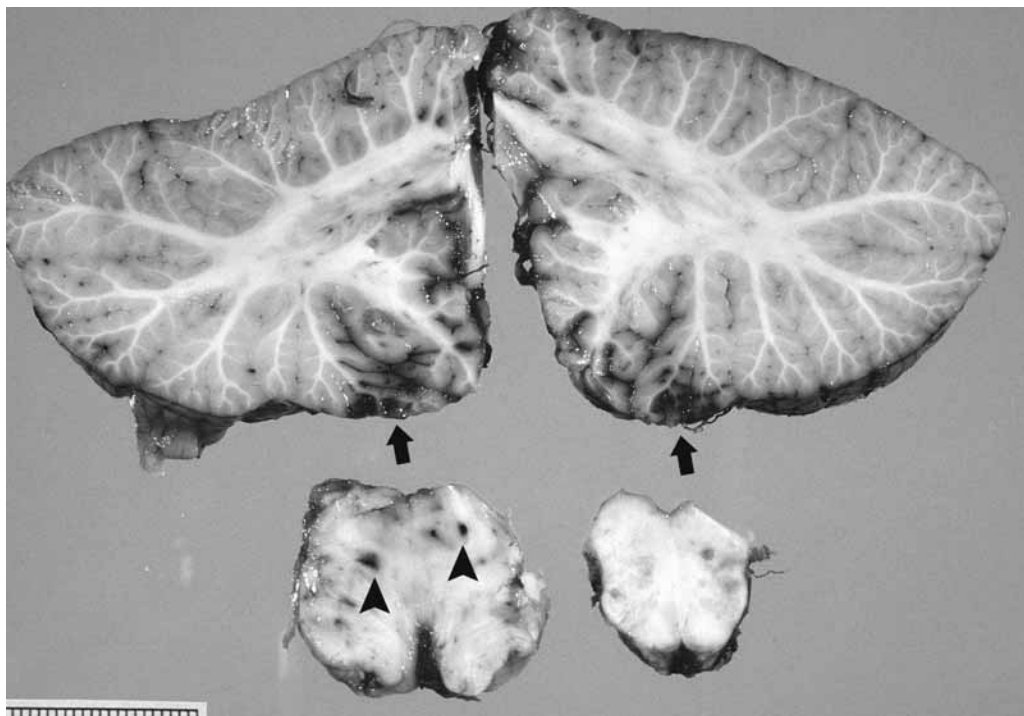


**Fig. 43.** Cerebral contusion (arrows) opposite (contrecoup) to the gunshot entry site (right temple). Formalin-fixed brain.

strikes the inner table and usually re-enters the brain, creating a superficial “gutter” on the surface (Fig. 50). The ricochet path can be extensive. A projectile, on its original path before it ricochets, can cause an impression or an outwardly displaced fracture at the site of impact on the inner skull table (Fig. 50; ref. 16). In most cases in which a ricochet from the contralateral skull surface occurs, the initial track of the bullet is the most prominent one but, in some cases in which fragmentation of the projectile has occurred, it may be difficult to determine the initial direction of the bullet.

### ***19.5. Tangential Gunshot Wounds***

Tangential gunshot wounds to the head occur when a bullet or bullet fragments do not penetrate the inner table of the skull. These injuries are sometimes fatal, but they are

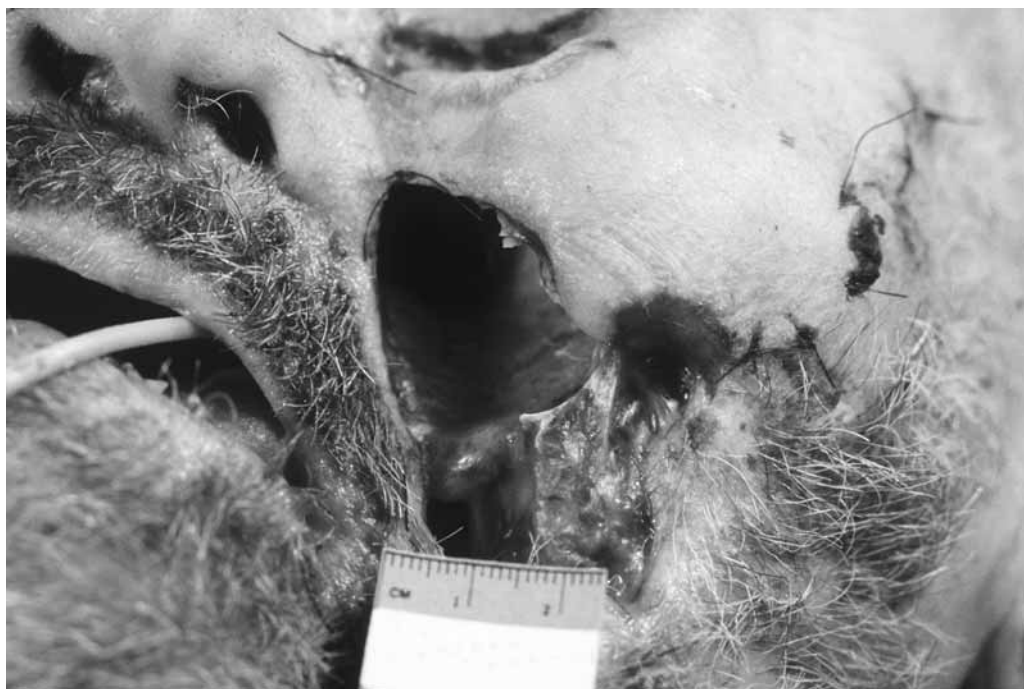

**Fig. 44.** Intraoral self-inflicted shotgun wound. Injuries remote from the wound track. Cerebellar tonsillar contusions (arrows). Brainstem hemorrhages (arrowheads). Formalin-fixed brain.


usually seen when the victim dies because of other injuries. In one series, on clinical examination, 25% of subjects with tangential gunshot wounds showed CT abnormalities, which included skull fractures, isolated cortical contusions, and isolated subarachnoid, subdural, or intracerebral hemorrhages (Fig. 51; ref. 207). In addition, intracranial hemorrhages at more than one site—including, on rare occasions, epidural hemorrhages—are found in 43% of cases with CT abnormalities. Bleeding in the cranium is also more likely if the victim lost consciousness at the time of impact or showed a Glasgow coma scale score of less than 15 when examined in the hospital. A temporal or parietal region impact site, skull fractures, and retained bullet fragments in the scalp or skull are also associated with a greater risk of intracranial hemorrhage.

## 20. REMOTE INTERNAL INJURIES

Ocular findings may be seen with contact head wounds. Periorbital hemorrhages (“raccoon eyes”) caused by orbital plate fractures from brain impact and cerebrospinal fluid pressure can be seen (*see* Subheading 19.3.; Fig. 48). Petechiae of the eyes have been associated with contact wounds of the head and neck and are likely secondary to gas expansion, particularly if these wounds are in proximity to the orbit (155). Ocular petechiae also have been seen in a case of a shotgun injury of the neck (155). Scleral and conjunctival hemorrhages have arisen from a venous pressure wave owing to a contact gunshot wound of the chest inflicted by a .357 magnum revolver (112).



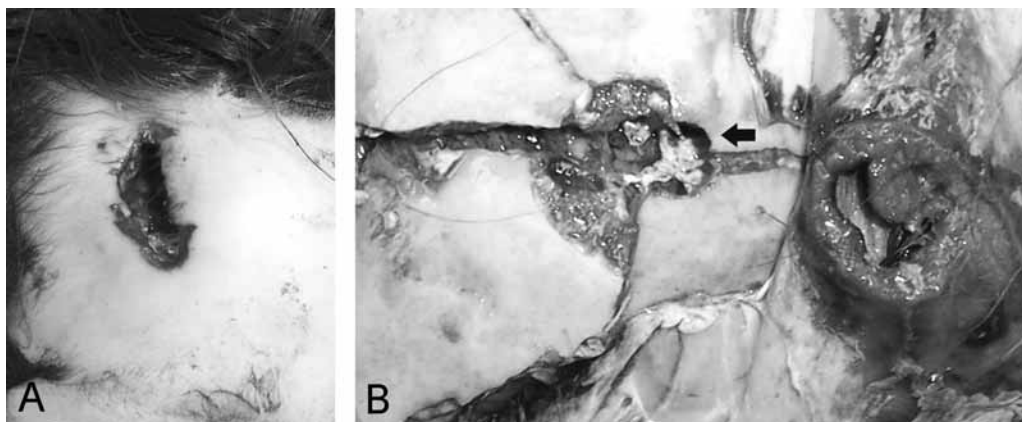
**Fig. 45.** Self-inflicted shotgun wound of face. Delayed death from sepsis.



**Fig. 46.** Intracranial gunshot wounds. (A) Gunshot entry. Inner table of skull: “beveled-in.” (B) Gunshot exit. Outer table of skull: “beveled-out.”

The effects of gas or “blast injury” owing to close-range discharge can result in vessel tears. For example, vascular rupture has been seen without an associated wound track in a tear gas cartridge discharge (93). A blank cartridge, which inflicted a neck wound, has been observed to cause carotid artery and jugular vein lacerations (92). A cardiac laceration has resulted from a blank cartridge discharge on the chest (73).





**Fig. 47.** “Keyhole” defect of skull. (A) Distant gunshot wound, right forehead. (B) “Keyhole” defect on skull (direction of bullet—arrow). (Courtesy of Dr. E. Tweedie, London Health Sciences Centre, London, Ontario, Canada.)

Wounds involving the head and other sites (e.g., abdomen) are associated with visible subendocardial hemorrhage in the interventricular septum (Fig. 52; ref. 208). Blunt head trauma can also cause this. The mechanism is thought to be sympathetic overactivity and consequent catecholamine excess (208). Microscopic examination revealed myocardial contraction bands in a case of a head wound sustained from a starter’s pistol (73).

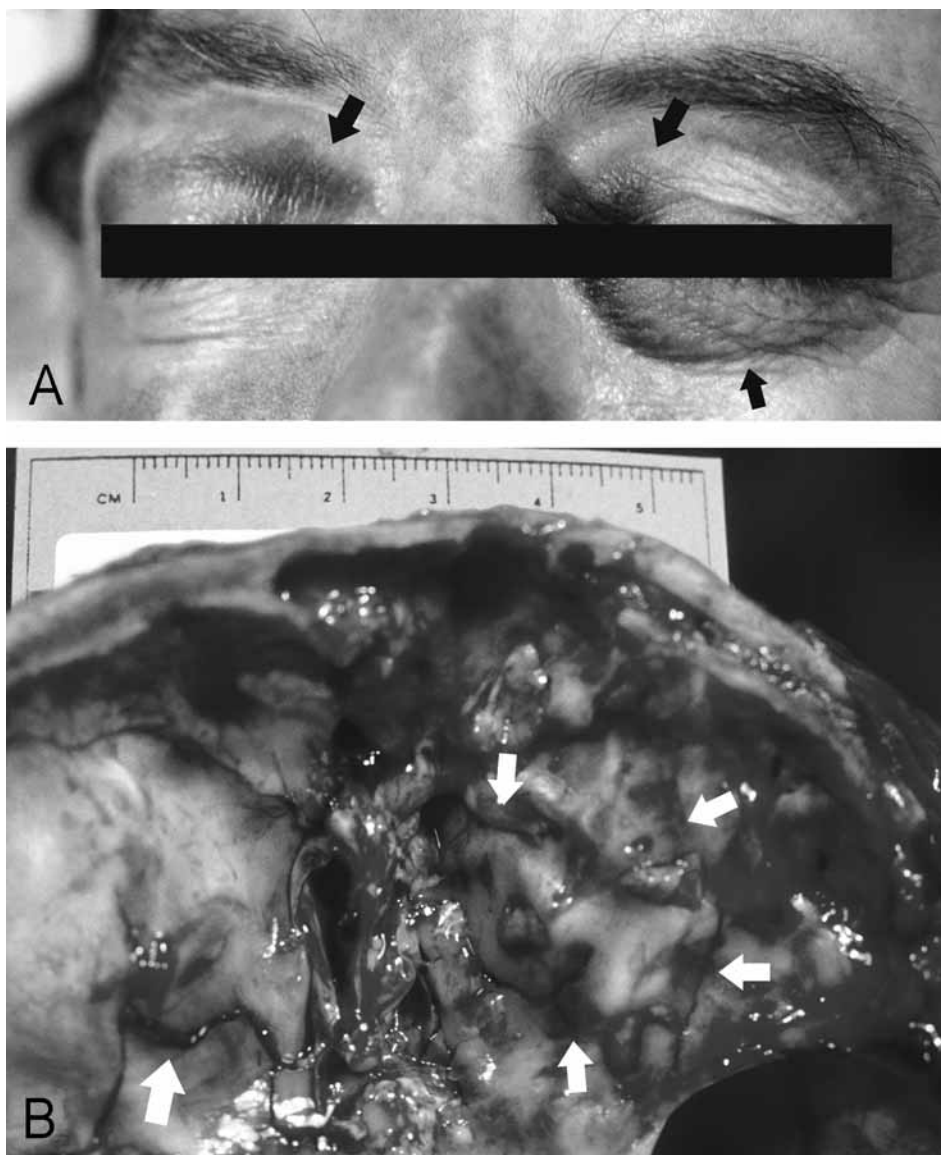
## 21. OTHER ASPECTS OF INTERNAL WOUND TRACK EXAMINATION

The deeper soft tissue and bone, if involved, need to be explored and sampled to determine the presence of soot (16,57,59,141). This is helpful in the determination of range, particularly if a multishot suicide has occurred. Soft tissue, such as muscle, can be stained bright red because of the expulsion of carbon monoxide from the muzzle (Fig. 30; ref. 16). In certain instances (e.g., tear gas cartridge), the track can be crepitant (93).

The direction of the wound track in relation to the deceased must be documented (101). The trajectory can favor self-infliction (37,51). A track extending anteriorly (back to front) or downward from the right temple is uncommon in suicide (37,51). An intra-oral wound, which has a track directed up, favors suicide. A track extending horizontally or down suggests a homicide (51,137,140). Self-inflicted chest wounds can be up, down, or horizontal, but left-to-right tracks are unusual (51,55,59,105). Unusual trajectories require reconstruction based on different body positions (209). Apparent hunting accidents, masking suicides, have contact wounds (see Heading 5. and ref. 16). If the victim is bent over the rifle or shotgun, then the wound track is down (16). Depending on whether the victim rotates counterclockwise with the right hand or clockwise with the left hand to reach the trigger of the long gun, the track passes to the victim’s left or right, respectively.

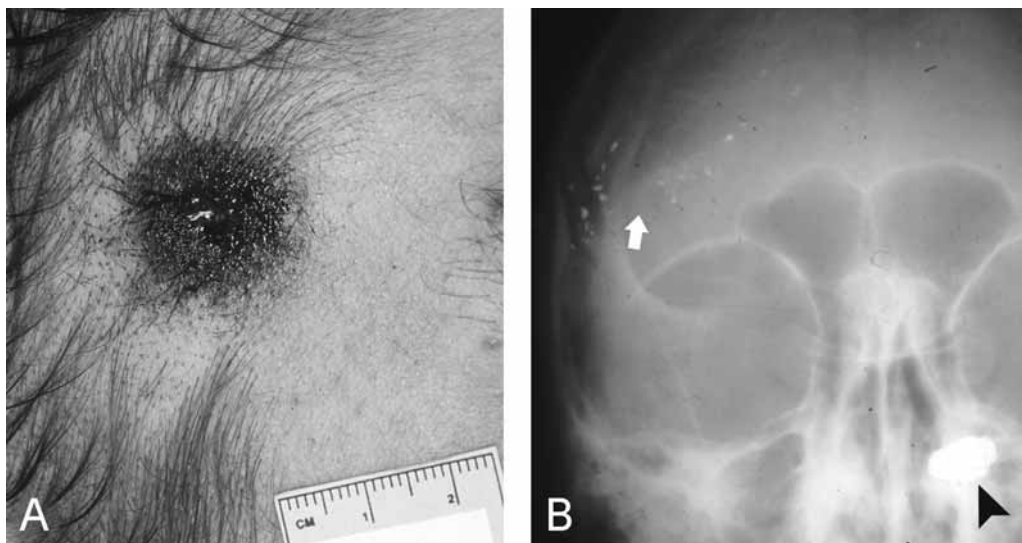
Recovery of an intact bullet allows a match of its rifling marks to the fired weapon (16). Care must be taken not to handle a relatively soft lead projectile with metal instruments, which can alter the rifling marks. If the bullet is partly jacketed, rifling markings on the jacket are better defined than those on the softer lead core (Fig. 40; ref. 16).





**Fig. 48.** Contact gunshot wound of head. (A) Periorbital hematomas (arrows) indicative of orbital plate fractures. (B) Orbital plate fractures (arrows).

Although shotgun barrels are smooth-bored, finding shotgun wadding provides a determination of the gauge of the weapon and the make of the ammunition (Fig. 9; ref. 16). Pellets can number in the hundreds, and only a representative number are collected for evidence (Fig. 9). Bullets do fragment, reducing their evidentiary value (e.g., .22 caliber bullets are less likely to be identified with a specific weapon); however, recovered fragments can be linked, by compositional analysis, to known bullets fired by a suspect gun (16,63). The degree of bullet deformation and fragmentation depends on the location of the wound (e.g., head [63]). Fragmentation of a bullet creates multiple wound tracks (176,210).



**Fig. 49.** Intracranial bullet ricochet. **(A)** Near contact gunshot wound of right temple. **(B)** Radiograph of skull showing path of bullet fragments (arrow) from entry site along wound track. Large bullet fragment on left skull base (arrowhead).

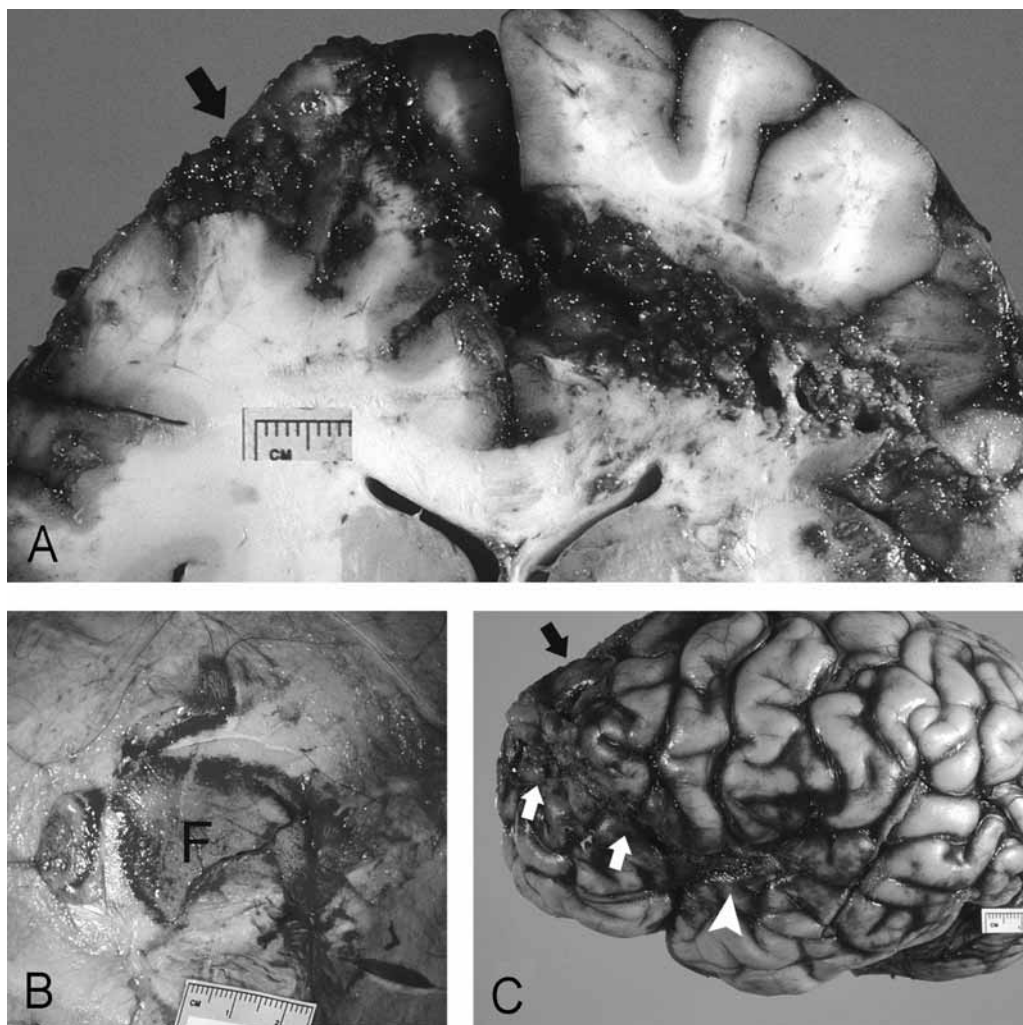
## 22. WOUND RETENTION AND MICROSCOPIC EXAMINATION

The wound, if intact, is excised and fixed in formalin (124). If there is considerable tissue destruction, then the margins of the entry need to be removed as well as possible. Submission of the wound for further analysis for soot and primer residue in probable suicide cases depends on the jurisdiction and circumstances of the case. If there are suspicions regarding the death, the wound must be submitted for further analysis. The pathologist can sample the skin and soft tissue of the entry to confirm the presence of soot, i.e., black-brown amorphous or granular material and possibly larger powder particles on or within the wound track (Fig. 53; refs. 16, 125, and 211). In addition to a skin defect, dermal collagen is homogeneously altered (Fig. 53; refs. 16 and 125). If an exit wound is studied by microscopy, the pathologist must be aware that small amounts of soot and larger powder particles may be seen deep in the wound track, particularly when the entry is close-range (16,125). Unlike entry wounds, which show progressive epidermal damage toward the defect, damage at exits is more sharply demarcated (125).

## 23. EXAMINATION OF FIREARM

Firearms need to be examined by other experts for evidence of misfiring (212). There may be a need to reconcile an apparent discrepancy among the autopsy, scene findings, and circumstances of the death (58,130). Fingerprints of the deceased may be seen on the cartridge or firearm (60,101,105). In one study, fingerprints were found on the gun in 12% of cases (106).

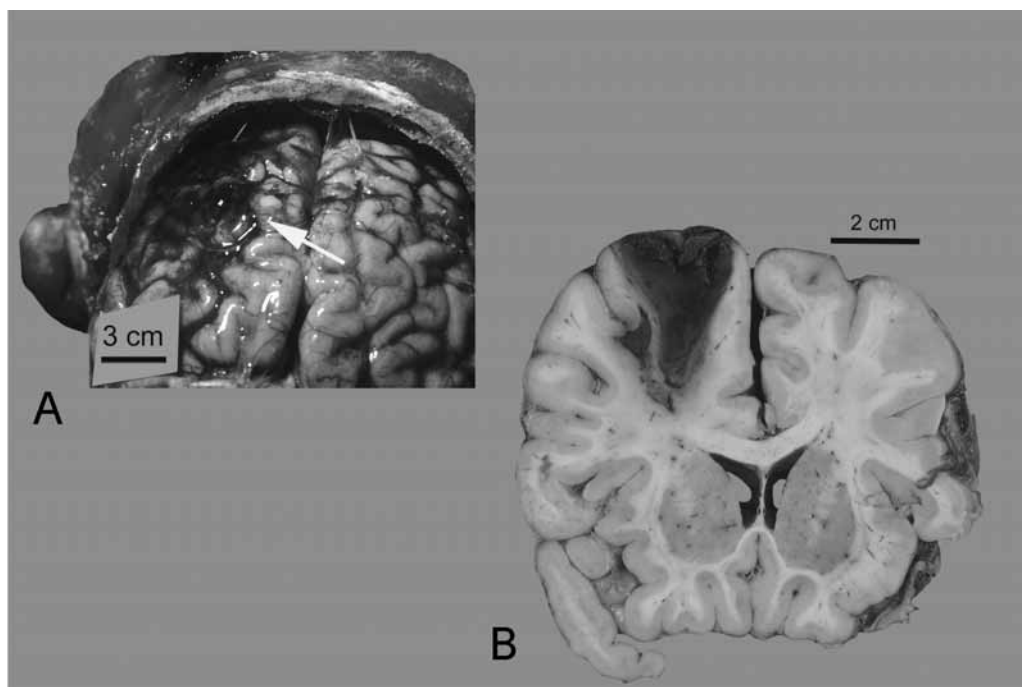
The presence of blood from the victim on or in the barrel of the weapon assists in the determination of range. The injection of propellant and gases at close range into the



**Fig. 50.** Intracranial bullet ricochet. Same case as Fig. 49. Formalin-fixed brain. **(A)** Wound track to left and forward relative to deceased (exit—arrow). Coronal slice of brain. **(B)** Bulging fracture (F) on cranium marking exit from left cerebral hemisphere. **(C)** Superficial path (“gutter”; white arrows) along surface of brain from exit (black arrow) to recovery site of bullet (arrowhead).

body, followed by closure of the temporary cavity, leads to backspatter, i.e., retrograde expulsion of blood and tissue aerosol, bone, and bullet particles from the wound (95,155,213,214). The finding of backspatter on the hand determines whether the victim actually fired the firearm (see Heading 13. and ref. 213). DNA analysis, if necessary, can confirm the link. Backspatter occurs frequently with close-range shots, but its absence does not necessarily indicate an intermediate or distant wound (213). Spatter on a weapon can be detected even if the weapon is fired again (63).

The following was found in one study conducted at the Office of the Medical Examiner in Dallas County, TX (63):



**Fig. 51.** Multishot suicide (see Fig. 24). **(A)** Subarachnoid hemorrhage of frontal lobe (arrow) owing to tangential self-inflicted wound of forehead. Cranium was not penetrated. **(B)** Coronal slice of section of formalin-fixed brain showing corresponding “coup” contusion.

Incidence of blood (as detected by leuchomalachite green)	Revolvers/pistols/rifles	Shotguns
Inside barrel	About one-half <sup>a</sup>	About three quarters
Outside barrel	About three-quarters <sup>b</sup>	About 85% <sup>b</sup>

<sup>a</sup>Positive result consistent with barrel within 7.5 cm (3 in.) of surface.

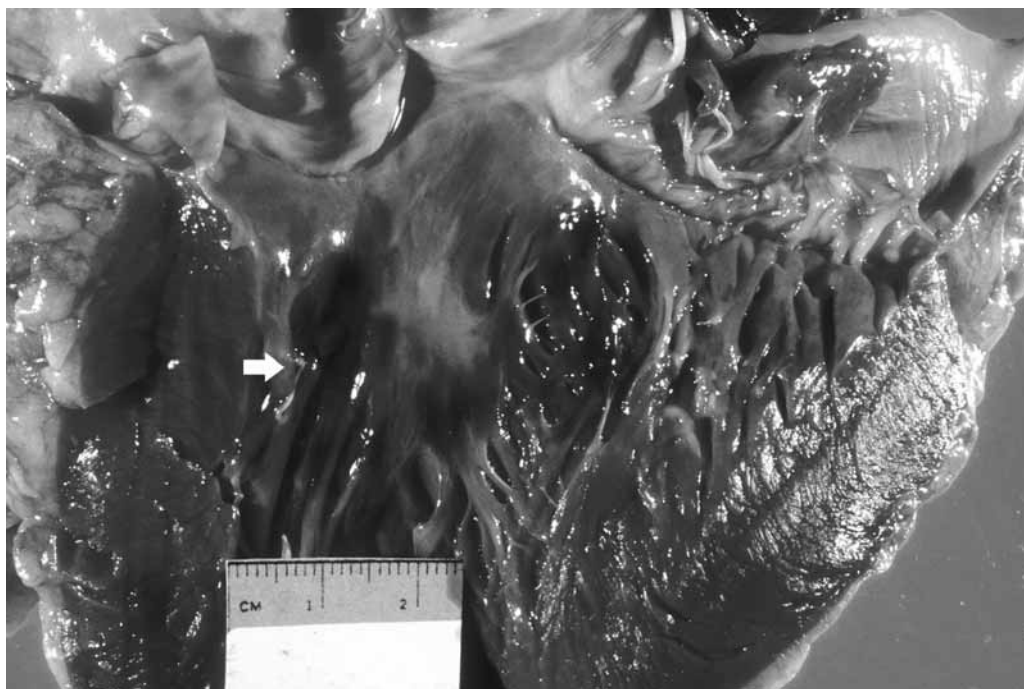
<sup>b</sup>Blood deposited up to several feet (about 1 m) away on the barrels of long guns.

## 24. DETERMINATION OF GUNSHOT RESIDUES

Gunshot residue (GSR) consists of burnt and unburnt powder particles, primer components (lead, barium, and antimony or other elements), and particles from the bullet, firearm, and cartridge case (16,159,215,216).

The detection of GSR can determine whether an individual fired a gun. GSR can escape from the muzzle end or breeches and blow onto the hand in contact or in close proximity to the firearm (159,215–218). Both hands should be tested (22). Long arms tend not to deposit as much residue on the hands as handguns (216). GSR can be on the palm or back of the firing hand or nonfiring hand used to steady the end of the muzzle (103,215,216). Primer residue can be transferred to the palm if a recently fired handgun is picked up and moved or the wound area is clutched (63,215,216). GSR can determine whether a hole on the skin and clothing is an entry (132,215). GSR can indicate firing distance. Residue (barium, antimony) has been observed on targets 3 to 4 ft (about 1 m) away depending on the type and caliber of pistol and revolver (219).





**Fig. 52.** Gunshot wound of head. Subendocardial hemorrhage, left ventricular outflow tract (arrow).

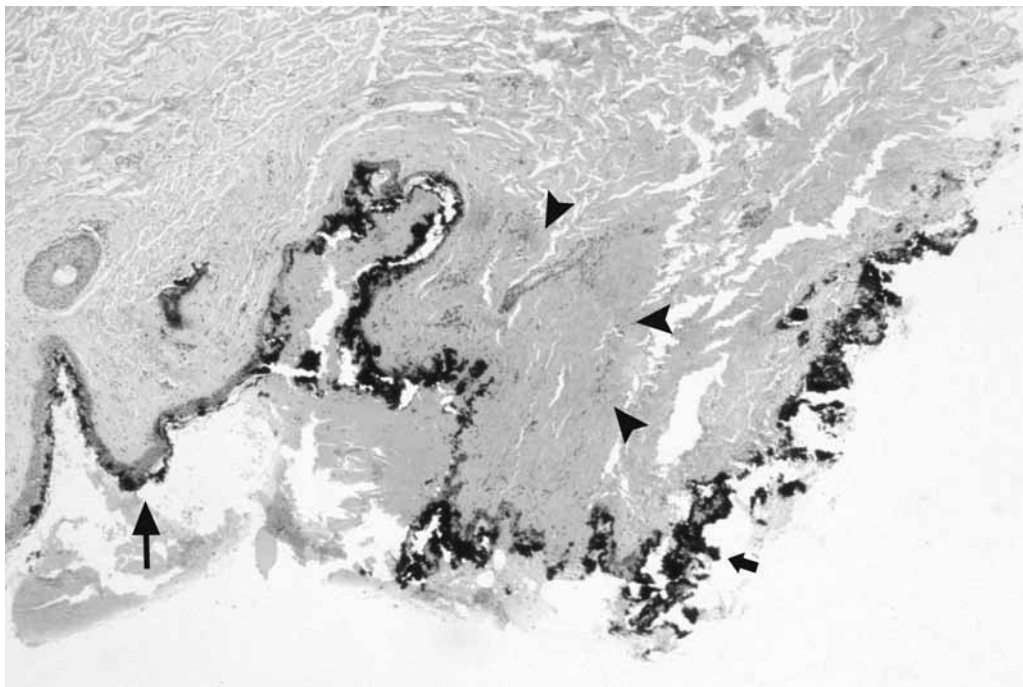
Detection of GSR is by inorganic analysis using flameless atomic absorption spectrometry or particle analysis (lead, barium, antimony) using scanning electron microscopy/energy-dispersive X-ray (16,159,215,216,220). Material is collected by swabs, wipings, or tapelifts from the hands (16,159,215,216). The best success is with dry clean hands protected by paper bags (Fig. 31). Analysis can be done on blood-spattered hands (221).

One study showed a GSR detection rate of 44% with revolvers and 24% for pistols (95). Another study showed that 38% of all suicides had a positive reaction on the shooting and nonshooting hands (221). The frequencies were 50 and 29%, respectively, when .22-caliber revolvers and pistols were excluded. Other studies also have shown a low detection rate with .22-caliber pistols/revolvers (*see* Heading 9 and refs. 63 and 221). The overall detection rate rose to 50% if more than one shot was fired. With rifles and shotguns, residue is almost never detected on the firing hand, but can be found on the nonfiring hand that steadied the end of the muzzle (16). Analysis by flameless atomic absorption spectrometry can detect trace metals deposited at close range, which is useful if there is a wound edge altered by drying or decomposition, a period of survival, or interposed clothing (159).

## 25. TOXICOLOGY

Not all jurisdictions do toxicological testing if the case is a suicide (37,110). Ethanol is found frequently; it is detected in one-fourth to one-half of self-inflicted injuries in various studies (19,30,32,34,35,37,49). Ethanol ( $\geq 20$  mg/dL) was found in





**Fig. 53.** Microscopic slide from edge of contact entry wound. Carbon material on intact epidermis (large arrow) and denuded dermis (small arrow). Dermal collagen altered (arrowheads; H&E, original magnification  $\times 25$ ).

65% (13 of 20) of perpetrators of murder–suicide in a Texas series (24). Other drugs are detected in one-fourth of suicides (37). In special circumstances, other agents have been detected (e.g., detection of cyanide, a breakdown product of tear gas, in blood [73,93]). Despite a history of depression in many elderly perpetrators of murder–suicide, few have detectable levels of antidepressants (52).

## 26. PATHOLOGIST’S APPROACH TO CLOSE-RANGE FIREARM INJURY

1. Examine the body prior to removal of clothing and cleaning. Items of clothing on which apparent firearm entries or exits are seen need to be retained. If clothing has been removed prior to the examination, it must be seized by investigators. The pathologist can attempt to correlate holes seen in the clothing with wounds present on the body. The clothing must not be altered, particularly if it is to be submitted as evidence. If the clothing is wet (e.g., blood-soaked), then this examination can be completed after drying. A description documenting the number of holes, dimensions, associated features, and location is included in the postmortem report. The number of holes does not necessarily equal the number of entries. Projectiles penetrating clothing do not always contact the skin surface because of folds in the clothes. As a result, more holes than skin entries can be observed (59). Also, the victim can move. The inner aspect of clothing exits can be covered by body tissue, missile fragments, and even powder, if the range is contact (132).
2. After the clothing has been removed, examine the body in the uncleaned state. Overall and close-up photographs of the body and wound/other injuries are taken.

3. Examine the hands prior to fingerprinting or washing (Fig. 32). If the hands have been bagged, the bags are removed and submitted as evidence to the police (Fig. 31). Observe and note the pattern of blood spatter or blackening from soot, if present, on the hands. The police can obtain tapings of the hands for GSR. Photograph the hands, particularly if there are positive findings (Figs. 33–37).
4. Examine any entry and exit sites that are present. The area around the entry wound is carefully cleaned (Fig. 14). The size of the cutaneous defects is measured. If there is any soot deposition or stippling on the skin surface, its dimensions are noted. These wounds are oriented to an anatomic landmark, and distances from the top of the head and midline of the body are measured.
5. Radiographs of the relevant body site are done next.
6. Wounds are excised (superior aspect of the wound can be oriented with a small cut from a scalpel) and submitted in formalin. If the wound is to be analyzed further, the pathologist can elect to take some underlying soft tissue to determine the microscopic presence of material consistent with soot (Fig. 53). Care must be taken not to alter the wound. If the wound is not to be submitted, then additional sections can be taken around the skin periphery. The remainder of the wound is retained as stock tissue in case investigative and legal issues arise later.
7. Internal examination documents the wound track, i.e., its path, direction, and relation to the deceased. Associated blood loss in body cavities is quantitated. In a case of a head wound, attempts should be made to slice the brain in such a way that the transcerebral course of the bullet is exposed by lining the knife up with the apparent brain entry and exit wounds.
8. Recovery of the bullet or, in the case of a shotgun, representative pellets and wadding must be done (Fig. 9). If the bullet has fragmented, the largest fragment is collected. If there is a jacket, it must be obtained (Fig. 40). Care must be taken not to handle any lead projectiles with metal forceps. Manipulation by fingers and plastic forceps does not damage rifling marks. If there is a projectile present on skull radiograph, a pan placed under the head will catch the projectile if it inadvertently falls out when the brain is removed.

## *REFERENCES*

1. Anonymous. Review of the Registrar General on Deaths by Cause, Sex and Age, in England and Wales 2001. Her Majesty's Stationery Office. National Statistics Publication, London, 2002.
2. Wilkins, K. Deaths involving firearms. Statistics Canada Health Reports, 14:37–43, 2005.
3. Anderson, R. N., Minino, A. M., Fingerhut, L. A., Warner, M., Heinen, M. A. Deaths: injuries, 2001. Natl. Vital Stat. Rep. 52:1–86, 2004.
4. Miller, M., Azrael, D., Hemenway, D. Firearm availability and unintentional firearm deaths, suicide, and homicide among 5–14 year olds. J. Trauma 52:267–274, 2002.
5. Miller, M., Azrael, D., Hemenway, D. Firearm availability and suicide, homicide, and unintentional firearm deaths among women. J. Urban Health 79:26–38, 2002.
6. Gill, J. R., Lenz, K. A., Amolat, M. J. Gunshot fatalities in children and adolescents in New York City. J. Forensic Sci. 48:832–835, 2003.
7. Meehan, P. J., Saltzman, L. E., Sattin, R. W. Suicides among older United States residents: epidemiologic characteristics and trends. Am. J. Public Health 81:1198–1200, 1991.
8. Sloan, J. H., Rivara, F. P., Reay, D. T., Ferris, J. A., Kellermann, A. L. Firearm regulations and rates of suicide. A comparison of two metropolitan areas. N. Engl. J. Med. 322:369–373, 1990.

9. Wintemute, G. J. Firearms as a cause of death in the United States, 1920–1982. *J. Trauma* 27:532–536, 1987.
10. Boyd, J. H., Moscicki, E. K. Firearms and youth suicide. *Am. J. Public Health* 76: 1240–1242, 1986.
11. Boyd, J. H. The increasing rate of suicide by firearms. *N. Engl. J. Med.* 308:872–874, 1983.
12. Felthous, A. R., Hempel, A. Combined homicide-suicides: a review. *J. Forensic Sci.* 40:846–857, 1995.
13. Brent, D. A., Perper, J. A., Allman, C. J., Moritz, G. M., Wartella, M. E., Zelenak, J. P. The presence and accessibility of firearms in the homes of adolescent suicides. A case-control study. *JAMA* 266:2989–2995, 1991.
14. Goren, S., Subasi, M., Tirasci, Y., Ozen, S. Female suicides in Diyarbakir, Turkey. *J. Forensic Sci.* 49:796–798, 2004.
15. Goren, S., Gurkan, F., Tirasci, Y., Ozen, S. Suicide in children and adolescents at a province in Turkey. *Am. J. Forensic Med. Pathol.* 24:214–217, 2003.
16. DiMaio, V. J. *Practical Aspects of Firearms, Ballistics and Forensic Techniques*. 2nd ed. CRC Press, New York, 1999.
17. Lee, C. J., Collins, K. A., Burgess, S. E. Suicide under the age of eighteen: a 10-year retrospective study. *Am. J. Forensic Med. Pathol.* 20:27–30, 1999.
18. Bennett, A. T., Collins, K. A. Suicide: a ten-year retrospective study. *J. Forensic Sci.* 45:1256–1258, 2000.
19. Bennett, A. T., Collins, K. A. Elderly suicide: a 10-year retrospective study. *Am. J. Forensic Med. Pathol.* 22:169–172, 2001.
20. Riddick, L., Wanger, G. P., Fackler, M. L., et al. Gunshot injuries in Mobile County, Alabama: 1985–1987. *Am. J. Forensic Med. Pathol.* 14:215–225, 1993.
21. Schmeling, A., Strauch, H., Rothschild, M. A. Female suicides in Berlin with the use of firearms. *Forensic Sci. Int.* 124:178–181, 2001.
22. Jacob, B., Barz, J., Haarhoff, K., Sprick, C., Worz, D., Bonte, W. Multiple suicidal gunshots to the head. *Am. J. Forensic Med. Pathol.* 10:289–294, 1989.
23. Hansen, J. P. Fatalities from firearms in Denmark. *Forensic Sci.* 4:239–245, 1974.
24. Felthous, A. R., Hempel, A. G., Heredia, A., et al. Combined homicide-suicide in Galveston County. *J. Forensic Sci.* 46:586–592, 2001.
25. Malphurs, J. E., Cohen, D. A newspaper surveillance study of homicide-suicide in the United States. *Am. J. Forensic Med. Pathol.* 23:142–148, 2002.
26. Campanelli, C., Gilson, T. Murder-suicide in New Hampshire, 1995–2000. *Am. J. Forensic Med. Pathol.* 23:248–251, 2002.
27. Hanzlick, R., Koponen, M. Murder-suicide in Fulton County, Georgia, 1988–1991. Comparison with a recent report and proposed typology. *Am. J. Forensic Med. Pathol.* 15:168–173, 1994.
28. Palermo, G. B., Smith, M. B., Jenzten, J. M., et al. Murder-suicide of the jealous paranoia type: a multicenter statistical pilot study. *Am. J. Forensic Med. Pathol.* 18:374–383, 1997.
29. Hannah, S. G., Turf, E. E., Fierro, M. F. Murder-suicide in central Virginia: a descriptive epidemiologic study and empiric validation of the Hanzlick-Koponen typology. *Am. J. Forensic Med. Pathol.* 19:275–283, 1998.
30. Cina, S. J., Ward, M. E., Hopkins, M. A., Nichols, C. A. Multifactorial analysis of firearm wounds to the head with attention to anatomic location. *Am. J. Forensic Med. Pathol.* 20:109–115, 1999.
31. Moug, S. J., Lyle, J. A., Black, M. A review of gunshot deaths in Strathclyde—1989 to 1998. *Med. Sci. Law* 41:260–265, 2001.
32. Kohlmeier, R. E., McMahan, C. A., DiMaio, V. J. Suicide by firearms: a 15-year experience. *Am. J. Forensic Med. Pathol.* 22:337–340, 2001.
33. Rouse, D., Dunn, L. Firearm fatalities. *Forensic Sci. Int.* 56:59–64, 1992.

34. Chapman, J., Milroy, C. M. Firearm deaths in Yorkshire and Humberside. *Forensic Sci. Int.* 57:181–191, 1992.
35. Thomsen, J. L., Albrechtsen, S. B. An investigation of the pattern of firearms fatalities before and after the introduction of new legislation in Denmark. *Med. Sci. Law* 31:162–166, 1991.
36. Selway, R. Firearm fatalities in Victoria, Australia 1988. *Med. Sci. Law* 31:167–174, 1991.
37. Druid, H. Site of entrance wound and direction of bullet path in firearm fatalities as indicators of homicide versus suicide. *Forensic Sci. Int.* 88:147–162, 1997.
38. Byard, R. W., Knight, D., James, R. A., Gilbert, J. Murder-suicides involving children: a 29-year study. *Am. J. Forensic Med. Pathol.* 20:323–327, 1999.
39. Ordog, G. J., Wasserberger, J., Schatz, I., et al. Gunshot wounds in children under 10 years of age. A new epidemic. *Am. J. Dis. Child.* 142:618–622, 1988.
40. Wintemute, G. J., Teret, S. P., Kraus, J. F. The epidemiology of firearm deaths among residents of California. *West. J. Med.* 146:374–377, 1987.
41. Wintemute, G. J., Teret, S. P., Kraus, J. F., Wright, M. A., Bradfield, G. When children shoot children. 88 unintended deaths in California. *JAMA* 257:3107–3109, 1987.
42. Morrow, P. L., Hudson, P. Accidental firearm fatalities in North Carolina, 1976–80. *Am. J. Public Health* 76:1120–1123, 1986.
43. Heins, M., Kahn, R., Bjordnal, J. Gunshot wounds in children. *Am. J. Public Health* 64:326–330, 1974.
44. Copeland, A. R. Accidental death by gunshot wound—fact or fiction. *Forensic Sci. Int.* 26:25–32, 1984.
45. Choi, E., Donoghue, E. R., Lifschultz, B. D. Deaths due to firearms injuries in children. *J. Forensic Sci.* 39:685–692, 1994.
46. Selway, R. Gunshot suicides in Victoria, Australia, 1988. *Med. Sci. Law* 31:76–80, 1991.
47. Thoresen, S. Fatal head injuries from firearms. An autopsy study of 270 cases. *Z. Rechtsmed.* 93:65–69, 1984.
48. Nowers, M. Gunshot suicide in the County of Avon, England. *Med. Sci. Law* 34:95–98, 1994.
49. Avis, S. P. Suicidal gunshot wounds. *Forensic Sci. Int.* 67:41–47, 1994.
50. Elfawal, M. A., Awad, O. A. Firearm fatalities in Eastern Saudi Arabia: impact of culture and legislation. *Am. J. Forensic Med. Pathol.* 18:391–396, 1997.
51. Karger, B., Billeb, E., Koops, E., Brinkmann, B. Autopsy features relevant for discrimination between suicidal and homicidal gunshot injuries. *Int. J. Legal Med.* 116:273–278, 2002.
52. Cohen, D., Llorente, M., Eisdorfer, C. Homicide-suicide in older persons. *Am. J. Psychiatry* 155:390–396, 1998.
53. Milroy, C. M., Dratsas, M., Ranson, D. L. Homicide-suicide in Victoria, Australia. *Am. J. Forensic Med. Pathol.* 18:369–373, 1997.
54. Copeland, A. R. Teenage suicide—the five-year Metro Dade County experience from 1979 until 1983. *Forensic Sci. Int.* 28:27–33, 1985.
55. Introna, F., Jr., Smialek, J. E. Suicide from multiple gunshot wounds. *Am. J. Forensic Med. Pathol.* 10:275–284, 1989.
56. Prahlow, J. A. Suicide by intrarectal gunshot wound. *Am. J. Forensic Med. Pathol.* 19:356–361, 1998.
57. Sekula-Perlman, A., Tobin, J. G., Pretzler, E., Ingle, J., Callery, R. T. Three unusual cases of multiple suicidal gunshot wounds to the head. *Am. J. Forensic Med. Pathol.* 19:23–29, 1998.
58. Jones, E. G., Hawley, D. A., Thompson, E. J. Atypical gunshot wound caused by cylinder index error. *Am. J. Forensic Med. Pathol.* 14:226–229, 1993.
59. al Alousi, L. M. Automatic rifle injuries: suicide by eight bullets. Report of an unusual case and a literature review. *Am. J. Forensic Med. Pathol.* 11:275–281, 1990.
60. Boxho, P. Fourteen shots for a suicide. *Forensic Sci. Int.* 101:71–77, 1999.
61. Murphy, G. K. Suicide by gunshot while driving a motor vehicle. Two additional cases. *Am. J. Forensic Med. Pathol.* 18:295–298, 1997.

62. Murphy, G. K. Suicide by gunshot while driving an automobile. *Am. J. Forensic Med. Pathol.* 10:285–288, 1989.
63. Stone, I. C. Characteristics of firearms and gunshot wounds as markers of suicide. *Am. J. Forensic Med. Pathol.* 13:275–280, 1992.
64. Wintemute, G. J., Teret, S. P., Kraus, J. F., Wright, M. W. The choice of weapons in firearm suicides. *Am. J. Public Health* 78:824–826, 1988.
65. Betz, P., Stiefel, D., Hausmann, R., Eisenmenger, W. Fractures at the base of the skull in gunshots to the head. *Forensic Sci. Int.* 86:155–161, 1997.
66. Azmak, D., Altun, G., Bilgi, S., Yilmaz, A. Firearm fatalities in Edirne, 1984–1997. *Forensic Sci. Int.* 95:231–239, 1998.
67. Hudson, P. Multishot firearm suicide. Examination of 58 cases. *Am. J. Forensic Med. Pathol.* 2:239–242, 1981.
68. Rouge, D., Telmon, N., Alengrin, D., Marril, G., Bras, P. M., Arbus, L. Fatal injuries caused by guns using shotshell: case reports and ballistic studies. *J. Forensic Sci.* 39:650–656, 1994.
69. Karger, B., Teige, K. Fatalities from black powder percussion handguns. *Forensic Sci. Int.* 98:143–149, 1998.
70. Shaw, M. D., Galbraith, S. Penetrating airgun injuries of the head. *Br. J. Surg.* 64:221–224, 1977.
71. Vaquero, J., Martinez, R., Areitio, E., Leunda, G. Pneumocephalus after air rifle wound of the brain. *Neuroradiology* 23:161–162, 1982.
72. Cohle, S. D., Pickelman, J., Connolly, J. T., Bauserman, S. C. Suicide by air rifle and shotgun. *J. Forensic Sci.* 32:1113–1117, 1987.
73. Jacob, B., Huckenbeck, W., Daldrup, T., Haarhoff, K., Bonte, W. Suicides by starter's pistols and air guns. *Am. J. Forensic Med. Pathol.* 11:285–290, 1990.
74. Ng'walali, P. M., Ohtsu, Y., Muraoka, N., Tsunenari, S. Unusual homicide by air gun with pellet embolisation. *Forensic Sci. Int.* 124:17–21, 2001.
75. Barnes, F. C., Helson, R. A. A death from an air gun. *J. Forensic Sci.* 21:653–658, 1976.
76. Frost, R. E. A suicidal wound inflicted by a "power head." *J. Forensic Sci.* 39:1321–1324, 1994.
77. Cingolani, M., Tsakri, D. Planned complex suicide: report of three cases. *Am. J. Forensic Med. Pathol.* 21:255–260, 2000.
78. Karger, B., DuChesne, A. Suicide with a signal pen gun. *Int. J. Legal Med.* 107:323–325, 1995.
79. Goonetilleke, U. K. Suicide by home-made gun. *Med. Sci. Law* 22:111–114, 1982.
80. Maglietta, R. A., Di Fazio, A., Greco, M. G., Introna, F., Jr., De Donno, A. A singular case of murder-suicide committed with a homemade firearm. *Am. J. Forensic Med. Pathol.* 26:89–91, 2005.
81. Hochmeister, M. N., Seifert, D., Smetana, R., Czernin, J. Suicide attempted by aiming slaughtering gun at pacemaker. *Am. J. Forensic Med. Pathol.* 10:268, 1989.
82. Viola, L., Constantinides, F., Di Nunno, C., Battista, G. M., Di Nunno, N. Suicide with a butcher's bolt. *J. Forensic Sci.* 49:595–597, 2004.
83. De Letter, E. A., Piette, M. H. An unusual case of suicide by means of a pneumatic hammer. *J. Forensic Sci.* 46:962–965, 2001.
84. Shakir, A., Koehler, S. A., Wecht, C. H. A review of nail gun suicides and an atypical case report. *J. Forensic Sci.* 48:409–413, 2003.
85. Opeskin, K., Cordner, S. Nail-gun suicide. *Am. J. Forensic Med. Pathol.* 11:282–284, 1990.
86. DiMaio, V. J., Spitz, W. U. Variations in wounding due to unusual firearms and recently available ammunition. *J. Forensic Sci.* 17:377–386, 1972.
87. Spitz, W. U., Wilhelm, R. M. Stud gun injuries. *J. Forensic Med.* 17:5–11, 1970.
88. Weedn, V. W., Mittleman, R. E. Stud guns revisited: report of a suicide and literature review. *J. Forensic Sci.* 29:670–678, 1984.



89. Stanbridge, R. D. Self-inflicted nail-gun injury of the heart and lung: a short report. *Injury* 14:285–286, 1982.
90. Viswanathan, R., MacArthur, D. C., Whittle, I.R. Nail gun injury to the brain: an unusual case of suicide. *Scott. Med. J.* 39:83, 1994.
91. Goonetilleke, U. K. A stud (cartridge) gun suicide (a case report). *Med. Sci. Law* 16: 181–184, 1976.
92. Rothschild, M. A., Vendura, K. Fatal neck injuries caused by blank cartridges. *Forensic Sci. Int.* 101:151–159, 1999.
93. Clarot, F., Vaz, E., Papin, F., Clin, B., Vicomte, C., Proust, B. Lethal head injury due to tear-gas cartridge gunshots. *Forensic Sci. Int.* 137:45–51, 2003.
94. Garavaglia, J. C., Talkington, B. Weapon location following suicidal gunshot wounds. *Am. J. Forensic Med. Pathol.* 20:1–5, 1999.
95. Stone, I. C. Observations and statistics relating to suicide weapons. *J. Forensic Sci.* 32:711–716, 1987.
96. Habbe, D., Thomas, G. E., Gould, J. Nine-gunshot suicide. *Am. J. Forensic Med. Pathol.* 10:335–337, 1989.
97. Parroni, E., Caringi, C., Ciallella, C. Suicide with two guns represents a special type of combined suicide. *Am. J. Forensic Med. Pathol.* 23:329–333, 2002.
98. Eisele, J. W., Reay, D. T., Cook, A. Sites of suicidal gunshot wounds. *J. Forensic Sci.* 26:480–485, 1981.
99. Collins, K. A., Lantz, P. E. Interpretation of fatal, multiple, and exiting gunshot wounds by trauma specialists. *J. Forensic Sci.* 39:94–99, 1994.
100. Ventura, F., Blasi, C., Celesti, R. Suicide with the latest type of slaughterer's gun. *Am. J. Forensic Med. Pathol.* 23:326–328, 2002.
101. Suwanjutha, T. Direction, site and the muzzle target distance of bullet in the head and neck at close range as an indication of suicide or homicide. *Forensic Sci. Int.* 37:223–229, 1988.
102. Gross, A., Kunz, J. Suicidal shooting masked using a method described in Conan Doyle's novel. *Am. J. Forensic Med. Pathol.* 16:164–167, 1995.
103. Prahlow, J. A., Long, S., Barnard, J. J. A suicide disguised as a homicide: return to Thor Bridge. *Am. J. Forensic Med. Pathol.* 19:186–189, 1998.
104. Gerdin, B. A case of disguised suicide. *Forensic Sci. Int.* 16:29–34, 1980.
105. Juvin, P., Brion, F., Teissiere, F., Durigon, M. Prolonged activity after an ultimately fatal gunshot wound to the heart: case report. *Am. J. Forensic Med. Pathol.* 20:10–12, 1999.
106. Danto, B. L., Streed, T. Death investigation after the destruction of evidence. *J. Forensic Sci.* 39:863–870, 1994.
107. Wetli, C. V., Krivosta, G., Sturiano, J. V. Open revolver cylinder at the suicide death scene. *Am. J. Forensic Med. Pathol.* 23:229–233, 2002.
108. Lew, E. O., Kennington, R. H. Not under the hammer: a revolver suicide. *J. Forensic Sci.* 41:317–319, 1996.
109. Fatteh, A. Murder or suicide? A case report. *J. Forensic Med.* 18:122–123, 1971.
110. Weinberger, L. E., Sreenivasan, S., Gross, E. A., Markowitz, E., Gross, B. H. Psychological factors in the determination of suicide in self-inflicted gunshot head wounds. *J. Forensic Sci.* 45:815–819, 2000.
111. Kury, G., Weiner, J., Duval, J. V. Multiple self-inflicted gunshot wounds to the head: report of a case and review of the literature. *Am. J. Forensic Med. Pathol.* 21:32–35, 2000.
112. Sperry, K. Scleral and conjunctival hemorrhages arising from a gunshot wound of the chest: a case report. *J. Forensic Sci.* 38:203–209, 1993.
113. Harruff, R. C., Llewellyn, A. L., Clark, M. A., Hawley, D. A., Pless, J. E. Firearm suicides during confrontations with police. *J. Forensic Sci.* 39:402–411, 1994.
114. Jenet, R. N., Segal, R. J. Provoked shooting by police as a mechanism for suicide. *Am. J. Forensic Med. Pathol.* 6:274–275, 1985.

115. Carter, G. L. Accidental firearm fatalities and injuries among recreational hunters. *Ann. Emerg. Med.* 18:406–409, 1989.
116. Blanco-Pampin, J. M., Suarez-Penaranda, J. M., Rico-Boquete, R., Concheiro-Carro, L. Planned complex suicide. An unusual suicide by hanging and gunshot. *Am. J. Forensic Med. Pathol.* 18:104–106, 1997.
117. Hirsch, C. S., Adelson, L. A suicidal gunshot wound of the back. *J. Forensic Sci.* 21: 659–666, 1976.
118. Padosch, S. A., Schmidt, P. H., Madea, B. Planned complex suicide by self-poisoning and a manipulated blank revolver: remarkable findings due to multiple gunshot wounds and self-made wooden projectiles. *J. Forensic Sci.* 48:1371–1378, 2003.
119. Jones, A. M., Reyna, M., Jr., Sperry, K., Hock, D. Suicidal contact gunshot wounds to the head with .38 Special Glaser Safety Slug ammunition. *J. Forensic Sci.* 32:1604–1621, 1987.
120. Rogers, D. R. Simultaneous temporal and frontal suicidal gunshots. *Am. J. Forensic Med. Pathol.* 10:338–339, 1989.
121. Milroy, C. M. The epidemiology of homicide-suicide (dyadic death). *Forensic Sci. Int.* 71:117–122, 1995.
122. Marzuk, P. M., Tardiff, K., Hirsch, C. S. The epidemiology of murder-suicide. *JAMA* 267:3179–3183, 1992.
123. Betz, P., Eisenmenger, W. Comparison of wound patterns in homicide and dyadic death. *Med. Sci. Law* 37:19–22, 1997.
124. Breitenacker, R. Shotgun wound patterns. *Am. J. Clin. Pathol.* 52:258–269, 1969.
125. Adelson, L. A microscopic study of dermal gunshot wounds. *Am. J. Clin. Pathol.* 35: 393–402, 1961.
126. Aguilar, J. C. Shored gunshot wound of exit. A phenomenon with identity crisis. *Am. J. Forensic Med. Pathol.* 4:199–204, 1983.
127. Dixon, D. S. Characteristics of shored exit wounds. *J. Forensic Sci.* 26:691–698, 1981.
128. Hanzlick, R. L., Eskew, R. Suicide by three shots with different muzzle to target distances. *Am. J. Forensic Med. Pathol.* 5:95, 1984.
129. Karger, B., Brinkmann, B. Multiple gunshot suicides: potential for physical activity and medico-legal aspects. *Int. J. Legal Med.* 110:188–192, 1997.
130. Dowling, G. P., Dickinson, J. A., Cooke, C. T. Shotgun petal abrasions in close range .410-caliber shotgun injuries. *J. Forensic Sci.* 33:260–266, 1988.
131. Thogmartin, J. R., Start, D. A. 9 mm ammunition used in a 40 caliber Glock pistol: an atypical gunshot wound. *J. Forensic Sci.* 43:712–714, 1998.
132. Stone, I. C., Petty, C. S. Interpretation of unusual wounds caused by firearms. *J. Forensic Sci.* 36:736–74, 1991.
133. King, D. E. An unusual entrance wound associated with rimfire rifles. *Am. J. Forensic Med. Pathol.* 13:177, 1992.
134. Di Maio, V. J., Kaplan, J. A. An unusual entrance wound associated with rimfire rifles. *Am. J. Forensic Med. Pathol.* 12:207–208, 1991.
135. Rogers, D. R. Wounds caused by tight contact with the barrel-cylinder gap of revolvers. *Am. J. Forensic Med. Pathol.* 5:131–136, 1984.
136. Skinker, D. M., Coyne, C. M., Lanham, C., Hunsaker, J. C., III. Chasing the casing: a 38 special suicide. *J. Forensic Sci.* 41:709–712, 1996.
137. Azmak, D., Altun, G., Koc, S., Yorulmaz, C., Ozaslan, A. Intra- and perioral shooting fatalities. *Forensic Sci. Int.* 101:217–227, 1999.
138. Harruff, R. C. Comparison of contact shotgun wounds of the head produced by different gauge shotguns. *J. Forensic Sci.* 40:801–804, 1995.
139. Shuck, L. W., Orgel, M. G., Vogel, A. V. Self-inflicted gunshot wounds to the face: a review of 18 cases. *J. Trauma* 20:370–377, 1980.
140. Fatteh, A. Homicidal gunshot wound of mouth. *J. Forensic Sci. Soc.* 12:347–349, 1972.

141. Zietlow, C., Hawley, D. A. Unexpectedly homicide. Three intraoral gunshot wounds. *Am. J. Forensic Med. Pathol.* 14:230–233, 1993.
142. Freytag, E. Autopsy findings in head injuries from firearms. Statistical evaluation of 254 cases. *Arch. Pathol.* 76:215–225, 1963.
143. Lee, K. A., Opekin, K. Gunshot suicide with nasal entry. *Forensic Sci. Int.* 71:25–31, 1995.
144. Canfield, T. M. Suicidal gunshot wounds of the abdomen. *J. Forensic Sci.* 14:445–452, 1969.
145. Marsh, T. O., Brown, E. R., Burkhardt, R. P., Davis, J. H. Two six-shot suicides in close geographic and temporal proximity. *J. Forensic Sci.* 34:491–494, 1989.
146. Shkrum, M. J. Suicide involving multiple cranial gunshot wounds. *Can. Soc. Forensic Sci. J.* 29:137–142, 1996.
147. Fatteh, A., Gore, S. B., Mann, G. T., Garvin, K. Suicide with two guns: a unique case. *J. Forensic Sci.* 25:883–885, 1980.
148. Hudson, P. Suicide with two guns fired simultaneously. *J. Forensic Sci.* 27:6–7, 1982.
149. Timperman, J., Cnops, L. Tandem bullet in the head in a case of suicide. *Med. Sci. Law* 15:280–283, 1975.
150. Simmons, G. T. Findings in gunshot wounds from tandem projectiles. *J. Forensic Sci.* 42:678–681, 1997.
151. Clark, M. A., Micik, W. Confusing wounds of entrance and exit with an unusual weapon. *Am. J. Forensic Med. Pathol.* 5:75–78, 1984.
152. Lantz, P. E. An atypical, indeterminate-range, cranial gunshot wound of entrance resembling an exit wound. *Am. J. Forensic Med. Pathol.* 15:5–9, 1994.
153. Grey, T. C. The incredible bouncing bullet: projectile exit through the entrance wound. *J. Forensic Sci.* 38:1222–1226, 1993.
154. Yen, K., Thali, M. J., Kneubuehl, B. P., Peschel, O., Zollinger, U., Dirnhofer, R. Blood-spatter patterns: hands hold clues for the forensic reconstruction of the sequence of events. *Am. J. Forensic Med. Pathol.* 24:132–140, 2003.
155. Betz, P., Peschel, O., Stiefel, D., Eisenmenger, W. Frequency of blood spatters on the shooting hand and of conjunctival petechiae following suicidal gunshot wounds to the head. *Forensic Sci. Int.* 76:47–53, 1995.
156. Karger, B., Nusse, R., Schroeder, G., Wustenbecker, S., Brinkmann, B. Backspatter from experimental close-range shots to the head. I. Macrobackspatter. *Int. J. Legal Med.* 109:66–74, 1996.
157. Karger, B., Nusse, R., Troger, H. D., Brinkmann, B. Backspatter from experimental close-range shots to the head. II. Microbackspatter and the morphology of bloodstains. *Int. J. Legal Med.* 110:27–30, 1997.
158. Karger, B., Kersting, C., Brinkmann, B. Prior exposure of the entrance wound region from clothing is uncommon in firearm suicides. *Int. J. Legal Med.* 110:79–81, 1997.
159. Stone, I. C., DiMaio, V. J., Petty, C. S. Gunshot wounds: visual and analytical procedures. *J. Forensic Sci.* 23:361–367, 1978.
160. Lantz, P. E., Jerome, W. G., Jaworski, J. A. Radiopaque deposits surrounding a contact small-caliber gunshot wound. *Am. J. Forensic Med. Pathol.* 15:10–13, 1994.
161. Oehmichen, M., Meissner, C., König, H. G., Gehl, H. B. Gunshot injuries to the head and brain caused by low-velocity handguns and rifles A review. *Forensic Sci. Int.* 146:111–120, 2004.
162. Straathof, D., Bannach, B. G., Wilson, A. J., Dowling, G. P. Radiography of perforating centerfire rifle wounds of the trunk. *J. Forensic Sci.* 45:597–601, 2000.
163. Rivers, R. L., Miller, L. B., Loquvam, G. S. Soft tissue radiography in determining contact and near-contact gunshot wounds. *J. Forensic Sci.* 21:373–377, 1976.
164. Froede, R. C., Pitt, M. J., Bridgemon, R. R. Shotgun diagnosis: “it ought to be something else.” *J. Forensic Sci.* 27:428–432, 1982.
165. Ellis, P. S. Fatal gunshot injury caused by an unusual projectile—a barrel-cleaning brush as a tandem bullet. *Am. J. Forensic Med. Pathol.* 18:168–171, 1997.

166. Nadesan, K. A fatal nail gun injury—an unusual ricochet? *Med. Sci. Law* 40:83–87, 2000.
167. McCorkell, S. J., Harley, J. D., Cummings, D. Nail-gun injuries. Accident, homicide, or suicide? *Am. J. Forensic Med. Pathol.* 7:192–195, 1986.
168. Goldin, M. D., Economou, S. G. Stud gun injuries. *J. Trauma* 5:670–677, 1965.
169. Michelassi, F., Pietrabissa, A., Ferrari, M., Mosca, F., Vargish, T., Moosa, H. H. Bullet emboli to the systemic and venous circulation. *Surgery* 107:239–245, 1990.
170. DiMaio, V. J., DiMaio, D. J. Bullet embolism: six cases and a review of the literature. *J. Forensic Sci.* 17:394–398, 1972.
171. Zafonte, R. D., Watanabe, T., Mann, N. R. Moving bullet syndrome: a complication of penetrating head injury. *Arch. Phys. Med. Rehabil.* 79:1469–1472, 1998.
172. Kocak, A., Ozer, M. H. Intracranial migrating bullet. *Am. J. Forensic Med. Pathol.* 25:246–250, 2004.
173. Shuman, M., Wright, R. K. Evaluation of clinician accuracy in describing gunshot wound injuries. *J. Forensic Sci.* 44:339–342, 1999.
174. Bhana, B. D., Kirk, G. M., Dada, M. A. Fatal firearm wounds: a clinicopathologic study. *Am. J. Forensic Med. Pathol.* 24:273–276, 2003.
175. Murphy, G. K. The study of gunshot wounds in surgical pathology. *Am. J. Forensic Med. Pathol.* 1:123–130, 1980.
176. Karger, B. Penetrating gunshots to the head and lack of immediate incapacitation. I. Wound ballistics and mechanisms of incapacitation. *Int. J. Legal Med.* 108:53–61, 1995.
177. Kirkpatrick, J. B., Di Maio, V. Civilian gunshot wounds of the brain. *J. Neurosurg.* 49:185–198, 1978.
178. Fackler, M. L., Malinowski, J. A. The wound profile: a visual method for quantifying gunshot wound components. *J. Trauma* 25:522–529, 1985.
179. DiMaio, V. J., Zumwalt, R. E. Rifle wounds from high velocity, center-fire hunting ammunition. *J. Forensic Sci.* 22:132–140, 1977.
180. Oehmichen, M., Meissner, C., Konig, H. G. Brain injury after survived gunshot to the head: reactive alterations at sites remote from the missile track. *Forensic Sci. Int.* 115:189–197, 2001.
181. Povlishock, J. T. Traumatically induced axonal injury: pathogenesis and pathobiological implications. *Brain Pathol.* 2:1–12, 1992.
182. Karger, B. Penetrating gunshots to the head and lack of immediate incapacitation. II. Review of case reports. *Int. J. Legal Med.* 108:117–126, 1995.
183. Oehmichen, M., Meissner, C., Konig, H. G. Brain injury after gunshot wounding: morphometric analysis of cell destruction caused by temporary cavitation. *J. Neurotrauma* 17:155–162, 2000.
184. Adekoya, N., Thurman, D. J., White, D. D., Webb, K. W. Surveillance for traumatic brain injury deaths—United States, 1989–1998. *MMWR Surveill. Summ.* 51:1–14, 2002.
185. Schmidt, P., Madea, B. Reflex mechanisms of death in missile injuries of the neck. *Forensic Sci. Int.* 66:53–60, 1994.
186. Selden, B. S., Goodman, J. M., Cordell, W., Rodman, G. H., Jr., Schnitzer, P. G. Outcome of self-inflicted gunshot wounds of the brain. *Ann. Emerg. Med.* 17:247–253, 1988.
187. Yoshida, G. M., Garland, D., Waters, R. L. Gunshot wounds to the spine. *Orthop. Clin. North Am.* 26:109–116, 1995.
188. Bono, C. M., Heary, R. F. Gunshot wounds to the spine. *Spine J.* 4:230–240, 2004.
189. Fitzgerald, L. F., Simpson, R. K., Trask, T. Locked-in syndrome resulting from cervical spine gunshot wound. *J. Trauma* 42:147–149, 1997.
190. Kirkpatrick, J. B. Gunshots and other penetrating wounds of the central nervous system. In: Leestma, J. E., ed. *Forensic Neuropathology*. Raven Press, New York, pp. 276–299, 1988.
191. Quatrehomme, G., Iscan, M. Y. Characteristics of gunshot wounds in the skull. *J. Forensic Sci.* 44:568–576, 1999.
192. Quatrehomme, G., Iscan, M. Y. Gunshot wounds to the skull: comparison of entries and exits. *Forensic Sci. Int.* 94:141–146, 1998.

193. Dixon, D. S. Keyhole lesions in gunshot wounds of the skull and direction of fire. *J. Forensic Sci.* 27:555–566, 1982.
194. Quatrehomme, G., Iscan, M. Y. Analysis of beveling in gunshot entrance wounds. *Forensic Sci. Int.* 93:45–60, 1998.
195. Coe, J. I. External beveling of entrance wounds by handguns. *Am. J. Forensic Med. Pathol.* 3:215–219, 1982.
196. Baik, S. O., Uku, J. M., Sikirica, M. A case of external beveling with an entrance gunshot wound to the skull made by a small caliber rifle bullet. *Am. J. Forensic Med. Pathol.* 12:334–336, 1991.
197. Bhoopat, T. A case of internal beveling with an exit gunshot wound to the skull. *Forensic Sci. Int.* 71:97–101, 1995.
198. Dixon, D. S. Exit keyhole lesion and direction of fire in a gunshot wound of the skull. *J. Forensic Sci.* 29:336–339, 1984.
199. Oehmichen, M., Gehl, H. B., Meissner, C., et al. Forensic pathological aspects of post-mortem imaging of gunshot injury to the head: documentation and biometric data. *Acta Neuropathol. (Berl)* 105:570–580, 2003.
200. Smith, O. C., Berryman, H. E., Lahren, C. H. Cranial fracture patterns and estimate of direction from low velocity gunshot wounds. *J. Forensic Sci.* 32:1416–1421, 1987.
201. Dixon, D. S. Pattern of intersecting fractures and direction of fire. *J. Forensic Sci.* 29:651–654, 1984.
202. Johnson, G. C. Unusual shotgun injury. Gas blowout of anterior head region. *Am. J. Forensic Med. Pathol.* 6:244–247, 1985.
203. Shepard, G. H. High-energy, low-velocity close-range shotgun wounds. *J. Trauma* 20:1065–1067, 1980.
204. Sights, W. P., Jr. Ballistic analysis of shotgun injuries to the central nervous system. *J. Neurosurg.* 31:25–33, 1969.
205. Lecso, P. A. Murder-suicide in Alzheimer's disease. *J. Am. Geriatr. Soc.* 37:167–168, 1989.
206. Cina, S. J., Smith, M. T., Collins, K. A., Conradi, S. E. Dyadic deaths involving Huntington's disease: a case report. *Am. J. Forensic Med. Pathol.* 17:49–52, 1996.
207. Anglin, D., Hutson, H. R., Luftman, J., Qualls, S., Moradzadeh, D. Intracranial hemorrhage associated with tangential gunshot wounds to the head. *Acad. Emerg. Med.* 5:672–678, 1998.
208. Harruff, R. C. Subendocardial hemorrhages in forensic pathology autopsies. *Am. J. Forensic Med. Pathol.* 14:284–288, 1993.
209. Karger, B., DuChesne, A. Who fired the gun? A casuistic contribution to the differentiation between self-inflicted and non-self-inflicted gunshot wounds. *Int. J. Legal Med.* 110:33–35, 1997.
210. Fackler, M. L., Surinchak, J. S., Malinowski, J. A., Bowen, R. E. Bullet fragmentation: a major cause of tissue disruption. *J. Trauma* 24:35–39, 1984.
211. Torre, C., Varetto, L., Ricchiardi, P. New observations on cutaneous firearm wounds. *Am. J. Forensic Med. Pathol.* 7:186–191, 1986.
212. McKinney, C. D., Brinkhous, W. K., Butts, J. D. Accidental deaths involving derringer handguns: a report of three cases. *J. Forensic Sci.* 35:730–734, 1990.
213. Karger, B., Nusse, R., Bajanowski, T. Backspatter on the firearm and hand in experimental close-range gunshots to the head. *Am. J. Forensic Med. Pathol.* 23:211–213, 2002.
214. Burnett, B. R. Detection of bone and bone-plus-bullet particles in backspatter from close-range shots to heads. *J. Forensic Sci.* 36:1745–1752, 1991.
215. Saverio, R. F., Margot, P. Identification of gunshot residue: a critical review. *Forensic Sci. Int.* 119:195–211, 2001.
216. Krishnan, S. S. Detection of gunshot residues on the hands by trace element analysis. *J. Forensic Sci.* 22:304–324, 1977.



217. Basu, S., Ferriss, S., Horn, R. Suicide reconstruction by glue-lift of gunshot residue. *J. Forensic Sci.* 29:843–864, 1984.
218. Kilty, J. W. Activity after shooting and its effect on the retention of primer residue. *J. Forensic Sci.* 20:219–230, 1975.
219. Cooper, R., Guileyardo, J. M., Stone, I. C., Hall, V., Fletcher, L. Primer residues deposited by handguns. *Am. J. Forensic Med. Pathol.* 15:325–327, 1994.
220. Andrasko, J., Maehly, A. C. Detection of gunshot residues on hands by scanning electron microscopy. *J. Forensic Sci.* 22:279–287, 1977.
221. Reed, G. E., McGuire, P. J., Boehm, A. Analysis of gunshot residue test results in 112 suicides. *J. Forensic Sci.* 35:62–68, 1990.

## Chapter 7

---

# *Penetrating Trauma*

## *Sharp-Force Injuries*

### **Summary**

Various sharp-force injuries—cutting and stabbing, nonhuman bites, venipunctures for medical or illicit purposes—are encountered in a forensic pathology practice. Most cutting and stabbing deaths are homicides, but all manners of death are possible. Multiple wounds, which can be mutilating, are seen in suicide victims. Postmortem examination of clothing and documentation of wound sites, including their grouping and orientation, as well as other injuries (“hesitation” vs “defense” wounds), assists in the determination of a self-inflicted act. Stab wound dimensions are affected by a number of factors.

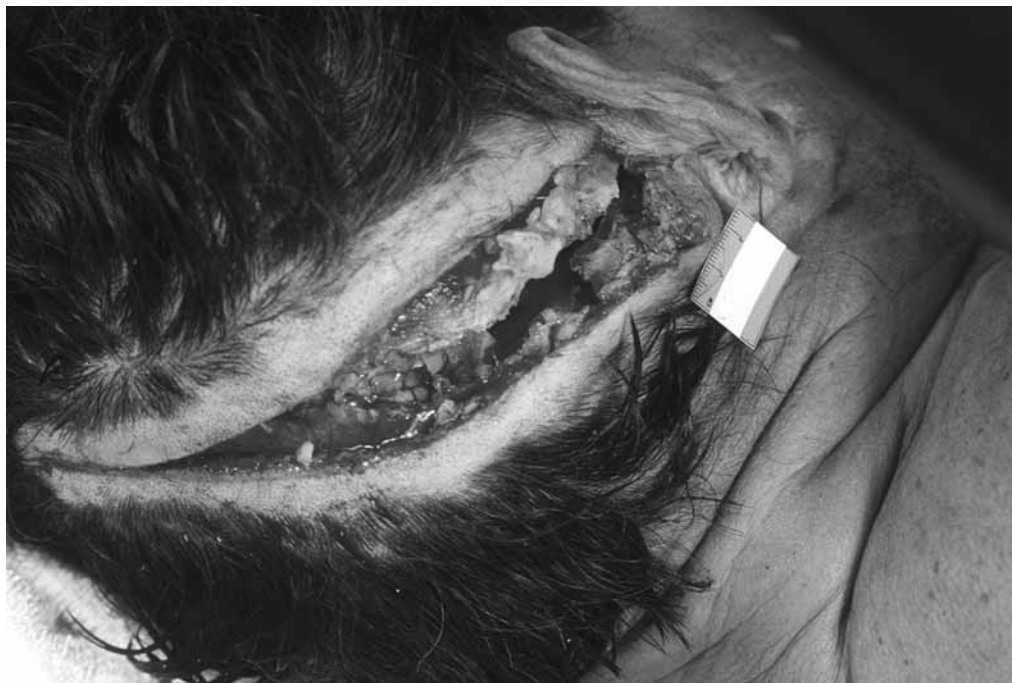**Key Words:** Stab wounds; bites; stings.

### *1. DEFINITIONS*

Incisions (cuts) and stabs are sharp-force injuries. The depth of the wound track, relative to the length of the cutaneous wound, distinguishes a stab from an incision. The depth of the stab wound is greater than the length of the skin injury. The depth of an incised wound is typically less than the length of the external wound. Stab wounds are caused by a thrusting motion, which can be either overhand or underhand. Slashing produces an incised wound. An instrument (e.g., knife) that has an edge and a point can both incise and stab. A pointed instrument lacking an edge (e.g., pin) can stab but not readily incise. A sharp-edged surface lacking a point incises but does not stab (Fig. 1). Depending on the sharpness of the edge of the instrument, associated blunt trauma injuries can occur (e.g., chopping with an axe). Impalement is another type of penetrating injury owing to a variably sharp or narrow object that becomes rigidly fixed within the body.

From: *Forensic Science and Medicine: Forensic Pathology of Trauma:  
Common Problems for the Pathologist*

By: M. J. Shkrum and D. A. Ramsay © Humana Press Inc., Totowa, NJ



**Fig. 1.** Incision, posterior scalp. Airplane propeller blade. Associated open skull fracture.

## *2. CIRCUMSTANCES: SHARP-FORCE INJURIES*

### *2.1. Homicides and Suicides*

Stabbing homicide is more common than firearm homicide in Europe, in contrast to the United States (1–6). A thorough and detailed investigation is necessary for proper certification of the manner of death (7). A study at the Dallas County Medical Examiner's Office showed that, of 630 deaths from sharp-force injury (i.e., stab, incision, chop), 90% were homicides, 7.5% suicides, and 3.5% accidents; 2 were undetermined (7). The same study showed that 0.29% of all accidents were from sharp-force trauma. A review of 120 sharp-injury fatalities in New York revealed that 84% were homicides, 14% were suicides, and 2% were accidents (8). A German review of 376 sharp-force deaths revealed 80% were homicides, 17% were suicides, and 3% were accidents (9). Although all manners of death are possible with single and multiple sharp-force injuries, given the frequency of homicides, all cases are considered murder until proven otherwise (Table 1; refs. 5, 6, 8, and 10).

A suicide may not be immediately obvious. For example, suspicions are aroused when there is only a single stab wound, stab wounds are in atypical locations (e.g., back), clothing has been cut, the weapon lies some distance from the body, other sharp-force injuries are seen away from the fatal wound, and other trauma (e.g., complex suicide) is present (2,8,10,14,25). A homicide can be staged as a suicide (8).

Various studies have shown a male predominance in all manners of death from sharp-force injuries (1–8,12,13,18). Suicide victims average about 15 yr older (mean about 50 yr of age) compared with homicides (6). The majority of suicides occur in the

**Table 1**  
**Sharp-Force Injury and Manner of Death**

	Homicide	Suicide	Accident
<b>% by manner</b> (7–9,11)	80–90%	<20% 2–4% of suicides (12,13)	<5%
<b>Weapon/sharp object at scene</b>	+ (62%) “Household Access” (4)	+ (see Subheading 2.1.)	+
<b>More than one weapon</b>	+	+ (18%) (2,14)	+
<b>Clothing involved</b>	+ (79%) (6) Exceptions possible (see Subheading 4.1.)	Uncommon (5%) (6) Common in some series 28% (2); 52% of torso injury cases (9)	+
<b>Sharp-force injury</b>			
• Type	Stabs > incisions	Incisions > stabs: 2:1 (6); 40% incisions, 37% stabs, 23% both (9)	Incisions or stabs
• Location	Thorax most common in single and multiple stab wounds (1,4–6). Facial and throat wounds only (multiple wounds) (4) Wrist, antecubital fossa uncommon (6)	Incisions—upper extremities (including antecubital fossa, wrist) (6,9,12,13) Both arms (12) Lower extremities (femoral area, dorsum of foot) uncommon (13) See Heading 5. (13) Stabs—chest > abdomen > neck > face (2,6–8,15–17) Neck “injuries” most frequent in one study (18) Neck stab uncommon (10,13,19–21) Genital area uncommon (6,18) Vessel bypass shunt (22)	Any site, wrist/ antecubital fossa > neck, torso (6,12)
• Injured area of body “Vulnerable” to lethal injury but inaccessible to victim	+/- Head, back wounds common (6)	— Stabs/incisions of head, back, uncommon (6,18)	+/-
• Single stab	34–45% (1,3–6) 20% women; 55% men (3)	Multiple wounds possible (10) + 19% (6)	

(Continued)

Table 1 (Continued)

	Homicide	Suicide	Accident
<b>Defense wounds</b>	18% women; 45% men (1) Majority of women had wounds in 3 or 4 body regions (1) + (7,8,23) Overall—38.5% (24), 41% (6), 45% (5) Typically upper extremity If single stab—2.6% (7), 15% (3), 22% (6) Multiple stabs—54% (3); 3–9 stabs— 54.7% (7) Male = 27%; female = 55% (3); no sex difference in another study (5) Of ethanol– positive victims, 44% (7)	37% (9) 64% (2) Rare (see Subheading 4.4.)	—
<b>Hesitation wounds</b>	Rare (see Subheading 4.4.)	55% (16) 62% (6) 64% (2) 77% (9) If single wound, 20% (6)	—
<b>Other sharp injuries</b>	Genital injuries uncommon (6)	Self-mutilation possible (16) (see ref. 16 Heading 5.)	—
<b>Other types of trauma</b>	+ 17% (3) 28% (6) Women = 39%; men = 34% (1)	“Complex” suicide (2,4,6,16)	+

victim's home, with the bathroom and bedroom being the most common rooms (2,6,8,13,18,26). Other locales have included hospitals, hotel rooms, detention facilities, and the workplace. Victims found in bathtubs may have believed that warm water dilates blood vessels and prevents coagulation (see Chapter 5, Subheading 13.2. and ref. 8). In jail, suicide victims are typically first-time offenders arrested on minor charges, intoxicated, strip-searched, and isolated (26). A history of prior suicide attempts is rare, and the self-infliction occurs within 24 h of incarceration. Improvised weapons (e.g., a broken piece of glass) are used.

In a Swedish study, more than 50% of homicidal sharp-force fatalities took place in either the victim's or the assailant's home (4). Another Scandinavian study revealed that



78% of women were killed in their own home, compared with 49% of males (1). Twenty-one percent of males were killed outdoors, as opposed to only 6% of the females (1). The high frequency of familiar locales in homicide may reflect the fact that about 80% of victims and assailants were acquainted with each other (4). Another review showed that the victim and assailant knew each other in 86% of cases (1). Single wounds were often a result of a quarrel or fight between drinking companions, but in cases of multiple wounds, an emotional relationship existed between the victim and perpetrator in 60% of cases (4). Kitchen knives and razor blades are common in suicides (2,6,9,13,18,27). In a Japanese series of 923 cases of suicidal self-stabbing, 57.2% used knives and 17.7% razors (18). Scissors and swords are uncommonly used (13,18). Rarely used items, such as broken glass, suggest a hasty decision to commit suicide (13,18). There is a case report of a physician who made a long incision, under local anesthesia, exposing his femoral artery (13).

A history of psychiatric illness, alcohol and drug abuse, and previous suicide attempts may be elicited (6,22). Studies have shown that almost half of sharp-force suicide victims had a history of alcoholism and/or mental illness (9,13). Suicide notes are found in a minority of cases (6). The Stockholm study showed that 19% of men and 31% of women (28% overall) left a suicide note (13). In contrast, a New York study revealed that about half of victims left a note (8). Verbalization of intent is more common (6). Voiced suicidal intention was expressed in 53%, and past attempts were known in 27% of the 105 sharp-force suicides studied in Stockholm (6).

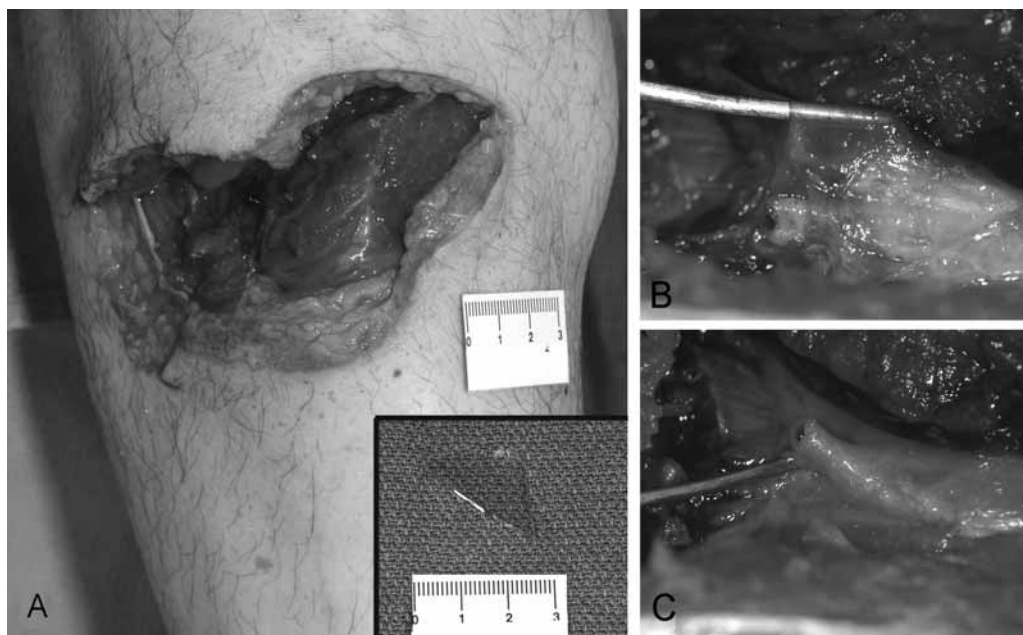
Suicide by sharp-force in the presence of another person is rare and indicates either a psychiatric disorder or a spur-of-the-moment decision during a highly emotional situation (28). In an English study of 28 self-stabbings, a close relative or friend was present nearby in half of the cases, but the stabbings were actually witnessed in only two incidents (2).

## 2.2. Accidents

Sharp-force injuries arising from accidents are relatively uncommon and comprise a spectrum of incised, stab, and chop wounds (7). Accidental stab and incised wounds tend to be single (Fig. 2; ref. 7). Incised wounds typically involve major arteries or veins in the extremities and neck, but puncture wounds and multiple cutaneous injuries also lead to fatal exsanguination (11,29,30). Alcohol is a factor in adult accidents (11,29).

Injuries from broken glass are usually accidental (Fig. 2; refs. 7, 29, and 31). Suicides and homicides by this means are rare (32). Various types of glass are described: annealed (plate) glass, which shatters into slim sharp fragments capable of penetration; tempered glass, which typically breaks into irregular rectangular fragments; laminated glass, which has a sheet of plastic interposed between glass layers and cracks but remains intact; and wired glass, which is held together by wire mesh (30). Serious injuries are caused by glass doors and windows (33). They usually occur in children and young individuals (7,30). A prospective study of 1086 consecutive injuries due to glass showed that the age range was 5 to 31 yr (peak at 15 yr of age), and about two-thirds of cases involved males (33). The most frequent locations were the home (39%), public places (31.3%), and the workplace (21.1%). Examples of household accidents include falling against or walking through a door panel or window, upsetting glass furniture, and breaking a window to gain entry into the house (Fig. 2; refs. 8, 11, 31, 34, and 35).

Wounds are either clean-edged or irregular and abraded, depending on the nature of the broken glass and the movements of the victim (11,31,35). Multiple superficial



**Fig. 2.** Accidental sharp force injury. Ethanol intoxication. **(A)** Large incised wound of leg. Inset: shard of glass from broken table. **(B)** Exploration of wound track. Probe in transected vein. **(C)** Adjacent transected peroneal artery (lifted by probe).

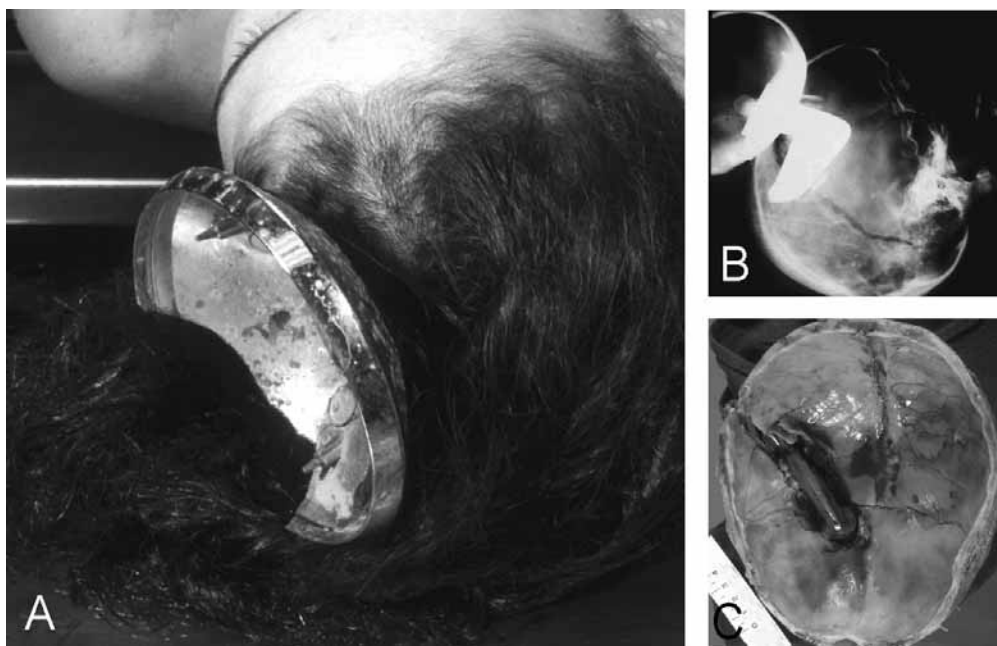
abrasions and cuts are seen when the victim falls (11). A tip of broken glass deep in the wound can arrest hemorrhage (31). Accidental stabbing by a knife has been described (11,36). Other sharp objects (e.g., sewing needle) can accidentally penetrate the torso (35,37,38). Individuals can be killed by flying sharp objects (39).

### 2.3. Impalement

All manners of death are associated with impalement, although homicide is rare (40,41). Falls cause impalement in adults and children (42–45). In children, impalement can occur during play. Falls in adults can be precipitated by alcohol and medication (46). Underlying disease (e.g., epilepsy) can be a factor (46). Falls occur in the workplace (e.g., fall onto a steel bar). Motor vehicle occupants have been impaled by fixed, rigid structures (e.g., fence, post, tree branch) following collisions (Fig. 3; refs. 47–51). Self-inflicted impalement happens in psychiatric patients, demented individuals, and the mentally challenged (see Subheading 6.2. and refs. 52–56).

### 2.4. Anorectal Injuries

Penetrating anorectal injuries occur under various circumstances. Clinical recognition may be delayed because of the trauma is not obvious, and symptoms evolve slowly (34,41,42). Autoerotic activities may involve insertion of foreign objects into the vagina and rectum (see Chapter 3, Subheading 2.7. and ref. 50). Children can sustain “straddle-type” injuries (42,57,58). The entry site can be vaginal, perineal, or transanal (42,57). Clothing does not prevent impalement (42). This injury arouses suspicion of molestation (42,57,58). Intraperitoneal extension can injure the urinary bladder, bowel,



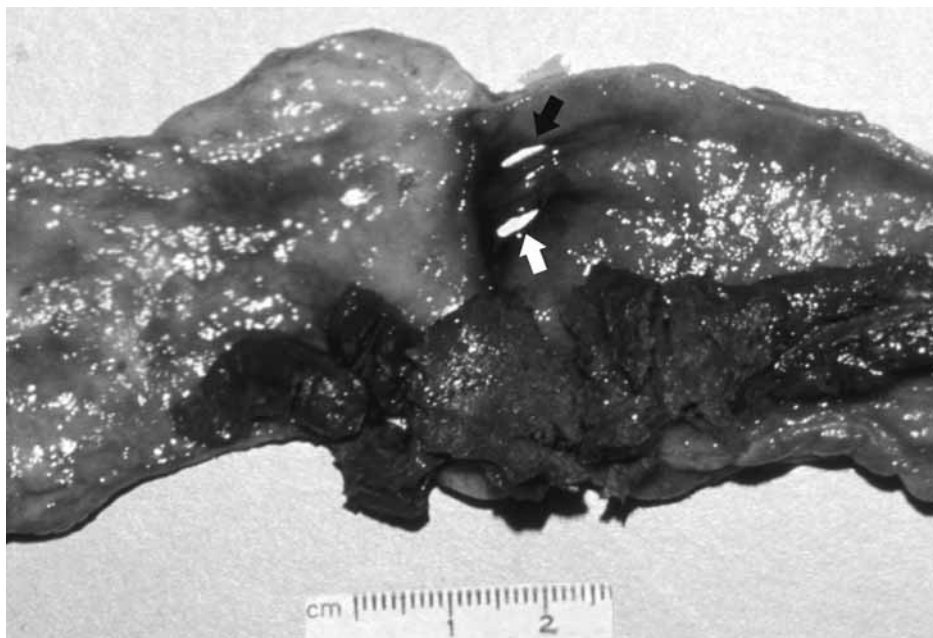
**Fig. 3.** Motor vehicle collision. (A) Impalement by car mirror. (B) Radiograph of skull. (C) Penetration of calvarium.

abdominal solid organs, and major vessels (41,42,57,58). Extension to the thorax is possible (42). Iatrogenic injuries (e.g., insertion of thermometer) have been described, particularly in children (Fig. 4; ref. 42).

### 2.5. Motorized Tools

Chain saws are designed for right-hand use, and injuries occur more frequently on the left side of the body (59). When the saw blade comes into contact with a hard object (“kickback”), the saw is directed into the upper body or downward toward the knee or foot (59–61). The edges of the skin wounds are either smooth or jagged (60–62). Secondary abrasions on the neck and extremities from other parts of the chain saw help reconstruct the deceased’s position (62). Characteristic parallel skin wounds with associated bruising and pointed skin flaps have been described (60,61). Facial wounds are characterized by severe lacerations and tearing of bone (59). Injuries of the neck vessels and upper respiratory tract can be sustained (59,61). A fatal pneumothorax caused by rupture of emphysematous bullae caused by a chest injury has been described (63). Hand injuries are common. Isolated accidental finger amputations are typically distal (64). Amputation of a proximal digit does not happen accidentally without accompanying injuries of the fingers and hand (64). The majority of the victims who have self-inflicted chain saw injuries have occupational experience and a psychiatric history (62). Chain saws have also been involved in suspicious deaths and homicides (60).

Other tools (e.g., band saw, circular saw, power drill) have caused injuries, either self-inflicted or accidental (Fig. 5; refs. 9 and 65–69). Certain devices (e.g., propeller) can cause multiple chopping injuries (Fig. 1; refs. 7, 70, and 71).



**Fig. 4.** Child. Peritonitis secondary to perforations (arrows) of distal large bowel. History of insertion of thermometer. (Courtesy of the Office of the Chief Medical Examiner, Chapel Hill, NC.)

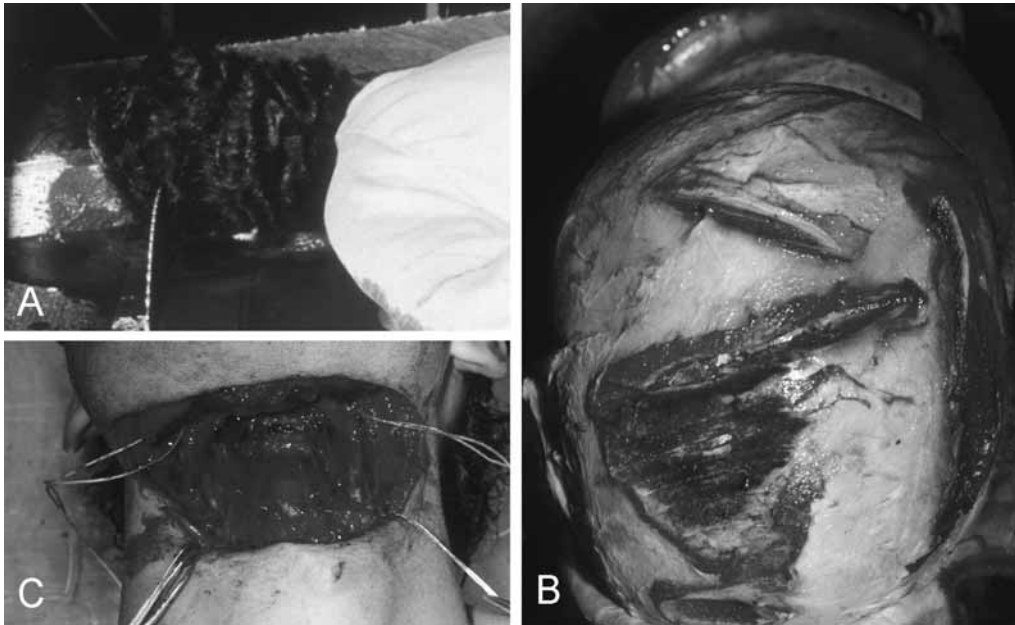
### *3. CORRELATION OF STAB AND INCISED WOUNDS WITH SHARP INSTRUMENT*

In some instances, a knife may be still in the individual (Fig. 6). In rare instances, the knife tip is broken from contact with bone and is revealed on a radiograph. Analysis showing the blood of the deceased on a suspected knife ties that weapon with the observed injuries (Fig. 7). If no knife is present, then postmortem measurements of the stab wound can, in a limited way, be linked with specific dimensions of the sharp instrument inflicting the injury. The stab wound depth, length, and width approximate the length, width, and thickness, respectively, of the weapon. These measurements assist investigators who, faced with a wide array of knives in a household, are able to focus their efforts in finding a weapon. Realizing that many knives can produce the wounds observed, the pathologist can usually only comment that the appearance and configuration of the wounds are consistent with a particular weapon. In contrast, sharp-edged instruments cannot be distinguished by incised wounds of varying lengths and depths. The measurement of an incision, including its depth, does provide information regarding severity of the injury.

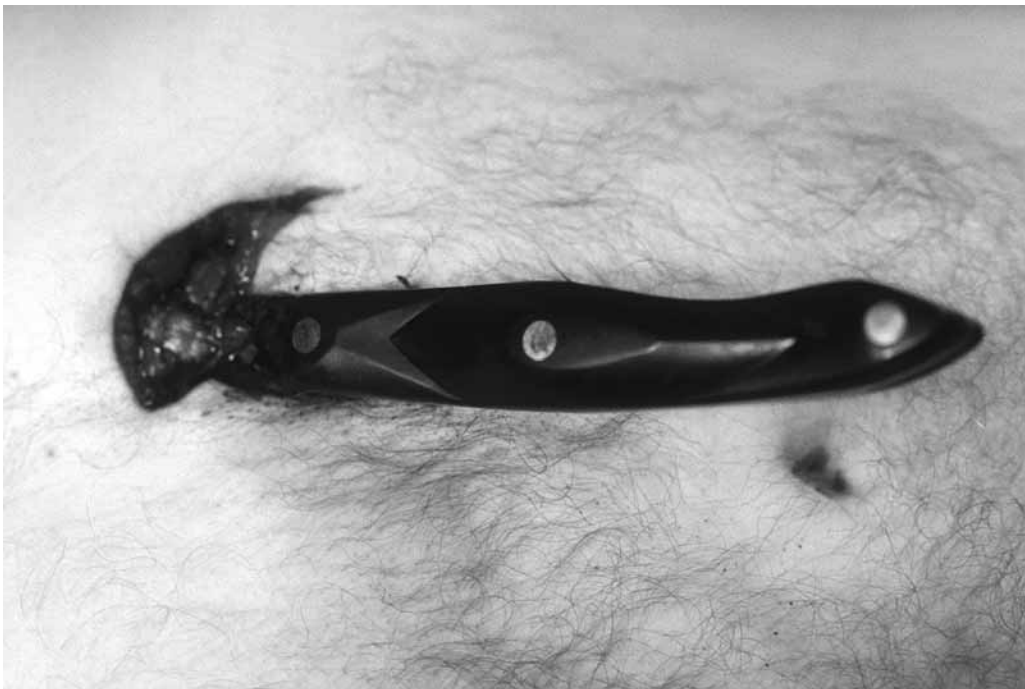An impaled object is embedded in the body (46). The end of the foreign body may have been cut at the scene by emergency personnel but left in place to ensure tamponade of internal injuries (47). Radiographs document the presence and position of the object. Its removal may require forceful manipulation and sawing (46).

The correlation of knife-blade and stab-wound dimensions can be altered by a number of factors:





**Fig. 5.** Suicide by table saw. (A) Victim found face down, flat on table with circular saw running. (B) Vertex of skull. Several saw cuts in different directions, some penetrating brain. (C) Incised wound of neck. Severed carotid arteries (tied). (Courtesy of Dr. D. King, Regional Forensic Pathology Unit, Hamilton, Ontario, Canada.)



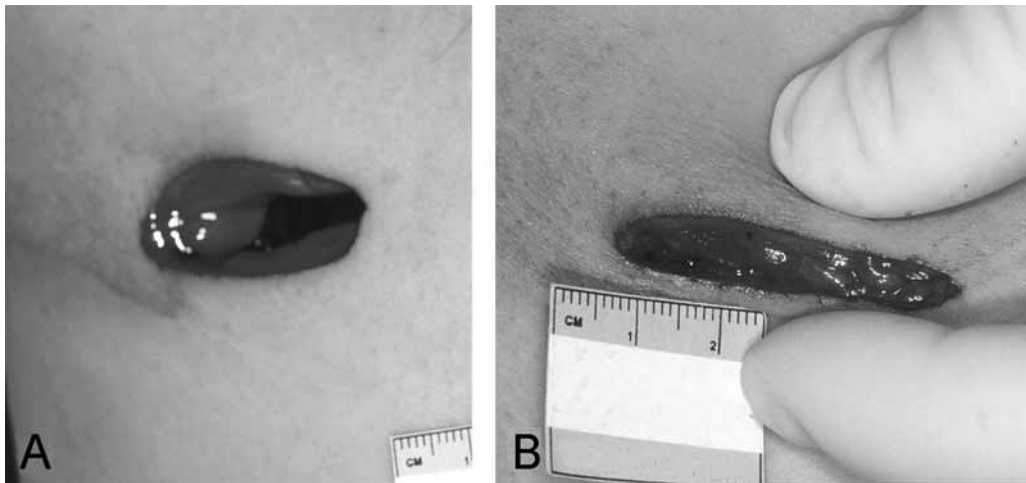
**Fig. 6.** Self-inflicted abdominal stab wound. Knife *in situ*.



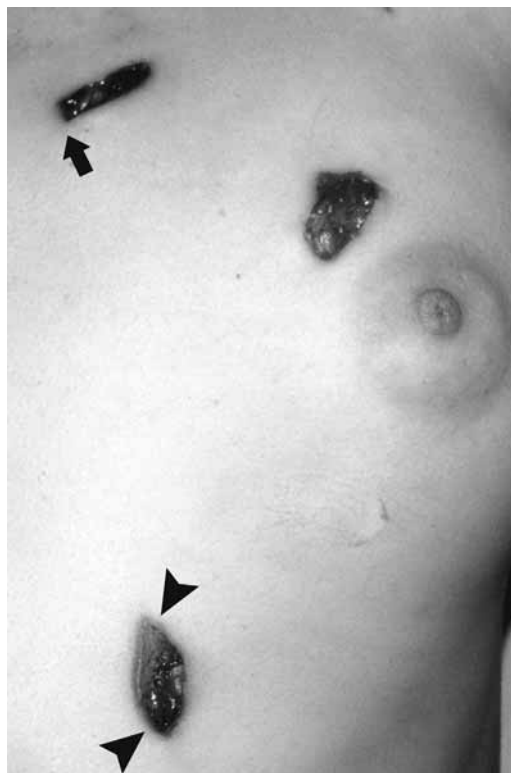

Fig. 7. Victim's blood (arrow) on knife blade.

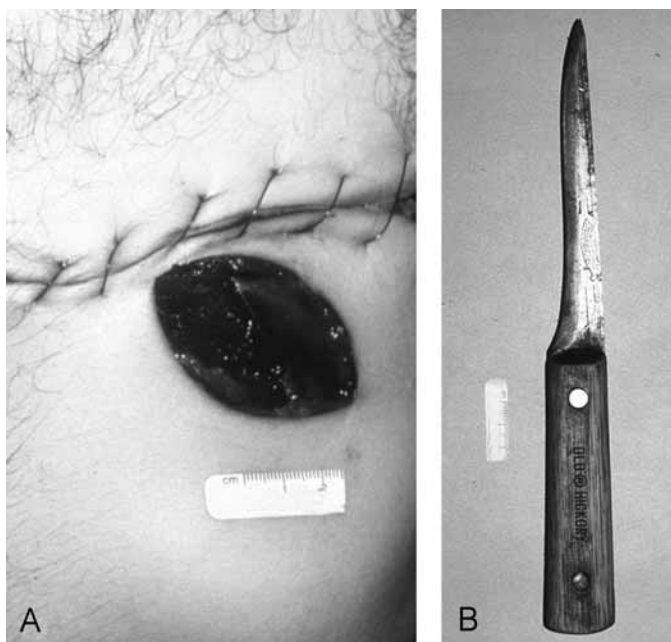
- **Skin elasticity:** The width of the stab wound is the least important measurement because most knife blades are in the order of 1- to 2-mm thick (about 0.0625 in.). If a wound is oriented parallel to tension lines created by skin elasticity (Langer's lines), then the wound is relatively narrow. A wound oriented perpendicular to lines of elasticity gapes. The length of a gaping skin wound is shortened (Fig. 8). Such a wound requires approximation of its edges to determine a more accurate length (72). One study observed that the lengths of skin wounds on the chest, abdomen, and flanks did not reach the full width of the blades, even after approximating the gaping edges (72).
- **Angle of knife relative to skin surface:** Many knife blades are single-edged, i.e., one sharp cutting edge and an opposite dull noncutting edge. Typically, when a knife is inserted perpendicular to the skin surface, one point of the resulting skin wound is sharp and the other blunt, conforming to the configuration of the blade edge (Fig. 9). If the blade is inserted at an angle, then the wound lengthens and both ends become sharp one corresponding to the entry initially of the tip of the knife and the other resulting from the following sharp blade edge (Fig. 9). The least "rocked" wound length corresponds to the blade width (Fig. 10). Movement of the knife and victim causes twisting of the knife blade, relative to its entry or exit, resulting in lengthening of the wound and possible notching of one end of the skin wound (Fig. 11). Considerable twisting of the knife leads to large, irregular injuries (Fig. 12). Multiple wound tracks are possible with a single cutaneous wound, if there has been re-entry or twisting of the knife (Fig. 13; refs. 2 and 73). Hemorrhage along single and multiple tracks indicates infliction before death (Fig. 14; ref. 10). Multiple tracks indicate intent (19).
- **Anatomical variation (antemortem and postmortem):** The wound depth provides important information about the blade length. In general, the deepest stab is a guide to the minimum blade length. The depth of a wound track can be altered after death. The postmortem measurement of the depth of a stab wound involving the anterior surface of the heart is only an approximate estimate of the blade length of the stabbing weapon (74). The removal of the sternum during autopsy results in detachment of the anterior



**Fig. 8.** Measurement of stab wound length. (A) Gaping stab wound. Length of wound shortened. (B) Stab wound edges apposed manually.



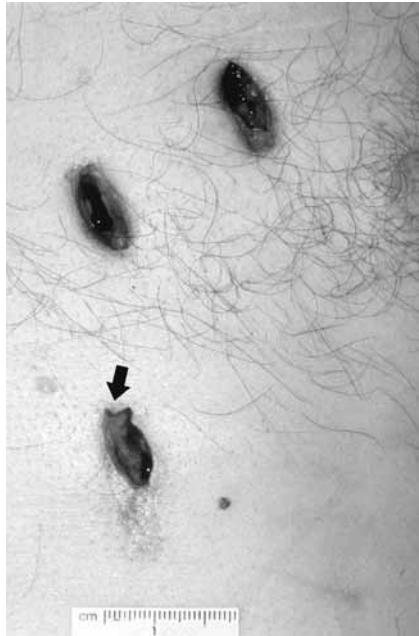**Fig. 9.** Multiple stab wounds on chest. Perpendicular insertion of knife—sharp and blunt ends (arrow). Angled insertion—both ends sharp (arrowheads). (Courtesy of the Office of the Chief Medical Examiner, Chapel Hill, NC.)



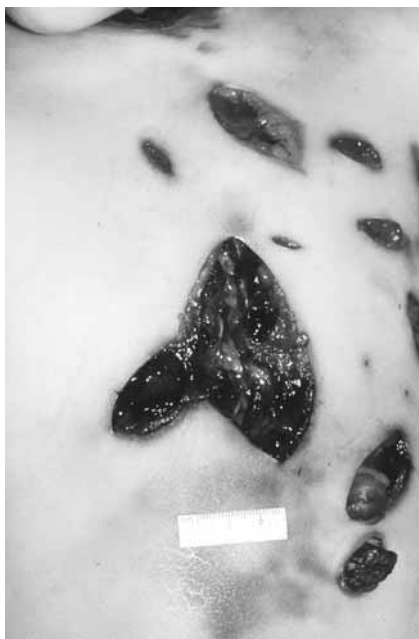**Fig. 10.** “Rocked” knife wound. **(A)** Gaping single stab wound of chest (below thoracotomy incision). Length of wound caused by relative movement of victim and knife. **(B)** Knife used to inflict injury. Note narrow blade width. (Courtesy of the Office of the Chief Medical Examiner, Chapel Hill, NC.)

part of the pericardium, which causes the heart to collapse back into the thoracic cavity. This increases the distance between the anterior chest surface and heart (7 mm or about 0.25 in. in one study [74]). If the track involves the heart, consequent hemopericardium also increases the distance between the chest surface and the heart wound (1 to 4 cm or about 0.5 to 1.5 in. [74]). If there is cardiac tamponade, the heart stops in systole, resulting in an apparent deeper wound at autopsy than at the time of infliction, when the heart may have been in diastole (74).

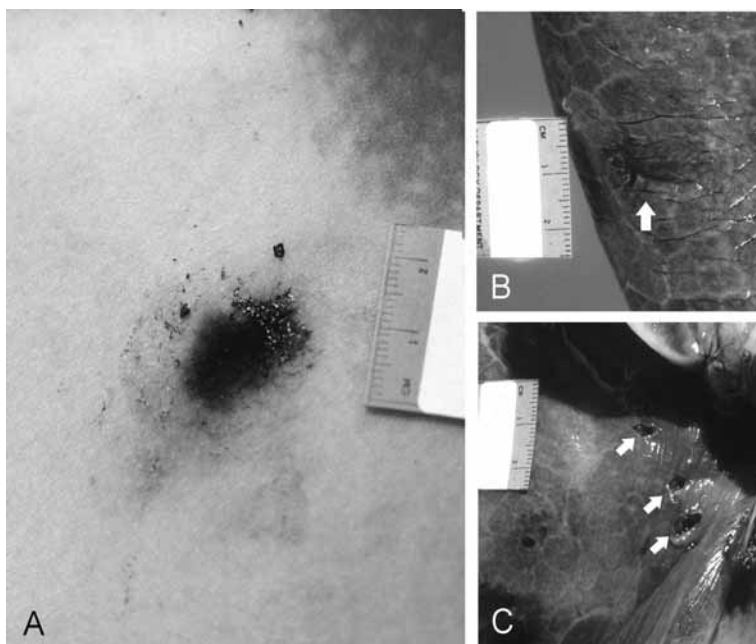
- **Degree of applied force:** The width of a knife blade progressively decreases as it tapers toward its point. If a knife is inserted superficially only to the depth of its tapered segment, then the cutaneous wound length is less than the maximum blade width. Forcefully thrusting the knife into the chest or abdomen can result in a wound depth that exceeds the knife blade length. Because the knife is inserted its full length, secondary blunt trauma injuries can be seen around the cutaneous wound, corresponding to the so-called hilt of the knife (i.e., handle, hand guard, or device for fixing the open blade; see Fig. 15 and ref. 75). In a study of 74 deaths resulting from stabbing, only 5 cases having a hilt mark were observed (76). *Thrust impact injury* describes firm surfaces, other than the hilt of the knife (e.g., the edge of the hand holding the knife) causing marks on the skin (3). Individuals sustaining self-inflicted wounds can brace a knife by various means (e.g., leaning forward while grasping a knife, hammering a knife to the hilt; see Fig. 16 and ref. 9).
  - The assessment of the degree of force required to penetrate the body is difficult to ascertain because of variables such as the sharpness of the weapon, the velocity at the moment the body is struck, the amount and nature of clothing worn, and the type of tissue penetrated (77–79). The sharpness of the tip of the weapon is considered



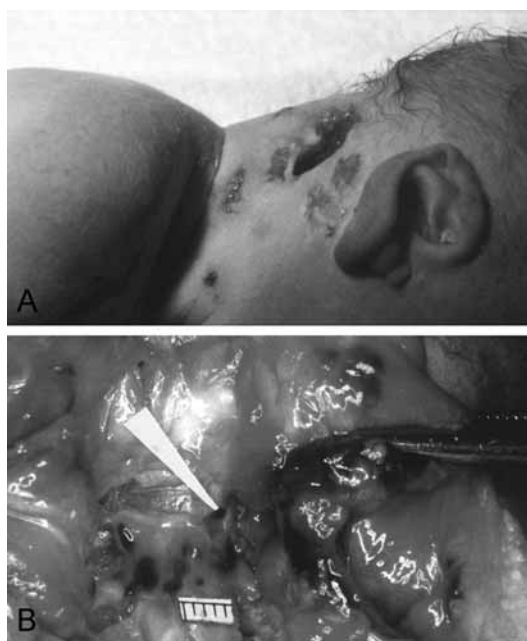
**Fig. 11.** Multiple stab wounds. Inferior wound “notched” (arrow) owing to twisting of knife blade. (Courtesy of the Office of the Chief Medical Examiner, Chapel Hill, NC.)



**Fig. 12.** Multiple stab wounds of different sizes. Large wound resulting from considerable twisting of knife blade. (Courtesy of the Office of the Chief Medical Examiner, Chapel Hill, NC.)

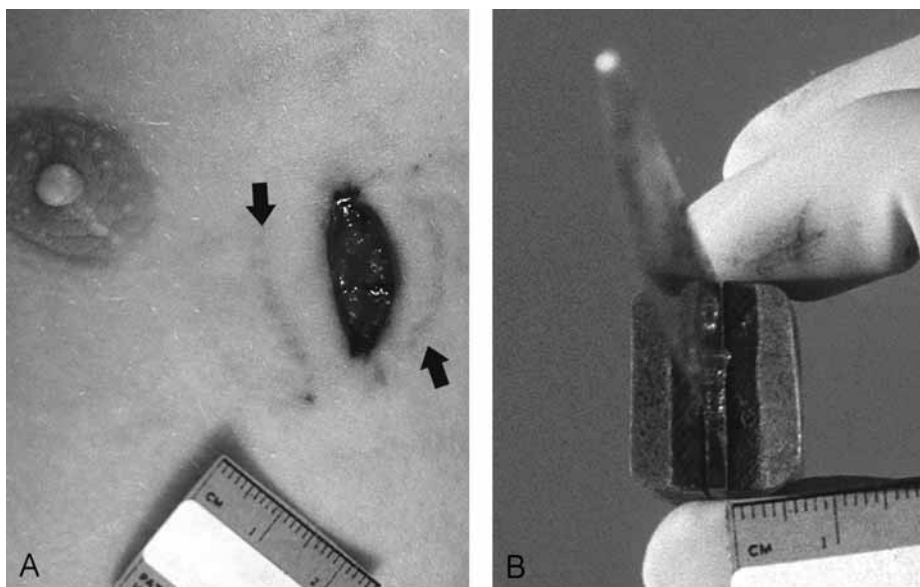


**Fig. 13.** Homicide. (A) Single stab wound on back. (B) Wound track continued into apex of right lower lobe of lung (arrow). (C) Multiple tracks at base of right lower lobe (arrows) indicating multiple insertions through same stab wound.



**Fig. 14.** Infanticide. Multiple stab wounds. (A) Stab wound, right neck. (B) Posterior neck dissection. Wound track extended into cervical spinal cord (autopsy arrowhead). Hemorrhage along track indicates victim was alive when wound inflicted.

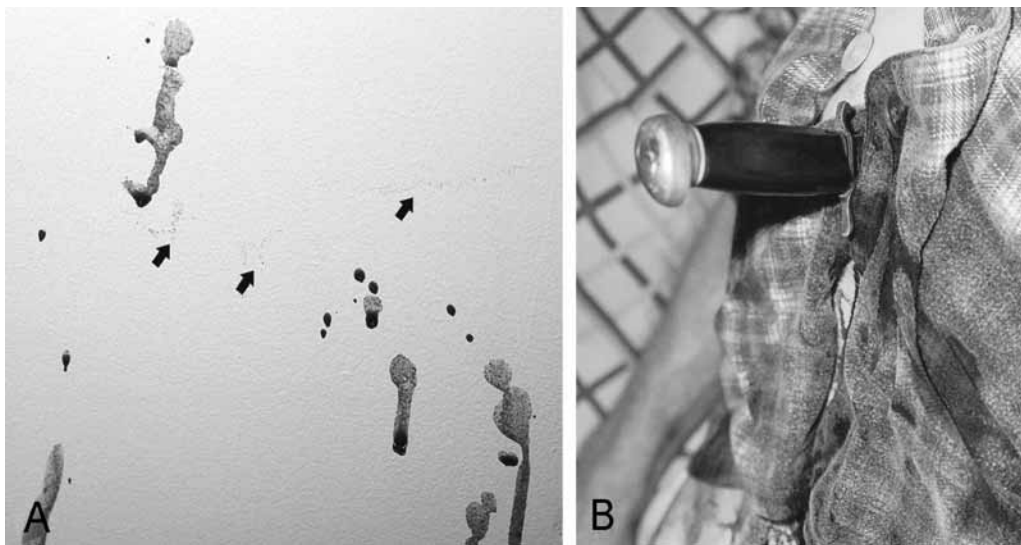




**Fig. 15.** “Hilt” mark caused by forceful thrusting of knife. Depth of wound exceeded length of blade. **(A)** Single stab wound of chest. Note two linear bruises (arrows) on either side of wound. **(B)** Bruises were caused by edges of wooden handle of knife that was forcefully thrust into victim.

the most important factor in allowing penetration. The pressure exerted by a single finger can be enough (77–79). A blunt tip requires more pressure and increases the possibility of associated blunt trauma injuries. Except for bone and calcified cartilage, skin has the greatest resistance to penetration. Once the skin is penetrated, little force is needed to penetrate further (77,78,80). Regional differences in penetrability exist (77). For example, the intercostal spaces are penetrated more easily than the upper abdomen because the tissues are more tightly stretched. Others have observed, using cadavers and amputation specimens, that there is significant resistance when muscle is penetrated (79,81).

- For a knife held either against the skin surface (stationary) or up to 15 cm (6 in.) away, 0.5 to 3 kg (1.1–6.6 lb) of pressure (0.5–3 N of force) is required to penetrate chest and abdominal skin (15,77,78). Knight observed the abdominal wall of an average-sized cadaver, when leaned forward 10 cm (4 in.) onto a firmly held knife, was easily penetrated supporting the scenario of “running onto” a knife (77). Green found that the skin of cadavers was also easily stabbed when a knife was held 15 cm (6 in.) away and suddenly pushed from behind (the “accidental stumble” [78]). A case report described a 42-yr-old man who committed suicide with a dagger (2.72 kg or 6 lb), which fell freely from a height of 10 cm (4 in.), penetrated the chest, and pierced the lung to a depth of about 12 cm (4.75 in.) [15]. More force is generated when a knife is moving. Greater mean terminal velocity and energy are generated in overarm stabs compared with underarm stabs (82,83). Stabs inflicted perpendicular to the skin surface generate more force than angled thrusts (80).
- Instruments with pointed tips can penetrate fabric, when held by one hand, but pressure from both hands is required when using a less sharp object (e.g., screwdriver



**Fig. 16.** Stabbing suicide. (A) Victim braced knife against wall. Note faint gray marks (arrows), adjacent to blood spatter, from metal transfer from handle of knife. (B) Knife in body. Note gray metal at the end of the handle of knife.

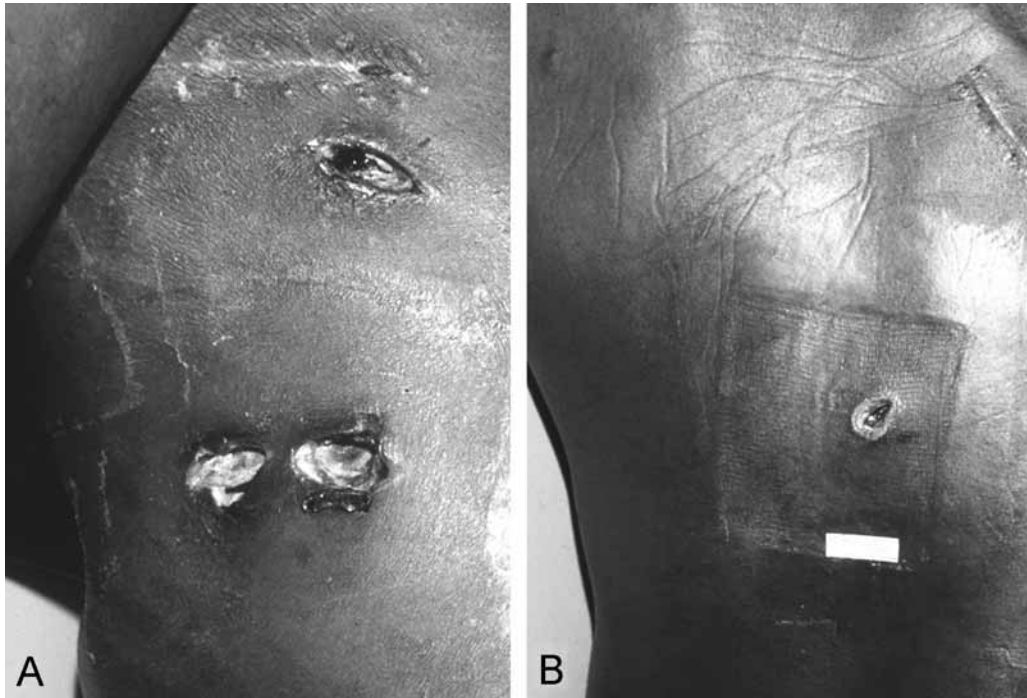
[84]). A blunt weapon can injure skin without penetrating fabric, which can embed in the wound. Cuts with frayed edges imply a blunt or serrated weapon, but blood can bind fibers, causing edges to appear “neat.” Green observed that pressure of 2 to 3 kg (4.4 to 6.6 lb), using a sharp weapon, could penetrate clothing (78).

- More effort may be required to remove a knife from a body (up to 15 kg or 33 lb of pressure in clothed cadavers [78]). This has implications regarding intent, if more than one wound is present (78). On the other hand, large forces were not required to remove a sharp blade from pig skin (79).
- **Medical care:** Prolonged hospitalization means wounds heal (Fig. 17). Medical interventions (e.g., thoracotomy) alter and create wounds (e.g., chest tube insertion; see Figs. 17 and 18). The pathologist must obtain accurate information from the medical record and clinical team to confidently assess the injuries observed.

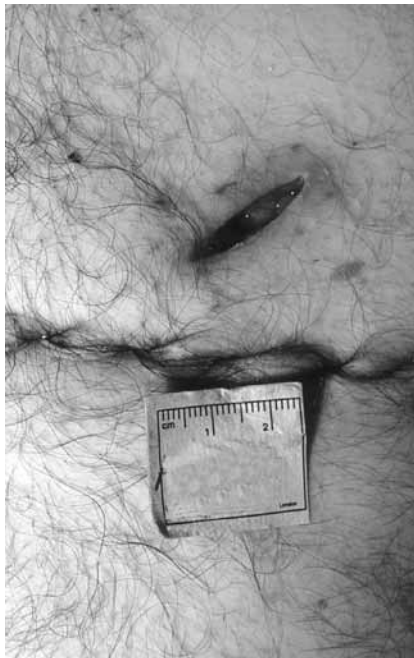
#### 4. OTHER FEATURES ON EXTERNAL EXAMINATION OF SHARP-FORCE INJURIES (TABLE 1)

##### 4.1. Clothing

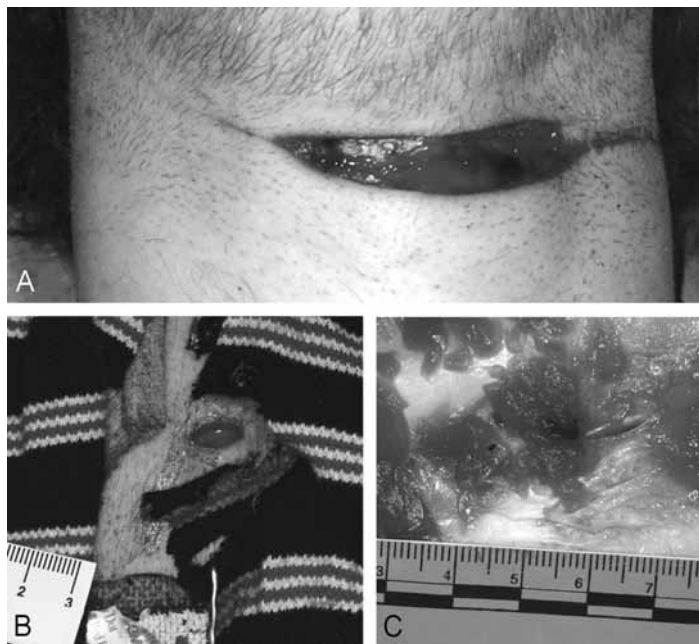In homicides, clothing is usually involved but is pushed aside in some victims (e.g., children [6,23]). In suicides, the victim tends to bare the skin by moving clothing aside; however, clothes can be involved (Fig. 19; refs. 2, 6, 7, 10, 13, 23, 85, and 86). Clothing tears may provide the only clue of tentative attempts at self-infliction, particularly when there are few skin injuries. This highlights the need for the pathologist to examine the clothing of the deceased, not only to match holes in the fabric with cutaneous wounds but also to appreciate that additional clothing tears can be present without corresponding skin injuries. Pieces of clothing can be forced into a wound track by impalement (46).



**Fig. 17.** Delayed death from sepsis following multiple stab wounds. **(A)** Multiple healing chest tube insertion sites. **(B)** Healing stab wound on back inflicted during altercation. (Courtesy of the Office of the Chief Medical Examiner, Chapel Hill, NC.)



**Fig. 18.** “Stab” wound, above thoracotomy incision, from chest tube insertion.



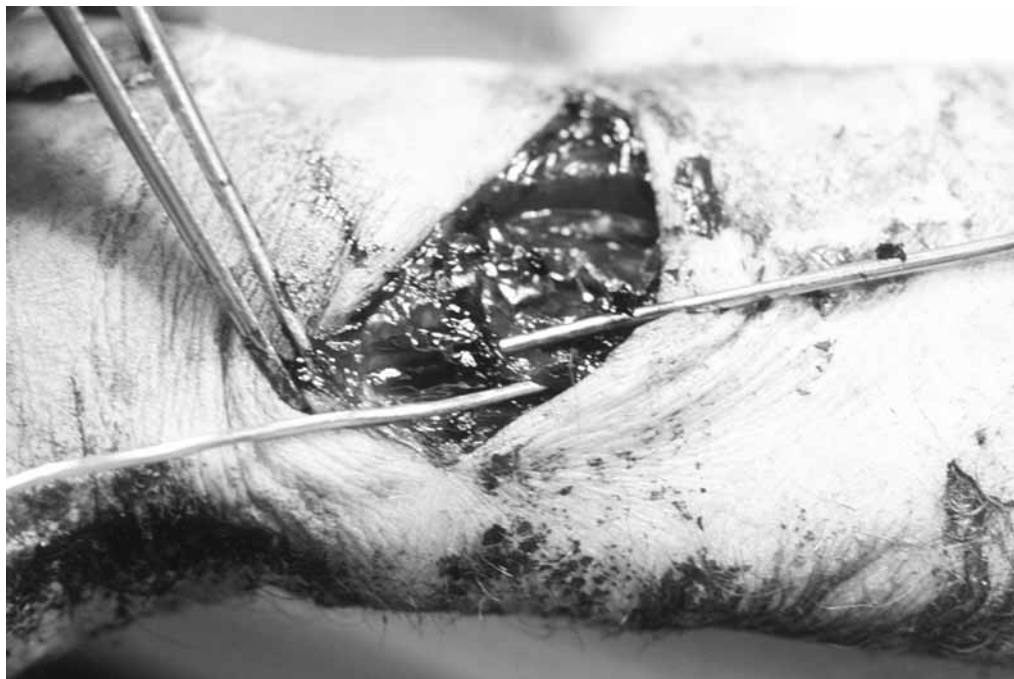
**Fig. 19.** Suicide by stabbing. (A) Superficial incision, neck. (B) Fatal stab wound of chest inflicted through shirt (indicated by probe). (C) Knife penetrated sternum. (Courtesy of Dr. E. Tweedie, London Health Sciences Centre, London, Ontario, Canada.)

#### 4.2. Number, Orientation, and Grouping

Single fatal stab wounds tend to involve the chest in homicides and suicides (6). Suicides with multiple wounds typically show extremity injuries (6). Multiple mutilating injuries suggest homicide (17). Ninety-eight wounds were seen in one homicide victim (3). One study revealed that suicide victims averaged 14.4 sharp injuries, compared with homicide victims who had a mean of 8.8 (average number of stab injuries/person, suicides = 6.8; homicides = 5.6; average number of cut injuries/person, suicides = 15.0, homicides = 3.5) (8). A significant number of suicide cases have more than one wound, but a single injury does not exclude a suicide (8,12,13,22). Single self-inflicted stab wounds of the extremities (e.g., involving the femoral artery) have been observed (8). Single incisions (e.g., radial or ulnar artery at wrist level) have been noted in suicides (Figs. 20 and 21; ref. 13). Single suicidal stab wound cases involving the abdomen are described (*see* Subheading 4.3.1; Fig. 6; ref. 8).

Vertical chest stab wounds tend to be seen in homicides (6,87). In a Stockholm study, homicidal stab wounds tended to be vertical and directed up and to the right of the deceased, whereas self-inflicted wounds were more likely horizontal and directed up and to the left of the victim (Fig. 22; ref. 13). The difference between the number of horizontal wounds in the chest in homicides and suicides was not significant in one series, but another study found that the majority of self-inflicted stab wounds to the left chest were aligned horizontally (6,9). The usual suicidal neck stab is downward (10). Suicidal stab wounds to the upper abdomen can be considered stabs to the heart, as the tracks are usually directed upward (9).





**Fig. 20.** Exsanguination caused by self-inflicted wrist incision involving radial artery (indicated by inserted probes).

The determination of the direction of infliction of an incised wound is problematic (88). Incised wounds tend to be deeper at their origin becoming more superficial at their terminal ends, but this is not invariable (*see* Subheading 4.4.; Fig. 23; and ref. 88). By scanning electron microscopy, a lateral accessory tail has been described at the origin of an incision, particularly noticeable when the wound direction is perpendicular to Langer's lines (88).

Self-inflicted wounds tend to be grouped in one area of the body (Fig. 22; ref. 10).

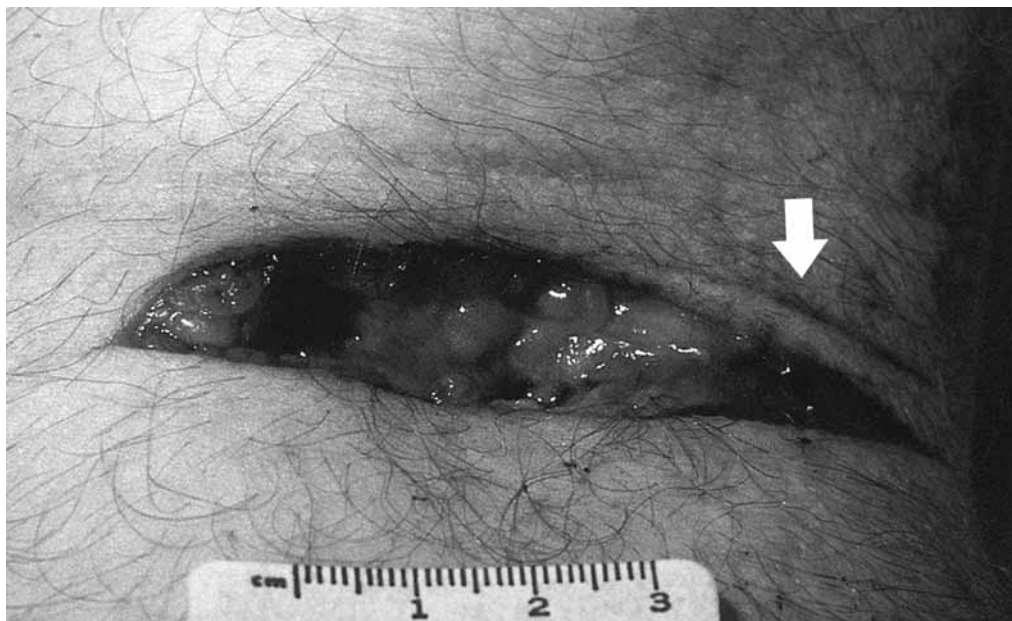
### 4.3. Wound Site

Wound sites, according to manner of death, are described in Table 1.

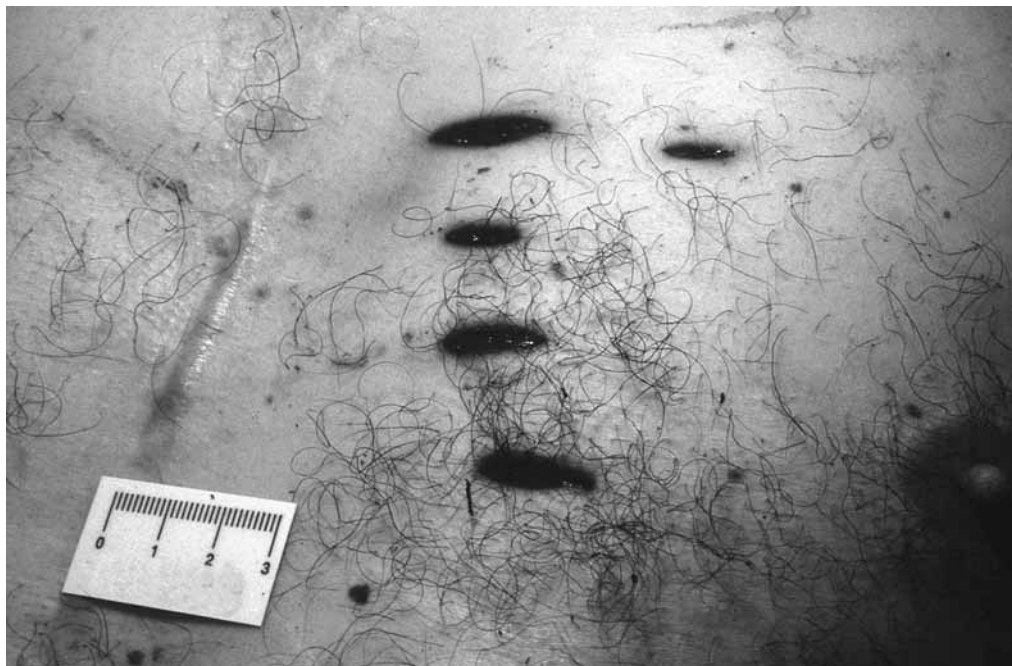#### 4.3.1. Hara-Kiri

Hara-kiri (*hara* = belly, *kiri* = to cut), a traditional form of suicide in Japan, is an uncommon type of self-inflicted abdominal wound (27,85). Classically, the victim thrusts the blade of a sword into the lower left quadrant of the abdomen, then cuts horizontally to the right, followed by an upward cut (27,85,89). The result is a painful L-shaped wound in the abdominal wall but no injury to the underlying viscera (85,89). Death is delayed and subsequent self-inflicted cuts of the neck, chest, and upper extremities hasten the demise of the victim (18,27,85,89). Traditionally, assistants were present to behead the individual following the abdominal incision (18,27). Individuals engaged in this ritual may have a psychiatric disorder or be intoxicated (85).

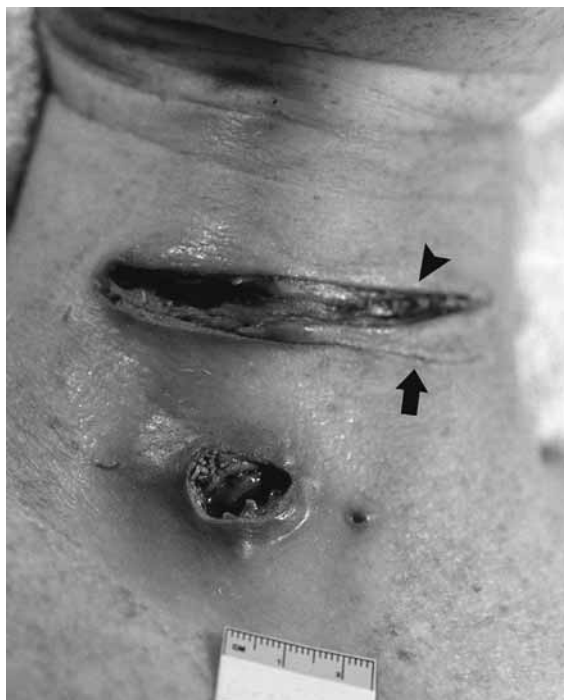



**Fig. 21.** Self-inflicted incised wound of antecubital fossa. Note superficial incision (“hesitation” wound; arrow) running parallel to deep wound.



**Fig. 22.** Precordial grouping of multiple self-inflicted stab wounds. All have a horizontal orientation.

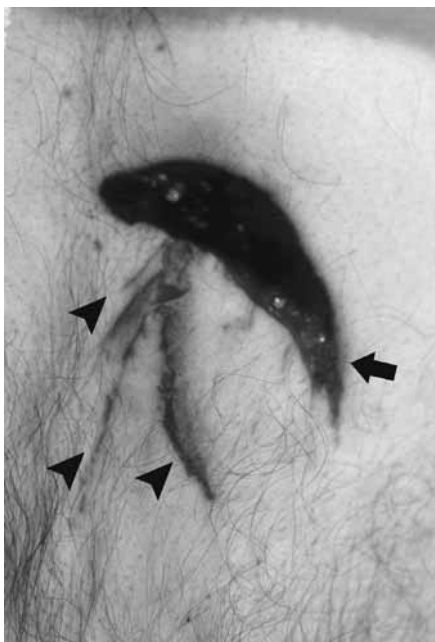

**Fig. 23.** Self-inflicted stab and incised wounds of the neck. Deep incision shows a “superficial tail” (arrowhead) and an adjacent superficial cut (“hesitation” injury; arrow).

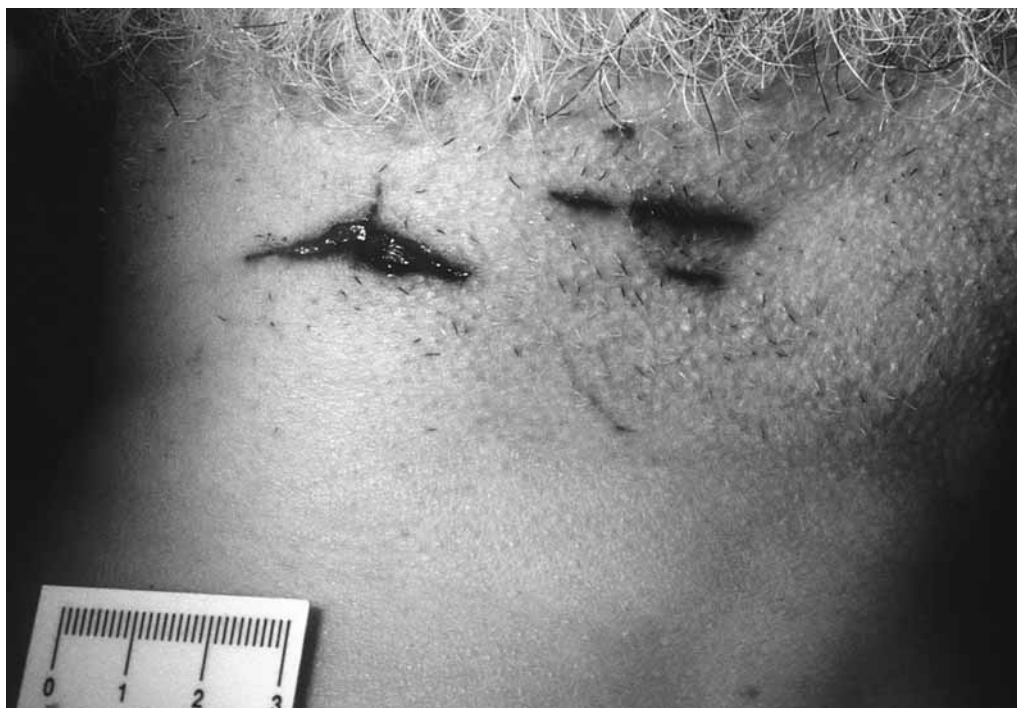#### ***4.4. Hesitation and Defense Injuries***

Tentative or “hesitation” injuries are self-inflicted sharp-force injuries. They are characterized by superficial incised or stab wounds usually, but not always, near the deeper fatal injury (Figs. 19, 21, 23–26 and refs 6, 8, 13, 16, 17, 23, 85, and 86). Superficial cuts run parallel to each other and extend as deep as the subcutaneum (16,90). Small punctures can be clustered together near a stab wound and be associated with bruising (16). A stab wound can be associated with a linear abraded tail or deeper incision (Fig. 24) (16). A greater number of hesitation marks is seen when more than one site is involved (16). Superficial cuts can be seen on the fingers of a suicide victim and mimic defense wounds (5,6,9,16,27). They are the result of mishandling of a knife or other sharp instrument (e.g., razor [10,16]). Tentative wounds have been seen on the skin of murdered children and rarely adults, incapacitated by disease, intoxication, or other trauma (6,17,23,90). Hemorrhage, associated with tentative wounds, indicates that the injuries were inflicted while the victim was alive. Superficial or deep hesitation wounds are observed in self-inflicted wounds with power tools (e.g., band or circular saw; see Fig. 5 and refs. 65 and 69).

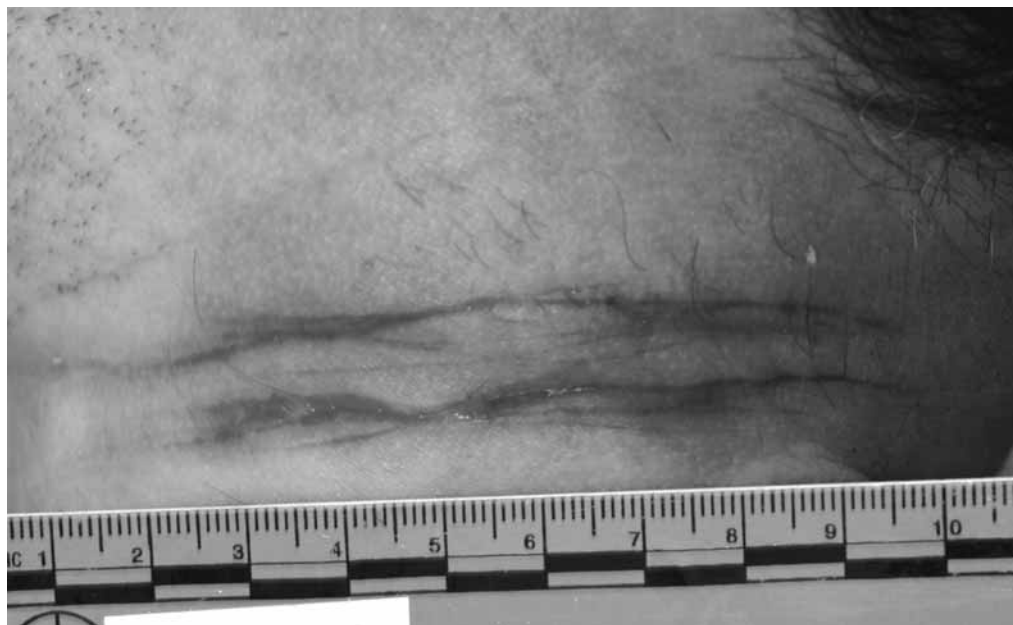
Defense wounds are sharp-force injuries typically of the extremities, usually involving the hands and arms, and they are consistent with the victim moving a part of the body between a sharp object and a potentially lethal body target, e.g., torso (Fig. 27; refs. 3 and 8). A knife can be grabbed by the victim (Fig. 28). A greater frequency of defense injuries is seen in women, because they may be more likely to be in protracted domestic disputes and ready to defend themselves (3).



**Fig. 24.** Self-inflicted abdominal wound. Deep wound has a “superficial” abraded tail (arrow). Note superficial incisions indicative of “hesitation” injuries (arrowheads).



**Fig. 25.** Superficial self-inflicted stabs of neck (“hesitation” wounds).



**Fig. 26.** Superficial “hesitation” incisions of neck. (Courtesy of Dr. E. Tweedie, London Health Sciences Centre, London, Ontario, Canada.)

#### ***4.5. Homicide or Suicide?***

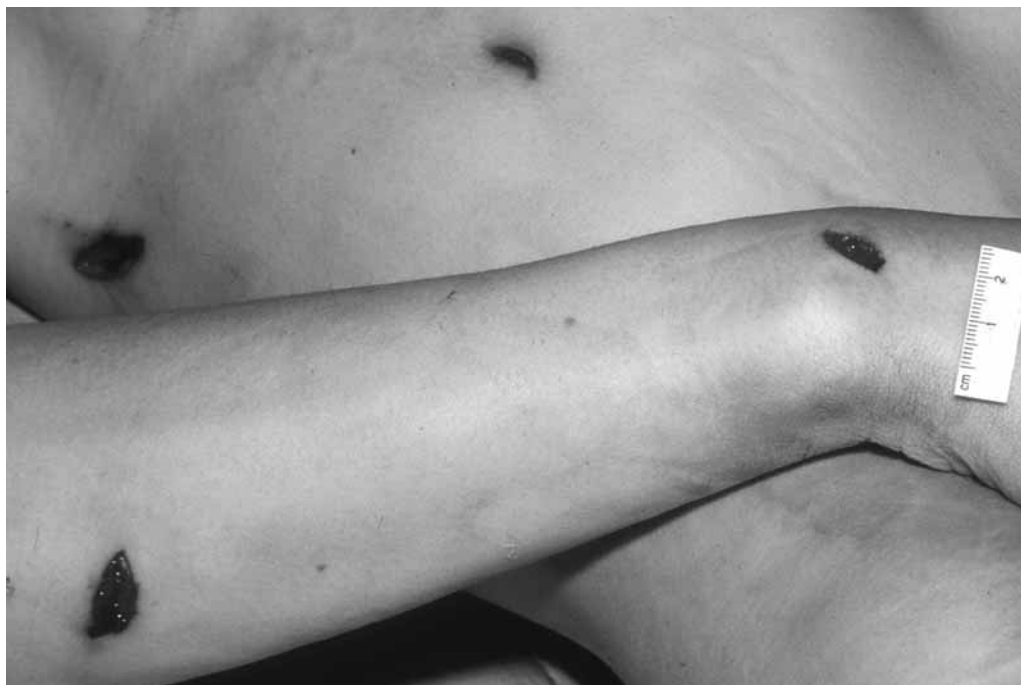Karlsson, using a model based on multivariate analysis, showed that positive predictors of homicidal stabbings were in descending order: injuries to clothing, blood alcohol level, presence of defense injuries, injuries owing to other types of violence, vertical chest stab wounds, sharp-force injuries to the upper extremity (except wrist and antecubital fossa), and sharp-force injuries to the head and back (91). Ranked in increasing positive correlation with deaths caused by suicidal stabbing were sharp-force injuries to the antecubital fossa (crook of the arm), death scene in the victim's home, presence of a suicide note, victim's age, sharp-force injuries to the wrist, known suicidal ideation, and the presence of tentative injuries (91).

### ***5. SELF-WOUNDING AND SELF-MUTILATION***

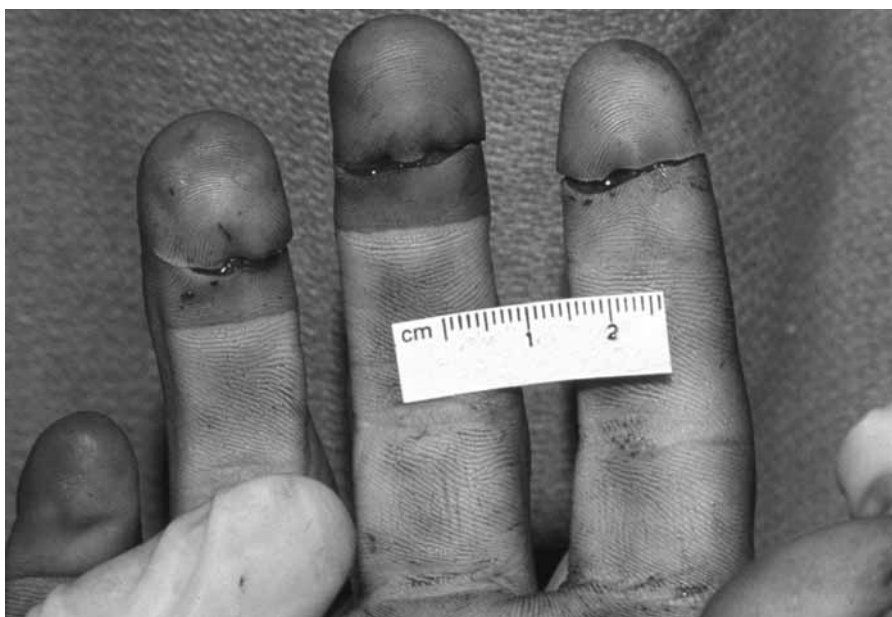Professional and self-administered body modifications (e.g., body piercings for insertion of jewelry in the tongue, nipples, and genital area) are coincidental observations at autopsy (56,92). Their presence is influenced by social, cultural, or religious customs (93–95).

Self-inflicted cutting can be part of either psychotic or nonpsychotic destructive behavior and is enhanced by alcohol or drug abuse (Fig. 29; refs. 56, 93, and 95–101). Self-cutting also occurs as a religious ritual or as a means for personal gain (e.g., malingering, insurance fraud [56,64,93,95,96]). Self-wounding of the skin of the extremities (e.g., wrist slashing) is common (56,99,101). Self-wounding injuries are usually relatively minor. Superficial skin wounds in less pain-sensitive areas are observed, and



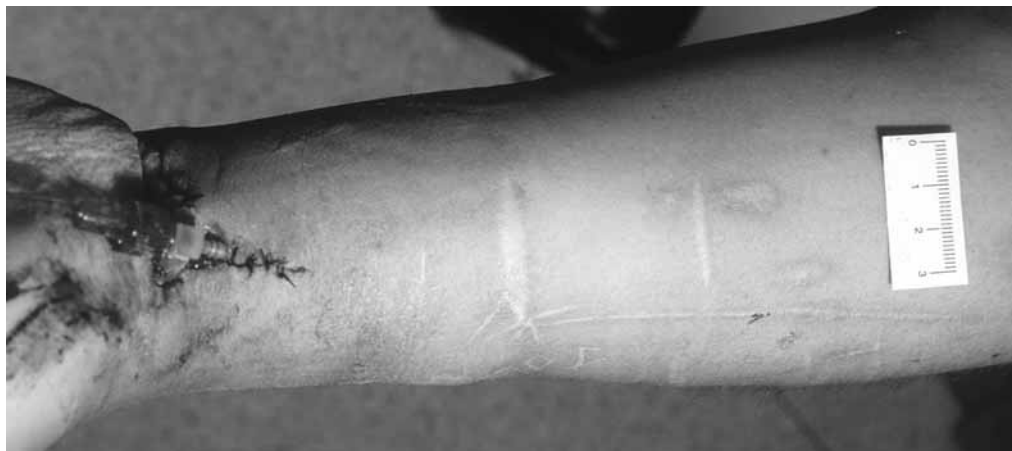

**Fig. 27.** Homicide. Multiple stab wounds. Wounds on arm indicative of victim's attempt at protection ("defense" injury). (Courtesy of the Office of the Chief Medical Examiner, Chapel Hill, NC.)



**Fig. 28.** Defense wound. Victim reached for knife, sustaining cut across fingers. (Courtesy of the Office of the Chief Medical Examiner, Chapel Hill, NC.)





**Fig. 29.** Death during hospitalization from acetaminophen toxicity. Radial line insertion. Multiple linear and irregular scars on forearm from previous self-wounding.

evidence of repetition is indicative of reactive or habitual activity (95,96,98). Some individuals inject drugs (e.g., lidocaine) to achieve analgesia (102). These injuries are not necessarily suicidal, although they are seen in fatal suicides by various means (Fig. 30; refs. 10, 56, 95, and 97). Healed wrist incisions indicate past suicide attempts and alert the investigator that a death may be a suicide (Fig. 31; refs. 7 and 12).

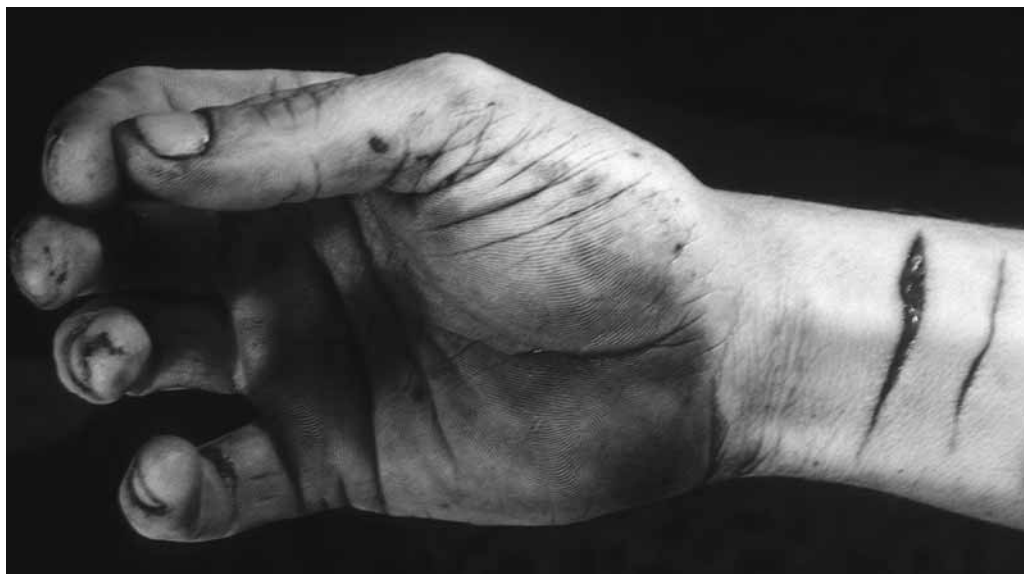More mutilating injuries, usually associated with psychosis, result in a major anatomical change affecting vital structures, require surgical intervention, and can cause death (Fig. 32; refs. 56 and 99). Some individuals have nonpsychotic disorders (94). People who are either intoxicated or demented can also self-mutilate (95,99). Self-mutilation can be part of Munchausen syndrome (56,95,96). Psychotic individuals can sustain unusual injuries: ocular trauma due to self-enucleation, sharp-force trauma or fingernail gouging, autoamputation, perforation of viscera by instrumentation, penetration of the skull, and castration (*see* Subheading 6.2. and refs. 53, 54, 56, 94, 99, 103, and 104). Autoamputation of an arm using either a kitchen knife or electric saw has been described (69,103).

Genital self-mutilators fall into three groups: psychotics (schizophrenics), transvestites, and patients with complex religious or cultural beliefs (93). These cases typically involve men (93). Women may mutilate their genitals to achieve abortion (93). A case of self-inflicted trauma by the insertion of needles through the abdominal wall to trigger abortion has been described (105).

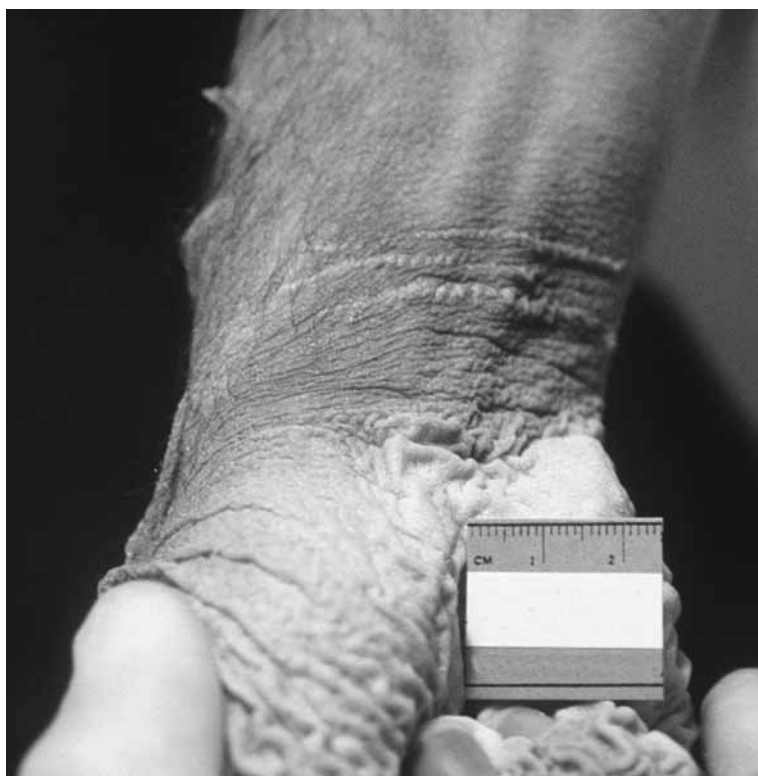
## 6. INTERNAL EXAMINATION

### 6.1. Skeletal and Cartilaginous Injuries

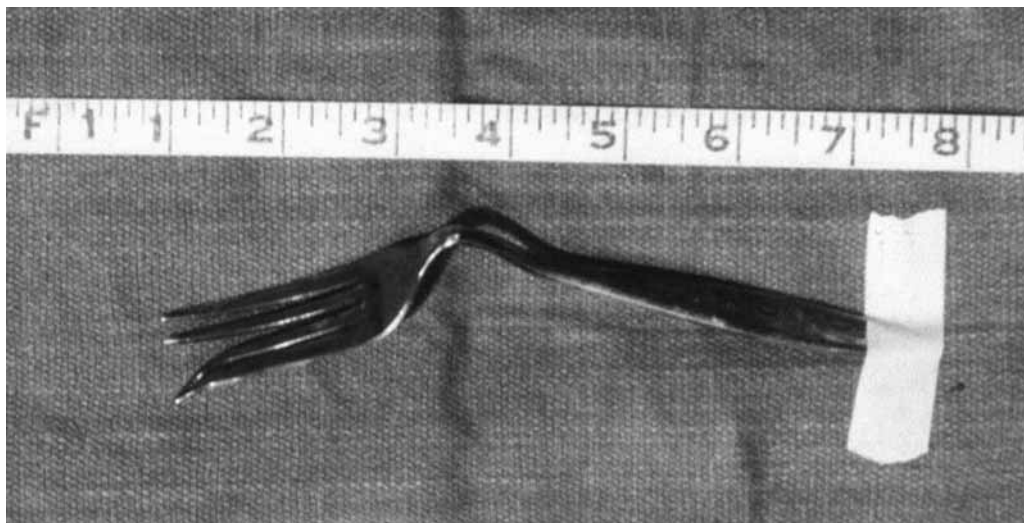
Bone and cartilaginous injuries are seen in homicides and suicides (6,106). Costal and sternal injuries were seen less frequently in homicides involving children (23). Chest wall injuries are more likely when multiple skin wounds are evident (106). The anatomic site of bone/cartilaginous wounds usually corresponds to the site of injuries responsible for death (106). In one study, laryngeal cartilage trauma occurred in cases of homicide and suicide,



**Fig. 30.** Recent self-inflicted wrist incisions. Suicidal shotgun wound of chest.



**Fig. 31.** Healed wrist incisions. Found dead in bathtub (pronounced wrinkling of hand resulting from water immersion). Diphenhydramine overdose.



**Fig. 32.** Schizophrenic. Self-inflicted head wounds from insertion of fork. Eye gouged and vertex of cranium penetrated causing subdural hemorrhage. The latter act bent the fork.

but injuries of the ribs, vertebrae, and skull were limited to homicides (*see* Subheading 6.2. and refs. 23 and 106). Injured ribs and sternal bone penetration/transection are possible in suicides (Fig. 19). Sternal transection has been described in severely mentally ill individuals (6). Rib and sternal wounds may have associated intercostal or internal mammary artery injuries (*see* Chapter 8, Subheading 6.1. and refs. 38, 73, and 107).

Tool classification is possible in the assessment of knife wounds involving rib cartilage (108). The consequent striations may have only general class characteristics, but small imperfections in the knife can produce individual marking patterns (108,109). These striations can be matched with the cutting edge of the knife using specialized techniques (109). Bone and cartilage from the injury site can excised and retained in formalin fixative (109).

## **6.2. Craniocerebral Trauma**

### **6.2.1. Skull Trauma**

Homicidal stab wounds of the head have been described (110). Self-inflicted penetration of the calvarium is rare (*see* Subheading 2.3; Fig. 32; ref. 14). Multiple hammer-type impacts against a braced knife may occur. A sharp-pointed object (e.g., nail) can be hammered into the head (111). Impalement through the skull by various objects has been described (e.g., pencil, crowbar [45,112]). Sharp objects readily penetrate the relatively thin squamous temporal bone in a fall (45). Power tools (e.g., band or circular saw) have caused self-inflicted cranial injuries (Fig. 5; refs. 65 and 69). An accidental power tool injury has mimicked a gunshot entry (67).

### **6.2.2. Transorbital Penetration**

Transorbital penetration into the brain is uncommon (54,113). The majority of cases are accidental, involving children or adults falling or slipping onto impaling

objects (e.g., pencil [7,11,31,53,54,110,113–118]). Suicides have been described (117,119,120). Homicidal sharp-force trauma can be inflicted on the eyes (52).

The penetrating object is usually greater than 5 cm (2 in.) long because the depth of the average adult orbital cavity (4 to 4.5 cm or about 1.75 in.) must be transversed before the cranium is penetrated (52,117). The orbital cavity anatomy directs objects along the medial wall (52). The globe is farther from the medial wall than the lateral (medial distance = 6.5 mm or about 0.25 in., lateral distance = 4.5 mm or about 0.2 in. [52]). The track can continue through the superior orbital fissure or thin orbital plate (52,77,114,117). Because of the toughness of the sclera and the mobility of the eye, the globe is usually spared, but trauma does result from larger objects (117–119). After an object penetrates the superior orbital fissure, it is directed to the cavernous sinus beneath the frontal lobe, and continues medial to the temporal lobe, above the petrous ridge and lateral to the brainstem (52,119). The carotid artery and optic nerve can be injured (119). Accidental wounds tend to travel up into the frontal lobe (119). A self-inflicted wound tends to track toward the posterior cranial fossa (117,121).

A transorbital injury can be invisible externally, particularly when periorbital swelling occurs and becomes manifest only when neurological symptoms develop (118,119). Radiological investigation (X-ray, CT) reveals radiopaque objects (122). MRI can delineate a wooden foreign body (123).

Trauma to the orbit can lead to fatal arrhythmia by vagal inhibition through various reflexes: oculocardiac, blepharocardiac, and trigeminocardiac (124–126).

### 6.2.3. Other Cranial Orifices (Fig. 33)

Impalement injuries of the palate are rarely associated with death (127). A typical scenario is a child falling forward while holding an object in its mouth (127). Injuries in the peritonsillar area can lead to internal carotid artery thrombosis (127).

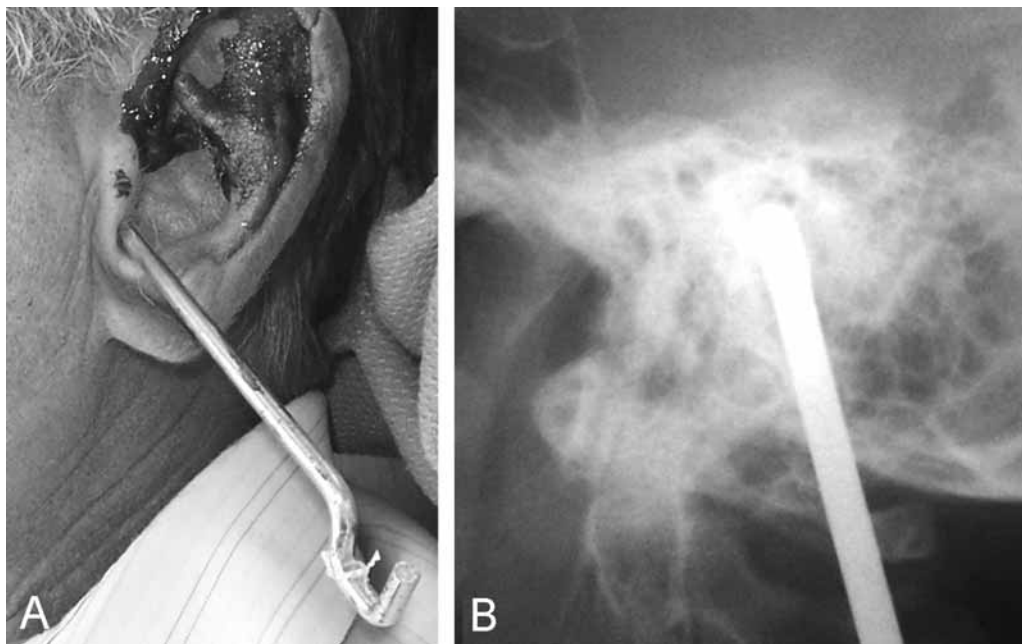
Transnasal insertion of a ballpoint pen has been observed (120).

## 7. PURPOSEFUL ACTIVITY AND SURVIVAL

Varying degrees of purposeful activity are possible prior to death (91).

One study documented physical activity in only 21% of sharp-force fatalities (128). Survival times from 5 min to 42 h were seen in some victims, although activity was generally limited (e.g., ascending a staircase prior to collapse [128]). Another series showed that some physical activity was possible in fatal stab wound cases, based on reliable witness accounts (28). Suicide victims may anticipate a severe injury and can be more physically active than homicide victims, who are frequently taken by surprise (28). Ethanol intoxication does not necessarily affect activity and survival time (128).

Victims are more likely to die immediately when there is a penetrating injury of the heart; however, hemodynamic instability following cardiac injury depends on a number of factors (see Heading 8 and refs. 73 and 128). Other vascular injuries (e.g., aorta) can contribute to shock (73,129). Injury of a coronary artery can precipitate myocardial ischemia (73). The location of the pericardial defect may allow sealing by adjacent mediastinal structures. If the pericardial hole is small, blood is less likely to escape into the pleural cavity. Cardiac tamponade is significant when a volume of 150 to 200 mL is reached (128). A slit-like stab wound, compared with the gaping defect

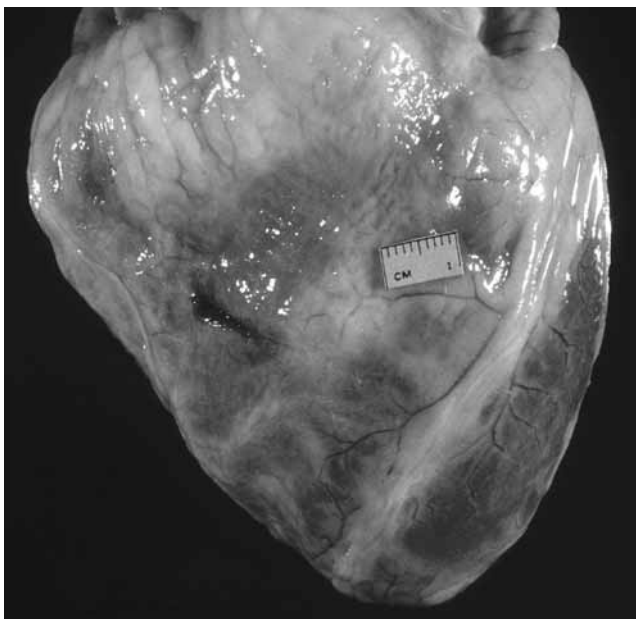


**Fig. 33.** Self-inflicted stabbing. An additional injury was seen in addition to a fatal chest wound. **(A)** Impalement of rod in ear; cranium not penetrated. **(B)** Radiograph shows position of rod. (Courtesy of Dr. E. Tweedie, London Health Sciences Centre, London, Ontario, Canada.)

of a gunshot hole, means the myocardium can contract and narrow the defect ([Fig. 34](#); ref. [28](#)). A hole in the ventricular myocardium less than 1 cm (about 0.5 in.) long can close spontaneously. Small perforations (0.7 to 1 cm; 0.25 to 0.5 in.) of the myocardium, compared with larger holes (up to 2 cm or 0.75 in.), are associated with a longer survival ([28](#)). Compared with gunshot wounds, survival time of victims from sharp-force trauma is longer and mortality lower ([28,130](#)). In a study of penetrating cardiac wounds, stabbing victims were more likely to reach the hospital ([73](#)). Despite a penetrating heart injury, even in the face of multiple injuries, purposeful activity is still possible for a short time ([128](#)). One case report described a suicidal stab wound to the chest that resulted in six stab wounds (0.5 to 1 cm or up to about 0.5 in. long) of the anterior left ventricle. Three hundred milliliters of blood collected in the pericardial cavity, and the left and right chest cavities contained 320 and 90 mL of blood, respectively. The 44-yr-old male victim was able to wash the knife, changed his bloody clothes, ate lunch in the presence of a relative and died 2 h later ([131](#)).

Transection of unilateral carotid and vertebral arteries leads to collapse within seconds, but if blood flow is not completely disrupted on one side, then physical activity is possible for several minutes ([28](#)). Exsanguination from a peripheral vein (e.g., great saphenous vein) is a rare event, and survival for several hours is possible ([28](#)). A 49-yr-old woman was found hanging after walking 100 m (330 ft) from a car where a knife was found. She had three chest wounds that punctured the lungs and incised her right internal jugular vein ([132](#)). Similarly, transection of peripheral arteries can be survived up to several hours ([28](#)).





**Fig. 34.** Slit-like stab of heart.

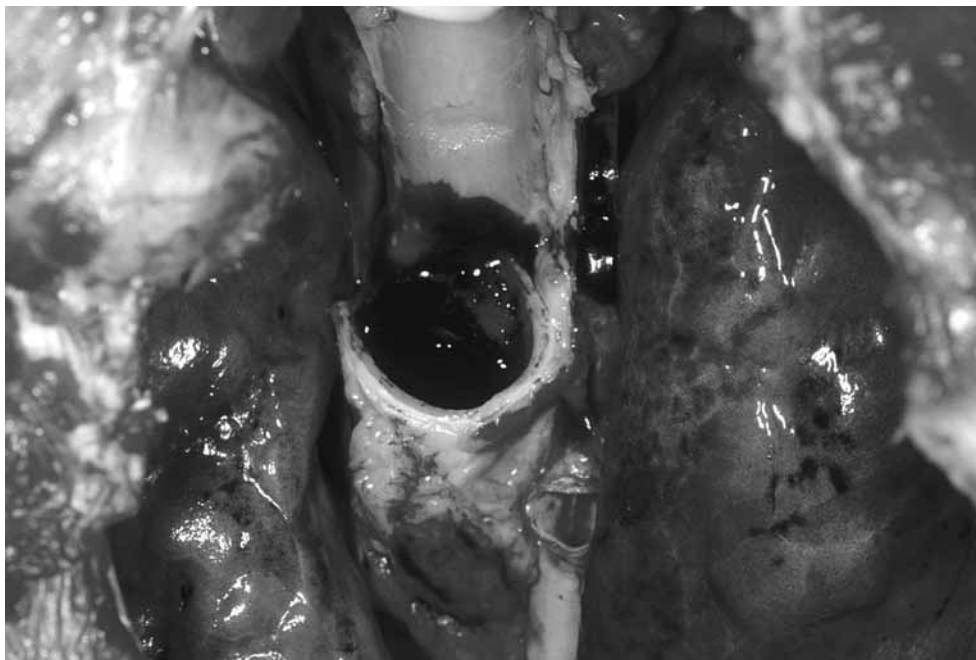Individuals can survive for hours with other multiple visceral injuries (liver, kidney, lungs), if the heart and great vessels are uninjured ([128](#)).

Internal bleeding may not be massive in victims dead at the scene; however, victims surviving longer can have considerable blood loss ([128](#)). Blood loss up to 1.5 L can be tolerated without unconsciousness ([128](#)). The amount of external blood loss can be estimated by weighing blood-soaked clothing and other linen articles and then reweighing them after washing ([26](#)). Evidence (e.g., DNA analysis) from these items takes priority.

## 8. MECHANISMS OF DEATH

Stab and incised wounds are “low-velocity” injuries, and the consequences are usually limited to the direct effects of a discrete wound track. Wound tracks require exploration to determine the cause of death based on the location of the wound and associated bleeding, i.e., quantitation of blood in cavities. Mechanisms of death include:

- Shock owing to exsanguination.
- Air embolism (when neck structures are involved; *see* Subheading 12.1; Chapter 5, Subheading 14.8.; and refs. [11](#), [73](#), and [129](#)).
- Asphyxia from aspirated blood (e.g., injury to lung, trachea or vertebral artery [[Fig. 35](#); refs. [15,19](#)]).
- Cardiac tamponade.
- Hemo- and/or pneumothorax.
- Brain and spinal cord injury ([Fig. 14](#); refs. [9](#), [11](#), [31](#), [32](#), [90](#), [133](#), and [134](#)).
- Delayed complications—marked hypotension during the immediate postoperative period; various postoperative complications including pulmonary embolism, pneumonia, wound sepsis ([Fig. 17](#)), rebleed, and cardiac ischemia ([73](#)); meningitis from skull wound ([119](#)).



**Fig. 35.** Stab wounds of neck. Trachea opened at autopsy. Lumen filled with blood.

Pathologists must be aware of the immediate and proximate causes of death in these cases (*see* Chapter 1, Heading 11).

### *9. PATHOLOGIST'S APPROACH TO STAB AND INCISED WOUNDS*

1. Photograph the body overall prior to removal of clothing. Note evidence of blood spatter.
2. Removed clothing is retained as evidence. Document holes and tears in clothing and correlate with cutaneous wounds.
3. Photograph unclothed body, including the injuries, prior to cleaning.
4. Note sharp-force injuries:
  - a. Length, width, and depth. If the wound is gaping, appose its edges and remeasure the length. The depth of the wound can be probed gently to determine direction (in relation to the deceased), realizing this may be revised when the wound track is explored internally.
  - b. Orientation of wound (horizontal, vertical, oblique) relative to the deceased.
  - c. Ends of wound—sharp or dull? Are there associated sharp or blunt trauma injuries?
  - d. Position of wound is measured from the top of the head, midline of the body, and an anatomical landmark. If there is more than one wound, they can be numbered arbitrarily.
5. Examine the remainder of the body, particularly the hands.
6. A radiograph of the injured body site must be done to exclude a broken knife tip.
7. Clean the body and re-examine the wounds. Photograph the wounds.
8. If the knife is *in situ*, protect it with a plastic bag during the examination. Attempt to determine the location of the knife tip during the dissection.

9. Document wound tracks, the presence of hemorrhage, and quantity of blood in cavities.
10. Document other types of injuries and evidence of disease.
11. Collect toxicology specimens. Collect a sample of blood for DNA analysis, if necessary.

## 10. DOG BITES

Deaths from dog attacks are rare (estimated 10 fatalities per year in the United States [135,136]). Although severe injuries are associated with large dogs (e.g., pit bulls, Rottweilers, German shepherds), any size dog can cause significant bites (136–140). Young (aged 1 to 5 yr) male dogs are more likely to bite people (140). The vulnerability of the victim is a factor. The majority of victims are young children or elderly individuals (135–143). Sleeping infants have been attacked (136,137).

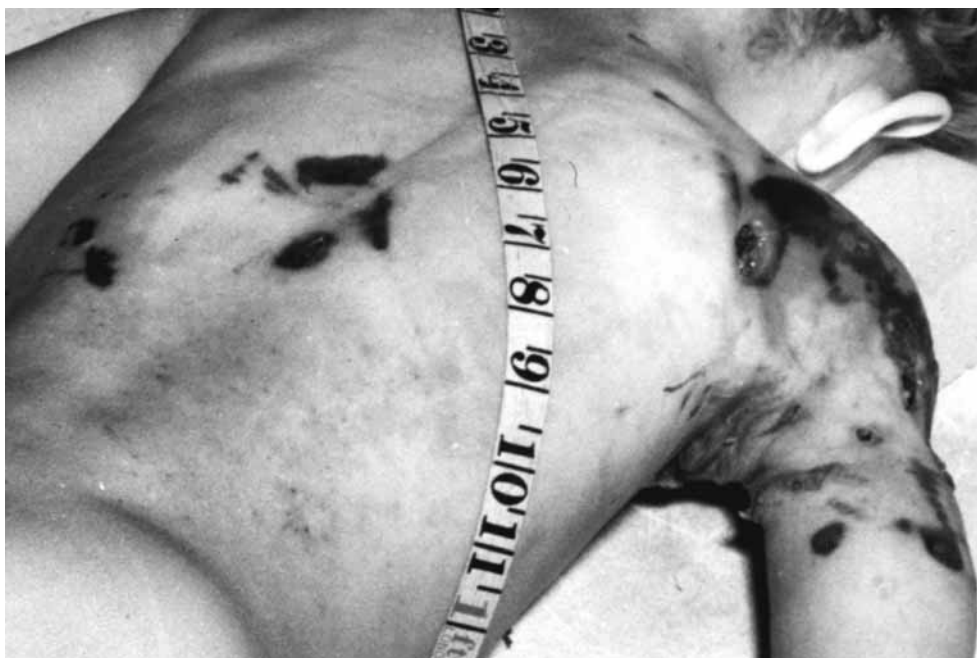Pet dogs are involved in most attacks (138,140). Attacks are more frequent in the vicinity of the dog owner's property, and the dog is usually unrestrained (136,144). There are various reasons why a dog is provoked: the animal's position in the family is unsettled (e.g., new baby); the dog fears that its territory, food, or toy is threatened and the animal's distress is unrecognized, particularly by young children; aggression is stimulated by a person's physical activity or vocalization; and the dog's behavior is changed by illness (e.g., rabies [136,138,140,143,145]). Starvation is not necessarily a motivating factor (135,145). Prior aggressive activity by the dog may have been observed (135,137,144).

Dog pack attacks are uncommon (135,143,145). Dogs have a natural pack instinct (143,145). Having engaged in past predatory activities and variable social interaction with humans, pack dogs either perceive threats or are stimulated by human activity (e.g., running [135,143,145]). Consequent defensive actions by the victim (e.g., flailing arms) can exacerbate the attack (135).

The greatest frequency of bites involves the lower extremities, followed by the upper extremities, head, face, neck, and torso (140). Stray dogs tend to bite the upper extremity. A typical scenario is a child attempting to pat the head of a stray dog (140). Pet dogs, which have closer contact with children, tend to bite the head, face, or neck as the child bends over the animal (140,143,144,146). Head and neck injuries are the most common fatal injuries (135,143,147). A pack attack has a greater chance of inflicting severe injury (135). Dogs immobilize prey by first biting the victim's hindquarters, and then the head, neck, and thorax when the victim falls (138,140,143,145).

The bite marks of dogs tend to be longer and narrower than those of cats (148). There can be extensive soft tissue loss on the head, neck, and torso with loss of viscera and extremities as an angry dog moves its head vigorously (135,143,147). Amputation is possible. Clothing can be shredded (135,149). Depressed skull fractures and cranial perforations are possible in a child (136,150,151). Infectious complications (e.g., cellulitis) can occur if the victim survives (143,147). Extensive injuries can mimic homicidal sharp-force trauma (Fig. 36) (149).

Blood, clothing, and hair of the victim can be found on the dog or in its mouth (135,138). The animal's gastrointestinal tract needs to be examined for human body parts by radiographs and during autopsy (136,138,143). An autopsy of the dog also rules out medical conditions that could have precipitated an attack (138). The animal's dentition can be compared with bite marks on the victim (136,138,142,148,149). Sets of



**Fig. 36.** Multiple wounds from dog attack on young child. (Courtesy of Dr. J.C.E. Kaufmann, The University of Western Ontario, London, Ontario, Canada.)

bite marks are found if a pack attack has occurred ([145](#)). Material from the dog's mouth may be seen in the wound by microscopy ([149](#)).

### *11. ANAPHYLAXIS: INSECT BITES AND INJECTIONS*

Anaphylaxis (anaphylactic shock) is an immediate type of hypersensitivity reaction leading to peripheral circulatory collapse ([152](#)). Anaphylaxis is estimated to cause about 500 deaths annually in the United States ([153](#)). Anaphylaxis is triggered by the release of histamine and other inflammatory mediators from tissue mast cells ([152](#)). Activation of mast cells is the result of interaction of an allergen and a specific IgE antibody on the mast cells, but certain drugs and diagnostic agents also directly cause mast cell histamine release ([152,154](#)). Situations triggering anaphylaxis include insect bites (e.g., *Hymenoptera* [wasps]), injection of drugs and therapeutic agents (e.g., antibiotics, an allergy shot), ingestion of certain foods (e.g., shellfish), and inhalation of pollen ([152,154](#)). Mast cell mediators contract smooth muscle (e.g., bronchospasm), dilate vessels, and increase capillary permeability ([152](#)). The most frequently presenting features are related to acute respiratory or circulatory failure (dyspnea, wheezing, chest pain [[152,155](#)]). Seizures, nausea and vomiting, and skin eruptions also occur ([152](#)). Symptoms onset typically within 20 min of exposure but can be delayed up to 2.5 h ([152](#)).

Histamine is unsuitable for postmortem analysis because of a very short half-life ([156](#)). Tryptase, a neutral protease found in mast cell secretory granules, has a longer

half-life and is a measure of mast cell activation in anaphylaxis (153,154,156,157). Tryptase becomes elevated in the serum 1 h after the triggering event and remains increased for several hours. It then declines to a normal level, if the victim survives (154). A normal tryptase level implies that an anaphylactic event did not occur. Alternatively, the blood sample may have been drawn either too early or too late. Tryptase levels are best analyzed on serum obtained from the patient while alive or within 24 h of death (153,154). Postmortem serum needs to be submitted on ice and frozen at  $-20^{\circ}\text{C}$ . Postmortem tryptase is elevated in nonanaphylactic deaths and must be interpreted in the context of the case (156,158). More specific is the determination of  $\beta$ -tryptase. Pleural and pericardial fluids are not useful for analysis (154). Elevation of IgE-specific antibodies indicates prior sensitization (154,159).

Postmortem findings in an anaphylactic death are nonspecific and vary (152). There are no findings in some cases (152,155). Congestion of lungs and other viscera is commonly observed and may be the only finding (152,154,155). Pulmonary emphysema reflecting airway obstruction is seen in some cases (152,154,155). Distension of lung parenchyma can alternate with atelectasis (152,155). Laryngeal edema is a more specific finding, but it is not always grossly apparent (152,153,155). Edema of the tongue and supraglottic area may be observed (155). In these cases, microscopic examination of the glottis shows edema in the lamina propria (152,155). Edema is also found in the trachea and bronchial lining (155). Hyperinflation can be seen in the lung microscopic sections (152,155). Underlying asthmatic changes (e.g., thickening of respiratory epithelial basement membrane) may be present (155). Microscopy of the liver and spleen can show an increased number of eosinophils, but this could reflect previous sensitization (155). Eosinophils may be conspicuous in the lungs and upper respiratory tract (152,155).

## 12. THERAPEUTIC MISADVENTURE

A fatality caused by a therapeutic misadventure is defined as a death that arises from an unexpected medical care-related injury or adverse outcome during or immediately following a medical procedure or treatment and that is not a consequence of an inherent disability or prior medical condition, side effect, or natural complication of the involved procedure or medication (160). Therapeutic misadventure includes mechanical manipulation for diagnosis or treatment; incorrect, mistaken, or substandard medical procedures; inappropriate drug dosage or administration; incorrect use of medical equipment; and use of inappropriate, malfunctioning medical equipment (160). Iatrogenic illness is defined as any illness that resulted from any medical procedure or treatment (161). Iatrogenic illness and therapeutic misadventures do not imply negligence (161,162).

For a hospital-based pathologist dealing with a therapeutic misadventure death, a potential conflict of interest arises if the death occurred in the pathologist's hospital. An autopsy may need to be done in another facility. If this is not feasible, the family should be assured that a thorough independent investigation will be overseen by a coroner or medical examiner. A complete autopsy, including microscopic examination and other necessary ancillary studies, is required (162,163). In the case of anesthetic/surgical deaths, the determination of the cause of death must take into consideration not only the nature of the surgery and potential complications, but also underlying disease that could



have contributed to the demise of the patient (163). The contribution of an iatrogenic complication arising during surgery to death causation is interpreted in the context of whether the surgery was elective or taken for a desperate life-threatening problem.

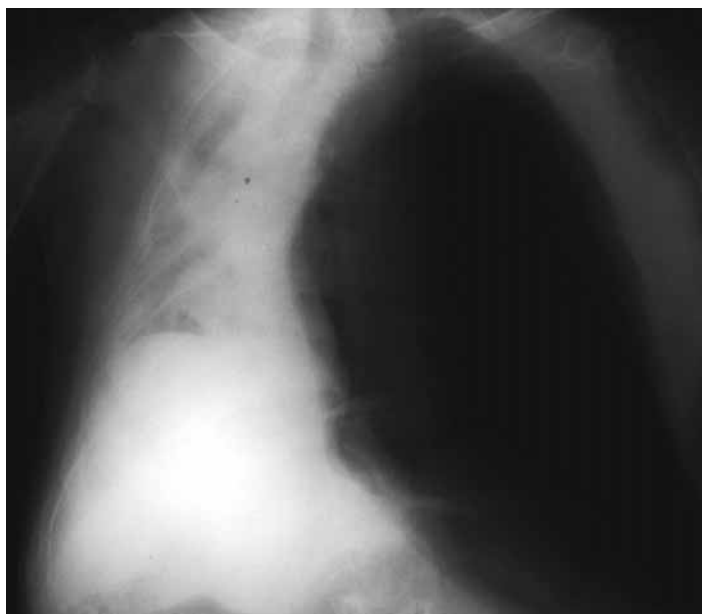A study of hospitalized patients in the state of New York showed that 3.7% of hospitalizations had an adverse event (164). About one-fourth were caused by negligence (164). Of 815 patients admitted to a medical service at a university teaching hospital, 36% had an iatrogenic illness (161). In 9%, the incident was major, threatening life or producing disability. In 2% of cases, patients died. The largest category was drug-related; however, the highest percentage of serious complications was caused by diagnostic and therapeutic procedures. Cardiac catheterization was most common. Patients admitted from a nursing home into an intensive care unit had a higher frequency of complications.

A series of deaths in Pennsylvania, classified as therapeutic misadventures, showed that about three-fourths resulted from treatments and the rest arose from diagnostic procedures (160). About half were traumatic in nature (most commonly fatal bleeds arising from catheter insertions), 17.5% from medication toxicity, about 13% owing to anaphylaxis (antibiotics, radiographic contrast material), and a similar percentage from airway obstruction (tracheostomy problems [160]). More than 90% occurred in hospitals, and university-affiliated hospitals had almost twice the complication rate of other institutions (160). Notification regarding a medicolegal investigation was initiated by the pathologist in some cases (160).

Forty-four cases classified as therapeutic misadventure, comprising 0.46% of 9497 deaths reported to the Office of the Coroner in Dayton, OH, had the following breakdown: surgery, 36% (most common: intraoperative vascular or visceral trauma with fatal hemorrhage; other causes: cardiorespiratory arrest, complications of tracheostomy, air embolism, poor surgical risk owing to severe natural disease, coagulopathy with exsanguination, aspiration of blood); anesthetic complications, 30% (most common: acute reaction with cardiorespiratory arrest during induction; other causes: aspiration during induction, respiratory arrest during a procedure or in the post-operative period, delayed liver failure, overdose); therapeutic procedures, 18% (most common: viscus perforation, cardiac arrest following electroconvulsive therapy; other causes: improper dialysis solution, therapeutic vascular overload, aspiration of blood, vascular laceration); diagnostic procedures, 14% (most common: vascular or cardiac lacerations; other causes: acute reaction to intravenous contrast medium, intra-esophageal installation of caustic material, cerebral vascular accident, air embolism); and drug reaction (penicillin allergy), 2% (162).

### ***12.1. Iatrogenic Penetrating Injuries (Central Vascular Lines)***

Leaving vascular lines in place is essential for the investigation of iatrogenic injuries (165). Multiple puncture sites are evidence of repeated attempts to insert a line (Fig. 37; ref. 166). The subclavian vein approach is the most frequently used approach for central venous and Swan-Ganz catheters. The purpose of central venous lines is to measure central venous pressure, allow rapid administration of fluid, circumvent the use of inadequate peripheral veins, allow prolonged fluid and parenteral administration, and guide placement of transvenous pacemakers and Swan-Ganz catheters (167). A subclavian line can also be used for hemodialysis, particularly for a patient who needs urgent

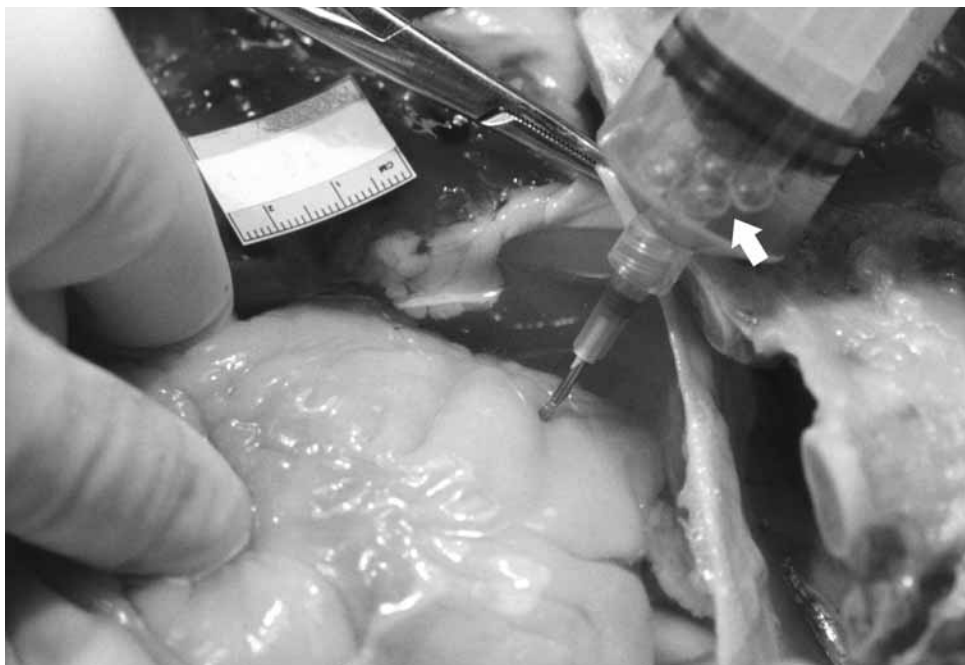


**Fig. 37.** Postmortem radiograph—pneumothorax. Repeated subclavian punctures during introduction of central venous line.

treatment ([168,169](#)). A Swan-Ganz catheter measures pulmonary intravascular pressure, which reflects cardiac function. A chest radiograph identifies line placement ([167](#)).

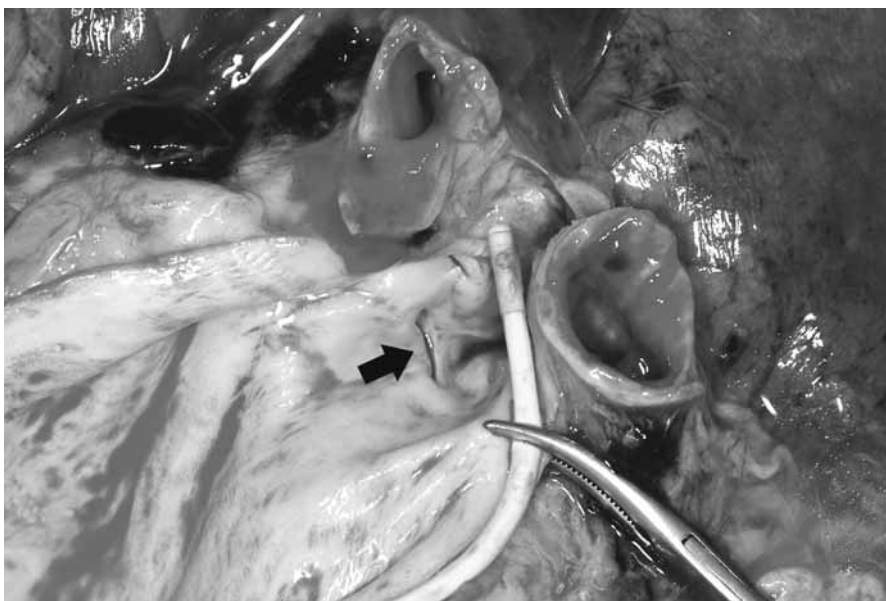### *12.1.1. Complications Resulting in Death*

- Air embolism (*see* Chapter 5, Subheading 14.8.)
  - Air embolism is a risk when central lines are inserted in the neck, thoracic and neuro-surgical procedures are performed, or pneumothorax occurs ([170–173](#)). Lines are inserted with the patient horizontal or in a head-down tilt position ([170–172,174](#)). Estimates of the quantity of air sufficient to cause death from venous air embolism vary from 10 to 480 mL ([171,175](#)). Large volumes are tolerated, if introduced slowly into the circulation ([176](#)). Air in the right ventricle obstructs the flow of blood to the lungs, resulting in cardiac failure ([173](#)). Air can be introduced during the insertion of the line or following its disconnection ([170](#)). Air in the venous circulation can reach the systemic circulation by either interatrial/interventricular shunts or through the transpulmonary capillary bed ([173,174,177](#)).
  - Postmortem external features of air embolism ([173,178](#)):
    - Cyanosis of face and neck.
    - Blood-stained fluid oozing from nose and mouth because of increased venous pressure.
    - Blisters of eyelids.
    - Protrusion of tongue.
    - Palpable subcutaneous emphysema.
    - Generalized cutaneous petechiae.
  - Internal features of air embolism include:
    - Aspiration of air from right side of heart ([Fig. 38](#)).
    - Air can be present in the left ventricle.

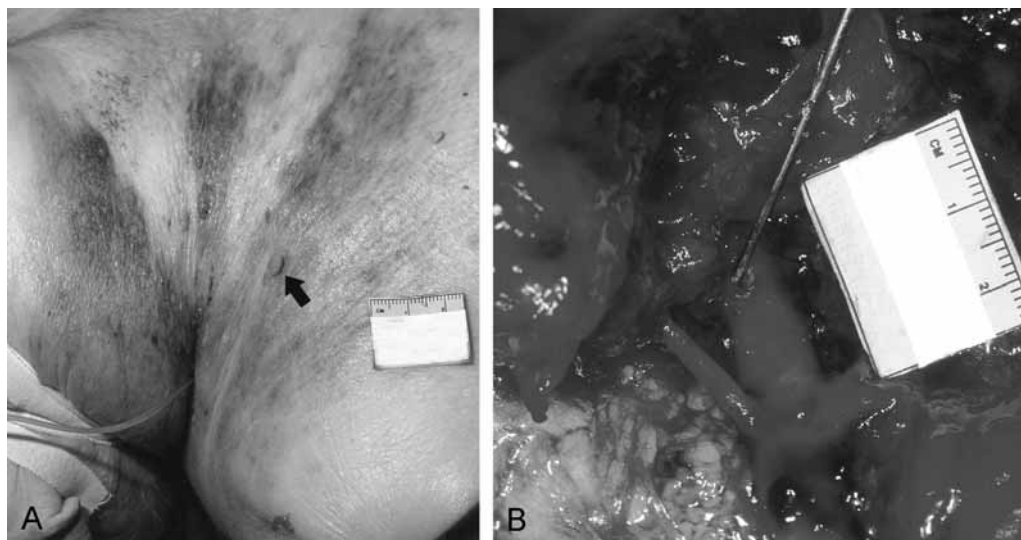


**Fig. 38.** Air embolism. Air aspirated from right ventricle. Bubbles (arrow) in syringe that contained a few milliliters of water.

- Air bubbles apparent in blood vessels (e.g., coronary veins).
- Microscopic examination of the lungs may reveal clear intravascular spaces surrounded by leukocytes and platelets (179).
- Perforation is a common cause of death (172).
  - Hydrothorax (hemodialysis), hydropericardium, hydromediastinum, chylothorax, hemothorax (penetration of heart or major vein), pneumothorax (subclavian puncture; see Fig. 37; and refs. 165, 167, 168, 170, 171, and 180–184).
    - Left-sided central vein approach is associated with damage to the thoracic duct (172).
    - The vascular line can penetrate a major vein, the heart, or a pulmonary artery branch, leading to leakage of fluid and blood into the mediastinal, pleural, or pericardial cavities (Fig. 39; refs. 167, 168, 170, 171, and 183); a major neck artery may be inadvertently punctured when a line is introduced (Fig. 40).
    - Pneumothorax is the most common complication because of the proximity of the lung apex to the subclavian vein (Fig. 37; ref. 167).
  - Thrombosis (167,172,180).
  - Retention of catheter fragment (167,170,180).
    - Most common cause is shearing of the tubing by the sharp beveled needle (iatrogenic or patient-caused [170,180]).
    - Can lead to myocardial perforation, pulmonary embolism, and thrombosis with infarction.
  - Infection/sepsis (172,180).
  - Arrhythmia.
  - Intracardiac placement of catheter irritating heart (167).



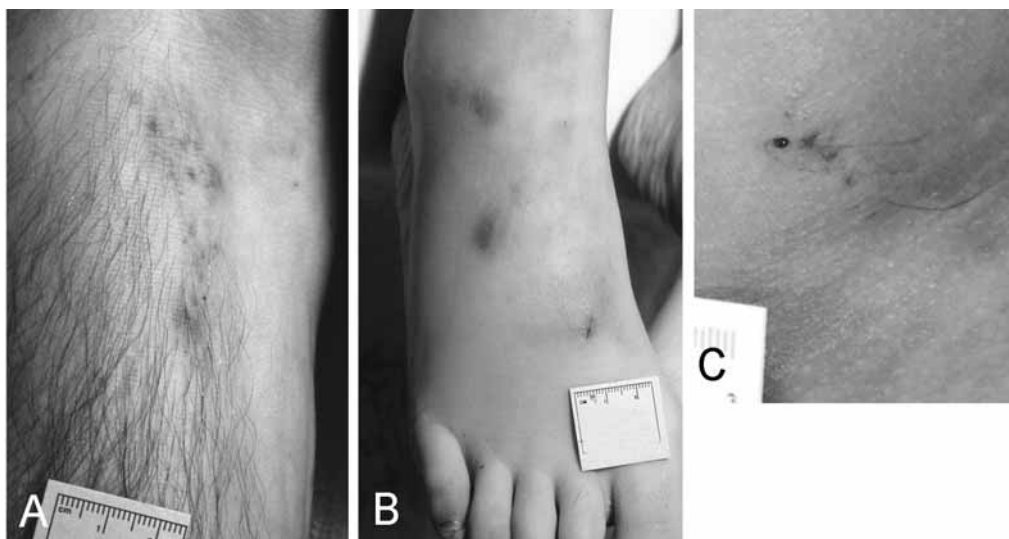
**Fig. 39.** Perforation (arrow) of pulmonary artery by tip of Swan-Ganz line (clamped during autopsy). (Courtesy of Dr. E. Tweedie, London Health Sciences Centre, London, Ontario, Canada.)



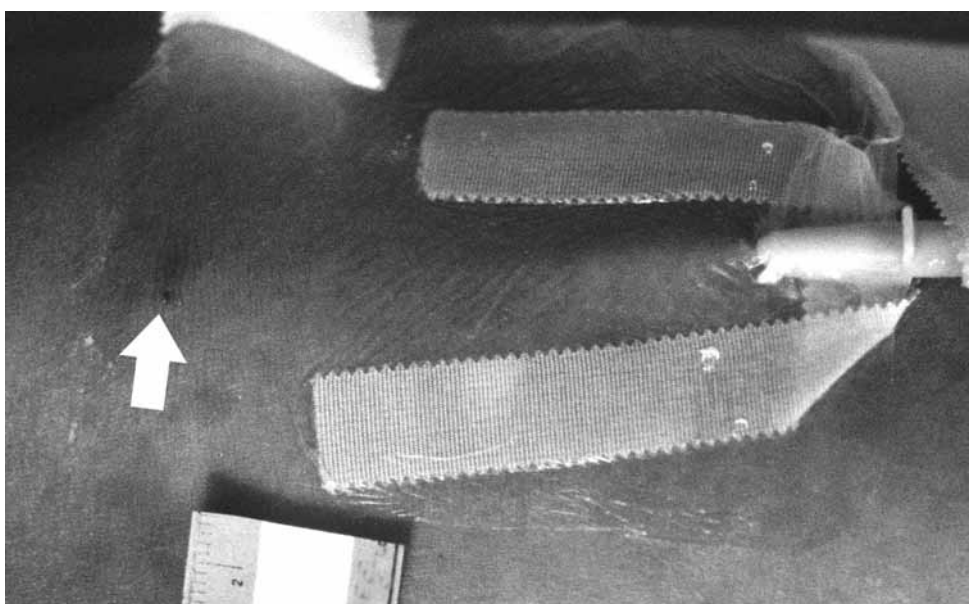
**Fig. 40.** Insertion of central venous line for hemodialysis. (A) Considerable bruising surrounding subclavian puncture (arrow). (B) Probe indicates accidental puncture of subclavian artery.

### *13. SELF-INFLICTED VENIPUNCTURES*

Single or multiple self-inflicted venipunctures are encountered in intravenous drug users. Venipunctures are seen in common sites (e.g., antecubital fossa) or are observed



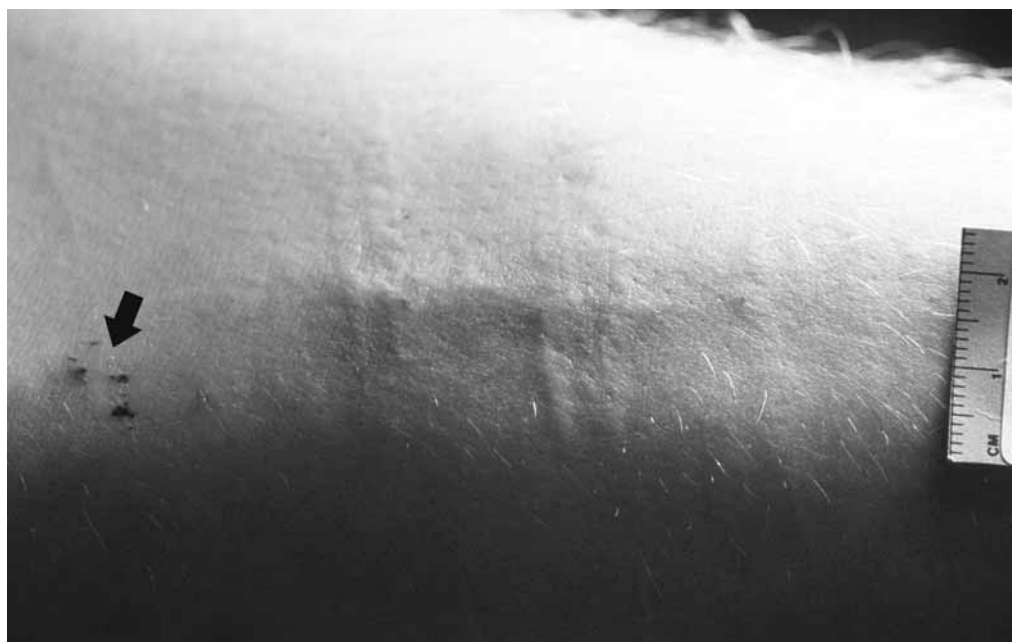**Fig. 41.** Recent venipunctures in drug abusers. (A) Antecubital fossa. (B) Dorsum of foot. (C) Neck. (Courtesy of Dr. E. Tweedie, London Health Sciences Centre, London, Ontario, Canada.)



**Fig. 42.** Venipunctures in a drug user can be caused by resuscitation. Intravenous line inserted. A witness indicated where the deceased had injected cocaine (arrow).

in less apparent locations (Fig. 41). Venipunctures owing to resuscitation need to be excluded, a determination made more difficult if intravenous lines have been removed (Fig. 42). “Track marks” indicative of scarring from previous injections may be seen (Fig. 43).





**Fig. 43.** “Track marks” (cutaneous scars on forearm) indicative of past intravenous drug abuse. Recent venipunctures (arrow).

### *REFERENCES*

1. Rogde, S., Hougen, H. P., Poulsen, K. Homicide by sharp-force in two Scandinavian capitals. *Forensic Sci. Int.* 109:135–145, 2000.
2. Start, R. D., Milroy, C. M., Green, M. A. Suicide by self-stabbing. *Forensic Sci. Int.* 56:89–94, 1992.
3. Hunt, A. C., Cowling, R. J. Murder by stabbing. *Forensic Sci. Int.* 52:107–112, 1991.
4. Ormstad, K., Karlsson, T., Enkler, L., Law, B., Rajs, J. Patterns in sharp-force fatalities—a comprehensive forensic medical study. *J. Forensic Sci.* 31:529–542, 1986.
5. Rouse, D. A. Patterns of stab wounds: a six year study. *Med. Sci. Law* 34:67–71, 1994.
6. Karlsson, T. Homicidal and suicidal sharp-force fatalities in Stockholm, Sweden. Orientation of entrance wounds in stabs gives information in the classification. *Forensic Sci. Int.* 93:21–32, 1998.
7. Prahlow, J. A., Ross, K. F., Lene, W. J., Kirby, D. B. Accidental sharp-force injury fatalities. *Am. J. Forensic Med. Pathol.* 22:358–366, 2001.
8. Gill, J. R., Catanese, C. Sharp injury fatalities in New York City. *J. Forensic Sci.* 47:554–557, 2002.
9. Karger, B., Niemeyer, J., Brinkmann, B. Suicides by sharp-force: typical and atypical features. *Int. J. Legal Med.* 113:259–262, 2000.
10. West, I. Single suicidal stab wounds—a study of three cases. *Med. Sci. Law* 21:198–201, 1981.
11. Karger, B., Rothschild, M. A., Pfeiffer, H. Accidental sharp-force fatalities—beware of architectural glass, not knives. *Forensic Sci. Int.* 123:135–139, 2001.
12. Byard, R. W., Klitte, A., Gilbert, J. D., James, R. A. Clinicopathologic features of fatal self-inflicted incised and stab wounds: a 20-year study. *Am. J. Forensic Med. Pathol.* 23:15–18, 2002.

13. Karlsson, T., Ormstad, K., Rajs, J. Patterns in sharp-force fatalities—a comprehensive forensic medical study: Part 2. Suicidal sharp-force injury in the Stockholm area 1972–1984. *J. Forensic Sci.* 33:448–461, 1988.
14. Fekete, J. F., Fox, A. D. Successful suicide by self-inflicted multiple stab wounds of the skull, abdomen, and chest. *J. Forensic Sci.* 25:634–637, 1980.
15. Ueno, Y., Asano, M., Nushida, H., Adachi, J., Tatsuno, Y. An unusual case of suicide by stabbing with a falling weighted dagger. *Forensic Sci. Int.* 101:229–236, 1999.
16. Vanezis, P., West, I. E. Tentative injuries in self stabbing. *Forensic Sci. Int.* 21:65–70, 1983.
17. Betz, P., Tutsch-Bauer, E., Eisenmenger, W. “Tentative” injuries in a homicide. *Am. J. Forensic Med. Pathol.* 16:246–248, 1995.
18. Kuroda, N., Saito, K., Takada, A., et al. Suicide by self-stabbing in the city of Tokyo—a review of accumulated data from 1976 to 1995. *Nippon Hoigaku Zasshi* 51:301–306, 1997.
19. Hasekura, H., Fukushima, H., Yonemura, I., Ota, M. A rare suicidal case of a ten-year-old child stabbing himself in the throat. *J. Forensic Sci.* 30:1269–1271, 1985.
20. Gee, D. J. Two suicidal transfixions of the neck. *Med. Sci. Law* 12:171–172, 1972.
21. Chadly, A., Marc, B., Paraire, F., Durigon, M. Suicidal stab wounds of the throat. *Med. Sci. Law* 31:355–356, 1991.
22. Marc, B., Baudry, F., Zerrouki, L., Ghaith, A., Garnier, M. Suicidal incised wound of a fistula for hemodialysis access in an elderly woman: case report. *Am. J. Forensic Med. Pathol.* 21:270–272, 2000.
23. Dettling, A., Althaus, L., Haffner, H. T. Criteria for homicide and suicide on victims of extended suicide due to sharp-force injury. *Forensic Sci. Int.* 134:142–146, 2003.
24. Katkici, U., Ozkok, M. S., Orsal, M. An autopsy evaluation of defence wounds in 195 homicidal deaths due to stabbing. *J. Forensic Sci. Soc.* 34:237–240, 1994.
25. Urban, R., Eidam, J., Kleemann, W., Troger, H. D. [Isolated stab wound without preliminary stab wounds—suicide or homicide?]. *Beitr. Gerichtl. Med.* 47:272–277, 1989.
26. Porter, K. K., Jones, M. J. Wrist slashing in a detention center. Case report and review of the literature. *Am. J. Forensic Med. Pathol.* 11:319–323, 1990.
27. Watanabe, T., Kobayashi, Y., Hata, S. Harakiri and suicide by sharp instruments in Japan. *Forensic Sci.* 2:191–199, 1973.
28. Karger, B., Niemeyer, J., Brinkmann, B. Physical activity following fatal injury from sharp pointed weapons. *Int. J. Legal Med.* 112:188–191, 1999.
29. Johnston, S. E., Langley, J. D., Chalmers, D. J. Serious unintentional injuries associated with architectural glass. *N. Z. Med. J.* 103:117–119, 1990.
30. Evans, R. Injuries produced by shattering annealed glass. *Resuscitation* 7:119–126, 1979.
31. Rothschild, M. A., Karger, B., Schneider, V. Puncture wounds caused by glass mistaken for with stab wounds with a knife. *Forensic Sci. Int.* 121:161–165, 2001.
32. Klose, W., Pribilla, O. [Unusual suicide caused by a stab wound in the neck]. *Arch. Kriminol.* 183:157–162, 1989.
33. Ousby, J., Wilson, D. H. 1086 consecutive injuries caused by glass. *Injury* 13:427–430, 1982.
34. Kelly, S. B. Penetrating injury of rectum caused by fall in shower. *Arch. Emerg. Med.* 3:115–118, 1986.
35. Shiono, H., Fujiwara, M., Tabata, N., Azumi, J., Morita, M. A single fatal penetrating chest wound caused by a dagger-shaped fragment of broken door glass. *Am. J. Forensic Med. Pathol.* 8:346–349, 1987.
36. Frazer, M., Rosenberg, S. Russian roulette with a knife. *J. Forensic Sci.* 28:268–272, 1983.
37. Shiono, H., Akane, A., Tanabe, K., Matsubara, K. Cardiac tamponade caused by a stab wound with a sewing needle left in a kimono. *Am. J. Forensic Med. Pathol.* 14:155–157, 1993.
38. Murphy, G. K. A single fatal penetrating chest wound from shattered wind-blown glass. *Am. J. Forensic Med. Pathol.* 6:332–335, 1985.
39. Katanick, D., Taff, M. L., Spitz, W. U. A work-related death due to a penetrating chest injury. *Am. J. Forensic Med. Pathol.* 7:163–164, 1986.

40. Torre, C., Varetto, L. A case of murder by impalement. *Z. Rechtsmed.* 91:83–84, 1983.
41. Marti, M. C., Morel, P., Rohner, A. Traumatic lesions of the rectum. *Int. J. Colorectal Dis.* 1:152–154, 1986.
42. Jona, J. Z. Accidental anorectal impalement in children. *Pediatr. Emerg. Care* 13:40–43, 1997.
43. Evans, R. J., Richmond, J. M. An unusual death due to screwdriver impalement: A case report. *Am. J. Forensic Med. Pathol.* 17:70–72, 1996.
44. Okumori, M., Futamura, A., Tsukuura, T., et al. Impalement wounds of the head and chest by reinforced steel bars with recovery: an unusual case report. *J. Trauma* 21:240–241, 1981.
45. Kaiser, M. C., Rodesch, G., Capesius, P. CT in a case of intracranial penetration of a pencil. A case report. *Neuroradiology* 24:229–231, 1983.
46. Missliwetz, J. Fatal impalement injuries after falls at construction sites. *Am. J. Forensic Med. Pathol.* 16:81–83, 1995.
47. Vaslef, S. N., Dragelin, J. B., Takla, M. W., Saliba, E. J., Jr. Multiple impalement with survival. *Am. J. Emerg. Med.* 15:70–72, 1997.
48. Ahmad, N., Busuttill, A. Impaling-type head injury in a road traffic incident. *Med. Sci. Law* 33:261–263, 1993.
49. Giusti, G. V., Bacci, M. Chain link fence impalements in a traffic accident. *Am. J. Forensic Med. Pathol.* 7:167–168, 1986.
50. Karger, B., Teige, K., Bajanowski, T. Bizarre impalement fatalities—where is the implement? *J. Forensic Sci.* 47:389–391, 2002.
51. Di Nunno, N., Solarino, B., Costantinides, F., Di Nunno, C. Fatal impalement with transfixion of the neck in a road traffic accident. *Am. J. Forensic Med. Pathol.* 25:164–168, 2004.
52. Lasky, J. B., Epley, K. D., Karesh, J. W. Household objects as a cause of self-inflicted orbital apex syndrome. *J. Trauma* 42:555–558, 1997.
53. Field, H. L., Waldfogel, S. Severe ocular self-injury. *Gen. Hosp. Psychiatry* 17:224–227, 1995.
54. Bowen, D. I. Self-inflicted orbitocranial injury with a plastic ballpoint pen. *Br. J. Ophthalmol.* 55:427–430, 1971.
55. Johansson, B., Eriksson, A. Suicide by driving an awl into the brain. *Am. J. Forensic Med. Pathol.* 9:331–333, 1988.
56. Eckert, W. G. The pathology of self-mutilation and destructive acts: a forensic study and review. *J. Forensic Sci.* 22:242–250, 1977.
57. Beiler, H. A., Zachariou, Z., Daum, R. Impalement and anorectal injuries in childhood: a retrospective study of 12 cases. *J. Pediatr. Surg.* 33:1287–1291, 1998.
58. Weber, S., Mauch, W., Kalayoglu, M., Moon, T. D. Intraperitoneal and extraperitoneal bladder rupture secondary to rectal impalement. *J. Trauma* 38:818–819, 1995.
59. Haynes, C. D., Webb, W. A., Fenno, C. R. Chain saw injuries: review of 330 cases. *J. Trauma* 20:772–776, 1980.
60. Reuhl, J., Bratzke, H. Death caused by a chain saw—homicide, suicide or accident? A case report with a literature review with 11 illustrations. *J. Forensic Sci. Int.* 105:45–59, 1999.
61. Koehler, S. A., Luckasevic, T. M., Rozin, L., et al. Death by chainsaw: fatal kickback injuries to the neck. *J. Forensic Sci.* 49:345–350, 2004.
62. Campman, S. C., Springer, F. A., Henrikson, D. M. The chain saw: an uncommon means of committing suicide. *J. Forensic Sci.* 45:471–473, 2000.
63. Segerberg-Kontinen, M. Suicide by the use of a chain saw. *J. Forensic Sci.* 29:1249–1252, 1984.
64. Bonte, W. Self-mutilation and private accident insurance. *J. Forensic Sci.* 28:70–82, 1983.
65. Rainov, N. G., Burkert, W. L. An unusual suicide attempt using a circular saw. *Int. J. Legal Med.* 106:223–224, 1994.
66. Lim, R. Y. Chain saw injury to the larynx. *W. V. Med. J.* 83:118–119, 1987.

67. Costantinides, F. A fatal case of accidental cerebral injury due to power drill. *Am. J. Forensic Med. Pathol.* 3:241–243, 1982.
68. Clark, S. P., Delahunt, B., Thomson, K. J., Fernando, T. L. Suicide by band saw. *Am. J. Forensic Med. Pathol.* 10:332–334, 1989.
69. Betz, P., Eisenmenger, W. Unusual suicides with electric saws. *Forensic Sci. Int.* 75:173–179, 1995.
70. Jackson, F. E. High speed propeller injuries of the brain. Report of two cases. *Am. J. Surg.* 110:473–476, 1965.
71. Hargarten, S. W., Karlson, T., Vernick, J. S., Aprahamian, C. Motorboat propeller injuries in Wisconsin: enumeration and prevention. *J. Trauma* 37:187–190, 1994.
72. Pollak, S., Fischer, A. [Morphometric findings of stab wounds]. *Beitr. Gerichtl. Med.* 49:219–225, 1991.
73. Demetriades, D., van der Veen, B. W. Penetrating injuries of the heart: experience over two years in South Africa. *J. Trauma* 23:1034–1041, 1983.
74. Ormstad, K., Rajs, J., Calissendorff, B., Ahlberg, N. E. Difference between in vivo and postmortem distances between anterior chest and heart surface. A combined autopsy and in vivo computerized tomography study. *Am. J. Forensic Med. Pathol.* 5:31–35, 1984.
75. Pollak, S., La Harpe, R. [Defined contusion marks caused by the knife handle]. *Arch. Kriminol.* 190:1–8, 1992.
76. Murray, L. A., Green, M. A. Hilts and knives: a survey of ten years of fatal stabbings. *Med. Sci. Law* 27:182–184, 1987.
77. Knight, B. The dynamics of stab wounds. *Forensic Sci.* 6:249–255, 1975.
78. Green, M. A. Stab wound dynamics—a recording technique for use in medico-legal investigations. *J. Forensic Sci. Soc.* 18:161–163, 1978.
79. Jones, S., Nokes, L., Leadbeatter, S. The mechanics of stab wounding. *Forensic Sci. Int.* 67:59–63, 1994.
80. Careless, C. M., Acland, P. R. The resistance of human skin to compressive cutting. *Med. Sci. Law* 22:99–106, 1982.
81. O’Callaghan, P. T., Jones, M. D., James, D. S., Leadbeatter, S., Holt, C. A., Nokes, L. D. Dynamics of stab wounds: force required for penetration of various cadaveric human tissues. *Forensic Sci. Int.* 104:173–178, 1999.
82. Chadwick, E. K., Nicol, A. C., Lane, J. V., Gray, T. G. Biomechanics of knife stab attacks. *Forensic Sci. Int.* 105:35–44, 1999.
83. Horsfall, I., Prosser, P. D., Watson, C. H., Champion, S. M. An assessment of human performance in stabbing. *Forensic Sci. Int.* 102:79–89, 1999.
84. Monahan, D. L., Harding, H. W. J. Damage to clothing—cuts and tears. *J. Forensic Sci.* 35:901–912, 1990.
85. Di Nunno, N., Costantinides, F., Bernasconi, P., Di Nunno, C. Suicide by hara-kiri: a series of four cases. *Am. J. Forensic Med. Pathol.* 22:68–72, 2001.
86. Marcikic, M., Mandic, N. Homicide-suicide by stabbing. *Am. J. Forensic Med. Pathol.* 11:312–315, 1990.
87. Scolan, V., Telmon, N., Blanc, A., Allery, J. P., Charlet, D., Rouge, D. Homicide-suicide by stabbing study over 10 years in the Toulouse region. *Am. J. Forensic Med. Pathol.* 25:33–36, 2004.
88. Luna, A., Solano, C., Gomez, M., Banon, R. Incised wound margins caused by steel blades. Scanning electron microscopy to determine wound direction. *Forensic Sci. Int.* 43:21–26, 1989.
89. Moriani, S., Cecchi, R., Cipolloni, L. Suicide by sharp instruments: a case of harakiri. *Int. J. Legal Med.* 108:219–220, 1996.
90. Herbst, J., Haffner, H. T. Tentative injuries to exposed skin in a homicide case. *Forensic Sci. Int.* 102:193–196, 1999.

91. Karlsson, T. Multivariate analysis ('forensimetrics')—a new tool in forensic medicine. Differentiation between sharp-force homicide and suicide. *Forensic Sci. Int.* 94:183–200, 1998.
92. Rothschild, M. A., Ehrlich, E., Klevno, W. A., Schneider, V. Self-planted subcutaneous penile balls—a new phenomenon in Western Europe. *Int. J. Legal Med.* 110:88–91, 1997.
93. Catalano, G., Morejon, M., Alberts, V. A., Catalano, M. C. Report of a case of male genital self-mutilation and review of the literature, with special emphasis on the effects of the media. *J. Sex Marital. Ther.* 22:35–46, 1996.
94. Kennedy, B. L., Feldmann, T. B. Self-inflicted eye injuries: case presentations and a literature review. *Hosp. Community Psychiatry* 45:470–474, 1994.
95. Tantam, D., Whittaker, J. Personality disorder and self-wounding. *Br. J. Psychiatry* 161: 451–464, 1992.
96. Kernbach-Wighton, G., Thomas, R. S., Saternus, K. S. The discrimination between overt and non-overt self-inflicted lesions. *Forensic Sci. Int.* 89:203–209, 1997.
97. Patel, V., de Moore, G. Harakiri: a clinical study of deliberate self-stabbing. *J. Clin. Psychiatry* 55:98–103, 1994.
98. Sachsse, U. Overt self-injury. *Psychother. Psychosom.* 62:82–90, 1994.
99. Leslie, J., Taff, M. L., Patel, I., Sternberg, A., Fernando, M. M. Self-inflicted ocular injuries. A rare form of self-mutilation. *Am. J. Forensic Med. Pathol.* 5:83–88, 1984.
100. Benecke, M. First report of nonpsychotic self-cannibalism (autophagy), tongue splitting, and scar patterns (scarification) as an extreme form of cultural body modification in a western civilization. *Am. J. Forensic Med. Pathol.* 20:281–285, 1999.
101. Favazza, A. R., Conterio, K. Female habitual self-mutilators. *Acta Psychiatr. Scand.* 79:283–289, 1989.
102. Gaillard, Y., Pepin, G. Case report of an unusual use of lidocaine during episodes of self mutilation. *J. Forensic Sci.* 43:235–238, 1998.
103. Rogers, D. R. Autoamputation of the left arm—a bizarre suicide. *Am. J. Forensic Med. Pathol.* 9:64–65, 1988.
104. Karabatsou, K., Kandasami, J., Rainov, N. G. Self-inflicted penetrating head injury in a patient with manic-depressive disorder. *Am. J. Forensic Med. Pathol.* 26:174–176, 2005.
105. Osuna, E., Toucedo, M. A., Sanchez-Espigares, G., et al. A case of self-inflicted wounding by the introduction of needles through the abdominal wall to induce abortion. *Forensic Sci. Int.* 128:141–145, 2002.
106. Banasr, A., de la Grandmaison, G. L., Durigon, M. Frequency of bone/cartilage lesions in stab and incised wounds fatalities. *Forensic Sci. Int.* 131:131–133, 2003.
107. Gupta, R. L., Keen, R. I. An unusual case of cardiac injury. *Lancet* 1:1157, 1958.
108. Bonte, W. Tool marks in bones and cartilage. *J. Forensic Sci.* 20:315–325, 1975.
109. Rao, V. J., Hart, R. Tool mark determination in cartilage of stabbing victim. *J. Forensic Sci.* 28:794–799, 1983.
110. Smrkolj, V., Balazic, J., Prinic, J. Intracranial injuries by a screwdriver. *Forensic Sci. Int.* 76:211–216, 1995.
111. Hemphill, R. E. Attempted suicide by hammering a nail into the brain. *S. Afr. Med. J.* 57:477–478, 1980.
112. Jacobs, L. M., Berrizbeitia, L. D., Ordia, J. Crowbar impalement of the brain. *J. Trauma* 25:359–361, 1985.
113. Sebag, J., Shillito, J., Robb, R. Transorbital penetrating injuries to the frontal lobe. *Ophthalmic Surg.* 17:631–634, 1986.
114. Siegel, E. B., Bastek, J. V., Mehringer, C. M., Yee, R. D. Fatal intracranial extension of an orbital umbrella stab injury. *Ann. Ophthalmol.* 15:99–102, 1983.
115. Albert, D. M., Burns, W. P., Scheie, H. G. Severe orbitocranial foreign-body injury. *Am. J. Ophthalmol.* 60:1109–1111, 1965.
116. Kirkby, G. R. Penetrating orbitocranial injury with a snooker cue. *Br. Med. J. (Clin. Res. Ed.)* 293:1646, 1986.



117. Lunetta, P., Ohberg, A., Sajantila, A. Suicide by intracerebellar ballpoint pen. *Am. J. Forensic Med. Pathol.* 23:334–337, 2002.
118. Rompen, J. C., Meek, M. F., van Andel, M. V. A cause celebre: the so-called “ballpoint murder.” *J. Forensic Sci.* 45:1144–1147, 2000.
119. De Villiers, J. C., Sevel, D. Intracranial complications of transorbital stab wounds. *Br. J. Ophthalmol.* 59:52–56, 1975.
120. Sharif, S., Roberts, G., Phillips, J. Transnasal penetrating brain injury with a ball-pen. *Br. J. Neurosurg.* 14:159–160, 2000.
121. Lynch, M. J., Parker, H. Forensic aspects of ocular injury. *Am. J. Forensic Med. Pathol.* 21:124–126, 2000.
122. Davis, N. L., Kahana, T., Hiss, J. Souvenir knife: a retained transcranial knife blade. *Am. J. Forensic Med. Pathol.* 25:259–261, 2004.
123. Specht, C. S., Varga, J. H., Jalali, M. M., Edelstein, J. P. Orbitocranial wooden foreign body diagnosed by magnetic resonance imaging. Dry wood can be isodense with air and orbital fat by computed tomography. *Surv. Ophthalmol.* 36:341–344, 1992.
124. Schaller, B., Probst, R., Strebel, S., Gratzl, O. Trigemino-cardiac reflex during surgery in the cerebellopontine angle. *J. Neurosurg.* 90:215–220, 1999.
125. Anderson, R. L. The blepharocardiac reflex. *Arch. Ophthalmol.* 96:1418–1420, 1978.
126. Lang, S., Lanigan, D. T., van der Wal M. Trigemino-cardiac reflexes: maxillary and mandibular variants of the oculocardiac reflex. *Can. J. Anaesth.* 38:757–760, 1991.
127. von Domarus, H., Poeschel, W. Impalement injuries of the palate. *Plast. Reconstr. Surg.* 72:656–658, 1983.
128. Thoresen, S. O., Rognum, T. O. Survival time and acting capability after fatal injury by sharp weapons. *Forensic Sci. Int.* 31:181–187, 1986.
129. Sugg, W. L., Rea, W. J., Ecker, R. R., Webb, W. R., Rose, E. F., Shaw, R. R. Penetrating wounds of the heart. An analysis of 459 cases. *J. Thorac. Cardiovasc. Surg.* 56:531–545, 1968.
130. Thourani, V. H., Feliciano, D. V., Cooper, W. A., et al. Penetrating cardiac trauma at an urban trauma center: a 22-year perspective. *Am. Surg.* 65:811–816, 1999.
131. Shiono, H., Takaesu, Y. Suicide by self-inflicted stab wound of the chest. *Am. J. Forensic Med. Pathol.* 7:72–73, 1986.
132. Maeda, H., Imura, M., Higuchi, T., Noguchi, K. An autopsy case of suicide by hanging with multiple stab wounds of the neck and chest. *Med. Sci. Law* 33:67–69, 1993.
133. Baghai, P., Sheptak, P. E. Penetrating spinal injury by a glass fragment: case report and review. *Neurosurgery* 11:419–422, 1982.
134. Hirt, M., Karger, B. Fatal brain injury caused by the free-flying blade of a knife—case report and evaluation of the unusual weapon. *Int. J. Legal Med.* 112:313–314, 1999.
135. Borchelt, P. L., Lockwood, R., Beck, A. M., Voith, V. L. Attacks by packs of dogs involving predation on human beings. *Public Health Rep.* 98:57–66, 1983.
136. Boglioli, L. R., Taff, M. L., Turkel, S. J., Taylor, J. V., Peterson, C. D. Unusual infant death: dog attack or postmortem mutilation after child abuse? *Am. J. Forensic Med. Pathol.* 21:389–394, 2000.
137. Sacks, J. J., Lockwood, R., Hornreich, J., Sattin, R. W. Fatal dog attacks, 1989–1994. *Pediatrics* 97:891–895, 1996.
138. Lauridson, J. R., Myers, L. Evaluation of fatal dog bites: the view of the medical examiner and animal behaviorist. *J. Forensic Sci.* 38:726–731, 1993.
139. Sacks, J. J., Sattin, R. W., Bonzo, S. E. Dog bite-related fatalities from 1979 through 1988. *JAMA* 262:1489–1492, 1989.
140. Wright, J. C. Canine aggression toward people. Bite scenarios and prevention. *Vet. Clin. North Am. Small Anim. Pract.* 21:299–314, 1991.
141. Langley, R. L. Fatal animal attacks in North Carolina over an 18-year period. *Am. J. Forensic Med. Pathol.* 15:160–167, 1994.

142. Bux, R. C., McDowell, J. D. Death due to attack from chow dog. *Am. J. Forensic Med. Pathol.* 13:305–308, 1992.
143. Kneafsey, B., Condon, K. C. Severe dog-bite injuries, introducing the concept of pack attack: a literature review and seven case reports. *Injury* 26:37–41, 1995.
144. Wright, J. C. Severe attacks by dogs: characteristics of the dogs, the victims, and the attack settings. *Public Health Rep.* 100:55–61, 1985.
145. Avis, S. P. Dog pack attack: hunting humans. *Am. J. Forensic Med. Pathol.* 20:243–246, 1999.
146. Wiseman, N. E., Chochinov, H., Fraser, V. Major dog attack injuries in children. *J. Pediatr. Surg.* 18:533–536, 1983.
147. Falconieri, G., Zanella, M., Malannino, S. Pulmonary thromboembolism following calf cellulitis: report of an unusual complication of dog bite. *Am. J. Forensic Med. Pathol.* 20:240–242, 1999.
148. Clark, M. A., Sandusky, G. E., Hawley, D. A., Pless, J. E., Fardal, P. M., Tate, L. R. Fatal and near-fatal animal bite injuries. *J. Forensic Sci.* 36:1256–1261, 1991.
149. Glass, R. T., Jordan, F. B., Andrews, E. E. Multiple animal bite wounds: A case report. *J. Forensic Sci.* 20:305–314, 1975.
150. Wilberger, J. E., Jr., Pang, D. Craniocerebral injuries from dog bites. *JAMA* 249:2685–2688, 1983.
151. Wilberger, J. E., Jr., Pang, D. Craniocerebral injuries from dog bite in an infant. *Neurosurgery* 9:426–428, 1981.
152. Delage, C., Irey, N. S. Anaphylactic deaths: a clinicopathologic study of 43 cases. *J. Forensic Sci.* 17:525–540, 1972.
153. Ansari, M. Q., Zamora, J. L., Lipscomb, M. F. Postmortem diagnosis of acute anaphylaxis by serum tryptase analysis. A case report. *Am. J. Clin. Pathol.* 99:101–103, 1993.
154. Yunginger, J. W., Nelson, D. R., Squillace, D. L., et al. Laboratory investigation of deaths due to anaphylaxis. *J. Forensic Sci.* 36:857–865, 1991.
155. James, L. P., Jr., Austen, K. F. Fatal systemic anaphylaxis in man. *N. Engl. J. Med.* 270:597–603, 1964.
156. Randall, B., Butts, J., Halsey, J. F. Elevated postmortem tryptase in the absence of anaphylaxis. *J. Forensic Sci.* 40:208–211, 1995.
157. Schwartz, L. B., Metcalfe, D. D., Miller, J. S., Earl, H., Sullivan, T. Tryptase levels as an indicator of mast-cell activation in systemic anaphylaxis and mastocytosis. *N. Engl. J. Med.* 316:1622–1626, 1987.
158. Edston, E., Hage-Hamsten, M. Mast cell tryptase and hemolysis after trauma. *Forensic Sci. Int.* 131:8–13, 2003.
159. Hoffman, D. R., Wood, C. L., Hudson, P. Demonstration of IgE and IgG antibodies against venoms in the blood of victims of fatal sting anaphylaxis. *J. Allergy Clin. Immunol.* 71:193–196, 1983.
160. Perper, J. A., Kuller, L. H., Shim, Y. K. Detection of fatal therapeutic misadventures by an urban medico-legal system. *J. Forensic Sci.* 38:327–338, 1993.
161. Steel, K., Gertman, P. M., Crescenzi, C., Anderson, J. Iatrogenic illness on a general medical service at a university hospital. *N. Engl. J. Med.* 304:638–642, 1981.
162. Murphy, G. K. Therapeutic misadventure. An 11-year study from a metropolitan coroner's office. *Am. J. Forensic Med. Pathol.* 7:115–119, 1986.
163. Reay, D. T., Eisele, J. W., Ward, R., Horton, W., Bonnell, H. J. A procedure for the investigation of anesthetic/surgical deaths. *J. Forensic Sci.* 30:822–827, 1985.
164. Brennan, T. A., Leape, L. L., Laird, N. M., et al. Incidence of adverse events and negligence in hospitalized patients. Results of the Harvard Medical Practice Study I. *N. Engl. J. Med.* 324:370–376, 1991.
165. Zeien, L. B., Noguchi, T. T. Fatal hydrothorax associated with subclavian vein catheterization for hemodialysis. *Am. J. Forensic Med. Pathol.* 13:326–328, 1992.

166. Kontozoglou, T., Mambo, N. Fatal retropleural hematoma complicating internal jugular vein catheterization. A case report. *Am. J. Forensic Med. Pathol.* 4:125–127, 1983.
167. Conces, D. J., Jr., Holden, R. W. Aberrant locations and complications in initial placement of subclavian vein catheters. *Arch. Surg.* 119:293–295, 1984.
168. Tapsen, J. S., Uldall, P. R. Fatal hemothorax caused by a subclavian hemodialysis catheter. Thoughts on prevention. *Arch. Intern. Med.* 144:1685–1687, 1984.
169. Cohle, S. D., Graham, M. A. Sudden death in hemodialysis patients. *J. Forensic Sci.* 30:158–166, 1985.
170. Feliciano, D. V., Mattox, K. L., Graham, J. M., Beall, A. C., Jr., Jordan, G. L., Jr. Major complications of percutaneous subclavian vein catheters. *Am. J. Surg.* 138:869–874, 1979.
171. Borja, A. R., Masri, Z., Shruck, L., Pejo, S. Unusual and lethal complications of infraclavicular subclavian vein catheterization. *Int. Surg.* 57:42–45, 1972.
172. Scott, W. L. Complications associated with central venous catheters. A survey. *Chest* 94:1221–1224, 1988.
173. Cohen, A. C., Glinsky, G. C., Martin, G. E., Fetterhoff, K. I. Air embolism. *Ann. Intern. Med.* 35:779–784, 1951.
174. McGill, M. P., Kumar, A., Rahko, P. S. Venous air embolism. Echocardiographic diagnosis of air bubbles in the left side of the heart in a patient with a previously diagnosed intrapulmonary shunt. *Chest* 111:826–828, 1997.
175. Saukko, P., Knight, B. *Knight's Forensic Pathology*. 3rd ed. Arnold, London, 2004.
176. Oppenheimer, M. J., Durant, T. M., Lynch, P. Body position in relation to venous air embolism and the associated cardiovascular-respiratory changes. *Am. J. Med. Sci.* 225:362–373, 1953.
177. Butler, B. D., Hills, B. A. Transpulmonary passage of venous air emboli. *J. Appl. Physiol.* 59:543–547, 1985.
178. Bunai, Y., Nagai, A., Nakamura, I., Kanno, S., Yamada, S., Ohya, I. An unusual case of fatal gas embolism. *Am. J. Forensic Med. Pathol.* 20:256–260, 1999.
179. Ritz-Timme, S., Eckelt, N., Schmidtke, E., Thomsen, H. Genesis and diagnostic value of leukocyte and platelet accumulations around “air bubbles” in blood after venous air embolism. *Int. J. Legal Med.* 111:22–26, 1998.
180. Doering, R. B., Stemmer, E. A., Connolly, J. E. Complications of indwelling venous catheters, with particular reference to catheter embolus. *Am. J. Surg.* 114:259–266, 1967.
181. Foley, F. D., Moncrief, J. A., Mason, A. D., Jr. Pathology of the lung in fatally burned patients. *Ann. Surg.* 167:251–264, 1968.
182. Pruitt, B. A., Jr., Flemma, R. J., DiVincenti, F. C., Foley, F. D., Mason, A. D., Jr., Young, W. G., Jr. Pulmonary complications in burn patients. A comparative study of 697 patients. *J. Thorac. Cardiovasc. Surg.* 59:7–20, 1970.
183. Adar, R., Mozes, M. Fatal complications of central venous catheters. *Br. Med. J.* 3:746, 1971.
184. Moylan, J. A., Jr., West, J. T., Nash, G., Bowen, J. A., Pruitt, B. A., Jr. Tracheostomy in thermally injured patients: a review of five years' experience. *Am. Surg.* 38:119–123, 1972.

## Chapter 8

---

# ***Blunt Trauma***

## *With Reference to Planes, Trains, and Automobiles*

### **Summary**

Blunt trauma is the most common injury seen in forensic pathology practice. Cutaneous injuries, in most cases, are not fatal and are seemingly unimportant; however, their documentation has evidentiary value. Unlike the relative specificity of a penetrating injury to its origin, patterned blunt trauma injuries are infrequent; however, the distribution of external and internal injuries can fit a pattern consistent with a particular injury scenario. Unique injury patterns can be observed in fatalities related to motorized vehicles (e.g., restraint system). The cause and mechanism of death (e.g., hemorrhage, physical disruption) is self-evident in most site-specific injuries; however, like certain types of craniocerebral trauma, how the victim died can be subtle (e.g., commotio cordis). In some cases (e.g., fat embolism), microscopy assists in the determination of death caused by blunt trauma.

**Key Words:** Nonpenetrating wounds; blunt injuries; motor vehicles; traffic accidents; air bags; seat belts; aircraft; railroads; accidental falls; cardiopulmonary resuscitation; decubitus ulcer; fat embolism; rhabdomyolysis.

### *1. GENERAL PRINCIPLES*

Blunt trauma is the most common type of injury a pathologist encounters when doing medicolegal autopsies. Many cases have a host of external and internal injuries, and their relative roles in causing death need to be interpreted by the pathologist. The significance of the observed trauma is not just limited to determination of cause of death; other issues need to be addressed. In a few cases, trauma is minimal. Deaths from blunt trauma can literally be “too much or too little” in terms of pathological findings.

From: *Forensic Science and Medicine: Forensic Pathology of Trauma:  
Common Problems for the Pathologist*

By: M. J. Shkrum and D. A. Ramsay © Humana Press Inc., Totowa, NJ

If the body hits or is hit by a blunt surface, then localized absorption of a critical amount of mechanical energy permanently alters the anatomic integrity of the affected site and creates a wound. Structural alteration can occur by pulling apart (tension), pressing (compression) or applying differential force (friction or shear). Contiguity between external (i.e., cutaneous injuries) and internal trauma is evidence of direct application of force, but internal disruption does occur without external signs. Internal injuries, without cutaneous trauma, also suggest forces acting remotely from the impact site. Visible trauma, usually internal, as seen at autopsy or under the microscope, is a sign of a pathophysiological disturbance leading to death. Rarely, fatal injury is not apparent.

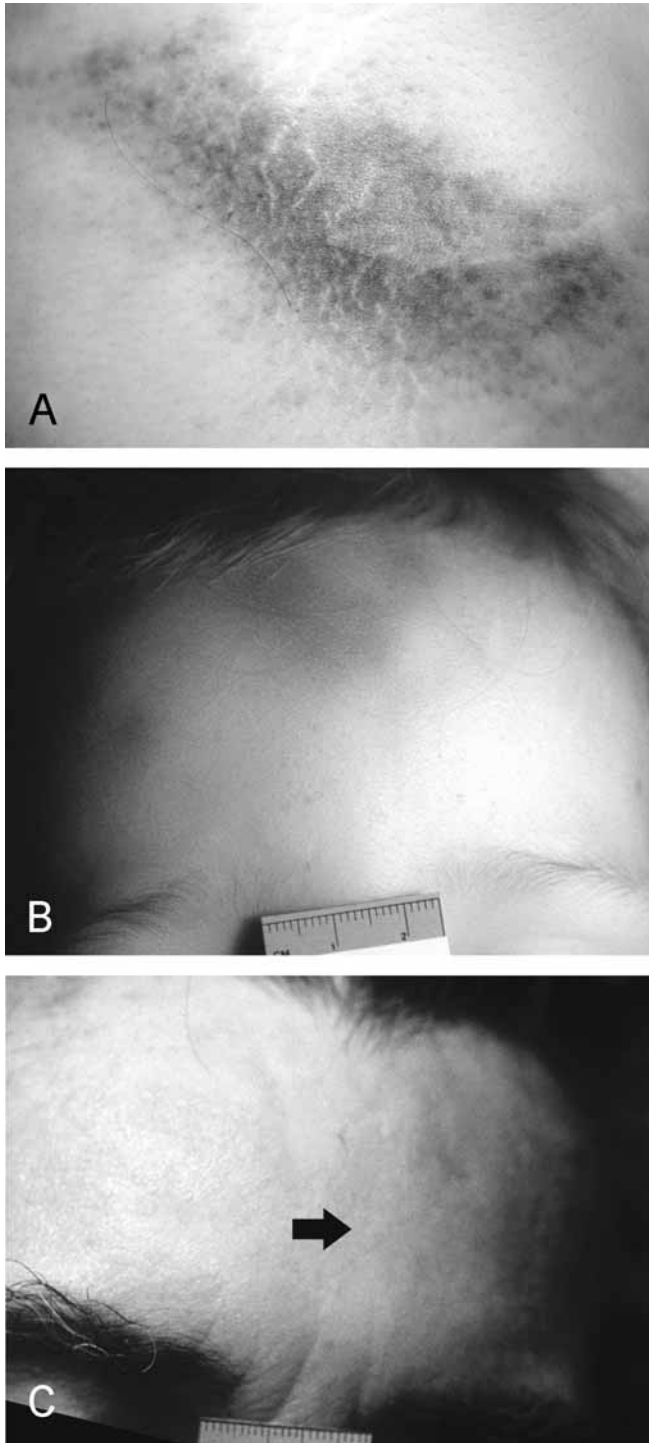
The presence and extent of injury depends on the amount of force exerted. Force is a product of mass  $\times$  acceleration (Newton's second law). Acceleration is the change in velocity ( $\delta V$ ) occurring over a period of time ( $\delta T$ ). An increase in the velocity of the moving surface (body or blunt surface) causes a proportional increase in force. If velocity change occurs over a short period of time (i.e., decreased  $\delta T$ ), then force increases proportionally (1–3). Force concentrated over a small area is more likely to be injurious (i.e., stress proportional to force/area) (2,3). The interrelation between the velocity ( $V$ ) of body deformation and degree of compression ( $C$ ) is an important factor in injury causation (4). Impact severity has been described as a product of these two factors ( $V \times C$  [4–6]). A visceral injury—e.g., lung contusion—can occur with minimal chest compression, as indicated by few or absent rib fractures, if the velocity of deformation is high. The resistance of an organ or tissue to compression and impact velocity is a reflection of its “viscous tolerance.”

Kinetic energy is energy associated with motion (kinetic energy =  $0.5 mv^2$ , where  $m$  is mass and  $v$  is velocity). The higher the amount of kinetic energy, the greater the potential for injury. The amount of kinetic energy absorbed is dependent on the nature of the surface impacted (3). Contact with a hard surface means that a considerable amount of mechanical energy is dissipated in the body (2). The greater elasticity of the skin and the rib cage of a young individual means less damage, but less elastic internal viscera (e.g., liver) can be severely disrupted. The structure and configuration of certain organs or body sites are predisposed to injury. For example, differential displacement causes shear stress at the transition between the mobile aortic arch and fixed descending thoracic aorta (see Subheading 6.5. and ref. 7). Energy absorption is magnified in gas-filled structures by shock-wave effects. Fluid-filled organs (e.g., heart) burst because of increased hydrostatic pressure (see Subheading 6.4.).

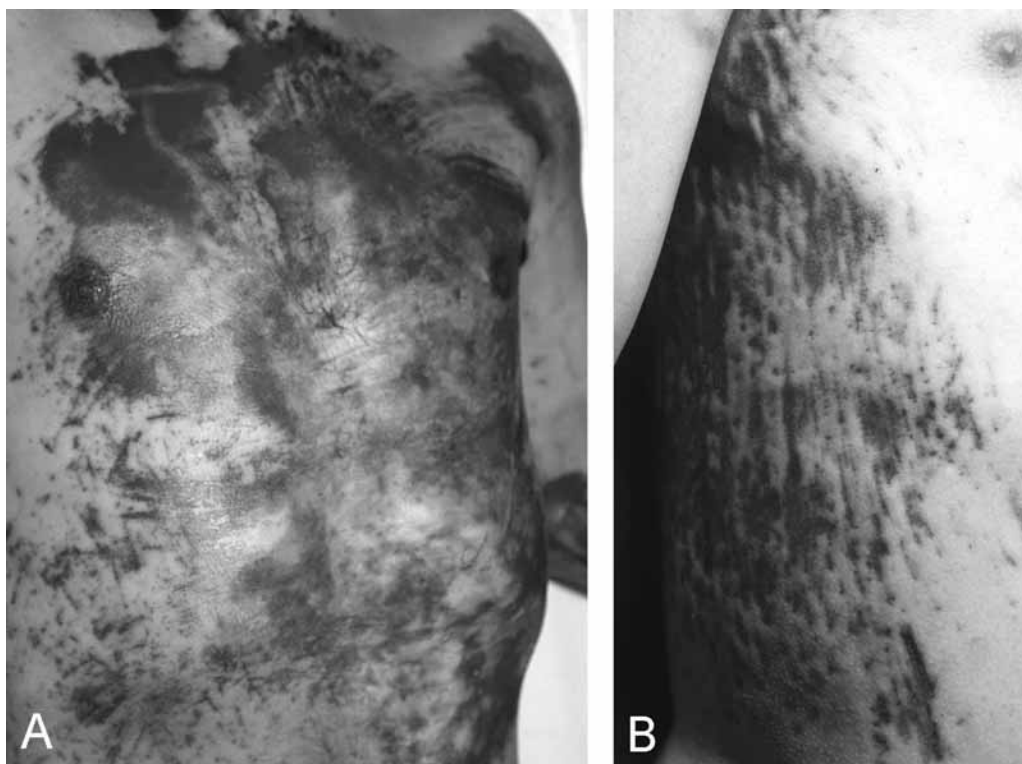
## 2. SKIN INJURIES

Three types of skin injuries are commonly seen: contusion (bruise), abrasion (scrape) and laceration (tear). Contusions have common characteristics (8–12). A contusion is manifest as skin discoloration from underlying extravasation of blood owing to blood vessel rupture as a result of trauma or disease (see Subheading 3.2. and Fig. 1). The surface is intact. Unlike “open” abrasions and lacerations, a contusion is “closed” and not liable to be infected. An abrasion occurs when the superficial skin layers are removed by friction, compression, or stretching (Fig. 2). A laceration is a tear of the tissue surface. A cutaneous laceration is distinguished from an incised wound caused by sharp force trauma by irregularity of the wound edge, strands of tissue bridging the

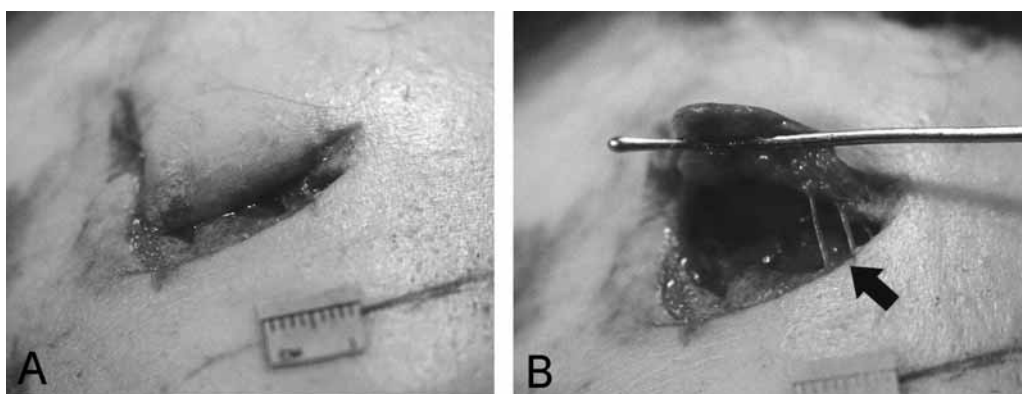




**Fig. 1.** Contusions of different ages. (A) Recent contusion; purple-red. (B) Healing contusion; brown. (C) Almost-healed contusion (arrow); yellow. (See Companion CD for color version of this figure.)



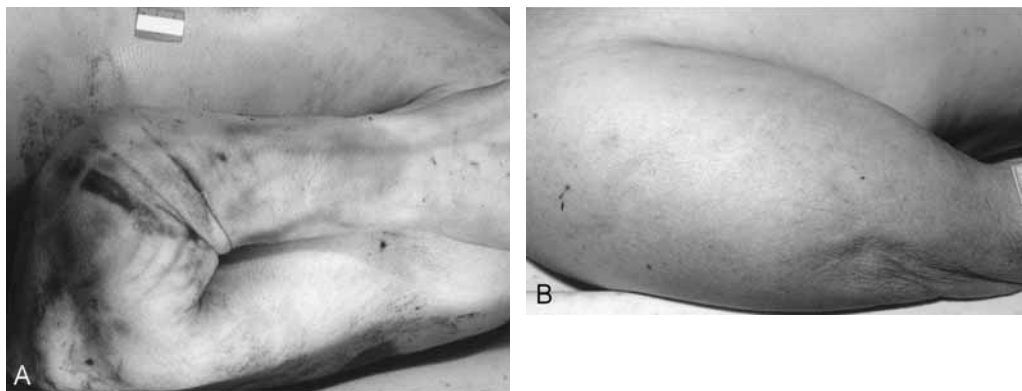
**Fig. 2.** Various abrasions. (A) “Brush” abrasions caused by relatively smooth surface (e.g., paved road). (B) Punctate and linear abrasions (“road rash”) owing to more uneven surface (e.g., gravel road).



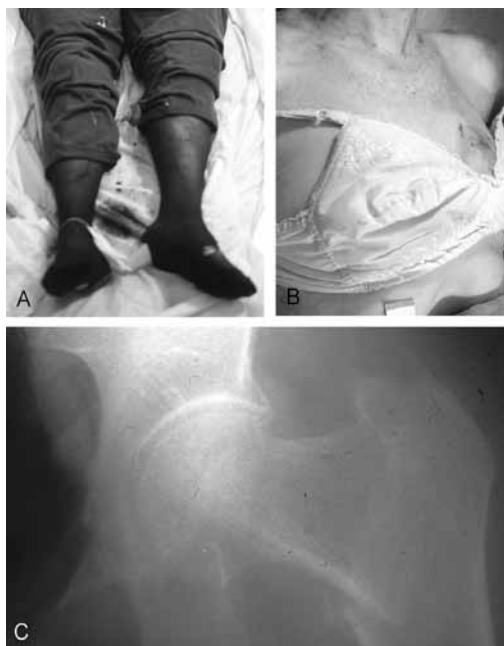
**Fig. 3.** Laceration. (A) Variable irregularity of wound edge. (B) Undermining and tissue bridging (arrow).

defect, and undermining (Fig. 3). The latter is caused by the lifting of the skin, which creates a pocket of soft tissue disruption.

Deformity and swelling are external signs of acute fracture (Figs. 4 and 5). A fracture can be confirmed by a postmortem radiograph (Fig. 5).



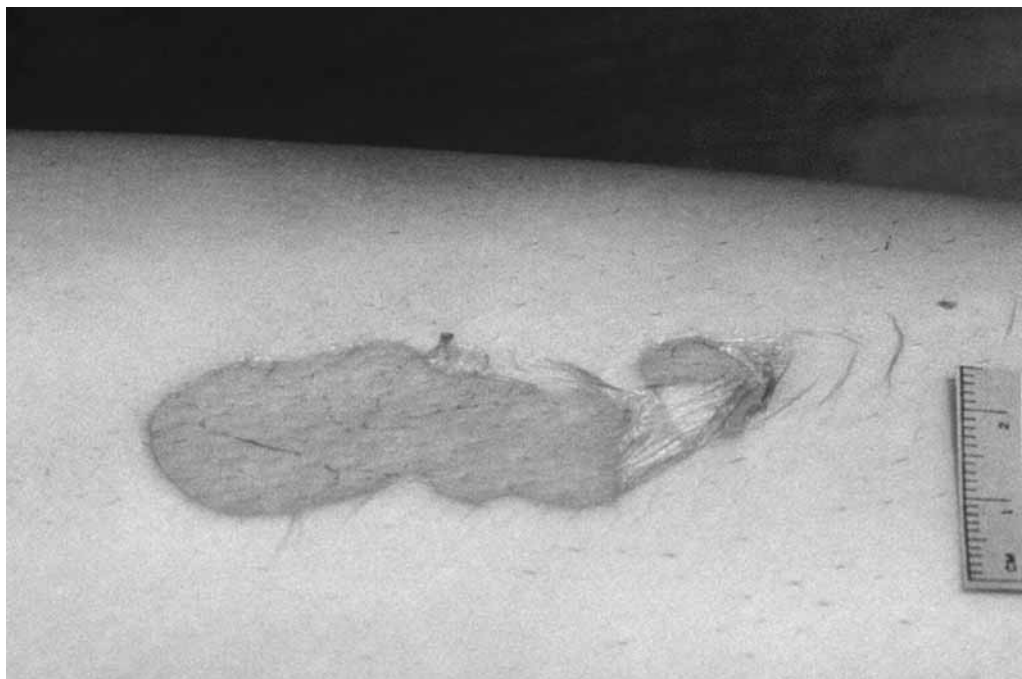**Fig. 4.** Fractures of upper extremity. (A) Deformity owing to fracture of radius-ulna. (B) Swelling; fractured humerus.



**Fig. 5.** Elderly woman found dead on patio in winter. Hypothermia (see Fig. 9). (A) Shortened and externally rotated left leg. (B) "Paradoxical" undressing. (C) Postmortem radiograph-fractured left femur, which incapacitated victim.

### 3. SIGNIFICANCE OF BLUNT TRAUMA SKIN INJURIES

The first step in the interpretation of cutaneous skin injuries is accurate documentation by narrative description, diagrams, and photographic/digital images. Once there is a proper record of the injuries, the interpretation of their significance is done, realizing that even minor injuries have considerable medicolegal importance (13).



**Fig. 6.** The typical yellow color of a postmortem abrasion. (See Companion CD for color version of this figure.)

### ***3.1. Antemortem or Postmortem***

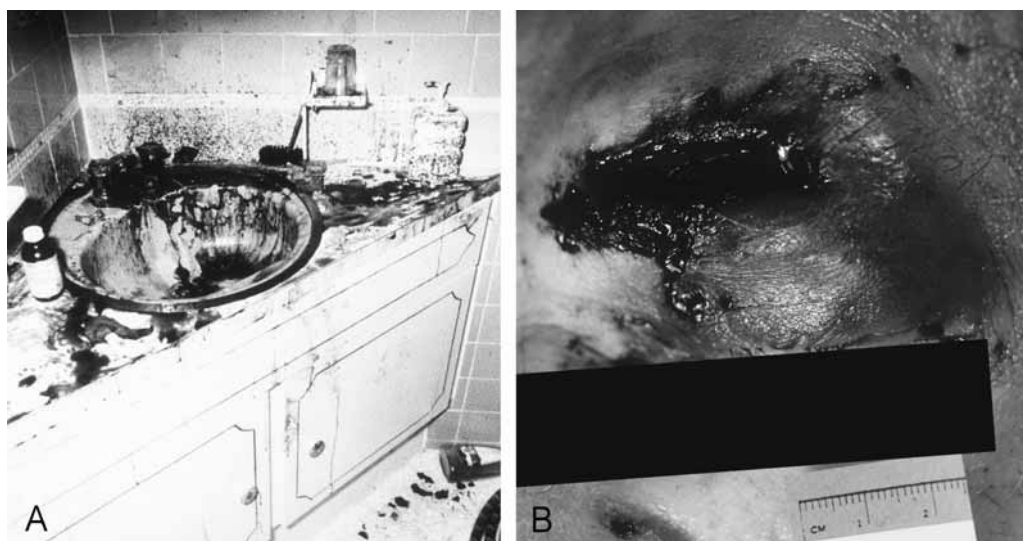The observed injury could have occurred after death. Bruises, either alone or in combination with other types of cutaneous injuries, are a sign of cardiac output; however, bleeding is diminished during the agonal phase preceding death because of declining heart function. Further injury can happen after infliction of fatal trauma. Injuries can occur during removal from the scene, transportation, and autopsy (Fig. 6). Postmortem changes can alter or mimic injuries (*see* Chapter 2, Subheadings 3.2., 3.3., and 5.2.).

### ***3.2. Degree and Direction of Force and Cause of Death***

Generally, multiple, extensive, and open cutaneous injuries imply a greater degree of force. Injuries distributed on different surfaces of the body may, depending on the circumstances of injury, represent multiple concurrent impacts or repetitive trauma. A cutaneous injury is an external sign of severe visceral injury and indicates significant absorption of energy at that site. Rarely, fatal exsanguination is caused by a skin laceration (Fig. 7). Extensive soft tissue trauma can be a cause of death (*see* Subheading 12.1. and refs. 3 and 14).

The degree of bruising reflects the amount of inflicted trauma, but a number of factors modify this interpretation (13).

Contusions can be extensive yet arise from minimal trauma. If an individual is taking medications (e.g., aspirin, anticoagulants) or has a bleeding diathesis (e.g., cirrhosis, hemophilia), then there is a predisposition to hemorrhage (*see* Subheading 3.4.1.1.; Fig. 7; and refs. 8 and 13). Children bruise more easily because of their loose, delicate skin (8,13). Elderly individuals, because of dermal atrophy and decreased capillary support,



**Fig. 7.** Alcoholic found dead in home. Acute ethanol intoxication (240 mg/dL). Cirrhosis seen at autopsy. **(A)** Evidence of considerable bleeding at scene. **(B)** Exsanguination from laceration on left eyebrow. Hematoma, upper eyelid.

develop senile ecchymoses (8,13,15). These bruises typically arise in individuals more than 60 yr of age and arouse suspicion of abuse (15). Senile ecchymoses are characterized by nonpalpable foci of hemorrhage with irregular edges. They typically involve the arms and to a lesser extent, the sides of the neck, and legs (Fig. 8). They are seen in nursing home patients, but they also occur in individuals in acute care hospitals and at home. Minimal trauma, such as lifting or other means of physical support, can precipitate ecchymoses. Obesity enhances bruising (8,13).

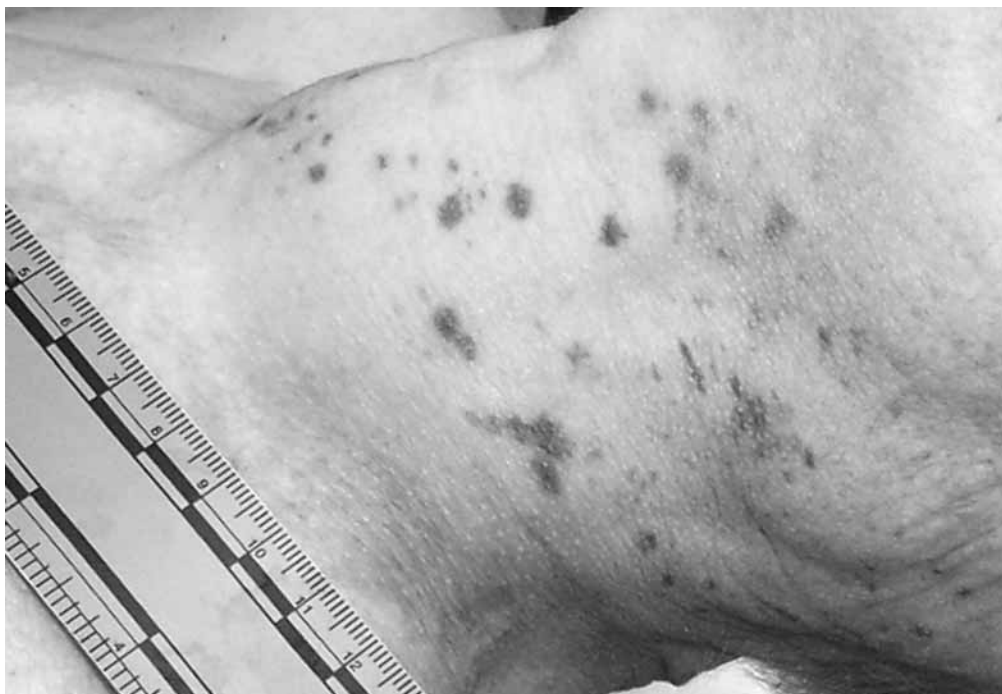The nature of the impacted site influences the skin injuries seen. Force inflicted over a bony prominence (e.g., orbital ridge) is more likely to cause laceration (Fig. 7).

Unlike abrasions and lacerations, contusions do not always indicate a direct impact site because of tracking of blood (Fig. 9). Direction of force can be determined in abrasions and lacerations (e.g., abraded layers of skin pushed to one side, unequal undermining of a laceration consistent with tangential force [3]). If extravasated blood collects in deep soft tissue (hematoma), bruising is not apparent initially and is appreciated only by incision of the suspected injured site (Fig. 10; refs. 3 and 8). The scalp is a site of “hidden” bruises (Fig. 11). Scalp hair covers contusions. A scalp contusion may not be appreciated externally until the scalp is reflected. Hemorrhage is typically seen at the scalp–skull interface, which shifts with blunt impact. If the individual survives, blood may reach the skin surface, and the consequent bruise can appear more recent. The extent of bleeding is increased if the injured tissue is loose, vascular, or both (e.g., periorbital, genital areas; see Fig. 7 and refs. 3, 8, and 13). Continued pressure on an injured site reduces bleeding (8).

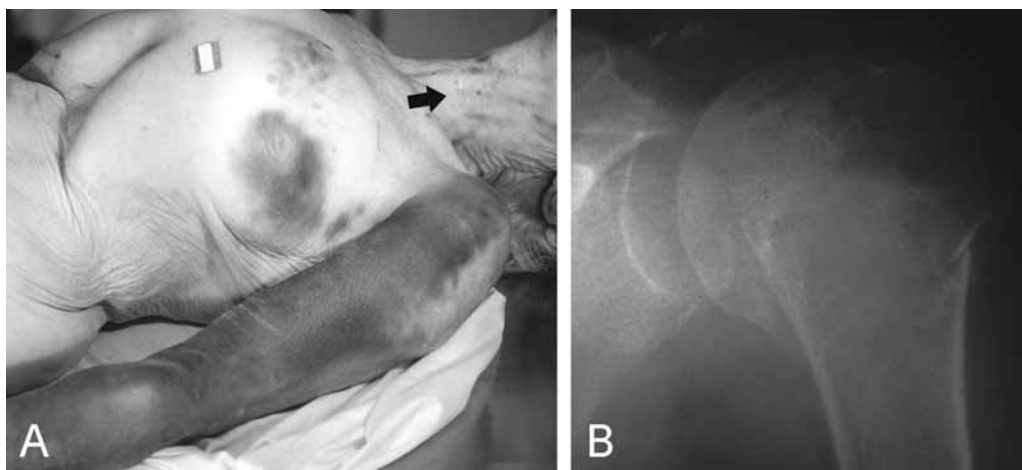
### 3.3. Aging of Injuries

A frequently asked question at autopsy and legal proceedings is, “How old are the injuries?” Attempts at aging of injuries can be done at the time of autopsy, by



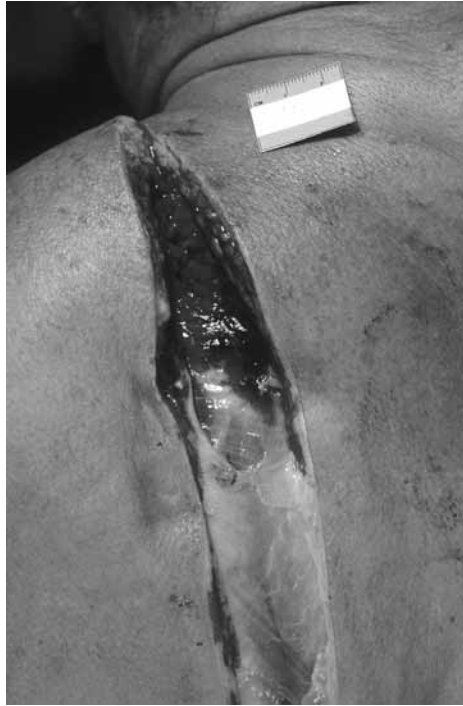

**Fig. 8.** Senile ecchymoses on neck. (Courtesy of Dr. E. Tweedie, London Health Sciences Centre, London, Ontario, Canada.)

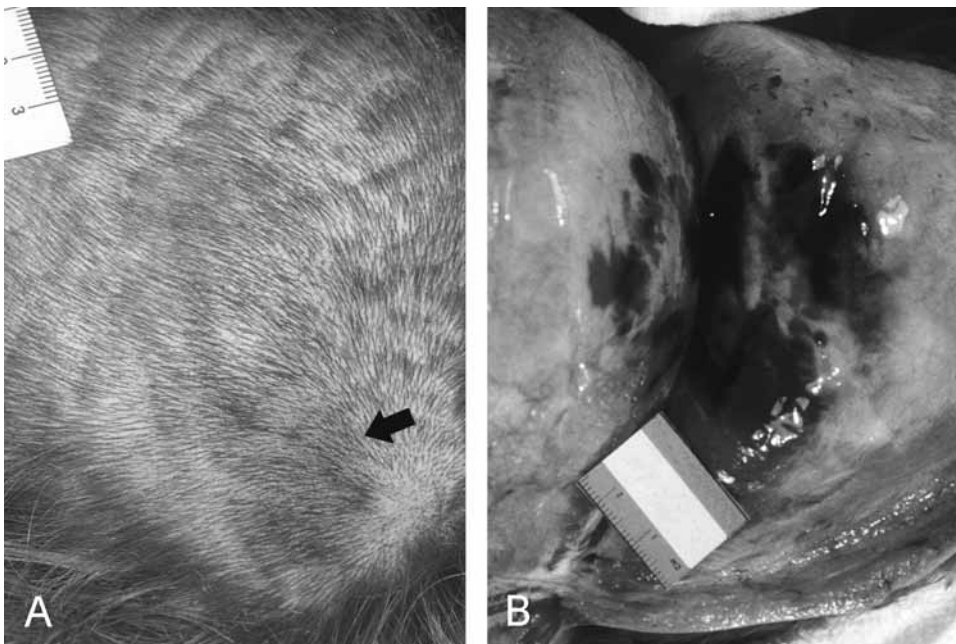


**Fig. 9.** Elderly woman found dead outdoors from hypothermia (see Fig. 5). **(A)** Extensive extravasation of blood in left arm and forearm from fractured humerus sustained 2 wk prior to death. Neck abrasions (arrow) raised the possibility of strangulation. There were no external petechiae. Internal neck trauma was absent. **(B)** Fracture of humerus demonstrated in postmortem radiograph.

microscopy and other specialized techniques. Generally, cutaneous injuries are not precisely linked to a specific time of infliction (3). The pathologist must consider that the observed injuries can be contemporaneous (i.e., at the time of death), coincidental



**Fig. 10.** Soft tissue hematoma, back. Note the absence of bruising on the skin surface.



**Fig. 11.** “Hidden” scalp contusions. (A) Contusion (arrow) hidden by scalp hair, which was partly cut at autopsy. (B) Another case showing reflected posterior scalp. Contusion at interface between scalp and skull. Bruising was not evident externally.

(i.e., before the fatal event and unrelated), and evolutionary (i.e., at the time of the injury but developed during a survival interval—e.g., subdural hemorrhage).

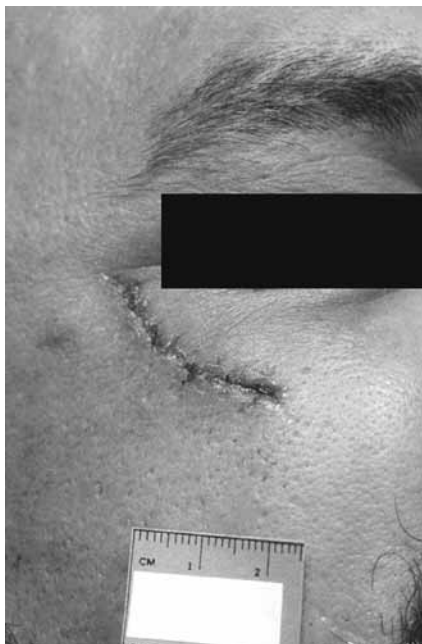Of the cutaneous injuries, a contusion is the most problematic to age. As hemoglobin degrades by macrophage ingestion, visible bruises undergo a series of color changes; this effect has been used to age injuries (Fig. 1). The perception of bruises is influenced by a number of factors. Dark skin pigmentation means that contusions are either missed or altered in color. The type of light available and color perception also influence observations (16,17). The color of a contusion is, at best, only an approximation of the time since injury, because of many variables involved (8–11,18–20). Free hemoglobin appears red (9,11). Biliverdin and bilirubin are green and yellow, respectively. Hemosiderin is also yellow. Darker colors, such as blue and purple, indicate blood reflecting light at different depths in the skin (9). Green can be a combination of blue and yellow discoloration (9). Generally, red, purple, or black discoloration happens in the “immediate” period—i.e., within 24 h following injury (8,12). A survival period of 24 to 72 h causes the bruise to become blue, dark purple, or brown. A yellow tinge can be seen at this stage, and this persists for days. In one study, which reviewed photographic images of bruises on patients, yellow discoloration was associated with an injury more than 18 h old (9). Green discoloration follows in the first week and lasts up to the 10th day after trauma. After 7 to 10 d, the bruise turns yellow. Disappearance of color begins at 2 wk or more (12).

There are divergent opinions regarding when certain colors appear (e.g., brown at 1 to 3 d as opposed to 1 wk; yellow at several days as opposed to 2 wk [11,20]). Bruises inflicted at the same time at different body sites can appear differently depending on the depth of hemorrhage, nature of the injurious agent, and the individual’s response to injury (10). Bruises resolve at different rates (9). Healing begins at the periphery of the bruise, meaning that central areas of large bruises may appear more recent (10,11). Resorption of blood is enhanced if a bruise occurs at the site of previous injury. The more the vascular the injured site, the faster the rate of healing. Faster healing has been observed in young individuals (11,21).

The appearance of “fresh” wounds (red, blue, purple) can persist for some days (9,10). Pathologists cannot express an opinion about the specific age of the bruise but can state that, based on certain colors (yellow, green, brown), the observed bruise is “older” (9,10,18,20). Photographic assessment of injuries in the clinical setting, particularly involving children, is not precise (10,16).

Representative cutaneous injuries need to be sampled for microscopic examination if there are issues related to the timing of injuries. The histological assessment of open injuries (abrasions and lacerations) is more definitive. There are three stages of healing: inflammation (1 to 3 d after injury), a proliferative phase (up to 10 to 14 d post-in infliction) and a reorganization or remodeling phase (more than 2 wk to months; see Fig. 12 and ref. 8). The healing of open skin wounds is summarized as follows (8,12,21,22):

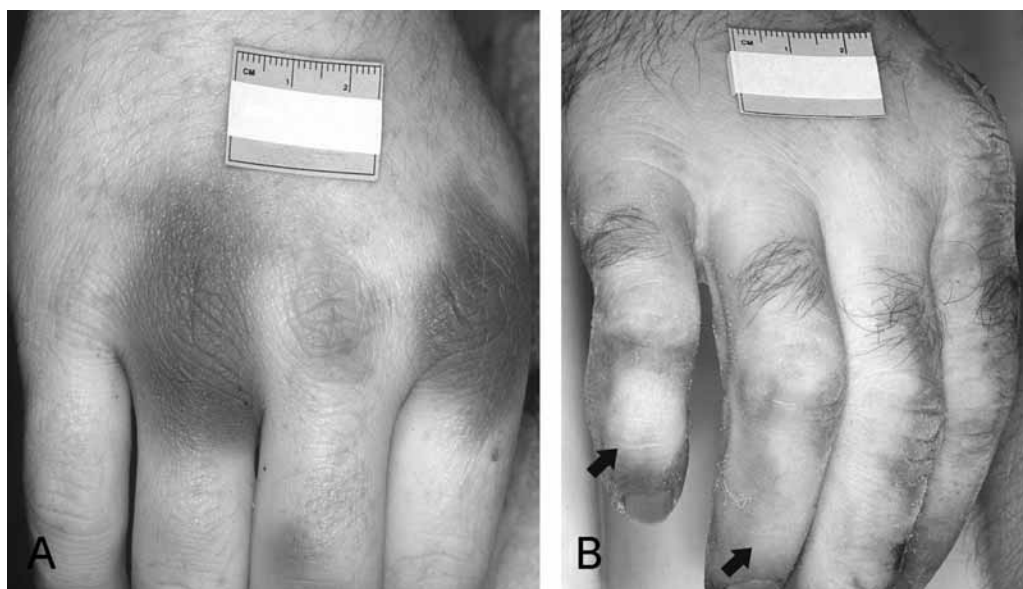
1. Scab formation
  - a. Up to 4 h, serum, red blood cells and fibrin deposit on the injured site (indicates survival).
  - b. From 2 to 6 h, perivascular polymorphonuclear leukocytes (PMNs) are seen.
  - c. By 8 h, a layer of PMNs is seen under the raw surface or crushed epidermis.



**Fig. 12.** Healing laceration. Note irregular ingrowth of epidermis into residual skin defect.

- d. By 12 h, three zones are present:
  - i. Superficial (fibrin and red blood cells on the surface)
  - ii. Middle (PMNs)
  - iii. Deep (damaged, abnormally stained collagen that, by 18 h, becomes infiltrated by PMNs).
- e. At 16 to 24 h, macrophages exceed PMNs.
2. Epithelial regeneration (from hair follicles and wound edges)
  - a. By 30 h in superficial injuries.
  - b. Visible by 72 h in most abrasions.
3. Subepidermal granulation (following complete epidermal covering of abrasion)
  - a. Fibroblasts at 1 d earliest, regular appearance by 5 d.
  - b. 5 to 8 d.
  - c. Hyperplastic epidermis, 9 to 12 d.
4. Regression
  - a. At 8 to 12 d, decrease in cellular activity (i.e., inflammation, capillary in growth, fibroblasts).
  - b. At about 12 d, epidermis thinned and collagen prominent.
  - c. At more than 14 d, shrinkage and maturation of connective tissue.

The aging of bruises is less defined. Following hemorrhage in the early stages neutrophils are detected in various wounds within 20 to 30 min (up to 4 h in subcutaneous fat); however, the usual range is 1 to 24 h (8,21). Care is required in the microscopic assessment of the aging of hemorrhage because inflammatory cells passively enter soft tissue with extravasated blood. Exudate is significant if seen away from accumulated red blood cells (21). Macrophages follow within a few hours but are clearly evident in 1 to 2 d. Siderophages appear in 24 to 72 h in a cutaneous injury and are demonstrated



**Fig. 13.** Injury pattern. (A) Knuckle bruises consistent with punch. (B) Contusions on middle phalanges of fingers. Central areas of pallor (arrows) within bruised areas due to deceased forcefully knocking on doors.

by a Perls' Prussian blue reaction (8,21,23,24). The appearance of siderophages is site-dependent (e.g., in the brain, minimum 3 to 5 d; in the lung, 17 h at the earliest [8]). A lack of hemosiderin does not provide information about the postinfection interval because its presence is dependent on the amount of bleeding initially, and complete resorption is possible with old wounds (8,24).

Various enzyme histochemical, biochemical, immunohistochemical, and other techniques have been applied attempting to age wounds (8,9,19,25–29).

### 3.4. Injury Pattern/Patterned Injury

#### 3.4.1. Injury Patterns

Many wounds caused by blunt trauma are nonspecific in determining the nature of the blunt surface that caused those injuries. An injury pattern is defined as a predictable but nonspecific injury having a characteristic distribution consistent with a particular traumatic event (Fig. 13). Blunt trauma injury patterns are seen in certain types of deaths.

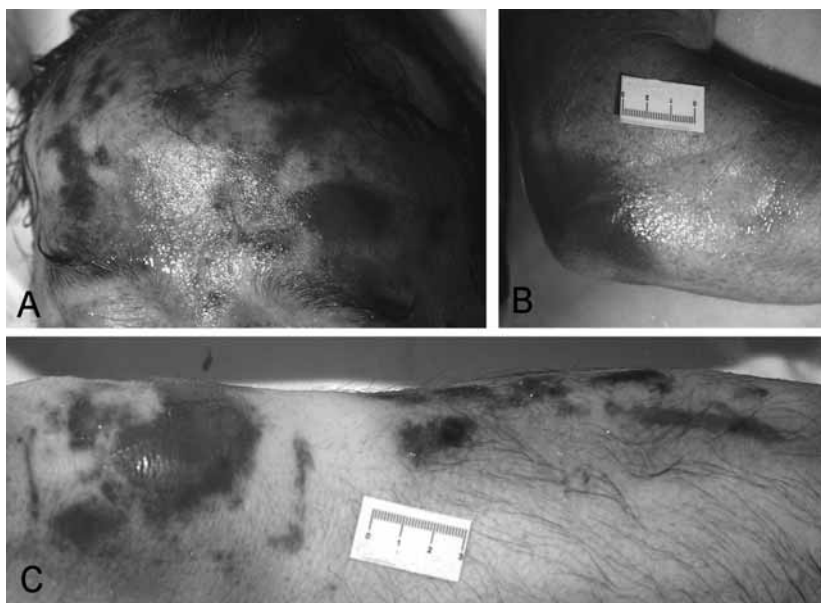
##### 3.4.1.1. CHRONIC ALCOHOLISM

Chronic alcoholics, when intoxicated, fall repeatedly. They are predisposed to bleeding because of abnormal coagulation caused by cirrhosis (Fig. 7). Multiple blunt trauma injuries (e.g., contusions) on the extremities, torso, and face suggest assault (Fig. 14; ref. 30). There may be associated internal injuries that heighten concern. The finding of external and internal trauma of different ages, supported by toxicological analysis and investigation of the circumstances of the death, provides reassurance.

##### 3.4.1.2. HYPOTHERMIA

Hypothermia occurs when the body temperature drops to less than 35°C (95°F [31–33]). Poor indoor heating, cold water immersion (see Chapter 5, Subheading 4.5.),



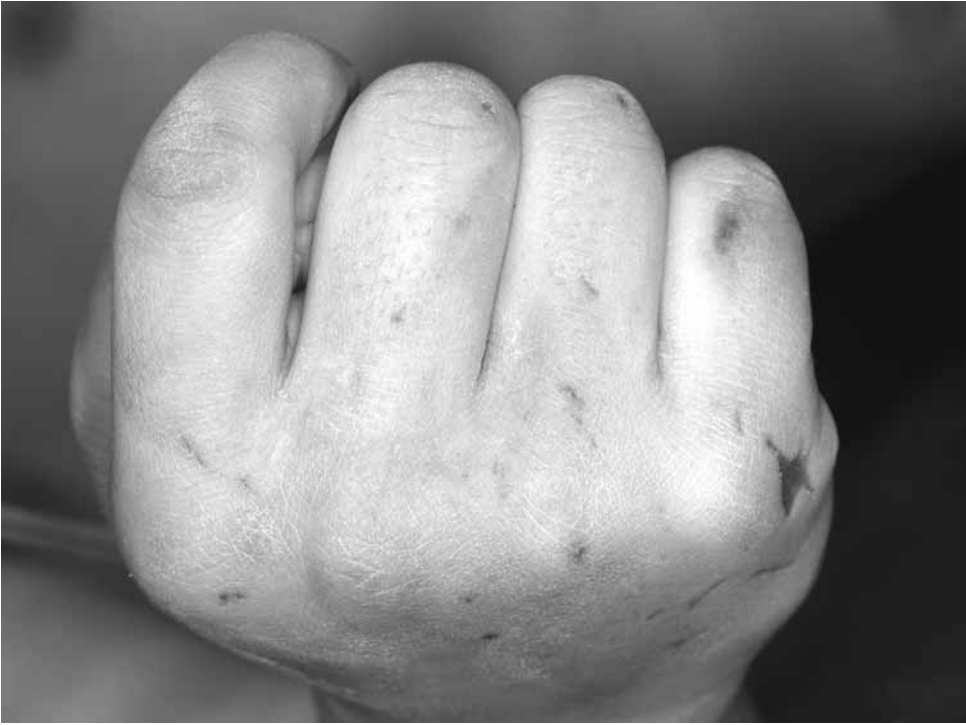

**Fig. 14.** Multiple contusions. Chronic alcoholic subject to repeated falls. (A) Forehead. (B) Elbow. (C) Knee and shin. (Courtesy of Dr. A. Tuck, London Health Sciences Centre, London, Ontario, Canada.)

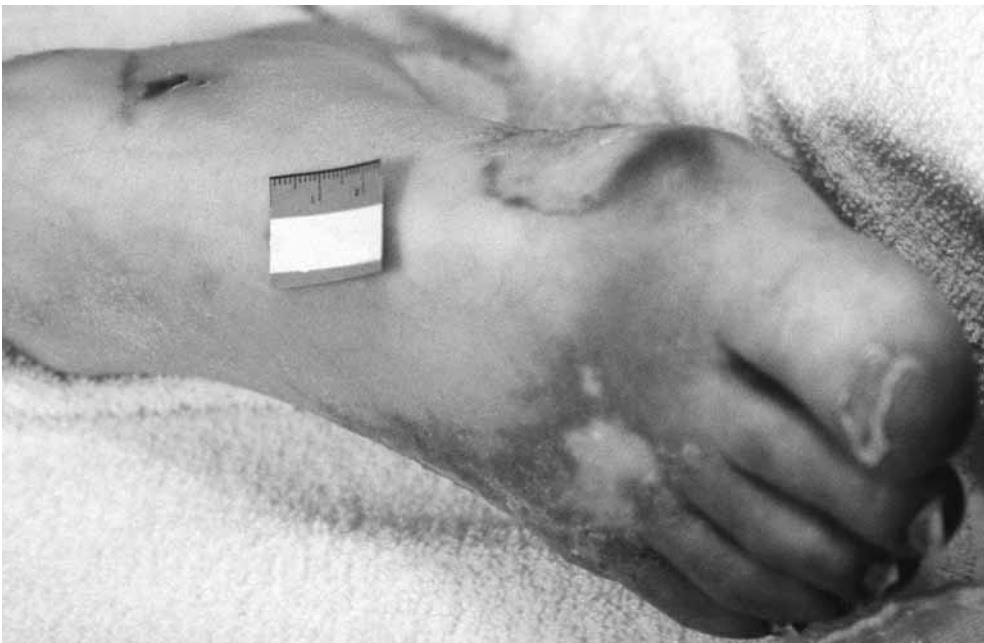and outdoor exposure are common scenarios (31,34). Certain predisposing factors play a role. Persons at the extremes of age are vulnerable (Fig. 5; refs. 31 and 34–36). Underlying disease or injury render an individual more vulnerable. Ischemic heart disease is a setting for cold-induced arrhythmia (36). Endocrine dysfunction (e.g., hypothyroidism, diabetes mellitus) alters perception of cold and decreases the ability to compensate (31). Neuropsychiatric illness (e.g., schizophrenia, dementia) can blunt the desire to seek shelter from the cold (31,37,38). Intoxicated individuals, either in wet clothes or dressed inadequately, are typical victims of cold weather exposure (31,34–36,38,39).

These cases can display a pattern of blunt trauma injuries. Abrasions occur commonly on the extremities, but other body sites may be involved (Figs. 5, 9, 15; refs. 35, 36, and 38). These scrapes can be caused by falling or rubbing. Their distribution on the dorsum of the hand suggests an altercation (Fig. 15). Suspicion is heightened if clothes have been removed. Paradoxical undressing varies from removal of footwear to complete nudity, which suggests sexual assault (Fig. 5; refs. 35,36, and 38–40). This phenomenon is the result of cold-induced vasoconstriction that is followed by vasodilation from loss of vascular tone (35,36,38,40). The result is a false sense of warmth, and there even may be evidence of rolling around in the snow (35,39). Paradoxical undressing occurs in the setting of dementia and suicide (37,39). Hypothermic victims can also be found in unusual locations (e.g., lying under a bed) because of “terminal burrowing behavior” (38).

Associated external findings include frostbite, edema of the face and extremities, and red livor mortis (Fig. 16; refs. 35, 36, and 41). Areas of purple or red-purple discoloration, particularly on the knees and elbows in nonlivid areas, have been described and



**Fig. 15.** Hypothermia death. Victim found lying face down on ice. Subtle abrasions on dorsum of hand from rubbing (see Fig. 9).



**Fig. 16.** Ischemic changes of right foot owing to frostbite.



**Fig. 17.** Hypothermia. Gastric erosions arranged in a rectangular distribution (arrow).

may be a postmortem change (35,36,41). When the body is thawed, veins are accentuated on extremities, and marbling caused by decomposition is enhanced (41).

Internal findings may be few. Acute changes include superficial gastric erosions, pancreatic hemorrhage, pulmonary edema, and “striped” hemorrhages in the iliopsoas muscles (Fig. 17; refs. 35, 36, 38, 40, and 41). Stomach lesions are likely caused by ischemia from vasoconstriction (40). A prolonged survival period can be complicated by coagulopathy, rhabdomyolysis, and renal failure (see Chapter 8, Heading 13; and ref. 31).

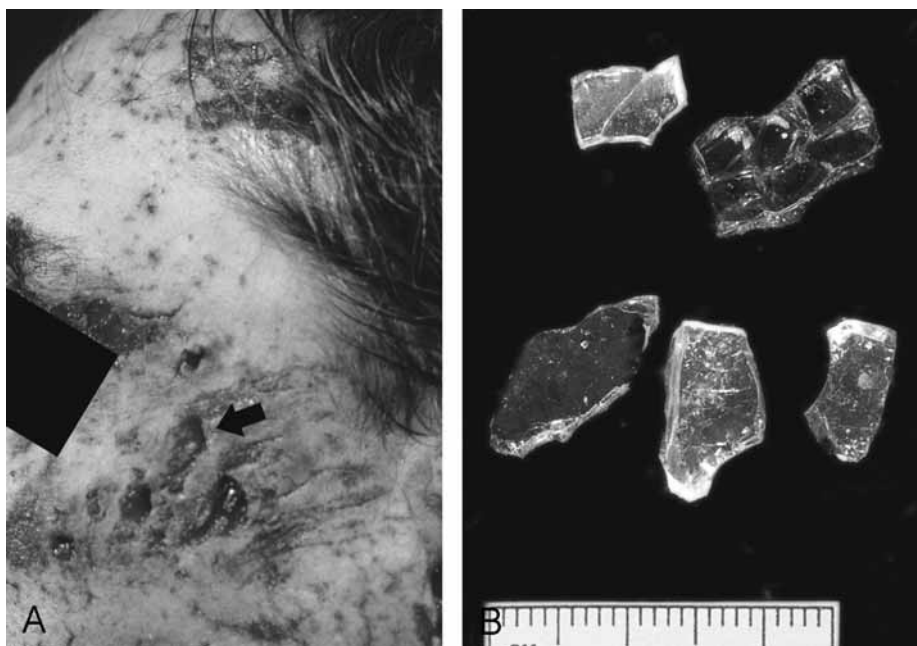
Toxicological testing is necessary to determine whether the victim was intoxicated. Acetone, detected in the urine, may be a sign of cold-induced ketosis (38).

### 3.4.2. Patterned Injury

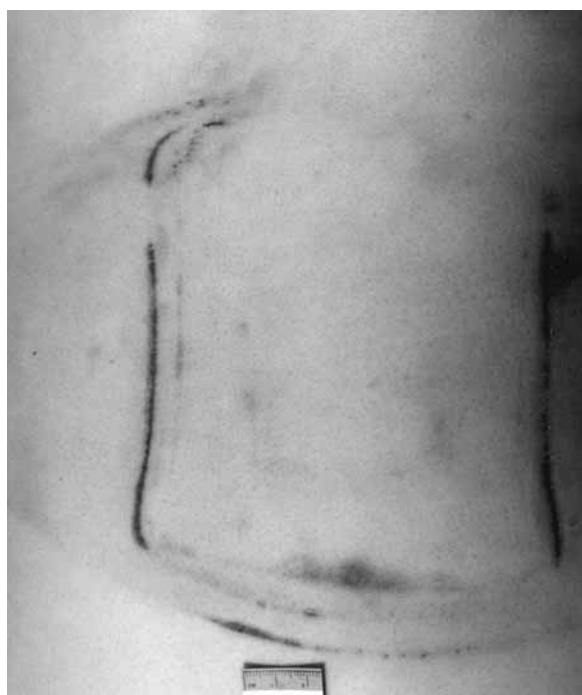
The finding of a patterned injury—i.e., the source of injury is reproduced on the skin surface—is less common but has important evidentiary value, particularly in homicide investigations (Figs. 18–23 and refs. 8 and 42–47). On occasion, the injury is the mirror image of the striking object (44). Linking a patterned skin wound with its injury source is done by various means (e.g., 1:1 transparent overlay, photographic comparison of wound and the object or its cast, ultraviolet light illumination [44–48]).

#### 3.4.2.1. HUMAN BITE MARK

A human bite can occur during a sexual assault, child abuse, certain types of sexual behavior, and self-defense. Some bite marks have more innocent explanations (e.g., self-inflicted, child biting child [12,49–56]). Human biting tears or crushes, resulting in contusions, abrasions, and lacerations in a circular or elliptical array (49,57). Often the bite mark is composed of two “U”-shaped marks, corresponding to the upper and lower teeth and separated by an open space (between 25 and 40 mm, or about 0.125 in.),



**Fig. 18.** Driver involved in near-side collision. **(A)** Multiple lacerations on left cheek. Reverse L-shaped laceration (arrow). Fragments of tempered glass embedded in wounds. **(B)** Characteristic rectangular fragments of broken tempered glass from a side window.

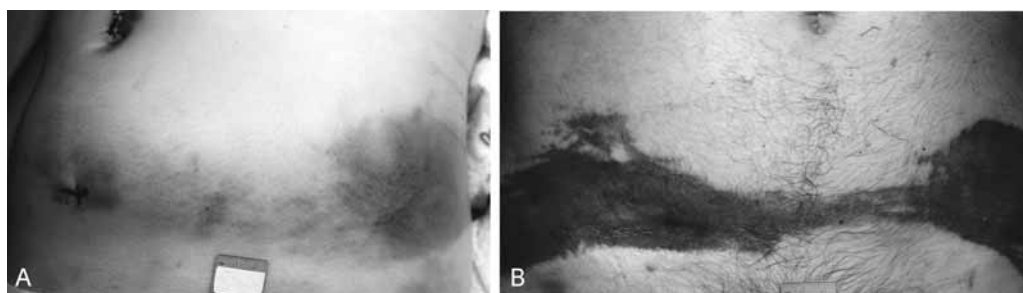


**Fig. 19.** Patterned abrasion on chest caused by steering wheel.





**Fig. 20.** Driver fatality. (A) Two parallel linear abrasions (arrows) on left cheek of driver. (Courtesy of Dr. C. McLean, London Health Sciences Centre, London, Ontario, Canada.) (B) Patterned injury caused by intrusion of A-pillar (A).

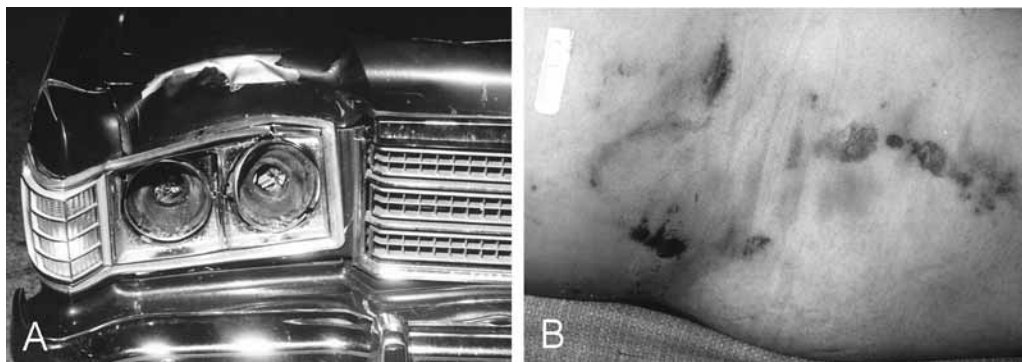


**Fig. 21.** Lower abdominal cutaneous injuries from lap belt ("seat-belt sign"). (A) Contusion. (B) Abrasion.

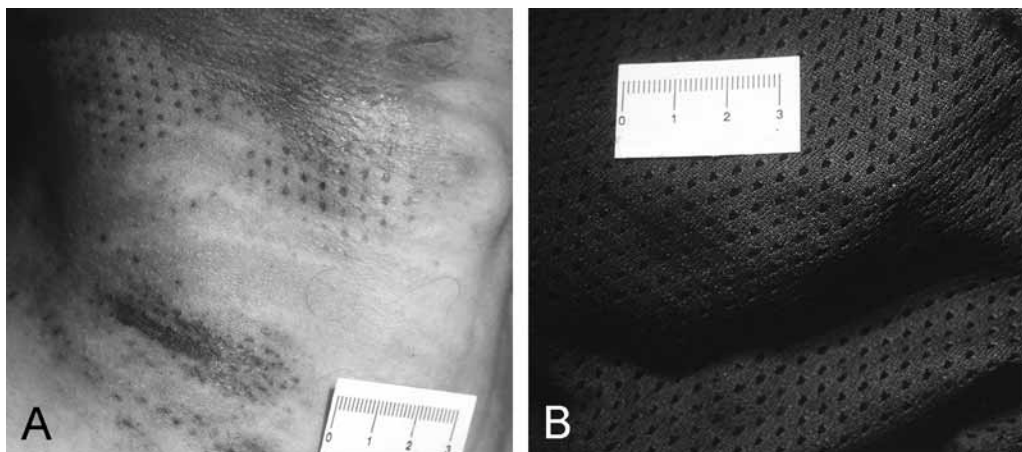
which can be contused from teeth pressure (49). Petechiae from sucking may be present (55). Usually, impressions are made by the anterior six teeth (canine to canine [49,55]). Studies of bite marks have shown that most victims of a criminal act are women (53,58). The breast is the most common location. Male victims are more frequently bitten on the arms (53,58). Male children can be bitten on their genitalia, and girls sustain bites to many locations. Multiple bite marks do occur (58).

If a bite mark is suspected, then consultation with a dentist specializing in forensic odontology is necessary (54,58,59). Examination of a bite mark is best done *in situ* (57). If a case involves an assault, then the bite mark is swabbed for saliva, for the purpose of DNA analysis (43,49,60). Tooth fragments or dental calculus can be found in





**Fig. 22.** “Secondary” impact by a pedestrian struck by a motor vehicle. **(A)** Impact with hood edge and front headlight. **(B)** Another case showing semicircular abrasion above right hip likely the result of headlight contact. (Courtesy of the Office of the Chief Medical Examiner, Chapel Hill, NC.)



**Fig. 23.** Run-over. **(A)** Patterned abrasions on neck. **(B)** Weave pattern of sweatshirt.

the bite mark (54). Photographs (color, black and white) with a proper reference (American Board of Forensic Odontology) scale, and models of the suspect’s dentition are required for comparison (49,61,62). The bite mark impression is a negative reproduction of teeth indentations, and is used to create a model (Fig. 24; refs. 59 and 62). A model of a suspect’s dentition can be compared either directly with a photograph of a bite mark or indirectly by use of an overlay created by computer, photocopy, or hand-tracing (49,59,61,63–65). A bite mark is mimicked by other types of skin trauma (e.g., sharp-force trauma, cardiac defibrillation [49,57,66,67]). Although a bite mark is a patterned injury, it is not always unique to one individual (49,68).

#### 4. DECUBITUS ULCERS (PRESSURE SORES)

Pressure on skin overlying bony prominences (e.g., spine including sacrum, scapulae, elbows, greater trochanters, heels, and ankles) can result in decubitus ulcers (69–75).



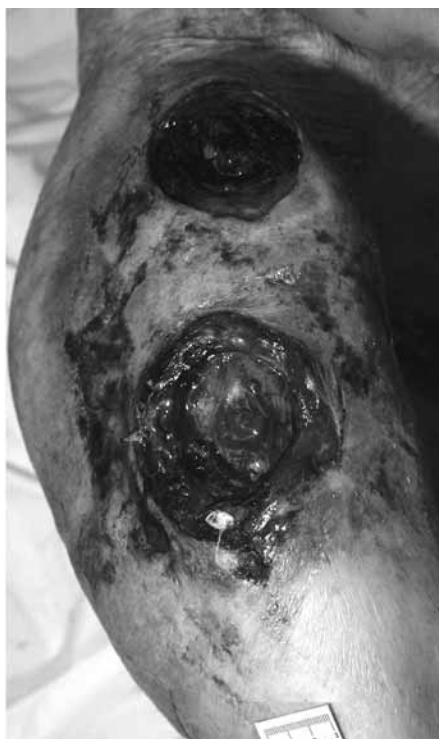**Fig. 24.** Bite mark on back. Dental impression on mold.

Decubiti occur in patients in nursing homes and hospitals or at home (73,76). Prevalence of ulcers in these patients was about 11% in one series (73). One prospective postmortem study showed a similar frequency (72). The frequency of decubitus ulcers varies from 0.1% in the community to 30% in spinal cord rehabilitation patients (73).

Any individual who is confined to bed can develop a decubitus ulcer. Poor nutrition, vascular insufficiency (e.g., diabetes mellitus), accumulation of urine and feces due to incontinence, and friction arising from the actions of caregivers (e.g., repositioning patient on the bed) are contributing factors (69,71–75,77). Rubbing of the skin likely removes an already devitalized epidermis (78). The area of pressure first shows erythema (stage 1), then proceeds to a blister or superficial ulcer (stage 2), full thickness cutaneous necrosis with extension into the subcutaneum and fascia (stage 3), and eventual involvement of underlying muscle and supporting structures (bone, tendon, joint capsule; stage 4 [69,71,73–75]).

Deep decubitus ulcers run the risk of sepsis secondary to cellulitis and osteomyelitis (71–74,76,79–81). Microscopic assessment can determine whether soft tissue and bony inflammation are present; however, clinical signs of sepsis and microbiological studies—i.e., a positive blood culture—support the role of the decubitus ulcers in the cause of death (70,72,74,75,78,80,81). Bacterial contaminants of the wound site are common (69,75). Bacteremia is aerobic (e.g., *Staphylococcus aureus*) or anaerobic (e.g., bacteroides [81]). Polymicrobial bacteremia does not necessarily indicate contamination. Other infectious foci must be excluded (80).

Decubitus ulcers in hospitalized patients have been associated with an increased mortality risk (73,75,76,79,82). Decubiti, irrespective of the stage, are markers of debilitation and indicate that multiple factors related to terminal illness led to the death of the patient (79,82). The development of advanced-stage ulcers raises concern about the



**Fig. 25.** Elderly individual. Prolonged immobilization in bed at home. Decubitus ulcers, right hip.

individual's care (Fig. 25; refs. 71, 72, 74, 76, 80, 83, and 84). Animal studies have shown that muscle necrosis develops after sustained pressure lasting 1 to 2 h (74,75). Frequent repositioning in a busy hospital setting is a challenge. There may be no intervention strategy that completely reduces the incidence of decubitus ulcers (77).

### *5. FREE FALLS FROM HEIGHTS*

All manners of death occur (7,85–89). Certain situations are encountered frequently:

- “Jumpers”: women comprise about one-fourth to one-half of suicides (7,87,90). A tendency to see older victims, in some series, likely reflects the demographics of the community (91,92). Most cases occur at the victim's residence (89). Some victims have traveled to sites (85,90,93). Many have a psychiatric history, substance abuse issues, or debilitating disease (90,92–95). Depression is more common than psychosis. A suicide note or ideation occurs in up to about one-third of victims (85,92). Other scene findings support intent (e.g., removal of shoes prior to falling, crawling through a narrow window, falling over a barrier higher than victim's center of gravity [85,89]). Psychotics have jumped through windows (96). Although some series show suicides associated with greater heights than accidents, this is not consistent (85,91,92,97,98). The distance a body is found from a structure is not necessarily reliable in determining intent, i.e., jump vs fall; however, one theoretical study showed that, depending on the take-off angle, a distance of 40 m (about 130 ft) suggested a running jump compared with 10 m (about 33 ft) for a fall from a standing jump (85,88). Bodies may have been moved after discovery (89).

- Workplace incidents and other accidental falls: falling from buildings, scaffolds, and ladders is a leading cause of death in the construction industry (85,99,100). Males aged 20 to 30 yr are the most frequent victims (7,85,87,99,100). Issues arise regarding workplace safety, intent, and the role of intoxication and disease (85,87,100,101). Intoxication and reckless behavior are factors in nonwork-related accidental falls. The use of ethanol and illicit drugs have been detected in up to one-third of accident and suicide victims (85,90). Defective barriers and lack of adult supervision lead to children falling from apartment buildings (102,103). Homicides occur in up to 2% of deaths (85,87).

Various factors determine the extent and distribution of injuries (2,104). The height fallen is a major, but not invariable, determinant (2,103–107). Generally, the greater the height, the greater the likelihood of multiple fatal injuries (85,87,97,106,108–111). The velocity of the fall is calculated as  $V = \sqrt{2gh}$ , where  $g$  is gravitational acceleration ( $9.8 \text{ m/s}^2$ ) and  $h$ , the distance fallen (103,112,113). A falling body from 2 stories (1 story = 3 to 4.5 m or 10 to 14.5 ft) reaches a velocity of 15 m/s (30 mph) and from 40 stories, about 60 m/s (120 mph [1,2,86,90,108,114]). For adults, falls from at least 5 stories to a hard surface are frequently fatal, although survival is possible up to 8 stories (2,85,86,97,114,115). A study of children hospitalized after falls showed that all who fell 3 stories or less survived (116). There was an extrapolated 50% mortality rate for those who fell from 5 to 6 stories. Another study of subjects, aged 15 years or younger, showed that three-fourths of those falling five stories were dead at the scene (117). Some falling from shorter heights succumbed because of delays in diagnosis (e.g., epidural hematoma). Falls from more than five stories were associated with multiple lethal head injuries.

Although the force:area ratio is high in a feet-first impact, this landing position is usually associated with less injury (87,105,112,118,119). Head-first impacts are most likely to be fatal (90).

Falling on a deformable surface (e.g., water, snow) lessens the degree of injury by increasing the impact duration; however, for any given surface, a spectrum of injuries occurs (1,2,85,87,90,91,98,105,106,114). Survivors of bridge jumps from about 75 m (250 ft) into water have been seen (90,119–121). High-altitude falls (up to 7000 m or 23,000 ft) into snow with survival have been recorded (122).

Children tolerate falls better than adults (2,103). Children have less mass and more flexible bones, and are cushioned by subcutaneous fat. They tend to fall in a more relaxed state. Younger individuals have a greater cardiopulmonary reserve, allowing recovery from injuries (90,105,106,114,123).

Clothing increases drag on the body, and air resistance at great heights can slow descent (90,112).

Injuries from falls arise from vertical decelerative forces during direct impact, secondary impact from objects intervening during the descent or after initial impact, and energy transfer to sites remote from the impact site (1,7,86,97,106,109,113,114,119). Vertical deceleration causes severe chest (e.g., aortic tear, cardiac rupture) and abdominal visceral trauma (1,2,7,119,120). Bouncing on impact occurs from great heights (2,106,124). Direct impacts occur on the head, buttocks, lateral body, and lower extremities, but the determination of the primary impact sites is not always obvious (7,110,113). One study of suicides showed that feet-first impacts were common in

jumps from lower floors (up to the 12th story), side-first up to the 13th floor, and head-first in free-falls from greater heights (90).

Depending on the impact site, injury patterns emerge (7):

- *Head.* Head impacts tend to occur in accidental falls of adults and children because the body's center of gravity is in the upper body (2,102,103). Skull fractures and brain injuries can be observed in isolation (2,7,113,118). Secondary impacts after striking the ground account for head injuries in other landing positions. Head injuries dominate in fatal falls regardless of height (7,87,90–92,115,116,125). One study showed fatal head injuries dominated in falls below 7 m (23 ft) and above 30 m (97 ft [111]). Another series found severe head injuries dominating in falls below 10 m (33 ft) and above 25 m (81 ft) (89).
- *Buttocks.* Pelvic and thoracolumbar fractures are common (2,7,104). There can be considerable retroperitoneal bleeding (115). Spinal fractures are typically caused by compression (7,109,115,125). Force transmitted through the spine causes basal skull fractures (“ring” fracture around the foramen magnum [7,104,113]).
- *Lateral body.* Rib fractures can directly tear viscera. Intrathoracic trauma can occur opposite the side of impact (7,119). One study showed that the number of rib fractures increased with the height of the fall such that in all falls above 40 m (130 ft), fractures were seen (111).
- *Lower extremities (feet-first).* Fractures can involve the feet, ankles, and shins but may be absent in water impacts (2,7,85,105). Force is transmitted to the femur, thoracolumbar spine, and base of skull (1,2,7). Unlike torso, buttock, and lower extremity impacts onto a hard surface, falls into water may have minimal cutaneous injuries but severe visceral trauma (85). Falls into water have been associated with “blast” effects (rib fractures, pulmonary contusions, pneumothorax; see Chapter 4, Subheading 8.1.; and refs. 1, 2, 105, 112, 113, 118, 119, 126, and 127). Some victims drown if they are unable to swim because of a leg fracture (87,105,118–120,126).

Generally, injuries are seen on the impacted side—i.e., one surface plane (89). Multiple blunt trauma skin injuries on different body surfaces, particularly if there are no corresponding extremity and thoracic fractures, arouse the suspicion of foul play (85,98). Multiple lethal injuries in children could indicate abuse (117).

Upper extremity fractures are possible if the victim is struck by objects while falling or attempts to brace the fall when landing (Fig. 26; refs. 85 and 113). If a victim's grip loosens, then injuries may be observed on the palms (Fig. 27; ref. 85).

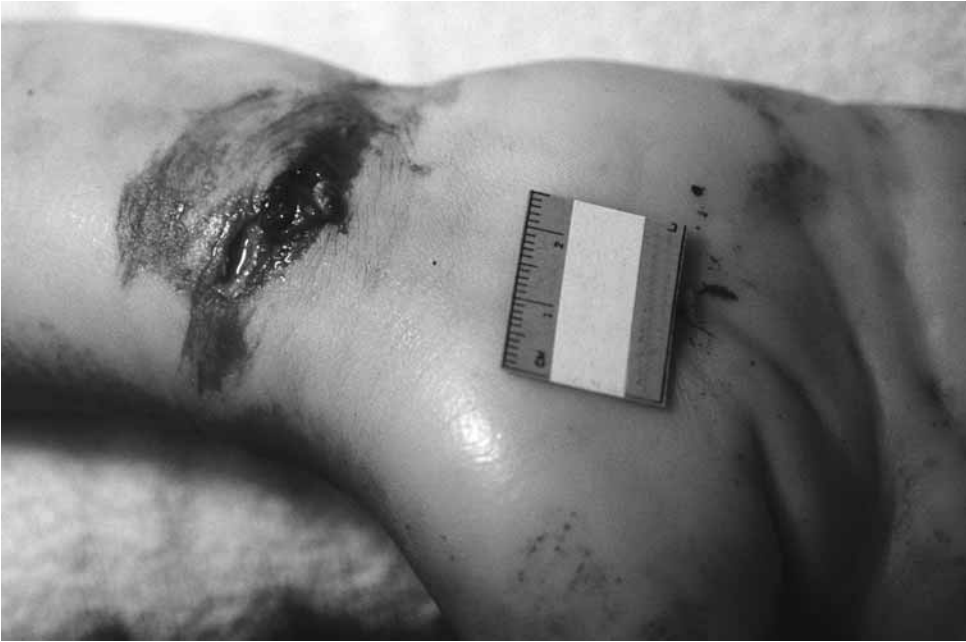
Hyoid and laryngeal fractures have been observed (89,118).

## 6. CHEST TRAUMA

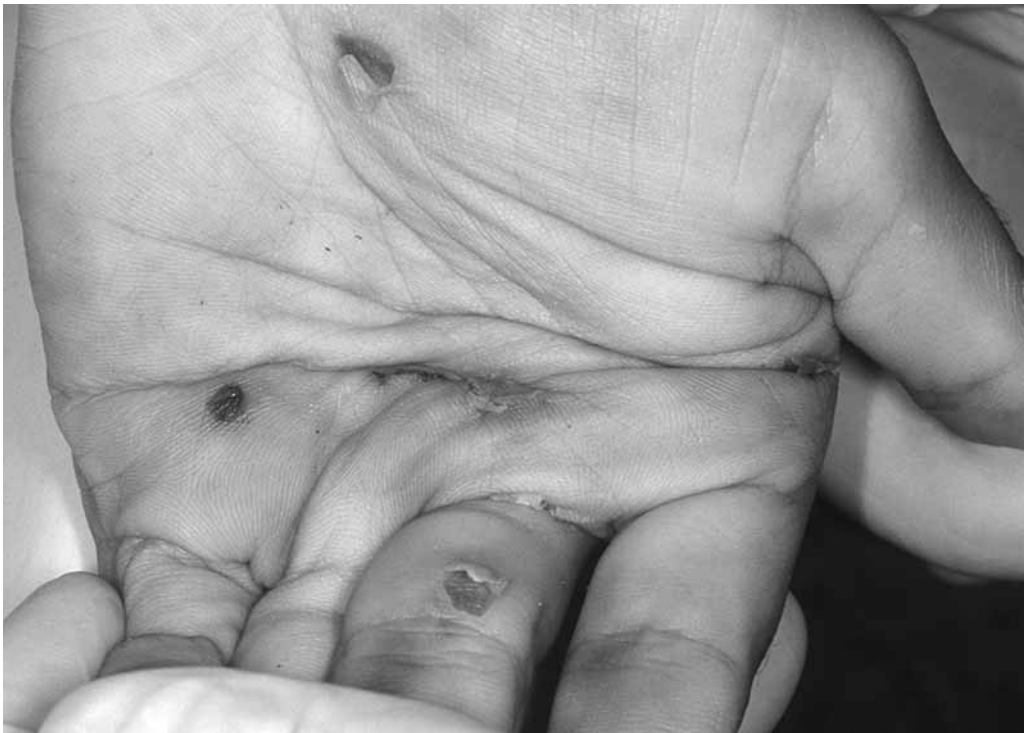### 6.1. Chest Wall

Direct compression causes rib and sternal fractures (128). Fractures indicate energy dissipation of the applied force (129). The weakest point of the chest wall is along its lateral aspect (128). Typical fracture patterns emerge depending on the site of compression: anterior compression—sternal and anterolateral rib fractures; posterior compression—posterior rib fractures; and lateral force—posterior fractures and costochondral disruption (128). Older individuals, because of osteoporosis and decreased musculature, are more likely to sustain chest wall fractures following injury (128,130–133). Chest wall fractures in children indicate a high degree of force (e.g., motor vehicle collision) applied to relatively more elastic ribs (128,134).





**Fig. 26.** Fall from a height. Abraded laceration of wrist and associated fracture. Victim may have attempted to brace fall.



**Fig. 27.** Victim grasped balcony rail before falling. Abrasions on palm.

Because chest wall trauma can contribute to death directly or indirectly, the autopsy examination is not limited simply to the dissection of organs, but the integrity of the chest wall must also be inspected (Fig. 28).

Contiguous fractures, involving at least three ribs and having two fracture sites along each of the affected ribs, create a loose segment that moves paradoxically with respiration (“flail chest” [128,135]). Fractures of any part of the thorax can lead to flail chest (128,136). A transverse sternal fracture enhances paradoxical movement (135). Posterior rib fractures are better supported by back muscles and the scapulae (135). Flail chest is complicated by respiratory insufficiency and, if the trauma victim is hospitalized, atelectasis and consequent pneumonia can develop (128,135,137–139).

The distribution and extent of rib fractures provide information about the direction of force, the relative severity of the applied force, and the presence of underlying visceral injuries (128,136,139,140). Visceral injuries are not invariably accompanied by chest wall fractures, particularly in young individuals (140). A sternal fracture points to mediastinal trauma. Lower rib fractures are a sign of diaphragmatic and abdominal organ injuries. Three or more rib fractures is associated with an increasing risk of visceral trauma and mortality (130,141). A clinical review of 1490 patients admitted with blunt chest injuries showed a mortality rate of 4.7% in those with more than two rib fractures and 17% in patients with flail chest (131). When compression overcomes the integrity of the chest wall (thoracic stability limit), then collapse and considerable visceral injuries result (6). Based on cadaver studies, the “limit” is at least six rib fractures (see ref. 6 and Subheading 6.5.).

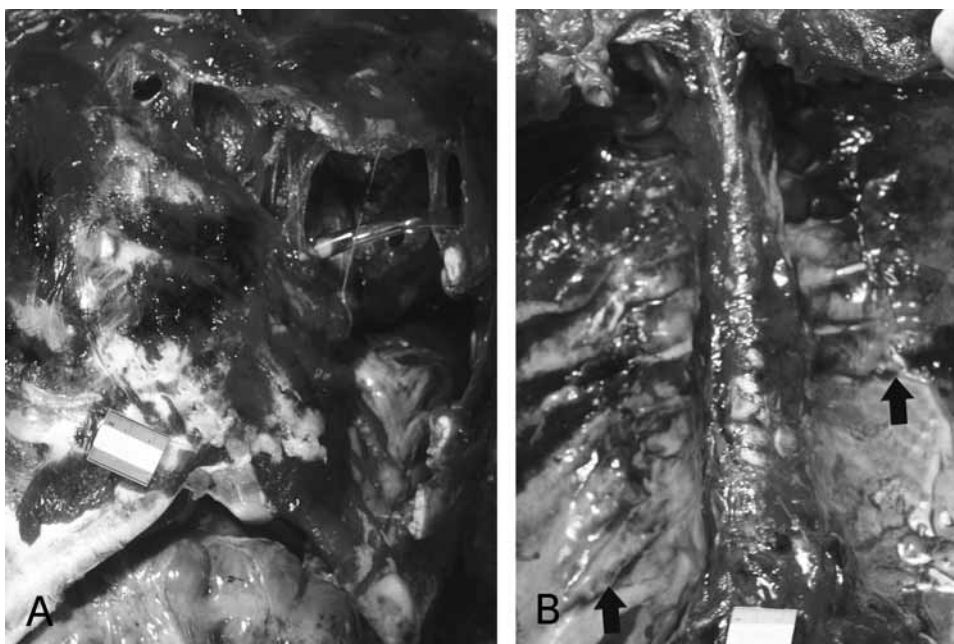
Hemothorax and pneumothorax are common findings when chest wall fractures are observed (137,140,141). The risk of these complications rises when the number of rib fractures increases (131,139). Pneumothorax is caused by lung laceration. Hemothorax is commonly caused by lung, heart, and great vessel trauma (see Subheadings 6.4.2., 6.5.–6.7. and ref. 140).

During the examination of the chest cavity, the pathologist must not only document any fractures, but also realize that injury to intercostal vessels is another source of hemothorax (142). Hemothorax following rib fractures can be delayed (143–146). The usual source of bleeding is from an intercostal artery (143–145). Delayed hemorrhage may occur during a period of clinical improvement when deep breathing and coughing increase chest movement (144). Rarely, no rib fractures are present (145). Failure to examine the sternum, separated from the chest during the autopsy, means that an internal mammary artery or vein tear can be missed (Fig. 29). This is a rare injury (147,148). It is also associated with clavicle or rib fractures (149). Sudden deceleration can avulse the internal mammary artery from its origin at the subclavian artery. The consequent hemothorax or mediastinal hematoma leads to shock in a few hours (147,149,150).

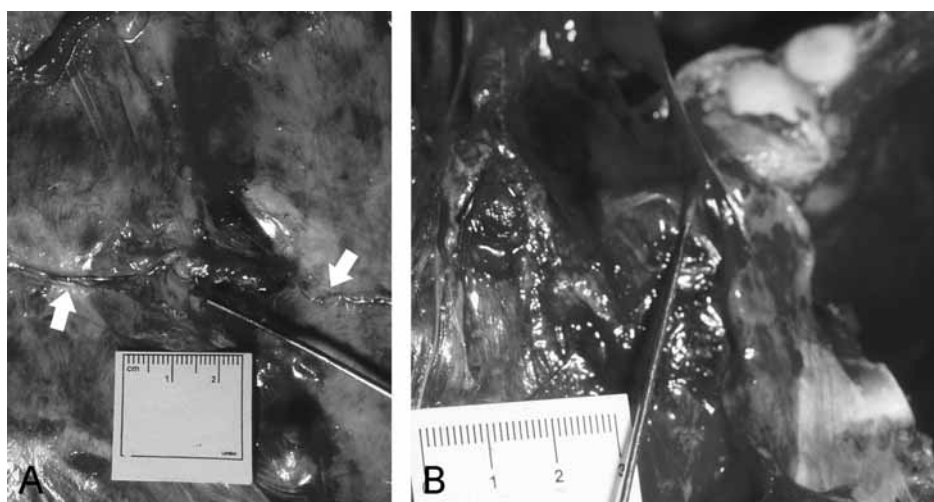
## 6.2. Closed-Chest Resuscitation Injuries

Complications from manual and device-assisted compression–decompression during cardiopulmonary resuscitation (CPR) have been described (Table 1; refs. 151 and 152).

Chest wall fractures are the most common injury (Fig. 30) (152,155,164,168,169, 173,174). In a study of 705 resuscitated individuals, 63% had five or more rib fractures,



**Fig. 28.** Rib fractures. **(A)** Massive anterior rib and sternal fractures (insertion of chest tube through left chest wall defect). **(B)** Multiple posterior rib fractures indicated by subpleural hemorrhage (arrows). These injuries are appreciated only if the chest cavity is examined following the removal of organs.



**Fig. 29.** Fracture of sternum (two cases). **(A)** The undersurface of the sternum showed an apparent “laceration” of the internal mammary artery (tip of probe), but this was an artifact of the scalpel cut (arrows) during removal of sternum. **(B)** Run-over. Sternum reflected superiorly (partly covered by label). Undersurface shows internal mammary vein tear (probe inserted into torn end).

**Table 1**  
**Complications of Closed-Chest Cardiac Resuscitation**

---

**Chest wall**

Ribs  $\pm$  sternum fracture-dislocation (151–160)

- Flail chest (155,161–163)
- Costochondral junction separation (163–165)

Chest wall hemorrhage (166,167)

Hemothorax (151,152,155,164,168,169)

Other fractures (clavicle, scapula, cervical spine, thoracolumbar [155,162,164,170])

**Diaphragm rupture (167)**

**Cardiovascular system**

Pericardial laceration (152,156,171)

Hemopericardium (151,153,155,158,164,172)

- Cardiac rupture
- Pericardiocentesis, pacemaker, central venous line (157,173–175)

Myocardial contusion (152,155,158)

Intramural hemorrhage (posteroseptal left ventricle common [154,155,157,164,169])

Myocardial rupture

- Atria (152,155,156,176)
- Ventricles
  - Normal myocardium (156,157,160,168,171,177)
  - Myocardial infarct (156,172,173,178)
  - By fractured rib or vertebral osteophyte (171,179)
- Papillary muscle (180)

Coronary artery laceration (152)

Aortic intimal laceration/rupture (ascending/descending thoracic aorta-associated atherosclerosis [152,156,164,168,181])

Aortic dissection (associated atherosclerosis [182])

Venous laceration (e.g., inferior vena cava, splenic vein, renal vein, internal mammary vein [155,159,164,169,183])

**Respiratory system**

Pleural laceration (152)

Pulmonary contusion/laceration (157,160,164,183)

Pulmonary barotrauma (pneumothorax, pneumopericardium, pneumoperitoneum, pneumomediastinum, pulmonary interstitial and subcutaneous emphysema [151,155,164,168,169,173,174,184])

Tracheal laceration/hemorrhage (157,184)

**Intra-abdominal organs**

Rupture of esophagus, stomach, colon (151,158,167,179,185–189)

Laceration of esophagus, stomach (167,184,189,190)

Gastric dilatation (155,158)

Hepatic laceration (151,154,155,158,159,164,168,169,191)

- Hepatic artery laceration (192)

Hepatic subcapsular hematoma (155,164)

Splenic laceration (154,155,159,164,168,169)


Pancreatic hemorrhage; pancreatitis (159,193–195)

Omental hemorrhage (155)

---



Table 1 (Continued)

**Retroperitoneal space**Hemorrhage ([155,159,164,184,194](#))Adrenal hemorrhage ([169](#))**Bone marrow and fat embolism** (see Subheadings 12.1. and 12.2.)**Rhabdomyolysis**—renal failure (see Heading 13; ref. [196](#))**Retinal hemorrhage (children)**—see Subheading 6.2 and ref. [197](#)

**Fig. 30.** Examination of sternum removed at autopsy revealed midline vertical fracture resulting from cardiopulmonary resuscitation.

and about three-fourths had bilateral involvement ([155](#)). Autopsy studies of CPR-caused chest wall fractures show a variable frequency. One study showed one to four rib fractures in 8.4% of adult cases and more than five fractures in 2.6% ([164](#)). Another older study found 2 to 8 fractures in 31% of cases, and more than 8 in 3.8% ([153](#)). Weakened bone structure from osteoporosis, excessive force, and misdirected application of chest compression increase the possibility of chest wall fractures and visceral trauma ([132,134,155–157,160,169,198](#)). Typically, fractures involve the anterolateral third to seventh ribs and mid-sternum ([132](#)). “High” hand placement results in upper rib (first, second) and sternal fractures ([155](#)). “Low” compression results in lower rib (below the sixth rib) and sternal fractures, and possible intra-abdominal injury ([155,159](#)). Hemorrhage at fracture sites indicates that cardiac output was achieved during chest compressions.

Rib fractures in children are unusual and considered suspicious of child abuse; however, they have been observed arising from CPR ([134,159,169](#)). Retinal hemorrhages in children after CPR are associated with prior severe trauma ([197](#)).

Tearing of a viscus or vessel can be the result of penetration by a fracture fragment ([160](#)). Increased hydrostatic pressure also contributes. Any serious injuries that arise



from resuscitation must be interpreted in the context of an agonal event (152,155). If the person is revived, then resuscitation-related trauma can contribute to morbidity and mortality. More than one injury can occur. In one study, 33% of individuals with CPR-related thoracic trauma had abdominal complications, 23% upper airway trauma, and about 15% pulmonary or cardiovascular sequelae (155). Life-threatening complications were seen in fewer than 1% of patients.

### 6.3. Pericardium

Pericardial laceration is frequently associated with penetration by chest wall fractures (199). Cardiac rupture and great vessel trauma are common, but not invariable, concomitant injuries (199,200). Laceration is observed on the diaphragmatic, superior mediastinal, or lateral aspects of the parietal pericardium (199). The left side is most common (199). Lateral pleuropericardial tears are usually vertical, vary in length, and sometimes involve the phrenic nerve (199).

Pericardial tears preclude cardiac tamponade (199,201). Instead, hemothorax, hemoperitoneum or mediastinal hemorrhage is seen. Cardiac herniation through lateral pleuropericardial defects, particularly on the left side, causes severe hemodynamic compromise (199,200,202). Delayed deaths are possible (199). Abdominal viscera can herniate through diaphragmatic defects, leading to cardiac tamponade (199,203).

### 6.4. Heart

Blunt trauma of the heart is caused directly by precordial impact, with or without lacerating rib and sternal fractures, and indirectly by increased intracardiac pressure from compression and deceleration (129,204–209).

#### 6.4.1. Myocardial Contusion

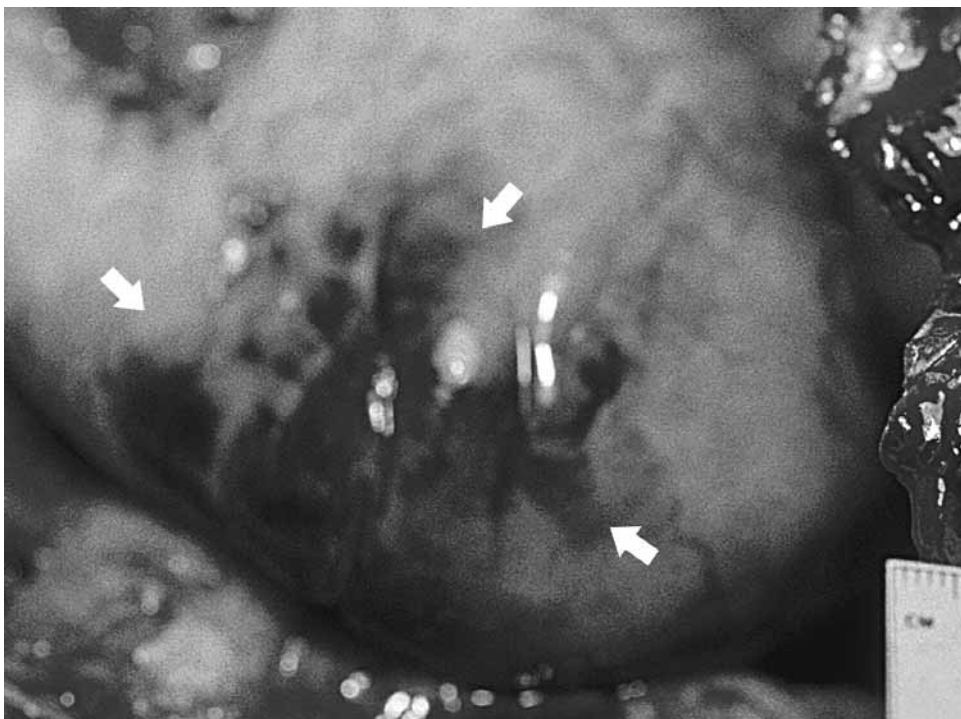
Myocardial contusion is an injury that is variably observed in the clinical and autopsy settings (129,204,205,210,211). Clinically, more serious injuries overshadow the presence of a contusion (205,210,212). Immediate death from other causes means that visible features of a contusion are not seen (210,211).

Transient arrhythmias usually arise within 24 h of hospital admission but can be delayed (204,205,207,208,210–214). Myocardial contusion is a rare cause of death, but fatal arrhythmias and heart failure can develop days after the initial injury (210–212, 215). Fatal electromechanical dissociation has been observed in experimental animals with myocardial contusions and elevated ethanol levels (204).

At autopsy, a circumscribed area, most commonly on the right ventricle and resembling an infarct, is observed, but unlike an infarct, hemorrhage is more prominent (Fig. 31; 204, 207, 210, and 211). Less severe contusions show subepicardial or subendocardial hemorrhage (205). Necrosis in a contusion can progress to rupture (216). Rarely, a true aneurysm or pseudoaneurysm forms and ruptures (216).

#### 6.4.2. Cardiac Laceration and Rupture

The anterior surface of the heart, underlying the chest wall, is composed as follows: 55% right ventricle, 20% left ventricle, 10% right atrium, 10% ascending aorta and pulmonary artery and 5% vena cavae (205). The frequency of cardiac rupture sites mirrors the surface anatomy (129,206,217–220). Septal ruptures are relatively uncommon.



**Fig. 31.** Myocardial contusion (delimited by arrows).

Atrial rupture most likely happens when the heart is squeezed during systole (204). Survivability is most likely with an atrial tear (206,209,219,221–223). Ventricular rupture occurs from a precordial blow during diastole (204,224). Other mechanisms of cardiac rupture include increased pressure caused indirectly by abdominal and extremity trauma, and deceleration (224–226). Cardiac lacerations can heal forming ventricular aneurysms (227). Cardiac aneurysms are complicated by rupture, congestive heart failure, arrhythmia, and systemic emboli. Delayed rupture can occur during healing (225,228).

#### 6.4.3. *Commotio Cordis (Cardiac Concussion)*

Commotio cordis (cardiac concussion) is characterized by sudden death from cardiac arrest after a seemingly minor precordial blow in the absence of serious structural cardiovascular disease or trauma (208,214,229–236). In some cases, a cutaneous contusion is observed in the precordial area (229,235). Usually, no chest wall fractures are seen (231,232,235). Lung contusions may be the only morphological clue that chest impact has occurred (237). Victims either collapse instantaneously following impact or remain conscious and active briefly before experiencing a cardiac arrest (229, 232,233,235). Usually, cardiopulmonary resuscitation is unsuccessful in restoring normal cardiac rhythm (229,233,235). Even when cardiac rhythm is restored, irreversible hypoxic brain damage has occurred (235). Complete recovery is possible in some cases, if there is prompt resuscitation and defibrillation (229,231,232,238). Rarely, commotio cordis resolves spontaneously (231).

The mechanism of ventricular dysrhythmia is precordial impact during the electrically vulnerable period of repolarization (T-wave) of the cardiac cycle (229,230,232,234–236,239). A premature beat is triggered, leading to ventricular fibrillation (231,232,235). The occurrence of commotio cordis is dependent on the type of mechanical stimulus, strength of impact, and impact site (mid- to lower sternum [230]). Swift mechanical impulse stimulation involving medium to high forces is the most likely scenario (230).

Commotio cordis is often associated with sports or play activities usually, but not exclusively, involving children and young adults (Fig. 32; refs. 231, 232, and 235). Young individuals are considered more vulnerable because of increased chest compliance allowing more energy transfer to the heart (207,234,235). Solid-core objects are more likely to trigger a fatal arrhythmia than air-filled balls (231). Baseball and softball games are the most common settings (229,231). Impact by baseballs was observed at estimated speeds of 48 to 80 km/h (30 to 50 mph) and at distances of 12 to 14 m (40 to 45 ft [231,235]). In experiments conducted on swine, chest strikes at 40 mph (64 km/h) were most likely to elicit commotio cordis (232–234, 240). Contact by other objects or surfaces (e.g., hockey stick, stone, part of the upper or lower extremity) has been described (175,207,231,232,234,235,241). Hockey pucks and lacrosse balls travel at speeds up to 144 km/h (90 mph [239]). In a few cases, broader surface trauma (e.g., tackling, “body check”) has been observed (229,231,232,235). Use of chest protectors does not necessarily reduce the risk (229,231). Commotio cordis is an injury mechanism in motor vehicle collisions (*see* Subheading 14.2.2. and ref. 241).

#### 6.4.4. Coronary Arteries

The sequelae—i.e., dissection, thrombosis, laceration–rupture, fistula, aneurysm—of coronary artery blunt trauma are rare (211,242–249). An associated myocardial contusion may be seen (211,250). All three major branches can be injured (245,250–252). Myocardial ischemia does occur, and atheroma is not always present (243–245, 248,249,251–254).

#### 6.4.5. Cardiac Valves

Blunt trauma can tear the tricuspid and mitral valves and their papillary muscles and chordae tendineae (255–269). Aortic valve tears occur (270,271). Valve insufficiency from an aortic intimal tear has been described (272).

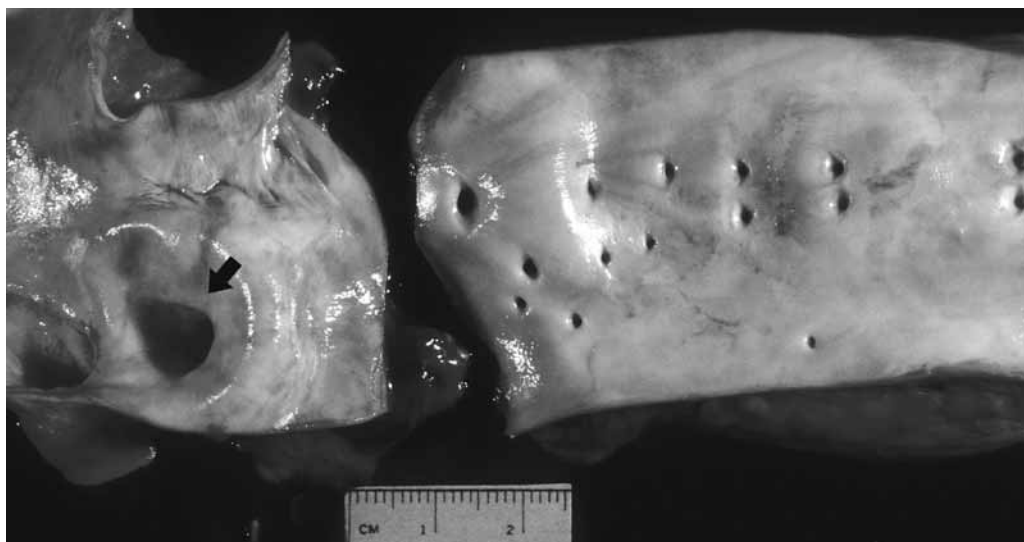
### 6.5. Aorta (Including Abdominal Aorta)

Motor vehicle trauma is a major cause of aortic trauma (273–275). Traumatic aortic rupture is seen in up to one-fourth of deceased motor vehicle occupants (273, 274,276–282). The large majority of traumatic aortic rupture victims are dead at the scene (273,276,283,284). There is usually other associated severe trauma, and aortic injury is rarely an isolated finding (273,275,283,285–287).

The isthmus—i.e., the area of the descending thoracic aorta below the left subclavian artery ostium—is the most commonly injured site (Fig. 33; refs. 273–275 and 283). The isthmus is a “fixation” point at the junction between the mobile proximal aorta and the descending thoracic segment bound to the spinal column (275,283). It is an inherently




**Fig. 32.** Commotio cordis. Young child playing baseball was hit in the chest by a hard plastic ball. Cardiac arrest at scene. Victim pronounced dead after 40 min of resuscitation.



**Fig. 33.** Transection of descending thoracic aorta (isthmus). Ostium of left subclavian artery (arrow).

weak part of the aorta because of the ligamentum arteriosum, the scarred remnant of the fetal ductus arteriosus (275). Increasing age and disease (e.g., atherosclerosis) further weaken the isthmus (288). Aortic tears are unusual in the young (275,289,290).



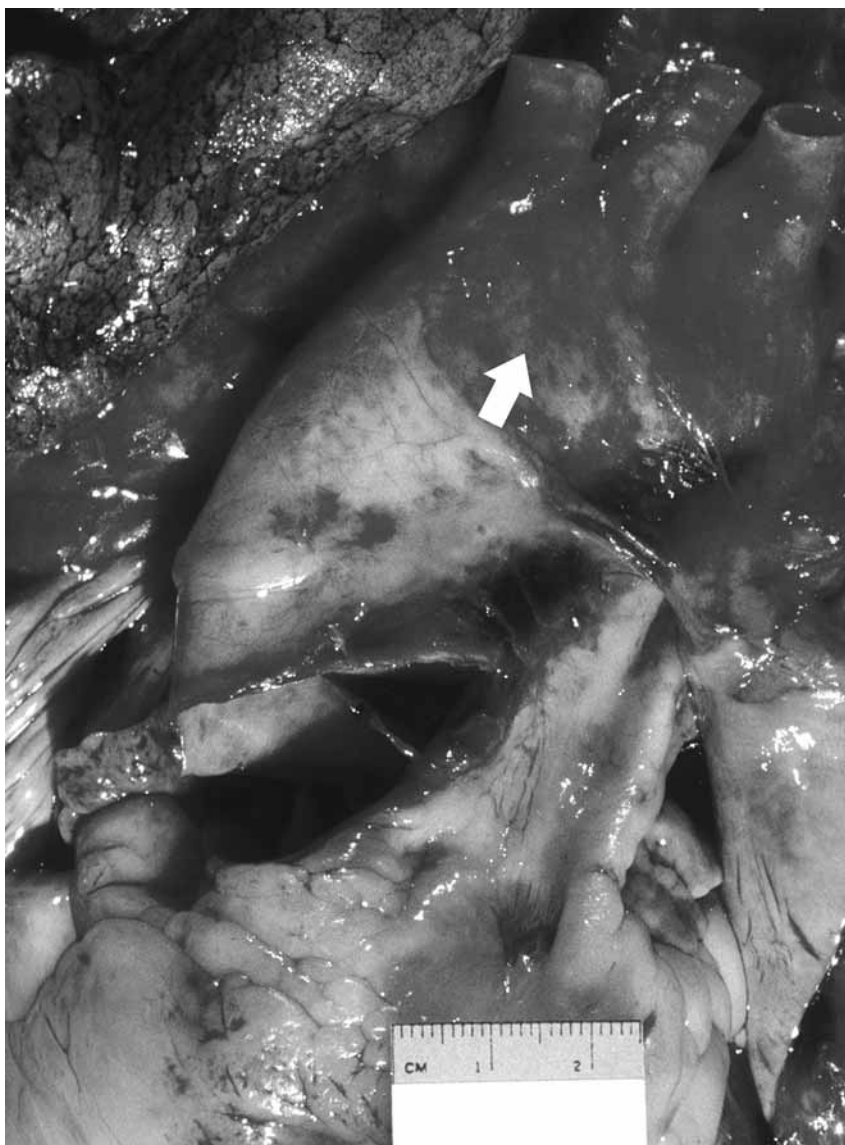**Fig. 34.** Multiple traumatic intimal tears (arrow) of descending thoracic aorta below a partial tear of the aortic isthmus. Multiple superficial tears have been considered a sign of increased aortic pressure at the time of impact. (Courtesy of Dr. E. Tweedie, London Health Sciences Centre, London, Ontario, Canada.)

Various theories have been proposed to explain why this relatively protected area of the aorta is predisposed to traumatic rupture (274,275,283,291). These explanations have included chest crush–compression, deceleration, increased intravascular pressure, and other hemodynamic forces (Fig. 34). The likely common pathway is longitudinal stress on the aortic isthmus leading to typical transverse tearing, ranging from intimal laceration to rupture (275). At autopsy, an isthmic tear is a cause of a left hemothorax. Following its quantitation, inspection of the course of the descending thoracic aorta along the thoracic spine, before removal of organs, reveals a pleural tear with an underlying isthmic rupture. Multiple rupture sites are possible (273,275). Rupture sites can heal (292). Rib fractures are not always present (140,275,283). In one study in adults, aortic rupture was associated with a minimum of five to seven rib fractures (*see* Subheading 6.1. and ref. 275).

The ascending aorta, another fixation point, is the second most frequently injured site (Fig. 35; refs. 274 and 275). Other fixed sites are the descending thoracic aorta at the diaphragmatic opening, the aortic arch, and the abdominal aorta above and below its bifurcation (273,275).

Rupture of the abdominal aorta is uncommon (5% of the frequency of thoracic aortic injuries [293–295]). This part of the aorta lies in a protected retroperitoneal location and is attached to the spine. A fractured vertebra can directly lacerate the aorta. Abdominal wall compression raises aortic intravascular pressure. Decelerative forces





**Fig. 35.** Tear of ascending aorta. Great vessels of arch (arrow).

acting on points of major arterial attachment (e.g., inferior mesenteric artery) and the iliac bifurcation can initiate tearing (293). Pre-existent atherosclerosis may be a factor predisposing to rupture. Instead of immediate retroperitoneal bleeding, a false aneurysm can form. Existing aneurysms can rupture (295).

Frontal and near-side motor vehicle collisions are associated with an increased risk of aortic rupture (274,296). The minimum equivalent barrier speed for isthmic and descending aorta tears in one study was 54 km/h (34 mph) in frontal collisions and 31 km/h (19 mph) for side collisions (275). In another study of aortic injury, the mean crash severity, expressed as  $\delta V$  (change in velocity) was 43 km/h or 27 mph (range 21–68 km/h, 13–42 mph) in near-side collisions and 57 km/h or 35 mph (range

21–160 km/h, 13–100 mph) in frontal collisions (284). In another recent study, the mean  $\delta V$  was 48.0 km/h (30 mph) in frontal impacts and 36 km/h (24 mph) in side collisions (283). Significant intrusion into the occupant compartment is observed in many cases (275,296). Occupants in near-side impacts have a higher risk of aortic trauma than those involved in frontal and far-side impacts (284). Seat belts and air bags reduce but do not eliminate the risk of aortic injury (276,283,284).

### 6.5.1. Traumatic Aortic Dissection

Dissection of the aorta and major branches (e.g., renal artery) has been described (293,294,297–300). Dissection can occur in any segment of the aorta. Intimal disruption of atherosclerotic plaque may be the initiating event (301). The determination of whether an aortic dissection occurred prior to or resulted from a traumatic incident depends on the circumstances and pathological findings. Chest or back pain prior to the incident and evidence of aortic degeneration (cystic medionecrosis) favor a spontaneous dissection.

### 6.5.2. Aortic Arch Vessels

Tears and dissections of major aortic arch vessels, as a result of blunt trauma, are uncommon (148,302–306). Stretching or rotational stress from neck hyperextension may play a role in this type of injury (302,307). The subclavian artery is well-protected by the clavicle and first rib. Fractures of these bones and the presence of a hemothorax raises the possibility of a subclavian vessel tear (307–309).

## 6.6. Other Major Intrathoracic Vessels

### 6.6.1. Main Pulmonary Vessels

Isolated rupture of the main pulmonary artery, its major branches, or a pulmonary vein from blunt trauma is rare (310–316).

### 6.6.2. Superior/Inferior Vena Cava

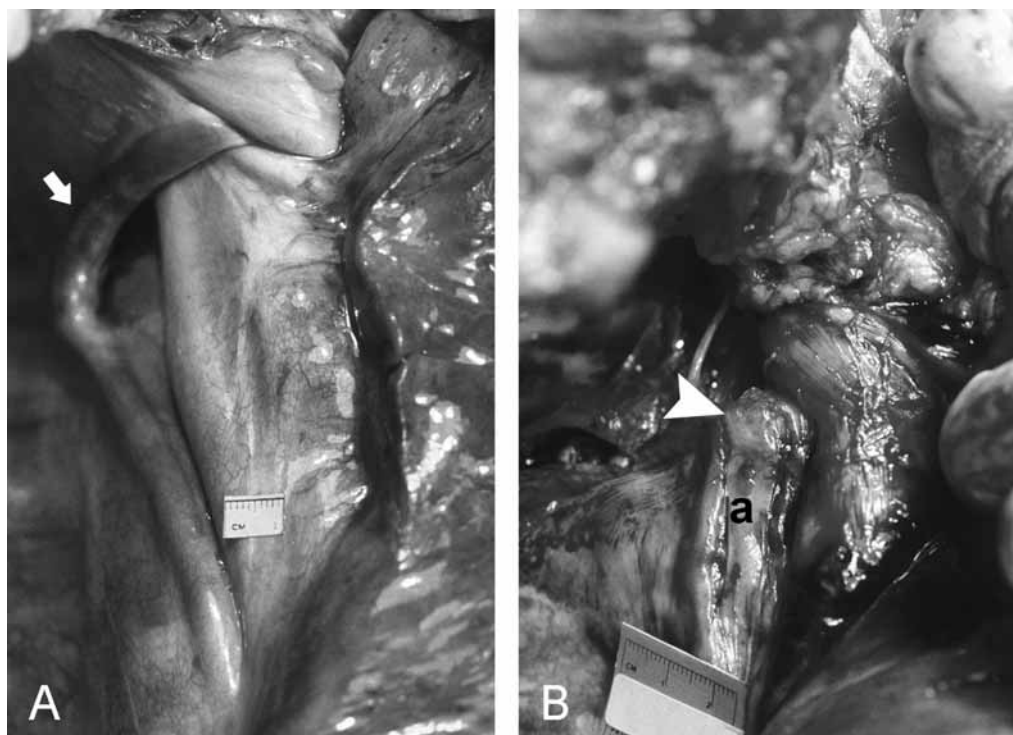
Laceration of the superior or inferior vena cava from blunt trauma is uncommon (see Subheading 14.2. and refs. 317–321). Rarely, thrombosis occurs (322).

### 6.6.3. Azygos Vein

The azygos vein runs under the pleura along the right aspect of the thoracic spine. At the fourth thoracic vertebra, the azygos vein arches over the pulmonary hilum to join the superior vena cava (see Fig. 36 and ref. 323).

Tearing of the azygos vein from blunt trauma is uncommon but must be considered in the differential diagnosis of an evolving hemothorax or hemomediastinum (323–327). Most cases have occurred in motor vehicle crashes (326). A survival interval of several hours, during which there is persistent hypotension despite vigorous resuscitative efforts and surgical repair of other bleeding sources, is characteristic (323,326). There can be an associated midthoracic spine fracture that can directly tear the vein, but most lacerations occur either close to the superior vena cava–azygos vein junction or along the azygos vein arch (Fig. 36; refs. 323 and 326). Shearing from deceleration is a proposed mechanism of injury (323,326,328).

If a right hemothorax is observed postmortem, the azygos vein must be inspected *in situ* after blood is removed from the pleural cavity. If this inspection is not done prior



**Fig. 36.** Azygos vein. **(A)** Autopsy demonstration of prominent azygos vein (arch-arrow) *in situ*, by pulling right lung medially. **(B)** Similar *in situ* inspection of transected azygos vein at junction of the arch and descending segment (arrowhead). The vein has been opened (a).

to removal of the heart and lungs, then this dissection will cut through the site of vein laceration.

## 6.7. Respiratory Tract

Motor vehicle impact is the most common cause of tracheobronchial and lung injury (329–331).

### 6.7.1. Trachea and Major Bronchi

Respiratory tract injury is rare, accounting for less than 1% of blunt chest trauma in adults (332). Isolated injuries are uncommon (332). Chest compression of the fixed trachea at the mediastinal inlet or of a mainstem bronchus against the spine are proposed mechanisms (332,333). Increased intrabronchial pressure against a closed glottis contributes (332). The trachea, within 2 cm of the carina, and right mainstem bronchus are common injury sites (330,332).

### 6.7.2. Lung

Pulmonary contusion is a very common thoracic visceral injury and is usually associated with rib fractures (*see* Subheading 6.1. and refs. 128, 136, 329, and 334). Various injury mechanisms have been described (329,334). A positive pressure concussive wave from chest impact overexpands and tears alveoli. Alveolar septae are

disrupted when a concussive wave encounters a liquid–gas interface. Inertial stress during sudden deceleration causes low-density alveoli to tear away from supporting bronchial structures.

Most pulmonary contusions heal within 2 wk without complications; however, involvement of at least 20% of the lung parenchyma is associated with a high risk for adult respiratory distress syndrome (82 vs 22% if <20% volume) and pneumonia (50 vs 28%; *see* Chapter 1, Subheading 4.3. and refs. 128, 329, and 335). Another study showed that ventilatory support was needed in some cases when 18 to 28% of lung parenchyma was contused, and in all cases above 28% (336).

### 6.7.3. Hemothorax and Pneumothorax

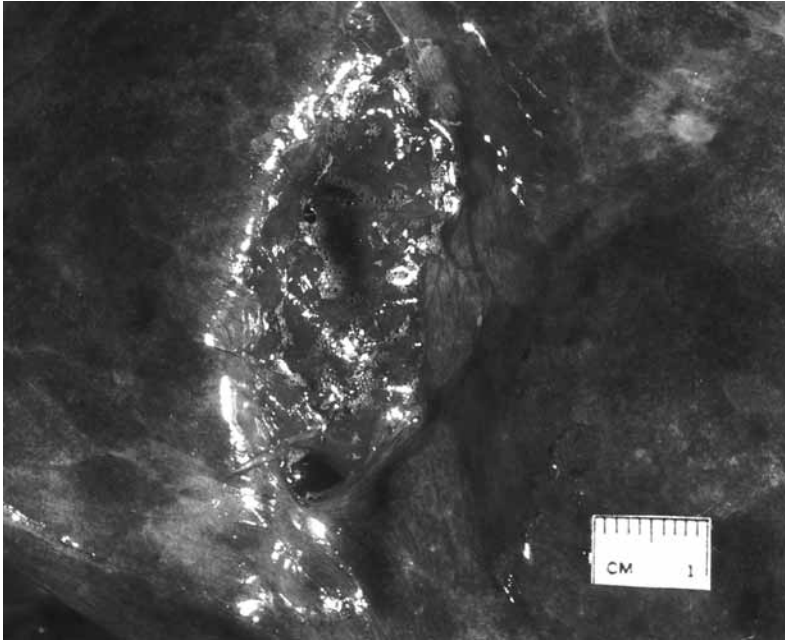
Hemothorax and pneumothorax are commonly caused by lung laceration caused by fractured rib ends (for technique for postmortem demonstration of pneumothorax, *see* Chapter 5, Subheading 14.8.; Fig. 37; and refs. 140, 329, 331, and 334). Shear forces account for pulmonary tears away from fracture sites (331). Other mechanisms of pneumothorax include increased intra-alveolar pressure caused by chest impact and tears of the tracheobronchial tree or esophagus (140,331,334,337). Associated subcutaneous emphysema and pneumomediastinum occur (332,337). Tears from rib fractures typically involve the pleural surface and lacerations, caused by other mechanisms, occur at the hilum (334). Bleeding from a pulmonary laceration can stop, persist, or recur (329).

## 7. DIAPHRAGM

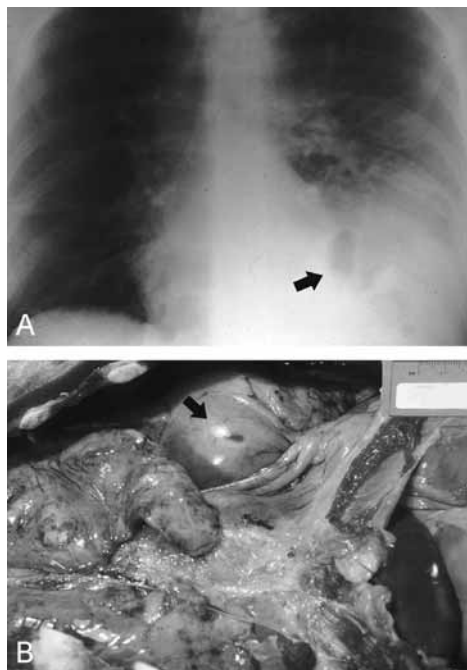
The incidence of diaphragm laceration caused by blunt trauma is about 2% (203,338,339). The most common cause is motor vehicle trauma; and occupants in near-side impacts are at greater risk than individuals in a frontal collision (339–344). A review of National Automotive Sampling System data from 1995 to 1999 showed a greater likelihood of diaphragm injury, if frontal or near-side occupant compartment intrusion was more than 30 cm (12 in.) or the velocity change ( $\delta V$ ) during impact was greater than 40 km/h (25 mph) (345). Injury mechanisms include shear stress on a stretched diaphragm, avulsion of diaphragm attachments, and sudden transmission of force by abdominal viscera (203,344).

Various series of diaphragm injury show a left-sided predominance (203,339, 343,346–348). The right hemidiaphragm is protected by the liver (203,338). Bilateral tears are uncommon (203,339,346,347,349,350). Intrathoracic herniation and strangulation of abdominal organs (e.g., stomach, intestine, omentum, spleen, liver) can occur (Fig. 38; refs. 346 and 351). The pressure gradient between the abdomen and thorax is increased by abdominal pressure and maximal respiratory effort; this promotes herniation into the chest cavity (203,338). One series showed that herniation occurred through defects 10 cm (4 in.) or more (339). Rupture of a hemidiaphragm results in diminished ventilation, compounded by a herniated organ compressing a lung (203). Mediastinal displacement leads to impaired venous return to the heart (203). Immediate death is uncommon (338).

Diaphragmatic tears are rarely isolated and are usually associated with other severe injuries (203,338,339,341–343,347,348,350,352). A significant number of



**Fig. 37.** Pulmonary laceration.



**Fig. 38.** Traumatic rupture of diaphragm. Motor vehicle collisions (two cases). **(A)** Chest radiograph. Herniation of large bowel. Bowel gas seen (arrow). **(B)** Another case shows herniation of stomach (arrow) through the torn left hemidiaphragm.



uncomplicated diaphragm tears are not diagnosed (203,339). In a literature review, a preoperative diagnosis was made in about 44% of cases and at autopsy or thoracotomy in 41%. The diagnosis was delayed in about 15%. Diaphragmatic tears rarely heal without surgical repair (338,339,341). Strangulation of herniated intra-abdominal viscera can be a delayed complication (338,347).

## 8. ABDOMINAL TRAUMA

### 8.1. Gastrointestinal Tract

#### 8.1.1. Stomach

Blunt impact of the left anterior torso rarely causes stomach injuries (353). A study of 1300 patients who suffered blunt abdominal trauma revealed seven cases of gastric trauma (incidence of 0.5% [353]). Motor vehicle collision is the most common cause (see Subheadings 6.2., 14.2. and ref. 353). Gastric injuries are usually associated with trauma of adjacent solid organs (e.g., spleen) and the chest wall (353,354). Distension from excessive food and liquid favors laceration (353,354). Blunt gastric rupture involves any portion of the stomach; there is usually a single site, most commonly the anterior wall, followed by the greater curve, lesser curve, and posterior wall (353). Depending on the survival interval, pneumoperitoneum and chemical peritonitis are sequelae (353). Subcutaneous emphysema and pneumomediastinum occur, if there is rupture near the gastroesophageal junction (353).

#### 8.1.2. Intestine and Mesentery


Intestinal and mesenteric injuries arise in motor vehicle collisions, and the occupant restraint system may be a factor (see Subheading 14.2.). The pathologist should inspect the mesentery prior to removal of the bowel to appreciate the presence and extent of mesenteric tearing (Fig. 39).

### 8.2. Liver

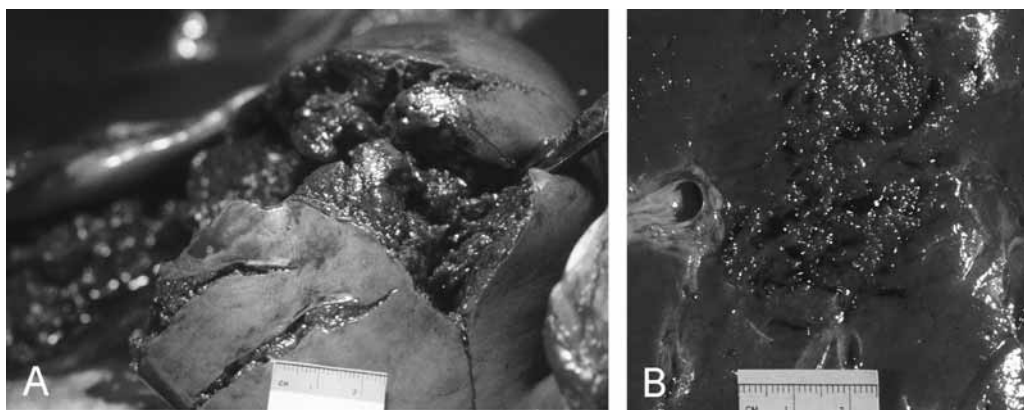
Motor vehicle impact is a frequent cause of hepatic injury (355,356). Hepatic injuries are often associated with other injuries (355,357). Right-sided rib fractures are not always seen (355). The posterior–superior area of the right lateral lobe is a frequently injured site (356). Compression of the liver, e.g., by a steering wheel, causes a typical bursting injury (Fig. 40; ref. 356). Other patterns of injury include a linear capsular laceration of variable depth; a hematoma under an intact capsule; and intraparenchymal tearing (Fig. 40; refs. 356 and 358). Injury of major hepatic vessels is infrequent. Because of a dual blood supply, liver infarcts are rare (356,359). Delayed bleeding (e.g., evolving hematoma) from hepatic injuries can occur hours to days after trauma (358,360,361).

### 8.3. Spleen

The spleen is the most common organ injured as a result of blunt abdominal trauma, mainly owing to motor vehicle collisions (Fig. 41; refs. 355 and 362–364). Splenic injury is frequently associated with other severe trauma (355,363–366). Consequent hemoperitoneum is either acute or delayed (363).



**Fig. 39.** Motor vehicle collision. Small bowel (arrow) reflected superiorly in the abdominal cavity to reveal a mesenteric laceration (arrowhead).



**Fig. 40.** Hepatic lacerations. Motor vehicle collisions. (A) Massive bursting injury. Rib cage intact. (B) Intraparenchymal tear.

McIndoe defined delayed splenic rupture as any case of delayed hemorrhage owing to splenic rupture that occurs 48 h after an episode of blunt abdominal trauma (367,368). Two scenarios are possible: delayed diagnosis of an acute rupture or a delayed presentation by an evolving splenic injury that eventually ruptures (363,368–373).

In the past, the incidence of delayed diagnosis of traumatic splenic rupture ranged from 2 to 40% (363,368,370,374–377). This was caused by a lack of sophisticated




**Fig. 41.** Lacerations of spleen.

investigative tools and the reliance on patient symptoms (e.g., left upper quadrant pain) and signs (e.g., abdominal wall rigidity), which could be indeterminate and masked by other serious injuries, unconsciousness, and intoxication (362,367,368,378). The frequency of delayed recognition has fallen to 1% because of the deep peritoneal lavage technique, which detects intra-abdominal bleeding, and computed tomography (CT) scan imaging (368,370,374,376,377,379–381). Even so, hemoperitoneum from acute splenic rupture may not be evident if bleeding temporarily ceases because of either shock or tamponade. The latter can be from pressure from accumulated clot and adjacent omental fat and viscera, or herniation of abdominal viscera through a torn hemidiaphragm (365,367,368,375,382–384).

Splenic injuries are graded on the basis of operative findings and radiology imaging (378). Less severe injuries include subcapsular hematoma, intraparenchymal hematoma, and superficial capsular tear. Severe lesions include lacerations extensively involving either the spleen or major blood vessels supplying it. Less severe, hemodynamically stable splenic injuries are managed conservatively (363,378).

Rupture of an expanding subcapsular–intrasplenic hematoma under an intact capsule, occurring spontaneously, triggered by minor trauma, or resulting from a slight increase in intra-abdominal pressure (straining at stool, coughing, vomiting, bending), is the likely reason for delayed presentation (Fig. 42; refs. 367, 370, 371, 380, and 381). A subcapsular–intrasplenic hematoma can be asymptomatic and is not detected by deep peritoneal lavage (362,368,372,379,382,383,385,386).

Intrasplenic pseudoaneurysms—i.e., ruptured vessels walled off by clot or thrombus, and splenic capsule stripping by traction from peritoneal fibrous adhesions—are



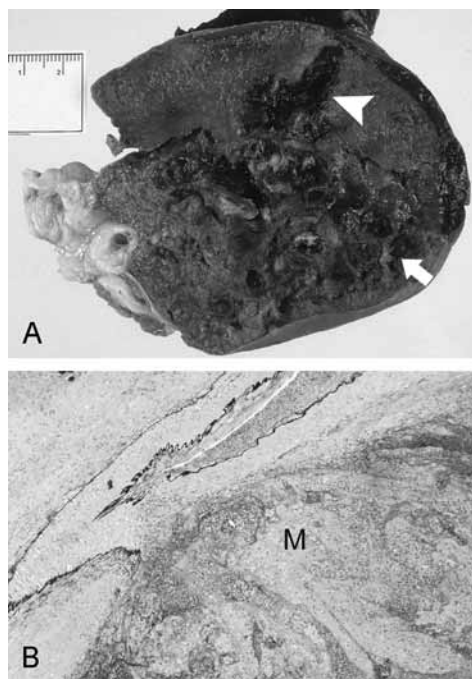
**Fig. 42.** One pattern of delayed traumatic rupture of spleen. Large expansile hematoma. Capsular rupture (arrow).

other causes of delayed rupture (Fig. 43; refs. 374 and 387). Although underlying pathology or medical conditions have been implicated in the predisposition of the spleen to tear after trauma or spontaneously, no microscopic abnormalities, other than caused by the trauma, are usually seen (368,369,388–390).

About 95% of cases of delayed rupture happen within 1 mo of injury, but cases have occurred up to 5.5 yr after trauma (367,370,385,387,391,392). During this latent period, splenic injuries heal (367,370,371,378,393). A traumatic lesion, either failing to heal or evolving to a more severe injury, as demonstrated by a repeat abdominal CT scan, has the potential for rupture (362,376,394).

The force causing rupture of a normal spleen is usually sudden, severe, and concentrated in the left upper abdominal quadrant (367). Being struck by the intruded side door is the most common source of trauma in motor vehicle side collisions (395). Seat belt loading is a factor in some cases (395). The degree of vehicle crush in a side impact cannot always be correlated with the extent of spleen injury (396). One study showed that the majority of splenic injuries in restrained and unrestrained occupants occurred in vehicles with greater than 30 cm (12 in.) of crush. This study showed that restrained drivers of small vehicles are subjected to greater contact with the intruding vehicle. The side doors of heavier vehicles provide greater protection. Unrestrained occupants can also sustain splenic trauma by steering wheel and instrument panel contact (395).

Although left-sided rib fractures are typically associated with spleen injury, right-sided fractures also occur (355,363,368,397). Rib fractures are more likely to occur in older individuals (368). Splenic injury with minimal or absent chest wall trauma is



**Fig. 43.** Another pattern of delayed traumatic rupture of spleen. **(A)** Multiple “micro-aneurysms” (arrow). Tracking of blood in parenchyma (arrowhead) resulting in capsular rupture. **(B)** Disrupted splenic artery branch with extravasation of blood (M, micro-aneurysm). (Movat stain. Original magnification  $\times 100$ ).

indicative of a viscous organ response, i.e., rate sensitivity of organ deformation (*see* Heading 1). This response is modified in a soft organ such as the spleen, which is covered by a tough capsule and protected by ribs. The result can be an evolving injury with delayed consequences.

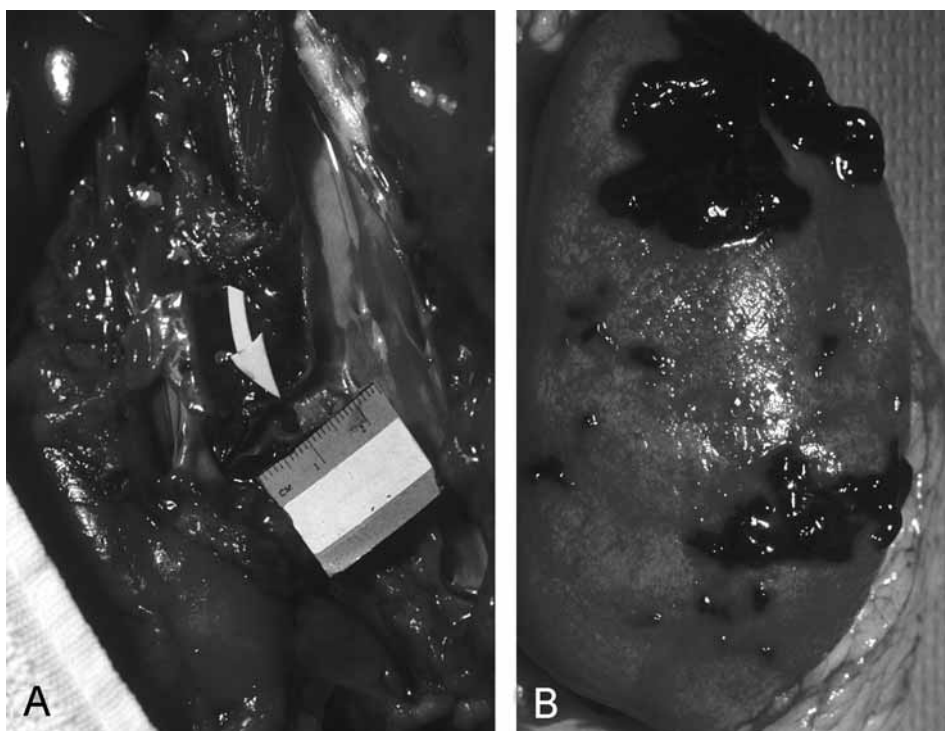
#### **8.4. Abdominal Compartment Syndrome**

The normal pressure of the peritoneal cavity is at most atmospheric and varies inversely with intrathoracic pressure during respiration (398). Intra-abdominal pressure (IAP) is elevated when any type of severe abdominal trauma is associated with massive fluid resuscitation, hemoperitoneum, bowel edema, attempted surgical closure of a non-compliant abdominal wall, and use of intra-abdominal packing. Circumferential burn eschar causes extrinsic compression (*see* Chapter 4, Subheading 5.2.). Increased IAP coexists with increased abdominal girth and obesity. Abdominal compartment syndrome occurs when IAP is associated with organ dysfunction, i.e., reduced cardiorespiratory and renal function. Most deaths associated with abdominal compartment syndrome are from sepsis or multiorgan failure.

### **9. RETROPERITONEAL HEMORRHAGE**

The most common source of traumatic retroperitoneal hemorrhage is a pelvic fracture (399). Associated urinary bladder tears and lacerations of major pelvic vessels are





**Fig. 44.** Retroperitoneal hemorrhage. (A) *In situ* demonstration of renal artery laceration (arrow). (B) Renal cortical lacerations covered by blood clot.

encountered (399). Perinephric hemorrhage necessitates an *in situ* inspection of the renal arteries and veins to exclude laceration (Fig. 44). Renal cortical tears also bleed (Fig. 44). Isolated psoas muscle hemorrhage has been described (400). Retroperitoneal hemorrhage, without a recognizable origin, does occur (399).

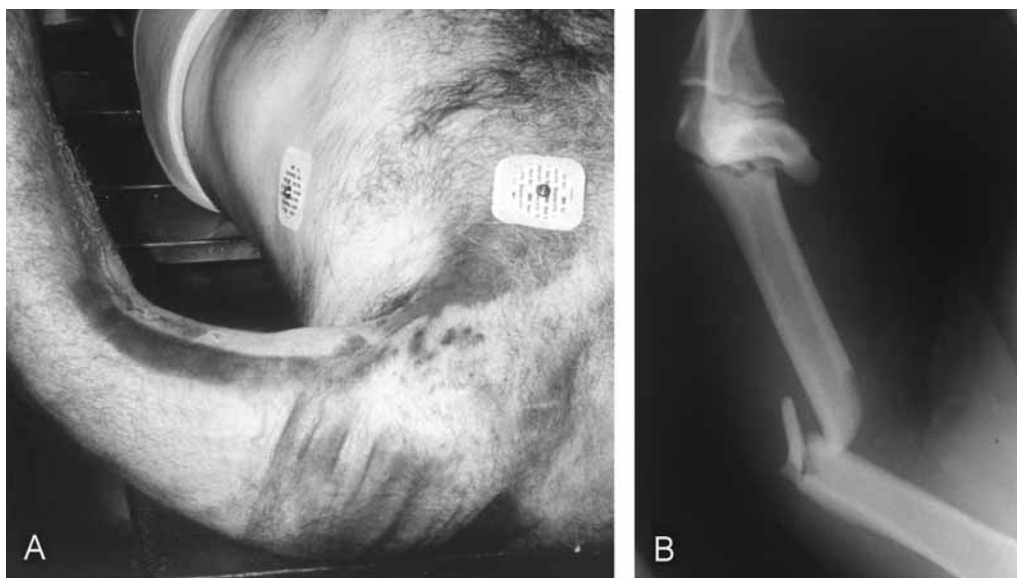## 10. PELVIS

The following points require consideration in the biomechanics of pelvic fractures (401–406):

- The pelvis is a rigid ring structure. Instability implies fracture–dislocation at more than one site.
- The pelvis is subject to vertical shear and compressive forces. Compression is either anterior–posterior or lateral. Forces are inflicted directly on the pelvic wall or indirectly (e.g., loading the femur by knee contact resulting in hip dislocation).
- The stability of the pelvis is dependent on the integrity of the posterior weight-bearing sacroiliac complex and major ligaments. Classification of pelvic fractures is based on the stability of the posterior pelvis.

Three types of pelvic fractures are recognized:

- Type A: A fracture that either does not involve the ring or is minimally displaced.
- Type B: A fracture that is rotationally unstable but vertically stable (e.g., symphysis pubis separation, pubic ramus fracture). Sacral compression fractures are included if posterior stability is partly preserved.



**Fig. 45.** Industrial accident: arm pinned in machinery. Victim dead at scene; no other injuries. **(A)** Crushed arm. **(B)** Postmortem radiograph shows fracture of humerus. (Courtesy of Dr. M. Moussa, London Health Sciences Centre, London, Ontario, Canada.)

Type C: Rotational and vertical instability because of posterior pelvic instability (e.g., vertical fracture of the ilium, sacroiliac joint dislocation, vertical sacral fractures). Posterior pelvic ring trauma is almost always associated with anterior ring injury.

Motor vehicle impact is the most common cause of pelvic fracture (403,407). The incidence of pelvic fracture increases in near-side collisions because of contact with an intruding door (402,408). About one-fourth of automobile fatalities have pelvic fractures (401,409). The majority are type C fractures consistent with severe crashes (401,409). The consequent retroperitoneal hemorrhage contributes to the cause of death (403,407,410,411). Other injuries are frequent (401,403,406,407, 411–413).

Externally, there may be visible distension of the abdomen and thigh (404). Deformity of the pelvis may be seen or palpated. During examination of the pelvic cavity, the pathologist can palpate the pelvic ring, taking care to avoid glove puncture. If necessary, a postmortem radiograph is more accurate (401,402,404,409,414). Instead of the usual anterior–posterior projection, angling the X-ray beams 45° toward the feet and head allows better visualization of the pelvic inlet and sacrum, respectively (404).

## 11. THE EXTREMITIES

Lower extremity injuries can assist in distinguishing an upright pedestrian from one who is recumbent (*see* Subheading 14.6.).

### 11.1. Tourniquet Syndrome

A pinned extremity, (e.g., by machinery), can cause death (Fig. 45; ref. 415). Shock from hemorrhage and hypoxic metabolites, as well as hyperkalemia, may be factors.

## 12. EMBOLISM

### 12.1. Fat Embolism

Fat embolism (FE) refers to fat in the circulation (416–418). Fat embolism syndrome (FES) indicates that FE is associated with pathophysiological effects (416–419).

A broad range of traumatic and nontraumatic conditions have been associated with FE and FES (416,417,419–424).

#### 12.1.1. Trauma

- Fractures (marrow/fat—in bones, particularly long bones of lower extremity and pelvis [423]).
- Soft-tissue injury only (425,426).
- Fatty liver injury.
- Severe burns (see Chapter 4, Subheading 4.5.).
- Blast injury (see Chapter 4, Heading 8.).
- Altitude sickness.
- Decompression sickness (see Chapter 5, Subheading 14.4.).

#### 12.1.2. Surgical Procedures

- *Orthopedic procedures.* Although the performance of certain procedures (e.g., intramedullary nailing) has been implicated in FES, the exact method of fracture fixation probably plays a minor role in the development of pulmonary dysfunction (418,427,428).
- Liposuction.
- Bone marrow transplantation.
- Renal transplantation.

#### 12.1.3. Diagnostic/Therapeutic Procedures

- *CPR (Table 1).* Gross rib/sternal fractures may not be evident despite inspection of the chest cavities. Fat embolism occurs in up to 80% of unsuccessfully resuscitated individuals (424).
- *Intraosseous infusion.* One animal study showed no increase in fat embolism when intraosseous lines were used during resuscitation (429). The author has observed pulmonary fat emboli in unsuccessfully resuscitated infants.
- Long-term hyperalimentation.
- Radiological procedures (e.g., lymphangiogram).
- Cardiopulmonary bypass circulation.
- Long-term corticosteroid therapy.

#### 12.1.4. Disease and Toxic Agents

- Various medical conditions (e.g., acute pancreatitis, alcoholic fatty liver, hepatic failure, acute osteomyelitis, bone infarction caused by sickle cell disease, epilepsy, diabetes mellitus, severe infection, hyperlipidemia [430]).
- Carbon tetrachloride poisoning.

The “mechanical” theory states that disruption of adipose tissue, either intraosseous (i.e., a fracture) or extraosseous, allows fat to enter torn veins (416,417,421–424,427,431,432). If there is a fracture, bone marrow accompanies fat emboli (see Subheading 12.2.). Entry of fat/bone marrow may be enhanced by increased

intramedullary pressure (416,421,432). “Depot-derived” fat embolism also occurs in inflammatory and degenerative conditions (e.g., acute pancreatitis, fatty liver). Fat globules vary from 2 to 200  $\mu\text{m}$  (420). Most fat emboli occlude lung vessels less than 75  $\mu\text{m}$  in diameter (420,421). Widespread occlusion of pulmonary vessels can cause rapid right heart failure; however, there is no correlation between the presence and amount of intravascular fat, and the severity of the clinical course (423). Smaller fat emboli (7–10  $\mu\text{m}$ ) can deform, pass through pulmonary capillaries, and enter the systemic circulation (e.g., brain, kidney [420,422,427]). Systemic embolization implies considerable pulmonary fat embolism, but systemic symptoms do occur without lung manifestations (416,421,422,431). Fat emboli can also reach the systemic circulation through intracardiac shunts (e.g., patent foramen ovale) and by pulmonary precapillary shunts flowing into pulmonary veins (416,420,422). Lipase activated in the lung breaks down the neutral fat present in the emboli (417,420–423,431,433). The generated free fatty acids (FFA) have histotoxic effects on surfactant-producing type II pneumocytes and stimulate inflammation (416,421–423,427,431–433). Adult respiratory distress syndrome (ARDS) can follow (*see* Chapter 1, Subheading 4.3. and refs. 423 and 427). The latent period between the time of injury and development of symptoms correlates with the generation of toxic FFA (424). Fat emboli may stimulate intravascular coagulation (434–436).

The “biochemical” theory states that fat droplets arise from the circulation (“plasma-derived”) because of a metabolic response to stress (424,431). Stressful stimuli and consequent catecholamine release mobilize FFA (416,417,420,431). The emulsion stability of circulating blood lipids is also altered (426,437). An increased level of C-reactive protein, an acute phase reactant, within 24 to 48 h of any tissue damage, causes agglutination of chylomicrons and very low-density lipoproteins, forming clumps 2 to 35  $\mu\text{m}$  in diameter (416,421,422,424,430,438).

The mechanical theory is favored because the FFA profile of fat emboli resembles marrow fat more than circulating plasma lipids (417,420,422,432).

The frequency of FE ranges from about half to all trauma cases (416–421,424).

FES is uncommon; some reports indicate a direct relationship to the number of major fractures (0.25 to 3% incidence in isolated long bone fractures, 10 to 30% in multiple long bone and concurrent pelvic fractures) and the delay in their operative stabilization (416–418,420–423,427,428,438,439). FES is more likely to develop with lower extremity and pelvic fractures, and is uncommon following an upper limb injury (418,420,422). One review showed that FES occurred more commonly in patients with closed fractures, suggesting that because intramedullary bone pressure is lower in an open fracture, FE is less likely to occur (418,439). Others have observed the reverse (418). The incidence in children is low, because the proportion of hematopoietic elements relative to fat in the medullary cavity is higher than in adults, and bone marrow fat in children contains less olein, a fatty acid toxic to the lung (420–423,427). The incidence of FES is not predicted solely on the amount of embolized fat. Other factors such as shock, sepsis, and disseminated intravascular coagulation contribute (*see* Chapter 1, Subheading 4.3. and refs. 421 and 438). FES is a contributory factor in up to 10% of trauma deaths (418,431). FES is uncommon in nontraumatic medical conditions.

FES is usually manifest 6 to 72 h after a pelvic or long-bone fracture (416–424,427,428,432,438). About 90% of cases happen within the first 3 d, but FES

has been observed up to 2 wk later (420,421). The following clinical features have been described:

- Acute respiratory distress is the most common presentation (417,418,421,431,432). This occurs in 75% of patients with FES, and 10% eventually require ventilatory support because of ARDS (417,422,423).
- Cerebral manifestations (confusion, drowsiness, lethargy, convulsions, coma) occur in up to 86% of cases and may be the sole manifestation of FES (417,418,422,423).
- Petechiae of the conjunctiva, mucous membranes, and skin, typically on the anterior part of the thorax and neck, are seen in up to 60% of FES cases (416–418,420–423, 432). Distribution on the neck and axilla has been attributed to an accumulation of fat droplets in the aortic arch; these are skimmed to the subclavian and carotid vessels when the patient is upright (416,417,423,427). Alternatively, platelet aggregation and fragmentation by fat in the lungs cause thrombocytopenia, leading to petechiae (see Chapter 3, Heading 1.4. and refs. 416, 417, and 431).

The presentation of FES varies. A fulminant variant occurs suddenly and rapidly after injury, resulting in death within a few hours (416,418,419,423). Mechanisms of death include respiratory failure and acute right heart failure (419). A fulminant course is associated with multiple fractures (419,421). Neurological symptoms may predominate (418,419).

Clinically, there are no specific laboratory or radiographic findings (427,428). At autopsy, fat emboli are not usually visible (Fig. 46). Examination of hematoxylin and eosin (H&E) microscopic slides of lung tissue reveals only clear spaces within vessels, and fat emboli may not be appreciated (Fig. 47). Postmortem, fat in the lungs and other tissues (e.g., kidney, brain) can be demonstrated (Fig. 47). An oil-red-O stain is used on frozen fresh tissue (417). Postfixation of formalin-fixed tissue with osmium tetroxide demonstrates fat (426,440).

The decision whether FE contributed to the cause of death is based on the circumstances, supported by clinical signs, and confirmed by histochemical demonstration of fat emboli. In cases of sudden death, FE can be considered a cause of death when bone fractures and soft tissue trauma have occurred and other fatal injuries have been excluded.


## **12.2. Bone Marrow Embolism**

Bone marrow emboli to the lungs are indicative of a bone trauma (441,442). Bone marrow embolism from fractured ribs during CPR is a sign of artificial circulation to the lungs and occurs in 10 to 50% of cases (Table 1; refs. 157, 167, 172, 173, 176, and 441). Bone marrow usually embolizes only to the lungs (Fig. 48; refs. 151 and 443). Bone marrow does not invariably embolize with fat (167). The microscopic finding of bone marrow emboli is not always associated with grossly visible trauma (153,167,172). Bone marrow emboli in apparently noninjured elderly individuals occur likely from microtrauma of osteoporotic bones (443). Pulmonary bone marrow embolism does not usually cause detrimental clinical effects unless there is massive occlusion of vessels (153,167).

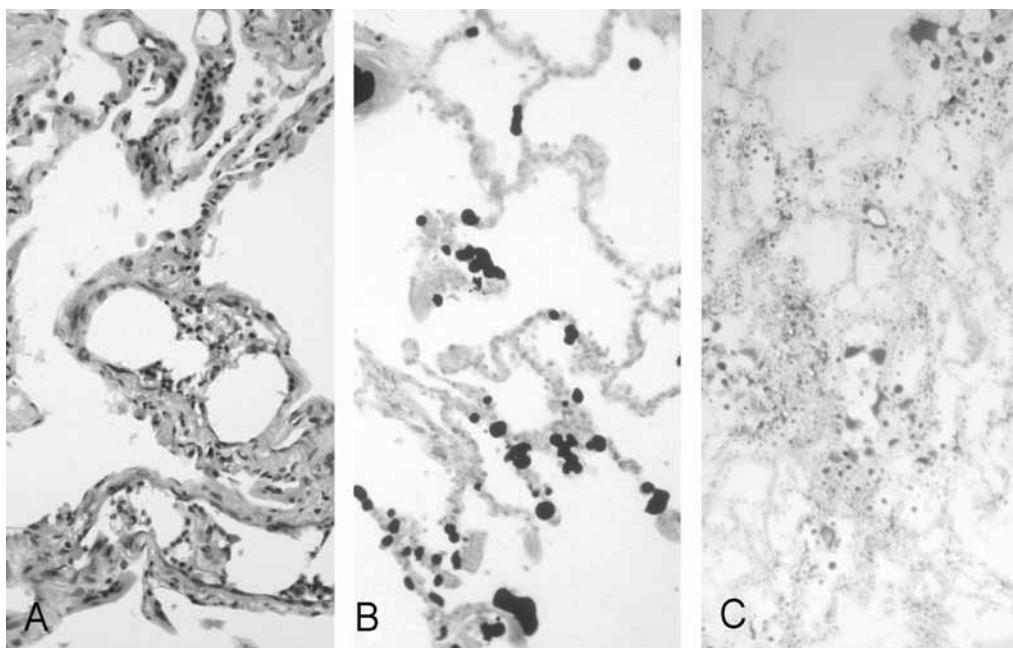
## **12.3. Pulmonary Thromboembolism**

Trauma patients are at risk for the development of deep venous thrombosis (DVT) and consequent pulmonary thromboembolism (PTE) (444–446). The evolution of DVT involves interplay between blood stasis, endothelial injury and hypercoagulability. Risk

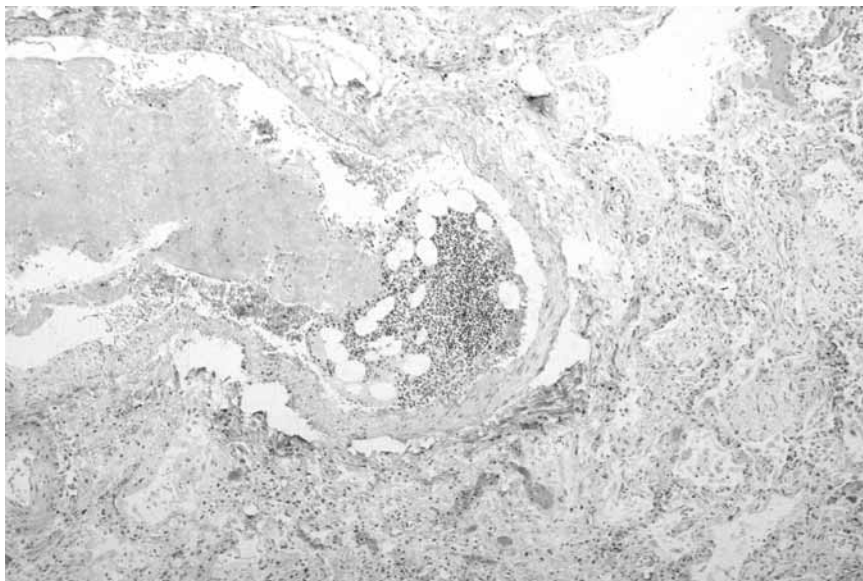




**Fig. 46.** Pulmonary fat embolism in a trauma case. Lung cut during autopsy. Numerous fat droplets on dissection board (arrows). (Courtesy of Dr. C. Armstrong, London Health Sciences Centre, London, Ontario, Canada.)



**Fig. 47.** Pulmonary fat embolism, microscopic examination. (A) Intravascular vacuoles (formalin-fixed tissue H&E. Original magnification  $\times 200$ ). (B) Multiple fat emboli (formalin-fixed tissue, postfixation with osmium tetroxide, original magnification  $\times 100$ ). (C) Multiple fat emboli (fresh frozen tissue, oil-red-O stain; original magnification  $\times 100$ ).



**Fig. 48.** Bone marrow embolus (H&E, original magnification  $\times 100$ ).

factors for DVT and PTE include the type of injury (fracture of a lower extremity or pelvis, head or spinal cord injury, vein trauma), age more than 40 yr, a thrombotic predisposition, prolonged time ( $>3$  d) on a ventilator, coma, an indwelling central venous line, and performance of a major surgical procedure (444–451).

Most cases of DVT start in the calf veins and resolve spontaneously (452). DVT can develop in the extremity contralateral to the injury (448). The frequency of asymptomatic DVT in the lower extremities in trauma cases, as determined by venography, is high. A study of 716 patients admitted to a regional trauma unit showed DVT in about half of cases of injuries of the head, face, chest, or abdomen, in about two-thirds of pelvic and spinal trauma victims, and in more than three-fourths of individuals with femoral and tibial fractures (451). Extension into the proximal veins runs the risk of embolization (452). PTE is not necessarily preceded by clinical evidence of DVT (451). About half of patients with symptomatic proximal DVT, without PTE symptoms, have ventilation–perfusion lung scan findings associated with a high probability of embolism (452). The clinical incidence of venous thromboembolic events (DVT, PTE) in admissions to US trauma centers was less than 1% in one study (447). Other studies have shown an incidence of PTE below 1% (445,451). The overall incidence of PTE in a series of pediatric trauma patients aged less than 19 yr, as documented in the US National Pediatric Trauma Registry, was 0.000069% (1.85% for spinal cord injury [449]).

Autopsy studies give a skewed perspective of the incidence of DVT and PTE (448). DVT has been found in 65% of fatal trauma cases, and PTE caused death in 20% (453,454). Young healthy individuals without cardiopulmonary disease can tolerate PTE (452). In about 10% of the PTE cases, there is sudden death (452). A large thromboembolus at the main pulmonary artery bifurcation (saddle embolus) or its main branches is usually rapidly fatal (Fig. 49; ref. 455). Smaller emboli filling more than half of secondary pulmonary artery branches can also be rapidly fatal (455).



**Fig. 49.** Bifurcation of main pulmonary artery opened to reveal “saddle” thromboembolus.

At autopsy, the pathologist must open and digitally examine the pulmonary artery bifurcation before the heart is removed from the body. If PTE is suspected by palpation, then the pulmonary artery can be clamped to prevent dislodging the embolus. The heart and lungs are then removed together and the pulmonary artery branches are opened further. Microscopic sections are required for confirmation of thromboembolism. Thigh and calf circumferences are compared to assess whether edema secondary to DVT has occurred. If there is a difference, then the bilateral femoral and popliteal veins, i.e., proximal veins, are opened. This limited dissection may be unproductive because the thrombus may have completely dislodged, lysed, or been situated at another site.

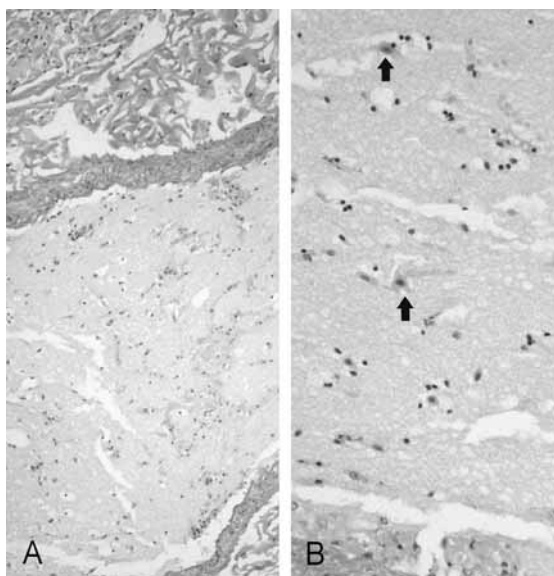
## ***12.4. Other Types of Embolism Associated With Trauma***

### ***12.4.1. Brain***

Severe head trauma rarely results in gross and microscopic pulmonary brain emboli and has been reported in birth trauma and adult injury cases ([Fig. 50](#); refs. [456–462](#)). The incidence varies from 2 to 10 % following severe head trauma ([458,459](#)). Dural sinus tears are not necessary for cerebral pulmonary embolization to occur ([460](#)). Brain tissue can also enter cerebral and meningeal veins.

### ***12.4.2. Liver***

Trauma to the inferior vena cava is associated with severe injuries of the liver ([463–465](#)). Consequent entry of hepatic tissue into the circulation leads to grossly evident emboli in the lungs ([463–465](#)). Microscopic evidence of hepatic tissue may not be seen in pulmonary vessels, raising the possibility that liver seen in the heart and pulmonary vessels was pushed there by external force ([463](#)). Microscopic emboli to the lungs support a vital reaction, i.e., an active circulation at the time of the trauma ([Fig. 51](#); ref. [466](#)).



**Fig. 50.** Craniocerebral trauma. **(A)** Embolic brain tissue to lungs (H&E, original magnification  $\times 200$ ). **(B)** Embolic brain tissue. Degenerated neurons (arrows; H&E, original magnification  $\times 400$ ).

#### 12.4.3. Amniotic Fluid

Amniotic fluid embolism can be seen coincidentally in a pregnant woman dead at the scene from blunt trauma injuries (Fig. 52). Amniotic fluid embolism can progress to cardiovascular collapse, respiratory failure, and coagulopathy (417,467–469). Fetal squames are seen in pulmonary vessels and sometimes in the systemic vasculature (468). They are more likely to be found if pregnancy is advanced. Multiple lung sections increase the chance of finding squames.

#### 12.4.4. Cartilage

A few case reports describe cartilagenous emboli to the lungs resulting from trauma, including closed-chest resuscitation and orthopedic surgery (470,471).

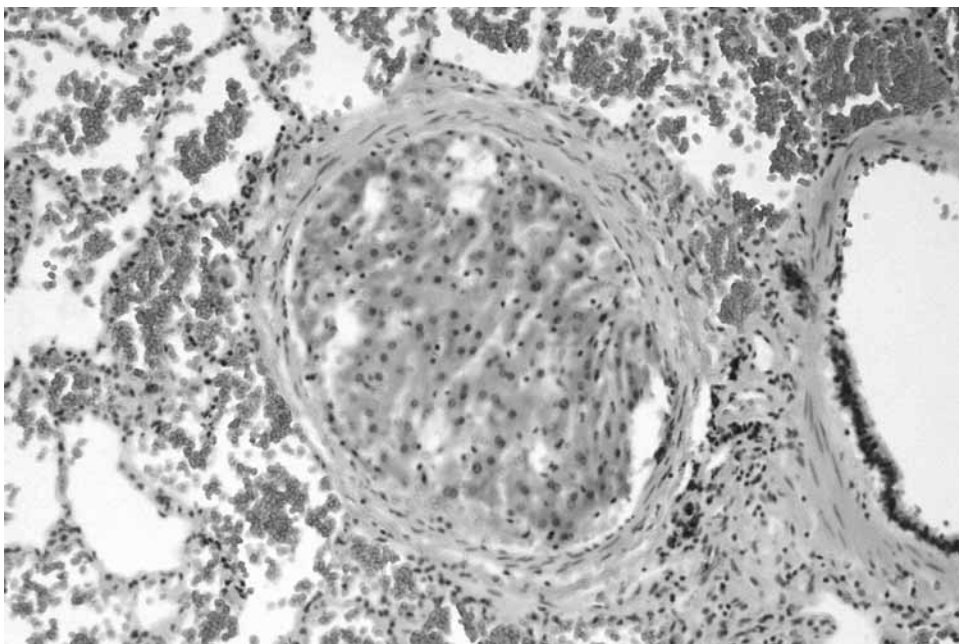
#### 12.4.5. Air

Air embolism does occur in trauma (see Chapter 7, Subheading 12.1.) (417,420, 472). Air enters a vein when it is open to the atmosphere and there is a negative pressure gradient. Large volumes of air obstruct the right ventricle and pulmonary outflow tract, and smaller volumes, lead to blockage of pulmonary arterioles. Systemic air embolization is possible through cardiac (e.g., patent foramen ovale) and intrapulmonary shunts.

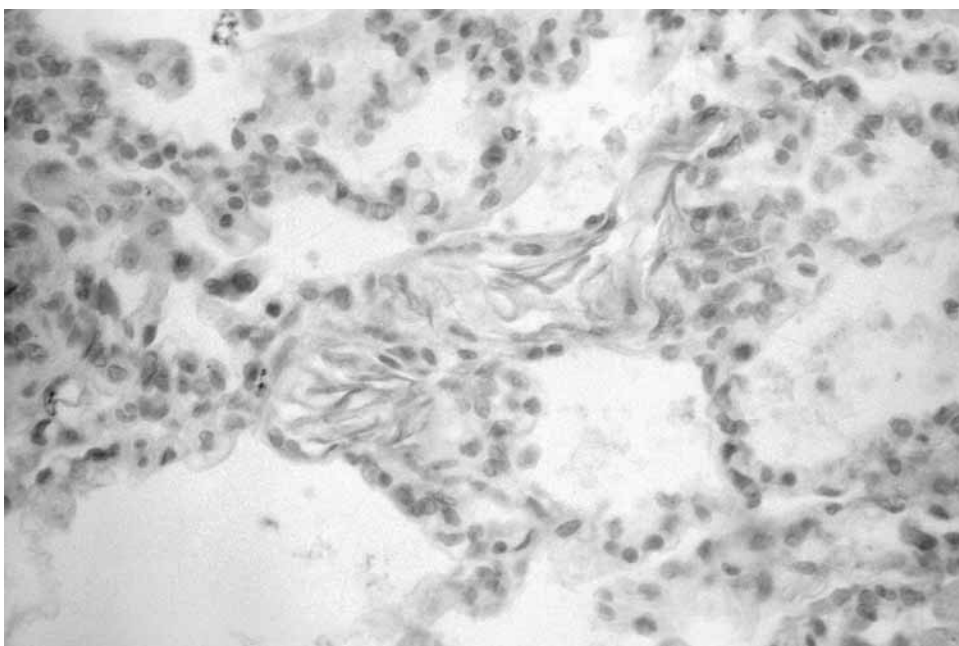
#### 12.4.6. Megakaryocytic Embolism

Although proposed as an indicator of antemortem skeletal trauma, the finding of prominent megakaryocytic nuclei in pulmonary capillaries is part of the normal production of platelets (Fig. 53; refs. 442 and 473).



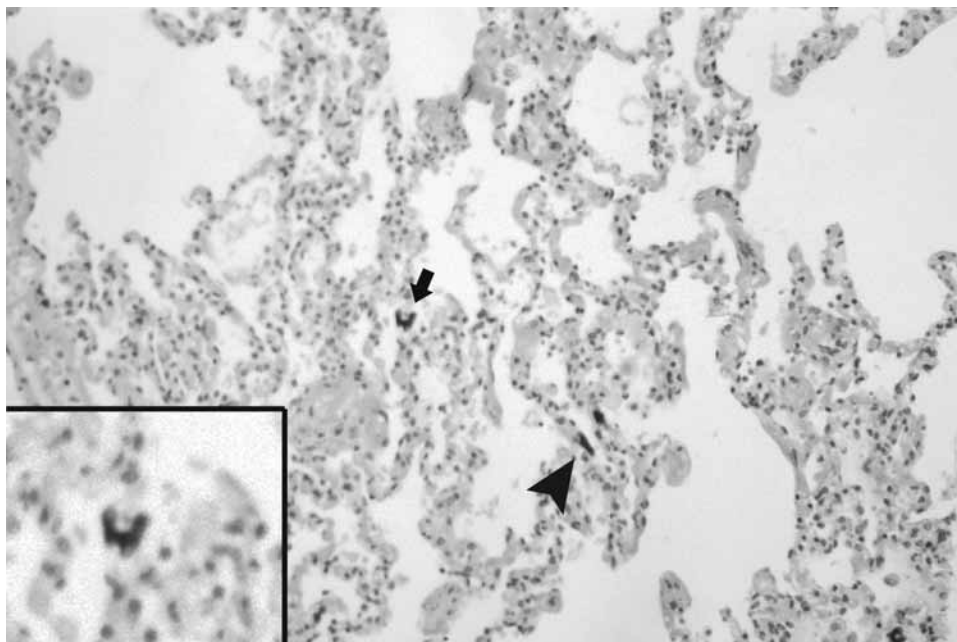


**Fig. 51.** Hepatic trauma. Embolization of liver tissue to lung (H&E, original magnification  $\times 200$ ).



**Fig. 52.** Pregnant driver in motor vehicle collision, dead at scene from multiple injuries. Amniotic fluid embolism to lungs. Fetal squames (cytokeratin positive by immunoperoxidase technique) in alveolar capillaries (original magnification  $\times 200$ ).





**Fig. 53.** Megakaryocytes (arrow and arrowhead) in alveolar capillaries (H&E, original magnification  $\times 50$ ). Inset shows arrowed megakaryocyte enlarged.

### 13. RHABDOMYOLYSIS

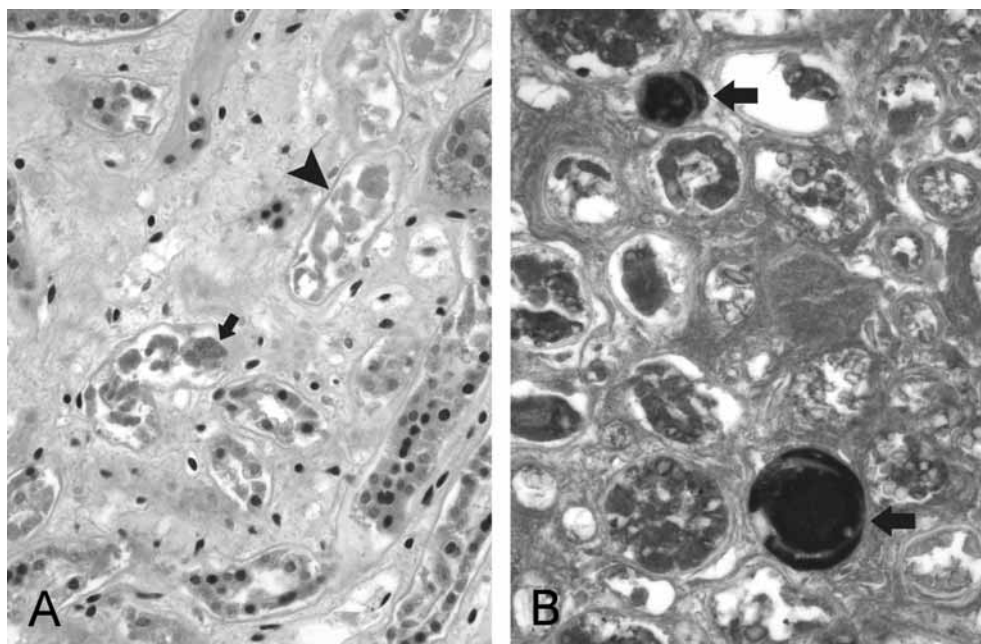
Rhabdomyolysis, as a result of muscle necrosis, occurs in various settings, such as drug use (e.g., cocaine) and trauma (e.g., blunt trauma, burns, electrocution, hypothermia, near-drowning [474–480]). Prolonged compression of a body site can lead to rhabdomyolysis, a possibility that should be considered in a comatose individual (e.g., drug overdose, ethanol intoxication [478,481,482]). A clinical picture of renal failure is associated with acute tubular necrosis and myoglobin casts (Fig. 54). Rhabdomyolysis does not necessarily result in myoglobinuria (478).

### 14. MOTOR VEHICLE COLLISIONS

The usual types of motor vehicle collisions are frontal impacts, side and side-swipe impacts, rear impacts, and rollovers. Motor vehicle trauma is a major cause of blunt trauma injuries. Injury patterns and patterned injuries are associated with various types of impacts (483,484). Understanding injury mechanisms requires correlation of injuries with vehicle dynamics and occupant kinematics (483). This information assists in distinguishing driver and passenger injuries (485–487).

#### 14.1. Frontal Impact

In a head-on collision, the principal force on the vehicle acts down the axis of the vehicle. On impact, an unrestrained occupant moves forward until there is contact with part of the interior. Occupant contact points can be marked by transfer of blood and other tissue from the victim. Interior components are deformed by body contact. The



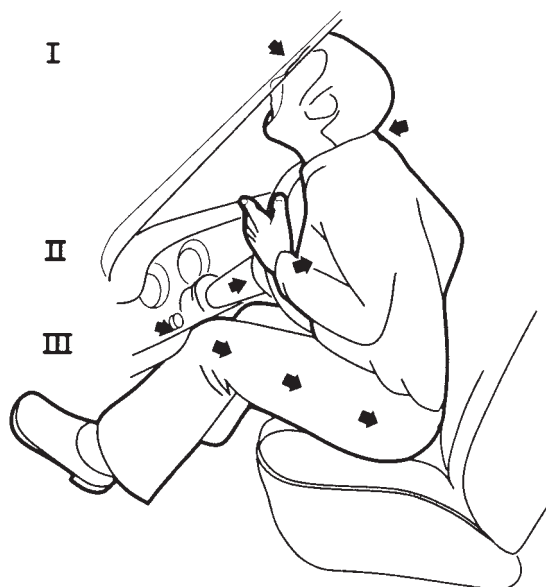
**Fig. 54.** Rhabdomyolysis—kidney. (A) Myoglobin casts (arrow). Necrotic renal tubule (arrowhead; H&E, original magnification  $\times 200$ ). (B) Immunoperoxidase technique showing positive myoglobin reaction in casts (arrows; original magnification  $\times 400$ ). (Courtesy of Dr. M. Moussa, London Health Sciences Centre, London, Ontario, Canada.)

occupant's head and face strike the windshield, A-pillar, or front header (Level I or upper-level injuries; *see* Figs. 20 and 55 and refs. 487–489). Energy is transmitted from the skull to the spinal column, where cervical spine fractures can occur. The instrument panel and steering column are struck by the torso of a passenger or driver, respectively (Level II or middle-level injuries; *see* Fig. 19; refs. 489 and 490). This can result in considerable deformation of the steering wheel (Fig. 56; ref. 491). The face and anterior neck can also strike the instrument panel or steering wheel (492). Damage to the lower instrument panel on both sides of the steering column is evidence that the driver's knees loaded the dashboard area. In the unrestrained occupant, the force generated by knee contact can fracture the femur and the pelvis (Level III or lower-level injuries [489]). Intrusion at floor level (toe pan) leads to foot and ankle injuries irrespective of restraint usage (Fig. 57; refs. 408, 487, and 493–496). Intrusion and deformation of the occupant compartment increase the possibility of occupant contacts (491,495,497). Occupant contacts can be external (e.g., intruding vehicles, fixed objects).

## 14.2. Occupant Restraint Systems

### 14.2.1. Seat Belt

A properly worn seat belt provides varying protection in almost all collision types by preventing occupant ejection and by reducing interior contacts, allowing the occupant to “ride down” the collision while crash energy is dissipated during vehicle deformation (484,487,498–502). To take full advantage of the time duration of vehicle crush, the

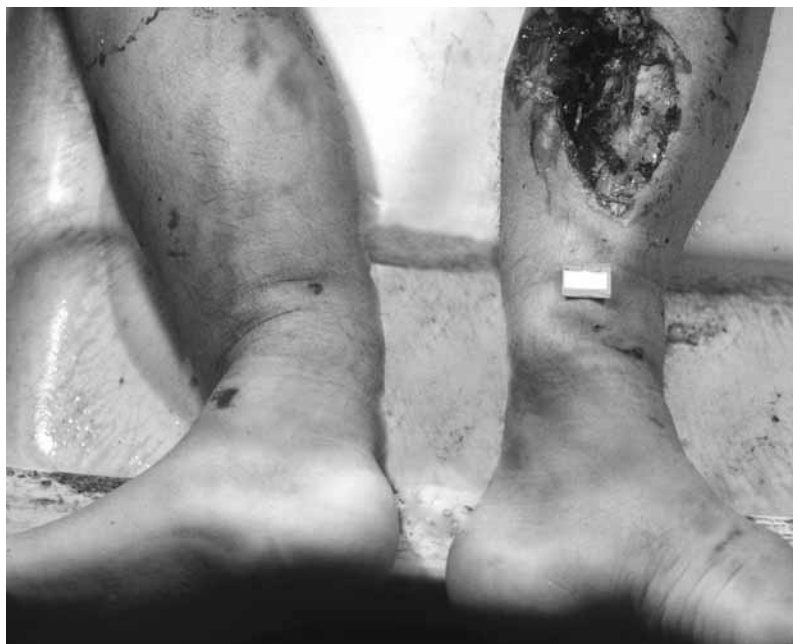

### THE THREE-LEVEL INJURY OF THE DRIVER

**Fig. 55.** Levels of injury potentially sustained by an unrestrained driver in a frontal collision. The pathologist must be aware that even restrained occupants can be injured by intrusion into the occupant compartment. (Reprinted from ref. 489 with permission of Lippincott Williams & Wilkins.)



**Fig. 56.** Frontal collision; intrusion and deformation of steering wheel. (Courtesy of Road Safety and Motor Vehicle Regulation Directorate, Transport Canada.)



**Fig. 57.** Toe pan intrusion. Deformity of ankles owing to fracture–dislocation; laceration of left shin.

occupant must be restrained by the seat belt as early as possible during a crash. In a frontal impact, the emergency locking retractor in a seat belt system locks, and as the driver moves forward, the belt system is loaded. The lap and shoulder components of the seat belt effectively restrain the pelvic girdle and torso, respectively, from moving forward. In a seat belt system, most of the stretching occurs in the shoulder belt portion. As a result, the occupant's upper torso pivots over the lap belt. Facial and head injuries are possible, even for fully restrained occupants, in severe frontal collisions. Relative seat belt slack increases seat belt loading of the occupants. Slack allows greater excursion distances during a crash, which increases occupant contacts with the interior (503). Pyrotechnic pretensioners in new cars eliminate seat belt slack. Load limiters, in conjunction with airbags, provide resistance but allow forward excursion to meet the deployed airbag. In rare cases of heavy loading, the belt fails, releasing the occupant (500).

The effectiveness of any restraint system in reducing serious injuries is compromised in high-severity collisions when there is intrusion into the occupant compartment (497–500,504–507).

Seat belt-associated injuries occur (Table 2).

Serious visceral injuries from seat belts are uncommon and are usually associated with the belt being worn improperly (502,503). Serious injuries are also a reflection of higher severity crashes (>48 km/h or 30 mph) and the nature of the collision (e.g., rollover increases the possibility of partial ejection and “hanging” in a restraint system [499,500,549,550]). The lap part of the belt must be worn on the bony pelvis, and the torso belt needs to be positioned across the chest (500,501,515). A lap belt worn higher on the abdomen can cause injury. Instead of loading the strong bony pelvis, the load is transmitted to the abdominal organs and the lumbar spine. Constitutional factors

**Table 2**  
**Seat Belt-Associated Internal Injuries**

---

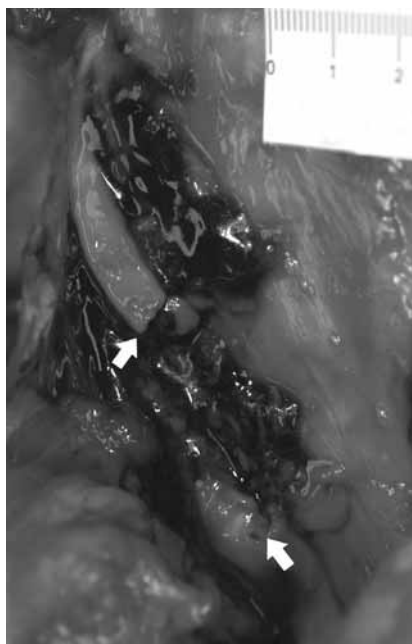
**Lap belt-related**

- Abdominal wall soft tissue disruption (*499,501,508–510*)
  - Transection of torso (*511*)
- Diaphragm tear (secondary herniation of abdominal viscera [*512*])
- Gastric rupture (*353*)
- Small and large bowel trauma (contusion, seromuscular laceration, perforation, transection, secondary infarction [*499,502,505,510,513–521*])
  - Transection of appendix (*522*)
- Omental tear (*499*)
- Mesentery injury (contusion, laceration, internal herniation [*499,501,502,508,510,515*])
- Pancreas (disruption, inflammation [*523*])
- Abdominal aorta trauma (contusion, intimal tear, dissection, thrombosis, secondary embolization, acute or delayed rupture with aneurysm [*293,294,301,524–530*])
  - Iliac artery (intimal tear [*499,531*])
- Inferior vena cava laceration (*319,532*)
  - Renal vein tear
- Kidney laceration (*532*)
- Lumbar spine fractures (*499,505,510,513,519,520,533*)
- Pelvic fractures (*499,500*)
- Pregnancy-related
  - Uterine rupture (*499,534–540*)
  - Fetal demise secondary to:
    - Abruptio placentae (*536,538,540–542*)
    - Trauma (craniocerebral, other viscera [*538–540,543,544*])

**Shoulder belt-related**

- Atlanto-occipital dislocation (*545*)
  - Cervical spine fractures (all levels including “hangman’s” fracture [*499,546–548*])
  - Decapitation (*499,548,549*)
  - Strangulation (*499,550*)
  - Larynx injury (fractures, transection [*499,546,548*])
  - Tracheal transection (*548,551–553*)
  - Cervical esophagus perforation (*554*)
  - Chest wall fractures (ribs, sternum, clavicle, chondrosternal dislocation [*499,502,555*])
  - Thoracic spine fractures (*546,547,556,557*)
  - Thoracic aorta trauma (laceration, transection [*275,502,556*])
  - Major arteries:
    - Carotid artery (transection, dissection [*530,546,551,558,559*])
    - Vertebral artery injury (*560*)
    - Subclavian artery (intimal tear [*555,560*])
    - Innominate artery rupture (*561*)
  - Heart (contusion, laceration [*502,562,563*])
  - Lung (contusion, laceration [*502*])
  - Pleura, pericardium (laceration [*502*])
  - Liver (laceration [*502,555*])
    - Avulsion of hepatic veins (*499*)
  - Spleen (laceration [*395,499,502*])
  - Kidney (laceration including renal artery and vein [*499*])
-





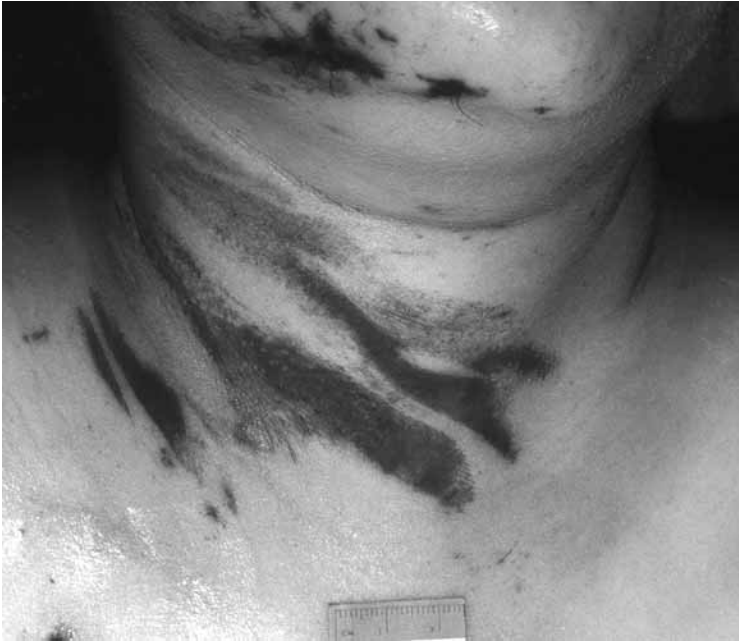**Fig. 58.** Short-statured driver wearing a lap–shoulder belt. Abrasions were noted on the left neck. Transected ends of left carotid artery (arrows).

(obesity, pregnancy) cause the lap restraint to be situated on the abdomen ([502,564,565](#)). A shoulder restraint on the neck of a short individual can cause injury ([Fig. 58](#); ref. [515](#)). Seat belt injuries occur in all age groups and are seen with two-point (lap) and three-point (lap–shoulder) belts ([510](#)). Adult seat belts do not provide adequate protection for children ([530,566](#)).

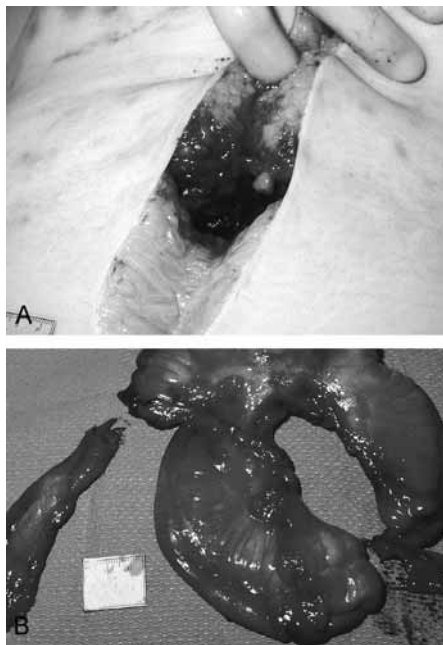
Cutaneous injuries are indicative of seat belt use and loading ([Figs. 21](#) and [59](#)). Seat belt use is also determined by evidence of loading marks on the belt fabric ([567](#)). Skin trauma, as a result of inappropriate placement of the belt, constitutes a “seat belt sign” and raises the possibility of internal trauma ([500,501,515,518,519,521,547,558,568](#)). The cutaneous injuries vary and are not always associated with visceral injury ([500,501](#)). Conversely, the absence of external trauma—for example, in a heavily clothed occupant—does not exclude underlying injury ([Fig. 60](#); refs. [499, 501, 514, 515](#), and [568](#)). Severe abdominal visceral injuries are more likely with lap-only restraints compared with lap–shoulder belts ([569](#)).

Proposed mechanisms of intra-abdominal injury caused by seat belt compression include:

1. Avulsion of fixed structures (e.g., duodenal–jejunal junction, jejunum at ligament of Treitz, terminal ileum, transverse-sigmoid colon junction, areas of fibrous adhesion) owing to deceleration.
2. Compression of viscera against the spine.
3. Closed-loop intestinal perforation from localized pressure.
4. Shock wave effects on hollow and solid viscera from increased intraperitoneal pressure ([505,515,516,518,521,570](#)).



**Fig. 59.** Front seat passenger. Cutaneous injuries (abrasions) on right neck caused by shoulder belt.



**Fig. 60.** Lap-belt injury. (A) Lower abdominal wall hematoma seen on abdominal incision. Only small scattered cutaneous bruises were observed in the vicinity. (B) Transected loops of small bowel.

Lap-belt loading tends toward hollow viscus injury (509,513).

Lumbar fractures (“Chance fractures”) from seat belt loading are thought to be caused by a lap belt improperly positioned at the umbilicus, allowing hyperflexion of the spine (505). Fractures involve the vertebral body and posterior elements, typically of the second, third or fourth lumbar vertebra (500,510,533). Compression fractures also occur in nonbelted occupants (533). Axial loading during vehicle rotation, multiple impacts, and “pancake” landings have been associated with lumbar fractures (500,533).

The leading cause of fetal demise in a motor vehicle crash is maternal death (571). The best protection for the mother is the use of a restraint system that reduces interior contacts, especially in lower-severity crashes (538,542,571,572). Fetal demise does occur in lower-severity crashes, and there can be minimal maternal injury (539,572–576). Seat belt loading of the abdomen raises pressure in the gravid uterus (539). Uterine distortion causes the less elastic placenta to tear, leading to abruptio placentae (571). Notably, the spectrum of injuries observed in restrained pregnant women—uterine rupture, abruption of the placenta, and fetal injury—are seen in unrestrained females (571,572). Associated maternal pelvic and femur fractures occur (577).

Anterior rib fractures, owing to shoulder belt loading, are distributed asymmetrically compared with those caused by air bag loading (133,504,578).

#### 14.2.2. Air Bag Deployment Injury Patterns

Front air bags supplement seat belts and protect front occupants in moderate to severe frontal crashes. The deployed air bag cushions the front seat occupant’s head and chest from contact with the steering wheel or dashboard. An air bag is activated when there is significant deceleration along the longitudinal axis of the vehicle; and most deployments are in frontal crashes (579). The threshold speed for deployment of a “first-generation” air bag in a frontal impact is 11 to 25 km/h (7 to 16 mph [579]). Side and undercarriage impacts can also trigger deployment (Fig. 61; ref. 579).

Most air bag injuries are minor (e.g., facial cutaneous trauma [580,581]). Ocular injuries and facial fractures have been described (580). Upper extremity fractures occur if the driver’s arm is positioned over the air bag module while the steering wheel is turned (580). The lower extremities are not protected if the occupant “submarines” under the air bag (582–585).

Because they are pyrotechnic devices, air bags can cause unusual isolated trauma by unique mechanisms (580,581,586). An “out-of-position” occupant—i.e., a driver’s chest within 25 cm (10 in.) of the steering wheel—is at risk for injury (579,586,587). There are multiple factors that predispose a front seat occupant being out of position (Table 3; Figs. 62 and 63).

During the “punch-out” phase—i.e., when the torso of the occupant is covering or very close to the air bag module—air bag inflation is blocked (588). If the air bag is partly inflated and further expansion is resisted (“membrane-force” phase), then thoracoabdominal injuries and head and neck injuries occur (Fig. 64; ref. 588). Because forces are being transmitted at high velocity (145 to 328 km/h or 90 to 211 mph), a spectrum of trauma, including blast-type injuries, can result (Table 4; ref. 579).

When assessing whether an air bag contributed to injury causation, the pathologist must realize that, in high-severity crashes, the protective capability of the airbag may be



**Fig. 61.** The driver died in this far-side collision that triggered deployment of the air bag. The front seat passenger in the target vehicle survived (see Figs. 63 and 64). (Courtesy of Road Safety and Motor Vehicle Regulation Directorate, Transport Canada.)

**Table 3**  
**“Out-of-Position” Front Seat Occupant: Predisposing Factors**

---

**Large physique-obesity**

**Short stature-adjustment of car seat forward to reach floor pedals**

Skeletal conditions (e.g., scoliosis, achondroplasia)

Driver  $\leq$  5 ft. 4 in. (160 cm) tall

**Other position changes**

Occupant of any age improperly seated, reaching, leaning forward

Driver slumped over steering wheel owing to drowsiness, medical condition, intoxication

Forward movement of occupant of any age owing to:

- Pre-impact braking
- Preceding minor ( $<$ air bag deployment threshold) impact(s) and exacerbated if manual restraint system
  - Not used
  - Slack (heavy clothing contributory); slow lock-up
  - Relaxation of inertia-activated belt after minor impact followed by air bag deployment in major impact
  - Improperly worn; lap belt only

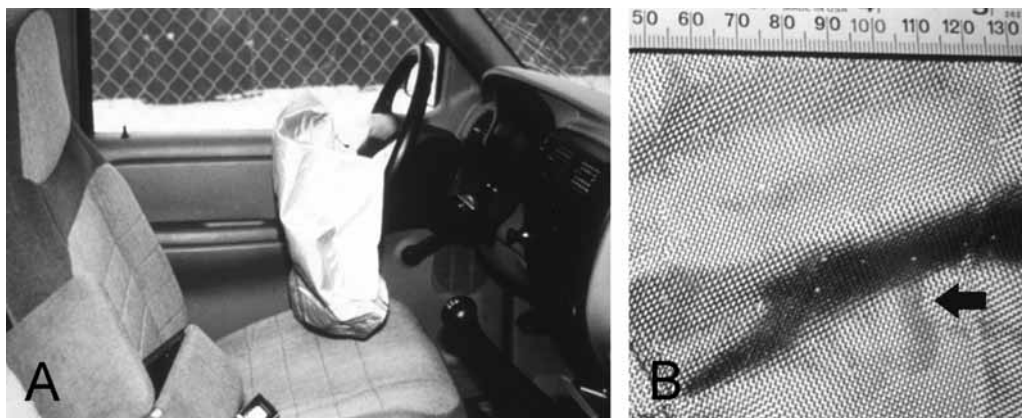
Child-safety seat in right front seat

---

Adapted from ref. 586 with permission from the Journal of Forensic Sciences.



**Fig. 62.** Minor collision. Deployment of air bag; driver dead at scene, likely slumped over steering wheel because of ethanol intoxication. At autopsy, a laceration of the left main pulmonary artery was found. (Reprinted from ref. 579 with permission from the Journal of Forensic Sciences.)

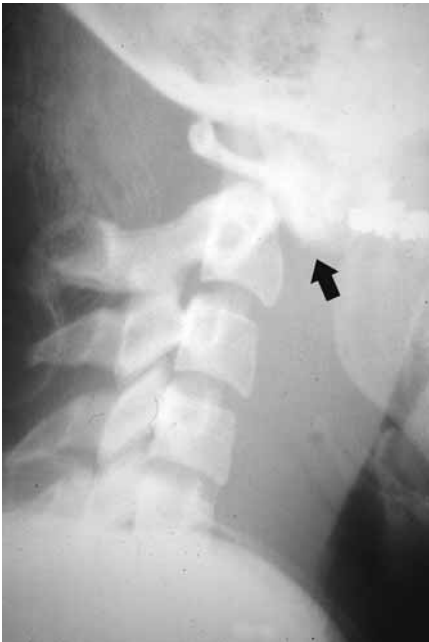

**Fig. 63.** Short-statured female driver had her seat positioned forward. (A) The victim was also observed leaning forward to better visualize the icy road. Her vehicle skidded into an oncoming vehicle and the air bag deployed (see Fig. 61). (Reprinted from ref. 579 with permission from the Journal of Forensic Sciences.) (B) Lipstick impression (arrow) on air bag.

exceeded because of occupant loading through the air bag (586,644). In multiple impacts, an air bag may deploy early and not be available to protect the occupant later in the crash sequence (Fig. 65).

If there are multiple injured occupants in a collision and the identity of the driver is unclear, then examination of the air bag, including swabbing for DNA analysis, assists in this determination (645).





**Fig. 64.** A postmortem radiograph demonstrated dislocation of C1-C2 vertebrae (atlanto-axial dislocation; arrow) caused by air bag deployment (see Figs. 61 and 63). (Reprinted from ref. 579 with permission from the Journal of Forensic Sciences.)

**Table 4**  
**Fatal and Nonfatal Serious Injuries in Drivers and Front Passengers Associated With Air Bag Deployment: Literature Review**

**Craniocerebral trauma**

- Skull fracture(s), nos<sup>a</sup> (589–591)
  - Base (nos, “ring,” “hinge”) ± calvarium<sup>a</sup> (579,589,592–595)
    - Associated vascular tear (cavernous sinus, carotid artery [589,596])
  - Depressed, nos<sup>b</sup> (589)
  - Occiput<sup>a</sup> (589,597)
  - Calvarium only<sup>b</sup> (598)
- Epidural, subdural/subarachnoid/intraventricular hemorrhage<sup>a</sup> (589,590,595,597,599–604)
- Brain injury, head injuries, nos<sup>a</sup> (589,591)
  - Maceration<sup>b</sup> (589)
  - Cerebral edema<sup>a</sup> (589,590,598,601)
  - Closed head injury<sup>a</sup> (579,589,598,605)
  - Diffuse axonal injury<sup>a</sup> (590,603,606)
  - Cerebral contusion<sup>a</sup> (589,590)
  - Cerebral hemorrhage, nos<sup>a</sup> (589,594,598)

**Brain stem–cervical spine trauma**

- Decapitation or neck transection<sup>b</sup> (589)
- Cervical spine injury or neck fracture, nos<sup>a</sup> (589,595)
  - Atlanto-occipital or atlanto-axial dislocation<sup>a</sup> (579,589,590,594,595,602,604,606–614)
  - Other fractures-dislocations (C2 to C7)<sup>a</sup> (579,589,590,593,594,600,610,615,616)

(Continued)

**Table 4** (Continued)

---

Brainstem injuries, nos (595)
Ponto-medullary tear or transection <sup>a</sup> (602,604,606)
Medullary hemorrhage/tear/transection (589)
Laceration or transection, nos <sup>a</sup> (589,593,595)
Brainstem or pons contusion/hemorrhage <sup>a</sup> (589,590,600)
Cervical spinal cord injuries, nos <sup>a</sup> (589,590)
Compression, laceration, or transection <sup>a</sup> (589,590,594,595,607-609,612)
Contusion <sup>b</sup> (594)
<b>Other neck injuries</b>
Transection or crushing of trachea–larynx <sup>a</sup> (589,617,618)
Blunt trauma to neck with asphyxia, neck swelling leading to airway closure, retropharyngeal hematoma, airway compromise owing to cervical spine fractures (589,593,607,619,620)
Neck injury, nos (589)
Vertebral artery tear <sup>a</sup> (621)
Internal carotid artery dissection (622)
<b>Thoracic injuries</b>
Massive intrathoracic hemorrhage (589)
Heart injury, nos (589)
Laceration of heart or myocardium, nos (589,590,595,623)
Laceration of atria/ventricles (579,589,595,600,611,623-626)
Laceration of valve(s), nos (589,595)
Tricuspid (589,627)
Aortic (270,628,629)
Contusions (589,600,611,623)
Blunt force trauma to the chest resulting in sudden heart stoppage (589)
Lacerations of great vessels
Aorta, nos (579,589,595,605)
Thoracic, nos (589,611)
Ascending thoracic (589,630,631)
Arch (589,623)
Descending thoracic–isthmus (602,625)
Abdominal (589,632)
Aortic dissection (589)
Vena cava
Superior (589,623)
Inferior <sup>a</sup> (317,594)
Brachiocephalic artery (intima) (625)
Pulmonary vein (589)
Pulmonary artery (579,607,619,633)
Azygos vein laceration (634)
Diaphragm rupture (635)
Lung injuries
Contusions <sup>a</sup> (589,590,594,595,600,611)
Hemorrhage = blast injury (579)
Lacerations (589,611)
(Hemo)-Pneumothorax (589,590,594,600,602,636)
Esophageal rupture (637)
Multiple rib fractures—crushing chest injury, flail chest (579,589,593,600,623) <sup>c,d</sup>

---

(Continued)

**Table 4** (Continued)

---

Thoracic spine fractures-spinal cord laceration <sup>a</sup> (589,594,595,615)
<b>Abdominal and retroperitoneal injuries</b>
Lacerations of spleen, liver, pancreas, bowel, mesentery (589,593,595,599,600,602,611,623,632,638,639)
Avulsion of kidney <sup>b</sup> (640)
<b>Pregnancy-related injury</b>
Abruptio placentae and fetal death (641)
Rupture of placental membranes (642)
Fetal trauma including blast injury (576,643)

---

<sup>a</sup>Injury described in children also.  
<sup>b</sup>Injury described in children only.  
<sup>c</sup>Rib fractures contributing to respiratory failure in 79-yr-old man with lung cancer, belted driver,  $\delta V = 35$  km/h (22 mph).  
<sup>d</sup>A 74-yr-old female, 220 lb (100 kg), 65 in. (163 cm).  
nos, not otherwise specified.  
(Adapted from ref. 586 with permission from the Journal of Forensic Sciences.)



**Fig. 65.** Multiple minor impacts and deployment of air bag early in crash sequence. Steering wheel deformation owing to loading by driver. Aortic transection. (Courtesy of Road Safety and Motor Vehicle Regulation Directorate, Transport Canada.)

**14.3. Side Impact and Side-Swipe**

In a frontal or rear impact, deformation of the vehicle absorbs significant collision energy and reduces the forces transmitted to the occupant compartment. Other features (e.g., energy-absorbing steering column, padded instrument panels) also absorb energy.




**Fig. 66.** Side collision; intrusion of driver's side door. (Courtesy of Road Safety and Motor Vehicle Regulation Directorate, Transport Canada.)

In contrast, the side of a vehicle has less crushable structure (Fig. 66). As a result, substantial forces are transmitted in less severe crashes directly to the occupant compartment, and intrusion is common, increasing the risk of injury (490,646–649). Being in a struck vehicle that has less mass than the striking vehicle increases this risk (648). A restraint system is less effective if there is intrusion (648).

In a side impact collision, an occupant moves laterally toward the side of impact and forward, if that is the direction in which the target vehicle was moving initially. Contacts with the side window, B-pillar, and interior door are common in near-side impacts (Fig. 18; refs. 4 and 650). Occupants, particularly if unrestrained, can be completely or partially ejected, contacting the ground, impacting vehicle, or a fixed object (Fig. 67; ref. 651). Serious head injuries can result if there is intrusion (651). In far-side impacts, unrestrained occupants can be displaced across the vehicle and injure restrained occupants (652,653). Restrained occupants sitting on the far side can also contact the opposite side interior and other occupants or be injured by their seat belts (651,654). A far-side occupant can come out of the shoulder part of a restraint (651). For individuals in far-side collisions, the presence of a near-side occupant mitigates injuries from contact with the opposite side interior (651,654).

Injuries from side impact collisions have a different pattern from those caused by frontal impacts. Head, neck, chest, and abdominal injuries are common in near-side impacts (4,647). Intrusion of the vehicle roof or B-pillar often leads to severe trauma directly to the head, a major contributor to death causation (650,655). Lateral impact to the torso is very common, producing multiple rib and pelvic fractures on the side of



**Fig. 67.** Side collision; intruding truck. Arrows indicate head contact by motor vehicle occupant. (Courtesy of Road Safety and Motor Vehicle Regulation Directorate, Transport Canada.)

intrusion (495). Severe thoracic, abdominal, and pelvic visceral trauma occurs (490,646). Head and torso injuries dominated in one study of far-side collisions (654).

A side-swipe crash occurs when a moving vehicle glances off another vehicle or fixed object. Injuries to occupants occur when there is either intrusion into the passenger compartment or significant energy transfer through the stiff vehicle structure. These injuries resemble those of the near-side impact crashes.

#### **14.4. Rear Impact**

High-velocity impacts into the rear of an automobile are not common. Intrusion of the striking vehicle into the passenger compartment causes impact injuries to persons riding in the rear of that vehicle. Failure of the front seat back allows it to collapse into the back of the vehicle, leading to crushing injury of rear seat passengers and possible rearward ejection of front seat occupants.

#### **14.5. Rollover**

A rollover collision is a complex sequence of events occurring at high velocity (>65 km/h or 40 mph) and is usually precipitated by a loss of control (656). There are different types of rollover collisions (657):

- Trip-over. This is the most common type. The lateral motion of a vehicle is suddenly slowed as the vehicle's wheels contact a surface (e.g., gravel).
- Fall-over. The center of gravity of a vehicle causes it to tilt down a slope.
- Flip-over. The vehicle's side is lifted by an elevated surface (e.g., guardrail).



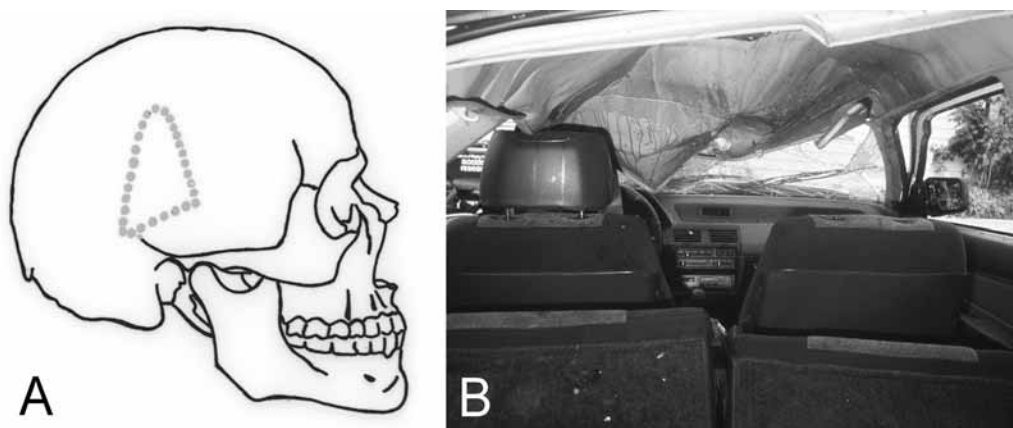


**Fig. 68.** Rollover; partial ejection of driver and head contact with edge of roof. Blood on roof (arrow). (Courtesy of Road Safety and Motor Vehicle Regulation Directorate, Transport Canada.)

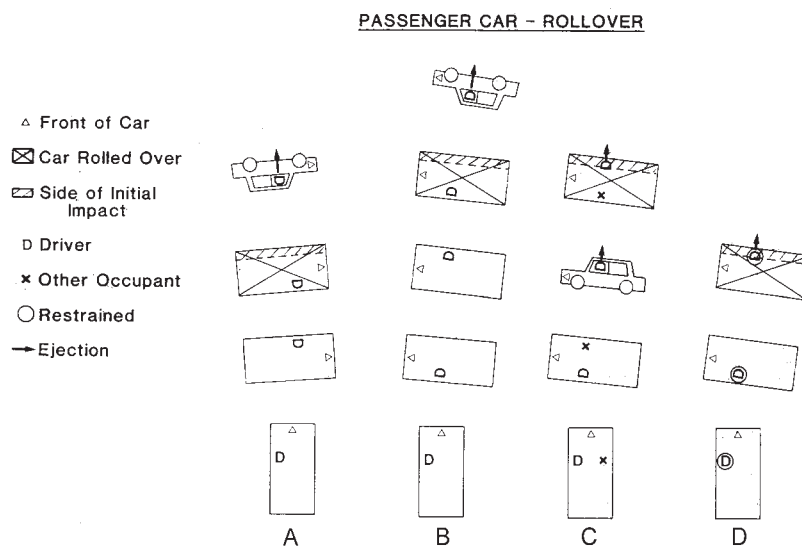
- Climb-over. The vehicle actually passes over a fixed object (e.g., guardrail).
- Bounce-over. The vehicle rebounds off a fixed object.
- Turnover. Centrifugal forces on a sharp turn or rotation, particularly when the vehicle has a high center of gravity, causes tilting.
- Collision with another vehicle.
- End-over-end. This is the least common.

During vehicle rollover, kinetic energy is dissipated progressively over time and distance. The impact forces in rollover are spread over several surfaces of the vehicle. Survival is enhanced if occupants are restrained and not ejected ([484,658,659](#)). Occupants can be ejected through side windows (closed or open), the windshield, doors that were originally closed but forced open by the crash, and the sunroof ([658](#)). Side window ejections are most common in fatalities. Closed windows can disintegrate secondary to crash forces. A person partly ejected during a rollover can also be injured if trapped between the vehicle and the outside ([658](#)).


Head and thoracic injuries are common ([657](#)). The former is the result of roof and pillar contact; the latter from interior contacts ([Figs. 68 and 69](#); refs [656 and 657](#)). Although an intruding or buckled roof may cause craniocerebral trauma, most such injuries are caused by ejection ([656](#)). Depending on the direction of vehicle rotation, side of initial roof impact with the ground (i.e., side opposite to the direction of rollover), and occupant number, location, kinematics, and seat belt use, head injury results from contact with either the vehicle interior (e.g., roof pillars, roof), vehicle exterior (e.g., roof), or the ground ([Fig. 70](#); refs. [656 and 657](#)). Occupants can be displaced across the vehicle ([656](#)). Some victims trapped in their vehicles may succumb from positional asphyxia (see Chapter 3, Subheading 3.7.; [Fig. 63](#); and ref. [660](#)).



**Fig. 69.** Rollover; restrained driver found dead in vehicle. **(A)** Triangular right parietotemporal skull fracture documented at autopsy. **(B)** Corresponding right scalp laceration caused considerable blood spatter on roof interior. Driver had been partially ejected on initial roof impact on the driver's side and was found in her seat (see Fig. 70D). (Reprinted from ref. 656 with permission from the Journal of Forensic Sciences.)



**Fig. 70.** Passenger car rollovers; observed rollover events leading to ejection of driver. Estimated speeds  $\geq 100$  km/h (60 mph). **(A)** Driver, unrestrained and sole occupant. Clockwise rotation, initial impact of rolled car on passenger side, driver ejected through left front window. **(B)** Driver, unrestrained and sole occupant. Counterclockwise rotation; driver shifted to passenger side. Initial impact on driver's side; driver ejected through right front window. **(C)** Driver, unrestrained. Right front passenger (with/without restraint). Counterclockwise rotation; driver either ejected completely through left front window early in rollover or partially during initial impact on driver's side. **(D)** Driver, restrained. Counterclockwise rotation; partial ejection on impacted (driver's) side of vehicle (see Fig. 69). (Reprinted from ref. 656 with permission from the Journal of Forensic Sciences.)



**Fig. 71.** Kinematic trajectories observed in motor vehicle (frontal)-pedestrian collisions. (Reprinted from ref. 656 with permission from the Journal of Forensic Sciences.)

## 14.6. Pedestrians

### 14.6.1. The Upright Pedestrian

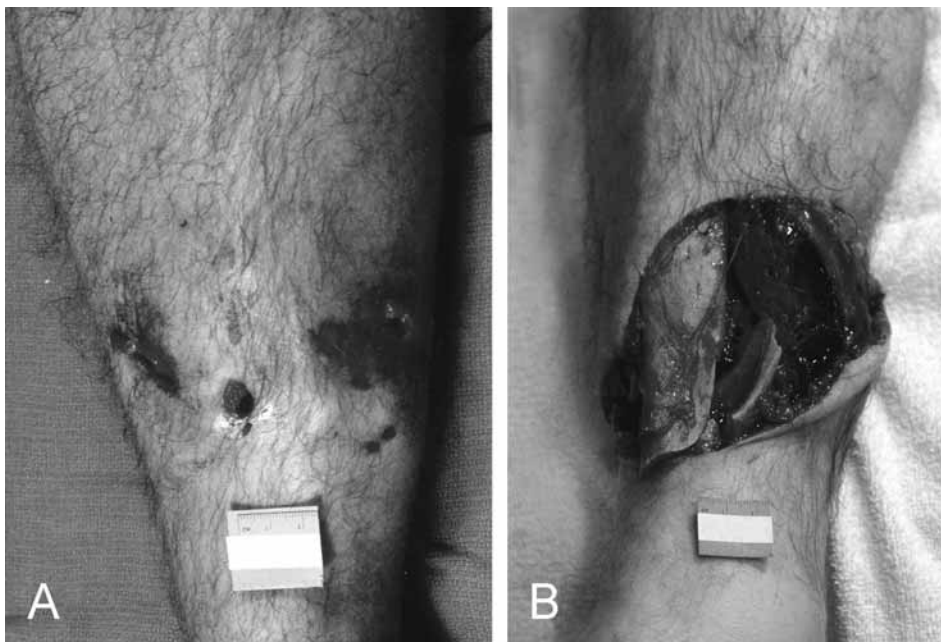
When faced with a pedestrian fatality, the pathologist needs to address other issues in addition to determining the cause of death:

- Was the pedestrian upright when struck?
- Is there evidence of intoxication? One study indicated that intoxicated pedestrians sustain more severe injuries (661).

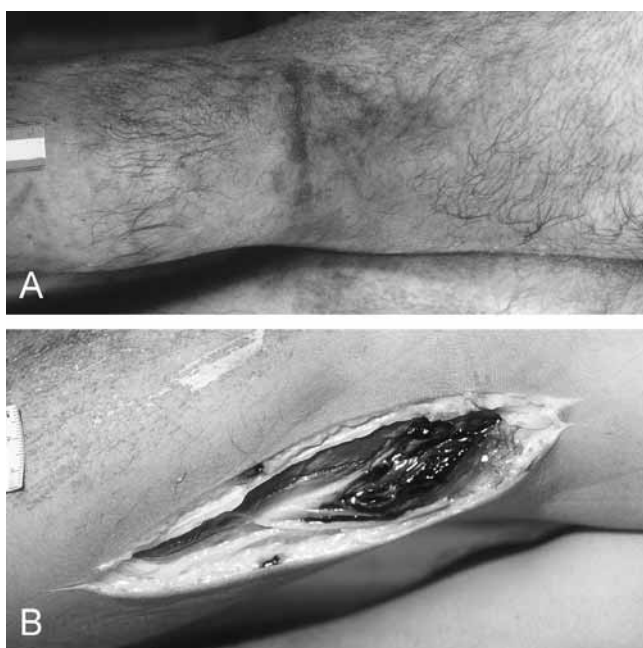
Frontal impacts are the most common type of collision involving pedestrians (662).

Various kinematic trajectories occurring in frontal motor vehicle–pedestrian collisions have been described (Fig. 71; refs. 656, 662, and 663).

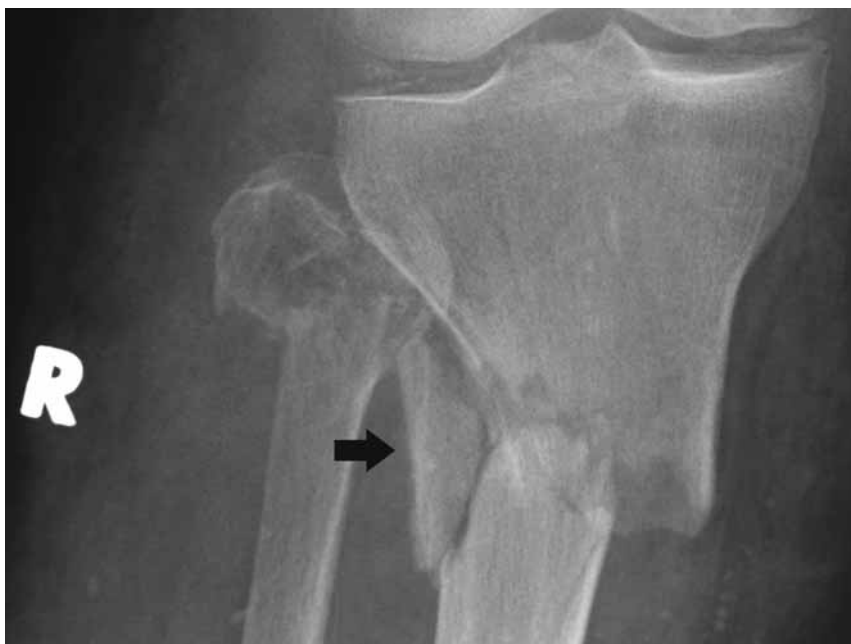Initial vehicle impact with an upright adult pedestrian can lead to “bumper” fractures, typically of the tibia and fibula (664–666). Fractured bone ends typically splay outward, stretching and even tearing overlying skin (Fig. 72). The impact site on the opposite side may not be visible, but soft tissue hemorrhage is revealed by skin incision (Fig. 73; ref. 665). The distance from the sole of the foot to the fracture site is an approximate indication of bumper height at the time of impact. Radiographs confirm visible or palpable fractures and also demonstrate fractures that are inapparent externally. The fracture may consist of a wedge-shaped bone (“butterfly” fracture or “Messerer’s wedge;” see Fig. 74). The apex of the wedge has been described as pointing in the direction of vehicle travel, but the opposite has been observed (667–669). Femur fractures occur from hood or ground contact (670). Amputation is possible (664,665,671). Bumper fractures can be absent, affect one leg in more than one site, or



**Fig. 72.** Cutaneous injuries on shin caused by dislocation of fractured bone ends opposite to bumper impact. **(A)** “Stretch” abrasions and small laceration. **(B)** Large laceration with visible fracture of tibia.



**Fig. 73.** Bumper contacts on legs. **(A)** Contusion, popliteal fossa. **(B)** Another case showing a soft tissue hematoma as evidence of bumper contact. This injury was demonstrated only by incision. There was no visible cutaneous contusion.

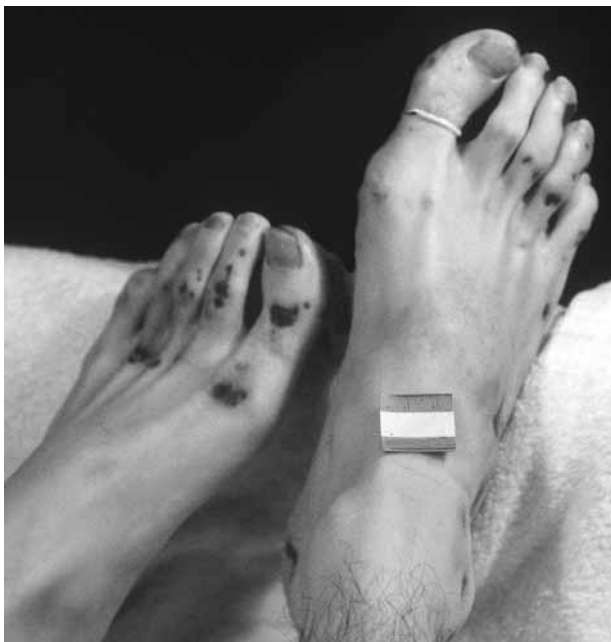

**Fig. 74.** Pedestrian struck by car. Wedge-shaped fracture of tibia (arrow). (Courtesy of Dr. E. Tweedie, London Health Sciences Centre, London, Ontario, Canada.)

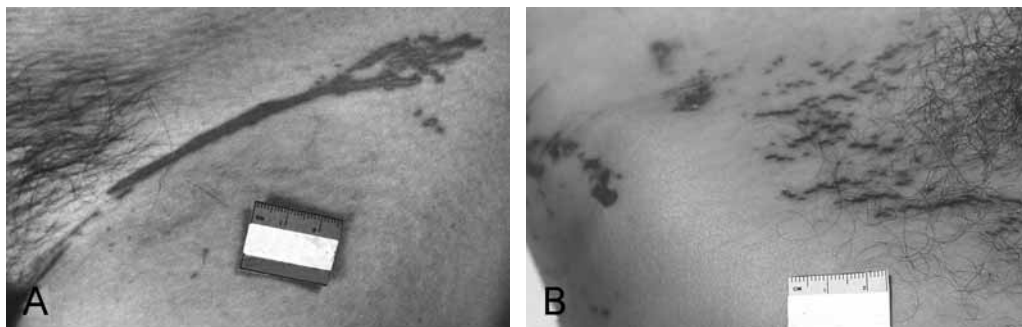
involve both legs (672). Leg impact in an upright individual can cause “bone bruises” demonstrated in cross-sections of the fibular and tibial epiphyses (665,666). Knee injuries can arise from flexion/hyperextension and dislocation, which lead, respectively, to condylar compression of the tibia and avulsion of knee ligaments. Bone bruises caused by the former mechanism are large and central, whereas avulsion leads to smaller more peripheral injury. Ankle-joint injuries (e.g., malleolar fractures), arising from pronation, supination, or flexion, also indicate an upright position (669). Like knee-joint injuries, the mechanism and consequent location of ankle-joint trauma is dependent on the direction of impact (665,666,669). Other indications of an upright position include traces of car paint on the legs and abrasions on shoe soles (664). Abrasions on toes may indicate forceful contact within a shoe following leg impact (Fig. 75).

Secondary impact with the hood edge or headlight assembly can cause pelvic and hip injuries (Fig. 22; ref. 670). Cutaneous “stretch” abrasions in the inguinal–femoral area are indicative of these fractures (Fig. 76). The wrap trajectory is most common (Fig. 71; refs. 656 and 673). When a decelerating vehicle hits an adult pedestrian it causes the upper body to bend over, striking the hood (Fig. 77 and 78). When the vehicle stops, the pedestrian hits the ground (674). Children, because of a lower center of gravity, frequently have head injury because of contact with the hood edge (Fig. 79; refs. 656, 675, and 676). Children tend to run out between parked cars or are backed over in the home driveway (675,677). The roof vault trajectory is associated with the most severe pedestrian injuries. A vehicle traveling at high speed lifts a pedestrian onto the hood, onto or over the windshield, roof, and even the trunk (Fig. 80; ref. 656).





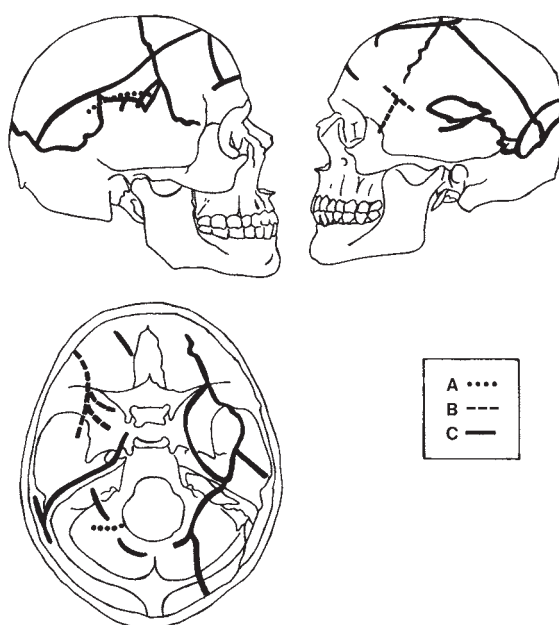
**Fig. 75.** Abrasions on toes of upright pedestrian from forceful rubbing against shoes after the pedestrian was hit by a vehicle.



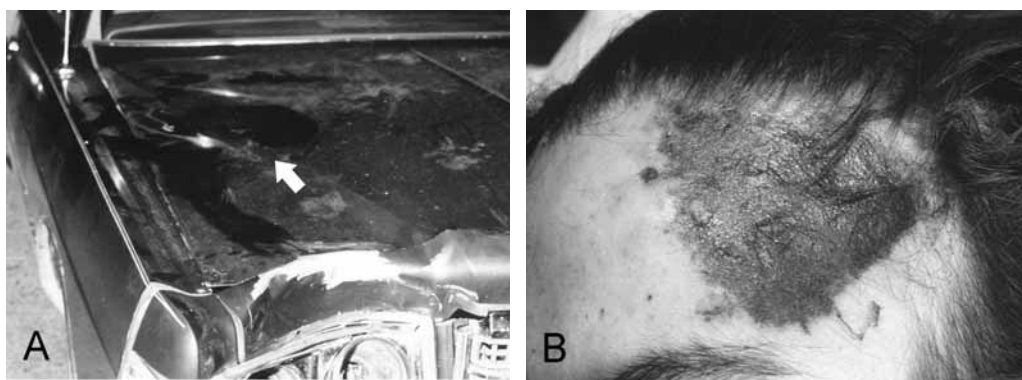
**Fig. 76.** Pedestrians struck by vehicle. Pelvic fractures resulting from “secondary” impact with hood edge. (A) and (B) Examples of “stretch” abrasions in inguinal–femoral region.

Forward projection most commonly occurs in children and in adults hit by trucks and vans (656,673,674,678). Compared with pedestrians struck by passenger cars, those struck by sports utility vehicles, light trucks, and vans at lower impact speeds ( $\leq 30$  km/h or 19 mph) were more likely to have severe injuries and die.

Head injuries are common in pedestrian cases (673,674,676). Hyperextension of the neck causes upper cervical spine dislocation (atlanto-occipital level, C1–C2, C2–C3) and isolated brainstem injury (Fig. 81; ref. 679 and 680). Associated tears of basal blood vessels (e.g., basilar artery) can occur (680). Hemorrhage into the lower insertions of the scalene and sternocleidomastoid muscles has been shown to correlate with the direction of force (681). The pathologist must be aware that brainstem lacerations




**Fig. 77.** Skull fractures observed in certain pedestrian-car collisions reflect the kinematic trajectories of the impacts (scenarios A–C; see [Figs. 78–80](#)). (Reprinted from ref. [656](#) with permission from the Journal of Forensic Sciences.)



**Fig. 78.** Scenario B (see [Fig. 77](#)). **(A)** 20-yr-old male hit by car going about 35 km/h (22 mph). Contacted hood of vehicle (arrow). (Reprinted from ref. [656](#) with permission from the Journal of Forensic Sciences.) **(B)** Large abrasion, left forehead (“contact point”).

(e.g., pontomedullary tears) can be subtle. Vigorous tugging of the brain, after removal from the cranium, can create an artifactual tear at this site.

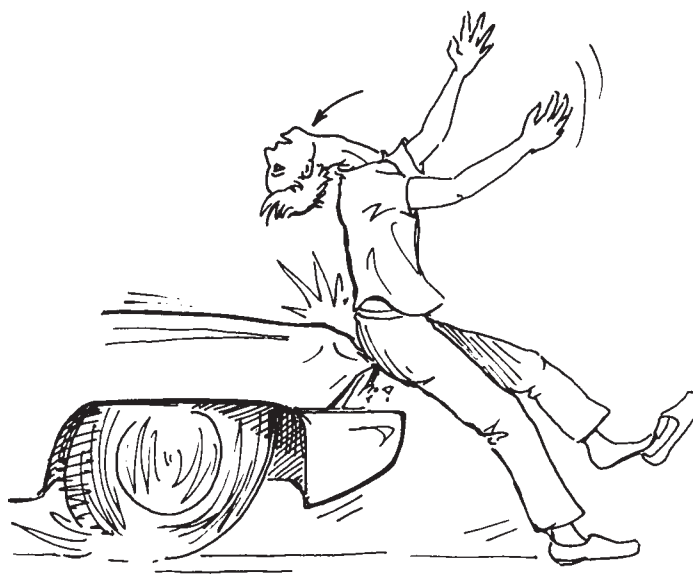A study of frontal motor vehicle–pedestrian collisions determined relationships between impact velocity and the resulting injury pattern ([682](#)). A correlation between a minimum impact velocity and the occurrence of certain injuries has been observed: spinal fractures (27.5 km/h or 17 mph); thoracic aortic rupture combined with a thoracic spine fracture (63 km/h or 39 mph); inguinal skin tearing (66 km/h or 41 mph); and dismemberment



**Fig. 79.** Scenario A (see Fig. 77). Two-yr-old female. Head contact with hood edge (arrow) of a car traveling about 50 km/h (30 mph). (Reprinted from ref. 656 with permission from the Journal of Forensic Sciences.)



**Fig. 80.** Scenario C (see Fig. 77). A 29-yr-old male was hit by a car traveling 80 km/h (50 mph). Contacted hood, windshield, and roof of vehicle (arrows). (Reprinted from ref. 656 with permission from the Journal of Forensic Sciences.)



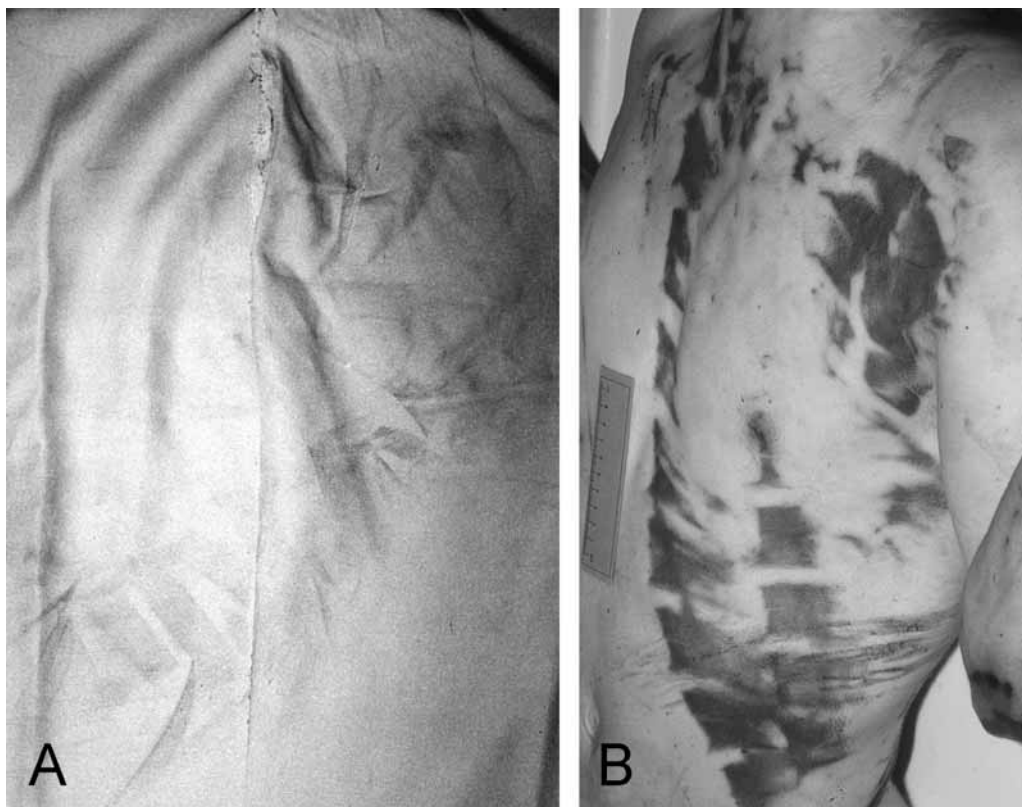
**Fig. 81.** Impact of motor vehicle with pedestrian's lower body ("secondary" impact) causes high-intensity shear forces at the high cervical spine. (Reprinted from ref. 679 with permission from the Journal of Forensic Sciences.)

of neck, trunk, or limb (98 km/h or 61 mph). Leg fractures from bumper impact occurred in the range of 18.5 to 142 km/h (12 to 88 mph) but was absent in some cases (highest impact velocity = 67 km/h or 42 mph).

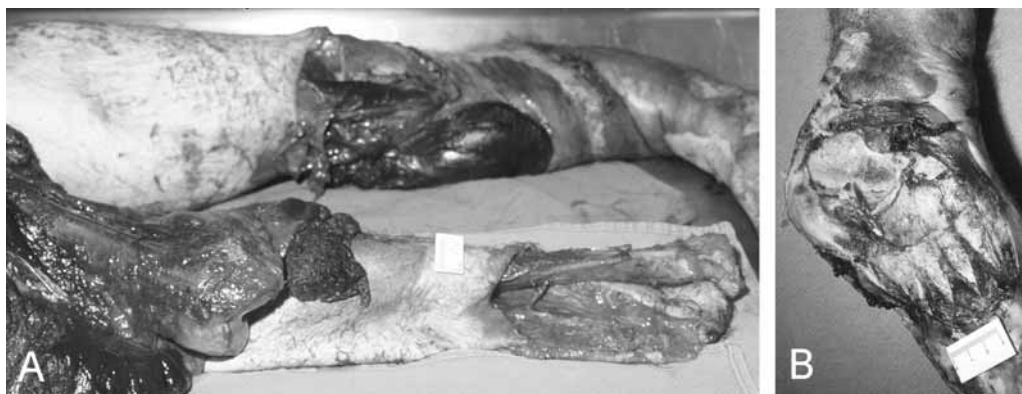During the autopsy, police investigators may document various body measurements that will assist them in determining the victim's center of gravity and consequent trajectory.

#### 14.6.2. *Recumbent Pedestrian*

Pedestrians who are lying on the road and run over by motor vehicles do not have bumper fractures. The exception is an individual who is hit initially while standing, then is run over repeatedly by other cars. Hip dislocation and pelvic injuries can be observed (665). Patterned injuries from the undersurface of the vehicle and pressure marks from clothing can be observed on the skin (Figs. 23 and 82; ref. 683). There may be considerable external trauma caused by the grinding from the road surface and the wheels. Clothes can be torn extensively (683,684). Markings from the car undersurface may transfer to clothing. Skin may separate from the subcutaneous fat, and amputation of limbs is possible (Fig. 83; ref. 665). Detachment of skin also occurs if an upright person is struck tangentially (665). Dragging and scraping may produce extensive "brush burning" (Fig. 2; refs. 683 and 685). Blackened abrasions may reflect thermal effects caused by friction (686). This is seen on bony protuberances (skull, joints, ribs [683,685]). Internal organs can be exposed (683,684). Bone grinding can occur (Fig. 83; ref. 683). Neck compression leads to fractures of the larynx and hyoid bone (Fig. 84; Chapter 3, Fig. 30; ref. 687). Ocular petechiae occur if there is chest compression. Severe compression results in tearing or avulsion injuries of viscera. Hemorrhage into the sites



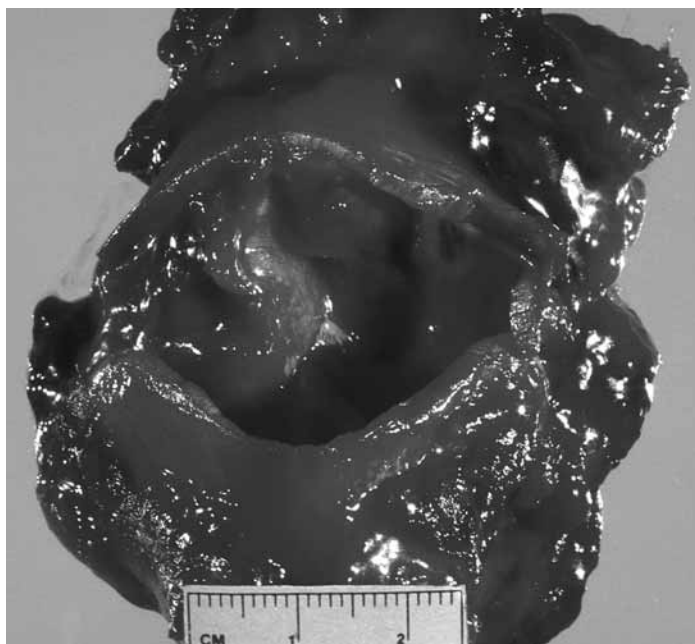
**Fig. 82.** Pedestrians run over. **(A)** Tire-tread marks on pants. (Courtesy of the Office of the Chief Medical Examiner, Chapel Hill, NC.) **(B)** Abrasions on torso from tire treads.



**Fig. 83.** Pedestrians run over and dragged. **(A)** Lower extremities. Avulsion injuries; amputation of right foot. **(B)** Left foot. Abrasions of bones due to grinding.

injured by dragging indicates antemortem injury (683). Aspiration of dirt is another sign the individual was alive while being dragged (683). Ethanol intoxication is commonly present in recumbent pedestrians (664).

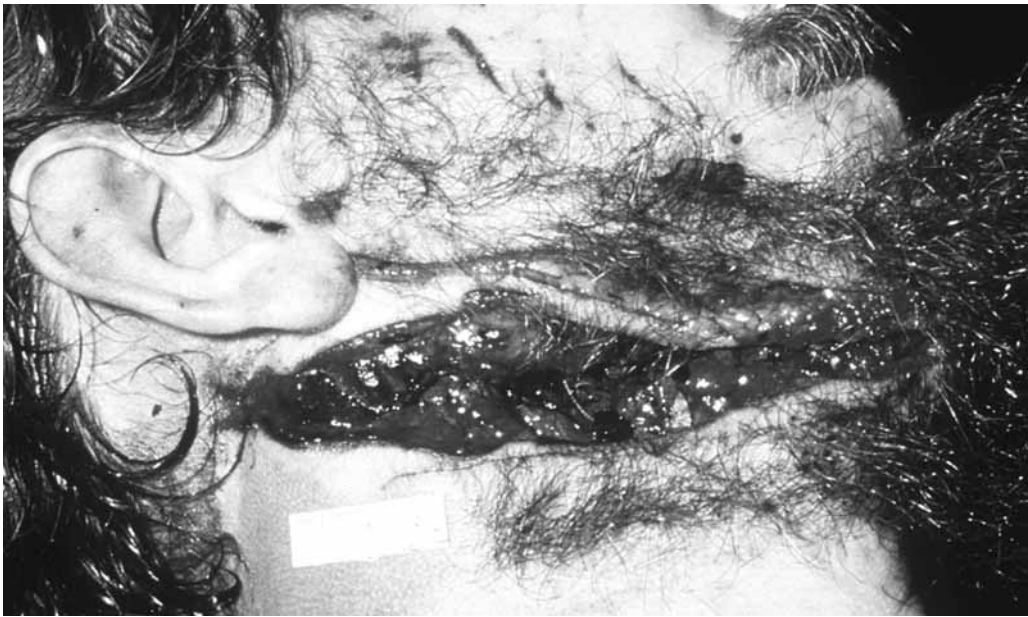



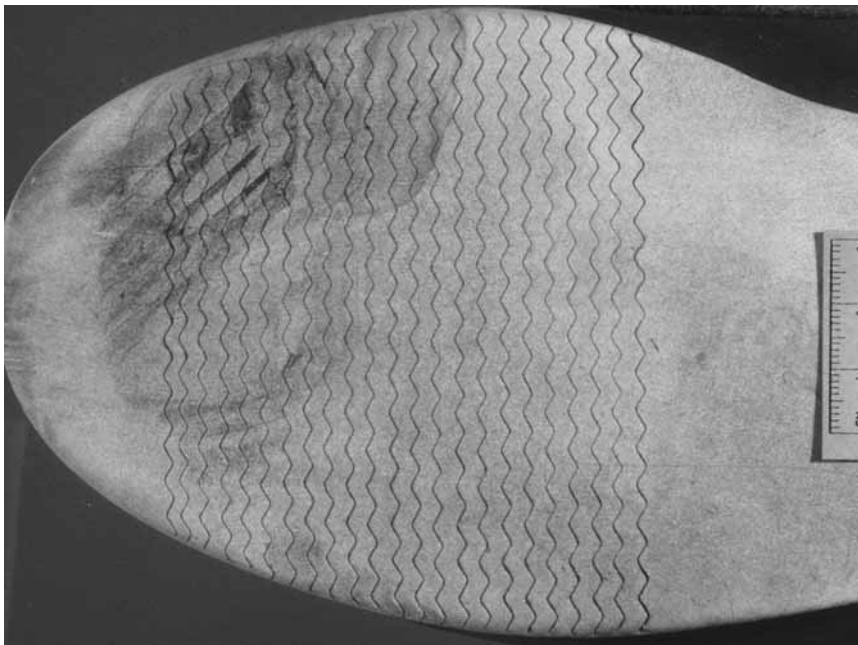
**Fig. 84.** Run-over. Transection of larynx.

### ***14.7. Motor Vehicles: All Manners of Death***

Although most cases of fatalities involving motor vehicles are caused by accidents, the pathologist must be aware that other manners of death do occur (484,688,689). Natural deaths of drivers behind the wheel (e.g., myocardial infarction or heart attack) do happen. Drivers may have warning symptoms that allow them to take appropriate actions to prevent serious injuries to themselves and others (690–693). Some drivers lose consciousness before the vehicle stops (693). The trauma in this situation is insufficient to account for death (693). Implanted heart rhythm devices can assist in determining the events preceding death (694). The pathologist must assess either the role of disease in accident causation or trauma exacerbating disease (695). Although many deaths from accidents occur shortly after the incident, some deaths are delayed due to various complications (*see* Chapter 1, Heading 11.). Some injuries sustained during an accident may mimic a homicide (Fig. 85). Other forms of accidents can occur in association with motor vehicles (e.g., carbon monoxide poisoning owing to faulty exhaust system; *see* Chapter 3, Subheading 3.9.1.). Acute intoxication by ethanol and other drugs, alcoholism, and psychiatric impairment increase the risk of motor vehicle collision (696,697). A motor vehicle may also be used as an instrument of suicide (697). A driver may deliberately drive either off the road (e.g., into a fixed object, another vehicle, water) or from a height (553,689,697–700). In these instances, there is an absence of skidmarks, indicating that braking did not occur, and an accelerator imprint may be present on the shoe sole (Fig. 86; refs. 483,688,689,697,701, and 702). Acceleration may be witnessed. A vehicle may be deliberately stopped on railroad tracks (*see* Heading 15). A pedestrian may step in front of a vehicle. An individual can deliberately be asphyxiated with carbon monoxide (e.g., running engine in closed



**Fig. 85.** Suspicious laceration of neck of truck driver, alone while driving on an interstate highway. Vehicle observed veering off road. Origin of injury in occupant compartment possibly from broken glass. (Courtesy of the Office of the Chief Medical Examiner, Chapel Hill, NC.)



**Fig. 86.** Brake pad imprint on sole of deceased's driver's right shoe indicating braking prior to impact.



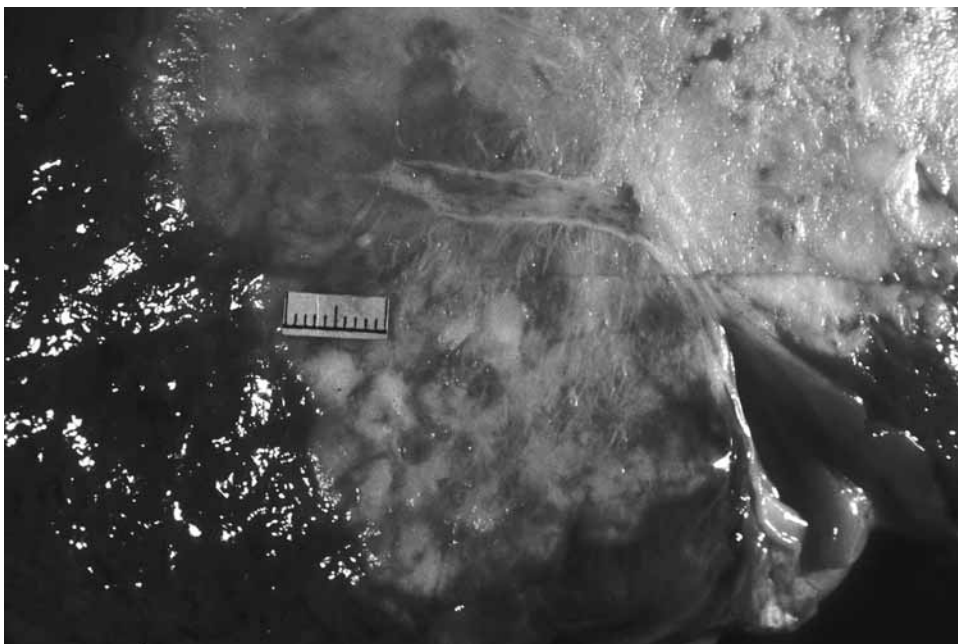**Fig. 87.** Motor vehicle-train collision.

garage; *see* Chapter 3, Subheading 3.9.1., Fig. 66; refs. 698 and 699). Unusual suicides (e.g., gunshot injury, self-immolation, hanging) arouse suspicions (Chapter 4, Fig. 1; refs. 698, 699, 701 and 703–705). Homicides can be committed using a motor vehicle (563). An individual may be deliberately run over by a vehicle. The more common situation is “hit-and-run.” Trace evidence collection, in these cases, is imperative (706,707). Homicides can masquerade as accidents (Chapter 4, Fig. 3).


### *15. RAILROAD-RELATED DEATHS*

A railroad-related death is defined as a death that either occurred or was discovered on railroad property, including railroad cars, tracks, and right-of-way (708). Various scenarios have been described, and all manners of death occur (708–713):

- Motor vehicle-train collisions (Fig. 87).
- Vehicles can stall or deliberately stop on the tracks. Drivers may be unaware of a train when driving through an unprotected crossing. Drivers ignore or bypass crossing gates.
- Pedestrian–train collisions.
- Individuals are found on or near railway tracks. Unwitnessed deaths arouse suspicion. In witnessed cases, pedestrians are observed lying or sitting on the tracks, walking on or near the tracks, bypassing a lowered crossing gate, or jumping in front of a train. Alcohol and other drugs are significant factors in accidental deaths, particularly in individuals lying on the tracks (708,710,712,714–716). Suicide victims may have a psychiatric history (709).
- Train passengers.
- Legitimate passengers and trespassers can fall from a train or be crushed between rail cars. Derailments occur. An individual murdered on a train may be thrown onto the tracks.



**Fig. 88.** Motor vehicle-train collision. The driver sustained multiple injuries. Cholangiocarcinoma of liver-an unsuspected finding discovered at autopsy.

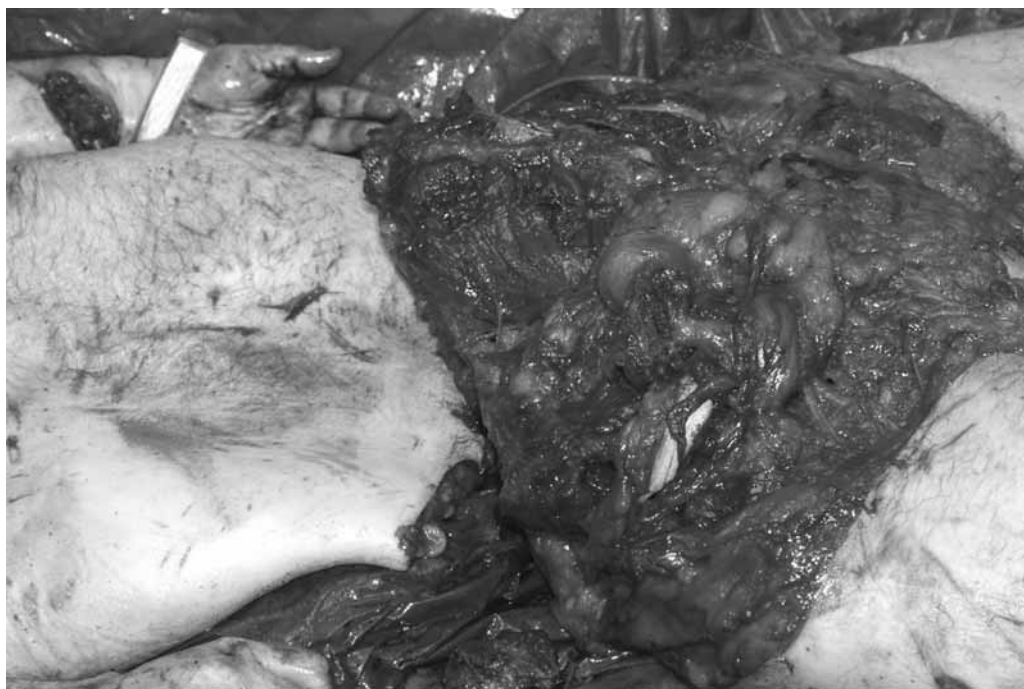

**Fig. 89.** Pedestrian-train collision; suicide. **(A)** Decapitation; extensive abrasions and adhered dirt on back. **(B)** Amputated foot.

In all circumstances, the postmortem examination needs to exclude pre-existent disease as a cause of death or as a contributing factor to the incident (Fig. 88; ref. 708).

The cause of death, in most cases, is obvious multiple blunt trauma (708,709,711,713,716). Most victims are male (713,714,717). Traumatic amputations are more frequent in pedestrians compared with motor vehicle occupants (Fig. 89; refs. 708,





**Fig. 90.** Pedestrian-train collision; suicide. Transection of abdomen.

714, and 717). Although traumatic amputation is considered less likely in upright individuals, these persons can be propelled onto the tracks after being hit (713). Others have observed no distinguishing injury pattern in different types of railway deaths (711,717). A pedestrian struck by a high-speed train sustains massive cranio-cerebral trauma, opening of body cavities, exenteration of organs, and dismemberment, including the trunk (Fig. 90; ref. 713). Decapitation is usually noted in suicide but can occur in high-speed collisions (Fig. 89; ref. 709, 713, and 716). Adhered dirt and grease on the body indicates that a pedestrian has been struck by a train (Fig. 89; ref. 713).

Because of extensive disruption of a body caused by train impact, a murderer may attempt to conceal a homicide by dumping the victim on railroad tracks (708, 709,711,716). Other types of injuries, aside from blunt trauma, may be seen (710). Train impact usually causes instantaneous death; however, bleeding associated with the observed blunt injuries indicates antemortem trauma (708). Extensive hemorrhage associated with scalp injuries and craniocerebral trauma is suspicious (709,716).

## 16. LIGHT AIRCRAFT

Light aircraft include general aviation aircraft (single or multiengine piston-powered planes with a maximum take-off weight less than 5700 kg or 12,500 lb), gyroplanes,



**Table 5**  
**Comparison of Injury Frequency in Studies of Light Aircraft Fatalities**

	Ontario study <sup>a</sup> % (n)	Reals et al. <sup>b</sup> % (n)	Stevens <sup>c</sup> % (n)
<b>Fracture(s) of</b>			
Skull	53 (20)	70 (104)	67 (63)
Facial bone(s)	55 (21)	—	48 (45)
Spine:			
Cervical	29 (11)	13 (19)	12 (11)
Thoracic	8 (3)	12 (18)	23 (21)
Lumbar	5 (2)	10 (15)	18 (17)
Rib(s)	63 (24)	56 (83)	63 (59)
Extremities:			
Upper	42 (16)	63 (94)	56 (52)
Lower	71 (27)	74 (110)	73 (68)
Pelvis	21 (8)	—	—
Visceral trauma (laceration/contusion)			
Brain	39 (15)	53 (78)	56 (52)
Brainstem <sup>d</sup>	13 (5)	—	—
Cervical cord <sup>d</sup>	16 (6)	—	—
Lungs	66 (25)	34 (50)	36 (33)
Heart	53 (20)	34 (51)	35 (33)
Aorta	34 (13)	23 (34)	39 (36)
Liver	47 (18)	49 (72)	35 (33)
Mesentery	13 (5)	—	—
Gastrointestinal tract	18 (7)	—	—
Spleen	29 (11)	41 (61)	34 (32)
Kidney <sup>e</sup>	18 (7)	19 (28)	23 (21)

Based on autopsy findings seen in:

<sup>a</sup>38 trauma victims (25 pilots, 13 passengers); 27 died of multiple injuries and 11 of head and neck trauma only (717).

<sup>b</sup>148 fatalities (pilots/passengers not specified [723]).

<sup>c</sup>93 deaths (70 pilots, 23 passengers [724]).

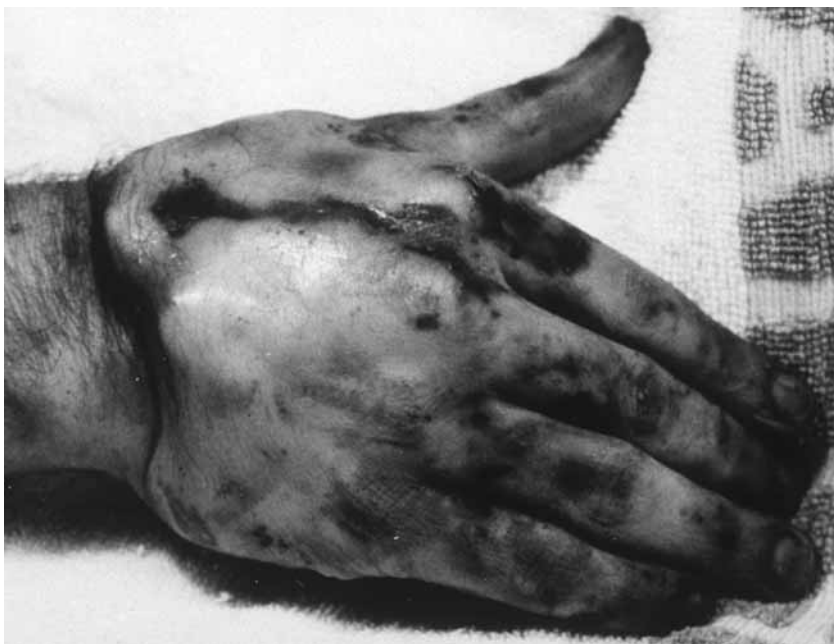<sup>d</sup>Includes transection.

<sup>e</sup>Includes perinephric hematoma, vessel lacerations.

(Adapted from ref. 718 with permission from the Journal of Forensic Sciences.)

ultralights, and gliders (718). Communication between the pathologist and various police and transportation investigators is essential to determine the cause of death, the cause of the crash, and the cause of the observed injuries. A complete autopsy must be done (719). Multiple trauma is the most common cause of death (Table 5; refs. 720 and 721). Injuries can be extensive (722).

Chest wall fractures are the most common type of musculoskeletal trauma. Fractures of the upper and lower extremities indicate control-stick and floor impact trauma, respectively (Fig. 91; ref. 725). The possibility of incapacitation by disease or intoxication needs to be assessed (718).



**Fig. 91.** Pilot. Fatal crash. Right hand deformity caused by wrist fracture; control column injury. (Courtesy of Dr. M. Joseph, London Health Sciences Centre, London, Ontario, Canada.)

### *REFERENCES*

1. Lowenstein, S. R., Yaron, M., Carrero, R., Devereux, D., Jacobs, L. M. Vertical trauma: injuries to patients who fall and land on their feet. *Ann. Emerg. Med.* 18:161–165, 1989.
2. Warner, K. G., Demling, R. H. The pathophysiology of free-fall injury. *Ann. Emerg. Med.* 15:1088–1093, 1986.
3. Davis, G. J. Patterns of injury. Blunt and sharp. *Clin. Lab. Med.* 18:339–350, 1998.
4. Viano, D. C., Lau, I. V., Asbury, C., King, A. I., Begeman, P. Biomechanics of the human chest, abdomen, and pelvis in lateral impact. *Accid. Anal. Prev.* 21:553–574, 1989.
5. Rouhana, S. W., Lau, I. V., Ridella, S. A. Influence of velocity and forced compression on the severity of abdominal injury in blunt, nonpenetrating lateral impact. *J. Trauma* 25:490–500, 1985.
6. Viano DC, Lau VK. Role of impact velocity and chest compression in thoracic injury. *Aviat. Space Environ. Med.* 54:16–21, 1983.
7. Goonetilleke, U. K. Injuries caused by falls from heights. *Med. Sci. Law* 20:262–275, 1980.
8. Vanezis, P. Interpreting bruises at necropsy. *J. Clin. Pathol.* 54:348–355, 2001.
9. Langlois, N. E., Gresham, G. A. The ageing of bruises: a review and study of the colour changes with time. *J. Forensic Sci.* 50:227–238, 1991.
10. Stephenson, T., Bialas, Y. Estimation of the age of bruising. *Arch. Dis. Child.* 74:53–55, 1996.
11. Wilson, E. F. Estimation of the age of cutaneous contusions in child abuse. *Pediatrics* 60:750–752, 1977.
12. Dailey, J. C., Bowers, C. M. Aging of bite marks: a literature review. *J. Forensic Sci.* 42:792–795, 1997.
13. Camps, F. E. Interpretation of wounds. *Br. Med. J.* 2:770–772, 1952.
14. Hiss, J., Kahana, T., Kugel, C. Beaten to death: why do they die? *J. Trauma* 40:27–30, 1996.

15. Giles, T. E., Williams, A. R. The postmortem incidence of senile ecchymoses. *Am. J. Forensic Med. Pathol.* 15:208–210, 1994.
16. Munang, L. A., Leonard, P. A., Mok, J. Y. Lack of agreement on colour description between clinicians examining childhood bruising. *J. Clin. Forensic Med.* 9:171–174, 2002.
17. Hughes, V. K., Ellis, P. S., Langlois, N. E. The perception of yellow in bruises. *J. Clin. Forensic Med.* 11:257–259, 2004.
18. Bariciak, E. D., Plint, A. C., Gaboury, I., Bennett, S. Dating of bruises in children: an assessment of physician accuracy. *Pediatrics* 112:804–807, 2003.
19. Raekallio, J. Estimation of time in forensic biology and pathology. An introductory review. *Am. J. Forensic Med. Pathol.* 1:213–218, 1980.
20. Schwartz, A. J., Ricci, L. R. How accurately can bruises be aged in abused children? Literature review and synthesis. *Pediatrics* 97:254–257, 1996.
21. Betz, P. Histological and enzyme histochemical parameters for the age estimation of human skin wounds. *Int. J. Legal Med.* 107:60–68, 1994.
22. Robertson, I., Hodge, P. R. Histopathology of healing abrasions. *J. Forensic Sci.* 1:17–25, 1972.
23. Spitz, W. V. Blunt force injury. In: Spitz W. V., ed. *Medicolegal Investigation of Death: Guidelines for the Application of Pathology to Crime Investigation*. Charles C. Thomas, Springfield, IL, pp. 199–251, 1993.
24. Betz, P., Eisenmenger, W. Morphometrical analysis of hemosiderin deposits in relation to wound age. *Int. J. Legal Med.* 108:262–264, 1996.
25. Ohshima, T. Forensic wound examination. *Forensic Sci. Int.* 113:153–164, 2000.
26. Ortiz-Rey, J. A., Suarez-Penaranda, J. M., Da Silva, E. A., et al. Immunohistochemical detection of fibronectin and tenascin in incised human skin injuries. *Forensic Sci. Int.* 126:118–122, 2002.
27. Fieguth, A., Feldbrugge, H., Gerich, T., Kleemann, W. J., Troger, H. D. The time-dependent expression of fibronectin, MRP8, MRP14 and defensin in surgically treated human skin wounds. *Forensic Sci. Int.* 131:156–161, 2003.
28. Raekallio, J. Timing of wounds—an introductory review. *Ann. Acad. Med. Singapore* 13:77–84, 1984.
29. Betz, P. Immunohistochemical parameters for the age estimation of human skin wounds. A review. *Am. J. Forensic Med. Pathol.* 16:203–209, 1995.
30. Thomsen, J. L., Albrechtsen, S. B. External appearance of forensic autopsy material of alcoholics. *Forensic Sci. Int.* 71:65–71, 1995.
31. Centers for Disease Control and Prevention. Hypothermia-related deaths—United States, 2003. *MMWR Morb. Mortal. Wkly. Rep.* 53:172–173, 2004.
32. Tipton, M. J. The initial responses to cold-water immersion in man. *Clin. Sci. (Lond.)* 77:581–588, 1989.
33. Golden, F. S., Tipton, M. J., Scott, R. C. Immersion, near-drowning and drowning. *Br. J. Anaesth.* 79:214–225, 1997.
34. Taylor, A. J., McGwin, G., Jr., Davis, G. G., Brissie, R. M., Holley, T. D., Rue, L. W., III. Hypothermia deaths in Jefferson County, Alabama. *Inj. Prev.* 7:141–145, 2001.
35. Wedin, B., Vanggaard, L., Hirvonen, J. “Paradoxical undressing” in fatal hypothermia. *J. Forensic Sci.* 24:543–553, 1979.
36. Albiin, N., Eriksson, A. Fatal accidental hypothermia and alcohol. *Alcohol Alcohol.* 19:13–22, 1984.
37. Kibayashi, K., Shoji, H. Accidental fatal hypothermia in elderly people with Alzheimer’s disease. *Med. Sci. Law* 43:127–131, 2003.
38. Rothschild, M. A., Schneider, V. “Terminal burrowing behaviour”—a phenomenon of lethal hypothermia. *Int. J. Legal Med.* 107:250–256, 1995.
39. Gormsen, H. Why have some victims of death from cold undressed? *Med. Sci. Law* 12:200–202, 1972.

40. Mizukami, H., Shimizu, K., Shiono, H., Uezono, T., Sasaki, M. Forensic diagnosis of death from cold. *Leg. Med. (Tokyo)* 1:204–209, 1999.
41. Hirvonen, J. Necropsy findings in fatal hypothermia cases. *J. Forensic Sci.* 8:155–164, 1976.
42. McGee, M. B. Unusual blunt force wound patterns due to a hexagonal steel bar. *Am. J. Forensic Med. Pathol.* 12:149–152, 1991.
43. Perper, J. A., Menges, D. J. The skin as a repository and masker of evidence. *Am. J. Forensic Med. Pathol.* 11:56–62, 1990.
44. Takizawa, H., Nakamura, I., Hashimoto, M., Maekawa, N., Yamamura, M. Toolmarks and peculiar blunt force injuries related to an adjustable wrench. *J. Forensic Sci.* 34:258–262, 1989.
45. Rao, V. J. Patterned injury and its evidentiary value. *J. Forensic Sci.* 31:768–772, 1986.
46. Zugibe, F. T., Costello, J. T. Identification of the murder weapon by intricate patterned injury measurements. *J. Forensic Sci.* 31:773–777, 1986.
47. Zugibe, F. T., Costello, J., Breithaupt, M. Identification of a killer by a definitive sneaker pattern and his beating instruments by their distinctive patterns. *J. Forensic Sci.* 41:310–313, 1996.
48. Zugibe, F. T., Costello, J. T. Identification of a murder weapon by a peculiar blunt force injury pattern and histochemical analysis. *J. Forensic Sci.* 30:239–242, 1985.
49. Pretty, I. A., Hall, R. C. Forensic dentistry and human bite marks: issues for doctors. *Hosp. Med.* 63:476–482, 2002.
50. Anderson, W. R., Hudson, R. P. Self-inflicted bite marks in battered child syndrome. *J. Forensic Sci.* 7:71–74, 1976.
51. Warnick, A. J., Biedrzycki, L., Russanow, G. Not all bite marks are associated with abuse, sexual activities, or homicides: a case study of a self-inflicted bite mark. *J. Forensic Sci.* 32:788–792, 1987.
52. Sobel, M. N., Perper, J. A. Self-inflicted bite mark on the breast of a suicide victim. *Am. J. Forensic Med. Pathol.* 6:336–339, 1985.
53. Vale, G. L., Noguchi, T. T. Anatomical distribution of human bite marks in a series of 67 cases. *J. Forensic Sci.* 28:61–69, 1983.
54. Dorion, R. B. Bite mark evidence. *J. Can. Dent. Assoc.* 48:795–798, 1982.
55. Furness, J. A general review of bite-mark evidence. *Am. J. Forensic Med. Pathol.* 2:49–52, 1981.
56. Beckstead, J. W., Rawson, R. D., Giles, W. S. Review of bite mark evidence. *J. Am. Dent. Assoc.* 99:69–74, 1979.
57. Sperry K, Campbell HR, Jr. An elliptical incised wound of the breast misinterpreted as a bite injury. *J. Forensic Sci.* 35:1226–1235, 1990.
58. Pretty, I. A., Sweet, D. Anatomical location of bitemarks and associated findings in 101 cases from the United States. *J. Forensic Sci.* 45:812–814, 2000.
59. American Board of Forensic Odontology. Guidelines for bite mark analysis. *J. Am. Dent. Assoc.* 112:383–386, 1986.
60. Sweet, D., Lorente, M., Lorente, J. A., Valenzuela, A., Villanueva, E. An improved method to recover saliva from human skin: the double swab technique. *J. Forensic Sci.* 42:320–322, 1997.
61. Kouble, R. F., Craig, G. T. A comparison between direct and indirect methods available for human bite mark analysis. *J. Forensic Sci.* 49:111–118, 2004.
62. Benson, B. W., Cottone, J. A., Bomberg, T. J., Sperber, N. D. Bite mark impressions: a review of techniques and materials. *J. Forensic Sci.* 33:1238–1243, 1988.
63. Sweet, D., Bowers, C. M. Accuracy of bite mark overlays: a comparison of five common methods to produce exemplars from a suspect's dentition. *J. Forensic Sci.* 43:362–367, 1998.
64. Pretty, I. A., Sweet, D. Digital bite mark overlays—an analysis of effectiveness. *J. Forensic Sci.* 46:1385–1391, 2001.

65. Dailey, J. C. A practical technique for the fabrication of transparent bite mark overlays. *J. Forensic Sci.* 36:565–570, 1991.
66. Grey, T. C. Defibrillator injury suggesting bite mark. *Am. J. Forensic Med. Pathol.* 10:144–145, 1989.
67. James, H., Cirillo, G. N. Bite mark or bottle top? *J. Forensic Sci.* 49:119–121, 2004.
68. Pretty, I. A., Turnbull, M. D. Lack of dental uniqueness between two bite mark suspects. *J. Forensic Sci.* 46:1487–1491, 2001.
69. Walker, P. Management of pressure ulcers. *Oncology (Williston Park)* 15:1499–1508, 1511, 2001.
70. Sugarman, B., Hawes, S., Musher, D. M., Klima, M., Young, E. J., Pircher, F. Osteomyelitis beneath pressure sores. *Arch. Intern. Med.* 143:683–688, 1983.
71. Di Maio, V. J., Di Maio, T. G. Homicide by decubitus ulcers. *Am. J. Forensic Med. Pathol.* 23:1–4, 2002.
72. Tsokos, M., Heinemann, A., Puschel, K. Pressure sores: epidemiology, medico-legal implications and forensic argumentation concerning causality. *Int. J. Legal Med.* 113:283–287, 2000.
73. Allman, R. M. Pressure ulcer prevalence, incidence, risk factors, and impact. *Clin. Geriatr. Med.* 13:421–436, 1997.
74. Evans, J. M., Andrews, K. L., Chutka, D. S., Fleming, K. C., Garness, S. L. Pressure ulcers: prevention and management. *Mayo Clin. Proc.* 70:789–799, 1995.
75. Allman, R. M. Pressure ulcers among the elderly. *N. Engl. J. Med.* 320:850–853, 1989.
76. Turk, E. E., Tsokos, M., Dellling, G. Autopsy-based assessment of extent and type of osteomyelitis in advanced-grade sacral decubitus ulcers: a histopathologic study. *Arch. Pathol. Lab. Med.* 127:1599–1602, 2003.
77. Thomas, D. R. Are all pressure ulcers avoidable? *J. Am. Med. Dir. Assoc.* 4:S43–S48, 2003.
78. Witkowski, J. A., Parish, L. C. Histopathology of the decubitus ulcer. *J. Am. Acad. Dermatol.* 6:1014–1021, 1982.
79. Berlowitz, D. R., Brandeis, G. H., Anderson, J., Du, W., Brand, H. Effect of pressure ulcers on the survival of long-term care residents. *J. Gerontol. A. Biol. Sci. Med. Sci.* 52:M106–M110, 1997.
80. Heinemann, A., Tsokos, M., Puschel, K. Medico-legal aspects of pressure sores. *Leg. Med. (Tokyo)* 5 Suppl 1:S263–S266, 2003.
81. Galpin, J. E., Chow, A. W., Bayer, A. S., Guze, L. B. Sepsis associated with decubitus ulcers. *Am. J. Med.* 61:346–350, 1976.
82. Thomas, D. R., Goode, P. S., Tarquine, P. H., Allman, R. M. Hospital-acquired pressure ulcers and risk of death. *J. Am. Geriatr. Soc.* 44:1435–1440, 1996.
83. Holmes, J. H., Guileyardo, J. M., Barnard, J. J., DiMaio, V. J. Pressure sores in a Christian Science sanatorium. *Am. J. Forensic Med. Pathol.* 14:10–11, 1993.
84. Shields, L. B., Hunsaker, D. M., Hunsaker, J. C., III. Abuse and neglect: a ten-year review of mortality and morbidity in our elders in a large metropolitan area. *J. Forensic Sci.* 49:122–127, 2004.
85. Gill, J. R. Fatal descent from height in New York City. *J. Forensic Sci.* 46:1132–1137, 2001.
86. Lewis, W. S., Lee, A. B., Jr., Grantham, S. A. “Jumpers syndrome.” The trauma of high free fall as seen at Harlem Hospital. *J. Trauma* 5:812–818, 1965.
87. Li, L., Smialek, J. E. The investigation of fatal falls and jumps from heights in Maryland 1987–1992. *Am. J. Forensic Med. Pathol.* 15:295–299, 1994.
88. Shaw, K. P., Hsu, S. Y. Horizontal distance and height determining falling pattern. *J. Forensic Sci.* 43:765–771, 1998.
89. Turk, E. E., Tsokos, M. Pathologic features of fatal falls from height. *Am. J. Forensic Med. Pathol.* 25:194–199, 2004.
90. Isbister, E. S., Roberts, J. A. Autokabalesis: a study of intentional vertical deceleration injuries. *Injury* 23:119–122, 1992.



91. Perret, G., Flomenbaum, M., La Harpe, R. Suicides by fall from height in Geneva, Switzerland, from 1991 to 2000. *J. Forensic Sci.* 48:821–826, 2003.
92. Copeland, A. R. Suicide by jumping from buildings. *Am. J. Forensic Med. Pathol.* 10:295–298, 1989.
93. Gunnell, D., Nowers, M. Suicide by jumping. *Acta Psychiatr. Scand.* 96:1–6, 1997.
94. Hanzlick, R., Masterson, K., Walker, B. Suicide by jumping from high-rise hotels. Fulton County, Georgia, 1967–1986. *Am. J. Forensic Med. Pathol.* 11:294–297, 1990.
95. Pounder, D. J. Suicide by leaping from multistorey car parks. *Med. Sci. Law* 25:179–188, 1985.
96. Sims, A., O'Brien, K. Autokabalesis: an account of mentally ill people who jump from buildings. *Med. Sci. Law* 19:195–198, 1979.
97. Risser, D., Bonsch, A., Schneider, B., Bauer, G. Risk of dying after a free fall from height. *Forensic Sci. Int.* 78:187–191, 1996.
98. Goren, S., Subasi, M., Tyrasci, Y., Gurkan, F. Fatal falls from heights in and around Diyarbakir, Turkey. *Forensic Sci. Int.* 137:37–40, 2003.
99. Kisner, S. M., Fosbroke, D. E. Injury hazards in the construction industry. *J. Occup. Med.* 36:137–143, 1994.
100. Cattledge, G. H., Hendricks, S., Stanevich, R. Fatal occupational falls in the U.S. construction industry, 1980–1989. *Accid. Anal. Prev.* 28:647–654, 1996.
101. Copeland, A. R. Accidental death due to falls at work. *Am. J. Forensic Med. Pathol.* 10:17–20, 1989.
102. Smith, M. D., Burrington, J. D., Woolf, A. D. Injuries in children sustained in free falls: an analysis of 66 cases. *J. Trauma* 15:987–991, 1975.
103. Roshkow, J. E., Haller, J. O., Hotson, G. C., Sclafani, S. J., Mezzacappa, P. M., Rachlin, S. Imaging evaluation of children after falls from a height: review of 45 cases. *Radiology* 175:359–363, 1990.
104. Steedman, D. J. Severity of free-fall injury. *Injury* 20:259–261, 1989.
105. Snyder, R. G. Human tolerance limits in water impact. *Aerosp. Med.* 36:940–947, 1965.
106. Kazarian, K. K., Bole, P., Ketchum, S. A., III, Mersheimer, W. L. High-flyer syndrome: survival after 17-story fall. *N. Y. State J. Med.* 76:982–985, 1976.
107. Mathis, R. D., Levine, S. H., Phifer, S. An analysis of accidental free falls from a height: the 'spring break' syndrome. *J. Trauma* 34:123–126, 1993.
108. Mellen, P. F., Sohn, S. S. Military parachute mishap fatalities: a retrospective study. *Aviat. Space Environ. Med.* 61:1149–1152, 1990.
109. Tomczak, P. D., Buikstra, J. E. Analysis of blunt trauma injuries: vertical deceleration versus horizontal deceleration injuries. *J. Forensic Sci.* 44:253–262, 1999.
110. Lau, G., Ooi, P. L., Phoon, B. Fatal falls from a height: the use of mathematical models to estimate the height of fall from the injuries sustained. *Forensic Sci. Int.* 93:33–44, 1998.
111. Atanasijevic, T. C., Savic, S. N., Nikolic, S. D., Djoki, V. M. Frequency and severity of injuries in correlation with the height of fall. *J. Forensic Sci.* 50:608–612, 2005.
112. Harvey, P. M., Solomons, B. J. Survival after free falls of 59 metres into water from the Sydney Harbour Bridge, 1930–1982. *Med. J. Aust.* 1:504–511, 1983.
113. Gupta, S. M., Chandra, J., Dogra, T. D. Blunt force lesions related to the heights of a fall. *Am. J. Forensic Med. Pathol.* 3:35–43, 1982.
114. Layton, T. R., Villella, E. R., Kelly, E. G. High free fall with survival. *J. Trauma* 21:983–985, 1981.
115. Scalea, T., Goldstein, A., Phillips, T., et al. An analysis of 161 falls from a height: the 'jumper syndrome'. *J. Trauma* 26:706–712, 1986.
116. Barlow, B., Niemirska, M., Gandhi, R. P., Leblanc, W. Ten years of experience with falls from a height in children. *J. Pediatr. Surg.* 18:509–511, 1983.
117. Hall, J. R., Reyes, H. M., Horvat, M., Meller, J. L., Stein, R. The mortality of childhood falls. *J. Trauma* 29:1273–1275, 1989.

118. Cetin, G., Gunay, Y., Fincanci, S. K., Ozdemir, K. R. Suicides by jumping from Bosphorus Bridge in Istanbul. *Forensic Sci. Int.* 116:157–162, 2001.
119. Lukas, G. M., Hutton, J. E., Jr., Lim, R. C., Mathewson, C., Jr. Injuries sustained from high velocity impact with water: an experience from the Golden Gate Bridge. *J. Trauma* 21:612–618, 1981.
120. Kurtz, R. J., Pizzi, W. F., Richman, H., Tiefenbrun, J. Jumping from the Brooklyn Bridge. *Surg. Gynecol. Obstet.* 165:60–62, 1987.
121. Snyder, R. G., Snow, C. C. Fatal injuries resulting from extreme water impact. *Aerosp. Med.* 38:779–783, 1967.
122. Snyder R. G. Terminal velocity impacts into snow. *Mil. Med.* 131:1290–1298, 1966.
123. Rozycki, G. S., Maull, K. I. Injuries sustained by falls. *Arch. Emerg. Med.* 8:245–252, 1991.
124. Thogmartin, J. R. Fatal fall of an aircraft stowaway: a demonstration of the importance of death scene investigation. *J. Forensic Sci.* 45:211–215, 2000.
125. Velmahos, G. C., Demetriades, D., Theodorou, D., et al. Patterns of injury in victims of urban free-falls. *World J. Surg.* 21:816–820, 1997.
126. Simonsen, J. Injuries sustained from high-velocity impact with water after jumps from high bridges. A preliminary report of 10 cases. *Am. J. Forensic Med. Pathol.* 4:139–142, 1983.
127. Robertson, H. T., Lakshminarayan, S., Hudson, L. D. Lung injury following a 50-metre fall into water. *Thorax* 33:175–180, 1978.
128. Wanek, S., Mayberry, J. C. Blunt thoracic trauma: flail chest, pulmonary contusion, and blast injury. *Crit. Care. Clin.* 20:71–81, 2004.
129. Bintz, M., Gall, W. E., Harbin, D. Blunt myocardial disruption: report of an unusual case and literature review. *J. Trauma* 33:933–934, 1992.
130. Lee, R. B., Bass, S. M., Morris, J. A., Jr., MacKenzie, E. J. Three or more rib fractures as an indicator for transfer to a Level I trauma center: a population-based study. *J. Trauma* 30:689–694, 1990.
131. Liman, S. T., Kuzucu, A., Tastepe, A. I., Ulasan, G. N., Topcu, S. Chest injury due to blunt trauma. *Eur. J. Cardiothorac. Surg.* 23:374–378, 2003.
132. Sperry, K. Anterior thoracic wall trauma in elderly homicide victims. The “CPR defense”. *Am. J. Forensic Med. Pathol.* 11:50–55, 1990.
133. Schmidt, G. Rib-cage injuries indicating the direction and strength of impact. *Forensic Sci. Int.* 13:103–110, 1979.
134. Feldman, K. W., Brewer, D. K. Child abuse, cardiopulmonary resuscitation, and rib fractures. *Pediatrics* 73:339–342, 1984.
135. Myllynen, P., Kivioja, A., Wilppula, E., Rokkanen, P., Mattila, S., Laakso, E. Flail chest—pathophysiology, treatment and prognosis. *Ann. Chir. Gynaecol.* 72:43–46, 1983.
136. Campbell, D. B. Trauma to the chest wall, lung, and major airways. *Semin. Thorac. Cardiovasc. Surg.* 4:234–240, 1992.
137. Duff, J. H., Goldstein, M., McLean, A. P., Agrawal, S. N., Munro, D. D., Gutelius, J. R. Flail chest: a clinical review and physiological study. *J. Trauma* 8:63–74, 1968.
138. Relihan, M., Litwin, M. S. Morbidity and mortality associated with flail chest injury: a review of 85 cases. *J. Trauma* 13:663–671, 1973.
139. Ciraulo, D. L., Elliott, D., Mitchell, K. A., Rodriguez, A. Flail chest as a marker for significant injuries. *J. Am. Coll. Surg.* 178:466–470, 1994.
140. Shorr, R. M., Crittenden, M., Indeck, M., Hartunian, S. L., Rodriguez, A. Blunt thoracic trauma. Analysis of 515 patients. *Ann. Surg.* 206:200–205, 1987.
141. Sirmali, M., Turut, H., Topcu, S., et al. A comprehensive analysis of traumatic rib fractures: morbidity, mortality and management. *Eur. J. Cardiothorac. Surg.* 24:133–138, 2003.
142. Kessel, B., Alfici, R., Ashkenazi, I., et al. Massive hemothorax caused by intercostal artery bleeding: selective embolization may be an alternative to thoracotomy in selected patients. *Thorac. Cardiovasc. Surg.* 52:234–236, 2004.

143. Ross, R. M., Cordoba, A. Delayed life-threatening hemothorax associated with rib fractures. *J. Trauma* 26:576–578, 1986.
144. Simon, B. J., Chu, Q., Emhoff, T. A., Fiallo, V. M., Lee, K. F. Delayed hemothorax after blunt thoracic trauma: an uncommon entity with significant morbidity. *J. Trauma* 45:673–676, 1998.
145. Bundy, D. W., Tilton, D. M. Delayed hemothorax after blunt trauma without rib fractures. *Mil. Med.* 168:501–502, 2003.
146. Sinha, P., Sarkar, P. Late clotted haemothorax after blunt chest trauma. *J. Accid. Emerg. Med.* 15:189–191, 1998.
147. Irgau, I., Fulda, G. J., Hailstone, D., Tinkoff, G. H. Internal mammary artery injury, anterior mediastinal hematoma, and cardiac compromise after blunt chest trauma. *J. Trauma* 39:1018–1021, 1995.
148. Madoff, D. C., Brathwaite, C. E., Manzione, J. V., et al. Coexistent rupture of the proximal right subclavian and internal mammary arteries after blunt chest trauma. *J. Trauma* 48:521–524, 2000.
149. Wilkinson, J., Jacob, T. D., Armitage, J., Zajko, A., Udekwu, A. O., Peitzman, A. B. Avulsion of the internal mammary artery caused by blunt trauma. *Ann. Emerg. Med.* 22:1762–1765, 1993.
150. Nomori, H., Ootsuka, T., Horio, H., Naruke, T., Suemasu, K. Bilateral internal thoracic artery injury induced by blunt trauma. *Jpn. J. Thorac. Cardiovasc. Surg.* 51:214–216, 2003.
151. Atcheson, S. G., Fred, H. L. Letter: Complications of cardiac resuscitation. *Am. Heart J.* 89:263–265, 1975.
152. Rabl, W., Baubin, M., Broinger, G., Scheithauer, R. Serious complications from active compression–decompression cardiopulmonary resuscitation. *Int. J. Legal Med.* 109:84–89, 1996.
153. Himmelhoch, S. R., Dekker, A., Gazzaniga, A. B., Like, A. A. Closed-chest cardiac resuscitation. A prospective clinical and pathological study. *N. Engl. J. Med.* 270:118–122, 1964.
154. Bynum, W. R., Connell, R. M., Hawk, W. A. Causes of death after external cardiac massage. Analysis of observations of fifty consecutive autopsies. *Cleve. Clin. Q.* 30:147–151, 1963.
155. Krischer, J. P., Fine, E. G., Davis, J. H., Nagel, E. L. Complications of cardiac resuscitation. *Chest* 92:287–291, 1987.
156. Klintschar, M., Darok, M., Radner, H. Massive injury to the heart after attempted active compression–decompression cardiopulmonary resuscitation. *Int. J. Legal Med.* 111:93–96, 1998.
157. Bedell, S. E., Fulton, E. J. Unexpected findings and complications at autopsy after cardiopulmonary resuscitation (CPR). *Arch. Intern. Med.* 146:1725–1728, 1986.
158. Nagel, E. L., Fine, E. G., Krischer, J. P., Davis, J. H. Complications of CPR. *Crit. Care Med.* 9:424, 1981.
159. Clark, D. T. Complications following closed-chest cardiac massage. *JAMA* 181:337–338, 1962.
160. Sokolove, P. E., Willis-Shore, J., Panacek, E. A. Exsanguination due to right ventricular rupture during closed-chest cardiopulmonary resuscitation. *J. Emerg. Med.* 23:161–164, 2002.
161. Enarson, D. A., Didier, E. P., Gracey, D. R. Flail chest as a complication of cardiopulmonary resuscitation. *Heart Lung* 6:1020–1022, 1977.
162. Kaplan, B. M., Knott, A. P., Jr. Closed-chest cardiac massage for circulatory arrest. Effectiveness in 100 consecutive cases. *Arch. Intern. Med.* 114:5–12, 1964.
163. Roser, L. A. Cardiopulmonary resuscitation experience in a general hospital. Review of 116 consecutive resuscitative attempts during a 2 1/2-year period. *Arch. Surg.* 95:658–663, 1967.

164. Patterson, R. H., Burns, W. A., Jannotta, F.S. Complications of external cardiac resuscitation: a retrospective review and survey of the literature. *Med. Ann. Dist. Columbia* 43:389–394, 1974.
165. Lawrence, R. M., Haley, E. M., Gillies, A. J. Closed-chest cardiopulmonary resuscitation: results and criteria for application. *N. Y. State J. Med.* 64:2523–2532, 1964.
166. Haugeberg, G., Bonarjee, V., Dickstein, K. Fatal intrathoracic haemorrhage after cardiopulmonary resuscitation and treatment with streptokinase and heparin. *Br. Heart J.* 62:157–158, 1989.
167. Silberberg, B., Rachmaninoff, N. Complications following external cardiac massage. *Surg. Gynecol. Obstet.* 119:6–10, 1964.
168. Bodily, K., Fischer, R. P. Aortic rupture and right ventricular rupture induced by closed chest cardiac massage. *Minn. Med.* 62:225–227, 1979.
169. Paaske, F., Hansen, J. P., Koudahl, G., Olsen, J. Complications of closed-chest cardiac massage in a forensic autopsy material. *Dan. Med. Bull.* 15:225–230, 1968.
170. Azuma, S. S., Mashiyama, E. T., Goldsmith, C. I., Abbasi, A. S. Chest compression-induced vertebral fractures. *Chest* 89:154–155, 1986.
171. Agdal, N., Jorgensen, T. G. Penetrating laceration of the pericardium and myocardium and myocardial rupture following closed-chest cardiac massage. *Acta Med. Scand.* 194:477–479, 1973.
172. Yamada, E. Y., Fukunaga, F. H. Cardiopulmonary complications of external cardiac massage. *Hawaii Med. J.* 29:114–117, 1969.
173. Powner, D. J., Holcombe, P. A., Mello, L. A. Cardiopulmonary resuscitation-related injuries. *Crit. Care Med.* 12:54–55, 1984.
174. Sommers, M. S. Potential for injury: trauma after cardiopulmonary resuscitation. *Heart Lung* 20:287–293, 1991.
175. Thakore, S., Johnston, M., Rogena, E., Peng, Z., Sadler, D. Non-penetrating chest blows and sudden death in the young. *J. Accid. Emerg. Med.* 17:421–422, 2000.
176. Wolfe, W. G., Dudley, A. W., Jr., Wallace, A. G. A pathological study of unsuccessful cardiac resuscitation. *Arch. Surg.* 96:123–126, 1968.
177. Baldwin, J. J., Edwards, J. E. Clinical conference: Rupture of right ventricle complicating closed chest cardiac massage. *Circulation* 53:562–564, 1976.
178. Noffsinger, A. E., Blisard, K. S., Balko, M. G. Cardiac laceration and pericardial tamponade due to cardiopulmonary resuscitation after myocardial infarction. *J. Forensic Sci.* 36:1760–1764, 1991.
179. Atcheson, S. G., Petersen, G. V., Fred, H. L. Ill-effects of cardiac resuscitation: report of two unusual cases. *Chest* 67:615–616, 1975.
180. Meyers, D. S., Rogers, W. Papillary muscle rupture due to external cardiac massage. Case report. *Mo. Med.* 70:721–722, 1973.
181. Nelson, D. A., Ashley, P. F. Rupture of the aorta during closed-chest cardiac massage. *JAMA* 193:681–683, 1965.
182. Mayers, C. P. Aortic aneurysm following external cardiac massage. *Br. J. Surg.* 59:238–239, 1972.
183. Cohn, L. H., Sayer, W. J. Multiple complications from external cardiac massage. Report of a case. *Calif. Med.* 98:220–221, 1963.
184. Moe, N. Complications following resuscitation. *Acta Med. Scand.* 182:773–779, 1967.
185. McClure, J. N., Jr., Skardasis, G. M., Brown, J. M. Cardiac arrest in the operating area. *Am. Surg.* 38:241–246, 1972.
186. Custer, J. R., Polley, T. Z., Jr., Moler, F. Gastric perforation following cardiopulmonary resuscitation in a child: report of a case and review of the literature. *Pediatr. Emerg. Care* 3:24–27, 1987.
187. Demos, N. J., Poticha, S. M. Gastric rupture occurring during external cardiac resuscitation. *Surgery* 55:364–366, 1964.

188. Tobias, S. Perforation of the transverse colon following external cardiac massage. *Arch. Surg.* 94:335–336, 1967.
189. Aguilar, J. C. Fatal gastric hemorrhage: a complication of cardiorespiratory resuscitation. *J. Trauma* 21:573–575, 1981.
190. Anthony, P. P., Tattersfield, A. E. Gastric mucosal lacerations after cardiac resuscitation. *Br. Heart J.* 31:72–75, 1969.
191. Lau, G. A case of sudden maternal death associated with resuscitative liver injury. *Forensic Sci. Int.* 67:127–132, 1994.
192. Barrowcliffe, M. P. Visceral injuries following external cardiac massage. *Anaesthesia* 39:347–350, 1984.
193. Jeresaty, R. M., Godar, T. J., Liss, J. P. External cardiac resuscitation in a community hospital. A three-year experience. *Arch. Intern. Med.* 124:588–592, 1969.
194. Cowan, D. Pancreatitis and pulmonary hemorrhage complicating closed-chest cardiac massage. *Can. Med. Assoc. J.* 95:976–977, 1966.
195. Waldman, P. J., Walters, B. L., Grunau, C. F. Pancreatic injury associated with interposed abdominal compressions in pediatric cardiopulmonary resuscitation. *Am. J. Emerg. Med.* 2:510–512, 1984.
196. Hojs, R., Sinkovic, A., Hojs-Fabjan, T. Rhabdomyolysis and acute renal failure following cardioversion and cardiopulmonary resuscitation. *Ren. Fail.* 17:765–768, 1995.
197. Kanter, R. K. Retinal hemorrhage after cardiopulmonary resuscitation or child abuse. *J. Pediatr.* 108:430–432, 1986.
198. Baubin, M., Rabl, W., Pfeiffer, K. P., Benzer, A., Gilly, H. Chest injuries after active compression-decompression cardiopulmonary resuscitation (ACD-CPR) in cadavers. *Resuscitation* 43:9–15, 1999.
199. Clark, D. E., Wiles, C. S., III, Lim, M. K., Dunham, C. M., Rodriguez, A. Traumatic rupture of the pericardium. *Surgery* 93:495–503, 1983.
200. Levine, A. J., Collins, F. J. Blunt traumatic pericardial rupture. *J. Accid. Emerg. Med.* 12:55–56, 1995.
201. May, A. K., Patterson, M. A., Rue, L. W., III, Schiller, H. J., Rotondo, M. F., Schwab, C. W. Combined blunt cardiac and pericardial rupture: review of the literature and report of a new diagnostic algorithm. *Am. Surg.* 65:568–574, 1999.
202. Janson, J. T., Harris, D. G., Pretorius, J., Rossouw, G. J. Pericardial rupture and cardiac herniation after blunt chest trauma. *Ann. Thorac. Surg.* 75:581–582, 2003.
203. Shah, R., Sabanathan, S., Mearns, A. J., Choudhury, A. K. Traumatic rupture of diaphragm. *Ann. Thorac. Surg.* 60:1444–1449, 1995.
204. Nirgiotis, J. G., Colon, R., Sweeney, M. S. Blunt trauma to the heart: the pathophysiology of injury. *J. Emerg. Med.* 8:617–623, 1990.
205. Salehian, O., Teoh, K., Mulji, A. Blunt and penetrating cardiac trauma: a review. *Can. J. Cardiol.* 19:1054–1059, 2003.
206. Banning, A. P., Pillai, R. Non-penetrating cardiac and aortic trauma. *Heart* 78:226–229, 1997.
207. Boglioli, L. R., Taff, M. L., Harleman, G. Child homicide caused by commotio cordis. *Pediatr. Cardiol.* 19:436–438, 1998.
208. Froede, R. C., Lindsey, D., Steinbronn, K. Sudden unexpected death from cardiac concussion (commotio cordis) with unusual legal complications. *J. Forensic Sci.* 24:752–756, 1979.
209. Martin, T. D., Flynn, T. C., Rowlands, B. J., Ward, R. E., Fischer, R. P. Blunt cardiac rupture. *J. Trauma* 24:287–290, 1984.
210. Vougiouklakis, T., Peschos, D., Doulis, A., Batistatou, A., Mitselou, A., Agnantis, N. J. Sudden death from contusion of the right atrium after blunt chest trauma: case report and review of the literature. *Injury* 36:213–217, 2005.
211. Darok, M., Beham-Schmid, C., Gatterig, R., Roll, P. Sudden death from myocardial contusion following an isolated blunt force trauma to the chest. *Int. J. Legal Med.* 115:85–89, 2001.



212. Macdonald, R. C., O'Neill, D., Hanning, C. D., Ledingham, I. M. Myocardial contusion in blunt chest trauma: a ten-year review. *Intensive Care Med.* 7:265–268, 1981.
213. Lindstaedt, M., Germing, A., Lawo, T., et al. Acute and long-term clinical significance of myocardial contusion following blunt thoracic trauma: results of a prospective study. *J. Trauma* 52:479–485, 2002.
214. Koehler, S. A., Shakir, A., Ladham, S., et al. Cardiac concussion: definition, differential diagnosis, and cases presentation and the legal ramification of a misdiagnosis. *Am. J. Forensic Med. Pathol.* 25:205–208, 2004.
215. Shanklin, D. R. Delayed fatal impact cardiopathy. *Forensic Sci. Int.* 25:283–291, 1984.
216. RuDusky, B. M. Myocardial contusion culminating in a ruptured pseudoaneurysm of the left ventricle—a case report. *Angiology* 54:359–362, 2003.
217. Ansari, M. Z., Chaudhry, M. A., Singal, A., Joshi, R. Unusual cardiac injury following blunt chest trauma. *Eur. J. Emerg. Med.* 8:229–231, 2001.
218. Chou, T. F., Hwang, J. J., Chu, S. H. Interventricular septum rupture due to falling from a height. *Thorac. Cardiovasc. Surg.* 39:379–381, 1991.
219. Degiannis, E., Brink, J., Haagensen, M., Williams, P., Boffard, K. Rupture of the auricle of the right atrium of the heart and pericardium after blunt trauma. *Eur. J. Surg.* 167:472–474, 2001.
220. Rao, G., Garvey, J., Gupta, M., Wisoff, G. Atrial septal defect due to blunt thoracic trauma. *J. Trauma* 17:405–406, 1977.
221. Hermans, K., Vermeulen, J., Meyns, B. Isolated rupture of the left atrial appendage after blunt chest trauma. *Acta Cardiol.* 59:663–664, 2004.
222. Tobin, H. M., Hiratzka, L. F., Vargish, T. Ruptured right atrium from nonpenetrating trauma of the chest. *South. Med. J.* 79:499–501, 1986.
223. Brathwaite, C. E., Rodriguez, A., Turney, S. Z., Dunham, C. M., Cowley, R. Blunt traumatic cardiac rupture. A 5-year experience. *Ann. Surg.* 212:701–704, 1990.
224. Durak, D. Cardiac rupture following blunt trauma. *J. Forensic Sci.* 46:171–172, 2001.
225. Pollak, S., Stellwag-Carion, C. Delayed cardiac rupture due to blunt chest trauma. *Am. J. Forensic Med. Pathol.* 12:153–156, 1991.
226. Cumberland, G. D., Riddick, L., McConnell, C. F. Intimal tears of the right atrium of the heart due to blunt force injuries to the abdomen. Its mechanism and implications. *Am. J. Forensic Med. Pathol.* 12:102–104, 1991.
227. Arcudi, G., Marchetti, D. Left ventricular aneurysm caused by blunt chest trauma. *Am. J. Forensic Med. Pathol.* 17:194–196, 1996.
228. Veinot, J. P., Acharya, V. Post-traumatic left ventricular false aneurysm. *J. Forensic Sci.* 46:396–398, 2001.
229. Futterman, L. G., Lemberg, L. Commotio cordis: sudden cardiac death in athletes. *Am. J. Crit. Care* 8:270–272, 1999.
230. Kohl, P., Nesbitt, A. D., Cooper, P. J., Lei, M. Sudden cardiac death by commotio cordis: role of mechano-electric feedback. *Cardiovasc. Res.* 50:280–289, 2001.
231. Maron, B. J., Gohman, T. E., Kyle, S. B., Estes, N. A., III, Link, M. S. Clinical profile and spectrum of commotio cordis. *JAMA* 287:1142–1146, 2002.
232. Link, M. S., Wang, P. J., Maron, B. J., Estes, N. A. What is commotio cordis? *Cardiol. Rev.* 7:265–269, 1999.
233. Link, M. S. Mechanically induced sudden death in chest wall impact (commotio cordis). *Prog. Biophys. Mol. Biol.* 82:175–186, 2003.
234. Link, M. S., Maron, B. J., Wang, P. J., Pandian, N. G., VanderBrink, B. A., Estes, N. A., III. Reduced risk of sudden death from chest wall blows (commotio cordis) with safety baseballs. *Pediatrics* 109:873–877, 2002.
235. Maron, B. J., Poliac, L. C., Kaplan, J. A., Mueller, F. O. Blunt impact to the chest leading to sudden death from cardiac arrest during sports activities. *N. Engl. J. Med.* 333:337–342, 1995.

236. McCrory, P. Commotio cordis. *Br. J. Sports Med.* 36:236–237, 2002.
237. Wang, N. D., Stevens, M. H., Doty, D. B., Hammond, E. H. Blunt chest trauma: an experimental model for heart and lung contusion. *J. Trauma* 54:744–748, 2003.
238. Wang, J. N., Tsai, Y. C., Chen, S. L., Chen, Y., Lin, C. S., Wu, J. M. Dangerous impact—commotio cordis. *Cardiology* 93:124–126, 2000.
239. Maron, B. J. Sudden death in young athletes. *N. Engl. J. Med.* 349:1064–1075, 2003.
240. Link, M. S., Maron, B. J., Wang, P. J., VanderBrink, B. A., Zhu, W., Estes, N. A., III. Upper and lower limits of vulnerability to sudden arrhythmic death with chest-wall impact (commotio cordis). *J. Am. Coll. Cardiol.* 41:99–104, 2003.
241. Frazer, M., Mirchandani, H. Commotio cordis, revisited. *Am. J. Forensic Med. Pathol.* 5:249–251, 1984.
242. Hirose, H. Posttraumatic right coronary artery aneurysm complicated with acute myocardial infarction shortly after blunt chest trauma. *J. Trauma* 44:937, 1998.
243. Straub, A., Beierlein, W., Kuttner, A., Hahn, U., Raygrotzki, S., Ziemer, G. Isolated coronary artery rupture after blunt chest trauma. *Thorac. Cardiovasc. Surg.* 51:97–98, 2003.
244. Mairesse, G. H., Timmermans, P. Post-traumatic myocardial infarction. *Acta Clin. Belg.* 48:128–131, 1993.
245. Fang, B. R., Li, C. T. Acute myocardial infarction following blunt chest trauma. *Eur. Heart J.* 15:705–707, 1994.
246. Dueholm, S., Fabrin, J. Isolated coronary artery rupture following blunt chest trauma. A case report. *Scand. J. Thorac. Cardiovasc. Surg.* 20:183–184, 1986.
247. Suzuki, I., Sato, M., Hoshi, N., Nanjo, H. Coronary arterial laceration after blunt chest trauma. *N. Engl. J. Med.* 343:742–743, 2000.
248. Fu, M., Wu, C. J., Hsieh, M. J. Coronary dissection and myocardial infarction following blunt chest trauma. *J. Formos. Med. Assoc.* 98:136–140, 1999.
249. Yoon, S. J., Kwon, H. M., Kim, D. S., et al. Acute myocardial infarction caused by coronary artery dissection following blunt chest trauma. *Yonsei Med. J.* 44:736–739, 2003.
250. Goktekin, O., Unalir, A., Gorennek, B., et al. Traumatic total occlusion of left main coronary artery caused by blunt chest trauma. *J. Invasive Cardiol.* 14:463–465, 2002.
251. Naseer, N., Aronow, W. S., McClung, J. A., et al. Circumflex coronary artery occlusion after blunt chest trauma. *Heart Dis.* 5:184–186, 2003.
252. Banzo, I., Montero, A., Uriarte, I., et al. Coronary artery occlusion and myocardial infarction: a seldom encountered complication of blunt chest trauma. *Clin. Nucl. Med.* 24:94–96, 1999.
253. Patel, R., Samaha, F. F. Right coronary artery occlusion caused by blunt trauma. *J. Invasive Cardiol.* 12:376–378, 2000.
254. Shapiro, M. J., Wittgen, C., Flynn, M. S., Zuckerman, D. A., Durham, R. M., Mazuski, J. E. Right coronary artery occlusion secondary to blunt trauma. *Clin. Cardiol.* 17:157–159, 1994.
255. Kugai, T., Chibana, M. Rupture in a mitral papillary muscle following blunt chest trauma. *Jpn. J. Thorac. Cardiovasc. Surg.* 48:394–397, 2000.
256. Wilke, A., Kruse, T., Hesse, H., Bittinger, A., Moosdorf, R., Maisch, B. Papillary muscle injury after blunt chest trauma. *J. Trauma* 43:360–361, 1997.
257. Grinberg, A. R., Finkielman, J. D., Pineiro, D., Festa, H., Cazenave, C. Rupture of mitral chorda tendinea following blunt chest trauma. *Clin. Cardiol.* 21:300–301, 1998.
258. Bruschi, G., Agati, S., Iorio, F., Vitali, E. Papillary muscle rupture and pericardial injuries after blunt chest trauma. *Eur. J. Cardiothorac. Surg.* 20:200–202, 2001.
259. Simmers, T. A., Meijburg, H. W., de la Riviere, A. B. Traumatic papillary muscle rupture. *Ann. Thorac. Surg.* 72:257–259, 2001.
260. McDonald, M. L., Orszulak, T. A., Bannon, M. P., Zietlow, S. P. Mitral valve injury after blunt chest trauma. *Ann. Thorac. Surg.* 61:1024–1029, 1996.
261. Munim, A., Chodoff, P. Traumatic acute mitral regurgitation secondary to blunt chest trauma. *Crit. Care Med.* 11:311–312, 1983.

262. Pathi, V., Jones, B., Davidson, K. G. Mitral valve disruption following blunt trauma: case report and review of the literature. *Eur. J. Cardiothorac. Surg.* 10:806–808, 1996.
263. Trotter, T. H., Knott-Craig, C. J., Ward, K. E. Blunt injury rupture of tricuspid valve and right coronary artery. *Ann. Thorac. Surg.* 66:1814–1816, 1998.
264. RuDusky, B. M., Cimochowski, G. Traumatic tricuspid insufficiency—a case report. *Angiology* 53:229–233, 2002.
265. Reardon, M. J., Conklin, L. D., Letsou, G. V., Safi, H. J., Espada, R., Baldwin, J. C. Mitral valve injury from blunt trauma. *J. Heart Valve Dis.* 7:467–470, 1998.
266. Salehian, O., Mulji, A. Tricuspid valve disruption and ventricular septal defect secondary to blunt chest trauma. *Can. J. Cardiol.* 20:231–232, 2004.
267. Bayezid, O., Mete, A., Turkay, C., Yanat, F., Deger, N., Isin, E. Traumatic tricuspid insufficiency following blunt chest trauma. *J. Cardiovasc. Surg. (Torino)* 34:69–71, 1993.
268. dos Santos J., Jr., de Marchi, C. H., Bestetti, R. B., Corbucci, H. A., Pavarino, P. R. Ruptured chordae tendineae of the posterior leaflet of the tricuspid valve as a cause of tricuspid regurgitation following blunt chest trauma. *Cardiovasc. Pathol.* 10:97–98, 2001.
269. Banning, A. P., Durrani, A., Pillai, R. Rupture of the atrial septum and tricuspid valve after blunt chest trauma. *Ann. Thorac. Surg.* 64:240–242, 1997.
270. Unal, M., Demirsoy, E., Gogus, A., Arbatli, H., Hamzaoglu, A., Sonmez, B. Acute aortic valve regurgitation secondary to blunt chest trauma. *Tex. Heart Inst. J.* 28:312–314, 2001.
271. ten Berg, J. M., Jaarsma, W., Hamerlynck, R. P., Suttorp, M. J. Rupture of the left coronary cusp of the aortic valve caused by blunt chest trauma: early diagnosis by transesophageal echocardiography. *J. Am. Soc. Echocardiogr.* 8:766–769, 1995.
272. Chang, J. P., Chu, J. J., Chang, C. H. Aortic regurgitation due to aortic root intimal tear as a result of blunt chest trauma. *J. Formos. Med. Assoc.* 89:41–43, 1990.
273. Burkhart, H. M., Gomez, G. A., Jacobson, L. E., Pless, J. E., Broadie, T. A. Fatal blunt aortic injuries: a review of 242 autopsy cases. *J. Trauma* 50:113–115, 2001.
274. Katyal, D., McLellan, B. A., Brenneman, F. D., Boulanger, B. R., Sharkey, P. W., Waddell, J. P. Lateral impact motor vehicle collisions: significant cause of blunt traumatic rupture of the thoracic aorta. *J. Trauma* 42:769–772, 1997.
275. Shkrum, M. J., McClafferty, K. J., Green, R. N., Nowak, E. S., Young, J. G. Mechanisms of aortic injury in fatalities occurring in motor vehicle collisions. *J. Forensic Sci.* 44:44–56, 1999.
276. Richens, D., Kotidis, K., Neale, M., Oakley, C., Fails, A. Rupture of the aorta following road traffic accidents in the United Kingdom 1992–1999. The results of the co-operative crash injury study. *Eur. J. Cardiothorac. Surg.* 23:143–148, 2003.
277. Newman, R. J., Rastogi, S. Rupture of the thoracic aorta and its relationship to road traffic accident characteristics. *Injury* 15:296–299, 1984.
278. Feczko, J. D., Lynch, L., Pless, J. E., Clark, M. A., McClain, J., Hawley, D. A. An autopsy case review of 142 nonpenetrating (blunt) injuries of the aorta. *J. Trauma* 33:846–849, 1992.
279. Hossack, D. W. The pattern of injuries received by 500 drivers and passengers killed in road accidents. *Med. J. Aust.* 2:193–195, 1972.
280. Sevvitt, S. Fatal road accidents in Birmingham: times to death and their causes. *Injury* 4:281–293, 1973.
281. Greendyke, R. M. Traumatic rupture of aorta; special reference to automobile accidents. *JAMA* 195:527–530, 1966.
282. Dischinger, P., Cowley, R., Shankar, B., Smialek, J. The incidence of ruptured aorta among vehicular fatalities. *Proceedings of the 32nd AAAM Conference. Association for the Advancement of Automotive Medicine, Des Plaines, IL*, 1988.
283. Siegel, J. H., Smith, J. A., Siddiqi, S. Q. Change in velocity and energy dissipation on impact in motor vehicle crashes as a function of the direction of crash: key factors in the production of thoracic aortic injuries, their pattern of associated injuries and patient

- survival. A Crash Injury Research Engineering Network (CIREN) study. *J. Trauma* 57:760–777, 2004.
284. Fitzharris, M., Franklyn, M., Frampton, R., Yang, K., Morris, A., Fildes, B. Thoracic aortic injury in motor vehicle crashes: the effect of impact direction, side of body struck, and seat belt use. *J. Trauma* 57:582–590, 2004.
285. Brundage, S. I., Harruff, R., Jurkovich, G. J., Maier, R. V. The epidemiology of thoracic aortic injuries in pedestrians. *J. Trauma* 45:1010–1014, 1998.
286. Siegel, J. H., Smith, J. A., Tenenbaum, N., et al. Deceleration energy and change in velocity on impact: key factors in fatal versus potentially survivable motor vehicle crash (mvc) aortic injuries (AI): the role of associated injuries as determinants of outcome. *Annu. Proc. Assoc. Adv. Automot. Med.* 46:315–338, 2002.
287. Hossack, D. W. Rupture of the aorta in road crash victims. *Aust. N. Z. J. Surg.* 50:136–137, 1980.
288. McGwin, G., Jr., Reiff, D. A., Moran, S. G., Rue, L. W., III. Incidence and characteristics of motor vehicle collision-related blunt thoracic aortic injury according to age. *J. Trauma* 52:859–865, 2002.
289. Eddy, A. C., Rusch, V. W., Fligner, C. L., Reay, D. T., Rice, C. L. The epidemiology of traumatic rupture of the thoracic aorta in children: a 13-year review. *J. Trauma* 30:989–991, 1990.
290. Strassmann, G. Traumatic rupture of the aorta. *Am. Heart J.* 33:508–515, 1947.
291. Richens, D., Field, M., Hashim, S., Neale, M., Oakley, C. A finite element model of blunt traumatic aortic rupture. *Eur. J. Cardiothorac. Surg.* 25:1039–1047, 2004.
292. Jensen, B. T. Fourteen years' survival with an untreated traumatic rupture of the thoracic aorta. *Am. J. Forensic Med. Pathol.* 9:58–59, 1988.
293. Roth, S. M., Wheeler, J. R., Gregory, R. T., et al. Blunt injury of the abdominal aorta: a review. *J. Trauma* 42:748–755, 1997.
294. Reisman, J. D., Morgan, A. S. Analysis of 46 intra-abdominal aortic injuries from blunt trauma: case reports and literature review. *J. Trauma* 30:1294–1297, 1990.
295. Bunai, Y., Nagai, A., Nakamura, I., Ohya, I. Traumatic rupture of an abdominal aortic aneurysm associated with the use of a seatbelt. *J. Forensic Sci.* 44:1304–1306, 1999.
296. McGwin, G., Jr., Metzger, J., Moran, S. G., Rue, L. W., III. Occupant- and collision-related risk factors for blunt thoracic aorta injury. *J. Trauma* 54:655–660, 2003.
297. Gammie, J. S., Katz, W. E., Swanson, E. R., Peitzman, A. B. Acute aortic dissection after blunt chest trauma. *J. Trauma* 40:126–127, 1996.
298. Munshi, I. A. Aortic dissection after blunt trauma. *J. Trauma* 55:1181, 2003.
299. Mimasaka, S., Yajima, Y., Hashiyada, M., Nata, M., Oba, M., Funayama, M. A case of aortic dissection caused by blunt chest trauma. *Forensic Sci. Int.* 132:5–8, 2003.
300. Sharples, E. J., Sobeh, M., Matson, M., Yaqoob, M. M. Renal artery dissection after blunt abdominal trauma: a rare cause of acute cortical necrosis. *Am. J. Kidney Dis.* 40:E11, 2002.
301. Mangiante, E. C., Voeller, G. R., Kisk, K. A., Fabian, T. C. Blunt injury of the abdominal aorta. *J. Tenn. Med. Assoc.* 82:255–256, 1989.
302. Hirose, H., Gill, I. S. Blunt injury of proximal innominate artery. *Ann. Thorac. Cardiovasc. Surg.* 10:130–132, 2004.
303. Karmy-Jones, R., DuBose, R., King, S. Traumatic rupture of the innominate artery. *Eur. J. Cardiothorac. Surg.* 23:782–787, 2003.
304. Sturm, J. T., Strate, R. G., Mowlem, A., Quattlebaum, F. W., Perry, J. F., Jr. Blunt trauma to the subclavian artery. *Surg. Gynecol. Obstet.* 138:915–918, 1974.
305. Yoak, M. B., Beaver, B. L., Denning, D. A. Blunt traumatic subclavian artery injury. *W. V. Med. J.* 96:403–404, 2000.
306. Kaplan, J. A. Delayed fatal hemothorax due to traumatic carotid dissection: a case report of a previously unreported cause of death. *J. Forensic Sci.* 39:552–556, 1994.

307. Posner, M. P., Deitrick, J., McGrath, P., et al. Nonpenetrating vascular injury to the subclavian artery. *J. Vasc. Surg.* 8:611–617, 1988.
308. Rozendaal, F. W., Bonjer, H. J., Bruining, H. A. Late haemorrhage from the subclavian vein due to a fracture of the first rib. *Injury* 26:57–58, 1995.
309. Galbraith, N. F., Urschel, H. C., Jr., Wood, R. E., Razzuk, M. A., Paulson, D. L. Fracture of first rib associated with laceration of subclavian artery. Report of a case and review of the literature. *J. Thorac. Cardiovasc. Surg.* 65:649–652, 1973.
310. Clements, R. H., Wagmeister, L. S., Carraway, R. P. Blunt intrapericardial rupture of the pulmonary artery in a surviving patient. *Ann. Thorac. Surg.* 64:258–260, 1997.
311. Katz, D. S., Groskin, S. A. Pulmonary artery laceration and tension pneumothorax in blunt chest trauma. *J. Thorac. Imaging* 8:156–158, 1993.
312. Collins, M. P., Robinson, G. C. Traumatic rupture of the pulmonary artery. *Ann. Thorac. Surg.* 47:612–613, 1989.
313. Ambrose, G., Barrett, L. O., Angus, G. L., Absi, T., Shaftan, G. W. Main pulmonary artery laceration after blunt trauma: accurate preoperative diagnosis. *Ann. Thorac. Surg.* 70:955–957, 2000.
314. Hanline, M. H., Jr. Blunt traumatic rupture of the main pulmonary vessels. *South. Med. J.* 76:541–542, 1983.
315. Le Guyader, A., Bertin, F., Laskar, M., Cornu, E. Blunt chest trauma: a right pulmonary vein rupture. *Eur. J. Cardiothorac. Surg.* 20:1054–1056, 2001.
316. Varghese, D., Patel, H., Cameron, E. W., Robson, M. Repair of pulmonary vein rupture after deceleration injury. *Ann. Thorac. Surg.* 70:656–658, 2000.
317. Kluth, M., Luiz, T., Lehnert, S., Boettcher, M. [Airbag associated deceleration trauma with complete infradiaphragmatic dissection of the inferior vena cava (IVC) and tear of liver veins]. *Anesthesiol. Intensivmed. Notfallmed. Schmerzther* 39:24–27, 2004.
318. Peitzman, A. B., Udekwu, A. O., Pevec, W., Albrink, M. Transection of the inferior vena cava from blunt thoracic trauma: case reports. *J. Trauma* 29:534–536, 1989.
319. van de Wal, H. J., Draaisma, J. M., Vincent, J. G., Goris, R. J. Rupture of the supradiaphragmatic inferior vena cava by blunt decelerating trauma: case report. *J. Trauma* 30:111–113, 1990.
320. Couves, C. M., Heughan, C. Laceration of superior vena cava due to blunt trauma: successful surgical management. *Can. J. Surg.* 24:402–403, 1981.
321. Fey, G. L., Deren, M. M., Wesolek, J. H. Intrapericardial caval injury due to blunt trauma. *Conn. Med.* 63:259–260, 1999.
322. Takeuchi, M., Maruyama, K., Nakamura, M., et al. Posttraumatic inferior vena caval thrombosis: case report and review of the literature. *J. Trauma* 39:605–608, 1995.
323. Shkrum, M. J., Green, R. N., Shum, D. T. Azygos vein laceration due to blunt trauma. *J. Forensic Sci.* 36:410–421, 1991.
324. Cagini, L., Boaron, M., Corneli, G., et al. Rupture of the azygos vein in blunt chest trauma. *J. Cardiovasc. Surg. (Torino)* 39:249–250, 1998.
325. Sharma, O. P., Rawitscher, R. E. Blunt vena azygos trauma: report of a case and review of world literature. *J. Trauma* 46:192–195, 1999.
326. Bowles, B. J., Teruya, T., Belzberg, H., Rivkind, A. I. Blunt traumatic azygous vein injury diagnosed by computed tomography: case report and review of the literature. *J. Trauma* 49:776–779, 2000.
327. Sugimoto, K., Asari, Y., Hirata, M., Imai, H., Ohwada, T. The diagnostic problem associated with blunt traumatic azygous vein injury: delayed appearance of right haemothorax after blunt chest trauma. *Injury* 29:380–382, 1998.
328. Inoue, H., Iwasaki, M., Shiota, S., Ogawa, J., Shohtsu, A. Total avulsion of the azygos vein and longitudinal laceration of the mediastinal pleura due to blunt chest trauma: a case report. *J. Cardiovasc. Surg. (Torino)* 34:67–68, 1993.
329. Boyd, A. D., Glassman, L. R. Trauma to the lung. *Chest Surg. Clin. N. Am.* 7:263–284, 1997.



330. Kiser, A. C., O'Brien, S. M., Detterbeck, F. C. Blunt tracheobronchial injuries: treatment and outcomes. *Ann. Thorac. Surg.* 71:2059–2065, 2001.
331. Hankins, J. R., McAslan, T. C., Shin, B., Ayella, R., Cowley, R. A., McLaughlin, J. S. Extensive pulmonary laceration caused by blunt trauma. *J. Thorac. Cardiovasc. Surg.* 74:519–527, 1977.
332. Mordehai, J., Kurzbart, E., Kapuller, V., Mares, A. J. Tracheal rupture after blunt chest trauma in a child. *J. Pediatr. Surg.* 32:104–105, 1997.
333. Pratt, L. W., Smith, R. J., Guite, L. A., Jr., Tryzelaar, J. F. Blunt chest trauma with tracheo-bronchial rupture. *Ann. Otol. Rhinol. Laryngol.* 93:357–363, 1984.
334. Tomlanovich, M. C. Pulmonary parenchymal injuries. *Emerg. Med. Clin. North Am.* 1:379–392, 1983.
335. Miller, P. R., Croce, M. A., Bee, T. K., et al. ARDS after pulmonary contusion: accurate measurement of contusion volume identifies high-risk patients. *J. Trauma* 51:223–228, 2001.
336. Wagner, R. B., Crawford, W. O., Jr., Schimpf, P. P., Jamieson, P. M., Rao, K. C. Quantitation and pattern of parenchymal lung injury in blunt chest trauma. Diagnostic and therapeutic implications. *J. Comput. Tomogr.* 12:270–281, 1988.
337. Kunisch-Hoppe, M., Hoppe, M., Rauber, K., Popella, C., Rau, W. S. Tracheal rupture caused by blunt chest trauma: radiological and clinical features. *Eur. Radiol.* 10:480–483, 2000.
338. Mansour, K. A. Trauma to the diaphragm. *Chest Surg. Clin. N. Am.* 7:373–383, 1997.
339. Rubikas, R. Diaphragmatic injuries. *Eur. J. Cardiothorac Surg.* 20:53–57, 2001.
340. Rodriguez-Morales, G., Rodriguez, A., Shatney, C. H. Acute rupture of the diaphragm in blunt trauma: analysis of 60 patients. *J. Trauma* 26:438–444, 1986.
341. Rosati, C. Acute traumatic injury of the diaphragm. *Chest Surg. Clin. N. Am.* 8:371–379, 1998.
342. Sama, S., Kivioja, A. Blunt rupture of the diaphragm. A retrospective analysis of 41 patients. *Ann. Chir. Gynaecol.* 84:261–265, 1995.
343. Lee, W. C., Chen, R. J., Fang, J. F., et al. Rupture of the diaphragm after blunt trauma. *Eur. J. Surg.* 160:479–483, 1994.
344. Kearney, P. A., Rouhana, S. W., Burney, R. E. Blunt rupture of the diaphragm: mechanism, diagnosis, and treatment. *Ann. Emerg. Med.* 18:1326–1330, 1989.
345. Reiff, D. A., McGwin, G., Jr., Metzger, J., Windham, S. T., Doss, M., Rue, L. W., III. Identifying injuries and motor vehicle collision characteristics that together are suggestive of diaphragmatic rupture. *J. Trauma* 53:1139–1145, 2002.
346. Leppaniemi, A., Pohjankyro, A., Haapiainen, R. Acute diaphragmatic rupture after blunt trauma. *Ann. Chir. Gynaecol.* 83:17–21, 1994.
347. Athanassiadi, K., Kalavrouziotis, G., Athanassiou, M., et al. Blunt diaphragmatic rupture. *Eur. J. Cardiothorac. Surg.* 15:469–474, 1999.
348. Holm, A., Bessey, P. Q., Aldrete, J. S. Diaphragmatic rupture due to blunt trauma: morbidity and mortality in 42 cases. *South. Med. J.* 81:956–962, 1988.
349. Humphreys, T. R., Abbuhl, S. Massive bilateral diaphragmatic rupture after an apparently minor automobile accident. *Am. J. Emerg. Med.* 9:246–249, 1991.
350. Chen, J. C., Wilson, S. E. Diaphragmatic injuries: recognition and management in sixty-two patients. *Am. Surg.* 57:810–815, 1991.
351. Estrera, A. S., Landay, M. J., McClelland, R. N. Blunt traumatic rupture of the right hemidiaphragm: experience in 12 patients. *Ann. Thorac. Surg.* 39:525–530, 1985.
352. Meyers, B. F., McCabe, C. J. Traumatic diaphragmatic hernia. Occult marker of serious injury. *Ann. Surg.* 218:783–790, 1993.
353. Tejerina Alvarez, E. E., Holanda, M. S., Lopez-Espadas, F., Dominguez, M. J., Ots, E., Diaz-Reganon, J. Gastric rupture from blunt abdominal trauma. *Injury* 35:228–231, 2004.
354. Shinkawa, H., Yasuhara, H., Naka, S., et al. Characteristic features of abdominal organ injuries associated with gastric rupture in blunt abdominal trauma. *Am. J. Surg.* 187:394–397, 2004.

355. Evers, K., DeGaeta, L. R. Abdominal trauma. *Emerg. Med. Clin. North Am.* 3:525–539, 1985.
356. Hardy, K. J. Patterns of liver injury after fatal blunt trauma. *Surg. Gynecol. Obstet.* 134:39–43, 1972.
357. Cox, E. F., Flancbaum, L., Dauterive, A. H., Paulson, R. L. Blunt trauma to the liver. Analysis of management and mortality in 323 consecutive patients. *Ann. Surg.* 207:126–134, 1988.
358. Taff, M. L., Wolodzko, A. A., Boglioli, L. R. Sudden death due to delayed rupture of hepatic subcapsular hematoma following blunt abdominal trauma. *Am. J. Forensic Med. Pathol.* 11:270–274, 1990.
359. Francque, S., Condat, B., Asselah, T., et al. Multifactorial aetiology of hepatic infarction: a case report with literature review. *Eur. J. Gastroenterol. Hepatol.* 16:411–415, 2004.
360. Aoki, Y., Nata, M., Hashiyada, M., Sagisaka, K. Laceration of the liver with delayed massive intra-abdominal hemorrhage: a case report of child abuse. *Nippon Hoigaku Zasshi* 51:44–47, 1997.
361. Goettler, C. E., Stallion, A., Grisoni, E. R., Dudgeon, D. L. Delayed hemorrhage after blunt hepatic trauma: case report. *J. Trauma* 52:556–559, 2002.
362. Cathey, K. L., Brady, W. J., Jr., Butler, K., Blow, O., Cephas, G. A., Young, J. S. Blunt splenic trauma: characteristics of patients requiring urgent laparotomy. *Am. Surg.* 64:450–454, 1998.
363. Bellemore, M. C., Power, A. R. Splenic trauma from blunt abdominal injury. *Aust. N. Z. J. Surg.* 51:39–45, 1981.
364. Arden, G. P., Christian, M. S., Williams, E. J. Traumatic rupture of the spleen. *Int. Surg.* 66:149–153, 1981.
365. Traub, A. C., Perry, J. F., Jr. Injuries associated with splenic trauma. *J. Trauma* 21:840–847, 1981.
366. Kairaluoma, M. I., Tarkka, M., Mokka, R. E., et al. Traumatic splenic rupture. *Ann. Chir. Gynaecol.* 66:154–159, 1977.
367. McIndoe, A. H. Delayed haemorrhage following traumatic rupture of the spleen. *Br. J. Surg.* 20:249–267, 1931.
368. Dang, C., Schlater, T., Bui, H., Oshita, T. Delayed rupture of the spleen. *Ann. Emerg. Med.* 19:399–403, 1990.
369. Parithivel, V. S., Sajja, S. B., Basu, A., Schein, M., Gerst, P. H. Delayed presentation of splenic injury: still a common syndrome. *Int. Surg.* 87:120–124, 2002.
370. Black, J. J., Sinow, R. M., Wilson, S. E., Williams, R. A. Subcapsular hematoma as a predictor of delayed splenic rupture. *Am. Surg.* 58:732–735, 1992.
371. Washburn, M. E., Balk, M. W., Mazat, B. A., Zurlo, J. A. Experimental subcapsular hematoma of the spleen: natural history and radioisotope scan correlation. *Ann. Surg.* 187:407–410, 1978.
372. Berlatzky, Y., Shiloni, E., Anner, H., Weiss, Y. “Delayed rupture of the spleen” or delayed diagnosis of the splenic injury? *Isr. J. Med. Sci.* 16:659–664, 1980.
373. Bergqvist, D., Hedelin, H., Lindblad, B. Traumatic splenic rupture during 30 years. An analysis of 88 cases with special attention to delayed rupture. *Acta Chir. Scand.* 146:41–45, 1980.
374. Hiraide, A., Yamamoto, H., Yahata, K., Yoshioka, T., Sugimoto, T. Delayed rupture of the spleen caused by an intrasplenic pseudoaneurysm following blunt trauma: case report. *J. Trauma* 36:743–744, 1994.
375. Clark, O. H., Lim, R. C., Jr., Margaretten, W. Spontaneous delayed splenic rupture—case report of a five-year interval between trauma and diagnosis. *J. Trauma* 15:245–249, 1975.
376. Fagelman, D., Hertz, M. A., Ross, A. S. Delayed development of splenic subcapsular hematoma: CT evaluation. *J. Comput. Assist. Tomogr.* 9:815–816, 1985.
377. Benjamin, C. I., Engrav, L. H., Perry, J. F., Jr. Delayed rupture or delayed diagnosis of rupture of the spleen. *Surg. Gynecol. Obstet.* 142:171–172, 1976.

378. Krause, K. R., Howells, G. A., Bair, H. A., et al. Nonoperative management of blunt splenic injury in adults 55 years and older: a twenty-year experience. *Am. Surg.* 66:636–640, 2000.
379. Gruenberg, J. C., Horan, D. P. Delayed splenic rupture: the phoenix. *J. Trauma* 23:159–160, 1983.
380. Brown, R. L., Irish, M. S., McCabe, A. J., Glick, P. L., Caty, M. G. Observation of splenic trauma: when is a little too much? *J. Pediatr. Surg.* 34:1124–1126, 1999.
381. Farhat, G. A., Abdu, R. A., Vanek, V. W. Delayed splenic rupture: real or imaginary? *Am. Surg.* 58:340–345, 1992.
382. Blatt, C. J., Meng, C. H. Traumatic subcapsular hematoma in delayed splenic rupture. *Am. J. Gastroenterol.* 60:592–601, 1973.
383. Jean-Baptiste, C., Suarez, J. R. Subcapsular hematoma of spleen. *N. Y. State J. Med.* 72:739–741, 1972.
384. Olsen, W. R. Editorial: Delayed rupture of the spleen as an index of diagnostic accuracy. *Surg. Gynecol. Obstet.* 138:82, 1974.
385. Leppaniemi, A., Haapiainen, R., Standertskjold-Nordenstam, C. G., Taavitsainen, M., Hastbacka, J. Delayed presentation of blunt splenic injury. *Am. J. Surg.* 155:745–749, 1988.
386. Lieberman, R. C., Welch, C. S. A study of 248 instances of traumatic rupture of the spleen. *Surg. Gynecol. Obstet.* 127:961–965, 1968.
387. Deva, A. K., Thompson, J. F. Delayed rupture of the spleen 5 1/2 years after conservative management of traumatic splenic injury. *Aust. N. Z. J. Surg.* 66:494–495, 1996.
388. Andersen, R., Pratt, D., Hitchcock, C. Splenectomy following abdominal trauma. Proceedings of the 13th AAAM Conference 1969. Association for the Advancement of Automotive Medicine, Des Plaines, IL, 1969.
389. Farhi, D. C., Ashfaq, R. Splenic pathology after traumatic injury. *Am. J. Clin. Pathol.* 105:474–478, 1996.
390. McMahon, M. J., Lintott, J. D., Mair, W. S., Lee, P. W., Duthie, J. S. Occult rupture of the spleen. *Br. J. Surg.* 64:641–643, 1977.
391. Sizer, J. S., Wayne, E. R., Frederick, P. L. Delayed rupture of the spleen. Review of the literature and report of six cases. *Arch. Surg.* 92:362–366, 1966.
392. Fernandes, C. M. Splenic rupture manifesting two years after diagnosis of injury. *Acad. Emerg. Med.* 3:946–947, 1996.
393. Lynch, J. M., Meza, M. P., Newman, B., Gardner, M. J., Albanese, C. T. Computed tomography grade of splenic injury is predictive of the time required for radiographic healing. *J. Pediatr. Surg.* 32:1093–1095, 1997.
394. Sziklas, J. J., Spencer, R. P., Rosenberg, R. J. Delayed splenic rupture: a suggestion for “predictive monitoring.” *J. Nucl. Med.* 26:609–611, 1985.
395. Reiff, D. A., McGwin, G., Jr., Rue, L. W., III. Splenic injury in side impact motor vehicle collisions: effect of occupant restraints. *J. Trauma* 51:340–345, 2001.
396. Huelke, D. F., Sherman, H. W., Steigmeyer, J. L. Side impacts to the passenger compartment—clinical studies from field accident investigations. SAE Report 890379. Society of Automotive Engineers, Inc., Warrendale, PA, 1989.
397. Magee, R. B., D’Luzansky, J. J. Acute blunt traumatic rupture of the spleen. *Arch. Surg.* 99:121–122, 1969.
398. Bailey, J., Shapiro, M. J. Abdominal compartment syndrome. *Crit. Care* 4:23–29, 2000.
399. Baylis, S. M., Lansing, E. H., Glas, W. W. Traumatic retroperitoneal hematoma. *Am. J. Surg.* 103:477–480, 1962.
400. Arrizabalaga, M., Benitez, J., Gallardo, C., Garrido, R., Casanueva, T. [Retroperitoneal hematoma secondary to traumatic rupture of the psoas muscle]. *Actas Urol. Esp.* 14:36–38, 1990.
401. Adams, J. E., Davis, G. G., Heidepriem, R. W., III, Alonso, J. E., Alexander, C. B. Analysis of the incidence of pelvic trauma in fatal automobile accidents. *Am. J. Forensic Med. Pathol.* 23:132–136, 2002.

402. Richter, M., Otte, D., Gansslen, A., Bartram, H., Pohlemann, T. Injuries of the pelvic ring in road traffic accidents: a medical and technical analysis. *Injury* 32:123–128, 2001.
403. Dalal SA, Burgess AR, Siegel JH, et al. Pelvic fracture in multiple trauma: classification by mechanism is key to pattern of organ injury, resuscitative requirements, and outcome. *J. Trauma* 29:981–1000, 1989.
404. MacLeod, M., Powell, J. N. Evaluation of pelvic fractures. *Clinical and radiologic. Orthop. Clin. North Am.* 28:299–319, 1997.
405. Tile, M. Pelvic ring fractures: should they be fixed? *J. Bone Joint Surg. Br.* 70:1–12, 1988.
406. McCoy, G. F., Johnstone, R. A., Kenwright, J. Biomechanical aspects of pelvic and hip injuries in road traffic accidents. *J. Orthop. Trauma* 3:118–123, 1989.
407. Demetriades, D., Karaiskakis, M., Toutouzas, K., Alo, K., Velmahos, G., Chan, L. Pelvic fractures: epidemiology and predictors of associated abdominal injuries and outcomes. *J. Am. Coll. Surg.* 195:1–10, 2002.
408. Banglmaier, R. F., Rouhana, S. W., Beillas, P., Yang, K. H. Lower extremity injuries in lateral impact: a retrospective study. *Annu. Proc. Assoc. Adv. Automot. Med.* 47:425–444, 2003.
409. Adams, J. E., Davis, G. G., Alexander, C. B., Alonso, J. E. Pelvic trauma in rapidly fatal motor vehicle accidents. *J. Orthop. Trauma* 17:406–410, 2003.
410. Rittmeister, M., Lindsey, R. W., Kohl, H. W., III. Pelvic fracture among polytrauma decedents. Trauma-based mortality with pelvic fracture—a case series of 74 patients. *Arch. Orthop. Trauma Surg.* 121:43–49, 2001.
411. Demetriades, D., Karaiskakis, M., Velmahos, G. C., Alo, K., Murray, J., Chan, L. Pelvic fractures in pediatric and adult trauma patients: are they different injuries? *J. Trauma* 54:1146–1151, 2003.
412. Gansslen, A., Pohlemann, T., Paul, C., Lobenhoffer, P., Tscherne, H. Epidemiology of pelvic ring injuries. *Injury* 27 Suppl. 1:S-A13–20, 1996.
413. Eastridge, B. J., Burgess, A. R. Pedestrian pelvic fractures: 5-year experience of a major urban trauma center. *J. Trauma* 42:695–700, 1997.
414. Isler, B., Ganz, R. Classification of pelvic ring injuries. *Injury* 27 Suppl. 1:S-12, 1996.
415. Suzuki, T., Yoshikawa, K., Umetsu, K., Harada, A. Sudden death from tourniquet shock. *Forensic Sci. Int.* 61:185–190, 1993.
416. Mellor, A., Soni, N. Fat embolism. *Anaesthesia* 56:145–154, 2001.
417. Dudley, T. M., Elliott, C. G. Pulmonary embolism from amniotic fluid, fat, and air. *Prog. Cardiovasc. Dis.* 36:447–474, 1994.
418. Bulger, E. M., Smith, D. G., Maier, R. V., Jurkovich, G. J. Fat embolism syndrome. A 10-year review. *Arch. Surg.* 132:435–439, 1997.
419. Fulde, G. W., Harrison, P. Fat embolism—a review. *Arch. Emerg. Med.* 8:233–239, 1991.
420. King, M. B., Harmon, K. R. Unusual forms of pulmonary embolism. *Clin. Chest Med.* 15:561–580, 1994.
421. Levy, D. The fat embolism syndrome. A review. *Clin. Orthop. Relat. Res.* 281–286, 1990.
422. ten Duis, H. J. The fat embolism syndrome. *Injury* 28:77–85, 1997.
423. Johnson, M. J., Lucas, G. L. Fat embolism syndrome. *Orthopedics* 19:41–48, 1996.
424. Hulman, G. The pathogenesis of fat embolism. *J. Pathol.* 176:3–9, 1995.
425. Lee, K. A., Opeskin, K. Death due to superficial soft tissue injuries. *Am. J. Forensic Med. Pathol.* 13:179–185, 1992.
426. Nichols, G. R., Corey, T. S., Davis, G. J. Nonfracture-associated fatal fat embolism in a case of child abuse. *J. Forensic Sci.* 35:493–499, 1990.
427. Richards, R. R. Fat embolism syndrome. *Can. J. Surg.* 40:334–339, 1997.
428. Parisi, D. M., Koval, K., Ego, I. K. Fat embolism syndrome. *Am. J. Orthop.* 31:507–512, 2002.
429. Fiallos, M., Kissoon, N., Abdelmoneim, T., et al. Fat embolism with the use of intraosseous infusion during cardiopulmonary resuscitation. *Am. J. Med. Sci.* 314:73–79, 1997.

- 430. Hulman, G. Pathogenesis of non-traumatic fat embolism. *Lancet* 1:1366–1367, 1988.
- 431. Peltier, L. F. Fat embolism. A current concept. *Clin. Orthop. Relat. Res.* 66:241–253, 1969.
- 432. Gossling, H. R., Donohue, T. A. The fat embolism syndrome. *JAMA* 241:2740–2742, 1979.
- 433. King, E. G., Wagner, W. W., Jr., Ashbaugh, D. G., Latham, L. P., Halsey, D. R. Alterations in pulmonary microanatomy after fat embolism. In vivo observations via thoracic window of the oleic acid-embolized canine lung. *Chest* 59:524–530, 1971.
- 434. Saldeen, T. The importance of intravascular coagulation and inhibition of the fibrinolytic system in experimental fat embolism. *J. Trauma* 10:287–298, 1970.
- 435. King, E. G., Weily, H. S., Genton, E., Ashbaugh, D. G. Consumption coagulopathy in the canine oleic acid model of fat embolism. *Surgery* 69:533–541, 1971.
- 436. Bradford, D. S., Foster, R. R., Nossel, H. L. Coagulation alterations, hypoxemia, and fat embolism in fracture patients. *J. Trauma* 10:307–321, 1970.
- 437. Tedeschi, C. G., Castelli, W., Kropp, G., Tedeschi, L. G. Fat macroglobulinemia and fat embolism. *Surg. Gynecol. Obstet.* 126:83–90, 1968.
- 438. Muller, C., Rahn, B. A., Pfister, U., Meinig, R. P. The incidence, pathogenesis, diagnosis, and treatment of fat embolism. *Orthop. Rev.* 23:107–117, 1994.
- 439. Robert, J. H., Hoffmeyer, P., Broquet, P. E., Cerutti, P., Vasey, H. Fat embolism syndrome. *Orthop. Rev.* 22:567–571, 1993.
- 440. Davison, P. R., Cohle, S. D. Histologic detection of fat emboli. *J. Forensic Sci.* 32:1426–1430, 1987.
- 441. Buchanan, D., Mason, J. K. Occurrence of pulmonary fat and bone marrow embolism. *Am. J. Forensic Med. Pathol.* 3:73–78, 1982.
- 442. Suzuki, T., Ikeda, N., Umetsu, K. Pulmonary bone marrow embolic phenomena. Antemortem reactions in traumatic immediate death. *Am. J. Forensic Med. Pathol.* 8:283–286, 1987.
- 443. Dzieciol, J., Kemon, A., Gorska, M., et al. Widespread myocardial and pulmonary bone marrow embolism following cardiac massage. *Forensic Sci. Int.* 56:195–199, 1992.
- 444. Shackford, S. R., Davis, J. W., Hollingsworth-Fridlund, P., Brewer, N. S., Hoyt, D. B., Mackersie, R. C. Venous thromboembolism in patients with major trauma. *Am. J. Surg.* 159:365–369, 1990.
- 445. Knudson, M. M., Ikossi, D. G. Venous thromboembolism after trauma. *Curr. Opin. Crit. Care* 10:539–548, 2004.
- 446. Anderson, F. A., Jr., Spencer, F. A. Risk factors for venous thromboembolism. *Circulation* 107:I9–I16, 2003.
- 447. Knudson, M. M., Ikossi, D. G., Khaw, L., Morabito, D., Speetzen, L. S. Thromboembolism after trauma: an analysis of 1602 episodes from the American College of Surgeons National Trauma Data Bank. *Ann. Surg.* 240:490–496, 2004.
- 448. Meissner, M. H. Deep venous thrombosis in the trauma patient. *Semin. Vasc. Surg.* 11:274–282, 1998.
- 449. McBride, W. J., Gadowski, G. R., Keller, M. S., Vane, D. W. Pulmonary embolism in pediatric trauma patients. *J. Trauma* 37:913–915, 1994.
- 450. Vavilala, M. S., Nathens, A. B., Jurkovich, G. J., Mackenzie, E., Rivara, F. P. Risk factors for venous thromboembolism in pediatric trauma. *J. Trauma* 52:922–927, 2002.
- 451. Geerts, W. H., Code, K. I., Jay, R. M., Chen, E., Szalai, J. P. A prospective study of venous thromboembolism after major trauma. *N. Engl. J. Med.* 331:1601–1606, 1994.
- 452. Kearon, C. Natural history of venous thromboembolism. *Circulation* 107:I22–I30, 2003.
- 453. Sevitt, S., Gallagher, N. Venous thrombosis and pulmonary embolism. A clinico-pathological study in injured and burned patients. *Br. J. Surg.* 48:475–489, 1961.
- 454. Sevitt, S. Fatal road accidents. Injuries, complications, and causes of death in 250 subjects. *Br. J. Surg.* 55:481–505, 1968.



455. McManus, B. M., Allard, M. F., Yanagawa, B. Hemodynamic disorders. In: Rubin, E., Gorstein, F., Rubin, R., Schwartz, R., Strayer, D., eds. *Rubin's Pathology: Clinicopathologic Foundations of Medicine*. 4th edition. Lippincott Williams and Wilkins, Baltimore, pp. 280–311, 2005.
456. Davis, G. J., McCloud, L. C., Nichols, G. R., Martin, A. W. Cerebral tissue pulmonary embolization due to head trauma: a case report with immunohistochemical confirmation. *J. Forensic Sci.* 36:921–925, 1991.
457. King, D. E. Discussion of "Cerebral tissue embolization due to head trauma: a case report with immunohistochemical confirmation." *J. Forensic Sci.* 37:682–684, 1992.
458. Collins, K. A., Davis, G. J. A retrospective and prospective study of cerebral tissue pulmonary embolism in severe head trauma. *J. Forensic Sci.* 39:624–628, 1994.
459. McMillan, J. B. Emboli of cerebral tissue in the lungs following severe head injury. *Am. J. Pathol.* 32:405–415, 1956.
460. Tackett, L. R. Brain tissue pulmonary emboli. *Arch. Pathol.* 78:292–294, 1964.
461. Karkola, K., Mottonen, M. Embolism of brain tissue to the pulmonary arteries after head injury. *Med. Sci. Law* 11:149–150, 1971.
462. Torry, J. M. Massive brain tissue and fat pulmonary embolism following severe head injury. *Med. Sci. Law* 27:128–131, 1987.
463. Takatsu, A., Shigeta, A., Abe, M., Kitune, K., Kawai, T. Embolism of massive hepatic tissue in inferior vena cava and right atrium after closed liver injury. *Am. J. Forensic Med. Pathol.* 9:233–235, 1988.
464. Voitek, A. J., Munkittrick, R. C. A fatal pulmonary embolus composed of gross liver tissue. *Can. J. Surg.* 29:218–219, 1986.
465. Michalodimitrakis, M., Tsatsakis, A. Massive pulmonary embolism by liver tissue. *Med. Sci. Law* 38:85–87, 1998.
466. Moar, J. J. Pulmonary embolism due to hepatic tissue—a forensic vital sign? A case report. *S. Afr. Med. J.* 66:699–700, 1984.
467. Olcott, C., Robinson, A. J., Maxwell, T. M., Griffin, H. A. Amniotic fluid embolism and disseminated intravascular coagulation after blunt abdominal trauma. *J. Trauma* 13:737–740, 1973.
468. Lau, G., Chui, P. P. Amniotic fluid embolism: a review of 10 fatal cases. *Singapore Med. J.* 35:180–183, 1994.
469. Judich, A., Kuriansky, J., Engelberg, I., Haik, J., Shabtai, M., Czerniak, A. Amniotic fluid embolism following blunt abdominal trauma in pregnancy. *Injury* 29:475–477, 1998.
470. Lau, G. Pulmonary cartilage embolism: fact or artefact? *Am. J. Forensic Med. Pathol.* 16:51–53, 1995.
471. Veinot, J. P., Edwards, W. D. Trauma-related embolization of cartilage to the lungs. Case report of a 41-year-old man. *Am. J. Forensic Med. Pathol.* 15:138–141, 1994.
472. Messmer, J. M. Massive head trauma as a cause of intravascular air. *J. Forensic Sci.* 29:418–424, 1984.
473. Slater, D. N. Bone marrow emboli. *Am. J. Forensic Med. Pathol.* 9:357–358, 1988.
474. Merigian, K. S., Roberts, J. R. Cocaine intoxication: hyperpyrexia, rhabdomyolysis and acute renal failure. *J. Toxicol. Clin. Toxicol.* 25:135–148, 1987.
475. Nolte, K. B. Rhabdomyolysis associated with cocaine abuse. *Hum. Pathol.* 22:1141–1145, 1991.
476. Korantzopoulos, P., Papaioannides, D., Sinapidis, D., Kolios, P. Acute rhabdomyolysis due to prolonged exposure to the cold. *Int. J. Clin. Pract.* 57:243–244, 2003.
477. Lazarus, D., Hudson, D. A. Fatal rhabdomyolysis in a flame burn patient. *Burns* 23:446–450, 1997.
478. Poels, P. J., Gabreels, F. J. Rhabdomyolysis: a review of the literature. *Clin. Neurol. Neurosurg.* 95:175–192, 1993.

479. Brumback, R. A., Feeback, D. L., Leech, R. W. Rhabdomyolysis following electrical injury. *Semin. Neurol.* 15:329–334, 1995.
480. Bonnor, R., Siddiqui, M., Ahuja, T. S. Rhabdomyolysis associated with near-drowning. *Am. J. Med. Sci.* 318:201–202, 1999.
481. Chaikin, H. L. Rhabdomyolysis secondary to drug overdose and prolonged coma. *South. Med. J.* 73:990–994, 1980.
482. Mercieca, J., Brown, E.A. Acute renal failure due to rhabdomyolysis associated with use of a straitjacket in lysergide intoxication. *Br. Med. J. (Clin. Res. Ed.)* 288:1949–1950, 1984.
483. Horowitz, R., Siegel, J., Flaster, M., Maldonado, W. E. Injury patterns in motor vehicle fatalities. *J. Forensic Sci.* 32:167–172, 1987.
484. Tonge, J. I., O'Reilly, M. J., Davison, A., Johnston, N. G., Wilkey, I. S. Traffic-crash fatalities 1968–73.: injury patterns and other factors. *Med. Sci. Law* 17:9–24, 1977.
485. Akane, A., Shiono, H., Matsubara, K., Takahashi, S. Identification of the driver in an automobile collision. *Am. J. Forensic Med. Pathol.* 11:246–251, 1990.
486. Smock, W. S., Nichols, G. R., Fuller, P. M., Weakley-Jones, B. The forensic pathologist and the determination of driver versus passenger in motor vehicle collisions. The need to examine injury mechanisms, occupant kinematics, vehicle dynamics, and trace evidence. *Am. J. Forensic Med. Pathol.* 10:105–114, 1989.
487. Daffner, R. H., Deeb, Z. L., Lupetin, A. R., Rothfus, W. E. Patterns of high-speed impact injuries in motor vehicle occupants. *J. Trauma* 28:498–501, 1988.
488. Sweitzer, R. E., Rink, R. D., Corey, T., Goldsmith, J. Children in motor vehicle collisions: analysis of injury by restraint use and seat location. *J. Forensic Sci.* 47:1049–1054, 2002.
489. Weisz, G. M., Schramek, A., Barzilai, A. Injury to the driver. *J. Trauma* 14:212–215, 1974.
490. Yoganandan, N., Pintar, F. A., Gennarelli, T. A., Maltese, M. R. Patterns of abdominal injuries in frontal and side impacts. *Annu. Proc. Assoc. Adv. Automot. Med.* 44:17–36, 2000.
491. Stefanopoulos, N., Vagianos, C., Stavropoulos, M., Panagiotopoulos, E., Androulakis, J. Deformations and intrusions of the passenger compartment as indicators of injury severity and triage in head-on collisions of non-airbag-carrying vehicles. *Injury* 34:487–492, 2003.
492. Mittleman, R. E. Cervical airway injuries as a result of impact with steering wheel rim. *J. Forensic Sci.* 33:1198–1205, 1988.
493. Fildes, B., Lenard, J., Lane, J., Vulcan, P., Seyer, K. Lower limb injuries to passenger car occupants. *Accid. Anal. Prev.* 29:785–791, 1997.
494. Acierno, S., Kaufman, R., Rivara, F. P., Grossman, D. C., Mock, C. Vehicle mismatch: injury patterns and severity. *Accid. Anal. Prev.* 36:761–772, 2004.
495. Siegel, J. H., Mason-Gonzalez, S., Dischinger, P., et al. Safety belt restraints and compartment intrusions in frontal and lateral motor vehicle crashes: mechanisms of injuries, complications, and acute care costs. *J. Trauma* 34:736–758, 1993.
496. Richter, M., Thermann, H., Wippermann, B., Otte, D., Schratt, H. E., Tscherne, H. Foot fractures in restrained front seat car occupants: a long-term study over twenty-three years. *J. Orthop. Trauma* 15:287–293, 2001.
497. Thomas, P., Bradford, M. The nature and source of the head injuries sustained by restrained front-seat car occupants in frontal collisions. *Accid. Anal. Prev.* 27:561–570, 1995.
498. Swierzewski, M. J., Feliciano, D. V., Lillis, R. P., Illig, K. A., States, J. D. Deaths from motor vehicle crashes: patterns of injury in restrained and unrestrained victims. *J. Trauma* 37:404–407, 1994.
499. Williams, J. S., Kirkpatrick, J. R. The nature of seat belt injuries. *J. Trauma* 11:207–218, 1971.
500. Garrett, J. W., Braunstein, P. W. The seat belt syndrome. *J. Trauma* 2:220–238, 1962.
501. Asbun, H. J., Irani, H., Roe, E. J., Bloch, J. H. Intra-abdominal seatbelt injury. *J. Trauma* 30:189–193, 1990.

502. Hill, J. R., Mackay, G. M., Morris, A. P. Chest and abdominal injuries caused by seat belt loading. *Accid. Anal. Prev.* 26:11–26, 1994.
503. Sato, T. B. Effects of seat belts and injuries resulting from improper use. *J. Trauma* 27:754–758, 1987.
504. Arajärvi, E., Santavirta, S. Chest injuries sustained in severe traffic accidents by seatbelt wearers. *J. Trauma* 29:37–41, 1989.
505. Reid, A. B., Letts, R. M., Black, G. B. Pediatric Chance fractures: association with intra-abdominal injuries and seatbelt use. *J. Trauma* 30:384–391, 1990.
506. Miltner, E., Salwender, H. J. Influencing factors on the injury severity of restrained front seat occupants in car-to-car head-on collisions. *Accid. Anal. Prev.* 27:143–150, 1995.
507. Santavirta, S., Arajärvi, E. Ruptures of the heart in seatbelt wearers. *J. Trauma* 32:275–279, 1992.
508. Munshi, I. A., Patton, W. A unique pattern of injury secondary to seatbelt-related blunt abdominal trauma. *J. Emerg. Med.* 27:183–185, 2004.
509. Rutledge, R., Thomason, M., Oller, D., et al. The spectrum of abdominal injuries associated with the use of seat belts. *J. Trauma* 31:820–825, 1991.
510. Prince, J. S., LoSasso, B. E., Senac, M. O., Jr. Unusual seat-belt injuries in children. *J. Trauma* 56:420–427, 2004.
511. Nadjem, H., Ropohl, D. Complete transection of the trunk of passengers in car accidents. *Am. J. Forensic Med. Pathol.* 17:167–171, 1996.
512. Bergqvist, D., Dahlgren, S., Hedelin, H. Rupture of the diaphragm in patients wearing seatbelts. *J. Trauma* 18:781–783, 1978.
513. Anderson, P. A., Rivara, F. P., Maier, R. V., Drake, C. The epidemiology of seatbelt-associated injuries. *J. Trauma* 31:60–67, 1991.
514. Tso, E. L., Beaver, B. L., Haller, J. A., Jr. Abdominal injuries in restrained pediatric passengers. *J. Pediatr. Surg.* 28:915–919, 1993.
515. Pedersen, S., Jansen, U. Intestinal lesions caused by incorrectly placed seat belts. *Acta Chir. Scand.* 145:15–18, 1979.
516. Arajärvi, E., Santavirta, S., Tolonen, J. Abdominal injuries sustained in severe traffic accidents by seatbelt wearers. *J. Trauma* 27:393–397, 1987.
517. Gaines, B. A., Shultz, B. S., Morrison, K., Ford, H. R. Duodenal injuries in children: beware of child abuse. *J. Pediatr. Surg.* 39:600–602, 2004.
518. Hughes, T. M., Elton, C. The pathophysiology and management of bowel and mesenteric injuries due to blunt trauma. *Injury* 33:295–302, 2002.
519. Vandersluis, R., O'Connor, H. M. The seat-belt syndrome. *CMAJ* 137:1023–1024, 1987.
520. Hudson, I., Kavanagh, T. G. Duodenal transection and vertebral injury occurring in combination in a patient wearing a seat belt. *Injury* 15:6–9, 1983.
521. Slavin, R. E., Borzotta, A. P. The seromuscular tear and other intestinal lesions in the seat-belt syndrome: a clinical and pathologic study of 29 cases. *Am. J. Forensic Med. Pathol.* 23:214–222, 2002.
522. Statter, M. B., Coran, A. G. Appendiceal transection in a child associated with a lap belt restraint: case report. *J. Trauma* 33:765–766, 1992.
523. Freeman, C. P. Isolated pancreatic damage following seat belt injury. *Injury* 16:478–480, 1985.
524. Warrian, R. K., Shoenut, J. P., Iannicello, C. M., Sharma, G. P., Trenholm, B. G. Seatbelt injury to the abdominal aorta. *J. Trauma* 28:1505–1507, 1988.
525. Randhawa, M. P., Jr., Menzoian, J. O. Seat belt aorta. *Ann. Vasc. Surg.* 4:370–377, 1990.
526. Siriwardena, A. K. Seat-belt aortic injury. *Eur. J. Vasc. Surg.* 4:649–650, 1990.
527. Ali, M. R., Jr., Norcross, E. D., Brothers TE. Iliac and femoral artery occlusion by thromboemboli from an abdominal aortic aneurysm in the setting of blunt abdominal trauma. *J. Vasc. Surg.* 27:545–548, 1998.
528. Dajee, H., Richardson, I. W., Iype, M. O. Seat belt aorta: acute dissection and thrombosis of the abdominal aorta. *Surgery* 85:263–267, 1979.

529. Naude, G. P., Back, M., Perry, M. O., Bongard, F. S. Blunt disruption of the abdominal aorta: report of a case and review of the literature. *J. Vasc. Surg.* 25:931–935, 1997.
530. Riches, K. J., James, R. A., Gilbert, J. D., Byard, R. W. Fatal childhood vascular injuries associated with seat belt use. *Am. J. Forensic Med. Pathol.* 23:45–47, 2002.
531. Dell'Erba, A., Di Vella, G., Giardino, N. Seatbelt injury to the common iliac artery: case report. *J. Forensic Sci.* 43:215–217, 1998.
532. DeCou, J. M., Abrams, R. S., Gauderer, M. W. Seat-belt transection of the pararenal vena cava in a 5-year-old child: survival with caval ligation. *J. Pediatr. Surg.* 34:1074–1076, 1999.
533. Huelke, D. F., Kaufer, H. Vertebral column injuries and seat belts. *J. Trauma* 15:304–318, 1975.
534. Astarita, D. C., Feldman, B. Seat belt placement resulting in uterine rupture. *J. Trauma* 42:738–740, 1997.
535. Matthews, C. D. Incorrectly used seat belt associated with uterine rupture following vehicular collision. *Am. J. Obstet. Gynecol.* 121:1115–1116, 1975.
536. Pepperell, R. J., Rubinstein, E., MacIsaac, I. A. Motor-car accidents during pregnancy. *Med. J. Aust.* 1:203–205, 1977.
537. van Enk, A., van Zwam, W. Uterine rupture. A seat belt hazard. *Acta Obstet. Gynecol. Scand.* 73:432–433, 1994.
538. Klinich, K. D., Schneider, L. W., Moore, J. L., Pearlman, M. D. Investigations of crashes involving pregnant occupants. *Annu. Proc. Assoc. Adv. Automot. Med.* 44:37–55, 2000.
539. Lavin, J. P., Jr., Polsky, S. S. Abdominal trauma during pregnancy. *Clin. Perinatol.* 10:423–438, 1983.
540. Lifschultz, B. D., Donoghue, E. R. Fetal death following maternal trauma: two case reports and a survey of the literature. *J. Forensic Sci.* 36:1740–1744, 1991.
541. Bunai, Y., Nagai, A., Nakamura, I., Ohya, I. Fetal death from abruptio placentae associated with incorrect use of a seatbelt. *Am. J. Forensic Med. Pathol.* 21:207–209, 2000.
542. Evrard, J. R., Sturner, W. Q., Murray, E. J. Fetal skull fracture from an automobile accident. *Am. J. Forensic Med. Pathol.* 10:232–234, 1989.
543. Fries, M. H., Hankins, G. D. Motor vehicle accident associated with minimal maternal trauma but subsequent fetal demise. *Ann. Emerg. Med.* 18:301–304, 1989.
544. Ford, R. M., Picker, R. H. Fetal head injury following motor vehicle accident; an unusual case of intrauterine death. *Aust. N. Z. J. Obstet. Gynaecol.* 29:72–73, 1989.
545. Gogler, H., Athanasiadis, S. Fatal cervical dislocation related to wearing a seat belt: a case report. *Injury* 10:196–200, 1979.
546. Skold, G., Voigt, G. E. Spinal injuries in belt-wearing car occupants killed by head-on collisions. *Injury* 9:151–161, 1977.
547. Sumchai, A., Eliastam, M., Werner, P. Seatbelt cervical injury in an intersection type vehicular collision. *J. Trauma* 28:1384–1388, 1988.
548. Spitz, D. J., Prator, P. C., Stratton, J. E., et al. Neck injuries caused by automatic two-point seat belts: an analysis of four cases. *J. Forensic Sci.* 50:159–163, 2005.
549. Saldeen, T. Fatal neck injuries caused by use of diagonal safety belts. *J. Trauma* 7:856–862, 1967.
550. Veenema, K. R. Strangulation associated with a passive restraint shoulder harness seatbelt: case report. *J. Emerg. Med.* 12:317–320, 1994.
551. McConnell, E. J., Macbeth, G. A. Common carotid artery and tracheal injury from shoulder strap seat belt. *J. Trauma* 43:150–152, 1997.
552. Roh, L. S., Fazzalaro, W. Transection of trachea due to improper application of automatic seat belt (submarine effect). *J. Forensic Sci.* 38:972–977, 1993.
553. Uemura, K., Yoshida, K. Seat belt induced transection of the trachea in a child on the lap of an adult. *J. Forensic Sci.* 46:714–716, 2001.

- 554. Gill, S. S., Dierking, J. M., Nguyen, K. T., Woollen, C. D., Morrow, C. E. Seatbelt injury causing perforation of the cervical esophagus: a case report and review of the literature. *Am. Surg.* 70:32–34, 2004.
- 555. Woelfel, G. F., Moore, E. E., Cogbill, T. H., Van, W. C., III. Severe thoracic and abdominal injuries associated with lap-harness seatbelts. *J. Trauma* 24:166–167, 1984.
- 556. Arajärvi, E., Santavirta, S., Tolonen, J. Aortic ruptures in seat belt wearers. *J. Thorac. Cardiovasc. Surg.* 98:355–361, 1989.
- 557. Hampson, S., Coombs, R., Hemingway, A. Fractures of the upper thoracic spine—an addition to the “seat-belt” syndrome. *Br. J. Radiol.* 1984; 57:1033–1034.
- 558. Reddy, K., Furer, M., West, M., Hamonic, M. Carotid artery dissection secondary to seat-belt trauma: case report. *J. Trauma* 30:630–633, 1990.
- 559. Baik, S., Uku, J. M., Joo, K. G. Seat-belt injuries to the left common carotid artery and left internal carotid artery. *Am. J. Forensic Med. Pathol.* 9:38–39, 1988.
- 560. Ruskey, J., Lieberman, M. E., Shaikh, K. A., Talucci, R. C. Unusual subclavian artery lacerations resulting from lap-shoulder seatbelt trauma: case reports. *J. Trauma* 29:1598–1600, 1989.
- 561. Wexler, L., Silverman, J. Traumatic rupture of the innominate artery—a seat-belt injury. *N. Engl. J. Med.* 282:1186–1187, 1970.
- 562. Hamilton, J. R., Dearden, C., Rutherford, W. H. Myocardial contusion associated with fracture of the sternum: important features of the seat belt syndrome. *Injury* 16:155–156, 1984.
- 563. Nadesan, K. Murder and robbery by vehicular impact: true vehicular homicide. *Am. J. Forensic Med. Pathol.* 21:107–113, 2000.
- 564. Pearlman, M. D., Phillips, M. E. Safety belt use during pregnancy. *Obstet. Gynecol.* 88:1026–1029, 1996.
- 565. Tyroch, A. H., Kaups, K. L., Rohan, J., Song, S., Beingesser, K. Pregnant women and car restraints: beliefs and practices. *J. Trauma* 46:241–245, 1999.
- 566. Agran, P. F., Dunkle, D. E., Winn, D. G. Injuries to a sample of seatbelted children evaluated and treated in a hospital emergency room. *J. Trauma* 27:58–64, 1987.
- 567. Gorski, Z. M., German, A., Nowak, E. S. Examination and analysis of seat belt loading marks. *J. Forensic Sci.* 35:69–79, 1990.
- 568. Chandler, C. F., Lane, J. S., Waxman, K. S. Seatbelt sign following blunt trauma is associated with increased incidence of abdominal injury. *Am. Surg.* 63:885–888, 1997.
- 569. Ball, S. T., Vaccaro, A. R., Albert, T. J., Cotler, J. M. Injuries of the thoracolumbar spine associated with restraint use in head-on motor vehicle accidents. *J. Spinal Disord.* 13:297–304, 2000.
- 570. Williams, R. D., Sargent, F. T. The mechanism of intestinal injury in trauma. *J. Trauma* 3:288–294, 1963.
- 571. Crosby, W. M., Costiloe, J. P. Safety of lap-belt restraint for pregnant victims of automobile collisions. *N. Engl. J. Med.* 284:632–636, 1971.
- 572. Agran, P. F., Dunkle, D. E., Winn, D. G., Kent, D. Fetal death in motor vehicle accidents. *Ann. Emerg. Med.* 16:1355–1358, 1987.
- 573. Sidky, I. H., Daikoku, N. H., Gopal, J. Insignificant blunt maternal trauma with lethal fetal outcome: a case report. *Md. Med. J.* 40:1083–1085, 1991.
- 574. Hagmann, C. F., Schmitt-Mechelke, T., Caduff, J. H., Berger, T. M. Fetal intracranial injuries in a preterm infant after maternal motor vehicle accident: a case report. *Pediatr. Crit. Care Med.* 5:396–398, 2004.
- 575. Lane, P. L. Traumatic fetal deaths. *J. Emerg. Med.* 7:433–435, 1989.
- 576. Karimi, P., Ramus, R., Urban, J., Perlman, J. M. Extensive brain injury in a premature infant following a relatively minor maternal motor vehicle accident with airbag deployment. *J. Perinatol.* 24:454–457, 2004.



577. Bowdler, N., Faix, R. G., Elkins, T. Fetal skull fracture and brain injury after a maternal automobile accident. A case report. *J. Reprod. Med.* 32:375–378, 1987.
578. Yoganandan, N., Morgan, R. M., Eppinger, R. H., Pintar, F. A., Sances, A., Jr., Williams, A. Mechanisms of thoracic injury in frontal impact. *J. Biomech. Eng.* 118:595–597, 1996.
579. Shkrum, M. J., McClafferty, K. J., Nowak, E. S., German, A. Driver and front seat passenger fatalities associated with air bag deployment. Part 1: A Canadian study. *J. Forensic Sci.* 47:1028–1034, 2002.
580. Sato, Y., Ohshima, T., Kondo, T. Air bag injuries—a literature review in consideration of demands in forensic autopsies. *Forensic Sci. Int.* 128:162–167, 2002.
581. Wallis, L. A., Greaves, I. Injuries associated with airbag deployment. *Emerg. Med. J.* 19:490–493, 2002.
582. McGwin, G., Jr., Metzger, J., Alonso, J. E., Rue, L. W., III. The association between occupant restraint systems and risk of injury in frontal motor vehicle collisions. *J. Trauma* 54:1182–1187, 2003.
583. Martin, P. G., Crandall, J. R., Pilkey, W. D. Injury trends of passenger car drivers in frontal crashes in the USA. *Accid. Anal. Prev.* 32:541–557, 2000.
584. Estrada, L. S., Alonso, J. E., McGwin, G., Jr., Metzger, J., Rue, L. W., III. Restraint use and lower extremity fractures in frontal motor vehicle collisions. *J. Trauma* 57:323–328, 2004.
585. McGovern, M. K., Murphy, R. X., Jr., Okunski, W. J., Wasser, T. E. The influence of air bags and restraining devices on extremity injuries in motor vehicle collisions. *Ann. Plast. Surg.* 44:481–485, 2000.
586. Shkrum, M. J., McClafferty, K. J., Nowak, E. S., German, A. Driver and front seat passenger fatalities associated with air bag deployment. Part 2: A review of injury patterns and investigative issues. *J. Forensic Sci.* 47:1035–1040, 2002.
587. McKay, M. P., Jolly, B. T. A retrospective review of air bag deaths. *Acad. Emerg. Med.* 6:708–714, 1999.
588. Lau, I. V., Horsch, J. D., Viano, D. C., Andrzejak, D. V. Mechanism of injury from air bag deployment loads. *Accid. Anal. Prev.* 25:29–45, 1993.
589. National Highway Traffic Safety Administration. Various reports provided at: <http://www-nrd.nhtsa.dot.gov/departments/nrd-30/ncsa/TextVer/SCI.html>, 2005.
590. Chidester, A. B., Rutland, K. W. Air bag crash investigations. Paper 98-S6-O-02. Proceedings of the 16th International Technical Conference on the Enhanced Safety of Vehicles. National Highway Traffic Safety Administration, Washington, DC, 1998.
591. Centers for Disease Control and Prevention. Air-bag-associated fatal injuries to infants and children riding in front passenger seats—United States. *JAMA* 274:1752–1753, 1995.
592. Werner, J. V., Sorenson, W. W. Survey of airbag involved accidents. An analysis of collision characteristics, system effectiveness and injuries. SAE Report 940802. Society of Automotive Engineers, Inc., Warrendale, PA, 1994.
593. Dalmotas, D. J., German, A., Hendrick, B. E., Hurley, R. M. Airbag deployments: the Canadian experience. *J. Trauma* 38:476–481, 1995.
594. Huelke, D. F., Reed, R. T. Front seat passenger and air bag deployments. Paper 96-S1-O-2. Proceedings of the 15th International Technical Conference on the Enhanced Safety of Vehicles. National Highway Traffic Safety Administration, Washington, DC, 1996.
595. Huelke, D. F., Reed, R. T. Cranial-vertebral fractures and dislocations associated with steering wheel airbag deployment. Paper 96-S1-O-01. Proceedings of the 15th International Technical Conference on the Enhanced Safety of Vehicles. National Highway Traffic Safety Administration, Washington, DC, 1996.
596. Perez, J., Palmatier, T. Air bag-related fatality in a short, forward-positioned driver. *Ann. Emerg. Med.* 28:722–724, 1996.
597. Hansen, T. P., Nielsen, A. L., Thomsen, T. K., Knudsen, P. J. Avulsion of the occipital bone—an airbag-specific injury. *Lancet* 353:1409–1410, 1999.

598. Huff, G. F., Bagwell, S. P., Bachman, D. Airbag injuries in infants and children: a case report and review of the literature. *Pediatrics* 102:e2, 1998.
599. Augenstein, J. S., Digges, K. H., Lombardo, L. V., et al. Occult abdominal injuries to airbag-protected crash victims: a challenge to trauma systems. *J. Trauma* 38:502–508, 1995.
600. Augenstein, J. S., Perdeck, E. B., Murtha, M., et al. Injuries sustained by drivers in air bag crashes. Paper 96-S10-O-01. Proceedings of the 15th International Technical Conference on the Enhanced Safety of Vehicles. National Highway Traffic Safety Administration, Washington, DC, 1996.
601. Smock, W. S., Nichols, G. R. Airbag module cover injuries. *J. Trauma* 38:489–493, 1995.
602. Brown, D. K., Roe, E. J., Henry, T. E. A fatality associated with the deployment of an automobile airbag. *J. Trauma* 39:1204–1206, 1995.
603. Hollands, C. M., Winston, F. K., Stafford, P. W., Shochat, S. J. Severe head injury caused by airbag deployment. *J. Trauma* 41:920–922, 1996.
604. Cooper, J. T., Balding, L. E., Jordan, F. B. Airbag mediated death of a two-year-old child wearing a shoulder/lap belt. *J. Forensic Sci.* 43:1077–1081, 1998.
605. German, A., Dalmotas, D. J., Hurley, R. M. Air bag collision performance in a restrained occupant population. Paper 98-S5-O-04. Proceedings of the 16th International Technical Conference on the Enhanced Safety of Vehicles. National Highway Traffic Safety Administration, Washington, DC, 1998.
606. Maxeiner, H., Hahn, M. Airbag-induced lethal cervical trauma. *J. Trauma* 42:1148–1151, 1997.
607. Dalmotas, D. J., Hurley, R. M., German, A. Supplemental restraint systems: friend or foe to belted occupants? Proceedings of the 40th AAAM Conference. Association for the Advancement of Automotive Medicine, Des Plaines, IL, 1996.
608. McCaffrey, M., German, A., Lalonde, F., Letts, M. Air bags and children: a potentially lethal combination. *J. Pediatr. Orthop.* 19:60–64, 1999.
609. German, A., Dalmotas, D. J., Comeau, J. L., Monk, B., Contant, P., Gou, M. In-depth investigation and reconstruction of an air bag induced child fatality. Paper 98-S5-W-19. Proceedings of the 16th International Technical Conference on the Enhanced Safety of Vehicles. National Highway Traffic Safety Administration, Washington, DC, 1998.
610. Morrison, A. L., Chute, D., Radentz, S., Golle, M., Troncoso, J. C., Smialek, J. E. Air bag-associated injury to a child in the front passenger seat. *Am. J. Forensic Med. Pathol.* 19:218–222, 1998.
611. Huelke, D. F. An overview of air bag deployment and related injuries. Case studies and a review of the literature. SAE Report 950866. Society of Automotive Engineers, Inc., Warrendale, PA, 1995.
612. Giguere, J. F., St. Vil, D., Turmel, A., et al. Airbags and children: a spectrum of C-spine injuries. *J. Pediatr. Surg.* 33:811–816, 1998.
613. Gossman, W., June, R. A., Wallace, D. Fatal atlanto-occipital dislocation secondary to airbag deployment. *Am. J. Emerg. Med.* 17:741–742, 1999.
614. Bailey, H., Perez, N., Blank-Reid, C., Kaplan, L. J. Atlanto-occipital dislocation: an unusual lethal airbag injury. *J. Emerg. Med.* 18:215–219, 2000.
615. Blacksin, M. F. Patterns of fracture after air bag deployment. *J. Trauma* 35:840–843, 1993.
616. Traynelis, V. C., Gold, M. Cervical spine injury in an air-bag-equipped vehicle. *J. Spinal Disord.* 6:60–61, 1993.
617. Perdakis, G., Schmitt, T., Chait, D., Richards, A. T. Blunt laryngeal fracture: another airbag injury. *J. Trauma* 48:544–546, 2000.
618. Roberts, D., Pexa, C., Clarkowski, B., Morey, M., Murphy, M. Fatal laryngeal injury in an achondroplastic dwarf secondary to airbag deployment. *Pediatr. Emerg. Care* 15:260–261, 1999.
619. Dalmotas, D. J., Hurley, J., German, A., Digges, K. Air bag deployment crashes in Canada. Paper 96-S1-O-05. Proceedings of the 15th International Technical Conference on the

- Enhanced Safety of Vehicles. National Highway Traffic Safety Administration, Washington, DC, 1996.
620. Tenofsky, P. L., Porter, S. W., Shaw, J. W. Fatal airway compromise due to retropharyngeal hematoma after airbag deployment. *Am. Surg.* 66:692–694, 2000.
621. Willis, B. K., Smith, J. L., Falkner, L. D., Vernon, D. D., Walker, M. L. Fatal air bag mediated craniocervical trauma in a child. *Pediatr. Neurosurg.* 24:323–327, 1996.
622. Duncan, M. A., Dowd, N., Rawluk, D., Cunningham, A. J. Traumatic bilateral internal carotid artery dissection following airbag deployment in a patient with fibromuscular dysplasia. *Br. J. Anaesth.* 85:476–478, 2000.
623. Augenstein, J. S., Perdeck, E., Williamson, J., et al. Heart injuries among restrained occupants in frontal crashes. SAE Report 970392. Society of Automotive Engineers, Inc., Warrendale, PA, 1997.
624. Lancaster, G. I., DeFrance, J. H., Borruso, J. J. Air-bag-associated rupture of the right atrium. *N. Engl. J. Med.* 328:358, 1993.
625. Pillgram-Larsen, J., Geiran, O. [Air bags influence the pattern of injury in severe thoracic trauma]. *Tidsskr. Nor. Laegeforen* 117:2437–2439, 1997.
626. Jumbelic, M. I. Fatal injuries in a minor traffic collision. *J. Forensic Sci.* 40:492–494, 1995.
627. Sharma, O. P., Mousset, X. R. Review of tricuspid valve injury after airbag deployment: presentation of a case and discussion of mechanism of injury. *J. Trauma* 48:152–156, 2000.
628. Hanna, K. M., Weiman, D. S., Pate, J. W., Wolf, B. A., Fabian, T. C. Aortic valve injury secondary to blunt trauma from an air bag. *Tenn. Med.* 90:195–196, 1997.
629. Reiland-Smith, J., Weintraub, R. M., Sellke, F. W. Traumatic aortic valve injury sustained despite the deployment of an automobile air bag. *Chest* 103:1603, 1993.
630. deGuzman, B. J., Morgan, A. S., Pharr, W. F. Aortic transection following air-bag deployment. *N. Engl. J. Med.* 337:573–574, 1997.
631. Dunn, J. A., Williams, M. G. Occult ascending aortic rupture in the presence of an air bag. *Ann. Thorac. Surg.* 62:577–578, 1996.
632. Coben, L. E. The risk and benefits of air bag systems: are they needlessly killing and injuring motorists? SAE Report 970492. Society of Automotive Engineers, Inc., Warrendale, PA, 1997.
633. McClafferty, K. J., Shkrum, M. J., Chan, J., German, A. A multi-disciplinary study of a Canadian airbag fatality. Proceedings of the Canadian Multi-disciplinary Road Safety Conference X. Vehicle Safety Research Centre, Ryerson Polytechnic University, Toronto, 1997.
634. Rebel, A., Ellinger, K., van Ackern, K. [New airbag-associated injuries in traffic accidents]. *Anaesthesist* 45:359–362, 1996.
635. Sharma, O. P. Pericardio-diaphragmatic rupture: five new cases and literature review. *J. Emerg. Med.* 17:963–968, 1999.
636. Morgenstern, K., Talucci, R., Kaufman, M. S., Samuels, L. E. Bilateral pneumothorax following air bag deployment. *Chest* 114:624–626, 1998.
637. Cullinan, M., Merriman, T. Oesophageal rupture resulting from airbag deployment during a motor vehicle accident. *Aust. N. Z. J. Surg.* 71:554–555, 2001.
638. Augenstein, J. S., Perdeck, E., Williamson, J., Stratton, J., Horton, T., Digges, K. Injury patterns in air bag equipped vehicles. Paper 98-S1-O-06. Proceedings of the 16th International Technical Conference on the Enhanced Safety of Vehicles., National Highway Traffic Safety Administration, Washington, DC, 1998.
639. Mbamalu, D., Banerjee, A., Shankar, A., Grant, D. Air bag associated fatal intra-abdominal injury. *Injury* 31:121–122, 2000.
640. Smith, D. P., Klein, F. A. Renal injury in a child with airbag deployment. *J. Trauma* 42:341–342, 1997.
641. Schultze, P. M., Stamm, C. A., Roger, J. Placental abruption and fetal death with airbag deployment in a motor vehicle accident. *Obstet. Gynecol.* 92:719, 1998.

642. Gimovsky, M. L., Nunez, G., Beck, P. Fetal heart rate monitoring casebook. Airbag-associated rupture of membranes: evaluation of trauma in pregnancy. *J. Perinatol.* 20:270–273, 2000.
643. Sherer, D. M., Abramowicz, J. S., Babkowski, R., Metlay, L. A., Ron, M., Woods, J. R., Jr. Extensive fetal intrathoracic injuries sustained in a motor vehicle accident. *Am. J. Perinatol.* 10:414–416, 1993.
644. Tanno, K., Kohno, M., Ono, K., et al. Fatal cardiovascular injuries to the unbelted occupant associated with airbag deployment: two case-reports. *Leg. Med. (Tokyo)* 2:227–231, 2000.
645. Grubwieser, P., Pavlic, M., Gunther, M., Rabl, W. Airbag contact in traffic accidents: DNA detection to determine the driver identity. *Int. J. Legal Med.* 118:9–13, 2004.
646. Miltner, E., Wiedmann, H. P., Leutwein, B., et al. Liver and spleen ruptures in authentic car-to-car side collisions with main impact at front door or B-pillar. *Am. J. Forensic Med. Pathol.* 13:2–6, 1992.
647. McLellan, B. A., Rizoli, S. B., Brennenman, F. D., Boulanger, B. R., Sharkey, P. W., Szalai, J. P. Injury pattern and severity in lateral motor vehicle collisions: a Canadian experience. *J. Trauma* 41:708–713, 1996.
648. Chipman, M. L. Side impact crashes—factors affecting incidence and severity: review of the literature. *Traffic Inj. Prev.* 5:67–75, 2004.
649. Howard, A., Rothman, L., McKeag, A. M., et al. Children in side-impact motor vehicle crashes: seating positions and injury mechanisms. *J. Trauma* 56:1276–1285, 2004.
650. Nirula, R., Mock, C., Kaufman, R., Rivara, F. P., Grossman, D. C. Correlation of head injury to vehicle contact points using crash injury research and engineering network data. *Accid. Anal. Prev.* 35:201–210, 2003.
651. Mackay, G. M., Hill, J., Parkin, S., Munns, J. A. Restrained occupants on the nonstruck side in lateral collisions. *Accid. Anal. Prev.* 25:147–152, 1993.
652. MacLennan, P. A., McGwin, G., Jr., Metzger, J., Moran, S. G., Rue, L. W., III. Risk of injury for occupants of motor vehicle collisions from unbelted occupants. *Inj. Prev.* 10:363–367, 2004.
653. Cummings, P., Rivara, F. P. Car occupant death according to the restraint use of other occupants: a matched cohort study. *JAMA* 291:343–349, 2004.
654. Augenstein, J. S., Perdeck, E. B., Martin, P., et al. Injuries to restrained occupants in far-side crashes. *Annu. Proc. Assoc. Adv. Automot. Med.* 44:57–66, 2000.
655. Miltner, E., Salvender, H. J. Injury severity of restrained front seat occupants in car-to-car side impacts. *Accid. Anal. Prev.* 27:105–110, 1995.
656. Shkrum, M. J., Green, R. N., McClafferty, K. J., Nowak, E. S. Skull fractures in fatalities due to motor vehicle collisions. *J. Forensic Sci.* 39:107–122, 1994.
657. Parenteau, C. S., Viano, D. C., Shah, M., et al. Field relevance of a suite of rollover tests to real-world crashes and injuries. *Accid. Anal. Prev.* 35:103–110, 2003.
658. Malliaris, A. C., DeBlois, J. H., Digges, K. H. Light vehicle occupant ejections—a comprehensive investigation. *Accid. Anal. Prev.* 28:1–14, 1996.
659. Howard, A., McKeag, A. M., Rothman, L., Comeau, J. L., Monk, B., German, A. Ejections of young children in motor vehicle crashes. *J. Trauma* 55:126–129, 2003.
660. Byard, R. W., Gilbert, J. D., Klitte, A., Felgate, P. Gasoline exposure in motor vehicle accident fatalities. *Am. J. Forensic Med. Pathol.* 23:42–44, 2002.
661. Williams, J. S., Graff, J. A., Uku, J. M. Pedestrian intoxication and fatal traffic accident injury patterns. *Prehospital Disaster Med.* 10:30–35, 1995.
662. Schlumpf, M. R., Niederer, P. F. Motion patterns of pedestrian surrogates in simulated vehicle-pedestrian collisions. *J. Biomech.* 20:371–384, 1987.
663. Ravani, B., Brougham, D., Mason, R. T. Pedestrian post-impact kinematics and injury patterns. SAE Report 811024. Society of Automotive Engineers, Inc., Warrendale, PA, 1981.
664. Karger, B., Teige, K., Fuchs, M., Brinkmann, B. Was the pedestrian hit in an erect position before being run over? *Forensic Sci. Int.* 119:217–220, 2001.

665. Teresinski, G., Madro, R. Evidential value of injuries useful for reconstruction of the pedestrian-vehicle location at the moment of collision. *Forensic Sci. Int.* 128:127–135, 2002.
666. Teresinski, G., Madro, R. Knee joint injuries as a reconstructive factors in car-to-pedestrian accidents. *Forensic Sci. Int.* 124:74–82, 2001.
667. Ubelaker, D. H., Adams, B. J. Differentiation of perimortem and postmortem trauma using taphonomic indicators. *J. Forensic Sci.* 40:509–512, 1995.
668. Spitz, W. V. The road traffic victim. In: Spitz, W. V., ed. *Medicolegal Investigation of Death: Guidelines for the Application of Pathology to Crime Investigation*. Charles C. Thomas, Springfield, IL, pp. 528–565, 1993.
669. Teresinski, G., Madro, R. Ankle joint injuries as a reconstruction parameter in car-to-pedestrian accidents. *Forensic Sci. Int.* 118:65–73, 2001.
670. Waddell, J. P., Drucker, W. R. Occult injuries in pedestrian accidents. *J. Trauma* 11:844–852, 1971.
671. Zivot, U., Di Maio, V. J. Motor vehicle-pedestrian accidents in adults. Relationship between impact speed, injuries, and distance thrown. *Am. J. Forensic Med. Pathol.* 14:185–186, 1993.
672. Copeland, A. R. Pedestrian fatalities. The Metropolitan Dade County experience, 1984–1988. *Am. J. Forensic Med. Pathol.* 12:40–44, 1991.
673. Lane, P. L., McClafferty, K. J., Nowak, E. S. Pedestrians in real world collisions. *J. Trauma* 36:231–236, 1994.
674. Roudsari, B. S., Mock, C. N., Kaufman, R., Grossman, D., Henary, B. Y., Crandall, J. Pedestrian crashes: higher injury severity and mortality rate for light truck vehicles compared with passenger vehicles. *Inj. Prev.* 10:154–158, 2004.
675. Byard, R. W., Green, H., James, R. A., Gilbert, J. D. Pathologic features of childhood pedestrian fatalities. *Am. J. Forensic Med. Pathol.* 21:101–106, 2000.
676. Harruff, R. C., Avery, A., Alter-Pandya, A. S. Analysis of circumstances and injuries in 217 pedestrian traffic fatalities. *Accid. Anal. Prev.* 30:11–20, 1998.
677. Brison, R. J., Wicklund, K., Mueller, B. A. Fatal pedestrian injuries to young children: a different pattern of injury. *Am. J. Public Health* 78:793–795, 1988.
678. Wyatt, J. P., Martin, A., Beard, D., Busuttill, A. Pedestrian deaths following collisions with heavy goods vehicles. *Med. Sci. Law* 41:21–25, 2001.
679. Shkrum, M. J., Green, R. N., Nowak, E. S. Upper cervical trauma in motor vehicle collisions. *J. Forensic Sci.* 34:381–390, 1989.
680. Ohshima, T., Kondo, T. Forensic pathological observations on fatal injuries to the brain stem and/or upper cervical spinal cord in traffic accidents. *J. Clin. Forensic Med.* 5:129–134, 1998.
681. Madro, R., Teresinski, G. Neck injuries as a reconstructive parameter in car-to-pedestrian accidents. *Forensic Sci. Int.* 118:57–63, 2001.
682. Karger, B., Teige, K., Buhren, W., DuChesne, A. Relationship between impact velocity and injuries in fatal pedestrian-car collisions. *Int. J. Legal Med.* 113:84–88, 2000.
683. Klintschar, M., Darok, M., Roll, P. Fatal truck-bicycle accident involving dragging for 45 km. *Int. J. Legal Med.* 117:226–228, 2003.
684. Dix, J. D., Bolesta, S. Dragging deaths: a case in point. *J. Forensic Sci.* 33:826–828, 1988.
685. Fukushima, H., Yonemura, I., Ota, M., Hasekura, H. A case of death due to dragging by a car: establishment of a homicide because of conscious negligence. *Nippon Hoigaku Zasshi* 44:186–190, 1990.
686. Fujiwara, S., Nishimura, A., Ueno, Y., Nakagawa, K., Tatsuno, Y., Mizoi, Y. Histo-pathological findings of abraded skins in the cases of automobile dragging. *Nippon Hoigaku Zasshi* 47:398–405, 1993.
687. Maxeiner, H., Ehrlich, E., Schyma, C. Neck injuries caused by being run over by a motor vehicle. *J. Forensic Sci.* 45:31–35, 2000.



688. Murphy, G. K. Suicide by gunshot while driving a motor vehicle. Two additional cases. *Am. J. Forensic Med. Pathol.* 18:295–298, 1997.
689. Macdonald, J. M. Suicide and homicide by automobile. *Am. J. Psychiatry* 121:366–370, 1964.
690. Kerwin, A. J. Sudden death while driving. *Can. Med. Assoc. J.* 131:312–314, 1984.
691. Kerwin, A. J. The electrophysiologic features of sudden death. *Can. Med. Assoc. J.* 131:315–317, 1984.
692. Baker, S. P., Spitz, W. U. An evaluation of the hazard created by natural death at the wheel. *N. Engl. J. Med.* 283:405–409, 1970.
693. Ostrom, M., Eriksson, A. Natural death while driving. *J. Forensic Sci.* 32:988–998, 1987.
694. Dolinak, D., Guileyardo, J. Automatic implantable cardioverter defibrillator rhythm strip data as used in interpretation of a motor vehicle accident. *Am. J. Forensic Med. Pathol.* 22:256–260, 2001.
695. Suarez-Penaranda, J. M., de la Calle, M. C., Rodriguez-Calvo, M. S., Munoz, J. I., Concheiro, L. Rupture of liver cell adenoma with fatal massive hemoperitoneum resulting from minor road accident. *Am. J. Forensic Med. Pathol.* 22:275–277, 2001.
696. Noyes, R., Jr. Motor vehicle accidents related to psychiatric impairment. *Psychosomatics* 26:569–6, 579, 1985.
697. Imajo, T. Suicide by motor vehicle. *J. Forensic Sci.* 28:83–89, 1983.
698. Byard, R. W., Gilbert, J. D. Cervical fracture, decapitation, and vehicle-assisted suicide. *J. Forensic Sci.* 47:392–394, 2002.
699. Hardwicke, M. B., Taff, M. L., Spitz, W. U. A case of suicidal hanging in an automobile. *Am. J. Forensic Med. Pathol.* 6:362–364, 1985.
700. Schmidt, C. W., Jr., Shaffer, J. W., Zlotowitz, H. I., Fisher, R. S. Suicide by vehicular crash. *Am. J. Psychiatry* 134:175–178, 1977.
701. Boglioli, L. R., Taff, M. L., Green, A. S., Lukash, L. I., Lane, R. A bizarre case of vehicular suicide. *Am. J. Forensic Med. Pathol.* 9:169–178, 1988.
702. von Bremen, A. The comparison of brake and accelerator pedals with marks on shoe soles. *J. Forensic Sci.* 35:14–24, 1990.
703. Prichard, P. D. A suicide by self-decapitation. *J. Forensic Sci.* 38:981–984, 1993.
704. Murphy, G. K. Suicide by gunshot while driving an automobile. *Am. J. Forensic Med. Pathol.* 10:285–288, 1989.
705. Durso, S., Del Vecchio, S., Ciallella, C. Hanging in an automobile: a report on a unique case history. *Am. J. Forensic Med. Pathol.* 16:352–354, 1995.
706. Zugibe, F. T., Costello, J. T. The jigsaw puzzle identification of a hit-and-run automobile. *J. Forensic Sci.* 31:329–332, 1986.
707. Drummond, F. C., Pizzola, P. A. An unusual case involving the individualization of a clothing impression on a motor vehicle. *J. Forensic Sci.* 35:746–752, 1990.
708. Murphy, G. K. Death on the railway. *J. Forensic Sci.* 21:218–226, 1976.
709. Romero Palanco, J. L., Gamero Lucas, J. J., Vizcaya Rojas, M. A., Arufe Martinez, M. I. An unusual case of railway suicide. *J. Forensic Sci.* 44:444–446, 1999.
710. Davis, G. G., Alexander, C. B., Brissie, R. M. A 15-year review of railway-related deaths in Jefferson County, Alabama. *Am. J. Forensic Med. Pathol.* 18:363–368, 1997.
711. Lerer, L. B., Matzopoulos, R. G. Fatal railway injuries in Cape Town, South Africa. *Am. J. Forensic Med. Pathol.* 18:144–147, 1997.
712. Copeland, A. R. Accidental railway-related fatalities. The Metro Dade County experience, 1980–1984. *Am. J. Forensic Med. Pathol.* 10:196–199, 1989.
713. Driever, F., Schmidt, P., Madea, B. About morphological findings in fatal railway collisions. *Forensic Sci. Int.* 126:123–128, 2002.
714. Shapiro, M. J., Luchtefeld, W. B., Durham, R. M., Mazuski, J. E. Traumatic train injuries. *Am. J. Emerg. Med.* 12:92–93, 1994.
715. Pelletier, A. Deaths among railroad trespassers. The role of alcohol in fatal injuries. *JAMA* 277:1064–1066, 1997.

- 716. Cina, S. J., Koelpin, J. L., Nichols, C. A., Conradi, S. E. A decade of train-pedestrian fatalities: the Charleston experience. *J. Forensic Sci.* 39:668–673, 1994.
- 717. Kligman, M. D., Knotts, F. B., Buderer, N. M., Kerwin, A. J., Rodgers, J. F. Railway train versus motor vehicle collisions: a comparative study of injury severity and patterns. *J. Trauma* 47:928–931, 1999.
- 718. Shkrum, M. J., Hurlbut, D. J., Young, J. G. Fatal light aircraft accidents in Ontario: a five year study. *J. Forensic Sci.* 41:252–263, 1996.
- 719. Ast, F. W., Kernbach-Wighton, G., Kampmann, H., et al. Fatal aviation accidents in Lower Saxony from 1979 to 1996. *Forensic Sci. Int.* 119:68–71, 2001.
- 720. Li, G., Baker, S. P. Injury patterns in aviation-related fatalities. Implications for preventive strategies. *Am. J. Forensic Med. Pathol.* 18:265–270, 1997.
- 721. Wiegmann, D. A., Taneja, N. Analysis of injuries among pilots involved in fatal general aviation airplane accidents. *Accid. Anal. Prev.* 35:571–577, 2003.
- 722. Hellerich, U., Pollak, S. Airplane crash. Traumatologic findings in cases of extreme body disintegration. *Am. J. Forensic Med. Pathol.* 16:320–324, 1995.
- 723. Reals, W. J., Davidson, W. H., Karnitsching, H. H. Pathology of light-aircraft accidents. *Aerosp. Med.* 35:133–135, 1964.
- 724. Stevens, P. J. The pathology of fatal public transport aviation accidents. *Med. Sci. Law* 8:41–48, 1968.
- 725. Krefft, S. Estimation of pilot control at the time of crash. In: Mason, J. K., Reals, W. J., eds. *Aerospace Pathology*. College of American Pathologists, Chicago, pp. 96–104, 1973.

## Chapter 9

---

# *Craniocerebral Trauma and Vertebrospinal Trauma*

### Summary

Trauma to the head and vertebral column results in focal or diffuse injuries affecting the skull and brain (“craniocerebral injuries”) or the vertebrae and spinal cord (“vertebrospinal injuries”). Focal injuries include: fractures; hematomas on either side of the dura (epidural hematomas and subdural hematomas); bleeding in the subarachnoid space; hematomas in the brain or spinal cord; bleeding in the cerebral ventricles; tears and fragmentation of central nervous system tissue (contusions and lacerations); and infarcts. Diffuse traumatic injuries include: brain swelling; diffuse or traumatic axonal injury; hypoxic–ischemic encephalopathy; widespread vascular injury. In many cases several different types of craniocerebral and vertebrospinal injuries coexist and their pattern may indicate the type of trauma that resulted in the injury. Craniocerebral and vertebrospinal injuries cause distinctive “syndromes” that may allow the pathologist to predict the type of neurological damage that will be encountered before an autopsy starts. These syndromes include patients who conform to the following states: “dead at the scene;” display a lucid interval between injury and death; coma from the time of injury; vegetative state; severe disability; moderate disability; minor disabilities; complete recovery after an injury; isolated quadriplegia or paraplegia.

**Key Words:** Brain injuries; brain edema; hypoxia–ischemia, brain; craniocerebral trauma; diffuse axonal injury; intracranial hemorrhage, traumatic; pituitary trauma; shaken baby syndrome; skull fractures; spinal cord injuries; spinal fractures.

### *1. INTRODUCTION*

Traumatic brain injury (TBI) is a common cause of death (18 per 100,000 population per year in the United States [1]), and most of these injuries are caused by motor vehicle accidents, falls, or assaults of various types. Accordingly, autopsies on cases of cranial, vertebral, and central nervous system (CNS) trauma are frequently performed. The examination of the CNS and its protective bone and soft tissue enclosures in these cases is concerned with a search for abnormalities that suggest, confirm, or prove that forcible injury to the CNS has occurred. The gross and microscopic characteristics of any

From: *Forensic Science and Medicine: Forensic Pathology of Trauma:  
Common Problems for the Pathologist*

By: M. J. Shkrum and D. A. Ramsay © Humana Press Inc., Totowa, NJ

abnormalities that are found, including those in the skin and soft tissues surrounding the brain and spinal cord, are used to infer, and make some general statements about, how force was applied, what the magnitude of the force was, and the degree to which the force disrupted CNS function. Such inferences and generalizations allow conclusions to be drawn about whether or not the injuries, with respect to the cause of death, were incidental, contributory, causal, or of undetermined significance.

CNS injuries in a given case commonly occur as consequence of one—or, more typically, more than one—of the following:

- Direct impact to the head.
- Rapid change in velocity or trajectory of the head with or without a head impact.
- Deformation of the atlanto-occipital junction and vertebrae beyond “normal” or physiological limits.
- Objects that penetrate (i.e., enter but do not exit) or perforate (i.e., pass through) the cranial cavity or spinal canal.

The effects of these forces on the CNS are particularly complex, compared with their effects elsewhere in the body, for many reasons:

- The functional consequences of small injuries may be disproportionately large.
- The pathological processes caused by traumatic injuries, which are readily dealt with by natural or medical means when they occur in other organs, are debilitating or fatal.
- The brain is suspended in meninges and cerebrospinal fluid (CSF) so it can, for a brief period, move independently of the skull or remain at rest when the skull starts moving, creating injuries because of differential movement between bone, dura, and brain.
- The anatomy of the atlanto-occipital junction and of the cervical vertebral column allows complex movements of the head in the coronal, horizontal, and sagittal planes and therefore differential movement of one part of the brain in relation to another part of the brain.
- Injured nerve cells and axons demonstrate specific changes that do not have an equivalent outside the nervous system.

Injuries to the cranium and brain (i.e., craniocerebral injuries) and to the vertebrae and spinal cord (i.e., vertebrospinal injuries) are either primary, in the sense that they are caused directly by the forces of trauma (breaking, tearing, and stretching of tissue, paralysis of axonal transport, and, possibly, the functional effects of percussion) or secondary, in the sense that they are a consequence of the primary injury (i.e., hemorrhage, ischemic injury, inflammation, swelling). Some secondary injuries occur almost instantaneously (e.g., hemorrhage as a consequence of tearing of tissue), whereas others evolve over hours to days (e.g., delayed hemorrhage, inflammation, brain swelling, and axonal swelling secondary to paralysis of axonal transport or tearing of axons). Primary and secondary injuries to the CNS are “focal” or “diffuse” in the sense that they are localized or widespread, respectively (the latter often with a multifocal distribution as opposed to a truly diffuse distribution).

The effects of mechanical forces on the CNS and its coverings are no different, in many respects, from the effects of similar forces on other areas of the body, their different functional consequences notwithstanding. When examining cases of suspected CNS trauma, it is useful to remember that injuries occur at sites where energy, in one form or another, has been absorbed and, to a greater or lesser extent, dissipated and that the effects of dissipation of energy are likely to generate multiple neuropathological

findings. For example, when the head strikes a hard surface after a fall backward, several injuries are expected, either immediately or within hours, including a fracture of the occipital bone; fronto-orbital contusions; focal traumatic axonal injury in the corpus callosum; brain swelling; and hypoxic ischemic neuronal injury in and around the contusions and, as a consequence of brain swelling, in “nonvascular” territories (i.e., in a complex distribution that does not correspond to the areas of distribution of the cerebral and penetrating arteries).

Craniocerebral and vertebrospinal injuries include:

- Scalp lacerations and contusions.
- Perivertebral soft tissue contusions.
- Skull fractures.
- Vertebral dislocations and fractures.
- Perimeningeal (epidural, subdural, subarachnoid) hemorrhages.
- Brain and spinal cord contusions, lacerations, tears, and hemorrhages.
- Intraventricular hemorrhage.
- Diffuse brain injury (swelling, axonal injury, hypoxic-ischemic injury, vascular injury).

The pattern of injury roughly reflects how energy was applied to the CNS. Two broad patterns are identifiable:

- Contact injury to the head causes bruises and lacerations of the scalp at the site of an impact, the underlying skull is fractured, and there is bleeding in, and tearing of, the meninges and brain tissues close to, or at a distance from, the impact site.
- “Inertial” (acceleration or deceleration) injuries that cause widespread deep brain tears and hemorrhages of various sizes and diffuse axonal injury (DAI) without scalp abnormalities and skull fractures.

Overlap between contact and inertial injuries is extremely common.

The examination of the CNS in cases of trauma may also reveal a nontraumatic CNS disease that accounts for an otherwise inexplicable incident that led to the fatal CNS injuries. For example, a brain tumor whose location along the visual pathways causes a homonymous hemianopia may explain why a driver made an otherwise inexplicable but controlled turn into oncoming traffic. The possibility of natural causes of otherwise typical traumatic injuries should also be remembered especially when a peridural hematoma is discovered with no apparent history of trauma (e.g., a ruptured berry aneurysm may cause an isolated subdural hemorrhage, and spinal perimeningeal hemorrhages are often spontaneous [2]).

## *2. PRACTICAL CONSIDERATIONS FOR AUTOPSY IN CASES OF CNS TRAUMA*

Many of the techniques involved in examining the scalp, skull, and brain are a matter of routine in the autopsy room. However, there are few things that should be borne in mind when an autopsy is planned to investigate a case of suspected CNS trauma:

- The findings from neuroimaging studies performed before death should be taken into account when planning the postmortem examination of, and interpreting gross and histopathological findings in, the CNS. Copies of neuroimaging reports should be filed with the case notes. (Neuroimaging studies include radiographic studies, computed tomography [CT], magnetic resonance imaging [MRI], angiography, and ultrasonography



that are used for examining the CNS.) There is also little doubt that postmortem neuroimaging will play a greater role in the autopsy in the future (refs. 3 and 4; see also Chapter 1, Subheading 6.2.).

- Naked eye inspection of the cranial vault and skull base is a more sensitive way of demonstrating a skull fracture than is skull radiology. However, a lateral skull radiograph prepared before the cranium is opened may reveal air in the cranial cavity, a reliable sign of a skull fracture as long as introduction of air into the subarachnoid space at the time of a diagnostic lumbar puncture is excluded.
- Methods in common use for opening the cranium can cause artifactual skull fractures or extension of an existing skull fracture (5). This risk of artifactual skull fractures can be minimized if the following precautions are taken:
  - Saw cuts should completely penetrate the cranium (it is easier to identify saw-blade lacerations of the brain surface than to distinguish between a small artifactual fracture and a pre-existing fracture).
  - Only gentle leverage should be used to separate the cut edges of the cranium.
  - A hammer and a chisel should never be employed to complete the cranial saw cuts.
- In cases in which a subdural or epidural hemorrhage is suspected, a pan should be placed under the head to catch the blood and allow its volume to be measured. Copious liquid blood can drain from the cranial sinuses when the skull is opened (particularly if the superior vena cava has not been opened during the general part of the autopsy) and this blood should not be confused with the blood of an acute peridural hematoma (5), which is usually at least partly clotted and partly adheres to the arachnoid or dura.
- The concentration of cocaine metabolites and alcohol in blood from peridural hemorrhages that are several hours old reflects the levels of these substances in the circulation at the time of injury (6–8).
- The dura should always be stripped from the skull vertex and base after the brain has been removed so that fracture lines can be sought. The skull base should be stressed to attempt to expose hairline fractures. Bony vascular markings have a gently curving course, whereas fracture lines, etched with a thin line of blood, show angular changes in direction.
- Any spatial association between a fracture or fractures and scalp injuries should be documented because this information is used to infer the site of an impact.
- All injuries, including those in the brain slices, should be recorded in diagrams (templates are available from the United States Armed Forces Institute of Pathology [9]), which are often more helpful and accurate than a photograph as an *aide memoire* for the findings at the time of autopsy. “Significant” injuries bearing on, or contributing to, the cause of death should also be photographed as a complement to the diagrams. Subtle fracture lines are effectively recorded by photographing them after they have been wiped dry and their course marked with a marker pen. An indentation of the skull around a comminuted fracture, whose size may correspond to that of an object struck by, or striking, the skull, can be outlined with string and photographed (see Subheading 3.4.).
- It is useful to run through a mental checklist as the brain is being removed:
  - Are the olfactory bulbs present and intact? (They may show hemorrhagic disruption in head injury, owing to tearing of the olfactory nerves as they pass through the cribriform plate.)
  - Are the internal carotid arteries normal? (They can be occluded or torn by a basilar fracture.)
  - Is the pituitary stalk intact? (It can be torn in head injuries.)

- Can the relationship between the medial temporal lobes (the uncus) and the edge of the tentorium be seen to the extent that uncal (transtentorial) herniation is observed?
- Is there an unexplained basilar subarachnoid hemorrhage (SAH)? (Be prepared to alter the autopsy approach in order to find the source of bleeding; *see* Chapter 10, Subheading 4.2.).
- Is the spinomedullary junction clearly visible and intact? (It is hemorrhagic, distorted, or compressed in cases of atlanto-occipital dislocation or high cervical fractures.)
- Are the vertebral arteries grossly normal? (Tears and dissections occur in association with head and neck trauma.)
- Leave a short segment of the vertebral arteries in the body to allow them to be identified and traced caudally if an arterial dissection is suspected.
- Make the final cut for removing the brain through the rostral spinal cord, well clear of the medulla oblongata.
- Are there difficulties in identifying and cutting the attached edge of the tentorium cerebelli, spinomedullary junction, and vertebral arteries to the extent that traction may have caused an artifactual tear in the cerebral peduncles or elsewhere (10)?
- Removal of the spinal cord should be considered in all cases of craniocerebral trauma in which there is brain swelling or a need to exclude vertebrospinal injury. Brain swelling may be caused by hypoxic–ischemic injury. The presence of ischemic neuronal necrosis in spinal motor neurons supports a systemic cause of hypoxic–ischemic injury (i.e., a cardiorespiratory arrest or profound hypotension) as opposed to hypoxic–ischemic injuring owing to regional traumatic disturbance of cerebral blood flow.
- There is currently considerable debate, particularly in the United Kingdom, regarding the circumstances under which the brain and other organs should be retained after an autopsy (11). The brain should be retained and fixed whenever there are “reasonable and defensible” grounds, in the opinion of the pathologist responsible for the autopsy, based on observations made at the time of autopsy or from the history of the case or both, to believe that there are neuropathological abnormalities that are “of medicolegal relevance or [whose identification] may assist in determining the contribution of natural or unnatural processes to death” (11).
- The fixed brain should be sliced systematically and all slices laid out for inspection and analysis. We cut the cerebral hemispheres into 1-cm-thick slices in the coronal plane, the brainstem into 0.5-cm-thick slices in the horizontal plane, and the cerebellum into approx 0.5-cm-thick slices, starting with a sagittal cut through the vermis and continuing with oblique or parasagittal cuts at right angles and perpendicular to the cerebellar folia. The brainstem and cerebellum can also be cut *en bloc* into 0.5-cm-thick horizontal slices. The latter method is useful for infants’ brains, because they are small, and it also clearly demonstrates hemorrhagic tears, in cases of DAI, in the dorsolateral pons and adjacent parts of the middle and superior cerebellar peduncles where cuts pass if the cerebellum is removed from the brainstem before these parts of the brain are sliced.
- The orientation of the brain cuts should be adjusted if specific abnormalities are suspected or present; for example, a sagittal slice through the pontomedullary junction is the best way to demonstrate a pontomedullary tear and oblique coronal slices along the course of a bullet track allow the entire track to be demonstrated in a single slice.
- Heavily blood-stained brain slices should be rinsed in water prior to laying them out, to ensure that abnormalities are not obscured by blood.

Special considerations are described elsewhere for spinovertebral injuries (*see* Subheading 8.1.), craniocerebral gunshot wounds (*see* Chapter 6, Heading 19.), and traumatic basilar SAH (*see* Chapter 10, Subheading 4.2.).

### 3. SKULL FRACTURES

#### 3.1. Epidemiology

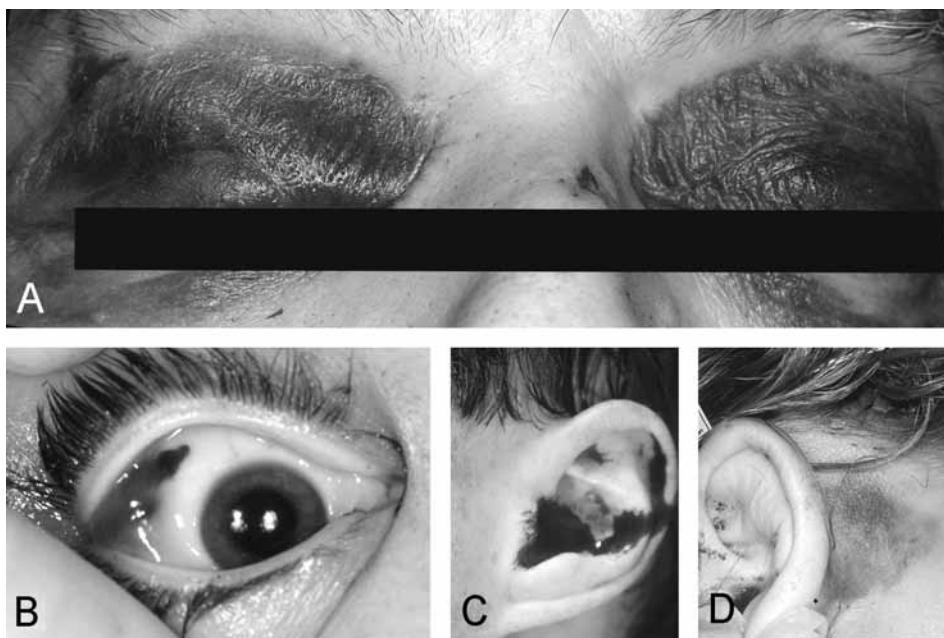The incidence of skull fractures in clinical population studies is 44 per 100,000 person-years. The majority (53%) are simple (i.e., linear or comminuted) fractures and basilar, depressed, and compound skull fractures form 19, 16, and 12%, respectively, of the remainder (12). Motor vehicle accidents (38% of cases) and falls (36% of cases) are the most common causes of skull fractures, and assault is responsible for fractures in 10% of cases (12). Simple fractures are more commonly associated with falls and tend to occur in infants and the elderly, whereas basilar, compound, and depressed fractures tend to be more common after motor vehicle accidents and assault (12). In contrast to clinical data, there is a dearth of population-based data regarding the incidence of fractures in fatal cases of head injury but approximately half of fatal cases of motor vehicle accidents have skull fractures (13), and most of these are basilar fractures or compound depressed fractures of the skull vault.

#### 3.2. Mechanical Aspects

A blow to the skull causes elastic deformation of the skull, including “inbending” of the bone at the site of impact and asymmetric and variably localized “outbending” at a distance from the impact (14,15). Fractures start at the site of skull deformation when the elastic properties of the skull are exceeded. In general terms, if force is applied over a small area (e.g., from a blow from a weapon) a fracture occurs at the site of inbending, whereas an impact over a larger skull area leads to fractures at the site of outbending (14,15). The shape of the skull convexity allows efficient dispersal of energy because of the large area occupied by the skull vertex; in many cases, linear fracture lines will branch along diastases to form a diastatic fracture. In contrast, energy passing through the skull base causes fracture lines that track through areas of weakness, owing to the presence of various foramina and air-filled sinuses, and converge on, or pass through, the sella turcica (16).

The degree of force required to produce a skull fracture is highly varied and related to the skull coverings (including the scalp, which reduces the force of an impact by 30% [15], and head coverings), the thickness of the skull, and where on the skull the impact occurred. A pathologist should make only very general comments about what sort of forces engendered a skull fracture. In broad terms, comminuted fractures are associated with more forcible head trauma compared with the forces that cause linear fractures of the skull vault, and depressed skull fractures indicate a localized application of force caused by, for example, a blow from a mallet, a fall against a protuberant object, or an impact to the head as a consequence of intrusion of part of the vehicle frame during a motor vehicle accident. Haphazardly arranged comminuted fractures indicate an impact between the head and a broad surface, and are characteristic of, but not restricted to, fractures associated with falls and motor vehicle accidents. Once the skull is broken, further fractures develop, or existing fractures extend, with the application of very little additional force (15).

Most skull fractures are caused by dynamic loading of the head (i.e., the head moves or stops moving after the impact). This means that the impact that produces the fracture is also associated with movement of the brain relative to the skull and, as a



**Fig. 1.** External manifestations of skull base fractures. (A) Marked periorbital bruising (“raccoon eyes”). (B) Scleral hemorrhage (the eyelids are retracted by the examiners’s gloved fingers). (C) Bleeding from the ear. (D) Bruising behind the ear (Battle’s sign).

consequence, “concussion” is frequently but not invariably associated with a skull fracture. Concussion is defined as a temporary period of altered brain function that manifests as disorientation, amnesia for the event causing concussion, and/or loss of consciousness. The structural basis for concussion remains conjectural and explanations for its functional basis are speculative (17,18).

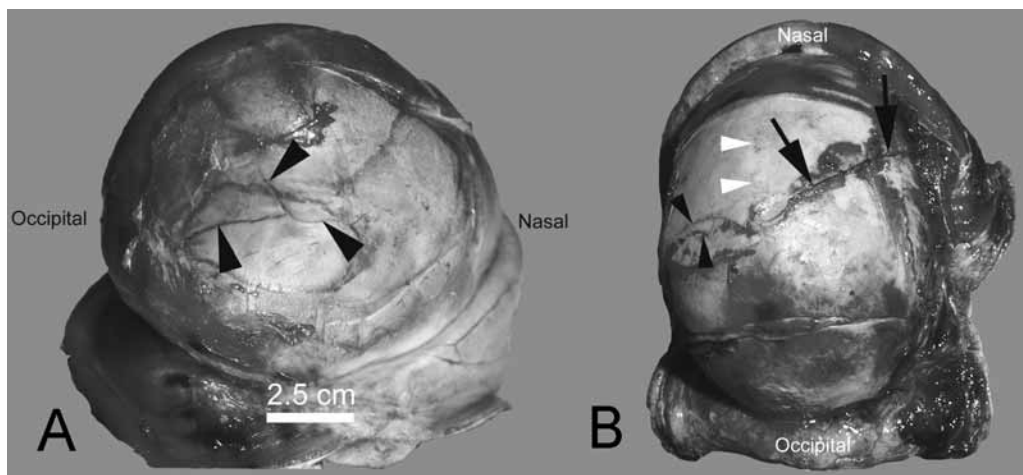
A skull fracture alone is not a cause of death. Rather, the skull fracture indicates that force has been applied to the head; it is the effects on the brain of the energy associated with this force or other complications of the fracture that cause death.

### 3.3. External Manifestations

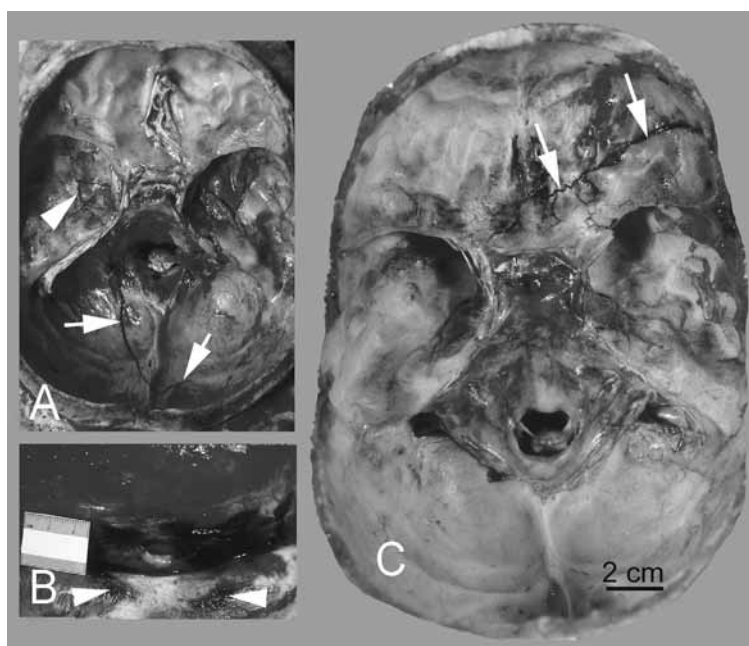
The external examination of the body may reveal indirect evidence of a basilar skull fracture, including periorbital bruising (“raccoon eyes” [19]), scleral hemorrhages, retroauricular bleeding (Battle’s sign), and bleeding from the ear (Fig. 1).

### 3.4. Classification and Pattern

The appearances of skull fractures are highly varied. Linear skull fractures are single fissures passing over the skull vertex (Fig. 2) or across the skull base (Fig. 3). Diastatic fractures follow bony suture lines (Fig. 4A). Comminuted skull fractures are formed by multiple fracture lines, which are haphazardly or concentrically arranged, or stellate in the sense that they radiate from the site of impact. Comminuted fractures (Fig. 4) may include fragments of free bone that, if displaced inward, form a depressed skull fracture (Fig. 4B) or, if displaced outward, an expressed fracture (Fig. 4C). A compound fracture allows communication between the external world and the cranial

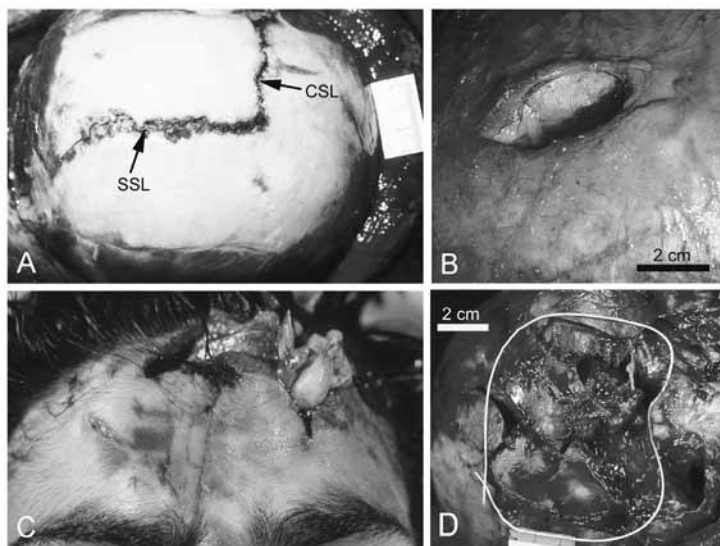


**Fig. 2.** Linear fractures of skull vault. **(A)** Right lateral view of skull vertex of an infant. A narrow, branching, linear fracture line is indicated (arrowheads). **(B)** Right oblique view of skull vertex in an adult. A linear fracture line (arrows) crosses the sagittal suture line (white arrowheads) and branches at its termination (black arrowheads). (Courtesy of Dr. L. C. Ang, London Health Sciences Centre, London, Ontario, Canada.)



**Fig. 3.** Linear basilar fractures. **(A)** Skull base. Occipital bone branched fracture (white arrows) extending into the left middle cranial fossa (arrowhead). **(B)** Occipital scalp. Scalp contusions (arrowheads) associated with (A), identifying the impact site. **(C)** Skull base. Linear basilar skull fracture (white arrows), secondary to a right lateral frontal impact.





**Fig. 4.** Various skull fractures. **(A)** Diastatic fractures involving the coronal suture line (CSL) and sagittal suture line (SSL). **(B)** Depressed skull fracture. **(C)** Compound comminuted expressed skull fracture with brain extrusion. **(D)** Comminuted depressed skull fracture. The string marks the margins of a depressed area of the skull whose dimension and shape correspond to those of the impact surface of the weapon that caused the injury.

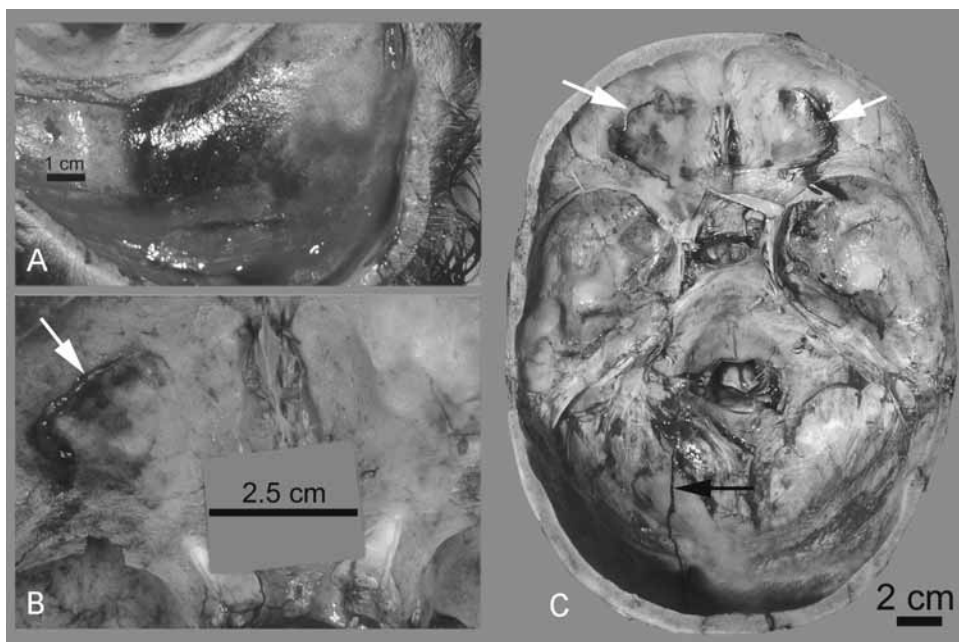
cavity, typically as a consequence of a scalp laceration over a vault fracture (Fig. 4C), a fracture of the cribriform plate establishing a route between the cranial cavity and the nasal cavity, or a petrous temporal bone fracture that opens the cranial cavity to the middle ear cavity (*see* Subheading 3.7.).

Contrecoup fractures (which should not be confused with coup and contrecoup contusions [*see* Subheading 5.4.]) are fractures in the anterior cranial fossa that involve the delicate bone of the orbital or ethmoid plates (Fig. 5). They occur after an occipital, parietal, or temporal impact (20,21) and are usually, but not always, associated with a fracture at the site of impact (20). The fractures appear as single delicate fissures or more complex, multiple, curved, or angular lines. They are associated with periorbital hematomas, which, when an occipital contusion or laceration is also present, may give the incorrect impression during the external examination of the body of more than one impact to the head.

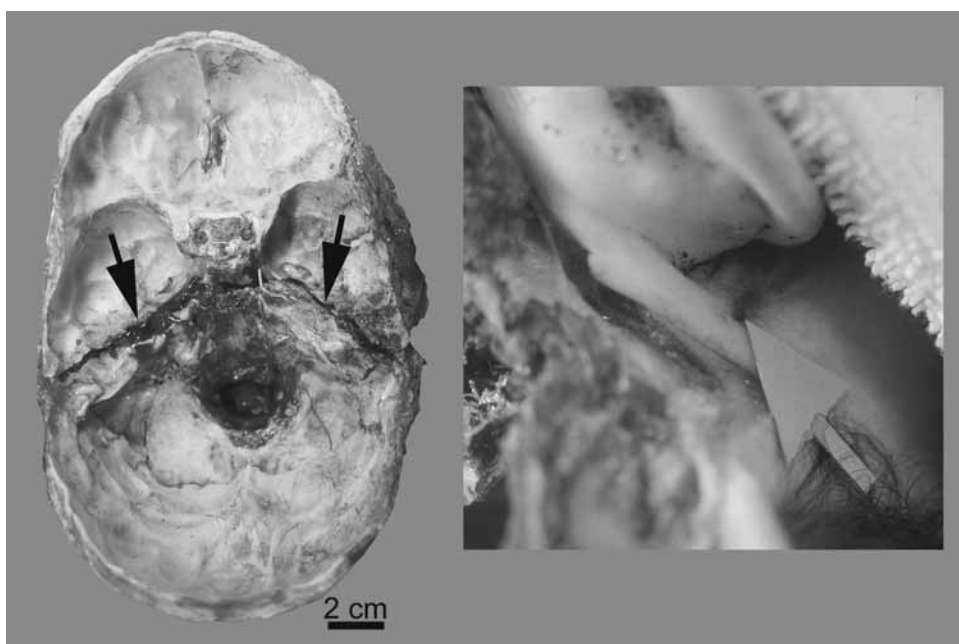
In general terms (16):

- The course of a fracture line roughly corresponds to the direction of the force that caused the fracture.
- The origin of a fracture line is close to, but not necessarily at, the site of impact.
- The fracture line passes through the site of impact.

The site of impact is inferred from the position of a localized scalp injury (which can be tiny; *see* Fig. 6). However, in many cases, the scalp injuries, particularly bruising in the deep layers, are too extensive to enable a precise determination of where the impact that caused a skull fracture occurred. In this case, the evidence of the distribution and pattern of a fracture, with the exception of a depressed skull fracture, should be used with some circumspection when attempting to localize the position of an impact.



**Fig. 5.** Contrecoup skull fractures (two cases). **(A)** Occipital scalp contusion associated with fracture illustrated in B. **(B)** Contrecoup fracture of the left orbital plate (arrow). **(C)** Bilateral contrecoup fractures of the orbital plate (white arrows) opposite a linear occipital fracture (black arrow) in a second case.



**Fig. 6.** Basilar ('hinge') fracture. A transverse basilar ('hinge') fracture (black arrows; left image) is associated with a tiny retroauricular bruise (arrow) marking the site of an impact (right image).

### **3.5. Basilar Skull Fractures**

Basilar skull fractures were elegantly and simply summarized by Rawling in 1912: “[A]nd yet the base is, in many respects, the weakest part of the skull. It is perforated by numerous foramina, it is hollowed out in places for the formation of air sinuses and for the reception of the integral portions of the auditory apparatus. Furthermore, it presents a more or less plane surface, one differing in all respects from the marked convexity of the vault. Those forces, therefore, which are received by the base of the skull, are not subjected to that diffusion which forms so conspicuous a feature in the case of the vault. ... [T]he base of the skull is more or less unsuited for the reception of severe blows, direct or transmitted, whilst, on the other hand nature has taken into consideration and provided fairly adequately against the dangers incident to vault injuries” (16).

Many basilar skull fractures originate from impacts in roughly the same plane as the skull base (i.e., the frontal eminence, supraorbital ridge, zygomatic process of the frontal bone, lower temporal bone, auricular and mastoid regions, occipital bone in a region bounded by the superior and inferior nuchal lines), and the fracture lines take predictable routes through the skull base (Fig. 7). In some cases, the fracture lines are discontinuous. A hinge fracture refers to a fracture that passes transversely across the base that allows movement of the separated halves of the skull base once the brain has been removed (“nodding face” sign; see Fig. 6).

#### **3.5.1. Ring Fractures**

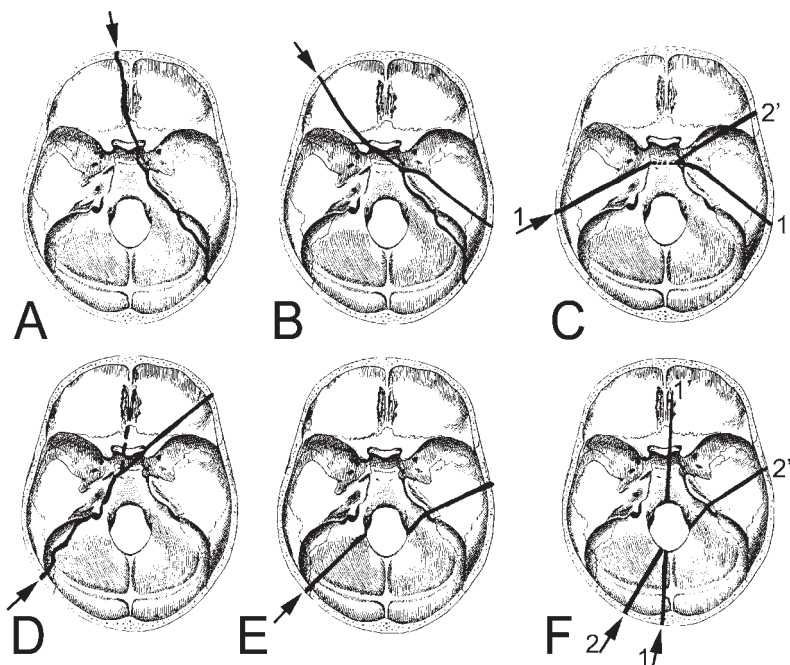
Although many basilar fractures conform to the principle that skull fracture lines radiate from the site of impact (22), similarly distributed fractures, remote from the site of application of force, are associated with impacts in the frontal and occipital regions and to the mandible (22,23). These fractures may be limited to the petrous temporal bone, but they characteristically extend, to a variable degree, through the squamous parts of the temporal and occipital bones, more or less encircling the foramen magnum at a variable distance to cause a “ring fracture” (23). A ring fracture that closely encircles the foramen magnum occurs after a fall from a height onto the buttocks or a blow to the vertex of the head, and is the consequence of an impact between the cervical vertebrae and the skull base (23). Ring fractures involving the petrous temporal bones are associated with contrecoup contusions in the temporal lobes and with anterior brainstem contusions or pontomedullary tears (22).

### **3.6. Fractures Caused by Crushing of Skull**

Static loading of the skull occurs when a stationary head is crushed between two heavy objects. There is minimal change in conscious level because of the lack of differential movement between the brain and skull, and so of the forces that cause concussion (see Subheading 3.2.). Basilar skull fracture lines extend perpendicularly from the site of applied force, which is usually bitemporal, and lead to separation of the petrous temporal bone from the greater wing of sphenoid and the squamous temporal bone (24).

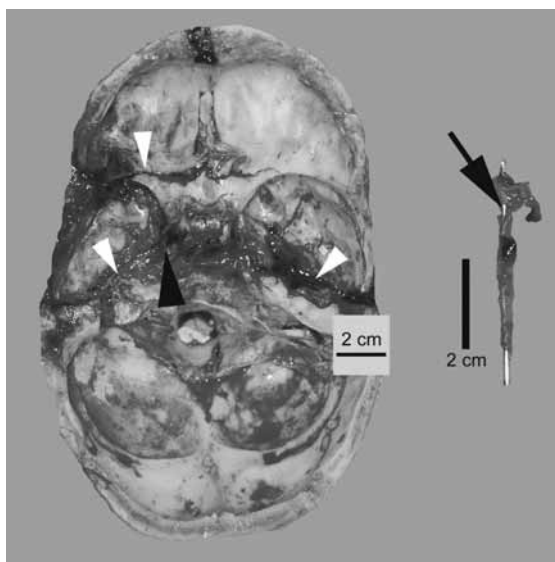
### **3.7. Complications of Skull Fractures**

A fracture that crosses the course of a blood vessel tears the vessel and causes an intracranial hemorrhage, usually an epidural hemorrhage. Fatal exsanguination through the ear (25) or bleeding from the nose (26) occurs when the intracavernous internal



**Fig. 7.** Approximate routes taken across the skull base by basilar fractures relative to the sites of impact, indicated by arrows. Note that “[w]hether the fracture completely traverses the base depends on the character of the force and the resistance offered, for bases, as well as vaults, vary greatly in strength. To every rule there must be exceptions, and cases are at hand in which the fracture appears to have obeyed no law, or in which the force applied was of so forcible a nature that the fracture traversed the base, regardless of the ordinary rule” (16). (A) Force applied to median frontal region. (B) Force applied to lateral frontal region (see Fig. 3C). (C) Force applied in the region of the external ear. Line 1–1’ is the most common route but route 1–2’ is also seen (see Figs. 6 and 8). (D) Force applied to the mastoid region. (E) Force applied to the lateral occipital region. (F) Force applied to the occipital region (see Figs. 3A and 5C). The direction of the applied force will determine which of routes 1–1’ and 2–2’ are taken. (Modified from ref. 16 by permission of Oxford University Press.)

carotid artery is torn by a basilar skull fracture (Fig. 8). Delayed fatal bleeding from traumatic carotid aneurysms at the same site also occurs (27). In general, in clinical series, symptomatic involvement of the carotid arteries, characterized by epistaxis, carotid–cavernous fistulae, pseudoaneurysms, or compression of the artery by an extravascular blood clot, occurs in a minority (10%) of cases of basilar fractures (26). Trapping (“incarceration”) of the basilar artery or a vertebral artery in the cleft of a longitudinal fracture of the clivus causes a brainstem infarct (28). Large tears in the walls of sinuses in compound fractures allow air to enter the venous system and to form pulmonary emboli (29,30) and embolization of cerebral tissue to the lungs occurs when extensive brain contusions lie close to a sinus torn by a fracture (see also Chapter 7, Subheading 12.1; Chapter 8, Subheading 12.4.; and ref. 31). Leakage of CSF from compound fractures of the cribriform plate and petrous temporal bone causes rhinorrhea and otorrhea, respectively; there is risk of infection, either as acute bacterial meningitis or a



**Fig. 8.** Basilar skull fracture and carotid artery tear. A comminuted basilar fracture (white arrowheads) passes through the left foramen lacerum (black arrowhead), causing a tear in the carotid artery (black arrow).

peridural abscess, from compound fractures (Fig. 9). Progressively enlarging linear fractures of the vault in children (“growing fractures”) occur when the fracture line is separated by an epidural hygroma (i.e., a localized epidural collection of clear or straw-colored fluid [32,33]). Displacement of the fracture edges toward the brain leads to linear tears on the brain surface, a “fracture contusion” (Fig. 10).

### 3.8. Occipital Condylar Fractures

Fractures of the occipital condyles are rare. Their effects range from neck pain (34), through multiple cranial nerve palsies (35), to death (36). If the supporting ligaments are intact the fracture is stable, but disruption of these ligaments causes fatal atlanto-occipital dislocation (37), which occurs in 2 to 4% of fatal road traffic accidents (36,38).

### 3.9. Skull Fractures and CNS Injuries in Burn Victims and After Gunshot Wounds

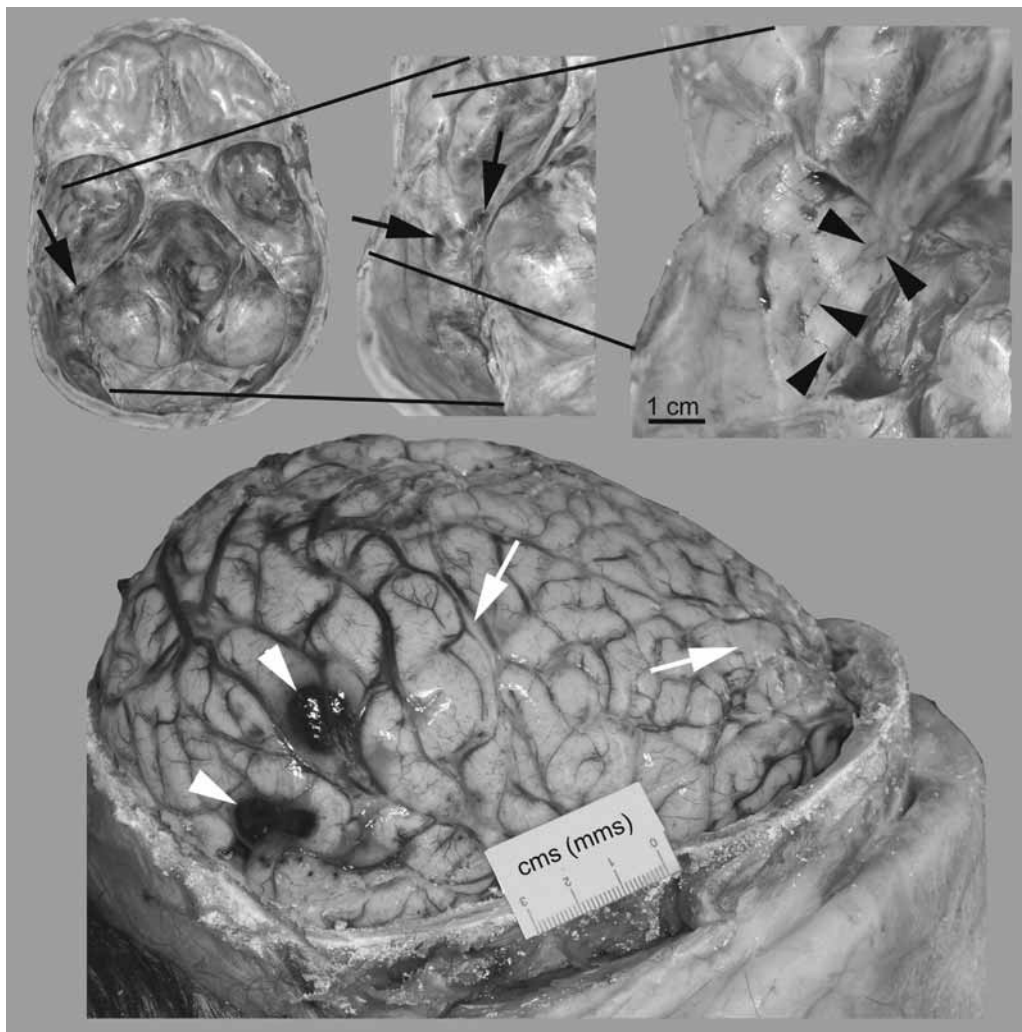
Skull fractures and CNS injuries related to thermal injury are covered in Chapter 4, Subheadings 3.1., 3.3., 4.3., 7.3., and 7.4. Skull fractures associated with gunshot wounds are described in Chapter 6, Headings 18. and 19.

## 4. TRAUMATIC INTRACRANIAL HEMORRHAGE

Hemorrhages mark the site of tearing, in some form or another, of tissue and blood vessels and therefore of sites through which energy has passed. Traumatic intracranial CNS hemorrhages occur in the following sites:

- Epidural space.
- Subdural space.



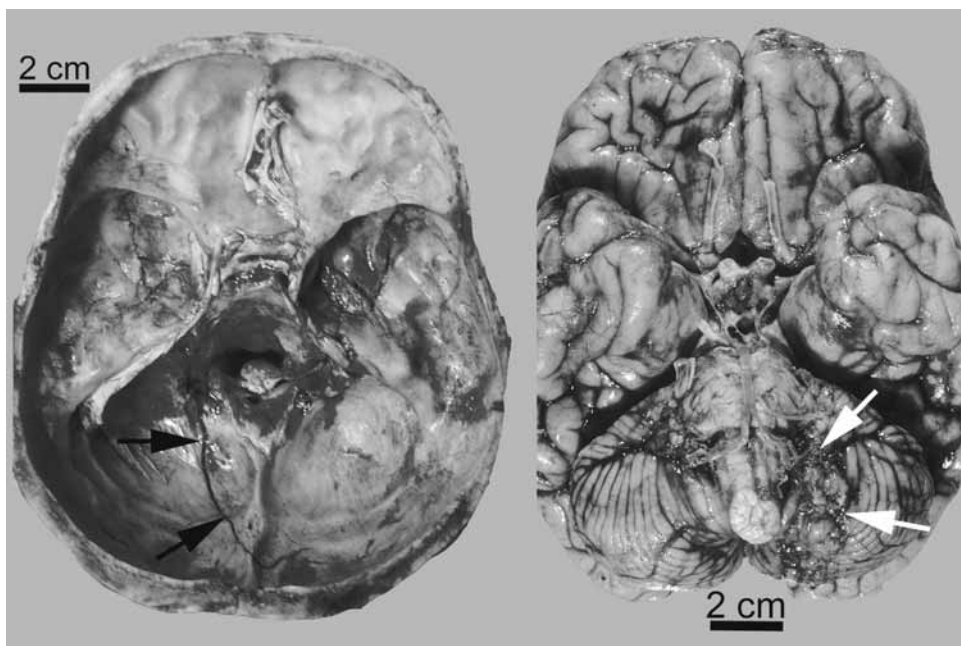


**Fig. 9.** Basilar fracture associated with acute bacterial meningitis. The lines indicate progressively closer views of the fracture site. Dural contusions (black arrows—dura in place) overlie hairline fractures of the petrous temporal bone (black arrowheads—dura stripped). Pyogenic exudates (white arrows), causing focal blurring of the sulci, and small coup contusions (white arrowheads), underlying the site of a blow to the head, are present on the brain surface.

- Subarachnoid space.
- Brain tissue (i.e., intracerebral bleeding).
- Cerebral ventricles.

#### **4.1. Traumatic Epidural Hematomas**

Epidural (extradural) hematomas (EDHs) are hemorrhages between the external layer of the dura and the inner face of the cranium. The interval between the impact that causes the EDH and the emergence of clinical signs of intracranial bleeding is usually short—a few hours at most—but in a minority of patients there may be a delay of several days before



**Fig. 10.** Fracture contusion. The linear occipital fracture (black arrows) is associated with a corresponding slightly hemorrhagic linear tear of the basilar cerebellar surface (white arrows). (Same case as illustrated in Fig. 3A,B.)

the bleeding becomes symptomatic (39,40) and there are rare reports of chronic expanding epidural hematomas, reminiscent in behavior of old subdural hematomas (SDHs [41]). The size and extent of an EDH is determined by whether the source of bleeding is venous or arterial and by the strength of attachment between the outer layer of the dura and the cranium. The latter varies between individuals, as evidenced by differences in the ease with which the dura is separated from the cranial vertex when the skull cap is raised during removal of the brain, and becomes more marked with increasing age.

EDHs are caused by a head injury (although there are rare exceptions [42]) that leads to a tear of an artery or cerebral sinus, which tear is usually, but not always, caused by a fracture. In rare cases in which a fracture is not responsible for an EDH, other explanations for the bleeding include avulsion and rupture of the diploic veins or stretching and tearing of a sinus wall. EDHs are usually in the temporal or parietal regions, where an impact to the temple causes a fracture of the squamous temporal bone, which is thin at this site, and tearing of the underlying middle meningeal artery by the jagged edges of the fractured bone.

EDHs also rarely occur at the skull vertex, where they are bilateral and associated with a skull fracture and consequent tears of the superior sagittal sinus (43,44), and in the posterior fossa, where the bleeding happens because of an occipital fracture and a tear in the wall of the straight sinus or sagittal sinus (45,46). Multiple EDHs are unusual but, when they do arise, they are more often venous than arterial, some of them take place without skull fractures, and the causal impact is more often in the midline than lateral (47–49). There is a single case report of an EDH on the opposite side of the head to an impact—in other words, a contrecoup EDH (50).

Victims with EDHs present to hospital with progressive neurological symptoms or they are found dead or *in extremis*. There may be a history from witnesses of a fall, trivial or otherwise, a few hours before. Patients die after neurosurgical intervention if the epidural bleeding was large enough to compress the brain and increase intracranial pressure to the extent that blood flow through the brain was hindered, and if the interval between the onset of clinical symptoms and the removal of the hematoma was long enough to allow irreversible ischemic brain injury to occur. As a consequence, progressive and fatal postoperative brain swelling develops in the hemisphere under the hematoma, which appears to be more severe than the swelling observed in cases that have not been treated surgically simply because drainage of the hematoma provides more space for expansion of the injured brain.

#### 4.1.1. Pathology

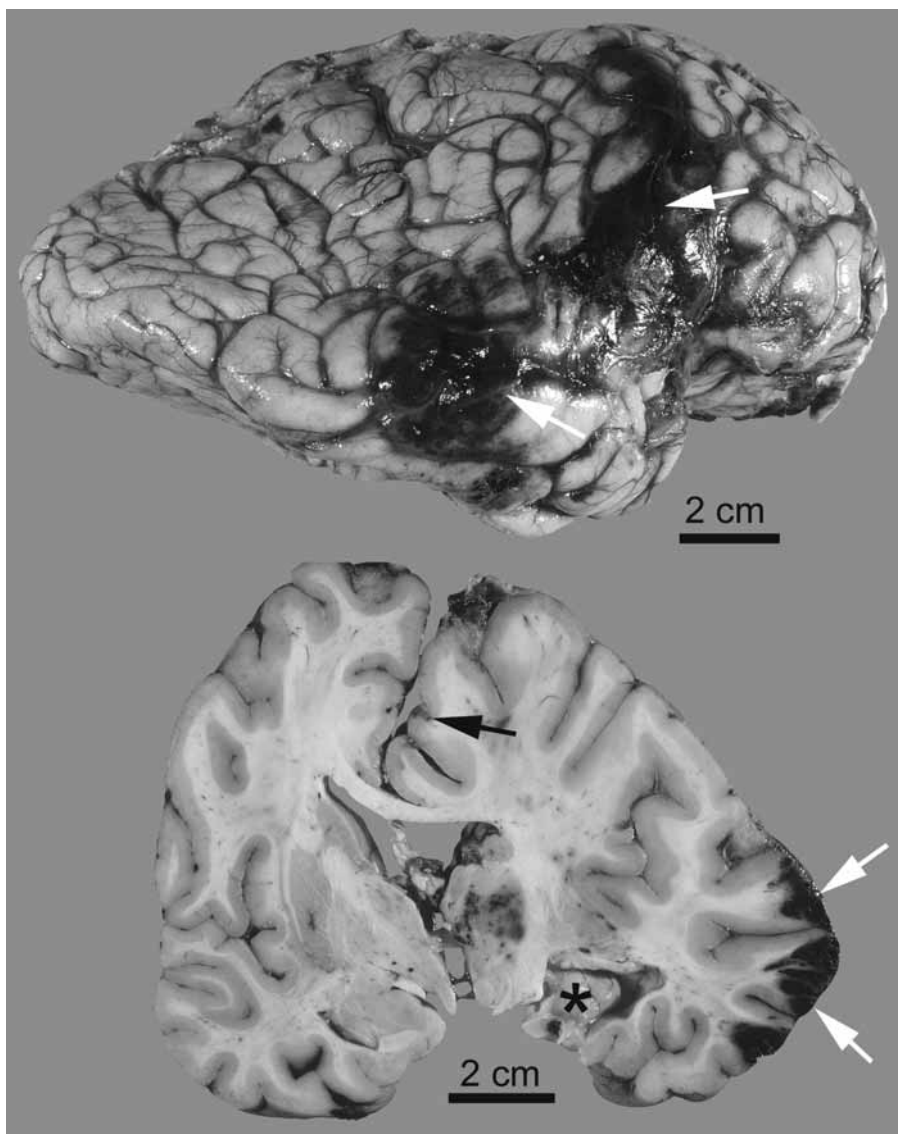
The autopsy findings in untreated EDHs are straightforward (Fig. 11). There is a temporal scalp contusion on the side of the hematoma, a large hematoma in the epidural space becomes visible as the skull cap is lifted, a fracture of the temporal bone overlying the hematoma traverses the course of the middle meningeal artery or one of its major branches, and a small thrombus on the surface of the middle meningeal artery marks the site of the arterial tear. Diffuse severe brain swelling is likely and the effects of intracranial “space occupancy” by the hematoma are observed, including subfalcine herniation extending from the side of the hematoma to the opposite side and transtentorial herniation, which is usually more marked on the side of the hematoma. Swelling of the cerebral hemisphere under the hematoma causes diminution in the sulcal subarachnoid space (effacement of sulci) and flatness of the crests of the gyri, which gives the brain surface a smooth appearance. Tonsillar herniation is observed but its absence is common, which applies both to EDHs and to other causes of rapidly rising intracranial pressure (51). Focal TBIs may be observed, particularly cerebral contusions.

#### 4.2. Traumatic SDHs

SDHs are classified in clinical terms as acute, subacute, chronic, or, sometimes, acute on chronic, depending on the length of history, the neuroimaging findings, and the appearance of the blood when the hematoma is drained. The SDH is acute if the blood is clotted (i.e., from the time of injury to around 48 h after injury), subacute if it is partly clotted and partly liquid (i.e., approx 2 d to 3 wk old), or chronic if it is liquid (i.e., greater than 3 wk old) (52). “Acute on chronic” SDHs are chronic SDHs (CSDHs) into which there has been recent bleeding to the extent that new neurological symptoms are precipitated in a patient who previously had no symptoms or trivial symptoms.

SDHs present to the pathologist in several ways:

- A small, thin recent hemorrhage (smear-type) SDH, which may or may not be associated with evidence of other craniocerebral trauma, particularly diffuse brain injury.
- A large recent hemorrhage, hours to a few days old (acute SDH [ASDH]), which may or may not have been surgically drained.
- An old SDH of variable size and with variable degrees of neomembrane formation around the hematoma (CSDH).
- Focal subdural hemosiderin staining with variable dural thickening, indicating the site of a small, healed hemorrhage.



**Fig. 11.** Effects of an acute epidural hemorrhage (EDH). This brain is from a patient who, while intoxicated with ethanol, fell and struck the left side of his head on the edge of a sofa without losing consciousness the evening before he was found dead in bed. An EDH (500 mL) was found at autopsy. There is marked flattening of the brain surface under the EDH, associated with coup contusions (white arrows). Above the site of right-to-left subfalcine herniation is a small right paramedian contusion (black arrow), which occurred either because of pressure necrosis secondary to the brain swelling or following an impact between the brain and the edge of the falx at the time of the fall (herniation contusion). Extensive disruption of the right medial temporal lobe structures owing to uncus herniation is indicated by an asterisk. The surface of the brain underlying the epidural hematoma is smooth, in contrast to the preservation of the gyral convolutions seen under acute subdural hemorrhages (see Fig. 12), and there is compression of the contralateral cerebral hemisphere.

The demonstration and interpretation of the significance, with respect to cause of death, of large ASDHs and large CSDHs is the most common problem facing the pathologist with respect to SDHs.

#### *4.2.1. Acute SDHs*

Acute subdural hematomas (ASDHs) are either simple (or “pure”), in the sense that no detectable brain injury is apparent, or complex, reflecting the coexistence of other more or less extensive brain injuries. ASDHs evolve rapidly or slowly, and, in the case of complex ASDHs, their symptomatology also reflects coexisting brain injuries. Small untreated ASDHs can resolve spontaneously and rarely evolve to CSDHs (53). There are also radiological descriptions of rapid spontaneous resolution of ASDHs, owing to the tamponading effect of a swollen brain (54).

##### *4.2.1.1. SIMPLE ASDHs*

Simple ASDHs, which comprise 13% (52) to 30% (55) of all traumatic ASDHs, are primary (when they appear to be spontaneous [56,57]), traumatic (when they occur after head trauma [55]), or secondary (reflecting bleeding into the subdural space because of a ruptured berry aneurysm or a vascular malformation, extension of an intracerebral hemorrhage into the subdural space, a hemorrhagic complication of a subdural neoplasm, or the coexistence of an acquired or iatrogenic disorder of coagulation [57,58]).

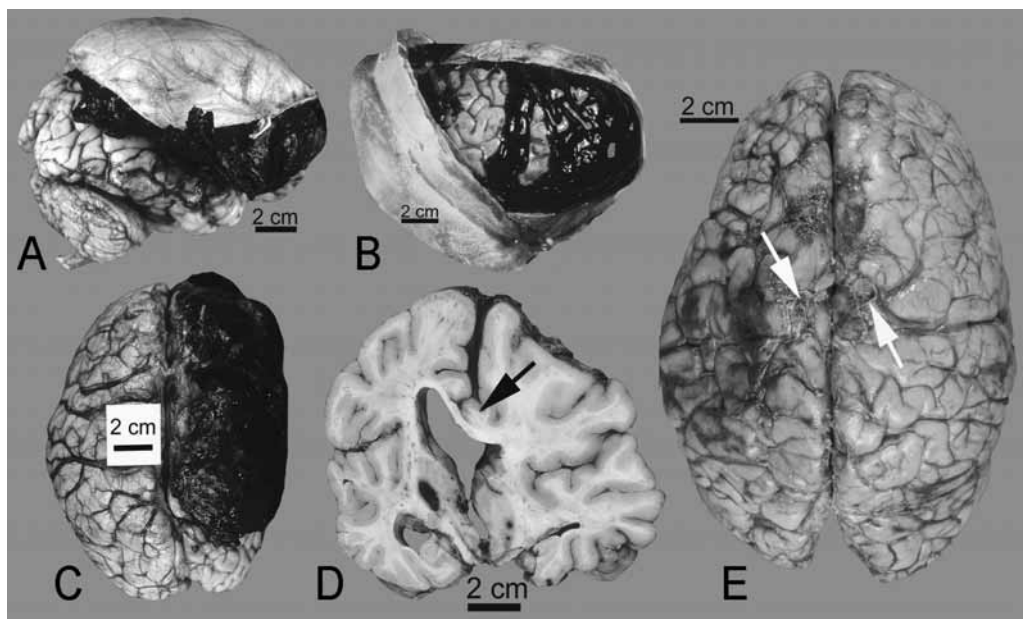
##### *4.2.1.2. COMPLEX ASDHs*

Complex ASDHs occur in approx 30 to 50% of patients admitted to the hospital with severe head injuries (59,60) and, because they are usually associated with extensive brain injuries, they are frequently fatal (61). (Although the prognosis reported in the literature for simple ASDHs is variously described as good [62] or poor [56], it is reasonable to assume that, for ASDHs of comparable size, duration, and method of treatment, the prognosis is better for simple ASDHs than for complex ASDHs because of the concomitant brain injury associated with the latter, and that the risk of death increases with the size and the duration of simple ASDHs.)

##### *4.2.1.3. PATHOGENESIS OF ASDHs*

ASDHs are caused by falls or assaults and, less often, by road traffic accidents (59). Correspondingly, in animal experiments, ASDHs occur in response to short-duration acceleration of the brain, relative to the skull, after impact, which is characteristic of falls, and increasingly severe injuries occur with increasing magnitude of acceleration (52,59). The source of bleeding is variable and its location is generally unrelated to the site of impact. ASDHs are caused by a tear of the bridging veins between the cortical surface and the dural sinuses (Fig. 12E) or of an arteriole or small artery on the cortical surface (55,63); ASDHs from the latter tend to be in the perisylvian region (55,62). Other ASDHs occur because of bleeding from torn blood vessels buried in large contusion–lacerations and massive, rapidly evolving ASDHs occur if an artery buried in the dura is torn by a fracture and bleeds into the subdural space. ASDHs are frequently associated with severe brain swelling (52) whose etiology has not been clearly established (61). It is likely, however, that this swelling reflects diffuse traumatic ischemic injury and diffuse traumatic brain swelling in complex ASDHs, but the tendency for the





**Fig. 12.** Acute subdural hemorrhages (SDHs). **(A,B)** Two examples of fatal acute SDHs. **(C)** Vertex view of (A) after removal of dura. **(D)** Coronal slice of (A). The outline of the gyral convolutions is preserved on the side of the hemorrhage, in contrast to the smooth outline of the contralateral hemisphere. Right-to-left subfalcine herniation is present (arrow). There is "paradoxical" dilation of the lateral ventricle opposite the hematoma. The septum pellucidum is torn. **(E)** The site of a third case of acute SDH is marked by a bloodstained depression in the left cerebral hemisphere. Bridging dural veins are indicated by white arrows. (A, C, and D courtesy of Dr. R. Hammond, London Health Sciences Centre, London, Ontario, Canada.)

swelling to be more prominent in the hemisphere next to the hematoma suggests an additive and possibly synergistic effect of the ASDH (in line with the clinical observations in simple ASDH that cerebral hemispheric swelling can be severe [55,56]), presumably related to local compressive effects leading to capillary closure, subsequent ischemic injury, and consequent localized brain swelling, as described above with respect to EDHs.

#### 4.2.1.4. GROSS FINDINGS

The external findings in cases of ASDH will reflect the cause of trauma (Fig. 12). Many cases of simple traumatic ASDH, whether caused by an assault or a fall, have external evidence of blunt force injury, more commonly to the face than to the head (55). Skull fractures are common. In cases in which the hematoma has not been treated surgically, the clotted or partly liquefied hematoma extends for a considerable distance under the dura because of the fragility of the dural boundary layer (*see* Subheading 4.2.2.2.) and, although the majority of ASDHs lie over the hemispheric convexities, they may extend to and line, or be localized to, the falx (64) or be restricted to the posterior fossa (46). There are no enclosing membranes. The hematoma molds to surface of the underlying brain so that the normal cortical undulations are preserved even in the presence of

severe diffuse brain swelling (in contrast to the smooth brain surface under an epidural hematoma; *see* Subheading 4.1.1.). The convexities of the gyri of the contralateral hemisphere are flat and the adjacent sulci are compressed, reflecting the space-occupying effect of the hematoma and of secondary brain swelling. Transtentorial herniation (usually more marked on the same side of the hematoma) and tonsillar herniation are often present and there is usually subfalcine herniation directed away from the side of the hematoma, associated with corresponding narrowing of the lateral ventricles. In severe cases of subfalcine herniation, the contralateral interventricular foramen of Monro may be occluded, leading to paradoxical dilation of the contralateral lateral ventricle. In cases in which the hematoma has been drained there is severe brain swelling, particularly of the hemisphere ipsilateral to the hematoma, with the usual herniation effects of the swelling. In complex ASDHs various other brain injuries are found. In severe cases, particularly those with injuries in the frontal and temporal regions, the ASDH may blend with a large area of fragmented and hemorrhagic (“pulped”) brain tissue or an intracerebral hematoma, giving the appearance of a “burst lobe” (52).

#### 4.2.1.5. MICROSCOPIC FINDINGS

Detailed accounts of the histopathology of SDH, both acute and chronic, are used as a basis for estimating the period between injury and death (65,66). However, these details (and the gross appearance of the blood clot) should be used only to give a rough estimate of the interval between injury and death because of the variability between individuals and between different regions of the blood clot in the rate of the evolution of the microscopic abnormalities and the possibility, in older SDHs, that bleeding is multiphasic. Of the various histological reactions at the margins of an SDH, the deposition of hemosiderin, demonstrated by an iron stain, is perhaps the most reliable in acute bleeding, but all that can be said if hemosiderin is detected is that the injury took place at least 2 to 3 d before death and even then only if samples of grossly unremarkable ipsilateral and contralateral dura have been examined to exclude pre-existing iron deposition from an older injury. Although undoubtedly ASDH and DAI do occur together (67), DAI is more likely to occur without ASDH and, conversely, ASDHs are more likely to be found without DAI, reflecting the different rates and durations of acceleration that are required to generate these injuries (59).

#### 4.2.2. Chronic SDHs

CSDHs appear in different forms (68). Most are of the “classical” form, with a characteristic inner membrane (91% of cases, Type I [68]). A few CSDHs manifest as hemosiderin-rich subdural granulation tissue without membrane formation, and may represent the healing phase of an unrecognized or untreated ASDH (6% of cases, Type II [68]). Rare examples are subdural hygromas that display bloodstaining of their normally straw-colored fluid (3% of cases, Type III [68]).

The majority of classic CSDHs become symptomatic because of slowly increasing space occupancy owing to gradual osmotically driven accumulation of fluid or repeated small capillary hemorrhages from the vascular outer membrane into the hematoma.

##### 4.2.2.1. EPIDEMIOLOGY (69,70)

The annual incidence of CSDHs is estimated to be 1 per 100,000 population of all ages and 7 per 100,000 population over 70 yr of age. The majority of patients are male, but the predisposition for males is less pronounced in the elderly (71). Most cases present

in the sixth and seventh decades. Symptoms and signs in elderly patients are nonspecific, and include falls, an alteration in mental state, or a progressive focal neurological deficit. About a third of elderly patients who present to a general medical clinic because of symptoms eventually attributable to a CSDH require neurosurgical treatment. In contrast to the symptoms in elderly patients, symptoms in younger patients are usually of raised intracranial pressure (72), perhaps reflecting the fact that the brain is less atrophic and therefore that there is less intracranial “leeway” space to allow brain swelling and expansion of the hematoma. Bilateral hematomas occur in approx 13% (patients 50 yr of age and younger [72]) to 25% (elderly patients [70]) of cases of SDH. A history of head trauma is elicited in 50 to 75% of cases (more frequently in younger patients). Death directly attributable to the hematoma occurs in 1 to 2% of younger patients with CSDHs and in 6% of older patients. Many factors increase the risk of CSDH, including cerebral atrophy, alcohol abuse (of which there is a history in 10% of cases), seizures, coagulopathies (both acquired and iatrogenic), subdural structural abnormalities (including meningiomas and metastases), conditions that cause intracranial hypotension (intraventricular shunts, CSF fistulae, lumbar puncture), and dehydration.

#### 4.2.2.2. PATHOGENESIS

The dura–arachnoid interface is not a “virtual” or “potential” space. Rather, it is a continuum of cells passing from the inner surface of the dura to the outer surface of the arachnoid. It includes the outer dural border layer of loosely adherent, poorly supported cells with scant intercellular junctions and minimal collagen and reticulin and the inner, more secure, arachnoid border cell layer whose interdigitating cells are attached to one another by numerous desmosomes and other types of intercellular junctions (73,74). Subdural hemorrhages start in the dural border cell layer because of its fragility.

Although the factors that lead to subdural bleeding are uncertain, CSDHs are presumed to arise from small asymptomatic ASDHs, and to evolve as a consequence of repeated small hemorrhages originating in the outer membrane (75). However, this sequence of events is inconsistent with several observations, including the occurrence of Type II CSDHs (*see* Subheading 4.2.2.) in which membrane formation does not occur (68), the tendency for CSDHs to occur in individuals with atrophic brains (the customary explanation of the atrophic brain stretching the bridging veins and rendering them more susceptible to tearing notwithstanding) and low intracranial pressure, and the tendency for untreated ASDHs to resolve spontaneously (53). An alternative (or additional) explanation to the assumption that CSDHs evolve from acute SDHs is that the fragile outer dural border cell layer is readily torn in mild head trauma, particularly in individuals with atrophic brains in whom this layer is not fully supported, or splinted, by the brain. The tear is followed by transudation of fluid into the subdural layer (*i.e.*, a small subdural hygroma occurs), which stimulates the development of membranes around the cavity. Vascularization of the outer membrane then leads to repeated small hemorrhages and expansion of what is now an SDH (76). Gradual expansion of the subdural space without hemorrhage causes a large subdural hygroma, which is also bounded by inner and outer membranes but contains straw-colored or clear fluid. The appearance of the latter suggests communication between the subdural and subarachnoid spaces, which accounts for an association between arachnoid cysts and subdural hygromas (77).

#### 4.2.2.3. GROSS APPEARANCES

CSDHs have varied appearances related to their size and age. In general, the hematoma cavity is narrow or spacious and contains liquid blood or bloodstained fluid of variable color. The hematoma is enclosed by a thin inner membrane and a thick outer membrane. The latter has a variegated appearance, formed by recent bleeding, older dusky hemorrhages, yellow hemosiderin, and pale collagen and other fibrous tissues. If the hematoma was the cause of death, the effects of its space occupancy in the form of subfalcine, uncal, and tonsillar herniation will be evident, reminiscent of the effects of an ASDH on the brain. Often, though, a CSDH is an incidental finding and, in older subjects, even when it is large, its effects on the gross anatomy of the brain may be minimal (Fig. 13). In some cases, CSDHs are associated with focal or diffuse superficial cortical siderosis (Fig. 14).

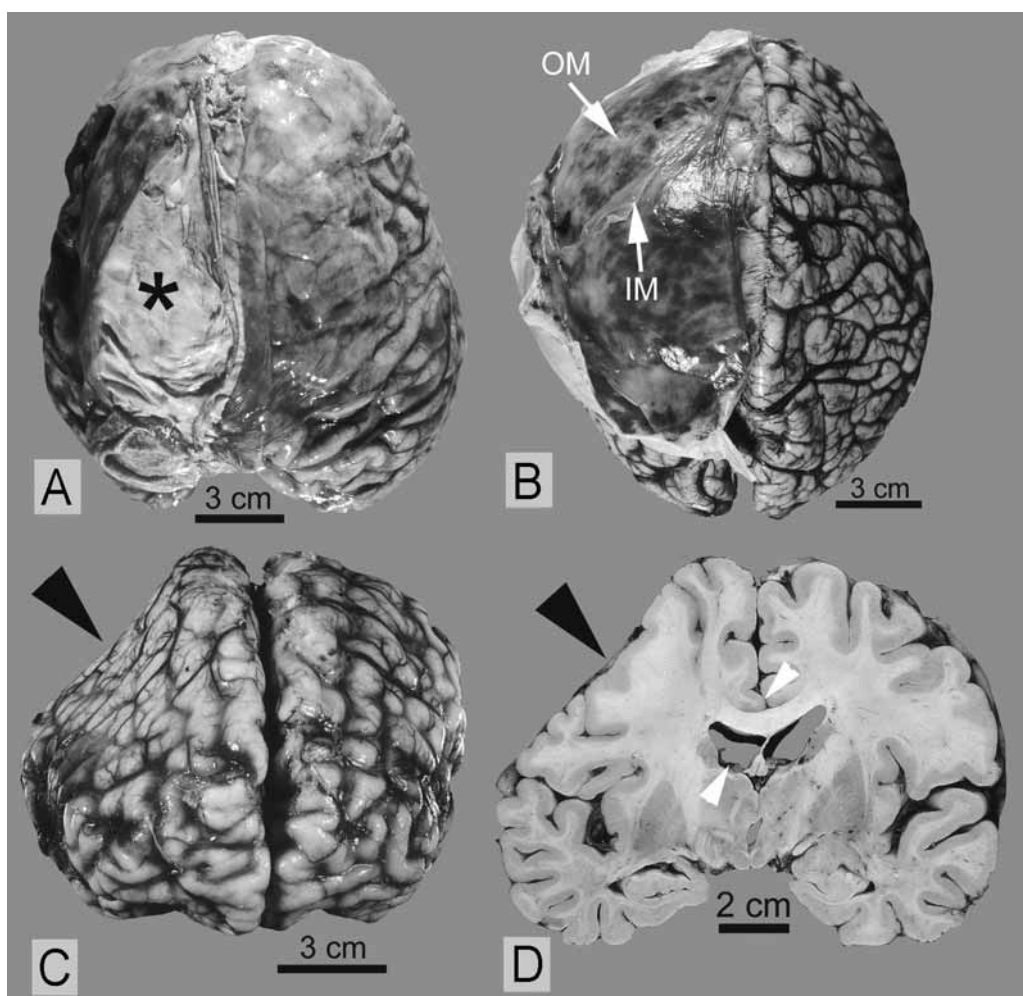
#### 4.2.2.4. MICROSCOPIC APPEARANCES

The inner membrane of a CSDH is a filmy, almost transparent, yellow-brown layer, 30 to 300  $\mu\text{m}$  thick, which is readily separated from the brain surface. The membrane is composed of disorganized collagen and elastic fibers and of cells that resemble the dural border layer cells, which are compactly arranged adjacent to the hematoma and loosely arranged next to the arachnoid. Variable numbers of macrophages, eosinophils, and red blood cells are also present (78). In contrast, the outer membrane, immediately under the dura, is thick and composed of smooth muscle, myofibroblasts, collagen fibers, and elastin fibers (79). Eosinophils may be conspicuous (80) and nucleated red cells, indicating extramedullary hematopoiesis, are a common finding. A prominent vascular plexus of thin-walled, sometimes large blood vessels is a characteristic feature of the outer membrane. The fragility of these vessels and the heightened fibrinolytic activity in and around the outer membrane accounts for the frequent finding of small recent hemorrhages in CSDHs and the tendency for these lesions to expand over time.

### 4.3. Cause of Death and Volume of Blood in EDHs and ASDHs

There are rare occasions when a scalp contusion, acute peridural hematoma (with or without a skull fracture), and some degree of subfalcine herniation are the only post-mortem findings in an individual who is presumed to have had a head injury. Although it may be reasonable to conclude, when such a case is definitely accidental (based on the evidence of reliable witnesses), that, in the absence of any other findings, the peridural hemorrhage is the cause of death, this diagnosis by exclusion of other causes of death comes under scrutiny when the death is suspicious and the possibility of homicide arises. A well-known forensic text states that 50 mL of rapidly accumulating subdural blood is sufficient to be life-threatening (81) but there is little information in the literature that precisely and definitively addresses this potentially contentious issue.

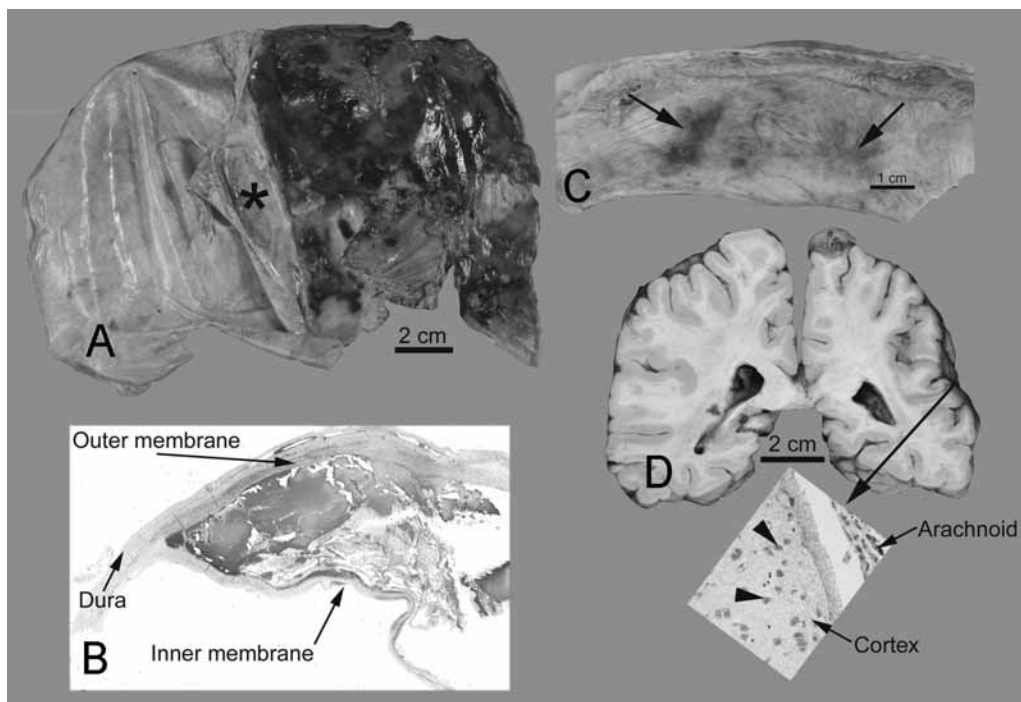
In one clinical study, a CT-based volumetric analysis of EDHs in 42 patients who were alive when they arrived in hospital showed that the volume of blood was greater than 50 mL in 5 of 6 fatal cases in which the patient died because of the hematoma, but in the remaining fatal case, in which the patient did not arrive in hospital until 20 h after injury, death occurred with an EDH volume of less than 20 mL (82). Moreover, of 35 survivors, 13 and 4, respectively, had EDHs of 50 to 100 mL and greater than 100 mL. In



**Fig. 13.** Chronic subdural hemorrhages (SDHs). **(A,B)** Two cases of chronic SDH show different degrees of inner membrane (IM) and outer membrane (OM) formation. The right convexity dura has been reflected to the left in both cases (asterisk in [A]). **(C)** The SDH has caused a marked depression of the surface of the right cerebral hemisphere (arrowhead—same case as [B]). **(D)** Coronal slice of (B). Despite the distortion of the right hemispheric outline (black arrowhead), there is only slight narrowing of the right lateral ventricle (lower white arrowhead), minimal evidence of right-to-left subfalcine herniation is apparent (upper white arrowhead), and there is no evidence of swelling of the contralateral cerebral hemisphere (compare effects of acute peridural hemorrhage shown in [Figs. 11](#) and [12](#)).

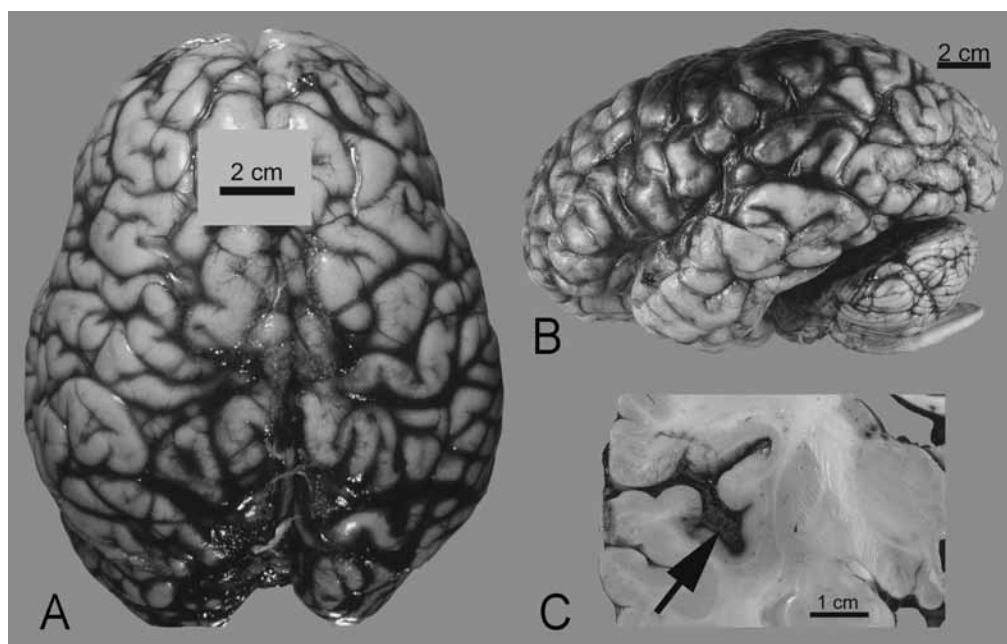
the same study, 57% of 102 patients with ASDHs died and none of the 8 patients with ASDHs of greater than 120 mL survived ([82](#)). Similar data are reported in another clinical study of 98 patients with EDHs and 91 patients with ASDHs for whom no statistically significant difference in blood volume was seen between the groups of patients with an “unfavorable” outcome (i.e., severe disability, persistent vegetative state, or death) or a “favorable” outcome (i.e., moderate or minor disability or complete recovery), although none of the patients with ASDHs greater than 110 mL survived ([83](#)).





**Fig. 14.** Dura from, and secondary leptomeningeal and cortical hemosiderosis in, chronic subdural hemorrhage. **(A)** Variegated appearance of a subdural hematoma (an asterisk marks the falx). **(B)** Whole-mount preparation, stained with HPS, showing dura and the outer and inner membranes around a chronic subdural hematoma. **(C)** Perifalcine “smear-type” old subdural hemorrhage (black arrows). **(D)** A concave area in the right cerebral hemisphere, caused by a chronic subdural hemorrhage, shows superficial slight (yellow) discoloration, which, as shown in the photomicrograph stained for iron with Perl’s method ( $\times 25$  objective), is caused by hemosiderin deposition in the subarachnoid space and in the astrocytes of the superficial layers of the cortex (arrowheads).

Although these observations are instructive, their usefulness for a pathologist is limited because the majority of the hematomas were surgically drained and it is likely that, had the patients been left alone, many more would have died as the hematomas expanded. Nevertheless, it is reasonable to presume that the presence of an EDH in any situation may or may not cause death (the likelihood increasing with increasing volume of blood and duration of injury and being greater in the presence of herniation phenomenon), that an ASDH of greater than 120 mL is invariably fatal, that an ASDH of 50 to 120 mL is more likely than not to cause death (particularly if there is significant and marked subfalcine herniation and uncal herniation), and that an ASDH of less than 50 mL is unlikely to be fatal. These cautious statements should be supplemented with a comment that complex ASDHs are associated with other potentially fatal brain injuries whose structural features may not have had time to appear if there was only a short interval between injury and death. In addition, the demonstration of a peridural hemorrhage, irrespective of its size, indicates forcible injury to the head and therefore the possibility of fatal medullary dysfunction, similar to that implicated in “commotio medullaris” (see Chapter 10, Subheading 4.3.), as an alternative cause of, or factor contributing to, death.



**Fig. 15.** Traumatic subarachnoid hemorrhage (SAH). **(A)** Sparse SAH in occipital (dependent) leptomeninges in a case of diffuse axonal injury. **(B)** Localized left frontal and parietal smear-type SAH. **(C)** Small sequestered subarachnoid hematoma in Sylvian fissure (arrow). (See also Fig. 19 for SAH associated with contusions.)

#### 4.4. Traumatic SAH

Bleeding in the subarachnoid space in association with craniocerebral trauma is often extensive because CSF and unclotted subarachnoid blood flow freely in the subarachnoid space. The amount of subarachnoid bleeding is proportional to the interval between trauma and death (it may be minimal when death occurs instantaneously or soon after craniocerebral trauma) and the size of the source of the bleeding, and, although subarachnoid blood staining may be widespread, it is usual most prominent close to its source.

Different patterns of traumatic SAH are encountered (Fig. 15):

- A small amount (smear) of localized subarachnoid blood staining over the cerebral convexities is almost invariable in cases of head injury, no matter how minor the trauma, and is presumed to reflect small tears in subarachnoid blood vessels.
- The SAH may be sequestered as a discrete hematoma, particularly in the depths of the sulci and the Sylvian fissure.
- Extensive subarachnoid bleeding in cases of suspected craniocerebral trauma occurs in the following situations:
  - Over contusions and lacerations where the extent of subarachnoid bleeding reflects the size of the brain injury and the interval between injury and death.
  - As a consequence of rupture of a traumatic intracerebral hemorrhage into the subarachnoid space or into the cerebral ventricles with subsequent flow of the blood through the foramina of Magendie and Luschka into the subarachnoid space.
  - In association with nontraumatic causes of intracranial hemorrhage. The most common cause is a ruptured berry aneurysm, whose onset may have been caused by, or

precipitated, the accident that caused craniocerebral trauma, but nontraumatic intracerebral hemorrhages, particularly when they are peripherally located in the cerebral hemispheres (usually associated with cerebral amyloid angiopathy), can also rupture into the subarachnoid space.

A thorough search for the source of the bleeding, before releasing the body to the undertakers, as outlined in Chapter 10, Subheading 4.2., should be carried out in all cases of extensive SAH, whether apparently traumatic or nontraumatic in nature, in which a source of bleeding is not immediately apparent during the autopsy.

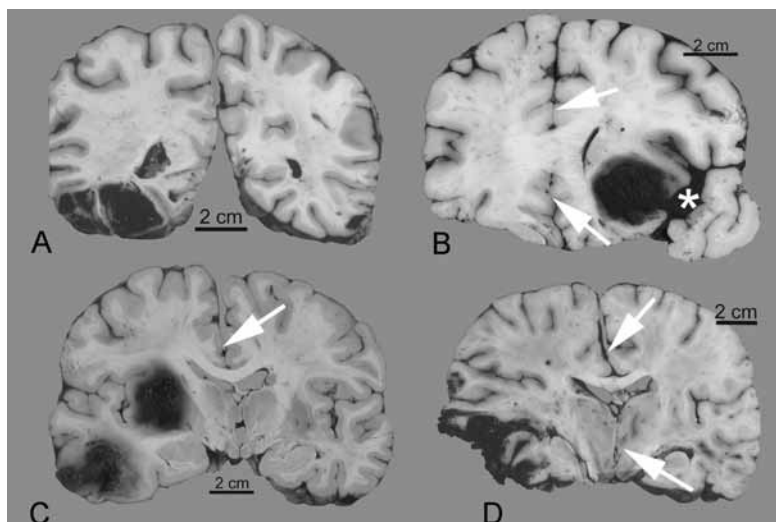
#### **4.5. Traumatic Intracerebral Hemorrhage**

Traumatic intracerebral bleeding occurs in the following forms:

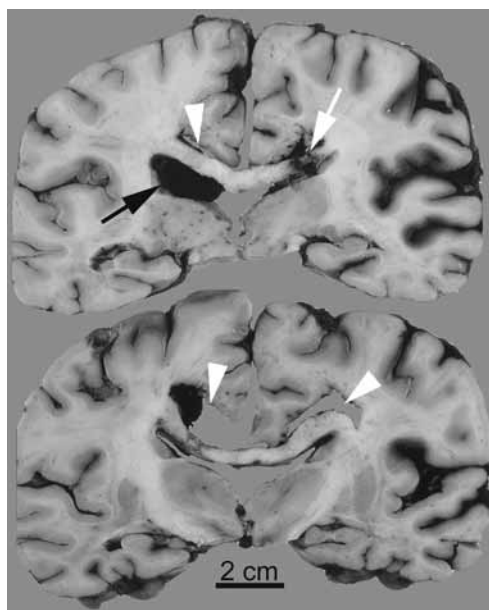
- Contusion–hematomas (*see* Heading 5.).
- Brainstem hemorrhages owing to transtentorial herniation (*see* Subheading 6.4.).
- Hematomas deep in the brain, remote from the hemispheric convexities, i.e., isolated traumatic intracerebral hemorrhages (“isolated” in the sense that they are isolated, or separate, in terms of location or pathogenesis or both, from contusions and from hemorrhages associated with brain swelling). Isolated traumatic intracerebral hemorrhages include:
  - Multiple small or moderate-sized hemorrhages that occur at the interface between gray matter and white matter, in the deep gray structures (Fig. 16), or at the sites of “pulling apart” (i.e., distraction) or shearing between two parts of the brain (usually the corpus callosum, cerebellar peduncles, or the “temporal stalk”—a discrete, rostroventrally located region of white matter that joins the rostral temporal lobe to the deep gray structures).
    - These hemorrhages are frequently, but not invariably, associated, with DAI (*see* Subheading 6.1.; and refs. 84 and 85).
  - Solitary medium-sized to large extraganglionic or lobar hematomas.
    - The cause of this type of hemorrhage is at times uncertain and a coincidental hypertensive hemorrhage or a hemorrhage associated with cerebral amyloid angiopathy may be difficult to exclude.
    - The exclusion of a hypertensive hemorrhage is presumptive, based on the lack of a history of high blood pressure and the absence of gross (e.g., cardiomegaly and renal granular atrophy) and microscopic features (hypertensive vascular changes in the basal ganglia and dentate nucleus, including hyalinization of the vessel walls and lipohyalinosis) of hypertension.
    - Hemorrhage owing to cerebral amyloid angiopathy is excluded when microscope sections stained with Congo red do not show amyloid in the cerebral vessels.
  - As isolated cerebellar hematomas (*see* Subheading 5.4.7.).
  - A rare type of intracerebral hemorrhage happens when tears occur between the dorso-lateral corpus callosum and the cingulate gyri, leading to bleeding into the ventricles and a hematoma that dissects the white matter between the lateral root of the corpus callosum and the cingulate gyri (Fig. 17).

##### **4.5.1. Delayed Traumatic Hematomas**

Traumatic intracerebral bleeding may be delayed (in the sense that progress in the bleeding causes new neurological symptoms after a stable period of usually a few hours to a day or so). In the context of a potential for delayed bleeding, traumatic intracerebral hemorrhages can be classified on the basis of serial neuroimaging studies as hematomas that decrease in size (Type I), small or medium-sized hematomas that



**Fig. 16.** Acute traumatic intracerebral hematomas. **(A)** Occipital contusion–hematoma. **(B)** Fronto-orbital contusion–hematoma with subarachnoid extension (white asterisk). **(C)** Isolated traumatic left intracerebral hematoma lateral to the basal ganglia and large temporal contusion–hematoma. **(D)** Extensive hemorrhagic disruption of the temporal lobe (“burst lobe”). The hemorrhages in (B), (C), and (D) are associated with various degrees of subfalcine herniation (white arrows).



**Fig. 17.** Acute pericallosal and subcingulate hematomas. This specimen is from an elderly patient who sustained a head injury from a fall down stairs. A tear of the right callosal root (white arrow) is associated with intraventricular blood (black arrow) and bilateral hematomas that dissect a space between the corpus callosum and cingulate gyri (white arrowheads). There was no evidence of traumatic axonal injury.

increase in size (Type II), hematomas that develop at sites that were previously normal (Type III), and hematomas that are associated with contusions (Type IV [86]).

#### ***4.6. Traumatic Intraventricular Hemorrhage***

The presence of copious blood in the fourth ventricle, viewed through the foramina of Luschka and Magendie prior to brain slicing, can be taken at the time of autopsy as indirect evidence of intraventricular bleeding prior to confirmation of this process when the brain is sliced. Traumatic intraventricular hemorrhage is primary or secondary.

##### ***4.6.1. Primary Intraventricular Hemorrhage***

Symptomatic primary traumatic intraventricular hemorrhage is rare but occurs after motor vehicle accidents and assaults (87–91), including those associated with relatively mild head trauma (92). Although the bleeding may be extensive, different patterns are described in neuroimaging studies, including hematomas around the foramen of Munro, hematomas unilaterally in the body and posterior horn of a lateral ventricle, and bleeding solely in one or both posterior horns of the lateral ventricles (in which case a CSF–blood demarcation level is frequent, owing to the supine position of the patient [91]). The source of bleeding is undetermined in most cases, but various sources are possible, including avulsion of the choroid plexus (65), tears in the tela choroidea (87), or tears in the wall of the ventricles that rupture the subependymal veins.

A variable but usually small amount of intraventricular hemorrhage is frequent when there is a tear of the septum pellucidum or a tear at the site of attachment of the fornices to the corpus callosum (*see* Heading 7.).

The possibility of a nontraumatic cause of intraventricular bleeding should also always be considered. Nontraumatic primary intraventricular hemorrhage originates from a ruptured berry aneurysm or vascular malformation or can be associated with a number of conditions, including hypertension, anticoagulant treatment, methamphetamine abuse, fibromuscular dysplasia, Moya Moya disease, and brain tumors (93–95); in many cases, though, the source of bleeding is undetermined in these nontraumatic cases.

##### ***4.6.2. Secondary Intraventricular Hemorrhage***

The explanation for secondary intraventricular hemorrhages, which is the common type of traumatic intraventricular bleeding (96,97), is usually self-evident when the brain is sliced and a traumatic intracerebral hematoma is found in continuity with the ventricles (e.g., *see* Fig. 38B; Subheading 6.4.).

#### ***4.7. Artifactual or Trivial Traumatic Intracranial Hemorrhage***

There are situations when generally small artifactual or inconsequential hemorrhages are found in the brain or its coverings. Many of these circumstances arise in individuals whose cerebral venous pressure was elevated before they died because of increased right heart pressure (as a consequence of acute heart failure or pulmonary embolus) or jugular venous obstruction (for example, by strangulation or hanging). In such cases cerebral vascular congestion is striking and sometimes more marked in dependent than in other areas of the brain (a cerebral form of livor) (*see also* Chapter 2, Subheading 5.2.). Agonal rupture of the congested vessels leads to focal sparse microscopic subarachnoid bleeding and intracerebral petechiae (which are common in the ventral



wall of the third ventricle) or thin grossly visible films of subdural and subarachnoid blood (*see also* Chapter 2, Subheading 5.2.). Although controversial, a similar explanation may account for small and microscopic intradural hemorrhages with minor epidural and subdural extension in infants in whom there is otherwise no reasonable basis for the suspicion of nonaccidental injury (98). The dorsal cervical and thoracic spinal peridural area (and therefore, with respect to the latter, the most dependent part of the vertebral column) may also appear hemorrhagic at the time of autopsy, particularly in infants, and histological examination of the tissue shows agonal acute hemorrhage and capillary rupture (99,100).

## 5. CONTUSIONS AND LACERATIONS

The forces associated with head trauma commonly cause focal areas of hemorrhagic disruption or tearing of CNS tissue.

### 5.1. Terminology

Areas of hemorrhagic disruption (tearing lesions) of the CNS that are peripherally located in the brain or spinal cord are customarily called *contusions* if the pia is intact and *lacerations* when the pia is torn (52). However, it is often difficult for a pathologist to be sure whether or not a tear of the pia has occurred unless step sections through every contusion are examined under the microscope, an unnecessary exercise because there is no difference in practical terms in the significance of contusions with intact pia compared with contusions with microscopic pial tears. Moreover, there is a tendency in general, and in neuroimaging descriptions of craniocerebral trauma in particular, to describe traumatic areas of hemorrhagic disruption or tearing lesions of the brain that are not hematomas simply as contusions. In reality, several types of lesions that signify traumatic hemorrhagic disruption or tearing of CNS tissues can be recognized when the fixed brain is examined. These include (with the terms that will be used for them in the rest of this text):

- Discrete areas with small, petechial or linear hemorrhages (simple contusions).
- More extensive areas of hemorrhagic tissue destruction than in simple contusions that include grossly evident pial tears or disruption (contusion–lacerations).
- Areas of hemorrhagic tissue destruction, usually in the characteristic distribution of simple contusions and contusion–lacerations, of various sizes that are associated with, or blend into, hematomas (contusion–hematomas). The stage at which contusion–lacerations should be classified as contusion–hematomas is difficult to define precisely.
- Large lacerations, evident to the naked eye, that are associated with minimal or mild perilesional hemorrhagic tissue destruction (lacerations). Cerebral lacerations are caused by depressed skull fractures and penetrating or perforating head injury.

These specific terms notwithstanding, the subsequent unqualified use here of the term “contusion” refers collectively to simple contusions, contusion–lacerations, and contusion–hematomas.

Deeply placed hemorrhagic tears are also encountered that are sometimes referred to as intermediate (*see* Fig. 18B) or deep contusions and are often indicative of DAI. These lesions are associated with multiple small or medium-sized isolated traumatic intracerebral hemorrhages (*see* Subheading 4.5.).

## 5.2. Pathogenesis

The pathophysiology of contusions is complex and multifactorial, but, in general terms, contusions are tissue tears in areas where movement of the brain relative to the skull has occurred. Contusions therefore mark sites of collision between the brain and its bony and dural coverings, sites of forcible separation of the brain from the dura, and sites of differential movement between the brain and dura and between adjacent areas of the brain.

It is usually a head impact that causes relative movement between the brain and its coverings, and a consequent contusion, and the lag in the initiation or cessation of movement of the brain with respect to the dura and the cranium is a form of inertial injury, impact inertial injury. However, the forces responsible are seldom of the magnitude and character that cause the characteristic impulsive inertial injuries when the head is exposed to acceleration and deceleration without a cranial impact (*see* Subheading 6.1.).

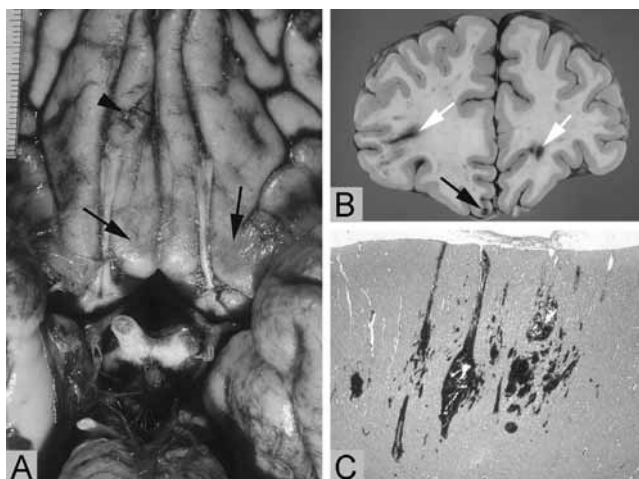
Contusions are more severe in terms of their size and extent when the skull has been fractured than when it is intact and contact injuries are more likely to cause contusions than are impulsive inertial injuries (101). There is a direct correlation between the force of injury and the extent of contusions for occipital impacts but not for lateral impacts (102). Contusions occurring as a consequence of an impact to the side of the skull occur at lower acceleration intensities than those caused by occipital impacts (102). Irrespective of the site of impact, contusions tend to occur at the frontal poles, in the frontal lobe overlying the orbital plates, in the lateral and basal areas of the temporal lobe, and in the walls of the Sylvian fissure (101–103). The predilection of the orbitofrontal cortex for contusions reflects the rougher surface of the orbital plate in comparison with the smooth inner surface of the skull vault (65,102), and a complex mechanical interaction between the bulwark of the sphenoid ridge and the rostral temporal lobe accounts for temporal and perisylvian contusions. Parietal and occipital contusions are usually small, but large examples are associated with adjacent skull fractures or are coup contusions (*see* Subheading 5.4.2.). Contusions develop at the time of injury, but their hemorrhagic appearance becomes more pronounced with the passage of time or when there are other factors that compromise blood clotting. Bleeding is more marked when necrosis is prominent or a large vessel is involved.

Intoxication by alcohol is associated with disproportionately large contusions, as drunk subjects tend to fall and, because of their blunted protective locomotor reflexes, they fall more heavily than do sober subjects. Moreover, concomitant liver disease and, possibly, acute alcohol intoxication hinder hemostasis.

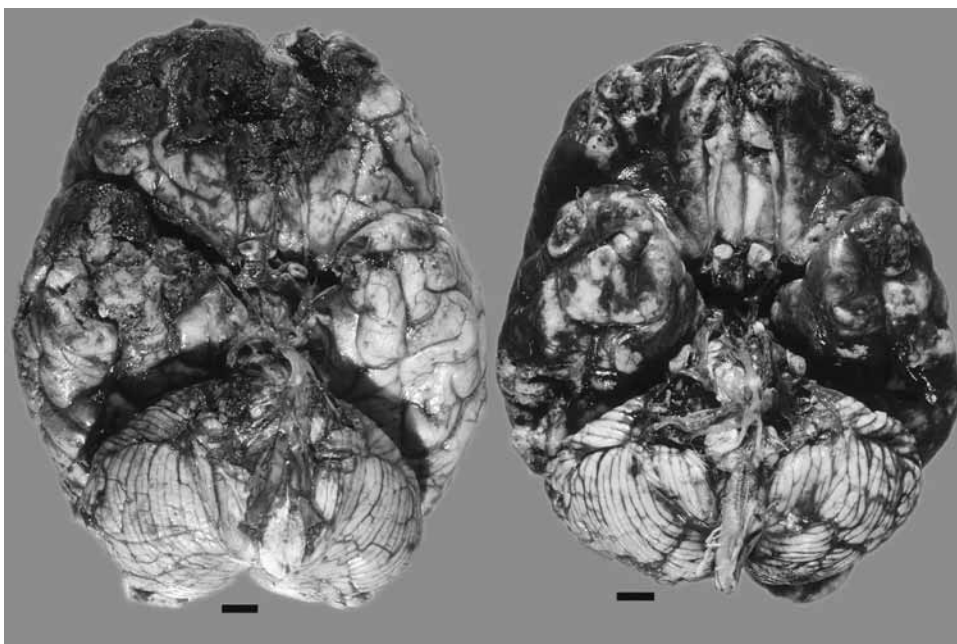
## 5.3. Pathology

### 5.3.1. Acute Contusions

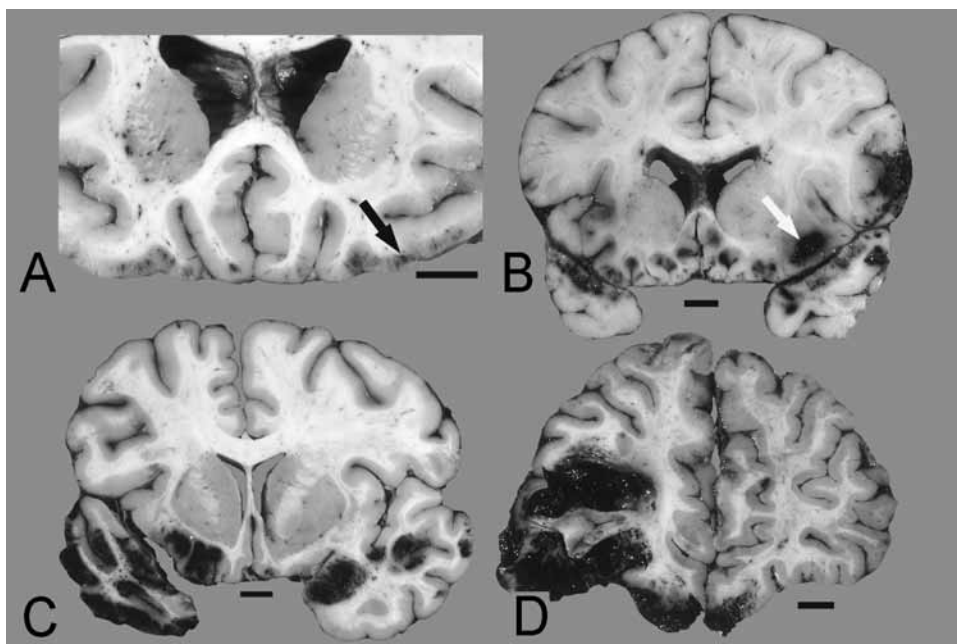
The gross appearance of acute contusions on the brain surface varies from faint discoloration of the brain surface (simple contusions; Fig. 18) to large areas of hemorrhagic destruction and necrosis (contusion–lacerations; Fig. 19). The brunt of the injury is borne by the gyral apices, but, depending on the severity of the injury, the changes may be localized to the gray matter or extend to a variable degree and with variable character into the adjacent white matter. SAH is associated with contusions (Fig. 19). In brain slices small contusions, or contusions in cases in which there is a short interval between injury and death, appear as linear hemorrhages perpendicular to



**Fig. 18.** Simple acute contusions. **(A)** Dusky discoloration of the caudal orbitofrontal cortex is typical of small simple contusions (arrows). (A small contusion laceration is indicated by an arrowhead.) **(B)** A simple contusion is present in the left gyrus rectus (black arrow). There are small white matter hematomas (white arrows). **(C)** A low-power photomicrograph of the cerebral cortex shows the linear nature of simple contusions, reflecting the route of torn small blood vessels perpendicular to the cortical surface (H&E:  $\times 1.6$  objective).



**Fig. 19.** Acute contusions—external appearances (bars = 1 cm). Large asymmetrical (left image) and symmetrical (right image) acute frontal and temporal contusion-lacerations are associated with marked secondary subarachnoid hemorrhage.

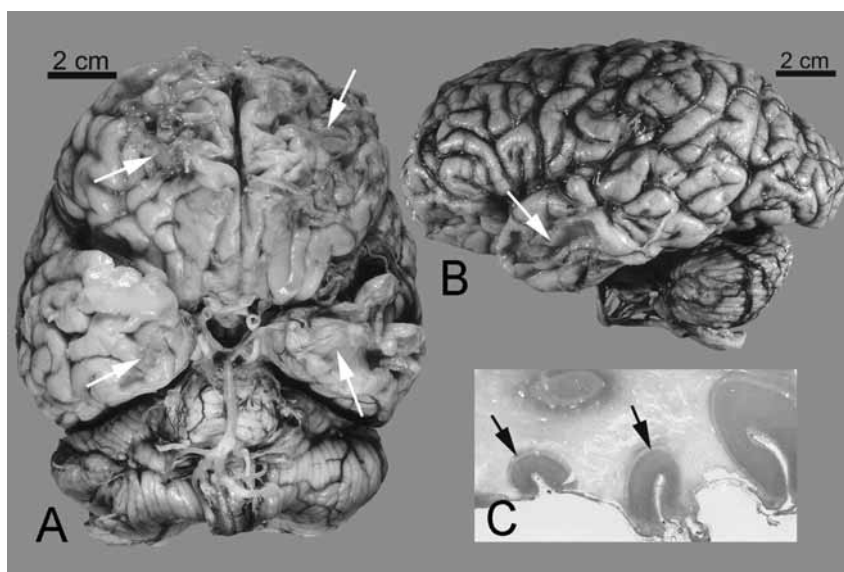


**Fig. 20.** Acute contusions—brain slices (bars = 1 cm). **(A)** Small linear simple contusions (example indicated by black arrow). **(B)** Simple contusions, contusion–hematoma (white arrow). **(C)** Multiple contusion–hematomas and simple contusions. **(D)** Large contusion–hematomas and contusion–lacerations.

the pial surface, reflecting the similarly oriented course of cortical blood vessels and illustrating how tearing of these vessels accounts for the contusions (Figs. 18 and 20). Large contusion–lacerations appear as fragmented and irregularly shaped hemorrhagic areas (Figs. 19 and 20). Coup contusions have a wedge shape whose base is at the pial surface (see Chapter 6, Fig. 51). Localized swelling of the brain around contusions is proportional to the size of the contusions.

Under the microscope acute contusions contain perivascular hemorrhages and various degrees of confluent hemorrhage. Almost immediately after injury, neurons in the vicinity show nonspecific changes, including dusky discoloration and distortion of their profiles, which may reflect mechanical injury or early ischemic neuronal change (see Subheading 6.3.). After 3 to 5 h the center of the contusions shows sharply demarcated areas of pallor and microvacuolation, which is an early sign of necrosis secondary to failure of cerebral perfusion at this site (104). After a survival interval of 6 to 24 h some neurons in the same area develop unequivocal features of ischemic injury, including cytoplasmic hypereosinophilia and nuclear pyknosis. Although some degree of neuronal injury is inevitable in contusions, necrosis is not.

The degree of the inflammatory response to contusions and its timing after injury are variable (105,106). As a general guide, margination of neutrophils is seen within 3 h, extravascular neutrophils appear in injured tissue from about 6 h of injury and continue to be found for 3 d or so, and a mixed infiltrate of macrophages, activated microglia, and lymphocytes appear at around 3 to 4 d after injury. Hemosiderin is noted in macrophage cytoplasm at around 2 to 3 d of injury. Reactive astrocytes are apparent



**Fig. 21.** Old contusions. Two specimens show (A) old fronto-temporal and (B) temporal contusion–lacerations (white arrows) in the form of pits and grooves on the brain surface. (C) Intact cortex, indicated by arrows, in the depths of two sulci with tearing of the gyral crests. White matter pallor extends below the intact gyrus on the right.

approx 5 to 7 d after injury. Axonal swellings are visible in the white matter margins of contusions from around 24 h after injury.

### 5.3.2. Old Contusions

Resorption of blood and necrotic tissue from contusions leaves, weeks to months after injury, sharply demarcated cavities, corresponding to contusion–hemorrhages, and cystic or softened areas of tissue loss with characteristic scalloping of the crests of the gyri, corresponding to large simple contusions and contusion–lacerations (Figs. 21 and 22). Hemosiderin deposition in, and corresponding yellowness of, old contusions vary unpredictably among cases from none or minimal to marked, and presumably reflect the volume of the original hemorrhage and variability between individuals in the efficacy of the inflammatory response to injury. The white matter under contusions and under adjacent histologically normal cortex is pale because of loss of myelinated axons (and possibly demyelination), secondary to localized ischemic injury and edema (Fig. 21C). Dura may adhere to the surface of old contusions (Fig. 22E). Small simple contusions are visible under the microscope as perpendicular linear arrays of astrocytes and siderophages at the sites of neuronal loss.

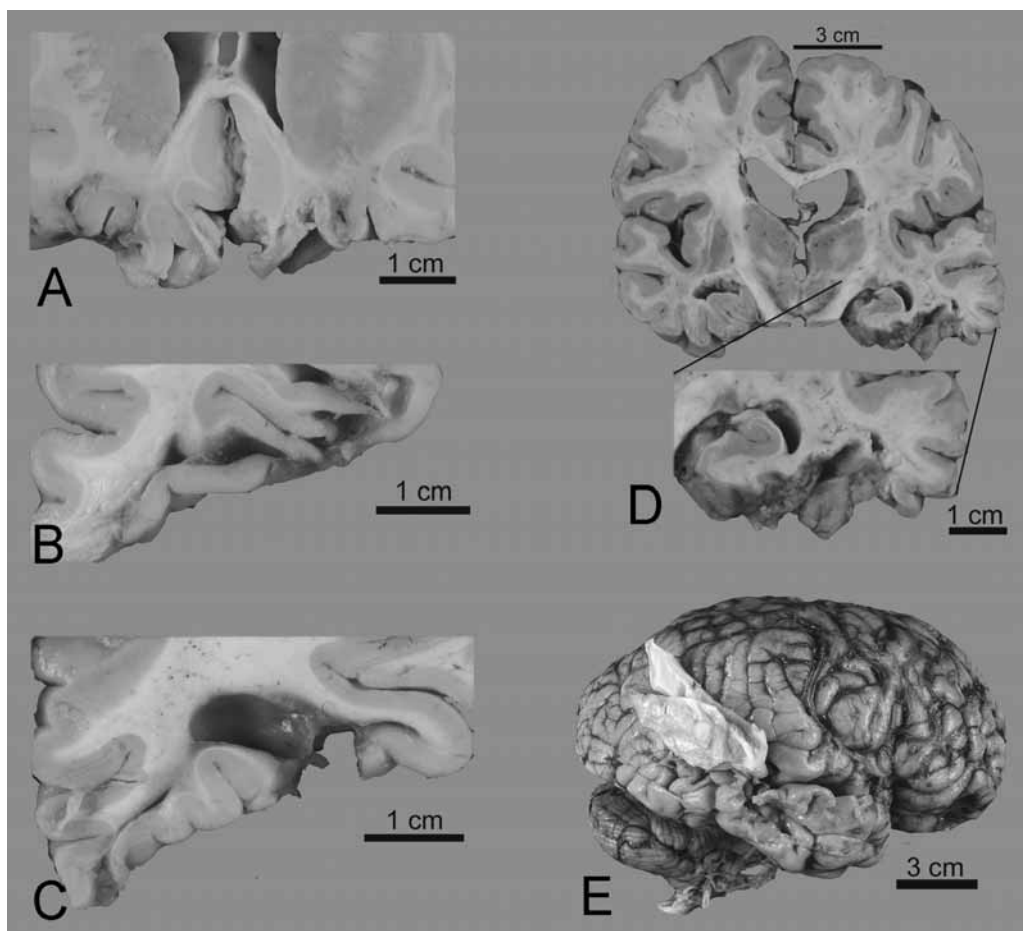
## 5.4. Contusion Patterns

There are several repeatedly encountered contusion patterns that allow tentative inferences to be made regarding the cause of a head injury.

### 5.4.1. Contrecoup Contusions

Contusions that occur in areas of the brain lying diagonally opposite the site of an impact to the skull are traditionally referred to as contrecoup contusions. Contrecoup

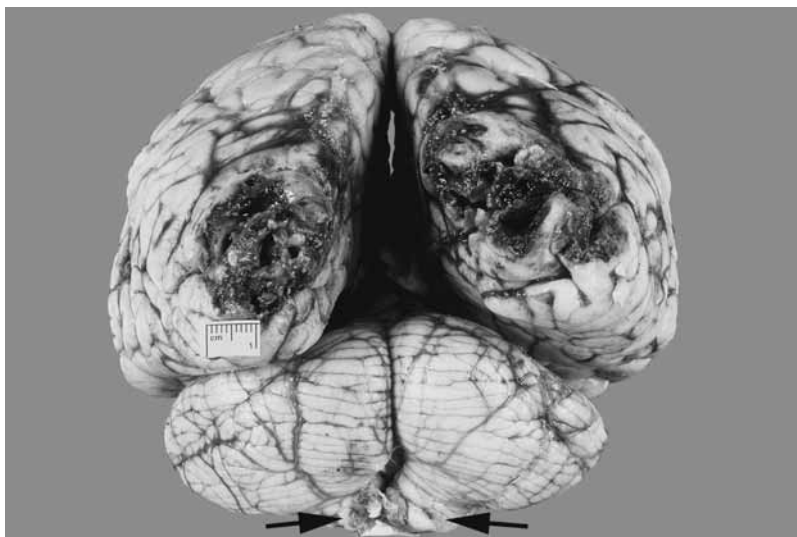




**Fig. 22.** Old contusions. (A) Old fronto-orbital contusion–lacerations. (B, C) Old fronto-orbital contusion–hematomas. (D) Old temporal contusion–laceration (lines localize the source of the close-up view). (E) Right temporal lobe contusion–laceration with adherent dura.

contusions occur when the brain continues moving after the skull has stopped, or when the brain remains stationary after an impact has caused the skull to start moving. The discrepancy between the movements of the skull and the brain causes tensile (stretching) or sliding (shearing) forces that overcome the elasticity of the blood vessels and other tissues at sites where the brain draws away from, or collides with, its coverings. In other words, movement of the brain, relative to its coverings, causes tearing and distortion of, or suction on, CNS tissue opposite the site of application of force to the cranium. A typical example of contrecoup contusions is the occurrence of frontotemporal contusions when a fall backward causes the occiput to strike a hard surface.

It is, however, commonplace to find contusions at other places in the brain than those precisely and diagonally opposite the site of a solitary impact to the head, as inferred from the location of scalp injuries or a fracture (101,102). There is also a tendency for contusions resulting from lower acceleration forces to appear in a contrecoup position, whereas those caused by greater acceleration forces are more widely distributed (102). This variability in the location of contusions with respect to the site of application



**Fig. 23.** Coup contusions. Bioccipital coup contusions caused during a boating accident by a blow to the occiput from a water-skiing tow bar. Tonsillar herniation, secondary to brain swelling, is severe (arrows). (Coup contusions caused by a glancing gunshot wound, a blow, and a fall against a protuberant object are illustrated in Chapter 6, Fig. 51, and Figs. 9 and 11 in this chapter, respectively.)

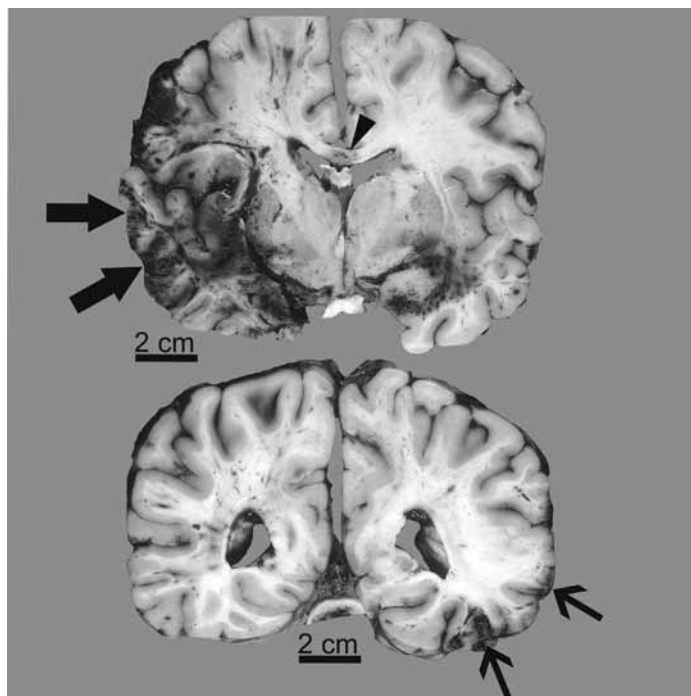
of force to the head is a reminder that the forces accompanying a head injury are complex and unpredictable, and justifies the suggestion that a contrecoup contusion, rather than merely being diagonally opposite an impact site, is “one that is not immediately below the site of impact, irrespective of its exact location” (52).

#### 5.4.2. Coup Contusions

Contusions that occur immediately under the site of a skull impact are coup contusions (Figs. 9, 11, and 23; Chapter 6, Fig. 51). They are caused by inward localized deformation of the skull by an impact, compression of, and consequent injury to, the underlying brain, and tensile (suction) injury to the brain as the deformed bone springs back into place. There may or may not be a skull fracture. The force of the impact is absorbed by the skull so that there is minimal acceleration of the head and the inertia of the brain is relatively undisturbed.

#### 5.4.3. Significance of Coup and Contrecoup Contusions

In general terms, contrecoup contusions are injuries caused by an impact between the head and a relatively large object that has a broad surface area, which either halts or, less commonly, initiates movement of the head. Coup contusions are contact injuries to the brain caused by an impact between the stationary head and an object with a relatively small surface area. In practical terms, contrecoup contusions are caused by a fall and coup contusions are the consequence of a blow. However, in the absence of other reliable information about a given case, these generalizations should be used with caution because there are exceptions to them. Specifically, coup contusions may be found if, during a fall, the head strikes a protuberant object with a small surface area (Fig. 11; ref. 65) and small coup contusions may accompany much larger contrecoup contusions in circumstances



**Fig. 24.** Coup and contrecoup contusions. This brain is from a person who died because of a road traffic accident. There was a large right occipital fracture, indicating blunt force injury to this area. Small coup contusions (small arrows) and massive contrecoup contusions (large arrows) are indicated. A focal hemorrhagic tear in the corpus callosum indicates abrupt right-to-left movement of the hemispheres during the accident (arrowhead).

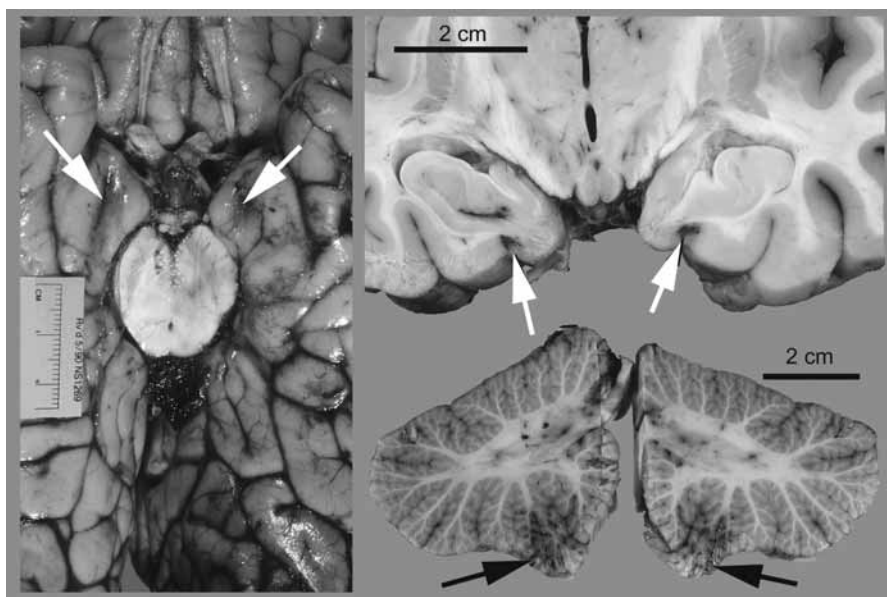
that are normally expected to produce contrecoup contusions (Fig. 24). Contrecoup contusions can occur after a blow, but in these cases, a coup contusion is also present, which is usually larger than the contrecoup contusion (65,81,107). Standard forensic texts mention that blows can cause contrecoup contusions in the absence of coup contusions (65,81), possibly because of a fall that follows the blow (81), but there is not enough information about the circumstances of the cases on which these observations are based to allow them to be reliably assessed. Cerebellar coup contusions are a special category because they are often caused by a fall on the occiput (see Subheading 5.4.7.).

#### 5.4.4. Herniation Contusions

Herniation contusions occur when the uncus and cerebellar tonsils collide with the edges of the tentorial incisura and the foramen magnum, respectively (Fig. 25). They occur after a severe head injury, particularly a fall from a height onto, or a blow to, the top of the head, a fall from a height onto the feet, or a gunshot injury (Chapter 6, Fig. 44). It may be difficult or impossible to distinguish between these contusions and hemorrhagic necrosis caused by uncal and tonsillar herniation secondary to traumatic brain swelling.

#### 5.4.5. Gliding (Parasagittal) Contusions

Gliding contusions are more commonly associated with motor vehicle accidents than with falls, and the victims generally have neither a lucid interval (see Subheading 11.2.)



**Fig. 25.** Herniation contusions. Small uncus (white arrows) and cerebellar tonsillar (black arrows) herniation contusions.

nor a skull fracture. They occur in the white matter and gray matter of the dorsal paramedian region (dorsal angle) of the cerebral hemispheres, particularly in the frontal and parietal lobes, and they are often bilateral. Gliding contusions are typically discrete simple contusions or contusion–lacerations but the forces responsible for them also result in large contusion–hematomas (Fig. 26), petechiae, or less well-defined areas of hemorrhagic discoloration (107). The term “gliding contusion” is sometimes also used for basilar brain contusions to underpin the idea that these contusions occur as the brain “glides” over the uneven surfaces of skull base (65,108). However, this broader use of the term is misleading because it obscures the important and common, but not invariable, association between contusions of the dorsal angles (i.e., “true” gliding contusions) and DAI (107,109), which does not exist for basilar brain contusions.

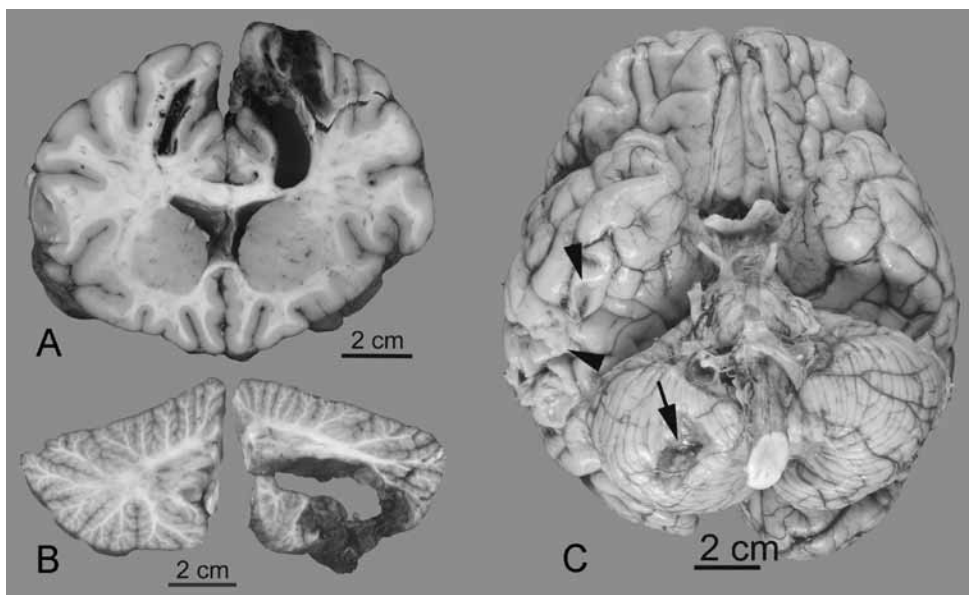
Gliding contusions are attributed to relative movement between the brain and the dura, which stretches and tears the tributaries or trunks of the parasagittal bridging veins as they pass from the cortex to the superior sagittal sinus or to differential movement between the cortex and subcortical white matter. A tear of the transmeningeal trunk of the parasagittal bridging veins accounts for an association between ASDHs and gliding contusions.

#### 5.4.6. Fracture Contusions

Linear contusion–lacerations lie under, or close to, undisplaced or depressed skull fractures (Fig. 10; see also Subheading 3.7.). They should not be mistaken, either in fact or in significance, for coup contusions.

#### 5.4.7. Cerebellar Contusions and Hemorrhages

Traumatic posterior fossa intracranial hemorrhages, excluding brainstem hematomas associated with DAI or brain swelling, are rare. In clinical practice they



**Fig. 26.** Cerebellar contusions and hematomas. The brain slices in (A) and (B) are from an individual who fell backward and struck his occiput. An occipital skull fracture was present. (A) Large bilateral frontal hematomas and contusion-hematomas. The location of these corresponds to gliding contusions (but diffuse axonal injury was not present). (B) Large cerebellar contusion-laceration. A hematoma fell out of the space above the contusion when the cerebellum was sliced. (C) An old cerebellar contusion-laceration (arrow) and small ipsilateral temporal contusion-lacerations (arrowheads) of similar etiology to (A) and (B).

occur in approx 3% of cases of head trauma that are admitted to hospital and investigated by CT or MRI scanning, and 40% of these cases are fatal (46). They include, in roughly equal proportions, EDHs (owing to a tear in the transverse or sigmoid sinus), SDHs, and cerebellar contusions or hematomas. The low incidence of cerebellar contusions is presumably related to the smooth contours of the occipital bone and splinting of the cerebellum by these surfaces and the tentorium cerebelli. Cerebellar contusions and hemorrhages are associated with a fall or blow to the back of the head and an occipital fracture (110), but there are rare exceptions in which a frontal impact may be the cause (111). They are isolated to the cerebellum or occur in association with cerebral hemispheric injury; the latter is more common in fatal cases of cerebellar contusions and hemorrhages (46,112,113). Hematomas may evolve from contusions, in which case they lie laterally in the cerebellum, but in some instances they appear in the deep cerebellar midline, physically distant from contusions (114). Their presentation is delayed for 12 h after the head impact, on average (46).

Cerebellar contusions and traumatic cerebellar hemorrhages are a potential source of confusion during an autopsy because their location immediately under the site of an impact (i.e., a coup location) suggests a blow from a weapon as opposed to a fall and their association with frontal and temporal contusions equally incorrectly raises the suspicion of more than one head impact (Fig. 26). Moreover, if the cerebellar lesion is predominantly a hemorrhage, a natural cause for the bleeding, particularly hypertension, may be used as an explanation for a fall leading to the supratentorial injuries. In this



situation, a hypertensive hemorrhage may be difficult to dismiss from consideration, but the absence of clinicopathological features of hypertension (*see* Subheading 4.5.) points to a traumatic etiology. The interpretation of cerebellar hemorrhages in trauma cases may be further complicated because surgical evacuation of a supratentorial SDH can precipitate a cerebellar hemorrhage for reasons unrelated to trauma (*115,116*), which may then be mistaken for a delayed type III intracerebral hematoma (*see* Subheading 4.5.1.).

### 5.5. Documentation and Quantification of Contusions

The marked variation in the distribution and prevalence of contusions in cases of TBI frequently makes their documentation difficult. The simplest method of documentation is to mark their location on brain slice diagrams (e.g., those available from the Armed Forces Institute of Pathology [*9*]), which will give a good impression of their distribution and severity. Representative brain slices—or, in cases of suspicious death, all brain slices—should be photographed. When formulating diagnoses an idea of the size and extent of contusions should be conveyed. The following is an example of an approach to listing neuropathological findings in a case of acute TBI caused by a fall backward onto a hard surface:

- Acute severe craniocerebral trauma:
  - Large left occipital scalp laceration.
  - Linear left occipital fracture.
  - Widespread “smear-type” bihemispheric SAH.
  - Widespread contusions:
    - Fronto-orbital region (right > left, numerous, medium-sized).
    - Right frontal lobe convexity (numerous, medium-sized).
    - Right temporal lobe (numerous, large, with contusion–hemorrhage).
    - Right parietal lobe (numerous, medium-sized, with large contusion–hemorrhage).
    - Occipital lobe (bilateral, scant, small).

Methods of quantifying contusions have been described (*101–103*), but, although they have proved effective for research purposes, they are too complicated for routine use. A simplified scheme is also available, which may be more acceptable to pathologists in general forensic practice (*117*).

### 5.6. Differential Diagnosis of Contusions

Acute contusions will not be mistaken for hemorrhagic infarcts if the customary frontotemporal and perisylvian location of the former and the inevitable distribution of the latter in a vascular territory are remembered. A small cortical capillary hemangioma or marked localized agonal dilation of small blood vessels and capillaries may resemble small contusions, but the distinction between them is readily made under the microscope. Old infarcts and old contusions are both characterized by localized areas of tissue necrosis and, on occasion, are difficult to tell apart. However, in contrast to infarcts in which the opposites are true, contusions tend to have well-demarcated and smooth margins, to favor a location at the crests of the gyri, to have cavities that are relatively free of traversing cobweb-like gliovascular strands, and to cross cerebral vascular territories (*106*). In addition, in old infarcts, the pial margin and layer 1 of the cortex are intact, whereas these regions are torn in old contusions.

## 6. DIFFUSE TBI

There are four forms of diffuse (or multifocal) TBI: DAI, diffuse vascular injury, hypoxic ischemic encephalopathy, and diffuse brain swelling. These categories overlap and they are often accompanied by various forms of focal TBI.

### 6.1. DAI and Traumatic Axonal Injury

DAI is a well-characterized clinicopathological condition in which the victim is unconscious from the time of injury and then either remains in a coma or enters a vegetative state (118–121). DAI occurs most commonly in road traffic accidents but it also arises during assaults (122) or after falls from heights (123). “Traumatic axonal injury” is a more general term that refers to cases in which there are widely distributed axonal swellings but the clinical history does not fit with that of DAI.

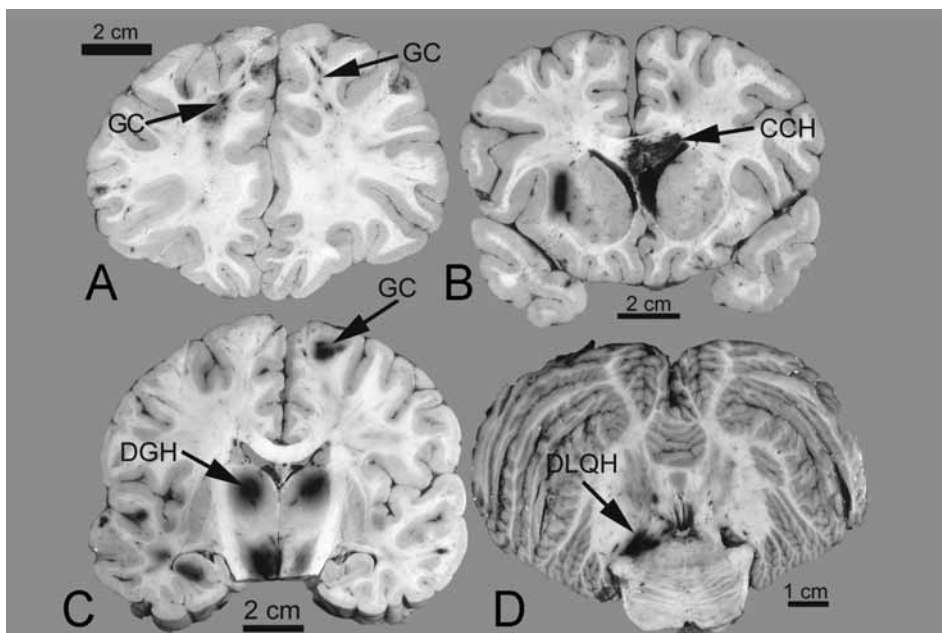
DAI has been replicated in experiments on primates in which head movements in the angular plane, particular the coronal plane (i.e., lateral movement of the head), cause axonal injury. These experiments demonstrate that, in comparison with the forces that occur when the head strikes a hard surface during a fall, the forces that cause DAI are of longer duration and the rate of acceleration or deceleration is slower. This can be understood, for example, if the effect on the momentum of a seat-belted driver’s head of the relatively slow crumpling of the body and frame of a car during a crash is compared in the imagination with the more abrupt change in the momentum of the head when a fall causes the head to strike a hard surface (59,124,125). In simple terms, the consequence of these forces is tugging (shearing) of various parts of the brain against one another. DAI is therefore the outcome of relative movement (shearing) between adjacent parts of the brain in widespread areas, which causes axonal injury and axonal dysfunction at the sites of movement.

Animal models of DAI show focal blockage of axoplasmic transport at the site of axonal injury and consequent accumulation of transported material, which causes enlargement and eventual rupture of the axon at the site (126,127) and the characteristic axonal swelling. Only in severe forms of DAI does the differential movement between parts of the brain immediately tear both axons (i.e., “immediate axotomy”) and small blood vessels, tearing of the latter causing petechiae and hematomas at characteristic sites (126,127).

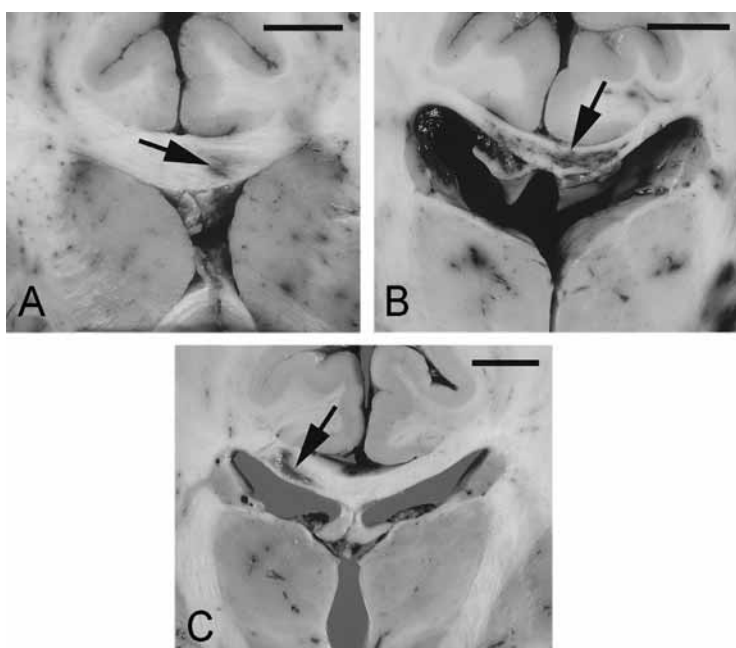
#### 6.1.1. Pathology of DAI

Contact injuries to the scalp and skull are often lacking, but the presence of a contact scalp injury is a reminder that the pathological features of contact and diffuse TBI frequently coexist. The findings on examination of the brain surfaces are minor and at times restricted to sparse SAH in acute cases (Fig. 15A). The brain slices are unremarkable to the naked eye or they contain hemorrhagic tears of various dimensions in the corpus callosum, at the dorsal angle of the cerebral hemispheres, and in the dorsolateral quadrants of the rostral brainstem in the vicinity of the superior and middle cerebellar peduncles (Figs. 27 and 28). Gliding contusions are common (see Subheading 5.4.5.) and hemorrhages in the thalamus and basal ganglia are frequent (Fig. 27; see Subheading 4.5.; and ref. 84).

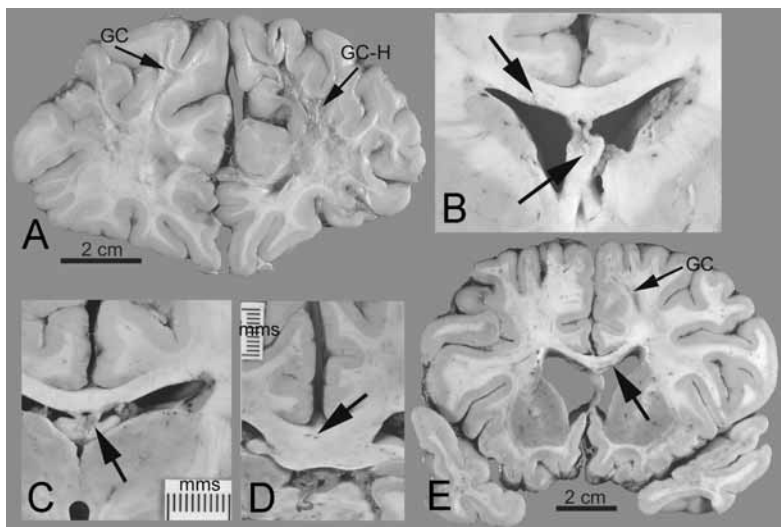
The gross evidence of DAI in subjects who survive for weeks to months is sometimes subtle and can be missed if it is not specifically sought (Figs. 28 and 29).



**Fig. 27.** Hemorrhagic tears associated with diffuse axonal injury. (A) Parasagittal gliding contusions (GCs). (B) Hemorrhagic tear of the corpus callosum (CCH). (C) GCs and hematomas in the deep gray matter (DGH). (D) Hematoma in the dorsolateral quadrant of the pons (DLQH).



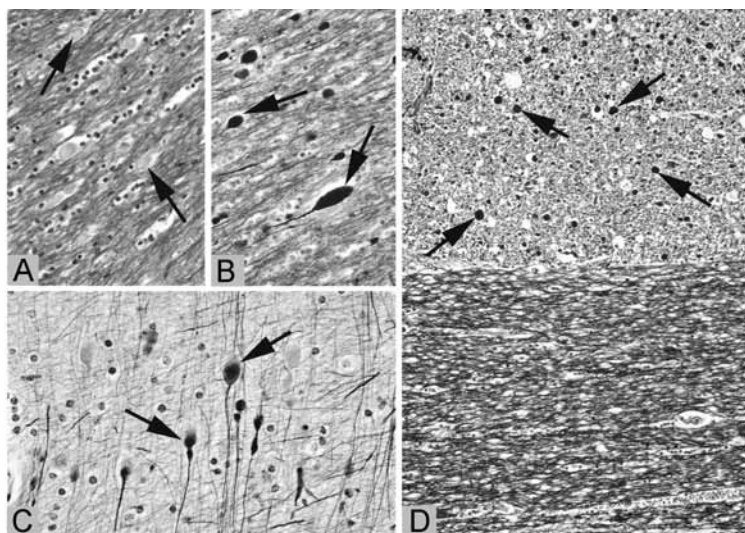
**Fig. 28.** Lesions of the corpus callosum in diffuse axonal injury (bars = 1 cm). (A) Acute callosal petechiae (arrow). (B) Moderate sized acute hemorrhagic tears (arrow). (C) Small old cystic lesion with faint yellow discoloration.



**Fig. 29.** Gross appearance in old diffuse axonal injury. **(A)** Old gliding contusions (GCs) or gliding contusion–hematomas (GC-Hs) in frontal white matter. **(B)** Granular appearance of a soft area in the body of the corpus callosum (top arrow) and of the descending fornix (lower arrow). **(C)** Focal (yellow) discoloration at the root of the fornix (arrow). **(D)** Small cystic lesion of splenium of corpus callosum (arrow). **(E)** Atrophy of the body of the corpus callosum with focal granular discoloration (arrow), asymmetric ventricular dilation, and an old GC in the dorsomedial frontal white matter.

There is atrophy of the corpus callosum, particularly of the caudal body and the splenium, and dilation of the cerebral aqueduct occurs secondary to the effects of brain-stem hemorrhagic tears. Scattered small or microscopic hemosiderin-tinged foci are found at sites where, in acute cases, hemorrhagic tears are expected. The atrophic areas have a granular appearance and are soft.

The microscopic features of acute DAI include widespread axonal swellings in the subcortical white matter, internal capsule, corpus callosum, cerebral peduncles, and basis pontis (Fig. 30). Numerous axonal swellings may be seen in tracts going in one direction and few or none in adjacent tracts passing at right angles, a pattern most obvious in the basis pontis. Focal areas of necrosis and perivascular hemorrhages are also seen in a similar distribution to that of the axonal swellings. Aggregates of microglia around axonal bulbs are visible within 5 d; microglial clusters are first detected at approx 10 to 11 d after injury and readily detectable a few days later. Activation of astrocytes can be detected with the use of immunohistochemistry for glial fibrillary acidic protein from around 9 d after injury (128). By one month after injury intensely cellular foci of hyperplastic astrocytes and microglia are evident, associated with lipid-laden macrophages (129). After survival of months to years these areas gradually become shrunken microcystic spaces that contain sparse siderophages (129). Secondary degeneration of axons can be inferred from the presence of microgliosis and astrocytosis in commissural tracts (including those in otherwise uninvolved areas of the corpus callosum) and in the long tracts of the brain stem (130).



**Fig. 30.** Microscopic appearances in acute diffuse axonal injury. **(A)** Axonal swellings in the corpus callosum (arrows) (H&E and Luxol fast blue:  $\times 40$  objective). **(B)** Axonal swellings in the corpus callosum (arrows; Bielschowsky's method:  $\times 40$  objective). **(C)** Axonal swellings in the subcortical frontal white matter (arrows; Bielschowsky's method:  $\times 40$  objective). **(D)** Axonal swellings in the basis pontis (arrows), which are more numerous in the descending fibers than in the crossing fibers (Bielschowsky's method:  $\times 10$  objective).

### 6.1.2. Sampling of Brain Regions in Cases of DAI and Traumatic Axonal Injury

Thorough sampling of the brain for microscopic examination in cases of suspected DAI is recommended by selecting tissue in areas of white matter that are likely to have been subjected to shearing or distracting (“tugging”) forces (*126*). These areas include the corpus callosum and attached caudal frontal white matter, splenium of the corpus callosum, deep gray matter (including the posterior limb of the internal capsule), cerebellar hemispheric white matter, caudal midbrain (at the level of the decussation of the superior cerebellar peduncle), and rostral pons (to include the basis pontis and the superior and middle cerebellar peduncles). Tissues sampled for the purposes of demonstrating DAI should be taken from sites that are not in the vicinity of focal brain lesions, such as areas of hemorrhage and infarction, because axonal swellings are customarily associated with these lesions owing to disruption of axons at their margins.

These numerous blocks ensure that DAI in particular, and traumatic axonal injury in general, can be excluded if axonal swellings are not found. However, in patients who have been in a coma since the head injury, DAI can be diagnosed simply by demonstrating numerous axonal swellings in the corpus callosum, subcortical frontal white matter, and basis pontis.

### 6.1.3. Special Stains and Immunohistochemical Methods in DAI and Traumatic Axonal Injury

Although axonal swellings are visible in sections stained with hematoxylin and eosin or a myelin stain (e.g., Luxol fast blue) from approx 24 to 36 h after injury,



additional sections from the blocks should be stained with a silver stain (for example, Bielschowsky's method, which will reliably detect axonal swellings 12 to 18 h after injury [131,132]) or treated with immunohistochemistry for neurofilaments. Sections can also be treated for  $\beta$ -amyloid precursor protein (BAPP) immunohistochemistry (which reveals axonal abnormalities approx 2 h after injury [132,133] and small axonal swellings at 3 h after injury [132,134], the maximal size of the axonal swellings being achieved by approx 85 h after injury [134]). Axonal swellings are still detectable several weeks after injury (131,135), although in diminished numbers and BAPP immunopositivity begins to wane in some axonal swellings approx 2 wk after injury (126). Microglial nodules will also be visible in routinely stained sections, but their identification is easier in sections treated with CD 68 immunohistochemistry. Focal microscopic injury may also be demonstrated by using an iron stain to detect hemosiderin deposits.

#### 6.1.4. Grading of DAI

The degree of severity of the pathological features of DAI conforms to three grades (136). Grade 1 DAI refers to cases in which the findings are restricted to axonal swellings at multiple characteristic sites, as listed previously. Grade 2 and 3 DAI refers to cases in which there are, in addition to widely distributed axonal swellings, focal hemorrhagic or necrotic lesions of the corpus callosum (Grade 2) and of the corpus callosum and dorso-lateral area of the rostral brainstem (Grade 3). These focal injuries, which can be visible to the naked eye or detectable only under the microscope, include necrosis or hemorrhage.

#### 6.1.5. Traumatic Axonal Injury (Mild DAI)

A number of observations indicate that a spectrum of brain injury exists whose cases have in common more or less widely distributed axonal swellings (137). In other words, and in general terms to include examples of DAI, the cases in this spectrum are characterized by traumatic axonal injury of variable severity (126). The spectrum includes, in order of decreasing severity:

- Classical DAI (severe traumatic axonal injury [126]).
  - Victims are unconscious from the outset.
- Traumatic axonal injury.
  - Victims display a lucid interval, then die (*see* Subheading 11.2.) or they do not lose consciousness and survive with moderate or mild neurological disability (123,130,136,138) or with minimal neurological abnormalities (131,133,135,139).
  - Fatal cases show axonal swellings, but not with such an extensive distribution or as numerous as would be expected in DAI. Death occurs in these patients because of focal TBI, brain swelling, hypoxic–ischemic encephalopathy, or extracranial injuries.
  - Note that small callosal hemorrhages may be seen in these cases.
- MRI traumatic leukoencephalopathy.
  - There is a mild head injury with full neurological recovery. Altered MRI brain signals are observed with a distribution reminiscent of that of the axonal swellings in DAI (140).

In line with these clinical and pathological observations, a spectrum of severity of axonal damage has been demonstrated in response to traumatic injuries of graded intensity in experimental animals, including, at the mild end of the spectrum, reversible axonal dysfunction (126,127,141).

#### 6.1.6. Axonal Injury in Nontraumatic Conditions

BAPP immunolabeling has proven to be a sensitive and specific method of detecting axonal abnormalities, of which the classical axonal swelling (“retraction ball,” “bulb”)

is only one example. BAPP accumulates in any axon in which focal slowing or cessation of axonal transport has occurred. Not unexpectedly, diffusely distributed (or, at least, widespread multifocal) abnormalities in BAPP immunolabeling, and therefore axonal injuries, have been demonstrated in nontraumatic diseases, including hypoglycemia, hypoxic brain injury, status epilepticus, carbon monoxide poisoning (*see* Chapter 3, Subheading 24.), and Creutzfeldt-Jakob disease (*139,142–144*). The cause of axonal swelling in some of these conditions is speculative but distortion of the brain (and therefore of the axons) caused by brain swelling, particularly in hypoxic–ischemic brain injury, plays a role (*139*). The term “diffuse axonal injury” should not be used for the axonal abnormalities in these conditions because of its precise association with trauma. Rather, expressions indicating the suspected cause of axonal injury are preferable—for example, “hypoglycemic axonal injury,” “hypoxic–ischemic axonal injury,” or even “axonal injury of indeterminate cause,” which avoid the risk of any confusion, particularly with respect to the possibility of regarding trauma as the etiology of the axonal changes (*128*).

#### *6.1.7. Interpretative Difficulties Engendered by Axonal Abnormalities Detected With BAPP Immunohistochemistry*

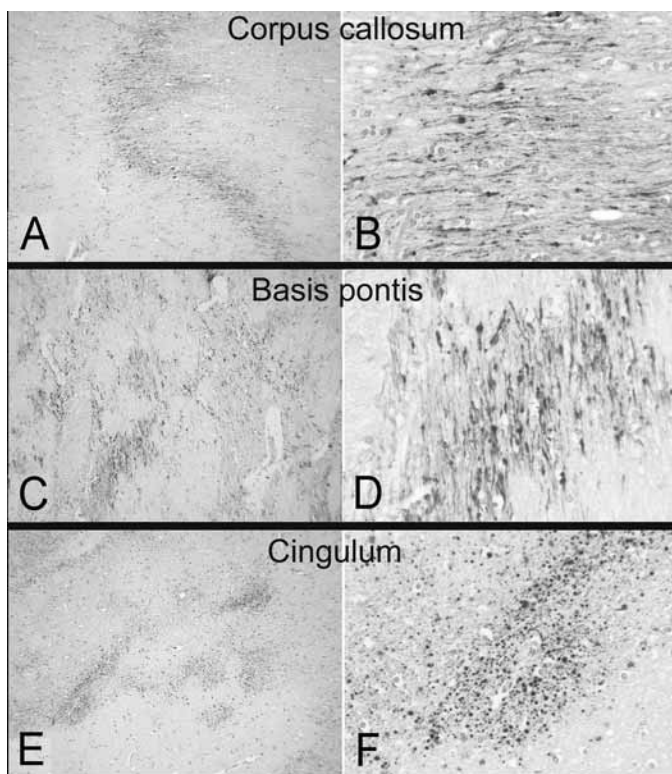
Although in most cases of nontraumatic axonal injury the cause of the axonal abnormalities is immediately apparent because of other histopathological characteristics of the nontraumatic causes (*145*), diagnostic difficulties are created when BAPP-immunopositive axonal abnormalities are found early in the evolution of a disease for two reasons:

- BAPP-immunopositive axonal abnormalities are detectable before there has been enough time for other indicators of the causative disease to become visible.
- BAPP immunolabeling at an early stage tends to be in the form of localized enhancement of axonal labeling as opposed to the discrete, well-formed axonal swellings that are so characteristic of traumatic axonal injury.

The interpretation of abnormalities detected by BAPP immunolabeling is particularly problematic with respect to trauma neuropathology in which the secondary effects or axons of brain swelling and ischemic injury mingle with traumatic axonal injury.

There is some evidence that geographic or linear arrays of BAPP-immunopositive axons, particularly in the pontine midline, and pleomorphic BAPP-immunopositive debris in the white matter are more suggestive of hypoxic than of traumatic axonal injury (*128,133*) and that axonal swellings (i.e., discrete round to oval-shaped structures with a tail), particularly in the characteristic locations of DAI, indicate traumatic axonal injury. However, in some cases, particularly those with a short survival after the onset of an illness, it may simply not be possible to make the distinction between hypoxia, brain swelling, and trauma as the cause of BAPP-immunopositive axonal abnormalities (*Fig. 31*).

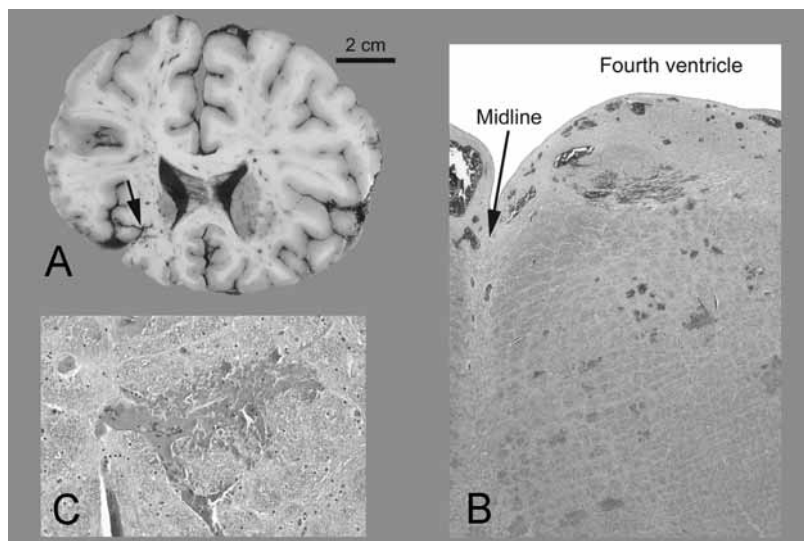
BAPP immunohistochemistry is therefore a sensitive means of detecting injured axons, particularly within a few hours of the onset of axonal dysfunction of whatever cause, but it is not specific for a particular mechanism of axonal injury. A consensus regarding the place of BAPP immunohistochemistry in the diagnostic armamentarium of the pathologist, particularly in the investigation of cases of suspicious deaths, has not been established. In view of these various uncertainties, a confident diagnosis of DAI in particular and traumatic axonal injury in general, should be rendered only when axonal swellings in multiple separate locations have been demonstrated in sections stained with silver stains or a myelin stain.



**Fig. 31.** BAPP immunohistochemistry. Axonal BAPP immunolabeling of indeterminate cause is shown at low power ( $\times 10$  objective) in (A), (C), and (E) and at high power ( $\times 40$  objective) in (B), (D), and (F) in the corpus callosum (A,B), basis pontis (C,D) and cingulum (E,F). The immunolabeled axons are arranged in ill-defined linear arrays in the form of multitudinous pleomorphic linear and granular immunostained debris. Although there are no definite axonal swellings, "microswellings" are present. The tissue is from an individual who was punched, fell to the ground, sustained a massive subdural hematoma, and died several hours after injury because of severe brain swelling, despite surgical evacuation of the hematoma.

## 6.2. Diffuse Vascular Injury

Diffuse vascular injury (Fig. 32) is invariably fatal; victims are either dead at the scene of injury or survive for only a few hours. Contact head injuries may not be apparent. Examination of the brain reveals sparse diffuse SAH and widely scattered petechial hemorrhages. The latter may be visible only under the microscope (146,147). The hemorrhages are prominent in many subependymal regions (of the third ventricle, cerebral aqueduct, and fourth ventricle), the lateral pons and midbrain, and the midline of the hypothalamus and the rostral brainstem. The medulla is often spared (147). The hemorrhages also occur in the thalamus and in the white matter of the temporal and frontal lobes, but they are rarely as prominent as those associated with DAI (52,146,147), possibly because not enough time has elapsed to allow them to develop. Bleeding occurs from capillaries, veins, or arteries (147). Diffuse vascular injury is probably caused by the same type of forces that cause DAI, except that the force is more intense and produces more extensive disruption of neuronal function so that death occurs before axonal swellings have a chance to evolve.



**Fig. 32.** Diffuse vascular injury. These specimens are from the brain of a man who died at the scene of a road traffic accident. His car had been shunted from the rear by a truck. There was a small scalp contusion and an occipital fracture. **(A)** Scattered inconspicuous white matter petechiae, left frontal laceration (arrow). **(B)** Numerous pontine petechiae (H&E and Luxol fast blue:  $\times 1.6$  objective). **(C)** Perivascular hemorrhages. These were widespread throughout the brainstem (H&E and Luxol fast blue:  $\times 25$  objective).

### 6.2.1. Differential Diagnosis of Multiple Brain Petechiae

The petechiae of diffuse vascular injury should not be confused with vascular congestion, which is common and often marked in the brain after fatal head injury. Vascular congestion can be identified by its predilection for dependent areas of the brain, its localization to the walls of the third ventricle, and its tendency to be absent from, or inconspicuous in, the brainstem.

Widespread petechiae also occur in many conditions other than trauma, including disseminated intravascular coagulation, thrombotic thrombocytopenic purpura, air embolism, fat embolism, and cerebral malaria (*see* Chapter 7, Subheading 12.1.; Chapter 8, Subheadings 12.1., 12.4.). The history will almost always prevent confusion between traumatic and nontraumatic causes of CNS petechiae.

## 6.3. Traumatic Hypoxic–Ischemic Brain Injury

Hypoxia is harmful because low tissue oxygen concentration causes failure of energy generation in the cell and consequent cell death. Ischemia is harmful because the flow of essential metabolites (including oxygen) to, and the drainage of toxic products of metabolism from, ischemic tissue are compromised. The adjective “hypoxic–ischemic” is used to describe the harmful effects of low oxygen and diminished blood flow because, despite much debate ([148](#)), it is impossible to disentangle the relative contributions to tissue injury of hypoxia and the effects of ischemia.

Hypoxic–ischemic injury to the brain in fatal TBI is common ([149,150](#)) but its etiology is not straightforward because of the complexity of events that occur during and after a head injury. Adequate whole brain and regional brain perfusion and oxygenation are

related to the cerebral perfusion pressure (i.e., the mean arterial pressure minus the intracranial pressure), the degree of oxygenation of hemoglobin, and the oxygen-carrying capacity of blood. All these factors are compromised in trauma cases because hypotension (or a cardiorespiratory arrest), brain swelling, respiratory insufficiency, and blood loss occur in various combinations.

The severity and distribution of hypoxic–ischemic pathological changes are proportional to the degree and duration of hypoxia and ischemia. In addition, the severity of the pathological effects of a hypoxic–ischemic episode of a given intensity varies between different cell types (neurons are more sensitive to hypoxic–ischemic injury than other cell types) and between different regions of the brain (the cerebellum, hippocampus, and some thalamic nuclei are more vulnerable than other brain regions). In practical terms, two patterns of hypoxic–ischemic injury are seen in any affected area: necrosis restricted to neurons (selective neuronal necrosis) and necrosis of all tissue elements (pan-necrosis).

Traumatic hypoxic–ischemic injury is diffuse (in which case the usual pattern is of selective neuronal necrosis) or focal/multifocal (in which case the histological pattern is of selective neuronal necrosis, pan-necrosis, or, at different sites, both).

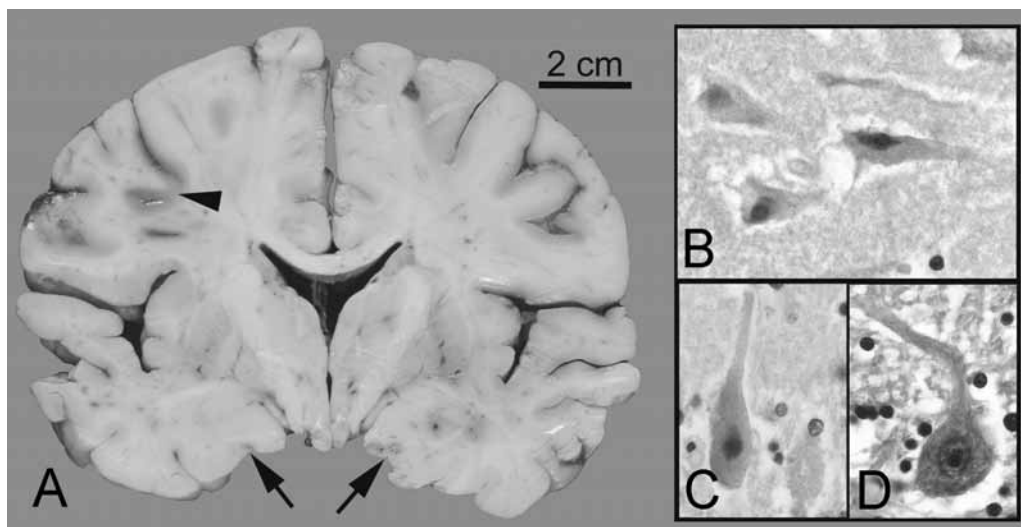
#### *6.3.1. Diffuse Traumatic Hypoxic–Ischemic Neuronal Injury*

Diffuse ischemic neuronal necrosis occurs in individuals in whom a cardiorespiratory arrest or severe hypotension has occurred during the management of their head injury. It is also seen in patients without a documented history of a cardiorespiratory arrest or hypotension who have been comatose since the time of injury and who have only sparse focal traumatic injuries. There are at least two explanations for this phenomenon. First, in many patients, neuroimaging assessment of cerebral blood flow suggests that there exists a period of global brain hypoperfusion of unknown etiology in the first few hours after injury of sufficient severity to cause hypoxic–ischemic brain injury, the brain blood flow improving by about 24 h after injury ([151,152](#)). Second, a self-limited cardiorespiratory arrest may have occurred at the moment of head impact, causing a global failure of cerebral perfusion (cardiac arrest encephalopathy). The latter explanation is favored if spinal cord neurons show ischemic injury, because spinal cord blood flow should not be affected by injuries that cause regional traumatic cerebral hypoperfusion. The mechanism underlying the phenomenon of self-limited traumatic cardiorespiratory arrest may be similar to that causing “commotio medullaris” (see Chapter 10, Subheading 4.3.).

#### *6.3.2. Focal/Multifocal Traumatic Hypoxic–Ischemic Neuronal Injury*

Focal ischemic neuronal injury restricted to the boundary zones between areas supplied by different cerebral arteries suggests hypotension as an etiology. Haphazardly distributed areas of ischemic necrosis are the consequence of regional defects in cerebral perfusion, secondary to localized brain swelling. A similar mechanism accounts for the frequent observation of ischemic neuronal injury in and around contusions, at the margins of intracerebral hematomas, and under peridural hematomas where early cerebral hypoperfusion is characteristic ([153,154](#)). In the swollen brain, entrapment of the posterior cerebral artery and its laterally directed branches between the uncus or medial temporal lobe and the edge of the tentorial incisure or of branches of the anterior





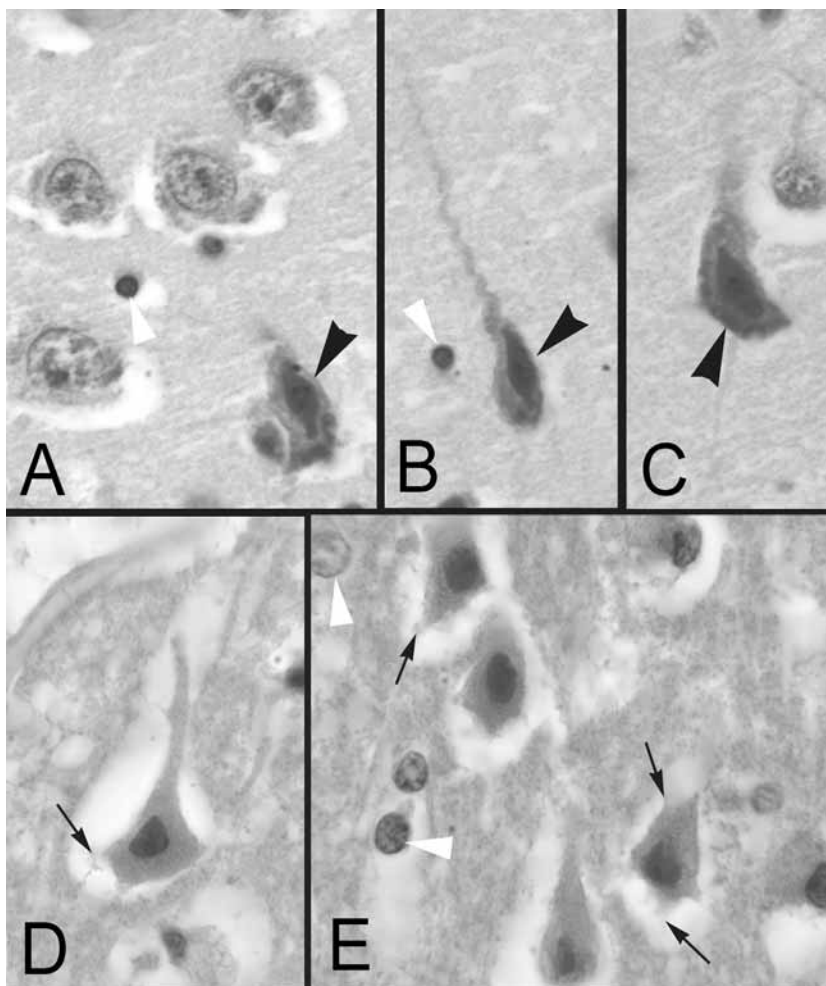
**Fig. 33.** Traumatic hypoxic–ischemic encephalopathy. **(A)** The coronal brain slice has a smooth profile, typical of brain swelling that, in this case, is secondary to hypoxic–ischemic injury. There is dusky discoloration in the cortex lining a sulcus in the “watershed” region of the left anterior and middle cerebral arteries (arrowhead). The uncus bear moderately prominent grooves (arrows) and the right uncus contains petechiae that indicate either a herniation contusion or pressure necrosis because of the brain swelling. The septum pellucidum is torn. **(B)** Characteristic ischemic neuronal necrosis in pyramidal neurons of the hippocampus. The neurons are shrunken, their cytoplasm is homogeneous (eosinophilic), and their nuclei are hyperchromatic, shrunken, and irregular in shape (H&E:  $\times 40$  objective; compare Figs. 34 and 35). **(C)** Purkinje cell showing similar changes to those shown in (B) (H&E:  $\times 40$  objective). **(D)** Normal Purkinje cell for comparison with (C). Note the crisp round nuclear outline and the (blue) granularity of the Nissl substance (H&E:  $\times 40$  objective).

cerebral artery between the cingulate gyrus and the free edge of the falx cerebri cause hemorrhagic infarcts of the medial occipital lobe (posterior cerebral artery territory) and the paramedian cerebral hemispheres (anterior cerebral artery territory), respectively (*see also* Subheading 6.4.). Arterial vasospasm secondary to severe traumatic SAH or involvement of the vertebral and internal carotid arteries by a fracture is another explanation for focal traumatic ischemic brain injury in specific vascular territories (155).

### 6.3.3. Pathology of Hypoxic–Ischemic Brain Injury

#### 6.3.3.1. SELECTIVE NEURONAL NECROSIS

The brain is grossly normal or localized or diffuse nonspecific brain swelling and discoloration are observed. Unequivocal features of selective neuronal necrosis can be demonstrated only under the microscope in the form of neurons with bright red cytoplasmic staining and shrunken hyperchromatic nuclei in sections stained with hematoxylin and eosin (ischemic neuronal necrosis, homogenizing cell change; *see* Figs. 33 and 34). The diagnostic histological features of ischemic neuronal necrosis do not become visible for 6 to 12 h after head injury and they may be obscured or delayed if,



**Fig. 34.** Dense (“dark”) neurons compared with ischemic neuronal necrosis. (A–C) Dense neurons are indicated by arrowheads. There are four normal neurons to the left and at the top in (A) for comparison. The dense neurons are characterized by accentuated dusky or murky cytoplasmic and nuclear staining. Their nuclei are elongated and denser than normal. In some cases apical dendrites of cortical pyramidal neurons have a corkscrew appearance (B) (H&E:  $\times 100$  objective). (D,E) Examples of neurons showing typical features of hypoxic–ischemic necrosis are shown. In comparison with the dense neurons in (A–C) their cytoplasm is more homogenous and, when viewed in color, more brightly eosinophilic. Perineuronal vacuolation (caused by swelling of the perineuronal astrocyte cytoplasm) is more marked than for dense neurons and the perineuronal vacuoles contain wisps of neuronal cytoplasm (encrustations) that are trapped by swollen astrocytic cytoplasm (black arrows). Note also that the glial cell nuclei are more vesicular than those adjacent to the dense neurons (white arrowheads). Other clues that help to distinguish ischemic neuronal necrosis from dense neurons (see also Fig. 35) include microvacuolation of the neuropil, distortion, shrinkage, or disintegration of some of the neuronal nuclei and swelling of the capillary endothelial cell cytoplasm (H&E:  $\times 100$  objective).

during this period, cerebral perfusion has ceased because of brain swelling, corporeal life having been maintained thereafter until death by mechanical ventilation. In other words, a brain subjected to severe ischemic injury may show minimal or no pathological features because not enough time has elapsed between the time of injury and when cerebral blood flow ceased to allow the pathological features of hypoxic–ischemic injury to emerge.

The distribution in the brain and spinal cord of ischemic neuronal necrosis is highly variable but two patterns are evident: diffuse or widespread ischemic neuronal necrosis (indicative of global failure of cerebral perfusion and classed as hypoxic–ischemic encephalopathy) or focal or multifocal ischemic neuronal necrosis (typically complicating other primary and secondary causes of TBI).

In cases of old selective neuronal necrosis, the brain is usually grossly normal or slightly atrophic, the corpus callosum may be narrow because of loss of myelinated fibers, and the sites of neuronal necrosis are recognized under the microscope by their astrocytic gliosis and dearth of neurons.

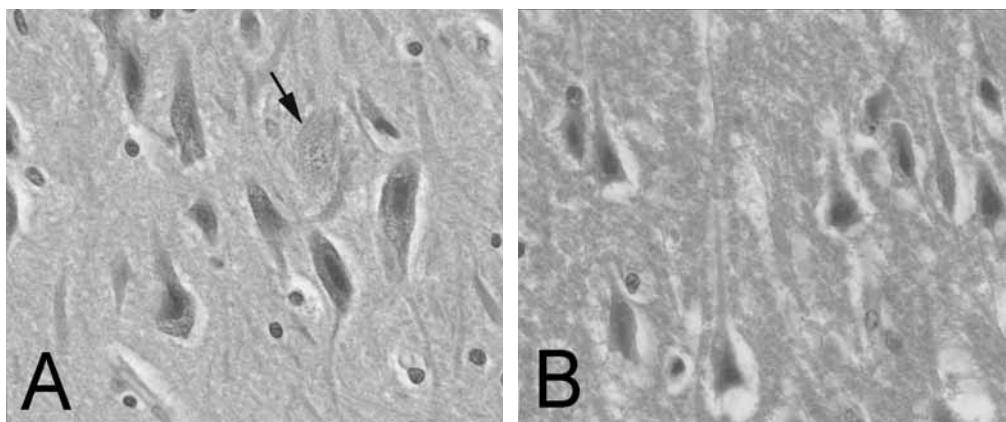
#### 6.3.3.2. DENSE OR DARK NEURONS AND SUBICULAR DUSKY RED NEURONS

Neurons with dense or dusky cytoplasm (“dense” or “dark” neurons) are common nonspecific features in brain injury, possibly as a consequence of mechanical distortion of the nerve cells (because of handling of the brain after death or massive mechanical perturbation of the brain following, for example, a fall), which should not be confused with ischemic neuronal necrosis (Fig. 34). The etiology of these neurons remains enigmatic but evidence from animal studies suggests that they are not always artifacts, they occur immediately after an injury, and they do not necessarily indicate a fatally injured neuron (156–158).

Another potential source of confusion is the finding of clusters of elongated duskily hypereosinophilic (dusky red) neurons with open vesicular nuclei, which on cursory inspection resemble ischemic neuronal necrosis, at the junction between sector CA1 of Ammon’s horn and the subiculum and in the subiculum of patients who die suddenly for various reasons, including “healthy” individuals who die suddenly, unexpectedly, and inexplicably (Fig. 35). These may be of similar pathogenesis to dense neurons, their location merely reflecting “selective vulnerability” of subicular neurons for whatever is the cause of the dense or dark neuronal changes.

#### 6.3.3.3. HYPOXIC–ISCHEMIC PAN-NECROSIS

The same comments regarding the delay after injury in the appearance of the microscopic features of selective neuronal necrosis apply to the evolution of the gross and microscopic features of pan-necrosis. The first gross evidence of pan-necrosis is localized swelling and discoloration. Eighteen to 24 h after injury the necrotic area is soft and at around 2 to 3 d after injury handling of the tissue during brain slicing causes grossly visible artifactual cracks to appear at the border between necrotic and intact tissues. The dead tissue is gradually resorbed over weeks to months and a complex area of gliosis and cysts appears. Under the microscope necrosis of all tissue elements is recognizable 12 to 18 h after injury and is followed by a similar sequence of events to those described for contusions (*see* Subheading 5.3.).



**Fig. 35.** Subicular “dusky red” neurons. **(A)** Dusky red neurons of indeterminate origin, such as these, are often found at the junction between sector CA1 of Ammon’s horn and the subiculum and in the subiculum in individuals who die suddenly and unexpectedly of various (including undetermined) causes. The arrow indicates a glancing section through a normal neuron (H&E:  $\times 40$  objective). **(B)** This photomicrograph, also from the subiculum, shows the features of ischemic neuronal necrosis. In contrast to the dusky red subicular neurons illustrated in (A), the neurons in this section are more shrunken, their cytoplasm is more evenly and brightly eosinophilic, and their nuclei are more pyknotic. There is a greater degree of perineuronal vacuolation and the background brain tissue displays fine microvacuolation (H&E:  $\times 40$  objective).

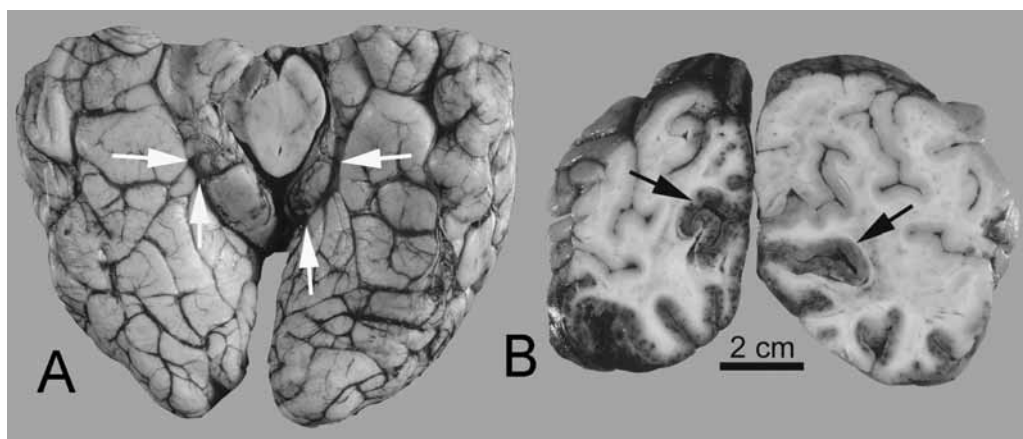
#### 6.4. Traumatic Brain Swelling

Brain swelling is common in TBI. It occurs in focal areas of brain injury, especially around contusions and intracerebral hematomas, and in association with hypoxic–ischemic injury. More extensive brain swelling occurs without other obvious structural brain damage in the cerebral hemisphere ipsilateral to a peridural hematoma or, particularly in childhood and adolescence, in one or both cerebral hemispheres, sometimes after an apparently relatively minor impact to the head and without evidence of other brain injuries ([159–161](#)). Brain swelling under a subdural hemorrhage becomes particularly evident after surgical removal of the hematoma, when the swelling may cause the brain to herniate through the craniotomy site.

The pathogenesis of the various patterns of traumatic brain swelling has not been clearly defined, particularly with respect to whether it is caused by vasodilation secondary to loss of cerebrovascular autoregulation (i.e., congestive brain swelling) or to an increase in brain water content (i.e., cerebral edema), or both ([52](#)). Rapid development of brain swelling within minutes to a couple of hours after injury is likely to be congestive ([52,159](#)), whereas swelling of the brain hours to a couple of days after injury in cases with obvious disruption of the brain tissues or severe hypoxic–ischemic brain injury is likely to be caused by cerebral edema ([52](#)).

##### 6.4.1. Pathology

The early pathological features of brain swelling are flattening of the surfaces of the gyri and narrowing, or effacement, of the sulci. The overall effect of brain swelling



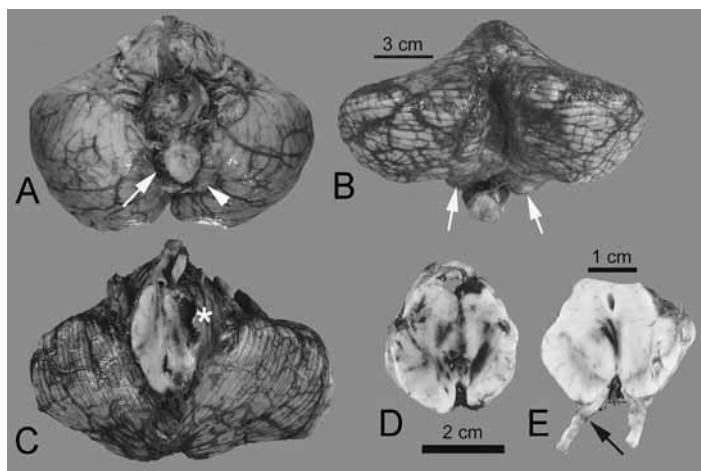
**Fig. 36.** Transtentorial herniation caused by brain swelling. **(A)** Bilateral grooves, caused by impingement of the brain on the edges of the tentorium cerebelli, of the medial temporal lobes are crossed at multiple points by branches of the posterior cerebral arteries (PCA; white arrows). **(B)** Acute bilateral hemorrhagic infarcts in the occipital PCA territory (black arrows) caused by transtentorial herniation and occlusion of branches of the PCA.

is to impose a smooth, flat outline on the normal undulations of the surface of the cerebral hemisphere, which is particularly evident in brain slices where the outline of the cerebral hemispheres resembles the smooth outer surface of a crash helmet (Fig. 33). Brains from young adults normally appear “full” and it is sometimes difficult to be sure whether or not there is brain swelling.

Brain swelling also causes narrowness of the cerebral ventricles and, when it is localized, displacement of swollen areas of the brain into adjacent intracranial compartments (herniation). Accordingly, if the cerebral hemispheres swell, the medial edges of the uncus, the parahippocampal gyri, and the basilar temporal and occipital lobes are pushed into the tentorial incisure, onto the edges of the tentorium cerebelli, causing the formation of a groove along the site of impingement between the brain and the edge of the dura. Early in this process the only evidence may be a prominent groove in each of the uncus (Fig. 33). Microscopic demonstration of neuronal distortion, ischemic change, or necrosis at the edges of the indentation, which are sensitive indicators of significantly raised intracranial pressure (51), is essential because indentations of the uncus without histological changes are normal findings in many individuals.

Progressive brain swelling forces the medial temporal regions into the posterior cranial fossa (uncus or transtentorial herniation) and branches of the posterior cerebral artery are trapped between the swelling hemispheres and the edge of the tentorial incisure (Fig. 36A). Occlusion of these vessels leads to infarcts in the distribution territory of the posterior cerebral artery. The infarcts are hemorrhagic because of intermittent restitution of blood flow through the injured brain, in part owing to clinical attempts to reduce brain swelling (Fig. 36B). It is useful, after the brain is fixed, to remove the brainstem and attached cerebellum, before the cerebral hemispheres are sliced, to expose the basal temporal and occipital lobes and any evidence of transtentorial herniation that is concealed by the cerebellum.

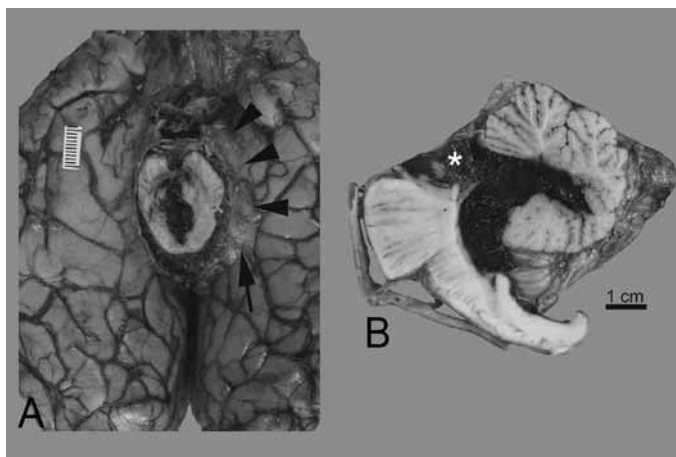




**Fig. 37.** Effects of brain swelling on the brain stem and cerebellum. **(A)** Basilar view of cerebellum showing prominent molded cerebellar tonsils (arrowhead) and tonsillar necrosis (arrow). **(B)** The white arrows indicate prominent cerebellar tonsils, viewed from the dorsal aspect. **(C)** The white asterisk marks an area of necrosis of the cerebral peduncle (Kernohan's notch), which occurs contralateral to a swollen hemisphere, creating motor signs on the same side as the swollen cerebral hemisphere (false localizing signs). **(D)** Secondary (Duret) brainstem hemorrhages. **(E)** There is a contusion in the oculomotor nerve (arrow) where it crossed the edge of the tentorium cerebelli, accounting for ipsilateral mydriasis ("blown pupil") caused by transtentorial herniation. A midline, linear secondary hemorrhage is also present.

The caudal displacement of the cerebral hemispheres caused by brain swelling also leads to stretching and distortion of the midline structures, including the thalamus and brainstem. In coronal slices of the brain the thalamus appears lower than it should be (central herniation) and, in the case of the brainstem, external examination may give an impression of angulation or "buckling" of the pons on the medulla, because of the limited space in the posterior fossa. The effect of the buckling, and the fact that the posterior cerebral arteries and, consequently, the basilar artery, are held in place at the edge of the tentorial incisure, leads to traction on, and tearing of, the small penetrating arteries of the brainstem that branch off the basilar artery and subsequent brainstem hemorrhages (and, sometimes, infarction). These secondary (Duret) hemorrhages are characteristically prominent in the rostral pontine midline or throughout the pontine and midbrain tegmentum (Figs. 37 and 38; ref. 147), and in severe cases they may extend into the fourth ventricle (Fig. 38).

Continued descent of the cerebral hemispheres and compression and swelling of the contents of the posterior fossa force the medial caudal region of the cerebellum through the foramen magnum (tonsillar herniation), causing the cerebellar tonsils to mold to the shape of the foramen magnum and then, as the process continues, to become necrotic (Fig. 37; see also Fig. 23). In established cases of tonsillar herniation, necrotic cerebellar tonsillar tissue may fragment and fall into the spinal subarachnoid space, sometimes passing as far caudally as the lumbar cistern. If there is no grossly discernible necrosis of the cerebellar tonsils but the degree of their prominence suggests molding owing to herniation, microscopic examination of them should be carried out to



**Fig. 38.** Brain swelling, secondary brainstem hemorrhage with intraventricular extension. **(A)** Marked midline secondary brainstem hemorrhage is present (which was secondary to a large acute left subdural hemorrhage). There is also unilateral transtentorial herniation (arrowheads) and branches of the posterior cerebral artery (e.g., arrow) cross the groove cause by the impression of the edge of the tentorial incisure. **(B)** A sagittal slice through the brainstem and cerebellar vermis from the same case as (A) shows extension of a secondary brainstem hemorrhage (asterisk) into the fourth ventricle.

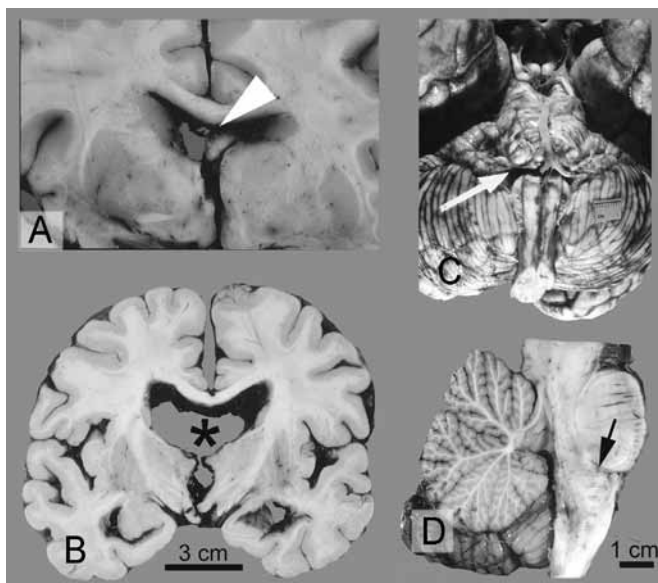
demonstrate neuronal injury and petechiae in the vicinity because prominent cerebellar tonsils, like uncus grooves, are commonly observed in normal individuals.

In cases of unilateral cerebral hemispheric swelling (e.g., under peridural hemorrhages or with large unilateral contusions) the medial aspect of the swollen hemisphere is forced under the free edge of the falx (subfalcine or cingulate herniation), which can be detected before the brain is sliced by looking into the interhemispheric fissure. Subfalcine herniation is readily demonstrable when the brain slices are examined (Figs. 11 and 12). Subfalcine herniation is also associated with narrowness of the lateral ventricles on the side of the swelling.

In rare cases, large posterior fossa intracerebellar hematomas force the rostral cerebellum through the tentorial incisure (upward herniation), the risk of which is increased if intraventricular drains are inserted to control secondary hydrocephalus caused by cerebellar hemorrhages.

## 7. MISCELLANEOUS FOCAL TBIs

Tears at the root of the fornix and of the septum pellucidum are common in many types of craniocerebral trauma; they are presumed to reflect localized distraction between these delicate areas and the overlying corpus callosum (Fig. 39A,B). These injuries may be found in patients with minimal or no neurological signs and symptoms who die of systemic traumatic injuries. They are usually associated with small intraventricular hemorrhages that pool in the posterior horns of the lateral ventricles in supine patients. Old tears in the septum pellucidum are common incidental findings, especially in severe brain atrophy and in patients with old contusions, whether or not there is a known history of craniocerebral trauma.



**Fig. 39.** Other focal traumatic brain injuries. **(A)** Tear at the site of attachment of fornix to the corpus callosum (arrowhead). **(B)** Complete avulsion and displacement of septum pellucidum giving the impression of a single large central ventricle (asterisk). **(C)** Tear at the pontomedullary junction with minimal bleeding (arrow). **(D)** A sagittal slice through the brainstem and cerebellar vermis illustrated in (C) shows an incomplete pontomedullary tear (arrow).

Tears (rents) of the ventral pontomedullary junction arise in cases of neck hyper-extension and skull base impacts, particularly after motorbike injuries (Fig. 39C,D) (10,23,162,163). They occur in approx 4% of cases of fatal road traffic accidents and, although most victims die before they reach the hospital, some survive for weeks or months (164). In most cases there is evidence of a facial impact, cerebellar lacerations are often present, and traumatic cerebral hemispheric lesions are found in about 50% of cases. High cervical injuries occur in the minority of cases, and are usually atlanto-occipital dislocations or fracture dislocations between the first (C1) and second (C2) cervical vertebrae.

## 8. VERTEBRAL AND SPINAL CORD TRAUMA

### 8.1. Practical Aspects of Investigation of Vertebrospinal Trauma

The postmortem examination of the spinal column and spinal cord is an awkward and potentially protracted procedure. The following are general comments concerning the examination of the spine in the autopsy room (various complex and detailed methods for excision and slicing of spinal elements are described but impractical for general forensic pathology practice [165,166]):

- Gross examination of the spinal column *in situ* is an insensitive method of demonstrating vertebral fractures and spinal ligamentous injuries.
- The most sensitive clinical method for demonstrating a vertebral fracture is premortem CT scanning. Premortem MRI scanning is a sensitive method for detecting ligamentous

and other soft tissue injuries, which indicate the possibility of a fracture in the adjacent vertebrae (e.g., [167]) and, with technological improvements, it is likely that MRI will become progressively more accurate in determining the nature and extent of spinal injuries and begin to play a role in the postmortem examination of the spinal cord (ref. 4; see also Chapter 1, Subheading 6.2.). Premortem CT and MRI findings should therefore form an important part of the assessment by the pathologist of cases of suspected vertebrospinal injuries.

- Radiographs of the neck, with extension and flexion views, should be carried out in all cases of suspected cervical spinal injury in which detailed premortem neuroimaging has not been performed (168). However, these radiographs will fail to detect many vertebral fractures (166,169).
- The spinal cord should be removed via a dorsal approach when there is a likelihood of spinal injury. If a rostral cervical injury is suspected the spinal dissection should be performed before the brain is removed. It is helpful to move the body so that the head is over the end of the autopsy table and the neck can be flexed, straightening the cervical curvature.
- The location of hemorrhage in the perivertebral soft tissues indicates the possibility, and approximate site, of a ligamentous or vertebral injury.
- Other clues suggestive of a cervical vertebral injury include unexplained bleeding in the prevertebral neck musculature, observed as the larynx is dissected, and, if the brain is removed before the spinal cord, drainage of heavily bloodstained cerebrospinal fluid from the spinal canal.
- If the brain is removed before the spinal cord, the possibility of a rostral cervical vertebral fracture can be crudely assessed by inspecting the spinal canal through the foramen magnum to ensure that the occipital condyles and the first and second cervical vertebrae are aligned and by manipulating the head with a finger placed in the foramen magnum to detect roughened edges of a fractured vertebra, bony crepitus, or narrowing of the spinal canal when the head is moved.
- The segmental level of a spinal cord lesion is determined by counting the nerve roots from the spinomedullary junction downward. Alternatively, the cervical expansion is usually easy to see and can be used to “set” cord cervical level 5 (C5) to cord thoracic level 1 (T1) (in rare cases the brachial plexus starts one segment below [“postfixed”] or one segment above [“prefixed”] its normal level).
- In cases of suspected vertebral artery dissection or tears the vertebral arteries must be exposed, particularly their course in relation to the first and second cervical vertebrae (refs. 170–172; see Chapter 10, Subheading 4.2.).

## 8.2. Pathogenesis and Classification of Vertebral Fractures

Forces acting on the vertebral column are rotational (accounting for flexion, extension, lateral flexion, and torsion) and linear (causing a pushing together [compression], a pulling apart [distraction], and a sliding across [translation] of various parts of the vertebral column [173]). These forces, acting in isolation or, more commonly, together, are either physiological, or, when they exceed the physical limits imposed by various anatomical structures, pathological. Exposure of the spinal column to pathological forces leads to tearing of perivertebral soft tissues, vertebral subluxation, vertebral fractures, and spinal cord injury (SCI). There are a few principles that should be remembered when the possibility of fatal vertebrospinal trauma is under consideration:

- Vertebral fractures are not invariably associated with spinal cord or nerve root injury.
- Vertebral fractures are frequently associated with injuries to the cranium and brain.

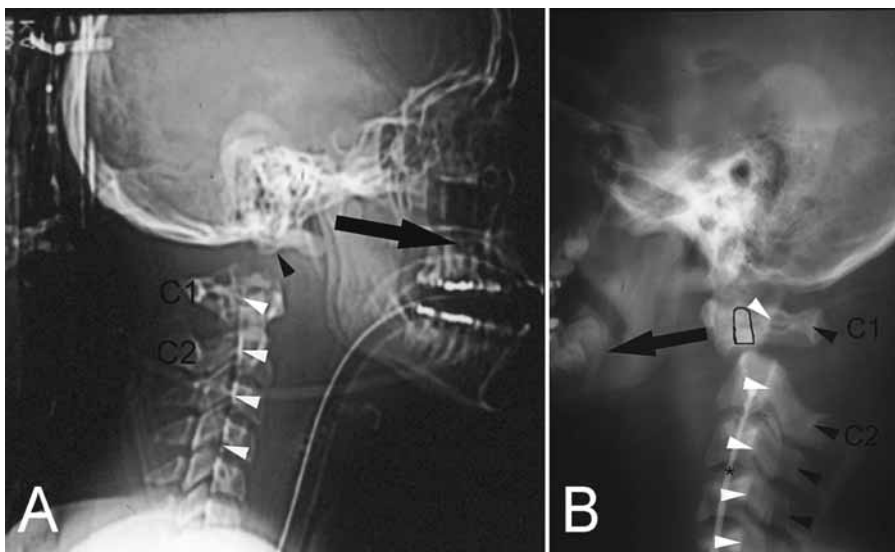
- Vertebral fractures are accompanied by ligamentous tears, which render the fracture unstable and account for fracture–dislocations and consequent SCI.
- Ligamentous tears occur in the absence of a vertebral fracture and are associated with fatal SCI.
- Asymmetric vertebral fractures indicate an injury occurring during rotational or lateral flexion.
- The distinctive anatomy in comparison with the rest of the vertebrae of the atlanto-occipital and atlantoaxial articulations causes patterns of vertebral injury peculiar to these vertebrae.
- Specific patterns of fracturing indicate, but do not prove, the mechanism of injury.
- In simple terms vertebrospinal injuries can be categorized, irrespective of their site and causation as follows (174):
  - Fracture of the vertebral body or posterior elements without subluxation.
  - Fracture with subluxation.
  - Subluxation without fracture.
  - SCI without radiographic evidence of fracture or subluxation.

There are numerous classification schemes for vertebral fractures that rely heavily on neuroimaging findings (173,175–178). They reflect the complexity and variety of fractures, and many classification systems have been developed by orthopedic surgeons and neurosurgeons to determine what pattern of fractures should be stabilized operatively and what type of fracture should be treated conservatively.

Certain patterns of injury recur frequently and include:

- Flexion injuries
  - Pure flexion injuries cause compression of the ventral components of the vertebral column (compression fracture) and distraction of the dorsal elements (leading to tearing of the interspinous ligaments and posterior longitudinal ligament, and facet dislocation or fracture).
  - In unstable fractures the vertebra above the torn soft tissues moves ventrally on the vertebra below (fracture–dislocation), which causes compression of the spinal cord between the lamina of the rostral vertebra and the posterior part of the body of the caudal vertebra.
  - If this sequence of events includes a rotational component an asymmetric fracture dislocation with preservation of one of the joint facets may occur.
  - In some cases, a bilateral fracture of the pedicle of the rostral vertebra may prevent spinal cord compression because only the vertebral body moves forward so that crimping of the spinal cord is avoided.
- Extension injuries
  - The sequence of events in forcible extension causes tearing of the anterior longitudinal ligament, avulsion of the intervertebral disk (which may tear a small fragment off the vertebral body above the tear), tearing of the posterior longitudinal ligament, fracture or dislocation of the articular facets, and fracture of the pedicle, leading to a fracture dislocation (Fig. 40).
- Compression injuries
  - The application of pure compressive force through axial loading of the vertebral column—for example, during a fall on the vertex of the head or on the buttocks—causes, in order of increasing severity, a compressive fracture of the vertebral body, comminution of the vertebral body fracture, and fractures of the pedicles (burst fractures).
  - The risk of this process is increased when the vertebral body is weakened by osteoporosis or a metastasis.





**Fig. 40.** High cervical vertebral injuries. **(A)** Atlanto-occipital dislocation (lateral plain film). The white arrowheads indicate the ventral margin of the spinal canal, which should be aligned with the centre of the occipital condyle (black arrowhead). The large arrow indicates the forward direction of movement of the head on the atlas (C1), causing the spinal cord to be crimped between the dorsal margin of the foramen magnum above the site of dislocation and the ventral margin of the spinal canal below the dislocation site. Note also the widening of the gap between the atlas and the skull base. (Courtesy of Dr. D. Lee, London Health Sciences Centre, London, Ontario, Canada.) **(B)** Atlanto-axial dislocation (CT lateral "scout" film). The odontoid process (outlined) is displaced forward and lies at an angle because of a type 2 odontoid fracture. The atlas has moved forward, in the direction indicated by the large arrow, causing the spinal cord to be crimped between the arch of the atlas above and the dorsal margin of the vertebral body of the axis below. The ventral margins of the spinal canal are indicated by the white arrowheads and the dorsal margins by the black arrowheads. Note the marked step deformity between cervical vertebrae 1 and 2 in the line of the ventral margin of the spinal canal. An endovascular catheter is indicated by an asterisk. (Odontoid fractures occur in the body [type 1] or base of the odontoid process [type 2] or in the body of the axis at the base of the odontoid process [type 3]) (Courtesy of Dr. D. Lee, London Health Sciences Centre, London, Ontario, Canada.)

- Displacement of bone fragments from these fractures may compress the spinal cord.
- In the case of the first cervical vertebra a similar force fractures the anterior and posterior laminae (Jefferson fracture).
- Compressive forces often occur in conjunction with flexion forces.

### ***8.3. Categorization of Spinal Injuries Encountered in Autopsy Room***

Cases of vertebrospinal injuries encountered in the autopsy room fall into one of three categories:

- Fatal atlanto-occipital and rostral cervical injuries.
- Cervical, thoracic, and lumbar spinal injury in patients who die of complications of the SCI or of unrelated causes.

- Vertebrospinal injury as one of a constellation of traumatic injuries in victims of severe multiple trauma.

In general, vertebrospinal injuries, irrespective of etiology, are more common in the cervical and lumbar regions than in the thoracic area because of the additional support provided to the latter by the rib cage (179).

#### 8.4. Cervical Fractures

Radiographic evidence of cervical spine injury in 34,069 emergency department patients with blunt trauma was found in 2.4% of cases (180). In these 818 patients:

- One-third of the injuries were trivial.
- The most common site of fracture was the second cervical (C2) vertebra (of which 32% were odontoid fractures).
- The third cervical (C3) vertebra was least likely to be fractured.
- Thirty-nine percent of the fractures occurred in the sixth cervical (C6) and seventh cervical (C7) vertebrae.
- The cervical vertebral body was the most common location of a fracture in a given vertebra.
- Fracture–dislocations were most likely between the C5 and C6 vertebrae and between the C6 and C7 vertebrae, and least likely at the atlanto-occipital junction and between the C7 vertebra and the T1 vertebra.

In children, approx 2% of all pediatric trauma cases admitted to the hospital have injuries to the cervical spine. Thirty percent of these cases are fatal; most of these fatalities are caused by motor vehicle accidents and are associated with other brain injuries (181).

In contrast to these clinical observations, at least 25% of patients involved in road traffic accidents who are dead at the scene or dead on arrival at the hospital have neck injuries (168,182,183). Most cervical injuries are caused by accidents involving motor vehicles, including pedestrians struck by a motor vehicle. These injuries are more likely to occur in drivers of motor vehicles who are not wearing a seat belt than in those who are. The majority of neck injuries are lesions of the craniocervical junction or the first and second cervical vertebrae (Fig. 40). Common fatal rostral cervical lesions include:

- Atlanto-occipital dislocation (an extension injury, rarely associated with fracture of the C1 vertebra, characterized by tears of various alar ligaments and anterior displacement of the skull in relation to the axis; see Fig. 40A; and refs. 184 and 185).
- Atlantoaxial dislocation, including:
  - A flexion injury causing rupture of the ligaments of the odontoid process (186) or a fracture of the base of the odontoid peg, allowing the head and the atlas to move ventrally in relation to the axis (Fig. 40B).
  - An extension injury causing a fracture the odontoid peg and allowing posterior dislocation of the atlas on the axis and fractures of C2 (of which the most common is the “hangman’s fracture,” caused by a bilateral fracture of the pedicle or pars interarticularis of the C2 vertebra, allowing displacement of the body of C2 on C3; see Chapter 3, Fig. 36; and refs 168, 182, 183, and 187).

Most of these injuries are associated with severe retropharyngeal hemorrhage and swelling.

Although rostral cervical injuries are frequently associated with skull and brain injuries (including skull fractures, cerebral contusions, and various intracranial hematomas [181,182,185,188–190]), a head impact is not necessary for a fatal cervical spinal injury

to occur (187) although abrupt and extensive movement (whiplash) of the neck is invariable (Chapter 8, Fig. 81). High cervical injuries are also sometimes accompanied by blunt force injuries to the mandible (183,189,191,192), but this may be, at least in some cases, a coincidental association against a background of multiple trauma (193,194). Deployment of airbags causes high cervical fractures if the subject is sitting too close to the air bag (*see* Chapter 8, Subheading 14.2., Fig. 64; and refs. 195 and 196).

In comparison with high cervical trauma, injuries to the low cervical spine are more common in clinical practice, as noted above, but less often fatal, the latter because the diaphragmatic motor supply from spinal cord levels C3, C4, and C5 is partly or completely spared and concomitant brain injuries are not as common as with higher cervical lesions (190). Accordingly, these injuries are less frequently encountered by a pathologist than are high cervical injuries, but, when they are, they are likely to be at least days to weeks old. Midcervical and low cervical injuries are usually not the direct cause of death, but their contribution to death is obvious (e.g., pulmonary embolism because of immobility and septicemia secondary to urinary sepsis). Although they occur in motor vehicle accidents, they are more typical of falls, assaults, and sporting accidents. Lower cervical hyperextension injuries may be associated with evidence of blunt force injury to the upper face (192), in contrast to the putative association between mandibular injuries and occipital and high cervical fractures described previously.

### **8.5. Thoracic Fractures**

Thoracic vertebral fractures and thoracic SCIs are less common than corresponding injuries lumbar and cervical because of the relative spaciousness of the spinal canal compared with the spinal cord at this level and the mechanical support provided by the costochondral articulations and the rib cage. Accordingly, considerable force is required to produce thoracic fractures, which, because rotation of the thoracic column is limited, occur as a consequence of flexion or axial loading, leading to compression fractures (197). Loading of the upper thoracic vertebrae can cause an indirect sternal fracture, which is characterized by posterior displacement of the upper sternal fragment relative to the lower sternal fragment (in contrast to the effects of a sternal impact from, for example, a steering wheel, which causes the converse relative positioning of the fracture ends; *see* Chapter 8, Subheadings 6.1., 14.1.). Thoracic fractures are more often multiple than are lumbar and cervical fractures (and correspondingly they are associated with SCI at multiple sites [*see* Subheading 8.8.]), concomitant fractures of the posterolateral and posteromedial ribs may occur, and the detection on plain chest films during the management of the patient of bleeding into the ventral paravertebral soft tissues may cause widening of the mediastinum and the incorrect diagnosis of a ruptured aorta (198).

### **8.6. Lumbar Fractures**

Fractures in the lumbar region include wedge fractures, the most common type in clinical practice, and burst fractures (both types caused by hyperflexion and compression forces), seat belt fractures (which occur in road traffic accidents when the trunk is not restrained by a diagonal shoulder belt, allowing hyperflexion of the lumbar spine around the anteriorly located fulcrum of the seat belt), and fracture–dislocation (the most common fracture of the thoracolumbar junction) (*see* Chapter 8, Subheading 14.2.). Wedge fractures are characterized by compression of the ventral

lumbar vertebral body, with preservation of the posterior interspinous ligaments, which prevents retropulsion of the vertebral body. Burst fractures affect the dorsal vertebral body and posterior spinal ligaments, and there is variable involvement of the components of the vertebral arch. The anterior location of the fulcrum of movement in lap-belt injuries causes a complex pattern of injury, including posterior separation or distraction of lumbar vertebrae, ligamentous disruption, and fractures of various elements of one and sometimes more than one lumbar vertebra. Fracture dislocations of the lumbar vertebrae characteristically occur at the thoracolumbar junction and appear as ventral displacement of thoracic vertebra 12 (T12) relative to lumbar vertebra 1 (L1) ([173,178,198](#)).

### **8.7. Traumatic SCIs Without Vertebral Fractures**


SCI associated with trauma can occur without neuroimaging evidence of a fracture or soft tissue injury (SCI without radiographic abnormality), particularly in adults whose spinal canal is congenitally narrow or narrowed by spondylosis or ossification of the posterior longitudinal ligament ([199](#)). These injuries are more likely to occur in extension because of the greater degree of narrowing of the spinal canal that occurs during this movement than during flexion. In children a similar phenomenon occurs during flexion, extension, and distraction of the spinal column, owing to the greater elasticity of pediatric soft tissues, and, in many cases, mild neurological symptoms at the time of trauma are the only sign that a severe traumatic myelopathy will emerge up to 4 d later (refs. [200](#) and [201](#); see also Chapter 10, Heading 8.). Patients who are comatose for a long period with their neck in flexion may also develop a traumatic myelopathy without evidence of soft tissue injury or a vertebral fracture ([202](#)).

### **8.8. Traumatic SCI**

#### **8.8.1. Pathogenesis**

The principal cause of SCI is mechanical compression of the spinal cord because of a fracture–dislocation during which loss of stability leads to the movement of one vertebra relative to an adjacent vertebra. As a consequence, the spinal cord is “pinched” between the dorsal surface of the body of one vertebra and the ventral surface of the lamina of the adjacent vertebra. The effects of these intrusions into the spinal canal are exacerbated by pre-existing narrowing of the spinal canal, including congenital narrowing and, in the elderly, osteoarthritis and other degenerative vertebral diseases. In some cases stretching of, or percussion damage to, the cord is another explanation for cord injury, particularly in cases in which unstable fractures and/or ligamentous tears cannot be demonstrated.

Whatever is the primary cause of SCI, a series of secondary events, including inflammation and ischemic injury, exacerbate the consequences of the primary injury and it is toward mitigating these that many treatment strategies are directed ([203](#)). Deterioration in spinal cord function soon after injury occurs in a few cases owing to further displacement of an unstable fracture during therapeutic manipulation (usually within 24 h of injury), hypotension secondary to neurogenic vascular instability induced by the SCI or other traumatic injuries (24 h to 7 d after injury), or vertebral artery occlusion because of involvement of the artery in its course through the neck by a vertebral injury



**Fig. 41.** Cervical fracture–dislocation, traumatic myelopathy (central gray necrosis pattern). **(A)** Fracture–dislocation through the lower body of C4 with a tear of the C4–C5 intervertebral disc (arrow). (Courtesy of Dr. E. Tweedie, London Health Sciences Centre, London, Ontario, Canada.) **(B)** Horizontal slices of the spinal cord from the same case as **(A)** at the C4 level are labeled 1 through 4 in rostral to caudal order (bar = 1 cm). Localized necrosis of the central gray matter is apparent. (Courtesy of Dr. L. C. Ang, London Health Sciences Centre, London, Ontario, Canada.)

(204). Deterioration in spinal cord function unrelated to evolving spasticity that occurs weeks, months, to years after injury is caused by cystic expansion (at the site of SCI and with rostral or caudal extension of the cyst—i.e., a syrinx), progressive deformation of the spinal canal secondary to a fracture, or superimposed degenerative vertebral disease (205).

### 8.8.2. Pathological Features

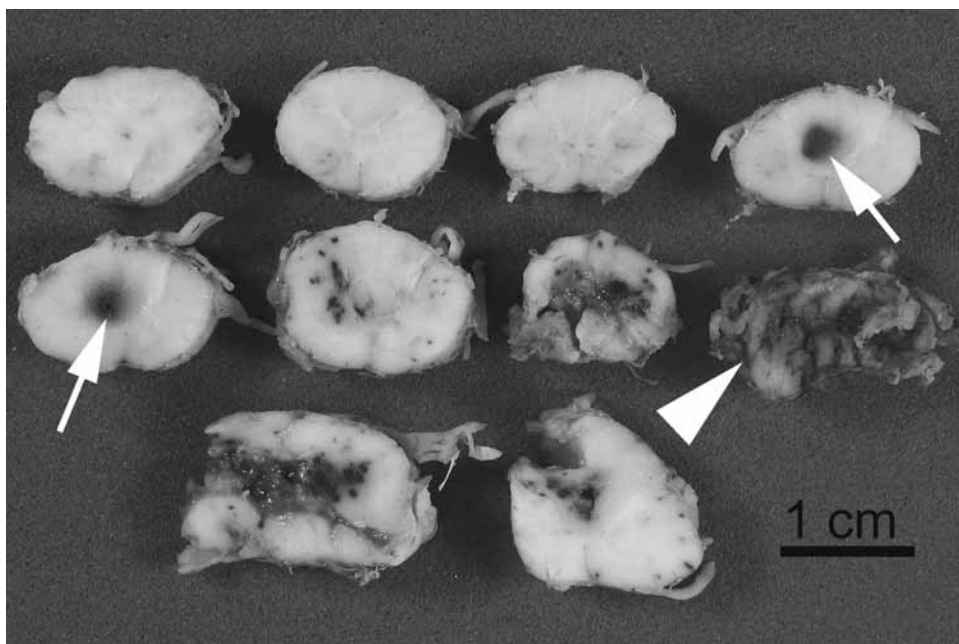
The appearance of the gross and microscopic abnormalities in the injured spinal cord is similar irrespective of the pathogenesis and site of the injury.

#### 8.8.2.1. GROSS FINDINGS

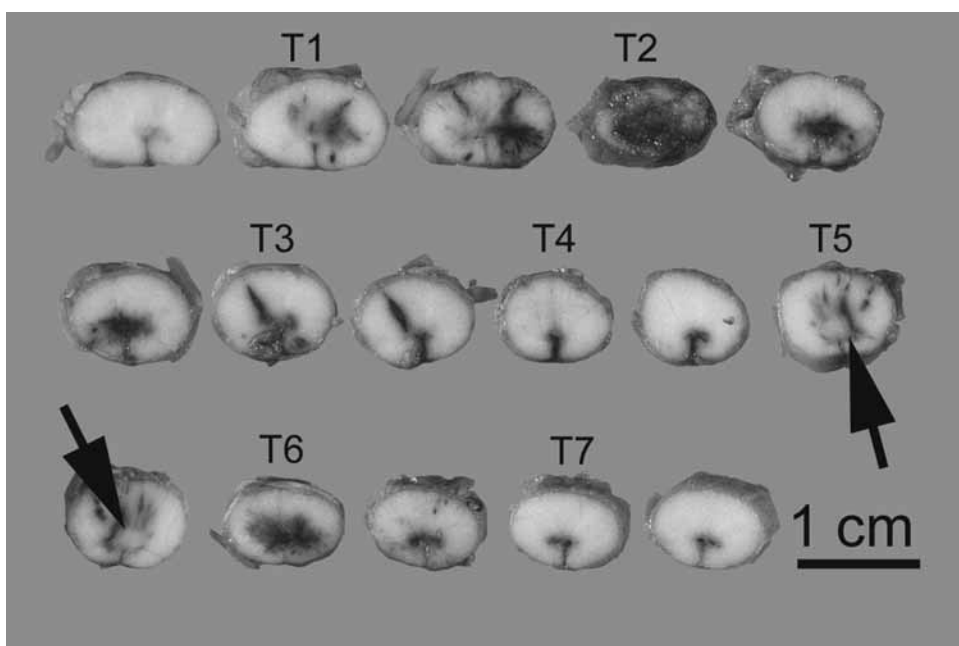
The dura is not usually torn in vertebrospinal injury, but the site of the SCI is indicated by peridural hemorrhage in acute cases and focal narrowing or slackness of the dura in chronic cases. The gross and microscopic appearances of the injured spinal cord depend on the age of the lesion, the severity of injury, and whether the pia is preserved. When the pia is intact, no gross abnormalities may be seen if death occurred at the time, or within minutes, of injury. In these cases reliance should be placed on the location of vertebral and perispinal injuries as a rough guide to the location of a SCI. This problem is usually encountered in cases of atlanto-occipital or atlantoaxial dislocation without cord transection.

Within a short period (up to a few hours) after injury the spinal cord becomes swollen, discolored, and hemorrhagic. Later, resorption of injured tissues causes softening and atrophy of the injured cord. Less severe older injuries may be more readily palpated than seen, because of their softness. If the pia has been torn, there will be an impression of separation of the torn ends of the cord, which remain more or less





**Fig. 42.** Traumatic myelopathy (maceration pattern). Transverse hemorrhagic tearing (maceration) marks the center of the lesion (arrowhead). Pencil-shaped necrosis is present in two rostral slices (arrows).



**Fig. 43.** Multifocal thoracic traumatic myelopathy. Transverse hemorrhagic tearing at T2 (maceration pattern) and central gray necrosis at T6 are a consequence of multiple thoracic fractures. Linear unilateral hemorrhagic necrosis lies in a posterior horn between T3 and T4. Pencil-shaped necrosis is present between T5 and T6 (arrows).

tenuously attached by bands of residual CNS tissue that are readily disrupted when the cord is handled.

In horizontal slices the spinal cord on either side of the separated area will show similar gross abnormalities to those seen in cases in which the pia is preserved. These changes in acute cases are principally hemorrhagic disruption and tearing of the injured tissue (Figs. 41–43) and, in older injuries, various degrees of cystic degeneration. The changes extend for one or two segments on both sides of the center of the lesion, the latter being defined simply as the area where the abnormalities are most prominent. The center of the lesion will roughly correspond in geographic position (but not in segmental level because of the rostralward precession of the cord segmental levels relative to the vertebral segmental levels such that the sacral spinal cord segments lie at the level of vertebrae 1 or 2) to the site of vertebral or perivertebral soft tissue injuries. The spatial association between the cord and bony injuries is not precise because of the relative movement of the spinal cord with respect to the vertebrae, particularly in the more mobile areas of the vertebral column.

#### 8.8.2.2. MICROSCOPIC FINDINGS

If death occurs within minutes of a SCI the characteristic features at the site of injury include dilation of the blood vessel profiles, petechial hemorrhages (particularly in the gray matter), and haphazard focal alteration in the orientation of bundles of nerve fibers in the white matter columns. After a few hours, the petechiae become more pronounced and more extensive, and the spinal motor neurons show ischemic neuronal necrosis (*see* Subheading 6.3.3.1.) or chromatolysis (characterized by dispersal of Nissl substance, cytoplasmic hypereosinophilia, and displacement of the nucleus to one side of the cell). Neutrophils enter injured tissue at around 24 to 36 h after injury (206), and macrophages at about 5 d. “Activated” microglia are readily seen in CD68 immunolabeled sections as cells with multiple blunt processes and rounded cell bodies as opposed to the elongated appearance of “resting” microglia.

The appearance of activated microglia and macrophages marks the beginning of tissue resorption so that progressively more marked cystic change appears. Debris-laden macrophages remain for many years. The distribution of acute and chronic inflammatory cells is almost always patchy, although macrophages show a predilection for the margins of necrosis. Lymphocytes are sparse and inconspicuous. Axonal swellings develop with a time course similar to that associated with cerebral lesions, and astrocytic activation is detectable within a week or so of injury. BAPP-immunopositive axonal abnormalities are also found at a distance from the SCI (162). The significance of this finding is unknown but it may represent either diffuse spinal traumatic axonal injury, by analogy with the diffuse effects of trauma on brain axons, or ongoing traumatic primary and transneuronal tract degeneration.

With long survival and after severe disruption of spinal cord tissue, fibrosis of the injured area occurs, particularly when the pia has been breached, and growth of Schwann cells and regenerating peripheral axons into the injured areas forms a pattern reminiscent of a traumatic neuroma.

At a distance from the spinal cord lesion, weeks to months after injury, there will be readily visible degeneration of the corticospinal tracts below the lesion and of the spinothalamic tracts and posterior columns above the lesion. The first sign of tract

degeneration with routine methods is the appearance of scattered debris-laden macrophages in the tracts. Subsequently there is progressive loss of myelinated axons, causing pallor of the tracts in sections stained with a myelin stain.

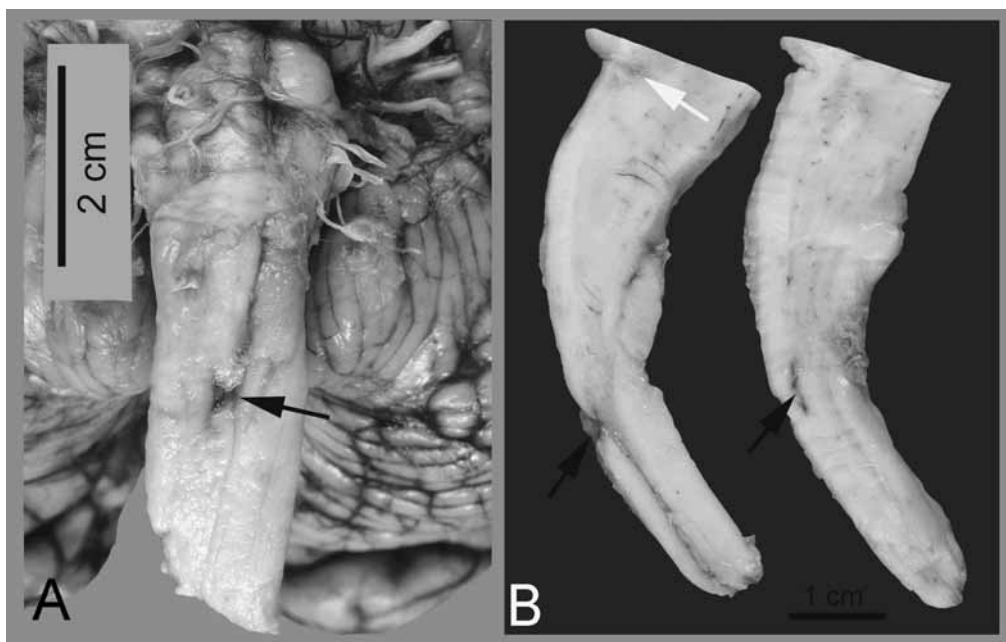
### 8.8.3. *Patterns of Traumatic SCI*

The cross-sectional distribution of changes in the most severely affected part of the spinal cord is highly variable, so much so that there is some justification in considering each SCI as unique in terms of its appearance. In general, in the most severe injuries, there is loss of continuity of CNS tissue (207). In many cases, however, a narrow, often incomplete rim of subpial tissue, including myelinated fibers, will be apparent around an extensive area of necrosis (in acute cases) or complex gliovascular cysts (in chronic cases) (208). Lesser injuries show a haphazard and asymmetric distribution of necrosis or cystic degeneration. White matter axonal injury predominates, suggesting a form of localized spinal traumatic axonal injury, in cases of “acute traumatic cervical central cord syndrome,” characterized clinically by disproportionate weakness of the arms compared with the legs after a neck injury, pre-existing narrowing of the spinal canal by degenerative bone or disk disease, and, usually, no evidence of a cervical fracture (207,209–211).

Despite the variability in their appearances, traumatic spinal cord lesions can be broadly classified (207) as contusion/cyst (an impact injury or brief compressive injury in which the pia is intact), maceration (an injury caused by extensive tearing of the spinal cord in cases of fracture–dislocation; Figs. 42, 43), laceration (restricted to penetrating and perforating spinal column injuries, usually caused by gunshot wounds) and solid cord injury (associated with the acute traumatic cervical central cord syndrome). In addition, in some cases of maceration necrosis predominates in the central gray matter (central gray necrosis), a pattern more characteristic of hypotensive vascular injury to the spinal cord (Fig. 41). Ventral midline spinal contusions, sometimes associated with a pontomedullary tear, may be a manifestation of a high cervical hyperextension or torsion injury, especially in children (Fig. 44). Early selective loss of myelin from axons that remain intact (demyelination) and subsequent remyelination (with the theoretical possibility of improvement in spinal cord function) is also a feature of SCI (207,208).

### 8.8.4. *Pencil-Shaped Necrosis (Longitudinal Spreading Lesion)*

A common finding associated with thoracic and low cervical traumatic SCI is a core of necrotic tissue with an oval or circular cross-sectional profile (“pencil-shaped necrosis,” “longitudinal spreading lesion”) that is usually above but continuous with the cord lesion (Figs. 42 and 43). It is localized to the ventral part of the posterior columns or unilaterally to a posterior horn and it may extend for several cord segments. No cellular reaction is seen in the adjacent white matter, but a rim of macrophages may be visible at the margin of the necrosis. The pathogenesis of pencil-shaped necrosis and its medicolegal significance are unknown, but the necrosis appears to be a direct consequence of vertebrospinal trauma as opposed to an artifact (212,213), and it can be reproduced experimentally (214). The difference between pencil-shaped necrosis and the allegedly artifactual “toothpaste” lesions with similar morphology that are ascribed to careless handling of the spinal cord is a matter for conjecture (215,216).



**Fig. 44.** Pontomedullary tear and spinal cord contusion in a young child. **(A)** A ventral midline high cervical spinal cord contusion–laceration is indicated (arrow). **(B)** Sagittal and parasagittal slices of the medulla and brainstem shown in **(A)**. The ventral spinal cord laceration is indicated by black arrows and a small pontomedullary tear by a white arrow.

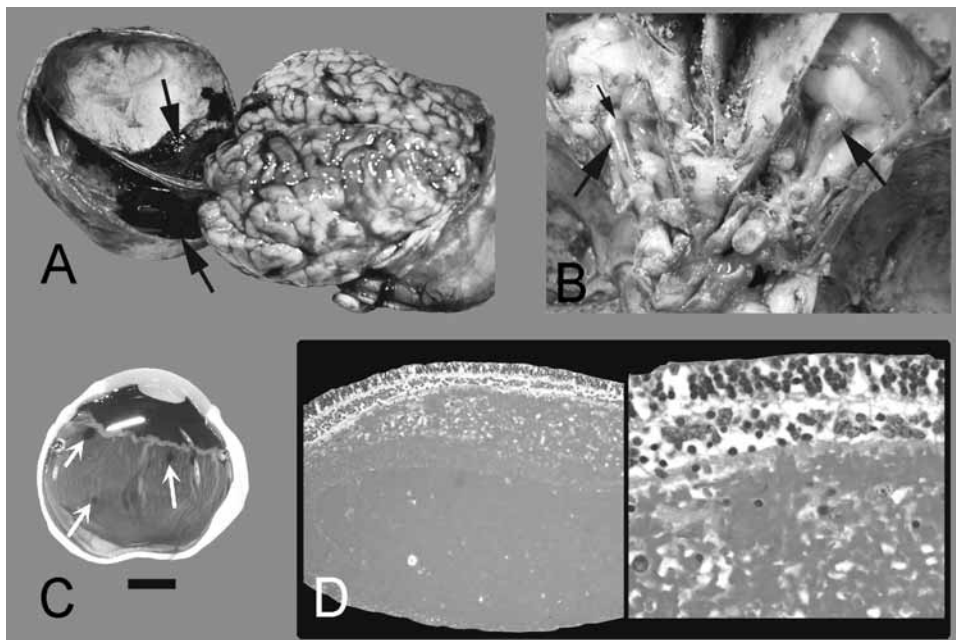
## 9. CRANIOCEREBRAL TRAUMA IN CHILDREN

The pathology of craniospinal trauma in children is similar to that noted in adults (160). The exceptions include a predisposition to injuries of the occipitoatlantoaxial complex in children under 10 yr of age (167), a greater risk of SCI without radiological abnormalities (174,217), localized indented skull vault depressions in infants as a consequence of birth injury, falls or motor vehicle accidents (“ping pong” fractures [218]), white matter tears in infants under 5 mo subjected to various types of head injury, particularly nonaccidental injury (219), “growing fractures” after simple linear fractures of the skull vault (32,33), and a greater risk of fulminant brain swelling after relatively minor head injuries (159–161).

### 9.1. Non-Accidental Injury in Infancy

Infants who, based on medical evidence and witness testimony accepted by the courts, have been shaken, or whose heads have been subjected to inflicted blunt force injury, or both (i.e., nonaccidental injury [NAI]), show an “indicator” triad of abnormalities (Fig. 45), namely:

- Intraretinal and periretinal hemorrhages, particularly in the peripheral retina.
- Hemorrhages under, or in, the dura surrounding the optic nerve (retro-orbital peripoptic subdural and intradural hemorrhages).
- Intracranial subdural hemorrhages, which are often small, bilateral, occipital, and perifalcine.



**Fig. 45.** Indicator triad in nonaccidental injury in infants. **(A)** Occipital subdural hemorrhages (arrows). **(B)** The orbital plates have been removed to expose the globes and the optic nerves. Bilateral retrobulbar perioptic subdural hemorrhages are present (large arrows). The small arrow indicates the border between the hematoma (below) and a visible segment of the optic nerve (above). **(C)** Opened globe (cornea uppermost). Small ventrally located retinal hemorrhages, two of which are close to the ora serrata, are indicated (arrows; scale bar = 0.5 cm). **(D)** Photomicrographs illustrated a hematoma lying under the retina (H&E: left =  $\times 10$  objective, right =  $\times 40$  objective).

This triad is inconsistently associated with evidence of hypoxic–ischemic encephalopathy (whose etiology is unproven), BAPP-immunopositive axonal changes (whose origin is controversial but which may at times be identical to traumatic axonal injury), and brain swelling. Brain swelling is often the final cause of death in these cases but its etiology may be uncertain or multifactorial. There are usually other injuries to the body, including multiphasic and multifocal cutaneous bruises, soft tissue injuries, and fractures of the ribs and limb bones. The discovery of an acute subdural hemorrhage in an infant should, therefore, always prompt the examination and removal of the eyes and optic nerves and consideration of the possibility of NAI.

In practice, a spectrum of cases of suspected NAI is seen, ranging from cases with the indicator triad, severe brain swelling, and skin, soft tissue, and bony injuries to cases in which the sole findings are those of the indicator triad. Some authorities regard the indicator triad as unequivocal evidence of NAI and, even if there are no extracranial injuries or brain swelling, sufficient to account for the death of the patient. However, in this context and particularly if the autopsy findings are restricted to the indicator triad, the basic principles of pathology must be maintained in order to answer the key question: After a complete autopsy and metabolic and toxicological testing, is there sufficient evidence to provide a sound and unequivocal structural, metabolic, or toxicological cause of death?



**Table 1**  
**Approach for Pathologists with Respect to Determination of Cause of Death in Cases of Suspected Nonaccidental Injury**

Triad present?	Fatal brain swelling?	Nonfatal extracranial injuries typical of NAI	Widespread histological changes <sup>a</sup>	Cause of death	Factors that may or may not have contributed to death
Yes	No	No	No	Undetermined <sup>b</sup>	Craniocerebral trauma
Yes	Yes	No	Yes or no	Craniocerebral trauma	None
Yes	No	Yes	Yes	Craniocerebral trauma	Extracranial blunt force injury
Yes	No	Yes	No	Undetermined <sup>b</sup>	Craniocerebral trauma, extracranial blunt force injury
Yes	Yes	Yes	Yes or no	Craniocerebral trauma	Extracranial blunt force injury
No	No	Yes	No	Undetermined	Extracranial blunt force injuries

<sup>a</sup> These changes are the histological features of hypoxic injury and axonal injury (whether believed to be ischemic or traumatic in nature). The changes must be so widespread and severe that it is “beyond reasonable doubt” to presume that they are the structural basis for fatal neurological dysfunction.

<sup>b</sup> The presence in these cases of the “indicator triad,” the elements of which, by themselves, are not fatal injuries, supports the inference that significant or dangerous force has passed through the CNS, but the lack of brain swelling and widespread histological changes neither supports nor refutes this contention. Such dangerous force may be fatal if it disrupts the vital centers of the brain stem and rostral spinal cord. Assuming the existence of a causal link between the indicator triad and the death of the infant, the lack of structural evidence of disruption of neural tissues indicates either that death occurred before pathological evidence of CNS injury could develop (i.e., death occurred within 2 h of injury [relying on the evidence of BAPP immunohistochemistry—see Subheading 6.1.7.] or 6 to 12 h of injury [relying on the demonstration of axonal or ischemic neuronal injury using various histological techniques—see Subheading 6.1.3. and 6.3.3.]) or that the percussive and other effects of the force responsible for the indicator triad are fatal without causing a structural correlate. The presence of the indicator triad and the death of the child are facts, but the conclusion that the indicator triad indicates the passage of inflicted deadly force through the CNS and, therefore, that craniocerebral trauma as the cause of death is a supposition. Whether or not this supposition and the theory or theories on which it is based are reasonable should be decided in a court of law after all the evidence concerning the case has been weighed and debated.

If there is insufficient evidence to answer this question in the affirmative, then the cause of death may be undetermined as far as the pathologist is concerned. [Table 1](#) provides an approach to classifying the cause of death in these cases.

## 9.2. Isolated SDHs in Infancy

All that should be said when gross or microscopic evidence of isolated sparse recent or old subdural bleeding is discovered in infants, in the absence of other evidence

of trauma, is that the bleeding has indeed occurred, that it has not directly contributed to the cause of death, and that although it may or may not be associated with NAI, peridural bleeding as a complication of birth is common and a small organizing hematoma from this source is a possible explanation.

## *10. CRANIOCEREBRAL TRAUMA AND PITUITARY GLAND*

The pituitary gland and its coverings show several abnormalities in cases of craniocerebral trauma. Capsular hemorrhage occurs in 59% of cases (220), although it is also associated with any cause of acute SAH (220). Bleeding in the form of petechiae and, less frequently, larger hemorrhages, presumably distraction (stretching) injuries, occur in the pituitary stalk and neurohypophysis (in a ratio of 1 to 7 [220]) in 45 to 48% of cases of craniocerebral trauma (220,221), but traumatic hemorrhage in the adenohypophysis is rare (221). Focal, multifocal or almost complete (massive) ischemic necrosis of the adenohypophysis happens (220,221), particularly in cases that survive for longer than 12 h after injury (35% of cases [220]), which is the minimum period that must elapse between the time of injury and death to allow the histological features of pituicyte death to evolve (220,222). The etiology of smaller areas of traumatic pituitary necrosis is uncertain. Several mechanisms are suggested to account for massive traumatic pituitary necrosis (222), but interruption of the blood supply to the adenohypophysis, which runs in the long hypophyseal portal system of the pituitary stalk, by stalk compression (owing to severe brain swelling [221,223,224]) or traumatic transection of the pituitary stalk (221) is a credible explanation.

The appearance of massive adenohypophyseal necrosis of whatever cause is highly distinctive (220–225). Approximately 90% of the adenohypophysis is necrotic (221), but the neurohypophysis is spared (221,225), the necrotic adenohypophysis is always enclosed by a narrow rim of histologically normal pituicytes (which derives its blood supply from capsular capillaries), and intact pituicytes are observed at the interface between the anterior and posterior pituitary gland where the blood supply is drawn from the intrasellar short hypophyseal portal system (223). Adenohypophyseal necrosis can also occur in many other clinical situations, including brain swelling (irrespective of cause), diabetes mellitus, and the postpartum period (222–226).

Necrosis of the neurohypophysis with sparing of the adenohypophysis has been described as a complication of intraoperative hypotension (227).

## *11. CLINICAL SYNDROMES ASSOCIATED WITH TRAUMATIC CNS INJURIES*

Although the effects of trauma on the brain, spinal cord, and its coverings produce myriad structural and clinical patterns, there are distinct clinical syndromes that are recognizable from the victim's history before the autopsy is started that are, more often than not, associated with specific neuropathological findings. It is useful to attempt to place the case in one of these categories in order to direct the post mortem examination. These syndromes are summarized in Table 2.

### *11.1. Dead at the Scene*

Most of the neuropathological abnormalities that are fatal at the time of, or soon after, traumatic CNS injuries are obvious (Fig. 46). They include severe comminuted fractures

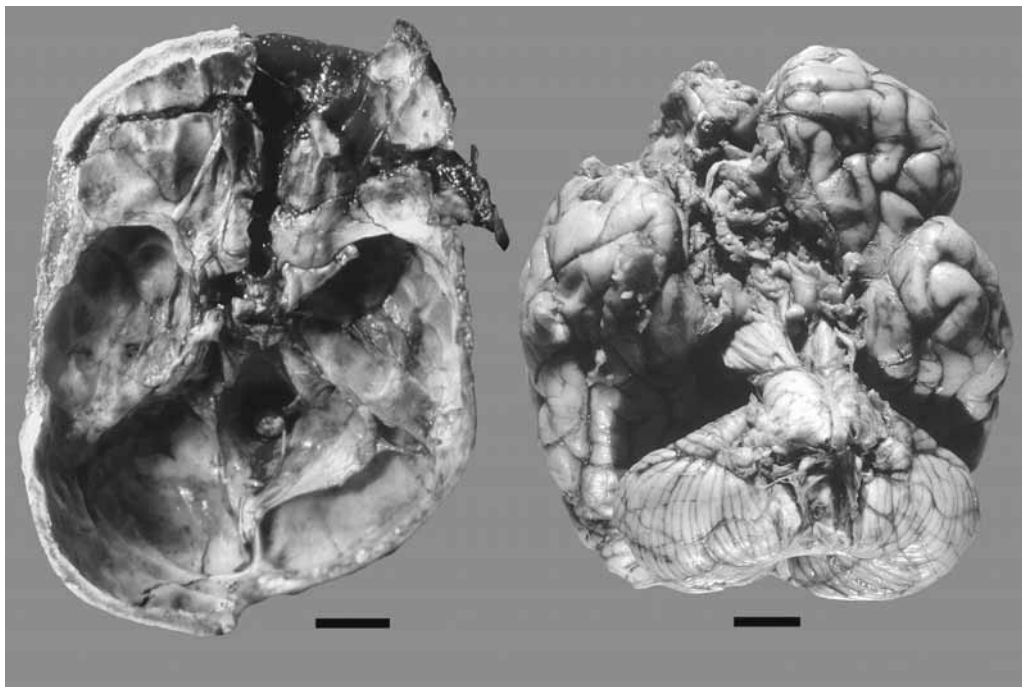
**Table 2**  
**Traumatic CNS Syndromes and Associated Neuropathology Diagnoses**

Traumatic clinical syndromes	Likely neuropathology diagnoses
“Dead at the scene”	<ul style="list-style-type: none"> <li>• Massive craniocerebral trauma</li> <li>• Diffuse vascular injury</li> <li>• Pontomedullary tear</li> <li>• High cervical spinal injury</li> <li>• “Commotio medullaris” (<i>see</i> Chapter 10, Subheading 4.3.)</li> <li>• Traumatic basilar subarachnoid hemorrhage (<i>see</i> Chapter 10, Subheading 4.2.)</li> </ul>
Patients who talk and die (228,229)	<ul style="list-style-type: none"> <li>• Peridural hemorrhage</li> <li>• Contusions/intracerebral hematoma</li> <li>• Brain swelling</li> <li>• Complications of skull fracture (<i>see</i> Subheading 3.7.)</li> </ul>
Coma and vegetative state (129)	<ul style="list-style-type: none"> <li>• Grades 2 and 3 DAI</li> <li>• Diffuse hypoxic–ischemic injury with thalamic involvement</li> </ul>
Severe disability (235)	<ul style="list-style-type: none"> <li>• Grades 2 and 3 DAI</li> <li>• Diffuse hypoxic–ischemic injury with or without thalamic involvement</li> <li>• Multiple focal brain injuries (ischemic injury, contusions)</li> <li>• Evidence of past raised intracranial pressure</li> <li>• History of surgically evacuated intracranial hematoma</li> </ul>
Moderate disability (130)	<ul style="list-style-type: none"> <li>• Grade 1 DAI</li> <li>• Mild to moderate contusions</li> <li>• History of surgically evacuated intracranial hematoma</li> <li>• Grade 1 DAI</li> <li>• SUDEP (<i>see</i> Chapter 10, Heading 5)</li> </ul>
History of minor disability after, or full recovery from, a head injury	<ul style="list-style-type: none"> <li>• Fronto-orbital contusions</li> <li>• Old smear-type subdural hemorrhage</li> <li>• Microscopic focal sparse subdural hemosiderosis</li> <li>• Scattered microscopic cysts or focal gliosis</li> <li>• No neuropathological abnormality</li> </ul>
Isolated quadriplegia or paraplegia	<ul style="list-style-type: none"> <li>• Spinal cord injury</li> </ul>

with secondary brain lacerations or rostral cervical spinal column injury. Other causes are diffuse vascular injury, traumatic basilar SAH (*see* Chapter 10, Subheading 4.2.), and an idiosyncratic response to head impact, “commotio medullaris,” which is a diagnosis of exclusion (*see* Chapter 10, Subheading 4.3.).

### ***11.2. Patients Who “Talk and Die:” The Lucid Interval***

Patients who “talk and die,” or, in other words, have a lucid interval, are well enough after a head injury to utter words, and therefore can be presumed, at that time, not to have a fatal primary brain injury, but they subsequently die of a delayed and there-



**Fig. 46.** Dead at the scene. Ejection of this victim from an all-terrain vehicle and a collision between his unprotected head and a tree has caused a comminuted, compound right frontal and basilar skull fracture and large cerebral lacerations. There can be no doubt in such cases that the cause of death is massive craniocerebral trauma!

fore potentially remediable complication of trauma (228,229). Approximately 6 to 10% of patients who talk after “severe” head injuries die of TBI. In comparison with those who survive, fatal cases tend to be older and to have more severe extracranial injuries and lower scores in the motor and eye-opening components of the Glasgow Coma Scale (229). Fatal neurological deterioration in these patients is caused by (229):

- Peridural hematomas (50% of cases), usually ASDHs.
- Contusions or intracerebral hematomas (40% of cases).
  - Large bilateral frontal contusions are particularly apt to cause delayed deterioration (230).
- Brain swelling (10% of cases).

A number of patients who are lucid after a head injury will also deteriorate for the same reasons but survive in a vegetative state or with severe disability.

Subjects with various complications of skull fractures (*see* Subheading 3.7.), particularly acute bacterial meningitis, may also die after a lucid interval, which can last for days or even weeks.

### 11.3. Vegetative State

The vegetative state is defined as “continuing unconsciousness with no evidence of awareness or cognitive responsiveness although there are periods of wakefulness with the eyes open” (231). There is a slender chance of some recovery in a patient in a vegetative state, but this becomes increasingly unlikely after 4 wk, when the condition is classified

as a “continuing” vegetative state. No recovery will, in any event, occur once the subject has survived for 12 mo, when the “permanent” vegetative state is entered (232). The vegetative state is usually associated with TBI or with hypoxic–ischemic brain injury following a cardiac arrest. Most cases of traumatic vegetative states are caused by Grade 2 and 3 DAI, or diffuse traumatic hypoxic–ischemic injury (reflecting a global failure in cerebral perfusion), or both (129). Ischemic injury to the thalamus is invariable in vegetative state cases in which there is no evidence of DAI: conversely, cerebral cortical ischemic injury, irrespective of its cause, does not cause the vegetative state unless there has been ischemic injury to the thalamus (233).

### ***11.4. Severe Disability***

Severe disability, in head-injured patients, is a state in which the affected individual requires some help with acts of daily living from another person (Glasgow Outcome Scale [234]). The degree of severe disability ranges from mobile subjects through individuals who are bedbound to patients in a minimally conscious state (235). The neuropathologic abnormalities underlying severe disability resemble those of vegetative state in approx 50% of cases. In the remainder, however, there is neither thalamic injury nor Grade 2 or 3 DAI. Rather, different types of focal brain injury appear to act in concert to create severe disability, including contusions, the residual miscellaneous effects on the brain of intracranial hematomas (which will have been surgically evacuated), focal ischemic brain injury, and brain stem lesions (usually ischemic injury and hemorrhages). In a few cases, Grade 1 DAI is the only abnormality. No marked differences in the incidence of hematomas, evidence of previously raised intracranial pressure, or ischemic injury exist between mobile, bedbound, and minimally conscious severely disabled patients (235).

### ***11.5. Moderate Disability***

Patients whose Glasgow Outcome Scale category is “moderate disability” after TBI are sufficiently independent to live on their own but have some persisting physical or mental impairment (234). Falls are the most common cause of the TBI; a history of a skull fracture is usual. The majority of these patients have posttraumatic seizures, and more than 70% have a history of a surgically evacuated intracranial hematoma. The neuropathology findings include surface contusions in most cases (none of which are extensive), Grade 1 DAI in 30% of cases, and, in a minority of cases, focal ischemic brain injury. There is rarely evidence of significant past brain swelling (130).

### ***11.6. Craniocerebral Trauma With Full Recovery or Minor Disability***

It is common to perform an autopsy on an individual with a history of a head injury with no, or only minor, residual neurological disability who has died of causes unrelated to the brain injury. In this context minor disability is defined as mild symptomatic cognitive disability, ostensibly dating from the time of a head injury. In most cases no neuropathological abnormalities are found but in some cases there are small old contusions, usually in the frontotemporal area, or focal or diffuse inconsequential subdural hemosiderin staining. The significance of the contusions with respect to the causation of mild posttraumatic symptomatology is uncertain because asymptomatic old contusions are frequent incidental postmortem findings. In some instances,



possibly representing the structural correlates of minor brain MRI signal abnormalities demonstrated after mild TBI (*see* Subheading 6.1.5. [140]), sparse small or microscopic white matter cystic lesions, usually with a few hemosiderin-laden macrophages, or subtle gray matter and white matter microglial hypercellularity are observed.

### ***11.7. Isolated Quadriplegia or Paraplegia***

In most cases the cause of quadriplegia and paraplegia is spinal injury, although in some instances brainstem injury is responsible.

### ***11.8. Cause of Death in Victims of Craniocerebral Trauma Who Are Not Dead at the Scene***

Most comatose patients with head injuries who are ventilator-dependent die when the ventilator is switched off. In these cases the CNS injury, having caused failure of control of respiration, is the immediate cause of death. The immediate cause of death in other patients who are in a coma, whether ventilator-dependent or not, or who are severely disabled, is usually an infectious or vascular complication of the CNS injury, the latter being the proximate cause of death. In some instances, however, a “formal” immediate cause of death cannot be demonstrated, despite the presence of severe brain injury, but death in these cases should be attributed to pervasive failure of the neural control of cardiorespiratory function. In milder forms of severe disability and in patients with moderate disability, the cause of death is usually unrelated to the CNS injury. If post-traumatic seizures are present, the criteria for sudden unexpected death in epilepsy may be met (*see* Chapter 10, Heading 5.).

## ***12. ACUTE NEUROGENIC PULMONARY EDEMA***

Neurogenic pulmonary edema (NPE) is pulmonary edema that is associated with neurological disease in patients in whom no other cardiac or pulmonary cause for the edema is apparent (236,237), and it may, from time to time, be the immediate cause of death in patients with head injuries. NPE is associated with several acute neurological diseases, including spontaneous intracranial hemorrhage in general (238) and SAH secondary to aneurysmal rupture in particular (239), sudden unexpected death in epilepsy (240), and head trauma of various sorts (241–243). It has also been reported in a case of presumed nonaccidental head injury in an infant (244).

NPE usually occurs, or presents, within a few hours of the onset of neurologic symptoms. There is also good clinical evidence that pulmonary edema can occur instantaneously or at least within minutes of a head injury, as evidenced by the following observations:

- A mean combined lung weight of 997 g (standard deviation 359 g) is recorded in 41 victims with head injuries who were dead at the scene of their head injuries (241).
- Twenty casualties of the Vietnam war who died within minutes of head injury caused by missile injuries or falls had combined lung weights of less than 800 g (2 cases), 800 to 1500 g (17 cases), and 1501 to 2000 g (1 case) (242).
- Twenty-three patients with “traumatic intracerebral hemorrhage” (which is not further specified) who “lived 1/2 hour or less” had a combined lung weight of more than 900 g (238).

The onset of pulmonary edema within minutes of TBI is also replicated in experimental studies in animals (245–248).

The pathobiology of NPE is uncertain. The principal theories evoke neurally mediated changes in the sympathetic control of pulmonary vascular resistance provoked by brain injury and a primary central process in which the pulmonary capillary permeability is increased independent of changes in vascular tone. If there is a delay of some hours in the onset of pulmonary edema the humorally mediated posttraumatic hypercatecholaminergic state may be responsible.

### 13. DEMENTIA AND TBI

Questions regarding an association between dementia and TBI arise when behavioral dysfunction owing to dementia is suspected as the cause of a fatal accident or when symptoms of dementia emerge some time after a head injury, leading to the suspicion that the cognitive disorder was caused by craniocerebral trauma.

#### 13.1. Dementia as Explanation for Fatal Accident

If a history of dementia is provided at the time of autopsy the pathologist should fix and retain the brain. A useful algorithm is available for the histopathological investigation of dementia (249) but, if at all possible, brains from patients with dementia should be assessed by a neuropathologist with a special interest in degenerative disorders because of the complexities of the various dementia classification schemes, the need in some cases for extensive sampling of tissue from the brain for microscopic examination, and the considerable battery of immunohistochemical procedures that may be needed to establish a diagnosis. However, the diagnosis of Alzheimer's disease (responsible for 50 to 70% of cases of dementia [250]) and of diffuse Lewy body disease (accounting for 10 to 25% of cases of dementia [250]) is relatively straightforward (250,251).

The diagnosis of Alzheimer's disease rests on the demonstration by silver stains and immunohistochemical methods of neuritic plaques and neurofibrillary tangles (NFTs) in the cerebral cortex and hippocampus. Semiquantitative methods of assessing the incidence of neuritic plaques and NFTs allow general statements to be made regarding the likelihood that a particular burden of neuritic plaques and NFTs caused dementia in any given case (252,253), but the presence of even severe histological changes of Alzheimer's disease does not guarantee that a specific patient was demented (254).

Diffuse Lewy body disease is characterised by eosinophilic, ubiquitin-immunopositive, and synuclein-immunopositive cytoplasmic inclusions in cortical neurons. Depigmentation, neuronal loss, and Lewy bodies in surviving neurons are almost always observed in the substantia nigra. The correlation between the prevalence of cortical Lewy bodies and the degree of cognitive and motor dysfunction is poor (255,256) but a simple and reproducible histopathological staging method is available (255,257).

In practical terms, when the possibility of dementia is raised as an explanation for events leading to a head injury, the following is recommended:

- In the absence of a history of dementia:
  - The pathologist should determine whether or not the pathological features of Alzheimer's disease or Lewy body disease are present.

- If such features are present, the pathologist should record them (e.g., as “Alzheimer’s disease-like changes” or “diffuse Lewy body disease-like changes”) and state that it is not possible to know with certainty if the patient was clinically demented.
- If compelling and credible clinical evidence of dementia is recorded:
  - The pathologist should state whether the likely cause was Alzheimer’s disease, diffuse Lewy body disease, or both (as these diseases often co-exist).
  - The pathologist should not state that behavioral dysfunction was responsible for an accident leading to a head injury, which is a speculation that should be left to a physician who is familiar with what the patient’s mental state was shortly before accident.
  - If the histopathological features of Alzheimer’s disease or diffuse Lewy body disease are not found, the pathologist should arrange with a neuropathologist for other causes of dementia to be sought (249,250).

### 13.2. TBI as Cause of Dementia

There is suggestive evidence of an association between head injury and dementia (258,259). A detailed assessment of this subject is beyond the scope of this book but, in summary, dementia and head injury appear to be linked in the following contexts:

- The degree of brain injury, including secondary ischemic injury arising from a head injury, may alone be sufficient to account for cognitive dysfunction originating immediately after injury and resembling dementia in patients surviving with major disability. The demonstration of ongoing neuronal loss in the hippocampus for at least months after a head injury could account for a progressive deterioration in cognitive function (260), as long as other causes of dementia are excluded.
- Dementia pugilistic is a well-known degenerative disorder, characterized by widespread NFTs in the cerebral cortical and brainstem neurons and sparse neuritic plaques (261), caused by repetitive, concussive blows to the head over a long period that typically occur in boxers.
- A previous head injury is a significant risk factor for the development of Alzheimer’s disease (262). Three observations suggest that this association may be more than fortuitous:
  - Patients with the  $\epsilon 4$  allele of the *ApoE* gene are at particular risk for developing Alzheimer’s disease (52).
  - Patients with the same allele show a poorer outcome after head injury than do patients who have other ApoE alleles (52).
  - $\beta$ -Amyloid protein deposition, involved in the pathogenesis of Alzheimer’s disease, is increased in 30% of patients who die after a single head injury, usually from a fall, most of whom are elderly (263).

It remains to be determined whether or not these observations indicate cause and effect or shared vulnerabilities between head injury and Alzheimer’s disease.

In practice, a pathologist should say only that the structural effects caused by TBI may cause cognitive dysfunction and that there is no definite proof that a past head injury can be solely blamed for the development of Alzheimer’s disease.

## REFERENCES

1. Langlois, J. A., Rutland-Brown, W., Thomas, K. E. Traumatic Brain Injury in the United States: Emergency Department Visits, Hospitalizations, and Deaths. Centers for Disease Control and Prevention, National Center for Injury Prevention and Control, Atlanta, GA, 2004.
2. Kreppel, D., Antoniadis, G., Seeling, W. Spinal hematoma: a literature survey with meta-analysis of 613 patients. *Neurosurg. Rev.* 26:1–49, 2003.

3. Rutty, G. N. Editorial: Are invasive autopsies necessary? *Forensic Sci. Med. Pathol.* 1:71–73, 2005.
4. Croul, S. E., Flanders, A. E. Neuropathology of human spinal cord injury. *Adv. Neurol.* 72:317–323, 1997.
5. Moritz, A. R. Classical mistakes in forensic pathology. *Am. J. Clin. Pathol.* 26:1382–1397, 1956.
6. Cassin, B. J., Spitz, W. U. Concentration of alcohol in delayed subdural hematoma. *J. Forensic Sci.* 28:1013–1015, 1983.
7. Smialek, J. E., Spitz, W. U., Wolfe, J. A. Ethanol in intracerebral clot. Report of two homicidal cases with prolonged survival after injury. *Am. J. Forensic Med. Pathol.* 1:149–150, 1980.
8. McIntyre, I. M., Hamm, C. E., Sherrard, J. L., Gary, R. D., Riley, A. C., Lucas, J. R. The analysis of an intracerebral hematoma for drugs of abuse. *J. Forensic Sci.* 48:680–682, 2003.
9. Armed Forces Institute of Pathology. Armed Forces Medical Examiner—Autopsy Diagrams. <http://www.afip.org/Departments/oafme/diagrams.html>, 2005.
10. Ezzat, W., Ang, L. C., Nyssen, J. Pontomedullary rent. A specific type of primary brainstem traumatic injury. *Am. J. Forensic Med. Pathol.* 16:336–339, 1995.
11. Royal College of Pathologists. Guidance for Retention of Brain and Spinal Cord Following Post-Mortem Examination and Where Criminal Proceedings are in Prospect: Available at <http://www.rcpath.org/resources/pdf/GUIDELINESBRAIN-ARNedited.pdf>. Royal College of Pathologists, London, 2002.
12. Nelson, E. L., Melton, J., Annegers, J. F., Laws, E. R., Offord, K. P. Incidence of skull fractures in Olmsted County, Minnesota. *Neurosurgery* 15:318–324, 1984.
13. Shkrum, M. J., Green, R. N., McClafferty, K. J., Nowak, E. S. Skull fractures in fatalities due to motor vehicle collisions. *J. Forensic Sci.* 39:107–122, 1994.
14. Gurdjian, E. S., Gurdjian, E. S. Acute head injury: a review. *Surg. Annu.* 12:223–241, 1980.
15. Gurdjian, E. S. Impact head injury: Mechanistic, clinical and preventive correlations. Charles C. Thomas, Springfield, IL, 1975.
16. Rawling, L. B. *The Surgery of the Skull and Brain*. Oxford Medical Publications, London, 1912.
17. McCrory, P. R., Berkovic, S. F. Concussion: the history of clinical and pathophysiological concepts and misconceptions. *Neurology* 57:2283–2289, 2001.
18. Shaw, N. A. The neurophysiology of concussion. *Prog. Neurobiol.* 67:281–344, 2002.
19. Herbella, F. A., Mudo, M., Delmonti, C., Braga, F. M., Del Grande, J. C. “Raccoon eyes” (periorbital haematoma) as a sign of skull base fracture. *Injury* 32:745–747, 2001.
20. Hirsch, C. S., Kaufman, B. Contrecoup skull fractures. *J. Neurosurg.* 42:530–534, 1975.
21. Hein, P. M., Schulz, E. Contrecoup fractures of the anterior cranial fossae as a consequence of blunt force caused by a fall. *Acta Neurochir. (Wien)* 105:24–29, 1990.
22. Harvey, F. H., Jones, A. M. “Typical” basal skull fracture of both petrous bones: an unreliable indicator of head impact site. *J. Forensic Sci.* 25:280–286, 1980.
23. Voigt, G. E., Skold, G. Ring fractures of the base of the skull. *J. Trauma* 14:494–505, 1974.
24. Russell, W. R., Schiller, F. Crushing injuries to the skull: Clinical and experimental observations. *J. Neurol. Neurosurg. Psychiat.* 12:52–60, 1949.
25. Pollanen, M. S., Deck, J. H., Blenkinsop, B., Farkas, E. M. Fracture of temporal bone with exsanguination: pathology and mechanism. *Can. J. Neurol. Sci.* 19:196–200, 1992.
26. Resnick, D. K., Subach, B. R., Marion, D. W. The significance of carotid canal involvement in basilar cranial fracture. *Neurosurgery* 40:1177–1181, 1997.
27. Ildan, F., Uzuneyupoglu, Z., Boyar, B., Bagdatoglu, H., Cetinalp, E., Karadayi, A. Traumatic giant aneurysm of the intracavernous internal carotid artery causing fatal epistaxis: case report. *J. Trauma* 36:565–567, 1994.
28. Sato, S., Iida, H., Hirayama, H., Endo, M., Ohwada, T., Fujii, K. Traumatic basilar artery occlusion caused by a fracture of the clivus—case report. *Neurol. Med. Chir. (Tokyo)* 41:541–544, 2001.

29. Adams, V. I., Hirsch, C. S. Venous air embolism from head and neck wounds. *Arch. Pathol. Lab. Med.* 113:498–502, 1989.
30. Adams, V., Guidi, C. Venous air embolism in homicidal blunt impact head trauma. Case reports. *Am. J. Forensic Med. Pathol.* 22:322–326, 2001.
31. Ogilvy, C. S., McKee, A. C., Newman, N. J., Donnelly, S. M., Kiwak, K. J. Embolism of cerebral tissue to lungs: report of two cases and review of the literature. *Neurosurgery* 23:511–516, 1988.
32. Ersahin, Y., Gulmen, V., Palali, I., Mutluer, S. Growing skull fractures (craniocerebral erosion). *Neurosurg. Rev.* 23:139–144, 2000.
33. Sugiultzoglou, M. K., Souweidane, M. M. Early management of craniocerebral injury with avoidance of post-traumatic leptomeningeal cyst formation. Report of two cases. *Pediatr. Neurosurg.* 35:329–333, 2001.
34. Tuli, S., Tator, C. H., Fehlings, M. G., Mackay, M. Occipital condyle fractures. *Neurosurgery* 41:368–376, 1997.
35. Legros, B., Fournier, P., Chiaroni, P., Ritz, O., Fusciardi, J. Basal fracture of the skull and lower (IX, X, XI, XII) cranial nerves palsy: four case reports including two fractures of the occipital condyle—a literature review. *J. Trauma* 48:342–48, 2000.
36. Bucholz, R. W., Burkhead, W. Z., Graham, W., Petty, C. Occult cervical spine injuries in fatal traffic accidents. *J. Trauma* 19:768–771, 1979.
37. Anderson, P. A., Montesano, P. X. Morphology and treatment of occipital condyle fractures. *Spine* 13:731–736, 1988.
38. Miltner, E., Kallieris, D., Schmidt, G., Muller, M. Injuries of the occipital condyles in fatal traffic accidents. *J. Legal Med.* 103:523–528, 1990.
39. Bonilha, L., Mattos, J. P., Borges, W. A., Fernandes, Y. B., Andrioli, M. S., Borges, G. Chronic epidural hematoma of the vertex. *Clin. Neurol. Neurosurg.* 106:69–73, 2003.
40. Domenicucci, M., Signorini, P., Strzelecki, J., Delfini, R. Delayed post-traumatic epidural hematoma. A review. *Neurosurg. Rev.* 18:109–122, 1995.
41. Watanabe, T., Nakahara, K., Miki, Y., Shibui, S., Takakura, K., Nomura, K. Chronic expanding epidural haematoma. Case report. *Acta Neurochir. (Wien)*. 132:150–153, 1995.
42. Ng, W. H., Yeo, T. T., Seow, W. T. Non-traumatic spontaneous acute epidural haematoma—report of two cases and review of the literature. *J. Clin. Neurosci.* 11:791–794, 2004.
43. Kett-White, R., Martin, J. L. Bilateral frontal extradural haematomas caused by rupture of the superior sagittal sinus: case report. *Br J. Neurosurg.* 13:77–78, 1999.
44. Miller, D. J., Steinmetz, M., McCutcheon, I. E. Vertex epidural hematoma: surgical versus conservative management: two case reports and review of the literature. *Neurosurgery* 45:621–624, 1999.
45. Gelabert, M., Prieto, A., Allut, A. G. Acute bilateral extradural haematoma of the posterior cranial fossa. *Br. J. Neurosurg.* 11:573–575, 1997.
46. d'Avella, D., Servadei, F., Scerrati, M., et al. Traumatic acute subdural haematomas of the posterior fossa: clinicoradiological analysis of 24 patients. *Acta Neurochir. (Wien)*. 145:1037–1044, 2003.
47. Gupta, S. K., Tandon, S. C., Mohanty, S., Asthana, S., Sharma, S. Bilateral traumatic extradural haematomas: report of 12 cases with a review of the literature. *Clin. Neurol. Neurosurg.* 94:127–131, 1992.
48. Franck, E., Berger, S., Tew, J. Bilateral epidural hematomas. *Surg. Neurol.* 17:218–222, 1982.
49. Huda, M. F., Mohanty, S., Sharma, V., Tiwari, Y., Choudhary, A., Singh, V. P. Double extradural hematoma: an analysis of 46 cases. *Neurol. India* 52:450–452, 2004.
50. Mishra, A., Mohanty, S. Contre-coup extradural haematoma: a short report. *Neurol. India* 49:94–95, 2001.
51. Graham, D. I., Lawrence, A. E., Adams, J. H., Doyle, D., McLellan, D. R. Brain damage in non-missile head injury secondary to high intracranial pressure. *Neuropathol. Appl. Neurobiol.* 13:209–217, 1987.



52. Graham, D. I., Gennarelli, T. A., McIntosh, T. K. Trauma. In: Graham, D. I., Lantos, E. R., eds. *Greenfield's Neuropathology, Seventh Edition, Volume 1*. Arnold, London, pp. 823–898, 2002.
53. Croce, M. A., Dent, D. L., Menke, P. G., et al. Acute subdural hematoma: nonsurgical management of selected patients. *J. Trauma* 36:820–826, 1994.
54. Edwards, R. J., Britz, G. W., Critchley, G. R. Spontaneous resolution of an acute subdural haematoma. *Br. J. Neurosurg.* 16:609–610, 2002.
55. Maxeiner, H., Wolff, M. Pure subdural hematomas: a postmortem analysis of their form and bleeding points. *Neurosurgery* 50:503–508, 2002.
56. Missori, P., Fenga, L., Maraglino, C., et al. Spontaneous acute subdural hematomas. A clinical comparison with traumatic acute subdural hematomas. *Acta Neurochir. (Wien)*. 142:697–701, 2000.
57. Depreitere, B., Van Calenbergh, F., van Loon, J. A clinical comparison of non-traumatic acute subdural haematomas either related to coagulopathy or of arterial origin without coagulopathy. *Acta Neurochir. (Wien)* 145:541–546, 2003.
58. Avis, S. P. Nontraumatic acute subdural hematoma. A case report and review of the literature. *Am. J. Forensic Med. Pathol.* 14:130–134, 1993.
59. Gennarelli, T. A. Head injury in man and experimental animals: clinical aspects. *Acta Neurochir. Suppl. (Wien)* 32:1–13, 1983.
60. Zygun, D. A., Laupland, K. B., Hader, W. J., et al. Severe traumatic brain injury in a large Canadian health region. *Can. J. Neurol. Sci.* 32:87–92, 2005.
61. Tandon, P. N. Acute subdural haematoma : a reappraisal. *Neurol. India* 49:3–10, 2001.
62. Matsuyama, T., Shimomura, T., Okumura, Y., Sakaki, T. Acute subdural hematomas due to rupture of cortical arteries: a study of the points of rupture in 19 cases. *Surg. Neurol.* 47:423–427, 1997.
63. Koc, R. K., Pasaoglu, A., Kurtsoy, A., Oktem, I. S., Kavuncu, I. Acute spontaneous subdural hematoma of arterial origin: a report of five cases. *Surg. Neurol.* 47:9–11, 1997.
64. Senel, A., Cokluk, C., Onder, A., Iyigun, O., Incesu, L. Acute interhemispheric subdural hematomas. Report of nine cases. *J. Neurosurg. Sci.* 45:97–102, 2001.
65. Leestma, J. E., Grcevic, N. Impact injuries to the brain and head. In: Leesma, J. E., ed. *Forensic Neuropathology*. Raven Press, New York, pp. 184–275, 1988.
66. Munro, D., Merritt, H. H. Surgical pathology of subdural hematoma. Based on a study of one hundred and five cases. *Arch. Neurol. Psychiatry* 35:64–78, 1936.
67. Sahuquillo-Barris, J., Lamarca-Ciuro, J., Vilalta-Castan, J., Rubio-Garcia, E., Rodriguez-Pazos, M. Acute subdural hematoma and diffuse axonal injury after severe head trauma. *J. Neurosurg.* 68:894–900, 1988.
68. Yamashima, T., Yamamoto, S. Clinicopathological classification of chronic subdural hematoma. *Zentralbl. Neurochir.* 46:304–314, 1985.
69. Iantosca, M. R., Simon, R. H. Chronic subdural hematoma in adult and elderly patients. *Neurosurg. Clin. N. Am.* 11:447–454, 2000.
70. Adhiyaman, V., Asghar, M., Ganeshram, K. N., Bhowmick, B. K. Chronic subdural haematoma in the elderly. *Postgrad. Med. J.* 78:71–75, 2002.
71. Jones, S., Kafetz, K. A prospective study of chronic subdural haematomas in elderly patients. *Age Ageing* 28:519–521, 1999.
72. Missori, P., Maraglino, C., Tarantino, R., et al. Chronic subdural haematomas in patients aged under 50. *Clin. Neurol. Neurosurg.* 102:199–202, 2000.
73. Friede, R. L., Schachenmayr, W. The origin of subdural neomembranes. II. Fine structural of neomembranes. *Am. J. Pathol.* 92:69–84, 1978.
74. Schachenmayr, W., Friede, R. L. The origin of subdural neomembranes. I. Fine structure of the dura-arachnoid interface in man. *Am. J. Pathol.* 92:53–68, 1978.
75. Munro, D. The diagnosis and treatment of subdural hematomas. *N. Engl. J. Med.* 210: 1145–1160, 1934.

76. Lee, K. S. Natural history of chronic subdural haematoma. *Brain Inj.* 18:351–358, 2004.
77. Albuquerque, F. C., Giannotta, S. L. Arachnoid cyst rupture producing subdural hygroma and intracranial hypertension: case reports. *Neurosurgery* 41:951–955, 1997.
78. Yamashima, T. The inner membrane of chronic subdural hematomas: pathology and pathophysiology. *Neurosurg. Clin. N. Am.* 11:413–424, 2000.
79. Killeffer, J. A., Killeffer, F. A., Schochet, S. S. The outer neomembrane of chronic subdural hematoma. *Neurosurg. Clin. N. Am.* 11:407–412, 2000.
80. Sarkar, C., Lakhtakia, R., Gill, S. S., Sharma, M. C., Mahapatra, A. K., Mehta, V. S. Chronic subdural haematoma and the enigmatic eosinophil. *Acta Neurochir. (Wien)* 144:983–988, 2002.
81. DiMaio, V. J., DiMaio, D. *Forensic Pathology*. Second Edition. CRC Press, Boca Raton, FL, 2001.
82. Firsching, R., Heimann, M., Frowein, R. A. Early dynamics of acute extradural and subdural hematomas. *Neurol. Res.* 19:257–260, 1997.
83. van den Brink, W. A., Zwienenberg, M., Zandee, S. M., van der Meer L., Maas, A. I., Avezaat, C. J. The prognostic importance of the volume of traumatic epidural and subdural hematomas revisited. *Acta Neurochir. (Wien)* 141:509–514, 1999.
84. Adams, J. H., Doyle, D., Graham, D. I., Lawrence, A. E., McLellan, D. R. Deep intracerebral (basal ganglia) haematomas in fatal non-missile head injury in man. *J. Neurol. Neurosurg. Psychiatry* 49:1039–1043, 1986.
85. Lee, J. P., Wang, A. D. Post-traumatic basal ganglia hemorrhage: analysis of 52 patients with emphasis on the final outcome. *J. Trauma* 31:376–380, 1991.
86. Fukamachi, A., Nagaseki, Y., Kohno, K., Wakao, T. The incidence and developmental process of delayed traumatic intracerebral hematomas. *Acta Neurochir. (Wien)* 74:35–39, 1985.
87. Berry, K., Rice, J. Traumatic tear of tela choroidea resulting in fatal intraventricular hemorrhage. *Am. J. Forensic Med. Pathol.* 15:132–137, 1994.
88. Chapman, R. C., Rossi, M. L. Cerebral intraventricular haemorrhage in a young adult. *Int. J. Legal Med.* 105:243–245, 1993.
89. Karavelis, A., Sirmos, C. Primary post-traumatic intraventricular hemorrhage. *J. Neurosurg. Sci.* 39:253–256, 1995.
90. Christie, M., Marks, P., Liddington, M. Post-traumatic intraventricular haemorrhage: a reappraisal. *Br. J. Neurosurg.* 2:343–349, 1988.
91. Sato, M., Tanaka, S., Kohama, A., Fujii, C. Traumatic intraventricular haemorrhage. *Acta Neurochir. (Wien)* 88:95–103, 1987.
92. Kim, C. H., Tanaka, R., Kawakami, K., Ito, J. Traumatic primary intraventricular hemorrhage. *Surg. Neurol.* 16:415–417, 1981.
93. Moriya, F., Hashimoto, Y. A case of fatal hemorrhage in the cerebral ventricles following intravenous use of methamphetamine. *Forensic Sci. Int.* 129:104–109, 2002.
94. Passero, S., Olivelli, M., Reale, F. Primary intraventricular haemorrhage in adults. *Acta Neurol. Scand.* 105:115–119, 2002.
95. Bakshi, R., Kamran, S., Kinkel, P. R., et al. MRI in cerebral intraventricular hemorrhage: analysis of 50 consecutive cases. *Neuroradiology* 41:401–409, 1999.
96. Lee, J. P., Lui, T. N., Chang, C. N. Acute post-traumatic intraventricular hemorrhage analysis of 25 patients with emphasis on final outcome. *Acta Neurol. Scand.* 84:85–90, 1991.
97. Zuccarello, M., Iavicoli, R., Pardatscher, K., et al. Posttraumatic intraventricular haemorrhages. *Acta Neurochir. (Wien)* 55:283–293, 1981.
98. Geddes, J. F., Tasker, R. C., Hackshaw, A. K., et al. Dural haemorrhage in non-traumatic infant deaths: does it explain the bleeding in “shaken baby syndrome”? *Neuropathol. Appl. Neurobiol.* 29:14–22, 2003.
99. Harris, L. S., Adelson, L. “Spinal injury” and sudden infant death. A second look. *Am. J. Clin. Pathol.* 52:289–295, 1969.

100. Ruttly, G. N., Squier, W. M., Padfield, C. J. Epidural haemorrhage of the cervical spinal cord: a post-mortem artefact? *Neuropathol. Appl. Neurobiol.* 31:247–257, 2005.
101. Adams, J. H., Scott, G., Parker, L. S., Graham, D. I., Doyle, D. The contusion index: a quantitative approach to cerebral contusions in head injury. *Neuropathol. Appl. Neurobiol.* 6:319–324, 1980.
102. Ryan, G. A., McLean, A. J., Vilenius, A. T., et al. Brain injury patterns in fatally injured pedestrians. *J. Trauma* 36:469–476, 1994.
103. Adams, J. H., Doyle, D., Graham, D. I., et al. The contusion index: a reappraisal in human and experimental non-missile head injury. *Neuropathol. Appl. Neurobiol.* 11:299–308, 1985.
104. Chieragato, A., Fainardi, E., Servadei, F., et al. Centrifugal distribution of regional cerebral blood flow and its time course in traumatic intracerebral hematomas. *J. Neurotrauma* 21:655–666, 2004.
105. Oehmichen, M., Raff, G. Timing of cortical contusion. Correlation between histomorphologic alterations and post-traumatic interval. *Z. Rechtsmed.* 84:79–94, 1980.
106. Lindenberg, R., Freytag, E. Morphology of cortical contusions. *AMA Arch. Pathol.* 63:23–42, 1957.
107. Lindenberg, R. The mechanism of cerebral contusions. A pathologic-anatomic study. *Arch. Pathol.* 69:440–469, 1960.
108. Leestma, J. E. Forensic neuropathology. In: Duckett, S., de la Torre, J. C., eds. *Pathology of the Aging Human Nervous System*. Second Edition. Oxford University Press, Oxford, pp. 572–586, 2001.
109. Adams, J. H., Doyle, D., Graham, D. I., Lawrence, A. E., McLellan, D. R. Gliding contusions in nonmissile head injury in humans. *Arch. Pathol. Lab. Med.* 110:485–488, 1986.
110. Vrankovic, D., Splavski, B., Hecimovic, H, et al. Anatomical cerebellar protection of contrecoup hematoma development. Analysis of the mechanism of 30 posterior fossa coup hematomas. *Neurosurg. Rev.* 23:156–160, 2000.
111. Olin, M. S., Young, H. A., Schmidek, H. H. Contrecoup intracerebellar hemorrhage: Report of a case. *Neurosurgery* 7:271–273, 1980.
112. Martin, A. J., Thomas, N. W. N. Evolving traumatic cerebellar hematoma. *Neurology* 57:1565, 2001.
113. Pozzati, E., Grossi, C., Padovani, R. Traumatic intracerebellar hematomas. *J. Neurosurg.* 56:691–694, 1982.
114. Nagata, K., Ishikawa, T., Ishikawa, T., et al. Delayed traumatic intracerebellar hematoma: Correlation between the location of the hematoma and the pre-existing cerebellar contusion—case report. *Neurol. Med. Chir. (Tokyo)* 31:792–796, 1991.
115. Kaplan, S. S., Lauryssen, C. Cerebellar haemorrhage after evacuation of an acute supratentorial subdural haematoma. *Br. J. Neurosurg.* 13:329–331, 1999.
116. Honegger, J., Zentner, J., Spreer, J., Carmona, H., Schulze-Bonhage, A. Cerebellar hemorrhage arising postoperatively as a complication of supratentorial surgery: A retrospective study. *J. Neurosurg.* 96:248–254, 2002.
117. Omalu, B. I., Nnebe-Agumadu, U. H., Shakir, A. M., Rozin, L., Wecht, C. H. Postmortem grading of cerebral contusions. A proposed modification of the Adams' contusion index with re-definition of anatomic markers. *Forensic Sci. Med. Pathol.* 1:105–112, 2005.
118. Adams, J. H., Graham, D. I., Murray, L. S., Scott, G. Diffuse axonal injury due to nonmissile head injury in humans: an analysis of 45 cases. *Ann. Neurol.* 12:557–563, 1982.
119. Pilz, P. Axonal injury in head injury. *Acta Neurochir. Suppl. (Wien)* 32:119–123, 1983.
120. Strich, S. J. Shearing of nerve fibres as a cause of brain damage due to head injury: a pathological study of twenty cases. *Lancet* ii:443–448, 1961.
121. Peerless, S. J., Rewcastle, N. B. Shear injuries of the brain. *Can. Med. Assoc. J.* 96:577–582, 1967.
122. Graham, D. I., Clark, J. C., Adams, J. H., Gennarelli, T. A. Diffuse axonal injury caused by assault. *J. Clin. Pathol.* 45:840–841, 1992.

123. Adams, J. H., Doyle, D., Graham, D. I., Lawrence, A. E., McLellan, D. R. Diffuse axonal injury in head injuries caused by a fall. *Lancet* 2:1420–1422, 1984.
124. Adams, J. H., Graham, D. I., Gennarelli, T. A. Head injury in man and experimental animals: neuropathology. *Acta Neurochir. Suppl. (Wien)* 32:15–30, 1983.
125. Gennarelli, T. A., Thibault, L. E., Adams, J. H., Graham, D. I., Thompson, C. J., Marcincin, R. P. Diffuse axonal injury and traumatic coma in the primate. *Ann. Neurol.* 12:564–574, 1982.
126. Geddes, J. F., Whitwell, H. L., Graham, D. I. Traumatic axonal injury: practical issues for diagnosis in medicolegal cases. *Neuropathol. Appl. Neurobiol.* 26:105–116, 2000.
127. Povlishock, J. T. Traumatically induced axonal injury: pathogenesis and pathobiological implications. *Brain Pathol.* 2:1–12, 1992.
128. Geddes, J. F., Vowles, G. H., Beer, T. W., Ellison, D. W. The diagnosis of diffuse axonal injury: implications for forensic practice. *Neuropathol. Appl. Neurobiol.* 23:339–347, 1997.
129. Adams, J. H., Jennett, B., McLellan, D. R., Murray, L. S., Graham, D. I. The neuropathology of the vegetative state after head injury. *J. Clin. Pathol.* 52:804–806, 1999.
130. Adams, J. H., Graham, D. I., Jennett, B. The structural basis of moderate disability after traumatic brain damage. *J. Neurol. Neurosurg. Psychiatry* 71:521–524, 2001.
131. Blumbergs, P. C., Jones, N. R., North, J. B. Diffuse axonal injury in head trauma. *J. Neurol. Neurosurg. Psychiatry* 52:838–841, 1989.
132. McKenzie, K. J., McLellan, D. R., Gentleman, S. M., Maxwell, W. L., Gennarelli, T. A., Graham, D. I. Is beta-APP a marker of axonal damage in short-surviving head injury? *Acta Neuropathol. (Berl)* 92:608–613, 1996.
133. Blumbergs, P. C., Scott, G., Manavis, J., Wainwright, H., Simpson, D. A., McLean, A. J. Topography of axonal injury as defined by amyloid precursor protein and the sector scoring method in mild and severe closed head injury. *J. Neurotrauma* 12:565–572, 1995.
134. Wilkinson, A. E., Bridges, L. R., Sivaloganathan, S. Correlation of survival time with size of axonal swellings in diffuse axonal injury. *Acta Neuropathol. (Berl)* 98:197–202, 1999.
135. Blumbergs, P. C., Scott, G., Manavis, J., Wainwright, H., Simpson, D. A., McLean, A. J. Staining of amyloid precursor protein to study axonal damage in mild head injury. *Lancet* 344:1055–1056, 1994.
136. Adams, J. H., Doyle, D., Ford, I., Gennarelli, T. A., Graham, D. I., McLellan, D. R. Diffuse axonal injury in head injury: definition, diagnosis and grading. *Histopathology* 15:49–59, 1989.
137. Gennarelli, T. A. The spectrum of traumatic axonal injury. *Neuropathol. Appl. Neurobiol.* 22:509–513, 1996.
138. Adams, J. H., Doyle, D., Graham, D. I., Lawrence, A. E., McLellan, D. R. Microscopic diffuse axonal injury in cases of head injury. *Med. Sci. Law* 25:265–269, 1985.
139. Dolinak, D., Smith, C., Graham, D. I. Global hypoxia per se is an unusual cause of axonal injury. *Acta Neuropathol. (Berl)* 100:553–560, 2000.
140. Mittl, R. L., Grossman, R. I., Hiehle, J. F., et al. Prevalence of MR evidence of diffuse axonal injury in patients with mild head injury and normal head CT findings. *AJNR Am. J. Neuroradiol.* 15:1583–1589, 1994.
141. Povlishock, J. T., Becker, D. P., Cheng, C. L., Vaughan, G. W. Axonal change in minor head injury. *J. Neuropathol. Exp. Neurol.* 42:225–242, 1983.
142. Dolinak, D., Smith, C., Graham, D. I. Hypoglycaemia is a cause of axonal injury. *Neuropathol. Appl. Neurobiol.* 26:448–453, 2000.
143. Liberski, P. P., Budka, H. Neuroaxonal pathology in Creutzfeldt-Jakob disease. *Acta Neuropathol. (Berl)* 97:329–334, 1999.
144. Oehmichen, M., Meissner, C., Schmidt, V., Pedal, I., König, H. G., Saternus, K. S. Axonal injury—a diagnostic tool in forensic neuropathology? A review. *Forensic Sci. Int.* 95:67–83, 1998.
145. Reichard, R. R., Smith, C., Graham, D. I. The significance of beta-APP immunoreactivity in forensic practice. *Neuropathol. Appl. Neurobiol.* 31:304–313, 2005.

146. Pittella, J. E., Gusmao, S. N. Diffuse vascular injury in fatal road traffic accident victims: its relationship to diffuse axonal injury. *J. Forensic Sci.* 48:626–630, 2003.
147. Tomlinson, B. E. Brain-stem lesions after head injury. *J. Clin. Pathol. Suppl. (R. Coll. Pathol.)* 4:154–165, 1970.
148. Auer, R. N., Sutherland, G. R. Hypoxia and related conditions. In: Graham, D. I., Lantos, E. R., eds. *Greenfield's Neuropathology, Seventh Edition, Volume 1*. Arnold, London, pp. 233–280, 2002.
149. Graham, D. I., Adams, J. H., Doyle, D. Ischaemic brain damage in fatal non-missile head injuries. *J. Neurol. Sci.* 39:213–234, 1978.
150. Graham, D. I., Ford, I., Adams, J. H., et al. Ischaemic brain damage is still common in fatal non-missile head injury. *J. Neurol. Neurosurg. Psychiatry* 52:346–350, 1989.
151. Marion, D. W., Darby, J., Yonas, H. Acute regional cerebral blood flow changes caused by severe head injuries. *J. Neurosurg.* 74:407–414, 1991.
152. Bouma, G. J., Muizelaar, J. P. Evaluation of regional cerebral blood flow in acute head injury by stable xenon-enhanced computerized tomography. *Acta Neurochir. Suppl. (Wien)* 59:34–40, 1993.
153. Schroder, M. L., Muizelaar, J. P., Bullock, M. R., Salvant, J. B., Povlishock, J. T. Focal ischemia due to traumatic contusions documented by stable xenon-CT and ultrastructural studies. *J. Neurosurg.* 82:966–971, 1995.
154. Schroder, M. L., Muizelaar, J. P., Kuta, A. J. Documented reversal of global ischemia immediately after removal of an acute subdural hematoma. Report of two cases. *J. Neurosurg.* 80:324–327, 1994.
155. Mirvis, S. E., Wolf, A. L., Numaguchi, Y., Corradino, G., Joslyn, J. N. Posttraumatic cerebral infarction diagnosed by CT: Prevalence, origin, and outcome. *AJNR Am. J. Neuroradiol.* 11:355–360, 1990.
156. Csordas, A., Mazlo, M., Gallyas, F. Recovery versus death of “dark” compacted. neurons in non-impaired parenchymal environment: light and electron microscopic observations. *Acta Neuropathol. (Berl.)* 106:37–49, 2003.
157. Ishida, K., Shimizu, H., Hida, H., Urakawa, S., Ida, K., Nishino, H. Argyrophilic dark neurons represent various states of neuronal damage in brain insults: some come to die and others survive. *Neuroscience* 125:633–644, 2004.
158. Zsombok, A., Toth, Z., Gallyas, F. Basophilia, acidophilia and argyrophilia of “dark” (compacted) neurons during their formation, recovery or death in an otherwise undamaged environment. *J. Neurosci. Methods* 142:145–152, 2005.
159. Bruce, D. A., Alavi, A., Bilaniuk, L., Dolinskas, C., Obrist, W., Uzzell, B. Diffuse cerebral swelling following head injuries in children: the syndrome of “malignant brain edema”. *J. Neurosurg.* 54:170–178, 1981.
160. Graham, D. I., Ford, I., Adams, J. H., et al. Fatal head injury in children. *J. Clin. Pathol.* 42:18–22, 1989.
161. Kazan, S., Tuncer, R., Karasoy, M., Rahat, O., Saveren, M. Post-traumatic bilateral diffuse cerebral swelling. *Acta Neurochir. (Wien)* 139:295–301, 1997.
162. Cornish, R., Blumbergs, P. C., Manavis, J., Scott, G., Jones, N. R., Reilly, P. L. Topography and severity of axonal injury in human spinal cord trauma using amyloid precursor protein as a marker of axonal injury. *Spine* 25:1227–1233, 2000.
163. Lindenberg, R., Freytag, E. Brainstem lesions characteristic of traumatic hyperextension of the head. *Arch. Pathol.* 90:509–515, 1970.
164. Pilz, P., Strohecker, J., Grobovschek, M. Survival after traumatic ponto-medullary tear. *J. Neurol. Neurosurg. Psychiatry* 45:422–427, 1982.
165. Hooper, A. D. A new approach to upper cervical injuries. *J. Forensic Sci.* 24:39–45, 1979.
166. Jonsson, H., Jr., Bring, G., Rauschnig, W., Sahlstedt, B. Hidden cervical spine injuries in traffic accident victims with skull fractures. *J. Spinal Disord.* 4:251–263, 1991.



167. Sun, P. P., Poffenbarger, G. J., Durham, S., Zimmerman, R. A. Spectrum of occipito-atlantoaxial injury in young children. *J. Neurosurg.* 93:28–39, 2000.
168. Alker, G. J., Jr., Oh, Y. S., Leslie, E. V. High cervical spine and craniocervical junction injuries in fatal traffic accidents: a radiological study. *Orthop. Clin. N. Am.* 9:1003–1010, 1978.
169. Leditschke, J., Anderson, R. M., Hare, W. S. The cervical spine in fatal motor vehicle accidents. *Clin. Exp. Neurol.* 29:263–271, 1992.
170. Bromilow, A., Burns, J. Technique for removal of the vertebral arteries. *J. Clin. Pathol.* 38:1400–1402, 1985.
171. Ludwig, J. *Handbook of Autopsy Practice*, Third Edition. Humana Press, Totowa, NJ, 2002.
172. Vanezis, P. Techniques used in the evaluation of vertebral artery trauma at post-mortem. *Forensic Sci. Int.* 13:159–165, 1979.
173. Vollmer, D. G., Gegg, C. Classification and acute management of thoracolumbar fractures. *Neurosurg. Clin. N. Am.* 8:499–507, 1997.
174. Hadley, M. N., Zabramski, J. M., Browner, C. M., Rekate, H., Sonntag, V. K. Pediatric spinal trauma. Review of 122 cases of spinal cord and vertebral column injuries. *J. Neurosurg.* 68:18–24, 1988.
175. Argenson, C., De Peretti, F., Ghabris, A., Eude, P., Lovet, J., Hovorka, I. A scheme for the classification of lower cervical spine injuries. [http://www.maitrise-orthop.com/corpus-maitri/orthopaedic/mo61\\_spine\\_injury\\_class/spine\\_injury.shtml](http://www.maitrise-orthop.com/corpus-maitri/orthopaedic/mo61_spine_injury_class/spine_injury.shtml), 2005.
176. Allen, B. L., Jr., Ferguson, R. L., Lehmann, T. R., O'Brien, R. P. A mechanistic classification of closed, indirect fractures and dislocations of the lower cervical spine. *Spine* 7:1–27, 1982.
177. Harris, J. H., Jr., Edeiken-Monroe, B., Kopaniky, D. R. A practical classification of acute cervical spine injuries. *Orthop Clin. N. Am.* 17:15–30, 1986.
178. Mirza, S. K., Mirza, A. J., Chapman, J. R., Anderson, P. A. Classifications of thoracic and lumbar fractures: rationale and supporting data. *J. Am. Acad. Orthop. Surg.* 10:364–377, 2002.
179. Fife, D., Kraus, J. Anatomic location of spinal cord injury. Relationship to the cause of injury. *Spine* 11:2–5, 1986.
180. Goldberg, W., Mueller, C., Panacek, E., Tigges, S., Hoffman, J.R., Mower, W. R. Distribution and patterns of blunt traumatic cervical spine injury. *Ann. Emerg. Med.* 38:17–21, 2001.
181. Brown, R. L., Brunn, M. A., Garcia, V. F. Cervical spine injuries in children: a review of 103 patients treated consecutively at a level 1 pediatric trauma center. *J. Pediatr. Surg.* 36:1107–1114, 2001.
182. Alker, G. J., Oh, Y. S., Leslie, E. V., Lehotay, J., Panaro, V.A., Eschner, E. G. Postmortem radiology of head neck injuries in fatal traffic accidents. *Radiology* 114:611–617, 1975.
183. Bucholz, R. W., Burkhead, W. Z. The pathological anatomy of fatal atlanto-occipital dislocations. *J. Bone Joint Surg. Am.* 61:248–250, 1979.
184. Adams, V. I. Neck injuries: I. Occipitoatlantal dislocation—a pathologic study of twelve traffic fatalities. *J. Forensic Sci.* 37:556–564, 1992.
185. Tepper, S. L., Fligner, C. L., Reay, D. T. Atlanto-occipital disarticulation: Accident characteristics. *Am. J. Forensic Med. Pathol.* 11:193–197, 2005.
186. Adams, V. I. Neck injuries: II. Atlanto-axial dislocation—a pathologic study of 14 traffic fatalities. *J. Forensic Sci.* 37:565–573, 1992.
187. Shkrum, M. J., Green, R. N., Nowak, E. S. Upper cervical trauma in motor vehicle collisions. *J. Forensic Sci.* 34:381–390, 1989.
188. Silver, J. R., Morris, W. R., Otfinowski, J. S. Associated injuries in patients with spinal injury. *Injury* 12:291–324, 1980.
189. Imaizumi, T., Sohma, T., Hotta, H., Teto, I., Imaizumi, H., Kaneko, M. Associated injuries and mechanism of atlanto-occipital dislocation caused by trauma. *Neurol. Med. Chir. (Tokyo)* 35:385–391, 1995.
190. Iida, H., Tachibana, S., Kitahara, T., Horiike, S., Ohwada, T., Fujii, K. Association of head trauma with cervical spine injury, spinal cord injury, or both. *J. Trauma* 46:450–452, 1999.

191. Ardekian, L., Gaspar, R., Peled, M., Manor, R., Laufer, D. Incidence and type of cervical spine injuries associated with mandibular fractures. *J. Craniomaxillofac. Trauma* 3:18–21, 1997.
192. Lewis, V. L., Jr., Manson, P. N., Morgan, R. F., Cerullo, L. J., Meyer, P. R., Jr. Facial injuries associated with cervical fractures: recognition, patterns, and management. *J. Trauma* 25:90–93, 1985.
193. Oller, D. W., Meredith, J. W., Rutledge, R., et al. The relationship between face or skull fractures and cervical spine and spinal cord injuries: a review of 13,834 patients. *Accid. Anal. Prev.* 24:187–192, 1992.
194. Sinclair, D., Schwartz, M., Gruss, J., McLellan, B. A retrospective review of the relationship between facial fractures, head injuries, and cervical spine injuries. *J. Emerg. Med.* 6:109–112, 1988.
195. Shkrum, M. J., McClafferty, K. J., Nowak, E. S., German, A. Driver and front seat passenger fatalities associated with air bag deployment. Part 1: A Canadian study. *J. Forensic Sci.* 47:1028–1034, 2002.
196. Shkrum, M. J., McClafferty, K. J., Nowak, E. S., German, A. Driver and front seat passenger fatalities associated with air bag deployment. Part 2: A review of injury patterns and investigative issues. *J. Forensic Sci.* 47:1035–1040, 2002.
197. Kinoshita, H. Pathology of spinal cord injuries due to fracture-dislocations of the thoracic and lumbar spine. *Paraplegia* 34:1–7, 1996.
198. Brandser, E. A., el Khoury, G. Y. Thoracic and lumbar spine trauma. *Radiol. Clin. N. Am.* 35:533–557, 1997.
199. Koyanagi, I., Iwasaki, Y., Hida, K., Akino, M., Imamura, H., Abe, H. Acute cervical cord injury without fracture or dislocation of the spinal column. *J. Neurosurg.* 93:15–20, 2000.
200. Pang, D., Wilberger, J. E. Spinal cord without radiographic abnormalities in children. *J. Neurosurg.* 57:114–129, 1982.
201. American College of Neurological Surgeons. Spinal cord injury without radiographic abnormality. *Neurosurgery* 50 (Suppl.):S100–S104, 2002.
202. Kaye, K. L., Ramsay, D. A., Young, B. Y. Cervical flexion myelopathy after valproic acid overdose. *Spine* 26:E459–E462, 2001.
203. Tator, C. H. Update on the pathophysiology and pathology of acute spinal cord injury. *Brain Pathol.* 5:407–413, 1995.
204. Harrop, J. S., Sharan, A. D., Vaccaro, A. R., Przybylski, G. J. The cause of neurologic deterioration after acute cervical spinal cord injury. *Spine* 26:340–346, 2001.
205. Kochan, J. P., Quencer, R. M. Imaging of cystic and cavitory lesions of the spinal cord and canal. The value of MR and intraoperative sonography. *Radiol. Clin. N. Am.* 29:867–911, 1991.
206. Fleming, J. C., Norenberg, M. D., Ramsay, D. A., et al. The acute cellular inflammatory response after human spinal cord injury. *J. Neurotrauma* 22:1170 (Abstract), 2005.
207. Bunge, R. P., Puckett, W. R., Becerra, J. L., Marcillo, A., Quencer, R. M. Observations on the pathology of human spinal cord injury. A review and classification of 22 new cases with details from a case of chronic cord compression with extensive focal demyelination. *Adv. Neurol.* 59:75–89, 1993.
208. Kakulas, B. A. A review of the neuropathology of human spinal cord injury with emphasis on special features. *J. Spinal Cord Med.* 22:119–124, 1999.
209. Jimenez, O., Marcillo, A., Levi, A. D. A histopathological analysis of the human cervical spinal cord in patients with acute traumatic central cord syndrome. *Spinal Cord* 38:532–537, 2000.
210. Martin, D., Schoenen, J., Lenelle, J., Reznik, M., Moonen, G. MRI–pathological correlations in acute traumatic central cord syndrome: case report. *Neuroradiology* 34:262–266, 1992.
211. Quencer, R. M., Bunge, R. P., Egnor, M., et al. Acute traumatic central cord syndrome: MRI–pathological correlations. *Neuroradiology* 34:85–94, 1992.

212. Ito, T., Oyanagi, K., Wakabayashi, K., Ikuta, F. Traumatic spinal cord injury: a neuropathological study on the longitudinal spreading of the lesions. *Acta Neuropathol. (Berl.)* 93:13–18, 1997.
213. Hashizume, Y., Iljima, S., Kishimoto, H., Hirano, A. Pencil-shaped softening of the spinal cord. Pathologic study in 12 autopsy cases. *Acta Neuropathol. (Berl.)* 61:219–224, 1983.
214. Balentine, J. D. Pathology of experimental spinal cord trauma. I. The necrotic lesion as a function of vascular injury. *Lab. Invest.* 39:236–253, 1978.
215. Hirano, A., Iwata, M., Ilena, J. F., Matsui, T. *Color Atlas of Pathology of the Nervous System*. Igaku-Shoin, New York, 1980.
216. Hirano, A. *A Guide to Neuropathology*. Igaku-Shoin, New York, 1981.
217. Ghatan, S., Newell, D. W., Grady, M. S., et al. Severe posttraumatic craniocervical instability in the very young patient. Report of three cases. *J. Neurosurg.* 101:102–107, 2004.
218. Ersahin, Y., Mutluer, S., Mirzai, H., Palali, I. Pediatric depressed skull fractures: analysis of 530 cases. *Childs Nerv. Syst.* 12:323–331, 1996.
219. Lindenberg, R., Freytag, E. Morphology of brain lesions from blunt trauma in early infancy. *Arch. Pathol.* 87:298–305, 1969.
220. Kornblum, R. N., Fisher, R. S. Pituitary lesions in craniocerebral injuries. *Arch. Pathol.* 88:242–248, 1969.
221. Treip, C. S. Hypothalamic and pituitary injury. *J. Clin. Pathol. Suppl. (R. Coll. Pathol.)* 4:178–186, 1970.
222. Kovacs, K. Necrosis of anterior pituitary in humans. II. *Neuroendocrinology* 4:201–241, 1969.
223. Daniel, P. M., Spicer, E. J., Treip, C. S. Pituitary necrosis in patients maintained on mechanical respirators. *J. Pathol.* 111:135–138, 1973.
224. Kovacs, K., Bilbao, J. M. Adenohypophysial necrosis in respirator-maintained patients. *Pathol. Microbiol. (Basel)* 41:275–282, 1974.
225. Kovacs, K. Adenohypophysial necrosis in routine autopsies. *Endokrinologie* 60:309–316, 1972.
226. Kovacs, K. Necrosis of anterior pituitary in humans. I. *Neuroendocrinology* 4:170–199, 1969.
227. Mooney, E. E., Toner, M., Farrell, M. A. Selective necrosis of the posterior pituitary gland—case report. *Clin. Neuropathol.* 14:42–44, 1995.
228. Reilly, P. L., Graham, D. I., Adams, J. H., Jennett, B. Patients with head injury who talk and die. *Lancet* 2:375–377, 1975.
229. Dunn, L. T., Fitzpatrick, M. O., Beard, D., Henry, J. M. Patients with a head injury who “talk and die” in the 1990s. *J. Trauma* 54:497–502, 2003.
230. Statham, P. F., Johnston, R. A., Macpherson, P. Delayed deterioration in patients with traumatic frontal contusions. *J. Neurol. Neurosurg. Psychiatry* 52:351–354, 1989.
231. Jennett, B., Plum, F. Persistent vegetative state after brain damage. A syndrome in search of a name. *Lancet* 1:734–737, 1972.
232. Working Group of the Royal College of Physicians of the United Kingdom. The permanent vegetative state. Review by a working group convened by the Royal College of Physicians and endorsed by the Conference of Medical Royal Colleges and their faculties of the United Kingdom. *J. R. Coll. Physicians. Lond.* 30:119–121, 1996.
233. Adams, J. H., Graham, D. I., Jennett, B. The neuropathology of the vegetative state after an acute brain insult. *Brain* 123:1327–1338, 2000.
234. Jennett, B., Bond, M. Assessment of outcome after severe brain damage. *Lancet* 1:480–484, 1975.
235. Jennett, B., Adams, J. H., Murray, L. S., Graham, D. I. Neuropathology in vegetative and severely disabled patients after head injury. *Neurology* 56:486–490, 2001.
236. Baigelman, W., O’Brien, J. C. Pulmonary effects of head trauma. *Neurosurgery* 9:729–740, 1981.

237. Fontes, R. B., Aguiar, P. H., Zanetti, M. V., Andrade, F., Mandel, M., Teixeira, M. J. Acute neurogenic pulmonary edema: case reports and literature review. *J. Neurosurg. Anesthesiol.* 15:144–150, 2003.
238. Weisman, S. J. Edema and congestion of the lungs resulting from intracranial hemorrhage. *Surgery* 6:722–729, 1939.
239. Weir, B. K. Pulmonary edema following fatal aneurysm rupture. *J. Neurosurg.* 49:502–507, 1978.
240. Terrence, C. F., Rao, G. R., Perper, J. A. Neurogenic pulmonary edema in unexpected, unexplained death of epileptic patients. *Ann. Neurol.* 9:458–464, 1981.
241. Rogers, F. B., Shackford, S. R., Trevisani, G. T., Davis, J. W., Mackersie, R. C., Hoyt, D. B. Neurogenic pulmonary edema in fatal and nonfatal head injuries. *J. Trauma* 39:860–866, 1995.
242. Simmons, R. L., Martin, A. M., Jr., Heisterkamp, C. A., III, Ducker, T. B. Respiratory insufficiency in combat casualties. II. Pulmonary edema following head injury. *Ann. Surg.* 170:39–44, 1969.
243. Ducker, T. B. Increased intracranial pressure and pulmonary edema. 1. Clinical study of 11 patients. *J. Neurosurg.* 28:112–117, 1968.
244. Rubin, D. M., McMillan, C. O., Helfaer, M. A., Christian, C. W. Pulmonary edema associated with child abuse: case reports and review of the literature. *Pediatrics* 108:769–775, 2001.
245. Beckman, D. L., Bean, J. W. Pulmonary damage and head injury. *Proc. Soc. Exp. Biol. Med.* 130:5–9, 1969.
246. Hucker, H., Frenzel, H., Kremer, B., Richter, I. E. Time sequence and site of fluid accumulation in experimental neurogenic pulmonary edema. *Res. Exp. Med. (Berl.)* 168:219–227, 1976.
247. Ducker, T. B., Simmons, R. L. Increased intracranial pressure and pulmonary edema. 2. The hemodynamic response of dogs and monkeys to increased intracranial pressure. *J. Neurosurg.* 28:118–123, 1968.
248. Simmons, R. L., Ducker, T. B., Anderson, R. W. Pathogenesis of pulmonary edema following head trauma. An experimental study. *J. Trauma* 8:800–811, 1968.
249. Lowe, J. Establishing a pathological diagnosis in degenerative dementias. *Brain Pathol.* 8:403–406, 1998.
250. Stewart, W., Black, M., Kalimo, H., Graham, D. I. Non-traumatic forensic neuropathology. *Forensic Sci. Int.* 146:125–147, 2004.
251. Ellison, D., Love, S., Chimelli, L., Harding, B., Lowe, J. S., Vinters, H. *Neuropathology, Second Edition—A Reference Text of CNS Pathology.* Mosby, Edinburgh, 2004.
252. Braak, H., Braak, E. Neuropathological staging of Alzheimer-related changes. *Acta Neuropathol. (Berl.)* 82:239–259, 1991.
253. Mirra, S. S., Heyman, A., McKeel, D., et al. The Consortium to Establish a Registry for Alzheimer's Disease (CERAD). Part II. Standardization of the neuropathologic assessment of Alzheimer's disease. *Neurology* 41:479–486, 1991.
254. Davis, D. G., Schmitt, F. A., Wekstein, D. R., Markesbery, W. R. Alzheimer neuropathologic alterations in aged cognitively normal subjects. *J. Neuropathol. Exp. Neurol.* 58:376–388, 1999.
255. Muller, C. M., de Vos, R. A., Maurage, C. A., Thal, D. R., Tolnay, M., Braak, H. Staging of sporadic Parkinson disease-related alpha-synuclein pathology: inter- and intra-rater reliability. *J. Neuropathol. Exp. Neurol.* 64:623–628, 2005.
256. McKeith, I. G., Galasko, D., Kosaka, K., et al. Consensus guidelines for the clinical and pathologic diagnosis of dementia with Lewy bodies (DLB): report of the consortium on DLB international workshop. *Neurology* 47:1113–1124, 1996.
257. Braak, H., Del Tredici, K., Rub, U., de Vos, R. A., Jansen Steur, E. N., Braak, E. Staging of brain pathology related to sporadic Parkinson's disease. *Neurobiol. Aging* 24:197–211, 2003.

- 258. Jellinger, K. A. Head injury and dementia. *Curr. Opin. Neurol.* 17:719–723, 2004.
- 259. Szczygielski, J., Mautes, A., Steudel, W. I., Falkai, P., Bayer, T. A., Wirths, O. Traumatic brain injury: cause or risk of Alzheimer's disease? A review of experimental studies. *J. Neural Transm.* 112:1147–1164, 2005.
- 260. Maxwell, W. L., Dhillon, K., Harper, L., et al. There is differential loss of pyramidal cells from the human hippocampus with survival after blunt head injury. *J. Neuropathol. Exp. Neurol.* 62:272–279, 2003.
- 261. Jordan, B. D. Chronic traumatic brain injury associated with boxing. *Semin. Neurol.* 20:179–185, 2000.
- 262. de la Torre, J. C. Brain trauma and the elderly. In: Duckett, S., de la Torre, J. C., eds. *Pathology of the Aging Human Nervous System*, Second Edition. Oxford University Press, Oxford, pp. 458–473, 2001.
- 263. Graham, D. I., Gentleman, S. M., Nicoll, J. A., et al. Altered beta-APP metabolism after head injury and its relationship to the aetiology of Alzheimer's disease. *Acta Neurochir. Suppl.* 66:96–102, 1996.



## Chapter 10

---

# *Sudden Neurological Death*

### Summary

Although neurological disease is a common cause of death that occurs soon after the onset of symptoms—usually after sufficient time has elapsed for a diagnosis to be established—it is a relatively uncommon cause of sudden death. The causes of sudden neurological death that are associated with trauma include massive craniocerebral trauma, high cervical vertebrospinal trauma, posttraumatic epilepsy leading to sudden unexplained death in epilepsy, acute trauma-associated brainstem dysfunction (“commotio medullaris”), subarachnoid hemorrhage associated with traumatic vertebral and basilar artery tears, and trauma-induced dislodgement of a vertebral artery thrombus leading to a brainstem infarct.

**Key Words:** Brain stem infarctions; cerebrovascular trauma; craniocerebral trauma; epilepsy, posttraumatic; sudden death; spinal cord injuries; subarachnoid hemorrhage, traumatic; sudden unexplained death in epilepsy.

### *1. INTRODUCTION AND DEFINITION OF TERMS*

The investigation of sudden unexpected death lies at the core of the practice of forensic pathology. The postmortem demonstration of severe coronary artery disease, not necessarily associated with recent thrombotic occlusion of a coronary artery or histological evidence of acute myocardial necrosis, is a finding that forms classical presumptive evidence for a fatal cardiac dysrhythmia if no other structural, metabolic, or toxic cause of death is found, reflecting the deadly vulnerability of cardiac activity to electric dysfunction. The function of the brain, itself an electric organ, is also periodically disrupted by “dysrhythmias,” usually in the form of a seizure but also when, during the course of various neurological disorders, brainstem function is disturbed and fatal failure in the neural control of cardiorespiratory function occurs (*1,2*). It is to be expected that craniocerebral and vertebrospinal trauma, under certain situations, precipitates fatal brainstem failure by compromising the electrical equilibrium of the brain. The purpose of this chapter is to discuss traumatic disorders of the central nervous system (CNS) that cause abrupt and unforeseen neurological death.

From: *Forensic Science and Medicine: Forensic Pathology of Trauma:  
Common Problems for the Pathologist*

By: M. J. Shkrum and D. A. Ramsay © Humana Press Inc., Totowa, NJ

Cases of unexpected death owing to neurological causes fall into two categories: unexpected neurological death, only briefly mentioned here for completeness, and sudden neurological death (SND).

### ***1.1. Unexpected Neurological Death***

There are two categories of unexpected neurological death. The first category includes acute neurological disease that, in retrospect, was symptomatic for at least a day or so before death (an example is the posturally related prodromal headache of a colloid cyst). The second category includes acute neurological disease whose premonitory symptoms and signs would have been recognized and whose pace of evolution would have allowed enough time for a correct diagnosis to be reached before death had the onset of the disease been witnessed. Accordingly, the second type of unexpected neurological death may occur during sleep or in socially isolated individuals who could not or were unwilling to call for help.

There are numerous causes of unexpected neurological death, but common causes include:

- Acute bacterial meningitis.
- Various cerebrovascular diseases, including:
  - Cerebral infarcts.
  - Nontraumatic intracerebral hemorrhage.
  - Ruptured berry aneurysm leading to subarachnoid hemorrhage (SAH).
- Craniocerebral trauma:
  - Epidural hematoma.
  - Acute subdural hematoma.

### ***1.2. Sudden Neurological Death***

SND is defined as death, or brain death, attributable to, and occurring immediately or soon after, the onset of a neurological illness or a neurological phenomenon. The practical importance of cases of SND is that it usually falls to the pathologist to account for the death.

#### ***1.2.1. Categories of SND***

Cases of SND fall into one of the following categories:

- Death is witnessed and occurs before clinical investigation of the signs and symptoms can be carried out. These cases include conditions in which the cause of death is obvious and, of great importance to the pathologist, situations in which the neurological cause of death is not realized until a postmortem examination has been performed.
- A witnessed cardiorespiratory arrest occurs because of the abrupt onset of a neurological disease or condition; resuscitation is performed; irreversible brain injury supervenes; the victim, though maintained on life support, is clinically “brain dead;” clinical and neuroimaging investigation fails to reveal the cause of the cardiorespiratory arrest; a neurological cause for the cardiorespiratory arrest is demonstrated at autopsy. This category will become less common as neuroimaging techniques become more sensitive.
- Unwitnessed or witnessed sudden death in a patient with epilepsy.

## 2. CAUSES OF SND

In most cases SND is caused, one way or another, by acute dysfunction of the brainstem or high cervical spinal cord, leading to failure of cardiorespiratory function. In conceptual terms, because of its very abruptness and the inferred underlying breakdown in the electrical homeostasis of the brain, SND corresponds closely to sudden cardiac death. In general terms, three mechanisms account for SND:

- Acute hydrocephalus, causing impaired cerebral perfusion or brainstem compression.
- Demonstrable structural disruption of the brainstem or rostral cervical spinal cord.
- Presumed functional disruption of brainstem activity without corresponding structural abnormalities detectable by standard autopsy techniques.

### 2.1. *Nontraumatic Neurological Diseases Possibly Associated With SND*

There are numerous case reports and small case series describing an apparent association between SND and various CNS diseases, including:

- Primary CNS neoplasms (0.17% of forensic autopsies [\[3\]](#)):
  - Meningioma [\(3\)](#).
  - Pituitary adenoma [\(3\)](#).
  - Colloid cysts [\(3,4\)](#).
  - Cerebral hemispheric gliomas [\(3,5\)](#).
  - Brain stem gliomas [\(6–8\)](#).
  - Cerebellar gliomas [\(7\)](#).
  - Medulloblastoma [\(3\)](#).
  - Pineal cysts [\(9\)](#).
  - Epidermal cysts [\(10\)](#).
- Bleeding into an occult primary or secondary brain tumor [\(11\)](#).
- CNS infections:
  - Acute pyogenic meningitis [\(11\)](#).
  - Acute lymphocytic meningitis [\(12\)](#).
  - Viral cerebellitis [\(13\)](#).
  - Neurosarcoidosis [\(14\)](#).
- Multiple sclerosis [\(15\)](#).
- Chiari 1 malformation [\(16\)](#) with or without chronic hydrocephalus.
- Vascular disorders, usually a ruptured berry aneurysm and acute SAH [\(17\)](#).

In some of these cases the presence, in retrospect, of an antecedent history indicates death should be classified as an unexpected neurological death.

### 2.2. *SND Caused by Trauma*

An association between SND and trauma is found in:

- Obvious (self-evident) cases.
- Less obvious or subtle (less than self-evident) cases in which craniocerebral and verte-brospinal trauma are directly responsible for death.
- Cases in which the complications of trauma lead to SND (usually epilepsy).
- Cases in which a neurological condition is suspected to have caused SND, which then led to craniocerebral trauma (for example, rupture of a berry aneurysm causes a cardiorespiratory arrest in the driver of a motor vehicle and an accident follows).

For the purposes of this chapter the following conditions and their relationship to trauma and SND will be discussed:

- Traumatic SND owing to self-evident causes.
- Other than self-evident causes of traumatic SND.
- Sudden unexpected death in posttraumatic epilepsy.
- Rupture of berry aneurysms, acute SAH, and stroke.
- “Spinal cord injury without radiographic abnormality.”

### 3. TRAUMATIC SND OWING TO SELF-EVIDENT CAUSES

These conditions have been described in Chapter 9. They include massive cranio-cerebral trauma, injuries to the high cervical spine, diffuse vascular injury, and ponto-medullary tears.

### 4. OTHER THAN SELF-EVIDENT CAUSES OF TRAUMATIC SND

#### 4.1. Minor Head Injury and SND

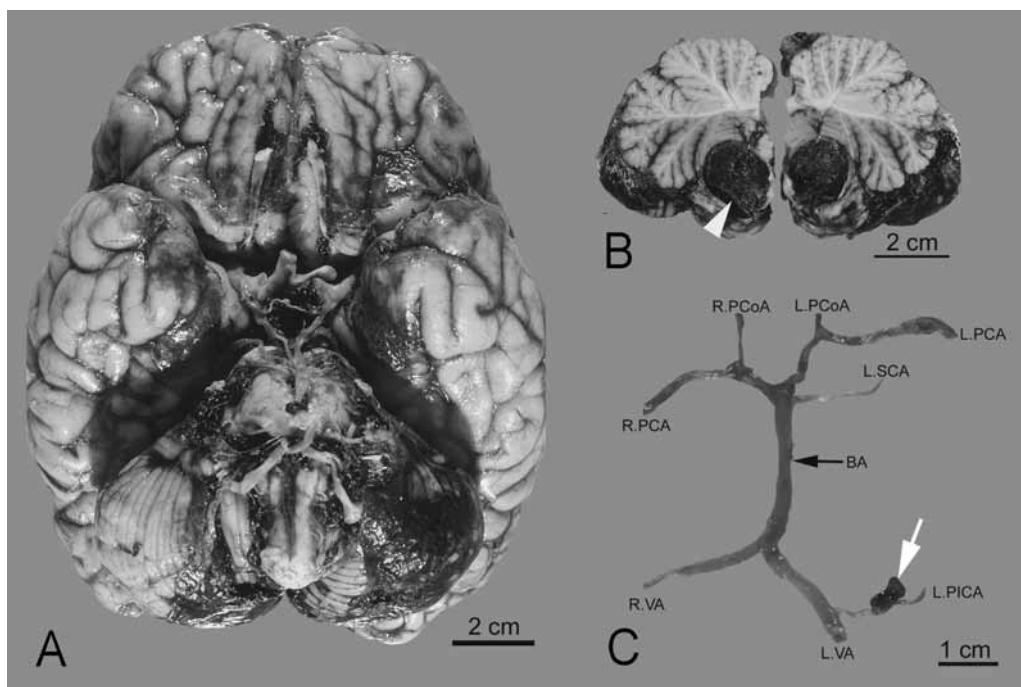
Head injury in this context is classified as “minor” in comparison with the severe head injuries caused by falls and motor vehicle crashes. The syndrome of minor head injury and SND has a characteristic clinical presentation:

- The victim, who is frequently but not always intoxicated with alcohol, dies while involved in an assault or fight (or, sometimes, following an apparently mild to moderate head impact from other causes).
- Blows to the victim’s head or neck, which may appear trivial, are described by witnesses or inferred from findings made during the autopsy.
- No structural, toxicological, metabolic, or infectious cause of death is demonstrated in the general postmortem examination.
- The neuropathological examination reveals either:
  - Acute SAH concentrated over the brain base (traumatic basilar SAH); or
  - No injuries or minor traumatic injuries.
    - There is some evidence in this situation that death is attributable to dysfunction of the medulla oblongata, which will be discussed in Subheading 4.3.
    - For ease of reference, this condition is referred to as *commotio medullaris*, by analogy with the syndrome of *commotio cordis* in which a blow to the precordium precipitates a fatal cardiac arrest (*see* Chapter 8, Subheading 6.4.).

#### 4.2. Traumatic Basilar SAH

An isolated fatal basilar SAH in the setting of a mild head injury is caused by rupture of a berry aneurysm (Fig. 1; *see* Heading 6) or is associated with a tear through the wall of a cerebral blood vessel, but in some instances the source of bleeding remains undetermined (18,19).

Cases with traumatic arterial tears often have bruises behind the ear and in the neck (20). The vertebral arteries are most commonly involved—either their intracranial (19–24) or extracranial segments (19,20,25)—but tears of the posterior inferior cerebellar arteries (19,26) and basilar artery (19,24) also occur. A fracture of the transverse process of the first cervical vertebra (19,20) or a developmental abnormality of the cervical vertebrae (27) is associated with the arterial tears in some cases, but in many cases there is no explanation for the tear other than its temporal association with trauma (21,28,29).



**Fig. 1.** Basilar subarachnoid hemorrhage (SAH). **(A)** Brain base. A moderate SAH is present over the caudal surfaces of the left and, to a lesser extent, the right cerebellar hemisphere. No source of bleeding was demonstrated until the fixed brain was sliced. **(B)** Sagittal slice through the cerebellar vermis from the brain illustrated in **(A)**. There is a large ruptured aneurysm, originating from a distal branch of the right posterior inferior cerebellar artery, buried in the caudal cerebellar midline (white arrowhead). **(C)** Circle of Willis. This specimen is from a young woman with a basilar SAH who, while intoxicated with ethanol, dropped dead during an altercation with her husband. He could not remember if she fell by herself or if he pushed her away. A small ruptured aneurysm of the left (L) posterior inferior cerebellar artery (PICA) is indicated by a white arrow. R, right; BA, basilar artery; SCA, superior cerebellar artery; PCA, posterior cerebral artery; PoCA, posterior communicating artery; VA, vertebral artery.

Various recommendations, which may or may not be practical depending on the time and resources available to the pathologist, are promulgated regarding the approach to identifying the source of bleeding. These include *in situ* dissection of the vertebral arteries, postmortem angiography of the vertebral arteries (20,30), and *en bloc* dissections of the lower brainstem, cervical spinal cord, brain base, and cervical vertebrae followed by decalcification and various examination procedures (21,27,31). Although any forensic autopsy unit should have a familiar and reliable protocol in place to deal with the exposure of the vertebrobasilar arterial arborization, this is a time-consuming and difficult procedure. Members of the autopsy service staff in smaller centers face difficult questions when a case of traumatic basilar SAH is encountered:

- Should the case be referred to a regional forensic unit (which, particularly in large countries, may be impractical)?
- Is it worth learning such complex procedures for a rarely encountered condition (approx 0.5 to 1 per 1000 forensic autopsies [19,20,27])?



- Is the demonstration of a basilar SAH in a patient who dies during a brawl not sufficient to determine that death was traumatic (provided gross and histological examination of the intracranial vertebral arteries has excluded pre-existing arterial disease)?
- How certain is it that abnormalities demonstrated by unfamiliar angiographic procedures and dissections are not artifactual?

In any event, a diligent search for the source of bleeding is obligatory when a basilar SAH is discovered at the time of autopsy. The following approach is practical and possible without special facilities:

- Gently remove the subarachnoid blood clot from the brain surface using a stream of saline from a syringe and buds of cotton wool attached to a stick.
- Expose the entire circle of Willis and its branches and tributaries, including the anterior, middle, and posterior cerebral arteries, superior cerebellar arteries, posterior inferior cerebellar arteries, and vertebral arteries.
- Remove the exposed circle of Willis and its branches and tributaries, and inspect them with a magnifying glass or dissecting microscope.
  - Submit any areas that have attached thrombus for microscopic examination and, separately, both vertebral arteries.
  - The vertebral arteries should be trimmed into short segments by cuts perpendicular to the longitudinal axis of the blood vessel just before they are embedded in paraffin wax.
  - The remainder of the circle of Willis should be retained.
- Return to the body and expose the origin of the ophthalmic artery from the carotid artery to exclude an aneurysm at this site.
- Examine any segments of the proximal vertebral arteries that remain in the cranial cavity and where they perforate the dura. Open the dura and explore the lateral extracranial course of the arteries as far as the transverse processes of the atlas. If this area is devoid of hemorrhage, pathological changes in the artery are unlikely but nevertheless remove the exposed vertebral arteries and submit them for microscopic examination.
- If there is bleeding around the distal extracranial vertebral arteries:
  - Complete a full vertebral artery dissection (32–34).
  - Excise the vertebral arteries.
  - Submit any hemorrhagic areas in the artery for microscopic examination.
  - Look for fractures of the transverse processes of the atlas.
  - Consider removal of cervical vertebrae 1 and 2 for defleshing and extracorporeal radiographs if local funeral practices allow.

Although the occurrence of sudden traumatic death and the demonstration of an acute basilar SAH and an appropriately located arterial tear seems to be a self-evident causal association, controversy still exists regarding the significance of arterial tears in this context (31,35,36), particularly with respect to the possibility that they are artifactual or a secondary phenomenon, the explanation for sudden death in these cases being trauma-induced spinomedullary dysfunction rather than the bleeding *per se*.

#### 4.2.1. Spontaneous Dissection of Carotid and Vertebral Arteries

A relatively common cause of stroke, particularly in younger patients, is a dissection of the wall of the carotid or vertebral arteries that arises when blood enters the vessel wall through an intimal tear and causes pain and symptoms of cerebral hypoxia–ischemia hours to days later (37). A subintimal hematoma causes stenosis of the lumen and a sub-adventitial hematoma leads to the formation of a pseudoaneurysm. “Spontaneous” dissections are sometimes temporally associated with abrupt neck movement (e.g., a sneeze),

more extreme than usual neck movement (e.g., while reversing a car or performing yoga asanas), mild neck trauma, and even normal neck movements. In practical terms, for a pathologist interested in the craniocerebral and vertebrospinal complications of trauma, the following is relevant with respect to spontaneous arterial dissections (37):

- Spontaneous arterial dissections rarely cause arterial rupture and are distinct in terms of their pathogenesis from the syndrome of traumatic basilar SAH.
- Spontaneous arterial dissection is not recognized as a cause of sudden neurological death (but *see* qualifying discussion in Heading 7.).
- The apparent causal association between neck movement or mild neck trauma and arterial dissection is a subject of controversy.
- It is not possible to say with certainty for a specific case that a temporal association between the onset of symptoms and neck movement or mild neck trauma is coincidental, contributory (when a primary arterial disease is demonstrated), or causal with respect to the dissection.
- Arterial abnormalities are found or inferred in many cases of spontaneous arterial dissection (and should also be excluded in cases of traumatic basilar SAH), including:
  - Fibromuscular dysplasia.
  - Cystic medial necrosis.
  - Hereditary connective tissue disorders (1 to 5% of cases), namely:
    - Ehlers-Danlos syndrome type IV.
    - Marfan's syndrome.
    - Autosomal-dominant polycystic kidney disease.
    - Osteogenesis imperfecta, type I.

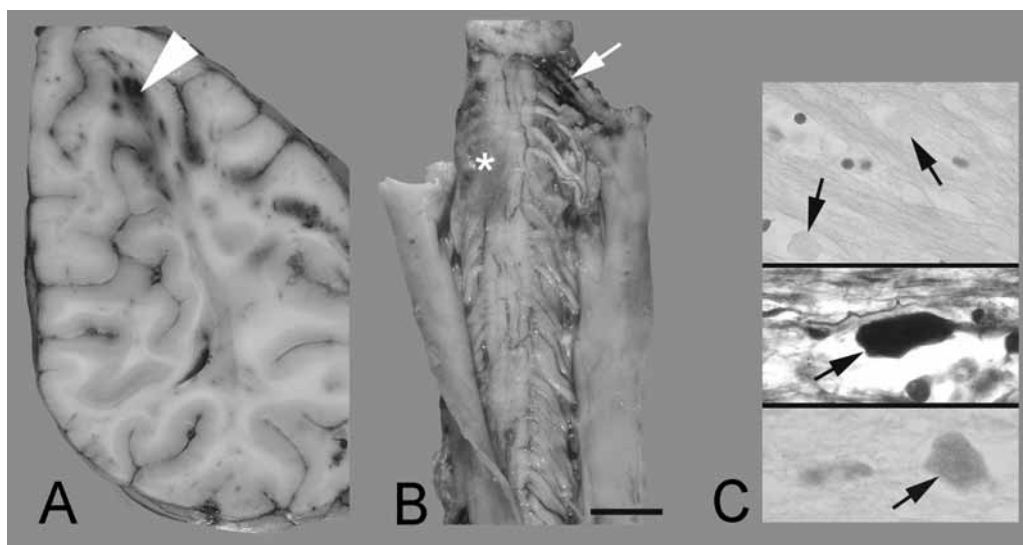
### 4.3. *Commotio Medullaris*

This form of death in which, strictly speaking, no conventional cause is apparent corresponds to a syndrome described by Di Maio and Di Maio in which “individuals who, while acutely intoxicated, are severely beaten about the face ... collapse at the scene ... and are subsequently found dead” (38) and later reviewed in more detail (refs. 39 and 40; Fig. 2). The identification of this syndrome is a relatively straightforward process of recognizing the entity and excluding other causes. The mechanism that causes death, however, remains undetermined, but details from animal experiments and from sparse clinical observations provide some guidance regarding the principal questions concerning the syndrome:

- How does mild to moderate head injury cause death?
- How does alcohol intoxication make matters worse?

#### 4.3.1. *Cardiorespiratory Changes After Head Injury*

Neurally mediated apnea and cardiac changes are described in experimental head injury models. Apnea occurs immediately after missile, contact, or acceleration head injuries and is self-limited in mild or moderate forms of concussion (41–43). The duration of apnea, which is usually less than 30 s, is proportional to the force of the injury (41,44). Sustained respiratory arrest appears to be limited to severe forms of experimental head injury (41,45). Head injuries of various types are also followed almost immediately by hypertension and bradycardia whose degree is proportional to the severity of the trauma (42,46,47). Changes in cardiac and respiratory function occur at lower intensities of head injury than does alteration in conscious level (42). The rise in blood pressure is



**Fig. 2.** Commotio medullaris. These specimens are from a young man, intoxicated with ethanol, who was struck with fists and kicked in the head and face by his assailant. A cardiorespiratory arrest occurred and resuscitation was delayed for 20 min. He was brain dead after resuscitation but mechanical ventilation was maintained for 3 d. **(A)** Coronal slice through right occipital lobe showing paramedian (gliding) contusions (white arrow-head). **(B)** Posterior surface of cervical spinal cord with opened dura. Small hemorrhages are present in the right posterior nerve roots of C1 (white arrow). Severe brain swelling has caused cerebellar tonsillar herniation and displacement of necrotic cerebellar tissue into the spinal subarachnoid space (asterisk). (scale bar = 1 cm.) **(C)** Photomicrographs from the vicinity of the nucleus of the tractus solitarius. Axonal swellings are indicated in this panel (Top panel, H&E; middle panel, Bielschowsky's method; bottom panel, neurofilament immunohistochemistry:  $\times 100$  oil immersion objective for all panels). (Modified from ref. 40 with permission of Lippincott Williams and Wilkins.)

mediated through sympathetic neural pathways in mildly and moderately injured animals; bradycardia is initiated by the parasympathetic nervous system (44,47).

There is little knowledge, for obvious reasons, of what happens to human cardiorespiratory activity immediately after a head injury. There is, however, some evidence that sustained primary apnea can complicate mild human head injury and may be a cause of death if assisted ventilation is not started (48); positional asphyxia (*see* Chapter 3, Subheading 3.7.) in an unconscious subject should be excluded when this explanation for death is under consideration.

The way in which head injury provokes the cardiorespiratory changes that accompany mild or moderate head injury is undetermined. The observation of axonal swellings in a single case supports the possibility that commotio medullaris is a clinical manifestation of traumatic axonal injury (Fig. 2; ref. 40). However, an alternative explanation is that stretching of the lower brainstem during abrupt movements of the head may also disrupt medullary function (41), for which tearing of the nerve roots in the upper cervical region would be suggestive evidence (Fig. 2; ref. 40). In either case, the explanation for the syndrome appears to be in the medulla, justifying the use of the term “commotio medullaris.”

#### 4.3.2. *Effect of Intoxication by Ethanol on Cardiorespiratory Changes Induced by Head Injury*

There is evidence from animal experiments that alcohol interferes with the function of the brainstem cardiorespiratory centers because of the relatively selective capacity of ethanol, which it may share with barbiturates (49), to enhance  $\gamma$ -aminobutyric acid-induced  $\text{Cl}^-$  influx (and thus increase the inhibitory action of  $\gamma$ -aminobutyric acid) and to suppress the *N*-methyl-D-aspartate receptor-mediated excitatory action of L-glutamate (49–51). The net effect on medullary vasomotor centers is enhancement of baroreceptor reflex inhibition of sympathetic nerve activity (49). Consequently, ethanol intoxication can hinder reflex attempts by the cardiorespiratory centers to correct excessive perturbation of cardiac and respiratory function that might occur after a head injury. In line with this conclusion, the administration of moderate amounts of ethanol to experimental animals fatally prolongs the apnea induced by moderate concussion (52). Two other experimental observations support the possibility that ethanol, in its role as a CNS suppressant, may exacerbate the effects of mild or moderate head injury: small doses of barbiturates given soon after head injury to lightly anesthetized animals can cause fatal cardiovascular collapse (53,54) and the administration of thiopentone shortly before head injury increases the immediate posttraumatic mortality rate (55).

Any discussion about the mechanism responsible for commotio medullaris in intoxicated subjects must also take into account the observation that the incidence of sudden unexpected death unrelated to head injury is increased after recent alcohol intake (56–58). However, the increased risk appears to be limited to middle-aged individuals with a history of long-term heavy alcohol intake (59,60) who, paradoxically, do not have pre-existing clinical and electrocardiographic evidence of ischemic heart disease (58). Accordingly, it is possible that ethanol intoxication alone is responsible for sudden unexpected death in apparent cases of commotio medullaris affecting middle-aged individuals with established histories of excessive alcohol intake and a break from drinking after a recent binge (“holiday heart syndrome” [56,57]), but any lack of significant coronary atheroma would mitigate against this conclusion.

#### 4.3.3. *Conclusions Regarding Pathogenesis of Commotio Medullaris*

Mild to moderate concussive head injury disturbs cardiorespiratory function but not usually to the extent that death from apnea or cardiac arrest occurs. In exceptional cases, however, an idiosyncratic augmentation of this response in a sober individual or an augmented response caused by the effects of ethanol on the medullary centers for cardiorespiratory control in intoxicated subjects leads to SND. The cardiorespiratory changes may be the consequence of traumatic axonal injury or of localized stretching and distortion of the medulla during an abrupt neck movement provoked by a head injury.

The phenomenon of commotio medullaris can also explain how death occurred in cases of head injury (as evidenced by reports of reliable witnesses and/or the presence of scalp contusions and/or skull fractures) in which the severity of traumatic brain injury (usually in the form of subarachnoid hemorrhage and small contusions) is insufficient to account convincingly for the death of the patient, or in which the structure of the brain is normal. In this situation, the victim is usually dead at the scene, alcohol intoxication need not be a factor, and no other structural, metabolic, or toxicological cause of death

is found. Death in such cases has also been described as being the result of cerebral concussion (38) or “cardiac neural discharge” (74).

### 5. SUDDEN UNEXPECTED DEATH IN EPILEPSY

Sudden unexpected death in epilepsy (SUDEP) is defined as “[s]udden unexpected, witnessed or unwitnessed, nontraumatic and non-drowning death in epilepsy, with or without evidence for a seizure and excluding documented status epilepticus where postmortem examination does not reveal a toxicological or anatomical cause of death” (61). A knowledge of SUDEP is essential for a pathologist because it is a relatively common cause of sudden unexpected death that can affect subjects who survive craniocerebral trauma with moderate disability (*see* Chapter 9, Subheading 11.5.). SUDEP accounts for approx 1 to 1.5% of all natural sudden unexpected deaths (62) and evidence of old craniocerebral trauma is found in 30% of cases of SUDEP (62,63).

Although estimates of the incidence of SUDEP vary with the characteristics of the epileptic population from which the data are derived, the incidence in the general epilepsy population appears to be around 1 to 2 cases per 1000 epilepsy cases per year (64,65), the incidence being greatest in young adults and adults in their early middle-age. This represents a substantial increase in the risk of sudden death when compared with the normal population (66). SUDEP is associated with generalized tonic-clonic seizures, inadequately controlled seizures, and poor compliance with anticonvulsant medication (64,67). Various other risk factors are also inconsistently reported to be associated with SUDEP (64). Most victims of SUDEP are found dead in bed or at home (64,65). If death is witnessed it usually occurs during or, less commonly, shortly after a seizure (64,65). The mechanism of death may be a seizure-induced cardiac dysrhythmia or apnea (65,68–70). In some cases fatal pulmonary edema is precipitated by the seizure (71).

The findings in the general autopsy include congested lungs. The tongue is bitten in a minority of cases (Chapter 5, Fig. 16). Histological cardiac abnormalities are present in at least some cases, including perivascular and interstitial myocardial fibrosis and myocyte vacuolization (72) of uncertain origin (but possibly related to intra-ictal hypoxic–ischemic injury). Old contusions are common in brains from cases of post-traumatic SUDEP (62,63,73). A structurally normal brain is the rule when the seizures are not a complication of trauma. In a minority of cases, nontraumatic epileptogenic brain abnormalities are observed, including gliomas, developmental cortical abnormalities, and vascular malformations (Chapter 5, Fig. 17) (62,63). In some cases, the effects of epileptic activity on brain structure are found in the form of multifocal neuronal loss and gliosis (especially in the hippocampus), secondary to intra-ictal ischemic and excitotoxic injury, or mesial temporal sclerosis (62).

The presence of a theoretically epileptogenic brain lesion, including old contusions, in an individual without a history of epilepsy who dies suddenly and unexpectedly should not be used as a reason to attribute the death to SUDEP.

### 6. RUPTURE OF BERRY ANEURYSMS AND SND

A pathologist will be faced on occasion with SND caused by rupture of an intracranial aneurysm, which occurred during an altercation or mild head injury. Less commonly, acute cerebral dysfunction attributable to a ruptured berry aneurysm may



appear to be the cause of an accident with or without serious ensuing traumatic injuries to the head or the rest of the body. In either case, two questions arise:

- Can trauma *per se* cause an aneurysm to rupture?
- Does rupture of a berry aneurysm cause SND?

### ***6.1. Can Mild Head Injury Cause Rupture of an Intracranial Aneurysm?***

This is a difficult question to answer, particularly in a medicolegal context. In general terms, the risk that an aneurysm will rupture increases as the aneurysm increases in size. Rupture of an aneurysm is well documented during exertion, when physiological surges in blood pressure may be responsible but, equally, aneurysmal rupture commonly occurs when a patient is at rest or asleep (17). In other words, an intracranial aneurysm can rupture at any time and, with reference to a given case, it is not possible to say with certainty, in most circumstances, whether the activity in which a patient was involved at the time of the onset of a SAH was causative, despite the human tendency to assume that a temporal association between events is evidence of a causal association.

### ***6.2. Does Rupture of Intracranial Aneurysm Cause SND?***

Although acute SAH secondary to rupture of a berry aneurysm is an intuitively obvious cause of SND, as defined previously, it is, nevertheless, an unusual one. In a series of 1592 autopsies at the Victoria Hospital, London, Ontario between 1991 and 1996, 28 deaths were associated with rupture of a berry aneurysm of which 4 (14%) caused SND, in line with large population studies in which approx 10% of patients die within 24 h of the onset of symptoms (17). The berry aneurysm in these cases does not appear to favor specific areas in the anterior or posterior cerebral circulation (11). As Leestma concludes: “Death due to the ... acute SAH [accompanying aneurysmal rupture] rarely occurs within minutes but generally within a few hours” (74).

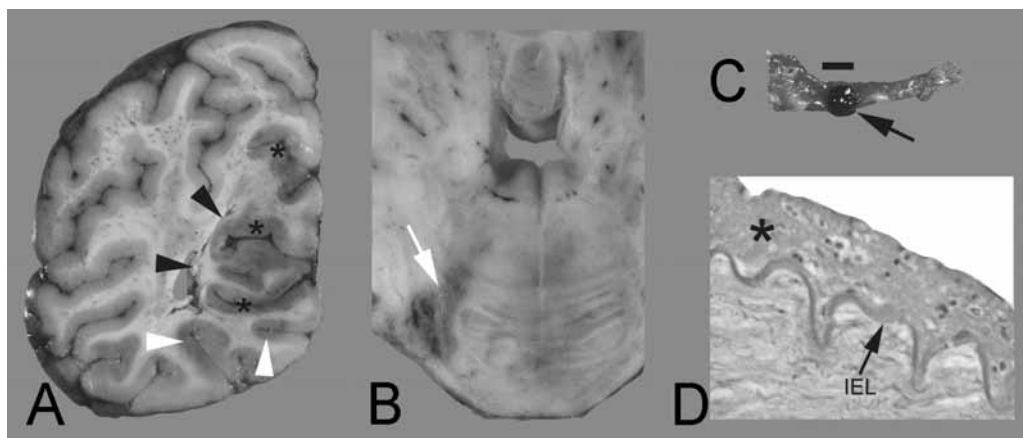
The mechanism of sudden death in acute SAH remains speculative but may be related to the percussive effects on the brainstem of an abrupt exposure of the low pressure cerebrospinal fluid-filled subarachnoid space to high intra-arterial pressure or to instantaneous vasospasm of major cerebral arteries.

## ***7. STROKE, SND, AND CRANIOCEREBRAL TRAUMA***

A stroke is an acute neurological disorder caused by a cerebral infarct (ischemic stroke) or intracerebral hemorrhage (hemorrhagic stroke): SAH is also sometimes regarded as a stroke. The association between aneurysmal rupture, SAH and SND has been discussed in the preceding section. Intracerebral hemorrhage is a rare cause of SND (although it is a common cause of unexpected neurological death as defined previously; *see also* ref. 11) and, owing to the readily visible bleeding, it is unlikely that an association between this type of hemorrhage and SND has been overlooked over the years.

The possibility of a causal relationship between an ischemic stroke and death at the onset of the infarct is hard to prove for several reasons:

- The gross and microscopic changes of an infarct take several hours to evolve, which means that there will be no structural changes observable in the brain when the patient dies within this period.
- Branches of the circle of Willis are almost never found to be occluded in cases of sudden unexpected death.



**Fig. 3.** Trauma-induced sudden neurological death after brainstem infarct. These samples are from a boy in his early teens who dropped to the ground without vital signs after he was pushed from behind during a playground altercation. Resuscitation was delayed and mechanical ventilation was withdrawn 2 d later. Three weeks before his death he had fallen and developed torticollis. Examination of the brain revealed infarcts in (A) the left occipital lobe, (B) right pons, and (C) focal acute hemorrhage in the adventitia of the right vertebral artery with (D) recently formed thrombus attached to the underlying intima and no evidence of arterial dissection. These findings are suggestive evidence of a localized vertebral artery injury from the fall, formation of thrombus at the site of arterial injury, bleeding in the arterial adventitia and displacement of the thrombus because of the abrupt neck movement caused by the push, embolization of thrombotic material to multiple sites in the posterior circulation, including the medulla, and a consequent cardiorespiratory arrest. No thrombus was found in the vicinity of the infarcts, presumably because it was removed by the fibrinolytic system. (A) Coronal slice through left occipital lobe. Although there was widespread microscopic evidence of hypoxic–ischemic hemorrhagic injury throughout the cerebral hemispheres, secondary to delayed resuscitation after a cardiorespiratory arrest, there was also localized softening and necrosis (i.e., an infarct) in the left posterior cerebral territory (asterisks) with separation of the necrotic tissue from the adjacent intact white matter (black arrowheads) and, at the margins of the infarct, more intense ischemic injury in the cortex in the depths of the sulci. (B) Horizontal slice through pons. A triangular-shaped infarct is indicated by the white arrow. (C) Right vertebral artery. Recent hemorrhage is present in the adventitia (black arrow). (scale bar = 0.5 cm.) (D) Right vertebral artery. A recently formed thrombus is attached to the intima. IEL, internal elastic lamina. (H&E;  $\times 40$  objective).

- The demonstration of a recent occlusion of the carotid bifurcation or a vertebral artery is of uncertain significance because asymptomatic or only mildly symptomatic occlusion of these arteries occurs.
- Many cases of sudden unexpected death in which an acute cerebral infarct may be suspected also have ischemic heart disease, which is invariably favored as an explanation for death.

With these difficulties in mind, it is still the impression from our autopsy practice that cerebral hemispheric infarcts are unlikely, at their onset, to cause sudden death (and to account for a fatal accident). However, fatal cardiac dysrhythmias may occur later in the evolution of a cerebral hemispheric infarct (75) or a brainstem infarct—in the latter case involvement of the nucleus of the tractus solitarius may trigger the fatal cardiac event (76–79). There are rare instances when an abrupt movement of the neck during a head or

neck injury may cause SND by exacerbating a pre-existing vertebral artery abnormality and causing a brainstem infarct, an example of which is illustrated in Fig. 3. In general terms, though, it is very unlikely that various types of trauma cause stroke-related SND.

### 8. *SND AND SPINAL CORD INJURY WITHOUT RADIOGRAPHIC ABNORMALITY*

In Chapter 9 (Subheading 8.7.) the subject of spinal cord injury without radiological abnormalities was described and, in particular, the increased risk of this entity in children whose vertebral columns are more elastic than in adults was noted (80,81). It is possible that severe forms of spinal cord injury without radiological abnormalities, which affect the high cervical vertebrae, are causes of SND, and there is some evidence in the literature that spinal cervical injury occurs in nonaccidental injury in infancy (82–86). Criteria for recognizing this entity include:

- An otherwise unexplained death.
- Eyewitness accounts of trauma causing extreme neck movement.
- Bleeding into the muscles of the neck.
- The demonstration of localized linear hemorrhage along the attachment of ligaments in the high cervical area.
- Peridural spinal bleeding.
- Petechial hemorrhages and distortion of myelinated fibers in the cervical white matter.

### REFERENCES

1. Natelson, B. H. Neurocardiology. An interdisciplinary area for the 80s. *Arch. Neurol.* 42:178–184, 1985.
2. Natelson, B. H., Chang, Q. Sudden death. A neurocardiologic phenomenon. *Neurol. Clin.* 11:293–308, 1993.
3. DiMaio, S. M., DiMaio, V. J., Kirkpatrick, J. B. Sudden, unexpected deaths due to primary intracranial neoplasms. *Am. J. Forensic Med. Pathol.* 1:29–45, 1980.
4. Aronica, P. A., Ahdab-Barmada, M., Rozin, L., Wecht, C. H. Sudden death in an adolescent boy due to a colloid cyst of the third ventricle. *Am. J. Forensic Med. Pathol.* 19:119–122, 1998.
5. Lindboe, C. F., Svenes, K. B., Slordal, L. Sudden, unexpected death in subjects with undiagnosed gliomas. *Am. J. Forensic Med. Pathol.* 18:271–275, 1997.
6. Dolinak, D., Matshes, E., Waghay, R. Sudden unexpected death due to a brainstem glioma in an adult. *J. Forensic Sci.* 49:128–130, 2004.
7. Gleckman, A. M., Smith, T. W. Sudden unexpected death from primary posterior fossa tumors. *Am. J. Forensic Med. Pathol.* 19:303–308, 1998.
8. Ortiz-Reyes, R., Dragovic, L., Eriksson, A. Sudden unexpected death resulting from previously nonsymptomatic subependymoma. *Am. J. Forensic Med. Pathol.* 23:63–67, 2002.
9. Milroy, C. M., Smith, C. L. Sudden death due to a glial cyst of the pineal gland. *J. Clin. Pathol.* 49:267–269, 1996.
10. Matschke, J., Stavrou, D., Puschel, K. Sudden death resulting from epidermoid cyst of the brain. *Am. J. Forensic Med. Pathol.* 23:368–370, 2002.
11. Black, M., Graham, D. I. Sudden unexplained death in adults caused by intracranial pathology. *J. Clin. Pathol.* 55:44–50, 2002.
12. Matschke, J., Makrigeorgi-Butera, M., Stavrou, D. Sudden death in a 35-year-old man with occult malformation of the brain and aseptic meningitis. *Am. J. Forensic Med. Pathol.* 24:83–86, 2003.
13. Levy, E. I., Harris, A. E., Omalu, B. I., Hamilton, R. L., Branstetter, B. F., Pollack, I. F. Sudden death from fulminant acute cerebellitis. *Pediatr. Neurosurg.* 35:24–28, 2001.

14. Maisel, J. A., Lynam, T. Unexpected sudden death in a young pregnant woman: unusual presentation of neurosarcoidosis. *Ann. Emerg. Med.* 28:94–97, 1996.
15. Barnett, M. H., Prineas, J. W. Relapsing and remitting multiple sclerosis: pathology of the newly forming lesion. *Ann. Neurol.* 55:458–468, 2004.
16. Wolf, D. A., Veasey, S. P., III, Wilson, S. K., Adame, J., Korndorffer, W. E. Death following minor head trauma in two adult individuals with the Chiari I deformity. *J. Forensic Sci.* 43:1241–1243, 1998.
17. Locksley, H. B. Natural history of subarachnoid haemorrhage, intracranial aneurysms and arteriovenous malformations. In: Sahs, A. L., ed. *Intracranial Aneurysms and Subarachnoid Haemorrhage: A Co-operative Study*. Lippincott, Philadelphia, pp. 35–108, 1969.
18. Dymock, R. B. Traumatic basal subarachnoid haemorrhage. *Med. J. Aust.* 2:216–218, 1977.
19. Simonsen, J. Fatal subarachnoid haemorrhages in relation to minor injuries in Denmark from 1967 to 1981. *Forensic Sci. Int.* 24:57–63, 1984.
20. Opekin, K., Burke, M. P. Vertebral artery trauma. *Am. J. Forensic Med. Pathol.* 19:206–217, 1998.
21. Coast, G. C., Gee, D. J. Traumatic subarachnoid haemorrhage: an alternative source. *J. Clin. Pathol.* 37:1245–1248, 1984.
22. Deck, J. H., Jagadha, V. Fatal subarachnoid hemorrhage due to traumatic rupture of the vertebral artery. *Arch. Pathol. Lab. Med.* 110:489–493, 1986.
23. Miyazaki, T., Kojima, T., Chikasue, F., Yashiki, M., Ito, H. Traumatic rupture of intracranial vertebral artery due to hyperextension of the head: reports on three cases. *Forensic Sci. Int.* 47:91–98, 1990.
24. Takahara, T., Terai, C., Okada, Y., Mimura, K., Mukaida, M. Fatal traumatic subarachnoid hemorrhage due to rupture of the vertebral artery. *Intensive Care Med.* 19:172–173, 1993.
25. Johnson, P., Burns, J. Extracranial vertebral artery injury—evolution of a pathological illusion? *Forensic Sci. Int.* 73:75–78, 1995.
26. Dolman CL. Rupture of posterior inferior cerebellar artery by single blow to head. *Arch. Pathol. Lab. Med.* 110:494–496, 1986.
27. Gross, A. Traumatic basal subarachnoid hemorrhages: autopsy material analysis. *Forensic Sci. Int.* 45:53–61, 1990.
28. Farag, A. M., Franks, A., Gee, D. J. Simple laboratory experiments to replicate some of the stresses on vertebro-basilar arterial walls. An investigation of possible mechanisms of traumatic subarachnoid haemorrhage. *Forensic Sci. Int.* 38:275–284, 1988.
29. Pollanen, M. S., Deck, J. H., Boutilier, L., Davidson, G. Lesions of the tunica media in traumatic rupture of vertebral arteries: histologic and biochemical studies. *Can. J. Neurol. Sci.* 19:53–56, 1992.
30. Dowling, G., Curry, B. Traumatic basal subarachnoid hemorrhage. Report of six cases and review of the literature. *Am. J. Forensic Med. Pathol.* 9:23–31, 1988.
31. Leadbeatter, S. Extracranial vertebral artery injury—evolution of a pathological illusion? *Forensic Sci. Int.* 67:33–40, 1994.
32. Bromilow, A., Burns, J. Technique for removal of the vertebral arteries. *J. Clin. Pathol.* 38:1400–1402, 1985.
33. Ludwig, J. *Handbook of Autopsy Practice*, Third Edition. Humana Press, Totowa, NJ, 2002.
34. Vanezis, P. Techniques used in the evaluation of vertebral artery trauma at postmortem. *Forensic Sci. Int.* 13:159–165, 1979.
35. Johnson, P., Burns J. Letter to the Editor. *Forensic Sci. Int.* 73:75–76, 1995.
36. Leadbeatter, S. Letter to the Editor: Reply to Johnson and Burns. *Forensic Sci. Int.* 73:77–78, 1995.
37. Schievink, W. I. Spontaneous dissection of the carotid and vertebral arteries. *N. Engl. J. Med.* 344:898–906, 2001.
38. DiMaio, V. J., DiMaio, D. *Forensic Pathology*. Second ed. CRC Press, Boca Raton, FL, 2001.
39. Milovanovic, A. V., DiMaio, V. J. Death due to concussion and alcohol. *Am. J. Forensic Med. Pathol.* 20:6–9, 1999.

40. Ramsay, D. A., Shkrum, M. J. Homicidal blunt head trauma, diffuse axonal injury, alcoholic intoxication, and cardiorespiratory arrest: a case report of a forensic syndrome of acute brainstem dysfunction. *Am. J. Forensic Med. Pathol.* 16:107–114, 1995.
41. Gennarelli, T., Segawa, H., Wald, U., Czernicki, Z., Marsh, K., Thompson, C. Physiological response to angular acceleration of the head. In: Grossman, R. G., Gildenberg, P. L., eds. *Head Injury: Basic and Clinical Aspects (Seminars in Neurological Surgery)*. Raven Press, New York, pp. 129–140, 1982.
42. Miller, J. D. Physiology of trauma. *Clin. Neurosurg.* 29:103–130, 1982.
43. Nilsson, B., Ponten, U., Voigt, G. Experimental head injury in the rat. Part 1: Mechanics, pathophysiology, and morphology in an impact acceleration trauma model. *J. Neurosurg.* 47:241–251, 1977.
44. Brown, F. D., Jafar, J. J., Krieger, K., Johns, L., Leipzig, T. J., Mullan, S. Cardiac and cerebral changes following experimental head injury. In: Grossman, R. G., Gildenberg, P. L., eds. *Head Injury: Basic and Clinical Aspects (Seminars in Neurological Surgery)*. Raven Press, New York, pp. 151–157, 1982.
45. Millen, J. E., Glauser, F. L., Zimmerman, M. Physiological effects of controlled concussive brain trauma. *J. Appl. Physiol.* 49:856–862, 1980.
46. Hilton, D. L., Jr., Einhaus, S. L., Meric, A. L., III, et al. Early assessment of neurological deficits in the fluid percussion model of brain injury. *J. Neurotrauma* 10:121–133, 1993.
47. Rosner, M. J. Systemic response to experimental brain injury. In: Becker, D. P., Povlishock, J. T., eds. *Central Nervous System Trauma Status Report*. National Institute of Neurological and Communicative Disorders and Stroke, Washington, DC, pp. 404–415, 1985.
48. Levine, J. E., Becker, D., Chun, T. Reversal of incipient brain death from head-injury apnea at the scene of accidents. *N. Engl. J. Med.* 301:109, 1979.
49. Sun, M. K., Reis, D. J. Effects of systemic ethanol on medullary vasomotor neurons and baroreflexes. *Neurosci. Lett.* 137:232–236, 1992.
50. Carlen, P. L., Zhang, L. A., Cullen, N. Cellular electrophysiological actions of ethanol on mammalian neurons in brain slices. *Ann. N. Y. Acad. Sci.* 625:17–25, 1991.
51. Engberg, G., Hajos, M. Ethanol attenuates the response of locus coeruleus neurons to excitatory amino acid agonists in vivo. *Naunyn Schmiedebergs Arch. Pharmacol.* 345:222–226, 1992.
52. Zink, B. J., Feustel, P. J. Effects of ethanol on respiratory function in traumatic brain injury. *J. Neurosurg.* 82:822–828, 1995.
53. Crockard, H. A., Brown, F. D., Calica, A. B., Johns, L. M., Mullan, S. Physiological consequences of experimental cerebral missile injury and use of data analysis to predict survival. *J. Neurosurg.* 46:784–794, 1977.
54. Crockard, H. A., Brown, F. D., Johns, L. M., Mullan, S. An experimental cerebral missile injury model in primates. *J. Neurosurg.* 46:776–783, 1977.
55. Bean, J. W., Beckman, D. L. Centrogenic pulmonary pathology in mechanical head injury. *J. Appl. Physiol.* 27:807–812, 1969.
56. Ettinger, P. O., Wu, C. F., De La Cruz, C., Jr., Weisse, A. B., Ahmed, S. S., Regan, T. J. Arrhythmias and the “Holiday Heart”: alcohol-associated cardiac rhythm disorders. *Am. Heart J.* 95:555–562, 1978.
57. Greenspon, A. J., Schaal, S. F. The “holiday heart”: electrophysiologic studies of alcohol effects in alcoholics. *Ann. Intern. Med.* 98:135–139, 1983.
58. Wannamethee, G., Shaper, A. G. Alcohol and sudden cardiac death. *Br. Heart J.* 68:443–448, 1992.
59. Gordon, T., Kannel, W. B. Drinking habits and cardiovascular disease: the Framingham Study. *Am. Heart J.* 105:667–673, 1983.
60. Lithell, H., Aberg, H., Selinus, I., Hedstrand, H. Alcohol intemperance and sudden death. *Br. Med. J. (Clin. Res. Ed.)* 294:1456–1458, 1987.
61. Nashef, L., Brown, S. Epilepsy and sudden death. *Lancet* 348:1324–1325, 1996.
62. Leestma, J. E., Hughes, J. R., Teas, S. S., Kalelkar, M. B. Sudden epilepsy deaths and the forensic pathologist. *Am. J. Forensic Med. Pathol.* 6:215–218, 1985.



63. Leestma, J. E., Kalelkar, M. B., Teas, S. S., Jay, G. W., Hughes, J. R. Sudden unexpected death associated with seizures: analysis of 66 cases. *Epilepsia* 25:84–88, 1984.
64. Opeksin, K., Berkovic, S. F. Risk factors for sudden unexpected death in epilepsy: a controlled prospective study based on coroners cases. *Seizure* 12:456–464, 2003.
65. Langan, Y., Nashef, L., Sander, J. W. A. S. Sudden unexpected death in epilepsy: a series of witnessed deaths. *J. Neurol. Neurosurg. Psychiatr.* 68:211–213, 2000.
66. Ficker, D. M. Sudden unexplained death and injury in epilepsy. *Epilepsia* 41 Suppl. 2:S7–S12, 2000.
67. Langan, Y. Sudden unexpected death in epilepsy (SUDEP): risk factors and case control studies. *Seizure* 9:179–183, 2000.
68. Dasheiff, R. M., Dickinson, L. J. Sudden unexpected death of epileptic patient due to cardiac arrhythmia after seizure. *Arch. Neurol.* 43:194–196, 1986.
69. Fincham, R. W., Shivapour, E. T., Leis, A. A., Martins, J. B. Ictal bradycardia with syncope: a case report. *Neurology* 42:2222–2223, 1992.
70. Nashef, L., Walker, F., Allen, P., Sander, J. W., Shorvon, S. D., Fish, D. R. Apnoea and bradycardia during epileptic seizures: relation to sudden death in epilepsy. *J. Neurol. Neurosurg. Psychiatry* 60:297–300, 1996.
71. Terrence, C. F., Rao, G. R., Perper, J. A. Neurogenic pulmonary edema in unexpected, unexplained death of epileptic patients. *Ann. Neurol.* 9:458–464, 1981.
72. Natelson, B. H., Suarez, R. V., Terrence, C. F., Turizo, R. Patients with epilepsy who die suddenly have cardiac disease. *Arch. Neurol.* 55:857–860, 1998.
73. Leestma, J. E., Walczak, T., Hughes, J. R., Kalelkar, M. B., Teas, S. S. A prospective study on sudden unexpected death in epilepsy. *Ann. Neurol.* 26:195–203, 1989.
74. Leestma, J. E. Forensic aspects of general neuropathology. In: Leestma, J. E., ed. *Forensic Neuropathology*. Raven Press, New York, pp. 24–156, 1988.
75. Abboud, H., Berroir, S., Labreuche, J., Orjuela, K., Amarenco, P. Insular involvement in brain infarction increases risk for cardiac arrhythmia and death. *Ann. Neurol.* 59:691–699, 2006.
76. Jaster, J. H., Smith, T. W. Arrhythmia mechanism of unexpected sudden death following lateral medullary infarction. *Tenn. Med.* 91:284, 1998.
77. Jaster, J. H., Porterfield, L. M., Bertorini, T. E., Dohan, F. C., Jr., Becske, T. Cardiac arrest following vertebrobasilar stroke. *J. Tenn. Med. Assoc.* 88:309, 1995.
78. Jaster, J. H., Porterfield, L. M., Bertorini, T. E., Dohan, F. C., Jr., Becske, T. Stroke and cardiac arrest. *Neurology* 47:1357, 1996.
79. De Caro, R., Parenti, A., Montisci, M., Guidolin, D., Macchi, V. Solitary tract nuclei in acute heart failure. *Stroke* 31:1187–1193, 2000.
80. Hadley, M. N., Zabramski, J. M., Browner, C. M., Rekate, H., Sonntag, V. K. Pediatric spinal trauma. Review of 122 cases of spinal cord and vertebral column injuries. *J. Neurosurg.* 68:18–24, 1988.
81. Pang, D., Wilberger, J. E. Spinal cord without radiographic abnormalities in children. *J. Neurosurg.* 57:114–129, 1982.
82. Geddes, J. F., Hackshaw, A. K., Vowles, G. H., Nickols, C. D., Whitwell, H. L. Neuropathology of inflicted head injury in children. I. Patterns of brain damage. *Brain* 124:1290–1298, 2001.
83. Geddes, J. F., Vowles, G. H., Hackshaw, A. K., Nickols, C. D., Scott, I. S., Whitwell, H. L. Neuropathology of inflicted head injury in children. II. Microscopic brain injury in infants. *Brain* 124:1299–1306, 2001.
84. Ghatan, S., Ellenbogen, R. G. Pediatric spine and spinal cord injury after inflicted trauma. *Neurosurg. Clin. N. Am.* 13:227–233, 2002.
85. Hadley, M. N., Sonntag, V. K., Rekate, H. L., Murphy, A. The infant whiplash-shake injury syndrome: a clinical and pathological study. *Neurosurgery* 24:536–540, 1989.
86. Piatt, J. H., Jr., Steinberg, M. Isolated spinal cord injury as a presentation of child abuse. *Pediatrics* 96:780–782, 1995.

# Index

---

## A

### Abdomen

- blunt trauma to, 442–446
- discoloration in, 42
- firearms injuries in, 313, 333f
- injury and air bag deployment, 469t
- seat belt injuries on, 462–463
- shotgun exit wounds in, 306, 307f
- stab wounds in, 371, 378f

### Abdominal Compartment Syndrome, 446

### Abdominal viscus, electrocution injury in, 225

### Abrasion rings, firearm injuries, 304, 305f

### Abrasions

- in cold weather exposure, 417
- described, 406, 408f
- direction of force determination in, 411
- histological assessment of, 414
- motor vehicle collisions, 476, 477
- postmortem, 410

### Accelerant use, determination of, 203

### Acceleration defined, 406

### Accidental death, determination of

- dementia in, 593–594
- by drowning, 271, 274–275, 277f
- by electrocution, 217
- falls from heights, 425
- hyoid fracture in, 97f
- in motor vehicle collision, 482
- overview, 3t
- sharp-force injuries, 358–362
- water aspiration in, 244

### AC circuit

- described, 213
- effects of, 215t, 218, 220, 226, 227
- lethality by, 214

### Acetone, hypothermia, 419

### Acid aspiration, 137

### Acute aspiration, 136–139

### Acute bacterial meningitis, 530, 532f, 608

### Acute traumatic cervical central cord syndrome, 584

### Adenohypophyseal necrosis, 588

### Adipocere described, 52, 53f

### Adolescents

- drowning in, 244
- gunshot wounds in, 296
- hanging death in, 75–78
- hypothermia in, 254

### Adult respiratory distress syndrome (ARDS)

- described, 6
- in drowning victims, 253
- fat embolism and, 450
- in post-burn victims, 208t

### Age

- burn epidemiology and, 206, 207
- and laryngeal fracture incidence, 98

### Air bag deployment injuries, 464–469, 579

### Air embolism, 392–393, 455

### Airways, soot in, 200, 201, 205, 206. *See also* Respiratory tract

### Alcohol

- and blunt trauma, 411f, 416, 417f
- and contusions, 548
- and drowning, 244, 245, 252, 256–257, 271
- in firearm injuries, 296, 345–346
- in fire incapacitation, 197
- and hyoid fracture, 96
- levels, determination of in peridural hemorrhages, 522
- neurogenic cardiorespiratory changes induced by, 615

- in sharp force injuries, 362, 379
  - and suicide, sharp-force, 361, 375
- Algor mortis. *See* Body cooling (algor mortis)
- Alzheimer's disease, 593, 594
- Amniotic fluid embolism, 455, 456f
- Anaphylaxis, 389–390
- Anatomical variation in wound depth, 366–368
- Aneurysms, 224, 444–445
- Aneurysms, cerebral, 616–617
- Animal predation, postmortem, 57–59, 85, 271f
- Anorectal injuries, penetrating, 362–363, 364f
- Antemortem injuries
  - alteration of, 57–59
  - mimicry of, 33, 42–43, 51f
- Anthropophagy and decomposition, 41, 49f, 55–57
- Anticonvulsant medication, 616
- Aorta, blunt trauma injury to, 406, 434–438
- Apnea, 613
- Applied force, degree of, sharp-force injury, 368, 371–372
- Arcing in electrical burns, 220
- ARDS. *See* Adult respiratory distress syndrome (ARDS)
- Arrectores pilorum, 24
- Artifacts, postmortem
  - burn (*See* Burn artifacts)
  - causes of, 4–5, 522
  - drowning, 268–271
  - embalming, 54–56
  - hemorrhage, intracerebral, 546–547
  - skull fractures, 522
  - submerged bodies, 268–271
- Asphyxia
  - autoerotic, 111–117
  - defined, 65
  - drowning (*See* Drowning)
  - mechanical (*See* Mechanical asphyxia)
  - mechanisms of, 65–66
  - microscopic indicators of, 70
  - plastic bag, 122–126, 129
  - positional (*See* Positional asphyxia)
  - stigmata, 66
  - subtle, 121
  - traumatic, 144–148
- Aspiration
  - acute, 136–139
  - base, 137
  - chronic, 137–138, 140f
  - in elderly persons, 136
  - foreign body (*See* Choking deaths)
  - of gastric contents, 136–137, 252
  - intubation and, 136
- Aspiration pneumonia, 137
- Assault
  - blunt trauma in, 416
  - sexual (*See* Sexual assault)
- Atlantoaxial dislocation, 578
- Atlantooccipital dislocation, 578
- Autoamputation, 381
- Autoerotic death
  - anorectal injuries, penetrating, 116, 118, 362
  - asphyxia, 111–117
  - atypical, 117–118
  - binding in, 80, 85
  - described, 110–111
  - suicide notes in, 112, 114
- Autolysis defined, 40
- Autopsy
  - complete (*See* Complete autopsy)
  - forensic (*See* Forensic autopsy)
  - hospital (*See* Hospital autopsy)
  - legal requirements of, organ retention, 13–14
  - limited (*See* Limited autopsy)
  - observers and, 15
  - overview, 1–4, 3t–4t, 11–12
  - prevalence, 12
  - religion and, 12
  - reports, 15–16
- Autopsy findings
  - burn victims, 210–211
  - carbon monoxide poisoning, 152–153
  - choking, 134–136
  - communication of, 15–16
  - EDHs, 534
  - hanging deaths, 86–102, 120–121
  - plastic bag asphyxia, 126
  - sharp-force injuries, 381–384
  - SIDS/smothering, 122, 128
  - submerged body, 258–265
  - SUDEP, 616
  - traumatic asphyxia, 147–148
- Autopsy procedures
  - basilar SAH, 612
  - CNS trauma, 521–523
  - diving deaths, 284–285
  - firearm injuries, 346–347
  - hanging deaths, 86–102, 120–121

- overview, 5f
- sharp-force injuries, 387–388
- Axons, injury to. *See* Diffuse axonal injury (DAI)
- Azygos vein, trauma to, 438–439
- B**
- Backscatter (blood spatter), firearm injuries, 318, 319, 328f, 330f, 343, 344,
- $\beta$ -Amyloid precursor protein (BAPP)
  - immunohistochemistry, 562–564
- Barbiturates and cardiovascular collapse, 615
- Barotrauma, 279–281
- Base aspiration, 137
- Bathtub drownings, 245, 248t, 249t, 251, 257, 257f, 267, 271–278
- Bathtub electrocutions, 216, 219, 277
- Bathtub suicides, 275, 276, 360, 382f
- Battle's sign, 525f
- Bed covers and smothering, 126–127
- Berry aneurysm rupture and SND, 616–617
- Beveling in firearms injuries, 332–333, 339f
- Bilirubin, 414
- Biliverdin, 414
- Birdshot, 302
- Blast injuries
  - described, 225–228, 230, 339
  - examination of, 231
  - mechanism, 228–231
- Blisters, postmortem, 47f
- Blood vessels
  - blunt trauma injury to, 406, 434–439
  - diffuse vascular injury, 564–565
  - electrocution injuries to, 225
  - injuries from firearms, 331, 339
  - injuries in skull fractures, 530
  - sharp-force injuries in, 383, 384, 385
  - spontaneous dissection of, 612–613
- Blood volume in EDH/ASDH, 540–542
- Blunt trauma
  - to the abdomen, 442–446
    - alcohol and, 411f, 416, 417f
  - to the aorta, 406, 434–438
  - in burn injuries, 194
  - to the cardiac valves, 434
  - cause of death determination, 410–411
  - cervical fractures in, 578, 579
  - chest/chest wall, 426–440, 487
  - coup contusions in, 553, 554f
  - to the diaphragm, 440–442
  - and drowning, 255
  - in electrocutions, 213, 225
  - in the extremities, 448–449
  - fat embolism in, 449–451
  - to the gastrointestinal tract, 442
  - to the heart, 406, 432–434
  - hematoma in, 411, 413f
  - hemorrhage from, 340, 410, 411
  - hemothorax from, 428, 430t, 432, 436, 438, 440
  - hypothermia in, 409f, 412f, 416–419
  - injury
    - aging of, 411–416
    - patterns/patterned, 416–422
    - and lightning, 220, 221, 221t
    - to the liver, 442
    - to the lungs, 439–441
    - in motor vehicle collisions, 420f, 421f, 422f
  - overview, 405–406
  - to the respiratory tract, 439–440
  - simulation of, 35–38
  - skin
    - described, 406–409
    - significance of, 409–422
  - to the spleen, 442–446
  - in stab wounds, 357, 371
  - to the trachea/bronchii, 439
  - in traumatic asphyxia, 147
- Body
  - diagrams, 9
  - electricity, effects on, 211, 213
  - floating, 269–270
  - habitus, effect on postmortem changes, 26, 41
  - injury in falls, 426
  - position, effect on postmortem changes, 41
  - state of at burn scene, 185–188, 194–203
  - submerged (*See* Submerged bodies)
  - tissues, electrical resistance in, 213–214
  - vitality of in fires, 194–202
- Body cooling (algor mortis)
  - in cold water submersion, 253–255
  - overview, 39–40
  - from unprotected heads, 254
- Bone
  - bullet fragmentation and, 327
  - diatom testing in, 267
  - electrical conduction in, 213, 214
  - injuries in homicide/suicide, 381, 383

- thermal damage of, 185, 190, 193, 203–205, 220
  - Bone marrow embolism, 451, 453f
  - Boyle's law defined, 279
  - Brain. *See also* Craniocerebral injuries
    - autopsy procedure, 522–523
    - blood vessel congestion in, 45f
    - burn artifact of, 194
    - contusions/lacerations, 547–557
    - cystic change in, 46
    - electrical damage to, 214–215
    - embolism of brain tissue, 454, 455f
    - function, disruption of, 607
    - herniation in, 538, 540, 542, 571, 572f
    - hypothermia in water submersion, 254, 255
    - injury
      - air bag deployment, 467t–469t
      - firearm, 328–330, 336–338, 344f
      - hypoxia, 254, 255
      - pedestrian collision, 477–478
      - sharp-force, 383–384
      - TBI (*See* Traumatic brain injury [TBI])
    - retention of, 13, 14, 523
    - swelling (*See* Brain swelling)
    - weights in drowning deaths, 264
  - Brainstem
    - autopsy procedure, 523
    - failure, mechanisms of, 607
    - hemorrhage in, 572, 573f
    - infarct, 617–619
  - Brain swelling
    - autopsy procedure, 523
    - in children, 585–587
    - contusions and, 536f
    - death from, 562–564, 589t, 590
    - described, 570–573
    - diffuse, 558
    - disability from, 591
    - hematoma and, 555
    - and hemorrhage, 544, 554
    - in hypoxic–ischemic encephalopathy, 566, 567, 569
    - in infants, 585–587
    - pathology, 570–573
    - peridural hemorrhage, 534, 537–538
    - and the pituitary gland, 588
  - Break point in drowning, 252
  - Breath holding, underwater swimming and, 252
  - Broken glass injuries, 361–362
  - Bruising. *See* Contusions
  - Buckets, drowning in, 245–246
  - Buckshot, 302
  - Bulimia and choking, 132
  - Bullet fragmentation
    - clothing, 310
    - factors affecting, 327
    - patterns in, 323, 334f
    - wound tracks of, 341
  - Bullets
    - firearm comparison with, 340
    - intracranial ricochet, 336–337, 342f, 343f
    - partial-jacketed, 334f
    - recovery of, 347
    - in skull injuries, 332–333
    - velocity of, 323, 324f, 326–327, 332–338 (*See* Firearm injuries to the skull)
  - Burial, 41
  - Burn artifacts
    - described, 186f, 190–196
    - red line, 193, 194f, 220
  - Burn classification, 185
  - Burn injuries. *See* Thermal injuries
  - Burn unit patients, 206–210, 215
  - Buttocks injury in falls, 426
- ## C
- Café coronary, 131
  - Canine predation, postmortem, 57–59
  - Carbon monoxide poisoning
    - autopsy findings, 152–153
    - described, 148–149, 482, 484
    - discoloration in, 32, 33, 34f
    - external examination, 152
    - in fires, 183, 184f, 197–198
    - in post-burn victims, 208t
    - scene of, 150–152
    - suicide notes in, 150
    - toxicology, 153–154, 563
  - Carboxyhemoglobin (COHb)
    - blood levels of, 148, 151, 152
    - in burn victims, 197–198, 201–203, 205, 206f
    - formation of, 148
    - half-life of, 149
    - symptoms of, 149t
    - toxicology, 153–154, 563
  - Cardiac concussion (Commotio cordis), 433–435
  - Cardiac tamponade, 368, 384, 432



- Cardiac valves, blunt trauma in, 434
- Cardiopulmonary resuscitation (CPR)
  - face/neck injuries and, 109
  - fat embolism and, 449
  - and petechiae development, 69
  - rib fractures from, 431
- Cartilage embolism, 455
- Cartilage injuries in homicide/suicide, sharp-force injury, 381, 383
- Casper's rule defined, 41
- Cat bites, 388
- Catheters, injury from, 391–393
- Cause of death determination
  - blunt trauma, 410–411
  - craniocerebral trauma, 592
  - and decomposition, 49
  - decubitus ulcers in, 423
  - defined, 16
  - diving deaths, 283
  - drowning, 243–244, 277
  - flame injury, 181, 199f
  - fractures in hanging, 100
  - motor vehicle collisions, pedestrians, 474
  - in non-accidental injury in infants, 587t
  - overview, 3t, 5, 9–11, 13, 16–17
  - in peridural hemorrhage, 540–542
  - post-burn victims, 208t–209t
  - sharp-force injuries, 386
  - smothering, 121
  - therapeutic misadventure, 390–391
- Central nervous system (CNS)
  - autopsy procedures, 521–523
  - electrocution injuries to, 226–227
  - examination of, 519–521
  - injury, syndromes associated with, 588–592
  - mammalian diving response in, 255
  - neoplasms of, 609
- Cerebellum
  - autopsy procedure, 523
  - contusions/hemorrhage, 555–557
  - swelling and, 572
- Cerebral contusions
  - acute, 548–551
  - aging, cutaneous, 414–416
  - brain, 547–557
  - cerebellar, 555–557
  - contrecoup, 551–554
  - coup, 344f, 548, 550, 553–554
  - differential diagnosis of, 557
  - documentation of, 557
  - in firearm injuries, cerebral, 328, 336, 337f, 338f, 344f, 554. *See also* Firearm injuries, contusions in.
  - fracture, 533f, 555
  - gliding (parasagittal), 554–555, 558, 559f, 560f, 614f
  - herniation, 554, 555f
  - old, 551, 552f, 557
- Cervical spine fractures, 99–101, 578–579, 581, 614f. *See also* Spinal cord injuries (SCI)
- Chain saws, 363
- Charring death
  - described, 185–187, 191f, 196f
  - in electrocutions, 220
  - and external injuries, 204
  - and identification, 189, 190
- Charring process
  - epidural hemorrhage in, 193, 196f
- Charts, review of, 5–6, 9, 75
- Chest injury
  - air bag deployment, 467t–469t
  - blunt trauma, 426–440, 487
  - in car crashes, 457–469, 470, 472
  - compression of, petechiae in, 68–69
  - firearm, 313, 315, 325f, 339, 340
  - resuscitation, closed-chest, 428–432
  - stab wounds, 367f, 368, 374–375, 374f, 381, 385
- Children
  - anorectal injuries in, 362, 363, 364f
  - brain swelling in, 585–587
  - broken glass injuries in, 361
  - bruising in, 410
  - burn epidemiology in, 207
  - cervical fractures in, 99, 578, 619
  - chest wall fractures, 426
  - choking deaths in, 131
  - commotio cordis in, 434, 435f
  - craniospinal trauma in, 585–588
  - decomposition in, 41
  - diving reflex in, 255
  - dog bites in, 388, 389f
  - drowning in, 245, 246, 275
  - electrocutions of, 216
  - falls from heights, 425
  - FES in, 450
  - growing fractures in, 531
  - gunshot wounds in, 296
  - hanging death in, 75–78, 82

- human bite marks in, 421
- hyoid fractures in, 94
- hypothermia in submersion, 254
- impalement in, 362
- in motor vehicle collisions, 476
- resuscitation injuries in, 109–111
- rib fractures in, 431
- SIDS in (*See* Sudden infant death syndrome [SIDS])
- SND in, 619
- thermal destruction of, 185
- wedging in, 129–130
- Chloride testing, drowning, 265
- Choking
  - in infants, 131, 133f
  - suicide, 134
  - xerostomia and, 132
- Choking deaths
  - autopsy, 134–136
  - described, 130–133
  - external examination, 134
  - inflammatory response to, 131, 136–138, 140f
  - pepper spray in, 133–134
  - psychiatric issues in, 132, 134, 136
  - SIDS and, 131
  - vagal stimulation in, 131
- Chop wounds
  - accidental, 361
  - defined, 357
  - motorized tools, 363
- Chronic aspiration, 137–138, 140f
- Chronic care facilities, hanging in, 74–75
- Circuit types in electricity, 213
- Circumrescue collapse, 254
- Clothing
  - in bathtub drownings, 277
  - decomposition and, 41
  - examination of, 10, 310, 372
  - and falls from heights, 425
  - and fire, 187
  - in firearms injuries, 310, 319–321, 346
  - in identification, 8, 188
  - personal effect, 189f
  - and sharp-force injuries, 359t, 371–372, 374f, 387
- CNS. *See* Central nervous system (CNS)
- Coagulopathy, transfusions, 7
- Coal gas suicides, 151
- Cocaine. *See also* Drug abuse
  - body temperature and, 40
  - in excited delirium, 142
  - injection of, 395f
  - levels, determination of, 522
  - and rhabdomyolysis, 457
  - and rigor mortis, 26
  - in taser deaths, 143
- Cold-shock response, 253
- Cold water, immersion in, 253–255
- Coma, 589–591
- Commotio cordis (cardiac concussion), 433–435
- Commotio medullaris (brainstem concussion), 566, 607, 613–616
- Communication, 2, 13, 15–16
- Complete autopsy, 2, 12
- Concurrence observations in time of death
  - determination, 59–60
- Concussion defined, 525
- Confined space deaths
  - described, 154–156
  - fire in, 182, 210
- Consensual sexual activity
  - bite marks in, 419
  - death from, 119
- Contraction band necrosis, electrocution, 224
- Contusions (*See* Cerebral contusions)
  - described, 406, 407f
  - mimicry of, 33, 42–43, 51f
  - multiple, alcoholics, 417f
  - origins of, 410, 411
  - perception of, 414
  - periorbital, 525f
  - pulmonary, 439–441
  - punch, 416f
  - scalp, 411, 413f, 526
- Coronary arteries, blunt trauma in, 434
- Corpus callosum, lesions of, 558–561
- Craniocerebral injuries
  - in brainstem failure, 607
  - cause of death determination, 592
  - described, 519–521
  - and the pituitary gland, 588
  - subarachnoid bleeding in, 543–544
  - syndromes of, 588–591
- Craniospinal trauma in children, 585–588
- C-reactive protein, 450
- Creche coronary, 131
- Cricoid fractures, 94t, 98, 100f
- Crocodile skin, 221, 222f
- Current in electricity, 214–215, 221–222
- Cutis anserina (goose bumps), 24, 268

Cyanide in incapacitation, 197

Cyanosis of the face, 33

Cylinder gap effect, 318, 329f

## D

DAD. *See* Diffuse alveolar damage (DAD)

DAI. *See* Diffuse axonal injury (DAI)

DC circuit, 213, 226. *See also* lightning strikes

Dead at the scene, 588–590

fire-related deaths, 185–188, 194–203

Decapitations, 100

Decomposition (*See* Trauma, decomposition and)

anthropophagy and, 41, 49f, 55–57

burial and, 41

cause of death determination, 49

changes, progression of, 41–49

in children, 41

and clothing, 41

discoloration in, 42–43

drowning and, 244, 268

environment and, 41, 49

factors promoting, 41

in firearm injuries, 49f

of hair, 46

overview, 40–41

and petechiae, 35, 36f

rigor mortis and, 26

soft tissue trauma and, 17

variations of, 49–52

Decompression sickness, 281–283

Decubitus ulcers, 422–424

Deep venous thrombosis (DVT), 451, 453–454

Defense wounds, 107t, 360t, 377–380, 419

Degradation described, 44, 46

Dementia and TBI, 593–594

Dementia pugilistic, 594

Depot-derived fat embolism, 450

Diaphragm, blunt trauma to, 440–442

Diatom analysis testing, 266–268

DIC. *See* Disseminated intravascular coagulation (DIC)

Diffuse alveolar damage (DAD), 6

Diffuse axonal injury (DAI), 520, 547, 555, 558–564, 583, 591

Diffuse Lewy body disease, 593, 594

Diffuse vascular injury, 564–565

Discoloration

in carbon monoxide poisoning, 32, 33, 34f

in decomposition, 42–43

ears in drowning victims, 264f

in hydrogen sulfide poisoning, 33

in livor mortis, 32–35

in strangulation injuries, 35f, 36

Disease

choking and, 134

and drowning, 256

fat embolism and, 449

in fire victims, 205

and impalement, 362

other CNS, as cause of unexpected neurological death, 608

other, CNS in TBI, 521

soot and, 205

and trauma similarities, 5

Dissection, aortic, 438

Disseminated intravascular coagulation (DIC)

described, 6–7

hemolysis

in drowning, 251

in decompression sickness, 283

in post-burn victims, 209t

Dissolution, 46–49

Distension, 43–44

Distribution in livor mortis, 31–32

Diving, types of, 279

Diving deaths, 255, 278–285

Diving reflex in cold-shock response, 251, 255

Documentation methodology, 9, 409

Dog bites, 388–389

Drowning

in accidental death, 271, 274–275, 277f

in adolescents, 244

alcohol and, 244, 245, 252, 256–257, 271

artifacts, postmortem, 268–271

bathtub, 245, 248t, 249t, 251, 257, 257f, 267, 271–278

blunt trauma and, 255

brain damage in, 251, 253

break point in, 252

in buckets, 245–246

cause of death determination, 243–244, 277

in children, 245, 246, 275

decomposition in, 244, 268

described, 243

determination of, 265–268

discoloration in petrous ridges, 264f

disease and, 256

- drug abuse and, 244, 257
  - dry, 252, 256, 266
  - elderly persons, suicide by, 275–276
  - electrolyte disturbance in, 251
  - and epilepsy, 256, 274, 274f, 275f, 276f
  - gastrointestinal tract in, 264, 267, 280
  - heart disease in, 254, 256
  - heart weights in, 263–264
  - homicide by, 244, 256, 268, 277, 278f
  - hypoxia in, 246, 250–254
  - in infants, 245, 246, 277f, 278f. *See also*  
    - Infants, drowning in.
  - lungs in, 260–263
  - in males, 244, 245, 258. *See also* males,  
    - drowning in.
  - manner of death determination, 243, 244,  
    - 272t–273t
  - mechanism of, 246, 250–251, 255–256
  - motor vehicle crashes and, 245, 255
  - natural death, 272t–273t, 277
  - near-drowning, 252–253
  - organ weights in, 263, 264
  - psychiatric issues in, 247t–249t
  - pulmonary edema in, 252, 260–263
  - respiratory arrest in, 251
  - risk factors, 244–246
  - saltwater, 250, 251, 260, 262, 265, 270
  - secondary, 252
  - suicide by, 244, 246, 247t–249t, 250f,  
    - 257, 258, 271, 275–277
  - suicide notes in, 246, 247t, 249t
  - in swimming pools, 245, 267
  - toxicology, 247t–249t, 256, 257, 274
  - vagal stimulation in, 250
  - wet (*See* Wet drowning)
  - witness to, 243
- Drug abuse. *See also* Cocaine.
  - asphyxia and, 142
  - and drowning, 244, 257
  - in fire incapacitation, 197
  - in sharp-force injuries, 379
  - and suicide attempts by hanging, 74, 76,  
    - 361
  - track marks, 396f
  - venipunctures, self-inflicted, 395f
- Drying. *See* mummification.
- Duct tape in smothering, 126
- E**
- Ears
  - barotrauma in, 280
  - contusions, 525f
  - in drowning victims, 264–265
- Edema
  - in anaphylactic shock, 390
  - cerebral, gunshot injury, 328 (*See* Brain  
    - swelling)
  - in post-burn victims, 208t
  - pulmonary (*See* Pulmonary edema)
- Education
  - and autopsy, 2, 11, 12, 15
  - photography in, 9–10
  - tissue retention in, 13–14
- Elderly persons
  - aspiration in, 136
  - bruising in, 410–411
  - burn injuries in, 182, 185
  - chest wall fractures, 426
  - COHb levels in, 198
  - cold-shock response in, 253
  - CSDHs in, 538–539
  - hanging in, 73f
  - hyoid fractures in, 95, 96
  - plastic bag asphyxia, 123–124
  - rigor mortis in, 26
  - SCI in, 580
  - suicide by drowning, 275–276
- Electrical appliances, electrocution by, 216
- Electrical cord injuries, 37f, 78
- Electrocution
  - accidental death, 217
  - bathtub, 216, 219, 277
  - charring in, 220
  - described, 211–215
  - epidemiology/circumstances, 215–217
  - homicide by, 217
  - hypoxia in, 214
  - internal injuries, 221t, 223–227
  - microscopy/trace evidence, 227–228
  - rigor mortis in, 30f, 213
  - suicide by, 217
  - water submersion, 255
- Electrolyte disturbance in drowning, 251
- Emaciation and rigor mortis, 26
- Embalming artifacts, 54–56
- Embalming procedure, 54
- Embolism
  - air, 392–393, 455
  - amniotic fluid, 455, 456f
  - bone marrow, 451, 453f
  - brain, 454, 455f
  - cartilage, 455

- fat, 206, 449–451
  - liver, 454, 456f
  - megakaryocytic, 455, 457f
  - thromboembolism (*See* Thromboembolism)
  - Endocrine dysfunction and hypothermia, 417
  - Endoscopy, limited autopsy, 12
  - Energy absorption/dissipation in injury, 520–521
  - Entry wounds
    - determination of, 342, 344, 346, 347
    - firearms, 302–304, 306–317, 320–321, 325–326
    - fracture patterns of, 333–335
    - handguns or rifles, 301f, 303f, 305f, 308f–311f, 313f–315f, 319f–322f, 324f, 333f, 335f, 342f. *See also* Shotguns, wounds by.
    - skull, 332–338
    - thermal injuries, 220
  - Environment and decomposition, 41, 49
  - Epidermal necrosis, electrocution, 220
  - Epidural hemorrhage (EDH)
    - in asphyxia, 122
    - autopsy procedure, 522
    - cause of death/blood volume in, 540–542
    - in charring deaths, 193, 196f
    - in firearms injuries, 338
    - posterior fossa, 556
    - in skull fractures, 529, 532–535, 540–542
    - in unexpected neurological death, 608
  - Epilepsy
    - and craniocerebral injuries, 592, 607
    - drowning and, 256, 274, 276f. *See also* Drowning and epilepsy.
    - sudden death from, 608, 616
    - SUDEP, 616
  - Equipment in diving deaths, 278, 283–284
  - Ethanol intoxication, 73f. *See also* Alcohol.
  - Evidence collection
    - in firearms injuries, 317, 326f
    - overview, 15
  - Excited delirium, 142
  - Exit wounds
    - examination of, 342, 347
    - firearm injuries, 304, 306, 308f, 315, 324, 328
    - fractures in, 333–335
    - mimicry of, 315, 322f
    - shored, 304, 307f
    - skull, 332, 333
    - thermal injuries, electrocution, 219f, 220
  - Explosions. *See* blast injuries
  - Exsanguination
    - from sharp-force injuries, 361, 375, 385, 386, 391. *See also* Sharp-force injuries, exsanguination.
    - from skin laceration, 410, 411f
    - from skull fractures, 529–530
    - in thermal injuries, apparent, 194
  - External examination
    - autoerotic asphyxia, 114–117
    - choking, 134
    - CO poisoning, 152
    - hanging deaths, 78–86, 119–120
    - overview, 8–11
    - plastic bag asphyxia, 126
    - SIDS/smothering, 122, 128
    - submerged body, 257–258
    - traumatic asphyxia, 146–147
  - Extra-Alveolar Air Syndrome, 279–281
  - Extremities
    - blunt trauma in, 448–449
    - charring of, 185, 195f
    - electrical burns on, 218
    - heat amputation of, 193
    - injury in falls, 426
  - Eyes
    - hemorrhage in, 36, 37f, 38f, 338, 525f
    - postmortem changes in, 49, 51, 51f (*See also* Periorbital hematomas; Taches noires sclérotiques)
    - sharp-force trauma, 384
    - in vitality determination, fire death, 199–200
- F**
- Face
    - chain saw injuries, 363
    - charring of, 185
    - cyanosis of, 33, 83
    - in identification, 8
    - injuries from firearms, 331, 336, 339f
    - injury, simulation of, 44
  - Falls from heights, 424–427
  - Fat embolism, 206, 449–451
  - Fat embolism syndrome (FES), 449–451
  - Feet, electrical burns on, 218, 219f
  - Feet, skin degloving in, 48f
  - Feline predation, postmortem, 57, 58



## Females

- adipocere in, 52
- autoerotic asphyxia in, 113, 114, 116
- defensive injuries in, 377
- firearm injuries in, 296
- homicide, location, 361
- human bite marks in, 421
- murder-suicides of, 296
- self-immolation in, 182
- sharp-force injuries in, 359t–360t
- suicide prevalence in falls, 424

## Fingerprinting

- of burn victims, 190
- of firearms, 342
- methodology, 10
- and mummification, 50f
- soot mimicry of, 327f

## Fingers, sharp-force injury, 363, 380f

Firearm injuries. *See also individual weapon**type by name*

- abdominal, 313, 333f
- accidental, 296
- accident creation in, 300
- alcohol in, 345–346
- autopsy procedures, 346–347
- backspatter in, 318, 319, 330f, 343, 344
- beveling in, 332–333, 339f
- blood vessels, 331, 339
- brain, 328–330, 336–338, 343f, 344f
- bullets, comparison of, 340
- cerebral contusions in, 328, 336, 337f, 338f, 344f, 554
- chest, 313, 315, 339, 340
- clothing in, 310, 319–321, 346
- concealment of, 184f
- decomposition in, 49f
- demographics of, 295–296, 300
- entry wounds (*See* Entry wounds)
- epidural hemorrhage in, 338
- evidence collection in, 317, 326f
- exit wounds, 304–306, 308f, 315, 324, 328
- face, 331, 336, 339f
- in females, 296
- fingerprinting of
  - firearm, 342
  - hands, 327f
- gunshot residue, determination of, 344–345
- head, 306, 327–328, 341f, 345f
- heart, 331, 339

hemorrhage in, 308, 309f, 338, 340, 344f, 345f

homicide, 297, 298, 307, 309f, 310f, 313, 333f

incapacitation in, 319, 328–329. *See also* Incapacitation, in firearm injuries.

infections from, 331

injury potential/lethality of, 326–331

internal, remote, 338–340

interpretation of, 9

intracranial ricochet, 336–337, 342f, 343f

in males, 296

mimicry of charred body, 193, 196f

mouth, 315–316, 323f

multishot, 313–315, 319f, 320f, 344f

psychiatric issues in, 299, 300

radiography in, 308, 309f, 312f, 321–325, 347

scene, examination of, 296–302

self-inflicted (*See also* Suicide, by firearm)

described, 295–302

entry wound range in, 306–311

hands in, 317–319

wound location in, 311–313

wound track in, 336f

and sepsis, 339f

skin, 315–316

skull, 323, 324f, 332–338

soft tissue, 340

soot in, 301f, 303, 307–311, 313–315, 318f, 321, 340, 342, 347

spinal cord injuries, 330

suicide notes in, 299

tangential, 337–338

toxicology, 345–346

## weapon

examination of, 342–344

removal of, 297–298

types of, 296–297, 302

witnesses to, 300

wound retention in, 342, 347

wound track in, 336f, 340–341, 343f

## Fires

circumstances of, 181–182

described, 182–185

lethality in, 194

Firing hand, 318, 345

First-pass phenomenon, 202–203

Flail chest, 428

- Flame injury, 181  
Flash burns, 216, 221  
Flashover, 182, 194, 223  
Flies, 55–57  
Force. *See also* Velocity  
    applied, degree of sharp-force injury, 368, 371–372  
    defined, 406  
    degree/direction of, 410–411, 428, 520, 524, 530f  
Foreign body aspiration. *See* Choking deaths.  
Forensic autopsy, 2, 3t–4t, 9  
Forensic entomology, 55–57  
Fractal defined, 223  
Fracture–dislocations  
    in cervical fractures, 574, 576, 578, 581f  
    classification of, 584  
    as complication of resuscitation, 430t  
    described, hanging, 99  
    examination of pelvis, 447  
    in lumbar fractures, 579, 580  
Fractures  
    burst, 580  
    butterfly, 474  
    cause of death determination in hanging, 100  
    cerebral contusions, 533f  
    cervical, 99–101, 578–579, 581, 614f  
    chest wall, 426, 428, 487  
    classification/patterns of, 525–528  
    contrecoup, of skull, 527, 528f  
    cricoid, 94t, 98, 100f  
    and DVT, 453  
    in entry/exit wounds, patterns of, 333–335  
    falls from heights, 426  
    fat embolism and, 450  
    in hanging deaths, 90–101, 121  
    heat, 185, 193, 195f  
    hemorrhage near, 87  
    hinge, of skull base, 529  
    hyoid bone, 92–99  
    incidence, age and hyoid fracture, 98  
    lumbar, 579–580  
    motor vehicle collisions, 474–476  
    and obesity, 100, 101f  
    occipital condylar, 531  
    pelvic, 447–448, 476, 477f, 480  
    pneumothorax from, 426, 428, 430t, 440  
    in ribs, 426, 428, 429f, 431, 445–446  
    in rigor mortis, 29f  
    ring, 529  
    from seat belts, 464  
    signs of, 408, 409f  
    skull (*See* Skull, fractures)  
    spinal cord injuries, 578–580  
    in strangulation injuries, 92–95  
    in suicide by hanging, 91–92, 94t  
    superior horn, 93f, 98, 99f, 105  
    thoracic, 579, 582f  
    thyroid cartilage, 98  
    vertebral  
        classification/pathogenesis, 575–577  
        detection of, 575  
        wedge, 579–580  
Free falls from heights, 424–427  
Frostbite, 418f  
**G**  
Gagging, 138. *See also* Choking deaths  
Gas outlet burns, 310  
Gastric contents  
    aspiration of, 136–137, 252  
    emptying, factors affecting, 54  
    in time of death determination, 52–54  
Gastroesophageal reflux in acute aspiration, 136, 137  
Gastrointestinal tract  
    blunt force trauma to, 442  
    in drowning victims, 264, 267, 280  
Gas use in smothering, 126  
Genital mutilation  
    in autoerotic asphyxia, 85, 115, 116  
    in consensual sexual activity, 119  
    described, 381  
    in homicide, ligature strangulation, 107t  
    in sexual assault, 102  
Gettler test, 265  
Goose bumps (*Cutis anserina*), 24, 268  
Gunshot residue, determination of, 344–345  
**H**  
Hair  
    decomposition of, 46  
    in fire situations, 189–190  
Handguns (*See* Rifles)  
    described, 302  
    entry, 309f (*see also* Entry wounds, handguns or rifles)  
    gunshot residue determination in, 345  
    in suicide, 296, 297, 300, 312 (*see also* Suicide, by firearm)

- velocity of, 326–327
- Hands
  - chain saw injuries, 363
  - cylinder gap effect, 318, 329f
  - electrical burns on, 218
  - examination of contact firearm wounds, 347
  - gunshot residue, determination of, 344–345
  - muzzle gap effect on, 330f, 331f
  - in suicide by firearm, 317–319, 326f, 332f
- Hanging deaths. *See also* Neck compression; Suicide, hanging
  - accidental, children/adolescents, 75–78, 82
  - autoerotic asphyxia, 111–117
  - autopsy procedures, 86–102, 120–121
  - described, 70–72
  - during incarceration, 72–74
  - external examination, 78–86, 119–120
  - fractures in, 90–101, 121
  - homicide, 72, 77–78, 80, 86
  - in nursing homes/chronic care facilities, 74–75
  - in psychiatric institutions, 74
  - judicial, 99, 102f
  - manner of death determination, 78
  - neck ligatures in, 78–80
  - petechiae in, 66–68, 83–84, 90, 102
  - suicide
    - males, 72, 74–76, 85
    - neck compression in, 65–66, 79–82, 301f
    - notes in, 72, 76
    - vagal stimulation in, 86, 111
- Hangman's fracture, 99, 102f
- Hara-kiri, 375
- Head-down position in asphyxia, 139–141
- Head injury
  - aneurysm rupture and, 617
  - in car crashes, 470, 472, 477–478
  - cardiorespiratory changes after, 613–616
  - disability following, 589t, 591–592, 594
  - in falls, 426
  - by firearm, 306, 327–328, 341f, 345f
  - and SND, 610
- Heart
  - blunt trauma injury to, 406, 432–434
  - cold water response of, 251, 254–255
  - electrical damage to, 214, 215, 220, 221t, 223
  - injuries from firearms, 331, 339
  - stab wounds in, 368, 384–386
  - weights in drowning deaths, 263–264
- Heart disease
  - in autoerotic death, 119f
  - and cold-induced arrhythmia, 417
  - in drowning death, 254, 256
  - petechiae in, 69
  - in SND, 618
  - in unexpected neurological death, 608
- Heating systems in CO poisoning, 151
- Heat loss, postmortem. *See* Body cooling (algor mortis)
- Heavy machinery, traumatic asphyxia in, 145–146
- Heights, free falls from, 424–427
- Heimlich maneuver, 136
- Hematoma
  - in blunt force injuries, 411, 413f
  - periorbital, 36, 37f, 38f, 338, 341f, 527
  - subcapsular–intrasplenic, 444
- Hemoglobin, contusion, 414
- Hemorrhage
  - aging, 415
  - from blunt trauma, 340, 410, 411
  - brainstem, 572, 573f
  - in burn victims, 200–201
  - cerebellar, 555–557
  - and CNS disease, 521
  - diffuse vascular injury, 564–565
  - Duret, 572
  - epidural (*See* Epidural hemorrhage [EDH])
  - eyes, 36, 37f, 38f, 338, 525f
  - in firearm injuries, 308, 309f, 338, 340, 344f, 345f
  - fractures, hanging, 87
  - frank coagulopathy, 6–7. *See* Disseminated intravascular coagulation (DIC)
  - intracerebral (*See* Intracerebral hemorrhage)
  - intracranial, 531–547
  - intraventricular, 546
  - livor mortis, 35–38
  - location and spinal cord injury, 575
  - in neck compression, 38, 39f, 105
  - peridural, 540, 542, 581
  - in post-burn victims, 208t, 209t
  - postmortem, 35–39, 80
  - retroperitoneal, 446–447

- in rib fractures, 429f, 431
- sites of hanging, 88–90
- and SND, 617, 618f
- in soft tissue, 38, 39f, 87–88, 93f, 193
- in stab wounds, 366, 370f, 377, 383f
- subarachnoid (*See* Subarachnoid hemorrhage [SAH])
- subdural (*See* Subdural hemorrhage [SDH])
- tongue, 101–102, 200
- Hemosiderin, 414, 416, 534, 538, 550, 551
- Hemosiderosis, 542f
- Hemothorax
  - from air bag deployment, 468t
  - from blunt trauma, 428, 430t, 432, 436, 438, 440
  - from catheter insertion, 393
  - and postmortem bleeding, 35
  - from stab/incision wounds, 386
- Henry's law defined, 279
- Herniation
  - brain, 538, 540, 542, 571, 572f
  - contusions, 554, 555f
- Hesitation wounds, 85, 360t, 376f, 377–379
- Hip injuries, 476, 480
- Histamine, 389
- Hog-tied prone position, 142
- Homicide
  - autoerotic asphyxia, 113
  - bone/cartilage injuries in, 381, 383
  - choking, 134
  - clothing in, 372
  - concealment of blunt trauma, 486
  - decomposition in, 49f
  - by drowning, 244, 256, 268, 277, 278f
  - by electrocution, 217
  - exit wounds in firearms, 306
  - females, location, 361
  - by firearm, 297, 298, 307, 309f, 310f, 313, 333f
  - in fire scene, 184f, 194–202
  - fractures in neck, 92–93
  - gagging, 138
  - genital mutilation in strangulation, 107t
  - hanging victims, 72, 77–78, 80, 86
  - intent, indication of, 3t, 366
  - ligature strangulation (*See* Ligature strangulation)
  - manual strangulation, 104–105, 108f, 109
  - mimicry of, by motor vehicle trauma, 482, 484
  - overview, 3t
  - patterned injury in, 419
  - purposeful activity after, 384
  - rifles in, 334, 334f
  - sexual assault and asphyxial deaths, 77, 102
  - sharp-force injuries in, 358–361, 370f, 374, 380f, 383
  - smothering, 121, 122, 124, 128
  - suicide, multishot, 313–315, 319f, 320f, 344f
  - traumatic asphyxia, 145
  - vs suicide, 379
- Hospital autopsy, 1, 2, 3t, 4t, 9, 11
- Human bite marks, 419, 421–423
- Hunting incidents, 300, 301f, 340
- Hydrogen sulfide poisoning, discoloration in, 33. *See also* Space-hypoxia syndrome
- Hydrothorax, 393
- Hygromas, subdural, 538
- Hyoid bone fractures, 92–99
- Hypercoagulability, 5. *See* Pulmonary thromboembolism.
- Hypostasis, 28, 37. *See* Livor mortis.
- Hypotension, 566
- Hypothermia
  - and blood coagulation, 7
  - blunt trauma and, 409f, 412f, 416–419
  - in cold water immersion, 253–255
  - in confined space death, 156
  - in diving deaths, 255, 284
  - and rectal temperature, 40
  - and rhabdomyolysis, 457
  - in SIRS, 6
- Hypoxia. *See also* Hypoxic–ischemic encephalopathy
  - in autoerotic asphyxia, 111, 118
  - brain damage from drowning, 254
  - brain protection from, 255
  - and capillary rupture, 67
  - in CO poisoning, 152, 155
  - in drowning, 246, 250–254
  - in electrocution, 214
  - in positional asphyxia, 141, 142
  - in SIDS, 122
  - in smothering deaths, 126
  - stagnant, 66
  - unconsciousness from, 252
- Hypoxic–ischemic encephalopathy, 523, 563, 565–570, 586, 591, 612

**I**

Iatrogenic illness, 390, 391

Identification

- of fire victims, 188–190, 191f, 192f
- overview, 3t–4t, 7–8
- photography, 10
- in suicide determination, 246

Immersion in cold water described, 253–255

Immersion response, 254

Immersion syndrome, 252

Immobilization, 5. *See* Pulmonary thromboembolism.

Impact severity, 406

Impalement

- described, 357, 362, 366
- of the palate, 384
- of the skull, 363f, 383, 385f
- stabbing, 364, 372

Incapacitation

- in accidental death, bathtub, 271
- asphyxia and assessment of, 137, 148, 487
- during fire, 194–197
- in firearm injuries, 319, 328–329
- in manner of death determination, 295
- tasers in, 143

Incision wounds

- accidental, 361
- autopsy procedures, 387–388
- correlation of, 364–373
- defined, 357, 358f
- direction, determination of, 375
- mechanism of death, 386–387
- self-inflicted, 374f–376f, 382f

Infanticide, 121, 122, 278f, 370f

Infants (*See* Non-accidental injury)

- body temperature in, 40
- brain swelling in, 585–587
- choking in, 131, 133f
- craniospinal trauma in, 585–587
- decomposition in, 41
- drowning in, 245, 246, 277f, 278f. *See also* Drowning, in infants.
- rigor mortis in, 26
- SDH in, 586–588
- smothering of, 121, 122, 126–128
- wedging in, 129–130

Infections

- from CSF leakage, 530–532
- of decubitus ulcers, 423
- from dog bites, 388
- from firearms injuries, 331

- in post-burn victims, 208t, 209t
- and sudden neurological death, 609

Inflammatory response

- in anaphylaxis, 389
- to animal predation, 58
- in antemortem changes, 46
- and ARDS, 6
- and cerebrocranial/vertebrospinal injuries, 520
- to choking, 131, 134, 136–138, 140f
- to contusions, 550–551
- in decubitus ulcers, 423
- in diving deaths, to stomach lacerations, 280

fat embolism in, 450

in injury aging, 414, 415

to neck compression, 105

SCI, 580, 583

in seat belt injury, pancreas, 461t

to smoke inhalation, 210

in thermal injuries, 193

Inhalants in autoerotic asphyxia, 118

Inhalation injury. *See also* Smoke inhalation

- burn epidemiology in, 207
- described, 200, 201f, 202f
- determination of, 210
- soot and, 205, 210

Injections, 389–390

Injury. *See also* Wounds

- aging of, 411–416
  - air bag deployment, 464–469
  - brain (*See* Brain, injury; Traumatic brain injury [TBI])
  - catheters, 391–393
  - causation, 406
  - documentation of, 10, 522
  - energy absorption/dissipation in, 520–521
  - head (*See* Head injury)
  - inflammatory response in, 414, 415
  - inhalation (*See* Inhalation injury; Smoke inhalation)
  - light aircraft fatalities, 487t
  - to neurons, 520, 566–567, 583
  - patterned, 419, 422f, 457
  - patterns of, 416–422, 425–426, 521
  - resuscitation, 4, 9, 85, 395f, 430t
  - seatbelt-associated, 460–463
  - spinal cord (*See* Spinal cord injuries [SCI])
  - vertebral column, 576–577
- Insects, 41, 49f, 55–57, 389–390
- Instantaneous rigor described, 26–27



Intensive care, complications during, 6–7

**Intent**

- accidental death, 3t, 150, 151, 152, 154
- homicidal, indication of, 3t, 366
- suicidal, 2, 3t, 53f, 105, 111, 246, 257, 295

Internal examination. *See* Autopsy findings

Internal jugular vein (IJV) valve, 68–69

**Intracerebral hemorrhage**

- artifactual/trivial, 546–547
- traumatic, 544–546

**Intubation**

- and aspiration, 136
- inflammatory response to smoke inhalation, 210
- injuries from, 109–110, 372, 373f

Involuntary muscle in rigor mortis, 24–25

Ischemia, 224. *See also* Hypoxic–ischemic encephalopathy

Isthmus of aorta, 434–436

**J**

Jackknife injury, 145

Jaw, examination of rigor mortis, 27

Joint stiffening in rigor mortis, 25–28

Joule's law defined, 213

Judicial hangings, 99, 102f

Jugular venous system and petechiae, 68

Jumpers, 424

**K**

Ketosis, cold-induced, 419

Kidney failure in post-burn victims, 208t, 209t, 224

Kidney weights in drowning deaths, 263

Kinetic energy, 406, 472

Kissing burns, 220

Knife angle and skin surface, 366

Knife wounds, correlation of, 364–372. *See also* Stab wounds

**L**

**Lacerations**

- brain, 547–557
- described, 406, 408
- direction of force determination in, 411
- histological assessment of, 414, 415f
- mesentery, 442, 443f
- pericardial, 432

Larynx, anatomical variations in, 97f

Lichtenberg figures, 223

**Ligature strangulation**

- accidental, 108f
- autoerotic asphyxia, 111–117
- described, 70
- in hanging deaths, 78–80
- homicide vs suicide, 106t–107t
- suicide by, 103–104
- toxicology, 105

Light aircraft fatalities, 486–488

**Lightning strikes**

- arcing in, 220
- effects of, 220–224, 226, 227
- formation of, 217
- nature of, 213–215

Limited autopsy, 12, 13

**Liver**

- blunt force trauma to, 442
- embolism, 454, 456f
- failure in post-burn victims, 208t
- injuries, motor vehicle collisions, 442
- weights in drowning deaths, 263

Lividity, patchy, 28–29, 31

**Livor mortis**

- described, 28–31, 33f–38f, 44f
- discoloration in, 32–35
- distribution/pressure points in, 31–32
- hemorrhage, postmortem, 35–38

Long guns. *See* Rifles; Shotguns

Longitudinal spreading lesion, 582f, 584

Long-scarf syndrome, 103–104, 108f

Lucid interval, 589–590

Lumbar fractures, 579–580

**Lungs**

- anaphylactic shock, postmortem assessment of, 390
- blast injuries in, 229
- blunt trauma to, 439–441
- diatoms in, 267
- disease and petechiae development, 69
- divers, volume in, 280
- in drowning deaths, 260–263
- edema in, 6 (*See also* Pulmonary edema; Neurogenic pulmonary edema)
- electrocution injury in, 225
- inhalation injury to, 200
- stab wounds in, 370f
- weight of drowning, 260–261

**M**

Maggots, significance of, 57

## Males

- autoerotic asphyxia in, 112, 116
- CO poisoning in, 150
- CSDHs in, 538
- drowning in, 244, 245, 258
- firearm injuries in, 296
- homicide, location, 361
- human bite marks in, 421
- hyoid development in, 95
- plastic bag asphyxia in, 125t
- railroad-related deaths in, 485
- sexual assault of, homicidal hanging, 77
- sharp-force injuries in, 358–361
- suicide
  - by hanging in, 72, 74–76, 85
  - by smothering/suffocation, 126
- tasers and, 143
- thermal injuries in, 181, 182, 216, 217

## Mammalian diving response, 255

## Manner of death determination

- drowning, 243, 244, 272t–273t
- flame injury, 181
- in hanging deaths, 78
- incapacitation in, 295
- overview, 3t, 5, 10–11
- sharp-force injuries, 358–360
- smothering, 121
- in suicide, 2, 3t, 10, 76

## Marbling defined, 42, 44f

## Mask squeeze, 280

## Masque ecchymotique, 146–147

## Mast cell activation, measurement of, 390

Mechanical asphyxia, 65–66. *See also*

- Hanging deaths; Wedging;
- Smothering; Choking; Choking deaths;
- Aspiration; Gagging; Positional
- asphyxia; Ligature strangulation;
- Strangulation injuries, manual;
- Drowning.

Medical care, 372, 381f, 390. *See also*

- Intubation; Resuscitation

Medical records. *See* Charts, review of

## Medicolegal death investigations

- autopsies in, 2, 5f, 10, 12
- microscopy in, 14
- photography in, 9–10

## Megakaryocytic embolism, 455, 457f

## Mendelson's syndrome, 136

## Mesentery lacerations, 442, 443f

## Messerer's wedge, 474

## Methemoglobinemia, discoloration in, 33, 34f

## Microgliosis, 560

## Microscopy, 14

## Minor neurological disability, 589t, 591–592

## Moderate neurological disability, 589t, 591, 592

MODS. *See* Multiple organ dysfunction syndrome (MODS)

## Motorbike injuries, 574

## Motorized tools, injuries by, 363, 365f, 377, 383

## Motor vehicle collisions

- air bag deployment injuries, 464–469, 579
- aortic trauma in, 434–438
- blunt trauma in, 420f, 421f, 422f
- cervical fractures in, 578
- coup contusions in, 553, 554f
- diaphragm, 440–442
- and drowning, 245, 255
- fatalities, types of, 482–484
- and fire, 189f, 203f–205f
- fire patterns in, 205
- frontal/head-on, 457–460, 474
- identification in, 189f, 192f
- and impalement, 362, 363f
- liver injuries, 442
- out-of-position front seat occupant, 465t, 466
- overview, 457
- pedestrians in, 474–481, 553, 554f
- rear-impact, 471
- respiratory tract injuries to, 439–440
- rollover collision, 471–473
- seat belts, 458–464, 470, 558
- side-impact/side swipe, 469–471
- skull fractures in, 478, 524–529
- spleen injuries, 445
- traumatic asphyxia in, 144–146

## Mouth

- examination of, 27
- in firearm injuries, 315–316, 323f

## Multiple organ dysfunction syndrome (MODS), 6

## Mummification, 49–52

## Munchausen syndrome, 381

## Murder–suicide

- classification of, 302
- perpetrators
  - demographics of, 296
  - motivations of, 299–300, 302
- temporal relationship in, 302

- toxicology, 345–346
  - witnesses to, 300
- Muscle
- electrical conduction in, 213, 214
  - electrocution injury in, 224, 225, 227
  - rigor mortis in, 24–28, 30f
  - tetany, electrocution, 213
- Mutilating injuries, 381. *See also* Genital mutilation
- Muzzle imprints, 316, 321f, 325f
- Myocardial contusion, 432, 433f
- Myocardium
- in electrocution injuries, 223, 224
  - in rigor mortis, 25
- N**
- Nail gun suicides, 323
- Natural death
- drowning, 277
  - hyoid fracture in, 96
  - in motor vehicle collision, 482
  - overview, 3t, 5–6
  - petechiae in, 69
  - water aspiration in, 244
- Near-drowning, 252–253
- Neck
- chain saw injuries, 363
  - damage, weight required, 71–72
  - furrow described, 80–83, 85f, 86f, 88f, 89f
  - postmortem hemorrhage in, 38, 39f
  - incision wounds in, 365f, 374f, 377f, 379f
  - injury and air bag deployment, 464–468
  - ligatures in hanging deaths, 78–80
  - stab wounds in, 359t, 370f, 374, 378f, 387f
- Neck compression. *See also* Hanging; Suicide, hanging
- described, 65–66
  - microscopic examination of, 105
  - petechiae in, 66–68, 83–84, 90, 102
  - signs of, 80–83
  - in suicide by hanging, 65–66, 79–82, 301f
  - tongue injuries in, 101–102
- Needle insertion, limited autopsy, 12
- Neurofibrillary tangles (NFTs), 593, 594
- Neurogenic pulmonary edema (NPE), 592–593
- Neuroimaging studies in CNS examination, 521–522
- Neurons
- dark/dusky red, 568f, 569, 570f
  - injury to, 520, 566–567, 583
  - selective neuronal necrosis, 566–569, 583
- Newborns, body temperature in, 40
- Nitrogen in decompression sickness, 281–283
- Nitrogen narcosis, 279
- Nonaccidental injury (NAI), 585–587
- Nonfiring hand, 318, 345
- Nursing homes
- burn epidemiology in, 206–207
  - decubitus ulcers in, 423
  - hanging in, 73–75
  - restraints, deaths due to, 74–75
- O**
- Obesity
- and adipocere, 52
  - bruising and, 411
  - carotid intimal tears in, 102
  - fractures and, 100, 101f
  - and rigor mortis, 26
- Observers at autopsies, 15
- Occupant restraint systems, 458–469
- Ohm's law defined, 211
- Oleoresin capsicum (OC), 133
- Organ harvesting, 12–13
- Organ retention, 13–14
- Osmolarity testing, 265
- Overlaying described in drowning, 122
- Oxygen toxicity in diving, 279
- P**
- Paradoxical undressing described, 417
- Paraphilia. *See* Autoerotic death
- Paraplegia, isolated, 589t, 592
- Particulate material, aspiration of, 137
- Pathologist, role of, 1–2, 12
- Pathway of electrical current in lethality, 214–215
- Patients who talk and die, 589–590
- PCP (phencyclidine [phenyl-cyclohexyl-piperidine]), 143
- Pedestrians in motor vehicle collisions, 474–481
- Pelvis
- fractures of, 447–448, 476, 477f, 480
  - mummification in, 52f
- Pencil-shaped necrosis, 582f, 584
- Pepper spray in choking deaths, 133–134
- Perforation injuries, catheter, 393–394

- Pericardial laceration, 432
- Periorbital hematomas, 36, 37f, 38f, 338, 341f, 527
- Personal effects in identification, 8, 188, 189f
- Petechiae (Tardieu spots)
  - by chest compression, 68–69
  - conjunctival, 68, 69
  - in craniocerebral injuries, 588
  - in deaths due to restraints, 84
  - decomposition and, 35, 36f
  - described, 36f, 37f, 38f
  - development of, 35, 69, 83–84
  - differential diagnosis of, in brain, 565
  - diffuse vascular injury, 564–565
  - in electrocution injuries, 223–224
  - in the eyes, from firearm injuries, 338
  - facial, 68, 69
  - in heart disease, 69
  - in human bite marks, 421
  - in neck compression, 66–68, 83–84, 90, 102
  - in plastic bag asphyxia, 126
  - in SCI, 583
  - in SIDS, 67f, 69–70
  - smothering and, 67
  - in strangulation injuries, 67
  - subgaleal, 67
  - on submerged bodies, 268
  - thymic, 67f
  - in traumatic asphyxia, 146–147
- Pet predation, postmortem, 57–59
- Phencyclidine (phenyl-cyclohexyl-piperidine [PCP]), 143
- Photography
  - in bite mark interpretation, 422
  - in the external examination, 9–10, 346
  - in identification, 8
  - interpretation of, 9
- Pica syndrome, 131, 132f
- Pink teeth/fingernails, 43, 45f
- Pituitary gland, 588
- Plasma specific gravity testing, 265
- Plastic bag asphyxia described, 122–126, 129
- Pleural effusions in drowning deaths, 260
- Pneumonia in post-burn victims, 208t, 210
- Pneumothorax
  - from air bag deployment, 468t
  - assessment of, 284
  - in blast injuries, 230t
  - in diving deaths, 280
  - from fractures, 426, 428, 430t, 440
  - from stab/incision wounds, 386, 392, 393
  - in traumatic asphyxia, 147
- Poisoning deaths, discoloration in, 32, 33.
  - See also* Carbon monoxide poisoning
- Pornographic material in autoerotic asphyxiation, 112f, 114
- Positional asphyxia, 139–144
- Postmortem changes, assessment of, 4, 16, 23–24
- Postmortem procedures, 60
- Powder grains in firearms, 302
- Power lines, electrocution by, 216
- Power tools, injuries by, 363, 365f, 377, 383
- Pressure points in livor mortis, 31–32
- Pressure sores, 422–424
- Prison inmates, 72, 73, 360
- Projectile travel, direction of angled firearm wounds, 308
- Prone restraint asphyxia, 142, 143
- Propane poisoning, discoloration in, 33
- Pseudoaneurysms, intrasplenic, 444–445
- Pseudostippling, 310
- Psychiatric institutions, hanging in, 74
- Psychiatric issues
  - in choking deaths, 132, 134, 136
  - in CO poisoning, 153
  - in drowning, 247t–249t
  - examination of, 4. *See* Psychological autopsy.
  - and hypothermia, 417
  - mutilating injuries, 381
  - in prison inmates, 73
  - in suicides, 76, 101f, 103, 299, 300, 361, 375
  - in thermal injuries, 181, 182, 227
- Psychological autopsy, 2
- Pulmonary edema
  - antemortem, 199f
  - in diving deaths, 283
  - in drowning, 252, 260–263
  - neurogenic, 592–593
  - in SIDS death, 137
  - in smothering/suffocation, 126
  - and volume resuscitation in burn patients, 207
- Pulmonary thromboembolism, 451–454, 530
- Pulmonary vessels, trauma to, 438
- Pupil size in rigor mortis, 25, 26f
- Purge described, 44, 46f

Putrefaction defined, 40–41, 43

Pyrolysis defined, 183, 185

## Q

Quadriplegia, isolated, 589t, 592

## R

Raccoon eyes, 338, 341f, 525

Radiography

- applications of, 11, 13, 203f
- of burn victims, 190, 191f, 203f
- catheter placement, 392
- in firearm injuries, 308, 309f, 312f, 321–325, 347
- of fractures, 95
- neck, 575
- sharp-force injuries, 364
- skull fractures, 522

Railroad-related deaths, 482, 484–486

Royal College of Pathologists tissue retention guidelines, 13, 14

Red line burn artifacts, 193, 194f, 220

Relatives, legal rights of, 13

Religion and autopsies, 12, 14

Research, tissue retention for, 13–14

Resistance in electricity, 213–214

Respiratory arrest

- and chronic aspiration, 137
- in cold-water immersion, 253
- in drowning, 251
- from electrocution, 214, 215t, 226, 227
- in excited delirium, 142
- in fire deaths, 195
- from gunshot wounds, 327
- and head injuries, 613, 614f, 618f
- hypotension and, 566
- in hypoxic–ischemic injury, 523
- pepper spray and, 133
- in SND, 608, 609
- from therapeutic misadventure, 391

Respiratory tract

- blunt trauma to, 439–440
- soot in, 200, 201, 205, 206
- tears in hanging, 102

Restraints, deaths caused by. *See also* Seat belts

- hyoid fractures in, 96
- in nursing homes, 74–75
- petechiae in, 84

Resuscitation

- children, injuries in, 109–111

closed-chest injuries, 428–432

CPR (*See* Cardiopulmonary resuscitation [CPR])

face/neck injuries, 107, 109–110

injury creation by, 4, 9, 85, 395f, 430t

pulmonary edema and, 207

Retroperitoneal hemorrhage, 446–447

Rhabdomyolysis, 457, 458f

Ribs

- fractures in, 426, 428, 429f, 431, 445–446
- sharp-force injuries in, 383

Rifles

- contact wounds by, 308, 310, 336
- described, 302
- gunshot residue determination in, 345
- in homicides, 334
- in suicide, 296–299, 312, 313f
- velocity of, 326, 327

Rigor mortis

- cocaine and, 26
- and decomposition, 26
- in elderly persons, 26
- in electrocution, 30f, 213
- emaciation and, 26
- fractures in, 29f
- in muscle, 24–28, 30f
- overview, 24–28
- semen deposition in, 25, 116

Rocked knife wound, 366, 368f

Rodent predation, postmortem, 57–59

## S

Scalding, 206–207

Scale requirements, photography, 10

Scene, examination of

- autoerotic asphyxia, 112–114
- carbon monoxide poisoning, 150–152
- firearm injuries, 296–302
- overview, 2–7, 9
- thermal injuries, 185–188, 194–203

Scrotum, mummification in, 51

Seat belts, 445, 458–464, 470, 558

Seat-belt sign, 421f

Selective neuronal necrosis, 566–569, 583

Self-immolation, 182, 183f, 203

Self-inflicted cutting, 379, 381

Semen deposition in rigor mortis, 25, 116

Senile ecchymoses, 411, 412f

Sepsis

- and body temperature, 40



- as complication of ICU, 6
- decomposition and, 41
- from decubitus ulcers, 423
- firearms injuries and, 339f
- in post-burn victims, 208t, 209t
- and rigor mortis, 26
- from stab wounds, 373f
- Septicemia, 209t
- Severe disability, 589t, 591, 592
- Sexual activity, death from, 119
- Sexual assault
  - anorectal injuries in, 362
  - bite marks in, 419, 421
  - electrical injury and, 220
  - genital mutilation in, 102
  - and homicide, 77, 102
  - of males, 77
  - paradoxical undressing in, 417
- Sharp-force injuries
  - accidental death, determination of, 358–362
  - alcohol in, 362, 379
  - autopsy findings, 381–386
  - autopsy procedures, 387–388
  - in blood vessels, 383, 384, 385
  - to the brain, 383–384
  - cause of death determination, 386, 387
  - clothing and, 359t, 371–372, 374f, 387
  - correlation of, 364–373
  - drug abuse in, 379
  - exsanguination from, 361, 375f, 385, 386, 391
  - in females, 359t, 360
  - in homicide, 358–361, 370f, 374, 380f, 383
  - in males, 358–361
  - manner of death determination, 358–362
  - mechanism of death, 386–387
  - number, orientation, grouping in, 374–375
  - overview, 357
  - purposeful activity after, 384–386
  - radiography, 364
  - simulation of, 44
  - in suicide, 358–361, 372f, 374, 375, 379, 381
  - survival of, 384–386
- Shock, 6, 208t
- Shotguns
  - comparison to bullets, 341
  - described, 302
  - gunshot residue determination in, 345
  - in suicide, 296, 300, 307f
  - wounds by, 304, 308f, 312f, 324, 325f, 336, 339f
- SIDS. *See* Sudden infant death syndrome (SIDS)
- SIRS. *See* Systemic inflammatory response syndrome (SIRS)
- Skeletal muscle in rigor mortis, 25–28, 30f
- Skin
  - blunt trauma injury
    - described, 406–409
    - significance of, 409–422
  - cyanosis in copoisoning, 152
  - elasticity in stab wound correlation, 366, 371
  - electrical burns on, 217–219
  - electrical resistance in, 213–214, 219
  - electrocution injury in, 224
  - in firearms injuries, 315–316
  - necrosis, electrocution, 220
  - seat belt injuries on, 462–463
  - slippage, 47f, 48f
- Skull
  - charring of, 185, 196f
  - firearms injuries to, 323, 324f, 332–338
  - fractures
    - artifactual, 522
    - basilar, 335–336, 526f, 529, 530f, 531f
    - classification/patterns of, 525–528
    - complications of, 529–531
    - crushing, 529
    - demonstration of, 522
    - in entry/exit wounds, patterns of, 333–335
    - epidural hemorrhage in, 529, 532–535, 540–542
    - exsanguination from, 529–530
    - heat-induced, 193
    - incisions and, 358f
    - motor vehicle collisions, 99, 478
    - overview, 524–525
    - radiography, 522
  - keyhole defect of, 340f
  - stab wounds to, 383
- Sleep position and smothering, 126–128
- Smoke inhalation
  - confirmation of, 205, 206f
  - and incapacitation, 195–196
  - injury from, 207–210

- in live vs dead determination, 183, 184f, 194, 197–200, 202
- mimicry of, 194
- in motor-vehicle related fires, 205
- Smothering
  - autopsy findings, 122, 128
  - bed covers and, 126–127
  - described, 121–129
  - duct tape in, 126
  - external examination, 122, 128
  - gas use in, 126
  - homicide by, 121, 122, 124, 128
  - hypoxia in, 126
  - of infants, 121, 122, 126–128
  - mimicry of, 107
  - and petechiae, 67
  - in SIDS, 122, 128
  - sleep position and, 126–128
  - suicide by, 126
  - toxicology, 128–129
- SND. *See* Sudden neurological death
- Soft tissue
  - burns, 220
  - firearms injuries in, 340
  - hemorrhage in, 38, 39f, 87–88, 93f, 193
  - trauma and decomposition, 17
- Soot
  - and accelerant use, 203
  - in airways, 200, 201, 206
  - body coverage by, 185
  - and disease, 205
  - in firearm injuries, 301f, 303, 307–311, 313–315, 318f, 321, 340, 342, 347
  - and inhalation injury, 205, 210
  - in live vs dead determination, 197–199
  - mimicry of, 327f
  - and smoke inhalation, 194
  - trauma and, 202f
  - visual recognition, 188
- Space-hypoxia syndrome, 155–156
- Spinal cord injuries (SCI). *See also* Vertebrospinal injuries
  - categorization of, 577–578
  - described, 574–584
  - and diving, 255, 283
  - falls from heights, 426
  - from firearms, 330
  - fractures in, 578–580
  - and SND, 619
  - stab wounds in, 370f
  - traumatic, 580–584
  - traumatic, no fracture, 580
- Spleen
  - rupture in blunt force trauma, 442–446
  - weights in drowning deaths, 263, 264
- Spontaneous human combustion, 187–188
- Stab wounds
  - accidental, 361
  - autopsy procedures, 387–388
  - correlation of, 364–373
  - defined, 357
  - mechanism of death, 386–387
  - multiple, 369f, 370f, 373f, 376f, 380f
  - self-inflicted, 375, 376f, 377f, 378f (*See also* suicide, sharp-force injuries in)
  - sites of, 359t–360t, 375–377
- Sternum, fractures in, 426, 429f, 431f
- Stippling (tattooing), 303, 304f, 310, 315f
- Stomach contents. *See* Gastric contents.
- Stomach injuries, 280, 442
- Strangulation injuries
  - bite marks in, 101
  - discoloration in, 35f, 36
  - fractures in, 92–95
  - ligature (*See* Ligature strangulation)
  - manual, 104–105, 108f, 109
  - petechiae in, 67
- Stroke, 617–619
- Subarachnoid hemorrhage (SAH)
  - acute, 588, 617
  - autopsy procedure, 523
  - basilar and SND, 610–613, 617
  - contusions and, 549f
  - in DAI, 558
  - death from, 607, 617
  - overview, 607–608
  - and petechiae development, 69
  - traumatic, 543–544
- Subdural hemorrhage (SDH)
  - acute, 534, 536–538, 540–542
  - association with cerebellar contusions, 556
  - autopsy procedure, 522
  - brain swelling under, 570, 573f
  - chronic, 534, 538–542
  - in infants, 586–588
  - in unexpected neurological death, 608
- Subdural hygromas, 538
- Submerged bodies. *See also* Drowning
  - artifacts, postmortem, 268–271

- autopsy findings, 258–265
- external examination, 257–258
- overview, 243–244
- Sudden infant death syndrome (SIDS)
  - and choking, 131
  - described, 111f
  - gastroesophageal reflux in, 137
  - hanging in, 76
  - intrathoracic petechiae in, 67f, 69–70
  - smothering in, 122, 128
- Sudden neurological death (SND)
  - and berry aneurysm rupture, 616–617
  - causes of, 607, 609–610
  - and SCIs, 619
  - stroke and, 617–619
- Sudden unexpected death in epilepsy (SUDEP), 616
- Suffocation. *See* Smothering
- Suicide
  - accelerant use in, 203
  - alcohol and, 361, 375
  - bathtub, 272–273, 275–276
  - bone/cartilage injuries in, 381, 383
  - carbon monoxide poisoning (*See* Carbon monoxide poisoning)
  - in children/adolescents, by hanging, 75–76
  - choking, 134
  - clothing in, 372
  - coal gas, 151
  - COHb levels in, 198
  - complex, 300–302
  - by drowning, 244, 246, 247t–249t, 250f, 257, 258, 271, 275–277
  - drug abuse and, 74, 76, 361
  - by electrocution, 217
  - falls from heights, 424–426
  - by fire, 182
  - by firearm
    - described, 295–302
    - entry wound features in, 313–317
    - entry wound location in, 306–319
    - entry wound range in, 306–311
    - exit wounds in, by shotgun, 306
    - hands in, 317–319, 326f, 327f–331f, 332f
    - wound track in, 336f
  - gagging, 138
  - handguns in, 296, 297, 300, 312
  - hanging
    - fractures in, 91–92, 94t
    - in general population, 72, 73f
    - hand positions in, 92f
    - lividity/petechiae in, 31f, 37f
    - males, 72, 74–76, 85
    - neck compression in, 65–66, 79–86, 301f
    - soft-tissue hemorrhages in, 93f
    - vertebral artery injuries in, 102
  - impalement, 362
  - intent determination in, 2, 3t, 53f, 105, 111, 246, 257, 295
  - by ligature strangulation (*See* Ligature strangulation)
  - manner of death determination in, 2, 3t, 10, 76
  - mirrors in, 114
  - by motor vehicle, 482, 484
  - multishot, 313–315, 319f, 320f, 344f
  - nail gun, 323
  - notes
    - in autoerotic asphyxia, 112, 114
    - in CO poisonings, 150
    - in drownings, 246, 247t, 249t
    - in firearms injuries, 299
    - in hangings, 72, 76
    - sharp-force injuries, 361, 379
  - paradoxical undressing in, 417
  - plastic bag asphyxia, 123–124
  - prevalence of falls, 424
  - psychiatric issues in, 76, 101, 103, 299, 300, 361, 375
  - purposeful activity after sharp-force injury, 384–386
  - rates
    - prison inmates, 72, 360
    - in psychiatric institutions, 74
  - rifles in, 296–299, 312, 313f
  - sharp-force injuries in, 358–361, 372f, 374, 375, 379, 381. *See also* Sharp-force injuries, in suicide.
  - shotguns in, 296, 300, 307f
  - table saw, 365f
  - by train, 484, 485f, 486f
  - vs homicide, 379
  - weapons, popular, sharp-force injury, 361
- Superior horn fractures, 98, 99f, 105
- Suspension deaths. *See* Hanging deaths
- Swimming pools, drowning in, 245, 267

Systemic inflammatory response syndrome (SIRS), 6

## T

Taches noires sclérotiques, 49, 51f

Tardieu spots. *See* Petechiae (Tardieu spots)

Taser, death by, 143–144

Tattooing. *See* Stippling.

Temperature

body, 40

and death in fires, 194

decomposition and, 41

in electrical fires, 214, 221

in fires, 182–183, 185–187

rectal, 40

and rigor mortis, 26

tissue destruction, electrocution, 211, 213

Terminal burrowing behavior, 417

Thalamus, 572, 591

Therapeutic misadventure, 390–394

Thermal injuries

autopsy findings in burn patients, 208t–209t

body, dead at scene

evidentiary support, 202–203

state of, 185–188

vitality of, 194–202

burn classification, 185

burn unit patients, 206–210

complications, 207

disease and, 205

electrical burns, 217–223

gas outlet burns, 310

microscopic evaluation of, 205–206

mortality, risk factors, 207

partial thickness, 212f

radiant heat, 212f

work-related, 182

Thoracic fractures, 579, 582f

Thromboembolism

mimicry of, 54, 55f

in natural death, 5

and petechiae, 69

post-burn injury, 208t, 209t

pulmonary, 451–454, 530

Thrombosis. *See* Electrocution, internal injuries; Pulmonary thromboembolism.

Thrust impact injury, 368

Thymus, petechiae of, 67f

Thyroid cartilage, fractures in, 98

Time of death determination

concurrency observations in, 59–60

factors compromising, 4–5

gastric contents in, 52–54

heat loss equations in, 40

injury aging in, 411–416

overview, 4t

and postmortem changes, 23–24, 27, 31, 41

Tissue hypoperfusion. *See* Systematic inflammatory response (SIRS)

Tissue retention, 13–14

Toddlers, drowning in, 245

Tongue

hemorrhage, 101–102, 200

mummification in, 50f, 51

Tongue injuries

by firearm, 313

in neck compression, 101–102

Tourniquet syndrome, 448–449

Toxic gases

in burn victims, 202–203

in incapacitation, 197

Toxicology

acute aspiration, 137

autoerotic death, 118–119

carbon monoxide poisoning, 153–154, 563

drowning, 247t–249t, 256, 257, 274

firearm injuries, 345–346

in fire victims, 186, 187

fly larvae, 57

gastric contents in, 52, 53f

and incapacitation, 137, 148, 487

ligature neck compression deaths, 105

murder–suicide, 345–346

overview, 15

smothering/suffocation, 128–129

Trace evidence recovery, factors affecting, 5

Trachea/bronchii, blunt trauma to, 439

Track marks, 395f, 396f

Trauma

autoerotic asphyxia, 116

blunt (*See* Blunt trauma)

in burn victims, 203–205

decomposition and, 41

diffuse, 519

in hanging deaths, 84–86

overview, 5–6, 9, 10, 16

penetrating (*See* Firearm injuries; Sharp-force injuries)

Traumatic amputation, 225f, 226f, 485–486

- Traumatic asphyxia described, 144–148
- Traumatic brain injury (TBI)  
and dementia, 593–594  
described, 519–521 (*See also* Central nervous system [CNS])  
diffuse, 558–573  
documentation of, 557  
focal, 573–574
- Trendelenburg position, 141
- Trocar punctures. *See* Embalming artifacts.
- Tryptase, 389–390
- U**
- Underwater swimming and breath holding, 252
- Unexpected neurological death, 608
- V**
- Vagal stimulation  
in choking deaths, 131  
in drowning deaths, 250  
in hanging deaths, 86, 111
- Vegetative state, 589–591
- Velocity. *See also* Force  
changes, 406  
falls from heights, 425  
and injury patterns in pedestrians, 478, 480
- Vena cava, trauma to, 438
- Venipunctures, self-inflicted, 394–396
- Venous stasis, 5. *See also* Pulmonary thromboembolism.
- Vertebrospinal injuries, 519–521, 574–584, 607
- Viewing of remains, 7–8
- Viscous tolerance described, 406
- Vitality, determination of in fire deaths, 194–202
- Voltage, 215
- W**
- Wadding, shotgun, 304, 305f, 323, 341
- Water in bathtub drownings, 277
- Wedging described, 129–130
- Wet drowning  
autopsy findings in, 257, 258f, 260, 261, 262f, 262–265, 268  
described, 246
- Witness to drownings, 243
- Workplace falls, 425
- Wounds. *See also* Injury  
blunt trauma (*See* Blunt trauma)  
broken glass, 361–362  
chain saws, 363  
medical care and, 372, 381f  
sites of, 359t–360t, 375–377  
skin, healing of, 414–415
- Wound track  
of bullet fragmentation, 341  
clothing in, 372  
in firearm injuries, 336f, 340–341, 343f  
stab vs incision, 357  
stab wounds, 366, 368, 370f
- Wrist incisions, self-inflicted, 382f
- X**
- Xerostomia and choking, 132