Atlas of the NEONATAL RAT BRAIN



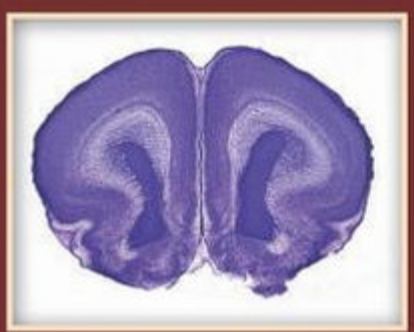



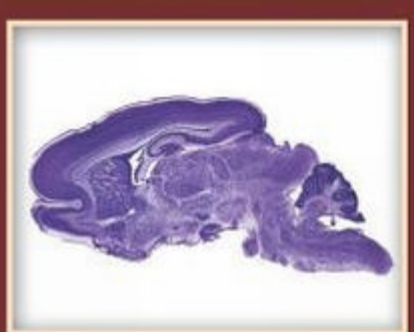

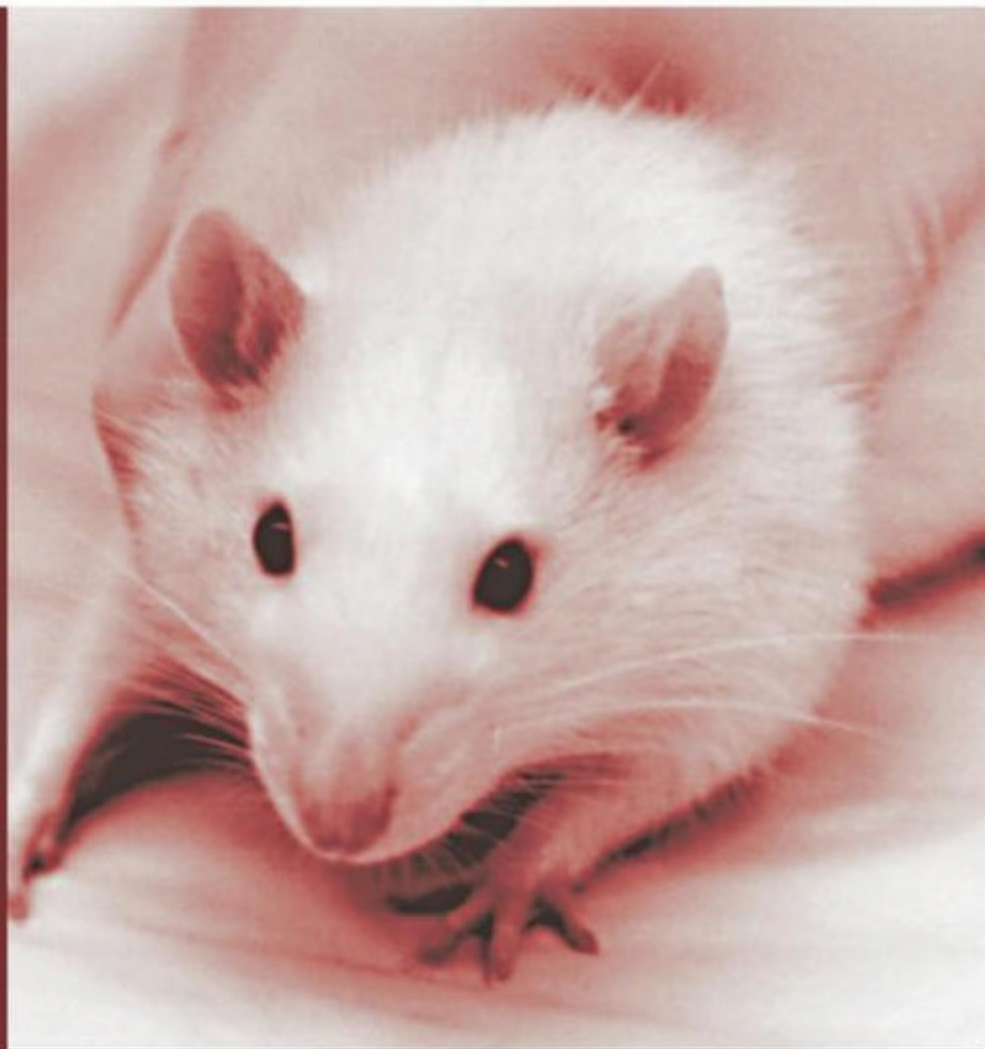

Renuka Ramachandra
Thyagarajan Subramanian

CRC Press
Taylor & Francis Group

Atlas of the
NEONATAL RAT BRAIN

© 2011 by Taylor and Francis Group, LLC

Atlas of the

NEONATAL RAT BRAIN

Renuka Ramachandra
Thyagarajan Subramanian

CRC Press
Taylor & Francis Group
Boca Raton London New York

CRC Press is an imprint of the
Taylor & Francis Group, an **informa** business

© 2011 by Taylor and Francis Group, LLC

CRC Press
Taylor & Francis Group
6000 Broken Sound Parkway NW, Suite 300
Boca Raton, FL 33487-2742

© 2011 by Taylor and Francis Group, LLC
CRC Press is an imprint of Taylor & Francis Group, an Informa business

No claim to original U.S. Government works

Printed in the United States of America on acid-free paper
10 9 8 7 6 5 4 3 2 1

International Standard Book Number: 978-1-4398-4012-2 (Hardback)

This book contains information obtained from authentic and highly regarded sources. Reasonable efforts have been made to publish reliable data and information, but the author and publisher cannot assume responsibility for the validity of all materials or the consequences of their use. The authors and publishers have attempted to trace the copyright holders of all material reproduced in this publication and apologize to copyright holders if permission to publish in this form has not been obtained. If any copyright material has not been acknowledged please write and let us know so we may rectify in any future reprint.

Except as permitted under U.S. Copyright Law, no part of this book may be reprinted, reproduced, transmitted, or utilized in any form by any electronic, mechanical, or other means, now known or hereafter invented, including photocopying, microfilming, and recording, or in any information storage or retrieval system, without written permission from the publishers.

For permission to photocopy or use material electronically from this work, please access www.copyright.com (http://www.copyright.com/) or contact the Copyright Clearance Center, Inc. (CCC), 222 Rosewood Drive, Danvers, MA 01923, 978-750-8400. CCC is a not-for-profit organization that provides licenses and registration for a variety of users. For organizations that have been granted a photocopy license by the CCC, a separate system of payment has been arranged.

Trademark Notice: Product or corporate names may be trademarks or registered trademarks, and are used only for identification and explanation without intent to infringe.

Visit the Taylor & Francis Web site at
http://www.taylorandfrancis.com

and the CRC Press Web site at
http://www.crcpress.com

© 2011 by Taylor and Francis Group, LLC

Dedication

We dedicate this scientific work to our parents who inspired us to follow our interests and provided unwavering support to us during all our struggles and successes.

© 2011 by Taylor and Francis Group, LLC

Contents

Preface ix
Acknowledgments xi
About the Authors xiii
Introduction xv
Abbreviations xix
References xxiii

SECTION I P-1 Brain

Coronal Plates (Figures 1 through 30) 3
Sagittal Plates (Figures 31 through 44) 33

SECTION II P-7 Brain

Coronal Plates (Figures 45 through 71) 49
Sagittal Plates (Figures 72 through 95) 76

SECTION III P-14 Brain

Coronal Plates (Figures 96 through 136) 103
Sagittal Plates (Figures 137 through 157) 144

© 2011 by Taylor and Francis Group, LLC

Preface

The rat brain develops enormously after birth and the changes are very rapid. We have attempted to prepare a photographic atlas representing the neonatal rat brain at postnatal (P) days P-1, P-7, and P-14. This atlas illustrates the main anatomical features at these three ages.

It will serve the needs of researchers and students who are interested in postnatal development, slice cultures, developmental disorders, neuroanatomy, neuropharmacology, neurobiochemistry, and neuropathology of rats. We hope that this atlas will provide a template for comparative studies with other species and numerous animal models of brain pathology in rats.

© 2011 by Taylor and Francis Group, LLC

Acknowledgments

We are grateful to the following individuals for making this atlas work possible through their moral, emotional, technical, and scientific support: David Good, Keith Elmslie, Kala Venkiteswaran, Sriram S. Shanmugavelandy, Christopher Lieu, Anand Rao, Mathew Berk, Timothy Gilmour, and Barbara Norwitz. We also acknowledge financial support for this work from research grants to Thyagarajan Subramanian from the National Institutes of Health (NS42402), Commonwealth of Pennsylvania Tobacco Settlement Biomedical Research Fund, and the Penn State University Brain Repair Research Fund. We also thank the U.S. Department of Health for the Physician Scientist Research Award.

© 2011 by Taylor and Francis Group, LLC

About the Authors

Renuka Ramachandra, is a postdoctoral researcher at the AT Still University in Kirksville, Missouri. She received her PhD degree in neurophysiology from India and her initial postdoctoral training at the National Brain Research Centre in India, a premier neuroscience institute. Dr. Ramachandra worked on the effect of barrel cortex lesions in rats and on the effects of drugs on the developing rat brain. She also worked as a research scientist in the embryonic stem cell group at Reliance Life Sciences, Mumbai, India, where she differentiated human embryonic stem cells into oligodendrocytes for spinal cord injury treatment. She went on to use her skills and knowledge of basic electrophysiology, brain anatomy, and histological techniques to develop an in vitro basal ganglia slice culture model in the Department of Neurology at Penn State College of Medicine. This model is used to study in vitro cell transplantation. During the development of this model, she recognized the need for a neonatal rat brain atlas. Dr. Ramachandra created this atlas for her project and decided to publish it so that it would be available to all neuroscientists and students who need one.

Thyagarajan Subramanian is a professor of neurology and neural and behavioral sciences at Penn State University Hershey Medical Center in Hershey, Pennsylvania. Dr. Subramanian received his initial medical training from Calicut Medical College in Calicut, India and his graduate training in developmental neurobiology and neural cell transplantation under the guidance of Dr. R. D. Lund at the University of Pittsburgh School of Medicine, Pittsburgh, Pennsylvania. He completed his neurology residency at the University of Pittsburgh followed by fellowship training in neurological research and movement disorders at Emory University in Atlanta, Georgia under the guidance of Drs. Mahlon R. DeLong, Ray L. Watts, and Roy A. E. Bakay. Dr. Subramanian's research interests are in developmental neurobiology, basal ganglia physiology, cell transplantation, gene therapy, and experimental neurotherapeutics. Using a variety of animal models, cell and tissue culture techniques, in vivo electrophysiology, and detailed histology, Dr. Subramanian and co-workers have described several novel findings in central nervous system (CNS) response to transplantation. Among his major scientific contributions are his work on creating an MRI based brain atlas of the Rhesus monkey, description of the effects of immunomodulation on host responses to CNS xenografting, and the description of the use of retinal pigment epithelial cell grafts for CNS repair. Dr. Subramanian has directed the medical neuroscience course for medical and graduate students and trained numerous medical students, as well as neurology, neurosurgery, physiatry, psychiatry, and geriatric residents. He has served as the education committee chair of the American Society for Neural Therapy and Repair (ASNTR) and has trained numerous scientists and physicians who now work as independent investigators in many institutions all over the world.

© 2011 by Taylor and Francis Group, LLC

Introduction

Rodents have frequently been used to model a number of neurological disorders. The neonatal rat in particular has been used in many developmental studies and extensively for preparing slice culture models that permit the study of interactions among different regions of the brain during development. Neonatal rats have also been used as models for neurotoxicological screening and mechanistic studies (Becker and Liu, 2006; Noraberg, 2004). During our attempts to develop a neonatal rat brain slice culture model of basal ganglia development, we realized that there was no published neonatal rat brain atlas. This took us by surprise as we knew of quite a few adult rat brain atlases. To remedy this situation, we developed this atlas showing representative development of the rat brain between postnatal day 1 (P-1) and postnatal day 14 (P-14). A number of animals from each litter were euthanized on the designated postnatal dates and the brains were sectioned, stained, photographed, and annotated to prepare this atlas.

This atlas is an effort to provide a guide to the neonatal rat brain. It contains a comprehensive set of histological images of the newborn rat brain from P-1, P-7, and P-14. Although we prepared brain sections for all the ages from P-1 to P-14, we have chosen to present these three ages as representative to provide a template of developmental maturation of the neonatal rat brain at various stages. Further, the inclusion of every age between P-1 and P-14 would needlessly add pages to this atlas without adding value. Additional images will be made available as electronic resources for individuals who seek images not represented in this volume. P-0 was covered earlier in *The Atlas of the Developing Rat Nervous System* (Paxinos et al., 1994), so we started at P-1, proceeded to P-7 (the midpoint in neonatal development), and concluded at P-14. This atlas contains both coronal and sagittal sections for all the three age groups. The P-1 section contains 30 coronal plates and 14 sagittal plates; P-7 includes 27 coronal plates and 24 sagittal plates. The final P-14 section shows 41 coronal plates and 21 sagittal plates. Each set consists of contiguous sections from individual animals with no substitutions or omissions. The sections were prepared carefully to ensure that their orientations were maintained and were consistently of the highest quality. The selections were based on the structural variability represented. Care was taken to minimize tears and distortions. Fixation and staining cause minimal amounts of shrinkage and damage to tissues. However, we feel that the structural details are well preserved.

This atlas has certain unique features. The sections are Nissl stained with cresyl violet—the most common staining technique used in the neurosciences. Future editions will include specific immunostains and special stains in the same format as these Nissl stains. The photomicrographs achieve high resolution and clarity. The structures are directly labeled on the images, making it easier for readers to correlate data. The electronic version will allow labels to be removed so the atlas can be used as a teaching tool.

© 2011 by Taylor and Francis Group, LLC

Animal Preparation

Sprague-Dawley rat pups were used for this work. Pregnant dams from Charles River Laboratories (Wilmington, MA) were received on day 13.5 of gestation and housed in standard laboratory conditions, with 12-hour dark and light cycles and administration of food and water ad libitum. All procedures complied with guidelines issued by the National Institutes of Health and were approved by Penn State University's Institutional Animal Care and Welfare Committee. After birth, rat pups ranging in age from P-1 to P-14 were sacrificed at the same time every day. The sexes of the newborns were not taken into consideration. The neonates were decapitated and the brains were removed carefully and postfixed in 4% paraformaldehyde for 3 to 4 days. This allowed preservation of the brain structures and made it easier to isolate the brains from the delicate skulls. The brains were then cryoprotected in 15% sucrose in phosphate buffered saline (PBS) and then in 30% sucrose in PBS.

The brains were positioned and frozen on sucrose blocks made on the base of a sliding microtome that was then used to cut the brains at 50-µm thickness for both coronal and sagittal views. For sagittal sections, each brain was cut along the midline carefully and placed with the midline facing the block. Care was taken to retain and mount every section cut. We noted all missing sections so that we could calculate the correct distance from the midline for the sagittal sections.

Section Processing

Every section was mounted on polylysine-coated slides, air dried, and stained for Nissl bodies using cresyl violet. In short, the slides with the sections were passed through the solutions for 3 minutes each in the following order except where noted: 100% ethanol, 100% ethanol, 95% ethanol, 75% ethanol, water (single dip), cresyl violet (3 to 4 minutes), water, 75% ethanol, 95% ethanol, 100% ethanol, 100% ethanol, and xylene. The slides were cover slipped using DPX mounting media and left to dry for 2 days before image capture.

To make 500 ml of 0.5% cresyl violet (pH about 3.9), we mixed 2.5 g cresyl echt violet, 300 mL water, 30 mL 0.1 M sodium acetate (13.6 g granular sodium acetate in 92 mL water), and 170 mL 1.0 M acetic acid (29 mL glacial acetic acid added to 471 mL water). This solution was mixed at least 7 days on a magnetic stirrer and then filtered.

Imaging

Using Neurolucida software (Version 8, MBF Biosciences), photomicrographs of all the serial sections were captured. We used the virtual slice feature of Neurolucida that allowed us to capture the images at 4× magnification in smaller blocks and finally merge them to yield a holistic image of an entire section. In digital format, the images can be zoomed in without losing much of the detail. The images were post processed in Adobe Photoshop to clear up the background. No changes were made to the actual photomicrographic images captured.

© 2011 by Taylor and Francis Group, LLC

Labeling

The images were labeled based on the nomenclature used by Paxinos, with some modifications to suit the need of the atlas. For the P-1 rat brain, we labeled most structures using *The Atlas of the Developing Rat Nervous System* (Paxinos et al., 1994). Because the P-7 and P-14 brain structures are similar to those of adult rat brains, we followed the nomenclature of *The Rat Brain in Stereotaxic Coordinates* (Paxinos et al., 1998).

The labeling of the respective structures was done on the actual photographic images rather than on the classic line diagrams that most atlases utilize. This allows the user to correlate the structures and their names easily. We decided not to demarcate the areas on the brain as the brain is a very plastic structure and the areas could not be distinguished from each other easily. The major parts of the brain were labeled via Adobe Photoshop without the inclusion of minor details.

We used cresyl violet stain to identify the structures. This posed limitations on identifying some of the smaller nuclei that required special staining. Most of the structures were identified based on the proximity to the surrounding structures and outstanding landmarks; for example, striatum was identified based on its patchy matrix and close proximity to the corpus callosum.

The most difficult structures to identify were the thalamic nuclei in the P-1 brains. We restricted our labeling to major nuclei only to avoid confusion. Since the brain develops very quickly in the first few days after birth, it is very difficult to demarcate the developing nuclei without in-depth knowledge of that area of research. The other structure that posed certain limitations in labeling was the cerebellum of the P-1 brain. The lobules are very different from those of the adult brain.

We tried to keep most of the sagittal brain sections intact. However, we encountered a few sections in which the cerebellum could not be kept intact with the rest of the brain. The distances between adjacent plates of the sagittal sections were estimated from the midline using the section thickness; the midline was considered the absolute zero.

This photographic atlas can assist neuroscientists and students to identify and understand the developing rat brain structure. However, it does not cover stereotaxic coordinates.

© 2011 by Taylor and Francis Group, LLC

Abbreviations

Numbers 1 through 10	Cerebellar lobules
aca	Anterior commissure
Acb	Accumbens nucleus
AcbC	Accumbens nucleus core
AcbSh	Accumbens nucleus shell
AICtx	Agranular insular cortex
Alv	Alveus of hippocampus
AM	Anteromedial thalamus
amy	Amygdala
Amy	Amygdaloid nuclei
AICtx	Agranular insular cortex
AO	Anterior olfactory bulb
APit	Anterior pituitary gland
apons	Anterior pons
APT	Anterorpretectal nuclei
AT	Anterior thalamus
AuCtx	Auditory cortex
AV	Anteroventral thalamus
Bamy	Basal amygdala
BLA	Basolateral amygdala
CA1	CA1 field of hippocampus
CA2	CA2 field of hippocampus
CA3	CA3 field of hippocampus
cc	Corpus callosum
Cer	Cerebellar peduncle
cer	Cerebellum
Cernu	Cerebellar nuclei
CG	Central gray matter
CgCtx	Cingulate cortex
CM	Central medial thalamic nuclei
Cop	Copula of pyramis
Cp	Caudate peduncle
CPu	Caudate putamen
Crus1	Crus 1 of ansiform lobule
Crus2	Crus 2 of ansiform lobule
Ctx	Cortex
Cu	Cuneate nucleus
D3V	Dorsal third ventricle
DG	Dentate gyrus
Dhippo	Dorsal hippocampal formation
DLG	Dorsolateral geniculate nuclei
DR	Dorsal raphe nuclei
DTg	Dorsal tegmental nuclei
E	Ependyma and subependymal layer
Ec	External capsule
Ent	Entorhinal cortex
EPl	External plexiform layer, olfactory bulb

© 2011 by Taylor and Francis Group, LLC

f	Fornix
fi	Fimbria of hippocampus
fmi	Forceps minor of corpus callosum
fmj	Forceps major of corpus callosum
FrCtx	Frontal cortex
gcc	Genu of corpus callosum
GI	Glomerular layer, olfactory bulb
CN	Geniculate nucleus
GP	Globus pallidus
GrO	Granular cell layer, olfactory bulb
hc	Hippocampal commissure
Hf	Hippocampal fissure
Hfor	Hippocampal formation
Hypo	Hypothalamus
IAD	Interanterodorsal thalamic nuclei
IC	Inferior colliculus
Ic	Internal capsule
InsCtx	Insular cortex
IPL	Internal plexiform layer, olfactory bulb
Lamy	Lateral amygdala
Lat	Lateral cerebellar nuclei
LD	Laterodorsal thalamic nuclei
LDVL	Laterodorsoventral thalamus
Lent	Lateral entorhinal cortex
LGP	Lateral globus pallidus
LPAG	Lateral periaqueductal gray matter
LPLR	Lateroposterior thalamic nuclei
LPM	Lateroposteromedial thalamic nuclei
LS	Lateral septal nuclei
LT	Lateral thalamus
LTh	Lateral thalamic nucleus
LV	Lateral ventricle
MCtx	Motor cortex
MD	Mediodorsal thalamic nuclei
MDTh	Mediodorsal thalamus
Med	Medulla
MEnt	Medial entorhinal cortex
MEPD	Medial amygdala nuclei
MGD	Medial geniculate nuclei, dorsal
MGN	Medial geniculate nuclei
MGV	Medial geniculate nuclei, ventral
Mret	Medullary reticular formation
MT	Medial thalamus
neoCtx	Neocortex
obn	Olfactory bulb neuroepithelium
OcCtx	Occipital cortex
Opt	Optic tract
Orb	Orbital cortex
OV	Olfactory ventricle
PAG	Periaqueductal gray matter
Pal	Pallidum
pcf	Precommissural fornix
Pi	Pineal gland
Pir	Piriform cortex
Pit	Pituitary gland
PLCtx	Prelimbic cortex
Plf	Posterolateral fissure
PM	Paramedian lobule

© 2011 by Taylor and Francis Group, LLC

Pn	Pontine nuclei
Po	Posterior thalamic nuclei
PrCtx	Parietal cortex
PrS	Presubiculum
PtACtx	Parietal association cortex
PTg	Posterior tegmental nuclei
PTh	Posterior thalamus
RsCtx	Retrospenial cortex
S	Subiculum
SC	Superior colliculus
SCtx	Somatosensory cortex
Sim	Simple lobule
SN	Substantia nigra
SNc	Substantia nigra compacta
SNr	Substantia nigra reticulata
Spn	Spinal nuclei
STn	Subthalamic nuclei
Sub	Submedial thalamic nucleus
SubG	Subgeniculate nucleus
Th	Thalamus
VCtx	Visual cortex
Ve	Vestibular nuclei
VH	Ventral hypothalamus
Vhippo	Ventral hippocampal formation
VL	Ventrolateral thalamic nuclei
VM	Ventromedial thalamus
VO	Ventral orbital cortex
VP	Ventral pallidum
VPL	Ventroposterolateral thalamic nuclei
VPM	Ventroposteromedial thalamic nuclei
VT	Ventral thalamus
VTh	Ventral thalamic nucleus
ZI	Zona incerta

© 2011 by Taylor and Francis Group, LLC

References

Altman, J. and Bayer, S. (1995). *The Atlas of Prenatal Rat Brain Development*. Boca Raton, FL: CRC Press.

Becker, S. and Liu, X. (2006). Evaluation of the utility of brain slice methods to study brain penetration. *Drug Metab Dispos* 34: 855–861.

Noraberg, J. (2004). Organotypic brain slice cultures: An efficient and reliable method for neurotoxicological screening and mechanistic studies. *Altern Lab Anim* 32: 329–337.

Paxinos, G. and Watson, C. (1998). *The Rat Brain in Stereotaxic Coordinates*. Fourth Edition. San Diego: Elsevier Academic Press.

Paxinos, G., Ashwell, K.W.S., and Tork, I. (1994). *The Atlas of the Developing Rat Nervous System.* San Diego: Elsevier Academic Press.

© 2011 by Taylor and Francis Group, LLC

Section
I

P-1 Brain

© 2011 by Taylor and Francis Group, LLC

Coronal Plates

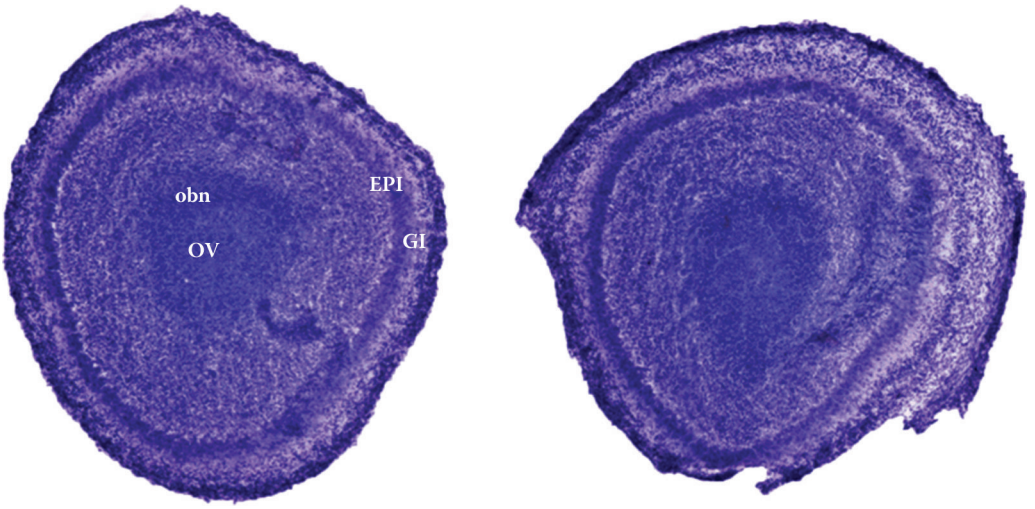

Figure 1
P-1, c1
EPI = External plexiform layer, olfactory bulb
GI = Glomerular layer, olfactory bulb
Obn = Olfactory bulb neuroepithelium
OV = Olfactory ventricle

© 2011 by Taylor and Francis Group, LLC

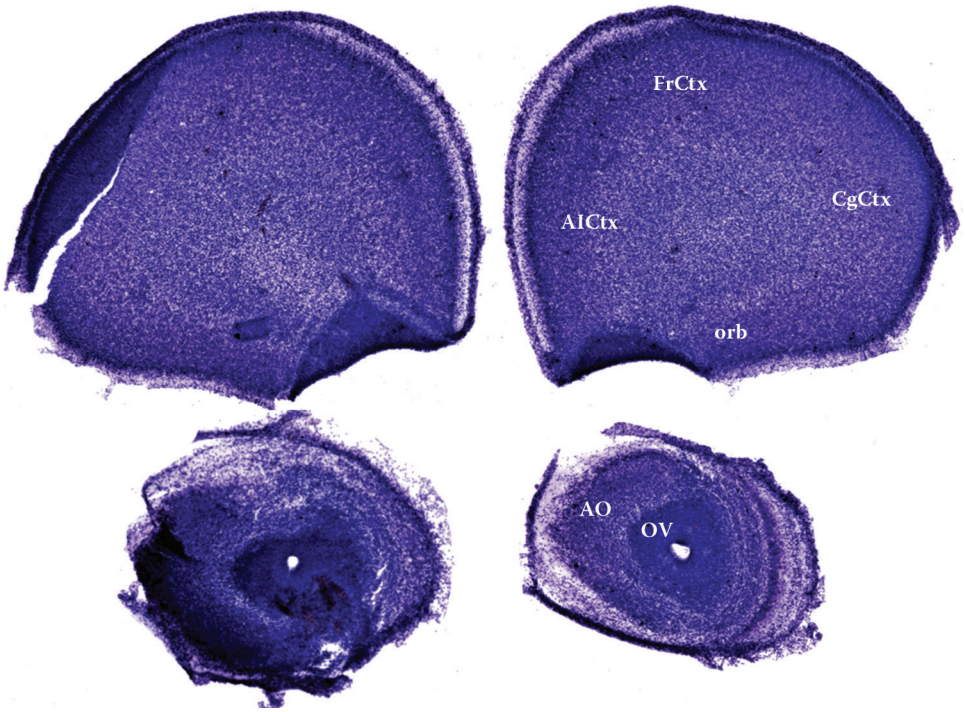

Figure 2
P-1, c2
AICtx = Agranular insular cortex
AO = Anterior olfactory bulb
CgCtx = Cingulate cortex
FrCtx = Frontal cortex
Orb = Orbital cortex
OV= Olfactory ventricle

© 2011 by Taylor and Francis Group, LLC

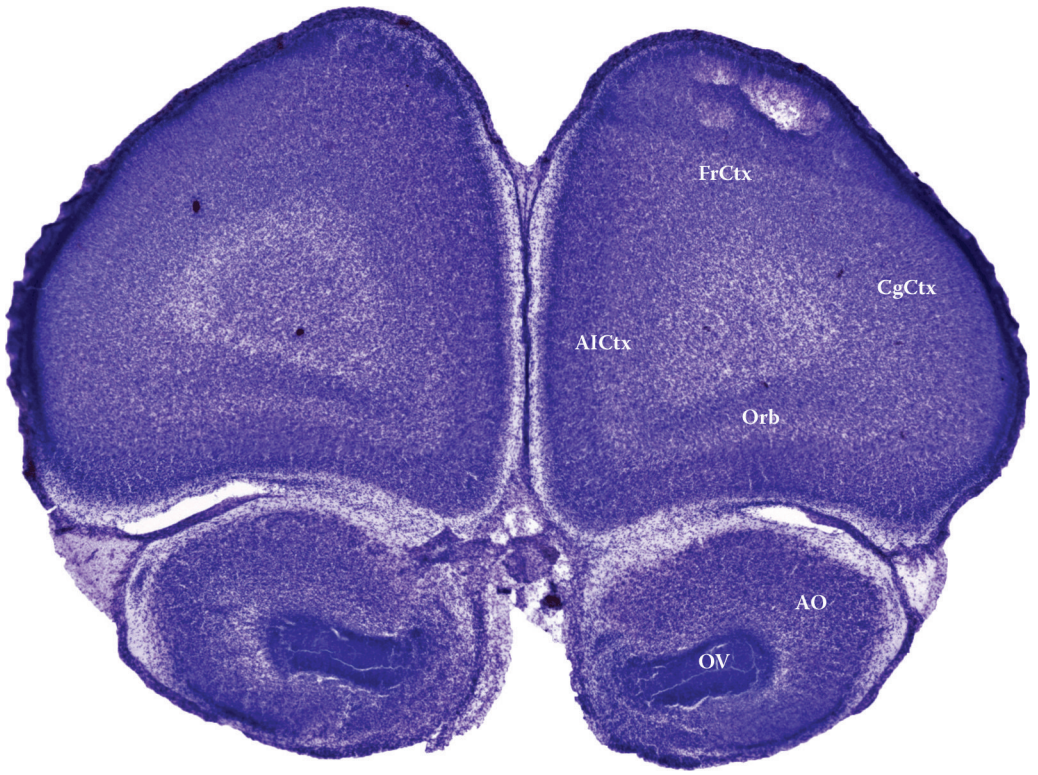

Figure 3
P-1, c3
AICtx = Agranular insular cortex
AO = Anterior olfactory bulb
CgCtx = Cingulate cortex
FrCtx = Frontal cortex
Orb = Orbital cortex
OV = Olfactory ventricle

© 2011 by Taylor and Francis Group, LLC

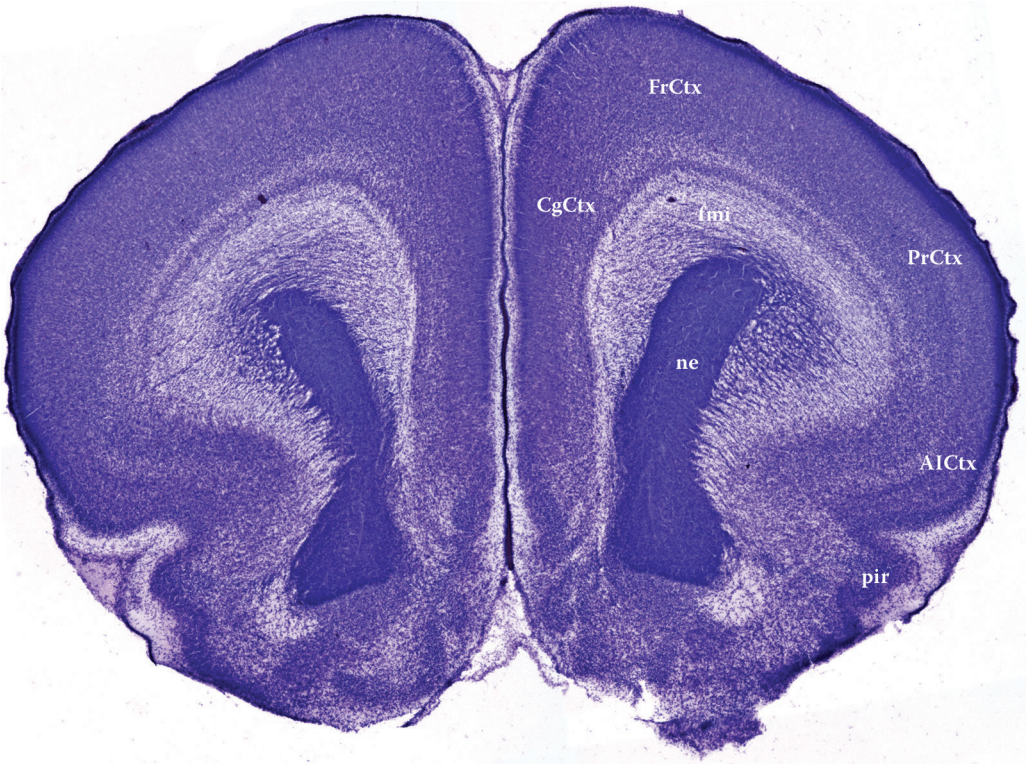

Figure 4
P-1, c4
AICtx = Agranular insular cortex
CgCtx = Cingulate cortex
fmi = Forceps minor of corpus callosum
FrCtx = Frontal cortex
Pir = Piriform cortex
PrCtx = Parietal cortex

© 2011 by Taylor and Francis Group, LLC

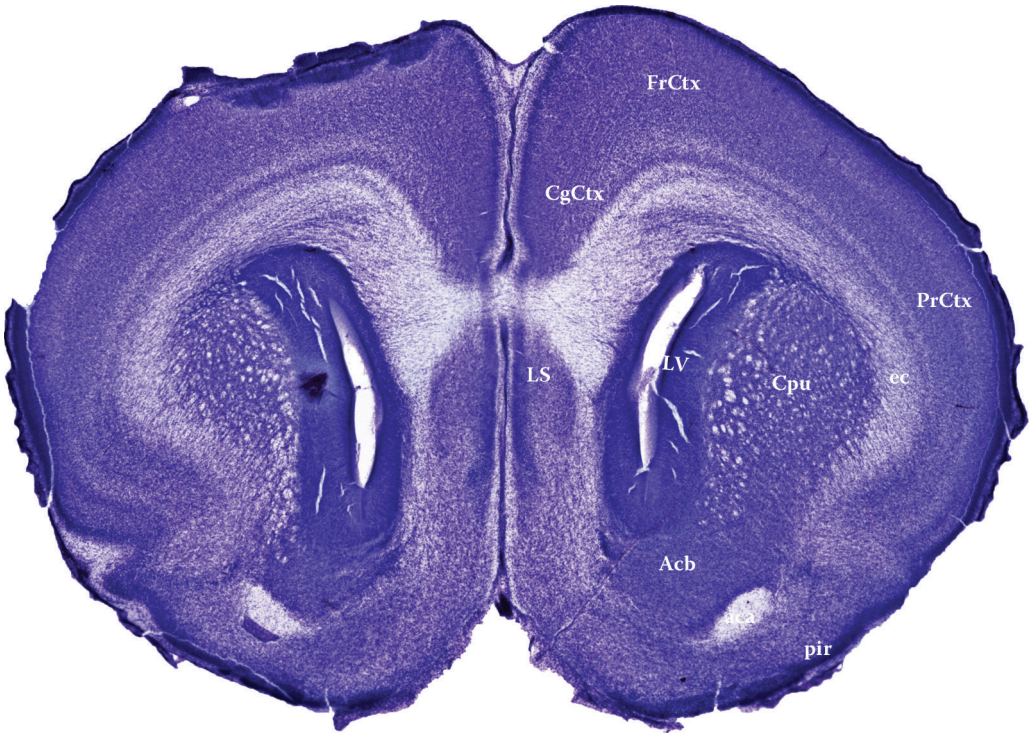

Figure 5
P-1, c5
aca = Anterior commissure
Acb = Accumbens nucleus
CgCtx = Cingulate cortex
CPu = Caudate putamen
ec = external capsule
FrCtx = Frontal cortex
LS = Lateral septal nuclei
LV = Lateral ventricle
pir = Piriform cortex
PrCtx = Parietal cortex

© 2011 by Taylor and Francis Group, LLC

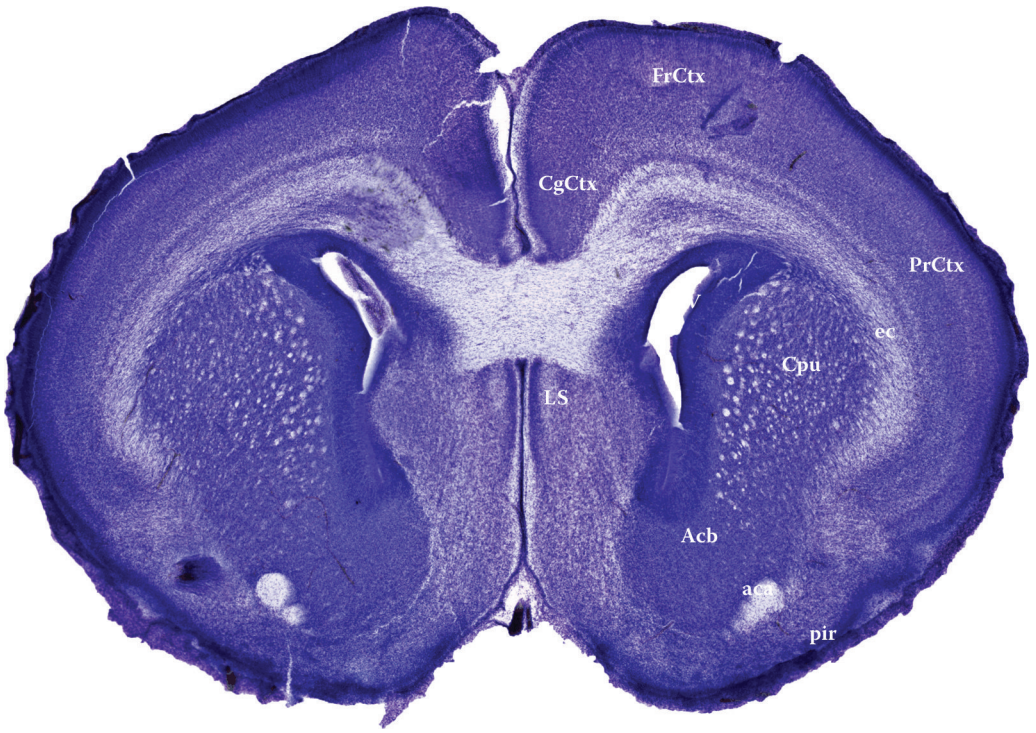

Figure 6
P-1, c6
aca = Anterior commissure
Acb = Accumbens nucleus
CgCtx = Cingulate cortex
CPu = Caudate putamen
ec = external capsule
FrCtx = Frontal cortex
LS = Lateral septal nuclei
LV = Lateral ventricle
Pir = Piriform cortex
PrCtx = Parietal cortex

© 2011 by Taylor and Francis Group, LLC

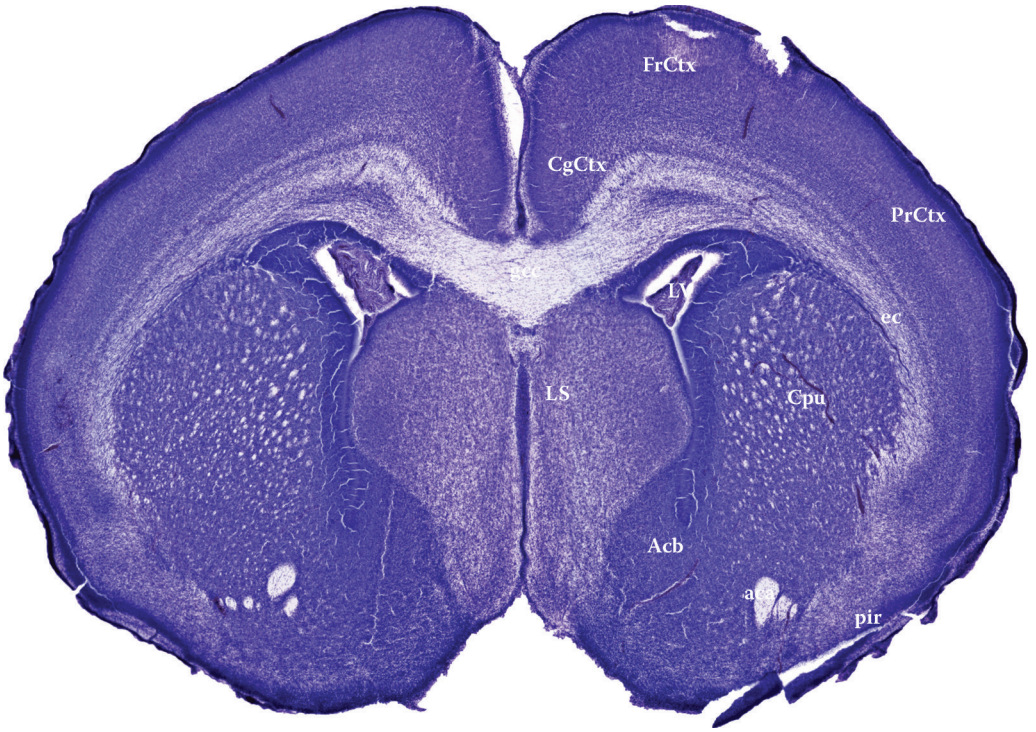

Figure 7
P-1, c7
aca = Anterior commissure
Acb = Accumbens nucleus
CgCtx = Cingulate cortex
CPu = Caudate putamen
ec = external capsule
FrCtx = Frontal cortex
gcc = Genu of corpus callosum
LS = Lateral septal nuclei
LV = Lateral ventricle
pir = Piriform cortex
PrCtx = Parietal cortex

© 2011 by Taylor and Francis Group, LLC

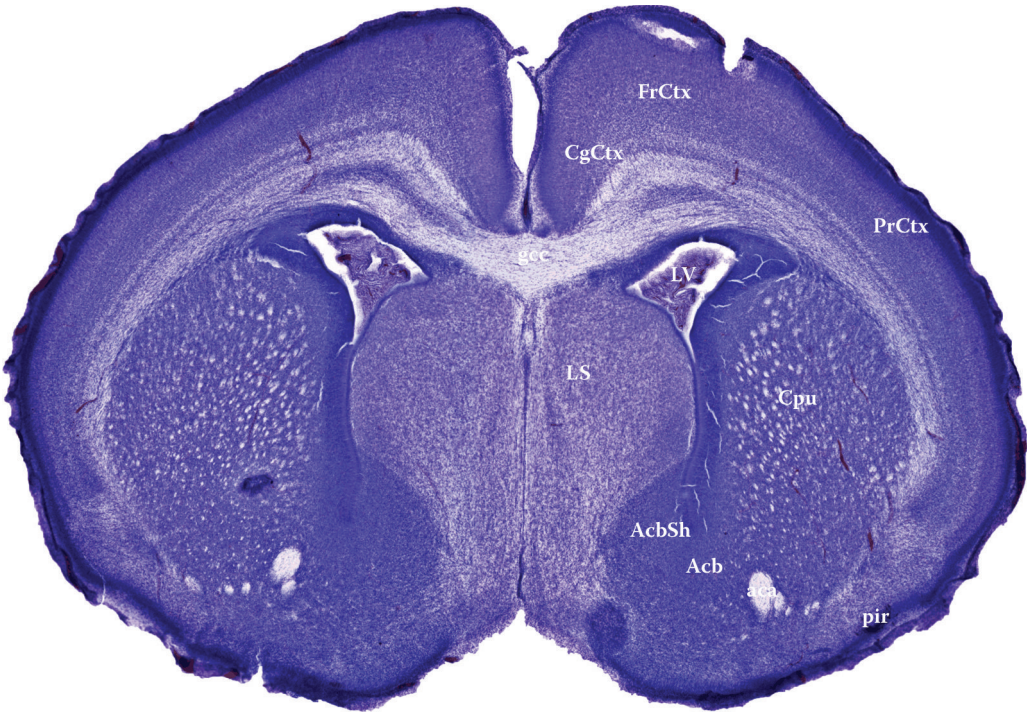

Figure 8
P-1, c8
aca = Anterior commissure
Acb = Accumbens nucleus
AcbSh = Accumbens nucleus shell
CgCtx = Cingulate cortex
CPu = Caudate putamen
ec = external capsule
FrCtx = Frontal cortex
gcc = Genu of corpus callosum
LS = Lateral septal nuclei
LV = Lateral ventricle
pir = Piriform cortex
PrCtx = Parietal cortex

© 2011 by Taylor and Francis Group, LLC

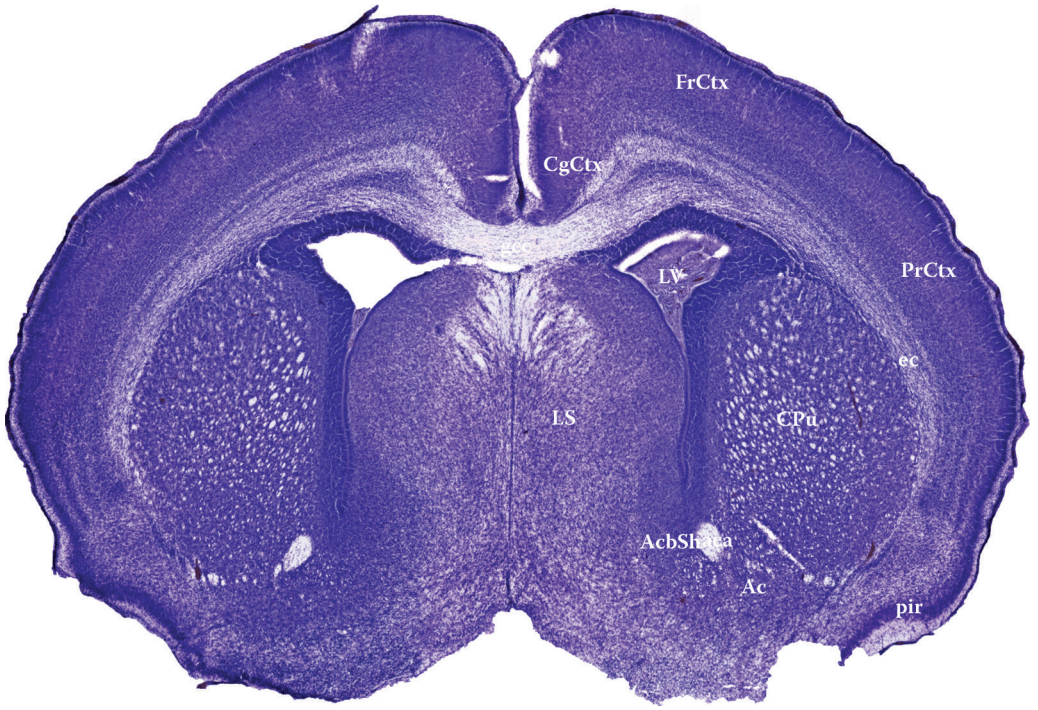

Figure 9
P-1, c9

aca = Anterior commissure
Acb = Accumbens nucleus
AcbSh = Accumbens nucleus shell
CgCtx = Cingulate cortex
CPu = Caudate putamen
ec = external capsule
FrCtx = Frontal cortex
gcc = Genu of corpus callosum
LS = Lateral septal nuclei
LV = Lateral ventricle
pir = Piriform cortex
PrCtx = Parietal cortex

© 2011 by Taylor and Francis Group, LLC

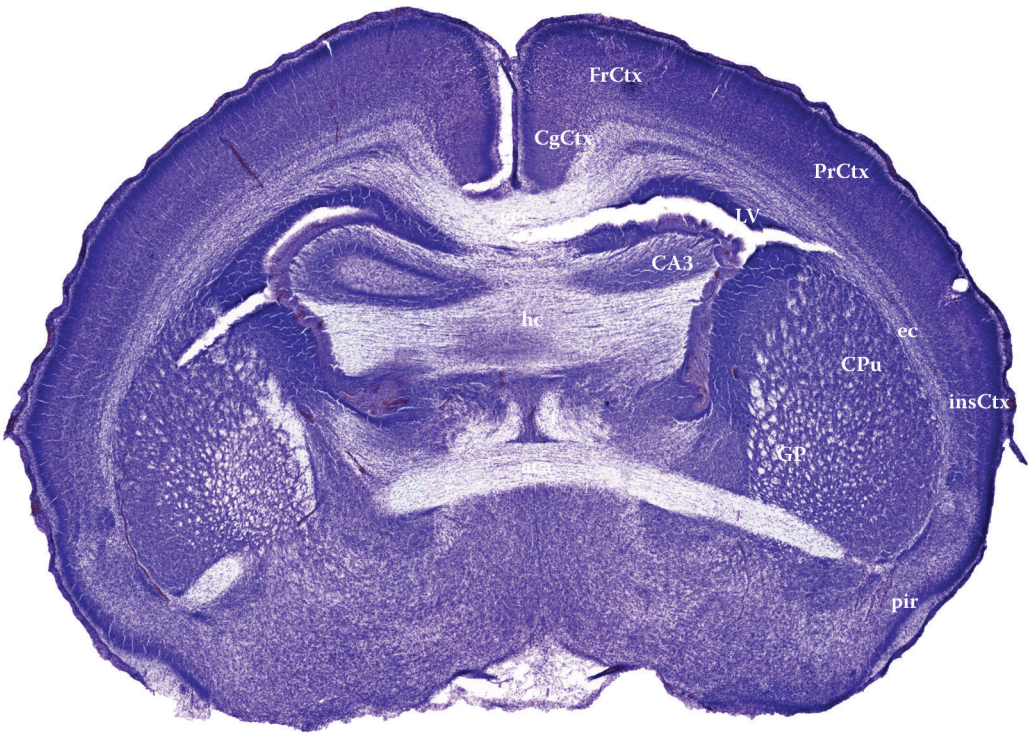

Figure 10
P-1, c10
aca = Anterior commissure
CA3 = CA3 field of hippocampus
CgCtx = Cingulate cortex
CPu = Caudate putamen
ec = external capsule
FrCtx = Frontal cortex
gcc = Genu of corpus callosum
GP = Globus pallidus
hc = Hippocampal commissure
InsCtx = Insular cortex
LS = Lateral septal nuclei
LV = Lateral ventricle
pir = Piriform cortex
PrCtx = Parietal cortex

© 2011 by Taylor and Francis Group, LLC

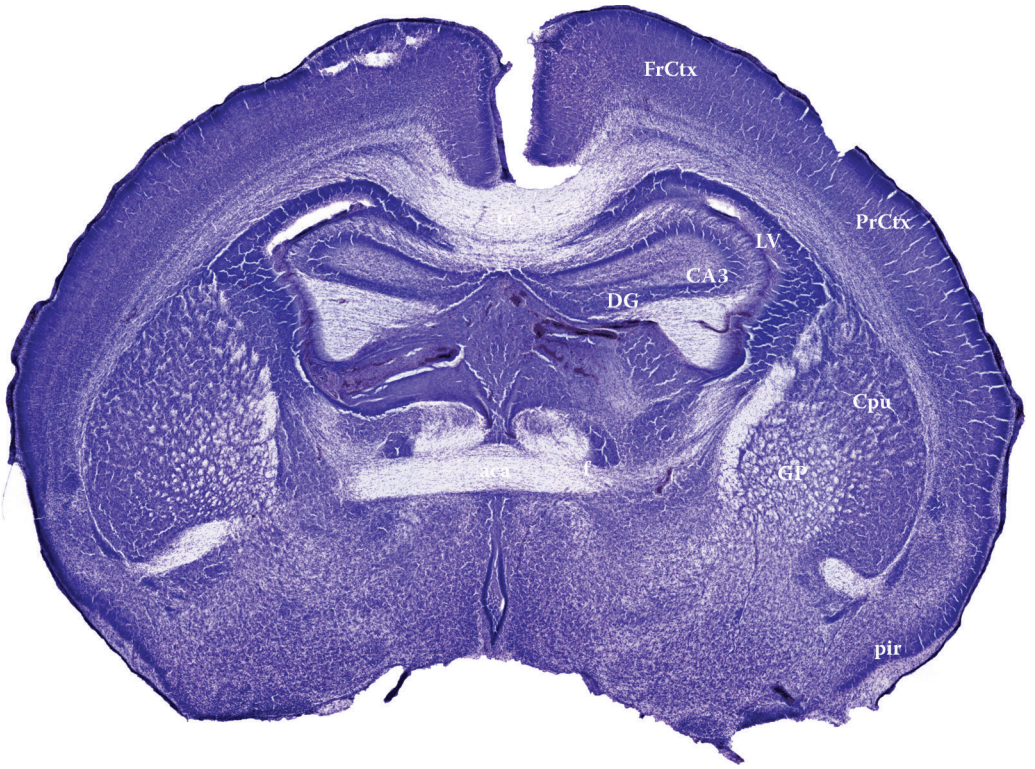

Figure 11
P-1, c11
aca = Anterior commissure
CA3 = CA3 field of hippocampus
CPu- = Caudate putamen
DG = Dentate gyrus
ec = external capsule
f = Fornix
FrCtx = Frontal cortex
cc = Corpus callosum
GP = Globus pallidus
insCtx = Insular cortex
LS = Lateral septal nuclei
LV = Lateral ventricle
pir = Piriform cortex
PrCtx = Parietal cortex

© 2011 by Taylor and Francis Group, LLC

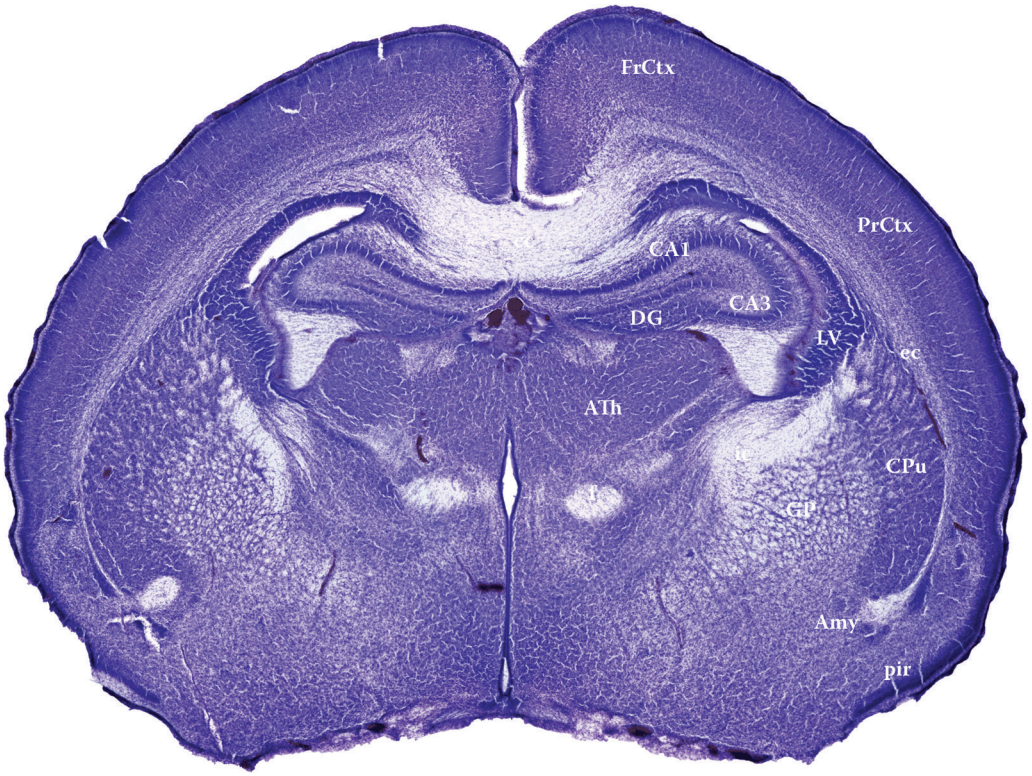

Figure 12
P-1, c12

Amy = Amygdaloid nuclei
ATh = Anterior thalamus
CA1 = CA1 field of hippocampus
CA3 = CA3 field of hippocampus
cc = Corpus callosum
CPu = Caudate putamen
DG = Dentate gyrus
ec = external capsule
f = Fornix
FrCtx = Frontal cortex
GP = Globus pallidus
LV = Lateral ventricle
pir = Piriform cortex
PrCtx = Parietal cortex

© 2011 by Taylor and Francis Group, LLC

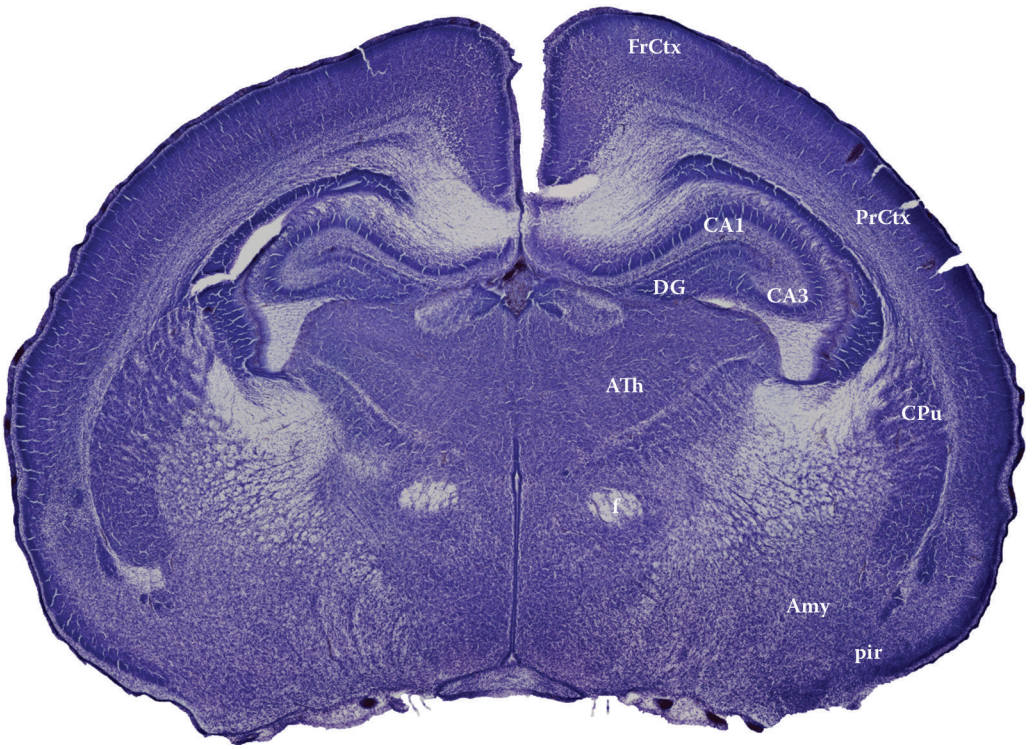

Figure 13
P-1, c13

Amy = Amygdaloid nuclei
ATh = Anterior thalamus
CA1 = CA1 field of hippocampus
CA3 = CA3 field of hippocampus
CPu = Caudate putamen
DG = Dentate gyrus
F = Fornix
FrCtx = Frontal cortex
pir = Piriform cortex
PrCtx = Parietal cortex

© 2011 by Taylor and Francis Group, LLC

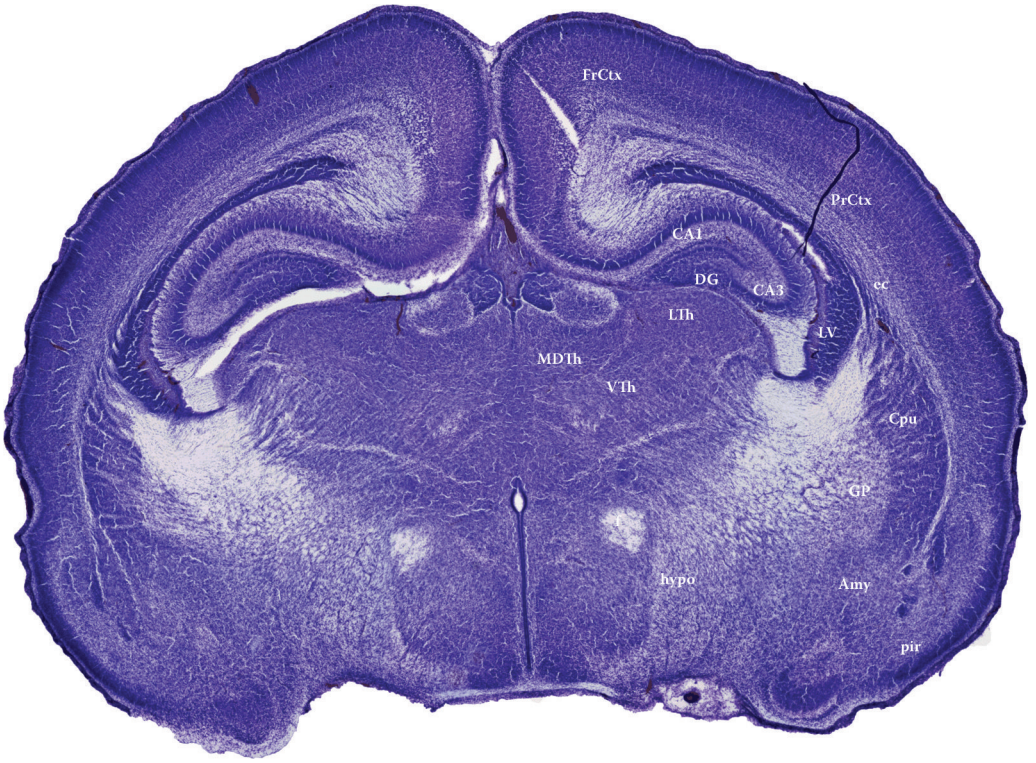

Figure 14
P-1, c14

Amy = Amygdaloid nuclei
CA1 = CA1 field of hippocampus
CA3 = CA3 field of hippocampus
CPu = Caudate putamen
DG = Dentate gyrus
ec = external capsule
F = Fornix
FrCtx = Frontal cortex
GP = Globus pallidus
Hypo = Hypothalamus
LTh = Lateral thalamus
LV = Lateral ventricle
MDTh = Mediodorsal thalamus
pir = Piriform cortex
PrCtx = Parietal cortex
VTh = Ventral thalamus

© 2011 by Taylor and Francis Group, LLC

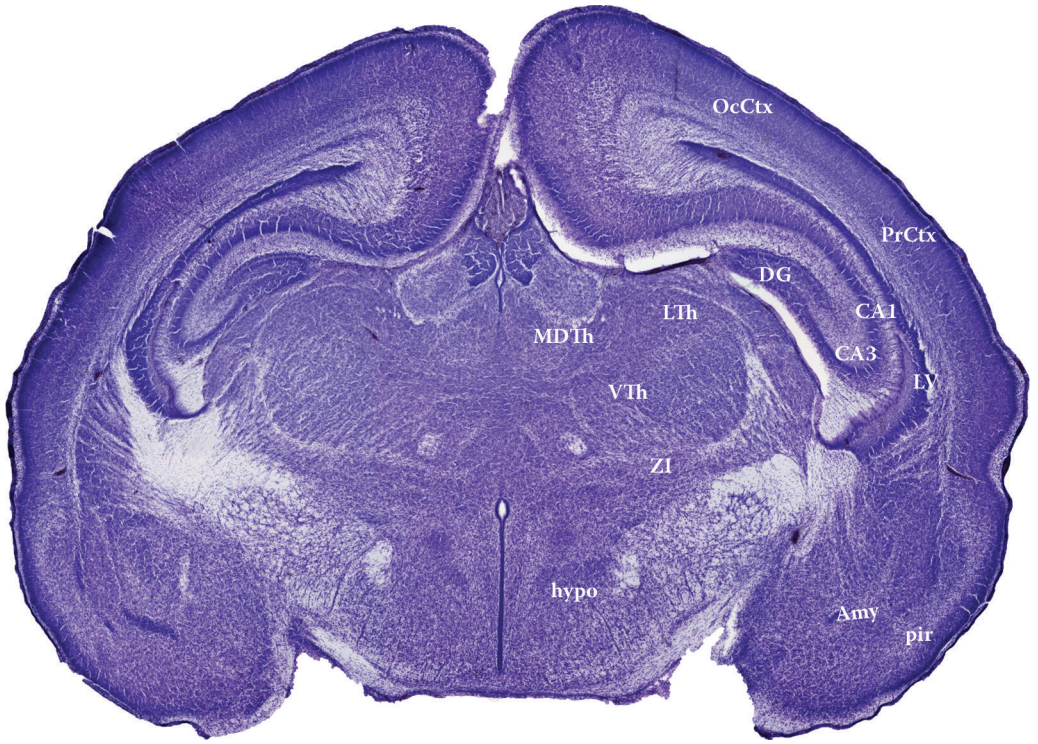

Figure 15
P-1, c15

Amy = Amygdaloid nuclei
CA1 = CA1 field of hippocampus
CA3 = CA3 field of hippocampus
DG = Dentate gyrus
FrCtx = Frontal cortex
Hypo = Hypothalamus
LTh = Lateral thalamus
LV = Lateral ventricle
MDTh = Mediodorsal thalamus
pir = Piriform cortex
PrCtx = Parietal cortex
VTh = Ventral thalamus
ZI = Zona incerta

© 2011 by Taylor and Francis Group, LLC



Figure 16
P-1, c16
Amy = Amygdaloid nuclei
CA1 = CA1 field of hippocampus
CA3 = CA3 field of hippocampus
DG = Dentate gyrus
FrCtx = Frontal cortex
LTh = Lateral thalamus
MDTh = Mediodorsal thalamus
pir = Piriform cortex
OcCtx = Occipital cortex

© 2011 by Taylor and Francis Group, LLC

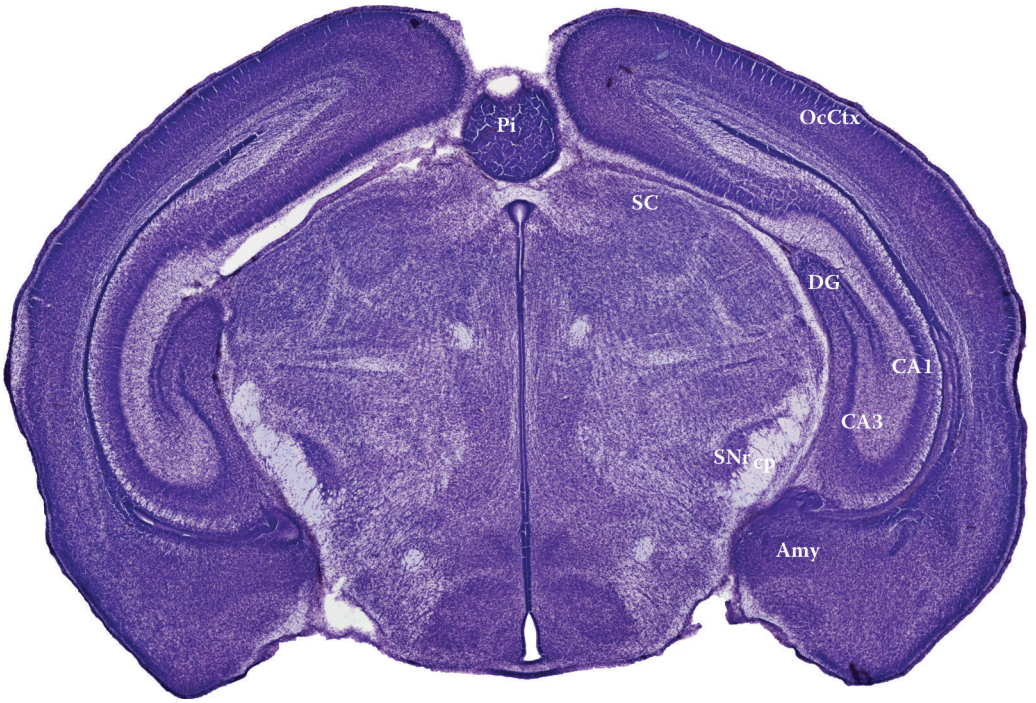

Figure 17
P-1, c17
Amy = Amygdaloid nuclei
CA1 = CA1 field of hippocampus
CA3 = CA3 field of hippocampus
DG = Dentate gyrus
OcCtx = Occipital cortex
Pi = Pineal gland
SC = Superior colliculus
SNr = Substantia nigra reticulata
ZI = Zona incerta

© 2011 by Taylor and Francis Group, LLC

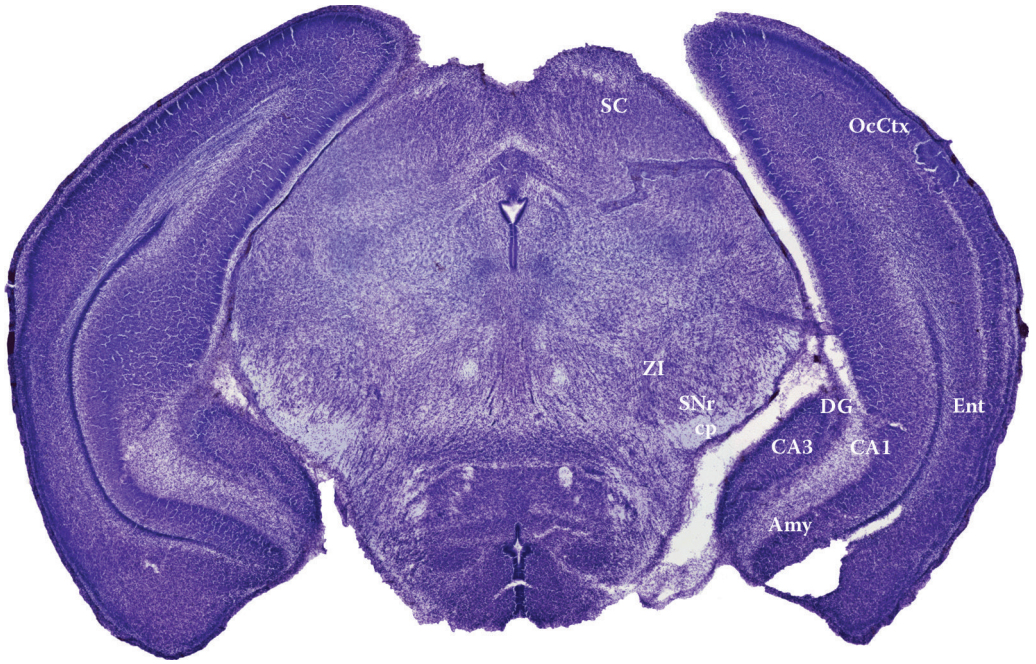

Figure 18
P-1, c18
Amy = Amygdaloid nuclei
CA1 = CA1 field of hippocampus
CA3 = CA3 field of hippocampus
cp = Caudate peduncle
DG = Dentate gyrus
Ent = Entorhinal cortex
OcCtx = Occipital cortex
SC = Superior colliculus
SNr = Substantia nigra reticulata
ZI = Zona incerta

© 2011 by Taylor and Francis Group, LLC



Figure 19
P-1, c19
CG = Central gray matter
DR = Dorsal raphe nuclei
Pn = Pontine nuclei
SC = Superior colliculus

© 2011 by Taylor and Francis Group, LLC



Figure 20
P-1, *c*20
CG = Central gray matter
SC = Superior colliculus

© 2011 by Taylor and Francis Group, LLC

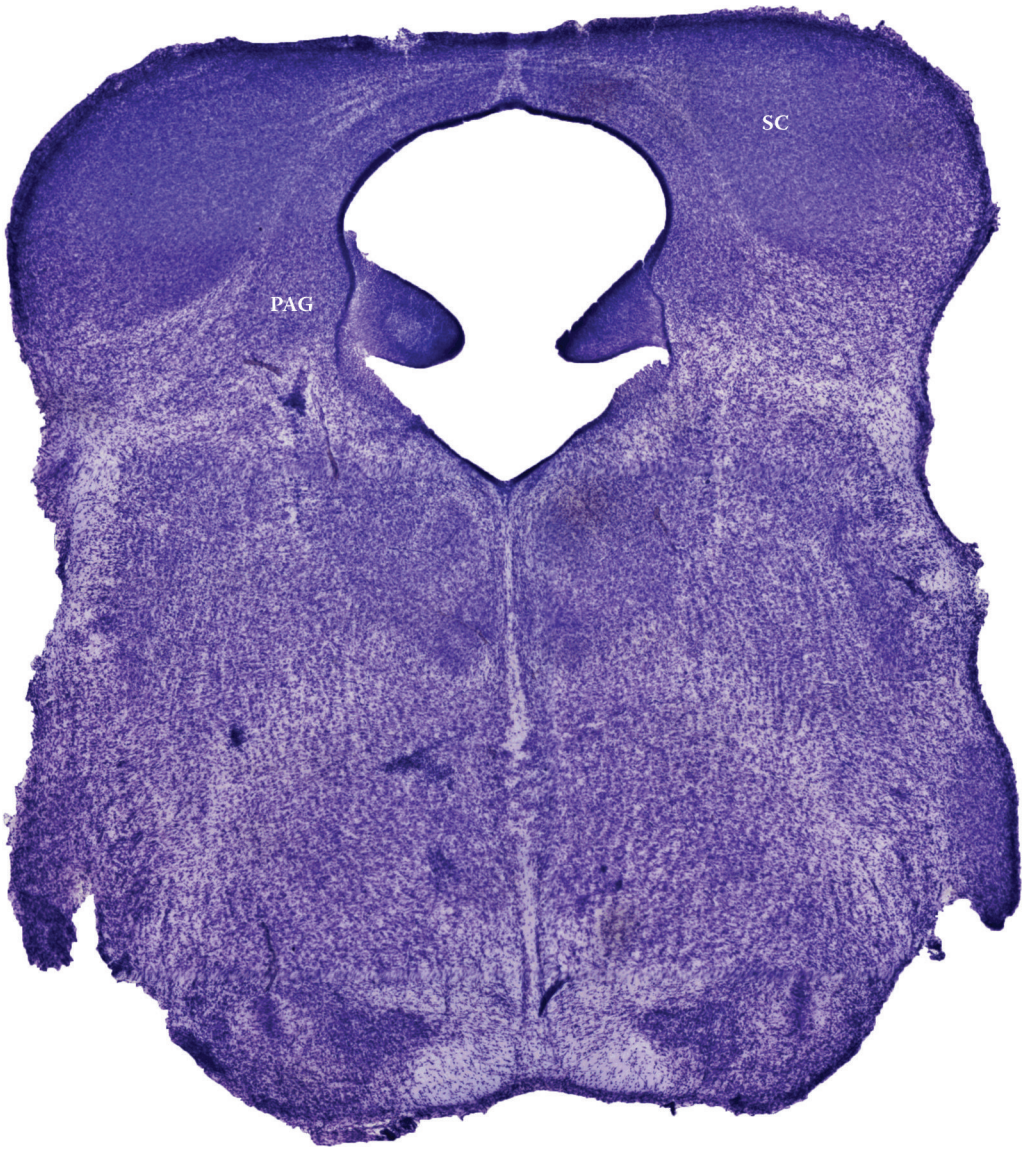

Figure 21
P-1, c21
PAG = Periaqueductal gray matter
SC = Superior colliculus

© 2011 by Taylor and Francis Group, LLC

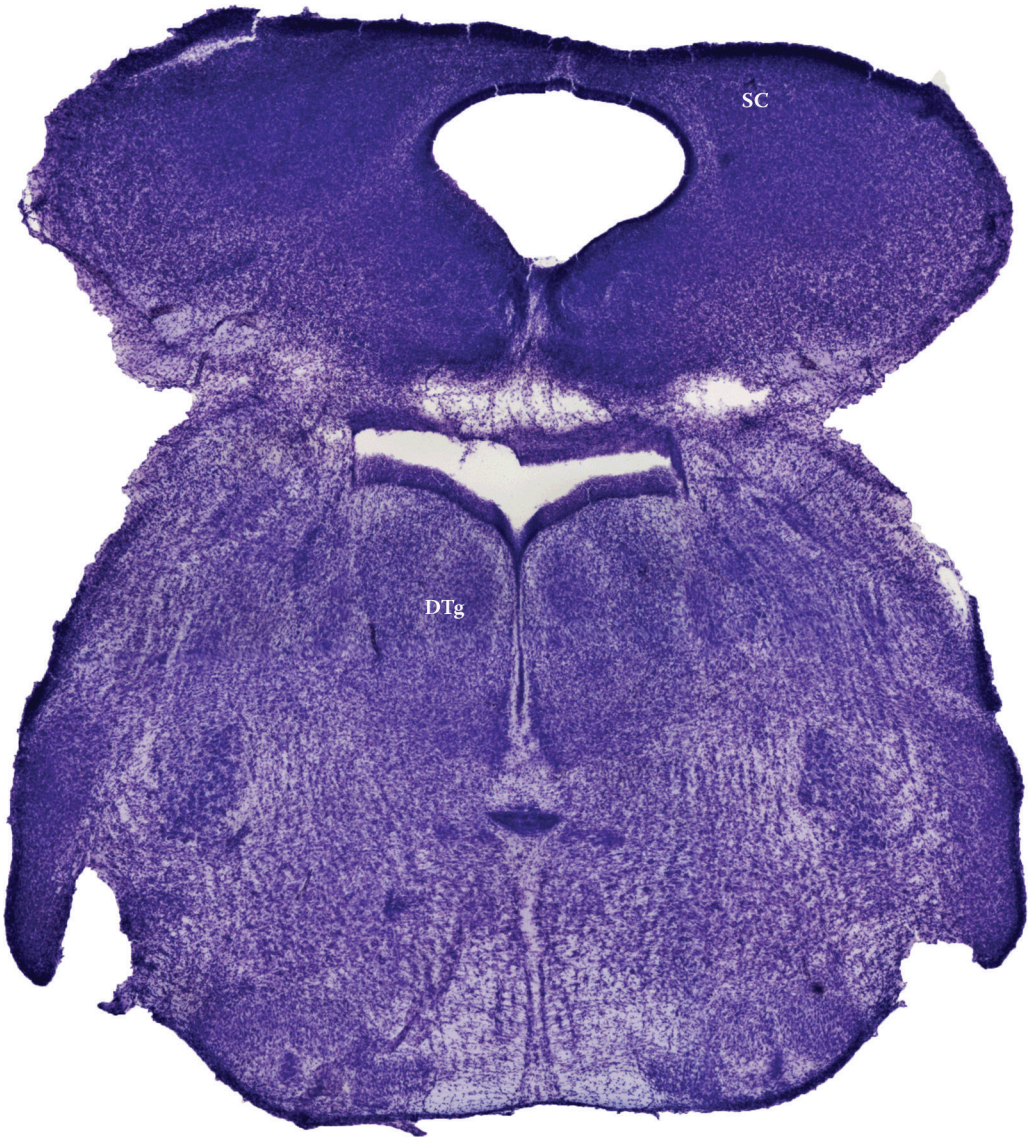

Figure 22
P-1, c22
DTg = Dorsal tegmental nuclei
SC = Superior colliculus

© 2011 by Taylor and Francis Group, LLC

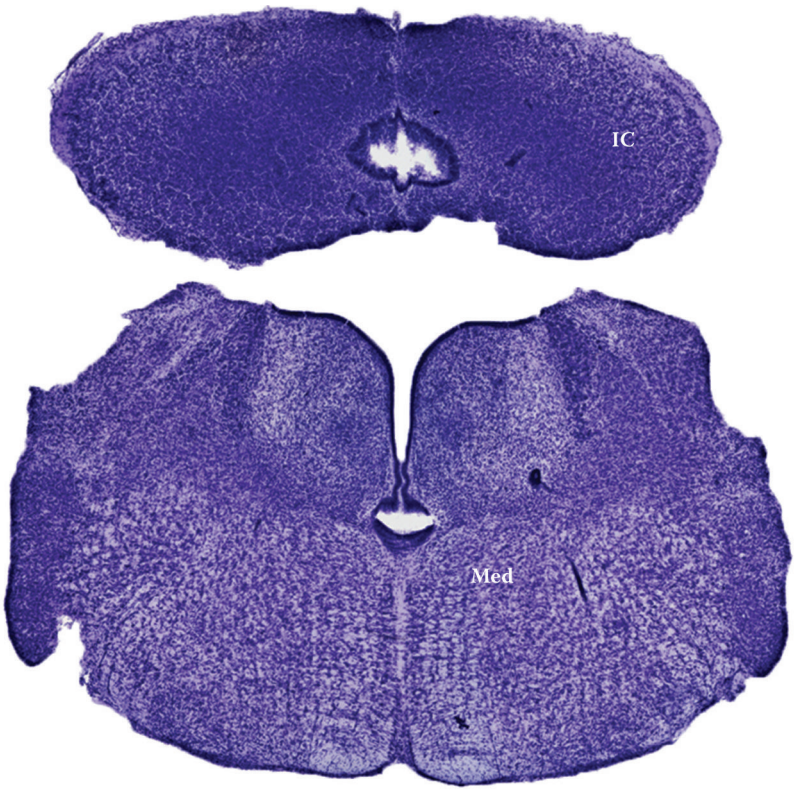

Figure 23
P-1, c22
IC = Inferior colliculus
Med = Medulla

© 2011 by Taylor and Francis Group, LLC



Figure 24
P-1, c24
Cer = Cerebellar peduncle
CG = Central gray matter
DTg = Dorsal tegmental nuclei
PTg = Posterior tegmental nuclei
IC = Inferior colliculus
SC = Superior colliculus

© 2011 by Taylor and Francis Group, LLC

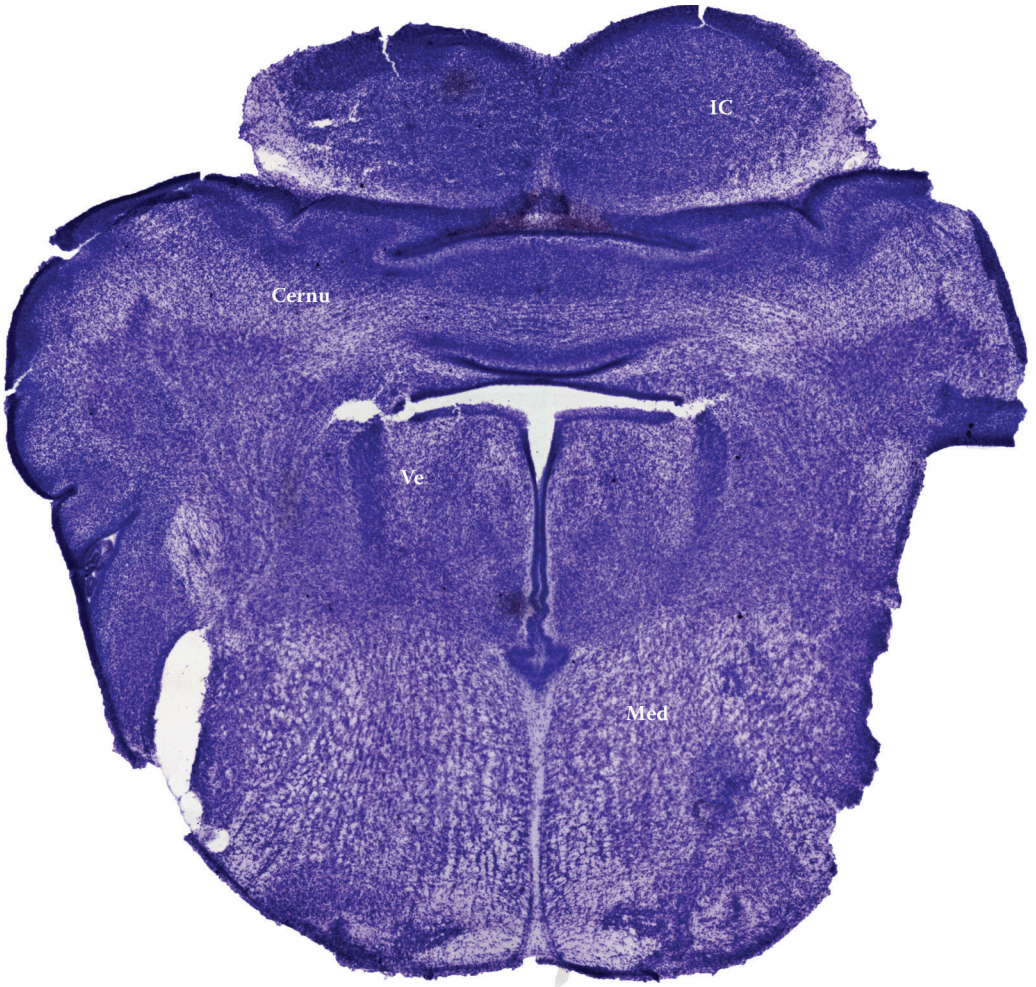

Figure 25
P-1, c25
Cernu = Cerebellar nuclei
IC = Inferior colliculus
Med = Medulla
Ve = Vestibular nucleus

© 2011 by Taylor and Francis Group, LLC



Figure 26
P-1, c26
Cernu = Cerebellar nuclei
IC = Inferior colliculus
Med = Medulla
Ve = Vestibular nuclei

© 2011 by Taylor and Francis Group, LLC

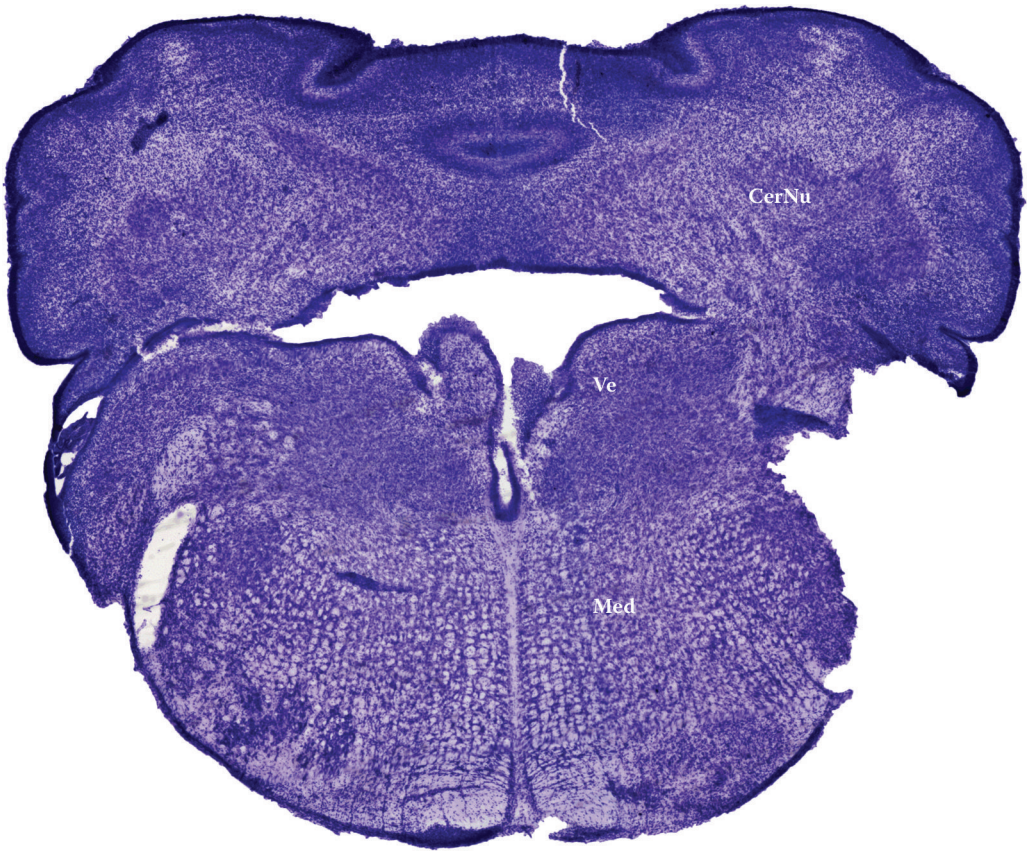

Figure 27
P-1, c27
Cernu = Cerebellar nuclei
Med = Medulla
Ve = Vestibular nuclei

© 2011 by Taylor and Francis Group, LLC

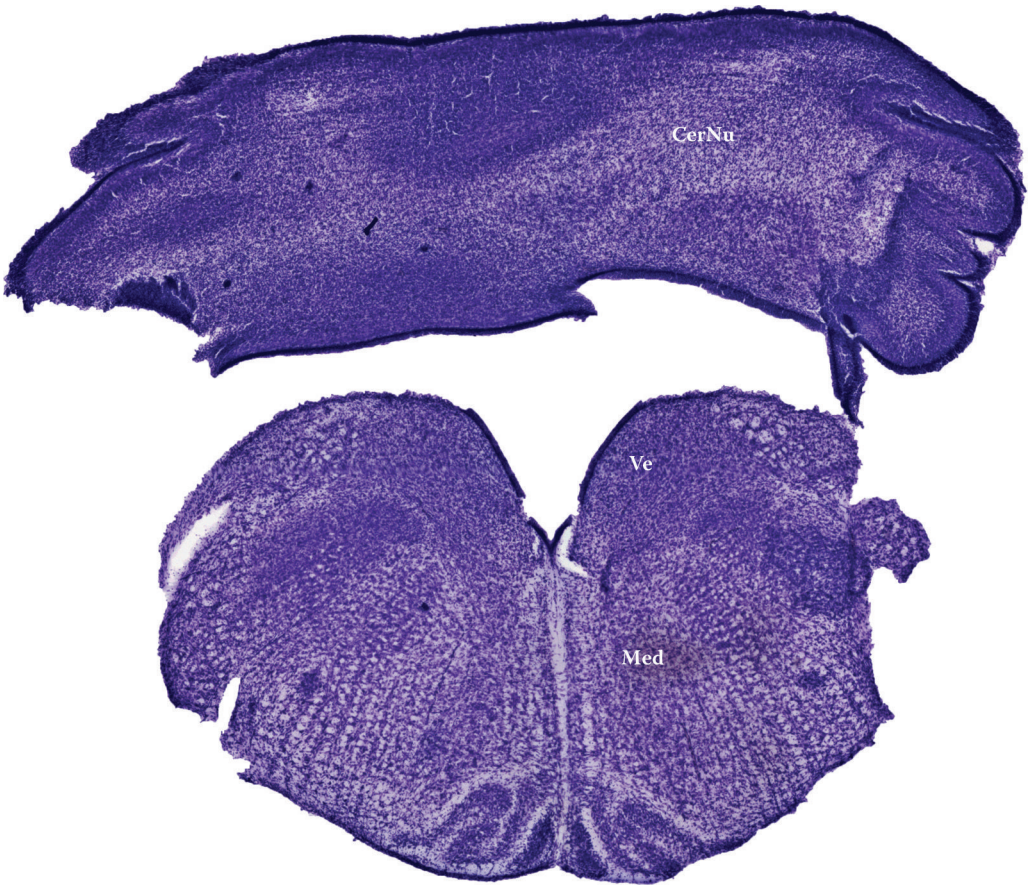

Figure 28
P-1, c28
Cernu = Cerebellar nuclei
Med = Medulla
Ve = Vestibular nuclei

© 2011 by Taylor and Francis Group, LLC

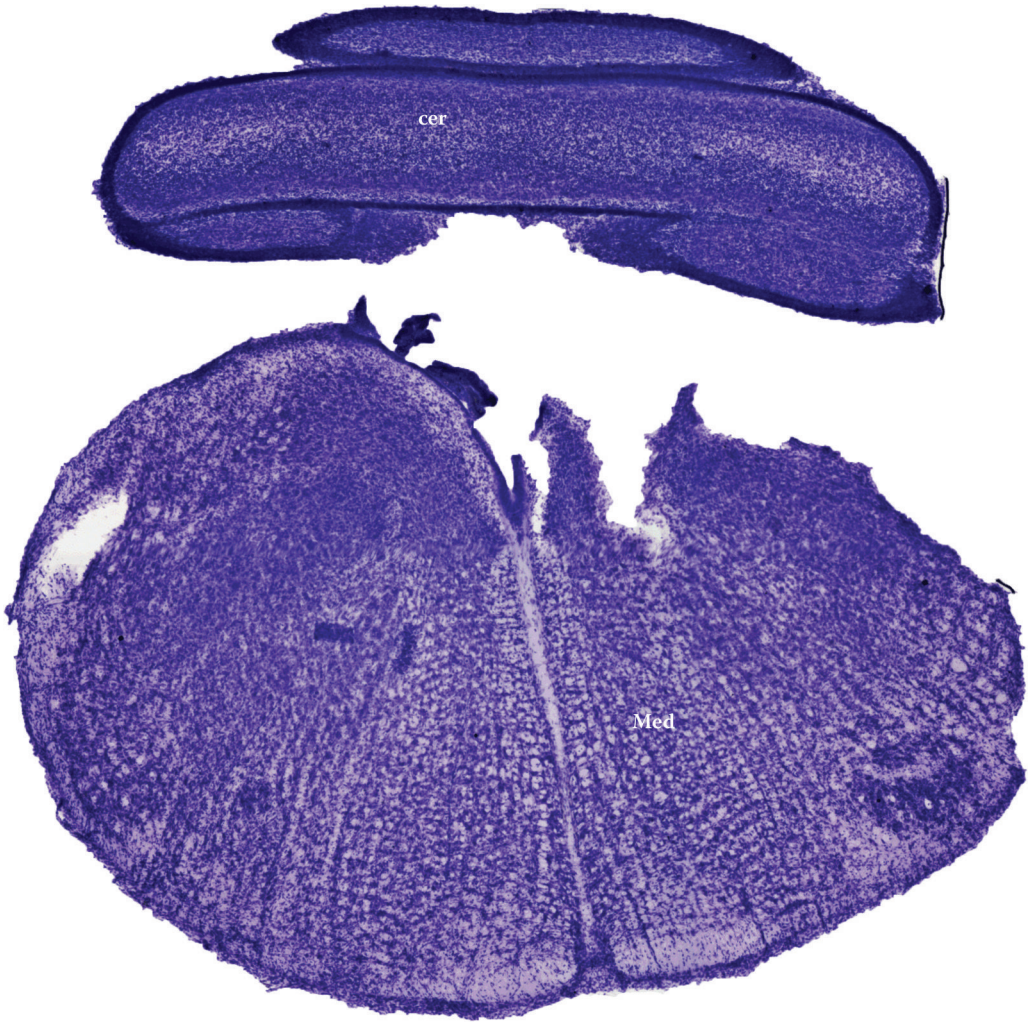

Figure 29
P-1, c29
Cernu = Cerebellar nuclei
Med = Medulla

© 2011 by Taylor and Francis Group, LLC

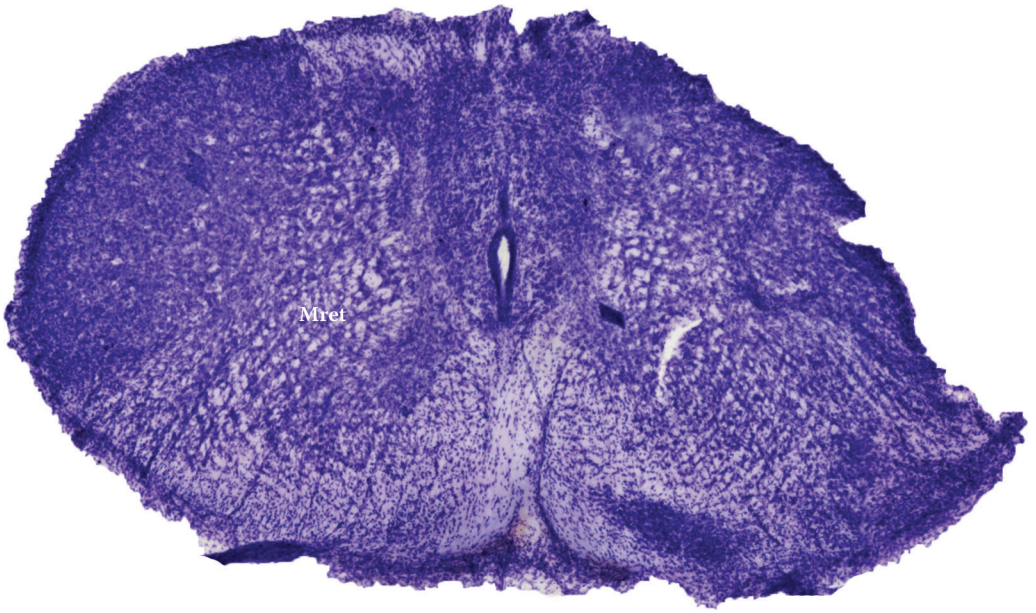

Figure 30
P-1, c30
Mret = Medullary reticular formation

© 2011 by Taylor and Francis Group, LLC

Sagittal Plates

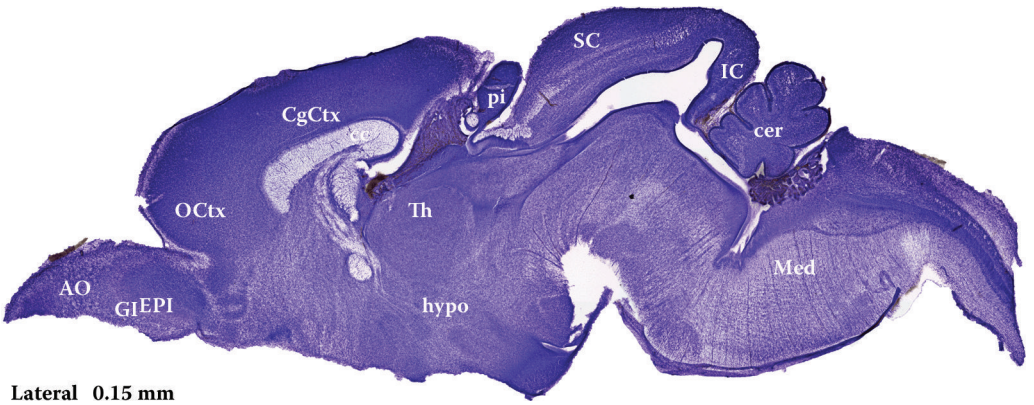

Figure 31
P-1, s1

AO = Anterior olfactory bulb
cc = Corpus callosum
Cer = Cerebellar peduncle
CgCtx = Cingulate cortex
EPI = External plexiform layer, olfactory bulb
GI = Glomerular layer, olfactory bulb
Hypo = Hypothalamus
IC = Inferior colliculus
PAG = Periaqueductal gray matter
Pi = Pineal gland
Med = Medulla
SC = Superior colliculus
Th = Thalamus

© 2011 by Taylor and Francis Group, LLC

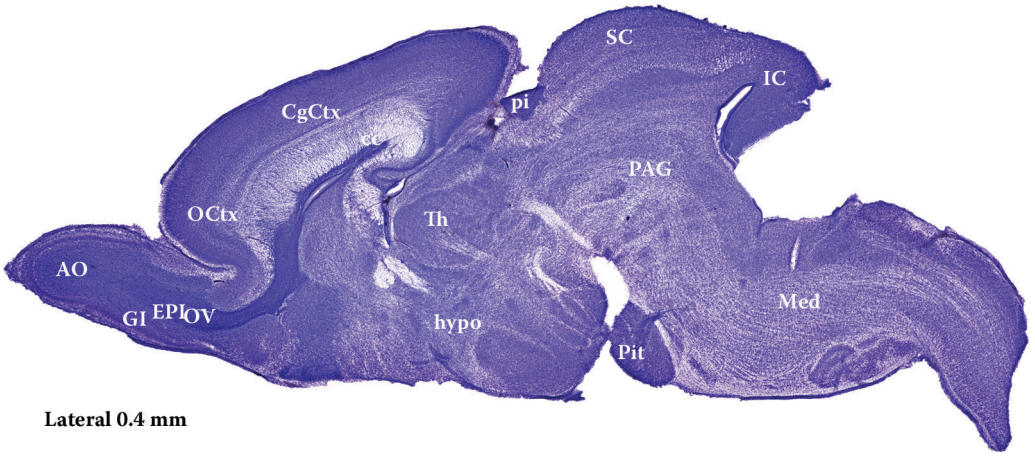

Figure 32
P-1, -s2
AO = Anterior olfactory bulb
cc = Corpus callosum
CgCtx = Cingulate cortex
EPI = External plexiform layer, olfactory bulb
GI = Glomerular layer, olfactory bulb
Hypo = Hypothalamus
IC = Inferior colliculus
Med = Medulla
OV = Olfactory ventricle
PAG = Periaqueductal gray matter
Pi = Pineal gland
Pit = Pituitary gland
SC = Superior colliculus
Th = Thalamus

© 2011 by Taylor and Francis Group, LLC

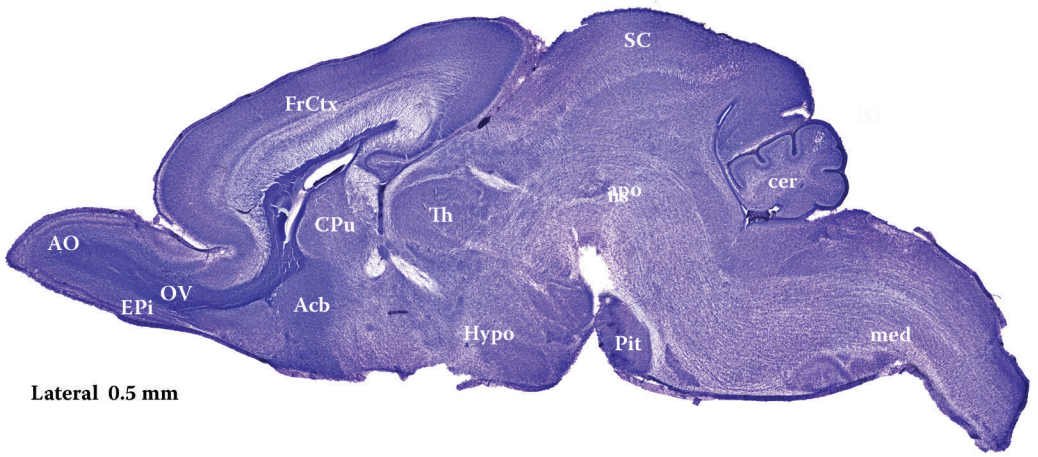

Figure 33
P-1, s3

Acb = Accumbens nucleus
AO = Anterior olfactory bulb
cer = Cerebellum
CPu = Caudate putamen
DG = Dentate gyrus
EPI = External plexiform layer, olfactory bulb
FrCtx = Frontal cortex
Hypo = Hypothalamus
Med = Medulla
OV = Olfactory ventricle
Pit = Pituitary gland
SC = Superior colliculus
Th = Thalamus

© 2011 by Taylor and Francis Group, LLC

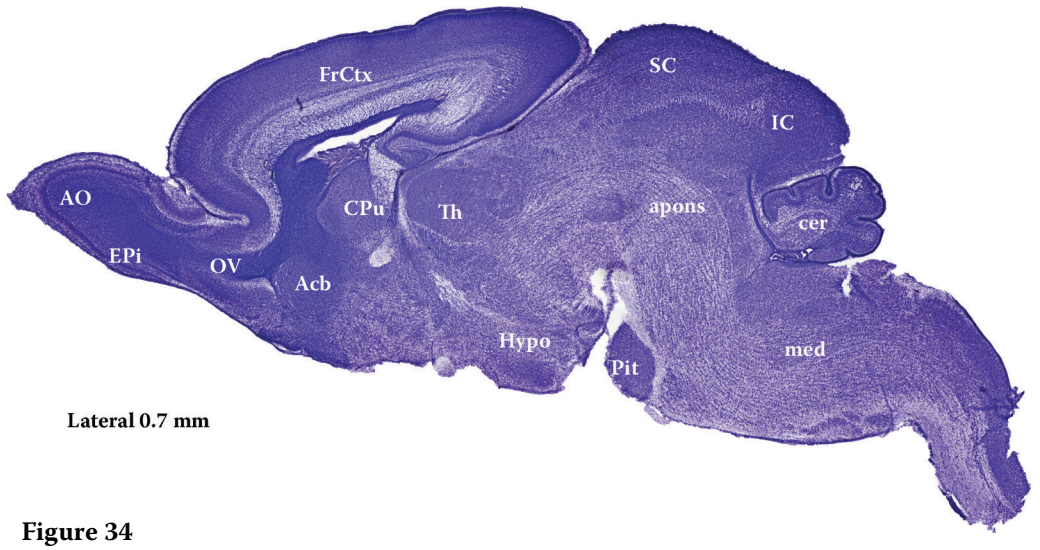

Figure 34
P-1, s4
Acb = Accumbens nucleus
AO = Anterior olfactory bulb
cc = Corpus callosum
cer = Cerebellum
CPu = Caudate putamen
EPI = External plexiform layer, olfactory bulb
FrCtx = Frontal cortex
GI = Glomerular layer, olfactory bulb
Hypo = Hypothalamus
IC = Inferior colliculus
Pit = Pituitary gland
Med = Medulla
SC = Superior colliculus
Th = Thalamus

© 2011 by Taylor and Francis Group, LLC

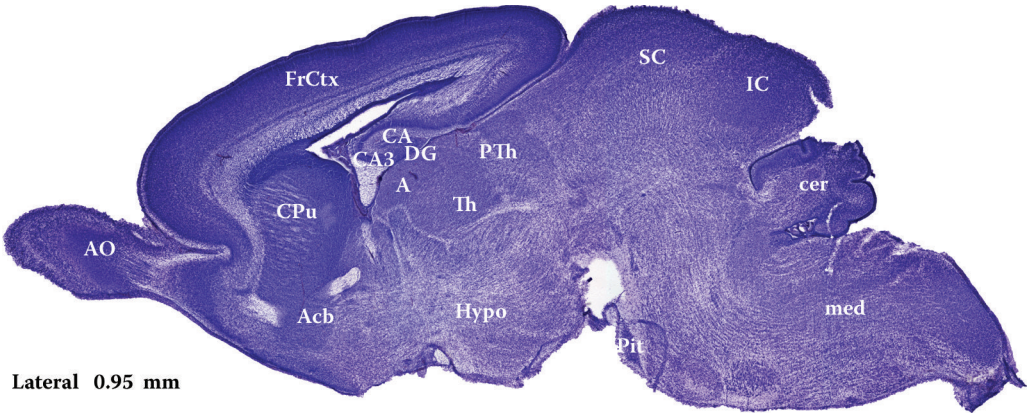

Figure 35
P-1, s5
Acb = Accumbens nucleus
ATh = Anterior thalamus
AO = Anterior olfactory bulb
apons = Anterior pons
CA1 = CA1 field of hippocampus
CA3 = CA3 field of hippocampus
cc = Corpus callosum
CPu = Caudate putamen
DG = Dentate gyrus
FrCtx = Frontal cortex
GP = Globus pallidus
Hypo = Hypothalamus
IC = Inferior colliculus
OV = Olfactory ventricle
Pit = Pituitary gland
PTh = Posterior thalamus
Med = Medulla
SC = Superior colliculus
Th = Thalamus

© 2011 by Taylor and Francis Group, LLC

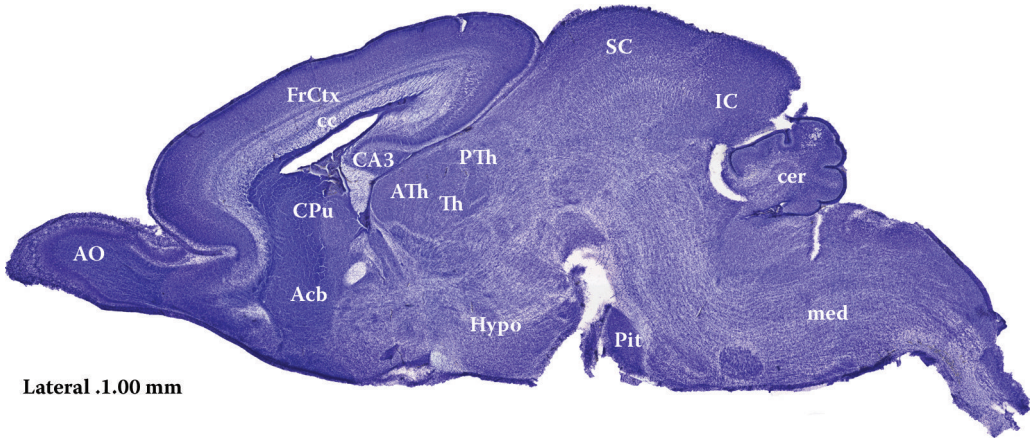

Figure 36
P-1, s6

Acb = Accumbens nucleus
AO = Anterior olfactory bulb
ATh = Anterior thalamus
CA1 = CA1 field of hippocampus
CA3 = CA3 field of hippocampus
cc = Corpus callosum
cer = Cerebellum
CPu = Caudate putamen
DG = Dentate gyrus
FrCtx = Frontal cortex
Hypo = Hypothalamus
IC = Inferior colliculus
Med = Medulla
OV = Olfactory ventricle
Pit = Pituitary gland
PTh = Posterior thalamus
SC = Superior colliculus
Th = Thalamus

© 2011 by Taylor and Francis Group, LLC

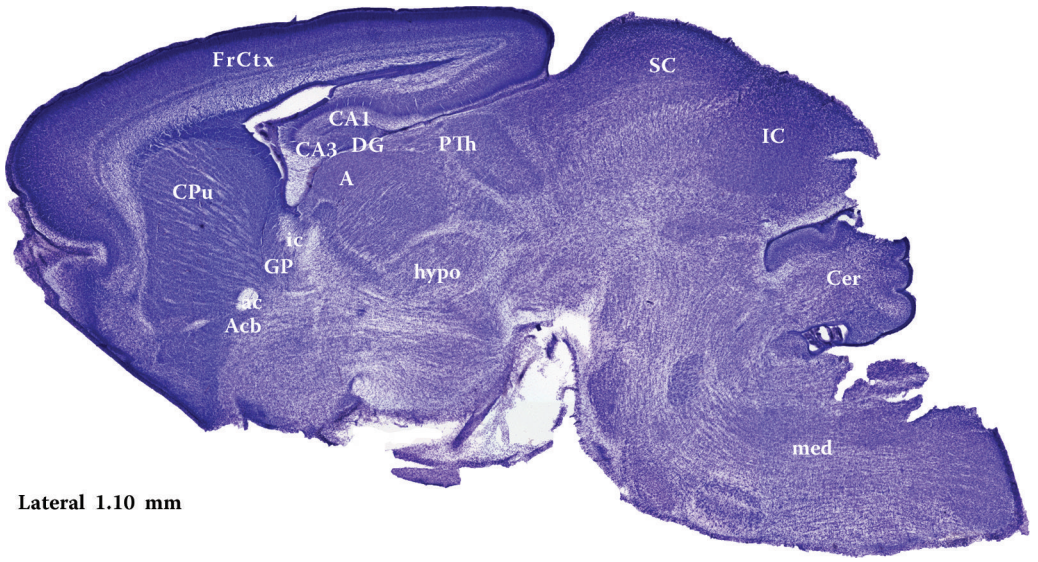

Figure 37
P-1, s7

Acb = Accumbens nucleus
ATh = Anterior thalamus
CA1 = CA1 field of hippocampus
CA3 = CA3 field of hippocampus
cc = Corpus callosum
cer = Cerebellum
CPu = Caudate putamen
DG = Dentate gyrus
FrCtx = Frontal cortex
Hypo = Hypothalamus
IC = Inferior colliculus
Ic = Internal capsule
Med = Medulla
OV = Olfactory ventricle
Pit = Pituitary gland
PTh = Posterior thalamus
SC = Superior colliculus
Th = Thalamus

© 2011 by Taylor and Francis Group, LLC

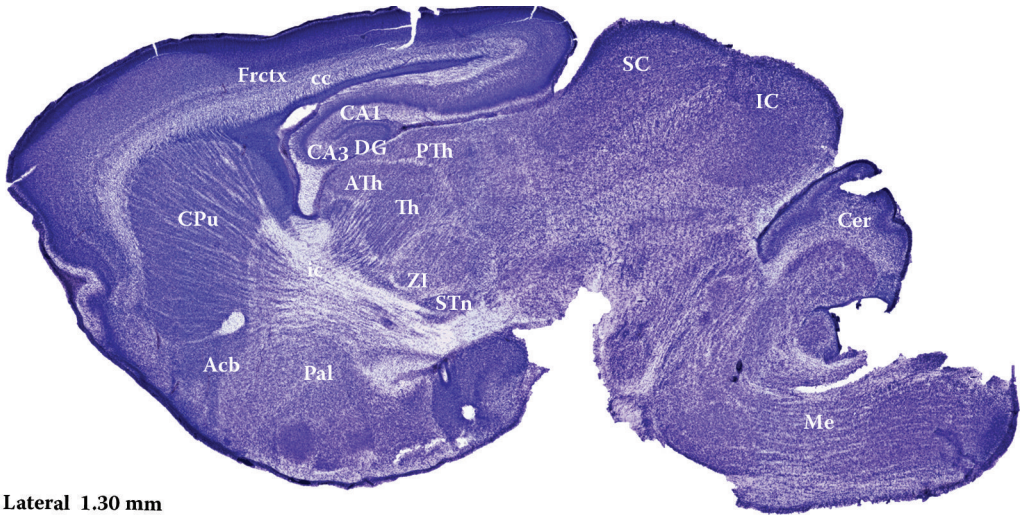

Figure 38
P-1, s8

Acb = Accumbens nucleus
ATh = Anterior thalamus
CA1 = CA1 field of hippocampus
CA3 = CA3 field of hippocampus
cc = Corpus callosum
cer = Cerebellum
CPu = Caudate putamen
DG = Dentate gyrus
Hypo = Hypothalamus
IC = Inferior colliculus
Ic = Internal capsule
Med = Medulla
Pal = Pallidum
Pit = Pituitary gland
PTh = Posterior thalamus
SC = Superior colliculus
STn = Subthalamic nuclei
Th = Thalamus
ZI = Zona incerta

© 2011 by Taylor and Francis Group, LLC

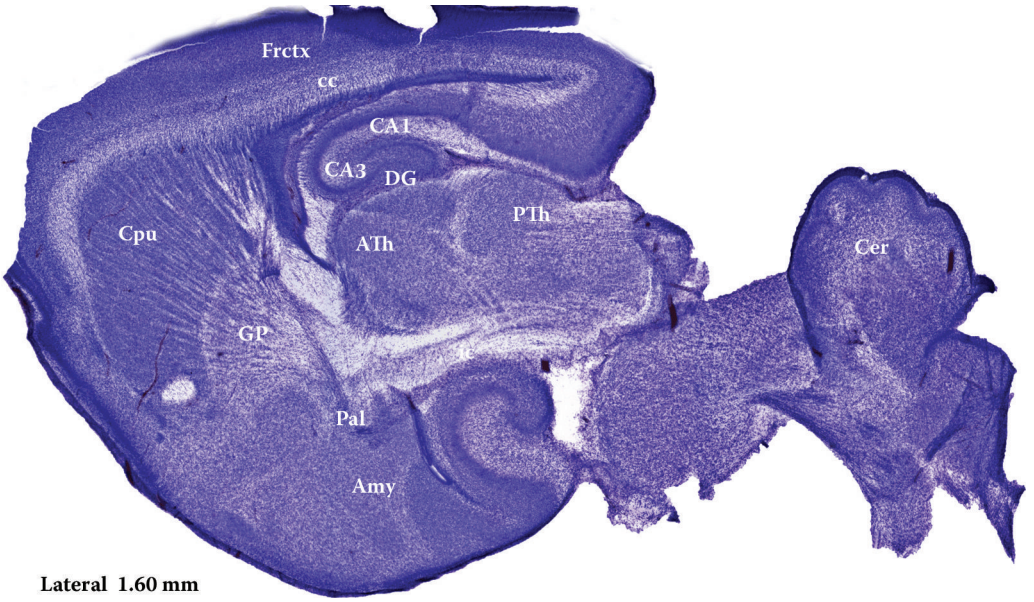

Figure 39
P-1, s9

Amy = Amygdaloid nuclei
ATh = Anterior thalamus
Acb = Accumbens nuclei
CA1 = CA1 field of hippocampus
CA3 = CA3 field of hippocampus
cc = Corpus callosum
cer = Cerebellum
CPu = Caudate putamen
DG = Dentate gyrus
Hypo = Hypothalamus
GP = Globus pallidus
Ic = Internal capsule
IC = Inferior colliculus
pal = Pallidum
PTh = Posterior thalamus

© 2011 by Taylor and Francis Group, LLC

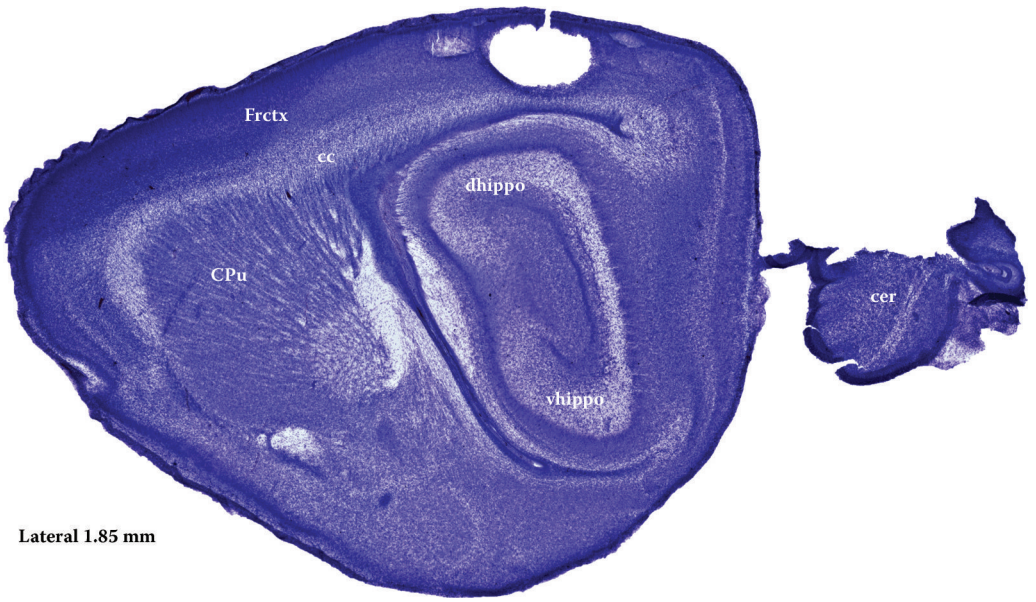

Figure 40
P-1, s10
Amy = Amygdaloid nuclei
CA1 = CA1 field of hippocampus
CA3 = CA3 field of hippocampus
cc = Corpus callosum
CPu = Caudate putamen
FrCtx = Frontal cortex
GP = Globus pallidus

© 2011 by Taylor and Francis Group, LLC



Figure 41
P-1, s11
cc = Corpus callosum
cer = Cerebellum
Cpu = Caudate putamen
dhippo = Dorsal hippocampal formation
FrCtx = Frontal cortex
vhippo = Ventral hippocampal formation

© 2011 by Taylor and Francis Group, LLC

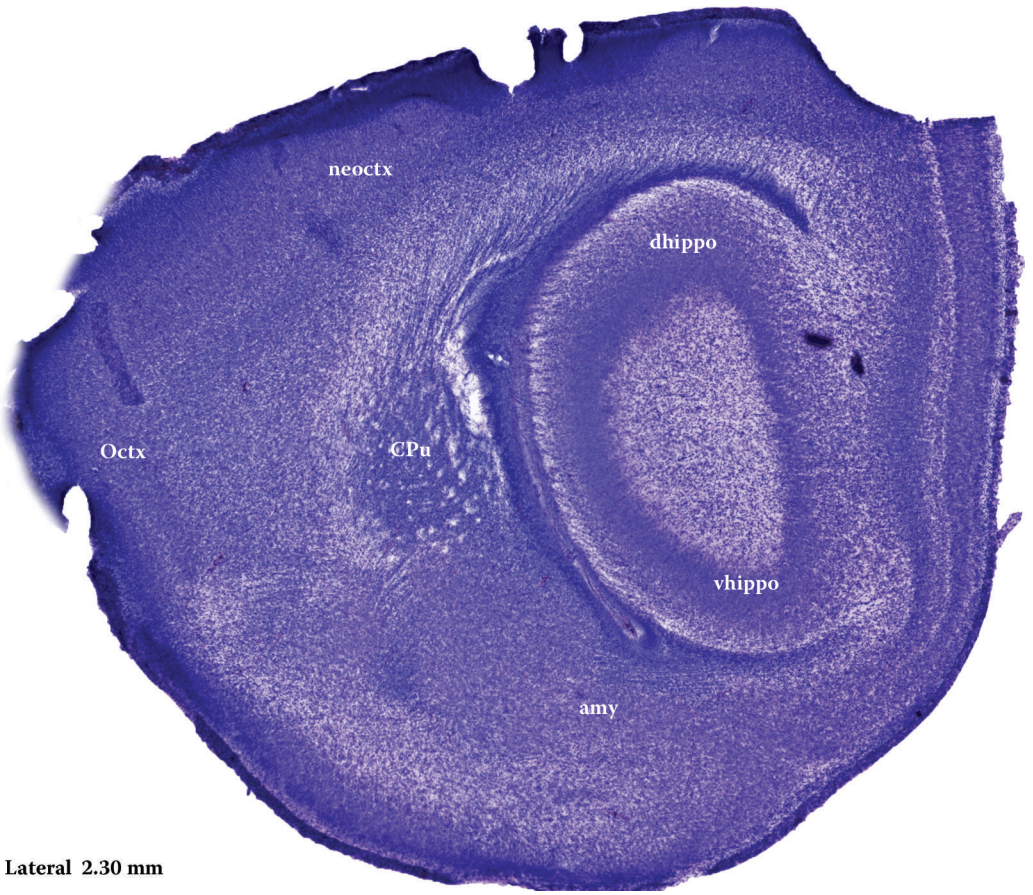

Figure 42
P-1, s12
Amy = Amygdaloid nuclei
Cpu = Caudate putamen
dhippo = Dorsal hippocampal formation
FrCtx = Frontal cortex
OCtx = Olfactory cortex
vhippo = Ventral hippocampal formation

© 2011 by Taylor and Francis Group, LLC

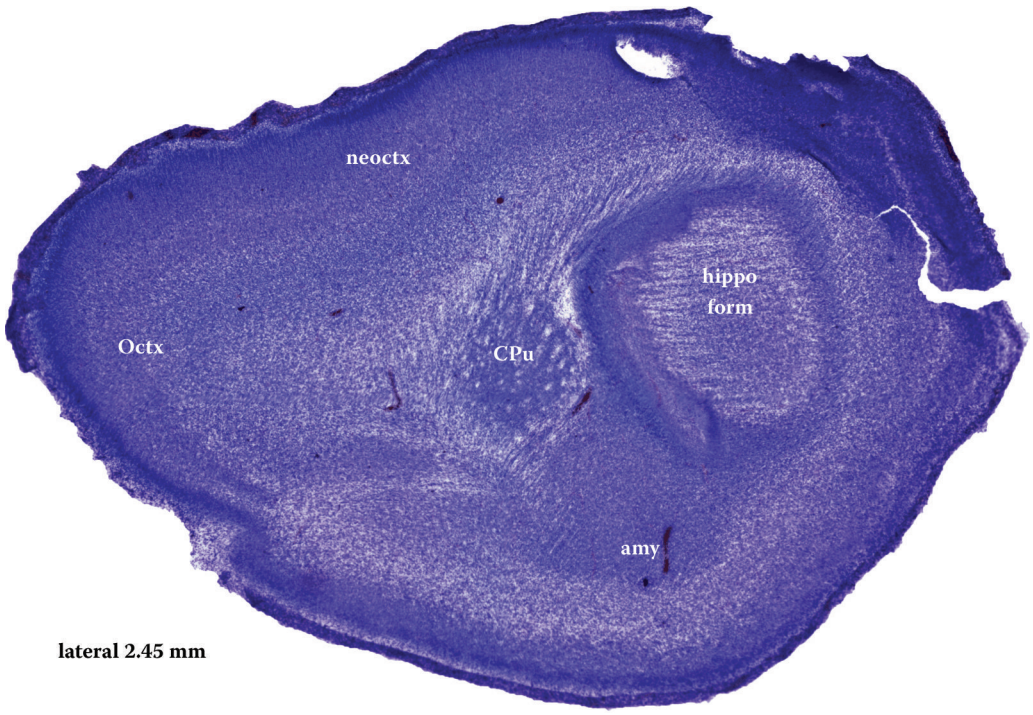

Figure 43
P-1, s13
Amy = Amygdaloid nuclei
Cpu = Caudate putamen
Hfor = Hippocampal formation
neoCtx = Neocortex
OCtx = Olfactory cortex

© 2011 by Taylor and Francis Group, LLC

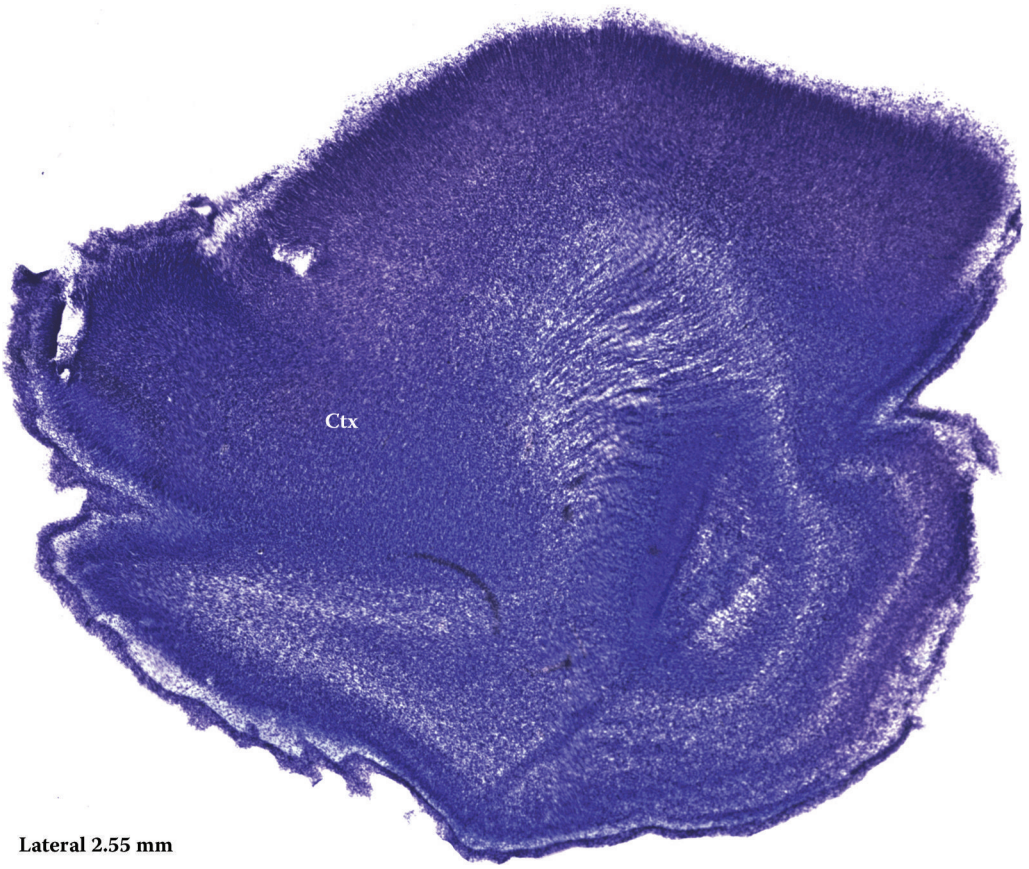

Figure 44
P-1, s14
Ctx = Cortex

© 2011 by Taylor and Francis Group, LLC

Section II

P-7 Brain

© 2011 by Taylor and Francis Group, LLC

Coronal Plates

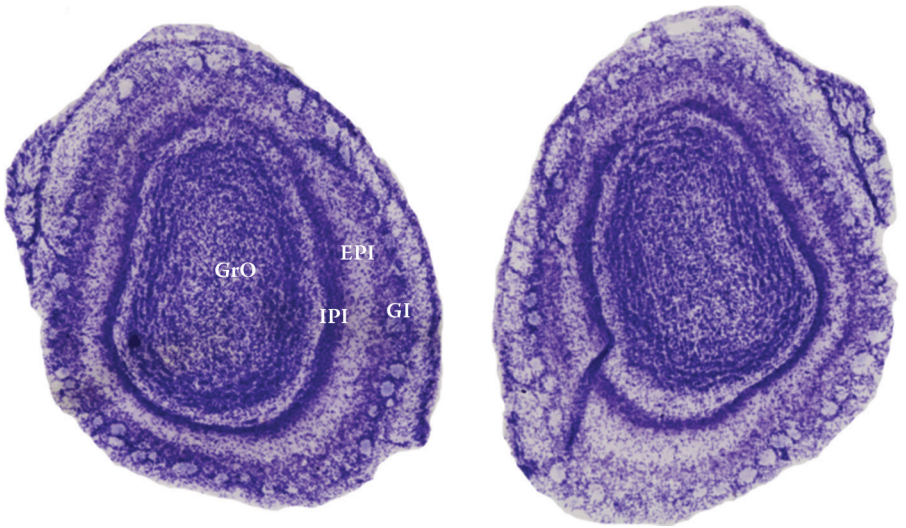

Figure 45
P-7, c1
EPI = External plexiform layer, olfactory bulb
GI = Glomerular layer, olfactory bulb
IPI = Internal plexiform layer, olfactory bulb
OV = Olfactory ventricle

© 2011 by Taylor and Francis Group, LLC

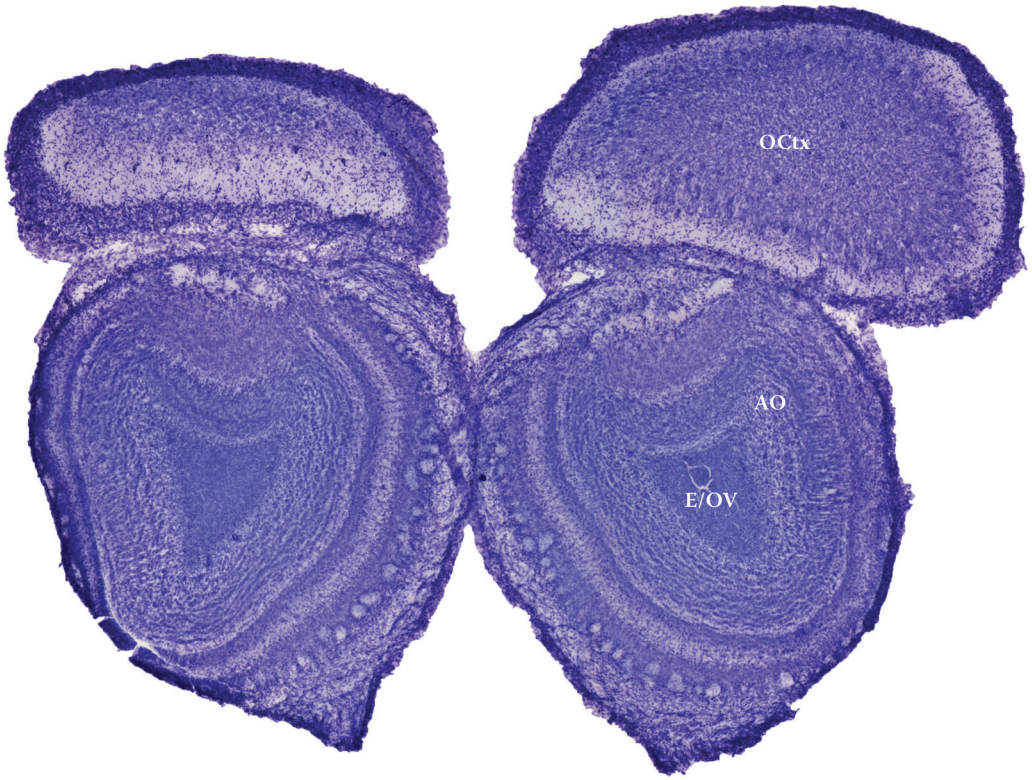

Figure 46
P-7, -c2
AO = Anterior olfactory bulb
E = Ependyma and subependymal layer
OCtx = Orbital cortex
OV = Olfactory ventricle

© 2011 by Taylor and Francis Group, LLC

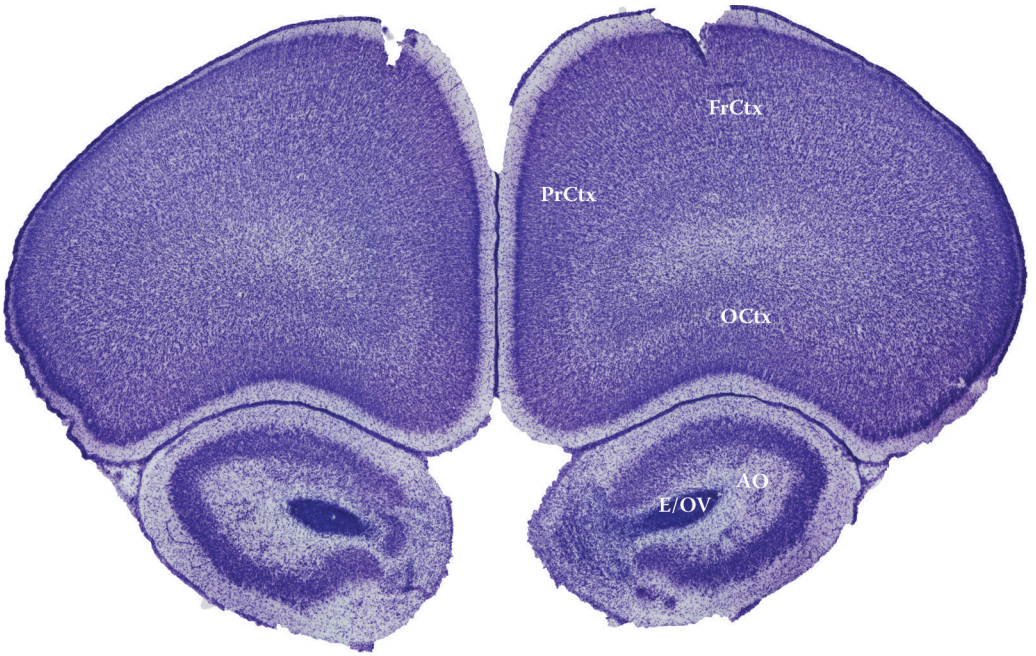

Figure 47
P-7, c3
AO = Anterior olfactory bulb
E = Ependyma and subependymal layer
FrCtx = Frontal cortex
OCtx = Orbital cortex
OV = Olfactory ventricle
PrCtx = Parietal cortex

© 2011 by Taylor and Francis Group, LLC

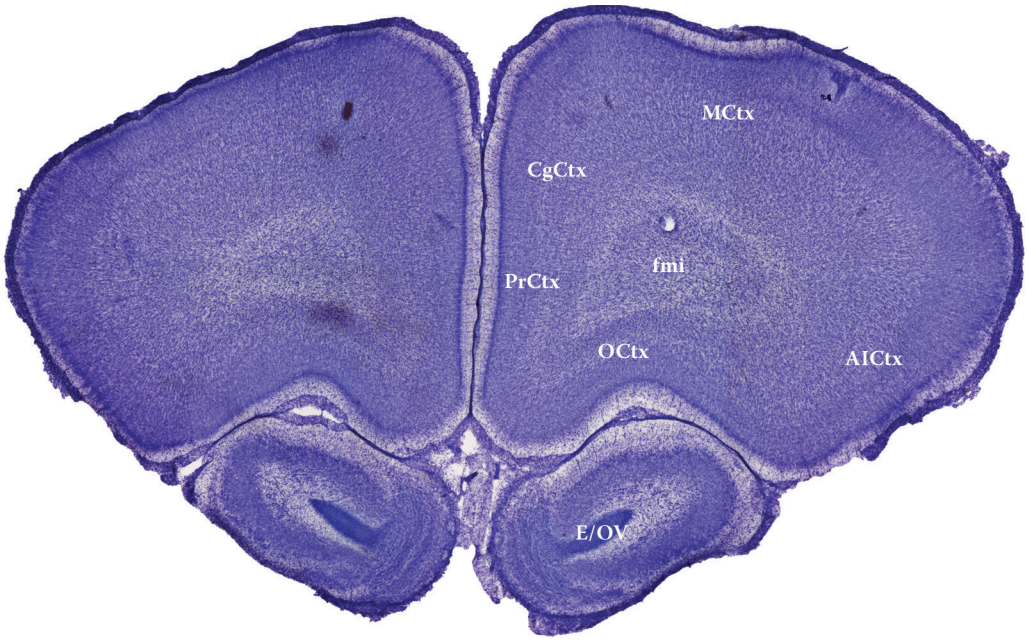

Figure 48
P-7, c4
AICtx = Agranular insular cortex
CgCtx = Cingulate cortex
E = Ependyma and subependymal layer
fmi = Forceps minor of corpus callosum
MCtx = Motor cortex
OCtx = Orbital cortex
OV = Olfactory ventricle
PrCtx = Parietal cortex

© 2011 by Taylor and Francis Group, LLC

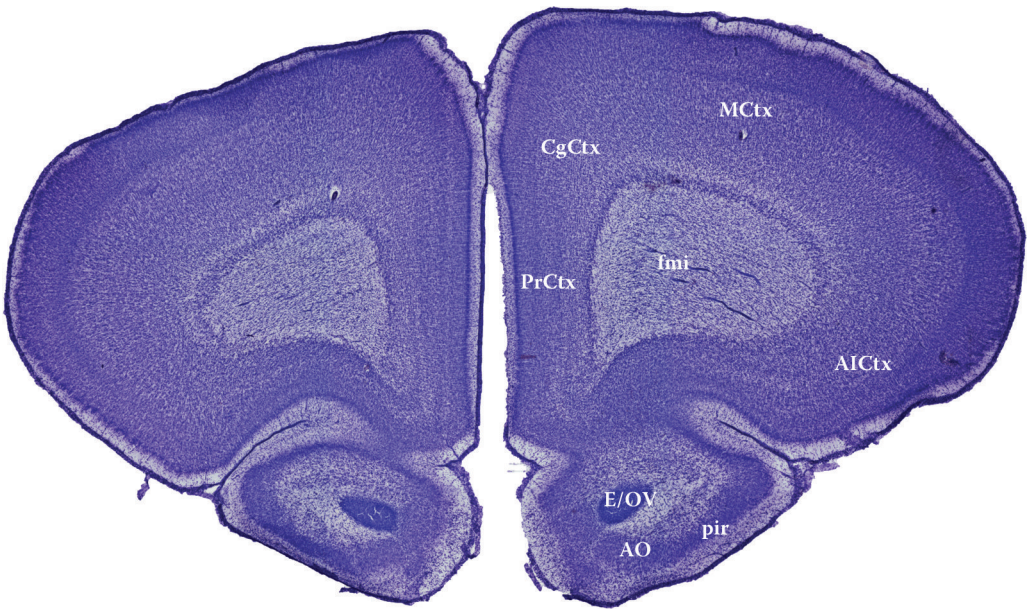

Figure 49
P-7, c5
AICtx = Agranular insular cortex
AO = anterior olfactory nuclei
CgCtx = Cingulate cortex
E = Ependyma and subependymal layer
fmi = Forceps minor of corpus callosum
MCtx = Motor cortex
OCtx = Orbital cortex
OV = Olfactory ventricle
pir = Piriform cortex
PrCtx = Parietal cortex

© 2011 by Taylor and Francis Group, LLC

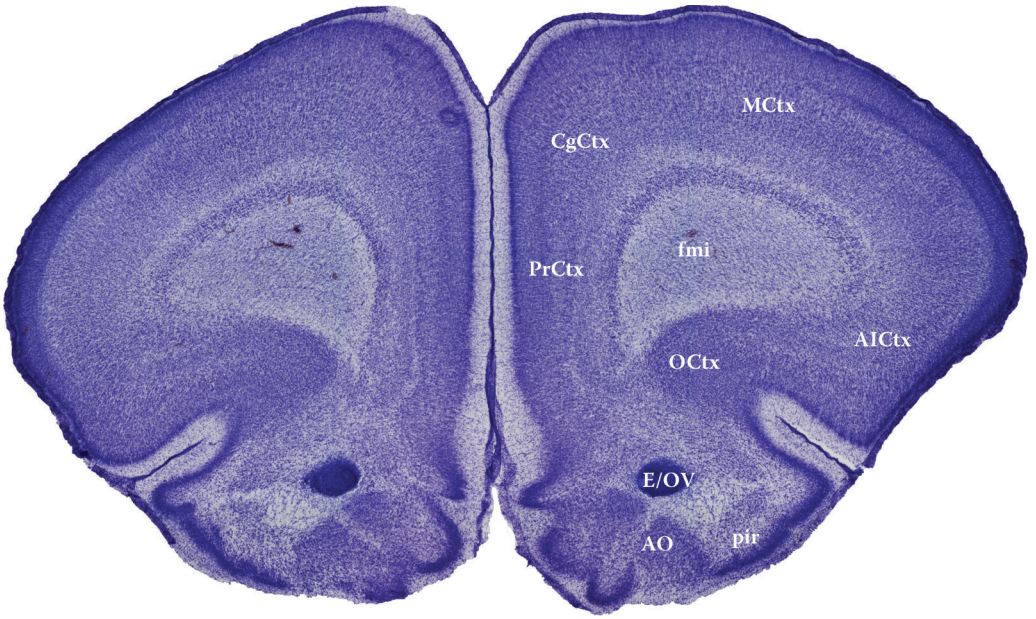

Figure 50
P-7, c6
AICtx = Agranular insular cortex
AO = Anterior olfactory nuclei
CgCtx = Cingulate cortex
E = Ependyma and subependymal layer
fmi = Forceps minor of corpus callosum
MCtx = Motor cortex
OCtx = Orbital cortex
OV = Olfactory ventricle
pir = Piriform cortex
PrCtx = Parietal cortex

© 2011 by Taylor and Francis Group, LLC

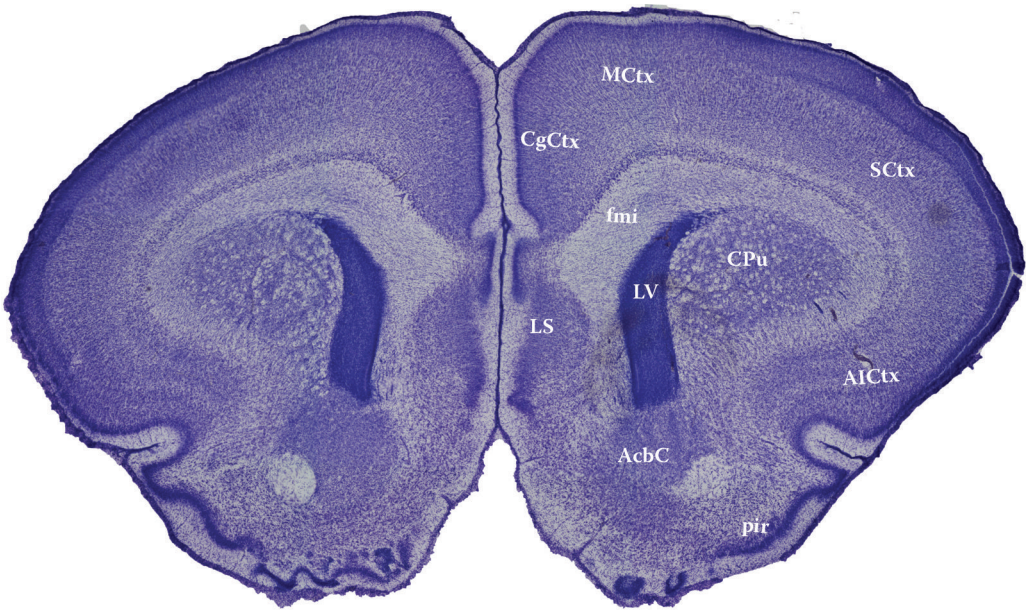

Figure 51
P-7, c7

AcbC = Accumbens nucleus core
AICtx = Agranular insular cortex
CgCtx = Cingulate cortex
CPu = Caudate putamen
fmi = Forceps minor of corpus callosum
LS = Lateral septal nuclei
LV = Lateral ventricle
MCtx = Motor cortex
pir = Piriform cortex
SCtx = Somatosensory cortex

© 2011 by Taylor and Francis Group, LLC



Figure 52
P-7, c8
aca = Anterior commissure
AcbC = Accumbens nucleus core
cc = Corpus callosum
CgCtx = Cingulate cortex
CPu = Caudate putamen
LS = Lateral septal nuclei
LV = Lateral ventricle
MCtx = Motor cortex
pir = Piriform cortex
SCtx = Somatosensory cortex

© 2011 by Taylor and Francis Group, LLC

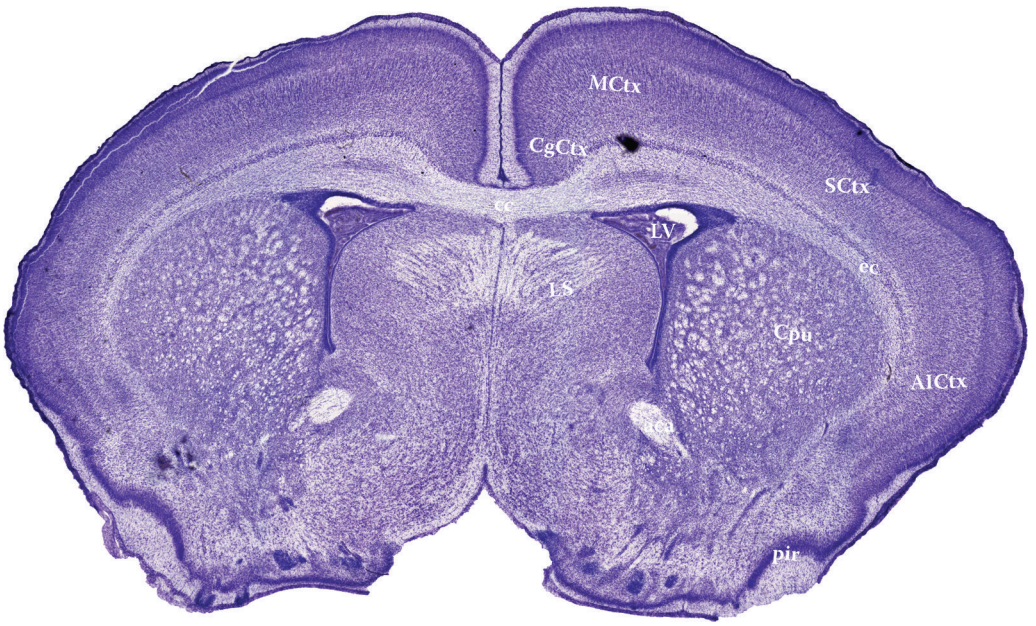

Figure 53
P-7, c9
aca = Anterior commissure
AICtx = Agranular insular cortex
CgCtx = Cingulate cortex
cc = Corpus callosum
CPu = Caudate putamen
ec = external capsule
LS = Lateral septal nuclei
LV = Lateral ventricle
MCtx = Motor cortex
pir = Piriform cortex
SCtx = Somatosensory cortex

© 2011 by Taylor and Francis Group, LLC

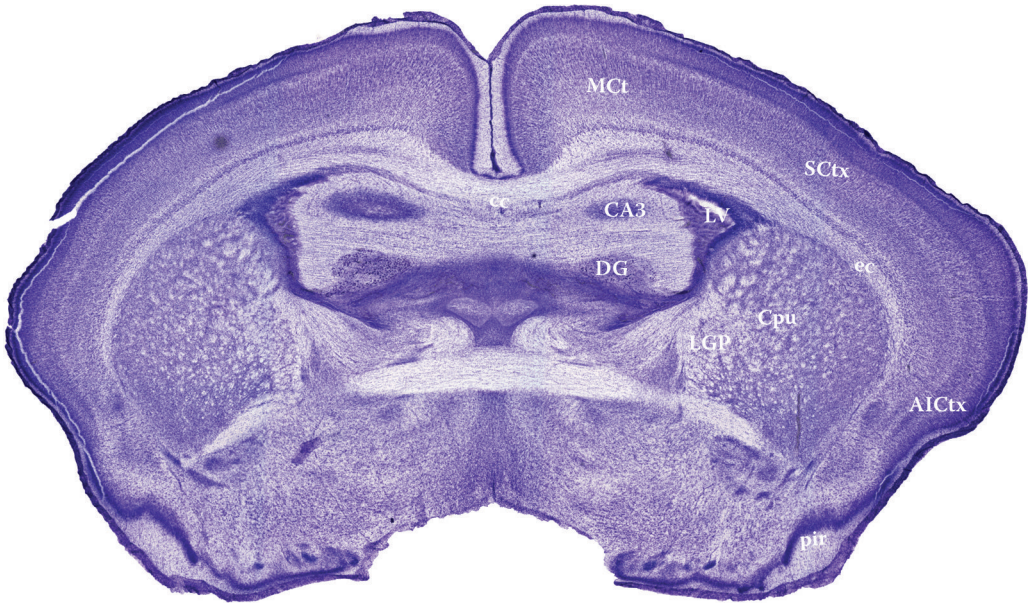

Figure 54
P-7, c10

AICtx = Agranular insular cortex
CA3 = CA3 field of hippocampus
cc = Corpus callosum
CPu = Caudate putamen
DG = Dentate gyrus
ec = external capsule
LGP = Lateral globus pallidus
LV = Lateral ventricle
MCtx = Motor cortex
pir = Piriform cortex
SCtx = Somatosensory cortex

© 2011 by Taylor and Francis Group, LLC

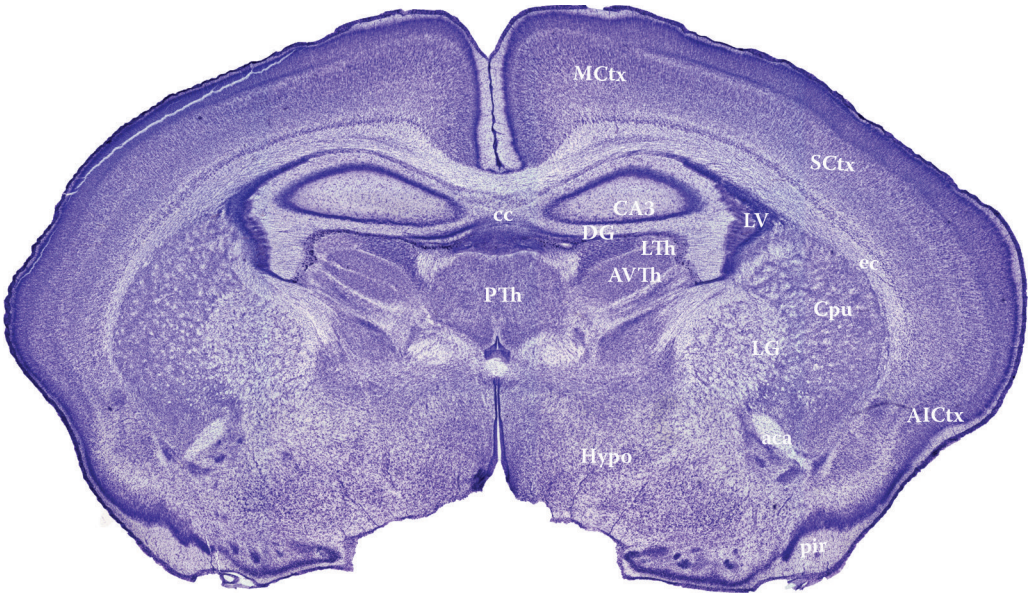

Figure 55
P-7, c11
aca = Anterior commissure
AICtx = Agranular insular cortex
AVTh = Anteroventral thalamic nucleus
CA3 = CA3 field of hippocampus
cc = Corpus callosum
CPu = Caudate putamen
DG = Dentate gyrus
ec = External capsule
Hypo = Hypothalamus
LGP = Lateral globus pallidus
LTh = Lateral thalamic nucleus
LV = Lateral ventricle
MCtx = Motor cortex
pir = Piriform cortex
PvTH = Paraventricular thalamic nucleus
SCtx = Somatosensory cortex

© 2011 by Taylor and Francis Group, LLC

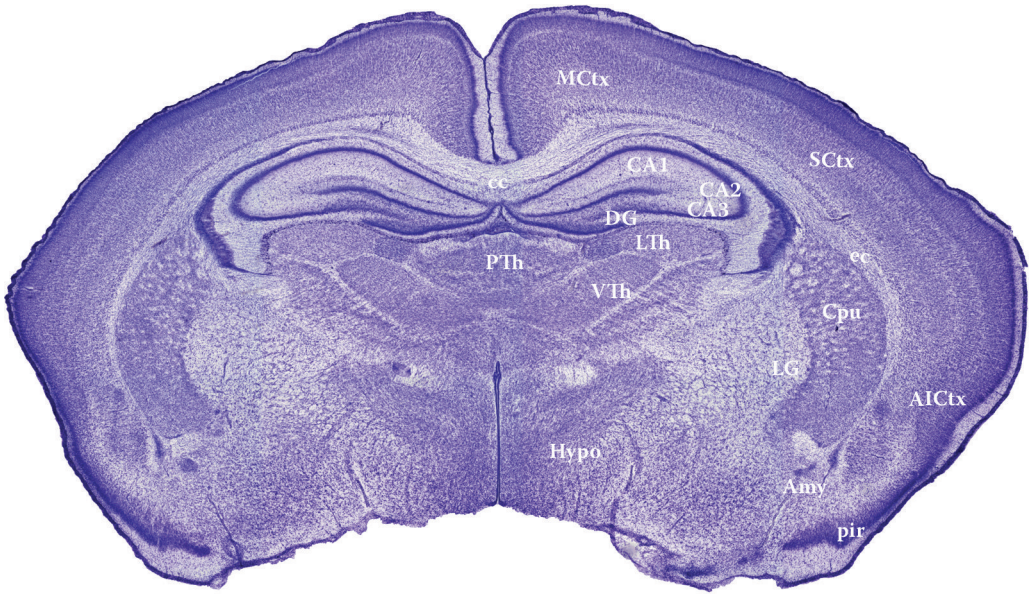

Figure 56
P-7, c12

AICtx = Agranular insular cortex
Amy = Amygdaloid nuclei
CA1 = CA1 field of hippocampus
CA2 = CA2 field of hippocampus
CA3 = CA3 field of hippocampus
cc = Corpus callosum
CPu = Caudate putamen
DG = Dentate gyrus
ec = External capsule
Hypo = Hypothalamus
LGP = Lateral globus pallidus
LTh = Lateral thalamic nucleus
LV = Lateral ventricle
MCtx = Motor cortex
pir = Piriform cortex
PvTH = Paraventricular thalamic nucleus
SCtx = Somatosensory cortex

© 2011 by Taylor and Francis Group, LLC

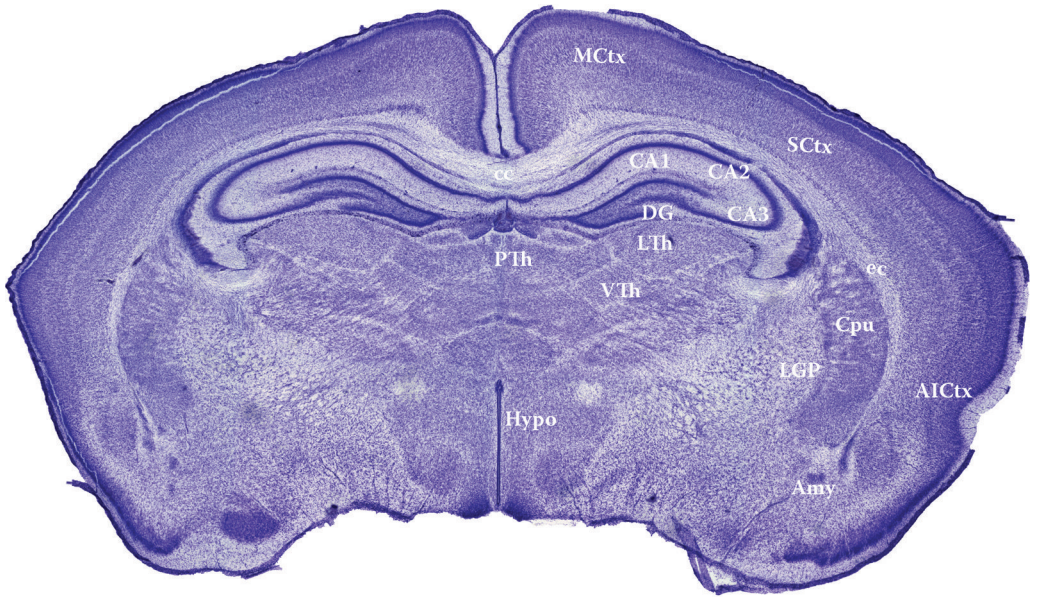

Figure 57
P-7, c13

Amy = Amygdaloid nuclei
CA1 = CA1 field of hippocampus
CA2 = CA2 field of hippocampus
CA3 = CA3 field of hippocampus
cc = Corpus callosum
CPu = Caudate putamen
DG = Dentate gyrus
ec = External capsule
Hypo = Hypothalamus
LGP = Lateral globus pallidus
LTh = Lateral thalamic nucleus
MCtx = Motor cortex
pir = Piriform cortex
PvTH = Paraventricular thalamic nucleus
SCtx = Somatosensory cortex
VTh = Ventral thalamic nucleus

© 2011 by Taylor and Francis Group, LLC

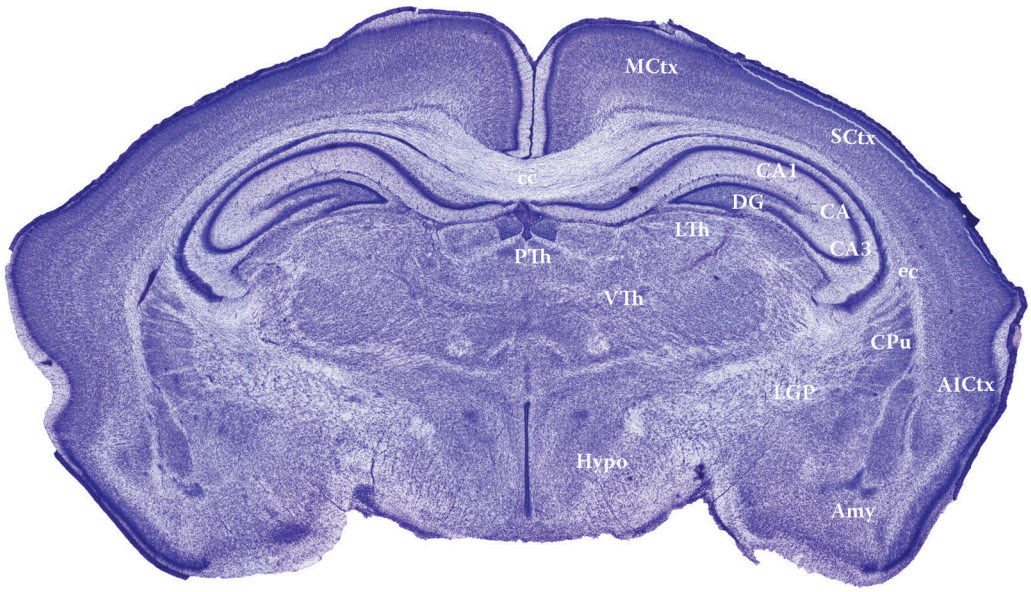

Figure 58
P-7, c14

Amy = Amygdaloid nuclei
CA1 = CA1 field of hippocampus
CA2 = CA2 field of hippocampus
CA3 = CA3 field of hippocampus
cc = Corpus callosum
CPu = Caudate putamen
DG = Dentate gyrus
ec = External capsule
Hypo = Hypothalamus
LGP = Lateral globus pallidus
LTh = Lateral thalamic nucleus
MCtx = Motor cortex
pir = Piriform cortex
PvTH = Paraventricular thalamic nucleus
SCtx = Somatosensory cortex
VTh = Ventral thalamic nucleus

© 2011 by Taylor and Francis Group, LLC

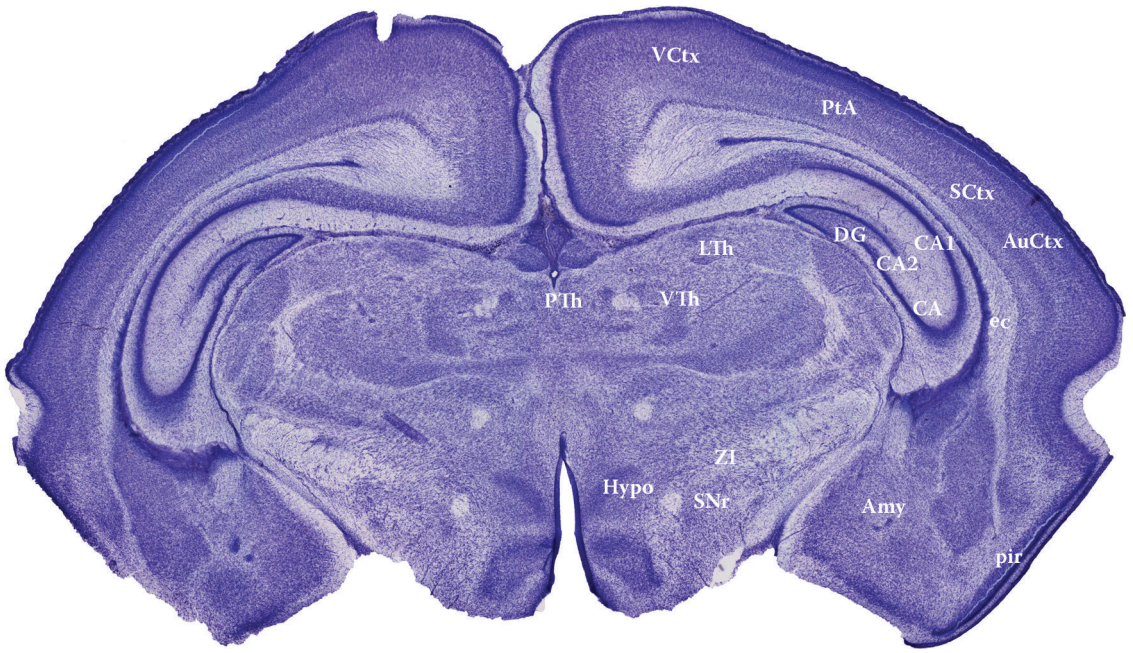

Figure 59
P-7, c15
Amy = Amygdaloid nuclei
AuCtx = Auditory cortex
CA1 = CA1 field of hippocampus
CA2 = CA2 field of hippocampus
CA3 = CA3 field of hippocampus
DG = Dentate gyrus
ec = External capsule
Hypo = Hypothalamus
LTh = Lateral thalamic nucleus
pir = Piriform cortex
PtA = Parietal association cortex
PvTH = Paraventricular thalamic nucleus
SCtx = Somatosensory cortex
SNr = Substantia nigra reticulate
VCtx = Visual cortex
VTh = Ventral thalamic nucleus
ZI = Zona incerta

© 2011 by Taylor and Francis Group, LLC

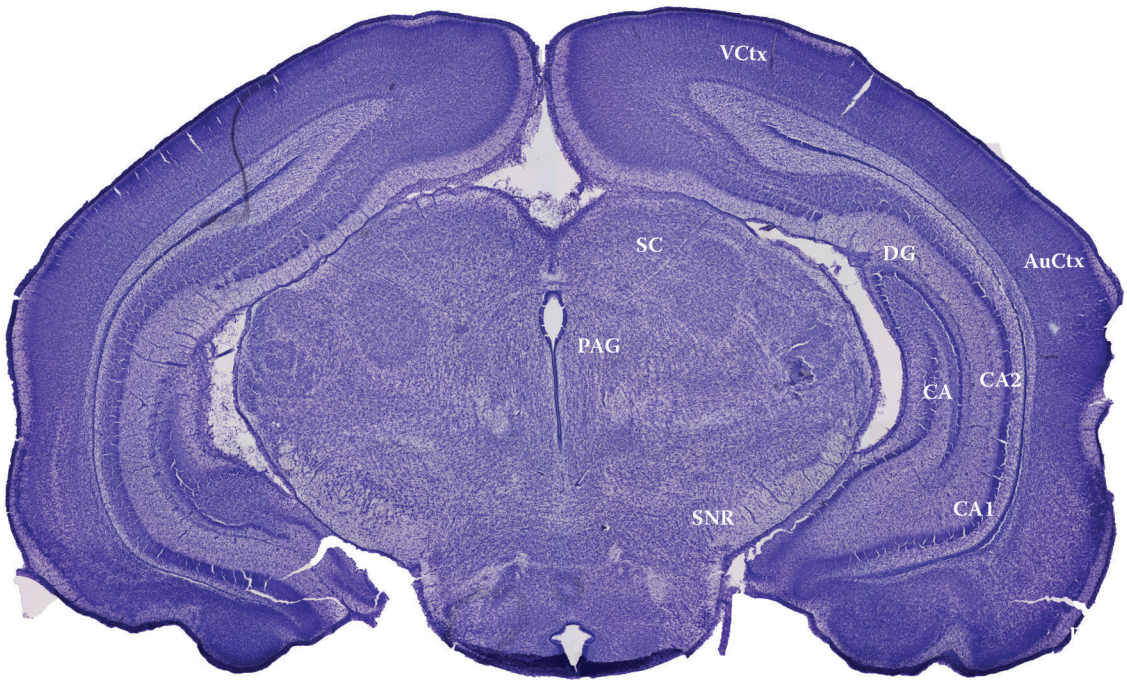

Figure 60
P-7, c16
AuCtx = auditory cortex
CA1 = CA1 field of hippocampus
CA2 = CA2 field of hippocampus
CA3 = CA3 field of hippocampus
DG = Dentate gyrus
PAG = Periaqueductal gray matter
SC = Superior colliculus
SNr = Substantia nigra reticulata
VCtx = Visual cortex

© 2011 by Taylor and Francis Group, LLC

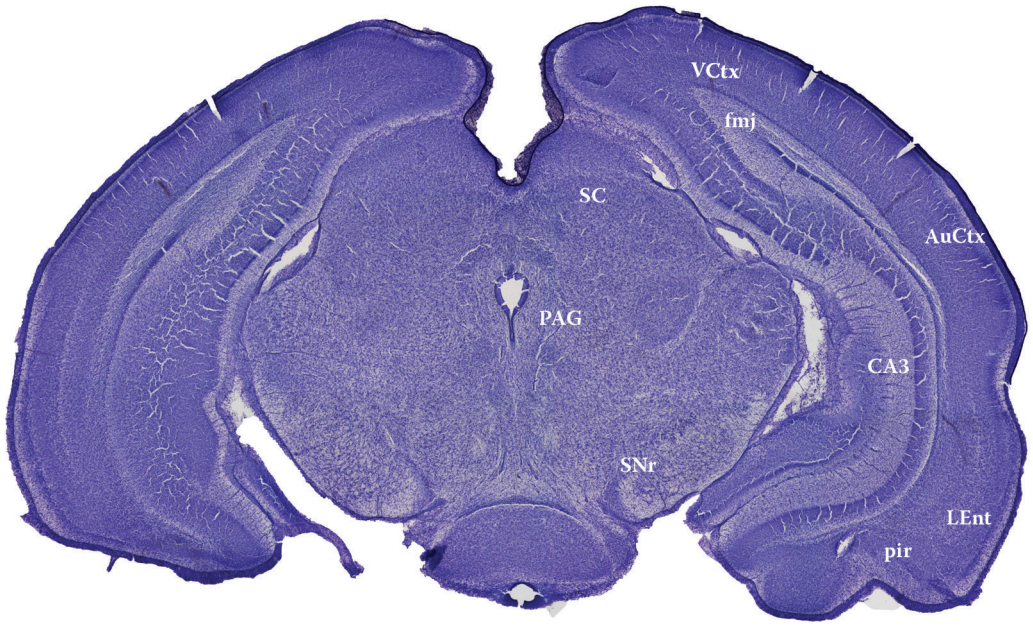

Figure 61
P-7, c17
AuCtx = Auditory cortex
CA3 = CA3 field of hippocampus
fmj = Forceps major of corpus callosum
Lent = Lateral entorhinal cortex
PAG = Periaqueductal gray matter
Pir = Piriform cortex
SC = Superior colliculus
SNr = Substantia nigra reticulate
VCtx = Visual cortex

© 2011 by Taylor and Francis Group, LLC

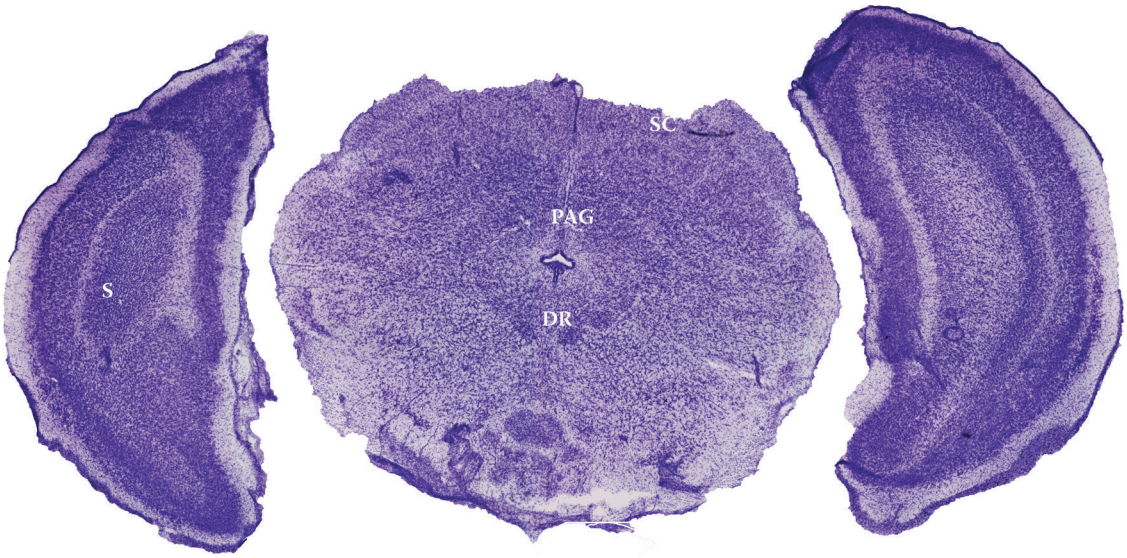

Figure 62
P-7, c18
S = Subiculum
DR = Dorsal raphe nucleus
PAG = Periaqueductal gray matter
SC = Superior colliculus

© 2011 by Taylor and Francis Group, LLC



Figure 63
P-7, c19
DR- = Dorsal raphe nucleus
PAG = Periaqueductal gray matter
Pn = Pontine nucleus
SC = Superior colliculus

© 2011 by Taylor and Francis Group, LLC

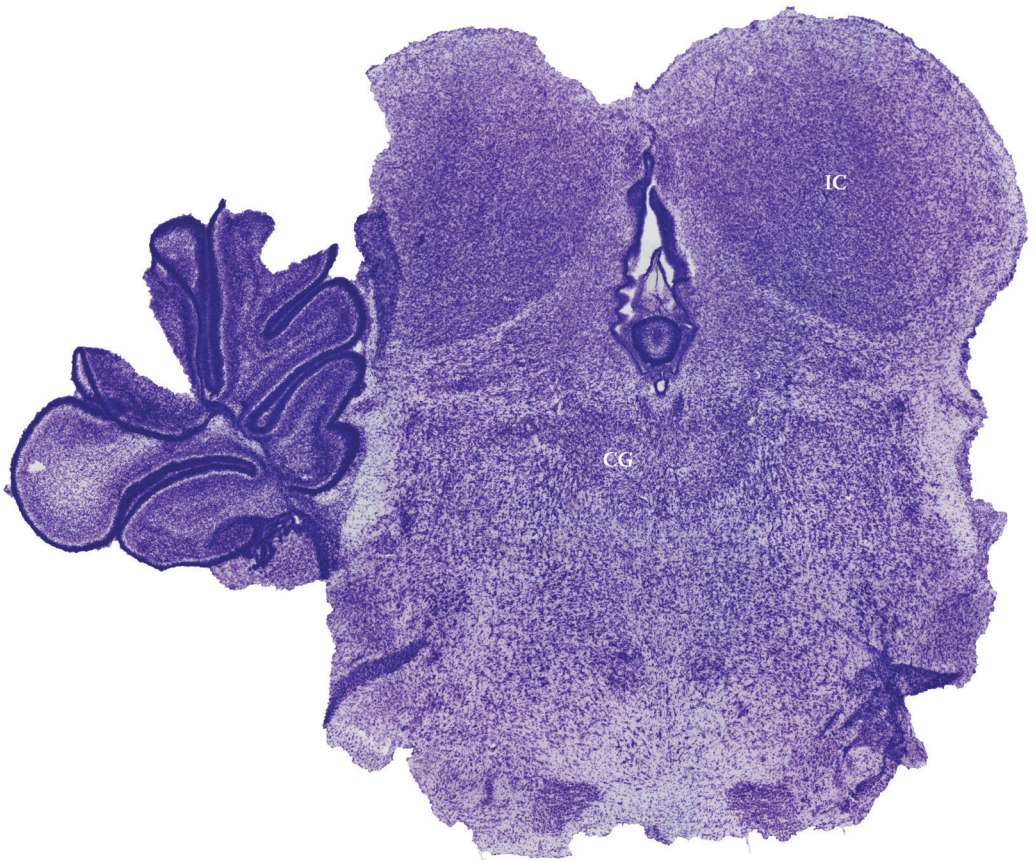

Figure 64
P-7, c20
CG- = Central gray matter
IC = Inferior colliculus

© 2011 by Taylor and Francis Group, LLC

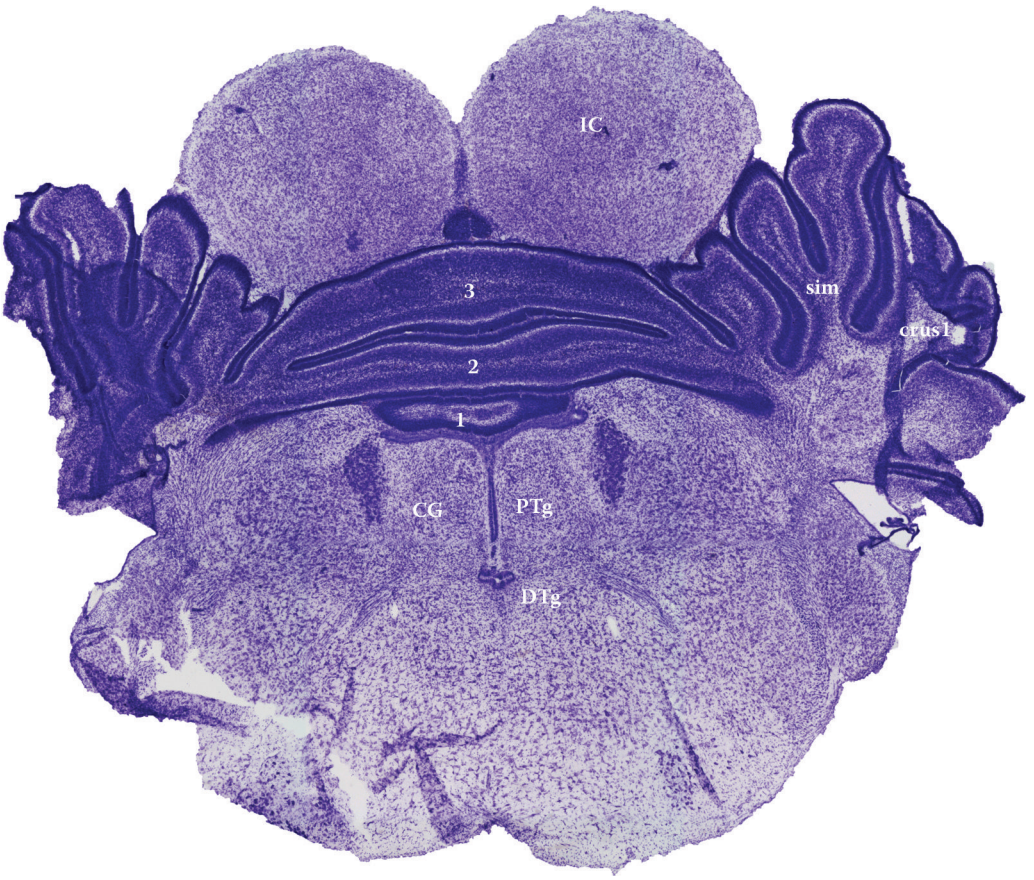

Figure 65
P-7, c21
1 through 3 = Cerebellar lobules
CG = Central gray matter
Crus1 = Crus 1 of ansiform lobule
DTg = Dorsal tegmental nuclei
IC = Inferior colliculus
PTg = Posterior tegmental nuclei
Sim = Simple lobule

© 2011 by Taylor and Francis Group, LLC



Figure 66
P-7, c22
Cu- = Cuneate nucleus
IC = Inferior colliculus
Ve = Vestibular nuclei

© 2011 by Taylor and Francis Group, LLC

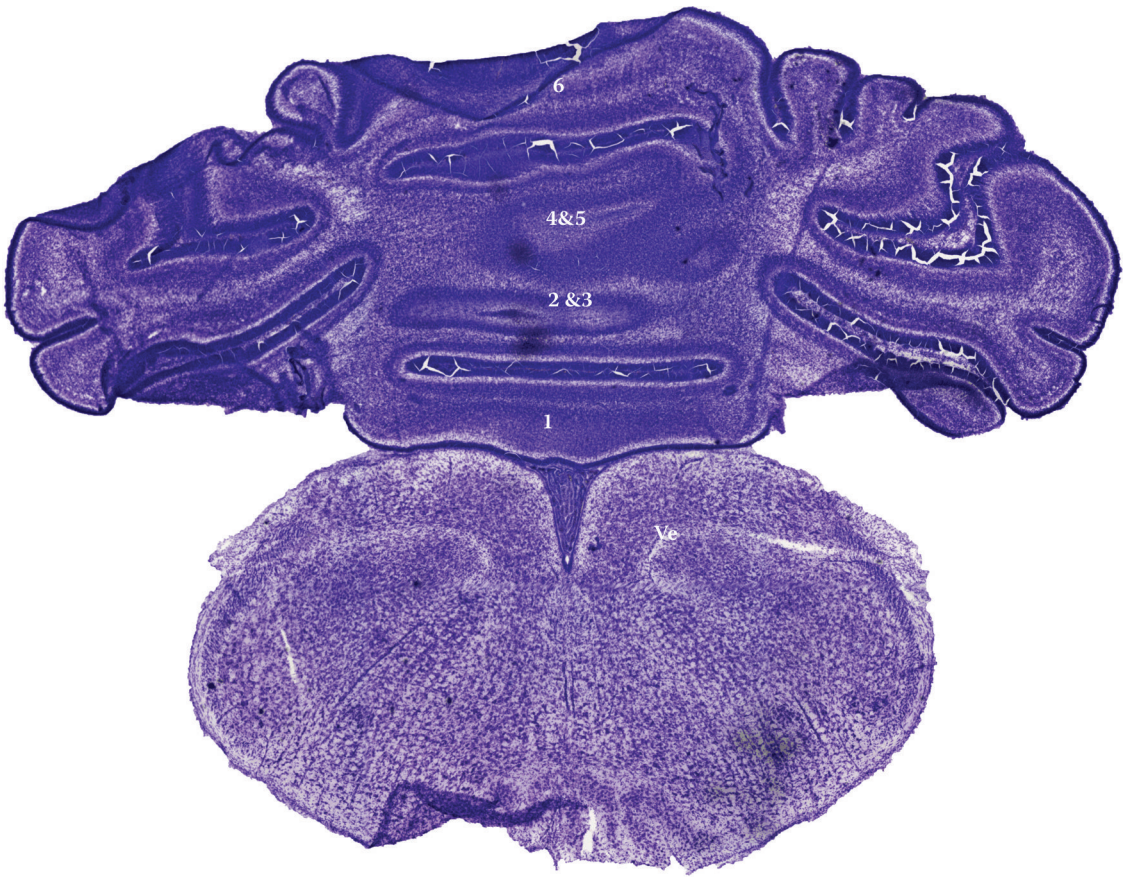

Figure 67
P-7, c23
1 through 6 = Cerebellar lobules
Ve = Vestibular nuclei

© 2011 by Taylor and Francis Group, LLC



Figure 68
P-7, c24
1 through 3 = Cerebellar lobules
Ve = Vestibular nuclei

© 2011 by Taylor and Francis Group, LLC

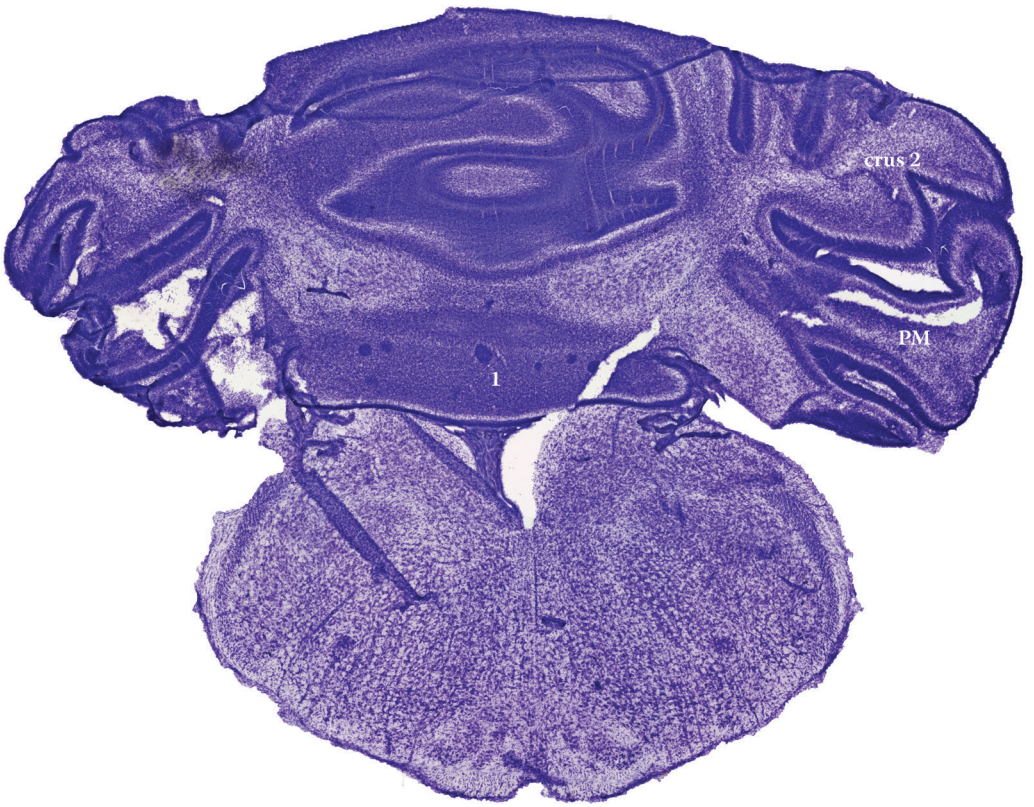

Figure 69
P-7, c25
1 = Cerebellar lobule
Crus 2 = Crus 2 of ansiform lobule
PM = Paramedian lobule

© 2011 by Taylor and Francis Group, LLC

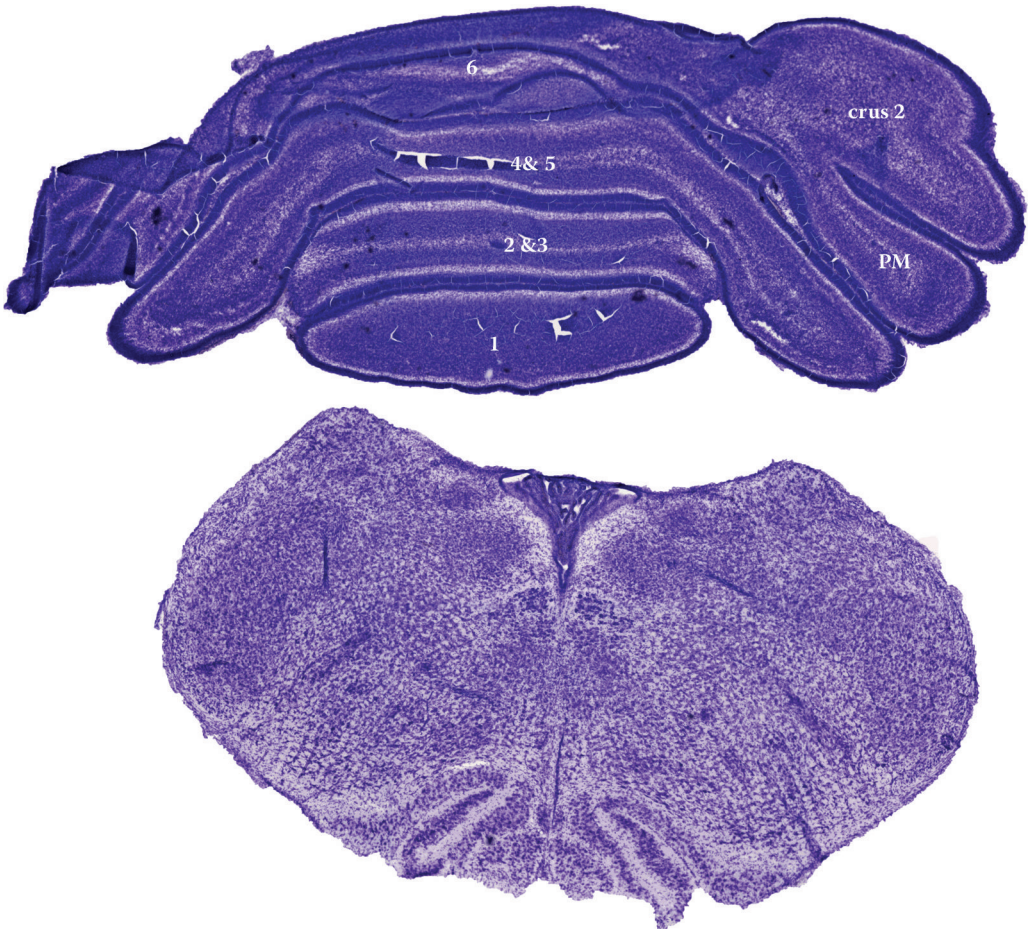

Figure 70
P-7, c26
1 through 6 = Cerebellar lobules
Crus 2 = Crus 2 of ansiform lobule
PM = Paramedian lobule

© 2011 by Taylor and Francis Group, LLC

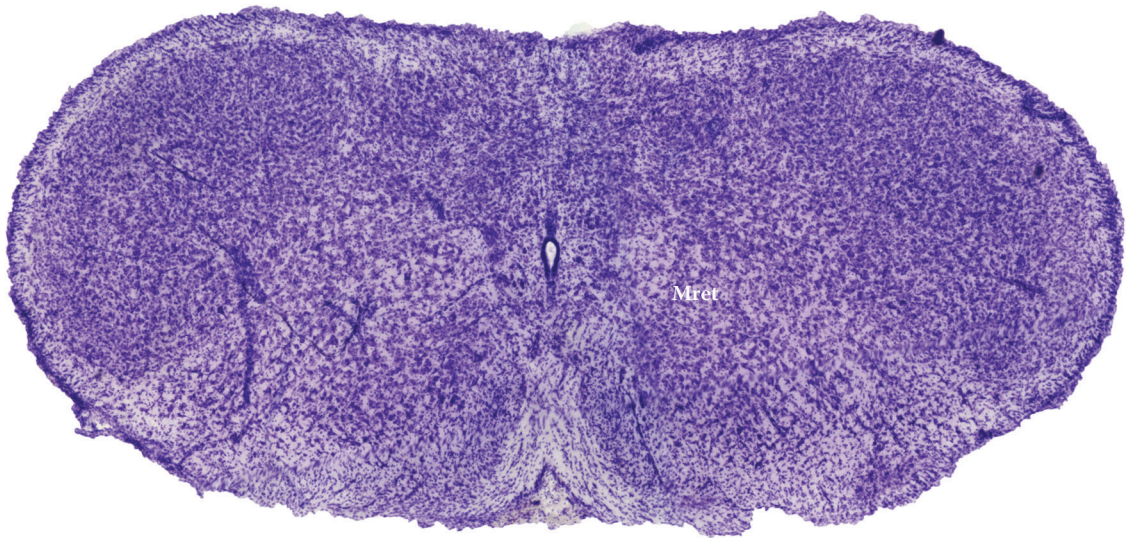

Figure 71
P-7, c27
Mret = Medullary reticular formation

© 2011 by Taylor and Francis Group, LLC

Sagittal Plates

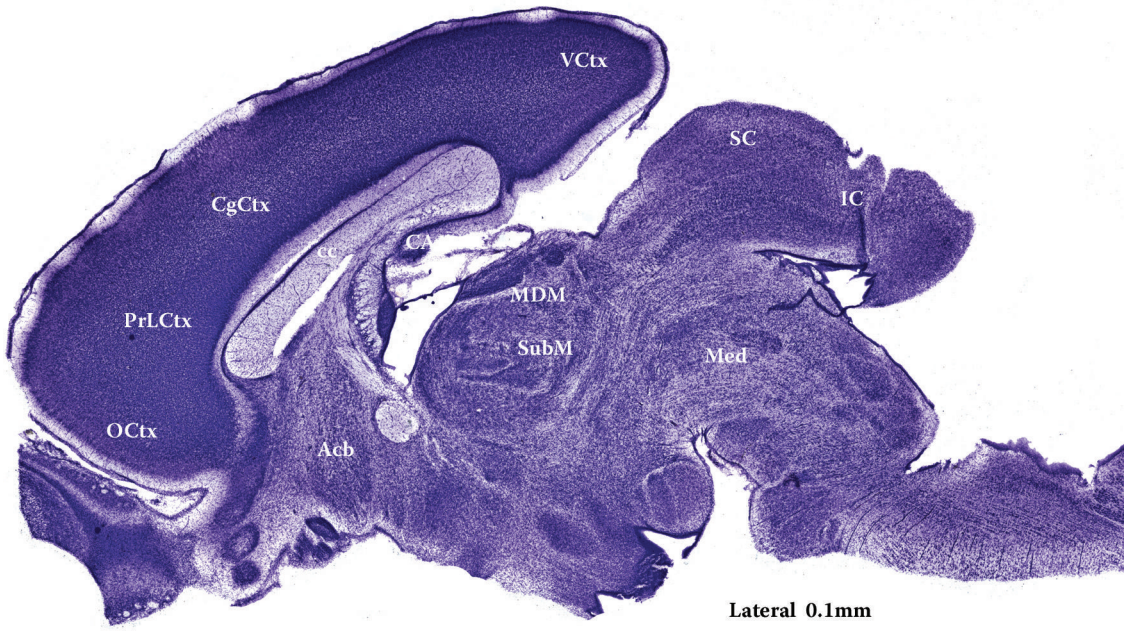

Figure 72
P-7, s1

Acb = Accumbens nucleus
AO = Anterior olfactory bulb
CA1 = CA1 field of hippocampus
cc = Corpus callosum
CgCtx = Cingulate cortex
IC = Inferior colliculus
MCtx = Motor cortex
MD = Mediodorsal thalamic nucleus
Med = Medulla
OCtx = Orbital cortex
PrLCtx = Prelimbic cortex
SC = Superior colliculus
SubM = Submedial thalamic nucleus
VCtx = Visual cortex

© 2011 by Taylor and Francis Group, LLC



Figure 73
P-7, s2

AO = Anterior olfactory bulb
Acb = Accumbens nucleus
CA1 = CA1 field of hippocampus
cc = Corpus callosum
CgCtx = Cingulate cortex
IC = Inferior colliculus
MCtx = Motor cortex
MD = Mediodorsal thalamic nucleus
Med = Medulla
OCtx = Orbital cortex
PrLCtx = Prelimbic cortex
SC = Superior colliculus
Sub = Submedial thalamic nucleus
VCtx = Visual cortex

© 2011 by Taylor and Francis Group, LLC

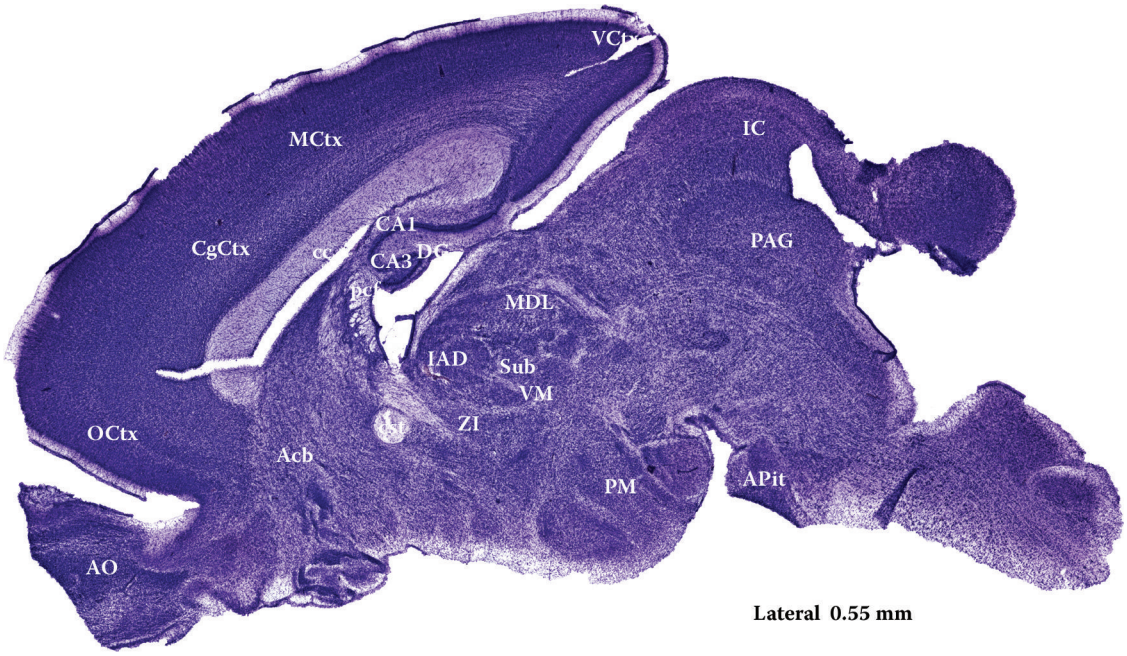

Figure 74
P-7, s3
Acb = Accumbens nucleus
AO = Anterior olfactory bulb
CA1 = CA1 field of hippocampus
CA3 = CA3 field of hippocampus
cc = Corpus callosum
CgCtx = Cingulate cortex
DG = Dentate gyrus
IAD = Interanterodorsal thalamic nucleus
IC = Inferior colliculus
MCtx = Motor cortex
MDL = Mediodorsal thalamus
Med = Medulla
OCtx = Orbital cortex
PAG = Periaqueductal gray matter
pcf = Precommissural fornix
Pit = Pituitary gland
Sub = Submedial thalamic nucleus
VCtx = Visual cortex
VM = Ventromedial thalamus
ZI = Zona incerta

© 2011 by Taylor and Francis Group, LLC

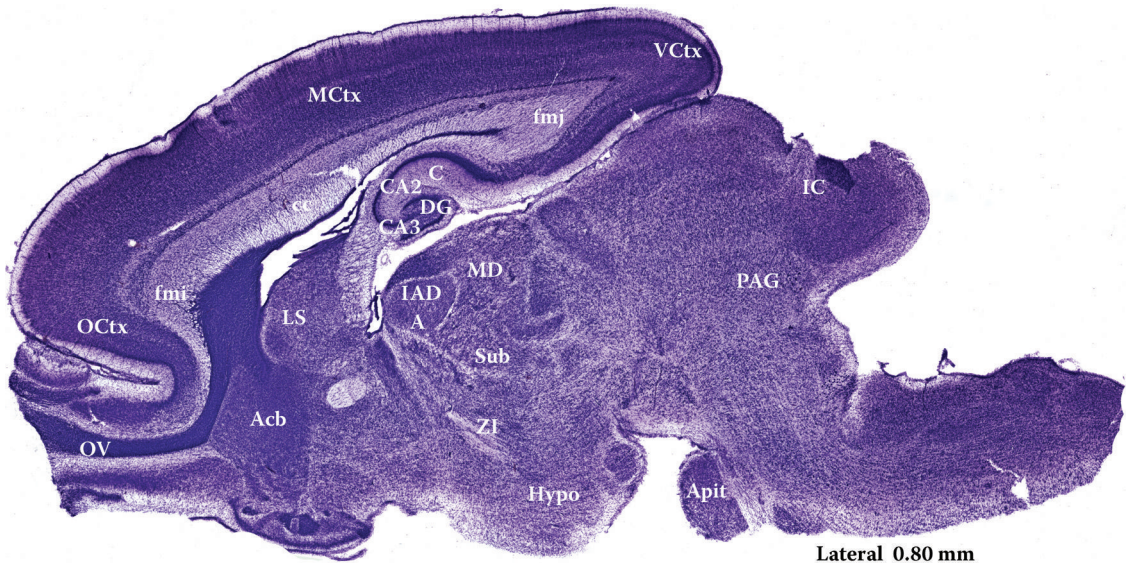

Figure 75
P-7, s4

aca = Anterior commissure
Acb = Accumbens nucleus
AM = Anteromedial thalamic nucleus
Apit = Anterior pituitary gland
CA1 = CA1 field of hippocampus
CA2 = CA2 field of hippocampus
CA3 = CA3 field of hippocampus
cc = Corpus callosum
DG = Dentate gyrus
fmi = Forceps minor of corpus callosum
fmj = Forceps major of corpus callosum
Hypo = Hypothalamus
IAD = Interanterodorsal thalamic nucleus
IC = Inferior colliculus
LS = Lateral septal nucleus
MCtx = Motor cortex
MD = Mediodorsal thalamus
OCtx = Orbital cortex
OV = Olfactory ventricle
PAG = Periaqueductal gray matter
Sub = Submedian thalamic nucleus
VCtx = Visual cortex
ZI = Zona incerta

© 2011 by Taylor and Francis Group, LLC

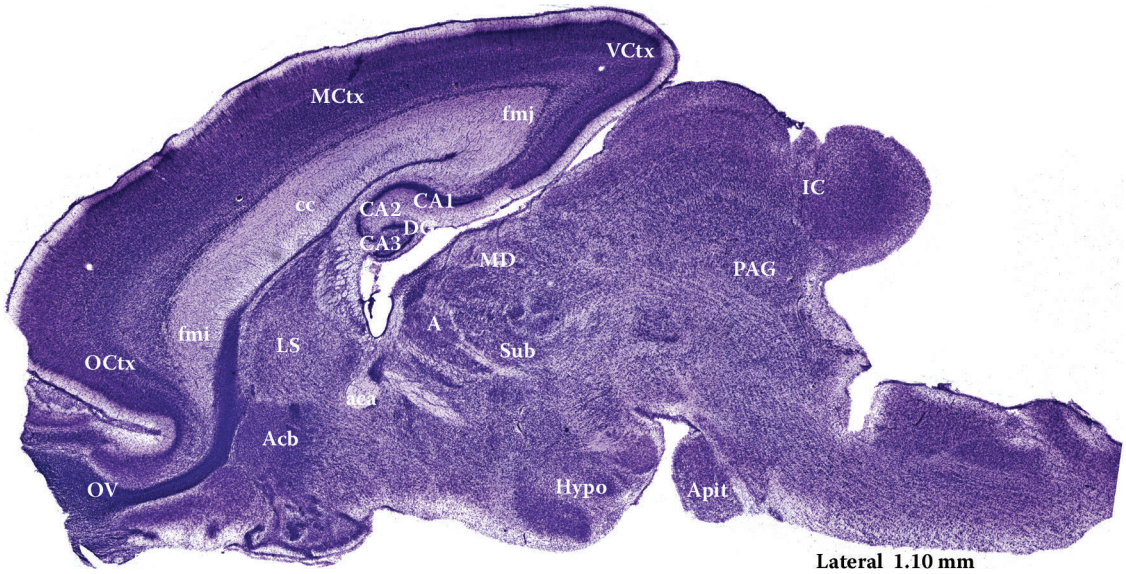

Figure 76
P-7, s5

aca = Anterior commissure
Acb = Accumbens nucleus
AM = Anteromedial thalamic nucleus
Apit =Anterior pituitary gland
CA1 = CA1 field of hippocampus
CA2 = CA2 field of hippocampus
CA3 = CA3 field of hippocampus
cc = Corpus callosum
DG = Dentate gyrus
fmi = Forceps minor of corpus callosum
fmj = Forceps major of corpus callosum
Hypo = Hypothalamus
IC = Inferior colliculus
LS = Lateral septal nucleus
MCtx = Motor cortex
MD = Mediodorsal thalamus
OCtx = Orbital cortex
OV = Olfactory ventricle
PAG = Periaqueductal gray matter
Sub = Submedian thalamic nucleus
VCtx = Visual cortex

© 2011 by Taylor and Francis Group, LLC

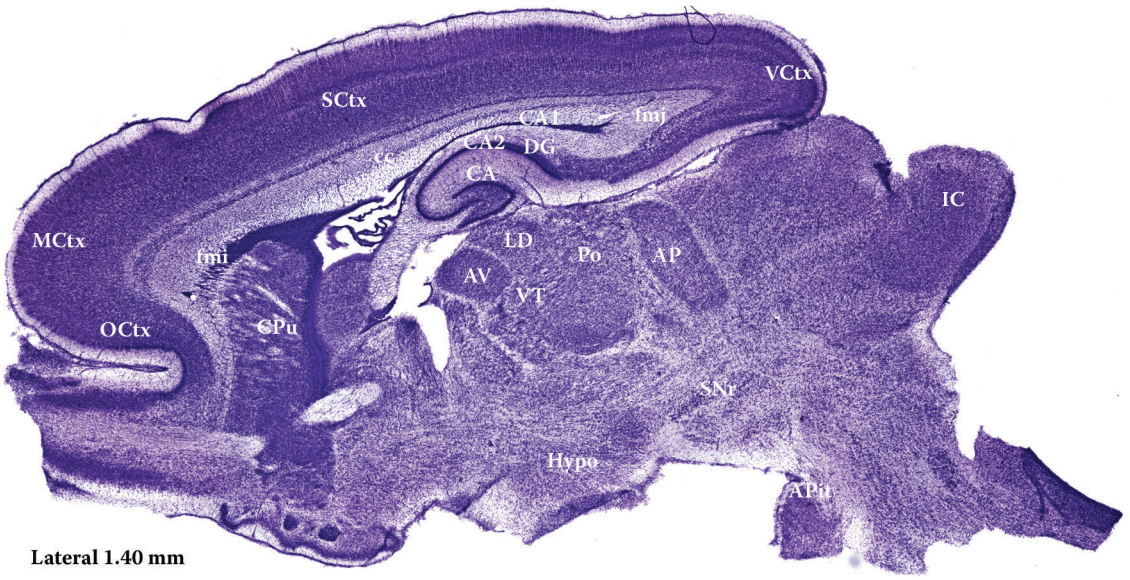

Figure 77
P-7, s6

AP = Anteroposterior thalamus
APit = Anterior pituitary gland
AV = Anteroventral thalamus
CA1 = CA1 field of hippocampus
CA2 = CA2 field of hippocampus
CA3 = CA3 field of hippocampus
cc = Corpus callosum
CPu = Caudate putamen
DG = Dentate gyrus
fmi = Forceps minor of corpus callosum
fmj = Forceps major of corpus callosum
Hypo = Hypothalamus
IC = Inferior colliculus
LD = Laterodorsal thalamic nucleus
MCtx = Motor cortex
Med = Medulla
OCtx = Orbital cortex
PM = Paramedian lobule
Po = Posterior thalamic nucleus group
SCtx = Somatosensory cortex
SNr = Substantia nigra reticulata
VCtx = Visual cortex
VT = Ventral thalamus

© 2011 by Taylor and Francis Group, LLC

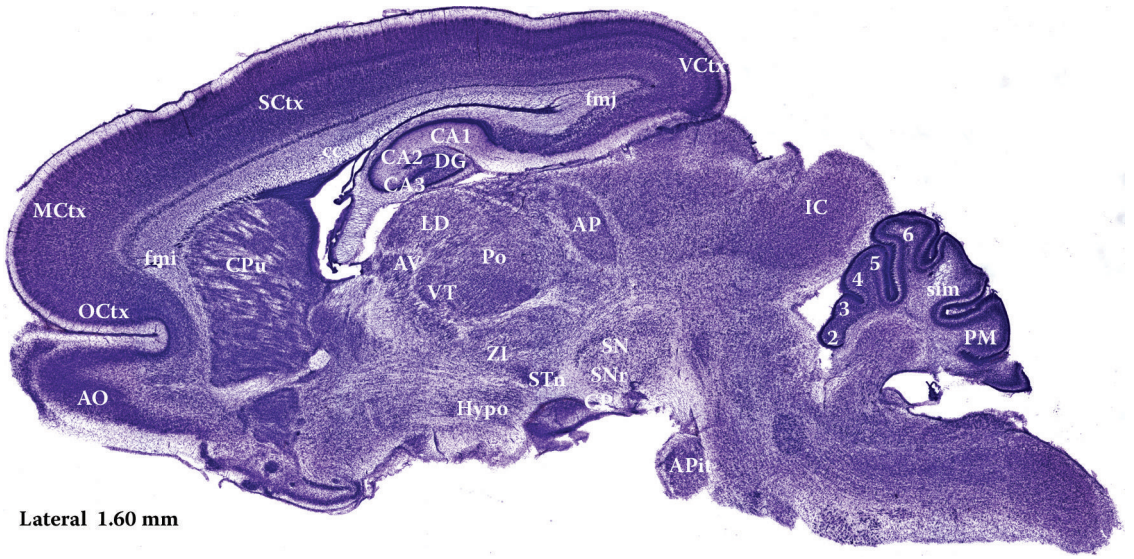

Figure 78
P-7, s7

2 through 6 = Cerebellar lobules
AO = Anterior olfactory bulb
AP = Anteroposterior thalamus
APit = Anterior pituitary gland
AV = Antero ventral thalamus
CA1 = CA1 field of hippocampus
CA2 = CA2 field of hippocampus
CA3 = CA3 field of hippocampus
cc = Corpus callosum
cp = Caudate peduncle
CPu = Caudate putamen
DG = Dentate gyrus
fmi = Forceps minor of corpus callosum
fmj = Forceps major of corpus callosum
Hypo = Hypothalamus
IC = Inferior colliculus
LD = Laterodorsal thalamic nuclei
MCtx = Motor cortex
Med = Medulla
OCtx = Orbital cortex
PM = Paramedian lobule
Po = Posterior thalamic nucleus group
SCtx = Somatosensory cortex
Sim = Simple lobule
SNc = Substantia nigra compacta
SNr = Substantia nigra reticulata
STn = Subthalamic nucleus
VCtx = Visual cortex
VT = Ventral thalamus
ZI = Zona incerta

© 2011 by Taylor and Francis Group, LLC

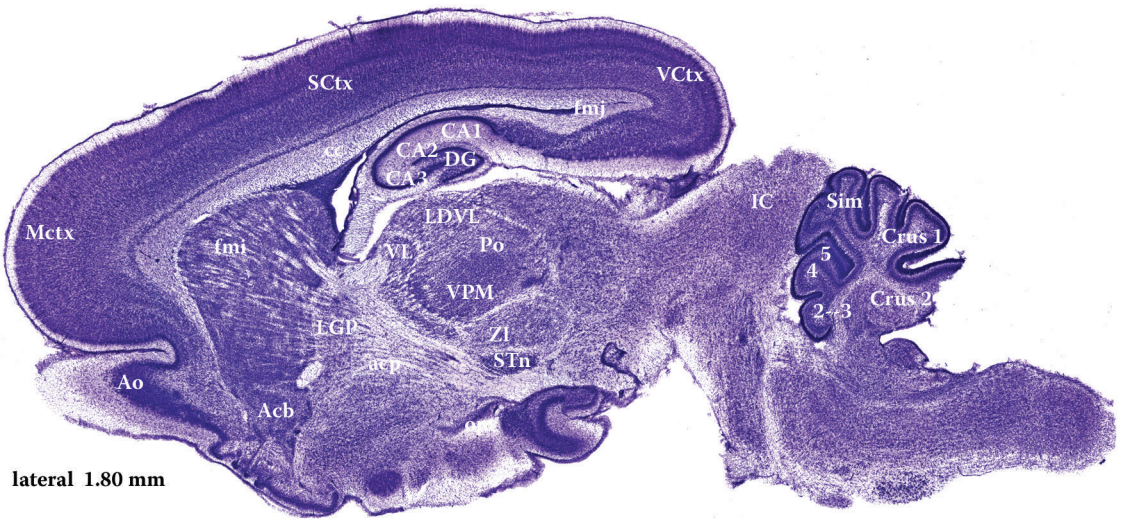

Figure 79

P-7, s8

2 through 5 = Cerebellar lobules
aca = Anterior commissure
AcbSh = Accumbens nucleus shell
AO = Anterior olfactory bulb
CA1 = CA1 field of hippocampus
CA2 = CA2 field of hippocampus
CA3 = CA3 field of hippocampus
cc = Corpus callosum
CPu = Caudate putamen
Crus1 = Crus 1 of ansiform lobule
Crus2 = Crus 2 of ansiform lobule
DG = Dentate gyrus
fmi = Forceps minor of corpus callosum
fmj = Forceps major of corpus callosum
IC = Inferior colliculus
LDVL = Laterodorsal ventral thalamic nuclei
LGP = Lateral globus pallidus
MCtx = Motor cortex
opt = Optic tract
Po = Posterior thalamus
SCtx = Somatosensory cortex
sim = Simple lobule
STn = Subthalamic nucleus
VCtx = Visual cortex
VL = Ventrolateral thalamic nucleus
VPM = Ventroposteromedial thalamic nucleus
VT = Ventral thalamus
ZI = Zona incerta

© 2011 by Taylor and Francis Group, LLC

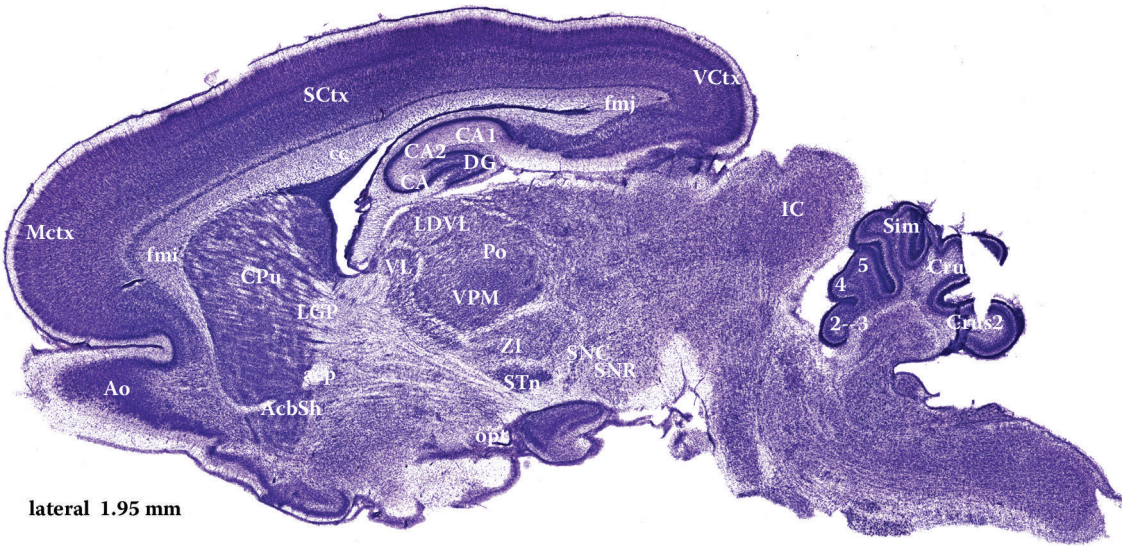

Figure 80
P-7, s9
2 through 5 = Cerebellar lobules
aca = Anterior commissure
AcbSh = Accumbens nucleus shell
AO = Anterior olfactory bulb
CA1 = CA1 field of hippocampus
CA2 = CA2 field of hippocampus
CA3 = CA3 field of hippocampus
cc = Corpus callosum
CPu = Caudate putamen
Crus1 = Crus 1 of ansiform lobule
Crus2 = Crus 2 of ansiform lobule
DG = Dentate gyrus
fmi = Forceps minor of corpus callosum
fmj = Forceps major of corpus callosum
IC = Inferior colliculus
LDVL = Laterodorsal ventral thalamic nucleus
LGP = Lateral globus pallidus
MCtx = Motor cortex
opt = Optic tract
Po = Posterior thalamus
SC = Superior colliculus
SCtx = Somatosensory cortex
sim = Simple lobule
SNc = Substantia nigra compacta
SNr = Substantia nigra reticulata
STn = Subthalamic nucleus
VCtx = Visual cortex
VL = Ventrolateral thalamic nucleus
VPM = Ventral posterior medial thalamic nucleus
VT = Ventral thalamus
ZI = Zona incerta

© 2011 by Taylor and Francis Group, LLC

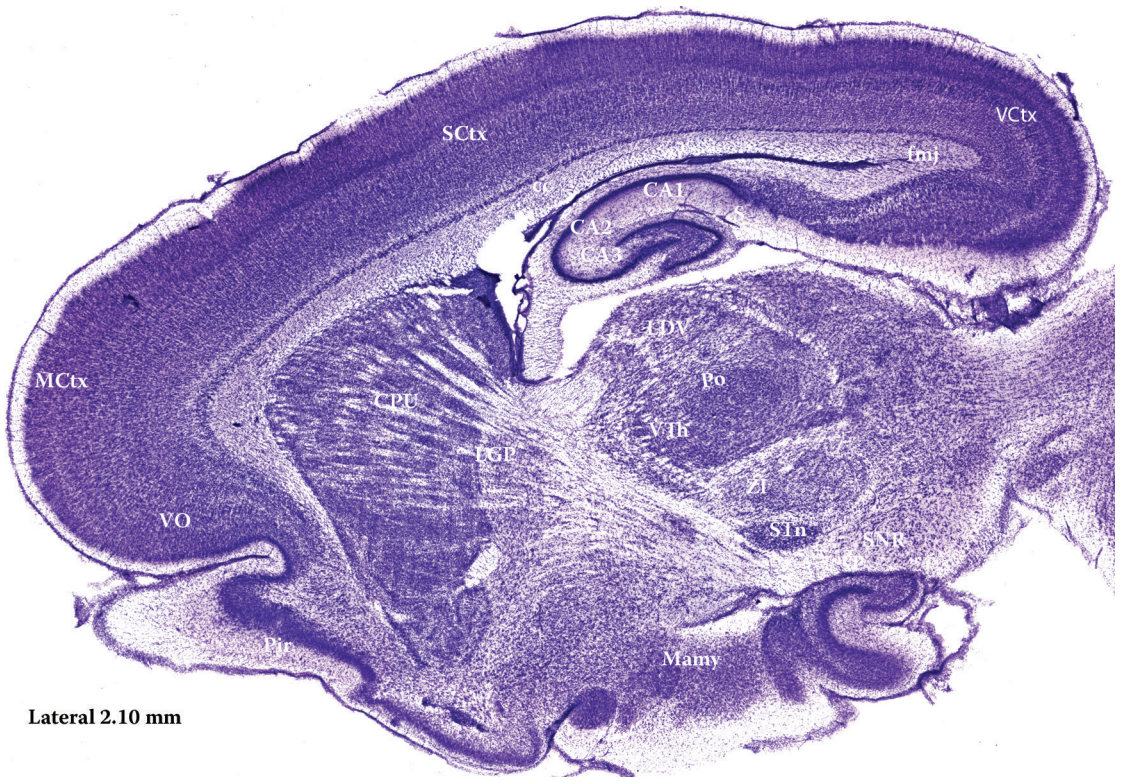

Figure 81
P-7, s10

aca = Anterior commissure
Amy = Amygdala
CA1 = CA1 field of hippocampus
CA2 = CA2 field of hippocampus
CA3 = CA3 field of hippocampus
cc = Corpus callosum
Cp = Caudate peduncle
CPu = Caudate putamen
DG = Dentate gyrus
fmj = Forceps major of corpus callosum
LDVL = Laterodorsal ventral thalamus
LGP = Lateral globus pallidus
MCtx = Motor cortex
Pir = Piriform cortex
PM = Paramedian lobule
Po = Posterior thalamic nucleus group
SCtx = Somatosensory cortex
SNr = Substantia nigra reticulata
STn = Subthalamic nucleus
VCtx = Visual cortex
VT = Ventral thalamus
ZI = Zona incerta

© 2011 by Taylor and Francis Group, LLC

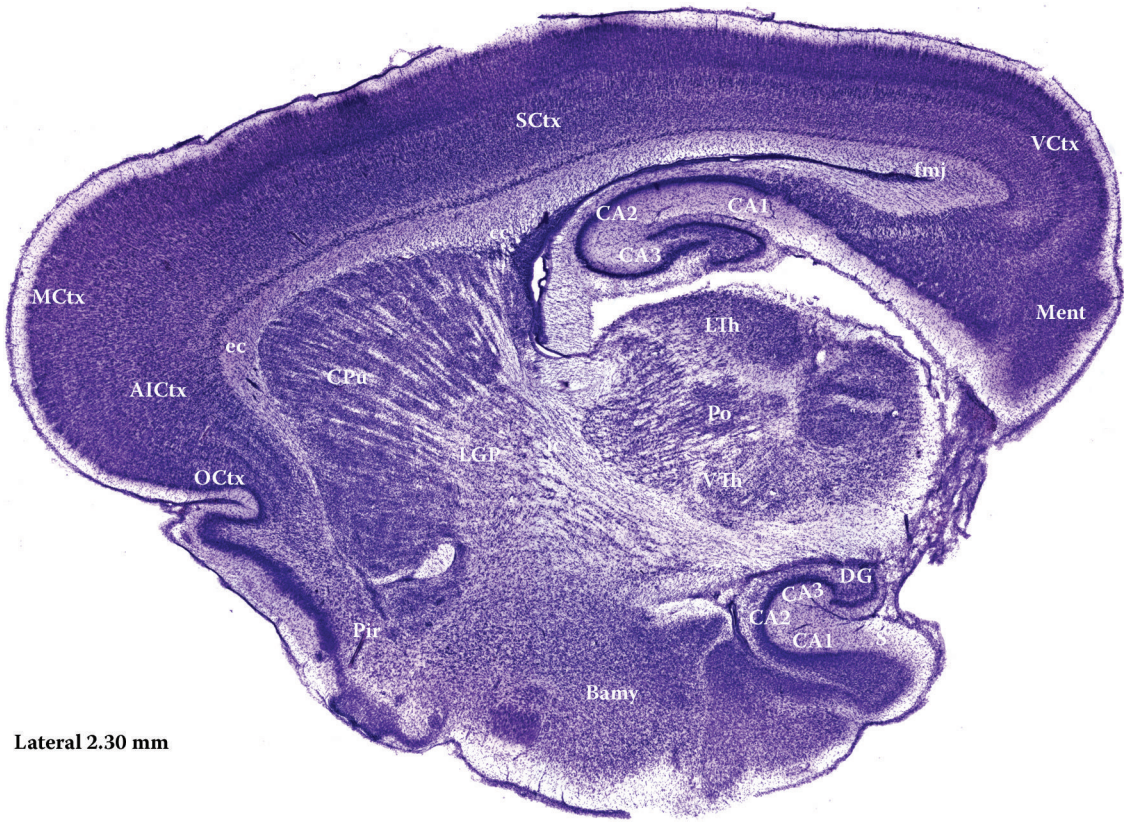

Figure 82
P-7, s11

AICtx = Agranular insular cortex
Bamy = Basal amygdala
CA1 = CA1 field of hippocampus
CA2 = CA2 field of hippocampus
CA3 = CA3 field of hippocampus
cc = Corpus callosum
CPu = Caudate putamen
DG = Dentate gyrus
ec = external capsule
Ic = Internal capsule
LGP = Lateral globus pallidus
LTh = Lateral thalamus
MCtx = Motor cortex
MEnt = Medial entorhinal cortex
OCtx = Orbital cortex
Pir = Piriform cortex
Po = Posterior thalamic nucleus group
SCtx = Somatosensory cortex
S = Subiculum
VCtx = Visual cortex
VTh = Ventral thalamus

© 2011 by Taylor and Francis Group, LLC

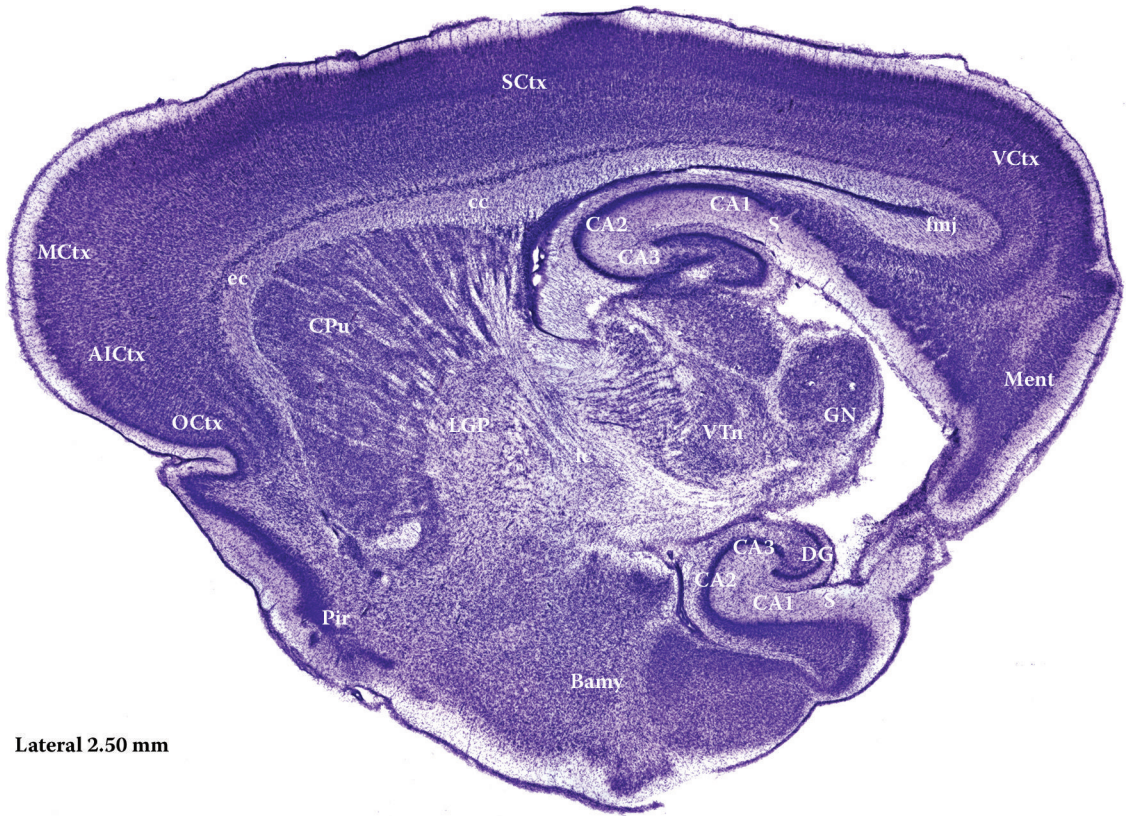

Figure 83
P-7, s12

AICtx = Agranular insular cortex
Bamy = basal amygdala
CA1 = CA1 field of hippocampus
CA2 = CA2 field of hippocampus
CA3 = CA3 field of hippocampus
cc = Corpus callosum
CPu = Caudate putamen
DG = Dentate gyrus
ec = external capsule
GN = Geniculate nucleus
Ic = Internal capsule
LGP = Lateral globus pallidus
MCtx = Motor cortex
MEnt = Medial entorhinal cortex
OCtx = Orbital cortex
Pir = Piriform cortex
SCtx = Somatosensory cortex
S = Subiculum
VCtx = Visual cortex
VT = Ventral thalamus

© 2011 by Taylor and Francis Group, LLC

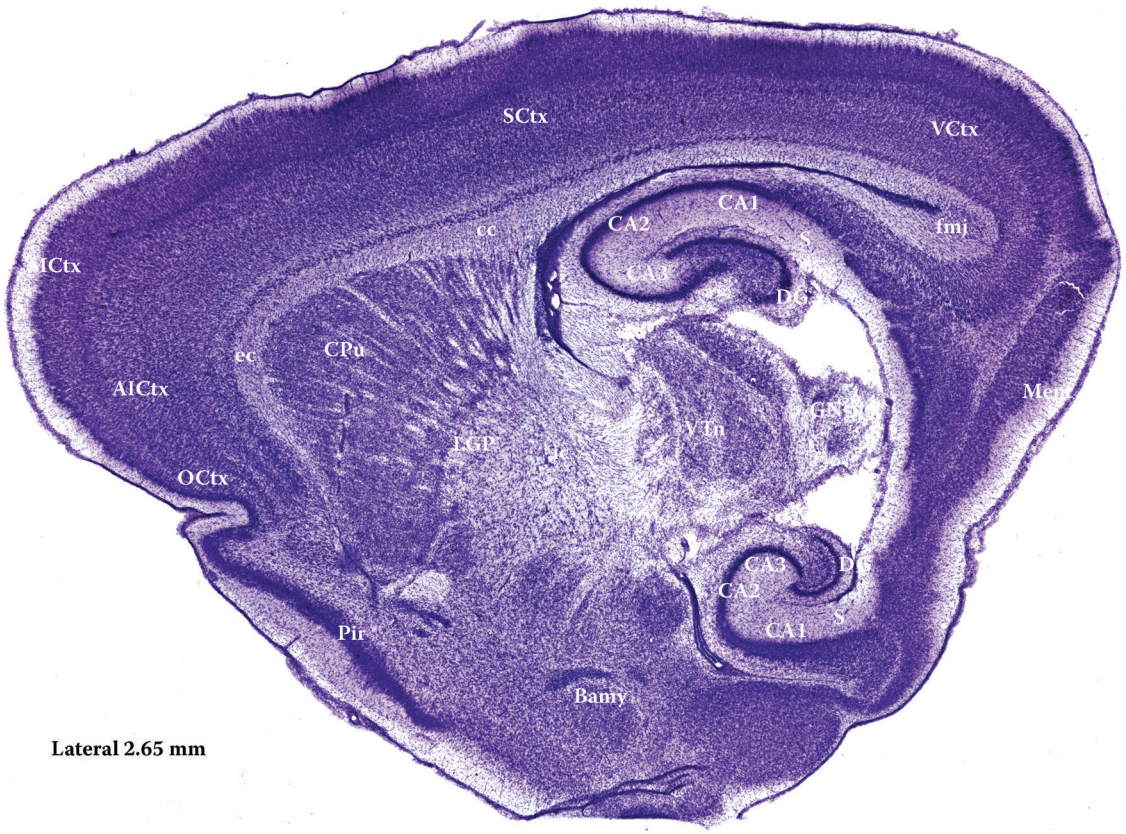

Figure 84
P-7, s13

AICtx = Agranular insular cortex
Bamy = Basal amygdala
CA1 = CA1 field of hippocampus
CA2 = CA2 field of hippocampus
CA3 = CA3 field of hippocampus
cc = Corpus callosum
CPu = Caudate putamen
DG = Dentate gyrus
ec = external capsule
GN = Geniculate nucleus
Ic = Internal capsule
LGP = Lateral globus pallidus
MCtx = Motor cortex
MEnt = Medial entorhinal cortex
OCtx = Orbital cortex
Pir = Piriform cortex
SCtx = Somatosensory cortex
S = Subiculum
VCtx = Visual cortex
VT = Ventral thalamus

© 2011 by Taylor and Francis Group, LLC

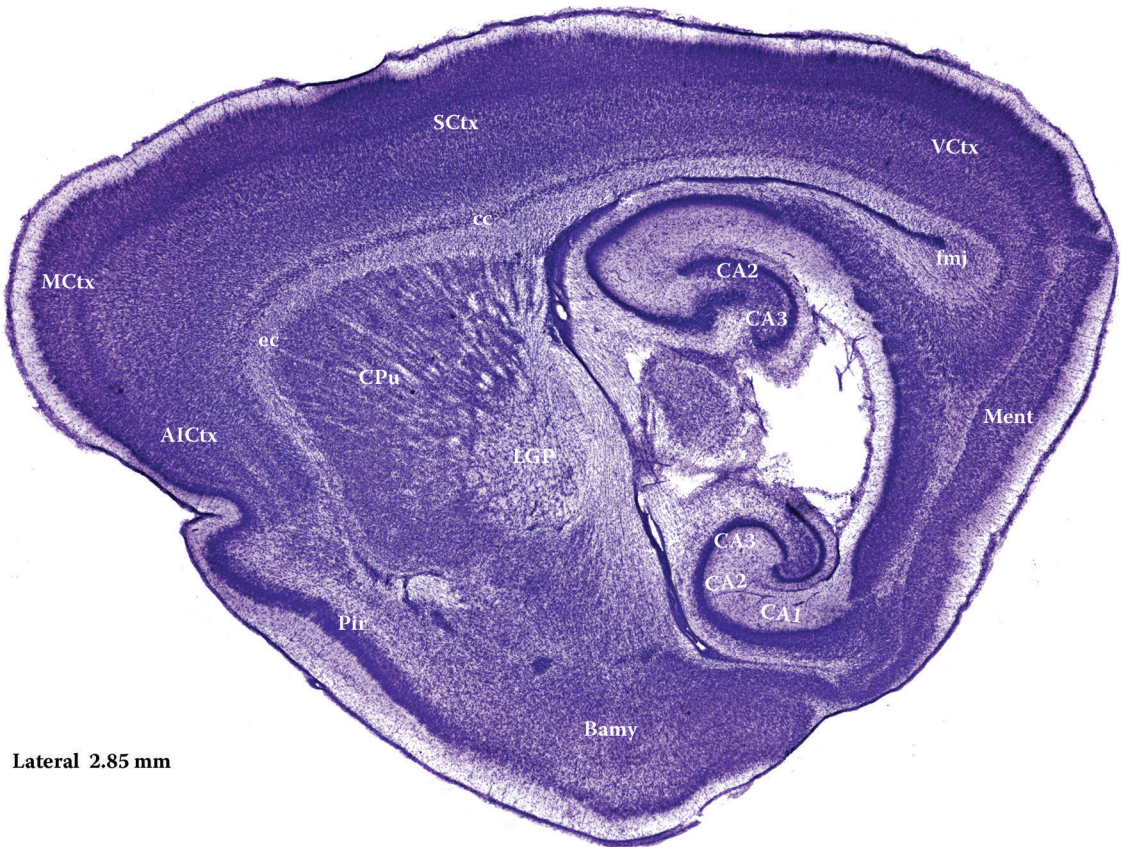

Figure 85
P-7, s14

AICtx = Agranular insular cortex
Bamy = Basal amygdala
CA1 = CA1 field of hippocampus
CA2 = CA2 field of hippocampus
CA3 = CA3 field of hippocampus
cc = Corpus callosum
CPu = Caudate putamen
ec = external capsule

© 2011 by Taylor and Francis Group, LLC

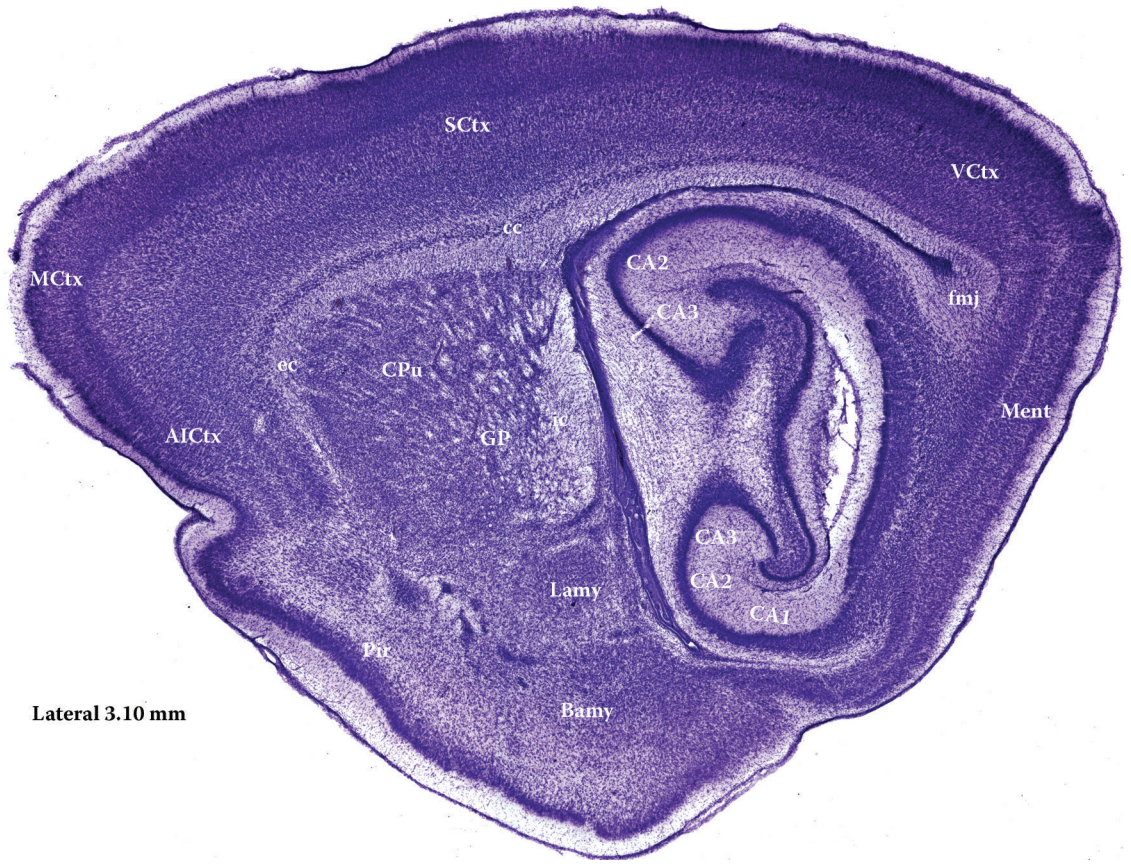

Figure 86
P-7, s15
AICtx = Agranular insular cortex
Bamy = Basal amygdala
CA1 = CA1 field of hippocampus
CA2 = CA2 field of hippocampus
CA3 = CA3 field of hippocampus
cc = Corpus callosum
CPu = Caudate putamen
ec = external capsule
fmj = Forceps major corpus callosum
GP = Globus pallidus
Ic = Internal capsule
Lamy = Lateral amygdaloid nucleus
MCtx = Motor cortex
MEnt = Medial entorhinal cortex
Pir = Piriform cortex
SCtx = Somatosensory cortex
VCtx = Visual cortex

© 2011 by Taylor and Francis Group, LLC

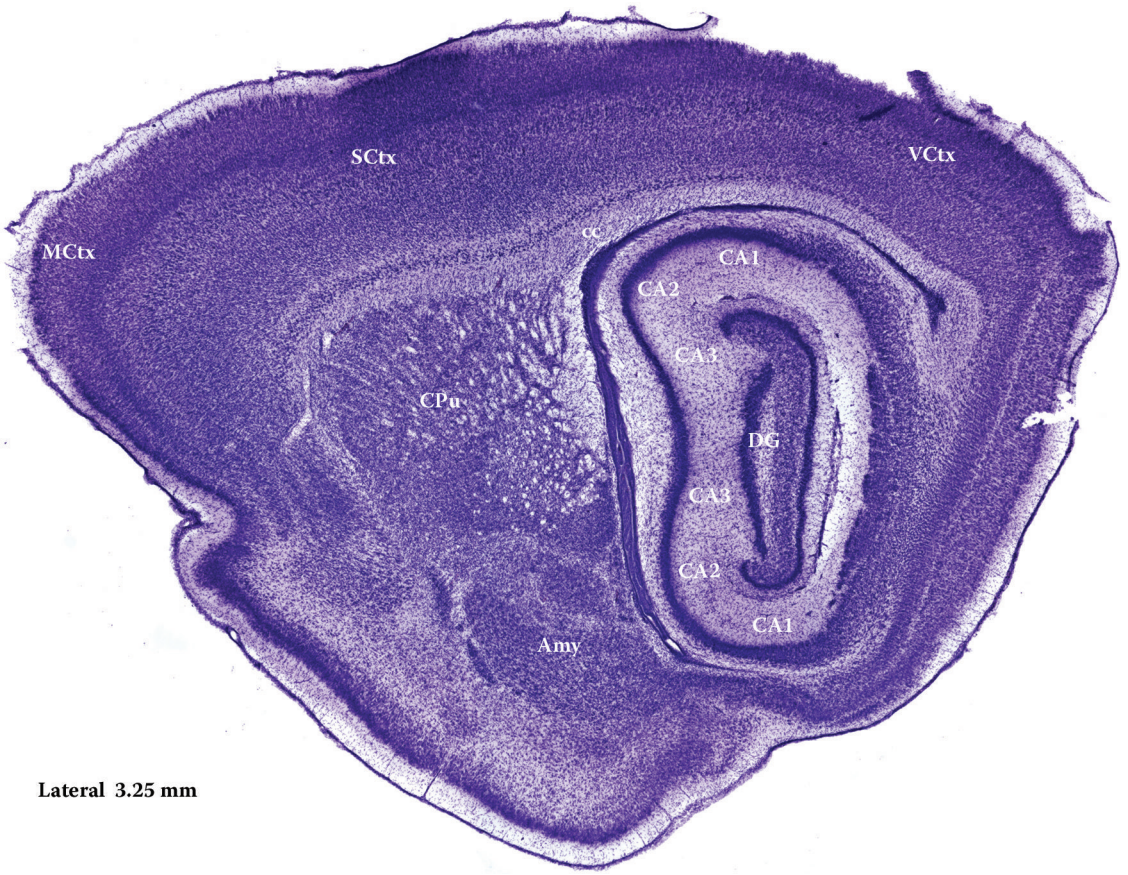

Figure 87
P-7, s16

Amy = Amygdaloid nuclei
CA1 = CA1 field of hippocampus
CA2 = CA2 field of hippocampus
CA3 = CA3 field of hippocampus
cc = Corpus callosum
CPu = Caudate putamen
DG = Dentate gyrus
MCtx = Motor cortex
SCtx = Somatosensory cortex
VCtx = Visual cortex

© 2011 by Taylor and Francis Group, LLC

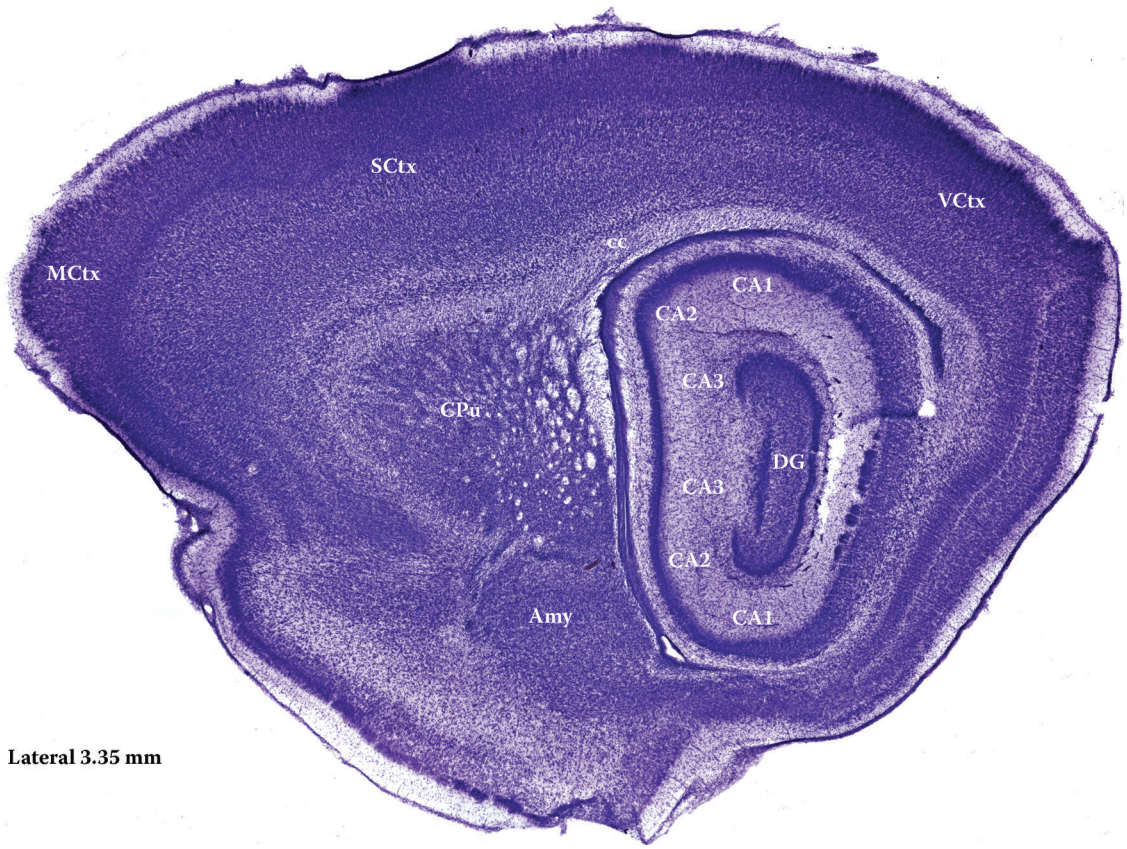

Figure 88
P-7, s17

Amy = Amygdaloid nuclei
CA1 = CA1 field of hippocampus
CA2 = CA2 field of hippocampus
CA3 = CA3 field of hippocampus
cc = Corpus callosum
CPu = Caudate putamen
DG = Dentate gyrus
MCtx = Motor cortex
SCtx = Somatosensory cortex
VCtx = Visual cortex

© 2011 by Taylor and Francis Group, LLC

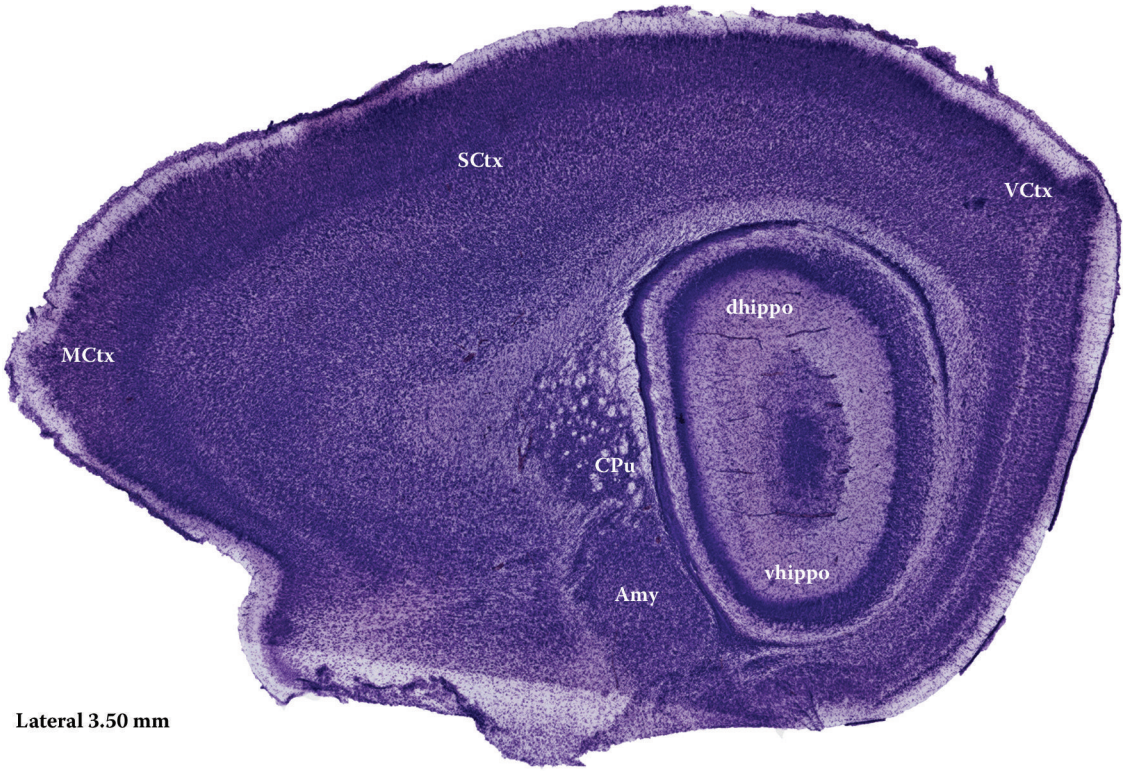

Figure 89
P-7, s18
Amy = Amygdaloid nuclei
CPu = Caudate putamen
dhippo = Dorsal hippocampal formation
MCtx = Motor cortex
SCtx = Somatosensory cortex
VCtx = Visual cortex
Vhippo = Ventral hippocampal formation

© 2011 by Taylor and Francis Group, LLC

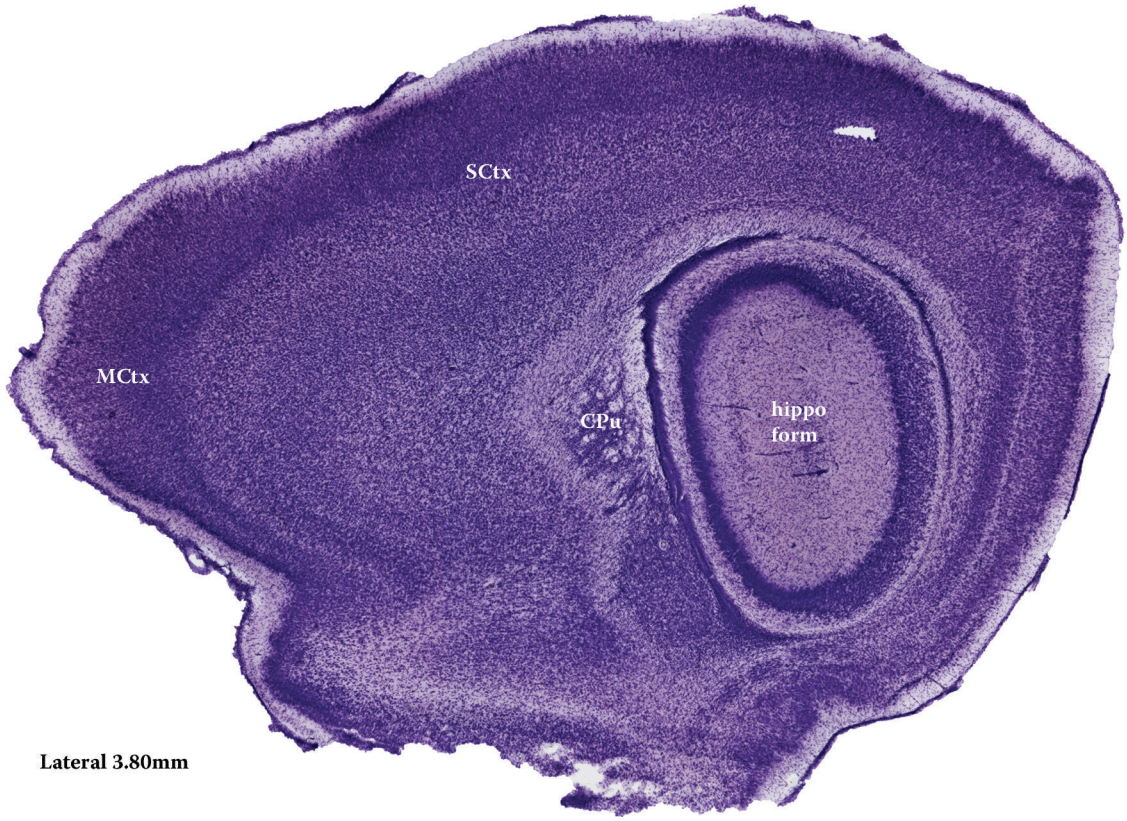

Figure 90
P-7, s19
CPu = Caudate putamen
MCtx = Motor cortex
SCtx = Somatosensory cortex
Hfor = Hippocampal formation

© 2011 by Taylor and Francis Group, LLC

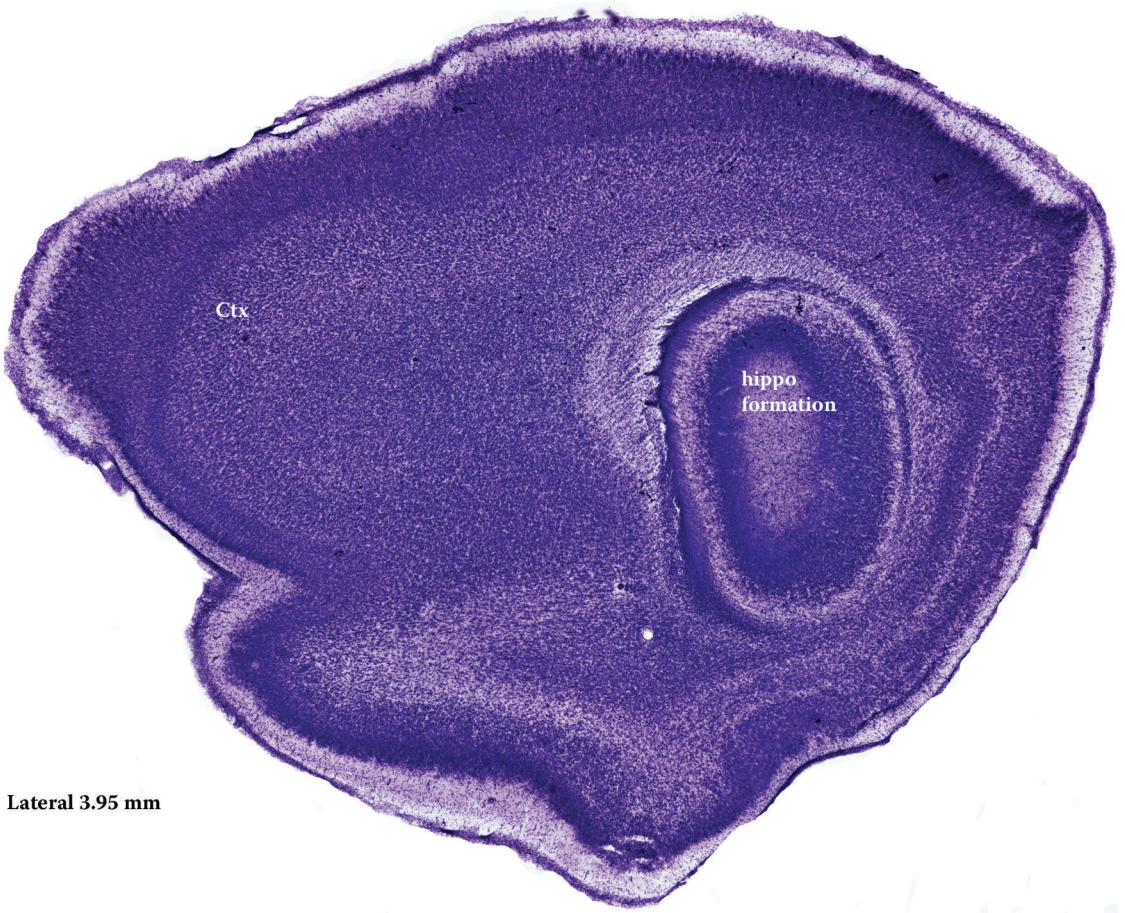

Figure 91
P-7, s20
Ctx = Cortex
Hfor = Hippocampal formation

© 2011 by Taylor and Francis Group, LLC

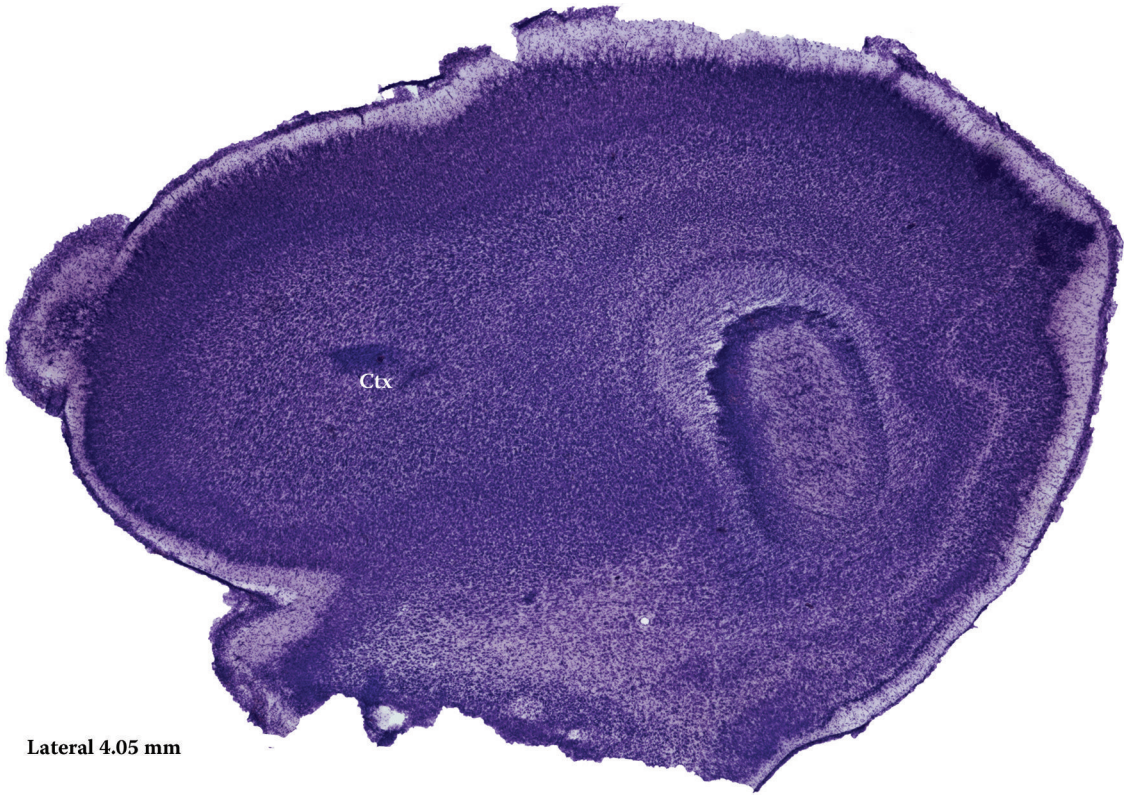

Figure 92
P-7, s21
Ctx = Cortex

© 2011 by Taylor and Francis Group, LLC

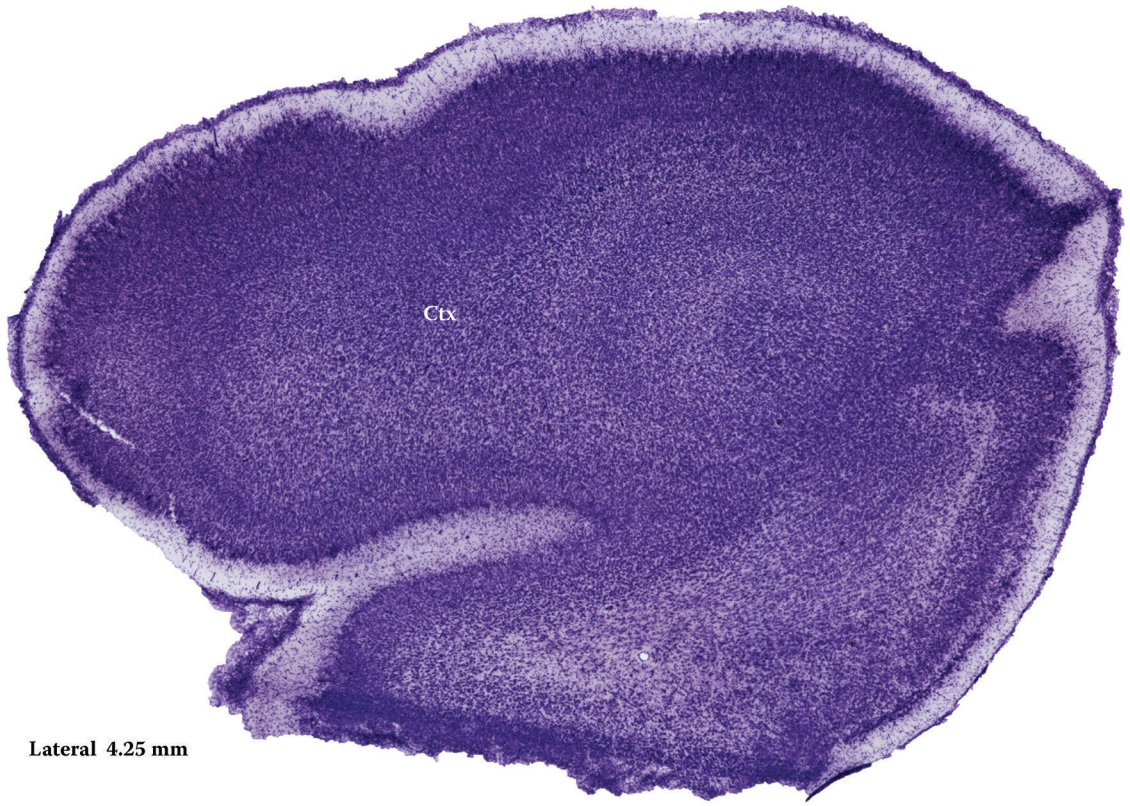

Figure 93
P-7, s22
Ctx = Cortex

© 2011 by Taylor and Francis Group, LLC

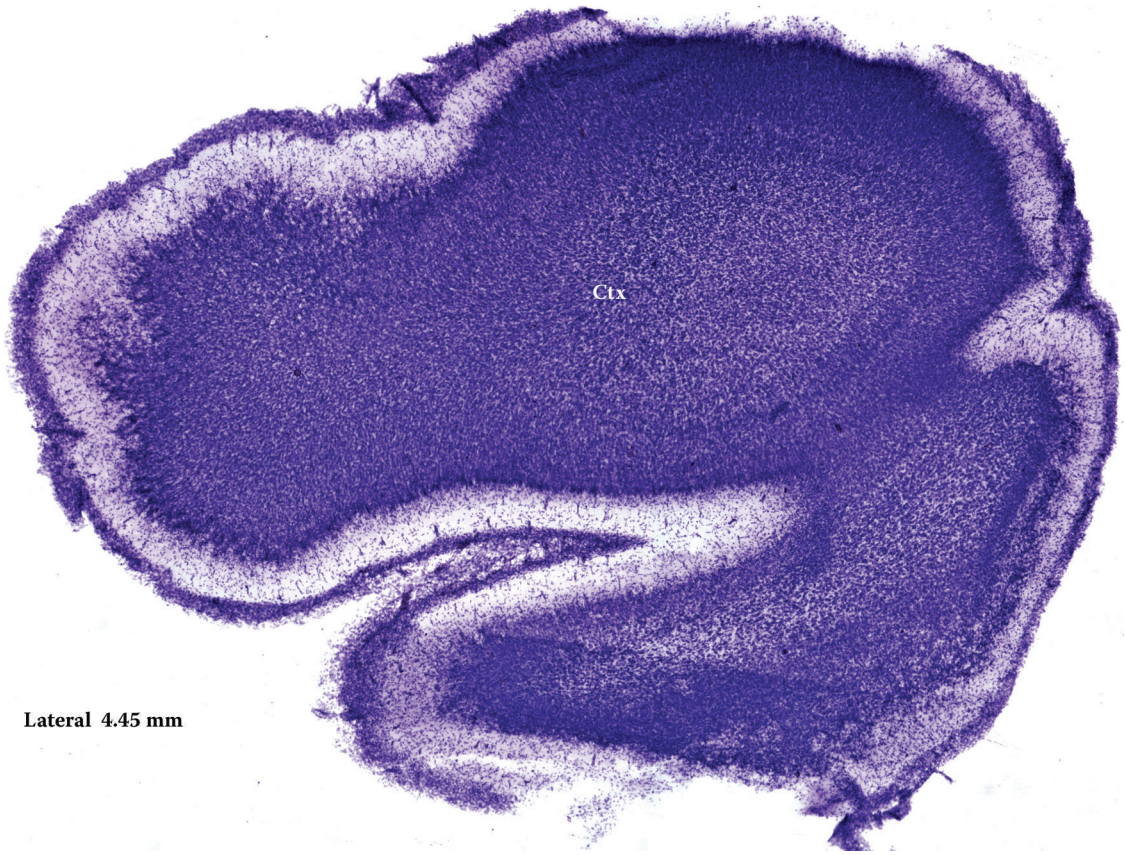

Figure 94
P-7, s23
Ctx = Cortex

© 2011 by Taylor and Francis Group, LLC



Figure 95
P-7, s24
Ctx-= Cortex

© 2011 by Taylor and Francis Group, LLC

Section III

P-14 Brain

© 2011 by Taylor and Francis Group, LLC

Coronal Plates

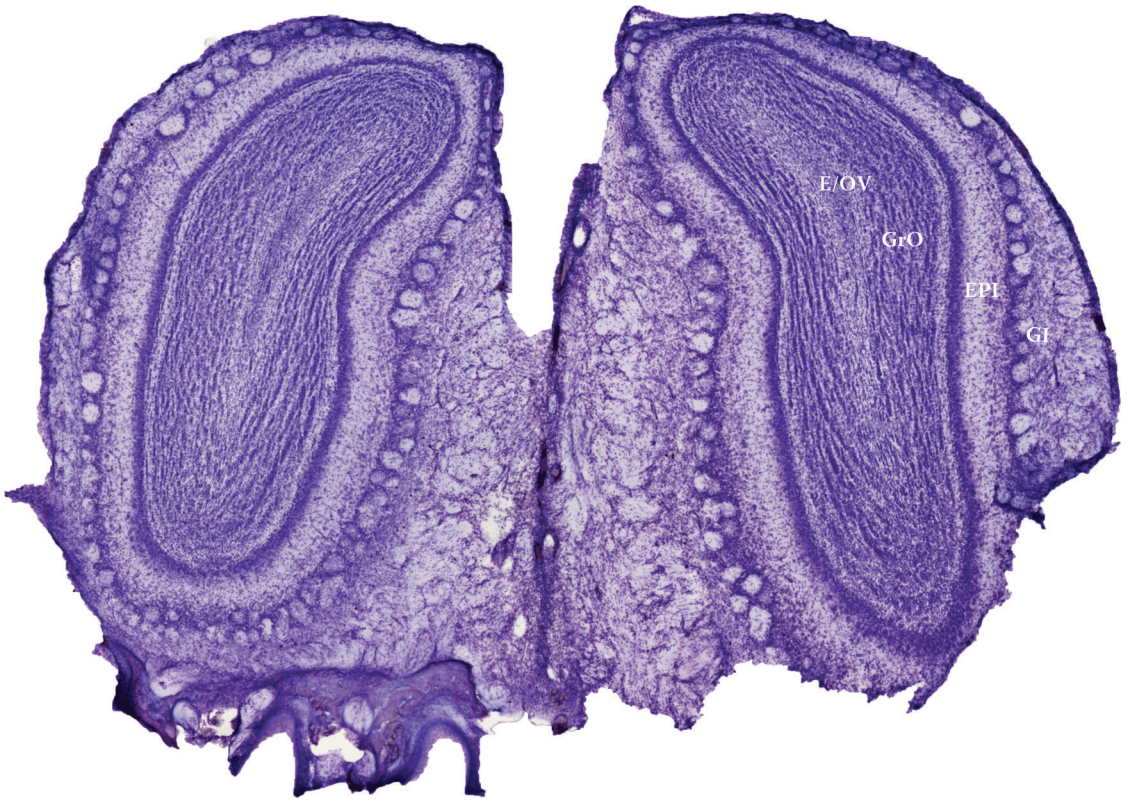

Figure 96
P-14, c1
E = Ependyma and subependymal layer
EPI = External plexiform layer, olfactory bulb
GI = Glomerular layer, olfactory bulb
GrO = Granular cell layer, olfactory bulb
OV = Olfactory ventricle

© 2011 by Taylor and Francis Group, LLC

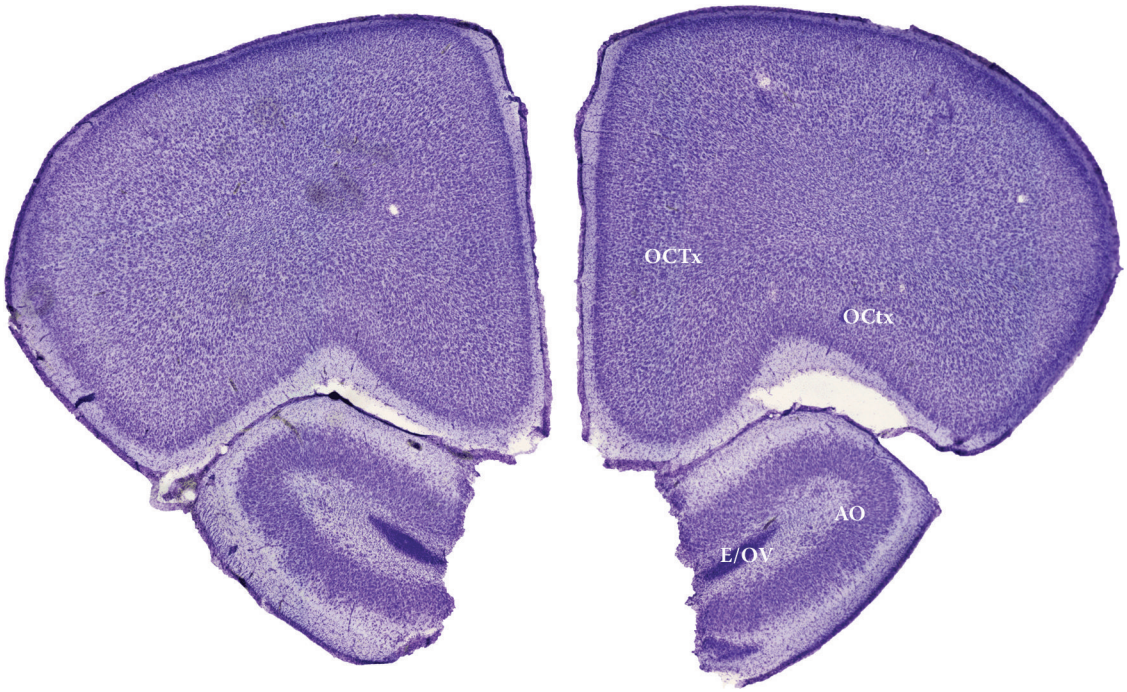

Figure 97
P-14, c2
AO = Anterior olfactory bulb
E = Ependyma and subependymal layer
OCtx = Orbital cortex
OV = Olfactory ventricle

© 2011 by Taylor and Francis Group, LLC

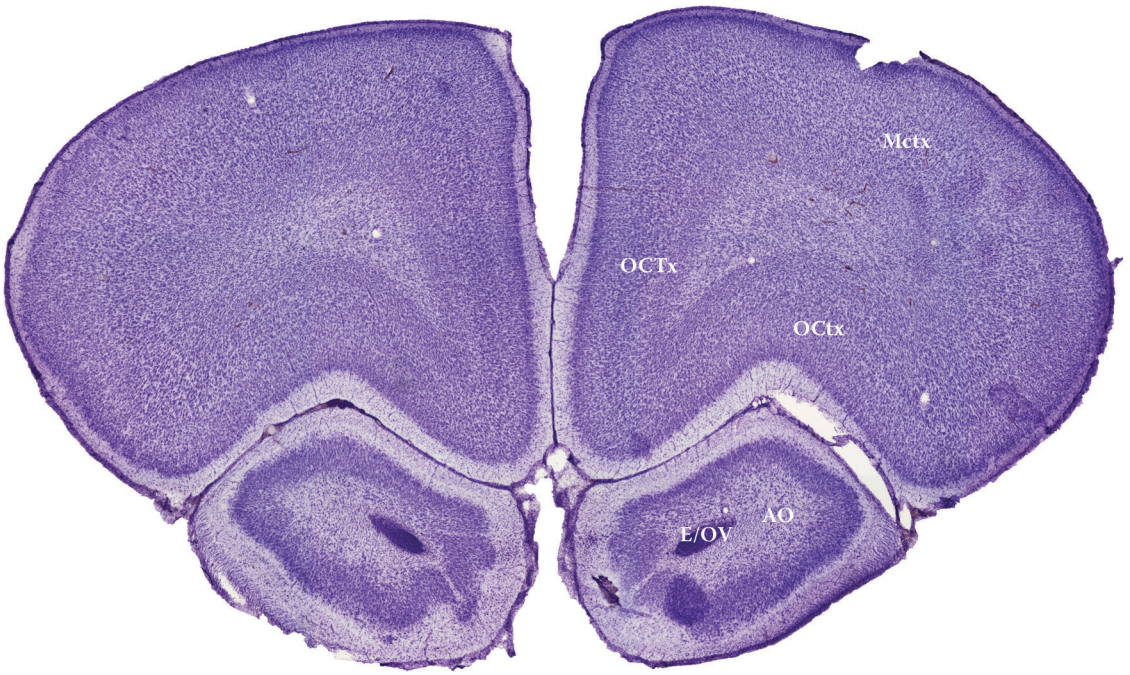

Figure 98
P-14, c3
AO = Anterior olfactory bulb
E = Ependyma and subependymal layer
MCtx = Motor cortex
OCtx = Orbital cortex
OV = Olfactory ventricle

© 2011 by Taylor and Francis Group, LLC



Figure 99
P-14, c4
AICtx = Agranular insular cortex
AO = Anterior olfactory nuclei
CgCtx = Cingulate cortex
E = Ependyma and subependymal layer
fmi = Forceps minor of corpus callosum
MCtx = Motor cortex
OCtx = Orbital cortex
OV = Olfactory ventricle
Pir = Piriform cortex
PrLCtx = Prelimbic cortex

© 2011 by Taylor and Francis Group, LLC

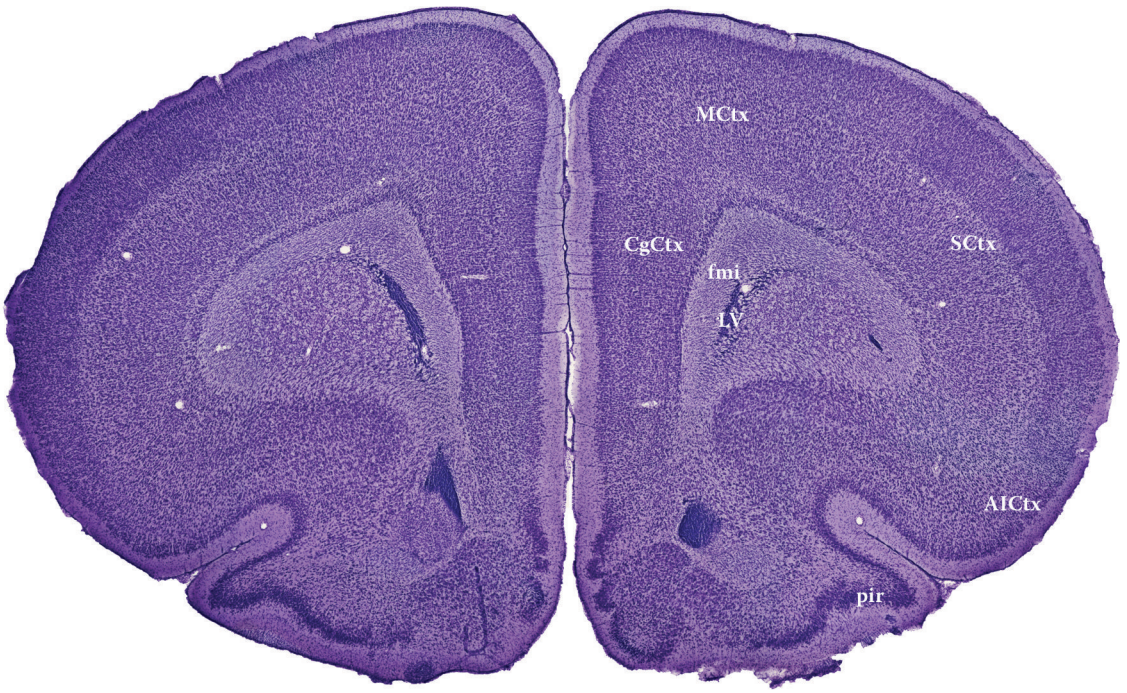

Figure 100
P-14, c5
AICtx = Agranular insular cortex
CgCtx = Cingulate cortex
fmi = Forceps minor of corpus callosum
LV = Lateral ventricle
MCtx = Motor cortex
pir = Piriform cortex
SCtx = Somatosensory cortex

© 2011 by Taylor and Francis Group, LLC

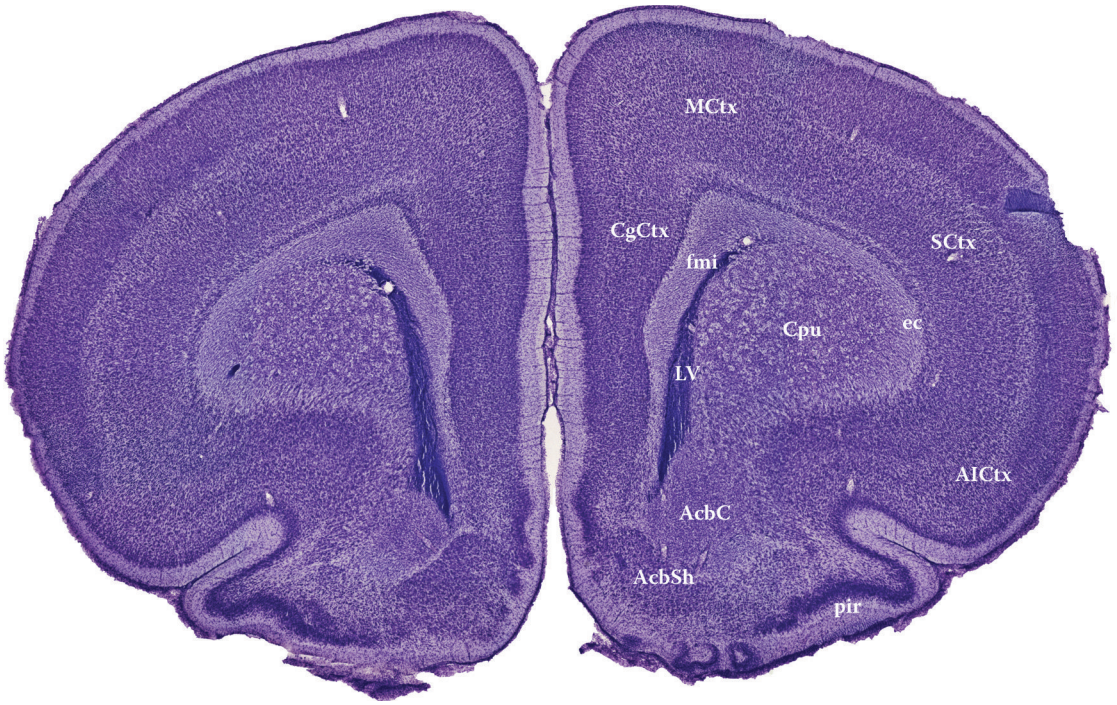

Figure 101
P-14, c6
AICtx = Agranular insular cortex
AcbC = Nucleus accumbens core
AcbSh = Nucleus accumbens shell
CgCtx = Cingulate cortex
CPu = Caudate putamen
ec = external capsule
fmi = Forceps minor of corpus callosum
LV = Lateral ventricle
MCtx = Motor cortex
pir = Piriform cortex
SCtx = Somatosensory cortex

© 2011 by Taylor and Francis Group, LLC

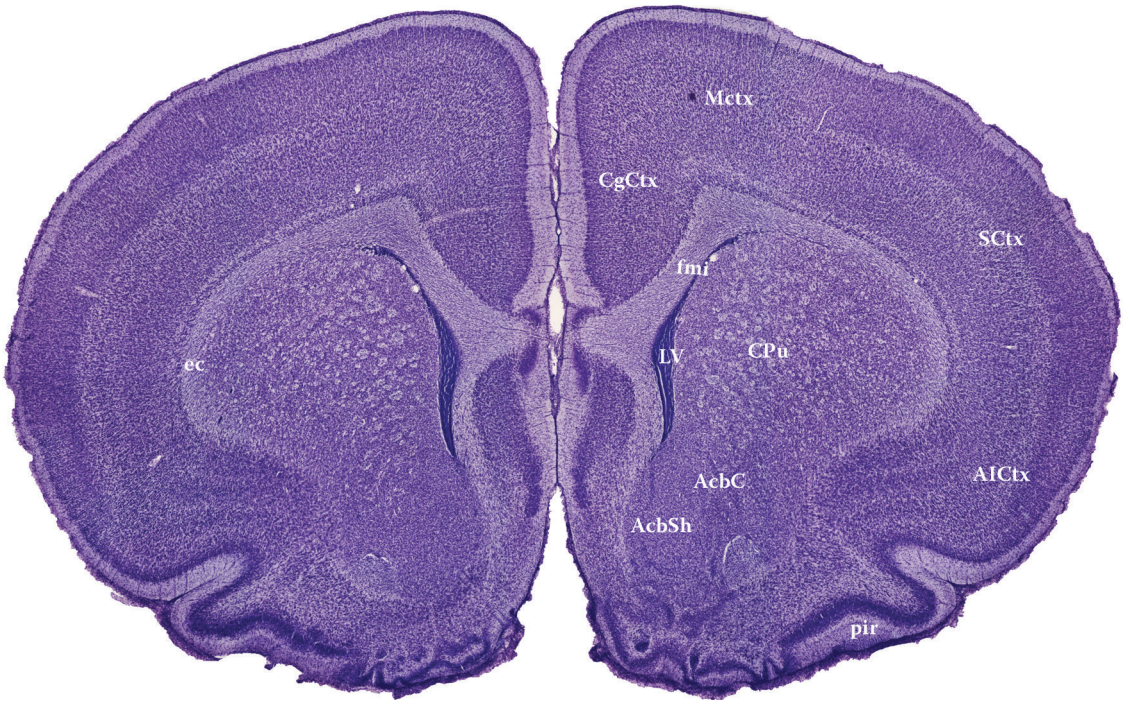

Figure 102
P-14, c7
AICtx = Agranular insular cortex
AcbC = Nucleus accumbens core
AcbSh = Nucleus accumbens shell
CgCtx = Cingulate cortex
CPu = Caudate putamen
ec = external capsule
fmi = Forceps minor of corpus callosum
LV = Lateral ventricle
MCtx = Motor cortex
pir = Piriform cortex
SCtx = Somatosensory cortex

© 2011 by Taylor and Francis Group, LLC



Figure 103
P-14, c8
aca = Anterior commissure
CgCtx = Cingulate cortex
CPu = Caudate putamen
cc = Corpus callosum
LS = Lateral septal nuclei
LV = Lateral ventricle
MCtx = Motor cortex
pir = Piriform cortex
SCtx = Somatosensory cortex

© 2011 by Taylor and Francis Group, LLC



Figure 104
P-14, c9
aca = Anterior commissure
CgCtx = Cingulate cortex
CPu = Caudate putamen
cc = Corpus callosum
LSI = Lateral septal nuclei
MCtx = Motor cortex
pir = Piriform cortex
SCtx = Somatosensory cortex

© 2011 by Taylor and Francis Group, LLC

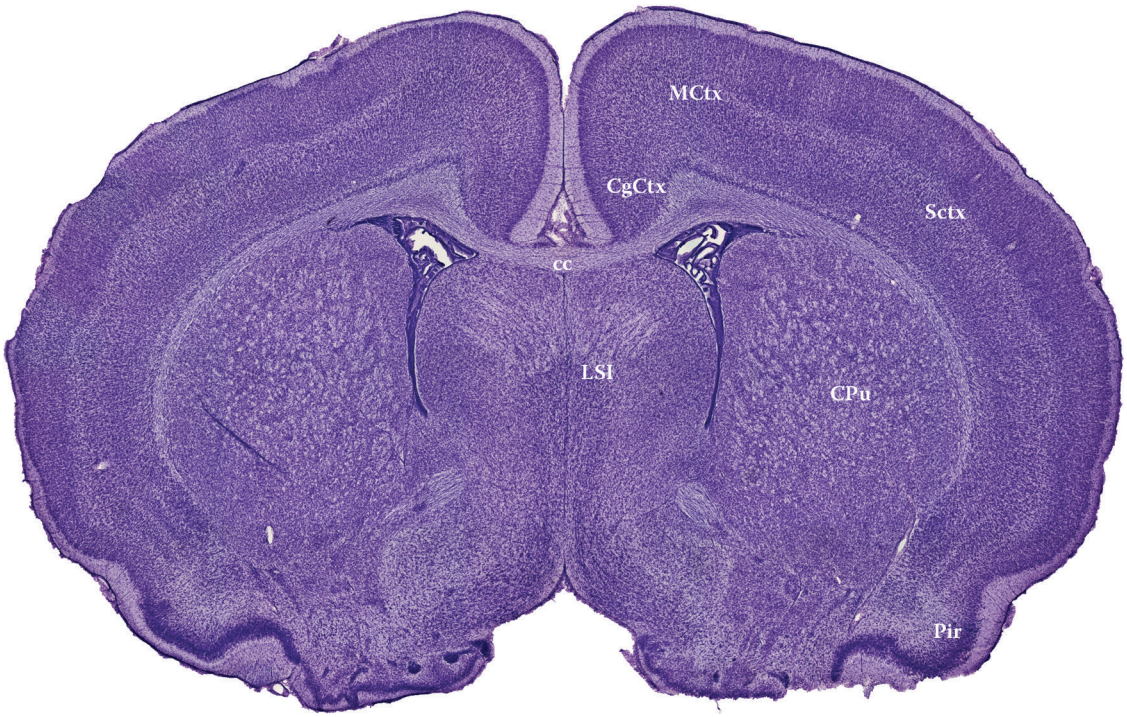

Figure 105
P-14, c10
cc = Corpus callosum
CgCtx = Cingulate cortex
CPu = Caudate putamen
LSI = Lateral septal nuclei
MCtx = Motor cortex
pir = Piriform cortex
SCtx = Somatosensory cortex

© 2011 by Taylor and Francis Group, LLC



Figure 106
P-14, c11
cc = Corpus callosum
CPu = Caudate putamen
LSI = Lateral septal nuclei
MCtx = Motor cortex
pir = Piriform cortex
SCtx = Somatosensory cortex

© 2011 by Taylor and Francis Group, LLC

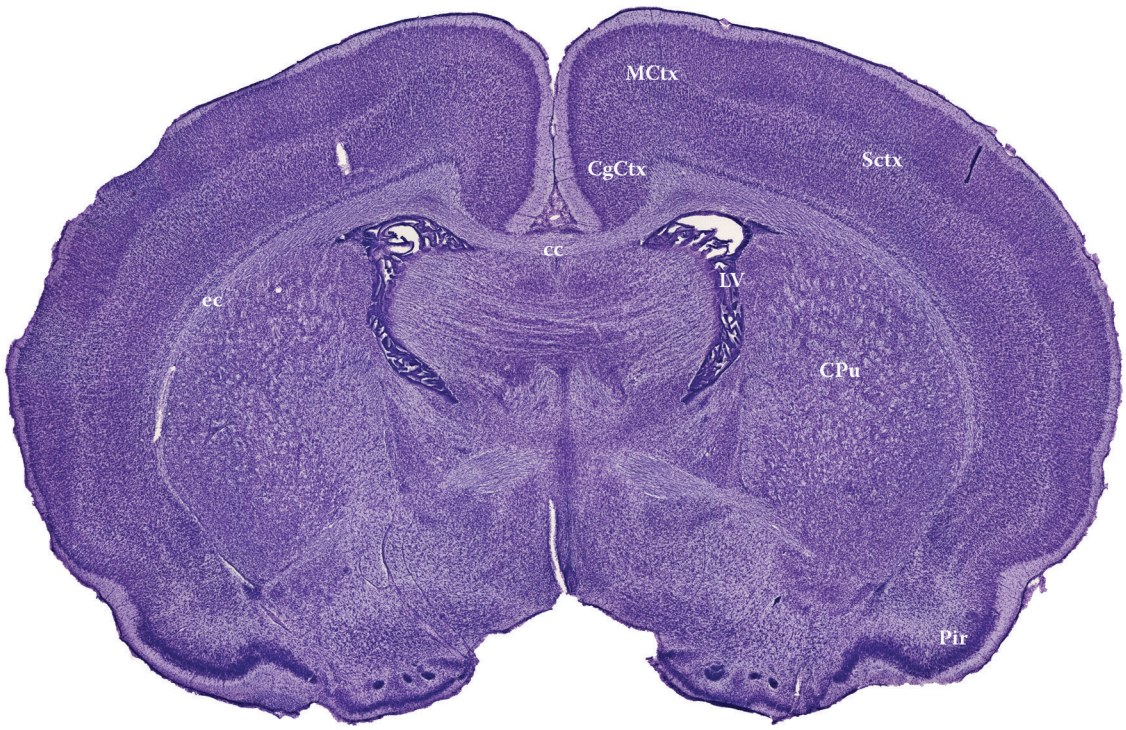

Figure 107
P-14, c12
cc = Corpus callosum
CgCtx = Cingulate cortex
CPu = Caudate putamen
Ec = External capsule
LV = Lateral ventricle
MCtx = Motor cortex
pir = Piriform cortex
SCtx = Somatosensory cortex

© 2011 by Taylor and Francis Group, LLC

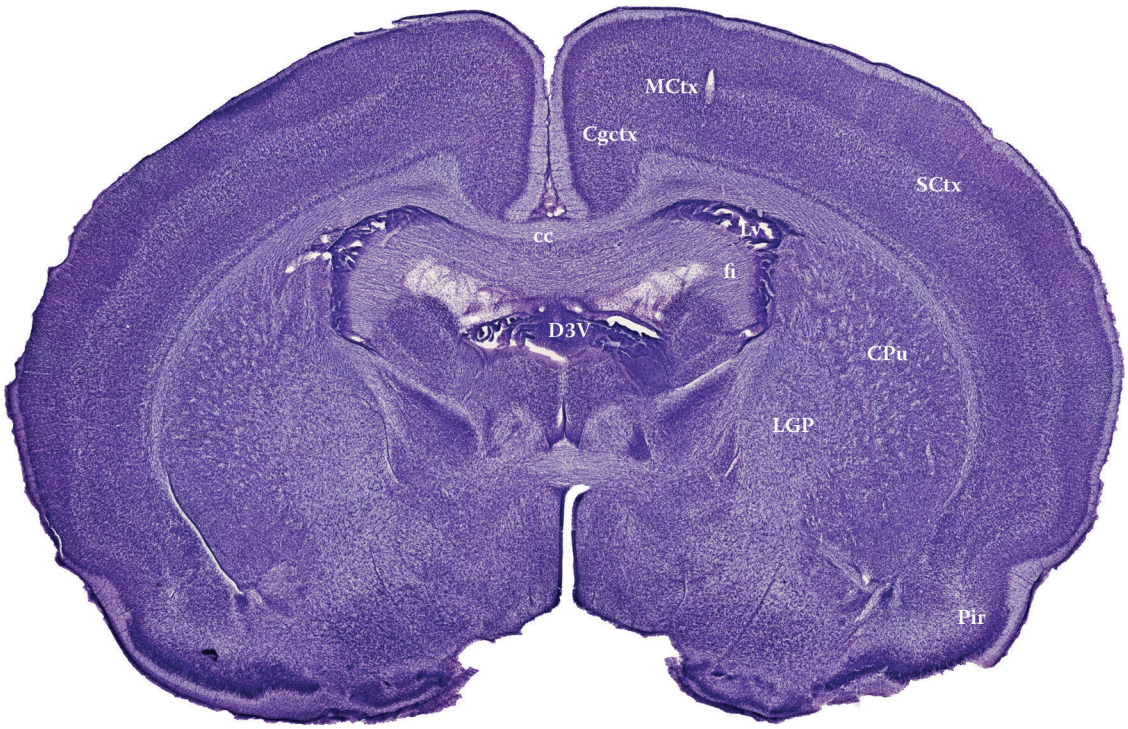

Figure 108
P-14, c13
cc = Corpus callosum
CgCtx = Cingulate cortex
CPu = Caudate putamen
D3V = Dorsal third ventricle
fi = Fimbria of hippocampus
LGP = Lateral globus pallidus
MCtx = Motor cortex
pir = Piriform cortex
SCtx = Somatosensory cortex

© 2011 by Taylor and Francis Group, LLC



Figure 109
P-14, c14
AT = Anterior thalamus
CA3 = CA3 field of hippocampus
cc = Corpus callosum
CPu = Caudate putamen
ec = external capsule
LGP = Lateral globus pallidus
MCtx = Motor cortex
pir = Piriform cortex
SCtx = Somatosensory cortex

© 2011 by Taylor and Francis Group, LLC

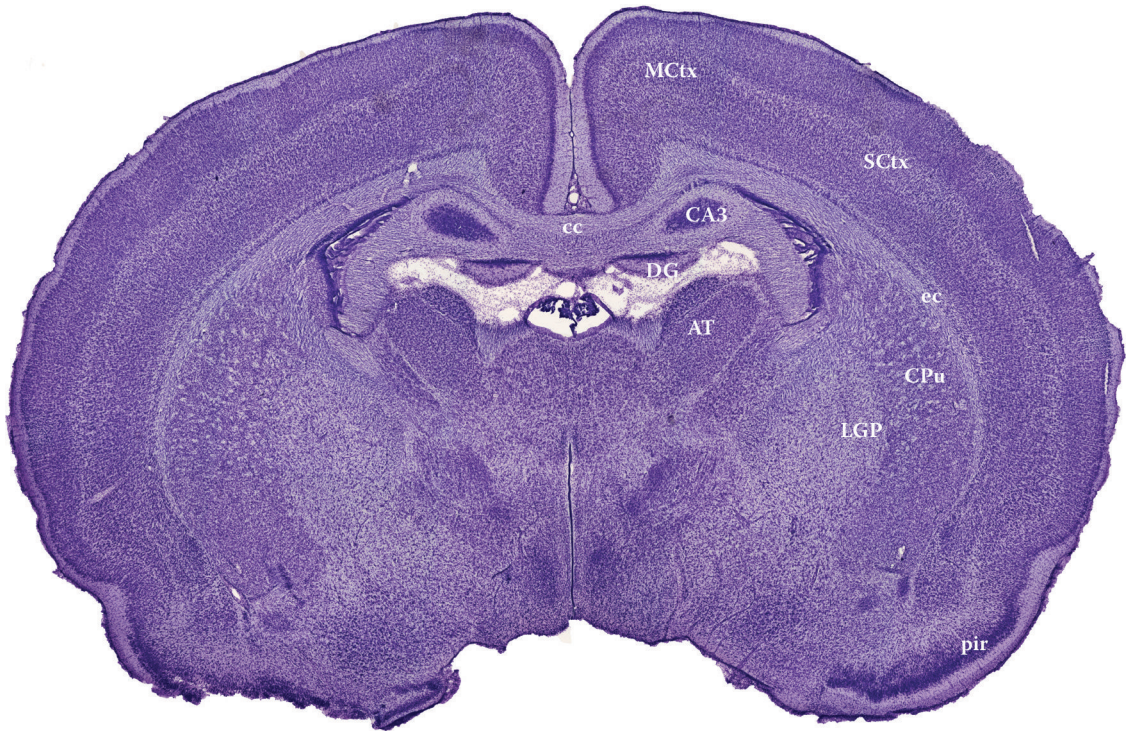

Figure 110
P-14, c15
AT = Anterior thalamus
CA3 = CA3 field of hippocampus
cc = Corpus callosum
CPu = Caudate putamen
DG = Dentate gyrus
ec = external capsule
LGP = Lateral globus pallidus
MCtx = Motor cortex
pir = Piriform cortex
SCtx = Somatosensory cortex

© 2011 by Taylor and Francis Group, LLC



Figure 111
P-14, c16

AICtx = Agranular insular cortex
Amy = Amygdaloid nuclei
AT = Anterior thalamus
AICtx = Agranular insular cortex
CA3 = CA3 field of hippocampus
cc = Corpus callosum
CPu = Caudate putamen
DG = Dentate gyrus
ec = external capsule
hypo = Hypothalamus
LGP = Lateral globus pallidus
MCtx = Motor cortex
pir = Piriform cortex
SCtx = Somatosensory cortex

© 2011 by Taylor and Francis Group, LLC



Figure 112
P-14, c17
AICtx = Agranular insular cortex
Amy = Amygdaloid nuclei
AT = Anterior thalamus
CA3 = CA3 field of hippocampus
cc = Corpus callosum
CPu = Caudate putamen
DG = Dentate gyrus
ec = external capsule
hypo = Hypothalamus
LDVL = Lateral dorsoventral thalamus
LGP = Lateral globus pallidus
MCtx = Motor cortex
pir = Piriform cortex
SCtx = Somatosensory cortex

© 2011 by Taylor and Francis Group, LLC

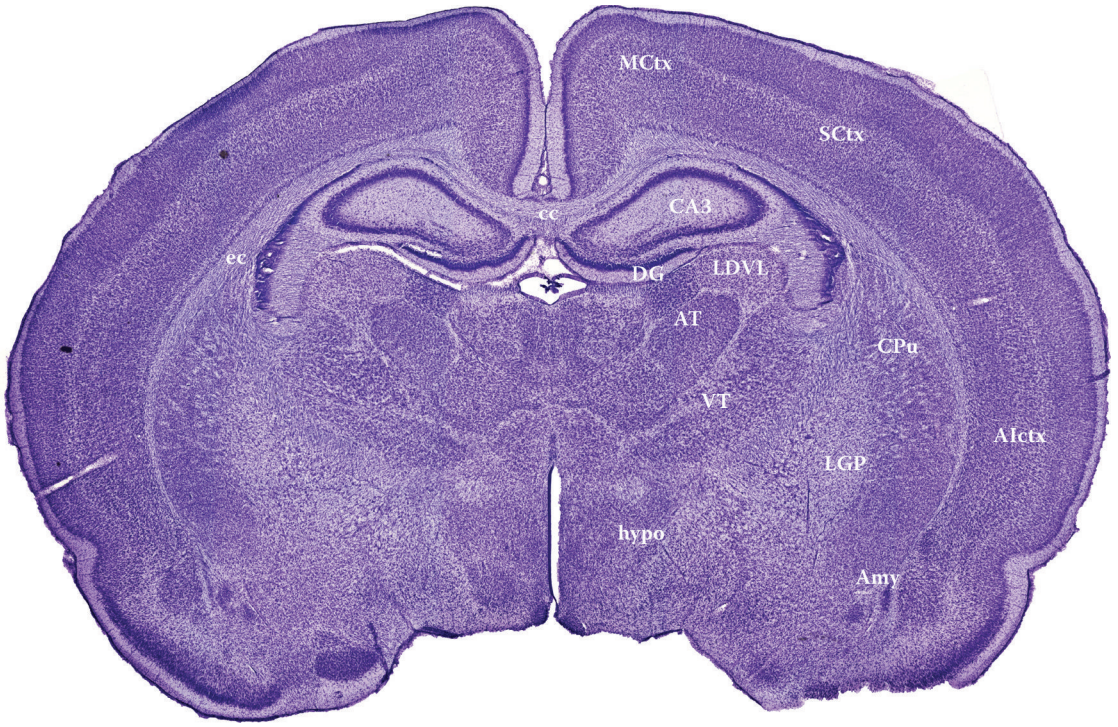

Figure 113
P-14, c18

AICtx = Agranular insular cortex
Amy = Amygdaloid nuclei
AT = Anterior thalamus
CA3 = CA3 field of hippocampus
cc = Corpus callosum
CPu = Caudate putamen
DG = Dentate gyrus
ec = external capsule
hypo = Hypothalamus
LDVL = Lateral dorsoventral thalamus
LGP = Lateral globus pallidus
MCtx = Motor cortex
SCtx = Somatosensory cortex
VT = Ventral thalamus

© 2011 by Taylor and Francis Group, LLC

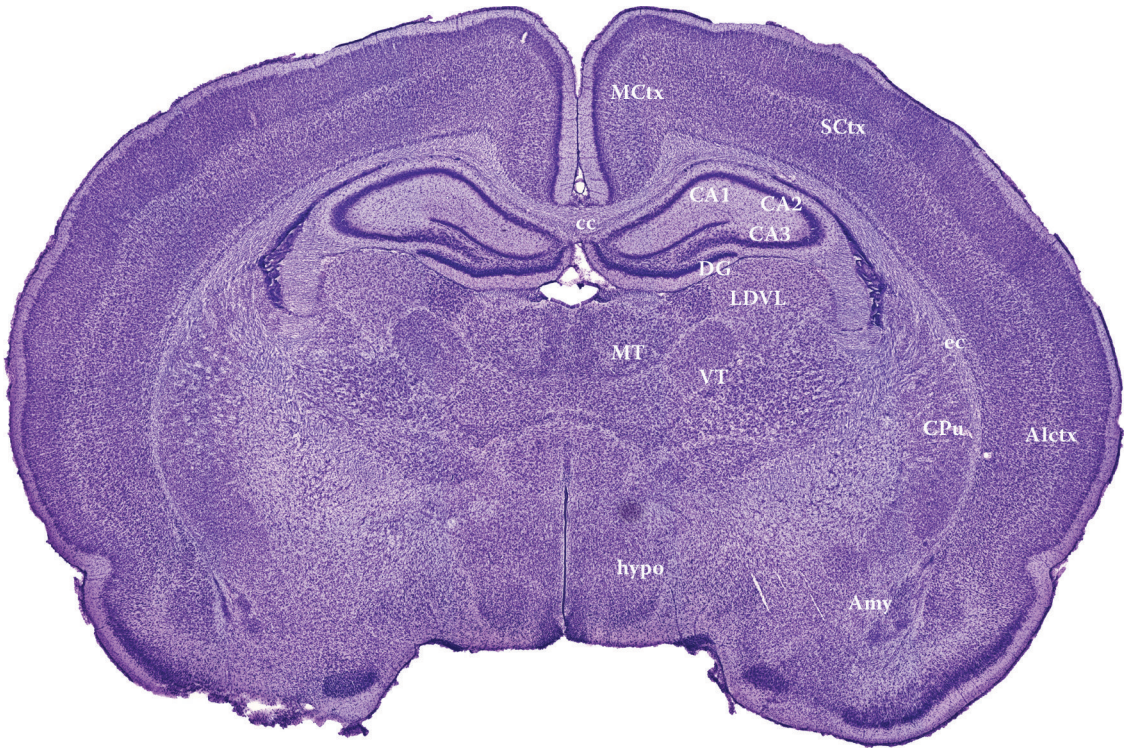

Figure 114
P-14, c19

AICtx = Agranular insular cortex
Amy = Amygdaloid nucleus
CA1 = CA1 field of hippocampus
CA2 = CA2 field of hippocampus
CA3 = CA3 field of hippocampus
cc = Corpus callosum
CPu = Caudate putamen
DG = Dentate gyrus
ec = external capsule
hypo = Hypothalamus
LDVL = Lateral dorsoventral thalamus
MCtx = Motor cortex
MT = Medial thalamus
SCtx = Somatosensory cortex
VT = Ventral thalamus

© 2011 by Taylor and Francis Group, LLC

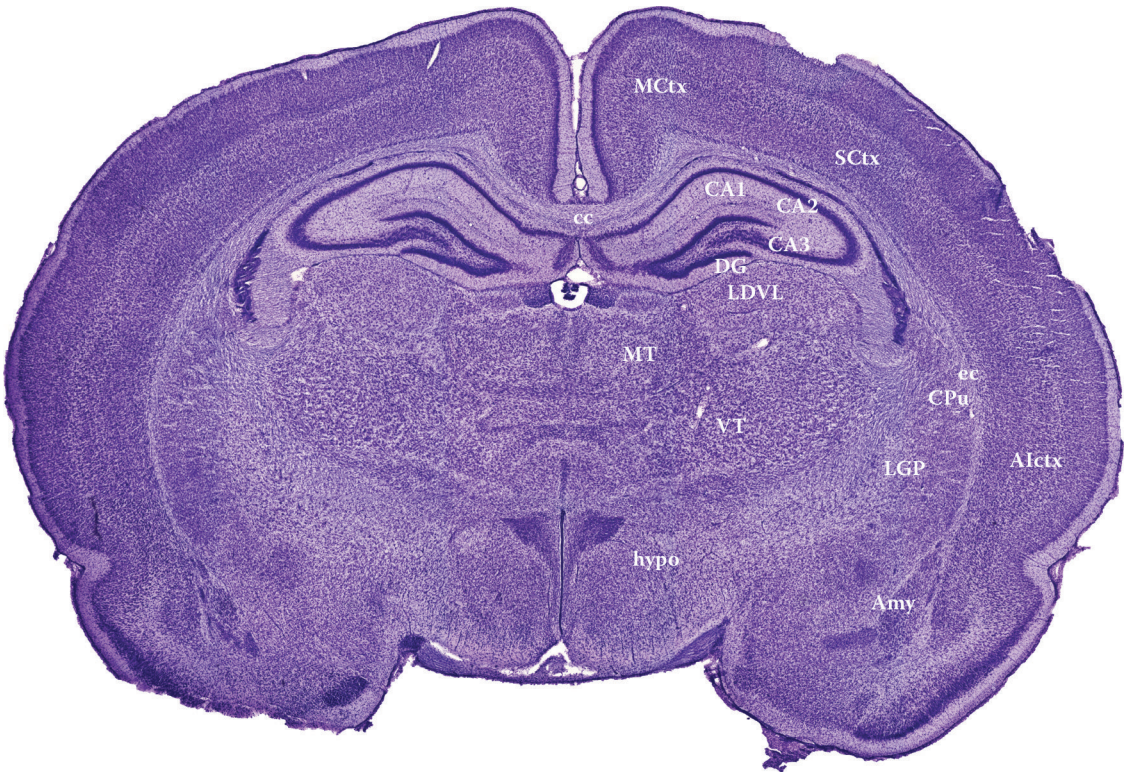

Figure 115
P-14, c20

AICtx = Agranular insular cortex
Amy = Amygdaloid nuclei
CA1 = CA1 field of hippocampus
CA2 = CA2 field of hippocampus
CA3 = CA3 field of hippocampus
cc = Corpus callosum
CPu = Caudate putamen
DG = Dentate gyrus
ec = external capsule
hypo = Hypothalamus
LDVL = Lateral dorsoventral thalamus
LGP = Lateral globus pallidus
MCtx = Motor cortex
MT = Medial thalamus
SCtx = Somatosensory cortex
VT = Ventral thalamus

© 2011 by Taylor and Francis Group, LLC

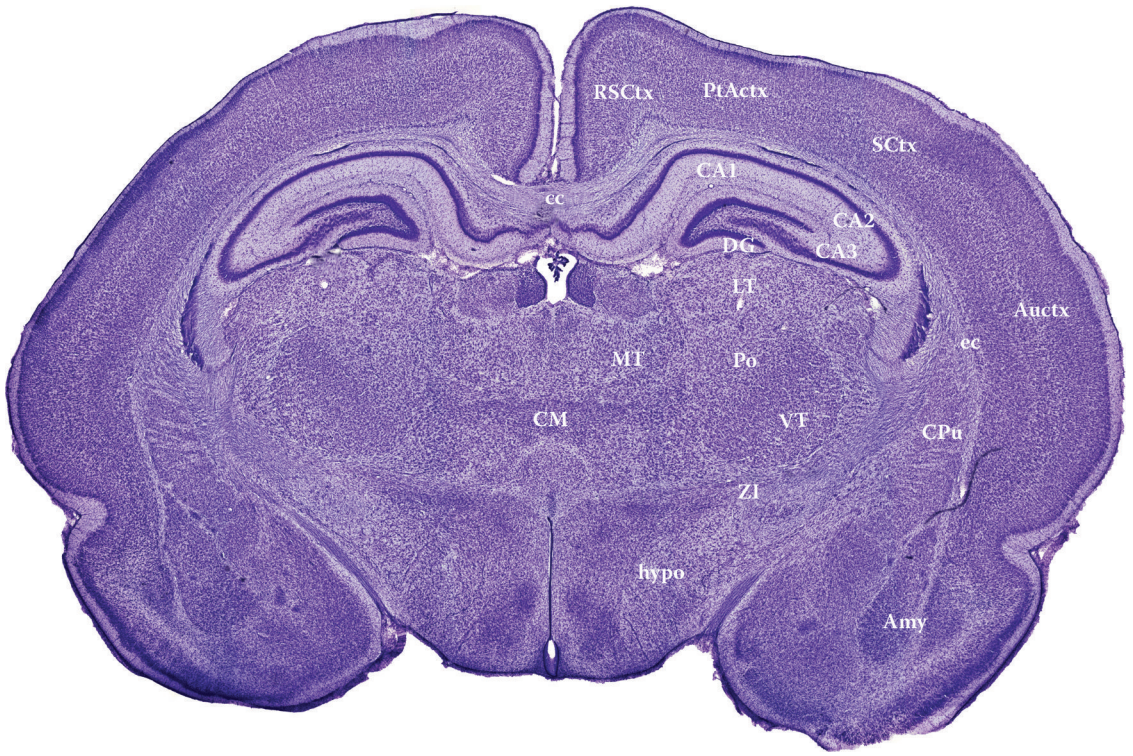

Figure 116
P-14, c21
Amy = Amygdaloid nuclei
AuCtx = Auditory cortex
CA1 = CA1 field of hippocampus
CA2 = CA2 field of hippocampus
CA3 = CA3 field of hippocampus
cc = Corpus callosum
CM = Central medial thalamic nucleus
CPu = Caudate putamen
DG = Dentate gyrus
ec = external capsule
hypo = Hypothalamus
LT = Lateral thalamus
MT = Medial thalamus
Po = Posterior thalamic nucleus group
PtACtx = Parietal association cortex
RsCtx = Retrospenial cortex
SCtx = Somatosensory cortex
VT = Ventral thalamus
ZI = Zona incerta

© 2011 by Taylor and Francis Group, LLC

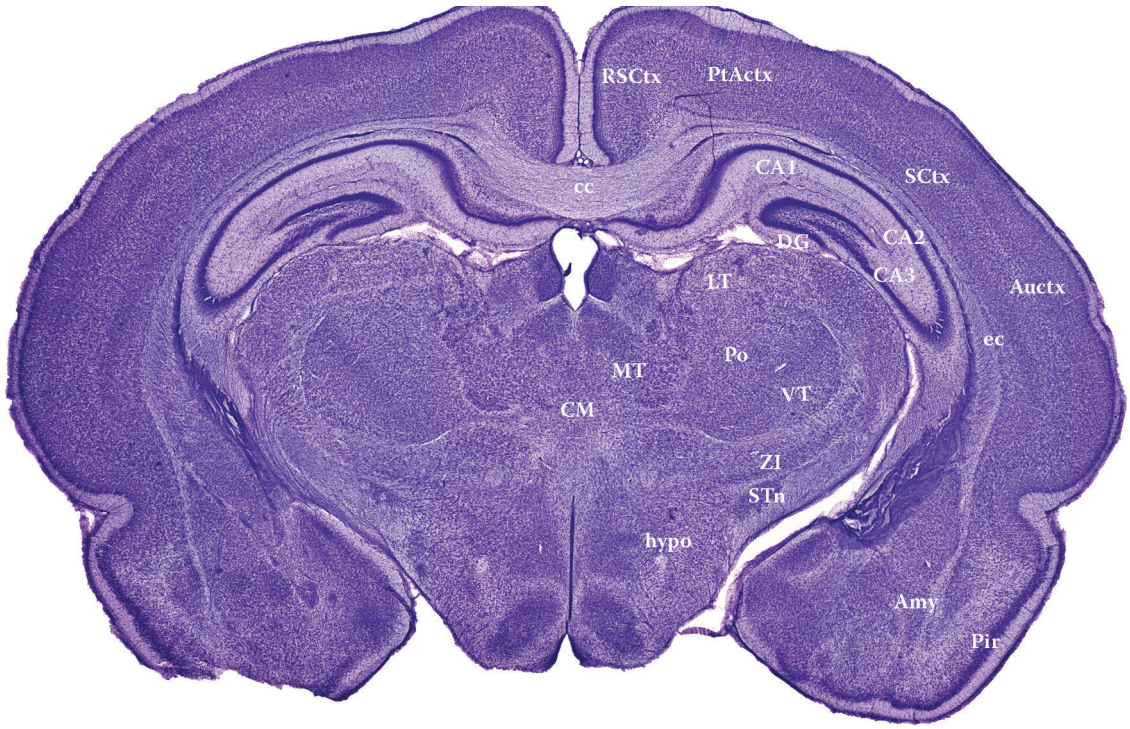

Figure 117

P-14, c22

Amy = Amygdaloid nuclei
AuCtx = Auditory cortex
CA1 = CA1 field of hippocampus
CA2 = CA2 field of hippocampus
CA3 = CA3 field of hippocampus
cc = Corpus callosum
CM = Central medial thalamic nucleus
DG = Dentate gyrus
ec = external capsule
hypo = Hypothalamus
LTh = Lateral thalamus
MT = Medial thalamus
pir = Piriform cortex
Po = Posterior thalamic nucleus group
PtACtx = Parietal association cortex
RsCtx = Retrospenial cortex
SCtx = Somatosensory cortex
STn = Subthalamic nucleus
VT = Ventral thalamus
ZI = Zona incerta

© 2011 by Taylor and Francis Group, LLC



Figure 118
P-14, c23
Amy = Amygdaloid nuclei
AuCtx = Auditory cortex
CA1 = CA1 field of hippocampus
CA2 = CA2 field of hippocampus
CA3 = CA3 field of hippocampus
DG = Dentate gyrus
LT = Lateral thalamus
Lent = Lateral entorhinal cortex
pir = Piriform cortex
PtACtx = Parietal association cortex
RsCtx = Retrospenial cortex
SNr = Substantia nigra reticulata
VCtx = Visual cortex
ZI = Zona incerta

© 2011 by Taylor and Francis Group, LLC

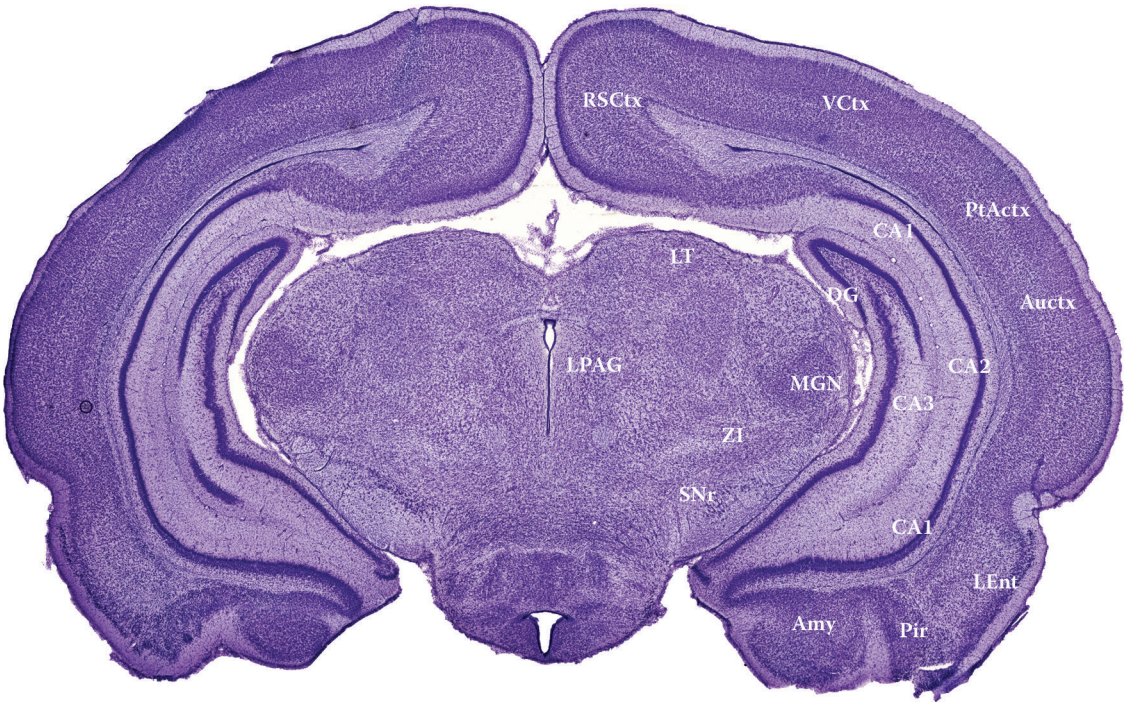

Figure 119
P-14, c24
Amy = Amygdaloid nuclei
AuCtx = Auditory cortex
CA1 = CA1 field of hippocampus
CA2 = CA2 field of hippocampus
CA3 = CA3 field of hippocampus
DG = Dentate gyrus
Lent = Lateral entorhinal cortex
LPAG = Lateral periaqueductal gray matter
LT = Lateral thalamus
MGN = Medial geniculate nucleus
pir = Piriform cortex
PtACtx = Parietal association cortex
RsCtx = Retrospenial cortex
SNr = Substantia nigra reticulata
VCtx = Visual cortex
ZI = Zona incerta

© 2011 by Taylor and Francis Group, LLC

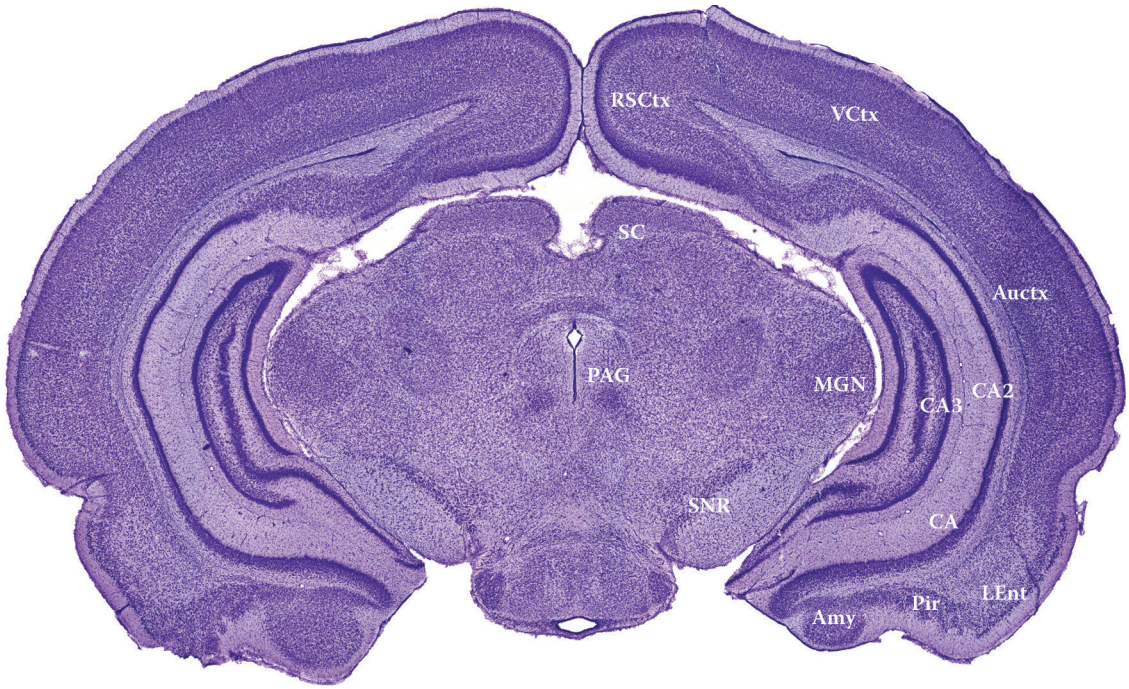

Figure 120
P-14, c25
Amy = Amygdaloid nuclei
AuCtx = Auditory cortex
CA1 = CA1 field of hippocampus
CA2 = CA2 field of hippocampus
CA3 = CA3 field of hippocampus
Lent = Lateral entorhinal cortex
MGN = Medial geniculate nucleus
PAG = Periaqueductal gray matter
Pir = Piriform cortex
RsCtx = Retrospenial cortex
SC = Superior colliculus
SNr = Substantia nigra reticulate

© 2011 by Taylor and Francis Group, LLC

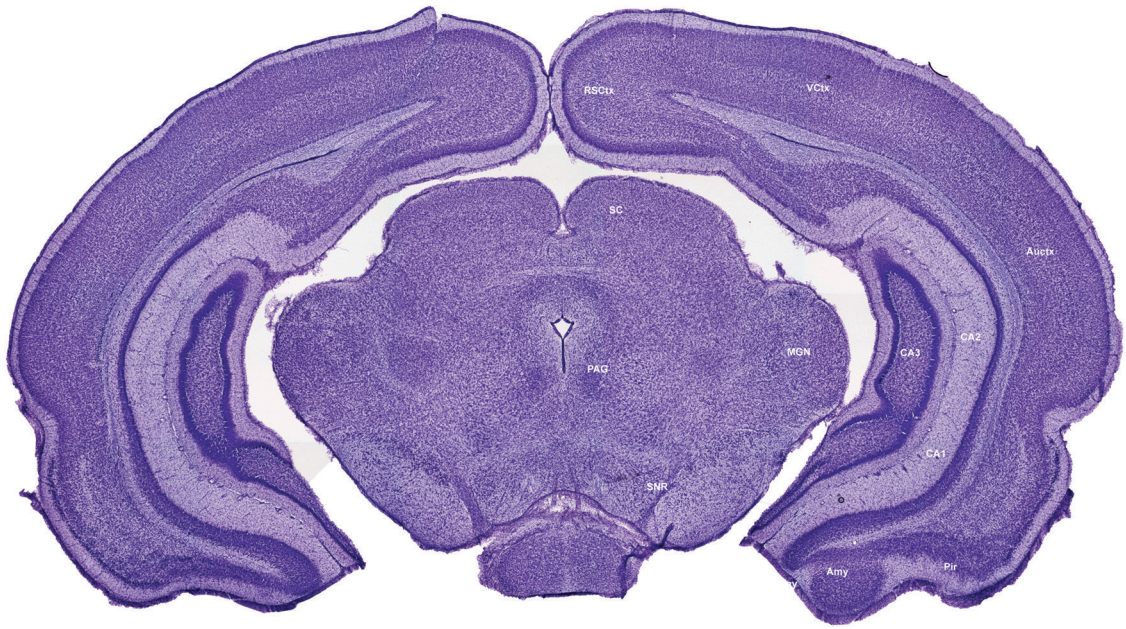

Figure 121
P-14, c26
Amy = Amygloid nucleus
AuCtx = Auditory cortex
CA1 = CA1 field of hippocampus
CA2 = CA2 field of hippocampus
CA3 = CA3 field of hippocampus
PAG = Periaqueductal gray
Pir = Piriform cortex
MGN = Medial geniculate nucleus
RsCtx = Retrospenial cortex
SC = Superior colliculus
SNr = Substantia nigra, reticulata

© 2011 by Taylor and Francis Group, LLC

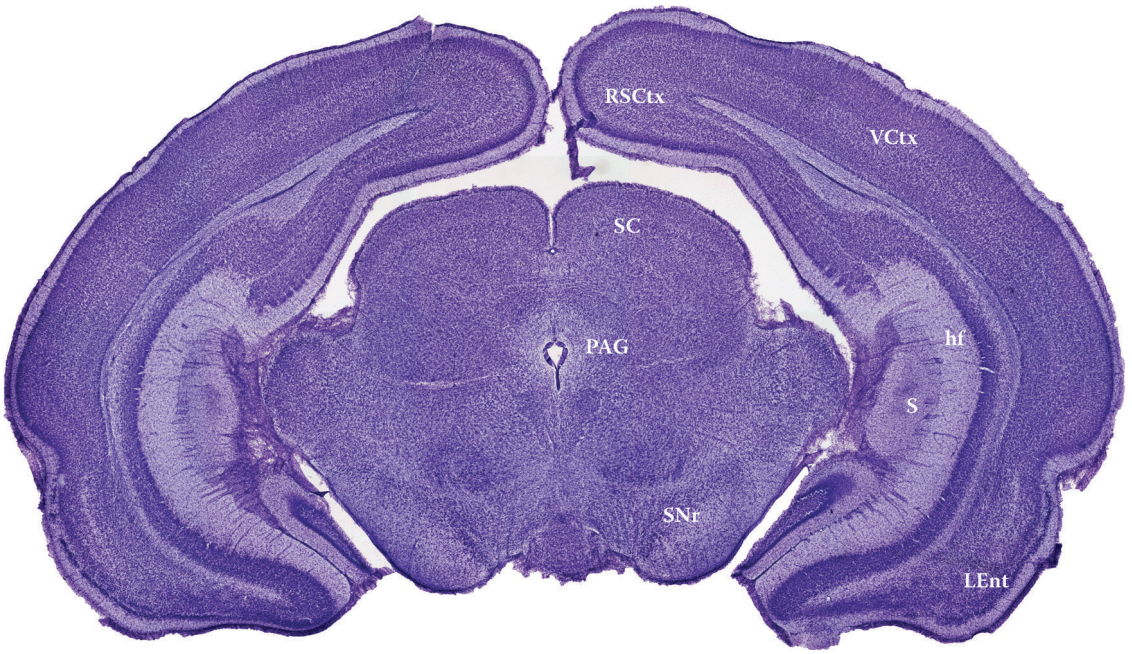

Figure 122
P-14, c27
Lent = Lateral entorhinal cortex
PAG = Periaqueductal gray matter
RsCtx = Retrospenial cortex
S = Subiculum
SC = Superior colliculus
SNr = Substantia nigra reticulata
VCtx = Visual cortex

© 2011 by Taylor and Francis Group, LLC

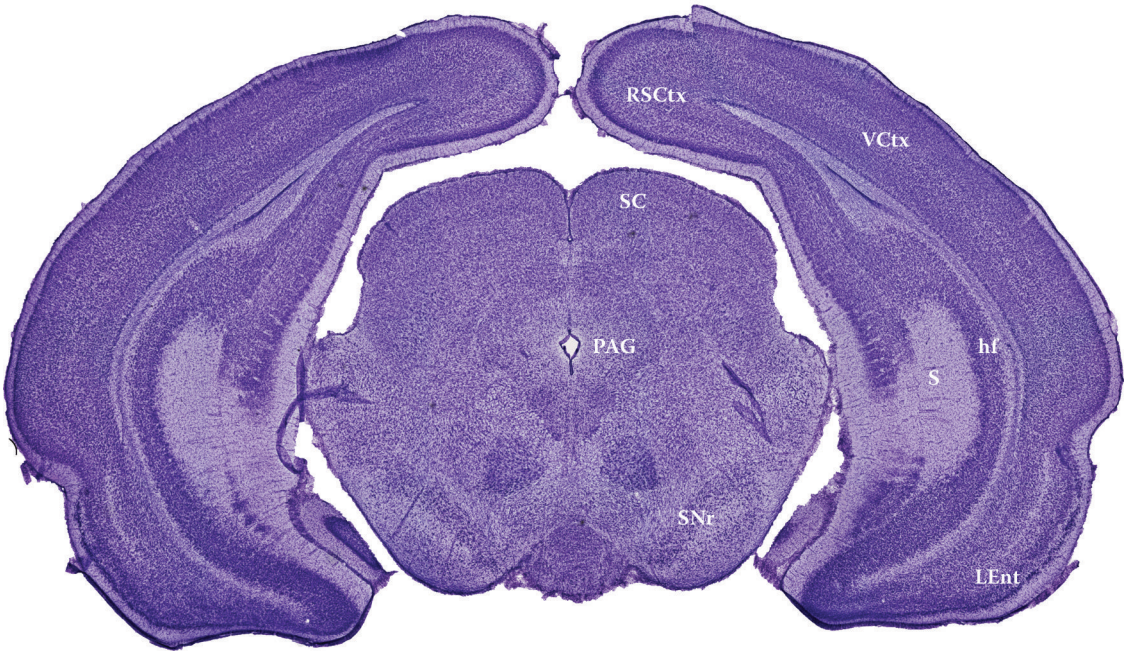

Figure 123
P-14, c28
Hf = Hippocampal fissure
Lent = Lateral entorhinal cortex
PAG = Periaqueductal gray matter
RsCtx = Retrospenial cortex
S = Subiculum
SC = Superior colliculus
SNr = Substantia nigra reticulata
VCtx = Visual cortex

© 2011 by Taylor and Francis Group, LLC

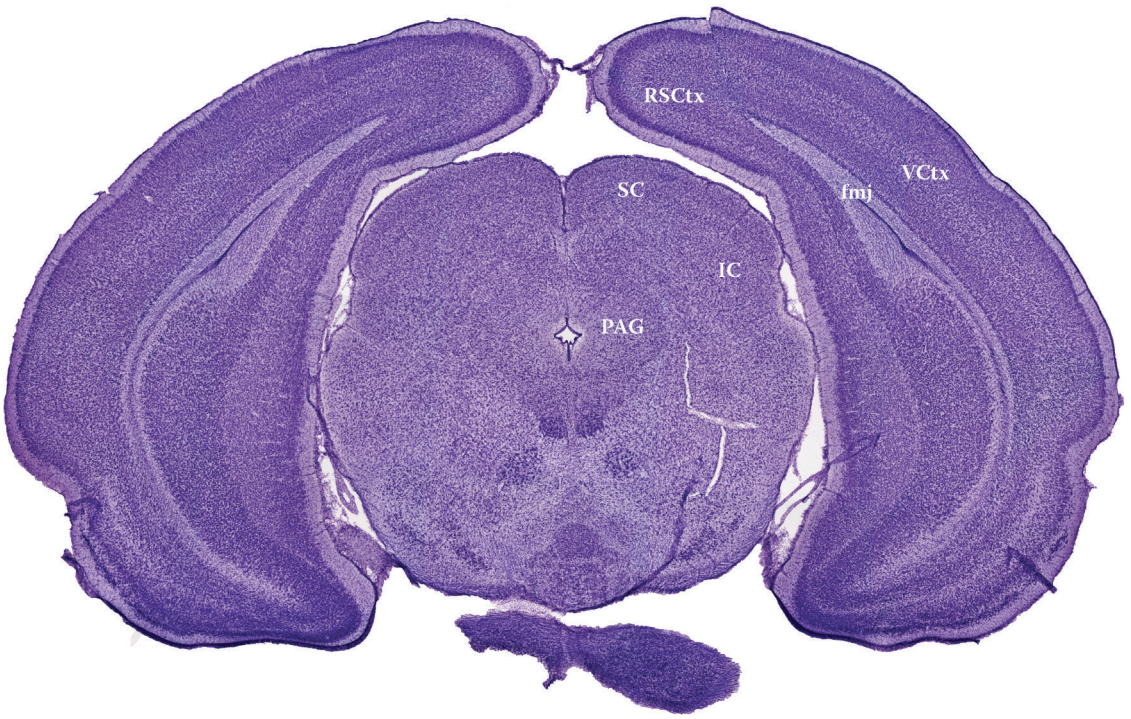

Figure 124
P-14, c29
fmj = Forceps major of corpus callosum
IC = Inferior colliculus
PAG = Periaqueductal gray matter
SC = Superior colliculus
RsCtx = Retrospenial cortex
VCtx = Visual cortex

© 2011 by Taylor and Francis Group, LLC

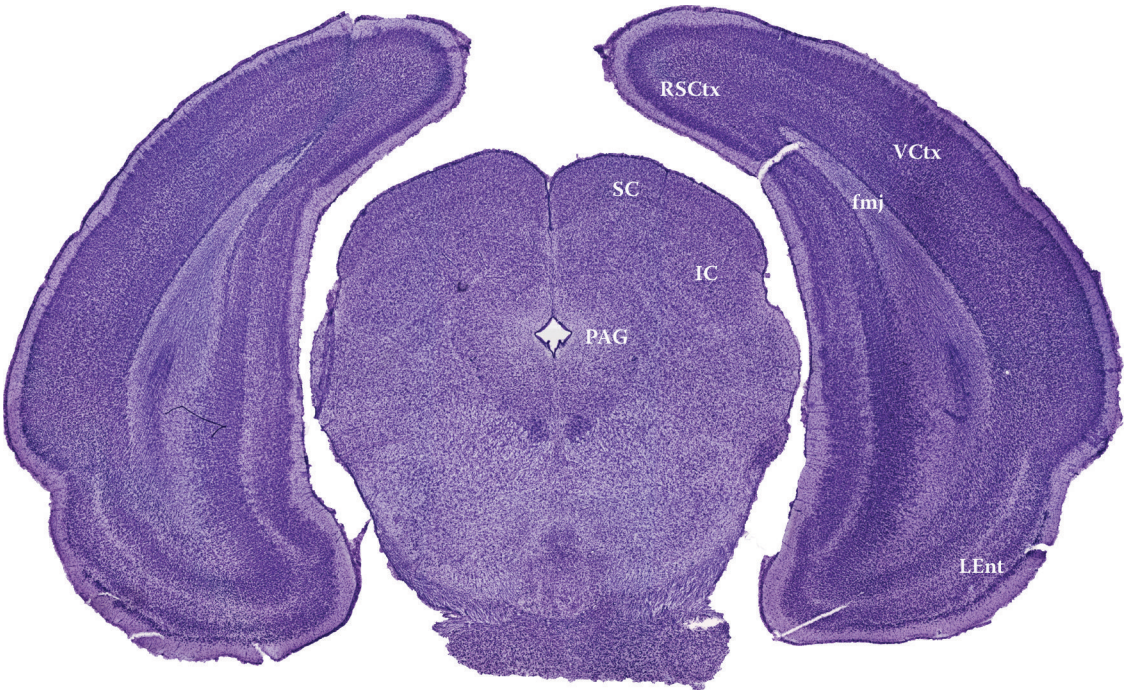

Figure 125
P-14, c30
fmj = Forceps major of corpus callosum
IC = Inferior colliculus
Lent = Lateral entorhinal cortex
PAG = Periaqueductal gray matter
SC = Superior colliculus
RsCtx = Retrospenial cortex
VCtx = Visual cortex

© 2011 by Taylor and Francis Group, LLC

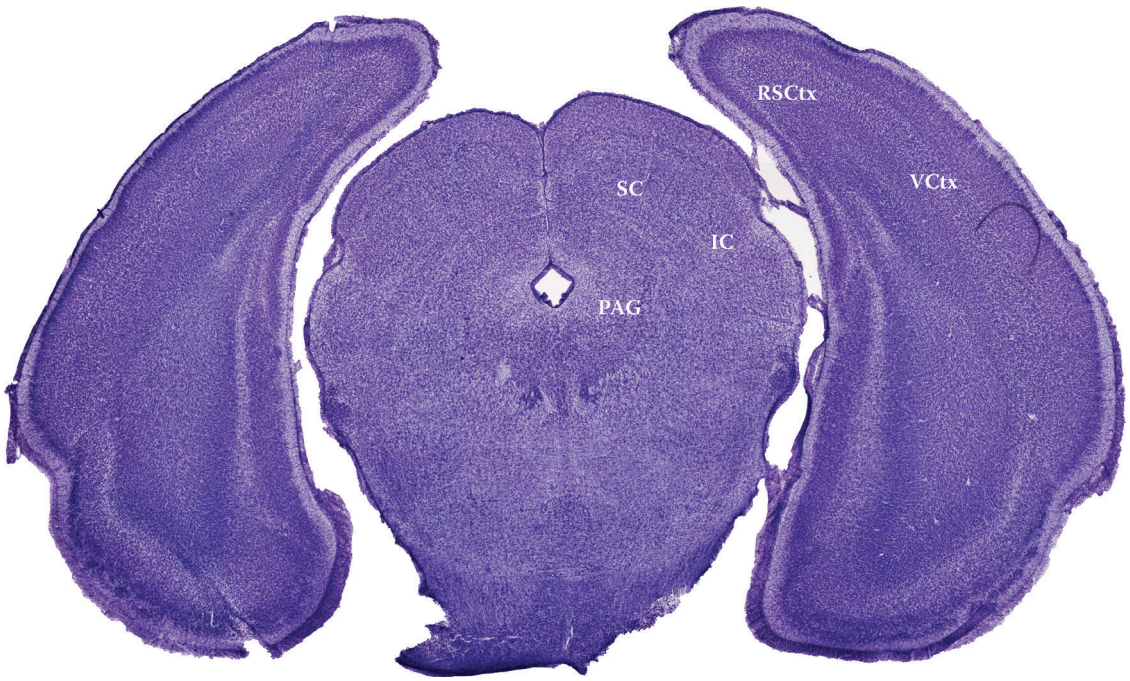

Figure 126
P-14, c31
IC = Inferior colliculus
PAG = Periaqueductal gray matter
RsCtx = Retrospenial cortex
SC = Superior colliculus
VCtx = Visual cortex

© 2011 by Taylor and Francis Group, LLC



Figure 127
P-14, c32
2 = Cerebellar lobule
DTg = Dorsal tegmental nucleus
IC = Inferior colliculus
Pn = Pontine reticular nucleus

© 2011 by Taylor and Francis Group, LLC

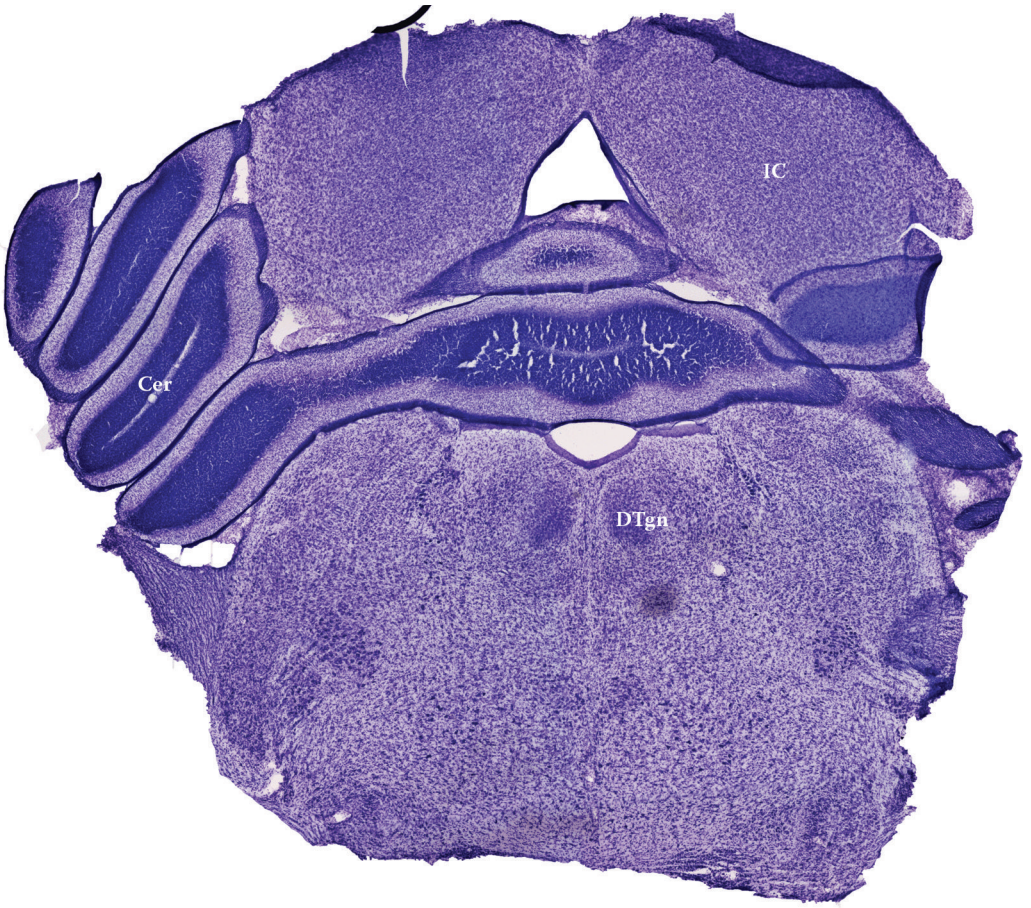

Figure 128
P-14, c33
Cer = Cerebellar nuclei
DTg = Dorsal tegmental nucleus
IC = Inferior colliculus

© 2011 by Taylor and Francis Group, LLC

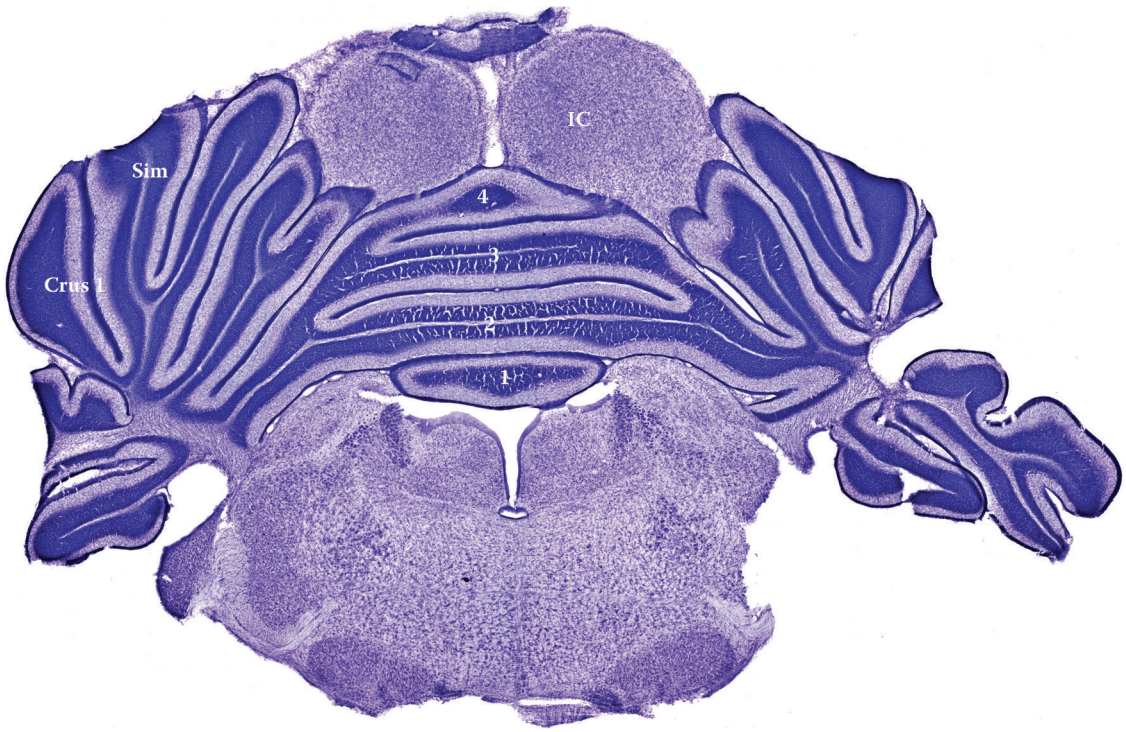

Figure 129
P-14, c34
1 through 4 = Cerebellar lobules
Crus1 = Crus1 of ansiform lobule
Sim = Simple lobule

© 2011 by Taylor and Francis Group, LLC



Figure 130
P-14, c35
1 through 4 = Cerebellar lobules
Crus1 = Crus1 of ansiform lobule
Sim = Simple lobule

© 2011 by Taylor and Francis Group, LLC



Figure 131
P-14, c36
1 through 4 = Cerebellar lobules
Crus1 = Crus1 of ansiform lobule
Sim = Simple lobule

© 2011 by Taylor and Francis Group, LLC

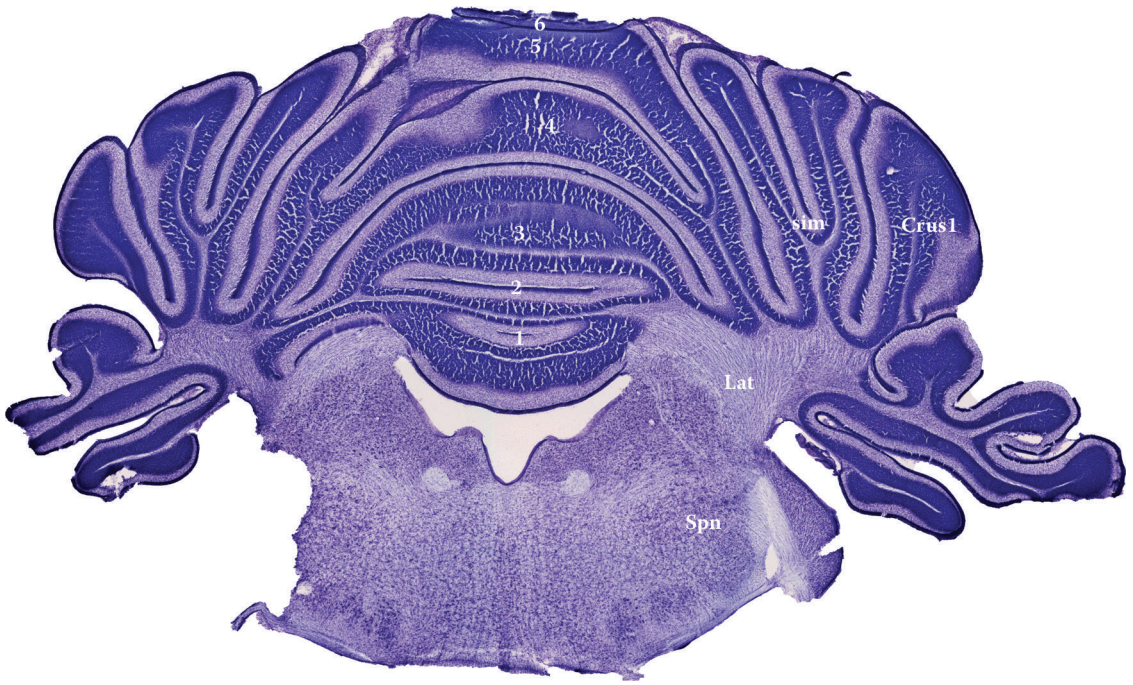

Figure 132
P-14, c37
1 through 6 = Cerebellar lobules
Crus1 = Crus1 of ansiform lobule
Lat = Lateral cerebellar nucleus
Sim = Simple lobule
Spn = Spinal nucleus

© 2011 by Taylor and Francis Group, LLC

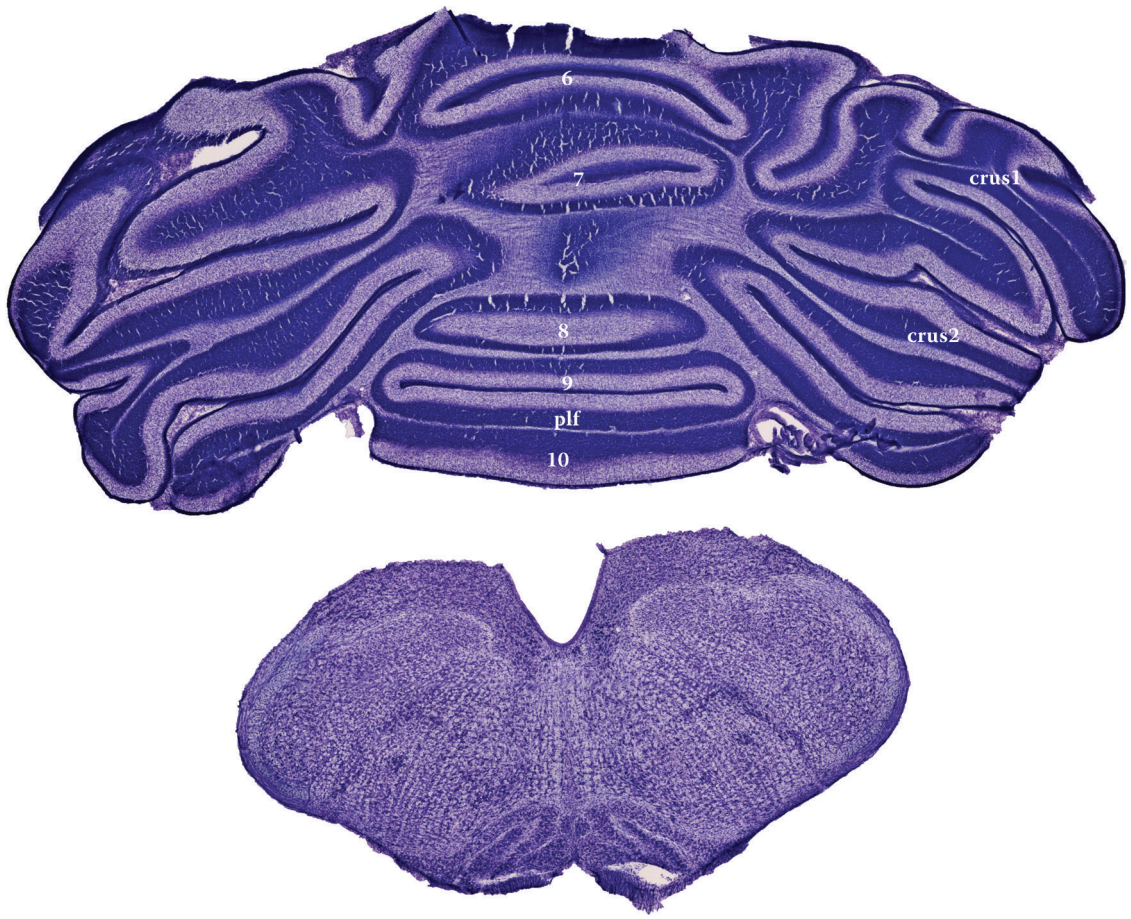

Figure 133
P-14, c38
6 through 10 = Cerebellar lobules
Crus1 = Crus1 of ansiform lobule
Crus2 = Crus2 of ansiform lobule
plf = Posterolateral fissure

© 2011 by Taylor and Francis Group, LLC



Figure 134
P-14, c39
6 through 10 = Cerebellar lobules
Crus1 = Crus1 of ansiform lobule
Crus2 = Crus2 of ansiform lobule

© 2011 by Taylor and Francis Group, LLC



Figure 135
P-14, c40
cer = Cerebellum
Spn = Spinal nucleus

© 2011 by Taylor and Francis Group, LLC

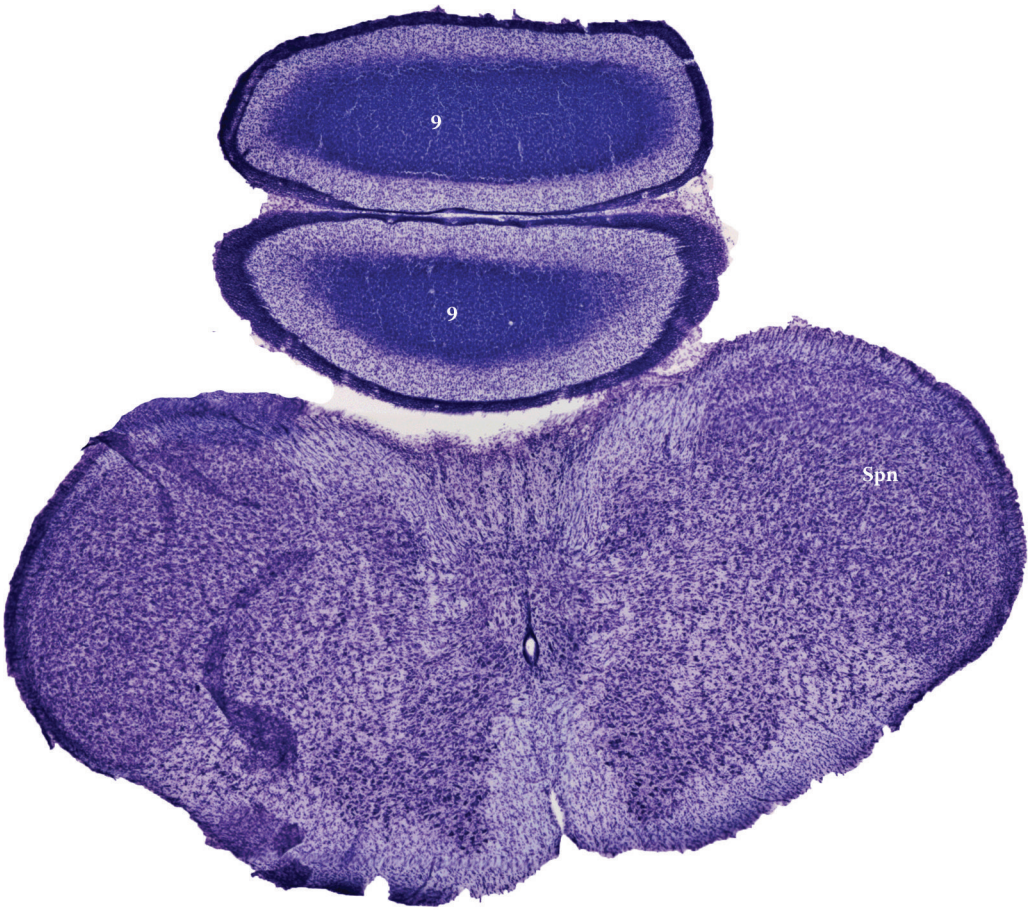

Figure 136
P-14, c41
9 = Cerebellar lobule
Spn = Spinal nucleus

© 2011 by Taylor and Francis Group, LLC

Sagittal Plates

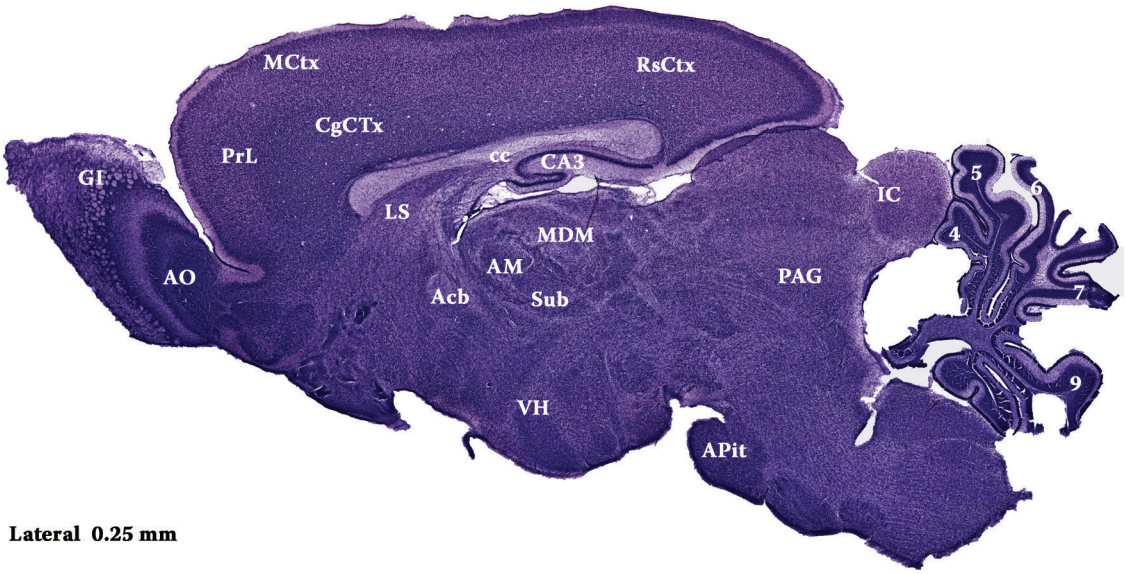

Figure 137
P-14, S1

4 through 9 = Cerebellar lobules
Acb = Accumbens nucleus
AO = Anterior olfactory bulb
AM = Anteromedial thalamus
APit = Anterior pituitary
CA3 = CA3 field of hippocampus
cc = Corpus callosum
CgCtx = Cingulate cortex
GI = Glomerular cell layer, olfactory bulb
IC = Inferior colliculus
LS = Lateral septal nucleus
MCtx = Motor cortex
MDM = Mediodorsal thalamic nucleus
PAG = Periaqueductal gray matter
PrLCtx = Prelimbic cortex
RSCtx = Retrospenial cortex
Sub = Submedial thalamic nucleus
VH = Ventral hypothalamus

© 2011 by Taylor and Francis Group, LLC

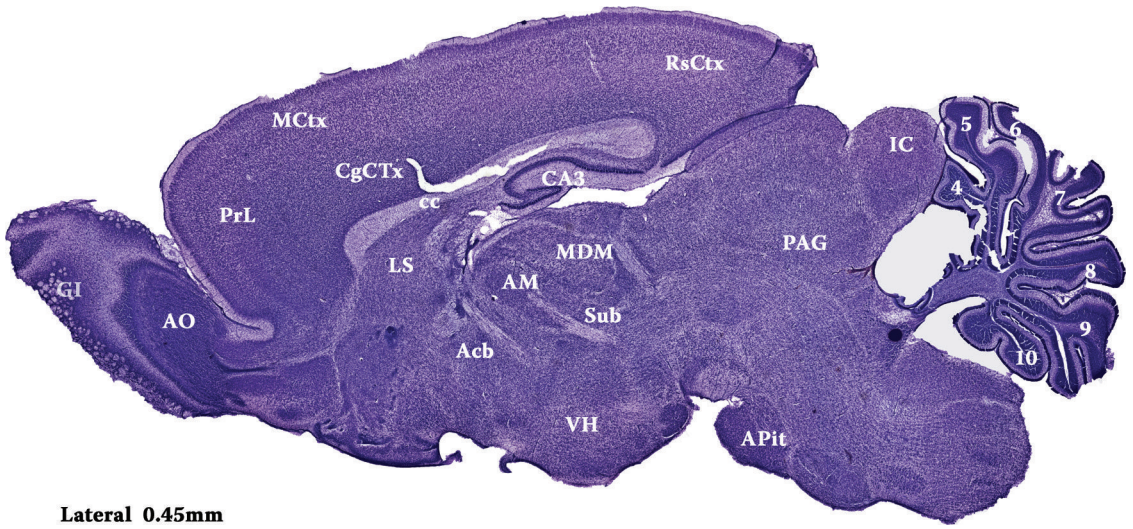

Figure 138
P-14, s2
4 through 10 = Cerebellar lobules
Acb = Accumbens nucleus
AM = Anteromedial thalamus
AO = Anterior olfactory bulb
APit = Anterior pituitary
CA3 = CA3 field of hippocampus
cc = Corpus callosum
CgCtx = Cingulate cortex
GI = Glomerular layer olfactory bulb
IC = Inferior colliculus
LS = Lateral septal nucleus
MCtx = Motor cortex
MDM = Mediodorsal thalamic nucleus
PAG = Periaqueductal gray matter
PrLCtx = Prelimbic cortex
RSCtx = Retrospenial cortex
Sub = Submedial thalamic nucleus
VH = Ventral hypothalamus

© 2011 by Taylor and Francis Group, LLC

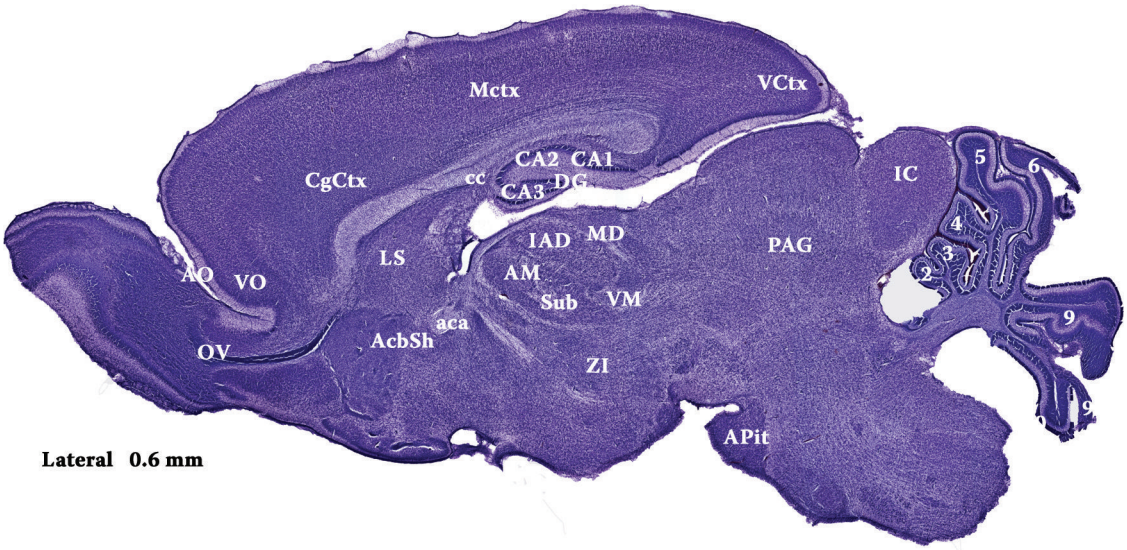

Figure 139
P-14, s3
1 through 9 = Cerebellar lobules
aca = Anterior commissure
AcbSh = Accumbens nucleus shell
AM = Anteriomedial thalamus
AO = Anterior olfactory bulb
APit = Anterior pituitary
CA1 = CA1 field of hippocampus
CA2 = CA2 field of hippocampus
CA3 = CA3 field of hippocampus
cc = Corpus callosum
CgCtx = Cingulate cortex
DG = Dentate gyrus
GI = Glomerular layer, olfactory bulb
IAD = Interanterodorsal thalamic nucleus
IC = Inferior colliculus
LS = Lateral septal nucleus
MCtx = Motor cortex
MD = Mediodorsal thalamic nucleus
OV= Olfactory ventricle
PAG = Periaqueductal gray matter
Sub = Submedial thalamic nucleus
VCtx = Visual cortex
VM = Ventromedial thalamus
VO = Ventral orbital cortex
ZI = Zona incerta

© 2011 by Taylor and Francis Group, LLC

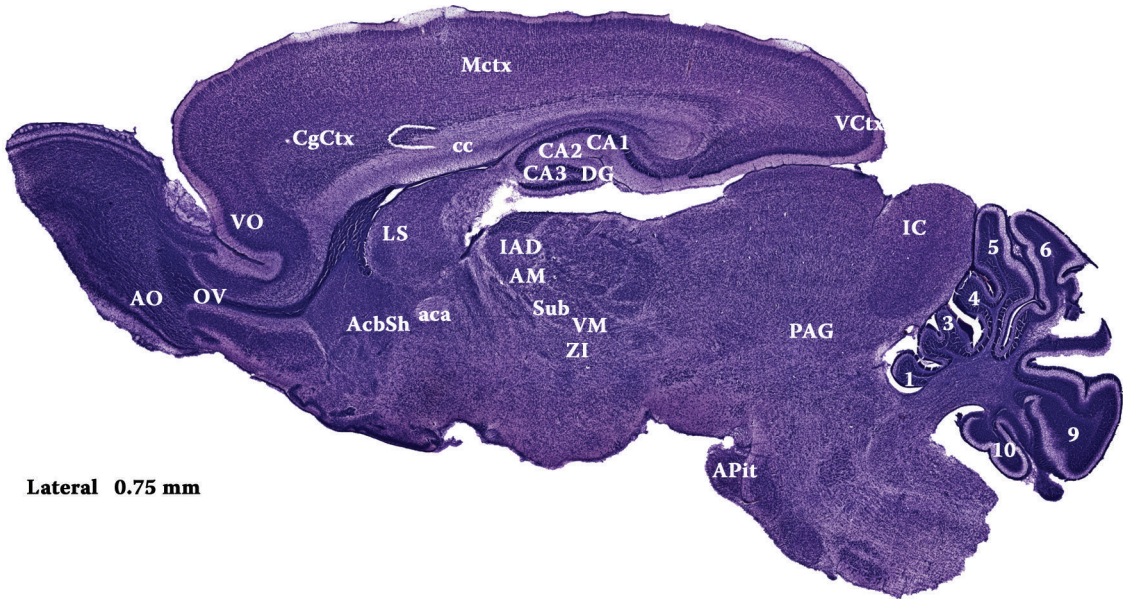

Figure 140
P-14, s4

1 through 10 = Cerebellar lobules
aca = Anterior commissure
AcbSh = Accumbens nucleus shell
AM = Anteromedial thalamus
AO = Anterior olfactory bulb
APit = Anterior pituitary
CA1 = CA1 field of hippocampus
CA2 = CA2 field of hippocampus
CA3 = CA3 field of hippocampus
cc = Corpus callosum
CgCtx = Cingulate cortex
DG = Dentate gyrus
GI = Glomerular layer, olfactory bulb
IAD = Interanterodorsal thalamic nucleus
IC = Inferior colliculus
LS = Lateral septal nucleus
MCtx = Motor cortex
MD = Mediodorsal thalamic nucleus
OV = Olfactory ventricle
PAG = Periaqueductal gray matter
Sub = Submedial thalamic nucleus
VM = Ventral medial thalamus
VO = Ventral orbital cortex
VCtx = Visual cortex
ZI = Zona incerta

© 2011 by Taylor and Francis Group, LLC

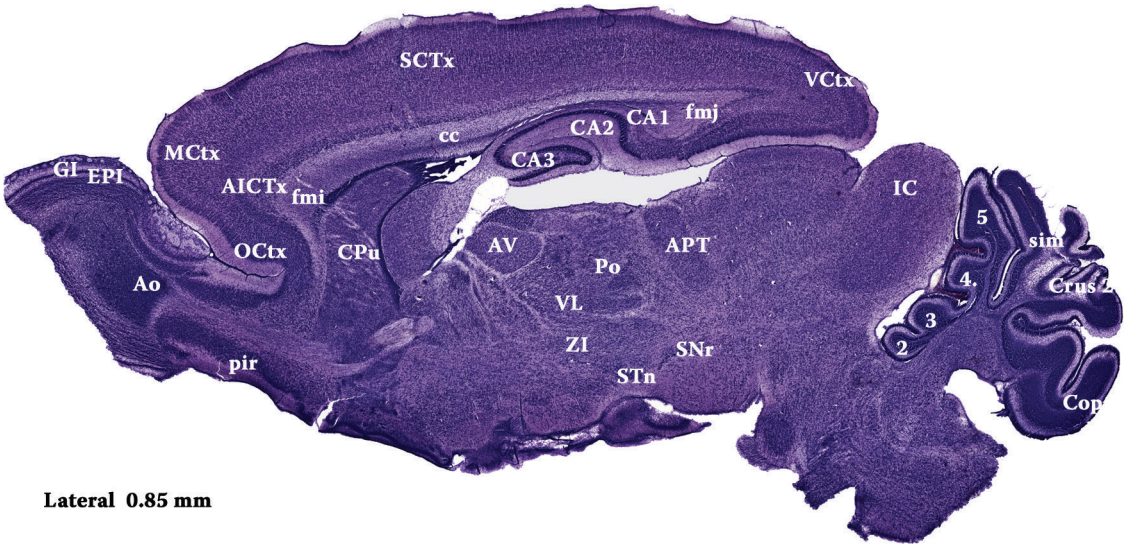

Figure 141
P-14, S5
2 through 6 = Cerebellar lobules
AICtx = Agranular insular cortex
AO = Anterior olfactory bulb
APT = Anteriorpretectal nucleus
AV = Anteroventral thalamus
CA1 = CA1 field of hippocampus
CA2 = CA2 field of hippocampus
CA3 = CA3 field of hippocampus
cc = Corpus callosum
CgCtx = Cingulate cortex
Cop = Copula of pyramis
CPu = Caudate putamen
Crus2 = Crus2 of ansiform lobule
EPI = External plexiform layer, olfactory bulb
fmi = Forceps minor of corpus callosum
fmj = Forceps major of corpus callosum
GI = Glomerular layer, olfactory bulb
IC = Inferior colliculus
MCtx = Motor cortex
OCtx = Orbital cortex
Pir = Piriform cortex
Po = Posterior thalamic nucleus group
SCtx = Somatosensory cortex
sim = Simple lobule
SNr = Substantia nigra reticulata
STn = Subthalamic nucleus
VCtx = Visual cortex
VL = Ventrolateral thalamic nucleus
ZI = Zona incerta

© 2011 by Taylor and Francis Group, LLC

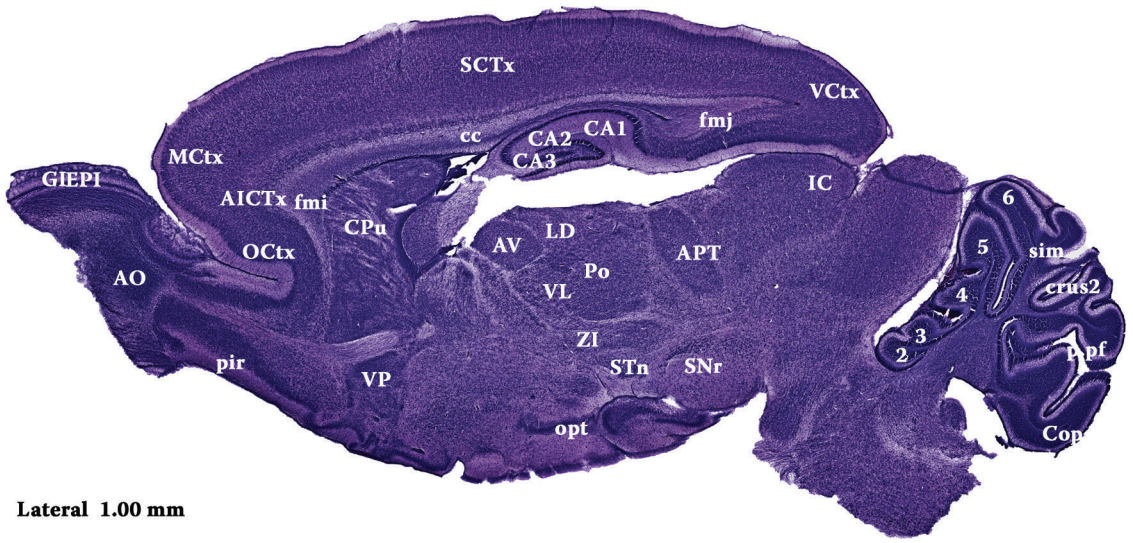

Figure 142
P-14, S6

2 through 6 = Cerebellar lobules
AICtx = Agranular insular cortex
AO = Anterior olfactory bulb
APT = Anteriorpretectal nucleus
AV = Anteroventral thalamus
CA1 = CA1 field of hippocampus
CA2 = CA2 field of hippocampus
CA3 = CA3 field of hippocampus
cc = Corpus callosum
CgCtx = Cingulate cortex
Cop = Copula of pyramis
CPu = Caudate putamen
Crus2 = Crus2 of ansiform lobule
EPI = External plexiform layer, olfactory bulb
fmi = Forceps minor of corpus callosum
fmj = Forceps major of corpus callosum
GI = Glomerular layer olfactory bulb
IC = Inferior colliculus
LD = Laterodorsal thalamus
MCtx = Motor cortex
OCtx = Orbital cortex
opt = Optic tract
Pir = Piriform cortex
Po = Posterior thalamic nucleus group
SCtx = Somatosensory cortex
sim = Simple lobule
SNr = Substantia nigra reticulata
STn = Subthalamic nucleus
VCtx = Visual cortex
VL = Ventrolateral thalamic nucleus
VM = Ventromedial thalamus
VP = Ventral pallidum
ZI = Zona incerta

© 2011 by Taylor and Francis Group, LLC

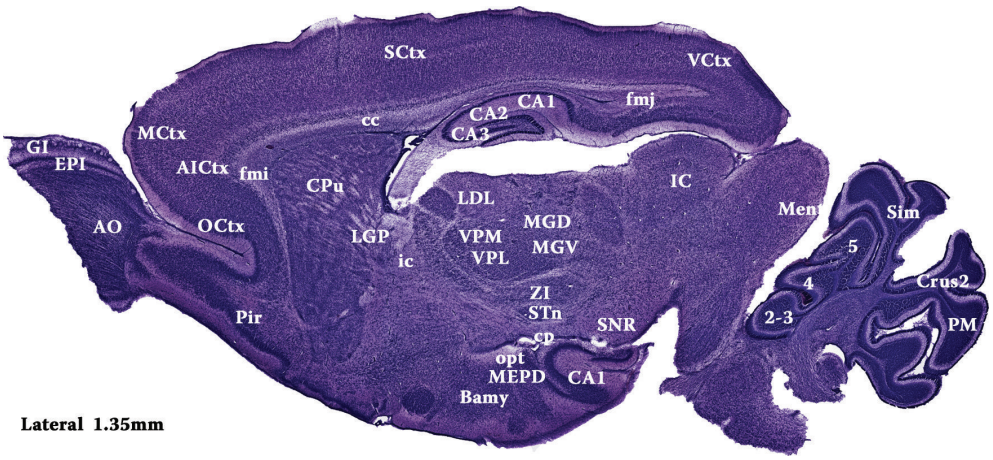

Figure 143
P-14, S7

2 through 5 = Cerebellar lobules
AICtx = Agranular insular cortex
AO = Anterior olfactory bulb
Bamy = Basal amygdala
CA1 = CA1 field of hippocampus
CA2 = CA2 field of hippocampus
CA3 = CA3 field of hippocampus
cc = Corpus callosum
cp = Caudate peduncle
CPu = Caudate putamen
Crus2 = Crus1 of ansiform lobule
EPI = External plexiform layer, olfactory bulb
fmi = Forceps minor of corpus callosum
fmj = Forceps major of corpus callosum
GI = Glomerular layer, olfactory bulb
IC = Inferior colliculus
Ic = Internal capsule
LD = Laterodorsal thalamic nucleus
LGP = Lateral globus pallidus
MCtx = Motor cortex
MEnt = Medial entorhinal cortex
MEPD = Medial amygdala nucleus
MGD = Medial geniculate nucleus, dorsal
MGV = Medial geniculate nucleus, ventral
OCtx = Orbital cortex
opt = Optic tract
Pir = Piriform cortex
SCtx = Somatosensory cortex
Sim = Simple lobule
SNr = Substantia nigra reticulata
STn = Subthalamic nucleus
VCtx = Visual cortex
VPM = Ventroposteromedial thalamic nucleus
VPL = ventroposterolateral thalamic nucleus
VM = Ventromedial thalamus
ZI = Zona incerta

© 2011 by Taylor and Francis Group, LLC

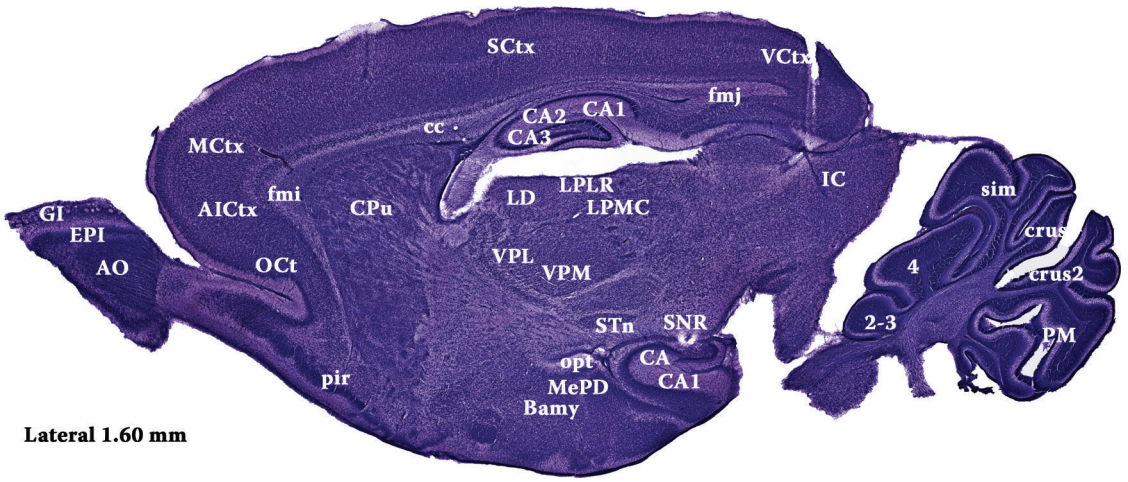

Figure 144

P-14, S8
2 through 4 = Cerebellar lobules
AICtx = Agranular insular cortex
AO = Anterior olfactory bulb
Bamy = Basal amygdala
CA1 = CA1 field of hippocampus
CA2 = CA2 field of hippocampus
CA3 = CA3 field of hippocampus
cc = Corpus callosum
CPu = Caudate putamen
Crus1 = Crus1 of ansiform lobule
Crus2 = Crus2 of ansiform lobule
EPI = External plexiform layer, olfactory bulb
fmi = Forceps minor of corpus callosum
fmj = Forceps major of corpus callosum
GI = Glomerular layer, olfactory bulb
IC = Inferior colliculus
LDVL = Laterodorsal thalamic nucleus
LGP = Lateral globus pallidus
LPLR = Lateroposterior thalamic nucleus
LPM = Lateroposteromedial thalamic nucleus
MCtx = Motor cortex
MEPD = Medial amygdala nucleus
OCtx = Orbital cortex
opt = Optic tract
Pir = Piriform cortex
PM = Paramedian lobule
SCtx = Somatosensory cortex
Sim = Simple lobule
SNr = Substantia nigra reticulata
STn = Subthalamic nucleus
VCtx = Visual cortex
VPM = Ventroposterimedial thalamic nucleus
VPL = Ventroposterolateral thalamic nucleus
ZI = Zona incerta

© 2011 by Taylor and Francis Group, LLC

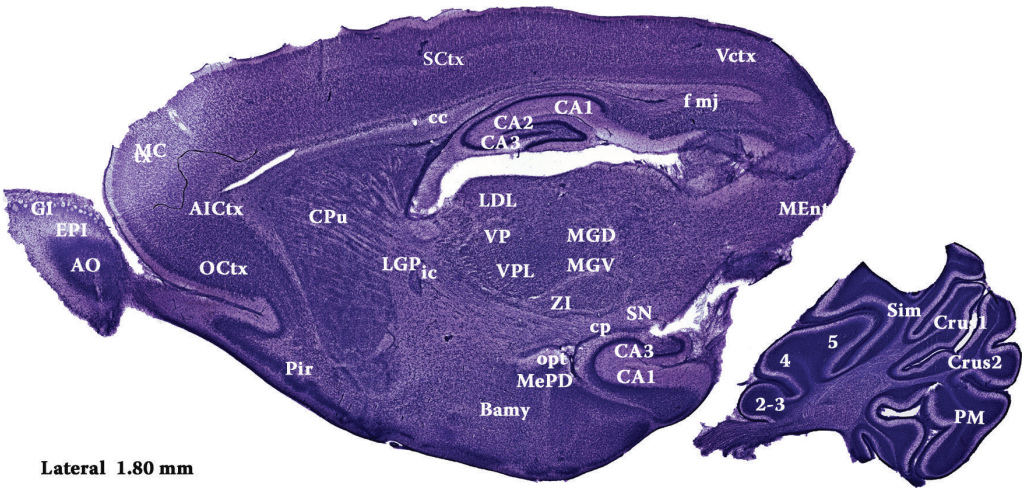

Figure 145
P-14, S9
2 through 5 = Cerebellar lobules
AICtx = Agranular insular cortex
AO = Anterior olfactory bulb
Bamy = Basal amygdala
CA1 = CA1 field of hippocampus
CA2 = CA2 field of hippocampus
CA3 = CA3 field of hippocampus
cc = Corpus callosum
cp = Caudate peduncle
CPu = Caudate putamen
Crus1 = Crus1 of ansiform lobule
Crus2 = Crus2 of ansiform lobule
EPI = External plexiform layer, olfactory bulb
fmi = Forceps minor of corpus callosum
fmj = Forceps major of corpus callosum
GI = Glomerular layer, olfactory bulb
IC = Inferior colliculus
Ic = Internal capsule
LDL = Laterodorsal thalamic nucleus
LGP = Lateral globus pallidus
MCtx = Motor cortex
MEnt = Medial entorhinal cortex
MEPD = Medial amygdala nucleus
MGD = Medial geniculate nucleus, dorsal
MGV = Medial geniculate nucleus, ventral
OCtx = Orbital cortex
opt = Optic tract
Pir = Piriform cortex
PM = Paramedian lobule
SCtx = Somatosensory cortex
Sim = Simple lobule
SN = Substantia nigra
VCtx = Visual cortex
VPL = Ventroposterolateral thalamic nucleus
VPM = Ventroposteromedial thalamic nucleus
ZI = Zona incerta

© 2011 by Taylor and Francis Group, LLC

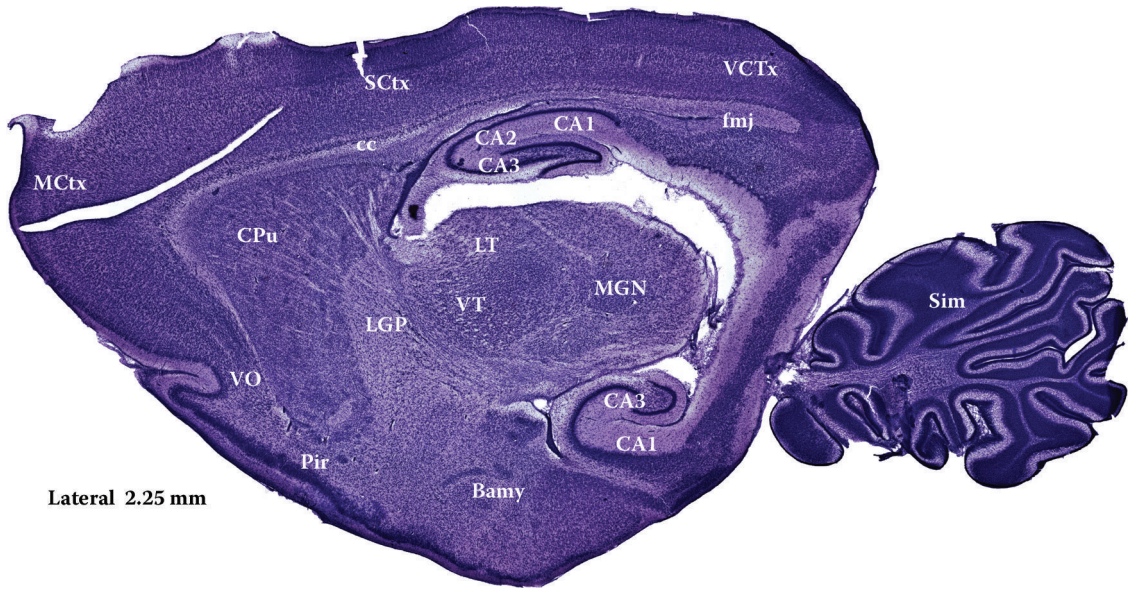

Figure 146
P-14, S10
Bamy = Basal amygdala
CA1 = CA1 field of hippocampus
CA2 = CA2 field of hippocampus
CA3 = CA3 field of hippocampus
cc = Corpus callosum
CPu = Caudate putamen
fmj = Forceps major of corpus callosum
LT = Lateral thalamus
LGP = Lateral globus pallidus
MCtx = Motor cortex
MGN = Medial geniculate nucleus
Pir = Piriform cortex
SCtx = Somatosensory cortex
Sim = Simple lobule
VCtx = Visual cortex
VO = Ventral orbital cortex
VT = Ventral thalamus

© 2011 by Taylor and Francis Group, LLC

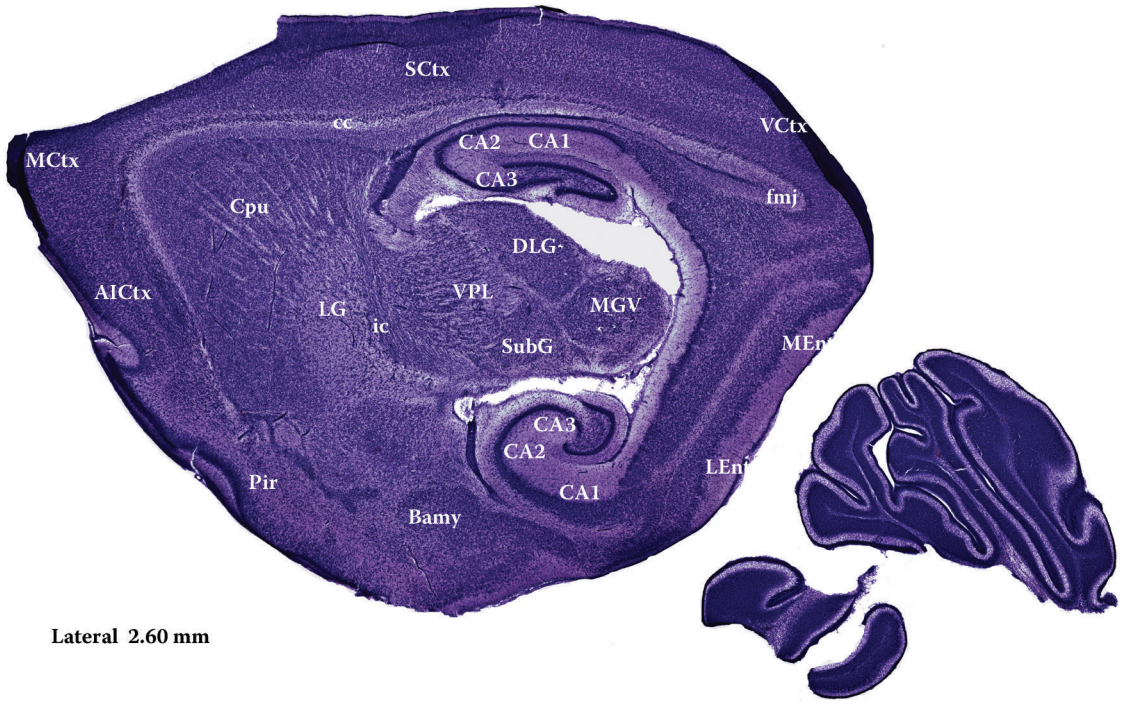

Figure 147
P-14, S11

AICtx = Agranular insular cortex
Bamy = Basal amygdala
CA1 = CA1 field of hippocampus
CA2 = CA2 field of hippocampus
CA3 = CA3 field of hippocampus
cc = Corpus callosum
CPu = Caudate putamen
DLG = Dorsolateral geniculate nucleus
fmj = Forceps major of corpus callosum
Ic = Internal capsule
Lent = Lateral entorhinal cortex
LGP = Lateral globus pallidus
MCtx = Motor cortex
MEnt = Medial entorhinal cortex
MGV = Medial geniculate nucleus
Pir = Piriform cortex
SCtx = Somatosensory cortex
SubG = Subgeniculate nucleus
VCtx = Visual cortex
VPL = Ventroposterolateral thalamic nucleus

© 2011 by Taylor and Francis Group, LLC

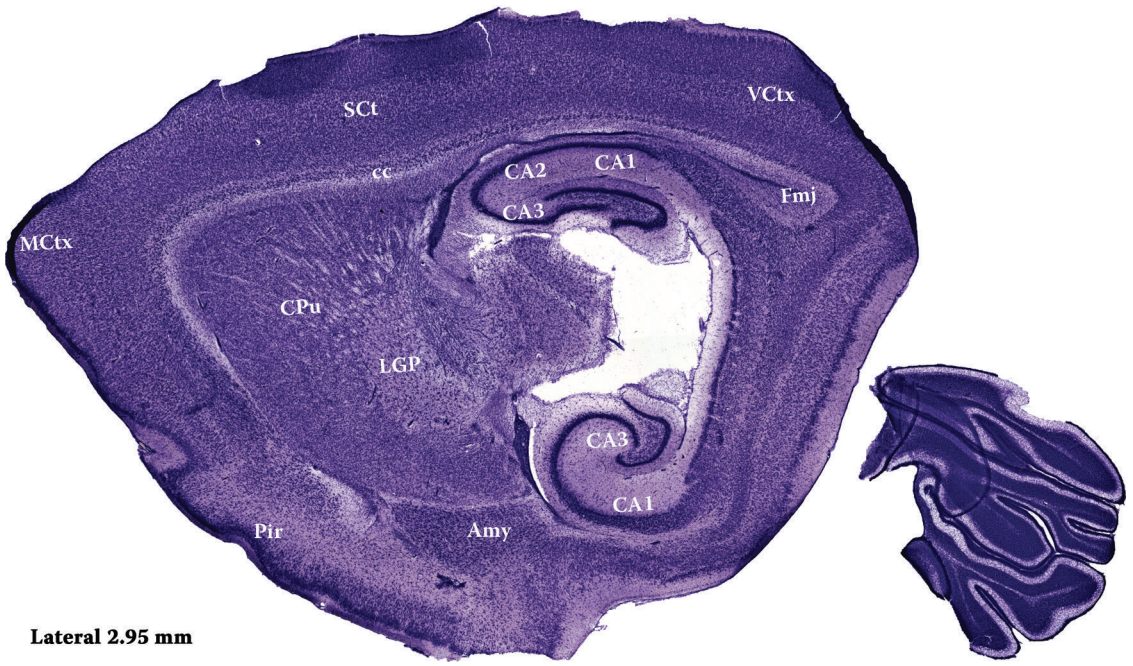

Figure 148
P-14, S12
AICtx = Agranular insular cortex
amy = Amygdala
CA1 = CA1 field of hippocampus
CA2 = CA2 field of hippocampus
CA3 = CA3 field of hippocampus
cc = Corpus callosum
CPu = Caudate putamen
fmj = Forceps major of corpus callosum
MCtx = Motor cortex
Pir = Piriform cortex
SCtx = Somatosensory cortex
VCtx = Visual cortex

© 2011 by Taylor and Francis Group, LLC

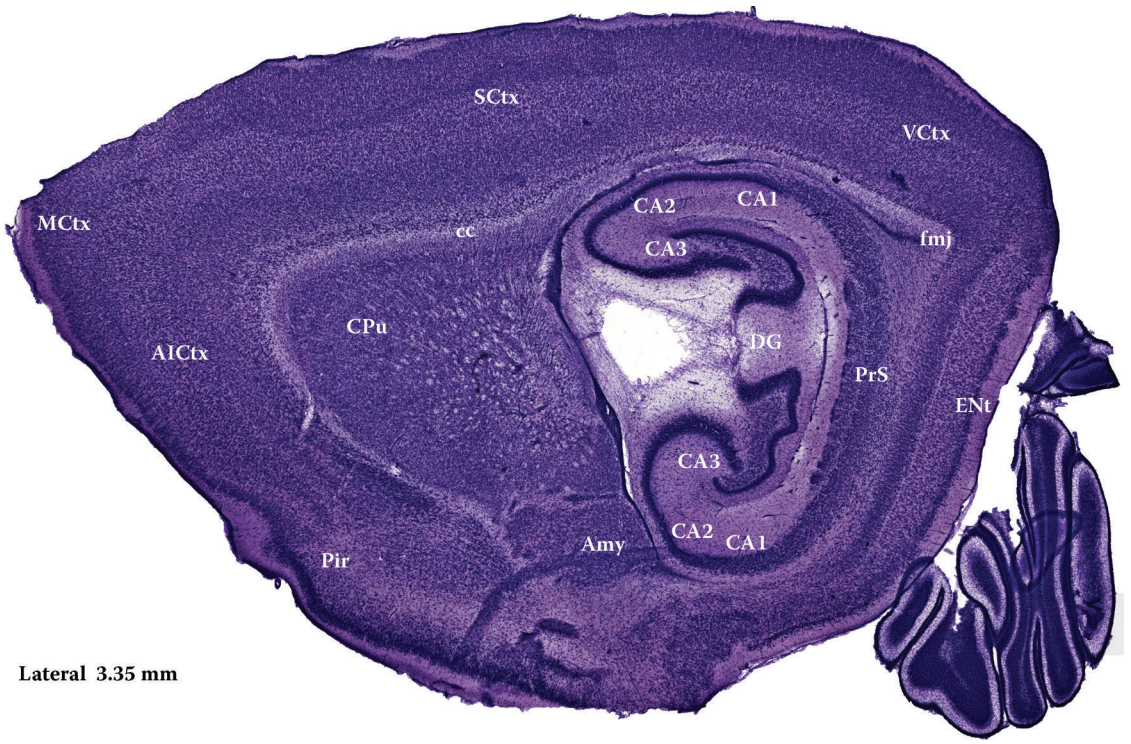

Figure 149
P-14, S13

AICtx = Agranular insular cortex
amy = Amygdala
CA1 = CA1 field of hippocampus
CA2 = CA2 field of hippocampus
CA3 = CA3 field of hippocampus
cc = Corpus callosum
CPu = Caudate putamen
DG = Dentate gyrus
Ent = Entorhinal cortex
fmj = Forceps major of corpus callosum
MCtx = Motor cortex
Pir = Piriform cortex
PrS = Presubiculum
SCtx = Somatosensory cortex
VCtx = Visual cortex

© 2011 by Taylor and Francis Group, LLC

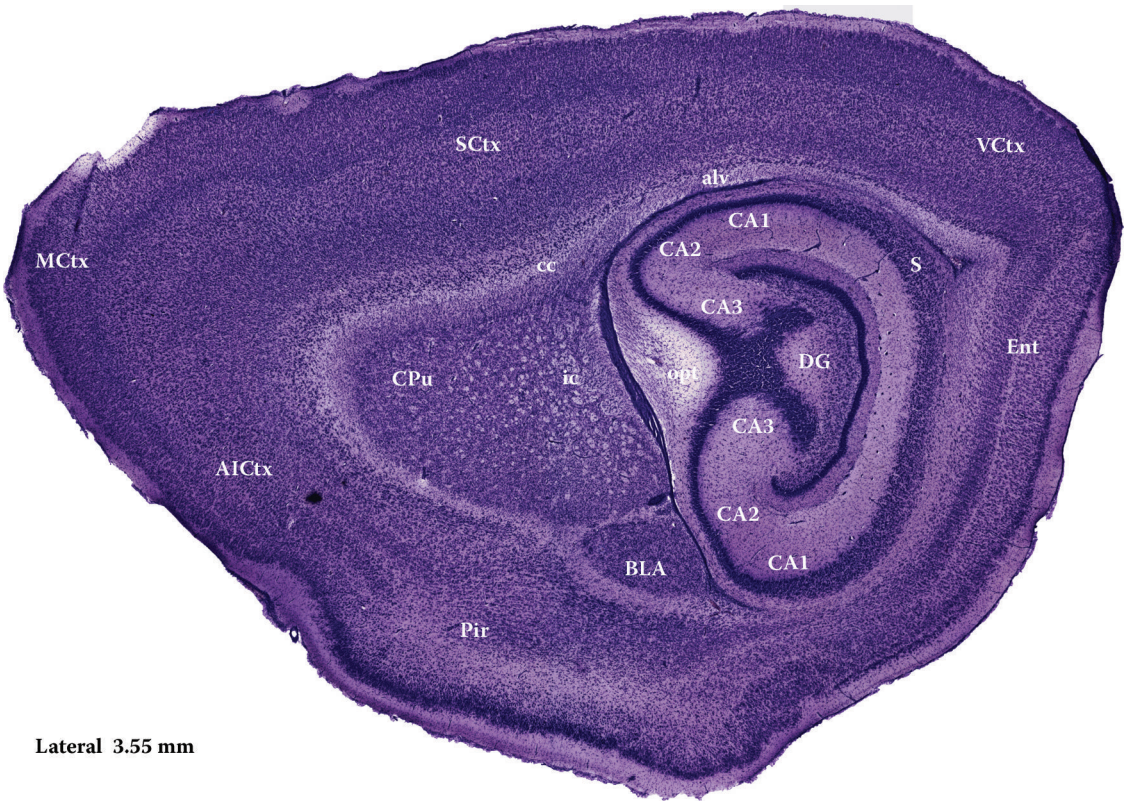

Figure 150
P-14, S14

AICtx = Agranular insular cortex
alv = Alveus of hippocampus
BLA = Basolateral amygdala
CA1 = CA1 field of hippocampus
CA2 = CA2 field of hippocampus
CA3 = CA3 field of hippocampus
cc = Corpus callosum
CPu = Caudate putamen
DG = Dentate gyrus
Ent = Entorhinal cortex
MCtx = Motor cortex
opt = Optic tract
Pir = Piriform cortex
S = Subiculum
SCtx = Somatosensory cortex
VCtx = Visual cortex

© 2011 by Taylor and Francis Group, LLC

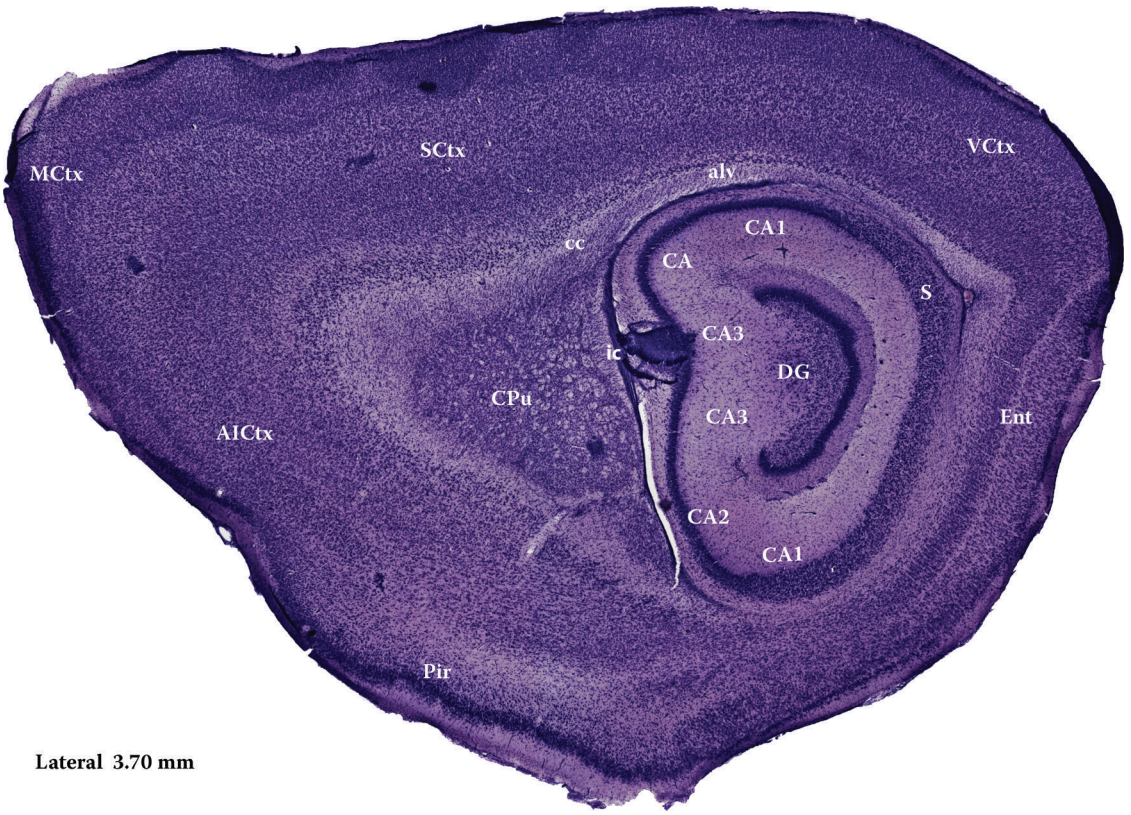

Figure 151
P-14, S15

AICtx = Agranular insular cortex
alv = Alveus of hippocampus
CA1 = CA1 field of hippocampus
CA2 = CA2 field of hippocampus
CA3 = CA3 field of hippocampus
cc = Corpus callosum
CPu = Caudate putamen
DG = Dentate gyrus
Ent = Entorhinal cortex
MCtx = Motor cortex
Pir = Piriform cortex
S = Subiculum
SCtx = Somatosensory cortex
VCtx = Visual cortex

© 2011 by Taylor and Francis Group, LLC

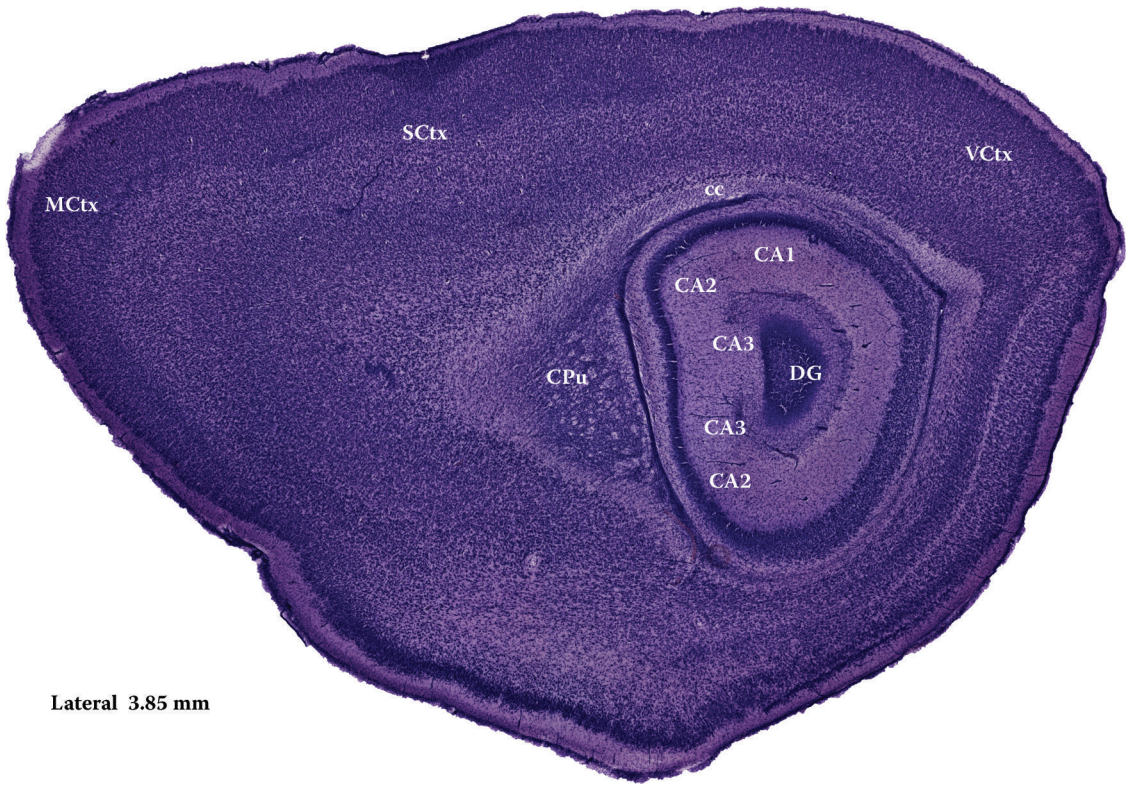

Figure 152
P-14, S16
CA1 = CA1 field of hippocampus
CA2 = CA2 field of hippocampus
CA3 = CA3 field of hippocampus
cc = Corpus callosum
CPu = Caudate putamen
DG = Dentate gyrus
MCtx = Motor cortex
SCtx = Somatosensory cortex
VCtx = Visual cortex

© 2011 by Taylor and Francis Group, LLC

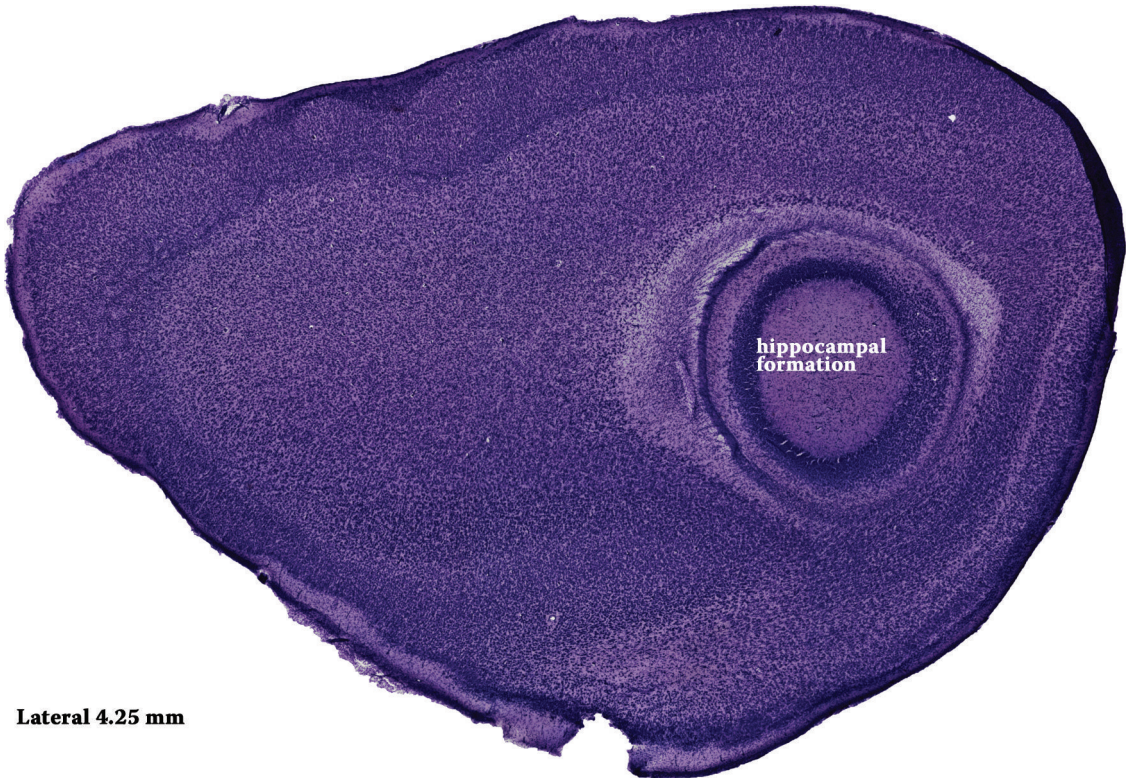

Figure 153
P-14, S17
Hfor = Hippocampal formation

© 2011 by Taylor and Francis Group, LLC

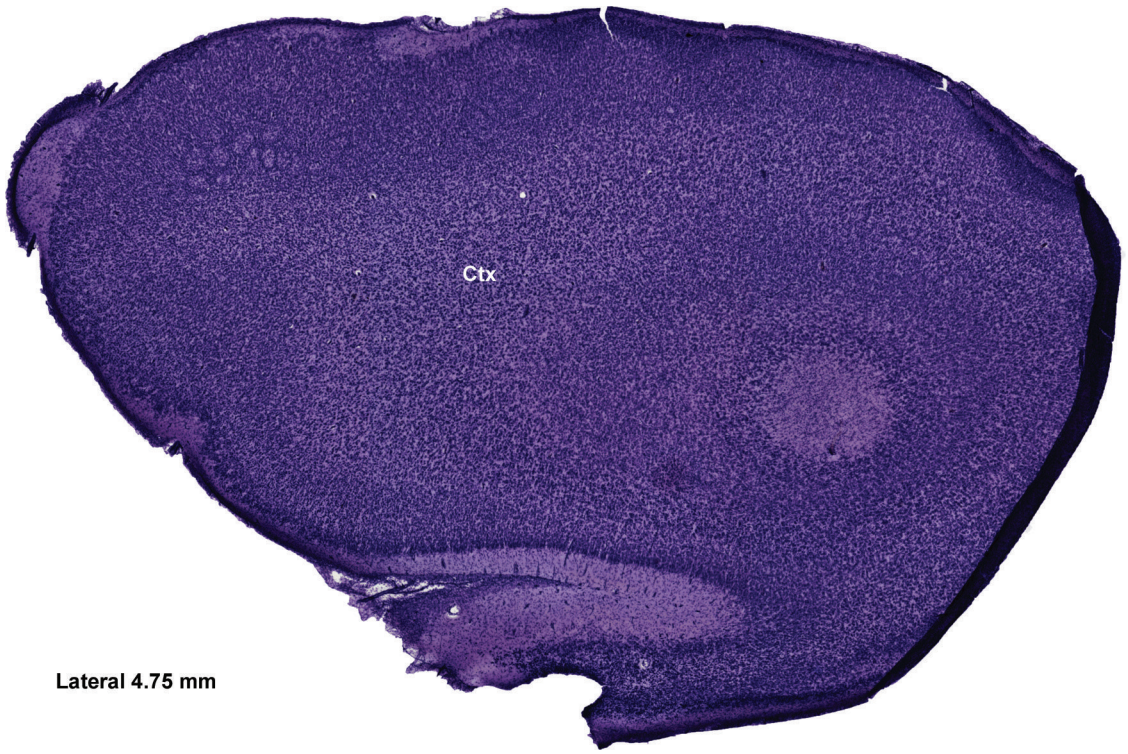

Figure 154
P-14, S18
Ctx = Cortex

© 2011 by Taylor and Francis Group, LLC



Figure 155
P-14, S19
Ctx = Cortex

© 2011 by Taylor and Francis Group, LLC

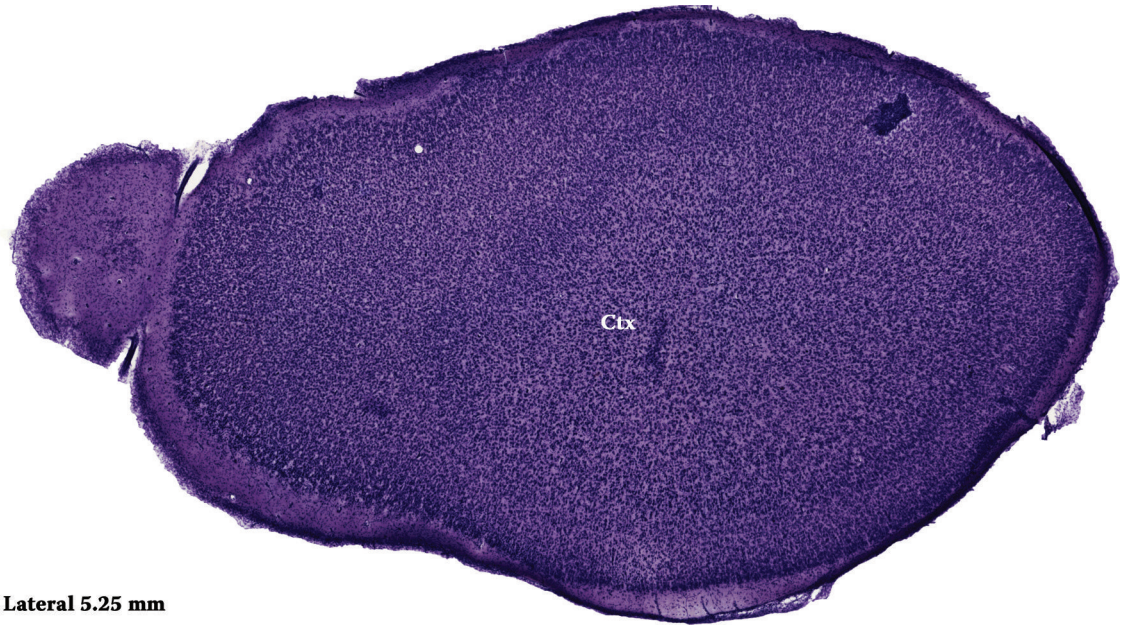

Figure 156
P-14, S20
Ctx = Cortex

© 2011 by Taylor and Francis Group, LLC

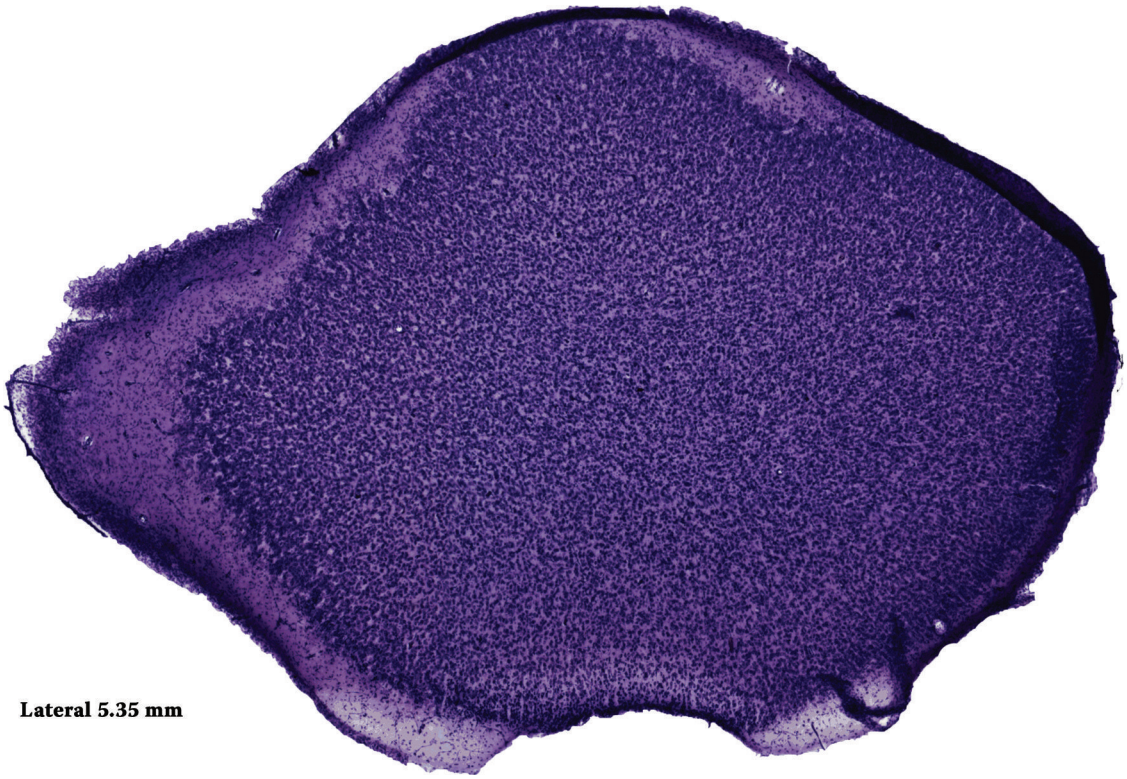

Figure 157

© 2011 by Taylor and Francis Group, LLC