


Prasad P. Godbole  
*Editor*

# Pediatric Endourology Techniques



# Pediatric Endourology Techniques

---

Prasad P. Godbole (Ed.)

---

# **Pediatric Endourology Techniques**

Prasad P. Godbole, FRCS, FRCS(Paeds)  
Consultant Paediatric Urologist  
Department of Paediatric Surgery and Urology  
Sheffield Children's NHS Trust  
Sheffield  
UK

British Library Cataloguing in Publication Data

Pediatric endourology techniques

1. Pediatric urology 2. Endourology 3. Laparoscopy 4. Genitourinary organs – Endoscopic surgery  
I. Godbole, Prasad  
618.9'2607545

ISBN-13: 9781846283864

ISBN-10: 1846283868

Library of Congress Control Number: 2006925623

ISBN-10: 1-84628-386-8 e-ISBN 1-84628-457-0 Printed on acid-free paper

ISBN-13: 978-1-84628-386-4

© Springer-Verlag London Limited 2007

The DVD accompanying this book and all material contained on it is supplied without any warranty of any kind. The publisher accepts no liability for personal injury incurred through use or misuse of the disk.

Apart from any fair dealing for the purposes of research or private study, or criticism or review, as permitted under the Copyright, Designs and Patents Act 1988, this publication may only be reproduced, stored or transmitted, in any form or by any means, with the prior permission in writing of the publishers, or in the case of reprographic reproduction in accordance with the terms of licences issued by the Copyright Licensing Agency. Enquiries concerning reproduction outside those terms should be sent to the publishers.

The use of registered names, trademarks, etc. in this publication does not imply, even in the absence of a specific statement, that such names are exempt from the relevant laws and regulations and therefore free for general use.

Product liability: The publisher can give no guarantee for information about drug dosage and application thereof contained in this book. In every individual case the respective user must check its accuracy by consulting other pharmaceutical literature.

9 8 7 6 5 4 3 2 1

Springer Sciencet+Business Media

springer.com

# Foreword

I am honored to provide a foreword to this important text. A decade or two ago, a textbook with this title would have contained a chapter about cystourethroscopy, perhaps one about stone management, and another about diagnostic laparoscopy for the undescended testis. Scanning the contents for this textbook gives the reader some idea of the creativity and courage of the editor and authors, all of whom have been pioneers in the adaptation of minimally invasive techniques in children. The chapters are arranged by system, making this a valuable and easily navigated reference work. In addition, the format of the chapters is uniform, and the detail allows adaptation of these techniques by anyone with the requisite skill.

The audience for a book like this should extend well beyond those with interest and experience in minimally invasive surgical techniques. At this stage in the evolution of pediatric urology, all practitioners should have an understanding of the full range of surgical options available to the children we serve. Once a curiosity or novelty, minimally invasive surgery has proven to be the gold standard for nephrectomy, management of nonpalpable testes, and management of renal and ureteral calculi. Many of the other techniques outlined in this text are likely to become standard approaches as time goes by. This impressive group of international authors, along with many others, will continue to define the forefront of pediatric urological surgery. I applaud their efforts, and look forward to the new techniques that will be revealed in future editions of this book.

Steven G. Docimo  
Professor and Director, Pediatric Urology  
The Children's Hospital of Pittsburgh  
Pittsburgh, PA, USA

# Preface

Pediatric urology has rapidly developed as a separate subspeciality in the last decade. During this time, significant advances in technology and instrumentation have meant that more procedures can be performed by the minimally invasive route. However, access to and availability of adequate training facilities and resources continues to hinder surgeons in acquiring experience and expertise in minimally invasive techniques in pediatric urology. This handbook, with its DVD, addresses these issues.

The aim of this handbook and DVD is to enable surgeons to carry out commonly performed minimally invasive pediatric urological procedures. It has been organized systematically for quick reference to each topic of interest. The chapters encompass the majority of commonly performed pediatric endourological procedures in a standardized format. A list of relevant references is given at the end of each chapter. Details of individual pediatric urological conditions are not covered, as there are several excellent texts on the subject. All the techniques demonstrated on the accompanying DVD are from the contributor's own practice. In some instances, the technique demonstrated may reflect the author's personal preference. This handbook/DVD is not only useful to pediatric urologists but also to pediatric surgeons, general surgeons, and adult urologists – that is, to any surgeon or surgeon in training who has an interest in minimally invasive surgery.

I am indebted to the outstanding panel of international contributors for their efforts and outstanding work toward the production of this handbook/DVD and for keeping to a tight deadline. I would also like to thank Eva Senior at Springer, UK, and Barbara Chernow at Chernow Editorial Services, Inc., USA, for their organization, assistance, and support for this project from conception to delivery.

And most importantly, I would like to thank my family without whose support and sacrifice I would not have been able to dedicate the time and effort required for the publication of this innovative venture.

Prasad P. Godbole

# Contents

## Section A: Laparoscopy

### Basic Principles

- 1 Laparoscopy in Children: Basic Principles ..... 3  
*Sean S. Marven and Prasad P. Godbole*

### Kidney

- 2 Nephrectomy and Heminephrectomy ..... 13  
*Imran Mushtaq*
- 3 Laparoscopic Pyeloplasty ..... 19  
*Pedro-José López, Patrick G. Duffy, and Imran Mushtaq*
- 4 Transposition of Lower Pole Vessels, “The Vascular Hitch” ..... 24  
*Prasad P. Godbole and Patrick G. Duffy*

### Adrenal Gland

- 5 Laparoscopic Adrenalectomy ..... 31  
*Imran Mushtaq*

### Bladder

- 6 Transvesicoscopic Cohen Ureteric Reimplantation for Vesico-Ureteral  
Reflux in Children ..... 39  
*Jean-Stéphane Valla*

### Genitalia

- 7 Impalpable Testis ..... 49  
*Mohan S. Gundeti and Duncan T. Wilcox*
- 8 Varicocelectomy (I) ..... 54  
*Job K. Chacko, Al Baha Barqawi, Jesse N. Mills, and Martin A. Koyle*
- 9 Varicocelectomy (II) ..... 56  
*Chris P. Kimber*
- 10 Intersex and Laparoscopy ..... 59  
*Chris P. Kimber and John M. Hutson*

## Section B: Endoscopy

### Lower Urinary Tract Endoscopy

11 General Principles of Cystourethroscopy .....	67
<i>Linda A. Baker</i>	
12 STING for Vesicoureteral Reflux .....	77
<i>Selcuk Yucel and Linda A. Baker</i>	
13 Bladder Outlet Injection for Urinary Incontinence .....	85
<i>Selcuk Yucel and Linda A. Baker</i>	
14 Posterior Urethral Valves .....	92
<i>Divyesh Y. Desai and Peter M. Cuckow</i>	
15 Endoscopic Management of Ureterocele and Syringocele .....	95
<i>Paul F. Austin and Douglas E. Coplen</i>	

### Urinary Calculi

16 Percutaneous Nephrolithotomy and Laparoscopic Management of Urinary Tract Calculi .....	101
<i>Pedro-José López, Michael J. Kellett, and Patrick G. Duffy</i>	
17 Ureteroscopy in Children .....	106
<i>Pedro-José López and Patrick G. Duffy</i>	
18 Minimally Invasive Management of Calculi in Augmented/ Neuropathic Bladders .....	110
<i>Jesse N. Mills, Al Baha Barqawi, Job K. Chacko, and Martin A. Koyle</i>	

## Section C: Miscellaneous

### Fecal Incontinence

19 Laparoscopic Assisted ACE Procedure for Fecal Incontinence in Children (I) .....	115
<i>Dominic Frimberger and Jeffrey B. Campbell</i>	
20 Laparoscopic Assisted ACE Procedure for Fecal Incontinence in Children (II) .....	120
<i>Prasad P. Godbole and Julian P. Roberts</i>	

### Robotics

21 Robotics and Pediatric Urology: Robotically Assisted Pyeloplasty in Children .....	125
<i>Craig A. Peters</i>	

Index .....	130
-------------	-----



# Contributors

*Paul F. Austin, MD, FAAP*  
Division of Urologic Surgery  
Washington University in St. Louis  
St. Louis Children's Hospital  
St. Louis, MO, USA

*Linda A. Baker, MD*  
Department of Urology  
University of Texas Southwestern Medical  
Center at Dallas  
Dallas, TX, USA

*Al Baha Barqawi, MB*  
Section of Urological Oncology  
The University of Colorado at Denver  
and Health Sciences Center  
Denver, CO, USA

*Jeffrey B. Campbell, MD*  
Department of Urology,  
Section of Pediatric Urology,  
University of Oklahoma  
Oklahoma City, OK, USA

*Job K. Chacko, MD*  
Division of Urology  
Department of Surgery  
The University of Colorado at Denver and  
Health Sciences Center  
Denver, CO, USA

*Douglas E. Coplen, MD, FAAP*  
Division of Urologic Surgery  
Washington University in St. Louis  
St. Louis Children's Hospital  
St. Louis, MO, USA

*Peter M. Cuckow, FRCS*  
Paediatric Urology and Urodynamics Unit  
Great Ormond Street Hospital for Children NHS  
Trust  
London, UK

*Divyesh Y. Desai, MBBS, MS, MCh(Urol)*  
Paediatric Urology and Urodynamics Unit  
Great Ormond Street Hospital for Children NHS  
Trust  
London, UK

*Patrick G. Duffy, MB, BChir, FRCS*  
Department of Paediatric Urology  
Great Ormond Street Hospital for Children NHS  
Trust  
London, UK

*Dominic Frimberger, MD*  
The University of Oklahoma Health  
Sciences Center  
Department of Urology,  
Section of Pediatric Urology  
Oklahoma City, OK, USA

*Prasad P. Godbole, FRCS, FRCS(Paeds)*  
Department of Paediatric Surgery  
and Urology  
Sheffield Children's NHS Trust  
Sheffield, UK

*Mohan S. Gundeti, MD*  
Department of Paediatric Urology  
Great Ormond Street Hospital for Children NHS  
Trust  
London, UK

*John M. Hutson, MD, FRACS, FAAP*  
 Department of General Surgery  
 Royal Children's Hospital  
 Parkville, Victoria, Australia

*Michael J. Kellet, MB, BChir, FRCR*  
 Department of Radiology  
 Great Ormond Street Hospital for Children NHS  
 Trust  
 London, UK

*Chris P. Kimber, MB, BS, FRACS, FRCS (Edin)*  
 Paediatric Surgery and Paediatric Urology  
 Southern Health  
 Monash Medical Centre  
 Melbourne, Victoria Australia

*Martin A. Koyle, MD, FAAP, FACS*  
 Division of Urology  
 The University of Colorado at Denver and  
 Health Sciences Center  
 Department of Pediatric Urology  
 The Children's Hospital  
 Denver, CO, USA

*Pedro-José López, MD*  
 Department of Paediatric Urology  
 Great Ormond Street Hospital for Children NHS  
 Trust  
 London, UK

*Sean S. Marven, FRCS*  
 Paediatric Surgical Unit  
 Sheffield Children's NHS Trust  
 Sheffield, UK

*Jesse N. Mills, MD*  
 Division of Urology  
 Department of Surgery  
 The Children's Hospital  
 The University of Colorado at Denver and  
 Health Sciences Center  
 Denver, CO, USA

*Imran Mushtaq, MBChB, FRCS, MD*  
 Department of Paediatric Urology  
 Great Ormond Street Hospital for Children NHS  
 Trust  
 London, UK

*Craig A. Peters, MD, FACS, FAAP*  
 Department of Urology  
 University of Virginia  
 Charlottesville, VA, USA

*Julian P. Roberts, BM, MS, FRCS*  
 Paediatric Surgical Unit  
 Sheffield Children's NHS Trust  
 Sheffield, UK

*Jean-Stéphane Valla, MD*  
 Department of Paediatric Surgery  
 Lenval Foundation  
 Nice, France

*Duncan T. Wilcox, MBBS, BSC, MD, FRCS*  
 Division of Pediatric Urology  
 Children's Medical Center  
 Dallas, TX, USA

*Selcuk Yucel, MD*  
 Children's Medical Center at Dallas  
 University of Texas Southwestern Medical  
 Center at Dallas  
 Dallas, TX, USA

# **Section A**

## **Laparoscopy**

### **Basic Principles**

# 1

## Laparoscopy in Children: Basic Principles

Sean S. Marven and Prasad P. Godbole

Minimal access surgery (MAS) in children is advancing, and the use of a video endoscope has entered all the surgical disciplines for children. Refinements of instrumentation have empowered surgeons, so that size and weight are no longer considered contraindications to an MAS approach. The pioneering era has passed, and virtually all procedures that could possibly be performed by an MAS technique in children have been accomplished. Further refinements will make the majority of these procedures the gold standard, but much work remains to be done and the evidence base needs consolidating.

### Preparation

In a minimally invasive procedure, the stomach and urinary bladder may need to be emptied following induction of anesthesia, but this is not routine. If the colon is loaded, administration of an enema might be considered preoperatively. Careful attention should be given to the preoperative preparation of the umbilicus, from which the cleaning of debris is important. Routine prophylactic antibiotics are unnecessary to cover the access component but may be indicated for the procedure.

Individual judgment should be applied to instances of preexisting coagulopathy or cardiorespiratory compromise that might be exacerbated by the pneumoperitoneum.<sup>1</sup> Previous extensive intraabdominal surgery, anterior abdominal wall infection, or an intraabdominal

mass require caution but are not absolute contraindications.

### Anesthesia

Nitrous oxide should be avoided as this may exacerbate gaseous intestinal distension.

### Positioning

An electronic table that allows for a variety of positions is ideal. If the legs are to be supported, all forms of leg support are potentially hazardous, so a splitting table is preferred. For securing and placing patients in a variety of positions, a vacuum “bean bag” may be useful.

### Access

Preinfiltration with long-acting local anesthetic and adrenaline of port sites is recommended. Furthermore, allowing the needle to penetrate the peritoneum or body wall helps to site secondary ports. Access for instrumentation and telescope is usually via ports. A port in its simplest form consists of a hollow tube or cannula with a cap that contains a valve to prevent gas leak but allows instruments to pass through. The solid trocar or obturator is often sharp but may be blunt. The primary port may be inserted by either a blind puncture after establishing a pneumoperitoneum

with a Veres needle or by open insertion using a minimal cut-down technique. Either is acceptable but certain principles must be adhered to (see later).

Ports for children should be of the dilating type; cutting trocars are problematic even if shielded and are associated with greater incidence of visceral injury, port site herniation, and bleeding. Increasingly secondary access by stab incisions may be successful and can avoid many of the intraprocedural problems associated with ports, such as dislodgement, gas leak, or limitation of instrument movement.<sup>2</sup>

## Approach

Approaches to the genitourinary tract using rigid telescopes and a video camera include the endoluminal or laparoscopic routes via either the transperitoneal or retroperitoneal approach; the choice depends on the procedure involved and the experience of the surgeon. The retroperitoneal approach is advantageous in avoiding ileus or injury to intraabdominal viscera, but skill is required to master the technique. Occasionally, approaches may be combined; this allows two images to be seen. Currently, most pediatric urologists with experience in laparoscopy would prefer a retroperitoneal approach, in which the patient may be in the prone, the lateral, or the supine position. Both the transperitoneal and retroperitoneal approaches are described below.<sup>3</sup>

## Transperitoneal Approach

### *Primary Port Insertion*

Primary port insertion is done by one of two methods: the Open or Hasson Technique and the Closed or Veres technique. Modifications of these techniques include a hybrid technique of limited open dissection with use of the Veres needle. A newer method of direct visualization is now available using a disposable optical trocar and standard scope that is 5 mm or 10 mm in diameter, or even a finer scope down an optical Veres needle. These may be most appropriate in the obese patient, but little experience of this method has been reported in children. Visual ports and smaller

scopes via a modified Veres needles are also available, but again experience with children is limited.<sup>4</sup>

No method has been shown to be superior, and each has its own proponents. The open insertion of the appropriately sized primary port by open placement is done under direct visualization of the fascia and peritoneum. Because the umbilicus is a natural scar and the approximate center of the abdomen, it is the usual site of the primary port for intraperitoneal procedures. Once the primary port is placed, the position should be checked with the scope before insufflation begins.

The least invasive method of open primary port insertion is the transumbilical method. In most children with a shallow umbilicus, this approach is quick, involves minimal dissection, and can easily be enlarged to accept 15 mm diameter ports without any obvious scar. Two pairs of hemostats are placed directly on the umbilical cicatrix to lift the abdominal wall gently. A no. 11 blade is used in a perpendicular plane in the longitudinal direction to create a vertical slit in the cicatrix and to enter the peritoneum. This can be confirmed by gently inserting a closed hemostat or blunt scissors.

For children with more than the average amount of subcutaneous fat or a deep umbilicus, the infraumbilical method is favored. A curved incision is made in the inferior umbilical fold and dissection carried down to the midline fascia. The linea alba is incised longitudinally at its junction with the umbilical tube. The underlying peritoneum may be cut with scissors or pierced with a hemostat. In the largest children, a pair of Littlewoods forceps are used to grasp the fascia before incising the fascia. Fascial stay sutures are sometimes placed to prevent outward displacement of the port. If used, these sutures can be secured to a Hasson port or around the tap of a simple port for insufflation. Sutures are usually unnecessary if with careful judgment the aperture is made just small enough to accept the port but still able to grip it, whether using the trans- or infraumbilical method. Inward displacement can be prevented by applying adhesive wound closure strips over the suture and around the port. Alternatively, a rubber catheter cut in small lengths can be pushed over the port; the rubber catheter is then sutured to the skin. A disposable port with an inflatable balloon

and moveable cuff is an advanced way of securing the primary port, particularly if the port is to be removed and replaced during a procedure, such as when a large amount of tissue either free or within a bag needs to be retrieved. The inflated balloon prevents outward displacement while a locking cuff prevents inward displacement but the port diameter is greater than 10 mm. A port that has a blunt obturator or trocar tip is safest, and may come as a bull-nosed or pencil-point type.

The closed method of primary port insertion depends on a Veres needle that is placed through a small incision of the infraumbilical fold just into the fascia with a no. 11 blade. A disposable needle is recommended. The Veres needle is held by thumb and forefinger down the shaft, like a dart, to allow it to just penetrate the peritoneal cavity. The entry may be associated with a double click. Its position is then ensured by the following tests.

1. The needle movement test
2. Irrigation test
3. Aspiration test
4. Hanging drop test
5. Insufflation of gas or Quadromanometric test
  - a) preset insufflation pressure
  - b) actual pressure
  - c) gas flow rate
  - d) total gas used

The pneumoperitoneum is established to a preset pressure for the procedure to the following suggested range:

newborns infants: <1 year of age, 6–8 mmHg  
children: 1–12 years of age, 8–10 mmHg;  
adolescents: 12–15 years of age, mmHg

The primary port is then inserted blind either through the same but enlarged incision or at another site. The only port that should really be used for such entry is a dilating type with Veres needle as the trocar; all other types of trocar are hazardous in the majority of children.

Once the primary port is placed the position should be checked with the scope and continuation of the insufflation.

### **Secondary Port Insertion**

Secondary ports are carefully planned based on the proposed procedure and performed under


direct visualization using the telescope. Manual elevation of the abdominal wall during trocar insertion facilitates placement and minimizes the risk of injury to the intraabdominal organs. Raising the intraabdominal pressure to as high as 30 mmHg transiently while siting secondary ports may improve safety.

Dilating ports based on a Veres needle are probably safest and, certainly, those with a sharp cutting, if retractable blade (shielded trocars), should be used with extreme caution. Other “dilating” port trocars are based on a sharp or blunt conical shape or a pyramidal cutting point with dilating shoulders, but neither of these types offer the reliable protection of a Veres needle. The pediatric peritoneum is very elastic and penetrating the peritoneum with a less than sharp or blunt trocar is sometimes problematic and even hazardous.

For many procedures, however, secondary ports may be unnecessary, and access can be gained by carefully creating stab wounds with a scalpel blade. Many surgeons use a no. 11 blade, but this can cut wider than necessary and may therefore cause bleeding or gas leak. A no. 69 blade (Swann-Morton, Sheffield, UK) on a Beaver handle (Figure 1.1) can be used to create a port hole for 2 mm instruments or by inserting the blade further it can be stretched gently to a 3 mm or 5 mm access hole without the need for a port. When the instrument is removed, gas leaks slowly. But then, as the abdominal wall begins to collapse, the layers of fascia and peritoneum begin to overlap to create a shutter valve that prevents complete deflation. This helpful phenomenon can be enhanced by placing a finger over the incision. This allows the pressure to rise, which then opens up the wound again. The light can be observed through the wound, and the instrument resited in the correct direction. Reducing the number of ports used helps to limit the invasion (e.g., single port nephrectomy).

### **Retroperitoneal Approach**

This approach may be performed with the patient in either a prone, lateral, or even supine position. The approach with the patient in the prone position is described here, as it is the preferred method of the authors.



**FIGURE 1.1.** Beaver handle with a no. 69 blade.

### **Anesthesia**

General anesthesia should be used via endotracheal intubation; muscles should be relaxed.

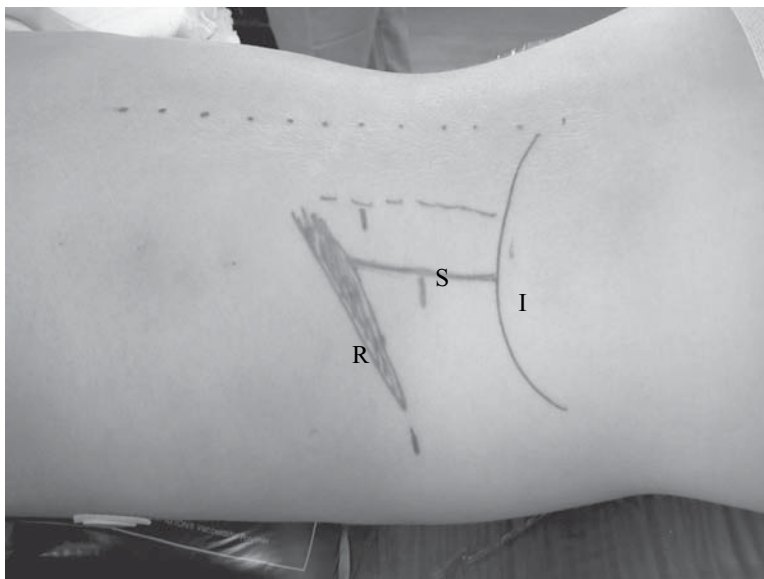
### **Patient Position**

The patient is placed in a prone position. A bolster/sandbag is placed under the pelvis and lower chest so that the renal angle is opened out. This space is bordered inferiorly by the iliac crest, medially by the lateral border of the sacrospinalis, and superiorly by the 11th and 12th ribs (Figure 1.2). Too much elevation will result in approximation of the ribs and the iliac crest, thereby reducing the working space. A useful way of ascertaining adequate support and elevation is by passing a hand below the elevated trunk. Easy passage of

the upturned palm indicates adequate positioning. The renal angle may be further opened out by slightly abducting the entire pelvis away from the affected side. Finally the patient should be positioned as shown in Figure 1.2 at the very edge of the table on the affected side to allow easy maneuverability of the instruments. The arms and legs should be well supported and padded (Figure 1.3).

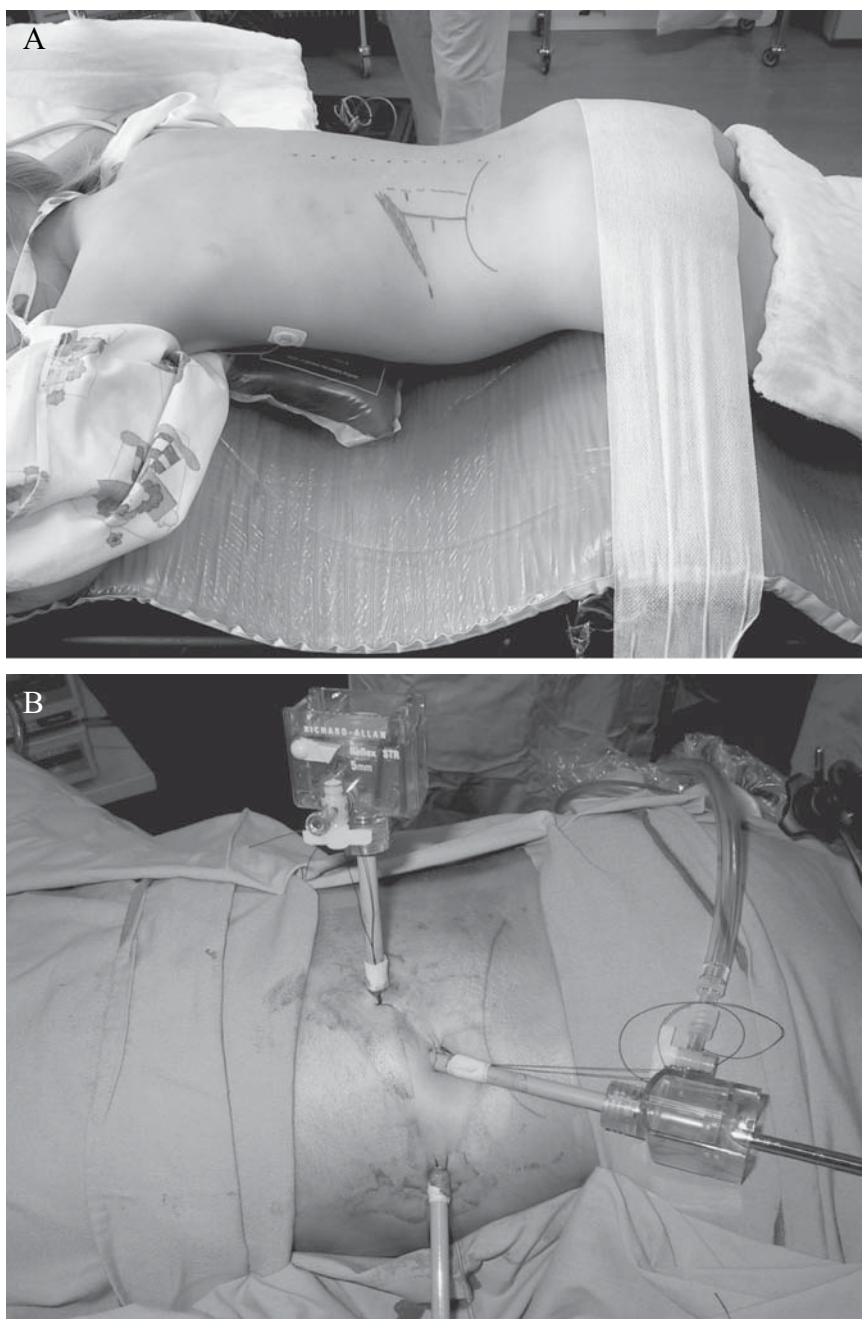
### **Access**

The primary port is inserted at the lateral border of the sacrospinalis midway between the iliac crest and the 12th rib. A 5 mm/10 mm incision, depending on the size of port, is made in the skin. A blunt artery forceps, such as a Dunhill forceps, is



**FIGURE 1.2.** Landmarks and boundaries of the renal space: ribs (R), sacrospinalis (S), and iliac crest (I).



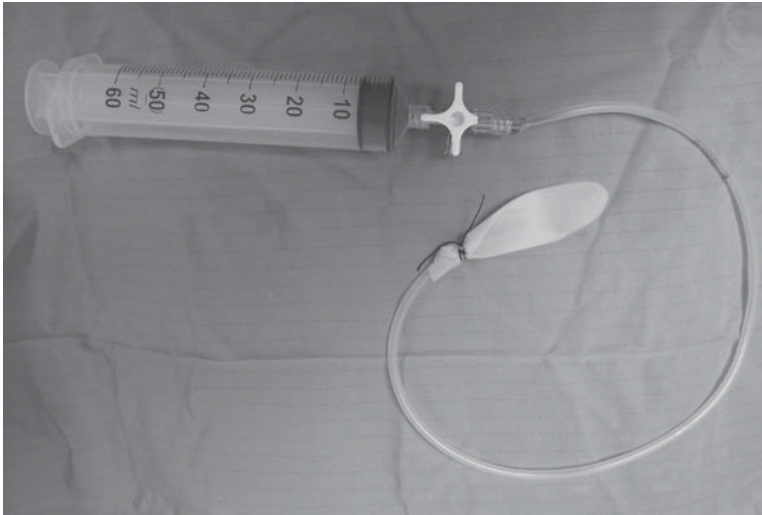


**FIGURE 1.3.** (A) Patient position for prone retroperitoneoscopic nephrectomy and (B) the ports in situ.

“walked” off the lateral border of the sacrospinalis through the dorsolumbar fascia until the perinephric area is reached. This is evidenced by a sudden give through the muscle and free move-

ment of the forceps. A ready-made balloon device or the middle finger of a 8.5 glove tied to a 12 Nelaton catheter with a three-way tap and 50ml Luer lock syringe is inserted into the perinephric



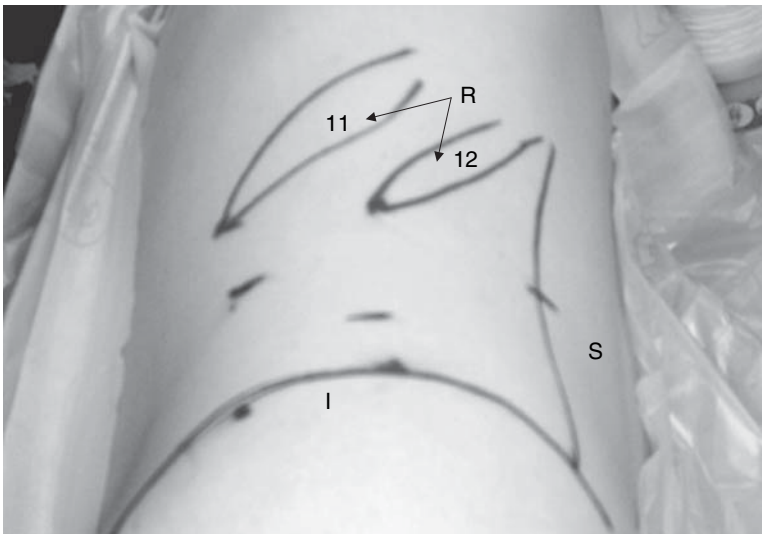


**FIGURE 1.4.** Inexpensive balloon dissector made with the middle finger of an 8.5 glove tied to a 12 Fr Nelaton catheter, a three-way tap, and a 50 ml Luer lock syringe.

space (the authors' preference) (Figure 1.4). The balloon is blown up gradually to approximately 200 ml. Too rapid inflation may result in rupture of the balloon. Alternatively, the port may be inserted and the space created using the telescope itself. Once the balloon is deflated, the balloon is removed and the port inserted. The working ports are placed just inferior to the tip of the 11th rib and, if required, a second working port is

placed under vision through the sacrospinalis muscle either in line with or superior to the primary port. The insufflation pressure is maintained at 10 mmHg to 12 mmHg at a flow rate of 1 L/min.<sup>5</sup>

In the case of a lateral approach, the landmarks remain the same but the port position changes (Figure 1.5). The primary port is inserted in a similar fashion to insertion in the prone approach.



**FIGURE 1.5.** The Patient in the right lateral position for a left nephrectomy. The sacrospinalis (S), Iliac crest (I), and ribs (R) are shown, as are the port sites.

Once the primary and working ports are inserted, the camera may be transferred to the port just above the iliac crest to get good triangulation.

## Visualization

Visualization in MAS depends on the creation and maintenance of a working space within an existing or potential body cavity, for example, creating a pneumoperitoneum in laparoscopy or a retroperitoneal space in retroperitoneoscopy. Abdominal wall lifting has not found a place in pediatric MAS. Therefore, potential retroperitoneal space is expanded initially with balloon devices and insufflation or pneumodissection performed in combination with a blunt or sharp instrument dissection. This will create an acceptable, if smaller, working space compared to the pneumoperitoneum. The initial maximum pressure limits chosen for the intraperitoneal insufflation can vary with the size of the child, but in essence the pressure should be limited to that required to achieve sufficient working space. Preparing a pneumovesicum for ureteric reimplantation will be discussed in another chapter.

Retracting adjacent organs within the working space may be desirable. If so, this is achieved by using retractor systems. Fan retractors are usually large and likely to cause injury. The most useful retractors are of the snake type, as they are flexible enough to allow insertion and then screwed tightly into a preconfigured shape. They may be used in association with a scope/instrument holding clamp that is adjustable or flexible.

## Instrumentation

In general, disposable equipment is not widely used in pediatric surgery. Note that 5 mm instruments may be useful, but the length and the precision is not always ideal for the smallest patients. Disposable instruments smaller than 5 mm have not yet been developed. Instruments that are 3 mm and 2 mm are becoming more popular, but the shaft's loss of rigidity becomes a problem. Disposable attachments for energy sources make

sense, but reusable instruments are generally the best given current developments. The ideal instrument would grasp, dissect, seal vessels, and cut tissue, while offering an ergonomically comfortable grip and a wide range of movements or degree of freedom. Because such an instrument does not exist, the selection of instruments is often a matter of personal choice. Robotic assistance may offer advantages with complex suturing procedures, but this remains largely experimental.

Five mm scopes may be suitable for neonates to adolescents, but a 10 mm scope might be helpful when visualization is difficult because of bleeding. Smaller scopes that are 2 mm and 3 mm in diameter are rarely advantageous because of the consequent reduction in light. Angled telescopes of 30 degrees or 45 degrees are ideal, as they have a distinct advantage over 0 degree scopes. They help create a view that looks down onto the tips of instruments rather than along the shaft. With practice, any disorientation from angled telescopes should diminish.

## Tissue Retrieval

Specimen retrieval in pediatric cases is occasionally complicated by the small size of the trocars employed. A 10 mm to 12 mm port will, however, accommodate most specimens. Removal of the port to retrieve tissue may be necessary. Use of a smaller laparoscope at a secondary site while the tissue is withdrawn from the largest port is a useful trick. Simply extending the port wound to the appropriate size is a reasonable maneuver, but use of a retrieval bag might make this unnecessary. Mechanical tissue morcellators are seldom used, although piecemeal removal from within a retrieval bag may be employed.

## Wound closure

Port site herniation can occur in even the smallest incisions and therefore attention should be directed to closing the fascial wound with a suture if at all possible. The umbilical site fascia and the fascia of all trocar sites are closed with absorb-

able sutures. A 5/8 curved, round-bodied needle or a J-shaped needle on 3/0 Vicryl suffices for children of all sizes. Skin closure is usually achieved using cyanoacrylate-based glue for speed and simplicity; newer preparations are quicker drying, more flexible, and create a covering that acts as a dressing. Approximation of skin edges with a subcuticular absorbable suture is still probably cheaper, but this can be tiresome to achieve. Any dressings are usually superfluous, unless there is persistent oozing, and simply cause discomfort on removal. Port site closure devices are available, but they are not widely used as the primary port can usually be closed under direct vision. Secondary ports of 2 mm to 5 mm may not require closure, although in small infants herniation of omentum has occurred in even 3 mm wounds.

## References

1. Bozkurt P, Kaya G, Yeker Y et al. The cardiorespiratory effects of laparoscopic procedures in infants. *Anesthesia* 1999;54:831–834.
2. McHoney M, Corizia L, Kiely EM et al. Carbon dioxide elimination during laparoscopy in children is age dependent. *J Pediatr Surg* 2003;38(1): 105–110.
3. Borzi PA. A comparison of the lateral and posterior retroperitoneoscopic approach for complete and partial nephroureterectomy in children. *BJU Int* 2001;87(6):517–520.
4. Humphrey GME, Najmaldin A. Modification of the Hasson technique in pediatric laparoscopy. *Br J Surg* 1994;81:1319.
5. Capolicchio JP, Jednak R, Anidjar M, Pippi-Salle JL. A modified access technique for retroperitoneoscopic renal surgery in children. *J Urol.* 2003;170(1): 204–206.

# Kidney

## 2

# Nephrectomy and Heminephrectomy

Imran Mushtaq

During the last decade, the minimally invasive approach (MAS) for the treatment of benign renal conditions has gained popularity over the traditional open approach. Nephrectomy, heminephrectomy, and nephroureterectomy have now become standard laparoscopic procedures by laparoscopy at centers where the necessary expertise is available.<sup>1,2</sup> Gaur first described the retroperitoneal approach, which is now the approach of choice for most laparoscopic surgeons,<sup>3,4</sup> but the transperitoneal route may still be employed, especially if the surgeon is relatively inexperienced. Regardless of the approach utilized, the benefits to the child in terms of a faster postoperative recovery and improved cosmesis are without question.

Refinements in techniques have now extended the role of laparoscopy in the authors' practice for managing end stage renal disease in children who require bilateral native nephrectomy. These can be performed in a synchronous fashion without breaching the peritoneum and is followed by insertion of a peritoneal dialysis catheter. Immediate postoperative peritoneal dialysis can be performed, avoiding the need for hemodialysis and its complications.

## Approach

Both the retroperitoneal and transperitoneal approaches have been well described. The surgeon should be familiar with both techniques, including their advantages and disadvantages. The retroperitoneal technique avoids colonic

mobilization, the risk of injury to hollow viscera, and the potential risk of adhesion formation. However the approach may be more difficult to master because of the reversed orientation of the kidney and hilum when the patient is in a semi-prone or prone position and the comparatively smaller working space. Another possible advantage of the retroperitoneoscopic approach is reduced postoperative pain because of the absence of peritoneal irritation by blood and/or urine.

For some procedures involving significant intracorporeal suturing or where previous surgery on the kidney has resulted in scarring/fibrosis, some surgeons may prefer the transperitoneal route. Such a case would be a patient who has had laparoscopic pyeloplasty. The transperitoneal route allows for a larger working space and facilitates intracorporeal suturing. The choice of approach will also be influenced by the surgeon's experience and training, which may result in one preferred option.

This chapter discusses only the retroperitoneoscopic approach, as this is the current technique of choice for laparoscopic nephrectomy and heminephrectomy.

## Indications and Contraindications

### Nephrectomy

A laparoscopic nephrectomy or nephroureterectomy is indicated in the following cases:

1. Congenital renal dysplasia with a poorly functioning or nonfunctioning renal unit.

2. Multicystic dysplastic kidneys, which on follow up have failed to involute or are associated with systemic hypertension.
3. Pelviureteric junction obstruction with loss of function.
4. Reflux-associated nephropathy.
5. Intractable protein loss associated with congenital nephrotic syndrome.
6. Pretransplant in children with focal segmental glomerulosclerosis.

## Heminephrectomy

A laparoscopic heminephrectomy is indicated in the following cases:

1. Renal duplication anomalies: An upper pole heminephrectomy is performed most commonly, typically in the setting of hydroureteronehrosis of the upper moiety with reduced or poor function.
2. Renal duplication in girls with ectopic insertion of upper moiety ureter with urinary incontinence and poorly functioning upper pole.
3. Lower pole heminephrectomy: A lower moiety heminephrectomy is performed in reflux-associated nephropathy with loss of function or rarely in cases of lower moiety pelviureteric junction obstruction with loss of function.

## Preoperative Workup

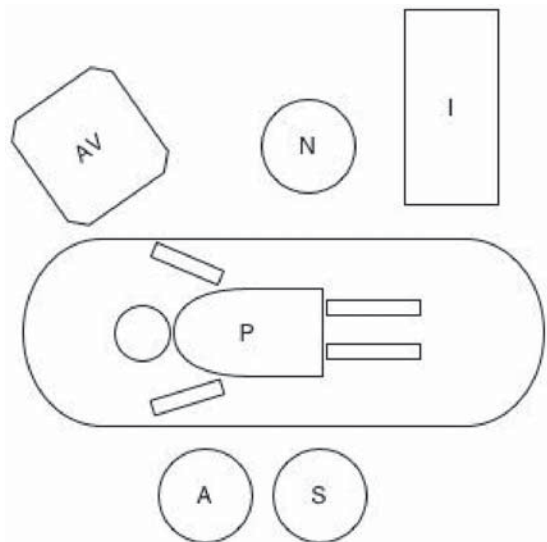
1. Recent imaging in the form of a recent renal ultrasound scan and MAG3/ DMSA scan must be available.
2. In children with a history of vesicoureteric reflux, the micturating cystogram images must also be available for review.
3. The renal ultrasound provides information about the size of the kidney, degree of hydronephrosis, and, in the case of a multicystic kidney, regarding the number and size of cysts. This allows for deciding the technique for specimen removal, that is, Endopouch, cyst aspiration, and so on.
4. Routine preoperative blood tests, which should include serum creatinine, hemoglobin level, and a group/save of serum. Clotting parameters do not need to be checked routinely, unless there is a history of bleeding disorders.
5. No other specific preoperative patient preparation is necessary.

All children receive single dose of appropriate intravenous antibiotic (the author prefers an aminoglycoside such as amikacin or gentamicin) either prior to leaving the ward or at the induction of anesthesia.

## Specific Instrumentation

1. Primary camera port: 6 mm or 10 mm Hasson, 2 secondary 5 mm ports (the author prefers 5 mm VersaStep radially dilating ports).
2. 30 degree 5 mm telescope.
3. Kelly forceps (×2) for dissection.
4. Metzanbeum scissors.
5. Harmonic scalpel for coagulation/division of vessels or 5 mm endoclips.
6. Endoloop to encircle the upper/lower moiety in a heminephrectomy.
7. Endopouch for specimen retrieval if large specimen.

The patient (P) is positioned prone for the operation. The monitor and stack system (AV) should be placed on the side opposite to the affected kidney, towards the head of the table, with the screen pointing towards the pelvis. The scrub nurse (N) should be positioned adjacent to the laparoscopic stack, with the operating surgeon (S) and assistant (A) both on the side of the affected kidney (Figure 2.1.).



**FIGURE 2.1.** Schematic representation of the room setup. P = patient, AV = audiovisual equipment, N = scrub nurse, I = instrument trolley, S = surgeon, A = camera holder.

## Anesthesia

Endotracheal intubation is required in all cases using either a cuffed or reinforced endotracheal tube, securely fastened. This is to prevent tube dislodgement when the child is positioned prone for the surgery. Preoperative and postoperative analgesia is provided by preemptive local infiltration of the planned incisions with 0.25% bupivocaine.

## Operative Technique

### Retroperitoneoscopic Nephrectomy

1. The patient is positioned fully prone under general anesthesia. Other approaches, including the lateral and anterolateral approaches, have been used by others. The exposed dorsal and lateral aspects of the trunk are prepared and draped in a sterile manner. Topographic landmarks and anticipated port sites are marked as shown. (Figures 2.1 and 2.3).

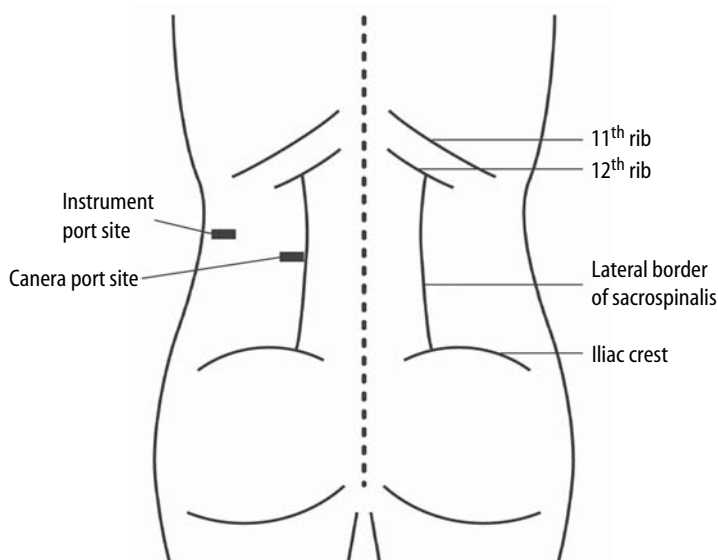
2. Retroperitoneal space is created outside Gerota's fascia by a technique described by Gill.<sup>5</sup> Several balloons are available for creation of the retroperitoneal space. The author prefers a simple and inexpensive balloon made by securing

the finger of a sterile surgical glove to the end of a 12Fr Jacques catheter with a silk tie. The catheter is connected to a three-way tap and a 50 ml Luer lock syringe. Depending on the size of the patient, 100 ml to 250 ml of air is injected slowly to develop the retroperitoneal space. The system is left inflated for two minutes to promote hemostasis, and is then deflated and withdrawn.

3. Insertion of primary and secondary ports: A 6 mm Hasson cannula is inserted into the port site, followed by insufflation of the retroperitoneum with CO<sub>2</sub> to pressure of 10 mmHg to 12 mmHg. The Hasson port is secured by a suture to the skin. A 5 mm instrument port is placed under direct vision below the tip of the 11th rib and above the iliac crest. A second working port (5 mm) can be placed through the paravertebral muscles, although in the author's experience the nephrectomy can be performed using a single working port.

4. Exposure of the kidney: Gerota's fascia is incised longitudinally adjacent to the posterior abdominal wall using scissors. The adventitious tissue is divided to gain adequate exposure and working space for the procedure.

5. Exposure of the hilum: The kidney is dissected commencing at the apex and along the medial aspect. The lateral and inferior attachments are not divided at this stage as they anchor



**FIGURE 2.2.** Schematic representation of port position.



the kidney in position and aid in exposure of the hilar vessels.

6. Division of the vascular pedicle: The vessels are divided between hemoclips or with a harmonic scalpel when the vessels are less than 3 mm in diameter. A minimum of three clips should be applied on all vessels, with at least two clips remaining on the proximal stump of the divided vessel.

7. Ureteric division: The ureter is traced as far into the pelvis as is necessary. In cases of reflux-associated nephropathy, the ureter may be ligated with an endoloop or transected without ligation and the bladder drained with a urethral catheter for 48 hours.

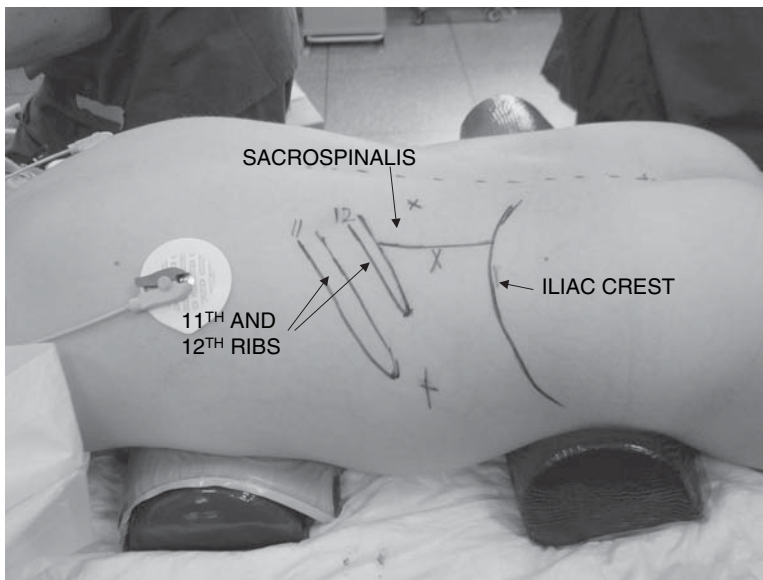
8. The remaining attachments of the kidney are divided using a combination of blunt dissection, monopolar diathermy, and/or the harmonic scalpel. In the case of a large multicystic dysplastic kidney, complete intracorporeal mobilization can be technically difficult and time-consuming and risks creating a tear in the closely attached peritoneum. In such cases, after all vessels have been divided and the cysts decompressed, the kidney can be withdrawn via the camera port incision and the remainder of the dissection completed in an extracorporeal manner.

9. Specimen retrieval: The specimen may be removed via the camera port depending on the size. A multicystic dysplastic kidney or hydronephrotic kidney may be decompressed by aspiration and withdrawn directly via the camera port wound. A larger specimen may be retrieved after engaging it in a 10 mm Endopouch retrieval device and removing it piecemeal with sponge forceps.

## Retroperitoneoscopic Heminephrectomy

The room setup, patient positioning, and the steps for surgical access are the same for a retroperitoneoscopic heminephrectomy as they are for a retroperitoneoscopic nephrectomy. In particular, the position of the patient and the port sites described in Steps 1 to 3 above are identical. This applies whether an upper or lower pole heminephrectomy is to be performed. Then, Steps 3 to 9 are as follows for the retroperitoneoscopic heminephrectomy.

3. Exposure of the kidney: The kidney is exposed as for a nephrectomy. It is essential to clearly visualize both moieties of the duplex system.



**FIGURE 2.3.** Patient position for prone retroperitoneoscopic nephrectomy/heminephrectomy.



4. Ligation of vessels: The vessels supplying the affected moiety are selectively identified and divided between clips or with a harmonic scalpel. In some cases, the polar vessels will be clearly evident, while in other cases there will be short segmental vessels originating from the main vessels close to the renal hilum. The latter scenario is seen more frequently when the affected renal moiety is small and dysplastic.

5. Isolation of the ureter: The ureter from the affected moiety is identified, as is the nonaffected ureter. The affected ureter is transected just distal to the pelviureteric junction, and this stump is used as a traction device to rotate the kidney to identify any further vessels, which are then divided.

6. The devascularized moiety will now be evident as an area of hypoperfusion. The renal capsule is scored with monopolar diathermy at the junction between the two moieties.

7. Resection of the affected moiety: The affected moiety is encircled with a 3/0 Vicryl endoloop, using the proximal end of the divided ureter as countertraction. The ligature is firmly tightened at the junction between the renal moieties. The parenchyma is transected with hook scissors 5 mm to 10 mm distal to the ligature. Any residual bleeding points are controlled with diathermy or a further endoloop suture.

8. The distal ureteric stump is traced down as far as is necessary in the pelvis, taking great care to isolate and preserve the normal ureter. The ureter is ligated when there is associated reflux prior to transaction.

9. Specimen retrieval: The specimen can be extracted directly through the camera port incision in the majority of cases. Larger specimens are extracted with the use of a 10 mm Endopouch specimen retrieval device. The wound is closed in layers, without the use of a drain.

## Postoperative Management

1. The patient can start fluids and diet on return to the ward.
2. A close eye needs to be kept on the possibility of hemorrhage.
3. As bacteremia may occur during the procedure, so oral antibiotics to cover the immediate

postoperative period may be required in some cases.

4. The patient is discharged when mobilizing with adequate control of pain with simple analgesia.

## Complications

### Peritoneal Tear

The posterior prone approach minimizes the risk of a peritoneal tear when compared with other approaches for retroperitoneoscopic surgery. A tear can occur if the dissecting balloon is inflated too rapidly or the balloon is too small for the size of the patient, as well as in adolescents and children on peritoneal dialysis.

### Balloon Rupture

Rupture of the dissecting balloon can occur when the balloon is inflated too rapidly, with overinflation of the balloon, or when excessive external pressure is applied over the balloon. When it occurs the ruptured balloon must be carefully examined for lost fragments, which should be sought and removed from the patient.

### Intraoperative Bleeding

Intraoperative bleeding is most likely the result of slipping of hemoclips from a renal vein or because of inadvertent damage to a renal vein or vena cava by a laparoscopic instrument. In most cases, hemorrhage can be controlled by the prompt application of hemoclips to the affected vessel. Uncontrollable hemorrhage will require conversion to an open approach to ligate or oversew the bleeding vessel.

### Urine Leak

A retroperitoneal urinoma can occur from the reflux of urine from the distal ureteric stump or from the cut surface of the kidney following heminephrectomy. The risk can be kept to a minimum by the use of an endoloop suture on the renal parenchyma and by endoloop ligation of refluxing

ureters as opposed to the use of hemoclips or the harmonic scalpel to seal the ureter. Most urinomas will resolve with the placement of a urethral catheter for at least 48 hours to 72 hours. A persistent urine leak or an infected urinoma may require the placement of a percutaneous wound drain.

## References

1. Harrell WB, Snow BW. Minimally invasive pediatric nephrectomy. *Curr Opin Urol* 2005;15(4):277–281.
2. Lee RS, Retik AB, Borer JG, Diamond DA, Peters CA. Pediatric retroperitoneal laparoscopic partial nephrectomy: comparison with an age matched cohort of open surgery. *J Urol* 2005;174(2):708–711.
3. Gaur DD. Laparoscopic operative retroperitoneoscopy: use of a new device. *J Urol* 1992;148(4):1137–1139.
4. Gaur DD, Agarwal DK, Purohit KC. Retroperitoneal laparoscopic nephrectomy: initial case report. *J Urol* 1993;149(1):103–105.
5. Gill IS, Munch LC, Lucas BA, Das S. Initial experience with retroperitoneoscopic nephroureterectomy: use of a double-balloon technique. *Urology* 1995;46(5):747–750.

# 3

## Laparoscopic Pyeloplasty

Pedro-José López, Patrick G. Duffy, and Imran Mushtaq

Currently the gold standard surgery for pelviureteric junction (PUJ) obstruction is the Anderson-Hynes dismembered pyeloplasty, with a success rate greater than 95%. With the advent of minimally invasive surgery (MIS), there is an increasing role for the laparoscopic approach to performing this operation. Kavoussi and Peters described the first laparoscopic pyeloplasty in children,<sup>1</sup> and three years later, Tan described the results in the first series of six pediatric patients.<sup>2</sup> In the last decade, laparoscopic pyeloplasty has produced success rates similar to the open approach, although the operative time remains somewhat greater.

Transperitoneal access is the more popular approach for this operation, as it provides a larger working space in which to manipulate the instruments and perform the anastomosis. Retroperitoneoscopic access will also be described, but it is less popular because of the limited working space.

The difficulty of intracorporeal suturing resulting in prolonged operating times and the prolonged learning curve are the main criticisms of laparoscopic pyeloplasty. Robotic technology, available since the early 1990s, has addressed some of these criticisms. The robotic device, with a range of movements comparable to the human wrist, allows a nonexperienced laparoscopic surgeon to perform difficult tasks with great precision and accuracy.

Robotic equipment, such as the daVinci system (Intuitive Surgical, Sunnyvale, California, US), costs almost €1.25 million and requires a spacious operative theatre as a result of its bulky

components. Future refinements of these systems and the associated technology hold the key to the further evolution of MIS.<sup>3</sup>

### Indications

Indications for laparoscopic pyeloplasty are similar to those for open surgery.

- Symptomatic PUJ obstruction (pain, infection, palpable mass).
- Worsening hydronephrosis.
- AP diameter of >20 mm with calyceal dilatation and renal function <40%.
- AP diameter of >30 mm.

The authors' preference is to offer a laparoscopic pyeloplasty primarily to the teenage group but also to suitable children 6 years of age and older. The reasons include: (1) the older child provides a larger intraperitoneal working space for suturing, (2) in infants, there is no significant difference in terms of pain and recovery to normal activity between the laparoscopic and open approach, and (3) in teenagers the incidence of crossing vessels is higher, and the vascular transposition may be an alternative to the more traditional dismembered pyeloplasty.<sup>4</sup>

Strictly speaking, there are no formal contraindications to this procedure. Nevertheless, there are situations where the surgeon has to evaluate the feasibility of the laparoscopic approach within his or her own spectrum of expertise. Contraindications may include previous abdominal surgery, redo pyeloplasty, and a small intrarenal pelvis.

The robotic-assisted pyeloplasty may facilitate redo surgery.<sup>5</sup>

## Investigations

Diagnosis of PUJ obstruction is traditionally based on an ultrasound scan and isotope renography (MAG3). Severity of hydronephrosis, thickness of renal parenchyma, kidney function, and drainage of the kidney are all assessed.

In anatomical variants, such as a horseshoe kidney or possible lower pole crossing vessels, an intravenous urogram (IVU) or magnetic resonance angiography (MRA) may be useful. In some instances, bowel preparation 24 hours before surgery, especially for a left-sided laparoscopic pyeloplasty, may be useful.

## Instrumentation

### Camera-video system

- 1 30° 5 mm laparoscope
- 5 mm laparoscopic instrument set which contains
  - 1 6 mm Hasson port
  - 3 instrument ports
  - 2 Kelly forceps
  - 1 bowel grasper
  - 1 Manhes grasper
  - 1 right angle dissector
  - 1 Metzenbaum scissor
  - 1 pyeloplasty scissor
  - 1 diathermy hook
  - 1 needle holder (3 mm)
  - 1 suction/irrigation device
- Long 19 Fr Teflon cannulae
- 5.2 Fr 8 cm to 20 cm multilength silicone JJ stent and guidewire

The daVinci robotic system (Intuitive Surgical, Sunnyvale, California, USA) has three components:

1. The endoscope and robotic arms mounted on a pedestal.
2. The surgeon's console with a 3D monitor and manipulator controls.
3. The control tower with an extra 2D monitor.

The robotic instruments include needle holder, graspers, round tip scissors, bipolar forceps, and harmonic scalpel. Currently these instruments are 8 mm; nevertheless, 5 mm instruments may become available in the near future.<sup>6</sup>

## Operative Technique

1. Under general anesthesia, the patient is positioned in a lateral decubitus position with the affected kidney superior. The patient is secured with adhesive tapes.

2. The patient is positioned facing the surgeon and placed to the edge of the operating table. This facilitates free movements of the instruments without hindrance from the table. The laparoscopic stack system with the screen should be placed opposite the surgeon.

3. The first port (Hasson) is placed by an open technique in the region of the umbilicus and secured with a skin suture. The gas flow is set at 2 L/min to 4 L/min and the abdominal pressure at 10 mmHg to 12 mmHg. Two working ports are inserted under direct vision: one under the costal margin and the other in the ipsilateral iliac fossa (Figure 3.1). The position of this latter port, which is used for the needle holder, is crucial, as it has to be in line with the anastomosis to facilitate suturing.

4. The kidney is identified by reflecting the colon medially or through a transmesenteric window.

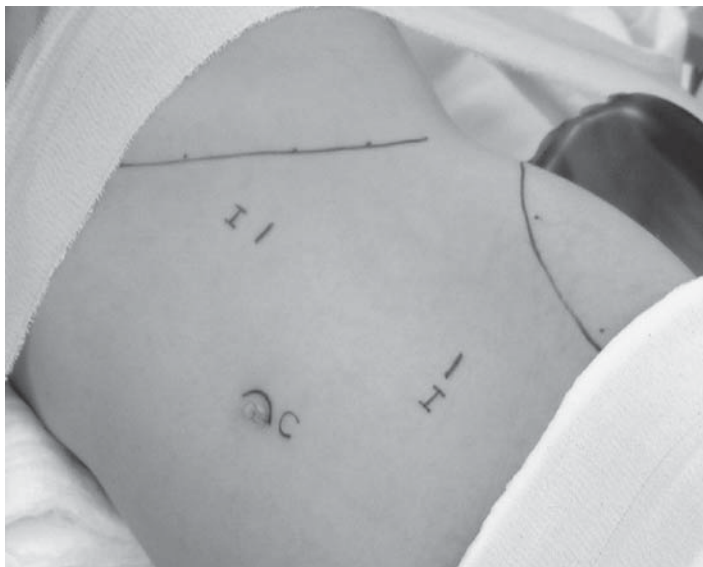5. Gerota's fascia is incised, and the PUJ is identified.

6. The renal pelvis is stabilized with a "hitch stitch" by passing a straight needle (3/0 Prolene) directly through the abdominal wall (Figure 3.2).

7. The renal pelvis is dismembered and a portion of the redundant dilated part may be excised. The ureter is spatulated and if necessary, it can be stabilized with another "hitch stitch" (Figure 3.3).

8. The inferior part of the anastomosis is sutured first. The remainder of anastomosis is performed with a continuous suture of 5/0 PDS cut to 12 cm in length.

9. After suturing the posterior wall, a trans-anastomotic stent is placed by inserting a 19 Fr Teflon cannula through the abdominal wall and

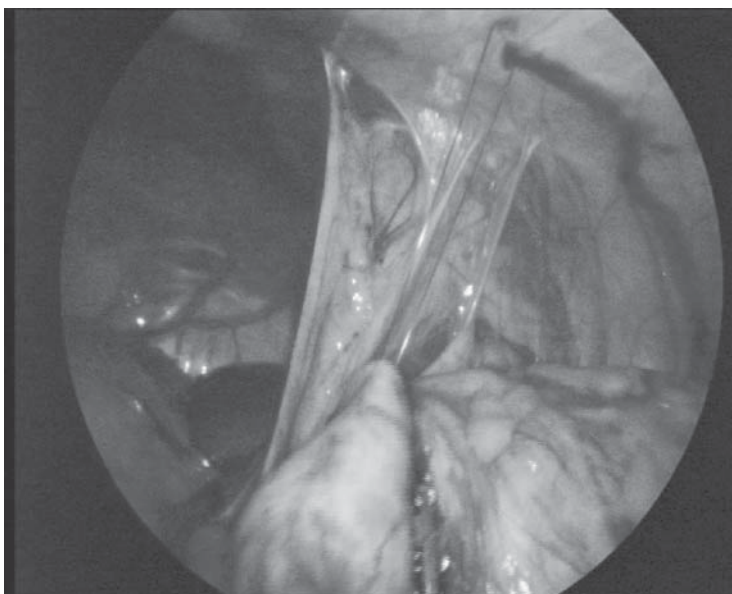


**FIGURE 3.1.** Port positions: one in the umbilicus, one under the costal margin, and a third in the ipsilateral iliac fossa.

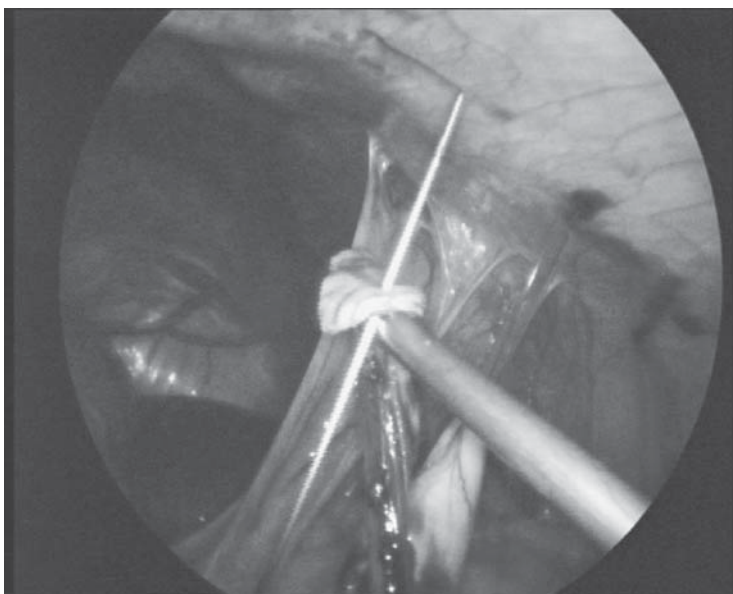
passing a guidewire through the cannula, down the ureter, and into the bladder. The cannula is removed and a JJ stent is advanced over the guidewire and placed between the renal pelvis and the bladder.

10. The remainder of the anastomosis is completed with a further continuous suture of 5/0 PDS of the same length.

11. The “hitch stitch” is removed, and the anastomosis is placed in normal anatomical



**FIGURE 3.2.** A “hitch stitch” is used to stabilize the renal pelvis.



**FIGURE 3.3.** The ureter can be stabilized with another “hitch stitch.”

position. The colon is replaced without a suture, and the mesenteric window is closed if a transmesenteric approach was used.

12. The ports are removed under direct vision and the incisions closed with 3/0 Vicryl to the fascia and 5/0 Monocryl or Dermabond to the skin.

13. For robotic-assisted laparoscopic pyeloplasty, the operative technique is the same except that the surgeon operates the instruments remotely from the console which provides the surgeon with a superior 3D view of the operative field. The assistant remains scrubbed and is responsible for changing the robotic instruments.

## Postoperative Management

The patient usually receives pain relief for 24 hours to 48 hours. The stent is removed 4 weeks to 6 weeks after surgery. Patients are then reviewed in three months with a USS scan and thereafter in 6 months to 9 months with an USS scan and a MAG3 study.

## Complications

The overall complication rate for an Anderson-Hynes pyeloplasty is less than 5%. The more frequent early postoperative complications are

bleeding, anastomotic leak, and infection. Post-surgery stricture is the most common long-term complications, but this is rare.

Complications as a result of the laparoscopic approach include bowel perforation, intraoperative bleeding, and the inability to complete anastomosis because of technical difficulties. In the hands of a well-trained laparoscopic surgeon, these complications should occur very infrequently.

## Conclusions

There is no doubt that the Anderson-Hynes technique is the current gold standard for PUJ obstruction. Although laparoscopic pyeloplasty combines the excellent outcomes of open surgery with a shorter hospital stay and better cosmesis, it is technically challenging surgery that is best carried out by a team of two experienced laparoscopic surgeons.

Robotic technology is evolving rapidly and will make MIS a possibility for even the less experienced laparoscopic surgeon. The advantages of the robotic system are the 3D view combined with the enhanced range of movements possible with the Endowrist technology. These factors greatly facilitate complex intracorporeal tasks, although it remains to be seen if the outcomes are any better

than with conventional laparoscopy. The limitations are, of course, the significant setup and running costs, the lack of tactile feedback, and the significant size of the equipment, which requires a spacious theater and adequate storage space.

## References

1. Peters CA. Laparoscopic and robotic approach to genitourinary anomalies in children. *Urol Clin N Am* 2004;31:595–605.
2. Tan LH. Laparoscopic Anderson-Hynes dismembered pyeloplasty in children. *J Urol* 1999;162: 1045–1048.
3. Gettman M, Peschel R, Neururer R et al. A comparison of laparoscopic pyeloplasty performed with the daVinci robotic system versus standard laparoscopic techniques: initial cases results. *Eur Urol* 2002; 42:453–458.
4. Godbole P, Wilcox D, Mushtaq I, Duffy PG. Laparoscopic transposition of lower pole vessels-the “vascular hitch”: an alternative for pelvicultureteric obstructions in children. *J Pediatr Urol* 2005; 1(3):210–211.
5. Inagaki T, Rha KH, Ong AM et al. Laparoscopic pyeloplasty: current status. *Br J Urol* 2005;95(S2): 02–105.
6. Binder J, Brautigam R, Jonas D et al. Robotic surgery in urology: fact or fantasy? *Br J Urol* 2004;94: 1183–1187.



# 4

## Transposition of Lower Pole Vessels: “The Vascular Hitch”

Prasad P. Godbole and Patrick G. Duffy

The traditional surgical technique for pelviureteric junction obstruction (PUJO) is the dismembered pyeloplasty, which may be open, laparoscopic, or robotic assisted. Hellstrom first described the technique of relocation of the lower pole vessels in PUJO. We therefore now perform laparoscopic transposition of lower pole vessels in a very select group of children, in whom the lower pole vessels were deemed to be the sole aetiology in the pathogenesis of PUJO. A prospective audit of this technique is underway, and the medium term results are encouraging.<sup>1-4</sup>

### Indications and Contraindications

Careful patient selection is paramount. Suspicion of lower pole vessels is based on a normal antenatal history, a late presentation with intermittent symptoms (typically pain), marked hydronephrosis at the time of pain with a mainly extrarenal pelvic dilatation, and an obstructed pattern on a MAG3 renogram. Although there are no contraindications to the technique, the surgeon must be prepared to proceed to a dismembered pyeloplasty, either laparoscopic or open, if there are no lower pole vessels or if these vessels do not seem to be the etiological factor.

### Preoperative Investigations

All imaging, including a renal ultrasound and MAG3, should be available in the operating theater. No further imaging is necessary. All chil-

dren should have a baseline full blood count and renal biochemistry and serum should be grouped and saved.

### Instrumentation

No specific instrumentation is necessary. We use a basic 5 mm laparoscopic set, which includes Kelly forceps, atraumatic graspers, scissors, diathermy hook, and needle holder. At the surgeon's discretion, additional instrumentation, such as bipolar diathermy forceps or harmonic scalpel (not essential), may be used.

### Operative Technique

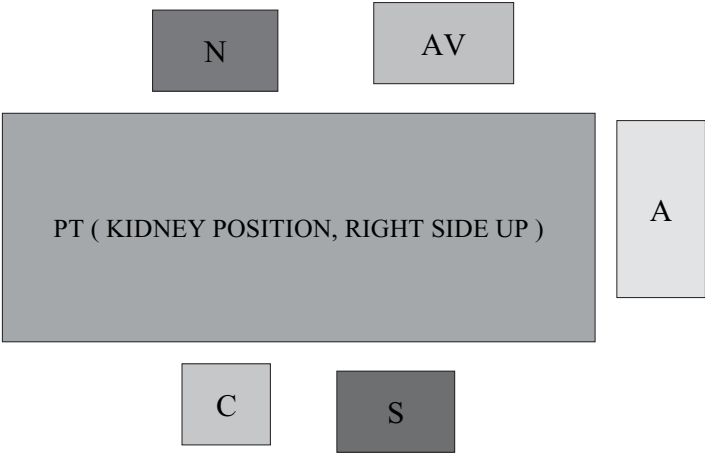
#### Patient Position

The patient is placed in a renal position with a sandbag under the lower costal margin to elevate the affected side. The patient should be well supported posteriorly. Anteriorly the patient can be supported in the region of the chest, but care should be taken not to support the trunk as this interferes with the working ports and instruments. The patient should be secured with broad tape over the pelvis and thorax. The patient position and position of assistants and equipment is shown in Figure 4.1.

#### Port Position

One primary and two working ports are required. The port position is depicted in Figure 4.2. The primary umbilical port is inserted via the open





**FIGURE 4.1.** Figure showing the position of patient (P), surgeon (S), camera holder (C), audiovisual equipment (AV), scrub nurse (N), and anesthetist (A) for a transposition of right renal vessels.

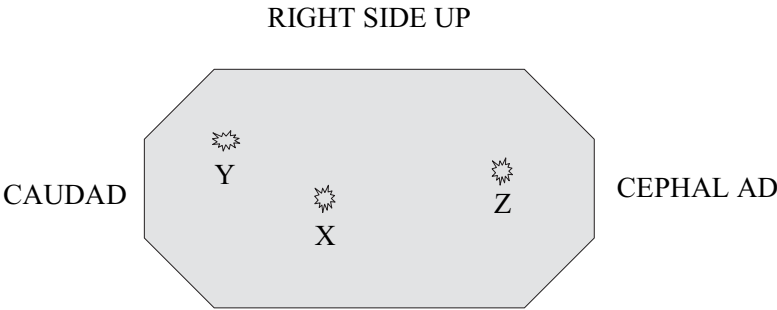
technique. Insertion is aided by rotating the operating table so that the patient is more supine than lateral.

### Technique

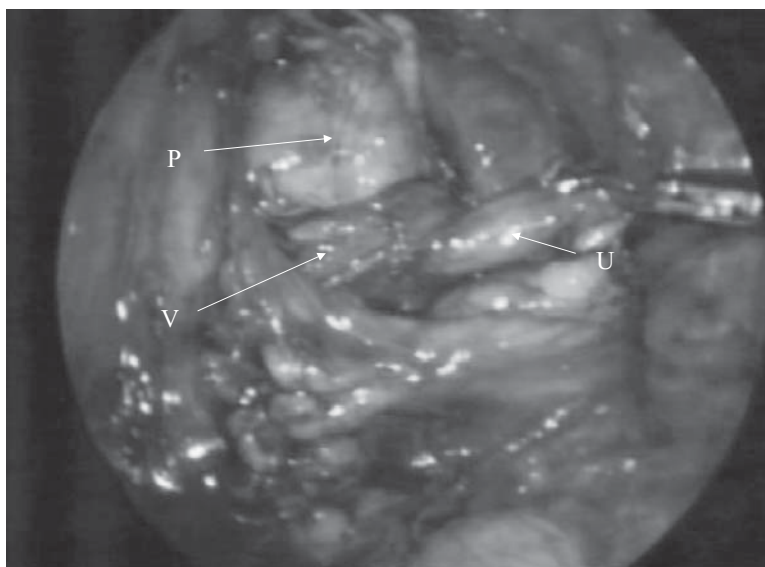
1. The ascending or descending colon is mobilized minimally, mainly at the flexure, to obtain good visualization of the perirenal fascia. Usually the bulging renal pelvis is clearly visible through the fascia.
2. The perirenal fascia is incised and reflected medially to create a small window over the kidney, the pelvis, and the ureter more inferiorly.
3. The adventitial tissue over the renal pelvis is cleared and traced down toward the pelviureteric junction. Alternatively the ureter can be identified and traced superiorly.
4. If lower pole vessels are present, these are evident, and the renal pelvis can be seen to be

overhanging the vessels. Dissection is continued, staying close to the pelvis/ureteric wall so that the vessels are mobilized completely off the pelvis.

5. Free mobilization of the pelvis is confirmed.
6. Usually, close to the hilar end of the lower pole vessels are some fibrous and vascular strands that tether the pelvis and ureter. These need to be divided by careful diathermy. This will fully mobilize the vessels off the pelvis.
7. When fully mobilized, the vessels can be transposed superiorly on the renal pelvis where they remain comfortably when the pelvis is released.
8. Careful inspection of the pelviureteric junction is now made. Any obvious kinks are straightened by divided the periureteric adventitial tissue.
9. If there are no vessels or if they are not deemed to be the sole etiology (presence of obvious stenosis at the pelviureteric junction), then consideration should be given to laparoscopic



**FIGURE 4.2.** Port position X (primary port) and positions Y and Z (secondary ports).



**FIGURE 4.3.** Renal pelvis (P), ureter (U), and vessels (V) exposed. (Reprinted from Godbole P. Mushtaq I, Wilcox DT, et al. Laparoscopic transposition of lower pole vessels – the “vascular hitch”: An alternative to dismembered pyeloplasty for pelvi-ureteric junction obstruction in children. *Journal of Pediatric Urology Company* Published by Elsevier Ltd, Copyright © 2006. In Press. Corrected Proof, Available online 18 April 2006)

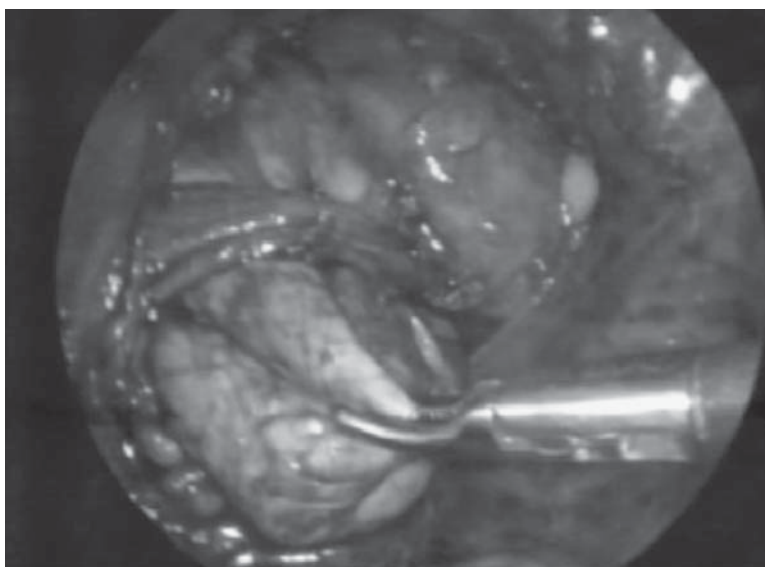
pyeloplasty/open pyeloplasty depending on surgical preference and experience.

10. The vessels are “fixed” in their transposed position by suturing together the renal pelvis on either side of the vessels with 2/3 absorbable 5.0

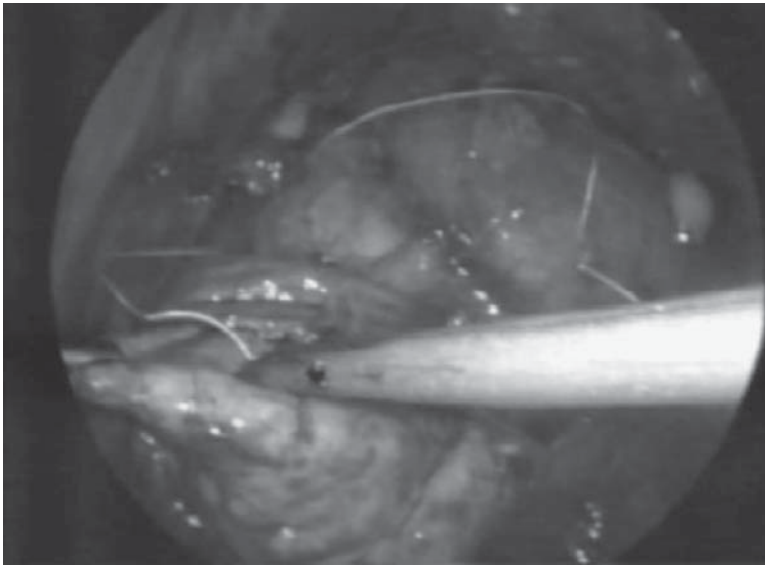
Vicryl sutures without tension and well clear of the pelviureteric junction.

11. No stents or drains are required, and the port sites are closed in the normal way.

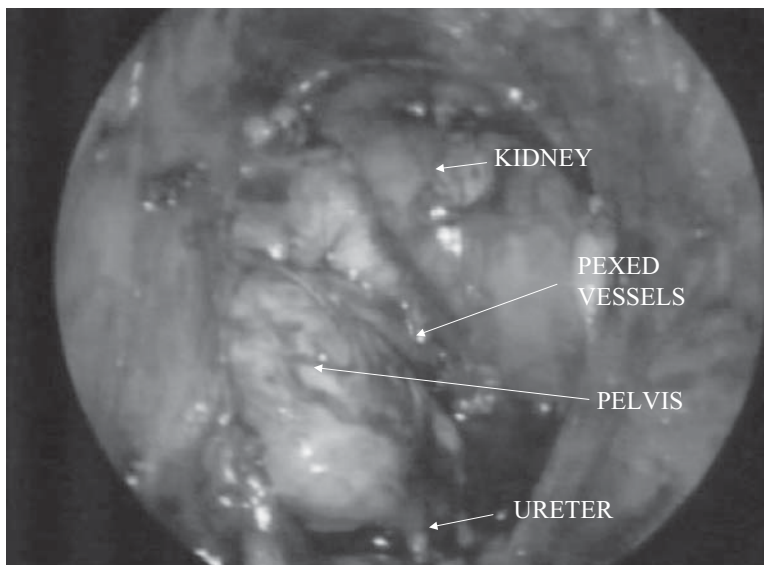
The steps are depicted in Figures 4.3 to 4.6.



**FIGURE 4.4.** Renal pelvis (P) fully mobilized. (Reprinted from Godbole P. Mushtaq I, Wilcox DT, et al. Laparoscopic transposition of lower pole vessels – the “vascular hitch”: An alternative to dismembered pyeloplasty for pelvi-ureteric junction obstruction in children. *Journal of Pediatric Urology Company* Published by Elsevier Ltd, Copyright © 2006. In Press. Corrected Proof, Available online 18 April 2006)



**FIGURE 4.5.** Vessels pexed superiorly. (Reprinted from Godbole P. Mushtaq I, Wilcox DT, et al. Laparoscopic transposition of lower pole vessels – the "vascular hitch": An alternative to dismembered pyeloplasty for pelvi-ureteric junction obstruction in children. *Journal of Pediatric Urology Company* Published by Elsevier Ltd, Copyright © 2006. In Press. Corrected Proof, Available online 18 April 2006)



**FIGURE 4.6.** Appearances at the end of the operation. (Reprinted from Godbole P. Mushtaq I, Wilcox DT, et al. Laparoscopic transposition of lower pole vessels – the "vascular hitch": An alternative to dismembered pyeloplasty for pelvi-ureteric junction obstruction in children. *Journal of Pediatric Urology Company* Published by Elsevier Ltd, Copyright © 2006. In Press. Corrected Proof, Available online 18 April 2006)

## Postoperative Care

No special postoperative care is necessary. Diet can be started the same day, and the patient is discharged when mobilizing. We routinely perform a renal ultrasound and MAG3 four to six weeks following surgery.

## Complications

The main complication is the recurrence of UPJ obstruction with recurrence of symptoms.

## Authors' Experience

We have now performed 19 procedures. The main symptom was intermittent pain. All had a normal antenatal history, a dilated predominantly extrarenal pelvis, and a MAG3 renogram with appearances typical of a PUJO. The median operating time was 92 minutes. At a median follow up of 15 months, 18 of the 19 are symptom free. An ultrasound showed improved appearances and a MAG3 showed good clearance. One girl had recurrent symptoms of loin pain at the time of her postoperative MAG3 after administration of the diuretic. In this case, ultrasound showed gross hydronephrosis. She required emergency insertion of a JJ stent. Subsequently, she underwent laparoscopic exploration and was noted to have a kink at the pelviureteric junction. This was corrected. A longitudinal pyelotomy was performed and closed transversely over the JJ stent, which was removed three months later. A further ultrasound and MAG3 showed improved appearances and good drainage.

## Conclusions

Our early experience suggests that laparoscopic transposition of lower pole vessels – the “vascular hitch” may be a useful alternative to dismembered pyeloplasty in the management of symptomatic children where lower pole vessels are deemed to be the sole etiology. The surgery is simpler than laparoscopic pyeloplasty, and there have been no serious side effects. Careful patient selection based on a normal antenatal history, intermittent symptoms, and a mainly extrarenal dilatation on ultrasound when symptomatic with an obstructed curve on a MAG3 renogram is paramount to ensure a successful outcome for this operation. Because the follow up is relatively short, longer term follow up is required.

## References

1. Churchill BM, Feng WC. Ureteropelvic junction anomalies: congenital UPJ problems in children. In: Gearhart J, Rink R, Mouriquand P (eds), *Pediatric Urology*. Philadelphia, WB Saunders, 2001:318–346.
2. Meng MV, Stoller ML. Hellstrom technique revisited: laparoscopic management of ureteropelvic junction obstruction. *Urology* 2003;62(3):404–408.
3. Cain MP, Rink RC, Thomas AC, Austin PF, Kaefer M, Casale AJ. Symptomatic ureteropelvic junction obstruction in children in the era of prenatal sonography – is there a higher incidence of crossing vessels? *Urology* 2001;57(2):338–341.
4. Pesce C, Campobasso P, Costa L, Battaglino F, Musi L. Ureterovascular hydronephrosis in children: is pyeloplasty always necessary? *Eur Urol* 1999;36(1):71–74.

## **Adrenal Gland**

# 5

## Laparoscopic Adrenalectomy

Imran Mushtaq

Laparoscopic adrenalectomy is considered the standard of care for the surgical excision of the adrenal gland. Since the initial report of laparoscopic adrenalectomy in 1992, it has evolved into a feasible and reproducible minimally invasive procedure for both benign and malignant adrenal tumors.<sup>1</sup> Transperitoneal and retroperitoneal approaches are the two principal laparoscopic routes to the adrenal gland.<sup>2,3</sup> Both have proven to be safe and effective when compared with open adrenalectomy, and they offer the benefits of decreased blood loss, less postoperative pain, shorter hospital stay, rapid convalescence, and improved cosmetic outcome.<sup>4</sup> Although the transperitoneal approach is used more widely, the retroperitoneal approach offers distinct advantages that make it a valuable alternative route to the adrenal gland. The retroperitoneal approach avoids colonic mobilization, the risk of injury to hollow viscera, and the potential risk of adhesion formation. The reversed orientation of the kidney and hilum when the patient is in a prone position, combined with the comparatively smaller working space that is required, may make this approach difficult to master. Because surgeons are more familiar with the retroperitoneal approach for renal surgery, it is the preferred approach for adrenal surgery in our institution.

### Anatomy

#### Left Adrenal Gland

The left adrenal gland is smaller than the right and lies in the renal fossa at the medial aspect of

the upper pole of the left kidney. The arterial supply is derived from the left superior (left inferior phrenic artery), middle (aorta), and inferior (left renal artery) adrenal arteries. The main left adrenal vein joins with the left inferior phrenic vein to drain into the left renal vein.

#### Right Adrenal Gland

The right adrenal gland is larger than the left and is of variable shape. It is located at the medial aspect of the upper pole of the right kidney, behind the vena cava in a very deep and high position. The arterial supply derives from the right superior (inferior phrenic artery), middle (aorta), and inferior (right renal artery) adrenal arteries. The main right adrenal vein drains into the posterior lateral aspect of the vena cava after a short horizontal course. Approximately 10% of individuals have an accessory adrenal vein, which drains into the right hepatic vein.

### Indications

A laparoscopic adrenalectomy is indicated in the following cases:

1. Pheochromocytoma.
2. Adrenal adenoma.
3. ACTH dependant Cushing's syndrome.
4. Neuroblastoma.
5. Incidentaloma.

## Contraindications

1. Previous surgery of the liver or kidney.
2. Large tumors (>8 cm–10 cm in diameter).
3. Coagulation disorders.
4. Known carcinoma of the adrenal gland.

## Preoperative Work Up

1. A detailed ultrasound of the kidneys and adrenal glands is an essential investigation in all children suspected of having an adrenal lesion. The ultrasound provides information regarding the presence of a distinct lesion, including its size and whether it is cystic or solid. In some cases, there will be bilateral diffuse enlargement of the adrenal glands without a focal lesion, such as in central Cushing's syndrome. It is also essential to determine if there is intravascular extension of a lesion into the adrenal vein and inferior vena cava. This information will serve as a guide to the suitability of the laparoscopic approach and also for deciding the technique for specimen removal, that is, Endopouch, cyst aspiration, and so on.

2. The information gained from an ultrasound must be supplemented with a CT scan and/or an MRI scan. Routine preoperative blood tests, which should include serum creatinine, hemoglobin level, and a group/save of serum. Clotting parameters do not need to be checked routinely, unless there is a history of bleeding disorders.

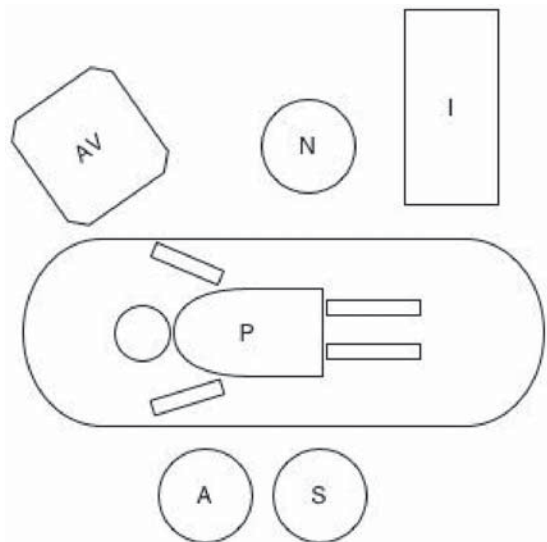
3. All hypertensive patients with a pheochromocytoma secrete excessive quantities of catecholamines, and the measurement of urinary catecholamines is diagnostic in 95% of patients. Preoperative preparation in such cases requires the administration of phenoxybenzamine for seven days prior to surgery. In addition, the administration of beta-blockers (propranolol) can decrease the risk of tachyarrhythmias, but should not be given without prior alpha-blockade.

All children receive a single dose of an appropriate intravenous antibiotic (the author prefers an aminoglycoside such as amikacin or gentamicin), either prior to leaving the ward or at the induction of anesthesia.

## Specific Instrumentation

1. Primary camera port – 6 mm or 10 mm Hasson, 2 secondary 5 mm ports (the author prefers 5 mm VersaStep radially dilating ports).
2. 30 degree 5 mm telescope.
3. Kelly forceps (×2) for dissection.
4. Metzanbeum scissors.
5. Harmonic scalpel for coagulation/division of vessels or 5 mm endoclips.
6. Endopouch for specimen retrieval if large specimen.

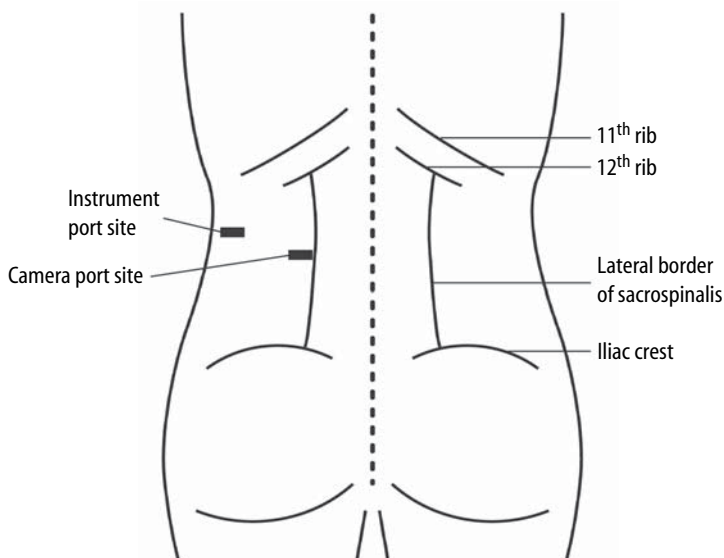
The patient (P) is positioned prone for the operation. The monitor and stack system (AV) should be placed on the side opposite to the affected kidney, towards the head of the table, with the screen pointing towards the pelvis. The scrub nurse (N) should be positioned adjacent to the laparoscopic stack, with the operating surgeon (S) and assistant (A) both on the side of the affected kidney (Figure 5.1).



**FIGURE 5.1.** Schematic representation of the room setup. P = patient, AV = audiovisual equipment, N = scrub nurse, I = instrument trolley, S = surgeon, A = camera holder.



**FIGURE 5.2.** Schematic representation of port position.



## Anesthesia

Endotracheal intubation is required in all cases using either a cuffed or reinforced endotracheal tube that is securely fastened to prevent tube dislodgement when the child is positioned prone for the surgery. Preoperative and postoperative analgesia is provided by preemptive local infiltration of the planned incisions with 0.25% bupivocaine.

## Operative Technique

### General Principles

The operative strategy is based on complete dissection of the adrenal gland outside the surrounding adipose tissue. This minimizes bleeding, which can occur with dissection on the surface of the gland. A left adrenalectomy is more difficult than a right adrenalectomy because of the absence of clear landmarks, such as the vena cava, the smaller size of the gland, and adrenal vein. The key to success is to begin dissection on the medial aspect to identify and ligate the vessels from an early stage in the operation.

### Retroperitoneoscopic Adrenalectomy

1. The patient is positioned fully prone under general anesthesia. The exposed dorsal and lateral aspects of the trunk are prepared and draped in a sterile manner. Topographic landmarks and anticipated port sites are marked as shown (Figure 5.2)

2. Creation of retroperitoneal space outside Gerota's fascia by a technique described by Gill.<sup>5</sup> Several balloons are available for creation of the retroperitoneal space. However the author prefers a simple and inexpensive balloon made by securing the finger of a sterile surgical glove to the end of a 12Fr Jacques catheter with a silk tie. The catheter is connected to a three-way tap and a 50 ml Luer lock syringe. Depending on the size of the patient, 100 ml to 250 ml of air is injected slowly to develop the retroperitoneal space. The system is left inflated for two minutes to promote hemostasis, and is then deflated and withdrawn.

3. Insertion of primary and secondary ports: A 6mm Hasson cannula is inserted into the port site, followed by insufflation of the retroperitoneum with CO<sub>2</sub> to pressure of 10mmHg to



12 mmHg. The Hasson port is secured by a suture to the skin. A 5 mm instrument port is placed under direct vision below the tip of the 11th rib and above the iliac crest. A second working port (5 mm) can be placed through the paravertebral muscles.

4. Exposure of the kidney: Gerota's fascia is incised longitudinally adjacent to the posterior abdominal wall using scissors. The adventitious tissue is divided to gain adequate exposure and working space for the procedure.

5. Exposure of the posterior surface of the kidney: the kidney is dissected commencing at the apex and along the medial aspect. Using blunt dissection and gentle pressure the kidney is reflected anteromedially to expose the posterolateral aspect of the kidney. The lateral and inferior attachments are not divided at this stage as they anchor the kidney in position and aid in exposure of the upper pole. The inferior margin of the adrenal gland can then be visualized at the superomedial border of the kidney.

6. Division of the adrenal vessels: The vessels are divided between hemoclips or with a harmonic scalpel when the vessels are less than 3 mm in diameter. A minimum of three clips should be applied on all vessels, with at least two clips remaining on the proximal stump of the divided vessel.

7. Removal of the gland: Once the vascular supply to the adrenal gland is completely divided, the gland is fully mobilized and freed of all attachments using either monopolar diathermy or a harmonics scalpel. The gland is then placed within an endobag and removed through the camera port incision, which can be slightly enlarged to facilitate removal.

4. The patient is discharged when mobilizing with adequate control of pain with simple analgesia.

## Complications

### Peritoneal tear

The posterior prone approach minimizes the risk of a peritoneal tear when compared with other approaches for retroperitoneoscopic surgery. It can occur if the balloon is inflated too rapidly or the balloon is too small for the size of the patient and in adolescents and children on peritoneal dialysis.

### Balloon Rupture

Rupture of the dissecting balloon can occur when the balloon is inflated too rapidly, with overinflation of the balloon or when excessive external pressure is applied over the balloon. When it occurs the ruptured balloon must be carefully examined for lost fragments, which should be sought and removed from the patient.

### Intraoperative Bleeding

Intraoperative bleeding is most likely the result of the slipping of hemoclips from an adrenal vein or because of inadvertent damage to an adrenal vein or vena cava by a laparoscopic instrument. In most cases, hemorrhage can be controlled by the prompt application of hemoclips to the affected vessel. Uncontrollable hemorrhage will require conversion to an open approach to ligate or oversew the bleeding vessel.

## Postoperative Management

1. Patient can start fluids and diet on return to the ward.
2. A close eye needs to be kept on the possibility of hemorrhage.
3. As bacteremia may occur during the procedure, oral antibiotics to cover the immediate postoperative period may be required in some cases.

## Author's Experience

Over a two-year period, we have performed eight retroperitoneoscopic adrenalectomy procedures in seven patients, including one bilateral synchronous adrenalectomy. Our patients included three boys and four girls, with a mean age at the time of surgery of 7.8 years (range, 1.1–14.7 years). Presentation was with hypertension ( $n = 3$ ), Cushing's syndrome ( $n = 2$ ), and abdominal pain. Our mean

operative time has been 154 minutes (range, 110–186 minutes). A single instrument port adrenalectomy technique was performed in three children. Histopathological diagnoses included adrenal cyst, cystic pheochromocytoma, adrenal cortical tumor, and ACTH-dependant Cushing disease. In these children, all lesions were completely excised, and all patients have remained symptom free in a mean follow-up of twenty months.

These cases represent our early experience with retroperitoneoscopic adrenalectomy. The general learning curve for laparoscopy has been long since surmounted for the senior reporting surgeons, and this experience has proved vital to expand our repertoire as a result of such encouraging early results. The technique confers excellent intraoperative hemodynamic stability, and we consider the retroperitoneoscopic approach the technique of choice for adrenalectomy in our institution.

## References

1. Gagner M, Lacroix A, Bolte E.N. Laparoscopic adrenalectomy in Cushing's syndrome and pheochromocytoma. *N Engl J Med* 1992;327(14):1033.
2. Nassrallah RA, Valla JS, Van Hoorde E, Steyaert H. Retroperitoneal minimally invasive endoscopic adrenalectomy in children. *Saudi Med J* 2003;24(5 Suppl):S11–S14.
3. Kappany HA, Shoma AM, El-Tabey NA, El-Nahas AR, Eraky I. Laparoscopic adrenalectomy: a single-center experience of 43 cases. *J Endourol* 2005;19(10):1170–1173.
4. Gonzalez R, Smith CD, McClusky DA III, et al. Laparoscopic approach reduces likelihood of perioperative complications in patients undergoing adrenalectomy. *Am Surg* 2004;70(8):668–674.
5. Gill IS, Munch LC, Lucas BA, Das S. Initial experience with retroperitoneoscopic nephroureterectomy: use of a double-balloon technique. *Urology* 1995;46(5):747–750.

## **Bladder**

# 6

## Transvesicoscopic Cohen Ureteric Reimplantation for Vesico-Ureteral Reflux in Children

Jean-Stéphane Valla

The surgical correction of vesico-ureteral reflux (VUR) is the most frequent operation on the upper urinary tract in children. Several classical surgical techniques (e.g., Leadbetter-Politano, Lich-Gregoir, Cohen) have been widely proven on long-term follow up to correct pathological VUR. The main criteria for selecting a technique has been the success rate. In this respect, Cohen's technique is probably the best, with resolution of reflux in approximately 98% of cases. However, bladder irritation and hematuria are the usual morbidities associated with bladder incision. The concept of minimally invasive management first appeared in 1984, with endoscopic correction by submucosal injection, an almost painless ambulatory method but one that is less effective than surgery (failure rate, 10% to 30%). Because of this competition between classical surgery and purely cystoscopic management, pediatric urologists loyal to the classical method have multiplied their efforts to simplify surgical techniques and to reduce postoperative pain and hospitalization. As a result, the classical surgical treatment of VUR in children has improved considerably in the last 15 years. Our philosophy follows this line of thinking and looks for a technique that associates the principles of genuine reimplantation according to Cohen with the advantages of minimally invasive surgery (MIS), thereby reducing the morbidity associated with the abdominal and bladder wall incision.

### Indications and Contraindications

All types of VUR could be corrected by the pneumovesicoscopic technique, including high grade reflux, bilateral reflux, reflux in a duplex system,

persistent reflux after endoscopic submucosal injection, reflux after ureterocele incision, and reflux associated with a large diverticulum.

However, the technical difficulty must not be underestimated. Expertise in intracorporeal suturing in confined spaces with fine 5/0 or 6/0 sutures is essential. The smaller the bladder, the more reduced the working space. Hence, this method seems difficult to apply to infants under six months of age. Still, surgical indications to correct VUR before 1 to 2 years of age are very few. The lack of space makes it difficult to manipulate a voluminous mega ureter in the bladder. So in cases of associated obstructive pathology, this technique could be only applied to smaller ureters.

### Preoperative Investigations

Preoperative imaging, including ultrasound, micraturating cystogram, and isotope renal scans are needed in all cases. Sometimes urodynamic investigations and uro-MRI are useful. Detailed information is given to the parents and, if possible, the patient regarding the techniques used for the ureteral reimplantation, possible technical difficulties and complications, and the possibility of intraoperative conversion to the open technique. Full informed consent is obtained.

There is no specific preoperative preparation. As with open surgery, preoperative urine samples confirm that no urinary infection is present. In case of associated constipation, the rectum could be emptied with a fleet enema, usually given the evening before.

The patient is prepared for general anesthesia with endotracheal intubation; muscle relaxation is essential to ensure good bladder insufflation. A broad-spectrum antibiotic is routinely given intravenously on induction of anesthesia. A nasogastric tube is usually not necessary.

## Specific Instrumentation

Telescope 5 mm in diameter, 0 or 30 degree.

3 mm instruments: hook, grasper, dissector, needle holder

5 mm trocars for the telescope, 5 mm or 3 mm for the two operative instruments; locking trocars (autosuture Pediport Vigon Ref.04024055) are very useful to avoid any slippage out of the bladder wall, but any type of trocars could be used if the bladder wall is suspended to the abdominal wall with a percutaneous transfixing suture.

A pneumatic or robotic camera holder is useful to achieve stability of vision, especially when suturing after dissection. As for all reconstruc-

tive surgery in a small space, this point seems essential.

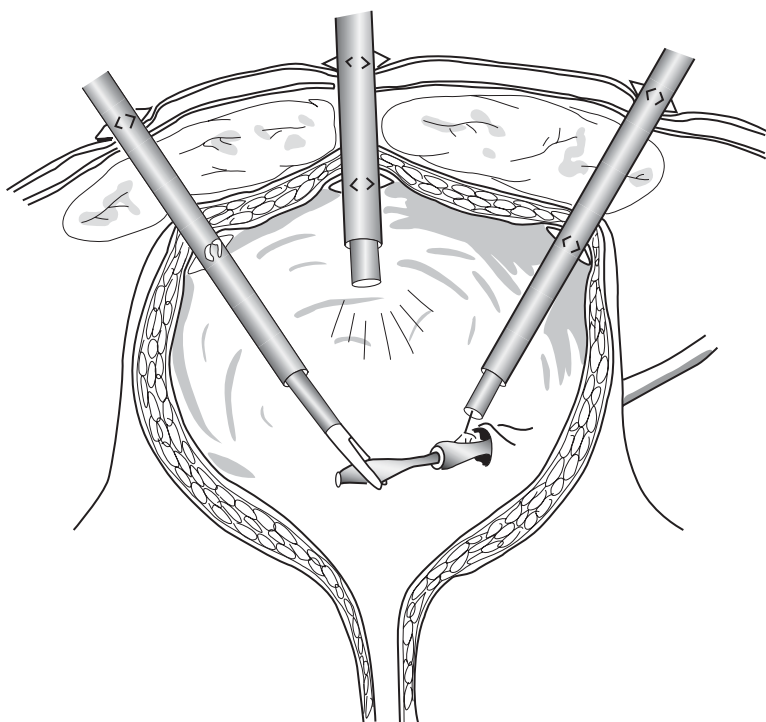
If a third operating instrument is needed, it could be introduced through the urethra in girls and suprapubically in boys.

A urethral catheter (8 Fr to 12 Fr) could be introduced into the bladder during the procedure to aspirate the smoke during the dissection and also to aspirate urine (additional suction irrigation device).

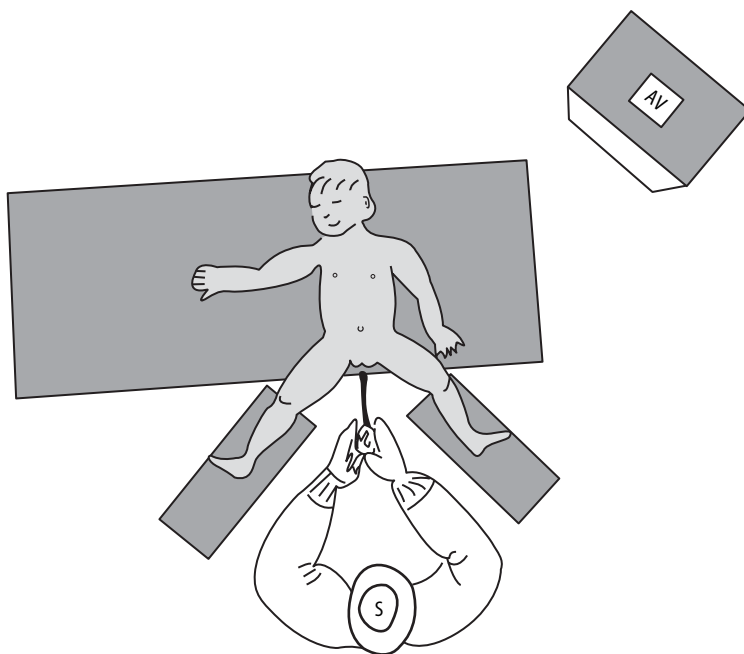
To close the trocar sites in the bladder, a special needle (suture passer 1.GSP01 Gore) is useful.

## Operative Technique

The principle of pneumovesicoscopic reimplantation consists of suprapubic insertion of three trocars into the bladder under cystoscopic control: one median for the telescope and two lateral trocars for operating instruments. The bladder is a limited cavity and after gas insufflation the endoscopic view is much better than with liquid filling (Figure 6.1).



**FIGURE 6.1.** Principle of ureteral reimplantation under pneumovesicoscopy.



**FIGURE 6.2.** First step: Cystoscopy under fluid distension and introduction of three trocars.

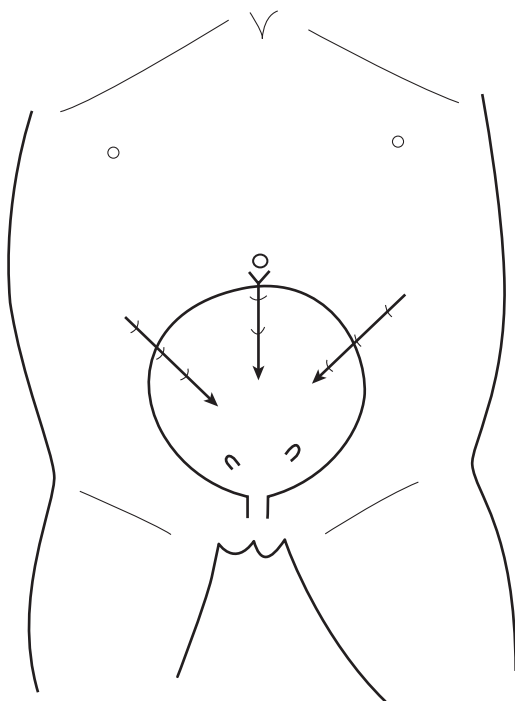
The patient is placed in the modified lithotomy position with abducted thighs. Small patients are placed transversally on the operating table. Taller patients are placed at the end of the operating table. The abdomen and genitalia are prepared and draped. The pelvis is tilted with a padding just below the buttocks. The patient is strapped on the table to prevent slipping during movement of the table (Trendelenburg position).

The procedure starts with cystoscopy with normal saline fluid distension to verify the urethra and the bladder and to determine the size, shape, and number of the ureteric orifices. During this first step, the surgeon stands between the patient's legs with the video column on the left side of the patient (Figure 6.2). Under visual control, the first midline 5 mm locking trocar is introduced suprapubically through the abdominal wall, then the perivesical space, and finally the bladder wall. In small children, the bladder wall is particularly soft and can be distorted or pushed away by the trocar tip before being entered. A useful technique before introducing the trocar is to suspend the bladder wall to the abdominal wall with a percutaneous transfixing suture under cystoscopic control. This

suture keeps the bladder wall in close contact with the abdominal wall and prevents inadvertent dislodgement of the trocar out of the bladder during the procedure.

The two lateral trocars (5 mm or 3 mm) are introduced through the anterolateral wall of the bladder also under cystoscopic control and not too close to the ureteric orifice. The position selected for insertion of the three ports could vary according to the size of the patient; in small children (younger than 3 years) the bladder is located in a more superior position, and the trocars are more close to the umbilicus. In older children, the bladder is deeper and lower in the pelvis, and the trocars are closer to the pubis. So usually the two lateral working ports are inserted in the anterior bladder wall in small children (Figure 6.3) and in the lateral bladder wall in older children (Figure 6.4). Once the three trocars are introduced, the bladder is emptied and the cystoscope removed.

The team and video column move for the second pneumovesicoscopic step. The bladder is insufflated via the dome port with CO<sub>2</sub> at a pressure of 10 cm to 12 cm H<sub>2</sub>O and a volume of 2 L/min to 3 L/min. Our experience has shown that



**FIGURE 6.3.** Introduction of trocars in young children (3–5 years): in the abdominal bladder, a trocar through the anterior wall of the bladder, with the tip of the trocar turned toward the lower part of the bladder.

there is no gas leak through the urethra even in girls, so it is not necessary to occlude it during the operation.

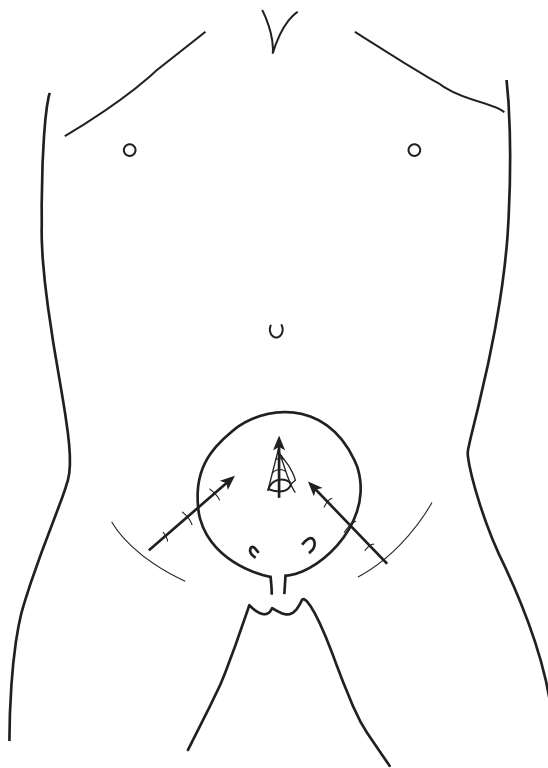
During that second step, the position of the patient and the team could vary according to the child's age. The more ergonomic position for the surgeon is to stand at the head of the child in the axis of the bladder trigone and the video column, which is positioned between the patients legs at the end of the table, with the cables coming from the patient's left side and fixed to the superior part of the operative field. The camera holder is fixed on the right side of the table. But this is possible only in small children under 5 years of age (Figure 6.5). In older children, the surgeon is positioned similar to when performing open bladder surgery. The surgeon is on the left side of the patient, and the monitor next to the patient's right leg (Figure 6.6).

All the successive steps of classical open Cohen's technique are faithfully reproduced: introduction

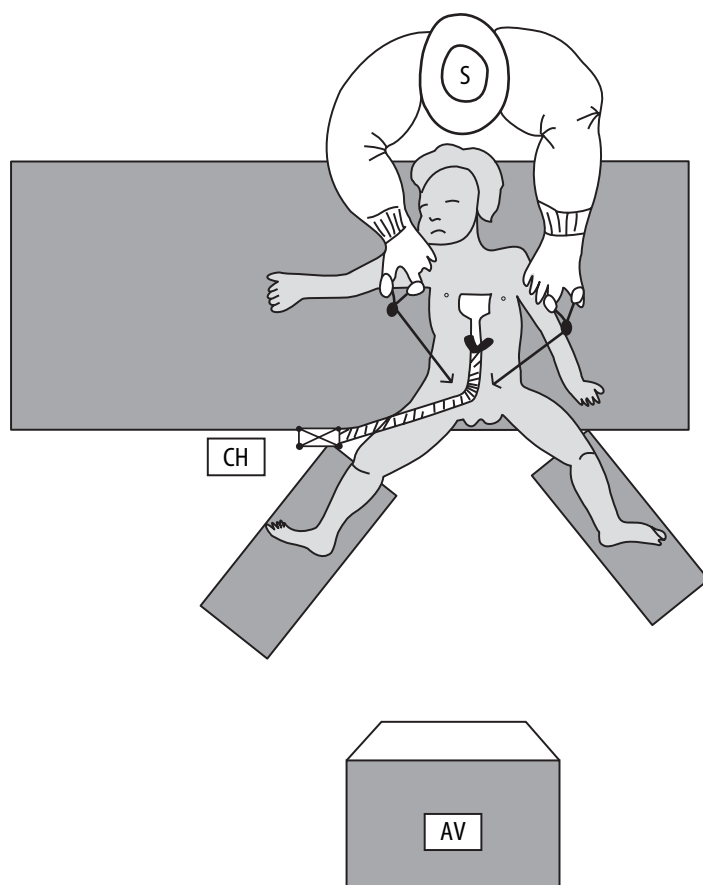
of a ureteric catheter (if not already done during cystoscopy) that is fixed by a 5/0 Maxon (extra-corporeal slipping knots), circumferential incision around the orifice using the 3 mm monopolar hook, dissection of the ureter with hook and peanuts over 3 cm to 5 cm, respecting its blood supply, narrowing of the enlarged vesical hiatus with two or three 5/0 Maxon sutures.

The closure of the muscular defect at the level of ureteral hiatus should be done as quickly as possible to avoid excessive leakage of carbon dioxide into the perivesical space, which could produce an extrinsic bladder compression and reduce the intravesical space. At that time, the ureter could be anchored superficially to the detrusor muscle with one stitch to avoid its retraction in the perivesical space.

A transversal submucosal tunnel, the length of which must be equal to three or four times the ureteral diameter, is created with 3 mm scissors. The ureter is gently threaded through its new



**FIGURE 6.4.** Introduction of trocars in children older than 5 years of age: with the bladder deep in the pelvis, the trocar is inserted through the lateral wall of the bladder, with the tip of trocar turned toward the upper part of the bladder.

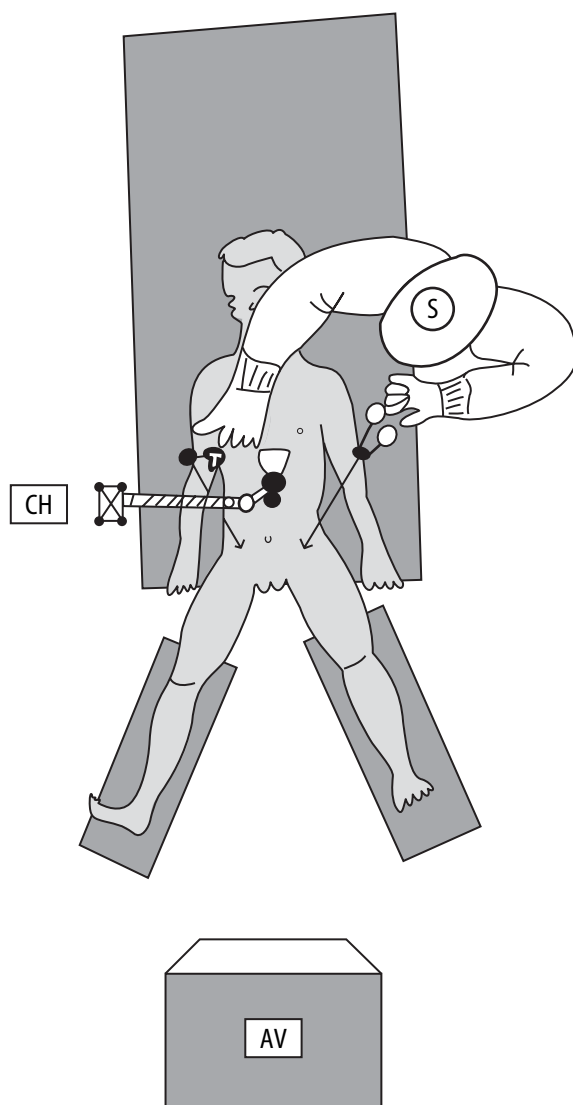


**FIGURE 6.5.** Second step: Position of the team in the case of a young child. The surgeon (S) at the head, with the the camera holder (CH) coming from the right side of the patient.

tunnel by grasping the catheter and/or the stay suture, taking care not to twist the ureter. We favor the resection of the terminal part of the ureter. The ureter is anchored to the detrusor by one or two full thickness sutures (5/0 Maxon extracorporeal slipping knots). Next, four to six 6/0 absorbable sutures are inserted between the bladder and ureteric mucosa (intracorporeal knots). The incision in the mucosa of the original orifice is closed with 6/0 absorbable interrupted or running sutures. The procedure can be unilateral or bilateral. Once the ureteroneocystostomy is completed, its patency is checked by introducing an ureteric catheter, but leaving a ureteric stent is usually not required. The lateral trocars

are extracted. If they are 3 mm trocars, the trocar sites in the bladder are left open; if they are 5 mm in diameter, they are closed using a technique of stitches passed with a Reverdin needle or a suture passer under visual control by the suprapubic telescope. These two lateral trocar sites could also be closed under visual control by using two 16 gauge Angiocaths (one with a 3/0 absorbable suture and one with a loop suture) according to a technique described by Yeung<sup>1,2</sup> and demonstrated on the DVD. The third 5 mm median hole could be closed directly under visual control in case of a thin abdominal wall; if this maneuver becomes difficult, the hole is left open and a 10 Fr suprapubic catheter is left in situ. The skin wounds





**FIGURE 6.6.** Second step: Position of the team in the case of a child older than five years of age. The surgeon (S) is on the left side.

are further closed with 5/0 subcuticular absorbable monofilament suture. In any case, a bladder drainage (transurethral or suprapubic) is left for two days. No perivesical drain is needed.

## Postoperative Management

Bladder drainage is maintained for two days after the operation. Persistent mild hematuria is usual for three to four days. As a result of caudal anes-

thesia, postoperative pain is usually mild and oral analgesics usually suffice. Postoperative antibiotic therapy and prophylaxis are given according to the preoperative urinalysis.

The patient is usually discharged from the hospital on the third day after the procedure. A follow-up ultrasound is performed at one week and two months. For our first 50 cases, a postoperative voiding cystogram was performed routinely at three to six months postoperatively, but in view of the very high reflux resolution rate, this cystogram is now only performed if there is a suspicion of persistent reflux or abnormal upper urinary tract dilatation.

## Results

Between October 2002 and November 2004, pneumovesicoscopic ureteral reimplantation according to the Cohen principle was attempted in 40 children between 6 months and 14 years of age (mean age, 6.2 years). The first 15 cases operated between June 2001 and September 2002 were eliminated because they corresponded to the learning curve (6 conversions, long operative time). Indication for pneumovesicoscopic Cohen reimplantation were as follows:

- 12 patients with grade 4–5 VUR (mean age, 2.8 years).
- 25 patients with grade 3 VUR (mean age, 7.2 years).
- 3 patients with grade 2 VUR (mean age, 12 years).

Lower grade reflux was treated only if the radio-nuclide scans showed renal scarring or patients had recurrent breakthrough UTIs while on chemoprophylaxis. Reflux was unilateral in 16 patients (5 duplications) and bilateral in 24 patients (9 duplications). A total of 78 ureters were reimplanted. Six patients were operated after endoscopic submucosal injection failure.

No cases were converted. The mean operative time was 82 minutes for unilateral reimplantation and 130 minutes for bilateral reimplantation. The longest operative time has been reported with bilateral duplex system. During the procedure, one patient developed a scrotal emphysema which

resolved spontaneously and six patients developed a pneumoperitoneum that required exsufflation with a Veres needle. All the patients recovered uneventfully. The mean hospital stay was 2.8 days. All patients were followed for a median of 11 months (3–26 months).

No procedure related complications were observed in any patients. Two patients (5%) developed a temporary ureteric dilatation without symptoms; however follow-up ultrasound showed no evidence of obstruction in any of the reimplanted ureters. One patient has had a symptomatic urinary infection without persistent reflux on cystogram. A follow-up voiding cystography was performed in 28 patients (49 ureters); reflux was persistent in one ureter at a lower grade (5 to 2). The reflux resolution rate was 27/28 patients (96%) and 48/49 ureters (98%). There was no difference in correction rate for high grade reflux or reflux in duplex systems.

Although the analgesic requirement for pain control was not prospectively studied because a systematic protocol was applied in each case, the medical and nurse staff have had the subjective impression that the postoperative pain could be generally assessed as a median value between postoperative pain after endoscopic subureteral injection and postoperative pain after classical open reimplantation.

## Author Remarks

Why try to develop a minimally invasive transvesical technique instead of a minimally invasive extravesical technique (such as Lich-Gregoir, which has been already described by transperitoneal route)? The Lich-Gregoir technique has been reported to give excellent results and is associated with significant less morbidity than transvesical reimplantation, particularly less hematuria and less bladder spasm. However extravesical reimplantation has a high risk of postoperative voiding dysfunction and urinary retention, especially in case of bilateral reimplantation. Moreover, the Lich-Gregoir technique is not suitable for all kinds of reflux, as, for example, cases of obstructed megaureter. Our goal is to develop a technique that could be useful for all intravesical procedures

including ureterocele management and bladder neck surgery.

As the urothelial lining is relatively impermeable to carbon dioxide, there are minimal systemic or physiologic disturbances due to CO<sub>2</sub> absorption. The escape of CO<sub>2</sub> in the perivesical space is usually minimal. The modification of the CO<sub>2</sub> parameters, recorded by our anesthesiologists, are the same than for short retroperitoneal insufflation. The advantages of reimplantation under pneumovesicoscopy according to the Cohen principle are:

1. Reduction of the abdominal wall trauma. The cosmetic aspect must be taken into account because seven out of ten operated patients are girls.
2. Reduction of the bladder trauma: No wide cystotomy, no mucosal irritation with gauze swabs, no intravesical retraction. This means potential reduction of postoperative hematuria, mucosal edema, and bladder spasms.

The preliminary results are excellent. Given that the surgical technique is similar, it seems probable that the long-term results in larger series will be superior to those obtained by open surgery. So there is no need for a second procedure under general anesthesia as is often the case with subureteric submucosal injection.

The development of assisted surgery by the daVinci robotic system, with new 5 mm instruments, will probably be a great technological contribution to perform these delicate maneuvers.<sup>3,4</sup>

## Conclusion

Several techniques compete to correct the primary vesicoureteral reflux in children. There is no consensus about the choice of an appropriate technique. This decision remains a parental and personal surgical choice motivated by specific advantages and disadvantages.

The classical techniques all offer a high rate of success, which is associated with a very small risk of complications. Currently, it seems difficult to improve on these results. However, the potential risks posed by open surgery can be significantly reduced by laparoscopic techniques. Even if the overall acceptance of laparoscopic techniques

among pediatric urologists remains limited, surgeons must take into account most parent's preference for the less aggressive and most effective therapeutic method for their child. This new technique represents an important alternative to other antireflux techniques and should be considered before open surgical correction.

## References

1. Yeung CK, Borzi PA. Pneumovesicoscopic Cohen ureteric reimplantation with carbon dioxide bladder insufflation for gross VUR. *Br J Urol Int* 2002;89(2): 15–86.
2. Yeung CK, Sihoe JD, Borzi PA. Endoscopic cross-trigonal ureteral reimplantation under carbon dioxide bladder insufflation: a novel technique. *J Endourol* 2005;19(3):295–299.
3. Olsen LH, Deding D, Yeung CK, Jorgensen TM. Computer assisted laparoscopic pneumovesical ureter reimplantation a.m. Cohen: initial experience in a pig model. *APMIS Suppl.* 2003;109:23–25.
4. Peters CA, Woo R. Intravesical robotically assisted bilateral ureteral reimplantation. *J Endourol* 2005; 19(6):618–621.

## Genitalia

# 7

## Impalpable Testis

Mohan S. Gundeti and Duncan T. Wilcox

Undescended testis is a common congenital anomaly occurring in approximately 1% of male infants. In approximately 20% of patients with an undescended testicle, the testis is not palpable.<sup>1</sup> The management of a child with a palpable testis is not controversial, but management of an infant with an impalpable testis can generate considerable clinical debate. Despite improvements in cross-sectional imaging, the most accurate evaluation of the undescended testicle is by a diagnostic laparoscopy.<sup>2</sup> Since the laparoscopic orchidopexy was first described by Jordan in 1992, a therapeutic procedure can be performed at the same anesthetic.<sup>3</sup>

Prior to embarking on a diagnostic laparoscopy, it is important to ensure that the patient has an isolated undescended testicle and is not suffering from an intersex disorder.<sup>4</sup> Once the child is under general anesthesia it is also vital to reexamine the patient, as previously undetected testicles can become palpable, thereby avoiding the need for laparoscopy.<sup>5</sup> In those patients who still have an impalpable testicle, it is reasonable to proceed with laparoscopy.

### Indications and Contraindications

A diagnostic laparoscopy is indicated if testes are impalpable despite careful examination under anesthesia.

Contraindications include bleeding disorders and children who have undergone previous abdominal surgery. In these patients, particular

attention should be paid to the placement of the ports.

### Preoperative Preparation

No specific preoperative preparation is necessary.

### Patient Position

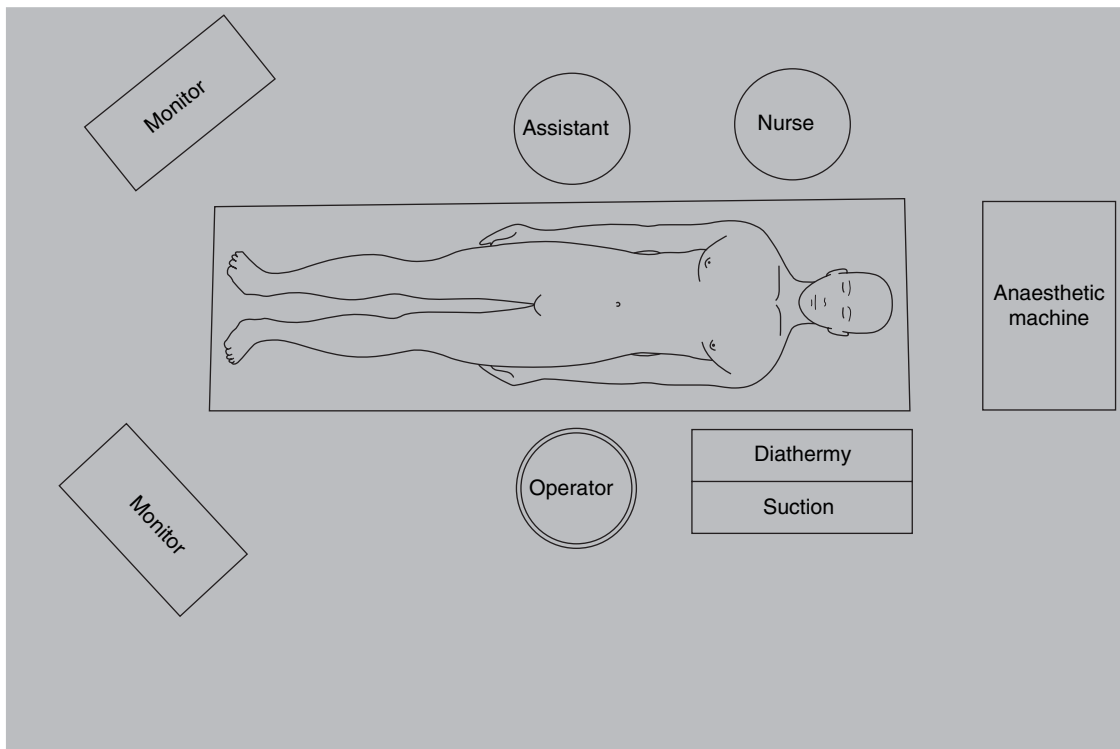
The patient is placed supine on the operating table. Once the ports are in position, the patient is then put head down to clear the small bowel from the operative field. The position of the anesthetist (A), surgeon (S), camera holder (C), scrub nurse (N), and audiovisual equipment are shown in Figure 7.1.

### Port Positioning

The camera port is placed either in a supra- or infraumbilical skin crease, using the open Hassan technique. Either a 5 mm or a 3 mm port is used.

### Operative Technique

A pneumoperitoneum is created using CO<sub>2</sub> gas, with a flow rate of 1 L/min to 2 L/min and a pressure of 10 mm to 12 mm of mercury. A 30 degree



**FIGURE 7.1.** Diagram showing the positioning of staff and equipment around the operating table.

laparoscope is usually used to aid visualization of the peritoneal cavity.

Once inside the peritoneal cavity, the normal side is examined first to reconfirm normal anatomy. The first landmark is the median umbilical fold (obliterated umbilical artery) on the anterior wall of the bladder. The vas deferens should cross over it from medial to lateral, running toward the internal ring. This is joined by the testicular vessels, which run parallel to iliac vessels (See the DVD) (Figure 7.2)

The findings that can be seen at diagnostic laparoscopy include:

1. Normal vas and vessels entering the canal with or without a patent process vaginalis. Occasionally a testicle can be seen peeping in from the internal ring (see DVD).

2. Intraabdominal testis with normal vas and vessels with adequate mobility. This is usually assessed by seeing if the testis can reach the opposite internal ring (see DVD).

3. Intraabdominal testis with short vessels and normal vas deferens (see DVD).

4. Vessels that become atretic before entering the internal ring. This represents an absent testicle. This is only true if the vessels can be seen and become atretic, not if the vas is not visualized alone (see DVD).

Once the diagnostic laparoscopy is performed, there are three treatment options if a testicle is seen: (1) a single-stage orchidopexy, (2) the first stage of a Fowler Stephens orchidopexy, or (3) a single-stage Fowler Stephens orchidopexy. Figure 7.3 proposes a management algorithm.

## Single-Stage Laparoscopic Orchidopexy

### Indication

An indication for this procedure is intraabdominal or peeping testis with good vas and vessels that appear to have adequate length.

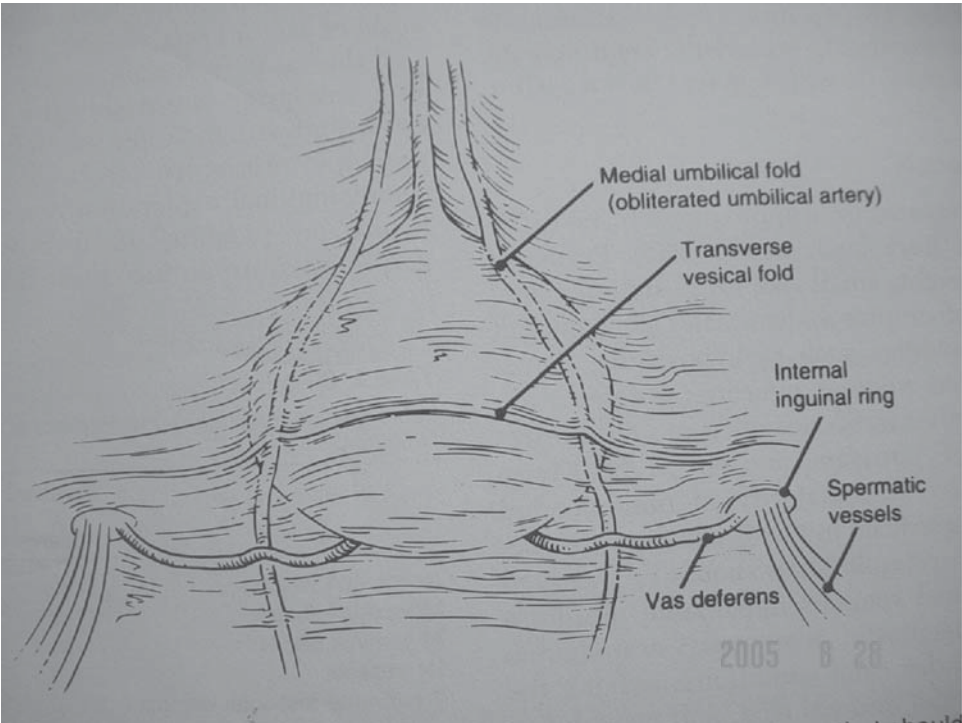


FIGURE 7.2. The normal anatomy of the internal ring.

**Port Position**

Following the placement of the camera port, two working ports are placed with local anaesthetic under direct vision. The position of ports for a standard orchidopexy is shown in Figure 7.4.

**Operative Technique**

The peritoneum is incised lateral to the testicular vessels (position A) and continued to the internal ring. The gubernaculum is divided, and the incision on the peritoneum is extended running par-

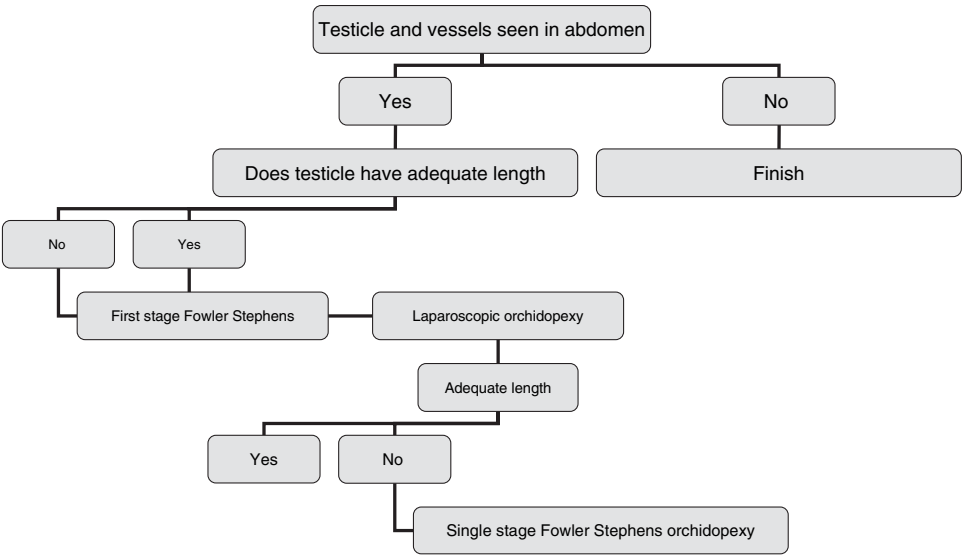
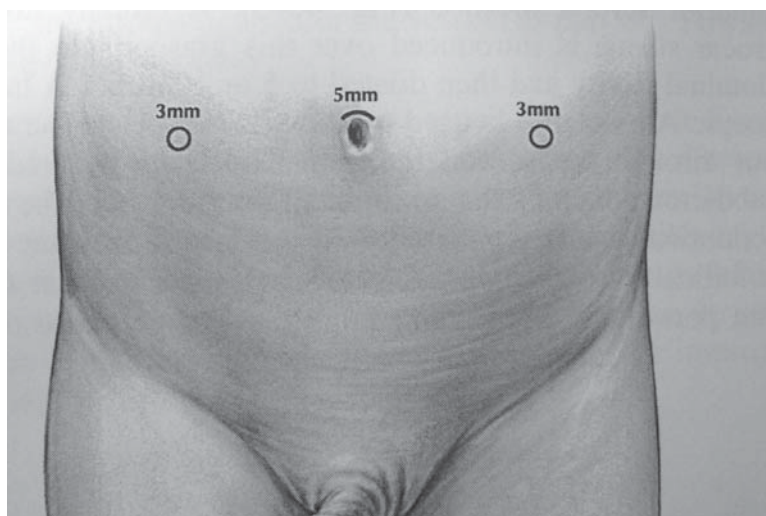


FIGURE 7.3. Algorithm for the management of a patient with an intraabdominal testicle.



**FIGURE 7.4.** Port site position for a unilateral or bilateral orchidopexy.

allel with the vas deferens. Care is necessary to ensure that the vas is not damaged. This maneuver is aided by grasping the gubernaculum that is still attached to the testicle and bringing it across to the contralateral internal ring. When this is completed, the peritoneum is incised over the testicular vessels and continued to join the incision at position A. This incision can then be continued down into the pelvis running parallel to the vas deferens. This approach allows the maximum mobilization of the testicle without ligating the vessels.

A subdartos pouch is created and a grasping forceps or a transscrotal port is placed into the peritoneum either through the inguinal ring or, if there is insufficient length, medial to the inferior epigastric vessels. The testis is then grasped and brought in to the subdartos pouch. If at this point there is insufficient length, then further dissection of the peritoneum can be performed. Occasionally removing the pneumoperitoneum allows for sufficient length (see DVD).

### **Fowler Stephens First-Stage Laparoscopic Orchidopexy**

#### **Indication**

The indication for this procedure is intraabdominal testis with short vessels.

#### **Port Placement**

Port placement is the same as for the single-stage orchidopexy discussed earlier.

#### **Operative Technique**

The testicular vessels are identified. Then, the peritoneum is carefully dissected off the vessels 1 cm to 2 cm from the testicle. Care is taken not to damage the peritoneal tissue between the vas and vessels, as this may be source of the future collateral blood supply. The vessels are then obliterated with a clip applicator, ligation or diathermy according to surgeon preference (see DVD).

### **Fowler Stephens Second-Stage Laparoscopic Orchidopexy**

#### **Indication**

The patient should have had a first-stage Fowler Stephens orchidopexy. The second stage is usually performed six months after the initial procedure.

#### **Port Placement**

The same as described for the first-stage orchidopexy.



### Operative Technique

The obliterated vessels are first divided. The peritoneum is incised lateral to the vessels and testis. This is continued to the internal ring, where the gubernaculum is divided. While still attached to the testis, the gubernaculum is then grasped and pulled toward the contralateral internal ring. The peritoneum is then incised parallel to the vas deferens on both the distal and proximal sides, ensuring a wide rectangle of peritoneum. The dissection of the rectangle of peritoneum is continued down into the bladder until sufficient length is achieved. The testis is then placed in a subdartos pouch as described previously. (see DVD).

### Single-Stage Fowler Stephens Orchidopexy

#### Indication

The indication is inability to complete a laparoscopic orchidopexy without ligating the testicular vessels.

#### Port Placement

The port placement is the same as described earlier.

#### Operative Technique

Both the first and second stage of the Fowler Stephens Orchidopexy are performed under a single anesthetic.

### Closure

Following completion of the laparoscopic procedure, insufflation pressure is reduced and any obvious bleeding is visualized and stopped. The ports are removed under direct vision. The port sites are sutured (deep fascial and then skin) to prevent wound herniation.

### Complications

The most common complication is that the testicle becomes ischemic. This depends on the original position of the testicle and the type of surgical procedure performed. The testicle can also retract out of the scrotum towards the inguinal canal.<sup>6</sup>

Bowel injury can occur either at the time of port insertion or from diathermy injury. Both of these are extremely rare.

### References

1. Baker LA, Docimo SG, Surer I et al. A multi-institutional analysis of laparoscopic orchidopexy. *Br J Urol Int* 2001;87(6):484–489.
2. Docimo S, Peters C. Paediatric Endourology and laparoscopy. In: Kavoussi Walsh P, Reitk A, Vaughan E. et al., (eds.), *Campbell's Urology*, 8th ed, pp 2265–2592.
3. Jordan GH, Winslow BH. Laparoscopic single stage and staged orchiopexy. *J Urol* 1994;152(4):1249–1252.
4. Kaefer M, Diamond D, Hendren WH et al. The incidence of intersexuality in children with cryptorchidism and hypospadias: stratification based on gonadal palpability and meatal position. *J Urol* 1999;162(3 Pt 2):1003–1006; discussion 1006–1007.
5. Cisek LJ, Peters CA, Atala A Current findings in diagnostic laparoscopic evaluation of the non-palpable testis. *J Urol* 1998;160:1145–1149; discussion 1150.
6. Lindgren BW, Franco I, Blick S, Levitt SB, Laparoscopic Fowler Stephens orchidopexy for the high abdominal testis. *J Urol* 1999;62:990–994.

### Video Clips

1. Normal anatomy of the internal ring
2. Intraabdominal testicle with adequate length for a single staged orchidopexy
3. A high intraabdominal testicle
4. Video showing atretic testicles associated with a vanishing testicle
5. Single staged laparoscopic orchidopexy
6. First stage of a Fowler Stephens orchidopexy
7. Second stage of a Fowler Stephens orchidopexy

# 8

## Varicocelectomy (I)

Job K. Chacko, Al Baha Barqawi, Jesse N. Mills, and Martin A. Koyle

The adolescent varicocele is a common entity with an incidence of 15% to 16% at age 10 to 15 years.<sup>1,2</sup> In the adult population, varicocele is a common entity among subfertile men and is thought to be a reversible cause of infertility.<sup>3</sup> The primary indication for varicocele correction in adolescence is the presence of testicular “hypotrophy” of the testis ipsilateral to the varicocele. The correction of varicocele in adolescence has been shown to improve both atrophy of the testicle and semen parameters.<sup>4</sup>

### Indications and Contraindications

As mentioned, the main indication for correction of varicocele is ipsilateral testicular hypotrophy. This is defined as a greater than 20% size discrepancy when compared with the contralateral testicle using a Prader orchidometer or ultrasound measurement. Catch-up growth can occur in up to 80% of testicles after correction of the varicocele.<sup>2</sup> Another possible indication is patients who have having symptoms related to the varicocele, such as pain, although this is rare in our experience. Also, an extremely rare indication for intervention is the older teenager (who is willing to give a semen analysis) that shows abnormal semen parameters.

### Preoperative Investigation

Preoperative investigation involves taking a patient history and giving the patient a physical exam with testicular measurement by orchi-

dometer and/or testicular ultrasound. We routinely measure the testis again intra-operatively.

### Preoperative Patient Preparation

Patients and parents should be counseled that data regarding indications for varicocelectomy are sorely lacking. They are thus offered four options: (1) Observation with semen analysis when they are age appropriate; (2) radiologic embolization under local anesthesia; (3) open surgical correction via all commonly used approaches; and (4) laparoscopic varicocele interruption.

### Specific Instrumentation

1. 3 mm or 5 mm umbilical port for camera/scope.
2. LigaSure (Valleylabs) device (5 mm clip applier or harmonic scalpel can be used as other options).
3. Maryland grasping forceps.

### Schematic Diagram

A schematic representation of the operating room setup is shown in the accompanying DVD.

## Operative Technique

All patients should be instructed to void prior to entering the operating room to avoid catheterization. After general anesthetic induction, the airway is maintained either with an endotracheal or a laryngeal mask airway. The patient is then placed in Trendelenberg position. A 3 mm or 5 mm port is used to gain umbilical access to the peritoneum. Insufflation is performed, keeping the pneumoperitoneum pressure at less than 15 mm Hg. Under laparoscopic guidance, two working sites are created using stab incisions rather than ports. One is located in the midline suprapubically (usually in the pubic hair to hide any scars) and one essentially in the area of McBurney's point. The Maryland forceps is placed through the right lower quadrant site, and the Ligasure device in the suprapubic site. Using only these two instruments, a small peritoneal window is created over the spermatic vessels, as cranial as possible to the vas deferens. The vessels are easily controlled and can be grasped into view to allow the Ligasure to be utilized to "seal" the vessels. We have made no attempt to isolate the artery separately nor to aggressively delineate lymphatics. The pneumoperitoneum is decompressed to assure that there is no bleeding, and traction is gently applied to the ipsilateral testicle to assure that there are no obvious attachments that might have been missed. Local anesthetic is injected into each working site and the instruments removed. We have used a 4/0 dissolvable suture to close the subumbilical fascia and used only Dermabond application to bring together the skin edges. Initially this technique might take 30 minutes or so to master, but with experience it should take no longer than 10 minutes to 15 minutes.

## Postoperative Management

Postoperatively, patients receive intravenous ketorolac prior to awakening and are discharged the same day. There are no bathing or activity restrictions. They are instructed to take acetaminophen and ibuprofen alternating every 4 hours for 48 hours and are given a prescription for narcotics to be filled as needed. The patients are seen post-

operatively between the sixth and twelfth week and then in one year.

## Complications

The most common complication is a reactive hydrocele. These usually resolve by themselves, but occasionally they require scrotal hydrocelectomy.

## Author's Remarks

This is a remarkably simple technique to master, even with basic laparoscopic skills. Importantly, it has well more than a 99% success rate in our hands and allows the patient immediate return to activity. We have not lost a testicle in >200 cases and the rate of catch-up growth has been 84%. To date, only 4 (2%) of patients have required hydrocelectomy, despite not routinely attempting to define lymphatic structures. Likewise, we have been impressed by the fact that this technique can safely be performed in patients who have already had prior inguinal and scrotal surgery, where collateral arterial vasculature might have been disrupted.<sup>5</sup> Given this experience, we feel that there are no contraindications to performing this procedure as the option of choice in patients requiring varicocele interruption.

## References

1. Kass EJ, Belman AB. Reversal of testicular growth failure by varicocele ligation. *J Urol* 1987;137:475-476.
2. Jarow JP. Effects of varicocele on male fertility. *Hum Reprod Update* 2001;7:59-64.
3. Okuyama A, Nakamura M, Namiki M et al. Surgical repair of varicocele at puberty: preventative treatment for fertility improvement. *J Urol* 1988;139:562-564.
4. Koyle M, Oottamasathien S, Barqawi A, Rajimwale A, Furness III P. Laparoscopic Palomo varicocele ligation in children and adolescents: results of 103 cases. *J Urol* 2004;172:1749-1752.
5. Barqawi A, Furness III P, Koyle M. Laparoscopic Palomo varicocelectomy in the adolescent is safe after previous ipsilateral inguinal surgery. *Br J Urol Int* 2002;89:269-272.

# 9

## Varicocelectomy (II)

Chris P. Kimber

Widespread debate still continues among pediatric surgeons, adult urologists, andrologists, and infertility experts as to the role of an asymptomatic varicocele in the subfertility issues of a man. Herz recently suggested that even some subfertile semen parameters exist in adolescent asymptomatic varicoceles without testicular asymmetry.<sup>1</sup> He also suggested that surgical varicocele ligation significantly improves these parameters. The exact cause of varicocele remains unknown. In prepubertal boys, a compressing malignancy, such as a Wilms' tumor, must always be considered and an ultrasound performed. Varicoceles are classified according to a grading system of 1 to 3, with or without testicular asymmetry. It should be remembered that boys going into puberty often have asymmetrical testicular growth and this finding may be coincidental. The grade of varicocele and testicular size may rarely correlate. Several operative techniques are available for surgical varicocele ligation.<sup>2-4</sup> Interventional radiology has an equal success to all surgical techniques, particularly in the adult population. For more than 20 years, my colleagues and I in Melbourne have been performing a testicular artery and vein ligation within the abdomen known as the Palomo technique. This technique is easily accomplished laparoscopically.

### Indications and Contraindications

Asymptomatic, mild Grade I varicoceles with no testicular asymmetry rarely require any operative intervention. Adolescents with Grade III varico-

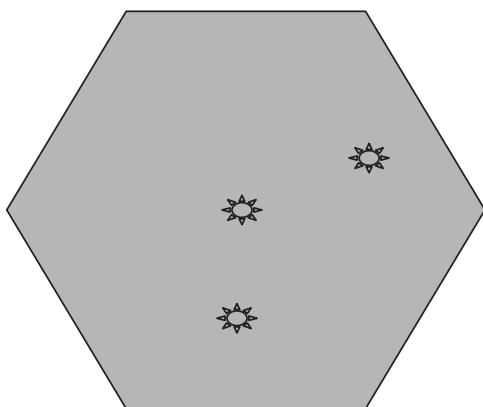
celes, asymmetrical testicular growth, and significant symptoms are all suitable candidates for laparoscopic varicocelectomy. Patients with a moderate varicocele who are asymptomatic and have equally sized testicles measured on an orchidometer rarely require surgical intervention. Many of these patients will be followed for several years and may demand the procedure on a cosmetic basis. I think this is a reasonable indication for surgery, provided the adolescents are fully informed as to risks.

### Preoperative Investigations

As stated earlier, prepubertal boys require ultrasound assessment for a compressing tumor mass. Apart from informed consent, no other preoperative workup is required in the adolescent patient.

### Operative Technique

This is a day case procedure. A 5 mm port is placed in the umbilicus, and there are two additional 3 mm or 5 mm port sites. Because more than 95% of varicoceles are left sided, I place one of these ports suprapubically and the remaining one in the left upper quadrant (Figure 9.1). The testicular veins are identified emerging from the internal ring. The peritoneum is incised approximately 2 cm proximal to the internal ring. The entire leash of vessels including the arteries, veins, and



**FIGURE 9.1.** Standard laparoscopic left varicocelelectomy with three 5 mm ports.

lymphatics are mobilized. A 2/0 Vicryl tie is initially tied distally and then proximally around the vessels. The vessels are cut between the two ligatures. Hemostasis is checked for, and the port sites closed. Routine operating time is less than 15 minutes. Occasionally a head down position may be required, particularly with the sigmoid colon loaded. It is my preference to ligate these vessels with 2/0 Vicryl rather than using expensive clip applicators that may require multiple firings. This technique also enables the trainee further suturing opportunities. There is a recent trend, based on the report from the large experience of more than 1,000 patients in Moscow, to sparing the lymphatic vessels during this procedure.<sup>5</sup> Many authors, including Hock Tan in Adelaide, have advocated the installation of methylene blue into the scrotal skin on the affected side to better identify lymphatic vessels.<sup>6</sup> The Moscow series has demonstrated that attempting to spare the lymphatics may reduce the postoperative hydrocele rate. In Melbourne we are currently ligating the artery, vein, and lymphatics.

## Postoperative Management

The patient is usually discharged home on the same day and has his dressings off one week later, with return to full sporting activity 7 days to 10 days after the procedure.

## Complications

1. Testicular atrophy: This is obviously the most devastating complication. Young boys and their parents must be fully informed that there is a risk of complete testicular atrophy with this procedure. I think it is important to have this documented and sent to them in writing. The reported risk of this occurring is less than 1/1000 from the large Moscow series.

2. Recurrence: Recurrent varicocele is certainly possible following laparoscopic varicocele ligation. There are additional venous and arterial blood supplies to the testes from the artery to the vas and from the cremasteric branch of the inferior epigastric artery. Subsequent additional varicoceles may develop and require secondary surgery.

3. Hydrocele: Up to 3% of patients may experience a reactive hydrocele from ligation of lymphatic vessels with the Palomo procedure. If this occurs, a subsequent Jaboulay procedure is required and is usually successful.

4. Genitofemoral nerve damage. Excessive electrosurgery or other energy devices in the retroperitoneum may damage the genitofemoral nerve.

## Author's Remarks

I believe the decision for surgical treatment in laparoscopic varicocele, particularly in the adolescent patient, should come from the patient himself. I recommend a full informed consent process, including supplying written and direct information of complications involved. In addition, I encourage the young patients to E-mail me over the subsequent few weeks with further questions that they may have felt embarrassed asking during the consultation, particularly with a parent present. Although the outcome for varicocele surgery is good, the risks and complications are significant. Full informed consent is paramount. A laparoscopic varicocelelectomy is a safe, well-tolerated, and simple procedure to perform.

## References

1. Herz D, Dillon B. Surgical varix ligation improves occult sub-fertile semen parameters in adolescent

- asymptomatic varicoceles without testicular asymmetry. Presented at the Joint ESPU-AAP meeting, Uppsala, Sweden, 16–18 June 2005.
2. Alukal JP, Zurakowski D, Atala A et al. Testicular hypotrophy does not correlate with grade of adolescent varicocele. *J Urol* 2005;174(6):2367–2370.
  3. Kocvara R, Dvoracek J, Sedlacek J et al. Lymphatic sparing laparoscopic varicocelectomy: a microsurgical repair. *J Urol* 2005;173(5):1751–1754.
  4. Varlet F, Becmeur F; Groupe d'Etudes en Coeliochirurgie Infantile. Laparoscopic treatment of varicoceles in children. Multicentric prospective study of 90 cases. *Eur J Pediatr Surg* 2001;11(6):399–403.
  5. Tan HL, Tecson B, Ee MZ, Tantoco J. Lymphatic sparing, laparoscopic varicocelectomy: a new surgical technique. *Pediatr Surg Int* 2004;20(10):797–798.
  6. Laparoscopic ligation of testicular veins for varicocele in children. Poddoubnyi IV, Department of Pediatric Surgery, Russian State Medical University, Filatov Children's Hospital #13, 15 Sadovaya-Koudrinskaya, 103001, Moscow, Russia. IPEG 2005 meeting Venice.

# 10

## Intersex and Laparoscopy

Chris P. Kimber and John M. Hutson

Significant intersex anomalies occur in up to 1 in 5,000 live born infants. These anomalies are caused by the following factors:<sup>1</sup>

1. Anomalies predictable by endocrine principles and these include defects in
  - a. genetic sexual determination
  - b. gonadal differentiation
  - c. hormonal production and action.
2. Anomalies not predictable by endocrine principles
  - a. morphological disorders of the perineum.

A child's gender is decided by its endocrine status, its morphological status including the possibility of fertility, and the prognosis for sexual function. In addition, the child's mental status and the likely gender behavior must be considered. These decisions are complex, individualized, and changing constantly with social expectations. Laparoscopy may have a role in aiding diagnosis in areas of insufficient virilization or mixed development (see Table 10.1).

### Indications

Laparoscopy has a role in intersex in several areas. In the initial assessment period, it may significantly aid diagnosis by determining the internal genital structures and gonadal type. This may ultimately influence the decision of gender assignment and the prognosis given to the parents regarding fertility. Laparoscopy is also used for surgical resection of internal structures, including Mullerian remnants, utriculi, and incompletely

virilized structures. It is also useful for assessment and management of the gonad, in particular the removal of streak gonads or dysgenetic intra-abdominal ovotestes.<sup>2,3</sup>

Many straightforward intersex disorders do not require laparoscopy. These include complete androgen insensitivity, congenital adrenal hyperplasia, and some partial androgen insensitivities. These conditions are easily evaluated by thorough endocrine and radiological workup and rarely require surgical intervention.

The indications can be summarized as follows:<sup>4</sup>

1. Laparoscopy may often have a role in true hermaphroditism. Of these patients, 20% have specific lateral disease with a testis generally present on the righthand side and the ovary on the left. In up to 30% of cases, the disease has bilateral ovotestes. The remaining 50% of patients have unilateral disease with a solitary ovotestis and a normal ovary or a testis on the contralateral side. True hermaphroditism often requires accurate gonadal assessment and biopsy.

2. Laparoscopy also aids in removing highly potentially malignant gonads. In mixed gonadal dysgenesis, 25% of testes with a Y cell line will have evidence of carcinoma in situ. Half of the carcinoma in situ gonads will go on to develop a complete germ cell tumor. Laparoscopy is often worthwhile in the removal of these gonads.

3. Multiple conditions can result in persistence of Mullerian duct remnants, and enlarged utriculi are often found behind the bladder associated with severe hypospadias. Small utriculus



**TABLE 10.1.** Insufficient Virilization

- |  |
|--|
| 1. Genetic male 46XY with defect androgen synthesis and/or action.   |
| 2. Biosynthetic defects.   |
| 3. Androgen resistance (mutation in androgen receptor and/or transport).   |
| 4. Gonadal differentiation defects (i.e., streak gonads or dysplastic testes, mixed development chromosomal defects with gonadal asymmetry.<br>a. mixed gonadal dysgenesis (45XY/45XO)<br>b. true hermaphroditism 46XY, 46XX |

remnants are often asymptomatic and do not require any surgical treatment. Some of these young males ultimately develop recurrent utriculus infections, that are worse following hypospadias repair. In these patients, laparoscopic utriculus resection is indicated.

4. Finally, children with complex morphological development anomalies exhibit abnormal perineal, bifid or rudimentary uteri, and dysplastic gonads. Ultrasound and MRI imaging is often unreliable in this group. Evaluation of the pelvic structures is often best achieved with laparoscopy. Preoperative patient preparation with infants with intersex disorders requires a multidisciplinary team that includes geneticists, endocrinologists, counselors, pediatric urologists, and pediatric surgeons. A baby born with an indetermined sex is best transferred urgently to a center with appropriate expertise, so that life threatening conditions can be excluded and laparoscopy only performed if deemed appropriate.

**Preoperative Investigations**

Standard preoperative investigations of a child with an indeterminate intersex disorder include a thorough clinical assessment, ultrasonography of the perineum and pelvis, and contrast study of urogenital sinuses. Karyotyping and a comprehensive endocrine evaluation is done, including adrenal sex steroid concentrations and a hormone binding globulin test for androgen sensitivity. Molecular genetic analysis is used to look at the androgen receptor gene and the 5-alpha reductase gene. Many of these investigations can be com-

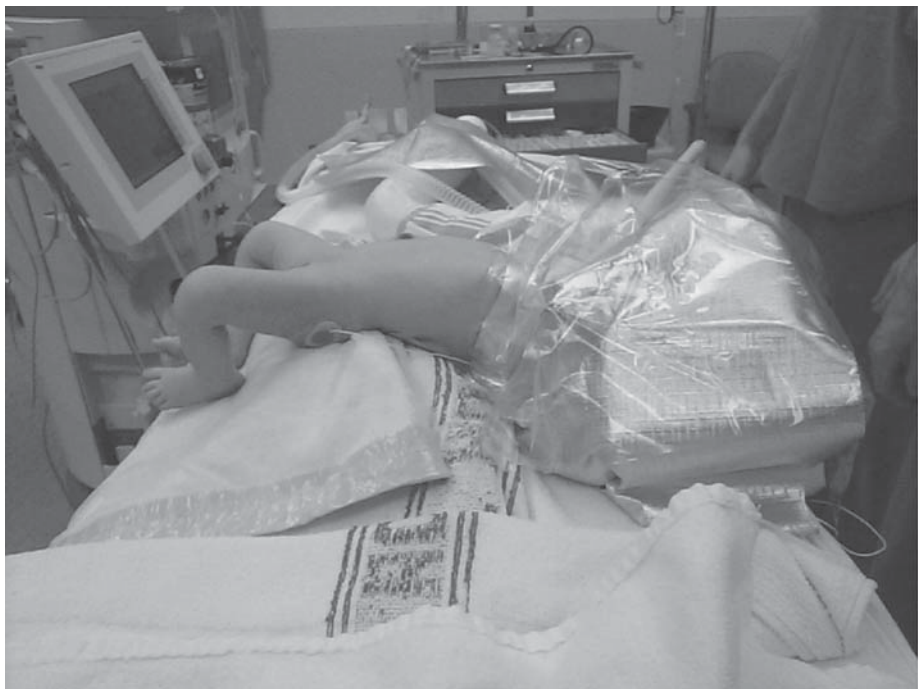pleted in a 48 hour neonatal period and laparoscopy is rarely required. There are several infants where the diagnosis and internal assessment still remains in doubt and the picture is mixed. In this case laparoscopic evaluation of the pelvic contents and gonadal biopsy is indicated in the neonatal period.

**Operative Technique**

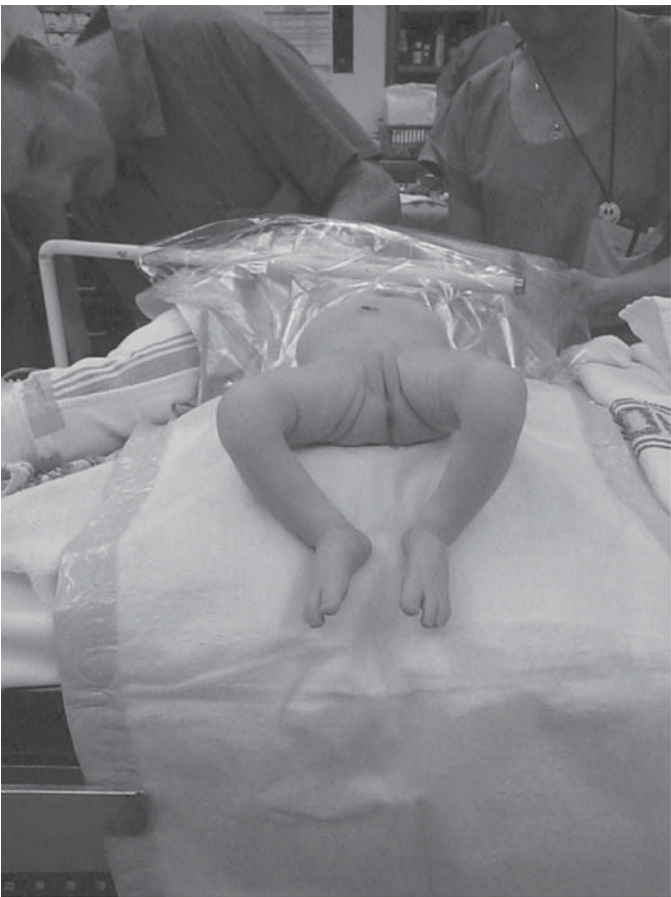**Procedure 1: Evaluation of Pelvic Structures for Indeterminant Gender in the Neonate**

The patient is placed transversely on the operating table with the surgeons standing at the child's head and a small towel placed under the buttock to elevate the pelvis and expose the external genitalia (Figures 10.1 and 10.2). A urethroscopy/cystoscopy/vaginoscopy is often performed prior to the laparoscopy. A 3 mm or 5 mm port is placed in the supra umbilical region via an open technique. This gives an appropriate operating angle and allows adequate insufflation. The pelvis is insufflated and the intestines displaced cranially so that a clear view can be obtained. A spinal needle is introduced through the left iliac fossa under direct vision. This blunted needle is very useful for manipulation of organ structures in the neonate and allows excellent visualization. Very rarely is a second port actually required. The spinal needle is used to trace out any uterine or Mullerian structures and identify the gonads. Biopsies are rarely required at this stage but can be achieved by either directly introducing a 3 mm biopsy forceps or a trucut biopsy needle. All ligamentous and/or vasal structures are traced into the inguinal area. Any open internal inguinal ring must be explored. A gonad is often located within the inguinal canal and can be reduced into the abdomen by concomitant pressure on the groin. Each gonad in turn must be examined completely for elements of ovotestis. A full media recording should be made of the whole procedure to allow peer review and subsequent opinion over the next few days. Accurate assessment of a neonatal uterus associated tubes and gonads is easily undertaken by this technique.

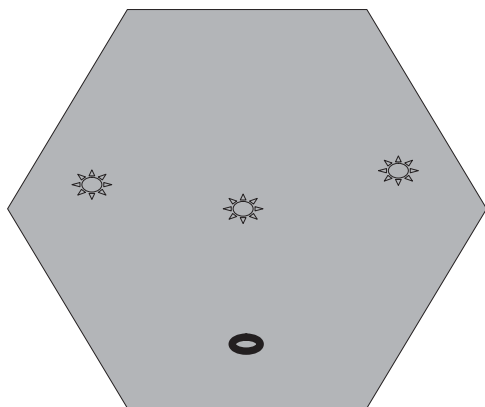




**FIGURE 10.1.** Patient position for neonatal intersex case.



**FIGURE 10.2.** Surgeon position for neonatal laparoscopy.



**FIGURE 10.3.** Standard laparoscopic intersex with three 5 mm ports and hitch stitch.

### Procedure 2: Laparoscopic Gonadal Excision

This is generally accomplished via a three port approach with an umbilical optic port (5 mm) and two working ports (Figure 10.3). Streak gonads are relatively easily identified and are best removed by preserving the Fallopian tube for use for assisted reproductive techniques in the future. Simple hook diathermy or ultrasonic dissection is required to remove streak gonads. Intraabdominal testes are easily removed in a similar fashion.

### Procedure 3: Removal of Persistent Mullerian Duct Structures

An initial cystoscopy and placement of a urethral catheter +/- a ureteric catheter in the remnant is performed. A similar three port orientation is used, but a single bladder hitch stitch is placed in the posterior bladder wall to elevate the pelvic structures. This stitch is held externally with mosquito forceps. The peritoneal reflection is opened and midline blunt dissection occurs until a utriculus is encountered and traction on this structure allows continued dissection down into the area of the prostate.

When the utriculus enters the prostate, significant thickening of tissue occurs with some bleeding. The distal utriculus is either endolooped or suture ligated. Directed sealing with ultrasonic dissectors is not recommended. A urethral catheter is required during the procedure to avoid any inadvertent urethral tightening. Many of these

procedures on children are day cases procedures. I generally leave a urethral catheter in for 3 days to 4 days but this is not essential.

## Complications

Most of the techniques in laparoscopy for intersex are simple and straightforward. The major difficulties occur in the clinical decision making, particularly in mixed phenotypes such as mixed gonadal dysgenesis or ovotestis. Many errors can be made in the visual inspection of the indeterminate gonad. A thorough examination of each gonad is required. Ovarian tissue can often appear to be deperitonealized (or detunicalized) within a testes. Incomplete excision can result in inappropriate hormone production and subsequent long-term risk of malignancy.

Poor positioning of the endoloop or suture ligature on the utriculus can result in urethral stricture (too tight) or a recurrent utriculus (inadequate dissection). This can result in recurrent pelvic sepsis and subsequent frozen pelvis. Optimum care must be made to ensure that dissection has been adequate and the clipped ligature has been placed close to the urethra without excessively tightening this structure.

## Conclusion

Laparoscopy has a major role to play in many intersex disorders. It may be useful in determining the sex of rearing and providing some prognostic indicators for fertility. The neonatal laparoscopy is reserved for accurate assessment in the rare and complex anomaly. Removal of gonadal tissue and Mullerian remnants are reasonably straightforward procedures. Careful case selection and close team coordination with the intersex team will minimize major complications and ensure appropriate case selection.

## References

1. Low Y, Hutson JM. Murdoch Childrens Research Institute Sex Study Group. Rules for clinical diagnosis in babies with ambiguous genitalia. *J Paediatr Child Health* 2003;39(6):406–413.

2. Yu TJ, Shu K, Kung Fi et al. Use of laparoscopy in intersex patients. *J Urol* 1995;154(3):1193–1196.
3. Heloury Y, Plattner V. Laparoscopy and Intersex. In: Bax NMA, Najmaldin A, Valla JS (eds). *Endoscopic Surgery in Children*. Springer Verlag, Berlin, 1999.
4. Hrabovszky Z, Hutson JM. Surgical treatment of intersex abnormalities: a review. *Surgery* 2002;131(1): 92–104.

# **Section B**

## **Endoscopy**

### **Lower Urinary Tract Endoscopy**

# 11

## General Principles of Cystourethroscopy

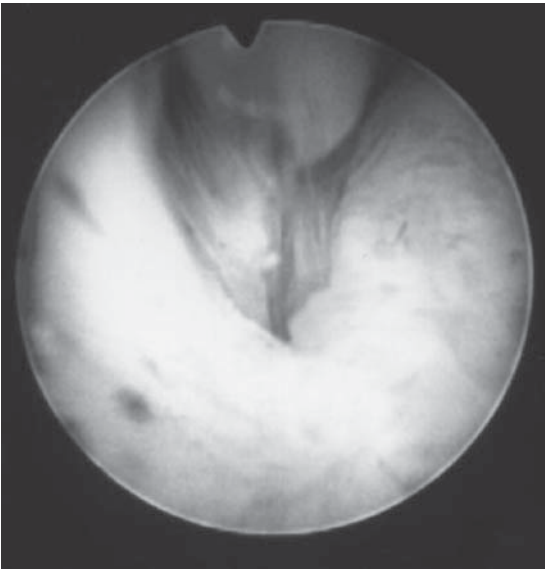
Linda A. Baker

As a form of minimally invasive surgery, endoscopy of the lower genitourinary tract of the pediatric patient can achieve diagnostic and therapeutic goals for a broad range of pathological entities. Advances in instrumentation have permitted endoscopic treatment of even premature infants and in utero fetal surgery.<sup>1</sup> This chapter focuses on general principles of pediatric cystourethroscopy. The reader is referred to other chapters for more detailed discussions of the management of other clinical entities.

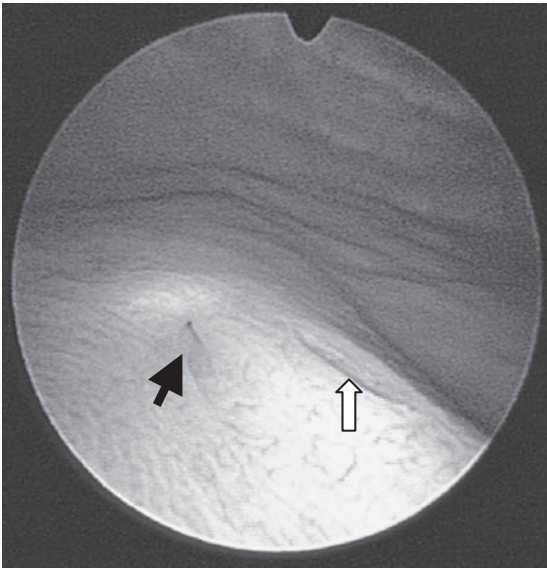
### Indications and Contraindications

Recurrent urinary tract infections (UTIs), urinary incontinence, obstructive uropathy, urosepsis, and radiological anomalies are the usual indications for lower tract endoscopy. Although many diagnoses are made before cystoscopy by using ultrasound, cystourethrography, CT scan, nuclear scan, IVP, and/or MRI, many pediatric cases require further delineation of the anatomy and physiology by endourological techniques. Cystoscopy followed by transurethral incision of posterior urethral valves for obstructive uropathy<sup>2</sup> is a common indication (Figure 11.1). Similarly, transurethral incision of ureterocele(s) for outlet obstruction or urosepsis<sup>3</sup> is another clear-cut indication (Figure 11.2), while prophylactic intervention after prenatal detection is more debated. Cystoscopically guided ureteral or bladder neck injection of bulking agents is frequently employed to treat vesicoureteral reflux (VUR) and urinary incontinence, respectively (see subsequent chap-

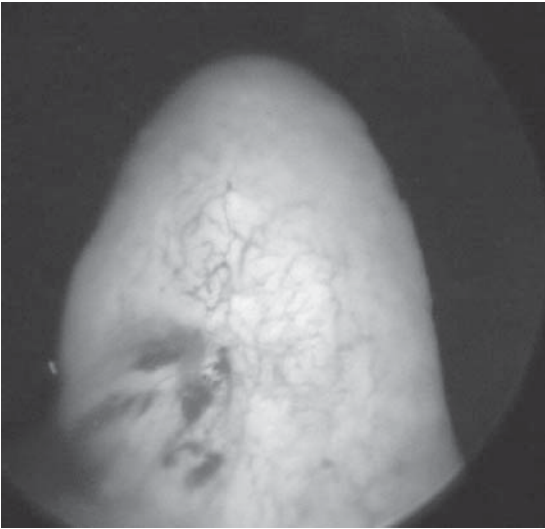
ters). Some surgeons recommend routine cystoscopy before open ureteral reimplantation to assess for the configuration of a prior refluxing ureter, missed ureteral duplication (Figure 11.3), or cystitis, which would cancel the open surgery. Male urinary incontinence should be evaluated cystoscopically after hypospadias repair or abnormal retrograde urethrogram, assessing for urethral stricture (Figure 11.4), urethral duplication (Figure 11.5) or urethrocuteaneous fistula. In rare cases, gross hematuria in the pediatric patient may warrant study after a thorough negative medical and radiological evaluation. If clot retention occurs, clot evacuation can be achieved cystoscopically with the instillation of therapeutic agents if indicated. Cystourethroscopy can serve the purpose of ureteral access for retrograde or antegrade upper tract imaging and lithotripsy techniques, however a trial of medical therapy is warranted because many stones pass in children. Retrograde placement of an occlusion balloon at the ureteropelvic junction can prevent antegrade migration of stone fragments during percutaneous nephrolithotripsy. Retrograde ureteral stenting may be useful at the time of extensive tumor resection or at the time of laparoscopic pyeloplasty. Bladder stones can be endoscopically removed or fragmented via urethra, appendicovesicostomy or percutaneous cystostomy approaches. At the time of cystoscopy in the child with an open bladder neck due to epispadias (Figure 11.6) or classic bladder exstrophy, a ballooned catheter can be used for cystography to measure bladder capacity under anesthesia and assess for vesicoureteral reflux.



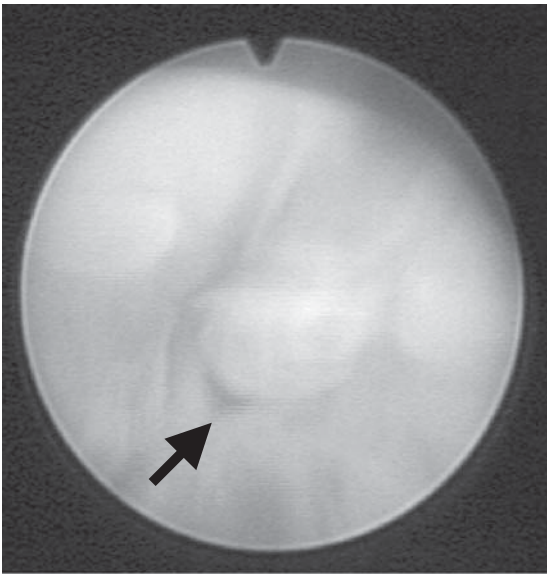
**FIGURE 11.1.** Cold knife incision of posterior urethral valves. The “half moon” knife, seen in the center of the image, is cutting through the right valve leaflet. The pink verumontanum is seen in the right third of the image. The left valve leaflet is out of the image.



**FIGURE 11.3.** Complete ureteral duplication. View of the right trigone reveals two ureteral orifices, the lateral, cephalad refluxing orifice (black arrow) serving the lower pole and the medial, caudal orifice (white arrow) serving the upper pole duplex kidney.

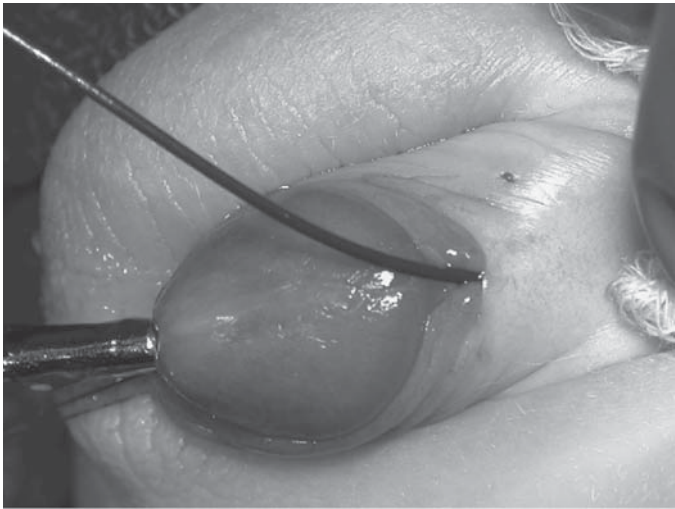


**FIGURE 11.2.** Ureterocele. Figure shows a right moderately sized ureterocele associated with febrile UTIs, right complete ureteral duplication, and a multicystic dysplastic hydronephrotic upper pole moiety. It was transurethraly incised.



**FIGURE 11.4.** Urethral stricture. Urethroscopy revealed a pinpoint lumen in the bulbar urethra at the site of a prior visual internal urethrotomy. Open primary urethroplasty was required to correct this recurrent urethral stricture.





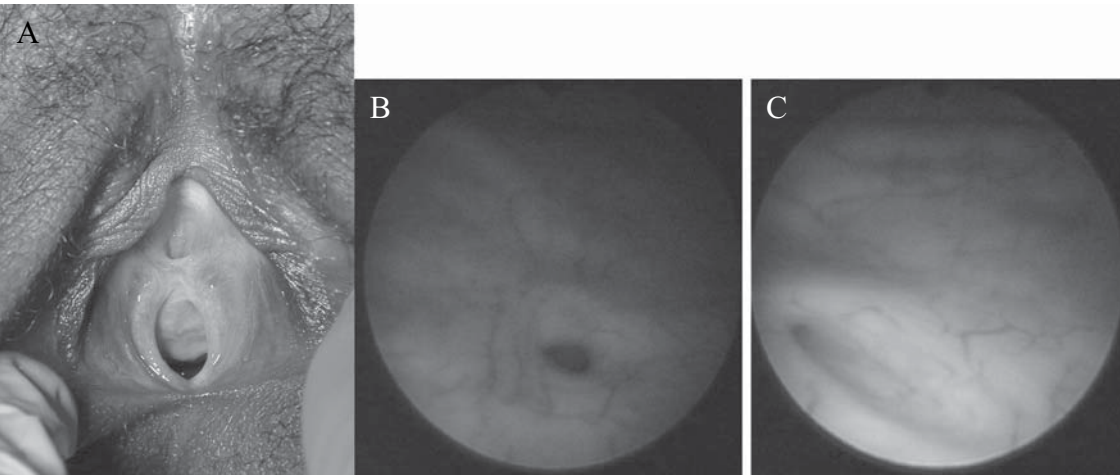
**FIGURE 11.5.** Urethral duplication. When a dorsally foreshortened foreskin was noted, cystoscopic inspection revealed a partial urethral duplication to the symphysis. In this image, with the foreskin

retracted, the black wire enters the dorsal nonfunctioning urethra and the metal urethral sound enters the ventral functioning urethral meatus.

Cystourethroscopy with vaginoscopy is indicated in the patient with intersex (Figure 11.7), urogenital sinus, or cloaca to delineate the surgical anatomy for repair. Tissue diagnosis of genitourinary malignancy (rhabdomyosarcoma, urothelial

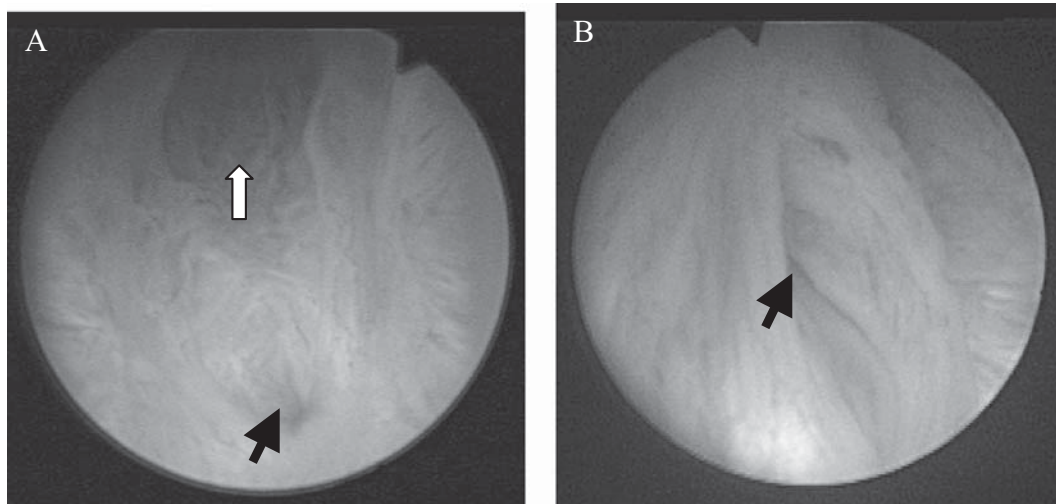
cancer) can be achieved by cystoscopy with tumor biopsy.

Contraindications include active bleeding disorders, hemodynamic instability, or untreated UTI/urosepsis.



**FIGURE 11.6.** Female epispadias with bilateral VUR. Exam under anesthesia reveals subtle case of female epispadias associated with bilateral VUR and urinary incontinence. Note the horizontally wide

urethral meatus with open urethral plate dorsally. The clitoris is bifid. The refluxing left (B) and right (C) ureteral orifices are seen.



**FIGURE 11.7.** Intersex. (A) Urogenital sinus of congenital adrenal hyperplasia (CAH). Cystourethroscopic evaluation of the urogenital sinus orifice reveals the bifurcation of the urethra (white arrow) and the vagina (black arrow). Cystourethroscopic placement of

fogarty balloons into the urethra and vagina aids the surgical reconstruction of the urogenital sinus. (B) Urethroscopic view of entrance into large utricle (arrow) on the verumontanum of an intersex patient with mixed gonadal dysgenesis.

## Preoperative Investigation

Cystourethroscopy generally requires general anesthesia. Therefore, a standard preoperative evaluation, considering cardiopulmonary, endocrinological, and hematologic disorders that increase anesthetic risks, is necessary. Children with identified disorders may require preoperative blood chemistries and children with congenital adrenal hyperplasia require stress steroid dosing. Preoperative radiological investigations often include ultrasound, cystourethrography, CT scan, nuclear scan, IVP, and/or MRI. Sterile urine is required to reduce risk of upper tract UTI prior to invasive instrumentation.

## Preoperative Patient Preparation

Once cleared for surgery and meeting NPO restrictions, an oral sedative is given to prevent separation anxiety. At this time, IV antibiotics may be administered in the child with recurrent UTIs, depending on physician preference.

## Specific Instrumentation

Most cystoscopic suites are equipped with monitors for fluoroscopic and videocamera imaging, which allow multiple viewers, teaching, optical magnification, and videorecording. A fiberoptic xenon light source and electrocautery are also required. Cystoscopic irrigant (sterile normal saline or sterile water) should be warmed to body temperature to diminish hypothermia. Several companies manufacture pediatric endoscopic equipment, including Wolf, Storz/Olympus, and ACMI. Given the delicate nature of this equipment, it is crucial to have several scopes available in case of equipment malfunction or unanticipated needs. Rigid pediatric cystoscopes range from 5 Fr to adult sizes, and the pubertal status of males should be noted to help judge the equipment needed. The 5 Fr “all in one” cystoscope is a one-piece instrument with united telescope and sheath; the 2.5 Fr to 3 Fr working channel is rather limiting. However the working channel increases in the larger scopes, with greatest caliber in the “all in one” cystoscopes. Other scopes consist of

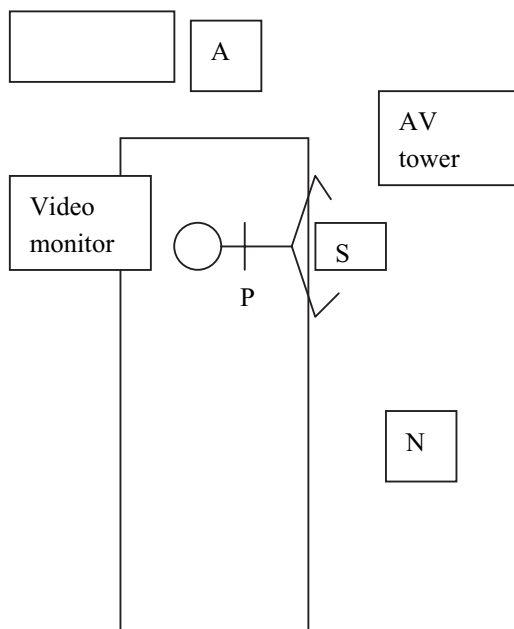


two pieces: the interchangeable telescope (0°, 30°, and 70°) and the sheath. A range of reusable and disposable equipment (graspers, biopsy forceps, bugbee electrode, wires, catheters, stents, balloons, baskets, laser fibers, and STING needles, to name a few) exist to achieve the indicated therapy, but may be impossible if the working channel caliber is <5 Fr. Pediatric cystoscopes with an offset lens allow straight entry into the working channel. 7.5 Fr flexible or semirigid ureteroscopes should be on hand if ureteral access is necessary. Pediatric resectoscopes, ranging from 7.5 FR to adult sizes, require loops, balls, blades, or hooks unique to the FR size of the resectoscope. Resectoscopes can be used cold or hot (with electrocautery), however, most recommend sparing use of electrocautery to minimize thermal damage and stricturing. Some have used holmium or Nd:YAG laser to cut valves or strictured tissue.<sup>4</sup> It is convenient to have urethral sounds and/or bougies available for urethral dilation if needed.

Endoscopic bladder stone management requires the use of rigid and flexible cystoscopes. If percutaneous access to the bladder is needed, cystoscopically guided suprapubic access sheaths can be quite useful and come in an assortment of sizes, with 13 Fr to 18 Fr the most useful. To achieve stone fragmentation, electrohydraulic, ultrasonic, combined ultrasonic and pneumatic (Swiss lithoclast), or holmium laser lithotripsy can be used. Rigid probes include the electrohydraulic probes (3 Fr or 5 Fr), ultrasonic probes (as small as 5 Fr) and the Swiss lithoclast (3.3 mm and 3.8 mm). Of the flexible probes, holmium laser fibers are 200, 400, 600, or 1000 microns, and Swiss lithoclast has an 0.9 mm flexible pneumatic probe.

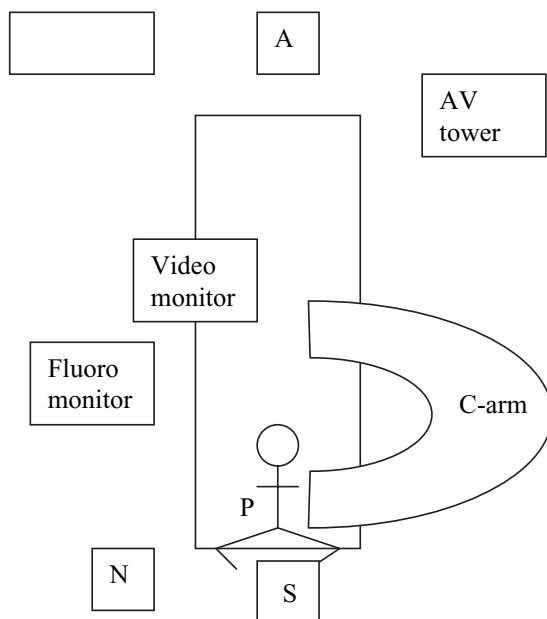
## Operative Technique

After the induction of anesthesia, the patient is properly padded, positioned, and grounded for electrocautery. In the infant, the supine frog-legged position may be adequate; however, an alternative is dorsal lithotomy position with leg suspension via towel rolls and tape at the padded knees. If fluoroscopy is not necessary, position the infant close to the anesthesiologist perpendicular on the bed to increase anesthetic safety (Figure 11.8). Otherwise, the child will need to be moved



**FIGURE 11.8.** If fluoroscopy is not necessary, position the infant close to the anesthesiologist perpendicular on the bed to increase anesthetic safety

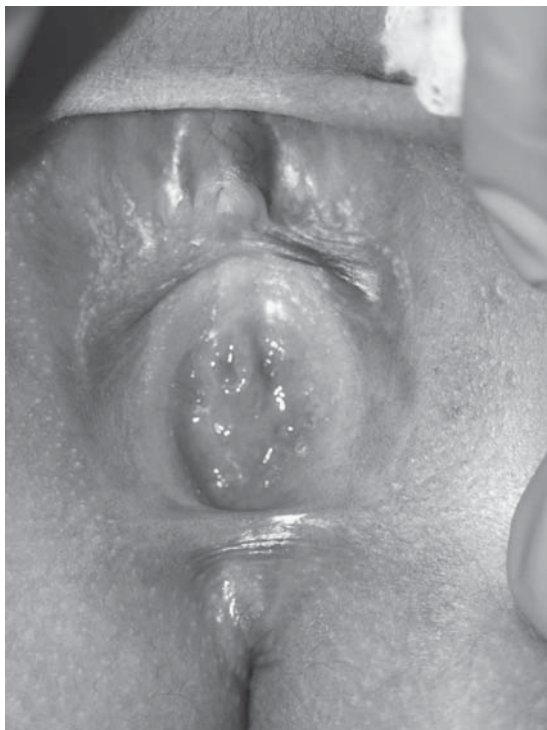down on the foot of the bed so the fluoroscopy arm can pass beneath (Figure 11.9). The older child should be placed in dorsal lithotomy position with the legs in properly fitted stirrups.



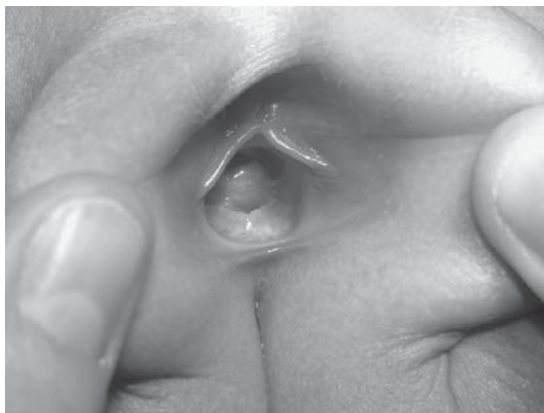**FIGURE 11.9.** If fluoroscopy is necessary, the child will need to be moved down on the foot of the bed so the fluoroscopy arm can pass beneath

Prior to the surgical preparation, a thorough examination under anesthesia is performed. The external genitalia are closely inspected for anomalies (genital configuration (Figure 11.10), masses (Figure 11.11), or ectopic orifices (Figure 11.12). After securing properly functioning instrumentation, a lubricated cystoscope is chosen of appropriate size for the child.

Cystourethroscopy of a female is straightforward and often the greatest challenge is entering the urethral meatus. To minimize bacterial contamination, every effort should focus on endoscopy of the urethra and bladder prior to vaginoscopy. In some challenging cases, the urethral meatus can be identified by gentle outward (not lateral or downward) pull on the labia majora and can be found in a hypospadiac position in some. The female urethral meatus should accept a 7.5Fr to 8Fr cystoscope in the term infant. Although the female urethra is significantly shorter than the male urethra, it shares the same

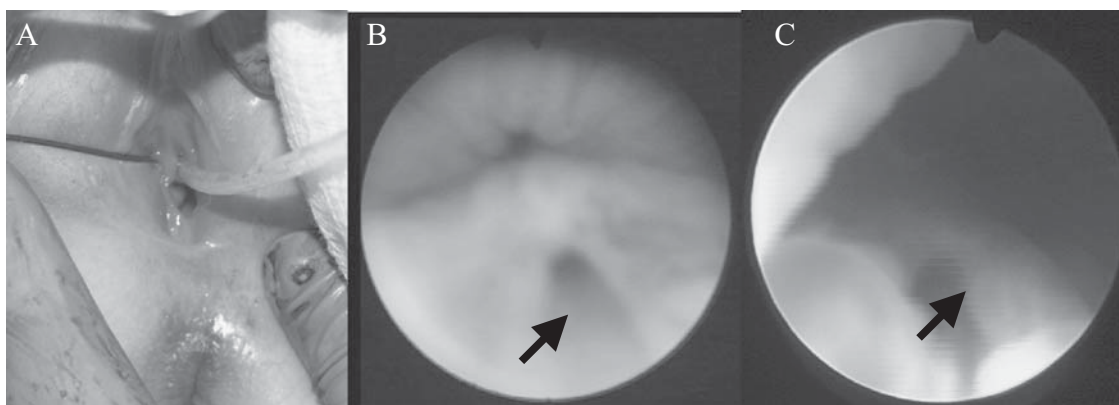


**FIGURE 11.10.** Vaginal agenesis. A thorough examination under anesthesia reveals complete vaginal agenesis in a prepubertal child with solitary kidney.



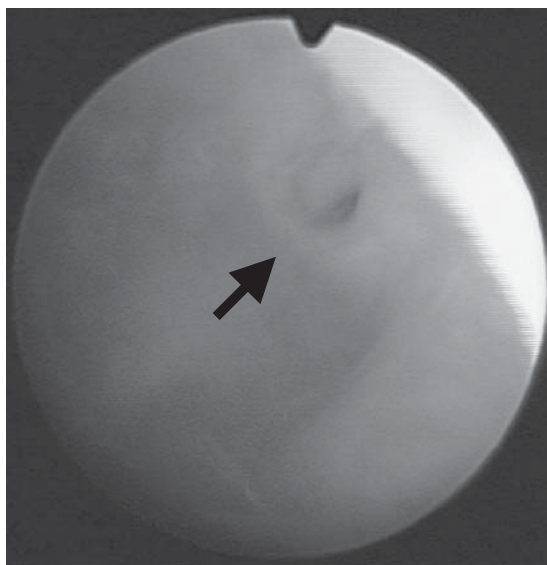
**FIGURE 11.11.** Perineal mass. A thorough examination under anesthesia reveals perineal mass which bulges with valsalva. The mass was a right upper pole large ectopic ureterocele. Radiographic contrast was needle injected into the mass, retrograde filling the massively dilated upper pole ureter. Cystoscopic retrograde right lower pole ureterogram revealed an equally massive lower pole grade 5 refluxing ureter. The entire right kidney was nonfunctional and removed laparoscopically.

mucosal vascular striations of the posterior urethra of the male, which should run parallel to the cystoscope. The female urethra is coapted to the bladder neck. On bladder entry, the yellow urine should be evacuated to aid visualization. Once distended with irrigant, the bladder should appear spherical with smooth walls and homogeneous epithelium. One slit-like ureteral orifice is usually seen on each lateral edge of the trigone, a triangular zone on the floor of the bladder. Pubertal estrogens will stimulate normal squamous metaplasia changes on the trigone. The location, number, and configuration of the ureteral orifices is noted, as abnormal orifices may reflux. The experienced cystoscopist will monitor the quantity of irrigant within the bladder, preventing overdistension and mucosal hemorrhage. If indicated, the same scope can be atraumatically passed thru the hymen into the vagina. To achieve complete visualization, the vaginal introitus must be compressed with gauze sponge to gain distension with irrigant. One midline cervix with os is typically seen with no vaginal mucosal or muscular wall lesions (Figure 11.13). In general, the female urethra, bladder, and vagina are thoroughly inspected for possible anomalies, which are listed in Table 11.1.



**FIGURE 11.12.** Ectopic ureters. (A) A thorough exam of an inconcontinent female under anesthesia detected a right ureter exiting on the perineum. The opaque catheter is in the urethra and the black wire enters the ectopic ureteral orifice. One left and one right orthotopic ureteral orifice was seen within the bladder cystoscopically. Vaginoscopy revealed an ectopic left upper pole ureteral orifice just within the hymenal ring. This child had bilateral complete duplication with bilateral upper pole ureteral ectopia. (B) In a different patient, cystourethroscopic view of an ectopic left upper

pole ureter (arrow) entering the female urethra. (C) An ectopic right ureter entering the top of the verumontanum serves this solitary functioning kidney in a male patient with recurrent febrile UTIs, Grade 5 left VUR, right trigonal diverticulum, and incompetent bladder neck. Intravenous administration of indigo carmine proved useful in locating the single system orifice (arrow), as blue dye consistently swirled from behind the tip of the cystoscope positioned cephalic to the bladder neck.



**FIGURE 11.13.** Vaginoscopy. With irrigant filling the vagina, the vaginoscopic appearance of a prepubertal cervix and its os is seen.

Cystourethroscopy of a male varies from the female procedure mainly by techniques to negotiate the male urethra. In the term, male pediatric patient, the urethra typically can accept a 7.5 Fr or 8 Fr caliber cystourethroscope. Occasionally, the foreskin and the urethral meatus will require dilation in order to admit this. The cystoscope tip is inserted with lubricant. With flow on, the scope is negotiated thru the uniform tubular anterior urethra. At all times, the lumen should be visualized ahead or the scope should be backed until lumen is seen. At the external urethral sphincter, the urethra becomes tighter even with irrigant flow. The mucosal vascular striations begin in this zone, indicating entry into the posterior urethra. At this point, the urethra turns sharply upward. To negotiate this turn, the cystoscopist must lower the penis, so the camera and eyepiece of the scope are below the level of the buttocks. As the scope is advanced, the round raised pink verumontanum is seen on the dorsal midline of the urethral wall. The bladder neck follows the verumontanum and then the bladder is entered. It is cystoscopically identical to the female bladder. The male urethra and bladder are thoroughly inspected for possible anomalies, which are also listed in Table 11.1.

Several other general cystoscopic tips are discussed below.

**TABLE 11.1.** Genitourinary Anomalies Identified by Cystourethroscopy.

Sex of child	Location of pathology	Pathology	Cystoscopic findings	Therapy options
Male or female	Anterior urethra	Urethral diverticulum	Dilated cavernous segment of urethra. In males, may have a wide mouth in the penoscrotal region +/- purulent debris or hair. In females, small mouthed with mass effect	Open urethroplasty
Male		Urethral stricture	Mild narrowing to pinpoint narrowing of urethral lumen, short membrane or long narrowed segment with whitish scarred epithelium	Endoscopic (VIU) via resectoscope or open urethroplasty
Male		Anterior urethral valves	Fenestrated diaphragmatic membrane or mucosal cusp arising from the ventral wall of the bulbar, penoscrotal or penile urethra	Endoscopic incision or open urethroplasty
Male or female		Urethral duplication	Additional channel with or without communication to the ventral urethra or bladder.	Test for communication via contrast or indigo carmine injection
Male		Megalourethra	Marked penile urethral dilation	Open urethroplasty
Male	Posterior urethra	Posterior urethral valves	Valve leaflets at the verumontanum. Bladder neck hypertrophy. Posterior urethral dilation. Bladder trabeculation	Endoscopic Transurethral resection of posterior urethral valves (TUR valves) or urinary diversions
Male or female		Ectopic ureteral orifice	Male orifice proximal to the external sphincter on veru or posterior urethra. Female orifice in the bladder neck, urethra, perineum, vagina, or cervix. If functional, can be identified by indigo carmine excretion.	If symptomatic open surgery, (ureteral reimplantation, ureteroureterostomy, heminephroureterectomy)
Male		Prostatic utricle/vaginal remnant	Fronlike mucosal projections surrounding orifice to utricle/ vaginal remnant on the center of the verumontanum.	If symptomatic, endoscopic fulguration of orifice or laparoscopic/open resection of utricle.
Male or female	Bladder neck	Ectopic ureteral orifice	Stenotic or gaping orifice at the bladder neck. If functional, can be identified by indigo carmine excretion.	If symptomatic, open surgery (ureteral reimplantation, ureteroureterostomy, heminephroureterectomy).
Male or female	Trigone/ureteral orifices	Ureterocele	Deformed trigone with ballooning bladder mucosa. May extend into bladder neck, urethra, and perineum.	Anatomy can be defined by needle retrograde ureteroceleogram. If indicated, transurethral incision of ureterocele for decompression.
Male or female		Deformation of the floor	May be feces, megaureter or ureterocele	Consider fecal disimpaction, retrograde ureterogram or ureterocele incision.
Male or female		Tumors	Papillary or sessile. Often bleeding. Screen in an augmented bladder.	Cold cup biopsy for diagnosis. Consider endoscopic resection.
Male or female		Ureteral duplication	Distal, medial orifice serves the upper pole moiety. Proximal, lateral orifice serves the lower pole moiety	May require no intervention. Retrograde ureterography may confirm occult or partial duplication. Consider STING for VUR if indicated.
Male or female		Diverticuli	Hutch diverticuli are adjacent to the ureteral orifice (paraureteral). Periureteral diverticuli may have the ureteral orifice within the diverticulum.	Typically no intervention. May be resected at ureteral reimplantation.
Male or female		Patulous ureteral orifice	Ureteral orifice configurations are not predictive of vesicoureteral reflux	If indicated, STING of refluxing ureter.

TABLE 11.1. *Continued*

Sex of child	Location of pathology	Pathology	Cystoscopic findings	Therapy options
Male or female	Bladder	Trabeculation	Irregular small bands of hypertrophied detrusor muscle beneath the bladder mucosa	Evaluate etiology (obstruction, neurogenic cause, functional elimination disorder) and treat.
Male or female		Diverticuli	May have a small or large mouth to the small or large sac.	May require resection if recurrent UTIs unresponsive to medical therapy.
Male or female		Calculi	Free-floating stone in the bladder or diverticulum	Open or endoscopic stone ablation techniques.
Male or female		Urachal anomalies	Urachal diverticulum may be seen in prune belly syndrome. Urachal sinus may appear infected at the dome.	Resect open or laparoscopically.
Female	Urogenital sinus		The orifice beneath the clitoris is the urogenital sinus. It bifurcates at a variable distance into the urethra and vagina.	Total urogenital sinus mobilization
Female	Vagina	Duplication/septation	Hematometocolpos may cause mass. Septae can be horizontal or vertical and partial or complete. May see two cervices.	Perforate obstructing membranes. Resect septae. May require formal vaginoplasty
		Imperforate hymen	Bulging perineal mass	Incision of hymen. Assess for urinary obstruction
Female		Foreign object	Persistent vaginal discharge prompts vaginoscopy, identifying the object	Removal of foreign object
Female		Cloaca	Single perineal opening with variable configurations leads to the urethra, vagina and anorectum	Diverting colostomy and possible urinary diversion. Total mobilization of the cloaca.

1. Posterior urethral valves are an obliquely oriented membrane extending from the distal verumontanum and attaching anteriorly to the urethral wall, with a small eccentric aperture. Prior urethral catheterization often alters the form of the valves. In the older child, minivalves can be missed. To improve detection, the bladder should be filled retrograde via the cystoscope. With the irrigant flow shut off, the cystoscope is placed just distal to the external sphincter and the Crede maneuver is performed. Antegrade flow will further open the valve leaflets. An alternative method is to guide a resectoscope hook blade in the troughs lateral to the verumontanum. Membranous valve leaflets can be identified and cut at 5 o'clock and 7 o'clock with this technique. Several techniques, such as electrocautery, fogarty balloon, or laser, have been used to ablate/fragment PUV, urethral polyps, or urethral strictures. The author's preference is cold knife incision, followed by temporary catheterization; this technique may result in less tissue damage. In the preterm male infant with obstructive uropathy, cystourethroscopy

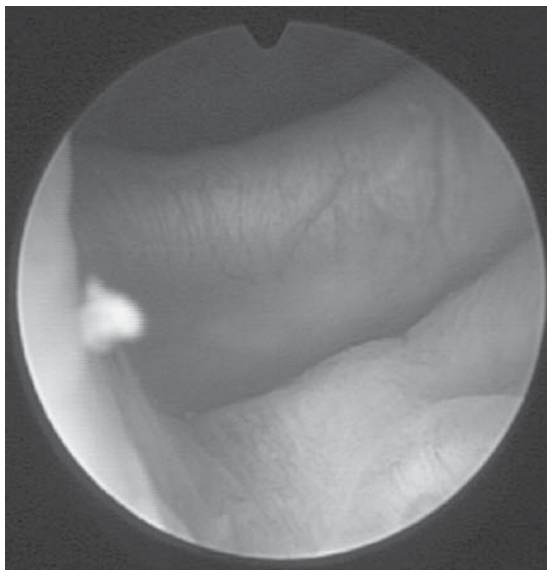
may be impossible if the urethra is small. To circumvent this problem, some have performed antegrade posterior urethral valve ablation via percutaneous cystotomy access effectively.<sup>5</sup> If this is also ineffective, a Foley catheter, suprapubic catheter or vesicostomy may be necessary to temporarily divert the obstructed system.

2. Bulging masses on the trigone may be the result of a significant fecal impaction elevating the floor of the bladder or, alternatively, a mega-ureter or large ureterocele. Needle retrograde injection can delineate ureterocele versus mega-ureter and can define their extent toward the perineum.

3. On the trigone, inspection of the ureteral orifices may reveal a hutch diverticulum. All trigonal diverticuli (Figure 11.14) should be inspected with low volumes of intravesical irrigant to rule out an effacing ureterocele.

4. The configuration of the ureteral orifice can be variable even within normal patients, but oftentimes takes on a golf-hole configuration when vesicoureteral reflux is present.





**FIGURE 11.14.** Bladder diverticulum. Large wide-mouthed trigonal diverticulum viewed from the incompetent deformed bladder neck (same patient as Figure 11.12C).

5. If double J ureteral stenting is planned in the male child, a two-piece scope is crucial. In this case, once wire access is achieved within the ureter, the scope is withdrawn and the sheath only is backloaded on the wire. The stent can then be passed over the wire through the cystoscope sheath positioned over the ureteral orifice, preventing wire coiling within the bladder.

6. In the intersex patient, close inspection of the verumontanum may show frondular projections around a central orifice, a hallmark sign indicating a prostatic utricle/vaginal remnant (Figure 11.7). The lengths of the urogenital sinus, vagina, and urethra aid surgical planning. Cystoscopically guided placement of fogarty balloons into the urethra and vagina of a urogenital sinus can guide surgical repair.

## Postoperative Management

Routine postoperative care is indicated, and most cases are performed on an outpatient basis. If purulence was detected, then antibiotics should be administered.

## Complications

Possible complications can include bladder or urethral perforation, hemorrhage, pain, ureteral obstruction, infection, and urethral or ureteral trauma with stricture formation or irritative voiding symptoms. Fortunately, these are rare.

## Author's Remarks

Cystourethroscopy is an extremely versatile tool for the urologist. It is used to confirm clinical suspicion of disease or to delineate the unusual case. As the technology has advanced, endoscopic tools have permitted minimally invasive therapeutic interventions. In many cases, these procedures negate the need for open reconstructive surgery and have revolutionized the management of these disorders.

## References

1. Welsh A et al. Fetal cystoscopy in the management of fetal obstructive uropathy: experience in a single European centre. *Prenat Diagn* 2003;23(13):1033–1041.
2. Mitchell ME, Close CE. Early primary valve ablation for posterior urethral valves. *Semin Pediatr Surg* 1996;5(1):66–71.
3. Coplen DE. Management of the neonatal ureterocele. *Curr Urol Rep* 2001;2(2):102–105.
4. Bhatnagar V et al. Fulguration of posterior urethral valves using the Nd:YAG laser. *Pediatr Surg Int* 2000;16(1–2):69–71.
5. Zaontz MR, Gibbons MD. An antegrade technique for ablation of posterior urethral valves. *J Urol* 1984;132(5):982–984.

# 12

## STING for Vesicoureteral Reflux

Selcuk Yucel and Linda A. Baker

Vesicoureteral reflux (VUR) is the retrograde flow of urine from the bladder into the upper urinary system. It affects 1% of boys and girls. The ureterovesical junction is compromised by short submucosal ureteral length, insufficient detrusor backing to the ureter, and/or periureteral diverticuli. Vesicoureteral reflux is present in 29% to 70% of children with urinary infections<sup>1,2</sup> and is typically diagnosed by contrast voiding cystourethrogram or nuclear cystogram. The association among VUR, urinary tract infections (UTIs), and renal scarring has been noted for years. The overall goal of managing the child with UTIs is to prevent renal scarring, hypertension, or chronic renal failure. In fact, 3% to 25% of children with end-stage renal disease lost their renal function because of reflux nephropathy.<sup>2,3</sup> Renal scarring is detected best by DMSA scanning. However, some of the radiologically detected changes are congenital in nature and not acquired from postnatal UTIs (males > females).<sup>4,5</sup>

Despite the seemingly straight-forward nature of the anomaly, management of the child with VUR is controversial for the following reasons.

1. Approximately 20% of children with prenatal hydronephrosis are diagnosed with VUR. Screening siblings of children with VUR is another means to diagnose VUR. Some of these patients in these two groups may never develop a UTI, and optimal care is not clear. Low pressure sterile reflux is believed to not be harmful to the kidney.

2. The radiological evaluation of the child with a UTI is currently a matter of vigorous debate,<sup>6</sup>

but the current recommendation of the American Academy of Pediatrics is to perform a renal sonogram and a voiding cystourethrogram.<sup>7</sup>

3. If VUR is diagnosed with UTI, medical management versus surgical management has been offered. The premise behind medical management is that Grades I-III VUR (International Reflux Study Classification system<sup>8</sup>) have a reasonably high enough spontaneous reflux resolution rate to warrant antibiotic prophylaxis, serial X-rays, UTI screening, and observation. However, serial X-rays, which require urethral catheterization, and antibiotic prophylaxis are the two interventions most unpalatable for physicians and families.

4. The role of surgical correction of VUR is continuously evolving. Controversial issues include the indication for surgical correction as well as the surgical method employed (endoscopic, laparoscopic, or open surgery).

This chapter discusses the endoscopic STING procedure, a mnemonic for Subureteral Teflon Injection.

### Indications and Contraindications

Many factors must be considered on a case-by-case basis when recommending VUR management. They include:

1. Prior and future morbidity of VUR.
2. Risk of uncorrected VUR.
3. Statistical likelihood of reflux resolution or down-grading.

4. The pros and cons of medical therapy.
5. The pros and cons of surgical therapy.
6. The pros and cons of radiological follow-up.
7. Economic factors.

Indications for treatment of vesicoureteral reflux may include:

1. Progressive renal scarring.
2. Poor renal growth.
3. Age of the patient and severity of VUR grade.
4. Breakthrough UTI under prophylaxis.
5. Renal transplantation candidate.
6. Medical noncompliance.
7. Multiple antibiotic allergies.
8. Parental preference.
9. Reflux unlikely to spontaneously resolve:
  - a. High grade (IV,V) in children >1 year age.
  - b. Associated with large paraureteral diverticula.
  - c. Duplication anomalies.
  - d. Symptomatic reflux in teenagers.
  - e. Girls with bladder instability.
  - f. Failure of resolution after satisfactory surveillance.
10. Secondary VUR
  - a. Neuropathic bladder.
  - b. Bladder exstrophy.
  - c. Posterior urethral valve.

Contraindications for treatment of vesicoureteral reflux may include:

1. Obstructing and Refluxing Megaureters.
2. Current UTI.

## Preoperative Investigation

STING requires general anesthesia. Therefore, a standard preoperative evaluation, considering cardiopulmonary, endocrinological, and hematologic disorders that increase anesthetic risks, is necessary. Children with identified disorders may require preoperative blood testing, and children with renal failure may require necessary drug dose adjustments for anesthesia. Preoperative radiological investigations often include ultrasound, contrast or nuclear cystourethrography, nuclear scan, and/or MRI. It is well recognized

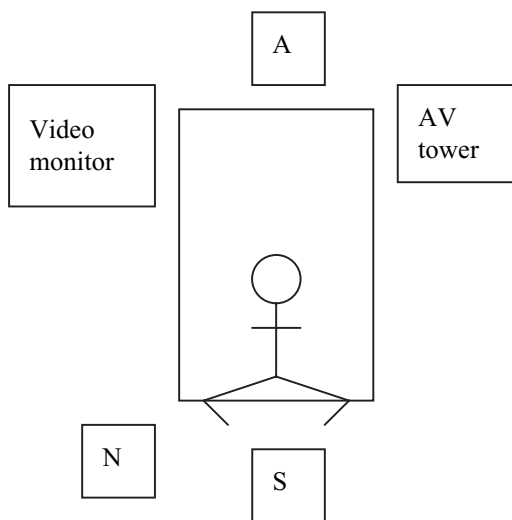
that a single VCUG may miss reflux in 12 % of cases; this entity, known as “occult reflux,” should be discussed with the family in the case of unilateral reflux. Sterile urine is required to reduce risk of upper tract UTI prior to invasive instrumentation.

## Preoperative Patient Preparation

Once cleared for surgery and meeting NPO restrictions, an oral sedative is given to prevent separation anxiety. If the child has taken daily prophylaxis antibiotic before the procedure, IV antibiotics may not be necessary

## Specific Instrumentation

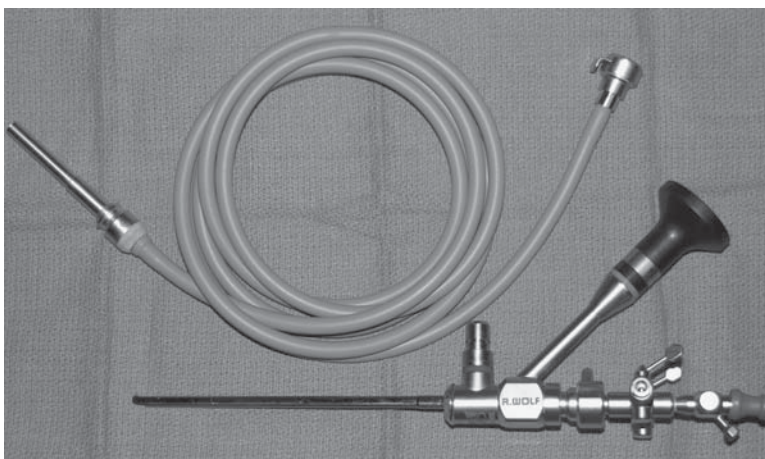
Most cystoscopic suites are equipped with a monitor for videocamera imaging, which allows multiple viewers, teaching, optical magnification, and videorecording (Figure 12.1). A fiberoptic xenon light source is also required. Cystoscopic irrigant (sterile normal saline or sterile water) should be warmed to body temperature to diminish hypothermia. Several companies manufacture



**FIGURE 12.1.** Most cystoscopic suites are equipped with a monitor for videocamera imaging, which allow multiple viewers, teaching, optical magnification, and video recording. A fiberoptic xenon light source is also required.



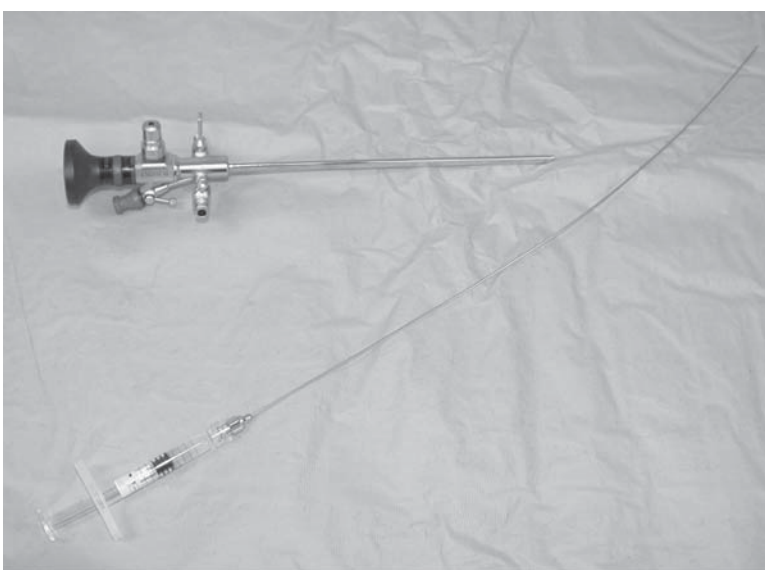
**FIGURE 12.2.** An example of an offset cystoscope. The working channel is straight so that the STING needle is not bent.



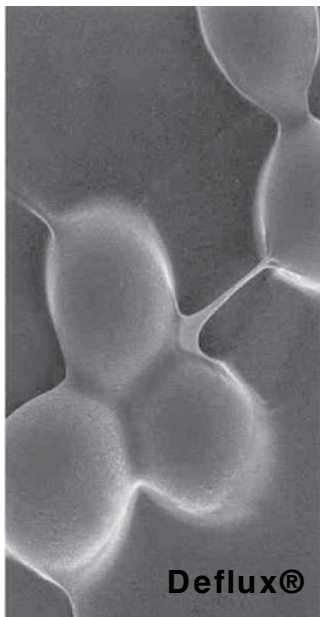
pediatric endoscopic equipment, including Wolf, Storz/Olympus, and ACMI. Rigid pediatric cystoscopes range from 5 Fr to adult sizes, and the pubertal status of males should be noted to help judge the equipment needed. Pediatric cystoscopes with an offset lens allow straight entry into the working channel for the use of the STING needle (Figure 12.2). However, a normal cystoscope can also be used by passing the needle from the working channel with some bending. STING needles can be found in sizes 3 F to 5 F and made from plastic body with metal end or metal body depending on the manufacturer (Figure 12.3). The

choice of the needle should be decided according to the bulking agent to be used. Some bulking agents with more viscous material such as Teflon and bioglass require a larger diameter needle and also a gun to push the injection.

The ideal injectable material for the urinary tract is nonmigrating, durable, biocompatible, nontoxic, noncarcinogenic, nonteratogenic, easily injectable, and affordable. The first injectable material used to correct VUR was Teflon (PTFE-polytetrafluoroethylene) but its use has been halted because of safety issues worldwide. Following the success of Teflon, other agents have been



**FIGURE 12.3.** STING needle and straight pediatric cystoscope. This needle is all metal with a black line marking 5 mm from the needle tip.



**FIGURE 12.4.** Microscopic appearance of dextranomer/hyaluronic acid copolymer (Deflux).

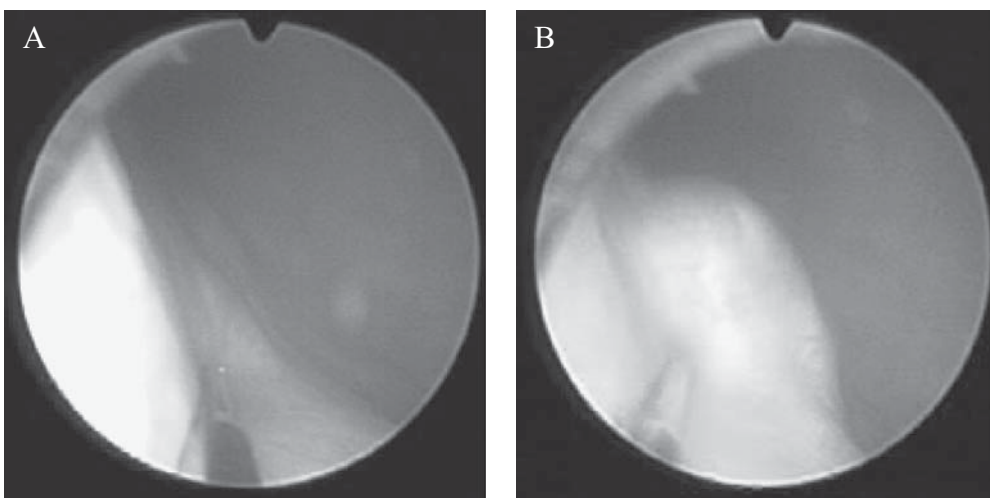
engineered and used, including glutaraldehyde cross linked bovine collagen (Zyplast), silicone particles (polydimethylsiloxane) (Macroplastique), dextranomer in sodium hyaluronan (Deflux) (Figure 12.4), synthetic calcium hydroxylapatite particles in a mainly glycerine and sodium carboxymethylcellulose (Coaptite), self-

detaching balloons filled with hydroxyethylmethacrylate (HEMA), biocompatible glass particles (Bioglass), and autologous substances, such as cultured bladder muscle cells, fibrin, fat, collagen, and chondrocytes. In 2001, the U.S. Food and Drug Administration (FDA) approved Deflux for use in children to correct VUR.

## Operative Technique

With the patient in the dorsal lithotomy position, the lubricated cystoscope is introduced into the urethra and bladder, inspecting for additional anomalies. The ureteral orifices are noted for location, configuration and number.<sup>10</sup> Ureteral orifice configuration has not been found to be related to the severity of the grade,<sup>2</sup> although the stadium, horseshoe and golf hole orifices are viewed suspiciously.

The classical technique for STING injection was described by O'Donnell and Puri in 1984.<sup>11</sup> In this technique, the injection needle is introduced into the 6 o'clock position 2 mm to 3 mm below the ureteral orifice, and the needle is advanced 0.5 cm into the space behind the intravesical ureter. Injection is slowly continued until a nipple or volcano appearance is obtained where the orifice turns into a crescentic slit that does not gape open under the pressure of irrigant flow from the cystoscope (Figure 12.5). Such a mound can be



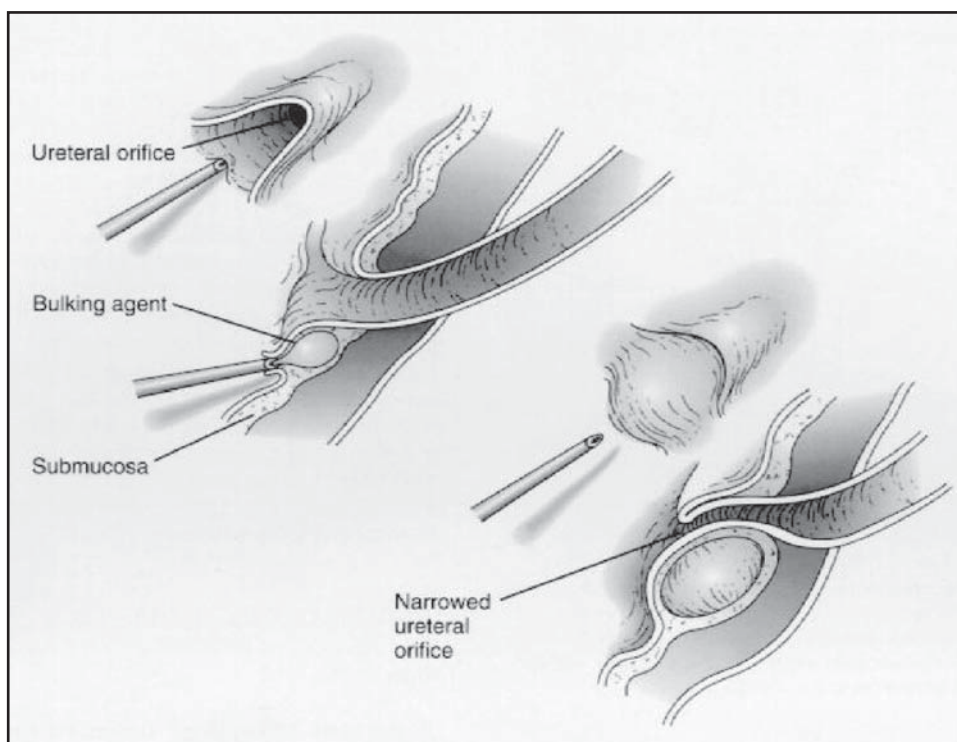
**FIGURE 12.5.** Cystoscopic appearance prior to (A) and after (B) right ureteral STING with Deflux via classical technique.

achieved by injecting 0.2 mL to 0.5 mL of bulking agent. However, in ureters with dilating reflux (Grades III, IV, and V), such mounds are difficult to obtain and are more likely to be unsuccessful. Puri presented a modified technique for Grades IV and V VUR in which the needle puncture was positioned inside the ureter at 6 o'clock position.<sup>12</sup> Kirsch and colleagues developed this technique further.<sup>13</sup> In the hydrodistention injection technique (HIT), hydrodistention of ureter is done first to identify the best location within the dilated distal ureter to submucosally position the needle. At the 6 o'clock position, the needle is placed into the mid intramural ureter and advanced 4 mm further submucosally. Injection is started with 0.1 mL to see if the implant is in the correct place. Once confirmed, the fluid irrigation is stopped and the material is slowly injected to coapt the intramural ureteral tunnel. The needle should be gradually pulled back with simultaneous injection, thereby injecting along the length of the distal ureter (Figure 12.6). If a good coaptation is

lacking at the orifice, the classical STING can also be performed. This technique requires higher volumes (up to 1.5 mL) for coaptation of the whole intramural ureter. Kirsch reported 89% success rate with his technique compared to 71% with classical STING.<sup>13</sup>

STING for duplicated ureters can be done similarly depending on the ureteral orifice locations with 63% to 73% success.<sup>14,15</sup> Widely separate orifices can be injected separately, while orifices closely located may require only single injection to the lower ureteral orifice. Elevation of the lower ureteral orifice can coapt the upper orifice as well.

STING for failed cross-trigonal ureteral reimplantation can be a challenging procedure because of the awkward position of the implanted ureters from the transurethral approach. Perez-Brayfield and colleagues reported 88% success in failed reimplantation cases.<sup>14</sup> In difficult cases, suprapubic access to the bladder via a percutaneous peel-away sheath improves the angles of access to the refluxing ureteral orifice.



**FIGURE 12.6.** Schematic of STING intraureteric injection procedure.

Management of unilateral reflux is controversial. As previously mentioned, reflux is missed in ~12% of cases on a single VCUG. After STING injection for unilateral reflux, reflux into the previously nonrefluxing contralateral ureter, called *de novo* reflux, has been noted in 3% to 5 % of patients.<sup>16,17</sup> This reflux is generally of low grade and may be the result of a pop-off mechanism or occult reflux. Several philosophies exist to prevent this scenario. Some advocate simultaneous STING to a nonrefluxing but abnormally configured (stadium, horseshoe and golf hole appearance) ureteral orifice while others may uniformly inject both ureters. So long as the possibility of *de novo* contralateral reflux is discussed preoperatively, most families are disappointed but understanding if it occurs to them.

In some patients with pyelonephritis and or renal scarring but no cystographic evidence of reflux, PIC cystogram has been advocated for the detection of “occult reflux.”<sup>18</sup> In this technique, the tip of the cystoscope is brought to the ureteral orifice in question and contrast material flow is directed to the orifice from a height of 100 cm. Simultaneous fluoroscopy assesses whether any reflux is present into the ureter and renal pelvis. The use of this technique is debated.

## Postoperative Management

STING is a day-case procedure. As a result of short anesthesia time, recovery is fast. Prophylaxis is continued after the procedure until the postoperative VCUG shows no reflux. Ultrasound can be done 4 weeks to 6 weeks later to check for hydroureteronephrosis and implant location in the bladder. Due to the low incidence of obstruction, many forego the postoperative ultrasound. Nuclear or contrast VCUG is done three months after STING to assess for reflux. If reflux has resolved, antibiotic prophylaxis is stopped.

The duration of follow-up after a successful STING remains controversial. The long-term durability of the implant is different for every material. For Deflux, the longest follow-up period is 7.5 years, with 96% of patients reflux free.<sup>19</sup> Puri had mentioned first, third and tenth year VCUG in the follow-up after Teflon injection.<sup>20</sup> If the three-month contrast or nuclear cystourethro-

gram shows no reflux, the most reasonable strategy seems to be to limit subsequent VCUGs to patients with further bouts of pyelonephritis.

## Complications

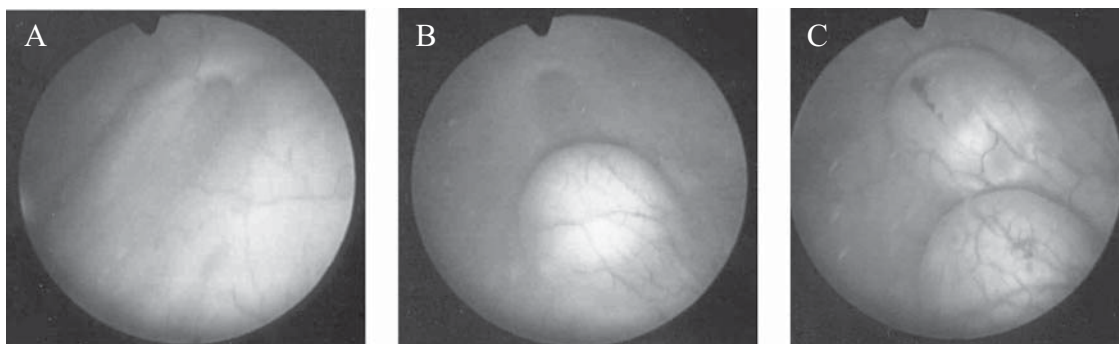
Since different materials have different material specific complications, such as migration of implanted particles to lungs and brain for Teflon, teratogenicity of silicone particles, and complete volume loss of collagen, only common complications of STING will be covered in this section.

The most important STING complication is the persistence of reflux. A recent meta-analysis showed that the failure rate is 21.5% for Grade I and II, 28% for Grade III, 37% for Grade IV and 49% for Grade V.<sup>21</sup> The reasons of failure have been classified as the material migration (35%) and volume loss (23%) or combination of them (29%), complete extrusion of the material (2%) and indeterminate (11%) in which the mound appears satisfactory.<sup>22</sup> The factors that contribute to failures may include improper technique, material fault, material migration or extrusion, voiding abnormalities, ureteral orifice configuration and location, bladder anomalies such as neuropathic bladder, posterior urethral valves or bladder extrophy, severity of reflux and duplication (Figure 12.7).

Post-STING VUR failures generally lead to a second or third injection depending on the physician and parent preferences. Second injection success is 68% and third is 34%.<sup>21</sup> Reports of the modified HIT STING technique for second injection suggest a higher success rate. A recent study of 39 patients with 53 refluxing ureters (mean grade of reflux = 2.2) found a 90% success rate, with Grades I-III resolving at 88%, 92%, and 84% respectively.<sup>23</sup> If repeat STING is not chosen, open ureteral reimplantation after STING has not been found to be particularly difficult or with increased complication.

Ureteral obstruction is uncommon and rare permanent obstruction had been reported<sup>24</sup> unless the ureter was meant to be obstructed on purpose. Rare transient dysuria has been reported. Cystitis is noted in 6% after STING and pyelonephritis in 1%.<sup>21</sup> *De novo* pop-off reflux into the contralateral





**FIGURE 12.7.** Failed bilateral STING for VUR. Patient was referred after prior bilateral STING. (A) Cystoscopic view of the left ureteral orifice showed little sign of prior injection. (B) View of the right orifice revealed malpositioned or migrated Deflux. (C) Repeat

Deflux injection of right ureteral orifice. Note the right orifice is now a crescent-shaped slit just cephalad to the small trickle of blood at the injection site. The old injection site is in the foreground.

ureter can be seen in 3–5% of cases but is almost always low-grade reflux.

Some may consider the overuse of STING by the medical community as a complication since observation under antibiotic prophylaxis or open reimplantation for severe reflux can be traded off with STING with no proven efficacy.

## Author's Remarks

STING is currently not in the AUA guidelines for vesicoureteral management. However, it is now regarded as the primary surgical treatment for Grade I–IV VUR by some authors. Further studies on the mechanisms of STING failure may lead us to define the best candidates for STING procedure and thereby help us obtain the success rates of open ureteral reimplantation.

## References

1. Kass EJ, Kerns KM, Carey JM. Paediatric urinary tract infection and the necessity of complete urological imaging. *Br J Urol Int* 2000;86(1):94–96.
2. Duckett JW. Vesicoureteral reflux: a “conservative” analysis. *Am J Kidney Dis* 1983; 3(2):139–144.
3. Avner ED et al. Renal transplantation and chronic dialysis in children and adolescents: the 1993 annual report of the North American Pediatric Renal Transplant Cooperative Study. *Pediatr Nephrol* 1995;9(1):61–73.
4. Marra G et al. Severe vesicoureteral reflux and chronic renal failure: a condition peculiar to male gender? Data from the ItalKid Project. *J Pediatr* 2004;144(5):677–681.
5. Nguyen HT et al. 99m Technetium dimercapto-succinic acid renal scintigraphy abnormalities in infants with sterile high grade vesicoureteral reflux. *J Urol* 2000;164(5): p. 1674–1678; discussion 1678–1679.
6. Hoberman A et al. Imaging studies after a first febrile urinary tract infection in young children. *N Engl J Med* 2003;348(3):195–202.
7. Elder JS et al. Pediatric Vesicoureteral Reflux Guidelines Panel summary report on the management of primary vesicoureteral reflux in children. *J Urol* 1997;157(5):1846–1851.
8. International Reflux Study Committee. Medical versus surgical treatment of primary vesicoureteral reflux: report of the International Reflux Study Committee. *Pediatrics* 1981;67(3):392–400.
9. Polito C et al. Cyclic voiding cystourethrography in the diagnosis of occult vesicoureteric reflux. *Pediatr Nephrol* 2000;14(1):39–41.
10. Lyon RP, Marshall S, Tanagho EA. The ureteral orifice: its configuration and competency. *J Urol* 1969;102(4):504–509.
11. O'Donnell B, Puri P. Treatment of vesicoureteric reflux by endoscopic injection of Teflon. *Br Med J (Clin Res Ed)* 1984;289(6436):7–9.
12. Chertin B, De Caluwe D, Puri P. Endoscopic treatment of primary grades IV and V vesicoureteral reflux in children with subureteral injection of polytetrafluoroethylene. *J Urol* 2003;169(5):1847–1849; discussion 1849.

13. Kirsch AJ et al. The modified sting procedure to correct vesicoureteral reflux: improved results with submucosal implantation within the intramural ureter. *J Urol* 2004;171(6 Pt 1):2413–2416.
14. Perez-Brayfield M et al. Endoscopic treatment with dextranomer/hyaluronic acid for complex cases of vesicoureteral reflux. *J Urol* 2004;172(4 Pt 2): 1614–1616.
15. Lackgren G et al. Endoscopic treatment of vesicoureteral reflux with dextranomer/hyaluronic acid copolymer is effective in either double ureters or a small kidney. *J Urol* 2003;170(4 Pt 2):1551–1555; discussion 1555.
16. Herz D et al. Efficacy of endoscopic subureteral polydimethylsiloxane injection for treatment of vesicoureteral reflux in children: a North American clinical report. *J Urol* 2001;166(5):1880–1886.
17. Kirsch AJ, Perez-Brayfield MR, Scherz HC. Minimally invasive treatment of vesicoureteral reflux with endoscopic injection of dextranomer/hyaluronic acid copolymer: the Children's Hospitals of Atlanta experience. *J Urol* 2003;170(1):211–215.
18. Rubenstein JN et al. The PIC cystogram: a novel approach to identify "occult" vesicoureteral reflux in children with febrile urinary tract infections. *J Urol* 2003;169(6): 2339–2343.
19. Lackgren G et al. Long-term followup of children treated with dextranomer/hyaluronic acid copolymer for vesicoureteral reflux. *J Urol* 2001;166(5): 1887–1892.
20. Chertin B et al. Endoscopic treatment of vesicoureteral reflux: 11 to 17 years of followup. *J Urol* 2002; 167(3):1443–1445; discussion 1445–1446.
21. Elder JS et al. Endoscopic Therapy for Vesicoureteral Reflux: A Meta-Analysis. I. Reflux Resolution and Urinary Tract Infection. *J Urol* 2006;175(2): 716–722.
22. Diamond DA et al. Mechanisms of failure of endoscopic treatment of vesicoureteral reflux based on endoscopic anatomy. *J Urol* 2003;170(4 Pt 2):1556–1558; discussion 1559.
23. Elmore JM, Scherz HC, Kirsch AJ. Dextranomer/Hyaluronic Acid for Vesicoureteral Reflux: Success Rates After Initial Treatment Failure. *J Urol* 2006;175(2):712–715.
24. Snodgrass WT. Obstruction of a dysmorphic ureter following dextranomer/hyaluronic acid copolymer. *J Urol* 2004;171(1):395–396.

# 13

## Bladder Outlet Injection for Urinary Incontinence

Selcuk Yucel and Linda A. Baker

Numerous pathological states can lead to urinary incontinence in children. The multifactorial nature of this problem requires both a complete analysis of the contributing factors and a logical approach to correct them.

Factors to consider in the incontinent child include<sup>1</sup>:

- What is the total quantity of urine produced daily? Does the quantity exceed the capacity of the urinary system?
- Is the bladder capable of storing urine?
  - What is the bladder capacity and detrusor compliance? Is there increased bladder contractility, such as in neurogenic bladder, infection, or detrusor hypertrophy?
  - Is the bladder outlet resistance low, such as an incompetent sphincteric mechanism because of congenital malformation, trauma, iatrogenic injury, or neurogenic deficiency?
- Is the bladder effectively emptying?
  - Is there decreased detrusor contractility, as seen in neurogenic states?
  - Is there increased outlet resistance, such as in urethral strictures, posterior urethral valves, or detrusor-sphincter dyssynergy?

Pediatric urologists are often faced with challenging congenital birth defects in which the incompetence of the bladder neck/sphincteric mechanism causes or contributes to the incontinence. Multiple medical and surgical management options exist, indicating that one simple solution does not exist to cure outlet incompetence. One viable alternative is the injection of bulking agents in the bladder outlet.

### Indications and Contraindications

Indications for bladder outlet bulking agents include bladder outlet incompetence with associated urinary incontinence. Specific pathological states with these problems often include neurogenic bladder, cloacal exstrophy, classic bladder exstrophy, epispadias, cecoureterocele, urethral duplication, or ectopic ureter with maldeveloped bladder outlet. In some cases, the bladder outlet incompetence is combined with a deficiency in bladder capacity because of maldevelopment and/or the absence of normal bladder cycling to stimulate bladder growth. Thus, in addition to improving bladder outlet resistance, an additional indication and goal of bladder outlet injection surgery may be to promote bladder growth and increase bladder capacity. More controversial indications include giggle or stress incontinence in children. An extension of this technique has been the injection of leaking catheterizable channels.

Contraindications would include hemodynamic instability or untreated UTI. A relative contraindication is the past history of multiple bladder outlet surgeries, as the success rates are greatly diminished in this population.

### Preoperative Investigation

The preoperative assessment of the child incontinent of urine includes a thorough history and physical examination, with attention to voiding

and bowel habits. The initial office evaluation may include a urinalysis, uroflow, and a postvoid bladder scan. A detailed voiding and elimination diary should be completed, with an assessment for vaginal voiding. If indicated, therapy should include behavioral modifications and laxative therapy. Further evaluation is tailored to the considered diagnoses. Videourodynamics is typically necessary to evaluate bladder capacity, bladder compliance, detrusor leak point pressure, and bladder instability. In cases with a high index of suspicion for an anatomical basis for the incontinence, radiological imaging is warranted, often including renal/bladder sonogram and VCUG. Further tests, such as MRI, and so on, may be needed to further delineate the anatomy.

## Preoperative Patient Preparation

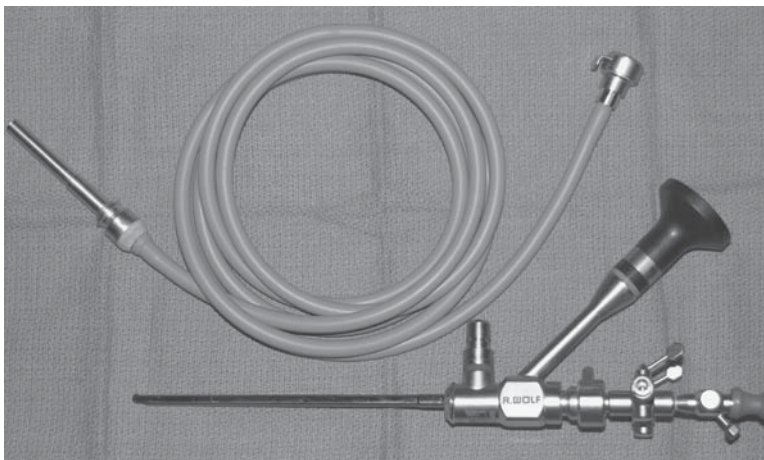
Once cleared for surgery and meeting NPO restrictions, an oral sedative is given to prevent separation anxiety. The physician may choose to give IV antibiotics preoperatively.

## Specific Instrumentation

Most cystoscopic suites are equipped with a monitor for videocamera imaging, which allow multiple viewers, teaching, optical magnification,

and video recording. A fiberoptic xenon light source is also required. Cystoscopic irrigant (sterile normal saline or sterile water) should be warmed to body temperature to diminish hypothermia. Several companies manufacture pediatric endoscopic equipment, including Wolf, Storz/Olympus, and ACMI. Rigid pediatric cystoscopes range from 5Fr to adult sizes, and the pubertal status of males should be noted to help judge the equipment needed. Pediatric cystoscopes with an offset lens allow straight entry into the working channel for the use of the injection needle (Figure 13.1). However, a normal cystoscope can also be used by passing the needle from the working channel with some bending. Injection needles, ranging from 3 Fr to 5 Fr, can be made of plastic with a metal beveled tip or of complete metal depending on the manufacturer. The needle selection depends upon the bulking agent used. Some bulking agents with higher viscosity, such as Teflon and bioglass, require a larger diameter needle and also a gun to accomplish the injection.

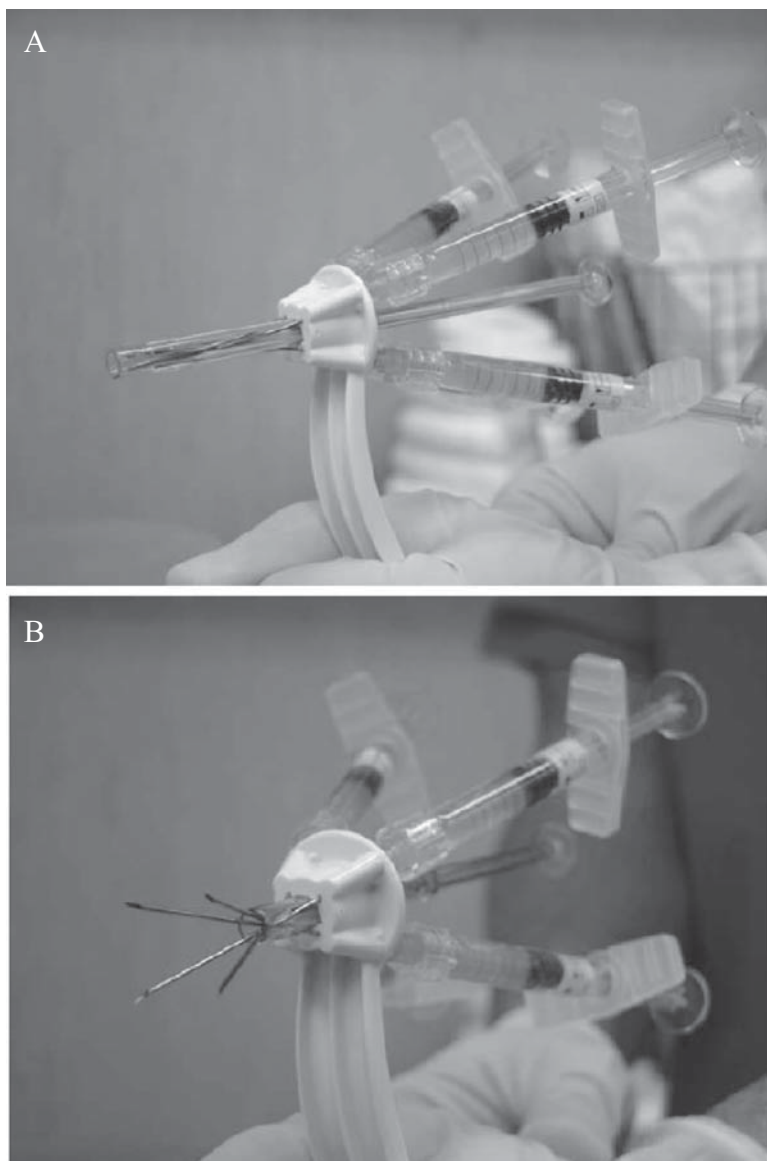
The ideal injectable material for the urinary tract is nonmigrating, durable, biocompatible, nontoxic, noncarcinogenic, nonteratogenic, easily injectable and affordable. The first injectable material used to treat urinary incontinence was Teflon (PTFE-polytetrafluoroethylene) in 1985<sup>2</sup> but it is now not in use due to risks of distant particle migration and granuloma formation. After Teflon, glutaraldehyde cross-linked bovine



**FIGURE 13.1.** An example of an offset cystoscope. The working channel is straight so that the injection needle is not bent.



**FIGURE 13.2.** The Zuidex system consists of (1) 4 syringes of 0.7 cc of Zuidex gel, (2) 0.80 mm  $\times$  50 mm (21 G) needles, and (3) the white Implacer (handpiece, head for syringes/needles, and clear retractable 16 Ch sheath covering the injection needles for protected urethral insertion. (A) The equipment prior to sheath retraction and (B) the sheath retracted, demonstrating the fanning of the four needles. This method does not require endoscopic guidance and has not been extensively tried in pediatric patients. (Reprinted from Capozza N, De Dominicis M, Collura G et al., First pediatric experience of a new device for “non-endoscopic” periurethral injection in urinary incontinence. *Pediatr Surg Int* 2005;21(9):770–772. With kind permission of Springer Science+Business Media.)



collagen (Zyplast), silicone particles (polydimethylsiloxane) (Macroplastique), dextranomer particles in 1% sodium hyaluranan solution (Deflux), synthetic calcium hydroxylapatite particles in glycerine and sodium carboxymethylcellulose (Coaptite), have been developed for injection.

Transurethral injection of the male bladder outlet is technically easier than the female outlet, primarily due to the differential urethral length. The short female urethra makes stabilizing a cystoscope and simultaneously positioning and injecting the bulking agent somewhat challenging.

Recently, a non-endoscopic periurethral injection device was created for adult females, called the Zuidex system (Q-Med, Uppsala, Sweden).<sup>3–6</sup> One recent short-term report on three females suggests its usefulness in girls as well,<sup>7</sup> but larger, long-term series are required to confirm this finding. The Zuidex system (Figure 13.2) consists of a special Implacer, which is a device that mounts four 21 G needles and four syringes of Zuidex (gel of dextranomer microspheres and nonanimal stabilized hyaluronic acid (NASHA)). The implacer has four lateral holes for the insertion of four

needles. A protective sheath covers the needles during sheath insertion into the urethra. Once in the midurethra, the sheath is retracted, exposing the needles and permitting lateral needle movement. Each needle and syringe are individually positioned submucosally and the Zuidex is injected.

## Operative Technique

Multiple approaches have been described, depending on (1) from where the leakage is occurring (transurethral leak or continent catheterizable stoma leak) and (2) the postsurgical anatomical configuration (open versus closed bladder neck or presence versus absence of continent catheterizable channel). Three basic options include (1) the retrograde transurethral approach, (2) the antegrade approach via a catheterizable channel or (3) the suprapubic access approach (Figures 13.3 and 13.4). Perineal paraurethral approaches for transurethral leaking have basically been abandoned.

### Transurethral Leak

#### Retrograde Transurethral Approach

The patient is in the dorsal lithotomy position. The lubricated cystoscope is introduced into the urethra and bladder, inspecting for additional anomalies and bladder neck appearance. In males,

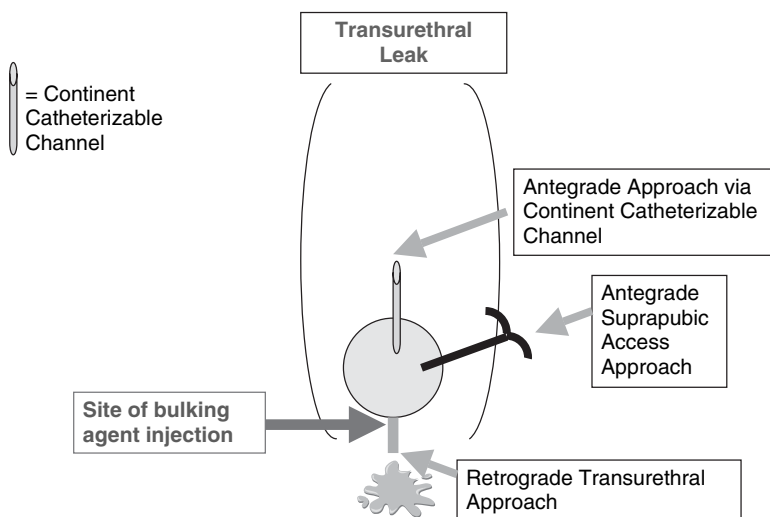
the needle is inserted submucosally at the level of verumontanum and advanced to the bladder neck.<sup>8</sup> Recently, injection below the verumontanum is also advocated.<sup>9</sup> In females, the scope is positioned in the midurethra and the needle injection occurs submucosally from bladder neck to the midproximal urethra. Circumferentially, the injection sites may be at two symmetrical points,<sup>10</sup> at three points,<sup>11</sup> or at multiple points.<sup>8</sup> Regardless of the injection number, the aim is to see complete coaptation of the bladder neck and proximal urethra (Figure 13.5).

#### Antegrade Approach

This approach performed via the continent catheterizable channel. With the patient in the supine position, the lubricated cystoscope is introduced into the catheterizable tunnel with careful manipulation not to harm the continent channel. The bladder neck and posterior urethra are inspected. The injection needle is introduced submucosally at the bladder neck and advanced towards the verumontanum if it can be seen in males and towards the midurethra in females.<sup>12</sup> Injection can be done at two,<sup>12</sup> three, or four points to obtain a well-coaptated bladder neck.

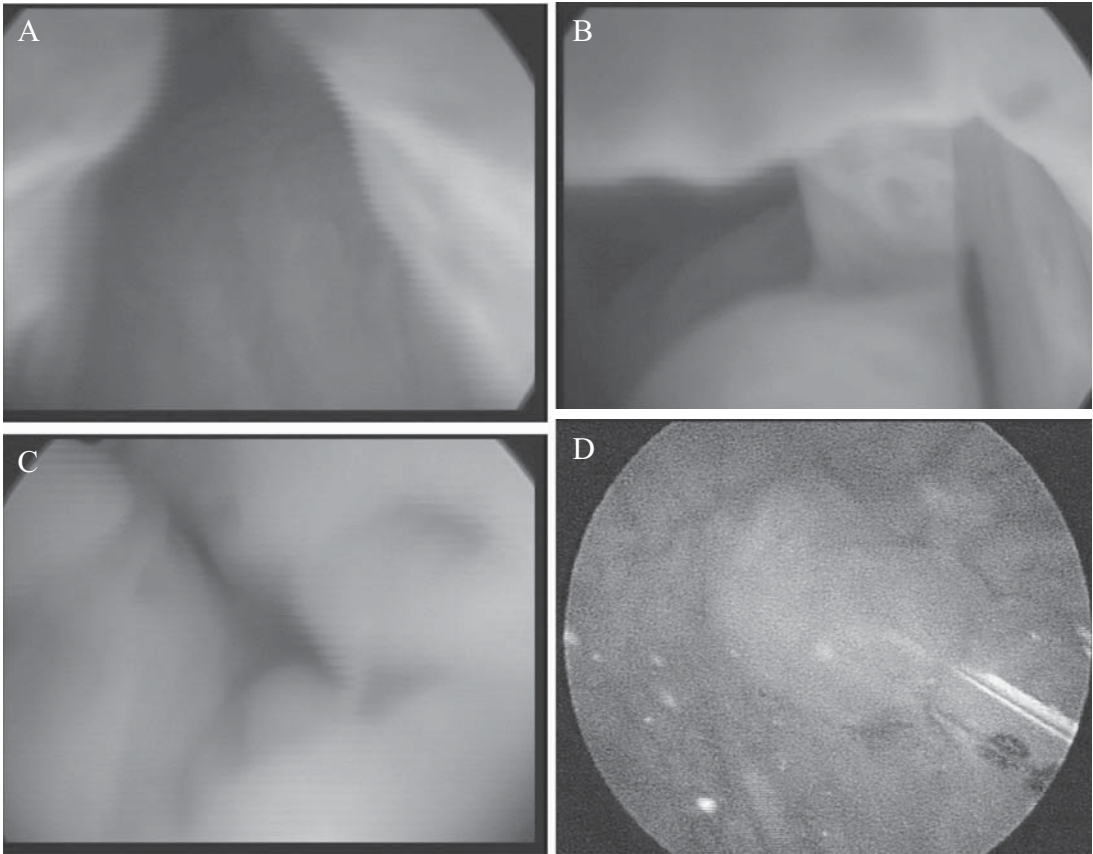
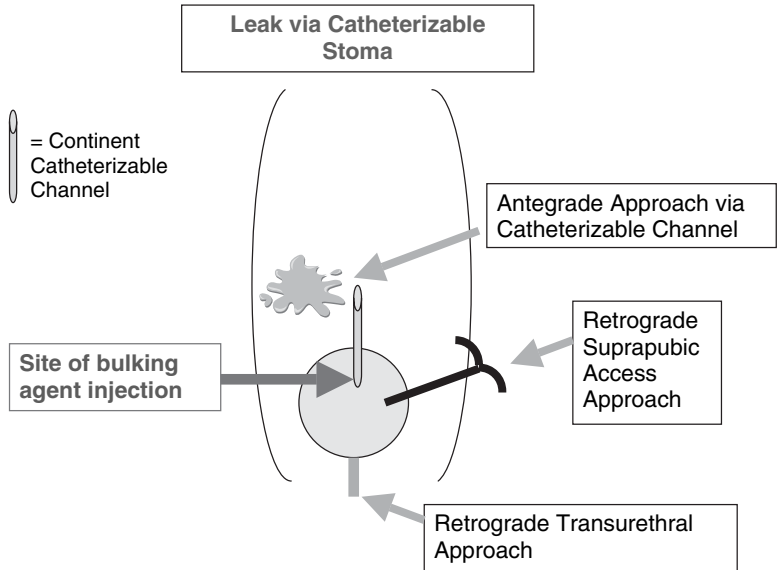
#### Antegrade Suprapubic Access Approach

This is an alternative and adjunctive technique is to gain temporary suprapubic puncture access to the bladder via a 2 mm laparoscopic trocar. The



**FIGURE 13.3.** Potential operative approaches to the child with transurethral urinary incontinence due to bladder outlet intrinsic deficiency.

**FIGURE 13.4.** Potential operative approaches to the child with urinary incontinence via catheterizable stoma.



**FIGURE 13.5.** Bladder neck injection for urinary incontinence. (A) Transurethral view of incompetent keyhole bladder neck. (B) Via the transurethral cystoscope, Deflux was injected into the bladder neck area. (C) After transurethral bladder neck injection, the ure-

thral mucosa appears coapted. (D) A cystoscope was passed into the appendicovesicostomy and the bladder neck injection site is viewed.

injection needle is inserted into the laparoscopic trochar and antegrade bladder neck injection is observed via a cystoscope in the continent catheterizable channel.<sup>13</sup> Injection is done as described above.

## **Leak via Catheterizable Channel**

### ***Catherizable Channel Injections***

These injections can be approached and performed in a similar fashion as that for transurethral leaking.<sup>14</sup> It is convenient to position the patient in the lithotomy position to permit simultaneous access to the channel and the urethra.

### ***Antegrade Approach via Continent Catheterizable Channel***

With the cystoscope in the channel, the walls and opening of the channel into the bladder are inspected. The needle is introduced submucosally 2 cm to 3 cm from the orifice and advanced to the orifice at the bladder. Injection is slowly performed until the whole proximal channel wall is elevated including the orifice at the bladder. Injection can be repeated at multiple locations circumferentially until the whole intramural channel is coapted.<sup>15</sup>

### ***Retrograde Transurethral Approach***

With the cystoscope placed transurethraly, the orifice of the catheterizable channel in the bladder is inspected. The needle is placed either into the spatulous channel at 6 o'clock position or a few millimeters below the orifice and advanced further along the intramural channel. Injection is continued until the orifice elevates and is coapted.

### ***Antegrade Suprapubic Access Approach***

If a cystoscope cannot be passed via urethra (impassable urethral strictures or closed bladder neck), the suprapubic access approach as described above can be performed temporarily.

Urine should be continuously diverted by an indwelling catheter for seven days to 14 days postoperatively. However, it should not be placed via the site of injection so as to avoid molding of the injection mound. Thus, a suprapubic tube may be necessary.

## **Postoperative Management**

Bladder outlet injection is an outpatient procedure. Continence is expected to be regained or improved right after the injection or sometimes it may take a few months until the bladder grows under increased bladder outlet pressure. The length of follow-up after a successful bladder neck injection is variable. Long-term duration of implant is different for every material. The published series with the longest follow-up period reported ~3 years; they observed the highest recurrence of incontinence within the first year.<sup>9,16</sup> VCUg can be done to detect de novo VUR after increased bladder outlet resistance in case of febrile UTIs.<sup>17</sup>

## **Complications**

Since different materials have different material specific complications such as migration of implanted particles to lungs and brain for Teflon, teratogenicity of silicone particles, and complete volume loss of collagen, only common complications of bladder neck injection will be covered in this section.

The most important complication is the persistence of incontinence. Bladder neck injection success rates vary between 5% to 50%, depending on the sex, previous bladder neck surgery, previous bladder augmentation, primary disease causing incontinence, catheterization, and follow-up period. Previous bladder neck surgery, male sex, no augmentation, bladder extrophy, and transurethral catheterization seems to have worse outcomes.<sup>9,10,12,16,17</sup> Few published reports exist on outcomes of injections for catheterizable stomas.<sup>14,15,17</sup> In the largest series of 14 patients, the success rate was 79% at mean follow-up of 1 year for leaking catheterizable stomas.<sup>15</sup> Approximately one-third of patients who achieve initial continence with bladder neck injection of bulking agents deteriorate in the first year and become wet.<sup>9</sup> The mechanisms of this initial success with later failure have not been elucidated, but implant displacement with or without volume loss seems conceivable.

Urinary retention after transurethral injection or inability to catheterize a channel after stomal injection has not been reported.

Repeated injections to the bladder neck may cause more difficult open bladder neck surgery. Hence, no more than two injections to the bladder neck have been recommended.<sup>9</sup>

Postoperatively, bladder compliance and upper tracts should be monitored. Increased bladder outlet resistance can cause vesicoureteral reflux and hydroureteronephrosis.<sup>17</sup>

## Author's Remarks

The success rates in adults with stress urinary incontinence have not been repeated in children with low bladder outlet resistance. This may be due to the multifactorial nature of incontinence in children with congenital birth defects. In many cases, bladder outlet injection failures are directly related to the anatomical or congenital functional abnormality of bladder rather than the reimplant injected or the technique preferred. Better success in injecting catheterizable stomas supports this idea although clinical experience is quite limited. However, the literature implies that there are some patients who definitely benefit from bladder neck injections. Studies to define these children are warranted. The Zuidex system is novel and may hold promise for pediatric patients however studies will be needed to test its efficacy.

## References

1. Wein AJ. Classification of neurogenic voiding dysfunction. *J Urol* 1981;125(5):605–609.
2. Vorstman B et al. Polytetrafluoroethylene injection for urinary incontinence in children. *J Urol* 1985;133(2):248–250.
3. Ferchaud J et al. Intraurethral injections of Zuidex: evaluation of the morbidity of the technique in the treatment of female urinary incontinence. *Prog Urol* 2005;15(3):494–497.
4. Chapple CR et al. An open, multicentre study of NASHA/Dx Gel (Zuidex) for the treatment of stress urinary incontinence. *Eur Urol* 2005;48(3):488–494.
5. van Kerrebroeck P et al. Treatment of stress urinary incontinence using a copolymer system: impact on quality of life. *Br J Urol Int* 2004;94(7):1040–1043.
6. van Kerrebroeck P et al. Efficacy and safety of a novel system (NASHA/Dx copolymer using the Implacer device) for treatment of stress urinary incontinence. *Urology* 2004;64(2):276–281.
7. Capozza N, De Dominicis M, Collura G et al. First paediatric experience of a new device for “non-endoscopic” periurethral injection in urinary incontinence. *Pediatr Surg Int* 2005;21(9):770–772.
8. Guys JM et al. Use of polydimethylsiloxane for endoscopic treatment of neurogenic urinary incontinence in children. *J Urol* 1999;162(6):2133–2135.
9. Guys JM et al. Endoscopic treatment of urinary incontinence: long-term evaluation of the results. *J Urol* 2001;165(6 Pt 2):2389–2391.
10. Leonard MP et al. Treatment of urinary incontinence in children by endoscopically directed bladder neck injection of collagen. *J Urol* 1996;156(2 Pt 2):637–640; discussion 640–641.
11. Caione P et al. Glutaraldehyde cross-linked bovine collagen in exstrophy/epispadias complex. *J Urol* 1993;150(2 Pt 2):631–633.
12. Misseri R et al. Alternative uses of dextranomer/hyaluronic acid copolymer: the efficacy of bladder neck injection for urinary incontinence. *J Urol* 2005;174(4 Pt 2):1691–1693; discussion 1693–1694.
13. Lund L, Yeung CK. Periurethral injection therapy for urinary incontinence using a laparoscopic port. *J Endourol* 2003;17(4):253–254.
14. Guys JM et al. Endoscopic cure of stomal leaks in continent diversion. *Br J Urol Int* 2002;89(6):628–629.
15. Prieto JC et al. The Treatment of Catheterizable Stomal Incontinence With Endoscopic Implantation of Dextranomer/Hyaluronic Acid. *J Urol* 2006;175(2):709–711.
16. Godbole P et al. Endourethral injection of bulking agents for urinary incontinence in children. *Br J Urol Int* 2003;91(6):536–539.
17. Halachmi S et al. Efficacy of polydimethylsiloxane injection to the bladder neck and leaking diverting stoma for urinary continence. *J Urol* 2004;171(3):1287–1290.



# 14

## Posterior Urethral Valves

Divyesh Y. Desai and Peter M. Cuckow

Posterior urethral valves (PUV) remains the most common cause of bladder outflow obstruction in male infants. The condition has an estimated incidence of 1/4000 to 1/5000 live births. It is a pan-urinary tract disorder with a variable spectrum of severity that can affect both the upper and lower urinary tract.<sup>1,2</sup>

The advent of antenatal ultrasound screening has dramatically changed the presentation, with more than 50% of cases being detected on antenatal screening. At our institution, currently more than 90% of boys with PUV have had the diagnosis suspected antenatally and confirmed in the first week of life.

With increasing awareness of this condition and a low threshold for aggressively investigating boys with urinary tract infections, the diagnosis is being made sooner. The advantage is that the potential detrimental effects of obstruction and recurrent urinary infections on the upper and lower urinary tract is minimized following early intervention.

In children who have not had an antenatal diagnosis, the presentation in the neonatal period is usually with symptoms of urinary tract infections, pyrexia, vomiting, poor weight gain, or dry diapers with a poor urinary stream. In the older child, they classically present with difficulty in passing urine, dribbling incontinence, or urinary retention.<sup>3,4</sup>

The initial management on suspecting the diagnosis usually involves draining the bladder preferably by a suprapubic catheter. Alternatively the bladder could be drained via a urethral catheter.

Subsequently radiological investigations are carried out to confirm the diagnosis. These include

an ultrasound examination of the urinary tract, a micturating cystourethrogram (VCUG), and an isotope renal scan to assess individual renal function (DMSA or MAG3 isotope scan).

While the child is on catheter drainage, biochemical parameters are monitored, awaiting stabilization of renal function and achievement of a nadir creatinine level. Following catheterization, the child may go through a phase of postobstructive diuresis. Therefore, fluid and electrolyte balance should be carefully monitored. Any concurrent urinary tract infection is treated with antibiotics.

In cases where there is significant renal impairment, the input of a pediatric nephrologist is extremely valuable. Following a period of stabilization (usually 10 days to two weeks), when the child is hemodynamically and biochemically stable, the obstructing valve membrane is ablated.

### Contraindications

To effectively deal with a large majority of infants with posterior urethral valves, appropriate endoscopy equipment must be available.

A relative contraindication to primary valve ablation would include premature infants, in whom the urethra is not of sufficient caliber to accommodate even the smallest of the paediatric endoscopes. The options available in this situation include a temporary diversion with the vesicostomy or, alternatively, one could try and serially dilate up the urethra by passing increasing

calibre urethral catheters over a 2 week to 4 week period.

In the past, other techniques have been described to ablate the obstructing leaflets. These include a suprapubic transvesical endoscopic approach through the bladder neck, ablation via a temporary perineal urethrostomy, Fogarty balloon ablation, and using Whitaker's hook. The availability of miniature endoscopes has made these techniques redundant.<sup>5,6</sup>

## Preoperative Investigation

Prior to resection of the posterior urethral valve membrane, ensure that the child is hemodynamically and biochemically stable. Specifically, one should check the serum values of creatinine, electrolytes, and acid base balance to ensure that the child is not acidotic. Radiological confirmation of the diagnosis with ultrasound and MCUG is arranged prior to endoscopy.

## Specific Instrumentation

Instrumentats that should be available for valve resection include:

1. Pediatric cystoscope (6F–7.5F)
2. Pediatric resectoscope (11F)
3. Cold knife, bugbee and diathermy electrodes.

## Operative Technique

The child is placed in a lithotomy position. Prior to instrumentation, a dose of intravenous antibiotic covering the gram negative spectrum of organisms is administered (usually Gentamycin or Amikacin).

The foreskin is separated to retract and visualize the meatal opening. The meatus is calibrated and if necessary serially dilated. An initial diagnostic cystoscopy is performed. I use the 6F to 7.5F graduated Wolfe cystoscope, which has an inbuilt 30° telescope and a 3/4F instrument channel.

Following the initial assessment, the valve ablation is carried out using a pediatric 11 Fr resecto-

scope, with a cold knife or a bugbee electrode. The advantage of the 11 F resectoscope (Storz) is that the tip of the sheath has no bakelite beak and is thus less traumatic and easier to introduce.

In situations where the neonatal urethra is too small to accommodate the resectoscope, the membrane can be ablated using the 7.5F cystoscope and a 3F ureteric catheter. (The technique is demonstrated in the DVD)

My preference is to use a cold blade (sickle blade) to cut valve membrane at the 5 o'clock, 7 o'clock, and 12 o'clock positions. There may be some bleeding encountered following the incision, which usually resolves spontaneously on passing a urethral catheter.

Following satisfactory ablation of the valve membrane, a urethral catheter is placed in the bladder and the suprapubic catheter (if present) is removed. Postoperatively the urethral catheter is left on drainage for a period of 48 hours and removed.

Following removal of the urethral catheter, urine output is monitored by assessing and weighing diapers and, if possible, observing the urinary stream. Plasma Creatinine value is checked prior to discharge.

The child is usually discharged on prophylactic antibiotics (Trimethoprim 2mg/Kg once a day). Follow up is planned in three months time, with repeat radiological investigations which include ultrasound, VCUG and assessment of renal function (MAG 3 Renography).

During this admission the child will also have a check cystoscopy to ensure adequacy of the valve ablation and consideration may be given to performing a circumcision.

## Complications

With miniaturization of the endoscopes, complications directly related to the procedure are uncommon. Potential complications associated with the procedure include:

1. Bleeding: This could be either the result of overzealous meatal dilatation resulting in a tear or occasionally one can encounter bleeding from the resected valve membrane, particularly with a cold knife incision technique.



2. Infection: It is prudent to ensure that any intervention is covered with broad spectrum parental antibiotics.

3. Damage to external sphincter: An uncommon complication when the procedure is carefully performed and the landmarks are well visualized and identified.

4. Urethral stricture: This is likely to be associated with diathermy ablation of posterior urethral valves. The incidence is increased if the urethra remains dry in the immediate post resection period. It can also occur with prolonged instrumentation particularly where the endoscope is a tight fit in the neonatal urethra.

5. Meatal stenosis: This occurs following forced meatal dilation to accommodate oversized instruments.

6. Incomplete resection: When using bugbee or diathermy electrodes, it is safer to err on the side of caution as overzealous diathermy causes greater damage to the neonatal urethra. It is our policy to reevaluate all boys three months following their primary ablation with a repeat MCUG as well as a check cystoscopy. Any residual valvular obstruction is ablated at the second sitting.

## Conclusions

Primary valve ablation is the preferred modality of treatment at our institution. It is physiological as it allows the bladder to continue cycling. The miniaturization of pediatric endoscopes allows for majority of valves to be ablated primarily. During the past five years, all boys with PUV have had the obstructing membrane primarily ablated at our institute following a period of temporary drainage.

In premature babies the urethra may not accommodate the smallest cystoscope and catheter drainage (replaced twice weekly with increasing caliber) may be required for a few weeks before ablation can be safely performed.

The disadvantage of ablating the valve with smaller endoscopes is that once you have a bugbee catheter in the instrument channel, the flow of irrigation fluid is significantly reduced. It is important to ensure adequate visualization of landmarks to minimize complications.

Check cystoscopy within three months of primary valve ablation ensures adequacy of treatment and allows residual obstruction to be treated early. Significant complications like urinary incontinence due to sphincter damage are uncommon and ensuring good visualization of important landmarks during the procedure will minimize problems.

## References

1. Cuckow PM. Posterior urethral valves. In: Stringer M, Oldham K, Mouriquand P, Howard E (eds). *Paediatric Surgery and Urology: Long-Term Outcomes*. Philadelphia: Saunders, 1998; pp 487–500.
2. Duffy PG. Posterior urethral valves and other urethral anomalies. In: Thomas DFM, Richwood AMK, Duffy PG (eds). *Essentials of Paediatric Urology*. London: Martin Dunitz, 2002; pp 88–97.
3. Glassberg KI. Posterior urethral valves: lessons learned over time. *Curr Opin Urol* 2003;13: 325–327.
4. Glassberg, KI. The valve bladder syndrome: 20 years later – review article. *J Urol* 2001;166:1406–1411.
5. Diamond DA, Ransley PG. Fogarty Balloon catheter ablation of neonatal posterior urethral valves. *J Urol* 1987;137:1209–1211.
6. Dean AM, Whitaker RH, Sherwood T. Diathermy hook ablation of posterior urethral valves in neonates and infants. *Br J Urol* 1988;62:593–594.

# 15

## Endoscopic Management of Ureterocele and Syringocele

Paul F. Austin and Douglas E. Coplen

Ureteroceles and syringoceles are congenital abnormalities that represent ballooning or dilated extensions of the ureter and bulbourethral gland duct (Cowper's duct) respectively. These abnormalities may result in obstruction of the urinary tract or abnormal urine flow causing urinary tract infections, pain, and other urinary symptoms. Since syringoceles occur infrequently, our primary focus is endoscopic treatment of ureteroceles, although the treatment principles are similar.

### Indications and Contraindications

Surgical treatment for ureteroceles is selective and individualized.<sup>1</sup> Multiple factors determine the role and method of intervention. A key determinant of treatment is the anatomic location of the ureterocele. If the ureterocele is located entirely within the bladder or intravesical, endoscopic treatment is the most accepted and definitive form of treatment. In contrast, endoscopic treatment of ectopic ureteroceles (e.g., ureteroceles with a portion of their submucosal wall at the bladder neck or extension into the urethra) is not generally a definitive form of therapy. There is a role, however for endoscopic treatment for ectopic ureteroceles particularly in a child who requires decompression in the setting of urosepsis or azotemia with bladder outlet obstruction.

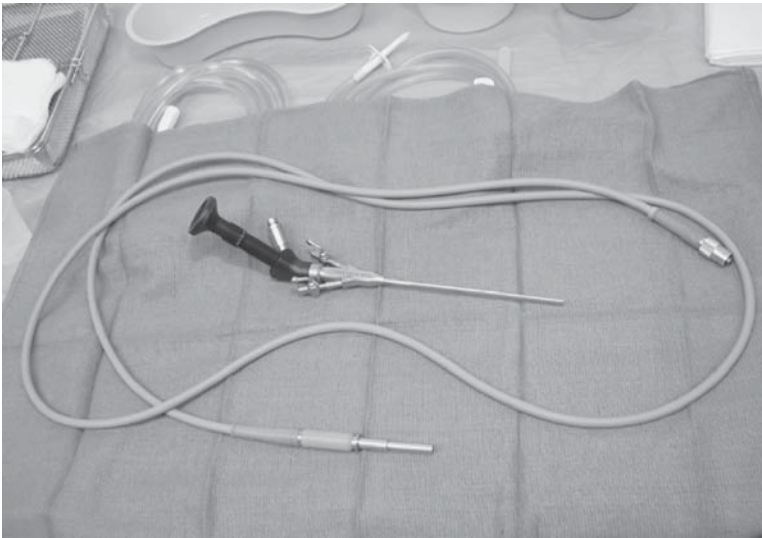
The majority of ureteroceles present antenatally and although treatment is based on the anatomic location of the ureterocele, other factors play a role in determining intervention including

renal function and the presence of vesicoureteral reflux. If there is poor renal function in the ureterocele moiety, an upper tract surgical approach may be taken (e.g., upper pole partial nephroureterectomy or "simplified approach"). Observation may also be adequate with poor renal function particularly if there is a multicystic, dysplastic kidney associated with the ureterocele and absent or low grade vesicoureteral reflux.<sup>2</sup> If vesicoureteral reflux is present at high grades or bilaterally, there is a high likelihood that surgical treatment will involve open lower tract reconstruction.<sup>3</sup>

### Preoperative Investigation and Preparation

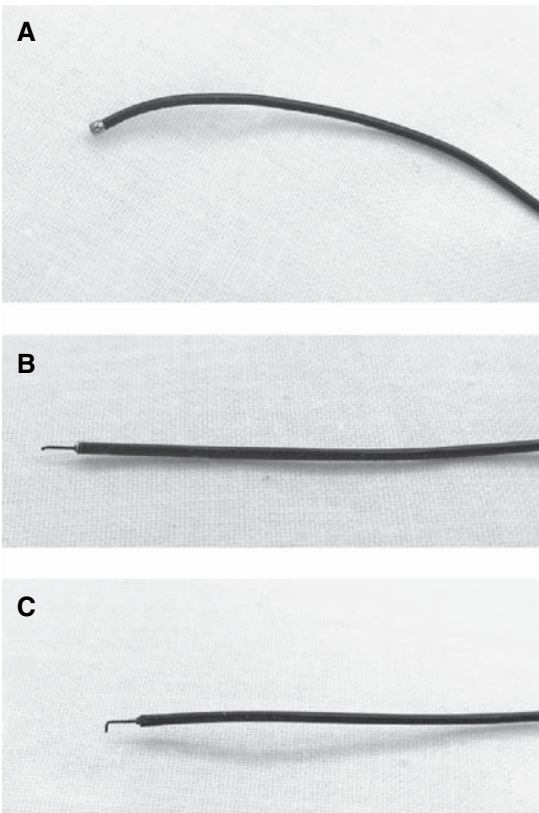
Children with ureteroceles will commonly present with either a history of antenatal hydronephrosis or of urinary tract infection. These clinical scenarios will generate a series of radiologic tests that we term "The Trifecta": (1) renal and bladder ultrasonography, (2) micturition cystourethrogram, and (3) diuretic nuclear renal scan. These tests provide information on the cystic appearance of the urinary tract, presence of vesicoureteral reflux, and renal function and drainage respectively.

After proper assessment of the urinary tract, patients should be placed on antibiotic prophylaxis in the presence of vesicoureteral reflux or obstruction. We also obtain a urine specimen 5 days to 7 days prior to the planned procedure to rule out any active infection.



**FIGURE 15.1.** Pediatric/infant offset cystoscope.

## Specific Instrumentation



**FIGURE 15.2.** A variety of probes are used for endoscopic treatment of ureteroceles and syringoceles: (A) bugbee, (B) needle, and (C) right angle.

Small endoscopic instrumentation is paramount in treating pediatric patients. A variety of scopes should be available depending on the age of child. We use a 9.5Fr offset cystoscope with a 5Fr working port (Figure 15.1). There are a variety of probes that may be used to puncture or incise the ureterocele depending on the surgeon's preference (Figure 15.2). These probes commonly involve electrocautery current to incise the tissue but utilization of laser energy may be substituted.

## Operative Technique

For infants and small children, a gel roll or towel roll underneath the legs is adequate to elevate the lower extremities in a lithotomy position. The legs will need to be secured to the table with tape to prevent any slippage. Accordingly, the skin will need protection with gauze or a small towel. Pediatric size stir-ups or candy canes may be used for toddlers and older children (Figure 15.3). Lastly, it is important to calibrate and dilate the urethra with sounds or bougies to accommodate the pediatric cystoscope and avoid trauma to the urethra. It is rarely necessary to perform a meatotomy to allow passage of the pediatric-size cystoscopes.

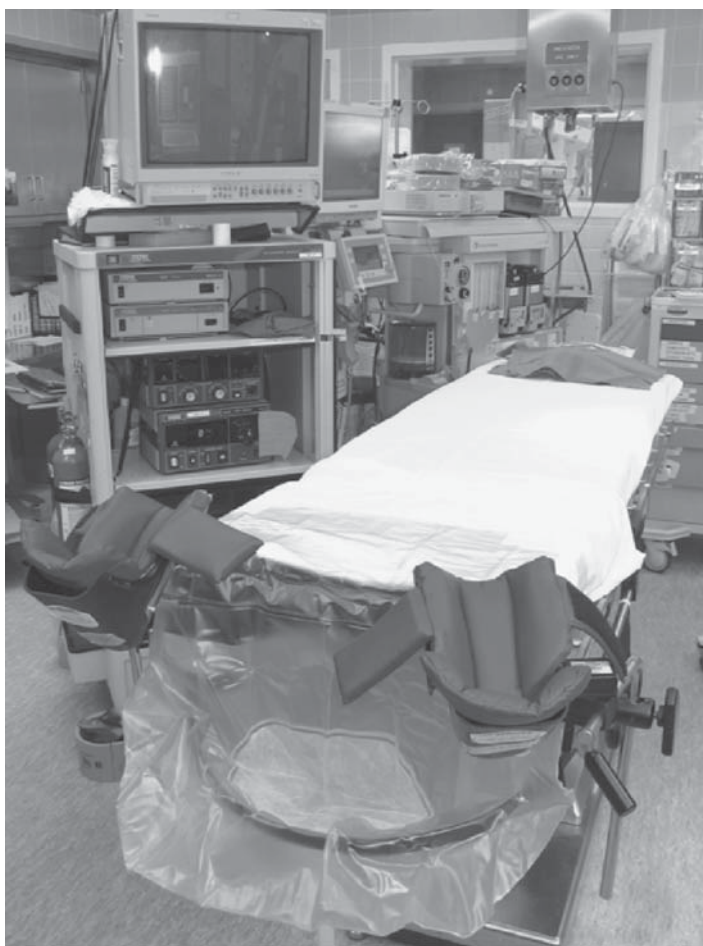## Ureterocele

During cystourethroscopy, it is important to view the urethral anatomy and bladder anatomy with the bladder empty and full. This avoids effacement or compression of the ureterocele when the bladder is distended. Maneuvers to distend the ureterocele may be helpful such as manually compressing the ipsilateral flank. As demonstrated on the DVD, we make a small incision or puncture near the base of the ureterocele. This incision site theoretically allows the superior tissue to serve as a “flap-valve” mechanism preventing iatrogenic vesicoureteral reflux. Adequate decompression of the ureterocele is the goal of endoscopic

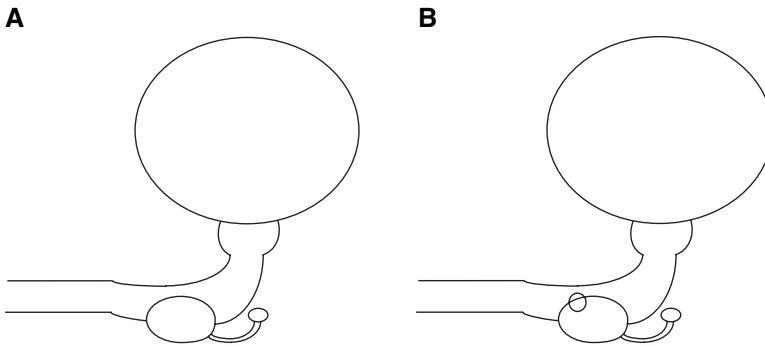
treatment of ureteroceles, but an overaggressive incision or puncture will result in an increased chance vesicoureteral reflux.

## Syringocele

We find the classification that differentiates open and closed Cowper’s syringocele useful for describing endoscopic treatment (Figure 15.4).<sup>4</sup> The closed-type syringocele may be incised for decompression using the same probes utilized for treatment of ureteroceles as described above. Open-type syringoceles may be unroofed by either a right-angle probe or an infant resectoscope.



**FIGURE 15.3.** Pediatric endoscopic table with pediatric-size stirrups.



**FIGURE 15.4.** Simple classification of types of syringoceles (Cowper's duct cysts).

## Postoperative Management

We do not typically employ any drainage after endoscopic treatment of ureteroceles. Children are placed on antibiotic prophylaxis and are followed up in the clinic with ultrasonography to document decompression. A micturition cystourethrogram is obtained to rule out iatrogenic vesicoureteral reflux. When evidence of decompression is verified and vesicoureteral reflux is excluded, antibiotic prophylaxis is stopped. Further followup is performed with ultrasonography and clinical assessment accordingly.

## Complications

There are few complications encountered with endoscopic treatment of ureteroceles. However, as with all endoscopic procedures, there is a risk of trauma to the urethra with resultant iatrogenic stricture. Proper pediatric instrumentation obviates this risk. Creation of iatrogenic vesicoureteral reflux is well known with endoscopic treatment of ureteroceles particularly with ectopic ureteroceles. Judicious use of incising or puncturing the intravesical ureterocele minimizes this risk.

## Author's Remarks

Endoscopic treatment of ureteroceles and syringoceles is relatively straightforward. Judging the appropriate incision site from large ectopic ureteroceles can be challenging. Key points for treating ureteroceles include avoiding overaggressive puncture causing iatrogenic reflux and utilization of infant-size endoscopic equipment and probes.

## References

1. Coplen DE. Management of the neonatal ureterocele. *Curr Urol Rep* 2001;2(2):102–105.
2. Coplen DE, Austin PF. Outcome analysis of prenatally detected ureteroceles associated with multicystic dysplasia. *J Urol* 2004;172(4 Pt 2):1637–1639; discussion 1639.
3. Husmann D, Strand B, Ewalt D, Clement M, Kramer S, Allen T. Management of ectopic ureterocele associated with renal duplication: a comparison of partial nephrectomy and endoscopic decompression. *J Urol* 1999;162(4):1406–1409.
4. Bevers RF, Abbekerk EM, Boon TA. Cowper's syringocele: symptoms, classification and treatment of an unappreciated problem. *J Urol* 2000;163(3):782–784.

## Urinary Calculi



# 16

## Percutaneous Nephrolithotomy and Laparoscopic Management of Urinary Tract Calculi

Pedro-José López, Michael J. Kellett, and Patrick G. Duffy

Urinary calculus in childhood is not common. The incidence in Great Britain is two cases per million per year, and it occurs more frequently in boys than girls (1.5:1). Nearly 62% of the stones are located in the kidney, and spontaneous passage is less frequent than recorded in adult series (35%–50%).

Coward et al. found that 45% of calculi are related to a metabolic abnormality, 30% present with a concomitant infection at the time of diagnosis. The rest (25%) do not have a clear etiology.<sup>1</sup> Concerning the stone composition, calcium oxalate is the main component in 50% to 65% of the cases, while calcium and magnesium phosphate are found in 30% to 40%. Stone composition can be crucial for planning treatment, as cystine stones may be especially difficult to fragment.

Urine supersaturation is one of the fundamental conditions for stone formation. This may be a result of an imbalance between promoters (calcium, oxalate, phosphate) and inhibitors (citrate, pyrophosphate, glycoaminoglycans). Infection that involves gram-negative organisms (*Proteus*, *Pseudomonas*) can lead to a lithogenic process with alkalisation of the urine due to hydrolysis of urea to ammonium. The alkalinized urine leads to supersaturation of compounds calcium, magnesium, and ammonium phosphate, among others.

Children rarely present with the classical colicky pain. The presence of hematuria should guide the clinician to the diagnosis of urolithiasis.<sup>2,3</sup> Nevertheless, symptoms vary with age; infants usually present with urinary tract infection (UTI) and

passing stones in diapers, while hematuria and pyuria are the main symptoms in older children. In teenagers, abdominal pain is the main symptom. Nearly 30% of children have a positive family history of renal stones at the time of diagnosis.

Many stones can be managed with conservative measures. In childhood emergency treatment for stones may be necessary if there is anuria because of obstruction, and sepsis. Usually, however, stone extraction or destruction can be a well-planned procedure in favorable conditions, that is, no infection and a planned surgical strategy.

Minimally invasive management of calculi implies extracorporeal shock wave lithotripsy (ESWL), percutaneous nephrolithotomy (PCNL), and laparoscopy. The main aim of these techniques is to approach the stone by the least invasive technique, with a high success rate, while avoiding damage to the urinary tract and other structures.

The principle of ESWL is to conduct an acoustic shock wave through a water medium and the body's soft tissues to fragment the stone. The success rate of this procedure is 90% and depends on factors such as patient selection (obesity presents higher failure rate), stone type (calcium stones are easier to fragment), and stone size (less than 20 mm in its largest dimension have shown better results). On the other hand, while a stag-horn calculus is one the contraindication for ESWL in adult series, it has been described in the infant population with a fragment free rate of 75% with one session of ESWL.



## Percutaneous Nephrolithotomy

The principle of PCNL is the percutaneous introduction of a working channel to the pelvicalyceal system, which allows identification, fragmentation, and removal of a stone or stones.

### Indications and Contraindications

The main indications for PCNL could be grouped as follows:

1. Stone
  - a. staghorn calculus
  - b. multiple calculi
  - c. renal pelvis stone >2 cm
  - d. Lower pole stone >1 cm
  - e. stone plus a foreign body
  - f. composition (cysteine, calcium oxalate monohydrate)
2. Anatomic abnormalities
  - a. UPJ obstruction
  - b. ureter obstruction
  - c. infundibular stenosis
  - d. calyceal diverticulum
3. Patient
  - a. obesity
  - b. scoliosis
  - c. vascular malformation
  - d. preference
4. Treatment failure
  - a. ESWL
  - b. ureteroscopy

While contraindications for PCNL are not so common, there are some concerns if the child presents with:

1. Infection
2. High blood pressure
3. Bleeding disorders

### Preoperative Investigation

Imaging is vital in the whole process, but radiation exposure can be an issue. A kidney-ureter-bladder X-ray (KUB) and urinary tract ultrasound (US) will detect approximately 90% of calculi, giving information such as side, number, size, renal parenchyma, obstruction, and signs of infection.

Intravenous urography, 3 to 4 films, is preferred when lithiasis is suspected and the abovementioned tests cannot detect a calculus (10%). It will also demonstrate the position of a ureteric stone and the associated ureteric anatomy. A CT scan, the gold standard for detecting calculus in adults, has been limited to difficult cases because of high radiation exposure. This test can be adapted to decrease radiation dose, by lowering the mAs. In children, it may involve a general anesthetic.

A DMSA scan is useful before PCNL to show differential kidney function and localized renal damage. It may be appropriate to remove a kidney with calculus disease if the kidney function is poor (<10%) and the contralateral kidney is normal. A DMSA scan after PCNL is useful to indicate that the procedure has caused no loss of function.

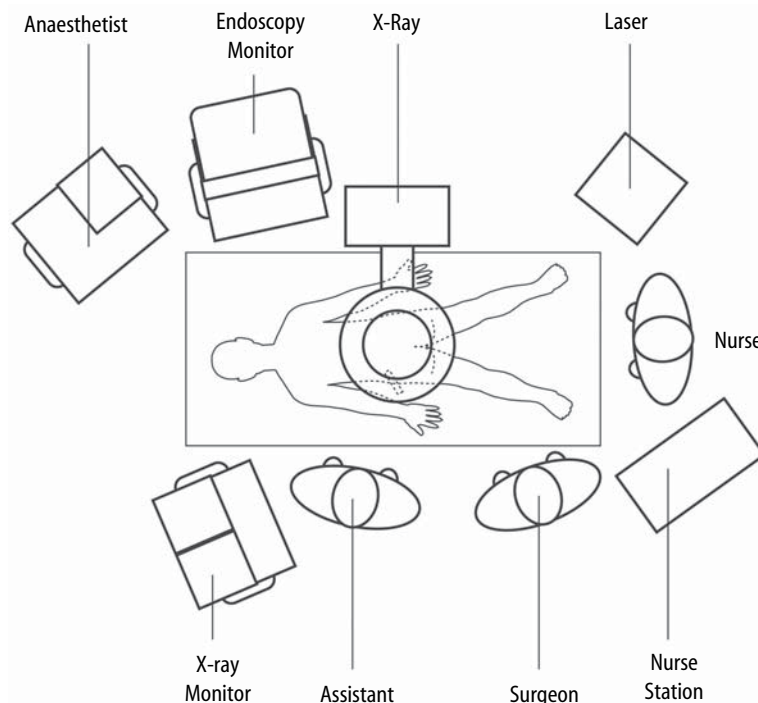
Blood samples should include serum electrolytes, urea, creatinine, bicarbonate, albumin, and uric acid (especially if the stone is radiolucent). It is also important to measure serum calcium, phosphate, and magnesium. Urinary studies should include microscopy and culture after a second void, a 24 hour collection (volume, osmolality), calcium, oxalate, uric acid, and citrate. It should also include urea, creatinine, sodium, and potassium.

Abdominal plain X-ray and ideally US should be updated 24 hours before surgery to confirm the presence and position of the stone.

### Specific Instrumentation

For an optimal PCNL, the specific instrument requirements are listed below:

1. An operative theater with room for an ultrasound machine, fluoroscopy equipment, the laser lithotripter, the ultrasonic lithotripter, the video and endoscopic equipment, a radiographer, and a radiologist, as well as the usual theater staff and equipment (see Figure 16.1).
2. A surgical table that allows multiple positions.
3. Nephroscope 30 degree connected to a camera-video system
4. Amplatz dilators set (8Fr–26Fr) and its sheaths
5. Balloon dilators



**FIGURE 16.1.** The layout and positioning of personnel and equipment in the operating suite for a left PCNL.

6. Alken telescopic dilators
7. J tip guidewire
8. 18 G to 22 G access needle
9. 4F to 6F ureteral catheter
10. Nephroscope grasper
11. Omnipaque with normal saline (50:50)
12. Methylene blue
13. Cystoscopy set
14. Ureteroscopy set
15. Fluoroscopy
16. Ultrasonic lithotripter (calcuson in conjunction with Uromat Storz)
17. Laser lithotripter (Lumenis Versapulse Powersuite Holmium yttrium aluminium garnet: HO:Yag)
18. Nephrostomy tube for drainage
19. Nephroscopy drape

## Operative Technique

The operative procedure is performed in following steps

1. Under general anaesthesia and after giving intravenous antibiotics, a cystoscopy is per-

formed. A catheter is then passed retrogradely up the ureter over a guidewire, which is then removed. Contrast medium (omnipaque plus methylene blue) is injected up the ureteric catheter to outline the pelvicalyceal system with fluoroscopy. The catheter may be used to flush fragments into the pelvis.

2. The patient is positioned prone with the stone side slightly up. The nephroscopy drape is positioned to direct the fluid into the plastic bag avoiding excess spillage on the table and also allows measurement of irrigation fluid.

3. Ultrasound can be used to confirm the calculus position and to plan the best calyx to puncture. Long-acting local anesthetic (marcaine) is infiltrated at the site of the planned track. Under fluoroscopy, the access needle is introduced along the posterior axillary line, to mark best puncture site to enter the calyx. Fluoroscopy and US is used to guide appropriate entry angle to the calyx.

4. When the calyx is punctured a J guidewire is inserted through into the pelvis.

5. After the needle is withdrawn, the dilators are passed over the wire. An Amplatz sheath

slightly bigger than the instrument is introduced to secure the tract (24 Fr–26 Fr).

6. It is possible that the stone could be removed without fragmentation with the grasping forceps.

7. When this is not possible, the stone can be fragmented. The safest lithotripter is the ultrasonic lithotripter with suction (Calcuson in conjunction with Uromat Storz), to permit simultaneous disintegration and removal.

8. When the lithotripsy is performed, larger fragments can be removed with forceps. Stones fragments should be sent for biochemical analysis and urine for culture.

9. If there is more than one stone, or one of the principal fragments has migrated to another calyx, a new access tract may be created to remove the stone or a needle can be used to push the stone into the pelvis for removal via the original tract.

10. A nephrostomy is left in the track. It may be small (6 Fr) for drainage or large (24 Fr) for both tamponade and drainage. All other catheters are removed. A Foley bladder catheter is rarely used.

## Postoperative Management

Postoperative pain control with oral analgesia is usually necessary for 24 hours. Urine is strained for fragments for 24 hours. The nephrostomy tube is clamped 24 hours after the procedure and, if there is no problem, it is removed 6 hours to 12 hours later. Thus, the child can be discharged 48 hours postsurgery. The three-month followup includes a new KUB and US. The patient remains on prophylactic antibiotics until stone free.

## Complications

The main complications of PCNL are residual calculi, bleeding, and renal perforation. Pyrexia after PCNL, nonetheless, is commonly seen, despite antimicrobial prophylaxis, and it usually resolves with continuing antibiotics for 48 hours.

Bleeding can occur at any step of the procedure: during the creation of the track, due to vascular injury after puncture, or after excessive dilatation. In general, most of the bleeding is venous and is controlled by the Amplatz sheath. If the bleeding

is excessive, the procedure should be stopped and a tamponading nephrostomy tube inserted. Blood transfusion is unusual.

Damage to the adjacent structures is rare but has been described. If the track was made above the 12th rib to gain access to the upper pole, pleural perforation can occur. Insertion of a pleural cavity drain is not always required. Perforation of the urinary tract can be managed with a nephrostomy or a ureteral catheter. Perforation of the colon or other abdominal organs has been described, but can be managed conservatively with adequate drainage.

Warm irrigation fluids and proper insulation of the patient's body is necessary because children can lose heat rapidly, and a PCNL can take one to two hours.

## Conclusions

The success of PCNL is more than 90% and it is due to a well-organized team, where the anesthetist is prepared to deal with possible lengthy surgery and bleeding and staff who know the complex equipment.

There is a suggestion that a single surgeon could perform a competent PCNL after doing more than 60 procedures, but with the low incidence of PCNL in children, it is recommended to work with an experienced urologist who has regular experience in forming percutaneous renal tracts.<sup>4</sup>

## Laparoscopy

The laparoscopic approach is feasible for stone extraction and, in particular, the large solitary stone in an extra renal pelvis. While it is a minimally invasive technique, it is still considered more aggressive than a PCNL for the kidney and an ureteroscopy for the ureter. It has a specific role in the treatment of the bladder calculi. The incidence of bladder calculi is nearly 10%, and it is more frequent among bladder augmentation patients (10%–50%).<sup>5</sup>

The logical approach for this type of calculus is to perform lithotripsy through the urethra with laser probes, but there are two main problems.

First, it is difficult to remove fragments and recurrence rate is higher than open surgery. Second, in an augmented bladder, it can be difficult to find the stone and its fragments. Hence, the aims of this approach are to try to remove the stone intact or to fragment it in a bag.

## Preoperative Investigations

The same basic investigations described for the PCNL are required for this procedure.

## Specific Instrumentation

The equipment required is:

- A standard laparoscopic set
- A 10 mm (ideally Hasson port) and 5 mm ports.
- An endobag is recommendable to remove the stone, but if it is not available, a finger cut from a sterile glove could be useful.
- Urethral catheter

## Operative Technique

1. Under general anesthesia, a cystoscopy is done to confirm the presence of the stone. Even with this procedure, to find the stone could be difficult and an US is probably required.

2. The 10 mm Hasson port with open technique is inserted into the bladder, fixing the bladder wall with the abdominal wall.

3. Gas flow is started at 3 L/min and pressure at 8 mmHg. If it is required, especially in augmented bladders, both flow and pressure can be increased.

4. Under direct vision, a 5 mm working port is inserted at the side. The television monitor can be at the end of the table or opposite this port.

5. When the stone is found, the camera is swapped from the 10 mm to the 5 mm port and an endobag is introduced through the 10 mm port.

6. A “fishing” technique is used to collect the stone. Once the stone is in the bag, depending on the size, it could be either extracted or fragmented. Stones fragments should be sent for stone analysis.

7. If another port is needed to hold the stone, or to introduce it to the bag, the urethra can be used.

8. A urethral catheter is inserted at the end of the surgery.

## Postoperative Management

The patient receives oral pain relief for at least 24 hours, and prophylactic antibiotics are continued for 48 hours. The urethral catheter is left in free drainage for 48 hours. The follow-up is in clinic in three months with a new KUB and US.

## Complications

Complications are few, and the most common are at the moment of the port insertion (i.e., bleeding and/or perforation of adjacent structures). The bleeding could be almost always controlled with diathermy. On the other hand, the perforation may require a minilaparotomy to repair the injury, and a drain may be required.

## Conclusions

Laparoscopic bladder stone surgery is a procedure with a success rate that is nearly 100%, with very low complications, and well tolerated by the patient. Thus it should be the first approach for a bladder calculus, especially if it has been augmented.

## References

1. Coward RJM, Peters CJ, Duffy PG et al. Epidemiology of paediatric renal stone disease in the UK, *Arch Dis Child* 2003;88:962–965.
2. Choong S, Whitfield H, Duffy P et al. The management of the paediatric urolithiasis, *Br J Urol* 2000; 86:857–860.
3. Lotmann H, Gagnadoux MF, Daudon M. Urolithiasis in children. In: Gearhart J, Rink R, Mouriquand P (eds). *Pediatric Urology*. Saunders, Philadelphia, 2001; pp 828–859.
4. Allen D, O'Brien T, Tiptaft R et al. Defining the learning curve for percutaneous nephrolithotomy, *J Endourol* 2005;19(3):279–282.
5. Kronner KM, Casale AJ, Cain MP et al: Bladder calculi in the paediatric augmented bladder, *J Urol* 1998;160:1096–1098.

# Ureteroscopy in Children

Pedro-José López and Patrick G. Duffy

Ureteric calculi in the pediatric population has presented a technical challenge because of the size of instruments required within a restricted field of vision and a narrow working channel.

In the last decade, nonetheless, ureteroscopic equipment has been adapted for children. While the number of procedures has increased since Shepherd published the first pediatric ureteroscopy in 1988, the total number of ureteroscopies done in a single center per year is still limited.<sup>1</sup> Both the lack of experience due to the limited number of cases and the availability of adequate equipment are currently the main problems in many institutions.

The principle of the ureteroscopy is the retrograde introduction of an endoscope through the ureterovesical junction (UVJ), which allows the surgeon to perform either a diagnostic or therapeutic procedure in the ureter and, in some cases, in the pelvis of the kidney.

But, in the presence of a calculus in the ureter, “the” question to be answered is if the stone would pass spontaneously. In general, stones <5 mm have a spontaneous passage rate of 50% to 95%, especially if they are located in the distal ureter. On the other hand, stones of 5 mm to 10 mm have a spontaneous passage rate of 10% to 50%, depending on the portion of the ureter in which they are located.<sup>2</sup>

Coll suggested that the rate of spontaneous passage of a stone is related to its position in the ureter: 75% in the distal, 60% in the middle, and 50% in the proximal.<sup>3</sup> Approximately 25% to 50% of children with a calculus in the ureter may need a surgical procedure, and ureteroscopy is an excellent modality.<sup>4,5</sup>

## Indications and Contraindications

The main indications for retrograde ureteroscopy are:

1. Stone
  - a. stone in the ureter
  - b. concomitant ureteral and kidney stones
2. Patient
  - a. obesity
  - b. patient with coagulopathy
  - c. preference for this procedure
3. Treatment failed
  - a. ESWL
  - b. conservative treatment

Contraindications for this procedure are stones >2 cm in the ureter, which should be removed with open or laparoscopic surgery, and urinary tract infection. Nevertheless, both lack of experience and adequate equipment may contribute to making this surgery difficult.

## Preoperative Investigation

With kidney-ureter-bladder plain X-ray (KUB) and a urinary tract ultrasound (US) nearly 90% of the calculi can be detected. These tests will demonstrate side, number, size, renal parenchyma, possible obstruction, and infection.

Intravenous pyelogram could be useful to give information related to a stone in the ureter or when a calculus is not seen with the previous tests (10%). CT scan has been limited to difficult cases, such as distorted ureters secondary to kyphoscoliosis or complex upper tract surgery.

Serum measurements should include electrolytes, urea, creatinine, uric acid, calcium, phosphate, magnesium, bicarbonate, and albumin. Urinary studies after second voided include microscopy and culture, and urine calcium, oxalate, uric acid, citrate, urea, creatinine, sodium, and potassium.

Preoperatively, a plain abdominal X-ray and ideally a repeat urinary ultrasound should be performed 24 hours before surgery.

## Specific Instrumentation

For a successful ureteroscopy the procedure set should contain:

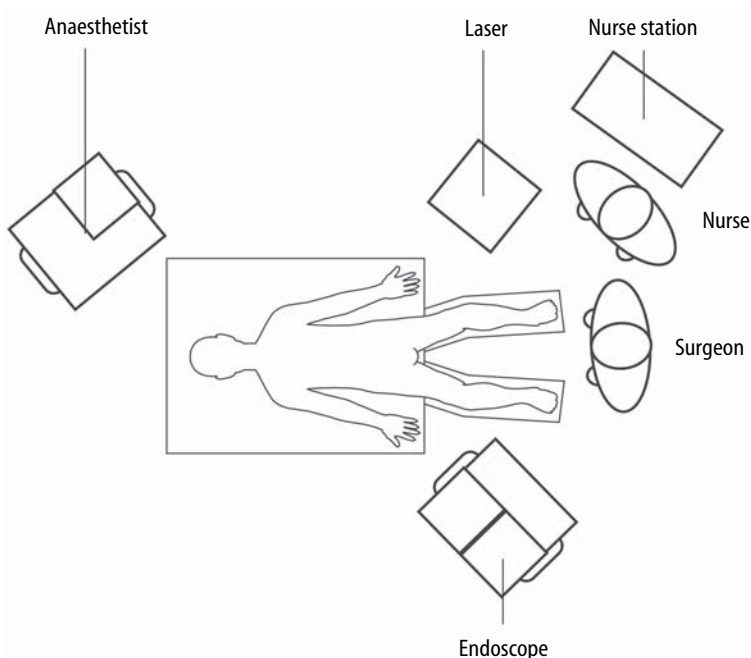
1. A surgical table that allows a lithotomy position. For the arrangement of the room and personnel, see Figure 17.1.
2. Camera-video system
3. Cystoscopy set
4. Semiflexible and flexible ureterscope of at least two different diameters. A large ureterscope presents the disadvantage of access, while a small one has a reduced flow, poorer vision and small

working channel. Considering vision and working channel, an ideal ureterscope outer diameter is 7.4Fr.

5. Ureteral guide wire
6. Double-J stents
7. Pressure manometric bag for fluid flow
8. Biopsy forceps
9. Laser lithotripter (Lumenis Versapulse Powersuite Holmium yttrium aluminium garnet: HO:Yag)
10. At least two laser fibres (365 micron requires a minimum of a 2.3Fr working channel)
11. Fluoroscopy
12. Omnipaque with normal saline (50:50)

## Operative Technique

1. Under general anesthesia and intravenous antibiotics, the patient is placed in the lithotomy position. The lower extremity contralateral to where the calculus is located should be positioned flatter than usual, allowing free movement of the ureterscope. If a PCNL procedure has been planned at the same time, ureteroscopy should be done first.



**FIGURE 17.1.** The arrangement of equipment and personnel in the operating suite for a ureteroscopy.



2. A cystoscopy is performed to introduce the safety guidewire, which should be left in situ until the procedure has finished. This guide wire would allow introducing a catheter in case of an emergency, such as bleeding or perforation.

3. Many centers use sterile water for the cystoscopy, but for ureteroscopy normal saline should be used.

4. The ureteroscope is introduced into the urethra, avoiding damage to the penile urethra.

5. UVJ dilatation is routinely done by some institutions, although, it is not necessary.

6. The pediatric ureteroscope would pass the UVJ helped by, firstly the hydrodilatation due to the high-pressure flow, secondly being guided by the safety-wire, and finally with oscillated movements allowing a rotation of the tip of the instrument, looking for the centre of the ureter.

7. If there is any problem to pass the UVJ, a double-J stent is placed and the procedure is postponed for 4 weeks to 6 weeks.

8. The ureteroscope should be advanced through the ureter with fine movements of the surgeon's hand.

9. Once the stone is found, the tip of the laser wire is advanced. The same tip is used to try to hold the stone against the ureteral wall to start the lithotripsy. Ideally, the laser should be located in the upper part of the stone. The laser is very precise and has a very limited depth of penetration, which allow fragmentation without damaging surrounding tissue. The Holmium-Yag laser is usually set at 0.6 joules of energy and 6 pulses/sec to 8 pulses/sec.

10. The procedure continues until there are fragments nearly the size of the ureteroscope. There is no need to use the basket as spontaneous passage of fragments is expected.

11. When the procedure is finished, the safety guidewire is removed and a urethral catheter is usually not necessary.

## Postoperative Management

The patient usually receives pain relief for 24 hours. Urine is strained for 24 hours looking for stone fragments which are analyzed. Follow-up is in three months with a new KUB and US.

## Complications

Problems related to the procedure are the inability to introduce the guidewire or to pass the ureteroscope through the UVJ. With regard to the first issue, the procedure should stop, because without a safety guidewire in the ureter, complications cannot be managed adequately. On the other hand, if the telescope does not pass, a double J stent can be placed for 4 weeks to encourage dilatation of the ureter and the UVJ.

During the surgery, the calculus could migrate up into the kidney and fluoroscopy is useful to detect the new position. Sometimes it is impossible to continue, a JJ stent is inserted in preparation for a further attempt at a later date.

Damage to the ureter such as laceration, perforation, or avulsion has been described. Because a guidewire was inserted beforehand, laceration and perforation can be managed inserting a JJ stent. Avulsion of the ureter has to be confirmed with contrast medium under fluoroscopy, and its correction must be with open surgery.

Strictures, VUR, and UTI have been described after ureteroscopy, but the incidence is <1%.

## Conclusions

Due to advances and improvements in ureteroscopic equipment with size reduction and improved vision, treatment of ureteric calculi in children has become easier. Development in flexible ureteroscope design will permit pediatric urologists to treat more calculi within the pelvic-calyceal system. While there are smaller instruments, it has been suggested that an ideal outside diameter for a flexible ureteroscope, which combine nicely the aforementioned characteristics, and also avoid dilatation of the UVJ, is the 7.4 Fr.

The procedure has a success rate of more than 95%, although, the enthusiastic pediatric urologist has to be aware that, overall, more than 50% of the ureteric stones would pass spontaneously, without surgical intervention.

Finally, to perform an uncomplicated ureteroscopy the surgeon should have adequate equipment and pay meticulous attention to details such



as patient position; safety guide wire insertion and fine movements of the ureteroscope.

## References

1. Shepherd P, Thomas R, Harmon EP. Urolithiasis in children: Innovations in management. *J Urol* 1988; 140:790–792.
2. Gettman M, Segura J. Management of ureteric stones: issues and controversies, *Br J Urol* 2005;95(S2): 85–93.
3. Coll DM, Varanelli MJ, Smith RC. Relationship of spontaneous passage of ureteral calculi to stone size and location as revealed by unenhance helical CT. *Am J Radiol* 2000;178:101–103.
4. De Dominicis M, Matarazzo E, Capozza N et al. Retrograde ureteroscopy for distal stone removal in children, *Br J Urol* 2005;95:1049–1052.
5. Fuchs G, Yuk JP. Retrograde endoscopic treatment of renal stones: indications and technique of retrograde intrarenal surgery. In: Moore R, Bishoff J, Leoning S, Docimo S (eds). *Minimal Invasive Urologic Surgery*, Taylor & Francis, 2005; p 449–478.

# 18

## Minimally Invasive Management of Calculi in Augmented/Neuropathic Bladders

Jesse N. Mills, Al Baha Barqawi, Job K. Chacko, and Martin A. Koyle

Calculi in the augmented bladder is a well-reported and troublesome complication of augmentation cystoplasty and neurogenic bladders. Its incidence has been quoted as low as 8%<sup>1</sup> and as high as 52%.<sup>2</sup> Within either limit, it is safe to say bladder stone management is a common component of the practicing pediatric urologist.

Bladder stones in the augmented bladder are most commonly composed of struvite and therefore are infectious in nature and associated with incomplete emptying. As a result, prevention is the first line of treatment. However, patient compliance with frequent augment irrigations is variable at best. Medical management can help increase urinary citrate concentrations in the percentage of patients with hypocitraturia. Surgical management remains the mainstay of struvite stones in the augmented bladder.

Open cystolithotomy carries the risk of devascularizing the augment and increasing the morbidity associated with incisional surgery. The large stone burden seen in some augmented bladders makes open surgery appealing as a means of shortening the operative time, however. The impetus for a minimally invasive approach to stone management in the augmented and neuropathic bladder is clear: maximize outcome and minimize morbidity.

### Preoperative Investigation

Routine upper and lower tract ultrasonography of the augmented urinary tract can usually reveal the presence of stones in the bladder. A preoperative

KUB is also helpful to measure the preoperative stone burden. Urine cultures are helpful in guiding preoperative antibiotic prophylaxis.

### Preoperative Patient Preparation

The patient and parents are made aware that surgical management of stone disease is only part of the picture. We make clear that prevention of stones is a burden placed on the family. In addition, the options of open cystolithotomy versus an endoscopic approach are discussed, along with our technique of placing a trochar in the augment under direct vision as a port for vacuuming out the stones to significantly decrease operative time. In our experience, we have found no added morbidity with this procedure.

### Specific Instrumentation

1. Rigid pediatric cystoscope: 14 Fr or 16 Fr sheath with 30 degree lens
2. Holmium laser fiber: 550 micron
3. 10 mm optivue trochar
4. Standard wall suction tubing
5. Laparoscopic grasping forceps
6. Super still 0.038 ureteral guidewire

### Operative Technique

Surgical preparation for this procedure includes a preoperative abdominal X-ray and urine cultures. Positive urine cultures will not preclude the

patient from surgical intervention; they merely serve as a guide for perioperative antibiotic administration. A febrile child with positive urine cultures will need to be treated prior to instrumentation of the urinary tract, however. The operative room setup is depicted on the accompanying DVD.

General anesthesia is induced with the patient in supine position on a table that allows for intraoperative fluoroscopy to be performed. The patient's abdomen is shaved, if necessary, and prepped with surgical detergent. Drapes are applied to expose from the subcostal abdomen to the pubis cranially to caudally and laterally to expose the anterior superior iliac spine. Cystoscopy of the catheterizable stoma commences the operation. At this point, the overhead lights are dimmed in the operating room and the bladder is surveyed for stones. The surgeon directs the cystoscope to the anterior abdominal wall where an assistant is pressing in on the abdomen to identify an appropriate puncture site for the trochar. In a thin patient, one can see the light from the cystoscope projecting through the skin. The assistant then inserts a 22 gauge spinal needle through the abdomen into the bladder under direct vision from the cystoscope. Next, the assistant makes a horizontal incision by the finder needle just wide enough to allow placement of the 10 mm trochar. The trochar is then placed under direct vision.

The assistant can now insert standard wall suction tubing, cut on a 45 degree bevel, into the laparoscopic port for suction of stone fragments and irrigation. The surgeon then inserts a 550 micron Holmium laser fiber through the working port of the cystoscope sheath and commences laser ablation of the stone burden. Fragmentation should be complete enough to allow passage of the stone pieces through the wall suction unit. The assistant simultaneously moves the suction tubing to the stone pieces. It is important to keep the bevel of the tubing up to prevent sucking of the bladder mucosa into the tubing. We have personally seen no more damage than mild petechiae, however, it slows the process significantly to stop suction until the mucosa relaxes out of the tubing. Once we feel stone fragmentation is complete, we obtain an intraoperative KUB to ensure there are no stone fragments hiding in mucosal folds.

To allow for maximal drainage, the surgeon leaves a small Foley catheter in the Mitrofanoff

(12 Fr or 14 Fr). The surgeon then passes a super stiff guide wire through the trochar and removes the trochar. An 18 Fr council tip catheter is then placed over the wire and into the bladder. The wire is removed and 5 cc sterile water is placed in the balloon port. This concludes the procedure.

## Operative Management

The patient usually spends one night in the hospital for observation. We remove the catheter from the Mitrofanoff on postoperative day one. We do not place any restrictions on activity or bathing. We follow up in approximately 10 days for removal of the suprapubic cystostomy tube. The patients continue to catheterize their stomas per usual routine.

## Complications

There have been no complications reported with this technique.

## Authors' Remarks

In our hands, this technique has reduced operative time for large stone burdens by more than 50%. It offers a minimally invasive solution to a common problem that carries significant morbidity to the patient. As we gain more experience with this technique, we hope to develop an instrument that is more suited to stone evacuation than standard wall suction tubing. Specifically, we are developing a device that allows for suction of stone fragments and prevents suction of mucosa into the tubing.

## References

1. Rink RC, Hollensbe D, Adams MC. Complications of augmentation in children and comparison of gastrointestinal segments. *Am Urol Assn Update Series* 1995;14:122-128.
2. Palmer LS, Franco I, Koan SJ et al. Urolithiasis in children following augmentation cystoplasty. *J Urol* 1993;150:726.

# **Section C**

## **Miscellaneous**

### **Fecal Incontinence**

# Laparoscopic Assisted ACE Procedure for Fecal Incontinence in Children (I)

Dominic Frimberger and Jeffrey B. Campbell

Neurogenic bowel conditions are often part of severe congenital malformations, such as spina bifida, cloaca, or imperforate anus. Affected patients frequently require aggressive daily bowel management to prevent constipation and continuous stool leakage. The regular application of retrograde enemas, often in combination with manual disimpaction, is necessary to ensure proper emptying of the rectal vault. Many of the affected children are either wheelchair bound or have limited dexterity, making them dependent on a caretaker to perform the rectal procedures.

The idea of accessing the cecum via a continent flap valve mechanism using the appendix as a catheterizable channel has been popularized by Malone.<sup>1,2</sup> The patients are now able to pass a catheter through the abdominal stoma into the cecum, which allows them to apply daily antegrade enemas while sitting on the toilet. The creation of such an antegrade colonic enema (ACE) stoma involves mobilization of the cecum, ascending colon, and appendix.<sup>3</sup> Care is taken to mobilize the appendix on its own blood supply without detaching it from the cecum. The cecum is then imbricated over the appendix and the free end is brought to the skin either at the level of the lower abdomen or through the umbilicus. The standard open technique requires a midline incision from a few centimeters above the pubis beyond the umbilicus to allow proper bowel mobilization and stoma positioning. But, in many cases, the same result can be achieved using a three-port minimal invasive technique, encompassing all the advantages of laparoscopy. In the following, we review the pre- and postoperative management, as well

as the technical aspects and complication possibilities, of the laparoscopic ACE procedure.

## Indications and Contraindications

The laparoscopic ACE procedure is indicated for patients with chronic constipation due to neurogenic malfunction of the bowel. A laparoscopic ACE procedure can be complicated by preexisting conditions that ultimately might require conversion to open surgery, such as:

- Previous abdominal surgery with extensive adhesions and scar formation.
- The presence of a non usable or absent appendix that requires the creation of a catheterizable conduit from ileum.
- Space limitations due to coexisting malformations of the spine that do not allow proper insufflation of the abdomen.

The most challenging part of the operation is the correct placement of the imbrication sutures over the appendix to avoid incontinence without compromising the blood supply of the appendix.

## Preoperative Investigation

As with the open technique, one has to ensure that a complete cleanout of the bowel using conventional enemas leads to the desired stool continence. Patients and caretakers have to be counseled that regular and correct use of the newly created

stoma is mandatory to ensure long-lasting proper function. Patients and their caretakers are enrolled postoperatively in a detailed stoma managing program to ensure proper usage. Preoperative imaging includes a plain abdominal film and renal and bladder ultrasound to evaluate for constipation and abnormalities of the urinary tract, respectively. Blood and serum tests are only necessary in case of suspected comorbidities. The procedure, as well as the complication possibilities including possible open conversion, are explained in detail. Child life services are contacted to accompany the family before and after the procedure.

### Site Selection

The options for site selection will be determined largely by the patient's own anatomy, but it can also be influenced by surgeon preference and experience. Generally, the skin site is dependent on the conduit's mobility and origin of blood supply, the presence of preexisting hernias, scars, and abdominal wall thickness. The most common sites are the right lower abdominal quadrant and the umbilicus. It is important to determine preoperatively the patient's handedness as well as upper extremity dexterity and reach. An obese patient, in particular, may benefit from a more cephalad located stoma that will be easier to visualize and catheterize. Ultimately, proper function of the stoma is the paramount concern, and the stoma has to reach the selected skin site with ease. However, for cosmetic purposes the stoma should be concealed within the umbilicus whenever possible.<sup>4</sup>

### Preoperative Patient Preparation

A complete bowel preparation is mandatory to avoid intraoperative stool spillage and ensure fast postoperative return of bowel function. In our institution, patients are admitted one day prior to surgery for a complete bowel preparation with oral Golyetly, antibiotics, and enemas as needed. After completion of the bowel cleanout electrolytes are determined and corrected if necessary.

### Operative Technique

Latex precautions should be applied. Following the administration of a general anesthetic, the patient is placed in the supine position, padded, and secured to the table. A Foley catheter is inserted per urethra into the bladder and connected to a closed drainage system. The patient is then prepped and draped in the usual fashion and placed in a slight Trendelenburg position. An incision is made in the stellate scar at the center of the umbilicus. Stay sutures are placed on either side of the incision to aid in elevating the abdominal wall during port placement. A Veres needle is attached to a 5 mm Step sheath and placed through the incision into the peritoneal cavity. Intraperitoneal access is confirmed with the drop test and by observing initial insufflation pressures. The peritoneal cavity is insufflated to 12 mmHg. The Step sheath is dilated to 5 mm. A laparoscope is inserted through the umbilical port. An open technique of insertion may be used depending on personal preference. Two additional 5 mm ports are inserted in a similar fashion under direct vision. The first port is placed at McBurney's point and the second in the midline between the symphysis pubis and the umbilicus. The table is placed at 45 degrees Trendelenburg with 45 degrees roll to the patient's left. The small bowel is swept medially. The appendix is mobilized on its mesentery, avoiding injury to the appendiceal artery. The cecum is mobilized superiorly. An endoscopic Babcock clamp is used to deliver the distal end of the appendix through the umbilical or right lower quadrant port site. The abdomen is desufflated. The tip of the appendix is excised. A 10Fr to 12Fr catheter is passed down the appendix to ensure patency and ease of passage. We prefer to imbricate the cecum over the appendix to improve continence and prevent later leakage of stool and flatus. The imbrication can be performed intra or extracorporeal.<sup>5</sup>

If performed extracorporeally, the cecum and appendix are delivered through the umbilical port site and released back into the abdominal cavity after the imbrication is completed. For the imbrication, using needlepoint electrocautery, an inverted Y incision is made in the serosa at the base of the appendix and extended superiorly along the tinea. The appendix is placed in the

mucosal trough. The serosa is imbricated over the appendix and its mesentery with interrupted sutures of 5/0 Vicryl with the catheter in place. Alternatively the serosa may be approximated over the appendix through appendiceal mesenteric windows. Later continence of the stoma is dependent on the length and quality of the submucosal cecal tunnel and not on the fascial or skin site fixture. Therefore continence and ease of catheter passing of the catheterizable channel should be tested before proceeding with the operation. The stoma has to reach the selected skin site without tension in a straight fashion avoiding kinking of the channel. Tension can cause impairment of the blood supply leading to stricture or necrosis, while kinking can make CIC difficult by causing false passages or the inability to enter the reservoir.<sup>6</sup>

For the stoma placement the correct skin site is identified and marked. A broad based triangular skin flap is outlined with the base pointing lateral and slightly cranial. The flap is incised with a scalpel avoiding electrocautery to prevent later necrosis. The flap is freed up and the underlying abdominal fascia dissected free. Redundant fat tissue is excised. The catheterizable channel is spatulated on the antimesenteric side and gently pulled through the incision to the skin level. The fascial opening should be wide enough to allow the channel to pass with ease to avoid stenosis, but small enough to prevent parastomal herniation. As a rule of thumb, the fascial gap should be 1.5 times the diameter of the catheterizable channel. Next, the tip of the triangular based flap is secured to the spatulated channel using absorbable sutures. The rest of the stoma is secured with interrupted sutures to the skin. The stoma is catheterized several times with a 10Fr to 12Fr catheter to ensure ease of catheterization before the wound is closed. A 10Fr to 12Fr balloon catheter is placed and secured to skin and left to drainage. To avoid kinking in a long channel, the conduit can be secured to the abdominal wall with four interrupted sutures placed in quadrants around the imbricated appendix. The abdomen is reinsufflated and inspected for occult injuries. The ports are removed under direct vision. The port sites are closed in the usual fashion. The bladder catheter is removed after the procedure.

An alternative technique is the use of a Mic Key gastrostomy button in the cecum as a caecostomy button. This is shown in the video. The only difference is that this can most often be accomplished with a single working port in the right lower quadrant at the site of the stoma. The appendix is delivered from this port site, transected at an appropriate level to ensure a straight track into the cecum, and the cut edges are sutured to the skin circumferentially. A 12F or 14F button is then placed through this into the cecum. The length of the button is determined using a button measuring device. No antireflux mechanism is necessary. If performed for idiopathic constipation, washouts can be performed within 48 hours after surgery.

## Postoperative Management

The patients receive intravenous Ketorolac for pain control; morphine is avoided to allow rapid return of bowel function. The patients are allowed to take fluids postoperatively and the diet is advanced as tolerated. The patient can leave the hospital when tolerating diet and oral pain control is achieved. The ACE is flushed initially with 30 mL of normal saline daily and slowly advanced. The caretaker and the patient are instructed in the management of the stoma catheter and washout procedure and released home with detailed instructions, follow up appointments and telephone numbers to call in case of complications or emergencies. The catheter is removed three weeks postoperatively in the clinic and stoma catheterization and bowel washout explained and actively instructed. Regular follow up is scheduled.

If a cecostomy button is used, the families are taught the use of the button and regular care of the button. A spare button is left with the families for elective change at six monthly intervals or in cases of emergencies.

## Complications

### Stomal Stenosis

Early stenosis is frequently related to ischemia of the conduit, while stenosis developing at later time points is more commonly due to repeated



catheter trauma or infection. Stenosis can be avoided by placing a broad based skin flap into a well-vascularized, widely spatulated, catheterizable conduit. Stomal stenosis remains a frequent problem independent from technique, tissue, or site used. It can, however, be treated most successfully with increased frequency of catheterizations or serial dilations. For stenosis of the ACE stoma, the authors favor placing a catheter plug in the ACE tube when not in use to act as a passive dilator. When a surgical revision is required, the results are generally favorable.

## Incontinence

A significant complication concerns fecal or flatus incontinence. The defect is always found at the level of the submucosal tunnel of the bladder or bowel and not at the level of the skin. Minor leaks can be successfully treated by endoscopic injection of a bulking substance into the submucosal tunnel. In case of failure or larger leaks, open revision of the flap valve mechanism might be necessary.

## Parastomal Hernias and Other Complications

The hernia occurs due to a fascial defect that is too large for the associated stoma. The defect can result from incorrect surgical technique, but can also be due to postoperative wound infection or abdominal distention. The herniation rates appear to be lower with the laparoscopic technique due to the smaller fascial defects. Affected patients present with complaints of abdominal wall deformity and asymmetry and less often with pain or associated incontinence. Surgical management include repair of the fascial defect with either running or interrupted polypropylene sutures for small defects or with the interposition of mesh for larger defects. Other complications include false passage, stricture, stomal breakdown and prolapse. A false passage may develop secondary to kinking of an excessively long conduit or poor catheterizing angles and can be treated by a properly placed balloon catheter which is left for 10

days to 14 days to allow the false passage to heal. Strictures within the conduit can be dilated but can also necessitate open or endoscopic revision in severe cases. Stomal breakdown will generally occur as an early ischemic related event due to either excessive tension on the vascular supply or constriction from a too narrow fascial hiatus.<sup>7</sup>

## Conclusion

The laparoscopic ACE procedure can be performed in a select patient population in need for regular, aggressive bowel management who do not require concomitant open urinary reconstruction. The procedure is well tolerated with minimal intraoperative risks. The surgery can be technically demanding, especially when performing the imbrication of the cecum intracorporally. Complications are common but usually easily manageable. Overall patient satisfaction remains high (>85%), indicating that patients are willing to accept a high rate of easily managed complications for an improvement or protection of lifestyle.<sup>8,9</sup>

## References

1. Malone PS, Ransley PG, Kiely EM. Preliminary report: the antegrade continence enema. *Lancet* 1990;336:1217-1218.
2. Malone PSJ, Wedderburn AW. Fecal Incontinence in Pediatric Urology. In: Gearhart J, Rink R, Mouriquand P (eds). *Pediatric Urology*, 1st ed. Philadelphia: Saunders. 2001; pp 1015-1023.
3. Lynch AC, Beasley SW, Robertson RW, Morreau PN. Comparison of results of laparoscopic and open antegrade continence enema procedures. *Pediatr Surg Int* 1999;15:343-346.
4. Bissada NK. Favorable experience with a simple technique to create a concealed umbilical stoma. *J Urol* 1998;159(4):1174-1175.
5. Casale P, Grady RW, Feng WC, Joyner BD, Mitchell ME: A novel approach to the laparoscopic antegrade continence enema procedure: intracorporeal and extracorporeal techniques. *J Urol* 2004;171: 817-819.
6. McAndrew HF and Malone PJ. Continent catheterizable conduits: which stoma, which

- conduit and which reservoir? *Br J Urol* 2002;89:86–89.
7. Barqawi A, De Valdenebro M, Furness PD, Koyle MA. Lessons learned from stomal complications in children with cutaneous catheterizable continent stomas. *Br J Urol* 2004;94:1344–1347.
  8. Curry JL, Osborne A, Malone PS. The MACE procedure: experience in the United Kingdom *J Pediatr Surg* 1999;34:338–340.
  9. Chung SY, Meldrum K, Docimo SG. Laparoscopic assisted reconstructive surgery: a 7-year experience. *J Urol* 2004;171:372–375.

# Laparoscopic Assisted ACE Procedure for Fecal Incontinence in Children (II)

Prasad P. Godbole and Julian P. Roberts

The ACE procedure for faecal incontinence in children incorporates several principles:

1. An empty colon can keep a patient faecally continent.
2. The colon can be emptied antegradely via a catheter or tube in the proximal colon as evidenced by the on table colonic washout.
3. The Mitrofanoff principle of continent catheterisable stomas.

Initially reported in 1990, the procedure is now practiced widely all over the world.

Traditionally the procedure has been done by the open technique often concomitantly with bladder augmentation in children with spinal dysraphism and neuropathic bladder, and bowel. However there is a place for a laparoscopic assisted approach in a select group of patients in whom intractable fecal incontinence/constipation/soiling is the main feature. Several laparoscopic assisted techniques are possible. We have mainly utilised the use of a caecostomy button for the ACE and this technique is described below.<sup>1-3</sup>

## Indications and Contraindications

The indications and contraindications are similar to those described in Chapter 19. However absence of the appendix or an appendix, which is not suitable, is NOT a contraindication for the laparoscopic assisted button caecostomy.

## Patient Selection

All conservative measures should have been tried prior to considering this procedure, including oral laxatives, enemas, a bowel training regime, and so on. The patients and caregivers should be counseled before the procedure. We would normally invite the family for a discussion with the surgeons and the support team as a visit separate from the outpatient visit. During this time, the procedure, technicalities, risks, and complications are discussed. The home support team, led by a nurse specialist, should discuss this further with the family in the home environment with the help of audiovisual aids. It is stressed that the child will need to sit on the toilet for approximately an hour on a daily or alternate day basis. Once patient and care motivation and compliance is confirmed, the procedure can then go ahead.

## Stoma/Caecostomy Tube or Caecostomy Button?

We give patients the option of having either a stoma needing intermittent catheterization or a cecostomy tube or cecostomy button (gastrotomy button in the cecum). In our experience, especially in children with idiopathic chronic constipation, the cecostomy button works very well and can be removed without the need for formal closure of the tract if washouts are no longer needed. If a button device or tube is to be used, the ACE is constructed in the right lower quadrant

in a position where it would be covered by the underpants. If a stoma is contemplated, this is best sited in the umbilicus or in the right lower quadrant depending on patient preference, body habitus, and siting of the mitrofanoff conduit if being done as a combined procedure.

## Preoperative Preparation

Formal bowel preparation is not required for a button cecostomy. Baseline hematology and biochemistry is usually not necessary unless indicated by the underlying diagnosis. Prophylactic antibiotics are given as a single dose at induction of anesthesia. Urinary catheterization is not required.

## Patient Position

The patient should be in the supine position.

## Anesthesia

The patient receives general anaesthesia through endotracheal intubation. Muscles must be relaxed. Nitrous oxide is not used for induction or maintenance of anesthesia.

## Position of the Team

Figure 20.1 shows the position of the team in the operating theater.

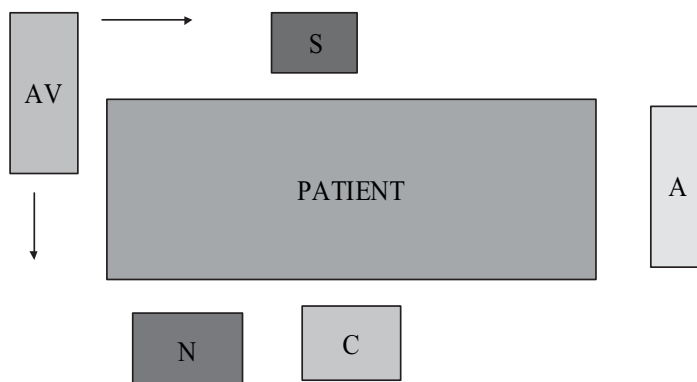
## Specific Instrumentation

1. Standard laparoscopic set.
2. Primary 5 mm or 10 mm port depending on size of the child.
3. Secondary ports: 2 mm × 5 mm (usually only one is required).
4. Telescope: 5 mm 30 degrees.

## Operative Technique

1. The button caecostomy is described and shown as on the DVD.
2. The primary port is inserted by the open Hasson technique and secured in the normal fashion.
3. Insufflation: CO<sub>2</sub> insufflation 8 mm to 12 mmHg, with a flow rate of 1 L/min.
4. Secondary port: An assessment of the cecum and appendix is made. A site for the button is chosen in the right lower quadrant and a 5 mm port is inserted under vision.
5. The cecum and appendix are identified. The appendix can usually be delivered out to the right lower quadrant via the port. In cases where this cannot be done, a second working port may be inserted in the suprapubic region to allow for mobilization of the cecum and appendix. This second port position should be altered depending on the position of the cecum (e.g., suphepatic).

The working port is then removed and the appendix delivered to the skin surface. The



**FIGURE 20.1.** Schematic representation of operative room setup for a laparoscopic assisted ACE-cecostomy button. The audiovisual equipment position can be adjusted as shown. Surgeon (S), C(Camera Holder), N (scrub nurse), AV (audiovisual equipment).

mesentery is divided and the appendix transected to a length such that the cecum is approximated to the anterior abdominal wall (on laparoscopic visualization), thereby preventing an iatrogenic internal hernia. The cut margins of the appendix are sutured to the edges of the port site incision with absorbable 3/0 or 4/0 sutures. The length of MicKey gastrostomy button required is measured with a standard measuring device (demonstrated on the DVD) and a 12 F or 14 F gastrostomy button is inserted and confirmed laparoscopically. When the appendix is not available, the cecum is mobilized and the surface closest to the abdominal wall is grabbed and extracted with the right lower quadrant port. The cecal wall is then opened and sutured to the skin as with the appendix.

## Postoperative Management

The patient is allowed fluids and diet immediately postoperatively. The first washout is done prior to discharge under supervision of the clinical nurse specialist at 24 hours to 48 hours following surgery. After discharge, the home care team coordinates subsequent washouts till the family are competent and confident to do the procedure.

## Complications

1. Leak: This may require a change of button to one of appropriate length. This is rarely a troublesome problem.

2. Persistent incontinence: This seems to be most common in the chronic idiopathic constipation group.
3. Button malfunction: Caregivers are provided with a spare button and are trained to insert this in case of displacement of the existing button.

## Conclusions

We have found the use of a button to be suitable in the majority of children requiring an ACE procedure as an alternative to creation of a catheterisable stoma. When performed laparoscopically, no bowel preparation is required and washouts can be commenced within 48 hours. Lack of a suitable appendix is not a contraindication to this technique. The technique is easy to perform and appropriate siting of the button ensures an aesthetically acceptable result to both the child and caregivers.

## References

1. Malone PS, Ransley PG, Kiely EM. Preliminary report: the antegrade continence enema. *Lancet* 1990;336:1217–1218.
2. Malone PSJ, Wedderburn AW. Fecal Incontinence in Pediatric Urology. In: Gearhart J, Rink R, Mouriquand P (eds). *Pediatric Urology*, 1st ed. Philadelphia: Saunders, 2001; pp 1015–1023.
3. Curry JL, Osborne A, Malone PS: The MACE procedure: experience in the United Kingdom. *J Pediatr Surg* 1999;34:338–340.

# Robotics

# 21

## Robotics and Pediatric Urology: Robotically Assisted Pyeloplasty in Children

Craig A. Peters

The evolution of pediatric laparoscopy techniques lagged behind that in adults largely because of the greater need, and greater challenge, to perform reconstructive procedures. This required a high level of skill and experience in delicate suturing techniques, which have been the most difficult to develop in conventional laparoscopy. As a result, although laparoscopic pyeloplasty was first described in children 10 years ago, it has not been widely used, despite the fact that in adult practice it has become a common procedure. In addition, the pediatric urologist is inherently a surgeon who performs a wide variety of procedures, even in an academic practice, making it difficult to focus the necessary time and energy on developing the skills for one procedure, such as laparoscopic pyeloplasty. The case volume for any one procedure is limited as well. With the advent of clinically useful robotic assistance in laparoscopic surgery, however, the potential for delicate pediatric reconstructive laparoscopy was realized. With enhanced visualization, including three-dimensional images, natural movement control without paradoxical movement, and delicate and tightly controlled working tool movements with high degree of freedom articulation, the DaVinci system now in use permits laparoscopic reduction of morbidity without sacrificing surgical accuracy and delicacy. This chapter describes the use of robotic assistance in laparoscopic surgery for children using pyeloplasty as an example of the technique that has been best developed.<sup>1-3</sup>

### Indications

The indications for robotically assisted pyeloplasty in children are the same as for open pyeloplasty. The system has been used in children as young as 2.5 months and children well into their teens. The usual indication is for functionally significant or symptomatic ureteropelvic junction obstruction. The benefit for the older child is more apparent, but this should not limit its use to older children. Even though we cannot measure or perhaps readily identify the reduction in perioperative morbidity, the fact that it is readily evident in older children should suggest its potential value in the younger child as well.

Therefore, we offer robotic pyeloplasty to all children needing a pyeloplasty. It should not alter the overall indications for pyeloplasty however, as it remains a procedure requiring a general anesthetic with the need for at least several hours of postoperative hospital stay.

### Preoperative Investigation

Patients undergo a preoperative evaluation identical to that undergone by patients undergoing open pyeloplasty. This requires a detailed knowledge of the anatomy to confirm that the level of obstruction is at the ureteropelvic junction and that the distal ureter is normal. This may require some form of contrast imaging to define the



normal ureter. While some would argue that the absence of dilation on an ultrasound suggests a normal ureter distal to the obstruction, this is not absolute. This author prefers to confirm this with either imaging of the ureter on some antegrade functional study (IVP, CT) or by performing a retrograde pyelogram at the time of surgery. While it is highly unusual to identify a critical abnormality beyond the UPJ, such an occurrence would create significant clinical challenges intraoperatively. It seems a small price to pay for surgical certainty. A functional study that demonstrates adequate residual function is important, and if this can be performed with quantitative measures, it offers a baseline for postoperative comparison. This can become important in outcomes that may not be perfect, where there may be ongoing dilation that is of uncertain functional significance. Therefore, our usual imaging sequence is an ultrasound to confirm the degree of hydronephrosis and a functional study such as a diuretic reno-

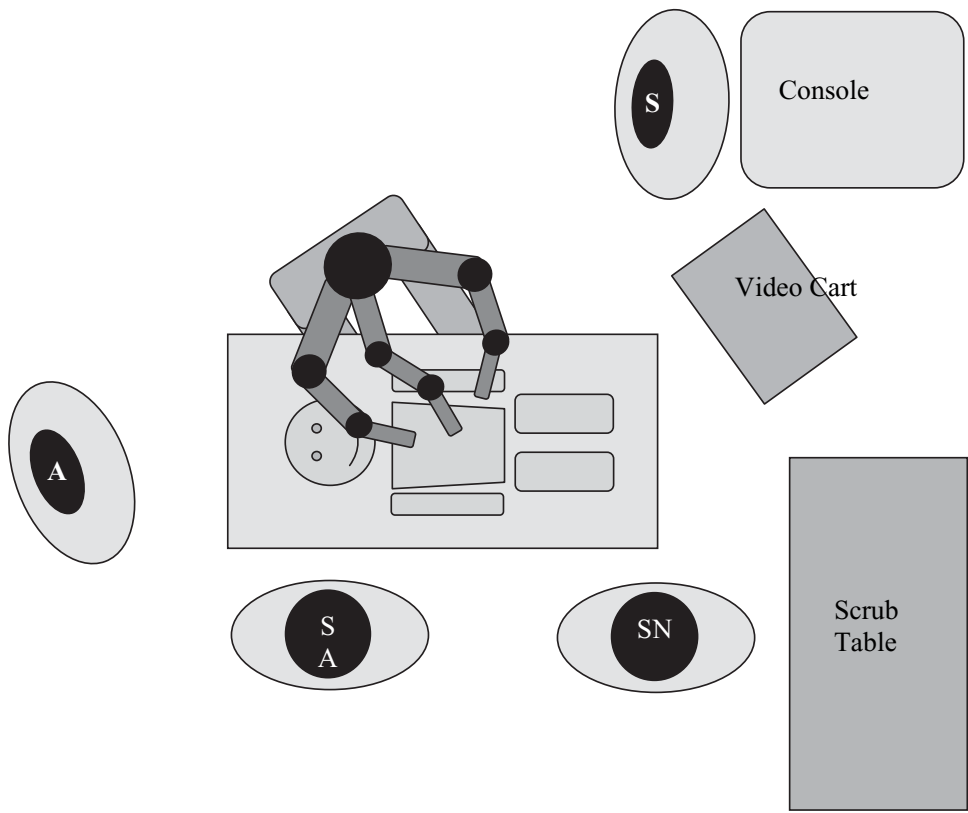
gram or IVP to show adequate renal function, provide a baseline for comparison, and assess the magnitude of relative obstruction. Visualization of the ureter distal to the obstruction is a highly recommended option.

**Preoperative Patient Preparation**

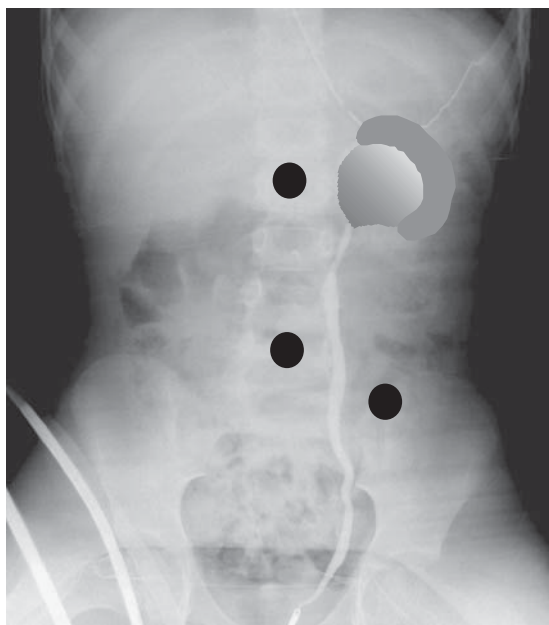
Patients are given a liquid diet for the 24 hours prior to the procedure and a single laxative to reduce colonic bulk. Parenteral antibiotics are given 30 minutes before incision. A bladder catheter is placed for intraoperative drainage.

**Specific instrumentation**

The robotic instruments used for a pediatric pyeloplasty are simple and few. A tissue grasping instrument (DeBakey or Maryland dissector),



**FIGURE 21.1.** Operating room layout.



**FIGURE 21.2.** Port placement.

hook cautery, scissors for suture cutting (round tip), needle driver (1) (microtip for 4/0 sutures and smaller), and a 5 mm conventional laparoscopic grasper or dissector to move the sutures into the field. A fourth port is rarely if ever needed for retraction. In more complex cases, this port may be of some benefit.

The 12 mm telescope is used in all cases. We have used the 5 mm endoscope with monocular vision on one occasion and, while it is very workable, the loss of a 3D image slowed down the efficacy of the case. The 5 mm instruments are used whenever possible. If this is not useful in the older child, the 8 mm instruments are then employed. Otherwise the 5 mm instruments are the option of choice.

In all laparoscopic cases, we have chosen to have an open vascular kit available in the room at all times. It remains unopened, but is available quickly should the need arise.

The setup in the operating room is shown in Figure 21.1.

Port placement (Figure 21.2) is extremely important, particularly in smaller patients where

there is less room within the abdominal cavity. The endoscope is passed through an umbilical port and the two working ports are arrayed around this symmetrically in line with the umbilicus and the UPJ. An upper abdomen port between xiphoid and umbilicus is placed with a lower quadrant port, ipsilaterally at the midclavicular line. The lower port should be moved further inferior and medially with a very large pelvis and in smaller children.

## Operative Techniques

Robotically assisted pyeloplasty follows the same algorithm for conventional laparoscopic pyeloplasty and is well described. The basic steps are:

1. Access using a transperitoneal method and the patient being in the decubitus position with the table rotated to permit this.
2. Three ports are placed: The camera in the umbilicus and then working ports in the midline between the xiphoid and the umbilicus and in the ipsilateral lower quadrant in the midclavicular line. The latter port should be moved more medially in the larger pelvis, smaller child, or lower kidney.
3. Exposure of the renal pelvis is by means of mobilizing the colon in all rightsided cases and in many leftsided cases. The alternative of the left for children is the transmesenteric approach. The transmesenteric approach reduces the amount of tissue injury surrounding the UPJ, but may limit the field of access. The ureter and UPJ are able to be seen through the mesentery on the left and the peritoneum is incised over the UPJ which is then mobilized and exposed with a hitch stitch.
4. The pelvis and UPJ are exposed and stabilized using a hitch stitch through the pelvis and secured through the abdominal wall or tied to the anterior abdominal wall. The former permits adjustment of tension during the procedure. The hitch stitch is placed before the ureter is dismembered.
5. The pelvis is incised first to use the pelvic portion of the UPJ to be used as a handle for mobilization since it will be removed and sent for pathological examination. This avoids handling the ureter that will be involved in the anastomosis.

Immediately after incising the pelvis, the ureter is spatulated on the lateral aspect for about 1 cm to 1.5 cm. This will permit a wide anastomosis to the pelvis.

6. The anastomosis is begun using a running or interrupted absorbable suture, usually a monofilament. Braided suture may be used, but tends to drag and saw through the tissues. The author prefers a running suture for its hemostasis, uniformity of tension and water-tight character, but the choice is up to the surgeon. The back or dependent wall of the anastomosis is performed first up to the level of the upper aspect of the ureter below where the pelvis will be trimmed. After the anastomosis of the back wall, the redundant pelvis and UPJ are cut away and sent for pathological evaluation.

7. At this point a JJ ureteral stent may be placed if preferred. This has become this author's approach as it offers a rapid recovery and obviates the need for drains. Removal is simple with a brief cystoscopy, although it does require a brief anesthesia. Most parents are very willing to have this in preference to other methods. Alternatively a stent may be placed with a string attached to permit in-office removal, but this requires a cystoscopy prior to the surgical procedure and managing the string postoperatively. For antegrade placement, a guidewire is passed down a 14 G angiocatheter through the abdominal wall with the stent passed over the wire and through the angiocatheter. The wire is guided down the ureter and followed by the stent. Once the proximal end of the stent is at the pelvis, the wire is withdrawn and the proximal curl is positioned in the renal pelvis. This should require no more than five minutes. If there is any uncertainty about the stent going into the bladder, methylene blue stained saline may be placed in the bladder and the stent inspected for reflux of blue dye to confirm positioning. Post-operatively, a KUB x-ray is useful to know that the stent is in the correct location.

8. Following correct stent placement, the anterior wall of the anastomosis is completed and the renal pelvis is fully closed to complete the repair. The peritoneum is closed if the transmesenteric approach has been used. Otherwise, no attempt is made to suture the colon back into position as it will move there on its own.

9. Port sites are removed under direct vision when any concern about bleeding from the abdominal wall is raised.

## Postoperative Management

Following robotically assisted pyeloplasty, a bladder catheter is left in place overnight and removed in the morning. The patients are encouraged to void. Fluids are given as tolerated and IV fluids are given at approximately one-half maintenance.

If a stent is placed, it is removed in 2 weeks to 4 weeks and a renal ultrasound obtained four weeks later. If there is any question about persisting obstruction, a functional study is performed, otherwise a subsequent ultrasound is performed in three months, and the decision regarding a functional study is based on the clinical scenario. If a wound drain is placed, it is removed in 1 day to 2 days when output is minimal.

## Complications

The most important complication of pyeloplasty is persisting obstruction. The basis for this complication is likely multifactorial and may relate to ischemia of the upper ureter, malposition of the anastomosis, periureteral fibrosis from urine leak, or a crossing vessel. Prevention should therefore be founded on careful tissue handling, limited dissection of the ureter, careful alignment of the anastomosis and a water-tight, stented, or drained repair. Recognition of an obstructing crossing vessel may occasionally be difficult and may challenge the surgeon in terms of knowing how to orient the ureter relative to the vessel. We have seen one case of unmistakable persisting obstruction due to a crossing vessel that was not recognized during a robotic retroperitoneal pyeloplasty (the only one we have performed).<sup>3</sup> Transmesenteric reoperation with transposition of the ureter resolved the obstruction.

Management of the persisting obstructed UPJ after pyeloplasty is a complex topic, but we have used robotic reoperative pyeloplasty in six cases with good results. The degree of fibrosis was

manageable, although in some, posed a significant surgical challenge, as it would have with an open approach.

## Author's Comment

The role of laparoscopy and robotics in pediatric urology is evolving. The appearance of these technologies in 10 years may be difficult to recognize, but several observations may be valid. Laparoscopy can provide an apparent reduction in surgical morbidity with equal safety and efficacy, even if it has not yet equaled the efficiency of open surgery. Robotic assistance in laparoscopic surgery clearly enhances the efficacy and efficiency of nearly all reconstructive procedures, and this technology is likely to be a critical element of our surgical armamentarium in pediatric urology in the next decade. Technology evolves

and it is almost certain that this will translate to more efficient, less expensive, and more flexible robotic systems for surgery and this may even extend to nonlaparoscopic applications. While we need to maintain a skeptical outlook, cautious enthusiasm for these developing technologies seems appropriate and offers an exciting new horizon for our specialty.

## Vancouver

1. Lee RS, Retik AB et al. Pediatric robot assisted laparoscopic dismembered pyeloplasty: comparison with a cohort of open surgery. *J Urol* 2006;175(2): 683–687.
2. Olsen LH, Jorgensen TM. Computer assisted pyeloplasty in children: the retroperitoneal approach. *J Urol* 2004;6(Pt 2):2629–2631.
3. Peters CA. Robotically assisted surgery in pediatric urology. *Urol Clin North Am* 2004;31(4):743–752.

# Index

- A**
- Adenoma, adrenal, as laparoscopic adrenalectomy indication, 31
  - Adrenalectomy, laparoscopic, 31–35
    - comparison with open adrenalectomy, 31
    - retroperitoneal approach in, 31, 33–34
    - transperitoneal approach in, 31
  - Anastomotic leaks
    - antegrade colonic enema procedure-related, 122
    - laparoscopic pyeloplasty-related, 22
  - Androgen insensitivity, 59
  - Anesthesia, in pediatric laparoscopy, 3
  - Antegrade colonic enema (ACE) procedure
    - laparoscopic, 115–119, 120–122
      - with cecostomy button, 117, 120–122
      - with stoma, 115–119, 120, 121, 122
    - open, 120
  - Anuria, urinary calculi-related, 101
  - Anus, imperforate, 115
  - Appendix, in antegrade colonic enema procedure, 115, 116–117, 120, 121–122
- B**
- Bladder
    - augmentation of, concomitant with antegrade colonic enema procedure, 120
    - augmented, urinary calculi in, 110–111
    - neurogenic, 85
    - neuropathic, urinary calculi in, 110–111
    - trabeculation of, 75
  - Bladder outlet injections
    - as urinary incontinence treatment, 67, 85–91
      - in females, 87–88
      - in males, 87
    - for transurethral leaks, 88–90, 91
    - via catheterization channels, 90
    - Zuidex system for, 87–88
  - as vesicoureteral reflux treatment, 77–84
  - instrumentation in, 78–80
  - operative technique in, 80–82
  - in unilateral reflux, 82
- C**
- Bladder stones. *See* Calculi, urinary
  - Bladder trigone, bulging masses on, 75, 76
  - Bulking agent injections. *See* Bladder outlet injections
  - Calculi, urinary, 101–105
    - causes of, 101
    - composition of, 101, 110
    - cystourethroscopic identification of, 75
    - spontaneous passage of, 101, 106
    - treatment/removal of, 67
      - in augmented/neuropathic bladder, 110–111
    - cytoscopic-guided access in, 71
    - with extracorporeal shock wave lithotripsy, 101
    - laparoscopic, 101, 104–105
    - with percutaneous nephrolithotomy, 101, 102–104
  - ureteric
    - spontaneous passage of, 106
    - ureteroscopy of, 106–109
  - Cecostomy button, in antegrade colonic enema procedure, 117, 120–122
    - malfunction of, 122
  - Cecoureterocele, as bladder outlet injection indication, 85
  - Cecum, in antegrade colonic enema procedure, 115–119, 121–122
  - Cervix, vaginoscopic appearance of, 73
  - Cloaca, 67, 69, 75, 85, 115
  - Congenital adrenal hyperplasia (CAH), 59, 70
  - Constipation, antegrade colonic enema procedure for, 115–119, 120–122
  - Cushing's syndrome, as adrenalectomy indication, 31
  - Cystitis, subureteral Teflon injection (STING)-related, 82
  - Cystolithotomy
    - minimally-invasive, 110–111
    - open, 110
  - Cystoplasty, augmentation, as urinary calculi cause, 110

- Cystourethroscopy  
 contraindications to, 69  
 in females, 72–73  
 general principles of, 67–69  
 indications for, 67–69  
 instrumentation in, 70–71  
 in males, 73  
 operative technique in, 71–76  
 Cytoscopes, 70–71
- D**  
 Dissecting balloon, rupture of, 34  
 Diverticulum, cystourethroscopic  
 identification of, 74, 75  
 Dysplasia, congenital renal, 13
- E**  
 Enema, antegrade colonic. *See*  
 Antegrade colonic enema  
 (ACE) procedure  
 Epispadias  
 as bladder outlet injection  
 indication, 85  
 in females, 69  
 as open bladder neck cause, 67  
 Extracorporeal shock wave  
 lithotripsy (ESWL), 101
- F**  
 Fecal impaction, as bladder trigone  
 mass cause, 75  
 Fecal incontinence  
 antegrade colonic enema  
 procedure for, 115–119,  
 120–122  
 persistent, after antegrade  
 colonic enema procedure,  
 118, 122  
 Fistula, urethrocuteaneous, 67  
 Fluoroscopy, with  
 cystourethroscopy, 71  
 Foreign objects, vaginal, 75
- G**  
 Genitofemoral nerve,  
 varicolectomy-related  
 injury to, 57  
 Genitourinary anomalies. *See also*  
 Intersex anomalies  
 cystourethroscopic identification  
 of, 74–75  
 Germ cell tumors, 59  
 Glomerulosclerosis, focal  
 segmental, 13–14  
 Gonadal dysgenesis, mixed, 59
- Gonads  
 dysplastic, 60  
 malignant, 59  
 streak, 59, 62
- H**  
 Helstrom technique, 24–28  
 Hematuria, 39, 67, 101  
 Heminephrectomy, laparoscopic,  
 13, 14, 16–18  
 transperitoneal approach in, 13  
 Hemorrhage  
 laparoscopic adrenalectomy-  
 related, 34  
 laparoscopic bladder stone  
 surgery-related, 105  
 laparoscopic pyeloplasty-related,  
 22  
 percutaneous nephrolithotomy-  
 related, 104  
 retroperitoneoscopic surgery-  
 related, 17  
 Hermaphroditism, 59  
 Hernia/herniation  
 parastomal, 118  
 of port sites, 9  
 Hydrocele  
 varicolectomy-related, 57  
 varicolectomy treatment of, 55  
 Hydrocelectomy, scrotal, 55  
 Hydroureteronephrosis  
 bladder outlet injection-related,  
 91  
 as heminephrectomy indication,  
 14  
 Hymen, imperforate, 75  
 Hypospadias  
 enlarged utriculi associated  
 with, 59  
 repair of, urinary incontinence  
 following, 67
- I**  
 Incidentaloma, as laparoscopic  
 adrenalectomy indication,  
 31  
 Incontinence  
 fecal. *See* Fecal incontinence  
 urinary. *See* Urinary  
 incontinence  
 Intersex anomalies  
 causes of, 59  
 cystourethroscopic evaluation  
 of, 60, 67, 69, 70, 76
- differentiated from undescended  
 impalpable testis, 49  
 incidence of, 59  
 laparoscopic evaluation of,  
 59–61  
 laparoscopic treatment of, 59, 62  
 vaginostomy of, 60, 67, 69  
 Ischemia, testicular, 53
- K**  
 Kidney  
 duplication of, 14  
 multicystic, dysplastic, 13–14, 95
- L**  
 Laparoscopy, in children. *See also*  
*specific laparoscopic*  
*procedures*  
 basic principles of, 3–10  
 access, 3–4  
 anesthesia, 3  
 instrumentation, 9  
 patient positioning, 3  
 retroperitoneal approach, 4,  
 5–9  
 tissue retrieval, 9  
 transperitoneal approach, 4–5  
 visualization, 9  
 wound closure, 9–10  
 Lithotripsy, 71  
 extracorporeal shock wave, 101
- M**  
 Meatal stenosis, posterior urethral  
 valve ablation-related, 94  
 Megalourethra, 74, 75  
 Megaureters, as bladder trigone  
 mass cause, 75  
 Minimal access surgery (MAS), in  
 children, 3. *See also*  
 Laparoscopy, in children  
 Müllerian duct remnants, 59, 62
- N**  
 Nephrectomy, laparoscopic, 13–14,  
 17–18  
 patient positioning for, 7, 8  
 retroperitoneal approach in, 7,  
 13, 15–16  
 transperitoneal approach in, 13  
 Nephrolithotomy, percutaneous,  
 101, 102–104  
 Nephropathy, reflux-associated,  
 13–14

- Nephrotic syndrome, congenital, 13–14
- Nephroureterectomy. *See* Nephrectomy, laparoscopic
- Neuroblastoma, as laparoscopic adrenalectomy indication, 31
- Neurogenic bowel, as constipation cause, 115
- O**
- Orchidopexy  
laparoscopic  
first-stage Fowler Stephens, 52–53  
single-stage, 50–52  
single-stage Fowler Stephens, 53
- Ovotestes, dysgenetic intra-abdominal, 59
- P**
- Palomo technique, 56–58
- Pelviureteric junction obstruction, laparoscopic treatment of  
dismembered pyeloplasty, 19–23, 24, 28  
comparison with lower pole vessel transposition, 28  
robotically-assisted, 19, 20, 22–23, 24, 125–129  
heminephrectomy, 14  
lower pole vessel transposition, 24–28  
nephrectomy, 13–14
- Perineum  
abnormal, 60  
mass in, 72  
morphological disorders of, 59
- Peritoneum, tears to  
laparoscopic adrenalectomy-related, 34  
retroperitoneoscopic surgery-related, 17
- Pheochromocytoma, 31
- Pneumoperitoneum, 9
- Port sites, closure of, 9–10
- Premature infants, posterior urethral valve treatment in, 92–93
- Pyelonephritis, subureteral Teflon injection (STING)-related, 82
- Pyeloplasty, laparoscopic  
dismembered, 19–23, 24  
“hitch stitch” use in, 20, 21–22  
open technique, 24, 127–128  
retroperitoneal approach in, 19  
robotically-assisted, 19, 20, 22–23, 24, 125–129  
transperitoneal approach in, 19, 20–22, 127
- Pyuria, urinary calculi-related, 101
- R**
- Renal stones. *See* Calculi, urinary
- Resectoscopes, 71
- Retroperitoneal approach, in  
laparoscopic procedures, 5–9  
access in, 6–9  
anesthesia for, 6  
in heminephrectomy, 13, 16–17  
in nephrectomy, 7, 13, 15–16  
patient positioning for, 6, 7, 8  
in pyeloplasty, 19
- Rhabdomyosarcoma, tissue  
diagnosis of, 69
- Robotic systems, 9  
daVinci, 19, 20, 22–23, 45, 125  
use in laparoscopic pyeloplasty, 19, 20, 22–23, 24, 125–129  
use in transvesicoscopic (pneumovesicoscopic)  
Cohen ureteric  
reimplantation procedure, 45
- S**
- Scarring, renal, vesicoureteral  
reflux-related, 77, 78, 82
- Semen analysis, 54
- Specimen retrieval, 9
- Spina bifida, 115
- Stents, JJ ureteral, 21, 22, 76, 108, 128
- STING. *See* Suburethral Teflon injections (STING)
- Stoma, for antegrade colonic  
enema (ACE), 115–119, 120, 121, 122
- Streak gonads, identification and  
removal of, 59, 62
- Subureteral Teflon injections (STING)  
as urinary incontinence  
treatment, 86  
as vesicoureteral reflux  
treatment, 77–84  
instrumentation in, 71, 78–80  
operative technique in, 80–82  
in unilateral reflux, 82
- Syringocele  
classification of, 97, 98  
definition of, 95  
endoscopic treatment of, 96, 97, 98
- T**
- Teflon injections, subureteral. *See* Subureteral Teflon injections (STING)
- Testes  
intra-abdominal, identification  
and removal of, 62  
undescended impalpable, 49–53  
differentiated from intersex  
disorders, 49  
laparoscopic orchidopexy  
treatment of, 50–53  
varicocele-related atrophy  
of, 57  
varicocele-related hypertrophy  
of, 54
- Testicular artery and vein, ligation  
of, 56–58
- Tissue retrieval, 9
- Transperitoneal approach, in  
laparoscopic procedures  
in nephrectomy, 13  
primary port insertion in, 4–5  
in pyeloplasty, 19, 20–22, 127  
secondary port insertion in, 5
- Transvesicoscopic  
(pneumovesicoscopic)  
Cohen ureteric  
reimplantation, for  
vesicoureteral reflux, 39–46  
comparison with Lich-Gregoir  
technique, 45  
instrumentation for, 40  
operative technique in, 40–44  
results of, 44–45  
use of da Vinci robotic system  
in, 45
- U**
- Urachal anomalies, 75
- Ureteral orifice  
ectopic, 74  
patulous, 74  
in vesicoureteral reflux, 75



- Ureteral reimplantation
    - cross-trigonal, failure of, 81
    - transvesicoscopic (pneumovesicoscopic)
      - Cohen procedure, 39–46
    - comparison with Lich-Gregoir technique, 45
    - instrumentation for, 40
    - operative technique in, 40–44
    - results of, 44–45
    - use of da Vinci robotic system in, 45
  - Ureterocele
    - as bladder trigone mass cause, 75
    - cystourethroscopic identification of, 74, 75
    - definition, 95
    - ectopic, 72, 95, 98
    - endoscopic management of, 95–98
    - low-grade vesicoureteral reflux associated with, 95
    - transurethral incision of, 67, 68
  - Ureteropelvic junction obstruction. *See* Pelviureteric junction obstruction
  - Ureterscopy, 106–109
  - Uretrovesical junction
    - ureteroscope passage through, 106, 109
    - in vesicoureteral reflux, 77
  - Ureters
    - calculi in
      - spontaneous passage of, 106
      - ureteroscopy of, 106–109
    - duplication of, 67, 68, 69
    - subureteral Teflon injection (STING) treatment of, 81
    - ectopic, 73, 85
    - obstruction of, 76, 82
    - strictures of, 76, 108
    - ureteroscopy-related injury to, 108
  - Urethra
    - anatomy of
      - in females, 72, 87
      - in males, 73, 87
    - duplication of, 74, 85
    - injury to
      - cystourethroscopy-related, 76
      - endoscopic ureterocele treatment-related, 98
    - recurrent, 62
    - strictures of, 62, 68, 74, 94
  - Urethral valves
    - anterior, 74
    - posterior, 74, 75, 92–94
      - ablation of, 92–94
      - evaluation of, 92
    - transurethral incision of, 67, 68
  - Urethroplasty, open primary, 68
  - Urinary incontinence
    - bladder outlet injection
      - treatment of, 67, 85–91
    - in females, 87–88
    - in males, 87
    - for transurethral leaks, 88–90, 91
    - via catheterization channels, 90
    - Zuidex system for, 87–88
  - cystourethroscopic treatment of, 67
  - evaluation of, 85
  - stress, 85
  - Urinary retention, bladder outlet injection-related, 91
  - Urinary tract infections
    - recurrent, 67
    - ureteroscopy-related, 108
    - urinary calculi-related, 101
    - vesicoureteral reflux-related, 77
  - Urinoma, retroperitoneal, 17–18
  - Urogenital sinus, 67, 69, 70, 76
  - Urolithiasis. *See* Calculi, urinary
  - Uropathy, obstructive,
    - cystourethroscopic treatment of, 67
  - Urothelial cancer, tissue diagnosis of, 69
  - Uterus, abnormal, 60
  - Utricle
    - enlarged, 59
    - laparoscopic resection of, 59–60
    - prostatic, 74, 76
- V**
- Vagina
    - agenesis of, 72
    - duplication of, 75
    - septation of, 75
  - Vaginal remnants, 74, 76
  - Vaginoscopy, 67, 69, 72, 73
  - Varicocele
    - incidence of, 54
    - as ipsilateral testicular hypertrophy cause, 54
    - recurrent, 57
    - varicolectomy treatment of, 54–55, 56–58
  - Varicolectomy, laparoscopic, 54–55, 56–58
  - “Vascular hitch,” 24–28
  - Vesicoureteral reflux (VUR)
    - bladder outlet injection-related, 91
    - bladder outlet injection
      - treatment of, 67, 77–84
    - definition of, 77
    - instrumentation in, 78–80
    - operative technique in, 80–82
    - in unilateral reflux, 82
    - endoscopic ureterocele treatment-related, 98
  - low-grade, ureterocele-associated, 95
  - transvesicoscopic (pneumovesicoscopic)
    - Cohen ureteric reimplantation for, 39–46
    - comparison with Lich-Gregoir technique, 45
    - instrumentation for, 40
    - operative technique in, 40–44
    - results of, 44–45
    - use of da Vinci robotic system in, 45
    - ureteroscopy-related, 108
  - Virilization, insufficient, 59, 60
- W**
- Wilm’s tumor, 56