


Christine M. Eckel

# Human Anatomy Laboratory Manual

THIRD EDITION



Mc  
Graw  
Hill  
Education

Christine M. Eckel

Carroll College

# HUMAN ANATOMY

## Laboratory Manual

Third Edition





## HUMAN ANATOMY LABORATORY MANUAL, THIRD EDITION

Published by McGraw-Hill, a business unit of The McGraw-Hill Companies, Inc., 1221 Avenue of the Americas, New York, NY 10020. Copyright © 2018 by The McGraw-Hill Companies, Inc. All rights reserved. Previous editions © 2012 and 2008. No part of this publication may be reproduced or distributed in any form or by any means, or stored in a database or retrieval system, without the prior written consent of The McGraw-Hill Companies, Inc., including, but not limited to, in any network or other electronic storage or transmission, or broadcast for distance learning.

Some ancillaries, including electronic and print components, may not be available to customers outside the United States.

This book is printed on acid-free paper.

1 2 3 4 5 6 7 8 9 LMN 21 20 19 18 17

ISBN 978-0-07-987268-6

MHID 1-259-87268-8

Chief Product Officer, SVP Products & Markets: *G. Scott Virkler*  
Vice President, Editor-in-Chief: *Marty Lange*  
Vice President, Content Design & Delivery: *Betsy Whalen*  
Director, Product Development: *Rose Koos*  
Managing Director: *Lynn M. Breithaupt*  
Executive Brand Manager: *Amy Reed*  
Brand Manager: *Chloe Bouxsein*  
Product Developer: *Mandy Clark*  
Marketing Managers: *James Connely/Kelly Brown*  
Program Manager: *Angie FitzPatrick*  
Content Project Managers: *Mary Jane Lampe/Brent dela Cruz*  
Senior Buyer: *Sandy Ludovissy*  
Senior Designer: *David W. Hash*  
Cover Image: © *Mike Powell/The Image Bank/Getty Images*  
Content Licensing Specialists: *Carrie K. Burger/Melisa Seegmiller*  
Photo Research: *Danny Meldung/Photo Affairs, Inc.*  
Compositor: *MPS Limited*  
Typeface: *10/12 STIX MathJax Main*  
Printer: *LSC Communications - Menasha*

All credits appearing on page or at the end of the book are considered to be an extension of the copyright page.

### Library of Congress Cataloging-in-Publication Data

Eckel, Christine M., author.

Human anatomy laboratory manual/Christine M. Eckel,  
Carroll College.

Third edition. | New York, NY : MHE, [2018] | Audience: Ages:

18+ | Includes index.

LCCN 2016052443 | ISBN 9781259872686 (alk. paper)

LCSH: Human anatomy—Laboratory manuals.

LCC QM34 .E16 2018 | DDC 612—dc23

LC record available at <https://lccn.loc.gov/2016052443>

Some of the laboratory experiments included in this text may be hazardous if materials are handled improperly or if procedures are conducted incorrectly. Safety precautions are necessary when you are working with chemicals, glass test tubes, hot water baths, sharp instruments, and the like, or for any procedures that generally require caution. Your school may have set regulations regarding safety procedures that your instructor will explain to you. Should you have any problems with materials or procedures, please ask your instructor for help.

## ABOUT THE AUTHOR

---



*This book is dedicated to  
my best friend, Zelda.*

**CHRISTINE MARIE ECKEL, Ph.D.** received her B.A. in Integrative Biology and M.A. in Human Biodynamics from the University of California, Berkeley, and her Ph.D. in Neurobiology and Anatomy from the University of Utah School of Medicine. Dr. Eckel is Associate Professor of Biology at Carroll College in her hometown of Helena, Montana. There she teaches the two-semester Anatomy and Physiology course for pre-nursing and pre-health-science majors, and an advanced dissection course for premedical students. Dr. Eckel is also the faculty advisor for pre-physician assistant students. Prior to her position at Carroll College, Dr. Eckel was Associate Professor and Course Director for the Medical Gross Anatomy and Medical Microanatomy courses at the West Virginia School of Osteopathic Medicine (WVSOM). While at WVSOM, Dr. Eckel also headed the Body Donor Program. In 2015, Dr. Eckel presented a TEDx talk about the value of human body donors in health sciences education.

## ACKNOWLEDGMENTS

---

I would like to thank the entire team at McGraw-Hill for their hard work on this laboratory manual. In particular, I am extremely grateful to Product Developer Mandy Clark and Brand Manager Chloe Boussein for finding solutions to layout problems and similar issues. Content Project Manager Mary Jane Lampe and Senior Content Licensing Specialist Carrie Burger worked relentlessly to bring this project to fruition, and they also have my profound thanks. The entire team at McGraw-Hill is a class act and I am grateful to work with such a talented group of people.

As always, I give my most sincere thanks to all the individuals who selflessly donated their bodies after death for medical education and research. Without their generous donations, none of us would have the opportunity to truly learn anatomy. They have given us the most precious gift.

In the years prior to her position at WVSOM, Dr. Eckel taught undergraduate Human Anatomy and Human Physiology courses at Salt Lake Community College (SLCC) and the University of California, Berkeley.

Dr. Eckel has received several teaching honors, including an Outstanding Graduate Student Instructor award from U.C. Berkeley, a Teaching Excellence award from SLCC, and the Atlas Club award for Outstanding Teaching at WVSOM. She was awarded the Frank L. Christensen Endowed Fellowship from the University of Utah and was named the Betty Cook Karrh Endowed P.E.O. Scholar for 2004–2005.

Dr. Eckel is the primary author of *Human Anatomy & Physiology Laboratory Manual, 2e* (McGraw-Hill Education). She has also authored several supplements and individual chapters for textbooks in Human Anatomy and Human Physiology. Dr. Eckel's cadaver dissections and photographs are featured in several textbooks and ancillary teaching materials, including this laboratory manual.

Dr. Eckel served as the Western Regional Director for the Human Anatomy & Physiology Society (HAPS) for two terms. She has also served on several committees for both HAPS and the American Association of Anatomists (AAA). Dr. Eckel is an ad hoc reviewer for the journals *Anatomical Sciences Education* and *Medical Education*. Her research is in the field of teaching innovation and educational outcomes research.

With over 25 years of experience engaging with students at all levels; including community college students, students at a 4-year private college, medical students, and medical residents in orthopedic surgery, pathology, and gynecologic surgery, Dr. Eckel has a unique appreciation for the learning challenges experienced by students at each of these levels. Dr. Eckel's passions for human anatomy, classroom and laboratory teaching, biological dissection, and photography are evident throughout the pages of this laboratory manual.

In her spare time, Dr. Eckel loves to hike with her English Setter, Zelda, mountain bike, road bike, skate, ski, and explore the great Montana outdoors—always with her camera in hand.

To the end users of this book, thank you in advance for any feedback, suggestions for improvement, or corrections that will help improve future editions. I am dedicated to producing the highest quality laboratory manual that will help students learn and develop a love of this most beautiful and fascinating subject. Thank you!

Christine M. Eckel, Ph.D.  
Department of Biology  
Carroll College  
1601 N. Benton Ave  
Helena, MT 59625  
ceckel@carroll.edu

# Contents

Preface v

## **NATIONAL PRINT:**

### **Chapter 1**

The Laboratory Environment 1

### **Chapter 2**

Orientation to the Human Body 19

### **Chapter 3**

The Microscope 31

### **Chapter 4**

Cellular Anatomy 43

### **Chapter 5**

Histology 55

### **Chapter 6**

Integument 87

### **Chapter 7**

Skeletal System Overview:  
Bone Anatomy 105

### **Chapter 8**

The Skeletal System: Axial Skeleton 123

### **Chapter 9**

The Skeletal System: Appendicular  
Skeleton 155

### **Chapter 10**

Articulations 191

### **Chapter 11**

Muscle Tissue and Introduction to the  
Muscular System 205

### **Chapter 12**

Axial Muscles 223

### **Chapter 13**

Appendicular Muscles 253

### **Chapter 14**

Nervous Tissues 285

### **Chapter 15**

The Nervous System: General and Special  
Senses 299

### **Chapter 16**

The Endocrine System 327

### **Chapter 17**

The Cardiovascular System: The Heart 343

### **Chapter 18**

Vessels and Circulation 363

### **Chapter 19**

The Lymphatic System 403

### **Chapter 20**

The Respiratory System 423

### **Chapter 21**

The Digestive System 445

### **Chapter 22**

The Urinary System 477

### **Chapter 23**

The Reproductive System 499

Index I-1

## **ONLINE ONLY/CREATE PRINT:**

### **Chapter 24**

The Brain and Cranial Nerves 529

### **Chapter 25**

The Spinal Cord and Spinal Nerves 573

### **Chapter 26**

The Autonomic Nervous System 593

### **Chapter 27**

The Cardiovascular System: Blood 603

## **Appendix**

Answer Keys A-1

# Preface

**H**uman anatomy is a complex but fascinating subject, and is perhaps one of the most personal subjects a student will encounter during his or her education. Yet it is also a subject that can create a great deal of anxiety for students because of the sheer volume of material, and a misconception among students that it's “all about memorization.” Too often, confusion in the anatomy laboratory only enhances this misconception and enhances student frustration with the subject. My goal in writing this laboratory manual was to create a manual that guides students through their laboratory experience in an organized and focused way, and to provide them with tools that make the material more relevant to the student's daily experiences with their own bodies and the world around them.

The study of human anatomy really comes to life in the anatomy laboratory. Here is where students get hands-on experience with human cadavers and bones, classroom models, preserved and fresh animal organs, and histology slides of human tissues. Many students are at a loss when it comes to knowing how to proceed in the anatomy laboratory. They are given numerous lists of structures to identify and histology slides to view, but comparatively little direction as to *how* to recognize structures or *how* to relate what they encounter in the laboratory to the material presented in lecture. In addition, most laboratory manuals on the market contain little more than material repeated from anatomy textbooks, which provides no real benefit to a student. All of these things lead to student frustration and take away from the joy that comes from discovering the beauty of the human body through touch, observation, and dissection. This laboratory manual is designed to be a user-friendly *manual* to the human anatomy laboratory that addresses just such issues.

---

## New in the Third Edition

The most exciting change in this edition is the inclusion of an all-new chapter. Chapter 1: The Laboratory Environment introduces safety procedures, use of cadavers in the laboratory, common laboratory equipment, and dissection techniques. A multitude of new photos that familiarize students with laboratory equipment are presented in the context of step-by-step exercises demonstrating proper usage of these tools. All subsequent chapters have been renumbered to accommodate the placement of this new chapter at the very beginning of the book. Another new chapter on the Autonomic Nervous System (Chapter 26) has also been added, and subsequent chapters renumbered to accommodate placement of the chapter within the laboratory manual.

Another major change is the substantial overhaul of bone and histology photos. Of particular note, the author photographed a series of new skull images using a first-grade skull. The high-quality specimen and improved contrast provide much clearer detail than seen in the previous edition. In addition, the author photographed several new tissue slides to obtain photos that coincide with specific steps in the histology activities so students see exactly what is described in the exercises.

Finally, much effort has been spent fine-tuning content accuracy and clarity. Every chapter in the book was carefully scrutinized, resulting in numerous tweaks to table entries, adjustments in terminology, strategic addition and/or reconfiguring of labels and leader lines in the figures, and general polishing to improve readability. Other content changes include the addition of new questions to nearly all of the Pre- and Post-Laboratory Worksheets to make them more challenging and more complete, and continuation of numbering the chapter learning objectives for easier reference and tracking. Post-Laboratory Worksheet questions in the section “Do You Know the Basics?” are keyed to each exercise and learning objective in the chapter. There is at least one question per objective. This organization makes it even easier for instructors to customize the content for their individual course.

In addition to the general changes above, the following list provides a chapter-by-chapter overview highlighting some (but by no means all) of the updates in the third edition.

1. The Laboratory Environment—All-new chapter introducing laboratory equipment and procedures.
2. Orientation to the Human Body—Added body planes to figure 2.1 and directional terms to figure 2.2.
3. The Microscope—More tips regarding microscope usage added to Focus Box: Caring for the Microscope and to table 2.2.
4. Cellular Anatomy—Added illustrations of each cell organelle to table 4.1. Replaced micrograph of interphase in table 4.2.
5. Histology—New micrographs added to the following figures: 5.3e (dense irregular connective tissue), 5.17 (elastic connective tissue), 5.19 (hyaline cartilage), 5.27 (smooth muscle). Added multiple new “Study Tip!” boxes, including clarification of basement membrane vs. basal surface, and suggestions for relating tissue appearance to everyday items. Elaborated on description of bone tissue.
6. Integument—Added new micrograph for figure 6.2 (pigmented skin) and a new Study Tip! regarding the tissue types found in leather. Expanded the description of keratinocytes and made various terminology updates for consistency. Added a Clinical View on melanoma.
7. Skeletal System Overview: Bone Anatomy—Enlarged photos in exercise 7.5 to make figures easier to label.
8. The Skeletal System: Axial Skeleton—New photos using better specimens and coloration provided for the following figures: 8.1 (anterior skull), 8.5 (lateral skull), 8.6 (posterior skull), 8.8 (inferior skull), 8.11 (cranial floor), 8.12 (hyoid bone). Improved contrast of existing photos for figures 8.7 (superior skull), 8.13 (fetal skull), 8.16–8.19 (vertebrae), 8.24 (rib).
9. The Skeletal System: Appendicular Skeleton—Improved contrast of photos in figure 9.3 (humerus) and added close-up view of ulnar notch to figure 9.4. New Study Tip! with mnemonic for remembering the carpal bones.
10. Articulations—New Focus box and accompanying photo on hip replacement.
11. Muscle Tissue and Introduction to the Muscular System—New Study Tip! clarifying the difference between flexion and contraction.

12. Axial Muscles—Modified figure 12.11 to indicate location of the linea alba. Provided innervations in table 12.1. New Study Tip! regarding conventions of muscle naming.
13. Appendicular Muscles—Revised muscle actions to refer to limbs rather than joints—for example, “flexes elbow” was changed to “flexes forearm.”
14. Nervous Tissues—Minor terminology and table updates.
15. The Nervous System: General and Special Senses—New micrographs for figures 15.3*d* (vallate papilla), 15.3*e* (foliate papilla), 15.8*c* (cochlea cross section). Added close-up photo of cochlea model to figure 15.16. Expanded structures covered in tables 15.7 and 15.8. Clarified descriptions of anterior cavity vs. anterior chamber.
16. The Endocrine System—Added illustrated reference icons to figures 16.7 (adrenal glands) and 16.8 (pancreas), and a new photo showing the hypothalamus and pituitary to figure 16.9 (endocrine organs).
17. The Cardiovascular System: The Heart—Increased size of figure 17.3 (heart in thoracic cavity) for easier labeling. Improved contrast of figure 17.4 (pericardial sac).
18. Vessels and Circulation—New micrographs for figures 18.1*b* (blood vessel wall), 18.2 (elastic artery). Increased size of figure 18.18 for ease of labeling. Modified shading in figure 18.21 (lower limb circulation) to differentiate superficial and deep vessels. Shaded capitate and cuboid bones for clarity in figures 18.20 and 18.23 respectively.
19. The Lymphatic System—Two new micrographs for figure 19.4 (Peyer patches). Added illustrated reference icons to figures 19.6 and 19.9.
20. The Respiratory System—Included a new exercise (exercise 20.3) and table on the histology of the bronchi and bronchioles. Added illustrated reference icons to figures 20.3–20.5. New photomicrograph of bronchus in Post-Laboratory Worksheet.
21. The Digestive System—Modified several anatomic descriptions for clarity. Added illustrated reference icon to figure 21.8, and a new micrograph of the ileum in Post-Laboratory Worksheet.
22. The Urinary System—Reorganized layout of several figures for ease of labeling. New micrographs (ureter, kidney cortex, urinary bladder wall) for Post-Laboratory Worksheet questions.
23. Reproductive System—New micrographs for figure 23.7*b* (epididymis), 23.8*b* (ductus deferens), and 23.11 (penis cross-section). Increased size of micrographs in table 23.6 (menstrual cycle phases) and figure 23.13 (model of female pelvic cavity) to improve visibility. Added new table 23.11, The Female Breast. New micrographs (ductus deferens and ovary) for Post-Laboratory Worksheet questions.
24. The Nervous System: General and Special Senses—Modified layouts of several figures and enlarged figure 24.6 (superior brain) for ease of labeling.
25. The Spinal Cord and Spinal Nerves—Reformatted text and enlarged several figures for easier labeling. Shaded the branches of the trigeminal nerve in figure 25.7*a* to match the sensory distribution map of 25.7*b*.
26. The Autonomic Nervous System—New Study Tip! for distinguishing anterior and posterior horns.
27. The Cardiovascular System: Blood—Minor tweaks for clarity and correctness.

## Distinguishing Features

### Overall Approach

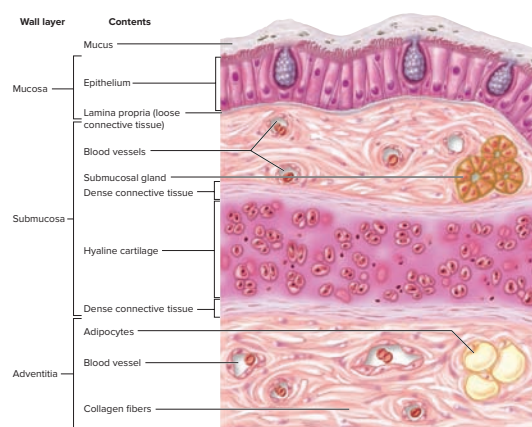
First and foremost, this laboratory manual was designed *not* to repeat textbook material. However, students still need critical information to proceed in the laboratory. Thus, as much as possible, reference information necessary for completing laboratory activities is presented in summary tables that act as a concise resource for students.

Laboratory exercises are presented in steps that guide students precisely through each activity. Interesting and pertinent points about the structures students are observing or dissecting are provided within the text of each exercise. Detailed anatomical descriptions of structures such as individual bones of the skull are left to the main textbook. Rather, the discussions in this laboratory manual give students alternative ways to understand, organize, and make sense of the material. The text is written in a friendly, conversational tone so as to not be intimidating to students, while at the same time not being overly chatty or brief on details.

### Photographs and Illustrations

The photographs in this laboratory manual are intended to truly capture the laboratory experience. The author, an accomplished prosectionist and biomedical photographer, personally prepared and shot the vast majority of the photographs of dissections, bones, human cadavers, and classroom models for this laboratory manual, as well as several of the histology images. While writing the dissection exercises, she performed the dissections herself and photographed each dissection at key stages that would be of most benefit for students as they perform the same steps. This gives each photo a unique perspective that could not be accomplished any other way.

Illustrations and photographs appearing in this manual have been tailored to the specific needs of the associated laboratory exercises, and are generally unique to avoid unnecessary repetition of lecture textbook images.



**Figure 20.1** Wall Layers of the Trachea. The walls of all structures of the respiratory tract are composed of three layers: mucosa, submucosa, and adventitia. This drawing depicts the wall of the trachea, which has an outer covering of connective tissue referred to as an adventitia.

### Organization

Because observation of histology slides and observation of human cadavers and classroom models are usually performed in separate physical spaces or at specific times within each laboratory classroom, chapters in this laboratory manual are similarly separated into two sections: Histology

and Gross Anatomy. Each exercise within these chapter sections has been designed with the student's actual experience in the anatomy laboratory in mind. Thus, each exercise covers only a single histology slide, classroom model, or region of the human body (for example: muscles of the abdominal wall, histology of cardiac muscle, model of the human ear). In addition, organization of each chapter into a series of discreet exercises makes the laboratory manual easily customizable to any anatomy classroom, allowing an instructor to assign certain exercises, while having students skip other exercises.

---

## Changes to the Third Edition

Certain changes to the third edition of this laboratory manual have been applied throughout all chapters.

- Word origins have been added to tables, where relevant.
- Chapter opening pages now include a list of reference tables.
- Pre-Laboratory Worksheets and Post-Laboratory Worksheets include a broader variety of question types.
- Drawing circles have been enlarged and standardized throughout to allow more space for student drawings.
- Tables have been reorganized to include headings and subheadings for ease of learning.
- Safety icons have been added throughout the manual to alert students to potential hazards in the lab.
- New content has been added in numerous places throughout the manual, including:
  - additional new exercises
  - new Concept Connection boxes
  - new Clinical View boxes
  - new Learning Strategy boxes

---

## Changes by Chapter

The following is a list of the most significant changes by chapter in the third edition of this lab manual.

### Chapter 1

- New Learning Strategy on studying anatomy and physiology
- Safety icons emphasizing safe dissection techniques

### Chapter 2

- New Figure 2.1 The Anatomic Position, Body Planes, and Directional Terms
- New Exercise 2.1B Sectioning a Specimen
- New Figure 2.3 Sections Through a Sheep Heart

### Chapter 3

- New Figure 3.3 Loading a Microscope Slide
- Revised Figure 3.5 Estimating Specimen Size

### Chapter 4

- New Exercise 4.1A: Preparing a Wet Mount of Human Cheek Cells
- Revised table 4.2 so it takes up only one page. Included space for students to draw the phases of mitosis in each row describing the stage

- Revised Figure 4.3 Classroom Model of a Prototypical Animal Cell
- Revised Exercise 4.3 Observing Classroom Models of Cellular Anatomy to include space for students to sketch a prototypical cell with organelles

### Chapter 5

- New Clinical View: Histopathology
- New Clinical View: Functions of epithelial surface modifications
- New Table 5.1 Classification of Epithelial Tissue by Number of Cell Layers
- New Learning Strategy: Differentiating osteoblasts from osteocytes and chondroblasts from chondrocytes
- New Learning Strategy: Differentiating the three types of cartilage from each other
- New Clinical View: Carcinomas and Sarcomas
- New Learning Strategy: "Lookalikes" in Histology, which includes six new histology images
- New Learning Strategy on identifying a histological slide of pseudostratified ciliated columnar epithelial tissue

### Chapter 6

- New Learning Strategy: Comparing layers of the skin to their component parts in a piece of leather
- Revised Figure 6.11 Classroom Model of the Integument
- New Learning Strategy comparing apocrine sweat glands and sebaceous glands

### Chapter 7

- New Exercise: 7.4: Identifying Classes of Bones Based on Shape
- Converted introductory material on long bones into an exercise: Exercise 7.5 Components of a long bone

### Chapter 8

- New introductory text on bone markings
- New Table 8.1 Bone Markings
- New Learning Strategy on relating skeletal structure to function
- New Learning Strategy on the word origins of bones and bone markings
- Revised Table 8.2 The Axial Skeleton: Skull Bones and Important Bony Landmarks to include word origins
- New Learning Strategy on visualizing structures as they travel through the foramina of the skull
- Revised Figure 8.12 The Hyoid Bone
- New Learning Strategy on learning the number of vertebrae in each region of the vertebral column
- Replaced Clinical View: Spina Bifida with new Clinical View: Spondylolisthesis
- New Concept Connection on the atlas and axis
- New Learning Strategy on identifying vertebrae from each region of the vertebral column
- Revised Figure 8.23 A Typical Rib



## Chapter 9

- New Concept Connection on learning the bony features of the appendicular skeleton
- Revised Exercise 9.1 Bones of the Pectoral Girdle
- Revised Exercise 9.2 Bones of the Upper Limb
- Revised Figure 9.8 Surface Anatomy of the Pectoral Girdle and Upper Limb
- Revised Exercise 9.4 Bones of the Pelvic Girdle
- Revised Learning Strategy on distinguishing a male versus a female pelvis
- New Learning Strategy on determining distinctive features for each bone
- Revised Exercise 9.5 Bones of the Lower Limb
- New Learning Strategy on remembering the names of the tarsal bones

## Chapter 10

- Revised Introduction to more clearly explain joint classification
- New Table 10.1: Structural (Anatomic) Classification of Joints
- Reorganized Exercise 10.1 Fibrous Joints to be consistent with Table 10.3 Classification of Fibrous Joints
- Revised Table 10.5 Components of Synovial Joints to include most relevant terms
- Revised Exercise 10.6 Structural Classification of Synovial Joints to include more detailed description of each type of synovial joint

## Chapter 11

- Revised Introduction to more concisely summarize the muscular system and chapter organization
- Reorganized the order of chapter topics and exercises: skeletal, cardiac, and smooth muscle
- New Learning Strategy describing how to distinguish smooth muscle tissue from dense regular connective tissue

## Chapter 12

- Reorganized Exercise 12.1 Muscles of Facial Expression
- New Learning Strategy on using word origins to assist with learning muscle attachments
- New Learning Strategy on learning the external and internal oblique muscles
- New Learning Strategy on the rationale behind using directional terms when naming certain muscles

## Chapter 13

- Revised Gross Anatomy introductory text: Muscles That Move the Pectoral Girdle/Glenohumeral Joint
- Revised Table 13.1: Muscles That Act About the Pectoral Girdle
- Revised Exercise 13.1: Muscles That Act About the Pectoral Girdle/Glenohumeral Joint to include Exercise 13.1A: Muscles That Move the Pectoral Girdle and Exercise 13.1B: Muscles That Move the Glenohumeral Joint
- New Clinical View: Winged Scapula
- Revised Table 13.2: Muscles That Move the Glenohumeral Joint

- Reorganized Table 13.6: Posterior (Extensor) Compartment of the Forearm
- Revised Gross Anatomy introductory text: Muscles That Move the Hip Joint/Thigh
- New Learning Strategy to aid in remembering muscles in the medial compartment of the thigh
- Revised Table 13.8: Muscles That Act About the Hip Joint/Thigh
- Revised Exercise 13.5: Muscles That Move the Hip
- Revised Exercise 13.6: Compartments of the Thigh
- New Table 13.9: Anterior Compartment of the Thigh
- New Table 13.10: Posterior Compartment of the Thigh

## Chapter 15

- Revised Table 15.3 Cells Associated with Taste Buds to include word origins
- Reorganized Table 15.1: Sensory Receptors in Thick Skin
- Revised Figure 15.10 Skin
- Revised Exercise 15.8 Gross Anatomy of the Eye to include Exercise 15.8A Accessory Structures of the Eye and Exercise 15.8B Internal Structures of the Eye
- Revised Figure 15.11 Accessory Structures of the Eye
- Revised Figure 15.12 Classroom Model of the Internal Eye

## Chapter 16

- New Learning Strategy on hormones secreted by the anterior pituitary gland
- Revised Figure 16.7 Adrenal Glands

## Chapter 17

- Revised Exercise 17.3 Location of the Heart and the Pericardium
- New Learning Strategy on remembering the atrioventricular valves on the right versus the left side of the heart
- Reorganized Table 17.3 Arterial Supply to the Heart

## Chapter 18

- New Clinical View: Great Saphenous Vein and Varicose Veins
- Revised Figure 18.11 Circulation to the Thoracic and Abdominal Walls

## Chapter 19

- Reorganized the order of chapter topics and exercises: thymus, lymph nodes, and the spleen
- New Clinical View: Appendicitis
- New Table 19.5 Major Lymphatic Vessels of the Body
- Revised Figure 19.8 Lymph Node and Its Components

## Chapter 20

- New Learning Strategy to remember the lobes of the right versus the left lung

## Chapter 21

- Reorganized Table 21.1 Histological Features of the Kidney to include headings and subheadings

## Chapter 22

- New Learning Strategy on distinguishing between gastric pits and gastric glands
- New Learning Strategy on distinguishing the three parts of the small intestine
- Revised Figure 22.5 The Small Intestine
- New Learning Strategy on villi as they relate to the GI Tract
- New Exercise 22.8 Overview of the GI Tract
- New Figure 22.10 Overview of the Digestive System
- Reorganized Table 22.7 Gross Anatomic Regions and Features Associated with the Stomach
- Revised Figure 22.12 Classroom Model of the Stomach
- Reorganized Table 22.8 Gross Anatomic Features of the Liver, Gallbladder, Pancreas, and Their Associated Ducts
- Reorganized Table 22.10 The Cecum, Large Intestine, Rectum, and Anus
- New Figure 22.18 The Cecum, Large Intestine, and Rectum

## Chapter 23

- New Learning Strategy on sustentacular cells in the testes
- Reorganized Table 23.4 Components of the Uterine Tube
- Reorganized Table 23.6 Phases of the Menstrual Cycle
- New Learning Strategy: “Lookalikes”—uterine tube and seminal vesicles
- New Concept Connection on lactation

## Chapter 24

- Reorganized Table 24.1 to separate meningeal structures into categories (e.g., Dural sinuses and Dural Septa)
- New Exercise 24.3 Circulation of Cerebrospinal Fluid (CSF)
- New Figure 24.5 Cerebrospinal Fluid (CSF) Production and Circulation
- Reorganized Table 24.3 Brain Structures Visible in Superficial Views of Whole or Sagittally Sectioned Brains
- New Learning Strategy on locating the trochlear nerve on models and the brain
- Merged separate chapters on the brain and cranial nerves into a single chapter
- Reorganized the content in Exercise 24.9 so the text and figures are more closely aligned with each other

## Chapter 25

- New Clinical View: Additional Nerves of the Brachial Plexus
- Revised Table 25.1 Regional Characteristics of the Spinal Cord to include word origins
- Reorganized Table 25.2 Histology of the Spinal Cord in Cross Section
- Reorganized Table 25.5 Major Nerves of the Brachial Plexus
- Revised Exercise 25.5 The Lumbar and Sacral Plexuses
- Reorganized original Table 25.6 into Table 25.6 Major Nerves of the Lumbar Plexus and Table 25.7 Major Nerves of the Sacral Plexus

## Chapter 26

- All new chapter! The Autonomic Nervous System

## Chapter 27

- Reoriented Table 27.3 Leukocyte Characteristics for better readability
- Inserted “Caution” symbol and text about precautions necessary if using human blood

## Pedagogy

This laboratory manual utilizes several pedagogical devices to assist students in learning human anatomy in the laboratory setting.

- **Outline and Objectives** Each chapter begins with an outline that lists the exercises within the chapter. Below each exercise is a list of objectives that conform to the activities the students are asked to complete within each exercise.
- **Pre- and Post-Laboratory Worksheets** Pre-Laboratory Worksheets at the beginning of each chapter are intended to give the student a “warm up” before entering the laboratory classroom. Some questions pertain to previous activities that are relevant to the upcoming activities (for example: review questions about nervous tissues in the Pre-Laboratory Worksheet for the chapter on the brain and cranial nerves), while others are basic questions that students should be able to answer if they have read the chapter from the main textbook before coming into the classroom. The goal of completing these worksheets is simple: have students arrive at the laboratory prepared to deal with the material they will be covering so they do not waste valuable in-class time reviewing necessary background information.

**Chapter 5: Histology**

Name: \_\_\_\_\_  
Date: \_\_\_\_\_ Section: \_\_\_\_\_

PRE-LABORATORY WORKSHEET

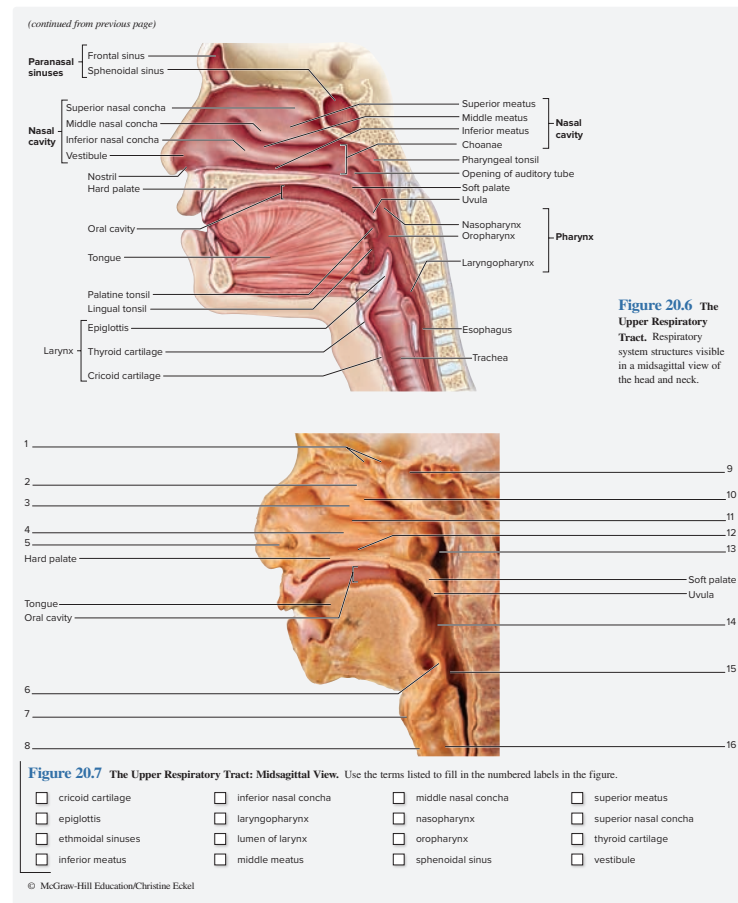
These Pre-laboratory Worksheet questions may be assigned by instructors through their **connect** course.

1. Which of the four basic tissue types is/are excitable? (Check all that apply.)  
 a. connective  
 b. epithelial  
 c. muscle  
 d. nervous
2. All connective tissues are derived from an embryonic connective tissue called mesenchyme. \_\_\_\_\_ (True/False)
3. Bone is classified as which of the following tissue types? (Circle one.)  
a. connective  
b. epithelial  
c. muscle  
d. nervous
4. Which of the four tissue types contains an extensive extracellular matrix (ECM)? (Circle one.)  
a. connective  
b. epithelial  
c. muscle  
d. nervous
5. Which of the three types of muscle tissue is/are striated? (Check all that apply.)  
 a. cardiac  
 b. skeletal  
 c. smooth

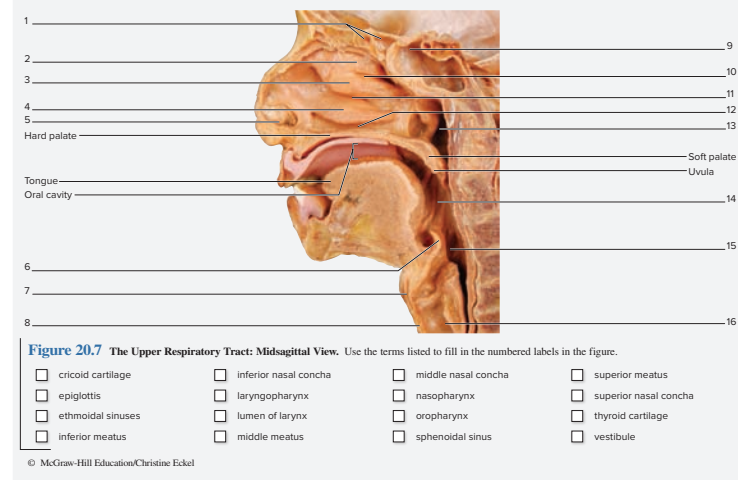
Post-Laboratory Worksheets at the end of each chapter help students review the material they just covered, and challenge them to apply the knowledge gained in the laboratory (for example: questions asking students to determine loss of function if a particular nerve or part of the brain is damaged).

The Post-Laboratory Worksheets contain more in-depth, critical thinking types of questions than the Pre-Laboratory Worksheets. Post-Laboratory Worksheets are perforated so they can be torn out of the manual and handed in to the instructor if so desired.

- In-Chapter Learning Activities** The exercises in this laboratory manual are about *doing*, not just observing. Exercises offer a mixture of activities including labeling exercises, sketching activities, coloring exercises, table completion, data recording, palpation of surface anatomy structures, and the like.



**Figure 20.6** The Upper Respiratory Tract. Respiratory system structures visible in a midsagittal view of the head and neck.



**Figure 20.7** The Upper Respiratory Tract: Midsagittal View. Use the terms listed to fill in the numbered labels in the figure.

- cricoid cartilage
- epiglottis
- ethmoidal sinuses
- inferior meatus
- inferior nasal concha
- laryngopharynx
- lumen of larynx
- middle meatus
- middle nasal concha
- nasopharynx
- oropharynx
- sphenoidal sinus
- superior meatus
- superior nasal concha
- thyroid cartilage
- vestibule

© McGraw-Hill Education/Christine Eckel

**Chapter 5: Histology**

Name: \_\_\_\_\_  
Date: \_\_\_\_\_ Section: \_\_\_\_\_

**POST-LABORATORY WORKSHEET**

The **●** corresponds to the Learning Objective(s) listed in the chapter opener outline.

**Do You Know the Basics?**

**Exercise 5.1: Identification and Classification of Epithelial Tissue**

- The epithelial type that protects against abrasion is **1**.
- Endothelium is a \_\_\_\_\_ epithelium that lines the walls of blood vessels and the heart. **2**
- Match the function listed in column A with the surface modifications and specialized cells found in epithelial tissues listed in column B. **3-5**

<p><b>Column A</b></p> <ul style="list-style-type: none"> <li>____ 1. provide lubrication</li> <li>____ 2. increase surface area for enhanced absorption</li> <li>____ 3. aid in movement of substances in one direction</li> <li>____ 4. imparts strength and protection</li> </ul>	<p><b>Column B</b></p> <ul style="list-style-type: none"> <li>a. cilia</li> <li>b. goblet cells</li> <li>c. keratinization</li> <li>d. microvilli</li> </ul>
--	--

- When observing a cross section of a tube that is lined with epithelial tissue (e.g., the gut tube), the epithelial surface that faces the lumen of the tube is the \_\_\_\_\_ (apical/basal) surface. **6**

**Exercise 5.2: Identification of Embryonic Connective Tissue**

- Embryonic connective tissue is called \_\_\_\_\_. **6**

**Exercise 5.3: Identification and Classification of Connective Tissue Proper**

- The extracellular matrix of connective tissue is composed of cells and fibers. \_\_\_\_\_ (True/False) **7-8**
- For each category of connective tissue listed in the following table, write in the major cell types, the fiber types, and the characteristics of the ground substance of the tissue. Refer to the textbook for assistance. **9-11**

	Connective Tissue Proper	Cartilage	Bone	Fluid Connective Tissue
Cells				
Fibers				
Ground Substance				

- Labeling Activities** In the gross anatomy exercises of this manual, images of things such as cranial bones, muscles of the body, and so on are *not* presented as labeled photos because the students *already have* labeled photos in their main textbook. Instead, each image is presented as a labeling activity with a checklist of structures. The checklists serve two purposes: (1) they guide students to what items they need to be able to identify on classroom models, fresh specimens, or cadavers (if the laboratory uses human cadavers), and (2) they double as a list of terms students can use to complete the labeling activities. Answers to the labeling activities are provided in the appendix. Thus, if a student does not know what a leader line is pointing to, or cannot remember the correct term, he or she can consult the appendix to locate the correct answer. This is a bit more challenging to students than having a pre-labeled image in the lab manual. However, that is precisely the goal: challenge the students!

- Learning Strategy** Handy “Learning Strategy” boxes coach students through the more problematic areas of study. They offer tips such as points of clarification and things to be aware of, and/or careful of when making certain observations.


**Learning Strategy**

When learning the processes, projections, foramina (holes), and other markings of the bones, view each structure, study it closely, and contemplate its function. The process may be an attachment point for a ligament, a tendon, or a muscle. The opening or hole may serve as a passageway for a nerve, artery, or vein. The smooth surface may be where the bone articulates with another bone. For each structure, relate form to function.

- What Do You Think? Questions** Placed at key points within exercises, these critical thinking questions challenge students to think beyond the “what” of the structures they are observing and start to think about the “why.” Answers are provided in the appendix.

**WHAT DO YOU THINK?**

- Why do you think the fontanelles persist until well after the birth of the infant?

- **Tables** Each chapter contains numerous tables, which concisely summarize necessary details. As stated previously, the goal of this manual was expressly not to repeat textual material. However, students still need the information as reference while in the laboratory classroom. Thus, critical information and key structures are covered in table format. A concerted effort has been made to include a column that provides word origins for each structure listed within the table. These word origins are intended to give students continual exposure to the origins of the language of anatomy, which is critical for learning.
- **Anatomy & Physiology | REVEALED® Correlations** <sup>3.2</sup> Where pertinent, optional activities indicated by the logo above direct students to where they can find related content on Anatomy & Physiology Revealed.

---

## Instructor Resources

### Assignable Questions

Pre- and Post-Laboratory questions, along with labeling questions, are available for use in online assignments via McGraw-Hill's Connect.

### Textbook Images

Image files for use in presentations and teaching materials are provided under the Instructor Resources tab within Connect.

### Instructor's Manual

A helpful manual containing materials lists, presentation ideas, and answer keys for the Pre- and Post-Laboratory Worksheets is available to instructors who use this laboratory manual.

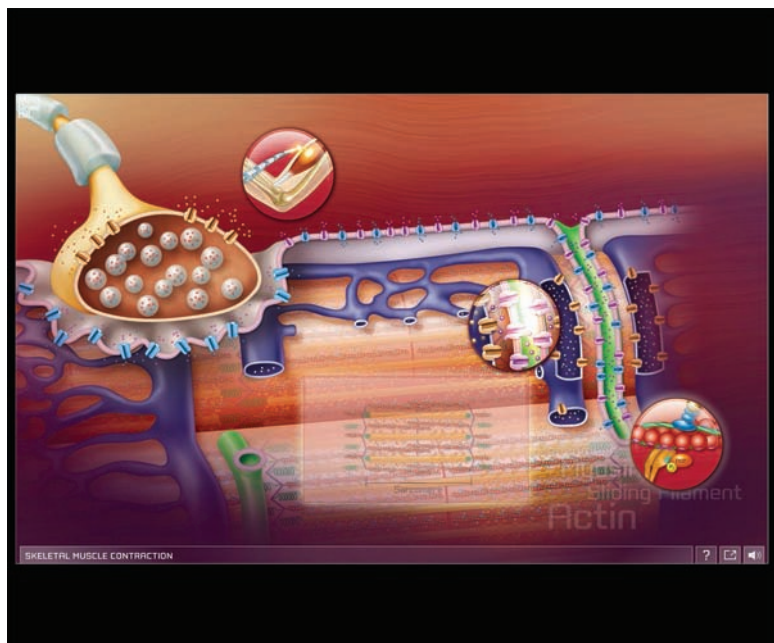
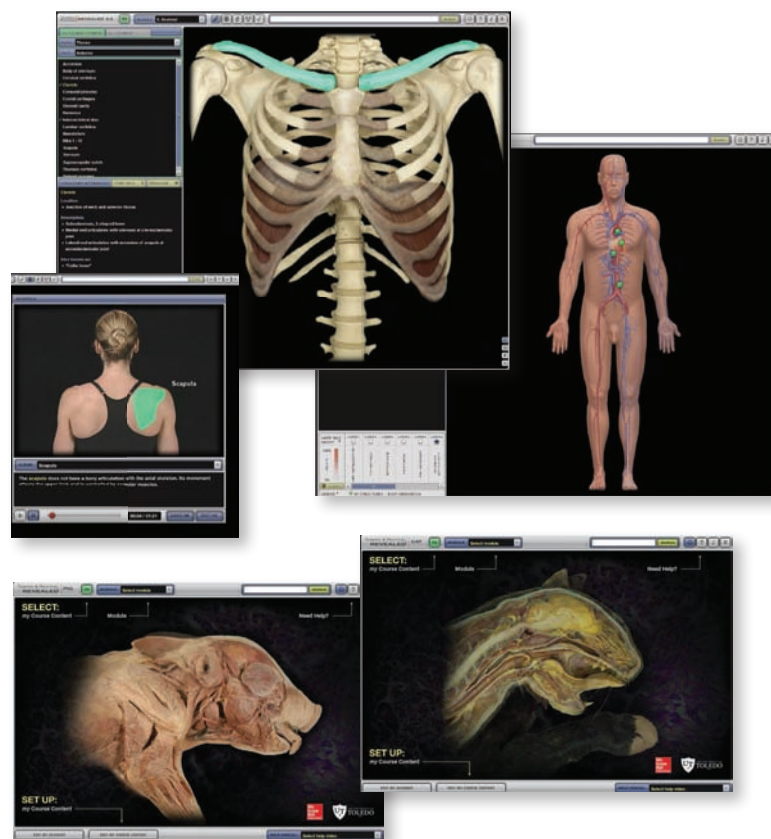
# An Interactive Cadaver Dissection Experience

## Anatomy & Physiology|Revealed 3.2® [www.aprevealed.com](http://www.aprevealed.com)

An **interactive cadaver dissection tool** to enhance lecture and lab. Make use of the custom structure list to focus learning! Now, mobile—get the experience anywhere, anytime!

**Anatomy & Physiology REVEALED 3.2 | Cat** and **Anatomy & Physiology REVEALED 3.2 | Fetal Pig** are online interactive cat dissection and fetal pig dissection experiences that use cat photos or fetal pig photos, combined with a layering technique that allows you to peel away layers to reveal structures beneath the surface.

Both **Anatomy & Physiology REVEALED 3.2 | Cat** and **Anatomy & Physiology REVEALED 3.2 | Fetal Pig** offer animations, histologic and radiologic imaging, audio pronunciations, and comprehensive quizzing.



## Concept Overview Interactives

Located within Anatomy & Physiology REVEALED 3.2, **Concept Overview Interactives** combine multiple concepts into one big-picture summary. These striking, visually dynamic presentations offer a review of previously covered material in a creatively designed environment to emphasize how individual parts fit together in the understanding of a larger mechanism or concept.

**Concept Overview Interactive** modules have assessable, auto-graded learning activities in Connect®, can be used as a self-study tool for students, and are also provided separately to instructors as classroom presentation tools.

## Roots, Combining Forms, Prefixes, and Suffixes

Many terms used in the biological sciences are compound words; that is, words made up of one or more word roots and appropriate prefixes and/or suffixes. Less than 400 roots, prefixes, and suffixes make up more than 90% of the medical vocabulary. These combining forms are most often derived from the ancient Latin or Greek. Prefixes are placed before the root term and suffixes are added after. The following list includes the most common forms used in anatomy and medicine and an example for each. This list, and the word origin information found throughout the text, is intended to facilitate learning an often unnecessarily complex-sounding vocabulary. Exclusively a learning tool, the entries are by intention brief. If you learn them, you will find your progress in your anatomy course swift, steady, and strong (the three “s”es” of success).

a-	without, lack of	asymptomatic (absence of symptoms)
ab-	away from	abstinence (to hold back from)
acou-	hearing	acoustics (science of sound)
-ac, -al	pertaining to	cardiac (the heart), myocardial (heart muscle)
ad-	to, toward, near to	adduction (move toward midline)
aden-, adeno-	gland	adenoma (tumor of a gland)
af-	toward	afferent (moving toward)
albi-	white	albuminuria (passing of pale or white urine)
-algia	painful condition	myalgia (muscle pain)
an-	without, lack of	anesthesia (absence of pain)
andro-	male	androgens (male hormones)
angi-, angio-	vessel	angiopathy (disease of blood vessels)
ante-	before	antepartum (before birth)
anti-	against	anticoagulant (prevents blood clotting)
apo-	separated from, off	apodia (congenital absence of feet)
arthr-, arthro-	joint	arthritis (inflammation of a joint)
-ary	associated with	urinary (associated with urine)
-asis, -asia	condition or state of	homeostasis (state of metabolic balance)
audio-	hearing	auditory (belonging to the hearing sense)
auri-	ear	auricle (ear-shaped structure)
auto-	self	autolysis (self breakdown)
baro-	weight, pressure	baroreceptor (receptor for pressure changes)
bi-	twice, double	bicuspid (two cusps)
-blast	germ, bud	chondroblast (cartilage-producing cell)
brachi-	arm	brachial (of the arm)
brady-	slow	bradycardia (slow heart rate)
bucc-	cheek	buccal cavity (inside cheek region)
callo-	thick	callosity (thickening of keratinized layer of epidermis)
carcin-	cancer	carcinogenic (causing cancer)
cardio-	heart	cardiogram (register of heart activity)
caud-	tail	caudal (by the tail)
cephal-	head	cephalic (by the head)
cerebro-	brain	cerebrospinal (of the brain and spinal cord)
chondro-	cartilage, gristle	chondrocyte (cartilage cell)
-cide	kill	spermicide (agent that kills sperm)
circum-	around	circumduction (movement forming a circle)
-clast	break	osteoclast (cell that breaks down bone)
co-, com-	with, together	cooperate, gray commissure (connects right/left horns)
contra-	against, opposite	contralateral (opposite side)
cost-	rib	intercostals (between the ribs)
crani-	skull	cranial cavity (where the brain is)
cune-	wedge	cuneiform (wedge shaped)
cuti-	skin	subcutaneous (under the skin)
cyan-	blue color	cyanosis (bluish discoloration of skin)
cysti-, cysto-	sac, bladder	cystoscope (instrument for examining inside of bladder)
-cyte, ctyo-	cell	erythrocyte (red blood cell), cytology (study of cells)
demi-	half	costal demifacet (half-moon facet on vertebra for rib articulation)
derm-	skin	dermatology (study of skin)
di-, diplo-	two	diploid (two sets of chromosomes)
duct-, -duct	lead, draw	ovarian duct, adduct (to lead away from)
dur-	hard	dura mater (tough meninx of CNS)
dys-	painful, difficult, bad	dysuria (painful urination)
e-, ec-, ef-, ex-	out, from	effluent (carries away from), excretion (eliminate from)
ecto-	outside, outer	ectocardia (displacement of heart)
-ectomy	to cut out	appendectomy (removal of appendix)
ede-, -edem	swelling	myoedema (muscle swelling)
-el, -elle	small	organelle (tiny structure that performs specific cellular functions)
endo-	within	endocardium (lining within heart chambers)
entero-	intestine	enteritis (inflammation of intestines)
epi-	upon, on	epicardium (membrane covering heart)
ex-, exo-	outside	exhale (breathe out); exocrine (gland that secretes to outside)
extra-	outside	extracellular (outside the cell)
-ferent	carry	afferent (carries toward)
-form	resembling, shape of	fusiform (spindle-shaped)
gastr-, gastro-	stomach	gastric ulcer (stomach ulcer)
-genesis, -genic	produce, origin	gluconeogenesis (glucose from another molecule), carcinogenic (causes cancer)
gloss-, glosso-	tongue	hypoglossal (under the tongue)
glyco-	sugar, sweet	glycolysis (breakdown of glucose)
gyn-	female, woman	gynecology (treatment of female reproductive organs)
hapto-	single	haploid (single set of chromosomes)
hem-, hemato-	blood	hematology (study of blood)
hepato-	liver	hepatitis (inflammation of the liver)
hetero-	different	heterosexual (involving different sexes)
hist-, histo-	tissue	histology (study of tissues)
holo-	whole, entire	hologynic (manifests only in females), holocrania (absence of all bones of skull vault)
homo-, homeo-	same	homeostasis (constancy of body parameters)
hydro-	water	hydroadipsia (absence of thirst for water)

— Continued from inside front cover

hyper-	over, above	hypertrophy (overgrowth of cells or part)
hypo-	below, under	hypoglycemia (low blood sugar)
idio-	self, distinct	idiopathic (disease of unknown cause)
infra-	below	infraspinatus (below the spine of scapula)
inter-	between	interosseous (between two bones)
intra-	within	intracellular (within the cell)
-issimus	greatest	latissimus (widest)
iso-	equal, same	isotonic (same concentration)
-itis	inflammation	neuritis (inflammation of nerve)
juxta-	near	juxtaglomerular (near the glomerulus)
labi-	lip	labia major (thickened folds of skin and connective tissue in female external genitalia)
lacto-	milk	lactose (milk sugar)
leuko-	white	leukocyte (white blood cell)
lip-	fat	lipid (an operational term denoting solubility characteristics; "fat soluble")
-logy	study	urology (study of urinary system)
-lysis	breaking up, dissolve	hemolysis (breaking up erythrocytes)
macro-	large	macrophage (certain large leukocytes)
mamm-, mast-	breast	mammary glands, mastectomy (breast removal)
medi-	middle	medial (toward the midline)
melano-	black	melanocyte (dark pigment-producing cell)
-mers, -meres	parts	polymers (larger molecules made of monomers)
meta-	after, beyond	metastasis (beyond the original position)
micro-	small	microorganism (very small organism)
mono-	one, single	monomer (a single part); monosaccharide (a simple or single sugar)
morph-	form, shape	morphology (study of shape)
myo-	muscle	myometrium (muscular wall of uterus)
necro-	dead	necrotic (being of dead tissue)
neo-	new	neonatal (newborn)
nephro-	kidney	nephrology (study of kidneys)
neuro-	nerve	neurilemma (nerve cell membrane)
oculo-, ophthalm	eye	oculomotor (movement of the eye), ophthalmology (study of the eye)
odonto-	tooth	odontoid (shaped like a tooth)
-ole	little	arteriole (small artery-like vessel)
oligo-	few, little, deficient	oliguria (little urine output)
-oma	tumor	carcinoma (cancerous tumor), osteoma (benign bone tumor)
oo-	egg	oocyte (egg cell)
-osis	condition of	osteoporosis (having bones that are porous)
osse-, osteo-	bone	osteoblast (bone-forming cell)
oto-	ear	otogenic (originating within the ear)
para-	near, beside	paranasal (by the nose)
-pathy	disease	neuropathy (nerve disease)
pelv-	basin	renal pelvis (collection area in kidney)
-penia	deficiency	leucopenia (deficiency of leukocytes)
peri-	around	periosteum (membrane covering bones)
phag-	eat	phagocytosis (cellular eating)
phil-	have an affinity for	lipophilic (associates with fat)
-plegia	paralyze, stroke	paraplegia (paralysis of lower extremities)
pneumo-	air, gas, lungs	pneumothorax (air in the pleural cavity)
-poie, -poiesis	make, formation of	erythropoietin (hormone that stimulates erythrocyte production)
poly-	many	polycythemia (excess erythrocytes)
post-	after	postnatal (after birth)
pre-	before in time, place	prenatal (before birth)
pro-	before in time, place	prosect (to cut for demonstration)
pseudo-	false	pseudostratified (not true layered)
quad-	fourfold	quadriceps femoris (4-headed muscle of anterior thigh)
rami-	branch	ramus (primary division of a nerve)
rect-	straight	rectus abdominis (straight muscle of abdomen)
reno-	kidney	renal (of the kidney)
retro-	backward, behind	retroperitoneal (posterior to the peritoneum)
sclero-	hard	arteriosclerosis (hardening of the arteries)
semi-	half	semilunar (half-moon shaped)
serrate-	saw-edged	serratus anterior (muscle of thorax)
somato-	body	somatotropin (growth hormone)
steno-	narrow	stenosis (narrowing of opening)
sterno-	breast, chest	sternum (bone over heart and medial to ribs)
stria-	stripe	striated (showing stripes or lines)
sub-	under	subcutaneous (under the skin)
super-, supra-	above, upper	supercilia (upper brows), suprarenal (superior to the kidney)
sym-, syn-	together, with	symphysis (growing together), synapse (where neurons, or neuron and muscle fiber, meet)
tachy-	fast	tachycardia (rapid heart rate)
therm-	heat	thermometer (tool to measure temperature)
thorac-	chest	thoracic cavity (body cavity containing heart, lungs)
thrombo-	blood clot	thrombocyte (platelet)
-tomy	cut, incise	appendectomy (removal of appendix)
topo-	place, position	ectopic (being out of position)
trans-	across	transdermal (across the skin)
tri-	three	triceps brachii (three-headed muscle)
-tropic	influencing	gonadotropic (effecting the gonads)
tunica-	layer, coat	tunica interna (inner part of blood vessel)
ultra-	beyond, excess	ultradian (more than every 24 hours)
uni-	one	unicellular (single cell)
-uria	urine	polyuria (excess urine)
vas-	vessel	vasodilation (widening of lumen of blood vessel)
vertebro-	spine	vertebrae (bones of the spine)
villo-	hair	microvilli (minute projections of cell membrane)
viscer-	internal organ	visceral (of the internal organs)
zyg-	yoked, paired, union	azygos (unpaired anatomical structure)

# The Laboratory Environment



## INTRODUCTION

Welcome to the human anatomy laboratory! Most students experience both excitement and anxiety about this course. The human body is a fascinating subject, and the study of human anatomy is an experience that is typically not forgotten.

This laboratory manual is designed for an integrated, systems-based course that combines both human gross anatomy and histology and gross anatomy. **Histology** is the study of tissues and requires the use of a microscope. **Gross anatomy** is the study of structures that can be seen with the naked eye. This includes any structure that can be seen without the use of a microscope. The hope is that upon completion of this course, students will have developed an understanding of and appreciation for how tissue structure relates to gross structure, and vice versa. That said, in the laboratory classroom itself, the two levels of structure are often studied somewhat separately. That is, laboratory studies in histology will likely involve observing histology slides with a microscope or using some sort of virtual microscopy system; laboratory studies in gross anatomy will likely involve observing classroom models, dissecting animal specimens, or making observations of human bones and/or human cadavers. To assist students in these endeavors, the exercises in this manual are divided into two types of activities: histology exercises and gross

## OUTLINE AND LEARNING OBJECTIVES

### Laboratory Equipment 4

#### EXERCISE 1.1: IDENTIFICATION OF COMMON DISSECTION INSTRUMENTS 4

- 1 Identify commonly used dissection tools

### Dissection Techniques 7

#### EXERCISE 1.2: PROPER DISPOSAL OF LABORATORY WASTE 8

- 2 Describe the proper disposal methods for tissues, instruments, and paper waste

#### EXERCISE 1.3: PLACING A SCALPEL BLADE ON A SCALPEL BLADE HANDLE 8

- 3 Demonstrate the proper technique for putting a scalpel blade on a scalpel handle
- 4 Demonstrate the proper technique for removing a scalpel blade from a scalpel handle

#### EXERCISE 1.4: DISSECTING WITH A SCALPEL 11

- 5 Demonstrate the proper technique for using a scalpel to cut tissues
- 6 Describe techniques used to prevent damage to underlying tissues when using a scalpel

#### EXERCISE 1.5: DISSECTING WITH SCISSORS 12

- 7 Demonstrate how to use scissors to dissect
- 8 Demonstrate “open scissors” technique

#### EXERCISE 1.6: BLUNT DISSECTION TECHNIQUES 13

- 9 Define “blunt dissection”
- 10 Demonstrate common blunt dissection techniques
- 11 Explain the importance of using blunt dissection techniques whenever possible



anatomy exercises. Where applicable, each chapter will begin with a section on histology and end with a section on gross anatomy. Although the two activities may be performed somewhat separately, the goal is to integrate the study of histology and gross anatomy, and to associate structure with function at all levels. “Concept Connection” boxes and questions within exercises in each chapter will assist students with this task.

The purpose of this introductory chapter is to familiarize students with common equipment, chemicals, and dissection instruments

encountered in the laboratory. Additional topics include the proper use of protective equipment, the proper disposal of waste materials, and common dissection techniques.

#### List of Reference Tables

Table 1.1	Common Dissection Instruments	p. 4
Table 1.2	Preservative Chemicals Encountered in the Human Anatomy Laboratory	p. 6

### Clinical View | Use of Human Cadavers in the Anatomy Laboratory

Where did that body lying on a table in the human anatomy laboratory come from? Typically, the body was donated by a person who made special arrangements before the time of death to donate his or her body to a body donor program so it could be used for education or research. Individuals who donate their bodies for these purposes make a conscious decision to do so. Such individuals have provided an incredible gift—the opportunity to learn human anatomy from an actual human body. It is important to remember that what that person has given is, indeed, a gift. The cadaver deserves the utmost of respect at all times. Making jokes about any part of the cadaver or intentionally damaging or “poking” at parts of the cadaver is unacceptable behavior.

The thought of learning anatomy by observing structures on what was, at one time, a living, breathing human being makes many individuals feel uncomfortable at first. It is quite normal to have an emotional response to the cadaver upon first inspection. It takes time and experience to become comfortable around the cadaver. Even if you think you will be just fine around the cadaver, it is important to be aware of your response and the responses of fellow classmates. If at any time you feel faint or light-headed, sit down immediately. Fainting, though rare, is a possibility, and can lead to injuries if a fainting person falls unexpectedly. Be aware of fellow students: if they appear to lose facial color or start to look sick—they may need assistance.

Typically the part of the body that evokes the most emotional response is the face, because it is most indicative of the person that the cadaver once was. Because of this, the face of the cadaver should remain covered most of the time. This does not necessarily mean that viewing the face is not allowed. However, before uncovering the face, make sure that other students in the room know that it will be uncovered. If you have a particularly strong emotional response to the cadaver, take a break and come back to it later when you are feeling better.

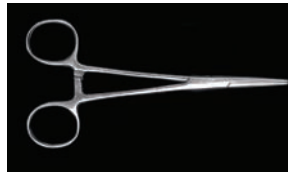
Individuals with a great deal of experience around cadavers had a similar emotional response the first time as well. In time one learns to disconnect emotions from the experience. Certainly at one time the body that is the cadaver in the laboratory was the home of a living human being. However, now it is just a body. Eventually students do become comfortable using the cadaver and find that it is an invaluable learning tool that is far more useful than any model or picture could ever be. There is nothing quite like the real thing to help students truly understand the structure of the human body. Make the most of this unique opportunity—and give thanks to those who selflessly donated their bodies to provide students with the ultimate learning experience in anatomy.

Students who are curious about the uses of cadavers in science and research are encouraged to check out the following book from the library: Mary Roach, *Stiff: The Curious Lives of Human Cadavers* (New York: W.W. Norton, 2003).

These Pre-laboratory Worksheet questions may be assigned by instructors through their **connect** course.

## PRE-LABORATORY WORKSHEET

1. Histology is the study of intracellular organelles. \_\_\_\_\_ (True/False)
2. Human cadaver tissue is disposed of in a biohazard waste bag. \_\_\_\_\_ (True/False)
3. List the pieces of equipment used for protection against the hazards associated with embalming chemicals.
  - a. \_\_\_\_\_
  - b. \_\_\_\_\_
  - c. \_\_\_\_\_
  - d. \_\_\_\_\_
  - e. \_\_\_\_\_
4. The dissection instrument shown here is a pair of: \_\_\_\_\_



© Christine Eckel

5. After dissecting a preserved cow eye, what receptacle should be used to dispose of the tissue?  
\_\_\_\_\_
6. Which of the following chemicals are commonly used as *preservatives*? (Check all that apply.)  
 a. ethanol  
 b. formalin  
 c. distilled water  
 d. phenol  
 e. glycerine
7. Which of the following chemicals require the use of personal protective equipment when handling them? (Check all that apply.)  
 a. ethanol  
 b. formalin  
 c. distilled water  
 d. phenol  
 e. glycerine
8. When removing a scalpel blade, point the blade away from you and others. \_\_\_\_\_ (True/False)
9. Which one of the following dissecting tools is the most beneficial for attempting to loosen the hold between a specimen's skin and the underlying fascia? (Circle one.)
  - a. dissecting probe
  - b. finger
  - c. scalpel
  - d. scissors
10. Blunt dissection technique is most useful for separating tissues without damaging delicate structures. \_\_\_\_\_ (True/False)

## Laboratory Equipment

The typical human anatomy classroom consists of laboratory tables or benches that provide ample room for use of microscopes, classroom models, and dissection materials. If human cadavers are used in the classroom, there will also be a space dedicated to the tables where the cadavers are stored. When entering the classroom for the first time, look around and become familiar with the environment. Pay particular attention to the

location of sinks, eyewash stations, and safety equipment such as first-aid kits and fire extinguishers. The instructor will most likely provide a detailed introduction specific to the laboratory classroom, safety procedures, and accepted protocol. The main purpose of the exercises in this chapter is to introduce common safety devices and dissection equipment. *Do not* use the information in this chapter as the sole source of information on laboratory safety. The exercises in this chapter are not intended to serve as a safety manual for the laboratory.

### EXERCISE 1.1 Identification of Common Dissection Instruments

Several dissection instruments are commonly found in the human anatomy laboratory classroom. **Table 1.1** describes each of these instruments and their uses.

1. Obtain a dissection kit from the laboratory instructor, or use your own dissection kit if you were required to bring your own to class.

2. Identify the instruments listed in **figure 1.1**, using table 1.1 as a guide. Then label figure 1.1.






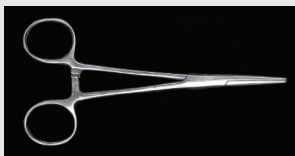




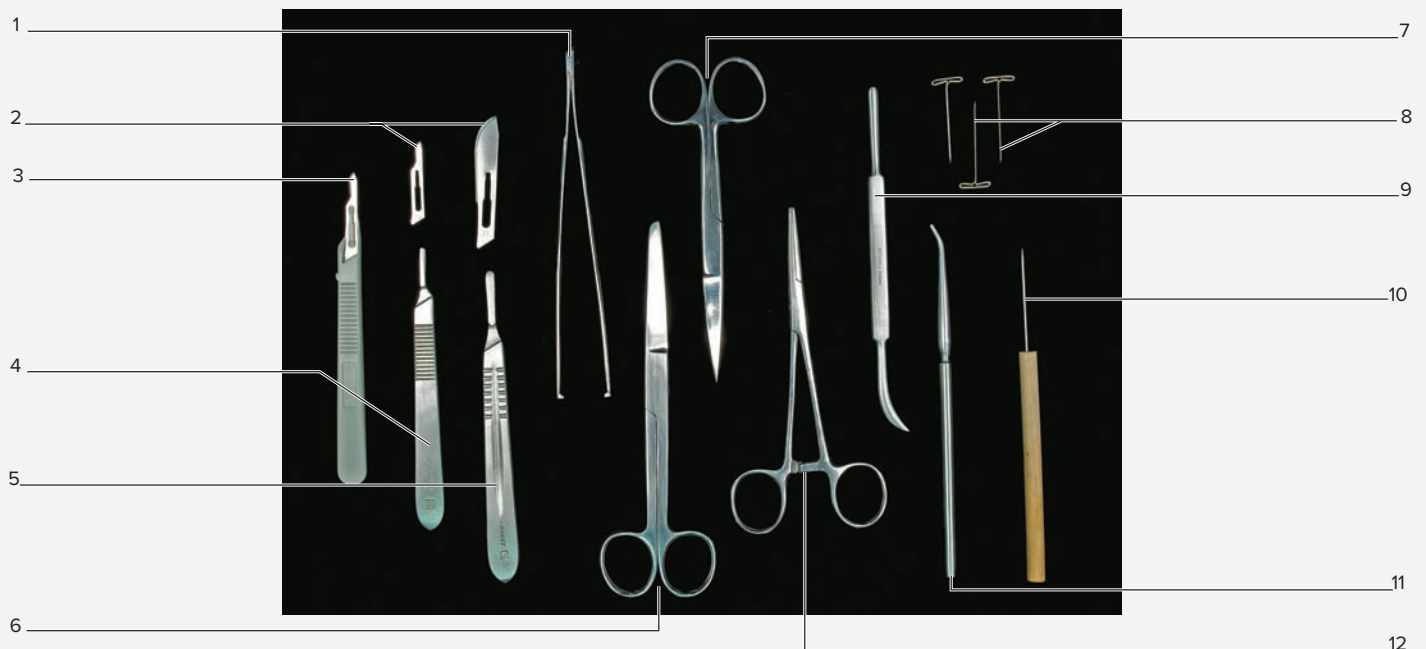
Table 1.1 Common Dissection Instruments			
Tool	Description and Use	Photo	Word Origin
<b>Blunt probe</b>	An instrument with a blunt (not sharp) end on it. This instrument is used to pry and poke at tissues without causing damage. Some probes come with a sharper point on the opposite end that can be used for “picking” at tissues.	 © Christine Eckel	<i>proba</i> , examination
<b>Dissecting needles</b>	Long, thick needles that have a handle made of wood, plastic, or metal. These needles are used to pick at tissues and to pry small pieces of tissue apart.	 © Christine Eckel	<i>dissectus</i> , to cut up
<b>Dissecting pins</b>	“T” shaped pins that are used to pin tissues to the wax or plastic pad within a dissecting tray. Pinning other structures away from the area of interest allows greater visibility within the dissection field and prevents unwanted damage to adjacent tissues.	 © Christine Eckel	<i>dissectus</i> , to cut up
<b>Dissecting tray</b>	Metal or plastic tray used to hold a specimen. The tray is filled with wax or plastic. The wax and/or plastic is soft enough to pin tissues to it.	 © Christine Eckel	<i>dissectus</i> , to cut up
<b>Forceps</b>	Resemble tweezers and are used for holding objects. Some are large and have tongs on the ends that assist with grabbing tough tissues. Some are small and fine (needle-nose) for picking up small objects. Forceps may also be straight-tipped or curve-tipped.	 © Christine Eckel	<i>formus</i> , form + <i>ceps</i> , taker
<b>Hemostat</b>	In surgery these are used to compress blood vessels and stop bleeding (hence the name). For dissection they are useful as “grabbing” tools. The handle locks in place, which allows the user to pull on tissues without causing hand and forearm muscles to fatigue.	 © Christine Eckel	<i>haimo-</i> , blood + <i>statikos</i> , causing to stop

Table 1.1 Common Dissection Instruments (continued)			
Tool	Description and Use	Photo	Word Origin
<b>Scalpel</b>	A sharp cutting tool. Generally the blade and the blade handle will be separate, unless using a disposable scalpel. Refer to specific directions in the text regarding proper use of a scalpel, as this instrument can be dangerous!	 © Christine Eckel	<i>scalpere</i> , to scratch
<b>Scalpel blade</b>	Both the cutting part and the disposable part of a scalpel. The number of the blade indicates blade size, and must be matched with an appropriately numbered blade handle. When a blade becomes dull, it may be removed and replaced with a new blade. Used blades must be disposed of in a sharps container.	 © Christine Eckel	<i>scalpere</i> , to scratch
<b>Scalpel blade handle</b>	The nondisposable part of a scalpel that is used to hold the blade. The number on the handle indicates the size of the handle and is used to match it with a particular blade size. A scalpel blade handle can be a useful tool for blunt dissection when used <i>without</i> a blade attached.	 © Christine Eckel	<i>scalpere</i> , to scratch
<b>Scissors</b>	Some scissors come with pointed blades and some have one curved (blunt) and one pointed blade. Scissors with the curved/blunt edge are used when extra care is needed to prevent damage to structures. To use, direct the curved blade toward the structures that could be damaged. Pointed-blade scissors are particularly helpful for using “open scissors” technique (see text).	 © Christine Eckel	<i>scindere</i> , to cut



**Figure 1.1 Identification of Common Dissection Instruments.** Use the terms listed to fill in the numbered labels in the figure. Answers may be used more than once.

- |  |   |  |   |
|--|---|--|---|
| <input type="checkbox"/> blunt probe       | <input type="checkbox"/> forceps              | <input type="checkbox"/> scalpel blade handle (#4) | <input type="checkbox"/> scissors (curved)  |
| <input type="checkbox"/> dissecting needle | <input type="checkbox"/> hemostat             | <input type="checkbox"/> scalpel blade handle (#3) | <input type="checkbox"/> scissors (pointed) |
| <input type="checkbox"/> dissecting pins   | <input type="checkbox"/> scalpel (disposable) | <input type="checkbox"/> scalpel blades            |   |

## Protective Equipment



The human anatomy laboratory poses few risks, although it is important to be aware of what these risks are. The main risks are damage to skin or eyes from exposure to laboratory chemicals (covered in the next section) or cuts from dissection tools. As a general precaution, wear protective gloves when working with fresh or preserved specimens (animal or human) to keep any potentially infectious or caustic agents from contacting the skin. If there is a risk of squirting fluid, then also wear protective eyewear (safety glasses or safety goggles). When wearing gloves, be sure to wear the correct size for your hands. If the gloves are too small, they may tear easily. If they are too big, they may make handling instruments and tissues difficult. When the gloves become dirty, remove them and put on a new pair. When removing a glove, start at the wrist and pull toward the fingers, turning the glove inside-out as it is removed. This will prevent any potentially damaging fluids from contacting the skin during removal of the gloves.

There is always a risk of cutting yourself or others when using sharp dissecting tools. To prevent injury from dissection instruments pay attention to the following rules. First and foremost—*never* wear open-toed shoes to the laboratory. Dissecting tools are often dropped and can cut feet if they are not covered by protective footwear. When using sharp tools such as scalpels, always be aware of the direction the sharp blades of those instruments are pointing. The sharp end should always point away from the user *and* away from others in the laboratory. When dissecting, be aware of where others are standing or sitting, and consider the risk posed to yourself and others if a hand were to slip. *Never* place hands in the dissecting field when anyone is actively dissecting. If another person asks for assistance holding tissues during a dissection, use forceps or some other device to hold the tissue to ensure that your hands are not within reach of the scalpel blade. Always be aware of the physical location of the scalpel, particularly when not using it. Individuals can be accidentally cut by reaching into a dissecting tray or

table and unexpectedly discovering a sharp scalpel in the dissection field. If using dissecting pins to hold back tissues, always remove them from the specimen before closing up for the day. This prevents unsuspecting individuals from getting jabbed by the pins when dissection continues at a later date.

## Hazardous Chemicals

Relatively few chemicals are used in the human anatomy laboratory. Most of these chemicals are used to preserve, or “embalm,” animal specimens or human cadavers. Generally these chemicals are not stored in the laboratory at full strength. Rather, most are diluted to about 10% of full strength. These chemicals will be encountered most commonly when using specimens or tissues that were previously injected with solutions containing the chemicals. Thus, safety measures in the laboratory are designed to protect users from the forms of these chemicals that are most likely to be encountered. The most common chemicals used for embalming purposes are formalin, ethanol, phenol, and glycerol.

**Table 1.2** summarizes the uses and hazards of these chemicals. The majority of these chemicals are used to fix tissues and prevent the growth of harmful microorganisms, such as bacteria, viruses, and fungi. “Fixation” refers to the ability of the chemical to solidify proteins, thus preventing breakdown. **Preservatives** both fix tissues and inhibit the growth of harmful microorganisms. Because most preservatives also dehydrate tissues, “humectants” are added to embalming solutions. **Humectants**, such as glycerol, attract water. When humectants act alongside preservatives, they help keep tissues moist. Other chemicals that may be added to embalming solutions are pigments, which make the tissues look more natural, or chemicals that mask the odors of the preservative chemicals. **Formalin** and **phenol** are the most toxic and odorous preservative chemicals. Luckily, exposure to them in the anatomy laboratory is very low. It may smell as if the concentrations of these chemicals are high, as the odor is often misleading because these chemicals can be detected by odor in extremely small quantities.

**Table 1.2** Preservative Chemicals Encountered in the Human Anatomy Laboratory

Chemical	Description	Use	Hazard	Preventing Exposure	Disposal
<i>Ethanol</i>	Inhibits growth of bacteria and fungi.	Preservative	Flammable, so requires storage in a fire-safe cabinet. Generally safe in small quantities.	Gloves and eye protection. Rinse tissues immediately if exposed, particularly eyes. Seek medical attention if irritation persists.	Small amounts may be flushed down the sink along with plenty of water to dilute the solution.
<i>Formalin</i>	Fixes tissues by causing proteins to cross-link (solidify). Destroys autolytic enzymes, which initiate tissue decomposition. Inhibits growth of bacteria, yeast, and mold.	Preservative	Flammable, so requires storage in a fire-safe cabinet. Toxic at full strength. Penetrates skin. Corrosive. Burns skin. Damages lungs if inhaled. May be carcinogenic.	Gloves and eye protection. Rinse tissues immediately if exposed, particularly eyes. Seek medical attention if irritation persists.	Do not pour into sinks.
<i>Glycerine (glycerol)</i>	Helps control moisture balance in tissues. When used with formalin, it counteracts the dehydrating effects of formalin.	Humectant	Flammable, so requires storage in a fire-safe cabinet. Generally safe. Can pose a slipping hazard if spilled on the floor.	Gloves and eye protection. Rinse tissues immediately if exposed, particularly eyes. Seek medical attention if irritation persists.	Small amounts may be flushed down the sink along with plenty of water to dilute the solution.
<i>Phenol</i>	Assists formalin in fixing tissues through protein solidification. Inhibits growth of bacteria, yeast, and mold.	Preservative	Flammable, so requires storage in a fire-safe cabinet. Extremely toxic at full strength. Rapidly penetrates the skin. Corrosive. Burns skin. Damages lungs if inhaled. NOTE: when used as embalming preservative concentration (and thus toxicity) is extremely low.	Gloves and eye protection. Rinse tissues immediately if exposed. Use an eyewash station if solution gets in the eyes. Seek medical attention if irritation persists.	Do not pour into sinks.

Although the concentrations of formalin and phenol users are exposed to are very low, if these chemicals have been used to preserve specimens, protective clothing must be worn to prevent the chemicals from contacting the skin or eyes. Use gloves whenever handling specimens, and use protective eyewear whenever there is a risk of chemicals getting into the eyes. If skin is exposed, rinse it immediately. If eyes are exposed, use the eyewash station in the laboratory to rinse the eyes thoroughly. If skin or eyes continue to be irritated after rinsing, consult a medical doctor.

### Proper Disposal of Laboratory Waste

There are several types of waste that must be disposed of in the human anatomy laboratory. Much of this waste is “normal” waste, such as tissues, paper towels, rubber gloves, and the like. Such waste should be disposed of in the regular classroom garbage/waste container. However, at times the waste materials may potentially be classified as **hazardous waste**. Hazardous waste must be disposed of in a special container. The general rule for determining if something is potentially hazardous or not is this: if the possibility exists that someone may be injured in any way from handling this waste, it is hazardous. Follow this rule, and be sure to ask the instructor how to properly dispose of something any time there is a question as to whether it is hazardous or not. It is always better to err on the side of caution.

What is hazardous waste?

- Any sort of fresh tissue and/or blood is potentially hazardous
- Laboratory chemicals
- Broken glass, scalpel blades, or any other sharp item that may cut an individual who handles the waste

### Sharps Containers

**Sharps containers** (figure 1.2) are plastic containers (often red or orange) that are used to dispose of anything “sharp,” such as needles, scalpel blades, broken glass, pins, or anything else that has the potential to cut or puncture a person who handles it. Such items should NEVER go in the garbage, because they may injure anyone who handles the garbage thereafter. When in doubt, put it in the sharps container.

### Biohazard Bags

Special **biohazard bags** may be available in the laboratory. These are used for biological materials such as blood or other fresh animal



**Figure 1.2 Sharps Containers.** Samples of two different models of sharps containers. Such containers allow one to place sharp objects into the container, but they cannot be removed once placed inside. Note the biohazard warning symbol on the containers.

© Christine Eckel



**Figure 1.3 Biohazard Waste Symbol.**

tissue that requires special disposal. When it comes to human blood, an item containing a small amount of blood (such as a band-aid) can be disposed of in a normal wastebasket. However, a blood-soaked towel or other item must be disposed of in a biohazard bag. A biohazard bag is usually red or clear with the symbol shown in **figure 1.3** on it. When dealing with tissues that must be disposed of in a biohazard bag, the instructor will generally inform students of this. Again, when in doubt, always ask before disposing of something potentially hazardous. Important note: human cadaveric tissues do *not* go into biohazard bags. They must be kept with the cadaver. Any piece of human tissue removed from a cadaver must eventually be returned to the cadaver to be cremated with the entire body.

### Dissection Techniques

The word *dissect* literally means to cut something up. Most individuals have been led to think that the first thing a surgeon or anatomist does when planning to dissect is to pick up a scalpel and cut. However, skilled dissection does not always involve actually cutting tissues. In fact, the dissector’s best friend is a technique called “blunt dissection.” Blunt dissection specifically involves separation of tissues *without* using sharp instruments (hence the term *blunt*). When dissecting tissues, always try using blunt dissection before picking up sharp instruments such as scissors and scalpels. Sharp instruments are very handy—as they are good at cutting things. However, often students will end up cutting many things they do not wish to cut, purely by accident. Thus, being sparse and prudent in the use of sharp tools is one of the most important tips for performing a good dissection.

For this exercise, the demonstration of techniques will be shown using a fresh chicken purchased from a grocery store. However, the instructor may choose another specimen to practice on. For now, the goal is to separate the skin from the underlying tissues such as bones and muscle (the “meat”) of the specimen.

### Sharp Dissection Techniques

“**Sharp dissection**” techniques are the techniques most familiar to individuals. These techniques involve the use of sharp instruments such as scissors and scalpels. They are “cutting” techniques. They are advantageous in that they can be used to separate tough tissues from each other, or to remove pieces of tissue from a dissection specimen. The danger of using sharp dissection techniques is that novice and experienced dissectors alike will often end up cutting things they do not wish to cut, such as blood vessels and nerves. Therefore, sharp dissection techniques should be used with care.

**EXERCISE 1.2** Proper Disposal of Laboratory Waste

1. Circle the letter (a, b, or c) of the correct waste receptacle (shown in **figure 1.4**) for each item listed here.

1. broken scissors      a    b    c
2. cotton swab        a    b    c
3. dissecting pins     a    b    c
4. glass slide         a    b    c

5. paper towel        a    b    c
6. rubber glove       a    b    c
7. scalpel blades     a    b    c




**Figure 1.4** Common Laboratory Waste Receptacles. (a) Sharps container. (b) Waste basket. (c) Hazardous waste bag.

© Christine Eckel

**EXERCISE 1.3** Placing a Scalpel Blade on a Scalpel Blade Handle

**Scalpels** come in many forms. Some are of the disposable type, which typically means that the handle and blade come as one unit and the handle is made out of plastic (**figure 1.5**). Often the blades and handles are separate items. This allows replacement of the blade when it becomes dull from use. This exercise covers how to properly place a scalpel blade on a scalpel blade handle, and how to properly remove the blade once finished.

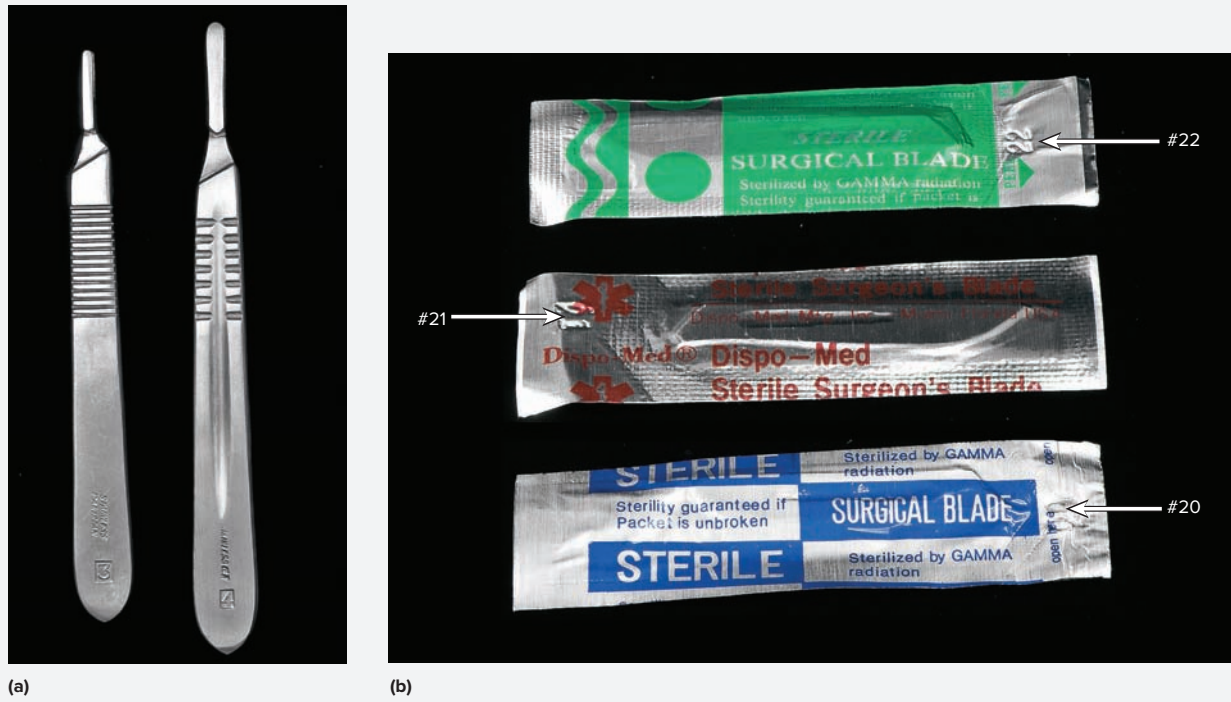1. Obtain a **scalpel blade** and **scalpel blade handle** from the instructor. Scalpel blades and handles come in various sizes, and it is important to match the size of the blade to the size of the blade handle. Observe the scalpel handle and look for a number stamped on it, which will be a 3 or a 4 (**figure 1.6a**). Next, observe the blade packet and note the number on it (**figure 1.6b**). A number 3 handle is used to fit number 10, 10A, 11, 12, 12D, and 15 blades. A number 4 handle is used to fit number 18, 20, 21, 22, 23, 24, 24D, or 25 blades. Larger handles and blades are generally used for making bigger, deeper cuts whereas the smaller handles and blades are generally used for finer dissection. A commonly used combination in anatomy laboratories is the number 4 handle matched with a number 22 blade.

2.  Once the scalpel handle and blade size are properly paired, carefully open the scalpel blade packet halfway (**figure 1.7a-1**). Note the bevel on the blade. This bevel matches the bevel on the blade handle, so that there is only one way to properly place the scalpel blade on the handle. The blade handle has a



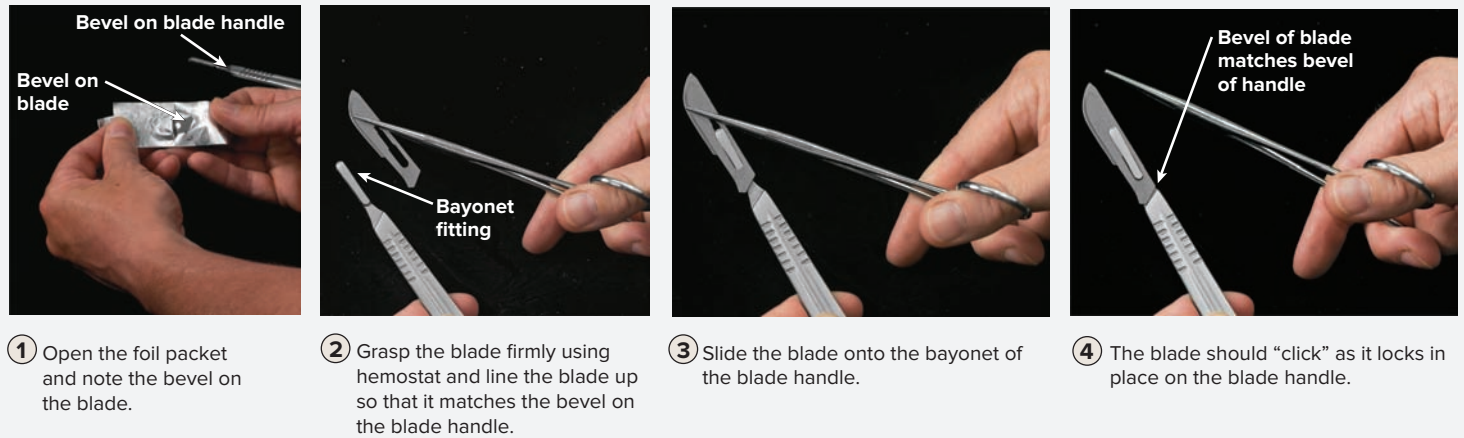
**Figure 1.5** Disposable Scalpel. The scalpel blade and scalpel blade handle are both disposable. The entire unit must be disposed of in a sharps container.

© Christine Eckel




**Figure 1.6 Scalpel Blade Handles and Blades.** (a) The number on the scalpel blade handle indicates what size blades will fit on the handle. (b) The number on the blade wrapper indicates the size of the blade. See text for how to fit proper blade size to blade handle.

© Christine Eckel



(a)



(b)

**Figure 1.7 Scalpel Blade Placement.** (a) Correct procedure. (b) Incorrect placement of a blade on a blade handle. Notice that the bevel on the blade does not match up with the bevel on the blade handle. If placed in this fashion, the blade will not be secure on the handle and may slip off the handle and injure someone.

© Christine Eckel

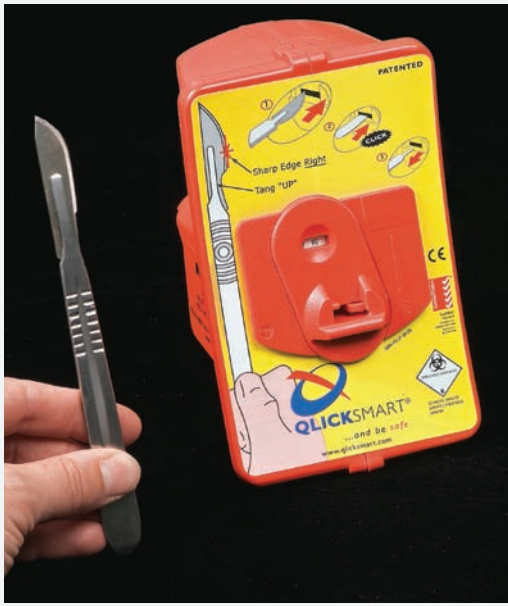bayonet fitting that is matched to the opening on the scalpel blade (figure 1.7a-2), which will lock the blade in place on the handle. The safest way to place the blade on the handle is to first grasp the end of the blade using **hemostats** (figure 1.7a-3; table 1.1). Then, while matching

the bevel on the blade to the bevel on the handle, slide the blade onto the handle until it clicks, indicating it is locked in place (figure 1.7a-4). If it does not go on easily, check to make sure that the blade has not been placed on the handle incorrectly, as in figure 1.7b. Now it is ready for use!

(continued on next page)



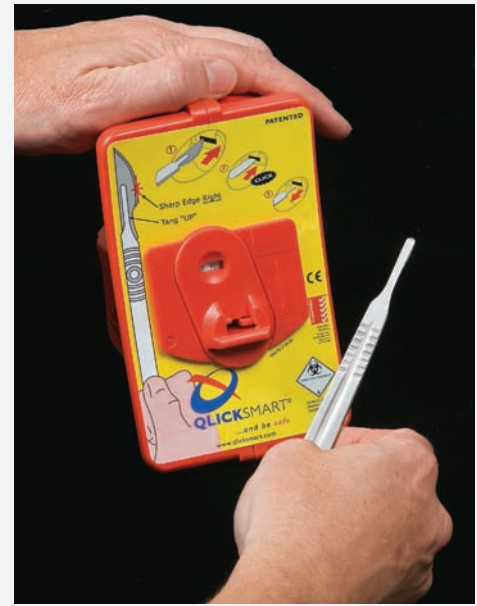(continued from previous page)



① Orient the blade and blade handle with sharp edge of the blade pointed to the right, as shown on the front of the device.



② Push the blade into the slot on the device until you hear and feel a distinct "click."



③ While holding the removal device firmly with your free hand, pull the blade handle out of the device.

**Figure 1.8** Removal of a Scalpel Blade from Handle Using All-in-One Blade Remover/Sharps Container.


© Christine Eckel

3. The safest way to remove a blade from a handle is to use a device that is both a **blade remover** and a sharps container all in one (an example is shown in **figure 1.8**).
4. If a blade remover is not available, obtain a pair of hemostats to remove the blade. Pointing the blade *away* from you (but not toward someone else), clamp the part of the blade nearest the handle with the

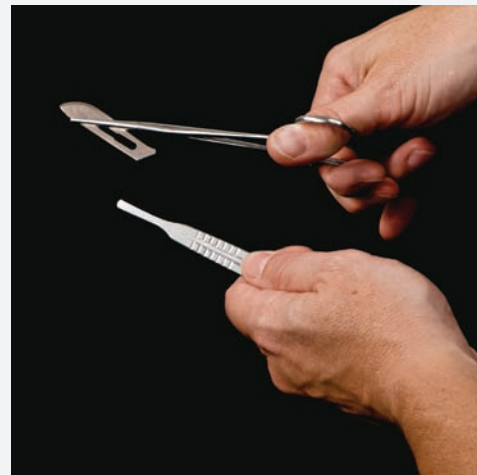
hemostats (**figure 1.9-1**). Grip the blade firmly with the hemostats, then slide the blade over the bayonet on the handle while keeping the tip of the blade pointing away from you until the blade comes off of the handle (**figure 1.9-2**). Keeping the blade clamped with the hemostats, transport the blade to a sharps container and dispose of it in the sharps container (**figure 1.9-3**).



① With the blade pointed away from you and the bayonet surface of the handle also directed away from you, grasp the base of the blade with hemostats and lock the hemostats firmly to the blade.



② Slide the blade off of the bayonet on the blade handle. Again, push it away from you (and away from others in your vicinity as well).



③ Once the blade has been removed from the handle, continue to grasp it firmly with the hemostats.

**Figure 1.9** Removal of a Scalpel Blade from Handle Using Hemostats.

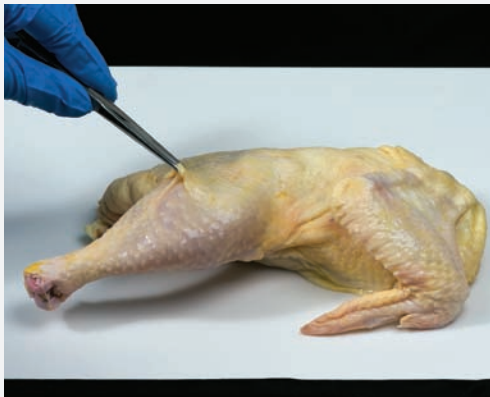© Christine Eckel

**EXERCISE 1.4** Dissecting with a Scalpel

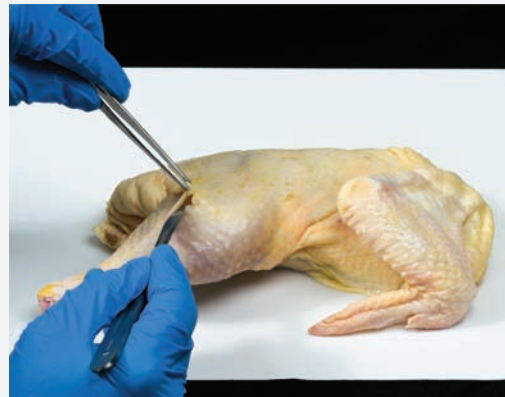1. Obtain a dissection specimen and place it on a dissecting tray.
2. Obtain a scalpel with a blade (see exercise 1.3) and some **tissue forceps** (table 1.1). If the tissue is difficult to grasp, use **hemostats** instead of forceps. Hemostats “lock” on to the tissue so the tissue is not dropped when the user’s grip on the handle is released.
3. Using the forceps or hemostats, pull the skin away from the muscle on the dissection specimen (**figure 1.10-1**). Carefully cut into the skin using the tip of the scalpel blade (**figure 1.10-2**). Note how easily a new blade cuts into the tissue. When cutting with a scalpel, take care not to cut too deep, or too aggressively, or underlying tissues will be damaged. Once a small slit has been created in the skin, observe the stringy tissue that lies between the

skin and the muscle. This tissue is a loose connective tissue called fascia (**figure 1.10-3**), which is discussed in detail in chapter 5. Because the goal is to separate the skin from the muscle, it is necessary to loosen the “grip” of the fascia that holds the skin and muscle together. One way to do this is to cut into the fascia using the scalpel.

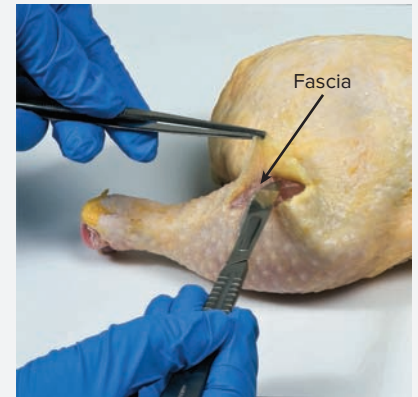4. Next, *without* holding the skin away from the muscle with forceps, cut into the skin using a considerable amount of pressure. Note how easy it is to cut through the skin directly into the muscle. This is not desirable. To avoid damaging the underlying tissues, push a blunt probe or scalpel handle (*without* blade attached!) into the space between the skin and muscle, thus protecting the underlying tissues. Then cut with the scalpel superficial to the probe (**figure 1.11**).



- ① Pull the skin away from the underlying tissues using tissue forceps.



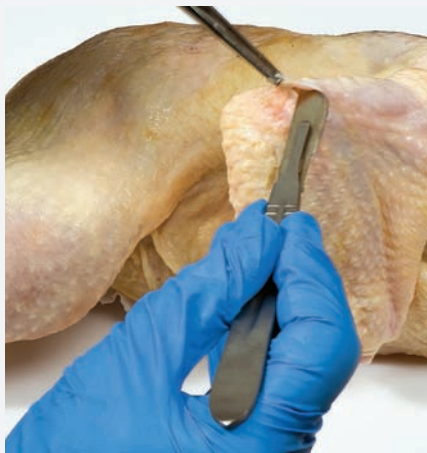- ② Begin cutting the skin with the scalpel, taking care not to cut delicate tissues deep to the skin.



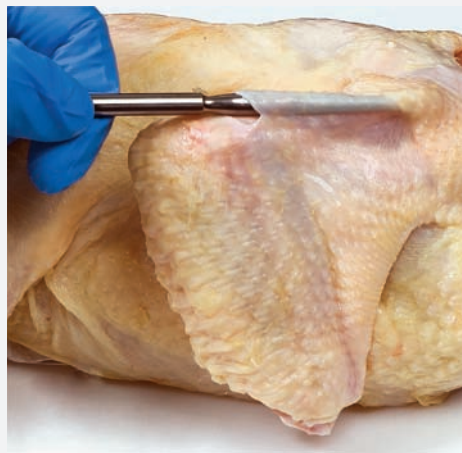
- ③ To assist with removal of the skin, use the scalpel to gently cut away the fascia that loosely holds the skin to the muscle. Maintain as much tension on the skin as possible and always keep the sharp end of the blade pointed toward the skin, not the underlying tissues.

**Figure 1.10** Dissecting with a Scalpel.

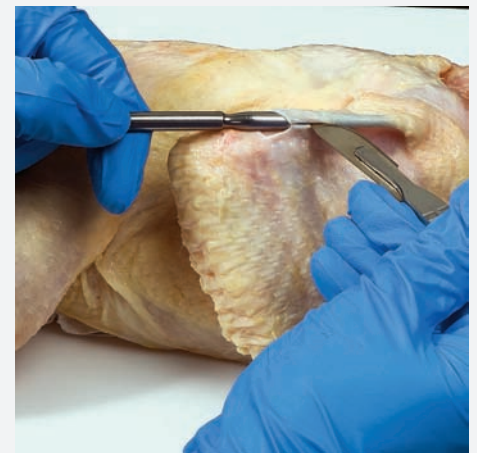© McGraw-Hill Education/Christine Eckel, photographer



- ① Pull the skin away from the underlying tissues using tissue forceps and cut a small slit in the skin with the scalpel, taking care not to cut delicate tissues deep to the skin.



- ② Push the probe under the skin along the line where the cut will be made.



- ③ Cut the skin superficial to the probe with the scalpel. Notice how the blunt probe limits the depth at which the scalpel can cut, thus protecting underlying tissues.

**Figure 1.11** Protecting Underlying Tissues with a Probe when Dissecting with a Scalpel.

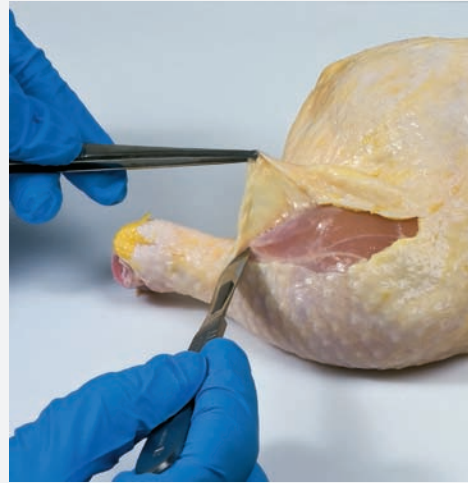© McGraw-Hill Education/Christine Eckel, photographer

(continued on next page)

(continued from previous page)

The probe limits the depth at which the scalpel blade can cut, thus protecting the underlying tissues.

- Once enough skin has been pulled back for it to be easily grasped with forceps or hemostats, put as much tension on the skin as possible, thus stretching out the fibers in the fascia (**figure 1.12**). Once the fascia is stretched, you can use the scalpel to cut the fascia and remove the skin from the specimen. When you cut with the scalpel, always point the sharp end of the blade toward the skin, not toward the underlying tissues, so as to protect those underlying tissues.
- Practice using the forceps, hemostats, blunt probe, and scalpel to remove the skin from part of the specimen. Note areas where this is more difficult than others. As you are practicing, consider carefully whether or not the scalpel is the best instrument for the job, or if using it is causing damage to tissues.

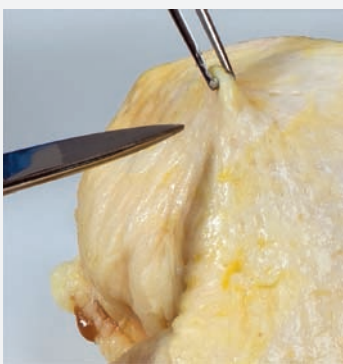


**Figure 1.12 Removing the Rest of the Skin with the Scalpel.** Use the forceps to pull the skin away from the underlying tissues. Keep as much tension as possible on the fascia. Cut the fascia with the scalpel, always keeping the sharp part of the scalpel blade directed toward the skin. This way, if the blade slips accidentally, it will cut the skin, not the underlying tissues.

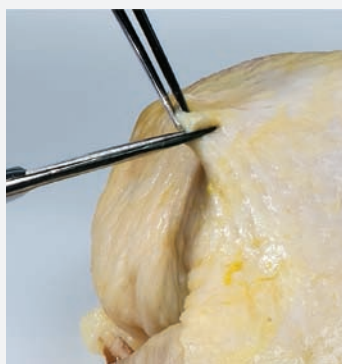
© McGraw-Hill Education/Christine Eckel, photographer

### EXERCISE 1.5 Dissecting with Scissors

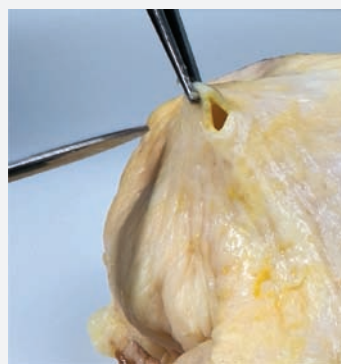
- Using the same dissection specimen as in exercise 1.4, practice using scissors to cut tissues.
- Obtain a pair of **pointed scissors** and **forceps** (table 1.1). Using the forceps, grasp part of the skin covering part of the specimen that has not already been dissected (**figure 1.13-1**). Pull the skin away from the muscle. Next, cut a slit into the skin large enough for the fascia beneath it to become visible (figure 1.13-2, 3). Continue to lengthen the cut until it is about 2 inches long (figure 1.13-4).
- Open scissors technique:** There are many tissues within the fascia that may need to be preserved, such as nerves and blood vessels. When using “sharp dissection” techniques, these structures may accidentally get cut. For this reason, the “blunt dissection” technique is preferred, to preserve important structures. One blunt dissection technique is called an “open scissors” technique, so named because the dissecting action of the scissors is performed by starting with the scissors closed and then actively opening them. This is exactly the opposite of how most scissors are used.



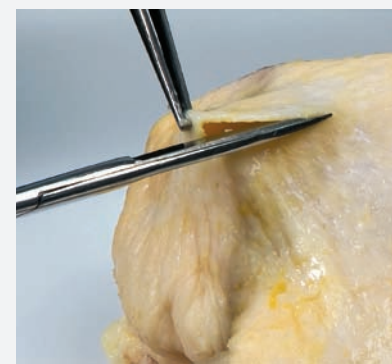
① Use tissue forceps to pull the skin away from underlying tissues.



② Make a small cut in the skin with the scissors.



③ A small hole has now been created in the skin. Insert the tip of the scissors into this hole and begin cutting directionally along the skin.

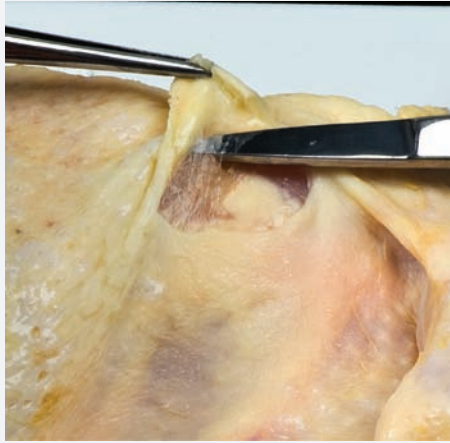


④ Continue the cut along the skin. Use the tissue forceps to pull the skin away from underlying tissues before making each cut to avoid damaging underlying structures.

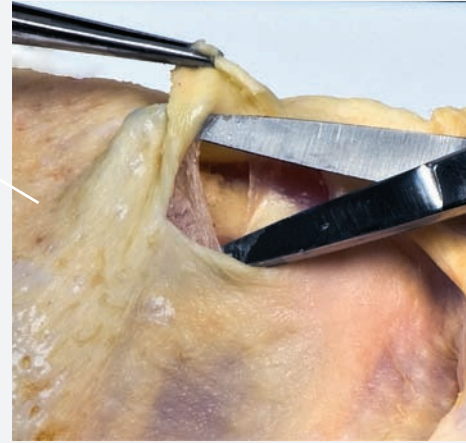
**Figure 1.13 Dissecting with Scissors.**

© McGraw-Hill Education/Christine Eckel, photographer

4. With the scissors closed, push the tip of the scissors into the space between the skin and the muscle so that it pierces the fascia (**figure 1.14-1**). Once the tip of the scissors is within the fascia, open the scissors (figure 1.14-2). Notice how this action causes the fibers within the fascia to separate from each other and loosens the hold between the skin and the fascia. When using the open scissors technique, keep the scissors open within the specimen. Remove the scissors completely prior to closing the scissors to prevent causing damage to surrounding tissues and structures while the scissors are still in the fascia.
5. Continue to loosen the fascia using the open scissors technique. While doing this, observe small structures such as blood vessels and nerves running in the space between the skin and the underlying tissues. Notice how the fibers in the fascia easily separate from each other without damaging the vessels and nerves when using the open scissors technique. At times, the hold of the fascia is too tight, and “open scissors” technique will no longer work effectively. At those times, switch to “normal” scissors technique to cut away the tough tissue.
6. Practice using both open and normal scissors techniques to continue to remove skin from underlying tissues.



- ① Make a small cut in the skin. Using forceps, pull the skin away from the underlying fascia. Push the tip of the *closed* scissors into the fascia that lies deep to the skin.



- ② Open the scissors, thus separating the fibers of the fascia and loosening the skin from the underlying tissues.

**Figure 1.14** Open Scissors Technique.

© McGraw-Hill Education/Christine Eckel, photographer

## Blunt Dissection Techniques

As we began to see in exercise 1.3, there are times when sharp dissection technique is undesirable, because tissues might be damaged if we use

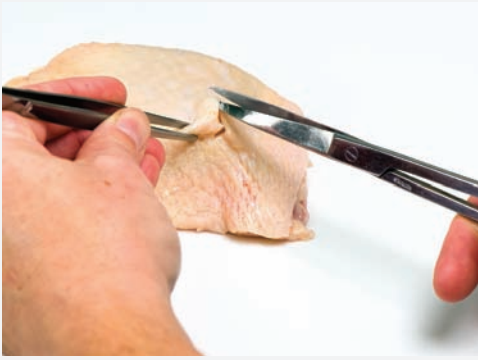sharp instruments. At these times it is best to switch to blunt dissection techniques. Blunt dissection is designed to separate tissues without damaging delicate structures.

### EXERCISE 1.6 Blunt Dissection Techniques

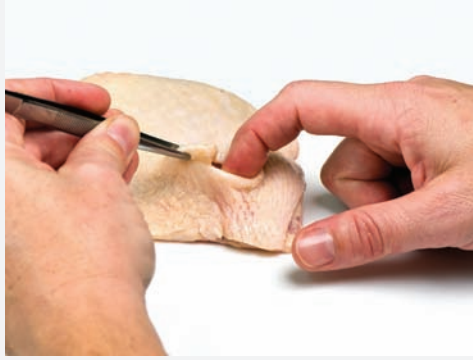1. Practice using blunt dissection techniques using the same dissection specimen as in exercises 1.4 and 1.5.
2. Obtain a pair of **pointed scissors** and **forceps** (table 1.1). Using the forceps, grasp part of the skin of the specimen not previously dissected and pull it away from the muscle. Next, make a small cut into the skin until the fascia beneath it is visible (**figure 1.15**). This is the “sharp dissection” technique previously described.
3. When attempting to preserve structures such as nerves and blood vessels, “sharp dissection” techniques may damage these structures. For this reason, use “blunt dissection” techniques whenever possible to prevent damage to important structures. “Open scissors,” described in exercise 1.4, is one blunt dissection technique. Use the open scissors technique to loosen the hold between the skin and the fascia on the specimen.
4. Once the space between the skin and muscle is large enough for a finger to be pushed in, set the scissors down. Proceed to separate the skin from the muscle using only your fingers (figure 1.15-2). Because sharp instruments are not used to perform this, it is also referred to as a “blunt dissection” technique.

(continued on next page)

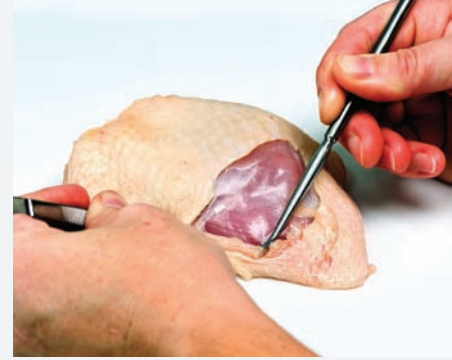(continued from previous page)



① Using tissue forceps and scissors, pull the skin away from the underlying tissues and make a cut in the skin. Use open scissors technique to loosen the fascia and to create a space where a blunt probe or your fingers may be pushed in.



② Using your fingers, pull the skin away from the underlying tissues. When necessary, use a sharp instrument to cut any fascia that is very tough and won't separate using blunt techniques.



③ A blunt probe can be moved around under the skin to gently separate the connective tissue without damaging underlying structures.



**Figure 1.15 Blunt Dissection.** Blunt dissection techniques involve separating tissues with fingers or blunt instruments such as a probe. When handling fresh tissue such as this chicken thigh, either use gloves or make sure to wash your hands thoroughly when the dissection is complete.

© Christine Eckel

5. Obtain a blunt probe (table 1.1). A blunt probe can be used in place of fingers to separate structures when fingers are too large (figure 1.15-3). Because the probe does not cut the tissue, this is also a “blunt dissection” technique.
6. Other items that can be used for blunt dissection are scalpel blade handles (*without* the blades on them!), or the rounded

ends of forceps. Practice using these tools to separate skin from muscle in different regions of the dissection specimen. The general rule of thumb is to start with sharp dissection techniques to cut slits in the skin, but then transition to blunt dissection techniques whenever possible to prevent accidental damage to underlying tissues.

### WHAT DO YOU THINK?

- ① One of the dissection instruments that may be used is a hemostat. The word “hemostat” comes from the Greek words *haemo-*, which means “blood,” and *-statos*, which means “stationary.” Given the name of the tool, and considering its function in dissection, what do you think these tools were originally designed for?


The **1** corresponds to the Learning Objective listed in the chapter opener outline.

## Do You Know the Basics?

### Exercise 1.1: Identification of Common Dissection Instruments

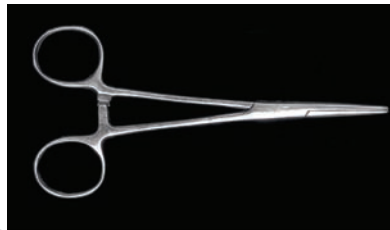
1. An instrument that resembles tweezers and is used to grasp objects is a \_\_\_\_\_. (Circle one.) **1**
  - a. blunt probe
  - b. forceps
  - c. hemostat
  - d. scalpel
  - e. scissors
2. Write the name of each dissection instrument in the space provided. **1**

a. \_\_\_\_\_



© Christine Eckel

b. \_\_\_\_\_



© Christine Eckel

c. \_\_\_\_\_



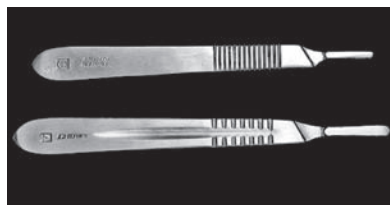© Christine Eckel

d. \_\_\_\_\_



© Christine Eckel

e. \_\_\_\_\_



© Christine Eckel

**Exercise 1.2: Proper Disposal of Laboratory Waste**

3. Which of the following items are described in the laboratory manual as “hazardous waste”? (Check all that apply.) **2**
- a. broken glass
  - b. cotton swab
  - c. fresh tissue
  - d. laboratory chemicals
  - e. paper towels
4. Which of the following is the correct waste receptacle for scalpel blades? (Circle one.) **2**
- a. hazardous waste bag
  - b. sharps container
  - c. wastebasket
5. Which of the following statement(s) is/are **true** of formalin and phenol? (Check all that apply.) **2**
- a. Formalin and phenol are potentially hazardous chemicals.
  - b. It is not necessary to wear gloves and eye protection when working with formalin and phenol.
  - c. Seek medical attention if irritation persists following exposure to formalin and phenol.
  - d. Skin and eyes should be rinsed immediately if exposed to formalin and phenol.

**Exercise 1.3: Placing a Scalpel Blade on a Scalpel Blade Handle**

6. Describe the proper technique for placing a scalpel blade on a scalpel blade handle. **3**

---

---

---

7. Describe the proper technique for removing a scalpel blade from a scalpel blade handle. **4**

---

---

---

**Exercise 1.4: Dissecting with a Scalpel**

8. List an example of an instance in which a scalpel is the preferred tool for dissection. **5**

---

9. Describe a technique used to prevent damage to underlying tissues when dissecting with a scalpel. **6**

---

---

**Exercise 1.5: Dissecting with Scissors**

10. List an example of an instance in which scissors are the preferred tool for dissection. **7**

---

---

11. When dissecting with scissors, what is an appropriate dissection tool for holding the tissue that is to be cut with the scissors (two answers possible here)? **7**

---

---

12. Describe the “open scissors” dissecting technique. 9

---

---

### Exercise 1.6: Blunt Dissection Techniques

13. Define blunt dissection. 9

---

---

14. List two dissection tools commonly used for blunt dissection: 10

- a) \_\_\_\_\_  
b) \_\_\_\_\_

15. Explain the importance of using blunt dissection techniques whenever possible. 11

---

---

### Can You Apply What You’ve Learned?

16. After dissecting a fresh cow bone as part of the day’s laboratory activities, what is the most appropriate way to dispose of this waste?

---

---

### Can You Synthesize What You’ve Learned?

17. A classmate is wearing open-toed shoes during a human cadaver dissection or demonstration. The student accidentally spills some unknown fluid from “inside” the human cadaver directly onto his skin. Discuss possible harmful chemicals that could be in the unknown fluid. What are the recommended steps the student should take to address the chemical exposure?

---

---

---

---

18. During a dissection of a chicken wing, the dissector encounters an area where the skin is held very tightly to the underlying tissues. Not wanting to damage the underlying tissues, what are some tools that can be used to remove the skin in this area? For each tool, describe how the tool is used to prevent damage to underlying tissues.

---

---

---

---



*This page intentionally left blank*

# Orientation to the Human Body

# 2

## INTRODUCTION

The human body is both beautiful and complex. A course in human anatomy allows one to develop a deeper understanding of, and appreciation for, that beauty and complexity. To be successful in this venture requires a lot of hard work. Success is achieved by putting in the time and by being persistent. The huge time commitment required for success means that most students find themselves putting in much more time to study human anatomy than they do studying for similar courses; even though the credit hours for the courses are the same.

To put things in perspective, consider this: a beginning student in human anatomy is typically asked to learn more new words in a one-semester anatomy class than a beginning student learns in the first semester of a foreign language class. In fact, it is a new language. This *language of anatomy* has its origins principally in Latin and Greek. To successfully learn this language it is important to establish a firm understanding of the meanings of common word origins. Lists of common word origins are located in the “Word Origin” columns of the tables, and within the context of exercises in this manual. A good study method is to look up the origins of all words that are new or unfamiliar. This will require a small amount of work for each new word encountered, but over time it will lead to the development of an impressive vocabulary of anatomical/medical terms. In addition, developing a

## OUTLINE AND LEARNING OBJECTIVES

### Gross Anatomy 22

#### Anatomic Terminology and the Anatomic Position 22

#### Anatomic Planes and Sections 22

##### EXERCISE 2.1: ANATOMIC PLANES AND SECTIONS 23

- 1 Demonstrate the anatomic position
- 2 Use correct anatomic terminology to define planes of the body
- 3 Identify the plane of section of four different views of the brain

#### Directional Terms 25

##### EXERCISE 2.2: USING DIRECTIONAL TERMS 25

- 4 Use directional terms to describe locations on the surface of the body

#### Regional Terms 26

##### EXERCISE 2.3: USING REGIONAL TERMS 26

- 5 Use regional terms to describe parts of the human body

#### Body Cavities and Membranes 27

##### EXERCISE 2.4: BODY CAVITIES 27

- 6 List the major organs located within each of the major body cavities

#### Abdominopelvic Regions and Quadrants 28

##### EXERCISE 2.5: LOCATING MAJOR BODY ORGANS USING ABDOMINOPELVIC REGION AND QUADRANT TERMINOLOGY 28

- 7 Describe the abdominopelvic regions and quadrants
- 8 Describe the locations of the major abdominopelvic organs using abdominopelvic region and quadrant terminology



rich knowledge base of this vocabulary early will make interpretation of new words encountered at a later date much easier.

Practice this by analyzing the origin of the word *anatomy*. The word *anatomy* can be broken down into two parts, *ana-* and *-tomé*. The word part *ana-* means “apart.” The word part *-tomé* means “to cut.” Thus, the word **anatomy** literally means “to cut apart.” Although undergraduate students might not be literally cutting up human bodies as medical students do and as early anatomists did, students will at the very least be *conceptually* “cutting up” the body to understand its component parts.

The laboratory exercises in this chapter reinforce the use of anatomically correct directional, regional, and sectional terms to describe the

body and its parts. Exercises within this chapter include identification of body organs on a human torso model. If the course utilizes human cadavers, these organs may also be identified on the cadaveric specimen. Additional exercises within this chapter are designed to familiarize students with the organ systems of the body and to allow students to practice using anatomic terminology to describe locations of the organs that compose these organ systems.

#### List of Reference Tables

Table 2.1	Anatomic Planes	p. 22
Table 2.2	Directional Terms	p. 25

These Pre-laboratory Worksheet questions may be assigned by instructors through their **connect** course.

1. Describe the anatomic position in your own words.

\_\_\_\_\_

\_\_\_\_\_

\_\_\_\_\_

2. A plane that separates the body into superior and inferior portions is a sagittal plane. \_\_\_\_\_ (True/False)

3. A plane that separates the body into right and left portions is a coronal plane. \_\_\_\_\_ (True/False)

4. A plane that separates the body into anterior and posterior portions is a frontal plane. \_\_\_\_\_ (True/False)

5. Match the definition listed in column A with the appropriate directional term listed in column B.

**Column A**

- \_\_\_\_ 1. closer to the attachment point of a limb to the trunk
- \_\_\_\_ 2. in front of; toward the front surface
- \_\_\_\_ 3. away from the midline of the body
- \_\_\_\_ 4. in back of; toward the back surface
- \_\_\_\_ 5. toward the midline of the body
- \_\_\_\_ 6. farther from the attachment point of a limb to the trunk

**Column B**

- a. anterior (ventral)
- b. distal
- c. lateral
- d. medial
- e. posterior (dorsal)
- f. proximal

6. Match the regional name listed in column A with the description listed in column B.

**Column A**

- \_\_\_\_ 1. brachial
- \_\_\_\_ 2. cephalic
- \_\_\_\_ 3. cervical
- \_\_\_\_ 4. femoral
- \_\_\_\_ 5. lumbar

**Column B**

- a. arm
- b. head
- c. lower back; loin
- d. neck
- e. thigh

7. The body cavity that encases the brain is the \_\_\_\_\_ (cranial cavity/vertebral canal) cavity, and the body cavity that encases the spinal cord is the \_\_\_\_\_ (cranial cavity/vertebral canal). These two cavities combined make up the \_\_\_\_\_ (posterior aspect/ventral cavity).

8. The body cavity that surrounds the heart is the \_\_\_\_\_ (pericardial/pleural) cavity.

9. The body cavity that contains most of the digestive, reproductive, and urinary system organs is the \_\_\_\_\_ (abdominal/abdominopelvic) cavity.

10. The abdominopelvic cavity can be divided into a total of \_\_\_\_\_ (four/nine) quadrants or \_\_\_\_\_ (four/nine) regions.

11. The central point of reference for dividing the abdominopelvic cavity into quadrants or regions is the umbilicus. \_\_\_\_\_ (True/False)

12. The urinary bladder is found within the umbilical region. \_\_\_\_\_ (True/False)

13. Identify which of the following are abdominopelvic regions. (Check all that apply.)

- \_\_\_\_ a. epigastric
- \_\_\_\_ b. hypergastric
- \_\_\_\_ c. left cervical
- \_\_\_\_ d. right hypochondriac
- \_\_\_\_ e. umbilical

## Gross Anatomy

### Anatomic Terminology and the Anatomic Position

When describing parts of the human body, it is important to use common terminology to relate to such parts because the human body can be placed in numerous positions. Each position has the potential to change the definition of terms. In the fields of anatomy and medicine all such terms refer to the body when it is in the **anatomic position**. The anatomic position (**figure 2.1a**) is the position of the body when one is standing up with the feet parallel and flat to the floor, and the upper limbs are at the sides of the body with the palms of the hands facing forward (anterior). In this position, no two bones of the body cross each other. The anatomic position is similar to the natural position of an individual when standing up, except for the position of the wrist and hand. Because the position of the wrist and hand is somewhat unusual in the anatomic position, always be extra careful when using directional terms that relate to the upper limbs.

### Anatomic Planes and Sections

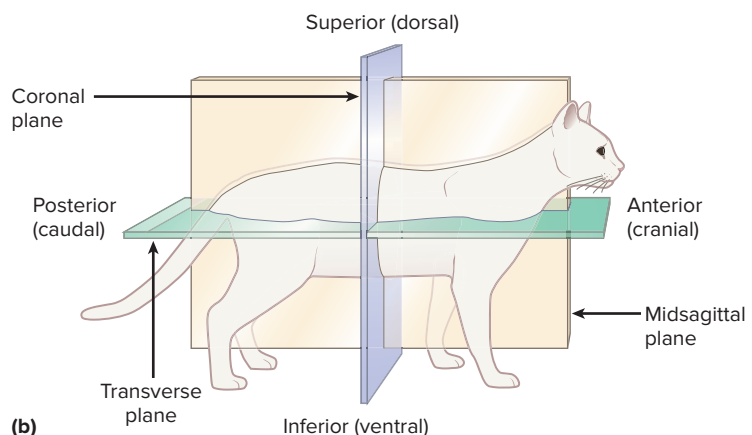
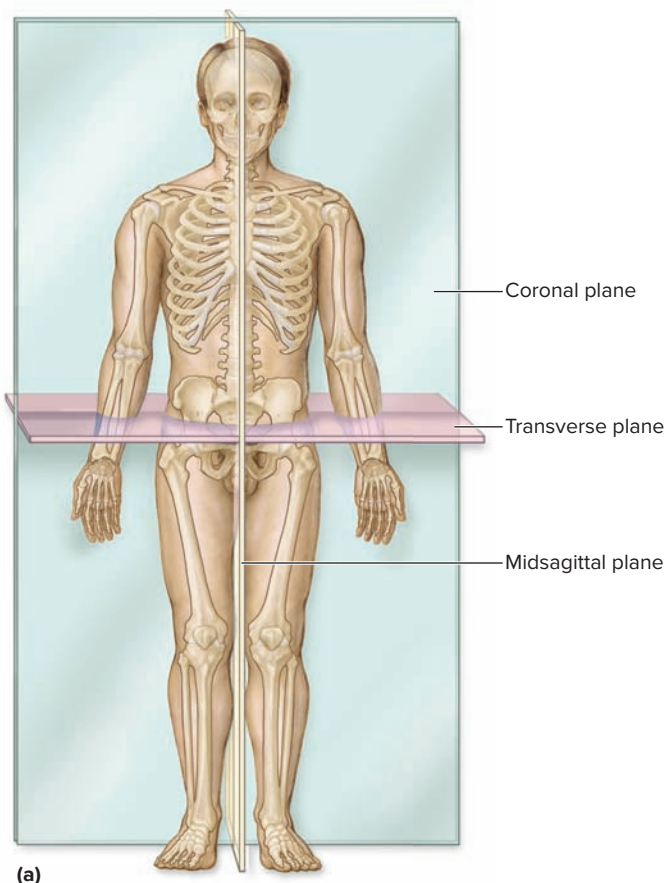
The study of anatomy that involves viewing sections (or slices) of an organ or the body is called **sectional anatomy**. An understanding of sectional anatomy is increasingly important in clinical settings, where medical imaging techniques such as CT (computed tomography) and MRI (magnetic resonance imaging) scans are used extensively. The ability to analyze such scans requires special skill that is developed over time. In

a one-semester human anatomy course, it is most important to focus on understanding the terms related to the three major planes that divide the body into sections: the coronal plane, the transverse plane, and the sagittal plane (**table 2.1** and **figure 2.1a,b**). Exercise 2.1 is an introduction to using sectional terms.

#### Learning Strategy

A **plane** (*planus*, flat) is an imaginary two-dimensional flat surface. One way of visualizing a plane is to imagine a transparency film passing through the body; a **section** (*sectio*, a cutting) is a slice made along one of these two-dimensional planes.

Body Plane	Description	Etymology
Coronal (frontal)	Separates anterior portions from posterior portions.	<i>corona</i> , resembling a crown
Midsagittal (median)	Separates right and left portions equally; runs down the midline of the body.	<i>mid-</i> , middle + <i>sagitta</i> , shaped like an arrow
Oblique	Runs at an angle to any of the three main planes of the body (coronal, transverse, or sagittal).	<i>obliquus</i> , slanted
Sagittal (parasagittal)	Separates right portions from left portions.	<i>sagitta</i> , shaped like an arrow
Transverse (horizontal)	Separates superior portions from inferior portions.	<i>trans</i> , across + <i>versus</i> , to turn



**Figure 2.1 Anatomic Position and Body Planes.** (a) In the human anatomic position, no two bones are crossed. (b) Although anatomic planes in four-legged animals such as the cat are essentially the same as in humans, directional terms are slightly different due to the upright posture in humans as compared to four-legged animals.

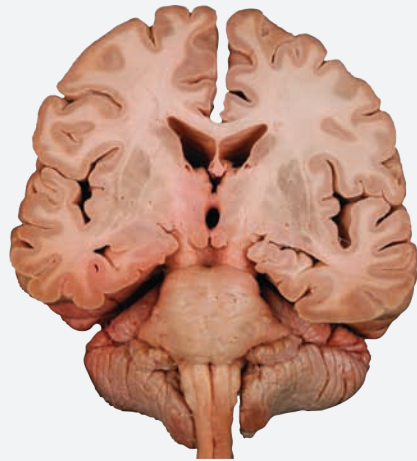**EXERCISE 2.1** Anatomic Planes and Sections

**EXERCISE 2.1A: Human Brain Sections**

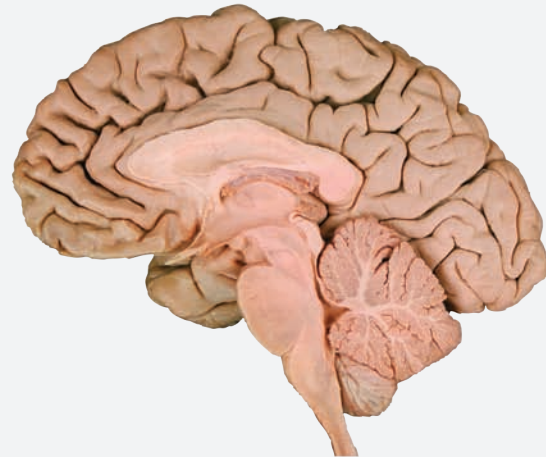1. **Figure 2.2** shows photographs of a brain that has been sectioned along different planes. Determine which plane the brain was sectioned along for each photo, then enter the information in the appropriate spaces in figure 2.2. Answer choices are provided in the figure legend, and each answer may only be used once. Refer to the chapter

on the brain in the main textbook for assistance in getting oriented.

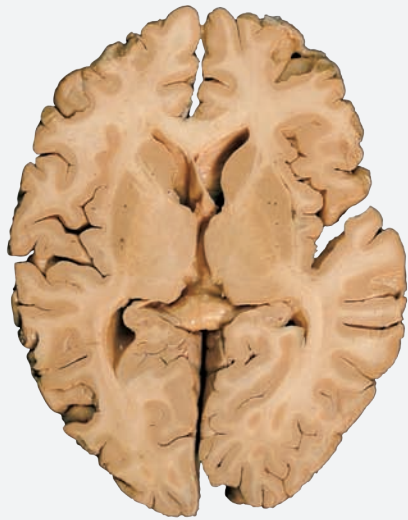2. *Optional Activity:* **AP|R**—**1. Body Orientation**—Review all dissections in this module to become familiar with general anatomic terminology.



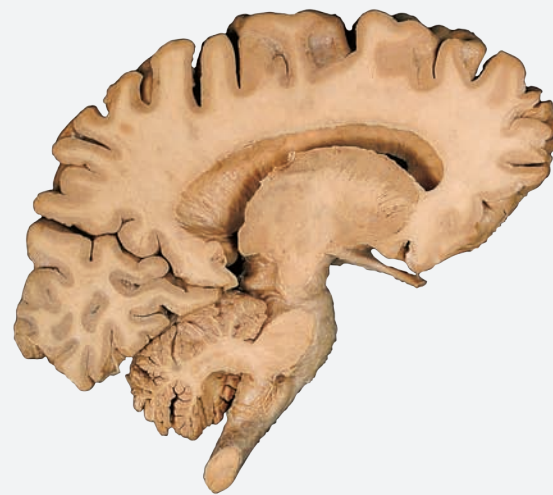1 \_\_\_\_\_  
Anterior view



2 \_\_\_\_\_  
Medial view



3 \_\_\_\_\_  
Superior view



4 \_\_\_\_\_  
Medial view

**Figure 2.2** Sections Through a Human Brain. Use the terms listed to fill in the appropriate anatomical plane in which each of the brain photos has been sectioned.

- coronal                       midsagittal                       sagittal                       transverse

(continued from previous page)

**EXERCISE 2.1B Sectioning a Specimen**

**Obtain the Following:**

- dissecting tray
- knife and/or scalpel
- specimen (e.g., sheep brain, sheep heart, sheep kidney)

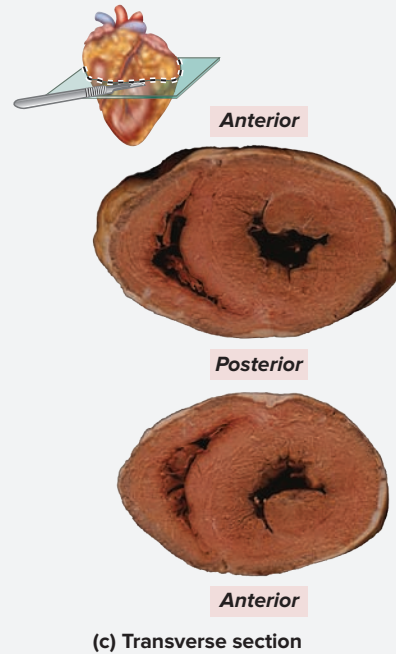
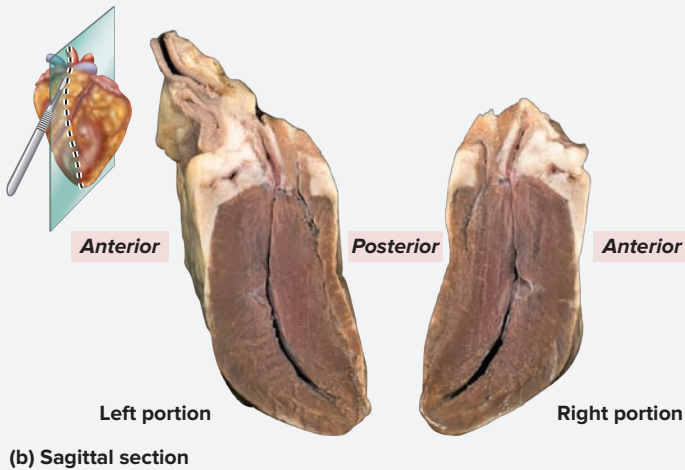
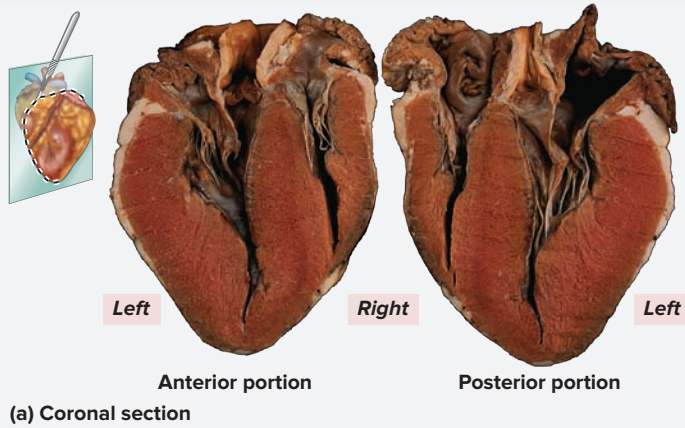
1. **Figure 2.3** demonstrates a sheep heart that has been sectioned along coronal, sagittal, and transverse planes. Using figure 2.3 as a guide, slice the specimen along the following planes:



- coronal     sagittal     transverse

2. Sketch the appearance of each of the resulting portions of the specimen in the spaces provided.

Coronal section	Sagittal section	Transverse section



**Figure 2.3** Sections Through a Sheep Heart. This figure demonstrates a sheep heart that has been sectioned along (a) coronal, (b) sagittal, and (c) transverse planes.

## Directional Terms

Everyday terms like “front” and “back,” and “on top of” or “on the bottom of” are often used to give directions. While this is perfectly appropriate in everyday language, it can create a great deal of confusion when referring to directions in the human body. For instance, when saying “on top of,” it is critical to know to what part of the body “on top of” refers. Different people might use the term in different ways or in reference to different structures. Furthermore, others may be thinking “on top of” relative to different body positions. This becomes problematic in a medical setting because it leads to confusion, which has the potential to create severe consequences for a patient. Thus, an agreed-upon set of directional terms is used in anatomy and medicine to be as specific as possible when describing directions. This also ensures that everyone is speaking the same language. **Table 2.2** lists these directional terms and gives definitions of each of them. Exercise 2.2 involves practicing the use of these directional terms.

Directional Term	Definition
Anterior (ventral)	Toward the front of the body (the belly side)
Posterior (dorsal)	Toward the back of the body (the back side)
Superior	Above; closer to the head
Inferior	Below; closer to the feet
Cranial (cephalic)	At the head end of the body
Caudal	At the tail end of the body
Medial	Toward the midline of the body
Lateral	Away from the midline of the body
Superficial	Toward the surface of the body; on the outside
Deep	Beneath the surface of the body; on the inside
Proximal	Near; closer to the attachment point of a limb to the trunk
Distal	Far; farther from the attachment point of a limb to the trunk

### EXERCISE 2.2 Using Directional Terms

**Figure 2.4** shows a posterior view of a human. Three locations marked on the body are denoted with the numbers 1–3. Describe the locations of markings 1–3 in spaces provided. Use correct anatomic terminology and be as specific as possible. When finished, compare answers with those of other students in the class to see how similar the answers are. Note that there is more than one correct answer for each of these.

**Location 1**

---



---

**Location 2**

---



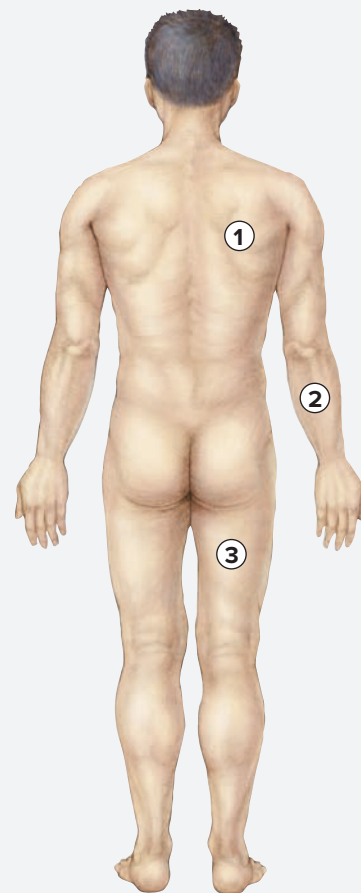
---

**Location 3**

---



---



**Figure 2.4** Posterior View of an Individual with Three Reference Locations (1–3) Marked. Number the terms listed to match the numbered reference locations in the figure.

- antebrachial       femoral       thoracic



## Regional Terms

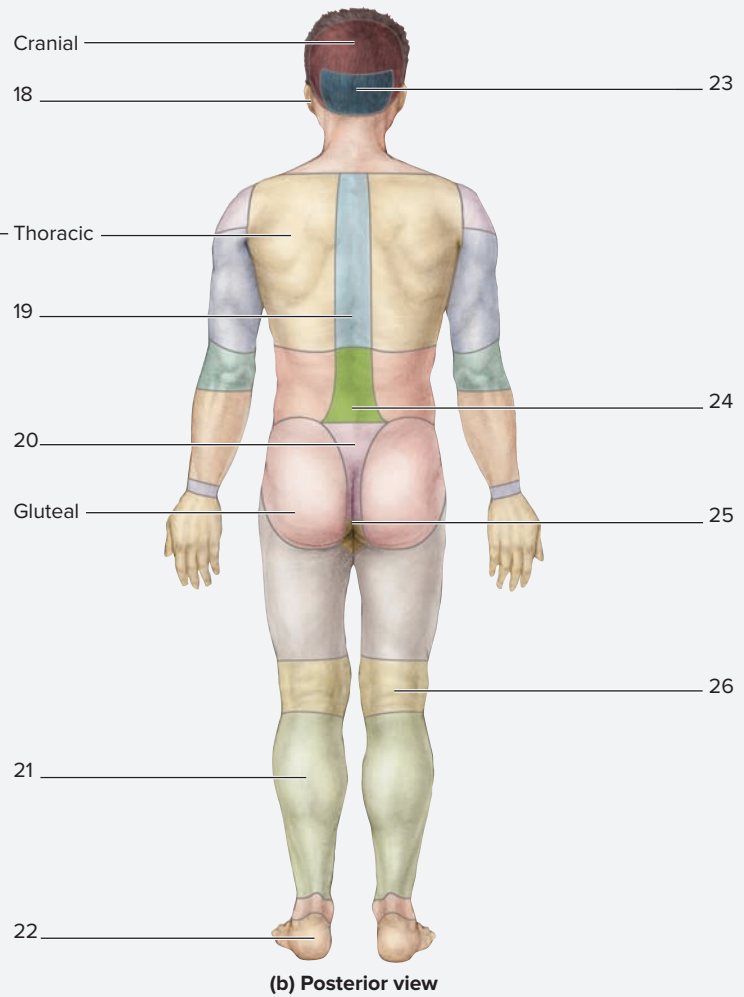
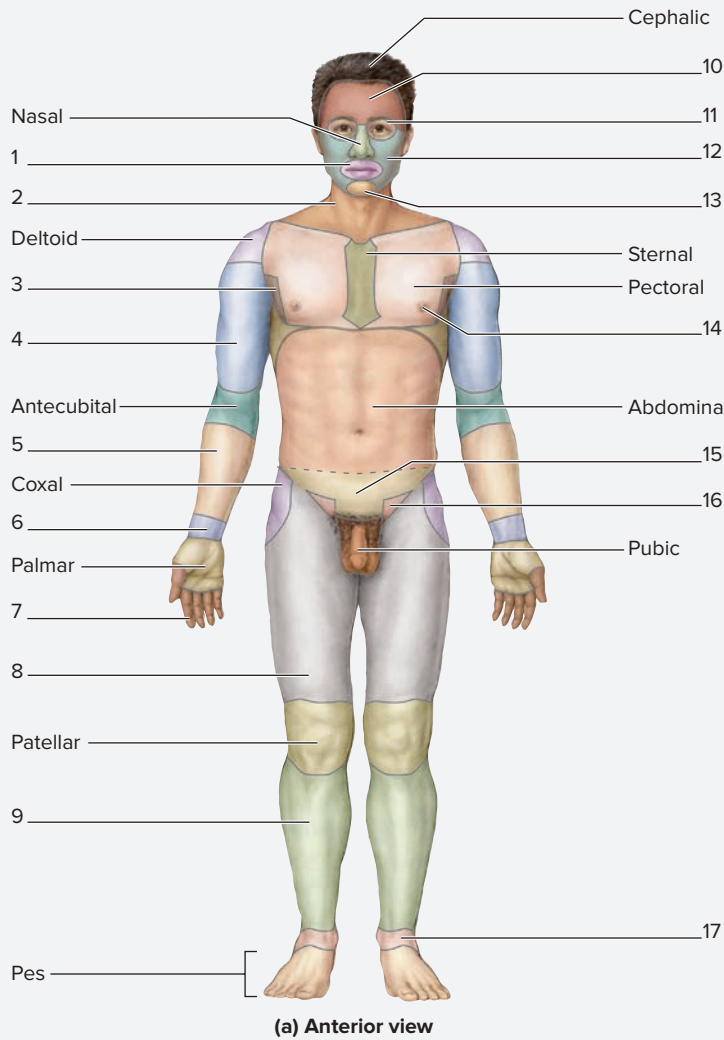
Just as with directional terms, there are common, everyday terms used to describe regions of the body, such as *arm* or *back*. The anatomic terms used to describe these regions of the body are basically synonyms for

the terms that most closely resemble their Latin or Greek derivatives. The section of the main textbook that covers regional terms defines anatomically correct regional terms alongside the terms commonly used to describe the regions using everyday language (i.e., “lay” terminology). Use the main textbook as a reference when completing exercise 2.3.

### EXERCISE 2.3 Using Regional Terms

1. Identify the body regions listed in **figure 2.5** on your own body.

2. Label figure 2.5 with the appropriate regional terms. Use the main textbook as a guide.



**Figure 2.5 Regional Terms.** Use the terms listed to fill in the numbered labels in the figure.

- |                                       |                                   |                                    |                                    |
|---------------------------------------|-----------------------------------|------------------------------------|------------------------------------|
| <input type="checkbox"/> antebrachial | <input type="checkbox"/> cervical | <input type="checkbox"/> mammary   | <input type="checkbox"/> popliteal |
| <input type="checkbox"/> auricular    | <input type="checkbox"/> crural   | <input type="checkbox"/> mental    | <input type="checkbox"/> sacral    |
| <input type="checkbox"/> axillary     | <input type="checkbox"/> digital  | <input type="checkbox"/> occipital | <input type="checkbox"/> sural     |
| <input type="checkbox"/> brachial     | <input type="checkbox"/> femoral  | <input type="checkbox"/> oral      | <input type="checkbox"/> tarsal    |
| <input type="checkbox"/> buccal       | <input type="checkbox"/> frontal  | <input type="checkbox"/> orbital   | <input type="checkbox"/> vertebral |
| <input type="checkbox"/> calcaneal    | <input type="checkbox"/> inguinal | <input type="checkbox"/> pelvic    |                                    |
| <input type="checkbox"/> carpal       | <input type="checkbox"/> lumbar   | <input type="checkbox"/> perineal  |                                    |

## Body Cavities and Membranes

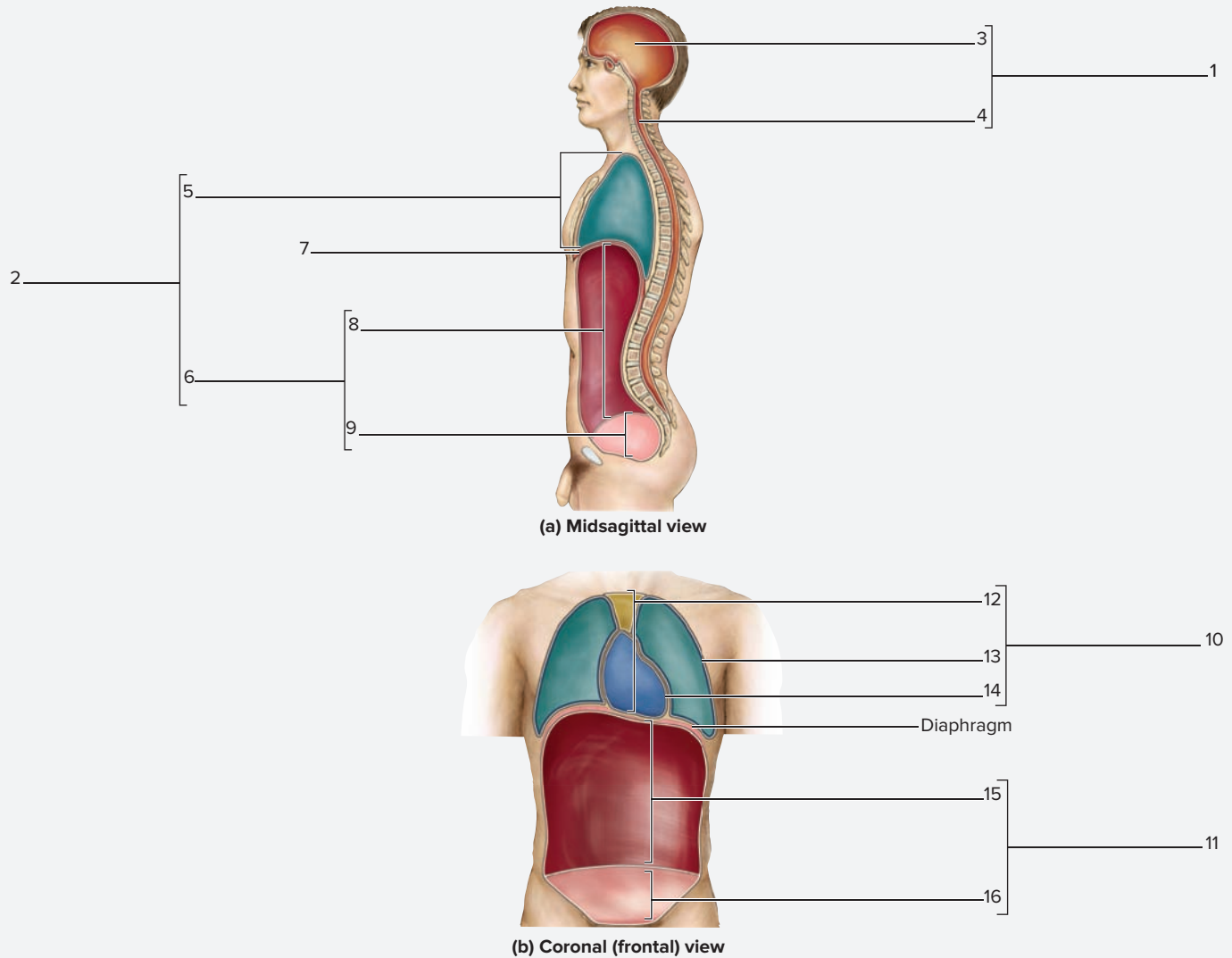
Many organs within the body are compartmentalized and separated from each other by a *body cavity*. Compartmentalizing the organs this way allows the separate organs to perform their functions without interfering

with the functioning of other organs. For example, the pumping action of the heart does not interfere with the expansion and contraction of the lungs because each organ is enclosed in its own cavity. In addition, the encasement of organs within separate cavities helps to prevent the spread of infection from one region of the body to another.

### EXERCISE 2.4 Body Cavities

1. Observe a human torso model or a human cadaver.

2. Identify the body cavities listed in **figure 2.6** on the torso model or human cadaver, using the textbook as a guide. Then label figure 2.6 with the appropriate terms.



**Figure 2.6 Body Cavities.** Use the terms listed to fill in the numbered labels in the figure. Answers may be used more than once.

- |  |   |   |  |
|--|---|---|--|
| <input type="checkbox"/> abdominal cavity      | <input type="checkbox"/> mediastinum        | <input type="checkbox"/> pleural cavity   | <input type="checkbox"/> ventral cavity  |
| <input type="checkbox"/> abdominopelvic cavity | <input type="checkbox"/> pelvic cavity      | <input type="checkbox"/> posterior aspect | <input type="checkbox"/> vertebral canal |
| <input type="checkbox"/> cranial cavity        | <input type="checkbox"/> pericardial cavity | <input type="checkbox"/> thoracic cavity  |  |

### Learning Strategy



The directional terms *superior* and *inferior* are used when describing one structure with respect to another structure on the trunk of the body. The directional terms *proximal* and *distal* are used

when describing the position of one structure with respect to another structure on the limbs. Thus, it is more appropriate to say the elbow is located *proximal* to the wrist, rather than to say it is superior to the wrist. On the other hand, it is quite appropriate to say the thorax is located *superior* to the abdomen.

## Abdominopelvic Regions and Quadrants

Describing locations of organs in the abdominopelvic cavity can be complicated because it is such a large cavity. Dividing the larger cavity into smaller sections allows the use of more specific descriptions of locations within the abdominopelvic cavity. There are two approaches used to do this. The first approach is to divide the abdominopelvic cavity into **quadrants** (*quad*, four). This is done by passing one imaginary line vertically through the *umbilicus* (belly button) and another horizontally through the umbilicus. The four resulting quadrants are: right upper, left upper, right lower, and left lower (**figure 2.7a**). Because this approach is simple, it is the approach used most often in a clinical setting. The second approach is to divide the abdominopelvic cavity into **regions**. This is done by drawing one vertical line to the left of the umbilicus and another

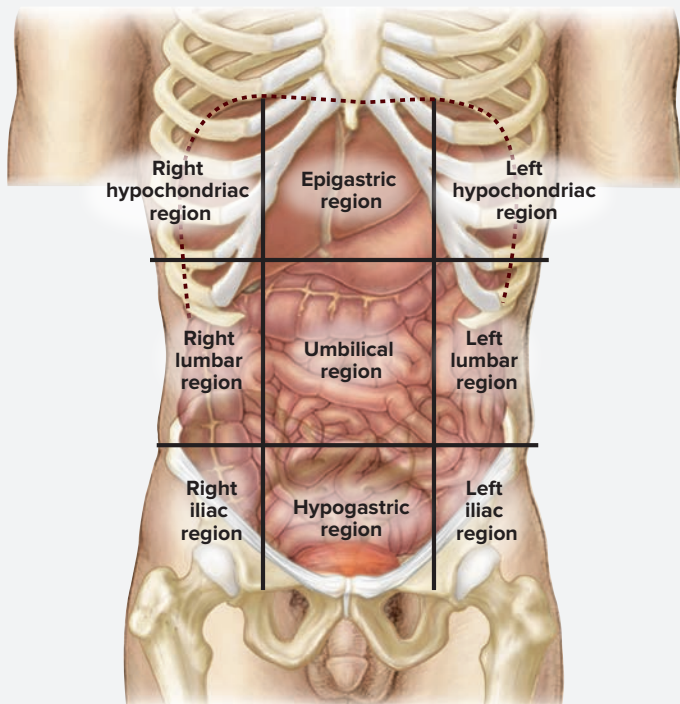
to the right of the umbilicus (at the *midclavicular line*; a vertical line that passes through the midpoint of the clavicle), then drawing one horizontal line superior to the umbilicus and another inferior to the umbilicus. The result is a grid similar to a tic-tac-toe layout, which creates nine regions (figure 2.7b). This approach allows greater specificity in describing the locations of organs and tissues within the abdominopelvic cavity. The nine regions are: umbilical, epigastric (*epi-*, above + *gastēr*, belly), hypogastric (*hypo-*, below + *gastēr*, belly), right and left hypochondriac (*hypo-*, below + *chondro-*, cartilage; as in the cartilages that attach ribs to sternum), right and left lumbar (*lumbus*, a loin), and right and left iliac (*ilium*, flank). Exercise 2.5 is designed as an introduction to the locations of major organs within the abdominopelvic cavity, and to help students become comfortable with the terms used to describe the quadrants and regions.

### EXERCISE 2.5 Locating Major Body Organs Using Abdominopelvic Region and Quadrant Terminology

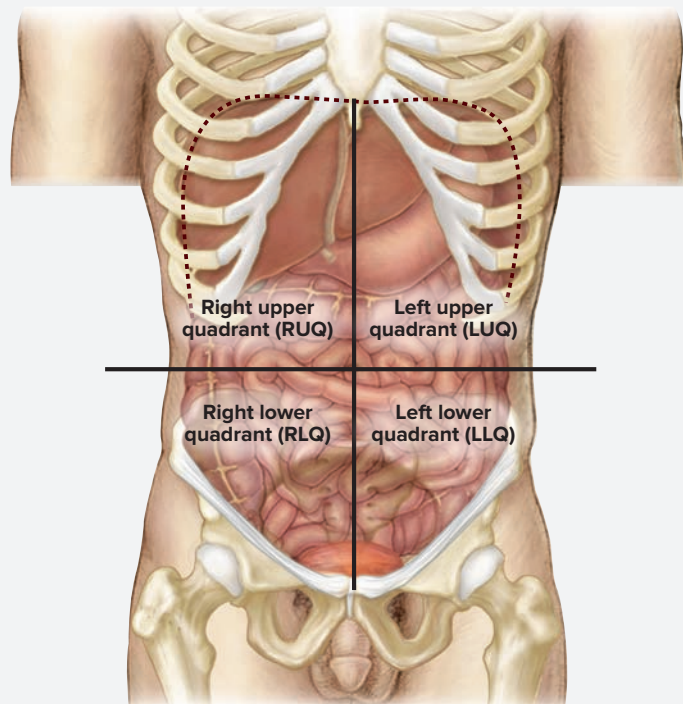
1. Identify the following structures on a human torso model or on a human cadaver, using figure 2.7 as a guide.

- |                                      |  |  |
|--------------------------------------|--|--|
| <input type="checkbox"/> left kidney | <input type="checkbox"/> small intestine | <input type="checkbox"/> stomach         |
| <input type="checkbox"/> liver       | <input type="checkbox"/> spleen          | <input type="checkbox"/> urinary bladder |
| <input type="checkbox"/> pancreas    |  |  |

2. Based on observations of the cadaver or human torso model, complete the chart on this page by indicating the quadrant(s) or region(s) in which each organ is found.



(a) Abdominopelvic regions



(b) Abdominopelvic quadrants

**Figure 2.7** The Abdominopelvic Cavity. The abdominopelvic cavity can be subdivided into (a) nine abdominopelvic regions, or (b) four abdominopelvic quadrants.


(a, b) Source: from McKinley, et al. Human Anatomy 4e. Reproduced with permission from McGraw-Hill Education

Organ	Quadrant(s)	Region(s)
Left kidney		
Liver		
Pancreas		
Small intestine		
Spleen		
Stomach		
Urinary bladder		

The 1 corresponds to the Learning Objective listed in the chapter opener outline.

## Do You Know the Basics?

### Exercise 2.1: Anatomic Planes and Sections

- Which of the following correctly describes the anatomic position? (Check all that apply.) 1
  - a. one can be sitting down or standing up
  - b. the feet are directed forward (anterior)
  - c. no two bones of the body cross each other
  - d. the palms of the hands are facing backward (posterior)
- A \_\_\_\_\_ (plane/section) is an imaginary two-dimensional flat surface. A \_\_\_\_\_ (plane/section) is a slice made along one of these two-dimensional flat surfaces. 2
- To divide this image of a heart  into equal sections, a \_\_\_\_\_ (coronal/midsagittal) section could be used. 3
- Match each definition listed in column A with the anatomic plane listed in column B. 4

#### Column A

- \_\_\_\_\_ 1. separates the right and left portions equally
- \_\_\_\_\_ 2. separates anterior portions from posterior portions
- \_\_\_\_\_ 3. separates superior portions from inferior portions
- \_\_\_\_\_ 4. runs at an angle to any of the three main planes of the body

#### Column B

- a. coronal (frontal)
- b. midsagittal (median)
- c. oblique
- d. transverse (horizontal)

- Which of the following shapes would end up with identical portions when sectioned along all of the following planes: midsagittal, transverse, and coronal? (Circle one.) 4
  - a. pyramid
  - b. rectangular box
  - c. egg
  - d. square box

### Exercise 2.2: Using Directional Terms

- For each of the following, insert the most appropriate directional term. 5
  - a. The elbow is located \_\_\_\_\_ to the wrist.
  - b. The mouth is located \_\_\_\_\_ to the ears.
  - c. The lungs are located \_\_\_\_\_ to the ribs.
  - d. The umbilicus is located \_\_\_\_\_ to the sternum.
  - e. The nose is located \_\_\_\_\_ and \_\_\_\_\_ to the ears.
  - f. A scratch wound, which does not penetrate the skin, is said to be a \_\_\_\_\_ wound. In contrast, a stab wound, which penetrates the skin, is referred to as a \_\_\_\_\_ wound.

### Exercise 2.3: Using Regional Terms

- Which of the following statements matches the regional term with the appropriate common term (example: the *tarsal* bones are in the ankle)? (Circle one.) 6
  - a. The *brachial* artery is in the wrist.
  - b. The *carpal* bones are in the ankle.
  - c. The *cervical* vertebrae are in the lower back.
  - d. The *femoral* nerve is in the arm.
  - e. The *popliteal* artery is in the knee.

**Exercise 2.4: Body Cavities**

8. Match the description listed in column A with the appropriate body cavity listed in column B. **7**

**Column A**

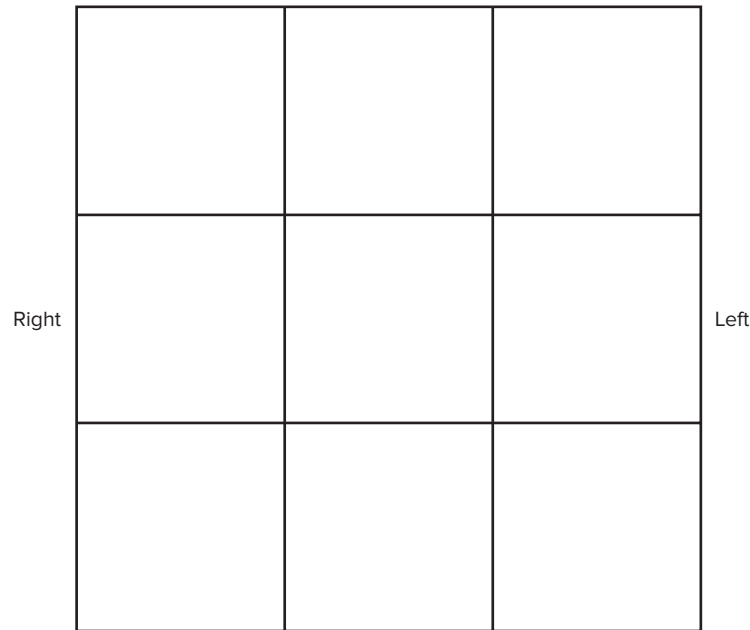
- \_\_\_\_\_ 1. encases the brain
- \_\_\_\_\_ 2. encases the heart
- \_\_\_\_\_ 3. contains most of the reproductive and urinary systems
- \_\_\_\_\_ 4. contains the cardiovascular and respiratory systems
- \_\_\_\_\_ 5. encases the lungs

**Column B**

- a. cranial cavity
- b. pelvic cavity
- c. pericardial cavity
- d. pleural cavity
- e. thoracic cavity

**Exercise 2.5: Locating Major Body Organs Using Abdominopelvic Region and Quadrant Terminology**

9. Fill in the figure provided with the names of the appropriate abdominopelvic regions. Note that the terms “Right” and “Left” refer to the body, *not* to the right and left side of the page. **8**



10. The left kidney is located in the \_\_\_\_\_ abdominopelvic quadrant and the \_\_\_\_\_ abdominopelvic region. **8**

**Can You Apply What You’ve Learned?**

11. Why does the anatomic position require that the forearm is rotated so the palm of the hand faces anteriorly?

**Can You Synthesize What You’ve Learned?**

12. The abdominopelvic region located directly lateral to the umbilical region is the \_\_\_\_\_ region.

13. A horizontal section through the tarsus would separate the \_\_\_\_\_ from the \_\_\_\_\_.

14. A patient was in a knife fight and suffered a 2-inch stab wound to his back. The knife entered the posterior thorax along the midsagittal (median) plane and entered the posterior aspect (posterior body cavity). What organ in the posterior aspect is likely to have been injured by this wound? \_\_\_\_\_

15. A teenage boy is diagnosed with appendicitis (inflammation of the appendix) and must undergo an operation. To remove the appendix, the surgeon will operate on the boy’s \_\_\_\_\_ abdominopelvic quadrant.

16. A man who had been in a car accident arrived at the emergency room. He was awake and alert and was able to tell the physician that he was experiencing severe pain near his lower ribs on the left side of his body and in his abdomen. Upon palpation, the patient’s abdomen was rigid, indicating the possibility of internal bleeding. The physician suspected that broken ribs may have injured an organ within the abdominal cavity. Which organ would most likely be injured in this case? What abdominopelvic **quadrant** is this organ located in? What abdominopelvic **region** is it located in?

# The Microscope

# 3

## OUTLINE AND LEARNING OBJECTIVES

### Histology 33

#### The Compound Microscope 33

##### EXERCISE 3.1: PARTS OF A COMPOUND MICROSCOPE 34

- 1 Identify the parts of a compound microscope
- 2 Calculate total magnification of the microscope using each objective lens

#### Focus and Working Distance 35

##### EXERCISE 3.2: VIEWING A SLIDE OF THE LETTER *e* 36

- 3 Define working distance, and estimate working distance of the microscope

#### Diameter of the Field of View 37

##### EXERCISE 3.3: MEASURING THE DIAMETER OF THE FIELD OF VIEW 37

- 4 Explain how the diameter of the field of view changes as total magnification increases
- 5 Given the diameter of the field of view at one total magnification, calculate the diameter of the field of view for a different total magnification

##### EXERCISE 3.4: ESTIMATING THE SIZE OF A SPECIMEN 38

- 6 Estimate the size of a specimen using known values for the diameter of the field of view

#### Depth of Field 39

##### EXERCISE 3.5: DETERMINING DEPTH OF FIELD 39

- 7 Explain how depth of field changes as total magnification increases

## INTRODUCTION

The study of anatomy involves observation of both gross (large) and microscopic (small) structures. Viewing the details of body tissues and cells is possible using a microscope. Both light microscopes and electron microscopes allow the user to view specific cellular components of tissues that make up the body. Such components include the shapes of the cells, intracellular components such as the nucleus of the cells, and modifications of the plasma membrane (e.g., cilia or microvilli). Observing specific cellular features provides a visual image that assists with the process of integrating structure and function.

To get the most from the experience of observing microscopic structures, it is important to know how to use the compound microscope properly. Even if you have used a microscope before, it is important to pay very careful attention to the instructions in this chapter. Many students have been taught the proper use and care of the microscope in the past. Yet, most continue to use poor technique. This, in turn, is a source of great frustration, which is a major impediment to the learning process. The exercises in this chapter provide an opportunity to refine and improve upon existing knowledge and technique. After performing these exercises, students will be prepared to make observations of cells and tissues (histology) in exercises to come in later chapters.

### List of Reference Tables

Table 3.1	Parts of the Microscope	p. 33
Table 3.2	Troubleshooting the Compound Microscope	p. 35

These Pre-laboratory Worksheet questions may be assigned by instructors through their **connect** course.

## PRE-LABORATORY WORKSHEET

1. Which of the following are proper procedures for holding, transporting, and storing a microscope? (Check all that apply.)

- \_\_\_\_ a. Always use both hands when carrying the microscope.
- \_\_\_\_ b. Place one hand on the base of the microscope and the other on the arm of the microscope.
- \_\_\_\_ c. Use care and move deliberately when carrying the microscope.
- \_\_\_\_ d. Slides may be left on the stage when storing a microscope.
- \_\_\_\_ e. Move the stage to its highest position when storing a microscope.
- \_\_\_\_ f. Wrap the power cord around the base and replace the dust cover after using the microscope.

2. Broken slides should be placed in a sharps container. \_\_\_\_\_ (True/False)

3. When holding a slide, be sure to hold it by the edges so as to not leave smudges and fingerprints on the slide. \_\_\_\_\_ (True/False)

4. Match the definition listed in column A with the microscope part listed in column B.

### Column A

- \_\_\_\_ 1. everything that is visible when looking through the eyepiece
- \_\_\_\_ 2. the part of the microscope that connects the head to the base
- \_\_\_\_ 3. the platform that a slide is placed upon
- \_\_\_\_ 4. lens that is attached to the nosepiece
- \_\_\_\_ 5. a knob that moves the mechanical stage up and down in small increments
- \_\_\_\_ 6. a knob that moves the mechanical stage up and down in large increments

### Column B

- a. arm
- b. coarse-adjustment knob
- c. field of view
- d. fine-adjustment knob
- e. mechanical stage
- f. objective lens

5. After placing a slide on the microscope stage, bring the tissue sample into focus using the \_\_\_\_\_ (highest/lowest) power objective lens.

6. Which of the following correctly describes how to properly calculate the total magnification of a microscope? (Circle one.)

- a. Add the ocular lens magnification and objective lens magnification.
- b. Subtract the ocular lens magnification from the objective lens magnification.
- c. Multiply the ocular lens magnification by the objective lens magnification.
- d. Divide the objective lens magnification by the ocular lens magnification.

7. As total magnification power increases, depth of field \_\_\_\_\_ (increases/decreases).

8. As total magnification power increases, diameter of the field of view \_\_\_\_\_ (increases/decreases).

## Histology

### The Compound Microscope

A compound microscope is used to view structures that are not visible to the naked eye. Most compound microscopes can magnify images anywhere from 40 to 1000 times (40× to 1000×) normal size. The total magnification of a compound microscope is achieved through a combination of the powers of both objective and ocular lenses (see **table 3.1** for definitions). The term “compound” comes from the fact that total magnification is “compounded” by the use of more than one lens.

### Caring for the Compound Microscope

Microscopes are very expensive instruments. Use great care when transporting, using, and storing microscopes.

- *Workspace:* Keep the workspace clear of all materials except for the microscope, laboratory manual, lens paper, and microscope slides. Remove or restrict any loose articles of clothing or jewelry. Long necklaces that dangle can damage the microscope. Long hair should be tied back.
- *Transport:* Always use both hands when carrying the microscope. Place one hand on the base of the microscope and the other on the arm. Use care to move deliberately when carrying the microscope (**figure 3.1**).
- *Lens care:* Lenses are some of the most expensive and parts of the microscope and should be treated with great care. Special lens paper is the only thing that should ever be used to

**Table 3.1** Parts of the Microscope

Term	Description and Usage
Arm	Connects the head to the base. When transporting the microscope, always grasp the arm with one hand.
Base	The bottom part of the microscope. It supports the entire microscope and encases much of the electrical wiring. When transporting the microscope, one hand should always be placed under the base for support.
Coarse adjustment knob	Moves the mechanical stage up and down in relatively large increments. It is used to position a specimen into the field of view when scanning a slide at low power. It should never be used with the higher powered objectives.
Condenser	A device used to focus the light coming from the illuminator/substage lamp. It generally works best in the position closest to the mechanical stage.
Depth of field	How much of the total thickness of the specimen is in focus.
Diopter adjustment ring	Changes the focus of the eyepiece. Used to make adjustments when the user has better vision in one eye and is not using corrective lenses. To use this device, begin by closing the eye that looks through the ocular lens containing the diopter adjustment ring. Looking through the other ocular lens, bring the sample into focus. Then, open the eye that was closed and bring the sample into focus for that eye using the diopter adjustment ring.
Eyepieces	The parts of the microscope that the user looks into. Always use both eyepieces. The eyepieces are movable so they can be adjusted to the distance between each user's eyes. Each eyepiece holds an ocular lens.
Field of view	Everything visible when looking through the eyepieces.
Fine-adjustment knob	Moves the mechanical stage up and down in small increments. Once a specimen is brought into view using the coarse adjustment knob, the fine adjustment is used to bring the specimen into focus.
Head	The part of the microscope that provides attachment and support for the objective and ocular lenses. It also serves as the support for the eyepieces.
Iris diaphragm	A part of the condenser that can be opened or closed to control the amount of light passing through the condenser. More light (iris open) decreases contrast between structures. Less light (iris closed) increases contrast.
Light control (voltage regulator)	Typically a rotating or sliding knob that alters the voltage going to the substage lamp to regulate the brightness of the light.
Mechanical stage	Platform that holds the specimen. It contains clips to hold a slide in place and knobs for positioning the slide on the stage.
Mechanical stage controls	Knobs used to position the slide on the stage.
Nosepiece	Device that connects the objective lenses to the head of the microscope; to change objective lenses.
Objective lenses	A typical microscope has three objective lenses, though some have four. Each objective lens has a label that tells how much it magnifies the image. For instance, a 4× objective lens magnifies the specimen four times normal size. The lowest-power objective lens is also called the “scanning” objective.
Ocular lenses	Lenses located within the eyepieces, which typically magnify the specimen ten times normal size.
Power switch	Usually located somewhere on the base of the microscope; used to turn the power on or off.
Substage lamp (illuminator)	The light source located in the base of the microscope. When it is turned on, light passes through the specimen on the stage, through the lenses of the microscope, and ultimately hits your eye, allowing you to see the specimen.
Working distance	The distance between the mechanical stage (and the slide on it) and the tip of the objective lens.





**Figure 3.1** Proper Technique for Carrying a Microscope.

© Christine Eckel

clean dirty lenses. This paper is designed so it will not scratch the lenses. *Never* use facial tissues, paper towels, articles of clothing, or anything else to clean the lenses because they may scratch the lenses. A special cleaning solution can be used with the lens paper, although lens paper generally does a fine job of cleaning when used alone. *Never* use saliva, water, or other fluids to moisten the lens paper.

- **Storage:** When finished using the microscope, move the stage to its lowest position. Make sure no slides are left on the stage. Rotate the nosepiece so the lowest-power objective lens is over the stage. Wrap the power cord around the base of the microscope then replace the dust cover.
- **Handling slides:** Always hold a slide by the edges to prevent forming smudges and fingerprints, which will interfere with the ability to view the slide clearly. If the slide is dirty, clean it using lens paper before placing it on the microscope stage. If a slide becomes cracked or broken, notify the instructor so it can be disposed of properly. Broken slides should be placed in a special broken glass container, never in the garbage can.


*Other things to be aware of:*



When removing the microscope cover, be careful not to pull the ocular lens off with the cover. When using the coarse adjustment knob, be careful not to allow the objective lens to smash into the slide, especially when using the high-power objective.

**EXERCISE 3.1** Parts of a Compound Microscope

1. Obtain a compound microscope.
2. Identify all the parts listed in table 3.1 on the compound microscope, using **figures 3.2** and **3.3** and table 3.1 as guides.
3. The ocular lens magnification is engraved on the eyepiece, and the objective lens magnification is etched on the silver tube that holds each objective lens. Record the magnifications of the lenses on your microscope in the spaces provided.



Ocular lens magnification: \_\_\_\_\_

Objective lens magnifications:

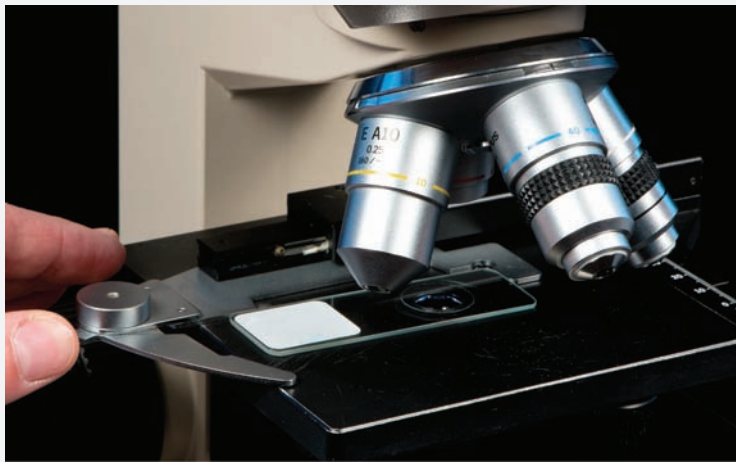
Scanning \_\_\_\_\_

Low \_\_\_\_\_

High \_\_\_\_\_

**Figure 3.2** Parts of a Compound Microscope.

© Christine Eckel



**Figure 3.3** Loading a Microscope Slide.

© Christine Eckel

- To determine the total magnification of an image, multiply the magnification of the ocular lens with that of the objective lens. For example, if the magnification of the ocular lens is 10× and the magnification of the objective lens is 4×, then the total magnification is 40×. Calculate the total magnification for each of these objective lenses—scanning, low-power, and high-power—for the microscopes used in your lab. Write the answers in the spaces provided.

*Total magnification* (ocular × objective):

Scanning \_\_\_\_\_ Low \_\_\_\_\_ High \_\_\_\_\_

- Use the information from steps 3 and 4 to answer question 4 of the Post-Laboratory Worksheet (p. 41).

### Focus and Working Distance


The purpose of this exercise is to become familiar with the microscope to develop an appreciation for the relationship between what is visible when looking directly at a slide and what is visible when looking at a

slide through the microscope lenses. If you experience difficulties and cannot see anything through the microscope or cannot focus the lenses, refer to **table 3.2**.

<b>Table 3.2</b>		<b>Troubleshooting the Compound Microscope</b>	
<b>Problem</b>	<b>Solution</b>		
“No light is coming from my illuminator.”	Make sure the microscope is plugged into a working power outlet.		
	Check the power switch and make sure it is turned on.		
	Check the light control/voltage regulator and make sure it isn’t turned all the way down.		
	If the first three steps don’t solve the problem, see the instructor. The bulb may have burned out.		
“I can’t find anything on my slide.”	Go back to scanning power. Lower the stage as far as it will go. Look at the slide on the stage and position it so the specimen is illuminated and the lower-power objective is in the lowest position (position closest to the stage). Look through the eyepiece and, using the coarse adjustment knob, slowly bring the stage up until the specimen comes into view.		
“I can’t use both eyes to view the slide.” or “I have to close one eye to view the slide.”	Move your head back from the eyepieces slightly. If you are too close, it is more difficult to see a single image.		
	Move the eyepieces (closer together or farther apart) until a single image is visible through the microscope.		
	If the first two steps don’t work, get a classmate to help measure the distance between your pupils using a ruler. Then use the ruler to move the eyepieces apart that same distance.		
“I see a dark crescent in the view.”	Make sure the objective lens is clicked into place.		
	Adjust the condenser.		
“I can’t get the specimen in clear focus.”	Make sure the slide is not upside-down on the mechanical stage.		

**EXERCISE 3.2 Viewing a Slide of the Letter *e*****EXERCISE 3.2A: Focusing the Microscope**

1. Obtain a compound microscope and a slide of the letter *e*.
2. *Always begin observations at the lowest possible total magnification (scanning objective in place).* Make sure the mechanical stage is in its lowest position, closest to the base of the microscope. Place the slide on the stage (see figure 3.3) and turn on the illuminator. Adjust the light control/voltage regulator so it is somewhere near the middle or low end of its range.
3. After making sure that light is coming out of the illuminator, position the microscope stage so the letter *e* on the slide is over the opening in the stage where light comes through. Do this by looking directly at the microscope stage (not through the eyepiece[s]). This ensures that the specimen will be in the field of view, or at least very close to it, when viewed through the eyepieces and lenses.
4. Check to see if the scanning objective is in place over the stage, and look into the eyepiece(s). Using the coarse adjustment knob, slowly move the stage up until the specimen comes into view. Then use the fine-adjustment knob to bring the specimen into focus. Next, adjust the iris diaphragm and light control/voltage regulator to see how each affects the clarity (the sharpness of the image) and contrast (the ability to distinguish the specimen from the background) of the image.
5. Draw what is visible within the field of view in the space provided. Record the total magnification.



Total magnification = \_\_\_\_\_ ×

6. How does the image seen through the microscope differ from what is seen when looking directly at the slide?  
 \_\_\_\_\_  
 \_\_\_\_\_
7. Without changing the position of the slide or the stage, rotate the nosepiece so the low-power objective is in place. Because the slide was in focus with the scanning

objective, use only the fine-adjustment knob to bring the specimen into focus with the low-power objective. Each time the magnification increases, use only the fine-adjustment knob to focus the specimen.

8. Repeat step 7 using the high-power objective. It may be necessary to adjust the light control to increase illumination, because light intensity decreases when changing from a low-power to a high-power objective.

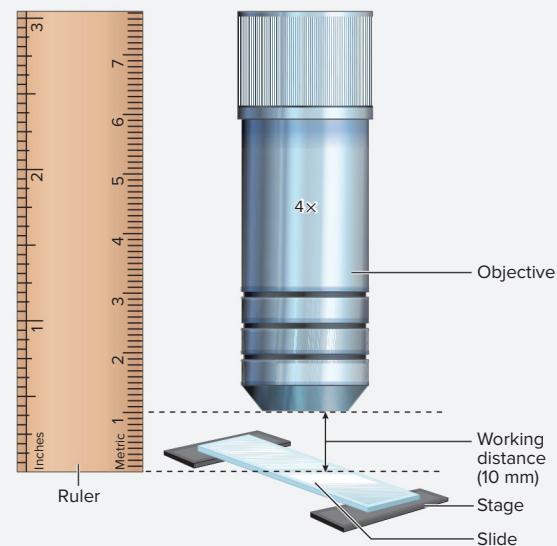
**EXERCISE 3.2B: Working Distance**

The **working distance** is the distance between the mechanical stage (and the slide upon it) and the tip of the objective lens (**figure 3.4**). The shorter the working distance, the more likely it is that the objective lens will touch the slide or the stage. Because of this, use only the fine-adjustment knob when viewing specimens with high-power objective lenses.

1. Begin with the microscope stage at its lowest position. Place the slide of the letter *e* on the stage and bring it into focus using the scanning objective.
2. Obtain a millimeter ruler. Measure the working distance: the distance between the top of the slide on the stage and the bottom of the objective lens. Record the distance here: \_\_\_\_\_ mm.
3. Change to the low-power objective lens and repeat the process in step 2. Record the distance here: \_\_\_\_\_ mm.
4. Change to the high-power objective and repeat the process in step 2. Record the distance here: \_\_\_\_\_ mm.
5. Use the results from steps 2 through 4 to answer question 4 of the Post-Laboratory Worksheet (p. 41).

**WHAT DO YOU THINK?**

- 1 How does working distance change as total magnification increases? What are the practical consequences of this change in working distance?



**Figure 3.4** How to Measure Working Distance.

## Diameter of the Field of View

The **field of view** is everything that is visible when looking through the eyepiece. As magnification increases, the field of view decreases. This activity involves determining the diameter of the field of view at the

various magnifications of the microscope. The diameter of the field of view is simply the distance (usually given in millimeters [mm]; sometimes in micrometers [ $\mu\text{m}$ ]) across the widest part of the visible field.

### EXERCISE 3.3 Measuring the Diameter of the Field of View

1. Obtain a compound microscope and a stage micrometer or clear ruler with mm increments.
2. Begin with the scanning objective in place. Place the stage micrometer slide on the stage and position it so the markings are visible within the field of view when looking through the eyepiece. Next, line up the first marking with the left-hand side of the field of view at its widest part. If you are using a ruler, line up one of the mm lines with the left-hand side of the field of view at its widest part.
3. Count the number of markings visible across the widest part of the field of view and record the number: \_\_\_\_\_ mm. This is the diameter of the field of view at scanning power.
4. Repeat steps 1 and 2 with the low-power objective in place. Record the diameter of the field of view at low power: \_\_\_\_\_ mm.
5. It is often difficult to use the method from steps 1 and 2 to determine the diameter of the field of view for the high-power objective. However, the diameter can be calculated based on the measurements recorded for the scanning or low-power objectives using the following formula (LP = low-power objective, HP = high-power objective):

$$\begin{aligned} \text{diameter at LP} \times \text{total magnification at LP} &= \\ \text{diameter at HP} \times \text{total magnification at HP} & \end{aligned}$$

#### Example:

- Diameter of the field of view using low-power objective: 4.8 mm
- Total magnification using low-power objective: 40 ×
- Diameter of field of view using high-power objective: unknown  
(this is what will be calculated)
- Total magnification using high-power objective: 400 ×
- Calculation:  $4.8 \text{ mm} \cdot 40\times = \text{unknown} \cdot 400\times$   
 $192 = \text{unknown} \cdot 400\times$   
 $192/400 = 0.48 \text{ mm}$  (round off the number if necessary)

The diameter of the field of view at a magnification of 400× is 0.48 mm.

6. Use the information recorded in this exercise to complete the table in question 3 of the Post-Laboratory Worksheet (p. 41).

### Learning Strategy



A *millimeter* (mm) is  $10^{-3}$  meters. A *micrometer* ( $\mu\text{m}$ ) is  $10^{-6}$  meters. At higher magnifications, the size of structures should be recorded in micrometers instead of millimeters. To convert 0.2 mm to micrometers, simply move the decimal point three positions to the right. Thus, a distance of 0.2 mm is a distance of 200  $\mu\text{m}$ .

Practice: If the diameter of the field of view at a magnification of 400× is 0.48 mm, what is the diameter in micrometers?  
\_\_\_\_\_  $\mu\text{m}$

**EXERCISE 3.4** Estimating the Size of a Specimen

Once the diameter of the field of view for each of the objective lenses of the microscope is known, the approximate size of a specimen can be determined by comparing the size of the specimen to the diameter of the field of view. Use calculations shown in exercise 3.3 to determine the size of the same specimen viewed at three different magnifications.

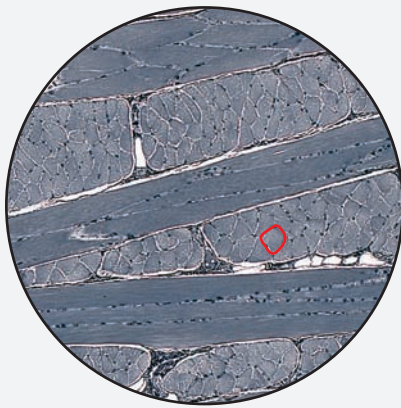- 1.** **Figure 3.5** shows a specimen (outlined in red) at various magnifications. First, calculate the diameter of each field of view before estimating the length of the object (0.48 is the diameter of the field of view for a total magnification of 40×).
- 2.** Next calculate the diameter of the object, which in this example (figure 3.5) is a cross section of a skeletal muscle fiber.

- 3.** Is it possible to measure or estimate the diameter of the specimen in figure 3.5c? \_\_\_\_\_

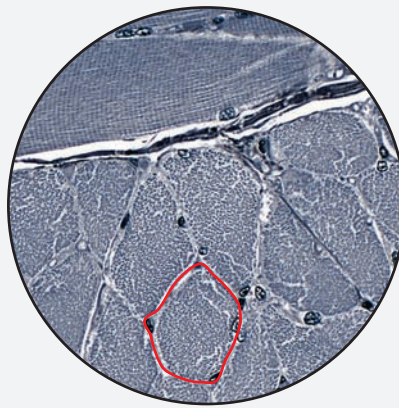
Explain your answer: \_\_\_\_\_  
 \_\_\_\_\_

**WHAT DO YOU THINK?**

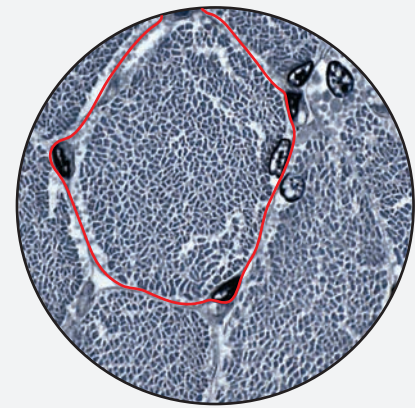
- 2** If 4 cells are visible within the field of view at its maximum diameter using a total magnification of 200×, how many cells will be visible at a total magnification of 500×?



(a) Total magnification = 40x  
 Diameter of field = 4.8 mm  
 Diameter of specimen = \_\_\_\_\_



(b) Total magnification = 200x  
 Diameter of field = 4.8 mm  
 Diameter of specimen = \_\_\_\_\_

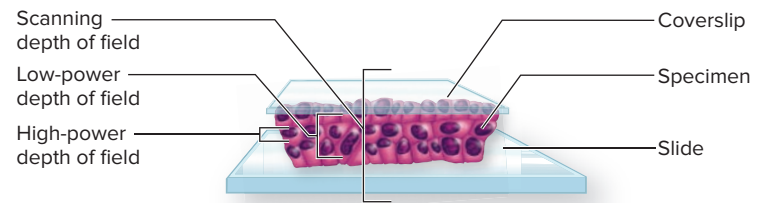


(c) Total magnification = 500x  
 Diameter of field = 4.8 mm  
 Diameter of specimen = \_\_\_\_\_

**Figure 3.5** Estimating Specimen Size. The circle indicates the field of view. The specimen to be measured is outlined in red.

## Depth of Field

The **depth of field** is how much of the total thickness of a specimen is in focus at each magnification. As total magnification increases, the depth of field decreases and a smaller portion of the specimen will be in focus. **Figure 3.6** demonstrates what happens to the depth of field as total magnification changes.



**Figure 3.6** Depth of Field. Depth of field narrows as total magnification increases.

### EXERCISE 3.5 Determining Depth of Field

1. Obtain a compound microscope and a slide of three crossed, colored threads.
2. Place the slide on the microscope stage and observe the slide with the scanning objective in place. Once three crossed threads are visible in the field of view, use the fine-adjustment knob to focus up and down in small increments to determine which of the threads is on top, which is in the middle, and which is on the bottom. Then record the answers in the spaces provided:

Color of top thread: \_\_\_\_\_

Color of middle thread: \_\_\_\_\_

Color of bottom thread: \_\_\_\_\_

3. Now observe the slide with the low-power objective in place. Does the fine-adjustment knob need to be moved more or less at this magnification to see all the threads than at the magnification with the scanning objective in place?  
\_\_\_\_\_

4. Finally, observe the slide with the high-power objective in place. At this magnification, each individual thread will take up almost the entire diameter of the field of view. Is the entire thickness of an individual thread in focus at this magnification? \_\_\_\_\_. What does this indicate about the depth of field at this magnification? \_\_\_\_\_  
\_\_\_\_\_

### Finishing Up

Upon completion of all the laboratory activities, follow proper cleanup procedures as listed here.

1. Remove the slide from the microscope stage and put it back where it belongs.
2. Turn the power switch to the “off” position, unplug the power cord, and wrap the power cord neatly around the base of the microscope.
3. Rotate the nosepiece so the scanning power objective clicks into place.
4. Lower the microscope stage to its lowest position.
5. Put the dust cover back on the microscope.
6. Return the microscope to its proper storage location.

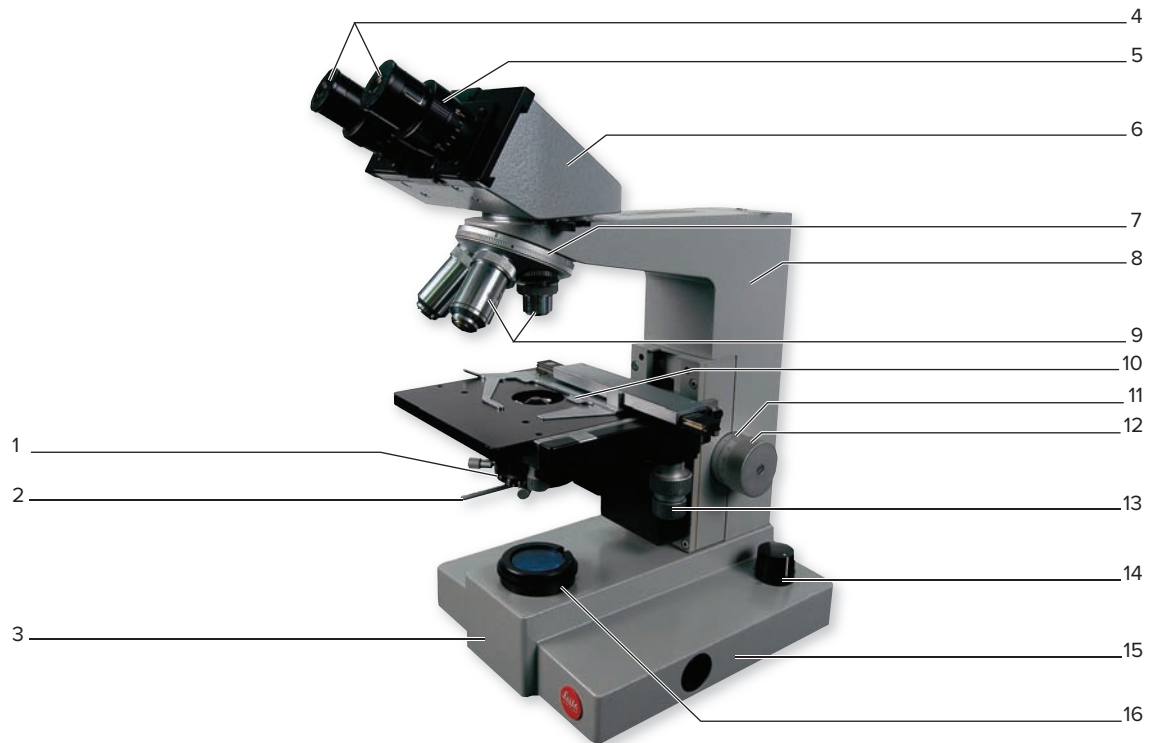
*This page intentionally left blank*

The **1** corresponds to the Learning Objective(s) listed in the chapter opener outline.

## Do You Know the Basics?

### Exercise 3.1: Parts of a Compound Microscope

1. Label the parts of the compound microscope. **1**



© Christine Eckel

### Exercise 3.2: Viewing a Slide of the Letter e

2. What is the total magnification of a microscope set up with an ocular lens magnification of 10x and an objective lens magnification of 43x? \_\_\_\_\_ **2**

### Exercise 3.3: Measuring the Diameter of the Field of View

3. Complete the following table with the numbers observed or calculated in exercises 3.1, 3.2, and 3.3. **3 4 5**

Power	Ocular Magnification	Objective Magnification	Total Magnification	Diameter of the Field of View	Working Distance
<i>Scanning</i>					
<i>Low</i>					
<i>High</i>					

### Exercise 3.4: Estimating the Size of a Specimen

4. Refer back to the calculations on the sample “specimens” in figure 3.5. Enter information from those calculations in the spaces provided. Pay attention to the units specified next to the answers, because they are not all the same. **6**

A.		B.		C.	
Total magnification	= <u>40x</u>	Total magnification	= <u>200x</u>	Total magnification	= <u>500x</u>
Diameter of field	= _____ mm	Diameter of field	= _____ mm	Diameter of field	= _____ $\mu\text{m}$
Length of object	= _____ mm	Length of object	= _____ mm	Length of object	= _____ $\mu\text{m}$



**Exercise 3.5: Determining Depth of Field**

5. Record the answers to the questions about colored threads on page 39 in the spaces provided. 7

Color of top thread: \_\_\_\_\_ Color of middle thread: \_\_\_\_\_ Color of bottom thread: \_\_\_\_\_

6. Explain why proper microscope technique requires always viewing a slide with the scanning objective first before moving to higher-power objectives. Use the concept of *depth of field* in the explanation. 7

---

---

---

---

---

**Can You Apply What You've Learned?**

7. What microscope structures are used to control the amount of light illuminating the specimen?

---

8. What happened to the light intensity when switching from low to high power?

---

9. What adjustment will typically have to be made to the light after changing from the low-power to the high-power objective?

---

10. a. How does working distance change as total magnification increases?

---

b. What are the practical consequences of this change in working distance?

---

11. If four cells are visible within the field of view at the field's maximum diameter, and the total magnification is 200x, how many cells will be visible at a total magnification of 500x?

---

**Can You Synthesize What You've Learned?**

12. A patient presented to his physician complaining of an unusual growth on the skin of his upper back. The physician was unable to identify the growth, so she decided to perform a biopsy (take a tissue sample). After obtaining a sample of the unusual growth on the patient's back, the physician sent the sample to the pathology lab. Discuss how the pathologist would make use of a compound microscope to correctly diagnose the identity of the unusual growth.

---

---

# Cellular Anatomy

# 4

## OUTLINE AND LEARNING OBJECTIVES

### Histology 46

#### Structure and Function of a Prototypical Cell 46

##### EXERCISE 4.1: OBSERVING CELLULAR ANATOMY WITH A COMPOUND MICROSCOPE 46

- 1 Prepare a wet mount of human cheek cells
- 2 Identify cellular organelles that are visible through a compound microscope
- 3 Associate a function with each organelle observed
- 4 Identify nucleus, nucleolus, and plasma membrane in a human cheek cell

#### Mitosis 49

##### EXERCISE 4.2: OBSERVING MITOSIS IN A WHITEFISH EMBRYO 51

- 5 Identify interphase and the four stages of mitosis on a slide of a whitefish embryo/blastula
- 6 Describe the events that occur during each stage of mitosis

### Gross Anatomy 51

#### Models of a Prototypical Cell 51

##### EXERCISE 4.3: OBSERVING CLASSROOM MODELS OF CELLULAR ANATOMY 51

- 7 Identify intracellular structures on a classroom model of a prototypical cell, and associate a function with each

## INTRODUCTION

The cell is the basic unit of life. Organisms can be unicellular or multicellular, but they must be composed of cells to be considered living entities. Human beings are, of course, multicellular organisms. Our bodies are composed of **tissues**: groups of similar cells and associated extracellular materials that function together as a unit. The study of tissues is called **histology** (*histos*, web [tissue] + *logos*, study). Understanding the study of histology first requires identifying cells and cellular organelles under the microscope. Most cells are easily seen with a light microscope, but most cellular organelles are too small to be seen without the use of a more powerful electron microscope. The purpose of the exercises in this chapter is to introduce the microscopic appearance of a variety of animal cells, provide a brief review of cellular anatomy and the stages of mitosis, and help students become more confident in their use of the compound microscope.

Most animal cells are transparent. Because of this, when tissue samples are prepared for use in the anatomy laboratory, the slides are stained so cellular details will be visible when viewed with a microscope. Different parts of a cell attract biological stains to different degrees, which makes some parts of the cell appear darker in color, while other parts appear lighter in color, or even transparent. The nucleus of the cell has

a high attraction for most biological stains, so it is often the most recognizable part of the cell.

Most of the slides that are viewed in the anatomy laboratory have been stained with hematoxylin and eosin, and are labeled “H and E.” This stain makes the **cytoplasm** of the cell appear pink in color and makes visible the outline of the cell where the **plasma membrane (cell membrane)** is located. The **nucleus** of the cell appears dark purple in color, and the **nucleolus** often appears as a dark spot within the nucleus. Note that these structures have been described using references to colors that result from the use of hematoxylin and eosin stains (i.e., pink and purple). It is important to remember that other types of stains may be used on slides prepared for the laboratory. Use of stains other than H and E will cause the same structures to have different colors. For this

reason, do not use color alone as an identifying feature when viewing slides. Instead learn to recognize cells and cellular organelles based on *shape*.

The exercises in the “histology” and “gross anatomy” sections of this chapter include identification of cellular organelles that are visible using a light microscope, identification of the stages of mitosis in a whitefish embryo, and an exercise that involves preparing a slide of your own cheek cells. This slide will be stained with methylene blue, a stain that enhances the visibility of the plasma membrane and nucleus of the cell.

#### List of Reference Tables

Table 4.1	Components of a Prototypical Cell	p. 48
Table 4.2	Appearance of Whitefish Embryo Cells Undergoing Mitosis During Phases of the Cell Cycle	p. 50

These Pre-laboratory Worksheet questions may be assigned by instructors through their **connect** course.

## PRE-LABORATORY WORKSHEET

1. Match the function listed in column A with the cell structure listed in column B.

### Column A

- \_\_\_\_\_ 1. provides a selectively permeable barrier between the intracellular and extracellular environment of the cell
- \_\_\_\_\_ 2. contains the cell's genetic material (DNA)
- \_\_\_\_\_ 3. synthesizes new proteins destined for the plasma membrane, for lysosomes, or for secretion from the cell
- \_\_\_\_\_ 4. a stack of flattened membranes that are the site where proteins from the ER are modified, packaged, and sorted for delivery to other organelles or to the plasma membrane of the cell
- \_\_\_\_\_ 5. often referred to as the "powerhouse" of the cell, these organelles are the site of cellular respiration

### Column B

- a. Golgi apparatus
- b. mitochondria
- c. nucleus
- d. plasma membrane
- e. rough endoplasmic reticulum (RER)

2. Number the following stages of mitosis in the correct order.

- \_\_\_\_\_ a. anaphase
- \_\_\_\_\_ b. metaphase
- \_\_\_\_\_ c. prophase
- \_\_\_\_\_ d. telophase

3. The stage of the cell cycle when cells are *not* undergoing mitosis is \_\_\_\_\_. During this phase individual chromosomes \_\_\_\_\_ (are/are not) visible within the nucleus of the cell.

4. Match the functions listed in column A with their cell structures listed in column B.

### Column A

- \_\_\_\_\_ 1. acts to suspend cellular organelles; contains enzymes that mediate many cytosolic reactions such as glycolysis and fermentation
- \_\_\_\_\_ 2. synthesizes rRNA and assembles ribosomes in the nucleus
- \_\_\_\_\_ 3. refers to the "colored stuff" found in the nucleus; consists of uncoiled chromosomes and associated proteins
- \_\_\_\_\_ 4. sites of protein synthesis: may be bound to the ER ("fixed") or found within the cytoplasm ("free")
- \_\_\_\_\_ 5. membrane-enclosed sacs that contain digestive enzymes and function in the breakdown of intracellular debris
- \_\_\_\_\_ 6. membrane-enclosed sacs that contain catalase and other oxidative enzymes
- \_\_\_\_\_ 7. paired organelles composed of microtubules that are used to organize the spindle microtubules that attach to chromosomes during mitosis
- \_\_\_\_\_ 8. composed of protein filaments called microtubules, intermediate filaments, and microfilaments; provides the main structural support for the cell

### Column B

- a. centrioles
- b. chromatin
- c. cytoplasm
- d. cytoskeleton
- e. lysosomes
- f. nucleolus
- g. peroxisomes
- h. ribosomes

## Histology

### Structure and Function of a Prototypical Cell

**Table 4.1** lists the parts of a prototypical cell and gives descriptions of the functions and microscopic features of each. The parts of a typical animal cell that are most readily visible under a light microscope are the nucleus, nucleolus, and plasma membrane (which is the boundary of the cell).

While observing animal cells under the light microscope, focus on finding these parts of a typical animal cell. Learning to recognize what parts of an animal cell are typically visible under the light microscope serves as preparation for observing different cell types that will be presented in future laboratory exercises.

### EXERCISE 4.1 Observing Cellular Anatomy with a Compound Microscope

#### EXERCISE 4.1A: Preparing a Wet Mount of Human Cheek Cells

This exercise involves taking a sample of cells from the inside of the cheek and preparing a wet mount. A wet mount is a procedure that involves placing a tissue sample in a wet medium onto a microscope slide. The “wet” medium is typically an isotonic saline solution. Why is it important for the solution to be isotonic? \_\_\_\_\_

The cells on the inside of the cheek are squamous cells, which are flattened cells. The inside of the cheek is lined with multiple layers of these cells. Therefore, it is possible to gently scrape off a few cells without causing damage to the entire epithelium (lining) of the inside of the mouth. These cells are covered within the context of epithelial tissues in chapter 5.

The cells obtained from inside the cheek will be placed on a slide, stained with methylene blue, and covered with a coverslip. The stain is necessary to visualize the cells because normal cells are nearly transparent. The stain is basophilic (base-loving) and is attracted to eosinophilic (acid-loving) components of the cell. The most eosinophilic part of the cell is the nucleus, which contains the nucleic acids DNA and RNA. Thus, the nucleus of the cell stains more intensely than other parts of the cell.

#### Obtain the following:


- compound microscope
- microscope slide and coverslip
- toothpick or wood applicator stick
- methylene blue solution with eyedropper
- fine tissue paper or KimWipes®

1. Place the microscope slide on a piece of white paper on the lab bench. The piece of white paper will facilitate observations.
2. Place a small drop of normal saline on the microscope slide (**figure 4.1a**). Very *gently* scrape the toothpick along the inside of your mouth to pick up a few cells. This should not be painful, and most definitely should not draw blood!


3. Next, place the tip of the toothpick in the drop of saline on the slide (**figure 4.1b**). Roll the toothpick around gently so the cells detach from the toothpick and drop into the drop of saline.
4. Obtain a vial of methylene blue solution. Place a single drop of methylene blue on the drop of saline containing cheek cells (**figure 4.1c**).
5. Obtain a coverslip and place it on the edge of the liquid on the microscope slide as shown in **figure 4.1d**. Carefully and slowly lower the coverslip onto the drop of liquid. The goal is to place the coverslip over the drop of saline without introducing air bubbles. If you simply drop the coverslip on the slide you will end up with large air bubbles, which interfere with the ability to see the cells on the slide. To prevent air bubbles from forming, carefully and slowly lower the coverslip, starting on one side and lowering it down at an angle (**figure 4.1d**). Obtain a piece of tissue paper or a KimWipe® and use it to dab any excess liquid on the sides of the coverslip (if necessary). A successful wet mount of cheek cells should resemble that shown in **figure 4.1e**.
6. Observe the slide with the naked eye. Is anything visible on the slide? In particular, are any cheek cells visible?
7. Arrange the objective lens on the microscope so it is set to use the scanning objective. Place the slide containing the cheek cells on the microscope stage and bring the tissue sample into focus using the scanning objective. Next, change to a higher power and bring the tissue sample into focus once again. The cells observed should somewhat resemble those in **figure 4.2**, although they will generally be isolated from each other rather than being in a sheet as in **figure 4.2**.




(a) Place a drop of normal saline on the slide.




(b) After collecting cheek cells, gently roll the tip of the toothpick in the drop of saline.



(c) Place a drop of methylene blue on the slide.



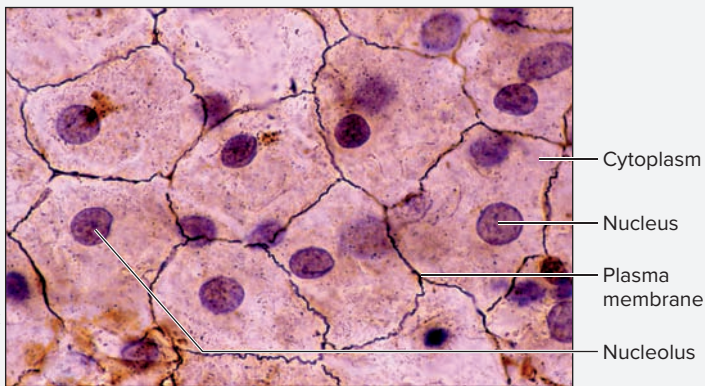
(d) Slowly lower a coverslip over the drop of liquid containing cheek cells.



(e) Make sure there are no air bubbles between the coverslip and the slide. The slide is now ready to view with the microscope.

**Figure 4.1** Preparing a Wet Mount of Human Cheek Cells.

© Christine Eckel



LM 250x

**Figure 4.2** Human Cheek Cells. Note that some of the cells appear to have more than one nucleus. This is an artifact. This artifact arises from the fact that there is more than one cell stacked on top of another, and the nuclei of both cells are visible. The cells observed using the preparation techniques described in exercise 4.1a will generally be separate from each other, as opposed to the view here, which is a continuous sheet of cells.

© Ed Reschke/Getty Images

**WHAT DO YOU THINK?**

- 1 What is the function of rough endoplasmic reticulum? Why do you think neurons might contain so much rough endoplasmic reticulum? Hint: Neurons are cells that need to be able to transport numerous ions into and out of the cell.

8. Scan the slide until cheek cells are visible in the field of view. Sketch the cheek cells as seen through the microscope in the space provided. Label the following on the sketch:

- cytoplasm
- nucleolus
- nucleus
- plasma membrane



\_\_\_\_\_ ×

(continued on next page)

(continued from previous page)

### Troubleshooting:

If the slide appears to consist mostly of cellular debris instead of intact cells, it is likely that distilled water was mistakenly used in place of saline when making the slide. Distilled water is a hypotonic solution. When cells are placed in a hypotonic solution, they will lyse, leaving only cellular debris on the slide.

Sometimes the view through the microscope appears to vibrate or shake, which makes it impossible to visualize the cells. If this

happens, there is too much fluid between the coverslip and the slide. Use a KimWipe® to draw some of the excess fluid out from under the coverslip. Then, observe the slide again.

9. **Optional Activity: APIR 2: Cells & Chemistry**—Examine the “Generalized cell” dissection and test yourself on cell structures in the Quiz area.


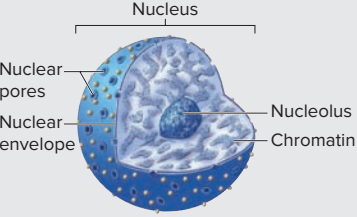
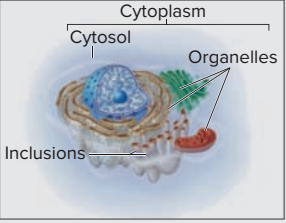
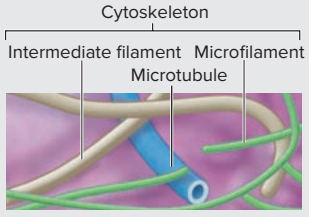
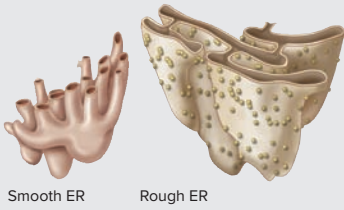
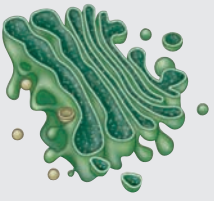

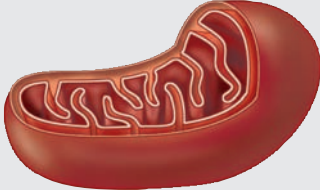
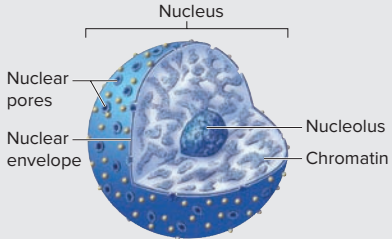

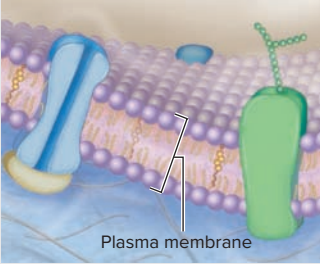
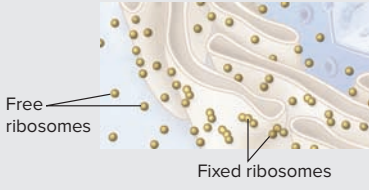
Table 4.1 Components of a Prototypical Cell				
Organelle/Structure	Function	Microscopic Features	Word Origins	Appearances
<b>Centrioles</b>	Paired organelles that are used to organize the spindle microtubules that attach to chromosomes during mitosis. The area next to the nucleus that contains the centrioles is called the <i>centrosome</i> .	Visible only when a cell is actively undergoing nuclear division (mitosis).	<i>kentron</i> , center	
<b>Chromatin</b>	Genetic material within the nucleus; consists of uncoiled chromosomes and associated proteins.	Most of the coloration seen in the nucleus (with exception of the nucleolus) consists of chromatin.	<i>chroma</i> , color	
<b>Cytoplasm</b>	Includes cellular organelles and cytosol. Cytosol contains enzymes that mediate cytosolic reactions such as glycolysis and fermentation.	Clear and homogeneous in appearance; may contain granular substances such as glycogen in certain cells (e.g., hepatocytes).	<i>kytos</i> , a hollow (cell) + <i>plasma</i> , something formed	
<b>Cytoskeleton</b>	Provides the main structural support for the cell and is composed of microtubules, intermediate filaments, and microfilaments.	Not generally visible under the light microscope.	<i>kytos</i> , a hollow (cell) + <i>skeletos</i> , dried	
<b>Endoplasmic Reticulum (ER)</b>	Site of lipid synthesis and detoxification of drugs and alcohol (smooth ER). Additionally, rough ER synthesizes proteins destined for the cell membrane, for lysosomes, or for secretion.	Not generally visible under the light microscope. In neurons, the rough ER stains very dark and is called chromatophilic substance (Nissl bodies).	<i>endon</i> , within + <i>plasma</i> , something formed + <i>rete</i> , a net	
<b>Golgi Apparatus</b>	A stack of flattened membranes that receive proteins from the rough ER and then modify, package, and sort them for delivery to other organelles or to the plasma membrane of the cell.	Not generally visible under a light microscope.	<i>Golgi</i> , Camillo, Italian histologist and Nobel laureate, 1843–1926	

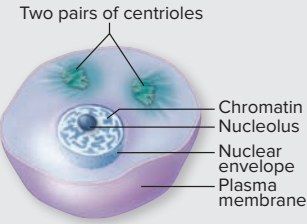
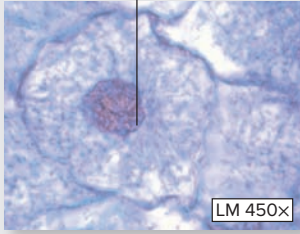

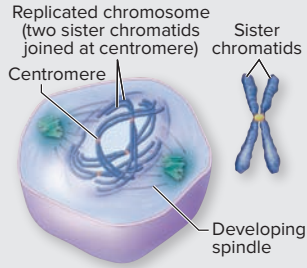
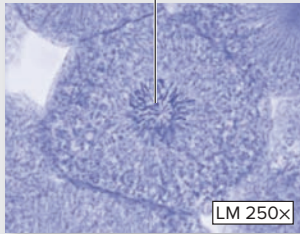

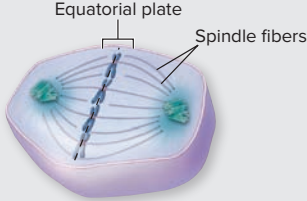
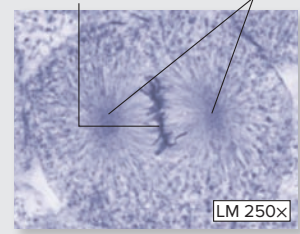

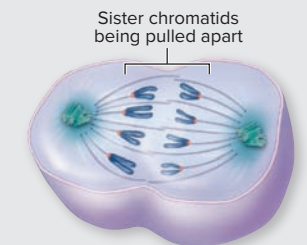
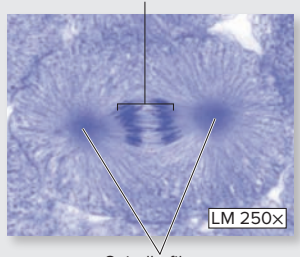

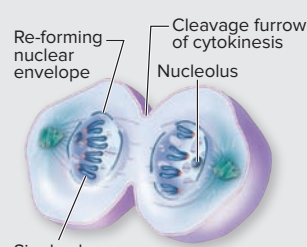
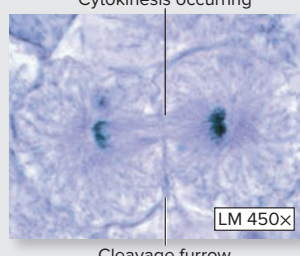

Table 4.1		Components of a Prototypical Cell (continued)		
Organelle/Structure	Function	Microscopic Features	Word Origins	Appearances
<i>Lysosomes</i>	Membrane-enclosed sacs that contain digestive enzymes; function in the breakdown of intracellular debris.	Not generally visible under a light microscope.	<i>lysis</i> , a loosening + <i>soma</i> , body	
<i>Mitochondria</i>	Often referred to as the “powerhouse” of the cell. These organelles are the site of cellular respiration: the metabolic pathway that utilizes oxygen in the breakdown of food molecules to produce ATP.	Not generally visible under a light microscope.	<i>mitos</i> , thread + <i>chondros</i> , granule	
<i>Nucleolus</i>	Synthesizes rRNA and assembles ribosomes in the nucleus.	Recognized as a small, dark, circular structure within the nucleus.	<i>nucleus</i> , a little nut	
<i>Nucleus</i>	Contains the cell’s genetic material (DNA).	The most noticeable feature of a cell; stains very dark.	<i>nucleus</i> , a little nut	
<i>Peroxisomes</i>	Membrane-enclosed sacs that contain catalase and other oxidative enzymes. The enzymes break down lipids and toxic substances by first converting them into hydrogen peroxide and then breaking down the hydrogen peroxide into water and oxygen.	Not generally visible under a light microscope.	<i>peroxi</i> , relating to hydrogen peroxide + <i>soma</i> , body	
<i>Plasma Membrane</i>	Provides a selectively permeable barrier between the intracellular and extracellular environments of the cell.	Visible only using an electron microscope. However, the outer border of the cell, where the cell membrane is located, is often visible under the light microscope.	<i>plasma</i> , something formed + <i>membrane</i> , a membrane	
<i>Ribosomes</i>	Sites of protein synthesis: may be bound to the ER (“fixed”) or found within the cytoplasm (“free”).	Not generally visible under a light microscope.	<i>ribose</i> , the sugar in RNA + <i>soma</i> , body	

## Mitosis

The cell cycle describes the events that occur during the process of forming a new cell. As a cell passes through the stages of the cell cycle, two identical daughter cells are formed from one original parent cell. The cell cycle is divided into two main phases: interphase and mitotic phase. Interphase is the time in which the genetic material is uncoiled as chromatin. Mitotic phase (*mitos*, thread) includes the processes by which cells reproduce and includes mitosis (nuclear division, which is divided into four stages) and cytokinesis (*cyto-*, cell + *kinesis*, movement), which is division of the cytoplasm. Note that casual usage of the term “mitosis” usually implies

that the cytoplasm and cellular organelles have also divided. **Table 4.2** describes the microscopic appearance of cells in interphase and each of the four stages of mitosis. The four stages are (in order): prophase, metaphase, anaphase, and telophase. (The stages of mitosis can be remembered with the acronym P-MAT.) In this laboratory exercise the goal is to locate cells in interphase and each of the stages of mitosis by observing whitefish embryos (blastulas). Whitefish embryos are very small and are rapidly developing, which makes them ideal specimens for observing cells undergoing mitosis.



Table 4.2		Appearance of Whitefish Embryo Cells Undergoing Mitosis During Phases of the Cell Cycle		
<p><b>Interphase</b> <i>inter</i>, between + <i>phasis</i>, an appearance</p>		 <p>© Michael Abbey/Science Source</p>	<p>Loose chromatin is visible within the nucleus of the cell. No chromosomes are visible because they are uncoiled at this stage.</p>	
<p><b>Prophase</b> <i>pro</i>, before + <i>phasis</i>, an appearance</p>		 <p>© Ed Reschke/Getty Images</p>	<p>Chromosomes become visible as the chromatin coils around histone proteins. If the cell is in early prophase, the fibers of the mitotic spindle may be visible adjacent to the nucleus.</p>	
<p><b>Metaphase</b> <i>meta</i>, after + <i>phasis</i>, an appearance</p>		 <p>© Ed Reschke/Getty Images</p>	<p>Chromosomes are lined up at the center of the cell along the equatorial plate. Spindle fibers can often be seen extending between the poles of the cell and the chromosomes in metaphase.</p>	
<p><b>Anaphase</b> <i>ana</i>, apart + <i>phasis</i>, an appearance</p>		 <p>© Ed Reschke/Getty Images</p>	<p>Chromosomes are being pulled towards opposite poles of the cell. Thus, they often appear to be "v" shaped. Spindle fibers can be seen extending between the poles of the cell and the centromeres of the chromosomes.</p>	
<p><b>Telophase</b> <i>telos</i>, end + <i>phasis</i>, an appearance</p>		 <p>© Michael Abbey/Science Source</p>	<p>Chromosomes are located almost entirely at the opposite ends of the cell. If the cell is undergoing cytokinesis (cell division) as well as mitosis (nuclear division), the two resultant daughter cells will appear to be pinching off from each other.</p>	

**EXERCISE 4.2** Observing Mitosis in a Whitefish Embryo

1. Obtain a compound microscope and a prepared slide of a whitefish embryo (blastula) or other slide of cells undergoing mitosis.
2. Scan the slide and locate cells in interphase and the four stages of mitosis that are listed in table 4.2. Once a cell in a particular phase has been located, switch to a higher-power objective to see the cell more clearly. Note that not all cells undergo mitosis simultaneously. Therefore, cells in various stages of mitosis and interphase may all be observed on the same slide.
3. Sketch the appearance of cells in each of the listed phases in the spaces provided in table 4.2.

- |                                     |                                    |
|-------------------------------------|------------------------------------|
| <input type="checkbox"/> anaphase   | <input type="checkbox"/> prophase  |
| <input type="checkbox"/> interphase | <input type="checkbox"/> telophase |
| <input type="checkbox"/> metaphase  |                                    |

**WHAT DO YOU THINK?**

2. Chemotherapy treatments are given to cancer patients in an attempt to halt or slow the growth of a tumor, which is composed of rapidly dividing cells. Certain chemotherapy drugs exert their actions by interfering with mitosis. For example, some drugs act to prevent microtubules from lengthening or shortening. Microtubules are protein filaments that attach to chromosomes and centrioles, forming the mitotic spindle, which moves the chromosomes during mitosis. Based on this role of microtubules during mitosis, with which stage(s) of mitosis would these drugs most likely interfere?

**Gross Anatomy****Models of a Prototypical Cell**

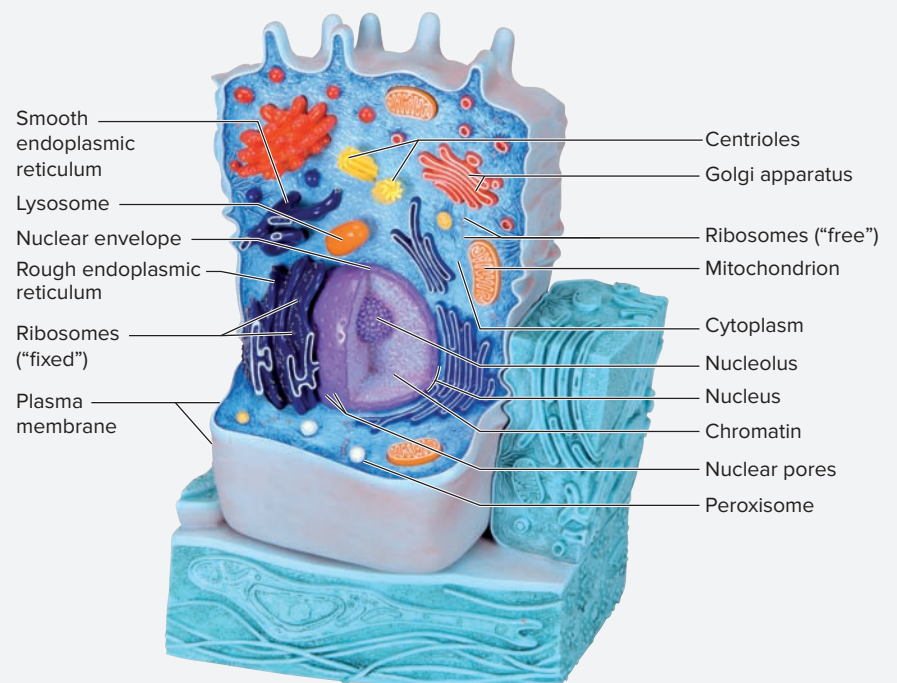
Exercises in this section involve observing classroom models demonstrating a prototypical cell. **Figure 4.3** is a photograph of a

classroom model of a prototypical cell, which has the organelles labeled for reference.

**EXERCISE 4.3** Observing Classroom Models of Cellular Anatomy

1. Obtain classroom models demonstrating a prototypical cell.
2. Identify the listed structures on the classroom model of a prototypical cell. Use figure 4.3, table 4.1, and the textbook as guides.

- |   |
|---|
| <input type="checkbox"/> centrioles                     |
| <input type="checkbox"/> chromatin                      |
| <input type="checkbox"/> cytoplasm                      |
| <input type="checkbox"/> Golgi apparatus                |
| <input type="checkbox"/> lysosome                       |
| <input type="checkbox"/> mitochondrion                  |
| <input type="checkbox"/> nuclear envelope               |
| <input type="checkbox"/> nucleolus                      |
| <input type="checkbox"/> nucleus                        |
| <input type="checkbox"/> peroxisome                     |
| <input type="checkbox"/> plasma membrane                |
| <input type="checkbox"/> ribosomes (“fixed” and “free”) |
| <input type="checkbox"/> rough endoplasmic reticulum    |
| <input type="checkbox"/> smooth endoplasmic reticulum   |



**Figure 4.3** Classroom Model of a Prototypical Animal Cell.

Model # R04 [1000523] © 3B Scientific GmbH, Germany, 2013 www.3bscientific.com

*This page intentionally left blank*

The ❶ corresponds to the Learning Objective(s) listed in the chapter opener outline.

## Do You Know the Basics?

### Exercise 4.1: Observing Cellular Anatomy with a Compound Microscope

- When preparing a wet mount of human cheek cells, the stain \_\_\_\_\_ (hematoxylin and eosin/methylene blue) must be used to visualize the parts of the cells. ❶
- Which of the following is most visible in a stained specimen demonstrating human cheek cells? (Circle one.) ❷
  - cytoplasm
  - nucleus
  - plasma membrane
  - rough endoplasmic reticulum
- Match the functions listed in column A with the appropriate cell structures listed in column B. ❸ ❹

#### Column A

- \_\_\_\_\_ 1. includes cellular organelles and cytosol; cytosol contains enzymes that mediate many cytosolic reactions such as glycolysis and fermentation
- \_\_\_\_\_ 2. composed of both protein and RNA; forms ribosomes
- \_\_\_\_\_ 3. sites of protein synthesis; may be bound to the ER ("fixed") or found within the cytoplasm ("free")
- \_\_\_\_\_ 4. membrane-enclosed sacs that contain oxidative enzymes (e.g., catalase)
- \_\_\_\_\_ 5. paired organelles composed of microtubules that are used to organize the mitotic spindles that attach to chromosomes during mitosis

#### Column B

- centrioles
- cytoplasm
- nucleolus
- peroxisomes
- ribosomes

### Exercise 4.2: Observing Mitosis in a Whitefish Embryo

- Match the features listed in column A with the appropriate stage of mitosis or interphase listed in column B. ❺ ❻

#### Column A

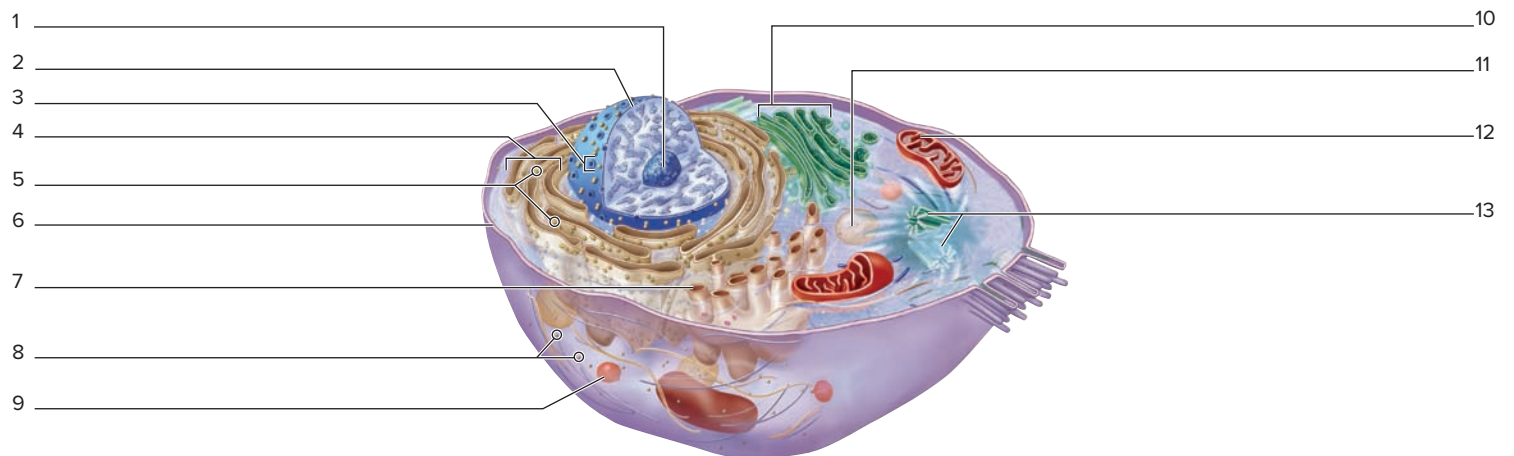
- \_\_\_\_\_ 1. chromosomes are located at opposite ends of the cell; a cleavage furrow may be visible
- \_\_\_\_\_ 2. chromosomes are being pulled toward the opposite poles of the cell
- \_\_\_\_\_ 3. chromatin coils into chromosomes, which become visible when viewed with a light microscope
- \_\_\_\_\_ 4. chromosomes line up at the center of the cell along the equatorial plate
- \_\_\_\_\_ 5. uncoiled chromatin exists within the nucleus of the cell; chromosomes are not visible when viewed with a light microscope

#### Column B

- anaphase
- interphase
- metaphase
- prophase
- telophase

### Exercise 4.3: Observing Classroom Models of Cellular Anatomy

- Label the structures in this diagram of a prototypical cell: ❼



*This page intentionally left blank*

## OUTLINE AND LEARNING OBJECTIVES

### Histology 58

#### Epithelial Tissue 58

##### EXERCISE 5.1: IDENTIFICATION AND CLASSIFICATION OF EPITHELIAL TISSUE 61

- 1 Identify the different types of epithelial tissues and their structures when viewed through a microscope
- 2 Classify an epithelial tissue. This includes classifying the tissue by cell shape, number of layers, and surface modifications
- 3 Identify the following specialized cells and surface modifications: goblet cells, keratinization, cilia, and microvilli
- 4 Identify apical and basal surfaces of epithelial tissues
- 5 Associate basic epithelial structures with associated functions

#### Connective Tissue 66

##### EXERCISE 5.2: IDENTIFICATION OF EMBRYONIC CONNECTIVE TISSUE 67

- 6 Identify mesenchyme

##### EXERCISE 5.3: IDENTIFICATION AND CLASSIFICATION OF CONNECTIVE TISSUE PROPER 69

- 7 Identify collagen and elastic fibers
- 8 Identify fibroblasts and adipocytes
- 9 Identify the types of connective tissue proper: areolar, adipose, reticular, dense regular, dense irregular, and elastic

##### EXERCISE 5.4: IDENTIFICATION AND CLASSIFICATION OF SUPPORTING CONNECTIVE TISSUE 74

- 10 Recognize the histological features unique to cartilage and bone
- 11 Compare and contrast the structure and locations of the three types of cartilage
- 12 List locations in the body where each type of cartilage is found
- 13 Identify osteons, osteoblasts, and osteocytes in a slide of compact bone

##### EXERCISE 5.5: IDENTIFICATION AND CLASSIFICATION OF FLUID CONNECTIVE TISSUE 76

- 14 Describe the properties of fluid connective tissue that characterizes it as a connective tissue
- 15 Identify the cells and extracellular matrix of fluid connective tissue

#### Muscle Tissue 77

##### EXERCISE 5.6: IDENTIFICATION AND CLASSIFICATION OF MUSCLE TISSUE 78

- 16 Compare and contrast the three types of muscle tissue
- 17 List locations in the body where each type of muscle tissue is found

#### Nervous Tissue 79

##### EXERCISE 5.7: IDENTIFICATION AND CLASSIFICATION OF NERVOUS TISSUE 80

- 18 Identify neurons and glial cells in a slide of nervous tissue
- 19 Describe the structural and functional differences between neurons and glial cells

## INTRODUCTION

This chapter of the laboratory manual introduces the practical study of **histology**, or tissue biology (*histo*, tissue + *logos*, the study of). **Tissues** consist of multiple cells that function together as a unit. An understanding of histology is important in the health sciences because many times the first manifestation of disease is seen at the tissue level of organization. For example, when a patient presents to his or her doctor with a tumor (*tumere*, to swell), one of the primary methods for determining the type of tumor and whether it is cancerous is to do a biopsy (take a tissue sample) and look at the tissue under a microscope. Thus, understanding normal histology is important for understanding histopathology (*histo*, tissue + *pathos*, disease). The Clinical View on p. 58 goes deeper into the important links between histology and histopathology.

This chapter introduces the key features of the four basic tissue types—epithelial, connective, muscle, and nervous. The text and figures provide descriptions of each tissue type and examples of where each tissue is located in the body.

The exercises in this chapter involve looking at tissues through the microscope. At first, it may seem as if every slide is simply a slide with a lot of “pink and purple stuff” on it. It may be difficult to identify particular tissue types and structures. However, with practice this will get easier.

Each section in this chapter covers one of the basic tissue types, and each exercise covers a specific tissue. The exercises need not be covered in a particular order. However, be sure to complete all exercises for one particular tissue type (e.g., epithelial tissues) before moving on to another tissue type.

**List of Reference Tables**

Table 5.1	Classification of Epithelial Tissue by Number of Cell Layers	p. 58
Table 5.2	Classification of Epithelial Tissue by Cell Shapes	p. 60
Table 5.3	Cell Surface Modifications and Specialized Cells of Epithelial Tissues	p. 60
Table 5.4	Connective Tissue Fibers	p. 67
Table 5.5	Connective Tissue Proper	p. 68
Table 5.6	Supporting Connective Tissue: Cartilage and Bone	p. 73
Table 5.7	Muscle Tissue	p. 77
Table 5.8	Nervous Tissue	p. 79

These Pre-laboratory Worksheet questions may be assigned by instructors through their **connect** course.

## PRE-LABORATORY WORKSHEET

- Which of the four basic tissue types is/are excitable? (Check all that apply.)  
 a. connective  
 b. epithelial  
 c. muscle  
 d. nervous
- All connective tissues are derived from an embryonic connective tissue called mesenchyme. \_\_\_\_\_ (True/False)
- Bone is classified as which of the following tissue types? (Circle one.)  
a. connective  
b. epithelial  
c. muscle  
d. nervous
- Which of the four tissue types contains an extensive extracellular matrix (ECM)? (Circle one.)  
a. connective  
b. epithelial  
c. muscle  
d. nervous
- Which of the three types of muscle tissue is/are striated? (Check all that apply.)  
 a. cardiac  
 b. skeletal  
 c. smooth
- Identify the basic tissue type that exhibits polarity (has both apical and basal surfaces). (Circle one.)  
a. connective  
b. epithelial  
c. muscle  
d. nervous
- Bone is a unique connective tissue that is avascular (lacking blood vessels). \_\_\_\_\_ (True/False)
- The loose connective tissue(s) that consists of fibers that stain black is/are \_\_\_\_\_. (Check all that apply.)  
 a. adipose  
 b. bone  
 c. dense regular  
 d. elastic  
 e. reticular
- Which of the following are classified as supportive connective tissues? (Check all that apply.)  
 a. adipose  
 b. bone  
 c. cartilage  
 d. muscle  
 e. reticular
- Fluid connective tissue includes both blood and lymph. \_\_\_\_\_ (True/False)




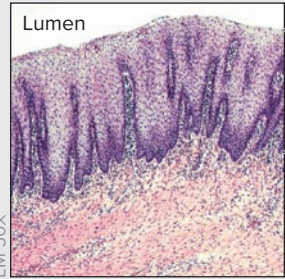
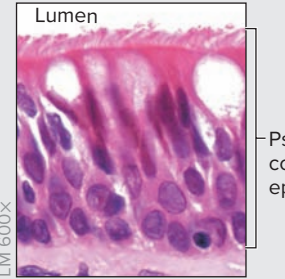
## Histology

### Epithelial Tissue

Epithelial tissues are tissues that cover body surfaces, line body cavities, and form the majority of glands. As such, they will have a free surface (see Learning Strategy on p. 61). Epithelial tissues are characteristically highly **cellular** (mostly composed of cells, with little extracellular material) and **avascular** (no blood vessels). Epithelial cells exhibit **polarity**; they have a distinct *basal* (bottom) and *apical* (top) surface. On their basal surface, they have a specialized extracellular structure called a **basement**

**membrane**, which anchors the epithelium to the underlying tissues. The characteristics used to classify epithelial tissue include (a) the number of layers of cells (simple, stratified, or pseudostratified) (**table 5.1**), (b) the shape of the cells on the *apical* surface of the epithelium (**table 5.2**), and (c) presence of any surface modifications (**table 5.3**).

**Figure 5.1** is a flowchart for classification of epithelial tissues that can be used as a tool when attempting to identify an unknown slide containing epithelial tissue. Following the flowchart will assist in the process of deciding how to classify an epithelial tissue.

Table 5.1 Classification of Epithelial Tissue by Number of Cell Layers			
Cell Layers	Simple Epithelium	Stratified Epithelium	Pseudostratified Epithelium
<b>Micrograph</b>	 <p>Lumen</p> <p>Simple columnar epithelium</p> <p>LM 70X</p> <p>© McGraw-Hill Education/AI Telser</p>	 <p>Lumen</p> <p>Stratified squamous epithelium</p> <p>LM 50X</p> <p>© McGraw-Hill Education/AI Telser</p>	 <p>Lumen</p> <p>Pseudostratified columnar epithelium</p> <p>LM 600X</p> <p>© McGraw-Hill Education/AI Telser</p>
<b>Description</b>	One cell layer thick; all epithelial cells make direct contact with the basement membrane.	Contains two or more layers of epithelial cells; only the deepest layer of cells makes direct contact with the basement membrane.	Appears stratified because all cell nuclei are not located the same distance from the basal surface; all epithelial cells make direct contact with the basement membrane.
<b>Generalized Functions</b>	Absorption, diffusion, filtration, or secretion	Protection or to resist abrasion	Absorption or secretion

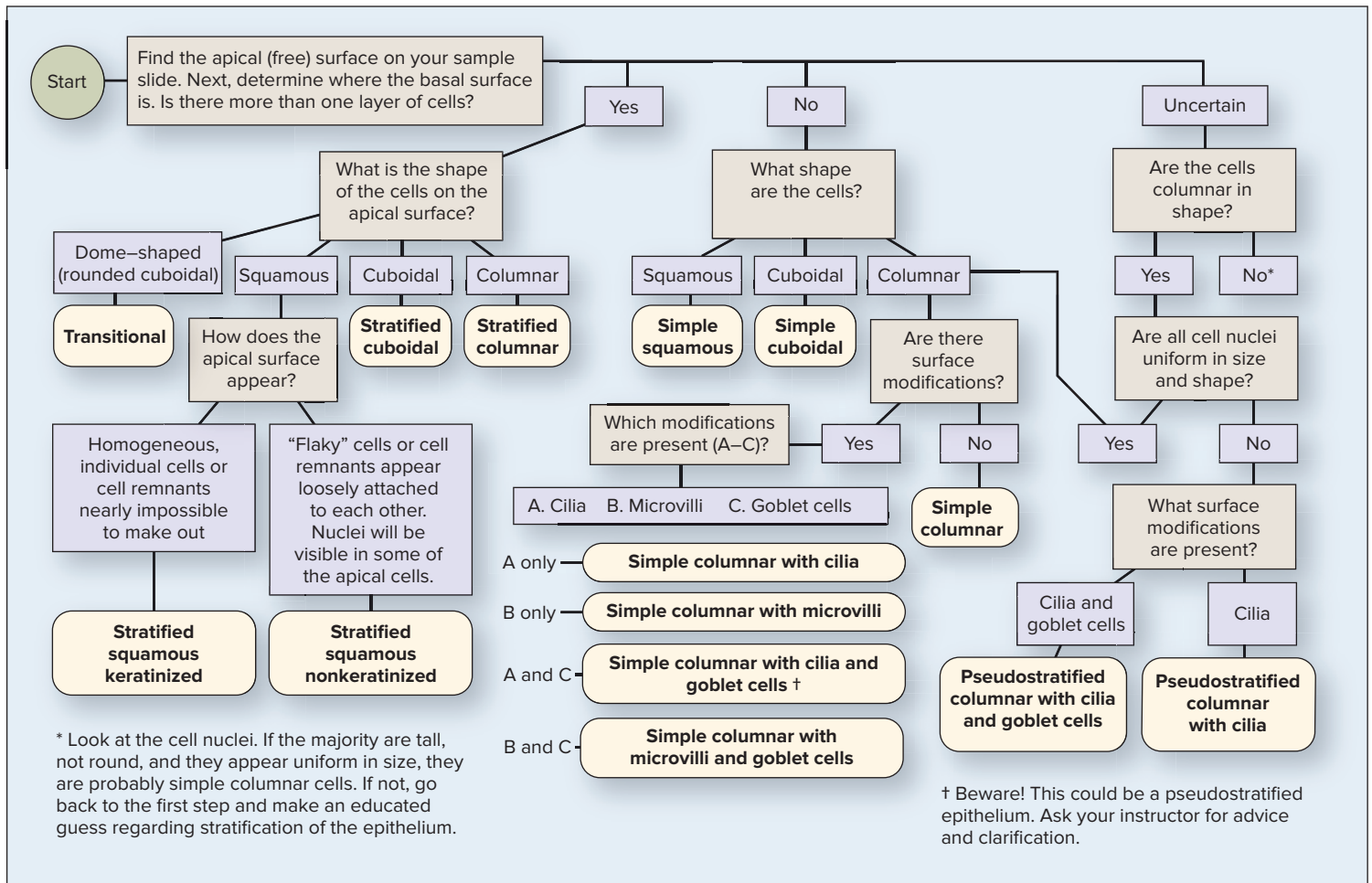
### Clinical View | Histopathology

Knowledge of the microscopic structure of tissues is critical for health professionals so they may be able to communicate with other medical professionals about tissue-level structures. Although most health professionals will rarely view slides of tissues in practice, nearly all health professionals will need to be able to interpret histopathology reports that are pertinent to their patients' diagnoses. A *histopathologist* is a physician and/or scientist who analyzes tissue samples that have been taken from a patient via biopsy (*bi*-two + *opsy*, inspection). Once the histopathologist receives the tissue sample in the laboratory, he or she goes through the following process to create a microscopic slide containing a slice of the tissue. This process is very similar to the process used to create the slides that are viewed in the anatomy & physiology laboratory.

Consider briefly how the slide shown in **figure 5.2** may have been prepared. The process of making a histology slide involves five general steps:

1. Obtain a tissue sample.
2. Prepare the tissue sample for slicing.
3. Cut thin slices of the tissue using a special knife called a microtome.
4. Transfer the tissue slices to a microscope slide.
5. Stain the slide.

After a tissue sample has been obtained, it must be made rigid so that it will be easy to slice. This is done either by freezing the tissue or by embedding the tissue in a block of paraffin wax. The next step

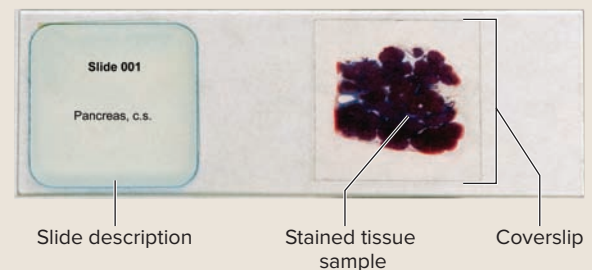


**Figure 5.1** Flowchart for Classifying Epithelial Tissues.

in preparing the slide involves slicing the frozen sample (or wax block) into very thin slices (on the order of micrometers—1 μm is 10<sup>-6</sup> meters) using a special knife called a microtome (*micro*-small + *tome* or *temmein*, to cut). The slices are cut so thin that often only a single layer of cells is contained in the slice. Once the slices are made, they are transferred to a microscope slide, which is then covered with a coverslip. Finally, the samples are stained to make intracellular and extracellular structures visible. The most common method of staining, hematoxylin and eosin (H and E), makes most structures appear pink or purple and makes the nucleus of the cell, in particular, easily visible.

Once a slide of a patient's tissue has been made, a histopathologist analyzes the sample to determine if the tissue appears as expected. Any variations from expected structure are then

characterized and described. These observations are analyzed in conjunction with lab tests to aid in making a clinical diagnosis of the patient's condition.



**Figure 5.2** Life-Size Histology Slide.

© Christine Eckel

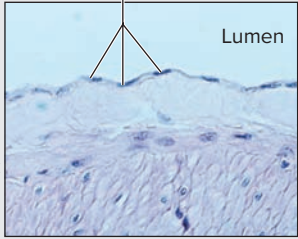

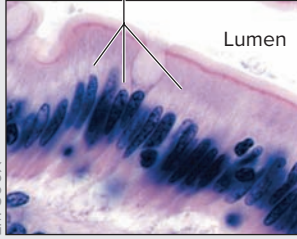

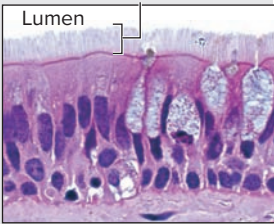
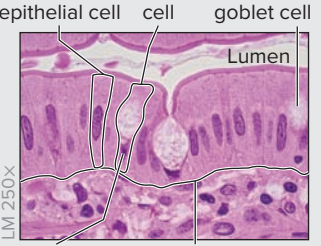
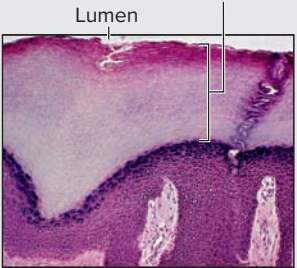
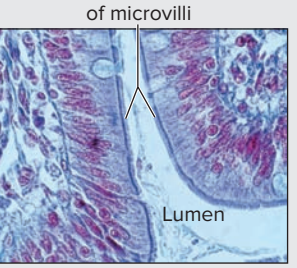
Table 5.2 Classification of Epithelial Tissue by Cell Shapes				
Cell Shape	Squamous	Cuboidal	Columnar	Transitional
<b>Micrograph</b>	<p>Squamous cells</p>  <p>LM 205X © Victor P. Eroschenko</p>	<p>Cuboidal cells</p>  <p>LM 165X © Victor P. Eroschenko</p>	<p>Columnar cells</p>  <p>LM 500X © McGraw-Hill Education/AI Telser</p>	<p>Transitional cell</p>  <p>LM 180X © McGraw-Hill Education/AI Telser</p>
<b>Description</b>	Cells are flattened and have irregular borders.	Cells are as tall as they are wide.	Cells are taller than they are wide.	Cells change shape depending on the stress on the epithelial tissue. The cells change between a cuboidal shape and a more flattened, squamous shape.
<b>Generalized Functions</b>	If the epithelium is only one cell layer thick, it provides a very thin barrier for <i>diffusion</i> . If the epithelium is several layers thick, the cells specialize in <i>protection</i> (as in epidermal cells of the skin).	The shape of the cell allows more room for cellular organelles (e.g., mitochondria, endoplasmic reticulum). Cuboidal cells generally function in <i>secretion</i> and/or <i>absorption</i> .	The large size of the cell allows even more room for cellular organelles (e.g., mitochondria, endoplasmic reticulum). Columnar cells generally function in <i>secretion</i> and/or <i>absorption</i> .	The fact that these cells change shape means that they are good at <i>resisting stretch</i> without being torn apart from each other. Transitional cells are only found lining structures of the urinary tract (e.g., ureters, urinary bladder).
<b>Identifying Characteristics</b>	In cross section, the nucleus is the most visible structure. The nucleus will be very flattened. In a surface view of the epithelium, the cell borders will be irregular in shape.	Generally, cuboidal cells are identified by their very round, plump nucleus, and by equal amounts of cytoplasm in the spaces between the nucleus and the plasma membrane on all sides.	The nuclei of columnar cells can be either oval or round in shape, and they generally line up in a row. If the nuclei are round, more cytoplasm will be visible between the nucleus and the plasma membrane on the apical side of the nucleus than on the other three sides.	Transitional cells are located on the apical surface of the epithelium. However, the transitional cells appear much more rounded or dome-shaped than typical cuboidal cells, and they are sometimes binucleate.

Table 5.3 Cell Surface Modifications and Specialized Cells of Epithelial Tissues				
Surface Modification	Cilia	Goblet Cells	Keratinization	Microvilli
<b>Micrograph</b>	<p>Cilia</p>  <p>LM 1000X © McGraw-Hill Education/Dennis Strete</p>	<p>Columnar epithelial cell, Goblet cell, Mucin within goblet cell</p>  <p>LM 250X © Ed Reschke/Getty Images</p> <p>Goblet Location of basement cell nucleus membrane</p>	<p>Keratinization</p>  <p>LM 25X © Ed Reschke/Getty Images</p>	<p>Brush border of microvilli</p>  <p>LM 130X © Victor P. Eroschenko</p>
<b>Description and Function</b>	Cilia are small, hairlike structures that extend from the apical surface of epithelial cells. Cilia actively move to <i>propel substances along the apical surface of an epithelial sheet</i> . Cilia move substances in only one direction.	Goblet cells are named for their shape. They are rounded near the apical surface and they narrow toward their basal surface. Goblet cells contain many small mucin granules and function in the <i>production of mucus</i> . The mucus is used to <i>assist in transport</i> of substances along an epithelial sheet, to <i>provide a protective barrier</i> along the apical surface of the epithelium, or to provide <i>lubrication</i> .	Stratified squamous epithelial cells of the skin contain keratin (an intermediate filament). Bundles of keratin fill up entire cells and bind to desmosomes, which firmly anchor the dead squamous epithelial cells together. The layers of cells appear to be a single homogeneous unit. Keratin imparts <i>strength</i> and <i>protection</i> to dead skin epithelial cells.	Microvilli are extremely small extensions of the plasma membrane of the apical surface of cells. Microvilli <i>increase the surface area</i> of the cell to enhance the process of <i>absorption</i> .
<b>Identifying Characteristics</b>	When cilia are present, and the slide is viewed at sufficient magnification, what appear to be individual “hairs” are visible on the apical surface of the epithelial cells.	Goblet cells are named for their shape. They are rounded near the apical surface and they narrow toward their basal surface. The shape is similar to the shape of a wine glass. The mucin inside the cells does not typically take up biological stains, so the cells often appear white or “empty.” If the slide is stained specifically for mucin, then the goblet cells will appear dark.	Keratinization is recognized as a homogeneous, acellular-looking portion of a stratified squamous epithelium.	Individual microvilli can be seen only when the specimen is viewed with an electron microscope. Thus, individual microvilli will <i>not</i> be visible with a light microscope. Instead, the apical surface of the epithelium will appear to be “fuzzy.” For this reason, epithelia containing microvilli are often said to have a “brush border.”

## Learning Strategy

When viewing a slide for the purpose of identifying an epithelial tissue, remember that epithelial tissues form linings and coverings of organs. Most histology slides typically contain more tissues than just epithelial tissues. To locate the epithelial tissue, first look for any white space, or “empty” space, on the slide. This space typically will be the outside of an organ or the lumen (inside) of the organ. The tissue that lies directly adjacent to the empty space will usually be an epithelial tissue.

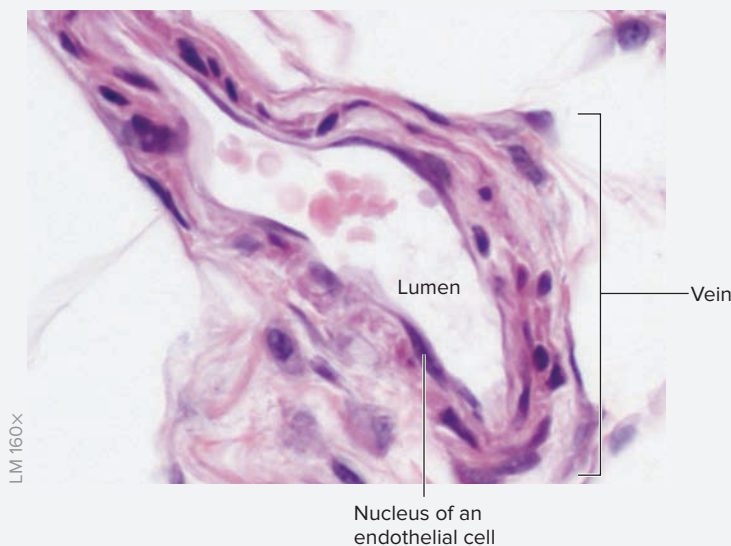
## Learning Strategy

A **simple** epithelium is only one cell layer thick. A **stratified** epithelium is two or more cell layers thick. Be aware that cell shape can vary in stratified epithelium. To avoid confusion, always identify the shapes of cells on the *apical* surface when classifying stratified epithelium.

### EXERCISE 5.1 Identification and Classification of Epithelial Tissue

#### EXERCISE 5.1A: Simple Squamous Epithelium

1. Obtain a slide of a small vein in cross section (**figure 5.3**) or a slide that the instructor has provided that contains simple squamous epithelium (e.g., kidney, mesentery).
2. Place the slide on the microscope stage and bring the tissue sample into focus using the scanning objective (low power).
3. Look for any “empty” space on the slide. The empty space on the slide will either be the inside of the vessel (the **lumen** of the vessel) or the outside edge of the tissue sample.



**Figure 5.3 Simple Squamous Epithelium.** Cross section through a small vein lined with endothelial cells, which are simple squamous epithelial cells.

© McGraw-Hill Education/AI Telsler

4. Locate the lumen of the vessel. Move the microscope stage so the tissue directly adjacent to the lumen is at the center of the field of view. Focus in on the epithelial tissue by first changing to medium power and then to high power. The lumen of all blood vessels, lymphatic vessels, and the heart is lined with a simple squamous epithelium called *endothelium*. This type of epithelium is always somewhat

difficult to see because it is extremely thin. If viewing a slide other than a vein, ask the instructor for assistance if a free surface or a lumen is not visible on the slide.

5. Once the lumen of the vessel has been identified and the epithelial tissue located (lining the lumen), change to high power. Look for the flattened nuclei of the squamous epithelial cells that line the lumen. It is unlikely that much, if any, of the cellular cytoplasm will be visible because the cells are extremely thin. Because simple squamous epithelium is extremely thin, it functions in diffusion—a process that occurs over very short distances (approximately 10  $\mu\text{m}$ ). Diffusion is the movement of particles from an area of high concentration to an area of low concentration, and is one mechanism by which substances are transported in the body.
6. Identify the following structures on the slide, using figure 5.3 and tables 5.2 and 5.3 as guides:
  - lumen of vein
  - nucleus of squamous epithelial cell
7. Sketch simple squamous epithelium as seen through the microscope in the space provided. Be sure to identify all the structures listed in step 6 in the drawing.



\_\_\_\_\_ ×

(continued on next page)

(continued from previous page)

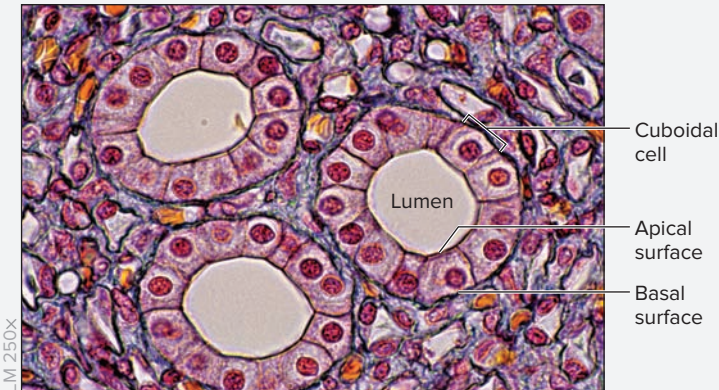
### Learning Strategy



Simple squamous epithelium lining the cardiovascular system is called **endothelium**. Simple squamous epithelium lining body cavities is called **mesothelium**. Thus, these terms (endothelium and mesothelium) indicate not only the *type* of epithelium (simple squamous), but also the *location* of the epithelium.

#### EXERCISE 5.1B: Simple Cuboidal Epithelium


1. Obtain a slide of the kidney (**figure 5.4**).
2. Place the slide on the microscope stage and bring the tissue sample into focus on low power.
3. Locate the lumen of a tubule in cross section (figure 5.4), and then identify the cells that lie next to the lumen. These cells should have plump, round nuclei and approximately equal amounts of cytoplasm surrounding each nucleus. These are cuboidal epithelial cells, which line the kidney tubules and function in secretion and absorption of substances across the epithelium (table 5.2).



**Figure 5.4** Simple Cuboidal Epithelium. Cross section of three kidney tubules demonstrating simple cuboidal epithelium.

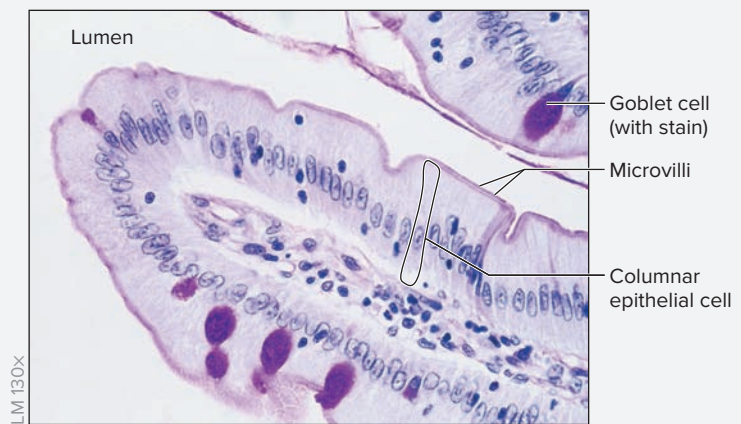© Ed Reschke/Getty Images

4. Identify the following structures on the slide, using figure 5.4 and table 5.2 as guides:
  - apical surface
  - basal surface
  - cuboidal cell
  - lumen of tubule
5. Sketch simple cuboidal epithelium as seen through the microscope in the space provided. Be sure to identify all the structures listed in step 4 in the drawing.



#### EXERCISE 5.1C: Simple Columnar Epithelium (nonciliated)

1. Obtain a slide of the small intestine (**figure 5.5**).
2. Place the slide on the microscope stage and bring the tissue sample into focus on low power.
3. This slide will show only a part of the wall of the intestine, so find some empty space on the slide first and then look for epithelium next to that empty space. Once the epithelium is in the center of the field of view, switch to high power. Look for epithelial cells with oval, elongated nuclei that have most of their cytoplasm on the apical side of the nucleus. Columnar cells are taller than they are wide, and their nuclei generally appear to be lined up in a row. The nuclei can be either elongated or round in shape.



**Figure 5.5** Simple Columnar Epithelium with Microvilli. Simple columnar epithelium with microvilli lining the lumen of the small intestine.


© Victor P. Eroschenko

4. This epithelium also demonstrates **goblet cells**, which secrete mucin, and **microvilli**, which increase the surface area of the epithelial cells for absorption (table 5.3).

5. Identify the following structures on the slide, using figure 5.5 and tables 5.2 and 5.3 as guides:

- columnar epithelial cell     lumen of intestine  
 goblet cell                     microvilli

6. Sketch simple columnar epithelium as seen through the microscope in the space provided. Be sure to identify all the structures listed in step 5 in the drawing.



4. Identify the following structures on the slide, using figure 5.6 and tables 5.2 and 5.3 as guides:

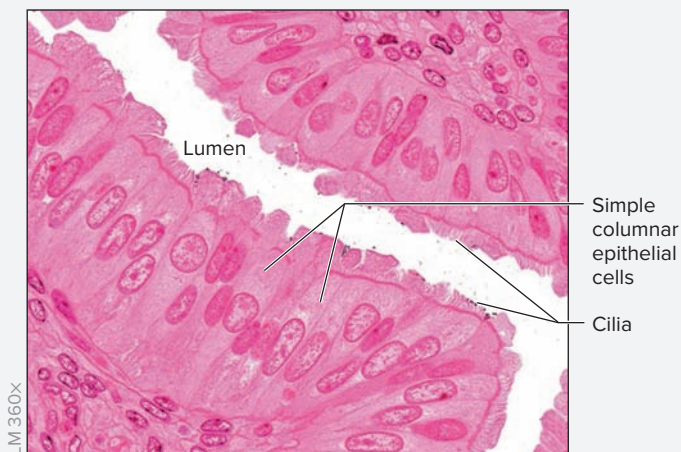
- cilia  
 lumen of uterine tube  
 simple columnar epithelial cell

5. Sketch simple columnar epithelium with cilia as seen through the microscope in the space provided. Be sure to identify all the structures listed in step 4 in the drawing.



#### EXERCISE 5.1D: Simple Columnar Epithelium (ciliated)

1. Obtain a slide of a uterine tube (figure 5.6).
2. Place the slide on the microscope stage and bring the tissue sample into focus on low power.
3. Look for a tubular structure cut in cross section (figure 5.6), and identify its lumen. Look for columnar epithelial cells next to the lumen. Once the epithelium is in the field of view, switch to high power. When cilia are present, the individual “hair”-like cilia should be visible on the apical surface of the epithelial cells.



**Figure 5.6** Simple Columnar Epithelium with Cilia. Simple columnar ciliated epithelium lining the lumen of the uterine tube.

© McGraw-Hill Education/Al Telser

#### WHAT DO YOU THINK?

- 3 What function do you think the cilia that line the uterine tube perform?

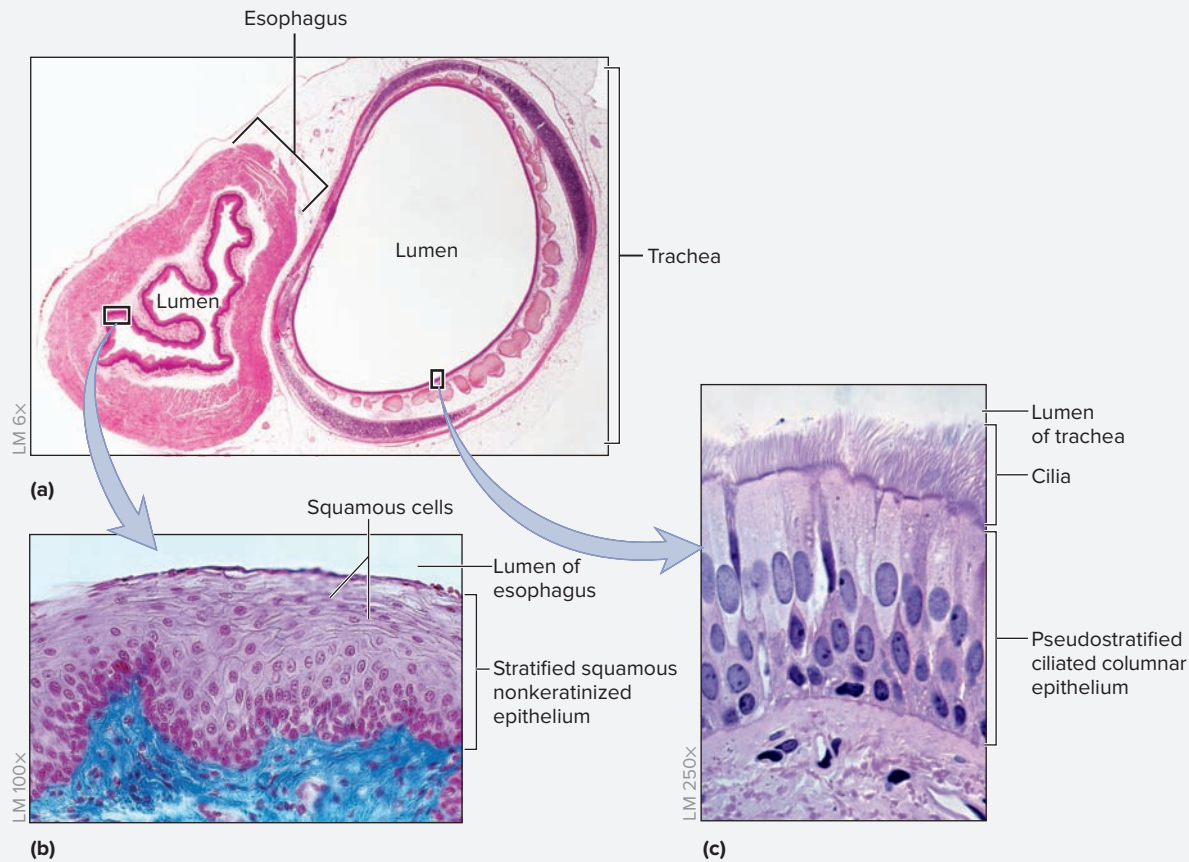
#### EXERCISE 5.1E: Stratified Squamous Epithelium (nonkeratinized)

1. Obtain a slide of the trachea and esophagus (figure 5.7a,b).
2. Place the slide on the microscope stage and bring the tissue sample into focus on low power.
3. The slide shown contains two different organs in cross section, the trachea and the esophagus. Look for the epithelium lining the esophagus, which consists of multiple layers of cells.
4. Locate the lumen of the esophagus (figure 5.7a), then identify stratified squamous nonkeratinized epithelium lining the lumen of the esophagus. The cells on the apical surface of this epithelium will appear flattened. This nonkeratinized stratified squamous epithelium is sometimes referred to as stratified squamous “moist” epithelium. It lines surfaces within the body that experience friction and abrasion, but where water loss is not a problem (e.g., lining the oral cavity, esophagus, and vagina).
5. Identify the following structures on the slide, using figure 5.7b and tables 5.2 and 5.3 as guides:

- lumen of esophagus  
 squamous epithelial cells  
 stratified squamous nonkeratinized epithelium

(continued on next page)


(continued from previous page)



**Figure 5.7 Trachea and Esophagus.** (a) Cross section through the trachea and esophagus. (b) Stratified squamous nonkeratinized epithelium lining the esophagus. (c) Pseudostratified ciliated columnar epithelium lining the trachea.

(a) © Science Stock Photography/Science Source; (b) © Victor P. Eroschenko; (c) © Ed Reschke/Getty Images

6. Sketch stratified squamous nonkeratinized epithelium as seen through the microscope in the space provided. Be sure to identify the structures listed in step 5 in the drawing.




7. Keep the slide on the microscope stage and proceed to exercise 5.1F to focus on the epithelium lining the trachea.

### EXERCISE 5.1F: Pseudostratified Columnar Epithelium

1. Obtain a slide of the trachea and esophagus (figure 5.7a).
2. Place the slide on the microscope stage and bring the tissue sample into focus on low power.
3. This slide will contain two organs in cross section, the trachea and the esophagus. Look for the epithelium lining the trachea, which contains ciliated cells.
4. Locate the lumen of the trachea (figure 5.7a), then identify pseudostratified columnar epithelium (figure 5.7c) lining the trachea. Once the epithelium is in the field of view, switch to high power. This epithelium is characterized by the presence of columnar cells that are not all the same height. All cells contact the basement membrane, but not all reach the apical surface. Because not all cells reach the apical surface of the epithelium, the nuclei will *not* be nicely lined up in rows as with simple columnar epithelium. Instead, the nuclei will appear to be layered. Hence, the name of this epithelium: **pseudostratified** (*pseudo-*, false). Most, but not all, pseudostratified epithelia also contain cilia and goblet cells.
5. Identify the following structures on the slide, using figure 5.7c and tables 5.2 and 5.3 as guides:

- cilia
- columnar epithelial cell
- lumen of trachea

- Sketch pseudostratified columnar epithelium as seen through the microscope in the space provided. Be sure to label the structures listed in step 5 in the drawing.




- Identify the following structures on the slide, using figure 5.8 and tables 5.2 and 5.3 as guides:
  - basement membrane
  - lumen of the duct
  - cuboidal epithelial cell

### Learning Strategy



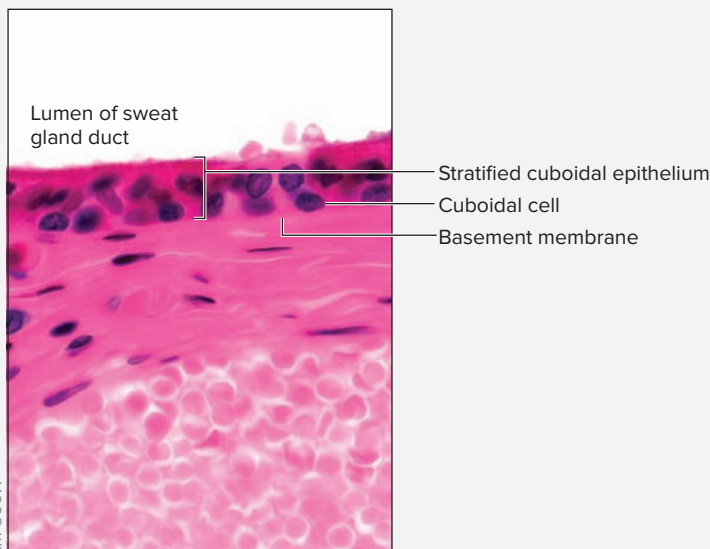
If the slide being viewed appears to be stratified columnar/cuboidal, but also has cilia, it *cannot* be stratified columnar/cuboidal. Only *pseudostratified* columnar epithelium can have cilia. That said, an epithelia *can* be pseudostratified and *not* have cilia, so the distinction only goes one way.

- Sketch stratified cuboidal (or stratified columnar) epithelium as seen through the microscope in the space provided. Be sure to label the structures listed in step 4 in the drawing.



### EXERCISE 5.1G: Stratified Cuboidal or Stratified Columnar Epithelium

- Obtain a slide of a merocrine sweat gland (figure 5.8).
- Place the slide on the microscope stage and bring the tissue sample into focus on low power.
- Locate the lumen of a duct of the sweat gland (figure 5.8). Identify stratified cuboidal epithelium next to the lumen. Once the epithelium is in the field of view, switch to high power. Stratified cuboidal epithelium is found lining the ducts of merocrine sweat glands, which are located in the dermis of the skin. Stratified cuboidal epithelium is generally only two cell layers thick. How many layers are visible on the slide? The laboratory may have other slides available that demonstrate stratified *columnar* epithelium lining the ducts of other exocrine glands. As with stratified cuboidal epithelium, stratified columnar epithelium is also rarely more than two cell layers thick.



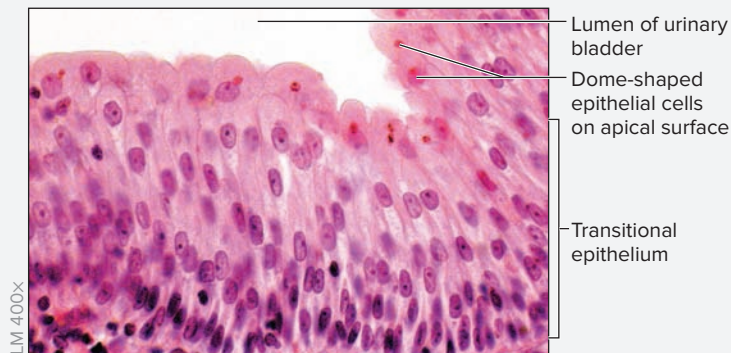
**Figure 5.8 Stratified Cuboidal Epithelium.** Epithelium lining the duct of a merocrine sweat gland.

### EXERCISE 5.1H: Transitional Epithelium

- Obtain a slide of the urinary bladder (figure 5.9).
- Place the slide on the microscope stage and bring the tissue sample into focus on low power.
- This slide will show only a part of the wall of the bladder, so first locate the empty space and then look for epithelium next to that empty space. Locate the transitional epithelium. Once the epithelium is in the field of view, switch to high power. Transitional epithelium is stratified, and it can look very similar to stratified squamous epithelium. However, the cells on the apical surface will appear cuboidal in shape, they will be much more rounded or dome-shaped than typical cuboidal cells, and they may contain more than one nucleus per cell (these cells are sometimes referred to as “dome” or “umbrella” cells).
- Observe the cells on the basal surface of the transitional epithelium. These cells are usually columnar in shape, in contrast to the cells on the basal surface of a stratified squamous epithelium, which tend to be more cuboidal in shape. Transitional epithelium is found lining the urinary bladder and other urine-draining structures. Its structure allows the epithelium to stretch easily to accommodate the



(continued from previous page)



**Figure 5.9 Transitional Epithelium.** Epithelium lining the urinary bladder.

© McGraw-Hill Education/Christine Eckel, photographer

passage or storage of urine without causing the epithelial cells to tear apart.

- Identify the following structures on the slide, using figure 5.9 and tables 5.2 and 5.3 as guides:
  - dome-shaped epithelial cells
  - lumen of urinary bladder
  - transitional epithelium
- Sketch transitional epithelium as seen through the microscope in the space provided. Be sure to label the structures listed in step 5 in the drawing.

### Learning Strategy

Students often confuse the terms *basement membrane* and *basal surface*. To clarify, the **basement membrane** is a connective tissue structure that lies at the **basal surface** of the epithelium. The two terms are not synonymous. That is, the basement membrane is a *structure*; the basal surface is a *location*. Also note that the

basement membrane is an extracellular structure on which the epithelium rests. The function of the basement membrane is to anchor the epithelium to the underlying connective tissue, provide physical support for the epithelium, and act as a barrier to regulate the passage of large molecules between the epithelium and the underlying tissues.

### Clinical View

The presence of epithelial modifications such as cilia, microvilli, and goblet cells in epithelial tissues reveals the overall function of the epithelium in question. In the exercises in this chapter, representative examples of each type of epithelial tissue are being observed. These examples will be revisited in the histology sections of subsequent chapters, where they will be covered in more detail. Rather than memorizing the locations of these tissues at this time, focus on identifying how the modification relates to tissue function.

Cilia aid in *movement/transport*, microvilli aid in *absorption*, and goblet cells aid in *lubrication*. For example, consider the epithelial tissue lining the upper respiratory structures: pseudostratified ciliated columnar epithelium. This epithelium contains goblet cells, which produce mucus, and cilia, which trap and transport mucus and debris along the epithelial surface. Together, these modifications form a “mucus escalator” that prevents foreign objects and pathogens from entering lower respiratory tract structures. Damage to this epithelium, specifically the cilia, is detrimental, because it renders the lower respiratory tract more prone to infection.

### Connective Tissue

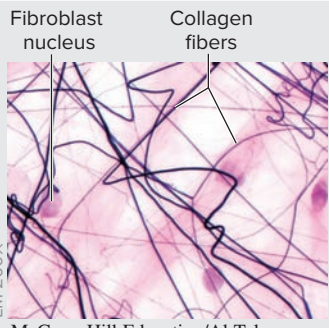

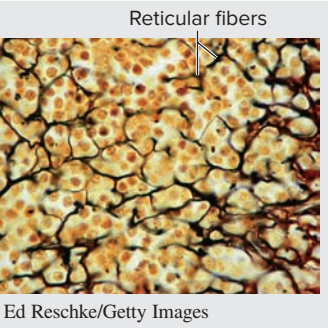
All connective tissues share three basic components: cells, protein fibers, and ground substance. The different types of protein fibers include collagen, elastic, and reticular (see **table 5.4**). Connective tissues are derived from an embryonic tissue called **mesenchyme** (**figure 5.10**). There are three broad categories of mature connective tissues: connective tissue proper, supporting connective tissues, and fluid connective tissues. **Connective tissue proper**

is the “glue” that holds things together (such as tendons and ligaments) and the “stuffing” that fills in spaces (such as the fat that fills in spaces between muscles). Subcategories of connective tissue proper include both loose connective tissue (areolar, adipose, and reticular) and dense connective tissue (dense regular, dense irregular, and elastic) as described in **table 5.5**. **Supporting connective tissues** (cartilage and bone) are specialized connective tissues that provide support and protection for the body. **Fluid connective tissues** (blood and lymph) are specialized connective tissues

- Optional Activity:* **AP|R 3: Tissues**—Watch the “Epithelial Tissue Overview” animation.

### WHAT DO YOU THINK?

- In table 5.1, cuboidal and columnar epithelial cells are described as having a shape that accommodates more cellular organelles than squamous epithelial cells. Because cuboidal and columnar epithelial cells function to transport substances across an epithelial lining for the processes of absorption and secretion, what organelles might they contain that would not be found in a simple squamous epithelial cell (which functions mainly as a thin barrier for diffusion)?

Table 5.4 Connective Tissue Fibers			
Fiber Type	Collagen	Elastic	Reticular
<b>Micrograph</b>			
<b>Identifying Characteristics</b>	Thicker than elastic or reticular fibers and usually somewhat <i>pale</i> in color. Collagen fibers stain either <i>pink</i> or <i>blue</i> , depending on the stain used.	Appear either as fine, thin <i>black</i> fibers (when a silver stain is used) or as thin, <i>wavy</i> fibers (when silver stain is not used).	Composed of a fine, thin type of collagen. Reticular fibers can be seen only when a silver stain is applied. The fibers appear as an <i>irregular network</i> of thin <i>black</i> fibers ( <i>reticular, network</i> ). Reticular fibers are much shorter than elastic fibers.
<b>Functions</b>	Collagen fibers are good at <i>resisting tensile (stretching) forces</i> . They are good at resisting stretch in only one direction, along the long axis of the fiber.	Elastic fibers have the <i>ability to stretch and recoil</i> . They will often stretch to greater than 150% of their resting length without damage. Too much stretch will break the fiber.	Reticular fibers <i>form a delicate inner supporting framework</i> for highly cellular organs such as the liver, spleen, and lymph nodes.

that function to transport substances throughout the body. The details of bone and blood are covered in chapters 7 and 20 of this laboratory manual.

### Connective Tissue Proper

Connective tissue proper is a kind of “grab bag” category that contains all of the unspecialized connective tissues (i.e., any connective tissue other than supporting or fluid connective tissues). These tissues are used either to hold things together (as with tendons and ligaments) or

to fill up space (as with adipose tissue). Loose connective tissues have a loose association of cells and fibers, whereas dense connective tissues have cells and fibers that are densely packed together, which makes them much tougher than loose connective tissues. Table 5.5 summarizes the characteristics of the different types of connective tissue proper. **Figure 5.11** is a flowchart for classification of connective tissue proper that can be used when attempting to identify an unknown slide containing connective tissue.

### EXERCISE 5.2 Identification of Embryonic Connective Tissue

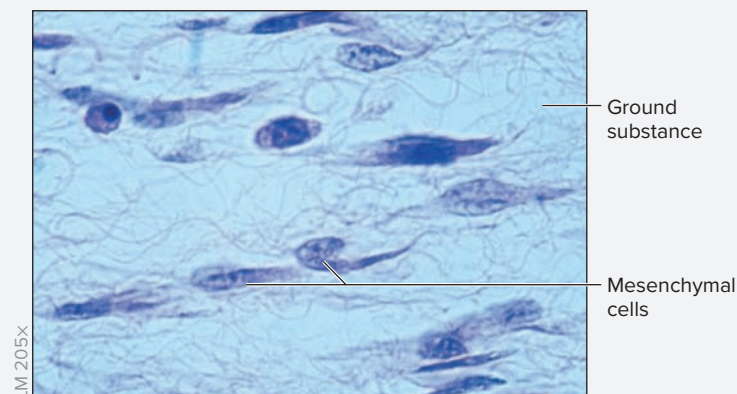
1. Obtain a slide of mesenchyme (figure 5.10).
2. Place the slide on the microscope stage and bring the tissue sample into focus on low power, then switch to high power.
3. Notice that there are no visible fibers within the extracellular matrix (mature fibers do not yet exist within mesenchyme). The **mesenchymal cells** are recognized by their large oval nuclei. Mesenchyme has the ability to differentiate into any of the mature connective tissue cell types. That is, mesenchymal cells can differentiate into any of the adult

connective tissue cell types (e.g., fibroblasts, chondroblasts, osteoblasts).

4. Identify the following structures on the slide, using figure 5.10 as a guide:


- ground substance**
- mesenchymal cell**

5. Sketch mesenchyme as seen through the microscope in the space provided. Be sure to label the structures listed in step 4 in the drawing.



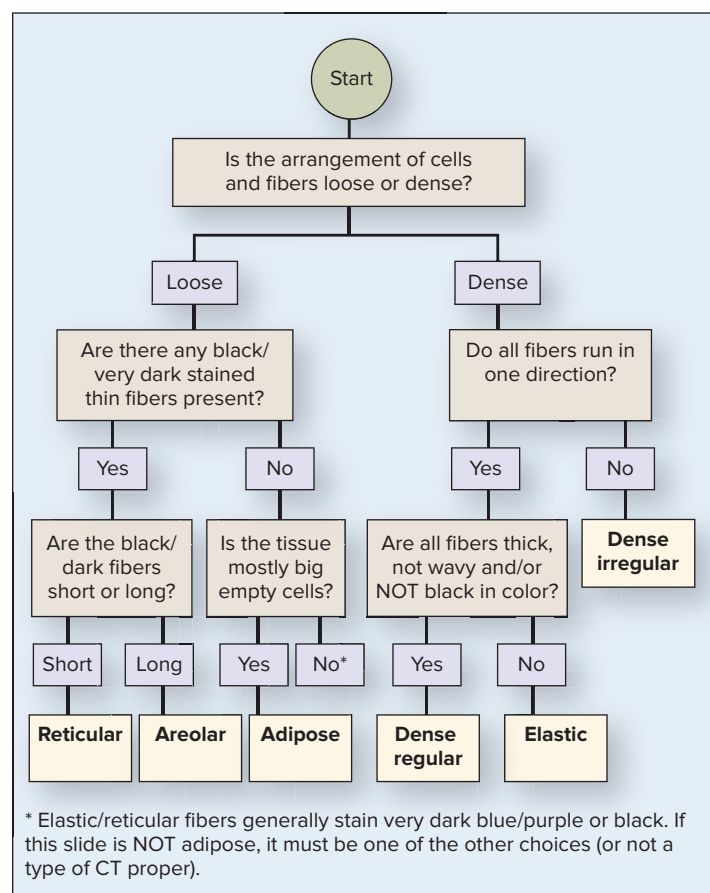
**Figure 5.10 Mesenchyme.** Mesenchyme is embryonic connective tissue.

© Victor P. Eroschenko



×

Table 5.5 Connective Tissue Proper		
Classification	Description and Function	Location(s)
<b>Loose Connective Tissue</b>		
<b>Areolar</b> (figure 5.12)	Consists of a loose arrangement of collagen and elastic fibers with numerous fibroblasts. Areolar connective tissue loosely anchors structures to each other or fills in spaces between organs.	Located in the superficial fascia below the skin, which anchors skin to underlying muscle. It is also found surrounding many organs.
<b>Adipose</b> (figure 5.13)	Characterized by adipocytes, which appear to be large, “empty” cells because the process of preparing the tissue removes all lipid within the cells. Collagen fibers located between the adipocytes hold the tissue together. Adipose tissue functions in insulation, protection, and energy storage.	Subcutaneous (under the skin). Surrounds organs such as the kidneys, where it provides protection. Fills in potential spaces such as within the popliteal fossa.
<b>Reticular</b> (figure 5.14)	Composed of reticular fibers, which form an inner supporting framework for highly cellular organs such as the liver.	The inner stroma ( <i>stroma</i> , bed) of organs such as the spleen, liver, and lymph nodes.
<b>Dense Connective Tissue</b>		
<b>Dense Regular</b> (figure 5.15)	Composed of regular bands of collagen fibers all oriented in the same direction. The flattened nuclei of fibroblasts can be seen between bundles of collagen fibers. Dense regular connective tissue is good at resisting tensile forces in one direction only.	Tendons (connect muscle to bone) and ligaments (connect bone to bone).
<b>Dense Irregular</b> (figure 5.16)	Composed of bundles of collagen fibers arranged in many directions. Fibroblast nuclei can be seen between bundles of collagen fibers. Some nuclei appear round (if cut in cross section) and some appear flattened (if cut in longitudinal section). Many of the collagen fibers appear wavy because they are not all cut along the same plane. This tissue is tough and resists tensile forces applied in multiple directions.	Organ capsules, dermis of the skin, periosteum (outer covering of bone), perichondrium (outer covering of cartilage).
<b>Elastic</b> (figure 5.17)	Consists of both collagen and elastic fibers all oriented in the same direction. Collagen fibers are thick and typically stain light pink or purple. Elastic fibers appear thin and black (if stained) or wavy. Fibroblast nuclei can be seen between the densely packed fibers. Elastic connective tissue is extensible and allows structures to stretch and recoil back to their original shape.	Walls of large arteries such as the aorta and some ligaments.



**Figure 5.11** Flowchart for Classifying Connective Tissue Proper.

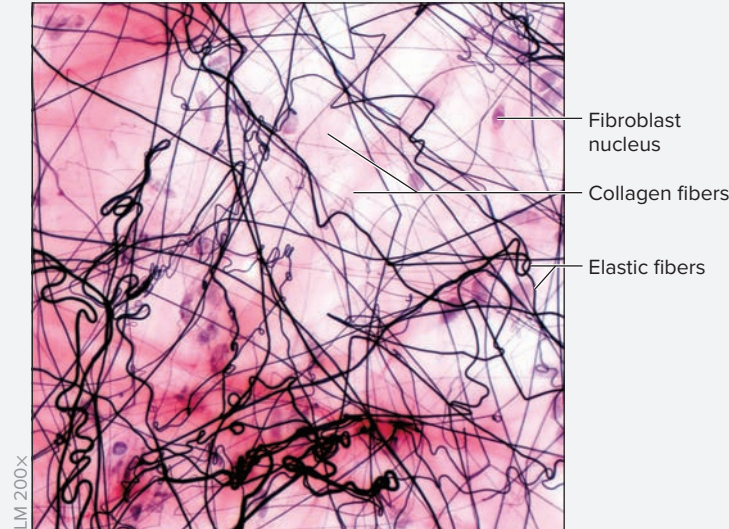
### Learning Strategy

Though a variety of stains are used for visualization of cells and tissues, certain tissues are visible only when special stains are used. In connective tissues, elastic and reticular fibers can be seen only when a special stain is used that stains the fibers black. Thus, if black fibers are visible, these are either elastic or reticular fibers. If the black fibers are very long and thin or wavy, they are elastic fibers. If they are short and form a network (*rete*, network), they are reticular fibers.

**EXERCISE 5.3 Identification and Classification of Connective Tissue Proper**


**EXERCISE 5.3A: Areolar Connective Tissue**

1. Obtain a slide of areolar connective tissue (**figure 5.12**).
2. Place the slide on the microscope stage and bring the tissue sample into focus on low power. Then change to high power.



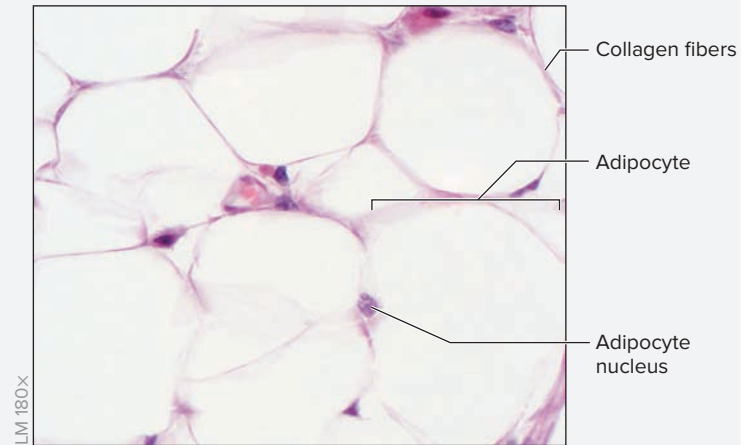
**Figure 5.12 Areolar Connective Tissue.** Areolar connective tissue contains predominantly fibroblasts, collagen fibers, and elastic fibers.  
© McGraw-Hill Education/AI Telser

3. Several small cells are scattered throughout the slide. Most of these cells are **fibroblasts**, which secrete the elastic and collagen fibers (table 5.5). Collagen fibers will generally be light pink in color and somewhat thick. Elastic fibers will generally be long and thin, and will stain very dark or black.
4. Identify the following structures on the slide, using figure 5.12 and tables 5.4 and 5.5 as guides:
  - collagen fibers
  - fibroblasts
  - elastic fibers
5. Sketch areolar connective tissue as seen through the microscope in the space provided. Be sure to label the structures listed in step 4 in the drawing.



**EXERCISE 5.3B: Adipose Connective Tissue**

1. Obtain a slide of adipose connective tissue (**figure 5.13**).
2. Place the slide on the microscope stage and bring the tissue sample into focus on low power. Then change to high power.



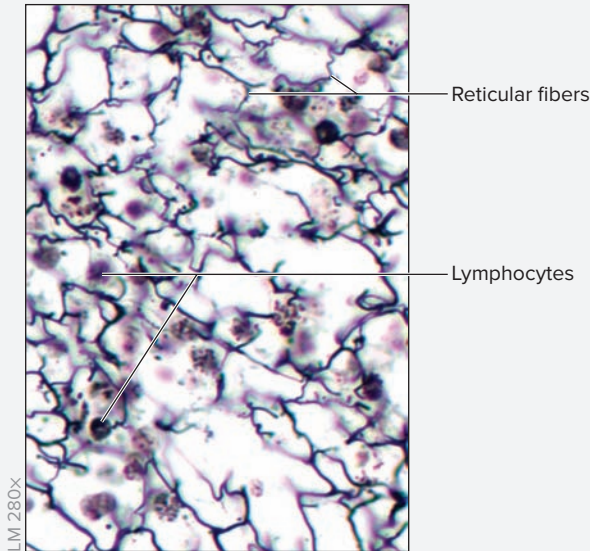
**Figure 5.13 Adipose Connective Tissue.** Adipose connective tissue is characterized by large adipocytes held together with a loose arrangement of collagen fibers.  
© McGraw-Hill Education/AI Telser

3. Identify the following structures on the slide, using figure 5.13 and tables 5.4 and 5.5 as guides:
  - adipocyte
  - collagen fibers
  - adipocyte nucleus
4. Sketch adipose connective tissue as seen through the microscope in the space provided. Be sure to label all the structures listed in step 3 in the drawing.



**EXERCISE 5.3C: Reticular Connective Tissue**

1. Obtain a slide of reticular connective tissue (**figure 5.14**).
2. Place the slide on the microscope stage and bring the tissue sample into focus on low power. Then change to high power.



**Figure 5.14 Reticular Connective Tissue.** Reticular connective tissue consists of reticular fibers (a fine, thin form of collagen) that are visible only when a special stain is used, which makes them appear black.  
© McGraw-Hill Education/AI Telser

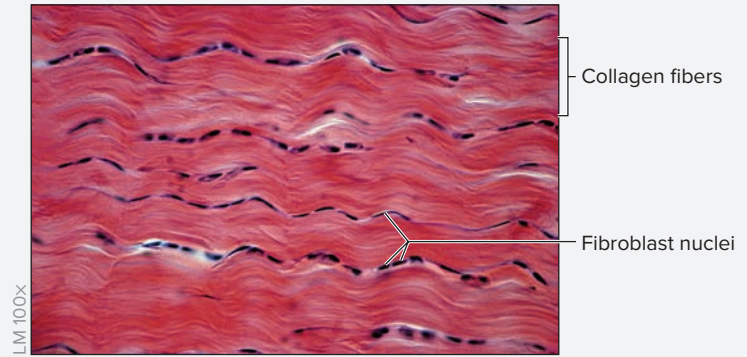
3. Identify the following on the slide, using figure 5.14 and tables 5.4 and 5.5 as guides:
  - lymphocytes
  - reticular fibers
4. Sketch reticular connective tissue as seen through the microscope in the space provided. Be sure to label all the structures listed in step 3 in the drawing.



**EXERCISE 5.3D: Dense Regular Connective Tissue**

1. Obtain a slide of a tendon or ligament (**figure 5.15**).
2. Place the slide on the microscope stage and bring the tissue sample into focus on low power. Then change to high power.
3. Identify the following structures on the slide, using figure 5.15 and tables 5.4 and 5.5 as guides:

- collagen fibers
- fibroblast nuclei



**Figure 5.15 Dense Regular Connective Tissue.** Dense regular connective tissue consists of bundles of collagen fibers all oriented in the same direction, with fibroblasts located between the bundles of collagen fibers.

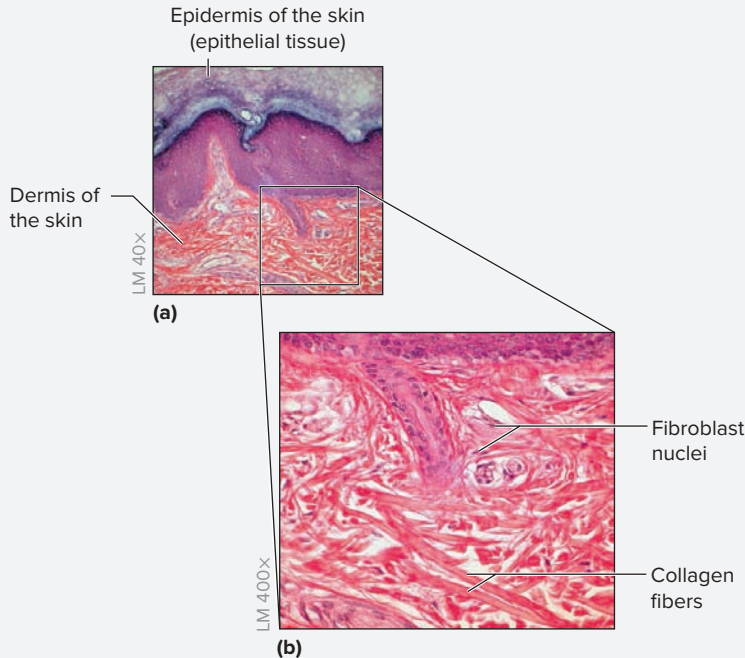
© Ed Reschke/Getty Images

4. Sketch dense regular connective tissue as seen through the microscope in the space provided. Be sure to label the structures listed in step 3 in the drawing.



**EXERCISE 5.3E: Dense Irregular Connective Tissue**

1. Obtain a slide of skin (**figure 5.16**). Skin consists of two major layers, an outer epidermis, composed of stratified squamous epithelial tissue, and an inner dermis, composed of connective tissue (areolar and dense irregular).



**Figure 5.16 Dense Irregular Connective Tissue.** Dense irregular connective tissue is located in the dermis of the skin. (a) Dense irregular connective tissue consists of bundles of collagen fibers oriented in many different directions, with fibroblasts located between the bundles of collagen fibers (b).

© McGraw-Hill Education/Christine Eckel, photographer

2. Place the slide on the microscope stage and bring the tissue sample into focus using the scanning objective. Identify the epithelial tissue in the epidermis (figure 5.16a), then move the stage so the lens focuses on the underlying connective tissue in the dermis (figure 5.16b). Switch to a higher-power objective.
3. Identify the following structures on the slide, using figure 5.16 and tables 5.4 and 5.5 as guides:

- collagen fibers
- fibroblast nucleus

4. Sketch dense irregular connective tissue as seen through the microscope in the space provided. Be sure to label the structures listed in step 3 in the drawing.

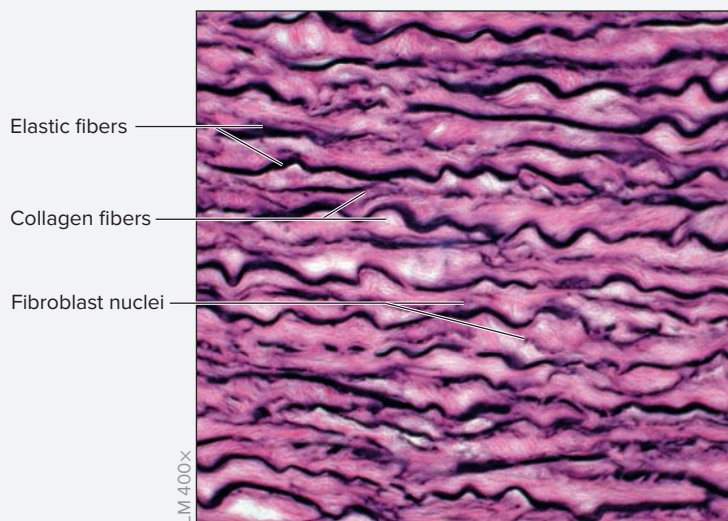
**EXERCISE 5.3F: Elastic Connective Tissue**

1. Obtain a slide of the aorta or an elastic artery (**figure 5.17**).
2. Place the slide on the microscope stage and bring the tissue sample into focus on low power. Then switch to high power.
3. Identify the following structures on the slide, using figure 5.17 and tables 5.4 and 5.5 as guides:
  - collagen fibers
  - elastic fibers
  - fibroblasts

**Learning Strategy**

Sometimes it helps to relate what is seen through the microscope to something that is already familiar. For example, the regular arrangement of collagen fibers in dense regular connective tissue often resembles uncooked lasagna noodles stacked upon each other, whereas the irregular arrangement of collagen and elastic fibers in areolar connective tissue often resembles a piece of abstract art.

(continued on next page)

*(continued from previous page)*

**Figure 5.17 Elastic Connective Tissue.** The wall of the aorta consists of dense regular elastic connective tissue, which contains both collagen and elastic fibers (which stain black). All the fibers are oriented in the same direction. In this slide, the collagen fibers are dark pink and the elastic fibers are black and wavy. Some fibroblast nuclei are visible between the bundles of fibers.

© McGraw-Hill Education/Christine Eckel, photographer

4. Sketch elastic connective tissue as seen through the microscope in the space provided. Be sure to label the structures listed in step 3 in the drawing.



## Supporting Connective Tissue

### Cartilage

Cartilage is a specialized connective tissue whose function is to provide strong, yet flexible, support. Cartilage is unique as a connective tissue in that it is avascular (*a-*, without + *vasa*, vessel). A dense irregular connective tissue covering, called the perichondrium, surrounds all types of cartilage except fibrocartilage. The innermost part of the perichondrium contains immature cartilage cells called chondroblasts. The function of the chondroblasts is to secrete the fibers and ground substance that compose the extracellular matrix of cartilage. As a chondroblast secretes extracellular matrix, it eventually becomes completely surrounded by the matrix; at this point it is considered a mature cell, a chondrocyte. The space in the matrix where a chondrocyte sits is a lacuna (*lacus*, a lake). The function of a chondrocyte is to maintain the matrix that has already been formed. All types of cartilage contain chondrocytes in lacunae and have a ground substance that consists largely of glycosaminoglycans (GAGs). The three types of cartilage differ mainly in the type and arrangement of fibers within the matrix. **Table 5.6** summarizes the characteristics of the different types of cartilage.

### Bone

Bone (table 5.6) is a specialized connective tissue whose function is to provide strong support. It protects vital organs and provides strong attachment points for skeletal muscles. Similar to cartilage, bone is surrounded by a dense irregular connective tissue covering, called the periosteum. The innermost part of the periosteum contains precursor bone cells called osteoprogenitor cells, which develop into immature bone cells called osteoblasts. Osteoblasts secrete the extracellular matrix (fibers and ground substance) of bone. When osteoblasts become completely enveloped by the bony matrix, they become mature osteocytes.

There are two types of bone tissue: compact bone (dense) and spongy bone (cancellous). The structural and functional unit of compact bone is an osteon, which consists of concentric layers of bony matrix (lamellae). Along the lamellae are lacunae that contain osteocytes. The details of the two types of bone tissue will be covered in chapter 7.

**Figure 5.18** is a flowchart for classification of supporting connective tissues that can be used when attempting to identify an unknown slide of connective tissue.

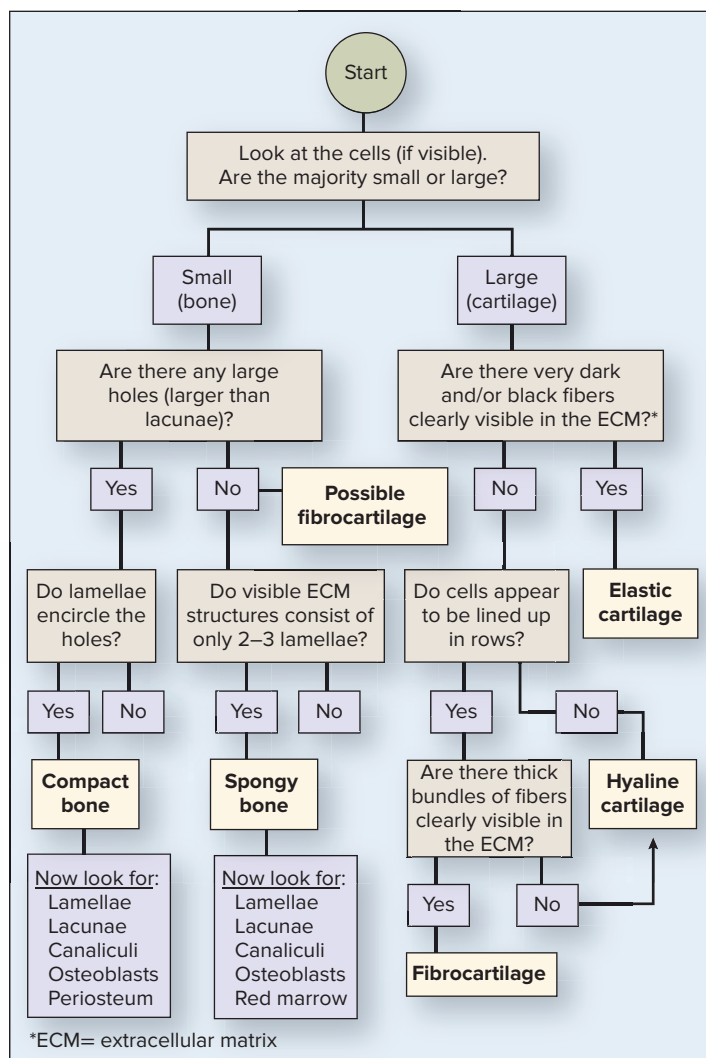
### Learning Strategy



Imagine that chondroblasts and osteoblasts, as immature cells, are akin to “immature” young adults who do not yet own a home. As these cells mature, they build the extracellular matrix (ECM) around themselves as if they are building the walls of a home. This “home” that chondrocytes and osteocytes eventually come to live in is a lacuna. Once a *chondroblast* or *osteoblast* occupies

a “home” (lacuna), it can be considered “mature,” so the name of the cell changes to *chondrocyte* or *osteocyte*, respectively. As for the “immature” young adults, once they have built a home—and signed a mortgage to pay for it—they, too, can be considered “mature.” The function of these mature cells (and adults) switches from building the home to repairing and maintaining the home that they have already built!

Table 5.6 Supporting Connective Tissue: Cartilage and Bone			
Tissue Type	Description	Functions and Locations	Identifying Characteristics
<b>Hyaline Cartilage</b>	Chondrocytes are located within lacunae. Contains a perichondrium of dense irregular connective tissue. Extracellular matrix consists of diffuse collagen fibers spread throughout a semi-rigid ground substance, which is composed mainly of glycoproteins and water.	Hyaline cartilage provides <i>strong, semiflexible support</i> for structures such as the nasal septum, costal cartilages, articular cartilages, larynx, and tracheal “C” rings.	Hyaline cartilage is recognized by the chondrocytes in lacunae and the fact that no fibers are visible in the extracellular matrix.
<b>Fibrocartilage</b>	Very similar to hyaline cartilage except there is no perichondrium and the collagen fibers form thick visible bundles.	The organization and density of the collagen fibers make fibrocartilage particularly effective at <i>resisting compressive forces</i> . Located in areas where compressive forces are high, such as intervertebral discs, the pubic symphysis, and the menisci of the knee joint.	Bands of fibers are easily visible. In addition, chondrocytes will appear to be lined up in rows because the thick bands of collagen fibers force them into this configuration.
<b>Elastic Cartilage</b>	Very similar to hyaline cartilage in all aspects. However, the addition of elastic fibers to the matrix makes elastic cartilage much more flexible than hyaline cartilage.	The addition of elastic fibers within the cartilage provides <i>flexible support</i> . Locations include the epiglottis, the lining of the auditory tube, and the external ear.	Elastic fibers are stained black in most preparations. The elastic fibers are generally higher in concentration near the lacunae.
<b>Compact Bone</b>	Composed of osteons (Haversian systems), which are concentric layers of bony matrix (lamellae) surrounding a central canal. Lamellae have lacunae located along them, with osteocytes inside the lacunae. Canaliculi connect adjacent lacunae, and perforating canals run perpendicular to the central canals.	Provides strong, rigid support. Compact bone is thickest in the diaphysis of long bones, but is also found as a thin layer forming the peripheral component of all bone.	Multiple osteons packed tightly together. No marrow spaces.



**Learning Strategy**

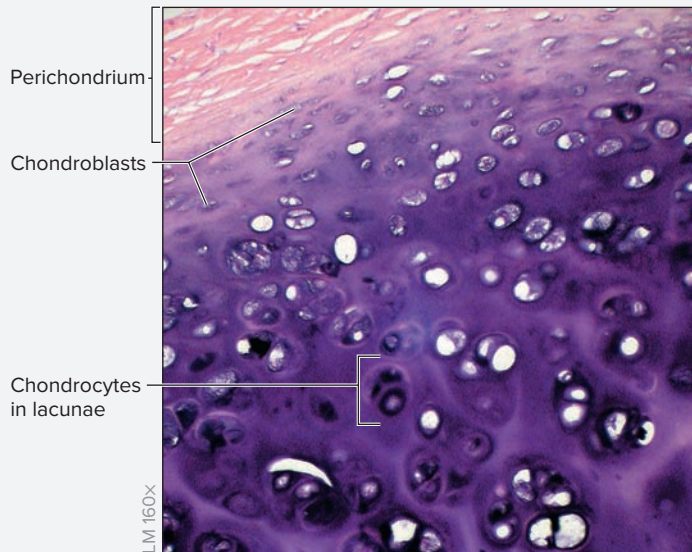
Some slides of hyaline cartilage are stained such that the ECM that surrounds the lacunae stains darker than the remainder of the ECM. When this is the case, students sometimes confuse it for elastic cartilage or fibrocartilage. Thus, always look very closely at figures/slides of cartilage. The presence of *any* visible fibers within the ECM indicates either elastic cartilage (if fibers are very dark) or fibrocartilage.

Figure 5.18 Flowchart for Classifying Supporting Connective Tissues.



**EXERCISE 5.4 Identification and Classification of Supporting Connective Tissue****EXERCISE 5.4A: Hyaline Cartilage**

1. Obtain a slide of the trachea and esophagus (see exercise 5.1F, p. 64).
2. Place the slide on the microscope stage and bring the tissue sample into focus on low power.
3. Find the lumen of the trachea and identify the epithelial tissue that lines the trachea (see exercise 5.1F, p. 64).
4. Move the microscope stage so that the tissue deep to the epithelium of the trachea is in the center of the field of view. A plate of hyaline cartilage will be visible here (**figure 5.19**).



**Figure 5.19 Hyaline Cartilage.** Hyaline cartilage contains prominent lacunae with chondrocytes. No fibers are visible in the extracellular matrix. At the top of this photograph the perichondrium (light pink) with small, flattened chondroblasts on its inner surface is visible.

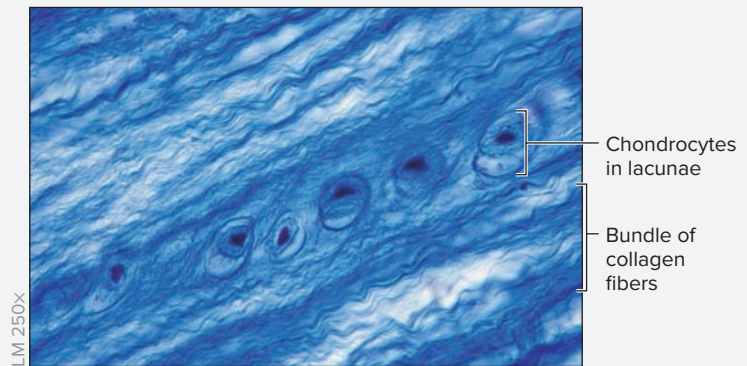
© McGraw-Hill Education/Christine Eckel, photographer

5. Observe the slide on the lowest magnification possible. Identify the perichondrium, which surrounds the cartilage plate.
6. Look for small nuclei on the inner surface of the perichondrium. These are the nuclei of chondroblasts.
7. Next, identify the chondrocytes located within lacunae. In hyaline cartilage there are no visible fibers in the matrix because the fibers are spread very diffusely throughout the matrix. Instead, the matrix will appear uniform and smooth.
8. Identify the following structures on the slide, using figure 5.19 and table 5.6 as guides:
 

<input type="checkbox"/> chondroblasts	<input type="checkbox"/> lacunae
<input type="checkbox"/> chondrocytes	<input type="checkbox"/> perichondrium
9. Sketch hyaline cartilage as seen through the microscope in the space provided. Be sure to label all the structures listed in step 8 in the drawing.

**EXERCISE 5.4B: Fibrocartilage**

1. Obtain a slide of an intervertebral disc (**figure 5.20**).
2. Place the slide on the microscope stage and bring the tissue sample into focus on low power. Then change to high power.




**Figure 5.20 Fibrocartilage.** Fibrocartilage contains visible bundles of collagen fibers within its matrix. The chondrocytes (in their lacunae) often appear to line up in rows.

© Ed Reschke/Getty Images

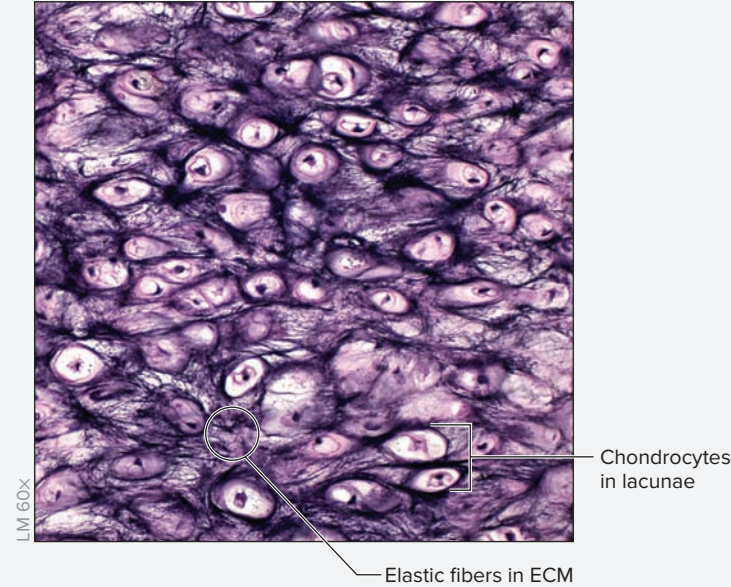
3. Identify the following structures on the slide, using figure 5.20 and table 5.6 as guides:
 

<input type="checkbox"/> bundle of collagen fibers	<input type="checkbox"/> chondrocytes
--	---------------------------------------
4. Sketch fibrocartilage as seen through the microscope in the space provided. Be sure to label all the structures listed in step 3 in the drawing.



**EXERCISE 5.4C: Elastic Cartilage**

1. Obtain a slide of elastic cartilage (**figure 5.21**).
2. Place the slide on the microscope stage and bring the tissue sample into focus on low power. Then change to high power.




**Figure 5.21 Elastic Cartilage.** Elastic cartilage contains chondrocytes in lacunae and visible elastic fibers (which stain dark blue/purple or black) in its extracellular matrix.

© Alvin Telser/Science Source

3. Identify the following structures on the slide, using figure 5.21 and table 5.6 as guides:

- |   |  |
|---|--|
| <input type="checkbox"/> chondroblasts  | <input type="checkbox"/> lacunae       |
| <input type="checkbox"/> chondrocytes   | <input type="checkbox"/> perichondrium |
| <input type="checkbox"/> elastic fibers |  |

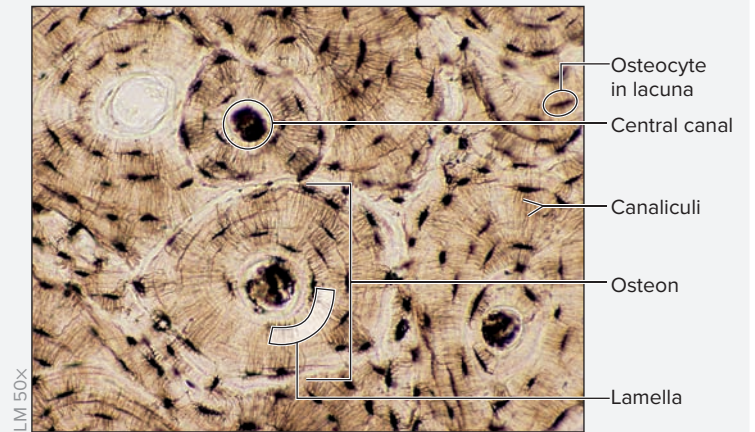
4. Sketch elastic cartilage as seen through the microscope in the space provided. Be sure to label all the structures listed in step 3 in the drawing.



**EXERCISE 5.4D: Bone**

1. Obtain a slide of compact bone (**figure 5.22**).
2. Place the slide on the microscope stage and bring the tissue sample into focus on low power. Then change to high power.
3. Identify the following structures on the slide, using figure 5.22 and table 5.6 as guides:


- |  |                                    |
|--|------------------------------------|
| <input type="checkbox"/> canaliculus   | <input type="checkbox"/> lamella   |
| <input type="checkbox"/> central canal | <input type="checkbox"/> osteocyte |
| <input type="checkbox"/> lacuna        | <input type="checkbox"/> osteon    |



**Figure 5.22 Compact Bone.** Compact bone is composed of multiple osteons. Each osteon is characterized by a central canal surrounded by concentric layers of bony matrix called lamellae.

© Ed Reschke/Getty Images

4. Sketch compact bone as seen through the microscope in the space provided. Be sure to label all the structures listed in step 3 in the drawing.



## Learning Strategy



When trying to remember the locations of the different types of cartilage, it is helpful to remember specific locations for fibrocartilage and elastic cartilage first, leaving hyaline cartilage as the answer for most other structures composed of cartilage.

For example, note the locations of each type of cartilage:

1. **Fibrocartilage:** intervertebral discs, pubic symphysis, and menisci.

2. **Elastic cartilage:** locations starting with the letter “E” (External ear, Eustachian tube (i.e., auditory tube), Epiglottis).
3. Almost every other structure composed of cartilage will be composed of hyaline cartilage because it is the most common type of cartilage. Thus, there is little need to “memorize” locations for hyaline cartilage, although it is necessary to remember a few common examples such as articular cartilages, costal cartilages, and tracheal “C” rings.

## Fluid Connective Tissue

Fluid connective tissue (blood and lymph) are specialized in that the extracellular matrix of these tissues consists of a liquid ground substance and soluble fibers that become insoluble only in response to tissue injury. These tissues will be covered in detail in chapters 19 and 27. In this chapter only the basic characteristics of blood as a connective tissue will be considered. The cell types in blood are **erythrocytes** (red blood cells), **leukocytes** (white blood cells), and **platelets** (thrombocytes). Platelets are

not actually cells. Instead they are cytoplasmic fragments of cells called **megakaryocytes**, which are found in the bone marrow. The extracellular matrix of blood consists of blood **plasma**. The ground substance is liquid, composed mainly of water and a number of dissolved substances. In addition, blood contains soluble proteins, some of which are called clotting proteins, such as **fibrinogen**. Fibrinogen becomes insoluble **fibrin** and forms fibers in response to tissue injury.

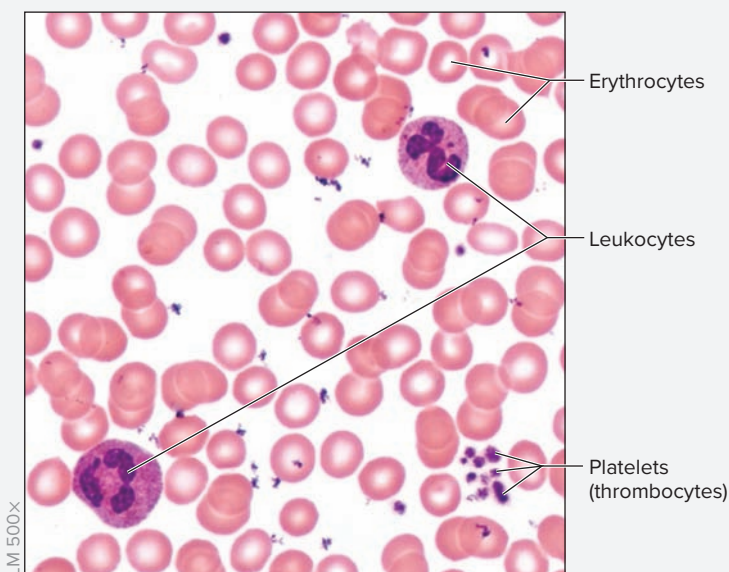
### EXERCISE 5.5 Identification and Classification of Fluid Connective Tissue

1. Obtain a slide of a blood smear (**figure 5.23**).
2. Place the slide on the microscope stage and bring the tissue sample into focus on low power. Change to medium power, and then bring the sample into focus using the oil immersion lens. Consult the instructor if assistance is needed using the oil immersion lens.

3. Identify the following structures on the slide, using figure 5.23 as a guide:


- erythrocytes
- leukocytes
- platelets (thrombocytes)

4. Sketch blood as seen through the microscope in the space provided. Be sure to label all the structures listed in step 3 in the drawing.



**Figure 5.23** Blood. Blood is a fluid connective tissue containing erythrocytes (red blood cells), leukocytes (white blood cells), platelets (thrombocytes), and an extracellular matrix called plasma.

© McGraw-Hill Education/AI Telsler



5. *Optional Activity:* **AP|R 3: Tissues**—Watch the “Connective Tissue Overview” animation.

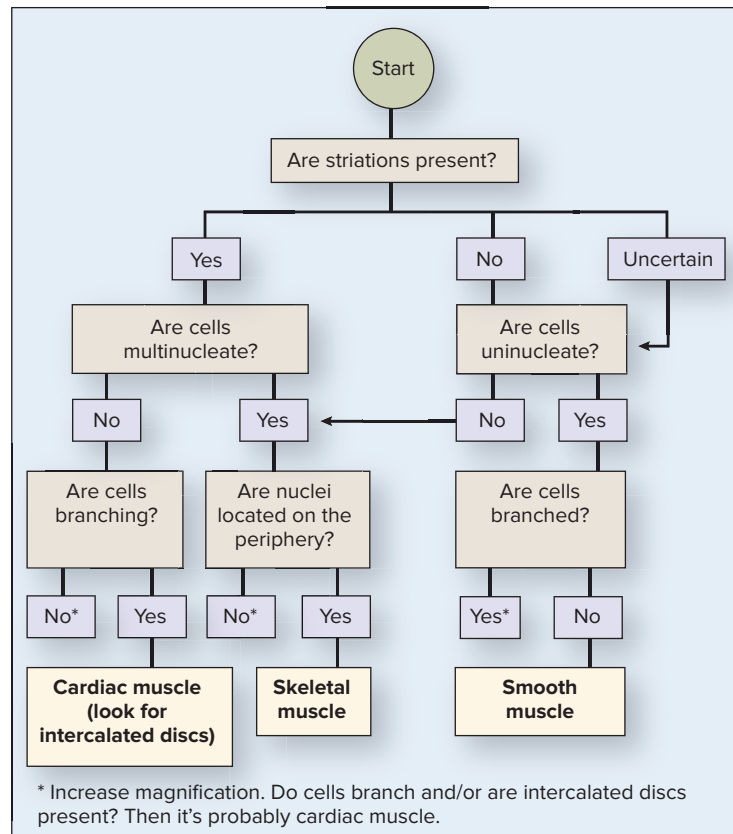
### Clinical View | Carcinomas and Sarcomas

Clinically, a tumor derived from epithelial tissues is called a *carcinoma* (*karkinos*, crab + *oma*, tumor), and a tumor derived from connective tissues is called a *sarcoma* (*sarc-*, flesh + *oma*, tumor). Carcinomas are considered noninvasive when they do not penetrate the basement membrane that lies between the epithelial and connective tissue layers. Once rapidly dividing cells penetrate the basement membrane, the cancer is considered invasive. While epithelial tissue is avascular, the underlying connective tissue is not. Thus, invading cancer cells can easily metastasize (*meta-*, change + *ize*, an action) to other locations of the body through blood and lymphatic vessels. Sarcomas, which arise from connective tissues, pose a similar risk. However, they tend to grow and metastasize much more readily than carcinomas because of the highly vascular nature of connective tissues.

## Muscle Tissue

Muscle tissue is both excitable and contractile. **Excitable** tissues are able to generate and propagate electrical signals called action potentials. As a **contractile** tissue, muscle has the ability to actively shorten and produce force. There are three types of muscle tissue: skeletal muscle, cardiac muscle, and smooth (visceral) muscle. The three types of muscle tissue are distinguished by their neural control (voluntary or involuntary), the presence or absence of visible striations, the shape of the cells, and the number and location of nuclei. **Skeletal muscle** is found in the voluntary muscles that move the skeleton and the facial skin. **Cardiac muscle** is found in the heart, and **smooth muscle** is found in the walls of soft viscera such as the blood vessels, stomach, urinary bladder, intestines, and uterus. **Table 5.7** compares the three types of muscle tissue, and the flowchart in **figure 5.24** explains steps that can be used to identify muscle tissues.

Type of Muscle	Description	Generalized Functions	Identifying Characteristics
Skeletal	Elongate, cylindrical cells with multiple nuclei. Nuclei are peripherally located. Tissue appears striated (light and dark bands along the length of the cell).	Produces voluntary movement of the skin and the skeleton.	Length of cells (extremely long), striations, multiple peripheral nuclei.
Cardiac	Short, branched cells with one to two nuclei. Nuclei are centrally located. Dark bands (intercalated discs) are seen where two cells come together. Tissue appears striated (light and dark bands along the length of each cell).	Performs the contractile work of the heart. Responsible for creating the pumping action of the heart.	Branched, uninucleate cells, striations, intercalated discs.
Smooth	Elongate, spindle-shaped cells (fatter in the center, narrowing at the ends) with single, “cigar-shaped” or “spiral” nuclei. Nuclei are centrally located. No striations are apparent.	Creates movement within viscera such as intestines, bladder, uterus, and stomach. Moves blood through blood vessels, etc.	Spindle shape of the cells, no striations, cigar-shaped nuclei that are centrally located.

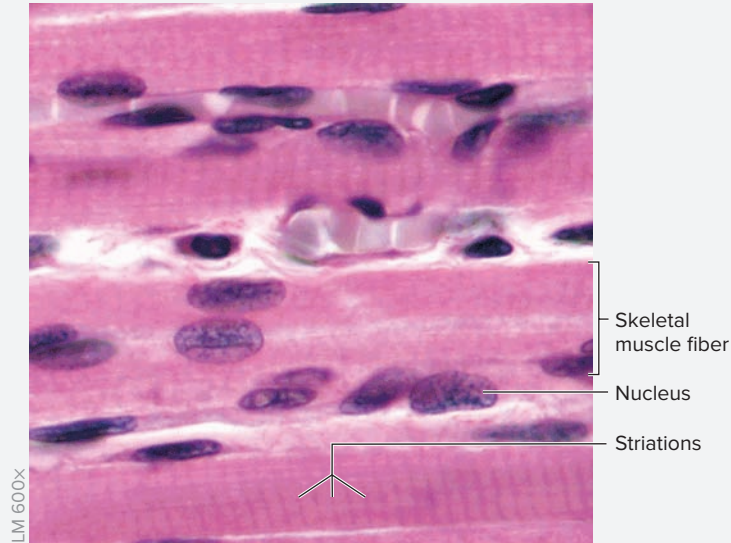


**Figure 5.24** Flowchart for Classifying Muscle Tissues.

**EXERCISE 5.6 Identification and Classification of Muscle Tissue**

**EXERCISE 5.6A: Skeletal Muscle Tissue**

1. Obtain a slide of skeletal muscle (**figure 5.25**).
2. Place the slide on the microscope stage and bring the tissue sample into focus using the scanning objective (low power). Then change to medium and then high power.



**Figure 5.25 Skeletal Muscle.** Skeletal muscle fibers are elongated and striated, and contain multiple peripherally located nuclei.

© McGraw-Hill Education/AI Telser

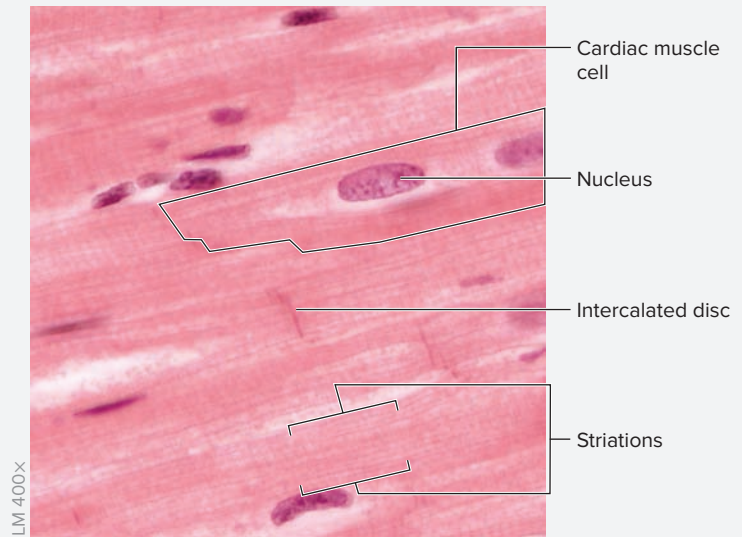
3. Identify the following structures on the slide, using figure 5.25 and table 5.6 as guides:
  - nucleus
  - skeletal muscle fiber
  - striations
4. Sketch both longitudinal and cross sections of skeletal muscle as seen through the microscope in the space provided. Be sure to label all the structures listed in step 3 in the drawing.



\_\_\_\_\_ ×

**EXERCISE 5.6B: Cardiac Muscle Tissue**

1. Obtain a slide of cardiac muscle (**figure 5.26**).
2. Place the slide on the microscope stage and bring the tissue sample into focus using the scanning objective (low power). Then change to medium and then high power.



**Figure 5.26 Cardiac Muscle.** Cardiac muscle cells are short and branched, striated, and generally contain only one centrally located nucleus.

© McGraw-Hill Education/AI Telser


3. Identify the following structures on the slide, using figure 5.26 and table 5.6 as guides:
  - cardiac muscle cell
  - intercalated disc
  - nucleus
  - striations
4. Sketch both longitudinal and cross sections of cardiac muscle as seen through the microscope in the space provided. Be sure to label all the structures listed in step 3 in the drawing.



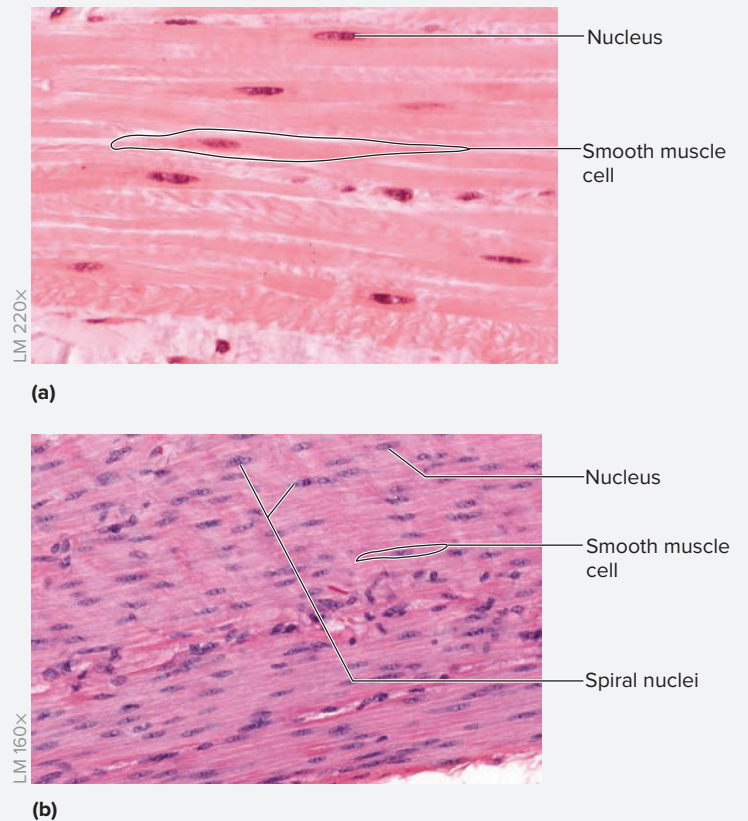
\_\_\_\_\_ ×

**EXERCISE 5.6C: Smooth Muscle Tissue**

1. Obtain a slide of smooth muscle (**figure 5.27**).
2. Place the slide on the microscope stage and bring the tissue sample into focus using the scanning objective (low power). Then change to medium and then high power.
3. Identify the following structures on the slide, using figure 5.27 and table 5.6 as guides:
  - nucleus
  - smooth muscle cell
4. Sketch both longitudinal and cross sections of smooth muscle as seen through the microscope in the space provided. Be sure to label all the structures listed in step 3 in the drawing.



5. *Optional Activity:* **AP|R 3. Tissues**—Watch the “Muscle Tissue Overview” animation.



**Figure 5.27 Smooth Muscle.** Smooth muscle fibers are short and spindle-shaped, not striated, and contain only one centrally located nucleus (a). In figure 5.27b a few nuclei that have taken on a “spiral” shape are visible. This happens when the muscle fibers contract. As the fibers shorten, the nuclei start to coil up, or “spiral.”  
 (a) © McGraw-Hill Education/AI Telser; (b) © Christine Eckel

**Nervous Tissue**

Nervous tissue is characterized by its *excitability*: the ability to generate and propagate electrical signals called action potentials. Nervous tissue is composed of two basic cell types (**table 5.8**). **Neurons** are excitable cells

that send and receive electrical signals. Neurons have a limited ability to divide and multiply in the adult brain. **Glial cells** are supporting cells that support and protect neurons. Glial cells maintain the ability to divide and multiply in the adult brain. Glial cells constitute over 60% of the cells found in neural tissue.

Table 5.8		Nervous Tissue
Cell Type	Description	Generalized Functions
Neurons	Though varied in shape, most neurons appear to have numerous branches coming off the cell body (soma). Neurons contain large amounts of rough endoplasmic reticulum (ER). The ribosomes and rough ER stain very dark and are collectively called chromatophilic substance.	Responsible for <i>generating and transmitting information via electrical impulses</i> within the nervous system. Thus, they are “excitable” cells.
Glial cells	Even more varied in shape than neurons, glial cells are generally much smaller than neurons with fewer (if any) branching processes.	Glial cells are the <i>general supporting cells</i> of the nervous system. Their jobs are to protect, nourish, and support the excitable cells, the neurons.

**EXERCISE 5.7** Identification and Classification of Nervous Tissue

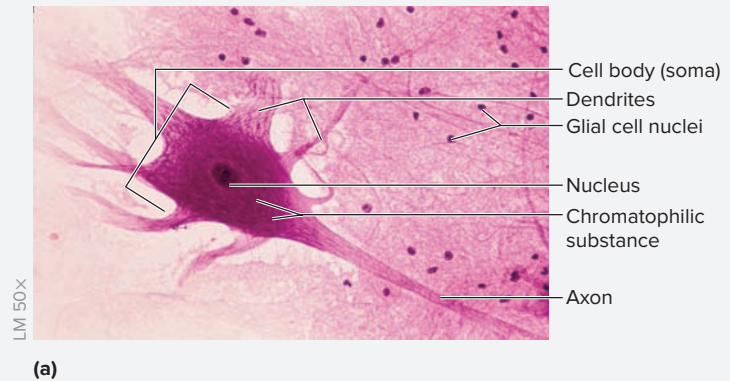
- Obtain a slide of nervous tissue (**figure 5.28**).
- Place the slide on the microscope stage and bring the tissue sample into focus using the scanning objective (low power). Then change to medium and then high power.
- Identify the following structures on the slide, using figure 5.28 and table 5.8 as guides:
 

<input type="checkbox"/> axon of neuron	<input type="checkbox"/> dendrite of neuron
<input type="checkbox"/> cell body of neuron	<input type="checkbox"/> nucleus of glial cell
<input type="checkbox"/> chromatophilic substance	<input type="checkbox"/> nucleus of neuron
- Sketch nervous tissue as seen through the microscope in the space provided. Be sure to label all the structures listed in step 3 in the drawing.

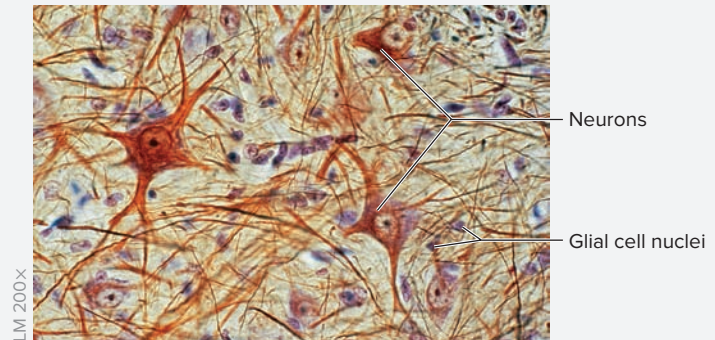


\_\_\_\_\_ ×

- Optional Activity:* **AP|R 3. Tissues**—Watch the “Nervous Tissue Overview” animation.



(a)



(b)

**Figure 5.28 Nervous Tissue.** (a) Neurons are very large cells with a prominent nucleus and nucleolus, and dark-staining endoplasmic reticulum (chromatophilic substance). (b) Glial cells are much smaller than neurons, and are also more abundant.

(a) © Ed Reschke/Getty Images; (b) © Biophoto Associates/Science Source

### WHAT DO YOU THINK?

- Most tumors arise in cells that are constantly undergoing cell division, or mitosis (e.g., skin cells). A patient has recently been diagnosed with a brain tumor. What type of cell do you think the tumor most likely arose from—a neuron or a glial cell?

## Learning Strategy

### Lookalikes in Histology

Alas! There are several tissues that are quite difficult to distinguish from each other histologically. These tissues require very careful inspection of finer details that distinguish them from

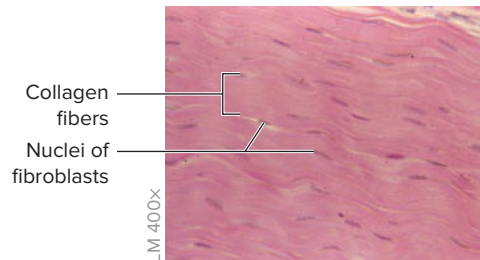
one another. Figure 5.29 gives examples of some histology “lookalikes” with helpful hints on how to distinguish them from each other. It’s a good idea to bookmark this page to make the Learning Strategy easier to locate in the future when these tissues are encountered in other chapters.

## Lookalikes 1

### Dense regular, and smooth muscle in longitudinal section.

#### Dense Regular CT

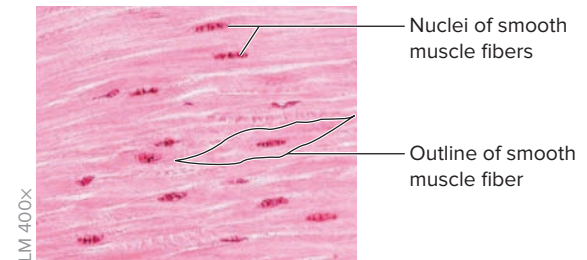
Most distinguishing characteristic: fibroblast nuclei are flat, and are located *in between* fibers.



© De Agostini Picture Library/Getty Images

#### Smooth Muscle

Most distinguishing characteristic: nuclei are cigar- or spiral-shaped and are located *within* fibers.



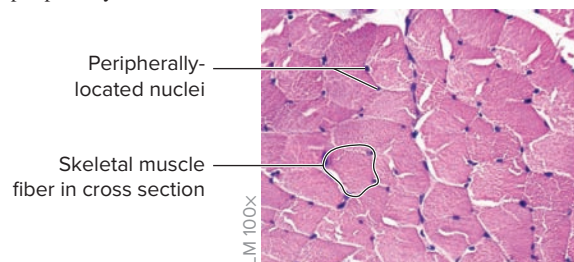
© McGraw-Hill Education/Al Telser

## Lookalikes 2

### Skeletal muscle and cardiac muscle in cross section.

#### Skeletal Muscle

Most distinguishing characteristic: Skeletal muscle nuclei are peripherally located.

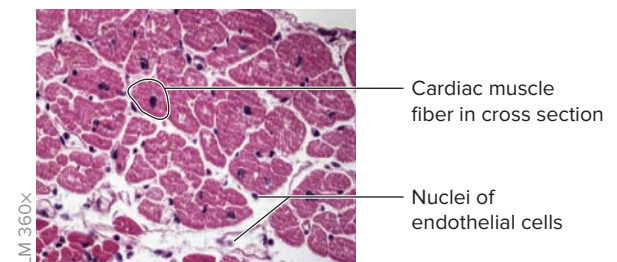


© Science Stock Photography/Science Source

Almost all nuclei in this image belong to the skeletal muscle fibers.

#### Cardiac Muscle

Most distinguishing characteristic: Cardiac muscle nuclei are centrally located.



© Alvin Telser/Science Source

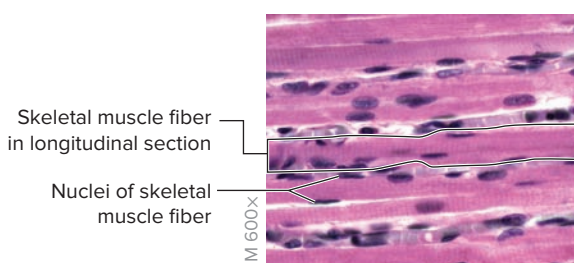
The larger and/or light nuclei are the nuclei of cardiac muscle fibers. The dark nuclei are nuclei of endothelial cells that line the numerous capillaries, which surround the cardiac muscle fibers.

## Lookalikes 3

### Skeletal muscle and cardiac muscle in longitudinal section.

#### Skeletal Muscle

Most distinguishing characteristic: peripherally located nuclei.

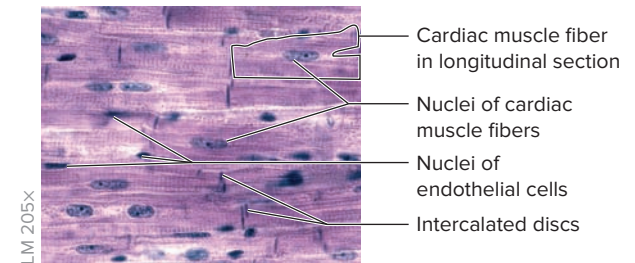


© McGraw-Hill Education/Al Telser

Almost all nuclei in this image belong to the skeletal muscle fibers. Some nuclei (those that lie clearly in between muscle fibers) are either endothelial cell nuclei or satellite cell nuclei.

#### Cardiac Muscle

Most distinguishing characteristic: intercalated discs.



© Victor P. Eroschenko

The light nuclei, with prominent nucleoli, belong to cardiac muscle fibers. The dark nuclei belong to endothelial cells that line the numerous capillaries, which surround the cardiac muscle fibers.

**Figure 5.29** Muscles.



*This page intentionally left blank*

The **1** corresponds to the Learning Objective(s) listed in the chapter opener outline.

## Do You Know the Basics?

### Exercise 5.1: Identification and Classification of Epithelial Tissue

- The epithelial type that protects against abrasion is \_\_\_\_\_. **1**
- Endothelium is a \_\_\_\_\_ epithelium that lines the walls of blood vessels and the heart. **2**
- Match the function listed in column A with the surface modifications and specialized cells found in epithelial tissues listed in column B. **3 5**

#### Column A

- \_\_\_\_ 1. provide lubrication
- \_\_\_\_ 2. increase surface area for enhanced absorption
- \_\_\_\_ 3. aid in movement of substances in one direction
- \_\_\_\_ 4. imparts strength and protection

#### Column B

- a. cilia
- b. goblet cells
- c. keratinization
- d. microvilli

- When observing a cross section of a tube that is lined with epithelial tissue (e.g., the gut tube), the epithelial surface that faces the lumen of the tube is the \_\_\_\_\_ (apical/basal) surface. **4**

### Exercise 5.2: Identification of Embryonic Connective Tissue

- Embryonic connective tissue is called \_\_\_\_\_. **6**

### Exercise 5.3: Identification and Classification of Connective Tissue Proper

- The extracellular matrix of connective tissue is composed of cells and fibers. \_\_\_\_\_ (True/False) **7 8**
- For each category of connective tissue listed in the following table, write in the major cell types, the fiber types, and the characteristics of the ground substance of the tissue. Refer to the textbook for assistance. **7 11**

	Connective Tissue Proper	Cartilage	Bone	Fluid Connective Tissue
<i>Cells</i>				
<i>Fibers</i>				
<i>Ground Substance</i>				

### Exercise 5.4: Identification and Classification of Supporting Connective Tissue

- The three types of cartilage are differentiated from one another by the type and arrangement of \_\_\_\_\_. **11**
- The pubic symphysis is composed of fibrocartilage. \_\_\_\_\_ (True/False) **12**
- Which of the following is/are a type of bone tissue? (Check all that apply.) **10 13**
  - \_\_\_\_ a. areolar
  - \_\_\_\_ b. compact
  - \_\_\_\_ c. elastic
  - \_\_\_\_ d. reticular
  - \_\_\_\_ e. spongy

### Exercise 5.5: Identification and Classification of Fluid Connective Tissue

- The two types of fluid connective tissue are \_\_\_\_\_ and \_\_\_\_\_. **14**
- The cells in fluid connective tissue are \_\_\_\_\_. The fibers in fluid connective tissue are \_\_\_\_\_. **15**

**Exercise 5.6: Identification and Classification of Muscle Tissue**

13. In the following table, compare and contrast the characteristics of the three types of muscle tissue. **16**

Characteristic	Skeletal Muscle	Cardiac Muscle	Smooth Muscle
<i>Location and Number of Nuclei</i>			
<i>Cell Shape</i>			
<i>Presence or Absence of Striations</i>			

14. List a location in the body where smooth muscle tissue might be found. \_\_\_\_\_ **17**

**Exercise 5.7: Identification and Classification of Nervous Tissue**

15. The two main cell types found in nervous tissue are \_\_\_\_\_ and \_\_\_\_\_. **18 19**

**Can You Apply What You've Learned?**

16. In the following table, compare and contrast epithelial and connective tissues with respect to the following:

Characteristic	Epithelial Tissues	Connective Tissues
<i>Cell Number and Arrangement</i>		
<i>Polarity</i>		
<i>Extracellular Matrix</i>		
<i>Vascularity</i>		

17. What does the presence of cilia indicate about the function of an epithelial tissue?

---



---

18. Explain the characteristics that make blood a connective tissue. (Hints: From what embryonic connective tissue is blood derived? What is the composition of the extracellular matrix? What is the cellular component? What are the fibers?)

---



---

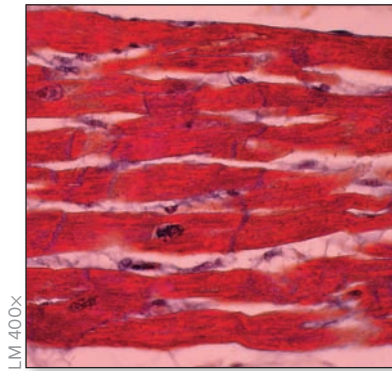


---



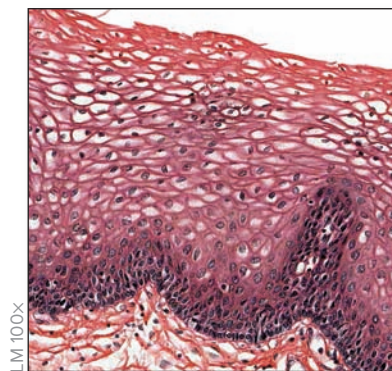---

19. Write the name of the specific tissue type below each photo.



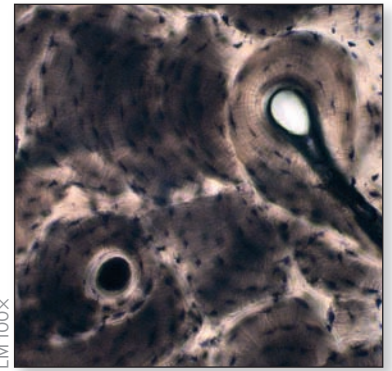
LM 400X

(a) \_\_\_\_\_  
© McGraw-Hill Education/Christine Eckel, photographer



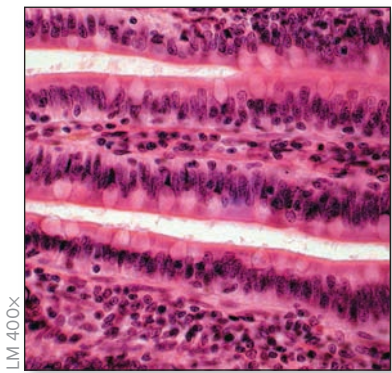
LM 100X

(b) \_\_\_\_\_  
© Christine Eckel



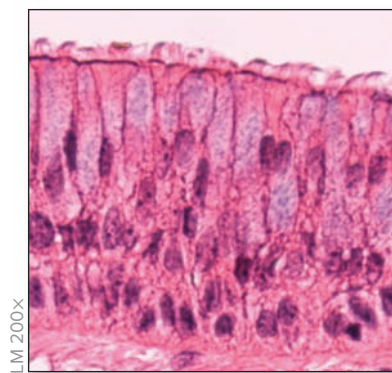
LM 100X

(c) \_\_\_\_\_  
© Christine Eckel



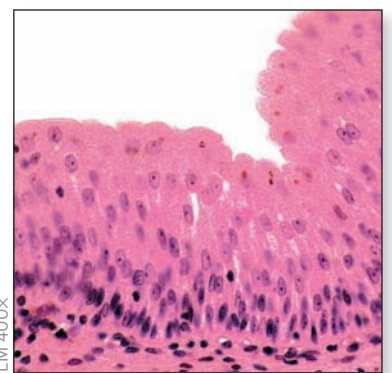
LM 400X

(d) \_\_\_\_\_  
© McGraw-Hill Education/Christine Eckel, photographer



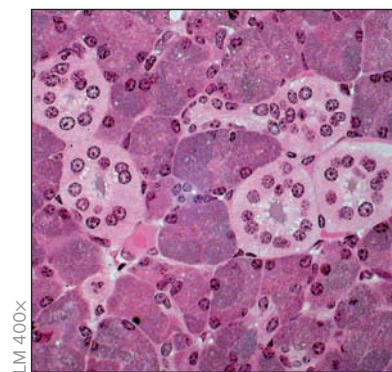
LM 200X

(e) \_\_\_\_\_  
© McGraw-Hill Education/Dennis Strete



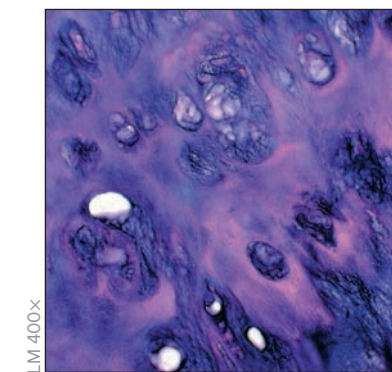
LM 400X

(f) \_\_\_\_\_  
© McGraw-Hill Education/Christine Eckel, photographer



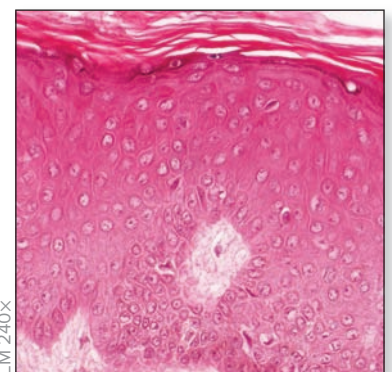
LM 400X

(g) \_\_\_\_\_  
© McGraw-Hill Education/Christine Eckel, photographer



LM 400X

(h) \_\_\_\_\_  
© McGraw-Hill Education/Christine Eckel, photographer



LM 240X

(i) \_\_\_\_\_  
© McGraw-Hill Education/Al Telser

20. A friend was recently diagnosed with a tumor called a glioma. From what basic type of tissue is the tumor derived? \_\_\_\_\_

**Can You Synthesize What You've Learned?**

21. For each of the examples given, is the structure likely to fit in its entirety on a microscope slide? (Circle yes or no for each.)

- a. cross section of the humerus (the arm bone)    Yes    No
- b. cross section of the large intestine    Yes    No
- c. cross section of a pinky finger    Yes    No
- d. cross section of a small blood vessel    Yes    No
- e. cross section of a ureter (~0.5 cm in diameter)    Yes    No

22. Match the description listed in column A with the name of the connective tissue listed in column B.

**Column A**

- \_\_\_ 1. makes up the cartilage discs between the vertebrae and between the pubic bones
- \_\_\_ 2. transports materials within blood vessels
- \_\_\_ 3. inner supporting framework of spleen, liver, and lymph nodes
- \_\_\_ 4. tough tissue that connects bone to bone and muscle to bone
- \_\_\_ 5. cartilage that retains its original shape after being deformed, such as in the cartilage of the ear
- \_\_\_ 6. allows the aorta (a large blood vessel) to stretch with each pulse of blood pumped into it from the heart and then return to its original size
- \_\_\_ 7. helps keep the body warm and stores excess fuel (energy)
- \_\_\_ 8. forms the ends of long bones, the larynx, the costal cartilages, and the embryonic skeleton

**Column B**

- a. adipose connective tissue
- b. blood
- c. dense regular connective tissue
- d. elastic cartilage
- e. elastic connective tissue
- f. fibrocartilage
- g. hyaline cartilage
- h. reticular connective tissue

23. Cartilage is unique as a connective tissue in that it is avascular. What limitations does avascularity impose on cartilage as a tissue?

---

---

---

---

24. Two of the surface modifications of epithelial cells, microvilli and cilia, are commonly confused with each other. Describe how you would teach a fellow student to distinguish between these two surface modifications.

---

---

---

---

25. A patient has recently been diagnosed with an osteosarcoma. Explain what cells this tumor most likely arose from and why.

---

---

---

---

# Integument

# 6

## OUTLINE AND LEARNING OBJECTIVES

### Histology 90

#### The Epidermis 90

##### EXERCISE 6.1: LAYERS OF THE EPIDERMIS 91

- 1 Describe the layers of the epidermis of thick skin, from deep to superficial
- 2 Compare and contrast structures and locations of thick skin and thin skin

##### EXERCISE 6.2: PIGMENTED SKIN 92

- 3 Identify melanocytes and keratinocytes containing melanin granules in pigmented skin

#### The Dermis 92

##### EXERCISE 6.3: LAYERS OF THE DERMIS 93

- 4 Differentiate the reticular and papillary layers of the dermis

##### EXERCISE 6.4: MEROCRINE (ECCRINE) SWEAT GLANDS AND SENSORY RECEPTORS 94

- 5 Identify merocrine sweat glands, tactile (Meissner) corpuscles, and lamellated (Pacinian) corpuscles
- 6 Describe the function of merocrine sweat glands, tactile corpuscles, and lamellated corpuscles

##### EXERCISE 6.5: THE SCALP—HAIR FOLLICLES AND SEBACEOUS GLANDS 95

- 7 Describe the parts of a hair follicle
- 8 Describe the location, structure, and function of sebaceous glands

##### EXERCISE 6.6: AXILLARY SKIN—APOCRINE SWEAT GLANDS 97

- 9 Identify apocrine sweat glands
- 10 Describe how apocrine sweat glands differ from merocrine sweat glands in both location and function

##### EXERCISE 6.7: STRUCTURE OF A NAIL 98

- 11 Describe the structure of a nail

### Gross Anatomy 99

#### Integument Model 99

##### EXERCISE 6.8: OBSERVING CLASSROOM MODELS OF INTEGUMENT 99

- 12 Identify skin layers and skin appendages on a model of the integument

## INTRODUCTION

The exercises in this chapter explore the body's largest organ system, the **integument** (*integumentum*, a covering). The integument is often mistakenly referred to as the "skin." However, the two terms do not refer to the same thing. The **skin** is the outer covering of the body and is composed of an **epidermis** (*epi-*, upon + *derma*, skin) and **dermis** (*derma*, skin). The integument is an organ system that includes the skin *plus* all of the accessory structures of skin, such as sensory organs, glands, hair, and nails.

One of the most obvious functions of the integument is protection from abrasions, ultraviolet (UV) radiation, and entry of pathogens. However, the integument plays numerous critical roles in the body, including thermoregulation and prevention of water loss. One of the integument's most important functions is to detect sensations arising from the environment around the body. This is accomplished using thousands of sensory receptors in the skin that sense pressure, pain, gentle touch, vibration, and temperature, among other things. The integument is a truly remarkable system whose functions are often underestimated. For example, damage to large areas of the integument (as might happen to a burn victim) can easily be life-threatening.

The materials used in the exercises in this chapter include histological slides of the skin and its accessory structures, and models of integument. While it is



### Module 4: INTEGUMENTARY SYSTEM

important to identify the structures of the integument as seen through the microscope and on the models, do not forget to use your own body as an example while working through this laboratory exercise. For example, while viewing slides of thin skin and thick skin, find locations on your own body that contain the same. See and feel the differences between the two and try to correlate what is seen and felt on your own body with what is seen through the microscope. Finally, be sure to compare the appearance and texture of your own skin and

hair with that of another student in the lab who has skin or hair of a different color or texture from your own.

#### **List of Reference Tables**

Table 6.1	Layers of the Epidermis	p. 90
Table 6.2	Glands in the Dermis	p. 94
Table 6.3	Sensory Receptors in the Dermis	p. 95
Table 6.4	Parts of a Hair Follicle	p. 95
Table 6.5	Parts of a Nail	p. 98

These Pre-laboratory Worksheet questions may be assigned by instructors through their **connect** course.

## PRE-LABORATORY WORKSHEET

- Which of the following are functions of the integument? (Check all that apply.)
  - a. mineral storage
  - b. movement
  - c. protection
  - d. secretion
  - e. structural support
- Identify the type of tissue that composes the epidermis of the skin. (Circle one.)
  - a. adipose connective tissue
  - b. areolar connective tissue
  - c. dense irregular connective tissue
  - d. simple squamous epithelial tissue
  - e. stratified squamous epithelial tissue
- Dense irregular connective tissue is found in the *dermis* of the skin. \_\_\_\_\_ (True/False)
- Number the following five layers of the epidermis of thick skin, starting with 1 for the layer closest to the basal surface.
  - a. stratum basale
  - b. stratum corneum
  - c. stratum granulosum
  - d. stratum lucidum
  - e. stratum spinosum
- Indicate which of the following are among the layers of the dermis. (Check all that apply.)
  - a. papillary layer
  - b. reticular layer
  - c. subcutaneous layer (hypodermis)
- Identify the main protein that composes a hair. Hairs mainly consist of protein fibers composed of \_\_\_\_\_ (collagen/keratin).
- The subcutaneous layer (hypodermis) of the skin is mainly composed of *adipose* connective tissue. \_\_\_\_\_ (True/False)
- Thick skin is located *only* on the palms of the hands and the dorsal surfaces of the feet. \_\_\_\_\_ (True/False)
- Sweat glands are composed of modified connective tissue. \_\_\_\_\_ (True/False)
- Sensory receptors located within dermal papillae are called \_\_\_\_\_ (lamellated/tactile) corpuscles.



## Histology

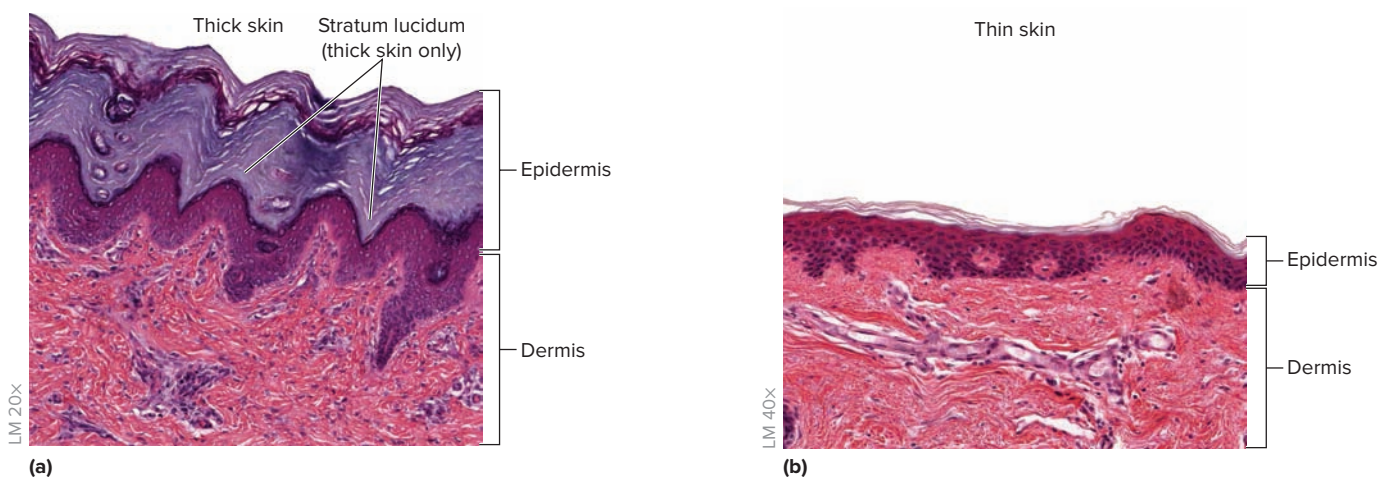
### The Epidermis

The **skin** is composed of an **epidermis** (*epi-*, upon + *derma*, skin) and **dermis** (*derma*, skin). The epidermis is the outermost layer of the skin and consists of stratified squamous keratinized epithelial tissue (**figure 6.1**). Thus there are no blood vessels in the epidermal layers. The main cell type composing the epithelial tissue in the skin is called a **keratinocyte**, so named because of its role in synthesizing the protein **keratin**. Keratin is an insoluble protein that imparts strength to the skin and makes it almost completely waterproof. The epidermis of *thin skin* (see figures 6.1*b* and 6.4), which is located on most of the body's surface, has four distinct layers, whereas the epidermis of *thick skin* (see figure 6.1*a* and **figure 6.2**), which is located on the palms of the hands and soles of the feet, has five distinct layers. **Table 6.1** summarizes the layers of the epidermis and their characteristics. Of the listed layers, thin skin is missing the *stratum lucidum*.

### Learning Strategy

The terms *thick skin* and *thin skin* refer only to the thickness of the epidermal layer. Technically, the thickest skin on the body is located on the back. However, that thickness takes into account not only the thickness of the epidermis, but that of the dermis as well. The thick skin on the palms of the hands and the soles of the feet is actually rather thin when considering the total thickness of the epidermis and the dermis combined. To understand this a little better, compare the total thickness of the skin on your back (by feel) to the total thickness of the skin on the middle arch of the sole of your foot or palm of your hand.

Table 6.1 Layers of the Epidermis		
Epidermal Layer	Description	Word Origins
<i>Stratum Corneum</i>	Consists almost entirely of keratin and remnants of dead keratinocytes, forming multiple layers. On the outer (apical) surface of the stratum corneum layers of dead cells in the process of <b>desquamation</b> ( <i>squamosus</i> , scaly, Fr. <i>squama</i> , scale) may be visible.	<i>stratum</i> , layer + <i>cornu</i> , horn, hoof
<i>Stratum Lucidum</i>	Present only in thick (glabrous) skin, which is located on the palm of the hand and sole of the foot. The layer is clear and homogeneous, and sometimes stains darker than the remainder of the stratum corneum, depending on the dye used.	<i>stratum</i> , layer + <i>lucidus</i> , clear
<i>Stratum Granulosum</i>	Consists of three to five layers of cells that appear granular and darker in color than those of the underlying stratum spinosum. The graininess of the cells in this layer makes it quite distinct. Keratinocytes begin to die within the stratum granulosum as organelles and nuclei degenerate and the cells accumulate bundles of keratin.	<i>stratum</i> , layer + <i>granulum</i> , a small grain
<i>Stratum Spinosum</i>	Named for the appearance of the keratinocytes when viewed at high magnification. In this layer, keratinocytes contain many cellular extensions, which make them appear somewhat “prickly” or “spiny.” The “spines” are artifacts of staining and are areas where the extensions of adjacent cells interdigitate with each other and are anchored to each other by numerous desmosomes.	<i>stratum</i> , layer + <i>spina</i> , a thorn
<i>Stratum Basale</i>	This layer is only one cell thick. At higher magnification, the cells appear large, with round nuclei, and undergoing cell division ( <i>mitosis</i> ) may be visible. In addition, melanin granules are most concentrated in this layer of the skin. Melanin granules and melanocytes are best visualized in a sample of pigmented skin.	<i>stratum</i> , layer + <i>basalis</i> , situated near the base

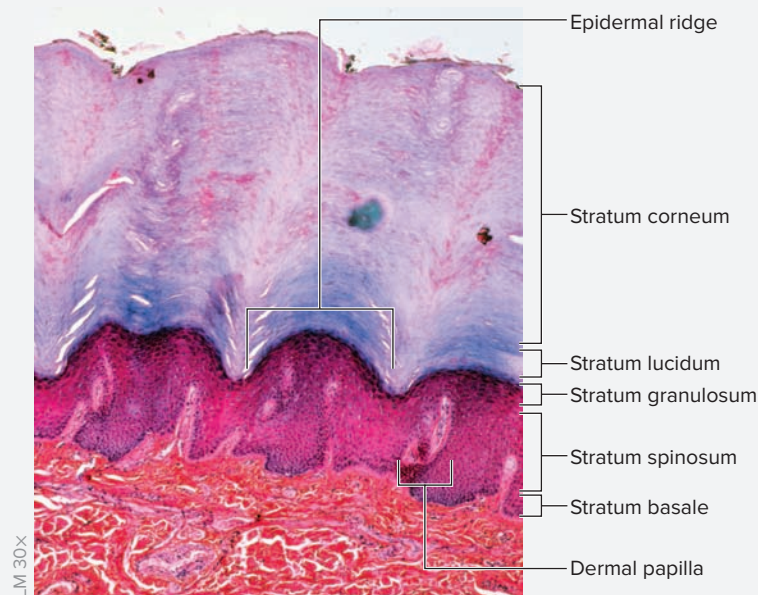


**Figure 6.1** Thick Skin and Thin Skin Differ Only in the Thickness of the Epidermis. The two micrographs shown here are approximately the same magnification. Note both the similarity of the dermis and the difference in epidermal thickness of both samples. Thick skin (a) has a “clear” layer called the stratum lucidum (see table 6.1), which thin skin (b) lacks.

**EXERCISE 6.1** Layers of the Epidermis

1. Obtain a histology slide of **thick skin** (from the palm of the hand or sole of the foot); (figures 6.1a and 6.2). Thick skin is also *glabrous* skin, meaning it lacks hair (*glaber*, smooth). It does, however contain all five epidermal layers, so it is an ideal slide for demonstrating characteristics of the epidermis.
2. Place the slide on the microscope stage and scan the slide at low power. Look for any empty or clear space present in the slide, and try to find the apical surface of the skin epithelium lying next to the clear space.
3. Once you have located the skin epithelium, switch to a higher power. Scan the slide until the basal surface of the epithelium is in the center of the field of view. Look for the junction between the epidermis and the dermis. Notice that the basal layer of the epidermis is thrown into folds that dip into the dermis. These folds are called **epidermal ridges**. Epidermal ridges are thickened layers of the epidermis that are located between upward extensions of the papillary layer of the dermis, which are called **dermal papillae** (*papilla*, nipple). The increased area of adhesion between the epidermis and the dermis in the areas of epidermal ridges and dermal papillae helps prevent the epidermis and dermis from coming apart in areas where the skin experiences large frictional forces. Epidermal ridges are deeper in the tips of the fingers and are the structures that form fingerprints. Observe the fingerprints on your own hand.
4. Identify the following structures on the slide of thick skin, using figures 6.1a and 6.2, and table 6.1 as guides:
 

<input type="checkbox"/> dermal papilla	<input type="checkbox"/> stratum granulosum
<input type="checkbox"/> epidermal ridges	<input type="checkbox"/> stratum lucidum
<input type="checkbox"/> stratum basale	<input type="checkbox"/> stratum spinosum
<input type="checkbox"/> stratum corneum	



**Figure 6.2 Thick Skin.** Epidermal layers in thick skin (found on the palms of the hands and soles of the feet).

© Astrid & Hanns-Frieder Michler/Science Source

### Learning Strategy

Follow these steps to identify the epidermal layers of the skin under the microscope:

1. **Determine if the layer is more superficial or deep.** Remember the stratum corneum is the most superficial layer (next to the free surface), whereas the stratum basale is the deepest epidermal layer.
2. **Examine the shape of the cells.** The stratum corneum and lucidum contain squamous cells, the stratum spinosum contains polygonal cells, and the stratum basale contains cuboidal to low columnar cells.
3. **Determine if the keratinocytes have a nucleus or not.** Living keratinocytes (as found in the stratum granulosum, spinosum, and basale) have prominent nuclei. Dead keratinocytes (as found in the stratum lucidum and corneum) no longer have a nucleus.
4. **Count the number of cells in the layer.** The stratum corneum contains 20 to 30 layers of cells. The stratum lucidum, granulosum, and spinosum contain two to five layers of cells each. The stratum basale contains only one layer of cells.
5. **Determine if the cytoplasm of the cells contains visible granules.** The only layer with visible (and generally dark) cytoplasmic granules is the stratum granulosum.

5. Sketch the layers of the epidermis of thick skin as seen under the microscope in the space provided. Be sure to label all of the structures listed in step 4 in the drawing.

### WHAT DO YOU THINK?

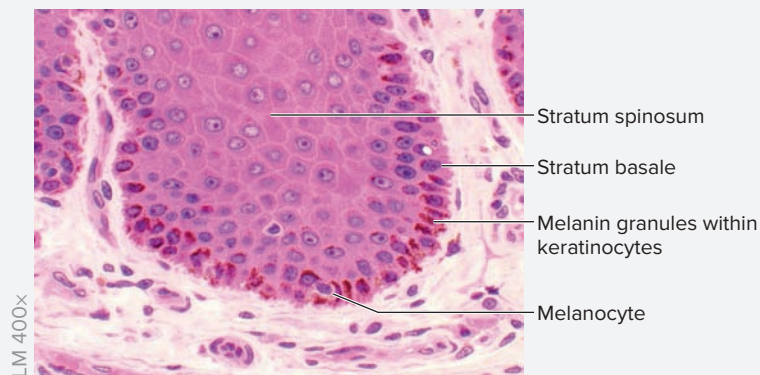
- 1 What layer of the epidermis represents the transition from living to dead epithelial cells? Why do keratinocytes begin to die within this layer?



\_\_\_\_\_ X

**EXERCISE 6.2** Pigmented Skin

The color of a person's skin comes from the pigment **melanin** (*melas*, black). Melanin is produced by cells called **melanocytes**, which are found along the base of the stratum basale of the epidermis. Melanocytes have long dendritic processes (*dendrites*, relating to a tree) that extend between keratinocytes and transfer the melanin granules they produce to the adjacent keratinocytes. The melanin then accumulates on the apical side of the nuclei of the keratinocytes, protecting them from harmful ultraviolet light that can damage the DNA of the keratinocytes. A single melanocyte produces melanin for a number of adjacent keratinocytes (the melanocyte plus the cells served by it are



**Figure 6.3** Pigmented Skin. Pigmented skin containing melanin granules (brown) within keratinocytes, particularly in the stratum basale of the epidermis. Melanocytes themselves are distinguished by a halo of clear cytoplasm that surrounds the nucleus.

© Dr. Thomas Caceci, Virginia-Maryland Regional College of Veterinary Medicine

referred to as an *epidermal-melanin unit*). Some areas of the body have a higher density of melanocytes than others. For example, the skin of the areola of the breast has more melanocytes than the skin on the rest of the breast. However, the *total number of melanocytes in light- and dark-skinned individuals is the same*. Differences in skin color have to do with the *amount of melanin* produced by melanocytes. The melanocytes of dark-skinned individuals simply produce greater amounts of melanin than those of light-skinned individuals.

1. Obtain a slide of pigmented skin and place it on the microscope stage. Observe at low power to locate the epidermis, and then change to a higher-power lens.
2. Focus in on the stratum spinosum of the pigmented skin. Look for distinct black/brown melanin granules within the keratinocytes (**figure 6.3**). Melanocytes themselves are located in the stratum basale and are characterized by small, round nuclei and pale-staining cytoplasm. Try to locate a melanocyte on the slide, keeping in mind that melanocytes are not easily identified on the standard slides found in the laboratory.

### WHAT DO YOU THINK?

- 2 Why do you think it is important that melanin is present in its highest concentration in the keratinocytes at or near the basal layer of cells? (Hint: Did you observe cells that were undergoing cell division in this layer?)

## The Dermis

The dermis of the skin is more complex than the epidermis because it contains numerous skin appendages such as hair follicles, glands, blood vessels, and nerves. The dermis consists of two layers: an outer **papillary layer**, and an inner **reticular layer** (**figure 6.4**). The papillary layer is the part of the dermis that contains “nipplelike” extensions that project into the epidermis (the dermal papillae). The papillary layer is generally quite thin and loosely defined. The reticular layer is named for its “networked”

appearance (*rete*, a net), not because it contains reticular fibers. In fact, the major fiber type found in this layer is the collagen that composes the dense irregular connective tissue. These collagen fibers are interwoven into a meshwork that surrounds structures of the dermis such as hair follicles, sweat glands, sebaceous glands, blood vessels, and nerves. The slide descriptions in this section of the laboratory manual serve as a guide for both general observation of the structure and function of the dermis, and identification of the various skin appendages found within the dermis.

### Learning Strategy



When looking at a piece of leather, observe it carefully and compare it to your own skin. The very tough tissue that composes most of the leather is dense irregular connective tissue (collagen fibers) from the dermis of the animal's skin.


### WHAT DO YOU THINK?

- 3 Contrast the epidermal/dermal junction in thick skin with that of thin skin. Specifically note the structure of the epidermal/dermal junction in each slide. Is there a difference in the number of dermal papillae? What function do you think such differences serve?

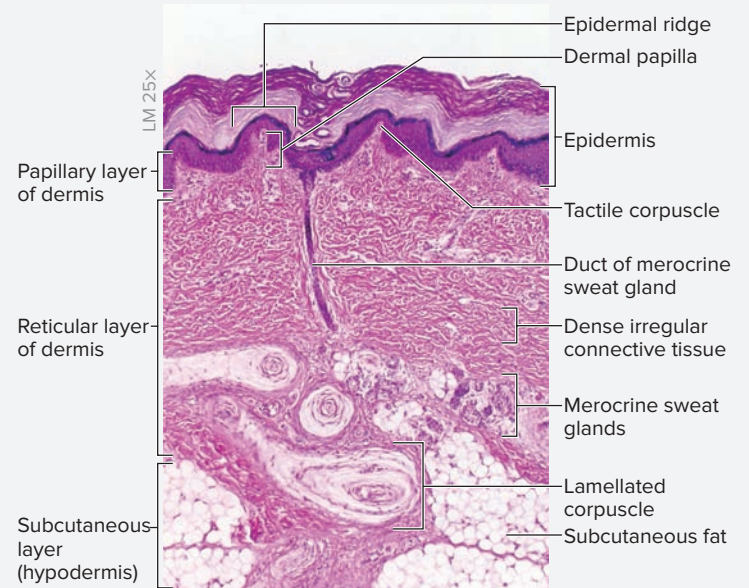
**EXERCISE 6.3** Layers of the Dermis

- Obtain a slide of thick skin or thin skin and place it on the microscope stage.
- Scan the slide at low power to identify the integument, and then bring on the dermal layer of the integument into the center of the field of view.
- Switch to high power and distinguish the papillary dermis from the reticular dermis (figure 6.4). Locate the tiny sensory receptors called **tactile (Meissner) corpuscles** (*tactus*, to touch + *corpus*, body) within a dermal papilla (figure 6.5). Tactile corpuscles are sensory receptors for fine touch (see table 6.3 for a more thorough description).
- Identify the following structures of the dermis on the slide, using figures 6.4 and 6.5 and tables 6.2 and 6.3 as guides:
 

<input type="checkbox"/> dense irregular connective tissue	<input type="checkbox"/> reticular dermis
<input type="checkbox"/> dermal papillae	<input type="checkbox"/> tactile (Meissner) corpuscle
<input type="checkbox"/> papillary dermis	
- Sketch the dermis as seen through the microscope in the space provided. Be sure to label all the structures listed in step 4 in the drawing.

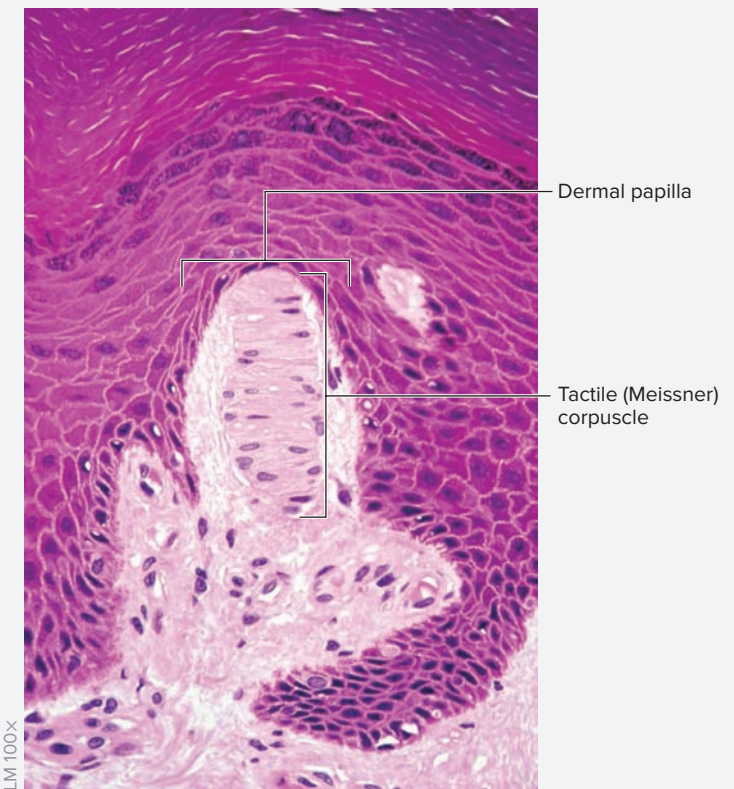
**WHAT DO YOU THINK?**

- What is the advantage of having tactile (Meissner) corpuscles located near the surface of the skin? Do you think there would be more of these sensory receptors per unit area in the skin on the palm of your hand or in the skin on your back (or would they be the same)?



**Figure 6.4** Dermis. Thick skin demonstrating several skin appendages, such as tactile corpuscles, lamellated corpuscles, and merocrine sweat glands in the dermis.

© Ed Reschke



**Figure 6.5** Tactile Corpuscle. High-magnification view of a dermal papilla containing a tactile corpuscle.

© Ed Reschke

**EXERCISE 6.4** Merocrine (Eccrine) Sweat Glands and Sensory Receptors

1. Obtain a slide of thick skin or thin skin and place it on the microscope stage. Begin by observing the epidermal and dermal layers of the skin. When viewing the current slide, focus on the numerous skin appendages found within the dermis.
2. Locate the coiled, tubular glands found deep within the reticular dermis (these glands open to the skin surface, and a duct traveling to the surface of the skin, may be visible). These are **merocrine (eccrine) sweat glands** (*meros-*, to share + *krino*, to separate) (figure 6.4). Merocrine sweat glands are located in skin covering nearly the entire body (as opposed to apocrine sweat glands, which are located only in the axillary, anal, and pubic regions, and the areola of the breast). **Table 6.2** lists the types of glands located in the dermis and describes their locations and functions.
3. Focus on sensory receptors found in the dermis. Table 6.3 summarizes the characteristics of sensory receptors in the dermis. Many of the receptors are difficult to identify histologically. Thus, also be sure to view these structures on classroom models of the integument (exercise 6.8). Observe the many dermal papillae found in the slide. Center one or more papillae in the field of view and increase the magnification.
4. Use figure 6.5 as a guide to locate the tactile (Meissner) corpuscles within the dermal papillae. These sensory receptors, appropriately located near the surface of the skin, are responsible for sensing fine touch.
5. After identifying the tactile corpuscles, change back to a lower magnification and scan the lower parts of the reticular dermis and the subcutaneous regions of the skin. Look for large onion-shaped organs. These

are sensory receptors called **lamellated (Pacinian) corpuscles** (*lamina-*, plate + *corpus*, body) (figure 6.4). Lamellated corpuscles, located deep within the dermis, are responsible for sensing deep pressure and vibration applied to the skin. The other main sensory receptors found within the dermis, the **tactile (Merkel) cells** and **free nerve endings**, are not easily identifiable under the light microscope. Observe these structures on classroom models of the integument (exercise 6.8) instead of trying to find them on microscope slides.

6. Finally, identify cross sections through the numerous small blood vessels located in the dermis.
7. Sketch the skin appendages observed under the microscope in the space provided.

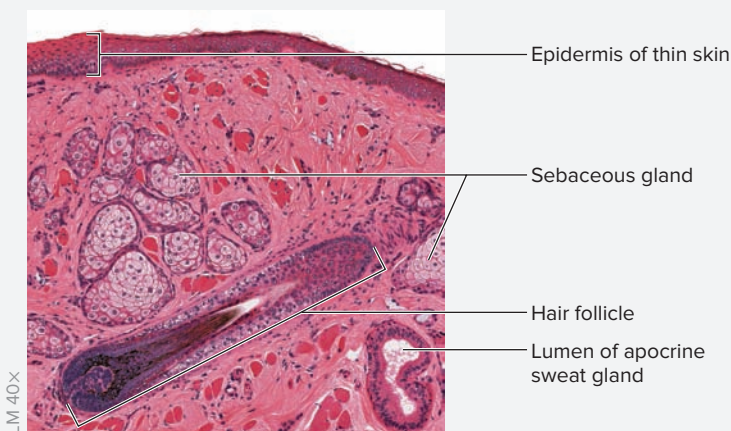**Table 6.2****Glands in the Dermis**

Gland	Location	Description	Mode of Secretion	Function	Word Origins
<i>Apocrine Sweat Glands</i>	Axilla, areola of the breast, and pubic/anal regions.	Coiled tubular glands located next to hair follicles. Ducts open into the hair follicle. The lumens of apocrine glands are larger than those of merocrine glands.	<i>Merocrine</i> —exocytosis of vesicles containing product into the duct of the gland.	Produce a thick, slightly oily sweat that may have pheromone-like properties.	<i>apo-</i> , away from + <i>krino</i> , to separate or secrete
<i>Merocrine (Eccrine) Sweat Glands</i>	Most of the surface of the body.	Coiled tubular glands whose main secretory portions are found deep within the reticular layer of the dermis. Ducts open to the surface of the skin.	<i>Merocrine</i> —exocytosis of vesicles containing product into the duct of the gland.	Produce the thin, watery sweat that cools the body.	<i>meros-</i> , share + <i>krino</i> , to separate or secrete
<i>Sebaceous Glands</i>	Wherever hair follicles are found. Particularly abundant on the scalp.	Glands located next to hair follicles. Ducts commonly open into the hair follicle.	<i>Holocrine</i> —disintegrated whole cells filled with product are discharged into the duct of the gland.	Produce sebum, an oily substance that lubricates the skin surface, keeps it from drying out, and inhibits the growth of bacteria.	<i>sebaceous</i> , relating to sebum; oily; <i>holos-</i> , whole + <i>krino</i> , to separate or secrete

Table 6.3		Sensory Receptors in the Dermis	
Sensory Receptor	Location	Structure/Appearance	Function
<i>Free Nerve Ending</i>	At the epidermal/dermal junction.	There is no special structure at the end of the nerve (hence “free” nerve ending).	General pain sensation.
<i>Lamellated (Pacini) Corpuscle</i>	Deep in the dermis and hypodermis.	Multiple layers of cells wrapped around each other like an onion.	Sensation of deep pressure and vibration.
<i>Tactile (Merkel) Cell</i>	At the epidermal/dermal junction.	Round cell located in the stratum basale of the epidermis. It associates with a sensory nerve ending in the dermis called a tactile disc.	Sensation of fine, delicate touch.
<i>Tactile (Meissner) Corpuscle</i>	Within the dermal papillae.	Oval-shaped structure with cells that appear coiled and/or layered on top of each other.	Sensation of fine, delicate touch.

### EXERCISE 6.5 The Scalp—Hair Follicles and Sebaceous Glands

1. Obtain a slide of the **scalp** and place it on the microscope stage. Begin by observing the epidermal and dermal layers of the scalp. The scalp epithelium is thin, but the dermis is thick and contains numerous **hair follicles** (figure 6.6 and table 6.4).
2. Scan the slide until a hair follicle that is sliced longitudinally is visible in the field of view. The entire hair, from the base of the hair follicle to where it exits the skin, should be visible. Notice that the color of the cells lining the hair follicle is similar to the color of the cells within the epidermis. This is because hair follicles are derivatives of the epidermis and they develop initially as down-growths of the stratum basale. There are three distinct regions to a hair: (1) the **shaft**, which is the portion of the hair that exits the skin surface; (2) the **root**, which is the portion of the hair within the skin itself; and (3) the **bulb**, which is the swelled base of the hair.
3. Observe the bulb of the hair at higher magnification (figure 6.7). Notice the **papilla**, a cone-shaped structure in the middle of the base of the follicle. The papilla is part of the dermis, and is separated from the hair follicle by the basement membrane of the hair follicle epithelium (this basement membrane continues external to the hair follicle as the “glassy membrane”). The papilla contains sensory nerve endings and numerous blood vessels, which are important in supplying nutrients to the developing hair.
4. Return to a lower magnification and look for the oil-secreting **sebaceous glands** (figure 6.6) that connect to the hair follicles in the region of the hair roots. Sebaceous glands secrete an oily substance, **sebum**, into the hair follicle.



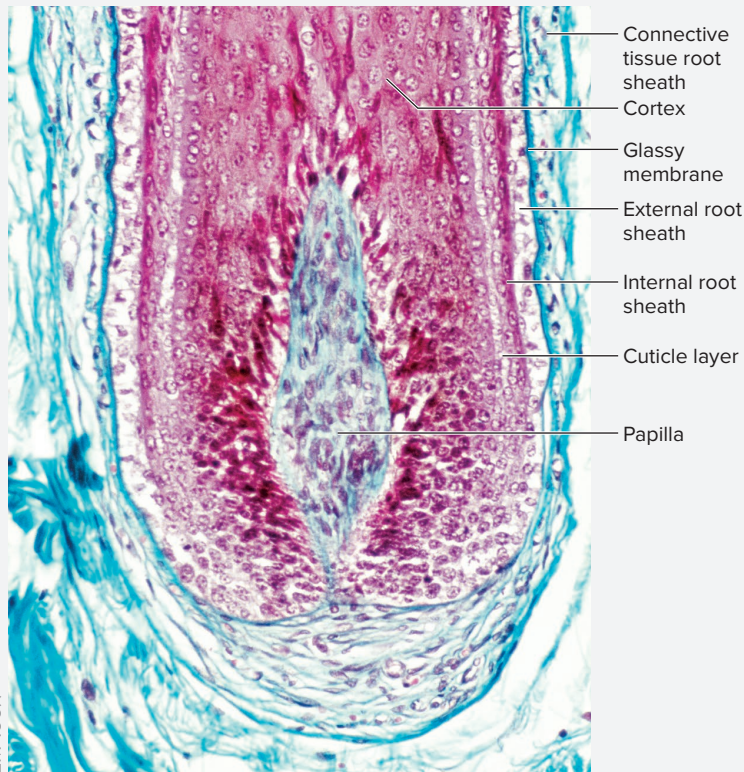
**Figure 6.6 Scalp.** Skin of the scalp, demonstrating a hair follicle and associated glands. The opening of the hair follicle to the surface is not visible in this photomicrograph. Sebaceous glands are the light-colored glands adjacent to the hair follicle. An apocrine sweat gland (see Exercise 6.6) is also visible. It has a large lumen and is lined with columnar epithelial cells. Both sebaceous and apocrine glands have ducts that open to a hair follicle. However, no ducts are visible in this photomicrograph.

© Christine Eckel

Table 6.4		Parts of a Hair Follicle	
Structure		Description and Function	
<i>Connective Tissue (Dermal) Root Sheath</i>		The connective tissue of the dermis (mainly dense collagen fibers) that surrounds the entire hair follicle.	
<i>Cortex</i>		Constitutes the bulk of the hair. Composed predominantly of keratin.	
<i>Cuticle Layer</i>		The outer portion of the hair itself, composed of several layers of hard plates of keratin that surround the cortex of the hair.	
<i>External Root Sheath</i>		The outer layers of the hair follicle, which are continuous with the stratum basale and stratum spinosum of the epidermis.	
<i>Glassy Membrane</i>		A specialized basement membrane located external to the external root sheath and internal to the connective tissue that surrounds the hair follicle (the connective tissue root sheath).	
<i>Internal Root Sheath</i>		A sheath derived from epithelial tissue that lies between the external root sheath and the hair itself.	

(continued on next page)

(continued from previous page)



**Figure 6.7** Close-up View of a Hair Bulb.

© Biophoto Associates/Science Source

5. Carefully observe several hair follicles to locate the small **arrector pili** muscles (*arrector-*, that which raises + *pili*, hair) that attach to the base of the hair follicle (not visible in figure 6.6; see figure 6.11). When these smooth muscles contract, they pull at the base of the hair follicle. This causes the hair to stand up straight, rather than lie flat against the surface of the skin. Muscle contraction pulls down on the epidermis of the skin, while the area where the hair shaft exits the epidermis remains elevated. Thus, in humans contraction of arrector pili muscles gives the appearance of “goose bumps” or “goose pimples.”

6. Identify the following structures related to the hair follicle, using figures 6.6 and 6.7, and the textbook as guides:

- |   |   |
|---|---|
| <input type="checkbox"/> arrector pili muscle     | <input type="checkbox"/> root of hair follicle  |
| <input type="checkbox"/> bulb of hair follicle    | <input type="checkbox"/> sebaceous gland        |
| <input type="checkbox"/> hair follicle            | <input type="checkbox"/> shaft of hair follicle |
| <input type="checkbox"/> papilla of hair follicle |   |

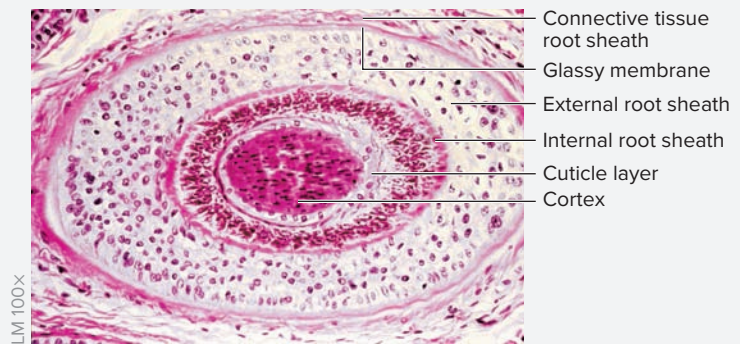
7. Sketch a hair follicle and associated skin appendages as viewed through the microscope in the space provided. Be sure to label all the structures listed in step 6 in the drawing.



8. Next, scan the slide until a hair follicle in cross section is visible within the field of view (**figure 6.8**).

9. Identify the following structures, using figure 6.8 and table 6.4 as guides:

- |   |   |
|---|---|
| <input type="checkbox"/> connective tissue (dermal) root sheath | <input type="checkbox"/> external root sheath |
| <input type="checkbox"/> cortex                                 | <input type="checkbox"/> glassy membrane      |
| <input type="checkbox"/> cuticle layer                          | <input type="checkbox"/> internal root sheath |



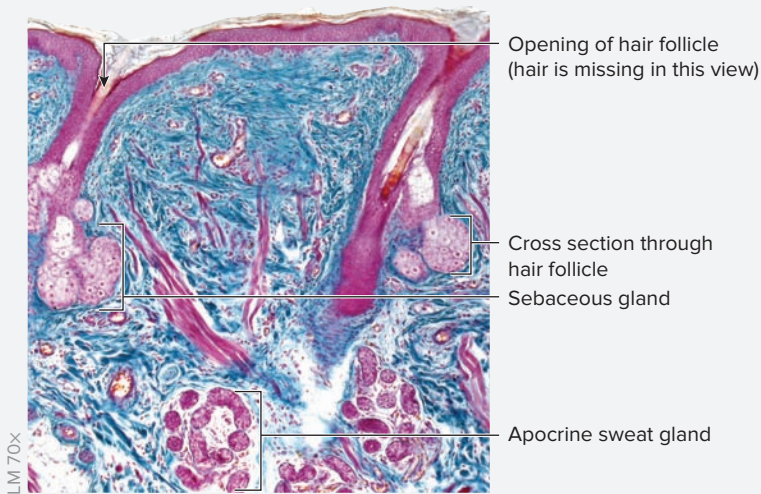
**Figure 6.8** Cross Section of a Hair Follicle.

© Biophoto Associates/Science Source

**EXERCISE 6.6** Axillary Skin—Apocrine Sweat Glands

1. Obtain a slide of **axillary skin** and place it on the microscope stage. Locate a hair follicle on the slide. Notice that the hair follicles in this skin are oriented at a fairly steep angle with respect to the apical surface of the epithelium. This, in part, is what makes the hairs in the axillary region curly.
2. Look for glands that open into the hair follicle. These are **apocrine sweat glands** (*apo-*, away from + *krino*, to separate or secrete) (**figure 6.9**). Apocrine sweat glands are predominantly located in the axillary and pubic/anal regions of the body, though they are also located in the areola of the nipple and in men's facial hair. These glands produce their secretions via exocytosis, the same mechanism used by merocrine glands. However, apocrine glands produce a secretion that is thicker and oilier than that of the merocrine glands. Thus, although the term *apocrine* historically referred to a different mode of secretion,\* these glands are still referred to as apocrine glands.

3. Sketch a hair follicle from axillary skin and its associated apocrine sweat gland in the space provided.



**Figure 6.9** Apocrine Sweat Glands. Axillary skin demonstrating apocrine sweat glands, which open to the hair follicle.

© McGraw-Hill Education/Al Telsler

### Learning Strategy



It can be tricky to initially distinguish apocrine sweat glands from sebaceous glands, because both of them open into hair follicles. However, sebaceous glands are located higher up (closer to the epidermis) along the hair follicle than apocrine glands. In addition, the lumen of an apocrine sweat gland is open, whereas the lumen of a sebaceous gland appears to be full of whitish cells with small nuclei.

\*Traditionally, *apocrine* referred to a process by which the apical part of the cell was discharged into the duct of the gland along with the secretion. However, we now know that this is not how apocrine glands produce their secretions.



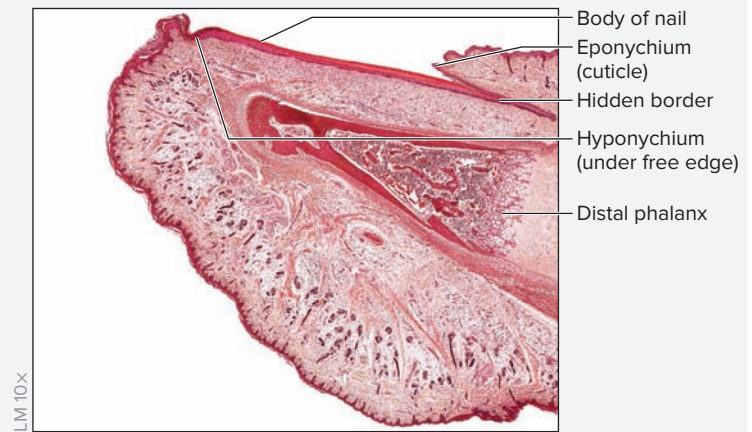
**EXERCISE 6.7** Structure of a Nail

1. Obtain a slide of a **nail**. A nail is a very specialized skin appendage that arises from epithelial tissue. **Table 6.5** lists the parts of a nail, and **figure 6.10** shows a longitudinal section of a nail.
2. Identify the following structures on the slide, using figure 6.10 and table 6.5 as guides:
 

<input type="checkbox"/> <b>body</b>	<input type="checkbox"/> <b>hidden border</b>
<input type="checkbox"/> <b>eponychium</b>	<input type="checkbox"/> <b>hyponychium</b>
3. Sketch a nail as seen through the microscope in the space provided. Be sure to label all of the structures listed in step 2 in the drawing.



Table 6.5		Parts of a Nail
Structure	Description	Word Origins
<i>Body</i>	The main portion of the nail.	
<i>Eponychium</i>	The fold of skin at the root of the nail that folds over the body of the nail.	<i>epi-</i> , upon + <i>onyx</i> , nail
<i>Hidden Border</i>	The portion of the nail that lies beneath the eponychium.	
<i>Hyponychium</i>	The skin underneath the free border of the nail.	<i>hypo-</i> , under + <i>onyx</i> , nail
<i>Lunula</i>	A white, curved area at the base of the nail.	<i>luna</i> , moon



**Figure 6.10** Longitudinal Section of a Nail.

© McGraw-Hill Education/Christine Eckel, photographer

## Gross Anatomy

### Integument Model

Viewing laboratory models or charts of integument allows identification of structures that are not easily visible under the light microscope.

**Figure 6.11** demonstrates structures that are typically visible in classroom models of the integument.

#### EXERCISE 6.8 Observing Classroom Models of Integument

1. Locate models or posters demonstrating the integument in the laboratory.
2. Identify the structures listed, using figure 6.11 as a guide. Pay particular attention to tactile corpuscles, lamellated corpuscles, melanocytes, and free nerve endings, because these structures are not easily visible under the microscope.

##### Epidermis

- |   |   |
|---|---|
| <input type="checkbox"/> epidermal ridges | <input type="checkbox"/> stratum granulosum |
| <input type="checkbox"/> stratum basale   | <input type="checkbox"/> stratum lucidum    |
| <input type="checkbox"/> stratum corneum  | <input type="checkbox"/> stratum spinosum   |

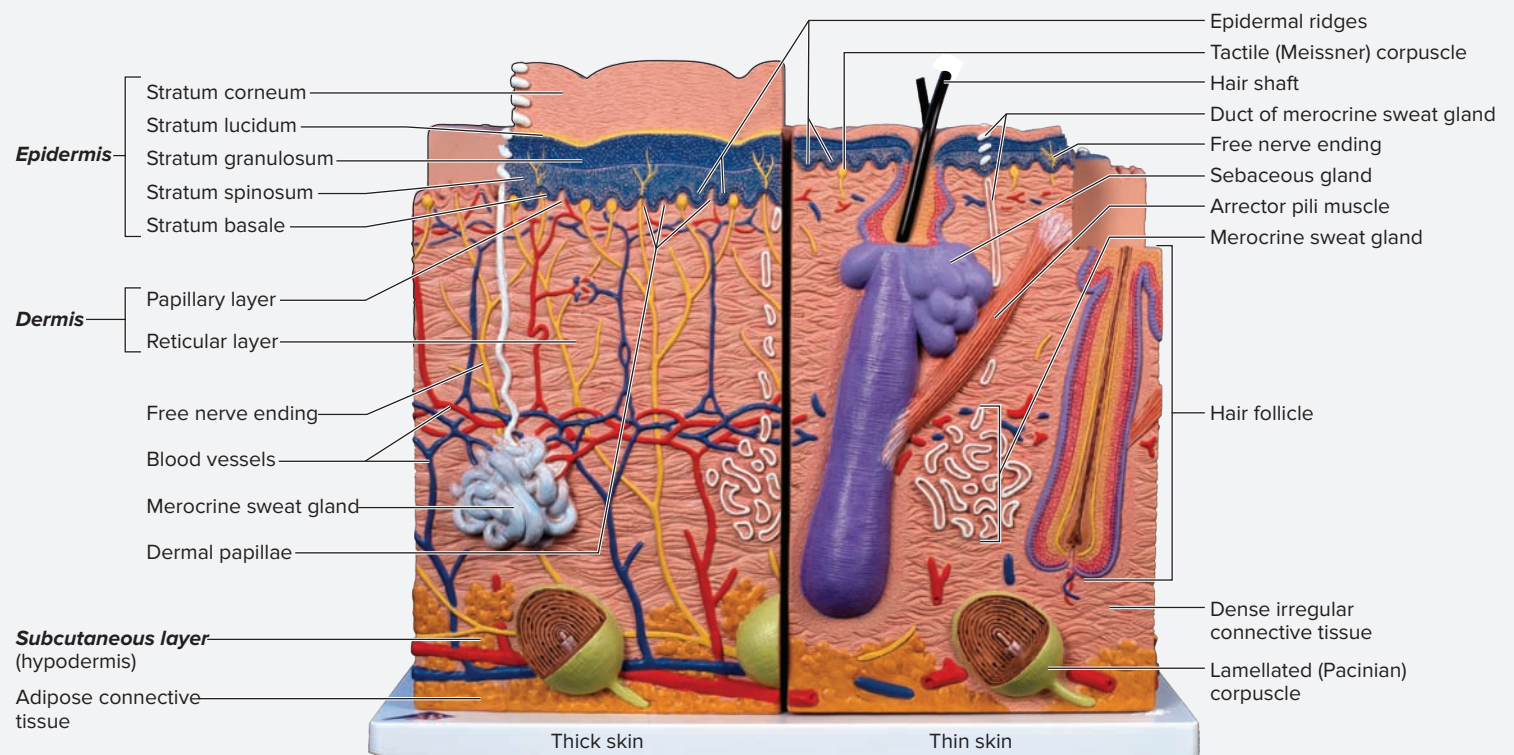
3. *Optional Activity:* **AP|R** 4: **Integumentary System**— Use the Quiz feature to review integumentary system structures.

##### Dermis

- |  |   |
|--|---|
| <input type="checkbox"/> blood vessels                     | <input type="checkbox"/> merocrine sweat gland        |
| <input type="checkbox"/> dense irregular connective tissue | <input type="checkbox"/> papillary layer              |
| <input type="checkbox"/> free nerve ending                 | <input type="checkbox"/> reticular layer              |
| <input type="checkbox"/> hair follicle                     | <input type="checkbox"/> sebaceous gland              |
| <input type="checkbox"/> lamellated (Pacian) corpuscle     | <input type="checkbox"/> tactile (Meissner) corpuscle |

##### Subcutaneous layer (hypodermis)

- |  |  |
|--|--|
| <input type="checkbox"/> adipose connective tissue | <input type="checkbox"/> lamellated (Pacian) corpuscle |
|--|--|



**Figure 6.11** Diagram of the Integument.

Model # J16 [1000294] © 3B Scientific GmbH, Germany, 2013 www.3bscientific.com/Photo by Christine Eckel, Ph.D.

*This page intentionally left blank*

The 1 corresponds to the Learning Objective listed in the chapter opener outline.

## Do You Know the Basics?

### Exercise 6.1: Layers of the Epidermis

- Which of the following is the type of tissue found in the most superficial layer of thick skin? (Circle one.) 1
  - adipose connective tissue
  - areolar connective tissue
  - dense irregular connective tissue
  - simple squamous epithelial tissue
  - stratified squamous epithelial tissue
- Identify the location(s) on the body where skin is glabrous and contains five layers in the epidermis. (Check all that apply.) 2
  - \_\_\_\_\_ a. back
  - \_\_\_\_\_ b. face
  - \_\_\_\_\_ c. palms of the hands
  - \_\_\_\_\_ d. scalp
  - \_\_\_\_\_ e. soles of the feet

### Exercise 6.2: Pigmented Skin

- Although melanocytes are the cells that produce melanin, the cells that actually *concentrate* the melanin in the apical region of the cell to protect the cell nucleus are \_\_\_\_\_. 3

### Exercise 6.3: Layers of the Dermis

- Match the definition listed in column A with the corresponding term listed in column B. 4
 

<p><b>Column A</b></p> <p>_____ 1. a cell located in the epidermis that produces melanin</p> <p>_____ 2. an epithelial cell composing the majority of the epidermis</p> <p>_____ 3. a fold of the epidermis that interdigitates with dermal papillae</p> <p>_____ 4. a "nipplelike" extension of the dermis into the epidermis</p>	<p><b>Column B</b></p> <p>a. dermal papilla</p> <p>b. epidermal ridge</p> <p>c. keratinocyte</p> <p>d. melanocyte</p>
--	---
- The \_\_\_\_\_ (papillary/reticular) layer of the dermis is the thickest layer of the dermis. 4

### Exercise 6.4: Merocrine (Eccrine) Sweat Glands and Sensory Receptors

- Match the description listed in column A with the corresponding gland listed in column B. 5
 

<p><b>Column A</b></p> <p>_____ 1. <i>merocrine</i> glands that empty into hair follicles</p> <p>_____ 2. <i>holocrine</i> glands that empty into hair follicles</p> <p>_____ 3. <i>merocrine</i> glands that open to the surface of the skin</p>	<p><b>Column B</b></p> <p>a. apocrine sweat glands</p> <p>b. eccrine sweat glands</p> <p>c. sebaceous glands</p>
---	--
- Lamellated (Pacian) corpuscles are located in the *papillary* layer of the dermis, whereas tactile (Meissner) corpuscles are located in the *reticular* layer of the dermis. \_\_\_\_\_ (True/False) 5
- Match the function listed in column A with the corresponding sensory receptor listed in column B. 6
 

<p><b>Column A</b></p> <p>_____ 1. sensation of fine touch, textures, and shapes</p> <p>_____ 2. sensation of light touch, temperature, pain, and pressure</p> <p>_____ 3. sensation of deep pressure and high-frequency vibration</p> <p>_____ 4. sensation of fine, light touch and texture</p>	<p><b>Column B</b></p> <p>a. free nerve ending</p> <p>b. lamellated (Pacian) corpuscle</p> <p>c. tactile (Meissner) corpuscle</p> <p>d. tactile (Merkel) cell</p>
---	---

**Exercise 6.5: The Scalp—Hair Follicles and Sebaceous Glands**

9. Arrector Pili muscles are small muscles that attach to the shaft of a hair. \_\_\_\_\_ (True/False) **7**
10. \_\_\_\_\_ (apocrine/sebaceous) glands produce a thick, oily sweat that has pheromone-like properties. **8**

**Exercise 6.6: Axillary Skin—Apocrine Sweat Glands**

11. Apocrine sweat glands open to hair follicles and secrete an oily substance whose function is to lubricate the hair follicle. \_\_\_\_\_ (True/False) **9**
12. Apocrine sweat glands open to hair follicles, whereas merocrine (eccrine) sweat glands open to the surface of the skin. \_\_\_\_\_ (True/False) **10**

**Exercise 6.7: Structure of a Nail**

13. Match the description listed in column A with the structure listed in column B. **11**

**Column A**

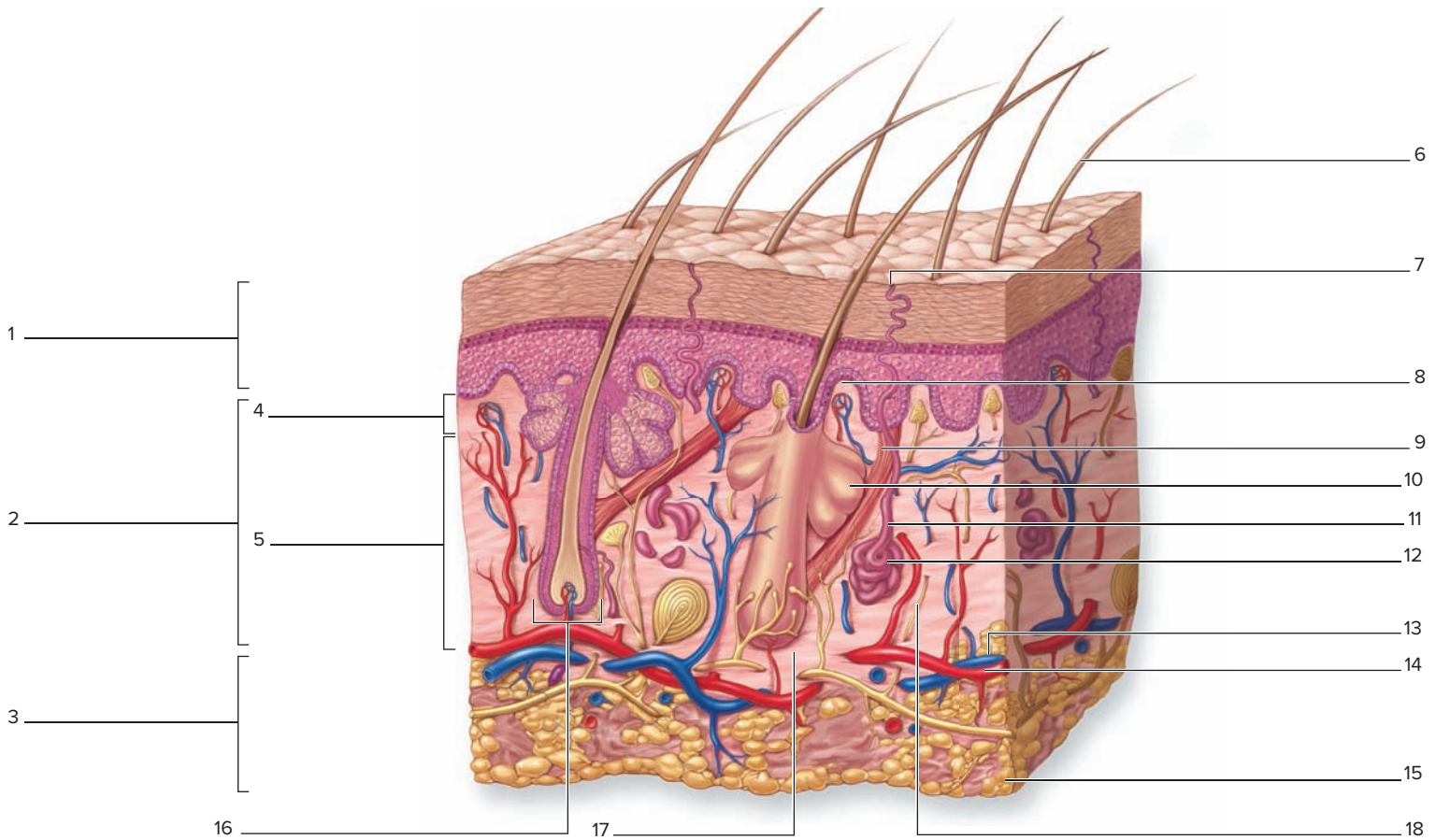
- \_\_\_\_\_ 1. skin underneath the free border of the nail
- \_\_\_\_\_ 2. main portion of the nail
- \_\_\_\_\_ 3. portion of the nail that lies beneath the eponychium
- \_\_\_\_\_ 4. white curved area at the base of the nail
- \_\_\_\_\_ 5. fold of skin at the root of the nail

**Column B**

- a. body
- b. eponychium
- c. hidden border
- d. hyponychium
- e. lunula

**Exercise 6.8: Observing Classroom Models of Integument**

14. Label the following diagram of the integument. **12**



**Can You Apply What You've Learned?**

15. While sitting on the couch reading your anatomy and physiology book, you realize that you left a window open because you feel a light breeze flowing across your arm. What type of sensory receptor in the skin is responsible for detecting this sensation? \_\_\_\_\_
16. When sitting down on a bench to wait for a bus to arrive, you notice that there is a rock on the bench that you didn't see before you sat down on it. What type of sensory receptor in the skin is responsible for detecting this sensation? \_\_\_\_\_
17. Susan accidentally tripped on the sidewalk and scraped her knee. The scrape was superficial and did not bleed. What is the deepest layer of her skin that could have been damaged without causing her to bleed? \_\_\_\_\_

**Can You Synthesize What You've Learned?**

18. What areas of the body lack sebaceous glands?  
\_\_\_\_\_
19. When part of the skin is exposed to a great deal of friction, such as when part of the foot rubs against a shoe, a **blister** often forms.
- A blister is a collection of fluid that accumulates between two layers of the skin as they separate from each other. Which two layers of the skin are these? \_\_\_\_\_ and \_\_\_\_\_
  - When the outer layers of skin are pulled off of a blister, exposure of the underlying tissue causes a great deal of pain. What type of sensory receptor is responsible for sensation of this pain?  
\_\_\_\_\_
  - Why is the pain worse after removal of the outer layer of the blister?  
\_\_\_\_\_  
\_\_\_\_\_
20. A hypodermic needle is used to give certain types of injections.
- Based on the name of the needle, what space is the tip of the needle usually directed into?  
\_\_\_\_\_
  - What layers of the skin must the hypodermic needle pass through, in order to get to this space? (In your answer, include all sublayers of the dermis or epidermis that may apply. Assume the needle is passing through thin skin.)  
\_\_\_\_\_  
\_\_\_\_\_  
\_\_\_\_\_  
\_\_\_\_\_
  - What structures do you think are the likely targets of these needles?  
\_\_\_\_\_  
\_\_\_\_\_
21. a. What layer of the epidermis represents the transition from living to dead epithelial cells?  
\_\_\_\_\_
- Why do keratinocytes begin to die within this layer?  
\_\_\_\_\_  
\_\_\_\_\_  
\_\_\_\_\_

22. Contrast the epidermal/dermal junction in thick skin with that of thin skin. Specifically note the structure of the epidermal/dermal junction in thick versus thin skin. Is there a difference in the number of dermal papillae? What function do you think such differences serve?

---

---

---

---

---

---

23. Why is it important that melanin is present in its highest concentration in the keratinocytes at or near the basal layer of cells? (Hint: Were cells that were undergoing cell division observed in this layer?)

---

---

---

---

24. a. What is the advantage of having tactile (Meissner) corpuscles located near the surface of the skin?

---

---

b. Do you think there would be more of these sensory receptors per unit area in the skin on the palm of the hand or in the skin on the back (or would they be the same)?

---

---

# Skeletal System Overview: Bone Anatomy

# 7

## INTRODUCTION

The human skeletal system is composed of bones, as well as cartilage, ligaments, and other connective tissues that stabilize or connect bones to each other. Bones are composed primarily of bone tissue, which serves as the rigid framework that supports the body. Bone is a highly specialized connective tissue that is both rigid and flexible. A common misconception about bones is that they are static, nonliving tissues. This misconception likely occurs because the type of bones commonly observed in the anatomy laboratory are preserved skeletons or individual bones. In reality, bone is a dynamic, versatile tissue that is in a constant state of turnover and is one of the most metabolically active kinds of tissues within the body. Bone tissue has a rich blood supply and an amazing ability to alter its structure in response to the changing stresses placed upon it. Indeed, prolonged absence of stress will cause a loss of bone density and strength. On the other hand, increased stress will cause bone to increase in density and strength.

The focus of the exercises in this chapter is to explore the general micro- and macrostructure of bone tissues, and to provide a brief overview of the structures and functions of the human skeleton. The detailed structures and functions of the bones that make up the human skeleton are covered in chapters 8 and 9.

## OUTLINE AND LEARNING OBJECTIVES

### Histology 107

#### Bone Tissue 107

##### EXERCISE 7.1: COMPACT BONE 108

- 1 Identify the histological features of compact bone
- 2 Describe the structure of an osteon

##### EXERCISE 7.2: SPONGY BONE 109

- 3 Identify the histological features of spongy bone

##### EXERCISE 7.3: ENDOCHONDRAL BONE DEVELOPMENT 110

- 4 Describe the process of endochondral bone development
- 5 Identify the five functional layers of the epiphyseal plate

### Gross Anatomy 111

#### Classification of Bones 111

##### EXERCISE 7.4: IDENTIFYING CLASSES OF BONES BASED ON SHAPE 112

- 6 List and identify the structural classifications of bones of the human skeleton

#### Structure of a Typical Long Bone 112

##### EXERCISE 7.5: COMPONENTS OF A LONG BONE 113

- 7 Identify the components of a typical long bone

##### EXERCISE 7.6: COW BONE DISSECTION 114

- 8 Identify specific types of bone and cartilage tissues through gross observation of a fresh cow bone

#### Survey of the Human Skeleton 116

##### EXERCISE 7.7: THE HUMAN SKELETON 116

- 9 Identify the bones of the human skeleton



## Module 5: SKELETAL SYSTEM

### List of Reference Tables

Table 7.1	Types of Bone Cells	p. 107
Table 7.2	Classification of Bones Based on Shape	p. 111



# Chapter 7: Skeletal System Overview: Bone Anatomy

Name: \_\_\_\_\_

Date: \_\_\_\_\_ Section: \_\_\_\_\_

## PRE-LABORATORY WORKSHEET

These Pre-laboratory Worksheet questions may be assigned by instructors through their **connect** course.

1. Which of the following is a function of the skeletal system? (Check all that apply.)

- a. hemopoiesis
- b. movement
- c. storage of minerals
- d. structural support

2. The type of bone that contains osteons, characterized by lamellae surrounding central canals, is called \_\_\_\_\_ (compact/spongy) bone.

3. Match the description and function listed in column A with the type of bone cell listed in column B.

### Column A

- 1. immature cell that lays down new bone
- 2. mature bone cell that maintains the bony matrix
- 3. phagocytic cell that breaks down bone
- 4. stem cell that differentiates into an osteoblast

### Column B

- a. osteoblast
- b. osteoclast
- c. osteocyte
- d. osteoprogenitor cell

4. There are \_\_\_\_\_ (3, 5) layers of the epiphyseal plate.

5. Match the descriptions of the components of a long bone listed in column A with the appropriate term listed in column B.

### Column A

- 1. the area where the epiphysis of a developing long bone meets the shaft
- 2. the end of a long bone
- 3. the shaft of a long bone

### Column B

- a. diaphysis
- b. epiphysis
- c. metaphysis

6. In *mature* skeleton, \_\_\_\_\_ (red/yellow) bone marrow fills the medullary cavity of a long bone, and \_\_\_\_\_ (red/yellow) bone marrow is located within the proximal epiphyses of long bones such as the humerus and femur.

7. The outer covering of bone, the periosteum, is composed of which type of connective tissue? (Circle one.)

- a. cartilage
- b. dense irregular connective tissue
- c. elastic connective tissue
- d. reticular connective tissue

8. The ribs are classified as bones of the axial skeleton. \_\_\_\_\_ (True/False)

9. The bones composing the appendicular skeleton include the upper limb bones, lower limb bones, and vertebrae. \_\_\_\_\_ (True/False)

10. The metacarpal bones are classified as \_\_\_\_\_ (long/short) bones. The humerus is classified as a \_\_\_\_\_ (long/short) bone.

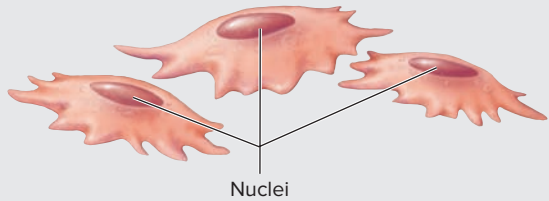
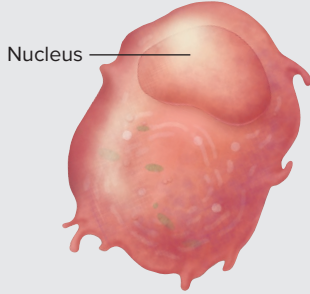
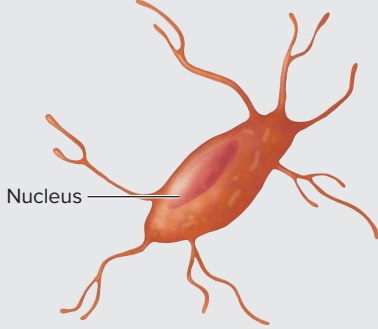
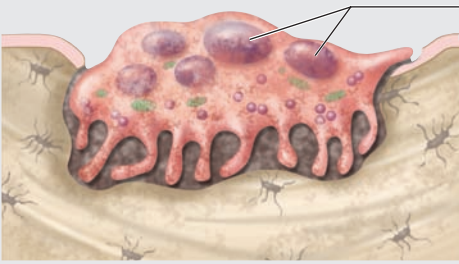
## Histology

The exercises in this chapter explore the histology of compact bone tissue, spongy bone tissue, and endochondral bone development. **Table 7.1** summarizes the characteristics of the types of bone cells that will be observed during histologic studies of bone tissue.

### Bone Tissue

There are two types of bone histology preparations generally observed in the human anatomy laboratory. In the first type of preparation, **ground bone** (see **figure 7.1**, exercise 7.1), a hard bone sample is ground down into a section that is thin enough to be viewed under a

microscope. This type of preparation destroys living cells. Thus, no osteocytes, osteoblasts, or other cells are visible. However, details of the bony matrix—such as central (Haversian) canals, perforating (Volkmann) canals, and canaliculi—are preserved. In the second type of preparation, **ground bone** (**figure 7.2**), a hard bone sample is ground down into **decalcified bone** (see **figure 7.3**, exercise 7.2); the rigid, mineralized (calcified) matrix of the bone is dissolved away so the tissue is soft enough to be sectioned in the traditional manner. This type of preparation preserves living cells such as **osteocytes** and **osteoblasts**, but the fine structure of the bony matrix cannot be visualized because of the removal of the rigid portion of the matrix.

Table 7.1		Types of Bone Cells	
Cell Name	Description and Function	Drawing	Word Origins
<i>Osteoprogenitor Cell</i>	A stem cell derived from mesenchyme that differentiates into an osteoblast. Located in the inner layers of the endosteum and periosteum. The histological appearance of this cell is shown in figure 7.2.		( <i>osteon</i> , bone + <i>pro</i> , before + <i>genesis</i> , origin)
<i>Osteoblast</i>	A small, immature bone cell derived from an osteoprogenitor cell that functions to lay down new bone for bone growth, remodeling, and repair. These cells often appear lined up in rows next to a trabecula of spongy bone. The histological appearance of this cell is shown in figure 7.3a.		( <i>osteon</i> , bone + <i>blastos</i> , germ)
<i>Osteocyte</i>	A mature bone cell derived from an osteoblast that functions to maintain the matrix surrounding it. These cells are located within lacunae. The histological appearance of this cell is shown in figure 7.2.		( <i>osteon</i> , bone + <i>kytos</i> , a hollow; a cell)
<i>Osteoclast</i>	A very large, multinucleate, phagocytic cell derived from bone marrow cells that also produce monocytes. Osteoclasts break down bone and are often found on the opposite side of a trabecula of spongy bone as the layer of osteoblasts. The histological appearance of this cell is shown in figure 7.3b.		( <i>osteon</i> , bone + <i>klastos</i> , broken)

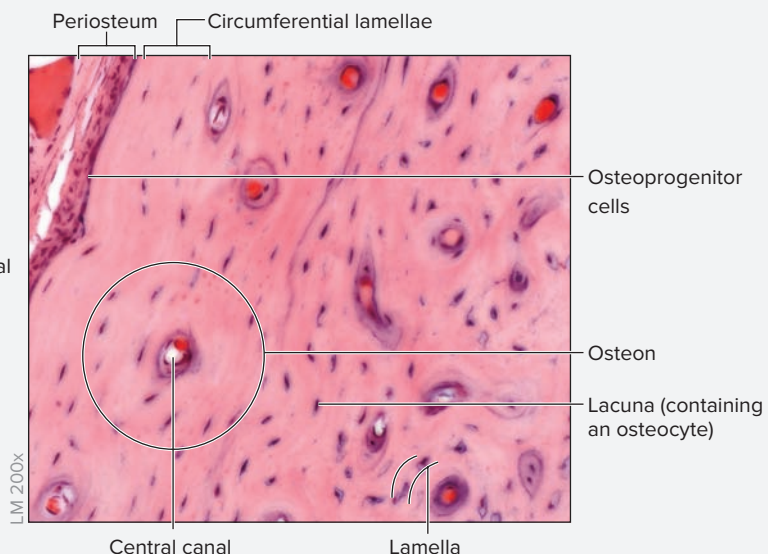
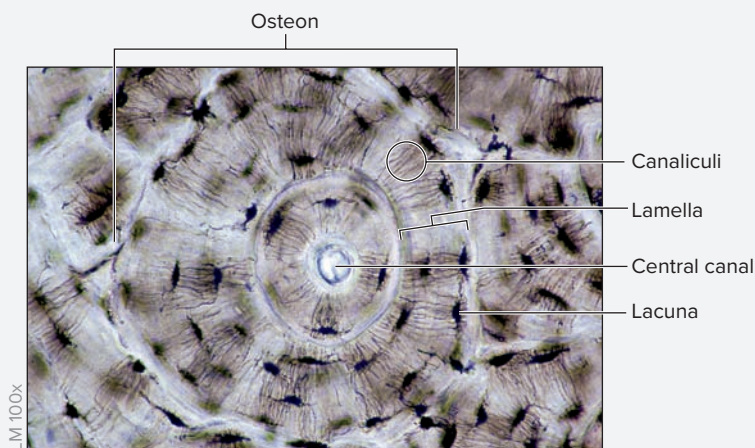
**EXERCISE 7.1 Compact Bone**

1. Obtain a slide of **ground compact bone** (figure 7.1) and place it on the microscope stage. Bring the tissue sample into focus on low power and locate an **osteon**. Remember, living cells are not visible in this tissue sample.
2. With the osteon at the center of the field of view, increase the magnification. The **central (Haversian) canals** will be the largest holes visible in the sample. (The blood vessels and nerves that are housed within these canals can be viewed in the slide of decalcified compact bone.) In contrast, **lacunae** will appear to be much smaller holes because they contain only a single cell in living bone. (Osteocytes present in lacunae can be viewed in the slide of decalcified compact bone.) **Concentric lamellae** extend outward from the central canals in concentric rings. Lacunae that house osteocytes are found at the border between two adjacent lamellae. **Interstitial lamellae** can be seen between osteons. **Circumferential lamellae** can be viewed by scanning the outer border of the bone sample, because circumferential lamellae surround the entire diaphysis of the bone. Lacunae appear very dark in color, and at very high magnification they may appear to be empty because of the lack of living osteocytes in the tissue.
3. Scan the slide to look for large canals that run perpendicular to the central canals. These canals are **perforating (Volkmann) canals**, which convey blood vessels from the outer **periosteum** into the central canals.

Observe this slide at the highest magnification possible (without using the oil immersion lens). Note what appear to be tiny little “cracks” or fractures that run perpendicular to the central canals. These are the tiny **canaliculi**, which contain cytoplasmic extensions of osteocytes in living bone tissue. Within the canaliculi osteocytes connect to each other via gap junctions, which allow them to exchange nutrients and other substances with each other.

4. Obtain a slide of **decalcified compact bone** (figure 7.2) and place it on the microscope stage. Bring the tissue sample into focus on low power and locate an osteon. This slide will demonstrate the remnants of living structures (cells, blood vessels, and nerves) within the bone.
5. With an osteon at the center of the field of view, increase the magnification. The central canals will be the largest holes visible in the sample. The central canals will likely appear to have “junk” inside their lumens. This “junk” consists of blood vessels and nerves. In contrast, lacunae will appear to be much smaller holes and there will only be one cell (an osteocyte) inside each lacuna. Lamellae are sometimes difficult to make out. First locate the lacunae, and then search for the lamellae. Lacunae are located at the border between two adjacent lamellae. Scan toward the outer border of the bone sample to identify circumferential lamellae, which surround the entire diaphysis of the bone.
6. Scan the outer edge of the bone tissue on the slide and identify the periosteum of the bone. The periosteum contains an outer layer of dense irregular connective tissue and an inner layer of **osteoprogenitor cells**, which may or may not be visible.
7. Sketch the appearances of ground compact bone and decalcified compact bone as viewed under the microscope in the spaces provided. Label the following on the sketches, using figures 7.1 and 7.2 and table 7.1 as guides:

- |   |   |
|---|---|
| <input type="checkbox"/> central canal            | <input type="checkbox"/> osteocyte            |
| <input type="checkbox"/> circumferential lamellae | <input type="checkbox"/> osteon               |
| <input type="checkbox"/> concentric lamellae      | <input type="checkbox"/> osteoprogenitor cell |
| <input type="checkbox"/> interstitial lamellae    | <input type="checkbox"/> perforating canal    |
| <input type="checkbox"/> lacuna                   | <input type="checkbox"/> periosteum           |
| <input type="checkbox"/> osteoblast               |   |




**AP|R Figure 7.1** Ground Compact Bone. No perforating canals are visible in this section.

© Ed Reschke/Getty Images


**Figure 7.2** Decalcified Compact Bone.

© McGraw-Hill Education/AI Telser

Ground compact bone



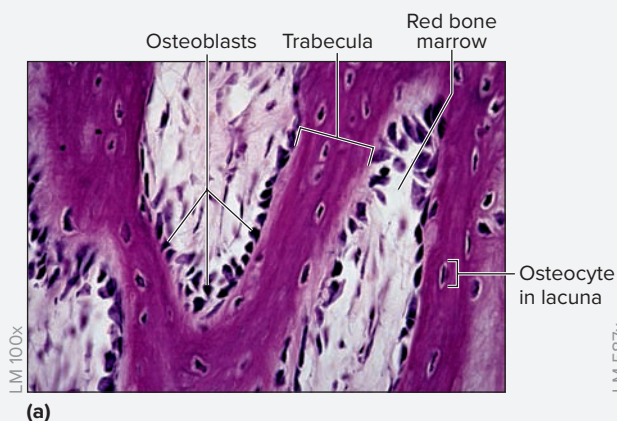
Decalcified compact bone



### EXERCISE 7.2 Spongy Bone

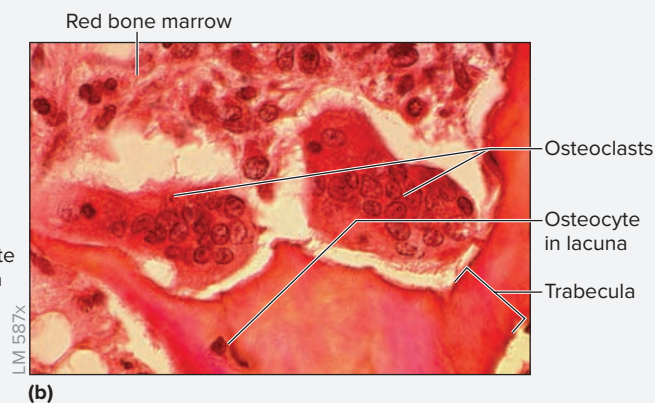
1. Obtain a slide of decalcified **spongy (cancellous) bone** (figure 7.3) and place it on the microscope stage. The sample of spongy bone will appear most similar to the slide of decalcified compact bone. The main difference between the two is that the spongy bone does *not* contain osteons, so neither central canals nor perforating canals are visible.
2. Observe the slide at high magnification and look for areas where several small cells are lined up next to each other on the edge of a trabecula. These are osteoblasts (figure 7.3a), which actively secrete new bony matrix. Are any very large, multinucleate cells visible on the slide? If so, these are bone-resorbing **osteoclasts** (figure 7.3b). Both osteoclasts and osteoblasts are actively involved in the process of bone remodeling.
3. Sketch the spongy bone as viewed under the microscope in the space provided. Label the following on the sketch, using figure 7.3 and table 7.1 as guides:

- |                                     |  |
|-------------------------------------|--|
| <input type="checkbox"/> lacuna     | <input type="checkbox"/> osteocyte       |
| <input type="checkbox"/> osteoblast | <input type="checkbox"/> red bone marrow |
| <input type="checkbox"/> osteoclast | <input type="checkbox"/> trabecula       |



### WHAT DO YOU THINK?

- 1 When a bone fractures and subsequently undergoes the process of repair, what bone cells will be involved in the repair process and how will each bone cell participate in the process?



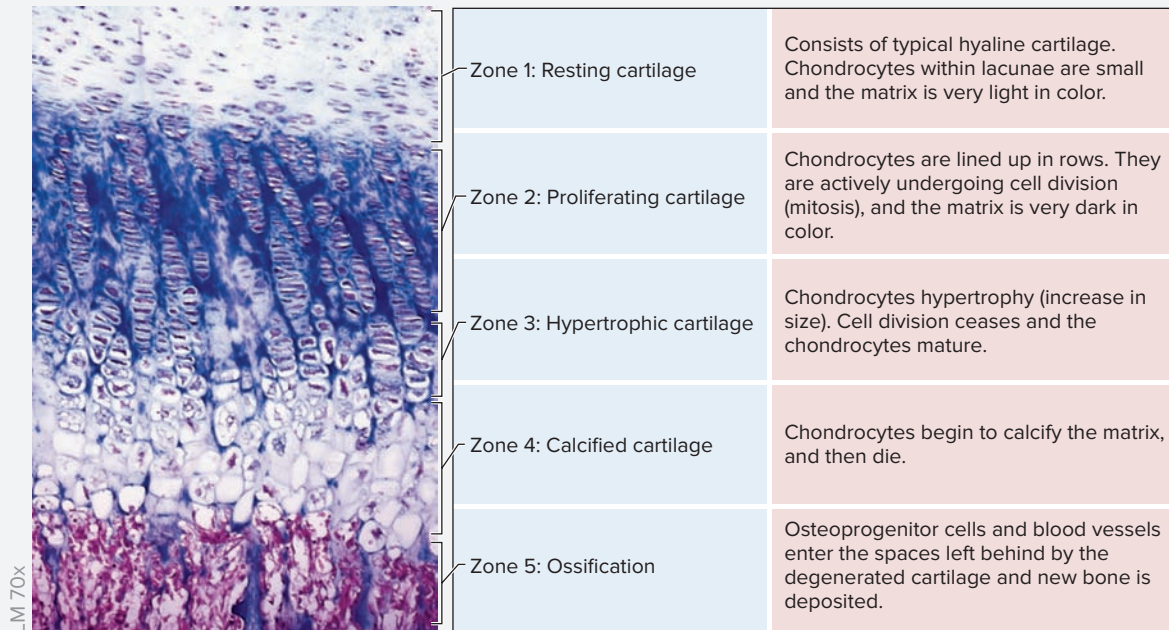
**AP|R** **Figure 7.3 Spongy Bone.** Decalcified sections of spongy bone showing (a) osteoblasts and (b) osteoclasts. Note how the osteoblasts appear to be lined up in rows along the trabecula in (a). The osteoclasts in (b) are very large compared to adjacent cells and are multinucleate.

(a) © Ed Reschke/Getty Images; (b) © Michael Klein/Getty Images

**EXERCISE 7.3 Endochondral Bone Development**

A developing long bone has five functional layers in the **epiphyseal (growth) plate**. As the bone develops, cartilage is gradually replaced by bone tissue. While the overall length of the bone increases, the width of the epiphyseal plate remains unchanged. Once the bone has grown to its maximum length, the growth of new cartilage ceases, allowing the epiphyseal plate to fully ossify. Once the process is complete, the epiphysis is completely fused with the diaphysis of the bone.

1. Obtain a slide of **developing long bone (figure 7.4)** and place it on the microscope stage. This slide will typically contain the developing femur of a young mammal. The femur develops using **endochondral ossification**, a process by which a hyaline cartilage model of the bone is gradually replaced by bone tissue.
2. Scan the slide at the lowest magnification and identify the parts of the bone—specifically, the epiphysis, diaphysis, and metaphysis. The metaphysis of a developing long bone contains an epiphyseal plate. Name the type of tissue found at this location: \_\_\_\_\_  
\_\_\_\_\_.
3. Position the metaphysis at the center of the field of view and increase the magnification. Identify the five functional layers within the epiphyseal plate, using figure 7.4 as a guide:



**Figure 7.4 Epiphyseal Plate.** The five functional layers of the epiphyseal plate. In this photomicrograph, the epiphyseal side of the plate is located at the top of the photo, whereas the diaphyseal side of the plate is located at the bottom of the photo.

© Biophoto Associates/Science Source

4. Sketch the epiphyseal plate as viewed under the microscope in the space provided. Label the following on the sketch, using figure 7.4 and the textbook as guides:

- zone of resting cartilage       zone of calcified cartilage
- zone of proliferating cartilage       zone of ossification
- zone of hypertrophic cartilage



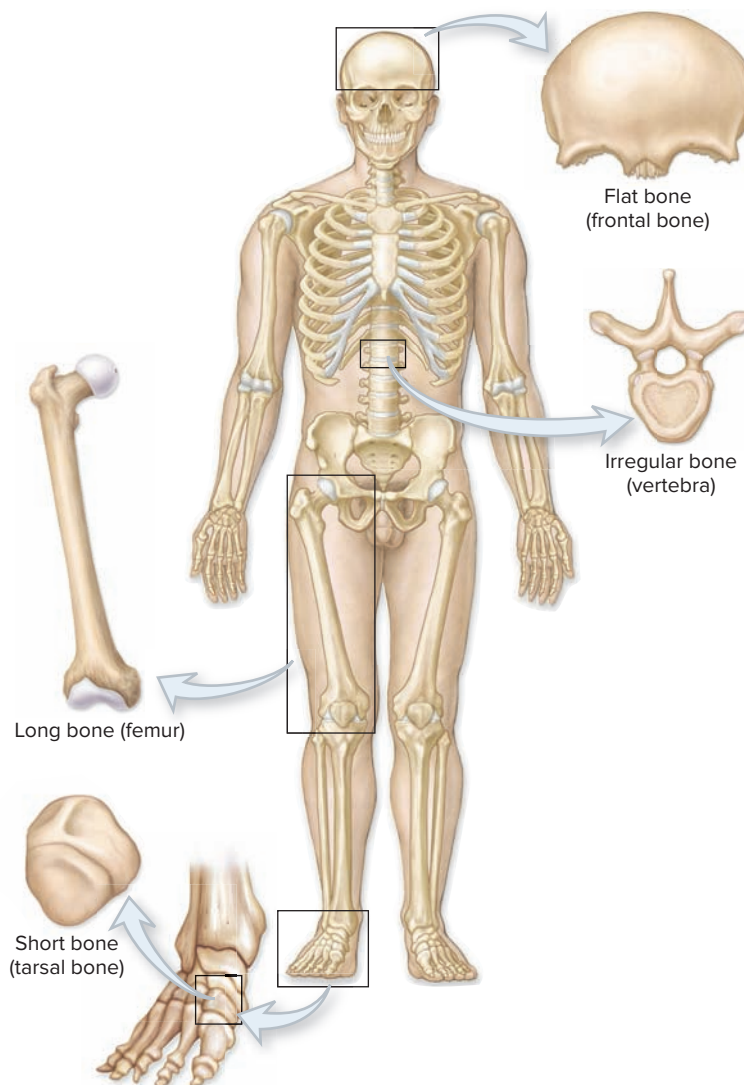
## Gross Anatomy

### Classification of Bones

Bones of the human skeleton appear in various shapes and sizes, depending on their function(s). The four categories of bone classified by shape

are flat, irregular, long, and short. The characteristics of this classification scheme are summarized in **table 7.2** and an example of each is shown in **figure 7.5**.

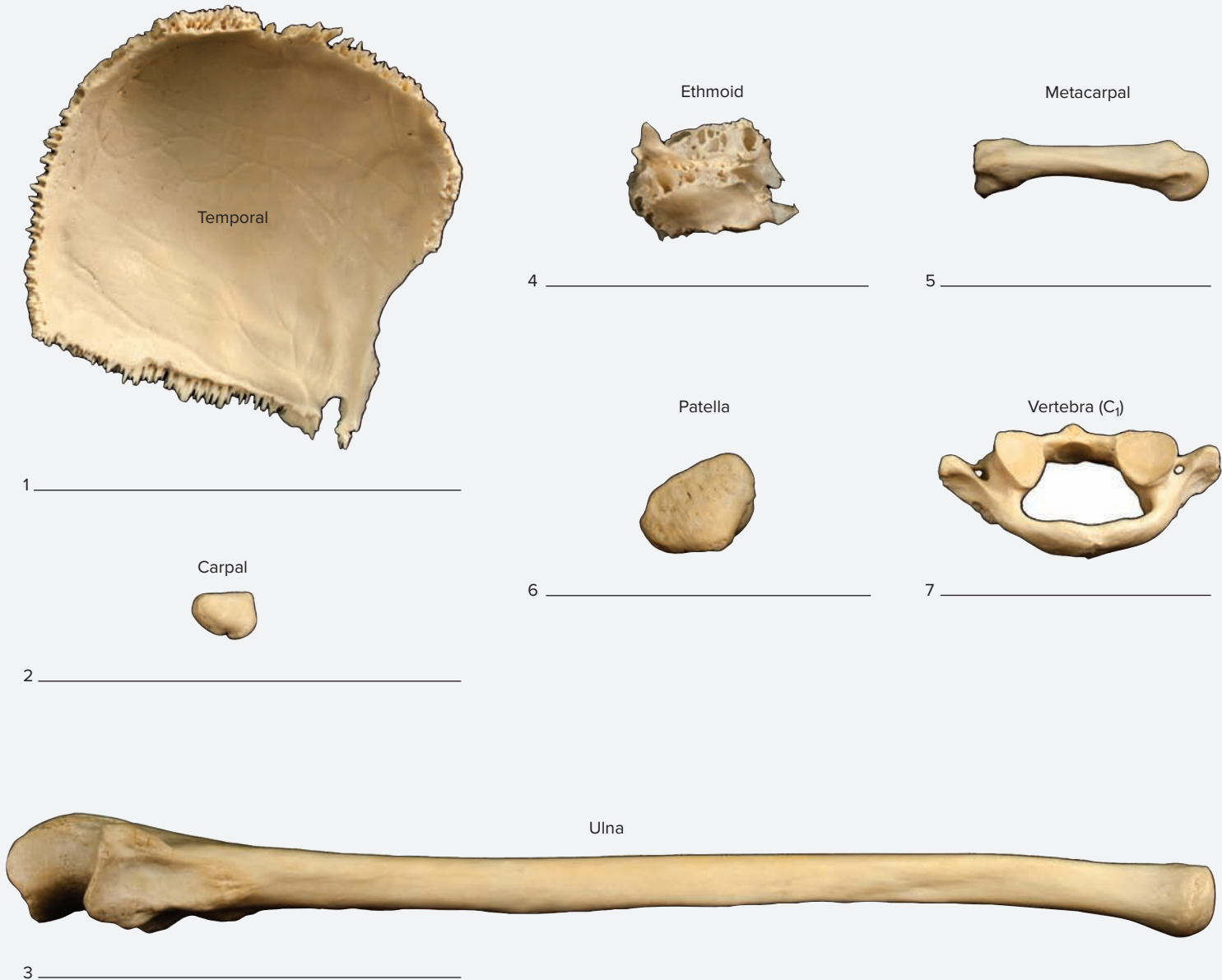
Table 7.2 Classification of Bones Based on Shape		
Class of Bone	Description	Examples
<i>Flat</i>	Have thin, flat surfaces; may be slightly curved	Many skull bones (e.g., frontal, parietal)
<i>Irregular</i>	Complex shape that does not fit into other classifications	Vertebrae, some skull bones (e.g., ethmoid, sphenoid)
<i>Long</i>	Greater in length than width	Most limb bones (e.g., humerus, femur, metacarpals)
<i>Short</i>	Nearly equal in length and width	Wrist and ankle bones (e.g., carpals, tarsals)



**Figure 7.5** Classifications of Bones Based on Shape.

**EXERCISE 7.4** Identifying Classes of Bones Based on Shape

- Obtain a box containing disarticulated human bones. Pull each bone out of the box and classify the bone according to its shape. Note that there is a fair amount of variability in the shape of bones within each classification.
- Figure 7.6** contains photographs of several disarticulated human bones. In the space next to each bone, name the category to which each bone belongs: flat, irregular, long, and short.



**Figure 7.6** Identifying Bones Based on Structure. Identify the structural classification of each bone above as flat, irregular, long, or short.

© Christine Eckel

### Structure of a Typical Long Bone

A typical long bone such as the femur (**figure 7.7**) is composed of a long shaft, called the **diaphysis** (*dia-*, through + *physis*, growth); rounded ends, called **epiphyses** (*epi-*, upon + *physis*, growth); and articulation points between the two, called **metaphyses** (*meta-*, between + *physis*, growth). Within the shaft is a large cavity called the **medullary cavity**, which is filled with **yellow bone marrow** (adipose tissue) in the adult. The walls of the diaphysis are composed of a thick layer of compact

bone tissue. The epiphyses of the bone are surrounded by a thin layer of compact bone and have **articular cartilages** on the ends. Spongy bone tissue is found within the epiphyses of the bone. In the fetus, the marrow spaces between the trabeculae of spongy bone are composed of red bone marrow. However, in the adult they are composed mainly of yellow bone marrow because of the conversion of red marrow to yellow marrow that occurs as the skeleton matures. In the adult, red bone marrow is primarily limited to the proximal epiphyses of the humerus and femur, the sternum, and the iliac crest. Observing a fresh bone specimen allows

observation of many of the tissues that normally associate with bones, such as periosteum, articular cartilages, muscles, tendons, ligaments, marrow, and blood vessels. The following exercises involve observing

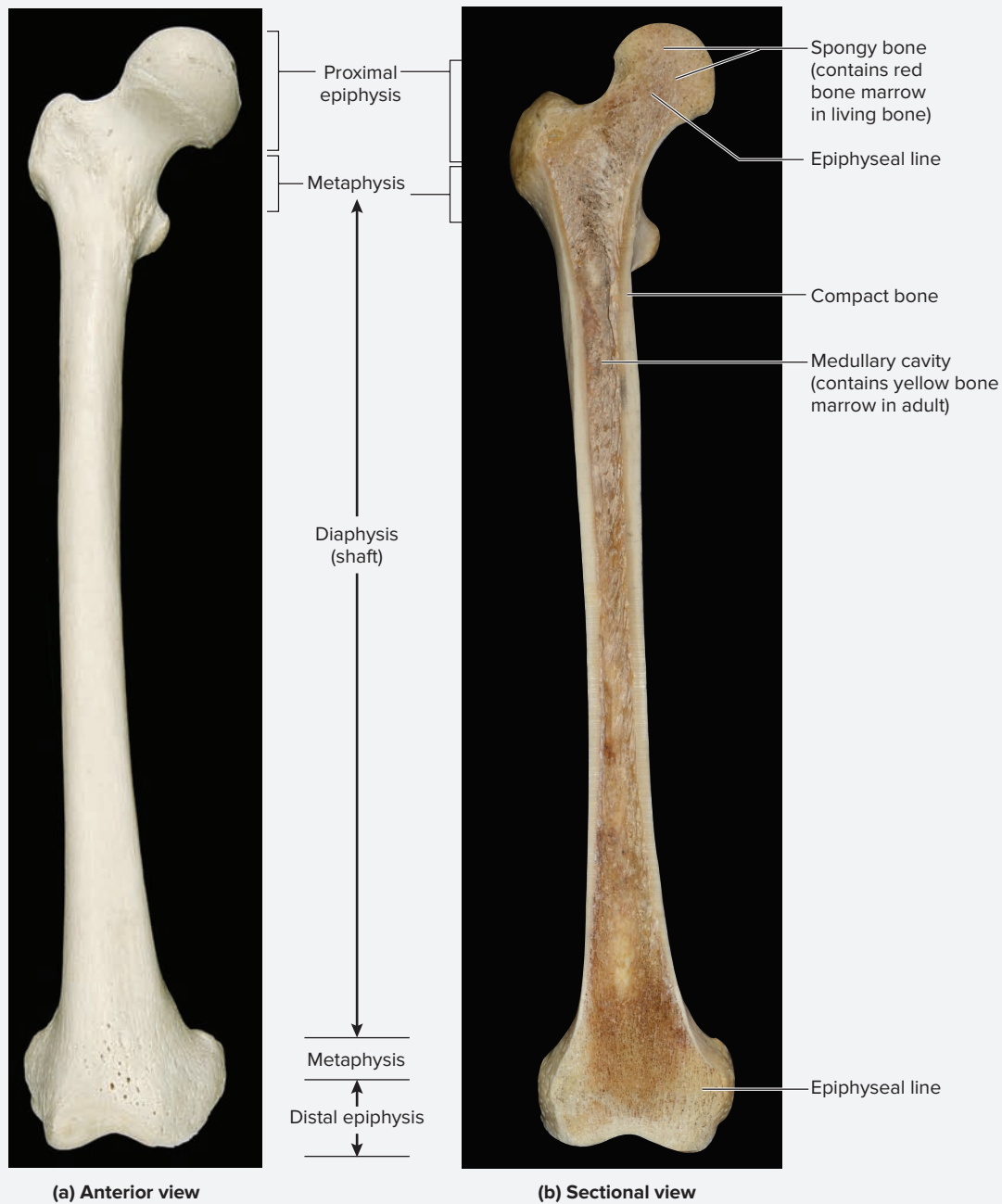
a fresh specimen of a long bone from a cow, and an articulated human skeleton. The goal of these exercises is to familiarize students with the major bones of the human body.

**EXERCISE 7.5** Components of a Long Bone

1. Obtain both an intact femur (not cut) and a femur that has been cut along its longitudinal axis.

2. Identify the following components of a long bone, using figure 7.7 as a guide:

- compact bone
- diaphysis
- epiphyseal line
- epiphysis
- medullary cavity
- spongy bone



**Figure 7.7** Gross Anatomy of a Typical Long Bone. The right femur.

(a) © McGraw-Hill Education/Photo and Dissection by Christine Eckel; (b) © Elizabeth Pennefather-O'Brien



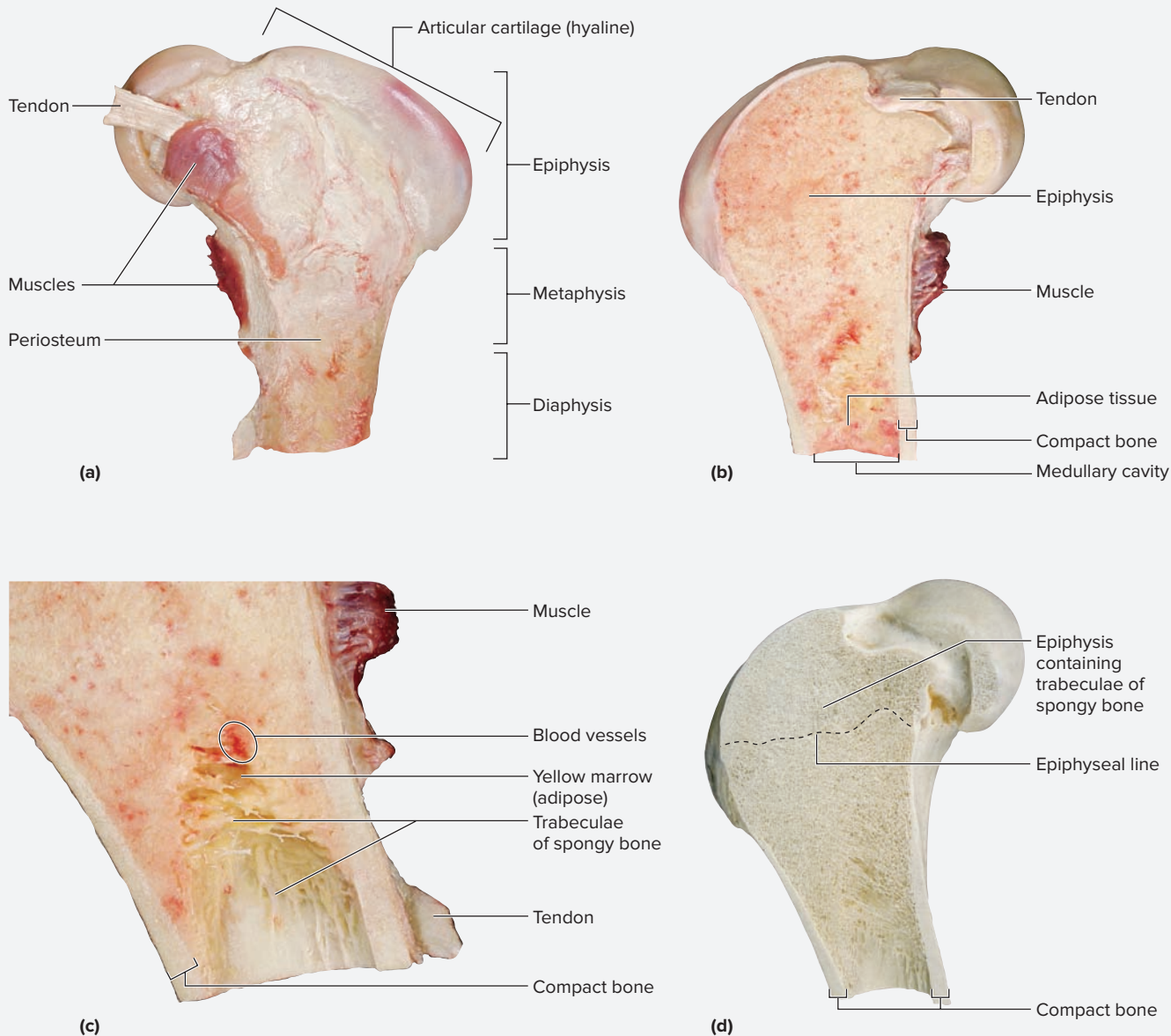
**EXERCISE 7.6** Cow Bone Dissection

1. Obtain a dissecting pan, blunt probe, forceps, and a fresh cow bone cut in longitudinal section. Place the bone in the dissecting pan and begin observations. Find the large medullary cavity that is filled with yellow bone marrow (**figure 7.8**). Notice the thick layer of compact bone that surrounds the medullary cavity.
2. If using a dissecting microscope or magnifying glass, use it to focus in on the compact bone tissue. Notice how “bloody” it appears. Are tiny dots of blood visible within

the compact bone? These result from the rupture of tiny blood vessels in the tissue when the bone was sectioned. This observation should reaffirm that living bone is a highly vascular, metabolically active tissue—quite different from the appearance of preserved bones.

**WHAT DO YOU THINK?**

- 2 Why do you suppose the medullary cavity of a long bone is filled with adipose connective tissue in the adult?



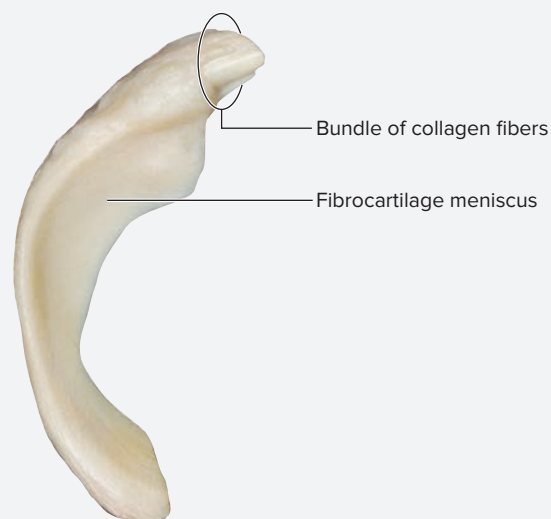
**Figure 7.8** Fresh Cow Bone. (a) Exterior view, (b) interior view, (c) close-up of the medullary cavity. (d) The same bone, with all of the fat, muscle, tendons, cartilage, and blood vessels removed.

© Christine Eckel

3. Using the blunt probe, carefully begin to clean out the adipose tissue from the medullary cavity (**figure 7.8b**). Gently probe for medium- to large-size blood vessels imbedded within the adipose tissue. If there is a blood vessel traveling from the outer surface of the diaphysis

into the medullary cavity, this is most likely the **nutrient artery**, an artery that grows into the diaphysis of the bone during the initial stages of ossification of the bone.

4. Continue to clean out the inside of the diaphysis of the bone and progress toward the inside of the epiphysis. Locate the small, hard “strings” of bony tissue. These are the **trabeculae** (*trabs*, beam) of spongy bone, which are located within the epiphysis and lining the inside of the diaphysis. These trabeculae will make it difficult to clean out the adipose tissue in the epiphysis, but spend some time poking around in there anyway—this will allow a more complete understanding of the arrangement of the trabeculae within. Some parts of the epiphysis may appear much more “bloody” than the rest of the inside of the bone. This area consists of **red bone marrow**—a **hemopoietic** (*hemo-*, blood + *poiesis*, a making) tissue that produces blood cells. Because these are adult cow bones, there should be very little red marrow; most of the spaces will be filled with yellow marrow.
5. Observe the structures on the outside of the bone. Using forceps, pick away at the dense connective tissue on the outside of the diaphysis (figure 7.8). This is the periosteum, or outer covering of the bone. The periosteum acts as an attachment point for tendons and ligaments and as an anchoring point for blood vessels and nerves that enter the bone.
6. Observe the outside of the epiphysis and look for the cut portion of a tendon or ligament where it attaches to the periosteum (figure 7.8*a,c*). Tendons and ligaments consist of a regular arrangement of shiny, white fibers (i.e., dense regular connective tissue). The tough collagen fibers are what impart the great tensile strength to tendons and ligaments.
7. Observe the shiny, white cartilage on the ends of the bone. This is the articular cartilage, which is composed of hyaline cartilage. Notice that the periosteum ends where the articular cartilage begins.
8. If observing the tibia of a cow, try to identify the C-shaped pads of fibrocartilage located on top of the articular cartilages. These are the **menisci** (s. *meniscus*) of the knee joint (figure 7.9). If no meniscus is present, find another group of students in the laboratory whose cow bone has a meniscus to observe. Many similar shiny, white collagen fibers that were seen in the tendons and ligaments are also visible within the meniscus. Recall from chapter 5 that fibrocartilage contains thick bundles of collagen fibers in its extracellular matrix. Note that the meniscus is somewhat “tied in to” the connective tissues surrounding the joint by these fibers.




**Figure 7.9 Meniscus.** One of the C-shaped meniscal cartilage pads removed from the end of the tibia of a fresh cow bone.

© Christine Eckel

9. Sketch the dissected fresh cow bone in the space provided. Label the following on the sketch, using figure 7.9 as a guide:

- |  |  |
|--|--|
| <input type="checkbox"/> articular cartilage | <input type="checkbox"/> periosteum      |
| <input type="checkbox"/> compact bone        | <input type="checkbox"/> spongy bone     |
| <input type="checkbox"/> medullary cavity    | <input type="checkbox"/> tendon/ligament |



10. When the dissection is complete, dispose of the cow bones according to the laboratory instructor’s directions, and clean all dissection instruments and the work space.

### WHAT DO YOU THINK?

- 3 Many people who have torn a ligament in the knee also have a torn meniscus. Why do you think it is so common for individuals who tear knee ligaments to also tear a meniscus?

## Survey of the Human Skeleton

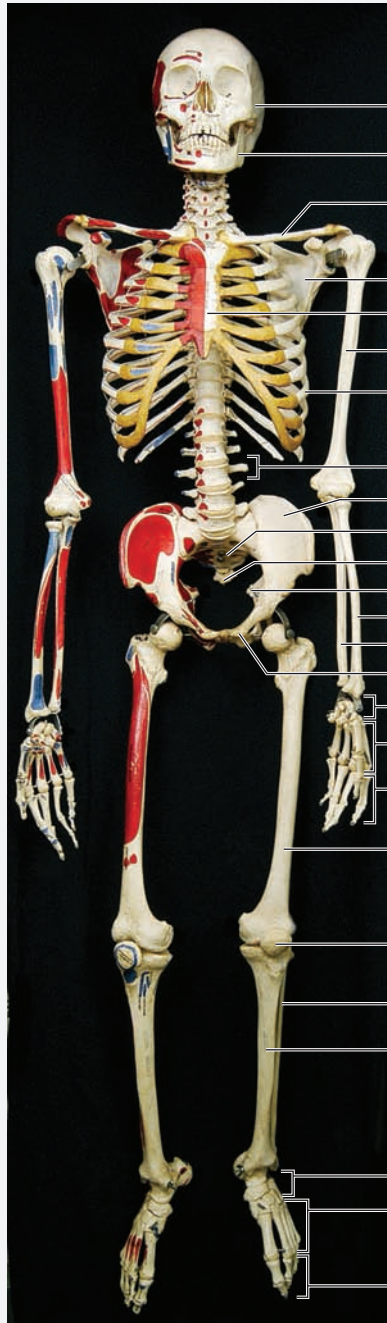
The human skeleton consists of two divisions: (1) the **axial skeleton**, which includes bones of the cranium, vertebrae, ribs, and sternum, and (2) the **appendicular skeleton**, which includes bones of the pectoral girdle, upper limb, pelvic girdle, and lower limb. The **pectoral girdle** consists of the scapula and clavicle. These bones provide support and attachment points for muscles that connect the limbs to the axial skeleton. The **pelvic girdle** consists of the bones composing the **os coxae** (*os-*, bone + *coxa*, hip): the

ilium, ischium, and pubis. These bones protect contents of the pelvic cavity and provide support and attachment points for muscles that connect the lower limb to the axial skeleton. When learning the names of all the bones in the human body and their features, it is best to break the larger task into many small tasks that can be tackled individually in short segments of time. An excellent “first task” is to learn the names of the bones that compose the skeleton. The exercises in chapters 8 and 9 will move beyond this and require learning the names of specific features unique to each bone of the skeleton.

### EXERCISE 7.7 The Human Skeleton

1. Observe an articulated human skeleton.

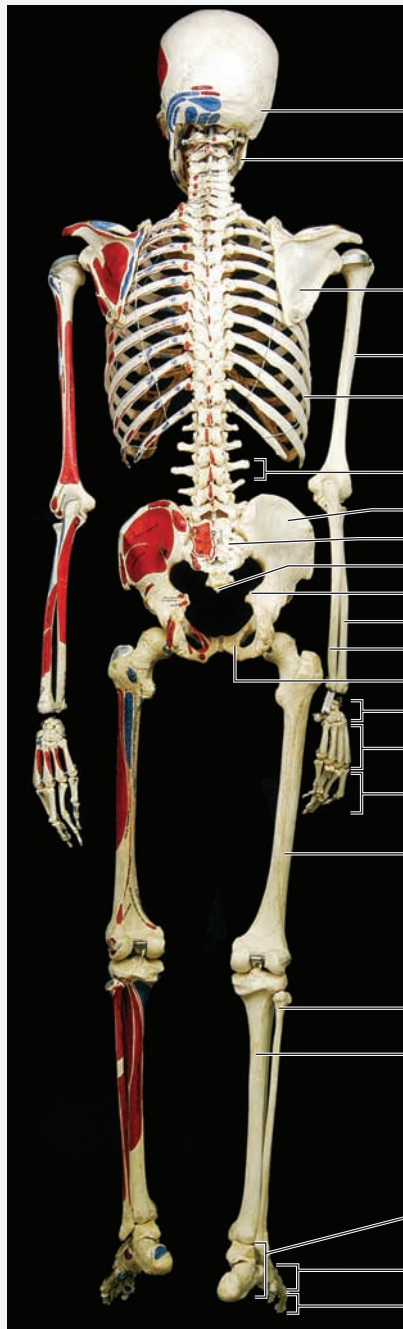2. Identify the bones listed in **figure 7.10** on the articulated skeleton, using the textbook as a guide. Then label them in figure 7.10.



(a) Anterior view

- carpals
- clavicle
- coccyx
- femur
- fibula
- humerus
- ilium
- ischium
- mandible
- metacarpals
- metatarsals
- patella
- phalanges (of the foot)
- phalanges (of the hand)
- pubis
- radius
- rib
- sacrum
- scapula
- skull
- sternum
- tarsals
- tibia
- ulna
- vertebra

**Figure 7.10** The Human Skeleton. Use the terms listed to fill in the numbered labels in the figure.



- carpals
- coccyx
- femur
- fibula
- humerus
- ilium
- ischium
- mandible
- metacarpals
- metatarsals
- phalanges (of the hand)
- phalanges (of the foot)
- pubis
- radius
- rib
- sacrum
- scapula
- skull
- tarsals
- tibia
- ulna
- vertebra

(b) Posterior view

**Figure 7.10** The Human Skeleton (*continued*). Use the terms listed to fill in the numbered labels in the figure.

© Christine Eckel

*This page intentionally left blank*

# Chapter 7: Skeletal System Overview: Bone Anatomy

Name: \_\_\_\_\_

Date: \_\_\_\_\_ Section: \_\_\_\_\_

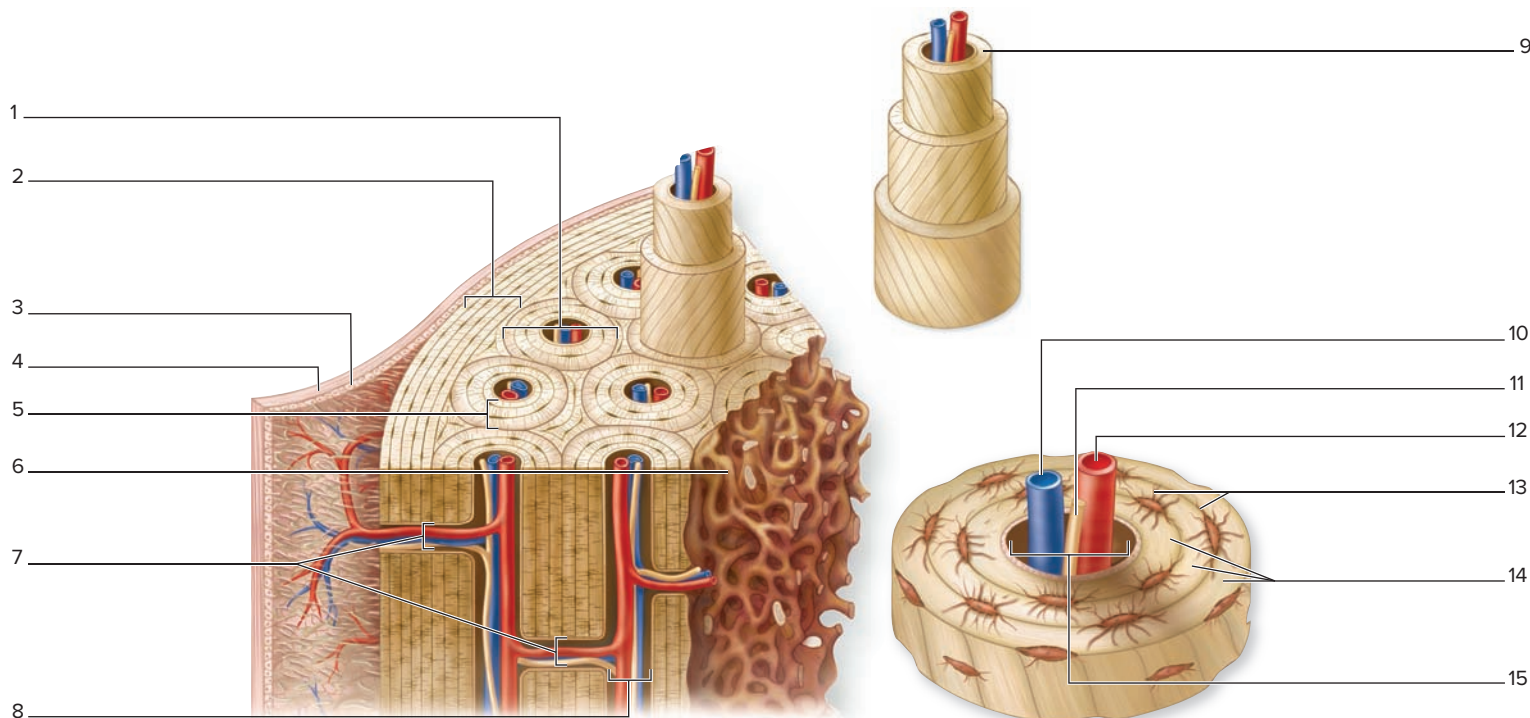
## POST-LABORATORY WORKSHEET

The ❶ corresponds to the Learning Objective(s) listed in the chapter opener outline.

### Do You Know the Basics?

#### Exercise 7.1: Compact Bone

1. Label the components of compact bone on the following diagram. ❶ ❷



#### Exercise 7.2: Spongy Bone

2. Which of the following is/are visible on a slide of decalcified spongy (cancellous) bone? (Check all that apply.) ❸

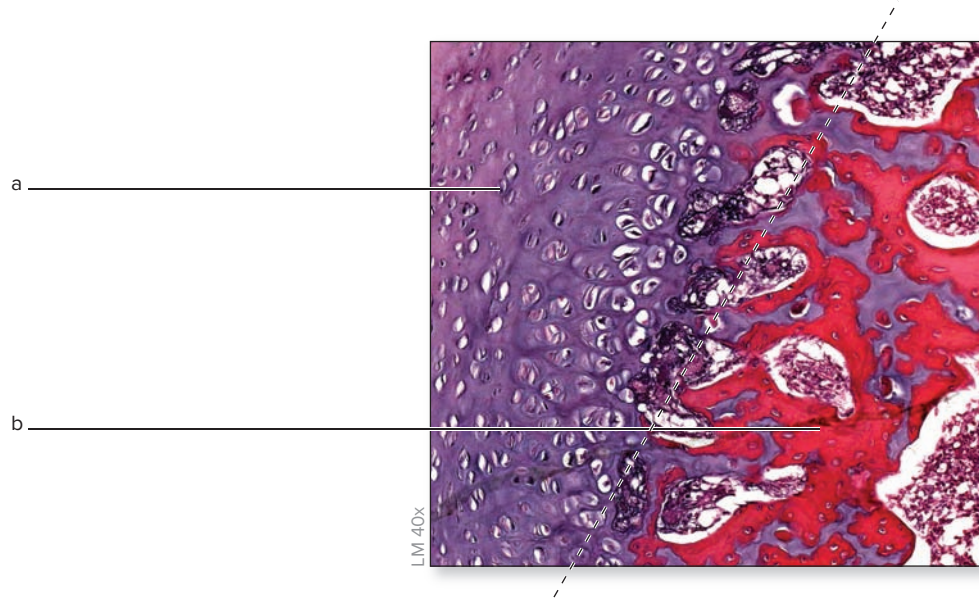
- a. central canal
- b. osteocyte
- c. osteon
- d. perforating canal
- e. red bone marrow
- f. trabecula

#### Exercise 7.3: Endochondral Bone Development

3. Which of the following bones does NOT form by endochondral ossification? (Check all that apply.) ❹

- a. femur
- b. frontal
- c. metacarpals
- d. tibia
- e. ulna

4. The figure shown is a light micrograph of developing endochondral bone. The dotted line divides the epiphyseal plate into two major regions, a and b. One region is **new bone tissue** and the other is **hyaline cartilage**. Label these two components of the developing bone on the following figure. 5



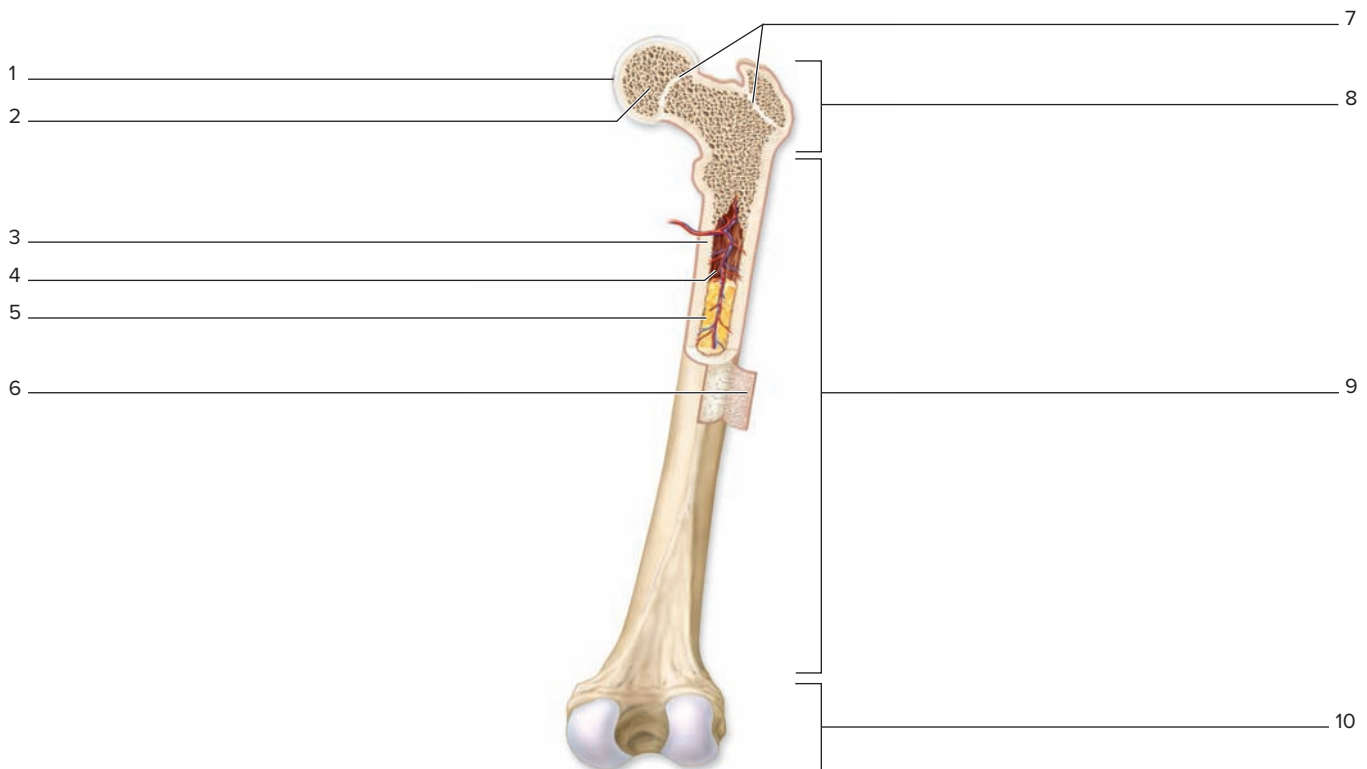
© Christine Eckel

**Exercise 7.4: Identifying Classes of Bones Based on Shape**

5. Which of the following is the correct classification for a vertebra based on shape? (Circle one.) 6
- a. flat      b. irregular      c. long      d. short

**Exercise 7.5: Components of a Long Bone**

6. Label the parts of a typical long bone on the following diagram. 7



**Exercise 7.6: Cow Bone Dissection**

7. Which of the following is the outer covering of bone that serves as an attachment point for tendons and ligaments? (Circle one.) **8**
- a. articular cartilage      b. medullary cavity      c. periosteum      d. trabeculae
8. The thick layer of bone surrounding the medullary cavity is composed of \_\_\_\_\_ (compact/spongy) bone tissue. **8**

**Exercise 7.7: The Human Skeleton**

9. Which of the following bone(s) is/are part of the axial skeleton? (Check all that apply.) **9**
- \_\_\_\_\_ a. pubis      \_\_\_\_\_ b. rib      \_\_\_\_\_ c. scapula      \_\_\_\_\_ d. skull      \_\_\_\_\_ e. sternum
10. Which of the following bones compose the os coxae? (Check all that apply.) **9**
- \_\_\_\_\_ a. coccyx      \_\_\_\_\_ b. ilium      \_\_\_\_\_ c. ischium      \_\_\_\_\_ d. pubis      \_\_\_\_\_ e. sacrum
11. The pectoral girdle consists of the scapula and clavicle, and the pelvic girdle consists of the os coxae. \_\_\_\_\_ (True/False) **9**

**Can You Apply What You've Learned?**

12. A biomedical researcher is interested in designing a drug to increase bone density. The researcher decided to take one of two approaches: (1) design a drug that stimulates bone to be built faster, or (2) design a drug that prevents bone from breaking down. To begin this process, the researcher must study the specific cells that would likely respond to either drug 1 or drug 2. What cells are these?
- a. \_\_\_\_\_ (build bone)      b. \_\_\_\_\_ (break down bone)
13. What process must stop in order for the epiphyseal plate to close? (That is, which layer of the plate must stop its development first?)

---



---

**Can You Synthesize What You've Learned?**

14. Compare and contrast the histologic structure of compact and spongy bone.

---



---



---



---



---

15. Describe the process of endochondral bone development (ossification).

---



---



---



---



---



*This page intentionally left blank*

# The Skeletal System: Axial Skeleton

# 8

## OUTLINE AND LEARNING OBJECTIVES

### Gross Anatomy 126

#### Bone Markings 126

#### The Skull 126

##### EXERCISE 8.1: ANTERIOR VIEW OF THE SKULL 129

- 1 Identify the bony landmarks visible in an anterior view of the human skull
- 2 List the bones that form the orbit of the eye
- 3 List the bones that form the nasal cavity
- 4 Identify the features of the mandible

##### EXERCISE 8.2: ADDITIONAL VIEWS OF THE SKULL 134

- 5 Identify the bony landmarks visible in lateral, posterior, superior, and inferior views of the human skull
- 6 List the bones that compose the zygomatic arch

##### EXERCISE 8.3: SUPERIOR VIEW OF THE CRANIAL FLOOR 137

- 7 Distinguish the three cranial fossae
- 8 Identify the bony landmarks found within each cranial fossa

##### EXERCISE 8.4: BONES ASSOCIATED WITH THE SKULL 139

- 9 Identify the features of the hyoid bone

#### The Fetal Skull 139

##### EXERCISE 8.5: THE FETAL SKULL 139

- 10 Identify the features of the fetal skull

#### The Vertebral Column 141

##### EXERCISE 8.6: VERTEBRAL COLUMN REGIONS AND CURVATURES 142

- 11 Describe the normal curvatures of the vertebral column

##### EXERCISE 8.7: STRUCTURE OF A TYPICAL VERTEBRA 143

- 12 Describe the features of a typical vertebra

##### EXERCISE 8.8: CHARACTERISTICS OF INDIVIDUAL VERTEBRAE 144

- 13 Identify the features unique to cervical, thoracic, lumbar, sacral, and coccygeal vertebrae
- 14 Describe modifications of the atlas ( $C_1$ ) and axis ( $C_2$ ) that permit them to allow for extensive movements of the neck
- 15 Describe the modifications of thoracic vertebrae that permit articulation with the ribs
- 16 Compare and contrast the features of a typical vertebra with the features of the fused vertebrae that compose the sacrum

#### The Thoracic Cage 148

##### EXERCISE 8.9: THE STERNUM 149

- 17 Identify the features of the sternum
- 18 Explain the clinical significance of the sternal angle

##### EXERCISE 8.10: THE RIBS 149

- 19 Describe the parts of a typical rib
- 20 Describe how a typical rib articulates with a thoracic vertebra

## INTRODUCTION

---

**T**he skeletal system (typically composed of 206 bones in an adult) is organized into two divisions: the axial skeleton and the appendicular skeleton. The term **axial** is a derivative of the term *axis*. The axial skeleton consists of bones that form the main axis of the body—the skull, vertebrae, ribs, and sternum, which collectively form the body’s core structural foundation. These bones are also critical for protection of the body’s most vital organs, such as the brain, heart, and lungs.

The exercises in this chapter require that a large number of structures must be learned in a short period of time. Many students find the process of trying to learn all of the processes, projections, and foramina (holes) of the bones an enormous effort in memorization. It need not be if approached with the proper attitude. When viewing features of each of the bones, contemplate why such features exist. Is a particular process an attachment point for a muscle? Is there a nerve, artery, or vein that runs through a foramen in the living human?

While completing the exercises in this chapter, be sure to view both individual disarticulated bones (e.g., the humerus) and the same bones on an articulated (completed) skeleton. This will increase understanding of how individual bones fit in with the rest of the axial skeleton (e.g., how the humerus articulates with the scapula, radius, and ulna).

The exercises in this chapter involve observing the bones that compose the axial skeleton on articulated human skeletons, on disarticulated bones of the human skeleton, or on bone models. The goal is to identify the major landmarks and identifying features of each bone, and associate the observed structures with associated functions.

### List of Reference Tables

Table 8.1	Bone Markings	p. 126
Table 8.2	The Axial Skeleton: Skull Bones and Important Bony Landmarks	p. 127
Table 8.3	The Axial Skeleton: Anterior View of the Skull	p. 130
Table 8.4	The Axial Skeleton: Vertebral Column	p. 141
Table 8.5	The Axial Skeleton: Sternum and Ribs	p. 148

# Chapter 8: The Skeletal System: Axial Skeleton

Name: \_\_\_\_\_

Date: \_\_\_\_\_ Section: \_\_\_\_\_

These Pre-laboratory Worksheet questions may be assigned by instructors through their **connect** course.

## PRE-LABORATORY WORKSHEET

1. Match the description of the bone feature listed in column A with the appropriate name listed in column B.

### Column A

- \_\_\_ 1. smooth, grooved, pulleylike process
- \_\_\_ 2. small, flat, shallow, articulating surface
- \_\_\_ 3. large, smooth, and round projection
- \_\_\_ 4. prominent, rounded epiphysis of a bone

### Column B

- a. condyle
- b. facet
- c. head
- d. trochlea

2. Which of the following is/are bony features that function as attachment points for tendons and ligaments? (Check all that apply.)

- \_\_\_ a. fossa
- \_\_\_ b. process
- \_\_\_ c. sinus
- \_\_\_ d. tuberosity

3. A foramen is a round hole that passes through a bone, whereas a fissure is a narrow, slitlike opening that passes through a bone. \_\_\_\_\_ (True/False)

4. In a typical human, how many vertebrae (individual or fused) does each section of the vertebral column contain? Write the number in the space provided.

- \_\_\_ a. cervical
- \_\_\_ b. thoracic
- \_\_\_ c. lumbar
- \_\_\_ d. sacral
- \_\_\_ e. coccygeal

5. The sella turcica is a feature of which bone? (Circle one.)

- a. ethmoid bone
- b. frontal bone
- c. occipital bone
- d. sphenoid bone

6. All ribs articulate with which of the following vertebrae? (Circle one.)

- a. cervical
- b. coccygeal
- c. lumbar
- d. sacral
- e. thoracic

7. Arrange the parts of the sternum from superior (1) to the inferior (3) by placing the numbers 1–3 next to the parts.

- \_\_\_ a. body
- \_\_\_ b. manubrium
- \_\_\_ c. xiphoid

8. Which is the only skull bone that is mobile (movable)? \_\_\_\_\_

9. Which of the following bone(s) contain(s) a paranasal sinus? (Check all that apply.)

- \_\_\_ a. ethmoid bone
- \_\_\_ b. frontal bone
- \_\_\_ c. mandible
- \_\_\_ d. maxilla
- \_\_\_ e. temporal bone

10. The suture that forms between the frontal and parietal bones is called the coronal suture. \_\_\_\_\_ (True/False)

## Gross Anatomy

### Bone Markings

Prior to learning the specific bones of the axial and appendicular skeleton, it is important to become familiar with general terminology that describes the features of each of the bones. Recall from chapter 7 that all bones undergo a process of ossification, whereby osteoblasts lay down new bony matrix (osteoid) during bone development. At the same time, muscles, tendons, and ligaments attach to these bones as they begin to develop, and blood vessels and nerves pass through or between bones as the vessels grow into their target organs. Continual movement during development, particularly when bones are soft and pliable, leads to the formation of distinguishing features on each bone. Once a bone completely ossifies, the markings become solid, recognizable features of the bone. In general, smooth surfaces are found on articulating surfaces (surfaces that form joints); projections represent points of muscle, ligament, and tendon attachment; and foramina are passageways for blood vessels and nerves. **Table 8.1** lists each of the major bone markings and provides a description and general definition for the marking. This information will assist in understanding what kind of structure to look for when identifying individual bones and their respective features in subsequent exercises.

### Learning Strategy



When learning the processes, projections, foramina (holes), and other markings of the bones, view each structure, study it closely, and contemplate its function. The process may be an attachment point for a ligament, a tendon, or a muscle. The opening or hole may serve as a passageway for a nerve, artery, or vein. The smooth surface may be where the bone articulates with another bone. For each structure, relate form to function.

### The Skull

The bones that make up the skull are separated into two functional categories: the **cranial bones** (frontal, parietal, temporal, occipital, sphenoid, and ethmoid) and the **facial bones** (maxilla, mandible, zygomatic, nasal,

General Structure	Anatomic Term	Description	Word Origin
<i>Articulating Surfaces</i>	Condyle	Large, smooth, round articulating structure	<i>kondylos</i> , a knuckle
	Facet	Small, flat, shallow articulating surface	<i>facet</i> , a small face
	Head	Prominent, rounded epiphysis	NA
	Trochlea	Smooth, grooved, pulleylike articular process	<i>trochlea</i> , a pulley block
<i>Depressions</i>	Alveolus (pl., <i>alveoli</i> )	Deep pit or socket in the maxillae or mandible	<i>alveus</i> , a hollow cavity
	Fossa (pl., <i>fossae</i> )	Flattened or shallow depression	<i>fossa</i> , a pit/cavity
	Sulcus	Narrow groove	<i>sulcus</i> , a furrow/groove
<i>Projections for Tendon and Ligament Attachment</i>	Crest	Narrow, prominent, ridge-like projection	<i>crista</i> , a crest
	Epicondyle	Projection adjacent to a condyle	<i>epi-</i> , above + <i>kondylos</i> , a knuckle
	Line	Low ridge	<i>linea</i> , line
	Process	Any marked bony prominence	<i>processus</i> , a projection
	Ramus (pl., <i>rami</i> )	Angular extension of a bone relative to the rest of the structure	<i>ramus</i> , a branch
	Spine	Pointed, slender process	<i>spinosus</i> , a spine
	Trochanter	Massive, rough projection found only on the femur	<i>trochanter</i> , to run
	Tubercle	Small, round projection	<i>tuberculum</i> , a small bump
	Tuberosity	Large, rough projection	<i>tuberosus</i> , knobby
<i>Openings and Spaces</i>	Canal	Passageway through a bone	<i>canalis</i> , channel
	Fissure	Narrow, slitlike opening through a bone	<i>fissura</i> , cleft
	Foramen (pl., <i>foramina</i> )	Rounded passageway through a bone	<i>foramen</i> , a hole
	Meatus	Passageway through a bone	<i>meatus</i> , a channel
	Sinus	Cavity or hollow space in a bone	<i>sinus</i> , a curve or bay

## Learning Strategy

Learning the names of bones and the bone markings is like learning a new language. In fact, most of the names are derived from Latin or Greek words. It is helpful to learn the meanings of each word as a way to remember each bone. For example, *femur* is the Latin word for thigh and mandible comes from the Latin word *mandere*, which means to chew. The names of the bones, then, often indicate location and/or function. The same is true for bone markings. *Foramen* comes from the Latin word *forare*, which means to bore. It should be no surprise, then, to discover that a foramen is a hole. For each bone and bone marking, the word origins listed in the tables in this chapter serve as a guide to learning their names.

lacrimal, palatine, inferior nasal conchae, and vomer). The roof of the cranium—the **calvaria**, or skullcap—is the dome-shaped part of the skull that protects the brain. In an adult, all of the skull bones, with the exception of the mandible, are fused to each other via synarthrotic joints called sutures.

**Table 8.2** describes each individual bone of the skull and lists the best view(s) for observing its features. An organized approach to learning the bones of the skull begins with viewing the skull from six points of reference: anterior view, lateral view, posterior view, superior view, inferior view, and superior view of the cranial floor. The first goal is to identify the individual bones visible in each view. The second goal is to identify all processes, foramina, and major features (often formed from multiple bones) that are visible in each view of the skull. While working on the second goal, always try to relate the bony processes, fossae, and foramina to the individual bone(s) from which they are formed.

Major Bone	Bone Features	Description and Related Structures of Importance	Best View	Word Origins
<i>Ethmoid</i>	Cribriform foramina	The olfactory nerve (CN I) passes through to the brain.	Cranial floor	<i>cribrum-</i> , sieve + <i>forma</i> , form + <i>foramen</i> , a hole
	Cribriform plate	Forms roof of nasal cavity and part of cranial floor.	Cranial floor	<i>ethmos-</i> , sieve + <i>oideos</i> , resembling <i>cribrum-</i> , sieve + <i>forma</i> , form + <i>platus</i> , flat
	Crista galli	Projection that serves as attachment point for falx cerebri.	Cranial floor	<i>crista galli</i> , cockscomb
	Middle nasal concha	Forms middle lateral wall of nasal cavity; causes turbulent airflow.	Anterior	<i>middle</i> , middle + <i>nasus</i> , nose + <i>concha</i> , shell
	Perpendicular plate	Forms superior part of nasal septum.	Anterior	<i>perpendicularum</i> , plumb line + <i>platus</i> , flat
	Superior nasal concha	Forms superior lateral wall of nasal cavity; causes turbulent airflow.	Anterior	<i>superus</i> , upper + <i>nasus</i> , nose + <i>concha</i> , shell
<i>Frontal</i>	Frontal sinus	A cavity within frontal bone.	Cranial floor	<i>frontellum</i> , forehead + <i>sinus</i> , a hollow
	Superciliary arch	Process that forms brow ridges; more pronounced in males than in females.	Anterior	<i>superus-</i> , upper + <i>cilium</i> , the eyelid + <i>arcus</i> , a bow
	Supraorbital foramen (notch)	A hole or notch on the superior ridge of orbit.	Anterior	<i>supra-</i> , above + <i>orbit</i> , eye socket + <i>foramen</i> , a hole
<i>Inferior Nasal Conchae</i>	NA	Forms inferior part of lateral wall of nasal cavity; causes turbulent airflow.	Anterior	<i>inferus</i> , lower + <i>nasus</i> , nose + <i>concha</i> , shell
<i>Lacrimal</i>	Lacrimal groove	Forms medial, inferior aspect of orbit of eye. Groove connects orbital and nasal cavities.	Lateral	<i>lacrima</i> , tear + <i>groove</i> , a pit
<i>Mandible</i>	Alveolar processes	Cavities that form tooth “sockets”.	Lateral	<i>alveolus</i> , a trough + <i>processus</i> , a projection
	Angle	Portion of mandible connecting the body to the ramus, forming a right angle.	Lateral	<i>angulus</i> , a corner
	Body	Anterolateral portion of mandible.	Lateral	NA
	Coronoid process	Insertion point for temporalis muscle.	Lateral	<i>corona-</i> , crown + <i>eidosis</i> , resembling + <i>processus</i> , a projection
	Head	Forms a joint with the mandibular fossa of temporal bone (temporomandibular joint).	Lateral	NA
	Mandibular foramen	Passageway for mandibular branch of the trigeminal nerve (CN V <sub>3</sub> ).	Lateral	<i>mandere-</i> , to chew + <i>bula</i> , a means + <i>foramen</i> , a hole
	Mental foramen	Passageway for mental artery and nerve (CN V <sub>3</sub> ).	Anterior	<i>mental</i> , chin + <i>foramen</i> , a hole
	Mental protuberance	Anterior projection of mandible that forms the chin.	Lateral	<i>mental</i> , chin + <i>protuberare</i> , to swell
Ramus	Part of bone that forms an angle with body of mandible.	Lateral	<i>ramus</i> , branch	

(continued on next page)

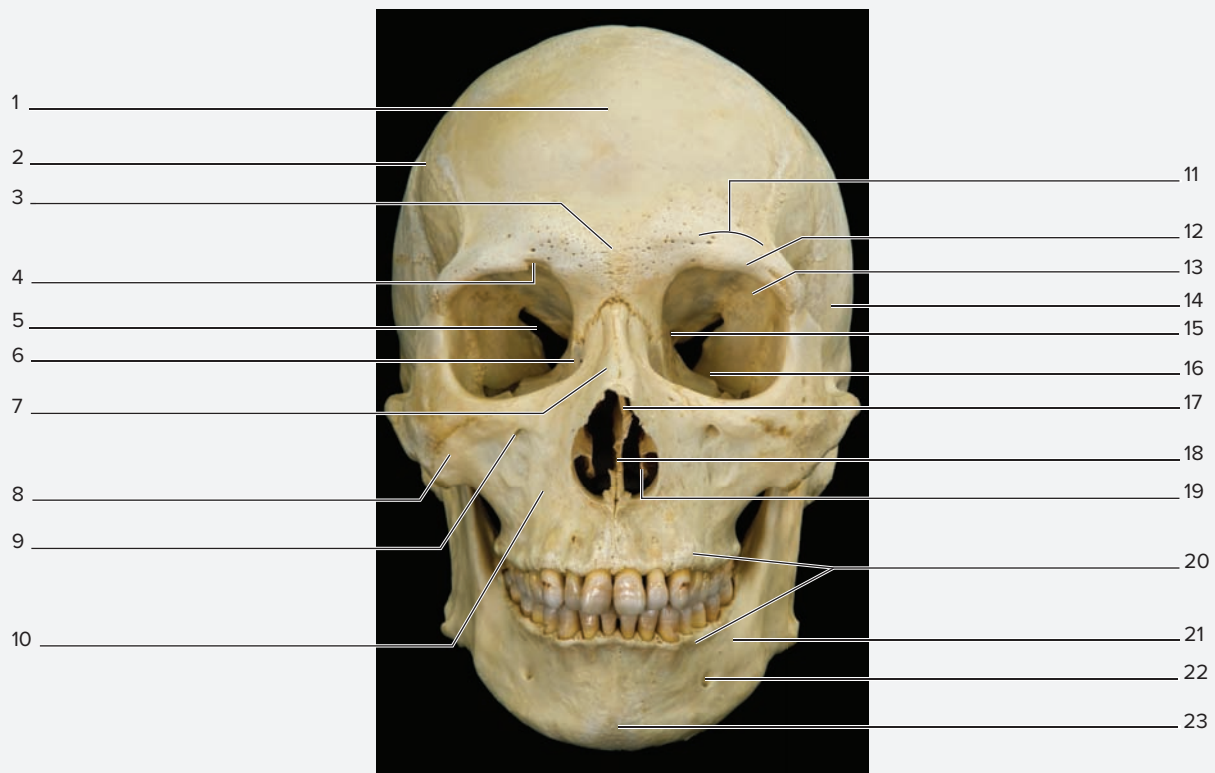
<b>Table 8.2 The Axial Skeleton: Skull Bones and Important Bony Landmarks (continued)</b>				
<b>Major Bone</b>	<b>Bone Features</b>	<b>Description and Related Structures of Importance</b>	<b>Best View</b>	<b>Word Origins</b>
<i>Maxilla</i>	Incisive foramen (fossa)	Contains arteries and nerves passing from nasal cavity into oral cavity.	Inferior	<i>incidere-</i> , to cut into + <i>foramen</i> , a hole
	Infraorbital foramen	Passageway for infraorbital artery and nerve.	Lateral	<i>infra-</i> , below <i>orbit</i> , eye socket + <i>foramen</i> , a hole
	Palatine process	Forms anterior floor and part of lateral wall of nasal cavity.	Inferior	<i>palatin-</i> , the palate + <i>processus</i> , a projection
<i>Nasal</i>	NA	Forms most of the bridge of nose.	Frontal	<i>nasus</i> , nose
<i>Occipital</i>	External occipital protuberance	Large projection palpated on the posterior aspect of the head; muscle attachment point.	Posterior	<i>externus</i> , outside + <i>occipital</i> , occipital bone + <i>protuberare</i> , to swell
	Foramen magnum	Large hole for passage of spinal cord.	Cranial floor	<i>foramen</i> , a hole + <i>magnus</i> , great
	Hypoglossal canal	Passageway for hypoglossal nerve (CN XII).	Cranial floor	<i>hypo-</i> , under + <i>glossus</i> , tongue + <i>canalis</i> , channel
	Jugular foramen	Passageway for internal jugular vein and several nerves (CN IX, X, and XI).	Cranial floor	<i>jugal</i> , throat + <i>foramen</i> , a hole
	Occipital condyle	Smooth surface for articulation with atlas (first cervical vertebra).	Inferior	<i>occipital</i> , occipital bone + <i>kondylos</i> , knuckle
<i>Palatine</i>	NA	Forms posterior floor of nasal cavity; part of orbit and hard palate.	Inferior	<i>palatin</i> , the palate
<i>Parietal</i>	NA	L-shaped bone that forms the lateral, superior wall of cranial cavity.	Lateral	<i>paries</i> , wall
<i>Sphenoid</i>	Foramen ovale	Passageway for mandibular branch of the trigeminal nerve (CN V <sub>3</sub> ).	Cranial floor	<i>foramen</i> , a hole + <i>ovalis</i> , oval
	Foramen rotundum	Passageway for maxillary branch of the trigeminal nerve (CN V <sub>2</sub> ).	Cranial floor	<i>foramen</i> , a hole + <i>rotundum</i> , round
	Foramen spinosum	Passageway for middle meningeal artery and vein and a branch of the trigeminal nerve (CN V).	Cranial floor	<i>foramen</i> , a hole + <i>spinosus</i> , spinelike
	Greater wing	Forms parts of posterior orbit and middle cranial fossa.	Cranial floor	NA
	Inferior orbital fissure	Passageway for maxillary branch of the trigeminal nerve (CN V <sub>2</sub> ) and infraorbital artery and vein.	Cranial floor	<i>inferus</i> , lower + <i>orbit</i> , eye socket + <i>fissura</i> , cleft
	Lesser wing	Forms part of anterior cranial fossa.	Cranial floor	NA
	Optic foramen	Passageway for optic nerve (CN II).	Cranial floor	<i>optikos</i> , eye + <i>foramen</i> , a hole
	Sella turcica	“Turkish saddle”-shaped depression housing the pituitary gland.	Cranial floor	<i>sella</i> , saddle + <i>turcica</i> , Turkish
	Superior orbital fissure	Passageway for oculomotor (CN III), trochlear (CN IV), trigeminal (CN V <sub>1</sub> ), and abducens (CN VI) nerves.	Cranial floor	<i>superus</i> , upper + <i>orbit</i> , eye socket + <i>fissura</i> , cleft
<i>Temporal</i>	Carotid canal	Passageway for internal carotid artery and associated nerves.	Inferior	<i>karotides</i> , arteries of the neck + <i>canalis</i> , channel
	External acoustic (auditory) meatus	Opening into external auditory canal.	Lateral	<i>externus</i> , outside + <i>auditorius</i> , related to hearing + <i>meatus</i> , channel
	Foramen lacerum	Largely covered by cartilage in living human; no structures pass entirely through it.	Cranial floor	<i>foramen</i> , a hole + <i>lacer</i> , mangled
	Internal acoustic (auditory) meatus	Passageway for facial (CN VII) and vestibulocochlear nerves (CN VIII).	Cranial floor	<i>internus</i> , inside + <i>auditorius</i> , related to hearing + <i>meatus</i> , channel
	Mandibular fossa	Point of articulation with head of mandible, forming the temporomandibular joint.	Lateral	<i>mandere-</i> , to chew + <i>bula</i> , a means + <i>fossa</i> , a pit/cavity
	Mastoid process	Attachment point for muscles of neck.	Lateral	<i>mastos-</i> , breast + <i>oideos</i> , resembling + <i>processus</i> , a projection
	Petrous part	Houses structures for hearing and equilibrium; separates middle and posterior cranial cavities.	Superior	<i>petrosus</i> , like a rock
	Squamous part	Forms inferior, posterior part of temporal fossa.	Lateral	<i>squamosus</i> , scalelike
	Styloid process	Serves as attachment point for muscles controlling tongue.	Lateral	<i>stylus-</i> , stylus + <i>oideos</i> , resembling + <i>processus</i> , a projection
	Zygomatic process	Projection that articulates with temporal process of the zygomatic bone.	Lateral	<i>zygoma</i> , a yoke + <i>processus</i> , a projection
<i>Vomer</i>	NA	Forms inferior and posterior part of nasal septum.	Inferior	<i>vomere</i> , to spew forth; vomit

Table 8.2 The Axial Skeleton: Skull Bones and Important Bony Landmarks (continued)				
Major Bone	Bone Features	Description and Related Structures of Importance	Best View	Word Origins
Zygomatic	Frontal process	Articulates with frontal bone.	Lateral	<i>frontellum</i> , forehead + <i>processus</i> , a projection
	Maxillary process	Articulates with zygomatic process of maxillary bone.	Lateral	<i>maxilla</i> , jawbone + <i>processus</i> , a projection
	Temporal process	Articulates with zygomatic process of temporal bone.	Lateral	<i>temporalis</i> , temple/time + <i>processus</i> , a projection

**EXERCISE 8.1 Anterior View of the Skull**

**EXERCISE 8.1A: Anterior View of the Skull**

1. Obtain a skull and observe it from an anterior view (**figure 8.1**). An anterior view of the skull reveals much of the detail of the facial bones. Facial bones play a role in mastication (chewing) and in the protection and support of special sensory organs such as the eye. **Table 8.3** describes bony structures of the face and lists the bones that compose each structure.
2. Identify the structures listed in figure 8.1 on a skull or model in the laboratory, using table 8.3 and the textbook as guides. Then, label figure 8.1.
3. *Optional Activity:* **AP|R Skeletal System**—Watch the “Skull” animation to see how the bones of the skull fit together.



**Figure 8.1 Anterior View of the Skull.** Use the terms listed to fill in the numbered labels in the figure.

- |   |  |   |   |
|---|--|---|---|
| <input type="checkbox"/> alveolar processes       | <input type="checkbox"/> lacrimal bone       | <input type="checkbox"/> optic canal                    | <input type="checkbox"/> supraorbital foramen (notch) |
| <input type="checkbox"/> frontal bone             | <input type="checkbox"/> mandible            | <input type="checkbox"/> parietal bone                  | <input type="checkbox"/> supraorbital margin          |
| <input type="checkbox"/> glabella                 | <input type="checkbox"/> maxilla             | <input type="checkbox"/> perpendicular plate of ethmoid | <input type="checkbox"/> temporal bone                |
| <input type="checkbox"/> inferior nasal concha    | <input type="checkbox"/> mental foramen      | <input type="checkbox"/> sphenoid bone                  | <input type="checkbox"/> vomer                        |
| <input type="checkbox"/> inferior orbital fissure | <input type="checkbox"/> mental protuberance | <input type="checkbox"/> superciliary arch              | <input type="checkbox"/> zygomatic bone               |
| <input type="checkbox"/> infraorbital foramen     | <input type="checkbox"/> nasal bone          | <input type="checkbox"/> superior orbital fissure       |   |



(continued from previous page)

<b>Table 8.3</b>			
<b>The Axial Skeleton: Anterior View of the Skull</b>			
<b>Facial Structure</b>	<b>Major Bone</b>	<b>Bone Feature</b>	<b>Description and Related Structures of Importance</b>
<i>Forehead</i>	Frontal	Squamous part Coronal suture Metopic suture	Remnant of a fetal joint between the two parts of the frontal bone. Suture between frontal and parietal bones. Suture between the two parts of the frontal bone; only named in the adult if the suture persists.
		Squamous suture Glabella Superciliary arch	Suture between frontal and temporal bones. Prominent bony ridge located immediately superior to the nose. The “brow” ridges, which are located superior to the supraorbital margin.
<i>Orbit</i>	Frontal	Supraorbital margin Supraorbital foramen	Bony support and protection of the superior border of the orbit. Supraorbital artery and nerve travel through. Sometimes the supraorbital foramen is just a notch.
	Sphenoid	Optic canal Superior orbital fissure  Inferior orbital fissure	Optic nerve (CN II) travels through. Oculomotor (CN III), trochlear (CN IV), trigeminal (CN V <sub>1</sub> ), and abducens (CN VI) nerves travel through. Maxillary branch of trigeminal nerve (CN V <sub>2</sub> ) and infraorbital artery and vein travel through.
	Ethmoid		Forms medial wall and part of the posterior wall of the orbit.
	Lacrimal	Lacrimal fossa	Drains tears from the surface of the eye into the nasal cavity.
	Maxilla	Infraorbital foramen	Forms medial and inferior walls of the orbit. Infraorbital nerve (a branch of CN V) and artery travel through.
	Zygomatic		Forms lateral border and wall of the orbit.
<i>Nose</i>	Nasal		Forms most of the bridge and the anterior portion of the bony skeleton of the nose.
	Maxilla	Frontal processes	Form lateral aspect of the bony skeleton of the nose.
	Frontal	Nasal spine	Forms superior aspect of the bony skeleton of the nose.
<i>Nasal Septum</i>	Ethmoid	Perpendicular plate	Forms superior portion of the nasal septum.
	Vomer		Forms the posterior-inferior portion of the nasal septum.
<i>Nasal Cavity</i>	Ethmoid	Cribriform foramina Cribriform plate Superior and middle conchae	Holes that olfactory nerves (CN I) travel through to get to the CNS. Forms roof of nasal cavity. Curved bony structures that form superior part of lateral wall and cause turbulent airflow.
	Inferior nasal concha		Curved bone that forms inferior part of lateral wall and causes turbulent airflow.
	Maxilla	Palatine process	Forms anterior floor and part of lateral wall of the nasal cavity.
	Palatine		Forms posterior floor of nasal cavity.
<i>Oral Cavity (Buccal)</i>	Palatine		Forms posterior roof of oral cavity.
	Maxilla	Palatine process Incisive foramen Alveolar processes Maxillary teeth	Forms anterior roof of oral cavity. Contains arteries and nerves passing from the nasal cavity into the oral cavity. Form joints with the teeth.
	Mandible	Alveolar processes Body Ramus Mandibular teeth	Form joints with the teeth. Forms anterior portion of lower border of oral cavity. Forms lateral portion of lower border of oral cavity.

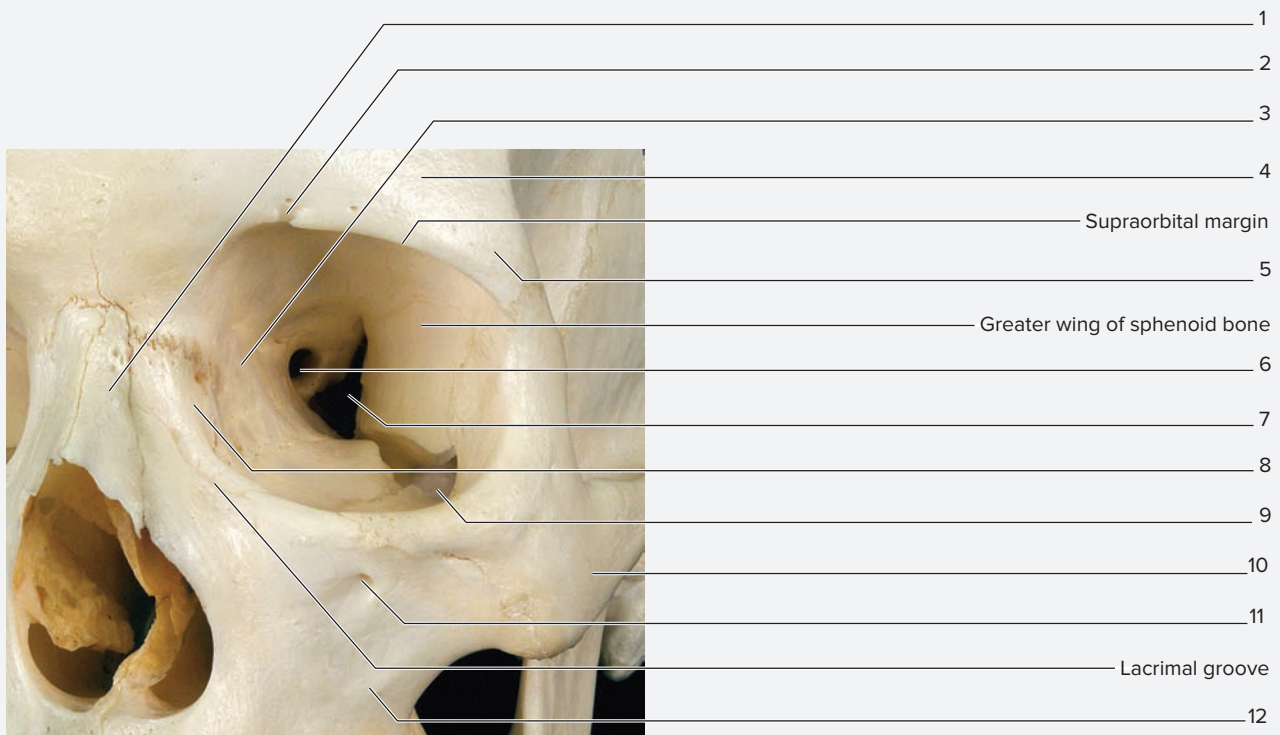
Table 8.3 The Axial Skeleton: Anterior View of the Skull (continued)			
Facial Structure	Major Bone	Bone Feature	Description and Related Structures of Importance
Chin	Mandible	Body	The anterolateral portion of the mandible.
		Angle	The portion of the mandible connecting the body to the ramus, forming a right angle.
		Mental foramen	Mental artery and nerve (CN V <sub>3</sub> ) travel through.
		Ramus	Part of the bone that forms an angle with the body of the mandible.
		Alveolar processes	Form joints with the teeth.
		Mental protuberance	Anterior projection of mandible, forming the anterior projection of the chin.

**EXERCISE 8.1B: The Orbit**

1. Observe the orbit (figure 8.2) on a skull or model.
2. The orbit is the bony casing that supports and protects the eyeball. Parts of the frontal, zygomatic, maxillary, ethmoid, and lacrimal bones form the anterior border of the orbit. The ethmoid and lacrimal bones form most of the medial wall of

the orbit, and the sphenoid bone forms most of the posterior wall. Identify the walls and borders of the orbit on your specimen.

3. Identify the features of the orbit listed in figure 8.2 on a skull, using table 8.3 and the textbook as guides. Then, label figure 8.2.



**Figure 8.2 The Orbit.** Anterior view. Use the terms listed to fill in the numbered labels in the figure.

- |   |  |  |
|---|--|--|
| <input type="checkbox"/> ethmoid bone             | <input type="checkbox"/> lacrimal bone | <input type="checkbox"/> superior orbital fissure          |
| <input type="checkbox"/> frontal bone             | <input type="checkbox"/> maxilla       | <input type="checkbox"/> supraorbital foramen (notch)      |
| <input type="checkbox"/> inferior orbital fissure | <input type="checkbox"/> nasal bone    | <input type="checkbox"/> zygomatic bone                    |
| <input type="checkbox"/> infraorbital foramen     | <input type="checkbox"/> optic foramen | <input type="checkbox"/> zygomatic process of frontal bone |

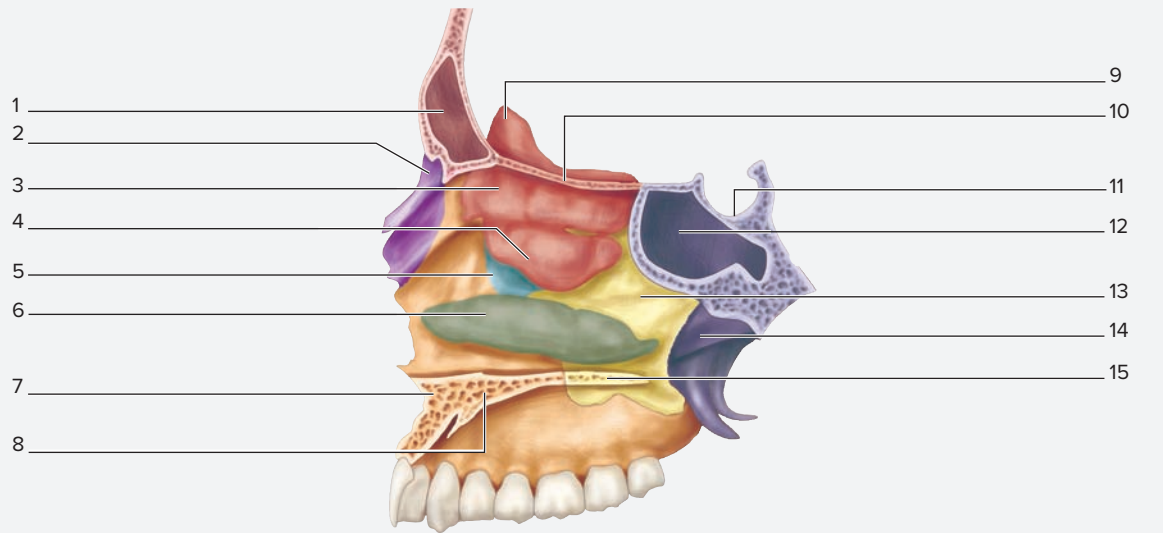
(continued from previous page)

**EXERCISE 8.1C: The Nasal Cavity**

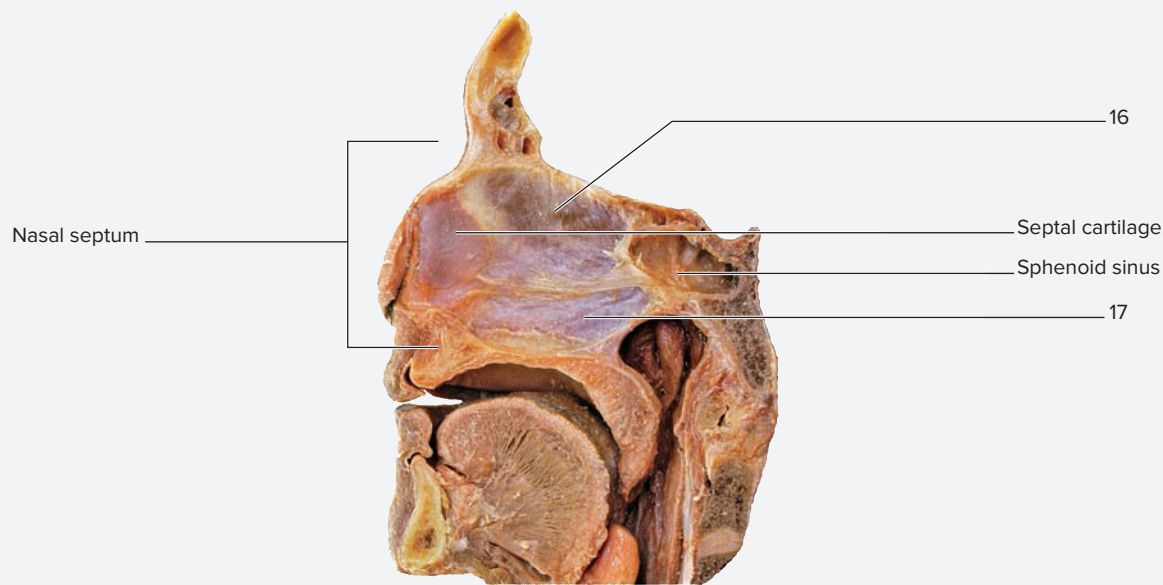
1. Observe the **nasal cavity (figure 8.3)** on a skull or model.
2. The nasal cavity is a large, complex cavity that is separated into two halves by a **nasal septum** (*saeptum*, a partition). The ethmoid bone forms parts of the roof, septum, and lateral walls. The **cribriform** (*cribrum-*, a sieve + *forma*, a form) **plate** of the ethmoid bone forms most of the roof. The **palatine processes of the maxillary bones** and the **palatine**

**bones** form the floor of the nasal cavity (and the roof of the oral cavity). The **nasal bones** form most of the bridge of the nose. Finally, the bony portion of the nasal septum is formed from the **perpendicular plate of the ethmoid bone** and the **vomer**.

3. Identify the features of the nasal cavity listed in figure 8.3 on a skull, using table 8.3 and the textbook as guides. Then, label figure 8.3.



(a)



(b)

**Figure 8.3 The Nasal Cavity.** Lateral views. The nasal septum is removed in (a) and present in (b). Use the terms listed to fill in the numbered labels in the figure.

- |  |  |  |
|--|--|--|
| <input type="checkbox"/> cribriform plate of ethmoid bone  | <input type="checkbox"/> maxilla                             | <input type="checkbox"/> sella turcica         |
| <input type="checkbox"/> crista galli (of ethmoid bone)    | <input type="checkbox"/> middle nasal concha                 | <input type="checkbox"/> sphenoid bone         |
| <input type="checkbox"/> frontal sinus                     | <input type="checkbox"/> nasal bone                          | <input type="checkbox"/> sphenoid sinus        |
| <input type="checkbox"/> horizontal plate of palatine bone | <input type="checkbox"/> palatine bone                       | <input type="checkbox"/> superior nasal concha |
| <input type="checkbox"/> inferior nasal concha             | <input type="checkbox"/> palatine process of maxilla         | <input type="checkbox"/> vomer                 |
| <input type="checkbox"/> lacrimal bone                     | <input type="checkbox"/> perpendicular plate of ethmoid bone |  |

**EXERCISE 8.1D: The Mandible**

1. Obtain an isolated mandible or observe the mandible on an articulated skeleton or complete skull.
2. The **mandible (figure 8.4)** is unique among skull bones, because it is the only bone that is independently movable. It shares an articulation with the temporal bone, forming the **temporomandibular joint**. Here, the **head of the mandible** articulates with the mandibular fossa of the temporal bone. The **mandibular condyle** is the rounded projection on the **head of the mandible** that actually forms the joint with the temporal bone. Place your fingers just anterior to your ears and then open and close your mouth to feel the movement of the joint formed between the mandible and temporal bone (the temporomandibular joint).
3. The mandible also has a prominent **coronoid process** (*corona-*, crown + *eidos*, form, resemblance), which serves as the insertion point for the temporalis muscle.
4. The mandible contains two paired prominent foramina. The first, found on the inner (medial) surface of the ramus of the mandible, is the **mandibular foramen**. A branch of the mandibular branch of the trigeminal nerve (CN V<sub>3</sub>) passes through this foramen into the interior of the bone. It then sends branches to the **alveolar processes** of the mandible to innervate the roots of the teeth in a living individual. When you are having dental work done on the teeth of your lower jaw, the dentist will direct a needle containing anaesthetic at the mucosa surrounding this foramen in order to bathe the nerve branches that travel into the mandible. Finally, the **mental foramen** (*mental*, chin) is located just superior to the lower border of the mandible at about the midpoint of the body of the mandible. The mental artery and nerve travel through the mental foramen in a living individual.
5. Identify the structures listed in figure 8.4 on a mandible, using table 8.3 and the textbook as guides. Then, label figure 8.4.



**Figure 8.4 The Mandible.** Lateral view. Use the terms listed to fill in the numbered labels in the figure.

- |   |   |  |
|---|---|--|
| <input type="checkbox"/> alveolar process | <input type="checkbox"/> coronoid process   | <input type="checkbox"/> mental foramen      |
| <input type="checkbox"/> angle            | <input type="checkbox"/> head of mandible   | <input type="checkbox"/> mental protuberance |
| <input type="checkbox"/> body             | <input type="checkbox"/> mandibular foramen | <input type="checkbox"/> mylohyoid line      |
| <input type="checkbox"/> condylar process | <input type="checkbox"/> mandibular notch   | <input type="checkbox"/> ramus               |

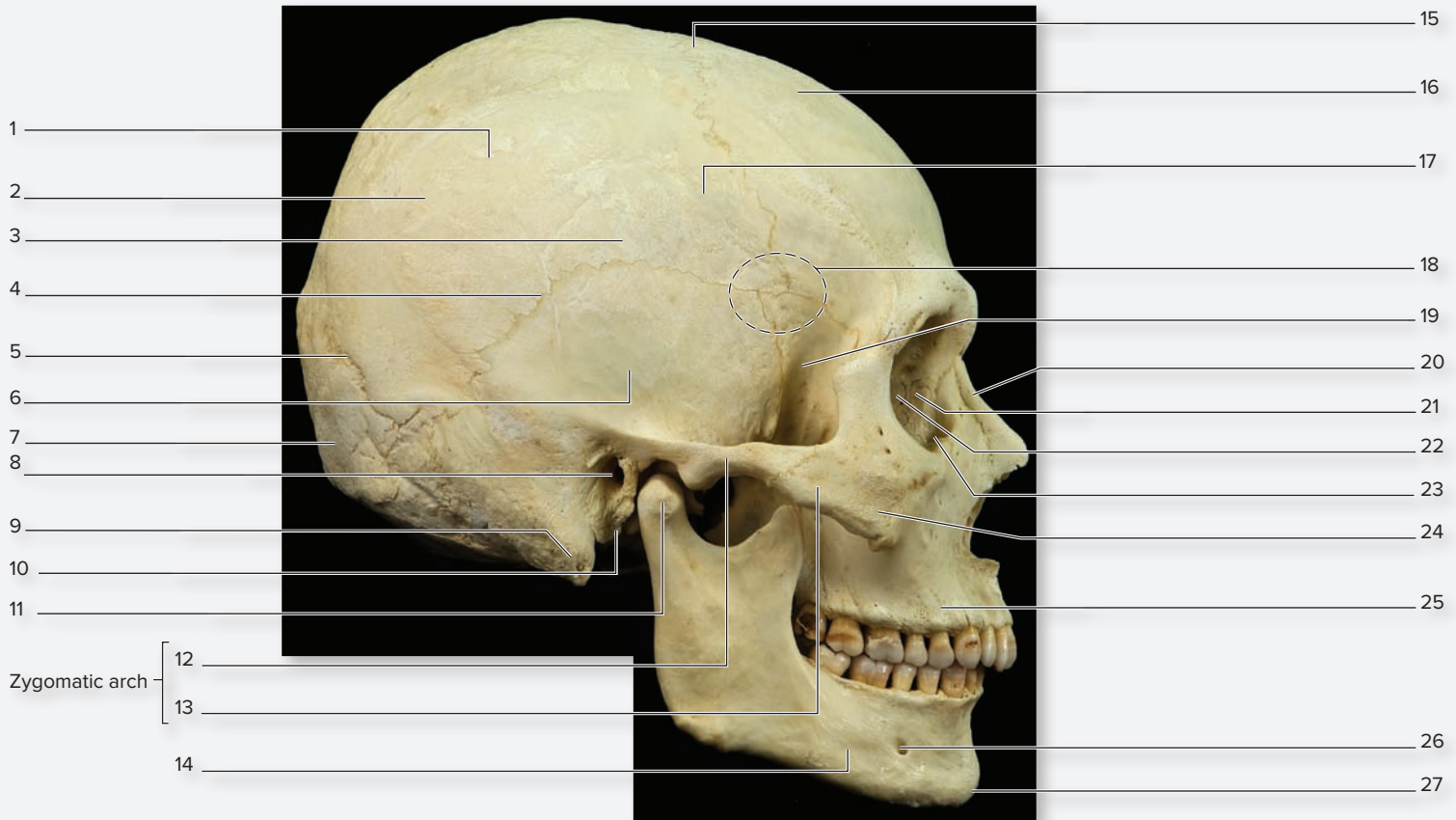**EXERCISE 8.2** Additional Views of the Skull

**EXERCISE 8.2A: Lateral View of the Skull**

1. Obtain a skull and observe it from a lateral view (figure 8.5).
2. The most notable feature in a lateral view of the skull is the **zygomatic arch**, which is the bony structure that forms the superior part of a person's cheek. It is formed from the

zygomatic process of the temporal bone, and the temporal process of the zygomatic bone.

3. Identify the structures listed in figure 8.5 on a skull, using table 8.2 and the textbook as guides. Then, label figure 8.5.



**Figure 8.5** Lateral View of the Skull. Use the terms listed to fill in the numbered labels in the figure.

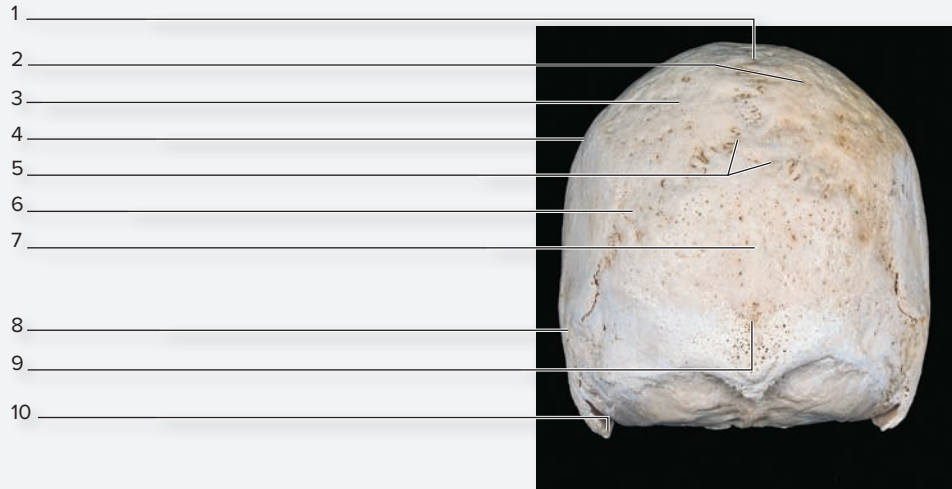- |  |  |   |
|--|--|---|
| <input type="checkbox"/> body of mandible              | <input type="checkbox"/> lacrimal groove     | <input type="checkbox"/> parietal eminence                  |
| <input type="checkbox"/> coronal suture                | <input type="checkbox"/> lambdoid suture     | <input type="checkbox"/> pterion                            |
| <input type="checkbox"/> ethmoid bone                  | <input type="checkbox"/> mastoid process     | <input type="checkbox"/> squamous part of temporal bone     |
| <input type="checkbox"/> external acoustic meatus      | <input type="checkbox"/> maxilla             | <input type="checkbox"/> squamous suture                    |
| <input type="checkbox"/> frontal bone                  | <input type="checkbox"/> mental foramen      | <input type="checkbox"/> styloid process                    |
| <input type="checkbox"/> greater wing of sphenoid bone | <input type="checkbox"/> mental protuberance | <input type="checkbox"/> superior temporal line             |
| <input type="checkbox"/> head of mandible              | <input type="checkbox"/> nasal bone          | <input type="checkbox"/> temporal process of zygomatic bone |
| <input type="checkbox"/> inferior temporal line        | <input type="checkbox"/> occipital bone      | <input type="checkbox"/> zygomatic bone                     |
| <input type="checkbox"/> lacrimal bone                 | <input type="checkbox"/> parietal bone       | <input type="checkbox"/> zygomatic process of temporal bone |

**EXERCISE 8.2B: Posterior View of the Skull**

1. Obtain a skull and observe it from a posterior view (**figure 8.6**).
2. The most notable feature in a posterior view of the skull is the **lambdoid suture** (*lambda-*, the Greek letter  $\lambda$  + *eidos*,

resemblance), which is named for its resemblance to the Greek letter lambda. Can you see the resemblance? Draw the letter lambda in the space provided here: \_\_\_\_\_.

3. Identify the structures listed in figure 8.6 on a skull, using table 8.2 and the textbook as guides. Then, label figure 8.6.



**Figure 8.6** Posterior View of the Skull.

Use the terms listed to fill in the numbered labels in the figure.


- external occipital protuberance
- lambdoid suture
- mastoid process
- occipital bone
- parietal bone
- parietal eminence
- parietal foramina
- sagittal suture
- sutural (wormian) bone
- temporal bone

© McGraw-Hill Education/Photo and Dissection by Christine Eckel

**EXERCISE 8.2C: Superior View of the Skull**

1. Obtain a skull (with the skullcap intact) and observe it from a superior view (**figure 8.7**).
2. The most notable feature in a superior view of the skull is the **sagittal suture**.

3. Identify the structures listed in figure 8.7 on a skull, using table 8.2 and the textbook as guides. Then, label figure 8.7.



**Figure 8.7** Superior View of the Skull.

Use the terms listed to fill in the numbered labels in the figure.

- coronal suture
- frontal bone
- lambdoid suture
- occipital bone
- parietal bone
- parietal foramina
- sagittal suture
- sutural (wormian) bone

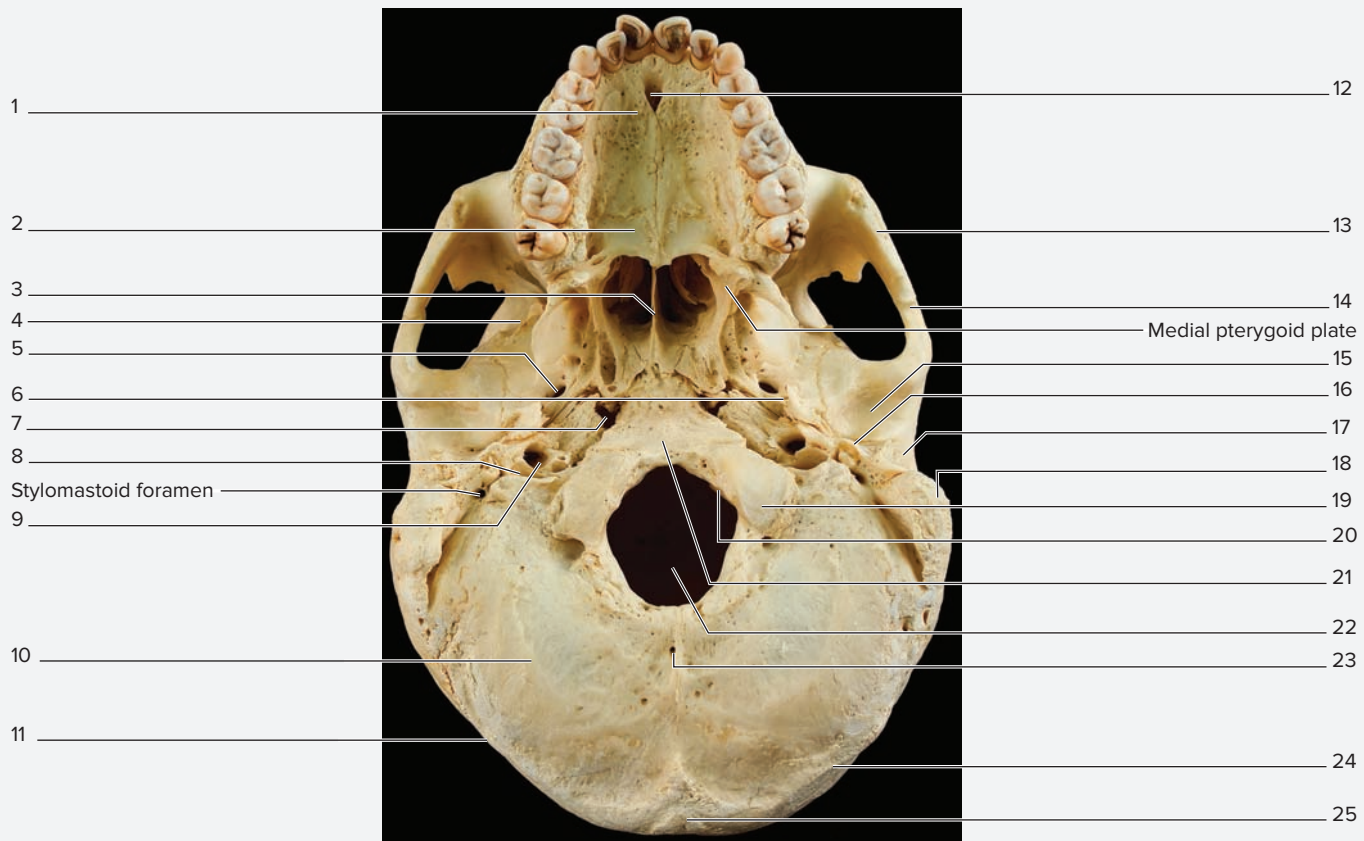
© McGraw-Hill Education/Photo and Dissection by Christine Eckel

(continued on next page)

(continued from previous page)

**EXERCISE 8.2D: Inferior View of the Skull**

1. Turn the skull over and observe it from an inferior view (**figure 8.8**). Many of the structures visible in this view are foramina that nerves and blood vessels pass through to get into and out of the cranial cavity.
2. Obtain a broom straw or other nonmarking pointing device such as a pipe cleaner (NO pens or pencils!) from the instructor. While identifying each foramen in the inferior view, pass the broom straw through the foramen and see where it comes out in the cranial floor. This activity will assist with visualization of the pathways that structures traveling through the foramina take to get into or out of the cranial cavity.
3. The **foramen lacerum** (*lacero*, to tear to pieces) is unique among cranial foramina. It is one of the longest canals in the skull (about a centimeter in length). However, no single structure passes completely through it from one opening to the other. Instead, several structures pass through small portions of the canal. Such structures include a number of nerves as well as the internal carotid artery. As the internal carotid artery travels superiorly from the thorax into the cranial cavity, it passes first through the **carotid canal** and then enters the superior portion of the foramen lacerum as it proceeds toward the brain.
4. Identify the structures listed in figure 8.8 on a skull, using table 8.2 and the textbook as guides. Then label figure 8.8.

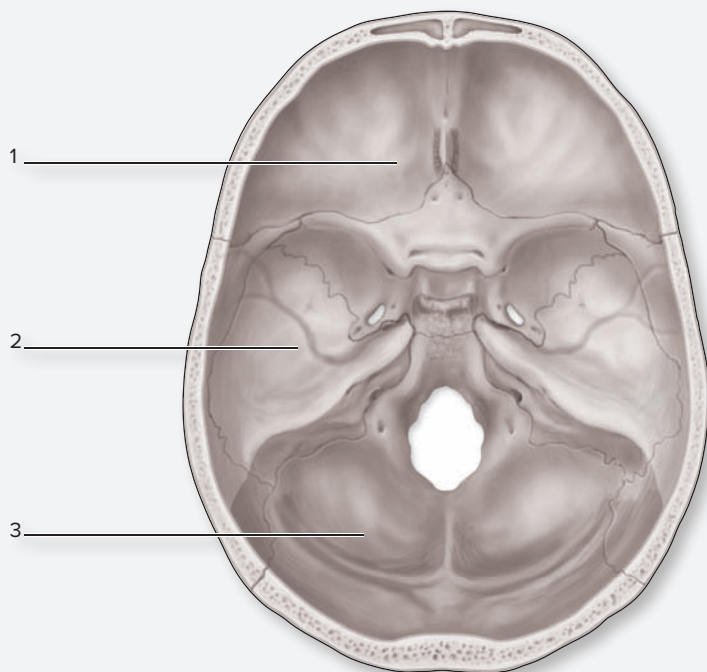


**Figure 8.8 Inferior View of the Skull.** Use the terms listed to fill in the numbered labels in the figure.

- |   |   |   |
|---|---|---|
| <input type="checkbox"/> basilar region of occipital bone | <input type="checkbox"/> incisive foramen     | <input type="checkbox"/> sphenoid bone                      |
| <input type="checkbox"/> carotid canal                    | <input type="checkbox"/> inferior nuchal line | <input type="checkbox"/> styloid process                    |
| <input type="checkbox"/> external occipital crest         | <input type="checkbox"/> jugular foramen      | <input type="checkbox"/> superior nuchal line               |
| <input type="checkbox"/> external occipital protuberance  | <input type="checkbox"/> mandibular fossa     | <input type="checkbox"/> temporal bone                      |
| <input type="checkbox"/> foramen lacerum                  | <input type="checkbox"/> mastoid process      | <input type="checkbox"/> temporal process of zygomatic bone |
| <input type="checkbox"/> foramen magnum                   | <input type="checkbox"/> maxilla              | <input type="checkbox"/> vomer                              |
| <input type="checkbox"/> foramen ovale                    | <input type="checkbox"/> occipital bone       | <input type="checkbox"/> zygomatic process of temporal bone |
| <input type="checkbox"/> foramen spinosum                 | <input type="checkbox"/> occipital condyle    |   |
| <input type="checkbox"/> hypoglossal canal                | <input type="checkbox"/> palatine bone        |   |

**EXERCISE 8.3 Superior View of the Cranial Floor**

1. Obtain a skull and remove the top of the cranium so the cranial floor is visible (**figure 8.9**).
2. Notice how the floor of the cranium is separated into three fossae: anterior, middle, and posterior. The **lesser wing of the sphenoid bone** forms the border between anterior and middle cranial fossae. The **petrous part of the temporal bone** (*petrosus*, a rock) forms the “rocky” border between the middle and posterior cranial fossae.
3. Using colored pencils, color and label the anterior, middle, and posterior cranial fossae in figure 8.9. While coloring the fossae, pay attention to the structures that form the natural divisions between these fossae.



**Figure 8.9 Cranial Fossae.** Use the terms listed to fill in the numbered labels in the figure. Use colored pencils to color in each cranial fossa to further differentiate them from each other.

- anterior cranial fossa       posterior cranial fossa  
 middle cranial fossa

4. Observe the **sella turcica** (*sella*, saddle + *turcica*, Turkish) in the central portion of the sphenoid bone. This structure gets its name from its resemblance to a Turkish saddle, which contains large, prominent horns (**figure 8.10**). The anterior part of the sella turcica contains a slight projection called the **tuberculum sellae** (*tuber*, a knob). Posterior to that is the **hypophyseal fossa** (*hypophysis*, an undergrowth), which houses the pituitary gland in a living human. The pituitary gland is a small pea-shaped endocrine gland that connects to the brain via a small stalk called the infundibulum (*infundibula*, a funnel). The larger projection in the posterior part of the sella is the **dorsum sellae**, which connects laterally to the two **posterior clinoid processes** (*klino*, to slope).

5. The temporal bone has two major portions; a lateral **squamous part**, which forms part of the lateral wall of the cranium, and a thick petrous part, which forms the border between the middle and posterior cranial fossae (although it is considered part of the middle cranial fossa).
6. Locate the petrous part of the temporal bone. Notice how it forms a sort of “rocky” ridge within the cranial floor. This portion of the temporal bone is very large and bulky because it contains the mechanisms for hearing (the cochlea) and equilibrium/balance (the semicircular canals). These structures cannot be seen from the surface of the bone. However, if the petrous part of the temporal bone was opened, they would be visible inside.
7. Find the internal and external acoustic (auditory) meatuses. The **internal acoustic (auditory) meatus** is the opening into the **internal auditory canal**, which is a passageway for the nerves that carry sensory information from the cochlea and semicircular canals to the brain. The **external acoustic (auditory) meatus** is the opening into the external auditory canal, which is a passageway through which sound waves travel to reach the tympanic membrane (eardrum).
8. Identify the structures listed in **figure 8.11** on a superior view of the cranial floor, using table 8.2 and the textbook as guides. Then label figure 8.11.

**Learning Strategy**

It is useful to focus observations of the cranial floor by viewing one fossa at a time. Then proceed to identify bony structures within each fossa. This is a natural way to divide the features of the cranial floor into manageable pieces of material. Taking this approach will ease the effort to recall each of the many foramina in the cranial floor. By first identifying the cranial fossa where a foramen is located the choices are greatly narrowed.



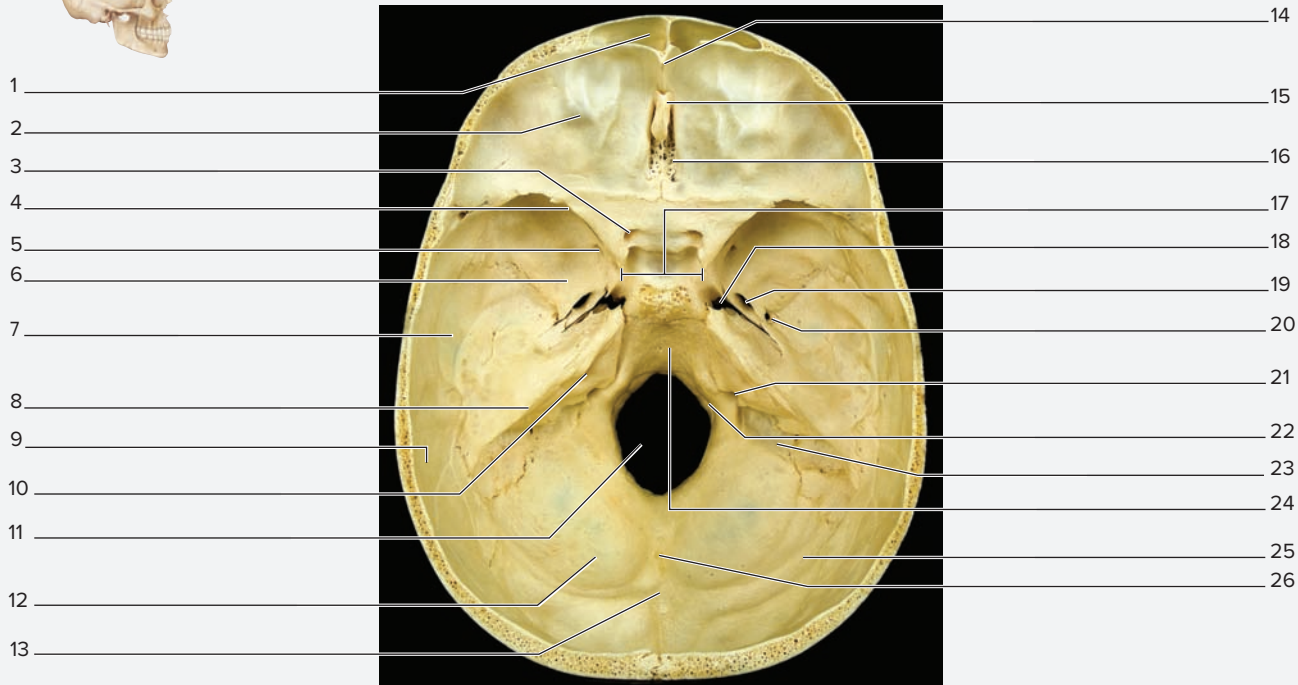
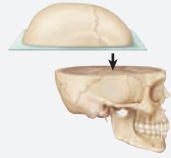**Figure 8.10 Photograph of a Turkish Saddle.**

© Andy Crawford/Dorling Kindersley Media Library

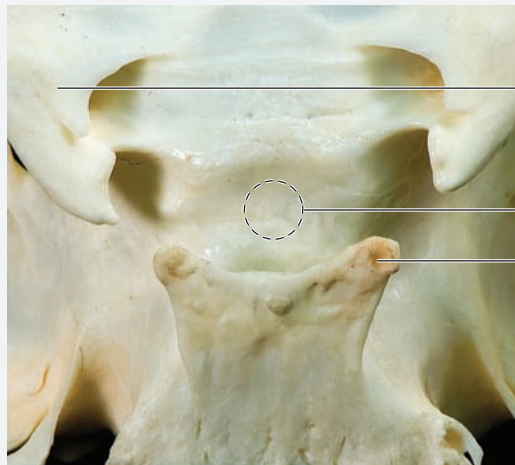(continued on next page)



(continued from previous page)



(a) Superior view



(b) Close-up of sella turcica

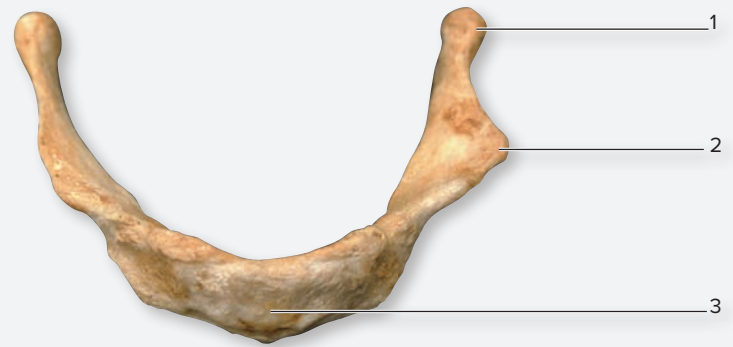
**Figure 8.11 Superior View of the Cranial Floor.** Use the terms listed to fill in the numbered labels in the figure.

- |   |  |  |   |  |
|---|--|--|---|--|
| <b>Anterior Cranial Fossa</b>                             | <b>Middle Cranial Fossa</b>                            | <input type="checkbox"/> hypophyseal fossa             | <b>Posterior Cranial Fossa</b>                          | <input type="checkbox"/> internal acoustic meatus        |
| <input type="checkbox"/> cribriform plate of ethmoid bone | <input type="checkbox"/> anterior clinoid process      | <input type="checkbox"/> optic canal                   | <input type="checkbox"/> basilar part of occipital bone | <input type="checkbox"/> internal occipital crest        |
| <input type="checkbox"/> crista galli                     | <input type="checkbox"/> foramen lacerum               | <input type="checkbox"/> petrous part of temporal bone | <input type="checkbox"/> foramen magnum                 | <input type="checkbox"/> internal occipital protuberance |
| <input type="checkbox"/> frontal bone                     | <input type="checkbox"/> foramen ovale                 | <input type="checkbox"/> posterior clinoid process     | <input type="checkbox"/> groove for sigmoid sinus       | <input type="checkbox"/> jugular foramen                 |
| <input type="checkbox"/> frontal crest                    | <input type="checkbox"/> foramen rotundum              | <input type="checkbox"/> sella turcica                 | <input type="checkbox"/> groove for transverse sinus    | <input type="checkbox"/> occipital bone                  |
| <input type="checkbox"/> frontal sinus                    | <input type="checkbox"/> foramen spinosum              | <input type="checkbox"/> temporal bone                 | <input type="checkbox"/> hypoglossal canal              | <input type="checkbox"/> parietal bone                   |
| <input type="checkbox"/> lesser wing of sphenoid bone     | <input type="checkbox"/> greater wing of sphenoid bone |  |   |  |

**EXERCISE 8.4** Bones Associated with the Skull

The hyoid bone and the auditory ossicles are bones of the axial skeleton that are associated with the skull, but they are not part of the skull proper. The auditory ossicles are part of the hearing apparatus and will be covered in chapter 18. This exercise will concentrate on the features of the hyoid bone.

1. Observe the hyoid bone (**figure 8.12**) on an articulated skeleton.
2. The **hyoid bone** (*hyoeidēs*, shaped like the Greek letter upsilon, υ) is the only bone in the body with no direct articulation with another bone. Muscles that move the tongue and pharynx attach to the hyoid.
3. Palpate your own hyoid by placing your thumb and index finger just medial to the angle of your mandible on either side and then moving them from side to side. Can you feel the rigid structure that you are moving?
4. Observe the articulated skeleton in the laboratory and look at the placement of the hyoid bone with respect to the mandible.
5. Identify the structures listed in figure 8.12 on a hyoid bone, using the textbook as a guide. Then label figure 8.12.



**Figure 8.12 The Hyoid Bone.** The hyoid bone is not in direct contact with any other bone of the skeleton. Use the terms listed to fill in the numbered labels in the figure.

- |                          |               |                          |              |
|--------------------------|---------------|--------------------------|--------------|
| <input type="checkbox"/> | body          | <input type="checkbox"/> | lesser cornu |
| <input type="checkbox"/> | greater cornu |                          |              |

© Alinari Archives/The Image Works

**The Fetal Skull**

Like all bones in the body, the skull bones of the fetus are still developing. Recall that they develop via intramembranous ossification, which involves replacing a connective tissue membrane with bone tissue. Thus, when a fetus is born, the sutures between skull bones have not yet formed, which allows the head to distort as it moves through the

birth canal. The spaces between the plates of bone in the developing skull still consist of connective tissue membranes, which are largest in places where more than two bones come together. These membranes are **fontanels** (*fontaine*, a small fountain), and can be felt as “soft spots” on a baby’s head. The fontanels will not fill in completely until between the ages of 2 and 3.

**EXERCISE 8.5** The Fetal Skull

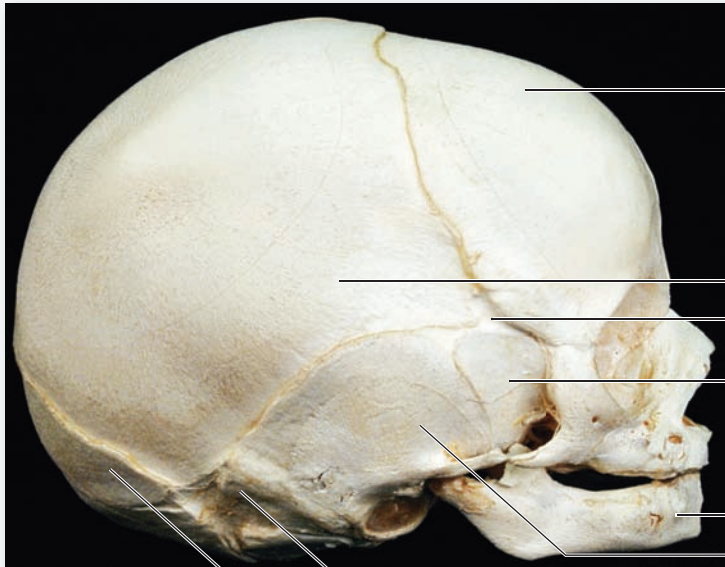
1. Observe a fetal skull or a model of a fetal skull (**figure 8.13**).
2. Based on observations of the adult skull, locate the major cranial bones on the fetal skull (e.g., frontal, parietal, occipital).
3. Identify the structures listed in figure 8.13 on a fetal skull or model of a fetal skull, using the textbook as a guide. Then label them in figure 8.13.

**WHAT DO YOU THINK?**

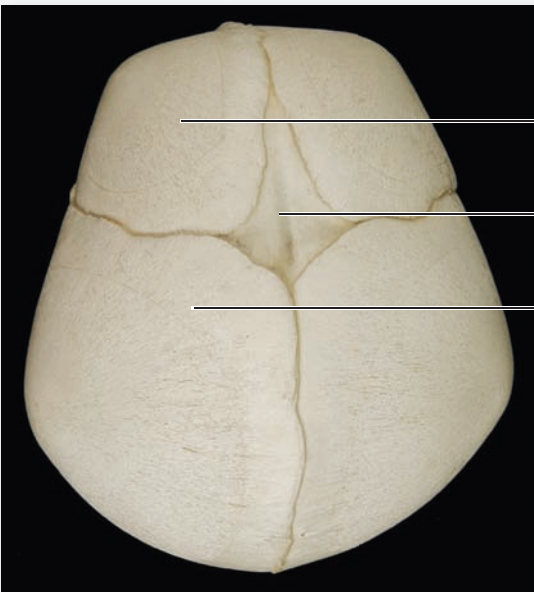- 1 Why do you think the fontanels persist until well after the birth of the infant?

(continued on next page)

(continued from previous page)



(a) Lateral view



(b) Superior view

**Figure 8.13 The Fetal Skull.** Use the terms listed to fill in the numbered labels in the figure. Some terms may be used more than once.

- |  |   |  |
|--|---|--|
| <input type="checkbox"/> anterior fontanel | <input type="checkbox"/> mastoid fontanel | <input type="checkbox"/> sphenoid bone       |
| <input type="checkbox"/> frontal bone      | <input type="checkbox"/> occipital bone   | <input type="checkbox"/> sphenoidal fontanel |
| <input type="checkbox"/> mandible          | <input type="checkbox"/> parietal bone    | <input type="checkbox"/> temporal bone       |

## The Vertebral Column

The vertebral column lies at the core of the human skeleton. It quite literally is the “backbone” that anchors nearly every major component of the skeletal support system. The vertebral column is divided into five major regions: **cervical**, **thoracic**, **lumbar**, **sacral**, and **coccygeal**. The vertebrae themselves change size and shape rather drastically from the cervical region to the sacral region. These changes reflect the different demands placed on the vertebrae in each region. **Cervical vertebrae** are small and light because they are not supporting a lot of weight (relatively speaking), and they are specialized to allow a lot of movement of the

neck, particularly rotation. **Thoracic vertebrae** are specialized to provide articulation points for the ribs. **Lumbar vertebrae** are very large, bulky vertebrae that are specialized for supporting the weight of the entire vertebral column and body structures above them. They do not allow much movement, but instead are designed to keep the vertebral column stable. The **sacrum**, which consists of fused vertebrae, is specialized to provide a stable anchoring point for the bones of the pelvic girdle. Finally, the **coccyx** consists of three to five small vertebrae, which have fused together during development. It serves as an attachment point for several ligaments and for muscles of the pelvic floor. **Table 8.4** summarizes the characteristics of each type of vertebra.

Vertebrae	Number of Vertebrae	Bone Feature	Description and Related Structures of Importance
<i>Typical Vertebra</i>	32	Lamina Pedicle Transverse processes Spinous process Inferior articular process  Superior articular process Vertebral foramen Body  Intervertebral foramina	Connects transverse process to spinous process. Connects body to transverse process. Processes that are directed laterally (one on each side). A process that is directed posteriorly. Contains a facet that forms a joint with the superior articular process of the vertebra one level below. Contains a process that forms a joint with the inferior articular process of the vertebra one level above. Location of the spinal cord. The largest part of the vertebra. Intervertebral discs are found between bodies of adjacent vertebrae. Formed when two vertebra come together; passageway for exit of spinal nerves.
<i>Cervical (C)</i>	7	Body Spinous process Vertebral foramen Transverse processes Transverse foramen Costal facets	Small body, oval/kidney-bean shape. Horizontal, bifid (forked) appearance on some (but not all). Large (especially with respect to size of the body), slight oval shape. Each contains a transverse foramina. Contain the vertebral artery and other structures. Located on the body and transverse processes; these form joints with the ribs.
<i>Atlas (C<sub>1</sub>)</i>		Body Arch	Has no body; the body has become the dens (odontoid process) of the axis. Contains the articulation surface for the dens of the axis and the posterior tubercle (no spinous process).
<i>Axis (C<sub>2</sub>)</i>		Body	Has odontoid process (dens), which is the fused body of C <sub>1</sub> .
<i>Vertebra Prominens (C<sub>7</sub>)</i>		Spinous processes	Very large and blunt, not bifid, not covered by ligamentum nuchae. Therefore, is the first spinous process easily felt under the skin.
<i>Thoracic (T)</i>	12	Body Spinous process Vertebral foramen Transverse processes Costa facets	Heart-shaped, contains demifacets for articulation of the head of a rib. Points inferiorly. Relatively small, circular in shape. Contain facets for articulation with the tubercle of a rib. Located on the body and transverse processes; these form joints with the ribs.
<i>Lumbar (L)</i>	5	Body Spinous process Vertebral foramen Transverse processes	Very large, heavy. Short and blunt, square shaped, horizontal. Small (especially with respect to size of body), round. Short and tapered at the ends.
<i>Sacrum (S)</i>	5 (fused)	Anterior sacral foramina Posterior sacral foramina Median sacral crest Auricular processes Superior articular processes Sacral hiatus Sacral promontory	Passageway for exit of ventral (anterior) rami of sacral spinal nerves. Passageway for exit of dorsal (posterior) rami of sacral spinal nerves. Represents fused spinous processes of sacral vertebrae (S <sub>1</sub> –S <sub>4</sub> ). Earlike ( <i>auris</i> , ear) processes that articulate with the iliac bones. Contains a facet to form a joint with the inferior articular processes of L <sub>5</sub> . The opening at the inferior end of the sacral canal. Formed by unfused laminae of S <sub>5</sub> . The anterosuperior border of the body of S <sub>1</sub> .
<i>Coccyx (Co)</i>	3 to 5 (fused)	Cornu (horns)	Small projections that point superiorly (part of Co <sub>1</sub> ).

**EXERCISE 8.6** Vertebral Column Regions and Curvatures

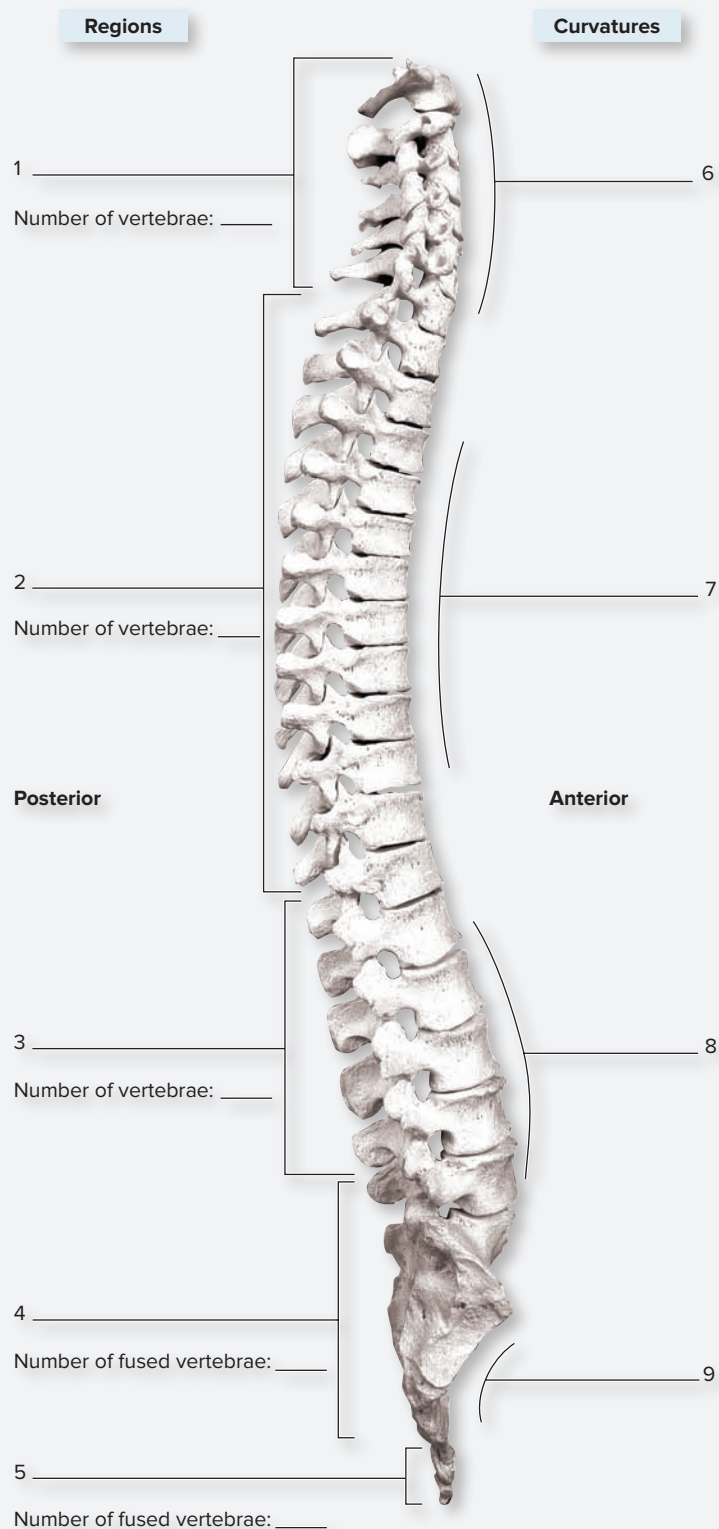
1. Observe the vertebral column of an articulated skeleton (figure 8.14).
2. Using colored pencils, color and label the regions of the vertebral column in figure 8.14. Use a different color for each region. While coloring each region, count the number of vertebrae that make up the region and write that number in the appropriate space in figure 8.14.
3. As the vertebral column develops, it forms several curvatures because of the stresses placed on it. The first curvatures to develop during the fetal period are **primary curvatures**. These form in the thoracic and sacral regions due to growth of the viscera. The second curvatures, which develop after birth, are **secondary curvatures**. These form in the cervical and lumbar regions. The cervical curvature forms when an infant begins to lift his head and the lumbar curvature forms when an infant begins to stand on his feet.
4. Locate all of the curvatures of the vertebral column on an articulated skeleton, and label the curvatures on figure 8.14.

**Learning Strategy**

Remember the number of vertebrae in each region using mealtimes as an aid. Breakfast is at *seven*, lunch is at *twelve*, dinner is at *five*, and a bedtime snack is at *nine*. That is, there are seven cervical vertebrae (C<sub>1</sub>-C<sub>7</sub>), twelve thoracic vertebrae (T<sub>1</sub>-T<sub>12</sub>), five lumbar vertebrae (L<sub>1</sub>-L<sub>5</sub>), five fused primitive vertebrae in the sacrum, and three to five small bones in the coccyx, with an average of four (5 + 4 = 9).

**Figure 8.14 Lateral View of the Vertebral Column.** Use the terms listed to fill in the numbered labels in the figure. Write the number of vertebrae that exist in each region in the space provided in the figure.

- cervical curvature
- cervical vertebrae
- coccygeal vertebrae
- lumbar curvature
- lumbar vertebrae
- sacral curvature
- sacral vertebrae
- sacrum
- thoracic curvature
- thoracic vertebrae



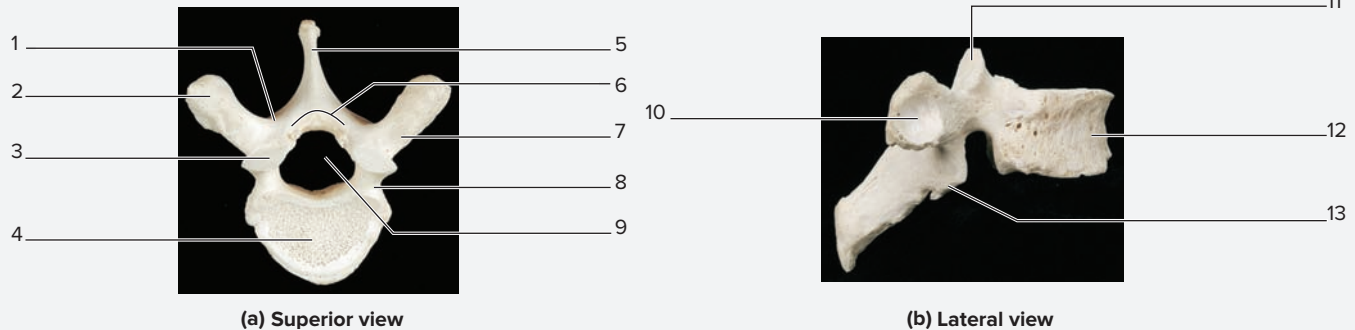
### Clinical View | Spondylolisthesis

**Spondylolisthesis** (*spondylos*, vertebra + *olisthesis*, a slipping, falling) is a condition that involves the anterior or posterior displacement of a vertebra, typically in the lumbar region of the vertebral column. Displacement may occur during development, or may be the result of degeneration or fracture of the pars interarticularis (i.e., pars defect), which is the structure located between the superior and inferior articular processes of the vertebrae. The displaced vertebra may compress nearby spinal nerves, resulting in low back pain or sciatica, a condition that can cause pain to radiate down the posterior aspect of the lower limb. A grading system rates the

severity of the displacement, with grade 1 being the least severe, and grade 4 being the most severe. In the most severe cases, the body of the superior vertebra may come to rest completely on the body of the inferior vertebra or the sacrum. The incidence of spondylolisthesis is particularly high in young athletes, particularly gymnasts, whose vertebrae experience trauma from repetitive lower back hyperextension and frequent, sudden impacts. Many confuse spondylolisthesis with a herniated disc, another common source of lower back pain. However, a herniated disc involves the bulging of an intervertebral disc rather than displacement of the vertebra itself.

### EXERCISE 8.7 Structure of a Typical Vertebra

1. Obtain a thoracic vertebra (**figure 8.15**) from the instructor or bone box—this will be an example of a “typical” vertebra. It is helpful to begin studying the vertebral column by taking a “typical” vertebra and identifying its component parts. This will provide a basis for observing normal variability among vertebrae.
2. Looking at the vertebra from the superior view, notice the large **body**. The body is generally the heaviest part of the vertebra, and connections between adjacent vertebral bodies (with intervertebral discs in between) provide the main support of the vertebral column. Just posterior to the body is the large foramen called the **vertebral (spinal) foramen**. The spinal cord runs through this foramen. The foramen itself is formed by a structure that is collectively referred to as the **vertebral arch**. The vertebral arch is composed of two sets of processes and the structures that connect them.
3. Observe the vertebral processes that project posteriorly and laterally from the vertebral arch. The largest vertebral processes are the **spinous processes**, which are directed posteriorly, and the **transverse processes**, which are directed laterally.
4. Observe the vertebral arch. Notice the bony connections between the vertebral body and the transverse processes. These structures are called **pedicles** (*L. pediculus*, dim. of *pes*, foot). The word *pedicle* comes from a word meaning “foot.” Imagine how the vertebral arch stands upon the body on its “feet.” Now notice the bony connections between the transverse processes and the spinous process. These structures are called **laminae** (*lamina*, layer).
5. Next, turn the vertebra to observe from an anterior view. Notice that there are two prominent structures that project superiorly from the vertebral arch and two that project inferiorly. The projections are respectively called the **superior articular processes** and **inferior articular processes**. Note that on each process there is a smooth, flat surface. These surfaces are called **facets** (*facette*, face). The term *facet* literally means “a little face.” This is the same term



**Figure 8.15** A Typical Vertebra. Use the terms listed to fill in the numbered labels in the figure. Some answers may be used more than once.

- |   |   |   |
|---|---|---|
| <input type="checkbox"/> body                       | <input type="checkbox"/> pedicle                    | <input type="checkbox"/> transverse process         |
| <input type="checkbox"/> inferior articular process | <input type="checkbox"/> spinous process            | <input type="checkbox"/> vertebral arch             |
| <input type="checkbox"/> lamina                     | <input type="checkbox"/> superior articular process | <input type="checkbox"/> vertebral (spinal) foramen |

(continued from previous page)

used to describe the surfaces on a diamond. Each vertebra contains upon its superior and inferior processes a pair of **superior articular facets** and **inferior articular facets**. These facets are the surfaces that form the joints between vertebrae, as described in step 6.

- Pick up a second vertebra that articulates (forms a joint) with the vertebra in your hand. While placing the two together, observe how the superior facets and inferior facets articulate with each other to form a joint. These joints are much more mobile than the intervertebral joints (the joints between the vertebral bodies), and they are the sites where most of the movement is allowed by the vertebral column.

- Once two vertebrae are articulated together, look at them from a lateral view. Notice the foramen that forms between the pedicles of adjacent vertebrae. This is the **intervertebral foramen**. This foramen is the location where spinal nerves (nerves that come off of the spinal cord) exit the vertebral canal to travel to their destinations throughout the body.
- Identify the structures listed in figure 8.15 on a typical vertebra, using table 8.4 and the textbook as guides. Then label them in figure 8.15.

**EXERCISE 8.8** Characteristics of Individual Vertebrae

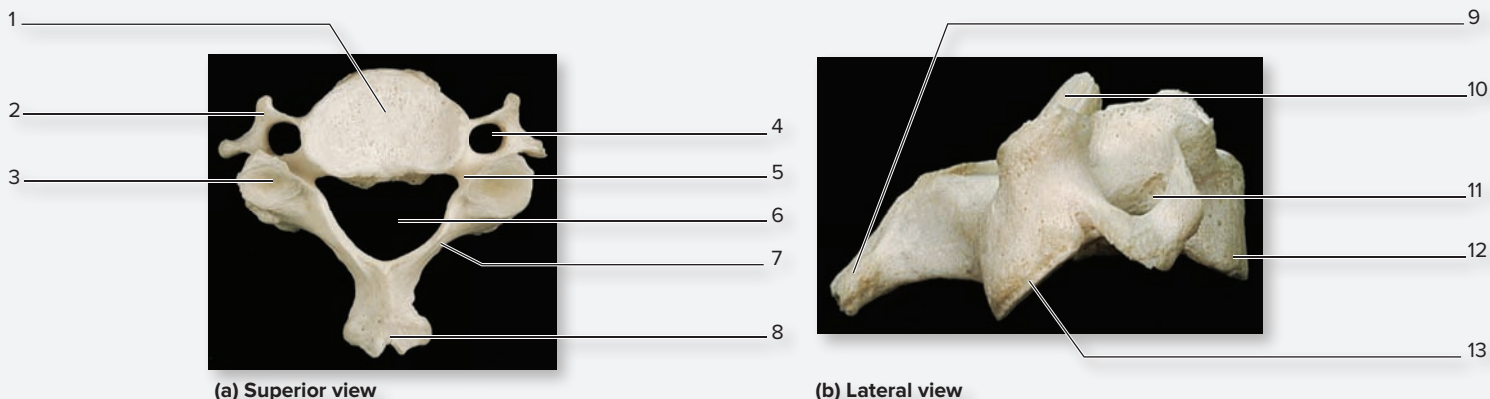
**Learning Strategy**



While observing individual vertebrae, always try to keep function in mind. Ask questions such as: Why does this vertebra have such a large/small body? Why does this vertebra have such a large/small vertebral canal? How does this vertebra “fit” with other aspects of the skeletal system? Asking these questions will assist with identification of each type of vertebra correctly. Finally, when observing isolated vertebrae, always be sure to identify the same vertebrae on an articulated skeleton to develop an appreciation for how the vertebral column is put together.

**EXERCISE 8.8A: Typical Cervical Vertebrae**

- Obtain a cervical vertebra (*cervix*, neck) (**figure 8.16**). While identifying the features of each of the individual cervical vertebrae, think about how modifications of the cervical vertebrae allow for a great deal of movement in the neck region of the vertebral column.
- Observe the vertebra from a superior view. Typical cervical vertebrae have a small, oval body and a large triangular vertebral foramen. The spinous process of some of them is forked, or **bifid** (*bifidus*, cleft in two parts).
- Observe cervical vertebrae on an articulated skeleton. Notice how the fork on one vertebra fits over the top of the spinous process of the vertebra below it.



**Figure 8.16** Cervical Vertebra. Use the terms listed to fill in the numbered labels in the figure. Some answers may be used more than once.

- |   |   |   |
|---|---|---|
| <input type="checkbox"/> body                                   | <input type="checkbox"/> pedicle                                | <input type="checkbox"/> transverse foramen         |
| <input type="checkbox"/> inferior articular process (and facet) | <input type="checkbox"/> spinous process                        | <input type="checkbox"/> transverse process         |
| <input type="checkbox"/> lamina                                 | <input type="checkbox"/> superior articular process (and facet) | <input type="checkbox"/> vertebral (spinal) foramen |

4. Observe the transverse processes on a cervical vertebra. Notice that it has a hole, or **transverse foramen**, in it. This foramen protects an artery, the **vertebral artery**, as it travels from the thorax to the cranial cavity to supply the brain with blood.
5. Identify the structures listed in figure 8.16 on a cervical vertebra, using table 8.4 and the textbook as guides. Then label them in figure 8.16.

**WHAT DO YOU THINK?**

- 2 How might the bifid spinous processes of cervical vertebrae affect anterior-posterior movement in the cervical region of the vertebral column?

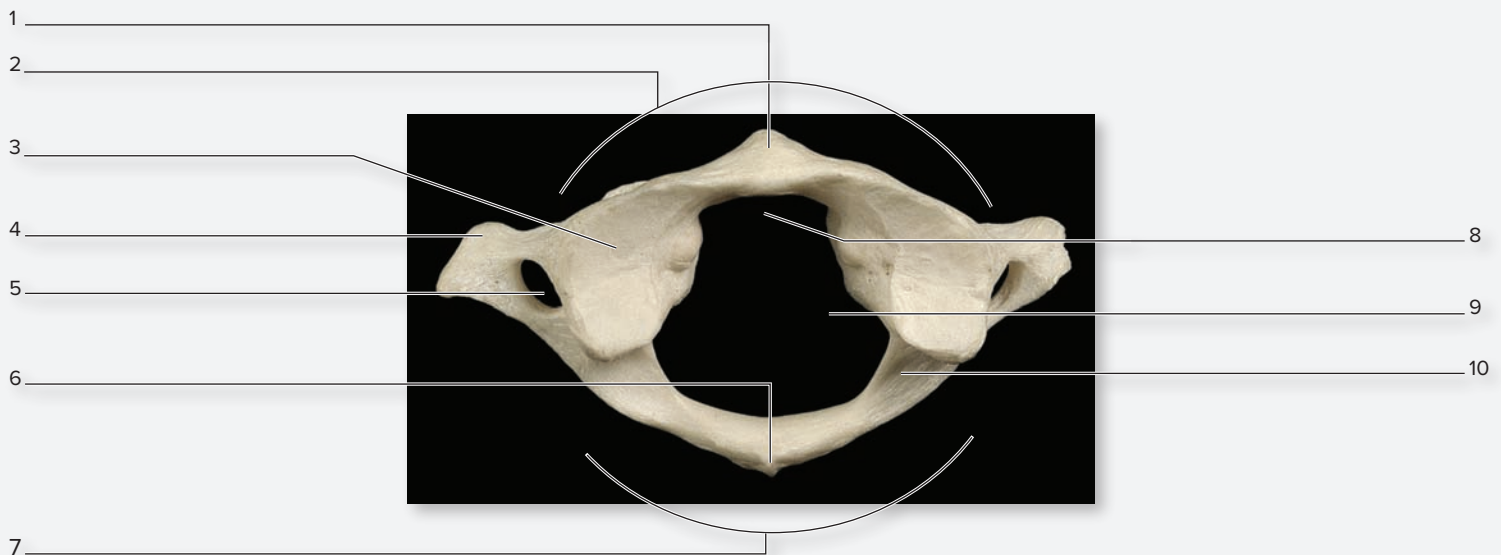
**Concept Connection**

**The Atlas (C<sub>1</sub>) and Axis (C<sub>2</sub>)**

The Greek Titan, Atlas, held up the heavens on his shoulders. The first cervical vertebra is named the **atlas** because it holds up the head in much the same way. The second cervical vertebra is called the **axis** because it forms an axis of rotation for the first cervical vertebra to rotate about. Both of these vertebrae are specialized to allow for extensive flexion, extension, and rotational movements of the neck. While observing the special modifications of the atlas and axis, try to visualize how these modifications allow extensive movement of the head and neck.

**EXERCISE 8.8B: The Atlas (C<sub>1</sub>)**

1. Obtain an atlas (C<sub>1</sub>) and an axis (C<sub>2</sub>).
2. Notice that the atlas is missing a body (**figure 8.17**). During development, the tissue that would normally become the body of the atlas fuses with the body of the axis, forming the **dens** (odontoid process) of the axis. This modification allows the atlas to rotate around the axis.
3. Instead of laminae and pedicles, the atlas has an **anterior arch** and **posterior arch**. Notice the **articular facet for the dens** on the inner surface of the anterior arch. Also note that instead of a spinous process there is a smaller **posterior tubercle** on the posterior arch.
4. Observe the **superior articular facets** of the atlas. These facets are oriented horizontally in the atlas, rather than vertically as with the other vertebrae. These facets articulate with the **occipital condyles**. Observe the occipital bone and atlas on an articulated skeleton to see how these structures fit together to form the **atlando-occipital joint**. This joint allows flexion and extension movements of the neck—as when nodding the head to indicate “yes.”
5. Identify the structures listed in figure 8.17 on an atlas (C<sub>1</sub> vertebra), using table 8.4 and the textbook as guides. Then label them in figure 8.17.



**Figure 8.17** The Atlas (C<sub>1</sub>). Superior view. Use the terms listed to fill in the numbered labels in the figure.

- |  |   |   |
|--|---|---|
| <input type="checkbox"/> anterior arch               | <input type="checkbox"/> posterior arch           | <input type="checkbox"/> transverse foramen |
| <input type="checkbox"/> anterior tubercle           | <input type="checkbox"/> posterior tubercle       | <input type="checkbox"/> transverse process |
| <input type="checkbox"/> articular facet for dens    | <input type="checkbox"/> superior articular facet | <input type="checkbox"/> vertebral foramen  |
| <input type="checkbox"/> groove for vertebral artery |   |   |



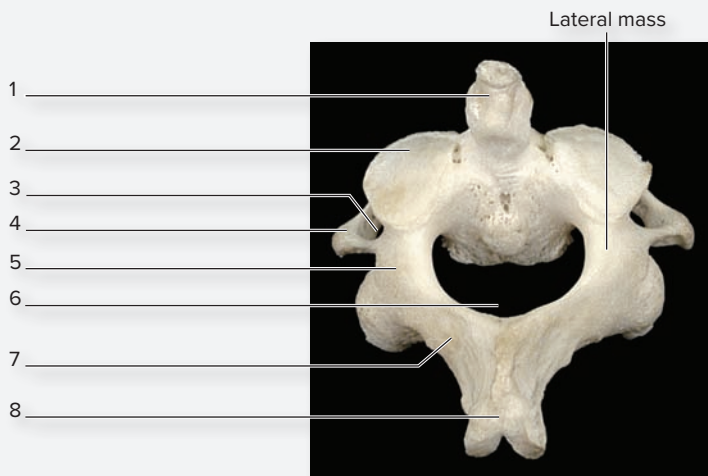
(continued from previous page)

**EXERCISE 8.8C: The Axis (C<sub>2</sub>)**

1. Obtain an atlas (C<sub>1</sub>) and an axis (C<sub>2</sub>).
2. The **axis** (**figure 8.18**) is more similar to a typical cervical vertebra than the atlas. However, it has an extra appendage that no other vertebra has. This appendage/process is the **dens**, or **odontoid process** (*odont*, tooth). Where did this process come from (developmentally)? \_\_\_\_\_
3. Place the atlas upon the axis and observe their articulation with each other to form the **atlantoaxial joint**. This joint allows lateral rotation of the neck—as when turning the head from side to side to indicate “no.” Holding the atlas (C<sub>1</sub>) in place, rotate the axis (C<sub>2</sub>) around the dens of the atlas to observe this movement.
4. Similar to the atlas (C<sub>1</sub>), the superior and inferior articular processes of the axis (C<sub>2</sub>) lie in a horizontal plane. In addition, the axis (C<sub>2</sub>) has a large bony surface where the laminae and pedicles come together called the **lateral mass**. The transverse processes connect to the lateral mass.
5. Identify the structures listed in figure 8.18 on an axis (C<sub>2</sub> vertebra), using table 8.4 and the textbook as guides. Then label them in figure 8.18.

**WHAT DO YOU THINK?**

- 3 How do the superior and inferior articular processes of the atlas differ from the same processes on a “typical” vertebra, and how does this difference contribute to the special movement allowed at the atlanto-occipital and atlantoaxial joints?

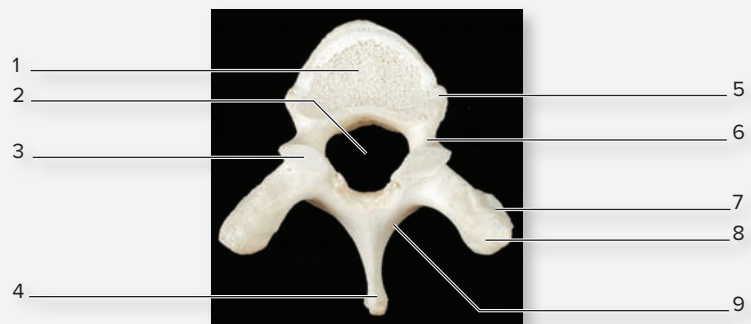


**Figure 8.18** The Axis (C<sub>2</sub>). Superior view. Use the terms listed to fill in the numbered labels in the figure.

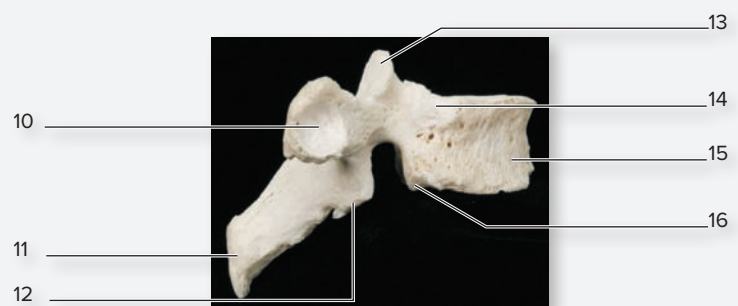- |  |   |
|--|---|
| <input type="checkbox"/> dens (odontoid process) | <input type="checkbox"/> superior articular process |
| <input type="checkbox"/> lamina                  | <input type="checkbox"/> transverse foramen         |
| <input type="checkbox"/> pedicle                 | <input type="checkbox"/> transverse process         |
| <input type="checkbox"/> spinous process         | <input type="checkbox"/> vertebral (spinal) foramen |

**EXERCISE 8.8D: Thoracic Vertebrae**

1. Obtain a thoracic vertebra (**figure 8.19**). Thoracic vertebrae are the only vertebrae that articulate with the ribs. Thus, these vertebrae have special articular surfaces (facets) in locations where the ribs and vertebrae meet and form joints.
2. Observe the thoracic vertebra from a superior view. Thoracic vertebrae typically have a heart-shaped body (medium in size), a round vertebral foramen, a spinous process that projects inferiorly, and superior and inferior articular processes with surfaces that lie in the frontal plane.
3. Look at the relationship between the ribs and vertebrae on an articulated skeleton. Notice that the **tubercle** of a rib articulates with the transverse process of a thoracic vertebra. Notice also that the head of the rib articulates at the junction between two vertebral bodies. Thus, it articulates with the **inferior costal facet** of the vertebra superior to it and the **superior costal facet** of the vertebra inferior to it.
4. Identify the structures listed in figure 8.19 on a thoracic vertebra, using table 8.4 and the textbook as guides. Then label them in figure 8.19.



(a) Superior view



(b) Lateral view

**Figure 8.19** Thoracic Vertebra. Use the terms listed to fill in the numbered labels in the figure. Some answers may be used more than once.

- |   |   |
|---|---|
| <input type="checkbox"/> body                       | <input type="checkbox"/> spinous process            |
| <input type="checkbox"/> costal demifacet           | <input type="checkbox"/> superior articular process |
| <input type="checkbox"/> costal facet               | <input type="checkbox"/> superior costal facet      |
| <input type="checkbox"/> inferior articular process | <input type="checkbox"/> transverse process         |
| <input type="checkbox"/> lamina                     | <input type="checkbox"/> vertebral (spinal) foramen |
| <input type="checkbox"/> pedicle                    |   |

**EXERCISE 8.8E: Lumbar Vertebrae**

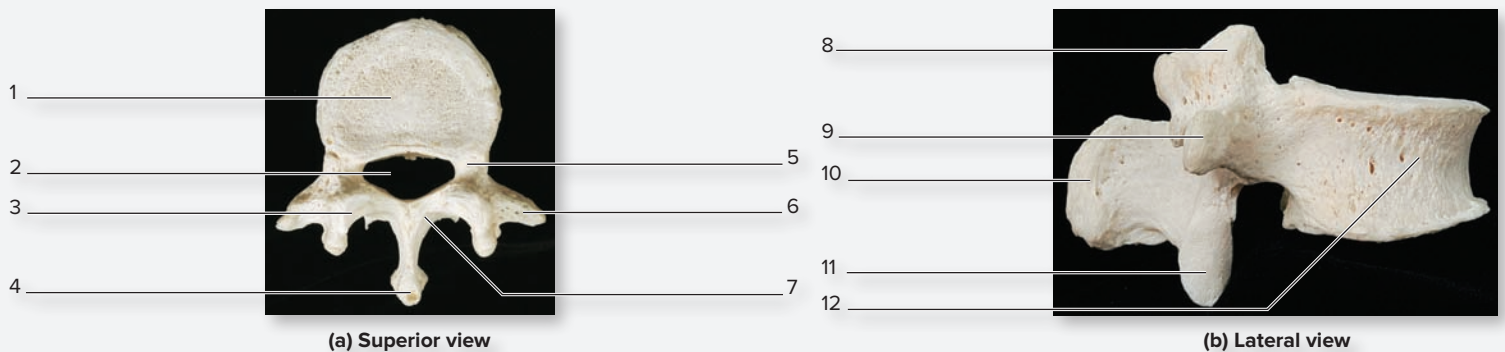
1. Obtain a lumbar vertebra (**figure 8.20**). Lumbar vertebrae have very large, round or oval bodies, small vertebral foramina, a short and blunt spinous process that projects posteriorly. The superior and inferior articular processes have facets that face medial and lateral, respectively.
2. Identify the structures listed in figure 8.20 on a lumbar vertebra, using table 8.4 and the textbook as guides. Then label them in figure 8.20.

**WHAT DO YOU THINK?**

- 4 Notice that when you put two lumbar vertebrae together, little to no lateral rotation is allowed because of the shape of the articulating bones. Why do you think they are built this way?

**EXERCISE 8.8F: The Sacrum and Coccyx**

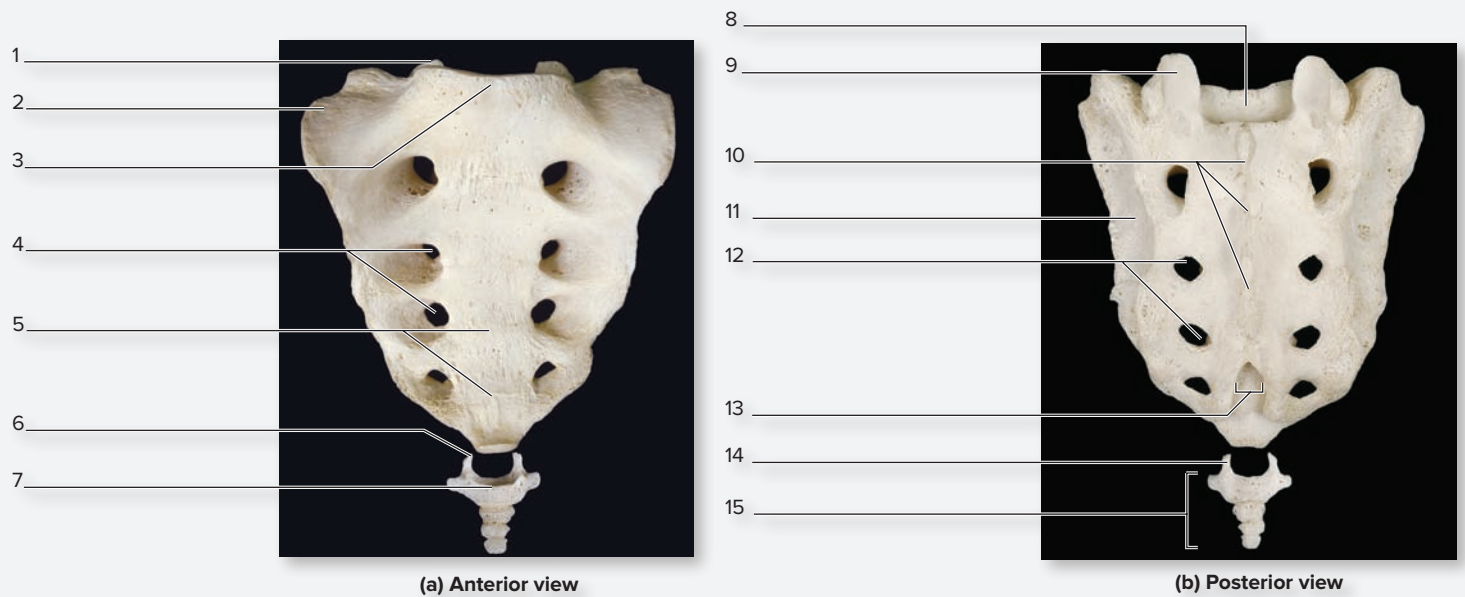
1. Obtain a sacrum and coccyx (**figure 8.21**), or observe them on an articulated skeleton.



**Figure 8.20 Lumbar Vertebra.** Use the terms listed to fill in the numbered labels in the figure. Some answers may be used more than once.

- |   |   |   |
|---|---|---|
| <input type="checkbox"/> body                                   | <input type="checkbox"/> pedicle                                | <input type="checkbox"/> transverse process         |
| <input type="checkbox"/> inferior articular process (and facet) | <input type="checkbox"/> spinous process                        | <input type="checkbox"/> vertebral (spinal) foramen |
| <input type="checkbox"/> lamina                                 | <input type="checkbox"/> superior articular process (and facet) |   |

© McGraw-Hill Education/Photos and Dissections by Christine Eckel



**Figure 8.21 Sacrum and Coccyx.** Use the terms listed to fill in the numbered labels in the figure. Some answers may be used more than once.

- |   |  |   |
|---|--|---|
| <input type="checkbox"/> ala                      | <input type="checkbox"/> median sacral crest       | <input type="checkbox"/> superior articular facet   |
| <input type="checkbox"/> anterior sacral foramina | <input type="checkbox"/> posterior sacral foramina | <input type="checkbox"/> superior articular process |
| <input type="checkbox"/> auricular surface        | <input type="checkbox"/> sacral canal              | <input type="checkbox"/> transverse ridges          |
| <input type="checkbox"/> coccygeal cornu          | <input type="checkbox"/> sacral hiatus             |   |
| <input type="checkbox"/> coccyx                   | <input type="checkbox"/> sacral promontory         |   |

© McGraw-Hill Education/Photos and Dissections by Christine Eckel

(continued on next page)

(continued from previous page)

- The **sacrum** (*sacrum*, sacred bone) forms by the fusion of five primitive vertebrae that subsequently form a single bony structure. As you identify the features of the sacrum, one of your goals is to recognize the parts of a typical vertebra within the sacrum.
- The **coccyx** is usually composed of three to five small bones. The vertebrae have only two prominent structures, the *cornu* (*cornu*, horn) and the *transverse processes*.
- Identify the structures listed in figure 8.21 on a sacrum and coccyx, using table 8.4 and the textbook as guides. Then label them in figure 8.21.

## The Thoracic Cage

The thoracic cage consists of the sternum, ribs, and thoracic vertebrae. Its main function is to protect vital organs such as the heart and lungs. However, the bones of the thoracic cage also serve as important attach-

ment sites for muscles involved with respiratory movements and muscles involved with movements of the back, chest, and neck. **Table 8.5** summarizes the key features of the sternum and ribs. Refer to Table 8.4 for descriptions of the features of the thoracic vertebrae, which articulate with the ribs.

Table 8.5 The Axial Skeleton: Sternum and Ribs		
Bone	Bone Feature	Description and Related Structures of Importance
<b>STERNUM</b>		
<i>Manubrium</i>	Clavicular notch Suprasternal notch Notch for rib 1 Sternal angle	Point of articulation with the clavicle. Depression at the superior border. Location of articulation with costal cartilage of rib 1. Joint between the manubrium and the body; point of articulation with the costal cartilage of rib 2.
<i>Body</i>	Notches for ribs 2–7 Xiphisternal joint	Point of articulation for the costal cartilages of ribs 2–7. The notch for rib 2 is a partial notch. Joint between the body and the xiphoid; point of articulation with the superior part of the costal cartilage of rib 7.
<i>Xiphoid</i>	Partial notch for rib 7	Point of articulation for the inferior part of the costal cartilage of rib 7.
<b>RIBS</b>		
<i>Typical Rib</i>	Head Superior articular facet  Inferior articular facet  Shaft Neck Tubercle  Angle Costal groove Cup	The part of a rib that articulates with the bodies of the thoracic vertebrae. A facet on the head of a rib that articulates with the inferior costal facet on the body of the vertebra that lies one level above it (i.e., superior articular facet of rib 6 with T <sub>5</sub> ). A facet on the head of a rib that articulates with the superior costal facet on the body of the numerically equivalent thoracic vertebra (i.e., inferior articular facet of rib 6 to T <sub>6</sub> ). The main part (body) of a rib, which begins at the angle of the rib and projects anteriorly. A narrow region where the head meets the tubercle of the rib. A projection at the junction between the shaft and neck; contains a facet for articulation with the transverse process of a thoracic vertebra. The location where the rib curves anteriorly. A groove on the inferior, deep border of the shaft; contains the intercostal artery, vein, and nerve. The point of articulation for a costal cartilage.
<i>First Rib</i>	Scalene tubercle Groove for subclavian artery Groove for subclavian vein Articular facet	Attachment for the anterior scalene muscle. A depression indicating the location where the subclavian artery passes out of the thoracic cavity. A depression indicating the location where the subclavian vein passes into the thoracic cavity. A singular facet on the head of the rib (a typical rib has two facets).
<i>Second Rib</i>	All markings of a typical rib	Unique features of rib 2 are a rough tuberosity and a shallow costal groove.
<i>11th and 12th Ribs</i>	Articular facet Tubercle Neck	A singular facet on the head of the rib (a typical rib has two facets). Absent. Absent.

### WHAT DO YOU THINK?

- What part of the vertebral column is removed when a laminectomy is performed? For what purpose(s) do you think a surgeon would perform this procedure?

**EXERCISE 8.9 The Sternum**

1. Observe the thoracic cage on an articulated skeleton and locate the sternum (**figure 8.22**). The sternum has three sections: the **manubrium**, the **body**, and the **xiphoid process** (*xiphos*, sword). The depression on the superior part of the manubrium is the **suprasternal notch**.
2. Palpate the sternal notch on your own body. Keeping your fingers on the manubrium, move your fingers inferiorly until a rough ridge is palpated. This is the **sternal angle**. The

sternal angle is located where the manubrium meets the body of the sternum. It is an important clinical landmark, because this is where the second rib articulates with the sternum.

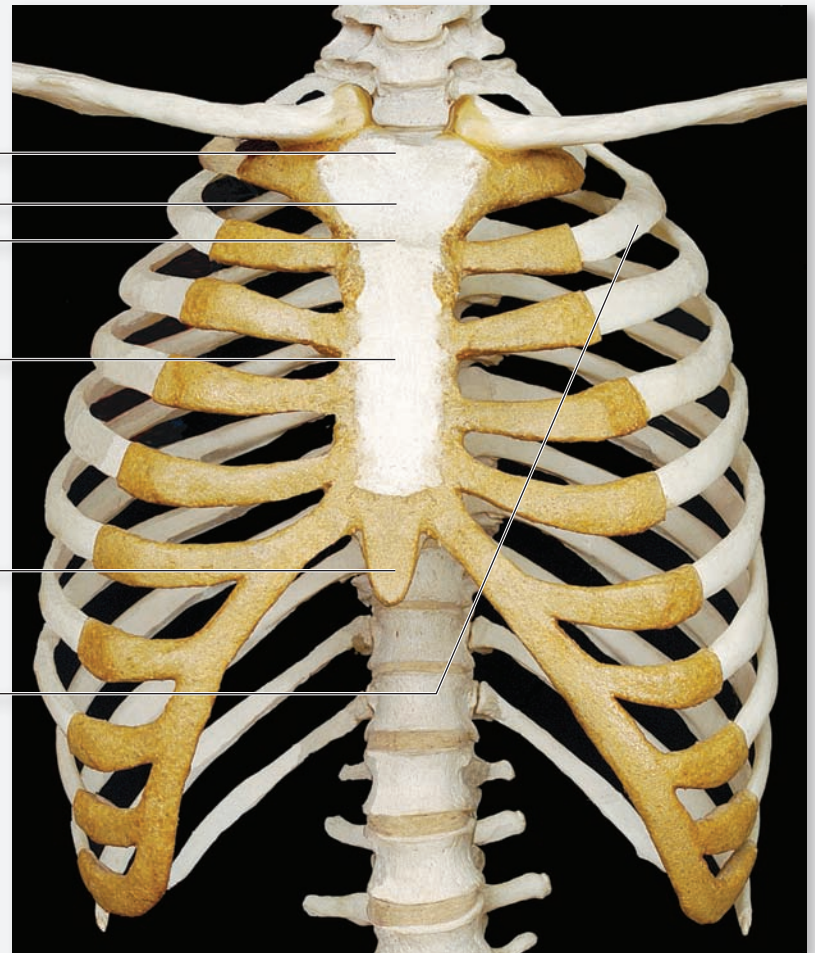
3. Identify the structures listed in figure 8.22 on a sternum, using table 8.5 and the textbook as guides. Then label them in figure 8.22.

**Figure 8.22 The Sternum.** Anterior view. Use the terms listed to fill in the numbered labels in the figure.

- body of sternum 1
- manubrium 2
- second rib 3
- sternal angle
- suprasternal notch
- xiphoid process 4

© McGraw-Hill Education/  
Photo and Dissection by  
Christine Eckel

- 5
- 6

**EXERCISE 8.10 The Ribs****EXERCISE 8.10A: Typical Ribs**

1. There are twelve pairs of **ribs**, one pair for each thoracic vertebra. Obtain a typical rib (any rib other than ribs 1, 2, 11, or 12) (**figure 8.23**).
2. While observing the features of a typical rib, pay particular attention to the surfaces of the rib that articulate with the thoracic vertebrae.
3. Observe the articulations between the ribs and the thoracic vertebrae on an articulated skeleton. Review the unique features of thoracic vertebrae that allow them to form articulations with the ribs.

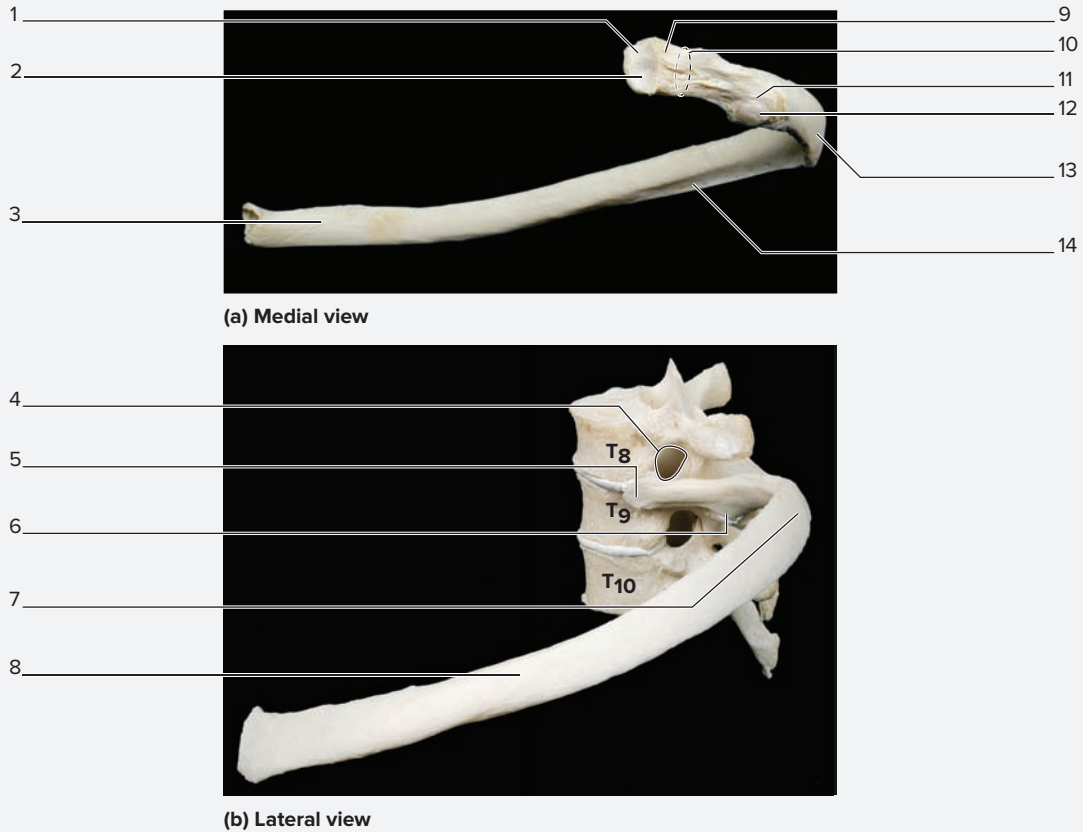
4. Identify the structures listed in figure 8.23 on a typical rib, using table 8.5 and the textbook as guides. Then label them in figure 8.23.

 **WHAT DO YOU THINK?**

- 6 Needles inserted into the thoracic cavity must always be placed along the superior border of a rib so as not to injure important structures. What important structures could be damaged by insertion of a needle too close to the inferior border of a rib? (Hint: Refer to table 8.5.)

(continued on next page)

(continued from previous page)



**Figure 8.23 A Typical Rib.** (a) Medial view; (b) lateral view of the 9th rib articulated with vertebrae  $T_8 - T_{10}$ . Use the terms listed to fill in the numbered labels in the figure. Some answers may be used more than once.

- |   |   |   |                                   |
|---|---|---|-----------------------------------|
| <input type="checkbox"/> angle                                  | <input type="checkbox"/> head                     | <input type="checkbox"/> neck                     | <input type="checkbox"/> tubercle |
| <input type="checkbox"/> articular facet for transverse process | <input type="checkbox"/> inferior articular facet | <input type="checkbox"/> shaft                    |                                   |
| <input type="checkbox"/> costal groove                          | <input type="checkbox"/> intervertebral foramen   | <input type="checkbox"/> superior articular facet |                                   |

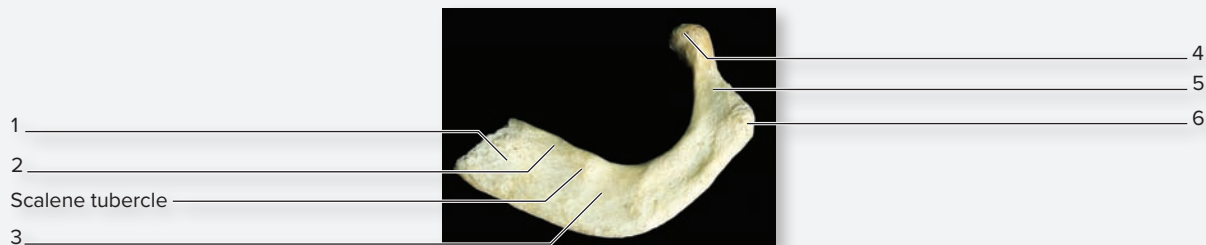
© McGraw-Hill Education/Photos and Dissections by Christine Eckel

**EXERCISE 8.10B: The First Rib**

1. Obtain a first rib (**figure 8.24**). Notice how it differs from a typical rib in size and shape.
2. The first rib is unusual in that it does not have all the features of the remaining 11 ribs (notable absence of an **angle**). It also has additional features such as the **scalene tubercle**, which is an attachment point for the anterior scalene muscle, a muscle that assists with elevation of the ribs during inhalation. On either side of the scalene tubercle you will find grooves for

the passage of the subclavian artery and vein. These vessels convey blood between the thoracic cavity and the upper limb.

3. Identify the structures listed in figure 8.24 on the first rib, using table 8.5 and the textbook as guides. Then label them in figure 8.24.
4. *Optional Activity:* **AP|R Skeletal System**—Visit the Quiz area to test yourself on the bones of the axial skeleton and their prominent features.



**Figure 8.24 The First Rib.** Superior view. Use the terms listed to fill in the numbered labels in the figure.

- |   |                               |                                   |
|---|-------------------------------|-----------------------------------|
| <input type="checkbox"/> groove for subclavian artery | <input type="checkbox"/> head | <input type="checkbox"/> shaft    |
| <input type="checkbox"/> groove for subclavian vein   | <input type="checkbox"/> neck | <input type="checkbox"/> tubercle |

© Christine Eckel

# Chapter 8: The Skeletal System: Axial Skeleton

Name: \_\_\_\_\_

Date: \_\_\_\_\_ Section: \_\_\_\_\_

## POST-LABORATORY WORKSHEET

The 1 corresponds to the Learning Objective listed in the chapter opener outline.

### Do You Know the Basics?

#### Exercise 8.1: Anterior View of the Skull

1. Which of the following bone(s) is/are visible from the anterior view of the skull? (Check all that apply.) 1  
\_\_\_\_ a. ethmoid bone    \_\_\_\_ b. frontal bone    \_\_\_\_ c. occipital bone    \_\_\_\_ d. parietal bone    \_\_\_\_ e. sphenoid bone
2. Which of the following skull bones form the orbit of the eye? (Check all that apply.) 2  
\_\_\_\_ a. ethmoid bone    \_\_\_\_ b. frontal bone    \_\_\_\_ c. lacrimal bone    \_\_\_\_ d. maxilla    \_\_\_\_ e. nasal bone  
\_\_\_\_ f. zygomatic bone
3. The perpendicular plate of the ethmoid bone and the vomer form the nasal septum. \_\_\_\_\_ (True/False) 3
4. The projection of the mandible that forms the anterior part of the chin is known as the \_\_\_\_\_. (Circle one.) 4  
a. alveolar process    b. angle    c. body    d. mental foramen    e. mental protuberance

#### Exercise 8.2: Additional Views of the Skull

5. Match the bone marking listed in column A with the bone it is associated with, listed in column B. Some answers in column B may be used more than once. 5

##### Column A

- \_\_\_\_ 1. foramen ovale
- \_\_\_\_ 2. mastoid process
- \_\_\_\_ 3. jugular foramen
- \_\_\_\_ 4. styloid process
- \_\_\_\_ 5. mental foramen
- \_\_\_\_ 6. foramen spinosum

##### Column B

- a. mandible
- b. occipital bone
- c. sphenoid bone
- d. temporal bone

6. The sagittal suture joins the two parietal bones. \_\_\_\_\_ (True/False) 5
7. The zygomatic arch is composed of which of the following? (Check all that apply.) 6  
\_\_\_\_ a. frontal process of the zygomatic bone    \_\_\_\_ d. temporal process of the zygomatic bone  
\_\_\_\_ b. mental foramen of the mandible    \_\_\_\_ e. zygomatic process of the temporal bone  
\_\_\_\_ c. palatine process of the maxilla

#### Exercise 8.3: Superior View of the Cranial Floor

8. a. What does the term *petrous* mean? 7 \_\_\_\_\_  
b. Why is this term used to describe the petrous part of the temporal bone?  
\_\_\_\_\_  
\_\_\_\_\_

9. Match the bony landmark listed in column A with the cranial fossa in which the landmark can be found, listed in column B. Some answers in column B may be used more than once. 8

##### Column A

- \_\_\_\_ 1. internal acoustic meatus
- \_\_\_\_ 2. sella turcica
- \_\_\_\_ 3. lesser wing of the sphenoid bone
- \_\_\_\_ 4. foramen ovale
- \_\_\_\_ 5. crista galli

##### Column B

- a. anterior cranial fossa
- b. middle cranial fossa
- c. posterior cranial fossa

10. a. What does the term *lacero* mean? **8** \_\_\_\_\_  
 b. Why is the term *lacero* used to describe the foramen lacerum? \_\_\_\_\_  
 \_\_\_\_\_  
 \_\_\_\_\_  
 c. What is unique about the foramen lacerum (as compared to other cranial foramina)? \_\_\_\_\_  
 \_\_\_\_\_  
 \_\_\_\_\_

**Exercise 8.4: Bones Associated with the Skull**

11. The only bone of the axial skeleton that does not articulate with any other bone is the \_\_\_\_\_. **9**

**Exercise 8.5: The Fetal Skull**

12. a. What is a fontanel? **10** \_\_\_\_\_  
 b. By what age do most of the fontanel completely close? \_\_\_\_\_

**Exercise 8.6: Vertebral Column Regions and Curvatures**

13. The primary curvatures of the vertebral column are the *cervical* and *lumbar* curvatures, whereas the secondary curvatures are the *thoracic* and *sacral* curvatures. \_\_\_\_\_ (True/False) **11**

**Exercise 8.7: Structure of a Typical Vertebra**

14. Which of the following compose the vertebral arch? (Check all that apply.) **12**  
 \_\_\_\_\_ a. inferior articular process    \_\_\_\_\_ b. lamina    \_\_\_\_\_ c. pedicle    \_\_\_\_\_ d. spinous process  
 \_\_\_\_\_ e. transverse process

**Exercise 8.8: Characteristics of Individual Vertebrae**

15. a. What foramen is present in cervical vertebrae, but is not present in other vertebrae? **13** \_\_\_\_\_  
 b. What structure runs through this foramen in a living human? \_\_\_\_\_
16. The superior and inferior articular processes of the atlas are oriented along a vertical plane, whereas the inferior articular processes of “typical” vertebrae are oriented along a horizontal plane. \_\_\_\_\_ (True/False) **14**
17. The dens (odontoid process) is a projection of the \_\_\_\_\_ (atlas/axis). The dens arose from the body of the \_\_\_\_\_ (atlas/axis). **14**
18. Identify the locations on a thoracic vertebra where the ribs articulate. (Check all that apply.) **15**  
 \_\_\_\_\_ a. inferior costal facets    \_\_\_\_\_ b. pedicle    \_\_\_\_\_ c. spinous process    \_\_\_\_\_ d. superior costal facets  
 \_\_\_\_\_ e. transverse process
19. The anterior and posterior sacral foramina are the equivalent of the intervertebral foramina in other regions of the vertebral column. \_\_\_\_\_ (True/False) **16**

**Exercise 8.9: The Sternum**

20. Identify the bones that compose the thoracic cage. (Check all that apply.) **17**  
 \_\_\_\_\_ a. cervical vertebrae    \_\_\_\_\_ b. clavicle    \_\_\_\_\_ c. ribs    \_\_\_\_\_ d. sternum    \_\_\_\_\_ e. thoracic vertebrae
21. The sternal angle is the point of articulation between which two structures? (Circle one.) **17**  
 a. body and manubrium of the sternum  
 b. body and xiphoid of the sternum  
 c. body of the sternum and second rib  
 d. manubrium of the sternum and clavicle  
 e. manubrium and xiphoid of the sternum
22. The clinical significance of the sternal angle is that it serves as the point of articulation of which rib? (Circle one.) **18**  
 a. first    b. second    c. third    d. fourth    e. fifth

**Exercise 8.10: The Ribs**

23. Match the description listed in column A with the features of the typical rib, listed in column B. **19**

**Column A**

- \_\_\_\_ 1. a projection between the shaft and neck
- \_\_\_\_ 2. the main part (body) of a rib
- \_\_\_\_ 3. a depression that contains the intercostal artery, vein, and nerve
- \_\_\_\_ 4. a narrow region where the head meets the tubercle

**Column B**

- a. costal groove
- b. neck
- c. shaft
- d. tubercle

24. The \_\_\_\_\_ of a rib articulates with the bodies of the thoracic vertebrae. **20**

**Can You Apply What You've Learned?**

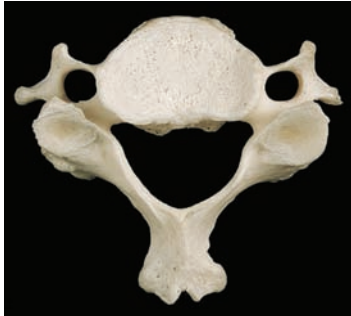25. What is a functional consequence of the shape (and arrangement) of the superior and inferior articular processes of the lumbar vertebrae? (Hint: Put two of them together and see what movement is, or is not, allowed.) \_\_\_\_\_

26. The optic nerve extends from the eye toward the brain by traveling through the optic foramen. The optic foramen is a hole in what bone? \_\_\_\_\_

27. Explain the difference between the vertebral foramen and the intervertebral foramen. \_\_\_\_\_

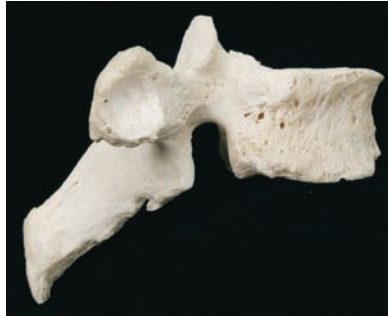28. Examine the skeleton and the different types of vertebrae to answer these questions.

a. Circle the features unique to cervical, thoracic, and lumbar vertebrae on the photo of each type of vertebra. Then describe and/or list these feature(s) in the numbered space(s) below each figure.



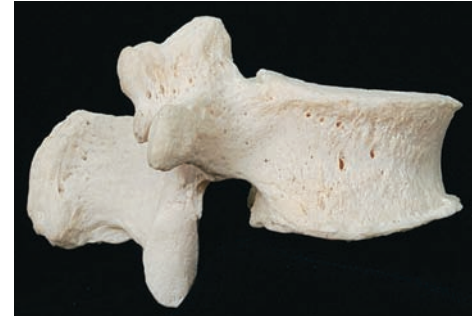Cervical

- 1. \_\_\_\_\_
- 2. \_\_\_\_\_
- 3. \_\_\_\_\_



Thoracic

- 1. \_\_\_\_\_
- 2. \_\_\_\_\_
- 3. \_\_\_\_\_



Lumbar

- 1. \_\_\_\_\_
- 2. \_\_\_\_\_
- 3. \_\_\_\_\_

© McGraw-Hill Education/Photos and Dissections by Christine Eckel

29. Identify the region of the vertebral column where the intervertebral foramina (or their equivalent) project anteriorly and posteriorly to allow for the exit of spinal nerves. (Circle one.)

- a. cervical
- b. coccygeal
- c. lumbar
- d. thoracic
- e. sacral

30. a. The cervical vertebra that does not have a body or a spinous process is the \_\_\_\_\_.

b. The cervical vertebra that does not have a bifid spinous process is \_\_\_\_\_.

c. The dens (odontoid process) is a component of this cervical vertebra: \_\_\_\_\_.



31. a. Does the atlanto-occipital joint allow the head movement that indicates “yes” or “no”? \_\_\_\_\_  
b. Does the atlantoaxial joint allow the head movement that indicates “yes” or “no”? \_\_\_\_\_
32. What bone(s) does the sacrum articulate with superiorly? \_\_\_\_\_ inferiorly? \_\_\_\_\_  
laterally? \_\_\_\_\_

33. Describe the two points of articulation between a rib and the thoracic vertebrae.

---

---

34. a. The manubrium of the sternum articulates with rib \_\_\_\_\_ and the body of the sternum articulates with ribs \_\_\_\_\_ to \_\_\_\_\_. Does the xiphoid process articulate with the ribs? \_\_\_\_\_
- b. True ribs articulate with the sternum by individual costal cartilages. The true ribs are \_\_\_\_\_ to \_\_\_\_\_. The rest (ribs \_\_\_\_\_ to \_\_\_\_\_) are false ribs. The two false ribs that are also floating ribs are \_\_\_\_\_ and \_\_\_\_\_.

**Can You Synthesize What You've Learned?**

35. Why do the fontanelles persist until well after the birth of an infant?

---

---

---

36. How might the bifid spinous processes of cervical vertebrae affect anterior-posterior movement in the cervical region of the vertebral column?

---

---

37. How do the superior and inferior articular processes of the atlas differ from the same processes on a “typical” vertebra? How does this difference contribute to the special movement allowed at the atlanto-occipital and atlantoaxial joints?

---

---

---

38. Notice that when two lumbar vertebrae are put together, little to no lateral rotation is allowed because of the shape of the articulating bones. Why do you think they interact in this manner?

---

---

39. What part of the vertebral column is removed when a laminectomy is performed? \_\_\_\_\_

40. Needles inserted into the thoracic cavity must always be placed along the superior border of a rib so as not to injure important structures. What important structures could be damaged by insertion of a needle too close to the inferior border of a rib? (Hint: Refer to table 8.5.)

---

---

# The Skeletal System: Appendicular Skeleton

# 9

## INTRODUCTION

The appendicular skeleton is composed of bones that attach to the axial skeleton. The term **appendicular** comes from the term *appendage*. A dictionary might define an appendage as *something that is added or attached to an item that is larger or more important, as an adjunct*. While the appendages of the human body may be described as simply “added” or “adjunct” structures, most would consider arms and legs to be essential. The exercises in chapter 8 covered the bones that constitute the main structural support of the body: the bones of the axial skeleton. The exercises in this chapter cover the bones composing the **pectoral girdle** and the **pelvic girdle**, which act as attachment points for muscles and ligaments that anchor the upper and lower limbs to the axial skeleton. Exercises also cover the bones of the **upper limb** and the **lower limb**, which act as attachment points for muscles and ligaments that allow movement and dexterity of the limbs. Successfully completing the exercises in this chapter will make learning muscles of the body much easier.

For example, bony features such as tuberosities, trochanters, and tubercles exist because of the pulling action of muscles that attach to them and stress them during development. If there was no sternocleidomastoid muscle pulling on the mastoid process of the temporal bone, the mastoid process would not exist! While observing the features of the bones,

## OUTLINE AND LEARNING OBJECTIVES

### Gross Anatomy 159

#### The Pectoral Girdle 159

##### EXERCISE 9.1: BONES OF THE PECTORAL GIRDLE 160

- 1 Identify the bony landmarks of the pectoral girdle
- 2 List the two bones that compose the pectoral girdle
- 3 Identify the joints of the pectoral girdle

#### The Upper Limb 162

##### EXERCISE 9.2: BONES OF THE UPPER LIMB 164

- 4 Identify the landmarks of upper limb bones and relate them to muscular attachments
- 5 Associate the shapes of carpal bones with their respective names

##### EXERCISE 9.3: SURFACE ANATOMY REVIEW—PECTORAL GIRDLE AND UPPER LIMB 170

- 6 Palpate the prominent bony structures of the pectoral girdle and upper limb

#### The Pelvic Girdle 171

##### EXERCISE 9.4: BONES OF THE PELVIC GIRDLE 172

- 7 Identify the bony landmarks of the pelvic girdle
- 8 List the three bones that compose the pelvic girdle

#### The Lower Limb 175

##### EXERCISE 9.5: BONES OF THE LOWER LIMB 177

- 9 Identify the landmarks of lower limb bones and relate them to muscular attachments
- 10 Associate the shapes of tarsal bones with their respective names
- 11 Compare and contrast the structure and function of tarsal and carpal bones

##### EXERCISE 9.6: SURFACE ANATOMY REVIEW—PELVIC GIRDLE AND LOWER LIMB 184

- 12 Palpate the prominent bony structures of the pelvic girdle and lower limb

remember that all bony features tell a story about the development and history of the entire musculoskeletal system.

While making observations of the different bones and their bony features, refer to the tables within the chapter for derivatives of the names of the features. A solid understanding of word origins facilitates the process of associating structure with its name. For example, the *conoid tubercle* of the clavicle gets its name from its conical shape (*konoeides*, cone-shaped). The *coracoid process* of the scapula is named for its resemblance to a crow's beak (*karakodes*, like a crow's beak). The two names look very similar and can be easily confused if one does not pay close attention to their meanings. The exercises in this chapter

involve studying the bones that compose the appendicular skeleton on an articulated human skeleton, on disarticulated bones of the human skeleton, and on bone models. The goal of these exercises is to identify the major bones, identify features of each bone, and associate the observed structures with their functions. Use the textbook as a reference for these exercises.

#### List of Reference Tables

Table 9.1	The Appendicular Skeleton: Pectoral Girdle	p. 159
Table 9.2	The Appendicular Skeleton: Upper Limb	p. 162
Table 9.3	The Appendicular Skeleton: Pelvic Girdle	p. 171
Table 9.4	The Appendicular Skeleton: Lower Limb	p. 175

### Learning Strategy



One way to take a step-by-step approach to learning the bones of the appendicular skeleton is to first learn to identify the entire bone (e.g., “femur”). Next, learn to identify the major

regions of the bone (e.g., head, shaft, and neck for typical long bones). Finally, begin a more detailed study of each bone by focusing on the finer features such as “trochanters,” “tuberosities,” and the like.

# Chapter 9: The Skeletal System: Appendicular Skeleton

Name: \_\_\_\_\_

Date: \_\_\_\_\_ Section: \_\_\_\_\_

## PRE-LABORATORY WORKSHEET

These Pre-laboratory Worksheet questions may be assigned by instructors through their **connect** course.

1. The appendicular skeleton is composed of which of the following? (Check all that apply.)

- \_\_\_ a. lower limb bones
- \_\_\_ b. pectoral girdle
- \_\_\_ c. pelvic girdle
- \_\_\_ d. thoracic cage
- \_\_\_ e. upper limb bones

2. Which of the following bones compose the pectoral girdle? (Check all that apply.)

- \_\_\_ a. clavicle
- \_\_\_ b. humerus
- \_\_\_ c. ribs
- \_\_\_ d. scapula
- \_\_\_ e. sternum

3. Which of the following bones composes part of the os coxa of the pelvic girdle? (Check all that apply.)

- \_\_\_ a. femur
- \_\_\_ b. ilium
- \_\_\_ c. ischium
- \_\_\_ d. pubis
- \_\_\_ e. sacrum

4. In the anatomic position, the radius lies \_\_\_\_\_ (medial/lateral) to the ulna.

5. In the anatomic position, the tibia lies \_\_\_\_\_ (medial/lateral) to the fibula.

6. Carpal bones are located in the wrist, whereas the tarsal bones are located in the ankle. \_\_\_\_\_ (True/False)

7. Match the description listed in column A with the appropriate bone listed in column B.

### Column A

- \_\_\_ 1. a bone that has two large tubercles on its proximal end
- \_\_\_ 2. a bone that has two large trochanters on its proximal end
- \_\_\_ 3. a bone that contains the olecranon process
- \_\_\_ 4. bones that form the wrist
- \_\_\_ 5. a sesamoid bone found in the knee
- \_\_\_ 6. the largest bone in the leg

### Column B

- a. carpals
- b. femur
- c. humerus
- d. patella
- e. tibia
- f. ulna

8. The lateral malleolus is a feature of which bone? (Circle one.)

- a. calcaneus
- b. femur
- c. fibula
- d. talus
- e. tibia

**158 Chapter Nine The Skeletal System: Appendicular Skeleton**

**9.** Identify the bone that has both an acromial and a coracoid process. (Circle one.)

- a. clavicle
- b. humerus
- c. radius
- d. scapula
- e. ulna

**10.** The calcaneus is located in the wrist, whereas the pisiform bone is located in the heel. \_\_\_\_\_ (True/False)

## Gross Anatomy

### The Pectoral Girdle

The **pectoral girdle** (*girdle*, a belt) consists of the paired clavicles and scapulae. The function of these bones is to act as the bony support for

muscles that attach the upper limb to the axial skeleton and to attach each upper limb to the axial skeleton by one bony joint, the sternoclavicular joint. **Table 9.1** lists the bones of the pectoral girdle and describes their key features.

Table 9.1		The Appendicular Skeleton: Pectoral Girdle	
Bone	Bony Landmark	Description	Word Origins
<b>Clavicle</b> <i>clavicula, a small key</i>	Acromial end (lateral)	The lateral end of the bone, which is flattened horizontally.	<i>akron-</i> , tip + <i>omos</i> , shoulder
	Conoid tubercle	A small “cone-shaped” tubercle on the lateral, inferior end of the bone.	<i>konoeides</i> , cone-shaped
	Costal tuberosity	A rough impression on the inferior surface of the sternal end of the bone that serves as the attachment point for the costoclavicular ligament.	<i>costa</i> , rib
	Sternal end (medial)	The medial end of the bone, which is triangular in shape.	<i>sternon</i> , chest
<b>Scapula</b> <i>scapula, the shoulder blade</i>	Acromion	The large process at the lateral tip of the scapular spine, which projects laterally and slightly anteriorly.	<i>akron-</i> , tip + <i>omos</i> , shoulder
	Coracoid process	The smaller of the two major scapular processes, which projects anteriorly.	<i>korakodes</i> , like a crow’s beak
	Glenoid fossa	A shallow depression that forms the articulation between the scapula and the humerus.	<i>glenoeides</i> , resembling a socket
	Inferior angle	The angle between the medial and lateral borders.	<i>inferior</i> , lower
	Infraglenoid tubercle	A rough projection at the inferior border of the glenoid fossa; attachment point for the long head of the triceps brachii muscle.	<i>infra-</i> , below + <i>glenoeides</i> , resembling a socket
	Infraspinous fossa	A large depression inferior to the scapular spine; origin for the infraspinatus and teres minor muscles.	<i>infra-</i> , below + <i>spina</i> , spine
	Lateral (axillary) border	The border of the scapula that has the glenoid fossa on its superior part.	<i>axilla</i> , armpit
	Medial (vertebral) border	The longest border of the scapula; contains very few remarkable features.	<i>medialis</i> , middle
	Spine	A long “spiny” process on the posterior surface; attachment point for trapezius and deltoid muscles.	<i>spina</i> , spine
	Subscapular fossa	A large depression on the anterior surface of the bone; origin of the subscapularis muscle.	<i>sub</i> , under + <i>scapula</i> , shoulder blade
	Superior angle	The angle between the superior and medial borders.	<i>superus</i> , above
	Superior border	The border from which the coracoid and acromial processes project.	<i>superus</i> , above
	Supraglenoid tubercle	A rough projection at the superior border of the glenoid fossa; attachment point for the long head of the biceps brachii muscle.	<i>supra-</i> , on the upper side + <i>glenoeides</i> , resembling a socket
	Suprascapular notch	A small deep notch just medial to the coracoid process; the suprascapular nerve, artery, and vein pass through.	<i>supra-</i> , on the upper side + <i>scapula</i> , shoulder blade
Supraspinous fossa	A large depression superior to the scapular spine; origin of the supraspinatus muscle.	<i>supra-</i> , on the upper side + <i>spina</i> , spine	

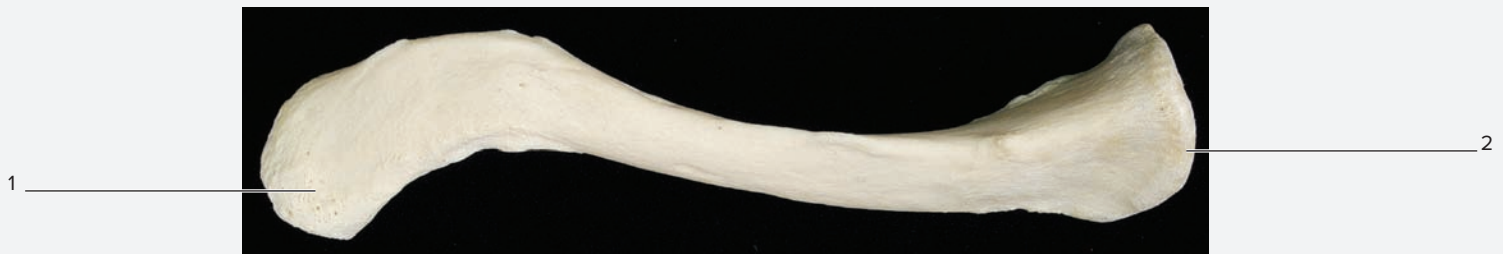**EXERCISE 9.1** Bones of the Pectoral Girdle

**EXERCISE 9.1A: The Clavicle**

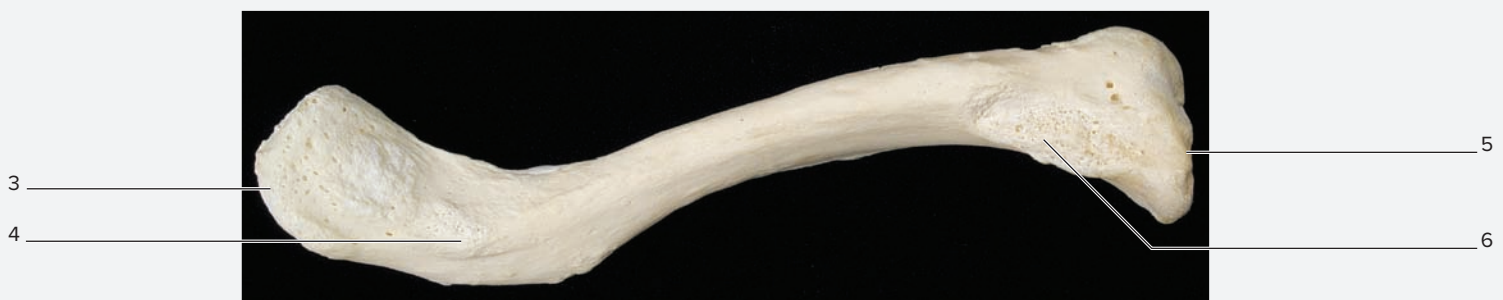1. Obtain a clavicle or observe the clavicle on an articulated skeleton (**figure 9.1**).
2. The **clavicle** forms part of the only articulation between the axial skeleton and the upper limb, at the **sternoclavicular joint**. The clavicle has very few muscular attachments, compared to other bones. Rather than acting as a rigid attachment point for muscles, the clavicle functions more like a strut that pushes the shoulders laterally and keeps them from collapsing anteriorly toward the sternum. The superficial location of the clavicle allows most parts of the bone to be easily palpated.
3. Palpate your own clavicle. While doing this, pay attention to the two ends of the clavicle. Name the bones that articulate with each end of the clavicle.
4. Identify the structures listed in figure 9.1 on the clavicle, using table 9.1 and the textbook as guides. Then label them in figure 9.1.
5. Obtain both a right and a left disarticulated clavicle. What distinguishes a right clavicle from a left clavicle? \_\_\_\_\_  
\_\_\_\_\_  
\_\_\_\_\_

**EXERCISE 9.1B: The Scapula**

1. Obtain a scapula or observe the scapula on an articulated skeleton (**figure 9.2**).
2. The **scapula** (*scapula*, shoulder blade) is a large, irregular bone that is not directly attached to the axial skeleton. Recall that the only location where the bones of the pectoral girdle attach to the axial skeleton is where the sternal end of the clavicle articulates with the manubrium of the sternum at the sternoclavicular joint.
3. Identify the structures listed in figure 9.2 on the scapula, using table 9.1 and the textbook as guides. Then label them in figure 9.2.
4. Obtain both a right and a left disarticulated scapula. What distinguishes a right scapula from a left scapula? \_\_\_\_\_  
\_\_\_\_\_  
\_\_\_\_\_
5. Locate the glenoid fossa. With what structure does this fossa articulate (articulate = form a joint)? \_\_\_\_\_



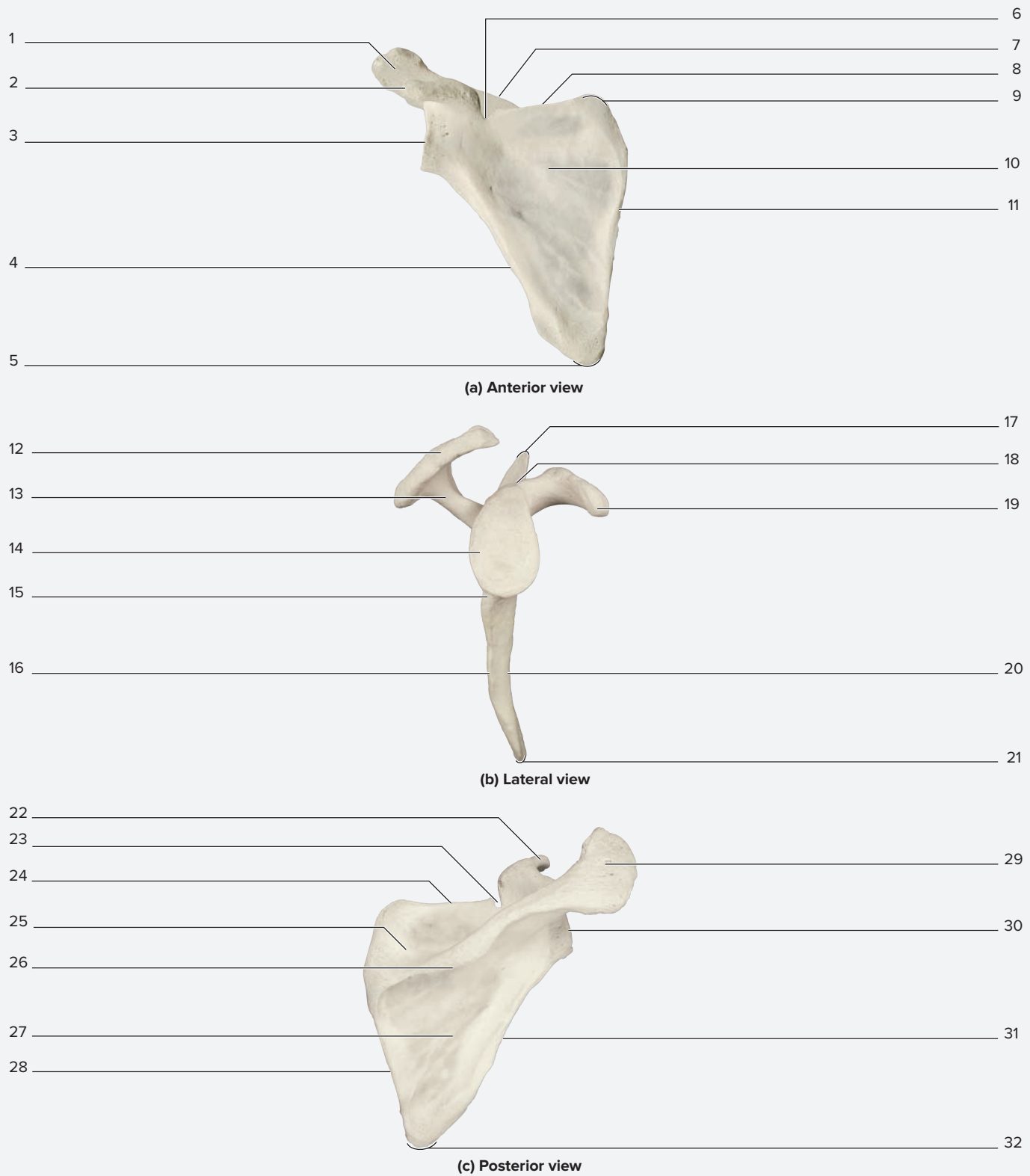
(a) Right clavicle, superior view



(b) Right clavicle, inferior view

**Figure 9.1** The Clavicle. Use the terms listed to fill in the numbered labels in the figure. Some answers may be used more than once.

- |   |   |
|---|---|
| <input type="checkbox"/> acromial end (lateral) | <input type="checkbox"/> costal tuberosity    |
| <input type="checkbox"/> conoid tubercle        | <input type="checkbox"/> sternal end (medial) |




**Figure 9.2 The Right Scapula.** Use the terms listed to fill in the numbered labels in the figure. Some terms may be used more than once.

- |  |  |  |
|--|--|--|
| <input type="checkbox"/> acromion              | <input type="checkbox"/> infraspinous fossa        | <input type="checkbox"/> superior angle        |
| <input type="checkbox"/> coracoid process      | <input type="checkbox"/> lateral (axillary) border | <input type="checkbox"/> superior border       |
| <input type="checkbox"/> glenoid cavity        | <input type="checkbox"/> medial (vertebral) border | <input type="checkbox"/> supraglenoid tubercle |
| <input type="checkbox"/> inferior angle        | <input type="checkbox"/> spine                     | <input type="checkbox"/> suprascapular notch   |
| <input type="checkbox"/> infraglenoid tubercle | <input type="checkbox"/> subscapular fossa         | <input type="checkbox"/> supraspinous fossa    |



(continued from previous page)

6. Obtain a right clavicle and right scapula and articulate them with each other. Sketch the relationship between the clavicle and the scapula in the space provided.
7. What is the name of the joint formed between the clavicle and the scapula? \_\_\_\_\_
8. Palpate this joint on your own upper limb. To do this, begin by palpating the clavicle. Then “walk” your fingers laterally until they reach the tip of the shoulder, where the acromion of the scapula can be palpated. Raise and lower the upper limb while keeping your fingers on the bones to feel the joint between the clavicle and scapula.



## The Upper Limb

The upper limb consists of the humerus, radius, ulna, carpals, metacarpals, and phalanges. Nearly all of the projections on these bones

serve as attachment points for the muscles that move the upper limb. **Table 9.2** lists the bones of the upper limb and describes their key features.

Table 9.2		The Appendicular Skeleton: Upper Limb	
Bone	Bony Landmark	Description	Word Origins
<b>Humerus</b> humerus, shoulder	Anatomical neck	The narrow part between the head and the tubercles; location of the former epiphyseal (growth) plate.	
	Capitulum	The rounded surface (condyle) that articulates with the radius.	<i>caput</i> , head
	Coronoid fossa	A depression for the coronoid process of the ulna.	<i>corona-</i> , crown + <i>eidos</i> , resemblance + <i>fossa</i> , trench
	Deltoid tuberosity	A rough projection on the proximal diaphysis.	<i>delta-</i> , triangle + <i>eidos</i> , resemblance
	Greater tubercle	A large lateral projection on the proximal epiphysis.	<i>tuber</i> , a knob
	Head	A rounded projection on the medial side of the proximal epiphysis; a facet that forms half of the glenohumeral joint.	<i>head</i> , the rounded extremity of a bone
	Intertubercular sulcus (groove)	A groove between the greater and lesser tubercles; sometimes referred to as the bicipital groove.	<i>inter-</i> , between + <i>tuber</i> , knob
	Lateral epicondyle	A rough ridge proximal to the capitulum.	<i>epi-</i> , above + <i>kondylos</i> , knuckle
	Lesser tubercle	A small, rough projection on the anterior side of the proximal epiphysis.	<i>tuber</i> , a knob
	Medial epicondyle	A rough ridge proximal to the trochlea.	<i>epi-</i> , above + <i>kondylos</i> , knuckle
	Olecranon fossa	A depression for the olecranon process of the ulna.	<i>olecranon</i> , the head of the elbow + <i>fossa</i> , trench
	Radial fossa	A depression for the head of the radius.	<i>radius</i> , spoke of a wheel + <i>fossa</i> , trench
	Supracondylar ridges	Sloped ridges (medial and lateral) proximal to the epicondyles.	<i>supra-</i> , on the upper side + <i>kondylos</i> , knuckle
	Surgical neck	The location where the head meets the shaft; the most common site of fracture.	
Trochlea	The rounded surface (condyle) that articulates with the ulna.	<i>trochileia</i> , a pulley	

Table 9.2		The Appendicular Skeleton: Upper Limb (continued)		
Bone	Bony Landmark	Description	Word Origins	
<b>Ulna</b> <i>ulna, elbow</i>	Coronoid process	A projection on the anterior surface of the ulna that articulates with the humerus.	<i>corona-</i> , crown + <i>eidos</i> , resemblance	
	Olecranon	A large projection on the proximal ulna, which forms the point of the “elbow” and serves as an attachment point for the triceps brachii muscle.	<i>olecranon</i> , the head of the elbow	
	Radial notch	A depression on the lateral, proximal surface of the ulna that articulates with the head of the radius.	<i>radius</i> , spoke of a wheel	
	Styloid process	A pointed process on the distal ulna that forms the medial aspect of the wrist.	<i>stylos-</i> , pillar + <i>eidos</i> , resemblance	
	Trochlear notch	A ridge on the middle of the anterior surface of the ulna that separates the two depressions that articulate with the condyles of the humerus.	<i>trochileia</i> , a pulley	
	Tuberosity of ulna	A process on the anterior surface of the proximal ulna that serves as an attachment point for the brachialis muscle.	<i>ulna</i> , elbow	
<b>Radius</b> <i>radius, spoke of a wheel</i>	Head	The disc-shaped proximal end of the radius.		
	Neck	Location where the head of the radius meets the shaft of the bone.		
	Radial tuberosity	A large projection on the medial surface distal to the proximal epiphysis of the bone that serves as an attachment point for the biceps brachii muscle.	<i>radio</i> , ray	
	Styloid process of the radius	A small pointed projection on the distal radius.	<i>stylos-</i> , pillar + <i>eidos</i> , resemblance	
	Ulnar notch	Location where the medial surface of the radius articulates with the distal end of the ulna.		
<b>Carpals</b> <i>carpus, wrist</i>	<i>Proximal row</i>	Capitate	A “head-shaped” bone that lies in the center of the wrist, at the base of the third metacarpal.	<i>caput</i> , head
		Hamate	A “hook-shaped” bone that lies at the base of the fifth metacarpal.	<i>hamus</i> , a hook
		Lunate	A “moon-shaped” bone that articulates with the radius.	<i>luna</i> , moon
		Pisiform	A “pea-shaped” bone on the medial, palmar surface of the wrist.	<i>pisum-</i> , pea + <i>forma</i> , appearance
	<i>Distal row</i>	Scaphoid	A large “boat-shaped” bone that articulates with the radius.	<i>skaphe-</i> , boat + <i>eidos</i> , resemblance
		Trapezium	A “table-shaped” bone that lies at the base of the first metacarpal (base of the thumb).	<i>trapezion</i> , a table
		Trapezoid	A “table-shaped” bone that lies at the base of the second metacarpal.	<i>trapezion-</i> , a table + <i>eidos</i> , resemblance
		Triquetrum	A triangular bone on the medial, proximal aspect of the wrist; articulates with the ulna.	<i>triquetrus</i> , three-cornered
<b>Metacarpals</b> <i>meta-, after + carpus, wrist</i>	Base	The proximal epiphysis of the metacarpal.		
	Body	The diaphysis of the metacarpal.		
	Head	The distal epiphysis of the metacarpal.		
<b>Phalanges</b> <i>II through V</i>	NA	Bones of the fingers and thumb.	<i>phalanx</i> , line of soldiers	
	Proximal	The phalanx closest to the palm of the hand.	<i>proximus</i> , nearest	
	Middle	The middle phalanx.		
<b>Pollex</b> <i>pollex, thumb</i>	Distal	The small cone-shaped distal bone of the digits.	<i>distalis</i> , away	
	Proximal	The phalanx closest to the palm of the hand.	<i>proximus</i> , nearest	
	Distal	The small cone-shaped distal bone of the thumb.	<i>distalis</i> , away	

**EXERCISE 9.2** Bones of the Upper Limb

**EXERCISE 9.2A: The Humerus**

1. Obtain a **humerus** or observe the humerus on an articulated skeleton (**figure 9.3**). Locate the articulation with the scapula to form the glenohumeral joint. Next, locate the points of articulation with the ulna and radius to form the elbow joint.
2. Identify the structures listed in figure 9.3 on the humerus, using table 9.2 and the textbook as guides. Then label them in figure 9.3.
3. Obtain both a right and a left humerus. What distinguishes a right humerus from a left humerus?

---



---



---

4. What distinguishes the proximal from the distal end of the humerus?

---



---



---

5. What distinguishes the anterior surface of the humerus from the posterior surface?

---

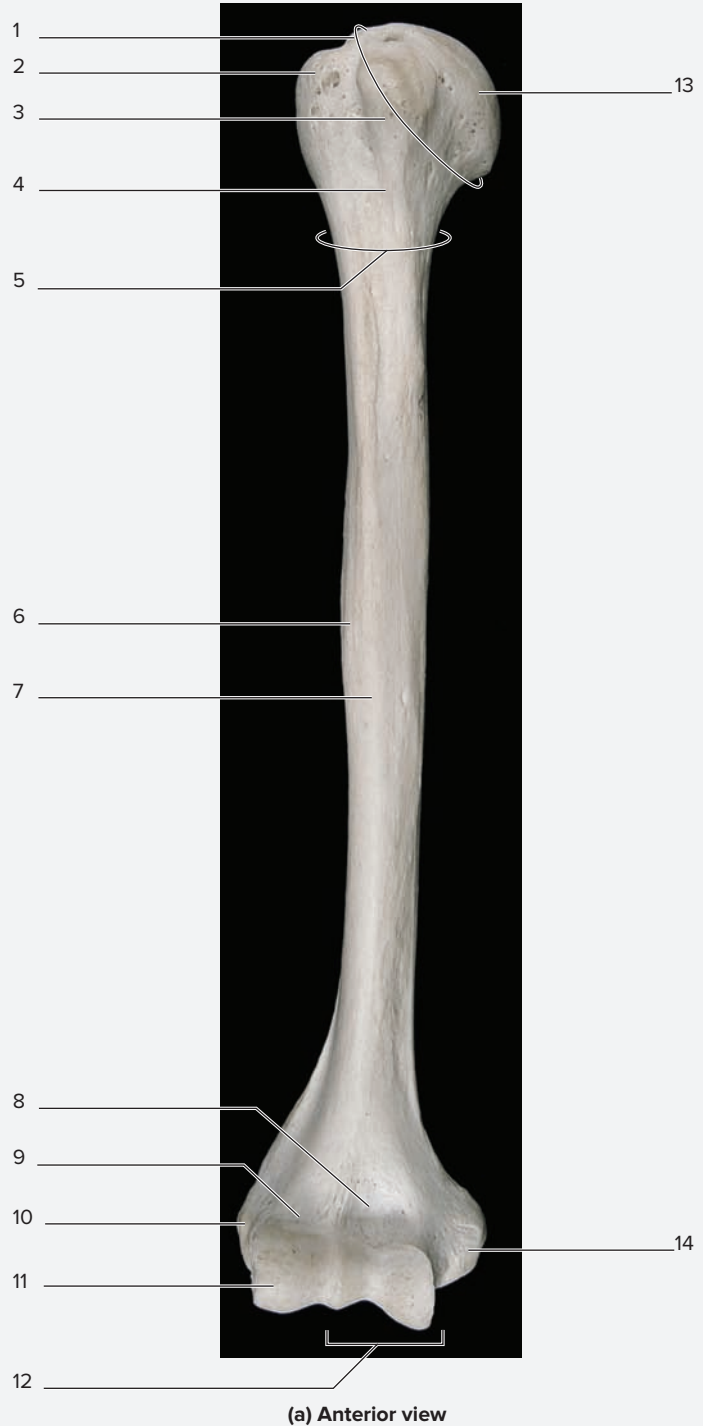



---



---

6. Obtain a scapula and a humerus and articulate them with each other. Sketch the relationship between the scapula and the humerus in the space provided.

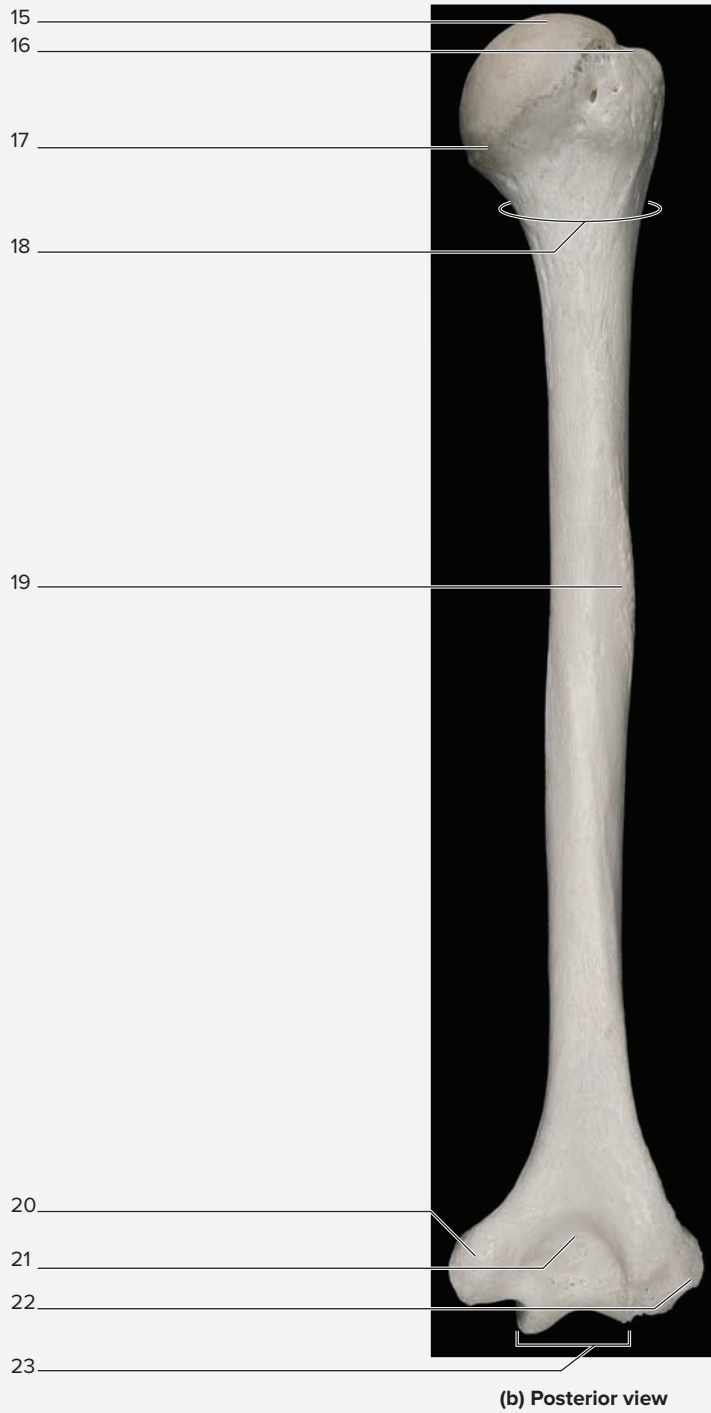


**Figure 9.3** The Right Humerus. Use the terms listed to fill in the numbered labels in the figure. Some answers may be used more than once.

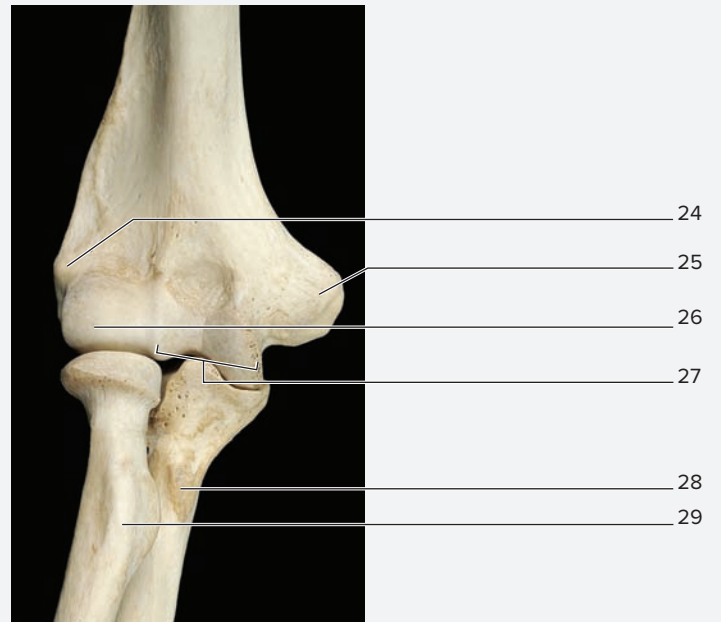
- |   |   |   |
|---|---|---|
| <input type="checkbox"/> anatomical neck    | <input type="checkbox"/> intertubercular sulcus | <input type="checkbox"/> radius               |
| <input type="checkbox"/> capitulum          | <input type="checkbox"/> lateral epicondyle     | <input type="checkbox"/> shaft of humerus     |
| <input type="checkbox"/> coronoid fossa     | <input type="checkbox"/> lesser tubercle        | <input type="checkbox"/> supracondylar ridges |
| <input type="checkbox"/> deltoid tuberosity | <input type="checkbox"/> medial epicondyle      | <input type="checkbox"/> surgical neck        |
| <input type="checkbox"/> greater tubercle   | <input type="checkbox"/> olecranon fossa        | <input type="checkbox"/> trochlea             |
| <input type="checkbox"/> head of humerus    | <input type="checkbox"/> radial fossa           | <input type="checkbox"/> ulna                 |
| <input type="checkbox"/> humerus            |   |   |

**WHAT DO YOU THINK?**

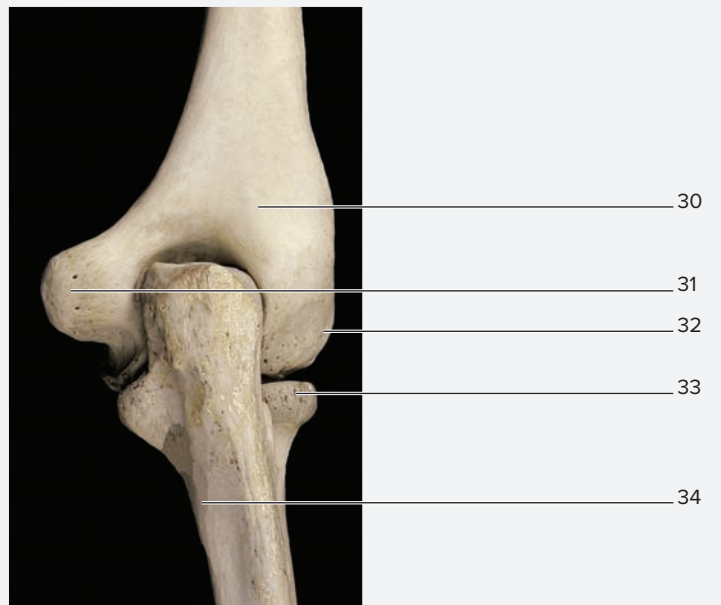
- 1 Which of the two necks of the humerus do you think is more likely to fracture in an accident? What is the name of the joint formed between the scapula and the humerus?



(b) Posterior view



(c) Bones of the elbow, anterior view



(d) Bones of the elbow, posterior view

**Figure 9.3** The Right Humerus (*continued*). Use the terms listed to fill in the numbered labels in the figure. Some answers may be used more than once.

- |   |   |  |  |
|---|---|--|--|
| <input type="checkbox"/> anatomical neck    | <input type="checkbox"/> head                   | <input type="checkbox"/> medial epicondyle | <input type="checkbox"/> surgical neck |
| <input type="checkbox"/> capitulum          | <input type="checkbox"/> humerus                | <input type="checkbox"/> olecranon fossa   | <input type="checkbox"/> trochlea      |
| <input type="checkbox"/> coronoid fossa     | <input type="checkbox"/> intertubercular sulcus | <input type="checkbox"/> radial fossa      | <input type="checkbox"/> ulna          |
| <input type="checkbox"/> deltoid tuberosity | <input type="checkbox"/> lateral epicondyle     | <input type="checkbox"/> radius            |  |
| <input type="checkbox"/> greater tubercle   | <input type="checkbox"/> lesser tubercle        | <input type="checkbox"/> shaft             |  |

(continued from previous page)

**EXERCISE 9.2B: The Radius**

1. Obtain a **radius** or observe the radius on an articulated skeleton (**figure 9.4**). Locate its articulation with the humerus at the elbow. Also locate its articulation with carpals at the wrist.
2. Identify the structures listed in figure 9.4 on the radius, using table 9.2 and the textbook as guides. Then label them in figure 9.4.
3. Obtain both a right and a left radius. What distinguishes a right radius from a left radius?

---



---



---

4. What distinguishes the proximal from the distal end of the radius?

---



---



---

5. What distinguishes the anterior surface of the radius from the posterior surface?

---



---



---

**EXERCISE 9.2C: The Ulna**

1. Obtain an **ulna** or observe the ulna on an articulated skeleton (**figure 9.5**).
2. Identify the structures listed in figure 9.5 on the ulna, using table 9.2 and the textbook as guides. Then label them in figure 9.5.
3. Obtain both a right and a left ulna. What distinguishes a right ulna from a left ulna?

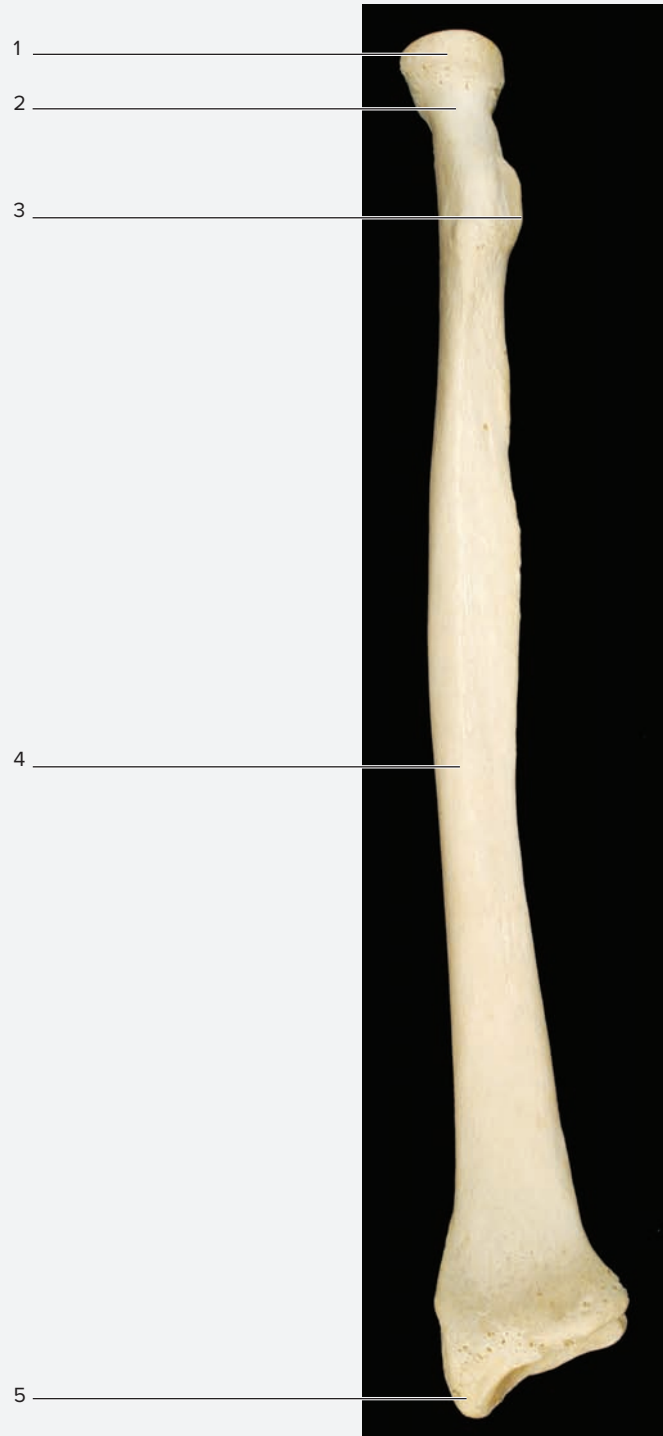
---



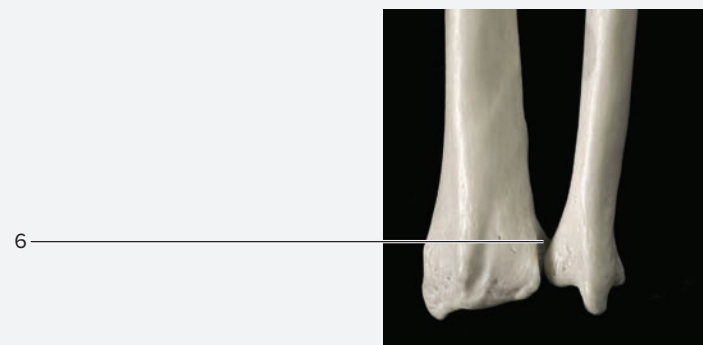---



---



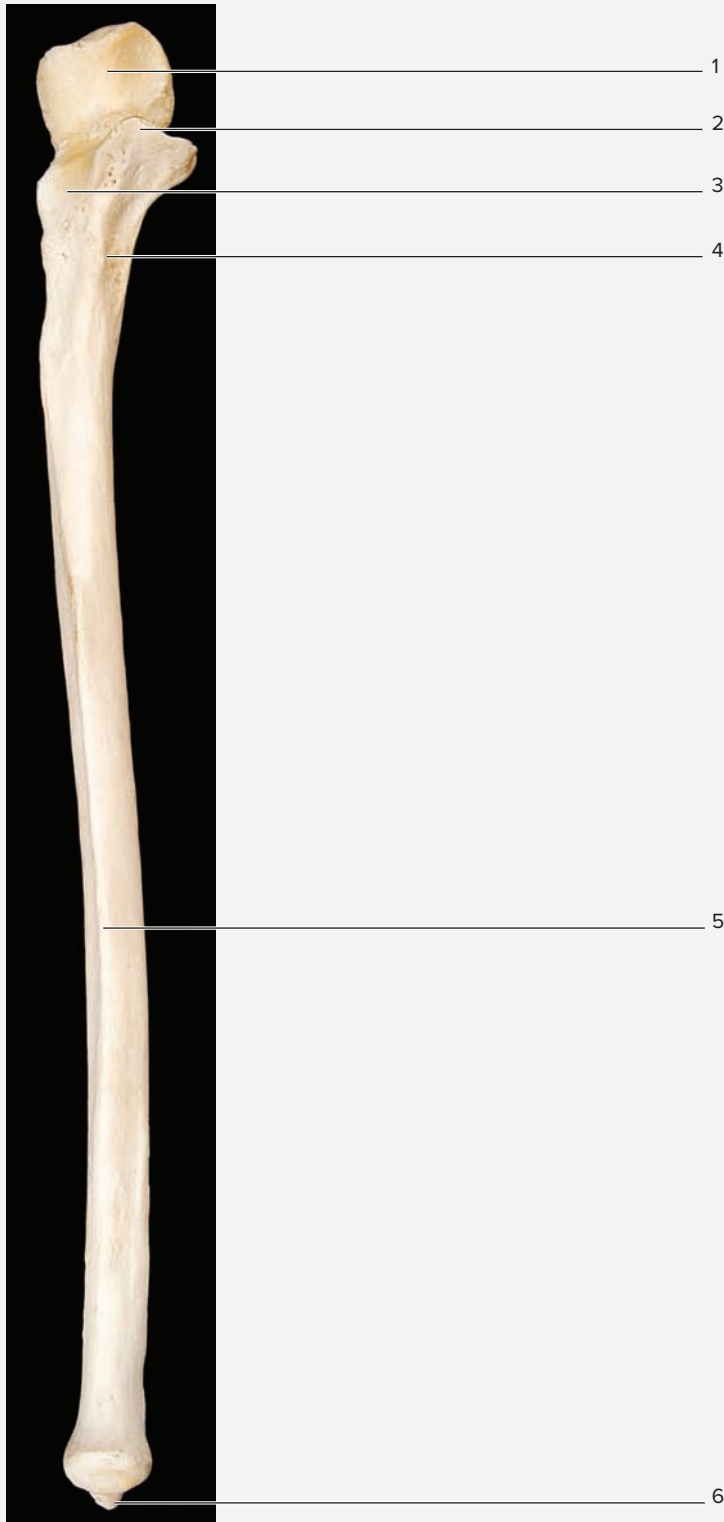
(a) Right radius, anterior view



(b) Distal radius

**Figure 9.4 The Radius.** Use the terms listed to fill in the numbered labels in the figure.

- |  |  |
|--|--|
| <input type="checkbox"/> head of radius    | <input type="checkbox"/> shaft of radius           |
| <input type="checkbox"/> neck of radius    | <input type="checkbox"/> styloid process of radius |
| <input type="checkbox"/> radial tuberosity | <input type="checkbox"/> ulnar notch               |



4. What distinguishes the proximal from the distal end of the ulna?

\_\_\_\_\_

\_\_\_\_\_

5. What distinguishes the anterior surface of the ulna from the posterior surface?

\_\_\_\_\_

\_\_\_\_\_

6. Obtain a humerus, radius, and ulna from the right side of the body and articulate them with each other. Sketch the relationship between the right humerus, radius, and ulna from an anterior view in the space provided.

(a) Right ulna, anterior view

**Figure 9.5 The Ulna.** Use the terms listed to fill in the numbered labels in the figure. Some answers may be used more than once.

- |   |  |
|---|--|
| <input type="checkbox"/> coronoid process of ulna | <input type="checkbox"/> styloid process of ulna |
| <input type="checkbox"/> olecranon of ulna        | <input type="checkbox"/> trochlear notch of ulna |
| <input type="checkbox"/> radial notch of ulna     | <input type="checkbox"/> tuberosity of ulna      |
| <input type="checkbox"/> shaft of ulna            |  |

(continued from previous page)

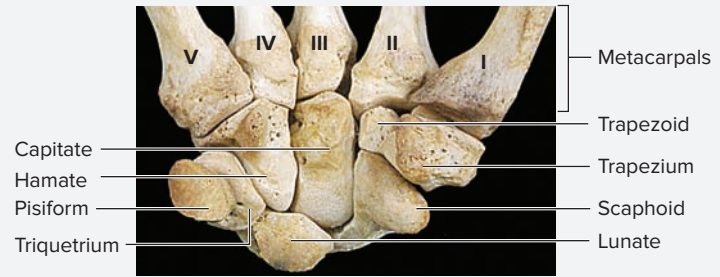
**EXERCISE 9.2D: The Carpals**

1. Obtain articulated bones of the wrist (carpals), or observe the **carpal** bones on an articulated skeleton (**figure 9.6**). The term *carpus* means “wrist.” Thus, the carpal bones are the bones of the wrist.
2. The eight carpal bones are arranged in two rows of four bones each. The proximal row, which is adjacent to the radius and ulna, contains the scaphoid, lunate, triquetrum, and pisiform. The bones of the distal row—the trapezium, trapezoid, capitate, and hamate—articulate with the metacarpals. Sketch the carpal bones of the proximal and distal rows as they would be positioned in an anterior view in the space provided. Then label the bones in each row.

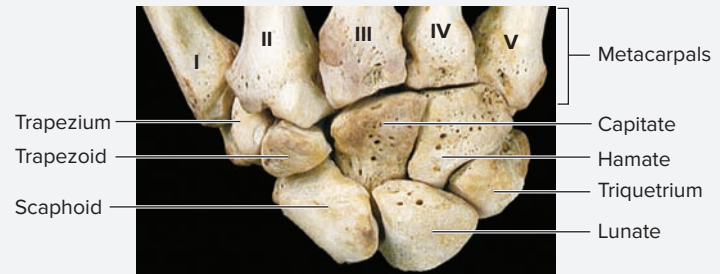
*Proximal row*

*Distal row*

3. Using word origins to associate the shape of each carpal bone with its name will help with identification of individual bones. Complete the following chart to assist with recall of the carpal bones. Use table 9.2 and figure 9.6 as guides.



(a) Right wrist and hand, anterior view



(b) Right wrist and hand, posterior view


**Figure 9.6** The Carpals.

© McGraw-Hill Education/Photos and Dissections by Christine Eckel

Carpal Bone	Word Origin	Bone Shape/ Appearance
<i>Scaphoid</i>		
<i>Lunate</i>		
<i>Triquetrum</i>		
<i>Pisiform</i>		
<i>Hamate</i>		
<i>Capitate</i>		
<i>Trapezium</i>		
<i>Trapezoid</i>		

4. *Optional Activity:* **AP|R** **Skeletal System**—Visit the Quiz area for focused drill and practice on the bones of the appendicular skeleton.

**Learning Strategy**



A mnemonic that may help with recall of the names of the carpal bones, and the order in which they are found, is: **So Long Top Part, Here Comes The Thumb**.  
So Long Top Part = Scaphoid, Lunate, Triquetrum, Pisiform

Here Comes The Thumb = Hamate, Capitate, Trapezium, Trapezoid  
For this mnemonic to work, the bones must be named using the proximal row first, moving from lateral to medial (anatomic position), and the distal row second, moving from lateral to medial (anatomic position).

**EXERCISE 9.2E: The Metacarpals and Phalanges**

1. Obtain articulated bones of the hand (metacarpals and phalanges), or observe bones of the hand on an articulated skeleton (**figure 9.7**).
2. **Metacarpals:** The prefix *meta-* means “after.” Thus, the metacarpal bones are the bones that come after the carpus, or wrist, and they are located in the palm of the hand. There are five metacarpal bones, numbered I through V. The first metacarpal is on the lateral surface of the hand and forms the base of the thumb, or *pollex*. Palpate the palm of your hand to feel the metacarpal bones.

3. **Phalanges:** The term *phalanx* means “a line of soldiers.” The next time you find yourself typing on a keyboard writing a term paper or some other assignment, think about how these little “soldiers” are marching along doing great work!

4. The **pollex** is the thumb. How do the phalanges of the pollex (metacarpal I) differ from the phalanges of digits II–V?

---

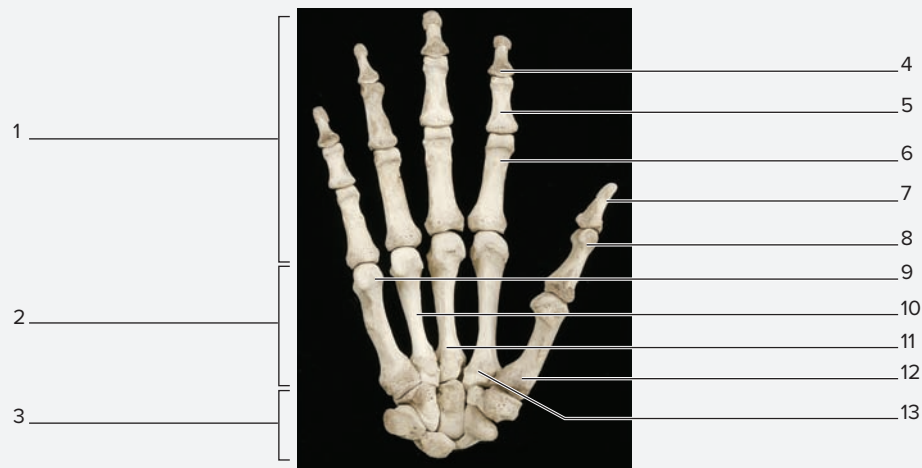


---

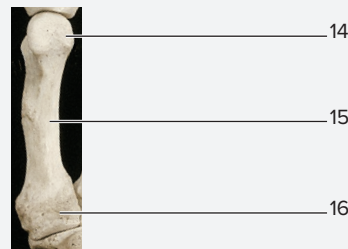

---

5. Identify the metacarpals and phalanges on an articulated skeleton, using table 9.2 and the textbook as guides. Then label them in figure 9.7.



(a) Right wrist and hand, anterior view



(b) Metacarpal V

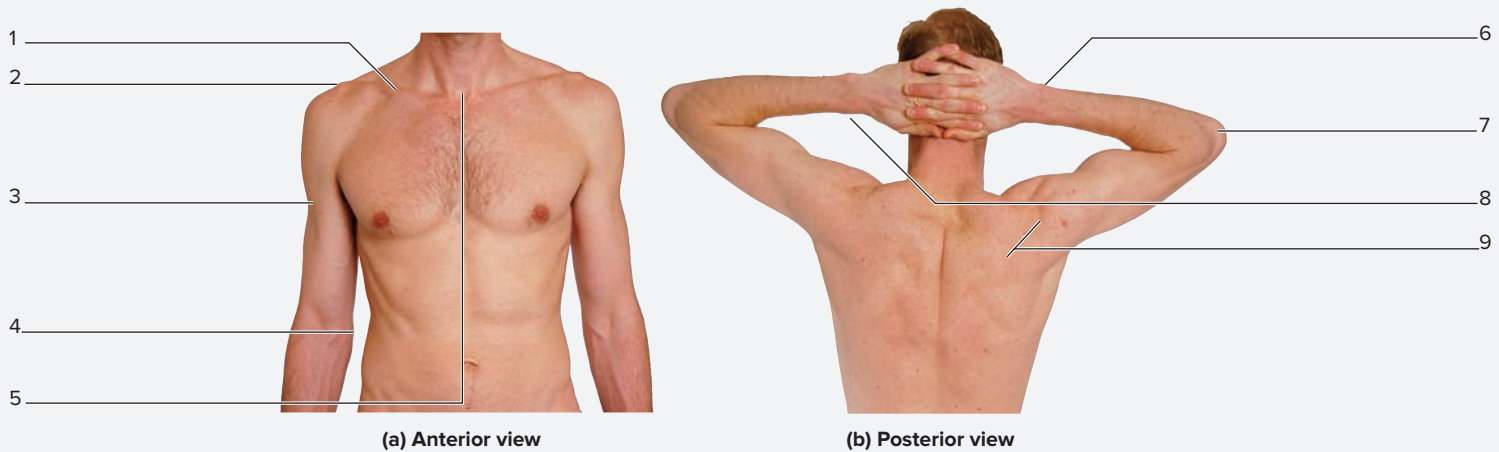
**Figure 9.7** The Metacarpals and Phalanges. Use the terms listed to fill in the numbered labels in the figure.

- |   |   |   |
|---|---|---|
| <input type="checkbox"/> base                     | <input type="checkbox"/> metacarpals    | <input type="checkbox"/> middle phalanx             |
| <input type="checkbox"/> body                     | <input type="checkbox"/> metacarpal I   | <input type="checkbox"/> phalanges                  |
| <input type="checkbox"/> carpals                  | <input type="checkbox"/> metacarpal II  | <input type="checkbox"/> proximal phalanx           |
| <input type="checkbox"/> distal phalanx           | <input type="checkbox"/> metacarpal III | <input type="checkbox"/> proximal phalanx of pollex |
| <input type="checkbox"/> distal phalanx of pollex | <input type="checkbox"/> metacarpal IV  |   |
| <input type="checkbox"/> head                     | <input type="checkbox"/> metacarpal V   |   |



**EXERCISE 9.3** Surface Anatomy Review—Pectoral Girdle and Upper Limb

1. Palpate the manubrium and suprasternal (jugular) notch on yourself. Move the fingers just lateral from the sternal notch to palpate the joint between the manubrium and the proximal end of the clavicle: the sternoclavicular joint. Recall that the only bony attachment between the pectoral girdle and the axial skeleton is at the sternoclavicular joint.
2. Palpate along the clavicle and make note of the curvatures of the clavicle as the fingers move from medial to lateral. The joint between the lateral aspect of the clavicle and the **acromial process** of the scapula can be palpated at the tip of the shoulder, forming the **acromioclavicular joint**.
3. Continue to palpate along the acromial process as it curves posteriorly and becomes the **spine of the scapula**.
4. Palpate the inferior, lateral border of the deltoid muscle. Where the deltoid attaches to the humerus, at the **deltoid tuberosity**, part of the diaphysis of the humerus can be palpated because there is very little muscle between the bone and the skin at that point.
5. Moving down to the elbow, palpate the large **olecranon** of the ulna. This is the bony process that rests on a table when you lean on the elbows.
6. Just proximal from the olecranon on the medial aspect of the elbow, palpate the **medial epicondyle of the humerus**. Place your thumb in the hollow between the olecranon of the ulna and the medial epicondyle of the humerus and feel for the cablelike **ulnar nerve**. This nerve is what causes the pain or tingly sensations that are felt when the “funny bone” gets hit.
7. Palpate the olecranon once again. Continue to palpate along the ulna distally until reaching the wrist joint. The bump felt on the medial aspect of the wrist is the **styloid process of the ulna**. Palpate the corresponding location on the lateral aspect of the wrist to feel the **styloid process of the radius**.
8. Finally, palpate the small metacarpal and phalangeal bones of the hand (see figure 9.7). While doing this, review the names of the bones.
9. Label the surface anatomy structures in **figure 9.8**, using the textbook as a guide.



**Figure 9.8** Surface Anatomy of the Upper Limb. Use the terms listed to fill in the numbered labels in the figure.

- |  |   |  |
|--|---|--|
| <input type="checkbox"/> acromion of scapula | <input type="checkbox"/> medial epicondyle of humerus | <input type="checkbox"/> styloid process of radius |
| <input type="checkbox"/> clavicle            | <input type="checkbox"/> olecranon                    | <input type="checkbox"/> styloid process of ulna   |
| <input type="checkbox"/> deltoid tuberosity  | <input type="checkbox"/> spine of scapula             | <input type="checkbox"/> suprasternal notch        |

## The Pelvic Girdle

The **pelvic girdle** consists of the paired **ilium**, **ischium**, and **pubis** bones. Together, the three bones compose the *os coxae* (*os*, bone + *coxa*, hip). **Table 9.3** lists the bones composing the *os coxae* and describes their key features. A complete pelvis is formed when right and left *os coxae* come together and articulate with the sacrum. Unlike the bones of the pectoral girdle, the bones of the pelvic girdle fuse together during development to become one solid structure.

The following exercises first cover the features of the *os coxae* as a whole. Subsequent exercises cover the features of the individual bones that

compose the *os coxae* and the structural differences between the male and female pelvic girdles.

### WHAT DO YOU THINK?

- Why do you think it is functionally important that the bones of the *os coxae* fuse together rather than remain independent bones?

Bone	Bony Landmark	Description	Word Origins
<i>Os Coxae</i> <i>os, bone + coxa, hip</i>	Acetabulum	A bony socket that forms the articulation with the head of the femur.	<i>acetabula</i> , a shallow cup
	Linea terminalis (pelvic brim)	An oblique ridge on the inner surface of the ilium and pubic bones that separates the true pelvis (below) from the false pelvis (above); consists of the pubic crest, pectineal line, and arcuate line.	<i>linea</i> , line + <i>terminalis</i> , ending
	Lunate surface	The half-moon shaped (curved) smooth surface on the superior border of the acetabulum, which articulates with the head of the femur.	<i>luna</i> , moon
	Obturator foramen	A large, oval hole in the inferior part of the <i>os coxae</i> located anterior and medial.	<i>obturo</i> , to occlude
<i>Ilium</i> <i>ilium, flank</i>	Anterior gluteal line	A rough line running obliquely on the lateral surface of the ilium from the iliac crest to the greater sciatic notch.	<i>gloutos</i> , buttock
	Anterior inferior iliac spine	A process inferior to the anterior superior iliac spine; origin of rectus femoris muscle.	<i>spina</i> , a spine
	Anterior superior iliac spine	A projection at the anteriormost part of the iliac crest; lateral attachment point for the inguinal ligament; origin for sartorius muscle.	<i>spina</i> , a spine
	Arcuate line	An oblique line between the ilium and ischium that composes the iliac part of the linea terminalis (pelvic brim) of the bony pelvis.	<i>arcuatus</i> , bowed
	Auricular surface	An “earlike” rough surface on the medial aspect of the ilium; the point of articulation with the sacrum.	<i>auris</i> , ear
	Greater sciatic notch	A deep notch on the posterior surface of the ilium inferior to the posterior iliac spines.	<i>sciaticus</i> , the hip joint
	Iliac crest	The superior border of the ilium, beginning at the sacrum and ending on the lateral aspect of the hip.	<i>crista</i> , a ridge
	Iliac fossa	A large fossa on the anteromedial (internal) surface of the ilium inferior to the iliac crest.	<i>ilium</i> , flank + <i>fossa</i> , a trench
	Iliac tuberosity	A large projection on the posterior, superior aspect of the ilium.	<i>ilium</i> , flank + <i>tuber</i> , a knob
	Inferior gluteal line	A rough line running transversely on the lateral surface of the ilium just superior to the acetabulum.	<i>gloutos</i> , buttock
	Posterior gluteal line	A rough line running vertically on the lateral surface of the ilium from the iliac crest to the posterior rim of the greater sciatic notch.	<i>gloutos</i> , buttock
	Posterior inferior iliac spine	A small projection on the posterior inferior point of the ilium.	<i>spina</i> , a spine
	Posterior superior iliac spine	A projection on the posterior superior point of the ilium.	<i>spina</i> , a spine

Bone	Bony Landmark	Description	Word Origins
<b>Ischium</b> ischion, hip	Ischial spine	A small, sharp spine on the posterior aspect of the ishium.	<i>ischion</i> , hip
	Ischial tuberosity	A large, rough projection on the posterior, inferior surface of the ischium; attachment point for hamstring muscles.	<i>ischion</i> , hip + <i>tuber</i> , a knob
	Lesser sciatic notch	A notch located immediately inferior to the ischial spine on the posterior surface of the ilium.	
	Ramus of ischium	The inferior part of the ischium that connects to the pubis anteriorly and forms the inferior part of the obturator foramen.	<i>ramus</i> , branch
<b>Pubis</b> pubis, pubic bone	Inferior pubic ramus	The inferior part of the pubis that joins with the ischium.	<i>ramus</i> , branch
	Pectineal line	Rough ridge on the medial surface of the superior ramus of the pubis.	<i>pectineal</i> , relating to the pubis
	Pubic crest	A ridge on the lateral part of the superior ramus of the pubis.	<i>crista</i> , crest
	Pubic tubercle	A projection composing the anterior most point of the bone; medial attachment point for the inguinal ligament.	<i>tuber</i> , a knob
	Superior pubic ramus	The superior part of the pubis that joins with the ilium.	<i>ramus</i> , branch

## EXERCISE 9.4 Bones of the Pelvic Girdle

### EXERCISE 9.4A: The Os Coxae

1. Obtain an **os coxae** or observe the os coxae on an articulated skeleton (**figure 9.9**).
2. Identify the structures listed in figure 9.9 on the os coxae, using table 9.3 and the textbook as guides. Then label them in figure 9.9.
3. Obtain both a right and a left os coxae. What distinguishes a right os coxae from a left os coxae?

---



---



---

4. What distinguishes the proximal from the distal end of the os coxae?

---



---



---

5. What distinguishes the anterior surface of the os coxae from the posterior surface?

---



---



---

6. With which part of the vertebral column does the os coxae articulate?

---

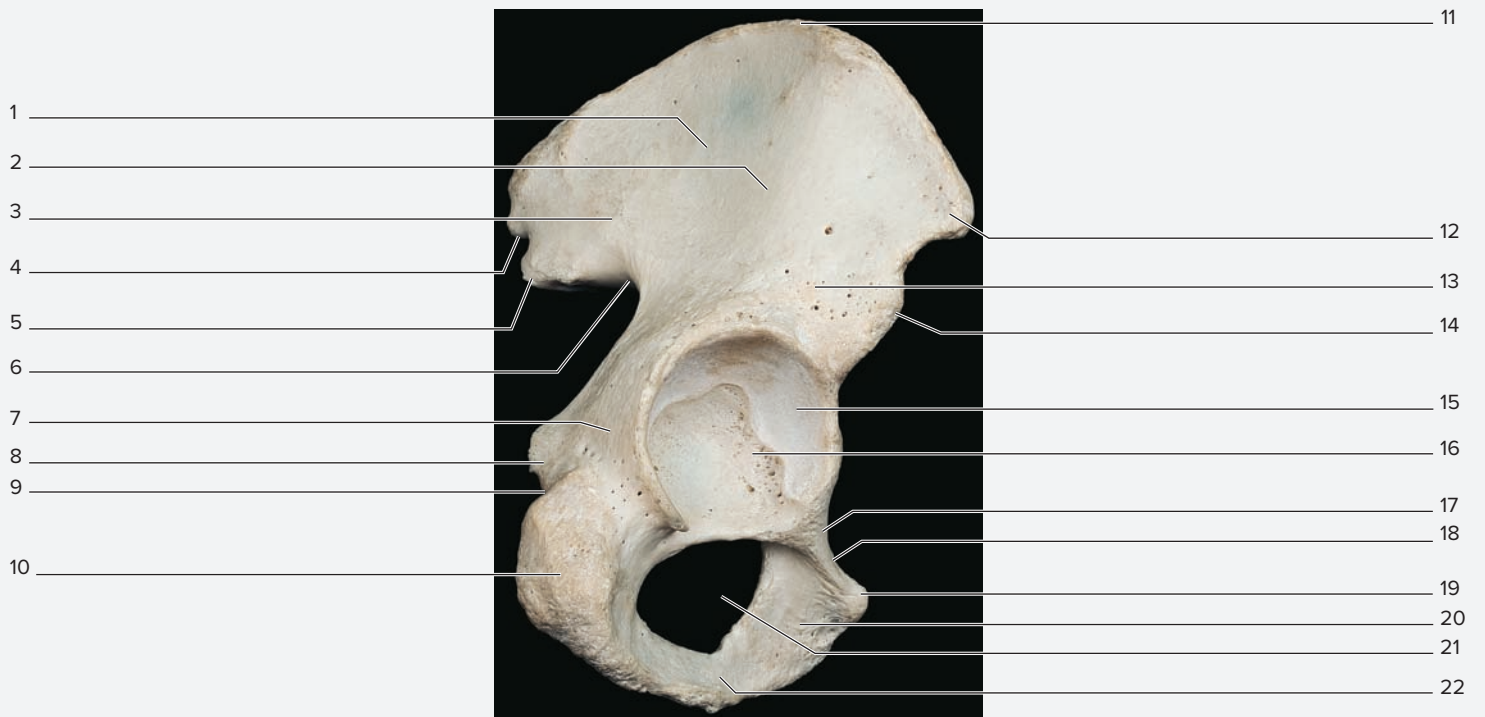### EXERCISE 9.4B: Male and Female Pelves

1. Obtain a male pelvis and a female pelvis and lay them next to each other on the workspace with the anterior surfaces facing toward you. **Figure 9.10** demonstrates the features of male and female pelves.
2. There are numerous features that help distinguish a **male pelvis** from a **female pelvis**. For example, a female pelvis is generally wider and more flared; has a broader subpubic angle; a smaller, triangular obturator foramen; a wide, shallow greater sciatic notch; and ischial spines that rarely project into the pelvic outlet. All of these are adaptations that allow for childbirth. However, no method of sexing a pelvis is completely foolproof. At the very least, a determination can be made that a pelvis is more malelike than femalelike, or vice versa. While observing male and female pelves, develop your own method of differentiating the male pelvis from the female pelvis.

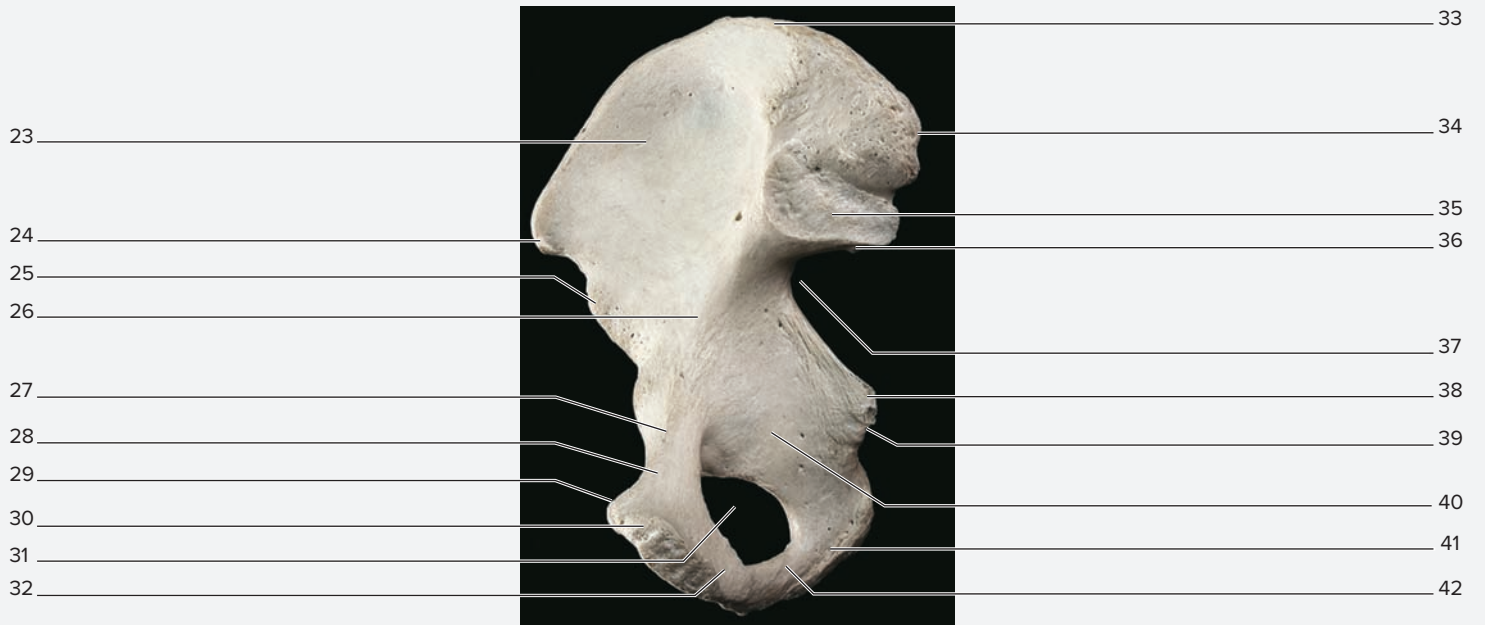### Learning Strategy



One method of estimating female versus male subpubic angles is to compare them to the angles formed between the digits on the hand when they are spread apart (abducted). For example, the angle between the thumb and index finger when they are spread apart approximates the wide subpubic angle of a female pelvis, whereas the angle formed between the index and middle fingers when they are spread apart approximates the narrower subpubic angle of a male pelvis.



(a) Lateral view



(b) Medial view

**Figure 9.9 The Right Os Coxae.** Use the terms listed to fill in the numbered labels in the figure. Some answers may be used more than once.

- |  |  |   |   |
|--|--|---|---|
| <input type="checkbox"/> acetabulum                    | <input type="checkbox"/> greater sciatic notch | <input type="checkbox"/> ischial tuberosity             | <input type="checkbox"/> posterior superior iliac spine   |
| <input type="checkbox"/> ala                           | <input type="checkbox"/> iliac crest           | <input type="checkbox"/> lesser sciatic notch           | <input type="checkbox"/> pubic crest                      |
| <input type="checkbox"/> anterior gluteal line         | <input type="checkbox"/> iliac fossa           | <input type="checkbox"/> lunate surface                 | <input type="checkbox"/> pubic tubercle                   |
| <input type="checkbox"/> anterior inferior iliac spine | <input type="checkbox"/> iliac tuberosity      | <input type="checkbox"/> obturator foramen              | <input type="checkbox"/> ramus of ischium                 |
| <input type="checkbox"/> anterior superior iliac spine | <input type="checkbox"/> inferior gluteal line | <input type="checkbox"/> pectineal line                 | <input type="checkbox"/> superior pubic ramus             |
| <input type="checkbox"/> arcuate line                  | <input type="checkbox"/> inferior pubic ramus  | <input type="checkbox"/> posterior gluteal line         | <input type="checkbox"/> symphyseal surface of pubic bone |
| <input type="checkbox"/> auricular surface             | <input type="checkbox"/> ischial spine         | <input type="checkbox"/> posterior inferior iliac spine |   |
| <input type="checkbox"/> body of ischium               |  |   |   |

(continued from previous page)

3. Sketch the male and female pelvises in the spaces provided. Then list the features you used to distinguish the male pelvis from the female pelvis. Use the photos in figure 9.10

as a guide if samples of both male and female pelvises are unavailable in the laboratory.

**Male Pelvis**




---

---

---

---

---

---

---

**Female Pelvis**




---

---

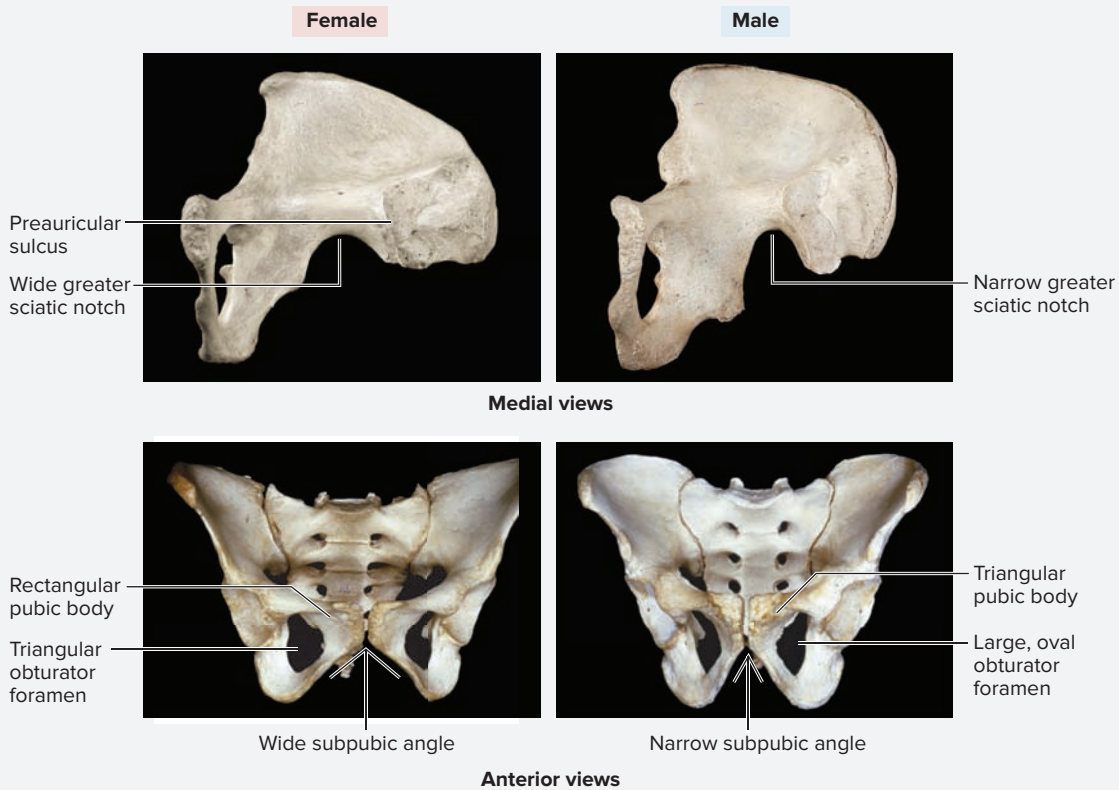
---

---

---

---

---



**Figure 9.10** Male and Female Pelvises.

(top left, right) © David Hunt/Smithsonian Institution; (bottom left, right) © VideoSurgery/Science Source

## The Lower Limb

The lower limb consists of the femur, patella, tibia, fibula, tarsals, metatarsals, and phalanges. Nearly all of the projections on these

bones are attachment points for the muscles that move the limb. **Table 9.4** lists the bones of the lower limb and describes their key features.

Table 9.4		The Appendicular Skeleton: Lower Limb	
Bone	Bony Landmark	Description	Word Origins
<b>Femur</b> femur, thigh	Adductor tubercle	A small projection above the medial condyle.	<i>tuber</i> , a knob
	Fovea	A circular depression on the proximal end of the head.	<i>fovea</i> , a dimple
	Gluteal tuberosity	A projection on the proximal aspect of the linea aspera; gluteus maximus muscle attaches to it.	<i>glutos</i> , buttock + <i>tuber</i> , a knob
	Greater trochanter	A very large projection on the lateral surface of the proximal epiphysis.	<i>trochanter</i> , a runner
	Head	A very large, ball-shaped structure on the proximal epiphysis.	NA
	Intercondylar fossa	A depression on the distal end of the femur between the two condyles; serves as an attachment point for the cruciate ligaments of the knee.	<i>inter-</i> , between + <i>kondylos</i> , knuckle
	Intertrochanteric crest	A large ridge that runs between the greater and lesser trochanters on the posterior surface.	<i>inter-</i> , between + <i>trochanter</i> , a runner
	Intertrochanteric line	A shallow ridge that runs between greater and lesser trochanters on the anterior surface.	<i>inter-</i> , between + <i>trochanter</i> , a runner
	Lateral condyle	A large rounded surface that articulates with the lateral condyle of the tibia.	<i>kondylos</i> , knuckle
	Lateral epicondyle	A rough surface superior to the lateral condyle.	<i>epi-</i> , above + <i>kondylos</i> , knuckle
	Lesser trochanter	A large projection on the medial surface of the proximal epiphysis.	<i>trochanter</i> , a runner
	Linea aspera	A “rough line” that runs along the posterior surface of the diaphysis.	<i>linea</i> , line + <i>aspera</i> , rough
	Medial condyle	A rounded surface that articulates with the medial condyle of the tibia.	<i>kondylos</i> , knuckle
	Medial epicondyle	A rough surface superior to the medial condyle.	<i>epi-</i> , above + <i>kondylos</i> , knuckle
	Neck	The narrow portion where the head meets the shaft of the bone; this is the part of the bone that is fractured in a “broken hip.”	
	Patellar surface	A smooth depression on the anterior surface of the distal epiphysis; location where the patella articulates with the femur.	(patella) <i>patina</i> , a shallow disk
	Pectineal line	A line on the posterior, superior aspect of the femur that serves as an attachment point for the pectineus muscle.	<i>pictineal</i> , ridged or comblike
	Popliteal surface	A triangular region on the posterior aspect of the distal femur.	<i>popliteal</i> , the back of the knee
Shaft	The diaphysis of the bone.	NA	

Table 9.4		The Appendicular Skeleton: Lower Limb ( <i>continued</i> )	
Bone	Bony Landmark	Description	Word Origins
<b>Tibia</b> <i>tibia, the large shin bone</i>	Anterior border	A ridge on the anterior surface extending distally from the tibial tuberosity; commonly referred to as the “shin.”	
	Intercondylar eminence	A prominent projection between the two condyles on the proximal epiphysis.	<i>eminentia</i> , a raised area on a bone
	Lateral condyle	A large, flat surface on the lateral aspect of the proximal epiphysis; the point of articulation with the lateral condyle of the femur.	<i>kondylos</i> , knuckle
	Medial condyle	A large, flat surface on the medial aspect of the proximal epiphysis; point of articulation with the medial condyle of the femur.	<i>kondylos</i> , knuckle
	Medial malleolus	A projection on the medial surface of the distal epiphysis.	<i>malleus</i> , hammer
	Shaft	The diaphysis of the bone.	
	Soleal line	A rough line running obliquely on the posterior surface of the proximal part of the bone; attachment for part of the soleus muscle.	<i>solea</i> , a sandal
	Tibial tuberosity	A projection on the anterior surface of the proximal epiphysis; attachment point for the patellar ligament (quadriceps femoris muscle attachment).	<i>tibia</i> , shin bone
<b>Fibula</b> <i>fibula, a clasp or buckle</i>	Head	The rounded proximal end of the bone.	
	Lateral malleolus	A projection on the lateral surface of the distal epiphysis.	<i>malleus</i> , hammer
	Neck	The narrow portion where the head meets the diaphysis.	
	Shaft	The diaphysis of the bone.	
<b>Tarsals</b> <i>tarsus, a flat surface</i>	Calcaneus	Bone that forms the heel of the foot; attachment point for the calcaneal tendon.	<i>calcaneus</i> , the heel
	Cuboid	A cube-shaped bone located at the base of the fourth metatarsal.	<i>kybos-</i> , cube + <i>eidos</i> , resemblance
	Intermediate cuneiform	A “wedge-shaped” bone located at the base of the second metatarsal.	<i>cuneus-</i> , wedge + <i>forma</i> , shape
	Lateral cuneiform	A “wedge-shaped” bone located at the base of the third metatarsal.	<i>cuneus-</i> , wedge + <i>forma</i> , shape
	Medial cuneiform	A “wedge-shaped” bone located at the base of the first metatarsal.	<i>cuneus-</i> , wedge + <i>forma</i> , shape
	Navicular	A bone shaped like a boat (“ship”) located just anterior to the talus.	<i>navis</i> , ship
	Talus	The major weight-bearing bone of the ankle; articulates with the tibia and fibula.	<i>talus</i> , ankle
<b>Metatarsals</b> <i>meta-, after + tarsus, a flat surface</i>	Base	The proximal epiphysis of the bone.	
	Head	The distal epiphysis of the bone.	
	Shaft	The diaphysis of the bone.	
<b>Phalanges</b> <i>phalanx, line of soldiers</i>			
	<b>II through V</b>		
	Proximal	The phalanx closest to the metatarsal bones.	<i>proximus</i> , nearest
	Middle	The middle phalanx.	
	Distal	The small cone-shaped distal bone of the digits.	<i>distalis</i> , away
<b>Hallux</b> <i>hallux, the big toe</i>	Proximal	The phalanx closest to the sole of the foot.	<i>proximus</i> , nearest
	Distal	The distal phalanx.	<i>distalis</i> , away

**EXERCISE 9.5** Bones of the Lower Limb

**EXERCISE 9.5A: The Femur**

1. Obtain a **femur** or observe the femur on an articulated skeleton (**figure 9.11**). Locate the points of articulation with the os coxa, tibia, and patella.
2. Identify the structures listed in figure 9.11 on the femur, using table 9.4 and the textbook as guides. Then label them in figure 9.11.
3. Obtain both a right and a left femur. What distinguishes a right femur from a left femur?

\_\_\_\_\_

\_\_\_\_\_

\_\_\_\_\_

4. What distinguishes the proximal from the distal end of the femur?

\_\_\_\_\_

\_\_\_\_\_

\_\_\_\_\_

5. What distinguishes the anterior surface of the femur from the posterior surface?

\_\_\_\_\_

\_\_\_\_\_


\_\_\_\_\_

6. Obtain a right os coxae and a right femur and articulate them with each other. Sketch the relationship between the bones of the os coxae and the femur in the space provided.

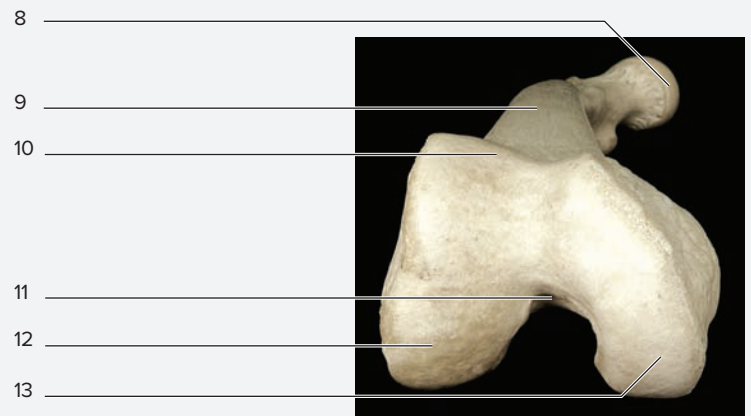


7. What is the name of the joint formed between the bones of the os coxae and the femur?

\_\_\_\_\_



(a) Right femur, medial view



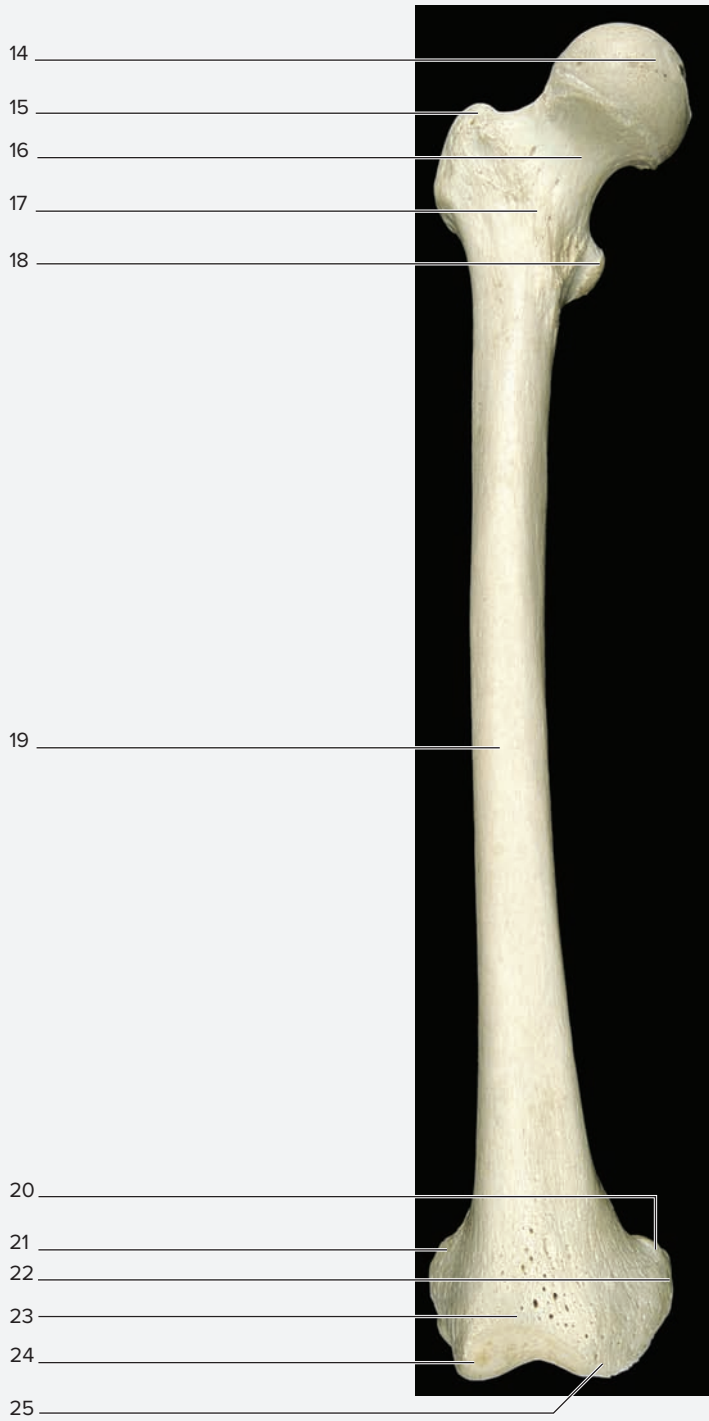
(b) Right femur, inferior view

**Figure 9.11 The Right Femur.** Use the terms listed to fill in the numbered labels in the figure. Some answers may be used more than once.

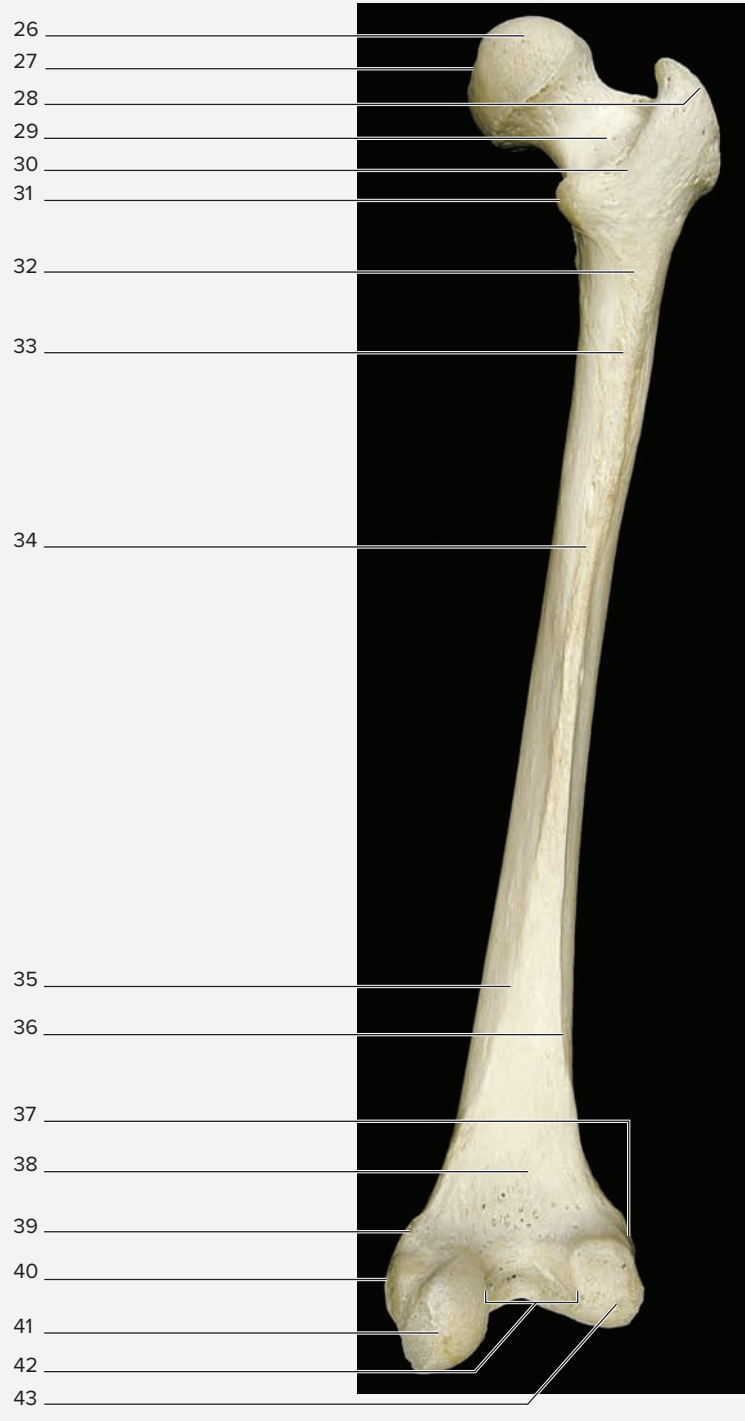
- |   |  |  |   |
|---|--|--|---|
| <input type="checkbox"/> adductor tubercle  | <input type="checkbox"/> greater trochanter  | <input type="checkbox"/> intertrochanteric crest | <input type="checkbox"/> lateral epicondyle         |
| <input type="checkbox"/> fovea              | <input type="checkbox"/> head of femur       | <input type="checkbox"/> intertrochanteric line  | <input type="checkbox"/> lateral supracondylar line |
| <input type="checkbox"/> gluteal tuberosity | <input type="checkbox"/> intercondylar fossa | <input type="checkbox"/> lateral condyle         | <input type="checkbox"/> lesser trochanter          |



(continued from previous page)



(c) Right femur, anterior view



(d) Right femur, posterior view

**Figure 9.11 The Right Femur (continued).** Use the terms listed to fill in the numbered labels in the figure. Some answers may be used more than once.

- |  |  |   |  |
|--|--|---|--|
| <input type="checkbox"/> linea aspera      | <input type="checkbox"/> medial supracondylar line | <input type="checkbox"/> patellar surface | <input type="checkbox"/> popliteal surface |
| <input type="checkbox"/> medial condyle    | <input type="checkbox"/> neck of femur             | <input type="checkbox"/> pectineal line   | <input type="checkbox"/> shaft of femur    |
| <input type="checkbox"/> medial epicondyle |  |   |  |

**EXERCISE 9.5B: The Tibia**

1. Obtain a **tibia** or observe the tibia on an articulated skeleton (**figure 9.12**). Locate the points of articulation with the femur, fibula, and talus.
2. Identify the structures listed in figure 9.12 on the tibia, using table 9.4 and the textbook as guides. Then label them in figure 9.12.

3. Obtain both a right and a left tibia. What distinguishes a right tibia from a left tibia?

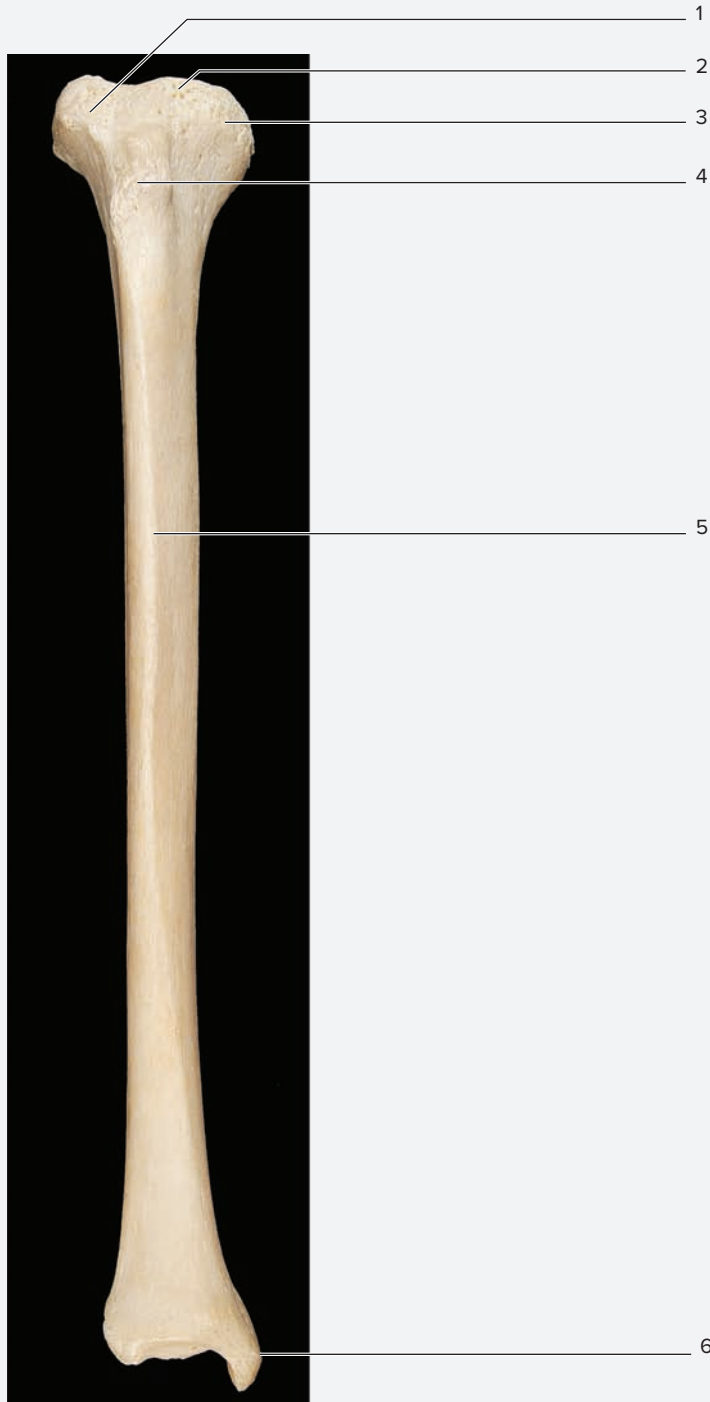
---



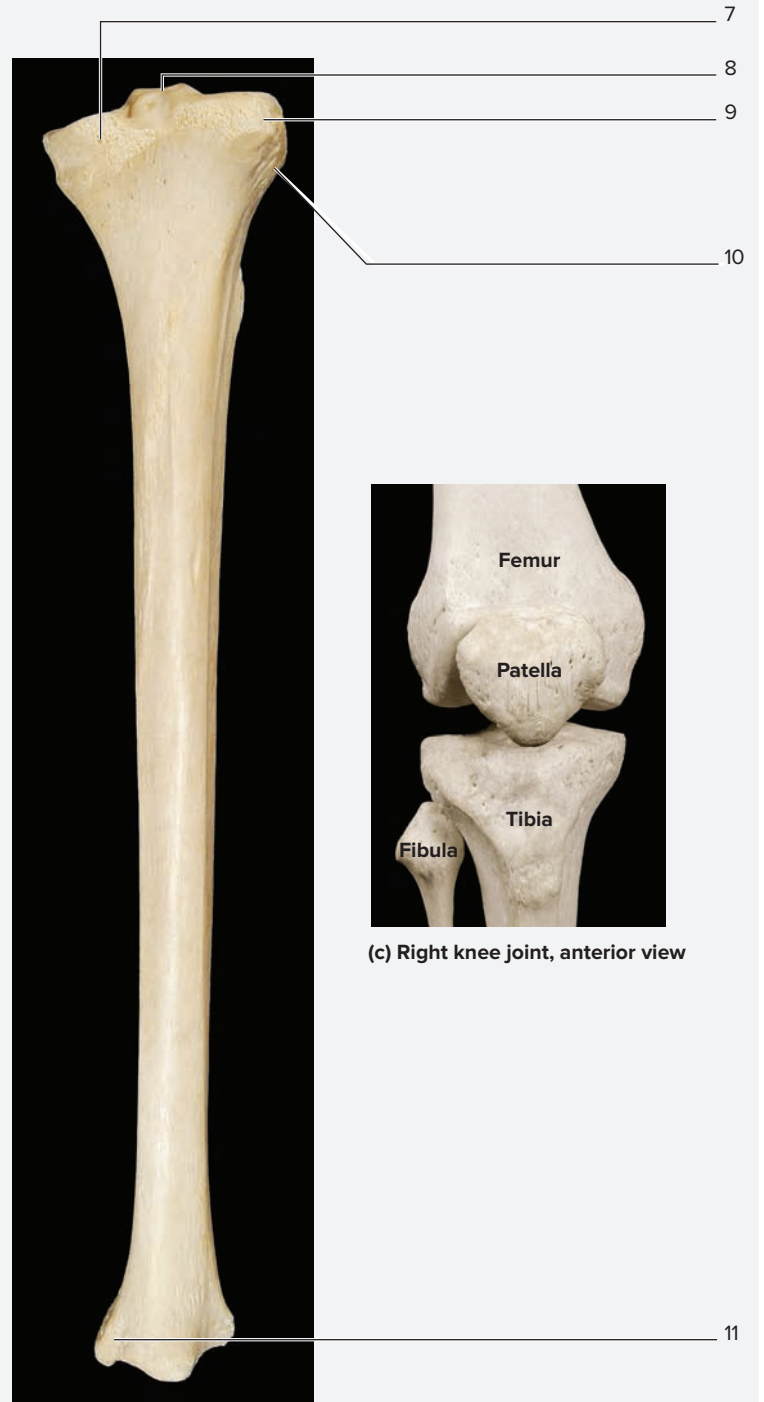
---



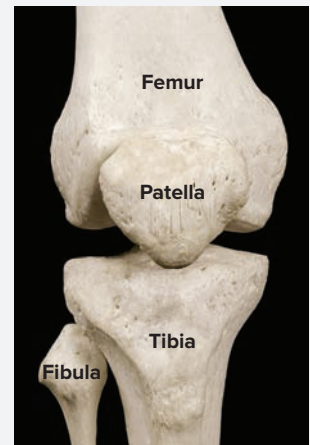
---



(a) Right tibia, anterior view



(b) Right tibia, posterior view



(c) Right knee joint, anterior view

**Figure 9.12 The Tibia.** Use the terms listed to fill in the numbered labels in the figure. Some answers may be used more than once.

- |  |   |   |  |
|--|---|---|--|
| <input type="checkbox"/> anterior border         | <input type="checkbox"/> intercondylar eminence | <input type="checkbox"/> medial condyle   | <input type="checkbox"/> tibial tuberosity |
| <input type="checkbox"/> fibular articular facet | <input type="checkbox"/> lateral condyle        | <input type="checkbox"/> medial malleolus |  |

(continued from previous page)

4. What distinguishes the proximal from the distal end of the tibia?

---



---



---

5. What distinguishes the anterior surface of the tibia from the posterior surface?

---



---



---

**EXERCISE 9.5C: The Fibula**

1. Obtain a **fibula** or observe the fibula on an articulated skeleton (**figure 9.13**). Locate its articulation with the tibia at both the proximal and distal ends.
2. Identify the structures listed in figure 9.13 on the fibula, using table 9.4 and the textbook as guides. Then label them in figure 9.13.



**Figure 9.13 The Right Fibula.** Lateral view. Use the terms listed to fill in the numbered labels in the figure.

- |  |                                |
|--|--------------------------------|
| <input type="checkbox"/> head              | <input type="checkbox"/> neck  |
| <input type="checkbox"/> lateral malleolus | <input type="checkbox"/> shaft |

3. Obtain both a right and a left fibula. What distinguishes a right fibula from a left fibula?

---



---



---

4. What distinguishes the proximal from the distal end of the fibula?

---



---



---

5. What distinguishes the anterior surface of the fibula from the posterior surface?

---



---



---

6. Obtain a right femur, tibia, and fibula and articulate them with each other. Sketch the relationship between the right femur, tibia, and fibula from an anterior view in the space provided. Include the location of the patella in the sketch.

7. Does the fibula form part of the knee joint?

---

8. Does the fibula form part of the ankle joint?

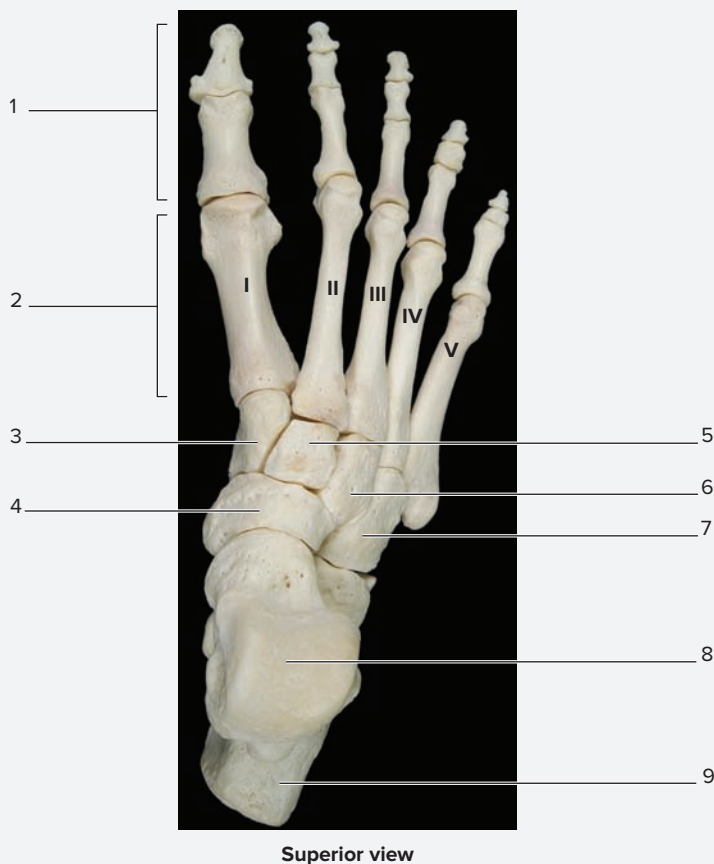
---

**WHAT DO YOU THINK?**

3 A fracture to which of the leg bones (tibia or fibula) would result in the greatest loss of function of the lower limb?

**EXERCISE 9.5D: The Tarsals**

1. Obtain bones of the ankle (tarsals) or observe the **tarsal** bones on an articulated skeleton (**figures 9.14 and 9.15**).
2. The term *tarsal* means “flat surface,” as in the sole of the foot. The tarsal bones are much larger than their counterparts in the wrist (the carpal bones). The largest differences in structure are seen in the talus and calcaneus, two bones that form a major part of the weight-bearing ankle joint.
3. Identify the tarsal bones on an articulated skeleton, using table 9.4 and the textbook as guides. Then label them in figure 9.14.
4. The seven tarsal bones are arranged in two rows. The proximal row includes the talus, calcaneus, and navicular. The bones of the distal row—the medial cuneiform, intermediate cuneiform, lateral cuneiform, and cuboid—articulate with the metatarsal bones. Use the spaces provided to diagram the tarsal bones of the proximal and distal rows as they would be positioned in a superior view. Then label the bones in each row.



**Figure 9.14** The Tarsals. Use the terms listed to fill in the numbered labels in the figure.

- |   |  |                                    |
|---|--|------------------------------------|
| <input type="checkbox"/> calcaneus              | <input type="checkbox"/> lateral cuneiform | <input type="checkbox"/> navicular |
| <input type="checkbox"/> cuboid                 | <input type="checkbox"/> medial cuneiform  | <input type="checkbox"/> phalanges |
| <input type="checkbox"/> intermediate cuneiform | <input type="checkbox"/> metatarsals       | <input type="checkbox"/> talus     |

*Proximal Row*

*Distal Row*



**Learning Strategy**



The following is a mnemonic that may help you remember the names of the tarsal bones and the order in which they are found:

**T**aking **C**lass **N**otes **M**akes **I**ntelligent **L**iterate **C**hampions.  
 Taking Class Notes = **T**alus, **C**alcaneus, **N**avicular  
 Makes Intelligent Literate Champions = **M**edial cuneiform, **I**ntermediate cuneiform, **L**ateral cuneiform, **C**uboid  
 Proximal row first, moving from lateral to medial (anatomic position).  
 Distal row second, moving from lateral to medial (anatomic position).

(continued from previous page)

5. The names of the tarsal bones provide good clues for identifying each bone. Complete the following chart to assist with recall of the shapes of the tarsal bones.

Tarsal Bone	Word Origin	Bone Shape/ Appearance
<i>Talus</i>		
<i>Calcaneus</i>		
<i>Navicular</i>		
<i>Medial Cuneiform</i>		
<i>Intermediate Cuneiform</i>		
<i>Lateral Cuneiform</i>		
<i>Cuboid</i>		

6. Obtain a right tibia, fibula, calcaneus, and talus and articulate them with each other. Sketch the relationship between the tibia, fibula, calcaneus, and talus in the space provided.

7. Which bones or parts of bones compose the ankle joint?

---



---

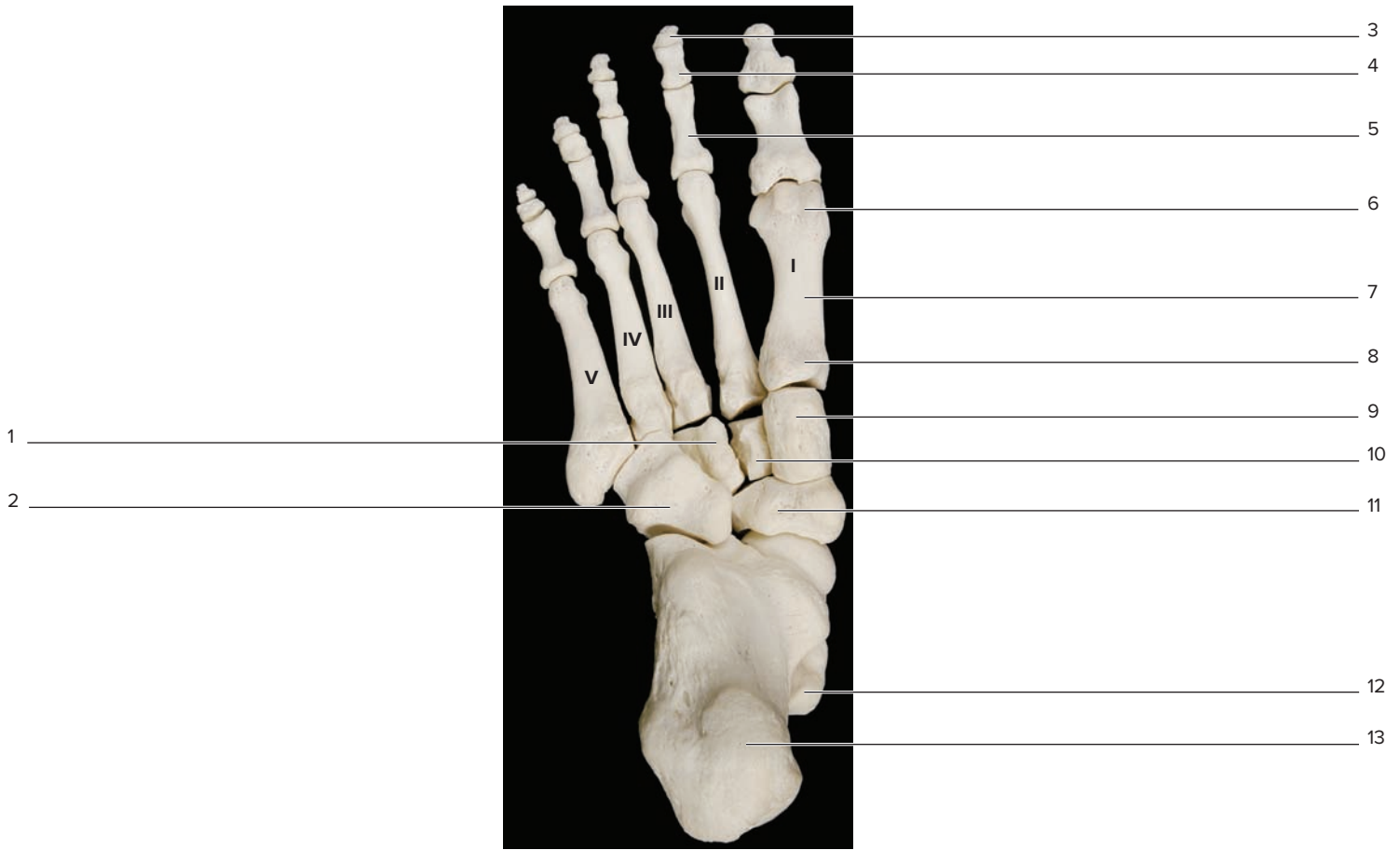


---

**EXERCISE 9.5E: The Metatarsals and Phalanges**

1. Obtain bones of the foot (metatarsals and phalanges) or observe the bones of the foot on an articulated skeleton (figures 9.14 and 9.15).
2. **Metatarsals:** The term *meta-* means “after.” Thus, the metatarsal bones are the bones that come after the tarsus. These bones are found in the sole of the foot. Palpate the sole of the foot and feel for the metatarsal bones. There are five metatarsal bones, numbered I through V. The first metatarsal is on the medial surface of the foot and forms the base of the big toe, or *hallux*.

3. The **hallux** is the big toe. How do its phalangeal bones differ from the phalanges of digits II–V?  
\_\_\_\_\_
4. Identify the metatarsal bones and phalanges on an articulated skeleton, using table 9.4 and the textbook as guides. Then label them in figure 9.15.



Inferior view

**Figure 9.15** The Metatarsals and Phalanges. Use the terms listed to fill in the numbered labels in the figure.

**Metatarsals**

- hallux (metatarsal I)
- base of metatarsal I
- shaft of metatarsal I

**Phalanges**

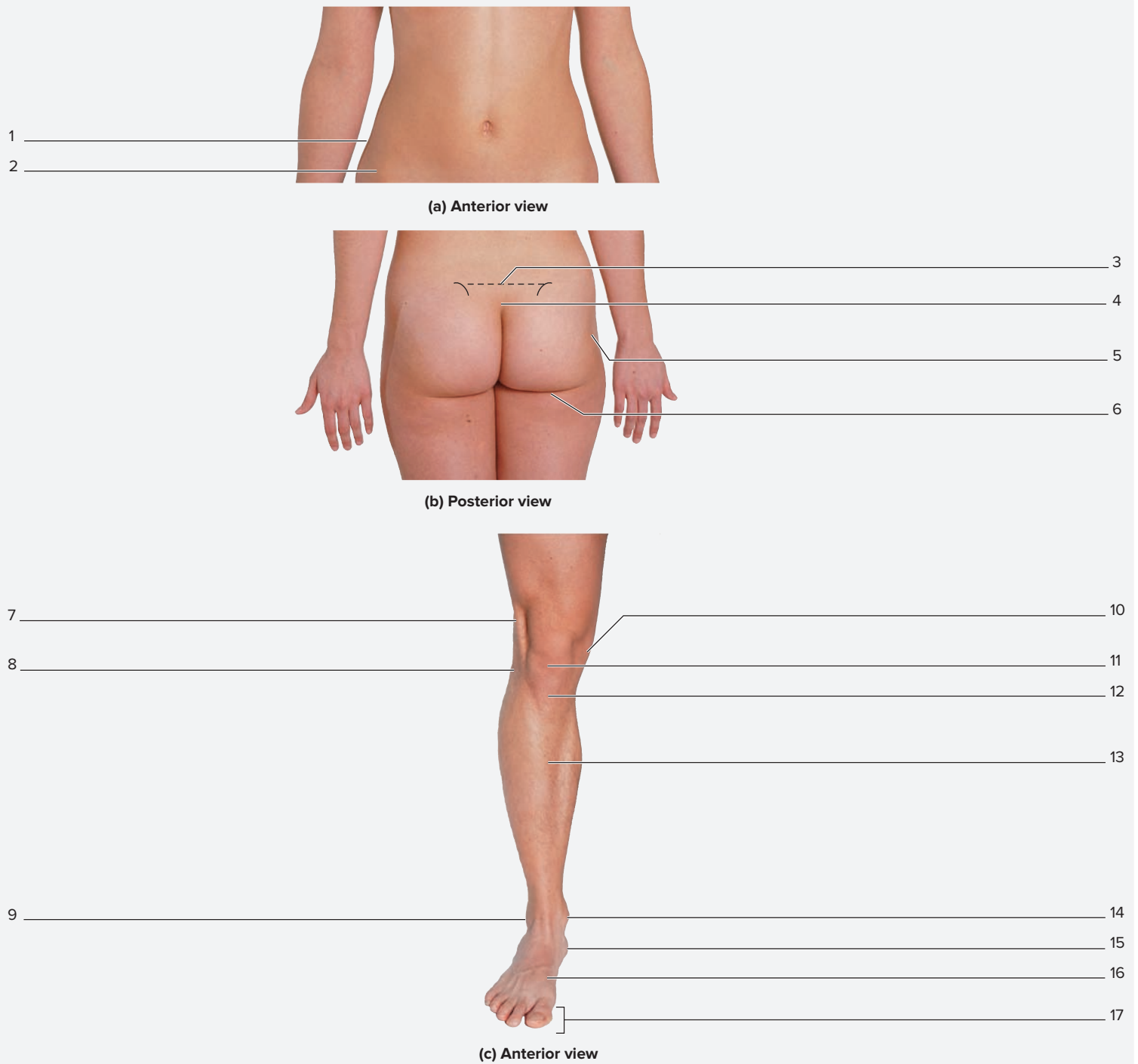
- proximal phalanx
- middle phalanx
- distal phalanx

**Tarsals**

- calcaneus
- cuboid
- intermediate cuneiform
- lateral cuneiform
- medial cuneiform
- navicular
- talus

**EXERCISE 9.6** Surface Anatomy Review—Pelvic Girdle and Lower Limb

1. Place your hands on your hips. The bony ridge felt under the skin is the **iliac crest**. The iliac crest is located at vertebral level L<sub>1</sub>/L<sub>2</sub>. Palpate anteriorly along the iliac crest until reaching the large bony projection on the anterior surface, the **anterior superior iliac spine**.
2. Palpate laterally along the iliac crest until the fingers are on the lateral aspect of the hip. Palpate the soft tissue of the gluteus medius muscle just inferior to the lateral portion of the iliac crest.
3. Continue to palpate inferiorly until another bony projection can be felt. This is the **greater trochanter of the femur**. Depending upon the amount of fat and muscle in the gluteal region, the **ischial tuberosities** deep within the posterior region of the buttocks may also be palpable.
4. Palpate the **patella** on the anterior aspect of the knee.
5. Place your thumb and pinky finger (fifth phalanx) on the medial and lateral aspects of the knee. Feel the large **medial and lateral epicondyles of the femur**.
6. Palpate the lateral epicondyle of the femur. Now move the fingers distally until the knoblike **head of the fibula** can be felt. While continuing to palpate distally, the shaft of the fibula will not be felt because of the fibularis muscles that overlie it.
7. Continue to palpate distally along the fibula toward the ankle joint until the **lateral malleolus** of the fibula in the ankle joint can be felt.
8. Palpate the patella once again. Distal to the patella on the anterior surface of the leg, is the **tibial tuberosity**. Continue to palpate distally along the tibia. Notice that the entire shaft of the bone can be felt because it is only covered with skin and a little bit of fat. The subcutaneous part of the tibia here is commonly referred to as the shin.
9. At the most distal end of the tibia, the **medial malleolus** of the tibia in the ankle joint can be palpated.
10. Palpate the large **calcaneus** in the heel. The talus and other tarsal bones are more difficult to palpate. However, if you wiggle the toes, the **metatarsal bones** and the **phalanges** can more easily be seen and palpated. As you palpate these bones, review their names. Recall that the first metatarsal is the metatarsal that lines up with the base of the big toe, or hallux, and the numbering continues, II through V, as you move toward the lateral aspect of the foot.
11. Label the surface anatomy structures in **figure 9.16**, using the textbook as a guide.



**Figure 9.16** Surface Anatomy of the Lower Limb. Use the terms listed to fill in the numbered labels in the figure.

- |  |   |   |  |
|--|---|---|--|
| <input type="checkbox"/> anterior superior iliac spine | <input type="checkbox"/> iliac crest              | <input type="checkbox"/> medial malleolus | <input type="checkbox"/> shaft of tibia    |
| <input type="checkbox"/> calcaneus                     | <input type="checkbox"/> ischial tuberosity       | <input type="checkbox"/> metatarsals      | <input type="checkbox"/> tibial tuberosity |
| <input type="checkbox"/> coccyx                        | <input type="checkbox"/> lateral condyle of femur | <input type="checkbox"/> patella          |  |
| <input type="checkbox"/> greater trochanter of femur   | <input type="checkbox"/> lateral malleolus        | <input type="checkbox"/> phalanges        |  |
| <input type="checkbox"/> head of fibula                | <input type="checkbox"/> medial condyle of femur  | <input type="checkbox"/> sacrum           |  |



*This page intentionally left blank*

# Chapter 9: The Skeletal System: Appendicular Skeleton

Name: \_\_\_\_\_

Date: \_\_\_\_\_ Section: \_\_\_\_\_

## POST-LABORATORY WORKSHEET

The 1 corresponds to the Learning Objective(s) listed in the chapter opener outline.

### Do You Know the Basics?

#### Exercise 9.1: Bones of the Pectoral Girdle

- The head of the humerus articulates with which bony landmark of the scapula? (Circle one.) 1
  - acromion
  - coracoid process
  - glenoid fossa
  - spine
  - suprascapular notch
- The only point of articulation between the pectoral girdle and the axial skeleton is the sternoclavicular joint. \_\_\_\_\_ (True/False) 2
- Match the bones listed in column A with the corresponding joint listed in column B. 1 2 3

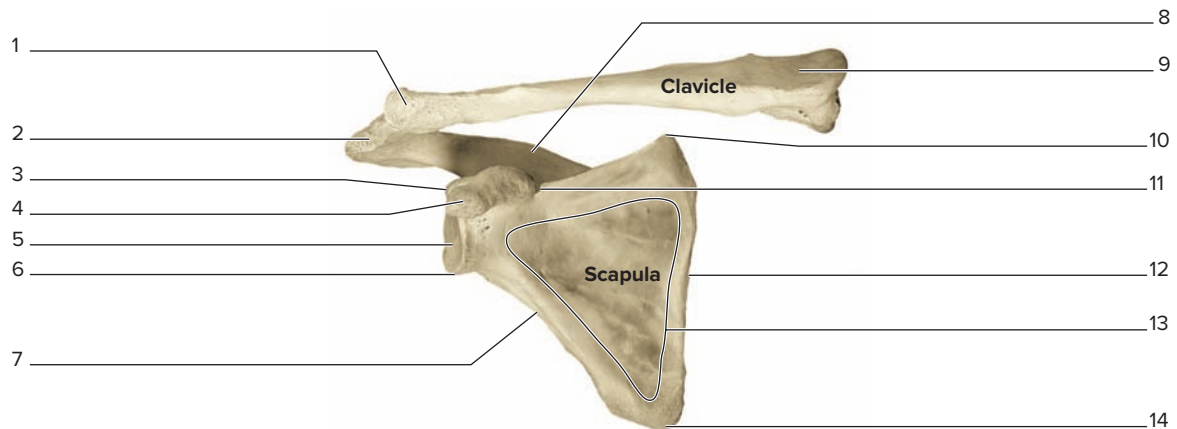
#### Column A

- \_\_\_\_\_ 1. clavicle and scapula
- \_\_\_\_\_ 2. humerus and ulna
- \_\_\_\_\_ 3. scapula and humerus
- \_\_\_\_\_ 4. ulna, radius, and carpal bones

#### Column B

- a. acromioclavicular joint
- b. elbow joint
- c. glenohumeral joint
- d. wrist joint

- Label the following diagram of an articulated shoulder girdle using the terms listed: 1 2



Right scapula and clavicle articulation, anterior view

© McGraw-Hill Education/Photos and Dissections by Christine Eckel

#### Scapula

- acromion
- coracoid process
- glenoid cavity
- inferior angle
- infraglenoid tubercle
- lateral border
- medial border
- spine
- subscapular fossa
- superior angle
- supraglenoid tubercle
- suprascapular notch

#### Clavicle

- acromial end
- sternal end

**Exercise 9.2: Bones of the Upper Limb**

5. Match the description listed in column A with the bone or marking listed in column B.
- 4**

**Column A**

- \_\_\_\_\_ 1. bone of the arm
- \_\_\_\_\_ 2. bone of the forearm that aligns with the thumb
- \_\_\_\_\_ 3. bone of the forearm that aligns with digit V (pinky finger)
- \_\_\_\_\_ 4. middle bone of the index finger
- \_\_\_\_\_ 5. part of the scapula that articulates with the humerus
- \_\_\_\_\_ 6. part of the scapula that articulates with the clavicle
- \_\_\_\_\_ 7. anterior projection of the scapula that resembles a crow's beak
- \_\_\_\_\_ 8. bone that articulates with both the sternum and scapula
- \_\_\_\_\_ 9. first bone composing the palm of the hand
- \_\_\_\_\_ 10. long bony ridge on the posterior aspect of the scapula
- \_\_\_\_\_ 11. bones of the wrist
- \_\_\_\_\_ 12. middle bone of the ring finger

**Column B**

- a. acromion
- b. carpals
- c. clavicle
- d. coracoid process
- e. glenoid cavity
- f. humerus
- g. metacarpal I
- h. middle phalanx II
- i. middle phalanx IV
- j. radius
- k. spine of scapula
- l. ulna

6. The anatomic name for the thumb is the pollex. \_\_\_\_\_ (True/False)
- 4**

7. Match the description listed in column A with the carpal bone listed in column B.
- 5**

**Column A**

- \_\_\_\_\_ 1. shaped like a half moon
- \_\_\_\_\_ 2. shaped like a "table" and located at the base of the *first* metacarpal (thumb)
- \_\_\_\_\_ 3. shaped like a "table" and located at the base of the *second* metacarpal (index finger)
- \_\_\_\_\_ 4. smallest carpal bone; shaped like a "pea"
- \_\_\_\_\_ 5. shaped like a hook and located at the base of the *fifth* metacarpal (pinky)

**Column B**

- a. hamate
- b. lunate
- c. pisiform
- d. trapezium
- e. trapezoid

**Exercise 9.3: Surface Anatomy Review—Pectoral Girdle and Upper Limb**

8. Which process of the scapula can be palpated at the tip of the shoulder? (Circle one.)
- 6**

- a. acromion
- b. coracoid
- c. infraglenoid tubercle
- d. spine
- e. supraglenoid tubercle

9. Match the description listed in column A with the bony landmark listed in column B.
- 6**

**Column A**

- \_\_\_\_\_ 1. forms the tip of the elbow
- \_\_\_\_\_ 2. process of the radius palpated at the wrist
- \_\_\_\_\_ 3. process of the ulna palpated on the medial aspect of the elbow

**Column B**

- a. medial epicondyle
- b. olecranon
- c. styloid process

**Exercise 9.4: Bones of the Pelvic Girdle**

10. Match the description listed in column A with the bone or marking listed in column B.
- 7**

**Column A**

- \_\_\_\_\_ 1. three bones fuse to form this bone of the pelvis
- \_\_\_\_\_ 2. bone that the pelvis rests on when sitting
- \_\_\_\_\_ 3. most anterior bone of the os coxa
- \_\_\_\_\_ 4. "hip" bone
- \_\_\_\_\_ 5. large hole in the os coxa
- \_\_\_\_\_ 6. structure that articulates with the femur at the hip

**Column B**

- a. acetabulum
- b. ilium
- c. ischium
- d. obturator foramen
- e. os coxa
- f. pubic bone

11. Identify the bones that form the os coxae. (Check all that apply.)
- 8**

- \_\_\_\_\_ a. coccyx
- \_\_\_\_\_ b. ilium
- \_\_\_\_\_ c. ischium
- \_\_\_\_\_ d. pubis
- \_\_\_\_\_ e. sacrum

**Exercise 9.5: Bones of the Lower Limb**

12. Match the bones listed in column A with the corresponding joint listed in column B. **9**

**Column A**

- \_\_\_\_\_ 1. os coxa and femur
- \_\_\_\_\_ 2. femur and tibia
- \_\_\_\_\_ 3. tibia, fibula, and talus

**Column B**

- a. ankle
- b. hip
- c. knee

13. The anatomic name for the big toe is talus. \_\_\_\_\_ (True/False) **9**

14. Match the description listed in column A with the tarsal bone listed in column B. **10**

**Column A**

- \_\_\_\_\_ 1. shaped like a “ship” and located anterior to the talus
- \_\_\_\_\_ 2. major weight-bearing bone that articulates with the tibia and fibula to form the ankle joint
- \_\_\_\_\_ 3. shaped like a “wedge” and located at the base of the first, second, and third metatarsals
- \_\_\_\_\_ 4. forms the heel

**Column B**

- a. calcaneus
- b. cuneiforms
- c. navicular
- d. talus

15. There are \_\_\_\_\_ (seven/eight) carpal bones and \_\_\_\_\_ (seven/eight) tarsal bones. **11**

**Exercise 9.6: Surface Anatomy Review—Pelvic Girdle and Lower Limb**

16. Match the description listed in column A with the bone or bony landmark listed in column B. **12**

**Column A**

- \_\_\_\_\_ 1. ridge of bone palpated when placing the hands on the hips
- \_\_\_\_\_ 2. palpated on the anterior part of the knee
- \_\_\_\_\_ 3. palpated on the lateral aspect of the knee
- \_\_\_\_\_ 4. palpated on the anterior leg, distal to the knee
- \_\_\_\_\_ 5. palpated on the medial aspect of the ankle
- \_\_\_\_\_ 6. palpated on the lateral aspect of the ankle
- \_\_\_\_\_ 7. palpated on the medial aspect of the knee

**Column B**

- a. iliac crest
- b. lateral epicondyle of the femur
- c. lateral malleolus of the fibula
- d. medial epicondyle of the femur
- e. medial malleolus of the tibia
- f. patella
- g. tibial tuberosity

**Can You Apply What You’ve Learned?**

17. What are the structural and functional differences between the anatomical and surgical necks of the humerus?

---



---



---

18. Construct a unique mnemonic to assist with recall of the carpal bones. Write the mnemonic here:

---



---



---

19. Compare and contrast both the appearance and the location of the carpal and tarsal bones.

---



---



---

20. Construct a unique mnemonic device to assist with recall of the tarsal bones. Write the mnemonic here:

---

---

---

21. List three of the features that help differentiate a male pelvis from a female pelvis.

**Male Pelvis**

**Female Pelvis**

- a. \_\_\_\_\_
- b. \_\_\_\_\_
- c. \_\_\_\_\_

- a. \_\_\_\_\_
- b. \_\_\_\_\_
- c. \_\_\_\_\_

22. What bone or bony process of the upper limb serves the same function as the patella in the lower limb? (Hint: The patella's function is to act as a lever. It forces the tendons of the muscles on the anterior surface of the thigh farther away from the center of rotation of the joint in order to give the muscles a greater mechanical advantage—greater leverage.) \_\_\_\_\_

23. Explain why one end of the clavicle is called the sternal end, and the other is called the acromial end.

---

---

---

**Can You Synthesize What You've Learned?**

24. What bony landmark of the upper limb is used as a reference point for locating the ulnar nerve at the elbow?

---

25. Which of the two necks of the humerus do you think is more likely to fracture in an accident? Why?

---

---

26. Observe the relationship between the carpal bones and the distal portion of the radius and ulna on an articulated skeleton. Which of the carpal bones do you think is most likely to fracture when someone falls on an outstretched hand?

---

27. Why do you think it is functionally important that the bones of the os coxae fuse together rather than remain independent bones?

---

---

28. A fracture to which of the leg bones (tibia or fibula) would result in the greatest loss of function of the lower limb? Why?

---

---

# Articulations

# 10

## OUTLINE AND LEARNING OBJECTIVES

### Gross Anatomy 194

#### Fibrous Joints 194

##### EXERCISE 10.1: FIBROUS JOINTS 194

- 1 Describe the structure of fibrous joints
- 2 Classify the three types of fibrous joints by structure and function (movement)
- 3 Give examples of places in the body where each type of fibrous joint is located

#### Cartilaginous Joints 195

##### EXERCISE 10.2: CARTILAGINOUS JOINTS 195

- 4 Describe the structure of cartilaginous joints
- 5 Classify the two types of cartilaginous joints by structure and function (movement)
- 6 Give examples of places in the body where each type of cartilaginous joint is located

#### Synovial Joints 196

##### EXERCISE 10.3: GENERAL STRUCTURE OF A SYNOVIAL JOINT 197

- 7 Identify the components of a synovial joint
- 8 Describe the functions of each component of a synovial joint

##### EXERCISE 10.4: CLASSIFICATION OF SYNOVIAL JOINTS 197

- 9 Describe the structural classifications of synovial joints
- 10 Give examples of places in the body where synovial joints are located

##### EXERCISE 10.5: PRACTICING SYNOVIAL JOINT MOVEMENTS 199

- 11 Demonstrate the movements that occur at synovial joints

##### EXERCISE 10.6: THE KNEE JOINT 200

- 12 Identify and describe the structures that compose the knee joint

## INTRODUCTION

When asked to name joints of the body, most people think of the ankle, knee, hip, wrist, elbow, and shoulder joints. However, the sutures between skull bones are also joints, as are the connections between the ribs and sternum. A joint, or **articulation** (*articulatio*, a forming of vines), is formed wherever one bone comes together with another bone. The study of joints is called **arthrology** (*arthron-*, a joint + *logos*, the study of). Joints are classified both by anatomic structure and by function. Joint classification based on structure reflects (1) whether a space called a joint cavity exists between the articulating bones, and (2) the type of connective tissue that holds the articulating surfaces of the bones together. The three *structural* categories of joints include fibrous joints, cartilaginous joints, and synovial joints. **Table 10.1** summarizes the structural (anatomical) classification of joints.

Joint classification based on function reflects the extent of movement permitted at the joint. The three functional categories of joints include synarthroses, which are immovable joints; amphiarthroses, which are slightly movable joints; and diarthroses, which are freely movable joints. **Table 10.2** summarizes the functional (movement) classification of joints.

The early exercises in this chapter provide an overview of fibrous and

cartilaginous joints. Later exercises focus on the details of synovial joints. The final laboratory exercises take an in-depth look at the structure and function of a representative synovial joint: the knee joint. All of the exercises in the chapter can be performed either on cadaver specimens or on joint models. The text is written as a guide to finding structures associated with each of the joints using resources that are available in the anatomy laboratory. Use the tables and figures provided in this manual, which contain detailed information about each type of joint, to guide laboratory observations.

#### List of Reference Tables

Table 10.1	Structural (Anatomic) Classification of Joints	p. 192
Table 10.2	Functional (Movement) Classification of Joints	p. 192
Table 10.3	Classification of Fibrous Joints	p. 194
Table 10.4	Classification of Cartilaginous Joints	p. 195
Table 10.5	Components of Synovial Joints	p. 197
Table 10.6	Structural Classification of Synovial Joints	p. 198
Table 10.7	Movements of Synovial Joints	p. 199
Table 10.8	Structures of the Knee Joint	p. 200

Table 10.1 Structural (Anatomic) Classification of Joints			
Type of Joint	Description	Examples	Word Origins
<i>Cartilaginous</i>	Bone connected to bone by cartilage.	Pubic symphysis	<i>cartilago</i> , cartilage
<i>Fibrous</i>	Bone connected to bone by collagen fibers.	Skull suture	<i>fibra</i> , fiber
<i>Synovial</i>	A complex structure involving a joint cavity lined with a synovial membrane.	Hip, knee, shoulder	<i>syn-</i> , together + <i>ova</i> , egg

Table 10.2 Functional (Movement) Classification of Joints			
Type of Joint	Description	Examples	Word Origins
<i>Synarthrosis</i>	An immobile joint.	Skull suture and tooth gomphosis	<i>syn-</i> , together + <i>arthron</i> , a joint
<i>Amphiarthrosis</i>	A slightly mobile joint.	Pubic symphysis	<i>amphi-</i> , on both sides + <i>arthron</i> , a joint
<i>Diarthrosis</i>	A freely mobile joint.	All synovial joints	<i>di-</i> , two + <i>arthron</i> , a joint

These Pre-laboratory Worksheet questions may be assigned by instructors through their **connect** course.

## PRE-LABORATORY WORKSHEET

1. An interosseous membrane is an example of a \_\_\_\_\_ joint. (Circle one.)

- \_\_\_\_\_ a. sutural
- \_\_\_\_\_ b. diarthrosis
- \_\_\_\_\_ c. syndesmosis
- \_\_\_\_\_ d. synarthrosis
- \_\_\_\_\_ e. synovial

2. Which of the following terms is used in the *functional* classification of an immobile joint? (Circle one.)

- a. cartilaginous
- b. diarthrosis
- c. fibrous
- d. synarthrosis
- e. synovial

3. Match the description of the fibrous joint listed in column A with the fibrous joint classification listed in column B.

### Column A

- \_\_\_\_\_ 1. between skull bones
- \_\_\_\_\_ 2. distal radioulnar or tibiofibular joints
- \_\_\_\_\_ 3. between alveolar processes of maxilla or mandible and the root of a tooth

### Column B

- a. gomphosis
- b. suture
- c. syndesmosis

4. Which of the following is classified as a synchondrosis joint? (Check all that apply.)

- \_\_\_\_\_ a. epiphyseal plate
- \_\_\_\_\_ b. intervertebral disc
- \_\_\_\_\_ c. public symphysis
- \_\_\_\_\_ d. sternocostal joint

5. Fibrous and cartilaginous joints may be classified based on movement as synarthrotic joints, amphiarthrotic joints, or diarthrotic joints.

\_\_\_\_\_ (True/False)

6. Based on movement allowed, all synovial joints are classified as \_\_\_\_\_. (Circle one.)

- a. amphiarthroses
- b. diarthroses
- c. synarthroses

7. There is a(n) \_\_\_\_\_ (direct/indirect) relationship between mobility and stability of a joint. Therefore, an increase in mobility leads to a(n) \_\_\_\_\_ (increase/decrease) in stability of the joint.

8. The joint formed between the humerus and the ulna is an example of a \_\_\_\_\_ joint. (Circle one.)

- a. ball-and-socket
- b. condylar
- c. hinge
- d. pivot
- e. plane

9. To adduct a limb is to move the limb away from the midline. \_\_\_\_\_ (True/False)

10. The components of the knee joint include the articular cartilages. Because of this, the knee joint is classified as a cartilaginous joint.

\_\_\_\_\_ (True/False)



## Gross Anatomy

### Fibrous Joints

**Fibrous joints** are characterized by having no joint cavity. Rather, fibrous connective tissue binds the neighboring bones. Functionally, fibrous joints are classified into two types that are immovable joints (gomphoses and

sutures) and one type that is slightly movable (syndesmoses; **table 10.3**). When working through the structural classifications of joints in subsequent exercises, also practice using the functional terms from table 10.1 to describe the movement allowed at each joint.

#### EXERCISE 10.1 Fibrous Joints

- Gomphosis** – Observe the maxilla and mandible on a skull or on an articulated skeleton. The joints between the teeth and their sockets are **gomphosis** joints (*gomphos-*, nail + *osis*, condition) (see table 10.3). The teeth might be very loose (or absent) in the skeleton because the **periodontal membrane** that normally holds them tightly in place was destroyed when the skeleton was prepared. If the skull has some empty tooth sockets (alveolar processes), observe the shape of the inside of the socket that the cone-shaped root of the tooth fits into. How is a gomphosis classified based on the amount of *movement* allowed? \_\_\_\_\_
- Suture** – Observe a skull on an articulated skeleton or by itself. Observe the numerous **sutures** (*sutura*, a seam) between the cranial bones. Notice how tightly the bones fit together. In a preserved skeleton, the sutural joints may be somewhat loose because the membranous connective tissue that normally holds the bones together was destroyed when the skeleton was prepared. However, in a living adult the skull bones are held tightly together by membranous connective tissue that lies in the spaces between the bones, and also by the interlocking shapes of the articulating bones. Recall that the flat bones of the skull form by **intramembranous ossification**. The fibrous connective

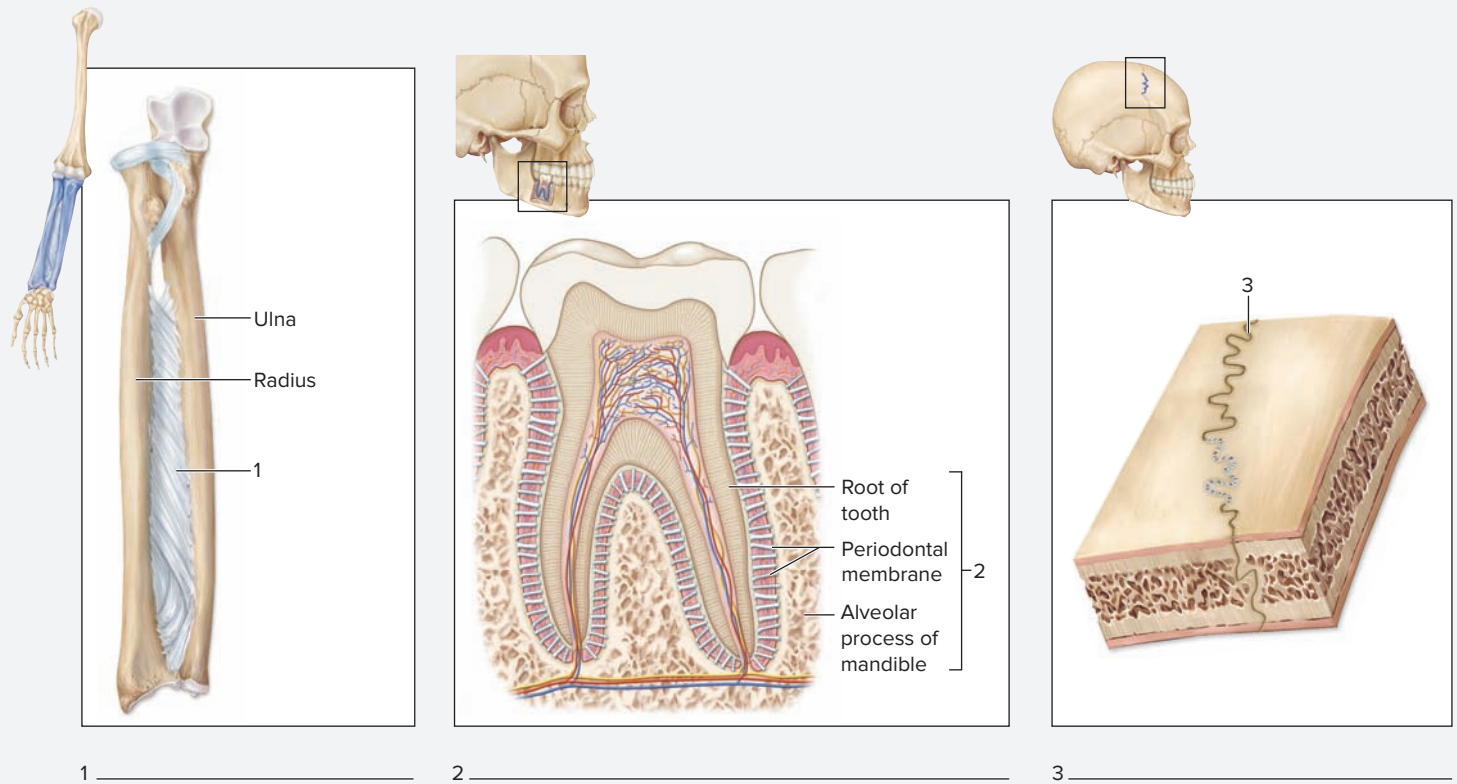
tissue within the sutures is a remnant of the original membrane that served as the structural framework for the developing bones. How is a sutural joint classified based on the amount of *movement* allowed? \_\_\_\_\_

- Syndesmosis** – Observe the radius and ulna on an articulated skeleton. Even though the articulated skeleton no longer contains a **syndesmosis** (*syn-*, together + *desmos*, a band) joint (it was destroyed during preparation of the skeleton), the movement at the distal radioulnar joint can still be observed. Take hold of the radius and ulna, and then move the bones to mimic the actions of supination and pronation of the forearm. Notice how the radius pivots around the ulna during this motion. In a living human, these two bones are anchored to each other by an **interosseous membrane** (**figure 10.1**), which composes the syndesmosis between these two bones. This membrane also contributes to the connective tissue that separates the forearm into anterior and posterior compartments. How is a syndesmosis classified based on the amount of *movement* allowed? \_\_\_\_\_
- Label the types of fibrous joints in figure 10.1, using table 10.3 and the textbook as guides.

**Table 10.3**

**Classification of Fibrous Joints**

Fibrous Joints	Structure and Description	Examples	Word Origins
<i>Gomphosis</i>	Consists of a cone-shaped peg fitting into a socket and anchored by the periodontal membrane.	Teeth articulating with alveolar processes of mandible or maxilla	<i>gomphos-</i> , nail + <i>osis</i> , condition
<i>Suture</i>	Found exclusively between skull bones; consists of a small amount of connective tissue (the sutural ligament) holding the bone surfaces together.	Lambdoid suture, sagittal suture	<i>sutura</i> , a seam
<i>Syndesmosis</i>	Consists of large surfaces of bones that are anchored together by a connective tissue membrane called an interosseous membrane.	Distal radioulnar joint; distal tibiofibular joint	<i>syn-</i> , together + <i>desmos</i> , a band



**Figure 10.1 Fibrous Joints.** Use the terms listed to fill in the numbered labels in the figure.

gomphosis

suture

syndesmosis

## Cartilaginous Joints

**Cartilaginous joints** are characterized by having no joint cavity. Rather, some sort of cartilage binds the neighboring bones. Cartilaginous joints are

classified based on the type of cartilage found in the joint. Synchondroses have hyaline cartilage and symphyses have fibrocartilage (**table 10.4**).

### EXERCISE 10.2 Cartilaginous Joints

#### EXERCISE 10.1A: Synchondrosis

A **synchondrosis** (*syn-*, together + *chondrion*, cartilage) consists of bone connected to bone with **hyaline cartilage**. Examples are the sternocostal joints (the joints between the ribs and sternum) and the epiphyseal plates. Synchondroses should not be confused with synovial joints (or vice versa). Although synovial joints have hyaline cartilage as *part* of their structure (the articular cartilages), that cartilage is not the *only* thing found in between the bones.

1. Observe the articulations between the ribs and sternum (the sternocostal joints) on an articulated skeleton. On the articulated skeleton, the “cartilage” between the ribs and sternum is some sort of replacement material such as plastic or rubber. In a living human, this would be hyaline cartilage.
2. Attempt to move the bones at one of the synchondroses of the articulated skeleton.

**Table 10.4** Classification of Cartilaginous Joints

Cartilaginous Joints	Structure and Description	Examples	Word Origins
<i>Symphysis</i>	Consists of bone connected to bone by fibrocartilage.	Pubic symphysis; intervertebral discs	<i>symphysis</i> , a growing together
<i>Synchondrosis</i>	Consists of bone connected to bone by hyaline cartilage.	Sternocostal joints; epiphyseal plates	<i>syn-</i> , together + <i>chondrion</i> , cartilage

(continued on next page)

(continued from previous page)

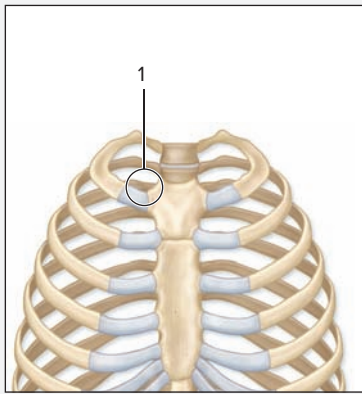
3. How are sternocostal joints classified based on the amount of movement allowed? \_\_\_\_\_

**EXERCISE 10.1B: Symphysis**

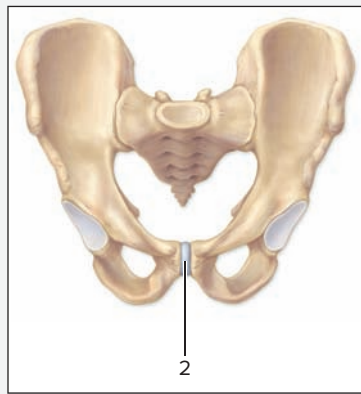
A symphysis joint consists of bone connected to bone with **fibrocartilage**. Examples are the pubic symphysis and the intervertebral discs. The intervertebral discs have a more complex structure than the pubic symphysis. They consist of an outer band of fibrocartilage, the **annulus fibrosus**, which surrounds a gel-like interior, the **nucleus pulposus**. A “ruptured,” “herniated,” or “slipped” disc occurs when the annulus fibrosus tears and the nucleus pulposus leaks out. The leaked

nucleus pulposus can compress nerve fibers and cause neurological problems such as pain and numbness.

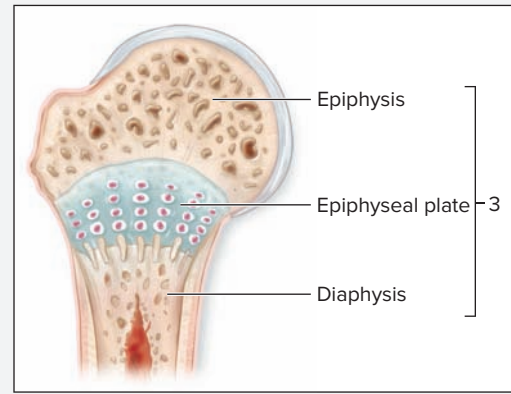
1. Observe the **pubic symphysis** and the **intervertebral discs** on the articulated skeleton. On the articulated skeleton, the “cartilage” is some sort of replacement material. In a living human this would be fibrocartilage.
2. How is a symphysis joint classified based on the amount of movement allowed? \_\_\_\_\_
3. Label the types of cartilaginous joints shown in **figure 10.2**, using table 10.4 and the textbook as a guide.



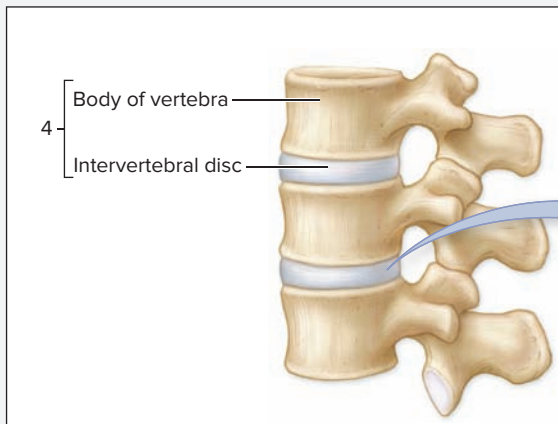
1 \_\_\_\_\_



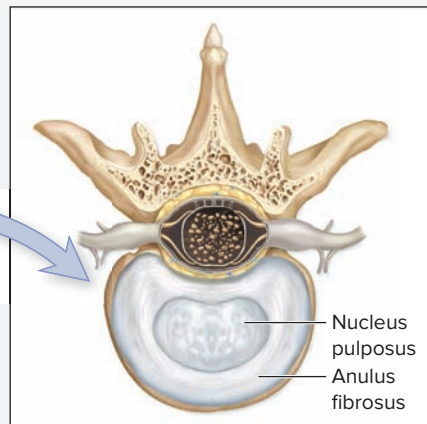
2 \_\_\_\_\_



3 \_\_\_\_\_



4 \_\_\_\_\_



**Figure 10.2 Cartilaginous Joints.** Use the terms listed to fill in the numbered labels in the figure. Some terms may be used more than once.

symphysis

synchondrosis

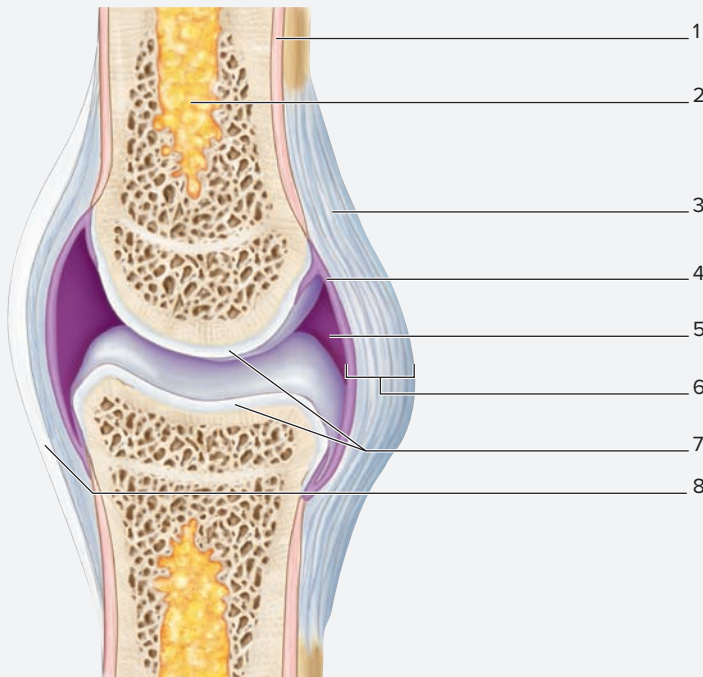
**Synovial Joints**

**Synovial joints** have a complex structure that includes a joint cavity filled with fluid. The term *synovial* literally means, “together with egg” (*syn-*, together + *ovum*, egg). This term refers to the fluid inside the joint (the synovial fluid), which has the consistency and appearance of

egg white. The joint cavity filled with synovial fluid allows the articulating bones to move easily past one another with very little friction in between the bones. Synovial joints are covered in detail in the next several exercises. These exercises include the general structure of a synovial joint, categories of synovial joints, and the specific types of movements allowed by synovial joints.

**EXERCISE 10.3** General Structure of a Synovial Joint

1. Observe a model of a synovial joint, preferably a model of the knee joint.
2. Identify the features of a typical synovial joint listed in **figure 10.3** on the model, using **table 10.5** and the textbook as guides. Then label them in figure 10.3.



**Figure 10.3** General Structure of a Synovial Joint. Use the terms listed to fill in the numbered labels in the figure.

- articular capsule
- articular cartilage
- fibrous layer of articular capsule
- ligament
- periosteum
- synovial (joint) cavity
- synovial membrane
- yellow bone marrow

3. *Optional Activity:* **AP|R** **Skeletal System**—Watch the “Synovial joint” animation for a summary of synovial joint structure and types.

Table 10.5 Components of Synovial Joints		
Structure	Description	Word Origins
<b>Articular Capsule</b>	Consists of two layers: an outer fibrous capsule and an inner synovial membrane.	<i>arthron</i> , a joint + <i>capsa</i> , a box
<b>Articular Cartilages</b>	Hyaline cartilage found on the epiphyses of the articulating bones.	<i>arthron</i> , a joint
<b>Bursae and Tendon Sheaths (most joints)</b>	Either small, round sacs (bursae) or elongated structures that wrap around tendons (tendon sheaths); lined with synovial membrane and filled with synovial fluid; function to reduce friction between joint structures.	<i>bursa</i> , a purse
<b>Fibrous Layer of Articular Capsule</b>	A dense irregular connective tissue that anchors the two articulating bones to each other; anchors to the periosteum of the articulating bones; thickenings of the fibrous capsule form several joint ligaments.	<i>fibra</i> , fiber
<b>Menisci (some joints)</b>	Crescent-shaped pads of fibrocartilage found within the joint that provide cushioning between the articulating bones.	<i>meniskos</i> , crescent
<b>Synovial Cavity</b>	A cavity within the joint that is lined with synovial membrane and filled with synovial fluid.	<i>syn-</i> , together + <i>ovum</i> , egg + <i>cavus</i> , hollow
<b>Synovial Fluid</b>	A very slippery fluid consisting of hyaluronic acid and other glycoproteins; primary function is to reduce friction in the joint.	<i>syn-</i> , together + <i>ovum</i> , egg + <i>fluidus</i> , to flow
<b>Synovial Membrane</b>	A thin connective tissue membrane that lines all structures within the joint, including intra-articular ligaments; responsible for the formation of synovial fluid.	<i>syn-</i> , together + <i>ovum</i> , egg + <i>membrana</i> , a skin

**EXERCISE 10.4** Classification of Synovial Joints

Synovial joints are classified using several different methods, most of which involve a description of the shape of the bones and the movement allowed at the joint (**table 10.6**). For example, in a ball-and-socket joint the “ball” (rounded) part of one bone fits into the “socket” (concave) part of another bone.

1. Observe an articulated skeleton to observe the following examples of synovial joints.
  - A. **Ball-and-Socket Joint**—Observe the ball-and-socket joint between the femur and the os coxae in **figure 10.4**.

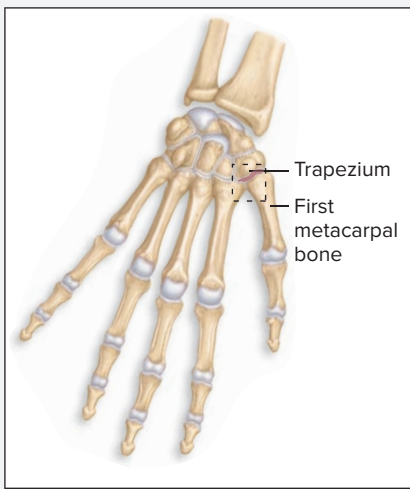
Now observe how the head of the femur articulates with the os coxae on an articulated skeleton. Notice that the head of the femur (“the ball”) fits into the acetabulum (“the socket”). What other joint in the body is also a ball-and-socket joint? \_\_\_\_\_

- B. **Condylar (Ellipsoid) Joint**—Observe the condylar joint between a metacarpal and proximal phalanx in figure 10.4. Now observe this joint on an articulated skeleton. Notice the shape of the two articulating

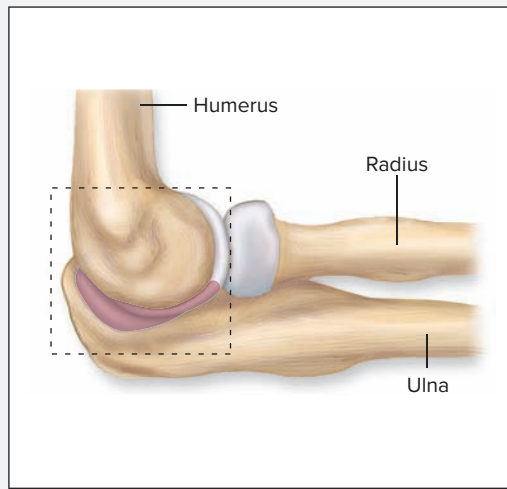
(continued on page 199)

(continued from previous page)

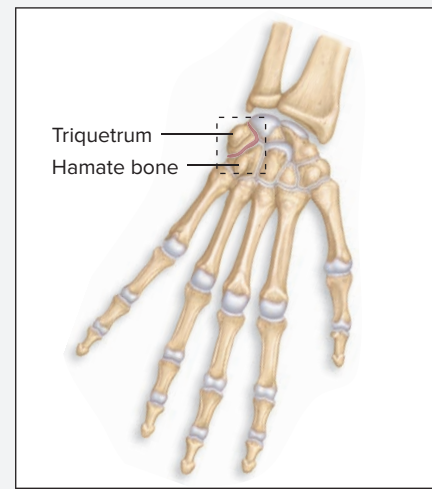
Table 10.6 Structural Classification of Synovial Joints			
Surface Shape	Structure and Description	Examples	Word Origins
<b>Ball-and-Socket</b>	Formed when a spherical head fits into a concave socket.	Hip joint; shoulder joint	<i>ball</i> , a round mass + <i>soccus</i> , a shoe or sock
<b>Condylar (Ellipsoid)</b>	Formed when a convex oval surface fits into an elliptical concavity.	Radiocarpal joints; metacarpophalangeal joints	<i>kondylos</i> , knuckle, or <i>ellips-</i> , oval + <i>eidos</i> , form
<b>Hinge (ginglymoid)</b>	Formed when a convex surface fits into a concave surface and only allows movement along a single plane.	Knee joint; elbow joint	<i>ginglymos</i> , a hinge joint
<b>Pivot</b>	Formed when a round surface fits into a ring formed by a ligament and a depression in another bone.	Atlantoaxial joint	<i>pivot</i> , a post upon which something turns
<b>Plane (Gliding)</b>	Formed when two flat surfaces come together.	Intermetatarsal joints; some intercarpal joints	<i>planus</i> , flat
<b>Saddle (Sellar) Joints</b>	Formed when bones having both concave and convex surfaces come together such that the concave surfaces are at right angles to each other.	Carpometacarpal joint of the thumb; ankle joint; calcaneocuboid joint	<i>sella</i> , saddle



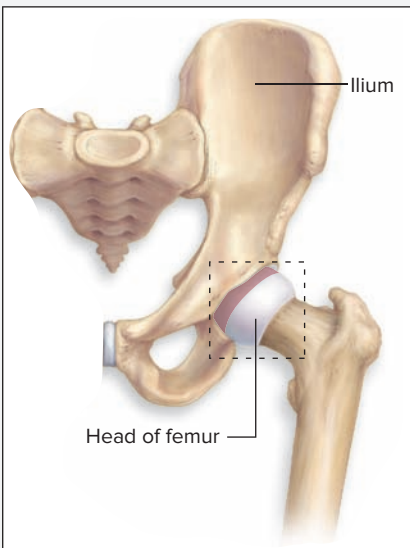
1 \_\_\_\_\_



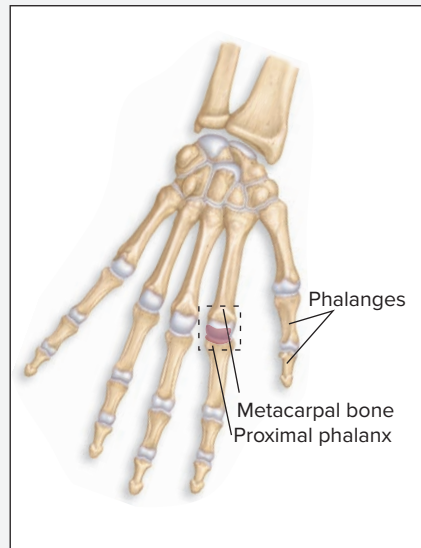
2 \_\_\_\_\_



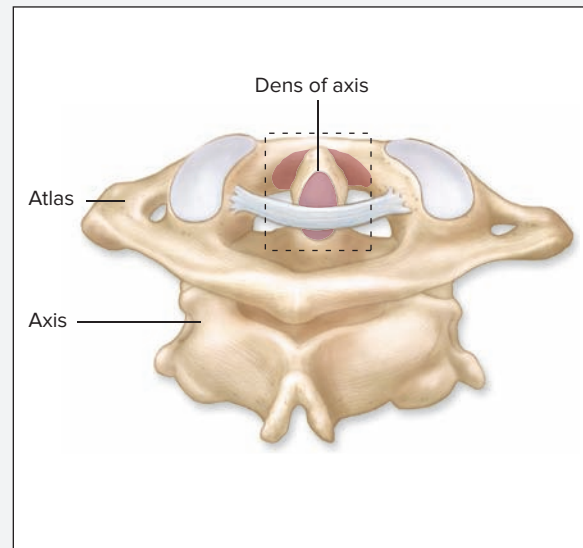
3 \_\_\_\_\_



4 \_\_\_\_\_



5 \_\_\_\_\_



6 \_\_\_\_\_

**Figure 10.4 Structural Classifications of Synovial Joints.** Use the terms listed to fill in the numbered labels in the figure.

- |  |                                |                                 |
|--|--------------------------------|---------------------------------|
| <input type="checkbox"/> ball-and-socket | <input type="checkbox"/> hinge | <input type="checkbox"/> plane  |
| <input type="checkbox"/> condylar        | <input type="checkbox"/> pivot | <input type="checkbox"/> saddle |

(continued from page 197)

bones. The bone with the convex oval surface is the \_\_\_\_\_ and the bone with the elliptical concavity is the \_\_\_\_\_.

- C. **Hinge Joint**—Observe the hinge joint between the humerus and ulna in figure 10.4. Now observe this joint on an articulated skeleton. The bone with the convex oval surface is the \_\_\_\_\_ and the bone with the concave surface is the \_\_\_\_\_.

- D. **Pivot Joint**—Observe the pivot joint between the dens of the axis and the atlas in figure 10.4. Now observe this joint on an articulated skeleton. The bone with the round surface is the \_\_\_\_\_ and the bone with the “ring” is the \_\_\_\_\_.

- E. **Plane Joint**—Observe the plane joint between two carpal bones in figure 10.4. Now observe this joint on an articulated skeleton. What other joints in the foot are plane joints? \_\_\_\_\_

- F. **Saddle Joint**—Observe the saddle joint at the base of the thumb in figure 10.4. Now observe this joint on an articulated skeleton. The two bones that have both a concave and a convex surface are the \_\_\_\_\_ and \_\_\_\_\_.

- Identify the synovial joints in figure 10.4, using table 10.6 and the textbook as guides.
- Identify the joints in figure 10.4 on the articulated skeleton, using table 10.6 and the textbook as guides. Then label each type of joint in figure 10.4.

### EXERCISE 10.5 Practicing Synovial Joint Movements

- All synovial joints are classified as **diarthrotic** (*di-*, two + *arthron*, a joint) because they are freely movable. There are different types of movement possible with the various

types of synovial joints. **Table 10.7** summarizes the types of movements possible at synovial joints.

Movement	Description	Opposite Movement	Word Origins
<b>Abduction</b>	Movement of a body part away from the midline.	Adduction	<i>ab-</i> , from + <i>duco</i> , to lead
<b>Adduction</b>	Movement of a body part toward the midline.	Abduction	<i>ad-</i> , toward + <i>duco</i> , to lead
<b>Circumduction</b>	Movement of the distal part of an extremity in a circle.	NA	<i>circum-</i> , around + <i>duco</i> , to lead
<b>Depression</b>	Movement of a body part inferiorly.	Elevation	<i>depressio</i> , to press down
<b>Dorsiflexion</b>	Movement of the ankle such that the foot moves toward the dorsum (back).	Plantar flexion	<i>dorsum-</i> , the back + <i>flexus</i> , to bend
<b>Elevation</b>	Movement of a body part superiorly.	Depression	<i>e-levo-atu</i> s, to lift up
<b>Eversion</b>	Movement of the ankle such that the plantar surface of the foot faces laterally.	Inversion	<i>e-</i> , out + <i>versus</i> , to turn
<b>Extension</b>	An increase in joint angle.	Flexion	<i>extensio</i> , a stretching out
<b>Flexion</b>	A decrease in joint angle.	Extension	<i>flexus</i> , to bend
<b>Inversion</b>	Movement of the ankle such that the plantar surface of the foot faces medially.	Eversion	<i>in-</i> , inside + <i>versus</i> , to turn
<b>Opposition</b>	Placement of the thumb (pollex) such that it crosses the palm of the hand and can touch all of the remaining digits.	Reposition	<i>op-</i> , against + <i>positio</i> , a placing
<b>Plantar Flexion</b>	Movement of the ankle such that the foot moves toward the plantar surface.	Dorsiflexion	<i>plantaris</i> , the sole of the foot + <i>flexus</i> , to bend
<b>Pronation</b>	Movement of the palm from anterior to posterior.	Supination	<i>pronatus</i> , to bend forward
<b>Protraction</b>	Movement of a body part anteriorly (especially: mandible and scapula).	Retraction	<i>pro-</i> , before + <i>tractio</i> , to draw
<b>Reposition</b>	Movement of the thumb to anatomic position after opposition.	Opposition	<i>re-</i> , backward + <i>positio</i> , a placing
<b>Retraction</b>	Movement of a body part posteriorly (especially, mandible and scapula).	Protraction	<i>re-</i> , backward + <i>tractio</i> , to draw
<b>Rotation</b>	Movement of a body part around its axis.	NA	<i>rotatio</i> , to rotate
<b>Supination</b>	Movement of the palm from posterior to anterior.	Pronation	<i>supinatus</i> , to bend backward

(continued on next page)

(continued from previous page)

- Practice all of the movements listed in table 10.7 with a laboratory partner to ensure an understanding of each movement such that you can demonstrate or describe them all. This knowledge is critically important for success in the later chapters of the laboratory manual that cover muscle actions. Muscle actions are described in terms of joint movements. The ability to describe the movement of a joint makes memorization of muscle

actions unnecessary. It also helps with the naming of muscles themselves (e.g., extensor digitorum = muscle that extends the digits). If you are able to describe the movement of the joint, you will also be able to describe the action of a muscle that acts about the joint.

- Optional Activity: AP|R Skeletal System**—Review the series of joint movement animations to see examples of multiple movements at each joint.

## EXERCISE 10.6 The Knee Joint

This exercise involves observation of the structure of the knee joint, a representative synovial joint. The knee joint is complex, as are most synovial joints. It contains several modifications such as bursae, tendon sheaths, and menisci that are often associated with synovial joints. The knee joint also contains several strong ligaments, which help to stabilize the joint. **Table 10.8** summarizes the structures composing the knee joint.

Most individuals have some peripheral knowledge of the knee joint, having known individuals who have suffered a ruptured ACL, torn meniscus, or other knee injury, even if they have very little knowledge of the anatomy of the knee. The ACL (anterior cruciate ligament) is one of two **cruciate ligaments** (*cruciatus*, resembling a cross) found in the knee joint, and a ruptured ACL is

a knee injury that is common in football players, downhill skiers, or others involved in contact sports.

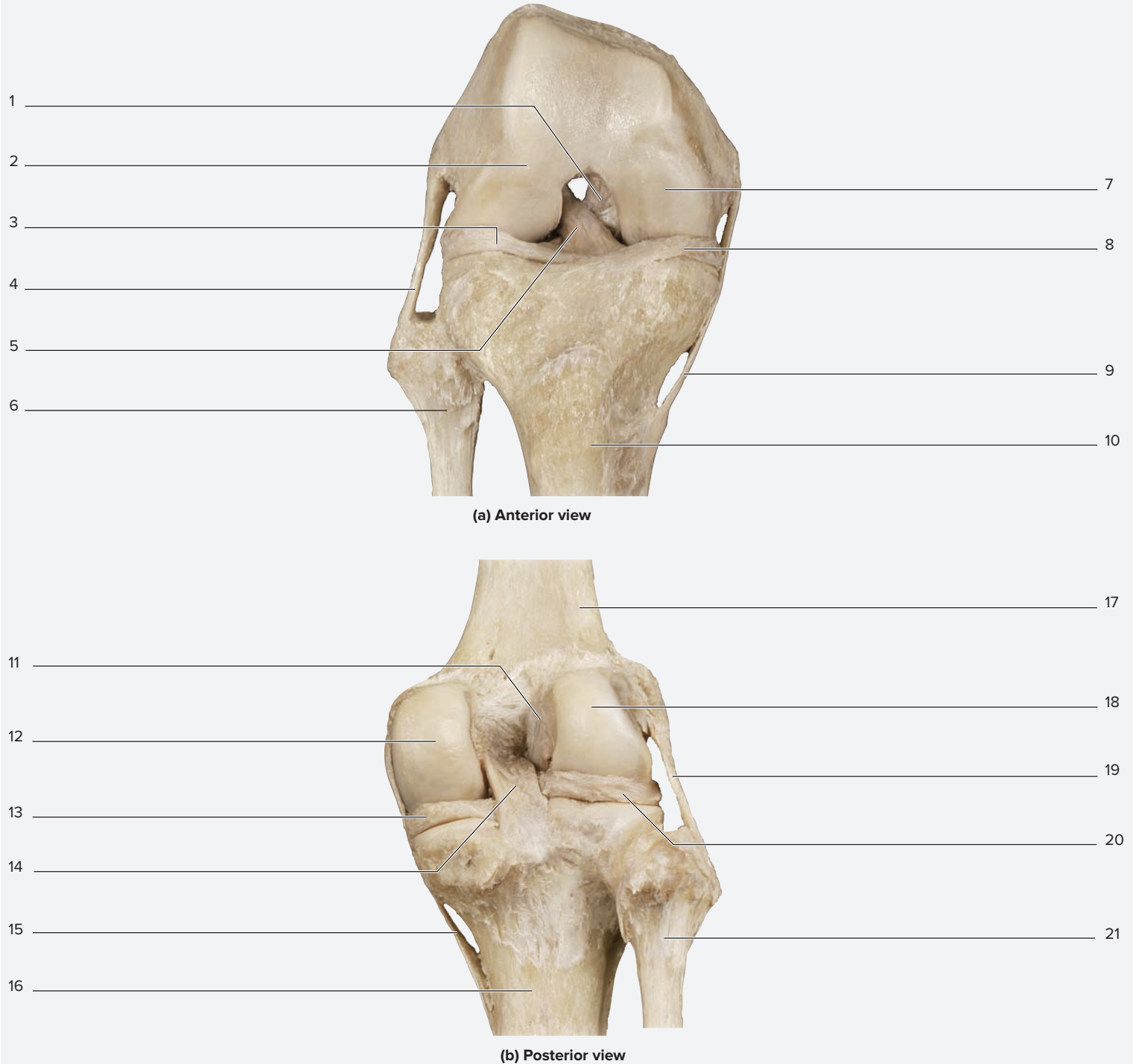
- Observe a model of the knee joint or the knee joint of a cadaver.
- The knee joint is actually two joints: the **tibiofemoral joint**, which is classified as a synovial hinge joint that acts in flexion and extension (though it allows for some rotational movement as well), and the **patellofemoral joint**, which is classified as a planar (gliding) joint. The bony structure of the tibiofemoral joint includes the medial and lateral femoral condyles, which sit on top of the medial and lateral tibial condyles. The bony structure of the patellofemoral

**Table 10.8** Structures of the Knee Joint

	Description	Word Roots
<b>Ligaments</b>		
<i>Anterior Cruciate Ligament</i>	Connects the anterior intercondylar eminence of the tibia to the medial surface of the lateral condyle of the femur.	<i>ante</i> , in front of + <i>cruciatus</i> , shaped like a cross
<i>Fibular (Lateral) Collateral Ligament</i>	Connects the lateral epicondyle of the femur to the head of the fibula.	<i>co-</i> , together + <i>latus</i> , side
<i>Patellar Ligament</i>	Connects the patella to the tibial tuberosity.	<i>patina</i> , a shallow disk
<i>Posterior Cruciate Ligament</i>	Connects the posterior intercondylar eminence of the tibia to the anterior part of the lateral surface of the medial condyle of the femur.	<i>post</i> , behind + <i>cruciatus</i> , shaped like a cross
<i>Tibial (Medial) Collateral Ligament</i>	Connects the medial epicondyle of the femur to the medial surface of the tibia; its deep surface is anchored to the medial meniscus.	<i>co-</i> , together + <i>latus</i> , side
<b>Menisci</b>		
<i>Lateral Meniscus</i>	A crescent-shaped pad of fibrocartilage located between the lateral condyle of the femur and the lateral condyle of the tibia.	<i>meniskos</i> , crescent
<i>Medial Meniscus</i>	A crescent-shaped pad of fibrocartilage located between the medial condyle of the femur and the medial condyle of the tibia.	<i>meniskos</i> , crescent
<b>Bursae</b>		
<i>Infrapatellar Bursa</i>	Located between the proximal tibia and the patellar ligament.	<i>infra-</i> , below + <i>patina</i> , a shallow disc + <i>bursa</i> , a purse
<i>Prepatellar Bursa</i>	Located between the patella and the overlying skin.	<i>pre-</i> , before + <i>patina</i> , a shallow disc + <i>bursa</i> , a purse
<i>Suprapatellar Bursa</i>	Located between the distal femur and the quadriceps femoris tendon; communicates with the synovial cavity of the knee joint.	<i>supra-</i> , on the upper side, <i>patina</i> , a shallow disc + <i>bursa</i> , a purse
<b>Tendon</b>		
<i>Quadriceps Femoris Tendon</i>	Connects the quadriceps femoris muscle to the patella.	<i>quad</i> , four + <i>femoris</i> , femur

joint includes the patellar surface of the femur, which consists of the smooth anterior surface between the femoral condyles, and the medial and lateral facets of the patella.

3. Identify the structures listed in **figure 10.5** on the model of the knee joint, using table 10.8 and the textbook as guides. Then label them in figure 10.5.



**Figure 10.5** A Representative Synovial Joint: The Right Knee Joint. Use the terms listed to fill in the numbered labels in parts (a), (b), and (c) in the figure. Some terms may be used more than once.

**Bones and Markings**

- femur
- fibula
- lateral condyle of femur
- medial condyle of femur
- patella

- quadriceps femoris tendon

**Ligaments**

- tibia
- anterior cruciate ligament
- fibular collateral ligament
- patellar ligament

- posterior cruciate ligament
- tibial collateral ligament

**Menisci**

- lateral meniscus
- medial meniscus

**Bursae and tendon sheaths**

- infrapatellar bursa

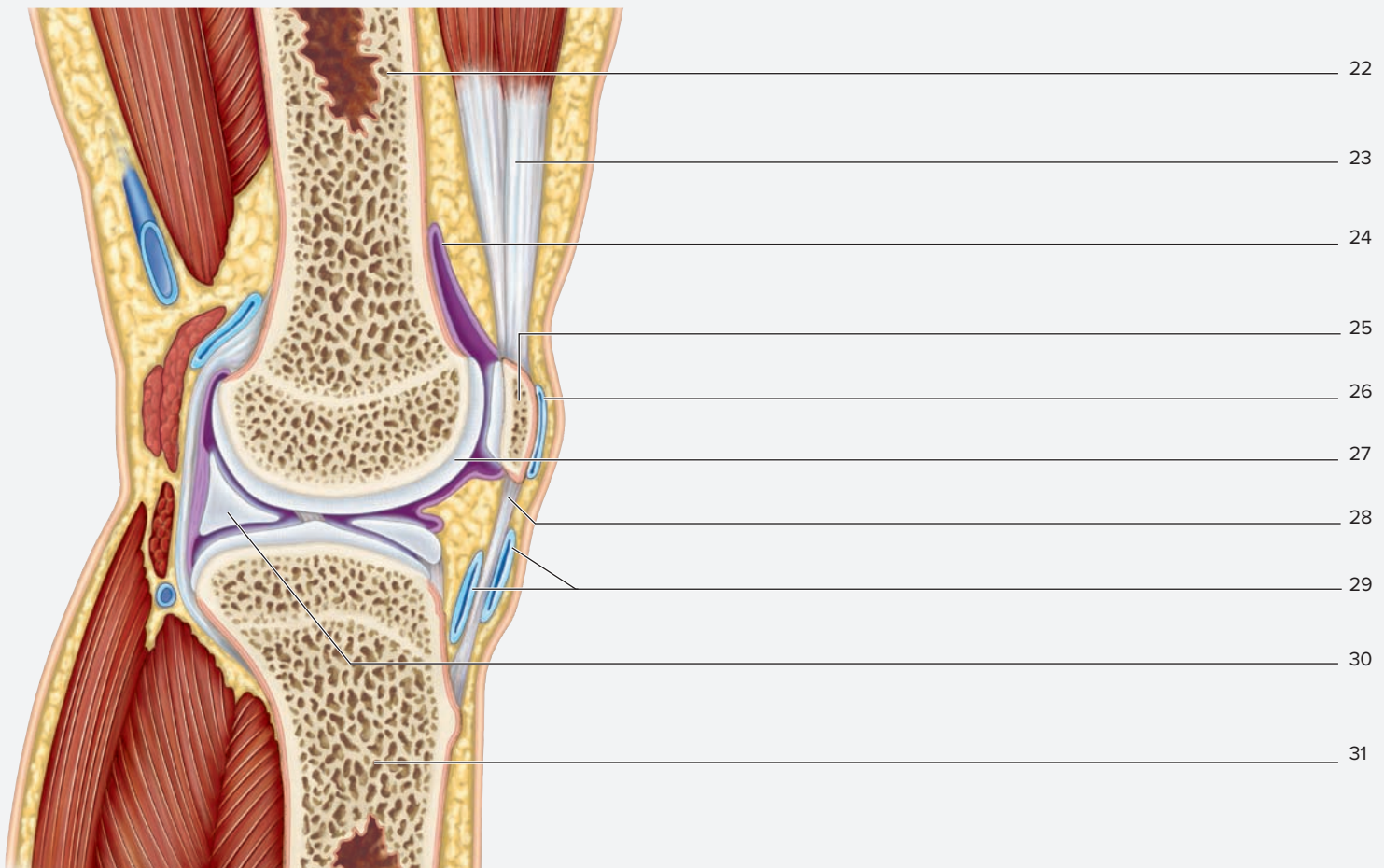
- prepatellar bursa
- suprapatellar bursa

**Other**

- articular cartilage
- quadriceps femoris tendon



(continued from previous page)



(c) Sagittal section

**Figure 10.5** A Representative Synovial Joint: The Right Knee Joint (continued). Use the terms listed to fill in the numbered labels in the figure. Some terms may be used more than once.

**WHAT DO YOU THINK?**

1 Why do you think the anterior cruciate ligament is so often injured during contact sports?

**WHAT DO YOU THINK?**

2 Injuries to the tibial collateral ligament are often accompanied by a torn medial meniscus. After observing the fibrous tissues that form the joint capsule of the knee, why do you think this pattern of injury is so common?

The **1** corresponds to the Learning Objective(s) listed in the chapter opener outline.

## Do You Know the Basics?

### Exercise 10.1: Fibrous Joints

- Which of the following joints contains an interosseous membrane? (Circle one.) **1**
  - gomphosis
  - suture
  - syndesmosis
- Which of the following is a structural classification for fibrous joints? (Circle one.) **2**
  - suture
  - symphysis
  - synchondrosis
  - synovial
- Which of the following correctly pairs the classification of a fibrous joint with an example of its proper location in the body? (Circle one.) **3**
  - gomphosis; between skull bones
  - gomphosis; distal tibiofibular joint
  - suture; distal radioulnar joint
  - syndesmosis; between skull bones
  - syndesmosis; distal radioulnar joint

### Exercise 10.2: Cartilaginous Joints

- Symphysis joints consist of bones connected to bones by \_\_\_\_\_ (fibrocartilage/hyaline cartilage), whereas synchondroses consist of bones connected to bones by \_\_\_\_\_ (fibrocartilage/hyaline cartilage). **4**
- Which of the following terms are used to classify a synchondrosis based on the extent of movement? (Check all that apply.) **5**

\_\_\_\_\_ a. amphiarthrosis    \_\_\_\_\_ b. diarthrosis    \_\_\_\_\_ c. synarthrosis
- The sternocostal joints are examples of cartilaginous joints. \_\_\_\_\_ (True/False) **6**

### Exercise 10.3: General Structure of a Synovial Joint

- Match the descriptions of synovial joint structures listed in column A with the corresponding structure listed in column B. **7 8**

#### Column A

- \_\_\_\_\_ 1. crescent-shaped pad of fibrocartilage found within the joint
- \_\_\_\_\_ 2. slippery fluid containing hyaluronic acid and glycoproteins
- \_\_\_\_\_ 3. small, round sac filled with fluid
- \_\_\_\_\_ 4. lining within the joint
- \_\_\_\_\_ 5. hyaline cartilage found on the ends of long bones

#### Column B

- a. articular cartilage
- b. bursa
- c. meniscus
- d. synovial fluid
- e. synovial membrane

### Exercise 10.4: Classification of Synovial Joints

- Match the description of the synovial joint listed in column A with the corresponding classification listed in column B. **9**

#### Column A

- \_\_\_\_\_ 1. biaxial; oval, convex, and concave
- \_\_\_\_\_ 2. multiaxial; head fits into a socket
- \_\_\_\_\_ 3. multiaxial; resembles the shape of a saddle
- \_\_\_\_\_ 4. uniaxial; convex and concave surfaces
- \_\_\_\_\_ 5. uniaxial; round surface in ring
- \_\_\_\_\_ 6. uniaxial; two flat surfaces

#### Column B

- a. ball-and-socket
- b. condylar
- c. hinge
- d. pivot
- e. plane
- f. saddle

9. Which of the following correctly pairs the classification of a synovial joint with an example of its location? (Circle one.) **10**
- ball-and-socket; elbow joint
  - hinge; shoulder joint
  - pivot; atlantoaxial joint
  - plane; radiocarpal joint
  - saddle; knee joint

### Exercise 10.5: Practicing Synovial Joint Movements

10. Match the description of the joint movement listed in column A with the appropriate term listed in column B. **11**

#### Column A

- \_\_\_\_\_ 1. palm turns from posterior to anterior
- \_\_\_\_\_ 2. palm turns from anterior to posterior
- \_\_\_\_\_ 3. inferior movement of the mandible or scapula
- \_\_\_\_\_ 4. body part is moved anterior in the horizontal plane
- \_\_\_\_\_ 5. sole of foot faces medial (inward)
- \_\_\_\_\_ 6. dorsum of foot moves superiorly
- \_\_\_\_\_ 7. superior movement of the mandible or scapula
- \_\_\_\_\_ 8. body part is moved posterior in horizontal plane
- \_\_\_\_\_ 9. sole of foot faces lateral (outward)
- \_\_\_\_\_ 10. dorsum of foot moves inferiorly

#### Column B

- depression
- dorsiflexion
- elevation
- eversion
- inversion
- plantar flexion
- pronation
- protraction
- retraction
- supination

### Exercise 10.6: The Knee Joint

11. Match the description listed in column A with its corresponding structure listed in column B. **12**

#### Column A

- \_\_\_\_\_ 1. ligament connecting femur to tibia
- \_\_\_\_\_ 2. ligaments that cross in the middle of the knee joint
- \_\_\_\_\_ 3. sesamoid bone located in the knee joint
- \_\_\_\_\_ 4. ligament connecting femur to fibula
- \_\_\_\_\_ 5. structure connecting patella to tibial tuberosity
- \_\_\_\_\_ 6. structure connecting quadriceps muscles to patella
- \_\_\_\_\_ 7. fibrocartilaginous structure within knee joint
- \_\_\_\_\_ 8. synovial sacs located above, below, and anterior to the patella

#### Column B

- ACL and PCL
- bursae
- fibular (lateral) collateral ligament
- meniscus
- patella
- patellar ligament
- patellar tendon
- tibial (medial) collateral ligament

### Can You Apply What You've Learned?

12. From where do the articular cartilages arise developmentally?

---

13. Define *bursitis*.

---

### Can You Synthesize What You've Learned?

14. Fully classify the glenohumeral joint both structurally and functionally (degree of movement).

---



---



---

# Muscle Tissue and Introduction to the Muscular System

# 11

## OUTLINE AND LEARNING OBJECTIVES

### Histology 208

#### Skeletal Muscle Tissue 208

##### EXERCISE 11.1: HISTOLOGY OF SKELETAL MUSCLE FIBERS 210

- 1 Identify skeletal muscle tissue through the microscope, and describe the features unique to skeletal muscle tissue
- 2 Name the visible bands that form the striations in skeletal muscle tissue

##### EXERCISE 11.2: CONNECTIVE TISSUE COVERINGS OF SKELETAL MUSCLE 210

- 3 Describe the layers of connective tissue that surround skeletal muscle tissue

#### The Neuromuscular Junction 211

##### EXERCISE 11.3: THE NEUROMUSCULAR JUNCTION 211

- 4 Define motor unit and describe how the concept of a motor unit applies to neuromuscular junctions

#### Cardiac Muscle Tissue 213

##### EXERCISE 11.4: IDENTIFICATION OF CARDIAC MUSCLE TISSUE 213

- 5 Identify cardiac muscle tissue through the microscope, and describe the features unique to cardiac muscle tissue
- 6 Compare and contrast the structure of skeletal, smooth, and cardiac muscle tissues

#### Smooth Muscle Tissue 213

##### EXERCISE 11.5: SMOOTH MUSCLE TISSUE 214

- 7 Identify smooth muscle tissue through the microscope, and describe the features unique to smooth muscle tissue
- 8 Describe how two layers of smooth muscle tissue act as antagonists

### Gross Anatomy 215

#### Gross Anatomy of Skeletal Muscles 215

##### EXERCISE 11.6: NAMING SKELETAL MUSCLES 215

- 9 Explain some of the logic behind the naming of skeletal muscles

##### EXERCISE 11.7: ARCHITECTURE OF SKELETAL MUSCLES 216

- 10 Use anatomic terminology to describe the architecture of skeletal muscles, and describe how the architecture of a skeletal muscle is related to its action

#### Organization of the Human Musculoskeletal System 218

##### EXERCISE 11.8: MAJOR MUSCLE GROUPS AND FASCIAL COMPARTMENTS OF THE LIMBS 219

- 11 Describe the location and major actions of the major muscle groups of the body
- 12 Describe the fascial compartments of the limbs, and explain the major actions associated with each fascial compartment

## INTRODUCTION

While reading the text on this page, skeletal muscles connected to the eyeballs (the *extrinsic* eye muscles) are contracting to produce the very fine movements necessary for the eyes to track the words on the paper. At the same time, smooth muscle within the ciliary bodies of the eyes are contracting (or relaxing) to alter the shape of the lens so the image on the page is focused clearly upon the retina. In addition, contraction of cardiac muscle in the heart is creating the force necessary to propel blood through the arteries to deliver oxygen and glucose to the working tissues within the eyes, brain, and the rest of the body. Indeed, proper function of all three types of muscle tissue is essential for survival.

There are three types of muscle tissue: skeletal muscle, smooth muscle, and cardiac muscle. **Skeletal muscle** composes the voluntary muscles that move the skin of the face and skeleton, **smooth muscle** is found mainly in the walls of the viscera (such as the blood vessels, stomach,

urinary bladder, intestines, and uterus), and **cardiac muscle** is found in the heart. These three types of muscle tissue are distinguished from each other based on location, neural control (voluntary vs. involuntary), the presence or absence of visible striations, the shape of the muscle fibers, and the number appearance, and location of nuclei.

The exercises in this chapter involve making observations of the detailed structure of skeletal, smooth, and cardiac muscle tissues as seen under the microscope, exploring the common morphologies of skeletal muscles, introducing some of the logic behind the naming of skeletal muscles, and providing an overview of the organization of the human musculoskeletal system.

### List of Reference Tables

Table 11.1	Muscle Tissues	p. 208
Table 11.2	Common Methods for Naming Skeletal Muscles	p. 215
Table 11.3	Common Architectures of Skeletal Muscles	p. 217
Table 11.4	Major Muscle Groups and Their Actions	p. 218
Table 11.5	Fascial Compartments of the Limbs and Their General Muscle Actions	p. 218

### Learning Strategy



Terminology related to the action of muscle fibers can be very confusing. Recall from chapter 10 that the term *flexion* refers to any joint movement in which the angle between two bones is decreased. However, people often use the term *flex* (as in, “flex your bicep for me”) when they are asking you to *contract* a muscle. The term

*contract* is the term scientists prefer to use to describe the action of a muscle fiber producing force. Even so, the term *contract* can also be misleading at times! Literally, to contract means to shorten. All muscle fibers have the ability to shorten when they produce force. However, striated muscle fibers can also produce force while remaining at a fixed length, or even while being forcibly lengthened.

# Chapter 11: Muscle Tissue and Introduction to the Muscular System

Name: \_\_\_\_\_

Date: \_\_\_\_\_ Section: \_\_\_\_\_

These Pre-laboratory Worksheet questions may be assigned by instructors through their **connect** course.

## PRE-LABORATORY WORKSHEET

1. Match the location in the body listed in column A with the corresponding muscle tissue type listed in column B.

### Column A

- \_\_\_ 1. face and skeleton
- \_\_\_ 2. heart
- \_\_\_ 3. visceral organs (e.g., bladder, intestine, stomach, uterus)

### Column B

- a. cardiac muscle
- b. skeletal muscle
- c. smooth muscle

2. Excitable tissues are able to propagate action potentials. \_\_\_\_\_ (True/False)

3. Which of the following are characteristics of muscle tissue? (Check all that apply.)

- \_\_\_ 1. contractile
- \_\_\_ 2. distensible
- \_\_\_ 3. elastic
- \_\_\_ 4. excitable
- \_\_\_ 5. extensible

4. Identify the structural and functional unit of skeletal muscle. (Circle one.)

- a. actin
- b. myofibril
- c. myofilament
- d. myosin
- e. sarcomere

5. Which type of tissue composes a tendon, the structure that attaches a muscle to a bone? (Circle one.)

- a. areolar connective tissue
- b. dense irregular connective tissue
- c. dense regular connective tissue
- d. elastic connective tissue
- e. reticular connective tissue

6. Intercalated discs are found in which type of muscle tissue? (Circle one.)

- a. cardiac
- b. skeletal
- c. smooth

7. The cylindrical bundles of contractile proteins located inside skeletal muscle fibers are called \_\_\_\_\_. (Circle one.)

- a. myofibers
- b. myofibrils
- c. myofilaments
- d. myosin
- e. sarcomeres

8. Skeletal muscles are given names that reflect location, shape, attachments, or other features related to the muscles. These names are based on Latin and Greek word roots. Match the meaning listed in column A with the word root listed in column B.

### Column A

- \_\_\_ 1. around
- \_\_\_ 2. belly
- \_\_\_ 3. between
- \_\_\_ 4. head
- \_\_\_ 5. upon
- \_\_\_ 6. within

### Column B

- a. *caput-*
- b. *endo-*
- c. *epi-*
- d. *gastro-*
- e. *inter-*
- f. *peri-*

## Histology

Muscle tissue is one of the most metabolically active tissues in the body and is the one tissue capable of creating movement of the body or body organs. All types of muscle tissue are characterized by the following properties: *excitability*, *contractility*, *elasticity*, and *extensibility*. **Excitable** tissues are able to generate and propagate special electrical signals called *action potentials* (APs). **Contractile** tissues are able to actively shorten themselves and produce force. **Elastic** tissues are able to be stretched and will spring back to their original shape once the stretching force is released. **Extensible** tissues are able to be lengthened by the pull of an external force (such as an external weight or the action of an opposing muscle).

The exercises in this chapter guide the user through observations of the histology of skeletal, smooth, and cardiac muscle tissues. **Table 11.1** lists the characteristics of the three types of muscle tissue, and serves as a reference for completing the exercises.

### Skeletal Muscle Tissue

Skeletal muscle fibers are some of the largest cells in the body. Their enormous size results from the fusion of hundreds of *myoblasts* during development into a single muscle fiber. A mature muscle fiber is multinucleate, containing 200 to 300 nuclei per millimeter of fiber length. The nuclei of normal skeletal muscle fibers are located peripherally, just under the *sarcolemma* (plasma membrane).


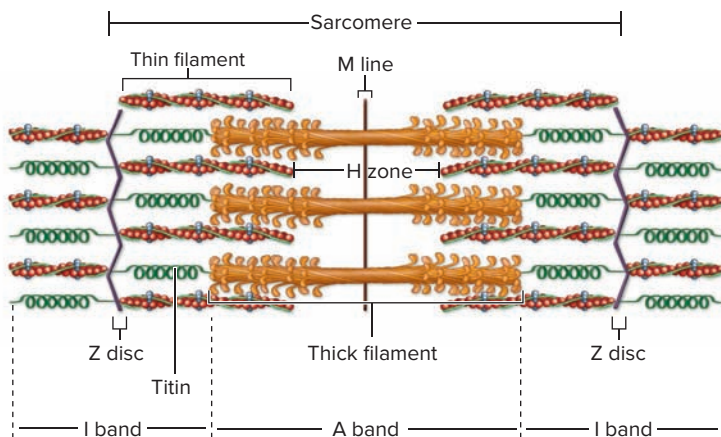
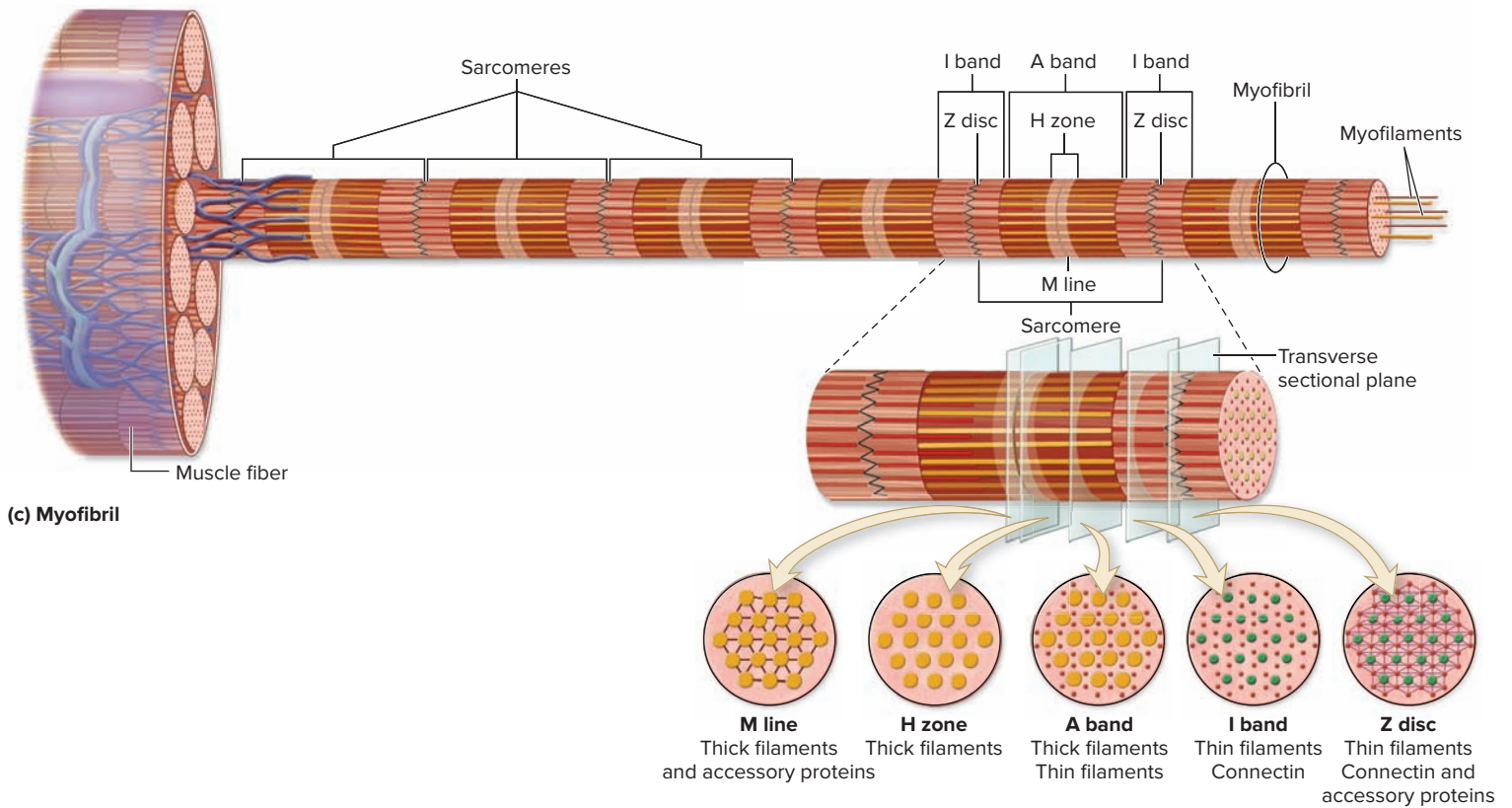
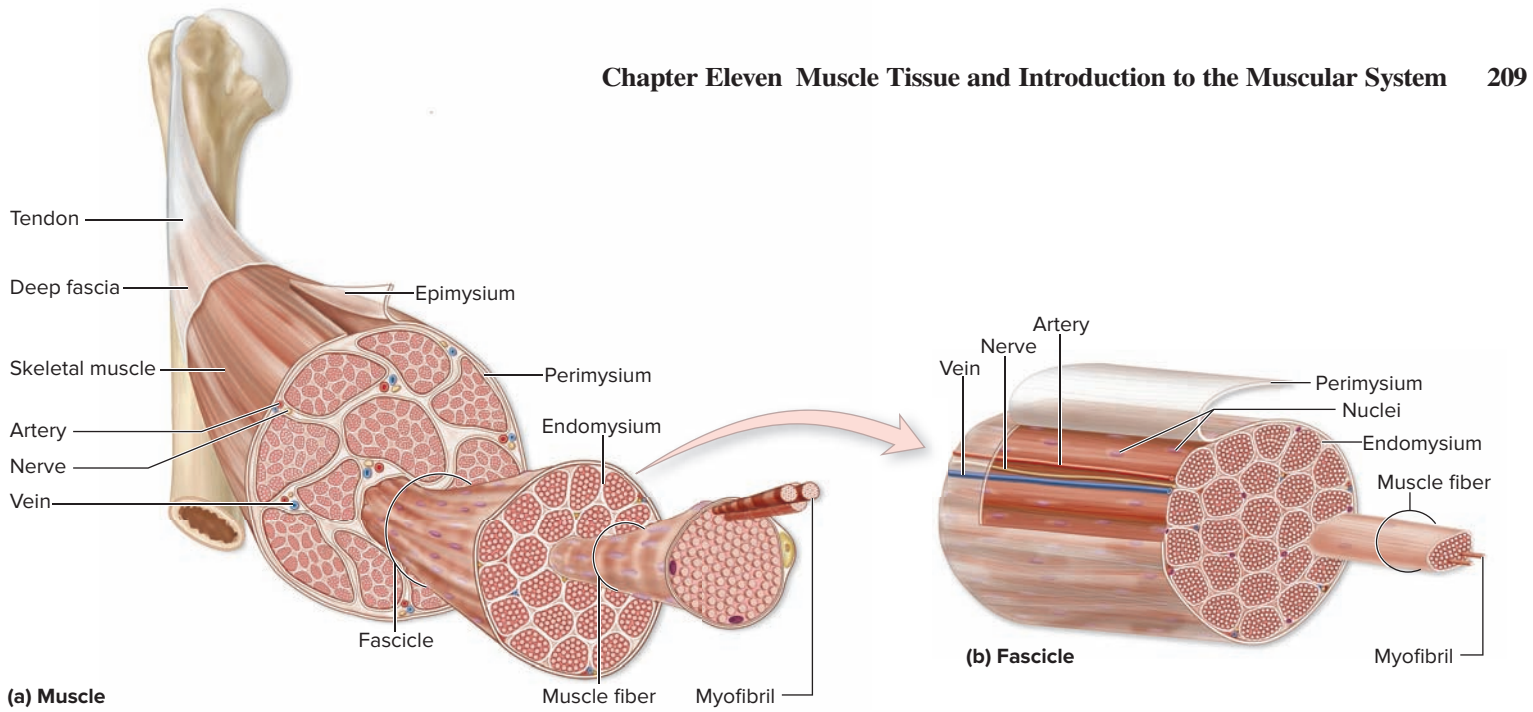
A whole muscle, such as the biceps brachii muscle of the arm, consists of several bundles, or **fascicles** (*fascis*, bundle), of muscle fibers (**figure 11.1a**). Each fascicle contains hundreds of long, cylindrical **muscle fibers** (**figure 11.1b**). Each muscle fiber contains within it a number of cylindrical bundles of contractile proteins called **myofibrils** (**figure 11.1c**). The myofibrils contain the **myofilaments** actin and myosin (the main contractile proteins of muscle), which are arranged into

**sarcomeres** (the structural and functional unit of skeletal muscle; **figure 11.1d**). The regular arrangement of actin and myosin into sarcomeres gives each myofibril a striated or banded appearance, with visible *A bands* (dark bands), *I bands* (light bands), and *Z discs* (a dark line in the middle of an I band; **figure 11.1d,e**). An adult skeletal muscle fiber typically contains about 2000 myofibrils per cell. Because intermediate filaments within the muscle anchor and align the Z discs of adjacent myofibrils to each other, the entire muscle fiber takes on the same regular striated appearance of A bands and I bands found in the myofibrils when viewed under the light microscope.

When viewed under the light microscope, the A band appears dark in color. The dark color is due to the presence of thick filaments composed of **myosin**. Because the filaments are very thick, they absorb light, which is what causes the A band to appear dark. On the other hand, the I band contains thin filaments composed primarily of **actin**. Because the filaments are so thin, light passes easily through them, causing the I band to appear light. Finally, there are anchoring proteins found at the **Z discs**, which makes them dense like the A bands and causes light to be absorbed in that location as well. Thus, Z discs appear dark and are visible in the middle of each I band when the slide is viewed at high power.

**Figure 11.1** demonstrates the relationships between the gross structure of a skeletal muscle and the microstructure of a skeletal muscle fiber. Though you will not be able to see myofibrils or myofilaments when you observe the muscle tissue under the microscope, you should be able to visualize A bands, I bands, and Z discs, and relate these bands to the corresponding arrangement of myofilaments into sarcomeres. That is, you should be able to relate what you see under the microscope to the structures shown in the drawing of a sarcomere in **figure 11.1**.

Type of Muscle	Description	Functions	Identifying Characteristics
<i>Skeletal</i>	Elongate, cylindrical fibers with multiple nuclei that are peripherally located. Tissue appears striated (light and dark bands along the length of the fiber).	Produces voluntary movement of the skin and the skeleton.	Length of fibers (extremely long); striations; multiple, peripheral nuclei.
<i>Cardiac</i>	Short, branched fibers with single nuclei that are centrally located. Dark lines (intercalated discs) are seen where two fibers come together. Tissue appears striated (light and dark bands along the length of each muscle fiber).	Performs the contractile work of the heart. Responsible for creating the pumping action of the heart.	Branched, uninucleate or binucleate fibers; striations; intercalated discs.
<i>Smooth</i>	Elongate, spindle-shaped fibers (fatter in the center, narrowing at the tips) with single, “cigar-shaped” or spiral nuclei that are centrally located. No striations.	Produces movement within visceral organs such as intestines, bladder, uterus, and stomach. Propels blood through blood vessels; food through the intestines, etc.	Spindle-shape of the fibers; lack of striations; cigar-shaped or spiral nuclei.



(d) Sarcomere

(e) Electron micrograph of a sarcomere

**AP|R Figure 11.1** Levels of Structural Organization of Skeletal Muscle. (a) A whole muscle, (b) a muscle fascicle, (c) a myofibril, (d) a sarcomere, (e) an electron micrograph of a sarcomere.



**EXERCISE 11.1** Histology of Skeletal Muscle Fibers


1. Obtain a slide of skeletal muscle tissue and place it on the microscope stage.
2. Bring the tissue into focus using the scanning objective. Switch to medium, then high power, and bring the tissue sample into focus once again. Many slides of skeletal muscle contain muscle fibers shown in both longitudinal section and cross section. Scan the slide and identify muscle fibers shown in both longitudinal section and cross section (**figures 11.2 and 11.3**).
3. Focus on muscle fibers shown in longitudinal section (figure 11.2) and observe them at high power. Identify an individual muscle fiber. Notice the numerous peripherally located nuclei. Most of the nuclei that are visible on the slide belong to the muscle fibers themselves. However, about 5%

15% of the visible nuclei are those of **satellite cells**, myoblast-like cells located between the muscle fibers. Satellite cells give skeletal muscle a limited ability to repair itself after injury. It is not possible to tell which nuclei belong to satellite cells when viewing the tissue under a light microscope.

4. Identify the following structures on the slide of skeletal muscle tissue, using table 11.1 and figure 11.2 as guides:

- |                                  |   |
|----------------------------------|---|
| <input type="checkbox"/> A band  | <input type="checkbox"/> sarcomere (if visible) |
| <input type="checkbox"/> I band  | <input type="checkbox"/> Z disc (if visible)    |
| <input type="checkbox"/> nucleus |   |

5. Sketch skeletal muscle fibers as seen under the microscope in the space provided. Be sure to label the structures listed in step 4 in your drawing.



**Figure 11.2** Skeletal Muscle in Longitudinal View.

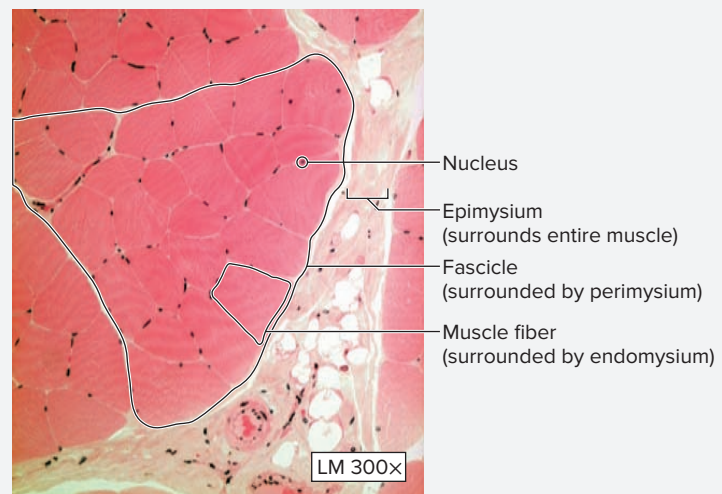
Z discs and sarcomeres are not visible in this micrograph.

© Victor P. Eroschenko

**EXERCISE 11.2** Connective Tissue Coverings of Skeletal Muscle

After observing the structure of individual muscle fibers, it is time to investigate the relationship between individual muscle fibers and whole muscles. A whole skeletal muscle, such as the biceps brachii muscle, consists of many individual muscle fibers bundled together with connective tissue (figure 11.3). Each individual muscle fiber is covered by a layer of connective tissue called the **endomysium** (*endo-*, within + *mys*, muscle). Several muscle fibers are bundled together into fascicles by a surrounding layer of connective tissue called the **perimysium** (*peri-*, around + *mys*, muscle). Finally, the entire skeletal muscle is surrounded by a layer of connective tissue called the **epimysium** (*epi-*, upon + *mys*, muscle). The epimysium is an extension of the **deep fascia**, which will be discussed shortly.

1. View the slide of skeletal muscle tissue at low magnification. Move the stage until muscle fibers in cross section are visible in the field of view. Identify the connective tissue that surrounds a muscle fiber, a fascicle, and the entire skeletal muscle (if present).



**Figure 11.3** Connective Tissue Coverings of Skeletal Muscle. Muscle fibers are seen in a cross-sectional view.

© Rick Ash

2. Identify the listed structures, using figure 11.3 as a guide:\*

- |                                     |                                       |                                     |
|-------------------------------------|---------------------------------------|-------------------------------------|
| <input type="checkbox"/> endomysium | <input type="checkbox"/> fascicle     | <input type="checkbox"/> nucleus    |
| <input type="checkbox"/> epimysium  | <input type="checkbox"/> muscle fiber | <input type="checkbox"/> perimysium |

3. Sketch the connective tissue coverings of skeletal muscle as viewed under the microscope in the space provided. Be sure to label the structures listed in step 2 in the drawing.

\*All three layers of connective tissue should be visible if the tissue on the slide is skeletal muscle from a small mammal such as a mouse. However, only endomysium and perimysium may be visible if the tissue on the slide is from a larger animal.



\_\_\_\_\_ ×

## The Neuromuscular Junction

Each skeletal muscle fiber is innervated by a somatic motor neuron. Each motor neuron branches to innervate several muscle fibers, which are dispersed throughout the muscle. A single motor neuron and all muscle fibers innervated by that motor neuron constitute a **motor unit**. When a nerve signal (an action potential) travels down the motor neuron to stimulate the muscle, all fibers within that motor unit contract. The point of

interaction between an axonal branch and an individual skeletal muscle fiber is called a **neuromuscular junction (figure 11.4)**. Each neuromuscular junction is composed of an oval-shaped **synaptic knob** of a motor neuron, a **motor end plate** of a skeletal muscle fiber, and a **synaptic cleft** (the space between the two). This exercise involves observing a neuromuscular junction in a histology slide that has been stained to show axonal branches and synaptic knobs of a motor neuron, and skeletal muscle fibers.

### EXERCISE 11.3 The Neuromuscular Junction

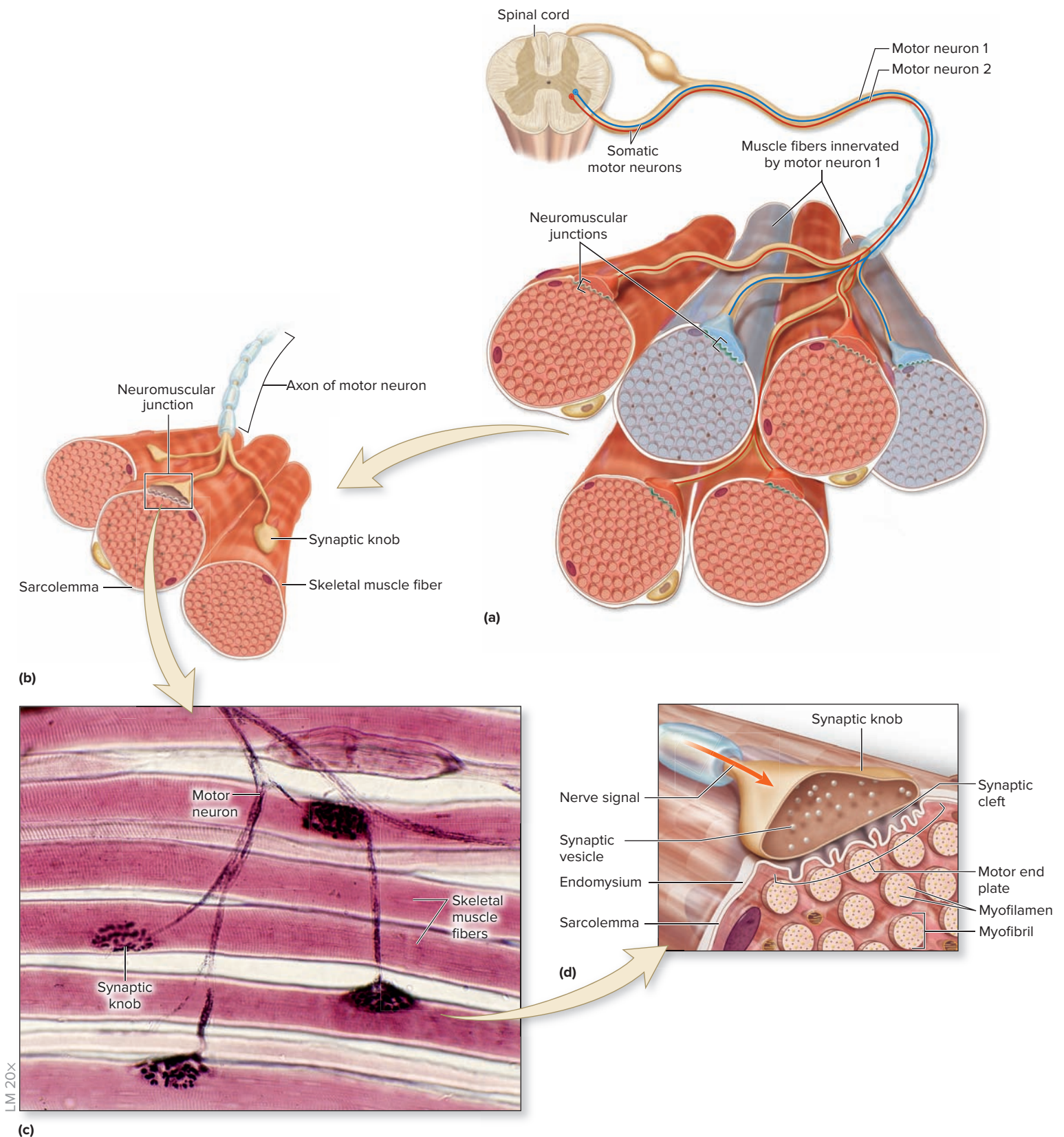
1. Obtain a slide of a neuromuscular junction and place it on the microscope stage.
2. Bring the tissue sample into focus using the scanning objective. Switch to low power and bring the tissue sample into focus once again. Then switch to high power. Scan the slide until skeletal muscle fibers are visible. Next, look for darkly staining thin fibers with “knobby” ends. The “fibers” are the **axonal branches** of a somatic motor neuron and the oval-shaped “knobs” are the neuromuscular junctions that contain the synaptic knobs of the somatic motor neuron (figure 11.4).
3. Identify the listed structures on the slide of the neuromuscular junction, using figure 11.4 as a guide:

- |  |   |
|--|---|
| <input type="checkbox"/> axonal branches of the somatic motor neuron | <input type="checkbox"/> skeletal muscle fibers |
| <input type="checkbox"/> synaptic knobs                              |   |

4. Sketch the neuromuscular junction as viewed through the microscope in the space provided. Be sure to label the structures listed in step 3.



\_\_\_\_\_ ×



**Figure 11.4 The Neuromuscular Junction.** (a) Diagram of somatic motor neurons that extend from the spinal cord to several skeletal muscle fibers. (b) Each of the fibers within the motor unit has an area where the synaptic knob of the motor neuron contacts the muscle fiber; the neuromuscular junction. (c) Light micrograph of a motor neuron and skeletal muscle fibers in a motor unit. Synaptic knobs are the darkly stained structures associated with skeletal muscle fibers. (d) At each synaptic knob, there are synaptic vesicles that contain the neurotransmitter acetylcholine (ACh).

(c) © Dr. Thomas Caceci, Virginia-Maryland Regional College of Veterinary Medicine

## Cardiac Muscle Tissue

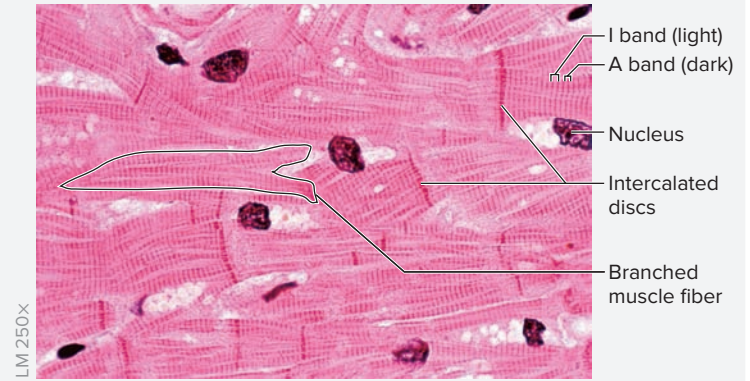
Branching cells with centrally located nuclei are characteristic of **cardiac muscle tissue** (figure 11.5). Like skeletal muscle fibers, cardiac muscle cells are striated. The striations appear because cardiac muscle cells also contain numerous myofibrils. Unlike skeletal muscle cells, the myofibrils

in cardiac muscle cells are not anchored to each other with intermediate filaments at the Z discs. The resulting slight offset of myofibrils within the muscle fiber means that the banding pattern isn't always as clear in cardiac muscle as it is in skeletal muscle.

### EXERCISE 11.4 Identification of Cardiac Muscle Tissue

1. Obtain a slide of cardiac muscle tissue and place it on the microscope stage.
2. Bring the tissue sample into focus using the scanning objective. Switch to low power, bring the tissue sample into focus once again, and then switch to high power. Notice that the muscle fibers contain only one or two nuclei, and are short and branched. Where two muscle fibers come together, there is a darkly stained line. This is an **intercalated disc**. Intercalated discs contain numerous **desmosomes**, which function to hold the muscle fibers together, and **gap junctions**, which allow electrical signals to be transmitted very rapidly from one muscle fiber to the next.
3. Identify the listed structures on the slide of cardiac muscle tissue, using table 11.1 and figure 11.5 as guides:

- A band
- branched muscle fibers
- I band
- intercalated disc
- nucleus
- Z disc (if visible)



**Figure 11.5** Cardiac Muscle Tissue.

© Ed Reschke/Peter Arnold, Inc./Photolibrary

4. Sketch cardiac muscle fibers as viewed under the microscope in the space provided. Be sure to label the structures listed in step 3.



## Smooth Muscle Tissue

Smooth muscle tissue differs from skeletal and cardiac muscle tissue in that it does not contain visible striations and it is under involuntary control. Smooth muscle tissue is located in the walls of organs such as the urinary bladder, stomach, and small intestine. Smooth muscle fibers are characterized by their spindle-like shape, cigar-shaped or spiral nuclei, and absence of striations. Individual fibers have

tapered ends, and there is only one centrally located nucleus per fiber. Most of the nuclei will appear to be somewhat cigar-shaped. However, in muscle fibers that have contracted, the nuclei take on a corkscrew or spiral appearance (figure 11.6a), which can be a key identifying feature.

Smooth muscle tissue is generally found in two layers around tubular organs such as the small intestine. The most common arrangement is an *inner circular layer* and *outer longitudinal layer* (figure 11.6b).

**EXERCISE 11.5** Smooth Muscle Tissue

1. Obtain a slide containing smooth muscle tissue (figure 11.6) and place it on the microscope stage.
2. Bring the tissue into focus using the scanning objective. Switch to low power, bring the tissue sample into focus once again, and then switch to high power. If viewing a slide of the small intestine, identify smooth muscle fibers that have been cut in both longitudinal section and cross section. Note that the fibers do not appear to be of uniform diameter when viewed in cross section. This is because some fibers are sliced through the tapered ends, while others are sectioned through the thickest part of the fiber, which contains the nucleus.
3. Identify the following structures on the slide of smooth muscle tissue, using table 11.1 and figure 11.6 as guides:

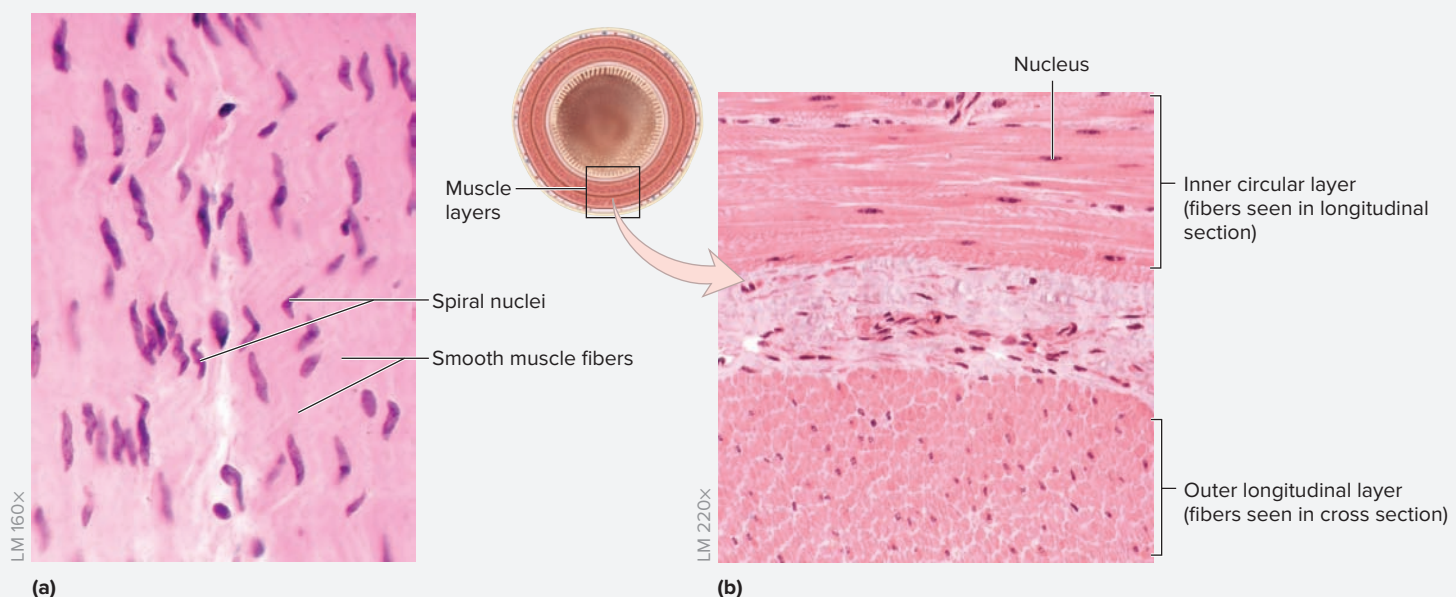
- |   |   |
|---|---|
| <input type="checkbox"/> inner circular layer                 | <input type="checkbox"/> nucleus                  |
| <input type="checkbox"/> muscle fiber in cross section        | <input type="checkbox"/> outer longitudinal layer |
| <input type="checkbox"/> muscle fiber in longitudinal section |   |

4. Sketch smooth muscle fibers as viewed under the microscope in the space provided. Be sure to label the structures listed in step 3 in the drawing.

**Learning Strategy**

Smooth muscle tissue and dense regular connective tissue can often be confused. A few key features can help distinguish them from each other. First, fibroblast nuclei (found in dense regular connective tissue) appear flattened and are located between fibers, whereas smooth muscle nuclei are plumper and can be seen *within* the cells. In addition, there will be relatively fewer

nuclei per unit area in dense regular connective tissue than in smooth muscle tissue. Finally, the appearance of spiral or corkscrew nuclei is a good clue that the tissue is smooth muscle, not dense regular connective tissue. Try to find a spiral nucleus on the slide of smooth muscle tissue to make sure you understand what it is. Review the “Lookalikes” section of chapter 5 (p. 81) for a side-by-side comparison of these tissue types.



**Figure 11.6** Smooth Muscle Tissue. (a) Close-up view of smooth muscle tissue demonstrating spiral nuclei, (b) inner circular and outer longitudinal layers of smooth muscle tissue located in the walls of the small intestine.

## Gross Anatomy

### Gross Anatomy of Skeletal Muscles

The names of skeletal muscles often seem overly complex. However, if you begin to understand the basis of their names, you will find them far less mysterious. Over time you will begin to discover that the name

of a muscle often gives you a clue to its location, size, shape, action, or attachment points. The efforts you have made to learn the Latin and Greek word roots of anatomical terms thus far will become even more valuable as you work through the next three chapters.

#### EXERCISE 11.6 Naming Skeletal Muscles

**Table 11.2** summarizes some of the common ways skeletal muscles are named and gives word origins for the muscle names. Plan to spend some time mastering these word origins to be better prepared to handle the material to come in chapters 12 and 13. To assist in this effort, the post-laboratory worksheet has a number of questions related to the naming of skeletal muscles.



#### WHAT DO YOU THINK?

- 1 You have discovered a new muscle in the body. The muscle is a long muscle that contains four heads. Based on your knowledge of word origins, suggest a logical name for this muscle.

Table 11.2		Common Methods for Naming Skeletal Muscles	
Name	Meaning	Word Origins	Example
<i>Naming Skeletal Muscles Based on Shape</i>			
Deltoid	Triangular	<i>delta-</i> , the Greek letter delta (a triangle) + <i>eidos</i> , resemblance	Deltoid
Gracilis	Slender	<i>gracilis</i> , slender	Gracilis
Lumbrical	Wormlike	<i>lumbricus</i> , earthworm	Lumbricals
Rectus	Straight	<i>rectus</i> , straight	Rectus abdominis
Rhomboid	Diamond-shaped	<i>rhombo-</i> , an oblique parallelogram with unequal sides + <i>eidos</i> , resemblance	Rhomboid major
Teres	Round	<i>teres</i> , round	Teres major
Trapezius	A four-sided geometrical figure having no two sides parallel	<i>trapezion</i> , a table	Trapezius
<i>Naming Skeletal Muscles Based on Size</i>			
Brevis	Short	<i>brevis</i> , short	Adductor brevis
Latissimus	Broadest	<i>latissimus</i> , widest	Latissimus dorsi
Longissimus	Longest	<i>longissimus</i> , longest	Longissimus capitis
Longus	Long	<i>longus</i> , long	Adductor longus
Major	Bigger	<i>magnus</i> , great	Teres major
Minor	Smaller	<i>minor</i> , smaller	Teres minor
<i>Naming Skeletal Muscles Based on the Number of Heads and/or Bellies</i>			
Biceps	2 heads	<i>bi-</i> , two + <i>caput</i> , head	Biceps brachii
Digastric	2 bellies	<i>bi-</i> , two + <i>gastro</i> , belly	Digastric
Quadriceps	4 heads	<i>quad-</i> , four + <i>caput</i> , head	Quadriceps femoris
Triceps	3 heads	<i>tri-</i> , three + <i>caput</i> , head	Triceps brachii
<i>Naming Skeletal Muscles Based on Position</i>			
Abdominis	Abdomen	<i>abdomen</i> , the greater part of the abdominal cavity	Rectus abdominis
Anterior	On the front surface of the body	<i>ante</i> , before, in front of	Serratus anterior

(continued on next page)

(continued from previous page)





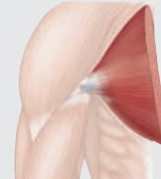

Table 11.2 Common Methods for Naming Skeletal Muscles (continued)			
Name	Meaning	Word Origins	Example
Brachii	Arm	<i>brachium</i> , arm	Biceps brachii
Dorsi	Back	<i>dorsum</i> , back	Latissimus dorsi
Femoris	Thigh	<i>femur</i> , thigh	Rectus femoris
Infraspinatus	Below the scapular spine	<i>infra-</i> , below + <i>spina</i> , spine	Infraspinatus
Interosseous	In between bones	<i>inter-</i> , between + <i>osseus</i> , bone	Interossei
Oris	Mouth	<i>oris</i> , mouth	Orbicularis oris
Pectoralis	Chest	<i>pectus</i> , chest	Pectoralis major
Posterior	On the back surface of the body	<i>posterus</i> , following	Serratus posterior
Supraspinatus	Above the scapular spine	<i>supra-</i> , on the upper side + <i>spina</i> , spine	Supraspinatus
<b>Naming Skeletal Muscles Based on Depth</b>			
Externus	External	<i>external</i> , on the outside	Obturator externus
Internus	Internal	<i>internal</i> , away from the surface	Obturator internus
Profundus	Deep	<i>pro-</i> , before + <i>fundus</i> , bottom	Flexor digitorum profundus
Superficialis	Superficial	<i>super-</i> , above + <i>facies</i> , face	Flexor digitorum superficialis
<b>Naming Skeletal Muscles Based on Action</b>			
Abductor	Moves a body part away from the midline	<i>ab-</i> , from + <i>ductus</i> , to bring toward	Abductor pollicis brevis
Adductor	Moves a body part toward the midline	<i>ad-</i> , toward + <i>ductus</i> , to bring toward	Adductor pollicis
Constrictor	Acts as a sphincter and closes an orifice	<i>cum-</i> , together + <i>stringo</i> , to draw tight	Superior pharyngeal constrictor
Depressor	Flattens or lowers a body part	<i>de-</i> , away + <i>pressus</i> , to press	Depressor anguli oris
Dilator	Causes an orifice to open, or dilate	<i>dilato</i> , to spread out	Dilator pupillae
Extensor	Causes an increase in joint angle	<i>ex-</i> , out of + <i>tensus</i> , to stretch	Extensor carpi ulnaris
Flexor	Causes a decrease in joint angle	<i>flectus</i> , to bend	Flexor carpi ulnaris
Levator	Raises a body part superiorly	<i>levatus</i> , a lifter	Levator scapulae
Pronator	Turns the palm of the hand from anterior to posterior	<i>pronatus</i> , to bend forward	Pronator teres
Supinator	Turns the palm of the hand from posterior to anterior	<i>supino</i> + <i>atus</i> , to bend backward	Supinator

### EXERCISE 11.7 Architecture of Skeletal Muscles

The overall architecture of a skeletal muscle affects how the muscle functions. When observing a whole muscle, the individual fibers and fascicles are visible, making it relatively easy to see how the fascicles are arranged within the muscle. Recall that when skeletal muscle contracts, it generally gets shorter and brings the two attachment points closer to each other. Thus, the orientation of the muscle fascicles compared to the attachment points of the muscle will directly affect the force produced by the muscle and the complexity of the muscle's actions. For instance, **pennate** architecture (*penna*, feather) allows a muscle to produce greater

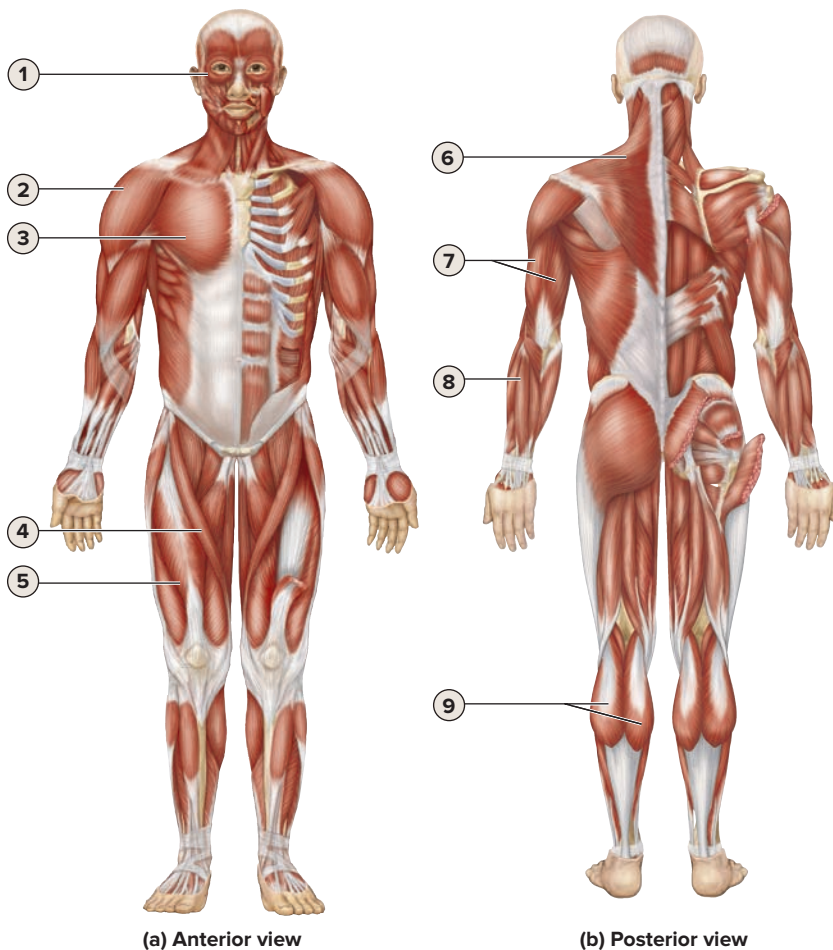
force per distance shortened than **parallel** architecture. In addition, muscles with more than two bony attachments (e.g., biceps and triceps) produce more complex movements than muscles with only two attachments (one proximal attachment and one distal attachment). **Table 11.3** summarizes the common patterns of fascicle arrangement that contribute to skeletal muscle architecture.

1. Using classroom models of skeletal muscles or a prosected human cadaver (if available), observe the arrangement of fascicles in several different skeletal muscles of the body. Use table 11.3 as a guide.

Table 11.3 Common Architectures of Skeletal Muscles						
<i>Diagram</i>						
<i>Name</i>	<b>Unipennate</b>	<b>Bipennate</b>	<b>Multipennate</b>	<b>Circular</b>	<b>Convergent</b>	<b>Parallel</b>
<i>Word Origins</i>	<i>uni-</i> , one + <i>penna</i> , feather	<i>bi-</i> , two + <i>penna</i> , feather	<i>multi-</i> , many + <i>penna</i> , feather	<i>circum</i> , around	<i>cum-</i> , together + <i>vergo</i> , to incline	<i>para</i> , alongside

- Locate the muscles listed in **figure 11.7** on the classroom models or the human cadaver, using the textbook as a guide. Then identify them in figure 11.7.
- Complete the table provided by listing the architecture for each of the muscles shown in figure 11.7, using table 11.3 and the textbook as guides.

Muscle Number	Muscle Name	Architecture
1		
2		
3		
4		
5		
6		
7		
8		
9		



- deltoid
- extensor digitorum
- gastrocnemius
- orbicularis oculi
- pectoralis major
- rectus femoris
- sartorius
- trapezius
- triceps brachii

**Figure 11.7** Muscles of the Human Body. (a) Anterior view, (b) posterior view.



## Organization of the Human Musculoskeletal System

**Table 11.4** lists the major muscle groups of the body and the common actions of each group of muscles. Obviously, each individual muscle within a group of muscles has its own specific actions. However, skeletal muscles do not act alone, so it makes functional sense to learn the muscles as groups and to learn the major actions of each group. Muscles contained within a group commonly act as synergists and often have a common nerve and blood supply. Thus, damage to the nerve and blood supply often affects a whole group of muscles, not just an individual muscle.

In the limbs, muscles are not only *functionally* organized into groups; they are also *physically* organized into groups. Muscle groups

are separated from each other by extensions of the deep fascia that form **compartments (table 11.5)**. Why is it important to learn this relationship? As an example, consider the muscles of the arm. In this laboratory session you will learn that the muscles located in the anterior compartment of the arm act primarily in flexion of the shoulder and elbow joints. In chapter 17 you will learn that this entire group of muscles is innervated by a single bundle of nerve fibers, the musculocutaneous nerve. Even if you forget the names of the individual muscles in the anterior compartment of the arm, you will be able to predict the loss of function that would result if the musculocutaneous nerve was damaged, based on your knowledge of compartments and muscle groups.

**Table 11.4** Major Muscle Groups and Their Actions

Major Muscle Group	General Description of Muscle Actions
Muscles of facial expression	Create facial expressions.
Muscles of mastication	Used for chewing.
Suprahyoid and infrahyoid muscles	Move the tongue and pharynx.
Muscles of the neck	Rotate, flex, and extend the head.
Muscles of respiration	Involved in breathing movements.
Muscles of the abdomen	Flex, bend, and rotate the spine.
Muscles of the back and spine	Extend, bend, and rotate the spine.
Muscles of the pelvic floor	Support pelvic contents and form sphincters around structures such as the urethra and the anus.
Muscles that act about the pectoral girdle	Stabilize the pectoral girdle and anchor the upper limb to the pectoral girdle.
Muscles that act about the pelvic girdle	Stabilize the pelvic girdle and anchor the lower limb to the pelvic girdle.

**Table 11.5** Fascial Compartments of the Limbs and Their General Muscle Actions

Compartment	General Description of Muscle Actions
<i>Compartments of the Arm</i>	
Anterior	Flexion of arm and forearm.
Posterior	Extension of arm and forearm.
<i>Compartments of the Forearm</i>	
Anterior	Flexion of the wrist and digits (fingers).
Posterior	Extension of the wrist and digits (fingers).
<i>Compartments of the Thigh</i>	
Anterior	Flexion of the thigh, extension of the leg.
Posterior	Extension of the thigh, flexion of the leg.
Medial	Adduction of the thigh.
<i>Compartments of the Leg</i>	
Anterior	Dorsiflexion and inversion of the ankle, extension of the digits (toes).
Posterior	Plantarflexion and inversion of the ankle, flexion of the digits (toes).
Lateral	Eversion of the ankle.

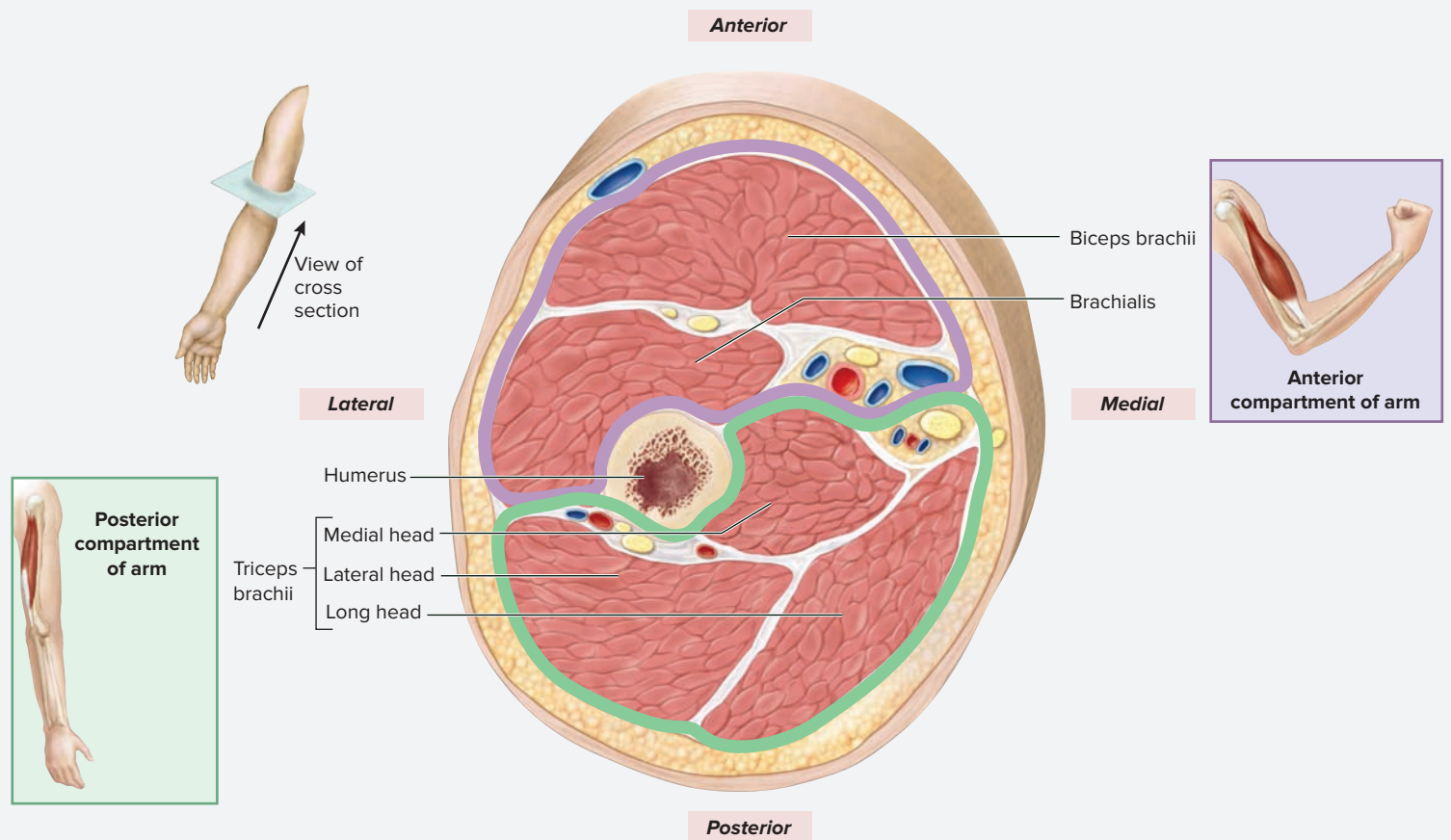
**EXERCISE 11.8** Major Muscle Groups and Fascial Compartments of the Limbs

1. Identify each of the major muscle groups and compartments of the body, using tables 11.4 and 11.5 as guides.
2. While identifying each muscle group or compartment, practice performing the actions listed in the tables. Try to feel the contraction of the muscles by palpating the skin overlying the muscle groups. If you have difficulty remembering joint actions, refer back to chapter 10 for descriptions.
3. **Figures 11.8** and **11.9** represent cross sections of the arm (brachium) and thigh, respectively. The details in cross-sectional views such as these are difficult to negotiate the first time through. Thus, right now just focus on the organization of the muscles into compartments. Visualize how the

cross-sectional diagram relates to your own arm or thigh. While performing the actions listed for each compartment, correlate the muscles used to perform each action with a specific compartment of the arm or thigh.

**WHAT DO YOU THINK?**

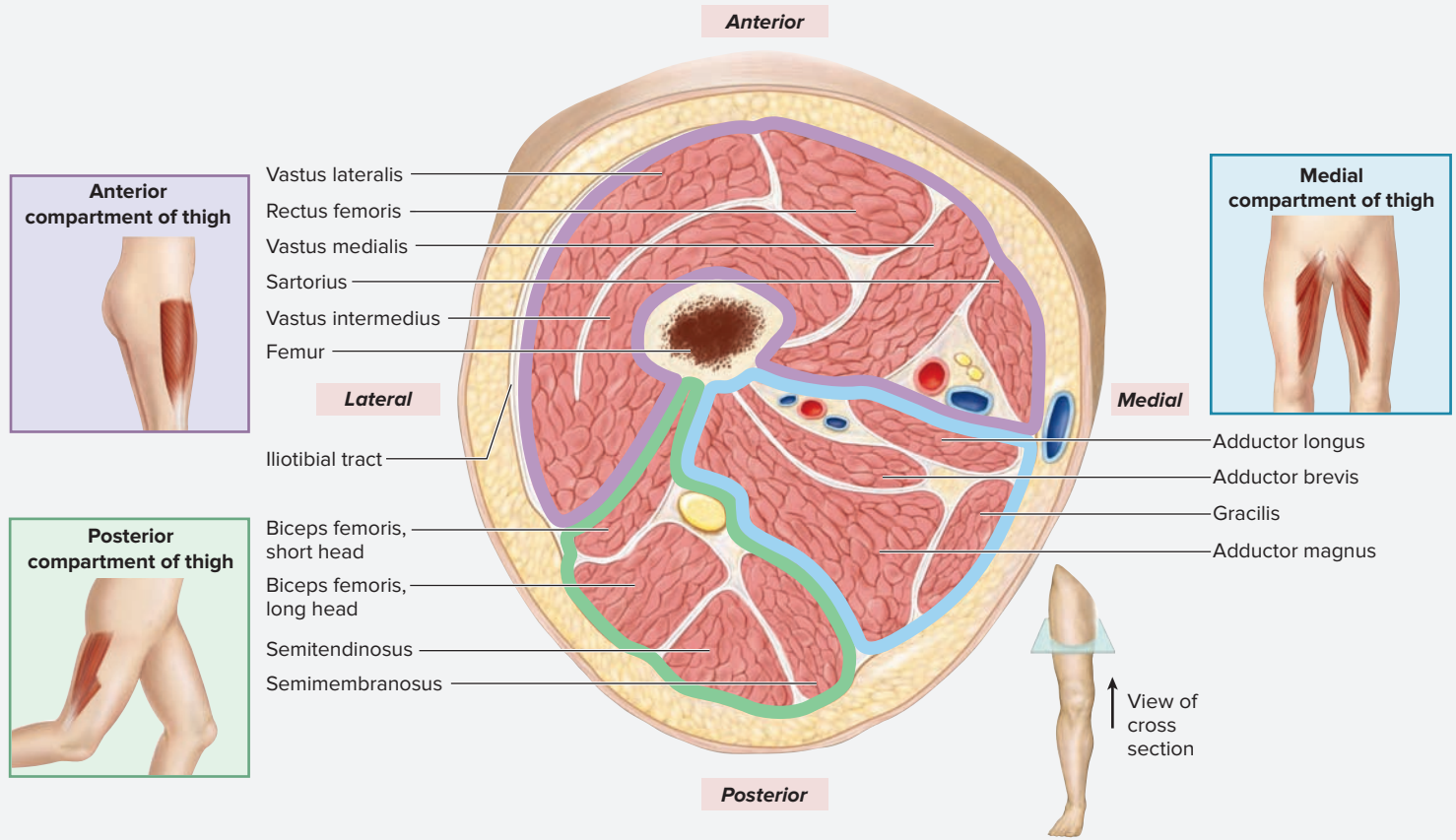
- 2 The proximal joint of the front limb of a dog contains two compartments of muscles, an anterior and a posterior compartment. If the muscles in the anterior compartment are all flexors, what is the common action of all the muscles in the posterior compartment?



**Figure 11.8** Fascial Compartments of the Right Arm (Brachium).

(continued on next page)

(continued from previous page)



**Figure 11.9** Fascial Compartments of the Right Thigh.

# Chapter 11: Muscle Tissue and Introduction to the Muscular System

Name: \_\_\_\_\_

Date: \_\_\_\_\_ Section: \_\_\_\_\_

## POST-LABORATORY WORKSHEET

The 1 corresponds to the Learning Objective listed in the chapter opener outline.

### Exercise 11.1: Histology of Skeletal Muscle Fibers

1. The nervous control of skeletal muscle is \_\_\_\_\_ (voluntary/involuntary). 1
2. Match the appropriate description listed in column A with the zone or band listed in column B. 2

#### Column A

- \_\_\_ 1. a dark line in the middle of the A band
- \_\_\_ 2. a light region in the middle of the A band
- \_\_\_ 3. contains only thin filaments (actin)
- \_\_\_ 4. the dark band in skeletal muscle
- \_\_\_ 5. edges of a sarcomere are determined by this

#### Column B

- a. A band
- b. H zone
- c. I band
- d. M line
- e. Z disc

### Exercise 11.2: Connective Tissue Coverings of Skeletal Muscle

3. Match the structure listed in column A with the connective tissue covering listed in column B. 3

#### Column A

- \_\_\_ 1. covers an entire skeletal muscle
- \_\_\_ 2. covers a fascicle
- \_\_\_ 3. covers a skeletal muscle fiber

#### Column B

- a. endomysium
- b. epimysium
- c. perimysium

### Exercise 11.3: The Neuromuscular Junction

4. A somatic motor neuron and all the muscle fibers innervated by that motor neuron comprises a motor unit. \_\_\_\_\_ (True/False) 4

### Exercise 11.4: Identification of Cardiac Muscle Tissue

5. Which of the following are properties of cardiac muscle tissue? (Check all that apply.) 5
  - \_\_\_ 1. involuntary
  - \_\_\_ 2. spindle-shaped fibers
  - \_\_\_ 3. striated
  - \_\_\_ 4. uninucleate
  - \_\_\_ 5. voluntary
6. For each the following, fill in the blank with the name of the muscle tissue that is described (skeletal, cardiac, or smooth). 6
  - a. Muscle tissue of the heart \_\_\_\_\_
  - b. A component of the iris that changes the size of the pupil in the eye \_\_\_\_\_
  - c. Muscle tissue that attaches to the skeleton \_\_\_\_\_
  - d. Changes the size of the opening (lumen) of an air passageway (bronchiole) \_\_\_\_\_
  - e. Responsible for forcing a baby from the uterus during childbirth \_\_\_\_\_
  - f. Changes the diameter of the lumen of blood vessels and helps regulate blood pressure \_\_\_\_\_
  - g. Helps (through involuntary control) to expel urine from the bladder and feces from the digestive tract \_\_\_\_\_

### Exercise 11.5: Smooth Muscle Tissue

7. Which of the following are properties of smooth muscle tissue? (Check all that apply.) 7
  - \_\_\_ 1. involuntary
  - \_\_\_ 2. spindle-shaped fibers
  - \_\_\_ 3. striated
  - \_\_\_ 4. uninucleate
  - \_\_\_ 5. voluntary

8. In smooth muscle tissue within the wall of a tubular organ (e.g., small intestine), when the inner circular layer of fibers contracts, the diameter of the tube \_\_\_\_\_ (increases/decreases) and the length of the tube \_\_\_\_\_ (increases/decreases). When the outer longitudinal layer of muscle contracts, the diameter of the tube \_\_\_\_\_ (increases/decreases) and the length of the tube \_\_\_\_\_ (increases/decreases). **8**

### Exercise 11.6: Naming Skeletal Muscles

9. Match the appropriate meaning listed in column A with the word origin listed in column B. **9**

#### Column A

- \_\_\_\_ 1. smaller
- \_\_\_\_ 2. round
- \_\_\_\_ 3. a lifter
- \_\_\_\_ 4. around
- \_\_\_\_ 5. to move away
- \_\_\_\_ 6. widest
- \_\_\_\_ 7. straight
- \_\_\_\_ 8. two-headed
- \_\_\_\_ 9. slender
- \_\_\_\_ 10. internal

#### Column B

- a. abductor
- b. biceps
- c. gracilis
- d. internus
- e. latissimus
- f. levator
- g. minor
- h. peri-
- i. rectus
- j. teres

### Exercise 11.7: Architecture of Skeletal Muscles

10. The orbicularis oris muscle has circular architecture. \_\_\_\_\_ (True/False) **10**

### Exercise 11.8: Major Muscle Groups and Fascial Compartments of the Limbs

11. Match the muscle actions listed in column A with the appropriate compartment and/or major muscle group listed in column B. **11**

#### Column A

- \_\_\_\_ 1. adduct the thigh
- \_\_\_\_ 2. allow one to chew
- \_\_\_\_ 3. create facial expressions
- \_\_\_\_ 4. dorsiflex and invert ankle
- \_\_\_\_ 5. evert the ankle
- \_\_\_\_ 6. extend the knee; flex the hip
- \_\_\_\_ 7. extend the wrist and digits
- \_\_\_\_ 8. flex, bend, and rotate the spine
- \_\_\_\_ 9. flex shoulder and elbow
- \_\_\_\_ 10. rotate, flex, and extend the head

#### Column B

- a. anterior compartment of the arm
- b. anterior compartment of the leg
- c. anterior compartment of the thigh
- d. lateral compartment of the leg
- e. medial compartment of the thigh
- f. muscles of the abdomen
- g. muscles of facial expression
- h. muscles of mastication
- i. muscles of the neck
- j. posterior compartment of the forearm

12. Flexor muscles are generally found in the \_\_\_\_\_ (anterior/posterior) compartment of the arm. **12**

# Axial Muscles

# 12

## OUTLINE AND LEARNING OBJECTIVES

### Gross Anatomy 226

#### Muscles of the Head and Neck 226

##### EXERCISE 12.1: MUSCLES OF FACIAL EXPRESSION 226

- 1 Identify the muscles of facial expression and describe their actions and innervation

##### EXERCISE 12.2: EXTRINSIC EYE MUSCLES 229

- 2 Identify the six extrinsic eye muscles and describe the actions performed by each muscle

##### EXERCISE 12.3: MUSCLES OF MASTICATION 230

- 3 Identify the muscles of mastication and describe their actions and innervation

##### EXERCISE 12.4: MUSCLES THAT MOVE THE TONGUE 231

- 4 Explain the difference between extrinsic and intrinsic tongue muscles
- 5 Identify the intrinsic tongue muscles and describe their actions

##### EXERCISE 12.5: MUSCLES OF THE PHARYNX 232

- 6 Identify muscles of the pharynx and explain their role in swallowing

##### EXERCISE 12.6: MUSCLES OF THE ANTERIOR NECK 233

- 7 Identify the major muscles that act about the anterior neck and describe their actions

##### EXERCISE 12.7: MUSCLES THAT MOVE THE HEAD AND NECK 234

- 8 Identify the major muscles that move the head and neck and describe their actions
- 9 Name the major muscles used to perform the following actions of the neck: flexion, extension, rotation, and lateral flexion/bending
- 10 Describe how the sternocleidomastoid and splenius capitis muscles can act as both synergists and antagonists to each other

##### EXERCISE 12.8: SUBOCCIPITAL MUSCLES AND THE SUBOCCIPITAL TRIANGLE 237

- 11 Name the three muscles that form the borders of the suboccipital triangle
- 12 List the structures located within the suboccipital triangle

#### Muscles of the Vertebral Column 238

##### EXERCISE 12.9: MUSCLES OF THE VERTEBRAL COLUMN 238

- 13 Describe the major muscle groups that stabilize and move the vertebral column

#### Muscles of Respiration 242

##### EXERCISE 12.10: MUSCLES OF RESPIRATION 242

- 14 Correlate specific respiratory movements (inspiration, expiration, coughing, etc.) with the muscles responsible for creating the movements
- 15 List the three major structures that pass through the diaphragm and explain the significance of the location where each passes through

#### Muscles of the Abdominal Wall 244

##### EXERCISE 12.11: MUSCLES OF THE ABDOMINAL WALL 244

- 16 Describe the layered arrangement of the abdominal musculature
- 17 Explain how the aponeuroses of the external obliques, internal obliques, and transverse abdominis create the rectus sheath

##### EXERCISE 12.12: THE RECTUS SHEATH, INGUINAL LIGAMENT, AND INGUINAL CANAL 246

- 18 Locate the inguinal canal and inguinal ligament on a cadaver or classroom model
- 19 Describe the structures that pass through the inguinal canal in both males and females

## INTRODUCTION

Imagine a time after sleeping on a horrible mattress and waking up the next morning to find the muscles in your back and neck incredibly stiff and sore. For the next few days, every action seemed to cause pain. The classic comment from such an experience is, “I discovered muscles I never knew I had!” It seems that the only time the muscles of our back and neck are contemplated is when they are injured. At such a time it is impossible *not* to contemplate these muscles—they constantly hurt. This example is a reminder of the importance of the muscles of the back, neck, and thorax for creating the most basic motions of our bodies. The exercises in this chapter guide exploration of the structure and function of muscles of the head, neck, back, thorax, and abdomen. In addition, the exercises guide exploration of the structure and function of muscles important for chewing, creating facial expressions, and controlling such vital bodily functions as breathing, coughing, defecating, and urinating. The exercises in this chapter involve identifying, naming, and exploring the structure and function of muscles that move the axial skeleton. Before beginning, ask the laboratory instructor exactly which muscles within the chapter will be covered. Highlight or star those muscles in the tables throughout the chapter to ensure the focus will be on required muscles only. The overview exercises in the Gross Anatomy section of

chapter 11 should be covered before beginning the detailed study of the axial muscles within this chapter. The exercises in chapter 11 introduced the major muscle groups and the common actions of those muscle groups (see table 11.4).

#### **List of Reference Tables**

Table 12.1	Muscles of Facial Expression	p. 227
Table 12.2	Extrinsic Eye Muscles	p. 229
Table 12.3	Muscles of Mastication	p. 230
Table 12.4	Muscles That Move the Tongue	p. 231
Table 12.5	Muscles of the Pharynx	p. 232
Table 12.6	Muscles of the Anterior Neck	p. 234
Table 12.7	Muscles That Move the Head and Neck	p. 237
Table 12.8	Muscles of the Suboccipital Region	p. 237
Table 12.9	Muscles of the Vertebral Column	p. 239
Table 12.10	Muscles of Respiration	p. 242
Table 12.11	Muscles of the Abdominal Wall	p. 244

These Pre-laboratory Worksheet questions may be assigned by instructors through their **connect** course.

1. Which of the following muscles are classified as muscles of facial expression? (Check all that apply.)

- a. buccinator
- b. masseter
- c. orbicularis oris
- d. temporalis
- e. zygomaticus major

2. Which of the following muscles are classified as muscles of mastication? (Check all that apply.)

- a. epicranii
- b. masseter
- c. platysma
- d. risorius
- e. temporalis

3. Match the definition listed in column A with the corresponding term listed in column B.

**Column A**

- 1. a broad, flat tendon
- 2. the "groin" region
- 3. an increase in joint angle
- 4. outside of
- 5. pertaining to the cheek

**Column B**

- a. aponeurosis
- b. extension
- c. extrinsic
- d. inguinal
- e. buccal

4. Identify the largest and most important respiratory muscle, which separates the thoracic cavity from the abdominal cavity. (Circle one.)

- a. anterior scalene
- b. diaphragm
- c. middle scalene
- d. posterior scalene
- e. transversus thoracis

5. Which of the following muscles compose the anterior abdominal wall? (Check all that apply.)

- a. external oblique
- b. internal oblique
- c. quadratus lumborum
- d. rectus abdominis
- e. transversus abdominis

6. Which of the following is *not* one of the three attachment points for the sternocleidomastoid muscle? (Circle one.)

- a. mastoid process of the temporal bone
- b. medial third of the clavicle
- c. spine of the scapula
- d. sternum

7. Match the muscle listed in column A with the corresponding muscle group to which it belongs, listed in column B.

**Column A**

- 1. splenius capitis
- 2. digastric
- 3. orbicularis oris
- 4. longissimus

**Column B**

- a. erector spinae
- b. muscles of facial expression
- c. semispinalis muscles
- d. suprahyoid muscles

8. The diaphragm changes from dome-shaped to flat when it contracts. \_\_\_\_\_ (True/False)

9. The actions of abdominal wall muscles include extension and rotation of the trunk. \_\_\_\_\_ (True/False)





## Learning Strategy

The following is an effective and efficient process for studying each major muscle group (e.g., muscles of the abdominal wall). The process is designed to build knowledge and understanding in logical steps. After mastering task 1, move on to task 2, task 3, and so on. Each successive task requires more detailed knowledge of muscles within the group. However, following the steps, in order, prepares the student to more easily process these increasing levels of knowledge.

### Stepwise Approach to Learning Muscles of the Body

1. Describe the general location of the muscle group.
2. Describe the general actions that all muscles of the group have in common.

3. List the names of all muscles belonging to that group (or just the ones required for the course).
4. Identify the muscles on a model and/or a cadaver (this can be done concurrently with step 3).
5. Learn the outliers—the muscles that DO NOT share the common actions of the group.
6. Learn specific attachment points and actions of the muscles the course requires mastery of in this amount of detail.

Follow these suggestions, study one muscle group at a time, take many breaks, study using frequent, short time intervals—and the tasks will no longer feel overwhelming. You will be amazed at how well the knowledge can be mastered in a relatively short period of time. The results are often pleasantly surprising!

## Gross Anatomy

### Muscles of the Head and Neck

Muscles of the head and neck include the muscles of the face (muscles of facial expression and muscles of mastication), extrin-

sic eye muscles, muscles that move the tongue, and muscles that move the neck.

#### EXERCISE 12.1 Muscles of Facial Expression

1. Observe muscles of the face on a human cadaver or a classroom model.
2. Muscles of the face fall into two groups based on function and innervation: muscles of facial expression and muscles of mastication (chewing). **Muscles of facial expression (table 12.1)** allow one to express emotions such as fright, delight, confusion, surprise, and the like. These muscles are unique in that they have distal attachments on skin instead of bone, so when the muscles contract, they pull on the skin. This movement is easily seen on the surface of the face as a facial expression. Over time, the pulling of these muscles on the face causes a characteristic wrinkling of the skin. For this reason, it's a good idea to practice using “smiling” muscles much more often than using “frowning” muscles. This practice makes a person look much younger and happier with age as opposed to older and grumpier. All of the muscles of facial expression are innervated by the **facial nerves**, which are the paired seventh cranial nerves (CN VII). A person with damage to the facial nerve will be unable to demonstrate facial expressions on the affected side.
3. Look into a mirror (this part of the exercise may need to be performed at home or in a campus bathroom if there

isn't a mirror in the laboratory classroom) and practice the facial expressions listed in this step. While performing each expression, name the muscles used to create the expression (use table 12.1 as a guide).

- |  |  |
|--|--|
| <input type="checkbox"/> anger or doubt                                  | <input type="checkbox"/> sadness (frowning)  |
| <input type="checkbox"/> happiness (smiling or laughter)                 | <input type="checkbox"/> surprise or delight |
| <input type="checkbox"/> kissing (close mouth, purse cheeks, close eyes) |  |

4. Identify all of the muscles of facial expression listed in **figure 12.1** on the cadaver or on a model of the face, using table 12.1 and the textbook as guides. Then label them in figure 12.1.
5. *Optional Activity:* **AP|R Muscular System**—Watch the muscle action animations to review the actions of many of the muscles mentioned in chapters 12 and 13. Also answer the action, origin, and insertion questions found in the quiz area for more challenging drills and practice.

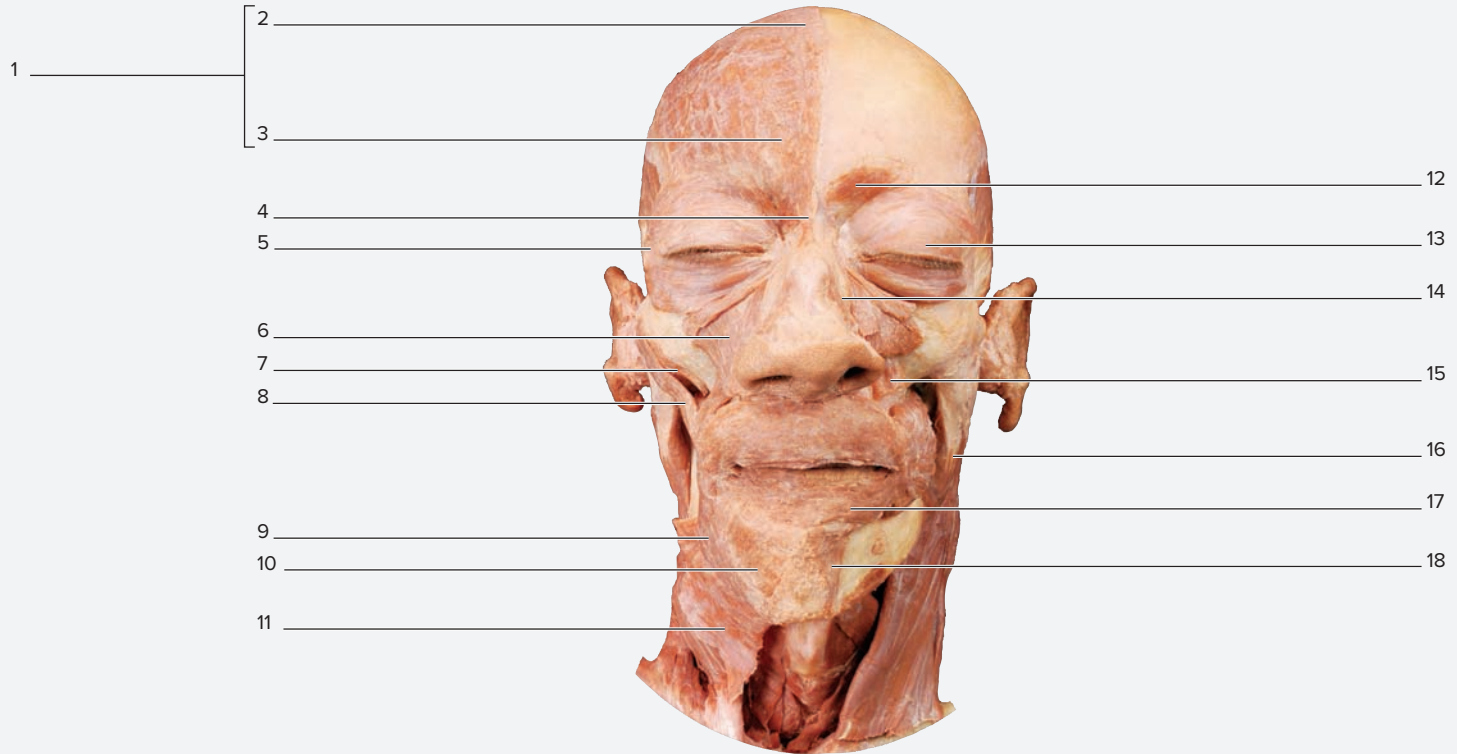
<b>Table 12.1 Muscles of Facial Expression*</b>					
<b>Muscle</b>	<b>Origin</b>	<b>Insertion</b>	<b>Action</b>	<b>Innervation</b>	<b>Word Origins</b>
<b>SCALP</b>					
<i>Epicranius (Occipitofrontalis)**</i>	Epicranial aponeurosis	Skin of the forehead (frontalis); superior nuchal line (occipitalis)	Elevates the eyebrows and creates horizontal wrinkles in the forehead, as in expressions of surprise or delight	Facial (CN VII)	<i>occiput</i> , the back of the head + <i>frontalis</i> , in front
<b>NOSE</b>					
<i>Nasalis</i>	Maxilla	Alar cartilages of the nose	Flares the nostrils, widens the anterior nasal aperture	Facial (CN VII)	<i>nasus</i> , nose
<i>Procerus</i>	Nasal bones and nasal cartilages	Aponeurosis at the bridge of the nose and the skin of the forehead	Depresses the eyebrows and elevates the nose producing wrinkles in the skin of the nose, as in frowning and squinting the eyes	Facial (CN VII)	<i>procerus</i> , long or stretched out
<b>MOUTH</b>					
<i>Buccinator</i>	Mandible, molar region of mandible and maxilla	Orbicularis oris (corners of the lips)	Presses cheek against molar teeth, as in chewing, whistling, or playing a wind instrument	Facial (CN VII)	<i>bucca</i> , cheek
<i>Depressor Anguli Oris</i>	Mandible (anterolateral surface of the body)	Muscles and skin in the lower lip near the angle of the mouth	Pulls corners of the mouth inferior, as in frowning	Facial (CN VII)	<i>depressus</i> , to press down + <i>angulus</i> , angle + <i>oris</i> , mouth
<i>Depressor Labii Inferioris</i>	Mandible (between the midline and the mental foramen)	Orbicularis oris and skin of the lower lip	Depresses the lower lip, as in expressions of doubt and sadness	Facial (CN VII)	<i>depressus</i> , to press down + <i>labia</i> , lip + <i>inferior</i> , lower
<i>Levator Anguli Oris</i>	Maxilla (lateral portion)	Skin at the superior corner of the mouth	Elevates the corners of the mouth and pulls them laterally, as in smiling	Facial (CN VII)	<i>levatus</i> , to lift + <i>labia</i> , lip + <i>superus</i> , above
<i>Levator Labii Superioris</i>	Maxilla (inferior to infraorbital foramen)	Orbicularis oris and skin of the upper lip	Elevates the upper lip, as in expressions of sadness or seriousness	Facial (CN VII)	<i>levatus</i> , to lift + <i>anguli</i> , angle + <i>oris</i> , mouth
<i>Mentalis</i>	Mandible (incisive fossa)	Skin of the chin	Wrinkles the skin of the chin and elevates and protrudes the lower lip, as in expressions of doubt	Facial (CN VII)	<i>mentum</i> , the chin
<i>Orbicularis Oris</i>	Deep surface of skin of maxilla and mandible	Mucous membrane of the lips	Purses and protrudes the lips, closes the mouth	Facial (CN VII)	<i>orbiculus</i> , a small disc + <i>oris</i> , mouth
<i>Risorius</i>	Fascia overlying the masseter muscles	Orbicularis oris and skin of the corner of the mouth	Pulls the corners of the mouth laterally, as in expressions of laughter and/or smiling	Facial (CN VII)	<i>risus</i> , to laugh
<i>Zygomaticus (Major and Minor)</i>	Zygomatic bone	Skin and muscle at corner of the mouth	Pulls the corners of the mouth posteriorly and superiorly, as in smiling	Facial (CN VII)	<i>zygon</i> , yoke
<b>EYE</b>					
<i>Corrugator Supercilii</i>	Superciliary arch	Skin of eyebrow	Creates vertical wrinkles in medial forehead, as in frowning	Facial (CN VII)	<i>corrugo</i> , to wrinkle + <i>superus</i> , above + <i>cilium</i> , eyelid
<i>Levator Palpebrae Superioris</i>	Sphenoid (lesser wing anterior and superior to the optic canal)	Skin of the upper eyelid	Elevates the upper eyelid	Oculomotor (CN III)	<i>levatus</i> , to lift + <i>palpebra</i> , eyelid + <i>superus</i> , above
<i>Orbicularis Oculi</i>	Skin around the margin of the orbit of the eye	Skin surrounding the eyelids	Closes the eyelids as in blinking	Facial (CN VII)	<i>orbiculus</i> , a small disc + <i>oculus</i> , eye
<b>NECK</b>					
<i>Platysma</i>	Fascia superficial to the deltoid and pectoralis major muscles at 1 and 2 ribs	Mandible (lower border) and skin of the cheek	Stretches the skin of the anterior neck, depresses the lower lip, as in expressions of fright	Facial (CN VII)	<i>platys</i> , flat, broad

\*All muscles in this table are innervated by the facial nerve (CN VII) with the exception of the levator palpebrae superioris, which is innervated by the oculomotor nerve (CN III).

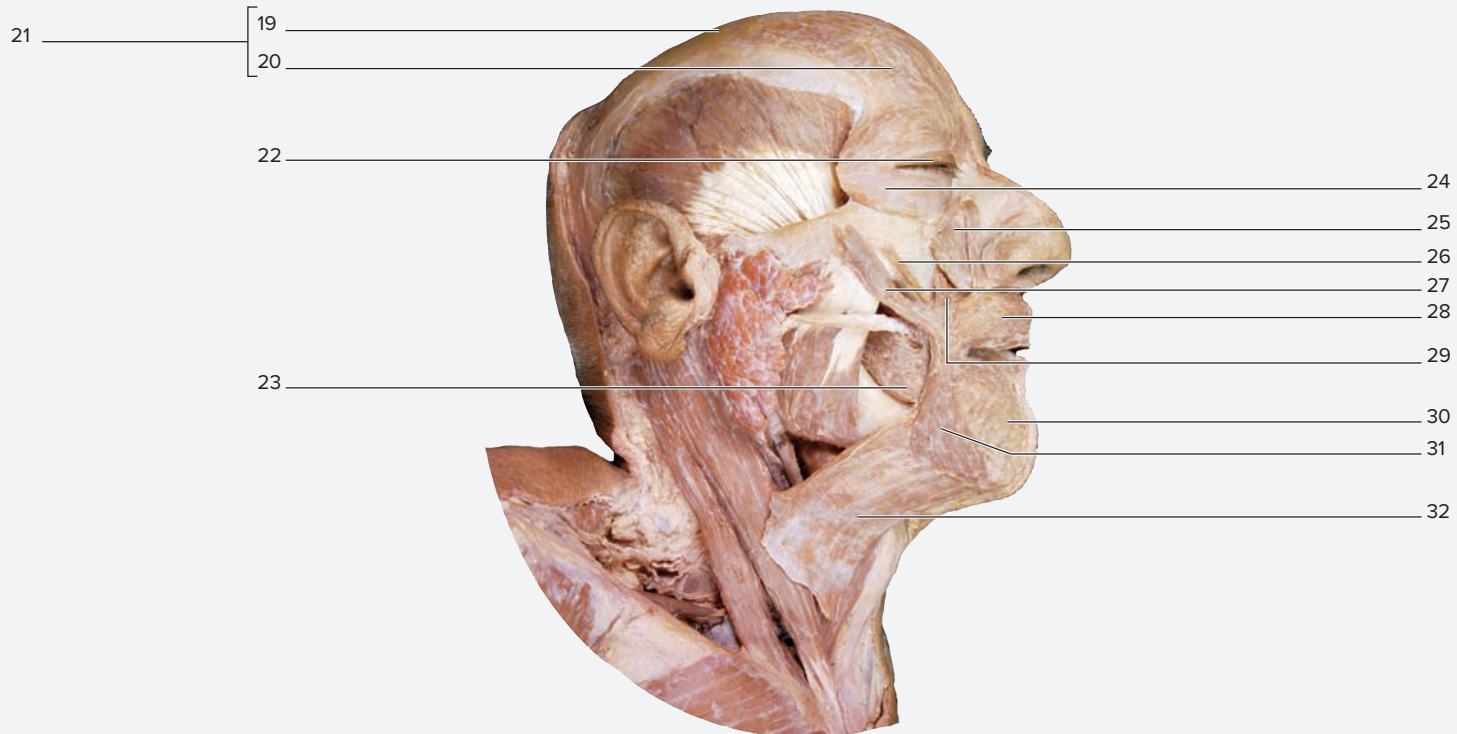
\*\*The epicranius consists of the epicranial aponeurosis and the occipitofrontalis muscle, which has two bellies: frontal belly of occipitofrontalis and occipital belly of occipitofrontalis.

(continued on next page)

(continued from previous page)



(a) Anterior view



(b) Lateral view

**Figure 12.1 Muscles of Facial Expression.** Use the terms listed to fill in the numbered labels in the figure. Some answers may be used more than once.

- |   |   |  |  |
|---|---|--|--|
| <input type="checkbox"/> buccinator                 | <input type="checkbox"/> epicranii (occipitofrontalis)      | <input type="checkbox"/> mentalis          | <input type="checkbox"/> procerus          |
| <input type="checkbox"/> corrugator supercilii      | <input type="checkbox"/> frontal belly of occipitofrontalis | <input type="checkbox"/> nasalis           | <input type="checkbox"/> zygomaticus major |
| <input type="checkbox"/> depressor anguli oris      | <input type="checkbox"/> levator anguli oris                | <input type="checkbox"/> orbicularis oculi | <input type="checkbox"/> zygomaticus minor |
| <input type="checkbox"/> depressor labii inferioris | <input type="checkbox"/> levator labii superioris           | <input type="checkbox"/> orbicularis oris  |  |
| <input type="checkbox"/> epicranial aponeurosis     | <input type="checkbox"/> levator palpebrae superioris       | <input type="checkbox"/> platysma          |  |

**EXERCISE 12.2** Extrinsic Eye Muscles

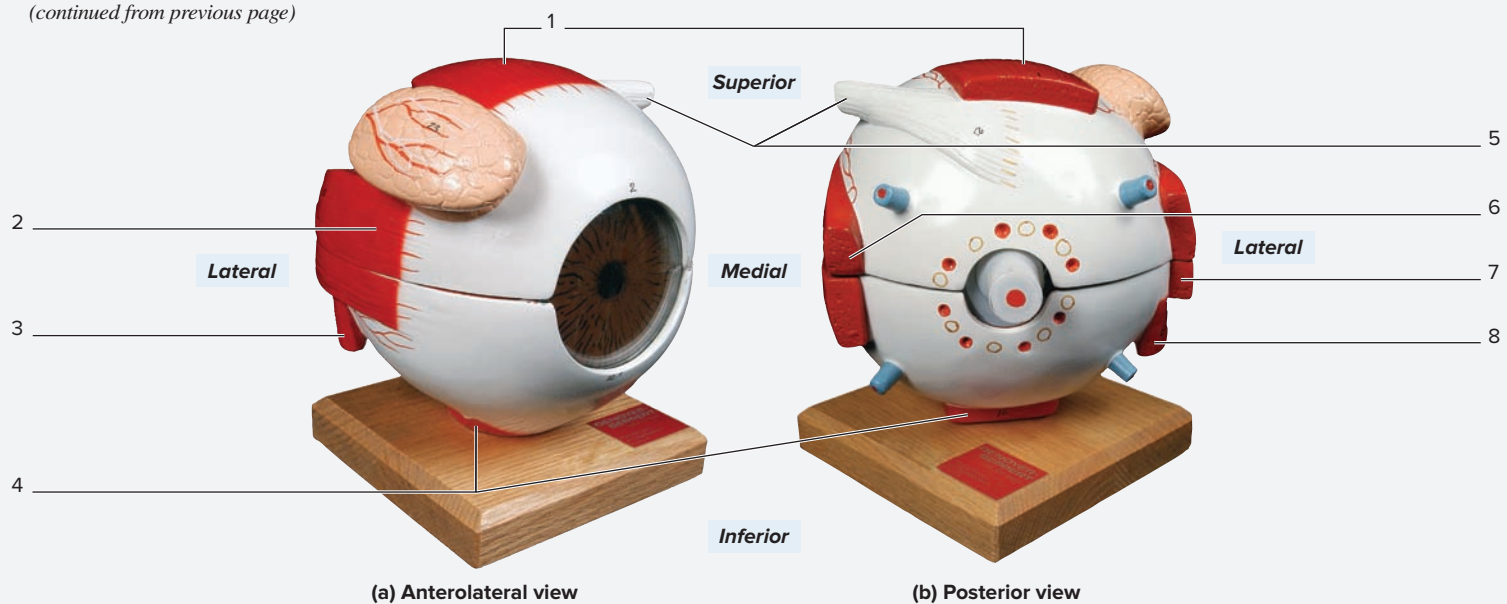
1. Observe a model of the eye with **extrinsic** muscles.
2. The extrinsic, or extraocular (*extra-*, outside of + *oculus*, eye), muscles of the eye (**table 12.2**) allow movement of the eyes up, down, side to side, and at an angle. These muscles originate on bone and insert onto the sclera of the eye. The **sclera** is the tough white connective tissue covering of the eyeball. The extrinsic eye muscles are named based on location, shape, or function, so they are quite easy to identify and remember. Coverage of the extrinsic eye muscles in this exercise will be brief. However, the muscles will be covered in more detail when covering cranial nerves and their functions in chapter 15. Understanding the structure and function of these muscles well now will make understanding the signs and symptoms of cranial nerve disorders much easier when completing the exercises in chapter 15.
3. Ask a laboratory partner to look in different directions and observe his or her eye movements. As his or her eyes move, name the muscles (in *both* eyes because they will be different!) used to create the movement (use table 12.2 as a guide).
4. Identify the **extrinsic eye muscles** listed in **figure 12.2** on the model of the eye, using table 12.2 and the textbook as guides. Then label the muscles in figure 12.2.

**Table 12.2****Extrinsic Eye Muscles**

Muscle	Origin	Insertion	Action	Innervation	Word Origins
<b>RECTUS MUSCLES</b>					
<i>Inferior rectus</i>	Sphenoid (tendinous ring around optic canal)	Sclera on the anterior, inferior surface of the eyeball	Depresses, adducts, and medially rotates the eyeball	Oculomotor (CN III)	<i>inferior</i> , lower + <i>rectus</i> , straight
<i>Lateral rectus</i>	Sphenoid (tendinous ring around optic canal)	Sclera on the anterior, lateral surface of the eyeball	Abducts the eyeball	Abducens (CN VI)	<i>lateralis</i> , lateral + <i>rectus</i> , straight
<i>Medial rectus</i>	Sphenoid (tendinous ring around optic canal)	Sclera on the anterior, medial surface of the eyeball	Adducts the eyeball	Oculomotor (CN III)	<i>medialis</i> , middle + <i>rectus</i> , straight
<i>Superior rectus</i>	Sphenoid (tendinous ring around optic canal)	Sclera on the anterior, superior surface of the eyeball	Elevates, adducts, and medially rotates the eyeball	Oculomotor (CN III)	<i>superus</i> , above + <i>rectus</i> , straight
<b>OBLIQUE MUSCLES</b>					
<i>Inferior oblique</i>	Maxilla (anterior portion of orbit)	Sclera on the anterior, lateral surface of the eyeball, deep to the lateral rectus muscle	Elevates, abducts, and laterally rotates the eyeball	Oculomotor (CN III)	<i>inferior</i> , lower + <i>obliquus</i> , slanting
<i>Superior oblique</i>	Sphenoid (tendinous ring around optic canal)	Sclera on the posterior, superiolateral surface of the eyeball just deep to the belly of the superior rectus muscle	Depresses, abducts, and medially rotates the eyeball	Trochlear (CN IV)	<i>superus</i> , above + <i>obliquus</i> , slanting

(continued on next page)

(continued from previous page)



**Figure 12.2** Extrinsic Eye Muscles. Use the terms listed to fill in the numbered labels in the figure. Some answers may be used more than once.

- |   |   |  |
|---|---|--|
| <input type="checkbox"/> inferior oblique | <input type="checkbox"/> lateral rectus | <input type="checkbox"/> superior oblique (tendon) |
| <input type="checkbox"/> inferior rectus  | <input type="checkbox"/> medial rectus  | <input type="checkbox"/> superior rectus           |

© Copyright by Denoyer-Geppert. Photos by Christine Eckel

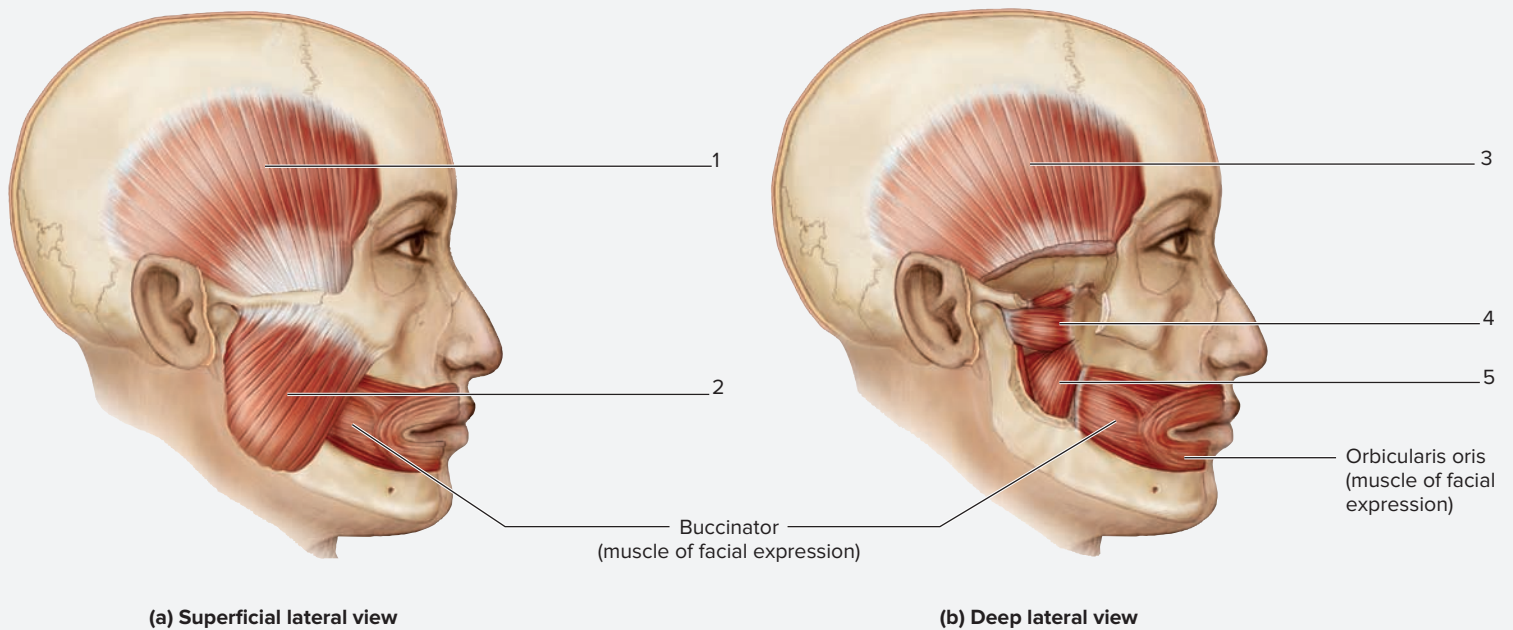
### EXERCISE 12.3 Muscles of Mastication

1. Observe muscles of the face on a human cadaver or a classroom model that demonstrates facial muscles.
2. **Muscles of mastication** (*masticate*, to chew) are used in chewing movements (**table 12.3**). These muscles attach to the only mobile bone of the skull, the mandible. The muscles of mastication are innervated by branches of the **trigeminal nerves**, which are the paired fifth cranial nerves (CN V). Damage to the trigeminal nerve causes an inability to chew on the affected side.
3. The two most powerful muscles of mastication are the **masseter** and **temporalis** muscles. Place your fingers over the angle and ramus of the mandible (just below the cheek) and close the jaw forcefully (elevate the mandible) to feel contraction of the masseter. Then repeat the process, only this time place your fingers over the temples to feel the contraction of the temporalis muscle. The antagonist muscles to the muscles of mastication (i.e., muscles that depress the mandible/open the mouth) are the infrahyoid muscles, which are covered in exercise 12.6.
4. Identify the muscles of mastication listed in **figure 12.3** on a cadaver or the model of the face, using table 12.3 and the textbook as guides. Then label the muscles in figure 12.3.

Table 12.3 Muscles of Mastication*					
Muscle	Origin	Insertion	Action	Innervation	Word Origins
<i>Lateral Pterygoid</i> **	Sphenoid (greater wing and lateral pterygoid plate)	Mandible (neck)	Protracts the mandible and depresses the chin; produces a side-to-side motion of the mandible	Trigeminal (CN V)	<i>pteryx</i> , wing + <i>eidōs</i> , resemblance
<i>Masseter</i>	Zygomatic arch	Mandible (lateral surface of the ramus)	Elevates and protracts the mandible	Trigeminal (CN V)	<i>masētēr</i> , chewer
<i>Medial Pterygoid</i> **	Sphenoid (lateral pterygoid plate) and maxilla	Mandible (medial surface of the ramus and neck)	Elevates and protracts the mandible; produces a side-to-side motion of the mandible	Trigeminal (CN V)	<i>pteryx</i> , wing + <i>eidōs</i> , resemblance
<i>Temporalis</i>	Temporal fossa	Mandible (coronoid process)	Elevates and retracts the mandible	Trigeminal (CN V)	<i>tempus</i> , temple

\*All muscles in this table are innervated by the trigeminal nerve (CN V).

\*\*Lateral and medial pterygoids, when acting alone (alternating one side at a time), produce a side-to-side grinding motion.



**Figure 12.3 Muscles of Mastication.** Use the terms listed to fill in the numbered labels in the figure. Some answers may be used more than once.

- lateral pterygoid
- medial pterygoid
- masseter
- temporalis

**EXERCISE 12.4 Muscles That Move the Tongue**

1. Observe a model of a head that has been cut in a midsagittal plane so the muscles of the tongue are visible.
2. The tongue has both intrinsic and extrinsic muscles (**table 12.4**). The *intrinsic* muscles, within the tongue

Table 12.4 Muscles That Move the Tongue					
Muscle	Origin	Insertion	Action	Innervation	Word Origins
<i>Genioglossus</i>	Mandible (mental spine)	Hyoid bone (body) and inferior portion of the tongue	Depresses and protrudes the tongue	Hypoglossal (CN XII)	<i>geneion</i> , chin + <i>glossa</i> , tongue
<i>Hyoglossus</i>	Hyoid bone (body and greater horn)	Inferior and lateral aspects of the tongue	Depresses and retracts the tongue	Hypoglossal (CN XII)	<i>hyo-</i> , hyoid bone + <i>glossa</i> , tongue
<i>Palatoglossus</i>	Soft palate (palatine aponeurosis)	Lateral aspect of the tongue	Depresses the soft palate and elevates the posterior aspect of the tongue	Vagus (CN X)	<i>palatum</i> , palate + <i>glossa</i> , tongue
<i>Styloglossus</i>	Styloid process of the temporal bone	Inferior and lateral aspects of the tongue	Retracts and elevates the tongue during swallowing	Hypoglossal (CN XII)	<i>stylo-</i> , styloid process + <i>glossa</i> , tongue

**Learning Strategy**

The term “glossa” refers to the tongue. All of the muscles that move the tongue must be attached to the tongue to be able to move the tongue. Thus, the muscles of the tongue listed in table 12.4 all have insertions on the tongue. These muscles

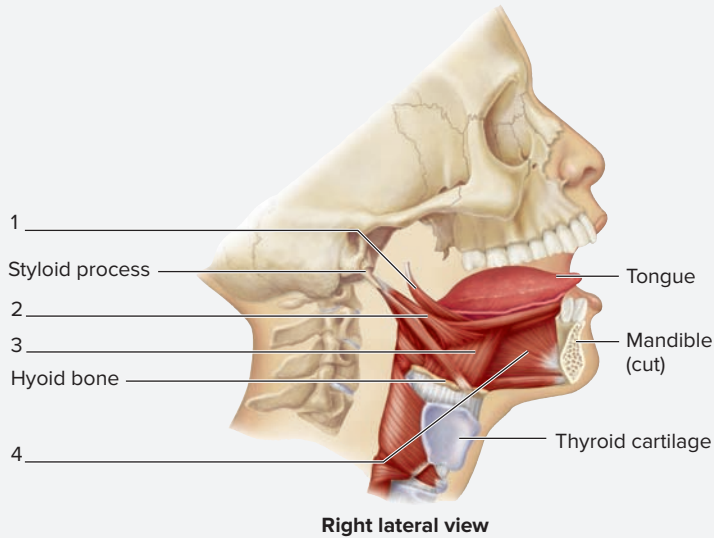
are also named for their attachments. Thus, to make the job of learning the attachments of these muscles easier, just focus on the first part of the muscle name (e.g., “palato” for palatoglossus). It will then be easy to recall that the muscle has its origin on the palate and its insertion on the tongue.

(continued on next page)

(continued from previous page)

itself, change the shape of the tongue. The *extrinsic* muscles, which connect the tongue to bony structures of the head and neck, create fine movements of the tongue necessary to form speech, manipulate food, and so on.

- Look into a mirror and stick your tongue out. This part of the exercise may have to be performed at home or in the dorm



if there are not mirrors available in the anatomy laboratory classroom. Next, pull the tongue back in, then back out, try to curl it, alter its shape, and so on. While performing these actions, decide if the muscles used are intrinsic or extrinsic muscles of the tongue.

- Identify the **muscles that move the tongue** listed in **figure 12.4** on a cadaver or on a model of the head and neck, using table 12.4 and the textbook as guides. (Note: The muscles in figure 12.4 and table 12.4 are all extrinsic muscles of the tongue.) Then label the muscles in figure 12.4.

**Figure 12.4** Muscles That Move the Tongue (and Associated Structures). Use the terms listed to fill in the numbered labels in the figure.

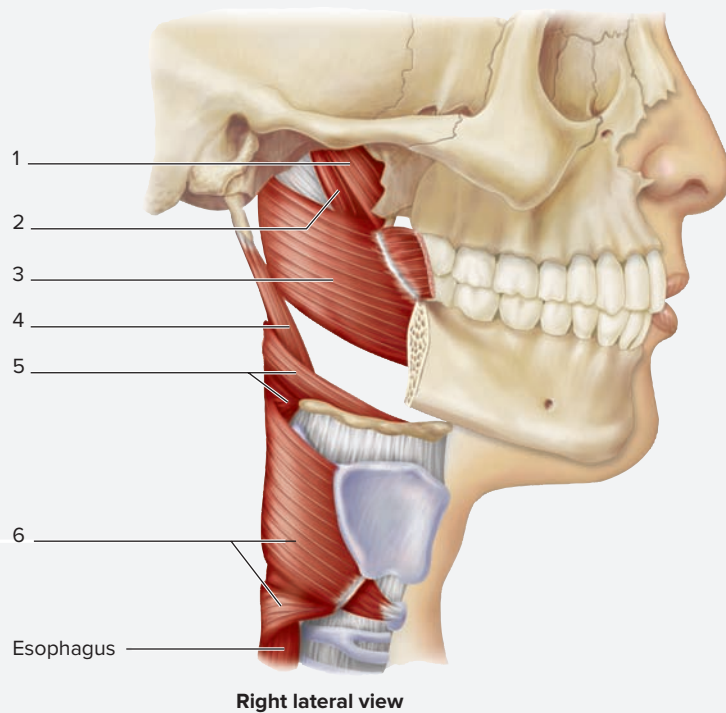
- genioglossus
- palatoglossus
- hyoglossus
- styloglossus

**EXERCISE 12.5** Muscles of the Pharynx

- Observe a prosected cadaver, a model of the larynx (which will also demonstrate muscles of the pharynx), or a model of the head and neck demonstrating muscles of the pharynx.
- The pharyngeal muscles (**table 12.5**) are used during the swallowing process. To get a feel for how these muscles function, swallow some saliva or a drink of water and pay

Table 12.5 Muscles of the Pharynx					
Muscle	Origin	Insertion	Action	Innervation	Word Origins
<b>PALATE MUSCLES</b>					
<i>Levator Veli Palatini</i>	Temporal bone (petrous portion) and cartilage of the auditory tube	Soft palate (palatine aponeurosis)	Elevates the soft palate, as in swallowing and yawning	Vagus (CN X)	<i>levatus</i> , to lift + <i>velum</i> , veil + <i>palatum</i> , palate
<i>Tensor Veli Palatini</i>	Sphenoid bone (pterygoid process)	Soft palate (palatine aponeurosis)	Elevates the soft palate	Trigeminal (CN V)	<i>tensus</i> , to stretch + <i>velum</i> , veil + <i>palatum</i> , palate
<b>PHARYNGEAL CONSTRICTORS</b>					
<i>Inferior Constrictor</i>	Larynx (thyroid and cricoid cartilages)	Posterior median raphe	Constricts the pharynx	Vagus (CN X)	<i>inferior</i> , lower + <i>constringo</i> , to draw together
<i>Middle Constrictor</i>	Hyoid bone	Posterior median raphe	Constricts the pharynx	Vagus (CN X)	<i>middle</i> , middle + <i>constringo</i> , to draw together
<i>Superior Constrictor</i>	Sphenoid bone (pterygoid process)	Posterior median raphe	Constricts the pharynx	Vagus (CN X)	<i>superus</i> , above + <i>constringo</i> , to draw together
<b>LARYNGEAL (VOICE BOX) ELEVATORS</b>					
<i>Palatopharyngeus</i>	Soft palate (palatine aponeurosis)	Lateral wall of the pharynx	Elevates the larynx and pharynx	Vagus (CN X)	<i>palatum</i> , palate + <i>pharyngo-</i> , pharynx
<i>Salpingopharyngeus</i>	Auditory tube	Lateral wall of pharynx	Elevates larynx and pharynx	Vagus (CN X)	<i>salpinx</i> , trumpet + <i>pharyngo-</i> , pharynx
<i>Stylopharyngeus</i>	Styloid process of temporal bone	Larynx (thyroid cartilage)	Elevates the larynx and pharynx	Glossopharyngeal (CN IX)	<i>stylo-</i> , styloid process + <i>pharyngo-</i> , pharynx

attention to the role these muscles play during swallowing. Notice that, while swallowing, the larynx moves superiorly. (The larynx is best felt by palpating the thyroid cartilage, or “Adam’s apple.” The larynx is located just anterior to



the pharynx.) The muscles that elevate the larynx *are not pharyngeal muscles*. Rather they are the suprahyoid muscles (see exercise 12.6). The muscles this exercise focuses on are the ones felt at the back of the throat at the very end of the swallowing process. The pharyngeal constrictors move the bolus of food, saliva, etc., from the mouth into the esophagus.

- Identify the **muscles of the pharynx** listed in **figure 12.5** on a cadaver, on a model of the head and neck, or on a model of the larynx, using table 12.5 as a guide. Then label the muscles in figure 12.5.

**Figure 12.5** Muscles of the Pharynx. Note: Salpingopharyngeus is not shown in this figure. Use the terms listed to fill in the numbered labels in the figure. Some answers may be used more than once.

- |  |   |
|--|---|
| <input type="checkbox"/> inferior constrictor  | <input type="checkbox"/> stylopharyngeus      |
| <input type="checkbox"/> levator veli palatini | <input type="checkbox"/> superior constrictor |
| <input type="checkbox"/> middle constrictor    | <input type="checkbox"/> tensor veli palatini |

### EXERCISE 12.6 Muscles of the Anterior Neck

- Observe a prosected cadaver or a classroom model demonstrating muscles of the neck.
- The most prominent muscle in the anterior neck is the **sternocleidomastoid** muscle. The attachment of this muscle can be easily palpated under the skin. To do this, place your fingers just behind the ears to palpate the **mastoid process**, the insertion of the sternocleidomastoid. Next, palpate the sternum, just lateral to the sternal notch while rotating the neck from right to left, and feel for the tendons of the **sternal head** of the sternocleidomastoid. Finally, palpate just superior

to the medial third of the clavicle while laterally flexing the neck to see if contraction of the **clavicular head** of the sternocleidomastoid can be felt. Understanding the locations of the attachments, bellies, and borders of the two heads of this muscle is important because the sternocleidomastoid is a major clinical landmark in the neck.

- Identify the muscles of the anterior neck listed in **figure 12.6** on a cadaver or a model of the head and neck, using **table 12.6** and the textbook as guides. Then label them in figure 12.6.

#### Learning Strategy

When studying muscles, or any other anatomical structure for that matter, remember that directional terms like “anterior/posterior” or “medial/lateral” are used in the naming of muscles only when necessary. That is, they are generally used only when there are two or more similar muscles with the same name. For

example: if there is a “major” (e.g., zygomaticus major), then there must also be a “minor” (e.g., zygomaticus minor); if there is a “superior” (e.g., superior oblique), there must also be an “inferior” (e.g., inferior oblique). This may seem simple, but it is not always obvious to the beginning student of anatomy.



Table 12.6

## Muscles of the Anterior Neck

Muscle	Origin	Insertion	Action	Innervation	Word Origins
<b>SUPRAHYOID MUSCLES</b>					
<i>Digastric</i>	Mastoid process (digastric groove on medial aspect)	Mandible (lower border near the midline)	When the mandible is fixed, it elevates the hyoid (posterior belly). When the hyoid is fixed, it depresses the mandible (anterior belly).	Posterior belly: facial (CN VII). Anterior belly: mandibular branch of the trigeminal (CN V)	<i>di-</i> , two + <i>gastro-</i> , belly
<i>Geniohyoid</i>	Mandible (mental spine)	Hyoid bone	Protraction of hyoid. When hyoid is fixed, it depresses the mandible.	Hypoglossal (CN XII)	<i>geneion</i> , chin + <i>hyoides</i> , shaped like the letter U
<i>Mylohyoid</i>	Mandible (mylohyoid line)	Hyoid bone	Elevates the floor of the mouth and tongue. When the hyoid is fixed it depresses the mandible.	Mandibular branch of the trigeminal (CN V)	<i>myle</i> , a mill + <i>hyoides</i> , shaped like the letter U
<i>Stylohyoid</i>	Styloid process of temporal bone	Hyoid bone	Elevates the hyoid	Facial (CN VII)	<i>stylos</i> , pillar + <i>hyoides</i> , shaped like the letter U
<b>INFRAHYOID MUSCLES</b>					
<i>Omoxyoid</i>	Scapula (between the superior angle and the scapular notch)	Hyoid bone	Depresses the hyoid	Cervical spinal nerves C1–C3 through ansa cervicalis	<i>omos</i> , shoulder + <i>hyoides</i> , shaped like the letter U
<i>Sternohyoid</i>	Manubrium of sternum (posterior surface) and first costal cartilage	Hyoid bone	Depresses the hyoid	Cervical spinal nerves C1–C3 through ansa cervicalis	<i>sternon</i> , chest + <i>hyoides</i> , shaped like the letter U
<i>Sternothyroid</i>	Manubrium of sternum (posterior surface) and first costal cartilage	Thyroid cartilage	Depresses the larynx	Cervical spinal nerves C1–C3 through ansa cervicalis	<i>sternon</i> , chest + <i>thyroid</i> , shaped like a shield
<i>Thyrohyoid</i>	Thyroid cartilage	Hyoid bone	Moves hyoid toward the larynx	First cervical spinal nerve C1 via hypoglossal (CN XII)	<i>thyro-</i> , thyroid + <i>hyoides</i> , shaped like the letter U

### Clinical Connection | Understanding the Actions of Agonists, Synergists, and Antagonists

An **agonist** (*agon*, a contest), or **prime mover**, is a muscle used to create a given action about a joint. An **antagonist** (*anti-*, against + *agon*, a contest) is a muscle whose action opposes the action of the agonist. In contrast, a synergist (*syn*, together) is a muscle whose action assists the agonist. The sternocleidomastoid and splenius capitis are muscles that provide a good example of how muscles can act as either synergists or antagonists depending upon the movement required. These muscles can act as synergists for the action of lateral rotation of the neck, whereas they act as antagonists for the actions of flexion and extension of the neck. Palpate the sternal head of the sternocleidomastoid on your right side, and then laterally rotate your head to the right. Do you feel tension in the muscle? \_\_\_\_\_ Still palpating the muscle, laterally rotate your head to the left. Do you feel tension in the muscle? \_\_\_\_\_ Based on your observations, which direction does the right sternocleidomastoid rotate the neck? \_\_\_\_\_

The most superficial muscle on the posterior side of the neck is the trapezius, a muscle that can move the neck, but is more of a prime mover of the scapula (see table 13.1). If you palpate the back of your neck as you rotate your neck, you can feel the trapezius muscle and a smaller muscle located deep to the trapezius, the splenius capitis, which is a prime mover of the neck (see **table 12.7** for reference to its actions). Place your right hand over the back of the right side of your neck and rotate your head to the right. Keeping your hand in the same location, rotate your head to the left. In which direction of rotation do you feel more tension in the muscles on the back of the neck? \_\_\_\_\_ Based on your observations, which direction does the right splenius capitis muscle rotate the neck? \_\_\_\_\_

In summary: to rotate your neck to the right, you use the sternal head of the sternocleidomastoid on the \_\_\_\_\_ side of the neck, and the splenius capitis muscle on the \_\_\_\_\_ side of the neck.

### EXERCISE 12.7 Muscles That Move the Head and Neck

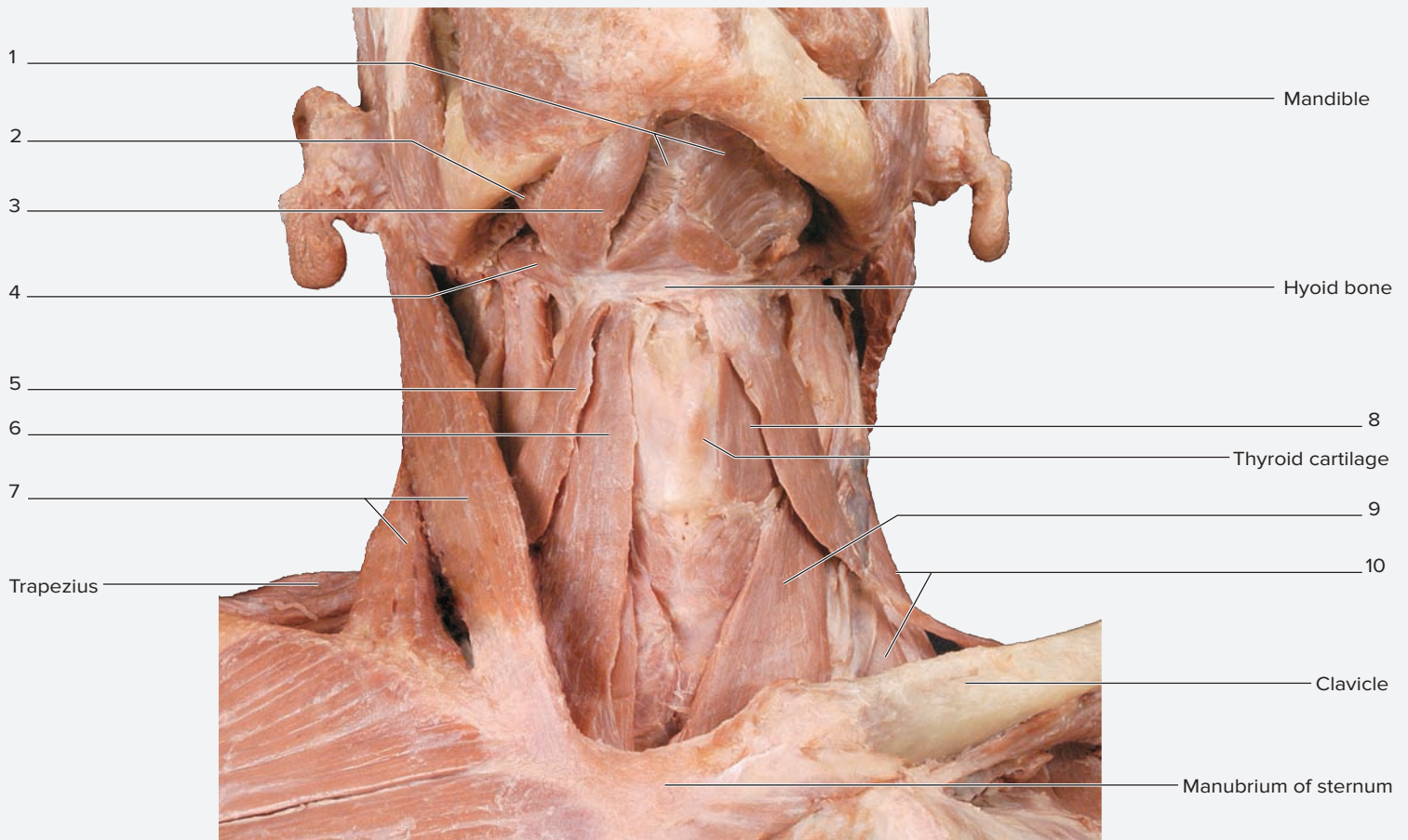
1. Observe a prosected cadaver or a classroom model demonstrating muscles of the anterior neck.
2. The muscles of the anterior neck include two groups of muscles: the **suprahyoid** and **infrahyoid** muscle groups. As

their names imply, suprahyoid muscles lie superior to the hyoid bone and infrahyoid muscles lie inferior to the hyoid bone. In general, these muscles are used for swallowing. Each plays a specific role in the process of swallowing. This process first involves elevation of the hyoid bone, which is

primarily a function of the suprahyoid muscles. Elevation of the hyoid bone initiates the swallowing process by moving a bolus (*bolus*, ball) of food from the oral cavity into the oropharynx. Next, the infrahyoid muscles come into play to move the bolus of food from the oropharynx into the esophagus, where esophageal muscles take over to transport the bolus of food to the stomach. The suprahyoid and infrahyoid muscles can be palpated in the anterior neck. To do this, first place the thumb and index finger just under the chin and toward the back of the throat (i.e., on either side of the larynx). Next, gently move the tissue between the thumb and index finger from side to side. It may be necessary to move the position of the thumb and finger a little bit to achieve the objective, which is to feel the hyoid bone. Recall that the hyoid bone is the only bone in the body with no attachment to any other bone in the body. Thus, it is held in place by the suprahyoid and infrahyoid muscle groups. Palpate just under the mandible and toward the hyoid bone. This is where the suprahyoid muscle group is located. Next,

palpate either side of the larynx. Here several things are felt, including the infrahyoid muscle group.

- To feel the *actions* of the suprahyoid muscle group, place the thumb and index finger on either side of the hyoid as was done in step 2, then swallow. What direction did the hyoid bone move? \_\_\_\_\_ To feel the actions of the infrahyoid muscle group, place the thumb and index finger on either side of the thyroid cartilage (the largest part of the larynx), then swallow. What direction did the larynx move? \_\_\_\_\_ Finally, look at the listed actions of the muscles of each of these groups of muscles to see the actions felt during swallowing are consistent with the actions of the muscles of each of these muscle groups.
- Identify the muscles that move the head and neck on a cadaver or model demonstrating muscles of the anterior neck, using table 12.6, figure 12.6, and the textbook as guides. Then, label the muscles in figure 12.6.

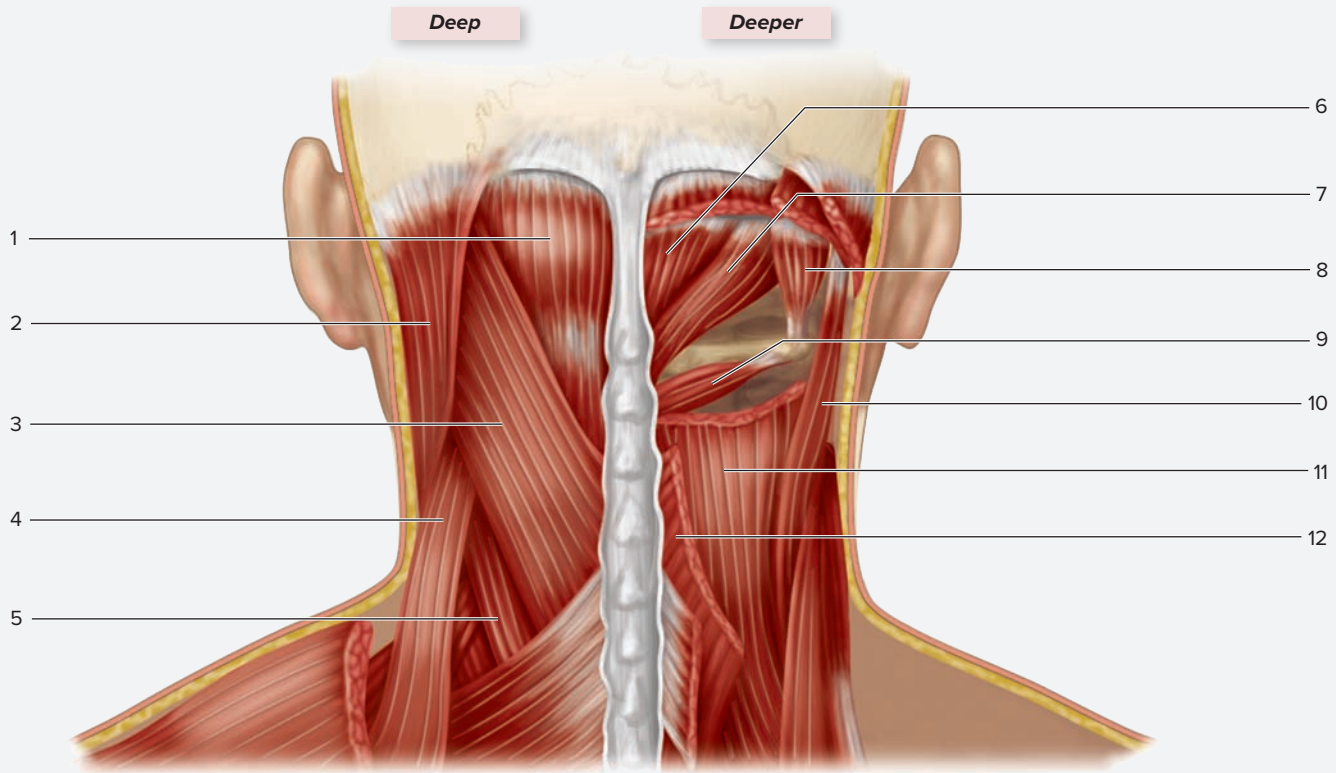


(a) Anterior view

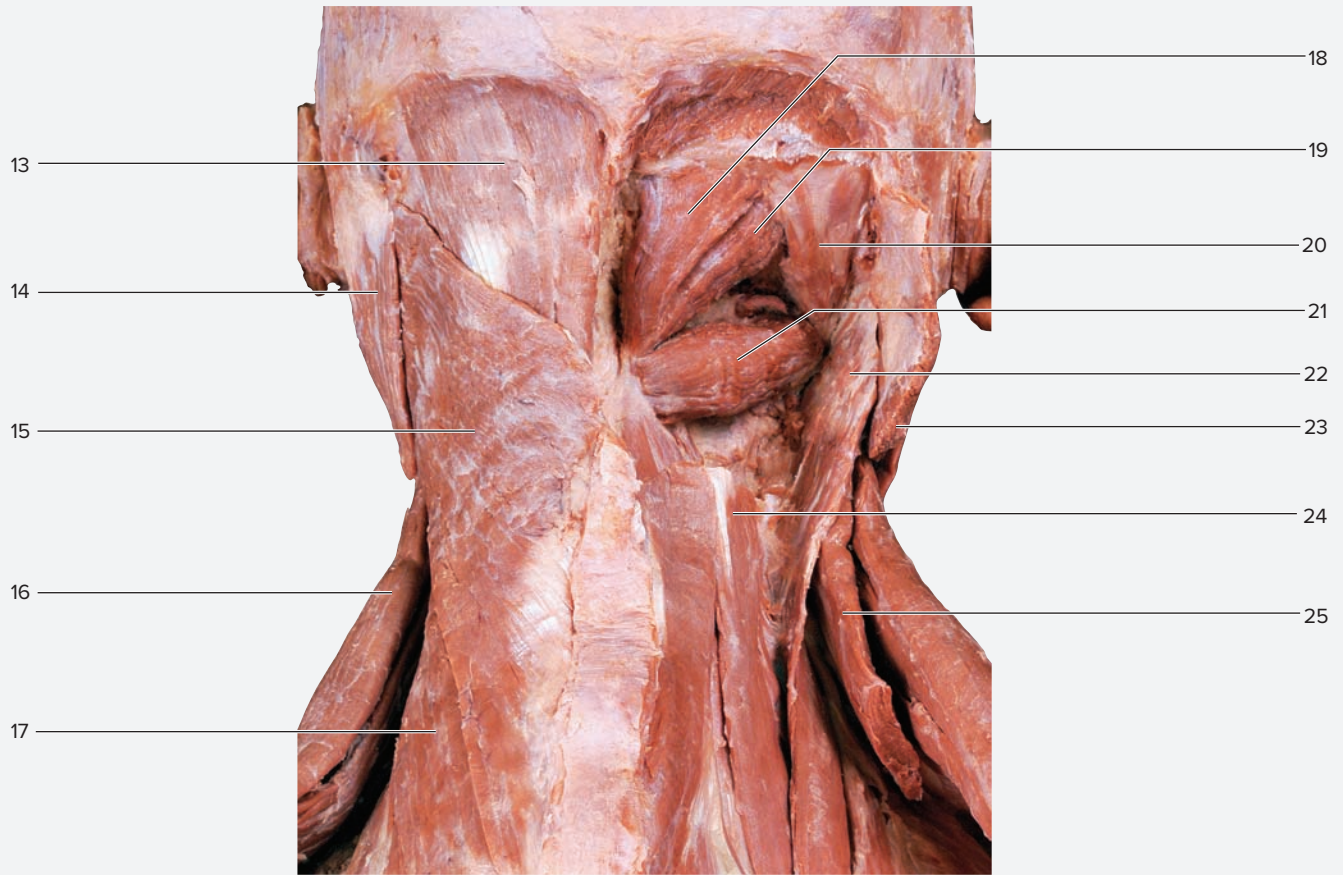
**Figure 12.6** Muscles of the Head and Neck. Use the terms listed to fill in the numbered labels in the figure. Some answers may be used more than once.

- |  |   |   |  |
|--|---|---|--|
| <input type="checkbox"/> digastric (anterior belly)  | <input type="checkbox"/> obliquus capitis inferior      | <input type="checkbox"/> rectus capitis posterior minor | <input type="checkbox"/> sternocleidomastoid |
| <input type="checkbox"/> digastric (posterior belly) | <input type="checkbox"/> obliquus capitis superior      | <input type="checkbox"/> scalenes                       | <input type="checkbox"/> sternohyoid         |
| <input type="checkbox"/> levator scapulae            | <input type="checkbox"/> omohyoid (inferior belly)      | <input type="checkbox"/> semispinalis capitis           | <input type="checkbox"/> sternothyroid       |
| <input type="checkbox"/> longissimus capitis         | <input type="checkbox"/> omohyoid (superior belly)      | <input type="checkbox"/> splenius capitis               | <input type="checkbox"/> stylohyoid          |
| <input type="checkbox"/> mylohyoid                   | <input type="checkbox"/> rectus capitis posterior major | <input type="checkbox"/> splenius cervicis              | <input type="checkbox"/> thyrohyoid          |

(continued from previous page)



(b) Posterior view



(c) Posterior view

**Figure 12.6** Muscles of the Head and Neck (*continued*). Use the terms listed to fill in the numbered labels in the figure. Some answers may be used more than once.

(b) Source: from McKinley, et al. Human Anatomy 4e. Reproduced with permission from McGraw-Hill Education; (c) © McGraw-Hill Education/Photos and Dissections by Christine Eckel

Table 12.7 Muscles That Move the Head and Neck					
Muscle	Origin	Insertion	Action	Innervation	Word Origins
<b>MUSCLES THAT MOVE THE NECK</b>					
<i>Longissimus Capitis</i>	T <sub>1</sub> –T <sub>4</sub> (transverse processes) and C <sub>4</sub> –C <sub>7</sub> (articular processes)	Mastoid process of temporal bone	Bilateral: extends the neck Unilateral: laterally rotates the neck to the same side	Cervical and thoracic spinal nerves	<i>longissimus</i> , longest + <i>caput</i> , head
<i>Semispinalis Capitis</i>	T <sub>1</sub> –T <sub>5</sub> (spinous processes), C <sub>4</sub> –C <sub>7</sub> (articular processes)	Occipital bone (between superior and inferior nuchal lines)	Bilateral: extends the neck Unilateral: laterally flexes the neck to the same side	Dorsal rami of cervical spinal nerves	<i>semi-</i> , half + <i>spina</i> , spine + <i>caput</i> , head
<i>Splenius Capitis</i>	Ligamentum nuchae and T <sub>1</sub> –T <sub>6</sub> (spinous processes)	Superior nuchal line of occipital bone (lateral aspect) and mastoid process of temporal bone	Bilateral: extends the neck Unilateral: laterally rotates and laterally flexes the neck to the same side	Dorsal rami of spinal nerves	<i>splenion</i> , a bandage + <i>caput</i> , head
<i>Sternocleidomastoid</i>	Sternal head: manubrium of the sternum Clavicular head: clavicle (medial third)	Mastoid process of temporal bone	Bilateral: flexes the neck Unilateral: laterally rotates the neck to the opposite side	Accessory (CN XI)	<i>sterno-</i> , sternum + <i>cleido-</i> , clavicle + <i>mastoid</i> , resembling a breast

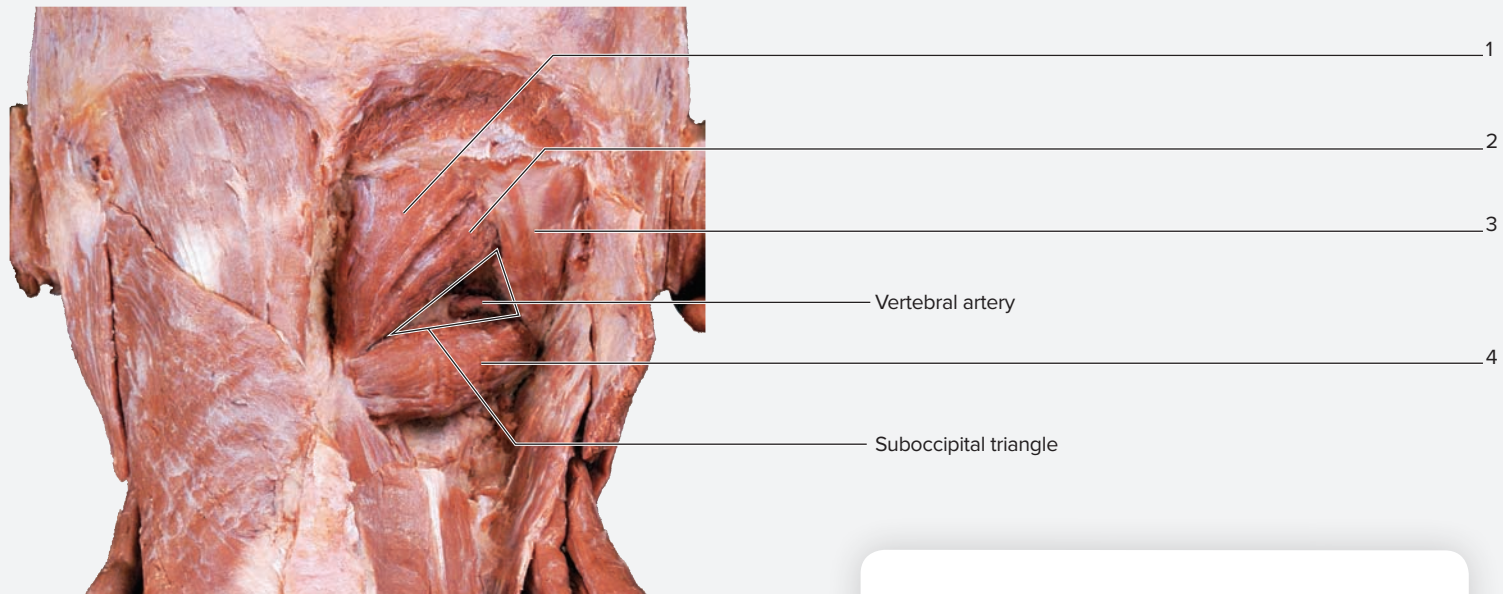
### EXERCISE 12.8 Suboccipital Muscles and the Suboccipital Triangle

1. Observe a prosected cadaver or a classroom model of the head and neck demonstrating the suboccipital muscles (table 12.8).
2. The suboccipital muscles are responsible for creating the small, fine movements of the head. They attach to the occipital bone, the atlas, and the axis. Before you study these muscles, recall the movements that occur at the **atlanto-occipital joint** and the **atlantoaxial joint**:  
*Atlanto-occipital joint*: flexion/extension, as in saying yes.  
*Atlantoaxial joint*: lateral rotation, as in saying no.
3. In addition to their role in creating fine neck movements, three of the muscles of the suboccipital region (the superior oblique, inferior oblique, and rectus capitis posterior major) compose a clinically relevant landmark called the **suboccipital triangle** (figure 12.7). The **vertebral artery** and **suboccipital nerve** are located within this triangle. Can you identify these structures on the cadaver or models?
4. Identify the **suboccipital muscles** listed in figure 12.7 on a cadaver or on a classroom model of the head and neck, using table 12.8 and the textbook as guides. Then label them in figure 12.7.

Table 12.8 Muscles of the Suboccipital Region					
Muscle	Origin	Insertion	Action	Innervation	Word Origins
<i>Obliquus Capitis Inferior</i>	Axis (spinous process)	Atlas (transverse process)	Laterally rotates the neck (at the atlantoaxial joint)	Suboccipital	<i>obliquus</i> , slanted + <i>capitis</i> , head + <i>inferior</i> , lower
<i>Obliquus Capitis Superior</i>	Atlas (transverse process)	Occipital bone (lateral third of the inferior nuchal line)	Extends and laterally rotates the neck (at the atlanto-occipital joint)	Suboccipital	<i>obliquus</i> , slanted + <i>capitis</i> , head + <i>superus</i> , above
<i>Rectus Capitis Posterior Major</i>	Axis (spinous process)	Occipital bone (middle portion of the inferior nuchal line)	Laterally rotates the neck	Suboccipital	<i>rectus</i> , straight + <i>caput</i> , head + <i>posterior</i> , the back + <i>magnus</i> , great
<i>Rectus Capitis Posterior Minor</i>	Atlas (posterior tubercle)	Occipital bone (medial third of the inferior nuchal line)	Laterally rotates the neck (at the atlanto-occipital joint)	Suboccipital	<i>rectus</i> , straight + <i>caput</i> , head + <i>posterior</i> , the back + <i>minor</i> , smaller

(continued on next page)

(continued from previous page)



**Figure 12.7 Suboccipital Muscles.** Posterior view of the neck. Use the terms listed to fill in the numbered labels in the figure.

- |  |   |
|--|---|
| <input type="checkbox"/> obliquus capitis inferior | <input type="checkbox"/> rectus capitis posterior major |
| <input type="checkbox"/> obliquus capitis superior | <input type="checkbox"/> rectus capitis posterior minor |

© McGraw-Hill Education/Photos and Dissections by Christine Eckel

5. Sketch the suboccipital muscles in the space provided. On top of the drawing, note the boundaries of the suboccipital triangle and the locations of the vertebral artery and the suboccipital nerve.

### WHAT DO YOU THINK?

- 1 How does the vertebral artery get into the suboccipital triangle from the thoracic cavity? (Hint: Refer back to the special characteristics of cervical vertebrae described in table 8.4 on p. 141.)

## Muscles of the Vertebral Column

Muscles that move the vertebral column are complex in both location and function. The ability to identify all of the muscles listed here will depend on the degree to which the cadaver in the laboratory is dissect-

ed or the type(s) of models available in the laboratory. To simplify the process of learning these muscles, initially focus attention on learning how the groups of muscles are arranged from superficial to deep, and from medial to lateral. Then focus on specifically identifying the individual muscles belonging to each group.

### EXERCISE 12.9 Muscles of the Vertebral Column

1. Observe a prosected cadaver or a classroom model of the thorax/abdomen that demonstrates muscles of the vertebral column (table 12.9).
2. Identify the **muscles of the vertebral column** listed in figure 12.8 on a cadaver or on models of the thorax and abdomen, using table 12.9 as a guide. Then label the muscles in figure 12.8.
3. The largest muscles of the back that move the vertebral column are collectively referred to as the **erector spinae** (*erector*, to make erect or straight + *spina*, spine). The erector spinae consist of three muscle groups that form long columns along both sides of the vertebral column. The muscle groups, from medial to lateral, are spinalis, longissimus, and iliocostalis. Deep to the erector spinae are

<b>Table 12.9 Muscles of the Vertebral Column</b>						
<b>Muscle Group</b>	<b>Individual Muscles</b>	<b>Origin</b>	<b>Insertion</b>	<b>Action</b>	<b>Innervation</b>	<b>Word Origins</b>
<b>SUPERFICIAL LAYER — SPLENIUS MUSCLES</b>						
<i>Splenius Muscles</i>	The splenius muscles are thick, flat muscles on the lateral and posterior aspect of the neck.	Midline	Cervical vertebrae and skull	Holds the deep neck muscles in position; extends, laterally flexes, and laterally rotates the neck	Dorsal rami of spinal nerves	<i>splenius</i> , bandage
<i>REGIONS</i>	Capitis (splenius capitis)	Ligamentum nuchae and T <sub>1</sub> –T <sub>6</sub> vertebrae (spinous processes)	Superior nuchal line (lateral aspect)	Bilateral: extends the neck Unilateral: laterally rotates and laterally flexes the neck to the same side Bilateral: extends the neck	Dorsal rami of spinal nerves	<i>splion</i> , a bandage + <i>caput</i> , head
	Cervicis (splenius cervicis)	Nuchal ligament and C <sub>7</sub> –T <sub>4</sub> (spinous processes)	C <sub>1</sub> –C <sub>3</sub> vertebrae (posterior tubercles)	Unilateral: laterally rotates and laterally flexes the neck to the same side	Dorsal rami of spinal nerves	<i>cervix</i> , neck
<b>INTERMEDIATE LAYER — ERECTOR SPINAE (SACROSPINALIS) MUSCLES</b>						
<i>Erector Spinae</i>	The erector spinae muscles compose the intermediate layer of back muscles. They are arranged into groups.	Broad tendon covering the posterior iliac crest, the lumbar vertebrae, and the sacrum	Vertebrae and ribs	Bilateral: extends the vertebral column and the head/neck Unilateral: laterally bends the vertebral column	Dorsal rami of spinal nerves	<i>erector</i> , to make erect + <i>spina</i> , spine
<i>GROUPS</i>	Iliocostalis (lateral group)	Broad tendon covering the posterior iliac crest, the lumbar vertebrae, and the sacrum	Ribs (angles of lower ribs) and cervical vertebrae (transverse processes)	Extends the vertebral column	Dorsal rami of spinal nerves	<i>ilium</i> , groin + <i>costal</i> , rib
	Longissimus (intermediate group)	Broad tendon covering the posterior iliac crest, the lumbar vertebrae, and the sacrum	Ribs (between tubercles and angles), cervical and thoracic vertebrae (transverse processes), and mastoid process of temporal bone	Extends the neck and vertebral column and laterally rotates the head	Dorsal rami of spinal nerves	<i>longissimus</i> , longest
	Spinalis (medial group)	Broad tendon covering the posterior iliac crest, the lumbar vertebrae, and the sacrum	Vertebrae (spinous processes of upper thoracic), and skull	Extends the neck and vertebral column and laterally rotates the head	Dorsal rami of spinal nerves	<i>spina</i> , spine
<b>SPINAL EXTENSOR AND LATERAL FLEXOR — QUADRATUS LUMBORUM</b>						
	Quadratus lumborum	Iliac crest and transverse processes of lower lumbar vertebrae	Rib 12, transverse processes of upper lumbar vertebrae	Abducts the trunk	Ventral rami of lumbar spinal nerves	<i>quadratus</i> , square + <i>lumbus</i> , loin
<b>DEEP LAYER — TRANSVERSOSPINALIS MUSCLES</b>						
<i>Multifidus</i>	NA	T <sub>1</sub> –T <sub>3</sub> vertebrae (transverse processes), C <sub>4</sub> –C <sub>7</sub> (articular processes), ilium and sacrum	Spinous process of vertebra located 2–4 segments superior to vertebra of origin	Assists with local extension and rotation of the vertebral column	Dorsal rami of spinal nerves	<i>multus</i> , much + <i>findo</i> , to cleave
<i>Regions</i>	Capitis (semispinalis capitis)	Inferior cervical and superior thoracic vertebrae (spinous and transverse processes)	Occipital bone (between superior and inferior nuchal lines)	Extends and rotates the vertebral column; stabilizes the vertebrae during local movements of the vertebral column	Dorsal rami of spinal nerves	<i>caput</i> , head

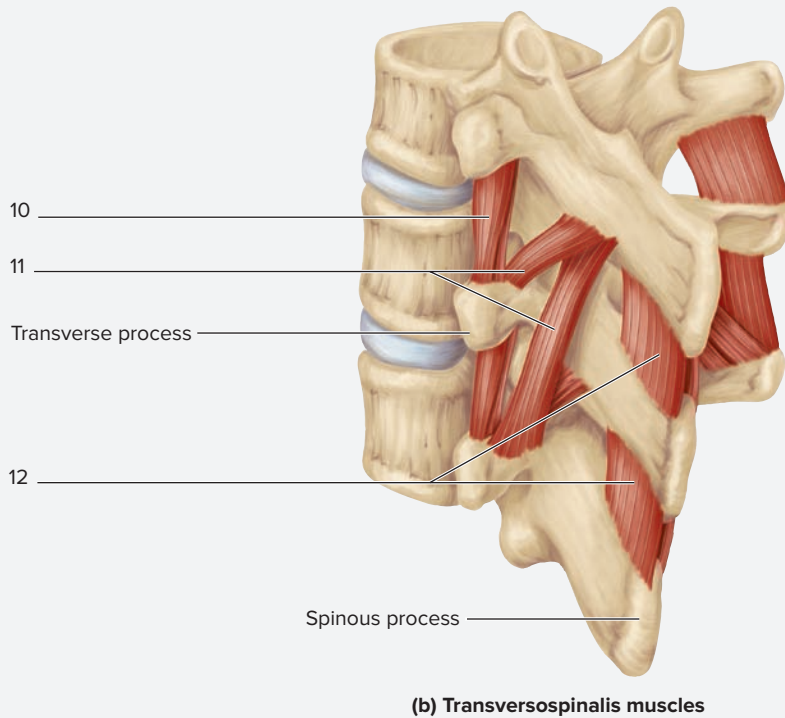
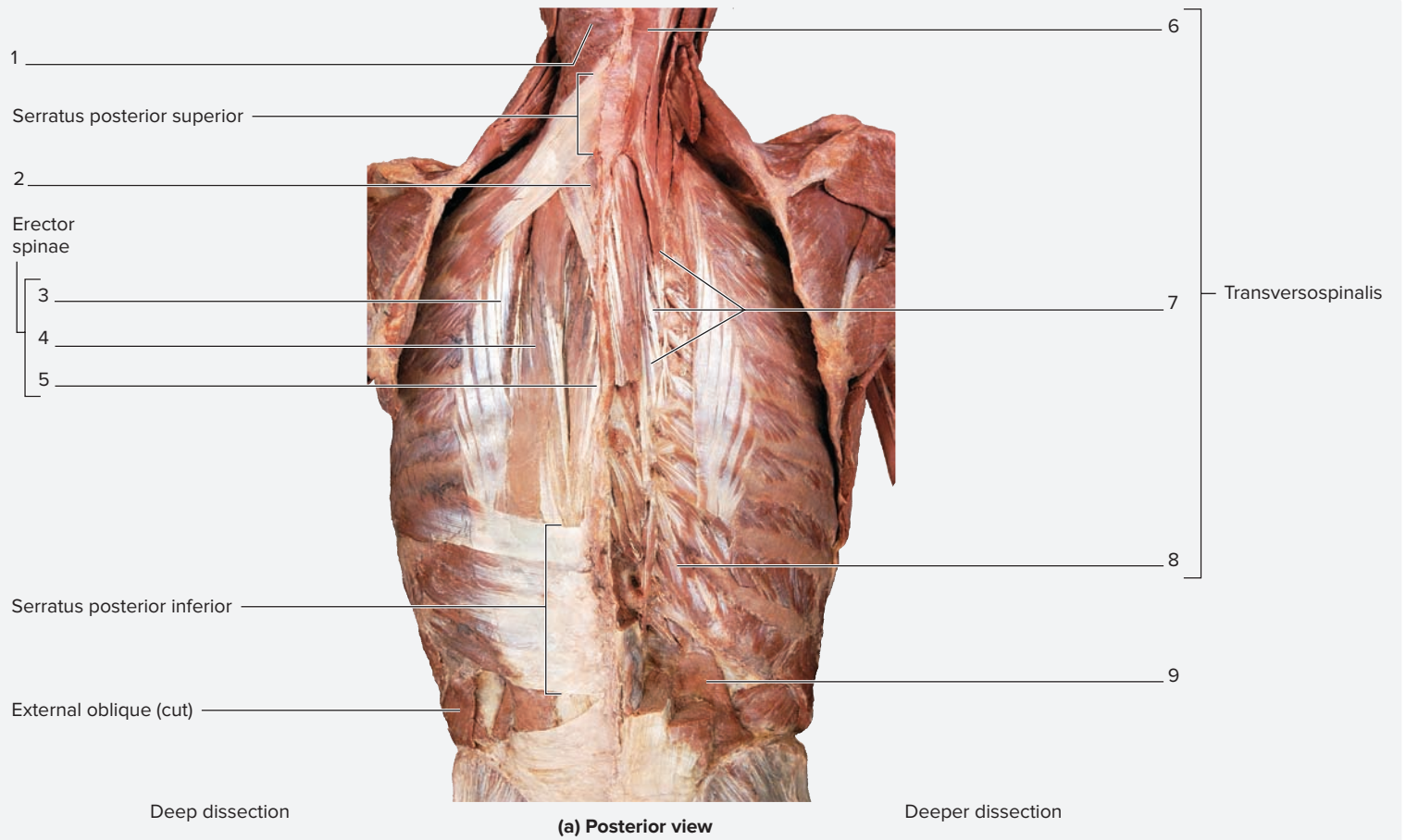
(continued on next page)

(continued from previous page)

Table 12.9 Muscles of the Vertebral Column (continued)						
Muscle Group	Individual Muscles	Origin	Insertion	Action	Innervation	Word Origins
<b>DEEP LAYER — TRANSVERSOSPINALIS MUSCLES (CONTINUED)</b>						
	Cervicis (semispinalis cervicis)	T <sub>1</sub> –T <sub>6</sub> vertebrae (transverse processes)	C <sub>2</sub> –C <sub>3</sub> vertebrae (spinous processes)	Extends and rotates the vertebral column; stabilizes the vertebrae during local movements of the vertebral column	Dorsal rami of spinal nerves	<i>cervix</i> , neck
	Thoracis (semispinalis thoracis)	T <sub>6</sub> –T <sub>10</sub> vertebrae (transverse processes)	C <sub>5</sub> –T <sub>4</sub> vertebrae (spinous processes)	Extends and rotates the vertebral column; stabilizes the vertebrae during local movements of the vertebral column	Dorsal rami of spinal nerves	<i>thoracis</i> , thorax
<b>Rotatores</b>	NA	Transverse processes of all vertebrae (most developed in the thoracic region)	Vertebral arch (between lamina and transverse process) of vertebra superior to the vertebra of origin	Assists with local extension and rotation of the vertebral column	Dorsal rami of spinal nerves	<i>rotatus</i> , to rotate
<b>Semispinalis Group</b>	The semispinalis muscles are the deepest muscles of the back and lie between transverse and spinous processes of adjacent vertebrae.	Transverse processes of inferior vertebrae	Spinous process of vertebra above and/or the posterior aspect of the occipital bone	Extends and rotates the vertebral column; stabilizes the vertebrae during local movements of the vertebral column	Dorsal rami of spinal nerves	<i>Semi-</i> , half + <i>spina</i> , spine
<b>Transversospinal Group</b>	The transversospinal muscles are the deepest muscles of the back and lie between transverse and spinous processes of adjacent vertebrae.	Transverse processes of inferior vertebrae	Spinous process of cervical and thoracic vertebra above and/or the posterior aspect of the occipital bone	Extends and rotates the vertebral column; stabilizes the vertebrae during local movements of the vertebral column	Dorsal rami of spinal nerves	<i>transverse</i> , across + <i>spina</i> , spine
<b>MINOR DEEP BACK MUSCLES</b>						
	Interspinales	Cervical and lumbar vertebrae (superior surfaces of spinous processes)	Spinous process of the vertebra superior to the vertebra of origin (inferior surface)	Extends and rotates the vertebral column	Dorsal rami of spinal nerves	<i>inter-</i> , between + <i>spina</i> , spine
	Intertransversarii	Cervical and lumbar vertebrae (transverse processes)	Transverse processes of vertebra above or below vertebra of origin	Laterally flexes the vertebral column	Dorsal rami of spinal nerves	<i>inter-</i> , between + <i>transversarii</i> , relating to the transverse process

the **transversospinal** group of muscles, so named because they attach to transverse and spinous processes of adjacent vertebrae. Smaller muscles that create fine movements of the vertebral column are the interspinales and intertransversarii. As their names imply, these run from spinous process to spinous process (interspinalis muscles) or from transverse process to transverse process (intertransversarii muscles). The deeper muscles can be difficult to identify on cadavers or models. In general, the **semispinalis** muscles are the most

superficial of the transversospinal muscles, they span five to six vertebrae, and they are most highly developed in the cervical and upper thoracic regions of the vertebral column. The **multifidus** muscles lie deep to the semispinalis muscles, span three to four vertebrae, and are most highly developed in the lumbar region of the vertebral column. Finally, the **rotatores** are the deepest muscles of the transversospinal group, span one to two vertebrae, and are most highly developed in the lower thoracic region of the vertebral column.



**Figure 12.8 Muscles of the Vertebral Column.** Use the terms listed to fill in the numbered labels in the figure. Some answers may be used more than once.

- |   |   |  |  |
|---|---|--|--|
| <input type="checkbox"/> iliocostalis       | <input type="checkbox"/> multifidus           | <input type="checkbox"/> semispinalis cervicis | <input type="checkbox"/> splenius capitis  |
| <input type="checkbox"/> interspinales      | <input type="checkbox"/> quadratus lumborum   | <input type="checkbox"/> semispinalis thoracis | <input type="checkbox"/> splenius cervicis |
| <input type="checkbox"/> intertransversarii | <input type="checkbox"/> rotatores            | <input type="checkbox"/> spinalis              |  |
| <input type="checkbox"/> longissimus        | <input type="checkbox"/> semispinalis capitis |  |  |



## Muscles of Respiration

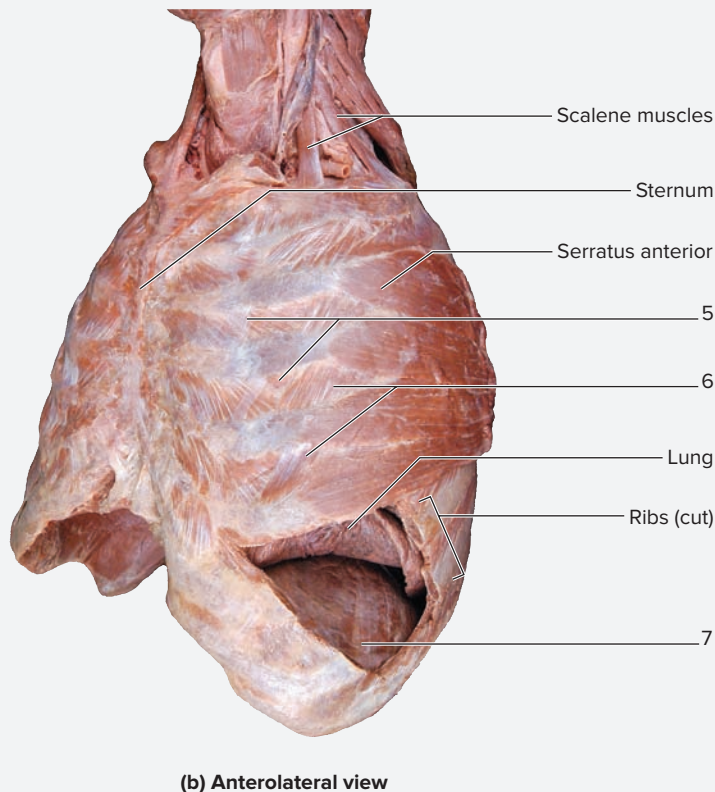
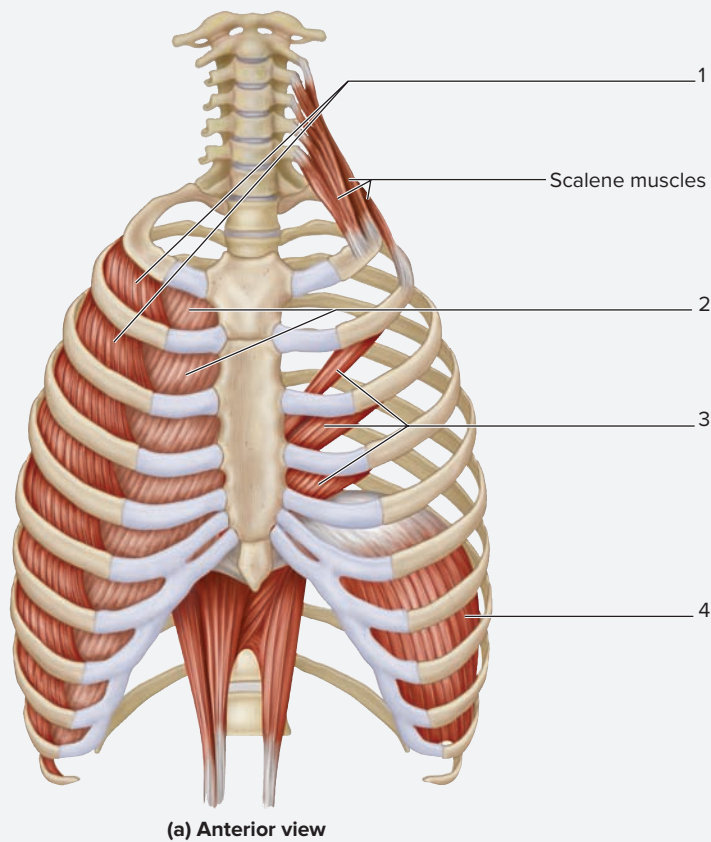
The muscles of the thoracic cage and the diaphragm are the primary **muscles of respiration** (table 12.10). These muscles include the

external and internal intercostals, the transversus thoracis, and the diaphragm.

Muscle	Origin	Insertion	Action	Innervation	Word Roots
<i>Diaphragm</i>	Inferior borders of rib 12, sternum, and the xiphoid process; costal cartilages of ribs 6–12, and lumbar vertebrae	Central tendon	Prime mover for inspiration; flattens when contracted, and increases intra-abdominal pressure and the size of the thoracic cavity	Phrenic nerves	<i>diaphragma</i> , a partition wall
<i>External Intercostals</i>	Inferior border of superior rib	Superior border of the rib below	Elevates the ribs	Intercostal nerves	<i>externus</i> , on the outside + <i>inter-</i> , between + <i>costal</i> , rib
<i>Internal Intercostals</i>	Superior border of inferior rib	Inferior border of the rib above	Depresses the ribs	Intercostal nerves	<i>internus</i> , away from the surface + <i>inter-</i> , between + <i>costal</i> , rib
<i>Transversus Thoracis</i>	Posterior surface of the lower half of the body of the sternum	Costal cartilages of ribs 2–6 (posterior surface)	Depresses the ribs	Intercostal nerves	<i>transversus</i> , crosswise + <i>thoracis</i> , thorax
<i>Anterior Scalene</i>	C <sub>3</sub> –C <sub>6</sub> (transverse processes)	First rib (scalene tubercle)	Elevates the first rib	Cervical plexus	<i>skalenos</i> , uneven
<i>Middle Scalene</i>	C <sub>2</sub> –C <sub>6</sub> (transverse processes)	First rib (posterior to groove for subclavian artery)	Elevates the first rib	Cervical plexus	<i>skalenos</i> , uneven
<i>Posterior Scalene</i>	C <sub>4</sub> –C <sub>6</sub> (transverse processes)	Second rib (lateral surface)	Elevates the second rib	Cervical and brachial plexuses	<i>skalenos</i> , uneven

### EXERCISE 12.10 Muscles of Respiration


1. Observe a prosected cadaver or a classroom model of the thorax/abdomen that demonstrates muscles of the thoracic cage.
2. Identify the muscles of respiration listed in **figure 12.9** on a cadaver or on a model of the thorax, using table 12.10 and the textbook as guides. Then label them in figure 12.9.
3. *Intercostals*—The majority of the muscle mass of the **external intercostal** muscles are located on the posterior and lateral thorax, extending from the vertebral column to the **midclavicular line** (a vertical line that passes through the middle of the clavicle; see **figure 12.10**) on the anterior surface of the thorax. The **external intercostal membrane** lies in place of the external intercostal muscles in the space between the midclavicular line and the sternum. Notice that the muscle fibers of the external intercostals are arranged obliquely, pointing in an inferomedial direction.
4. On a cadaver the external intercostal membrane can be identified by the connective tissue fibers which parallel the direction of the muscle fibers of the external intercostal muscles. In fact, close observation will demonstrate a muscle adjacent to the sternum in the intercostal spaces. That muscle is an *internal* intercostal muscle. If observing classroom models, the external intercostal membrane will most likely not be visible.
5. In contrast to the external intercostal muscles, the majority of the muscle mass of the **internal intercostal** muscles is located on the anterior surface of the thorax. These muscles extend from the sternum to the **scapular line** (a vertical line that passes through the inferior angle of the scapula; figure 12.10) on the posterior thorax. The **internal intercostal membrane** lies in place of the internal intercostal muscles on the posterior thorax between the scapular line and the vertebral column. The muscle fibers of the internal intercostals are arranged obliquely, pointing in an inferolateral direction, at right angles to the fibers of the external intercostals.
6. If possible, remove the breast plate on the cadaver (or on a model of the thorax) and observe its interior surface. Here, lying adjacent to the inferior part of the sternum, the **transversus thoracis** muscle will be visible. This muscle, consists of several muscle bellies running obliquely. The transversus thoracis muscle assists in depression of the ribs during forced expiration.



**Figure 12.9 Muscles of Respiration.** Use the terms listed to fill in the numbered labels in the figure. Some answers may be used more than once.


- diaphragm
- external intercostals
- internal intercostals
- transversus thoracis

7. Sketch the intercostal muscles in the space provided, noting the fiber orientation for each of them.

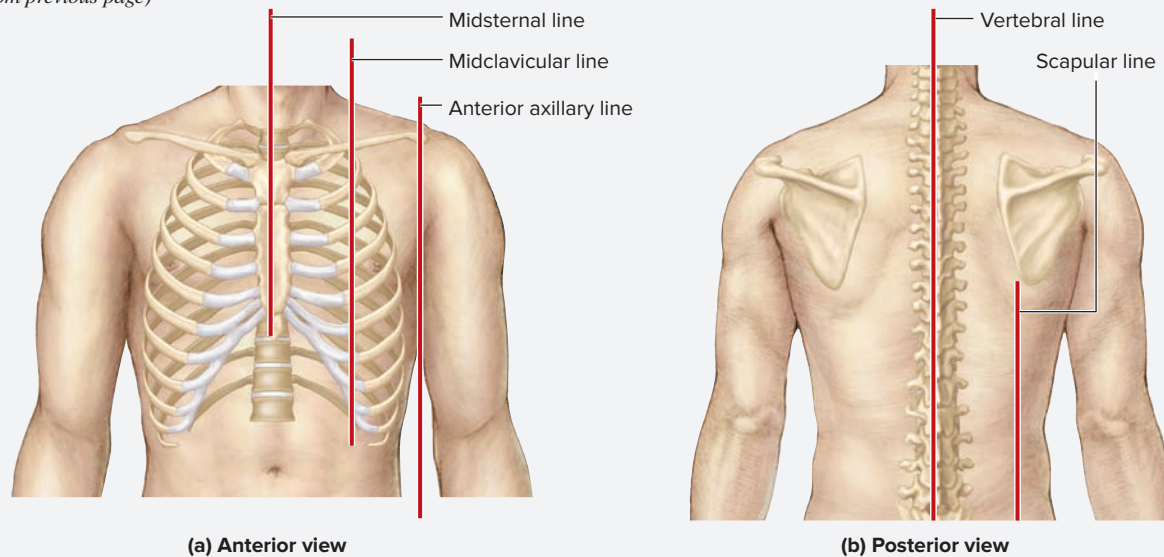


8. *Diaphragm*—Remove the breast plate from the cadaver or model and observe the diaphragm. The structures within the diaphragm are best seen from an inferior view. If possible, try and observe the diaphragm from both superior and inferior points of view. The **diaphragm** has a broad origin along the bones that constitute the lower border of the thoracic cage. The muscle has a unique central attachment, the **central tendon of the diaphragm**. Several important structures pass through the diaphragm, including the aorta, inferior vena cava, and esophagus. The aorta and inferior vena cava have passages through the central tendon, whereas the passage for the esophagus is surrounded by the muscle fibers of the diaphragm. Very practical consequences result from this arrangement. As the diaphragm contracts during inspiration, its muscle fibers squeeze the esophagus and act as a sphincter to prevent stomach contents from being pushed back into the esophagus. In contrast, because the aorta and inferior vena cava pass through the central tendon, they are not constricted during inspiration.

9. Sketch the diaphragm in the space provided, noting the locations of the passages for the aorta, inferior vena cava, and esophagus.



(continued from previous page)



**Figure 12.10** Points of Reference on the Anterior and Posterior Thorax.

## Muscles of the Abdominal Wall

Muscles of the abdominal wall include the external obliques, internal obliques, transversus abdominis, and rectus abdominis.

### EXERCISE 12.11 Muscles of the Abdominal Wall

1. Observe a prosected cadaver or a model of the thorax/abdomen that demonstrates muscles of the abdominal wall (table 12.11 and figures 12.11–12.13).
2. The muscle fiber orientation of the abdominal muscles parallels the muscle fiber orientation of the intercostal muscles. Like the external intercostal muscles, the **external oblique**

**Table 12.11** Muscles of the Abdominal Wall

Muscle	Origin	Insertion	Action	Innervation	Word Origins
<i>External Oblique</i>	Anterior surface of inferior 8 ribs	Linea alba and the anterior iliac crest	Flexes and rotates the trunk; compresses the abdominal viscera	Spinal nerves T8–T12, L1	<i>externus</i> , on the outside + <i>obliquus</i> , slanting
<i>Internal Oblique</i>	Thoracolumbar fascia, lateral half of inguinal ligament, and iliac crest	Linea alba, iliac crest, pubic tubercle, and the inferior border of last 4 ribs, costal cartilages of ribs 8–10	Flexes and rotates the trunk; compresses the abdominal viscera	Spinal nerves T8–T12, L1	<i>internus</i> , away from the surface + <i>obliquus</i> , slanting
<i>Rectus Abdominis</i>	Pubic symphysis and crest	Xiphoid process and the costal cartilages of ribs 5–7	Flexes and rotates the trunk; compresses the abdominal viscera	Spinal nerves T7–T12	<i>rectus</i> , straight + <i>abdominis</i> , the abdomen
<i>Transversus Abdominis</i>	Lateral third of inguinal ligament, iliac crest, costal cartilages of inferior 6 ribs	Linea alba and pubic crest	Compresses the abdominal viscera	Spinal nerves T8–T12, L1	<i>transversus</i> , crosswise + <i>abdominis</i> , the abdomen

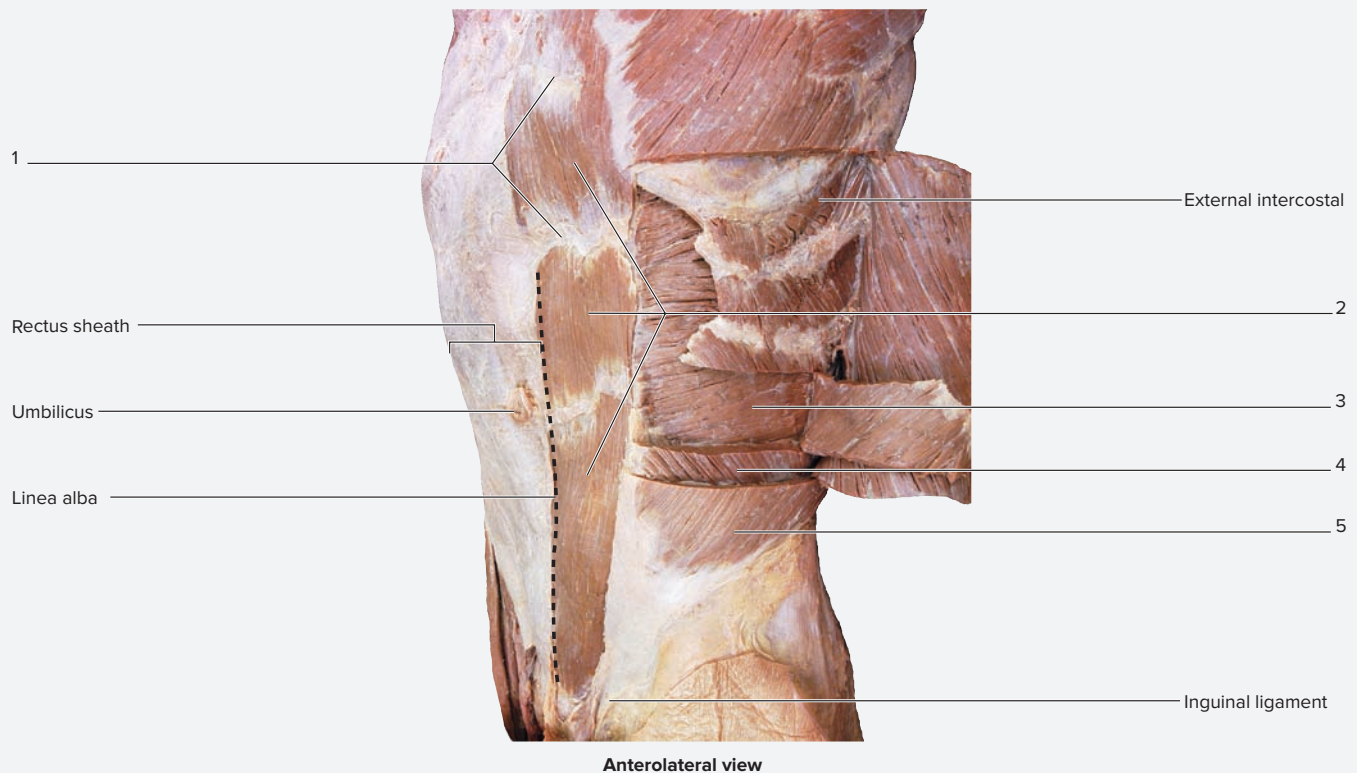
#### STRUCTURES RELATED TO ABDOMINAL MUSCULATURE

Structure	Attachment 1	Attachment 2	Description	Innervation	Word Origins
<i>Aponeurosis</i>	NA	NA	A broad, flat tendon, such as those connecting abdominal muscles to the linea alba	NA	<i>apo-</i> , from + <i>neuron</i> , sinew
<i>Inguinal Canal</i>	NA	NA	An oblique passage in the anterior abdominal wall located superior to the inguinal ligament; it is formed from the aponeuroses of the external and internal oblique muscles	NA	<i>inguen</i> , groin

(continued on next page)

(continued from previous page)

Table 12.11 Muscles of the Abdominal Wall (continued)					
Structure	Attachment 1	Attachment 2	Description	Innervation	Word Origins
<b>Inguinal Ligament</b>	Anterior superior iliac spine	Pubic tubercle	A structure formed from the aponeurosis of the external oblique muscle; an important anatomical landmark in the inguinal region	NA	<i>inguen</i> , groin
<b>Linea Alba</b>	Xiphoid process of the sternum	Pubic symphysis	Literally, the “white line”; a tendinous structure that acts as the insertion point for the oblique and transversus abdominis muscles	NA	<i>linea</i> , line + <i>alba</i> , white
<b>Rectus Sheath</b>	NA	NA	A connective tissue sheath that surrounds the rectus abdominis muscle and is formed from the aponeuroses of the external oblique, internal oblique, and transversus abdominis muscles	NA	<i>rectus</i> , referring to the rectus abdominis muscle
<b>Tendinous Intersections</b>	NA	NA	Tendinous bands that run across a muscle; in this case, the tendinous intersections are the structures that separate the parts of the rectus abdominis muscle	NA	<i>tendo-</i> , to stretch out + <i>inscribere</i> , to write on



**Figure 12.11** Muscles of the Abdominal Wall. Use the terms listed to fill in the numbered labels in the figure. Some answers may be used more than once.

- external oblique
- internal oblique
- rectus abdominis
- tendinous intersections
- transversus abdominis

© McGraw-Hill Education/Photos and Dissections by Christine Eckel

muscles have muscle fibers that point in an inferomedial direction. Like the internal intercostal muscles, the **internal oblique** muscles have muscle fibers that point in an inferolateral direction. Deep to the internal oblique muscles, the **transversus abdominis** muscle has muscle fibers that run in a transverse, or horizontal, direction. All three of these muscles have broad, flat tendons called **aponeuroses** (*apo-*, from + *neuron*, sinew). The aponeuroses of these muscles

begin at the midclavicular line and extend to a central, tendonlike structure called the **linea alba**. In addition, the aponeuroses of these muscles form the **rectus sheath**, which surrounds the fourth abdominal muscle, the **rectus abdominis**.

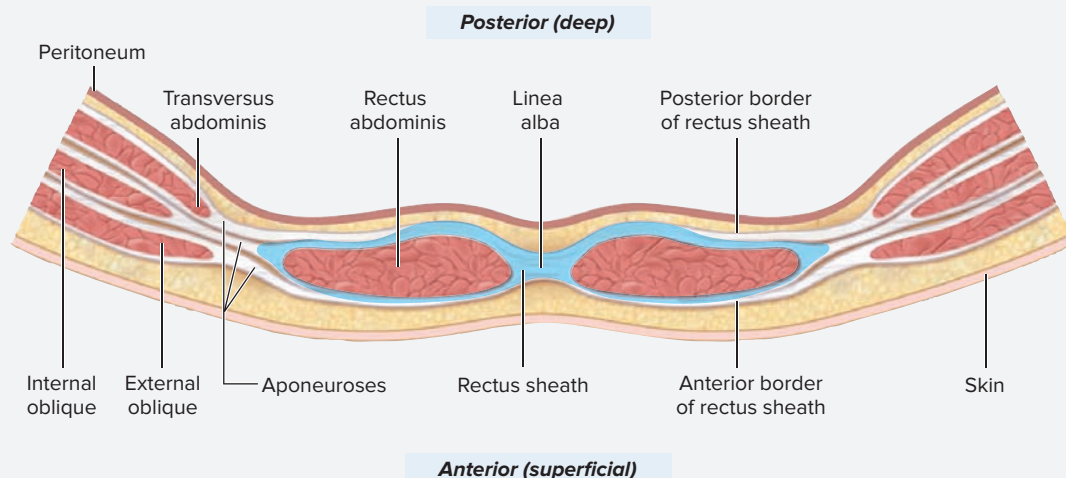
- Identify the **abdominal muscles** listed in figure 12.11 on a cadaver or on a classroom model of the abdomen, using table 12.11 as a guide. Then label them in figure 12.11.

**EXERCISE 12.12** The Rectus Sheath, Inguinal Ligament, and Inguinal Canal

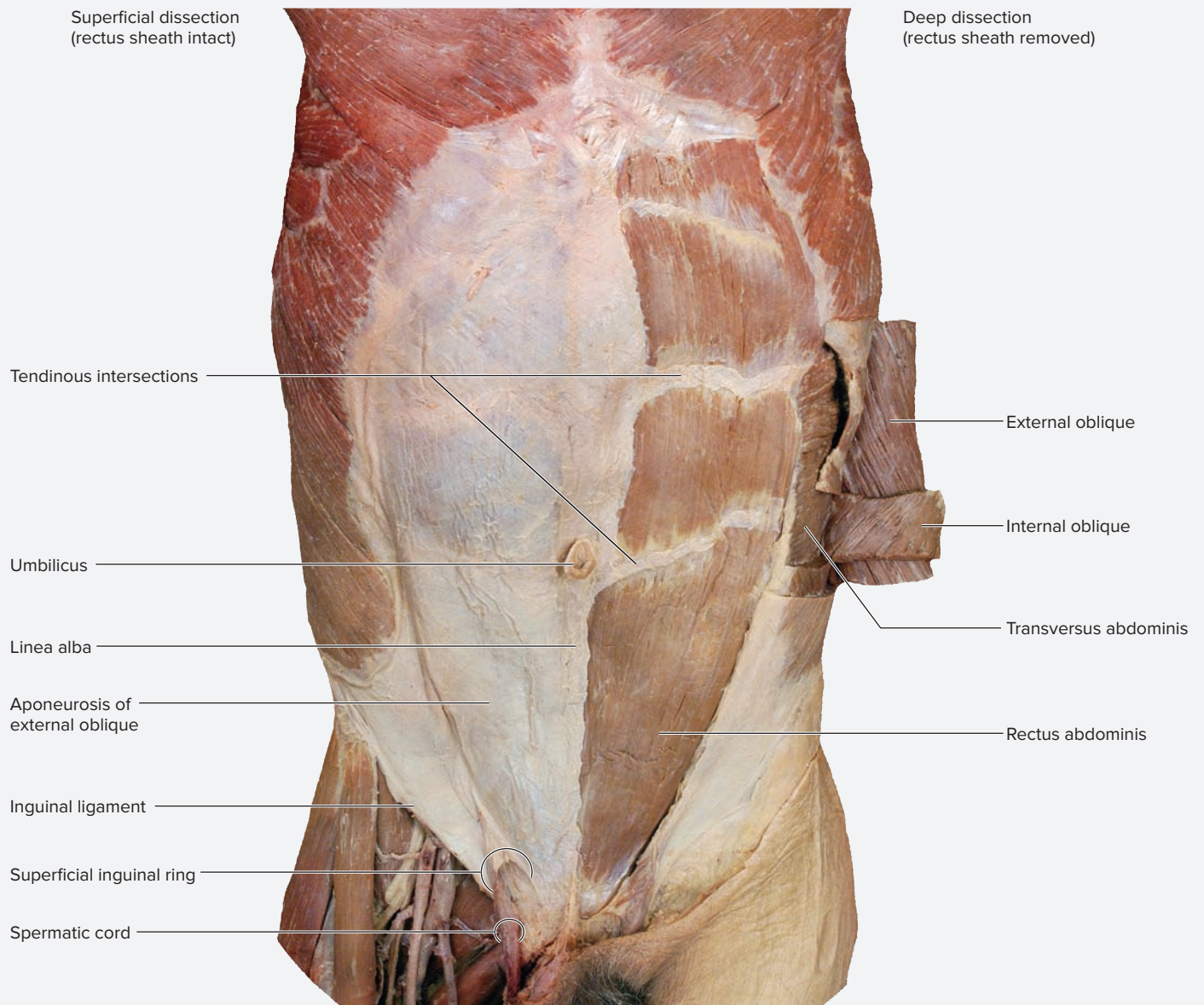
1. Observe a prosected cadaver or a classroom model of the thorax/abdomen that demonstrates muscles of the abdominal wall. The focus of this exercise is to identify important structures associated with the abdominal musculature.
2. The **rectus sheath** (figure 12.12; see table 12.11) is a structure formed from the aponeuroses of the external and internal obliques and the transversus abdominis muscles (this relationship is true only of the sheath superior to the umbilicus, so observations should be made in that location). The sheath has an *anterior border* formed by the aponeurosis of the external oblique and part of the aponeurosis of the internal oblique. It has a *posterior border* formed by the remaining part of the aponeurosis of the internal oblique and the aponeurosis of the transversus abdominis. The rectus abdominis muscle is located within the rectus sheath, and is divided into four sections by connective tissue partitions called **tendinous intersections**. The tendinous intersections effectively divide one very long muscle into four smaller muscles, arranged in a series. This allows the muscle as a whole to make a greater overall change in length, in addition to increasing its force of contraction.
3. The **inguinal ligament** (figure 12.13; table 12.11) is formed by the *aponeurosis of the external oblique* muscle. This ligament extends from the anterior superior iliac spine (ASIS) laterally, to the pubic tubercle medially. Instead of being a straight ligament, the ligament folds back upon itself, forming a trough. The inguinal ligament is an important landmark of the abdomen and thigh. In addition, the trough formed by the aponeurosis of the external oblique forms part of the *inguinal canal*.
4. The **inguinal canal** (figure 12.13; table 12.11) is an oblique passageway in the inferior abdominal wall. Its floor is formed by the trough of the **aponeurosis of the external oblique**. Its roof is formed by fibers of the **aponeurosis of the internal oblique**. Within this canal, structures pass from the abdomen into the subcutaneous tissues of the **perineum** (*perneon*, the area between the thighs below the pelvic diaphragm). In males, structures that pass through compose the **spermatic cord**, which consists of the testicular artery, vein, and nerve; lymphatic vessels; and the ductus deferens. In females, the **round ligament of the uterus**, a suspensory ligament, passes through. The **superficial inguinal ring** is located lateral to the pubic symphysis. It is composed of fibers of the aponeuroses of the external oblique aponeurosis, and it is the path of exit for structures that pass through the inguinal canal. Identify the spermatic cord as it passes through the superficial inguinal ring on a male cadaver or on a classroom model of the abdomen. Attempt to identify the round ligament of the uterus on a female cadaver, keeping in mind that identification of the round ligament of the uterus is often quite difficult.

**WHAT DO YOU THINK?**

- 2 In an **indirect inguinal hernia**, abdominal contents, such as a loop of small intestine, pass into the inguinal canal. Why do you think such hernias are more common in males than in females?



**Figure 12.12** The Rectus Sheath. A transverse section through the abdominal wall demonstrates components of the rectus sheath.



**Figure 12.13** The Anterior Abdominal Wall.

© McGraw-Hill Education/Photos and Dissections by Christine Eckel

*This page intentionally left blank*

The 1 corresponds to the Learning Objective(s) listed in the chapter opener outline.

**Exercise 12.1: Muscles of Facial Expression**

1. Match each muscle of facial expression listed in column B with its movement listed in column A. 1

**Column A**

- \_\_\_\_\_ blink or close eyes
- \_\_\_\_\_ close mouth
- \_\_\_\_\_ wrinkle forehead, raise eyebrows
- \_\_\_\_\_ tense skin of neck
- \_\_\_\_\_ compress cheeks

**Column B**

- a. buccinator
- b. epicranii
- c. orbicularis oculi
- d. orbicularis oris
- e. platysma

2. The muscles of facial expression are innervated by the \_\_\_\_\_ nerve. 1

**Exercise 12.2: Extrinsic Eye Muscles**

3. For each of the eye movements listed, provide the extrinsic eye muscle that creates that action (consider only movement of the right eye). 2

Look lateral only: \_\_\_\_\_

Look up and out (lateral): \_\_\_\_\_

Look medial only: \_\_\_\_\_

Look down and in (medial): \_\_\_\_\_

Look up and in (medial): \_\_\_\_\_

Look down and out (lateral): \_\_\_\_\_

**Exercise 12.3: Muscles of Mastication**

4. Match each muscle of mastication listed in column B with its movement listed in column A. 3

**Column A**

- \_\_\_\_\_ grind food side to side (2 answers)
- \_\_\_\_\_ elevate mandible (3 answers)
- \_\_\_\_\_ depresses the chin
- \_\_\_\_\_ protract mandible, depress chin (3 answers)

**Column B**

- a. temporalis
- b. medial pterygoid
- c. lateral pterygoid
- d. masseter

5. The muscles of mastication are innervated by the \_\_\_\_\_ nerve. 3

6. If the facial nerve is severed, which of the following muscles will not be paralyzed? (Circle all that apply.) 1 2

- a. buccinator
- b. masseter
- c. frontalis
- d. zygomaticus
- e. epicranii

**Exercise 12.4: Muscles That Move the Tongue**

7. Explain the difference in location of the intrinsic muscles of the tongue and extrinsic muscles of the tongue. 4

\_\_\_\_\_

\_\_\_\_\_

8. The genioglossus muscle is a(n) intrinsic/extrinsic (circle one) muscle of the tongue. 5

**Exercise 12.5: Muscles of the Pharynx**

9. The pharyngeal muscles that narrow the diameter of the pharynx during swallowing are called pharyngeal \_\_\_\_\_. 6



**Exercise 12.6: Muscles of the Anterior Neck**

10. Match the muscles listed in column A with the class of muscles each belongs to in column B. Answers may be used more than once. 7 8

**Column A**

- \_\_\_\_\_ mylohyoid
- \_\_\_\_\_ longissimus capitis
- \_\_\_\_\_ omohyoid
- \_\_\_\_\_ stylohyoid

**Column B**

- a. infrahyoid muscle
- b. muscle that moves the neck
- c. suprahyoid muscle (2 answers)

**Exercise 12.7: Muscles That Move the Head and Neck**

11. Explain how the sternocleidomastoid and splenius muscles can act as either synergists or antagonists for the actions of neck flexion, extension, and lateral rotation. 8 9 10

---



---



---

**Exercise 12.8: Suboccipital Muscles and the Suboccipital Triangle**

12. The three muscles that form the borders of the suboccipital triangle are the \_\_\_\_\_, \_\_\_\_\_, and \_\_\_\_\_. 11

13. The \_\_\_\_\_ artery is located within the suboccipital triangle. 12

**Exercise 12.9: Muscles of the Vertebral Column**

14. The erector spinae is a collective term for posterior/anterior (circle one) groups of muscles that function to straighten the spine. 13

15. List the three muscle groups that compose the erector spinae: 13

- a. \_\_\_\_\_
- b. \_\_\_\_\_
- c. \_\_\_\_\_

**Exercise 12.10: Muscles of Respiration**

16. When the diaphragm is contracted, is it flat or dome shaped? \_\_\_\_\_ 14

17. There are two sets of intercostals muscle (muscles between the ribs). The \_\_\_\_\_ intercostals are superficial to the \_\_\_\_\_ intercostals. 14

18. What is the primary muscle used for breathing? 14

---

19. Which muscles assist in forced inspiration? (Hint: these muscles lift the ribs or elevate the spine.) 14

---

20. Which muscles assist in forced expiration? (Hint: these muscles depress the ribs or compress the abdomen.) 14

---

21. List the three major structures that pass through the diaphragm. 15

- a. \_\_\_\_\_
- b. \_\_\_\_\_
- c. \_\_\_\_\_

**Exercise 12.11: Muscles of the Abdominal Wall**

22. List the muscles of the abdominal wall. 16

- a. \_\_\_\_\_
- b. \_\_\_\_\_
- c. \_\_\_\_\_
- d. \_\_\_\_\_

23. There are two sets of oblique abdominal muscles (muscles running at an angle). The most superficial is the \_\_\_\_\_. Deep to this is the \_\_\_\_\_. 16

24. Match the muscle of the abdominal wall listed in column A with the direction of the fibers listed in column B. 16 17

**Column A**

- \_\_\_ external obliques
- \_\_\_ internal obliques
- \_\_\_ rectus abdominis
- \_\_\_ transverse abdominis

**Column B**

- a. horizontal
- b. inferiolateral (down and away from middle)
- c. inferioromedial (down and toward middle)
- d. vertical

**Exercise 12.12: The Rectus Sheath, Inguinal Ligament, and Inguinal Canal**

25. What structures divide the rectus abdominis into four segments (forming the traditional “six-pack” of muscles)? \_\_\_\_\_  
 The fibrous sheath that encloses the rectus abdominis is the \_\_\_\_\_. The sheath comes together at the midline to form a vertical fibrous strip called the \_\_\_\_\_ (which sometimes darkens during pregnancy). 18

26. What structures run through the inguinal canal? 19

Males: \_\_\_\_\_

Females: \_\_\_\_\_

**Can You Apply What You’ve Learned?**

27. Explain the major difference in muscular movement produced by the masseter and the temporalis during mastication (chewing). \_\_\_\_\_

---



---

28. Explain how the suprahyoid and infrahyoid muscles are named. \_\_\_\_\_

---

29. a. Describe the action of the sternocleidomastoid if both heads are contracted simultaneously. \_\_\_\_\_

---

b. Describe the action of the sternocleidomastoid if only the right clavicular head contracts. \_\_\_\_\_

---

30. Explain how the external obliques, internal obliques, and transversus abdominis muscles relate to the rectus sheath.

---



---

31. In a **indirect inguinal hernia**, abdominal contents, such as a loop of small intestine, pass into the inguinal canal. Why do you think such hernias are more common in males than in females?

---



---

*This page intentionally left blank*

# Appendicular Muscles

# 13

## OUTLINE AND LEARNING OBJECTIVES

### Gross Anatomy 256

#### Muscles That Move the Pectoral Girdle and Glenohumeral Joint 256

##### EXERCISE 13.1: MUSCLES THAT MOVE THE PECTORAL GIRDLE AND GLENOHUMERAL JOINT 256

- 1 Identify the muscles that connect the pectoral girdle to the thorax and describe their actions
- 2 Demonstrate the actions of the trapezius, and name a muscle that acts as a synergist for the actions of elevation and adduction of the scapula
- 3 Describe the consequences of damage to the serratus anterior
- 4 List the four muscles that make up the rotator cuff, and explain the functional importance of these muscles

#### Upper Limb Musculature 259

##### EXERCISE 13.2: COMPARTMENTS OF THE ARM 259

- 5 Identify the muscles of the anterior and posterior compartments of the arm, and describe their locations and actions
- 6 Explain the role of the biceps brachii in the actions of elbow flexion and forearm supination

##### EXERCISE 13.3: COMPARTMENTS OF THE FOREARM 261

- 7 Identify the muscles of the anterior and posterior compartments of the forearm, and describe their locations and actions
- 8 Demonstrate the location of the palmaris longus on yourself
- 9 Describe the relationship between the tendons of the flexor digitorum superficialis and the flexor digitorum profundus as they attach to the phalanges
- 10 List the three structures forming the boundaries of the anatomic snuffbox, and explain why the anatomic snuffbox is a relevant clinical landmark

##### EXERCISE 13.4: INTRINSIC MUSCLES OF THE HAND 266

- 11 Identify the intrinsic muscles of the hand
- 12 Describe the locations of the thenar eminence and the hypothenar eminence
- 13 Describe the actions of the dorsal and palmar interossei

#### Muscles That Act About the Hip Joint/Thigh 268

##### EXERCISE 13.5: MUSCLES THAT MOVE THE HIP 268

- 14 Identify the muscles that act about the hip, and describe their actions
- 15 Explain the roles of the gluteus medius and gluteus minimus in locomotion
- 16 Explain the importance of the piriformis as a clinically relevant landmark
- 17 Describe the composition, location, and function of the iliopsoas

#### Lower Limb Musculature 270

##### EXERCISE 13.6: COMPARTMENTS OF THE THIGH 271

- 18 Identify the muscles of the anterior, medial, and posterior compartments of the thigh and describe their locations and actions
- 19 Name the two muscles of the anterior compartment of the thigh that flex the hip joint
- 20 Identify the borders of the femoral triangle, and explain the clinical significance of the femoral triangle

##### EXERCISE 13.7: COMPARTMENTS OF THE LEG 275

- 21 Identify the muscles of the anterior, lateral, and posterior compartments of the leg, and describe their locations and actions
- 22 Name two muscles that act as antagonists to the fibularis muscles for the function of everting the ankle
- 23 Name the muscles that compose the triceps surae

##### EXERCISE 13.8: INTRINSIC MUSCLES OF THE FOOT 278

- 24 Identify the intrinsic muscles of the foot, and describe their locations and actions

## INTRODUCTION

**T**he **appendicular muscles** are familiar muscles to most people. Anyone who has gone to a gym and lifted weights, or who has admired the muscular body of a basketball player or gymnast, has at least some familiarity with these muscles. They are the muscles used to perform active tasks such as typing, walking, running, and lifting. They are the bulging muscles seen in the arms and legs of elite athletes. When lifting a heavy weight, the muscles in the upper limbs feel the strain as they are working. Thus, it is relatively easy to determine which muscles are being used to perform a particular action. If this cannot be figured out right away from the fatigue or pain experienced immediately in the working muscle, it is most definitely apparent in the next two days as delayed-onset muscle soreness (DOMS) sets in.

All of these activities provide a fascination and curiosity about the muscles responsible for creating movement. However, once a student is required to view these muscles on a model, photo, or cadaver, and is asked to know the names, attachments, and actions of those same muscles in the context of a human anatomy course, it is easy to forget about those same muscles in practical terms (such as, “What muscles am I using to perform this action?”). Instead, they become the bane of the anatomy student, their study dreaded as one of the most difficult tasks in the course.

However, this task need not be feared as long as it is approached with the right frame of mind. While working through the task of learning names, attachments, and actions for appendicular muscles, try to identify the muscles on your own body. Practice using them. An excellent way to do this is to go to a gym that has weight machines. Observe the illustrations on the weight machines that demonstrate what muscle or muscles the exercise is meant to work on. Then practice the movement *without using any weights* (especially if you have never lifted weights before). While performing the stated action of the muscle(s), feel the muscle(s) produce tension under the skin. Once you make the connection

between the muscles in your own body and the muscles seen on a model, in a photograph, or in a cadaver, it becomes much easier and pleasant to truly appreciate their functions. In addition, the one “cheat sheet” you *can* bring into the laboratory with you on exam day is yourself!

The exercises in this chapter involve identifying, naming, and exploring the structure and function of muscles that move the appendicular skeleton on models, photos, or a human cadaver. Prior to beginning, find out from the laboratory instructor which muscles will be assessed on practical exams. Then, place check marks in the summary tables of this chapter so as to focus on the muscles that are required for the course. In addition, prior to beginning the more detailed study of the appendicular musculature in this chapter, make sure to complete the exercises related to appendicular musculature in chapter 11. Those exercises introduced the major muscle groups and the common actions of those groups. Refer to tables 11.4 and 11.5 to review the muscle compartments of the upper and lower limbs, and the major actions of the muscles in each compartment.

### List of Reference Tables

Table 13.1	Muscles That Act About the Pectoral Girdle	p. 256
Table 13.2	Muscles That Act About the Glenohumeral Joint	p. 258
Table 13.3	Anterior (Flexor) Compartment of the Arm	p. 259
Table 13.4	Posterior (Extensor) Compartment of the Arm	p. 260
Table 13.5	Anterior (Flexor) Compartment of the Forearm	p. 262
Table 13.6	Posterior (Extensor) Compartment of the Forearm	p. 264
Table 13.7	Intrinsic Muscles of the Hand	p. 267
Table 13.8	Muscles That Act About the Hip Joint/Thigh	p. 268
Table 13.9	Anterior Compartment of the Thigh	p. 271
Table 13.10	Medial Compartment of the Thigh	p. 272
Table 13.11	Posterior Compartment of the Thigh	p. 273
Table 13.12	Anterior Compartment of the Leg	p. 275
Table 13.13	Lateral Compartment of the Leg	p. 276
Table 13.14	Posterior Compartment of the Leg	p. 278
Table 13.15	Intrinsic Muscles of the Foot	p. 280

These Pre-laboratory Worksheet questions may be assigned by instructors through their **connect** course.

## PRE-LABORATORY WORKSHEET

1. Match the action(s) described in column A with the compartment listed in column B. Actions are those performed by the majority of muscles within the listed compartment.

**Column A**

- \_\_\_\_\_ 1. extension of arm and forearm
- \_\_\_\_\_ 2. extension of the wrist and digits
- \_\_\_\_\_ 3. flexion of arm and forearm
- \_\_\_\_\_ 4. flexion of the wrist and digits

**Column B**

- a. anterior compartment of the arm
- b. anterior compartment of the forearm
- c. posterior compartment of the arm
- d. posterior compartment of the forearm

2. Match the action(s) described in column A with the compartment listed in column B. Actions are those performed by the majority of muscles within the listed compartment.

**Column A**

- \_\_\_\_\_ 1. eversion of the ankle
- \_\_\_\_\_ 2. extension of the leg, flexion of the thigh
- \_\_\_\_\_ 3. extension of the thigh, flexion of the leg
- \_\_\_\_\_ 4. dorsiflexion and inversion of the ankle, extension of the toes
- \_\_\_\_\_ 5. adduction of the thigh
- \_\_\_\_\_ 6. plantar flexion and inversion of the ankle, flexion of the toes

**Column B**

- a. anterior compartment of the leg
- b. anterior compartment of the thigh
- c. lateral compartment of the leg
- d. medial compartment of the thigh
- e. posterior compartment of the leg
- f. posterior compartment of the thigh

3. Which of the following terms describes a muscle that is primarily responsible for causing a given action about a joint? (Circle one.)

- a. agonist      b. antagonist      c. protagonist      d. synergist

4. The upper limb includes the arm, forearm, and wrist. \_\_\_\_\_ (True/False)

5. The portion of the lower limb from the hip to the knee is the \_\_\_\_\_ (leg/thigh).

6. The portion of the lower limb from the knee to the ankle is the \_\_\_\_\_ (leg/thigh).

7. Which of the following muscles compose the rotator cuff? (Check all that apply.)

- \_\_\_\_\_ a. infraspinatus
- \_\_\_\_\_ b. subscapularis
- \_\_\_\_\_ c. supraspinatus
- \_\_\_\_\_ d. teres major
- \_\_\_\_\_ e. teres minor

8. Which of the following muscles compose the hamstring muscles? (Check all that apply.)

- \_\_\_\_\_ a. biceps femoris
- \_\_\_\_\_ b. gracilis
- \_\_\_\_\_ c. rectus femoris
- \_\_\_\_\_ d. semimembranosus
- \_\_\_\_\_ e. semitendinosus

9. Identify the most superficial muscle of the chest. (Circle one.)

- a. deltoid      b. pectoralis major      c. pectoralis minor      d. rhomboid major      e. trapezius

10. Which of the following muscles moves both the pectoral girdle and the glenohumeral joint? (Circle one.)

- a. coracobrachialis      b. latissimus dorsi      c. levator scapulae      d. pectoralis minor

## Gross Anatomy

### Muscles That Move the Pectoral Girdle and Glenohumeral Joint

The **pectoral girdle** consists of the clavicle and scapula. As learned in chapter 10, the shoulder joint (glenohumeral joint) is a highly movable joint. This is largely because there is only minimal bony attachment between the pectoral girdle and the axial skeleton (the only point of bony attachment is the sternoclavicular joint). This anatomic arrangement requires very strong muscular attachments between the pectoral girdle

and the axial skeleton. The muscles that act about the pectoral girdle both stabilize the scapula and move the pectoral girdle, and are classified as either anterior or posterior thoracic muscles (**table 13.1**).

The **glenohumeral joint** (or shoulder joint) consists of the head of the humerus articulating with the relatively shallow glenoid cavity of the scapula. This anatomic arrangement allows a great deal of flexibility, but requires numerous muscular attachments. These muscles both stabilize and create movement about this joint and are classified as muscles originating on the axial skeleton and muscles originating on the scapula (table 13.1).

Table 13.1 Muscles That Act About the Pectoral Girdle					
Muscle	Origin	Insertion	Action*	Innervation	Word Origins
<b>Anterior Muscles</b>					
<i>Pectoralis Minor</i>	Coracoid process of scapula	Ribs 3–5 (anterior surface)	Protracts and depresses the scapula; elevates the rib cage	Medial pectoral nerve	<i>pectus</i> , chest + <i>minor</i> , smaller
<i>Serratus Anterior</i>	Ribs 1–8 (outer surface)	Scapula (medial border)	Protracts the scapula and rotates it superiorly; most important for holding the scapula flat against the rib cage; damage causes a “winging” of the scapula	Long thoracic nerve	<i>serratus</i> , a saw + <i>anterior</i> , the front surface
<b>Posterior Muscles</b>					
<i>Levator Scapulae</i>	Transverse processes of C <sub>1</sub> –C <sub>4</sub>	Scapula (superior vertebral border)	Elevates the scapula and tilts the glenoid inferiorly	Dorsal scapular nerve	<i>levatus</i> , to lift + <i>scapula</i> , the shoulder blade
<i>Rhomboid Major</i>	Spines of T <sub>2</sub> –T <sub>3</sub>	Scapula (medial border)	Retracts, adducts, and stabilizes the scapula; tilts the glenoid inferiorly	Dorsal scapular nerve	<i>rhomboid</i> , resembling an oblique parallelogram + <i>major</i> , larger
<i>Rhomboid Minor</i>	Spines of C <sub>7</sub> –T <sub>1</sub>	Scapula (medial border)	Retracts, adducts, and stabilizes the scapula; tilts the glenoid inferiorly	Dorsal scapular nerve	<i>rhomboid</i> , resembling an oblique parallelogram + <i>minor</i> , smaller
<i>Trapezius</i>	Occipital bone, ligamentum nuchae, spinous processes of C <sub>7</sub> –T <sub>12</sub>	Clavicle (lateral third) and scapula (acromial process and spine)	Superior fibers: Elevate and superiorly rotate scapula Middle fibers: Retract scapula Inferior fibers: Depress scapula	Accessory nerve (CN XI)	<i>trapeza</i> , a table

\*Only actions that apply to movement of the pectoral girdle are listed.

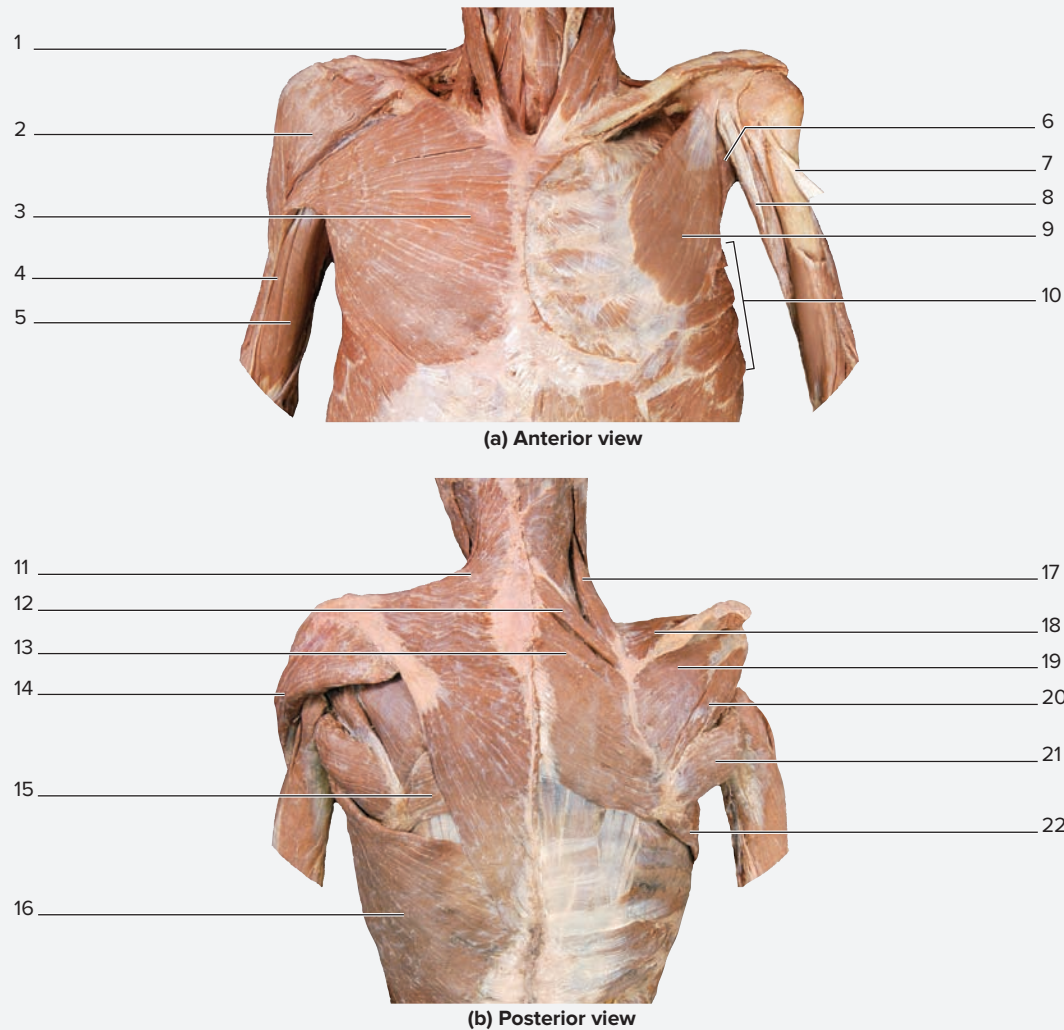
### EXERCISE 13.1 Muscles That Move the Pectoral Girdle and Glenohumeral Joint

#### EXERCISE 13.1A: Muscles That Move the Pectoral Girdle

1. Observe a prosected human cadaver or a classroom model demonstrating muscles of the thorax and upper limb.
2. Identify the **muscles that move the pectoral girdle** listed in **figure 13.1** on the cadaver or on a classroom model, using table 13.1 and the textbook as guides. Then label them in figure 13.1.
  - a. **Anterior Muscles**—The **pectoralis minor** is a small muscle that can have multiple actions, depending upon what other muscles of the thorax and shoulder are contracting at the same time. If the scapula is fixed, the pectoralis minor assists in elevation of the rib cage (as in inspiration). If the scapula is not fixed, the pectoralis minor acts to pull the scapula anteriorly. The **serratus anterior** is a large, flat, fan-shaped muscle positioned

between the ribs and the scapula; it is named based on the saw-toothed (serrated) appearance of its origin on the ribs. This muscle helps to both stabilize and move the scapula.

- b. **Posterior Muscles**—The largest posterior muscle that moves the pectoral girdle is the superficial **trapezius** muscle, which acts to anchor the scapula to the entire superior two-thirds of the vertebral column and to the back of the head. As noted in table 13.1, this muscle performs multiple actions on the scapula, depending upon which part of the muscle contracts at a given time. Deep to the trapezius are smaller, more numerous muscles that act as **synergists** of the trapezius muscle. These include the **rhomboids** (major and minor) and the **levator scapulae**. When identifying these muscles



**Figure 13.1** Muscles That Move the Pectoral Girdle and Glenohumeral Joint. Use the terms listed to fill in the numbered labels in the figure. Some answers may be used more than once.

- |  |  |   |  |
|--|--|---|--|
| <input type="checkbox"/> biceps brachii (long head)  | <input type="checkbox"/> levator scapulae  | <input type="checkbox"/> subscapularis                        | <input type="checkbox"/> trapezius       |
| <input type="checkbox"/> biceps brachii (short head) | <input type="checkbox"/> pectoralis major  | <input type="checkbox"/> supraspinatus                        | <input type="checkbox"/> triceps brachii |
| <input type="checkbox"/> coracobrachialis            | <input type="checkbox"/> pectoralis minor  | <input type="checkbox"/> tendon of biceps brachii (long head) |  |
| <input type="checkbox"/> deltoid                     | <input type="checkbox"/> rhomboid major    | <input type="checkbox"/> teres major                          |  |
| <input type="checkbox"/> infraspinatus               | <input type="checkbox"/> rhomboid minor    | <input type="checkbox"/> teres minor                          |  |
| <input type="checkbox"/> latissimus dorsi            | <input type="checkbox"/> serratus anterior |   |  |

© McGraw-Hill Education/Photos and Dissections by Christine Eckel

on the cadaver or models, think about the actions they share with the trapezius. Practice performing the actions listed in table 13.1 to correlate the actions with the location and fiber orientation of the muscles.

**EXERCISE 13.1B: Muscles That Move the Glenohumeral Joint**

Muscles that move the pectoral girdle and glenohumeral joint can be classified into two groups: a. Muscles Originating on the Axial Skeleton and b. Muscles Originating on the Scapula. A discussion of the major muscles within each of these groups follows.

1. Observe a prosected human cadaver or a classroom model demonstrating muscles of the thorax and upper limb.

2. Identify muscles that act about the glenohumeral joint listed in figure 13.1 on the cadaver or on a classroom model, using **table 13.2** and the textbook as guides. Then label them in **figure 13.2**.

- a. *Muscles Originating on Axial Skeleton*—The posteriorly located **latissimus dorsi** is a broad, triangular muscle located on the inferior part of the back originating on the axial skeleton and inserting on the humerus. It is often called the “swimmer’s muscle” because its actions are required for many swimming strokes. Contraction of this muscle extends, adducts, and medially rotates the arm. The anteriorly located **pectoralis major** is the large, thick, fan-shaped muscle

(continued on next page)



(continued from previous page)

**Table 13.2** Muscles That Act About the Glenohumeral Joint

Muscle	Origin	Insertion	Action*	Innervation	Word Origin
<b>Muscles Originating on Axial Skeleton</b>					
<i>Latissimus Dorsi</i>	Spinous process of T <sub>6</sub> –L <sub>5</sub> , iliac crest, and ribs 10–12	Humerus (intertubercular groove)	Extends, adducts, medially rotates arm	Thoracodorsal nerve	<i>latissimus</i> , widest + <i>dorsum</i> , the back
<i>Pectoralis Major</i>	Sternum, medial clavicle, and costal cartilages 2–6	Lateral part of intertubercular groove of humerus	Flexes and adducts arm	Medial pectoral nerve	<i>pectus</i> , chest + <i>major</i> , larger
<b>Muscles Originating on Scapula</b>					
<i>Biceps Brachii (Long Head)</i>	Supraglenoid tubercle	Radial tuberosity	Flexes arm (weak)	Musculocutaneous nerve	<i>bi-</i> , two + <i>caput</i> , head + <i>brachium</i> , arm
<i>Biceps Brachii (Short Head)</i>	Coracoid process of scapula	Radial tuberosity	Flexes arm (weak)	Musculocutaneous nerve	<i>bi-</i> , two + <i>caput</i> , head + <i>brachium</i> , arm
<i>Coracobrachialis</i>	Coracoid process of scapula	Midhumerus (medial surface)	Flexes and adducts arm	Musculocutaneous nerve	<i>coraco-</i> , referring to the coracoid process + <i>brachium</i> , arm
<i>Deltoid</i>	Clavicle (lateral third), acromion and spine of scapula	Humerus (deltoid tuberosity)	Anterior fibers: Flex and medially rotate arm Middle fibers: Prime movers of arm abduction Posterior fibers: Extend and laterally rotate arm	Axillary nerve	<i>deltoid</i> , resembling the Greek letter delta (a triangle)
<i>Pectoralis Minor</i>	Anterior surfaces of ribs 3–5	Coracoid process of scapula	Flexes, adducts, medially rotates arm	Lateral pectoral nerve	<i>pectus</i> , chest + <i>minor</i> , smaller
<i>Teres Major</i>	Posterior surface of scapula at inferior angle	Crest of lesser tubercle on anterior humerus	Extends, adducts, medially rotates arm	Lower subscapular nerve	<i>teres</i> , round + <i>major</i> , larger
<i>Triceps Brachii (Long Head)</i>	Infraglenoid tubercle of scapula	Olecranon process of ulna	Extends, adducts arm	Radial nerve	<i>tri-</i> , three + <i>caput</i> , head + <i>brachium</i> , arm
<b>Rotator Cuff Muscles</b>					
<i>Infraspinatus</i>	Infraspinous fossa of scapula	Greater tubercle of humerus	Adducts and laterally rotates arm	Suprascapular nerve	<i>infra-</i> , below + <i>spina</i> , referring to the spine of the scapula
<i>Subscapularis</i>	Subscapular fossa	Lesser tubercle of humerus	Medially rotates arm	Upper and lower scapular nerves	<i>sub-</i> , under + <i>scapula</i> , the shoulder blade
<i>Supraspinatus</i>	Supraspinous fossa	Humerus (greater tubercle)	Stabilizes arm, assists in abduction	Suprascapular nerve	<i>supra-</i> , above + <i>spina</i> , referring to the spine of the scapula
<i>Teres Minor</i>	Inferior angle of scapula	Greater tubercle of humerus	Adducts and laterally rotates arm	Axillary nerve	<i>teres</i> , round + <i>minor</i> , smaller

\*Only actions that apply to movement of the glenohumeral joint are listed.

that covers the superior part of the chest, and acts to flex and adduct the arm.

- b. Muscles Originating on the Scapula**—Numerous muscles originate on the scapula and insert on the humerus (table 13.2). One important group of muscles is the rotator cuff muscles. The rotator cuff is a musculotendinous cuff formed by four muscles that impart strength and stability to the glenohumeral joint. These muscles include the **subscapularis** (located in the

subscapular fossa) and the **supraspinatus**, **infraspinatus**, and **teres minor**. More than any other factor, the strength of these muscles determines how stable the joint is. Weaknesses in these muscles contribute to many musculoskeletal problems in the glenohumeral joint. Rotator cuff injuries are common in baseball players and in older adults who fall on an outstretched arm. The term *rotator cuff* comes from the fact that these muscles act to medially or laterally rotate the humerus, in addition to stabilizing the glenohumeral joint.

### Learning Strategy



The following mnemonic is helpful for remembering the names of the rotator cuff muscles. “A baseball pitcher who tears his rotator cuff **SITS** out the season.” (**SITS**: **S** = supraspinatus,

**I** = infraspinatus, **T** = teres minor, **S** = subscapularis.) To remember it is the teres **minor** (not the teres major) that forms part of the rotator cuff, know that this injured pitcher will then be relegated to the **minor** leagues.

## Upper Limb Musculature

The upper limb consists of the **arm** and the **forearm**. Each is divided into anterior and posterior compartments. The **anterior compartment** is collectively referred to as a **flexor compartment** because its muscles act to flex the arm, forearm, or wrist and fingers. The **posterior compartment** is collectively referred to as an **extensor compartment** because its muscles act to extend the arm, forearm,

or wrist and fingers. Understanding the compartmental nature of the muscles not only is important for simplifying the task of learning the muscles within each compartment—it becomes even more important when you learn the distribution of peripheral nerves. In most cases, one nerve innervates one compartment. Understanding the common function of the muscles in an entire compartment helps to more easily determine the deficits an individual will suffer when a particular nerve is damaged.

### EXERCISE 13.2 Compartments of the Arm

#### EXERCISE 13.2A: Anterior Compartment of the Arm

1. Observe a prosected human cadaver or a classroom model demonstrating muscles of the upper limb.
2. Identify the **muscles of the anterior compartment of the arm** listed in figure 13.2 on the cadaver or on a classroom model, using **table 13.3** and the textbook as guides. Then label them in figure 13.2. While identifying these muscles, make note of the following:

*Common Actions:* Muscles in this compartment flex the arm or forearm.

*Exceptions:* The coracobrachialis muscle acts only about the glenohumeral joint.

The brachialis muscle acts only about the elbow joint.

3. *Brachialis and Biceps Brachii:* A common misconception is that the biceps brachii muscle is the most powerful flexor of the forearm (elbow). It is not. This can be tested by performing the following activity. With your right wrist pronated, place the palm of the left hand over the belly of the biceps brachii on the right arm. Flex the forearm and note the degree to which the biceps brachii muscle produces tension. Next, supinate the wrist and perform the flexion action again. Did the biceps brachii produce more tension when the wrist was pronated or supinated? \_\_\_\_\_. A large difference in the amount of tension produced under the two conditions should have occurred. This is because the **prime mover**, or **agonist**, for the action of forearm flexion is the **brachialis** muscle, not the biceps brachii muscle. The biceps brachii is a **synergist** for this action. The biceps brachii itself is a very powerful **supinator** of the wrist and forearm. Thus, actions

that require both flexion of the forearm and supination of the wrist and forearm use the biceps brachii to its full capacity. Think about this the next time when attempting to twist off a stubborn bottle lid.

4. When identifying the biceps brachii muscle on models or cadavers, do not be confused by what is seen. Because the **long head of the biceps brachii** disappears into the intertubercular groove of the humerus on its way to its attachment on the supraglenoid tubercle, only a small portion of its tendon is visible. On the other hand, the entire tendon of the **short head of the biceps brachii** is visible attaching to the coracoid process of the scapula. Thus, on models and cadavers, the short head of the biceps brachii will generally appear to be longer.

#### EXERCISE 13.2B: Posterior Compartment of the Arm

1. Observe a prosected human cadaver or a classroom model demonstrating muscles of the upper limb.
2. The posterior compartment of the arm consists of one muscle, the triceps brachii, with three heads (long, lateral, and medial).
3. Identify the **muscles of the posterior compartment of the arm** listed in **figure 13.3** on the cadaver or on a classroom model, using **table 13.4** and the textbook as guides. Then label them in figure 13.3. While identifying these muscles, make note of the following:

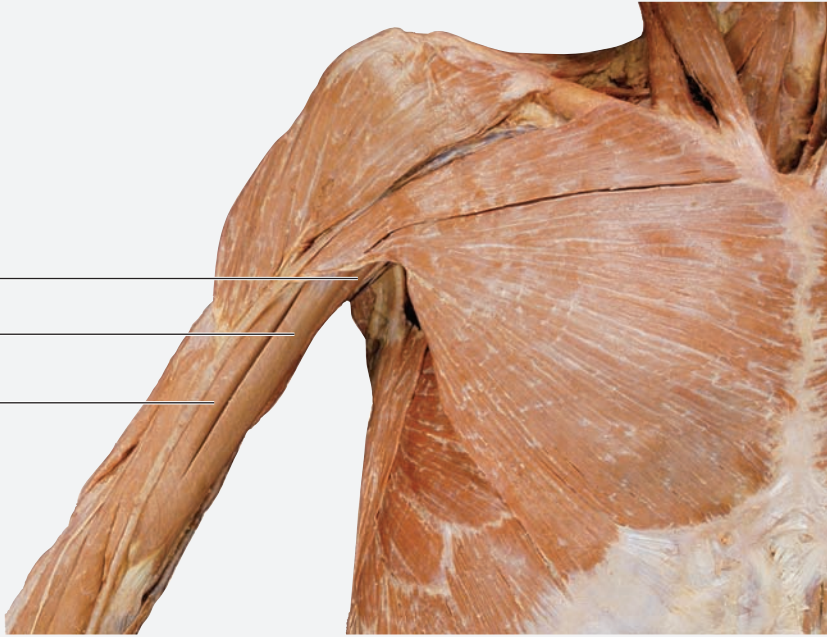
*Common Actions:* Extend the forearm (elbow).

*Exception:* The long head also extends the arm.

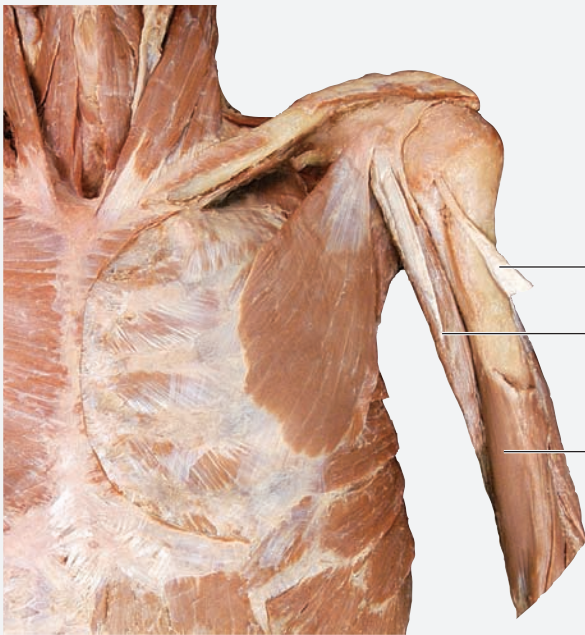
Table 13.3 Anterior (Flexor) Compartment of the Arm					
Muscle	Origin	Insertion	Action	Innervation	Word Roots
<i>Biceps Brachii (Long Head)</i>	Supraglenoid tubercle of scapula	Radial tuberosity	Supinates forearm and flexes forearm (weak)	Musculocutaneous nerve	<i>bi-</i> , two + <i>caput</i> , head + <i>brachium</i> , arm
<i>Biceps Brachii (Short Head)</i>	Coracoid process of scapula	Radial tuberosity	Supinates forearm and flexes forearm (weak)	Musculocutaneous nerve	<i>bi-</i> , two + <i>caput</i> , head + <i>brachium</i> , arm
<i>Brachialis</i>	Humerus (lower half of anterior surface)	Ulna (coronoid process and ulnar tuberosity)	Flexes forearm	Musculocutaneous nerve	<i>brachium</i> , the arm
<i>Coracobrachialis</i>	Coracoid process of scapula	Midhumerus (medial surface)	Flexes arm and adducts (weak)	Musculocutaneous nerve	<i>coraco-</i> , referring to the coracoid process + <i>brachium</i> , the arm

(continued on next page)

(continued from previous page)



(a) Right anterior arm, superficial view



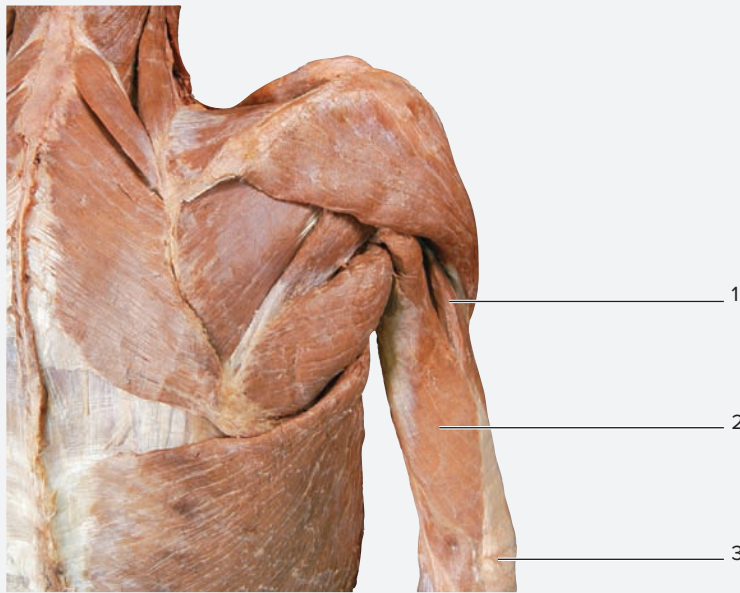
(b) Left anterior arm, deep view

**Figure 13.2** Anterior (Flexor) Compartment of the Arm. Use the terms listed to fill in the numbered labels in the figure. Some answers may be used more than once.

- biceps brachii (long head)
- biceps brachii (short head)
- brachialis
- coracobrachialis
- tendon of the long head of biceps brachii

© McGraw-Hill Education/Photos and Dissections by Christine Eckel

Table 13.4 Posterior (Extensor) Compartment of the Arm					
Muscle	Origin	Insertion	Action	Innervation	Word Roots
<b>TRICEPS BRACHII</b>					<i>tri-</i> , three + <i>caput</i> , head + <i>brachium</i> , arm
<i>Lateral Head</i>	Proximal half of posterior humerus	Olecranon of ulna	Extends forearm	Radial nerve	
<i>Long Head</i>	Infraglenoid tubercle of scapula	Olecranon of ulna	Extends forearm, extends arm	Radial nerve	
<i>Medial Head</i>	Distal half of posterior humerus	Olecranon of ulna	Extends forearm	Radial nerve	



Right posterior arm, superficial view

**Figure 13.3** Posterior (Extensor) Compartment of the Arm. Use the terms listed to fill in the numbered labels in the figure.

- lateral head of triceps brachii
- long head of triceps brachii
- olecranon process of ulna

© McGraw-Hill Education/Photos and Dissections by Christine Eckel

### Learning Strategy



The *long* head of the *triceps brachii* attaches to the *infraglenoid tubercle* (of the scapula), while the *long* head of the *biceps brachii* attaches to the *supraglenoid tubercle* (of the scapula). Also, the medial head of the *triceps brachii* can be visualized only if the lateral head is bisected. It is a deep muscle, and it attaches directly to the humerus.

## EXERCISE 13.3 Compartments of the Forearm

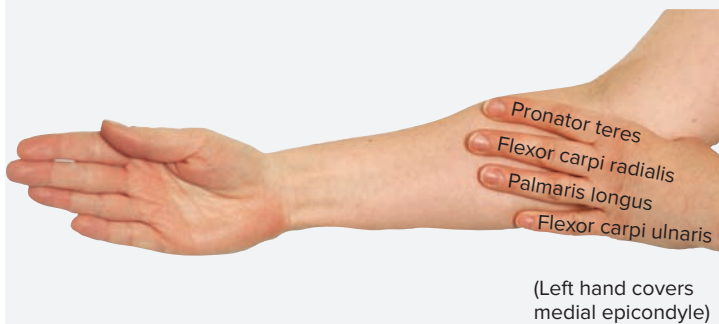### EXERCISE 13.3A: Anterior Compartment of the Forearm

1. Observe a prosected human cadaver or a classroom model demonstrating muscles of the upper limb.
2. The muscles of the **anterior compartment of the forearm** (figure 13.5) cause flexion of the wrist and the digits (fingers). They are arranged into two layers—a superficial group and a deep group. In most cases, the name of the muscle tells exactly what the muscle does or where the muscle is located. Thus, although the names of the muscles seem long, they can be very useful if the meanings of the names are understood.

3. *Identification of Superficial Muscles and Tendons:* Place your left palm on the medial epicondyle of the right humerus (figure 13.4). In this position, the order of the muscles, on the right forearm from lateral to medial, is:

- Index finger—pronator teres (PT)
- Middle finger—flexor carpi radialis (FCR)
- Ring finger—palmaris longus (PL)
- Pinky finger—flexor carpi ulnaris (FCU)

While performing this exercise, flex the wrist and digits to identify the tendons, from lateral to medial, of the flexor carpi radialis, palmaris longus (if present, see step 4), and flexor carpi ulnaris.



**Figure 13.4** Locating Superficial Anterior Forearm

**Muscles.** Locate the superficial anterior forearm muscles by placing the left hand on the right forearm and noting the position of the digits, which correspond to the locations of the superficial forearm muscles.

© McGraw-Hill Education/JW Ramsey

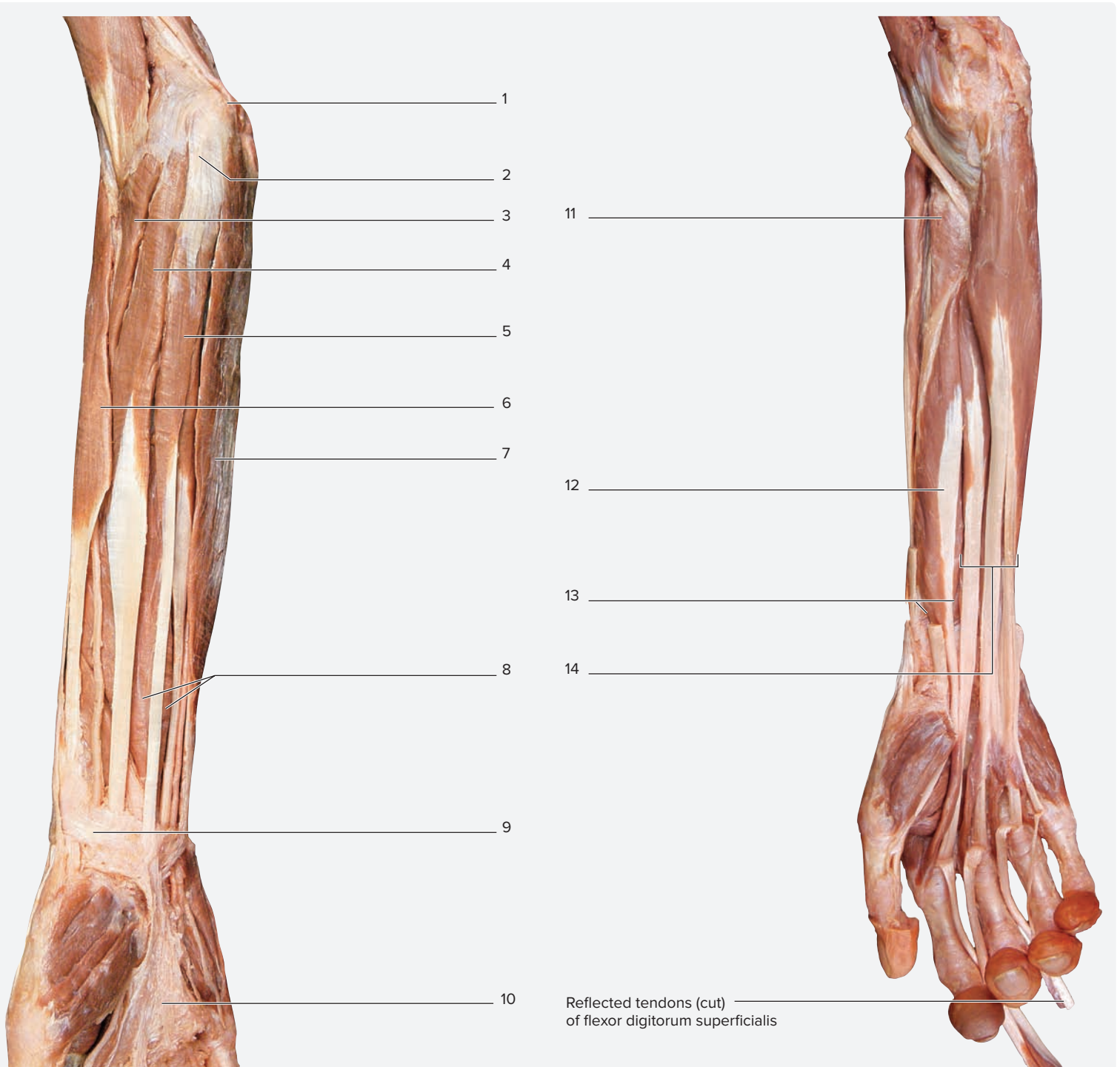
(continued on next page)

(continued from previous page)

4. **Palmaris Longus:** Approximately 7% of humans do not have a palmaris longus muscle. The palmaris longus passes *superficial* to the **flexor retinaculum** (a band of connective tissue that wraps around the wrist) and inserts onto the **palmar aponeurosis**. Perform the following exercise to determine whether you have a palmaris longus muscle. With the forearm supinated, touch the tips of the first and fifth digits (thumb and pinky finger) together and flex the wrist *slightly*. If palmaris longus is present, its tendon will be visible passing longitudinally in the middle of the wrist. If no tendon is visible, the muscle is probably absent.
5. **Flexor Digitorum:** There are two muscles that flex the digits, the **flexor digitorum superficialis** (superficial) and the **flexor digitorum profundus** (deep) (**figure 13.6**). These muscles, as their names suggest, flex the fingers. They do so by attaching to the phalanges. These muscles take somewhat unique routes to get to their respective attachments on the phalanges. The flexor digitorum profundus tendon attaches to the **distal phalanx**. Thus, it must pass through the tendon of the more superficial muscle (the tendon of the flexor digitorum superficialis) as it travels to the distal phalanx. Observe a cadaver or a classroom model of the hand, and locate the middle and distal phalanges of one digit. The tendon of flexor digitorum superficialis inserts onto the **middle phalanx** of the digit. Before it reaches its insertion point, it has a slit through which the tendon of flexor digitorum profundus passes. Thus, though both muscles flex the digits, they do so at different joints. Perform an experiment to test the function of these two muscles. With your right hand, pull the tip of the third digit (middle finger) of your left hand posteriorly. This stretches the flexor digitorum profundus muscle beyond the point at which it can contract. Now try to flex the other digits of your hand. Notice that you can flex the joint between your proximal and middle phalanges, but you cannot flex the joint between your middle and distal phalanges. Once you release your hold on the third digit, you will be able to flex all the interphalangeal joints together.
6. Identify the muscles of the anterior compartment of the forearm listed in figure 13.5 on the cadaver or on a classroom model, using **table 13.5** and the textbook as guides. Then label them in figure 13.5.
7. **Optional Activity:** **AP|R Muscular System**—Visit the quiz area for drill and practice on muscles of the upper limb.

**Table 13.5** Anterior (Flexor) Compartment of the Forearm

Muscle	Origin	Insertion	Action	Innervation	Word Origin
<b>Superficial Group</b>					
<i>Flexor Carpi Radialis</i>	Humerus (medial epicondyle)	Metacarpals II and III (base)	Flexes and abducts wrist	Median nerve	<i>flex</i> , to bend + <i>carpus</i> , wrist + <i>radialis</i> , radius
<i>Flexor Carpi Ulnaris</i>	Humerus (medial epicondyle)	Pisiform, hamate, and metacarpal V (base)	Flexes and adducts wrist	Ulnar nerve	<i>flex</i> , to bend + <i>carpus</i> , wrist + <i>ulnaris</i> , ulna
<i>Flexor Digitorum Superficialis</i>	Humerus (medial epicondyle)	Middle phalanx of digits 2–5	Flexes the metacarpophalangeal and proximal interphalangeal joints of digits 2–5	Median nerve	<i>flex</i> , to bend + <i>digit</i> , finger + <i>superficialis</i> , surface
<i>Palmaris Longus</i>	Humerus (medial epicondyle)	Palmar aponeurosis	Flexes wrist	Median nerve	<i>palmaris</i> , the palm + <i>longus</i> , long
<i>Pronator Teres</i>	Humerus (medial epicondyle)	Radius (lateral shaft)	Pronates forearm and flexes forearm (weak)	Median nerve	<i>pronatus</i> , to bend forward + <i>teres</i> , round
<b>Deep Group</b>					
<i>Flexor Digitorum Profundus</i>	Ulna (anteromedial surface) and interosseous membrane	Distal phalanx of digits 2–5	Flexes the distal phalanx of digits 2–5	Ulnar and median nerves	<i>flexus</i> , to bend + <i>digitorum</i> , finger + <i>profundus</i> , deep
<i>Flexor Pollicis Longus</i>	Radius (anterior surface) and interosseous membrane	Distal phalanx of the thumb	Flexes the distal phalanx of the thumb	Median nerve	<i>flexus</i> , to bend + <i>pollex</i> , the thumb + <i>longus</i> , long
<i>Pronator Quadratus</i>	Ulna (distal anterior shaft)	Radius (distal, anterior shaft)	Pronates the forearm	Median nerve	<i>pronatus</i> , to bend forward + <i>quadratus</i> , square



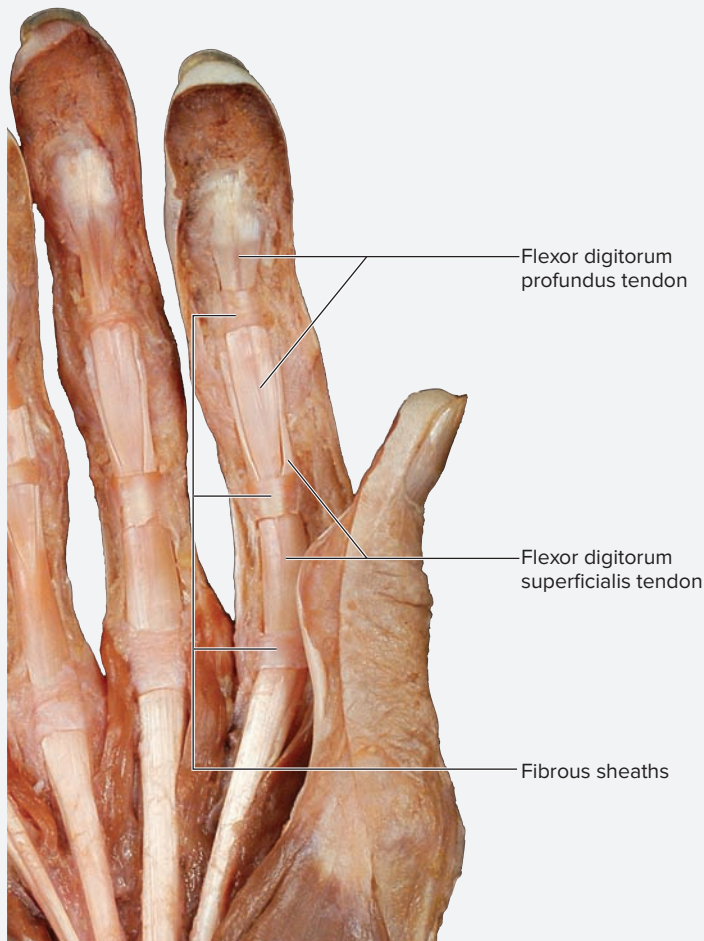
(a) Right anterior forearm, superficial view

(b) Right anterior forearm, deep view

**Figure 13.5** Anterior (Flexor) Compartment of the Forearm. Use the terms listed to fill in the numbered labels in the figure. Some answers may be used more than once.

- |  |   |   |   |
|--|---|---|---|
| <input type="checkbox"/> brachioradialis       | <input type="checkbox"/> flexor digitorum profundus     | <input type="checkbox"/> medial epicondyle of humerus | <input type="checkbox"/> pronator quadratus |
| <input type="checkbox"/> common flexor tendon  | <input type="checkbox"/> flexor digitorum superficialis | <input type="checkbox"/> palmar aponeurosis           | <input type="checkbox"/> pronator teres     |
| <input type="checkbox"/> flexor carpi radialis | <input type="checkbox"/> flexor pollicis longus         | <input type="checkbox"/> palmaris longus              | <input type="checkbox"/> supinator          |
| <input type="checkbox"/> flexor carpi ulnaris  | <input type="checkbox"/> flexor retinaculum             |   |   |

(continued from previous page)



Right hand, palmar view

**Figure 13.6 Flexor Tendons Within the Hand.** The tendon of the flexor digitorum profundus pierces the tendon of the flexor digitorum superficialis as it travels to its attachment point on the distal phalanx.

© McGraw-Hill Education/Photos and Dissections by Christine Eckel

### EXERCISE 13.3B: Posterior Compartment of the Forearm

1. Observe a prosected human cadaver or a classroom model demonstrating muscles of the upper limb.
2. Identify the **muscles of the posterior compartment of the forearm** listed in **figure 13.7** on the cadaver or on a classroom model, using **table 13.6** and the textbook as guides. Then label them in figure 13.7.
3. *The Anatomic Snuffbox:* The tendons of the **abductor pollicis longus**, **extensor pollicis longus**, and **extensor pollicis brevis** muscles form the borders of a triangular area called the **anatomic snuffbox**. To see the anatomic snuffbox, extend the thumb as far as it will go (as if signaling to hitch a ride). The tendons of the bordering muscles will pop up, and a concavity can be seen between them. The anatomic snuffbox is clinically important because the radial artery is located in its floor and it is an area of palpation to evaluate fractures of the scaphoid bone. With the thumb relaxed, place a finger on the snuffbox and see if the pulse of the radial artery can be felt.
4. Sketch the anatomic snuffbox in the space provided, noting the locations of the three muscles that form its boundaries.


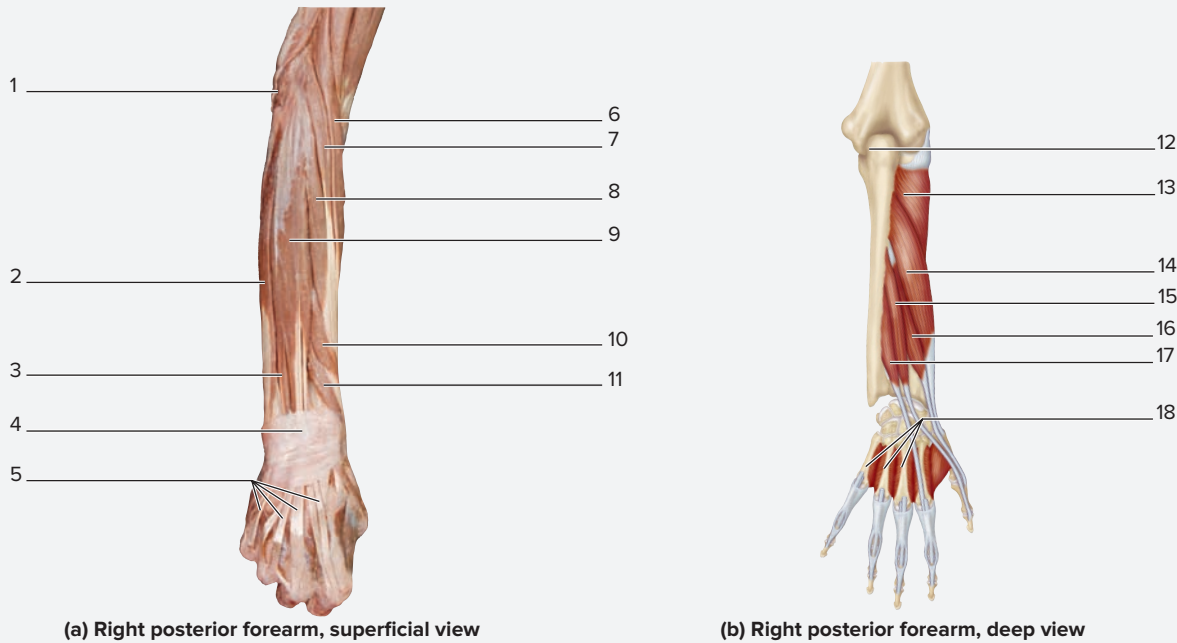


Table 13.6

## Posterior (Extensor) Compartment of the Forearm

Muscle	Origin	Insertion	Action	Innervation	Word Origin
<i>Abductor Pollicis Longus</i>	Ulna and radius (posterior surface) and interosseous membrane	Metacarpal I (base)	Abducts the thumb	Radial nerve	<i>abduct</i> , to move away from the midline + <i>pollex</i> , thumb + <i>longus</i> , long
<i>Brachioradialis</i>	Humerus (lateral supracondylar ridge)	Radius (styloid process)	Flexes the forearm	Radial nerve	<i>brachium</i> , arm + <i>radialis</i> , radius
<i>Extensor Carpi Radialis Brevis</i>	Humerus (lateral epicondyle)	Metacarpal III (base)	Extends and abducts the wrist	Radial nerve	<i>extendo</i> , to stretch out + <i>carpus</i> , wrist, + <i>radialis</i> , radius + <i>brevis</i> , short
<i>Extensor Carpi Radialis Longus</i>	Humerus (lateral supracondylar ridge)	Metacarpal II (base)	Extends and abducts the wrist	Radial nerve	<i>extendo</i> , to stretch out + <i>carpus</i> , wrist + <i>radialis</i> , radius + <i>longus</i> , long
<i>Extensor Carpi Ulnaris</i>	Humerus (lateral epicondyle) and proximal ulna	Metacarpal V (base)	Extends and adducts the wrist	Radial nerve	<i>extendo</i> , to stretch out + <i>carpus</i> , wrist + <i>ulnaris</i> , ulna

Table 13.6 Posterior (Extensor) Compartment of the Forearm ( <i>continued</i> )					
Muscle	Origin	Insertion	Action	Innervation	Word Origin
<i>Extensor Digiti Minimi</i>	Humerus (lateral epicondyle)	Proximal phalanx of digit 5 (little finger)	Extends the little finger at the metacarpophalangeal and interphalangeal joints	Radial nerve	<i>extendo</i> , to stretch out + <i>digit</i> , finger + <i>minimi</i> , smallest
<i>Extensor Digitorum</i>	Humerus (lateral epicondyle)	Distal and middle phalanges of digits 2–5	Extends digits 2–5 at the metacarpophalangeal joint, extends the wrist	Radial nerve	<i>extendo</i> , to stretch out + <i>digit</i> , finger
<i>Extensor Indicis</i>	Ulna (posterior surface) and interosseous membrane	Tendon of extensor digitorum of digit 2 (index finger)	Extends the index finger	Radial nerve	<i>extendo</i> , to stretch out + <i>indicis</i> , the forefinger
<i>Extensor Pollicis Brevis</i>	Radius (posterior surface) and interosseous membrane	Proximal phalanx of the thumb	Extends the proximal phalanx of the thumb at the metacarpophalangeal joint	Radial nerve	<i>extendo</i> , to stretch out + <i>pollex</i> , thumb + <i>brevis</i> , short
<i>Extensor Pollicis Longus</i>	Ulna (middle third, posterior surface) and interosseous membrane	Distal phalanx of the thumb	Extends the distal phalanx of the thumb at the metacarpophalangeal and interphalangeal joints	Radial nerve	<i>extendo</i> , to stretch out + <i>pollex</i> , thumb + <i>longus</i> , long
<i>Supinator</i>	Humerus (lateral epicondyle) and proximal ulna	Radius (proximal third)	Supinates the forearm	Radial nerve	<i>supinatus</i> , to move backward



**Figure 13.7** Posterior (Extensor) Compartment of the Forearm. Use the terms listed to fill in the numbered labels in the figure. Some answers may be used more than once.

- |   |   |   |
|---|---|---|
| <input type="checkbox"/> abductor pollicis brevis       | <input type="checkbox"/> extensor carpi radialis longus | <input type="checkbox"/> extensor pollicis brevis |
| <input type="checkbox"/> abductor pollicis longus       | <input type="checkbox"/> extensor carpi ulnaris         | <input type="checkbox"/> extensor pollicis longus |
| <input type="checkbox"/> anconeus                       | <input type="checkbox"/> extensor digiti minimi         | <input type="checkbox"/> extensor retinaculum     |
| <input type="checkbox"/> brachioradialis                | <input type="checkbox"/> extensor digitorum             | <input type="checkbox"/> olecranon of ulna        |
| <input type="checkbox"/> dorsal interossei              | <input type="checkbox"/> extensor digitorum tendons     | <input type="checkbox"/> supinator                |
| <input type="checkbox"/> extensor carpi radialis brevis | <input type="checkbox"/> extensor indicis               |   |



**EXERCISE 13.4** Intrinsic Muscles of the Hand

1. Observe a prosected human cadaver or a model demonstrating muscles of the hand.
2. The **intrinsic muscles of the hand** consist of the lumbricals, the interossei, and the thenar and hypothenar groups of muscles. The **thenar** group of muscles forms the large pad at the base of the thumb, the **thenar eminence**. Muscles in this group create special movements of the pollex (thumb), the most important of which is **opposition**. The **hypothenar** group of muscles forms a pad at the base of the fifth digit, the **hypothenar eminence**. Muscles in this group create special movements of the fifth digit (little finger). Observe both the thenar and hypothenar eminences on one of your hands. The **midpalmar** group is a group of muscles that lies between the thenar and hypothenar muscle groups. The midpalmar group consists of the lumbricals, interossei, and adductor pollicis. The **lumbricals** and **interossei** muscles are small muscles,

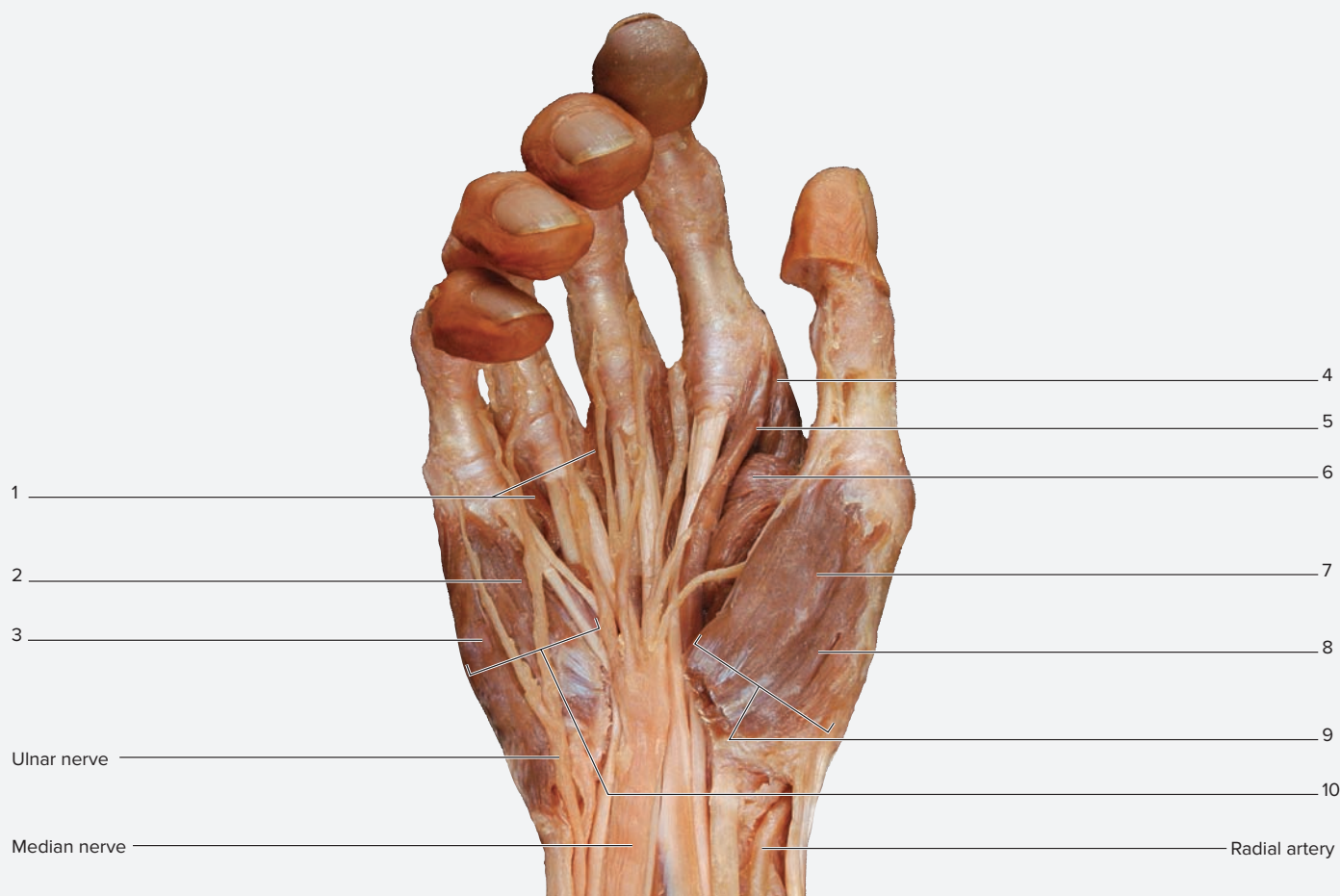located very deep in the hand, that create small, intricate movements of the fingers.

3. Identify the intrinsic muscles of the hand listed in **figure 13.8** on the cadaver or on a classroom model, using **table 13.7** and the textbook as guides. Then label them in figure 13.8.
4. *The Interossei:* The two groups of interossei muscles act to abduct and adduct the digits. There are two groups of

**Learning Strategy**



The **D**orsal interossei **AB**duct the digits (mnemonic is **DAB**), whereas the **P**almar interossei **AD**duct the digits (mnemonic is **PAD**).



**Figure 13.8** Intrinsic Muscles of the Hand. Use the terms listed to fill in the numbered labels in the figure.

- |  |  |   |
|--|--|---|
| <input type="checkbox"/> abductor digiti minimi    | <input type="checkbox"/> flexor digiti minimi brevis | <input type="checkbox"/> medial lumbrical |
| <input type="checkbox"/> adductor pollicis         | <input type="checkbox"/> flexor pollicis brevis      | <input type="checkbox"/> thenar group     |
| <input type="checkbox"/> abductor pollicis brevis  | <input type="checkbox"/> hypothenar group            |   |
| <input type="checkbox"/> first dorsal interosseous | <input type="checkbox"/> lateral lumbricals          |   |

Table 13.7		Intrinsic Muscles of the Hand			
Muscle	Origin	Insertion	Action	Innervation	Word Origin
<b>Thenar Group</b>					<i>thenar</i> , the palm of the hand
<i>Abductor Pollicis Brevis</i>	Flexor retinaculum, scaphoid and trapezium (tubercles)	Base of the proximal phalange of the thumb (lateral side)	Abducts the thumb	Recurrent branch of the median nerve	<i>abduct</i> , to move away from the midline + <i>pollex</i> , thumb + <i>brevis</i> , short
<i>Flexor Pollicis Brevis</i>	Flexor retinaculum and trapezium (tubercles)	Base of the proximal phalange of the thumb (lateral side)	Flexes the thumb	Recurrent branch of the median nerve	<i>flexus</i> , to bend + <i>pollex</i> , thumb + <i>brevis</i> , short
<i>Opponens Pollicis</i>	Flexor retinaculum and trapezium (tubercles)	Metacarpal I (lateral side)	Assists in opposition and medial rotation of the thumb	Recurrent branch of the median nerve	<i>oppono</i> , to place against + <i>pollex</i> , thumb
<b>Hypothenar Group</b>					<i>hypo-</i> , under + <i>thenar</i> , the palm of the hand
<i>Abductor Digiti Minimi</i>	Pisiform bone and tendon of flexor carpi ulnaris	Base of the proximal phalanx of digit 5 (medial side)	Abducts digit 5	Ulnar nerve	<i>abduct</i> , to move away from the median plane + <i>digitus</i> , a finger + <i>minimi</i> , smallest
<i>Flexor Digiti Minimi Brevis</i>	Hamate (hook) and flexor retinaculum	Base of the proximal phalanx of digit 5 (medial side)	Flexes the proximal phalanx of digit 5	Ulnar nerve	<i>flex</i> , to bend + <i>digitus</i> , a finger + <i>minimi</i> , smallest
<i>Opponens Digiti Minimi</i>	Hamate (hook) and flexor retinaculum	Metacarpal V (medial border)	Medially rotates and opposes digit 5 toward the thumb	Ulnar nerve	<i>oppono</i> , to place against + <i>digitus</i> , a finger + <i>minimi</i> , smallest
<b>Midpalmar Group</b>					
<i>Adductor Pollicis</i>	Capitate bone, metacarpals II–III	Medial side of proximal phalanx of thumb	Adducts thumb	Ulnar nerve	<i>adduct</i> , to move toward the midline + <i>pollex</i> , thumb
<i>Dorsal Interossei</i>	Metacarpals II–IV (medial and lateral surface)	Tubercle of the proximal phalanx and dorsal aponeurosis	Abducts digits 2–4	Ulnar nerve	<i>dorsal</i> , the back + <i>inter-</i> , between + <i>os</i> , bone
<i>Lumbricals</i>	Flexor digitorum profundus tendon	Lateral side of the dorsal expansion of digits 2–5	Flexes metacarpal-phalangeal joint	Ulnar and median nerves	<i>lumbricus</i> , earthworm
<i>Palmar Interossei</i>	Metacarpals (medial and lateral surface)	Tubercle of the proximal phalanx and the dorsal aponeurosis	Adducts digits 2–5	Ulnar nerve	<i>palmar</i> , the palm of the hand, + <i>inter-</i> , between, + <i>os</i> , bone

interossei, dorsal and palmar. The *dorsal interossei* abduct the digits, and the *palmar interossei* adduct the digits. To feel the belly of the first dorsal interosseous muscle, forcibly press (adduct) the thumb and index finger together. Then palpate between metacarpals I and II using the other hand to feel the first dorsal interosseous muscle. Try this out on yourself now.

5. *Lumbricals*: The lumbricals are relatively easy to identify because they appear slim and “wormlike,” as their name implies. There is a lumbrical muscle located between every metacarpal bone. The lumbricals flex the metacarpophalangeal joints and extend the interphalangeal joints.

## Muscles That Act About the Hip Joint/Thigh

The **muscles that move the hip** include the gluteal muscles, the deep lateral rotators, and the iliopsoas muscle. The gluteal muscles and the

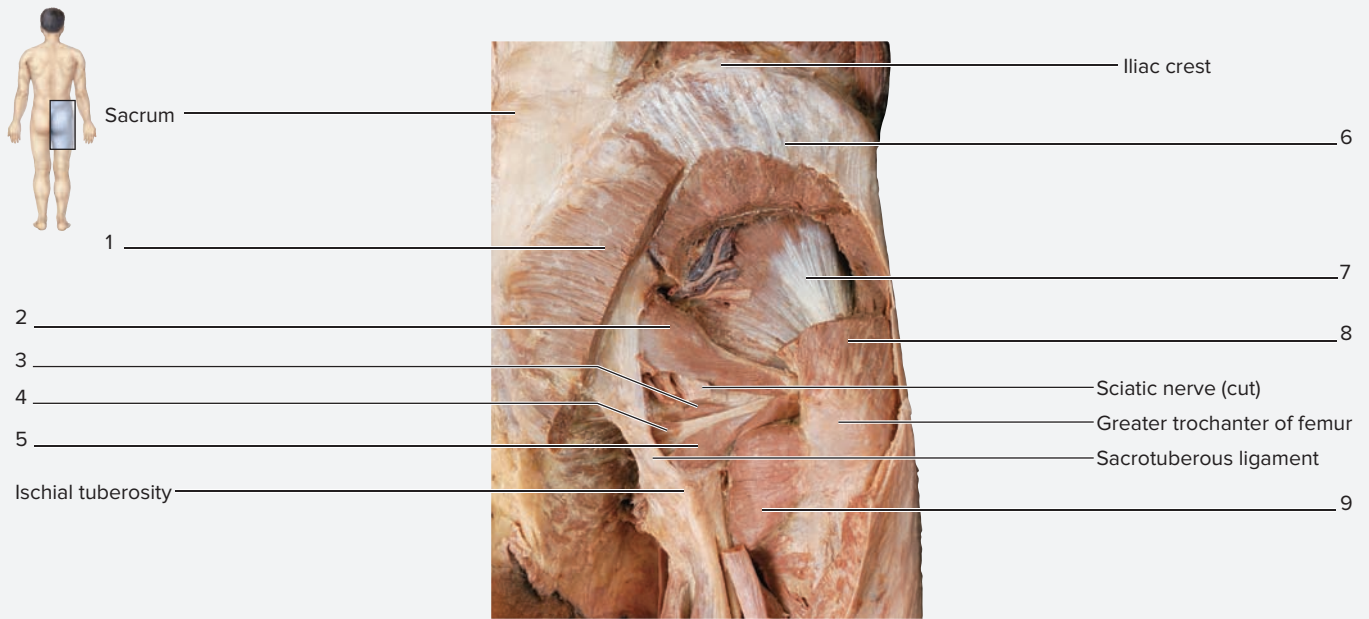iliopsoas are very large and powerful muscles. We use them for standing, walking, running, cycling, and just about every other locomotor activity. Failure of these muscles to work properly leads to gait disturbances.

### EXERCISE 13.5 Muscles That Move the Hip

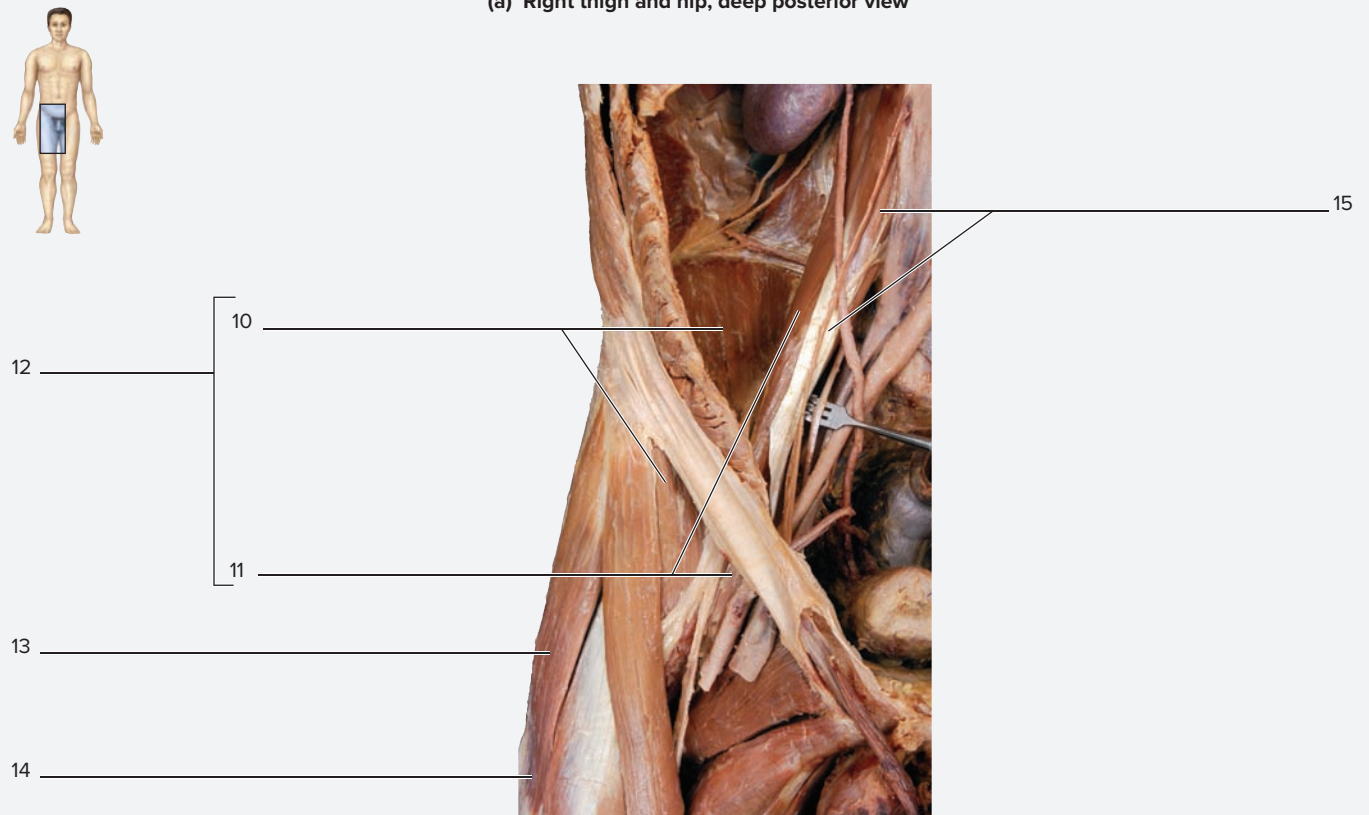
1. Observe a prosected human cadaver or a model demonstrating muscles of the hip.
2. Identify the muscles that move the hip listed in **figure 13.9** on the cadaver or on a classroom model, using **table 13.8** and the textbook as guides. Then label them in figure 13.9.
3. **Gluteal Muscles:** The gluteus maximus extends and *laterally* rotates the thigh. The gluteus medius and minimus muscles abduct and *medially* rotate the thigh.
4. Consider the action of **hip abduction**. It may not seem that this action is performed very often, except perhaps in a

**Table 13.8** Muscles That Act About the Hip Joint/Thigh

Muscle	Origin	Insertion	Action	Innervation	Word Origin
<b>Anterior Thigh Compartment (Thigh Flexors)</b>					
<i>Iliacus</i>	Iliac bone (iliac fossa)	Femur (lesser trochanter)	Flexes the thigh	Femoral nerve (L <sub>2</sub> –L <sub>3</sub> )	<i>ilium</i> , groin
<i>Psoas Major</i>	T <sub>12</sub> –L <sub>5</sub> (bodies and transverse processes)	Femur (lesser trochanter)	Flexes the thigh	Lumbar plexus (L <sub>2</sub> –L <sub>3</sub> )	<i>psoa</i> , the muscles of the loins
<i>Rectus Femoris</i>	Anterior inferior iliac spine	Tibial tuberosity	Extends the leg, flexes the thigh	Femoral nerve (L <sub>2</sub> –L <sub>4</sub> )	<i>rectus</i> , straight + <i>femur</i> , thigh
<i>Sartorius</i>	ASIS (anterior superior iliac spine)	Medial tibia	Crosses legs, flexes the thigh and leg, abducts and laterally rotates the thigh	Femoral nerve (L <sub>2</sub> –L <sub>4</sub> )	<i>sartor</i> , a tailor
<b>Medial Thigh Compartment (Thigh Adductors)</b>					
<i>Adductor Brevis</i>	Pubis	Femur (linea aspera)	Adducts and laterally rotates the thigh	Obturator nerve (L <sub>2</sub> –L <sub>3</sub> )	<i>adduct</i> , to bring toward the median plane + <i>brevis</i> , short
<i>Adductor Longus</i>	Pubis	Femur (linea aspera)	Adducts and laterally rotates the thigh	Obturator nerve (L <sub>2</sub> –L <sub>4</sub> )	<i>adduct</i> , to bring toward the median plane, + <i>longus</i> , long
<i>Adductor Magnus</i>	Pubis	Femur (linea aspera)	Adducts and laterally rotates the thigh	Obturator nerve (L <sub>2</sub> –L <sub>4</sub> )	<i>adduct</i> , to bring toward the median plane + <i>magnus</i> , large
<i>Gracilis</i>	Pubis	Tibia (medial condyle)	Adducts the thigh	Obturator nerve (L <sub>2</sub> –L <sub>4</sub> )	<i>gracilis</i> , slender
<i>Obturator Externus</i>	Margin of obturator foramen and obturator membrane	Femur (trochanteric fossa)	Laterally rotates thigh	Obturator nerve (L <sub>3</sub> –L <sub>4</sub> )	<i>obturator</i> , structure that occludes opening + <i>externus</i> , outside
<i>Pectineus</i>	Pubis	Femur (pectineal condyle)	Adducts and laterally rotates the thigh	Obturator or femoral nerve (L <sub>2</sub> –L <sub>4</sub> )	<i>pectineal</i> , a ridged or comblike structure



(a) Right thigh and hip, deep posterior view

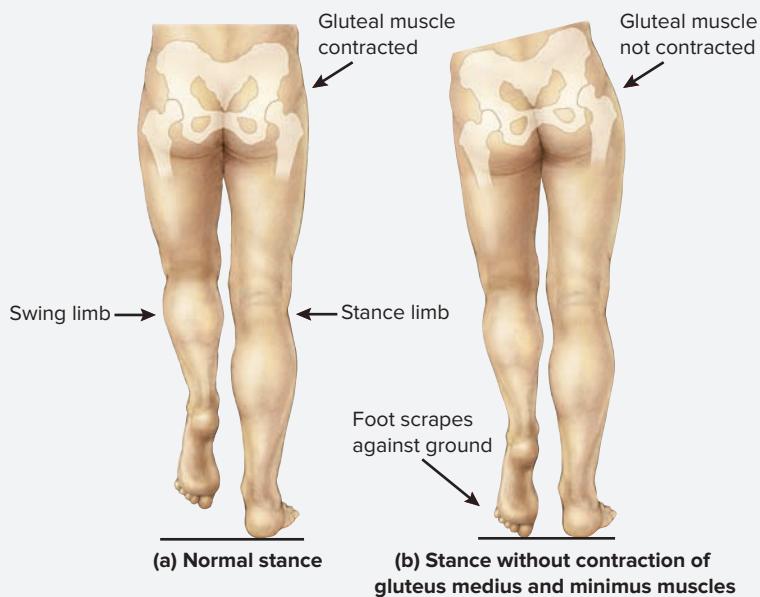


(b) Right thigh and hip, deep anterior view

**Figure 13.9** Muscles That Act About the Hip Joint/Thigh. Use the terms listed to fill in the numbered labels in the figure. Some answers may be used more than once.

- |  |   |  |   |
|--|---|--|---|
| <input type="checkbox"/> gluteus maximus | <input type="checkbox"/> iliopsoas          | <input type="checkbox"/> piriformis        | <input type="checkbox"/> superior gemellus    |
| <input type="checkbox"/> gluteus medius  | <input type="checkbox"/> iliotibial tract   | <input type="checkbox"/> psoas major       | <input type="checkbox"/> tensor fasciae latae |
| <input type="checkbox"/> gluteus minimus | <input type="checkbox"/> inferior gemellus  | <input type="checkbox"/> psoas minor       |   |
| <input type="checkbox"/> iliacus         | <input type="checkbox"/> obturator internus | <input type="checkbox"/> quadratus femoris |   |

(continued from previous page)



**Figure 13.10** Actions of the Gluteal Muscles During Locomotion.

The gluteus medius and minimus support the hip on the right side of the body when the right leg is the stance (supporting) leg. This allows the foot on the swing leg to clear the ground.

kickboxing class. In fact, the gluteus medius and minimus muscles are rarely used for extreme abduction of the hip, as in kicking the lower limb out to the side. Instead, when attempting to abduct the hip against resistance, as when standing on one leg, these muscles prevent the hip from *adducting*, which would cause the hip on the side of the stance (standing) leg to protrude laterally (**figure 13.10**). To test the function of the gluteus medius and minimus muscles, first take a standing position. Next, place the palm of your right hand flat against the right lateral hip (superficial to the location of the gluteus medius and minimus muscles). Now flex the leg on the left lower limb bringing the left foot off the ground so you are balancing on the right limb only. Do you feel tension in the muscles deep to your palm? If holding the hip vertical, you will. If you then relax the gluteus medius and minimus muscles, you will find that the hip protrudes laterally and the hip tilts to the unsupported side. The gluteus medius and minimus hold the hip in the vertical position every time the limb is in its stance position. By holding the hip in such a position, they allow the foot on the swing limb to move forward without scraping against the ground. It may seem like a minor action but it can be quite problematic for an individual whose muscles are not functioning properly due to nerve injury or other disease.

5. **Iliotibial Tract:** The iliotibial tract (also called the IT band) is a thickening of the deep fascia of the thigh, which extends

from the anterior iliac crest to the lateral tibia. Two muscles insert onto it: the **gluteus maximus** and the **tensor fasciae latae**. When these muscles become stiff from overuse, they put excessive tension on the IT band. Most commonly this causes pain in the knee joint because the tight IT band compresses structures in the lateral knee and the underlying vastus lateralis muscle.

6. **Lateral Rotators:** Several small muscles extend between the margins of the obturator foramen of the pelvis and insert onto the greater trochanter of the femur. They are called lateral rotators because lateral rotation of the thigh is their primary action. However, they are also very important in stabilizing the hip joint, in much the same way that the rotator cuff muscles stabilize the shoulder joint. A very important lateral rotator is the **piriformis** muscle because it is a major landmark in the gluteal region. For example, the sciatic nerve exits inferior to this muscle, and the superior and inferior gluteal arteries and nerves are named for their passages above and below the piriformis, respectively.
7. Observe a prosected cadaver or a model in which the gluteus maximus muscle has been reflected or cut away. First identify the gluteus medius and minimus muscles. Inferior to the gluteus medius is the pear-shaped piriformis muscle. Note the tough **sacrospinous ligament** that overlies the medial attachment of the piriformis, and the large **sciatic nerve**, which exits inferior to the piriformis. Finally, locate the following lateral rotators, from superior to inferior:
- superior gemellus**
  - obturator internus (in this location, you will only see its tendon)**
  - inferior gemellus**
  - quadratus femoris**
8. **Iliopsoas:** The **iliacus** and **psoas major** are considered together as the **iliopsoas** muscle. They have separate origins, but they come together and insert together on the **lesser trochanter** of the femur. These muscles are difficult to identify on the cadaver and models if looking at the anterior thigh to find them, because only a small portion of the insertion is visible there. The bellies of these muscles are located deep within the pelvis on the posterior abdominopelvic wall. Thus, when identifying them on the cadaver or on models, be sure to view the inside of the abdominopelvic cavity where the muscles originate. The longer of the two muscles is the psoas major. It is an important landmark in the pelvis because structures such as the ureters course superficial to it. In the anterior thigh, the iliopsoas muscle forms the floor of the **femoral triangle** (see exercise 13.6). Look deep to the structures in the femoral triangle (the femoral nerve, artery, and vein) in order to see the iliopsoas muscle here.

## Lower Limb Musculature

The lower limb is composed of the **thigh** (from hip to knee), the **leg** (from knee to ankle), and the **foot**. The thigh and the leg each consist of three

compartments. As with the upper limb, each compartment consists of muscles that perform similar actions, and each compartment is served by one peripheral nerve branch.

**EXERCISE 13.6** Compartments of the Thigh

**EXERCISE 13.6A: Anterior Compartment of the Thigh**

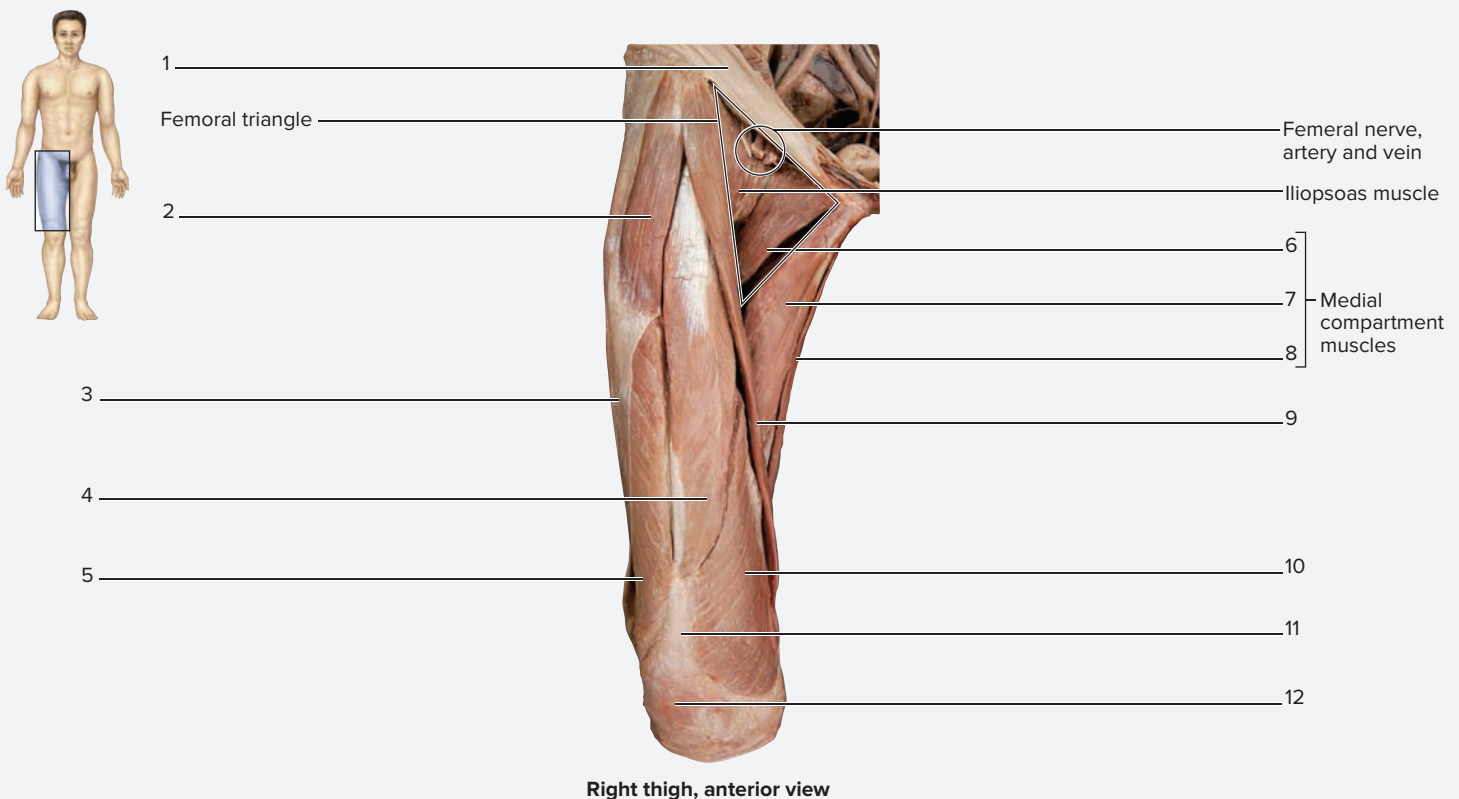1. Observe a prosected human cadaver or a classroom model demonstrating muscles of the thigh.
2. Identify the **muscles of the anterior compartment of the thigh** listed in **figure 13.11** on the cadaver or on a classroom

model, using **table 13.9** and the textbook as guides. Then label them in figure 13.11. While identifying these muscles, make note of the following:

*Common Actions:* Extend the leg.

*Exceptions:* The rectus femoris and sartorius muscles flex the thigh. Sartorius also flexes the leg.

Table 13.9 Anterior Compartment of the Thigh					
Muscle	Origin	Insertion	Action	Innervation	Word Roots
<i>Sartorius</i>	ASIS (anterior superior iliac spine)	Medial tibia	Crosses legs: flexes the thigh and leg, abducts and laterally rotates the thigh	Femoral nerve (L <sub>2</sub> -L <sub>4</sub> )	<i>sartor</i> , a tailor
<b>QUADRICEPS FEMORIS GROUP</b>					
<i>Rectus Femoris</i>	Anterior inferior iliac spine	Tibial tuberosity	Extends the leg, flexes the thigh	Femoral nerve (L <sub>2</sub> -L <sub>4</sub> )	<i>rectus</i> , straight + <i>femur</i> , thigh
<i>Vastus Intermedius</i>	Femur (medial and lateral)	Tibial tuberosity	Extends the leg	Femoral nerve (L <sub>2</sub> -L <sub>4</sub> )	<i>vastus</i> , great + <i>intermedius</i> , in between
<i>Vastus Lateralis</i>	Femur (medial and posterior)	Tibial tuberosity	Extends the leg	Femoral nerve (L <sub>2</sub> -L <sub>4</sub> )	<i>vastus</i> , great + <i>lateralis</i> , to the side
<i>Vastus Medialis</i>	Femur (inferior and posterior)	Tibial tuberosity	Extends the leg	Femoral nerve (L <sub>2</sub> -L <sub>4</sub> )	<i>vastus</i> , great + <i>medialis</i> , medial



**Figure 13.11** Anterior Compartment of the Thigh. Use the terms listed to fill in the numbered labels in the figure. The adductor magnus is not visible in this photo.

- |   |  |  |   |
|---|--|--|---|
| <input type="checkbox"/> adductor longus  | <input type="checkbox"/> inguinal ligament | <input type="checkbox"/> quadriceps tendon | <input type="checkbox"/> tensor fasciae latae |
| <input type="checkbox"/> gracilis         | <input type="checkbox"/> patella           | <input type="checkbox"/> rectus femoris    | <input type="checkbox"/> vastus lateralis     |
| <input type="checkbox"/> iliotibial tract | <input type="checkbox"/> pectineus         | <input type="checkbox"/> sartorius         | <input type="checkbox"/> vastus medialis      |

(continued from previous page)

- Sartorius:** The word *sartorius* literally means “tailor.” If you remember this and think about the typical cross-legged position tailors take to mend something by hand, it is easy to remember the actions of the sartorius muscle. Try this out for yourself. Sit in a chair and cross the right leg over the left so that the right ankle is resting on the left knee. Next, note the positions of the right hip and knee joints. The hip is flexed and laterally rotated, and the knee is also flexed. These are the actions of the sartorius muscle.
- Femoral Triangle:** The **femoral triangle** is a triangular space in the upper, anterior thigh. Its borders are the **sartorius**, the **adductor longus**, and the **inguinal ligament**. It is clinically relevant because of the structures located within the space, which include the femoral nerve, artery, and vein. The only structures superficial to these are fat and skin, so it is a location where the vascular system can be accessed with relative ease.
- Sketch the femoral triangle in the space provided. Label the structures that form its boundaries, and draw and label the contents found within the triangle.



### Learning Strategy



The femoral triangle contains some very important structures. The mnemonic for remembering the contents of the femoral triangle is **NAVEL**, which lists the contents of the femoral triangle from lateral to medial:

- N**—femoral **N**erve
- A**—femoral **A**rtery
- V**—femoral **V**ein
- E**—Empty space
- L**—Lymphatic vessel

### EXERCISE 13.6B: Medial Compartment of the Thigh

- Observe a prosected human cadaver or a classroom model demonstrating muscles of the thigh.
- Identify the **muscles of the medial compartment of the thigh** listed in **figure 13.12** on the cadaver or on a classroom model, using **table 13.10** and the textbook

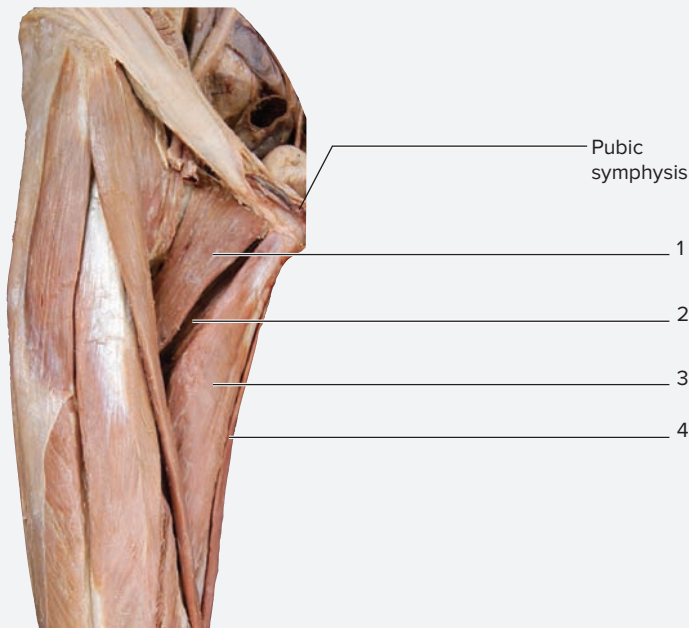
### Learning Strategy



- All the muscles in the medial compartment of the thigh attach to the pubic bone and, except for the gracilis, to the linea aspera of the femur.
- Think of these muscles as “the short one” (adductor brevis), “the long one” (adductor longus), “the really big one” (adductor magnus), and “the graceful one” (gracilis) to make them easier to identify relative to each other.
- As you view the anterior thigh, you will see these muscles medial to the sartorius. From superior to inferior, the order of muscles is pectineus, adductor longus, and adductor magnus. The adductor brevis is located deep to the pectineus and adductor longus muscles, so you will have to move them aside to see it clearly.

**Table 13.10** Medial Compartment of the Thigh

Muscle	Origin	Insertion	Action	Innervation	Word Roots
<i>Adductor Brevis</i>	Pubis	Femur (linea aspera)	Adducts and laterally rotates the thigh	Obturator nerve (L <sub>2</sub> –L <sub>3</sub> )	<i>adduct</i> , to bring toward the median plane + <i>brevis</i> , short
<i>Adductor Longus</i>	Pubis	Femur (linea aspera)	Adducts and laterally rotates the thigh	Obturator nerve (L <sub>2</sub> –L <sub>4</sub> )	<i>adduct</i> , to bring toward the median plane + <i>longus</i> , long
<i>Adductor Magnus</i>	Pubis	Femur (linea aspera)	Adducts and laterally rotates the thigh	Obturator nerve (L <sub>2</sub> –L <sub>4</sub> )	<i>adduct</i> , to bring toward the median plane + <i>magnus</i> , large
<i>Gracilis</i>	Pubis	Tibia (medial condyle)	Adducts the thigh and flexes the leg	Obturator nerve (L <sub>2</sub> –L <sub>4</sub> )	<i>gracilis</i> , slender
<i>Pectineus</i>	Pubis	Femur (pectineal line)	Adducts and laterally rotates the thigh	Obturator or femoral nerve (L <sub>2</sub> –L <sub>4</sub> )	<i>pectineal</i> , a ridged or comblike structure



Right thigh, anterior view

**Figure 13.12 Medial Compartment of the Thigh.** Use the terms listed to fill in the numbered labels in the figure. Some answers may be used more than once. The adductor magnus is not visible in this photo.

- adductor brevis                       gracilis
- adductor longus                       pectineus

© McGraw-Hill Education/Photo and Dissection by Christine Eckel


as guides. Then label them in figure 13.12. While identifying these muscles, make note of the following:

*Common Action:* Adduct the thigh.

*Exceptions:* Although also an adductor of the thigh, the gracilis muscle does not attach to the femur. It is also the only muscle of the group to cross and flex the knee joint.

- Gracilis:** In addition to being the outlier in terms of its attachments, this muscle is a weak adductor of the thigh—so weak, in fact, that it can be removed without a patient experiencing great loss in function. When a patient needs a muscle graft, a common muscle used for this purpose is the **gracilis**. The superficial location and limited function of this muscle make it a good candidate for grafting procedures.

- Sketch the muscles of the medial compartment of the thigh in the space provided.



- Optional Activity:* **AP|R Muscular System**—Visit the quiz area for drill and practice on muscles of the lower limb.

**EXERCISE 13.6C: Posterior Compartment of the Thigh**

- Observe a prosected human cadaver or a classroom model demonstrating muscles of the thigh.
- The **posterior compartment of the thigh** contains only three muscles: the semimembranosus, the semitendinosus, and the biceps femoris. These muscles are collectively referred to as the **hamstring** muscles. They received this name because of their association with the analogous muscles in pigs. The meat we call ham comes from these posterior thigh muscles of a pig. In a slaughterhouse, pig thighs are hung by the long tendons of these muscles, hence the term *hamstrung*. In fact, when we say that we feel “hamstrung,” we say that we feel (figuratively) crippled. If our hamstring muscles were severed, we literally would be crippled.
- Identify the **muscles of the posterior compartment of the thigh** listed in **figure 13.13** on the cadaver or on a classroom model, using **table 13.11** and the textbook as guides. Then label them in figure 13.13. While identifying these muscles, make note of the following:

*Common Actions:* Extend the thigh and flex the leg.

*Exceptions:* The short head of the biceps femoris does not cross the hip joint. Thus, it does not extend the thigh.

Table 13.11		Posterior Compartment of the Thigh			
Muscle	Origin	Insertion	Action	Innervation	Word Origin
<i>Biceps Femoris</i>	Ischial tuberosity	Head of fibula	Flexes the leg	Tibial nerve (long head) Common fibular nerve (short head)	<i>bi-</i> , two + <i>caput</i> , head + <i>femur</i> , thigh
<i>Gracilis</i>	Pubis	Tibia (medial condyle)	Flexes the leg	Obturator nerve (L <sub>2</sub> –L <sub>4</sub> )	<i>gracilis</i> , slender
<i>Semimembranosus</i>	Ischial tuberosity	Medial tibia	Flexes the leg	Tibial nerve	<i>semi</i> , half + <i>membrane</i> , a thin layer of skin or tissue
<i>Semitendinosus</i>	Ischial tuberosity	Medial tibia	Flexes the leg	Tibial nerve	<i>semi</i> , half + <i>tendere</i> , to stretch

(continued on next page)



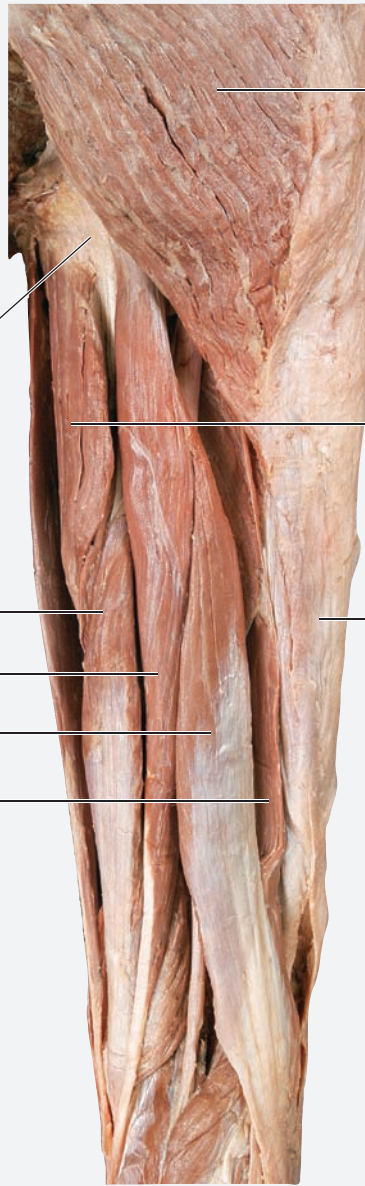(continued from previous page)



Ischial tuberosity

Posterior compartment muscles

- 1
- 2
- 3
- 4



5

6

7

Right thigh, posterior view

**Figure 13.13** Posterior Compartment of the Thigh. Use the terms listed to fill in the numbered labels in the figure. Some answers may be used more than once.

- |   |   |  |
|---|---|--|
| <input type="checkbox"/> adductor magnus            | <input type="checkbox"/> gluteus maximus  | <input type="checkbox"/> semimembranosus |
| <input type="checkbox"/> biceps femoris, long head  | <input type="checkbox"/> iliotibial tract | <input type="checkbox"/> semitendinosus  |
| <input type="checkbox"/> biceps femoris, short head |   |  |

© McGraw-Hill Education/Photo and Dissection by Christine Eckel

4. *Semitendinosus* and *Semimembranosus*: These two muscles are named for the appearance of their connective tissue components. The **semitendinosus** is the more superficial of the two muscles. At its *distal* end it forms a long,

slender tendon, hence the name ending “tendinosus.” The **semimembranosus** muscle is the deeper of the two muscles. At its *proximal* end, it forms a broad, flat tendon that looks like a membrane, hence the name ending “membranous.”

**EXERCISE 13.7** Compartments of the Leg

**EXERCISE 13.7A: Anterior Compartment of the Leg**

1. Observe a prosected human cadaver or a classroom model demonstrating muscles of the leg.
2. Identify the **muscles of the anterior compartment of the leg** listed in **figure 13.14** on the cadaver or on a classroom model, using **table 13.12** and the textbook as guides. Then label them in figure 13.14. While identifying these muscles, make note of the following:

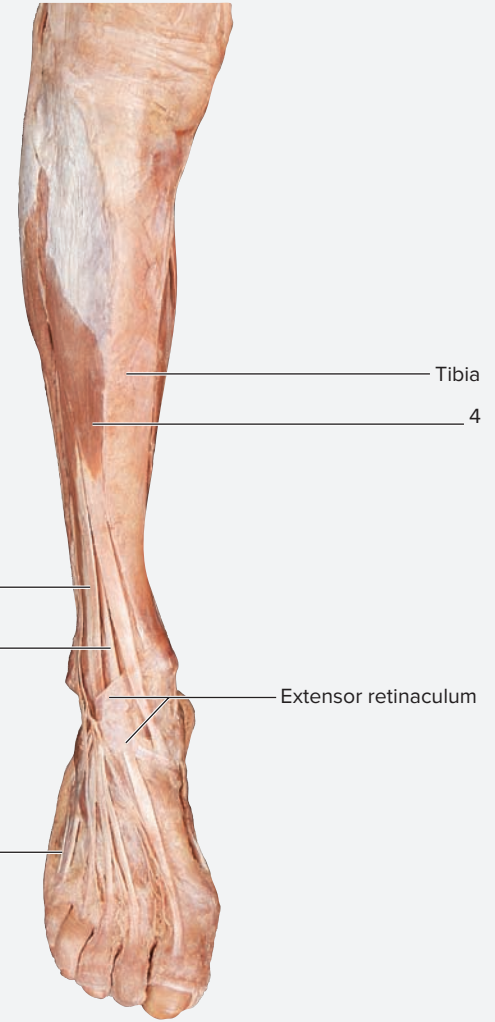
*Common Actions:* Dorsiflex the ankle and extend the digits.  
*Exception:* The tibialis anterior does not act on the digits. In addition, it inverts the ankle as it dorsiflexes.

**EXERCISE 13.7B: Lateral Compartment of the Leg**

1. Observe a prosected human cadaver or a classroom model demonstrating muscles of the leg.
2. Identify the **muscles of the lateral compartment of the leg** listed in **figure 13.15** on the cadaver or on classroom models, using **table 13.13** and the textbook as guides. Then label them in figure 13.15.
3. *Fibularis Longus and Brevis:* The fibularis muscles were formerly referred to as peroneus muscles. Thus, you should be aware that the terms relate to the same muscles. The **fibularis (peroneus) longus** has a very long tendon that lies superficial to the belly of the **fibularis (peroneus) brevis** muscle. The tendons of both muscles pass immediately posterior to the lateral malleolus en route to their attachments on the plantar surface of the foot. Their major action is to evert the ankle.

**Learning Strategy**

pEroneus (fibularis) muscles always **E**vert, whereas tIbialis muscles always **I**vert.



Right leg, anterior view

**Figure 13.14** Anterior Compartment of the Leg. Use the terms listed to fill in the numbered labels in the figure.

- extensor digitorum longus
- fibularis tertius tendon
- extensor hallucis longus
- tibialis anterior

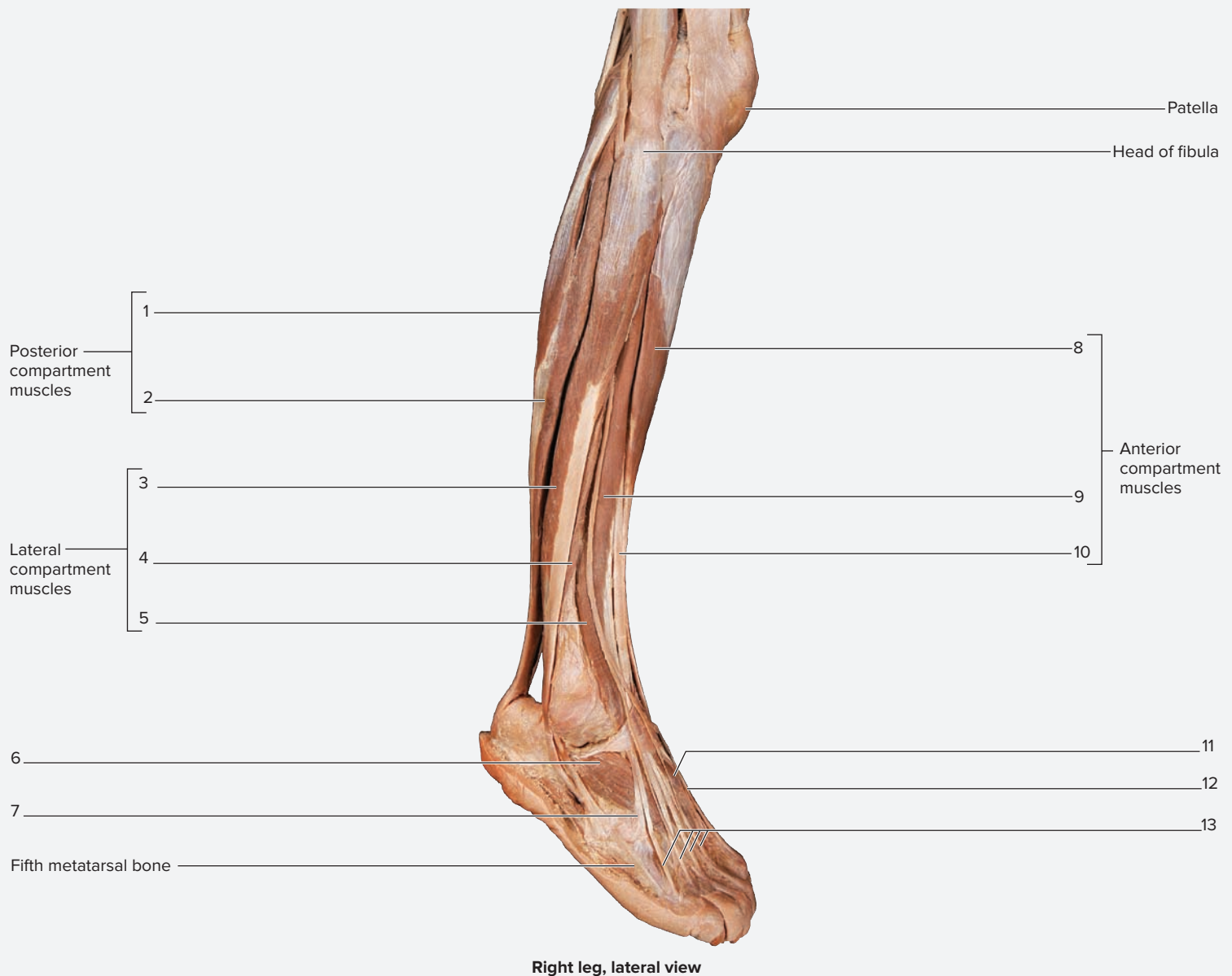© McGraw-Hill Education/Photo and Dissection by Christine Eckel

Table 13.12 Anterior Compartment of the Leg					
Muscle	Origin	Insertion	Action	Innervation	Word Roots
<i>Extensor Digitorum Longus</i>	Tibia (lateral condyle and proximal three-fourths)	2nd and 3rd phalanges of digits 2–5	Extends digits 2–5 and dorsiflexes the ankle	Deep fibular nerve	<i>extendo</i> , to stretch out + <i>digit</i> , a toe + <i>longus</i> , long
<i>Extensor Hallucis Longus</i>	Fibula (anteromedial surface) and interosseous membrane	Distal phalanx of big toe	Extends the great toe and dorsiflexes the ankle	Deep fibular nerve	<i>extendo</i> , to stretch out + <i>hallux</i> , the great toe + <i>longus</i> , long
<i>Fibularis Tertius</i>	Fibula (anterior, distal surface) and interosseous membrane	Base of metatarsal V	Dorsiflexes and weakly everts foot	Deep fibular nerve	<i>fibularis</i> , fibula + <i>tertius</i> , third
<i>Tibialis Anterior</i>	Tibia (lateral condyle and upper two-thirds)	Middle cuneiform (inferior surface) and metatarsal I	Dorsiflexes and inverts the foot	Deep fibular nerve	<i>tibia</i> , the shinbone + <i>anterior</i> , the front surface

(continued on next page)

(continued from previous page)

Table 13.13 Lateral Compartment of the Leg					
Muscle	Origin	Insertion	Action	Innervation	Word Roots
<i>Fibularis Brevis</i>	Distal fibula	Metatarsal V	Everts the foot and plantar flexes the ankle	Superficial fibular nerve	<i>fibularis</i> , relating to the fibula + <i>brevis</i> , short
<i>Fibularis Longus</i>	Head of fibula	Metatarsal I and middle cuneiform	Everts the foot and plantar flexes the ankle	Superficial fibular nerve	<i>fibularis</i> , relating to the fibula + <i>longus</i> , long

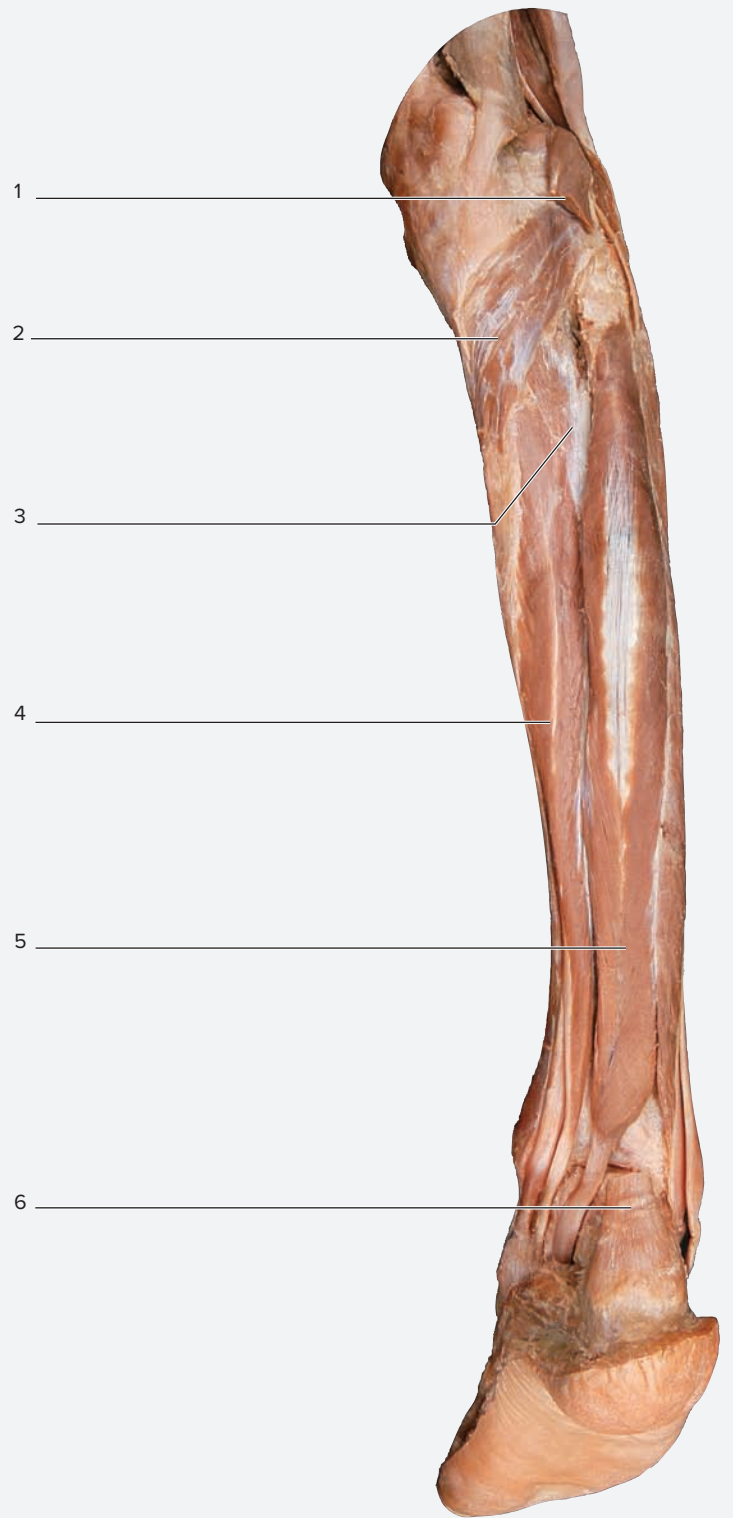


**Figure 13.15 Lateral View of the Leg.** In a lateral view of the leg, muscles from all three leg compartments can be seen. Use the terms listed to fill in the numbered labels in the figure.

- |  |  |   |
|--|--|---|
| <input type="checkbox"/> extensor digitorum brevis         | <input type="checkbox"/> extensor hallucis longus        | <input type="checkbox"/> fibularis tertius tendon |
| <input type="checkbox"/> extensor digitorum longus         | <input type="checkbox"/> extensor hallucis longus tendon | <input type="checkbox"/> gastrocnemius            |
| <input type="checkbox"/> extensor digitorum longus tendons | <input type="checkbox"/> fibularis brevis                | <input type="checkbox"/> soleus                   |
| <input type="checkbox"/> extensor hallucis brevis          | <input type="checkbox"/> fibularis longus                | <input type="checkbox"/> tibialis anterior        |
|  | <input type="checkbox"/> fibularis tertius               |   |

**EXERCISE 13.7C: Posterior Compartment of the Leg**

1. Observe a prosected human cadaver or a classroom model demonstrating muscles of the leg.
2. Identify the **muscles of the posterior compartment of the leg** listed in **figure 13.16** on the cadaver or on a classroom model, using **table 13.14** and the textbook as guides. Then label them in figure 13.16.
3. *Triceps Surae*: The **triceps surae** includes the **soleus** and the two-headed **gastrocnemius** muscle. The tendons of these muscles come together to insert onto the calcaneus via the calcaneal (Achilles) tendon. The most superficial of the muscles is the gastrocnemius, though the lateral edges of the soleus can be seen as they poke out beneath the inferior portion of the gastrocnemius. The **plantaris** is a small muscle that can be seen only by reflecting or removing the gastrocnemius and soleus muscles. The plantaris has a very small belly, located just below the popliteal fossa in the back of the knee. It has a very long, flat tendon that often resembles ribbon used to decorate presents. The muscle itself is a very weak flexor of the leg. Because its actions are minimal and its tendon is long, the tendon is often removed and used for tendon grafts. If you are viewing a cadaver and cannot find the plantaris, this may be because it isn't there. The plantaris is absent in approximately 6% to 8% of humans, and it is more commonly absent in the left leg than in the right leg.



**Figure 13.16 Posterior Compartment of the Leg.** Use the terms listed to fill in the numbered labels in the figure.

- |  |   |
|--|---|
| <input type="checkbox"/> calcaneal tendon        | <input type="checkbox"/> plantaris          |
| <input type="checkbox"/> flexor digitorum longus | <input type="checkbox"/> popliteus          |
| <input type="checkbox"/> flexor hallucis longus  | <input type="checkbox"/> tibialis posterior |

© McGraw-Hill Education/Photo and Dissection by Christine Eckel

**Right leg, deep posterior view**

*(continued on next page)*

(continued from previous page)

Table 13.14 Posterior Compartment of the Leg					
Muscle	Origin	Insertion	Action	Innervation	Word Origin
<i>Flexor Digitorum Longus</i>	Posterior tibia	Distal phalanx of digits 2–5	Flexes digits 2–5	Tibial nerve (L <sub>5</sub> –S <sub>1</sub> )	<i>flexus</i> , to bend + <i>digit</i> , a toe + <i>longus</i> , long
<i>Flexor Hallucis Longus</i>	Inferior two-thirds of fibula	Distal phalanx of the great toe	Flexes the great toe	Tibial nerve (L <sub>5</sub> –S <sub>1</sub> )	<i>flexus</i> , to bend + <i>hallux</i> , the great toe + <i>longus</i> , long
<i>Gastrocnemius</i>	Femoral condyles	Calcaneus	Plantar flexes the ankle and flexes the leg (weak)	Tibial nerve (L <sub>4</sub> –S <sub>1</sub> )	<i>gaster-</i> , belly + <i>kneme</i> , leg
<i>Plantaris</i>	Femur (supracondylar ridge)	Calcaneus	Plantar flexes the ankle and flexes the leg (weak)	Tibial nerve (L <sub>4</sub> –S <sub>1</sub> )	<i>plantar</i> , relating to the sole of the foot
<i>Popliteus</i>	Lateral condyle of femur	Posterior, proximal surface of tibia	Flexes leg, unlocks the knee joint	Tibial nerve	<i>poplit</i> , back of the knee
<i>Soleus</i>	Proximal tibia, fibula	Calcaneus	Plantar flexes the ankle	Tibial nerve (L <sub>4</sub> –S <sub>1</sub> )	<i>solea</i> , a sandal, sole of the foot
<i>Tibialis Posterior</i>	Proximal tibia and fibula	Medial cuneiform and navicular	Inverts the foot and plantar flexes the ankle	Tibial nerve (L <sub>5</sub> –S <sub>1</sub> )	<i>tibia</i> , the shinbone + <i>posterior</i> , the back surface

### EXERCISE 13.8 Intrinsic Muscles of the Foot

1. Observe a prosected human cadaver or a classroom model demonstrating muscles of the foot.
2. The intrinsic muscles of the plantar surface of the foot are arranged in four layers, named layer 1 to layer 4 from superficial to deep. The foot also contains two neurovascular planes (a neurovascular plane is a region where the nerves and blood vessels that serve the region are located). The first is located between muscle layers 1 and 2, and the second is located between layers 3 and 4.
3. Identify the **intrinsic muscles of the foot** listed in **figure 13.17** on the cadaver or on a classroom model, using **table 13.15** and the textbook as guides. Then label them in figure 13.17.
4. *Adductor Hallucis*: The **adductor hallucis** muscle is located in the third plantar muscle layer. It is a good landmark for the identification of other muscles in the foot. In addition, its two heads (oblique and transverse) appear like the number 7 when viewed together. To

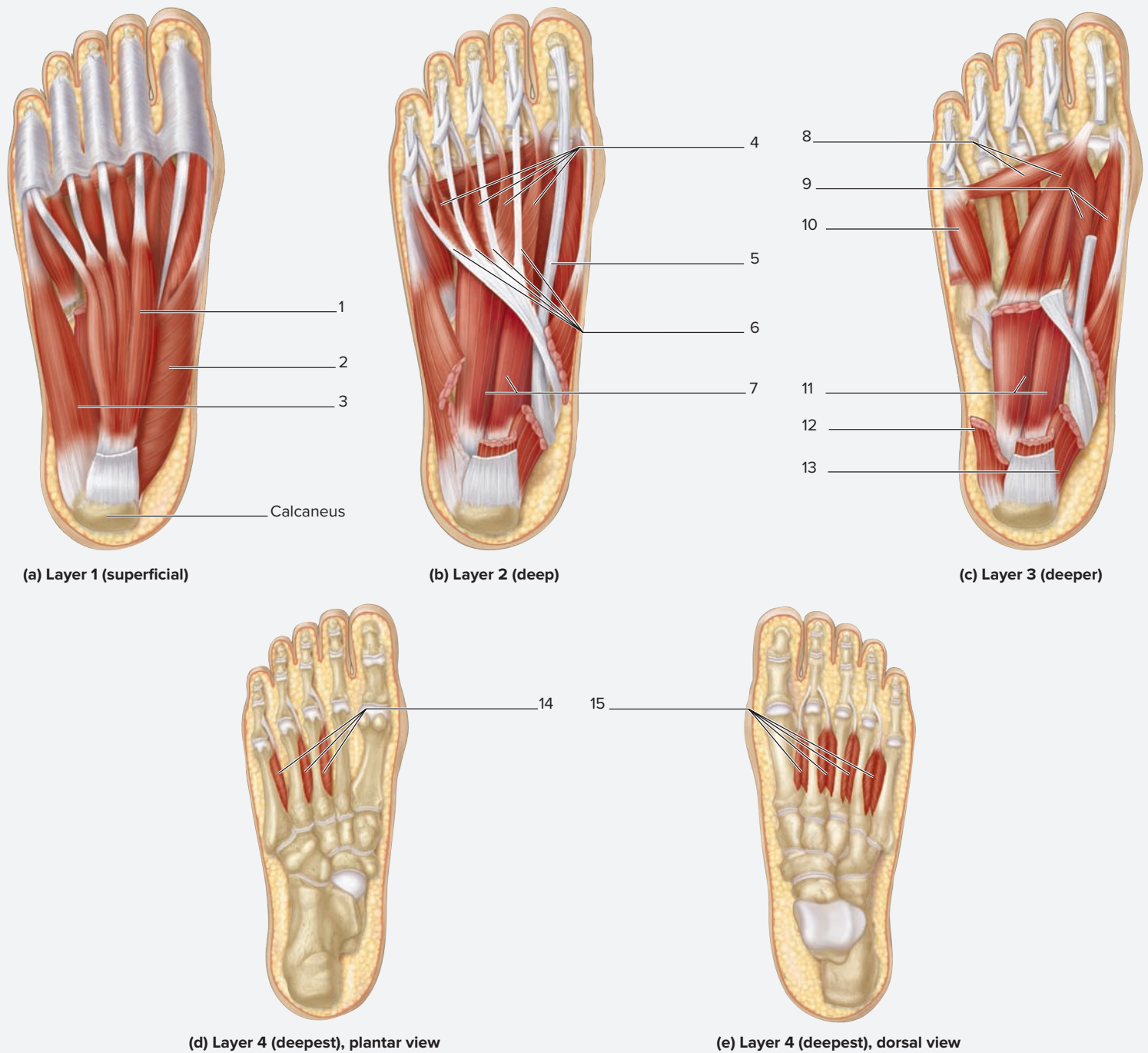
identify this muscle and others in the deeper layers of the foot, the tough **plantar aponeurosis** must first be cut and reflected.

5. *Interossei*: Just like in the hand, there are two groups of interosseous muscles in the foot, though they are called dorsal and *plantar*, instead of dorsal and *palmar*. The functions of the interossei in the foot are the same as in the hand: the dorsal interossei abduct the digits, whereas the plantar interossei adduct the digits.

#### Learning Strategy



Conveniently, the mnemonic for remembering the functions of the interossei in the foot is the same as in the hand: **DAB** and **PAD**. The **D**orsal interossei **AB**duct the digits (**DAB**), whereas the **P**lantar interossei **AD**duct the digits (**PAD**).



**Figure 13.17** Intrinsic Muscles of the Foot. Use the terms listed to fill in the numbered labels in the figure.

- |  |  |   |
|--|--|---|
| <input type="checkbox"/> abductor digiti minimi      | <input type="checkbox"/> flexor digitorum brevis | <input type="checkbox"/> quadratus plantae                  |
| <input type="checkbox"/> abductor hallucis           | <input type="checkbox"/> flexor hallucis brevis  | <input type="checkbox"/> tendon of flexor hallucis longus   |
| <input type="checkbox"/> dorsal interossei           | <input type="checkbox"/> lumbricals              | <input type="checkbox"/> tendons of flexor digitorum longus |
| <input type="checkbox"/> flexor digiti minimi brevis | <input type="checkbox"/> plantar interossei      |   |

(continued on next page)

(continued from previous page)

<b>Table 13.15</b>					
<b>Intrinsic Muscles of the Foot</b>					
<b>Muscle</b>	<b>Origin</b>	<b>Insertion</b>	<b>Action</b>	<b>Innervation</b>	<b>Word Origin</b>
<b>Dorsal Musculature</b>					
<i>Extensor Digitorum Brevis</i>	Calcaneus and extensor retinaculum (inferior surface)	Digits 2–4 (dorsal surfaces)	Extends the proximal phalanx of digits 2–4	Deep fibular nerve	<i>extendo</i> , to stretch out + <i>digitus</i> , toe + <i>brevis</i> , short
<i>Extensor Hallucis Brevis</i>	Calcaneus and extensor retinaculum (inferior surface)	Dorsal surface of the great toe	Extends the proximal phalanx of the great toe	Deep fibular nerve	<i>extendo</i> , to stretch out + <i>hallux</i> , the great toe + <i>brevis</i> , short
<b>Plantar Musculature—Layer 1</b>					
<i>Abductor Digiti Minimi</i>	Calcaneus and plantar aponeurosis	Base of the proximal phalanx of digit 5 (lateral surface)	Abducts and flexes digit 5 (the little toe)	Lateral plantar nerve	<i>abduct</i> , to move away from the median plane + <i>digitus</i> , toe + <i>minimi</i> , smallest
<i>Abductor Hallucis</i>	Calcaneus and plantar aponeurosis	Base of the proximal phalanx of digit 1 (medial side)	Abducts the great toe	Medial plantar nerve	<i>abduct</i> , to move away from the median plane + <i>hallux</i> , the great toe
<i>Flexor Digitorum Brevis</i>	Calcaneus and plantar aponeurosis	Middle phalanx of digits 2–5	Flexes digits 2–5	Medial plantar nerve	<i>flex</i> , to bend + <i>digitus</i> , toe + <i>brevis</i> , short
<b>Plantar Musculature—Layer 2</b>					
<i>Lumbricals</i>	Tendons of the flexor digitorum longus	Tendons of the extensor digitorum longus	Flex the proximal phalanges and extend the distal phalanges of digits 2–5	Medial and lateral plantar nerve	<i>lumbricus</i> , earthworm
<i>Quadratus Plantae</i>	Calcaneus (medial surface and lateral margin)	Tendon of the flexor digitorum longus (lateral side)	Flexes digits 2–5	Lateral plantar nerve	<i>quadratus</i> , having four sides + <i>plantae</i> , sole of the foot
<b>Plantar Musculature—Layer 3</b>					
<i>Adductor Hallucis (Oblique Head)</i>	Base of metatarsals II–V	Base of the proximal phalanx of the great toe	Adducts the great toe and helps maintain the transverse arch of the foot	Lateral plantar nerve	<i>adduct</i> , to move toward the median plane + <i>hallux</i> , the great toe
<i>Adductor Hallucis (Transverse Head)</i>	Capsules of the metatarsophalangeal joints III–V	Base of the proximal phalanx of the great toe	Adducts the great toe and helps maintain the transverse arch of the foot	Lateral plantar nerve	<i>adduct</i> , to move toward the median plane + <i>hallux</i> , the great toe
<i>Flexor Digiti Minimi Brevis</i>	Base of metatarsal V	Proximal phalanx of digit 5	Flexes the proximal phalanx of digit 5 (the little toe)	Lateral plantar nerve	<i>flex</i> , to bend + <i>digitus</i> , a toe + <i>minimi</i> , smallest + <i>brevis</i> , short
<i>Flexor Hallucis Brevis</i>	Cuboid and lateral cuneiform (plantar surfaces)	Proximal phalanx of the great toe	Flexes the proximal phalanx of the great toe	Medial plantar nerve	<i>flex</i> , to bend + <i>hallux</i> , the great toe + <i>brevis</i> , short
<b>Plantar Musculature—Layer 4</b>					
<i>Dorsal Interossei</i>	Metatarsals I–V (adjacent surfaces)	Proximal phalanges of digits 2–4 (sides)	Abduct digits 2–4 and flex the metatarsophalangeal joints	Lateral plantar nerve	<i>dorsal</i> , the back + <i>inter-</i> , between + <i>os</i> , bone
<i>Plantar Interossei</i>	Bases of metatarsals III–V	Bases of proximal phalanges of digits 3–5 (medial side)	Adduct digits 2–4 and flex the metatarsophalangeal joints	Lateral plantar nerve	<i>plantae</i> , the sole of the foot + <i>inter-</i> , between + <i>os</i> , bone

## POST-LABORATORY WORKSHEET

The 1 corresponds to the Learning Objective(s) listed in the chapter opener outline.

### Do You Know the Basics?

#### Exercise 13.1: Muscles That Move the Pectoral Girdle and Glenohumeral Joint

1. Match the movements listed in column A with the corresponding muscle that creates the movement listed in column B. 1

##### Column A

- \_\_\_\_\_ 1. extends, adducts, and medially rotates arm
- \_\_\_\_\_ 2. flexes and medially rotates arm; prime mover of arm abduction; extends and laterally rotates arm
- \_\_\_\_\_ 3. prime mover of arm extension; adducts and medially rotates arm (big muscle)
- \_\_\_\_\_ 4. prime mover of arm flexion; adducts and medially rotates arm (big muscle)

##### Column B

- a. deltoid
- b. latissimus dorsi
- c. pectoralis major
- d. teres major

2. A synergist of the trapezius for the action of *adduction* of the scapula is the rhomboid major, whereas a synergist of the trapezius for the action of *elevation* of the scapula is the levator scapulae. \_\_\_\_\_ (True/False) 2

3. Damage to the serratus anterior muscle is tested by having a patient push against a wall with an outstretched upper limb. If there is weakness or paralysis of the muscle, the scapula will do which of the following? (Circle one.) 3

- \_\_\_\_\_ a. adduct excessively
- \_\_\_\_\_ b. abduct excessively
- \_\_\_\_\_ c. “wing” (medial border moves posterior)
- \_\_\_\_\_ d. depress excessively

4. One or more of the rotator cuff muscles cause which of the following movements of the arm? (Check all that apply.) 4

- \_\_\_\_\_ a. abduction
- \_\_\_\_\_ b. adduction
- \_\_\_\_\_ c. extension
- \_\_\_\_\_ d. flexion
- \_\_\_\_\_ e. lateral rotation
- \_\_\_\_\_ f. medial rotation

#### Exercise 13.2: Compartments of the Arm

5. The \_\_\_\_\_ (anterior/posterior) compartment of the arm consists largely of forearm flexors, whereas the \_\_\_\_\_ (anterior/posterior) compartment consists largely of forearm extensors. 5

6. The biceps brachii is a prime mover for the action of forearm \_\_\_\_\_ (flexion/supination). The biceps brachii is a synergist with the brachialis muscle for the action of forearm \_\_\_\_\_ (flexion/supination). 6

#### Exercise 13.3: Compartments of the Forearm

7. Match the muscles listed in column A with the appropriate compartment of the forearm listed in column B. Each compartment may be used more than once. 7

##### Column A

- \_\_\_\_\_ 1. extensor indicis
- \_\_\_\_\_ 2. flexor carpi ulnaris
- \_\_\_\_\_ 3. palmaris longus
- \_\_\_\_\_ 4. pronator quadratus
- \_\_\_\_\_ 5. supinator

##### Column B

- a. anterior compartment
- b. posterior compartment

8. The palmaris longus is \_\_\_\_\_ (deep/superficial) to the flexor retinaculum and inserts onto the palmar aponeurosis. 8



9. The tendons of the flexor digitorum superficialis muscle attach to the (proximal/middle/distal) phalanges, whereas the tendons of the flexor digitorum profundus attach to the (proximal/middle/distal) phalanges. 9

#### Exercise 13.4: Intrinsic Muscles of the Hand

10. Which of the following is an intrinsic muscle of the hand? (Check all that apply.) 10
- \_\_\_\_ a. abductor digiti minimi  
 \_\_\_\_ b. abductor pollicis brevis  
 \_\_\_\_ c. dorsal interossei  
 \_\_\_\_ d. flexor digitorum brevis  
 \_\_\_\_ e. lumbricals
11. The large pad at the base of the thumb is called the \_\_\_\_\_ (hypothenar/thenar) eminence and it contains muscles collectively referred to as \_\_\_\_\_ (hypothenar/thenar) muscles. The large pad at the base of the pinky finger (digit V) is called the \_\_\_\_\_ (hypothenar/thenar) eminence, and it contains muscles collectively referred to as \_\_\_\_\_ (hypothenar/thenar) muscles. 11
12. The dorsal interossei \_\_\_\_\_ (abduct/adduct) the digits, whereas the palmar interossei \_\_\_\_\_ (abduct/adduct) the digits. 12

#### Exercise 13.5: Muscles That Move the Hip

13. Which of the following muscles is a major thigh extensor whose antagonist is the psoas major muscle (a major flexor of the thigh)? (Circle one.) 13
- a. gluteus maximus      b. gluteus medius      c. iliacus      d. quadratus femoris      e. tensor fascia latae
14. During normal locomotion, which of the following muscles on the stance limb must function correctly for the foot of the swing limb to clear the ground? (Check all that apply.) 14
- \_\_\_\_ a. gluteus maximus  
 \_\_\_\_ b. gluteus medius  
 \_\_\_\_ c. piriformis  
 \_\_\_\_ d. psoas major  
 \_\_\_\_ e. quadratus femoris
15. A deep muscle of the posterior hip that is an important clinical landmark due to its association with the gluteal arteries and nerves, and the sciatic nerve, is the piriformis muscle. \_\_\_\_\_ (True/False) 15
16. The iliopsoas muscle is composed of two muscles with a common insertion. The two muscles that compose the iliopsoas are the iliacus and psoas minor muscles. \_\_\_\_\_ (True/False) 16

#### Exercise 13.6: Compartments of the Thigh

17. Match the muscle listed in column A with the appropriate compartment of the thigh in column B. Each compartment may be used more than once. 17

##### Column A

- \_\_\_\_ 1. adductor magnus  
 \_\_\_\_ 2. biceps femoris  
 \_\_\_\_ 3. gracilis  
 \_\_\_\_ 4. rectus femoris  
 \_\_\_\_ 5. sartorius  
 \_\_\_\_ 6. semitendinosus  
 \_\_\_\_ 7. vastus lateralis

##### Column B

- a. anterior compartment  
 b. medial compartment  
 c. posterior compartment

18. The only two muscles of the anterior compartment of the thigh that cross the hip joint are the rectus femoris and the sartorius muscles. The action of these two muscles about the hip is to \_\_\_\_\_ (flex/extend) the thigh. 18
19. Identify the structures that form the borders of the femoral triangle. (Check all that apply.) 19
- \_\_\_\_ a. adductor longus muscle  
 \_\_\_\_ b. inguinal ligament  
 \_\_\_\_ c. sartorius muscle  
 \_\_\_\_ d. sacrotuberous ligament

**Exercise 13.7: Compartments of the Leg**

20. Match the muscle listed in column A with the appropriate compartment of the leg listed in column B. Each compartment may be used more than once. 20

**Column A**

- \_\_\_ 1. extensor digitorum longus
- \_\_\_ 2. fibularis (peroneus) brevis
- \_\_\_ 3. fibularis (peroneus) longus
- \_\_\_ 4. flexor hallucis longus
- \_\_\_ 5. gastrocnemius
- \_\_\_ 6. soleus
- \_\_\_ 7. tibialis anterior

**Column B**

- a. anterior compartment
- b. lateral compartment
- c. posterior compartment

21. The fibularis longus and brevis evert the foot at the ankle joint. Both the tibialis anterior and the tibialis posterior oppose this action by inverting the foot at the ankle joint. \_\_\_\_\_ (True/False) 21

22. The triceps surae is composed of which of the following? (Check all that apply.) 22 23

- \_\_\_ a. flexor hallucis longus
- \_\_\_ b. gastrocnemius
- \_\_\_ c. plantaris
- \_\_\_ d. soleus
- \_\_\_ e. tibialis anterior

**Exercise 13.8: Intrinsic Muscles of the Foot**

23. Which of the following is an intrinsic muscle of the foot? (Check all that apply.) 24

- \_\_\_ a. abductor hallucis
- \_\_\_ b. dorsal interossei
- \_\_\_ c. flexor digitorum brevis
- \_\_\_ d. soleus

**Can You Apply What You've Learned?**

24. Name three muscles that attach to the coracoid process of the scapula.

- a. \_\_\_\_\_
- b. \_\_\_\_\_
- c. \_\_\_\_\_

25. One action of the gluteal muscles (gluteus maximus, medius, and minimus) is to rotate the thigh.

- a. Which gluteal muscle(s) laterally rotate the thigh? \_\_\_\_\_
- b. Which gluteal muscle(s) medially rotate the thigh? \_\_\_\_\_

26. Which muscle of the medial compartment of the thigh does *not* insert onto the linea aspera of the femur? \_\_\_\_\_

27. Which muscle of the quadriceps muscle group is the only muscle to cross the hip joint? \_\_\_\_\_ What is the *origin* (proximal attachment) of this muscle? \_\_\_\_\_. What is the *insertion* (distal attachment)? \_\_\_\_\_

28. Describe the difference between the patellar *tendon* and the patellar *ligament*, and describe the location of each. (Hint: Think about the specific definitions of *tendon* and *ligament*.)

---



---



---



---

29. Describe how to distinguish between the semitendinosus muscle and the semimembranosus muscle.

---

---

---

---

30. The tendons of which three of the rotator cuff muscles hold the humerus into the glenoid cavity on the posterior surface? \_\_\_\_\_  
\_\_\_\_\_. The tendon of the rotator cuff muscle that holds the humerus into the glenoid cavity on the anterior surface is the tendon of the \_\_\_\_\_ muscle.

31. What two muscles insert onto the iliotibial tract (IT band)?

- a. \_\_\_\_\_ b. \_\_\_\_\_

32. The gluteus maximus muscle is a major extensor of the thigh. What muscle acts as the major antagonist to the gluteus maximus muscle? (Hint: The muscle you name would be a prime mover for thigh *flexion*.) \_\_\_\_\_

33. Describe the involvement of the biceps in the following movements:

a. Flexion of the forearm:

---

---

b. Supination of the forearm/wrist:

---

---

34. A patient is told he has a “torn hamstring.” List the possible muscles that could have been torn in this case. Then, describe the actions that would demonstrate weakness in the muscle as a result of the tear.

---

---

---

# Nervous Tissues

# 14

## OUTLINE AND LEARNING OBJECTIVES

### Histology 287

#### EXERCISE 14.1: GRAY AND WHITE MATTER 287

- 1 Recognize gray matter and white matter in a slide of nervous tissue
- 2 Describe the parts of a typical neuron

#### Neurons 287

#### EXERCISE 14.2: GENERAL MULTIPOLAR NEURONS—ANTERIOR HORN CELLS 288

- 3 Identify anterior horn cells in a slide of the cross section of the spinal cord

#### EXERCISE 14.3: CEREBRUM—PYRAMIDAL CELLS 289

- 4 Identify pyramidal cells and white matter (nerve tracts) in slides of the cerebral cortex

#### EXERCISE 14.4: CEREBELLUM—PURKINJE CELLS 290

- 5 Identify Purkinje cells in a slide of the cerebellum

#### Glial Cells 291

#### Glial Cells of the Central Nervous System 291

#### EXERCISE 14.5: ASTROCYTES 291

- 6 Identify astrocytes in a histology slide of the cerebellum stained with the silver impregnation method

#### EXERCISE 14.6: EPENDYMAL CELLS 292

- 7 Identify ependymal cells in a histology slide of the cerebrum or choroid plexus

#### Glial Cells of the Peripheral Nervous System 293

#### EXERCISE 14.7: NEUROLEMMOCYTES (SCHWANN CELLS) 293

- 8 Identify neurolemmocytes and neurofibril nodes in a histology slide of a longitudinal section of a peripheral nerve

#### EXERCISE 14.8: SATELLITE CELLS 293

- 9 Identify a posterior root ganglion (peripheral nerve ganglion) and its associated unipolar neurons and satellite cells

#### Peripheral Nerves 295

#### EXERCISE 14.9: COVERINGS OF A PERIPHERAL NERVE 295

- 10 Locate epineurium, perineurium, and endoneurium in a cross-sectional slide of a peripheral nerve

## INTRODUCTION

Structures of the nervous system are not particularly impressive in the absence of any knowledge of what they do. Imagine how unimpressed early anatomists must have been with the brain. All they saw was a very dense, oatmeal-colored mass of tissue with no known function. Their observations of brain tissue could hardly have been as fascinating or romantic as their observations of the heart. At first, the most inspiring names they could find for brain tissues were “gray matter” and “white matter.” In the present day, the nervous system is known to be critical to the functioning of the body. It also holds fascinating clues to the nature of its incredible complexity. Scientists are just starting to understand the complexity of the nervous system. This information has been gained through dynamic studies of the brain using techniques such as magnetic resonance imaging (MRI).

The exercises in this chapter involve making observations of the histological structure of nervous tissues. In subsequent chapters, which cover the gross structures of the nervous system, it will be important to return to this chapter and relate what was observed microscopically with what is being observed at the gross anatomical level.

### List of Reference Tables

Table 14.1	Parts of a Neuron	p. 288
Table 14.2	Multipolar Neurons in the Cerebrum and Cerebellum	p. 288
Table 14.3	Glial Cells	p. 291

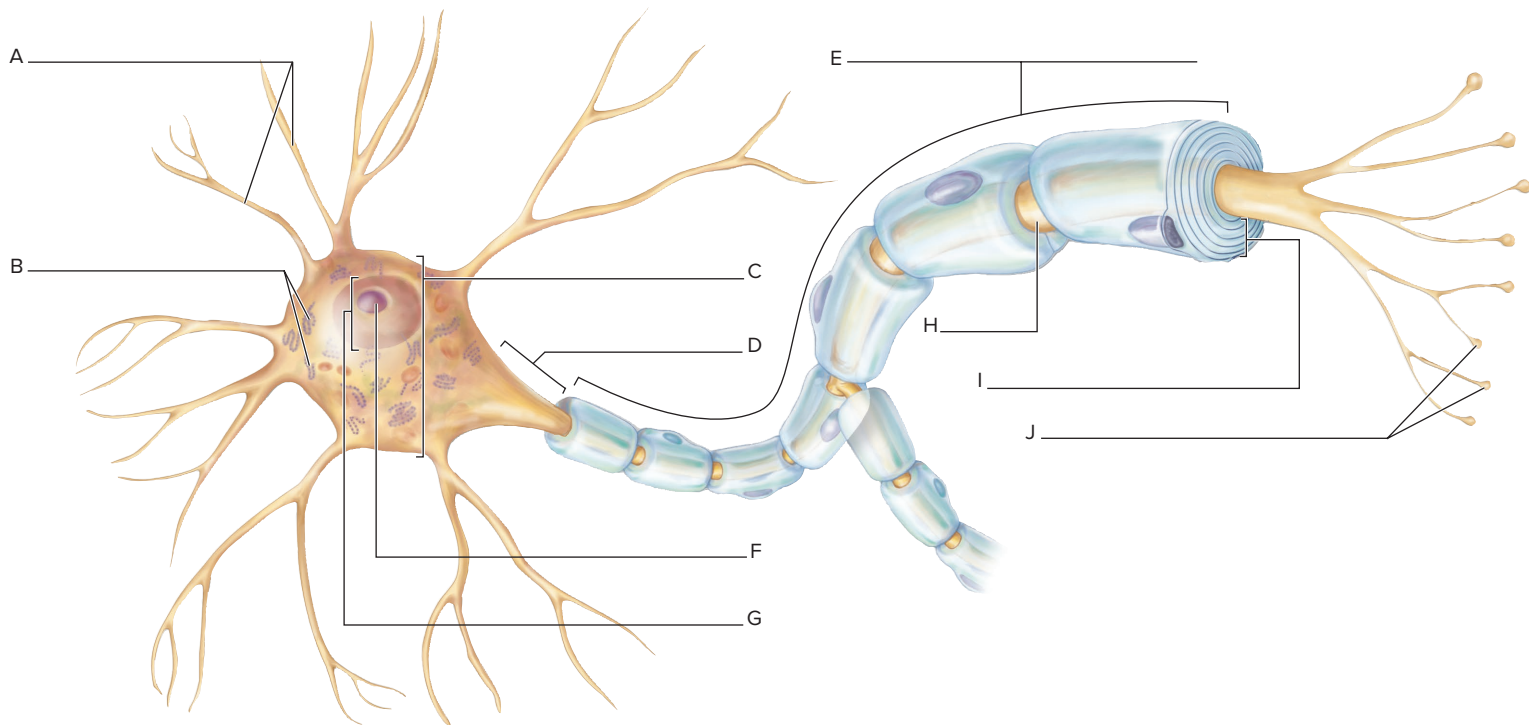
These Pre-laboratory Worksheet questions may be assigned by instructors through their **connect** course.

## PRE-LABORATORY WORKSHEET

1. For each structure listed, write the corresponding letter as labeled in the diagram.

- \_\_\_ axon
- \_\_\_ axon hillock
- \_\_\_ cell body (soma)
- \_\_\_ chromatophilic substance
- \_\_\_ dendrite

- \_\_\_ myelin sheath/neurolemmocyte (Schwann cell)
- \_\_\_ neurofibril node (node of Ranvier)
- \_\_\_ nucleolus
- \_\_\_ nucleus
- \_\_\_ synaptic knobs



2. Match the description listed in column A with the corresponding cell type listed in column B.

### Column A

- \_\_\_ 1. cells that myelinate axons in the central nervous system
- \_\_\_ 2. cells that help reinforce the blood-brain barrier
- \_\_\_ 3. glial cells found in peripheral nerve ganglia
- \_\_\_ 4. cells that myelinate axons in the peripheral nervous system
- \_\_\_ 5. cells that engage in phagocytosis in response to tissue injury
- \_\_\_ 6. cells that line the ventricles of the brain

### Column B

- a. astrocytes
- b. ependymal cells
- c. microglia
- d. neurolemmocytes (Schwann cells)
- e. oligodendrocytes
- f. satellite cells

3. Match the description listed in column A with the corresponding connective tissue structure listed in column B.

### Column A

- \_\_\_ 1. surrounds a fascicle of axons
- \_\_\_ 2. surrounds an individual axon
- \_\_\_ 3. surrounds the entire nerve

### Column B

- a. endoneurium
- b. epineurium
- c. perineurium

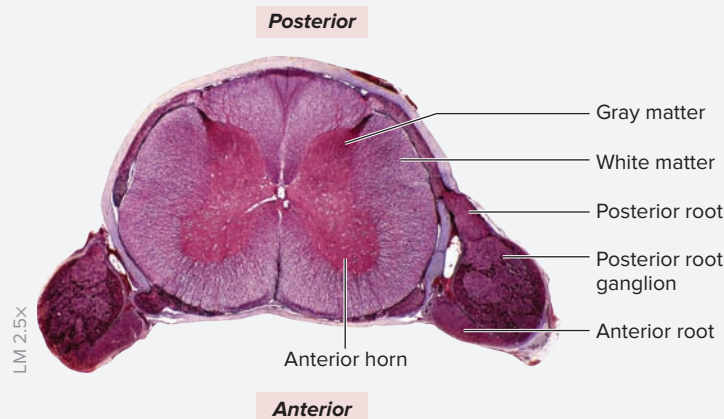
## Histology

At the gross level, nervous tissue is classified as either white matter or gray matter. **White matter** consists mainly of myelinated axons. Bundles of white matter in the central nervous system are **tracts**, and bundles of white matter in the peripheral nervous system are **nerves**. White matter is white because of the presence of myelin, a fatty substance produced by glial cells that is used to insulate axons to increase the speed of conducting action potentials along the axon. **Gray matter** consists mainly of neuron

cell bodies, dendrites, and unmyelinated axons. Collections of gray matter within the central nervous system are **nuclei**, and collections of gray matter within the peripheral nervous system are **ganglia**. Gray matter is gray because of an absence of myelin. The exercises in this chapter begin with observations of the histological appearance of white matter and gray matter. Subsequent exercises guide observations of specific cell types found within nervous tissues.

### EXERCISE 14.1 Gray and White Matter

1. Obtain a slide of a cross section of the spinal cord.
2. Observe the slide with the naked eye before placing it on the microscope stage. Notice that the spinal cord consists of an inner, butterfly-shaped core of gray matter surrounded by an outer region of white matter (**figure 14.1**). What neuronal structures are expected to be located within the gray matter? \_\_\_\_\_ What neuronal structures are expected to be located within the white matter?  
\_\_\_\_\_



**Figure 14.1** Gray Matter and White Matter. A stained, histological cross section through the spinal cord showing gray matter (pink) and white matter (purple).

© Ed Reschke/Getty Images

3. Make a simple line drawing of microscopic observations in the space provided. Label the listed terms in the drawing:

gray matter       white matter



### WHAT DO YOU THINK?

- 1 Which type of neural tissue is more involved with the integration of information (rather than the transmission or conducting of information)—white matter or gray matter?

## Neurons

Neurons are typically the largest cells seen in any slide of nervous tissue. They have very large, light-colored nuclei with prominent nucleoli. The **cell body** (soma) of the neuron contains a large amount of rough endoplasmic reticulum that stains darkly and is called **chromatophilic substance** (Nissl bodies). Generally **dendrites** are not easily observed, even at high magnification. On the other hand, a single large **axon** leaving the cell body can often be observed within the slide. There is an absence of chromatophilic substance at the location where the axon leaves the cell body,

an area of the neuron called the **axon hillock**. **Table 14.1** summarizes the parts of a typical neuron and the function of each.

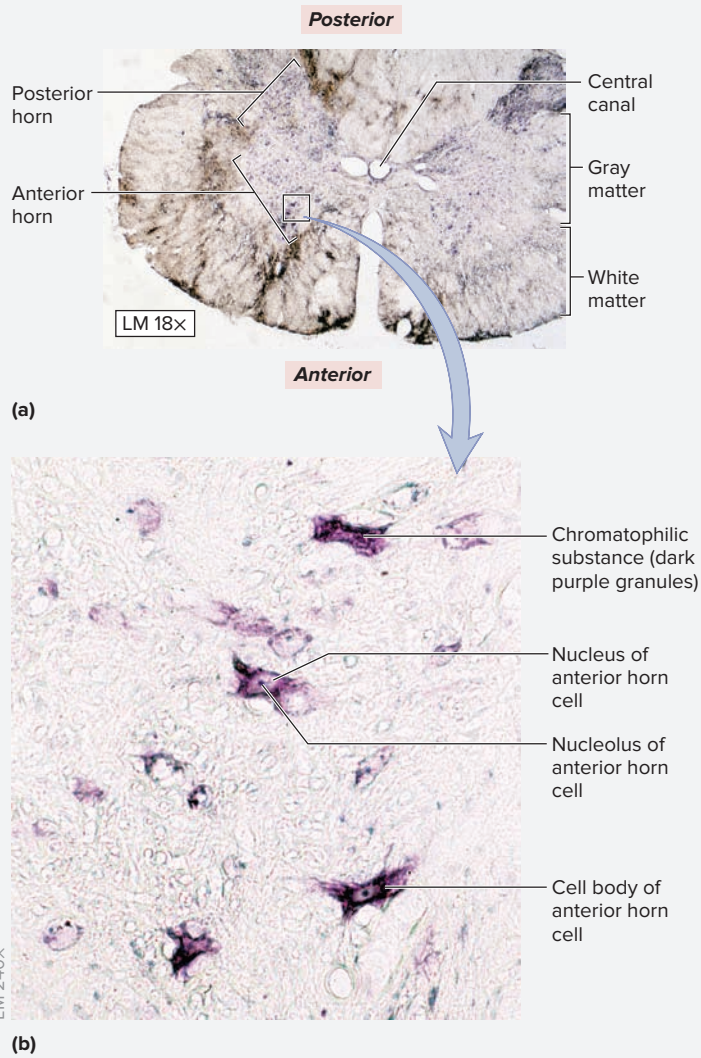
Neurons are classified based on the number of cellular processes that come off of the cell body. **Multipolar** neurons (**table 14.2**) have many dendrites and a single axon. **Bipolar** neurons, found only in special sensory organs such as the retina, have one dendrite and one axon. Finally, **unipolar** neurons have a single process (*uni*, one). Unipolar neurons are found only in the posterior (dorsal) root ganglia, which are peripheral nerve ganglia.

Part of the Neuron	Description and Function	Word Origins
<i>Axon</i>	A single large process of a neuron that conducts information away from the cell body of a neuron.	<i>axon</i> , axis
<i>Axon Hillock</i>	A light-staining region where the axon leaves the cell body of a neuron; devoid of chromatophilic substance; the location where action potentials are generated by a neuron.	<i>hillock</i> , a small elevation
<i>Cell Body (Soma)</i>	The part of the neuron that contains the nucleus and cellular organelles.	<i>soma</i> , body
<i>Chromatophilic (Nissl) Substance</i>	Dark-staining material found within the soma of a neuron, but absent in the axon hillock region; rough endoplasmic reticulum that functions in the production of membrane-associated proteins.	<i>chroma</i> , color + <i>phileo</i> , to love
<i>Dendrite</i>	Multiple branching processes of a neuron that bring information into the cell body.	<i>dendron</i> , tree
<i>Neurofibril Node (Node of Ranvier)</i>	A bare region on a myelinated axon where there is an absence of myelin and where action potentials are generated.	<i>neuron</i> , nerve + <i>fibrilla</i> , fiber; Louis Ranvier, French pathologist
<i>Synaptic Knobs</i>	Swellings on the ends of an axon that form synapses with effector organs such as glands and muscle fibers.	<i>syn-</i> , together + <i>hapto</i> , to clasp + <i>knob</i> , a protuberance
<i>Telodendria (Axon Terminals)</i>	Branches at the end of an axon, with each process containing a synaptic knob at its end.	<i>telos</i> , end + <i>dendron</i> , tree

Neuron Type	Location	Features
<i>Anterior Horn Cell</i>	Anterior horn of the spinal cord	Very large neuron with prominent chromatophilic substance. Cell body is irregularly shaped with multiple dendrites extending from the soma.
<i>Purkinje Cell</i>	Cerebellum	Cell bodies appear “basket-like” with a rounded area facing the granular layer of the cerebellum, and a tuft of dendrites extending into the molecular layer of the cerebellum.
<i>Pyramidal Cell</i>	Cerebral cortex	Cell body has a triangular shape and multiple dendrites extend from the cell body.

### EXERCISE 14.2 General Multipolar Neurons—Anterior Horn Cells

- Obtain a slide of the *spinal cord in cross section*.
- Place the slide on the microscope stage and bring the tissue sample into focus on low power (**figure 14.2a**). Again, note the inner core of gray matter surrounded by an outer region of white matter. Move the microscope stage so the inner gray matter is in the center of the field of view and then switch to high power (**figure 14.2b**). Look for very large, multipolar neurons found in the anterior (ventral) horn of the gray matter. These cells are called **anterior horn cells**, for their location. They are large motor neurons whose axons exit the spinal cord and travel through peripheral nerves to skeletal muscles in the body. Because their axons are so long, the cell bodies of these neurons are quite large and easy to see.
- Identify the listed structures on the spinal cord slide. Use tables 14.1 and 14.2 and figure 14.2 as guides.
  - cell body of anterior horn cell**
  - chromatophilic substance**
  - gray matter**
  - nucleolus of anterior horn cell**
  - nucleus**
  - white matter**



**Figure 14.2** Gray Matter of the Spinal Cord. (a) Cross section of spinal cord. (b) Close up showing large motor neurons (anterior horn cells).

© Rick Ash

4. Sketch anterior horn cells as seen through the microscope in the space provided.



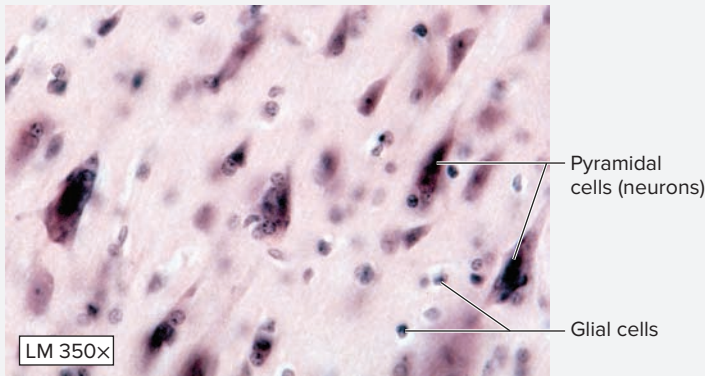
### EXERCISE 14.3 Cerebrum—Pyramidal Cells

- Obtain a slide of the cerebrum that has been stained with Nissl stain. Nissl stain colors the **rough endoplasmic reticulum** (the chromatophilic substance) of the neurons an intense blue color.
- Place the slide on the microscope stage and bring the tissue sample into focus on low power. Identify areas of gray matter and white matter on the slide (figure 14.3).
- Bring an area of gray matter to the center of the field of view and switch to high power. Note the very large cells located within the gray matter. These cells are **neurons**. Note the very large nuclei of the *neurons*, which are surrounded by many cells with much smaller nuclei, the *glial cells*. Locate large neurons whose cell bodies appear triangular in shape. These cells are special neurons of the cerebrum called **pyramidal cells** (figure 14.3, table 14.2).

(continued on next page)



(continued from previous page)



**Figure 14.3** **Pyramidal Cells in the Cerebral Cortex.** The pyramidal cells (neurons) are the large, triangular cells. The smaller nuclei visible in the slide are mainly those of glial cells.

© Rick Ash

4. Sketch the structures observed under the microscope in the space provided. Label the listed structures in the drawing:


- glial cells                       pyramidal cells



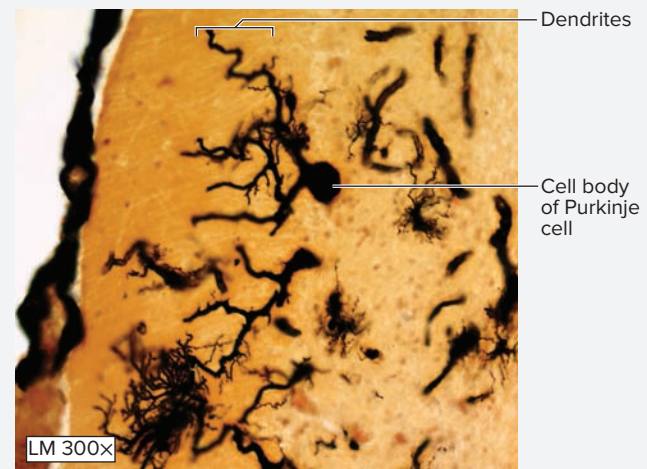
**EXERCISE 14.4** **Cerebellum—Purkinje Cells**

1. Obtain a slide of the **cerebellum**. Place it on the microscope stage and bring the tissue sample into focus on low power (figure 14.4a).
2. Note the folds of tissue with an outer region, the *molecular layer*, and an inner region, the *granular layer* (figure 14.4a). Deep to the folds is the white matter of the cerebellum. Move the microscope stage to bring the junction between the molecular and granular layers to the center of the field of view. Then switch to high power (figure 14.4b). Identify the very large cells located at this juncture. These cells are **Purkinje cells** (table 14.2), also known as basket cells, which are large multipolar neurons of the cerebellum (the layer where they are located is the *Purkinje cell layer*).
3. Sketch the structures observed at high power in the space provided. Label the listed structures in the drawing:
 

<input type="checkbox"/> granular layer	<input type="checkbox"/> Purkinje cells
<input type="checkbox"/> molecular layer	<input type="checkbox"/> white matter



(a)



(b)

**Figure 14.4** **Cerebellum—Purkinje Cells.** The cerebellum, demonstrating Purkinje cells between the granular and molecular layers. (a) Low power. (b) High power.

© Rick Ash

## Glial Cells

**Glial cells**, or **neuroglia** (literally, “nerve glue”), are much more abundant than neurons in the nervous system. Glial cells retain the capacity for cell division. Thus, most brain tumors arise from glial cells and are referred to as *gliomas*. The two most abundant glial cells in the central nervous system are **astrocytes** and **oligodendrocytes**. Because of their large size, these cells are collectively referred to as *macroglia*. The central nervous system also contains resident macrophages called **microglia**. As their name implies, microglia are very tiny cells. Their name is a bit of a misnomer, however, because these cells become very large phagocytic cells

when tissue injury occurs. Microglial cells are not visible in laboratory slides. Special epithelial cells found lining the fluid-filled ventricles of the brain are **ependymal cells**.

The peripheral nervous system contains only one type of glial cell, but it is named differently—and functions differently—depending upon its location. Thus, the glial cells in the peripheral nervous system are considered to be two separate glial cell types: *neurolemmocytes* (*Schwann cells*) and *satellite cells*. **Table 14.3** summarizes the characteristics of each type of glial cell.

Cell Name	Location	Description	Function(s)	Word Origins
<i>Astrocytes</i>	CNS	Star-shaped cells that are very abundant in the central nervous system.	General supporting cells in the CNS. Transfer nutrients to neurons from the blood. Reinforce the blood-brain barrier. Maintain the extracellular environment around neurons.	<i>astron-</i> , star + <i>kytos</i> , cell
<i>Ependymal Cells</i>	CNS	Cuboidal to columnar shaped cells with microvilli and cilia on their apical surfaces.	Ependymal cells are epithelial cells that line the ventricles (fluid-filled spaces) of the brain and the central canal of the spinal cord. Unlike other epithelia, they DO NOT have a basement membrane.	<i>ependyma</i> , an upper garment
<i>Microglia</i>	CNS	Small cells with oval nuclei and multiple branching processes.	Microglia are derived from blood monocytes, and they are the resident macrophages in the CNS. They are normally very small (hence the name), but transform into very large, phagocytic cells (macrophages) when tissues are injured. As macrophages they engulf dead tissue and/or pathogens and remove them from the CNS.	<i>mikros-</i> , small + <i>glia</i> , glue
<i>Neurolemmocytes (Schwann Cells)</i>	PNS	Large cells that wrap their plasma membrane around peripheral nerve axons.	Myelinate axons in the peripheral nervous system. Each neurolemmocyte can myelinate only one axon.	<i>neuron</i> , nerve + <i>-lemma</i> , husk + <i>kytos</i> , cell; <i>Theodor Schwann</i> , German histologist and physiologist
<i>Oligodendrocytes</i>	CNS	Cells with a few long processes that wrap around axons in the CNS.	Myelinate axons in the central nervous system. Each oligodendrocyte can myelinate multiple axons.	<i>oligos-</i> , few + <i>dendro-</i> , like a tree + <i>kytos</i> , cell
<i>Satellite Cells</i>	PNS	Small glial cells found surrounding the cell bodies of somatic sensory cells in the posterior (dorsal) root ganglion.	Satellite cells sit right outside the cell bodies of somatic sensory neurons, hence the appearance of “satellites” around those neurons. They provide general support for the neurons and are analogous in function to astrocytes in the CNS.	<i>satelles</i> , attendant

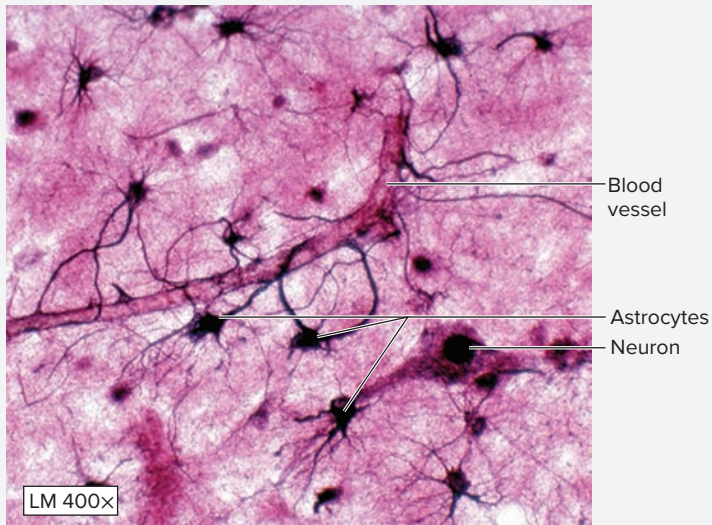
## Glial Cells of the Central Nervous System

### EXERCISE 14.5 Astrocytes

1. Obtain a slide of the cerebrum or cerebellum that has been stained with silver stain. Silver stain makes the general supporting cells of the central nervous system, the astrocytes, stain very dark so they are visible under the microscope (**figure 14.5**).
2. Place the slide on the microscope stage and bring the tissue sample into focus on low power. Then switch to high power and bring the tissue sample into focus once again.
3. The two most prominent cell types visible in this slide are the large neurons (are pyramidal cells or Purkinje cells visible on the slide?) and the smaller astrocytes. Astrocytes, as their name implies, are shaped like stars (*astron-*, star). They have multiple long cellular processes that wrap themselves around neurons and around blood vessels in the central nervous system. These processes allow them to perform one of their main functions, which is to transport nutrients from the bloodstream to the neurons.

(continued on next page)

(continued from previous page)



4. Sketch an astrocyte as seen through the microscope in the space provided.



**Figure 14.5** Astrocytes. Two astrocytes in the center of the slide have processes that can be seen touching a blood vessel.

© Rick Ash

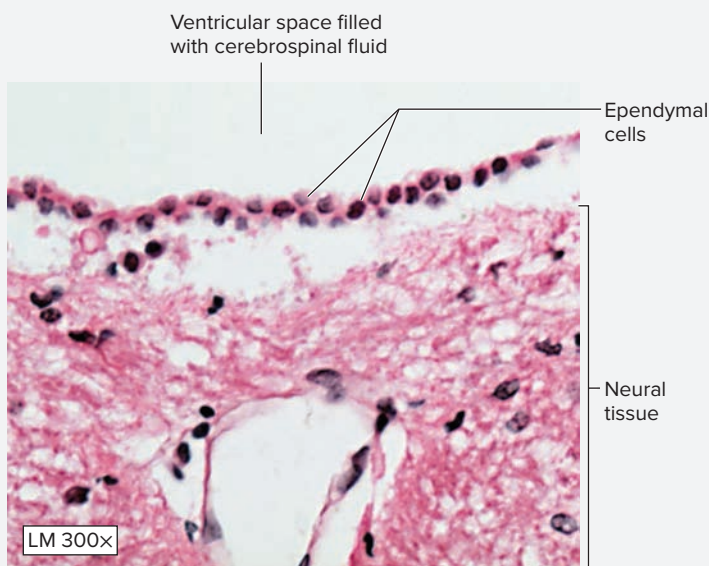
### EXERCISE 14.6 Ependymal Cells

1. Obtain a slide of the brain or of choroid plexus and place it on the microscope stage. Bring the tissue sample into focus on low power. Then switch to high power and bring the tissue sample into focus once again. Look for the “empty” spaces on the slide, because those spaces will likely be the ventricular spaces that are lined with ependymal cells.
2. **Ependymal cells (figure 14.6)** are cuboidal to columnar-shaped epithelial cells that line the ventricles of the brain and the central canal of the spinal cord. They also form the outer layer of the choroid plexus. They have both *cilia* and

*microvilli* on their apical surfaces, but they are unique as epithelia in that they do not have a basement membrane.

3. Locate ependymal cells on the slide, using figure 14.6 as a guide.
4. Sketch ependymal cells as seen through the microscope in the space provided. Label the listed structures in the drawing:

- choroid plexus (if visible)
- ependymal cells
- ventricular space



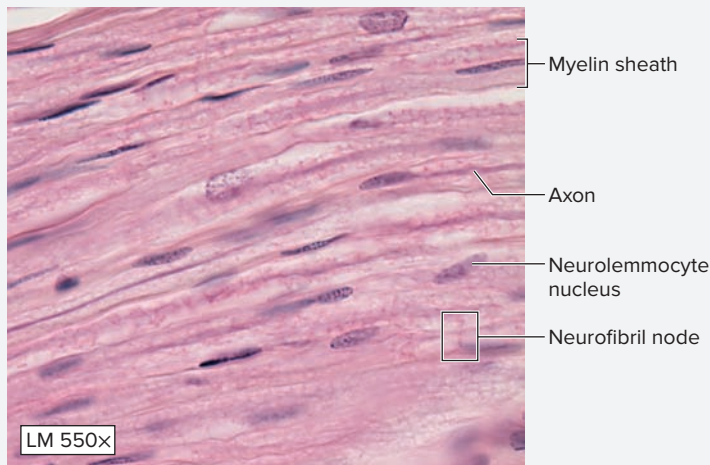
**Figure 14.6** Ependymal Cells. Cuboidal ependymal cells lining a ventricular surface of the brain. Choroid plexus is not visible in this slide.

© Rick Ash

## Glial Cells of the Peripheral Nervous System

### EXERCISE 14.7 Neurolemmocytes (Schwann Cells)

1. Obtain a slide of a longitudinal section of a peripheral nerve and place it on the microscope stage (**figure 14.7**). A nerve is a bundle of myelinated axons. Axons, myelin sheaths, and connective tissue should all be visible on this slide.
2. Bring the tissue sample into focus on low power and note the wavy appearance of the axons. The axons appear wavy because the nerve is not stretched. When a nerve is stretched, the axons also stretch out. The fact that peripheral nerves have elasticity is important because it allows the nerves to stretch during movement without being damaged. This elasticity is imparted to the nerves by the connective tissue coverings that surround the axons.
3. Observe the slide on high power. Note the very dark lines, which are the axons. Each axon is surrounded by light




**Figure 14.7 Neurofibril Nodes.** Longitudinal section of a nerve demonstrating neurofibril nodes.

© Rick Ash

material, which is the **myelin sheath**. Note the elongated nuclei seen throughout the slide. These nuclei belong to **neurolemmocytes (Schwann cells)**, the glial cells responsible for myelinating axons in the peripheral nervous system. Each individual neurolemmocyte myelinates only a single axon and a single axon has hundreds of neurolemmocytes along its length. The bare areas of axon found between myelin sheaths are called **neurofibril nodes**, or **nodes of Ranvier**.

4. Scan the slide to locate a neurofibril node.
5. Sketch a peripheral nerve as seen through the microscope in the space provided. Label the listed structures in the drawing:

- |  |   |
|--|---|
| <input type="checkbox"/> axon          | <input type="checkbox"/> neurofibril node       |
| <input type="checkbox"/> myelin sheath | <input type="checkbox"/> neurolemmocyte nucleus |



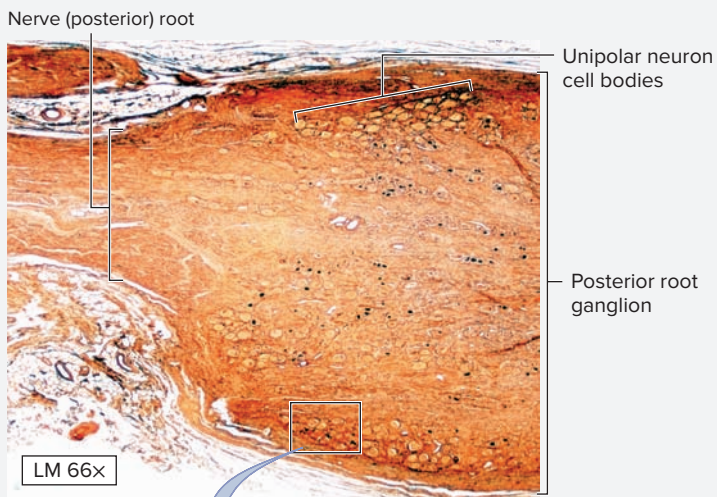
### EXERCISE 14.8 Satellite Cells

1. Obtain a slide of a spinal ganglion (the slide may be labelled dorsal root ganglion, posterior root ganglion, or peripheral nerve ganglion) and place it on the microscope stage.
2. Bring the tissue sample into focus on low power and locate both the nerve *root* and the *ganglion* (**figure 14.8a**).
3. Recall that the peripheral nervous system is mainly composed of nerves, which are bundles of myelinated axons. Occasionally collections of neuron cell bodies are found along these nerves. A collection of neuron cell bodies in the peripheral nervous system is called a **ganglion** (*ganglion*, swelling). The name comes from the fact that the area where the neuron cell bodies aggregate appears as a “swelling” on the cordlike nerve. The posterior roots of the spinal cord contain swellings called


**posterior (dorsal) root ganglia** (peripheral nerve ganglia). These structures contain the neuron cell bodies of somatic sensory neurons, which are classified as unipolar neurons. Unipolar neurons have only a single process extending from the cell body of the neuron. The absence of multiple dendrites coming right off the cell bodies of the neurons allows the glial cells (which are also found within the ganglion) to lie directly adjacent to the cell bodies of the neurons. They look like small “satellites” surrounding the neuron cell body, and are called **satellite cells**. Satellite cells are general supporting cells for neurons within the posterior root ganglia. They have the same embryonic origin as neurolemmocytes, but not the same function, which is why they are given a different name.

(continued on next page)

(continued from previous page)



(a)



(b)

**Figure 14.8** Posterior (Dorsal) Root Ganglion. (a) On low power the nerve root and the ganglia are visible. (b) On high power the unipolar neurons surrounded by satellite cells are visible.

© Rick Ash

4. Observe the ganglion at high power. The large nuclei that contain prominent nucleoli are the cell bodies of unipolar neurons. The small nuclei found surrounding the neurons are the nuclei of the satellite cells (figure 14.8b).

5. Sketch the spinal ganglion as seen under the microscope in the space provided. Label the listed structures in the drawing:

- nerve root
- satellite cells
- posterior root ganglion
- unipolar cells



6. *Optional Activity:* **AP|R Tissues**—Watch the “Nervous tissue overview” animation in Module 3 to review the structure and functions of neurons and glial cells.

**WHAT DO YOU THINK?**

2 Multiple sclerosis (MS) is a disease in which the immune system attacks myelin sheaths. Often a patient suffering from MS will experience a bout of illness, which involves muscle weakness and sensory alterations, followed by a period of recovery, in which normal function partially or completely returns. Using knowledge of glial cells, explain the biological basis for the partial or complete recovery of nerve function in an MS patient.

## Peripheral Nerves


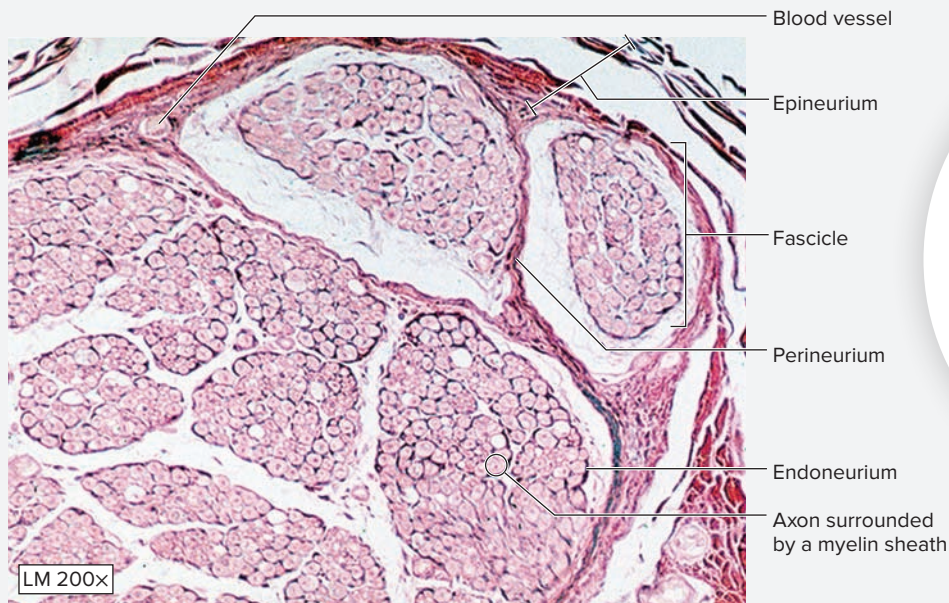
Both cranial nerves and spinal nerves are collections of myelinated axons that are bundled together with connective tissue. The bundling pattern is exactly like the bundling pattern seen with skeletal muscle, and the prefixes used for the names of the connective tissue coverings are also the same. An entire peripheral nerve is bundled by connective tissue called

**epineurium**. Within an entire nerve, the axons are grouped into bundles called **fascicles**. Each fascicle is surrounded by a connective tissue covering called the **perineurium**. Within each fascicle are individual axons. Each individual axon is surrounded by a connective tissue covering called the **endoneurium**. Blood vessels that supply nutrients to the nerve are located between the fascicles.

### EXERCISE 14.9 Coverings of a Peripheral Nerve

1. Obtain a slide of a cross section of a peripheral nerve and place it on the microscope stage.
2. Bring the tissue sample into focus on low power. Identify epineurium, fascicles, and perineurium, using **figure 14.9** as a guide.
3. Observe the slide at high power to observe the individual *axons* in cross section. Each axon is surrounded by a myelin sheath, which is then surrounded by a connective tissue covering of endoneurium. Locate the many small blood vessels that lie in between the fascicles.
4. Sketch a cross section of a peripheral nerve in the space provided. Label the listed structures in the drawing:

- |                                       |  |
|---------------------------------------|--|
| <input type="checkbox"/> axon         | <input type="checkbox"/> fascicle      |
| <input type="checkbox"/> blood vessel | <input type="checkbox"/> myelin sheath |
| <input type="checkbox"/> endoneurium  | <input type="checkbox"/> perineurium   |
| <input type="checkbox"/> epineurium   |  |



**Figure 14.9** Cross Section Through a Peripheral Nerve.

© Rick Ash

### WHAT DO YOU THINK?

- 3 When a peripheral nerve is compressed, blood vessels that run between fascicles of axons are also compressed. What might a consequence of this be?

*This page intentionally left blank*

## POST-LABORATORY WORKSHEET

The ❶ corresponds to the Learning Objective(s) listed in the chapter opener outline.

### Exercise 14.1: Gray and White Matter

1. a. A collection of neuron cell bodies in the CNS is called a(n) \_\_\_\_\_. ❶  
 b. A collection of neuron cell bodies in the PNS is called a(n) \_\_\_\_\_.  
 c. A bundle of myelinated axons in the CNS is called a(n) \_\_\_\_\_.  
 d. A bundle of myelinated axons in the PNS is called a(n) \_\_\_\_\_.
2. Which of the following parts of a neuron contain excitable membranes? (Check all that apply.) ❷  
 axon       axon hillock       dendrites       soma
3. The branches at the end of an axon are called \_\_\_\_\_, and they contain swellings called \_\_\_\_\_. ❷
4. a. What is chromatophilic substance? ❷  
 \_\_\_\_\_  
 b. Where is chromatophilic substance found?  
 \_\_\_\_\_  
 c. The part of a neuron distinguished by its notable *absence* of chromatophilic substance is called the \_\_\_\_\_.

### Exercise 14.2: General Multipolar Neurons—Anterior Horn Cells

5. A multipolar neuron has many \_\_\_\_\_ and a single \_\_\_\_\_. The large multipolar neurons located in the anterior horn of the spinal cord are called \_\_\_\_\_. ❸

### Exercise 14.3: Cerebrum—Pyramidal Cells

6. a. Large multipolar neurons located in the cerebral cortex are called \_\_\_\_\_. ❹  
 b. Briefly describe the appearance of these cells.  
 \_\_\_\_\_  
 \_\_\_\_\_

### Exercise 14.4: Cerebellum—Purkinje Cells

7. a. Large multipolar neurons located in the cerebellum are called \_\_\_\_\_. ❺  
 b. Briefly describe the appearance of these cells.  
 \_\_\_\_\_  
 \_\_\_\_\_
8. Give the location where each of these neuron types is found: ❸ ❹ ❺  
 a. Purkinje cell \_\_\_\_\_  
 b. anterior horn cell \_\_\_\_\_  
 c. pyramidal cell \_\_\_\_\_

### Exercise 14.5: Astrocytes

9. List three functions of astrocytes. ❻  
 a. \_\_\_\_\_  
 b. \_\_\_\_\_  
 c. \_\_\_\_\_



10. A patient with an *astrocytoma* (-oma, tumor) has a tumor that is derived from \_\_\_\_\_. This tumor would be located in what part of the nervous system? \_\_\_\_\_ 6

**Exercise 14.6: Ependymal Cells**

11. Ependymal cells are unique as epithelia in that they do not have a \_\_\_\_\_. 7

**Exercise 14.7: Neurolemmocytes (Schwann Cells)**

12. Glial cells in the CNS derived from circulating monocytes are \_\_\_\_\_. 8

13. The counterpart of a neurolemmocyte (Schwann cell) in the CNS is a(n) \_\_\_\_\_. 8

14. Compare and contrast the structure, location, and function of neurolemmocytes. 8

---

---

15. a. What is a neurofibril node (node of Ranvier)? 8

---

- b. What is the function of a neurofibril node?

---

16. Describe the structure and function of neurolemmocytes. 8

---

---

**Exercise 14.8: Satellite Cells**

17. Satellite cells are glial cells that surround the cell bodies of \_\_\_\_\_ neurons. These are located within a structure called the \_\_\_\_\_, which lies just outside and lateral to the spinal cord. 9

18. Describe the structure, function, and specific location of satellite cells. 9

---

---

**Exercise 14.9: Coverings of a Peripheral Nerve**

19. A fascicle of axons is surrounded by a connective tissue sheath called the \_\_\_\_\_. 10

20. Which type of neural tissue is more involved with the integration of information (rather than the transmission or conduction of information)—white matter or gray matter? Explain.

---

---

---

# The Nervous System: General and Special Senses

# 15

## OUTLINE AND LEARNING OBJECTIVES

### Histology 302

#### General Senses 302

##### EXERCISE 15.1: TACTILE (MEISSNER) CORPUSCLES 302

- 1 Identify dermal papillae and tactile corpuscles when viewed with a microscope
- 2 Describe the structure and function of tactile corpuscles

##### EXERCISE 15.2: LAMELLATED (PACINIAN) CORPUSCLES 303

- 3 Identify the reticular layer of the dermis and lamellated corpuscles when viewed with a microscope
- 4 Describe the structure and function of lamellated corpuscles

#### Special Senses 304

##### EXERCISE 15.3: GUSTATION (TASTE) 304

- 5 Identify different types of tongue papillae and identify taste buds when viewed under the microscope
- 6 Describe the structure and function of taste buds

##### EXERCISE 15.4: OLFACTION (SMELL) 306

- 7 Identify olfactory epithelium when viewed with a microscope
- 8 Identify the general location and describe the function of basal cells, olfactory receptor cells, and supporting cells within olfactory epithelium

##### EXERCISE 15.5: VISION (THE RETINA) 308

- 9 Identify the retina when viewed with a microscope
- 10 Identify the rod and cone layer, bipolar cell layer, and ganglion cell layer in a histology slide of the retina
- 11 Describe the functional importance of the fovea centralis and the optic disc, and describe how the histology of the retina is modified in these areas to match those functions

##### EXERCISE 15.6: HEARING 310

- 12 Identify the cochlea when viewed with a microscope
- 13 Identify the scala vestibuli, scala media, and scala tympani of the cochlea when viewed with a microscope
- 14 Identify the histological structure of the spiral organ when viewed with a microscope
- 15 Describe how cells within the spiral organ function to transmit the special sensation of hearing to the brain

### Gross Anatomy 312

#### General Senses 312

##### EXERCISE 15.7: SENSORY RECEPTORS IN THE SKIN 312

- 16 Describe the general location and function of tactile discs, tactile corpuscles, lamellated corpuscles, and free nerve endings

#### Special Senses 314

##### EXERCISE 15.8: GROSS ANATOMY OF THE EYE 314

- 17 Identify structures of the eye on a classroom model of the eye

##### EXERCISE 15.9: COW EYE DISSECTION 316

- 18 Identify internal and external eye structures on a fresh cow eye
- 19 Describe the ways in which a cow eye is both similar to and different from a human eye

##### EXERCISE 15.10: GROSS ANATOMY OF THE EAR 319

- 20 Identify structures of the ear on a classroom model of the ear
- 21 Describe the gross structure, location, and functions of the external, middle, and inner ear

## INTRODUCTION

---

**R**eading this chapter and performing the laboratory activities within this book are both activities that are dependent upon the proper functioning of sensory systems. The special sense of vision is used to read the words typed on the page. The special sense of hearing is used to respond to the instructions delivered by the instructor and to discuss the material with classmates. The special sense of equilibrium maintains the body's three-dimensional position in space so the body doesn't fall over when moving about the classroom. In addition, sensory receptors in the skin constantly perceive stimuli from the environment relaying touch, pressure, and temperature sensations, thus allowing the body to remain oriented in space and protected from harm. Indeed, reading this chapter introduction while enjoying a cup of coffee or other food or drink requires special senses of olfaction (smell) and gustation (taste). In fact, enjoyment of things like music, warm baths, food, drink, and a good book are all completely dependent on the multitude of sensory receptors that are used to detect stimuli from the environment. Of course, it is the brain that actually *interprets* such sensory input. However, without the appropriate input, there would be nothing for the brain to interpret. The exercises within this chapter guide

the student in exploring the intricate structure and function of many of the amazing, beautiful, and incredibly *functional* sensory receptors and organs found throughout the body.

The histology and gross anatomy exercises in this chapter explore the histology of a select few somatic sensory receptors and special sensory organs of the body and the gross structure of two special sensory organs (the eye and ear) through observations of classroom models and by dissection of a cow eye.

### List of Reference Tables

Table 15.1	Sensory Receptors in Thick Skin	p. 302
Table 15.2	Tongue Papillae	p. 305
Table 15.3	Cells Associated with Taste Buds	p. 305
Table 15.4	Olfactory Epithelium	p. 307
Table 15.5	The Retina	p. 308
Table 15.6	The Cochlea	p. 311
Table 15.7	Accessory Structures of the Eye	p. 314
Table 15.8	Internal Structures of the Eye	p. 318
Table 15.9	Structures of the External, Middle, and Internal Ear	p. 320

# Chapter 15: The Nervous System: General and Special Senses

Name: \_\_\_\_\_

Date: \_\_\_\_\_ Section: \_\_\_\_\_

These Pre-laboratory Worksheet questions may be assigned by instructors through their **connect** course.

## PRE-LABORATORY WORKSHEET

1. Which of the following sensory receptors is/are involved in general sensation? (Check all that apply.)

- \_\_\_\_\_ a. cochlear hair cells      \_\_\_\_\_ b. free nerve endings      \_\_\_\_\_ c. olfactory receptors  
\_\_\_\_\_ d. photoreceptors      \_\_\_\_\_ e. tactile corpuscles

2. Which of the five special senses have receptor organs located within the petrous part of the temporal bone? (Check all that apply.)

- \_\_\_\_\_ a. equilibrium      \_\_\_\_\_ b. gustation      \_\_\_\_\_ c. hearing  
\_\_\_\_\_ d. olfaction      \_\_\_\_\_ e. vision

3. Tactile corpuscles are located within the \_\_\_\_\_ (papillary/reticular) layer of the dermis.

4. Lamellated corpuscles are located within the \_\_\_\_\_ (papillary/reticular) layer of the dermis.

5. Match the special sense listed in column A with the corresponding cranial nerve that transmits the sensation to the brain, listed in column B. (Some answers may be used more than once because some special senses are transmitted by more than one cranial nerve.)

### Column A

- \_\_\_\_\_ 1. equilibrium  
\_\_\_\_\_ 2. gustation  
\_\_\_\_\_ 3. hearing  
\_\_\_\_\_ 4. olfaction  
\_\_\_\_\_ 5. vision

### Column B

- a. facial nerve (CN VII)  
b. glossopharyngeal nerve (CN IX)  
c. olfactory nerve (CN I)  
d. optic nerve (CN II)  
e. vestibulocochlear nerve (CN VIII)

6. Olfactory nerves extend through which part of the ethmoid bone? (Circle one.)

- a. cribriform plate  
b. crista galli  
c. middle nasal concha  
d. perpendicular plate  
e. superior nasal concha

7. The vestibulocochlear nerve carries the special senses of \_\_\_\_\_ (equilibrium/olfaction) and \_\_\_\_\_ (hearing/vision).

8. Taste receptors on the posterior third of the tongue are innervated by the \_\_\_\_\_ (facial/glossopharyngeal) nerve, whereas taste receptors on the anterior two-thirds of the tongue are innervated by the \_\_\_\_\_ (facial/glossopharyngeal) nerve.

9. The \_\_\_\_\_ (cochlea/vestibule) is involved with hearing, whereas the \_\_\_\_\_ (cochlea/vestibule) is involved with equilibrium and balance.

10. Free nerve endings are associated with the sensation of \_\_\_\_\_ (deep pressure/pain).

## Histology

### General Senses

Sensory receptors can be classified based on receptor distribution in the body. The two distribution types are the general senses and the special senses. Receptors of the **general senses** are simple structures composed of dendritic endings of sensory neurons that are located throughout the body in the skin and internal organs. They are organized into two categories based upon their location in the body. **Somatic sensory receptors** are housed within the skin for monitoring tactile sensations (e.g., pressure,

vibrations, and pain) and within joints, muscles, and tendons for detection of stretch and pressure relative to position and movement of the skeleton and muscles. **Visceral sensory receptors** are located within the wall of the viscera (internal organs); they respond to temperature, chemicals, stretch, and pain. In comparison, receptors of the **special senses** are complex structures located only in the head, and are associated with taste, smell, vision, hearing, and equilibrium.

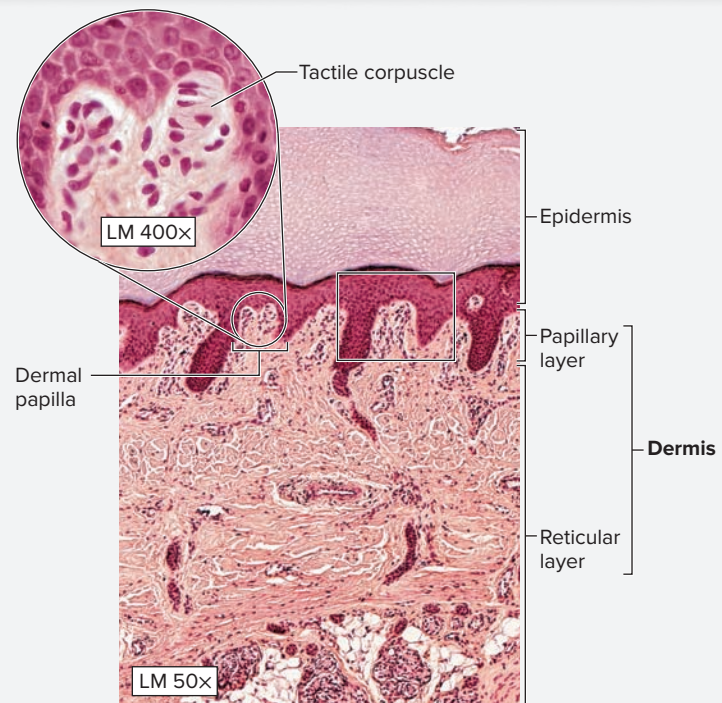
The exercises in this section focus on somatic sensory receptors in the skin (**table 15.1**).

Receptor	Location	Structure	Senses	Word Origins
<b>UNENCAPSULATED TACTILE RECEPTORS</b>				
<i>Free Nerve Ending</i>	Primarily the papillary layer of the dermis with some extending into the epidermis; associated with glands and hair follicles.	An unmodified, unencapsulated nerve ending.	Temperature, pain, and pressure.	<i>free</i> , referring to the fact there are no connective tissue coverings
<i>Tactile (Meissner) Corpuscle</i>	Within dermal papillae, especially in lips, palms of the hand, eyelids, nipples, and external genitalia.	An oval structure consisting of modified neurolemmocytes and connective tissue encapsulating a nerve ending.	Fine, discriminative touch to determine textures and shapes; light touch.	<i>tactus</i> , to touch + <i>corpus</i> , body
<b>ENCAPSULATED TACTILE RECEPTORS</b>				
<i>Lamellated (Pacinian) Corpuscle</i>	Deep within the reticular layer of the dermis.	Concentric layers of modified neurolemmocytes and connective tissue surrounding a nerve ending at the core.	Deep pressure and high frequency vibration.	<i>lamina</i> , plate + <i>corpus</i> , body
<i>Tactile Disc (Merkel Disc)</i>	At the junction between the dermis and the epidermis.	An association between a modified keratinocyte in the epidermis, called a tactile cell, with a specialized nerve ending in the dermis, called a tactile disc.	Fine, light touch.	<i>tactus</i> , to touch

### EXERCISE 15.1 Tactile (Meissner) Corpuscles

Sensory receptors called **tactile corpuscles** are located within the dermal papillae of thick skin. These receptors are oval in shape with a surrounding capsule of connective tissue (**figure 15.1** and **table 15.1**), and they function in sensing light touch. Look for a tactile corpuscle within a dermal papilla. If a tactile corpuscle is not visible, scan the slide for other papillae that may have tactile corpuscles within.

1. Obtain a histology slide of thick skin and place it on the microscope stage. Bring the tissue sample into focus using the scanning objective.
2. Observe the slide on low power and review the layers of the skin (**figures 6.1** and **15.1**).
  - **Epidermis:** stratum basale, stratum spinosum, stratum granulosum, stratum lucidum, and stratum corneum
  - **Dermis:** papillary layer and reticular layer
3. Move the microscope stage so the junction between the dermis and epidermis is in the center of the field of view. Locate the **dermal papillae** (**figure 15.1**). Next, move the stage so a single papilla is in the center of the field of view. Then change to high power.



**Figure 15.1** Thick Skin and Tactile (Meissner) Corpuscles. Tactile corpuscles are found within the dermal papillae of the skin and are sensory receptors for fine touch.

4. Sketch a tactile corpuscle within a dermal papilla in the space provided.



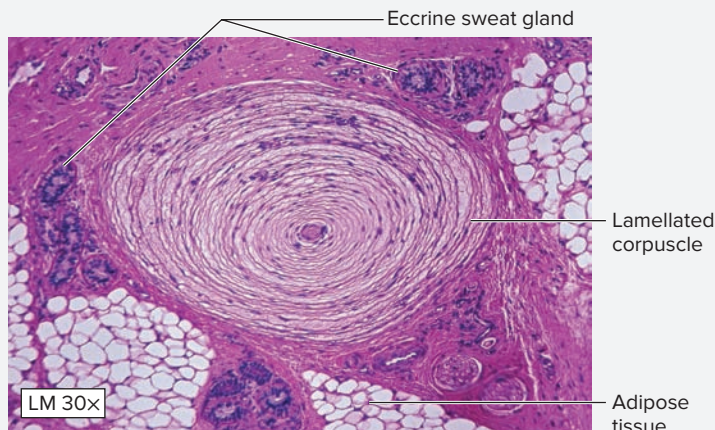**WHAT DO YOU THINK?**

- 1 Why do you think tactile (Meissner) corpuscles are located relatively close to the surface of the skin rather than deep within the dermis? (What advantage does this serve?)

**EXERCISE 15.2 Lamellated (Pacinian) Corpuscles**

**Lamellated corpuscles** resemble onions in cross section because they have several layers of cells forming circular layers around a central sensory receptor (figure 15.2 and table 15.1). Lamellated corpuscles function in the sensation of deep pressure. When enough pressure is applied to the surface of the skin, the layers of connective tissue surrounding the central sensory receptor are compressed, and transmit nerve signals to the brain.

1. Obtain a histology slide of thick skin and place it on the microscope stage.
2. Observe the slide on low power and identify the dermis and epidermis (figure 15.1).
3. Move the microscope stage so the deepest part of the reticular layer of the dermis is in the center of the field of view.




**Figure 15.2 Lamellated Corpuscles.** Lamellated corpuscles are located deep within the reticular layer of the dermis and are sensory receptors for deep pressure.

© Carolina Biological Supply Company/Phototake

Within this portion of the dermis there are cross sections through numerous sweat glands and blood vessels. Cross sections of lamellated corpuscles should also be visible.

4. Locate a lamellated corpuscle and then move the microscope stage so the lamellated corpuscle is in the center of the field of view. Change to a higher power to view its structure in more detail to identify the layers of cells that surround the nerve ending.
5. Sketch a lamellated corpuscle in the space provided. Make note of the location of the tactile corpuscle in the skin.



**WHAT DO YOU THINK?**

- 2 Why do you think lamellated corpuscles are located deep within the dermis instead of relatively close to the surface of the skin?

## Special Senses

**Special senses** are specialized organs within the head that respond specifically to the modalities of olfaction, taste, vision, hearing, and equilibrium.

The laboratory exercises in this section guide the student in exploring the structure and function of these special sensory organs.

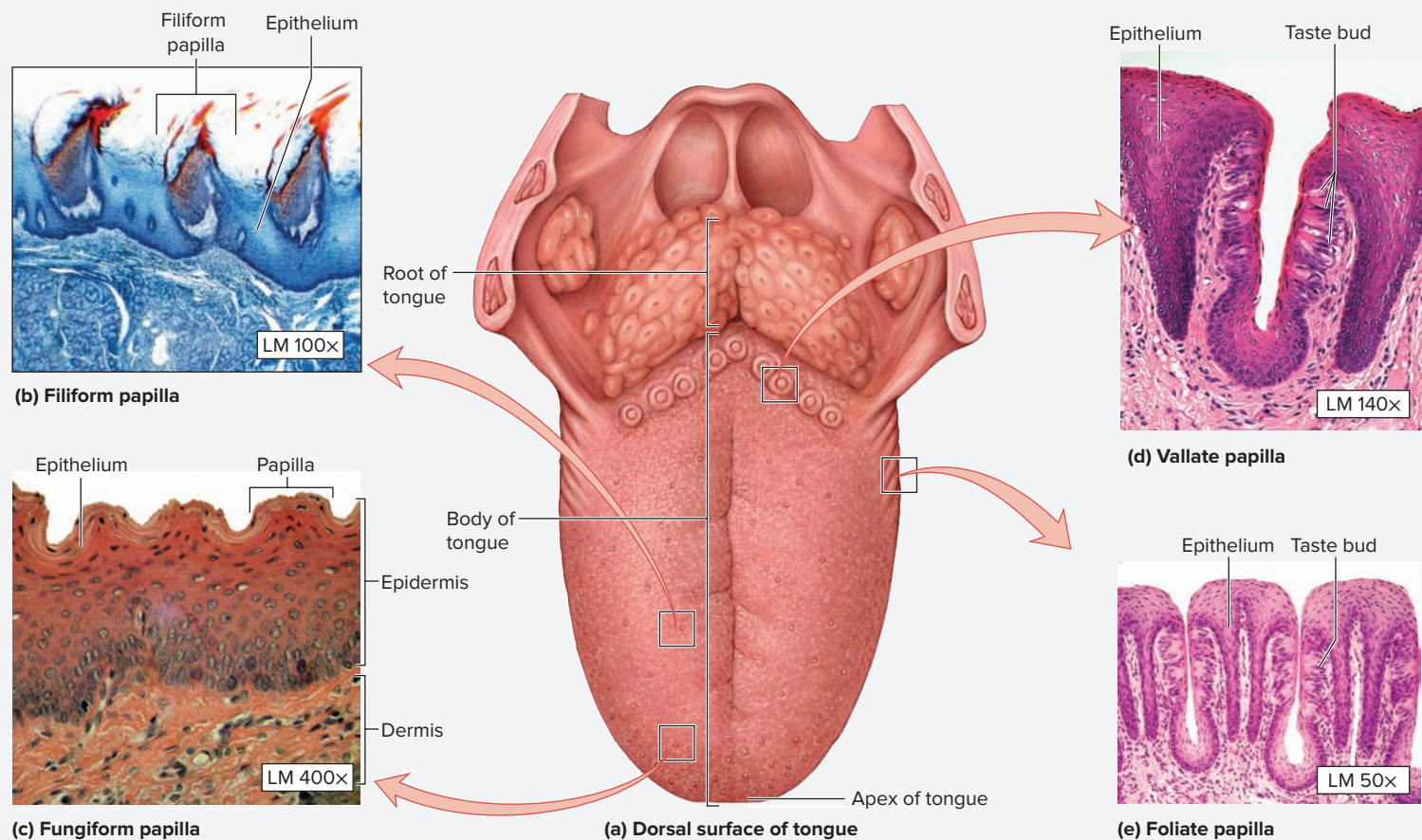
### EXERCISE 15.3 Gustation (Taste)

Gustation (taste) is one of the most pleasurable sensations humans can experience. However, to have a complete sense of gustation, the olfactory sense must also be functioning. In fact, without the ability to smell, the ability to taste suffers tremendously. Perhaps one reason gustation is so pleasurable is that the gustatory and olfactory pathways relay sensory input to the limbic system, the emotional brain.

There are four types of papillae located on the tongue: filiform, fungiform, vallate (circumvallate), and foliate. The detailed structure, function, and locations of the tongue papillae are shown in **figure 15.3** and summarized in **table 15.2**. The sensory receptor specialized for gustatory sensation is a **taste bud** (gustatory bud) (**table 15.3**). Taste buds are located throughout the oral cavity and pharynx, but are particularly concentrated on the tongue, and are associated with the raised epithelial ridges on the tongue (papillae). In this exercise we will explore the types of tongue papillae and the location and function of taste buds associated with the papillae.

The large papillae are the **foliate** and **vallate (circumvallate)** papillae. In addition to being the largest papillae, the vallate papillae house more than half of the taste buds in the walls of the crypts that surround each papilla. Taste buds are particularly concentrated on the papillae of the tongue, but are also located throughout the oral cavity and pharynx. This exercise guides students in exploring the types of tongue papillae and the location and function of taste buds associated with the papillae.

1. Obtain a histology slide of the tongue or a histology slide demonstrating mammalian *vallate papillae* (figure 15.3d). Scan the slide at low power and identify the papillae on the surface of the tongue. Move the microscope stage so one or two papillae are in the center of the field of view. Then increase the magnification, first to medium and then to high power. Locate a taste bud at the edge of the papilla (figure 15.4).

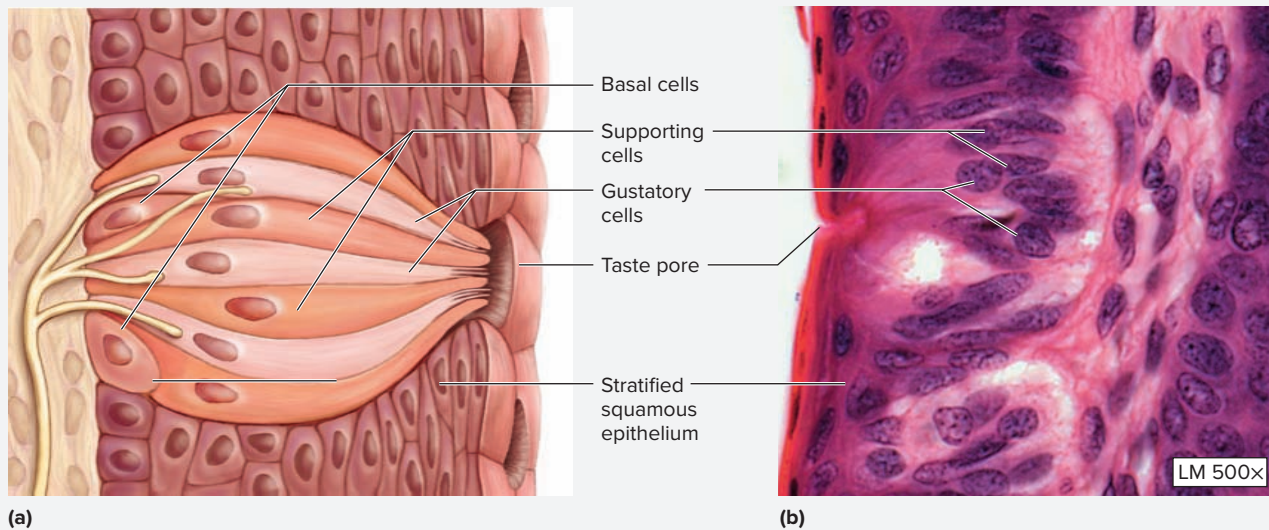


**Figure 15.3 Taste Buds.** Gustation (taste) requires taste buds, which are associated with tongue papillae. (a) Dorsal surface of tongue. (b) Filiform papilla. (c) Fungiform papilla. (d) Vallate papilla. (e) Foliate papilla.

(b) © CNRI/Science Photo Library/Corbis RF; (c) © McGraw-Hill Education/Christine Eckel, photographer; (d) © McGraw-Hill Education/Al Telser; (e) © Jose Luis Calvo/Shutterstock.com RF

Table 15.2 Tongue Papillae				
Type of Papilla	Location	Description	Function	Word Origins
<i>Filiform</i>	Anterior two-thirds of the tongue.	The most numerous of the papillae. They are conical in shape and contain sensory nerve endings.	General sensation.	<i>filum</i> , thread + <i>forma</i> , shape
<i>Foliate</i>	Sides of the tongue.	Large papillae with deep crypts that house taste buds in their walls in infants and children.	Taste sensation.	<i>foliate</i> , resembling a leaf
<i>Fungiform</i>	Anterior part of the tongue; most numerous at the tip.	Less numerous than filiform papillae. They are shaped like mushrooms and contain some taste buds.	Taste sensation.	<i>fungus</i> , a mushroom + <i>forma</i> , shape
<i>Vallate (Circumvallate)</i>	Posterior part of the tongue along the sulcus terminalis.	The largest papillae. They contain deep crypts that house taste buds in their lateral walls.	Taste sensation.	<i>circum-</i> , around + <i>vallum</i> , wall

Table 15.3 Cells Associated with Taste Buds			
Structure	Description	Function	Word Origins
<i>Basal Cells</i>	These are small stem cells found at the base of the taste bud.	Precursor cells to the supporting cells and gustatory cells.	<i>basalis</i> , situated near the base + <i>cella</i> , a chamber
<i>Gustatory Cells</i>	These cells have round nuclei and are very light in color. They are epithelial cells that are composed of microvilli twisted around each other, and a taste hair on the apical surface.	Detect chemicals dissolved in solution; transmit nerve signals for taste sensation to the CNS.	<i>gustus</i> , a tasting + <i>cella</i> , a chamber
<i>Supporting Cells (Sustentacular Cells)</i>	Located between the gustatory cells, these cells have more oval-shaped nuclei and stain darkly.	Support the gustatory cells by producing a glycoprotein; may also function in taste sensation.	<i>supporto</i> , to carry + <i>cella</i> , a chamber



**Figure 15.4 Detailed Structure of a Taste Bud.** (a) Illustration. (b) Photomicrograph.

(b) © McGraw-Hill Education/Al Telser

(continued on next page)



(continued from previous page)

2. Identify the listed structures, using figures 15.3 and 15.4, and tables 15.2 and 15.3 as guides. (Note that all of the types of papillae may not be visible on a single slide.)

- |   |   |
|---|---|
| <input type="checkbox"/> basal cells        | <input type="checkbox"/> supporting cells                 |
| <input type="checkbox"/> filiform papillae  | <input type="checkbox"/> taste pores                      |
| <input type="checkbox"/> foliate papillae   | <input type="checkbox"/> vallate (circumvallate) papillae |
| <input type="checkbox"/> fungiform papillae |   |
| <input type="checkbox"/> gustatory cells    |   |

3. Locate a taste bud at the edge of the papilla in the crevice (crypt) between two papillae (figure 15.4).

4. Sketch a vallate papillae in the space provided. Label the taste buds in the sketch.

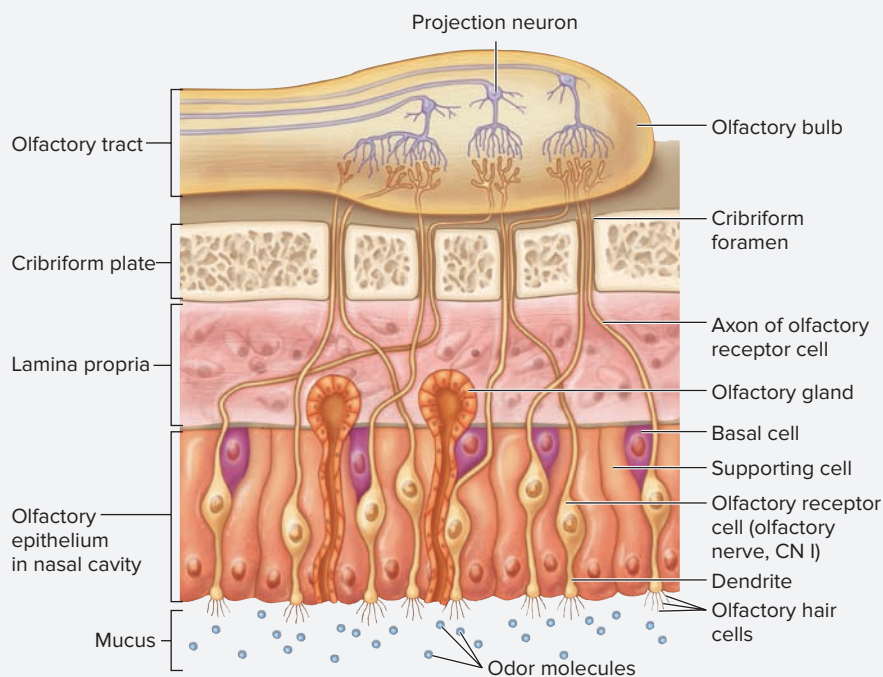


### EXERCISE 15.4 Olfaction (Smell)

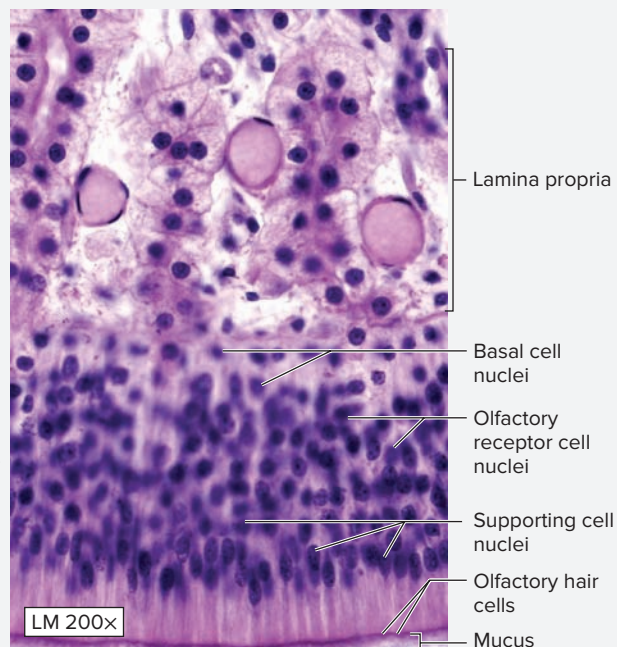
Olfaction is the sense of smell. It is an important sensory modality, not just for smell, but also for gustation (taste). Olfactory sensation is detected by special sensory cells found within the epithelium lining the roof of the nasal cavity—**olfactory epithelium** (figure 15.5a and table 15.4). The **olfactory receptor cells** are neurons, but they are unique because they are continuously replaced. The olfactory receptor cells compose the **olfactory**

**nerves (CN I)**. The axons of the olfactory nerves travel through the **cribriform foramina** within the cribriform plate of the ethmoid bone to synapse with neurons within the **olfactory bulbs**, which subsequently transmit the information to the brain via the **olfactory tract**.

1. Obtain a histology slide of olfactory epithelium (figure 15.5b) and place it on the microscope stage.



(a) Olfactory receptor cells



(b) Olfactory epithelium

**Figure 15.5 Olfactory Epithelium.** (a) Cell types within the olfactory epithelium. (b) Histology of the olfactory epithelium.


(b) © Cultura RM/Alamy

Table 15.4		Olfactory Epithelium	
Structure	Description	Function	Word Origins
<b>Basal Cells</b>	Cuboidal (triangular) cells whose nuclei are located near the basal surface of the olfactory epithelium.	Thought to be the precursor cells to the olfactory receptor cells and supporting cells.	<i>basalis</i> , situated near the base + <i>cella</i> , a chamber
<b>Cilia</b>	Surface modifications of epithelial cells that contain microtubules; specialized cilia in that they are not motile.	Apical ends are the site of interaction between dissolved odiferous substances and the olfactory receptor cells.	<i>cilium</i> , eyelash
<b>Cribriiform Foramina</b>	Numerous small holes in the cribriform plate of the ethmoid.	Allow for the passage of axons of the olfactory receptor cells from the olfactory epithelium to the olfactory bulb, where they will synapse with other neurons.	<i>cribriform</i> , shaped like a sieve + <i>foramen</i> , to pierce
<b>Cribriform Plate of the Ethmoid Bone</b>	The superior portion of the ethmoid bone containing olfactory foramina.	Forms the roof of the nasal cavity.	<i>cribriform</i> , shaped like a sieve + <i>ethmoid</i> , resembling a sieve
<b>Olfactory Bulb</b>	A white swelling on the superior and anterior aspect of the cribriform plate of the ethmoid bone.	The location where axons from olfactory receptor cells synapse with other neurons that will carry the information to the brain via the olfactory tract.	<i>olfactus</i> , to smell + <i>bulb</i> , a globular structure
<b>Olfactory Receptor Cells</b>	Columnar cells whose large nuclei are located in the middle of the olfactory epithelium (between apical and basal surfaces) and have cilia on their apical surfaces.	Bipolar neurons that function as sensory receptors for olfaction (smell).	<i>olfactus</i> , to smell + <i>recipio</i> , to receive + <i>cella</i> , a chamber
<b>Olfactory Tract</b>	A white extension of the olfactory bulb that lies superior to the frontal bone and inferior to the frontal lobe of the brain.	Consists of myelinated axons of neurons that originate in the olfactory bulb and carry olfactory information to the brain.	<i>olfactus</i> , to smell + <i>tractus</i> , a drawing out
<b>Supporting (Sustentacular) Cells</b>	Columnar cells whose nuclei are located near the apical surface of the olfactory epithelium.	Surround and support the specialized olfactory receptor cells.	<i>supporto</i> , to carry + <i>cella</i> , a chamber

- Bring the tissue sample into focus on low power. Increase magnification to medium power, and then to high power so the cells composing the olfactory epithelium are clearly visible. It may be difficult to distinguish between the three major cell types of the olfactory epithelium: basal cells, olfactory receptor cells, and supporting cells. In general, the nuclei closest to the basement membrane of the epithelium are the nuclei of *basal cells* (the cells appear triangular in shape), the nuclei in the middle of the epithelium are the nuclei of *olfactory receptor cells*, and the nuclei closest to the apical surface of the epithelium are the nuclei of *supporting cells*.
- Identify the listed structures on the histology slide of olfactory epithelium, using figure 15.5 and table 15.4 as guides.

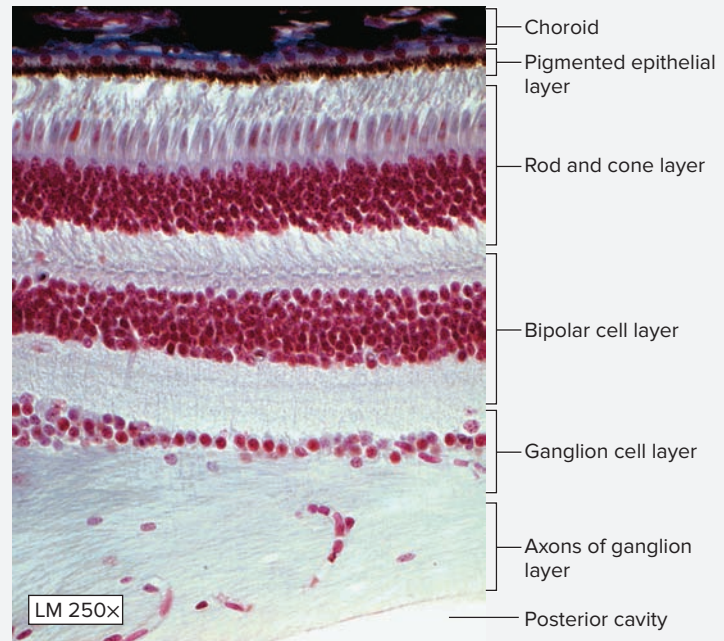
- basal cells
- cilia
- olfactory receptor cells
- supporting cells

- Sketch the olfactory epithelium as seen through the microscope in the space provided. Label all of the structures listed in step 3.



**EXERCISE 15.5** Vision (The Retina)

The **retina** (figure 15.6, table 15.5) of the eye is called the **neural tunic**, because this layer is composed of neural tissue. The retina develops as a direct outgrowth of the brain. Thus, the retina is the only part of the brain visible without surgical intervention (though an ophthalmoscope is required). Axons from neurons within the retina travel to the brain through the **optic nerve (CN II)**. The retina is responsible for transducing light rays into electrical signals (action potentials) that eventually travel through the optic nerves (CN II) to the brain. This information is relayed from photoreceptor cells (rods and cones) to bipolar cells to the ganglion cells within the retina. Axons of ganglion cells extend from the back of the eye as the optic nerve to synapse with neurons within the **thalamus**. These neurons extend to the **occipital lobe** of the brain. Here, the visual information is processed and interpreted. The retina is a very complex yet beautifully organized structure. Rods function in dim light and cones function in high-intensity light and in color vision. The exercises in this part of the chapter guide students in exploring the structure and function of the retina by observing the cells that are visible histologically. Laboratory exercises within the gross anatomy section of this chapter will place the retina in the context of other structures of the eye.



**Figure 15.6** Histology of the Retina.

© McGraw-Hill Education/Al Telser

Table 15.5		The Retina	
Structure	Description	Function	Word Origins
<b>Bipolar Cell Layer</b>	Middle layer of the retina, composed of cells with intermediate-sized nuclei; as the name suggests, these neurons are bipolar neurons.	Receives signals from rods and cones and transmits them to ganglion cells.	<i>bipolar</i> , relating to bipolar neurons
<b>Choroid*</b>	The vascular and pigmented layer of the eye located between the retina (internal) and the sclera (external); recognized histologically by numerous blood vessels and by dark staining characteristics of the melanin.	Blood vessels of the choroid supply nutrients to the tissues of the retina and sclera, and the pigment absorbs excess light waves.	<i>choroideus</i> , like a membrane
<b>Cones</b>	Photoreceptor cells with a light-transducing portion located in the outermost layer of the retina and with nuclei located in the layer just internal to that. Rods cannot be distinguished from cones using a light microscope.	Photoreceptor cell specializing in color vision.	<i>conus</i> , shaped like a cone
<b>Fovea Centralis</b>	An area of the retina devoid of bipolar and ganglion cell layers; the photoreceptor layer is composed exclusively of cones.	Area of highest visual acuity in the eye. Focusing on an object requires moving the eyes so the light entering the eye is focused on the fovea.	<i>fovea</i> , a pit + <i>centralis</i> , in the center
<b>Ganglion Cell Layer</b>	Innermost layer of the retina, composed of cells with very large nuclei.	Receives information from bipolar cells and sends that information to the brain.	<i>ganglion</i> , a swelling or knot
<b>Photoreceptor Cells</b>	Outermost layer of the retina (closest to the choroid and sclera), containing the light-transducing portions of photoreceptor cells (rods and cones); layer immediately internal to this layer contains the nuclei of rods and cones, the smallest and most numerous nuclei of the retina.	Layer of the retina where light waves are initially transduced into neuronal action potentials; the cells in this layer synapse with neurons in the bipolar cell layer.	NA
<b>Pigmented Layer</b>	Outermost portion of retina attached to choroid.	Absorbs extraneous light; provides vitamin A for photoreceptor cells.	NA
<b>Retina</b>	Referred to as the “neural tunic” of the eye; consists of numerous layers of neurons involved in phototransduction.	Phototransduction: transduction of light waves that enter the eye into nerve signals (action potentials) that can be interpreted by the brain.	<i>rete</i> , a net
<b>Rods</b>	Photoreceptor cells with a light-transducing portion located in the outermost layer of the retina and with nuclei located in the layer just internal to that; not distinguishable from cones using a light microscope.	Photoreceptor cells specializing in black-and-white vision; very sensitive, most useful when light is dim.	<i>rod</i> , shaped like a rod
<b>Sclera*</b>	Dense irregular connective tissue that surrounds the entire eye except for its anterior aspect where the cornea is located; histologically, the most external layer, composed of collagen fibers and fibroblasts.	Protects the eye, serves as an attachment point for extraocular eye muscles, and helps maintain the round shape of the eye.	<i>skleros</i> , hard

\*Note that the choroid and sclera are tunics of the eye, rather than structures of the retina; however, both tunics are visible on histological slides of the retina.

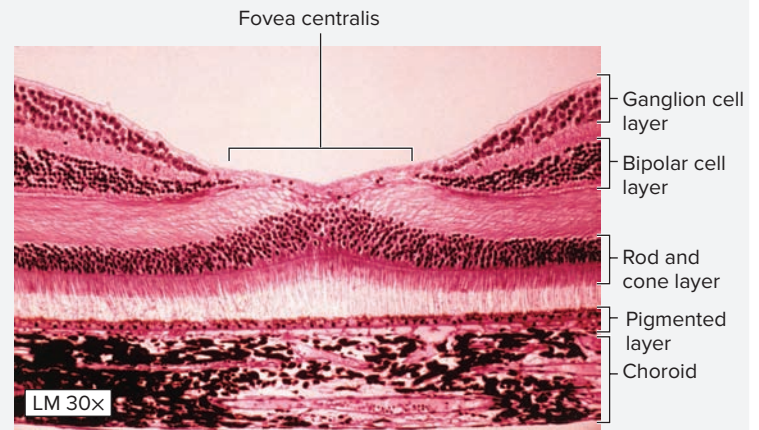
1. Obtain a histology slide of the retina and place it on the microscope stage.
2. Bring the tissue sample into focus on low power, then move the microscope stage so the retina (figure 15.6) is in the center of the field of view. Switch to medium power and bring the tissue sample into focus once again.
3. Identify the listed structures on the slide of the retina, using table 15.5 and figure 15.6 as guides. (High power may be required to view all of the structures or to see them in greater detail.)

- |  |   |
|--|---|
| <input type="checkbox"/> bipolar cell layer  | <input type="checkbox"/> pigmented layer    |
| <input type="checkbox"/> choroid             | <input type="checkbox"/> rod and cone layer |
| <input type="checkbox"/> ganglion cell layer | <input type="checkbox"/> sclera             |

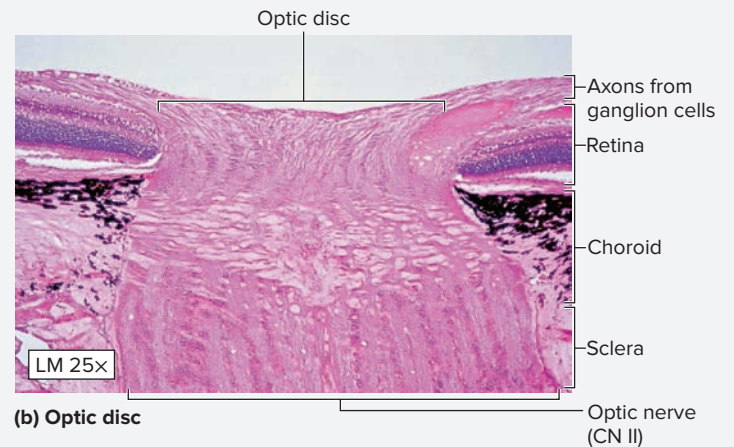
4. With the medium-power objective in place, scan the slide and locate the **fovea centralis** (figure 15.7a). The fovea centralis is a thinner than normal area of the retina. The fovea centralis contains photoreceptor cells and is devoid of bipolar and ganglion cell layers. This area has the highest concentration of cones of the entire retina, thus it is the area of highest visual acuity. When we focus our gaze on an object of interest, we turn our heads so the light entering the eye focuses on the fovea centralis to generate the sharpest image of the object.
5. Scan the slide and locate the **optic disc**, the location where the optic nerve leaves the eye (figure 15.7b). The optic disc (blind spot) is easily identifiable because all retinal layers are absent at this location. Notice that the optic disc and optic nerve are approximately the same texture and color as the cells in the ganglion cell layer of the retina. This becomes helpful in understanding that the ganglion cell layer, the optic disc, and the optic nerve all contain parts of the axons of ganglion cells. The axons of the ganglion cell layer leave the eye at the optic disc and extend from the eye to the brain as the optic nerve. Axons of the optic nerve are the only portion of the ganglionic axons that are myelinated.
6. Sketch the retina as seen through the microscope in the space provided. Label the following layers: rod and cone layer, bipolar cell layer, and ganglion cell layer.



7. **Optional Activity:** **APR** **Nervous System**—Watch the “Vision” animation to learn the sequence of events involved in vision and the functions of cells in the retina.



(a) Fovea centralis



(b) Optic disc

**Figure 15.7 Specialized Areas of the Neural Tunic of the Eye.**

(a) The fovea centralis is the area of the retina where visual acuity is the highest. Ganglion and bipolar cell layers are absent, and there is an abundance of cones in the photoreceptor layer. (b) The optic disc is the area of the retina where the axons of ganglion cells exit the retina to become the optic nerve. There are no rods or cones in this area, which is why the optic disc is also referred to as the “blind spot” of the retina.

(a) © Gene Cox/Science Source; (b) © Victor P. Eroschenko

**WHAT DO YOU THINK?**

- 3 The optic disc is referred to as the “blind spot” of the eye. Based on your histological observation of the optic disc, explain why this is the case.

**EXERCISE 15.6** Hearing

Hearing is a function of the **cochlea**. This special sensory organ is located within the petrous part of the temporal bone. The gross anatomy section of this chapter focuses on the location, gross structure, and function of this organ. This section of the chapter focuses on the histological features of the highly specialized epithelium that lines the cochlea, the **spiral organ** (organ of Corti), which will provide insight into how this organ performs its function: transforming sound waves into nerve signals that can be interpreted by the brain.

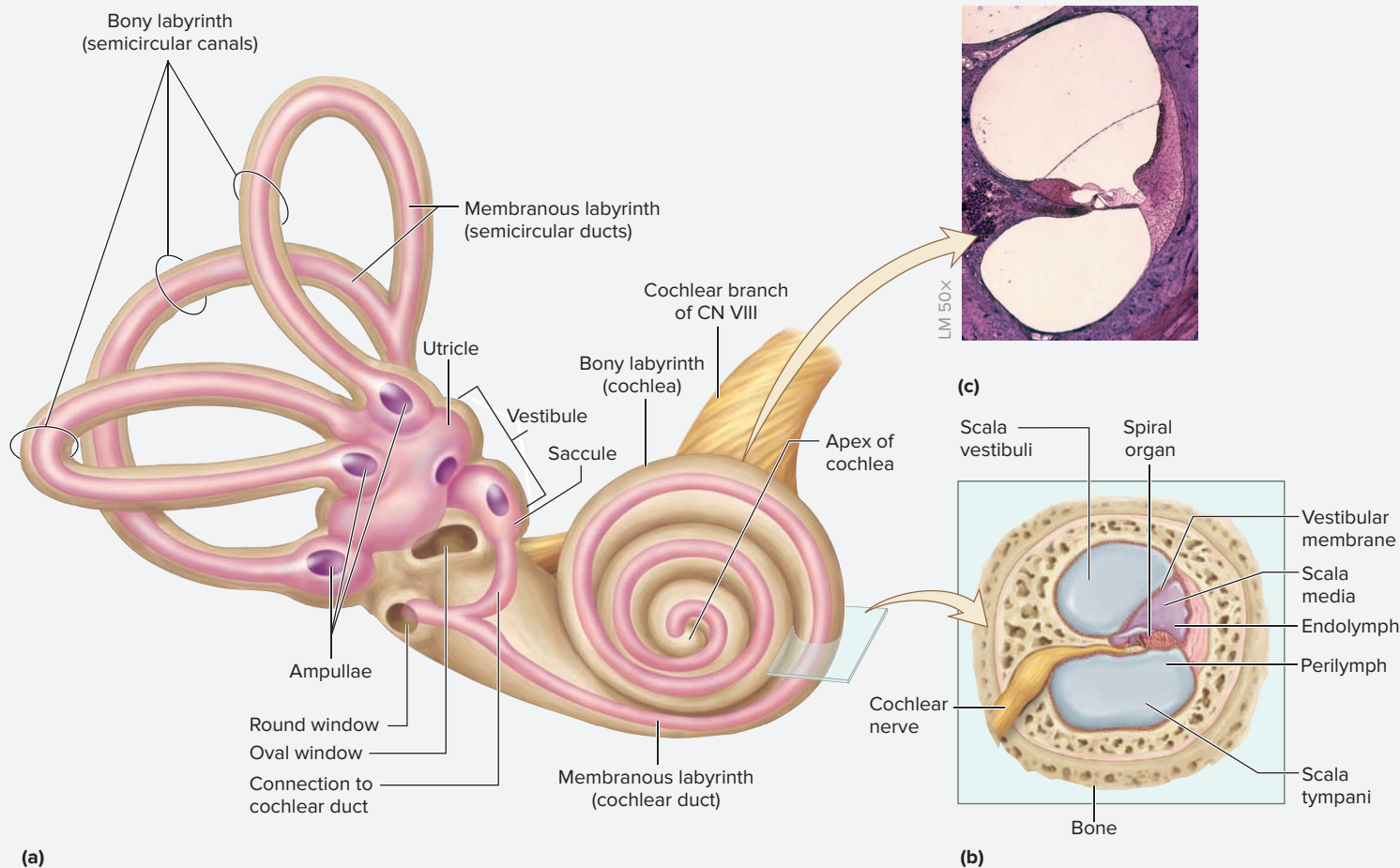
The cochlea (**figure 15.8**) is the organ responsible for transducing fluid vibrations received at the oval window into nerve signals that are sent to the thalamus and then on to the **temporal lobe** of the brain, where they are interpreted. Within the cochlea, the spiral organ (organ of Corti) sits upon the **basilar membrane**, within the **scala media** (cochlear duct). The scala media is surrounded by the **scala tympani** and **scala vestibuli** (**table 15.6**). As the basilar membrane vibrates due to movement of the fluid (perilymph) in the scala tympani, the sensory cells attached to the basilar membrane also vibrate. Cilia of the **hair cells** of the cochlea are embedded in the immobile **tectorial membrane** that lies above them. Thus, vibrations of the basilar membrane cause the cilia to bend. As the cilia bend, nerve signals (action potentials) are generated by the hair cells. These

action potentials are transmitted to the brain by the **cochlear branch** of the **vestibulocochlear nerve (CN VIII)**. The fluid vibrations are eventually dampened when vibrations of the perilymph reach the **round window** at the end of the scala tympani.

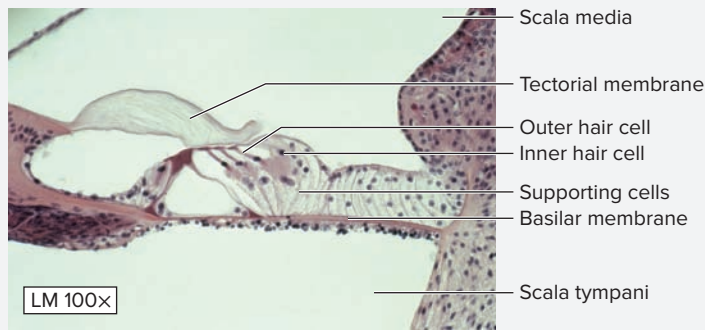
1. Obtain a slide of the *cochlea* (**figure 15.9**) and place it on the microscope stage. Bring the tissue sample into focus on low power and then increase the magnification. Move the microscope stage until a single cross section through the cochlea is in the center of the field of view.
2. Identify the three chambers within the cochlea and the membranes that separate the chambers from each other listed here, using figures 15.8 and 15.9 and table 15.6 as guides:

- |  |  |
|--|--|
| <input type="checkbox"/> basilar membrane            | <input type="checkbox"/> scala tympani       |
| <input type="checkbox"/> scala media (cochlear duct) | <input type="checkbox"/> scala vestibuli     |
|  | <input type="checkbox"/> vestibular membrane |

3. Once the *scala media* (cochlear duct) has been identified, move the microscope stage so the scala media is in the center of the field of view. Increase the magnification to high power and focus in on the *spiral organ* (organ of Corti) (**figure 15.9**).



**Figure 15.8** The Cochlea. (a) The semicircular canals and cochlea are part of the inner ear. (b) The cochlea houses the spiral organ, which contains specialized cells that translate sound waves into sensory impulses. (c) Light micrograph demonstrating a cross section through the cochlea.



4. Identify the listed structures on the slide of the cochlea, using table 15.6 and figure 15.9 as guides:

- basilar membrane
- cochlear nerve
- endolymph
- hair cells (sensory cells)
- perilymph
- scala media
- scala tympani
- scala vestibuli
- spiral ganglion
- tectorial membrane
- vestibular membrane

**Figure 15.9** Histology of the Spiral Organ.

© Biophoto Associates/Science Source

Table 15.6		The Cochlea	
Structure	Description	Function	Word Origins
<b>Basilar Membrane</b>	Forms the floor of the scala media and supports the cells of the spiral organ.	Vibrates in response to fluid vibrations of the perilymph in the scala tympani.	<i>basalis</i> , situated near the base + <i>membrana</i> , a membrane
<b>Endolymph</b>	Fluid within the scala media (cochlear duct) that has a composition similar to that of intracellular fluid (high in potassium).	Nourishes the epithelial cells of the spiral organ.	<i>endon</i> , within + <i>lymph</i> , a clear fluid
<b>Hair Cells (Sensory Cells)</b>	Highly specialized epithelial cells of the spiral organ that contain stereocilia, which embed in the tectorial membrane.	Bending of the stereocilia generates action potentials in the hair cells; axons of sensory cells project into the spiral ganglion and synapse with neurons that relay the signals to the brain.	<i>sensus</i> , to sense
<b>Helicotrema</b>	An opening at the end of the cochlea that is shaped like a half moon.	Allows perilymph from the scala tympani to communicate with perilymph from the scala vestibuli.	<i>helix</i> , a spiral + <i>trema</i> , a hole
<b>Perilymph</b>	Fluid contained within the scala vestibuli and scala tympani that has a composition similar to that of extracellular fluid (high in sodium).	Transmits pressure waves through the scala tympani and scala vestibuli; vibrations of the stapes at the oval window create the vibrations, and they are dampened when they reach the round window.	<i>peri-</i> , around + <i>lymph</i> , a clear fluid
<b>Scala Media (Cochlear Duct)</b>	Middle chamber of the cochlea, containing the spiral organ and filled with endolymph.	Contains the special sensory organ of sound, the spiral organ.	<i>scala</i> , a stairway + <i>medialis</i> , middle
<b>Scala Tympani</b>	Chamber inferior to the scala media; filled with perilymph.	Transmits pressure waves of the perilymph from the helicotrema to the round window.	<i>scala</i> , a stairway + <i>tympani</i> , relating to the tympanic membrane
<b>Scala Vestibuli</b>	Chamber superior to the scala media; filled with perilymph.	Transmits pressure waves of the perilymph from the oval window to the helicotrema.	<i>scala</i> , a stairway + <i>vestibulum</i> , entrance court
<b>Spiral Ganglion</b>	Nerve ganglion located on the cochlear part of the auditory nerve.	Contains the cell bodies of bipolar neurons, which receive input from sensory cells of the spiral organ and then relay those signals to the brain.	<i>spiralis</i> , a coil + <i>ganglion</i> , a swelling or knot
<b>Spiral Organ (Formerly Organ of Corti)</b>	Composed of specialized epithelium that sits on the basilar membrane; the epithelium is composed of sensory cells and supporting cells.	Special inner and outer sensory cells have stereocilia embedded in the tectorial membrane; when the basilar membrane vibrates, the stereocilia bend and the sensory cells send action potentials to the brain.	<i>spiralis</i> , a coil + <i>organum</i> , a tool, instrument
<b>Tectorial Membrane</b>	Gelatinous membrane in which the cilia of hair cells of the spiral organ are embedded.	Does not vibrate itself, but when the basilar membrane vibrates, the cilia of the hair cells embedded in the tectorial membrane bend, causing the hair cells to generate action potentials.	<i>tectus</i> , to cover + <i>membrana</i> , a membrane
<b>Vestibular Membrane</b>	Thin membrane between the scala vestibuli and the scala media.	Forms a partition separating endolymph within the scala media from perilymph within the scala vestibuli.	<i>vestibulum</i> , relating to the vestibule + <i>membrana</i> , a membrane
<b>Vestibulocochlear Nerve (CN VIII)</b>	Cranial nerve arising from axons of sensory cells of the spiral organ and from the vestibular apparatus.	Transmits sound information to the brain.	<i>vestibulum</i> , relating to the vestibule + <i>cochlea</i> , snail shell

(continued on next page)

(continued from previous page)

5. Sketch a cross section through the cochlea in the space provided. Label the locations of the structures listed in step 4 on the sketch.



\_\_\_\_\_ ×

## Gross Anatomy

### General Senses

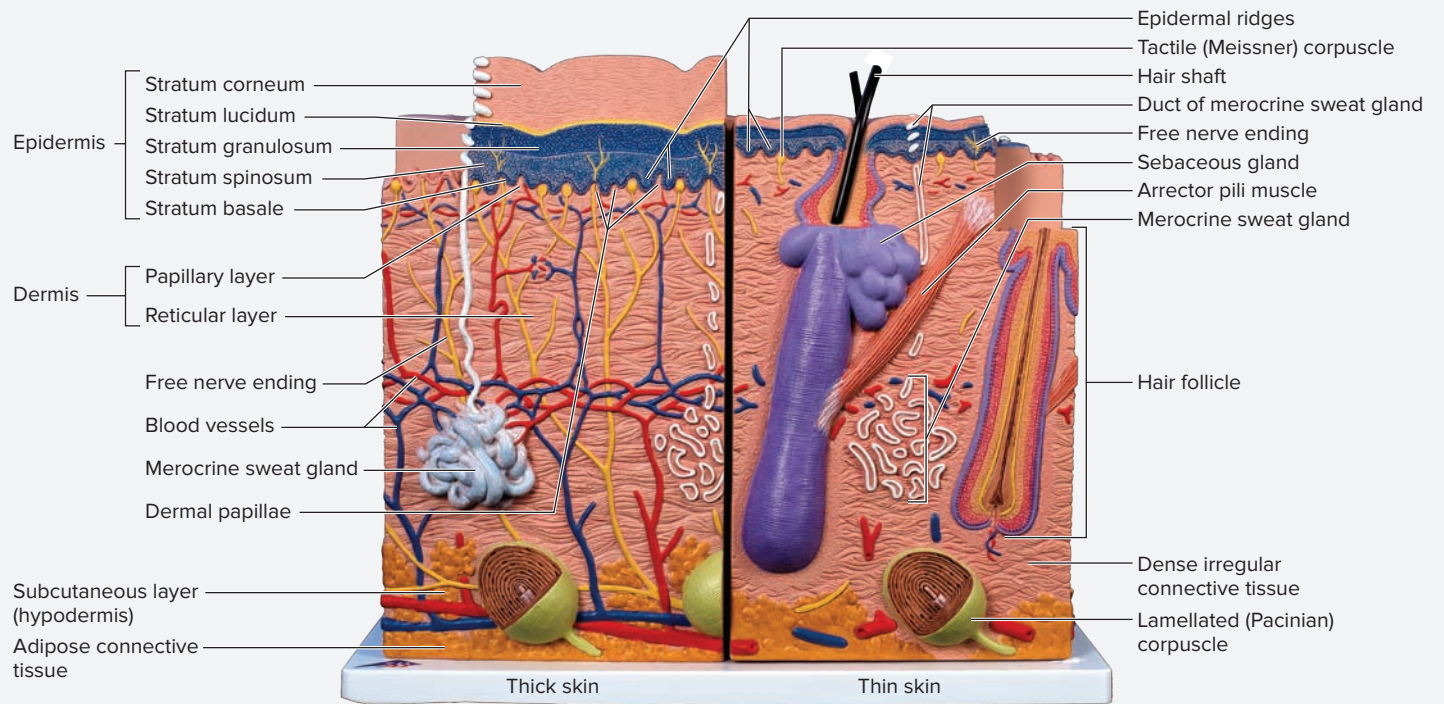
The definitions of general senses and special senses are described at the beginning of the histology section of this chapter. If starting laboratory observations with the gross anatomy exercises, read the introduction to general senses on page 302 before proceeding.

Most sensory receptors responsible for general sensation (things such as: touch, pain, pressure, temperature) are located in the skin. Exercise 15.7 involves observing a classroom model of the skin, with a special emphasis placed on observing sensory receptors located within the skin.

### EXERCISE 15.7 Sensory Receptors in the Skin

1. Observe a classroom model of thick skin (**figure 15.10**). Some somatic sensory receptors in the skin, such as tactile discs and free nerve endings, are too small to view under the microscope. Therefore, these structures will be observed on classroom models.
2. Locate a tactile disc. **Tactile discs** (Merkel discs) are located at the dermal/epidermal junction of thick skin, although their location is not restricted to dermal papillae, unlike tactile corpuscles. The function of tactile discs is the sensation of light touch.
3. Find some free nerve endings on the skin model. **Free nerve endings** are just that—nerve endings with no specialized cells surrounding them. The ends of these neurons are located near the dermal/epidermal junction, with many of them extending into the epidermis. They also have endings in hair follicles and glands. Free nerve endings function in

the sensation of sustained touch, temperature, itching, and pain. Recall a time when you had a blister that ripped open. A blister is created when the dermis separates from the epidermis, and fluid accumulates between the layers. When the epidermis is removed from a blister, it is very painful! Why? The free nerve endings in the dermis are now exposed to the environment, and this causes them to generate action potentials. This is why large superficial wounds (“scrapes”) on the skin are much more painful than deep wounds. A deep wound is perceived as a more severe wound (as it typically is), but is often confusing because it causes less pain than a more superficial wound. The greater the surface area exposed, the greater the number of nerve endings stimulated. Hence the common exclamation, “It’s only a scrape, but it hurts like crazy!”




**Figure 15.10 Skin.** Model of the skin demonstrating sensory receptors such as free nerve endings and lamellated corpuscles.

Model # J16 [1000294] © 3B Scientific GmbH, Germany, 2013 www.3bscientific.com/Photo by Christine Eckel, Ph.D.

4. Identify the listed structures on a model of the skin, using figure 15.10, table 15.1, and the textbook as guides:

- dermal papillae
- free nerve endings
- lamellated corpuscle
- papillary dermis
- reticular dermis
- stratum basale
- stratum corneum
- stratum granulosum
- stratum lucidum
- stratum spinosum
- tactile corpuscle
- tactile disc

5. Sketch thick skin in the space provided. Label the locations of the sensory receptors listed in table 15.1.





## Special Senses

The definitions of general senses and special senses are described at the beginning of the histology section of this chapter. If starting laboratory observations with the gross anatomy exercises, read the introduction

to special senses on page 304 before proceeding. The gross anatomy exercises in this section focus on two special sensory organs: the eye and the ear.

### EXERCISE 15.8 Gross Anatomy of the Eye

This laboratory exercise explores the accessory structures of the eye. Identify all structures listed in **table 15.7** on a classroom model or on yourself. Subsequent exercises will explore internal

structures of the eye and structure and function of both external and internal structures of a cow eye.

**Table 15.7** Accessory Structures of the Eye

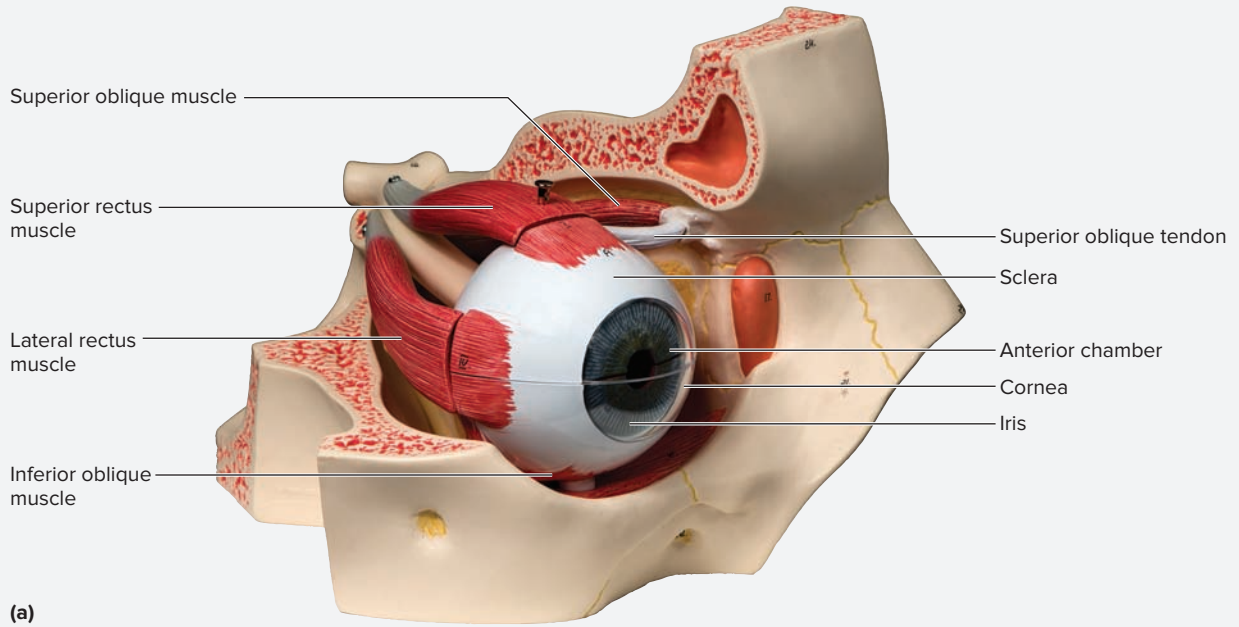
Structure	Description	Function	Word Origin
<i>Cornea</i>	Transparent tissue on the anterior surface of the eye consisting of an external layer of stratified squamous epithelium, a middle layer of regularly arranged collagen fibers, and an inner layer of endothelium.	The primary structure used to refract (bend) light waves in the eye.	<i>corneus</i> , horny
<i>Extrinsic Eye Muscles</i>	Muscles that originate from a common tendinous ring and insert on the sclera of the eye.	Responsible for movement of eye within the orbit.	<i>extrinsecus</i> , on the outside + <i>oculus</i> , eye
<i>Fibrous Tunic</i>	Tough outer connective tissue covering of the eye, composed of the sclera and cornea.	Included elsewhere in this table, for sclera and cornea.	<i>fibro</i> , fiber + <i>tunic</i> , a coat
<i>Lacrimal Caruncle</i>	Small, fleshy mound of tissue at the medial aspect of the eye containing ciliary glands (modified sweat glands) and tarsal glands.	Ciliary glands that form secretions to lubricate eyelashes.	<i>lacrima</i> , a tear + <i>caruncula</i> , a small fleshy mass
<i>Lacrimal Gland</i>	Almond-shaped serous gland located in the superior and lateral aspect of the orbit.	Secretes tears.	<i>lacrima</i> , a tear
<i>Lacrimal Puncta</i>	Two small openings in the lacrimal caruncle; the tiny holes on the “bump” at the inferomedial aspect of the eye.	Opening for the drainage of lacrimal fluid into the lacrimal sac.	<i>lacrima</i> , a tear + <i>punctum</i> , a prick or point
<i>Lacrimal Sac</i>	A swelling at the superior part of the nasolacrimal duct, medial to the lacrimal bone, lateral to the nasal bone, and deep to the maxilla.	Receives lacrimal fluid from the lacrimal canals and transports it to the nasolacrimal duct.	<i>lacrima</i> , a tear
<i>Nasolacrimal Duct</i>	A duct that runs from the lacrimal sac into the nasal cavity.	Conducts lacrimal fluid from the lacrimal sac into the nasal cavity.	<i>nasal</i> , relating to the nose + <i>lacrima</i> , a tear + <i>ductus</i> , to lead
<i>Optic Nerve</i>	CN II; a large nerve exiting the posteromedial region of the eye that exits the orbit through the optic foramen; consists of myelinated axons of ganglion cells.	Transmits nerve signals from the eye to the brain.	<i>optikos</i> , relating to the eye or vision
<i>Orbital Fat Pad</i>	A thick capsule of adipose connective tissue that fills in all the spaces between the eye, extrinsic eye muscles, nerves, and orbit.	Cushions the eye and helps support and hold it in place.	<i>orbital</i> , relating to the orbit of the eye
<i>Sclera</i>	Dense irregular connective tissue that surrounds the entire eye except for the eye’s anterior surface where the cornea is located.	Protects the eye, serves as an attachment point for extrinsic eye muscles, and helps maintain the round shape of the eye.	<i>skleros</i> , hard

**EXERCISE 15.8A: Accessory Structures of the Eye**

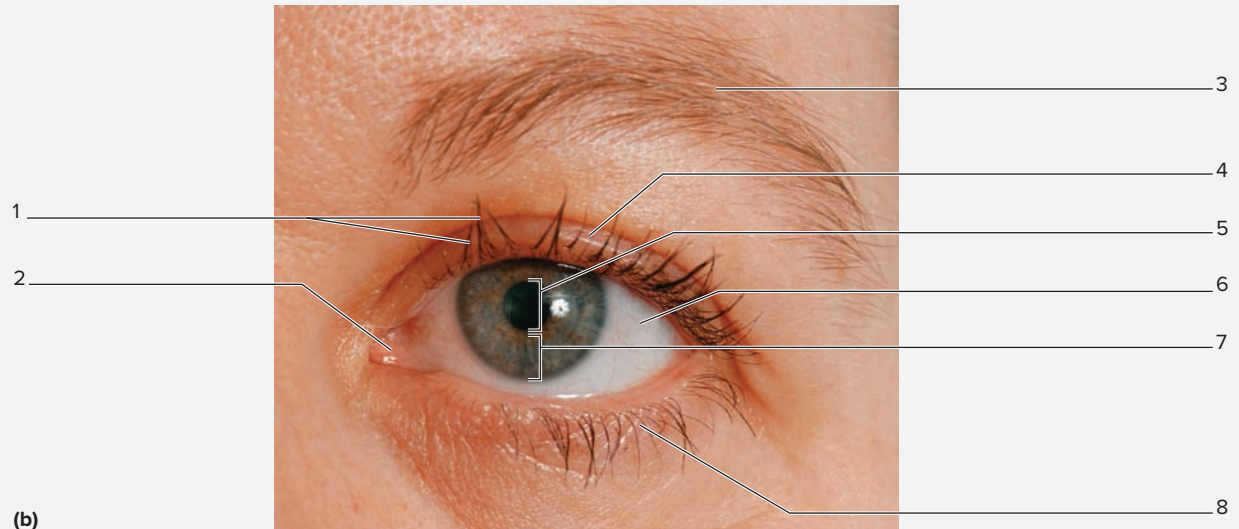
1. Observe a classroom model of the eye (**figure 15.11a**).
2. Identify the listed structures on a model of the eye, using figure 15.11, table 15.7, and the textbook as guides:

- |   |  |
|---|--|
| <input type="checkbox"/> cornea         | <input type="checkbox"/> optic disc (“blind spot”) |
| <input type="checkbox"/> iris           | <input type="checkbox"/> optic nerve               |
| <input type="checkbox"/> lacrimal gland | <input type="checkbox"/> sclera                    |

3. Obtain a mirror and observe the externally visible structures of your eye. If you have no mirror, perform this observation on a lab partner. Identify all of the structures listed in figure 15.11 on your eye (or a lab partner’s eye), using table 15.7 and the textbook as guides. Then label them in figure 15.11b.



(a)



(b)

**Figure 15.11** Accessory Structures of the Eye. (a) Anterolateral view. (b) Internal view.

(a) Model # F13 [1000258] © 3B Scientific GmbH, Germany, 2015 www.3bscientific.com/Photo by Christine Eckel, Ph.D.; (b) © McGraw-Hill Education/JW Ramsey

(continued from previous page)

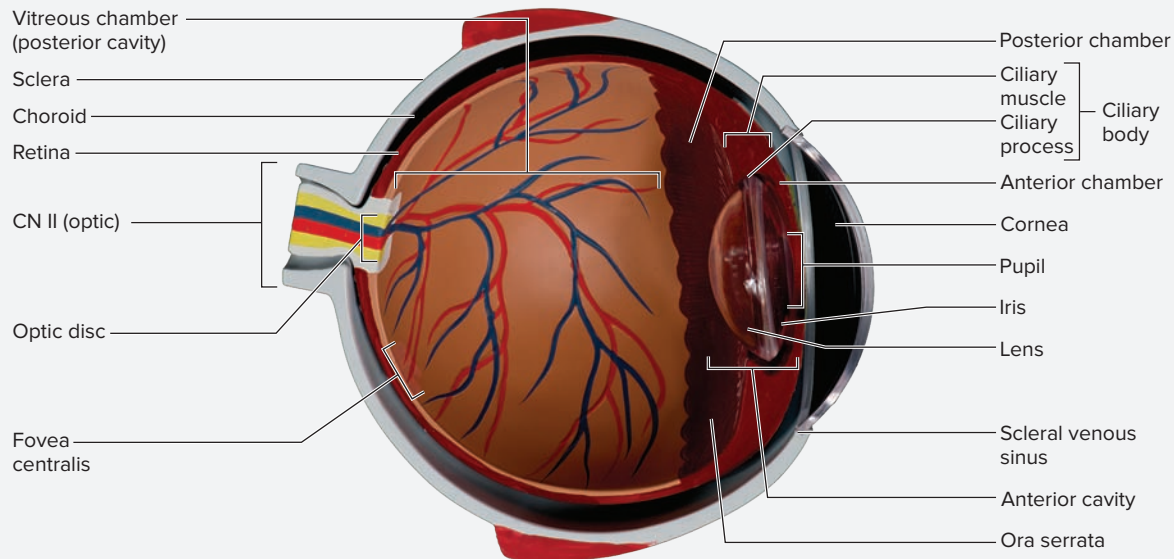
### EXERCISE 15.8B: Internal Structures of the Eye

The internal structures of the eye (**table 15.8**) are structures that function in the transmission of light, nourishment of the eye, and the processing of visual information.

1. Observe a classroom model of the eye where internal structures are visible (**figure 15.12**). Many classroom models of the eye contain both external and internal eye structures. Viewing internal eye structures may require disassembly of the eye model to access the structures.

2. Identify the following structures on the model of the eye, using figure 15.12, table 15.8, and the textbook as guides:

- |   |  |
|---|--|
| <input type="checkbox"/> anterior cavity  | <input type="checkbox"/> fovea centralis |
| <input type="checkbox"/> anterior chamber | <input type="checkbox"/> iris            |
| <input type="checkbox"/> choroid          | <input type="checkbox"/> lens            |
| <input type="checkbox"/> ciliary body     |  |



**Figure 15.12** Classroom Model of the Internal Eye.

Model # F15 [1000259] © 3B Scientific GmbH, Germany, 2015 www.3bscientific.com/Photo by Christine Eckel, Ph.D.

### EXERCISE 15.9 Cow Eye Dissection

This exercise explores the anatomy of the eye, using a cow eye as a model organ. Although there is some variance in structure between a cow eye and a human eye, cow eyes are much easier to obtain and they are larger, which greatly facilitates making internal observations of the eye. This exercise is designed to be done using fresh cow eyes, although preserved cow or pig eyes may be substituted if necessary. If dissecting a preserved cow or pig eye, the tissues will be tougher and the cornea will be opaque instead of transparent.

1. Obtain a dissecting pan, dissecting tools, and a fresh cow eye. Observe the gross structure of the eye before making any cuts. Identify the listed structures, using tables 15.7 and 15.8 and **figure 15.13a** as guides:

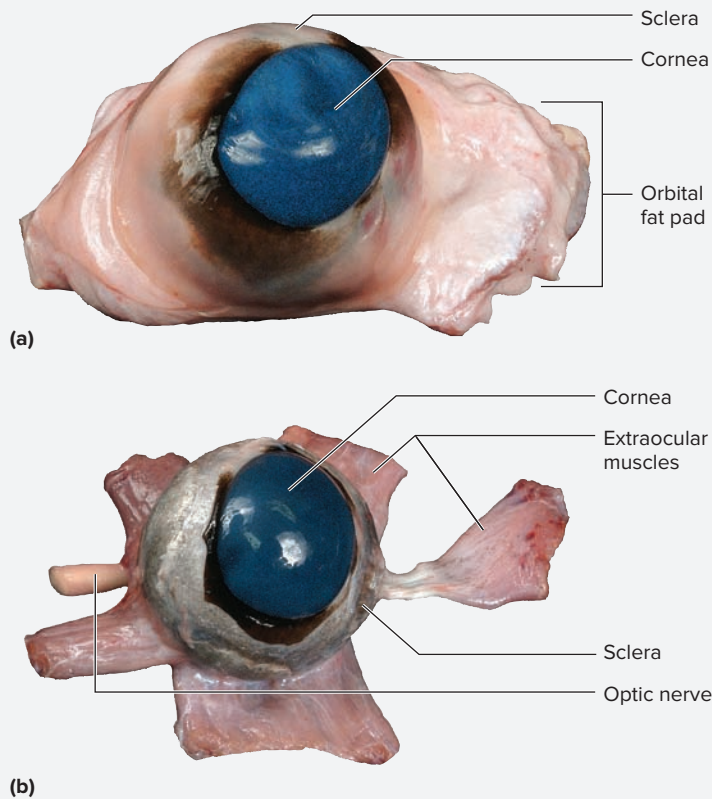
- cornea
- extrinsic muscles
- optic nerve
- orbital fat pad
- sclera



2. Using scissors and forceps (the tissue will be slippery!), remove the orbital fat pad and extraocular

muscles, leaving the optic nerve intact (**figure 15.13b**). Once these structures have been removed, the entire eye should be visible. Notice the toughness of the outer covering or **sclera** of the eye. This is the layer of tissue to cut through in order to see structures within the eye.

3. Using scissors and forceps, cut the eye open by making a coronal incision through the sclera that completely encircles the eye. Once this has been done, notice that a jellylike fluid oozes out of the posterior cavity of the eye. This fluid is the **vitreal humor** which fills the **posterior cavity (figure 15.14b)**. This fluid's functions include holding the retina against the posterolateral walls of the eye. In the cow eye, much of the **choroid**, which contains black pigment, becomes mixed into the vitreal humor once the eye is cut open. Thus, it has the potential to create a gooey, black mess almost immediately. Before things get too "mixed up," identify structures in the posterior half of the dissected eye. Look for a yellowish, thin membrane that is connected to the posterior of the eye at only one spot (**figure 15.14a**). This is the retina. The retina contains neurons responsible for detecting visual stimuli and initiating nerve signals to the brain (histology

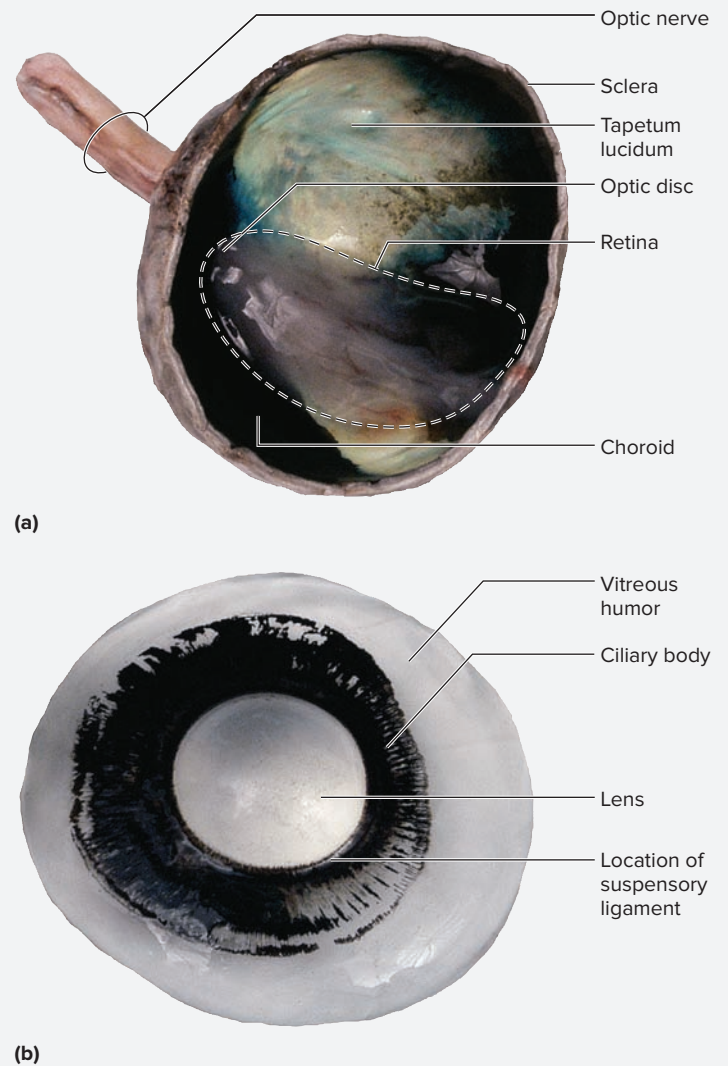


**Figure 15.13** Fresh Cow Eye. (a) Before dissection with orbital fat pad intact. (b) After dissecting away the orbital fat pad to expose the extraocular muscles and optic nerve.

© McGraw-Hill Education/Photos and Dissections by Christine Eckel

of the retina was covered in detail in exercise 15.5). The retina is very delicate and easily falls away from the posterior wall of the eye when the vitreous humor is not present to hold it in place.

- Find the location where the retina attaches to the posterior wall of the eye (it will “pucker” in this area). If you have difficulty finding this spot, first find the optic nerve on the outside of the eye and then look inside the eye for the location where the optic nerve leaves the eye. This spot within the eye is the optic disc (blind spot). It is called a “blind” spot because it is devoid of photoreceptors. This is where axons from the ganglion cell layer of the retina (see exercise 15.5) leave the eye and travel through the brain via the optic nerve (CN II).
- Observe the inner walls of the posterior half of the eye. Notice the very colorful, iridescent **tapetum lucidum** (figure 15.14a). This structure is not present in humans, but it is present in animals that must be able to see well in dim light. The tapetum lucidum reflects light. Thus, when it is dark outside and very little light is entering the eye, the tapetum lucidum causes light waves to bounce around within the eye and increases the frequency with which light rays stimulate the retina. This makes things more visible, but the image does not become sharper. It is the reflection of light waves from the tapetum lucidum that causes a cat’s eyes (or those of other animals) to “glow” when a light shines on them at night. The next time you are out at night, notice that this does not happen in



**Figure 15.14** Coronal Sections of Cow Eye. (a) Posterior part demonstrating the retinal, optic disc, and tapetum lucidum. (b) Anterior part demonstrating the choroid, lens, and iris.

© McGraw-Hill Education/Photos and Dissections by Christine Eckel

humans. In humans, the inside of the eye is completely coated with a black choroid, which absorbs excess light. This makes it more difficult for us to see things in the dark. On the plus side, the images seen by humans are sharper.

- Now focus on the anterior portion of the eye (figure 15.14b). Again, it may be somewhat difficult to see many structures because the choroid covers everything, making the structures very dark. Notice the semitransparent **lens**, which is suspended in place by a ring of black-colored tissue. This tissue is the **ciliary body**, whose function is to suspend the lens. The cavity anterior to the lens and posterior to the cornea is the **anterior cavity** of the eye. The anterior cavity is further subdivided by the iris into an **anterior chamber** (between the cornea and the iris) and a **posterior chamber** (between the iris and the lens). In a living organism, the anterior cavity is filled with a clear, watery fluid called **aqueous humor**. Try to find the fine, delicate structures composing the **suspensory ligament**, which runs between the ciliary body and the lens.

(continued on next page)

(continued from previous page)

<b>Table 15.8 Internal Structures of the Eye</b>			
<b>Structure</b>	<b>Description</b>	<b>Function</b>	<b>Word Origin</b>
<i>Anterior Cavity</i>	The space anterior to the lens and posterior to the cornea. It is subdivided by the iris into the anterior and posterior chambers.	Filled with aqueous humor.	<i>anterior</i> , the front surface + <i>cavus</i> , hollow
<i>Anterior Chamber</i>	The space between the cornea and the iris.	Filled with aqueous humor, as described elsewhere in this table.	<i>anterior</i> , the front surface + <i>camera</i> , an enclosed space
<i>Aqueous Humor</i>	Watery fluid, similar in composition to cerebrospinal fluid. It is secreted by the ciliary processes and circulates within the anterior and posterior chambers of the eye.	Provides nourishment to the avascular lens and cornea.	<i>aqueous</i> , watery + <i>humor</i> , fluid
<i>Choroid Layer</i>	The pigmented, vascular layer located between the retina and the sclera.	Blood vessels of the choroid supply nutrients to the tissues of the retina and sclera; pigment in the choroid absorbs light after it passes through the retina.	<i>choroideus</i> , like a membrane
<i>Ciliary Body</i>	The thickened extension of the vascular tunic, located between the choroid and the iris; composed of both the ciliary process and the ciliary muscle.	Produces aqueous humor; contraction of the ciliary muscle within the ciliary body alters the shape of the lens.	<i>cilium</i> , eyelid + <i>bodig</i> , a thing or substance
<i>Ciliary Muscle</i>	Smooth muscle found within the ciliary body that is composed of both circular and radial fibers.	Contraction of this muscle relaxes the suspensory ligaments that attach it to the lens, which increases the lens curvature to accommodate for near vision.	<i>cilium</i> , eyelid
<i>Fovea Centralis</i>	The depression (“central pit”) in the macula lutea that contains only cones and lacks blood vessels.	The area of highest visual acuity in the eye.	<i>fovea</i> , a pit + <i>centralis</i> , in the center
<i>Iris</i>	The colored portion of the eye, which makes up the anterior portion of the vascular tunic; the dilator pupillae and sphincter pupillae muscles are located within the iris.	Controls the amount of light entering the eye. Contraction of the radially arranged dilator pupillae muscle (under sympathetic stimulation) increases pupil diameter, whereas contraction of the circularly arranged sphincter pupillae muscle (under parasympathetic stimulation) decreases the diameter of the pupil.	<i>iris</i> , rainbow
<i>Lens</i>	A transparent, biconvex structure composed of a highly specialized, modified epithelium.	Bends light waves (refraction) so that they hit the retina optimally for clear vision.	<i>lens</i> , a lentil
<i>Macula Lutea</i>	A “yellow spot” on the retina located medial to the optic disc on the posterior wall of the eye, which contains the fovea centralis within it.	Contains the fovea centralis.	<i>macula</i> , a spot + <i>luteus</i> , yellow
<i>Optic Disc (“Blind Spot”)</i>	An area of the retina where there is an absence of photoreceptors because it is where the axons of ganglion cells exit the eye to become the optic nerve.	The location where axons of ganglion cells exit the eye.	<i>optikos</i> , the eye + <i>discus</i> , disc
<i>Ora Serrata</i>	Antermost portion of the retina, which appears serrated (hence the name).	Demarcates the division of the visual retina from the nonvisual retina.	<i>ora</i> , an edge + <i>serratus</i> , a saw
<i>Posterior Cavity (Vitreous Chamber)</i>	A space posterior to the lens and anterior to the retina.	Occupied by the vitreous humor, which is described elsewhere in this table.	<i>vitreus</i> , glassy + <i>camera</i> , an enclosed space
<i>Posterior Chamber</i>	The space between the lens and the iris.	Filled with aqueous humor, as described elsewhere in this table.	<i>posterior</i> , the back surface + <i>camera</i> , an enclosed space
<i>Pupil</i>	The space (opening) in the center of the iris.	The size of the pupil (which is controlled by the smooth muscle within the iris) determines the amount of light entering the eye.	<i>pupilla</i> , pupil
<i>Retina</i>	Also called the neural tunic of the eye; it is the inner layer of the eye composed of a pigmented layer, rods, cones, bipolar cells, and ganglion cells.	Transduces light that enters the eye as light waves into nerve signals (action potentials) that are interpreted by the brain.	<i>rete</i> , a net
<i>Suspensory Ligaments</i>	Ligaments that extend between the ciliary muscles and the lens.	Attaches the lens to the ciliary muscles so that contraction and/or relaxation of ciliary muscles can alter the shape of the lens.	<i>suspensio</i> , to hang up + <i>ligamentum</i> , a bandage
<i>Tapetum Lucidum</i>	Metallic-appearing, opalescent inner layer of the sclera; present in many animals (e.g., the cow eye) but not in humans.	Scatters light waves within the eye; allows for better vision in dim limited light (humans do not have this layer).	<i>tapeta</i> , a carpet + <i>lucidus</i> , clear
<i>Vascular Tunic</i>	Middle layer of the wall of the eye; consists of the choroid, the ciliary body, and the iris.	Provides nourishment to structures within the eye.	<i>vasculum</i> , a small vessel
<i>Vitreous Humor</i>	Clear, gelatinous mass within the vitreous chamber (posterior cavity).	Helps maintain the round shape of the eye and is critical in keeping the retina against the wall of the eye.	<i>vitreus</i> , glassy + <i>humor</i> , fluid

- Carefully remove the lens from the eye. Notice that it is somewhat, but not completely transparent. Place the lens on a piece of paper containing text. As shown in **figure 15.15**, with the lens over a letter or two of text, note change in appearance of the text, if any, as seen through the lens. What happens?
- Identify the listed structures on the interior of the dissected cow eye (use tables 15.7 and 15.8 and figures 15.13 through 15.15 as guides):

- |  |  |
|--|--|
| <input type="checkbox"/> anterior cavity | <input type="checkbox"/> posterior cavity    |
| <input type="checkbox"/> choroid         | <input type="checkbox"/> retina              |
| <input type="checkbox"/> ciliary body    | <input type="checkbox"/> suspensory ligament |
| <input type="checkbox"/> lens            | <input type="checkbox"/> tapetum lucidum     |
| <input type="checkbox"/> optic disc      | <input type="checkbox"/> vitreous humor      |

- When finished with the dissection, clean up the workspace: Dispose of the cow eye debris in the organic waste receptacle. Dispose of used scalpel blades in the sharps container. Dispose of used paper towels and other paper waste in the wastebasket. Rinse off the dissecting tray and dissection instruments, and lay them out to dry. Finally, wipe down the laboratory workstation with disinfectant so it is clean for the next person who comes into the laboratory.



**Figure 15.15** Lens. After removing the lens from the cow eye, place it over some text to see how it changes the image of the text.

© Christine Eckel

**WHAT DO YOU THINK?**

- An individual who suffers a strong blow to the head may end up with a detached retina that causes visual problems. Why do you think the retina easily detaches from the posterior wall of the eye? What structure normally holds the retina in place?

**EXERCISE 15.10** Gross Anatomy of the Ear

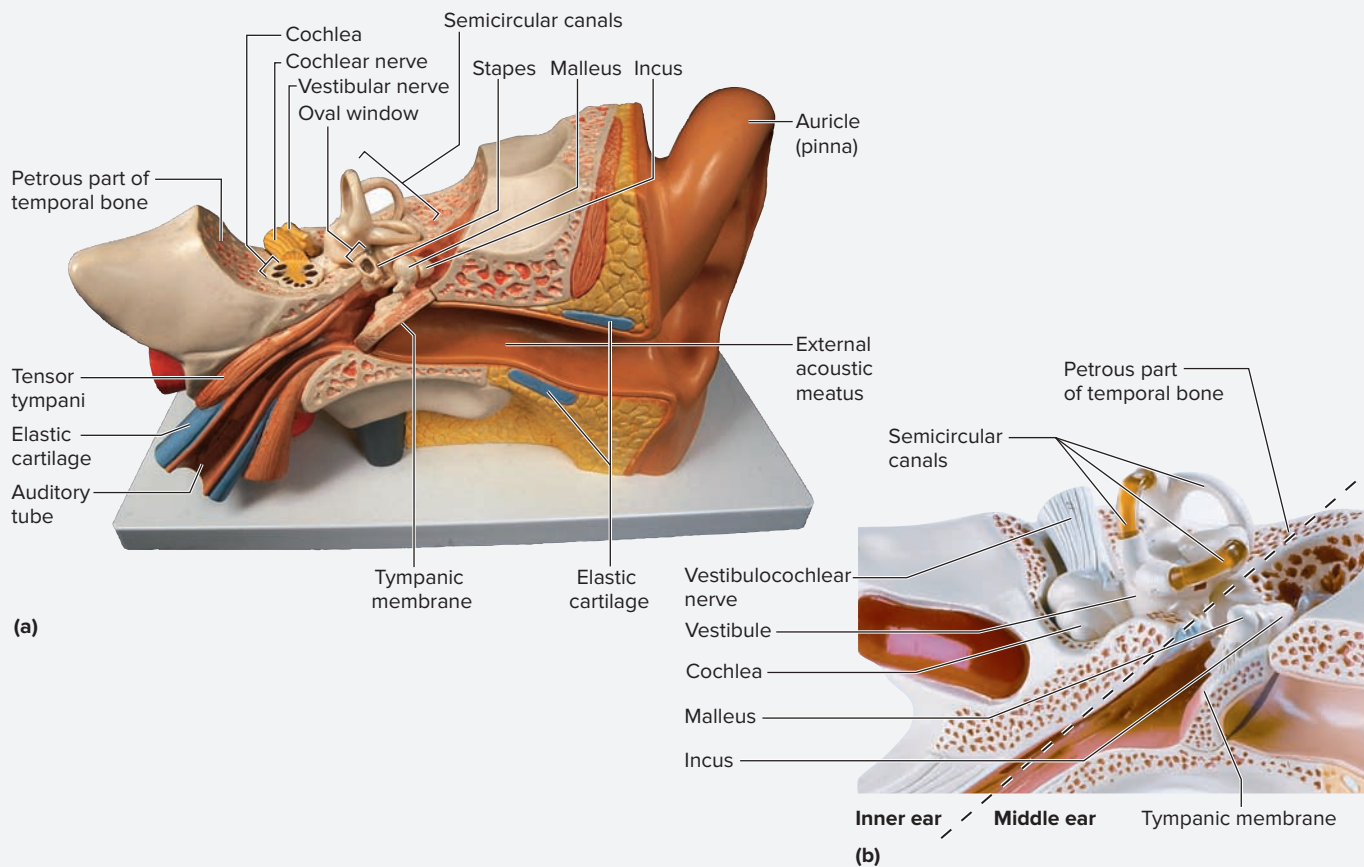
The ear is responsible for two important special sensory modalities: equilibrium (balance) and hearing. The organs responsible for both of these are located deep within the *petrous part of the temporal bone*, and therefore they are nearly impossible to identify on a cadaver. Thus, exploration of the gross anatomy of the ear will be accomplished using models of the ear.

- Obtain a model of the ear (**figure 15.16**). On the model, first distinguish between the external-ear, middle-ear, and inner-ear cavities, and the structures that link the cavities to each other (**table 15.9**). The tympanic membrane is the link between the external-ear and the middle-ear cavities, while the oval window is the link between the middle- and inner-ear cavities.
- Identify the listed structures on the model, using figure 15.16 and table 15.9 as guides:

- |   |  |
|---|--|
| <input type="checkbox"/> auditory tube            | <input type="checkbox"/> round window          |
| <input type="checkbox"/> auricle                  | <input type="checkbox"/> saccule               |
| <input type="checkbox"/> cochlea                  | <input type="checkbox"/> semicircular canals   |
| <input type="checkbox"/> ear ossicles             | <input type="checkbox"/> spiral organ          |
| <input type="checkbox"/> endolymph                | <input type="checkbox"/> stapedius muscle      |
| <input type="checkbox"/> external acoustic meatus | <input type="checkbox"/> stapes                |
| <input type="checkbox"/> incus                    | <input type="checkbox"/> tectorial membrane    |
| <input type="checkbox"/> malleus                  | <input type="checkbox"/> tensor tympani muscle |
| <input type="checkbox"/> oval window              | <input type="checkbox"/> tympanic membrane     |
| <input type="checkbox"/> perilymph                | <input type="checkbox"/> utricle               |

(continued on next page)

(continued from previous page)



**Figure 15.16 Classroom Model of the Ear.** (a) Anterior view of the petrous part of the temporal bone. (b) Close-up view of the inner ear on the model.

(a) Model # E10 [1000250] © 3B Scientific GmbH, Germany, 2015 www.3bscientific.com/Photo by Christine Eckel, Ph.D.; (b) © Copyright by Denoyer-Geppert. Photo by Christine Eckel

Table 15.9 Structures of the External, Middle, and Internal Ear			
Structure	Description	Function	Word Origins
<b>EXTERNAL EAR</b>			
<i>Auricle (Pinna)</i>	External ear, composed of an elastic cartilage skeleton that is covered with skin.	Collects sound waves from the environment and funnels them into the external auditory meatus.	<i>pinna</i> , a wing
<i>External Acoustic Meatus</i>	Canal leading from the auricle of the ear to the tympanic membrane.	Transmits sound vibrations that arrive at the auricle to the tympanic membrane, where they cause it to vibrate.	<i>externa</i> , outside + <i>acoustic</i> , relating to sound + <i>meatus</i> , a passage
<b>MIDDLE EAR</b>			
<i>Auditory Ossicles</i>	Three tiny bones (malleus, incus, and stapes) found within the middle ear.	Transmits pressure vibrations from the tympanic membrane to the oval window of the cochlea, creating fluid vibrations in the perilymph of the scala vestibuli.	<i>ossiculum</i> , a bone
<i>Incus</i>	Tiny bone located within the middle-ear cavity that is shaped like an anvil.	Transmits pressure vibrations from the malleus to the stapes, thus participating in the amplification of vibrations of the tympanic membrane.	<i>incus</i> , an anvil
<i>Malleus</i>	Tiny bone located within the middle-ear cavity that is shaped like a hammer.	Transmits pressure vibrations from the tympanic membrane to the incus thus participating in the transmission and amplification of the vibrations that arrive as sound waves on the tympanic membrane.	<i>malleus</i> , a hammer

<b>Table 15.9 Structures of the External, Middle, and Internal Ear (continued)</b>			
<b>Structure</b>	<b>Description</b>	<b>Function</b>	<b>Word Origins</b>
<i>Stapes</i>	Tiny bone located within the middle-ear cavity that is shaped like a stirrup.	Transmits pressure vibrations from the incus to the oval window of the cochlea, creating fluid vibrations in the perilymph of the scala vestibuli, also participates in amplification of the vibrations of the tympanic membrane.	<i>stapes</i> , a stirrup
<i>Auditory (Pharyngotympanic or Eustachian) Tube</i>	Tube lined with elastic cartilage that connects the middle-ear cavity to the nasal cavity.	Opening of this channel allows air to enter or leave the middle ear cavity such that the pressure in the middle ear equilibrates with the environmental pressure; this allows the tympanic membrane to vibrate freely.	<i>audio</i> , to hear + <i>tubus</i> , a canal
<i>Oval Window</i>	Opening into the scala vestibuli that is covered by the foot of the stapes.	Vibrations of the stapes at the oval window create fluid vibrations in the perilymph of the scala vestibuli.	<i>oval</i> , egg-shaped + <i>window</i> , an opening
<i>Stapedius Muscle</i>	Small muscle connecting the neck of the stapes to the temporal bone.	Contraction of this muscle acts to dampen vibrations of the stapedius as a protective measure against excessive vibration on the oval window from very loud noises.	<i>stapedius</i> , relating to the stapes
<i>Tensor Tympani Muscle</i>	Small muscle connecting the handle of the malleus to the cartilage of the auditory tube.	Contraction of this muscle pulls the malleus medially and tenses the tympanic membrane as a protective measure against excessive vibration from very loud noises.	<i>tensus</i> , to stretch + <i>tympani</i> , relating to the tympanic membrane
<i>Tympanic Membrane</i>	Drumlike, tight, thin membrane that separates the middle-ear cavity from the external-ear cavity.	Vibrates in response to sound waves that strike it as they reach the end of the external acoustic meatus, these vibrations cause vibrations in the ossicles of the middle-ear cavity (malleus, incus, and stapes).	<i>tympanon</i> , drum + <i>membrana</i> , a membrane
<b>INNER EAR</b>	Chamber located within the petrous part of the temporal bone that contains the cochlea and the vestibule.	Holds the organs responsible for the sensation of hearing (cochlea) and balance and equilibrium (vestibule).	
<i>Cochlea</i>	Spiral-shaped organ found within the inner ear.	Contains the spiral organ and associated structures that allow for the special sense of hearing.	<i>cochlea</i> , a snail shell
<i>Spiral Organ (Organ of Corti)</i>	Organ composed of specialized epithelium that is found within the scala media (cochlear duct) of the cochlea.	Special sensory organ for hearing.	<i>spiralis</i> , a coil + <i>organon</i> , a tool or instrument
<i>Semicircular Canals</i>	Three ringlike canals that are oriented at right angles to each other and communicate with the vestibule.	Sense angular acceleration.	<i>semicircular</i> , shaped like a half circle + <i>canalis</i> , a duct or channel
<i>Vestibule</i>	Located between the cochlea and the semicircular canals; contains the saccule and utricle.	Detect acceleration and deceleration movements.	<i>vestibulum</i> , entrance court
<i>Saccule</i>	Smallest membranous sac in the vestibule; connects with the cochlear duct.	Contains receptors that sense linear vertical acceleration.	<i>saccus</i> , a sac
<i>Utricle</i>	The largest membranous sac in the vestibule; semicircular canals arise from it.	Contains receptors that sense linear horizontal acceleration.	<i>uter</i> , leather bag
<i>Vestibulocochlear Nerve</i>	CN VIII; travels through the internal acoustic meatus.	Cranial nerve carrying information on balance, equilibrium, and hearing to the brain.	<i>vestibulo-</i> , referring to the vestibule + <i>cochlea</i> , referring to the cochlea

(continued on next page)



(continued from previous page)

3. Sketch the ear in the space provided. Label the structures listed in step 2.



4. After identifying all of the gross structures of the ear at least once, review the sequence of events required for the transmission of sound waves from the environment to the cochlea. While doing this, name all of the structures involved in the sequence. The sequence is as follows:

- Sound waves are focused on the **external acoustic meatus** by the contours of the outer ear (**auricle**) and

create vibrations of the **tympanic membrane**. The **auditory tube** ensures that air pressure in the middle ear is the same as air pressure in the environment so the tympanic membrane can vibrate freely. The auditory tube is lined with elastic cartilage and remains collapsed unless there is a large difference in pressure between the environment and the middle-ear cavity. When a difference in pressure exists, the auditory tube opens briefly and air moves to equalize the pressure in the middle ear with the pressure in the environment.

- Vibrations of the tympanic membrane create vibrations of the **auditory ossicles** (malleus, incus, and stapes). Excessive vibrations (from a loud noise) cause a reflexive contraction of the **tensor tympani** and **stapedius** muscles to dampen the vibrations of the ear ossicles and help protect the delicate cells of the inner ear.
  - Vibration of the foot of the stapes against the **oval window** creates vibrations of the **perilymph**.
  - Vibrations of the perilymph cause the **basilar membrane** to vibrate (see exercise 15.6). Vibrations of the basilar membrane cause stereocilia of the hair cells of the spiral organ to bend, sending nerve signals to the brain.
  - Remaining pressure waves exit the inner ear by way of the round window.
5. *Optional Activity:* **AP|R Nervous System**—Watch the “Hearing” animation to review the sequence of events involved in hearing.

# Chapter 15: The Nervous System: General and Special Senses

Name: \_\_\_\_\_

Date: \_\_\_\_\_ Section: \_\_\_\_\_

## POST-LABORATORY WORKSHEET

The ❶ corresponds to the Learning Objective(s) listed in the chapter opener outline.

### Do You Know the Basics?

#### Exercise 15.1: Tactile (Meissner) Corpuscles

1. Match the location listed in column A with its appropriate sensory receptor listed in column B. ❶ ❷ ❸

##### Column A

- \_\_\_\_\_ 1. located at dermal/epidermal junction
- \_\_\_\_\_ 2. located deep in the reticular layer of the dermis
- \_\_\_\_\_ 3. located within the dermal papillae
- \_\_\_\_\_ 4. located throughout the dermis

##### Column B

- a. free nerve ending
- b. lamellated corpuscle
- c. tactile corpuscle
- d. tactile disc

2. Which of the following corresponds to the mode of sensation detected by tactile (Meissner) corpuscles? (Check all that apply.) ❷

- \_\_\_\_\_ a. deep pressure
- \_\_\_\_\_ b. fine touch
- \_\_\_\_\_ c. light touch
- \_\_\_\_\_ d. vibration

#### Exercise 15.2: Lamellated (Pacini) Corpuscles

3. Which of the following corresponds to the mode of sensation detected by lamellated (Pacini) corpuscles? (Check all that apply.) ❸ ❹

- \_\_\_\_\_ a. deep pressure
- \_\_\_\_\_ b. fine touch
- \_\_\_\_\_ c. light touch
- \_\_\_\_\_ d. vibration

#### Exercise 15.3: Gustation (Taste)

4. The foliate and vallate papillae are considered large. \_\_\_\_\_ (True/False) ❺

5. Cells that detect chemicals dissolved in solution and transmit nerve signals for taste sensation to the CNS are known as \_\_\_\_\_ (basal/gustatory) cells. ❻

#### Exercise 15.4: Olfaction (Smell)

6. The following table lists the cell types associated with olfactory epithelium. Next to each cell type, give a brief description of the location of the cell within the olfactory epithelium and the function of the cell. ❼ ❽

Cell Type	Location	Function
<i>Basal Cells</i>		
<i>Olfactory Receptor Cells</i>		
<i>Supporting Cells</i>		

#### Exercise 15.5: Vision (The Retina)

7. Rank the following layers of the retina from the innermost to outermost layer. ❾ ❿

- \_\_\_\_\_ a. bipolar cell layer
- \_\_\_\_\_ b. choroid
- \_\_\_\_\_ c. ganglion cell layer
- \_\_\_\_\_ d. photoreceptor cell layer
- \_\_\_\_\_ e. pigmented layer

8. The area of highest visual acuity and largest density of cones in the retina is the \_\_\_\_\_ (fovea centralis/optic disc). ❶

**Exercise 15.6: Hearing**

9. The cochlea is innervated by CN VIII. \_\_\_\_\_ (True/False) **12**
10. The scala tympani and vestibuli both contain \_\_\_\_\_ (endolymph/perilymph), whereas the scala media contains \_\_\_\_\_ (endolymph/perilymph). **13**
11. Which of the following structures in the cochlea corresponds to the location of the spiral organ? (Circle one.) **14**
- \_\_\_\_ a. scala media  
 \_\_\_\_ b. scala tympani  
 \_\_\_\_ c. scala vestibuli
12. Vibration of which membrane allows for sound transmission in the cochlea? (Circle one.) **15**
- \_\_\_\_ a. basilar membrane  
 \_\_\_\_ b. tectorial membrane  
 \_\_\_\_ c. vestibular membrane

**Exercise 15.7: Sensory Receptors in the Skin**

13. Match the location listed in column A with its appropriate sensory receptor listed in column B. **16**

**Column A**

- \_\_\_\_ 1. located at the dermal/epidermal junction  
 \_\_\_\_ 2. located deep in the reticular layer of the dermis  
 \_\_\_\_ 3. located within the dermal papillae  
 \_\_\_\_ 4. located throughout the dermis

**Column B**

- a. free nerve ending  
 b. lamellated corpuscle  
 c. tactile corpuscle  
 d. tactile disc

**Exercise 15.8: Gross Anatomy of the Eye**

14. Match the description listed in column A with the part of the eye listed in column B. **17**

**Column A**

- \_\_\_\_ 1. anteriormost part of the retina, which appears serrated  
 \_\_\_\_ 2. colored part of the eye  
 \_\_\_\_ 3. ligament extending between ciliary muscles and the lens  
 \_\_\_\_ 4. metallic-appearing, opalescent inner layer of the sclera; it is present in many animals (e.g., the cow eye), but not the human eye  
 \_\_\_\_ 5. neural tunic of the eye; composed of several layers of neurons involved with transducing light energy into nerve signals  
 \_\_\_\_ 6. smooth muscle within the ciliary body composed of both circular and radial muscle fibers  
 \_\_\_\_ 7. transparent, biconvex structure composed of highly specialized, modified epithelium  
 \_\_\_\_ 8. watery fluid that circulates within the anterior and posterior chambers of the eye

**Column B**

- a. aqueous humor  
 b. ciliary muscle  
 c. iris  
 d. lens  
 e. ora serrata  
 f. retina  
 g. suspensory ligament  
 h. tapetum lucidum

**Exercise 15.9: Cow Eye Dissection**

15. A cow eye has a prominent, colorful structure on its posterior wall, which is not present in the human eye, called the tapetum lucidum. \_\_\_\_\_ (True/False) **18 19**

**Exercise 15.10: Gross Anatomy of the Ear**

16. Match the description listed in column A with the part of the ear listed in column B. **20 21**

**Column A**

- \_\_\_\_\_ 1. cavity between the external ear and inner ear; contains ossicles
- \_\_\_\_\_ 2. drumlike, tight, thin membrane that separates the external ear cavity to the middle ear
- \_\_\_\_\_ 3. external ear, composed of an elastic cartilage skeleton that is covered with skin
- \_\_\_\_\_ 4. largest membranous sac in the vestibule; contains receptors for sensing horizontal acceleration
- \_\_\_\_\_ 5. portion of ear located within the petrous part of the temporal bone that includes the cochlea, vestibule, and semicircular canals
- \_\_\_\_\_ 6. three ringlike canals that are oriented at right angles to each other and communicate with the vestibule

**Column B**

- a. auricle
- b. inner ear
- c. middle ear
- d. sacculle
- e. semicircular canals
- f. tympanic membrane

**Can You Apply What You've Learned?**

17. A fracture of the cribriform plate of the ethmoid bone can result in a loss of the sense of smell. Given knowledge of the location of olfactory receptor cells and the pathway taken by their axons to reach the brain, explain why this can happen.

---



---



---



---

18. The optic disc is referred to as the “blind spot” of the eye. Based on histological observation of the optic disc, explain why this is the case.

---



---



---



---

19. Why do you think tactile (Meissner) corpuscles are located relatively close to the surface of the skin rather than deep within the dermis?

---



---



---



---

20. An individual who suffers a strong blow to the head may end up with a detached retina that causes visual problems. Why do you think the retina easily detaches from the posterior wall of the eye? What structure normally holds the retina in place?

---



---



---



---

*This page intentionally left blank*

# The Endocrine System

# 16

## INTRODUCTION

**H**ow long has it been since you last ate? One hour? Two? Five? Even if it has been several hours since that last meal, blood glucose and blood calcium levels remain remarkably stable, fluctuating only minor amounts around the body's normal physiological level (unless, of course, a disease such as diabetes is present). Maintenance of blood glucose and blood calcium levels are physiological imperatives, for if their levels are too high or too low, severe impairment of nervous and muscular activity will occur. However, it is not often that blood glucose or calcium levels move drastically out of the normal range. This is because they are under tight regulation by the **endocrine system**. The hormones insulin and glucagon, produced by the pancreas, regulate blood glucose levels, and the hormones calcitonin and parathyroid hormone, produced by the thyroid and parathyroid glands, respectively, regulate blood calcium levels.

This brief description of these hormones and the variables they regulate provides only a glimpse at the functioning of the endocrine system, a system of chemical messengers that travel in the bloodstream and act on distant target cells. The endocrine system (**figure 16.1**) consists of a number of “classical” endocrine organs, such as the pituitary gland, adrenal glands, pancreatic islets, and thyroid gland. However, nearly every organ in the body contains cells or tissues that produce and

## OUTLINE AND LEARNING OBJECTIVES

### Histology 330

#### EXERCISE 16.1: THE HYPOTHALAMUS AND PITUITARY GLAND 330

- 1 Differentiate between the anterior and posterior lobes of the pituitary gland on a histology slide of the pituitary gland
- 2 List the hormones produced by acidophils and basophils of the anterior lobe of the pituitary
- 3 Describe the relationship between neurons in the paraventricular and supraoptic nuclei of the hypothalamus and the secretion of hormones by the posterior lobe of the pituitary

#### EXERCISE 16.2: THE PINEAL GLAND 333

- 4 Identify the pineal gland on a histology slide
- 5 Describe the structure and functions of pinealocytes and pineal sand
- 6 Describe the functional importance of pineal sand to radiologists

#### EXERCISE 16.3: THE THYROID AND PARATHYROID GLANDS 333

- 7 Identify thyroid follicles, parafollicular cells, and the parathyroid glands on a histology slide of the thyroid gland
- 8 List the hormones produced by the thyroid follicles, parafollicular cells, and chief cells
- 9 Briefly describe the function of thyroid hormone, calcitonin, and parathyroid hormone

#### EXERCISE 16.4: THE ADRENAL GLANDS 335

- 10 Identify the zona glomerulosa, zona fasciculata, zona reticularis, and adrenal medulla on a histology slide of the adrenal gland
- 11 List the hormones produced by the zona glomerulosa, zona fasciculata, zona reticularis, and adrenal medulla
- 12 Briefly describe the functions of the hormones aldosterone, cortisol, androgens, norepinephrine and epinephrine

#### EXERCISE 16.5: THE ENDOCRINE PANCREAS—PANCREATIC ISLETS (OF LANGERHANS) 337

- 13 Identify pancreatic islets on a histology slide of the pancreas
- 14 Describe the structure and function of the endocrine part of the pancreas
- 15 Briefly describe the functions of the hormones insulin, glucagon, and somatostatin
- 16 List the cell types that produce insulin, glucagon, and somatostatin

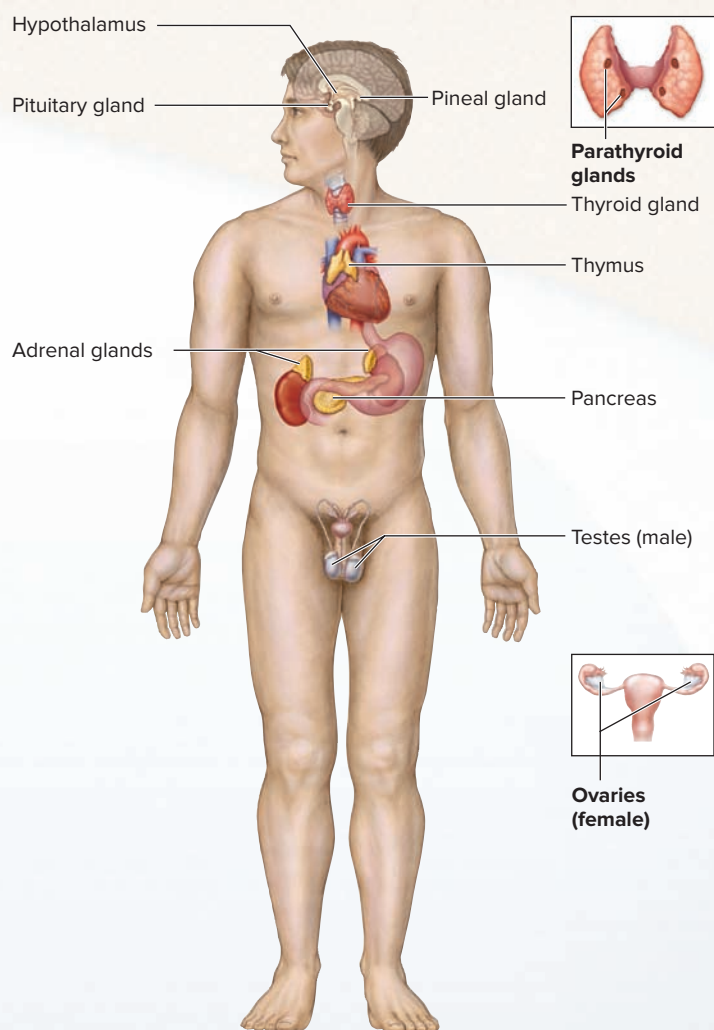
### Gross Anatomy 338

#### EXERCISE 16.6: GROSS ANATOMY OF ENDOCRINE ORGANS 339

- 17 Identify the classical endocrine glands on classroom models or a human cadaver



## Module 8: ENDOCRINE SYSTEM



**Figure 16.1** Classical Endocrine Glands of the Human Body.

secrete hormones. For instance, cells in the walls of the stomach secrete hormones that regulate appetite, gastric motility, and acid secretion. Cells in the testes (males) and ovaries (females) are responsible for the secretion of hormones that regulate the maturation of sperm and eggs, respectively.

Although the thymus is considered an endocrine organ due to its secretion of the hormone *thymosin*, it plays a larger role in the immune system, as described in chapter 19.

The exercises in this chapter explore the structure and function of the classical endocrine organs. Many of the organs explored contain cells that secrete hormones (thus the organ has an endocrine role). However, the entire organ is not necessarily referred to as an endocrine *gland* because the organ has other functions as well. The few organs that are strictly endocrine in nature are generally quite small. Only the thyroid and adrenal glands can be viewed easily on a cadaver. Thus, the exploration of the endocrine system in the anatomy and physiology laboratory will be carried out predominantly at the microscopic level; however, there is also an exercise that involves locating the major (large) endocrine organs on a cadaver or on classroom models. When examining histology slides, make associations between the tissues viewed under the microscope and the gross anatomic location where the tissue is found. In addition, consider the names and function(s) of the hormone(s) secreted by each organ. Subsequent chapters covering the cardiovascular, lymphatic, digestive, urinary, and reproductive systems contain exercises that further explore the structure and function of endocrine cells and tissues (and associated hormones) related to each specific system.

#### List of Reference Tables

Table 16.1	Histology of the Pituitary Gland	p. 331
Table 16.2	Histology of the Thyroid and Parathyroid Glands	p. 334
Table 16.3	Histology of the Adrenal Glands	p. 337
Table 16.4	Histology of the Pancreatic Islets (of Langerhans)	p. 338

These Pre-laboratory Worksheet questions may be assigned by instructors through their **connect** course.

## PRE-LABORATORY WORKSHEET

- Glands that produce and release chemical messengers (hormones) to be transported in the blood are \_\_\_\_\_ (endocrine/exocrine) glands.
- Glands that produce a product that is released into a duct, which transports the product directly to its target organ or tissue, are \_\_\_\_\_ (endocrine/exocrine) glands.
- Identify the gland where parafollicular cells are located. (Circle one.)
  - adrenal
  - pineal
  - pituitary
  - thymus
  - thyroid

- Match the description listed in column A with the appropriate endocrine gland listed in column B.

### Column A

- \_\_\_\_\_ 1. consists of a cortex and medulla, with each part having different embryological origins
- \_\_\_\_\_ 2. consists of follicles lined with a simple cuboidal epithelium
- \_\_\_\_\_ 3. four small endocrine glands that secrete a hormone that regulates blood calcium levels
- \_\_\_\_\_ 4. secretes hormones to regulate hormone release by the anterior pituitary gland
- \_\_\_\_\_ 5. secretes the hormone melatonin

### Column B

- a. adrenal gland
- b. hypothalamus
- c. parathyroid glands
- d. pineal gland
- e. thyroid gland

- Which of the following is the major endocrine gland that secretes sex steroid hormones in the female? (Circle one.)
  - adrenal
  - ovaries
  - pineal
  - pituitary
  - testes
- Which of the following hormone(s) is/are secreted by the posterior pituitary gland? (Check all that apply.)
  - \_\_\_\_\_ a. antidiuretic hormone
  - \_\_\_\_\_ b. growth hormone
  - \_\_\_\_\_ c. oxytocin
  - \_\_\_\_\_ d. prolactin
  - \_\_\_\_\_ e. thyroid stimulating hormone
- The hormone released by the anterior pituitary gland that induces ovulation in females is \_\_\_\_\_ (follicle stimulating hormone/luteinizing hormone).
- The pancreas has both endocrine and exocrine functions. \_\_\_\_\_ (True/False)
- Which of the following occurs when thyroid hormone levels increase? (Check all that apply.)
  - \_\_\_\_\_ a. decreased metabolic rate
  - \_\_\_\_\_ b. increased body temperature
  - \_\_\_\_\_ c. increased glycogenesis
  - \_\_\_\_\_ d. increased lipolysis
  - \_\_\_\_\_ e. increased oxygen consumption
- A decrease in thyroid hormone \_\_\_\_\_ (inhibits/stimulates) the release of thyrotropin releasing hormone by the hypothalamus.



## Histology

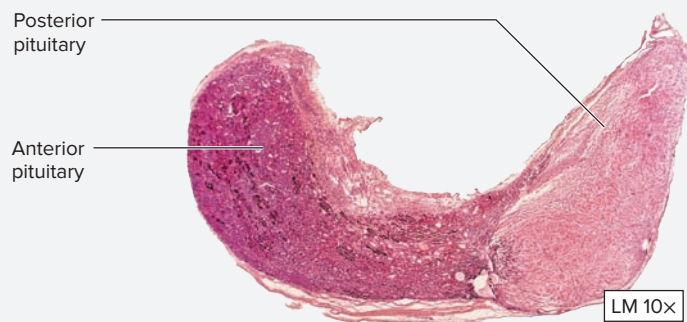
In the following exercises the microscopic anatomy of the various endocrine glands are described in detail. The tables in these exercises list the glands, the hormones they produce, and the functions of each of the listed

hormones. A major goal in completing the following exercises will be to differentiate the various endocrine glands from each other when viewing them under the microscope.

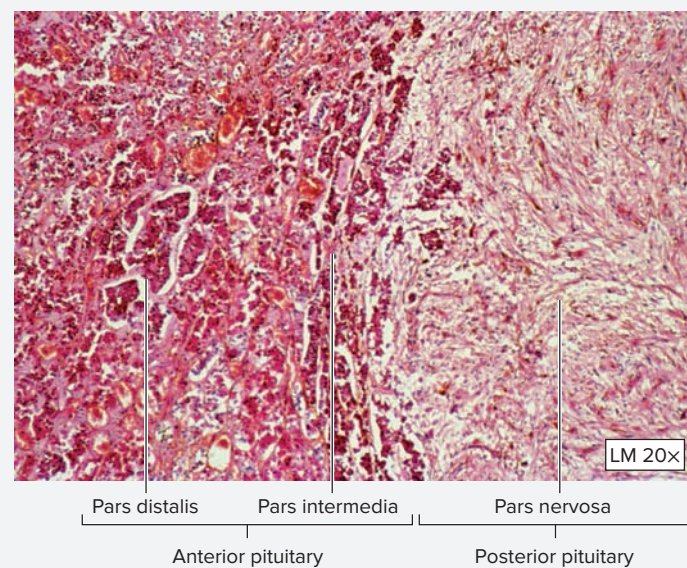
### EXERCISE 16.1 The Hypothalamus and Pituitary Gland

The **pituitary gland**, or hypophysis (*hypophysis*, an undergrowth), is a remarkable organ, for this incredibly tiny organ plays a gigantic role in endocrine regulation of the body. It is about the size and shape of a pea, but it secretes hormones that regulate the growth and development of nearly every other endocrine organ in the body. The secretion of pituitary hormones is tightly controlled by cells within the **hypothalamus**, a part of the brain whose structure and function was discussed in chapter 24. The primary textbook covers the structure, function, and relationships between the hypothalamus and pituitary gland in detail. Because it is not possible to visualize the details of these relationships in the laboratory, the focus of the exercises in this chapter is on the structure and function of the pituitary gland alone. **Table 16.1** summarizes the cells and structures that compose the pituitary gland and lists the hormones secreted by each cell type. The releasing or inhibiting hormones secreted by the hypothalamus that influence the secretion of hormones by the pituitary gland are also included in this table.

1. Obtain a histology slide of the pituitary gland (**figure 16.2**). Before placing it on the microscope stage, observe the slide with the naked eye. Notice there is a distinctive difference in color between the two parts, or lobes, of the pituitary gland. The darker area is the **anterior pituitary** (also called the anterior lobe, or **adenohypophysis** [*adeno-*, a gland + *hypophysis*, an undergrowth]), whereas the lighter area is the **posterior pituitary** (also called the posterior lobe, or **neurohypophysis** [*neuro-*, relating to nervous tissue + *hypophysis*, referring to the pituitary]).
2. Place the slide on the microscope stage and bring the tissue sample into focus on low power. Once again, identify the anterior and posterior lobes (figure 16.2a). Recall that the anterior pituitary is derived embryologically from an outpocketing of the roof of the mouth and consists of epithelial tissue. Thus, the cells have an appearance that is characteristic of glandular epithelial tissue (figure 16.2b). The posterior pituitary is derived embryologically from a downgrowth of the diencephalon of the brain and consists of nervous tissue. Thus, the cells have an appearance that is characteristic of nervous tissue (figure 16.2b).
3. **Anterior Pituitary**—Identify the anterior pituitary gland, using figures 16.2 and 16.3 as guides. Next, move the microscope stage so the anterior pituitary is in the center of the field of view.
4. Increase the magnification to observe the glandular nature of the cells (**figure 16.3**). There are three cell types within the anterior pituitary: acidophils, basophils, and chromophobes. The first two kinds of cells are named for their “love” (*-phil*, to love) of acidic or basic dyes. *Acidophils* attract acidic dyes, and appear red in color. *Basophils* attract basic dyes



(a)



(b)

**Figure 16.2 Pituitary Gland.** (a) Low magnification view of both parts of the pituitary. (b) Medium magnification view of the anterior and posterior pituitary.

(a) © McGraw-Hill Education/Al Telser; (b) © Astrid & Hanns-Frieder Michler/ Science Source

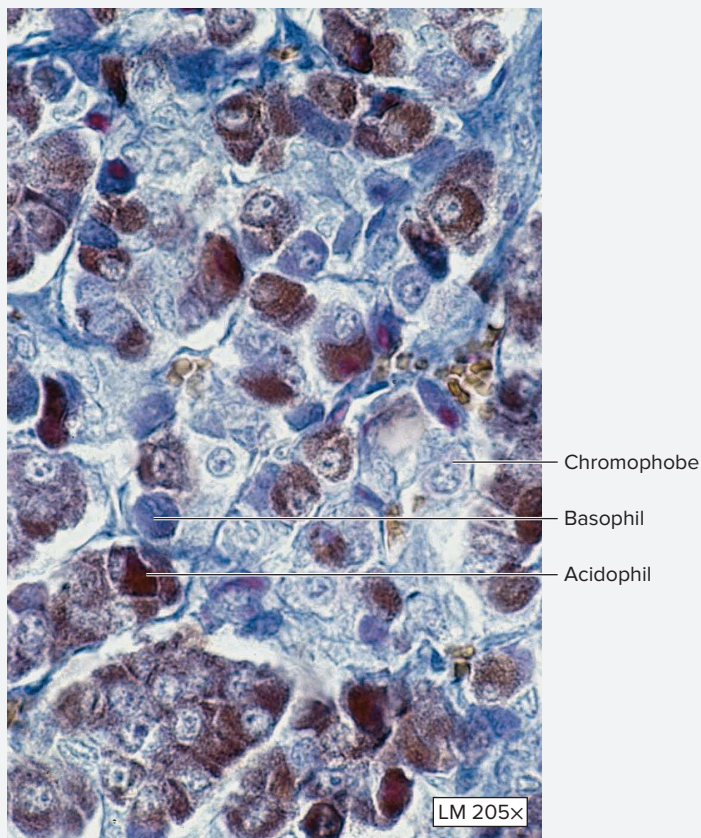
and appear blue in color. *Chromophobes* (*chroma-*, color + *phobos*, fear) are cells that attract neither acidic nor basic dyes, and are thought to be cells that have released their hormone(s). It can be difficult to identify the various cell types within the anterior lobe using standardly prepared slides. However, it is useful to know the cell types because this knowledge allows the use of a couple of handy mnemonic devices to remember the names of the hormones produced by each cell (see Learning Strategy).

5. **Posterior Pituitary**—Identify the posterior pituitary, using figure 16.2 as a guide. Next, move the microscope stage so the posterior pituitary is in the center of the field of view.

Table 16.1

## Histology of the Pituitary Gland

Pituitary Gland	Cells	Description	Hormones Produced	Action of Pituitary Hormone(s)	Hypothalamic Releasing or Inhibiting Hormone	Word Origins	
<b>Anterior Pituitary (Adenohypophysis)</b>	Acidophils	Appear red in color due to their attraction for acidic stains.	GH, PRL	NA	NA	<i>acidus-</i> , sour (relating to acidic dyes) + <i>phil</i> , to love	
			Growth hormone (GH)	Stimulates the liver and other tissues to produce IGF-1 (insulin-like growth factor-1), which promotes bone and muscle growth.	Growth-hormone-releasing hormone (GHRH) stimulates release, whereas growth-hormone-inhibiting hormone (GHIH, somatostatin) inhibits release.	<i>grōthr</i> , growth + <i>hormon</i> , to set in motion	
			Prolactin (PRL)	Stimulates the mammary glands to develop and produce milk.	Prolactin-inhibiting hormone (PIH) inhibits release.	<i>pro-</i> , before + <i>lac</i> , milk	
	Basophils	Appear blue in color due to their attraction for basic stains.	FSH, LH, ACTH, TSH	See below.	See below.	See below.	<i>baso-</i> , basic (relating to basic dyes) + <i>phil</i> , to love
			Follicle-stimulating hormone (FSH)	Stimulates the growth and maturation of ovarian follicles (females); stimulates spermatogenesis (males).	Gonadotropin-releasing hormone (GnRH) stimulates release, whereas the hormone inhibin inhibits its release.	<i>folliculus</i> , a small sac (referring to the ovarian follicles)	
			Luteinizing hormone (LH)	Induces ovulation, stimulates the production of estrogen and progesterone by cells of the corpus luteum (females); stimulates interstitial cells to produce testosterone (males).	Gonadotropin-releasing hormone (GnRH) stimulates release.	<i>luteus</i> , yellow (referring to the corpus luteum of the female ovary)	
			Adrenocorticotropic hormone (ACTH)	Stimulates the growth, development, and secretion of steroid hormones by the adrenal cortex.	Corticotropin-releasing hormone (CRH) stimulates release.	<i>adrenocortico-</i> , referring to the adrenal cortex + <i>trophe</i> , nourishment	
			Thyroid-stimulating hormone (TSH)	Stimulates the secretion of thyroid hormones by the thyroid gland.	Thyrotropin-releasing hormone (TRH) stimulates release.	<i>thyroid</i> , shaped like an oblong shield	
	Chromophobes	Appear very light in color due to a lack of staining.	Thought to be devoid of hormone, hence the lack of staining properties	NA	NA	<i>chroma-</i> , color + <i>phobos</i> , fear	
	Pituitary Gland	Cells	Description	Hypothalamic Hormones Stored and Released	Action of Pituitary Hormone(s)	Hypothalamic Nucleus Containing Neuron Cell Bodies	Word Origins
<b>Posterior Pituitary (Neurohypophysis)</b>	Axon terminals	Axon terminals store hormone that was produced in the cell bodies of the neurons within the hypothalamus.	Oxytocin	Stimulates uterine contractions and milk ejection by mammary glands.	Paraventricular nucleus and supraoptic nucleus.	<i>axon</i> , axis + <i>terminus</i> , the limit; <i>para-</i> , next to + <i>ventricular</i> , relating to the third ventricle of the brain + <i>nucleus</i> , a collection of neuron cell bodies; <i>okytckos</i> , swift birth	
	Axon terminals	Axon terminals store hormone that was produced in the cell bodies of the neurons within the hypothalamus.	Antidiuretic hormone (ADH, vasopressin)	Increases water retention by the kidneys (increases blood volume and blood pressure); vasoconstriction.	Paraventricular nucleus and supraoptic nucleus.	<i>axon</i> , axis + <i>terminus</i> , the limit; <i>supra-</i> , above + <i>optic</i> , relating to the optic tract + <i>nucleus</i> , a collection of neuron cell bodies; <i>anti-</i> , against + <i>diuresis</i> , excretion of urine	
	Pituicytes	Derived from glial cells; have processes that surround axon terminals of the hormone-secreting neurons.	NA	NA	NA	<i>pituica-</i> , a phlegm (relating to the pituitary gland) + <i>cyte</i> , cell	




**Figure 16.3 Anterior Pituitary.** The three cell types in the anterior pituitary are basophils, which stain blue, acidophils, which stain red, and chromophobes, which don't take up biological stains.

© Victor P. Eroschenko

- Increase the magnification to observe the cells clearly (**figure 16.4**). The majority of the nuclei visible within the slide are the nuclei of **pituicytes**, which are derived from glial cells. Pituicytes surround the axon terminals of neurons whose cell bodies are located in the paraventricular and supraoptic nuclei of the hypothalamus. These neurons secrete the hormones oxytocin and antidiuretic hormone (ADH, vasopressin).
- Identify the listed structures on the slide of the pituitary gland, using figures 16.2 through 16.4, and table 16.1 as guides.
 

<input type="checkbox"/> acidophils	<input type="checkbox"/> chromophobes
<input type="checkbox"/> anterior pituitary	<input type="checkbox"/> pituicytes
<input type="checkbox"/> basophils	<input type="checkbox"/> posterior pituitary
- Sketch the pituitary gland in the space provided. Label, the structures listed in step 7 in the sketch.



### Learning Strategy

The mnemonics for remembering which hormones are produced by which cells of the anterior pituitary are as follows:

**Mnemonic for acidophils: GPA** (as in Grade Point Average: If a student does not remember this information, it could be harmful to his or her GPA.)

**G** = growth hormone (GH)

**P** = prolactin (PRL)

**A** = acidophil

**Mnemonic for basophils: B-FLAT** (as in the musical note: If a student remembers this information, it will be beneficial to his or her GPA and he or she will be happily singing to the tune of B-Flat!)

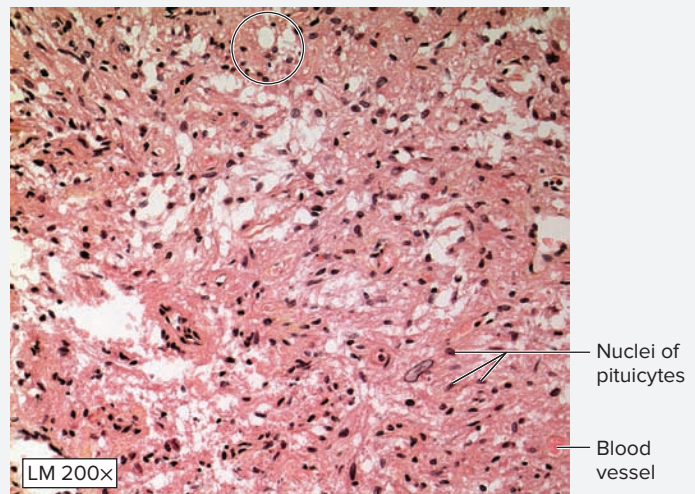
**B** = basophil

**F** = follicle-stimulating hormone (FSH)

**L** = luteinizing hormone (LH)

**A** = adrenocorticotrophic hormone (ACTH)

**T** = thyroid-stimulating hormone (TSH)



**Figure 16.4 Posterior Pituitary.** The majority of the nuclei seen in this micrograph are of pituicytes, which are glial cells.

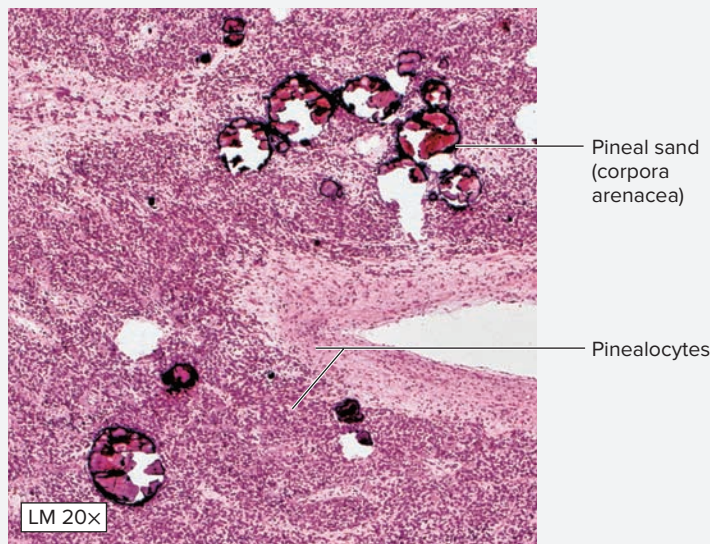
© McGraw-Hill Education/Christine Eckel, photographer

### WHAT DO YOU THINK?

- Tumors of the pituitary gland are not that uncommon. Symptoms of pituitary tumors often result from oversecretion of pituitary hormones. For instance, an increase in bone and muscle growth can occur if the tumor secretes excess growth hormone (GH). Often the first symptom experienced when a pituitary tumor is present is a problem with vision (sight). Based on an understanding of the location of the pituitary gland with respect to other brain structures, explain why individuals with pituitary gland tumors often also experience visual disorders. (Hint: none of the hormones secreted by the pituitary gland influence vision, so think about structures located next to the pituitary.)

**EXERCISE 16.2** The Pineal Gland

The **pineal gland** (*pineus*, relating to a pine, shaped like a pinecone), also called the **pineal body**, is a small region in the epithalamus of the brain. Its primary cells, called **pinealocytes** (figure 16.5), secrete the hormone **melatonin**. Melatonin's effects in humans are unsubstantiated, but in other organisms melatonin is responsible for regulation of circadian rhythms. In humans, it may have a role in determining the onset of puberty. Pinealocytes are innervated by neurons from the sympathetic nervous system. Their secretion of hormone is affected by the amount of light received by the individual, which is relayed to the pineal through these neurons. Melatonin secretion increases when light levels are low (at night) and decreases when light levels are high (during the day). Pinealocytes appear in groups of cells within the pineal gland. They are surrounded




**Figure 16.5** The Pineal Gland. Histology of the pineal gland.

© McGraw-Hill Education/AI Telser

by glial cells, whose function is similar to that of astrocytes in other parts of the brain. Clinically, one of the most important features of the pineal gland is the presence of calcium concretions, termed "**pineal sand**" (*corpora arenacea*). These concretions are easily visible in radiographs of the head. Pineal sand provides radiologists with a landmark that is consistent and easy to identify. The number of concretions in the pineal gland increases with age.

1. Obtain a histology slide of the pineal gland. Place the slide on the microscope stage and bring the tissue sample into focus on low power.
2. Identify the listed structures on the slide, using figure 16.5 as a guide:
 

<input type="checkbox"/> pinealocytes	<input type="checkbox"/> pineal sand
---------------------------------------	--------------------------------------
3. Sketch the pineal gland as seen at medium or high magnification, in the space provided. Label pinealocytes and pineal sand on the sketch.

**EXERCISE 16.3** The Thyroid and Parathyroid Glands

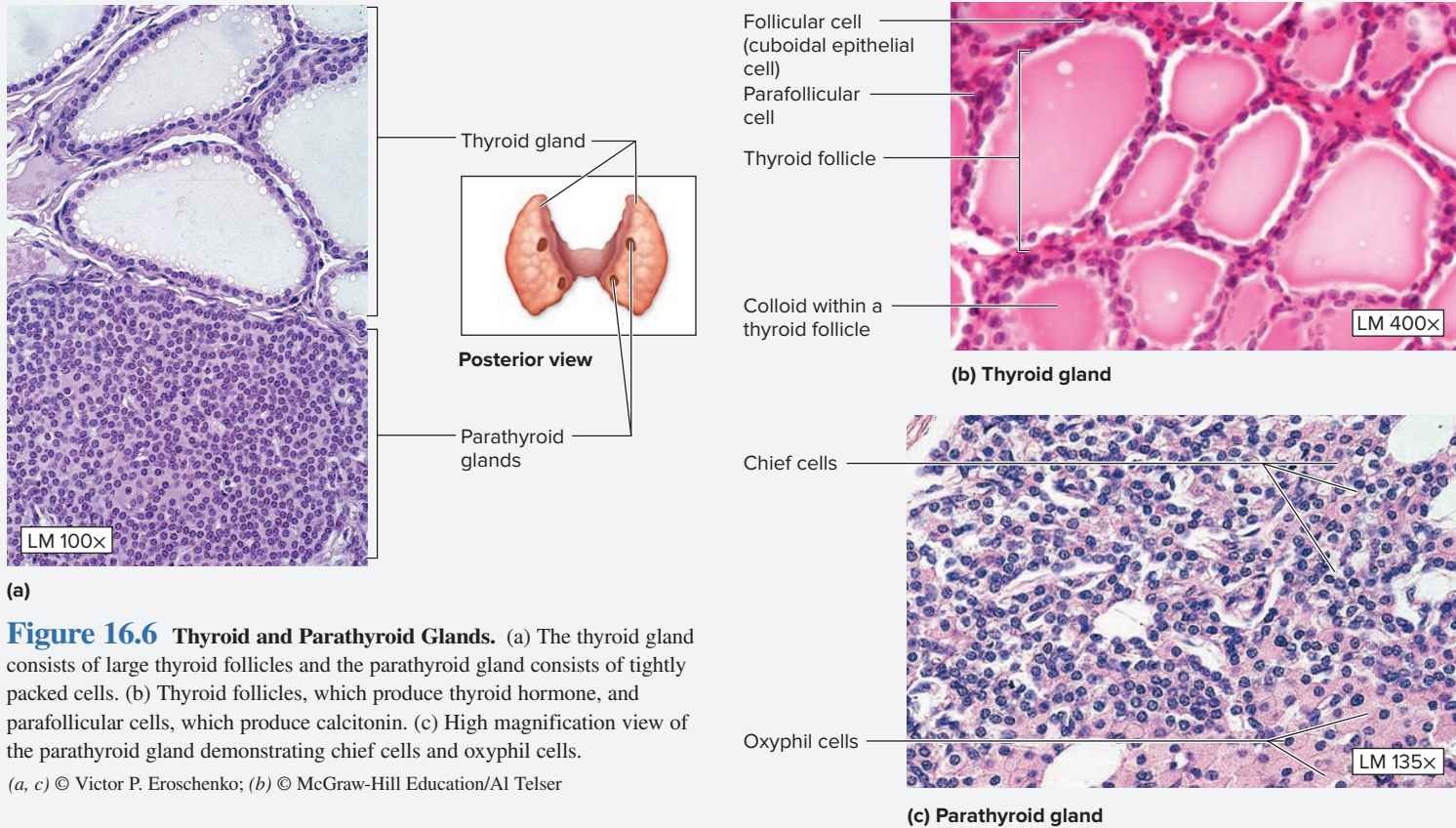
The **thyroid gland** (figure 16.6; table 16.2) is a butterfly-shaped gland located anterior to the trachea and inferior to the thyroid cartilage of the larynx. It consists of two main lobes connected to each other anteriorly by a narrow **isthmus** (*isthmus*, neck). The functional units of the thyroid gland are **thyroid follicles**, which are lined with a simple cuboidal epithelium. Inside each follicle is a mass of **colloid**, consisting largely of precursors to the thyroid hormones, called **thyroglobulins**. When combined with iodine, **thyroid hormone** breaks off from the colloid and is transported out of the follicles and into the blood. The spaces between the follicles contain another cell type, called **parafollicular cells**. These cells secrete the hormone **calcitonin**.

Closely related to the thyroid gland are a series of small glands (usually four) called **parathyroid glands**. These glands consist of two cell types: **chief (principal) cells**, which are smaller, more abundant cells with relatively clear cytoplasm that produce **parathyroid hormone** (parathormone), and **oxyphil cells**, which are larger, less abundant cells with granular pink cytoplasm, and whose function is unknown.

1. Obtain a histology slide of the thyroid and parathyroid glands and place it on the microscope stage. Bring the tissue sample into focus on low power and then change to high power.

(continued on next page)

(continued from previous page)



**Figure 16.6** **Thyroid and Parathyroid Glands.** (a) The thyroid gland consists of large thyroid follicles and the parathyroid gland consists of tightly packed cells. (b) Thyroid follicles, which produce thyroid hormone, and parafollicular cells, which produce calcitonin. (c) High magnification view of the parathyroid gland demonstrating chief cells and oxyphil cells.

(a, c) © Victor P. Eroschenko; (b) © McGraw-Hill Education/AI Telsner

Table 16.2 Histology of the Thyroid and Parathyroid Glands					
Cell Types	Description	Hormones Produced	Action of Hormone	Mechanism of Action	Word Origins
<b>THYROID GLAND</b>	<i>A shield- or butterfly-shaped gland located anterior to the trachea and inferior to the thyroid cartilage. Consists of two lobes connected by a narrow isthmus anteriorly.</i>				<i>thyroid, shaped like an oblong shield</i>
<b>Follicular Cells</b>	Simple cuboidal epithelial cells that line the thyroid follicles; they have very dark nuclei.	Thyroid hormone	Increase basal metabolic rate (BMR); important in early development of the central nervous system.	Stimulates or inhibits transcription of certain genes in target cells.	<i>folliculus, a small sac</i>
<b>Parafollicular Cells</b>	Lighter-staining cells found in the interstitial spaces between the thyroid follicles; larger than the follicular cells, with nuclei that have an appearance similar to a clock face.	Calcitonin	Decrease blood calcium levels.	Inhibits the action of osteoclasts, increases urinary excretion of calcium, decreases digestive absorption of calcium.	<i>para-, next to + folliculus, a small sac</i>
<b>PARATHYROID GLANDS</b>	<i>Four to six small glands located on the posterior surface of the thyroid gland.</i>				<i>para-, next to + thyroid, shaped like an oblong shield</i>
<b>Chief (Principal) Cells</b>	Relatively small cells that contain a centrally located, round nucleus with one or more nucleoli.	Parathyroid hormone (parathormone)	Increase blood calcium levels.	Indirectly increases the action of osteoclasts, decreases urinary excretion of calcium, and stimulates synthesis of vitamin D, which increases dietary absorption of calcium.	<i>Principal, the predominant cell type of a gland</i>
<b>Oxyphil Cells</b>	Larger than chief cells and more reddish in color.	Unknown	NA	NA	<i>oxys-, sour acid + phil, to love</i>

2. Identify the listed structures on the slide, using figure 16.6 and table 16.2, as guides:

- |   |   |
|---|---|
| <input type="checkbox"/> chief (principal) cells                      | <input type="checkbox"/> oxyphil cells        |
| <input type="checkbox"/> colloid                                      | <input type="checkbox"/> parafollicular cells |
| <input type="checkbox"/> follicular cells (cuboidal epithelial cells) | <input type="checkbox"/> parathyroid gland    |
|   | <input type="checkbox"/> thyroid follicles    |

3. Sketch the thyroid and parathyroid glands in the space provided. Label all of the listed structures on the sketch.



### EXERCISE 16.4 The Adrenal Glands

The adrenal glands are located directly superior to each kidney (*ad-*, to + *ren*, kidney). They are similar to the pituitary gland in that they are composed of two regions (figure 16.7), each with a separate embryological origin. The outer region, the **adrenal cortex**, is derived from mesoderm and has the appearance of typical glandular epithelium. The inner region, the **adrenal medulla**, is derived from modified postganglionic sympathetic neurons (which are derived from neural crest cells) and has the appearance of nervous tissue. The cells of the adrenal cortex synthesize steroid hormones (specifically, **corticosteroids**, *cortico-*, relating to the adrenal cortex + *steroid*, steroid hormone), whereas the cells of the adrenal medulla synthesize **catecholamine** hormones (i.e., hormones derived from the amino acid tyrosine and that contain a catechol ring). The entire gland is surrounded by a dense irregular connective tissue **capsule**, which protects the gland and helps anchor it to the superior border of the kidney. The adrenal cortex has three recognizable zones, and each zone has cells that predominantly secrete one category of corticosteroid hormones. Characteristics of the zones, and descriptions of the hormones secreted by cells within each zone, are summarized in table 16.3.


1. Obtain a histology slide of the adrenal gland (figure 16.7) and place it on the microscope stage. Bring the tissue sample into focus on low power and identify the two major regions, the cortex and the medulla (figure 16.7a).
2. Move the stage so the *adrenal cortex* (figure 16.7b) is in the center of the field of view. Then change to high power.
3. Identify the following zones of the adrenal cortex: zona glomerulosa, zona fasciculata, and zona reticularis, using figure 16.7 and table 16.3 as guides.
4. Change back to the low-power objective, move the microscope stage so the *adrenal medulla* is in the center of the field of view, and then change back to high power. The nuclei visible within the adrenal medulla are nuclei of *chromaffin cells*, which are modified post ganglionic

sympathetic neurons. What hormone(s) do these cells secrete? \_\_\_\_\_

5. Identify the listed structures on the slide of the adrenal glands, using figure 16.7 and table 16.3 as guides:

- |   |   |
|---|---|
| <input type="checkbox"/> adrenal cortex   | <input type="checkbox"/> zona fasciculata |
| <input type="checkbox"/> adrenal medulla  | <input type="checkbox"/> zona glomerulosa |
| <input type="checkbox"/> capsule          | <input type="checkbox"/> zona reticularis |
| <input type="checkbox"/> chromaffin cells |   |

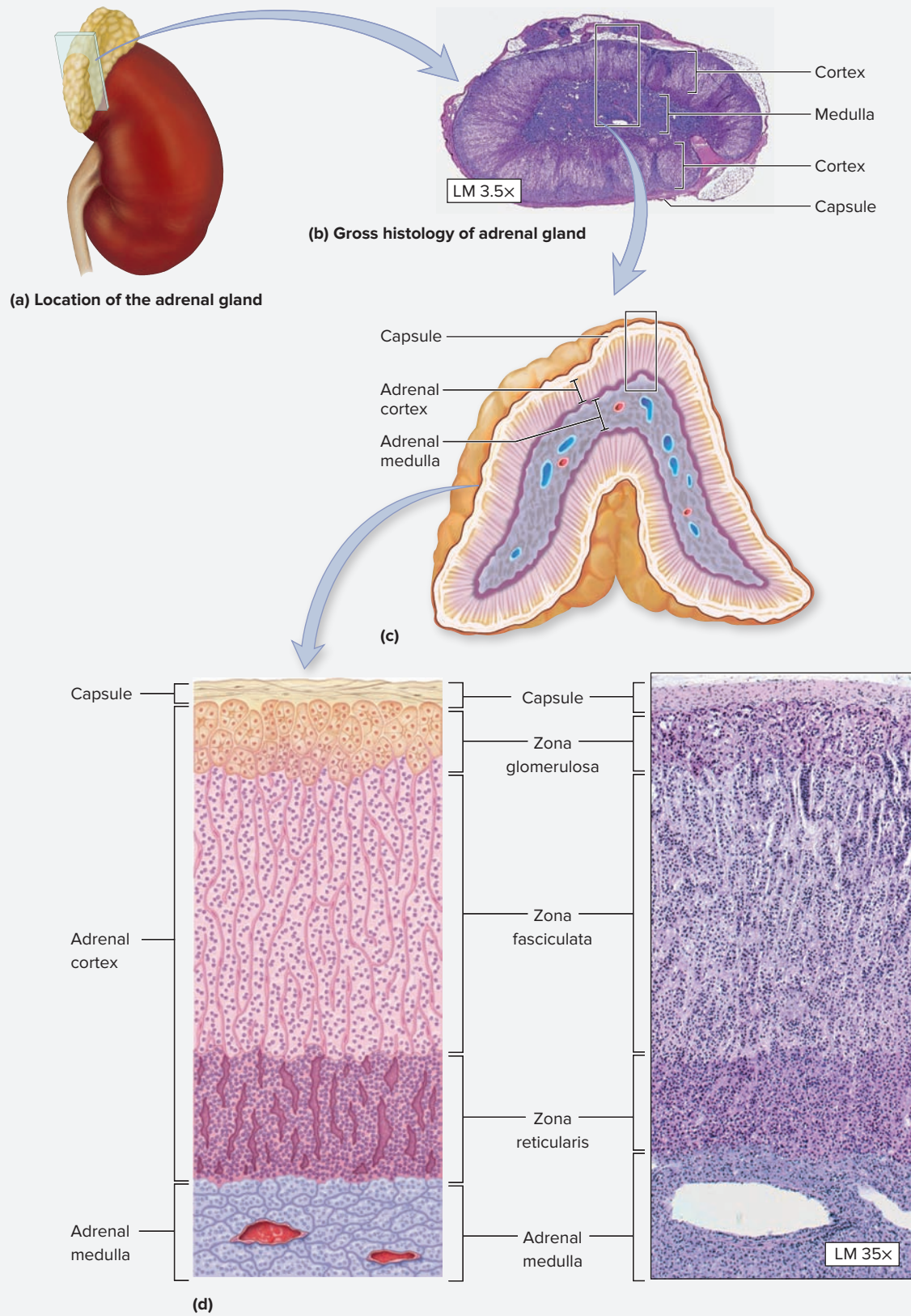
6. Sketch the adrenal gland, in the space provided. Label all of the listed structures in the sketch.



7. *Optional Activity:* **AP|R Endocrine System**—Review the histology slides of the adrenal (suprarenal) gland, as well as the pituitary gland, thyroid gland, and endocrine pancreas.

(continued on next page)

(continued from previous page)



**Figure 16.7 Adrenal Glands.** (a) The adrenal glands are located superior to each kidney. (b) Low-magnification micrograph of the adrenal glands. (c) Line art depicting a coronal section of one adrenal gland. (d) Line art accompanied by high-magnification micrograph demonstrating the three layers of the adrenal cortex and part of the adrenal medulla.

(b) © Carolina Biological Supply Company/Phototake; (d) © McGraw-Hill Education/Al Telser

Adrenal Gland Region	Zone and/or Cells	Description	Hormones Produced	Action of Hormone(s)	Word Origins
<i>Adrenal Cortex</i>	Zona glomerulosa	The outermost region of the adrenal cortex, containing “balls” of cells, located immediately deep to the capsule of the adrenal gland.	Mineralocorticoids: aldosterone	Increases sodium and water retention by the kidneys (thus increasing blood volume and blood pressure); vasoconstriction.	<i>zona</i> , zone + <i>glomus</i> , a ball of yarn
	Zona fasciculata	The middle and largest region of the adrenal cortex, containing long cords, or “bundles,” of cells.	Glucocorticoids: cortisol	Mobilization of glucose by stimulating protein breakdown and gluconeogenesis (the production of new glucose from amino acids), and lipolysis of adipose tissue.	<i>zona</i> , zone + <i>fasciculus</i> , a bundle
	Zona reticularis	The innermost region of the adrenal cortex, containing a “network” of cells, located between the zona fasciculata and the cells of the adrenal medulla.	Glucocorticoids and gonadocorticoids: androgens	Androgens are similar in structure and function to the male sex steroid hormone testosterone; in females they are responsible for sex drive, in males they have little function because they are secreted in very low amounts compared to testosterone secretion by the testes.	<i>zona</i> , zone + <i>rete</i> , a net
<i>Adrenal Medulla</i>	Chromaffin cells	Large, spherical cells that have a yellowish-brown tint when specially stained due to their reaction with chrome salts.	Catecholamines: epinephrine and norepinephrine	Epinephrine, secreted in the largest quantity (80–90% of all hormone secretion by the adrenal medulla), increases heart rate and contractility (force of heart muscle contraction); norepinephrine is a powerful vasoconstrictor.	<i>chroma-</i> , color + <i>affinis</i> , affinity, attraction for

### EXERCISE 16.5 The Endocrine Pancreas—Pancreatic Islets (of Langerhans)

The **pancreas** is largely an exocrine gland. **Exocrine** glands produce substances that are secreted into ducts. The majority of the cells within the exocrine pancreas produce digestive enzymes and bicarbonate, which are secreted into ducts that empty into the small intestine. The clusters of exocrine cells are **pancreatic acini** (singular: acinus; *acinus*, berry). Interspersed between the acini are small islands of cells that have an endocrine function. **Endocrine** glands secrete hormones into the blood. The endocrine part of the pancreas consists of the **pancreatic islets** (islets of Langerhans). These islets contain hormone-secreting cells and a rich supply of blood capillaries. Four distinct cell types exist within the islets, although they cannot be distinguished in a normal histological preparation. Thus, when observing the slide of the pancreas, the goal is to simply identify the pancreatic islets, not the specific cell types within. Nonetheless, it is imperative to know which cell type secretes each hormone. The cell types and hormones secreted by each cell type are listed in **table 16.4**.

1. Obtain a histology slide of the pancreas, place it on the microscope stage, and bring the tissue sample into focus on low power. The majority of the cells will look somewhat like cuboidal epithelial cells. These are the *exocrine* cells of the pancreas (**figure 16.8**). Scan the slide until some small islands of cells come into the field of view. These islands of cells are the **pancreatic islets**, which (typically) stain lighter in color than the exocrine (acinar) cells.
2. Locate a pancreatic islet and move the microscope stage so the islet is in the center of the field of view.

3. Increase the magnification to view the islet in greater detail. Identify the listed structures on the slide, using figure 16.8 and table 16.4 as guides:

- pancreatic acini** (exocrine cells)       **pancreatic islets**  
 **secretory ducts**

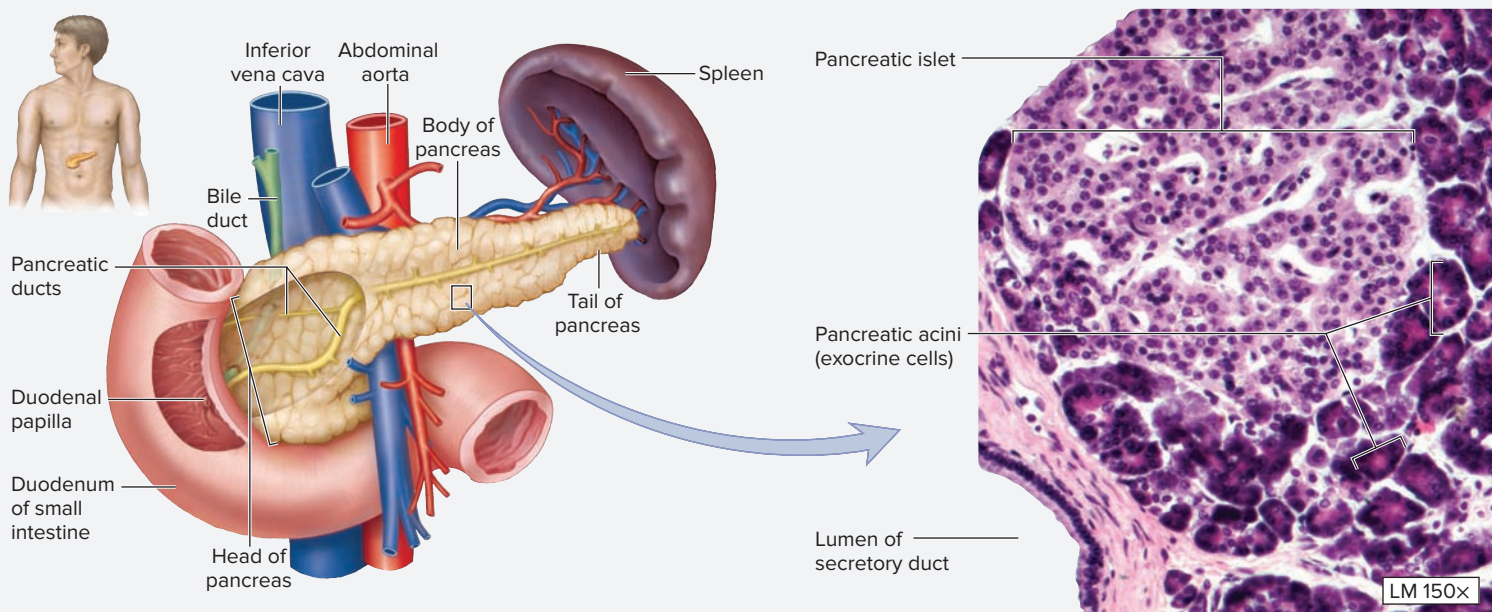
4. Sketch a pancreatic islet and the exocrine cells that surround it in the space provided. Label the structures listed in step 3 in the sketch.





(continued from previous page)

Table 16.4 Histology of the Pancreatic Islets (of Langerhans)					
Cell Types	Description	Hormones Produced	Action of Hormone	Mechanism of Action	Word Origins
<b>Alpha Cells</b>	Compose about 30% of islet cells; located on the periphery of the islet.	Glucagon	Increases blood glucose levels.	Stimulates glycogenolysis (breakdown of glycogen) in the liver, and gluconeogenesis (formation of new glucose from amino acids or fats).	<i>alpha</i> , the first letter of the Greek alphabet; <i>glucose</i> , sugar + <i>ago</i> , to lead
<b>Beta Cells</b>	Compose about 65% of islet cells; located in the center of the islet.	Insulin	Decreases blood glucose levels.	Stimulates glucose uptake by muscle cells, liver cells, and adipocytes, and stimulates glycogenesis (formation of glycogen from glucose) in the liver.	<i>beta</i> , the second letter of the Greek alphabet; <i>insula</i> , an island
<b>Delta Cells</b>	Compose about 4% of islet cells; located on the periphery of the islet.	Somatostatin	Inhibits the release of glucagon and insulin by alpha and beta cells.	Inhibits the release of glucagon and insulin when nutrient levels in the bloodstream are high.	<i>delta</i> , the 4th letter of the Greek alphabet; <i>soma</i> , body + <i>stasis</i> , standing still
<b>F Cells</b>	All other (rare) cell types in the pancreatic islets (~1%) are grouped together and given this name.	Pancreatic polypeptide	Inhibits somatostatin release from delta cells.	Regulates secretion of somatostatin from delta cells.	NA



**Figure 16.8 Endocrine Pancreas.** The endocrine part of the pancreas consists of the pancreatic islets, which are the lighter colored regions in this micrograph. The darker cells surrounding the islet are acinar cells, which compose the exocrine part of the pancreas.

© McGraw-Hill Education/Al Telser

## Gross Anatomy

Some endocrine glands are difficult to identify on the cadaver. However, most classical glands and associated structures can be identified on the

cadaver or on classroom models. These structures are the focus of the gross anatomy section of this chapter.

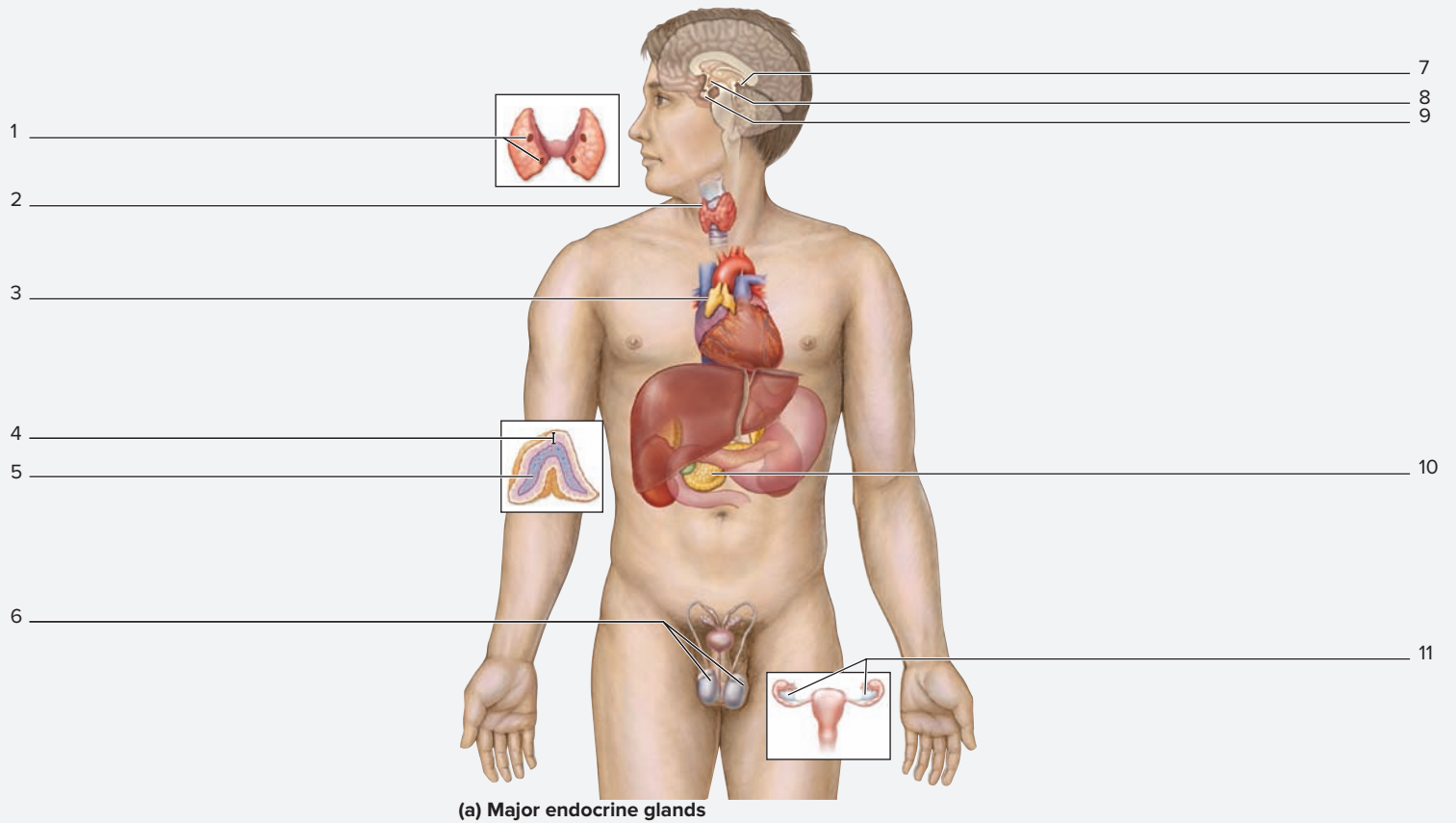
**EXERCISE 16.6** Gross Anatomy of Endocrine Organs

1. Observe a human cadaver or classroom models of the brain, thorax, abdomen, and skull.
2. Identify the listed organs or structures on the human cadaver or on classroom models, using figure 16.1 (p. 328) and the textbook as guides. Next label the structures in **figure 16.9**.

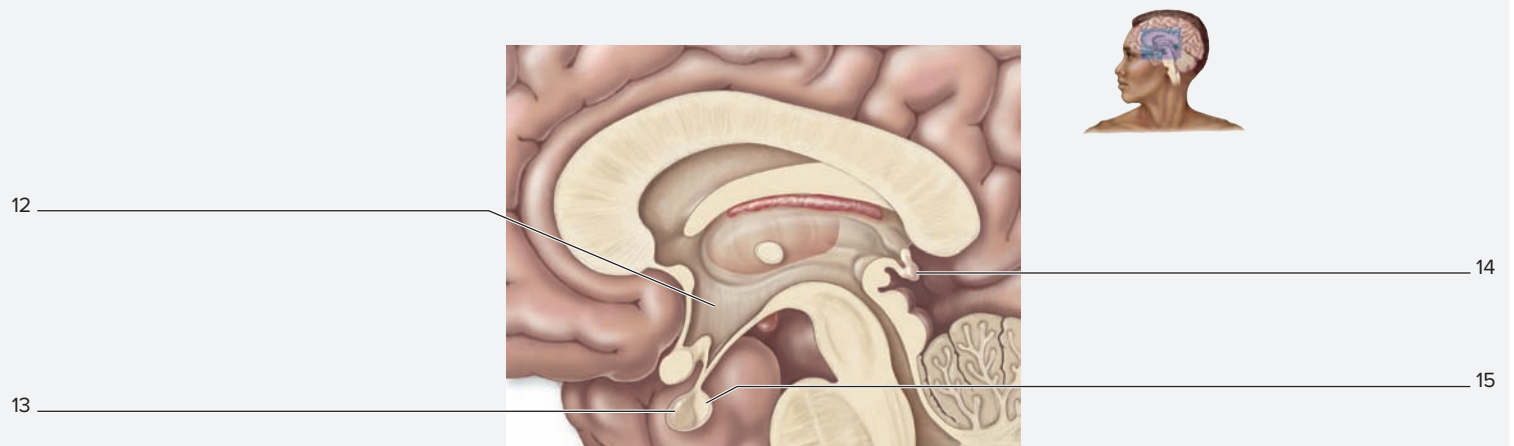
- |   |   |
|---|---|
| <input type="checkbox"/> adrenal cortex           | <input type="checkbox"/> ovaries            |
| <input type="checkbox"/> adrenal medulla          | <input type="checkbox"/> pancreas           |
| <input type="checkbox"/> anterior pituitary gland | <input type="checkbox"/> parathyroid glands |
| <input type="checkbox"/> hypothalamus             | <input type="checkbox"/> pineal gland       |

- |  |  |
|--|--|
| <input type="checkbox"/> pituitary gland           | <input type="checkbox"/> thymus        |
| <input type="checkbox"/> posterior pituitary gland | <input type="checkbox"/> thyroid gland |
| <input type="checkbox"/> testes                    |  |

3. *Optional Activity:* **AP|R Endocrine System**—Watch the endocrine system animations to review the structure and function of the hypothalamus and pituitary gland, pancreas, thyroid and parathyroid glands, and adrenal (suprarenal) glands.



(a) Major endocrine glands



(b) Sagittal section of the brain

**Figure 16.9** Labeling Major Endocrine Glands of the Body. (a) Major endocrine glands of the body on a human torso model. (b) Sagittal section of the brain demonstrating endocrine structures in the CNS. Use the terms listed to fill in the numbered labels in the figure. Some answers may be used more than once.

*This page intentionally left blank*

## POST-LABORATORY WORKSHEET

The **1** corresponds to the Learning Objective listed in the chapter opener outline.

### Do You Know the Basics?

#### Exercise 16.1: The Hypothalamus and Pituitary Gland

- The anterior pituitary gland is composed of glandular tissue, which consists of acidophils, basophils, and chromophobes; thus it generally stains \_\_\_\_\_ (darker/lighter) than the posterior pituitary gland. **1**
- Which of the following hormone(s) is/are produced by acidophils of the anterior pituitary gland? (Check all that apply.) **2**
  - \_\_\_\_\_ a. adrenocorticotrophic hormone (ACTH)
  - \_\_\_\_\_ b. follicle-stimulating hormone (FSH)
  - \_\_\_\_\_ c. growth hormone (GH)
  - \_\_\_\_\_ d. luteinizing hormone (LH)
  - \_\_\_\_\_ e. prolactin
- The supraoptic and paraventricular nuclei contain cell bodies of neurosecretory cells whose axons extend along the infundibulum to axon terminals in the posterior pituitary that release antidiuretic hormone (ADH) and oxytocin. \_\_\_\_\_ (True/False) **3**

#### Exercise 16.2: The Pineal Gland

- One defining histological feature of the pineal gland are the small islands of “crystal” looking structures that compose pineal sand (corpora arenacea). \_\_\_\_\_ (True/False) **4**
- Melatonin, the hormone secreted by pinealocytes of the pineal gland, \_\_\_\_\_ (decreases/increases) when light levels are low, and \_\_\_\_\_ (decreases/increases) when light levels are high. **5**
- Pineal sand is important to radiologists since it is an easily identifiable landmark. \_\_\_\_\_ (True/False) **6**

#### Exercise 16.3: The Thyroid and Parathyroid Glands

- The thyroid gland consists of follicles lined with simple columnar epithelial tissue. \_\_\_\_\_ (True/False) **7**
- Follicular cells of the thyroid gland produce \_\_\_\_\_ (calcitonin/thyroid hormone), whereas parafollicular cells produce \_\_\_\_\_ (calcitonin/thyroid hormone). **8**
- The major action of parathyroid hormone, produced by the parathyroid gland, is to \_\_\_\_\_ (decrease/increase) blood calcium levels by \_\_\_\_\_ (decreasing/increasing) the action of osteoclasts and \_\_\_\_\_ (decreasing/increasing) urinary excretion of calcium. **9**

#### Exercise 16.4: The Adrenal Glands

- Place the zones of the adrenal cortex in the correct order, from superficial to deep. **10**
  - \_\_\_\_\_ a. zona fasciculata
  - \_\_\_\_\_ b. zona glomerulosa
  - \_\_\_\_\_ c. zona reticularis
- Match the region of the adrenal gland listed in column A with the corresponding hormones produced by that region, listed in column B. **11**

##### Column A

- \_\_\_\_\_ 1. medulla
- \_\_\_\_\_ 2. zona fasciculata
- \_\_\_\_\_ 3. zona glomerulosa
- \_\_\_\_\_ 4. zona reticularis

##### Column B

- a. androgens and glucocorticoids
- b. catecholamines
- c. glucocorticoids
- d. mineralocorticoids

12. Match the hormone description and/or action(s) listed in column A with the appropriate hormone, listed in column B. **12**

**Column A**

- \_\_\_\_\_ 1. increased heart rate, contractility, and vasoconstriction
- \_\_\_\_\_ 2. increased glucose synthesis through protein breakdown, gluconeogenesis, and lipolysis
- \_\_\_\_\_ 3. increased sodium and water retention by the kidneys
- \_\_\_\_\_ 4. similar in structure and function to testosterone

**Column B**

- a. aldosterone
- b. androgens
- c. cortisol
- d. epinephrine and norepinephrine

**Exercise 16.5: The Endocrine Pancreas—Pancreatic Islets (of Langerhans)**

13. The small islands of lighter-staining cells of the pancreas are known as pancreatic \_\_\_\_\_ (acini/islets). **13**

14. The pancreatic islets compose the portion of the pancreas dedicated to \_\_\_\_\_ (endocrine/exocrine) function, whereas the pancreatic acini compose the portion of the pancreas dedicated to \_\_\_\_\_ (endocrine/exocrine) function. **14**

15. Insulin is released in response to a(n) \_\_\_\_\_ (increase/decrease) in blood glucose levels, whereas glucagon is released in response to a(n) \_\_\_\_\_ (increase/decrease) in blood glucose levels. **15**

16. Match the cell type of the pancreatic islets, listed in column A, with the hormones secreted by each cell, listed in column B. **16**

**Column A**

- \_\_\_\_\_ 1. alpha cells
- \_\_\_\_\_ 2. beta cells
- \_\_\_\_\_ 3. delta cells
- \_\_\_\_\_ 4. F cells

**Column B**

- a. glucagon
- b. insulin
- c. pancreatic polypeptide
- d. somatostatin

**Exercise 16.6: Gross Anatomy of Endocrine Organs**

17. The adrenal glands are located superior to each kidney. \_\_\_\_\_ (True/False) **17**

18. Match the cells or structures listed in column A with the endocrine gland in which they are found in column B. Some answers will be used more than once. **18**

**Column A**

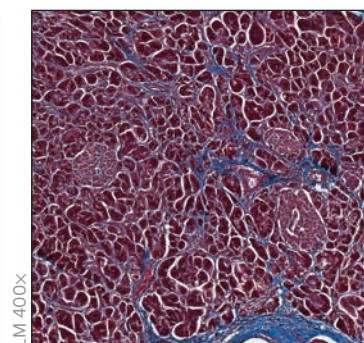
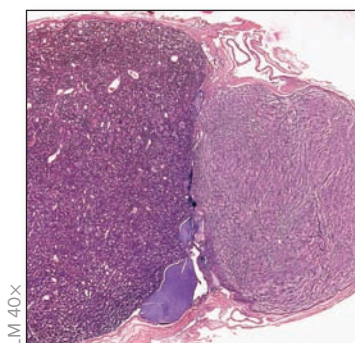
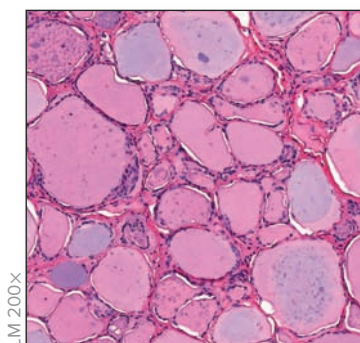
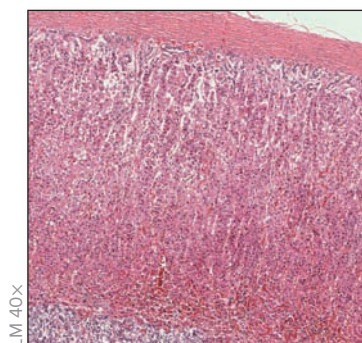
- \_\_\_\_\_ 1. alpha cells
- \_\_\_\_\_ 2. chief (principal) cells
- \_\_\_\_\_ 3. chromaffin cells
- \_\_\_\_\_ 4. chromophobes
- \_\_\_\_\_ 5. colloid
- \_\_\_\_\_ 6. oxyphil cells
- \_\_\_\_\_ 7. parafollicular cells
- \_\_\_\_\_ 8. pinealocytes
- \_\_\_\_\_ 9. pituicytes
- \_\_\_\_\_ 10. zona fasciculata

**Column B**

- a. adrenal gland
- b. anterior pituitary
- c. pancreas
- d. parathyroid gland
- e. pineal gland
- f. posterior pituitary
- g. thyroid gland

**Can You Apply What You've Learned?**

19. Identify each of the following glands by writing in the name of the gland under the photo.



(a) \_\_\_\_\_

(b) \_\_\_\_\_

(c) \_\_\_\_\_

(d) \_\_\_\_\_

# The Cardiovascular System: The Heart

# 17

## OUTLINE AND LEARNING OBJECTIVES

### Histology 346

#### EXERCISE 17.1: CARDIAC MUSCLE 346

- 1 Describe how cardiac muscle differs structurally and functionally from skeletal muscle

#### EXERCISE 17.2: LAYERS OF THE HEART WALL 347

- 2 Name the layers of the heart wall and describe the structures that make up each layer

### Gross Anatomy 348

#### EXERCISE 17.3: THE PERICARDIAL CAVITY 348

- 3 Name and describe the layers of the pericardial sac

#### EXERCISE 17.4: GROSS ANATOMY OF THE HUMAN HEART 349

- 4 Explain how the atria and ventricles of the heart differ in their wall structure
- 5 Describe the specialized structures found within the right atrium of the heart, including pectinate muscle, the coronary sinus, and the fossa ovalis
- 6 Differentiate between pectinate and papillary muscles
- 7 Describe the structure and function of the atrioventricular valves, including tendinous cords (chordae tendineae), valve cusps, and papillary muscles
- 8 Compare and contrast the structure and function of the right atrioventricular valves and the left atrioventricular (mitral) valves
- 9 Compare and contrast the structure and function of the right and left ventricles
- 10 Describe the structure and function of the pulmonary and aortic semilunar valves
- 11 Trace the flow of blood from the right atrium, through the heart and lungs, to the aorta
- 12 Locate the fossa ovalis and the ligamentum arteriosum, and name the fetal structures of which they are remnants

#### EXERCISE 17.5: THE CORONARY CIRCULATION 353

- 13 Identify the right and left coronary arteries, their major tributaries, and the areas of the heart served by each vessel
- 14 Describe the location and function of the coronary sinus

#### EXERCISE 17.6: SUPERFICIAL STRUCTURES OF THE SHEEP HEART 356

- 15 Identify superficial structures on the sheep heart and explain the function of each
- 16 Observe the visceral and parietal pericardium on the sheep heart
- 17 Identify the great vessels on the sheep heart
- 18 Trace the flow of blood through the sheep heart

#### EXERCISE 17.7: CORONAL SECTION OF THE SHEEP HEART 357

- 19 Make a coronal section through the sheep heart, and measure the thicknesses of the right and left ventricular walls
- 20 Explain the functional consequences of the difference in wall thickness between right and left ventricles
- 21 Identify internal structures of the sheep heart as seen in a coronal section

#### EXERCISE 17.8: TRANSVERSE SECTION OF THE SHEEP HEART 359

- 22 Make a transverse section through the sheep heart, and measure the thicknesses of the right and left ventricular walls
- 23 Explain the functional consequences of the difference in wall thickness between right and left ventricles

## INTRODUCTION

The heart is an amazing organ that has been viewed with awe for ages. For many centuries physicians thought the heart, not the brain, was the control center and spiritual/emotional center of the body. Perhaps this is because structure and function relationships in the heart are relatively straightforward and easy to see, whereas such relationships are nearly impossible to discover through gross observation of the brain. A student of anatomy who has studied the brain knows that emotions come not “from the heart” but from the brain. Yet the heart is still the organ that many individuals associate with strong “life” forces, as well as that elusive force called love. Even though scientists and laypeople alike recognize that the brain, not the heart, controls the functioning of the rest of the body, they also recognize that the heart is essential for the survival of all organs and tissues in the body: for if the heart fails to pump blood, and that failure results in a lack of flow of oxygenated blood to the tissues, the tissues will die.

Consider for a moment how amazing it is that the heart continues to beat, day and night, day after day, year after year, without ever stopping. It is an enormous job. Failure of this amazing organ to perform its job results in the direst of consequences. Perhaps it is no surprise that heart disease is the number one cause of death for Americans (it accounts for approximately 32% of all deaths, while cancer, at number two, accounts for 23% of all deaths). A thorough understanding of the structure and function of the heart is

critical for everyone whether involved in the health sciences or not. For those individuals whose future career involves health care, dealing with individuals suffering from heart disease will occur on a daily basis. Even the individuals whose future career does not involve the health sciences, the heart is a critical organ for survival. The degree to which an individual takes care of his or her heart in the present day may very well determine the length and overall quality of his or her life.

The exercises in this chapter review the structure of cardiac muscle and identify heart structures on preserved human hearts or models of the heart, along with dissection of a preserved sheep heart. While working through the exercises, be aware that most textbook figures of the heart are drawn to make identification of the chambers and vessels very straightforward. When observing a real heart, identification of structures is more challenging because the chambers do not lie directly superior, inferior, or lateral to each

other as they are often depicted in textbook drawings. In fact, most of the heart structures labeled “right” (such as the right atrium and right ventricle) lie not only on the right side of the heart, but also on the *anterior* surface of the heart. Likewise, most of the structures labeled “left” (such as the left atrium and left ventricle) lie not only on the left side of the heart, but also on the *posterior* surface of the heart.

#### List of Reference Tables

Table 17.1	Comparisons Between Cardiac and Skeletal Muscle Tissues	p. 346
Table 17.2	Layers of the Heart Wall	p. 350
Table 17.3	Arterial Supply to the Heart	p. 354
Table 17.4	Venous Drainage of the Heart	p. 356

# Chapter 17: The Cardiovascular System: The Heart

Name: \_\_\_\_\_

Date: \_\_\_\_\_ Section: \_\_\_\_\_

## PRE-LABORATORY WORKSHEET

These Pre-laboratory Worksheet questions may be assigned by instructors through their **connect** course.

1. The \_\_\_\_\_ (pulmonary/systemic) circuit pumps blood to all organs of the body, and the \_\_\_\_\_ (pulmonary/systemic) circuit pumps blood to the lungs.
2. The term *coronary* means “crown.” \_\_\_\_\_ (True/False)
3. A(n) \_\_\_\_\_ (artery/vein) is a vessel that always carries blood away from the heart.
4. A(n) \_\_\_\_\_ (artery/vein) is a vessel that always carries blood toward the heart.
5. The \_\_\_\_\_ (pulmonary/systemic) circuit pumps blood at a higher pressure than the \_\_\_\_\_ (pulmonary/systemic) circuit.
6. The muscles that attach to tendinous cords (chordae tendineae) are called \_\_\_\_\_. (Circle one.)
  - a. papillary muscles
  - b. pectinate muscles
  - c. pectoral muscles
  - d. trabeculae carneae
7. The region where the great vessels such as the aorta and pulmonary trunk are attached to the heart is called the \_\_\_\_\_ (apex/base) of the heart.
8. The wall of the \_\_\_\_\_ (right/left) ventricle is much thicker than the wall of the \_\_\_\_\_ (right/left) ventricle.
9. The layer of the pericardial sac that adheres to the heart is the \_\_\_\_\_ (parietal/visceral) layer.
10. Most of the anterior surface of the heart receives oxygenated blood from a branch of the \_\_\_\_\_ (left/right) coronary artery.
11. The valve between the right atrium and the right ventricle is the \_\_\_\_\_ (bicuspid/tricuspid) valve.
12. The valve between the left atrium and the left ventricle is the \_\_\_\_\_ (bicuspid/tricuspid) valve.
13. The left ventricle pumps blood into the \_\_\_\_\_ (aorta/pulmonary trunk).
14. The superior and inferior vena cava drain blood into the \_\_\_\_\_ (left/right) atrium.
15. Fill in the following paragraph with the appropriate terms.

Blood that enters the heart through the inferior vena cava (IVC) and the superior vena cava (SVC) enters the \_\_\_\_\_ (left/right) atrium. Blood then flows past the \_\_\_\_\_ (bicuspid/tricuspid) valve and enters the \_\_\_\_\_ (right/left) ventricle. Next, blood is pumped past the \_\_\_\_\_ (aortic/pulmonary) semilunar valve and enters the \_\_\_\_\_ (aorta/pulmonary trunk), which carries it to the \_\_\_\_\_ (pulmonary/systemic) circuit. Blood returns to the heart through the \_\_\_\_\_ (pulmonary veins/vena cavae), and enters the \_\_\_\_\_ (left/right) atrium. From here, blood flows past the \_\_\_\_\_ (bicuspid/tricuspid) valve and enters the \_\_\_\_\_ (left/right) ventricle. The blood is then pumped past the \_\_\_\_\_ (aortic/pulmonary) semilunar valve into the \_\_\_\_\_ (aorta/pulmonary trunk). Finally, blood travels through the \_\_\_\_\_ (pulmonary/systemic) circuit and returns to the heart through the SVC and IVC.



## Histology

### EXERCISE 17.1 Cardiac Muscle

This activity is a review of observations of muscle tissue that were covered in chapter 11 of this laboratory manual. Depending on the time available in the laboratory, the instructor may want you to repeat observations of cardiac muscle tissue, or may simply have you refer back to notes on cardiac muscle tissue made in chapter 11.

1. Obtain a slide of cardiac muscle and place it on the microscope stage. Bring the tissue sample into focus on low power, and then switch to high power. As you make your observations of cardiac muscle tissue, compare and contrast the structure and function of cardiac muscle with the structure and function of skeletal muscle by filling in **table 17.1**.
2. Identify the structures listed in **figure 17.1** on the slide, using table 17.1 as a guide. Then label them in figure 17.1.

What two types of cellular junctions are found in the intercalated discs?

\_\_\_\_\_ and \_\_\_\_\_

What is the purpose of each of these cellular junctions in the intercalated discs?

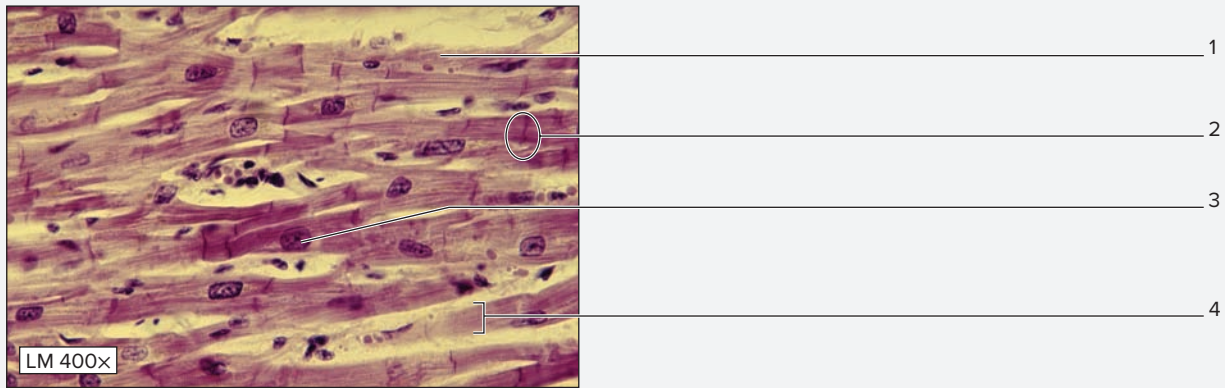
\_\_\_\_\_  
 \_\_\_\_\_  
 \_\_\_\_\_

3. Sketch cardiac muscle as seen through the microscope in the space provided. Label all of the structures listed in figure 17.1.



\_\_\_\_\_ ×

Table 17.1	Comparisons Between Cardiac and Skeletal Muscle Tissues	
Muscle Tissue	Cardiac Muscle	Skeletal Muscle
<i>Appearance of Cells</i>		
<i>Location of Nuclei</i>		
<i>Nervous Control</i>		
<i>Number of Nuclei</i>		



**Figure 17.1 Cardiac Muscle Tissue.** Cardiac muscle tissue is characterized by short, branching cells with single, centrally located nuclei. Intercalated discs are dark lines visible between the cells. A bands and I bands are also visible, indicating the presence of sarcomeres within the myofibers. Use the terms listed to fill in the numbered labels in the figure.

- cardiac muscle cell       intercalated disc       nucleus       striations

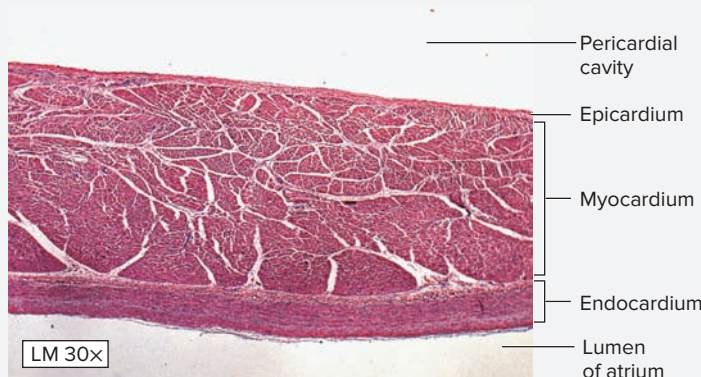
© Fuse/Getty Images RF

### EXERCISE 17.2 Layers of the Heart Wall

1. Obtain a slide demonstrating the atria of the heart. Place it on the microscope stage and observe on low power. The wall of the heart is composed of three layers, the endocardium, myocardium, and epicardium. The **endocardium** consists of the simple squamous epithelium that lines the heart, called **endothelium**, plus an underlying layer of connective tissue (**figure 17.2**). The **myocardium** is composed of cardiac muscle and is by far the thickest layer of the heart wall. The **epicardium** is the same tissue that composes the visceral layer of the pericardial sac—a serous membrane referred to as the visceral layer of serous pericardium. What to call this layer of tissue depends on the context. When referring to it as part of the heart wall, the appropriate term is *epicardium*. When referring to it as part of the pericardial sac, the appropriate term is *visceral layer of serous pericardium*.


Look for cross sections of the coronary vessels which lie deep to the epicardium.

2. Identify the following on the slide of the atrium, using figure 17.2 as a guide:
- endocardium (endothelium)**       **myocardium (cardiac muscle)**
- epicardium (visceral, serous pericardium)**
3. Sketch the layers of the heart wall as seen through the microscope in the space provided. Label all of the structures listed in step 2 in the drawing.



**Figure 17.2 Histology of the Heart Wall.** This slide demonstrates the wall layers of the atrium of the heart. In the atrium, the endocardium is thick, consisting of endothelium plus a layer of underlying connective tissues. The myocardium is the thickest layer, consisting of cardiac muscle tissue, and the epicardium is the thinnest layer, consisting of the visceral pericardium (a serous membrane) with a thin layer of underlying connective tissue.

© Rick Ash



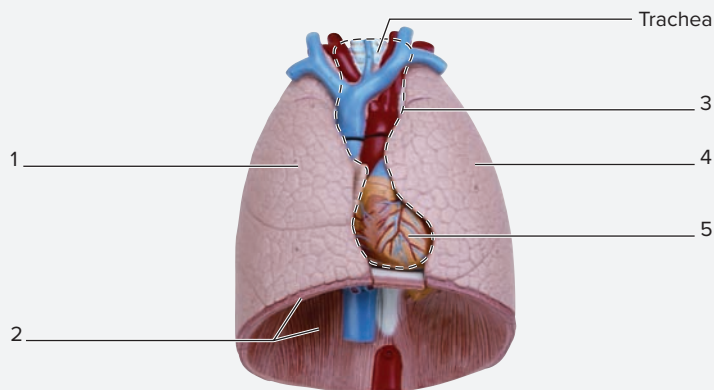
### WHAT DO YOU THINK?

- 1 Figure 17.2 shows an atrial wall that has a fairly thick myocardium. Is this more indicative of the right atrium or the left atrium of the heart? Explain.

Gross Anatomy

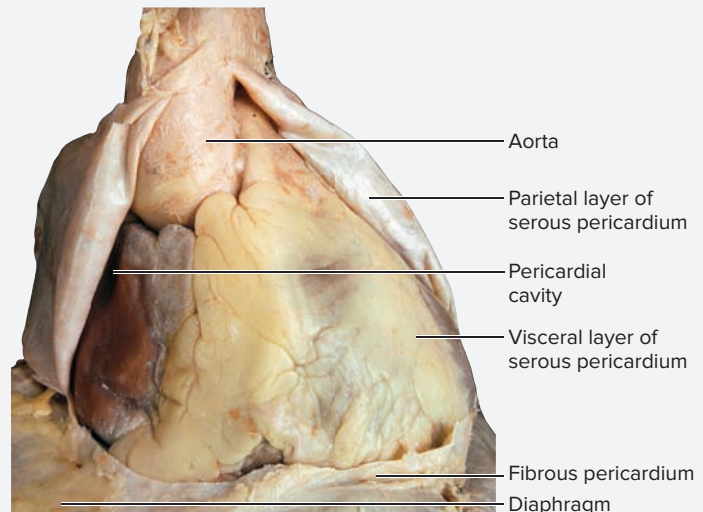
**EXERCISE 17.3** The Pericardial Cavity

1. Observe a model of a human thorax or the thoracic cavity of a human cadaver (**figure 17.3**).
2. The heart is located within the **thoracic cavity**, a cavity that also houses the lungs, trachea, esophagus, and a variety of nerves and blood vessels. Within the thoracic cavity, the heart is located within a space called the **mediastinum**. The mediastinum is the space between the two pleural cavities. The mediastinum contains the trachea, esophagus, thymus, nerves, and blood vessels, as well as the pericardial cavity. The **pericardial cavity** encases the heart.
3. Identify the structures listed in figure 17.3 on a classroom model of the thorax or on a human cadaver, using the textbook as a guide. Then label them in figure 17.3.
4. **Optional Activity:** **APR Cardiovascular System**—Explore the “Thorax” dissections to view the heart in the thoracic cavity and appreciate the surrounding structures.
5. The pericardial cavity has two layers to it, an outer, **parietal layer** (parietal, *wall*), and an inner, **visceral layer** (viscus, *internal organ*). The parietal layer is anchored to surrounding structures and helps hold the pericardial sac in place within the mediastinum. Observe the pericardial cavity within the thorax and name the structures the parietal pericardium is anchored to on each of the following surfaces:  
 Superior: \_\_\_\_\_  
 Inferior: \_\_\_\_\_  
 Lateral: \_\_\_\_\_
6. The **visceral layer** of the pericardium is in contact with the heart itself. To remove the heart from the pericardial sac, the parietal layer of the pericardial sac must be cut away from the visceral layer (**figure 17.4a, b**).

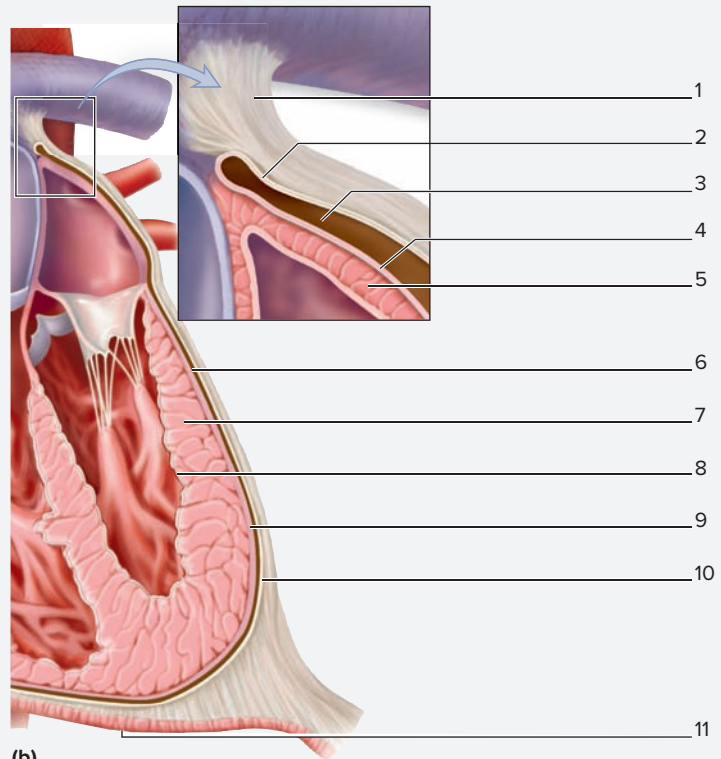


**Figure 17.3** Location of the Heart Within the Thoracic Cavity. In the thoracic cavity, the heart is located within the mediastinum, the space between the two pleural cavities, which house the lungs. Use the terms listed to fill in the numbered labels in the figure.

- |                                    |                                      |
|------------------------------------|--------------------------------------|
| <input type="checkbox"/> diaphragm | <input type="checkbox"/> mediastinum |
| <input type="checkbox"/> heart     | <input type="checkbox"/> right lung  |
| <input type="checkbox"/> left lung |                                      |



(a)



(b)

**Figure 17.4** The Pericardial Sac. (a) Location of the heart within the pericardial sac of a cadaver. The parietal pericardium has been cut and reflected to reveal the heart, which is covered by visceral pericardium. (b) Layers and tissues composing the pericardial sac. Use the terms listed to fill in the numbered labels in the figure. Some terms may be used more than once.

- |  |  |   |
|--|--|---|
| <input type="checkbox"/> diaphragm           | <input type="checkbox"/> of serous pericardium | <input type="checkbox"/> of serous pericardium (epicardium) |
| <input type="checkbox"/> endocardium         | <input type="checkbox"/> pericardial cavity    |   |
| <input type="checkbox"/> fibrous pericardium | <input type="checkbox"/> serous pericardium    |   |
| <input type="checkbox"/> myocardium          | <input type="checkbox"/> visceral layer        |   |
| <input type="checkbox"/> parietal layer      |  |   |

Upon removal of the parietal layer, the visceral layer will remain with the heart itself. Note that the terms *parietal* and *visceral* refer only to the physical layers of the pericardial sac. The actual *tissue* that composes each layer is either a *serous tissue* or a *fibrous tissue* (serous pericardium or fibrous pericardium). **Serous pericardium** is composed of simple squamous epithelium called **mesothelium**. The serous tissue is a smooth, shiny layer of tissue that produces a small amount of **pericardial fluid**, which lubricates the inside of the pericardial sac. Which layers of the pericardium (parietal

and/or visceral) contain serous pericardium?

\_\_\_\_\_ **Fibrous pericardium** is composed of dense irregular connective tissue (collagen fibers and fibroblasts), which strengthens the sac and anchors it to surrounding structures. Which layers of the pericardium (parietal and/ or visceral)

contain fibrous pericardium? \_\_\_\_\_

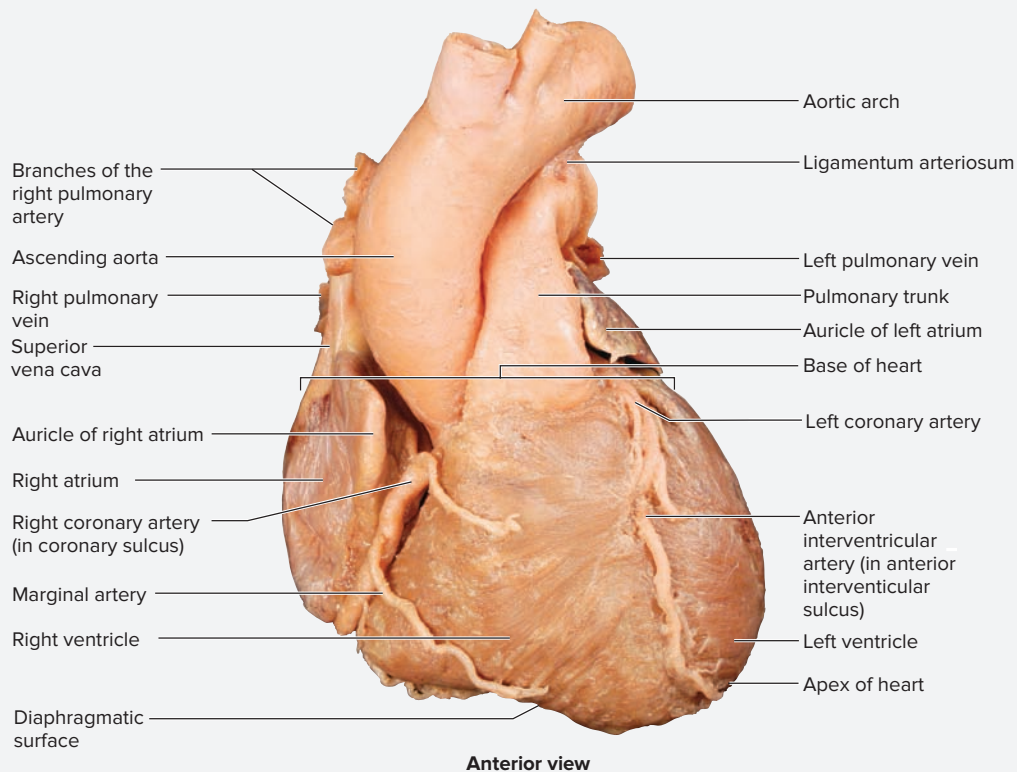
- Identify the structures listed in figure 17.4b on the model of the thorax or on a human cadaver, using figure 17.4a as a guide. Then label them in figure 17.4b.

### EXERCISE 17.4 Gross Anatomy of the Human Heart

Obtain a preserved human heart from a cadaver or a classroom model of the heart. If using a preserved heart, place it in a dissecting pan and keep it moist while making observations. In addition, use only a blunt probe to point out structures on the heart so as not to damage the heart.

- Note the size and shape of the heart. A normal heart is about the size and shape of a human fist. Based on this information, is the heart being observed normal size? \_\_\_\_\_ If the heart appears to be enlarged, make note of that observation, as it can be (though not necessarily) indicative of heart disease. One of the first things to notice about the heart being observed is that it looks very little like the drawings in the textbook. The heart is a twisted

organ, so identification of chambers can be challenging at first. Begin by identifying the **apex** (the pointed, inferior portion of the heart) and the **base** (the superior point where the great vessels enter and leave). In most instances of naming parts of organs of the body, the term *base* refers to the bottom of the organ or tissue. Is this generalization true with the heart? \_\_\_\_\_ The heart has a relatively flat inferior surface, the **diaphragmatic surface**, which is the surface of the heart that lies on top of the diaphragm. Once the apex and base of the heart have been identified, place the heart in your right hand with the diaphragmatic surface in the palm of your hand, the apex directed toward your thumb and wrist, and the base directed toward the space between the tip of the thumb and the second digit (**figure 17.5**). This



**Figure 17.5 Orientation of the Heart in the Right Hand of the Observer.** The heart shown here is oriented with the anterior surface facing the observer, which is how it should look when it is in the observer's right hand with the apex pointed toward the thumb and wrist, and the great vessels directed toward the space between the tip of the thumb and the second digit.

(continued from previous page)

is an anterior view of the heart in a position that very closely resembles the heart's orientation within the thorax. If you are unsure if the view is of the anterior surface, check with the instructor before proceeding.

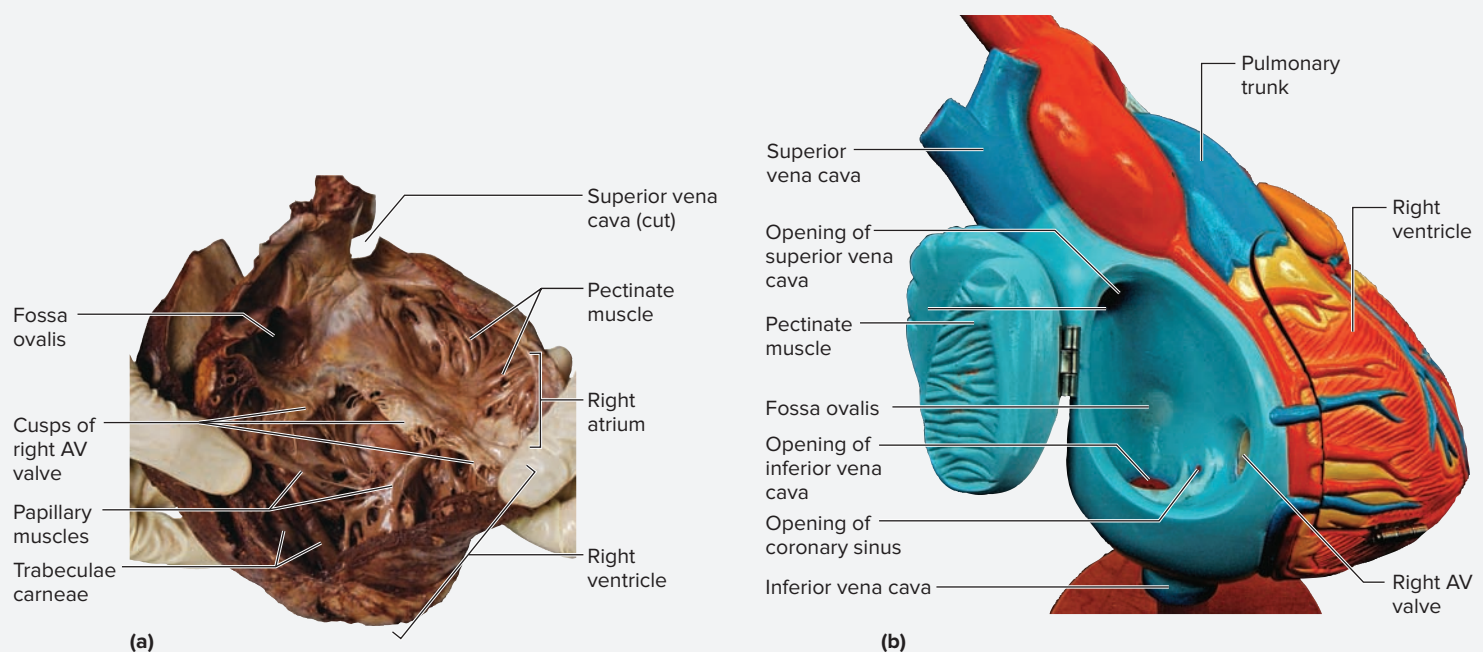
- Identify the **right and left ventricles** (figure 17.5). Because the anterior surface of the heart is being viewed, the left ventricle will be on the *observer's* (i.e., your) right, and the right ventricle will be on the *observer's* left. Notice that the mass of the left ventricle fills up nearly the entire palm of the hand because it has a much thicker myocardium than the right ventricle. Identify the **right atrium** superior and lateral to the right ventricle. The left atrium is not visible in this view. The following steps guide the observer to first identify the layers of the heart wall. Subsequent steps guide the observer in identifying the heart chambers and major heart structures within each chamber.
- Layers of the Heart Wall:** Both atria and ventricles are composed of a three-layered wall. The layers of the heart wall, from outside to inside, are the epicardium, myocardium, and endocardium (these are described in greater detail in exercise 17.2). **Table 17.2** summarizes the characteristics of the wall layers of the heart.

- Identify the listed components of the heart wall on a heart model or on a human heart, using table 17.2 and figure 17.4 as guides:

- endocardium                       myocardium  
 epicardium

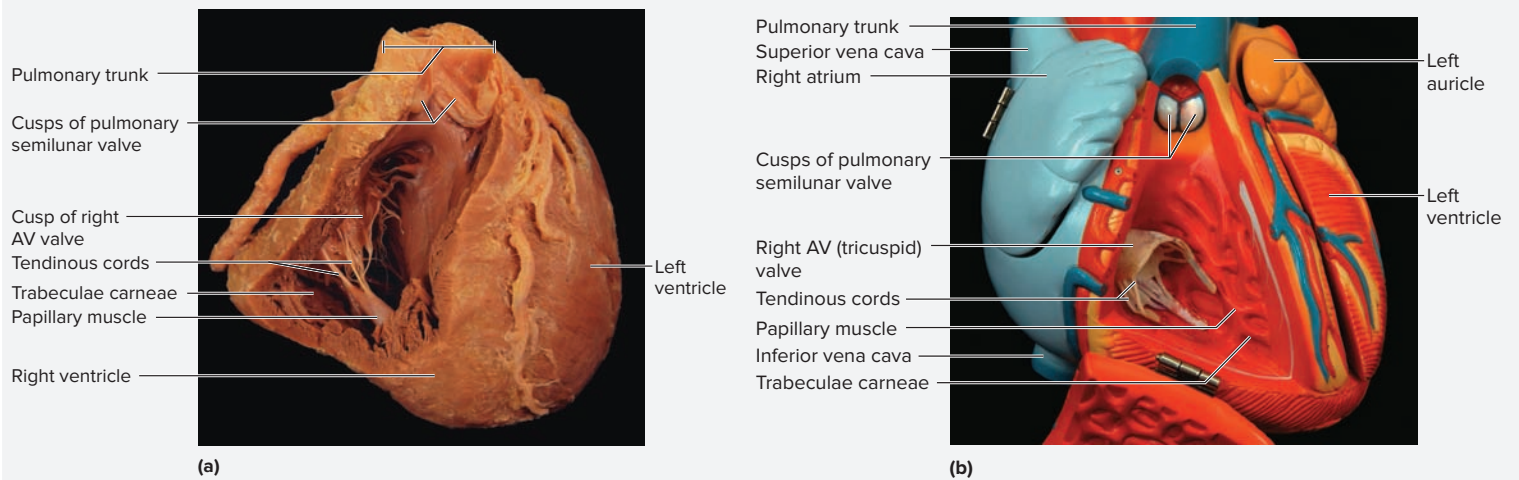
- The Right Atrium:** Once again, hold the heart in your right hand with the anterior surface directed toward you. Identify the **superior and inferior vena cava** entering the right atrium (figure 17.5). Within the thorax, these vessels run vertically and meet at the right atrium. Next, look inside the right atrium. Notice the thin strands of **pectinate muscle** in the wall of the right atrium (**figure 17.6**). Pectinate muscle is found only in the wall of the right atrium (although some pectinate muscle is also found within the walls of both *auricles*, which are extensions of the atria). Thus, the presence of pectinate muscle in the wall of the chamber is a reliable indicator that the right atrium—not the left atrium—is being observed. Locate the shallow depression covered with a thin membrane in the interatrial septum. This is the **fossa ovalis**, a remnant of a fetal shunt between the right and left atria, which is called the **foramen ovale** in the fetus. Is the hole completely closed off in the specimen

Wall Layer	Tissue	Description	Word Origins
<b>Endocardium</b>	Endothelial cells plus some connective tissue and smooth muscle.	This layer is relatively thick in the atria, and thin in the ventricles.	<i>endon</i> , within + <i>kardia</i> , heart
<b>Myocardium</b>	Composed of layers of cardiac muscle in addition to elastic fibers and loose connective tissue between the layers.	This is the thickest layer of the heart wall.	<i>mys</i> , muscle + <i>kardia</i> , heart
<b>Epicardium</b>	Composed of a serous membrane with an underlying layer of elastic fibers and adipose connective tissue.	This is the visceral pericardium. It is relatively thicker in the ventricles than in the atria.	<i>epi-</i> , upon + <i>kardia</i> , heart



**Figure 17.6** The Right Atrium of a Human Heart. (a) Gross specimen. (b) Heart model.

(a) © Christine Eckel; (b) Copyright by Denoyer-Geppert. Photo by Christine Eckel



**Figure 17.7 The Right Ventricle of a Human Heart.** (a) Gross specimen. (b) Heart model.

(a) © McGraw-Hill Education/Photo and Dissection by Christine Eckel; (b) © Copyright by Denoyer-Geppert. Photo by Christine Eckel

being observed? If not, what might some of the consequences be (this condition is called a *patent* foramen ovale [*pateo*, to lie open])? \_\_\_\_\_ Just inferior to the fossa ovalis, look for the small opening of the **coronary sinus**. The coronary sinus is a vein that drains nearly all deoxygenated blood from the heart wall. Finally, observe the **right atrioventricular (AV) valve** and count the cusps. How many cusps are there? \_\_\_\_\_ Based on that information, is the right AV valve a tricuspid or bicuspid valve? \_\_\_\_\_

6. *The Right Ventricle:* Place a blunt probe in the right atrium, and direct it into the right ventricle (**figure 17.7**). If the right ventricle is not already cut open, ask the instructor to cut it open to identify the structures inside. The most prominent features in the walls of the right ventricles are the strands of cardiac muscle in the walls of the ventricle called **trabeculae carneae** (*trabs*, a beam + *carneus*, fleshy), and the nipplelike **papillary muscles** (*papilla*, a nipple), which attach to the cusps of the right AV valve by stringlike structures called **tendinous cords** (*chordae tendineae*, *chorda*, cord + *tendo*, to stretch out). When the ventricles contract, the papillary muscles also contract and pull down on the cusps of the AV valve. Because blood is being pushed up against the underside of the valve cusps as the ventricles contract, the action of the papillary muscles pulling down on the valve cusps keeps the valve closed. This prevents blood from flowing back into the right atrium, and instead forces the blood out through the **pulmonary trunk**.

7. Identify the listed structures in the right ventricle of a human heart or heart model, using figure 17.7 as a guide:

- cusps of the right AV valve
- tendinous cords
- papillary muscles
- trabeculae carneae

8. Place the tip of a blunt probe in the right ventricle and pass it out through the **pulmonary trunk**. To enter the pulmonary trunk, the probe will have to pass through the **pulmonary semilunar valve**. If the vessel has been cut open, the cusps of the semilunar valve will be visible. Notice they are shaped like “half moons,” hence their name. How many cusps are there? \_\_\_\_\_

Where will the blood travel after it leaves the pulmonary trunk? \_\_\_\_\_

9. Sketch the right atrium and right ventricle in the space provided. Include and label all of the listed structures in the drawing.

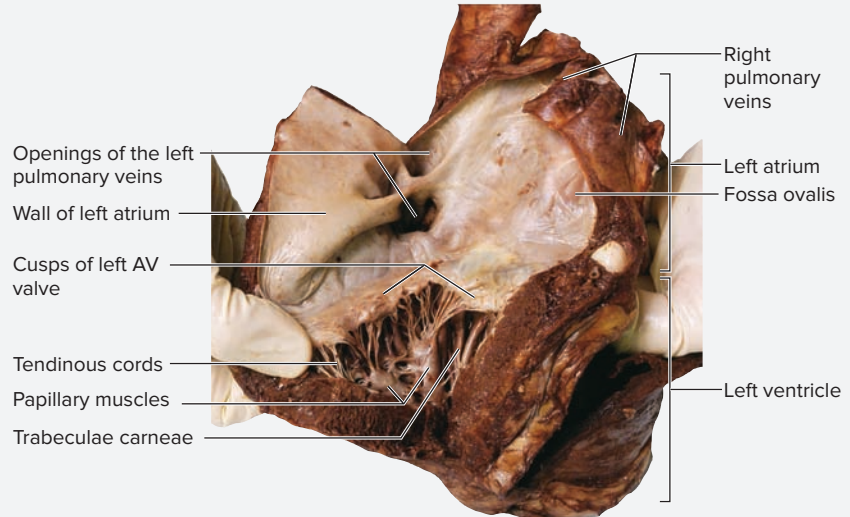
- fossa ovalis
- inferior vena cava
- opening of coronary sinus
- papillary muscles
- pectinate muscle
- pulmonary semilunar valve
- pulmonary trunk
- right atrium
- right AV valve
- right ventricle
- superior vena cava
- tendinous cords
- trabeculae carneae

(continued on next page)

(continued from previous page)

### Learning Strategy

One way to remember which of the atrioventricular (AV) valves is on the right side of the heart and which is on the left is to use the saying, “**Try** before you **Buy**.” The **TRI**cuspid (“Try”) valve, which is on the right side of the heart, comes before the **BI**cuspid (“Buy”) valve, which is on the left side of the heart.



**Figure 17.8 The Left Atrium of a Human Heart.** Posterior view of a human heart with left atrium and left ventricle cut open. Note that this heart is a diseased heart. The wall of the left atrium has been stretched (from blood backing up into it: “congestion”). This specimen was chosen for this figure because it demonstrates the lack of pectinate muscle in the left atrium. © Christine Eckel

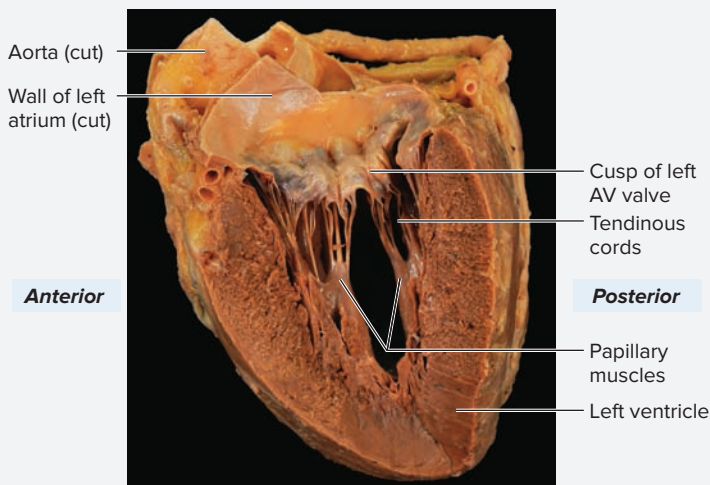
10. *The Left Atrium:* Rotate the heart until its posterior surface is visible (**figure 17.8**). Note the four **pulmonary veins**, which collectively drain into the **left atrium**. Look inside the left atrium. Notice that the wall of the left atrium is thin and smooth and does *not* have pectinate muscles (although the wall of the left *auricle* does). The left atrium is little more than an expansion of the tissue where the four pulmonary veins come together. Thus, its walls are not always easy to identify. Now that both right and left atria have been identified, place your index finger in the right atrium and your thumb in the left atrium and again find the **fossa ovalis**, which lies in the **interatrial septum**. What is the name of the fetal structure of which the fossa ovalis is a remnant? \_\_\_\_\_ Next, observe the **left atrioventricular (AV) valve** and count the cusps. How many cusps are there? \_\_\_\_\_ Based on that information, is the left AV valve a tricuspid or

bicuspid valve? \_\_\_\_\_ What is another name for this valve? \_\_\_\_\_

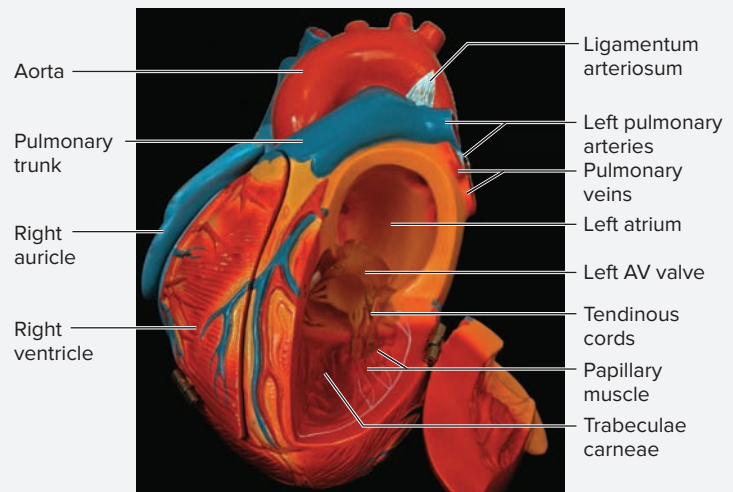
11. *The Left Ventricle:* Place a blunt probe in the left atrium and pass it into the **left ventricle** (**figure 17.9**). If the left ventricle is not already cut open, ask the instructor to cut it open so the structures within are visible. The left ventricle contains all of the same structures as the right ventricle, and the **left atrioventricular (AV) valve** functions the same way the right AV valve functions. The biggest difference between the two chambers is the thickness of the ventricular walls.

12. Identify the listed structures in the left ventricle, using figure 17.9 as a guide:

- left AV valve
- tendinous cords
- papillary muscles
- trabeculae carneae



(a)



(b)

**Figure 17.9 The Left Ventricle of a Human Heart.** (a) Gross specimen. (b) Classroom model.

(a) © McGraw-Hill Education/Photo and Dissection by Christine Eckel; (b) © Copyright by Denoyer-Geppert. Photo by Christine Eckel

13. Note the difference in thickness between the myocardium in the wall of the left ventricle as compared to that of the right ventricle. What are the consequences of this difference? \_\_\_\_\_


Does the chamber size (volume) of the left ventricle appear to be greater than that of the right ventricle? \_\_\_\_\_

14. Place a probe in the left ventricle and pass it out through the **aorta**. To enter the aorta, the probe will have to pass through the **aortic semilunar valve**. If the vessel has been cut open, the cusps of the semilunar valve will be visible. Notice they are shaped like “half moons,” hence their name. How many cusps are there? \_\_\_\_\_ Where will the blood travel after it leaves the aorta? \_\_\_\_\_

15. Observe the outside of the arch of the aorta where it passes just superior to the pulmonary trunk. Look for a small ligament attaching the pulmonary trunk to the aorta (see figure 17.5 and figure 17.9b). This is the **ligamentum arteriosum**. Of what fetal structure is the ligamentum arteriosum a remnant? \_\_\_\_\_ This fetal structure shunts blood from the \_\_\_\_\_ to the \_\_\_\_\_, thereby shunting blood away from the \_\_\_\_\_.

16. Sketch the left atrium and left ventricle in the space provided. Include and label all of the listed structures in the drawing.

- |   |   |
|---|---|
| <input type="checkbox"/> aorta                  | <input type="checkbox"/> left ventricle     |
| <input type="checkbox"/> aortic semilunar valve | <input type="checkbox"/> papillary muscles  |
| <input type="checkbox"/> fossa ovalis           | <input type="checkbox"/> pulmonary veins    |
| <input type="checkbox"/> left atrium            | <input type="checkbox"/> tendinous cords    |
| <input type="checkbox"/> left AV valve          | <input type="checkbox"/> trabeculae carneae |



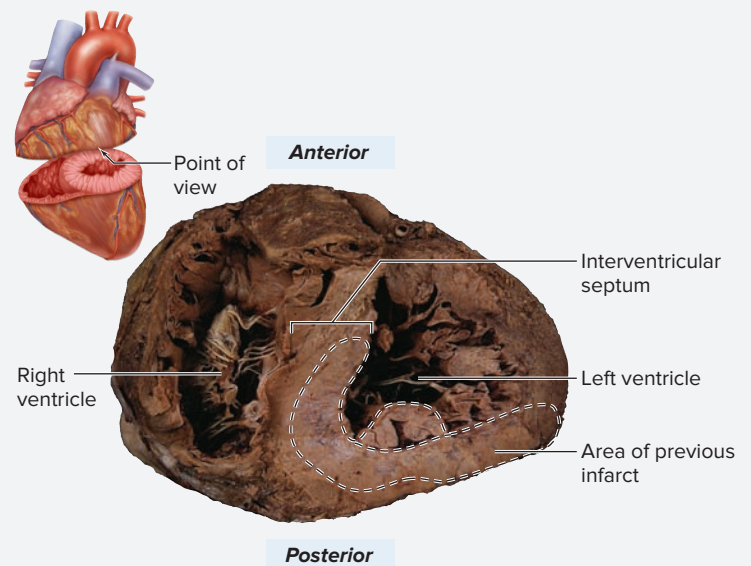
17. *Optional Activity:* **APR Cardiovascular System**—Watch the “Heart” animation to gain a 3-D fly-through perspective of the internal heart.

**WHAT DO YOU THINK?**

2 Should the volume of blood pumped by each ventricle be different? Explain.

**EXERCISE 17.5 The Coronary Circulation**

1. Obtain a preserved human heart or a classroom model of the heart.
2. The coronary circulation is the circulation to the heart wall itself. Adequate blood flow through the coronary arteries is absolutely essential for the functioning of the heart. If any coronary vessel becomes blocked due to disease or other processes, the area served by the vessel may become **ischemic**, meaning it lacks blood flow (*ischio-*, to keep back + *chymos*, juice). Prolonged ischemia to heart muscle leads to **hypoxia** (*hypo-*, too little + *oxia*, oxygen). When cardiac muscle lacks an oxygen supply for more than a few minutes, the tissue dies, or becomes **necrotic** (*nekrosis*, death). The area of dead tissue composes a **myocardial infarction** (*myocardial*, referring to the myocardium + *in-farctio*, to stuff into), otherwise known as a “heart attack” or “MI.” If a myocardial infarction results in vast tissue destruction, the heart may no longer be effective as a pump, which can lead to the death of the individual. If the individual survives the attack, the body will eventually repair the area of dead tissue and replace it with scar tissue. Scar tissue is mainly composed of a dense collection of collagen fibers. **Figure 17.10** demonstrates a human heart with evidence of a healed myocardial infarction. If observing a human heart, does the specimen show any evidence of (scarring from) past myocardial infarctions (scar tissue is



**Figure 17.10 Inferior View of a Transverse Section Through a Human Heart.** Scar tissue, which is evidence of a previous myocardial infarction, can be seen in the interventricular septum and posterior wall of the left ventricle.

© McGraw-Hill Education/Photo and Dissection by Christine Eckel

(continued on next page)



(continued from previous page)

Table 17.3 Arterial Supply to the Heart			
Vessel	Description	Areas Served	Word Origins
<b>Anterior Interventricular Artery</b>	Located in the anterior interventricular sulcus (groove). Physicians typically refer to this as the “LAD” (left anterior descending).	Anterior parts of the right and left ventricles.	<i>inter-</i> , between + <i>ventricular</i> , referring to the ventricles of the heart (from <i>ventriculus</i> , belly)
<b>Circumflex Artery</b>	Located in the coronary sulcus between the left atrium and left ventricle.	Left atrium and left ventricle (lateral part).	<i>circum-</i> , around + <i>flexus</i> , to bend
<b>Left Coronary Artery</b>	Located posterior to the pulmonary artery; branches into the anterior interventricular and circumflex arteries just after it emerges from behind the pulmonary artery.	Anterior interventricular and circumflex arteries.	<i>corona</i> , a crown
<b>Marginal Artery</b>	Branches off of the right coronary artery at the right margin of the heart and is located on the lateral part of the right ventricle.	Lateral part of the right ventricle.	<i>margo</i> , border or edge
<b>Posterior Interventricular Artery</b>	Continuation of the right coronary artery located in the posterior interventricular sulcus.	Posterior parts of the right and left ventricles.	<i>inter-</i> , between + <i>ventricular</i> , referring to the ventricles of the heart (from <i>ventriculus</i> , belly)
<b>Right Coronary Artery</b>	Located in the coronary sulcus between the right atrium and the right ventricle. Branches include the SA nodal artery, which supplies blood to the sinoatrial node within the right atrium.	Right atrium and marginal and posterior interventricular arteries.	<i>corona</i> , a crown

generally clear to whitish in appearance and is much tougher than muscle tissue)? \_\_\_\_\_

3. The blood supply to the heart arises from two main coronary vessels, the **right and left coronary arteries** (table 17.3). The openings into these arteries arise behind the cusps of the aortic semilunar valve. **Figure 17.11** shows the relationship between the cusps of the aortic semilunar valve and the openings to the right and left coronary arteries. Observe the aortic semilunar valve and identify the openings into the right and left coronary arteries (figure 17.11). When the left ventricle contracts and pushes blood into the aorta, the cusps of the semilunar valve fold over the openings to the coronary arteries. What consequence does this have in terms of blood flow to the heart during ventricular contraction (systole)? \_\_\_\_\_
- \_\_\_\_\_
- \_\_\_\_\_

When the ventricles relax, the cusps of the semilunar valves fall shut as they fill with blood. Thus, they are no longer covering the openings to the coronary arteries. What consequence does this have in terms of blood flow to the heart during ventricular relaxation (diastole)? \_\_\_\_\_

\_\_\_\_\_

\_\_\_\_\_

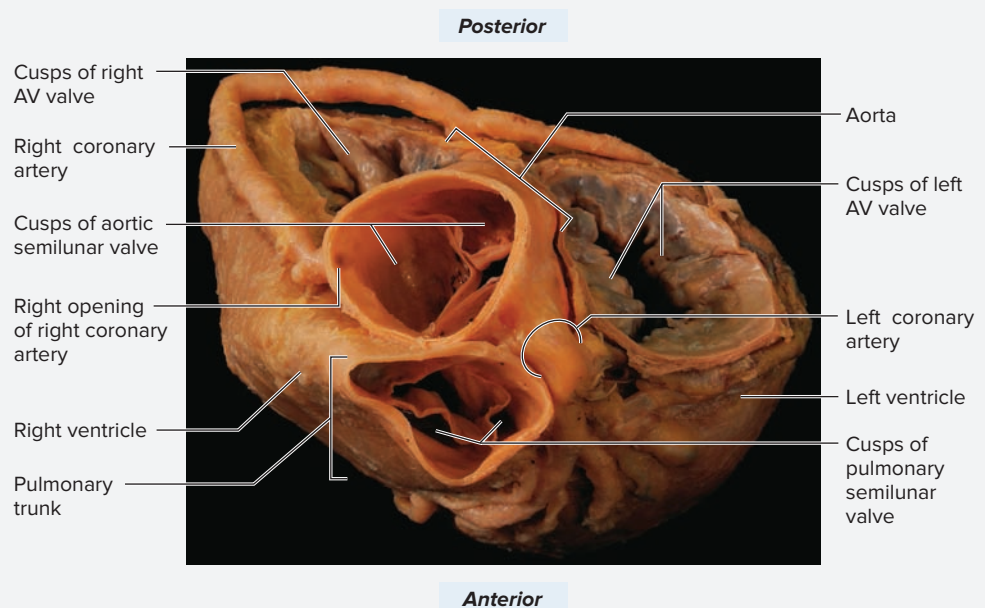
4. **Cardiac Veins:** For the most part, venous drainage from the heart wall parallels the arterial supply. However, all venous blood draining the heart wall (with one exception, see table 17.4) eventually drains into one large vessel, the **coronary sinus**. The coronary sinus is located on the posterior surface of the heart and runs in the coronary sulcus. What heart chamber does the coronary sinus empty into? \_\_\_\_\_
- \_\_\_\_\_
- \_\_\_\_\_

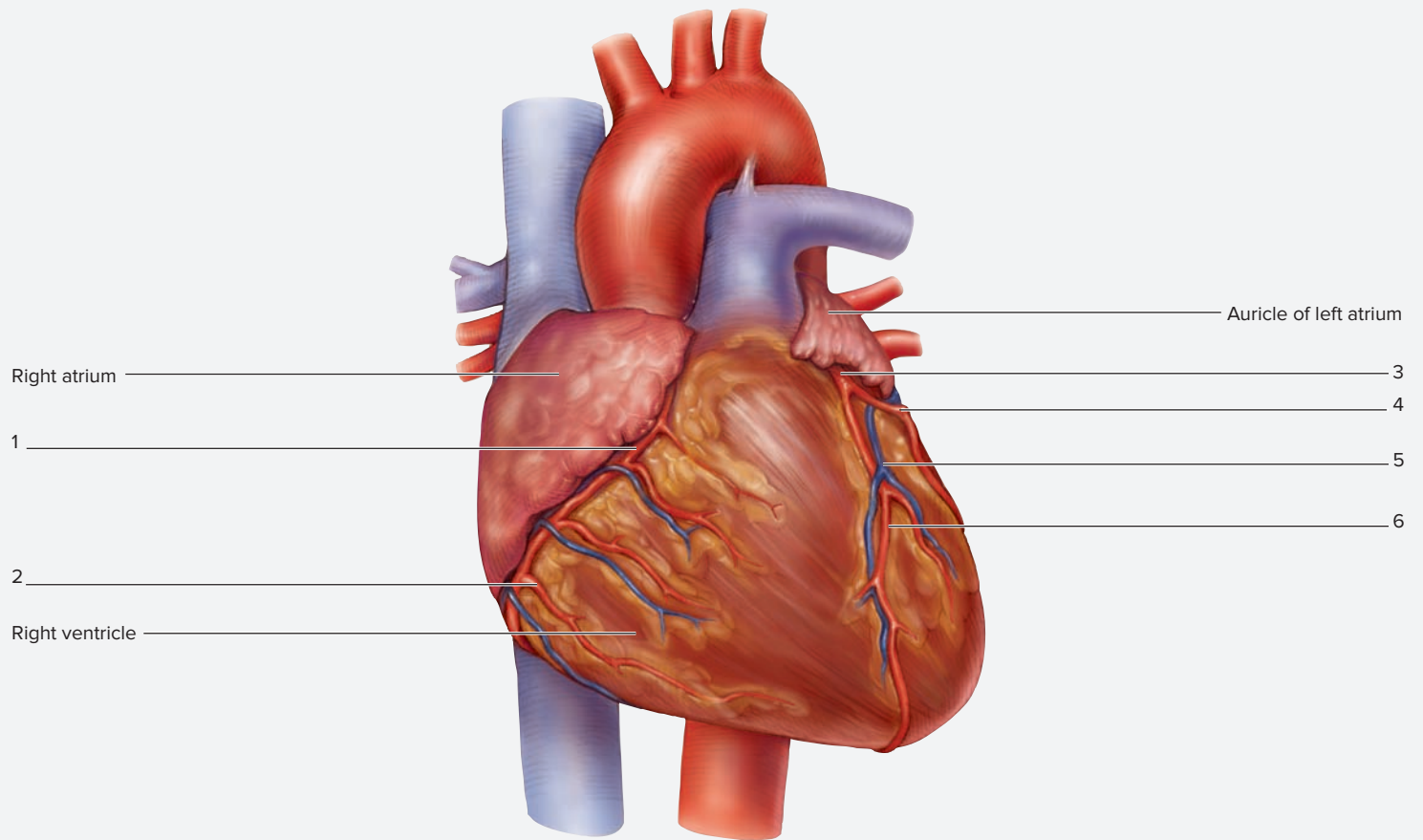
5. Identify the vessels shown in **figure 17.12** on the cadaver heart or on the classroom model of the heart, using

### Figure 17.11 The Coronary Circulation

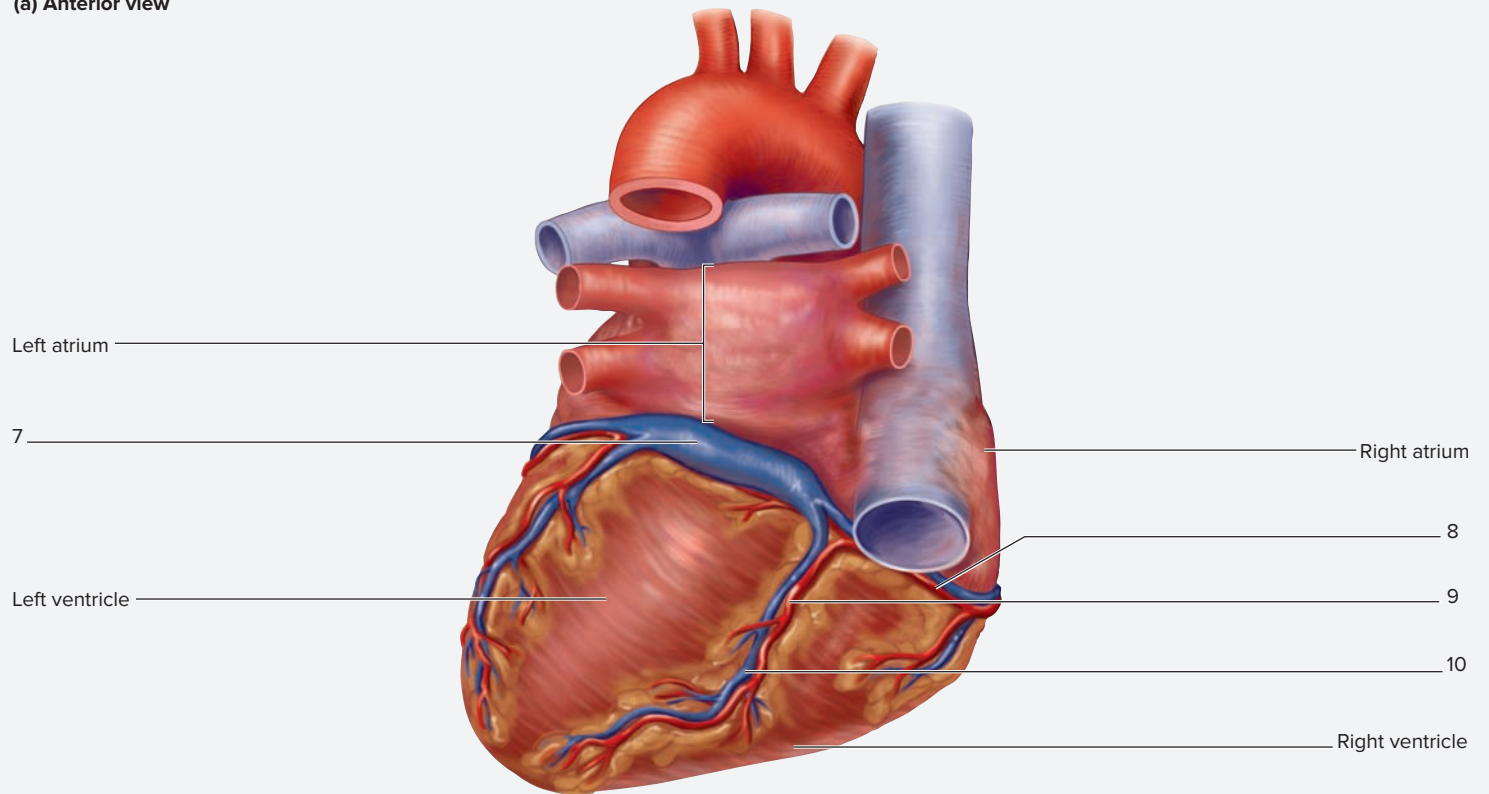
**Circulation.** Superior view of the human heart with the atria removed. All four valves of the heart can be seen in this view. The openings to the right and left coronary arteries are located behind the cusps of the aortic semilunar valve. The location of the right and left coronary arteries are visible arising from inside the cusps of the aorta in this photo. The cusps of the aortic semilunar valve and the cusps of the pulmonary semilunar valve are also visible within the lumens of each respective vessel.

© McGraw-Hill Education/Photo and Dissection by Christine Eckel





(a) Anterior view



(b) Posterior view

**Figure 17.12** Circulation to and from the Heart Wall. Use the terms listed to fill in the numbered labels in the figure. Some answers may be used more than once.

**Coronary arteries**

- |   |  |  |
|---|--|--|
| <input type="checkbox"/> anterior interventricular artery | <input type="checkbox"/> left coronary artery              | <input type="checkbox"/> right coronary artery |
| <input type="checkbox"/> circumflex artery                | <input type="checkbox"/> marginal artery                   | <input type="checkbox"/> coronary sinus        |
| <input type="checkbox"/>                                  | <input type="checkbox"/> posterior interventricular artery | <input type="checkbox"/>                       |

**Cardiac veins**

- |  |
|--|
| <input type="checkbox"/> great cardiac vein  |
| <input type="checkbox"/> middle cardiac vein |
| <input type="checkbox"/> small cardiac vein  |

(continued on next page)

(continued from previous page)

Table 17.4 Venous Drainage of the Heart			
Vessel	Description	Areas Drained	Word Origins
<i>Coronary Sinus</i>	Located in the coronary sinus on the posterior surface of the heart. The coronary sinus is the largest vein of the heart, and its opening can be located within the right atrium of the heart just inferior to the fossa ovalis.	Entire heart; all veins of the heart drain into the coronary sinus, with the exception of a few small veins of the right ventricle, which drain directly into the right atrium.	<i>corona</i> , a crown + <i>sinus</i> , cavity
<i>Great Cardiac Vein</i>	Located in the anterior interventricular sulcus next to the anterior interventricular artery.	Anterior parts of the right and left ventricles.	<i>cardiacus</i> , heart + <i>vena</i> , vein
<i>Middle Cardiac Vein</i>	Located in the posterior interventricular sulcus next to the posterior interventricular artery.	Posterior parts of the right and left ventricles.	<i>cardiacus</i> , heart + <i>vena</i> , vein
<i>Small Cardiac Vein</i>	Located on the lateral part of the right ventricle, near the marginal artery.	Lateral part of the right ventricle.	<i>cardiacus</i> , heart + <i>vena</i> , vein

tables 17.3 and 17.4, and the textbook as guides. Then label them in figure 17.12.

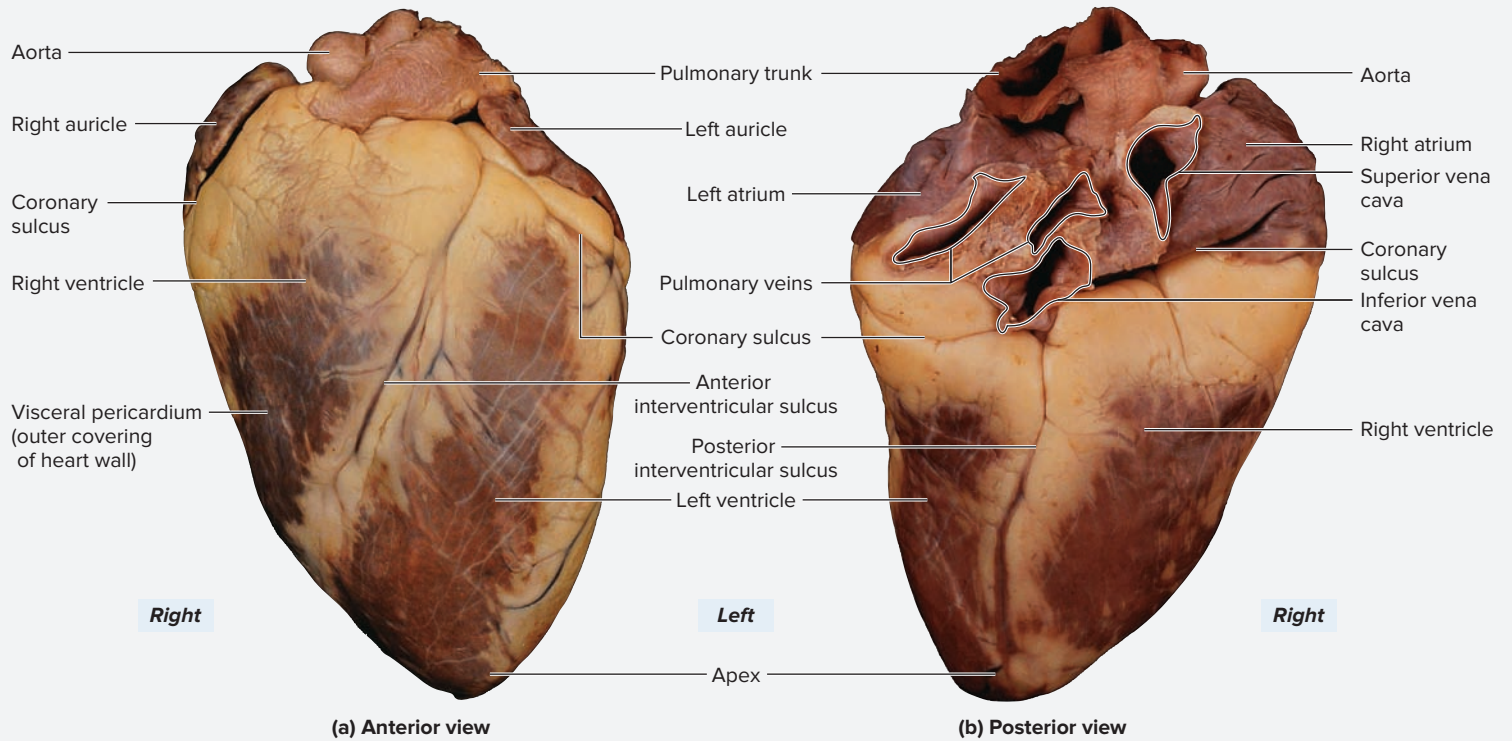
6. **Optional Activity:** **APR Cardiovascular System**—Study the “Heart” dissections to review the vasculature and features

of the heart, then use the Quiz feature to test yourself on these structures.

## EXERCISE 17.6 Superficial Structures of the Sheep Heart

- Obtain a dissecting pan, dissecting instruments, gloves, and a preserved sheep heart. Rinse the heart with water to remove any dried blood or other debris, and place it in the dissecting pan to begin superficial observations.
- Figure 17.13** demonstrates superficial structures of the sheep heart from both anterior and posterior views. Begin observing the heart by distinguishing the anterior surface from the posterior surface. One way to distinguish and identify the anterior surface of the heart is that the fairly distinctive ruffled borders of both the right and left **auricles** are visible in an anterior view. The auricles are extensions of the right and left atria.
- Observe the surface of the heart closely to locate the visceral pericardium (epicardium). Then observe the outer surfaces of the great vessels of the heart to see if any remnants of the parietal pericardium can be seen where it was attached to these vessels. Note the large amount of fatty tissue deep to the epicardium (epicardial fat). One of the functions of this fatty tissue is to help cushion the heart within the pericardial cavity.
- Identify the superficial features listed here on the sheep heart, using figure 17.13 as a guide:
 

<input type="checkbox"/> anterior interventricular sulcus	<input type="checkbox"/> left ventricle	<input type="checkbox"/> aorta	<input type="checkbox"/> pulmonary veins
<input type="checkbox"/> apex	<input type="checkbox"/> posterior interventricular sulcus	<input type="checkbox"/> inferior vena cava	<input type="checkbox"/> superior vena cava
<input type="checkbox"/> coronary sulcus	<input type="checkbox"/> right atrium	<input type="checkbox"/> pulmonary trunk	
<input type="checkbox"/> left atrium	<input type="checkbox"/> right auricle		
<input type="checkbox"/> left auricle	<input type="checkbox"/> right ventricle		
- Next, identify the great vessels: the aorta, pulmonary trunk, and the venae cavae. These vessels are often cut very close to their attachments to the heart, which can make identification difficult. To make the task easier, carefully remove as much of the epicardial fat as possible from the superior aspect of the heart (leave the fat in place on the ventricles for now).
- Once as much fat as possible has been cleaned away, proceed with identification of the great vessels of the heart. Begin by viewing the anterior surface of the heart (figure 17.13a). The two most prominent vessels coming off the heart are the pulmonary trunk and the aorta. Both vessels have thick, tough walls, which helps with identification. The pulmonary trunk is located the most anterior and points to the right (from the observer’s point of view). The aorta is directly posterior to the pulmonary trunk and points to the left (from the observer’s point of view).
- Turn the heart over to view the posterior surface (figure 17.13b). Here the pulmonary veins are visible. The pulmonary veins, will be more to the left side of the heart (from the observer’s point of view), than the superior and inferior venae cavae, which will be more to the right (from the observer’s point of view). Identify the listed vessels:



**Figure 17.13** Superficial Structures of the Sheep Heart. (a) Anterior view. (b) Posterior view.

© Christine Eckel

8. To verify that the great vessels have been identified correctly, use a blunt probe or fingers (or both) to see where each vessel comes from, or leads to, in the heart. Place the tip of the probe into the lumen of one of the vessels and see where it goes. If the vessel is large enough, put your index finger into the lumen of the vessel and *feel* where it goes. Now answer the following questions by giving the name of the heart chamber the probe will go into when placed into each vessel: A probe in the pulmonary

trunk will lead into the \_\_\_\_\_; a probe in the aorta will lead into the \_\_\_\_\_; a probe in the pulmonary veins will lead into the \_\_\_\_\_; and a probe in the superior or inferior vena cava will lead into the \_\_\_\_\_.

In the next two exercises the entire heart will be cut in half to compare wall thicknesses of the right and left ventricles. Approximately two-thirds of the dissection groups in the laboratory should make coronal sections of the heart. The remaining third will make transverse sections. The different

sections yield different views of the chambers and the structures within each chamber. All students should observe hearts that have been sectioned both ways. Ask the laboratory instructor which type of section your group should make before beginning.

**EXERCISE 17.7** Coronal Section of the Sheep Heart

1. Obtain a scalpel or a knife with a 6-inch blade and a plastic ruler with millimeter increments. Either the scalpel or the knife will work for this next task, although the knife will make a cleaner cut. Turn the heart upside down so the base is on the dissecting pan, the apex is pointed toward your body, and the anterior surface of the heart is facing your body. Make a coronal section through the entire heart to separate it into anterior and posterior portions (**figure 17.14**).

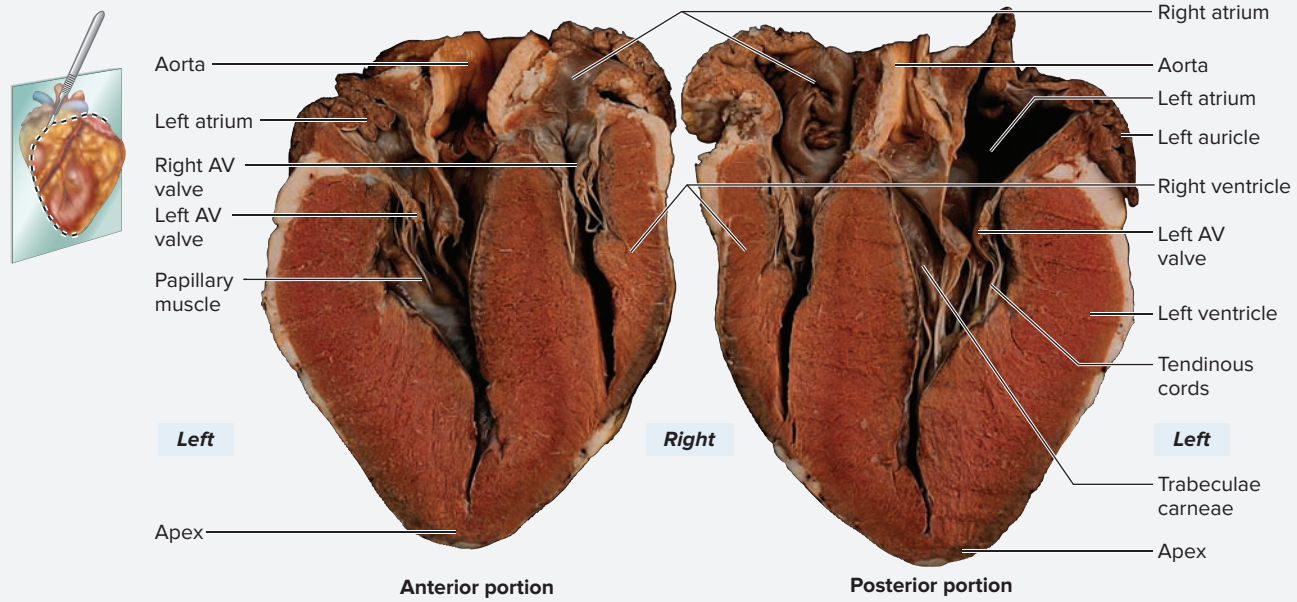
2. Once the cut is complete, identify the listed structures within the ventricles, using figure 17.14 as a guide:

- papillary muscles
- trabeculae carneae
- tendinous cords

3. Using a small ruler, measure the thickness of the right ventricular wall approximately 1 cm below the valve ring (where the right atrioventricular valve is located)

(continued on next page)

(continued from previous page)



**Figure 17.14** Coronal Section of the Sheep Heart.

© Christine Eckel

and record it here: \_\_\_\_\_ cm. Next measure the thickness of the left ventricular wall approximately 1 cm below the valve ring (where the left atrioventricular valve is located) and record it here: \_\_\_\_\_ cm. Approximately how much thicker is the wall of the left ventricle compared to the wall of the right ventricle?

\_\_\_\_\_ What is the *functional* consequence of this difference? \_\_\_\_\_  
 \_\_\_\_\_  
 \_\_\_\_\_

4. Do the chambers of the right and left ventricles appear to differ in *volume* (i.e., the amount of blood each could hold)? \_\_\_\_\_ Explain the consequences of having each chamber pump a different volume of blood. \_\_\_\_\_  
 \_\_\_\_\_  
 \_\_\_\_\_

5. Sketch the coronal view of the ventricles in the space provided. Label the listed structures in the drawing.

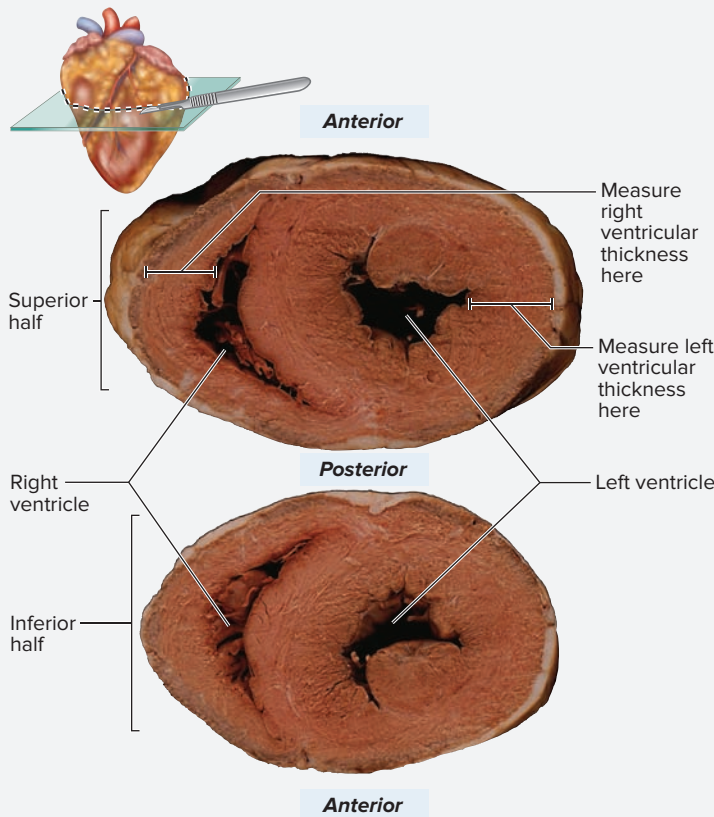
- |  |   |
|--|---|
| <input type="checkbox"/> aorta         | <input type="checkbox"/> papillary muscle   |
| <input type="checkbox"/> apex          | <input type="checkbox"/> right atrium       |
| <input type="checkbox"/> left atrium   | <input type="checkbox"/> right AV valve     |
| <input type="checkbox"/> left auricle  | <input type="checkbox"/> tendinous cords    |
| <input type="checkbox"/> left AV valve | <input type="checkbox"/> trabeculae carneae |



6. After all observations are complete discard the scalpel blade in the sharps container, clean the dissection instruments with soap and water and let them air dry, and put the sheep heart back into the container it came in—or dispose of it according to the instructor’s directions.

**EXERCISE 17.8** Transverse Section of the Sheep Heart

1. Obtain an intact sheep heart, a scalpel or a knife with a 6-inch blade, and a plastic ruler with millimeter increments. Either the scalpel or the knife will work for this next task, although the knife will make a cleaner cut. To make this cut, slice the heart transversely approximately 1 cm inferior to the coronary sulcus (**figure 17.15**) to separate the entire heart into superior and inferior portions. Observe the cut ends of the heart. Using a small ruler, measure the thickness of the right ventricular wall and record it here: \_\_\_\_\_ cm. Next measure the thickness of the left ventricular wall and record it here: \_\_\_\_\_ cm.




**Figure 17.15** Transverse Section of the Sheep Heart.  
© Christine Eckel

Approximately how much thicker is the wall of the left ventricle compared to the wall of the right ventricle?  
\_\_\_\_\_ What is the *functional* consequence of this difference? \_\_\_\_\_

2. Do the chambers of the right and left ventricles appear to differ in *volume* (i.e., the amount of blood each could hold)? \_\_\_\_\_ Explain the consequences of having each chamber pump a different volume of blood.  
\_\_\_\_\_  
\_\_\_\_\_

3. Sketch the transverse view of the ventricles in the space provided. Label the right and left ventricles in the drawing:



4. When you have finished your observations, discard the scalpel blade in the sharps container, clean your dissection instruments with soap and water and let them air dry, and put the sheep heart back into the container it came in—or dispose of it according to your instructor’s directions.

**Learning Strategy**



Although the preserved sheep heart is a common specimen for classroom dissection, it is often difficult to observe structures on these hearts because the preservative/fixative makes the structures very firm. One great way to view the AV valves, papillary muscles, tendinous cords, and trabeculae carneae is to obtain a fresh heart from a local meat processing facility or grocery store. Beef hearts in particular are wonderful because they have huge

papillary muscles. Pig and lamb hearts are also good specimens, as their heart structures are easily visible and they have the additional benefit of being about the same size as a human heart. In a fresh heart, the valves and other structures are much more supple because they have not been fixed with preservative. If the anatomy lab does not have fresh specimens to observe, beef hearts are often easily available in the meat section of a local grocery store.

*This page intentionally left blank*

# Chapter 17: The Cardiovascular System: The Heart

Name: \_\_\_\_\_

Date: \_\_\_\_\_ Section: \_\_\_\_\_

## POST-LABORATORY WORKSHEET

The 1 corresponds to the Learning Objective listed in the chapter opener outline.

### Do You Know the Basics?

#### Exercise 17.1: Cardiac Muscle

1. Cardiac muscle is \_\_\_\_\_ (voluntary/involuntary), whereas skeletal muscle is \_\_\_\_\_ (voluntary/involuntary). 1

#### Exercise 17.2: Layers of the Heart Wall

2. The endothelium, which lines the heart and blood vessels, is composed of simple squamous epithelium. \_\_\_\_\_ (True/False) 2

#### Exercise 17.3: The Pericardial Cavity

3. Match the descriptions listed in column A with the corresponding structure listed in column B. 3

##### Column A

- \_\_\_\_\_ 1. inner portion of the parietal pericardium  
\_\_\_\_\_ 2. layer of the pericardium that is tightly adhered to the heart  
\_\_\_\_\_ 3. outer portion of the parietal pericardium

##### Column B

- a. fibrous pericardium  
b. parietal layer of the serous pericardium  
c. visceral layer of the serous pericardium

#### Exercise 17.4: Gross Anatomy of the Human Heart

4. The atria and ventricles of the heart both contain three layers of the heart wall: endocardium, myocardium, and epicardium. \_\_\_\_\_ (True/False) 4
5. The chamber that contains pectinate muscles in its walls is the \_\_\_\_\_ (atrium/ventricle). 5
6. The structures that increase forcefulness of contraction within the right atrium are \_\_\_\_\_ (papillary/pectinate) muscles, whereas the structures that prevent eversion of AV valves are \_\_\_\_\_ (papillary/pectinate) muscles. 6
7. Papillary muscles attach directly to \_\_\_\_\_ (atrioventricular/semilunar) valve cusps. 7
8. The right atrioventricular valve is also known as the \_\_\_\_\_ (bicuspid/tricuspid) valve, whereas the left atrioventricular valve is also known as the \_\_\_\_\_ (bicuspid/tricuspid) valve. 8
9. The right ventricle pumps a smaller volume of blood than the left ventricle. \_\_\_\_\_ (True/False) 9
10. Pulmonary and aortic semilunar valves each contain \_\_\_\_\_ (two/three) cusps and prevent backflow of blood into the \_\_\_\_\_ (atria/ventricles). 10
11. Place the following structures in the order in which a drop of blood would travel through the right side of the heart, beginning with the superior and inferior venae cavae and ending with the lungs. 11
- \_\_\_\_\_ a. pulmonary arteries  
\_\_\_\_\_ b. pulmonary semilunar valve  
\_\_\_\_\_ c. pulmonary trunk  
\_\_\_\_\_ d. right atrioventricular valve  
\_\_\_\_\_ e. right atrium  
\_\_\_\_\_ f. right ventricle
12. Match the description listed in column A with the structure listed in column B. (Answers will be used more than once.) 12
- ##### Column A
- \_\_\_\_\_ 1. located between the pulmonary trunk and aorta  
\_\_\_\_\_ 2. located between the right and left atria  
\_\_\_\_\_ 3. remnant of the ductus arteriosus  
\_\_\_\_\_ 4. remnant of the foramen ovale
- ##### Column B
- a. fossa ovalis  
b. ligamentum arteriosum



**Exercise 17.5: The Coronary Circulation**

13. The anterior interventricular artery branches from the \_\_\_\_\_ (right/left) coronary artery. 13
14. The coronary sinus is located on the \_\_\_\_\_ (anterior/posterior) surface of the heart. 14

**Exercise 17.6: Superficial Structures of the Sheep Heart**

15. The right ventricle is visible in an anterior view of the sheep heart. \_\_\_\_\_ (True/False) 15
16. The \_\_\_\_\_ (parietal/visceral) layer of the serous pericardium is tightly adhered to the heart, whereas the \_\_\_\_\_ (parietal/visceral) layer of the serous pericardium is tightly adhered to the fibrous pericardium. 16
17. When viewing the anterior surface of the sheep heart, the \_\_\_\_\_ (aorta/pulmonary trunk) is located most anteriorly. 17
18. Oxygenated blood returns to the left atrium through the pulmonary \_\_\_\_\_ (arteries/veins). 18

**Exercise 17.7: Coronal Section of the Sheep Heart**

19. A coronal section of the sheep heart reveals that the left ventricular wall is significantly \_\_\_\_\_ (thicker/thinner) than the right ventricular wall. 19
20. The systemic circuit has \_\_\_\_\_ (more/less) resistance than the pulmonary circuit. Therefore, the left ventricle contracts with a \_\_\_\_\_ (greater/lesser) force than the right ventricle. 20
21. Tendinous cords in the sheep heart tether the cusps of \_\_\_\_\_ (atrioventricular/semilunar) valves to prevent the backflow of blood. 21

**Exercise 17.8: Transverse Section of the Sheep Heart**

22. When viewing a transverse section of the sheep heart, the right ventricular wall is \_\_\_\_\_ (thicker/thinner) than the left ventricular wall. 22
23. The right and left ventricles pump different volumes of blood due to the difference in ventricular wall thickness. \_\_\_\_\_ (True/False) 23

**Can You Apply What You've Learned?**

24. Define *mediastinum*: \_\_\_\_\_  
\_\_\_\_\_
25. The simple squamous epithelium that lines the heart and blood vessels is called \_\_\_\_\_.
26. A heart surgeon is about to perform a heart transplant. She has already cut through the sternum and entered the thoracic cavity and mediastinum. The heart, however, remains enclosed in the pericardial sac. The tissues the surgeon must cut through, from superficial to deep, to enter the pericardial cavity are these:  
a. \_\_\_\_\_ b. \_\_\_\_\_
27. Will the surgeon need to cut through the visceral layer of serous pericardium to remove the heart from the pericardial sac? Why or why not?  
\_\_\_\_\_
28. Figure 17.10 on page 353 demonstrates a myocardial infarction in the interventricular septum and posterior wall of a human heart. This infarct occurred because one of the arteries to the heart wall was blocked and the tissue was starved of oxygen. Which artery was the most likely source of the blockage? (Hint: Think about the areas of the heart wall served by each vessel. Use table 17.3 as a guide if necessary.) \_\_\_\_\_  
\_\_\_\_\_  
\_\_\_\_\_
29. Describe how papillary muscles and tendinous cords (chordae tendineae) function to keep the AV valves closed when the ventricles contract.  
\_\_\_\_\_  
\_\_\_\_\_  
\_\_\_\_\_

# Vessels and Circulation

# 18

## OUTLINE AND LEARNING OBJECTIVES

### Histology 366

#### Blood Vessel Wall Structure 366

##### EXERCISE 18.1: BLOOD VESSEL WALL STRUCTURE 367

- 1 Name the three layers (tunics) present in the walls of all blood vessels (except capillaries)
- 2 Describe the basic structure of each layer of a blood vessel wall

#### Elastic Arteries 368

##### EXERCISE 18.2: ELASTIC ARTERY—THE AORTA 368

- 3 Describe the unique features of the tunica media of an elastic artery
- 4 Explain how elastic fibers in the wall of an elastic artery facilitate blood flow through the vessel
- 5 Define vasa vasorum

#### Muscular Arteries 368

##### EXERCISE 18.3: MUSCULAR ARTERY 369

- 6 Identify the internal and external elastic laminae and smooth muscle in the tunica media of a muscular artery
- 7 Compare and contrast elastic and muscular arteries based on structure, location, and function

#### Arterioles 369

##### EXERCISE 18.4: ARTERIOLE 369

- 8 Describe the role arterioles play in the regulation of blood flow

#### Veins 370

##### EXERCISE 18.5: VEIN 370

- 9 Identify veins under the microscope, and explain the characteristics you would use to determine that a blood vessel is a vein
- 10 Describe the structure and function of venous valves

#### Capillaries 371

##### EXERCISE 18.6: OBSERVING ELECTRON MICROGRAPHS OF CAPILLARIES 371

- 11 Describe the structure, function, and location of the three types of capillaries

### Gross Anatomy 374

#### Pulmonary Circuit 374

##### EXERCISE 18.7: PULMONARY CIRCUIT 374

- 12 Trace the flow of blood from the right ventricle of the heart through the pulmonary circulation and back to the left atrium of the heart

#### Systemic Circuit 375

##### EXERCISE 18.8: CIRCULATION TO THE HEAD AND NECK 375

- 13 Identify the major arteries and veins that compose the circulation to the head and neck
- 14 Trace the flow of blood from the left ventricle of the heart to the skin overlying the right parietal bone of the skull and back to the right atrium of the heart

##### EXERCISE 18.9: CIRCULATION TO THE BRAIN 377

- 15 Identify the major arteries and veins that compose the circulation to the brain
- 16 Trace the flow of blood from the left ventricle of the heart to the right parietal lobe of the brain and back to the right atrium of the heart

##### EXERCISE 18.10: CIRCULATION TO THE THORACIC AND ABDOMINAL WALLS 380

- 17 Identify the major arteries and veins that compose the circulation to the thoracic and abdominal walls
- 18 Trace the flow of blood from the left ventricle of the heart to the right kidney and back to the right atrium of the heart

**EXERCISE 18.11: CIRCULATION TO THE ABDOMINAL CAVITY 383**

- 19 Identify the major arteries and veins that compose the circulation to the abdominal cavity
- 20 Name the three major veins that compose the hepatic portal circulation and describe the functional significance of the hepatic portal circulation
- 21 Trace the flow of blood from the left ventricle of the heart to the spleen, duodenum, and sigmoid colon, and back to the right atrium of the heart

**EXERCISE 18.12: CIRCULATION TO THE UPPER LIMB 387**

- 22 Identify the major arteries and veins that compose the circulation to the upper limb
- 23 Trace the flow of blood from the left ventricle of the heart to the anterior surface of the index finger and to the capitate bone and back along a superficial route to the right atrium of the heart

**EXERCISE 18.13: CIRCULATION TO THE LOWER LIMB 392**

- 24 Identify the major arteries and veins that compose the circulation to the lower limb
- 25 Trace the flow of blood from the left ventricle of the heart to the dorsal surface of the big toe (hallux), and the cuboid bone in the foot and back along a superficial route to the right atrium of the heart

**Fetal Circulation 397****EXERCISE 18.14: FETAL CIRCULATION 397**

- 26 Identify the cardiovascular structures unique to the fetal circulation and describe the function of each
- 27 Trace the flow of blood from the left ventricle of the heart to the placenta and back to the right atrium of the heart in the fetus
- 28 Identify postnatal structures that are remnants of the fetal circulation

## INTRODUCTION

While proper functioning of the heart is necessary to create the pressure required for adequate blood flow, the vast system of blood vessels provides the necessary conduits (channels) to direct the blood to locations in the body where it is most in demand by the tissues. **Arteries** are blood vessels that carry blood *away* from the heart, whereas **veins** are blood vessels that carry blood *toward* the heart. Arteries are high-pressure blood conduits (*conduit*, a channel) that carry blood at high pressure and high velocity toward the tissues. Arteries branch into smaller and smaller channels, ultimately forming **arterioles** (*arteriole*, a small artery). Arterioles have the special function of controlling the flow of blood into **capillary beds**. Capillaries are the site of exchange of substances such as respiratory gases, nutrients, and waste products between the blood and the tissues.

Blood flows out of capillaries into small veins called **venules**, which merge to form the larger veins that return blood to the heart. **Veins** are low-pressure blood reservoirs (*reservoir*; a receptacle) that carry blood back to the heart. Generally, a vein is positioned next to each major artery and has the same name as the artery it accompanies (the major exception to this rule is the hepatic portal system within the abdominal cavity). However, there are typically more veins draining a structure as there are arteries supplying it. In the limbs, most of the veins that do not accompany an artery are superficial veins, located just under the skin. For example, the brachium (arm) is supplied by the brachial artery, which has the brachial vein traveling next to it. The brachial artery and vein travel fairly deep within the arm, where they are protected by the musculature of the arm. In addition to the brachial vein, two superficial

veins also drain blood from the arm. These are the cephalic and basilic veins. Note that there is considerably more variation among individuals in the branching patterns and locations of veins than there is with arteries. Such variation often has clinical significance. For example, when blood samples need to be collected from a patient, blood is commonly drawn from the median cubital vein. However, not all individuals have a median cubital vein. When tracing blood flow through the venous system, remember that veins *drain* blood from an area of the body. This means that descriptions of blood flow through veins start by naming the most distal veins first, and then naming the veins blood travels through as it proceeds toward the heart.

The exercises in this chapter begin with an exploration of the histological characteristics of the different types of blood vessels (arteries, arterioles, capillaries, and veins). Subsequent exercises involve identification of the major arteries and veins of the body on a human cadaver or on classroom models of the cardiovascular system. Upon completion of the gross anatomy exercises in this chapter, a student should be able to describe the pathway a drop of blood takes as it is transported from the heart to a target organ and back to the heart once again.

**List of Reference Tables**

Table 18.1	Layers of a Blood Vessel Wall	p. 366
Table 18.2	Characteristics of Wall Layers in Specific Types of Blood Vessels	p. 366
Table 18.3	Characteristics of the Three Types of Capillaries	p. 372
Table 18.4	Fetal Cardiovascular Structures and Associated Postnatal Structures	p. 397

These Pre-laboratory Worksheet questions may be assigned by instructors through their **connect** course.

## PRE-LABORATORY WORKSHEET

1. The tunica \_\_\_\_\_ (externa/intima/media) is the innermost layer of a blood vessel wall, whereas the tunica \_\_\_\_\_ (externa/intima/media) is the outermost layer.
2. The wall of a capillary consists only of endothelium. \_\_\_\_\_ (True/False)
3. The most permeable type of capillary is a \_\_\_\_\_ (continuous/fenestrated/sinusoidal) capillary, whereas the least permeable type of capillary is a \_\_\_\_\_ (continuous/fenestrated/sinusoidal) capillary.
4. Which of the following is an anatomic feature unique to veins?
  - a. smooth muscle in the tunica media
  - b. valves to prevent backflow of blood
  - c. vasa vasorum in the tunica externa
  - d. tunica media consists only of endothelium and a basement membrane
5. The hepatic portal system is a system of veins that drains blood into the \_\_\_\_\_ (inferior vena cava/liver).
6. Which of the following is *not* one of the unpaired branches of the abdominal aorta? (Circle one.)
  - a. celiac trunk
  - b. inferior mesenteric artery
  - c. renal artery
  - d. superior mesenteric artery
7. The ligamentum arteriosum is a remnant of the fetal \_\_\_\_\_ (ductus arteriosus/foramen ovale), whereas the fossa ovalis is a remnant of the fetal \_\_\_\_\_ (ductus arteriosus/foramen ovale).
8. The major vein that drains blood from the inferior half of the body and empties into the right atrium of the heart is the \_\_\_\_\_ (inferior/superior) vena cava.
9. Which of the following is *not* a component of the hepatic portal system? (Circle one.)
  - a. hepatic portal vein
  - b. hepatic veins
  - c. inferior mesenteric vein
  - d. splenic vein
  - e. superior mesenteric vein
10. Which of the following is *not* a branch of the aortic arch? (Circle all that apply.)
  - a. brachiocephalic trunk
  - b. left common carotid artery
  - c. left subclavian artery
  - d. right common carotid artery
  - e. right subclavian artery

## Histology

### Blood Vessel Wall Structure

All blood vessels except capillaries have three tunics (layers) forming their walls. These layers, called the tunica intima, tunica media, and tunica externa, are analogous in both structure and function to the three layers of the heart wall (endocardium, myocardium, and epicardium). The

differences in structure and function between the different types of blood vessels arise primarily from modifications of these three wall layers. In particular, the type of tissue that composes the tunica media greatly affects the function of the vessel. **Table 18.1** describes the general composition of the three layers of a blood vessel wall, and **table 18.2** summarizes unique features in different types of blood vessels.

Wall Layer	Location	Components	Word Origins
<i>Tunica Intima</i>	Innermost layer, in contact with the lumen of the vessel	Endothelium (simple squamous epithelium) and a subendothelial layer composed of areolar connective tissue	<i>tunic</i> , a coat + <i>intimus</i> , innermost
<i>Tunica Media</i>	Middle layer	Varied amounts of collagen fibers, elastic fibers, and smooth muscle cells	<i>tunic</i> , a coat + <i>medius</i> , middle
<i>Tunica Externa</i>	Outermost layer	Areolar connective tissue that anchors the vessel to surrounding structures	<i>tunic</i> , a coat + <i>externus</i> , on the outside

Type of Vessel	Tunica Intima	Tunica Media	Tunica Externa	Diameter	Characteristics and Special Functions
<i>Elastic Artery</i>	Endothelium and subendothelial layer; an internal elastic lamina is present but not easily distinguished from the elastic tissue of the tunica media.	Contains numerous elastic and reticular fibers; also contains smooth muscle cells.	Underdeveloped in contrast to other vessels. Contains vasa vasorum, lymphatics, and nerves.	2.5 cm–1 cm	Expansion and contraction of elastic tissues smooths out the flow of blood.
<i>Muscular Artery</i>	Endothelium and subendothelial layer; contains a very prominent internal elastic lamina.	Contains up to 40 layers of smooth muscle, and a prominent external elastic lamina.	Contains vasa vasorum, lymphatics, and nerves.	1 cm–3 mm	Recoil of wall and contraction of smooth muscle continues to push blood through the arterial system.
<i>Arteriole</i>	Endothelium and subendothelial layer; an internal elastic lamina is present only in the largest arterioles.	Contains less than six layers of smooth muscle, with no external elastic lamina.	Very thin	3 mm–10 $\mu$ m	Size of lumen is regulated by contraction/relaxation of smooth muscle to control the flow of blood into capillary beds.
<i>Capillary</i>	Endothelium and a basement membrane only.	NA	NA	8–10 $\mu$ m	Thin wall allows for exchange between the blood and tissues.
<i>Postcapillary Venule</i>	Endothelium and a thin subendothelial layer.	Very thin with very few smooth muscle cells.	Very thin	10–50 $\mu$ m	Drains blood from capillary beds. Site where leukocytes leave the circulation and enter the tissues via diapedesis.*
<i>Venule</i>	Endothelium and a thin subendothelial layer.	Very thin with very few smooth muscle cells.	Thickest layer of the wall.	50–100 $\mu$ m	Venules are simply small veins, and are the counterpart to arterioles.
<i>Vein</i>	Endothelium and subendothelial layer; infoldings form valves, which prevent the backflow of blood. Not all veins have valves.	Very thin with a small amount of smooth muscle.	Thickest layer of the wall. Contains vasa vasorum.	Greater than 100 $\mu$ m	Low-pressure conduits; valves aid in preventing backflow of blood. Thick tunica externa anchors the vessel to surrounding structures, which assists blood flow when skeletal muscles contract.

\*diapedesis (*dia-*, through + *pedesis*, a leaping)—the passage of leukocytes through the walls of blood vessels.

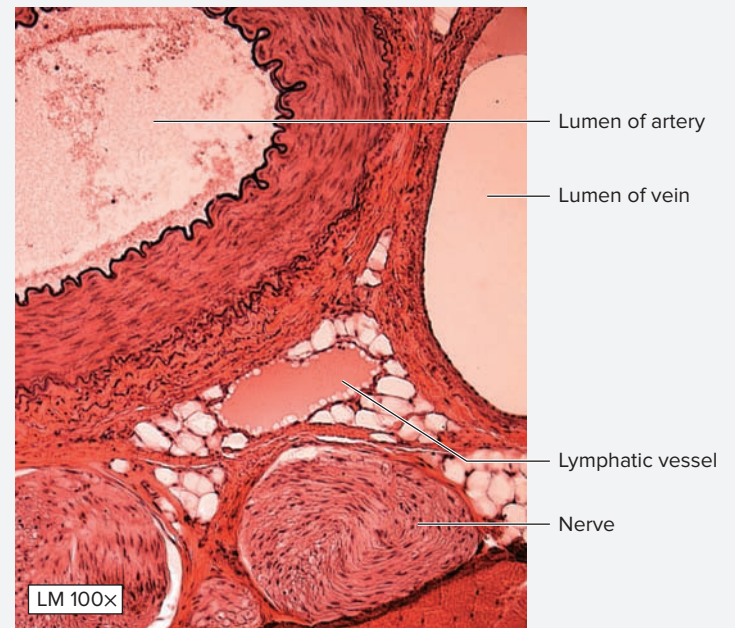
**EXERCISE 18.1 Blood Vessel Wall Structure**

1. Obtain a slide showing an artery and a vein (they may both be on the same slide, or you may have two different slides).
2. Place the slide on the microscope stage and bring the tissue sample into focus on low power. Scan the slide and look for the circular or oval cross section of a vessel. If more than one vessel is visible on the slide, determine which vessel is an artery and which is a vein. In general, arteries have relatively thick walls and small lumens, whereas veins have relatively thin walls and large lumens (**figure 18.1**). In addition, the lumens of veins are often collapsed because of the relative thinness of the blood vessel wall.
3. After identifying an artery, and a vein, move the microscope stage so the wall of the *artery* is in the center of the field of view. Increase the power on the microscope until all the layers of the artery wall are visible.
4. Identify the structures listed, using figure 18.1*b* and table 18.1 as guides. Keep in mind that the innermost layer of the vessel (the tunica intima) will be incredibly thin and difficult to identify except on high power. Most likely only the flattened nuclei of the endothelial cells, and very little of the rest of the cells, will be visible.

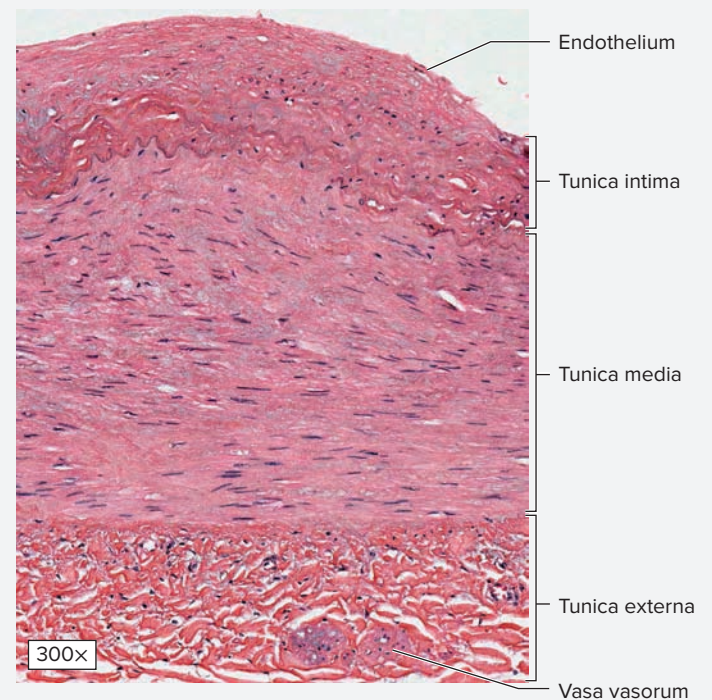
- |   |  |
|---|--|
| <input type="checkbox"/> artery         | <input type="checkbox"/> tunica intima |
| <input type="checkbox"/> lumen          | <input type="checkbox"/> tunica media  |
| <input type="checkbox"/> tunica externa | <input type="checkbox"/> vein          |

**Figure 18.1 Blood Vessel Wall Structure.** (a) Cross section through the center of a neurovascular bundle containing a nerve, artery, vein, and lymphatic vessel. (b) The three layers of the wall of a blood vessel: tunica intima, tunica media, and tunica externa. The tunica externa has its own blood supply, the vasa vasorum (literally the “vessels of the vessels”).

© McGraw-Hill Education/Christine Eckel, photographer



(a)



(b)

## Elastic Arteries

Arteries are classified as elastic arteries, muscular arteries, and arterioles (see table 18.2). The aorta is an example of an **elastic artery**. Only the aorta and the pulmonary, brachiocephalic, common carotid, subclavian, and common iliac arteries are classified as elastic arteries (see **figure 18.2**, table 18.2). These arteries, generally located very close to the heart, have walls that are thick enough to withstand the pressure of blood that is pumped into them from the ventricles of the heart. The ventricles create enough force to move blood through these vessels, so they need very little smooth muscle in their tunica media to assist with blood flow.

Instead, elastic arteries have an abundance of collagen and elastic fibers in their tunica media, which makes them both tough (collagen fibers) and expandable (elastic fibers). The ability of the vessel wall to expand and recoil as it receives blood from the ventricles greatly smooths out the flow of blood through these arteries.

Large vessels such as the aorta have tiny blood vessels called *vasa vasorum* (literally, “the vessels of the vessels,” see figure 18.1*b*) in the tunica externa. The vasa vasorum are analogous in both structure and function to the coronary arteries in the outer layer of the heart wall (epicardium). That is, the vasa vasorum supplies blood to the walls of larger vessels just as the coronary arteries supply blood to cardiac muscle tissue.

### EXERCISE 18.2 Elastic Artery—The Aorta


1. Obtain a slide of the aorta (figure 18.2) and place it on the microscope stage. Bring the wall of the aorta into focus on low power.
2. Identify the listed structures on the slide of the aorta, using figure 18.2 and tables 18.1 and 18.2 as guides:
 

<input type="checkbox"/> elastic fibers	<input type="checkbox"/> tunica intima
<input type="checkbox"/> lumen	<input type="checkbox"/> tunica media
<input type="checkbox"/> tunica externa	<input type="checkbox"/> vasa vasorum
3. Sketch the wall of the aorta as seen through the microscope in the space provided.



#### WHAT DO YOU THINK?

- 1 Why do you think large blood vessels have their own blood vessels (*vasa vasorum*) in the tunica externa?



**Figure 18.2 Elastic Artery.** The wall of the aorta, an elastic artery, contains numerous elastic fibers (black) in the tunica media. No vasa vasorum are visible in the tunica externa in this micrograph.

© McGraw-Hill Education/Christine Eckel, photographer

## Muscular Arteries

As blood moves through the elastic arteries and travels farther away from the heart, the force of the heart is no longer great enough to keep the blood moving through the vessels. Thus, the amount of elastic tissue in the tunica media of the arteries starts to decrease and the amount of smooth muscle in the tunica media starts to increase. Contraction of the smooth muscle keeps blood moving through the arteries as the blood gets farther

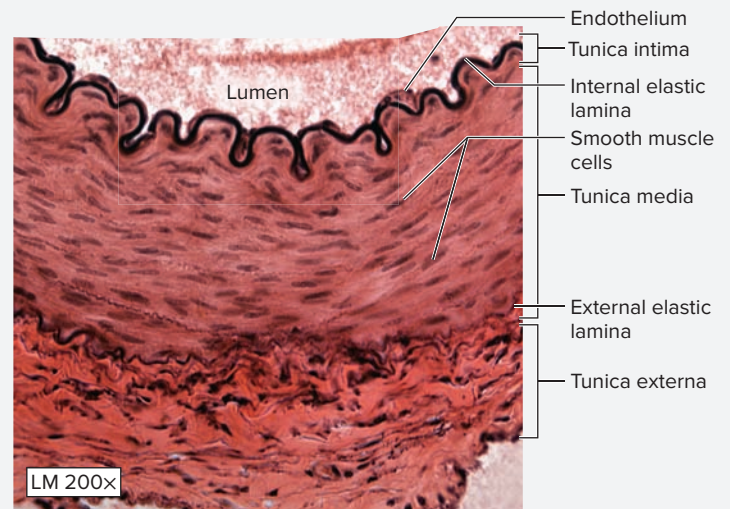

away from the heart. Most named vessels, including the brachial, anterior tibial, and inferior mesenteric arteries are muscular arteries. **Muscular arteries** are easily distinguished from elastic arteries by the presence of two prominent bands of elastic fibers: the **internal elastic lamina**, which is the outermost layer of the tunica intima, and the **external elastic lamina**, which is adjacent to the tunica externa. There are several layers of smooth muscle sandwiched in between the two prominent elastic laminae (see **figure 18.3**, table 18.2).

**EXERCISE 18.3 Muscular Artery**

1. Obtain a slide of a small, muscular artery, and place it on the microscope stage. Bring the tissue sample into focus on low power, then locate the wall of the vessel (figure 18.3).
2. Identify the listed structures on the slide of the muscular artery, using figure 18.3 and tables 18.1 and 18.2 as guides:

- |  |   |
|--|---|
| <input type="checkbox"/> external elastic lamina | <input type="checkbox"/> tunica externa |
| <input type="checkbox"/> internal elastic lamina | <input type="checkbox"/> tunica intima  |
| <input type="checkbox"/> lumen                   | <input type="checkbox"/> tunica media   |
| <input type="checkbox"/> smooth muscle           |   |

3. Sketch the wall of the muscular artery as seen through the microscope in the space provided.



**Figure 18.3 Muscular Artery.** Muscular arteries contain distinct internal and external elastic laminae bordering the tunica media, which is predominantly smooth muscle.

© McGraw-Hill Education/Christine Eckel, photographer

**Arterioles**

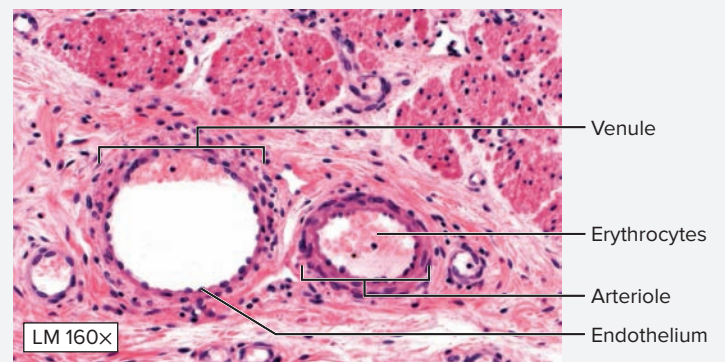
**Arterioles** have a unique function in the cardiovascular system. Arterioles control the flow of blood into capillary beds (see table 18.2). As such, the most prominent feature of the wall of an arteriole is a layer of circular

smooth muscle in the tunica media. Cells of these layers are regulated to contract and relax to alter the diameter of the lumen of the vessel, thus regulating the flow of blood into the capillary beds.

**EXERCISE 18.4 Arteriole**

1. Obtain a slide of an arteriole and place it on the microscope stage. Bring the tissue sample into focus on low power. Scan the slide to locate an arteriole in cross section (**figure 18.4**).
2. Identify the listed structures on the slide of the arteriole, using figure 18.4 and tables 18.1 and 18.2 as guides:

- |                                |  |
|--------------------------------|--|
| <input type="checkbox"/> lumen | <input type="checkbox"/> smooth muscle |
|--------------------------------|--|



**Figure 18.4 Arteriole.** The tunica media of the arteriole contains circular smooth muscle that functions as a sphincter to alter the diameter of the vessel.


© McGraw-Hill Education/Al Telser

(continued on next page)



(continued from previous page)

3. Sketch the arteriole as seen through the microscope in the space provided.



### WHAT DO YOU THINK?

- 2 Local factors are important for regulating blood flow to tissue capillary beds. For example, in skeletal muscle tissue that is actively contracting (as during exercise), levels of oxygen start to decrease as the oxygen is utilized, and levels of carbon dioxide increase as it is produced during cellular metabolism. Keeping this in mind, do you think that increasing levels of carbon dioxide in the tissues would cause the smooth muscle forming the sphincters in arterioles to contract or relax? Why? What effect do you think increasing levels of oxygen would have on the action of arteriolar smooth muscle?

## Veins

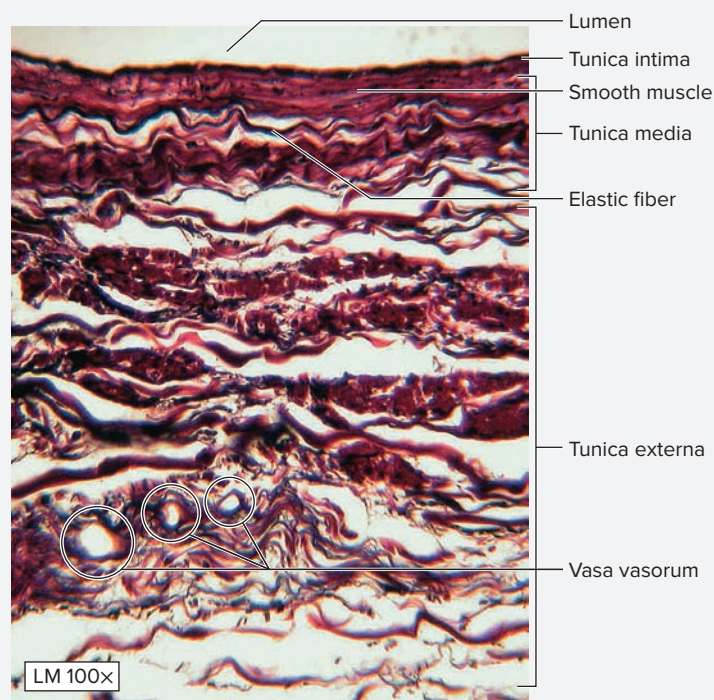

**Veins** are vessels that function to return blood to the heart at low pressure. They are characterized by having large lumens and thin walls (see **figure 18.5**, table 18.2). They may also contain valves, which are infoldings of the tunica intima. These valves prevent blood from flowing backward.

Large veins, like large arteries, also contain vasa vasorum. **Venules** are simply small veins. The venules that come immediately after capillary beds, **postcapillary venules**, are the site where most white blood cells leave the circulation to enter the tissues via diapedesis (see table 18.2).

### EXERCISE 18.5 Vein

- Place a slide of a large vein on the microscope stage and bring the tissue sample into focus on low power.
- Identify the listed structures on the slide of the large vein, using figure 18.5 and tables 18.1 and 18.2 as guides:
 

<input type="checkbox"/> elastic fiber	<input type="checkbox"/> tunica media
<input type="checkbox"/> smooth muscle cells	<input type="checkbox"/> valve (may not be visible on the slide)
<input type="checkbox"/> tunica externa	<input type="checkbox"/> vasa vasorum
<input type="checkbox"/> tunica intima	
- Sketch a cross section of a large vein as seen through the microscope in the space provided.



**Figure 18.5 Vein.** Cross section through the wall of a vein. The thickest layer of the vessel wall is the tunica externa, which contains vasa vasorum. (Spaces within the tunica externa are artifacts produced during slide preparation.)

© McGraw-Hill Education/Christine Eckel, photographer

## Clinical View | Great Saphenous Vein and Varicose Veins

**Varicose veins** are veins that become enlarged and engorged with blood as a result of incompetent valves. The most common site of varicose veins is in the great saphenous vein, the longest vein in the body. The great saphenous vein runs from the medial malleolus to the inguinal region to the femoral vein. As a superficial vein, the great saphenous vein has little external support to assist the movement of blood. Thus, venous valves are critically important to the proper functioning of the great saphenous vein.

Eventually, the varicose veins become problematic because they remain engorged with blood and they form unsightly, tortuous masses beneath the skin of the medial leg. Treatment of varicose veins begins with application of compression stockings, which helps prevent the veins from expanding. Also, the veins can be functionally removed either by surgery or by injection of a substance that causes the vein to permanently collapse, no longer allowing blood to flow within it.

## Capillaries

**Capillaries** are unique blood vessels in that they consist *only* of a tunica intima (endothelium and basement membrane). This allows for the exchange of substances between the blood and the tissues. There are several different types of capillaries in the body, which

vary in their degree of permeability. For instance, capillaries in the spleen and liver, organs where a lot of blood processing takes place, allow a great deal of exchange to occur. In contrast, capillaries in the brain, an organ that must be protected from harmful substances such as toxins and viruses that might be present in the blood, allow very little exchange.

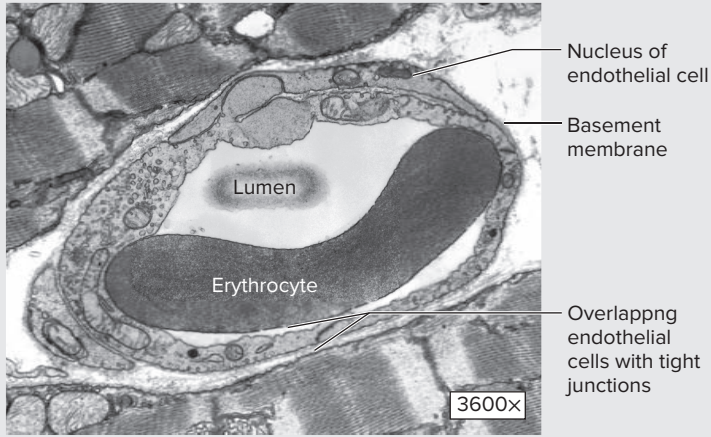
### EXERCISE 18.6 Observing Electron Micrographs of Capillaries

1. Because capillaries are so small, the only way to truly appreciate their structure is to view them with an electron microscope. Obviously most anatomy laboratories do not have access to an electron microscope. Thus, this portion of the exercise will be performed by viewing the electron micrographs in **table 18.3**.
2. Observe the electron micrograph of the **continuous capillary** in table 18.3a. Continuous capillaries are the most common type of capillaries. They are found within muscle, the skin, the lungs, and central nervous system. They are composed of a continuous lining of simple squamous cells resting on a complete basement membrane. Identify the endothelial cells in the micrograph and then look for the areas where two endothelial cells come in contact with each other. Notice that the endothelial cells overlap each other in these areas. Where the cells come together to form a continuous lining around the lumen they do not form a complete “seal.” The gaps between the endothelial cells are called **intercellular clefts**. Substances can move into and out of the blood either through endothelial cells by cellular transport processes (e.g., diffusion, pinocytosis) or between endothelial clefts by diffusion and bulk flow.
3. Observe the electron micrograph of the **fenestrated capillary** in table 18.3b. Identify endothelial cells in the micrograph. In contrast to the smooth surface of the endothelial cells of the continuous capillaries, the endothelial cells of the fenestrated capillaries appear wavy, particularly in the area adjacent to the nucleus of the endothelial cell. As with continuous capillaries, the endothelial cells of fenestrated capillaries form a continuous barrier between the blood and the tissues (i.e., there are no spaces between endothelial cells). However, the endothelial cells themselves have pores, or **fenestrations**, which are regions where the endothelial cells are extremely thin. Fenestrations are approximately 10–100 nm in diameter, and allow any substance that is smaller than the size of the fenestrations to be exchanged easily between the blood and the tissues. Thus, fenestrated capillaries allow much greater exchange than continuous capillaries. Fenestrated capillaries are found in organs where a greater amount of exchange is necessary, such as within endocrine glands, in the small intestine for absorption of nutrients, and in the kidneys for filtering blood.
4. Observe the electron micrograph of the **sinusoidal capillary** in table 18.3c. Sinusoidal capillaries are located within organs that do a lot of processing of the blood, such as the liver and spleen. Sinusoidal capillaries are characterized by having *discontinuous* endothelial cells, which do not overlap each other. In fact, there are open spaces between endothelial cells. The endothelial cells themselves are also fenestrated. Thus, the open spaces and fenestrations together create a minimal barrier between the blood and the tissues, which allows for maximum exchange. The micrograph in table 18.3c demonstrates a sinusoidal capillary within the liver. Inside the lumen of the capillary is a macrophage. The one large, prominent nucleus visible in the micrograph is that of a liver cell, or hepatocyte, which contains many small lipid droplets. There is another hepatocyte at the top of the micrograph. Observe the edges of the hepatocytes that face the lumen of the sinusoidal capillary. Observe the thin endothelial cells that line the capillary. Now observe the area where there should be endothelium between the macrophage and the hepatocyte containing the lipid droplets and nucleus. Notice that there is no endothelial cell in between the two. Also, in the location between the macrophage and the hepatocyte above it, toward the left side of the micrograph, fenestrations are visible when looking very closely. The magnification of this micrograph is not quite high enough to see the fenestrations clearly, but they are there.

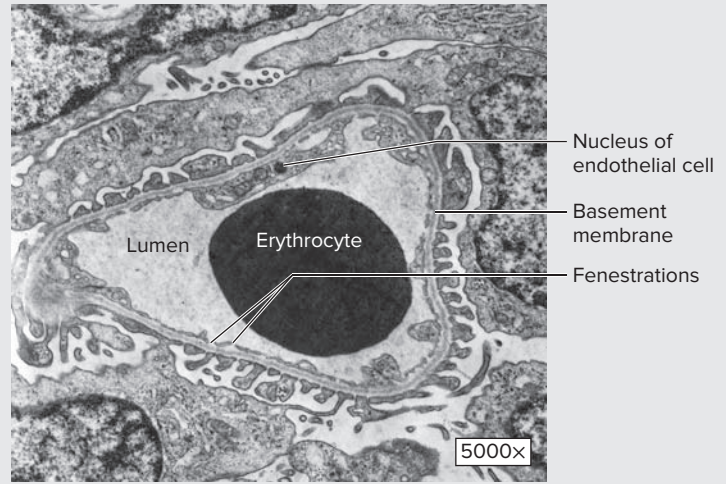
(continued on next page)

(continued from previous page)

**Table 18.3** Characteristics of the Three Types of Capillaries



© Thomas Deerinck, NCMIR/Science Source



© Biophoto Associates/Science Source

**(a) Continuous Capillary**

<b>Basement Membrane</b>	Continuous.
<b>Characteristics</b>	Endothelial cells connected to each other by tight junctions.
<b>Description and Function</b>	Form a continuous barrier between blood and tissues for tight regulation of exchange.
<b>Endothelial Cells</b>	Not fenestrated.
<b>Locations</b>	Muscle tissues, skin, connective tissues, exocrine glands, and nervous tissues.
<b>Word Origin</b>	<i>continuus</i> , continued.

**(b) Fenestrated Capillary**

<b>Basement Membrane</b>	Continuous.
<b>Characteristics</b>	Endothelial cells contain fenestrations (pores) covered by a thin diaphragm. Macromolecules pass through fenestrations to get into the tissues.
<b>Description and Function</b>	Allow for increased exchange between blood and tissues.
<b>Endothelial Cells</b>	Fenestrated.
<b>Locations</b>	Glomerulus of kidney, lamina propria of intestine, choroid plexus of brain, ciliary body, and most endocrine glands.
<b>Word Origin</b>	<i>fenestra</i> , a window.

**Continuous**



**Fenestrated**



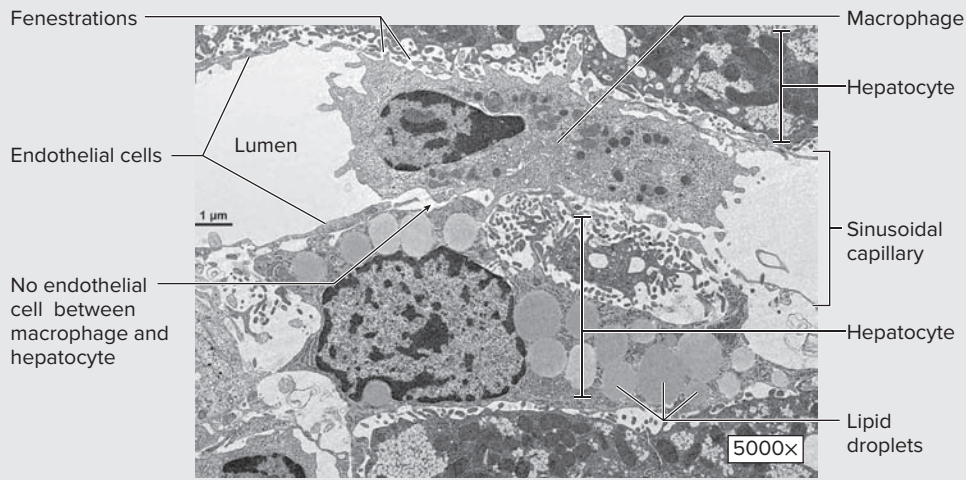


Image and © Dr. H. Jastrow from Dr. Jastrow's electron microscopic atlas <http://www.drjastrow.de>

**(c) Sinusoidal Capillary**

<b>Basement Membrane</b>	Discontinuous.
<b>Characteristics</b>	Endothelial cells are separated from each other by wide spaces. Endothelial cells are fenestrated without diaphragms. Macrophages are located among the endothelium.
<b>Description and Function</b>	Allow blood and tissues to come into intimate contact with each other, which allows for maximum exchange between blood and tissues.
<b>Endothelial Cells</b>	Fenestrated.
<b>Locations</b>	Liver, spleen, bone marrow, and some endocrine glands.
<b>Word Origins</b>	<i>sinus</i> , a channel + <i>eidos</i> , resemblance.

5. Sketch each of the three types of capillaries in the spaces provided. Label the listed structures on the drawings.

- basement membrane
- endothelial cells
- fenestrations (if present)
- lumen of capillary

**WHAT DO YOU THINK?**

- 3 Recall from chapter 14 (nervous tissues) that the blood vessels of the brain are surrounded by glial cells called astrocytes, which collectively form the *blood-brain barrier*. What type of capillaries would you expect to find in this area of the brain, and why?
- 4 Also recall from chapter 14 that the blood vessels that form the choroid plexus within the brain ventricles are surrounded by glial cells called ependymal cells, which collectively form the *blood-cerebrospinal fluid (CSF) barrier*. What type of capillaries would you expect to find in this area of the brain and why?
- 5 Given the answers to questions 3 and 4, which of the two barriers (blood-brain or blood-CSF) represents a more complete barrier between the blood and the tissues of the brain?

*Sinusoidal*



## Gross Anatomy

The following laboratory exercises guide the student in identification of the major arteries and veins of the body on a prosected human cadaver or on classroom models or charts. While identifying each vessel, consider the area of the body supplied by or drained by the vessel, and try to determine what tissue(s) or organ(s) would suffer damage if the vessel were blocked or cut.

Exercises then guide students in tracing the flow of blood from the heart to an organ within each region, and back to the heart (see Learning Strategy box on this page). Initial traces will be done using figures and will include only vessels that are relatively close to the target organ. However, more complicated traces will require students to write out the complete trace in words. This means completing the trace that was started in the figure by extending the list of blood vessels to include the vessels close to the heart that are not shown in the figures (for example: the aorta). When asked to do a complete trace on a laboratory practical exam, blood flow through the heart and the pulmonary circulation will also need to be included. In addition, all of the heart valves blood travels past on its journey must be named as they are encountered. A complete trace both begins and ends in the right atrium of the heart.

### Learning Strategy



The task of tracing the flow of blood through the blood vessels of the body is challenging for many students. If you find yourself having difficulty with this task, use the analogy of driving a car to your school. A drop of blood or a red blood cell represents your car, and the blood vessels represent the roads and highways. The organs represent your destination (school, the supermarket, and so on), and the heart represents your home. For example, to travel from your home to school, you must drive your car along a series of roadways that lead to the school. Each street has a name, which helps direct people driving their cars to their destinations. Similarly, as blood travels from the heart to a destination in the body (for example, the right hand), it must follow a given route. This route consists of several “streets,” each with an identifying name. As you trace the flow of blood from your heart to your right hand, imagine yourself driving a car inside the blood vessels, and write down the names of the arteries you pass through as you travel to your destination. Of course, once at your destination, you must eventually return “home” to the heart. Thus, you also need to visualize the trip through the veins that you would take to get from the hand back to the heart.

## Pulmonary Circuit

The **pulmonary circuit** is the system of blood vessels that carry blood from the right ventricle of the heart to the lungs and back to the left atrium of the heart. Blood leaves the right ventricle relatively

deoxygenated, and returns to the left atrium highly oxygenated, having picked up oxygen as it moves through the pulmonary capillaries.

### EXERCISE 18.7 Pulmonary Circuit

1. Observe the thoracic cavity of a human cadaver or observe classroom models or charts demonstrating blood vessels of the heart and lungs.
2. Identify the structures listed in **figure 18.6** on the cadaver, models, or charts, using the textbook as a guide. Then label them in figure 18.6.
3. *Optional Activity:* **AP|R Cardiovascular System**—Watch the “Pulmonary and Systemic Circulation” animation to review the differences between these two circuits.
4. Trace the flow of blood from the right ventricle of the heart through the pulmonary circuit to the left atrium of the heart in words in the space provided. Be sure to indicate any valves that are passed along the way.

---



---



---



---



---



---



---



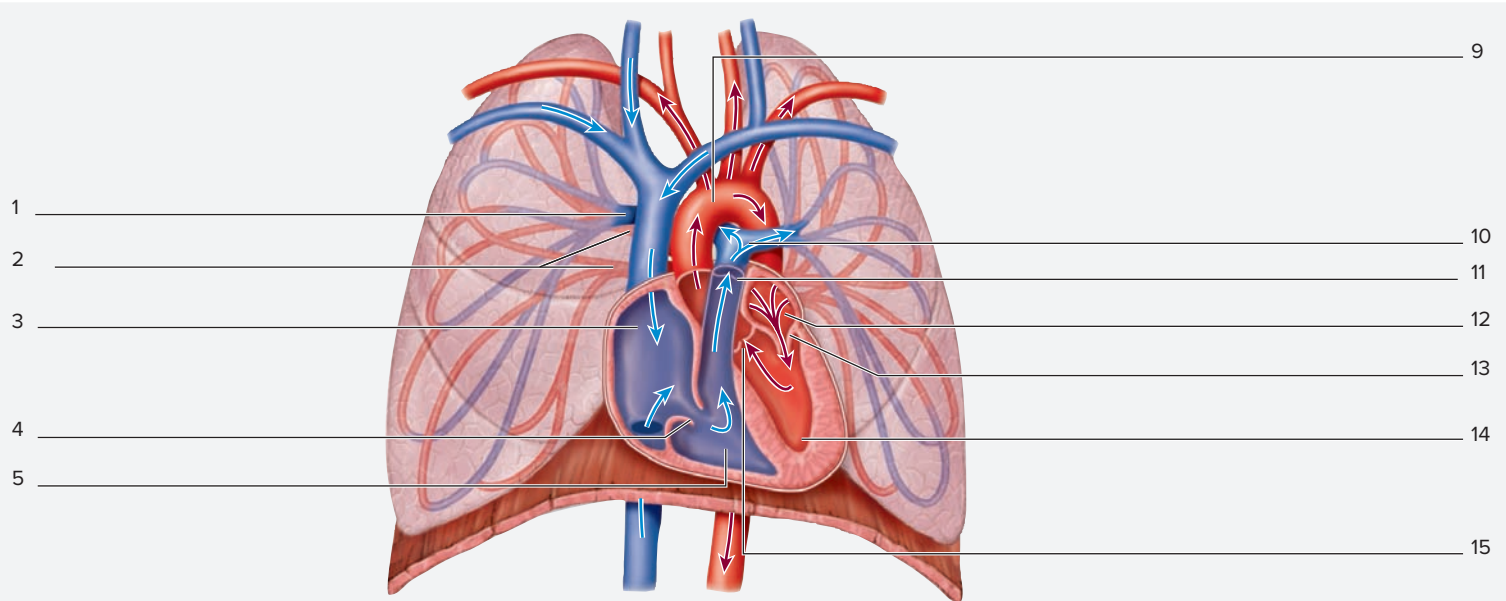
---



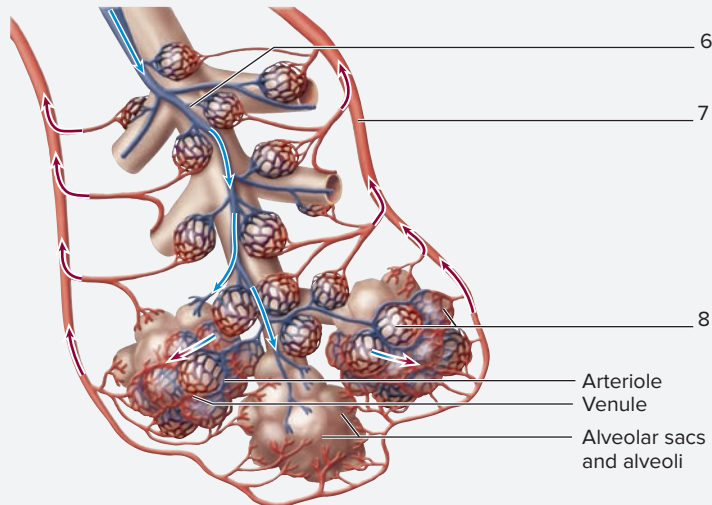
---



---



(a) Heart and lungs



(b) Close-up of vessels within lung

**Figure 18.6 Pulmonary Circuit.** Blue arrows indicate the path of deoxygenated blood. Red arrows indicate the path of oxygenated blood. Use the terms listed to fill in the numbered labels in the figure.

- |   |  |
|---|--|
| <input type="checkbox"/> aorta                      | <input type="checkbox"/> pulmonary capillaries     |
| <input type="checkbox"/> aortic semilunar valve     | <input type="checkbox"/> pulmonary semilunar valve |
| <input type="checkbox"/> branch of pulmonary artery | <input type="checkbox"/> pulmonary trunk           |
| <input type="checkbox"/> branch of pulmonary vein   | <input type="checkbox"/> pulmonary veins           |
| <input type="checkbox"/> left atrium                | <input type="checkbox"/> right atrium              |
| <input type="checkbox"/> left AV valve              | <input type="checkbox"/> right AV valve            |
| <input type="checkbox"/> left ventricle             | <input type="checkbox"/> right ventricle           |
| <input type="checkbox"/> pulmonary arteries         |  |

### Systemic Circuit

The **systemic circuit** is the system of blood vessels that carry blood from the left ventricle of the heart to body organs and back to the right atrium

of the heart. Blood leaves the left ventricle highly oxygenated, and returns to the right atrium relatively deoxygenated.

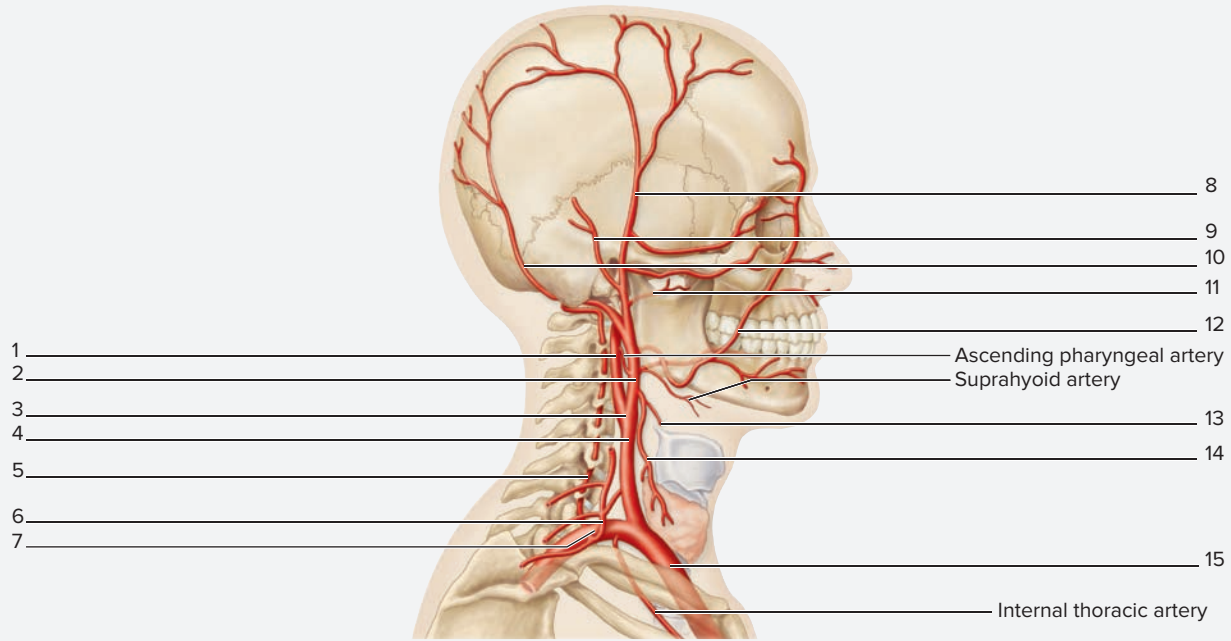
### EXERCISE 18.8 Circulation to the Head and Neck

1. Observe the head and neck regions of a prosected human cadaver or observe classroom models or charts demonstrating blood vessels of the head and neck.
2. The major arteries carrying blood to structures of the head and neck are the external and internal carotid arteries

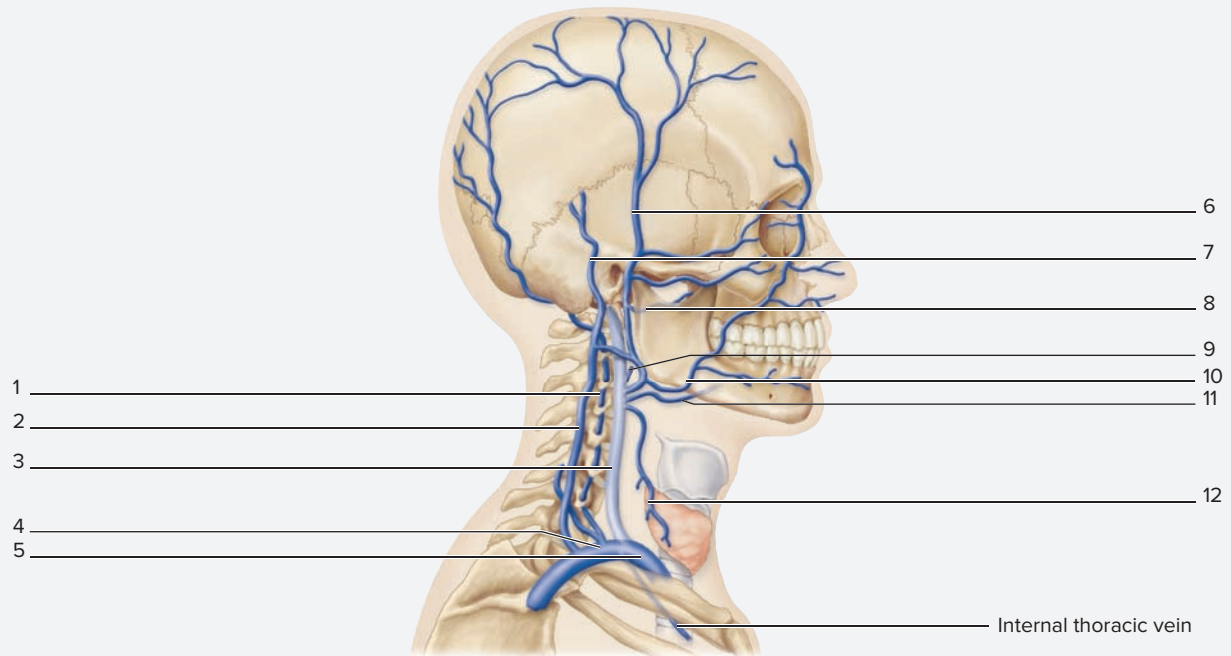
(figure 18.7). The **external carotid arteries** supply most superficial structures of the head and neck. The **external jugular veins** drain most superficial areas of the scalp, face, and neck.

(continued on next page)

(continued from previous page)



(a) Arteries, right lateral view



(b) Veins, right lateral view

**Figure 18.7** Circulation to the Head and Neck. Use the terms listed to fill in the numbered labels in the figure. Some answers may be used more than once.

**(a) Arterial Supply**

- brachiocephalic trunk
- carotid sinus
- common carotid artery
- external carotid artery
- facial artery
- internal carotid artery
- maxillary artery

- occipital artery
- posterior auricular artery
- subclavian artery
- superficial temporal artery
- superior laryngeal artery
- superior thyroid artery
- thyrocervical trunk
- vertebral artery

**(b) Venous Drainage**

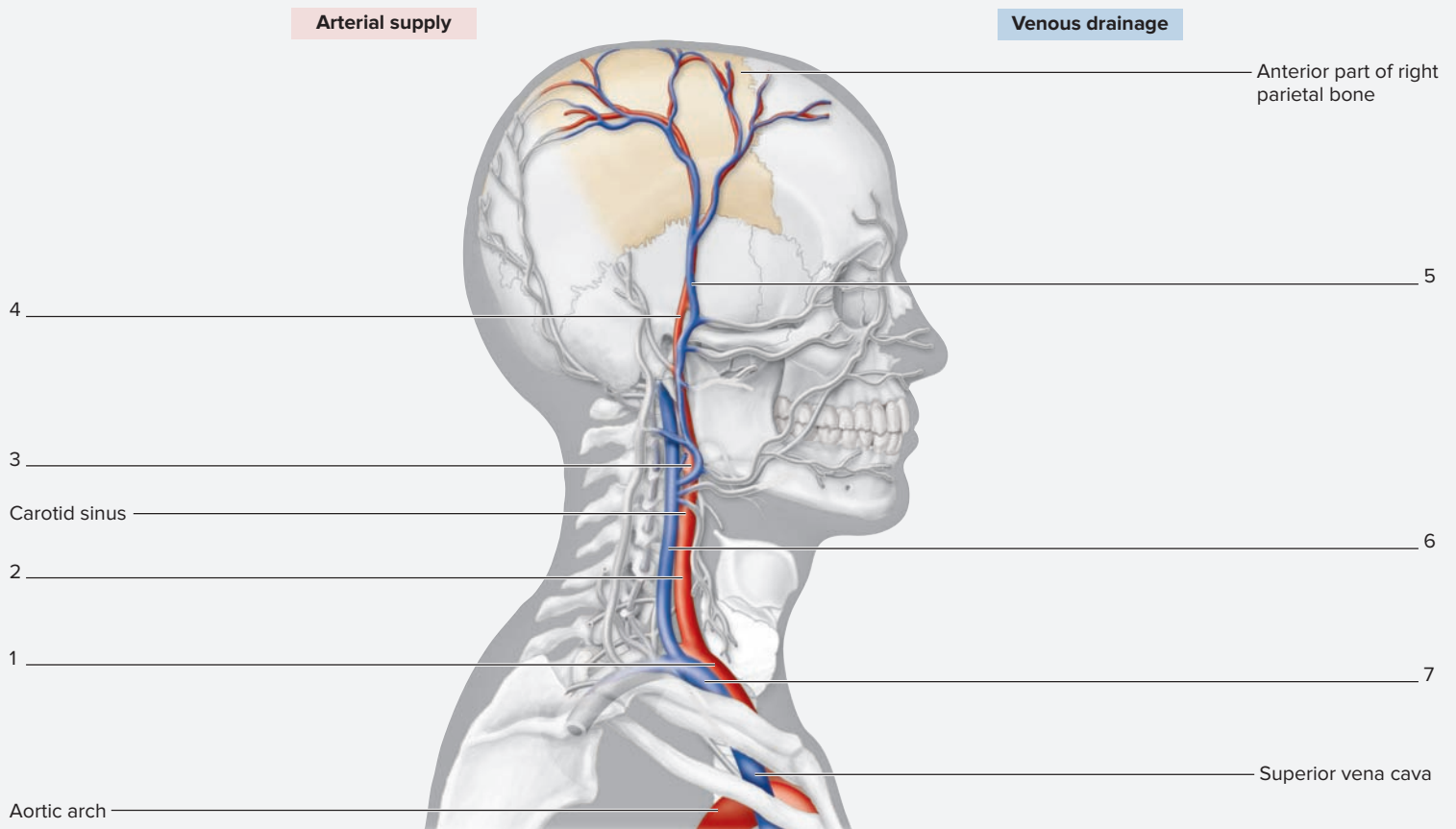
- external jugular vein
- facial vein
- internal jugular vein
- lingual vein
- maxillary vein
- pharyngeal vein

- posterior auricular vein
- right brachiocephalic vein
- subclavian vein
- superficial temporal vein
- superior thyroid vein
- vertebral vein

- Identify the *arteries* listed in figure 18.7a that supply blood to the head and neck, using the textbook as a guide. Then label them in figure 18.7a.
- Identify the *veins* listed in figure 18.7b that drain blood from the head and neck, using the textbook as a guide. Then label them in figure 18.7b.
- The pathway a drop of blood takes to get from the aortic arch to the *skin overlying the anterior part of the right parietal bone* and back to the superior vena cava is shaded

in **figure 18.8**. Trace this flow of blood by writing in the names of the vessels in the figure. Label the vessels in order, starting at number 1, so as to figuratively trace the pathway and name the vessels the blood flows through along the way.

- Optional Activity:** **AP|R Cardiovascular System—Anatomy & Physiology Revealed** includes numerous dissections showing vascular supply to all body regions; review these dissections and use the Quiz feature to test yourself on each region.



**Figure 18.8** Circulation from the Aortic Arch to the Anterior Part of the Right Parietal Bone and Back to the Superior Vena Cava. Use the terms listed to fill in the numbered labels in the figure.

- |   |  |  |
|---|--|--|
| <input type="checkbox"/> right brachiocephalic trunk (artery) | <input type="checkbox"/> right external carotid artery | <input type="checkbox"/> right superficial temporal artery |
| <input type="checkbox"/> right brachiocephalic vein           | <input type="checkbox"/> right internal jugular vein   | <input type="checkbox"/> right superficial temporal vein   |
| <input type="checkbox"/> right common carotid artery          |  |  |

### EXERCISE 18.9 Circulation to the Brain

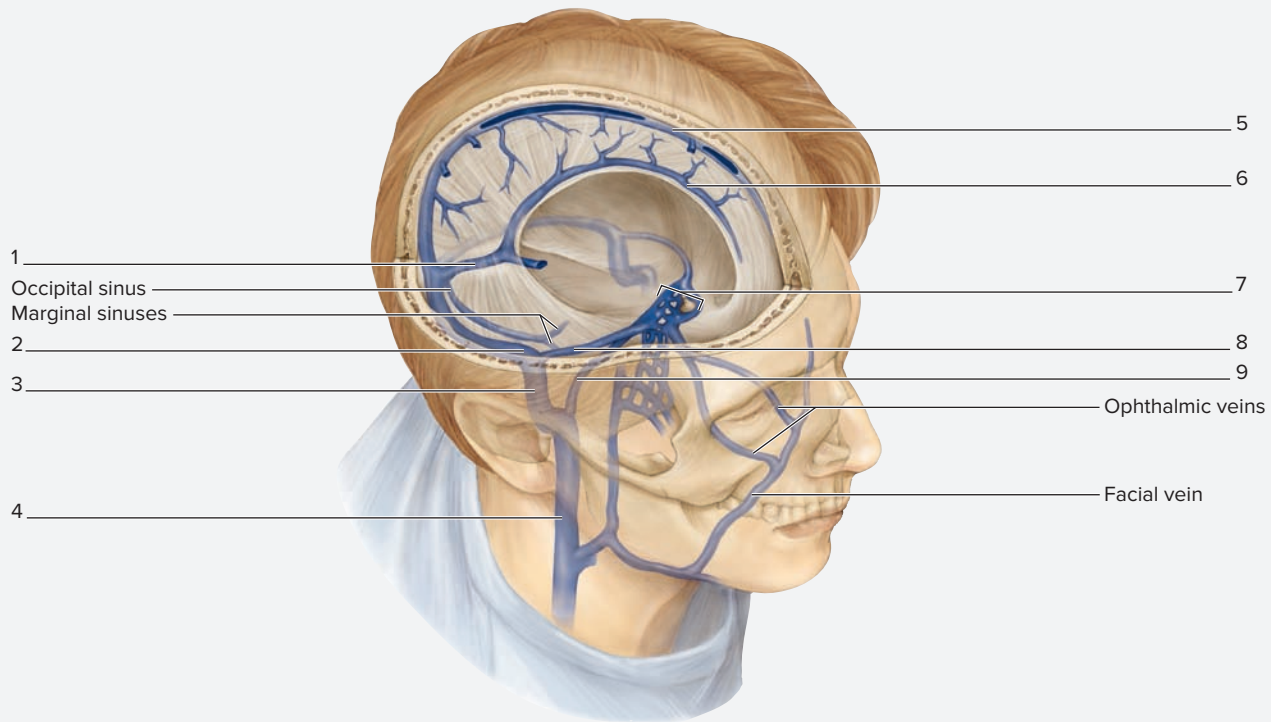
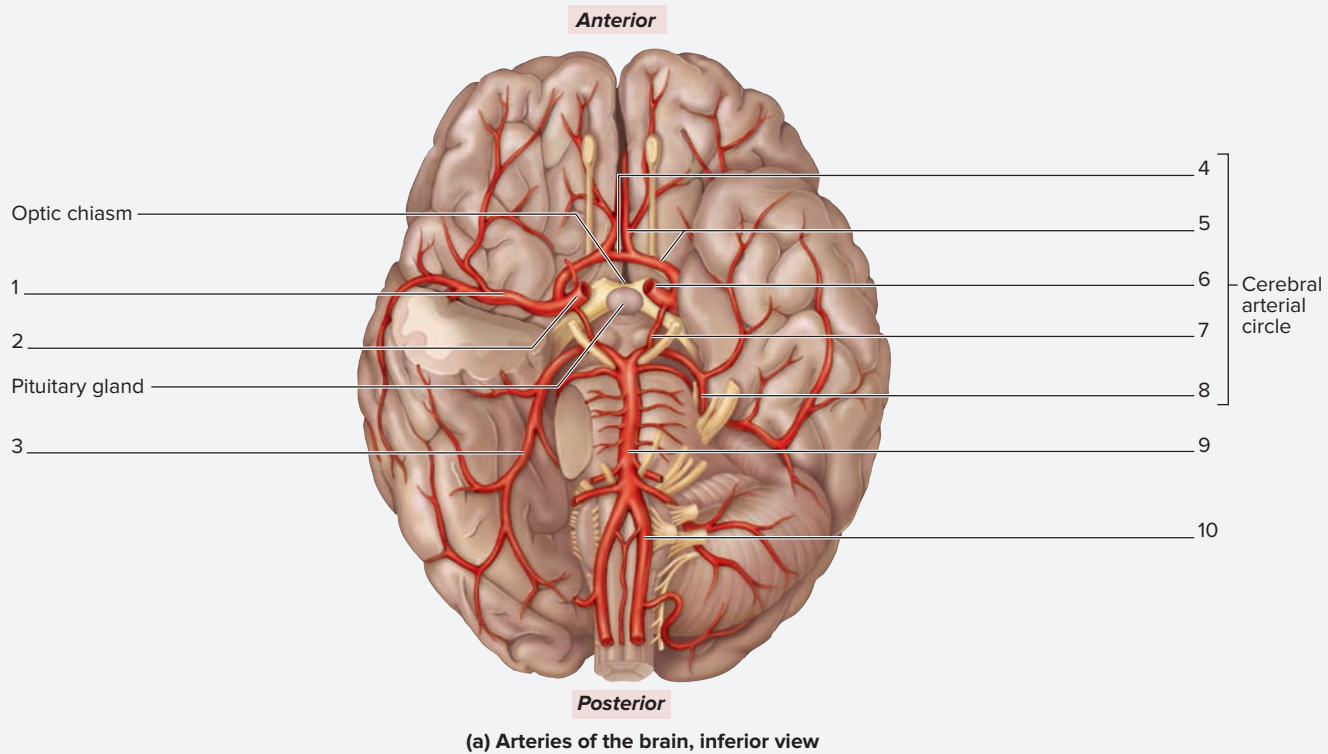
- Observe the cranium and brain of a prosected human cadaver or observe classroom models or charts demonstrating blood vessels of the cranium and brain.
- The major arteries carrying blood to structures of the brain are the internal carotid arteries and the vertebral arteries (figures 18.7 and 18.9). The **internal carotid arteries**

supply ~75% of the blood flow to the brain, while the **vertebral arteries** supply ~25% of the blood flow to the brain. Both pairs of vessels supply blood to the **cerebral arterial circle** (figure 18.9a). The major veins draining blood from the head, neck, and brain are the external and internal jugular veins. The **internal jugular veins** drain all

(continued on next page)



(continued from previous page)



**Figure 18.9** Circulation to the Brain. Use the terms listed to fill in the numbered labels in the figure. Some answers may be used more than once.

**(a) Arterial Supply**

- anterior cerebral artery
- anterior communicating artery
- basilar artery

internal carotid artery

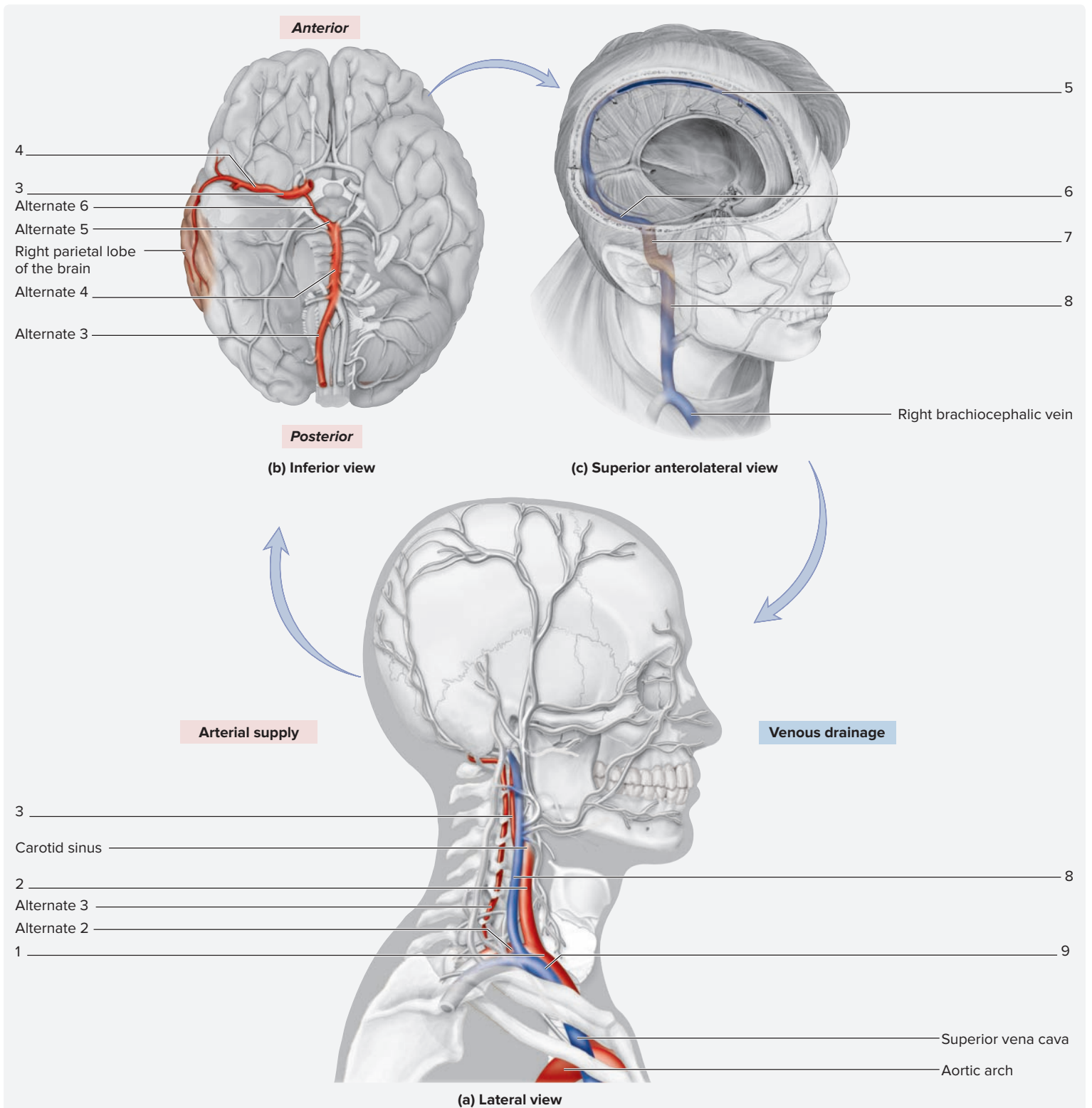
- middle cerebral artery
- posterior cerebral artery
- posterior communicating artery
- vertebral artery

**(b) Venous Drainage**

- cavernous sinus
- inferior petrosal sinus
- inferior sagittal sinus
- internal jugular vein

sigmoid sinus

- straight sinus
- superior petrosal sinus
- superior sagittal sinus
- transverse sinus



**Figure 18.10** Circulation from the Aortic Arch to the Right Parietal Lobe of the Brain and Back to the Right Brachiocephalic Vein. Use the terms listed to fill in the numbered labels in the figure. Some answers may be used more than once.

- |  |   |  |  |
|--|---|--|--|
| <input type="checkbox"/> basilar artery            | <input type="checkbox"/> posterior communicating artery | <input type="checkbox"/> right internal carotid artery | <input type="checkbox"/> superior sagittal sinus |
| <input type="checkbox"/> internal jugular vein     | <input type="checkbox"/> right brachiocephalic artery   | <input type="checkbox"/> right subclavian artery       | <input type="checkbox"/> transverse sinus        |
| <input type="checkbox"/> middle cerebral artery    | <input type="checkbox"/> right brachiocephalic vein     | <input type="checkbox"/> right vertebral artery        |  |
| <input type="checkbox"/> posterior cerebral artery | <input type="checkbox"/> right common carotid artery    | <input type="checkbox"/> sigmoid sinus                 |  |

(continued on next page)

(continued from previous page)

blood from inside the cranial cavity plus some superficial areas of the face. Blood draining from brain tissues first enters the **dural venous sinuses**, which collectively drain into the internal jugular vein (figure 18.9b).

3. Identify the *arteries* listed in figure 18.9a that supply blood to the brain, using the textbook as a guide. Then label them in figure 18.9a.
4. Identify the *veins* listed in figure 18.9b that drain blood from the brain, using the textbook as a guide. Then label them in figure 18.9b.
5. The pathway a drop of blood takes to get from the aortic arch to the *right parietal lobe of the brain* and back to

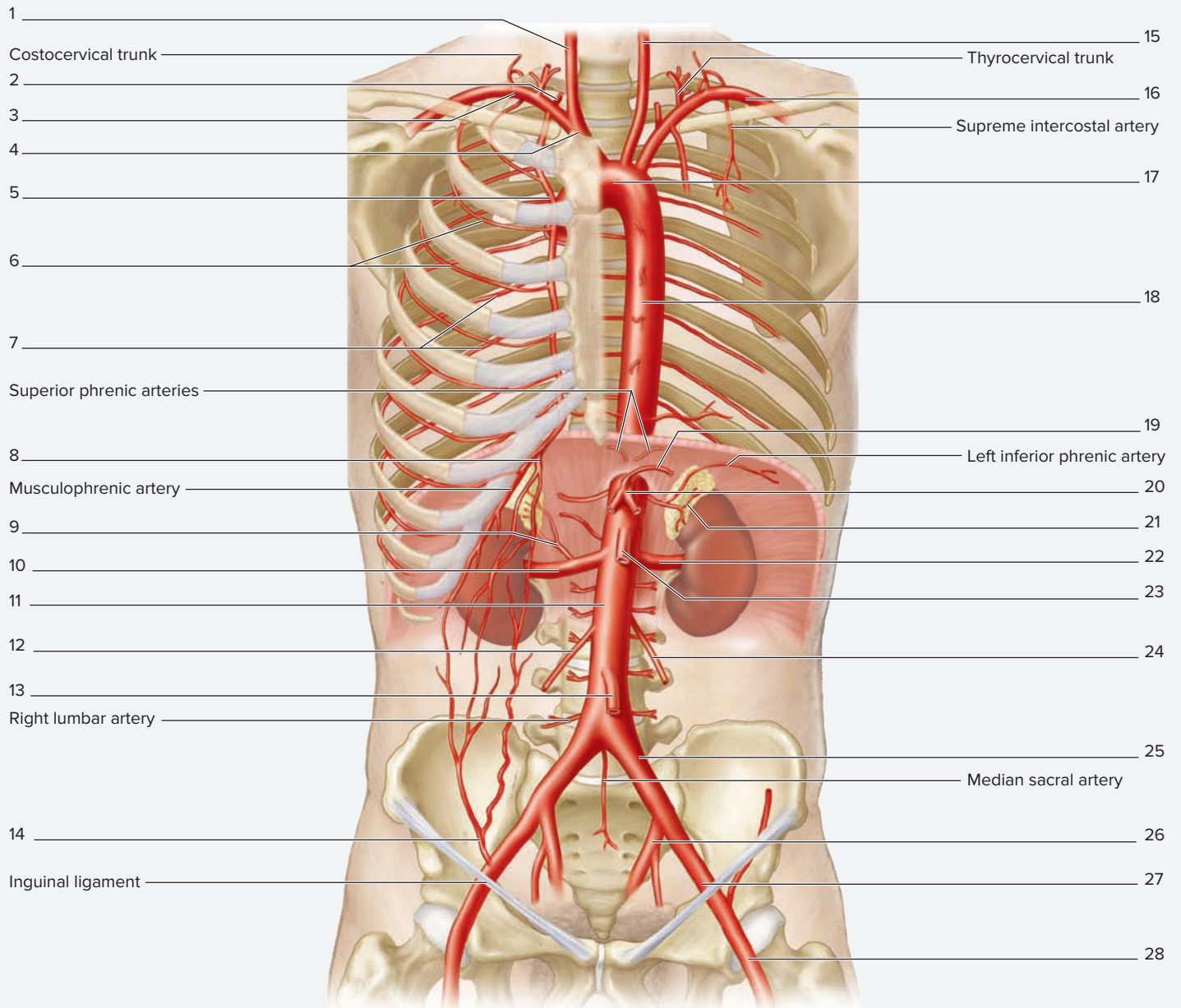
the right brachiocephalic vein is shaded in **figure 18.10**. Trace this flow of blood by writing in the names of the vessels in the figure. Label the vessels in order, starting at number 1, so as to figuratively trace the pathway and name the vessels the blood flows through along the way.

### WHAT DO YOU THINK?

- 6 A patient suffers a stroke of the middle cerebral artery that cuts off the blood supply to the right parietal lobe of the brain. What neurological deficits would result? (Hint: See table 15.3 on p. 305.)

## EXERCISE 18.10 Circulation to the Thoracic and Abdominal Walls

1. Observe the thoracic cavity on a prosected human cadaver or observe classroom models or charts demonstrating blood vessels of the thoracic and abdominal cavities.
2. Identify the *arteries* listed in **figure 18.11a** that supply blood to the thoracic and abdominal walls, using the textbook as a guide. Then label them in figure 18.11a.
3. Identify the *veins* listed in figure 18.11b that drain blood from the thoracic and abdominal walls, using the textbook as a guide. Then label them in figure 18.11b.
4. The pathway a drop of blood takes to get from the left ventricle of the heart to the *right kidney* and back to the right atrium of the heart is shaded in **figure 18.12**. Trace this flow of blood by writing in the names of the vessels in the figure. Label the vessels in order, starting at number 1, so as to figuratively trace the pathway and name the vessels encountered along the way.



(a)

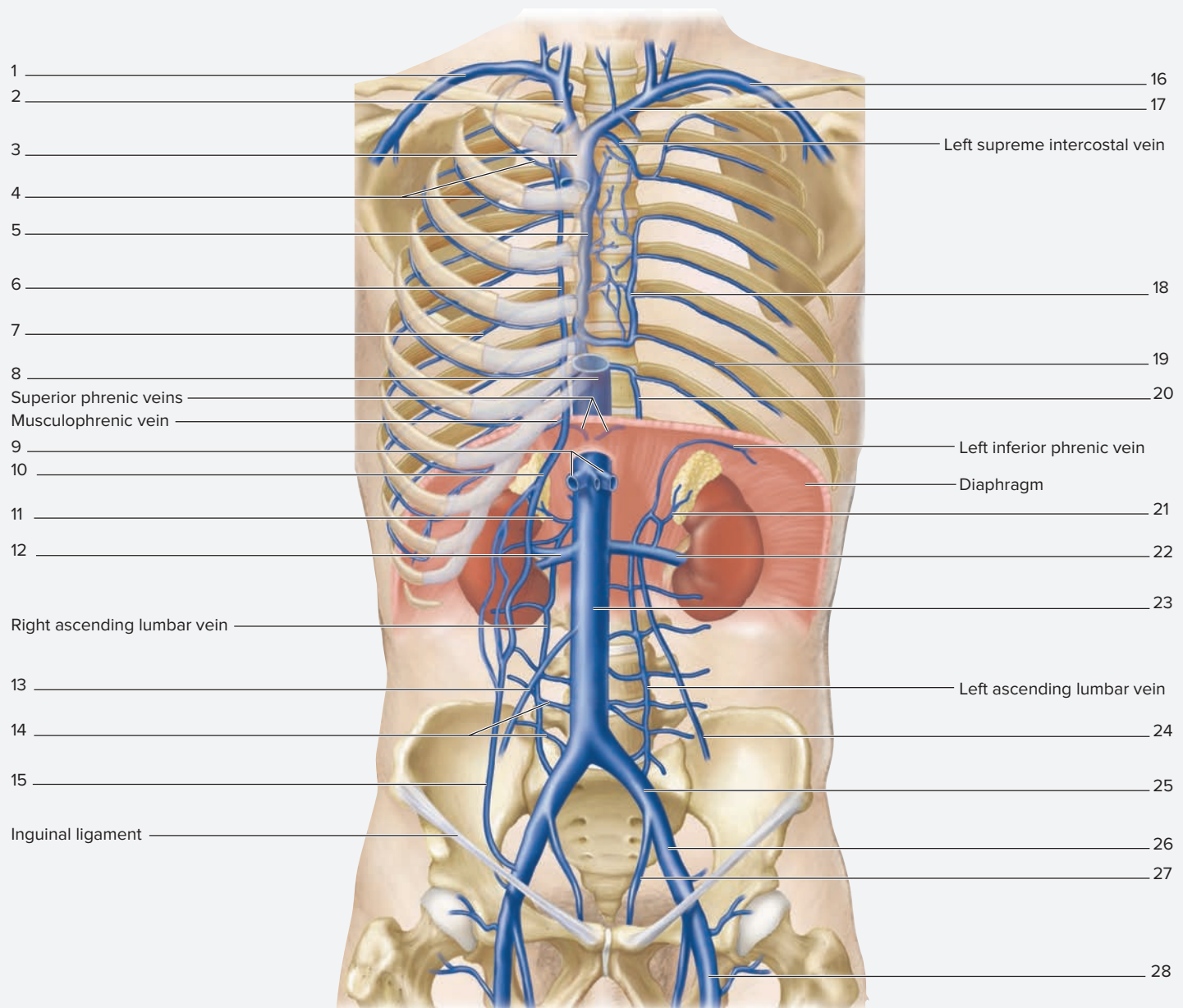
**Figure 18.11** Circulation to the Thoracic and Abdominal Walls. Use the terms listed to fill in the numbered labels in the figure. Some answers may be used more than once.

**(a) Arterial Supply**

- |  |  |   |
|--|--|---|
| <input type="checkbox"/> anterior intercostal arteries | <input type="checkbox"/> left common iliac artery                  | <input type="checkbox"/> right common carotid artery                |
| <input type="checkbox"/> aortic arch                   | <input type="checkbox"/> left external iliac artery                | <input type="checkbox"/> right gonadal artery                       |
| <input type="checkbox"/> brachiocephalic trunk         | <input type="checkbox"/> left femoral artery                       | <input type="checkbox"/> right inferior suprarenal (adrenal) artery |
| <input type="checkbox"/> celiac trunk                  | <input type="checkbox"/> left gastric artery                       | <input type="checkbox"/> right renal artery                         |
| <input type="checkbox"/> descending abdominal aorta    | <input type="checkbox"/> left gonadal artery                       | <input type="checkbox"/> right subclavian artery                    |
| <input type="checkbox"/> descending thoracic aorta     | <input type="checkbox"/> left internal iliac artery                | <input type="checkbox"/> superior epigastric artery                 |
| <input type="checkbox"/> inferior epigastric artery    | <input type="checkbox"/> left renal artery                         | <input type="checkbox"/> superior mesenteric artery                 |
| <input type="checkbox"/> inferior mesenteric artery    | <input type="checkbox"/> left subclavian artery                    | <input type="checkbox"/> vertebral artery                           |
| <input type="checkbox"/> internal thoracic artery      | <input type="checkbox"/> left superior suprarenal (adrenal) artery |   |
| <input type="checkbox"/> left common carotid artery    | <input type="checkbox"/> posterior intercostal arteries            |   |

(continued on next page)

(continued from previous page)



(b)

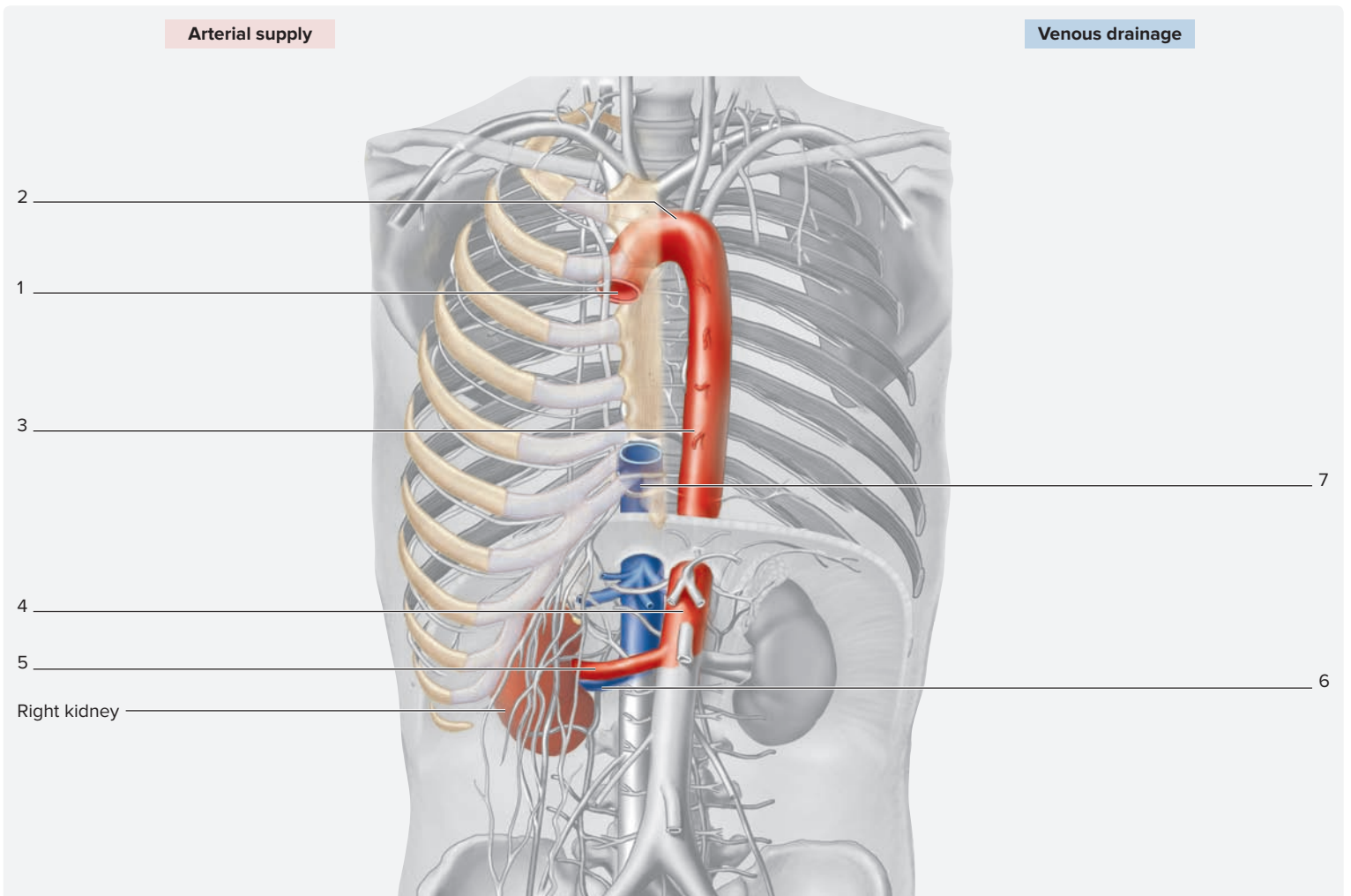
**Figure 18.11** Circulation to the Thoracic and Abdominal Walls (continued). Use the terms listed to fill in the numbered labels in the figure. Some answers may be used more than once.

**(b) Venous Drainage**

- accessory hemiazygos vein
- anterior intercostal veins
- azygos vein
- hemiazygos vein
- hepatic veins
- inferior vena cava
- internal thoracic vein
- left brachiocephalic vein
- left common iliac vein

- left external iliac vein
- left femoral vein
- left gonadal vein
- left internal iliac vein
- left posterior intercostal vein
- left renal vein
- left subclavian vein
- left suprarenal vein
- right brachiocephalic vein

- right gonadal vein
- right inferior epigastric vein
- right lumbar veins
- right posterior intercostal vein
- right renal vein
- right subclavian vein
- right superior epigastric vein
- right suprarenal vein
- superior vena cava



**Figure 18.12** Circulation from the Left Ventricle of the Heart to the Right Kidney and Back to the Right Atrium of the Heart. Use the terms listed to fill in the numbered labels in the figure.

- |  |  |   |   |
|--|--|---|---|
| <input type="checkbox"/> abdominal aorta | <input type="checkbox"/> ascending aorta           | <input type="checkbox"/> inferior vena cava | <input type="checkbox"/> right renal vein |
| <input type="checkbox"/> aortic arch     | <input type="checkbox"/> descending thoracic aorta | <input type="checkbox"/> right renal artery |   |

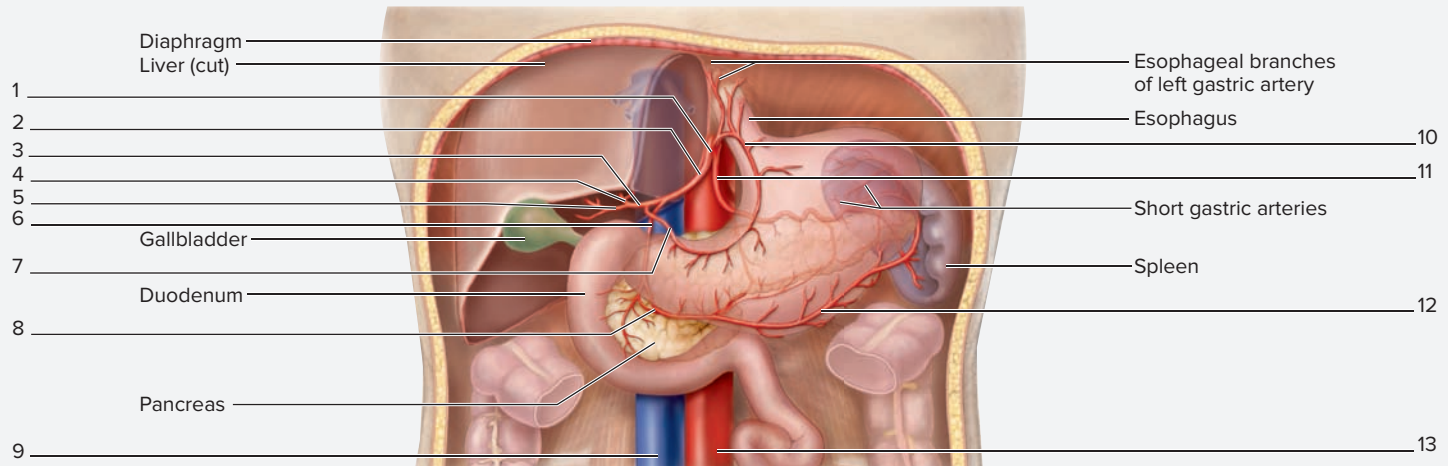
**EXERCISE 18.11** Circulation to the Abdominal Cavity

1. Observe the abdominal cavity on a prosected human cadaver and/or observe classroom models or charts demonstrating blood vessels of the abdominal cavity.
2. Identify the *arteries* listed in **figure 18.13** that supply blood to structures in the abdomen, using the textbook as a guide. Then label them in figure 18.13.
3. Venous drainage of abdominal organs is unique in that it is an example of a portal system, called the **hepatic portal system**. In this system there are two capillary beds—the first in an abdominal organ, and the second in the liver—connected to each other by a **portal vein**. An artery supplies blood to the first capillary bed, which is located in an abdominal organ such as the stomach, intestine, or spleen. Blood drains from

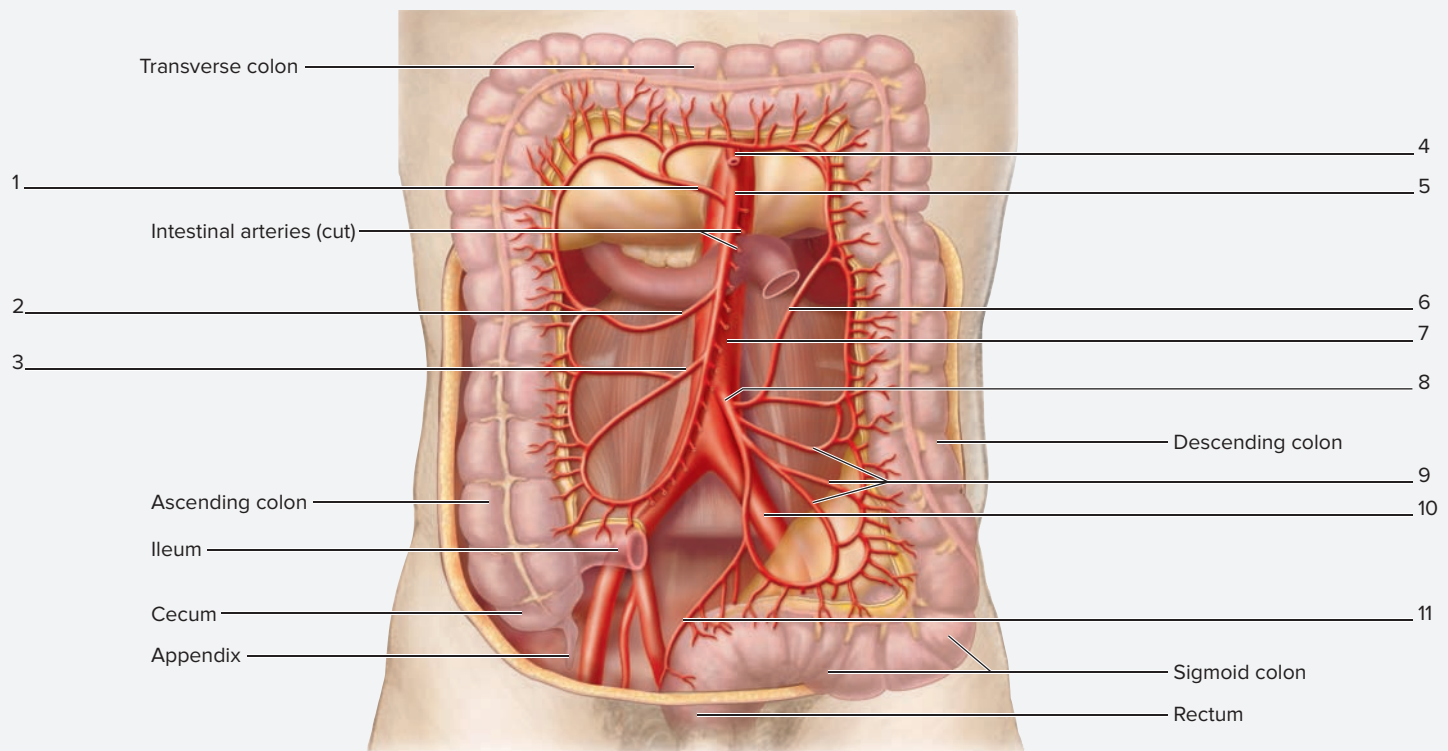
abdominal organs into three veins: the **splenic, inferior mesenteric, or superior mesenteric** veins. These veins then drain into the **hepatic portal vein**, which carries blood to the second capillary bed in the liver. This blood is high in nutrient content, but also may be transporting toxins, bacteria, and other potentially dangerous substances from the GI tract to the liver. Because the blood flows from the abdominal organs directly to the liver, the liver is allowed to do its job of storing nutrients, detoxifying drugs, and removing bacteria from the blood before the blood enters the general circulation. Thus, the liver is said to have “first pass” at the blood that drains from the abdominal organs. Finally, venous blood drains from liver capillaries into **hepatic veins**, which carry it to the inferior vena cava and back to the heart.

(continued on next page)

(continued from previous page)



(a) Celiac trunk branches



(b) Superior and inferior mesenteric arteries

**Figure 18.13** Arterial Supply to Abdominal Organs. Use the terms listed to fill in the numbered labels in the figure.

**(a) Arterial Supply to the Stomach, Spleen, Pancreas, Duodenum, and Liver**

- |   |   |  |   |
|---|---|--|---|
| <input type="checkbox"/> celiac trunk               | <input type="checkbox"/> hepatic artery proper      | <input type="checkbox"/> left hepatic artery         | <input type="checkbox"/> right hepatic artery |
| <input type="checkbox"/> common hepatic artery      | <input type="checkbox"/> inferior vena cava         | <input type="checkbox"/> right gastric artery        | <input type="checkbox"/> splenic artery       |
| <input type="checkbox"/> descending abdominal aorta | <input type="checkbox"/> left gastric artery        | <input type="checkbox"/> right gastroepiploic artery |   |
| <input type="checkbox"/> gastroduodenal artery      | <input type="checkbox"/> left gastroepiploic artery |  |   |

**(b) Arterial Supply to the Small and Large Intestines**

- |   |   |  |   |
|---|---|--|---|
| <input type="checkbox"/> celiac trunk               | <input type="checkbox"/> inferior mesenteric artery | <input type="checkbox"/> middle colic artery | <input type="checkbox"/> superior mesenteric artery |
| <input type="checkbox"/> descending abdominal aorta | <input type="checkbox"/> left colic artery          | <input type="checkbox"/> right colic artery  | <input type="checkbox"/> superior rectal artery     |
| <input type="checkbox"/> ileocolic artery           | <input type="checkbox"/> left common iliac artery   | <input type="checkbox"/> sigmoid arteries    |   |

4. Identify the *veins* listed in **figure 18.14** that compose the hepatic portal system, using your textbook as a guide. Then label them in figure 18.14.
5. The pathway a drop of blood takes to get from the abdominal aorta to the *spleen* and back to the right atrium of the heart is shaded in **figure 18.15**. Trace this flow of blood by writing in the names of the vessels in the figure. Label the vessels in order, starting at number 1, so as

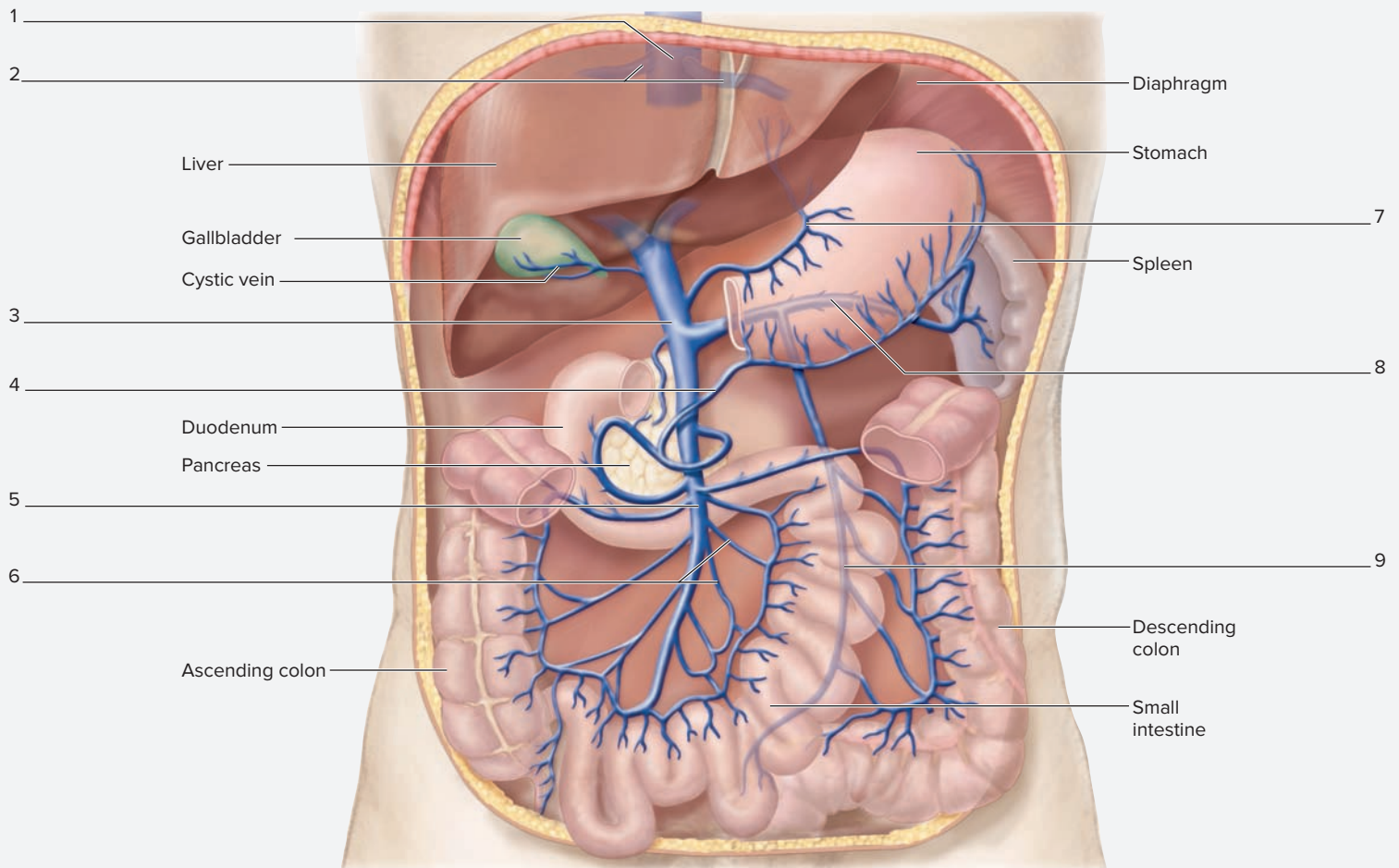
to figuratively trace the pathway and name the vessels encountered along the way.

6. The pathway a drop of blood takes to get from the abdominal aorta to the *duodenum* and back to the right atrium of the heart is shaded in **figure 18.16**. Trace this flow of blood by writing in the names of the vessels in the figure. Label the vessels in order, starting at number 1, so as to figuratively trace the pathway and name the vessels encountered along the way.

7. The pathway a drop of blood takes to get from the abdominal aorta to the *sigmoid colon* and back to the right atrium of the heart is shaded in **figure 18.17**. Trace this flow of blood by writing in the names of the vessels in the figure. Label the vessels in order, starting at number 1, so as to figuratively trace the pathway and name the vessels encountered along the way.

**WHAT DO YOU THINK?**

- 7 What type of capillaries are located within the liver? Given what you have just learned about the contents of the blood entering the liver from the hepatic portal system, why do you think it is advantageous for the liver capillaries to be of this type?



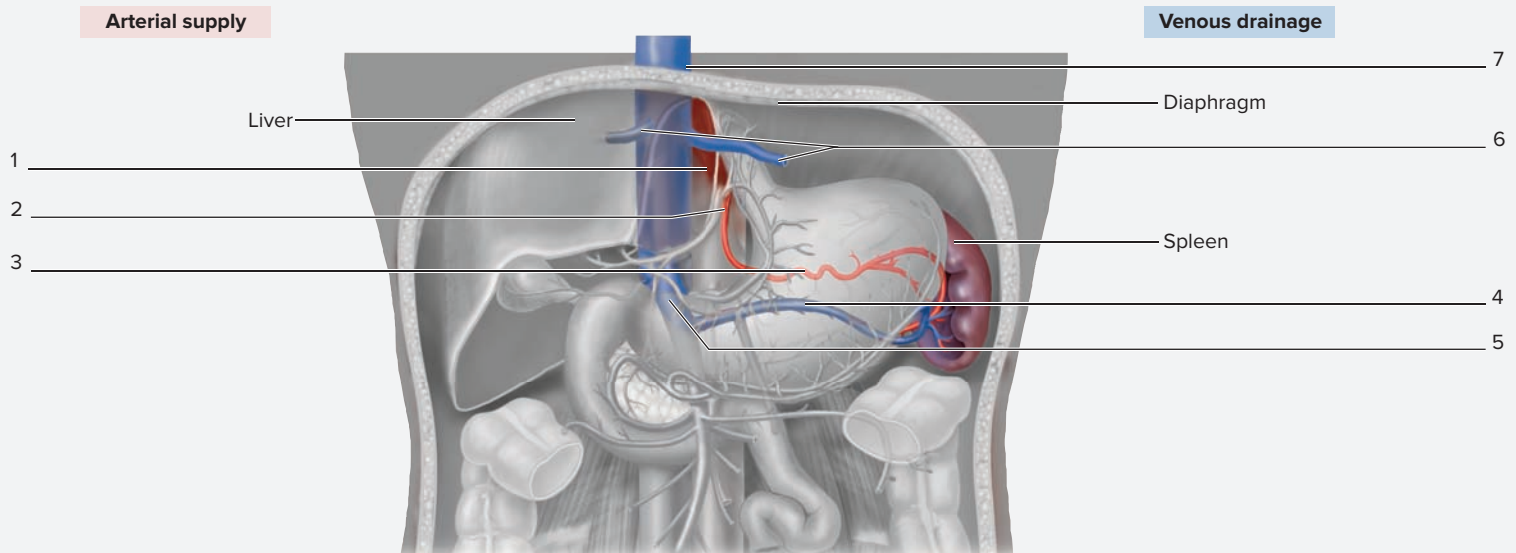
**Figure 18.14 The Hepatic Portal System.** Use the terms listed to fill in the numbered labels in the figure.

- |  |   |  |
|--|---|--|
| <input type="checkbox"/> gastric veins       | <input type="checkbox"/> inferior mesenteric vein | <input type="checkbox"/> right gastroepiploic vein |
| <input type="checkbox"/> hepatic portal vein | <input type="checkbox"/> inferior vena cava       | <input type="checkbox"/> splenic vein              |
| <input type="checkbox"/> hepatic veins       | <input type="checkbox"/> intestinal veins         | <input type="checkbox"/> superior mesenteric vein  |

(continued on next page)

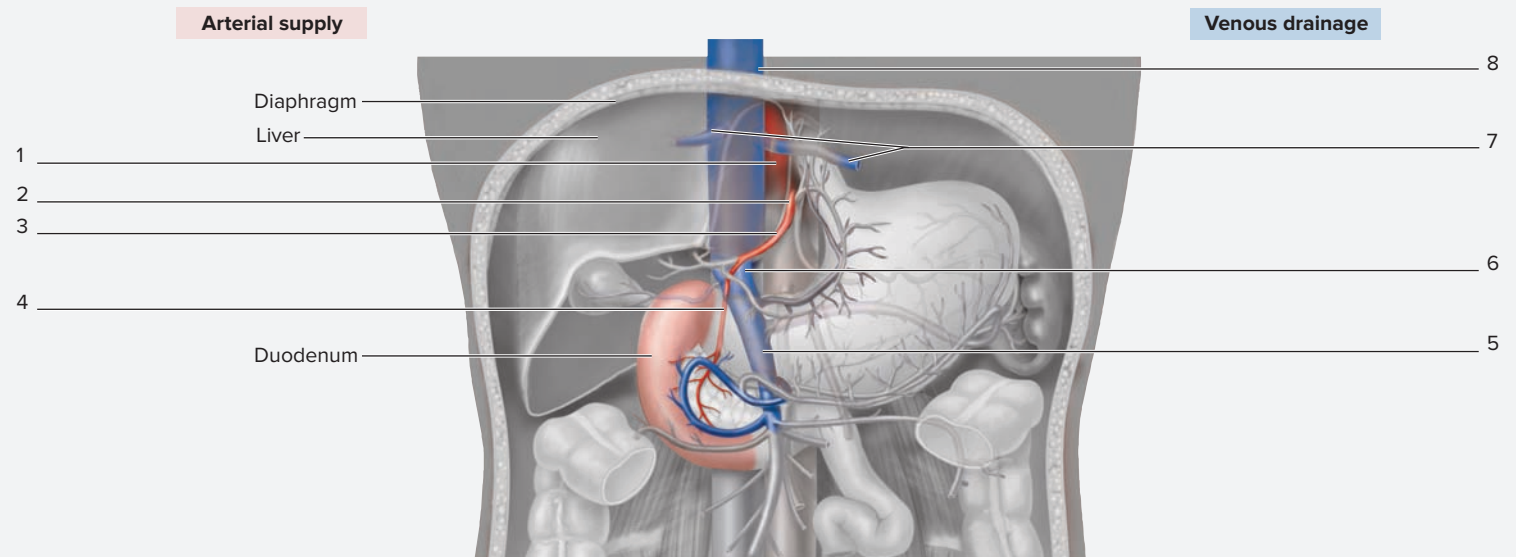


(continued from previous page)



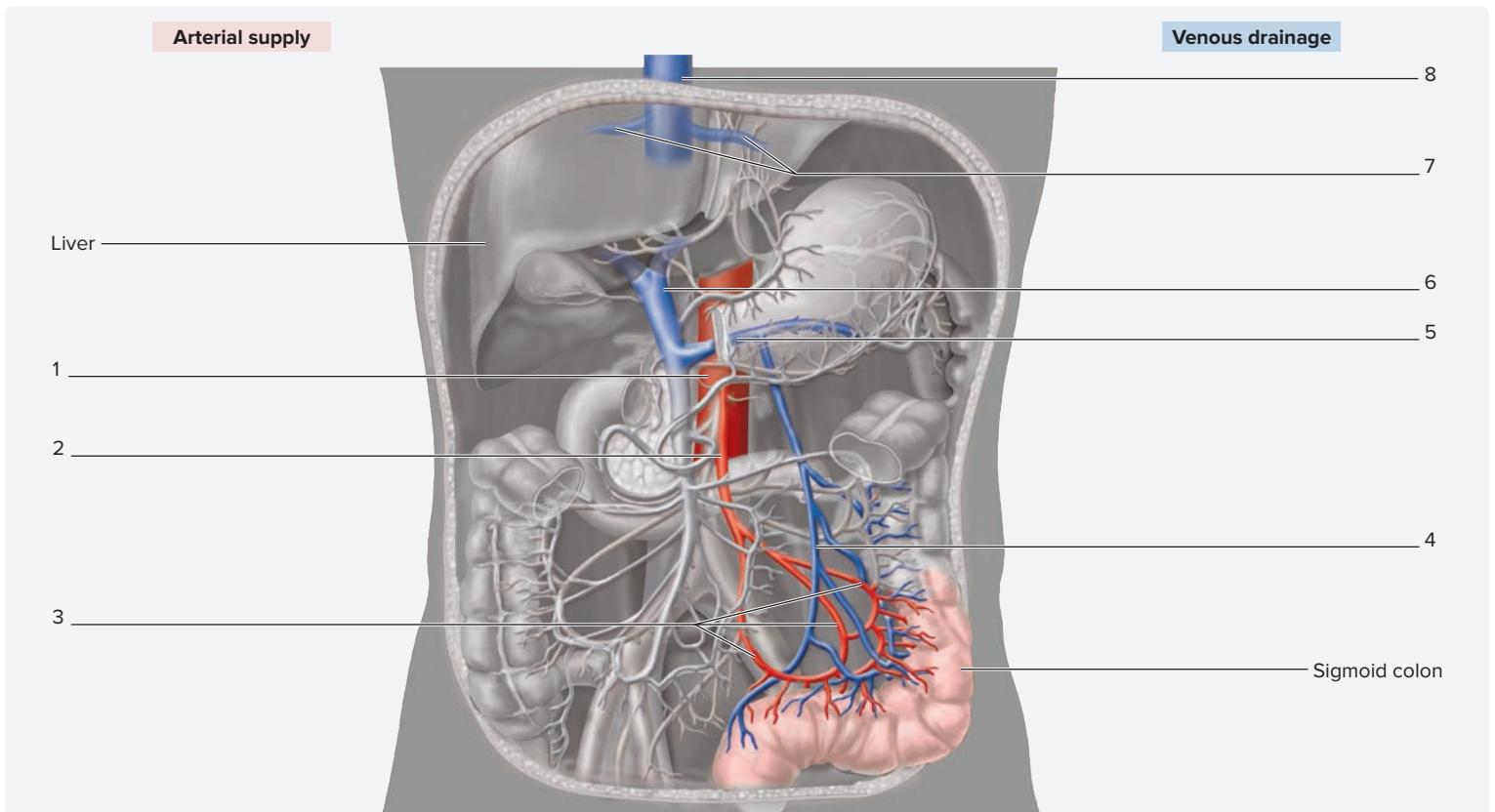
**Figure 18.15** Circulation from the Abdominal Aorta to the Spleen and Back to the Right Atrium of the Heart. Use the terms listed to fill in the numbered labels in the figure.

- |  |   |   |
|--|---|---|
| <input type="checkbox"/> abdominal aorta     | <input type="checkbox"/> hepatic veins      | <input type="checkbox"/> splenic artery |
| <input type="checkbox"/> celiac trunk        | <input type="checkbox"/> inferior vena cava | <input type="checkbox"/> splenic vein   |
| <input type="checkbox"/> hepatic portal vein |   |   |



**Figure 18.16** Circulation from the Abdominal Aorta to the Duodenum and Back to the Right Atrium of the Heart. Use the terms listed to fill in the numbered labels in the figure.

- |  |  |   |
|--|--|---|
| <input type="checkbox"/> abdominal aorta       | <input type="checkbox"/> gastroduodenal artery | <input type="checkbox"/> inferior vena cava       |
| <input type="checkbox"/> celiac trunk          | <input type="checkbox"/> hepatic portal vein   | <input type="checkbox"/> superior mesenteric vein |
| <input type="checkbox"/> common hepatic artery | <input type="checkbox"/> hepatic veins         |   |



**Figure 18.17** Circulation from the Abdominal Aorta to the Sigmoid Colon and Back to the Right Atrium of the Heart. Use the terms listed to fill in the numbered labels in the figure.

- |  |   |   |
|--|---|---|
| <input type="checkbox"/> abdominal aorta     | <input type="checkbox"/> inferior mesenteric artery | <input type="checkbox"/> sigmoid arteries |
| <input type="checkbox"/> hepatic portal vein | <input type="checkbox"/> inferior mesenteric vein   | <input type="checkbox"/> splenic vein     |
| <input type="checkbox"/> hepatic veins       | <input type="checkbox"/> inferior vena cava         |   |

### Clinical View | Portal-Systemic Anastomoses

Veins of the portal system are unique in that they have *no valves*. Thus, when blood backs up in this system, it can back up into systemic veins and will attempt to take an alternate route to the inferior vena cava through anastomoses (s. anastomosis). An **anastomosis** (*anastomo*, to furnish with a mouth) is a connection between two blood vessels. The major anastomoses of the portal circulation are found in veins of the esophagus and the rectum and surrounding the umbilicus. These vessels are common sites of **varicosities** (*varix*, a dilated vein). Varicosities of the esophageal veins are extremely serious because rupture of varicose veins of the esophagus can cause a patient to bleed to

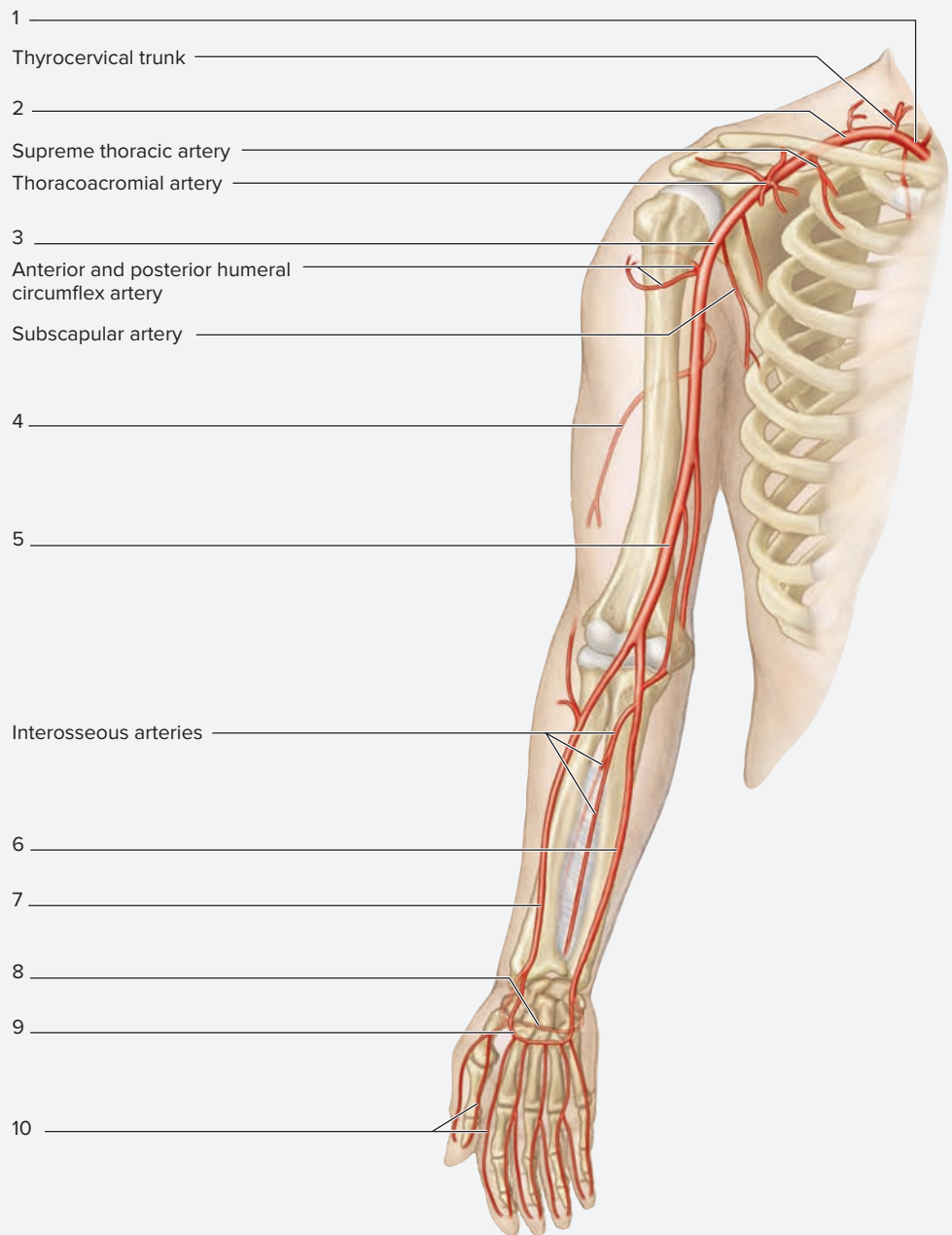
death. Varicosities of the rectal veins cause **hemorrhoids** (*haima*, blood + *rhoia*, a flow), and varicosities of the umbilical veins form a *caput medusa*—because the varicose vessels radiating out from the umbilicus resemble the snakes on Medusa’s head (from Greek mythology). Long time alcoholics often incur liver damage leading to **cirrhosis** (*Kirrhos*, yellow + *-osis*, condition). With cirrhosis, normal liver tissue is replaced over time with scar tissue, decreasing the size of the liver and the number of capillaries within. This creates resistance to blood flow through the liver, which causes blood to back up into the veins of the hepatic portal system.

### EXERCISE 18.12 Circulation to the Upper Limb

1. Observe the upper limb of a prosected human cadaver or observe classroom models or charts demonstrating blood vessels of the upper limb.
2. Identify the *arteries* listed in **figure 18.18a** that supply blood to the upper limb, using the textbook as a guide. Then label them in figure 18.18a.
3. Identify the *veins* listed in figure 18.18b that drain blood from the upper limb, using the textbook as a guide. Then label them in figure 18.18b.
4. *Superficial Trace:* The pathway a drop of blood takes to get from the aortic arch to the *anterior surface of the index finger* and back along a superficial route to the

(continued on next page)

(continued from previous page)

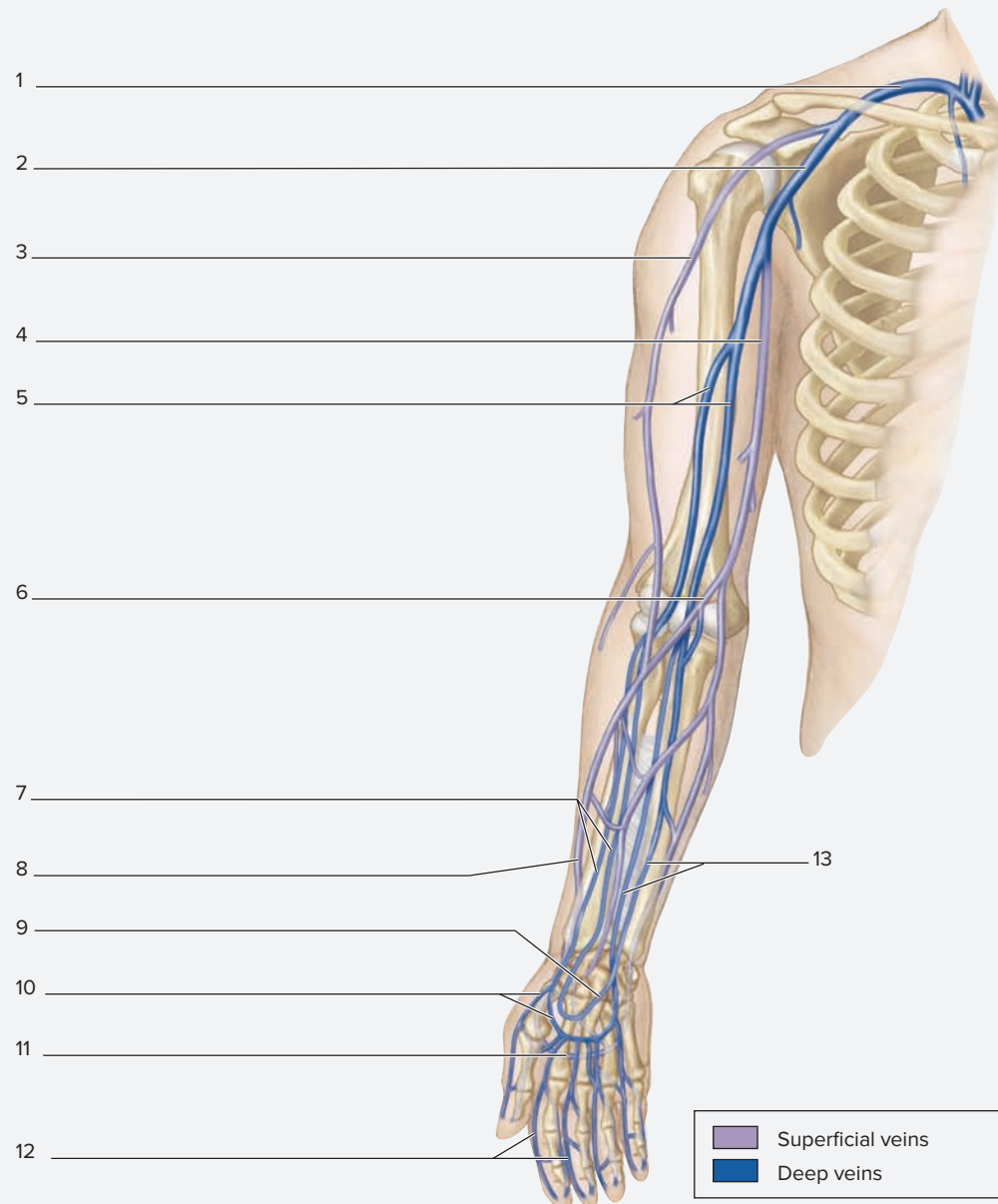


(a) Arteries of right upper limb

**Figure 18.18** Circulation to the Upper Limb. Use the terms listed to fill in the numbered labels in the figure.

**(a) Arterial Supply**

- |   |   |  |  |
|---|---|--|--|
| <input type="checkbox"/> axillary artery        | <input type="checkbox"/> deep brachial artery | <input type="checkbox"/> radial artery     | <input type="checkbox"/> superficial palmar arch |
| <input type="checkbox"/> brachial artery        | <input type="checkbox"/> deep palmar arch     | <input type="checkbox"/> subclavian artery | <input type="checkbox"/> ulnar artery            |
| <input type="checkbox"/> brachiocephalic artery | <input type="checkbox"/> digital arteries     |  |  |



(b) Veins of right upper limb

(b) Venous Drainage. Use the terms listed to fill in the numbered labels in the figure. Some answers may be used more than once.

- |   |  |  |   |
|---|--|--|---|
| <input type="checkbox"/> axillary vein  | <input type="checkbox"/> cephalic vein           | <input type="checkbox"/> dorsal venous network | <input type="checkbox"/> subclavian vein                |
| <input type="checkbox"/> basilic vein   | <input type="checkbox"/> deep palmar venous arch | <input type="checkbox"/> median cubital vein   | <input type="checkbox"/> superficial palmar venous arch |
| <input type="checkbox"/> brachial veins | <input type="checkbox"/> digital veins           | <input type="checkbox"/> radial veins          | <input type="checkbox"/> ulnar veins                    |

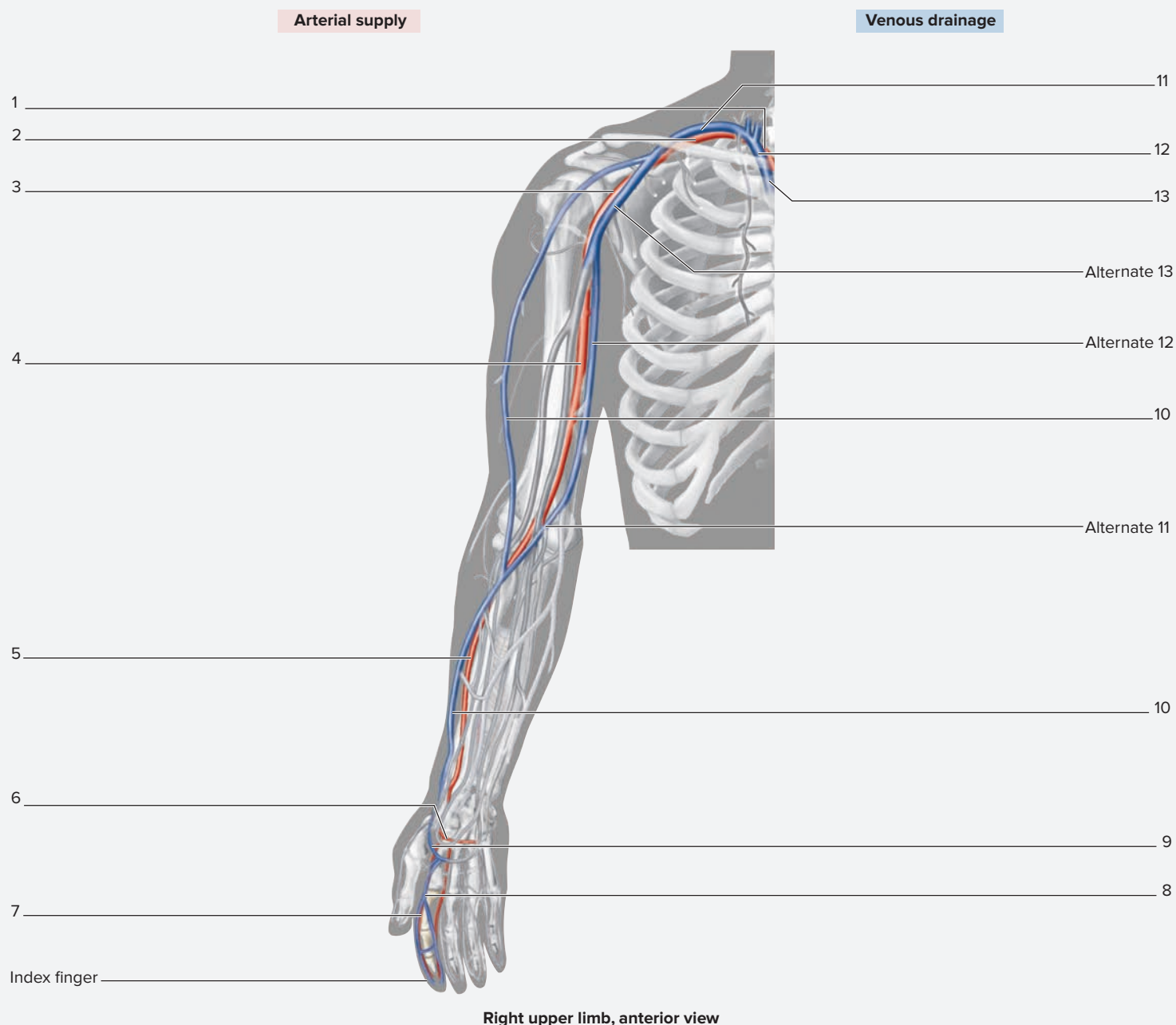
(continued on next page)

(continued from previous page)

superior vena cava is shaded in **figure 18.19**. Trace this flow of blood by writing in the names of the vessels in the figure. Label the vessels in order, starting at number 1, so as to figuratively trace the pathway and name the vessels encountered along the way.

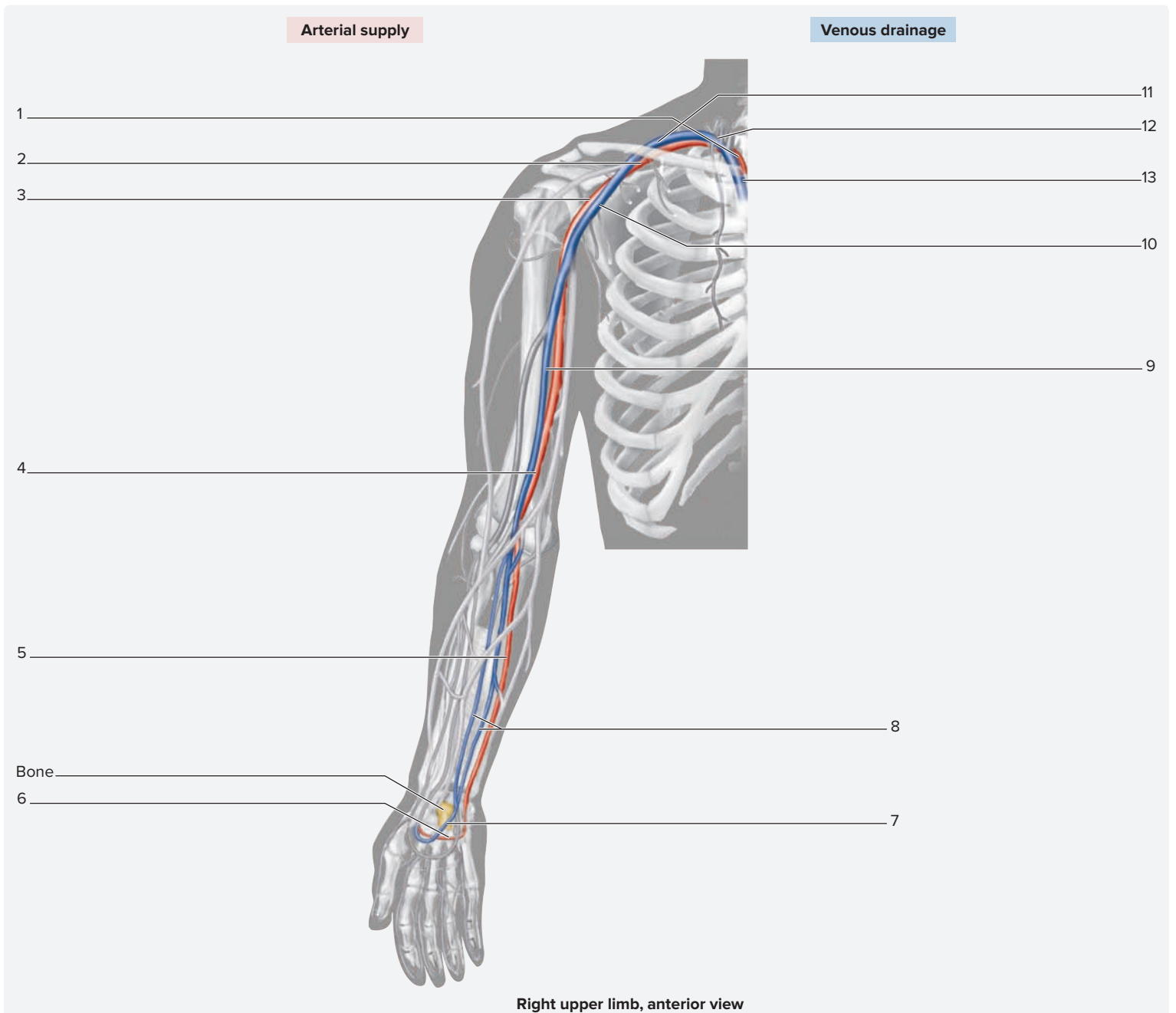
along a deep route to the superior vena cava is shaded in **figure 18.20**. Trace this flow of blood by writing in the names of the vessels in the figure. Label the vessels in order, starting at number 1, so as to figuratively trace the pathway and name the vessels encountered along the way.

5. *Deep Trace:* The pathway a drop of blood takes to get from the aortic arch to the *capitate bone in the wrist* and back



**Figure 18.19** Circulation from the Aortic Arch to the Anterior Surface of the Index Finger and Back Along a Superficial Route to the Superior Vena Cava. Use the terms listed to fill in the numbered labels in the figure. Some answers may be used more than once.

- |  |   |  |   |
|--|---|--|---|
| <input type="checkbox"/> axillary artery | <input type="checkbox"/> brachiocephalic trunk (artery) | <input type="checkbox"/> digital vein        | <input type="checkbox"/> subclavian vein                |
| <input type="checkbox"/> axillary vein   | <input type="checkbox"/> brachiocephalic vein           | <input type="checkbox"/> median cubital vein | <input type="checkbox"/> superficial palmar arch        |
| <input type="checkbox"/> basilic vein    | <input type="checkbox"/> cephalic vein                  | <input type="checkbox"/> radial artery       | <input type="checkbox"/> superficial palmar venous arch |
| <input type="checkbox"/> brachial artery | <input type="checkbox"/> digital artery                 | <input type="checkbox"/> subclavian artery   | <input type="checkbox"/> superior vena cava             |

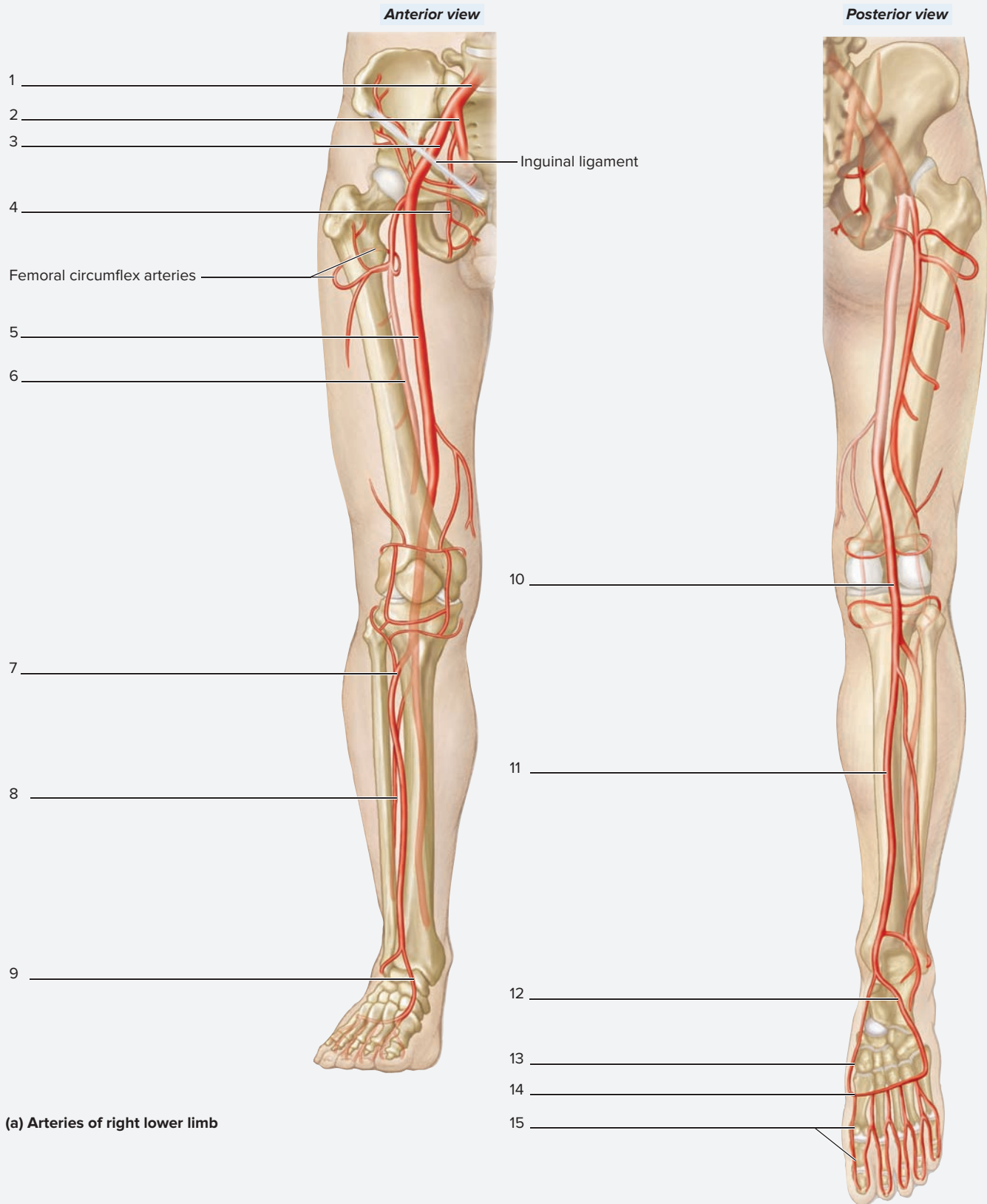


**Figure 18.20** Circulation from the Aortic Arch to the Capitate Bone of the Wrist and Back Along a Deep Route to the Superior Vena Cava. Use the terms listed to fill in the numbered labels in the figure.

- |   |  |   |
|---|--|---|
| <input type="checkbox"/> axillary artery        | <input type="checkbox"/> deep brachial artery    | <input type="checkbox"/> superior vena cava |
| <input type="checkbox"/> axillary vein          | <input type="checkbox"/> deep palmar arch        | <input type="checkbox"/> ulnar artery       |
| <input type="checkbox"/> brachial vein          | <input type="checkbox"/> deep palmar venous arch | <input type="checkbox"/> ulnar vein         |
| <input type="checkbox"/> brachiocephalic artery | <input type="checkbox"/> subclavian artery       |   |
| <input type="checkbox"/> brachiocephalic vein   | <input type="checkbox"/> subclavian vein         |   |

**EXERCISE 18.13** Circulation to the Lower Limb

1. Observe the lower limb of a prosected human cadaver or observe classroom models or charts demonstrating blood vessels of the lower limb.
2. Identify the *arteries* listed in **figure 18.21a** that supply blood to the lower limb, using the textbook as a guide. Then label them in figure 18.21a.
3. Identify the *veins* listed in figure 18.21b that drain blood from the lower limb, using the textbook as a guide. Then label them in figure 18.21b.
4. *Superficial Trace:* The pathway a drop of blood takes to get from the abdominal aorta to the *dorsal surface of the big toe (hallux)* and back along a superficial route to the inferior vena cava is shaded in **figure 18.22**. Trace this flow of blood by writing in the names of the vessels in the figure. Label the vessels in order, starting at number 1, so as to figuratively trace the pathway and name the vessels encountered along the way.
5. *Deep Trace:* The pathway a drop of blood takes to get from the abdominal aorta to the *cuboid bone in the foot* and back along a deep route to the inferior vena cava is shaded in **figure 18.23**. Trace this flow of blood by writing in the names of the vessels in the figure. Label the vessels in order, starting at number 1, so as to figuratively trace the pathway and name the vessels encountered along the way.



**Figure 18.21** Circulation to the Lower Limb. Use the terms listed to fill in the numbered labels in the figure.

**(a) Arterial Supply**

- anterior tibial artery
- common iliac artery
- deep femoral artery

- digital arteries
- dorsalis pedis artery
- external iliac artery
- femoral artery

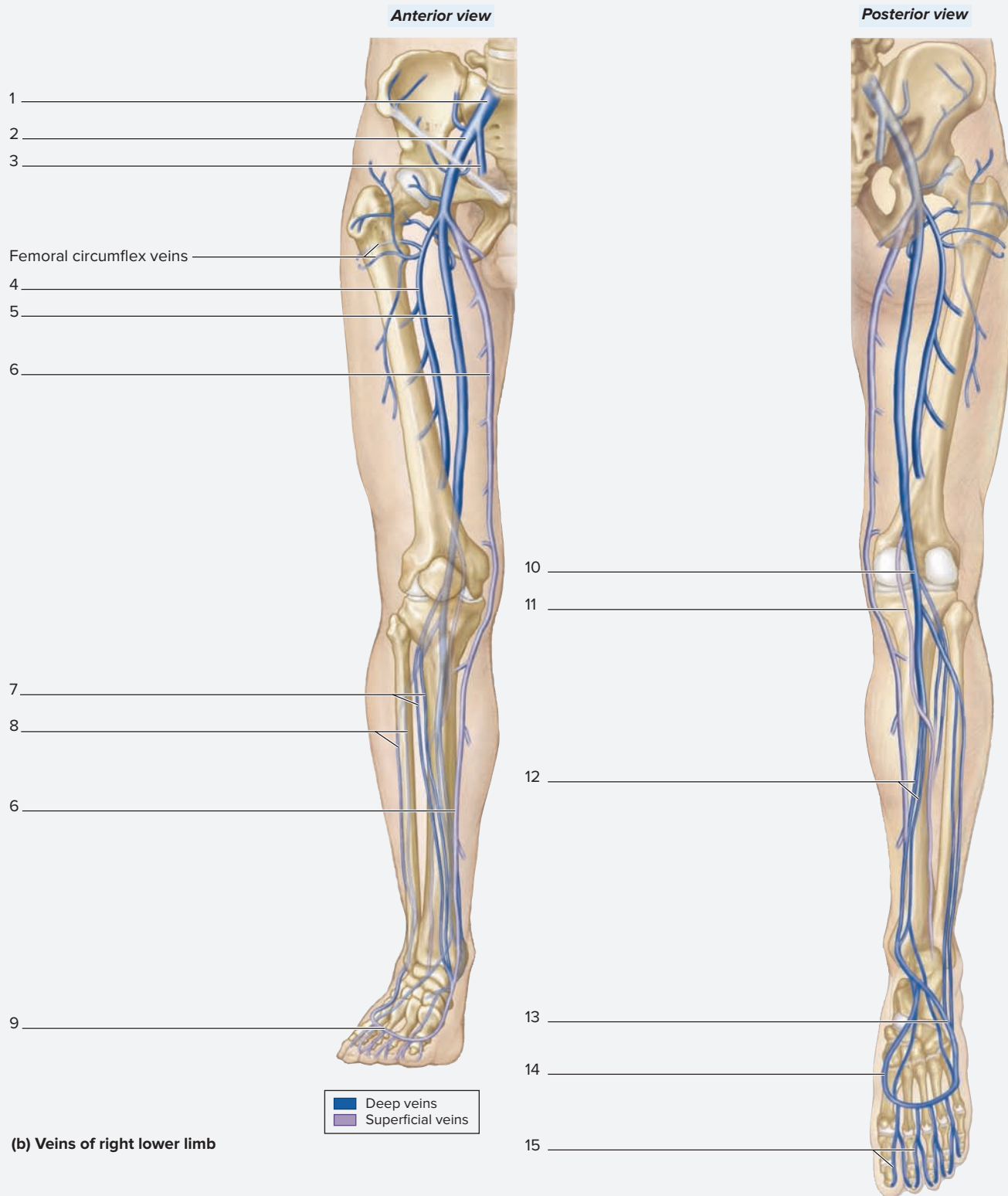
- fibular artery
- internal iliac artery
- lateral plantar artery
- medial plantar artery

- obturator artery
- plantar arch
- popliteal artery
- posterior tibial artery

(continued on next page)



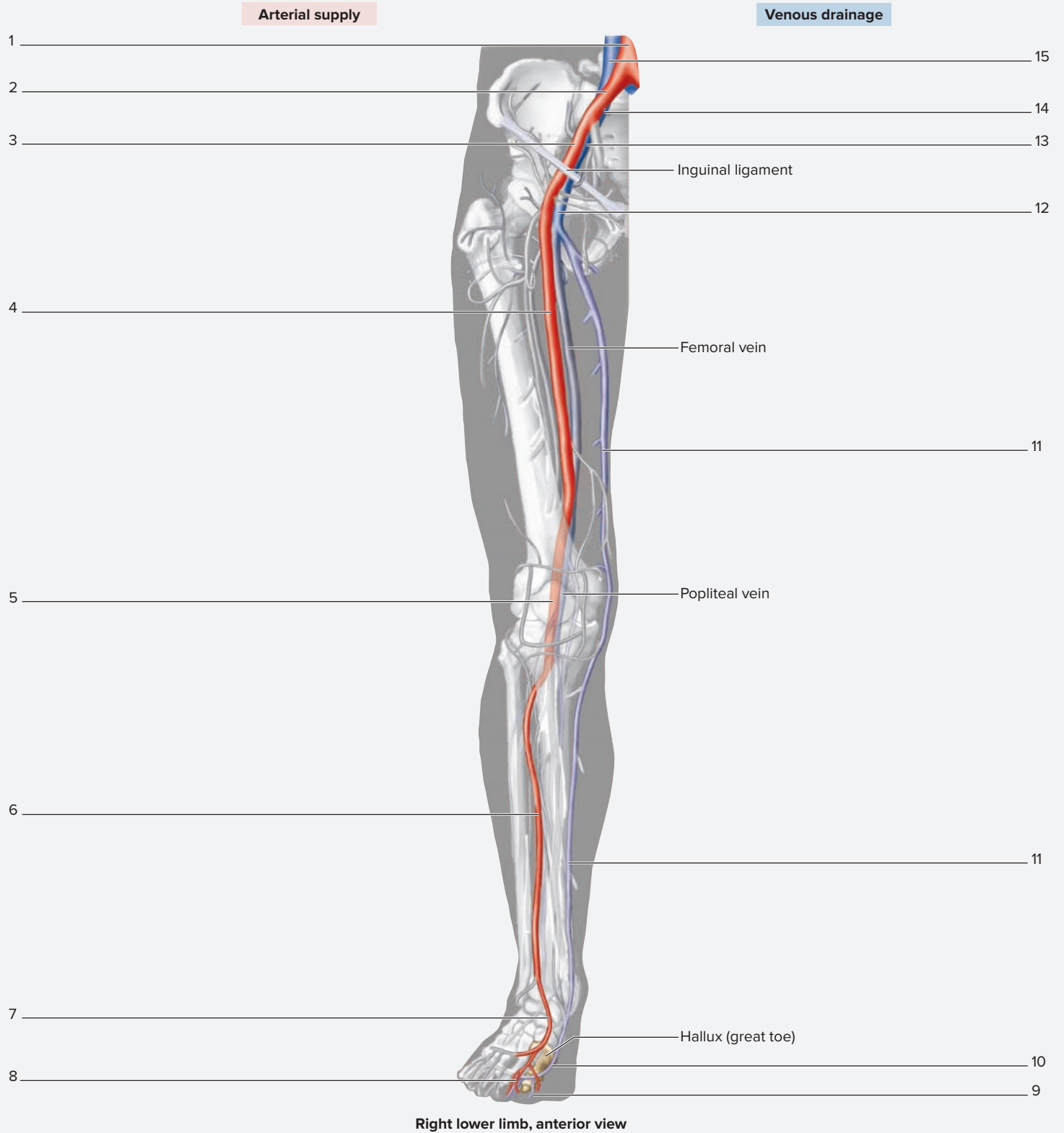
(continued from previous page)



**Figure 18.21** Circulation to the Lower Limb (continued). Use the terms listed to fill in the numbered labels in the figure. Some answers may be used more than once.

**(b) Venous Drainage**

- |  |  |   |   |
|--|--|---|---|
| <input type="checkbox"/> anterior tibial veins | <input type="checkbox"/> dorsal venous arch  | <input type="checkbox"/> great saphenous vein | <input type="checkbox"/> popliteal vein         |
| <input type="checkbox"/> common iliac vein     | <input type="checkbox"/> external iliac vein | <input type="checkbox"/> internal iliac vein  | <input type="checkbox"/> posterior tibial veins |
| <input type="checkbox"/> deep femoral vein     | <input type="checkbox"/> femoral vein        | <input type="checkbox"/> lateral plantar vein | <input type="checkbox"/> small saphenous vein   |
| <input type="checkbox"/> digital veins         | <input type="checkbox"/> fibular veins       | <input type="checkbox"/> medial plantar vein  |   |

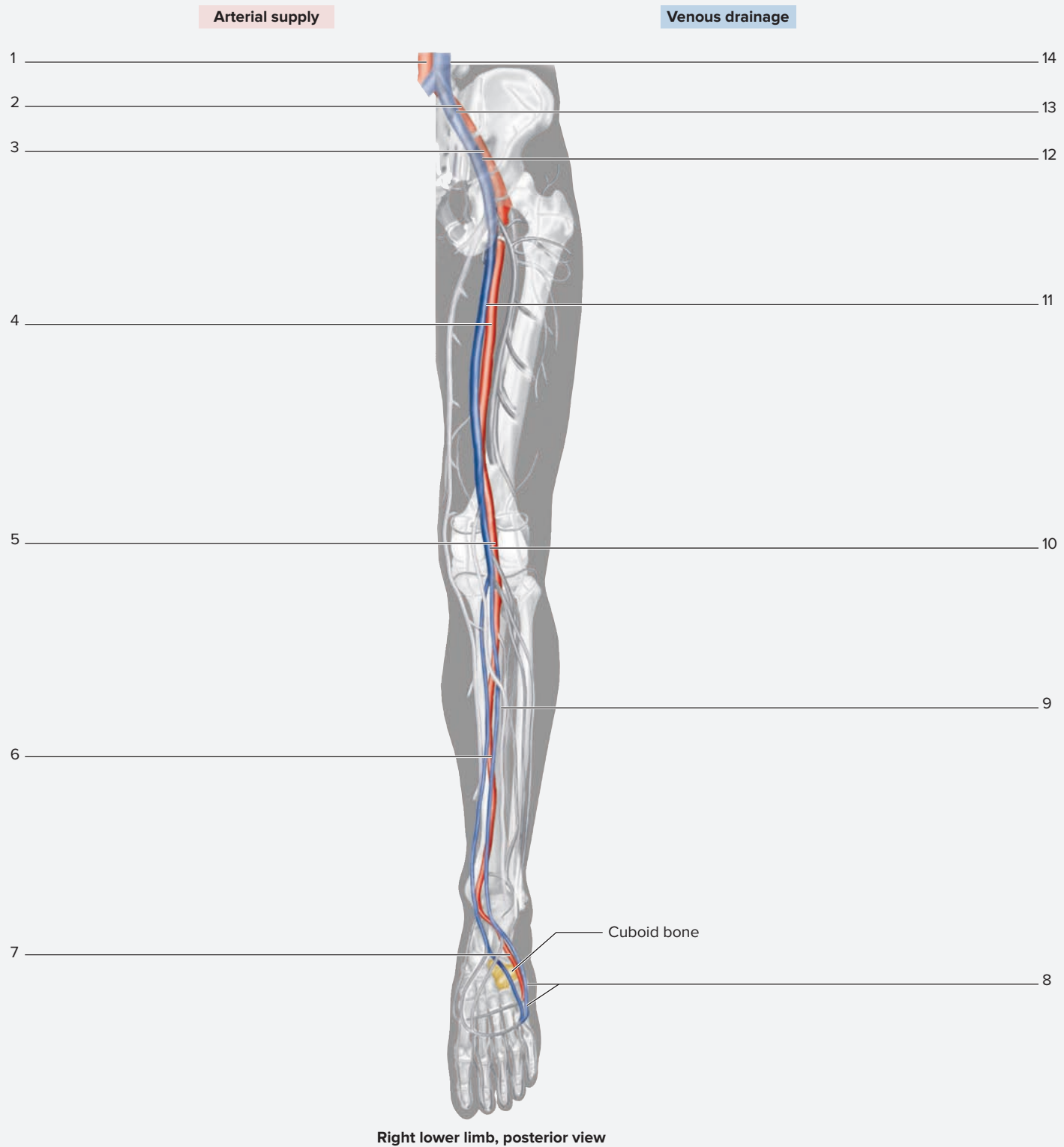


**Figure 18.22** Circulation from the Abdominal Aorta to the Dorsal Surface of the Big Toe (Hallux) and Back Along a Superficial Route to the Inferior Vena Cava. Use the terms listed to fill in the numbered labels in the figure.

- |   |  |  |   |
|---|--|--|---|
| <input type="checkbox"/> abdominal aorta        | <input type="checkbox"/> digital artery        | <input type="checkbox"/> external iliac artery | <input type="checkbox"/> great saphenous vein |
| <input type="checkbox"/> anterior tibial artery | <input type="checkbox"/> digital vein          | <input type="checkbox"/> external iliac vein   | <input type="checkbox"/> inferior vena cava   |
| <input type="checkbox"/> common iliac artery    | <input type="checkbox"/> dorsalis pedis artery | <input type="checkbox"/> femoral artery        | <input type="checkbox"/> popliteal artery     |
| <input type="checkbox"/> common iliac vein      | <input type="checkbox"/> dorsal venous arch    | <input type="checkbox"/> femoral vein          |   |

(continued on next page)

(continued from previous page)

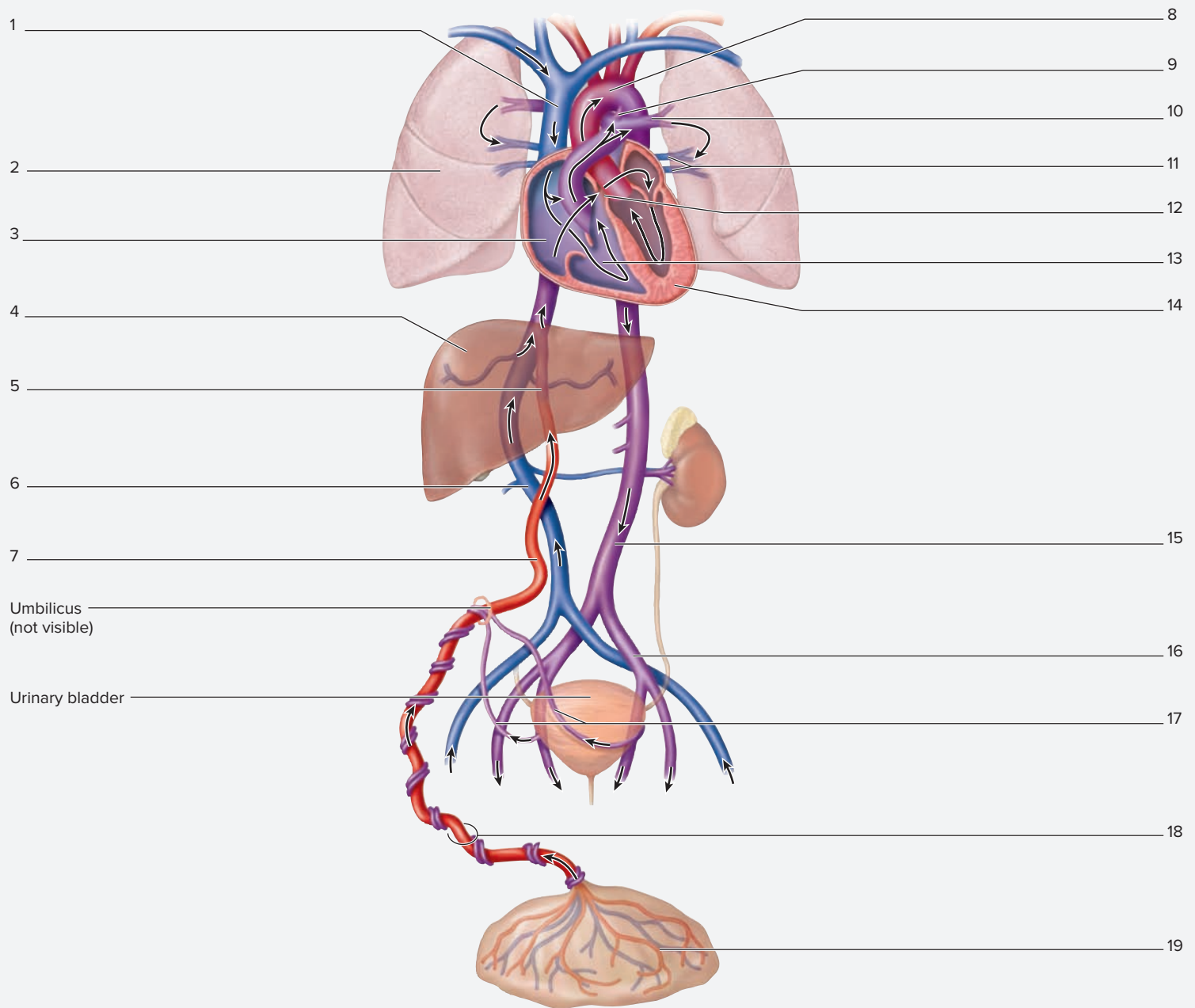


**Figure 18.23** Circulation from the Abdominal Aorta to the Cuboid Bone in the Foot and Back Along a Deep Route to the Inferior Vena Cava. Use the terms listed to fill in the numbered labels in the figure.

- |  |  |   |  |
|--|--|---|--|
| <input type="checkbox"/> abdominal aorta       | <input type="checkbox"/> external iliac vein | <input type="checkbox"/> lateral plantar artery | <input type="checkbox"/> posterior tibial artery |
| <input type="checkbox"/> common iliac artery   | <input type="checkbox"/> femoral artery      | <input type="checkbox"/> lateral plantar vein   | <input type="checkbox"/> posterior tibial vein   |
| <input type="checkbox"/> common iliac vein     | <input type="checkbox"/> femoral vein        | <input type="checkbox"/> popliteal artery       |  |
| <input type="checkbox"/> external iliac artery | <input type="checkbox"/> inferior vena cava  | <input type="checkbox"/> popliteal vein         |  |



(continued from previous page)



**Figure 18.24 Fetal Circulation.** Use the terms listed to fill in the numbered labels in the figure.

- |   |   |   |   |
|---|---|---|---|
| <input type="checkbox"/> aortic arch                | <input type="checkbox"/> foramen ovale      | <input type="checkbox"/> placenta         | <input type="checkbox"/> superior vena cava |
| <input type="checkbox"/> common iliac artery        | <input type="checkbox"/> heart              | <input type="checkbox"/> pulmonary artery | <input type="checkbox"/> umbilical arteries |
| <input type="checkbox"/> descending abdominal aorta | <input type="checkbox"/> inferior vena cava | <input type="checkbox"/> pulmonary veins  | <input type="checkbox"/> umbilical cord     |
| <input type="checkbox"/> ductus arteriosus          | <input type="checkbox"/> liver              | <input type="checkbox"/> right atrium     | <input type="checkbox"/> umbilical vein     |
| <input type="checkbox"/> ductus venosus             | <input type="checkbox"/> lung               | <input type="checkbox"/> right ventricle  |   |

## POST-LABORATORY WORKSHEET

The 1 corresponds to the Learning Objective(s) listed in the chapter opener outline.

### Do You Know the Basics?

#### Exercise 18.1: Blood Vessel Wall Structure

1. The tunic in blood vessels that is composed of simple squamous epithelium (or endothelium) and a subendothelial layer composed of areolar connective tissue is known as the tunica \_\_\_\_\_ (interna/externa). 1 2

#### Exercise 18.2: Elastic Artery—The Aorta

2. Which of the following statements correctly describes an elastic artery? (Check all that apply.) 3
- \_\_\_ a. contains an internal elastic lamina
  - \_\_\_ b. contains multiple layers of smooth muscle
  - \_\_\_ c. tunica media contains numerous elastic fibers
  - \_\_\_ d. typical diameters are 1–2.5 cm in diameter
  - \_\_\_ e. very thin with no smooth muscle cells
3. Elastic fibers allow for turbulent flow in elastic arteries. \_\_\_\_\_ (True/False) 4
4. The vasa vasorum refers to “the vessels of the vessels,” and they function to deliver blood to larger vessels. \_\_\_\_\_ (True/False) 5

#### Exercise 18.3: Muscular Artery

5. A characteristic feature of a muscular artery is the presence of an internal and external elastic lamina. \_\_\_\_\_ (True/False) 6
6. Elastic arteries are typically located closest to the heart where pressures are \_\_\_\_\_ (highest/lowest). 7

#### Exercise 18.4: Arteriole

7. Constriction of arterioles \_\_\_\_\_ (decreases/increases) blood flow into capillary beds. 8

#### Exercise 18.5: Vein

8. Veins are considered \_\_\_\_\_ (high/low) pressure vessels. 9
9. A venous valve is formed by an infolding of the tunica intima. \_\_\_\_\_ (True/False) 10

#### Exercise 18.6: Observing Electron Micrographs of Capillaries

10. Rank the following types of capillaries from most to least permeable. 11
- \_\_\_ continuous
  - \_\_\_ fenestrated
  - \_\_\_ sinusoidal

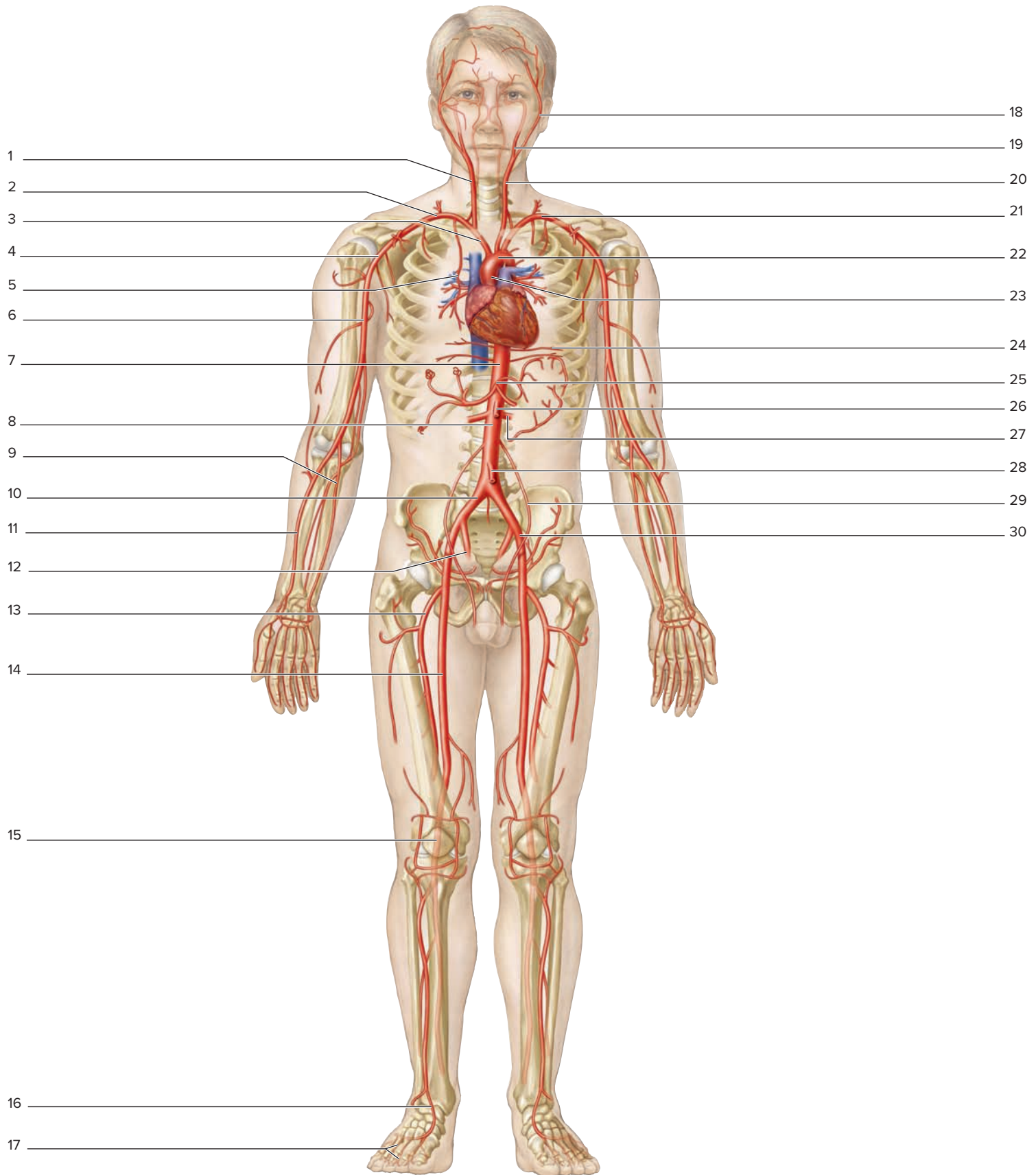
#### Exercise 18.7: Pulmonary Circuit

11. Trace the flow of blood from the right ventricle of the heart through the pulmonary circulation and back to the left atrium of the heart. Be sure to identify heart valves through which the blood flows. 12

right ventricle → \_\_\_\_\_ → \_\_\_\_\_ → \_\_\_\_\_ → \_\_\_\_\_ →  
 \_\_\_\_\_ → left atrium

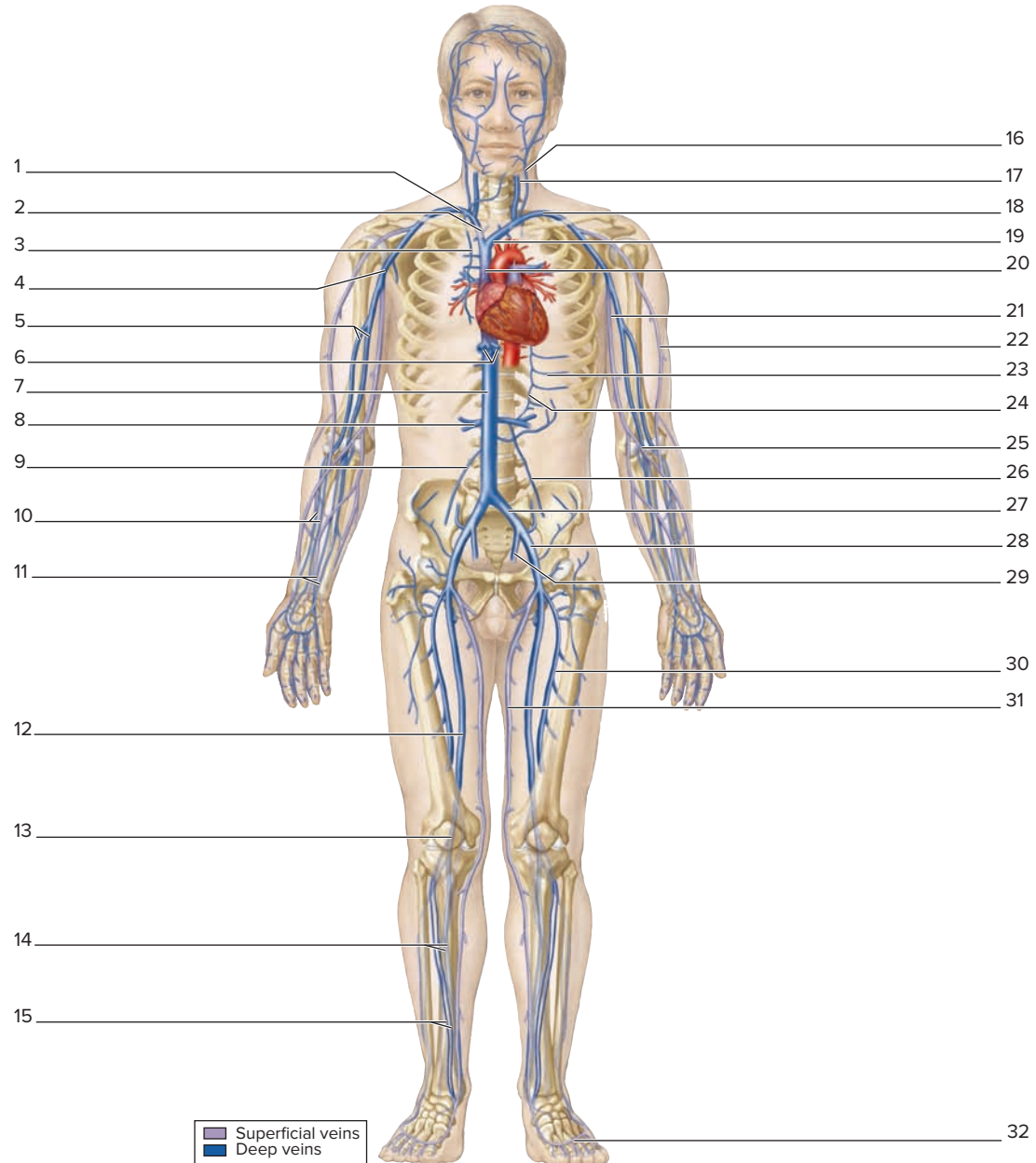
Exercises 18.8–18.13: Systemic Circuit

12. Label the diagram with the appropriate artery names. 13–25



(a) Arteries, anterior view

13. Label the diagram with the appropriate vein names. 13-25



(b) Veins, anterior view

14. Which of the following are veins that compose the hepatic portal circulation? (Check all that apply.) 20

- a. celiac trunk
- b. inferior mesenteric vein
- c. inferior vena cava
- d. splenic vein
- e. superior mesenteric vein

**Exercise 18.14: Fetal Circulation**

15. In the fetus, the umbilical vein carries \_\_\_\_\_ (oxygenated/deoxygenated) blood, whereas the umbilical arteries carry \_\_\_\_\_ (oxygenated/deoxygenated) blood. 26

16. In fetal circulation, oxygenated blood flows from the placenta, to the umbilical \_\_\_\_\_ (arteries/vein), to the right atrium of the heart. Blood returns to the placenta via the umbilical \_\_\_\_\_ (arteries/vein). 27

17. When referencing a structure present in the interatrial septum, the prenatal structure is called the \_\_\_\_\_ (foramen ovale/fossa ovalis), whereas the postnatal structure is called the \_\_\_\_\_ (foramen ovale/fossa ovalis). 28



**Can You Apply What You've Learned?**

18. Explain why large blood vessels have their own blood vessels (vasa vasorum) in the tunica externa.

---



---

19. A physician wishes to place a central line (a catheter used to repeatedly administer drugs such as chemotherapy drugs into a patient's circulatory system) into the right atrium of the patient's heart. To do this, the physician will place the catheter into the basilic vein just superior to where it branches from the median cubital vein. The physician will then guide the catheter along the venous system until it reaches the right atrium. List, in order, the veins through which the central line passes as it travels from the basilic vein to the right atrium of the heart.

Basilic vein → \_\_\_\_\_ → \_\_\_\_\_ → \_\_\_\_\_ → \_\_\_\_\_ → \_\_\_\_\_  
 Right atrium

20. A physician wishes to place a balloon catheter into the left coronary artery of a patient. A catheter is placed into the femoral artery just inferior to the inguinal ligament, and is threaded backward through the arterial system until it reaches the ascending aorta. From there, the catheter will be threaded into the left coronary artery. List all of the arteries, in order, that the catheter will pass through as it travels from the femoral artery to the left coronary artery.

Femoral artery → \_\_\_\_\_ → \_\_\_\_\_ → \_\_\_\_\_ → \_\_\_\_\_ → Left coronary artery

21. After the central line was placed (question 20), it pinched off and failed to work when the patient held a heavy weight in her hand and the inferior movement of her clavicle compressed the central line within the subclavian vein. The physician decided to remove the central line from the basilic vein and place another central line into the internal jugular vein (IJV). The IJV provides a more direct route to the heart and avoids the problem of catheter pinch-off. List the veins, in order, through which the central line passes as it travels from the internal jugular vein to the right atrium of the heart.

IJV → \_\_\_\_\_ → \_\_\_\_\_ → \_\_\_\_\_ → Right atrium

22. A venous valve is an infolding of the tunica \_\_\_\_\_ of the vessel; the valve contains \_\_\_\_\_ cusps, and its function is to \_\_\_\_\_

---

23. Fill in the chart with examples of locations in the body where each type of capillary is located.

Type of Capillary	Locations
<i>Continuous</i>	
<i>Fenestrated</i>	
<i>Sinusoidal</i>	

24. Describe how to determine if a histological cross section of an artery is an elastic artery or a muscular artery.

---



---



---

25. Describe the role arterioles play in regulation of blood flow.

---



---



---

# The Lymphatic System

# 19

## OUTLINE AND LEARNING OBJECTIVES

### Histology 406

#### Lymphatic Vessels 406

##### EXERCISE 19.1: LYMPHATIC VESSELS 406

- 1 Identify lymphatic vessels and valves when viewed with a dissecting microscope
- 2 Identify lymphatic vessels and valves when viewed with a compound microscope
- 3 Compare and contrast the structure and function of a lymphatic vessel with the structure and function of a vein

#### Mucosa-Associated Lymphatic Tissue (MALT) 407

##### EXERCISE 19.2: TONSILS 408

- 4 Identify the three different types of tonsils and their characteristic structures when viewed with a microscope
- 5 Distinguish pharyngeal, palatine, and lingual tonsils from each other histologically
- 6 Describe the structure and function of a tonsil

##### EXERCISE 19.3: PEYER PATCHES 409

- 7 Identify Peyer patches when viewed with a microscope
- 8 Describe the structure and function of a Peyer patch

##### EXERCISE 19.4: THE VERMIFORM APPENDIX 410

- 9 Identify the vermiform appendix and its structures when viewed with a microscope
- 10 Describe the structure and function of the vermiform appendix

#### Lymphatic Organs 410

##### EXERCISE 19.5: THE THYMUS 410

- 11 Identify the thymus gland and its structures when viewed with a microscope
- 12 Describe the structure and function of the thymus
- 13 Identify thymic corpuscles under the microscope, and explain their functional significance

##### EXERCISE 19.6: LYMPH NODES 412

- 14 Identify the parts of a lymph node and its structures when viewed with a microscope
- 15 Describe the structure and function of a lymph node
- 16 Trace the flow of lymph through a lymph node

##### EXERCISE 19.7: THE SPLEEN 415

- 17 Identify the spleen and its structures when viewed with a microscope
- 18 Explain the structural and functional differences between red pulp and white pulp of the spleen

### Gross Anatomy 417

##### EXERCISE 19.8: GROSS ANATOMY OF LYMPHATIC STRUCTURES 417

- 19 Identify gross anatomical lymphatic structures on classroom models



## Module 10: LYMPHATIC SYSTEM

## INTRODUCTION

The lymphatic system functions in close association with two other body systems: the **circulatory system** and the **immune system**. The lymphatic system's circulatory function comes from the role lymphatic vessels play in the circulation of body fluids. The lymphatic system's immune function comes from the roles that lymphocytes play in the body defenses. The lymphatic system has a number of functions, which include: returning interstitial fluid to the cardiovascular system, filtration of lymph by lymph nodes, destruction of bloodborne antigens, production of lymphocytes, and absorption of dietary fats from the digestive system (through lymphatic capillaries in the small intestine called **lacteals**).

The terms *lymph* and *lymphatic* come from the Latin word *lympha*, which means "pure spring water." Although lymph isn't exactly comparable to spring water in its composition, the fluid is relatively clear and free of suspended material because it contains no erythrocytes or plasma proteins. Lymphatic vessels return approximately 1–3 L of fluid to the cardiovascular system each day. When lymphatic vessels become blocked or damaged so lymph cannot flow freely through them, severe **edema** (*oidema*, a swelling) results in the body part distal to the location of the obstruction.

Because most lymphatic structures are anatomically small and difficult to see in a human cadaver or on isolated organ preparations, the majority of the exercises in this chapter involve histological observations

of lymphatic tissues and organs. Histological observations will be complemented by observations of classroom models that show lymphatic organs such as lymph nodes, the spleen, and the thymus. If human cadavers are used in the laboratory, most lymphatic structures will be studied on the cadaver in conjunction with other organ systems, such as the respiratory and digestive systems, rather than within these laboratory exercises.

#### List of Reference Tables

Table 19.1	Named Aggregations of MALT (Mucosa-Associated Lymphatic Tissue)	p. 407
Table 19.2	Tonsils	p. 408
Table 19.3	Parts of a Lymph Node	p. 414
Table 19.4	Parts of the Spleen	p. 416
Table 19.5	Major Lymphatic Vessels of the Body	p. 417

These Pre-laboratory Worksheet questions may be assigned by instructors through their **connect** course.

- Which of the following is *not* a function of the lymphatic system? (Circle one.)
  - absorption of dietary fats
  - production and proliferation of lymphocytes
  - production of erythrocytes
  - transport excess interstitial fluid back into the blood
- Which of the following is *not* a named aggregation of MALT (mucosa-associated lymph tissue)? (Circle one.)
  - lymph node
  - palatine tonsil
  - Peyer patch
  - pharyngeal tonsil
  - vermiform appendix
- The structure of lymphatic vessels most closely resembles \_\_\_\_\_ (arteries/veins).
- The right lymphatic duct drains lymph from the right side of the head and neck, the right lower limb, and the right side of the thoracic and abdominopelvic cavities. \_\_\_\_\_ (True/False)
- Which of the following is a lymphatic organ that filters blood? (Circle one.)
  - lymph node
  - Peyer patch
  - spleen
  - thymus
  - vermiform appendix
- Lymphatic vessels contain valves, which prevent the backflow of lymph. \_\_\_\_\_ (True/False)
- Which of the following is a lymphatic organ located in the thoracic cavity just deep to the sternum? (Circle one.)
  - Peyer patch
  - spleen
  - thymus
  - tonsil
  - vermiform appendix
- The basic unit of lymphatic tissue is called a lymph node. \_\_\_\_\_ (True/False)
- Which of the following is a lymphatic organ that has both afferent and efferent lymphatic vessels? (Circle one.)
  - lymph node
  - spleen
  - thymus
  - tonsil
  - vermiform appendix
- Which of the following is a lymphatic organ that contains crypts? (Circle one.)
  - lymph node
  - spleen
  - thymus
  - tonsil
  - vermiform appendix

# Histology

## Lymphatic Vessels

Lymphatic vessels are most similar in structure to veins because they carry fluid at low pressure and velocity from the tissues back toward the

heart. Lymphatic vessels are thin walled and have valves, which prevent the backflow of fluid. Similar to veins, the contraction of skeletal muscle assists the movement of fluid within lymphatic vessels toward the heart.

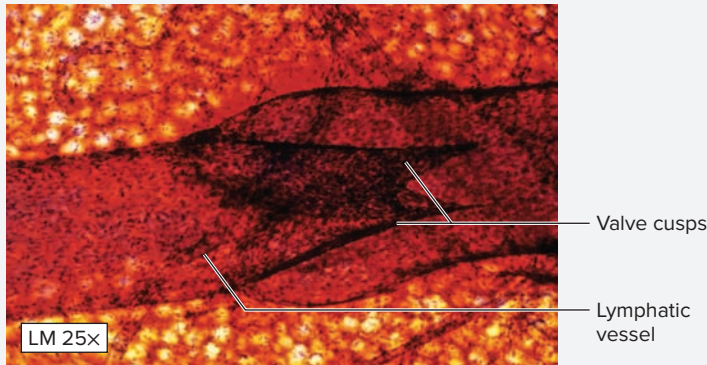
### EXERCISE 19.1 Lymphatic Vessels

1. Obtain a *dissecting* microscope and a slide demonstrating lymphatic vessels.
2. Place the slide on the microscope stage. Bring the tissue sample into focus on low power and locate a lymphatic vessel (**figure 19.1**). Then move the microscope stage to scan the length of the vessel until a valve is visible within the field of view. If necessary, change to high power and focus in on the valve to see its structure more clearly.
3. Identify the listed structures, using figure 19.1 as a guide:
 

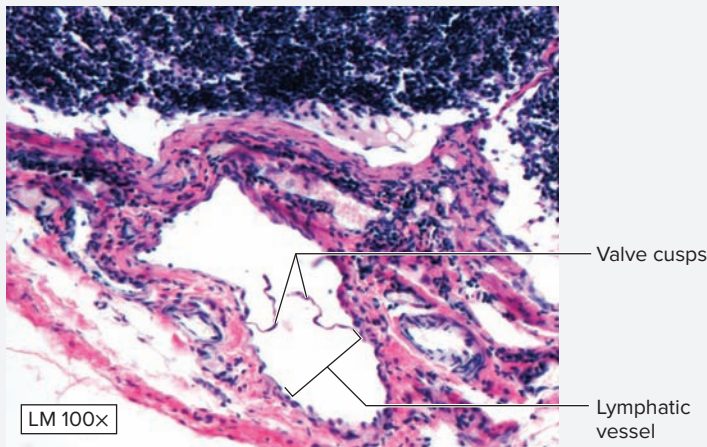
lymphatic vessel
 valve cusps
4. Obtain a compound microscope and a slide demonstrating lymphatic vessels.

5. Place the slide on the microscope stage. Bring the tissue sample into focus on low power and locate a cross section through a lymphatic vessel (figure 19.1*b*). The walls of lymphatic vessels contain the same three tunics as the walls of blood vessels, but they are not as well defined. Like veins, the valves are extensions of the tunica interna of the vessel. Are any erythrocytes visible within the lumen of the vessel? \_\_\_\_\_ Should any erythrocytes be visible within the lumen of the vessel? \_\_\_\_\_ Are there any white blood cells within the lumen of the vessel? Should there be any white blood cells within the lumen of the vessel? \_\_\_\_\_
6. Identify the listed structures, using figure 19.1*b* as a guide:
 

lymphatic vessel
 valve cusps
7. Sketch the lymphatic vessel as viewed through both the dissecting and the compound microscopes in the spaces provided.



(a)



(b)

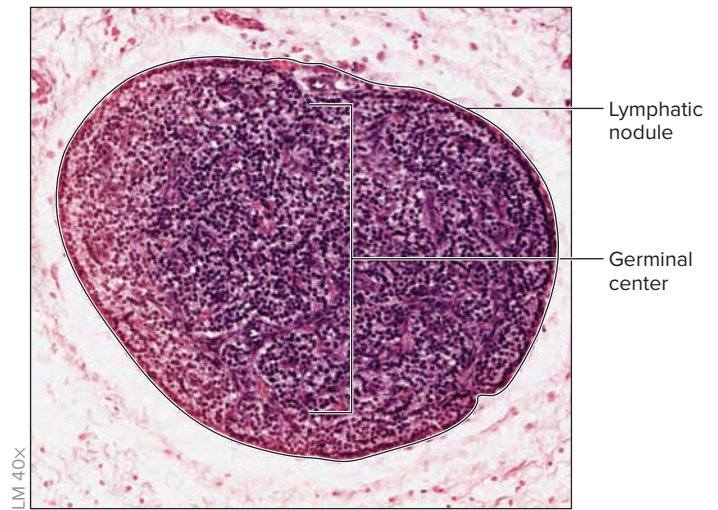
**Figure 19.1 Lymphatic Vessels.** (a) View of lymphatic vessels and valves as seen through a dissecting microscope. (b) Cross section through a lymphatic vessel demonstrating a valve as seen through a compound microscope.

(a) © Ed Reschke; (b) © McGraw-Hill Education/Al Telser



## Mucosa-Associated Lymphatic Tissue (MALT)

The basic functional unit of lymphatic tissue is a **lymphatic nodule (follicle)**. A lymphatic nodule is a ball of cells that are predominantly B-lymphocytes, with some macrophages and T-lymphocytes on its outer borders. **Figure 19.2** demonstrates a lymphatic nodule as seen under a compound microscope on high power. Notice that the central region stains lighter than the surrounding area. The central region, called the **germinal center** (*germen*, sprout), is where B-lymphocytes are most actively proliferating. Lymphatic nodules are found in hundreds of locations throughout the body. They are commonly found just deep to epithelial tissues and are even more common in locations where the epithelium changes from one type to another (such as where epithelium of the gut tube transitions from stratified squamous lining the esophagus to simple columnar lining the stomach). Lymphatic nodules are particularly abundant in the nasal and oral cavities, and in the walls of the digestive tract. Such tissue is collectively referred to as **MALT**, or **mucosa-associated lymphatic tissue**. In several regions of the respiratory and digestive tracts, the aggregations of MALT are so consistent in structure and so regular in location that they are given names. Such named aggregations of MALT include **tonsils**, **Peyer patches**, and the **vermiform appendix**. **Table 19.1** summarizes the characteristics of MALT.



**Figure 19.2 Lymphatic Nodule.** The germinal center of the nodule consists of actively proliferating B-lymphocytes.

© McGraw-Hill Education/Christine Eckel, photographer

Table 19.1		Named Aggregations of MALT (Mucosa-Associated Lymphatic Tissue)	
Named Aggregation of MALT	Description and Location	Function	Word Origins
<i>Peyer Patches</i>	Lymphatic nodules in the submucosa (deep to the epithelium) of the ileum of the small intestine.	Protect against pathogens that enter the body through the intestinal mucosa.	<i>Peyer</i> , Johan K. Peyer, a Swiss anatomist (1653–1712)
<i>Tonsils</i>	Lymphatic nodules deep to the epithelium lining the pharynx. (See table 19.2 for descriptions and locations of specific tonsils.)	Protect against pathogens that enter the body through the mucosa of the pharynx.	<i>tonsilla</i> , a stake
<i>Vermiform Appendix</i>	A diverticulum (blind-ended pouch) extending from the cecum just past the ileocecal junction that contains lymphatic nodules in its walls.	Protect against pathogens that enter the body through the mucosa of the cecum.	<i>vermis</i> , wormlike + <i>forma</i> , shape + <i>appendix</i> , appendage

### Clinical View | Appendicitis

**Appendicitis** refers to a condition in which the vermiform appendix is inflamed (*-itis*, inflammation). Appendicitis, most commonly caused by a blockage of the opening of the appendix into the cecum of the large intestine, can happen to individuals of any age. Patients with appendicitis generally present with pain in the lower right quadrant of the abdomen near **McBurney's point**, a surface landmark used to approximate the location of the vermiform appendix. **McBurney's point** is located by drawing a line from the umbilicus to the anterior superior iliac spine and marking a point approximately one-third of the way along the line away from the umbilicus. If a patient has appendicitis, pressure placed on the abdomen near **McBurney's point** is likely to elicit sharp, intense pain and rebound tenderness (tenderness associated with the “rebound” of the anterior abdominal wall as pressure is taken away).

The appendix is covered with visceral peritoneum (peritoneum is the lining of the abdominal cavity). Irritation of visceral peritoneum is associated with dull, diffuse pain because visceral peritoneum is innervated by autonomic nerves. In contrast, irritation of the parietal peritoneum (which lines the inside of the anterior abdominal wall) is associated with sharp, localized pain because parietal peritoneum is innervated by somatic nerves. When contact is made between visceral and parietal peritoneum at a source of irritation or inflammation, the dull, diffuse autonomic pain is suddenly felt as sharp, intense somatic pain. It is for this reason that pressure placed around **McBurney's point** causes the sharp, intense pain of appendicitis. Presence of a fever and blood tests showing elevated leukocytes (particularly neutrophils) may further confirm appendicitis and help distinguish it from other potential sources of right lower quadrant pain.

**EXERCISE 19.2 Tonsils**

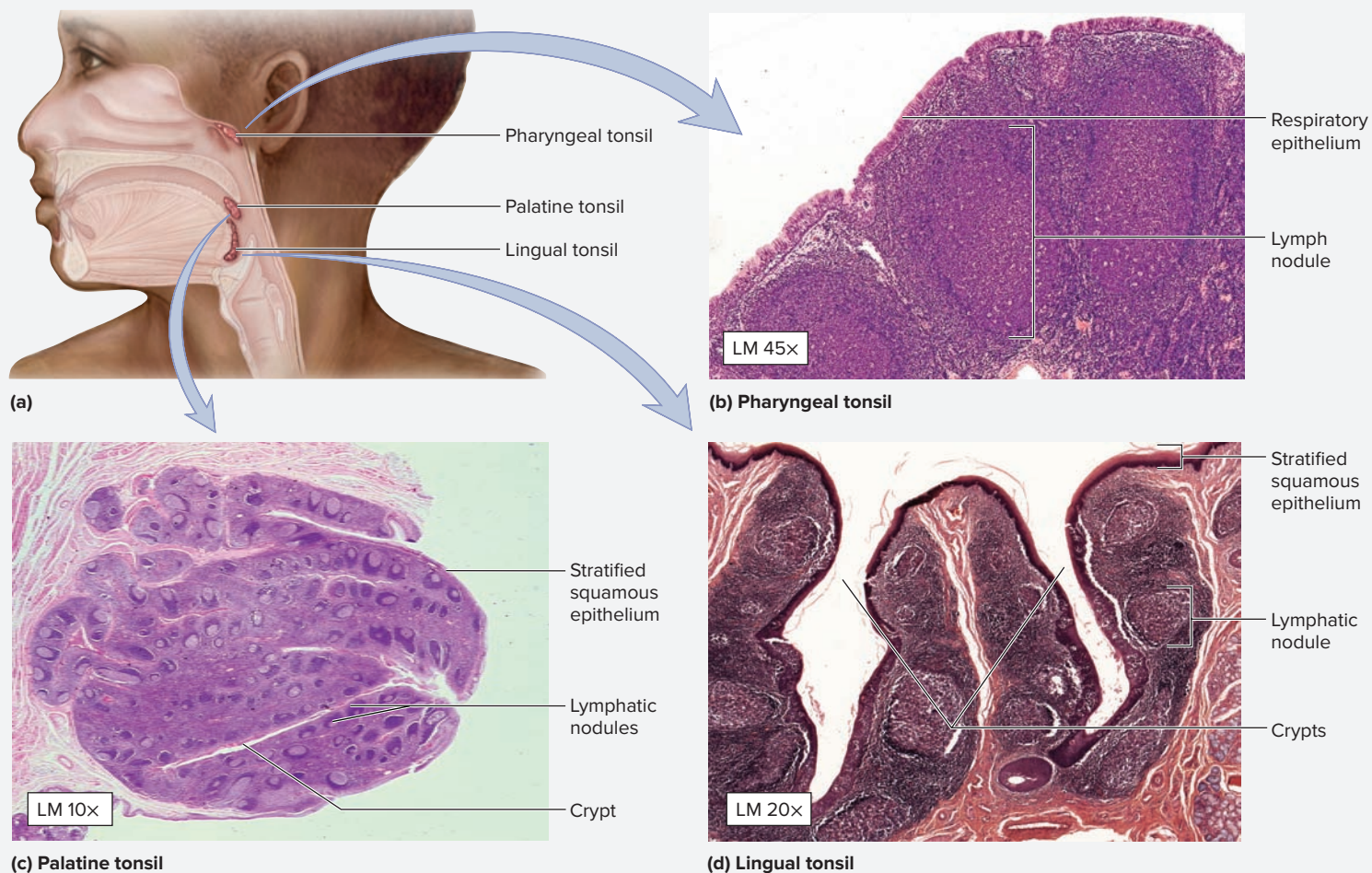
1. Obtain a slide demonstrating tonsils and place it on the microscope stage.
2. Tonsils are lymphatic nodules located in the walls of the oral cavity and pharynx. They consist of lymphatic nodules interspersed between deep **crypts** (*crypt*, a pitlike depression) that open to the surface of the tonsil. The tonsils are covered superficially by the same epithelium that lines the part of the body in which they are located. There are three sets of tonsils: **pharyngeal tonsils** (called *adenoids* when they are

swollen), **palatine tonsils**, and **lingual tonsils**. Table 19.2 lists characteristics of the three kinds of tonsils.

3. Identify the listed structures on the microscope slide of a tonsil, using figure 19.3, table 19.2, and the textbook as guides:

- crypt
- epithelium
- lymphatic nodule


Table 19.2		Tonsils		
Tonsil	Description and Location	Crypts	Epithelium	Word Origins
Lingual	Small, paired tonsils at the base of the tongue.	1–2 short crypts	Stratified squamous nonkeratinized	<i>lingua</i> , tongue
Palatine	Paired tonsils located in the fauces (the space between the mouth and pharynx) just posterior to the soft palate.	10–20 deep crypts	Stratified squamous nonkeratinized	<i>palatum</i> , palate
Pharyngeal (Adenoid)	Single tonsil projecting from the roof of the nasopharynx.	None	Respiratory (ciliated pseudostratified columnar)	<i>pharynx</i> , the throat; <i>adenos</i> , a gland + <i>eidos</i> , appearance



**Figure 19.3 Tonsils.** (a) Location of tonsils within the pharynx. (b) Pharyngeal tonsils are lined with respiratory epithelium (pseudostratified columnar with cilia and goblet cells). (c) Palatine tonsils contain numerous deep crypts and are lined with stratified squamous epithelium. (d) Lingual tonsils contain a few shallow crypts and are lined with stratified squamous epithelium.

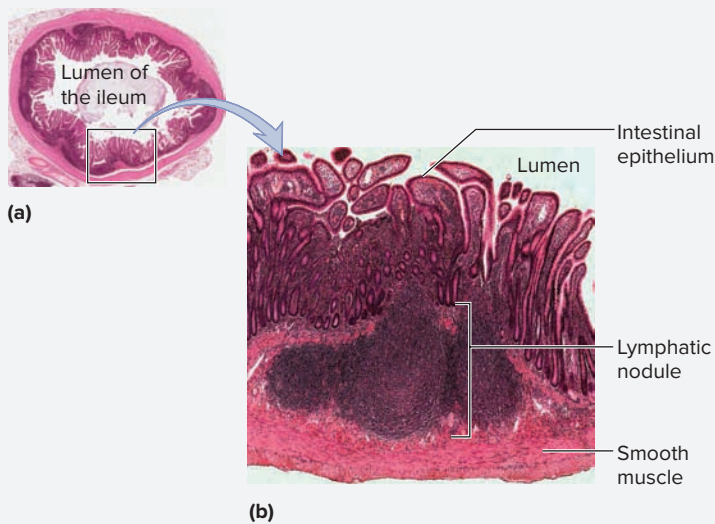
(b, d) © McGraw-Hill Education/Al Telser; (c) © Biophoto Associates/Science Source

- Based on the type of epithelium covering the tonsil and the number and length of the crypts, list the type of tonsil (pharyngeal, palatine, or lingual) that is shown on the slide being observed. \_\_\_\_\_
- Sketch the tonsil(s) observed under the microscope in the space provided.



**EXERCISE 19.3** Peyer Patches

- Obtain a slide of the ileum and place it on the microscope stage.
- Bring the tissue sample into focus on low power and scan the slide to locate the epithelial lining of the ileum, which is a simple columnar epithelium. Deep to the epithelium, look for aggregations of purple-staining cells (**figure 19.4**). These are the aggregations of lymphocytes that compose the **Peyer patches** (aggregated lymphatic nodules of the small intestine).



**Figure 19.4 Peyer Patches.** A cross section of the ileum of the small intestine is shown in (a). Deep to the intestinal epithelium and superficial to the smooth muscle that surrounds the ileum are the lymphatic nodules called Peyer patches. Peyer patches are shown in detail in (b).

© McGraw-Hill Education/Christine Eckel, photographer

- Move the microscope stage until a Peyer patch is the center of the field of view. Then change to medium or high power to observe the cells within the Peyer patch. What kind of cells are located within the Peyer patches?  
\_\_\_\_\_
- Identify the listed structures on the slide of the ileum, using table 19.2 and figure 19.4 as guides:
 

<input type="checkbox"/> B-lymphocytes	<input type="checkbox"/> lymphatic nodule
<input type="checkbox"/> epithelium	<input type="checkbox"/> Peyer patch
- Sketch a Peyer patch as seen through the microscope in the space provided.



**WHAT DO YOU THINK?**

- Why are lymphatic nodules so abundant in the wall of the small intestine?

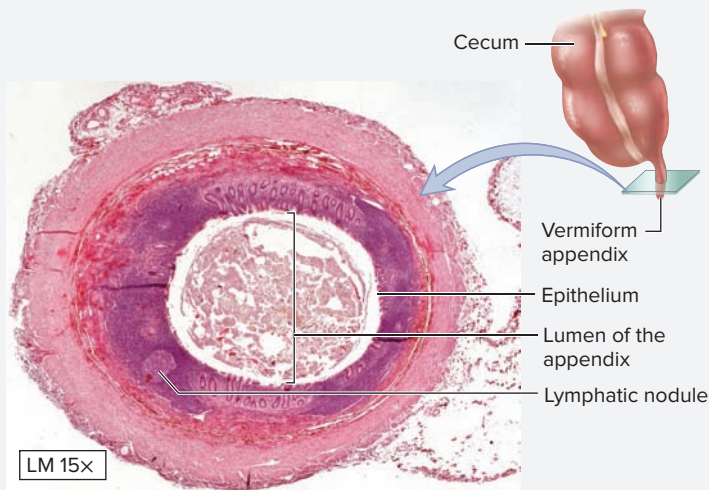


**EXERCISE 19.4** The Vermiform Appendix

The **vermiform appendix** (*vermiform*, shaped like a worm) projects from the inferior region of the cecum. It is usually about 2–4 centimeters in length and about 0.5 centimeter in diameter. It is an evagination of the cecum and, as such, has a lumen that opens into the lumen of the cecum. Its epithelium is also a continuation of the epithelium of the cecum, and contains numerous lymphatic nodules in its walls.

1. Obtain a slide demonstrating a cross section of the appendix and place it on the microscope stage.
2. Bring the tissue sample into focus on low power and scan the slide until the lumen of the appendix is within the field of view (**figure 19.5**). Then change to medium power and bring the tissue sample into focus once again. Is there anything present within the lumen of the appendix?

\_\_\_\_\_ One identifying feature of the appendix is that



**Figure 19.5** Vermiform Appendix. A cross section through the appendix, demonstrating epithelium, lymphatic nodules, and a lumen that contains breakdown products of food.

© McGraw-Hill Education/AI Telsler


its lumen usually appears to have a lot of “junk” inside it. This “junk” is typically cellular debris, bacteria, and other breakdown products of food that are left over after digestion in the small intestine. What type of epithelium lines the inside

of the appendix? \_\_\_\_\_

3. Observe the tissues located deep to the epithelial tissue of the appendix to locate the lymphatic nodules, which are aggregations of purple-staining lymphocytes.
4. Identify the listed structures on the slide of the appendix, using table 19.2 and figure 19.5 as guides:

- epithelium                       lymphatic nodule  
 lumen of the appendix

5. Sketch a cross section of the appendix as seen through the microscope in the space provided.

**Lymphatic Organs**

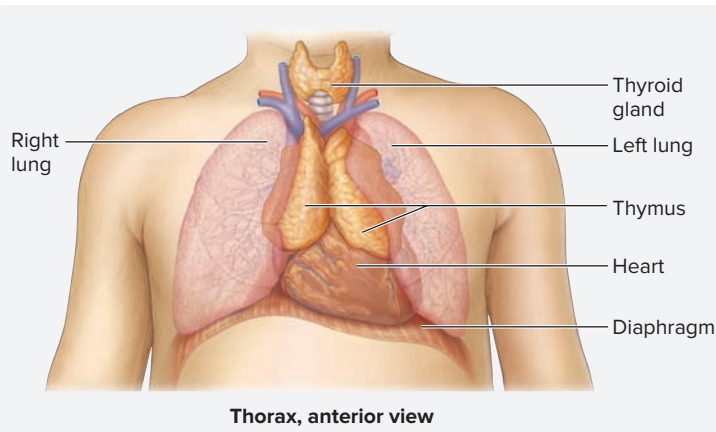
Lymphatic organs differ from mucosa-associated lymphatic tissue (MALT) in that they are covered by a dense connective tissue capsule and are more

highly organized (they have a regular blood and nerve supply, along with other characteristics of body organs). Lymphatic organs include lymph nodes, the thymus, and the spleen.

**EXERCISE 19.5** The Thymus

The thymus is a small gland located in the superior mediastinum (**figure 19.6**). It is the site of T-lymphocyte maturation. The thymus is also an endocrine organ, secreting the hormone **thymosin**. The thymus is composed of two **lobes**, each separated into smaller **lobules** by connective tissue **septae** (singular: septa) (**figure 19.7**). Each lobule has a darker-staining outer cortex and a lighter-staining inner medulla. The majority of the cells within the thymus are T-lymphocytes, which are surrounded by cells of epithelial origin. Lymphocytes migrate to the thymus from the bone marrow early on in life. Once in the thymus, T-lymphocytes

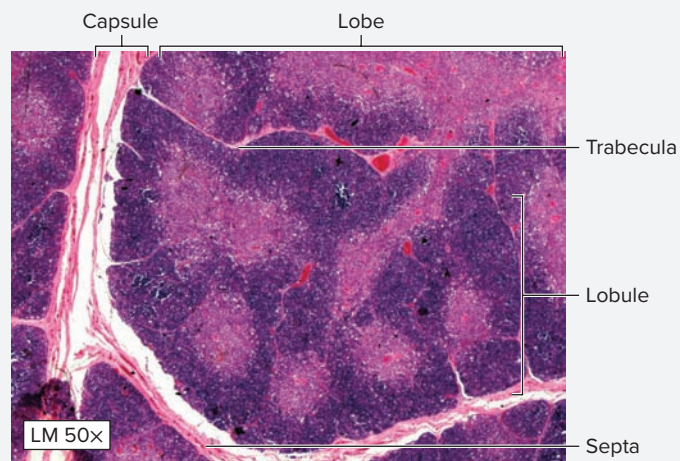
travel from the outer cortex to the inner medulla as they complete the process of **selection**. Selection is a process by which only those T-lymphocytes that are able to recognize self-antigen, and react to foreign antigen, are permitted to leave the thymus. Selection occurs in the outer cortex, and once selection of T-lymphocytes is complete the cells leave the thymus through venules located in the medulla. The majority of T-lymphocytes that migrate to the thymus from the bone marrow either fail to recognize self-antigen or fail to react to foreign antigen. These cells are destroyed through a process called **apoptosis** (programmed cell death),



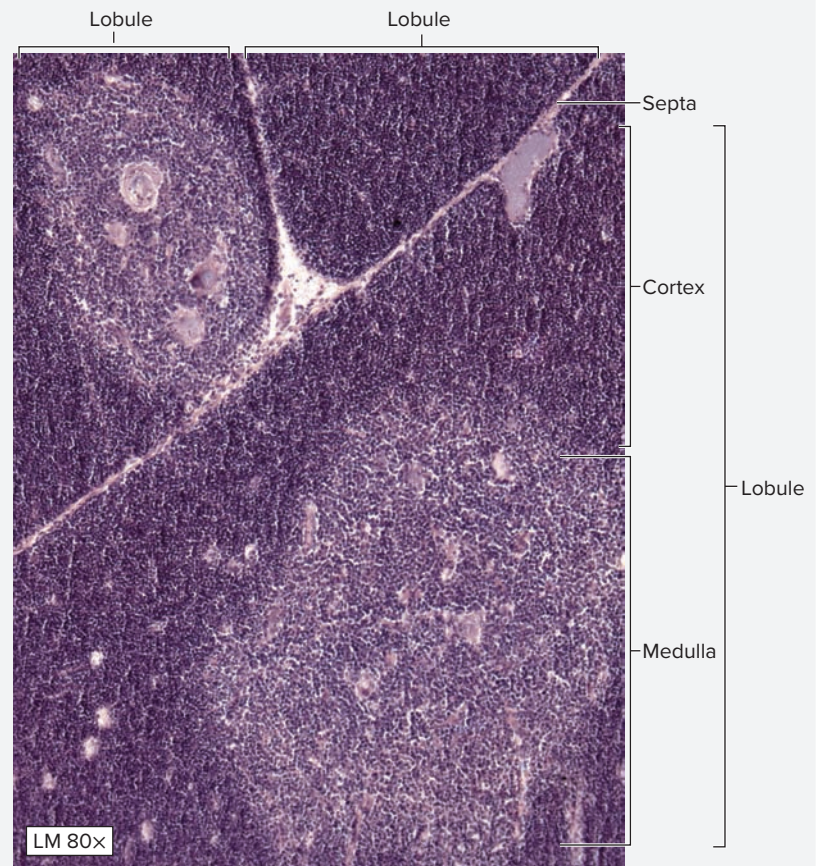
**Figure 19.6** Location of the Thymus. The thymus is located in the superior mediastinum, deep to the sternum.

which occurs within the thymic cortex. After puberty the thymus begins a gradual decline in size with age. Epithelial-derived cells in the medulla come together and form small, onionlike masses of tissue called **thymic corpuscles**. Thymic corpuscles produce chemical signals that induce development of T-regulatory cells, which patrol the body looking for “bad” T-lymphocytes and destroying them so they cannot produce autoimmune disease. A large number of thymic corpuscles in the thymic medulla indicates an aging thymus.

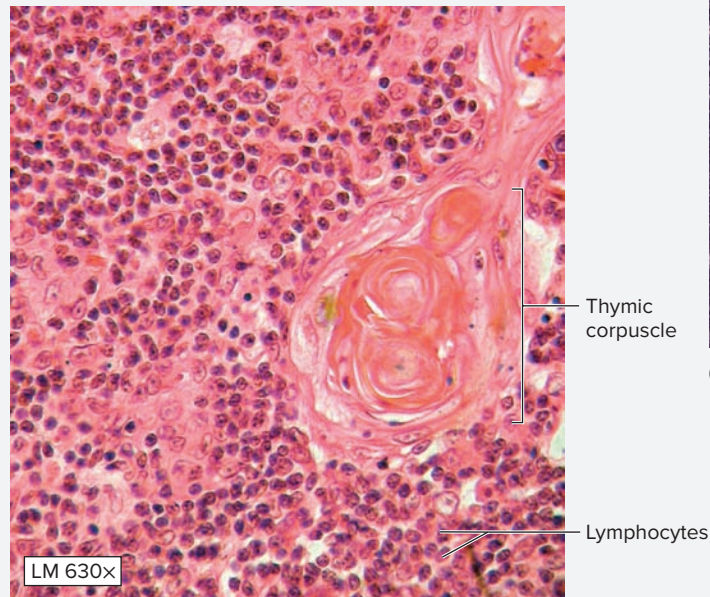
1. Obtain a slide of the thymus and place it on the microscope stage.
2. Bring the tissue sample into focus at low power, then scan the slide to locate the connective tissue trabeculae that separate the gland into lobules (figure 19.7).



(a)



(b)



(c)

**Figure 19.7** Histology of the Thymus. (a) A thymic lobe, which is divided into lobules. (b) Each thymic lobule consists of an outer cortex and an inner medulla. (c) Thymic corpuscles are located within the medullary region of a thymic lobule, and are indicative of an aging thymus.

(a, b) © McGraw-Hill Education/AI Telser; (c) © McGraw-Hill Education/Christine Eckel, photographer


(continued on next page)

*(continued from previous page)*

3. Identify the listed structures, using figure 19.7 as a guide:

- |   |  |
|---|--|
| <input type="checkbox"/> cortex           | <input type="checkbox"/> thymic lobule |
| <input type="checkbox"/> medulla          | <input type="checkbox"/> trabeculae    |
| <input type="checkbox"/> thymic corpuscle |  |

4. Sketch the thymus as seen through the microscope in the space provided. Be sure to label all the structures listed in step 3.



### EXERCISE 19.6 Lymph Nodes

Lymph nodes are tiny lymphatic organs located along lymphatic vessels. They filter lymph that flows through the lymphatic vessels to identify and attack lymph-born foreign antigens.

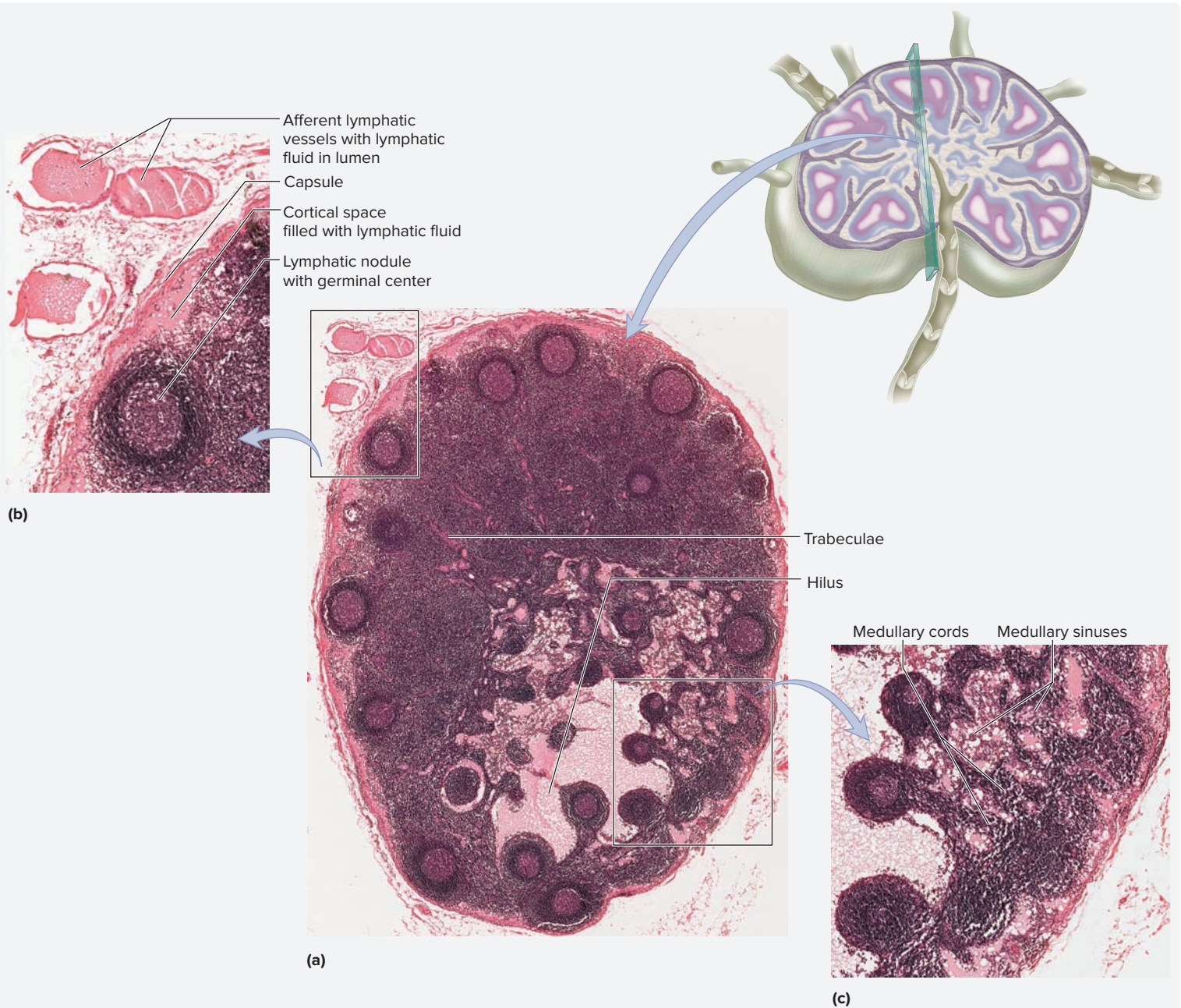
- Obtain a slide demonstrating a lymph node (**figure 19.8**) and place it on the microscope stage.
- Bring the tissue sample into focus on low power. Identify the dense irregular connective tissue **capsule**, and notice the kidney-bean shape of the lymph node (if an entire node is on the slide). A lymph node is composed of an outer **cortex** and an inner **medulla**. The indented region of the lymph node is the **hilum**. This is where blood vessels enter and leave the node, and where the **efferent lymphatic vessels** drain lymph from the lymph node. **Afferent lymphatic vessels** bring lymph into the lymph node on the regions that lie opposite the hilum of the lymph node.
- Note the dense irregular connective tissue **trabeculae** that partition the cortex into smaller regions. Each region of the cortex contains one or two **lymphatic nodules**. What types of cells are found within lymphatic nodules?  
\_\_\_\_\_
- Scan the slide until the medulla is at the center of the field of view, and locate the dark-staining **medullary cords**. These contain mainly T-lymphocytes and macrophages.

Can B- and T-lymphocytes be distinguished from each other using light microscopy? \_\_\_\_\_

- Identify the listed structures on the histology slide of the lymph node:
 

<input type="checkbox"/> capsule	<input type="checkbox"/> medulla
<input type="checkbox"/> cortex	<input type="checkbox"/> medullary cords
<input type="checkbox"/> hilum	<input type="checkbox"/> trabeculae
<input type="checkbox"/> lymphatic nodules	
- Observe the numerous spaces, called **medullary sinuses**, where lymph travels as it flows through the lymph node. **Figure 19.9** demonstrates the pathway taken by lymph as it flows through a lymph node.
- Identify the listed spaces or vessels on the slide of the lymph node, using figure 19.8 and **table 19.3** as guides:
 


<input type="checkbox"/> afferent lymphatic vessels	<input type="checkbox"/> efferent lymphatic vessels
<input type="checkbox"/> cortical sinuses	<input type="checkbox"/> medullary sinuses



**Figure 19.8 Lymph Node** (a) Photomicrograph of a cross section of a lymph node that has been sectioned through the hilus. On the surface opposite the hilus three cross sections of afferent lymphatic vessels are visible, as well as the capsule and lymphatic fluid within the cortical sinus (b). Medullary cords and sinuses are visible in (c).

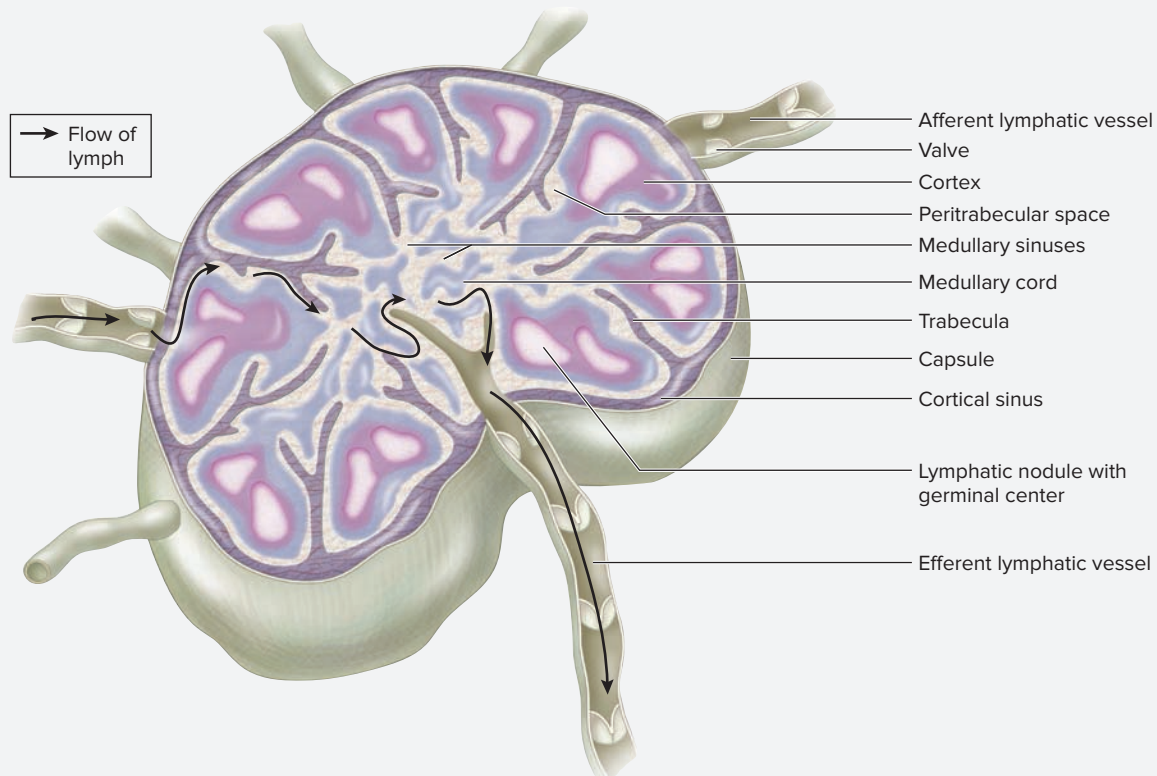
(a-c) © McGraw-Hill Education/Christine Eckel, photographer

8. Sketch a lymph node as seen through the microscope in the space provided. Label all of the structures listed in steps 5 and 7. Then, using arrows, indicate the pathway taken by lymph as it flows through the lymph node.



\_\_\_\_\_ X  
(continued on next page)

(continued from previous page)



**Figure 19.9** Lymph Node. Pathway that lymph takes as it flows through a lymph node.

Table 19.3		Parts of a Lymph Node
Structure	Description	Word Origins
<i>Afferent Lymphatic Vessel</i>	Vessel that carries lymph into the lymph node.	<i>ad-</i> , to + <i>ferro</i> , bring
<i>Capsule</i>	Dense irregular connective tissue that surrounds the entire lymph node to support and protect it.	<i>capsula</i> , a box
<i>Cortex</i>	Outer portion of the lymph node that lies deep to the capsule and contains lymphatic nodules.	<i>cortex</i> , bark
<i>Efferent Lymphatic Vessel</i>	Vessel that carries lymph away from the lymph node; located at the hilum.	<i>effero</i> , to bring out
<i>Hilum</i>	Indented area where blood vessels enter and leave and where efferent lymphatic vessels also exit.	<i>hilum</i> , a small bit
<i>Lymphatic Nodule</i>	Ball of lymphocytes containing a germinal center, where B-lymphocytes are actively proliferating.	<i>lympha</i> , clear spring water + <i>nodulus</i> , a small knot
<i>Medulla</i>	Inner portion of the lymph node that contains medullary cords of B-lymphocytes and macrophages.	<i>medius</i> , middle
<i>Medullary Cord</i>	Strand-like cluster of B-lymphocytes and macrophages located in the medulla of a lymph node.	<i>medius</i> , middle + <i>chorda</i> , a string
<i>Medullary Sinuses</i>	Spaces between the medullary cords in a lymph node through which lymphatic fluid flows.	<i>medius</i> , middle
<i>Peritrabecular Space</i>	Space located between a lymphatic nodule and a trabecula in the cortex of the lymph node.	<i>peri-</i> , around + <i>trabecula</i> , trabeculae
<i>Subcapsular Space</i>	Space located between a lymphatic nodule and the capsule of the lymph node.	<i>sub-</i> , under + <i>capsular</i> , capsule
<i>Trabeculae</i>	Invaginations of the dense irregular connective tissue capsule of a lymph node that partition the cortex into smaller compartments.	<i>trabs</i> , a beam

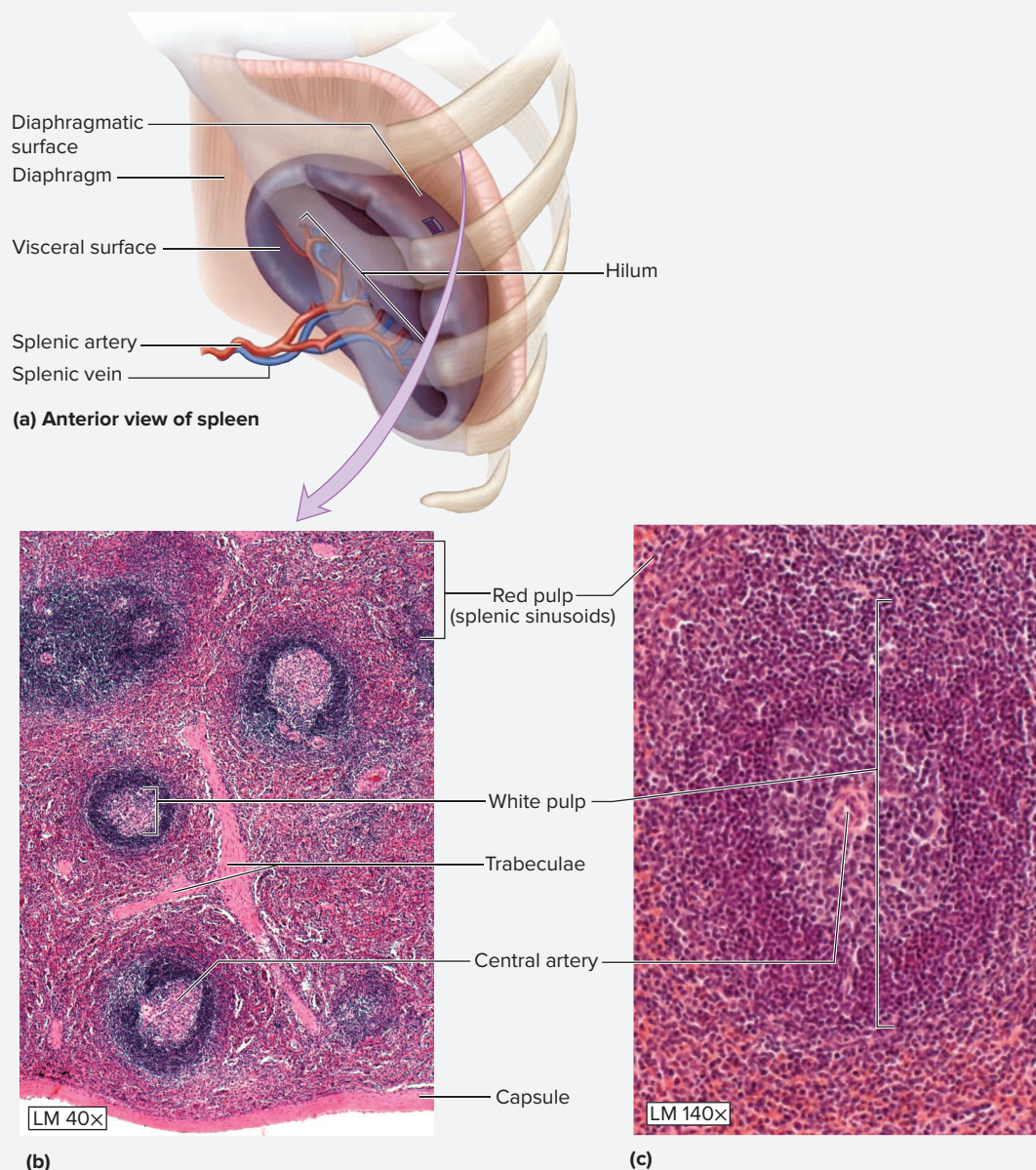
**EXERCISE 19.7 The Spleen**

The spleen is similar to a lymph node in many ways, with one major exception: the spleen filters *blood*, whereas a lymph node filters *lymph*. However, both organs filter their fluid for the purpose of identifying and fighting antigens that may be present in the fluid. The spleen receives blood through the **splenic artery**, which is a branch of the celiac trunk. Blood leaves the spleen through the **splenic vein**, which drains into the hepatic portal vein (see figures 18.13 and 18.14, pp. 384–385).

When a fresh spleen is cut, two types of tissue are clearly visible: red pulp and white pulp. **Red pulp**, which consists of splenic sinusoids, is red due to the large amount of blood contained within the sinusoids. It composes the majority of the splenic tissue. **White pulp**, which consists of aggregations of lymphocytes, is white due to the white blood cells (leukocytes) within each mass of tissue. Because histological observations will be made using a stained histology slide

of the spleen, red and white pulp will not appear red and white in color. Instead, red pulp will be reddish-pink in color, but the white pulp will be darker purple, with a lighter-colored central region.

1. Obtain a slide of the spleen and place it on the microscope stage. Bring the tissue sample into focus on low power and locate the dense irregular connective tissue capsule of the spleen, if present in the section on the slide (**figure 19.10**). Connective tissue trabeculae, which are invaginations of the capsule that separate the spleen into distinct regions, may also be visible on the slide.
2. Notice the circular purple aggregations of cells. These aggregations constitute the white pulp of the spleen, which consists mainly of B-lymphocytes, T-lymphocytes, and some macrophages.



**Figure 19.10 The Spleen.** The spleen contains two predominant tissues: red pulp, which consists of splenic sinusoids, and white pulp, which contains lymphocytes. (a) Location of spleen. (b) Low magnification and (c) high magnification.

(b, c) © McGraw-Hill Education/AI Telsler

(continued on next page)

(continued from previous page)

3. Look for a **central artery**, which is found within each mass of white pulp. Central arteries receive blood from **trabecular arteries**, whose cross sections can sometimes be seen in the surrounding red pulp of the spleen that surrounds the white pulp. Blood coming into the spleen travels from the splenic artery to the trabecular arteries to the central arteries, and finally empties into the sinusoids or surrounding tissues of the spleen (the exact nature of capillary-type blood flow within the spleen remains unknown) before entering into splenic veins.
4. Move the microscope stage until a mass of white pulp is in the center of the field of view and then change to high power. At this magnification, individual small purple-staining cells should be visible. These cells are lymphocytes.
5. Move the microscope stage so the red pulp of the spleen is in the center of the field of view. The red pulp of the spleen consists mainly of *splenic sinusoids* containing numerous erythrocytes. The blood-filled splenic sinusoids also contain numerous lymphocytes and macrophages. As blood travels slowly through the spleen, the lymphocytes and macrophages monitor the blood for **bloodborne antigens**, which, if present, will be removed or attacked by these immune cells. In addition, the structure and function of the splenic sinusoids is designed to destroy abnormal erythrocytes. What is the life span of a typical erythrocyte? \_\_\_\_\_ days. (Hint: the answer is in chapter 27.)

6. Identify the listed structures on the histology slide of the spleen, using **table 19.4** and figure 19.10 as guides:

- |   |                                     |
|---|-------------------------------------|
| <input type="checkbox"/> capsule        | <input type="checkbox"/> sinusoids  |
| <input type="checkbox"/> central artery | <input type="checkbox"/> trabecula  |
| <input type="checkbox"/> red pulp       | <input type="checkbox"/> white pulp |

7. Sketch the spleen as seen through the microscope in the space provided. Label all the structures listed in step 6.




Table 19.4 Parts of the Spleen		
Structure	Description	Word Origins
<i>Capsule</i>	Dense irregular connective tissue that supports and protects the outside of the spleen; surrounds the entire spleen.	<i>capsula</i> , a box
<i>Central Arteries</i>	Arteries located within the white pulp of the spleen.	<i>centrum</i> , center + <i>arteria</i> , the windpipe
<i>Hilum</i>	The indented area of the spleen where the splenic artery enters and the splenic vein leaves.	<i>hilum</i> , a small bit
<i>Red Pulp</i>	Splenic tissue consisting of splenic sinusoids lined by T-lymphocytes and macrophages.	<i>pulpa</i> , flesh
<i>Splenic Sinusoids</i>	Sinusoidal capillaries, which consist of fenestrated endothelial cells and a discontinuous basement membrane.	<i>sinus</i> , cavity + <i>eidōs</i> , resemblance
<i>Trabeculae</i>	Invaginations of the connective tissue capsule of the spleen that partition the cortex into smaller compartments.	<i>trabs</i> , a beam
<i>White Pulp</i>	Splenic tissue consisting of lymphatic nodules that contain lymphocytes; each mass of white pulp contains a central artery.	<i>pulpa</i> , flesh

Gross Anatomy

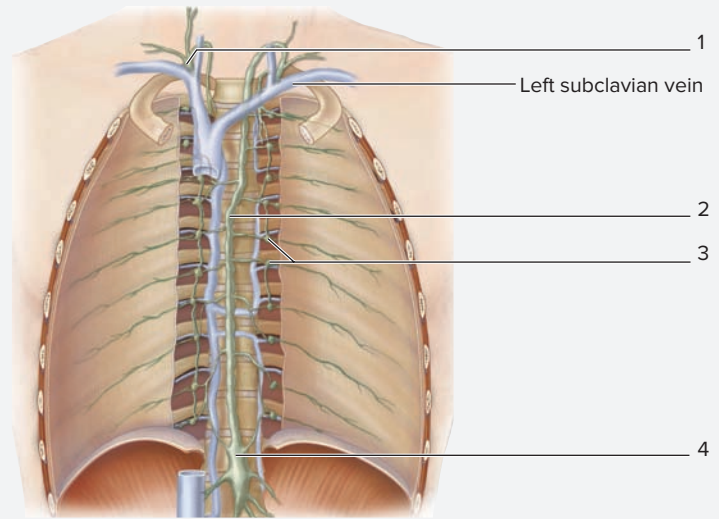
**EXERCISE 19.8** Gross Anatomy of Lymphatic Structures

1. *Major Lymph Vessels of the Body:* Obtain a model of the thorax and abdomen. Remove the heart and lungs from the thorax and the stomach and intestines from the abdomen. Identify the structures listed in **figure 19.11** on the model, using **table 19.5** and the textbook as a guide. Then label them in figure 19.11.

**Learning Strategy**



Identification of the thoracic duct within the thoracic cavity of a cadaver can be challenging because of its relatively small diameter and lack of color (because lymph does not contain erythrocytes). It travels between the esophagus and the azygos vein. Anatomists thus refer to it as the “duck between two geese.” The “duck” is the thoracic duct, and the “geese” are the “azygoose” (azygos vein) and the “esophagoose” (esophagus).



Thorax, anterior view

**Figure 19.11 Major Lymph Vessels of the Body.** Use the terms listed to fill in the numbered labels in the figure. Some answers may be used more than once.

- cisterna chyli
- lymph nodes
- right lymphatic duct
- thoracic duct

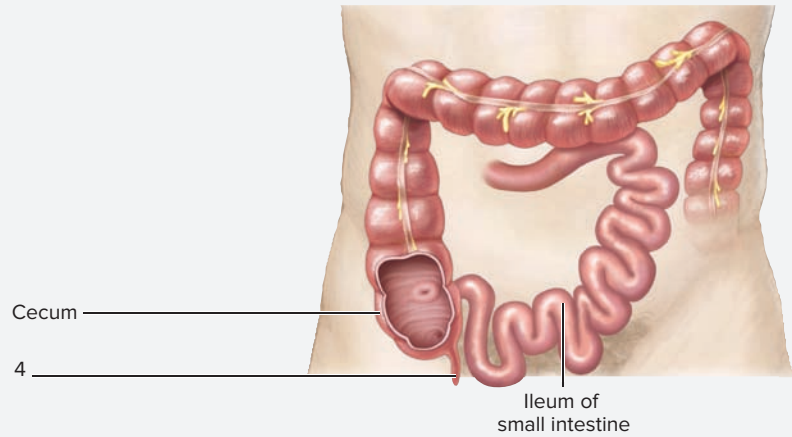
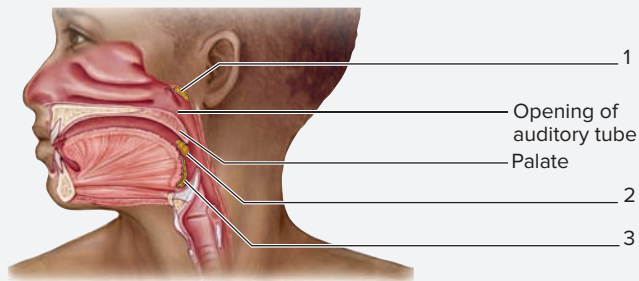
Table 19.5 Major Lymphatic Vessels of the Body			
Lymphatic Vessel	Location	Function	Word Origins
<i>Cisterna Chyli</i>	A “swelling” located at approximately vertebral level L <sub>1</sub> /L <sub>2</sub> . Lymph draining from the cisterna chyli flows into the thoracic duct.	Receives lymph from multiple smaller ducts that drain the lower limbs and abdominal cavity.	<i>cista</i> , box + <i>chylos</i> , juice
<i>Right Lymphatic Duct</i>	A small duct that returns lymph to the cardiovascular system at the junction of the right internal jugular vein and the right subclavian vein.	Receives lymph from the right side of the head, neck, and thorax.	<i>right</i> , the right side + <i>lymph</i> , clear water + <i>ductus</i> , a leading
<i>Thoracic Duct</i>	Begins at the cisterna chyli, extends along the posterior thoracic wall between the azygous vein and the esophagus, and returns lymph to the cardiovascular system at the junction of the left internal jugular vein and the left subclavian vein.	Receives lymph from the entire body below the diaphragm, and the left side of the head, neck, and thorax.	<i>thoracic</i> , the thoracic cavity + <i>ductus</i> , a leading

2. *Mucosa-Associated Lymphatic Tissue (MALT):* Obtain a model demonstrating a midsagittal section of the head and neck, and a model of the abdomen. Identify the structures listed in **figure 19.12** on the model, using the textbook as a guide. Then label them in figure 19.12.
3. *Lymph Node:* Obtain a classroom model of a lymph node. Identify the structures listed in **figure 19.13** on the model, using table 19.3 and the textbook as guides. Then label them in figure 19.13.
4. *The Spleen:* Obtain a classroom model of the abdominal cavity, or observe the abdominal cavity of a human cadaver. Locate the spleen and identify the structures listed in **figure 19.14** on the model or the cadaver. Then label them in figure 19.14.
5. *Optional Activity:* **AP|R Lymphatic System**—Watch the “Lymphatic System Overview” animation for a summary of the primary lymphatic structures.

(continued on next page)

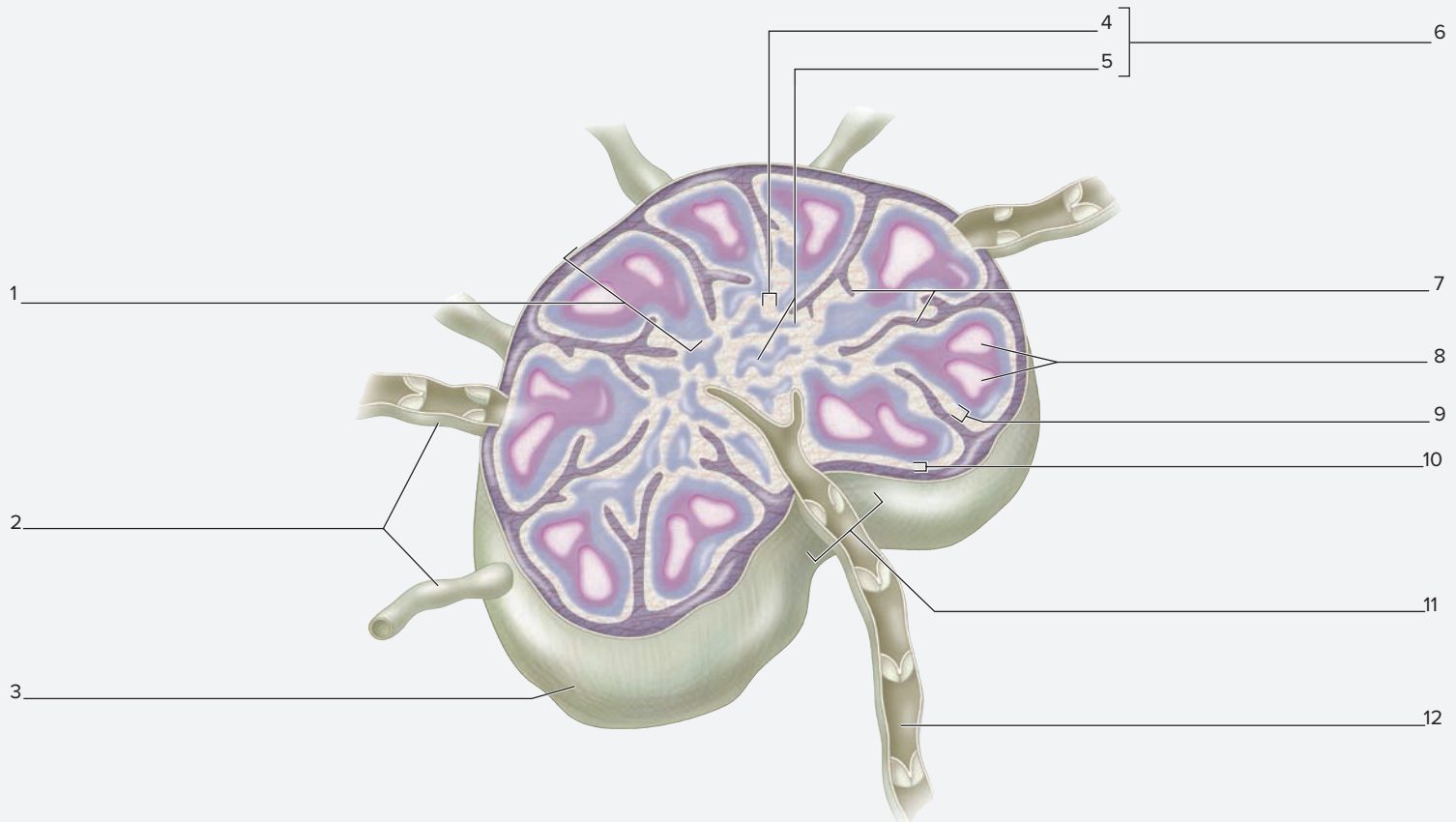


(continued from previous page)



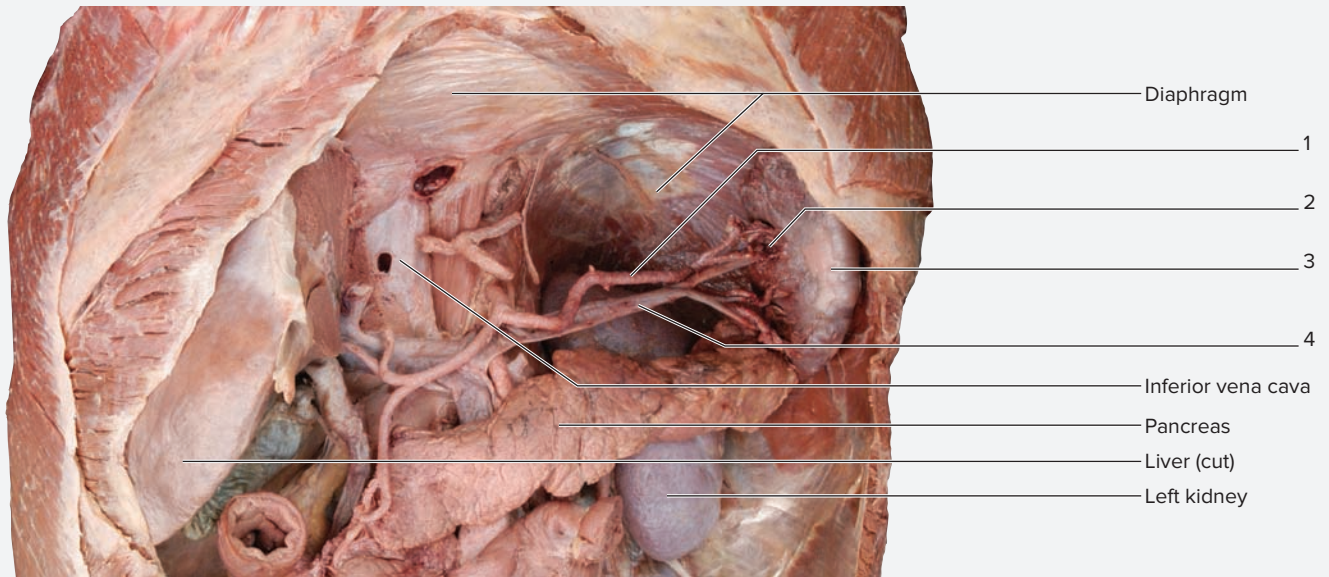
**(a)** **Figure 19.12 Mucosa-Associated Lymphatic Tissue (MALT).** Use the terms listed to fill in the numbered labels in the figure. Some answers may be used more than once.

- lingual tonsils
- palatine tonsils
- pharyngeal tonsils
- vermiform appendix



**Figure 19.13 Lymph Node and Its Components.** Use the terms listed to fill in the numbered labels in the figure. Some answers may be used more than once.

- afferent lymphatic vessels
- capsule
- cortex
- efferent lymphatic vessel
- hilum
- lymphatic nodules
- medulla
- medullary cords
- medullary sinus
- peritubercular space
- subcapsular space
- trabeculae



**Figure 19.14 Gross Anatomy of the Spleen.** Use the terms listed to fill in the numbered labels in the figure. Some answers may be used more than once.

- hilum of the spleen     
  spleen     
  splenic artery     
  splenic vein

*This page intentionally left blank*

## POST-LABORATORY WORKSHEET

The 1 corresponds to the Learning Objective(s) listed in the chapter opener outline.

### Do You Know the Basics?

#### Exercise 19.1: Lymphatic Vessels

- Lymphatic vessels have valves. \_\_\_\_\_ (True/False) 1 2
- Lymphatic vessels are most similar in structure to \_\_\_\_\_ (arteries/veins). 3

#### Exercise 19.2: Tonsils

- Match the description listed in column A with the type of tonsil listed in column B. (Some answers may be used more than once.) 4 5 6

##### Column A

- \_\_\_\_\_ 1. covered with pseudostratified ciliated columnar epithelium
- \_\_\_\_\_ 2. covered with stratified squamous (nonkeratinized) epithelium
- \_\_\_\_\_ 3. located at the base of the tongue
- \_\_\_\_\_ 4. located at the junction of the nasopharynx and oropharynx at the posterior aspect of the soft palate
- \_\_\_\_\_ 5. projects from the roof of the nasopharynx

##### Column B

- a. lingual
- b. palatine
- c. pharyngeal

#### Exercise 19.3: Peyer Patches

- Peyer patches have a darker-staining germinal center and a lighter-staining outer region. \_\_\_\_\_ (True/False) 7
- Peyer patches are located in the duodenum. \_\_\_\_\_ (True/False) 8

#### Exercise 19.4: The Vermiform Appendix

- The vermiform appendix is lined with which type of epithelial tissue? (Circle one.) 9
  - a. pseudostratified ciliated columnar epithelium
  - b. simple columnar epithelium
  - c. simple cuboidal epithelium
  - d. simple squamous epithelium
  - e. stratified squamous epithelium
- An individual suffering from an inflamed appendix will most commonly have pain in the \_\_\_\_\_ (upper/lower) \_\_\_\_\_ (left/right) abdominopelvic quadrant. 10

#### Exercise 19.5: The Thymus

- The thymus contains connective tissue septae that separate the gland into lobules. \_\_\_\_\_ (True/False) 11
- The thymus is the site of \_\_\_\_\_ (B-lymphocyte/T-lymphocyte) maturation. 12
- An increase in the number of thymic corpuscles indicates that the thymus is \_\_\_\_\_ (older/younger). 13

#### Exercise 19.6: Lymph Nodes

- Match the descriptions listed in column A with the structure listed in column B. 14 15

##### Column A

- \_\_\_\_\_ 1. space through which lymph travels within a lymph node
- \_\_\_\_\_ 2. structure in the medulla of the lymph node that contains T-lymphocytes and macrophages
- \_\_\_\_\_ 3. vessel bringing lymph into the lymph node
- \_\_\_\_\_ 4. vessel taking lymph away from the lymph node

##### Column B

- a. afferent
- b. efferent
- c. medullary cord
- d. sinus

12. Imagine a virus is circulating in the lymph. Place the following structures in the order in which the virus travels. 16

- \_\_\_\_\_ a. afferent lymphatic vessel
- \_\_\_\_\_ b. cortical sinus
- \_\_\_\_\_ c. efferent lymphatic vessel
- \_\_\_\_\_ d. medullary sinus

**Exercise 19.7: The Spleen**

13. Splenic sinusoids filter \_\_\_\_\_ (blood/lymph). 17

14. The \_\_\_\_\_ (white/red) pulp of the spleen contains lymphocytes and serves to fight pathogens, whereas the \_\_\_\_\_ (white/red) pulp of the spleen contains sinusoids and filters blood. 18

**Exercise 19.8: Gross Anatomy of Lymphatic Structures**

15. Imagine a bacterium has entered a lymph capillary in the right arm. Place the following structures in order as the bacterium travels from a lymph node in the axilla to the right atrium of the heart. 19

- \_\_\_\_\_ a. efferent lymphatic vessel
- \_\_\_\_\_ b. right brachiocephalic vein
- \_\_\_\_\_ c. right lymphatic duct
- \_\_\_\_\_ d. right subclavian vein
- \_\_\_\_\_ e. superior vena cava

**Can You Apply What You've Learned?**

16. When pharyngeal tonsils become inflamed, they are referred to as adenoids. Based on the location of the adenoids (pharyngeal tonsils), what kinds of symptoms might a patient experience due to the presence of swollen adenoids?

\_\_\_\_\_

17. What is a thymic corpuscle, and what does the presence of many thymic corpuscles tell you about the thymus? \_\_\_\_\_

\_\_\_\_\_

18. When an individual suffers from a ruptured spleen, the spleen is surgically removed so the patient does not die from internal bleeding. Using knowledge of the circulation of the spleen, explain why a ruptured spleen bleeds so profusely. (Hint: What type of capillaries are found in the spleen?)

\_\_\_\_\_

\_\_\_\_\_

19. The white pulp of the spleen is composed of \_\_\_\_\_ and functions to \_\_\_\_\_.

20. Discuss why lymphatic nodules are so abundant in the wall of the small intestine. \_\_\_\_\_

\_\_\_\_\_

\_\_\_\_\_

21. The red pulp of the spleen is composed of \_\_\_\_\_ and functions to \_\_\_\_\_.

22. Lacteals are specialized lymphatic capillaries found in the small intestine that have the special function of absorbing dietary fats. Absorbed fats first enter lymphatic capillaries and are transported as a component of lymph within lymph vessels. Using knowledge of the flow of both lymph and blood in the body, describe the route a dietary lipid would take to get from its location of absorption in the small intestine to its entry into the right atrium of the heart.

\_\_\_\_\_

\_\_\_\_\_

23. At what age does the thymus reach its maximum size? \_\_\_\_\_

24. An individual suffering from an inflamed appendix will most commonly have pain in which abdominopelvic quadrant?

\_\_\_\_\_

# The Respiratory System

# 20

## OUTLINE AND LEARNING OBJECTIVES

### Histology 426

#### Upper Respiratory Tract 426

##### EXERCISE 20.1: OLFACTORY MUCOSA 427

- 1 Describe the three layers (mucosa, submucosa, adventitia) of the wall of the respiratory tract
- 2 Identify olfactory epithelium when viewed with a microscope
- 3 Compare and contrast the structure and function of olfactory receptor cells, basal cells, and supporting (ciliated) cells

#### Lower Respiratory Tract 428

##### EXERCISE 20.2: THE TRACHEA 428

- 4 Identify the trachea and its associated structures when viewed with a microscope
- 5 Describe the epithelium that lines the trachea
- 6 Describe the function of the C-shaped tracheal cartilages and the trachealis muscle

##### EXERCISE 20.3: THE BRONCHI AND BRONCHIOLES 430

- 7 Identify large and small bronchi, and bronchioles when viewed with a microscope
- 8 Describe the changes that occur with epithelium, cartilage, and smooth muscle, moving from large bronchus to small bronchus, to bronchioles

#### Lungs 431

##### EXERCISE 20.4: THE LUNGS 432

- 9 Identify a slide of the lung and its associated structures when viewed with a microscope
- 10 Describe the three structures that compose the respiratory membrane
- 11 Explain the function of type I alveolar cells, type II alveolar cells, and alveolar macrophages
- 12 Identify respiratory zone structures on a histology slide of the lung

### Gross Anatomy 433

#### Upper Respiratory Tract 433

##### EXERCISE 20.5: MIDSAGITTAL SECTION OF THE HEAD AND NECK 433

- 13 Identify structures of the respiratory system in a sagittal section of the head and neck

#### Lower Respiratory Tract 435

##### EXERCISE 20.6: THE LARYNX 436

- 14 Compare and contrast vocal ligament, vocal fold, vestibular ligament, and vestibular fold, and explain how these relate to the “true vocal cords”
- 15 List the main cartilaginous structures of the larynx and identify them on classroom models of the larynx
- 16 Explain the function of the larynx in sound production

#### The Pleural Cavities and the Lungs 437

##### EXERCISE 20.7: THE PLEURAL CAVITIES 437

- 17 Describe the layers of the pleural cavities

##### EXERCISE 20.8: THE LUNGS 437

- 18 Identify the right and left lungs and describe the unique features of each
- 19 Identify branches of the pulmonary arteries and veins, and bronchi in the hilum of a right and left lung
- 20 Differentiate between the left and right lung based on the number of lobes, fissures, airways, and impressions of thoracic viscera

##### EXERCISE 20.9: THE BRONCHIAL TREE 439

- 21 Describe the branching pattern of the bronchial tree
- 22 Associate the branches of the bronchial tree with the segments of the lungs that are served by each branch

## INTRODUCTION

---

**B**reathe in deeply. What muscles had to contract for this to occur? Recollect from chapter 12, that the **external intercostal muscles** and the **diaphragm** are the key muscles used for inspiration. Contraction of these muscles increases the size of the thoracic cavity, which pulls on the **parietal pleura**, causing the lungs to expand. As the lungs expand and the volume of the lungs increases, the pressure within the lungs becomes lower than atmospheric pressure and air flows into the lungs. This air brings with it a fresh supply of oxygen that is subsequently picked up by **erythrocytes** in the blood flowing through the lung capillaries. This freshly oxygenated blood will be transported back to the left ventricle of the heart and pumped to the working tissues of the body via the aorta. Take another deep breath. This time focus on the process of **expiration** (breathing out). Normal expiration is a passive process, which does not require muscular effort. As soon as contraction of the external intercostal muscles and diaphragm cease, the volume of the thoracic cavity (and the lungs) decreases as the rib cage “falls” under the weight of the structures attached to the thorax (including the upper limbs). As the volume of the thoracic cavity decreases, the pressure increases. As soon as the pressure in the lungs becomes greater than atmospheric pressure, air flows out of the lungs. This air is rich in carbon dioxide, a waste product from cellular respiration that must be removed from the body. The exercises in this chapter focus on the histology and anatomy of the respiratory system. The focus of these exercises is to guide students

in their observations of the anatomical structures used in the process of transporting air into and out of the lungs. Histology exercises will focus on guiding student observations of the histological features of the lung tissues themselves. Microscopic observation of lung tissues allows for an appreciation of how their structure is ideally suited to the task of exchanging gases between the lungs and the blood.

The exercises in this chapter explore the histological and gross structure of the respiratory tract and the lungs. They begin with an investigation into the general layering pattern of the walls of the respiratory tract to prepare the student to identify specific histological structures located within each layer. This will be followed by analysis of the histology of major respiratory tract structures, including the lungs. Histological observations will be followed by observations of the gross anatomy of the upper airways and the lungs, using either cadaveric specimens, fresh sheep specimens, models, or some combination of these.

### List of Reference Tables

Table 20.1	Olfactory Epithelium	p. 427
Table 20.2	Histology of the Trachea	p. 428
Table 20.3	Histology of the Bronchial Tree	p. 430
Table 20.4	Structures Composing the Respiratory Zone	p. 432
Table 20.5	Microscopic Structures Within the Lungs	p. 433
Table 20.6	Cartilaginous Structures of the Larynx	p. 435
Table 20.7	Noncartilaginous Structures of the Larynx	p. 435
Table 20.8	The Bronchial Tree	p. 440

These Pre-laboratory Worksheet questions may be assigned by instructors through their **connect** course.

## PRE-LABORATORY WORKSHEET

- Respiratory epithelium, which lines the nasal cavity and upper respiratory tract, is classified as (Circle one.):
  - pseudostratified columnar with cilia and goblet cells
  - pseudostratified columnar with microvilli
  - simple columnar with cilia
  - simple columnar with cilia and goblet cells
  - simple cuboidal with microvilli
- The left lung contains \_\_\_\_\_ (two/three) lobes, whereas the right lung contains \_\_\_\_\_ (two/three) lobes.
- Which of the following bones does *not* form a border of the nasal cavity? (Circle one.)
  - ethmoid
  - mandible
  - maxilla
  - palatine
  - vomer
- The pulmonary arteries carry \_\_\_\_\_ (oxygenated/deoxygenated) blood from the \_\_\_\_\_ (right/left) ventricle of the heart to the lungs, and the pulmonary veins carry \_\_\_\_\_ (oxygenated/deoxygenated) blood from the lungs to the \_\_\_\_\_ (right/left) atrium of the heart. This circuit is referred to as the \_\_\_\_\_ (pulmonary/systemic) circuit.
- Contraction of the diaphragm decreases the volume of the thoracic cavity. \_\_\_\_\_ (True/False)
- Which of the following is *not* a component of the respiratory membrane? (Circle one.)
  - capillary endothelial cell
  - fused basement membranes
  - type I cell
  - type II cell
- Which of the following are cells that produce surfactant? (Circle one.)
  - alveolar macrophages
  - capillary endothelial cell
  - fused basement membranes
  - type I cell
  - type II cell
- A \_\_\_\_\_ (lobar/main/segmental) bronchus leads into each lung; a \_\_\_\_\_ (lobar/main/segmental) bronchus leads into a lobe of a lung; a \_\_\_\_\_ (lobar/main/segmental) bronchus leads into a bronchopulmonary segment.
- The \_\_\_\_\_ (parietal/visceral) pleura covers the outer surface of each lung, whereas the \_\_\_\_\_ (parietal/visceral) pleura lines the inner surfaces of the thoracic cavity.
- All structures that compose the \_\_\_\_\_ (conducting/respiratory) division of the respiratory tree contain alveoli.



## Histology

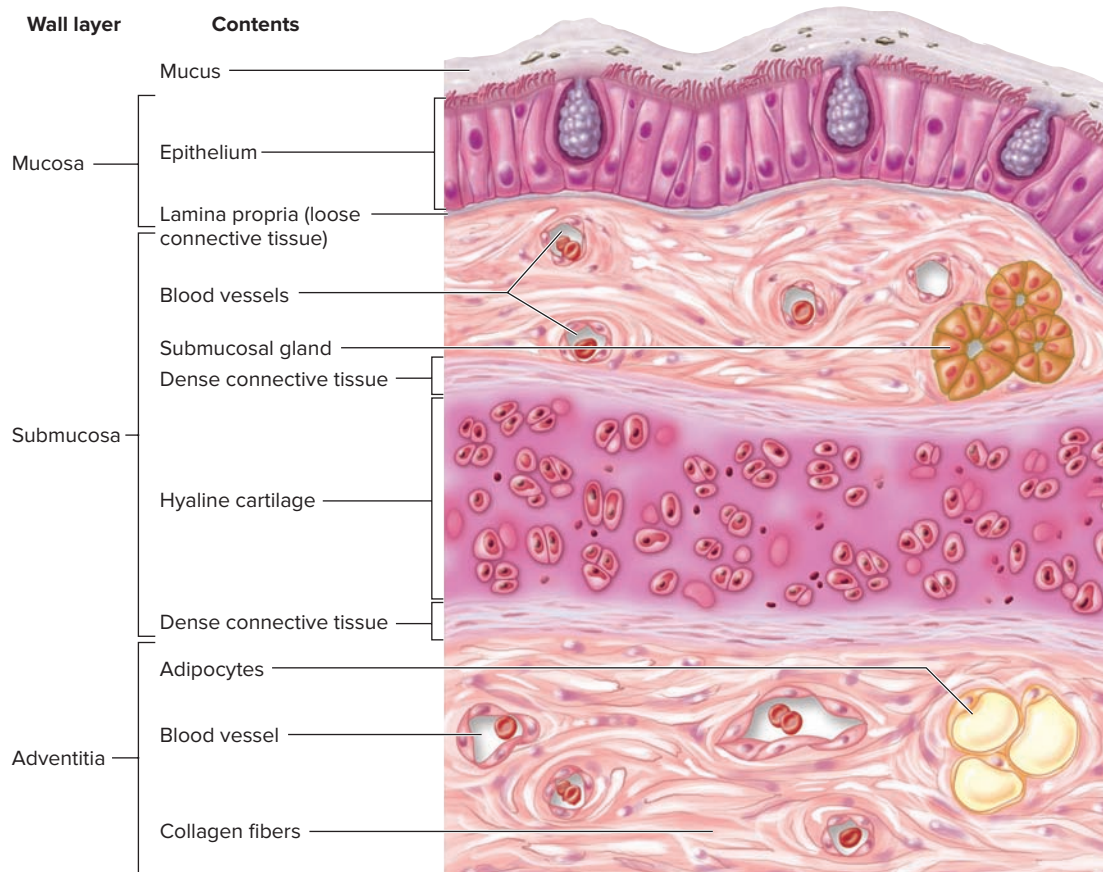
### Upper Respiratory Tract

The respiratory system is organized into two structural regions: an upper respiratory tract and a lower respiratory tract. The upper respiratory tract consists of the nose, nasal cavity, paranasal sinuses, and pharynx. The lower respiratory tract includes the larynx, trachea, bronchi, bronchioles, alveolar ducts, and alveoli. The structures of the respiratory system are also categorized based on function.

Passageways that serve to transport or conduct air compose the **conducting zone**; these structures include the passageways from the nasal cavity to the terminal bronchioles. Structures that participate in gas exchange with the blood—including the respiratory bronchioles, alveolar ducts, and alveoli—compose the **respiratory zone**.

The walls of the respiratory passageways are lined by a mucous membrane, called a mucosa. The **mucosa** (*mucosus*, mucus) consists of the epithelium, its basement membrane, and an underlying layer of loose

connective tissue and blood vessels called the **lamina propria** (*lamina*, layer + *proprius*, one's own). Typically, there are more layers deep to the mucosa including both the **submucosa** (*sub-*, under + *mucosa*), and the **adventitia** (*adventicius*, coming from abroad). The submucosa (*sub-*, under + *mucosus*, mucus) consists of areolar connective tissue, in addition to glands, blood vessels, nerves, and smooth muscle. The adventitia is composed of loose connective tissue, blood vessels, and nerves. In some portions of the respiratory passageway, including the trachea and bronchi, there are partial rings or plates of hyaline cartilage, which provide support to the airway. The cartilage is ensheathed in dense irregular connective tissue, and is positioned between the submucosa and adventitia. **Figure 20.1** shows the layers of the tracheal wall. While viewing slides of respiratory system structures, it is helpful to identify these three layers first, particularly the mucosa and submucosa. This will make subsequent identification of specific cell types within each layer easier.

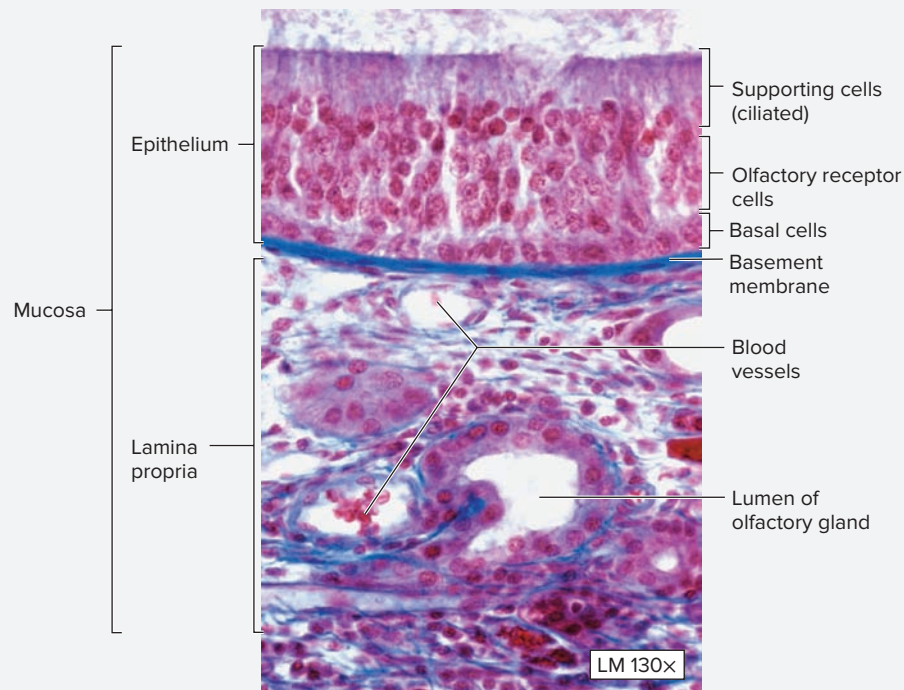


**Figure 20.1** Wall Layers of the Trachea. The walls of all structures of the respiratory tract are composed of three layers: mucosa, submucosa, and adventitia. This drawing depicts the wall of the trachea, which has an outer covering of connective tissue referred to as an adventitia.

**EXERCISE 20.1** Olfactory Mucosa

The epithelium that lines the nasal cavity is highly specialized—it serves to warm, moisten, and filter the air as it enters the respiratory passageway. In addition, the epithelium located in the superior portions of the nasal cavity (**olfactory epithelium**) acts as a special sensory organ to detect odors (**figure 20.2**). **Table 20.1** describes the appearance and function of the various cell types and structures within the olfactory epithelium.

1. Obtain a compound microscope and a slide of olfactory epithelium. Place the slide on the microscope stage and bring the tissue sample into focus on low power.
2. Identify the **mucosa** and **epithelium**. Move the microscope stage so the epithelium is at the center of the field of view, then change to high power.



**Figure 20.2 Olfactory Epithelium.** Olfactory epithelium contains three cell types: basal cells, olfactory receptor cells, and supporting (ciliated) cells.

© Victor P. Eroschenko

Table 20.1		Olfactory Epithelium
Structure	Description and Function	Word Origins
<b>Basal Cells</b>	Small, triangular cells that lie on the basement membrane and do not reach the apical surface of the epithelium. Their <i>nuclei</i> are located on the basal surface of the epithelium. These cells are the precursor cells to the other cell types and are responsible for regeneration of the epithelium.	<i>basis</i> , bottom
<b>Olfactory Glands</b>	Serous-secreting glands located in the lamina propria of the olfactory epithelium that open to the surface. They secrete a serous fluid that “washes” the olfactory hairs, clearing the surface so that new odors can be sensed by the olfactory cells.	<i>olfacio</i> , to smell
<b>Olfactory Receptor Cells</b>	Bipolar neurons that contain 6–8 cilia-like extensions on their apical surface called olfactory hairs. These hairs function to detect odorous substances. The cell <i>nuclei</i> are located in the middle of the epithelium. Axons of these cells travel through the cribriform foramina of the ethmoid bone to synapse with CNS neurons in the olfactory bulbs.	<i>olfacio</i> , to smell
<b>Supporting Cells (Ciliated)</b>	The most prominent and abundant cells. Their <i>nuclei</i> are located near the apical surface of the epithelium. They are columnar epithelial cells with cilia on their apical surfaces. They function to propel mucus and particulate matter along the apical surface of the epithelium toward the pharynx.	<i>cilium</i> , eyelash


(continued on next page)

(continued from previous page)

3. Identify the listed structures on the slide, using table 20.1 and figure 20.2 as guides:

- basal cells                       olfactory receptor cells  
 olfactory glands                 supporting cells (ciliated)

4. Sketch the olfactory epithelium as viewed under the microscope in the space provided. Label all the structures listed in step 3 in the drawing.



## Lower Respiratory Tract

The lower respiratory tract includes the larynx, **trachea**, **bronchi**, bronchioles, alveolar ducts, and alveoli. As the airways extend progressively deeper into the lungs from the trachea to the bronchi and bronchioles, the amount of cartilage in the submucosa decreases and the relative amount of

smooth muscle increases. In addition, the epithelium transitions from the pseudostratified ciliated columnar epithelium of the trachea to the simple squamous epithelium of the alveoli within the lungs. **Table 20.2** describes the wall structure of the trachea.

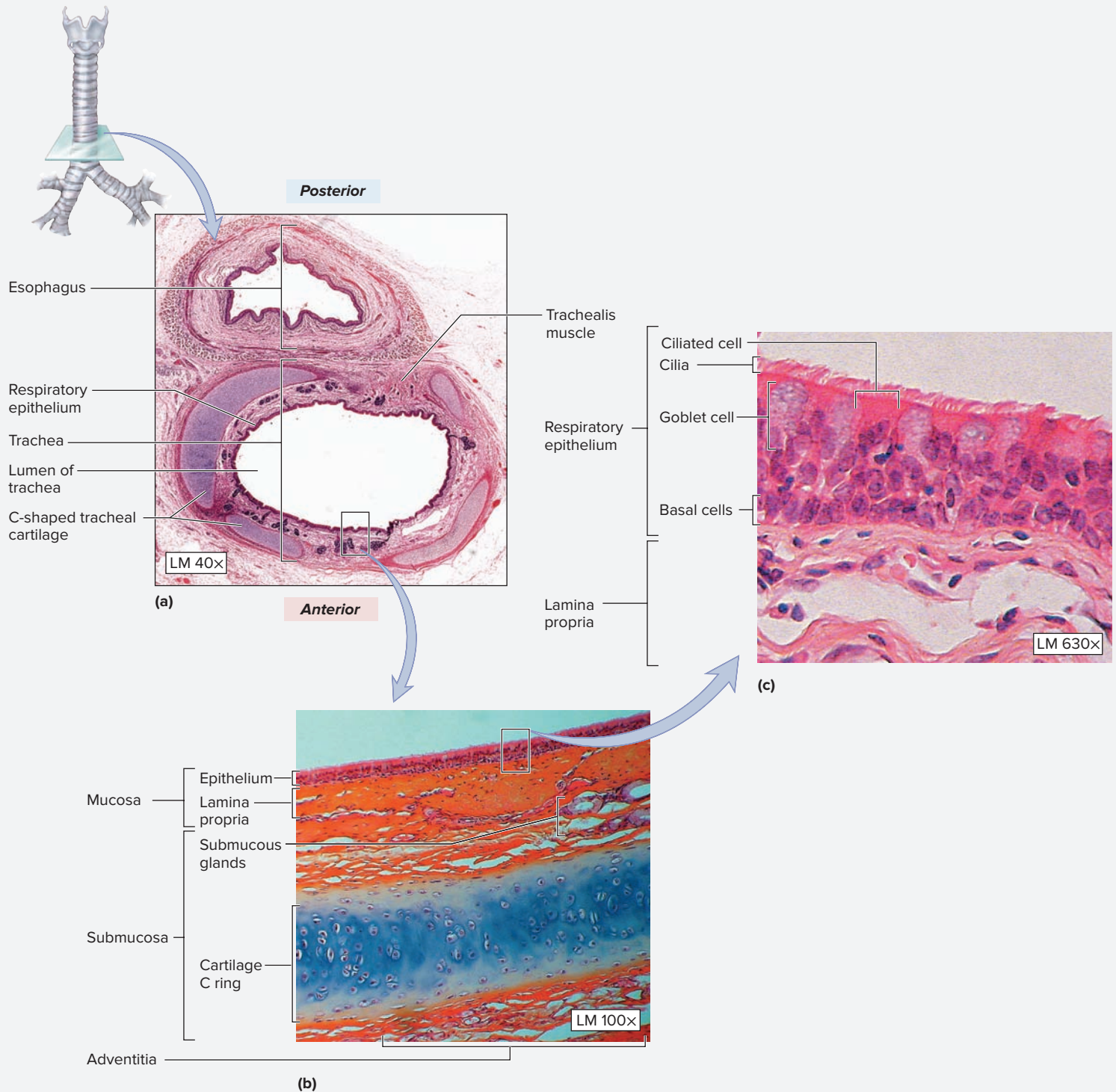
### EXERCISE 20.2 The Trachea

- Obtain a slide of the trachea (*tracheia*, rough artery) and place it on the microscope stage. This slide will also contain the esophagus (*oisophagos*, gullet) because the two structures lie next to each other in vivo.
- Bring the tissue sample into focus on low power and distinguish the trachea from the esophagus. Move the microscope stage so the lumen and epithelium of the trachea are in the center of the field of view. Then switch to high power.
- While observing the trachea, first identify the layers of the wall of the trachea (mucosa, submucosa, and adventitia). Then identify the structures located within each layer. Table 20.2 describes the wall structure of the trachea and the structures located within each layer, and **figure 20.3** demonstrates the histological appearance of the wall of the trachea.

**Table 20.2** Histology of the Trachea

Structure	Description and Functions
<b>MUCOSA</b>	Innermost layer that lines the tracheal wall; consists of respiratory epithelium and underlying lamina propria. The lamina propria is separated from the underlying submucosa by a layer of elastic connective tissue (the <i>elastic lamina</i> ).
<i>Epithelium</i>	Pseudostratified columnar epithelium with cilia and goblet cells.
<i>Basal Cells</i>	Small triangular cells that lie on the basal lamina and do not reach the apical surface of the epithelium. These cells are the precursor cells to the other cell types and are responsible for regeneration of the epithelium.
<i>Ciliated Cells</i>	The most prominent and abundant cells. These are pseudostratified ciliated columnar cells of the epithelium. They function to propel mucus and particulate matter via the “mucus escalator” along the epithelial sheet toward the pharynx.
<i>Goblet Cells</i>	Large round cells that appear white or clear. They secrete mucus onto the surface of the epithelium. The mucus traps particulate matter that enters the trachea while the cilia move the mucus superiorly (a “mucus escalator”) toward the pharynx so that it may be swallowed.
<i>Lamina Propria</i>	A layer of loose connective tissue that underlies the respiratory epithelium. In the trachea this layer can be seen in the area between the epithelial folds and the trachealis muscle or C-shaped cartilages.
<b>SUBMUCOSA</b>	The middle layer of the tracheal wall containing seromucus glands, blood vessels, the trachealis muscle, C-shaped cartilages, and nerves.
<i>Submucous Glands</i>	These produce a substance that is part watery (serous) and part viscous (mucus).
<i>Tracheal Cartilages</i>	C-shaped plates of hyaline cartilage located on the anterior surface of the trachea. There are 16–20 of them. They are C-shaped so there is room on the posterior aspect of the trachea for expansion of the esophagus during swallowing and to allow the trachialis muscle to alter the diameter of the trachea.

Structure	Description and Functions
<b>Trachealis Muscle</b>	A layer of smooth muscle found on the posterior aspect of the trachea where the trachea lies against the esophagus. Laterally, the trachealis muscle is anchored to the ends of the cartilage C rings, and its contraction decreases the diameter of the trachea, which is important for coughing and sneezing. The decreased diameter of the trachea causes the air to exit more forcefully, which helps dislodge substances within the airways.
<b>ADVENTITIA</b>	Loose connective tissue on the outermost surface of the tracheal wall.



**Figure 20.3 Histology of the Trachea.** (a) Cross section through the trachea and esophagus. (b) Layers of the tracheal wall. (c) Close-up view of the tracheal mucosa.

© McGraw-Hill Education/Christine Eckel, photographer


(continued on next page)

*(continued from previous page)*

4. Identify the listed structures on the slide of the trachea, using table 20.2 and figure 20.3 as guides:

- |   |  |
|---|--|
| <input type="checkbox"/> adventitia     | <input type="checkbox"/> mucosa              |
| <input type="checkbox"/> basal cells    | <input type="checkbox"/> submucosa           |
| <input type="checkbox"/> ciliated cells | <input type="checkbox"/> submucous glands    |
| <input type="checkbox"/> epithelium     | <input type="checkbox"/> tracheal cartilages |
| <input type="checkbox"/> goblet cells   | <input type="checkbox"/> trachealis muscle   |
| <input type="checkbox"/> lamina propria |  |

5. Sketch the cross section of the trachea as viewed under the microscope in the space provided. Label all of the structures listed in step 4 in the drawing.



### EXERCISE 20.3 The Bronchi and Bronchioles

- Obtain a slide of the lungs and place it on the microscope stage. Bring the tissue sample into focus on low power and scan the slide to locate cross sections of **large bronchi**, **small bronchi**, and **bronchioles** (figure 20.4).
- The different characteristics of the conducting zone structures are listed in **table 20.3**. In general, as the airways travel deeper into the lung and become progressively smaller, three changes take place: (1) The epithelium transitions from pseudostratified columnar to simple cuboidal, and the number of cilia decrease, (2) large plates of hyaline cartilage in the walls give way to smaller and smaller pieces of cartilage, and (3) the amount of smooth muscle in the airways increases.
- Identify the listed structures on the slide of the lungs, using figure 20.4 and table 20.3 as guides:

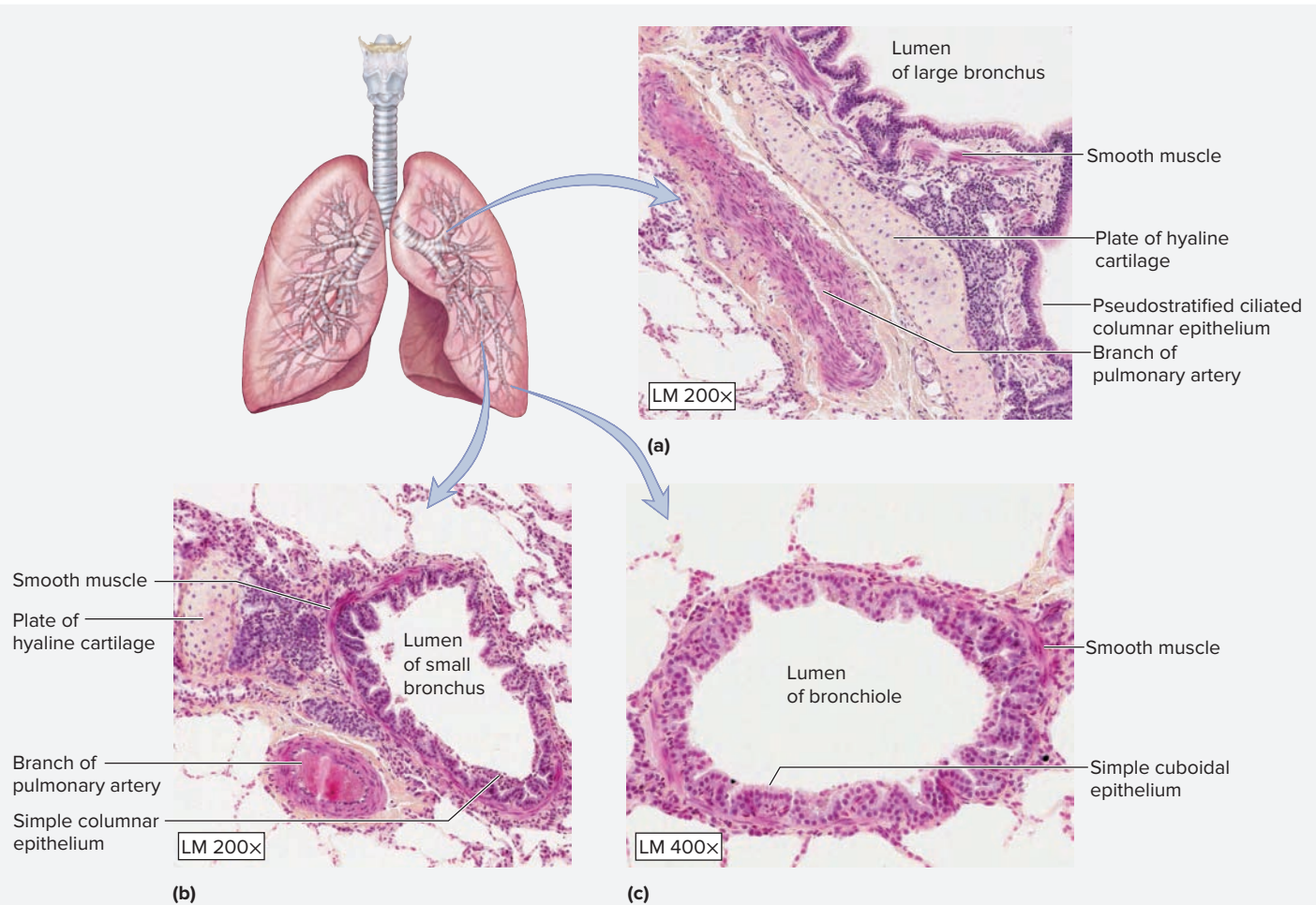
- |   |   |
|---|---|
| <input type="checkbox"/> branch of pulmonary artery | <input type="checkbox"/> large bronchus |
| <input type="checkbox"/> bronchiole                 | <input type="checkbox"/> small bronchus |
| <input type="checkbox"/> hyaline cartilage          | <input type="checkbox"/> smooth muscle  |

4. Sketch a cross section of a bronchiole as viewed under a microscope in the space provided.



**Table 20.3** Histology of the Bronchial Tree

Structure	Epithelium	Hyaline Cartilage	Smooth Muscle
<i>Large Bronchi</i>	Pseudostratified columnar with cilia	Large plates, which keep airway open	Encircles the lumen
<i>Small Bronchi</i>	Simple columnar with cilia	Small plates	Encircles the lumen
<i>Bronchioles</i>	Simple columnar to simple cuboidal	None	Encircles the lumen and is an important regulator of airway diameter



**Figure 20.4 The Bronchial Tree.** Cross sections of portions of the bronchial tree are visible in a histological image of a lung. (a) The walls of larger bronchi are lined with a ciliated pseudostratified columnar epithelium, with relatively large plates of hyaline cartilage along with smooth muscle. (b) The wall of smaller bronchi are lined with a simple ciliated columnar epithelium, with smaller plates of cartilage in the walls, and relatively more smooth muscle than in the larger bronchi. (c) Bronchioles are characterized by having a simple ciliated columnar epithelium, no cartilage, and a thin ring of smooth muscle.

© McGraw-Hill Education/Christine Eckel, photographer

## Lungs

The lungs consist of functional units called **alveoli** (*alveus*, hollow sac), which are the sites of gas exchange between the air within the alveoli and the blood within the pulmonary capillaries. The alveoli are lined with simple squamous epithelium, which provides the thinnest possible barrier to diffusion between the air within the alveoli and the blood within the capillaries that surround them. In a slide of the lung, numerous alveoli and cross sections of some of the smaller airways (such as respiratory

bronchioles) will be visible scattered throughout the slide. The transition from conducting zone structures to respiratory zone structures occurs deep within the lungs. The key feature in distinguishing conducting zone structures from respiratory zone structures is the presence of alveoli. Any structure that has at least one alveolus coming off of it (as may be the case with a respiratory bronchiole) participates in gas exchange and, thus, is part of the respiratory zone.

**EXERCISE 20.4** The Lungs

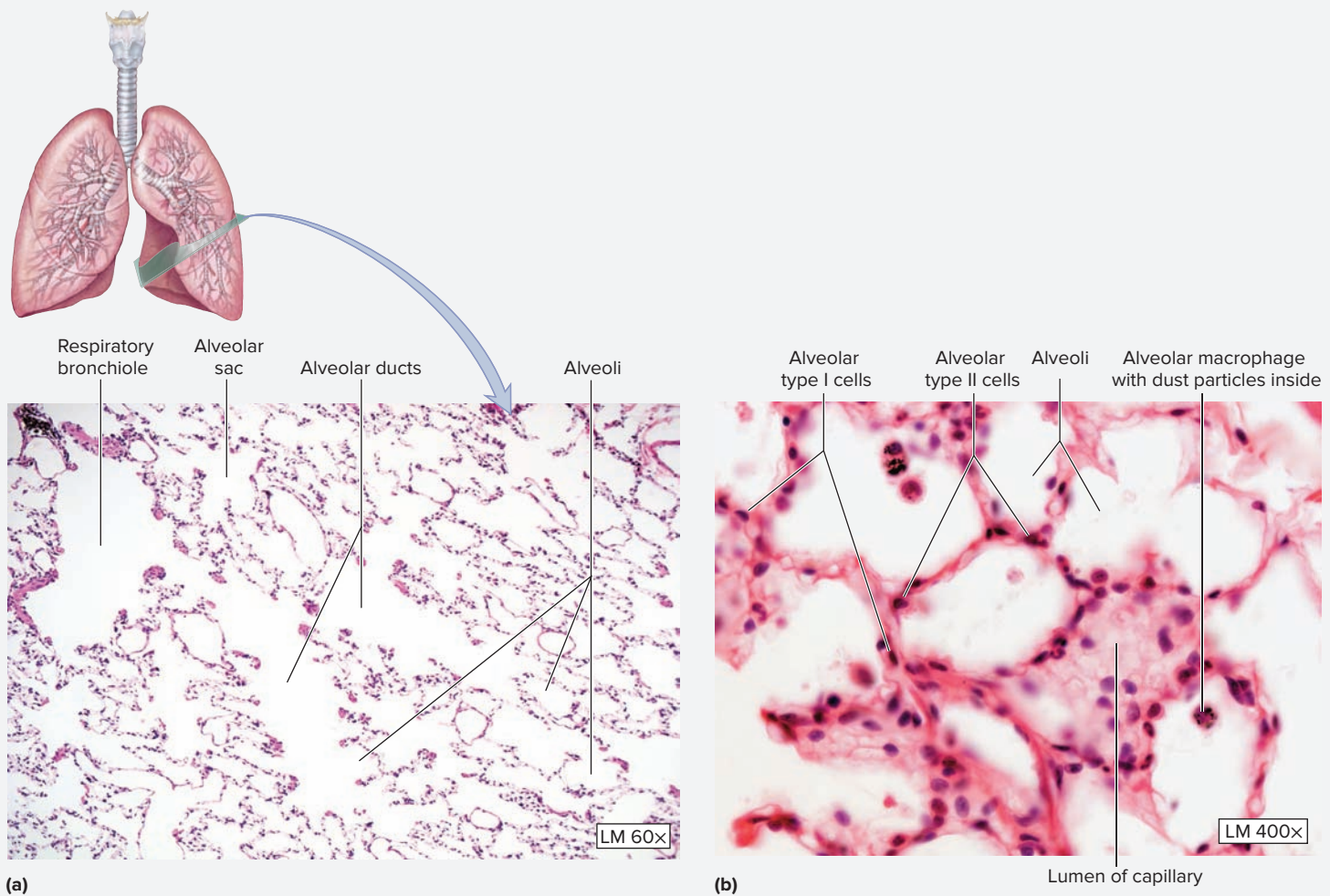
Table 20.3 describes the structure of the airways that compose the respiratory portion of the bronchial tree.

**Table 20.4** describes the structure of the cell types within the alveoli. For gas exchange to occur, gas molecules must pass between the alveoli and the capillaries that surround them. The structures lining the alveoli and the capillaries collectively form the **respiratory membrane**. The respiratory membrane is composed of (1) **alveolar type I cells**, (2) the

fused basement membrane of alveolar type I cells and endothelial cells of the capillaries, and (3) the endothelial cells lining the capillaries.

1. Obtain a slide of the lungs and place it on the microscope stage. Bring the tissue sample into focus on low power and scan the slide to locate cross sections of **bronchioles** (**figure 20.5**).

Table 20.4		Structures Composing the Respiratory Zone
Structure	Description	Epithelium
<i>Respiratory Bronchioles</i>	Ducts with alveoli scattered along the passageway.	Ciliated simple cuboidal
<i>Alveolar Ducts</i>	Ducts with alveoli lining the entire passageway.	Simple squamous
<i>Alveolar Sacs</i>	Shaped like a bunch of grapes with several alveoli (the “grapes”) bunched together.	Simple squamous
<i>Alveoli</i>	A balloon-like structure that is the site of gas exchange.	Simple squamous



**Figure 20.5** Histology of the Lungs. (a) Low-magnification view demonstrating respiratory portion structures. (b) High-magnification view demonstrating alveolar macrophages with particles of dust inside the cells.

Table 20.5	Microscopic Structures Within the Lungs
Structure	Description
<i>Alveolar Macrophages</i>	Derived from monocytes. Engulf particulate matter or pathogenic organisms.
<i>Alveolar Type I Cell</i>	Simple squamous epithelial cells covering 97% of the alveolar surface area. They are connected to each other with tight junctions.
<i>Alveolar Type II Cell</i>	Compose about 3% of alveolar surface area. Joined to type I cells by desmosomes and tight junctions. Contain a large nucleus, foamy cytoplasm, and vesicles containing <b>pulmonary surfactant</b> (a mixture of phospholipids, glycosaminoglycans, and proteins that functions to reduce surface tension of alveoli).

2. Increase the magnification to observe the smaller airways and the air sacs (alveoli) in greater detail.

3. Identify the listed structures on the slide of the lungs, using table 20.4 and **table 20.5**, and figure 20.5 as guides:

- |   |  |
|---|--|
| <input type="checkbox"/> alveolar ducts       | <input type="checkbox"/> alveolar type II cell   |
| <input type="checkbox"/> alveolar macrophages | <input type="checkbox"/> alveoli                 |
| <input type="checkbox"/> alveolar sacs        | <input type="checkbox"/> capillary               |
| <input type="checkbox"/> alveolar type I cell | <input type="checkbox"/> respiratory bronchioles |

4. Sketch the respiratory membrane in the space provided. Then label the three components that make up the respiratory membrane.



5. *Optional Activity:* **AP|R Respiratory System**—Watch the “Diffusion Across Respiratory Membrane” animation to visualize the microscopic structure and function of lung tissue.

## Gross Anatomy

### Upper Respiratory Tract

The following exercises guide the student in exploring the gross anatomy of the respiratory structures that convey air into the lungs, the cavities that house the lungs (the pleural cavities), and the lungs themselves. Recall, however, that the process of breathing requires muscular action. Details of the structure, location, and actions of the respiratory muscles are covered in chapter 12. This is a good point in time to go back to exercise 12.10 on

p. 242 and review the actions of the respiratory musculature, paying particular attention to the location and actions of the diaphragm.

Structures of the upper respiratory tract are best seen through gross observation of a sagittal section of the head and neck. This provides the best view for observing the gross structures within the nasal cavity that warm and clean the air before it enters the respiratory passageways.

### EXERCISE 20.5 Midsagittal Section of the Head and Neck

1. Obtain a classroom model of a midsagittal section of the head and neck (or a cadaveric specimen that has been sectioned along the sagittal plane). **Figure 20.6** shows respiratory system structures that are visible in a midsagittal section of the head and neck.

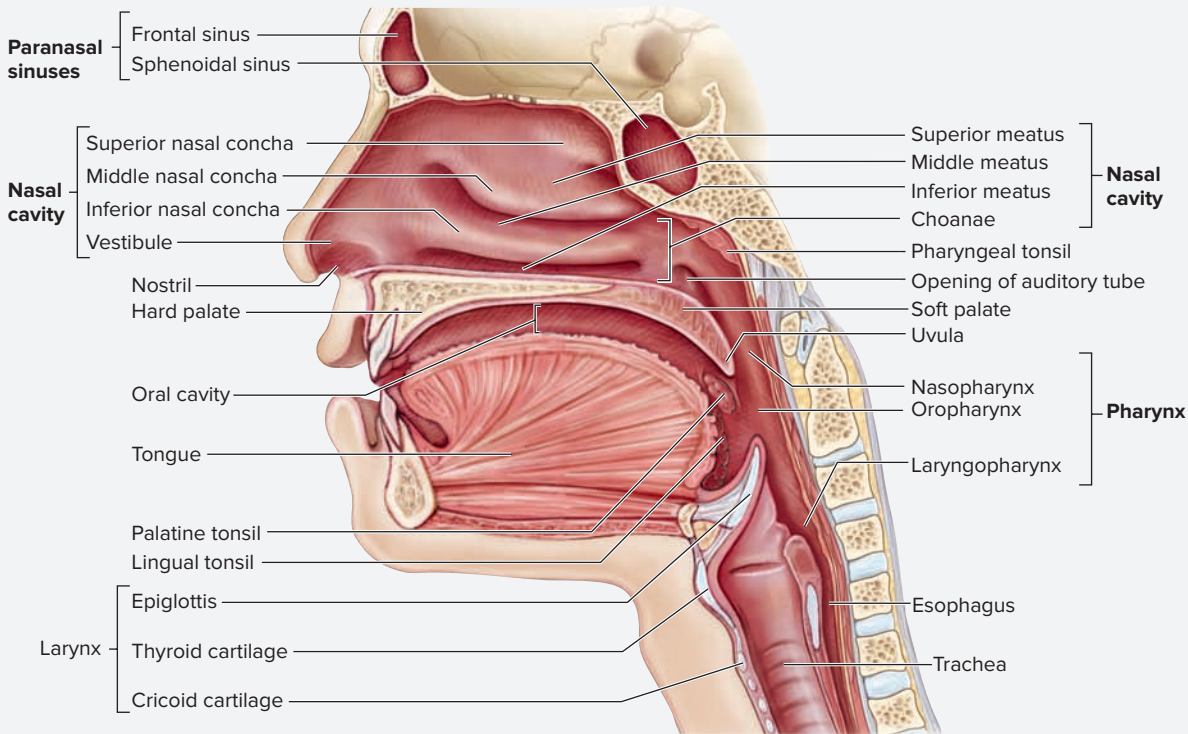
2. Identify the structures listed in **figure 20.7** on the classroom model or cadaveric specimen, using the textbook as a guide. Then label them in figure 20.7.

3. *Optional Activity:* **AP|R Respiratory System**—Watch the “Respiratory System Overview” to review the structures of the upper and lower respiratory tracts.

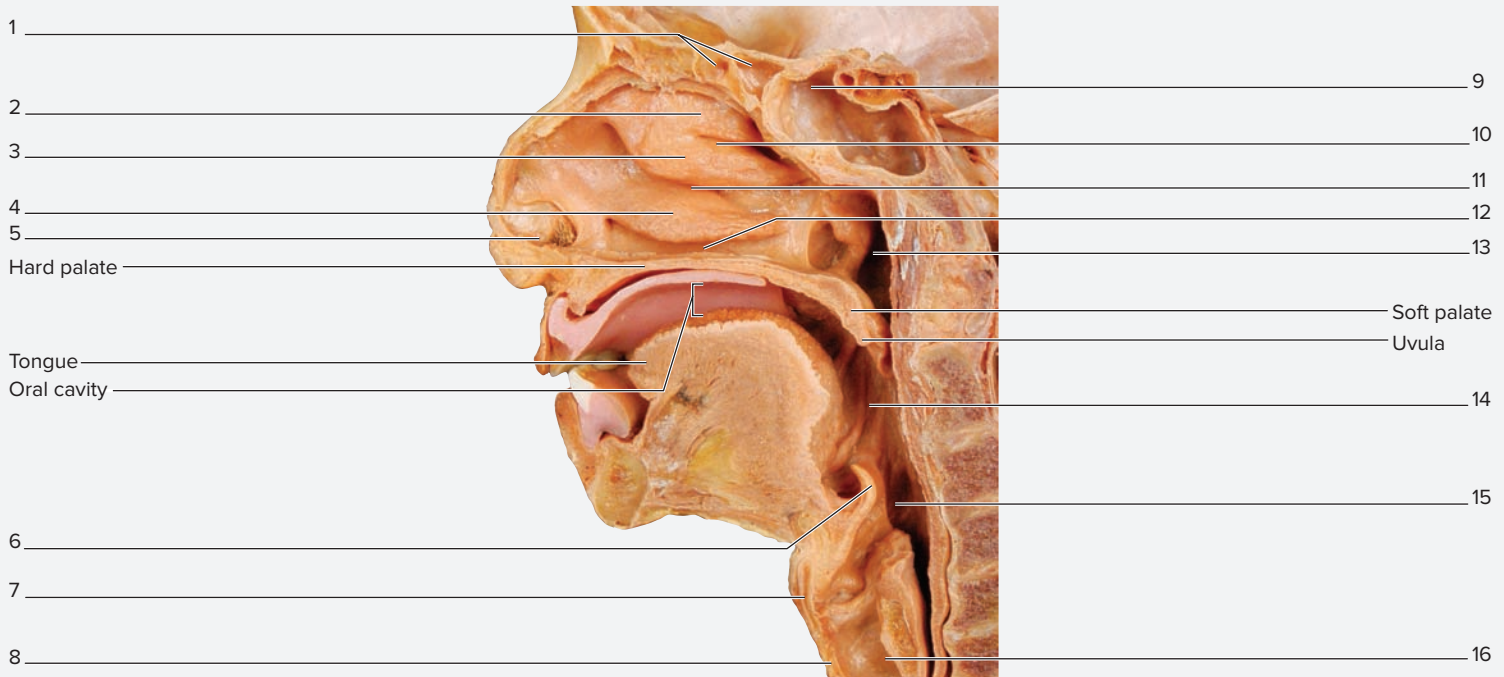
(continued on next page)



(continued from previous page)



**Figure 20.6**  
**The Upper Respiratory Tract.** Respiratory system structures visible in a midsagittal view of the head and neck.



**Figure 20.7** The Upper Respiratory Tract: Midsagittal View. Use the terms listed to fill in the numbered labels in the figure.

- |  |  |  |  |
|--|--|--|--|
| <input type="checkbox"/> cricoid cartilage | <input type="checkbox"/> inferior nasal concha | <input type="checkbox"/> middle nasal concha | <input type="checkbox"/> superior meatus       |
| <input type="checkbox"/> epiglottis        | <input type="checkbox"/> laryngopharynx        | <input type="checkbox"/> nasopharynx         | <input type="checkbox"/> superior nasal concha |
| <input type="checkbox"/> ethmoidal sinuses | <input type="checkbox"/> lumen of larynx       | <input type="checkbox"/> oropharynx          | <input type="checkbox"/> thyroid cartilage     |
| <input type="checkbox"/> inferior meatus   | <input type="checkbox"/> middle meatus         | <input type="checkbox"/> sphenoidal sinus    | <input type="checkbox"/> vestibule             |

## Lower Respiratory Tract

The lower respiratory tract is composed of structures of both the conducting portion (larynx, trachea, bronchi, and bronchioles) and the respiratory portion (respiratory bronchioles, alveolar ducts, alveolar sacs, and alveoli). The **larynx** (*larynx*, organ of voice production) is much more than just an opening into the lower respiratory tract. It also houses the **vocal folds**, referred to as the “true vocal cords,” which are responsible for phonation (sound production), and intrinsic muscles that control the

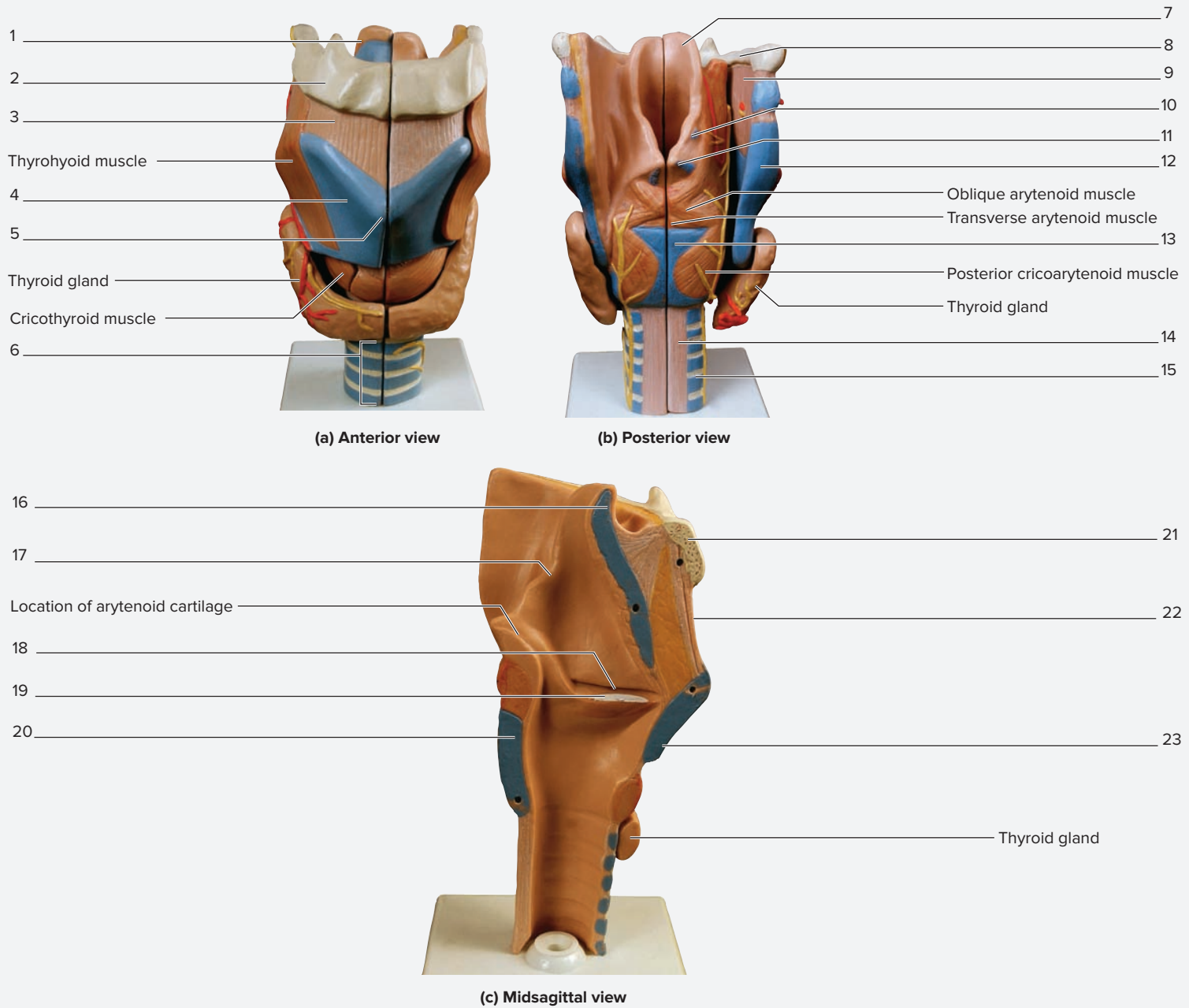
length and tension of the vocal folds. The structural framework of the larynx is composed of several paired and unpaired cartilages, which act as attachment sites for the intrinsic musculature. The muscles of the larynx are all innervated by branches of the vagus nerve (CN X). Thus, lesions of the vagus nerve result in problems with phonation, such as hoarseness. **Table 20.6** describes the cartilaginous structures of the larynx, and **table 20.7** describes the noncartilaginous structures of the larynx.

Table 20.6 Cartilaginous Structures of the Larynx		
Cartilage	Description	Word Origins
<i>Arytenoid</i>	Small paired pyramid-shaped cartilages found on the superior, posterior aspect of the cricoid cartilage. The vocal ligaments (true vocal cords) attach to them.	<i>arytania</i> , a ladle + <i>idos</i> , resemblance
<i>Corniculate</i>	Small paired cartilages found superior to the arytenoid cartilages. The vestibular folds (“false vocal cords”) attach to them.	<i>cornicatus</i> , horned
<i>Cricoid</i>	The second largest laryngeal cartilage, this ring-shaped cartilage serves as an attachment point for muscles.	<i>krikos</i> , a ring + <i>idos</i> , resemblance
<i>Cuneiform</i>	Small paired cartilages found within the aryepiglottic fold.	<i>cuneus</i> , a wedge + <i>forma</i> , form
<i>Epiglottis</i>	A plate of elastic cartilage at the superior aspect of the larynx that closes over the opening to the larynx during swallowing to prevent substances from entering the larynx. It is covered by stratified squamous epithelium on its superior aspect and by respiratory epithelium on its inferior aspect.	<i>epi-</i> , above + <i>glottis</i> , the mouth of the windpipe
<i>Thyroid</i>	The largest of the laryngeal cartilages, located superior to the isthmus of the thyroid gland. The vocal ligaments (true vocal cords) attach to it.	<i>thyreos</i> , an oblong shield + <i>idos</i> , resemblance

Table 20.7 Noncartilaginous Structures of the Larynx		
Structure	Description and Function	Word Origins
<i>Glottis</i>	Consists of the rima glottis plus the vocal folds.	<i>glottis</i> , the mouth of the windpipe
<i>Rima Glottidis</i>	The space between the true vocal cords; also known as the true glottis.	<i>rima</i> , a slit + <i>glottis</i> , the mouth of the windpipe
<i>Vestibular Folds</i>	The “false vocal cords,” which are the vestibular ligaments plus the folds of mucous membrane that lie over them.	<i>vestibulum</i> , a small cavity at the entrance of a canal
<i>Vestibular Ligaments</i>	Ligaments that stretch between the angle of the thyroid cartilage to the corniculate cartilages.	<i>vestibulum</i> , a small cavity at the entrance of a canal + <i>ligamentum</i> , a bandage
<i>Vocal Folds (“True Vocal Cords”)</i>	The vocal ligaments plus the mucosa overlying them. Form the “true vocal cords.” Involved directly in voice production. Alterations in tension of the cords affect the pitch of the sound.	<i>vocalis</i> , pertaining to the voice + <i>chorda</i> , cord
<i>Vocal Ligaments</i>	Ligaments that stretch between the thyroid and arytenoid cartilages.	<i>vocalis</i> , pertaining to the voice + <i>ligamentum</i> , a bandage

**EXERCISE 20.6 The Larynx**

1. Obtain a classroom model of the larynx (figure 20.8).
2. Identify the structures listed in figure 20.8 on the model of the larynx, using tables 20.6 and 20.7 and the textbook as guides. Then label figure 20.8.
3. *Optional Activity:* **AP|R Respiratory System**—Take the “Lower Respiratory Tract” test in the Quiz section to review the larynx and other lower respiratory structures.



**Figure 20.8 Classroom Model of the Larynx.** Use the terms listed to fill in the numbered labels in the figure. Some answers may be used more than once.

- |  |  |   |  |  |
|--|--|---|--|--|
| <input type="checkbox"/> arytenoid cartilage   | <input type="checkbox"/> cuneiform cartilage | <input type="checkbox"/> laryngeal prominence | <input type="checkbox"/> trachea           | <input type="checkbox"/> vestibular ligament (“false vocal cords”) |
| <input type="checkbox"/> corniculate cartilage | <input type="checkbox"/> epiglottis          | <input type="checkbox"/> thyrohyoid membrane  | <input type="checkbox"/> tracheal C ring   | <input type="checkbox"/> vocal folds (“true vocal cords”)          |
| <input type="checkbox"/> cricoid cartilage     | <input type="checkbox"/> hyoid bone          | <input type="checkbox"/> thyroid cartilage    | <input type="checkbox"/> trachealis muscle |  |

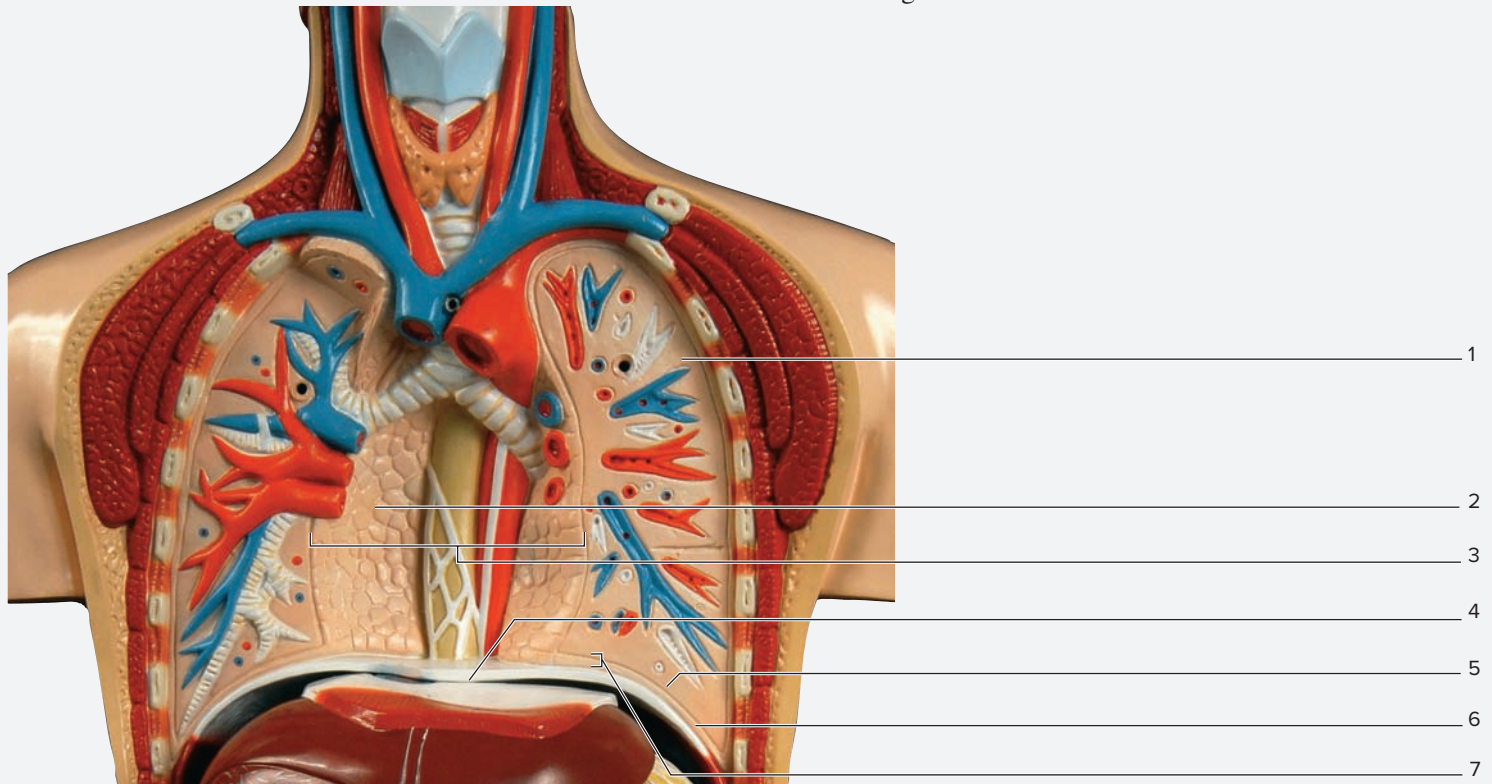
## The Pleural Cavities and the Lungs

Within the thoracic cavity, the lungs are located within separate **pleural cavities** (*pleura*, a rib). The space within the thoracic cavity between the two pleural cavities is the **mediastinum** (*medius*, middle). Because the mediastinum is simply the space between the two pleural cavities, if one of the lungs and its surrounding pleural cavity collapse, the mediastinum will shift toward the side of the collapsed lung. The pleural cavities form in much the same way as the pericardial cavity. Each pleural cavity is composed of mesothelium (simple squamous epithelium), which is referred to as the **pleura**. The pleura are composed of two layers: visceral and parietal (**figure 20.9**). The **visceral pleura** is the inner layer and is tightly adhered to, and inseparable from, the outer surface of the lung. The **parietal pleura**

is the outer layer and forms the wall of the pleural cavity. On a human cadaver the parietal pleura can often be seen as a shiny tissue attached to the innermost part of the rib cage or the superior surface of the diaphragm. Between the two serous membranes is a fluid-filled space called the **pleural cavity**. Note that the lungs are contained within the pleurae, which contain serous fluid. The serous fluid reduces friction and increases surface tension of the pleurae. The latter allows the lungs to expand and contract as the thoracic cavity changes volume, because it keeps the visceral and parietal layers “stuck” together. Incidentally, if air is introduced into this pleural space, a condition called pneumothorax (*pneumo-*, air + *thorax*, breastplate, chest), the lungs will collapse, thereby making ventilation impossible.

### EXERCISE 20.7 The Pleural Cavities

1. Observe the thoracic cavity of a human cadaver or a model of the thorax (figure 20.9).
2. Identify the structures listed in figure 20.9 on the cadaver or model of the thorax, using the textbook as a guide. Then label figure 20.9.



**Figure 20.9** The Pleural Cavities. Use the terms listed to fill in the numbered labels in the figure.

- |                                      |  |  |
|--------------------------------------|--|--|
| <input type="checkbox"/> diaphragm   | <input type="checkbox"/> parietal pleura | <input type="checkbox"/> right lung      |
| <input type="checkbox"/> left lung   | <input type="checkbox"/> pleural cavity  | <input type="checkbox"/> visceral pleura |
| <input type="checkbox"/> mediastinum |  |  |

© Copyright by Denoyer-Geppert. Photo by Christine Eckel

### EXERCISE 20.8 The Lungs

This exercise involves comparing and contrasting the structures of the right and left lungs, and observing the branching pattern of the respiratory tree. Although it is easy to distinguish the right and left lungs from each other based on the number of lobes (two for the left, three for the right), locating the structures

that enter the hilum of the lung (pulmonary arteries, pulmonary veins, and bronchi) is more challenging. There are patterns for recognizing these structures that are described in this laboratory exercise. Additional observations will focus on identifying several **impressions** on the surfaces of the lungs by the structures

(continued on next page)

(continued from previous page)

that surround them. These impressions are visible in preserved human cadaver lungs and on classroom models of the lungs, but may not be visible in fresh lungs. This is because the process of fixing the lungs with preservative also fixes the impressions of adjacent organs onto the lungs (e.g., the aortic impression). The impressions are not found in fresh lungs because they have not been fixed with preservative.

**EXERCISE 20.8A: The Right Lung**

1. Observe the lungs of a human cadaver, a fresh or preserved sheep pluck (a *pluck* contains the heart, lungs, and trachea), or a classroom model of the lungs.
2. Begin by observing the right lung (**figure 20.10**). How many lobes does the right lung have? \_\_\_\_\_
3. Turn the lung so the hilum is visible (medial view; figure 20.10b). The hilum of the right lung contains branches of the pulmonary arteries and veins, bronchi, and small bronchial arteries and veins, which represent the systemic

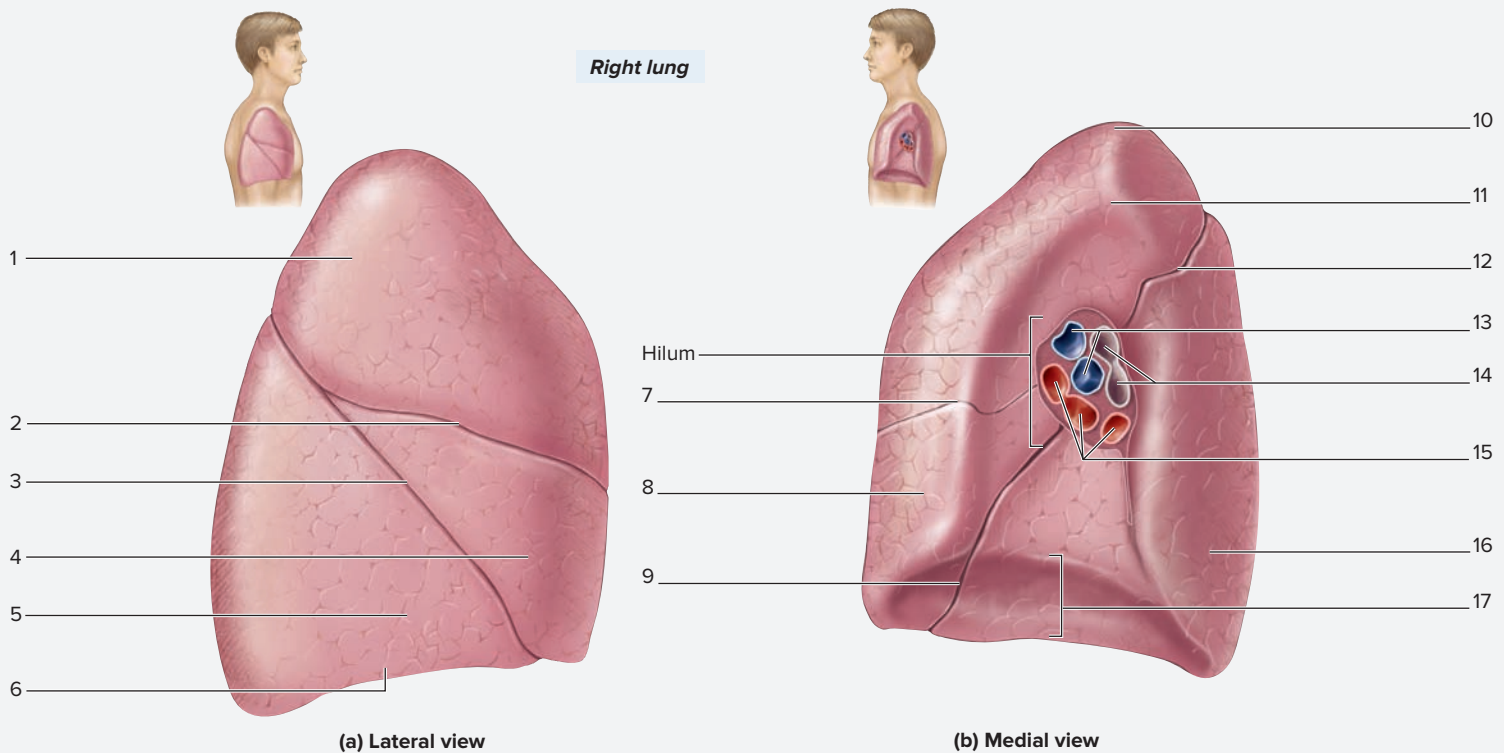
circulation to the lungs. Which of the vessels (pulmonary arteries or pulmonary veins) do you think will have thicker walls? Explain your answer:

\_\_\_\_\_

\_\_\_\_\_

\_\_\_\_\_

4. In general, the pulmonary arteries are located on the superior aspect of the hilum of the right lung, the pulmonary veins are located on the inferior and anterior aspect of the hilum of the right lung, and the bronchi are located on the superior and posterior aspect of the hilum of the right lung. If viewing cadaveric lungs, these structures will be more difficult to differentiate from each other because they are not color-coded. Thus, relying on the texture and locations of the vessels is necessary for proper identification.
5. Identify the structures listed in figure 20.10 on the lung, using the textbook as a guide. Then label figure 20.10.



**Figure 20.10 The Right Lung.** Use the terms listed to fill in the numbered labels in the figure. Some answers may be used more than once.

- |                               |   |  |   |  |
|-------------------------------|---|--|---|--|
| <input type="checkbox"/> apex | <input type="checkbox"/> horizontal fissure | <input type="checkbox"/> middle lobe     | <input type="checkbox"/> primary bronchi    | <input type="checkbox"/> pulmonary veins |
| <input type="checkbox"/> base | <input type="checkbox"/> inferior lobe      | <input type="checkbox"/> oblique fissure | <input type="checkbox"/> pulmonary arteries | <input type="checkbox"/> superior lobe   |

**Learning Strategy**



When learning the number of lobes in the right versus the left lung, think of heart anatomy as a guide. Recall the *tricuspid* valve of the heart, which has *three* cusps, is located on the

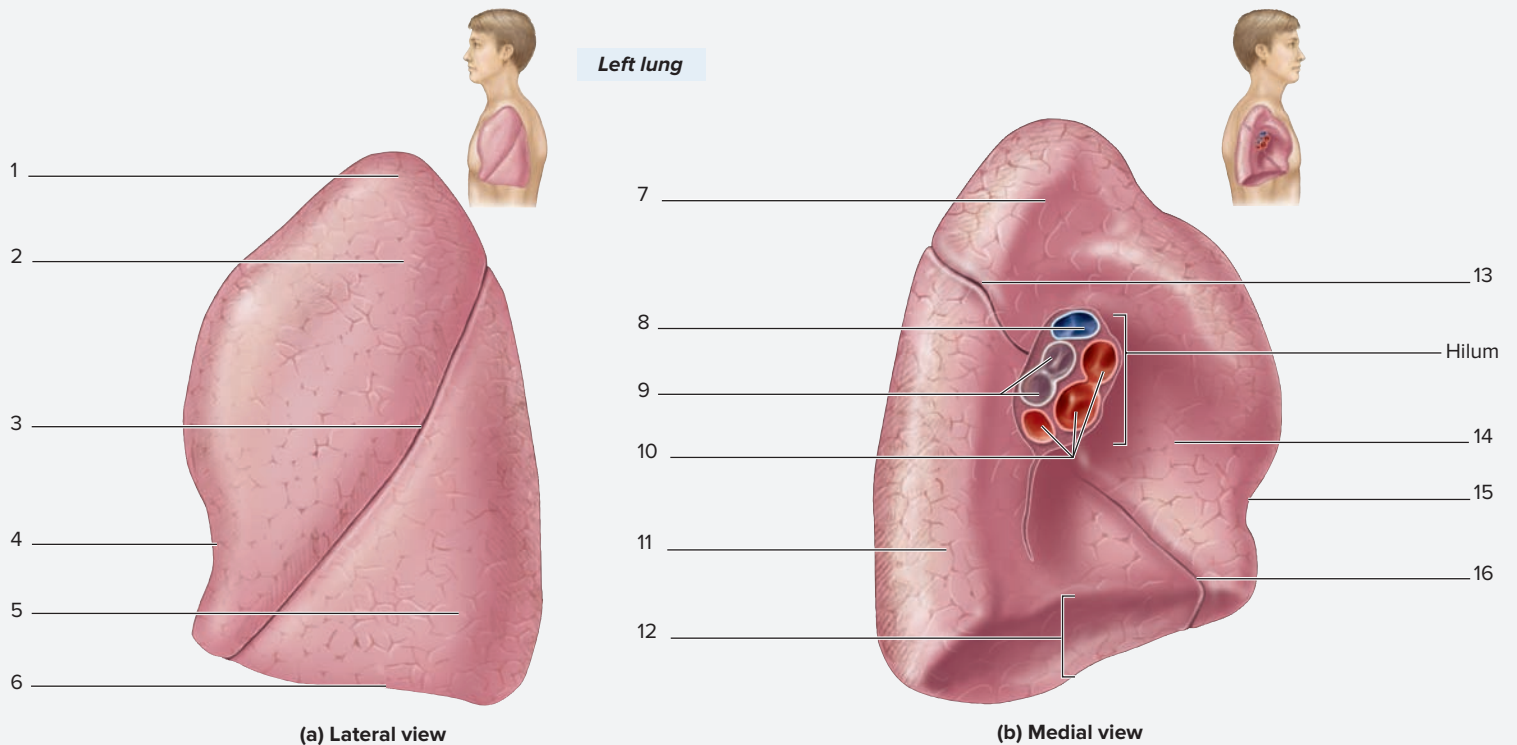
*right* side of the heart. Similarly, the *right* lung has *three* lobes. Recall the *bicuspid* valve of the heart, which has *two* cusps, is located on the *left* side of the heart. Similarly, the *left* lung has two lobes.

**EXERCISE 20.8B: The Left Lung**

1. Observe the lungs of a human cadaver, a fresh or preserved sheep pluck, or a classroom model of the lungs.
2. Observe the left lung (**figure 20.11**). How many lobes does the left lung have? \_\_\_\_\_ Is the left lung larger or smaller than the right lung? \_\_\_\_\_ Explain the reason for this difference. \_\_\_\_\_
3. Turn the lung so the hilum is visible (medial view; **figure 20.11b**). Identify the branches of the pulmonary arteries and veins, bronchi, and small bronchial arteries and veins (which represent the systemic circulation to the lungs).
4. In general, the pulmonary arteries are located on the superior aspect of the hilum of the left lung, the pulmonary veins

are located on the inferior and anterior aspect of the hilum of the left lung, and the bronchi are located on the superior and posterior aspect of the hilum of the left lung. If viewing cadaveric lungs, these structures will be more difficult to differentiate from each other because they are not color-coded. Thus, relying on the texture and location of the vessels is necessary for proper identification. The medial view of the left lung allows visualization of several impressions in the lung that are made by adjacent structures in the living human. The most prominent of these impressions is the **cardiac impression** made by the heart.

5. What features distinguish the left lung from the right lung?  
\_\_\_\_\_  
\_\_\_\_\_  
\_\_\_\_\_
6. Identify the structures listed in **figure 20.11** on the lung, using the textbook as a guide. Then label **figure 20.11**.



**Figure 20.11 The Left Lung.** Use the terms listed to fill in the numbered labels in the figure. Some answers may be used more than once.

- |   |  |   |  |
|---|--|---|--|
| <input type="checkbox"/> apex               | <input type="checkbox"/> cardiac notch   | <input type="checkbox"/> primary bronchi    | <input type="checkbox"/> pulmonary veins |
| <input type="checkbox"/> base               | <input type="checkbox"/> inferior lobe   | <input type="checkbox"/> pulmonary arteries | <input type="checkbox"/> superior lobe   |
| <input type="checkbox"/> cardiac impression | <input type="checkbox"/> oblique fissure |   |  |

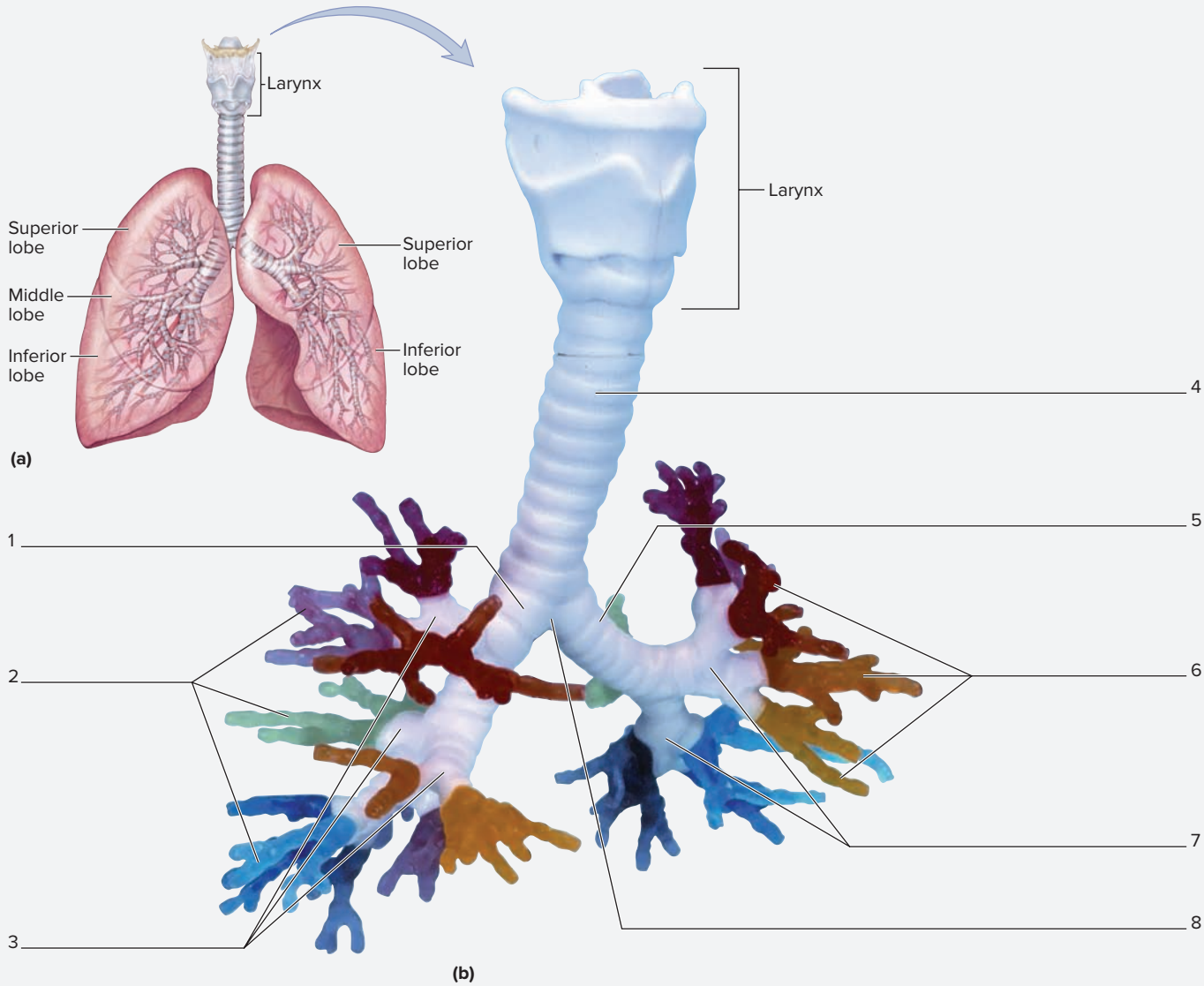
**EXERCISE 20.9 The Bronchial Tree**

The lungs are segmental by nature and are subdivided, from larger to smaller units, into **lobes**, **bronchopulmonary segments**, and **lobules**. The branching pattern of the bronchial tree follows the segmentation of the lungs (**figure 20.12**). For example, lobar (secondary) bronchi lead into lobes of the lung so three

lobar bronchi lead into the three lobes of the right lung, and two lobar bronchi lead into the two lobes of the left lung. **Table 20.8** describes the levels of the bronchial tree that serve each segment of the lungs. This segmental nature of the lungs and bronchial tree makes it relatively easy to remove a segment of the lung

*(continued on next page)*

(continued from previous page)



**Figure 20.12 The Bronchial Tree.** (a) Relationships between the bronchi and the lungs. (b) Divisions of the bronchial tree. Use the terms listed to fill in the numbered labels in the figure.

- carina (internal structure)
- left main bronchus
- right lobar bronchi
- right segmental bronchi
- left lobar bronchi
- left segmental bronchi
- right main bronchus
- trachea

Model # G23 [1000274] © 3B Scientific GmbH, Germany, 2015 www.3bscientific.com

Table 20.8	The Bronchial Tree
Portion of Bronchial Tree	Description
<b>Main (Primary) Bronchi</b>	One to each lung. The right is more vertical than the left, so foreign objects are more likely to lodge in it.
<b>Lobar (Secondary) Bronchi</b>	One to each lobe (2 on the left, 3 on the right).
<b>Segmental (Tertiary) Bronchi</b>	One to each bronchopulmonary segment.

that contains a tumor, for example, without interfering with the other parts of the lung. The **carina** (*carina*, keel of a ship) is the *internal* ridge between the most inferior tracheal cartilage and the start of the main bronchi. In the laboratory the location of the carina will be identified externally, where the main bronchi split off from the trachea; however, it is important to realize that the actual structure is internal. The carina is an important landmark for physicians performing bronchoscopy.

1. Observe the lungs of a human cadaver, a fresh or preserved sheep pluck, or a classroom model of the lungs.
2. Identify the structures listed in figure 20.12 on the cadaver lungs, sheep pluck, or classroom model of the lungs, using table 20.8 and your textbook as guides. Then label figure 20.12.

The **1** corresponds to the Learning Objective(s) listed in the chapter opener outline.

## Do You Know the Basics?

### Exercise 20.1: Olfactory Mucosa

1. Place the following layers of the wall of the respiratory tract in order from innermost to outermost. **1**

- \_\_\_\_\_ a. adventitia
- \_\_\_\_\_ b. mucosa
- \_\_\_\_\_ c. submucosa

2. Stratified squamous epithelial tissue lines the nasal cavity. \_\_\_\_\_ (True/False) **2**

3. Number the following cells that compose the olfactory epithelium in the correct order from superficial to deep. **3**

- \_\_\_\_\_ a. basal cells
- \_\_\_\_\_ b. olfactory receptor cells
- \_\_\_\_\_ c. supporting cells

### Exercise 20.2: The Trachea

4. The trachea is \_\_\_\_\_ (anterior/posterior) to the esophagus. **4**

5. Which of the following cell surface modifications and/or specialized cells may be found within the epithelium that lines the trachea? (Check all that apply.) **5**

- \_\_\_\_\_ a. cilia
- \_\_\_\_\_ b. goblet cells
- \_\_\_\_\_ c. keratinization
- \_\_\_\_\_ d. microvilli

6. The C-shaped tracheal cartilages allow the trachea to \_\_\_\_\_ (close/open), whereas the trachealis muscle allows the trachea to \_\_\_\_\_ (close/open). **6**

### Exercise 20.3: The Bronchi and Bronchioles

7. Which of the following epithelia and/or cell surface modifications are present in large bronchi? (Check all that apply.) **7 8**

- \_\_\_\_\_ a. cilia
- \_\_\_\_\_ b. goblet cells
- \_\_\_\_\_ c. microvilli
- \_\_\_\_\_ d. pseudostratified ciliated columnar epithelium
- \_\_\_\_\_ e. stratified squamous epithelium

### Exercise 20.4: The Lungs

8. Alveoli are sac-like structures that serve as the site of gas exchange. \_\_\_\_\_ (True/False) **9**

9. The respiratory membrane, through which a molecule of carbon dioxide must travel in order to diffuse from the blood into the alveoli, is composed of alveolar epithelium, a fused basement membrane, and a capillary endothelium. \_\_\_\_\_ (True/False) **10**

10. Alveolar type \_\_\_\_\_ (I/II) cells are responsible for producing surfactant. **11**

### Exercise 20.5: Midsagittal Section of the Head and Neck

11. The nasal cavity contains the superior, middle, and inferior nasal \_\_\_\_\_ (conchae/meatuses), and the spaces between, known as the superior, middle, and inferior \_\_\_\_\_ (conchae/meatuses). **12**

### Exercise 20.6: The Larynx

12. The structures located more superior in the larynx are the \_\_\_\_\_ (vestibular/vocal) folds. **13 14**



13. Which of the following are unpaired cartilages of the larynx? (Check all that apply.) 15

- a. arytenoid
- b. cricoid
- c. cuneiform
- d. epiglottis
- e. thyroid

14. The larynx houses vestibular folds, which are responsible for sound production. \_\_\_\_\_ (True/False) 16

### Exercise 20.7: The Pleural Cavities

15. The outermost layer of the pleura is the \_\_\_\_\_ (parietal/visceral) pleura. 17

### Exercise 20.8: The Lungs

16. The left lung is smaller than the right lung. \_\_\_\_\_ (True/False) 18

17. The hilum of the right or left lung contains pulmonary arteries and veins. \_\_\_\_\_ (True/False) 19

18. The right lung contains \_\_\_\_\_ (one/two) fissures, whereas the left lung contains \_\_\_\_\_ (one/two) fissures. 20

### Exercise 20.9: The Bronchial Tree

19. Rank the following branches of the bronchial tree in the order a molecule of oxygen would encounter them as it moves from the trachea into the left lung. 21

- a. left lobar bronchus
- b. left main bronchus
- c. left segmental bronchus

20. Two lobar bronchi lead into the right lung. \_\_\_\_\_ (True/False) 22

### Can You Apply What You've Learned?

21. Trace the pathway a molecule of oxygen must take to travel from the nasal cavity to an alveolus in the inferior lobe of the right lung. Be sure to name all the conducting and respiratory portion structures the molecule will pass through along the way.

---



---



---

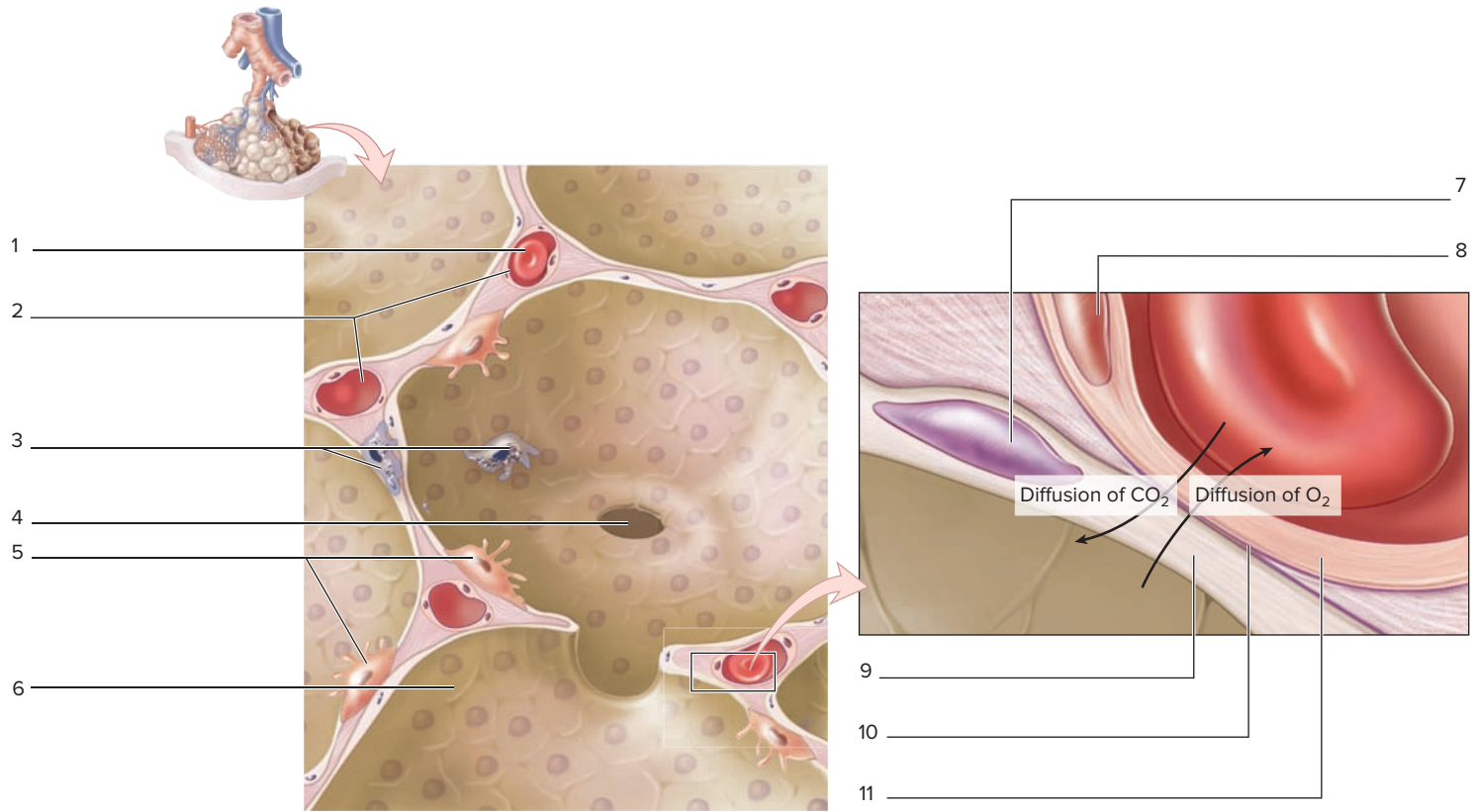
22. A toddler coughs when attempting to swallow a bite of hot dog, and the hot dog is directed into the respiratory tree instead of the esophagus.

The piece of hot dog is most likely to become lodged in the airways leading to the \_\_\_\_\_ lung because the primary bronchus to this lung is more vertically oriented than the primary bronchus to the other lung. (Note: In 2010 the FDA listed hot dogs as a major choking hazard for children. It even suggested that hot dogs should have warning labels on them because of the large number of children who choke on them.)

23. A fracture of the ethmoid bone, as might occur in an auto accident involving severe facial injuries, can cause an individual to lose his or her sense of \_\_\_\_\_. This is due to damage to the \_\_\_\_\_ nerves, which travel through the \_\_\_\_\_ of the ethmoid bone en route to the brain.

24. Label the structures in the figure. Then list, in order, the three structures through which a molecule of carbon dioxide must travel in order to diffuse from the blood into the alveoli.

- a. \_\_\_\_\_
- b. \_\_\_\_\_
- c. \_\_\_\_\_



25. Hyaline membrane disease of the newborn, a disease in which the infant experiences great difficulty breathing, is characterized by a lack of pulmonary surfactant production. Which cells within the lung are responsible for producing surfactant? \_\_\_\_\_

26. The following questions refer to the micrograph shown here.

a. What type of airway is indicated in this micrograph? (The star is in the lumen of the airway in question.)

\_\_\_\_\_

\_\_\_\_\_

b. Explain the reasoning for the answer to part (a) of this question. That is, explain the histological features of the airway (epithelium, cartilage, etc.) that were used to determine the answer.

\_\_\_\_\_

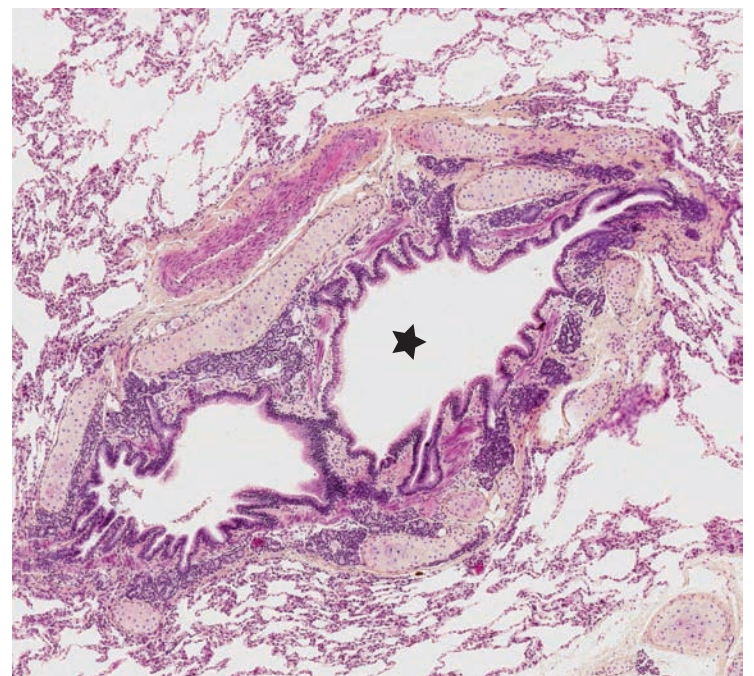
\_\_\_\_\_

\_\_\_\_\_

\_\_\_\_\_

\_\_\_\_\_

\_\_\_\_\_



*This page intentionally left blank*

# The Digestive System

# 21

## OUTLINE AND LEARNING OBJECTIVES

### Histology 448

#### Salivary Glands 448

##### EXERCISE 21.1: HISTOLOGY OF THE SALIVARY GLANDS 449

- 1 Identify mucous and serous cells in histology slides of salivary glands
- 2 Distinguish the parotid, submandibular, and sublingual salivary glands from each other when viewed with a microscope, using histological characteristics unique to each gland

#### The Stomach 450

##### EXERCISE 21.2: WALL LAYERS OF THE STOMACH 450

- 3 Identify the layers of the stomach wall when viewed with a microscope
- 4 Describe the tissues located in each layer of the stomach wall
- 5 Classify the epithelium that lines the stomach

##### EXERCISE 21.3: HISTOLOGY OF THE STOMACH 453

- 6 Identify gastric pits and gastric glands in histology slides of the stomach
- 7 Identify chief cells, mucous neck cells, parietal cells, and surface mucous cells on histology slides of the stomach

#### The Small Intestine 455

##### EXERCISE 21.4: HISTOLOGY OF THE SMALL INTESTINE 456

- 8 Describe the structures that increase the total surface area of the small intestine
- 9 Classify the epithelium that lines the small intestine
- 10 Distinguish the three parts of the small intestine (duodenum, jejunum, and ileum) from each other when viewed through a microscope, using histological characteristics unique to each

#### The Large Intestine 457

##### EXERCISE 21.5: HISTOLOGY OF THE LARGE INTESTINE 457

- 11 Identify the large intestine when viewed through a microscope
- 12 Classify the epithelium that lines the large intestine
- 13 Describe the wall layers of the large intestine

#### The Liver 458

##### EXERCISE 21.6: HISTOLOGY OF THE LIVER 459

- 14 Identify the liver and its associated structures when viewed through a microscope
- 15 Describe the structure of a hepatic lobule
- 16 Explain how blood flows through a hepatic lobule

#### The Pancreas 459

##### EXERCISE 21.7: HISTOLOGY OF THE PANCREAS 460

- 17 Identify the histological structure of the exocrine part of the pancreas when viewed through a microscope
- 18 Distinguish the exocrine and endocrine parts of the pancreas from each other
- 19 Describe the histological structure of the exocrine part of the pancreas

### Gross Anatomy 461

##### EXERCISE 21.8: OVERVIEW OF THE GI TRACT 461

- 20 List the structures encountered along the GI tract, in order, from mouth to anus

#### The Oral Cavity, Pharynx, and Esophagus 461

##### EXERCISE 21.9: GROSS ANATOMY OF THE ORAL CAVITY, PHARYNX, AND ESOPHAGUS 462

- 21 Identify structures of the digestive system as seen in a midsagittal section of the head and neck

#### The Stomach 463

##### EXERCISE 21.10: GROSS ANATOMY OF THE STOMACH 464

- 22 Identify the gross anatomic features of the stomach

#### The Duodenum, Gallbladder, Liver, and Pancreas 465

##### EXERCISE 21.11: GROSS ANATOMY OF THE DUODENUM, LIVER, GALLBLADDER, AND PANCREAS 467

- 23 Describe the anatomic relationships between the duodenum, gallbladder, liver, and pancreas
- 24 Identify the gross anatomic features of the liver
- 25 Trace the flow of a drop of bile from the gallbladder to the duodenum

#### The Jejunum and Ileum of the Small Intestine 469

##### EXERCISE 21.12: GROSS ANATOMY OF THE JEJUNUM AND ILEUM OF THE SMALL INTESTINE 470

- 26 Describe the structure of encroaching fat, arterial arcades, and vasa recta
- 27 Distinguish the jejunum and ileum from each other using gross anatomic characteristics

#### The Large Intestine 470

##### EXERCISE 21.13: GROSS ANATOMY OF THE LARGE INTESTINE 471

- 28 Identify the three major regions of the large intestine
- 29 Identify the segments of the colon

## INTRODUCTION

The digestive (*digero*, to force apart, dissolve) system is responsible for the breakdown and absorption of molecules that are needed by the body for energy, maintenance, and ultimately survival. The gastrointestinal (GI) tract, or digestive tract, consists of a long tube that is composed of the mouth, pharynx, esophagus, stomach, small intestine, and large intestine. In addition, accessory structures including the salivary glands, liver, gallbladder, and pancreas add secretions to the GI lumen, which are required for digestion of ingested food. The wall that composes each portion of the GI tract is composed of four layers, which include the mucosa, submucosa, muscularis, and adventitia or serosa. This is very similar to the way the walls of upper respiratory tract structures are layered.

Consider that the GI tract is open to the environment at both ends (the oral cavity and the anus). This means that the lining of the GI tract is open to the external environment. Thus, the interface between the lumen of the GI tract and the internal environment of the body presents a special problem. The GI tract must transport needed substances from the lumen of the GI tract into the blood capillaries and lymph capillaries within the GI wall, while also preventing pathogens from entering. For this reason, the wall of the entire GI tract is densely populated with lymphatic tissues.

The laboratory exercises in this chapter guide students in exploring how the wall layers of the various parts of the GI tract are modified to suit the particular needs of each organ. Further exercises explore the structure and function of organs such as the liver and pancreas. While observing the structures of the digestive system, various circulatory and lymphatic structures associated with these structures will also be reconsidered in the context of their specific roles within the digestive system.

Specific exercises within the chapter begin with a guide to observations of both the histological structure and the gross structure of the GI tract. The materials in the “Histology” and “Gross Anatomy” sections are organized so the order of structures studied begins at the mouth and ends at the anus. In other words, the structures are studied in the order in which they would be encountered by a bolus of food that encounters the mouth and subsequently moves through the GI tract until it reaches the anus. It is not imperative that the structures are observed in this order; however, the advantage of studying the structures in this order is that it allows one to reflect on how the different parts of the GI tract work together to accomplish the overall process of digestion.

### List of Reference Tables

Table 21.1	Histological Characteristics of Salivary Glands	p. 449
Table 21.2	Salivary Gland Structures	p. 450
Table 21.3	Wall Layers of the Stomach	p. 452
Table 21.4	Regional Characteristics of the Gastric Pits and Glands of the Stomach	p. 454
Table 21.5	Cell Types in the Gastric Pits and Glands of the Stomach	p. 454
Table 21.6	Regional Differences in the Small Intestine	p. 455
Table 21.7	Gross Anatomic Regions and Features Associated with the Stomach	p. 463
Table 21.8	Gross Anatomic Features of the Liver, Gallbladder, Pancreas, and Their Associated Ducts	p. 466
Table 21.9	Gross Anatomic Differences Between the Jejunum and the Ileum	p. 469
Table 21.10	The Cecum, Large Intestine, Rectum, and Anus	p. 470

These Pre-laboratory Worksheet questions may be assigned by instructors through their **connect** course.

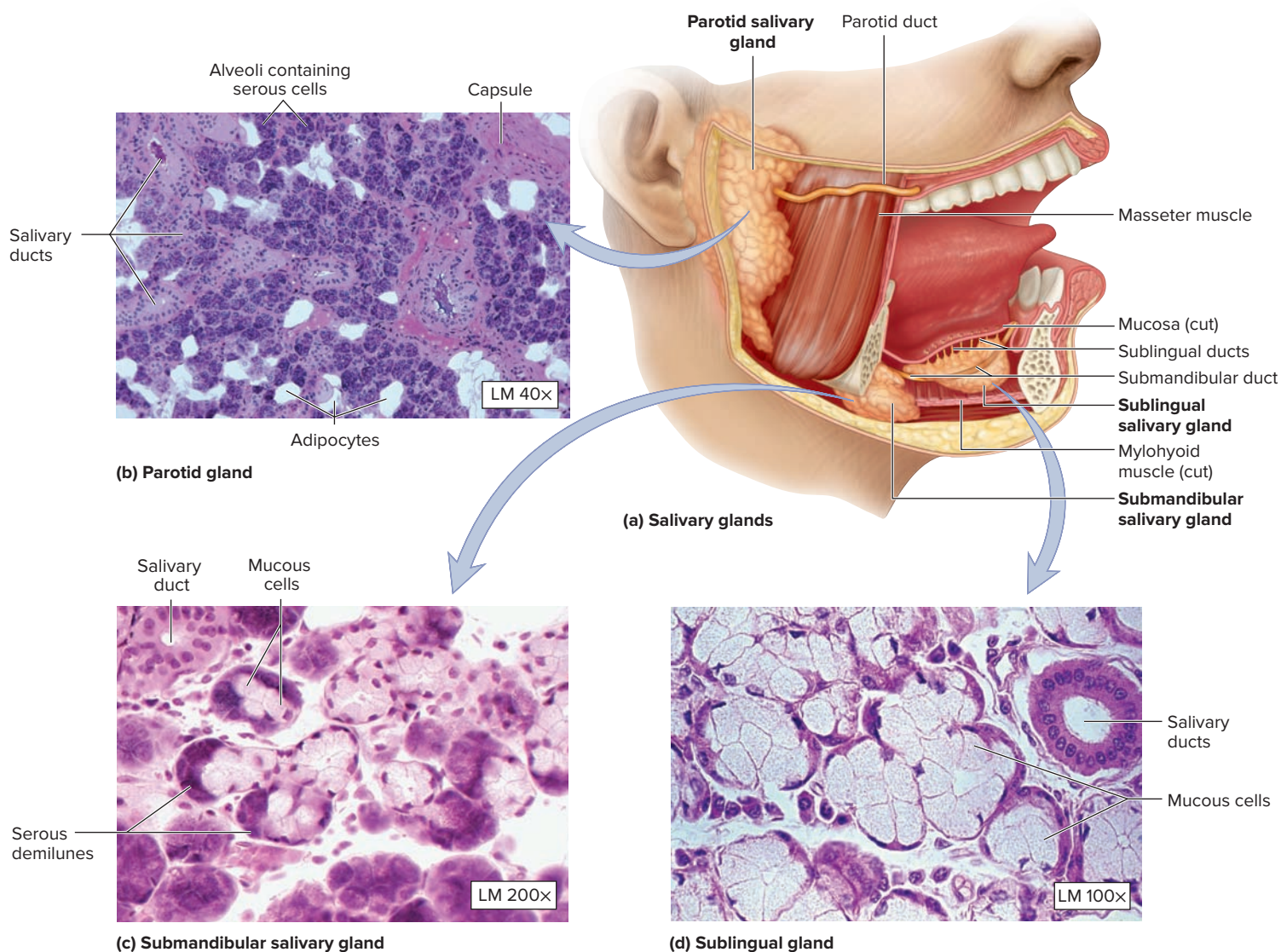
1. Humans have \_\_\_\_\_ (two/three) pairs of salivary glands.
2. The oral cavity opens into the \_\_\_\_\_ (nasopharynx/laryngopharynx/oropharynx).
3. The esophagus is located \_\_\_\_\_ (anterior/posterior) to the trachea.
4. The wall of the stomach contains \_\_\_\_\_ (two/three) layers of smooth muscle.
5. Which of the following types of epithelial tissue lines the small and large intestine? (Circle one.)
  - a. simple columnar with goblet cells
  - b. simple columnar with goblet cells and cilia
  - c. simple columnar with goblet cells and microvilli
  - d. simple cuboidal with goblet cells
  - e. simple cuboidal with goblet cells and cilia
6. Which of the following places the three segments of the small intestine in order? (Circle one.)
  - a. duodenum, ileum, jejunum
  - b. duodenum, jejunum, ileum
  - c. ileum, jejunum, duodenum
  - d. jejunum, duodenum, ileum
  - e. jejunum, ileum, duodenum
7. The ducts from the liver, gallbladder, and pancreas empty into the \_\_\_\_\_ (pylorus/duodenum).
8. The liver consists of \_\_\_\_\_ (two/four) lobes. The largest lobe of the liver is the \_\_\_\_\_ (right/left) lobe.
9. The cecum is located at the beginning of the \_\_\_\_\_ (ascending/descending) colon.
10. Which of the following is NOT an unpaired branch that comes directly off of the aorta and provides arterial blood to portions of the GI tract? (Circle one.)
  - a. celiac trunk
  - b. common hepatic artery
  - c. inferior mesenteric artery
  - d. splenic artery
  - e. superior mesenteric artery
11. The gallbladder is located near the \_\_\_\_\_ (beginning/end) of the GI tract.

## Histology

### Salivary Glands

The **salivary glands** (figure 21.1) are accessory digestive glands composed of modified epithelial tissue that produce **saliva**, a watery secretion that helps dissolve foodstuffs and contains an enzyme, **salivary amylase**, which begins the initial digestion of carbohydrates. There are three pairs of salivary glands: parotid, submandibular, and sublingual. All of the salivary glands empty their secretions into the oral cavity through ducts. Salivary glands contain two cell types: serous cells and mucous cells.

**Serous cells** produce watery secretions containing proteins, electrolytes, and the enzymes salivary amylase and lysozyme. **Mucous cells** produce mucin, which, when hydrated becomes mucus. Both serous fluid anducus function as lubricants to ease the passage of the wet mass of food called the **bolus** (*bolos*, lump) through the pharynx and esophagus. Details of the structure and function of each of the salivary glands are listed in **table 21.1**. Definitions of structures related to salivary glands are described in **table 21.2**.



**Figure 21.1 Salivary Glands.** (a) Location of the salivary glands. Histology of the (b) parotid, (c) submandibular, and (d) sublingual glands.

(b) © Carolina Biological Supply Company/Phototake; (c) © McGraw-Hill Education/AI Telser; (d) ©Victor P. Eroschenko

Gland	Secretory Cells	Type of Secretion	% of Saliva	Opening	Word Origins
<i>Parotid</i>	All <b>serous</b> —serous cells occupy about ~90% of the gland's volume (the rest is adipose connective tissue)	Mostly water; 25% of dissolved solutes are glycoproteins; high amylase content.	26–30%	Empties via the parotid duct opposite the second upper molar.	<i>para-</i> , beside + <i>ous</i> , ear
<i>Sublingual</i>	<b>Mixed</b> : 60–70% serous, 30–40% mucus; serous cells are located in serous demilunes	90% of solutes are glycoproteins (the most viscous secretion); low amylase content.	3–5%	Empties via multiple ducts into either the submandibular duct or directly into the oral cavity.	<i>sub-</i> , under + <i>lingual</i> , the tongue
<i>Submandibular</i>	<b>Mixed</b> : 80% serous, 20% mucus, contains a few serous demilunes	40–60% of dissolved solutes are glycoproteins; low amylase content; contains lysozyme, an enzyme that inhibits the growth of bacteria.	60–70%	Empties via the submandibular ducts between the lingual frenulum and the mandible.	<i>sub-</i> , under + <i>mandible</i> , the mandible

### EXERCISE 21.1 Histology of the Salivary Glands

- Obtain a compound microscope and histology slides of the parotid, submandibular, and sublingual salivary glands.
- Place the slide of the **parotid gland** on the microscope stage. Bring the tissue sample into focus on low power and then switch to high power.
- Identify the listed structures on the slide of the parotid gland, using figure 21.1a and tables 21.1 and 21.2 as guides:
  - adipocytes
  - serous cells
- Place the slide of the **submandibular gland** on the microscope stage. Bring the tissue sample into focus on low power and then switch to high power.
- In the submandibular and sublingual salivary glands, the serous cells are located surrounding the mucous cells and are shaped like half-moons. Thus, they are referred to as *serous demilunes* (*demi-*, half + *luna*, moon). Scan the slide to locate serous demilunes (figure 21.1b and 21.1c).
- Identify the listed structures on the slide of the submandibular gland, using figure 21.1c and tables 21.1 and 21.2 as guides:
  - adipocytes
  - serous demilunes
  - salivary duct
- Place the slide of the **sublingual gland** on the microscope stage. Bring the tissue sample into focus on low power and then switch to high power.
- The sublingual gland is similar to the submandibular gland in that it contains serous demilunes. Two characteristics help distinguish the sublingual gland from the submandibular gland. The sublingual gland contains fewer adipocytes and greater numbers of mucous cells than the submandibular gland (table 21.2 and figure 21.1d).
- Identify the listed structures on the slide of the sublingual gland, using figure 21.1c and tables 21.1 and 21.2 as guides:
  - mucous cells
  - serous demilunes
  - salivary duct

(continued on next page)




(continued from previous page)

Structure	Description and Location	Functions	Word Origin
<i>Alveolus</i>	The grape-shaped secretory portion of a gland.	NA	<i>alveolus</i> , a trough or basin
<i>Mucous Cells</i>	Cells have flattened nuclei that are located on the basal surface. Mainly located along the tubules of salivary glands.	Secrete mucus.	<i>mucosus</i> , mucous
<i>Myoepithelial Cells</i>	Cells are not visible in light microscopy. Located around the alveoli and the long axes of the ducts.	Contraction of these cells expels the secretions from salivary glands.	<i>myo-</i> , muscle + <i>epithelial</i> , relating to epithelial tissues
<i>Serous Cells</i>	Cells have round nuclei and contain numerous secretory granules. Located in the alveoli of the parotid gland and in the demilunes of the submandibular and sublingual glands.	Secrete proteins, electrolytes, and salivary amylase.	<i>serous</i> , having a watery consistency
<i>Serous Demilunes</i>	Crescent- or moon-shaped groups of serous cells located at the periphery of a mucous alveolus.	Secrete proteins, electrolytes, and salivary amylase.	<i>serous</i> , having a watery consistency + <i>demilune</i> half-moon

10. Sketch the histological appearance of the parotid, submandibular, and sublingual salivary glands in the spaces

provided. Label mucous cells, serous cells, and serous demilunes in the drawings.

*Parotid gland**Sublingual gland**Submandibular gland*

\_\_\_\_\_ ×



\_\_\_\_\_ ×



\_\_\_\_\_ ×

## The Stomach

The **stomach** is an organ that digests food using both mechanical and chemical mechanisms. The mechanical mixing of food occurs via the action of smooth muscle in the wall of the stomach. The chemical dissolving of food occurs as stomach enzymes and a highly acidic environment convert the bolus of food into a liquid puree called **chyme**

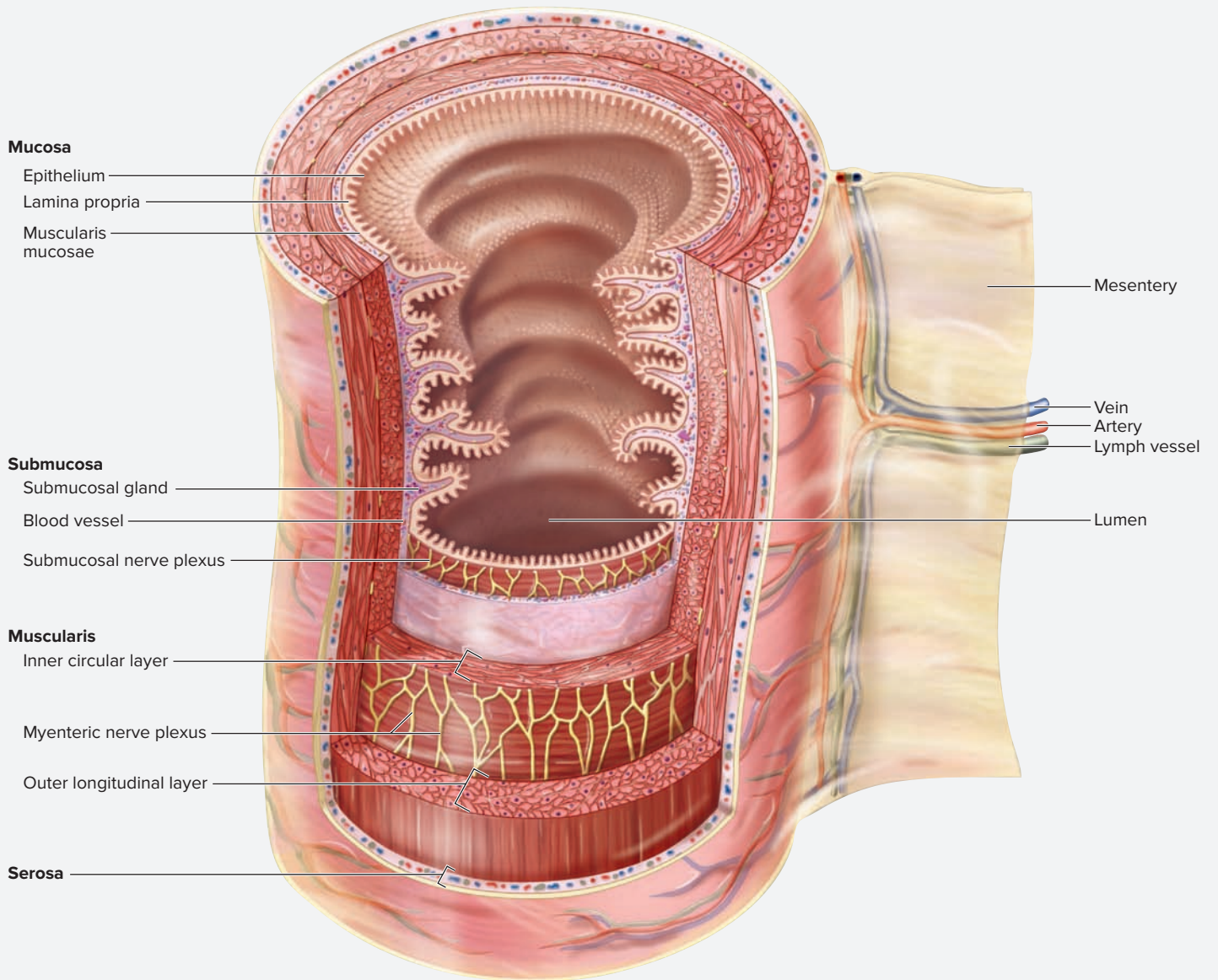
(*chymos*, juice). The exercises in this section of the chapter begin by guiding students in making observations of the wall layering pattern of the stomach. This will be followed by exercises that guide students in observing regional characteristics of the epithelium that lines the stomach wall.

### EXERCISE 21.2 Wall Layers of the Stomach

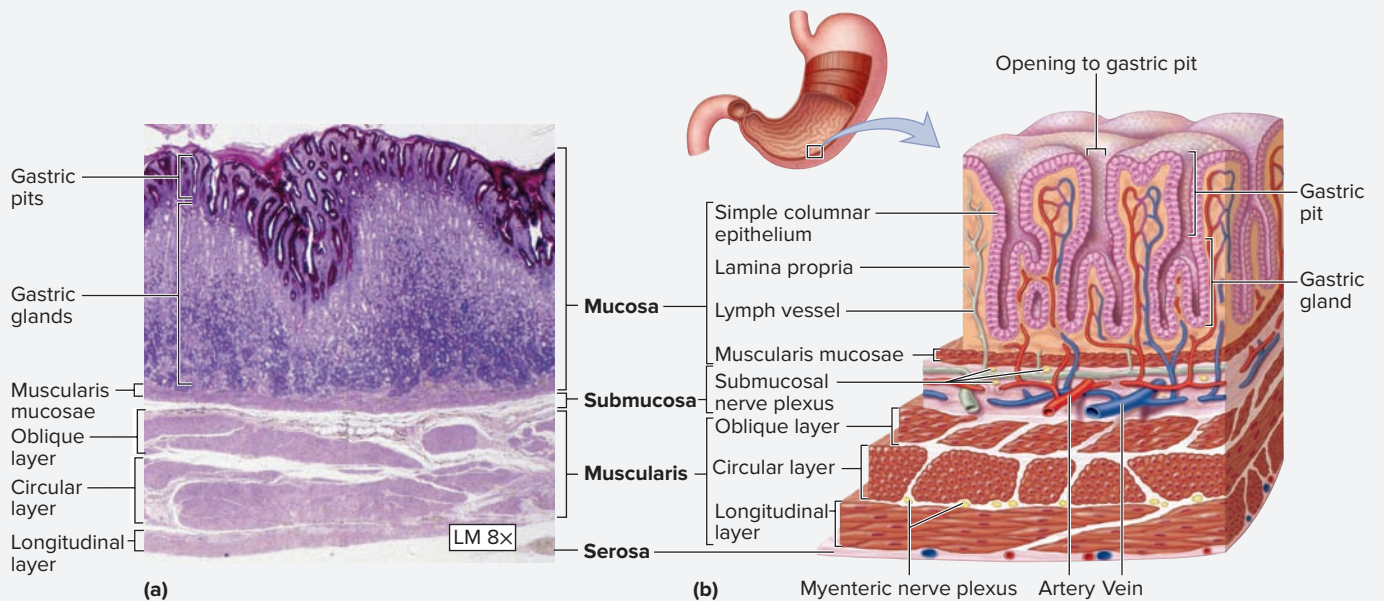
The walls of the digestive tract, much like the walls of the respiratory tract, are composed of four layers, the **mucosa**, **submucosa**, **muscularis**, and **adventitia/serosa**. **Figure 21.2** demonstrates the general wall layering pattern of organs of the digestive tract, and **figure 21.3**

demonstrates how these wall layers are modified in the stomach. **Table 21.3** describes the types of tissues that are located in each of the layers of the stomach wall.

(continued on page 452)



**Figure 21.2** Wall Layers of the Digestive Tract. The four wall layers of the digestive tract are the mucosa, submucosa, muscularis, and adventitia/serosa.



**Figure 21.3** The Stomach Wall. (a) Histology of the stomach wall. (b) Layers of the stomach wall.

(a) © Victor P. Eroschenko

(continued on next page)

*(continued from page 450)*

- Obtain a histology slide of the stomach (figure 21.3) and place it on the microscope stage. Bring the tissue sample into focus on low power.
- Identify the listed layers of the stomach wall on the slide, using figure 21.3 and table 21.3 as guides:

- |   |  |
|---|--|
| <input type="checkbox"/> blood vessels                | <input type="checkbox"/> muscularis                      |
| <input type="checkbox"/> epithelium                   | <input type="checkbox"/> muscularis mucosa               |
| <input type="checkbox"/> inner oblique muscle layer   | <input type="checkbox"/> nerves                          |
| <input type="checkbox"/> lamina propria               | <input type="checkbox"/> outer longitudinal muscle layer |
| <input type="checkbox"/> middle circular muscle layer | <input type="checkbox"/> serosa                          |
| <input type="checkbox"/> mucosa                       | <input type="checkbox"/> submucosa                       |

- Sketch the histology of the stomach wall as seen through the microscope in the space provided. Label the structures listed in step 2 in the drawing.

**Table 21.3****Wall Layers of the Stomach**

Layer	Sublayer	Characteristics
<i>Mucosa</i>	Epithelium	Simple columnar epithelium containing five distinct cell types (see table 21.5).
	Lamina propria	Highly cellular, contains reticular connective tissue below and in between glands. Free lymphocytes and lymphatic nodules are common.
	Muscularis mucosae	Composed of thin layer of smooth muscle.
<i>Submucosa</i>	Connective tissue	Composed of coarse bundles of collagen fibers, many elastic fibers, and adipose tissue.
	Vessels	Contains both blood and lymphatic vessels.
	Nerves	Submucosal nerve plexus.
<i>Muscularis</i>	Inner oblique	Contains muscle fibers responsible for creating the “twisting” action of the stomach.
	Middle circular	Forms the thickest layer of the three layers of muscle. Thickenings of this layer form the inferior esophageal (cardiac) and pyloric sphincters.
	Outer longitudinal	Found in the greater and lesser curvatures only.
	Nerves	Myenteric nerve plexus is located between the layers of smooth muscle.
<i>Serosa</i>	NA	Thin connective tissue and mesothelium.

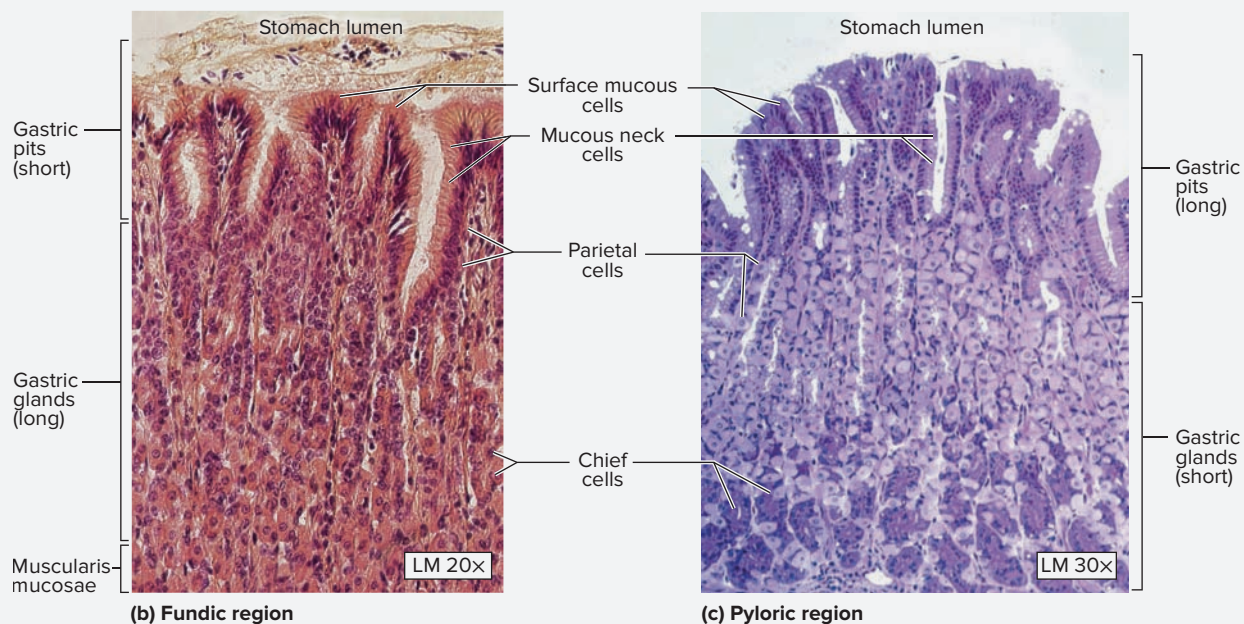
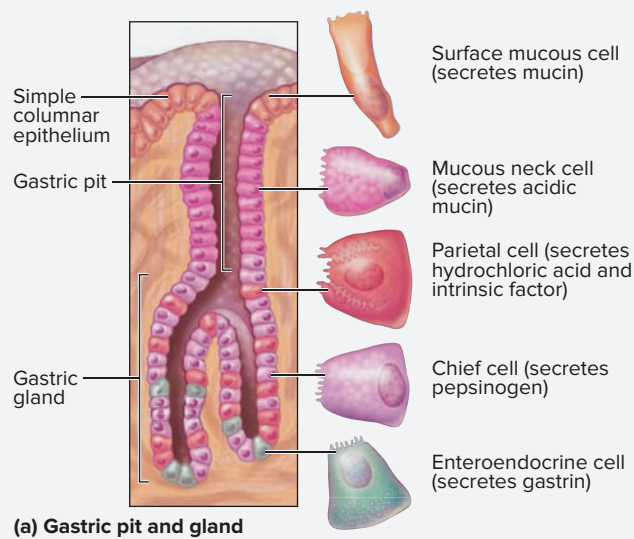
**EXERCISE 21.3** Histology of the Stomach

The epithelium of the stomach is modified in a way that will be unfamiliar to most students up to this point. The reason for this is that, instead of having folds that project into the lumen of the organ, the stomach's "folds" run deep into the epithelium. They also generate new cells differently than typical epithelia. Typical epithelial regenerate new cells from the basal layer. Thus, the newest cells are on the basement membrane and the oldest cells are on the apical surface (if it is a stratified epithelium, that is). Either way, the cells typically regenerate along the entire sheet of epithelium at the same rate. The gastric epithelium consists of deep/inward folds of epithelia called **gastric pits**. At the bottom of the gastric pits are smaller openings into what are called gastric glands. The cells that line the **gastric glands** (figure 21.4) are responsible for producing secretions that will travel through the gastric pits to enter the lumen of the stomach. **Epithelial stem cells** are located at the

junction between the gastric pits and the gastric glands. These cells continuously renew the epithelial lining of the stomach, the epithelium lining the gastric pits, and the epithelial cells that form the gastric

**Learning Strategy**

Understanding the relationship between **gastric pits** and **gastric glands** can be difficult. Let's imagine a hypothetical scenario: Imagine a person standing inside the stomach (mind you: this is a very tiny person!). The person is standing on surface mucous cells and sees a "hole" in the distance. This "hole" is the opening into a *gastric pit*. The person moves toward the gastric pit and jumps in. As the person falls into the pit, he or she is surrounded by the walls of the gastric pit, which are lined with mucous neck cells (thus, the person would probably be "slimed" while moving through the pit). Eventually, the gastric pit narrows such that the person's movement will be stopped. At this point the person is standing at the junction between a gastric pit and the opening of a *gastric gland*. Looking down, the person sees an even smaller hole below, which is too small to move into. This hole is the lumen of a *gastric gland*. The gastric gland is lined with parietal cells and chief cells, which make HCl and pepsinogen, respectively. From the point of view of the person standing at the junction between the gastric pit and the gastric gland, a mixture of HCl and pepsinogen can be seen squirting upward into the lumen of the gastric pit. Luckily, the mucous neck cells protect the lumen of the gastric pit from the incoming acid. Unfortunately, the tiny person may not be so protected!



**Figure 21.4 Gastric Pits and Gastric Glands.** (a) Gastric pits are lined with light-staining, simple columnar mucous cells. The upper regions of the gastric pits contain large, light-staining parietal cells that resemble fried eggs, while the lower regions of the gastric pits contain smaller, dark-staining chief cells. (b) The fundic region of the stomach is characterized by short pits and long glands. (c) The pyloric region of the stomach is characterized by long pits and short glands.

(b) © Science Stock Photography/Science Source; (c) © Victor P. Eroschenko

(continued on next page)

(continued from previous page)


Region	Pit Structure	Main Cell Type(s)	Gland Structure
Cardia	Short pits with long glands	All mucous	Simple branched tubular glands
Fundus/Body	Short pits with long glands	Parietal and chief cells with mucous neck cells	Branched, tubular glands
Pylorus	Long pits with short, coiled glands	Mostly mucous	Branched, tubular glands

glands. Thus, the youngest cells are located at the junction between the gastric pits and gastric glands. The epithelial cells of the stomach are replaced approximately every three days. Stem cells that will line the gastric pits and the lumen of the stomach migrate *up* from the pit/gland junction, whereas stem cells that form the gastric glands migrate *down* from the pit/gland junction. The cell types in the gastric pits and glands vary in different regions of the stomach. **Table 21.4** describes the structure of the pits and glands in each of the major regions of the stomach (cardia, fundus/body, and pylorus), **table 21.5** describes the five cell types that compose the gastric pits and glands, and the type and function of the secretions produced by each cell.

1. Obtain a histology slide of the stomach and place it on the microscope stage. Bring the tissue sample into focus on low power and then scan the slide to locate the epithelial lining of the stomach (figure 21.4). Once the epithelium of the stomach is in the center of the field of view, change to high power and bring the tissue sample into focus once again. How is the epithelium that lines the stomach classified?  
\_\_\_\_\_
2. Once the epithelium lining the stomach wall has been identified, locate a gastric pit and gland and move the microscope stage so the gastric pit/gastric gland junction is in the center of the field of view.
3. Identify the listed structures on the slide:
 

<input type="checkbox"/> chief cells	<input type="checkbox"/> mucous neck cells
<input type="checkbox"/> gastric glands	<input type="checkbox"/> parietal cells
<input type="checkbox"/> gastric pits	<input type="checkbox"/> surface mucous cells

4. Sketch the gastric glands and pits as seen through the microscope in the space provided. Label the locations of the specialized cell types in the drawing. Determine which part of the stomach wall is demonstrated on the slide based on the structure of the gastric pits and glands, using table 21.4 as a guide. \_\_\_\_\_



5. *Optional Activity:* **AP|R Digestive System**—Watch the “Stomach” animation for a review of the stomach wall layers and their histology.

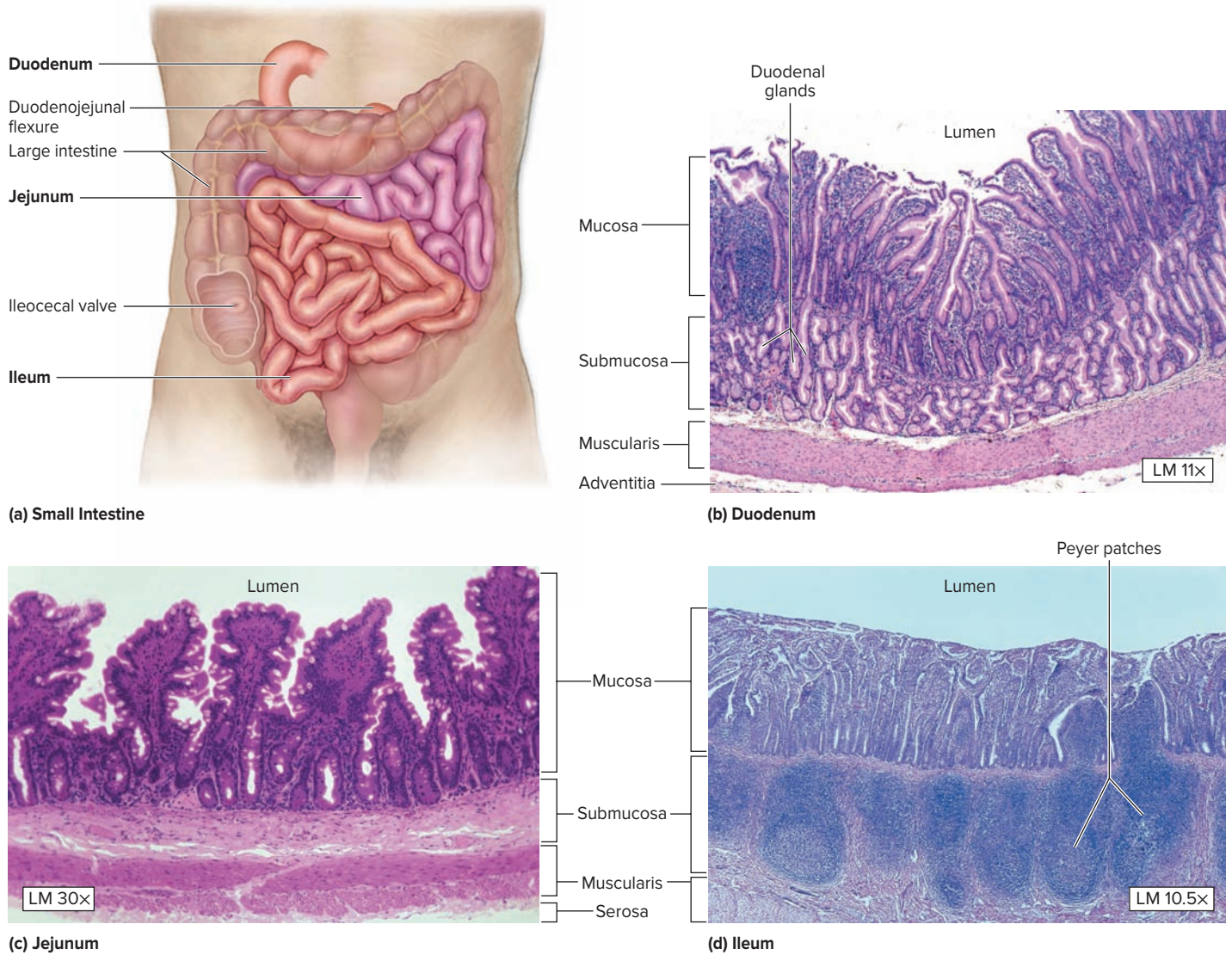
Cells	Location	Secretions	Action of Secretion
<b>Chief Cells (Zymogenic)</b>	Lower 1/2 to 1/3 of the gastric glands. Contain numerous eosinophilic (red) granules.	Pepsinogen	A zymogen* that is converted to pepsin when it encounters the acidic environment of the stomach. Pepsin is a protease (it breaks down proteins).
<b>Enteroendocrine Cells</b>	Scattered throughout the gastric glands.	Gastrin	Hormone that stimulates chief cells and parietal cells to secrete their products, and stimulates the smooth muscle in the stomach walls to contract.
<b>Mucous Neck Cells</b>	Lining the interior of the gastric pits.	Mucin	Glycoprotein that protects the mucosa from HCl.
<b>Parietal Cells</b>	Upper 2/3 of the gastric glands in the fundus and body of the stomach. A few are found in the pylorus. None are found in the cardia.	HCl (hydrochloric acid) Intrinsic factor	Decreases the pH of the stomach to about 2 (very acidic). Necessary for vitamin B <sub>12</sub> absorption in the small intestine.
<b>Surface Mucous Cells</b>	Covering the ridges between the gastric pits.	Mucin	Glycoprotein that protects the mucosa from HCl.

\*Zymogen is a general term for an inactive protein. Generally, the names of zymogens end in -ogen, as in *pepsinogen*.

## The Small Intestine

After initial digestion in the mouth and stomach, the mixture of digested food and gastric juices is collectively called chyme. When this chyme leaves the stomach, it enters the small intestine, where digestion of the chyme is completed and nutrients from the food are transported into the circulatory system. The walls of the small intestine contain several modifications that hugely increase the surface area of the small intestine for the purpose of absorption. These modifications, listed from largest to smallest, are circular folds, villi, and microvilli. **Circular folds** (plicae circulares)

are folds of the mucosal and submucosal layers of the small intestine. **Villi** (s., *villus*) are folds of mucosa that lie on top of the circular folds. Each villus is lined with a simple columnar epithelium containing **microvilli** and goblet cells. Goblet cells in the small intestine produce mucus, which helps protect the epithelial lining and lubricates the passage of chyme through the small intestine. **Figure 21.5** demonstrates histology slides of the three parts of the small intestine (duodenum, jejunum, and ileum), and **table 21.6** summarizes the distinguishing histological features of each part.



**Figure 21.5 The Small Intestine.** (a) Parts of the small intestine. (b) Histology of the duodenum, demonstrating duodenal glands in the submucosa. (c) Histology of the jejunum, which lacks duodenal glands and Peyer patches. (d) Histology of the ileum, demonstrating Peyer patches in the submucosa. (b) © Victor P. Eroschenko; (c, d) © Carolina Biological Supply Company/Phototake

Table 21.6 Regional Differences in the Small Intestine		
Region	Distinguishing Histological Characteristics	Word Origins
<i>Duodenum</i>	Contains duodenal glands, which produce an alkaline secretion that protects the duodenum from stomach acids.	<i>duodeno-</i> , breadth of twelve fingers
<i>Jejunum</i>	Identified by prominent circular folds and a lack of duodenal glands and Peyer patches.	<i>jejunus</i> , empty
<i>Ileum</i>	Peyer patches are scattered throughout the submucosa. Goblet cells increase in number closer to the ileocecal valve.	<i>eileo</i> , to roll up, twist

**EXERCISE 21.4** Histology of the Small Intestine

- Obtain a histology slide of the small intestine and place it on the microscope stage. If the laboratory is equipped with slides of each section of the small intestine (duodenum, jejunum, and ileum), be sure to view all three. If not, use figure 21.5 and table 21.6 to decide which part of the small intestine is represented on the slide.
- Bring the tissue sample into focus at low power and move the microscope stage until the epithelium is at the center of the field of view. Then change to high power. What type of epithelium lines the small intestine? \_\_\_\_\_  
 \_\_\_\_\_  
 What surface modifications are present? \_\_\_\_\_  
 \_\_\_\_\_  
 What is the purpose of these surface modifications? \_\_\_\_\_  
 \_\_\_\_\_

- Identify the listed structures on the slide(s), using figure 21.5 and table 21.6 as guides.

- |  |  |
|--|--|
| <input type="checkbox"/> blood vessels   | <input type="checkbox"/> muscularis        |
| <input type="checkbox"/> duodenal glands | <input type="checkbox"/> muscularis mucosa |
| <input type="checkbox"/> epithelium      | <input type="checkbox"/> Peyer patches     |
| <input type="checkbox"/> goblet cells    | <input type="checkbox"/> serosa            |
| <input type="checkbox"/> lamina propria  | <input type="checkbox"/> submucosa         |
| <input type="checkbox"/> microvilli      | <input type="checkbox"/> villi             |
| <input type="checkbox"/> mucosa          |  |


- Sketch the histology of the duodenum, jejunum, and ileum of the small intestine in the spaces provided (if only one slide was observed, draw that one). Identify the histological features that will allow for differentiation between the three portions of the small intestine when viewing histology slides of the small intestine (refer to table 21.6 for reference).

*Duodenum*



\_\_\_\_\_ ×

*Jejunum*



\_\_\_\_\_ ×

*Ileum*



\_\_\_\_\_ ×

**Learning Strategy**



The three parts of the small intestine can be distinguished from each other by characteristic features present or absent in the submucosal layer. The **duodenum** is characterized by the presence of **duodenal glands** in the submucosa. Duodenal glands produce an alkaline secretion that protects the duodenum from acidic chyme. The **jejunum** is characterized by its **lack of specialized structures** in the submucosa. The term *jejunum* comes from the Latin word *jejunus*, which means “empty.” Remember that the submucosa of the jejunum is “empty” because it lacks specialized structures in the submucosa. The **ileum** is characterized by the presence of **Peyer patches** (aggregates of lymphatic tissue) scattered throughout the submucosa.

## The Large Intestine


Chyme leaving the small intestine enters the **large intestine** at the ileocecal junction. A valve, the **ileocecal valve**, controls the passage of chyme from the small intestine to the large intestine. Because the vast majority of nutrients have been absorbed in the small intestine, the function of the large intestine is mainly to absorb water and some electrolytes from the chyme that remains, and compact the waste products as **feces** for elimination from

the body. The epithelium of the large intestine contains many goblet cells. The goblet cells produce vast quantities of mucus, which helps lubricate the epithelium to ease the passage of feces through the large intestine. As with the stomach, the epithelium of the large intestine consists of **intestinal glands** that project deep into the mucosa. This is in contrast to the villi of the small intestine, which project into the lumen of the small intestine.

### EXERCISE 21.5 Histology of the Large Intestine

- Obtain a histology slide of the large intestine (colon) and place it on the microscope stage.
- Bring the tissue sample into focus on low power and identify the epithelial layer (**figure 21.6**). Move the microscope stage so the epithelium is at the center of the field of view and then change to high power.
- Identify the listed structures on the slide of the large intestine, using figure 21.6 and the textbook as guides:
 

<input type="checkbox"/> blood vessels	<input type="checkbox"/> muscularis
<input type="checkbox"/> epithelium	<input type="checkbox"/> muscularis mucosae
<input type="checkbox"/> goblet cells	<input type="checkbox"/> nerves
<input type="checkbox"/> inner circular muscle layer	<input type="checkbox"/> outer longitudinal muscle layer
<input type="checkbox"/> lamina propria	<input type="checkbox"/> serosa
<input type="checkbox"/> mucosa	<input type="checkbox"/> submucosa
- Sketch the histology of the large intestine as seen through the microscope in the space provided. Label the four major layers of the wall of the large intestine in the drawing.



\_\_\_\_\_ ×

### WHAT DO YOU THINK?

- What special cell type is prominent in the epithelium of the large intestine? Why is this cell type particularly abundant in the large intestine?

### Learning Strategy

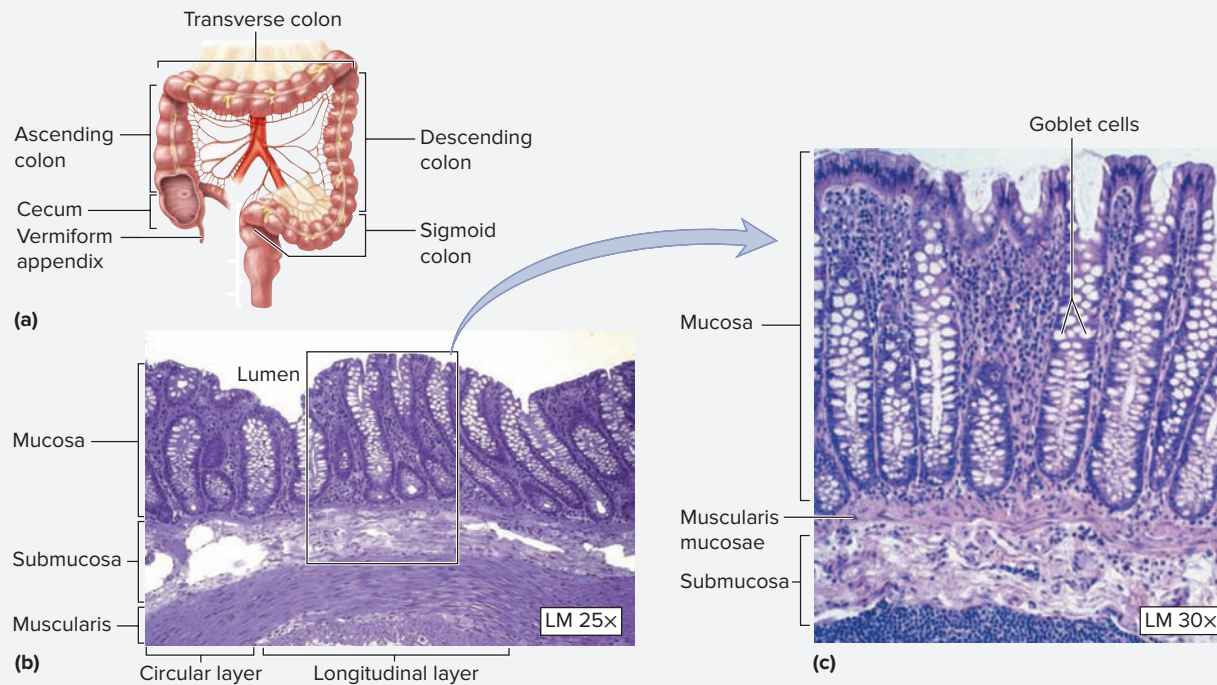
Of the three major regions of the GI tract within the abdomen (stomach, small intestine, and large intestine), the only region that contains villi is the small intestine. Both the stomach and the large intestine have pits that have pores that empty contents

into the lumen of the organ. An easy way to distinguish the large intestine from the stomach is to observe the huge numbers of goblet cells present in the large intestine, which are not present in the stomach.

*(continued on next page)*



(continued from previous page)



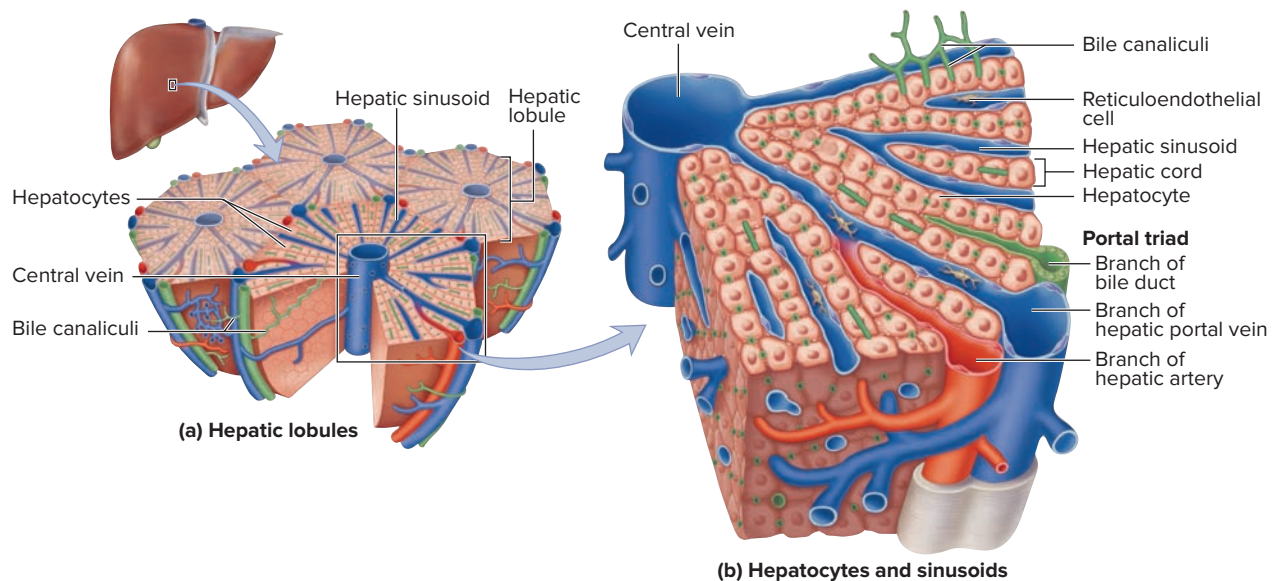
**Figure 21.6 The Large Intestine.** (a) Parts of the large intestine. (b) Histology of the wall of the large intestine. (c) Close-up of the epithelium lining the large intestine; numerous goblet cells are present.

(b, c) © Victor P. Eroschenko

## The Liver

The **liver** is the largest accessory organ in the digestive system. Indeed, it is the largest internal organ in the human body. The liver performs numerous vital functions, which include producing bile, detoxifying the blood, storing nutrients, and producing plasma proteins. However, its primary function in digestion is the production of bile. The structural and functional unit of the liver is a **hepatic lobule**. A hepatic lobule is a hexagonally shaped structure consisting of strands of **hepatocytes** (the strands of hepatocytes are **hepatic cords**) radiating outward from a **central vein** in the middle

(**figure 21.7**). In the areas where the outer edges of the hepatic lobules come together there are **portal triads**. Portal triads, as the name implies, consist of three structures: a branch of the hepatic artery, a branch of the hepatic portal vein, and a branch of a bile duct. Within the hepatic lobules, in between the hepatic cords, are **hepatic sinusoids**: capillaries that carry blood from the branches of the hepatic artery and hepatic portal vein in the portal triads to the central veins. Along the sinusoids are several macrophage-like cells, called **reticuloendothelial (Kupffer) cells**. These cells engulf bacteria that enter the liver from the portal circulation.




**Figure 21.7 Structure of a Hepatic Lobule.**

**EXERCISE 21.6** Histology of the Liver

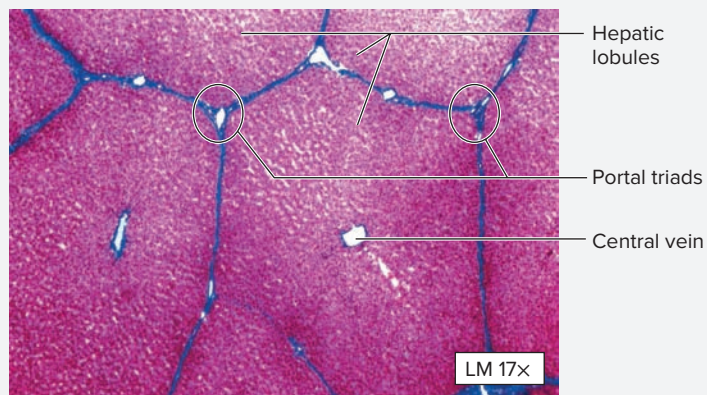
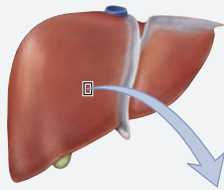
- Obtain a histology slide of the liver and place it on the microscope stage. Bring the tissue sample into focus on low power and locate a hepatic lobule (**figure 21.8a**).
- Move the microscope stage until the hepatic lobule is at the center of the field of view, and then change to high power (figure 21.8b). Identify the listed structures on the slide of the liver, using figures 21.7 and 21.8 as guides:

- |  |  |
|--|--|
| <input type="checkbox"/> branch of bile duct           | <input type="checkbox"/> hepatic lobule            |
| <input type="checkbox"/> branch of hepatic artery      | <input type="checkbox"/> hepatic sinusoids         |
| <input type="checkbox"/> branch of hepatic portal vein | <input type="checkbox"/> hepatocyte                |
| <input type="checkbox"/> central vein                  | <input type="checkbox"/> portal triad              |
| <input type="checkbox"/> hepatic cords                 | <input type="checkbox"/> reticuloendothelial cells |

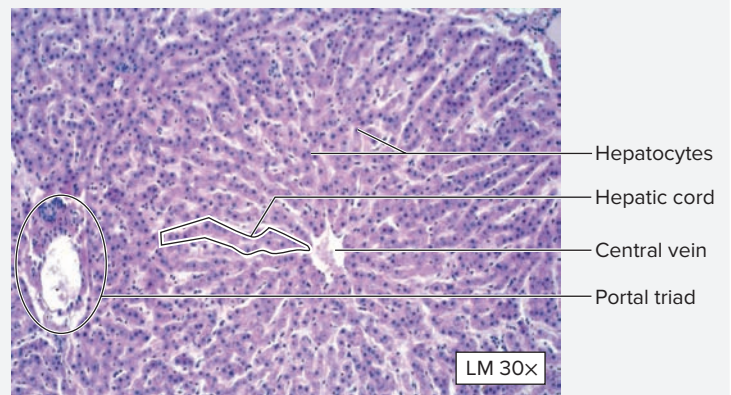
- Sketch the liver as seen through the microscope in the space provided. Label all of the structures listed in step 2 in the drawing.



- Optional Activity:** **AP|R** Digestive System—Watch the “Liver” animation to help you visualize the organization and structure of a liver lobule.



(a)



(b)

**Figure 21.8 The Liver.** (a) Low-magnification histology slide demonstrating multiple hepatic lobules with portal triads in the spaces between lobules. (b) Medium-magnification histology slide demonstrating a central vein, hepatocytes arranged into hepatic cords, and a portal triad.

(a, b) © Victor P. Eroschenko

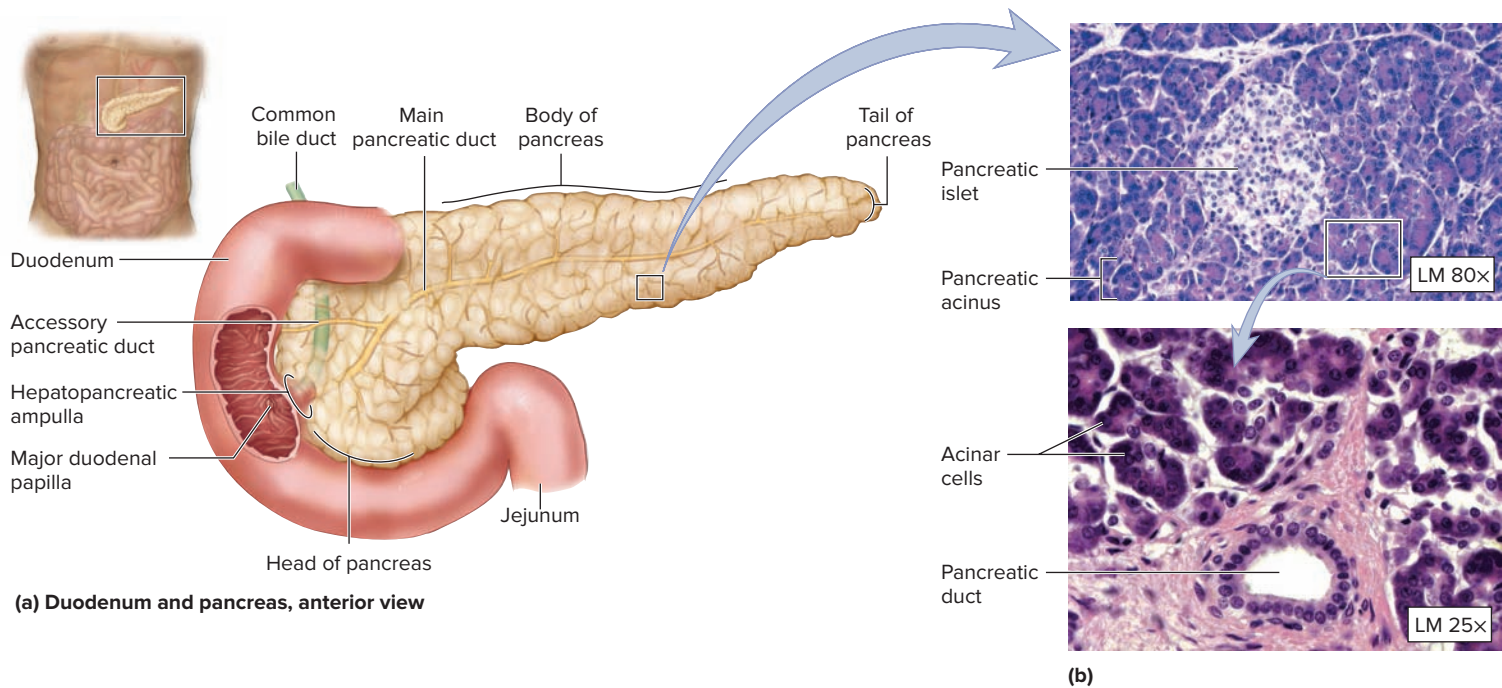
## The Pancreas

The **pancreas** is the second-largest accessory organ in the digestive system after the liver. It is both an endocrine and an exocrine gland. The histology of the endocrine part of the pancreas (the pancreatic islets) was covered in chapter 16 (The Endocrine System). The **exocrine** portion

of the pancreas consists of grapelike bunches of cells called **acini** (s., *acinus*), which are similar in many ways to the cells that compose the salivary glands. The **acinar cells** composing the acini produce many substances important for digestion, including digestive enzymes (e.g., pancreatic amylase). Cells of pancreatic ducts produce bicarbonate ion

( $\text{HCO}_3^-$ ). Collectively, these secretions are called **pancreatic juice**. Pancreatic juice is transported from the acinar cells into small ducts that become larger ducts and eventually dump the secretions into the

duodenum via the **main pancreatic duct** (or accessory pancreatic duct) (**figure 21.9**).



**Figure 21.9 The Pancreas.** (a) Location of the pancreas. (b) Histology of the pancreas demonstrating acinar cells, which secrete digestive enzymes and pancreatic islets, which contain the hormone-secreting cells of the pancreas.

(b) (top) © Victor P. Eroschenko; (bottom) © Alvin Telser, PhD/Science Source

**EXERCISE 21.7 Histology of the Pancreas**

1. Obtain a histology slide of the **pancreas** and place it on the microscope stage. Bring the tissue sample into focus on low power. Scan the slide until a pancreatic islet surrounded by acinar cells is at the center of the field of view (figure 21.9a).
2. Move the microscope stage so the acinar cells that surround the pancreatic islet are in the center of the field of view. Then change to high power. Identify the listed structures on the slide, using figure 21.9 as a guide:

- |  |   |
|--|---|
| <input type="checkbox"/> acinar cells      | <input type="checkbox"/> pancreatic duct  |
| <input type="checkbox"/> pancreatic acinus | <input type="checkbox"/> pancreatic islet |

3. Sketch the pancreas as seen through the microscope in the space provided. Label all of the structures listed in step 2 in the drawing.



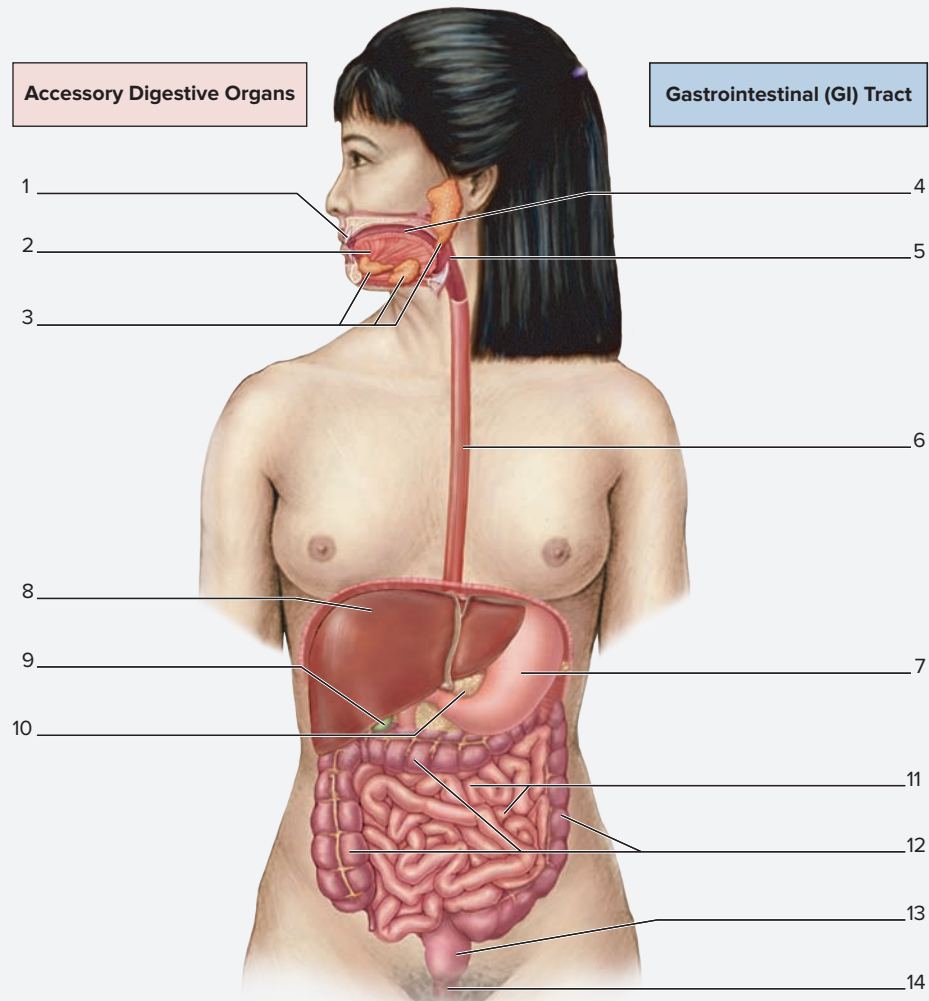
## Gross Anatomy

## EXERCISE 21.8 Overview of the GI Tract

Before covering the details of individual organs that compose the digestive system, it is useful to do a short review of the structures encountered in the GI tract as one moves from mouth to anus.

1. Identify the structures listed in **figure 21.10** on a torso model, using the textbook as a guide.

2. Label the organs of the GI tract in figure 21.10. When labeling each organ, identify at least one digestive function of that organ.



**Figure 21.10** Overview of the Digestive System. Use the terms listed to fill in the numbered labels in the figure.

- |                                      |  |                                   |   |  |                                 |
|--------------------------------------|--|-----------------------------------|---|--|---------------------------------|
| <input type="checkbox"/> anal canal  | <input type="checkbox"/> large intestine | <input type="checkbox"/> pancreas | <input type="checkbox"/> salivary glands (parotid, sublingual, submandibular) | <input type="checkbox"/> small intestine | <input type="checkbox"/> teeth  |
| <input type="checkbox"/> esophagus   | <input type="checkbox"/> liver           | <input type="checkbox"/> pharynx  |   | <input type="checkbox"/> stomach         | <input type="checkbox"/> tongue |
| <input type="checkbox"/> gallbladder | <input type="checkbox"/> oral cavity     | <input type="checkbox"/> rectum   |   |  |                                 |

### The Oral Cavity, Pharynx, and Esophagus

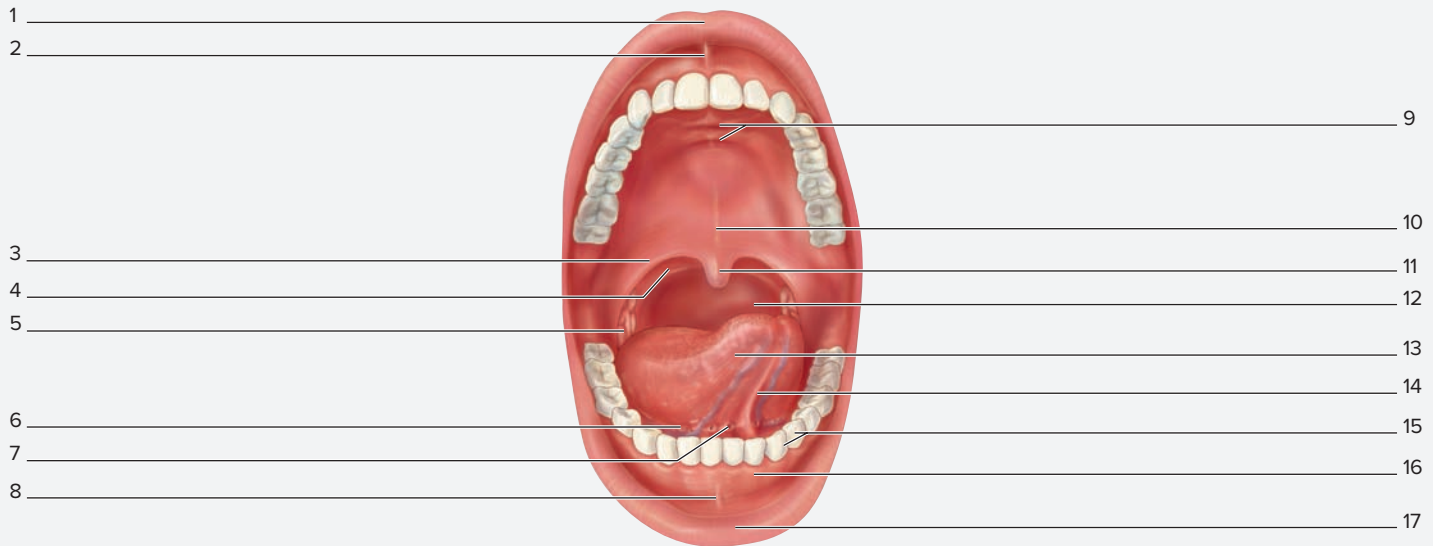
The oral cavity contains a number of digestive system structures, including teeth, salivary glands, lips, and tongue. These structures are important for wetting and manipulating food as it enters the digestive tract. The resulting bolus (*bolos*, lump; *bolus* + a wet mass of food) leaves the oral cavity,

travels through the **oropharynx** (*oris*, mouth + *pharynx*, the throat), and enters the **esophagus** (*oisophagos*, gullet). The esophagus then transports the bolus to the stomach for further digestion. The esophagus enters the stomach just after it pierces through the esophageal hiatus in the diaphragm.

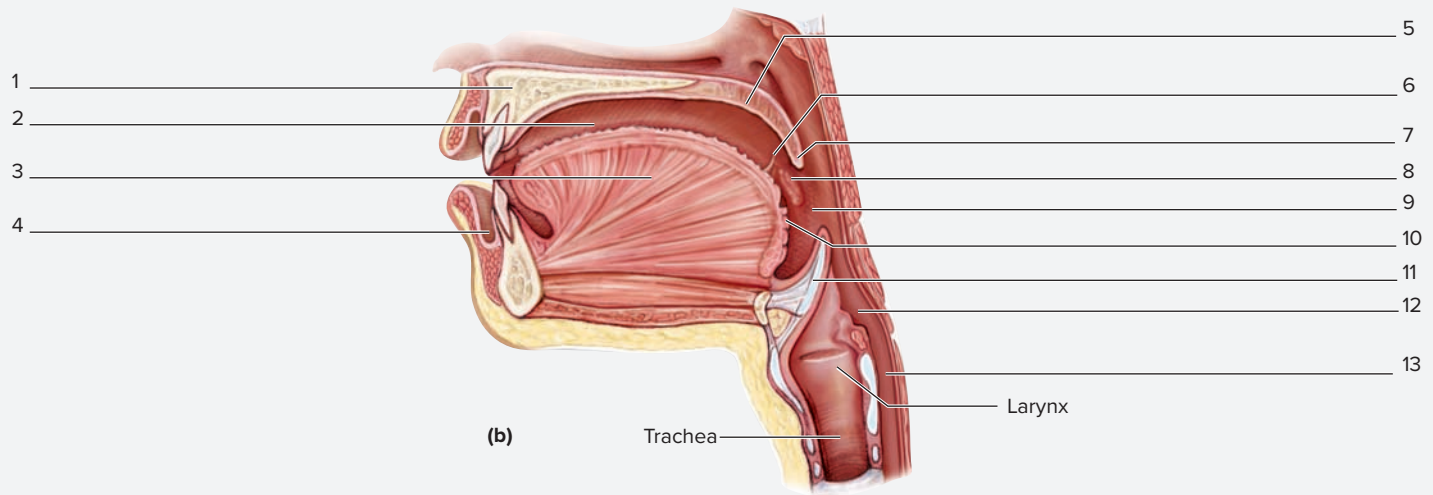
**EXERCISE 21.9** Gross Anatomy of the Oral Cavity, Pharynx, and Esophagus

1. Observe a cadaver specimen or a classroom model demonstrating the head and neck.

2. Identify the structures listed in **figure 21.11** on the cadaver or classroom model, using the textbook as a guide. Then label them in figure 21.11.



(a)



(b)

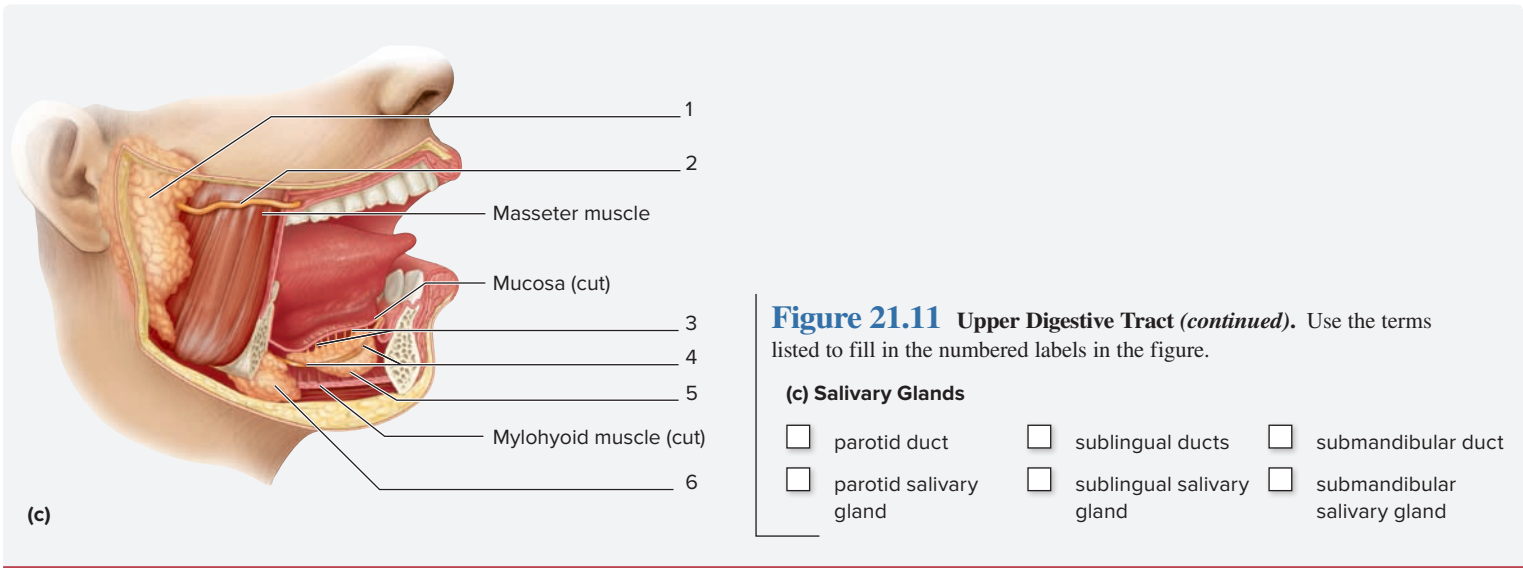
**Figure 21.11** Upper Digestive Tract. Use the terms listed to fill in the numbered labels in the figure.

**(a) Anterior View of the Oral Cavity**

- |  |   |
|--|---|
| <input type="checkbox"/> fauces                                | <input type="checkbox"/> pharyngopalatine arch      |
| <input type="checkbox"/> gingivae                              | <input type="checkbox"/> soft palate                |
| <input type="checkbox"/> glossopalatine arch                   | <input type="checkbox"/> sublingual duct orifice    |
| <input type="checkbox"/> hard palate/transverse palatine folds | <input type="checkbox"/> submandibular duct orifice |
| <input type="checkbox"/> inferior labial frenulum              | <input type="checkbox"/> superior labial frenulum   |
| <input type="checkbox"/> inferior lip                          | <input type="checkbox"/> superior lip               |
| <input type="checkbox"/> lingual frenulum                      | <input type="checkbox"/> teeth                      |
| <input type="checkbox"/> palatine tonsil                       | <input type="checkbox"/> tongue                     |
|  | <input type="checkbox"/> uvula                      |

**(b) Midsagittal View of the Oral Cavity and Pharynx**

- |   |   |
|---|---|
| <input type="checkbox"/> epiglottis     | <input type="checkbox"/> palatine tonsil    |
| <input type="checkbox"/> esophagus      | <input type="checkbox"/> palatoglossal arch |
| <input type="checkbox"/> hard palate    | <input type="checkbox"/> soft palate        |
| <input type="checkbox"/> laryngopharynx | <input type="checkbox"/> tongue             |
| <input type="checkbox"/> lingual tonsil | <input type="checkbox"/> uvula              |
| <input type="checkbox"/> oral cavity    | <input type="checkbox"/> vestibule          |
| <input type="checkbox"/> oropharynx     |   |



## The Stomach

The stomach is a large, sac-like organ where both mechanical and chemical digestion continues on the bolus of food that arrives from the esophagus.

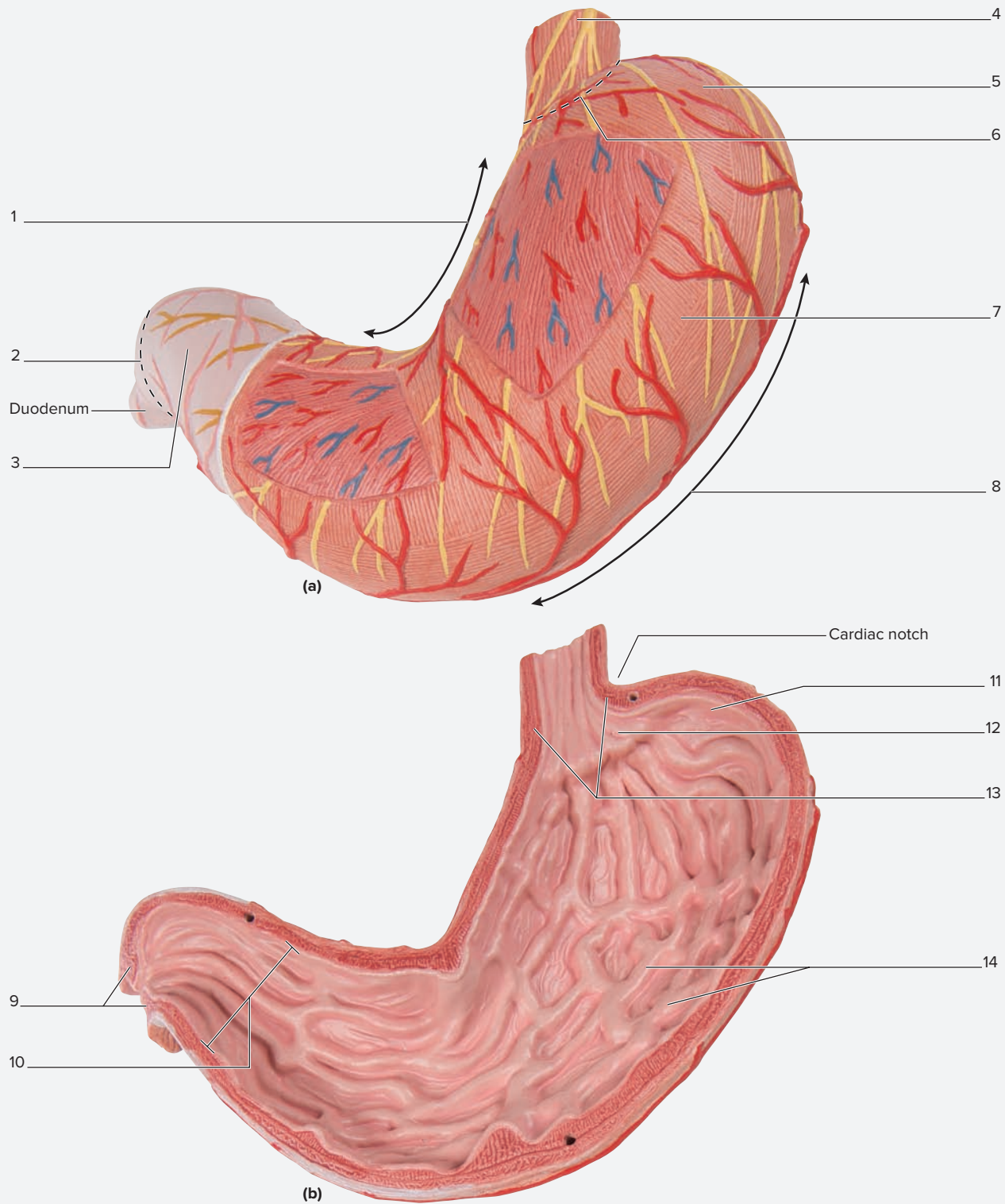
The stomach is located in the epigastric abdominopelvic region, superficial to the pancreas, and deep to the anterior abdominal wall. **Table 21.7** lists the major features of the stomach and describes the function of each.

Structure	Description	Word Origins
<b>REGIONS</b>		
<i>Body</i>	Main part of the stomach located between the fundus and the pylorus.	<i>body</i> , the principal mass of a structure
<i>Cardia</i>	The region of the stomach that the esophagus opens into.	<i>kardia</i> , heart; relating to the part of the stomach nearest the heart
<i>Fundus</i>	The dome-shaped part of the stomach that lies superior to the cardiac notch.	<i>fundus</i> , bottom
<i>Pylorus</i>	The region of the stomach that opens into the duodenum.	<i>pyloros</i> , a gatekeeper
<b>FEATURES</b>		
<i>Cardiac Notch</i>	A deep notch located between the fundus of the stomach and the esophagus.	<i>kardia</i> , heart; relating to the part of the stomach nearest the heart + <i>notch</i> , indentation
<i>Gastric Folds (Rugae)</i>	Folds of the mucosal lining of the stomach.	<i>ruga</i> , a wrinkle
<i>Greater Curvature</i>	The large, inferior curvature of the stomach. It is one attachment point for the greater omentum.	<i>greater</i> , larger
<i>Greater Omentum</i>	A fold of four layers of peritoneum that stretches from the greater curvature of the stomach to the transverse colon.	<i>omentum</i> , the membrane that encloses the bowels
<i>Inferior Esophageal (Cardiac) Sphincter</i>	A physiological sphincter (band of muscle), composed of the part of the diaphragm that surrounds the esophagus. When the diaphragm contracts, it closes off this opening, preventing reflux of stomach contents back into the esophagus. Some circular smooth muscle in the wall of the esophagus also contributes to this sphincter, but its contribution is weak.	<i>kardia</i> , heart; relating to the sphincter of the stomach nearest the heart
<i>Lesser Curvature</i>	The small, superior curvature of the stomach. It is one attachment point of the lesser omentum.	<i>lesser</i> , smaller
<i>Lesser Omentum</i>	A fold of four layers of peritoneum that stretches from the liver to the lesser curvature of the stomach.	<i>omentum</i> , the membrane that encloses the bowels
<i>Pyloric Sphincter</i>	An anatomic sphincter (band of muscle), composed of smooth muscle in the wall of the pylorus. It controls passage of chyme from the stomach to the duodenum (and vice versa).	<i>pyloros</i> , a gatekeeper + <i>sphinkter</i> , a band

**EXERCISE 21.10** Gross Anatomy of the Stomach

1. Observe a cadaver specimen or a classroom model demonstrating the stomach.


2. Identify the structures listed in **figure 21.12** on the cadaver or classroom model, using table 21.7 and the textbook as guides. Then label them in figure 21.12.



**Figure 21.12** Classroom Model of the Stomach. Use the terms listed to fill in the numbered labels in the figure. Some answers may be used more than once. (a) Anterior surface. (b) Interior.

- |                                    |  |  |  |
|------------------------------------|--|--|--|
| <input type="checkbox"/> body      | <input type="checkbox"/> fundus                | <input type="checkbox"/> inferior esophageal (cardiac) sphincter | <input type="checkbox"/> pyloric sphincter |
| <input type="checkbox"/> cardia    | <input type="checkbox"/> gastric folds (rugae) | <input type="checkbox"/> lesser curvature                        | <input type="checkbox"/> pylorus           |
| <input type="checkbox"/> esophagus | <input type="checkbox"/> greater curvature     |  |  |

3. Sketch the stomach in the space provided. Label all of the structures listed in figure 21.12 in the drawing.



### The Duodenum, Gallbladder, Liver, and Pancreas

The **duodenum** (*duodeno-*, breadth of twelve fingers) is the first part of the small intestine. It is C-shaped, and mostly retroperitoneal, which allows it to be anchored to the posterior abdominal wall. This is advantageous because a number of ducts coming from the gallbladder, pancreas, and liver empty their contents into the duodenum. The relationships between the duodenum and the gallbladder, liver, and pancreas are critically important for the process of digestion. The liver produces **bile**, a substance that emulsifies fats. Bile is temporarily stored within the **gallbladder** between meals. The pancreas produces **bicarbonate**, which

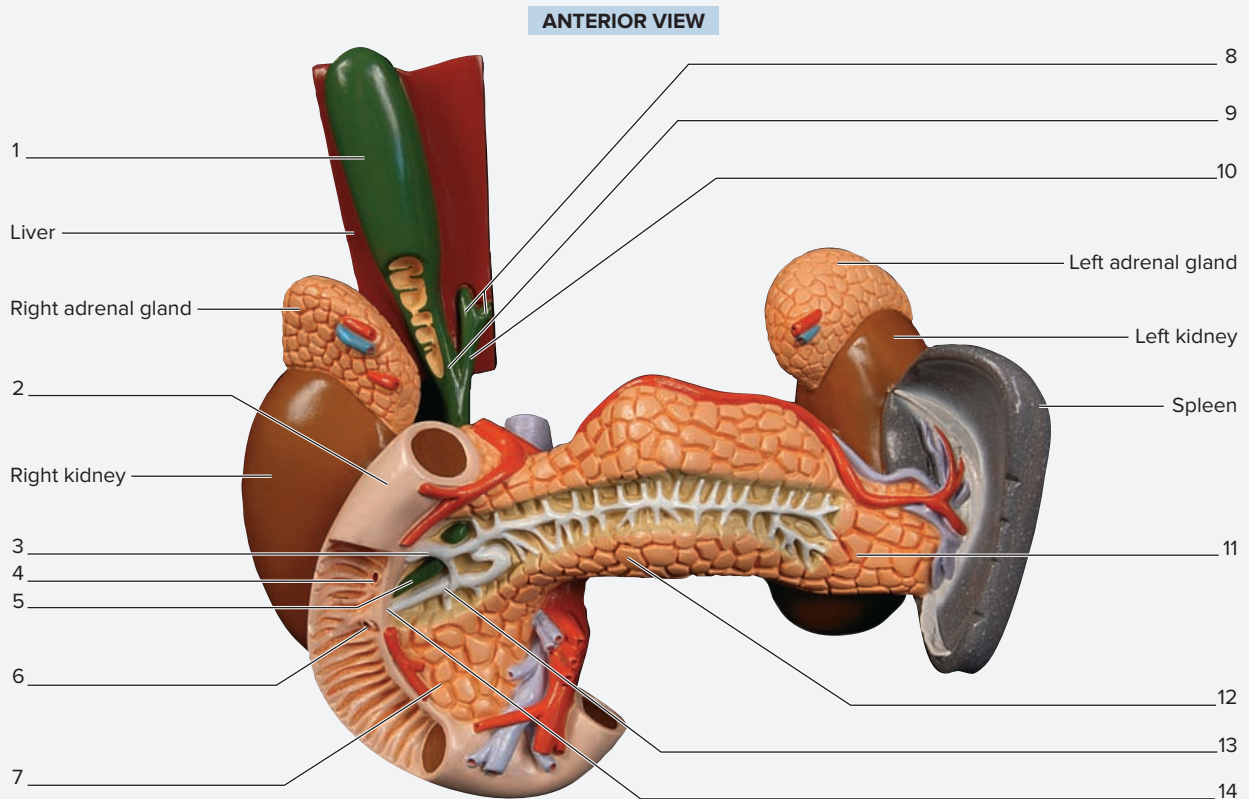
neutralizes stomach acids; and **pancreatic juice**, which contains bicarbonate and enzymes that break down proteins, fats, and carbohydrates. When these organs dump their secretions into the duodenum, the acidity of the chyme (*chymos*, juice) that has entered the duodenum from the stomach is neutralized and the digestion of proteins and carbohydrates continues. Here the digestion of fats and nucleic acids also begins. In addition to their functions in the breakdown of food, the duodenum, liver, and pancreas all produce hormones that are important in signaling processes of digestion. **Table 21.8** lists the major features of the duodenum, gallbladder, liver, and pancreas, and describes the functions of each component.



<b>Table 21.8</b>		
<b>Gross Anatomic Features of the Liver, Gallbladder, Pancreas, and Their Associated Ducts</b>		
<b>Structure</b>	<b>Description</b>	<b>Word Origins</b>
<b>LIVER</b>		
<i>Falciform Ligament</i>	A fold of peritoneum that extends from the diaphragm and anterior abdominal wall to the liver. Its free inferior border contains the round ligament of the liver.	<i>falx</i> , sickle + <i>forma</i> , form
<i>Left Lobe of the Liver</i>	The second largest lobe of the liver. Extends from the falciform ligament toward the midline of the body.	<i>lobos</i> , lobe
<i>Porta Hepatis</i>	A depression on the inferomedial part of the liver that contains the hepatic artery, hepatic portal vein, and common bile duct.	<i>porta</i> , gate + <i>hepatikos</i> , liver
<i>Right Lobe of the Liver</i>	The largest lobe of the liver, it is on the right side of the abdomen and composes over half of the mass of the liver.	<i>lobos</i> , lobe
<i>Caudate Lobe of the Liver</i>	A small lobe of the liver located between the right and left lobes and on the posterior, inferior part of the liver.	<i>caudate</i> , possessing a tail + <i>lobos</i> , lobe
<i>Quadrate Lobe of the Liver</i>	A small lobe of the liver located between the right and left lobes and on the anterior, inferior part of the liver between the gallbladder and the round ligament.	<i>quadratus</i> , square + <i>lobos</i> , lobe
<i>Round Ligament of the Liver (Ligamentum Teres)</i>	A remnant of the fetal umbilical vein, which connects to the umbilicus. Located within the free edge of the falciform ligament on the anterior abdominal wall.	<i>ligamentum</i> , a bandage + <i>teres</i> , round
<b>GALLBLADDER AND DUCT SYSTEM</b>		
<i>Accessory Pancreatic Duct</i>	Excretory duct located in the head of the pancreas. Empties into duodenum at the minor duodenal papilla.	<i>pankreas</i> , the sweetbread
<i>Common Bile Duct</i>	The bile duct formed from the union of the common hepatic duct and the cystic duct. Empties into the duodenum at the major duodenal papilla.	<i>bilis</i> , a yellow/green fluid produced by the liver
<i>Common Hepatic Duct</i>	The bile duct formed from the union of the right and left hepatic ducts. Drains bile into the common bile duct.	<i>hepatikos</i> , liver
<i>Cystic Duct</i>	The bile duct that transports bile from the gallbladder to the junction of the common hepatic duct and common bile duct.	<i>cystic</i> , relating to the gallbladder
<i>Hepatopancreatic Ampulla</i>	The space within the major duodenal papilla that contains the common bile duct and the main pancreatic duct.	<i>hepatikos</i> , relating to the liver + <i>pancreatic</i> , relating to the pancreas + <i>ampulla</i> , a two-handled bottle
<i>Gallbladder</i>	A sac-like appendage of the liver that stores and concentrates bile.	<i>gealla</i> , bile + <i>blaedre</i> , a distensible organ
<i>Main Pancreatic Duct</i>	The main excretory duct of the pancreas. Runs longitudinally in the center of the gland and empties into the duodenum at the major duodenal papilla.	<i>pankreas</i> , the sweetbread
<i>Major Duodenal Papilla</i>	A raised “nipple-like” bump located on the posterior wall of the descending part of the duodenum. The main pancreatic duct and the common bile duct empty their contents here.	<i>major</i> , great + <i>papilla</i> , a nipple
<i>Minor Duodenal Papilla</i>	A small raised “nipple-like” bump located superior to the major duodenal papilla. Contains the opening of the accessory pancreatic duct.	<i>minor</i> , smaller + <i>papilla</i> , a nipple
<i>Right/Left Hepatic Duct</i>	Ducts that drain bile from the right and left lobes/areas of the liver. They come together at the common hepatic duct.	<i>hepatikos</i> , liver
<b>PANCREAS</b>		
<i>Body of the Pancreas</i>	The main portion of the pancreas extending between the head and the tail.	<i>pankreas</i> , the sweetbread
<i>Head of the Pancreas</i>	The portion of the pancreas that sits in the depression formed by the curvature of the duodenum.	<i>pankreas</i> , the sweetbread
<i>Tail of the Pancreas</i>	The tapered, right end of the pancreas located near the hilum of the spleen.	<i>pankreas</i> , the sweetbread

**EXERCISE 21.11** Gross Anatomy of the Duodenum, Liver, Gallbladder, and Pancreas

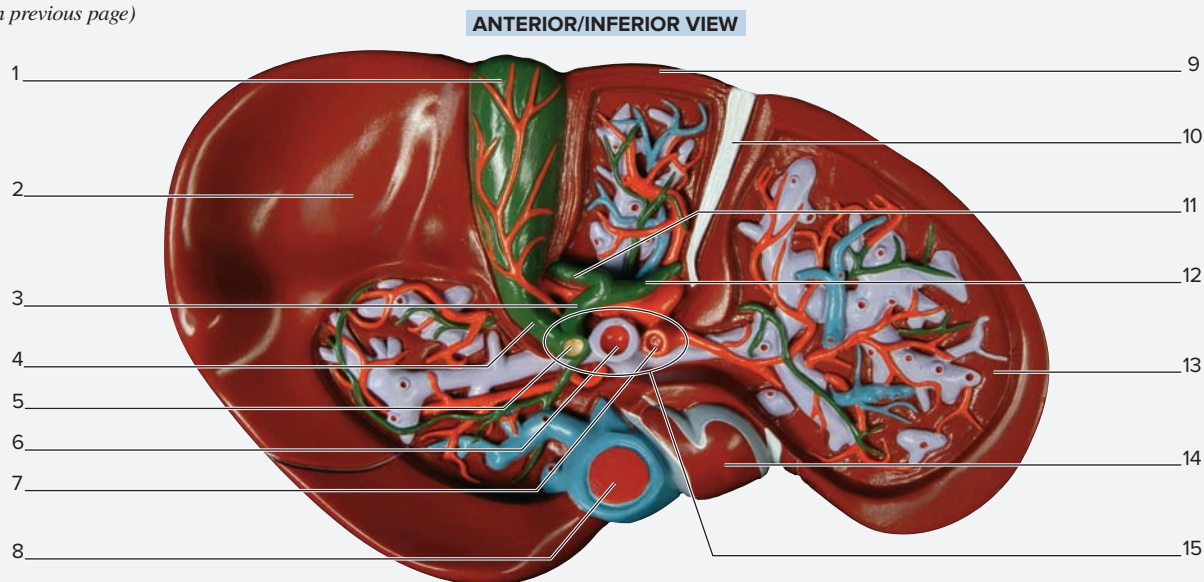
1. Obtain a classroom model demonstrating the relationships between the duodenum, liver, gallbladder, and pancreas (figure 21.13), or view these structures in the superior abdominal cavity of a prosected human cadaver.
2. Identify the structures listed in figure 21.13 on the classroom model or human cadaver, using table 21.8 and the textbook as guides. Then label them in figure 21.13.
3. Sketch the ducts coming from the gallbladder, liver, and pancreas in the space provided, using table 21.8 and the textbook as guides. Show how the ducts merge to eventually empty their contents into the pancreas. Label each duct and organ in the drawing.
4. Obtain a classroom model demonstrating the liver (figure 21.14), or view the liver from a human cadaver.
5. Identify structures listed in figure 21.14 on the classroom model or human cadaver, using table 21.8 and the textbook as guides. Then label them in figure 21.14.



**Figure 21.13** Classroom Model of the Duodenum, Gallbladder, Liver, and Pancreas. Use the terms listed to fill in the numbered labels in the figure.

- |  |   |   |   |
|--|---|---|---|
| <input type="checkbox"/> accessory pancreatic duct | <input type="checkbox"/> cystic duct      | <input type="checkbox"/> hepatopancreatic ampulla     | <input type="checkbox"/> minor duodenal papilla |
| <input type="checkbox"/> body of pancreas          | <input type="checkbox"/> duodenum         | <input type="checkbox"/> left and right hepatic ducts | <input type="checkbox"/> tail of pancreas       |
| <input type="checkbox"/> common bile duct          | <input type="checkbox"/> gallbladder      | <input type="checkbox"/> main pancreatic duct         |   |
| <input type="checkbox"/> common hepatic duct       | <input type="checkbox"/> head of pancreas | <input type="checkbox"/> major duodenal papilla       |   |

(continued from previous page)



**Figure 21.14 Classroom Model of the Liver.** Use the terms listed to fill in the numbered labels in the figure. In this view, the anterior surface of the liver has been rotated away from the observer's point of view so the structures on the inferior surface of the liver are visible.

- |  |  |   |   |
|--|--|---|---|
| <input type="checkbox"/> caudate lobe of liver | <input type="checkbox"/> falciform ligament    | <input type="checkbox"/> inferior vena cava | <input type="checkbox"/> quadrate lobe of liver |
| <input type="checkbox"/> common bile duct      | <input type="checkbox"/> gallbladder           | <input type="checkbox"/> left hepatic duct  | <input type="checkbox"/> right hepatic duct     |
| <input type="checkbox"/> common hepatic duct   | <input type="checkbox"/> hepatic artery proper | <input type="checkbox"/> left lobe of liver | <input type="checkbox"/> right lobe of liver    |
| <input type="checkbox"/> cystic duct           | <input type="checkbox"/> hepatic portal vein   | <input type="checkbox"/> porta hepatis      |   |

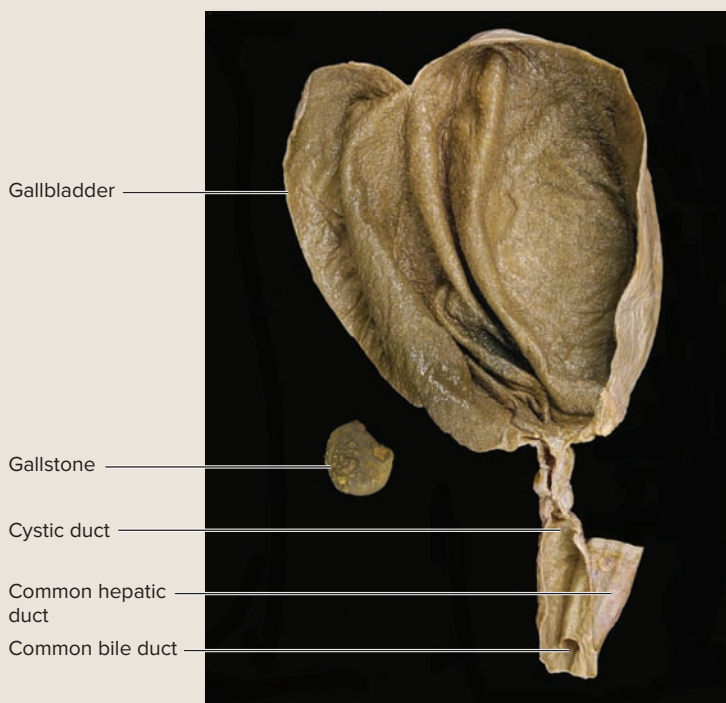
© Copyright by Denoyer-Geppert. Photo by Christine Eckel

### Clinical View | Gallstones

Gallstones are hard stones that form from cholesterol and bile deposits in the gallbladder (**figure 21.15**). The condition of having gallstones is called *cholelithiasis* (*chole-*, bile + *lithos*, stone + *-iasis*, condition). One of the most serious complications resulting from a gallstone occurs when the stone passes into the cystic duct and makes its way toward the duodenum, but becomes lodged somewhere en route to the duodenum. This blocks the flow of bile from the liver and gallbladder to the duodenum. If it lodges farther down, near the hepatopancreatic ampulla, it can also block the flow of pancreatic juice from the pancreas. Normally some of the pancreatic enzymes (proteolytic enzymes) are not activated until they enter the duodenum. However, when these enzymes build up within the pancreas because of a blockage of flow of pancreatic juice from the pancreas, these enzymes become activated and begin to digest the pancreas itself. This causes *pancreatitis* (inflammation of the pancreas), which can be life threatening.

**Figure 21.15 Gallbladder and Gallstone.** The gallstone is a mass of bile salts that have crystallized and condensed. Note the small crystals that have formed on the larger stone. A stone of this size might not cause problems for the patient if it were too large to enter into the cystic duct.

© McGraw-Hill Education/Photo and Dissection by Christine Eckel

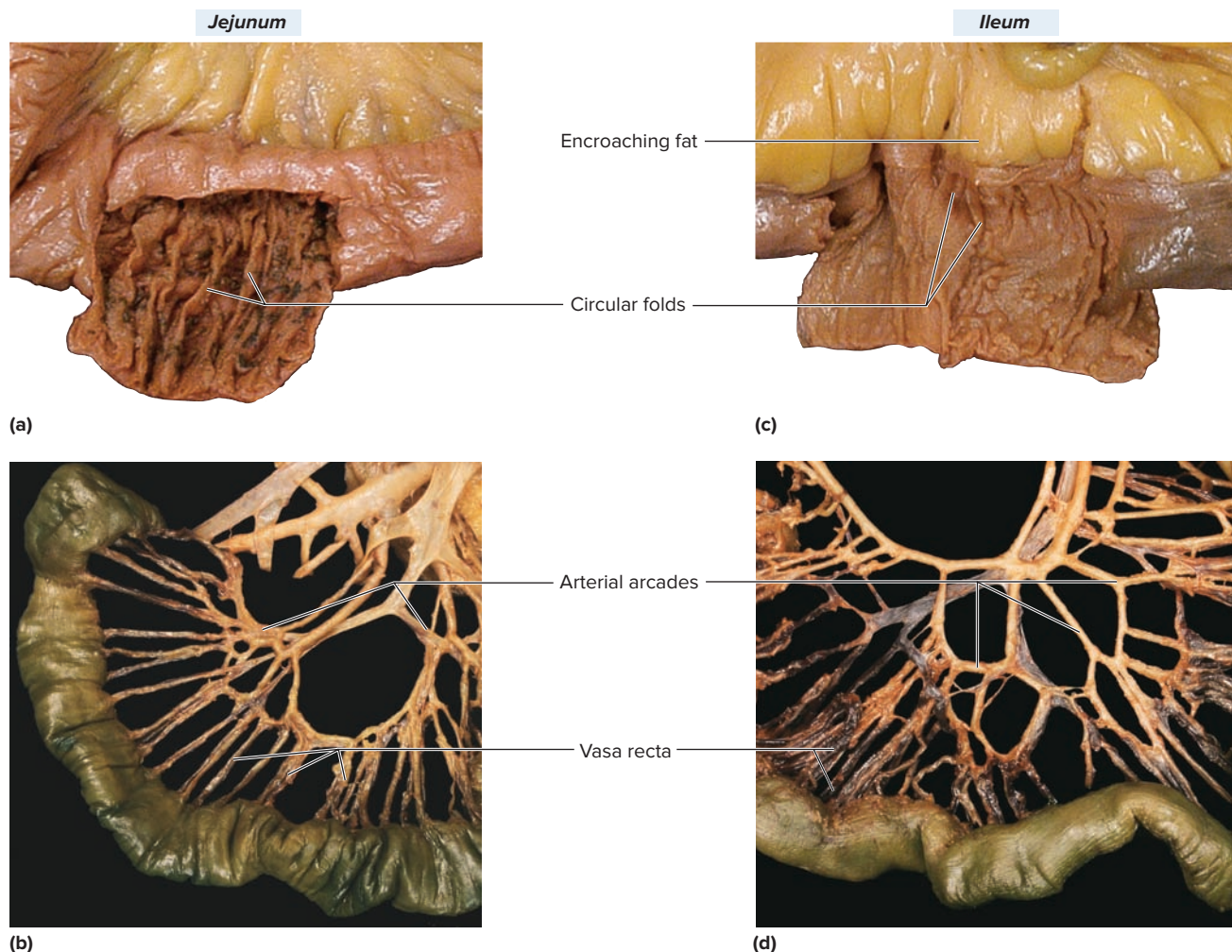


## The Jejunum and Ileum of the Small Intestine

The **jejunum** and **ileum** compose the longest part of the small intestine. In general the jejunum is located in the upper left quadrant of the abdominal cavity and the ileum is located in the lower right quadrant of the abdominal cavity. **Table 21.9** summarizes the gross anatomical features that distinguish the jejunum from the ileum. The two parts can be distinguished from each other both histologically and grossly. Distinguishing the two via gross

anatomic features involves comparing four anatomic features: circular folds, encroaching fat, arterial arcades, and vasa recta (**figure 21.16**). **Circular folds** are the mucosal folds found within the lumen of the small intestine. **Encroaching fat** is mesenteric fat that “rides up” upon the wall of the intestine. **Arterial arcades** are arching branches of the mesenteric arteries, and **vasa recta** (*vasa*, vessel + *rectus*, straight) are straight vessels that come off of the arterial arcades and enter the small intestine proper.

Table 21.9 Gross Anatomical Differences Between the Jejunum and the Ileum				
Part of the Small Intestine	Circular Folds	Encroaching Fat	Arterial Arcades	Vasa Recta
<i>Jejunum</i>	Deep, many	No	Fewer, larger	Longer
<i>Ileum</i>	Shallow, few	Yes	More, smaller, stacked upon each other	Shorter



**Figure 21.16 The Jejunum and Ileum.** (a) The jejunum contains many deep circular folds and has no encroaching fat. (b) The blood vessels serving the jejunum consist of short arterial arcades and long vasa recta. (c) The ileum contains few shallow circular folds and has encroaching fat. (d) The blood vessels serving the ileum consist of large arterial arcades and short vasa recta.

- arterial arcades
- circular folds
- encroaching fat
- ileum
- jejunum
- vasa recta

**EXERCISE 21.12** Gross Anatomy of the Jejunum and Ileum of the Small Intestine

1. Observe a classroom model of the abdominal cavity or the abdominal cavity of a prosected human cadaver in which the small intestine is intact.
2. Identify the gross structures listed in figure 21.16 on the classroom model of the abdomen or in the abdominal cavity of the human cadaver, using table 21.9 and the textbook as guides.

**The Large Intestine**

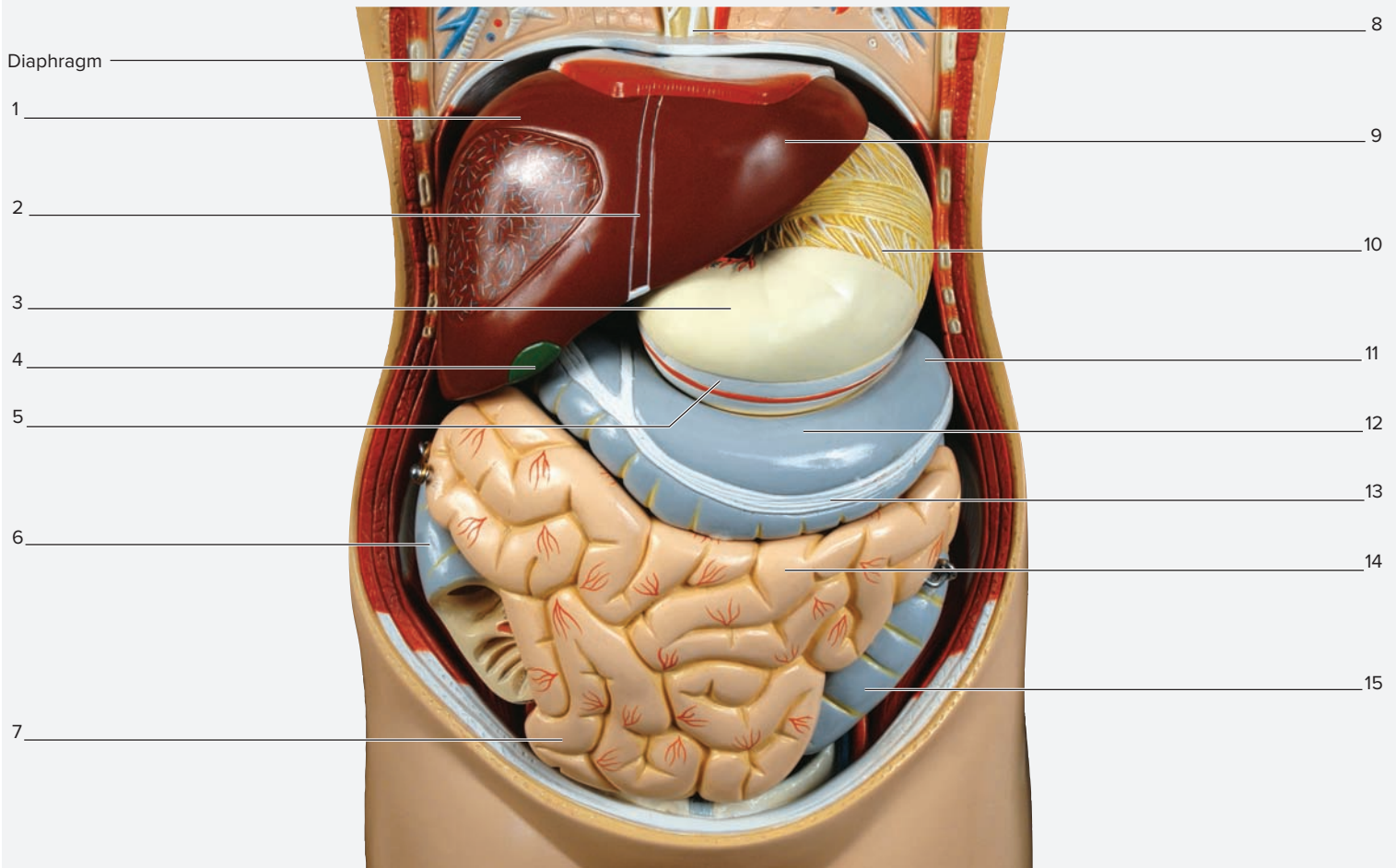
The large intestine begins as a large sac called the **cecum**, which is located in the right lower abdominopelvic quadrant. Exiting the cecum, the **colon** runs along the borders of the abdominal cavity as the ascending colon,

transverse colon, and descending colon before entering the pelvic cavity via the sigmoid colon. The sigmoid colon empties into the **rectum**, which is located within the pelvic cavity proper. The rectum ends at the **anus**. **Table 21.10** summarizes these structures.

<b>Table 21.10</b>		
<b>The Cecum, Large Intestine, Rectum, and Anus</b>		
<b>Structure</b>	<b>Description</b>	<b>Word Origins</b>
<b>STRUCTURE</b>		
<i>Cecum</i>	Blind-ended sac located at the junction between the ileum of the small intestine and the ascending colon.	<i>caecus</i> , blind
<i>Ileocecal Valve</i>	Smooth muscle sphincter located where the ileum opens into the cecum.	<i>ileo-</i> , ileum + <i>cecal</i> , cecum
<b>Colon</b>		
<i>Ascending Colon</i>	Part of the colon that extends from the cecum to the liver.	<i>kolon</i> , the part of the large intestine from cecum to rectum
<i>Left Colic (Splenic) Flexure</i>	A curve of the colon medial to the spleen, where the transverse colon becomes the descending colon.	<i>splenic</i> , relating to the spleen + <i>flexura</i> , a bend
<i>Transverse Colon</i>	The part of the colon that extends between the liver and the spleen, and connects to the greater omentum.	<i>transversus</i> , crosswise
<i>Right Colic (Hepatic) Flexure</i>	Curve of the colon medial to the liver, where the ascending colon becomes the transverse colon.	<i>hepatikos</i> , relating to the liver + <i>flexura</i> , a bend
<i>Sigmoid Colon</i>	The S-shaped part of the colon that extends from the descending colon to the rectum.	<i>sigma</i> , the letter <i>S</i> + <i>eidōs</i> , resemblance
<i>Rectum</i>	Final portion of the digestive tract, located within the pelvic cavity and extending from the sigmoid colon to the anus.	<i>rectus</i> , straight
<i>Anus</i>	Inferior opening of the digestive tract.	<i>anus</i> , the lower opening of the digestive tract
<b>ASSOCIATED STRUCTURES</b>		
<i>Haustra</i>	Pouches of the colon formed when the taenia coli (longitudinal smooth muscle) contract.	<i>haustus</i> , to draw up
<i>Omental (Epiplonic) Appendices</i>	Small, fatty appendages that hang off of the colon.	<i>omentum</i> , the membrane that encloses the bowels; <i>epiploic</i> , related to the omentum
<i>Taenia Coli</i>	Three small bands of longitudinal smooth muscle of the muscularis externa of the colon; contraction of this muscle creates pouches (haustra) in the colon.	<i>tainia</i> , a band + <i>coli</i> , colon

**EXERCISE 21.13** Gross Anatomy of the Large Intestine

1. Observe a classroom model of the abdominal cavity demonstrating the large intestine or the large intestine of a prosected human cadaver (figures 21.17 and 21.18).
2. Identify the gross structures listed in figures 21.17 and 21.18 on the classroom model of the abdomen or in the abdominal cavity of the human cadaver, using table 21.10 and the textbook as guides.
3. *Optional Activity:* **AP|R Digestive System**—Review the locations and functions of the major organs of the digestive system by watching the “Digestive System Overview” animation.

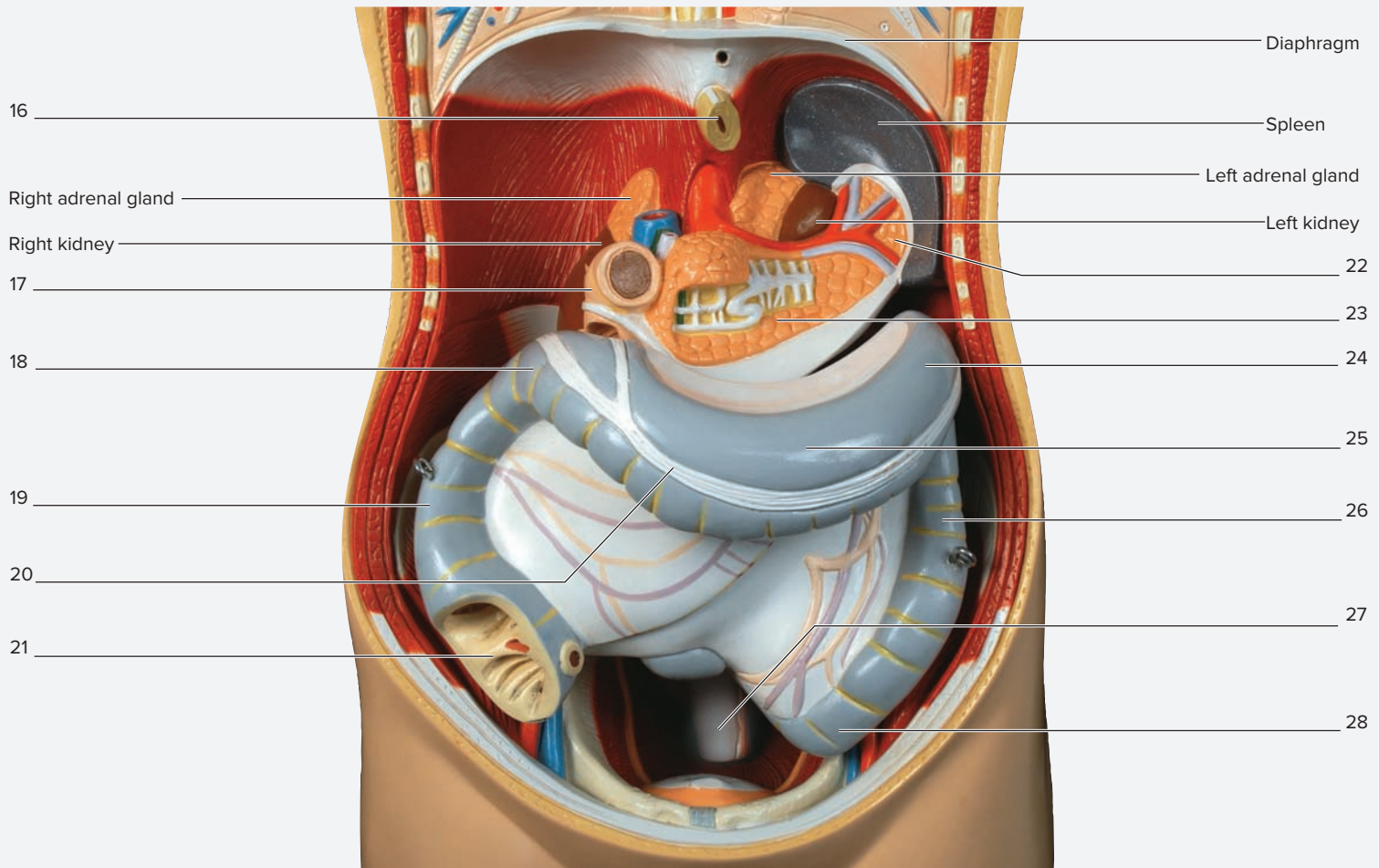


(a) Superficial View

**Figure 21.17** Classroom Model of the Abdominal Cavity and Large Intestine. Use the terms listed to fill in the numbered labels in the figure. Some answers may be used more than once. (a) Superficial view. (b) Deep view with the liver, stomach, and small intestine removed.

- |   |   |  |  |
|---|---|--|--|
| <input type="checkbox"/> ascending colon  | <input type="checkbox"/> falciform ligament           | <input type="checkbox"/> jejunum of small intestine            | <input type="checkbox"/> pylorus of stomach  |
| <input type="checkbox"/> body of stomach  | <input type="checkbox"/> gallbladder                  | <input type="checkbox"/> left colic (splenic) flexure of colon | <input type="checkbox"/> right lobe of liver |
| <input type="checkbox"/> descending colon | <input type="checkbox"/> greater curvature of stomach | <input type="checkbox"/> left lobe of liver                    | <input type="checkbox"/> taenia coli         |
| <input type="checkbox"/> esophagus        | <input type="checkbox"/> ileum of small intestine     |  | <input type="checkbox"/> transverse colon    |

(continued from previous page)

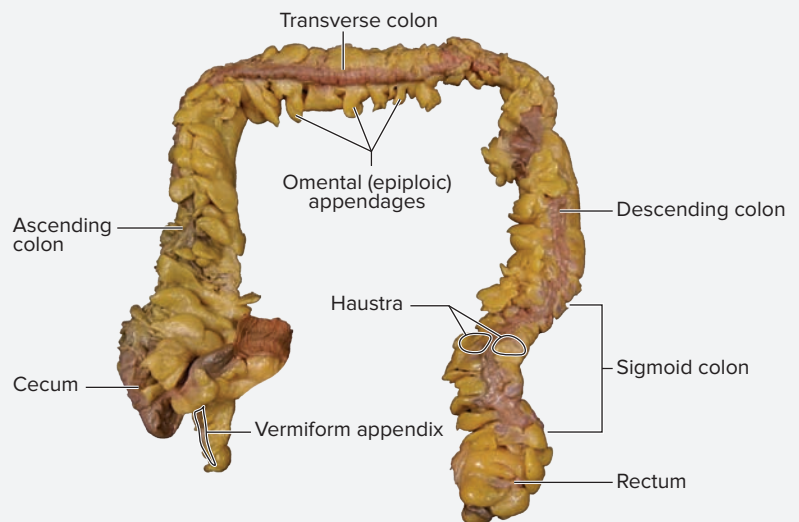


(b) Deep View

**Figure 21.17** Classroom Model of the Abdominal Cavity and Large Intestine (continued). Use the terms listed to fill in the numbered labels in the figure.

- |   |  |   |   |
|---|--|---|---|
| <input type="checkbox"/> ascending colon  | <input type="checkbox"/> duodenum                              | <input type="checkbox"/> rectum                                 | <input type="checkbox"/> taenia coli      |
| <input type="checkbox"/> body of pancreas | <input type="checkbox"/> esophagus                             | <input type="checkbox"/> right colic (hepatic) flexure of colon | <input type="checkbox"/> tail of pancreas |
| <input type="checkbox"/> cecum            | <input type="checkbox"/> left colic (splenic) flexure of colon | <input type="checkbox"/> sigmoid colon                          | <input type="checkbox"/> transverse colon |
| <input type="checkbox"/> descending colon |  |   |   |

© Copyright by Denoyer-Geppert. Photo by Christine Eckel



**Figure 21.18** The Cecum, Large Intestine, and Rectum. The large intestine (cecum and ascending, transverse, and descending colon) contains haustra and omental appendices. The sigmoid colon is S-shaped and extends from the descending colon to the rectum. The vermiform appendix is a pouch that extends from the cecum.

© McGraw-Hill Education/Photo and Dissection by Christine Eckel

The ❶ corresponds to the Learning Objective(s) listed in the chapter opener outline.

## Do You Know the Basics?

### Exercise 21.1: Histology of the Salivary Glands

- The cells within salivary glands that produce salivary amylase are \_\_\_\_\_ (mucous/serous) cells. ❶
- Mary likes sour foods, and she decided to eat a slice of lemon. As she bit down on the lemon, she felt an uncomfortable squeezing-type sensation in her cheek as one of her salivary glands emptied its secretions into her mouth. Which of the three pairs of salivary glands did she feel? (Circle one.) ❷
  - parotid
  - sublingual
  - submandibular

### Exercise 21.2: Wall Layers of the Stomach

- Place the layers of the stomach wall in the correct order, from innermost to outermost. ❸
  - \_\_\_\_\_ mucosa
  - \_\_\_\_\_ muscularis
  - \_\_\_\_\_ serosa
  - \_\_\_\_\_ submucosa
- The stomach contains \_\_\_\_\_ (two/three) layers of smooth muscle in its muscularis layer. ❹
- The mucosa of the stomach is lined with simple \_\_\_\_\_ (columnar/cuboidal) epithelial tissue. ❺

### Exercise 21.3: Histology of the Stomach

- In the cardia of the stomach, gastric pits are \_\_\_\_\_ (short/long), whereas gastric glands are \_\_\_\_\_ (short/long). ❻
- Mucous neck cells are found in gastric \_\_\_\_\_ (glands/pits). ❼

### Exercise 21.4: Histology of the Small Intestine

- Which of the following structure(s) increase(s) the total surface area of the small intestine? (Check all that apply.) ❽
  - \_\_\_\_\_ cilia
  - \_\_\_\_\_ circular folds
  - \_\_\_\_\_ microvilli
  - \_\_\_\_\_ villi
- \_\_\_\_\_ (Goblet/Transitional) cells in the small intestine produce mucus, which protects and lubricates the epithelium of the small intestine. ❾
- The presence of Peyer patches is unique to the ileum. \_\_\_\_\_ (True/False) ❿

### Exercise 21.5: Histology of the Large Intestine

- Which of the following is the epithelial modification that is particularly abundant in the large intestine? (Circle one.) ❾ ❿
  - circular folds
  - goblet cells
  - microvilli
  - submucosal glands
- Place the wall layers of the large intestine in order from innermost to outermost. ❿
  - mucosa
  - muscularis
  - muscularis mucosa
  - serosa
  - submucosa

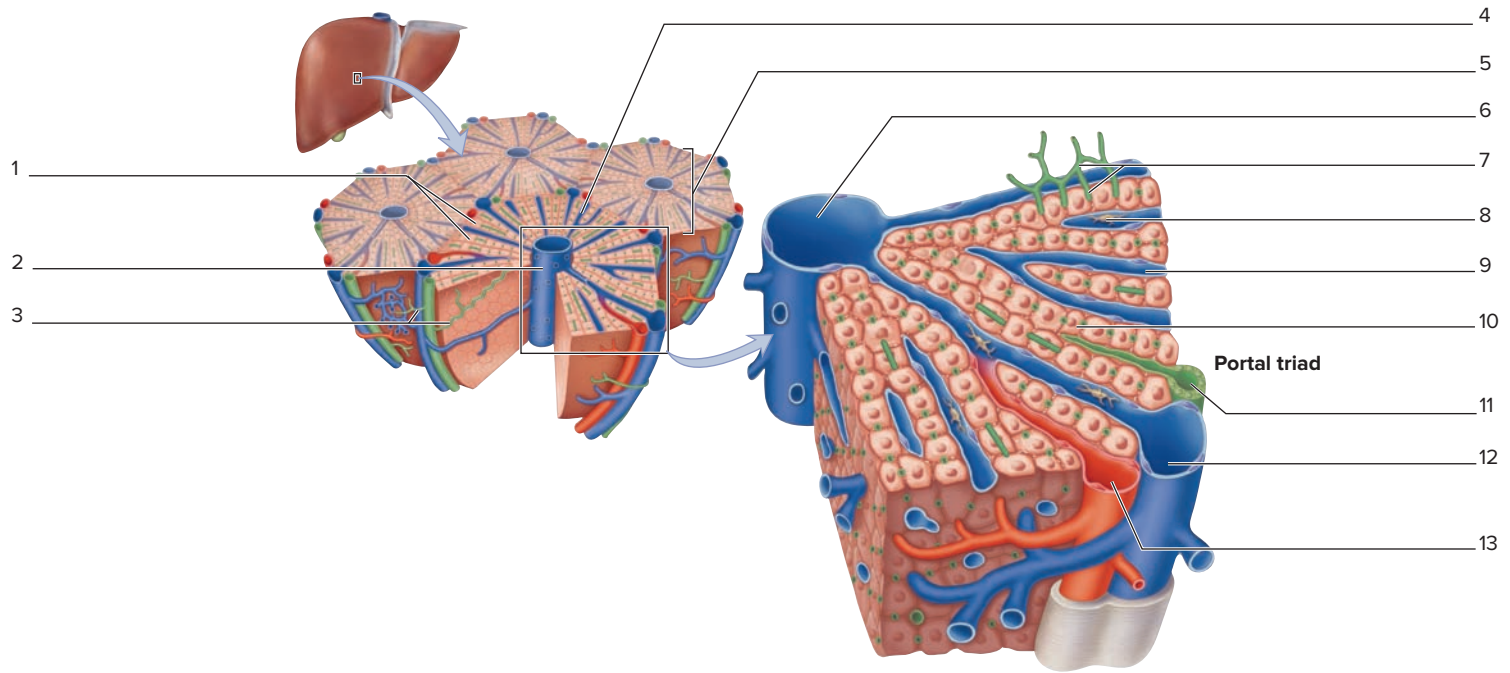


13. Goblet cells are abundant in the epithelium of the large intestine in order to provide lubrication for the passage of feces.

\_\_\_\_\_ (True/False) 13

**Exercise 21.6: Histology of the Liver**

14. Label the parts of a hepatic lobule in this figure. 14



15. Hepatic lobules contain \_\_\_\_\_ (continuous, sinusoidal) capillaries, which receive both oxygen-rich blood from branches of the \_\_\_\_\_ (hepatic artery/hepatic portal vein) and nutrient-rich blood from branches of the \_\_\_\_\_ (hepatic artery/hepatic portal vein). This blood is transported to the central vein. 15 16

**Exercise 21.7: Histology of the Pancreas**

16. The two substances that are produced by the pancreas and released into the duodenum are \_\_\_\_\_ (bicarbonate/digestive enzymes), which is/are produced by acinar cells, and \_\_\_\_\_ (bicarbonate/digestive enzymes), which is/are produced by cells that line the pancreatic ducts. 17

17. An exocrine substance produced by \_\_\_\_\_ (acinar/islet) cells in the pancreas includes \_\_\_\_\_ (amylase/bicarbonate), which digests carbohydrates. 18

18. The endocrine part of the pancreas consists of \_\_\_\_\_ (acinar/islet) cells that produce \_\_\_\_\_ (hormones/pancreatic juice). 19

**Exercise 21.8: Overview of the GI Tract**

19. Place the organs of the GI tract in the correct order, from proximal to distal. 20

- \_\_\_\_\_ a. anus
- \_\_\_\_\_ b. esophagus
- \_\_\_\_\_ c. large intestine
- \_\_\_\_\_ d. rectum
- \_\_\_\_\_ e. small intestine
- \_\_\_\_\_ f. stomach

**Exercise 21.9: Gross Anatomy of the Oral Cavity, Pharynx, and Esophagus**

20. The portion of the pharynx that lies directly posterior from the oral cavity is the \_\_\_\_\_ (laryngopharynx/nasopharynx/oropharynx). 21
21. The esophagus passes through the esophageal \_\_\_\_\_ (hiatus/sphincter) in the diaphragm prior to entering the stomach. 21

**Exercise 21.10: Gross Anatomy of the Stomach**

22. A patient is suffering from gastroesophageal reflux disease (GERD). When she lies down, she feels a burning sensation in her esophagus caused by the reflux of stomach acids into the esophagus. This occurs because one of the sphincters in her stomach is not working properly. The sphincter that is not functioning properly is the \_\_\_\_\_ (cardiac/pyloric) sphincter. This sphincter is considered a(n) \_\_\_\_\_ (anatomic/physiologic) sphincter. The type of muscle tissue that composes this sphincter is \_\_\_\_\_ (skeletal/smooth) muscle. 22

**Exercise 21.11: Gross Anatomy of the Duodenum, Liver, Gallbladder, and Pancreas**

23. The ducts leading from the gallbladder and liver empty into the \_\_\_\_\_ (duodenum/pancreas). 23
24. Which of the following is/are a lobe of the liver? (Check all that apply.) 24
- \_\_\_\_\_ a. caudate
  - \_\_\_\_\_ b. left
  - \_\_\_\_\_ c. posterior
  - \_\_\_\_\_ d. quadrate
  - \_\_\_\_\_ e. right
25. Place the following terms in the correct order in which bile is transported from its site of production in the liver to its entry into the duodenum. Assume that bile does not enter the gallbladder. 25
- \_\_\_\_\_ a. bile canaliculus
  - \_\_\_\_\_ b. common bile duct
  - \_\_\_\_\_ c. common hepatic duct
  - \_\_\_\_\_ d. left hepatic duct

**Exercise 21.12: Gross Anatomy of the Jejunum and Ileum of the Small Intestine**

26. The jejunum is mainly located in the \_\_\_\_\_ (left upper/right upper) abdominopelvic quadrant, whereas the ileum is mainly located in the \_\_\_\_\_ (left lower/right lower) abdominopelvic quadrant. 26 27
27. Loops of arteries that supply blood to the small intestine are called \_\_\_\_\_ (arterial arcades/vasa recta), whereas straight vessels that supply blood to the small intestine are called \_\_\_\_\_ (arterial arcades/vasa recta). 26
28. The ileum of the small intestine has \_\_\_\_\_ (few/many) arterial arcades and \_\_\_\_\_ (short/long) vasa recta, whereas the jejunum of the small intestine has \_\_\_\_\_ (few/many) arterial arcades and \_\_\_\_\_ (short/long) vasa recta. 27

**Exercise 21.13: Gross Anatomy of the Large Intestine**

29. Which of the following places the four parts of the colon in order? (Circle one.) 28
- a. ascending colon, sigmoid colon, transverse colon, descending colon
  - b. ascending colon, transverse colon, descending colon, sigmoid colon
  - c. descending colon, transverse colon, ascending colon, sigmoid colon
  - d. transverse colon, sigmoid colon, ascending colon, descending colon
30. The \_\_\_\_\_ (hepatic/splenic) flexure is located on the right side of the abdomen, whereas the \_\_\_\_\_ (hepatic/splenic) flexure is located on the left side of the abdomen. 29

**Can You Apply What You've Learned?**

31. The image provided here is a cross section through part of the small intestine.

a. What part of the small intestine is it (duodenum, jejunum, or ileum)?

\_\_\_\_\_

b. What characteristic(s) were used in determining which part of the small intestine this sample was taken from?

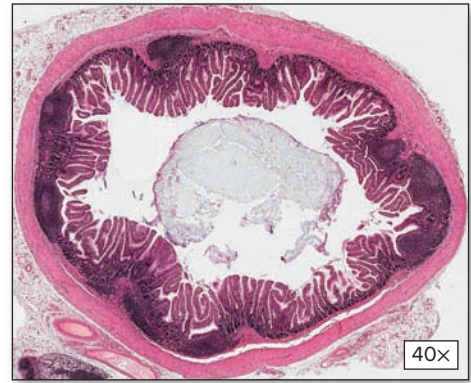\_\_\_\_\_

\_\_\_\_\_

\_\_\_\_\_

\_\_\_\_\_

\_\_\_\_\_



© McGraw-Hill Education/Christine Eckel, photographer

32. Using knowledge of the ducts draining bile from the liver and gallbladder and the pancreatic ducts, propose a location where a gallstone might become lodged, block the ducts, and cause pancreatitis. \_\_\_\_\_

\_\_\_\_\_

33. A patient presented to his physician with pain in the left lower quadrant of his abdomen. The source of the pain was an adhesion\* between the visceral peritoneum covering part of the patient's colon and the parietal peritoneum lining his anterolateral abdominopelvic wall in that region. What part of the colon was most likely adhered to the abdominopelvic wall?

\_\_\_\_\_

\_\_\_\_\_

\*An adhesion (*adhaereo*, to stick to) in the abdominopelvic cavity is an area where two layers of peritoneum are stuck to each other with connective tissue. It usually is the result of some sort of injury or inflammation.

# The Urinary System

# 22

## OUTLINE AND LEARNING OBJECTIVES

### Histology 480

#### The Kidney 480

##### EXERCISE 22.1: HISTOLOGY OF THE RENAL CORTEX 482

- 1 Describe the structure and function of each component of the nephron
- 2 Describe the type of epithelium found in each part of the nephron, and describe how it matches its function
- 3 List the components of the renal corpuscle
- 4 Describe the three structures that compose the filtration membrane
- 5 Identify the renal cortex and associated structures when viewed with a microscope

##### EXERCISE 22.2: HISTOLOGY OF THE RENAL MEDULLA 483

- 6 Identify the renal medulla and associated structures when viewed with a microscope
- 7 Describe the epithelium that lines the nephron loops and collecting ducts

#### The Urinary Tract 484

##### EXERCISE 22.3: HISTOLOGY OF THE URETERS 485

- 8 Describe the wall-layering pattern of the ureters
- 9 Identify the layers of the ureter and the type of tissue found in each layer when viewed with a microscope

##### EXERCISE 22.4: HISTOLOGY OF THE URINARY BLADDER 486

- 10 Describe the wall-layering pattern of the urinary bladder
- 11 Identify the layers of the urinary bladder and the type of tissue found in each layer when viewed with a microscope

### Gross Anatomy 486

#### The Kidney 486

##### EXERCISE 22.5: GROSS ANATOMY OF THE KIDNEY 486

- 12 Identify structures associated with the kidney on classroom models and/or on preserved kidneys

- 13 Describe the location of the kidneys with respect to the abdominal cavity and vertebral levels
- 14 Describe the three layers of the capsule of the kidney
- 15 Define retroperitoneal

##### EXERCISE 22.6: BLOOD SUPPLY TO THE KIDNEY 487

- 16 Identify the blood vessels associated with the kidney on classroom models and/or on preserved kidneys
- 17 Trace the path of a drop of blood through the kidney, from its entry via the renal artery to its exit via the renal vein

##### EXERCISE 22.7: URINE-DRAINING STRUCTURES WITHIN THE KIDNEY 490

- 18 Identify the minor and major calyces, renal pelvis, and ureter on a gross specimen of the kidney or on a classroom model of a coronal section of the kidney
- 19 Trace the path of a drop of filtrate from its exit from the distal convoluted tubule to its entry into the ureter

#### The Urinary Tract 490

##### EXERCISE 22.8: GROSS ANATOMY OF THE URETERS 490

- 20 Trace the path of a drop of urine from its exit from the kidney (via the renal pelvis) to its removal from the body via the urethra
- 21 Identify the urinary bladder and urethra and their associated structures on classroom models and/or on a cadaver

##### EXERCISE 22.9: GROSS ANATOMY OF THE URINARY BLADDER AND URETHRA 491

- 22 Name the three structures that compose the urinary trigone
- 23 Name the three sections of the male urethra
- 24 Explain the structural and functional differences between the internal and external urethral sphincters

## INTRODUCTION

The urinary system is responsible for maintaining blood volume and composition. It accomplishes this task through the process of **ultrafiltration**, which involves forcing fluid out of the blood across a membrane called the **filtration membrane**. The fluid thus formed is called **filtrate**. As the filtrate flows through the structural and functional units of the kidney, the **nephrons**, it is further processed. Many substances, including over 90% of the water in the filtrate, are **reabsorbed** back into the bloodstream so they are not lost from the body. Other substances, such as **urea** (a breakdown product of protein metabolism), are **secreted** into the filtrate so they can be removed from the body. Ultimately, after the blood and filtrate have made their way through the kidney, a small (relative to the volume of blood that is filtered) amount of filtrate leaves the kidney as **urine**, which will be transported via the **ureters** to the **urinary bladder** for storage. At a time that is convenient for the individual, the urine is emptied from the bladder and exits the body through the **urethra**.

The structural and functional unit of the kidney is the **nephron**. Each kidney contains more than 1.25 million nephrons. Remarkably, the kidneys can maintain their function even when 85–90% of their nephrons have been destroyed through disease. However, further losses will result in **kidney failure**. If an individual's kidneys fail, he or she must be placed on **dialysis** (*dialyo*, to separate). This involves filtering the blood using a dialysis machine, or artificial kidney. A patient on dialysis must undergo three to four sessions a week, each session lasting approximately 4 hours. Without dialysis, the individual cannot survive because the balance of fluid, electrolytes, and waste products in the blood cannot be maintained at appropriate levels. The consequences of kidney failure underscore the enormous role the kidneys play in maintaining health.

### List of Reference Tables

Table 22.1	Histological Features of the Kidney	p. 480
Table 22.2	Urine-Draining Structures	p. 485

These Pre-laboratory Worksheet questions may be assigned by instructors through their **connect** course.

## PRE-LABORATORY WORKSHEET

- Which of the following is a function of the urinary system? (Check all that apply.)
  - \_\_\_\_\_ a. acid-base balance of the blood
  - \_\_\_\_\_ b. long-term blood pressure regulation
  - \_\_\_\_\_ c. regulation of erythrocyte production
  - \_\_\_\_\_ d. regulation of leukocyte production
  - \_\_\_\_\_ e. excretion of wastes
- Urine flows through the \_\_\_\_\_ (ureters/urethra) to exit the kidneys.
- Which of the following is the structural and functional unit of the kidney? (Circle one.)
  - a. collecting duct
  - b. glomerulus
  - c. minor calyx
  - d. nephron
  - e. renal pelvis
- Identify the type of epithelial tissue that lines the urinary bladder. (Circle one.)
  - a. pseudostratified ciliated columnar epithelium
  - b. simple squamous epithelium
  - c. stratified squamous epithelium
  - d. transitional epithelium
- Which of the following structures is lined with simple cuboidal epithelium with microvilli? (Circle one.)
  - a. collecting duct
  - b. distal convoluted tubule
  - c. parietal layer of the glomerular capsule
  - d. proximal convoluted tubule
- The glomerulus of the kidney consists of \_\_\_\_\_ (continuous/fenestrated) capillaries.
- The kidneys, ureters, and urinary bladder are all retroperitoneal structures. \_\_\_\_\_ (True/False)
- Place the following vessels in the correct order in which a drop of blood flowing through the kidneys would encounter them.
  - \_\_\_\_\_ a. afferent arteriole
  - \_\_\_\_\_ b. arcuate vein
  - \_\_\_\_\_ c. interlobar artery
  - \_\_\_\_\_ d. peritubular capillaries
  - \_\_\_\_\_ e. renal artery
- The components of the urinary trigone are (Circle all that apply):
  - a. 2 ureteral openings
  - b. 2 urethral openings
  - c. 1 ureteral opening
  - d. 1 urethral opening
- The capsule of the kidney consists of \_\_\_\_\_ (one/three) layer(s).

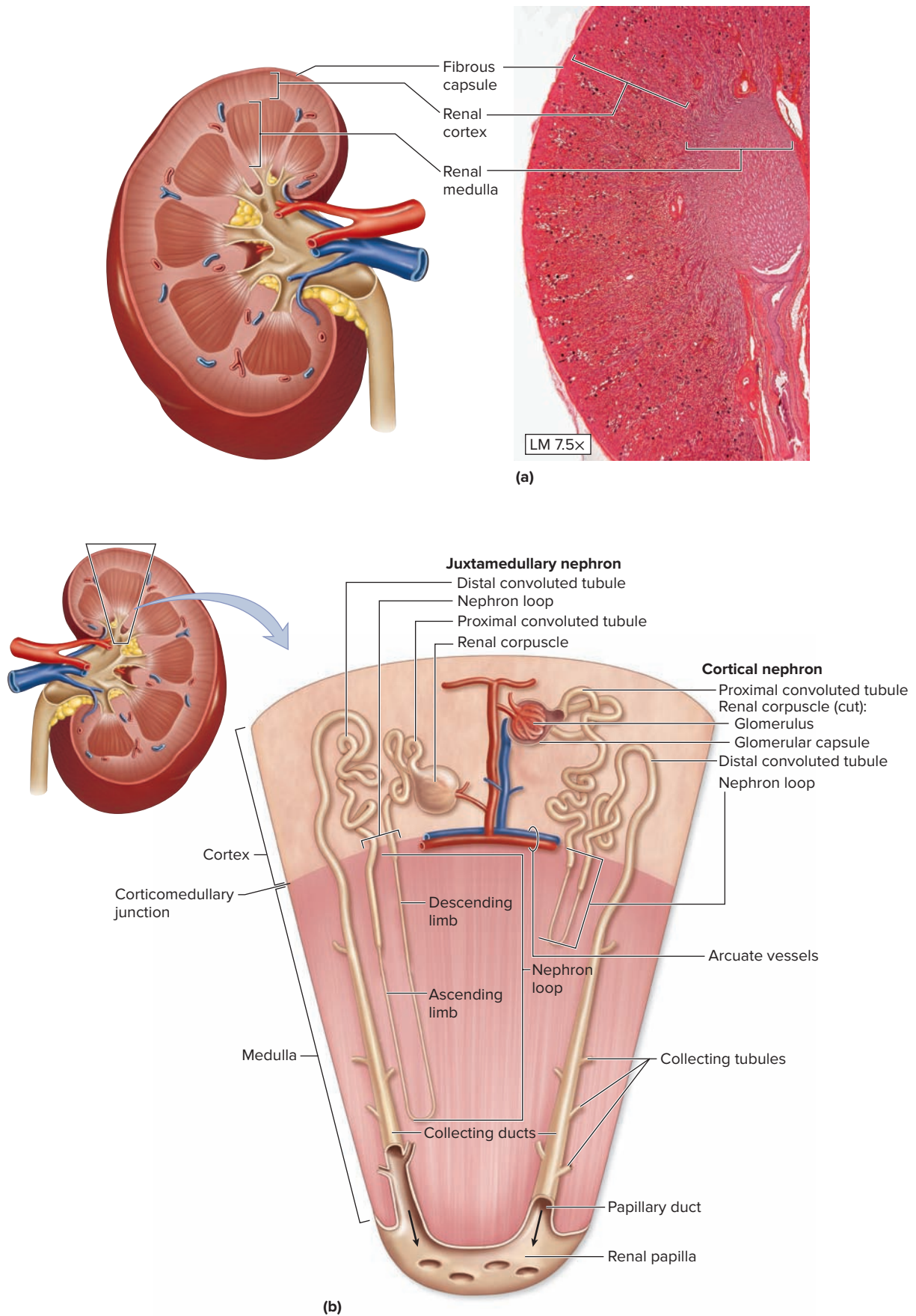
## Histology

### The Kidney

Each kidney is composed of two major regions: an outer **renal cortex** and an inner **renal medulla** (figure 22.1). The arrangement of nephrons along the **corticomedullary junction** means that some nephron components fall predominantly in the renal cortex and others in the renal medulla. Thus, the two regions exhibit distinct histological features. The renal cortex contains the renal corpuscles, proximal convoluted tubules

(PCTs), distal convoluted tubules (DCTs), and peritubular capillaries. The renal medulla contains the nephron loops, collecting ducts (CDs), and vasa recta. Most structures within the kidney can be identified histologically by recognition of both the region (cortex or medulla) and the type of epithelium lining the structure. **Table 22.1** summarizes the type of epithelium that lines each of the structures and lists the major functions of each structure.

<b>Table 22.1</b> Histological Features of the Kidney			
<b>Structure</b>	<b>Epithelium</b>	<b>Function</b>	<b>Region Where Structure Is Predominantly Located</b>
<b>RENAL CORTEX</b>			
<b>Glomerular Capsule</b>			
<i>Glomerulus</i>	Fenestrated endothelium (simple squamous).	Filtration	Cortex
<i>Visceral Layer of Glomerular Capsule</i>	Simple squamous modified to form podocytes.	Secondary processes of podocytes have pedicels, which contain actin filaments. The spaces between the pedicels, called filtration slits, participate in the filtration process.	Cortex
<i>Parietal Layer of Glomerular Capsule</i>	Simple squamous.	Forms an outer wall to the capsule.	Cortex
<i>Proximal Convoluted Tubule (PCT)</i>	Simple cuboidal with long, dense microvilli. Nuclei are located near the basal surface of the cells.	Reabsorbs glucose, amino acids, $\text{Ca}^{2+}$ , $\text{PO}_4$ , $\text{HCO}_3^-$ , and 80% of the water and NaCl present in the filtrate. Secretes substances like penicillin and toxins after they have undergone modification by the liver. Also secretes organic acids and bases.	Cortex
<i>Distal Convoluted Tubule (DCT)</i>	Simple cuboidal with few, short microvilli. Nuclei are located near the apical surface of the cells.	Secretes $\text{H}^+$ and $\text{K}^+$ . Reabsorbs $\text{Na}^+$ and water. Contains the macula densa of the juxtaglomerular apparatus, which is involved with the sensation and regulation of blood pressure.	Cortex
<b>RENAL MEDULLA</b>			
<i>Collecting Tubule and Duct (CD)</i>	Simple cuboidal epithelium. Cells have very precise boundaries. Overall tube diameter is the same as the PCT, but the CD has a larger lumen and no microvilli. Cells are paler than those of the thick segment of the nephron loop.	Concentrates urine under the influence of antidiuretic hormone (ADH). ADH causes CD epithelial cells to transport aquaporins (membrane proteins that transport water) to their apical surface, allowing water to be reabsorbed into the vasa recta.	Medulla
<b>Nephron Loop</b>			
<i>Descending Limb of the Nephron Loop</i>	Begins as simple cuboidal, then transitions to simple squamous.	Epithelial cells are impermeable to sodium, but water is drawn out into the interstitial spaces. Thus, the filtrate becomes more concentrated as it moves down the descending nephron loop.	Medulla
<i>Ascending Limb of the Nephron Loop—Thin Segment</i>	Simple squamous.	Epithelial cells are impermeable to water, but sodium passively diffuses out.	Medulla
<i>Ascending Limb of the Nephron Loop—Thick Segment</i>	Simple cuboidal. Cells are darker than in the collecting duct.	The epithelial cells are impermeable to water, and they actively transport sodium out of the tubule. Thus, the filtrate becomes less concentrated as it moves up the ascending nephron loop.	Medulla



**Figure 22.1 Histology of the Kidney.** (a) Histological appearance of the kidney at low power demonstrates the fibrous capsule, outer cortex, and inner medulla. (b) Placement of nephron structures within the renal cortex and renal medulla.

(a) © McGraw-Hill Education/AI Telser



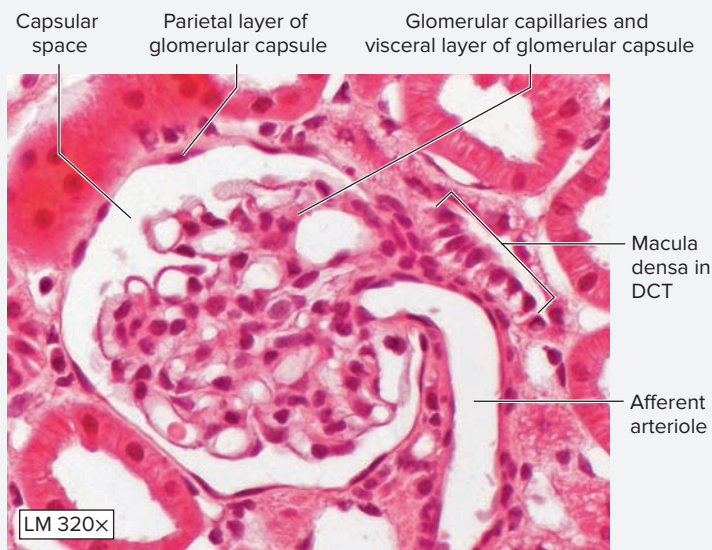
**EXERCISE 22.1 Histology of the Renal Cortex**

The renal cortex contains **renal corpuscles**, which are the site of filtration. Each renal corpuscle is composed of a ball of capillaries, the **glomerulus**, surrounded by the first part of the tubular system of the nephron, the **glomerular capsule** (also known as Bowman's capsule). The glomerular capsule itself is composed of an inner **visceral layer**, which consists of modified simple squamous epithelial cells called **podocytes**, and an outer **parietal layer**, which consists of unmodified simple squamous epithelium. The renal cortex also contains **proximal convoluted tubules (PCTs)**, which are the site of most reabsorption, and **distal convoluted tubules (DCTs)**, which are involved in both reabsorption and secretion and compose part of the **juxtaglomerular apparatus**.

**EXERCISE 22.1A: The Renal Corpuscle**

1. Obtain a compound microscope and a histology slide of the kidney and place the slide on the microscope stage.
2. Bring the tissue sample into focus at low power and scan the slide to distinguish between the outer cortex and inner medulla (figure 22.1). Next, move the microscope stage so the renal cortex is in the center of the field of view.
3. Scan the slide in the region of the cortex to locate a circular **renal corpuscle (figure 22.2)**. Bring the renal corpuscle into the center of the field of view and then change to high power. Although the visceral layer of the glomerular capsule is not distinguishable from the glomerular capillaries, identify the tissue that contains both the visceral layer of the glomerular capsule and the glomerular capillaries (figure 22.2). Next, identify the parietal layer of the glomerular capsule. What type of epithelium composes the parietal layer of the glomerular capsule? \_\_\_\_\_

What is the name of the space located between the visceral and parietal layers of the glomerular capsule?  
\_\_\_\_\_




**Figure 22.2 The Renal Corpuscle.** The renal corpuscle consists of the glomerulus and the glomerular capsule.

© McGraw-Hill Education/AI Telser

The space between visceral and parietal layers of the glomerular capsule becomes continuous with the lumen of which of the following? (Circle one.)

PCT      nephron loop      DCT      collecting duct

4. Sketch the renal corpuscle as seen under the microscope in the space provided. Label both the visceral and parietal layers of the glomerular capsule on the drawing.



5. *Optional Activity:* **AP|R Urinary System**—Review the “Kidney—microscopic anatomy” animation to visualize the parts of the nephron and their placement in the renal cortex and medulla.

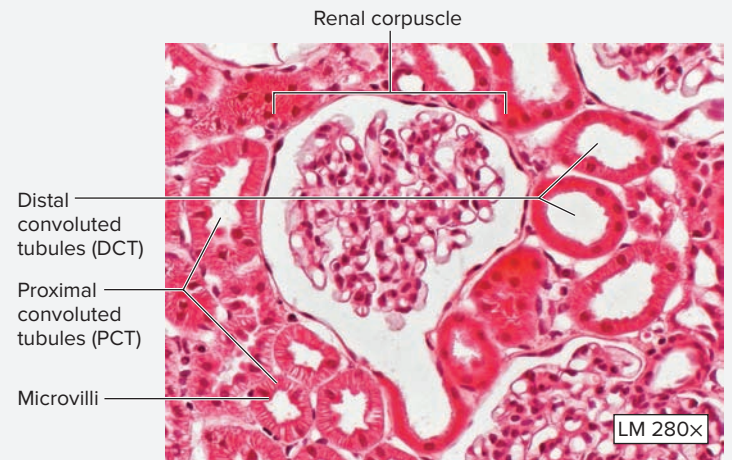

**EXERCISE 22.1B: Proximal and Distal Convoluted Tubules**

1. After completing exercise 22.1A, a slide of the kidney will be on the microscope stage with the outer cortex in the center of the field of view. If exercise 22.1A has not yet been performed, go through steps 1–2 of exercise 22.1A and then continue with this exercise.
2. Scan the slide in the region of the cortex to locate proximal and distal convoluted tubules (PCTs and DCTs) (**figure 22.3**). When viewing a histology slide of the cortex of the kidney, cross sections of PCTs and DCTs, with a few renal corpuscles scattered throughout are all visible. Although both PCTs and DCTs are lined with simple cuboidal epithelium, the *proximal* convoluted tubules have long, dense microvilli, which make the lumens of the PCTs appear “fuzzy.” The distal convoluted tubules have very few, short microvilli, which make the lumens appear to be clear. What does the presence of microvilli indicate about the function of an epithelium? \_\_\_\_\_

\_\_\_\_\_

- Sketch cross sections of proximal and distal convoluted tubules in the space provided.
- Identify the listed structures on the slide of the cortex of the kidney, using figures 22.1 to 22.3 and table 22.1 as guides:

- capsular space
- distal convoluted tubule
- microvilli
- parietal layer of glomerular capsule
- proximal convoluted tubule
- renal corpuscle
- visceral layer of glomerular capsule and glomerular capillaries



**Figure 22.3 The Renal Cortex.** The renal cortex contains renal corpuscles, proximal convoluted tubules (PCTs), and distal convoluted tubules (DCTs). PCTs have “fuzzy” lumens because of the presence of microvilli.

© McGraw-Hill Education/Al Telser

## EXERCISE 22.2 Histology of the Renal Medulla

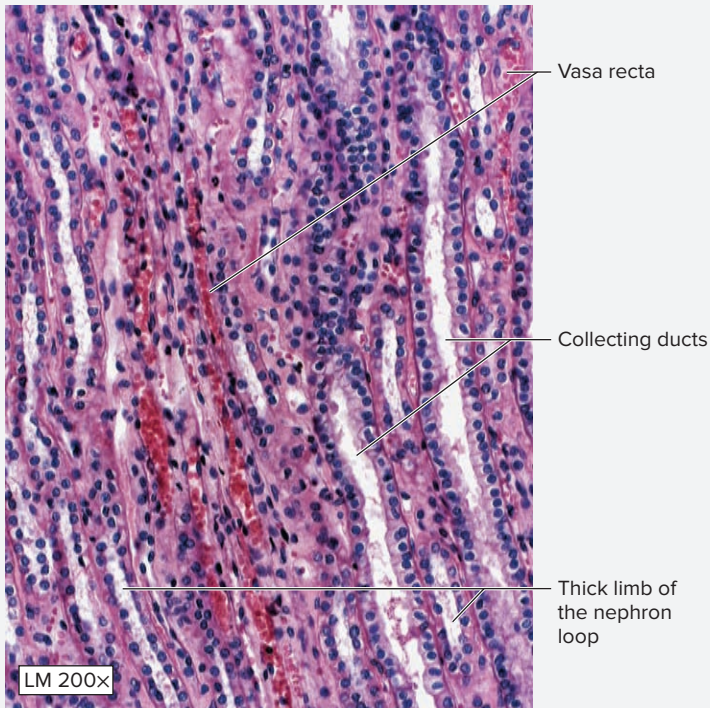
The renal medulla contains **nephron loops** (loops of Henle) and **collecting ducts**, with surrounding capillaries called the **vasa recta**. These structures are all elongated tubules that lie next to each other and function together to concentrate the urine formed by the nephrons.

- Obtain a compound microscope and a histology slide of the kidney. Note the section type, whether longitudinal or cross section, of the kidney. Place the slide of a longitudinal section on the microscope stage.
- Bring the tissue sample into focus at low power and scan the slide to distinguish between the outer cortex and inner medulla. Next, move the microscope stage so the renal medulla is in the center of the field of view (see figure 22.1).
- With the medulla in the center of the field of view, switch to high power and bring the tissue sample into focus once again. In this region of the kidney thick

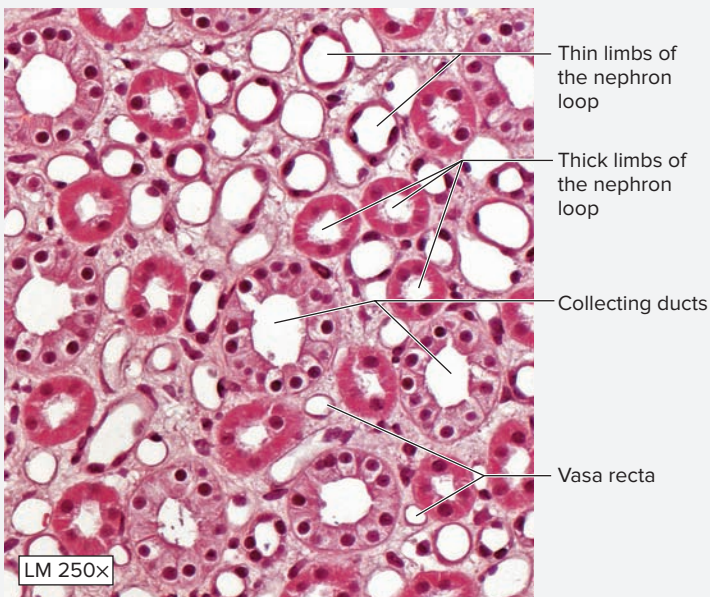
and thin limbs of the nephron loops, collecting ducts, and possibly vasa recta will be visible (table 22.1, **figure 22.4**). Notice how, in longitudinal section, these structures appear as row after row of cells lined up next to each other. The main objective in viewing this part of the kidney is to gain an appreciation for the way these structures line up next to each other, which is critical to their function. An additional objective is to distinguish thick limbs of the nephron loops from the collecting ducts based on the diameter of the lumens. Both structures are lined with simple cuboidal epithelium, but the collecting ducts have lumens with very large diameters compared to those of the thick nephron loops. It will be difficult to identify the vasa recta because of the extreme thinness of their walls and because they cannot easily be distinguished from thin limbs of the nephron loops (unless erythrocytes can be seen inside the lumen of the vessels, in which case the structures must be vasa recta).

(continued on next page)

(continued from previous page)



(a) Longitudinal section



(b) Cross section

**Figure 22.4** The Renal Medulla. (a) Collecting ducts, thick and thin nephron loops, and vasa recta as seen in (a) longitudinal section, and (b) cross-section.

© McGraw-Hill Education/Al Telser

4. Identify the listed structures on the histology slide of the medulla of the kidney, using figure 22.4a and table 22.1 as guides:

- collecting duct
- thick limbs of the nephron loop
- thin limbs of the nephron loop
- vasa recta

5. Sketch the histology of the renal medulla as observed through the microscope in the space provided. Label structures listed in step 4 in the drawing.

6. Obtain a slide demonstrating a cross section of the kidney. Repeat steps 1–4 using figure 22.4b as a reference.



## The Urinary Tract

The **urinary tract** consists of structures that function to transport or store urine: the ureters, urinary bladder, and urethra. The exercises in this section involve making observations of the histological structure of the walls of the ureters and urinary bladder. **Table 22.2** lists the type of

epithelium that lines the calyces of the kidney (the areas of the kidney that drain urine from the kidney into the urinary tract) and the type of epithelium that lines each of the structures of the urinary tract (ureters, urinary bladder, and urethra).

Table 22.2 Urine-Draining Structures		No. of Cell Layers	Word Origins
<b>Structure</b>	<b>Epithelium</b>		
<i>Calyces</i>	Transitional	2–3	<i>calyx</i> , cup of a flower
<i>Ureter</i>	Transitional	4–5	<i>oureter</i> , urinary canal
<i>Urinary Bladder</i>	Transitional	>6	<i>urinary</i> , relating to urine
<i>Urethra</i>	In males, the proximal portions are lined with transitional epithelium and the distal portions are lined with stratified squamous epithelium. In females, the epithelial tissue lining the entire urethra is primarily stratified squamous.	NA	<i>ourethra</i> , canal leading from the bladder

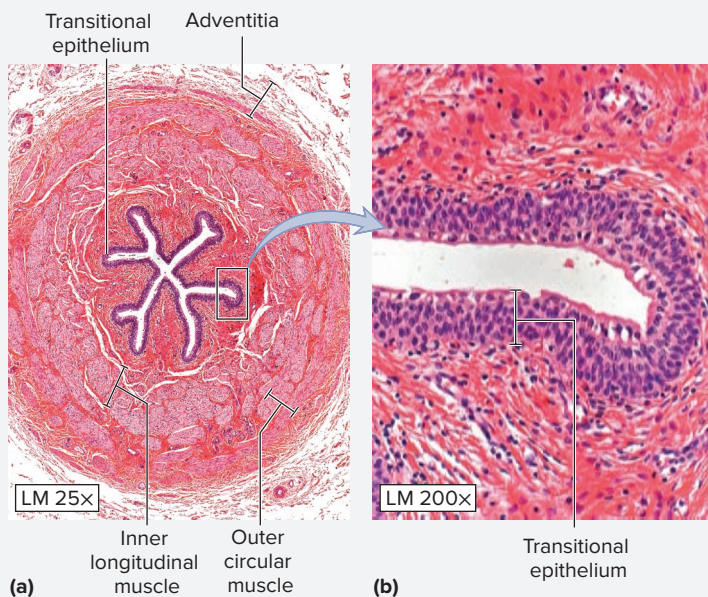
**EXERCISE 22.3 Histology of the Ureters**

The **ureters** are long, muscular tubes that transport urine from the hilum of the kidney to the urinary bladder. They are lined with **transitional epithelium**, which has the ability to stretch when urine is being transported through the ureters. As with other tubular structures in the body, the wall of each ureter is composed of multiple layers. The walls of the ureters, however, do not have a submucosa. There are three layers to the walls of the ureters: the mucosa, muscularis, and adventitia (**figure 22.5**). Contraction of smooth muscle in the muscularis layer of the ureters transports urine from the renal pelvis to the urinary bladder. The arrangement of smooth muscle layers in the muscularis of the ureters is just the opposite of that of the digestive tract organs. The inner layer is composed of **longitudinal** smooth muscle, whereas

the outer layer is composed of **circular** smooth muscle. In addition, the outer layer is an adventitia (and not serosa) because the ureters are **retroperitoneal** (*retro-*, behind + *peritoneal*, referring to the peritoneum) and are not covered by visceral peritoneum.

1. Obtain a histology slide demonstrating a cross-sectional view of a ureter. Place it on the microscope stage and bring the tissue sample into focus on low power.
2. Identify the listed structures on the slide of the ureter, using figure 22.5 as a guide:
 

<input type="checkbox"/> <b>adventitia</b>	<input type="checkbox"/> <b>outer circular muscle</b>
<input type="checkbox"/> <b>inner longitudinal muscle</b>	<input type="checkbox"/> <b>transitional epithelium</b>
3. Sketch a cross section of a ureter as seen through the microscope in the space provided. Label the structures listed in step 2 in the drawing.



**Figure 22.5 The Ureter.** (a) Cross section through entire ureter. (b) Close-up of the mucosa of the ureter.

© McGraw-Hill Education/AI Telser



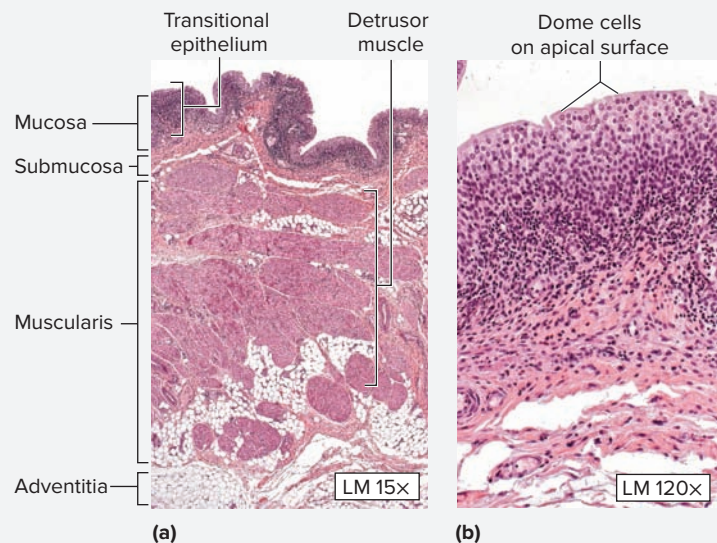
**EXERCISE 22.4** Histology of the Urinary Bladder

The wall of the urinary bladder has a more typical arrangement of layers, similar to that of other organs in the body: the mucosa, submucosa, muscularis, and adventitia (with serosa only on the superior surface of the urinary bladder) (**figure 22.6**). Similar to the ureters, the urinary bladder is lined with transitional epithelium, which allows it to stretch as it fills with urine. Its outermost layer is an adventitia because the bladder lies outside the peritoneal cavity. The muscularis layer of the bladder wall is composed of several individual layers of smooth muscle that are collectively referred to as the **detrusor muscle** (*detrudo*, to drive away).

1. Obtain a histology slide of the wall of the urinary bladder. Place it on the microscope stage and observe at low power. Identify the following structures, using figure 22.6 as a guide:

- |  |   |
|--|---|
| <input type="checkbox"/> <b>adventitia</b>                   | <input type="checkbox"/> <b>serosa</b>                  |
| <input type="checkbox"/> <b>mucosa</b>                       | <input type="checkbox"/> <b>submucosa</b>               |
| <input type="checkbox"/> <b>muscularis (detrusor muscle)</b> | <input type="checkbox"/> <b>transitional epithelium</b> |

2. Move the microscope stage so the epithelium is at the center of the field of view, then change to high power. Look for rounded epithelial cells on the apical surface of the epithelium, which are often binucleate. These cells are sometimes referred to as **dome cells** because of their shape.



**Figure 22.6** Histology of the Urinary Bladder.

(a) Section of the wall of the bladder. (b) Close-up of the transitional epithelium.

© McGraw-Hill Education/Al Telser

## Gross Anatomy

This set of exercises involves making observations of the gross anatomy of the kidneys, ureters, urinary bladder, and urethra. Particular attention will focus on the location of these structures within the abdominopelvic cavity and their relationships with surrounding organs of the digestive and reproductive systems.

### The Kidney

The kidneys are located along the posterior body wall from vertebral levels T<sub>12</sub> to L<sub>3</sub>, with the right kidney slightly lower than the left kidney because of the location of the liver. The kidneys, like the ureters and urinary blad-

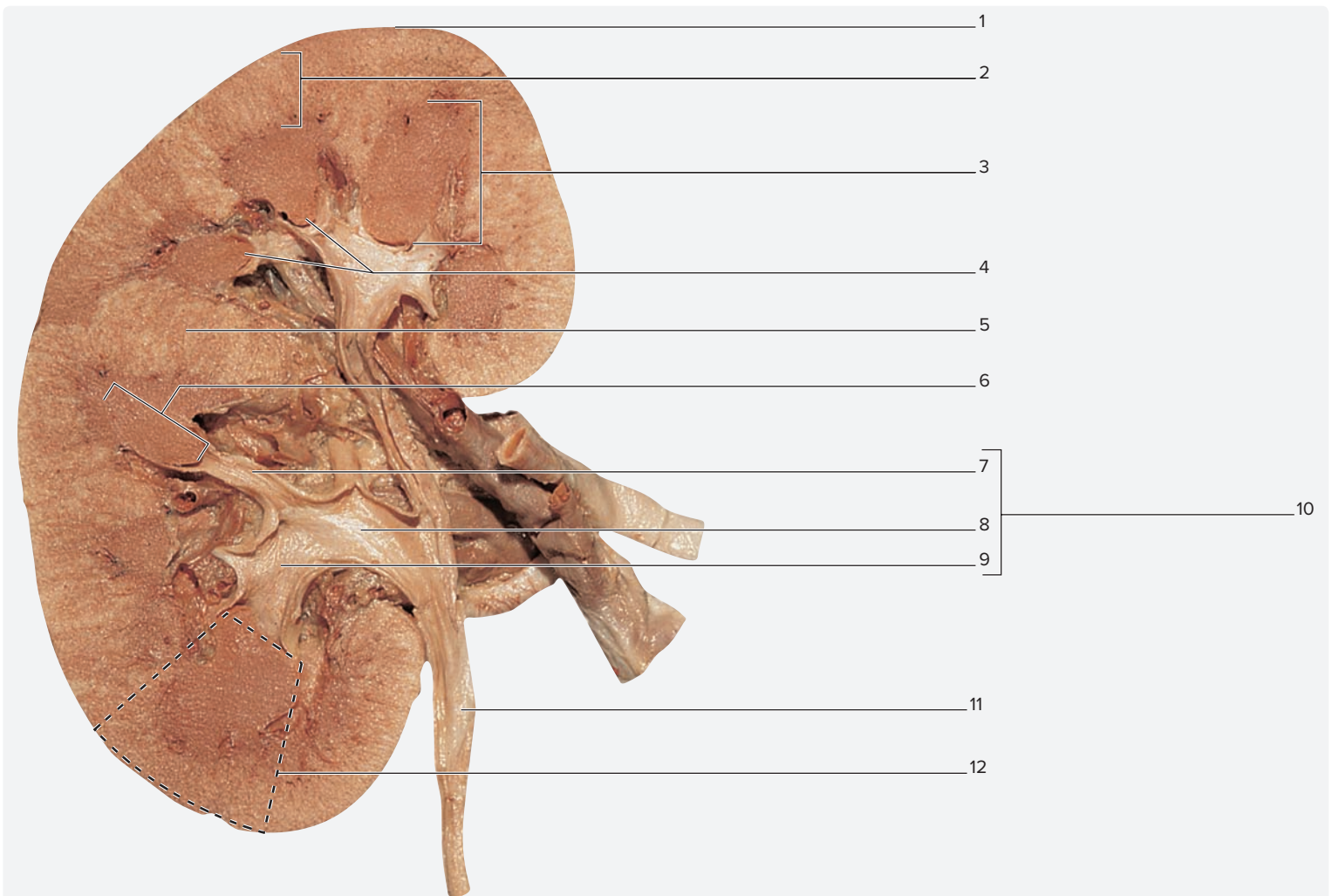der, are retroperitoneal structures (*retro-*, behind + *peritoneal*, referring to the peritoneum). The following exercises involve making observations of the gross anatomy of the kidney, the blood supply to the kidney, and the urine-draining structures within the kidney.

**EXERCISE 22.5** Gross Anatomy of the Kidney

1. Obtain a kidney that has been sectioned along a coronal plane or a classroom model of a coronal section of the kidney (**figure 22.7**). Whether the specimen being observed is an actual kidney or a model of the kidney, the outermost part of the specimen is actually the innermost layer of the capsule: the **fibrous capsule**. The entire capsule of the kidney is composed of three layers: the renal fascia, perinephric fat, and fibrous capsule. The first two of these

layers, the **renal fascia** and **perinephric fat**, are not often visualized in the gross anatomy laboratory unless an intact cadaver is available because the kidney must be extracted from these two protective layers of its capsule to be removed from the body for observation of its internal structure.

2. Identify the structures listed in figure 22.7 on the kidney or classroom model of the kidney. Then label them in figure 22.7.



**Figure 22.7** Coronal Section Through the Right Kidney. Use the terms listed to fill in the numbered labels in the figure.

- |  |                                       |  |  |                                      |
|--|---------------------------------------|--|--|--------------------------------------|
| <input type="checkbox"/> fibrous capsule | <input type="checkbox"/> renal column | <input type="checkbox"/> renal medulla             | <input type="checkbox"/> renal papilla | <input type="checkbox"/> renal sinus |
| <input type="checkbox"/> major calyx     | <input type="checkbox"/> renal cortex | <input type="checkbox"/> renal (medullary) pyramid | <input type="checkbox"/> renal pelvis  | <input type="checkbox"/> ureter      |
| <input type="checkbox"/> minor calyx     | <input type="checkbox"/> renal lobe   |  |  |                                      |

© McGraw-Hill Education/Rebecca Gray

### EXERCISE 22.6 Blood Supply to the Kidney

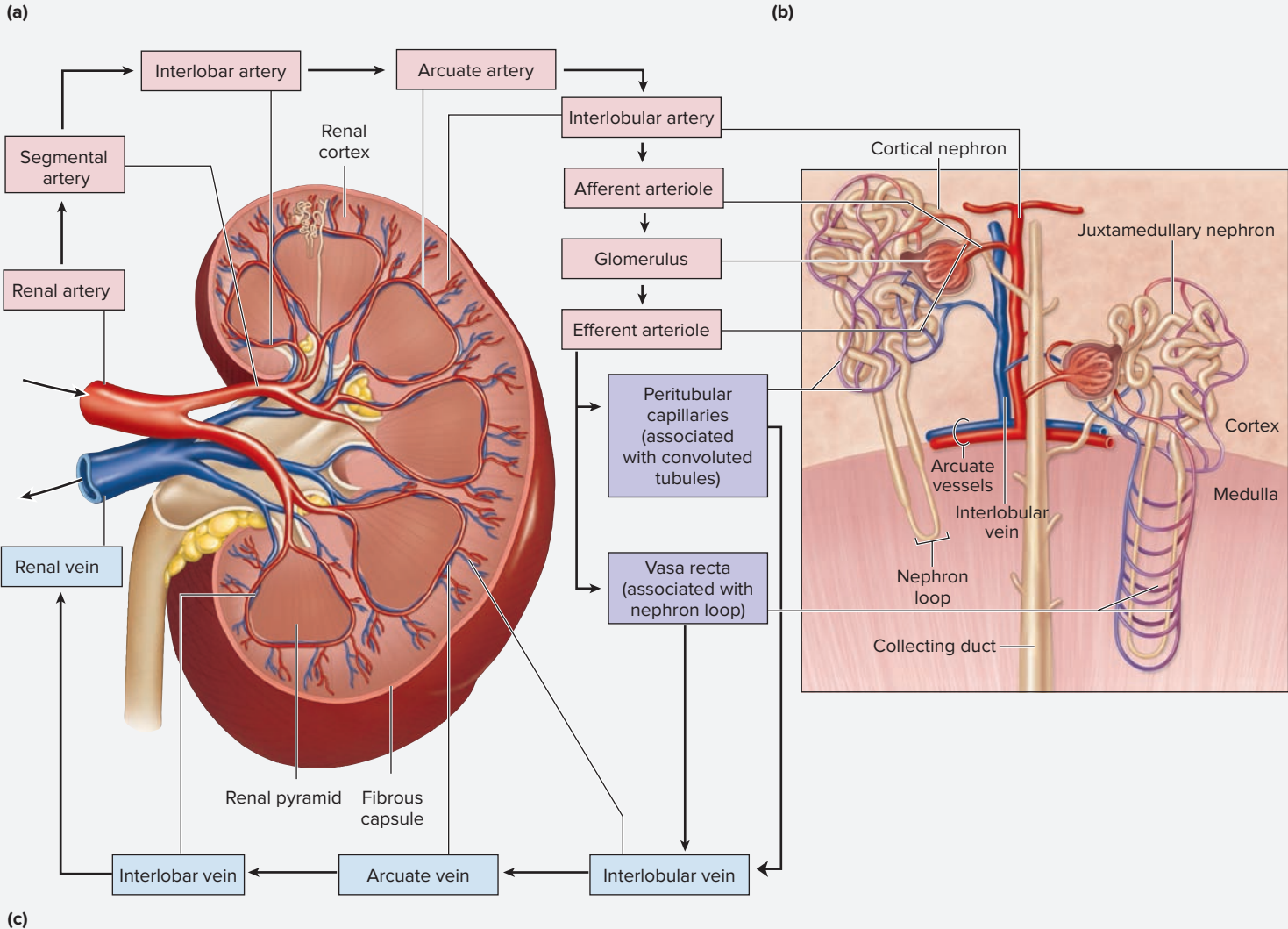
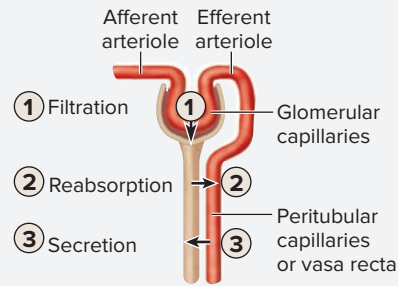
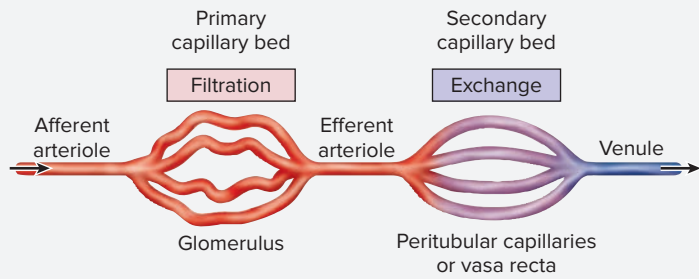
The kidneys receive approximately 20–25% of the blood leaving the heart each minute. This is not because they have a huge demand for oxygen or nutrients, but instead because their major function is to filter the blood to alter its volume and composition. The kidney accomplishes this through the processes of filtration, absorption, and secretion, which all involve transport of fluids and other substances between the functional units of the kidney (nephrons) and the blood. Thus, an understanding of blood flow through the kidney is critical to understanding the function of the kidney.

1. Observe a classroom model of the kidney that demonstrates blood vessels of the kidney.
2. **Figure 22.8** diagrams the flow of blood through the kidney. Blood enters the kidney through the renal artery

(a branch of the abdominal aorta). Blood is transported into the kidney by progressively smaller arteries until reaching the capillaries. The arrangement of capillaries around the nephrons of the kidney is unique. There are three capillary beds associated with each nephron: the glomerulus (within the renal corpuscle), the peritubular capillaries, and the vasa recta. The **glomerulus**, the first capillary bed, is the site of *filtration*: movement of fluid (filtered plasma) from the blood across the filtration membrane to the capsular space of the renal corpuscle (figure 22.8a,b). Blood enters the glomerulus through an afferent arteriole and leaves through an efferent arteriole. The efferent arteriole then leads into the second capillary bed, which is either the **peritubular capillaries** (within the cortex) or the **vasa recta** (within the medulla). The

(continued on next page)

(continued from previous page)



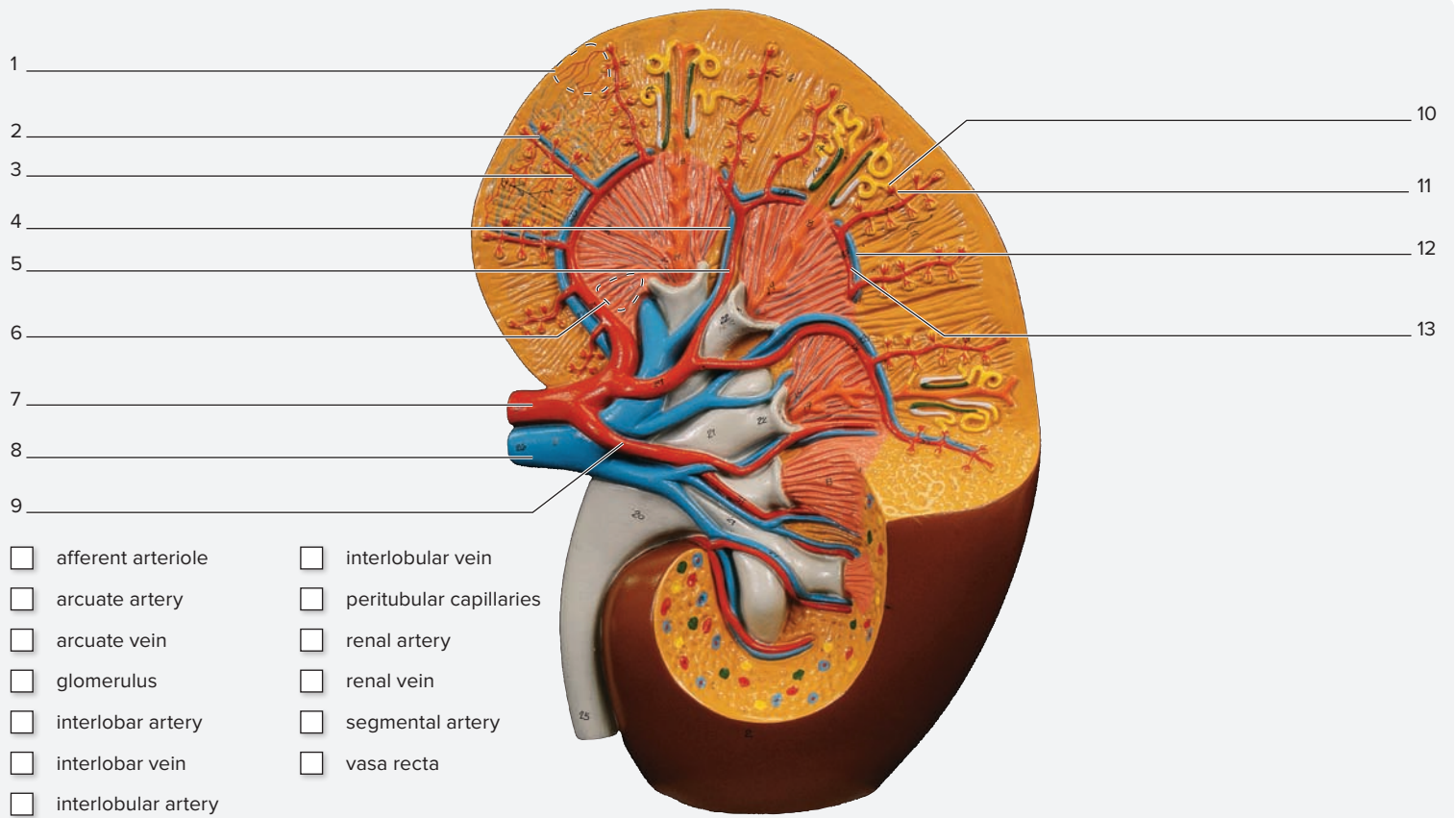
**Figure 22.8 Blood Supply to the Kidney.** (a) Blood flows through two capillary beds in the kidney. The first capillary bed, the glomerulus, is the site of filtration. The second capillary bed, peritubular capillaries in the cortex or vasa recta in the medulla, is the site of exchange (reabsorption or secretion). (b) The basic renal processes are filtration, reabsorption, and secretion. (c) Blood flow through the kidney.

second capillary bed is the site of *exchange* of fluids, electrolytes, respiratory gases, and nutrients between the tubular portions of the nephron and the blood. Exchange in these capillaries involves either *reabsorption* (movement of substances from the tubular lumen into the blood), or *secretion* (movement of substances from the blood into the tubular lumen). Finally, blood leaving the peritubular capillaries and vasa recta drains into progressively larger veins that carry the blood out of the kidney to the inferior vena cava.

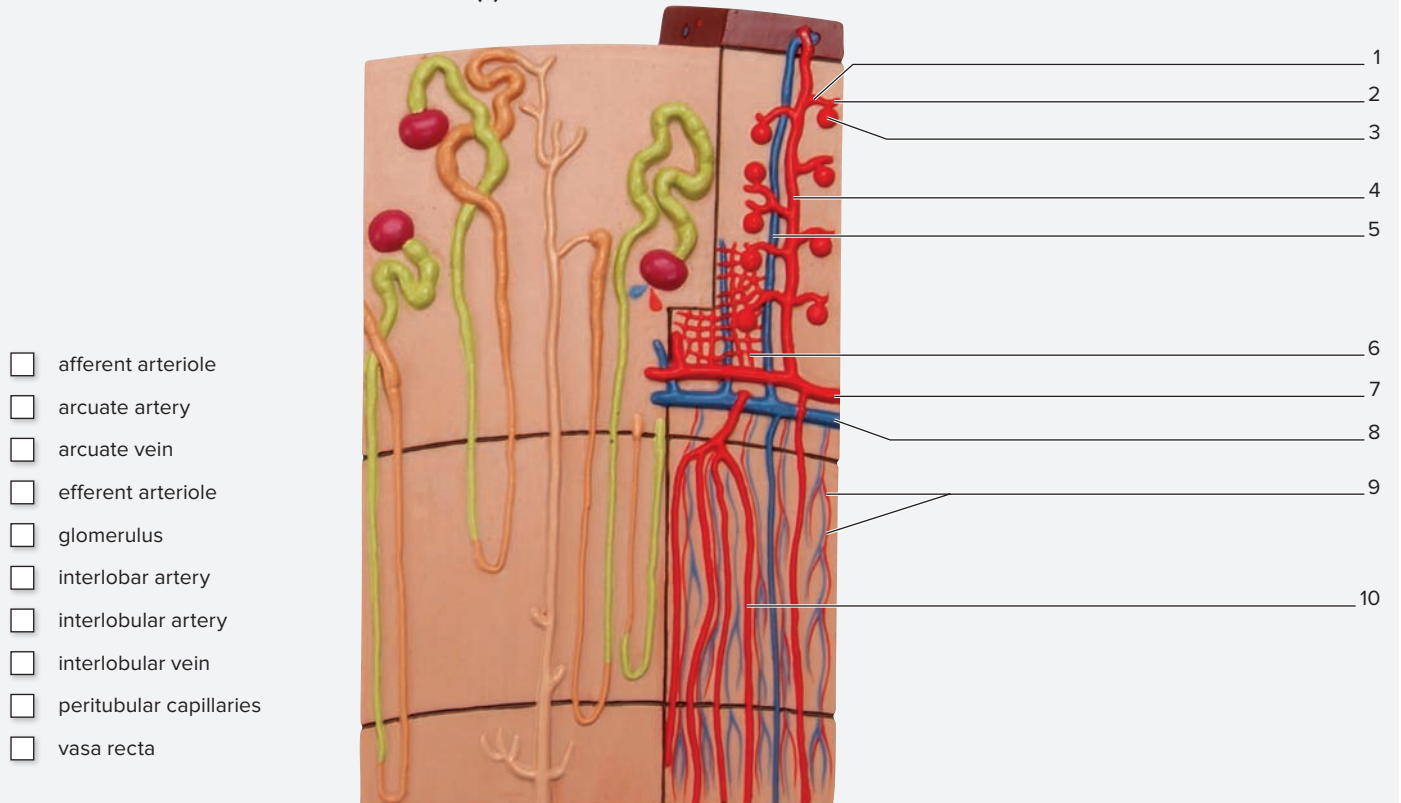
- Identify the blood vessels listed in **figure 22.9** on the classroom model of the kidney, using the textbook as a guide. Then label the structures in figure 22.9.

What parts of the nephron do the peritubular capillaries surround?

What parts of the nephron do the vasa recta surround?



(a)



(b)

**Figure 22.9 Models of the Kidney Demonstrating the Blood Supply to the Kidney.** (a) Coronal section. (b) Close-up of the renal cortex and renal medulla. Use the terms listed to fill in the numbered labels in the figure.

(a) © Copyright by Denoyer-Geppert. Photo by Christine Eckel; (b) Model # K11 [1000299] © 3B Scientific GmbH, Germany, 2015 www.3bscientific.com

(continued on next page)



*(continued from previous page)*

4. In the space provided, list the vessels that blood moves through as it travels through the kidney. Start at the abdominal aorta and end at the inferior vena cava.

---



---



---



---



---



---



---

### EXERCISE 22.7 Urine-Draining Structures Within the Kidney

Once filtrate has been formed by the nephrons, the fluid is processed as it passes through the nephron tubules (PCT, nephron loop, and DCT), collecting tubules, and collecting ducts. This fluid is called **tubular fluid**. Fluid leaving the collecting ducts and entering the papillary ducts is called **urine**. Urine will drain through the minor calyx, major calyx, and renal pelvis within the kidney before entering the ureter.

1. Observe a classroom model of a coronal section of a kidney, or a gross sample of a kidney that has been sectioned along a coronal plane.
2. Identify the listed urine-draining structures of the kidney, using figures 22.7 and 22.9, and table 22.2 as guides.

- |  |   |
|--|---|
| <input type="checkbox"/> collecting duct | <input type="checkbox"/> minor calyx    |
| <input type="checkbox"/> major calyx     | <input type="checkbox"/> papillary duct |

- |  |  |
|--|--|
| <input type="checkbox"/> renal papilla | <input type="checkbox"/> renal pyramid |
| <input type="checkbox"/> renal pelvis  | <input type="checkbox"/> ureter        |

3. *Optional Activity:* **AP|R Urinary System**—Watch the “Kidney—gross anatomy” and “Urine formation” animations for an overview of kidney anatomy, vasculature, and function.

## The Urinary Tract

The urinary tract consists of the ureters, urinary bladder, and urethra. Within the kidney, urine draining from the calyces begins to collect in the renal pelvis. Every 2 to 3 minutes, peristaltic contractions of the smooth muscle lining the ureters conveys the urine into the ureters, which transport

it into the urinary bladder. Urine is then stored within the urinary bladder until a time when it is convenient to allow the urine to exit the body through the urethra. The process of voiding urine is called **micturition**. The exercises in this section involve making observations of the gross anatomy of the structures composing the urinary tract.

### EXERCISE 22.8 Gross Anatomy of the Ureters

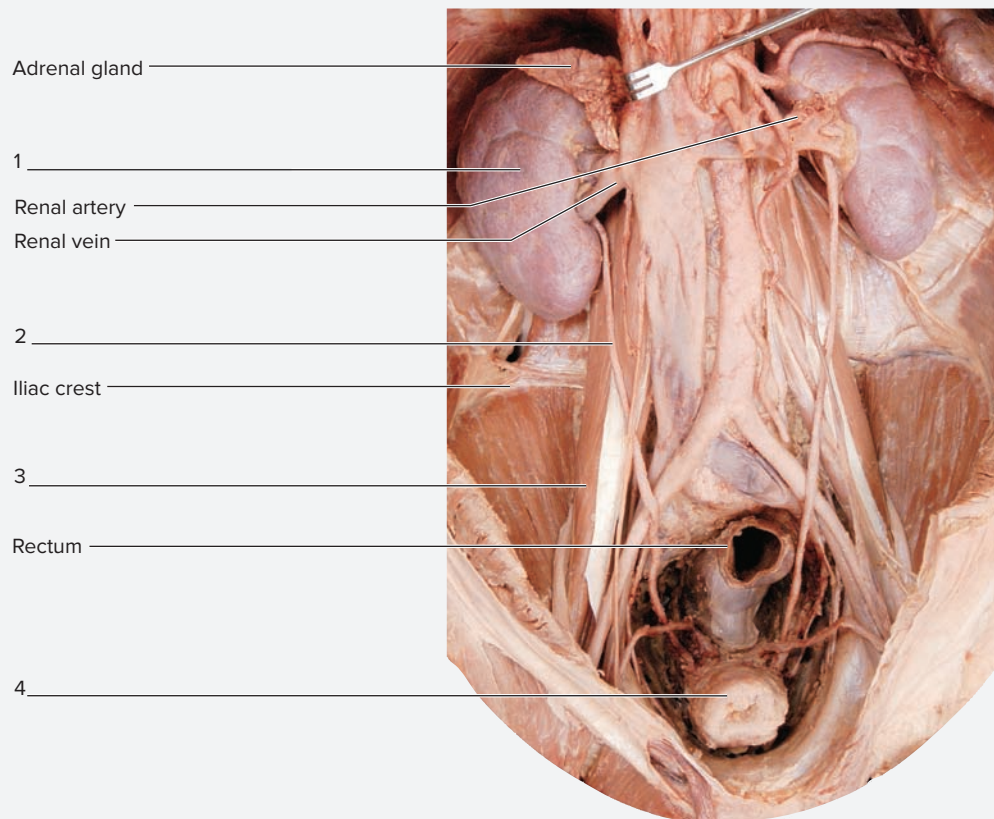
The ureters are long, thin, epithelia-derived fibromuscular tubes that run from the hilum of the kidney to the posterior, inferior surface of the urinary bladder (**figure 22.10**). Like the kidney, they are located retroperitoneally.

1. Observe a human cadaver or a classroom model of the abdomen.
2. Identify the structures listed in figure 22.10 on the cadaver or classroom model. Then label figure 22.10.

3. Follow the pathway of the ureter from its site of origin near the hilum of the kidney to its entry into the urinary bladder. What major muscle does the ureter cross over to get to the urinary bladder? \_\_\_\_\_

#### WHAT DO YOU THINK?

- 1 Why do you think muscular contractions are used to transport urine through the ureters?



**Figure 22.10** Location of the Ureters Within the Abdominopelvic Cavity. Use the terms listed to fill in the numbered labels in the figure.

© McGraw-Hill Education/Photo and Dissection by Christine Eckel

### EXERCISE 22.9 Gross Anatomy of the Urinary Bladder and Urethra

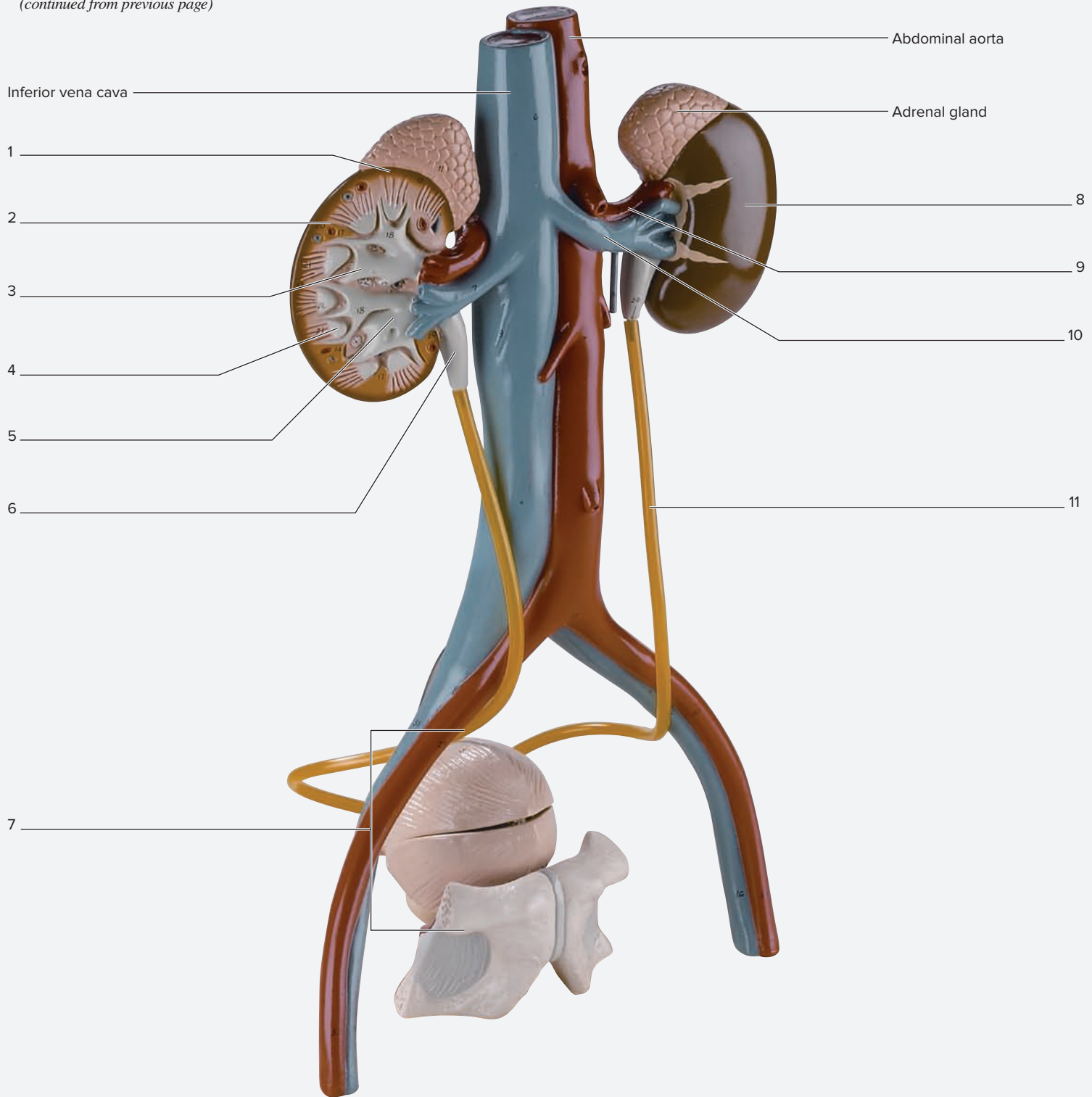
Like the kidneys and ureters, the **urinary bladder** is a retroperitoneal structure. The superior surface of the bladder is covered with peritoneum, but the rest is not. The urinary bladder lies in the pelvic cavity, just posterior to the pubic symphysis. The **urethra** is a passageway running from the inferior surface of the urinary bladder to the external urethral orifice. The urethra is much longer in males than in females because of its dual purpose in the male (i.e., the urethra also serves as a passageway for sperm during ejaculation). Both males and females have internal and external urethral sphincters that surround the urethra. The **internal urethral sphincter** is composed of smooth muscle in the wall of the urinary bladder. The internal urethral sphincter encircles the entrance into the urethra from the urinary bladder. It is under involuntary control. The **external urethral sphincter** is composed of skeletal muscle of the **urogenital diaphragm**. The external urethral sphincter is under voluntary control.

1. Observe the abdominopelvic cavity of a male human cadaver or a classroom model of the abdominopelvic cavity of a male (**figure 22.11**). The urinary **trigone** is the area in the floor of the urinary bladder (in both males and females) that is enclosed by two imaginary lines that extend between the openings of the two ureters and the urethra. This area is clinically significant because urinary tract infections often establish themselves in this location. If the urinary bladder is cut open on the cadaver or if the classroom model demonstrates the interior of the urinary bladder, identify the urinary trigone in the floor of the urinary bladder.

2. Identify the structures listed in figure 22.11 on the cadaver or classroom model, using the textbook as a guide. Then label them in figure 22.11.
3. Sketch the structures forming the boundaries of the urinary trigone as viewed from the interior of the urinary bladder in the space provided.

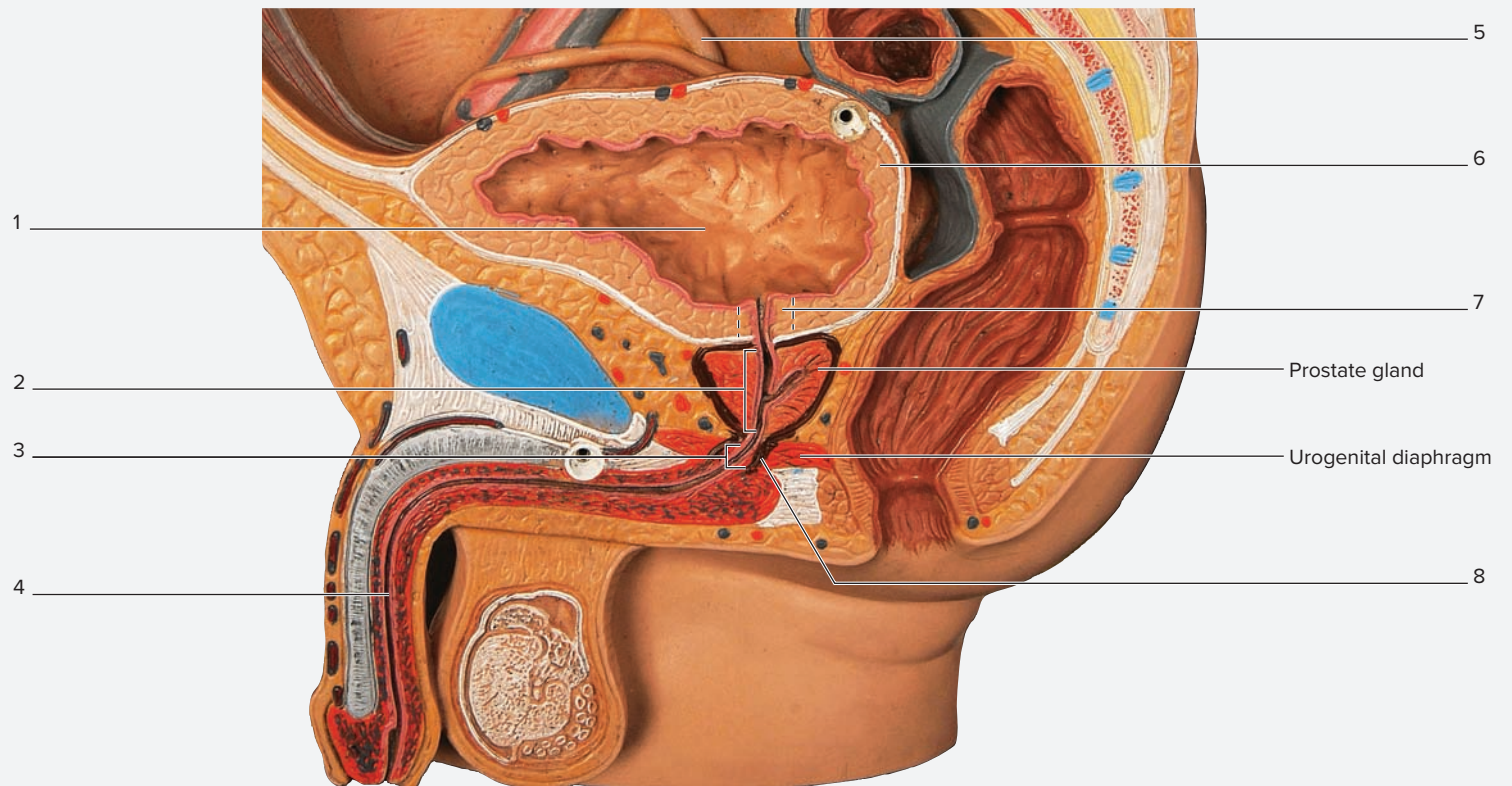
(continued on next page)

(continued from previous page)



**Figure 22.11** Classroom Model of Male Urinary System Structures. Use the terms listed to fill in the numbered labels in the figure.

- |                                       |  |  |
|---------------------------------------|--|--|
| <input type="checkbox"/> left kidney  | <input type="checkbox"/> renal cortex              | <input type="checkbox"/> renal vein      |
| <input type="checkbox"/> major calyx  | <input type="checkbox"/> renal (medullary) pyramid | <input type="checkbox"/> ureter          |
| <input type="checkbox"/> minor calyx  | <input type="checkbox"/> renal papilla             | <input type="checkbox"/> urinary bladder |
| <input type="checkbox"/> renal artery | <input type="checkbox"/> renal pelvis              |  |



**Figure 22.12** Classroom Model of a Midsagittal Section Through the Male Pelvis. Use the terms listed to fill in the numbered labels in the figure.

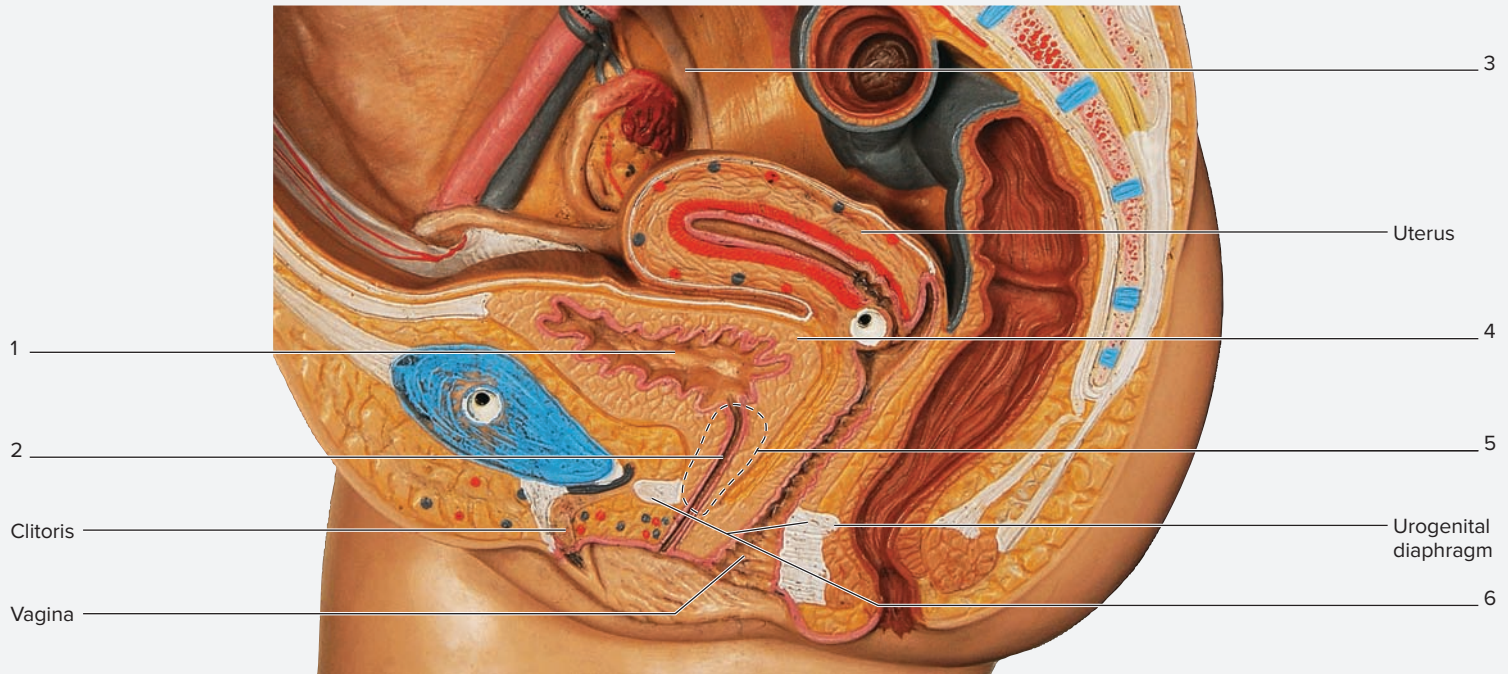
- |  |   |  |  |
|--|---|--|--|
| <input type="checkbox"/> external urethral sphincter | <input type="checkbox"/> membranous urethra           | <input type="checkbox"/> prostatic urethra | <input type="checkbox"/> ureter          |
| <input type="checkbox"/> internal urethral sphincter | <input type="checkbox"/> muscularis (detrusor muscle) | <input type="checkbox"/> spongy urethra    | <input type="checkbox"/> urinary bladder |

Model # H10 [1000282] © 3B Scientific GmbH, Germany, 2015 www.3bscientific.com/Photo by Christine Eckel, Ph.D.

- Observe the male urethra on a classroom model demonstrating a midsagittal section through the male pelvis (**figure 22.12**). The male urethra has three parts: the **prostatic urethra**, the **membranous urethra**, and the **spongy urethra**. The internal urethral sphincter of the male is located between the urinary bladder and the prostate gland, and the external urethral sphincter is the skeletal muscle that composes the urogenital diaphragm (which surrounds the membranous urethra).
- Identify the structures listed in figure 22.12 on the classroom model, using the textbook as a guide. Then label them in figure 22.12.
- Observe the female urethra on a classroom model demonstrating a midsagittal section through the female pelvis (**figure 22.13**). The female urethra is short, and the external urethral orifice is located between the clitoris and the vagina. The entire urethra is surrounded by the internal urethral sphincter. The external urethral sphincter is skeletal muscle of the urogenital diaphragm, just as it is in the male.
- Identify the structures listed in figure 22.13 on the classroom model, using the textbook as a guide. Then label them in figure 22.13.

(continued on next page)

(continued from previous page)



**Figure 22.13** Classroom Model of a Midsagittal Section Through the Female Pelvis. Use the terms listed to fill in the numbered labels in the figure.

- |   |  |
|---|--|
| <input type="checkbox"/> external urethral sphincter  | <input type="checkbox"/> ureter          |
| <input type="checkbox"/> internal urethral sphincter  | <input type="checkbox"/> urethra         |
| <input type="checkbox"/> muscularis (detrusor muscle) | <input type="checkbox"/> urinary bladder |

Model # H10 [1000281] © 3B Scientific GmbH, Germany, 2015 www.3bscientific.com/Photo by Christine Eckel, Ph.D.

The ❶ corresponds to the Learning Objective(s) listed in the chapter opener outline.

## Do You Know the Basics?

### Exercise 22.1: Histology of the Renal Cortex

1. Which of the following are components of the nephron? (Check all that apply.) ❶

- a. collecting duct
- b. distal convoluted tubule
- c. glomerulus
- d. nephron loop
- e. proximal convoluted tubule

2. Fill in the table with the type of epithelium lining each structure and a brief description of the function of each structure. ❶ ❷

Structure	Epithelium	Function
<i>DCT</i>		
<i>Glomerulus</i>		
<i>Parietal Layer of Glomerular Capsule</i>		
<i>PCT</i>		
<i>Visceral Layer of Glomerular Capsule</i>		

3. The renal corpuscle consists of the glomerular capsule and glomerular capillaries. \_\_\_\_\_ (True/False) ❸

4. Filtration slits in the filtration membrane are formed by which of the following structures? (Circle one.) ❹

- a. basement membrane of glomerular capillaries
- b. endothelium of glomerular capillaries
- c. podocytes of the glomerular capsule

5. Which of the following structures are located in the renal cortex? (Check all that apply.) ❺

- a. collecting ducts
- b. distal convoluted tubule
- c. nephron loop
- d. proximal convoluted tubule
- e. renal corpuscle

### Exercise 22.2: Histology of the Renal Medulla

6. Which of the following structures are located in the renal medulla? (Check all that apply.) ❻

- a. collecting ducts
- b. distal convoluted tubule
- c. nephron loop
- d. proximal convoluted tubule
- e. renal corpuscle

7. The thick limbs of the nephron loop are composed of simple \_\_\_\_\_ (cuboidal/squamous) epithelium, whereas the thin limbs of the nephron loop are composed of simple \_\_\_\_\_ (cuboidal/squamous) epithelium. **7**

### Exercise 22.3: Histology of the Ureters

8. Place the layers of the wall of the ureter in order, from innermost to outermost. **8**
- \_\_\_\_ a. adventitia
- \_\_\_\_ b. mucosa
- \_\_\_\_ c. muscularis
9. The muscularis layer of the ureter consists of an inner \_\_\_\_\_ (circular/longitudinal) layer of smooth muscle and an outer \_\_\_\_\_ (circular/longitudinal) layer of smooth muscle. **9**

### Exercise 22.4: Histology of the Urinary Bladder

10. The urinary bladder has \_\_\_\_\_ (three/four) layers in its wall. **10**
11. The urinary bladder is lined with which type of epithelial tissue? (Circle one.) **11**
- a. simple cuboidal epithelium
- b. simple squamous epithelium
- c. stratified squamous epithelium
- d. transitional epithelium

### Exercise 22.5: Gross Anatomy of the Kidney

12. The layer of dense irregular connective tissue that surrounds the entire kidney is called the renal capsule. \_\_\_\_\_ (True/False) **12**
13. The \_\_\_\_\_ (right/left) kidney is located more superiorly than the other. **13**
14. Place the following structures in order from innermost to outermost. **14**
- \_\_\_\_ a. paranephric fat
- \_\_\_\_ b. perinephric fat
- \_\_\_\_ c. renal capsule
- \_\_\_\_ d. renal fascia
15. Retroperitoneal structures are located behind the peritoneum. \_\_\_\_\_ (True/False) **15**

### Exercise 22.6: Blood Supply to the Kidney

16. The renal \_\_\_\_\_ (artery/vein) supplies oxygen-rich blood to each kidney, whereas the renal \_\_\_\_\_ (artery/vein) drains blood from each kidney to the inferior vena cava. **16**
17. Place the following vessels in the correct order, from the entry into the kidney via the renal artery to the glomerulus. **17**
- \_\_\_\_ a. afferent arteriole
- \_\_\_\_ b. arcuate artery
- \_\_\_\_ c. interlobar artery
- \_\_\_\_ d. interlobular artery
- \_\_\_\_ e. segmental artery

**Exercise 22.7: Urine-Draining Structures Within the Kidney**

18. Fluid that passes through nephron tubules, collecting tubules, and collecting ducts is called urine. \_\_\_\_\_ (True/False) 18
19. Place the following structures in the correct order of urine flow. 19
- \_\_\_\_\_ a. major calyx
  - \_\_\_\_\_ b. minor calyx
  - \_\_\_\_\_ c. renal papilla
  - \_\_\_\_\_ d. renal pelvis

**Exercise 22.8: Gross Anatomy of the Ureters**

20. Place the following structures in the correct order of urine flow from the kidney to the exterior of the body. 20
- \_\_\_\_\_ a. ureter
  - \_\_\_\_\_ b. urethra
  - \_\_\_\_\_ c. urinary bladder
21. The urinary bladder is located in the \_\_\_\_\_ (abdominal/pelvic) cavity. 21

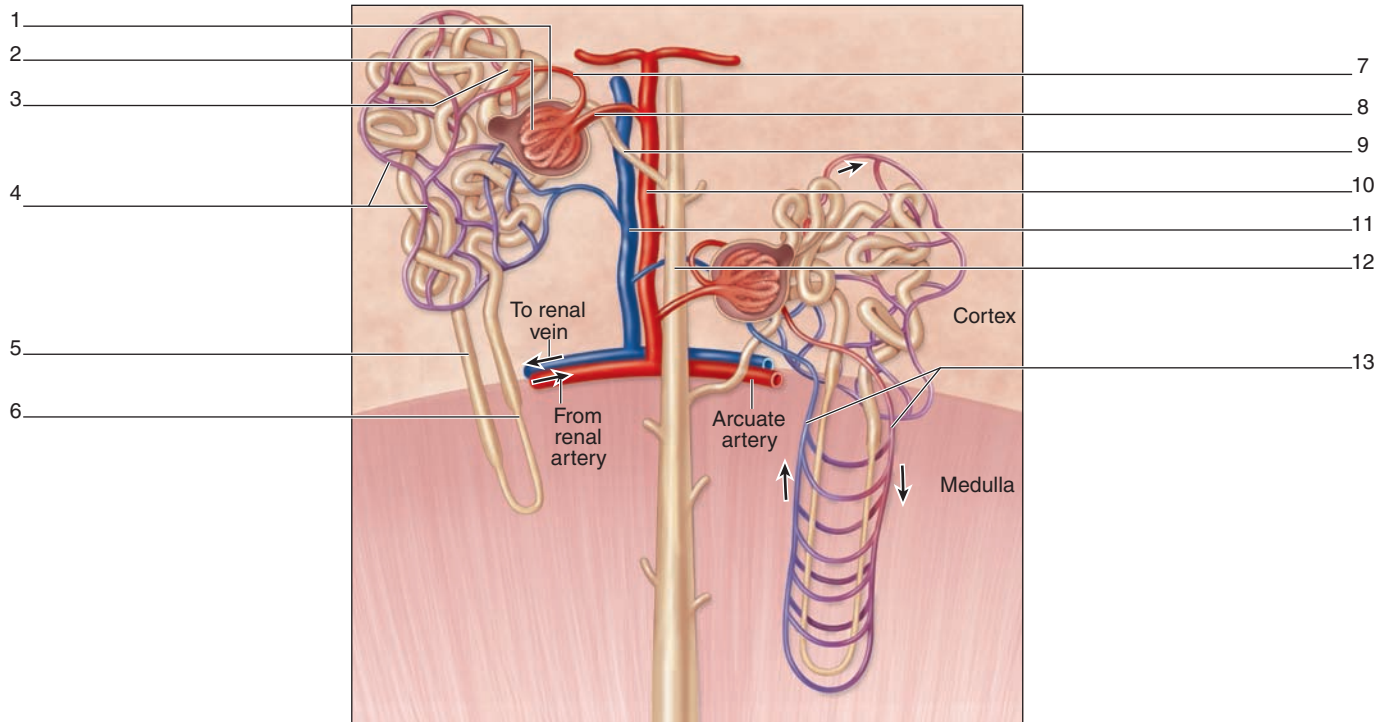
**Exercise 22.9: Gross Anatomy of the Urinary Bladder and Urethra**

22. Identify the three structures that form the boundaries of the urinary trigone. (Check three.) 22
- \_\_\_\_\_ a. left renal artery
  - \_\_\_\_\_ b. left ureter
  - \_\_\_\_\_ c. right renal artery
  - \_\_\_\_\_ d. right ureter
  - \_\_\_\_\_ e. urethra
23. Number the three sections of the male urethra in the correct order from proximal to distal. 23
- \_\_\_\_\_ a. membranous urethra
  - \_\_\_\_\_ b. prostatic urethra
  - \_\_\_\_\_ c. spongy urethra
24. The internal urethral sphincter is composed of \_\_\_\_\_ (skeletal/smooth) muscle, whereas the external urethral sphincter is composed of \_\_\_\_\_ (skeletal/smooth) muscle. 24

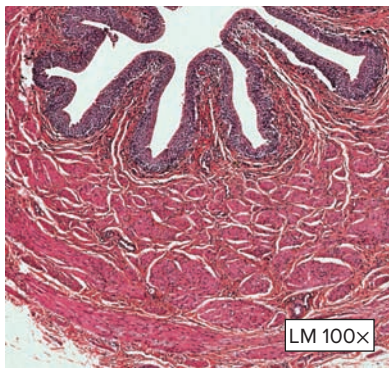


**CAN YOU APPLY WHAT YOU'VE LEARNED?**

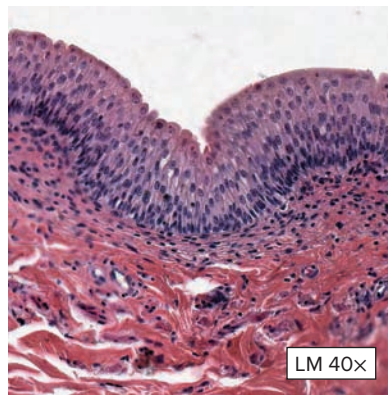
25. Label the parts of a nephron and the blood supply to the nephron in this figure.



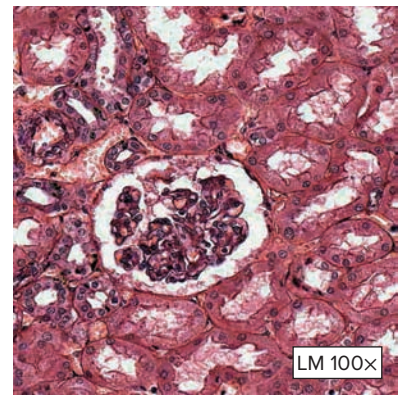
26. For each photomicrograph shown, identify the organ. Then explain the characteristics used to determine what the organ is.



(a)  
© McGraw-Hill Education/Christine Eckel, photographer



(b)  
© Christine Eckel



(c)  
© Christine Eckel

Organ: \_\_\_\_\_

Organ: \_\_\_\_\_

Organ: \_\_\_\_\_

Identifying characteristics: \_\_\_\_\_

Identifying characteristics: \_\_\_\_\_

Identifying characteristics: \_\_\_\_\_

\_\_\_\_\_

\_\_\_\_\_

\_\_\_\_\_

\_\_\_\_\_

\_\_\_\_\_

\_\_\_\_\_

\_\_\_\_\_

\_\_\_\_\_

\_\_\_\_\_

# The Reproductive System

# 23

## OUTLINE AND LEARNING OBJECTIVES

### Histology 502

#### Female Reproductive System 502

##### EXERCISE 23.1: HISTOLOGY OF THE OVARY 502

- 1 Identify the ovary and associated structures when viewed through a microscope
- 2 Recognize the stages of ovarian follicle development on histology slides of the ovary

##### EXERCISE 23.2: HISTOLOGY OF THE UTERINE TUBES 506

- 3 Identify the uterine tubes and associated structures when viewed through a microscope
- 4 Describe the wall structure of the uterine tubes
- 5 Classify the epithelium that lines the uterine tubes

##### EXERCISE 23.3: HISTOLOGY OF THE UTERINE WALL 508

- 6 Identify the uterus and layers of the uterine wall when viewed through a microscope
- 7 Describe the tissues that compose the three layers of the uterine wall

##### EXERCISE 23.4: HISTOLOGY OF THE VAGINAL WALL 509

- 8 Identify the vagina and layers of the vaginal wall when viewed through a microscope
- 9 Classify the epithelium that lines the vaginal wall

#### Male Reproductive System 509

##### EXERCISE 23.5: HISTOLOGY OF SEMINIFEROUS TUBULES 509

- 10 Identify seminiferous tubules and associated cells when viewed through a microscope
- 11 Recognize the stages of sperm development in histology slides of the testes
- 12 Describe the location and function of interstitial cells and sustentacular cells of the testes

##### EXERCISE 23.6: HISTOLOGY OF THE EPIDIDYMIS 511

- 13 Identify the epididymis when viewed through a microscope
- 14 Classify the epithelium that lines the epididymis
- 15 Describe the structure and function of stereocilia

##### EXERCISE 23.7: HISTOLOGY OF THE DUCTUS DEFERENS 513

- 16 Identify the ductus deferens when viewed through a microscope
- 17 Describe the structures that compose the walls of the ductus deferens
- 18 Classify the epithelium that lines the ductus deferens

##### EXERCISE 23.8: HISTOLOGY OF THE SEMINAL VESICLES 514

- 19 Identify the seminal vesicles when viewed through a microscope
- 20 Classify the epithelium that lines the seminal vesicles

##### EXERCISE 23.9: HISTOLOGY OF THE PROSTATE GLAND 515

- 21 Identify the prostate gland when viewed through a microscope
- 22 Identify prostatic calculi in slides of the prostate gland

##### EXERCISE 23.10: HISTOLOGY OF THE PENIS 515

- 23 Identify the penis when viewed through a microscope
- 24 Describe the components that are visible in a cross-sectional view of the penis

### Gross Anatomy 516

#### Female Reproductive System 516

##### EXERCISE 23.11: GROSS ANATOMY OF THE OVARY, UTERINE TUBES, UTERUS, AND SUSPENSORY LIGAMENTS 516

- 25 Describe the structure and function of the ovary, uterine tubes, and uterus
- 26 Locate the eight suspensory ligaments of the ovary, uterine tubes, and uterus on classroom models of the female reproductive system
- 27 Identify the parts of the uterine tubes and uterus on classroom models of the female reproductive system

##### EXERCISE 23.12: GROSS ANATOMY OF THE FEMALE BREAST 520

- 28 Describe the structure and function of the female breast

#### Male Reproductive System 522

##### EXERCISE 23.13: GROSS ANATOMY OF THE SCROTUM, TESTIS, SPERMATIC CORD, AND PENIS 523

- 29 Describe the location and function of the epididymis ductus deferens, seminal vesicles, and prostate gland
- 30 Identify the three parts of the male urethra on classroom models of the male reproductive system
- 31 Describe the relationship between the parts of the male urethra and the male accessory reproductive structures such as the prostate, seminal vesicles, and bulbourethral glands
- 32 Explain the contributions of accessory male reproductive glands (seminiferous tubules and prostate) to semen
- 33 Describe the components that make up the spermatic cord
- 34 Trace the pathway of sperm through the male reproductive tract during ejaculation, starting at the epididymis

## INTRODUCTION

Of all the systems of the human body, the **reproductive system** (*re-*, again + *productus*, to lead forth) is the only system that is not required for the survival of the human body. Instead, its function is to ensure the survival of the species by allowing for the creation of another human being. Thus far the exercises in this laboratory manual have focused on the amazing complexity and beauty of the human body. The exercises in the current chapter turn the attention to the process by which this amazingly complex human comes into being. Reproduction requires two separate **sexes**: male and female. Each sex produces **gametes** (sperm in males; ova in females), which are haploid cells that combine to form a **zygote**, the first stage in the development of a new human. Male and female gametes are both formed by **meiosis**, which occurs within the **gonads** (*gone*, seed). The human body invests a great deal of energy in the formation of gametes and in the maintenance of characteristics that are meant to attract members of the opposite sex. This much energy expenditure may seem counterintuitive when one thinks about homeostasis as the primary driving force for most organ system functions. However, when failure to reproduce could result in extinction of the species, the amount of energy invested makes much more sense.

Although the reproductive structures in males and females are different, all human embryos develop from the same overall plan. Certain embryonic structures degrade in males but not in females. On the other hand, many embryonic structures persist in both males and females—forming what appear to be very different adult structures. Such structures are called **homologues** (*homos*, the same + *logos*, relation). Ovaries and testes are

examples of homologous structures. While exploring the male and female reproductive systems, pay particular attention to homologous structures. This will not only simplify the task of learning reproductive system structures, it will also highlight the similarities between the male and female reproductive systems.

The exercises in this chapter guide the student in making observations of the histological and gross anatomic structures of the male and female reproductive systems, with a focus on the histology of the primary reproductive organs of both females and males: the *ovaries* and *testes*. The focus of gross anatomic observations of the reproductive systems is on regional relationships between gross reproductive structures and structures of other body systems (e.g., urinary system). Additional exercises guide the student in making observations that focus on homologous relationships between male and female reproductive structures.

### List of Reference Tables

Table 23.1	Developmental Stages of an Oocyte	p. 502
Table 23.2	Developmental Stages of Ovarian Follicles	p. 504
Table 23.3	Components of a Vesicular Follicle	p. 505
Table 23.4	Components of the Uterine Tube	p. 507
Table 23.5	Wall Layers of the Uterus	p. 508
Table 23.6	Phases of the Menstrual Cycle	p. 508
Table 23.7	Developmental Stages of Sperm	p. 510
Table 23.8	Accessory Cells of the Testis	p. 511
Table 23.9	Male Accessory Reproductive Structures	p. 512
Table 23.10	Suspensory Ligaments of the Ovary, Uterine Tubes, and Uterus	p. 517
Table 23.11	The Female Breast	p. 522

These Pre-laboratory Worksheet questions may be assigned by instructors through their **connect** course.

## PRE-LABORATORY WORKSHEET

- Which of the following is the female gonad? (Circle one.)
  - clitoris
  - oocyte
  - ovary
  - uterus
  - vagina
- Which of the following is the male gonad? (Circle one.)
  - epididymis
  - penis
  - prostate
  - seminiferous tubules
  - testis
- Human somatic cells contain twenty-two pairs of autosomal chromosomes and one pair of sex chromosomes. \_\_\_\_\_ (True/False)
- Spermatogenesis is the \_\_\_\_\_ (maturation/production) of sperm, whereas spermiogenesis is the \_\_\_\_\_ (maturation/production) of sperm.
- Vesicular (Graafian) follicles contain a \_\_\_\_\_ (primary/secondary) oocyte.
- A secondary (maturing) follicle contains a \_\_\_\_\_ (primary/secondary) oocyte.
- Which of the following wall layers of the uterus is shed during menstruation? (Circle one.)
  - endometrium
  - myometrium
  - perimetrium
- Which of the following are male accessory reproductive structures? (Check all that apply.)  
 a. bulbourethral glands  
 b. epididymis  
 c. penis  
 d. prostate gland  
 e. seminal vesicles
- Which of the following ligaments anchors the ovary to the body wall of the uterus? (Circle one.)
  - broad ligament
  - ovarian ligament
  - round ligament of the uterus
  - suspensory ligament of the ovary
  - uterosacral ligament
- In the female, the vagina is located \_\_\_\_\_ (anterior/posterior) to the clitoris.

## Histology

### Female Reproductive System

The female reproductive system has two important functions: produce the female gametes (ova) and support and protect the developing embryo/fetus that is formed when an ovum becomes fertilized by a sperm. Components

of the female reproductive system include the ovaries, uterine tubes, uterus, vagina, and mammary glands. Exercises 23.1 to 23.4 explore the internal detail and wall structures of the ovary, uterine tube, uterus, and vagina. Mammary glands are covered in exercise 23.12.

#### EXERCISE 23.1 Histology of the Ovary

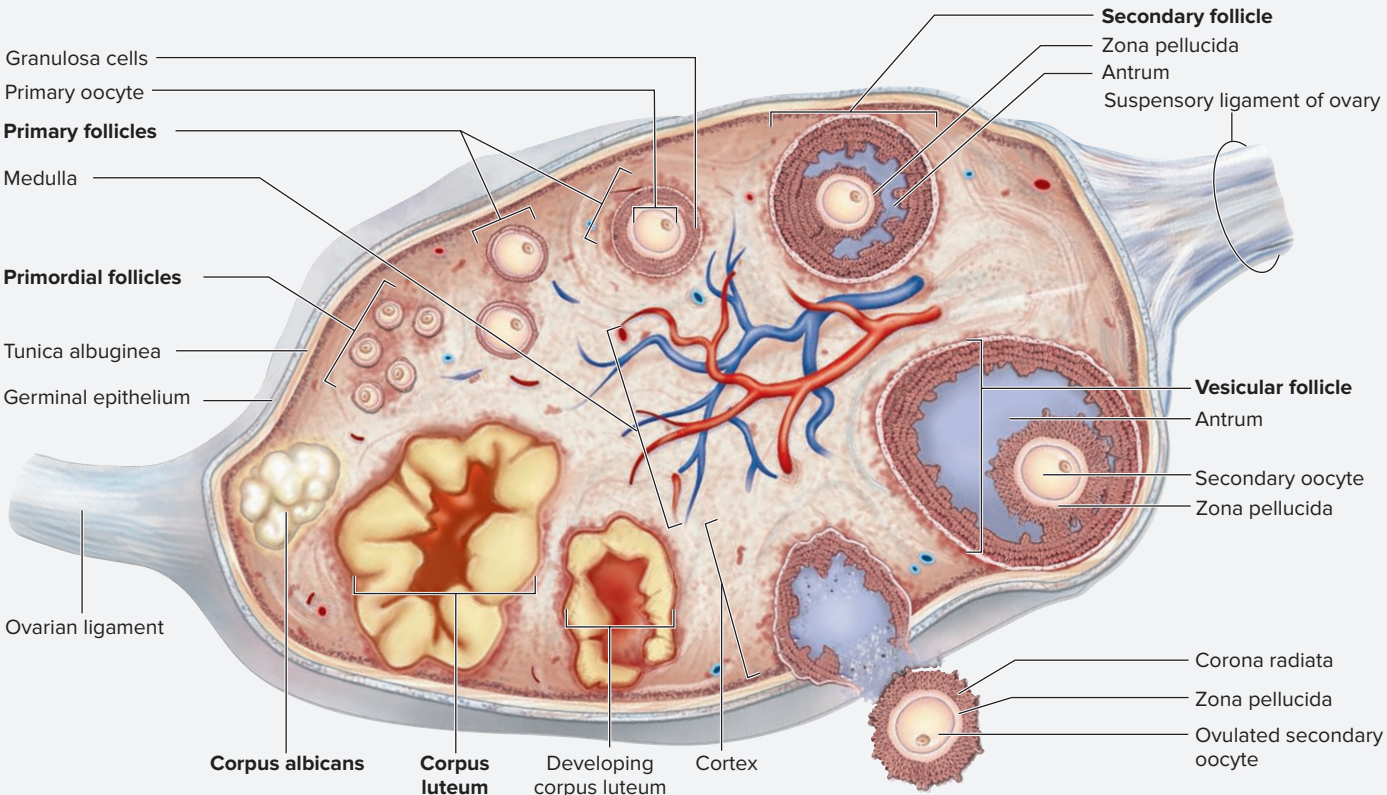
The **ovary** is the primary reproductive organ in the female and functions in the production of the ova (eggs) and the female sex steroid hormones **estrogen** and **progesterone**. The ovaries contain several **ovarian follicles**, all at various stages of development. Each follicle contains a developing **oocyte** (table 23.1). The structure and function of the ovary is best viewed at the histological level because characteristics of ovarian follicles are evident at each stage of development.

- Obtain a histology slide of an ovary and place it on the microscope stage.
- Bring the tissue sample into focus on low power and identify the outer **cortex** and inner **medulla** of the ovary (figure 23.1). Next, move the microscope stage so the ovarian cortex is at the center of the field of view. Then change to high power.
- Observe the outermost region of the ovarian cortex. Locate the two layers of tissue that compose the outer coverings of the ovary: the **germinal epithelium** and the **tunica albuginea** (figure 23.2). The **germinal epithelium** (*germen*, a sprout) is a simple cuboidal epithelium that forms the outermost covering of the ovary. The name *germinal* refers to the fact that scientists once believed the germ cells (oocytes) were formed from this epithelial layer. Most ovarian cancers arise in the germinal epithelium. Deep to the germinal epithelium is the **tunica albuginea** (*tunica*, a coat + *albugineus*, white spot), which is composed of dense irregular connective tissue.
- Focus on the cortex and identify follicles in each stage of follicular development listed in table 23.2.
- Identify the listed structures on the slide of the ovary, using tables 23.1 and 23.2 and figures 23.1 and 23.2 as guides:
 

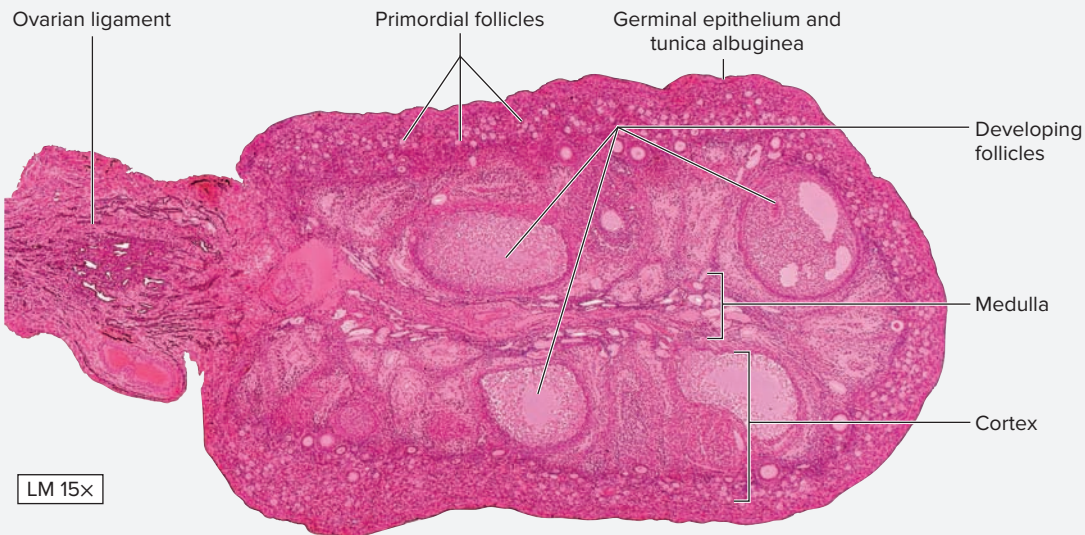
<input type="checkbox"/> corpus albicans	<input type="checkbox"/> primordial follicle
<input type="checkbox"/> corpus luteum	<input type="checkbox"/> secondary follicle
<input type="checkbox"/> germinal epithelium	<input type="checkbox"/> secondary oocyte
<input type="checkbox"/> primary follicle	<input type="checkbox"/> tunica albuginea
<input type="checkbox"/> primary oocyte	<input type="checkbox"/> vesicular (Graafian) follicle
- Next move the microscope stage so a vesicular follicle is in the center of the field of view. A **vesicular (Graafian) follicle** (figure 23.3) is a mature follicle that is ready to be released during ovulation. Ovulation is stimulated by a surge in luteinizing hormone (LH) secreted by the anterior pituitary

**Table 23.1** Developmental Stages of an Oocyte

Cell Name/Oocyte Stage	Description and Function	Stage of Mitosis/Meiosis	Ploidy	Word Origins
<i>Oogonia</i>	Primitive germ cells that undergo mitosis in the second to fifth months of embryonic life to form approximately 7 million oogonia that will subsequently develop into primary oocytes. Approximately 70% of the primary oocytes will degenerate in a process called atresia.	Formed by mitosis; undergo mitosis to form primary oocytes.	Diploid (2n)	<i>oon</i> , egg + <i>gonia</i> , generation
<i>Primary Oocyte</i>	Oogonia that begin the process of meiosis and arrest in prophase of meiosis I. Primary oocytes will not undergo subsequent meiotic divisions unless the follicle is stimulated to mature by follicle-stimulating hormone (FSH) and luteinizing hormone (LH).	Arrested in prophase I of meiosis.	Diploid (2n)	<i>primary</i> , first + <i>oon</i> , egg + <i>kytos</i> , cell
<i>Secondary Oocyte</i>	Under the influence of FSH and LH, primary oocytes complete meiosis I to become secondary oocytes, which will not undergo subsequent meiotic divisions unless fertilization occurs.	Arrested in metaphase II of meiosis.	Haploid (1n)	<i>secondary</i> , second + <i>oon</i> , egg + <i>kytos</i> , a cell
<i>Definitive Oocyte</i>	Upon fertilization, the secondary oocyte undergoes the second meiotic division to become an ovum.	Formed after secondary oocyte is fertilized and completes meiosis.	Haploid (1n)	<i>oon</i> , egg + <i>kytos</i> , cell



(a)



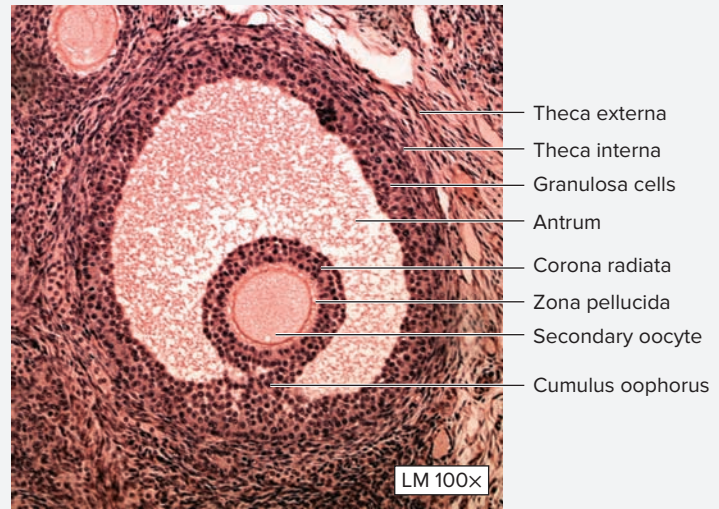
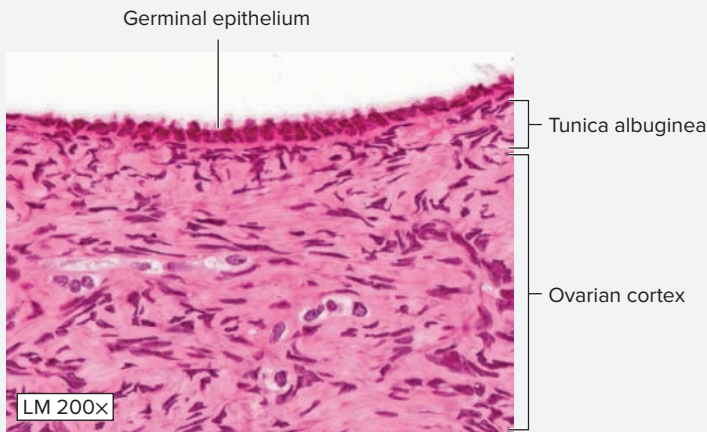
(b)

**Figure 23.1 The Ovary.** (a) The ovary is the primary reproductive organ of the female and produces the female gametes, the ova. (b) Histological structure of the ovary demonstrating the outer cortex containing follicles in various stages of development, and the inner medulla, which consists mainly of blood vessels and nerves.

(b) © McGraw-Hill Education/Al Telser

(continued on next page)

(continued from previous page)



**Figure 23.2** Germinal Epithelium and Tunica Albuginea of the Ovary. The germinal epithelium is the most common origin site for ovarian cancers. The tunica albuginea is a “white coat” of dense irregular connective tissue that surrounds the entire ovary.

**Figure 23.3** Vesicular (Graafian) Follicle. A vesicular follicle contains a secondary oocyte and a single antrum.

© McGraw-Hill Education/Christine Eckel, photographer

© McGraw-Hill Education/AI Telser

gland. **Table 23.3** lists the histological features of a vesicular follicle. Identify the listed parts of a vesicular follicle, using table 23.3 and figure 23.3 as guides:

- antrum
- corona radiata
- cumulus oophorus
- granulosa cells
- secondary oocyte
- theca externa
- theca interna
- zona pellucida

7. Sketch primordial, primary, secondary, and vesicular follicles as seen through the microscope in the spaces provided.



**Table 23.2**

**Developmental Stages of Ovarian Follicles**

Photograph	Primordial Follicle	Primary Follicle	Secondary (Maturing) Follicle
 © McGraw-Hill Education/AI Telser	 © McGraw-Hill Education/AI Telser	 © Ed Reschke/Peter Arnold, Inc./Photolibrary	
<b>Follicle Stage</b>	<b>Primordial Follicle</b>	<b>Primary Follicle</b>	<b>Secondary (Maturing) Follicle</b>
<b>Description and Function</b>	Contains a primary oocyte surrounded by a single layer of flattened follicular cells.	Contains a primary oocyte surrounded by one or more layers of cuboidal follicular cells.	Contains a full-size primary oocyte surrounded by an extracellular glycoprotein coat (the zona pellucida), which separates it from a peripheral layer of follicular cells. Contains one or more fluid-filled antra. Thecal cells develop into internal and external layers.
<b>Oocyte Stage</b>	Primary oocyte	Primary oocyte	Primary oocyte
<b>Word Origins</b>	<i>primus</i> , first + <i>ordior</i> , to begin + <i>folliculus</i> , a small sac	<i>primus</i> , first + <i>ordior</i> , to begin + <i>folliculus</i> , a small sac	<i>secunda</i> , second + <i>ordior</i> , to begin + <i>folliculus</i> , a small sac

Table 23.3 Components of a Vesicular Follicle		
Structure	Description and Function	Word Origins
<i>Antrum</i>	The fluid-filled space in the center of the follicle.	<i>antron</i> , a cave
<i>Corona Radiata</i>	A single layer of columnar cells derived from the cumulus oophorus that attach to the zona pellucida of the oocyte.	<i>corona</i> , a crown + <i>radiatus</i> , to shine
<i>Cumulus Oophorus</i>	A “mound” of granulosa cells that supports and surrounds the ovum within the follicle.	<i>cumulus</i> , a heap + <i>oophoron</i> , ovary
<i>Granulosa Cells</i>	Epithelial cells lining the follicle that will become the luteal cells of the corpus luteum after ovulation. They secrete the liquor folliculi, which is the fluid that fills the antrum.	<i>granulum</i> , a small grain
<i>Theca Externa</i>	The external fibrous layer of a well-developed vesicular follicle. The cells and fibers are arranged in concentric layers.	<i>theca</i> , a box + <i>externus</i> , external
<i>Theca Interna</i>	The inner cellular layer of the vesicular follicle; these cells secrete androgen that is converted to estrogen by granulosa cells.	<i>theca</i> , a box + <i>internus</i> , internal
<i>Zona Pellucida</i>	A thick coat of glycoproteins that surrounds the oocyte.	<i>zona</i> , zone + <i>pellucidus</i> , clear

*Primary follicle*




\_\_\_\_\_ ×

*Secondary follicle*

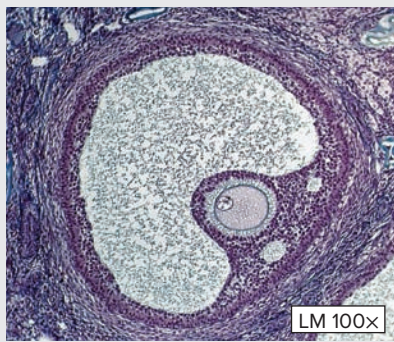


\_\_\_\_\_ ×

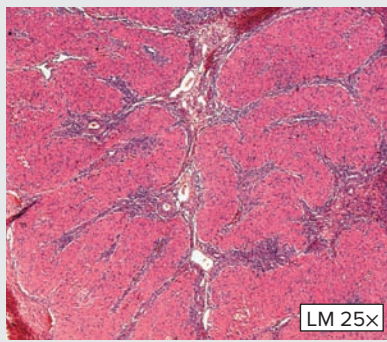
*Vesicular follicle*



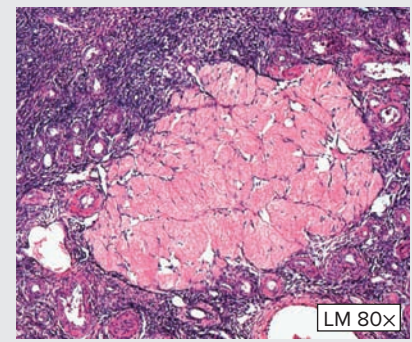
\_\_\_\_\_ ×



© Ed Reschke/Peter Arnold, Inc./Photolibrary



© McGraw-Hill Education/Al Telsler



© McGraw-Hill Education/Al Telsler

**Vesicular (Graafian) Follicle**

Has nearly the same structure and function as a secondary follicle, but contains only a single large antrum.

Secondary oocyte

*vesicular*, a blister + *folliculus*, a small sac

**Corpus Luteum**

A “yellow body” that gets its color from the steroid hormones it secretes, which are lipids. After ovulation, the theca interna cells enlarge and continue to secrete the steroid hormones estrogen and progesterone. In the center of the corpus luteum is a large blood clot.

NA

*corpus*, body + *luteus*, yellow

**Corpus Albicans**

If fertilization does not occur, the corpus luteum stops secreting hormones after two weeks and becomes a smaller “white body” consisting mainly of scar tissue.

NA


*corpus*, body + *albus*, white



(continued from previous page)

- Locate a corpus luteum and corpus albicans on the slide, using table 23.2 as a guide.
- Sketch a corpus luteum and a corpus albicans as seen through the microscope in the spaces provided.

*Corpus luteum*



*Corpus albicans*



### WHAT DO YOU THINK?

- What is a method for distinguishing a secondary follicle from a vesicular follicle?
- During which phase of the ovarian cycle is the corpus luteum present?
- What is the function of the corpus luteum?


## EXERCISE 23.2 Histology of the Uterine Tubes

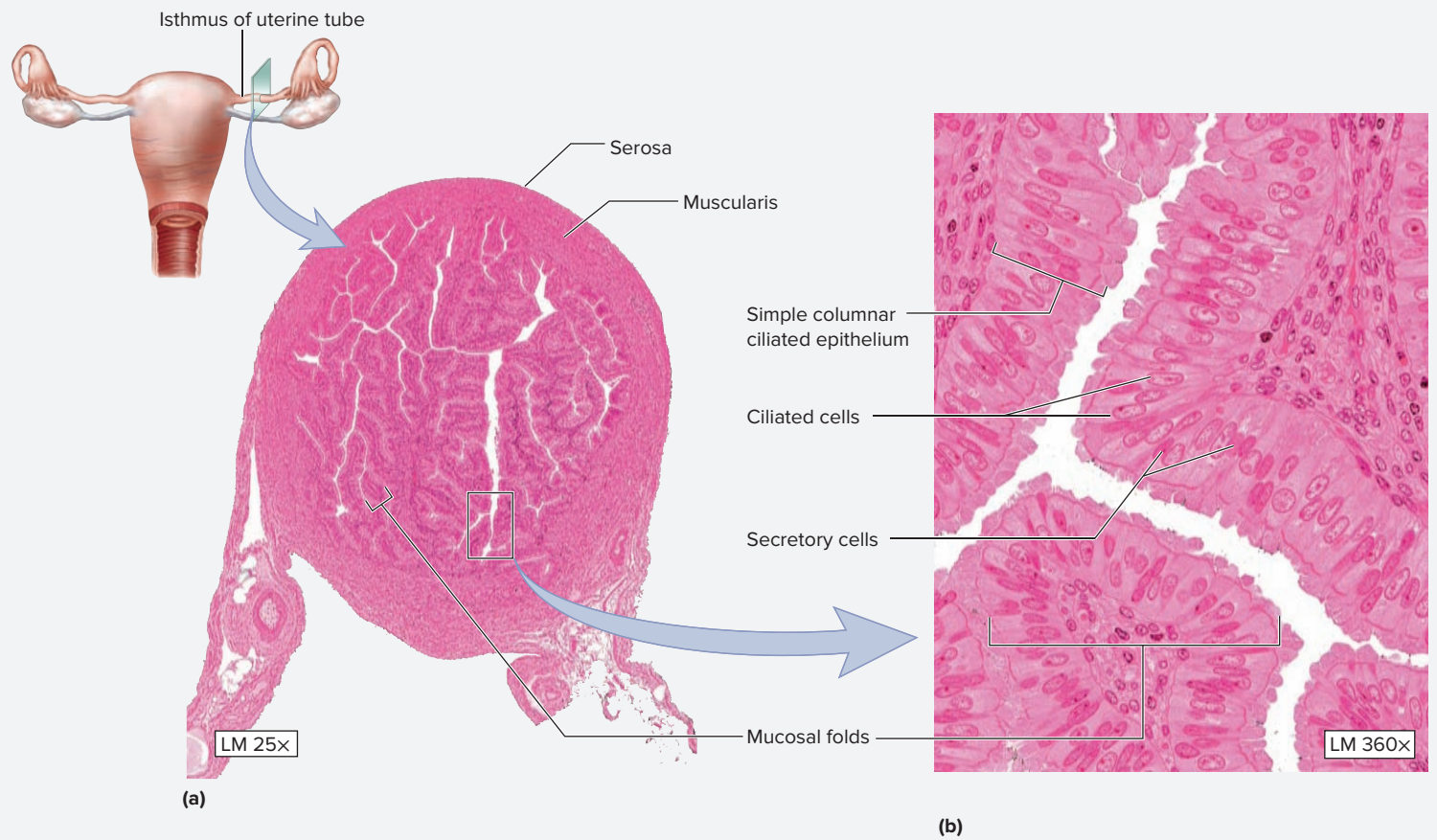
The **uterine tubes** (fallopian tubes, or oviducts) are epithelial-lined fibromuscular tubes that extend from an ovary to the uterus. These tubes transport the ovum (or, if fertilization occurs, the developing zygote) from the ovary to the uterus. The wall of the uterine tube is composed of three layers: mucosa, muscularis, and serosa.

- Obtain a histology slide demonstrating a cross-sectional view of a uterine tube.
- Place the slide on the microscope stage and bring the tissue sample into focus on low power. Note the highly folded **mucosa** of the tube (**figure 23.4**).
- Move the microscope stage until an area of folded mucosa appears at the center of the field of view. Then switch to high power. The epithelium of the uterine tube contains two cell types, **ciliated epithelial cells** and **secretory cells**. **Table 23.4** describes the histological components of the uterine tubes. Focus on the epithelial cells that line the uterine tube, and distinguish ciliated cells from secretory cells (**figure 23.4b**).
- Identify the following structures on the slide of the uterine tube, using table 23.4 and figure 23.4 as guides:

- |   |  |                                 |
|---|--|---------------------------------|
| <input type="checkbox"/> ciliated cells | <input type="checkbox"/> muscularis      | <input type="checkbox"/> serosa |
| <input type="checkbox"/> mucosal folds  | <input type="checkbox"/> secretory cells |                                 |

- Sketch a cross section of the uterine tube, as seen through the microscope in the space provided. Label the structures listed in step 4 in the drawing.





**Figure 23.4 Histology of the Uterine Tubes.** (a) Cross section through the isthmus of the uterine tubes demonstrating the many folds of the mucosa. (b) The epithelial cells lining the uterine tubes contain two cell types: ciliated cells and secretory cells. Ciliated cells have light nuclei, whereas secretory cells have dark nuclei.

© McGraw-Hill Education/Al Telser

Table 23.4 Components of the Uterine Tube		
Uterine Tube Structure	Description and Function	Word Origins
<b>REGIONS</b>		
<i>Ampulla</i>	The wide part of the uterine tube located medial to the infundibulum. Its mucosa is highly folded and lined with simple columnar epithelium containing ciliated cells and secretory cells. Fertilization most commonly occurs in the ampulla.	<i>ampulla</i> , a two-handled bottle
<i>Infundibulum</i>	The funnel-like expansion of the ovarian end of the uterine tube. Fingerlike extensions of the infundibulum are fimbriae ( <i>fimbria</i> , fringe).	<i>infundibulum</i> , a funnel
<i>Isthmus</i>	The narrow part of the uterine tube located right next to the uterus.	<i>isthmus</i> , a constriction
<i>Uterine Part (Intramural Part)</i>	The part of the uterine tube that penetrates the wall of the uterus.	<i>intra-</i> , within + <i>muralis</i> , wall
<b>LAYERS</b>		
<i>Mucosa</i>	The inner layer of the wall of the uterine tube. It is highly folded in the infundibulum and ampulla of the uterine tube. Contains ciliated columnar epithelium and a layer of areolar connective tissue.	<i>mucosus</i> , mucous
<i>Muscularis</i>	The middle layer of the wall of the uterine tube. It consists of smooth muscle whose contraction assists in transporting the ovum toward the uterus.	<i>musculus</i> , mouse (referring to muscle)
<i>Serosa</i>	The outer layer of the uterine tube. It consists of simple squamous epithelium (a fold of peritoneum).	<i>serosus</i> , serous
<b>CELLS</b>		
<i>Ciliated Cells</i>	Columnar epithelial cells that contain cilia that beat toward the uterus to transport the ovum to the uterus. Nuclei stain lighter than those of the secretory cells.	<i>cilium</i> , eyelash
<i>Secretory Cells</i>	Nonciliated columnar epithelial cells that promote the activation of spermatozoa (capacitation) and provide nourishment for the ovum. Nuclei stain darker than those of the ciliated cells.	<i>secretus</i> , to separate

**EXERCISE 23.3** Histology of the Uterine Wall

The **uterus** is a hollow, pear-shaped, muscular organ whose primary function is to support, protect, and nourish the developing embryo/fetus.

The uterine wall is composed of three layers: endometrium, myometrium, and perimetrium. The inner lining of the uterus, the **endometrium**, goes through its own cycle of growth throughout the ovarian cycle. Each time a woman's ovary undergoes a single ovarian cycle, the endometrium of the uterus becomes prepared for the possibility that a fertilized egg will become implanted. If no implantation occurs, the innermost layer of the endometrium, the **functional layer**, sloughs off in the process of **menstruation** (*menstruus*, monthly). The **basal layer** of the endometrium stays within the uterus. The basal layer contains basal epithelial cells that will develop into a new functional layer during the next menstrual cycle. **Table 23.5** describes the layers of the uterine

wall and the components that make up each layer. **Table 23.6** summarizes three phases of the menstrual cycle and demonstrates the appearance of the endometrium during each phase.

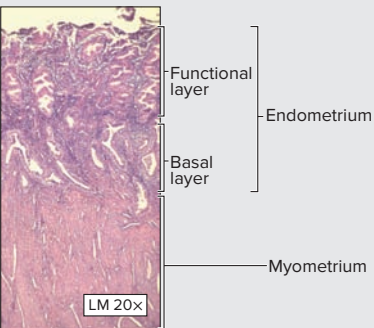
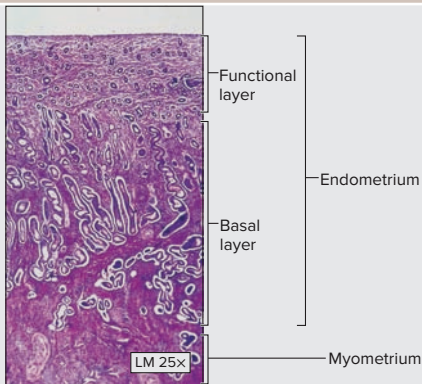
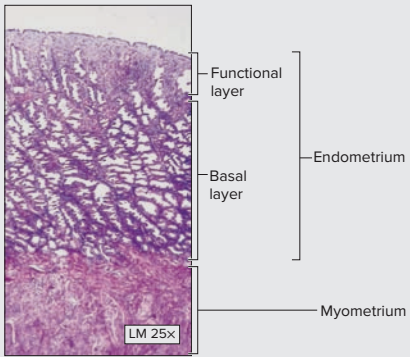
1. Obtain a histology slide demonstrating a portion of the uterine wall. Place it on the microscope stage and bring the tissue sample into focus on low power.
2. Identify the listed structures on the slide of the uterus, using tables 23.5 and 23.6 as guides:
 

<input type="checkbox"/> endometrium (basal layer)	<input type="checkbox"/> myometrium
<input type="checkbox"/> endometrium (functional layer)	<input type="checkbox"/> perimetrium
3. Move the microscope stage so the functional layer of the endometrium is in the center of the field of view. Switch to high power and identify **uterine glands**.

**Table 23.5** Wall Layers of the Uterus

Wall Layer	Description and Function	Word Origins
<b>Endometrium</b>	The mucous membrane composing the inner layer of the uterine wall. Consists of simple columnar epithelium and a lamina propria with simple tubular uterine glands. The structure, thickness, and state of the endometrium undergo marked change during the menstrual cycle.	<i>endon</i> , within + <i>metra</i> , uterus
<b>Functional Layer (Stratum Functionalis)</b>	The apical layer of the endometrium. Most of this layer is shed during menstruation.	<i>stratum</i> , a layer + <i>functus</i> , to perform
<b>Basal Layer (Stratum Basalis)</b>	The basal layer of the endometrium. It undergoes minimal changes during the menstrual cycle and serves as the basis for regrowth of the more apical stratum functionalis.	<i>stratum</i> , a layer + <i>basalis</i> , basal
<b>Myometrium</b>	The muscular wall of the uterus composed of three layers of smooth muscle.	<i>mys</i> , muscle + <i>metra</i> , uterus
<b>Perimetrium</b>	The outermost covering of the uterus; a serous membrane formed from peritoneum.	<i>peri-</i> , around + <i>metra</i> , uterus

**Table 23.6** Phases of the Menstrual Cycle

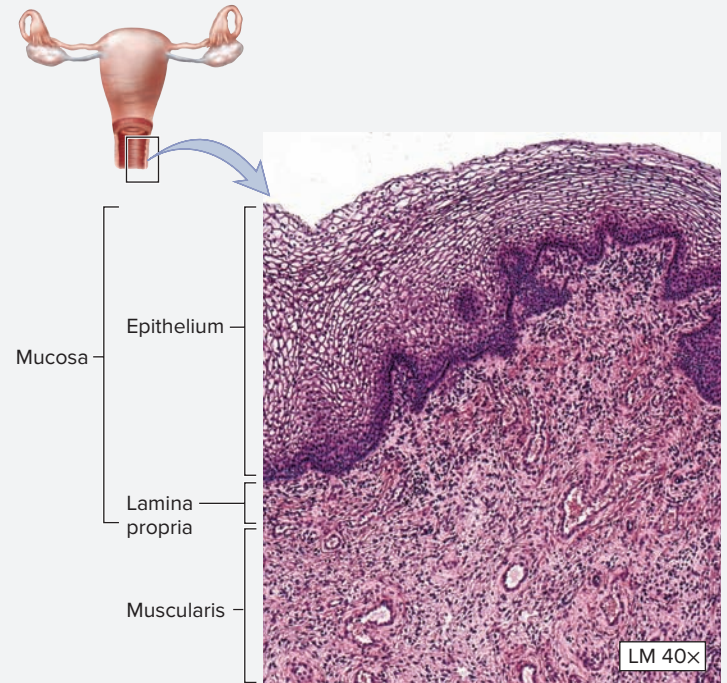
(a) Menstrual	(b) Proliferative (Follicular)	(c) Secretory (Luteal)
 <p>© Educational Images LTD/CustomMedical/Newscom</p>	 <p>© Biophoto Associates/Science Source</p>	 <p>© Biophoto Associates/Science Source</p>
Days 1–5; Degeneration of the corpus luteum causes progesterone and estrogen levels to drop. The functional layer of the endometrium becomes necrotic due to constriction of the coiled arteries and is shed.	Days 5–14; The basal layer of the endometrium begins to regenerate the functional layer.	Days 14–28; Begins at ovulation. Progesterone secreted by the corpus luteum stimulates the uterine glands to begin secretion.

**EXERCISE 23.4** Histology of the Vaginal Wall

The **vagina** (*vagina*, sheath) is a muscular tube that functions as the organ of copulation, serves as the passageway for menses, and serves as the birth canal during parturition (*parturio*, to be in labor).

1. Obtain a histology slide demonstrating a portion of the vaginal wall. Place it on the microscope stage and bring the tissue sample into focus on low power. The walls of the vagina are composed of a mucosa and muscularis. The mucosa is lined with a nonkeratinized stratified squamous epithelium (**figure 23.5**).
2. Identify the listed structures on the slide of the vagina, using figure 23.5 as a guide:
 

<input type="checkbox"/> lamina propria	<input type="checkbox"/> nonkeratinized stratified squamous epithelium
<input type="checkbox"/> mucosa	
<input type="checkbox"/> muscularis	
3. *Optional Activity:* **AP|R Reproductive System**—Watch the “Female reproductive system overview” animation to review the female reproductive organs and their histological features.



**Figure 23.5** Histology of the Vaginal Epithelium. The epithelium is nonkeratinized stratified squamous.

© McGraw-Hill Education/Al Telser

## Male Reproductive System

The male reproductive system consists of the testes, epididymis, ductus deferens, seminal vesicles, prostate gland, bulbourethral glands, and penis. Unlike the female reproductive system, which must support and nourish a developing fetus, the functions of the male reproductive system are somewhat less complex than the female reproductive system. The primary

functions of the male reproductive system are to produce the male gamete (sperm), produce testosterone, and provide nourishment for the sperm and a mechanism for the sperm to be delivered to the female reproductive tract. As with female reproductive organs, male reproductive organs have unique histological features that will facilitate microscopic identification.

**EXERCISE 23.5** Histology of Seminiferous Tubules

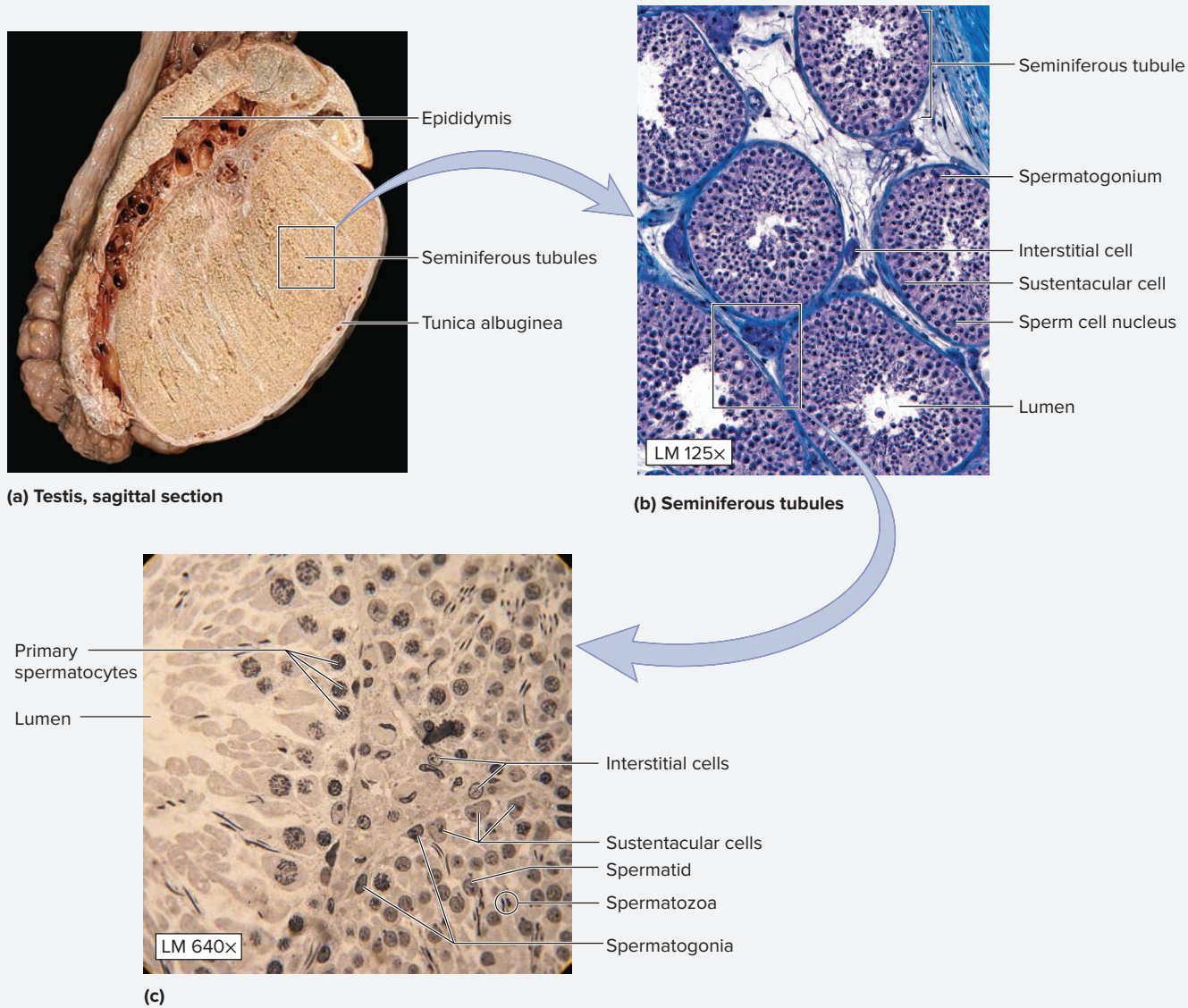
The **testes** are the primary reproductive organs in the male. The testes function in the production of sperm and production of the male sex steroid hormone, **testosterone**. Within each testis are several hundred long, coiled **seminiferous tubules** (**figure 23.6**), which are the site of sperm production, or **spermatogenesis** (*sperma*, seed + *genesis*, origin). Within each tubule, **spermatogonia** undergo successive meiotic divisions as they move from the basal to the apical surface of the tubule epithelium. **Table 23.7** describes the developmental stages of the sperm, and **table 23.8** describes

the structure and function of the accessory cell types located within the testes.

1. Obtain a slide demonstrating seminiferous tubules (or testes) and place it on the microscope stage.
2. Observe the slide on low power and identify several cross sections of the seminiferous tubules. Move the microscope stage until one tubule is at the center of the field of view. Then change to high power.

(continued on next page)

(continued from previous page)



**Figure 23.6 Testes and Seminiferous Tubules.** (a) Testes and epididymis showing seminiferous tubules within the testes and tunica albuginea surrounding the testes. (b) Medium-power histological appearance of seminiferous tubules. (c) High-power histological view of seminiferous tubules demonstrating stages of spermatogenesis and sustentacular cells.

(a) From *Anatomy & Physiology Revealed*, © McGraw-Hill Education/The University of Toledo, photography and dissection; (b) © McGraw-Hill Education/AI Telser; (c) McGraw-Hill Education/Christine Eckel, photographer

**Table 23.7** Developmental Stages of Sperm

Cell Name	Description and Function	Stage of Mitosis/Meiosis	Ploidy	Word Origins
<i>Spermatogonia</i>	Primitive male gametes that are formed by mitosis from male germline stem cells.	Formed by mitosis; undergo mitosis to form primary spermatocytes.	Diploid (2n)	<i>sperma</i> , seed + <i>gonia</i> , generation
<i>Primary Spermatocyte</i>	Male gamete that has replicated its DNA in preparation for meiosis. It will subsequently undergo meiosis I to form two secondary spermatocytes.	DNA is replicated in prophase of meiosis I.	Diploid (2n)	<i>primary</i> , first + <i>sperma</i> , seed + <i>kytos</i> , a cell
<i>Secondary Spermatocyte</i>	Male gamete that has completed meiosis I and will subsequently undergo meiosis II to form two spermatids.	Formed after the first meiotic division.	Haploid (1n)	<i>secondary</i> , second + <i>sperma</i> , seed + <i>kytos</i> , a cell
<i>Spermatid</i>	Male gamete that has completed meiosis, but has not undergone spermiogenesis, the process of becoming a mature spermatozoon.	Formed after the second meiotic division.	Haploid (1n)	<i>sperma</i> , seed + <i>-id</i> , a young specimen
<i>Spermatozoon (Sperm)</i>	A mature male gamete that has undergone spermiogenesis.	Formed by maturation of spermatids.	Haploid (1n)	<i>sperma</i> , seed + <i>zoon</i> , animal

3. Identify the listed structures on the slide, using tables 23.7 and 23.8 and figure 23.6 as guides:

- interstitial cell
- primary spermatocyte
- secondary spermatocyte
- seminiferous tubule
- spermatids
- spermatogonia
- sustentacular cell

4. Sketch the histology of a seminiferous tubule as seen through the microscope in the space provided. Label the structures listed in step 3 in the drawing.



5. *Optional Activity:* **AP|R Reproductive System**—Watch the “Spermatogenesis” animation to visualize the formation of sperm in the seminiferous tubules.

### Learning Strategy



Sustentacular cells of the testis are difficult to visualize because the only part(s) of the cell that are visible are their nuclei. Recall that a single sustentacular cell can envelop several developing spermatogonia. The following analogy may be useful in assisting in the visualization of the structures viewed in a cross section of a seminiferous tubule.

Imagine the entire cross section of the seminiferous tubule is a pepperoni pizza that has been cut into eight slices. The area of the seminiferous tubule taken up by one sustentacular cell is represented by one slice of pizza. The cell itself composes the crust, sauce, and cheese of the pizza (remember: sustentacular cells provide nourishment for the developing spermatogonia). The spermatogonia and other cells in various stages of development are represented by the pieces of pepperoni on the pizza.

Thus, this visualization helps one to understand how one sustentacular cell can assist in the development of several spermatogonia. The only thing the analogy does not account for is the location of the nuclei of the sustentacular cells. Perhaps if one were to place a single yellow pepper that was cut in half on the outside edge of each slice of the pizza, the peppers could represent the nuclei of the sustentacular cells.

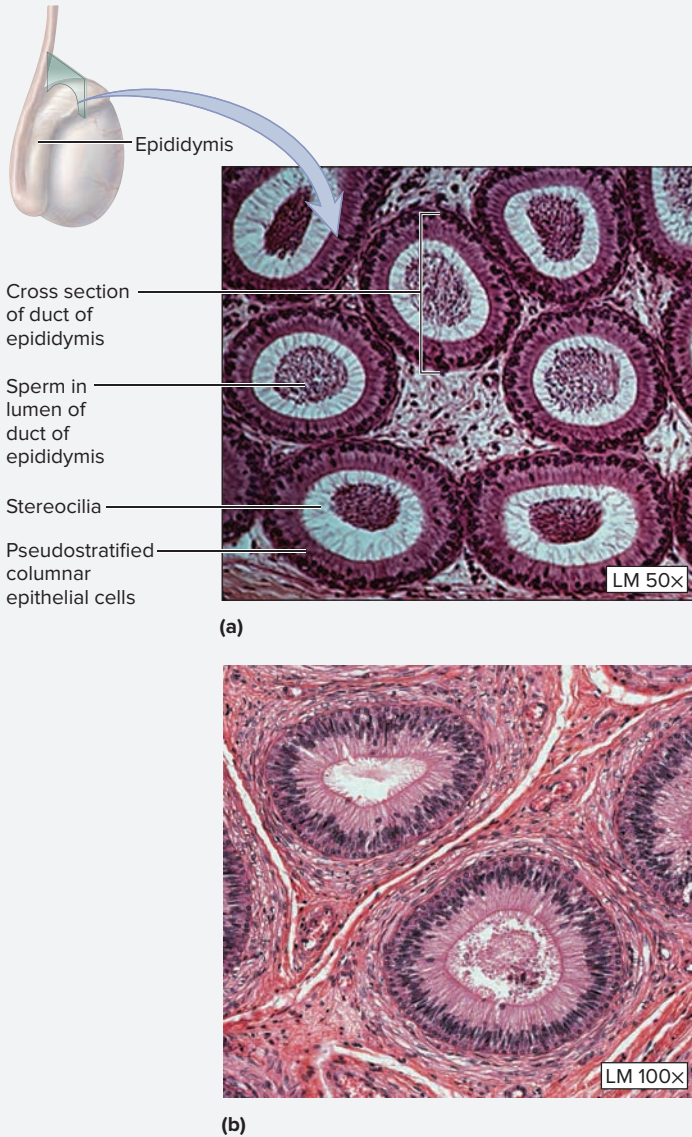
Table 23.8		Accessory Cells of the Testis
Cell Name	Description and Function	Word Origins
<i>Interstitial (Leydig) Cells</i>	Produce the steroid hormone testosterone, which is required for proper sperm development and for the development of male secondary sex characteristics.	<i>inter-</i> , between + <i>sisto</i> , to stand
<i>Sustentacular (Sertoli) Cells</i>	Surround multiple developing spermatocytes to provide them with support and nourishment. Phagocytize excess cytoplasm from developing spermatocytes. Form the blood-testis barrier, which protects the developing spermatocytes from antigens that circulate in the blood. Produce androgen-binding protein (ABP), which concentrates testosterone around the developing spermatocytes.	<i>sustento</i> , to hold upright

### EXERCISE 23.6 Histology of the Epididymis


After spermatozoa are formed in the seminiferous tubules, they are transported through the straight tubules, rete testes, and efferent ductules to enter the long, coiled tube of the **epididymis** (*epi*, upon + *didymos*, a twin [related to *didymoi*, testes]). Spermatozoa undergo the process of maturation and are stored in the epididy-

mis until ejaculation takes place. One of the most characteristic features of the epididymis is the presence of thousands of sperm in the lumen of the tube (**figure 23.7**). **Table 23.9** describes the structure and function of the male accessory reproductive structures, including the epididymis.

(continued from previous page)



1. Obtain a slide of the epididymis and place it on the microscope stage. Bring the tissue sample into focus on low power and identify several cross sections of the epididymis. Move the microscope stage so that one part of the lumen of the epididymis is at the center of the field of view. Then change to high power. Notice the sperm inside the lumen of the tubule, and how they do not lie right up against the apical surface of the columnar epithelial cells. This is because of the stereocilia on the apical surface of the epithelial cells. **Stereocilia** (*stereo*, solid + *cilium*, eyelid) are single, long microvilli (ironically, they are not cilia at all!) that increase the surface area of the epithelial cells for the purposes of secreting substances that nourish the sperm and absorbing substances from the sperm as the sperm undergo maturation.
2. Identify the listed structures on the slide of the epididymis, using table 23.9 and figure 23.7 as guides:
  - columnar epithelial cells
  - sperm cells
  - stereocilia
3. Sketch the histology of the epididymis as seen through the microscope in the space provided. Label the structures listed in step 2 in the drawing.



**Figure 23.7** Cross Section Through the Epididymis. The epididymis is a long, coiled tube. These tissue sections demonstrate several cross sections through the duct of the epididymis. (a) Note the numerous sperm within the lumen of the epididymis. (b) A higher magnification view demonstrates pseudostratified columnar epithelium with stereocilia.

(a) © Ed Reschke/Peter Arnold, Inc./Photolibrary; (b) © McGraw-Hill Education/Christine Eckel, photographer

Table 23.9 Male Accessory Reproductive Structures			
Structure	Epithelium	Function	Word Origins
<b>Bulbourethral Glands</b>	Glandular epithelium consisting of simple and pseudostratified columnar.	Accessory reproductive gland that produces a mucus-like lubricating substance during sexual arousal that lubricates the urethra and neutralizes the acidity of the urine, thus preparing the way for the spermatozoa to pass.	<i>bulbus</i> , bulb + <i>urethral</i> , relating to the urethra
<b>Ductus Deferens (vas deferens)</b>	Pseudostratified columnar epithelium with stereocilia.	A thick, muscular tube whose walls undergo peristaltic contractions during ejaculation to propel sperm into the urethra.	<i>ductus</i> , to lead + <i>defero</i> , to carry away
<b>Epididymis</b>	Pseudostratified columnar epithelium with stereocilia.	Site of storage and maturation of sperm. Walls contain some smooth muscle that will propel sperm into the ductus deferens during ejaculation.	<i>epi</i> , upon + <i>didymos</i> , a twin (related to <i>didymoi</i> , testes)
<b>Prostate Gland</b>	Glandular epithelium resembling pseudostratified or simple columnar.	Accessory reproductive gland that contributes approximately 25% of the volume of semen. The fluid produced is rich in Vitamin C (citric acid) and enzymes (such as PSA, prostate-specific antigen) that are important for proper sperm function.	<i>prostates</i> , one standing before
<b>Seminal Vesicles</b>	Pseudostratified columnar.	Accessory reproductive gland that contributes approximately 60% of the volume of semen. The fluid produced is rich in fructose, which is a source of energy for the sperm. They also produce prostaglandins, which are important in promoting sperm motility and may stimulate uterine contractions.	<i>seminal</i> , relating to sperm + <i>vesicula</i> , a blister

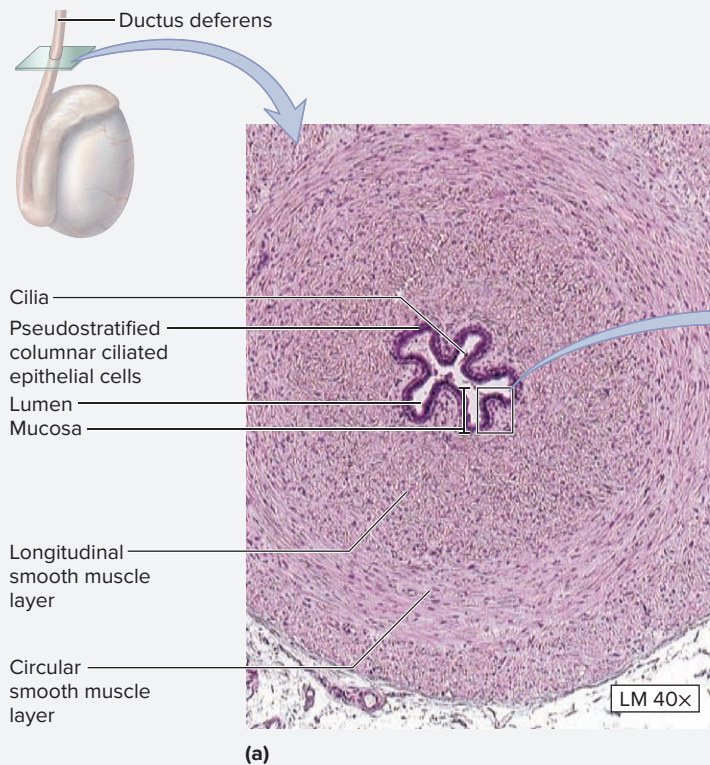

**EXERCISE 23.7** Histology of the Ductus Deferens

The **ductus deferens** (vas deferens) is a continuation of the epididymis and is the route by which sperm travel from the epididymis to the urethra during ejaculation (*ejaculo*, to shoot out). The ductus deferens is a highly muscular tube lined with pseudostratified columnar epithelium with stereocilia (**figure 23.8**).

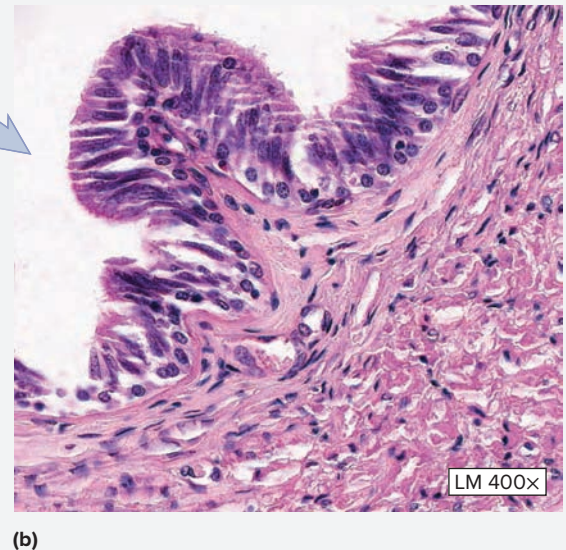
1. Obtain a slide demonstrating the ductus deferens and place it on the microscope stage. Bring the tissue sample into focus on low power and identify the cross section of the ductus deferens (figure 23.8). Move the microscope stage so the lumen of the ductus deferens is at the center of the field of view and then change to high power.
2. Identify the listed structures on the slide of the ductus deferens, using table 23.9 and figure 23.8 as guides:

- |                                 |  |
|---------------------------------|--|
| <input type="checkbox"/> cilia  | <input type="checkbox"/> pseudostratified columnar epithelial cells with stereocilia |
| <input type="checkbox"/> lumen  | <input type="checkbox"/> smooth muscle   |
| <input type="checkbox"/> mucosa |  |

3. Sketch the histology of a cross section of the ductus deferens as seen through the microscope in the space provided. Label the structures listed in step 2 in the drawing.

**? WHAT DO YOU THINK?**

4. Unlike the lumen of the epididymis, the lumen of the ductus deferens is highly unlikely to have visible sperm cells inside when viewed histologically. Why do you think this is?



**Figure 23.8 Ductus Deferens.** (a) Cross section through the entire ductus deferens, demonstrating thick layers of smooth muscle surrounding the lumen. (b) Close-up view of the pseudostratified columnar epithelium with stereocilia.

(a) © McGraw-Hill Education/AI Telser; (b) © McGraw-Hill Education/Christine Eckel, photographer



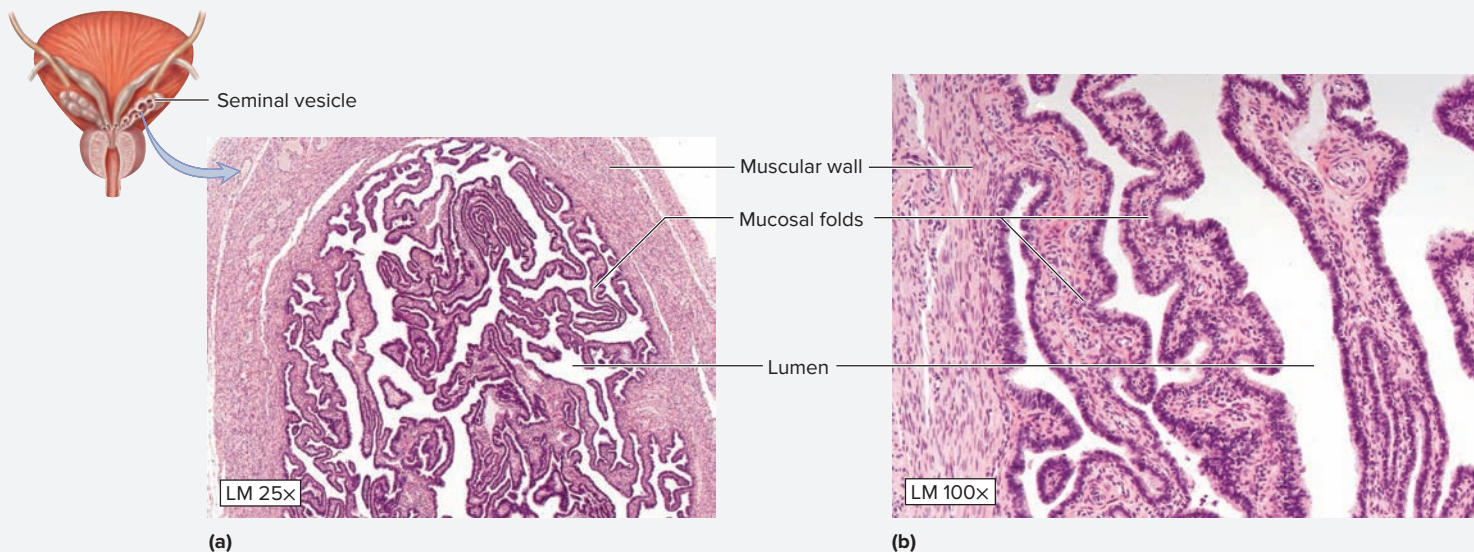

**EXERCISE 23.8** Histology of the Seminal Vesicles

Near the posterior wall of the urinary bladder, each ductus deferens approaches the posterior wall of the bladder, and each comes together with the duct of a **seminal vesicle** (figure 23.9). These accessory reproductive glands are lined with pseudostratified columnar epithelium and produce substances (including fructose, which is a source of energy for the sperm) that are an important component of **semen**. Semen is the fluid expelled from the penis during ejaculation (table 23.9).

1. Obtain a slide of the seminal vesicles and place it on the microscope stage. Bring the tissue sample into focus on low power. Identify cross sections of the seminal vesicles. Move the microscope stage so the lumen of a portion of the seminal vesicle is at the center of the field of view. Then change to high power.
2. Identify the listed structures on the slide of the seminal vesicles, using table 23.9 and figure 23.9 as guides:

- lumen                                       muscular wall  
 mucosal folds

3. Sketch the seminal vesicles as seen through the microscope in the space provided. Label the structures listed in step 2 in the drawing.



**Figure 23.9** The Seminal Vesicles. (a) Low magnification. (b) Medium magnification.

© McGraw-Hill Education/Al Telser

### Learning Strategy



**Warning:** Histology slides of the uterine tube and the seminal vesicle are “look alikes”!

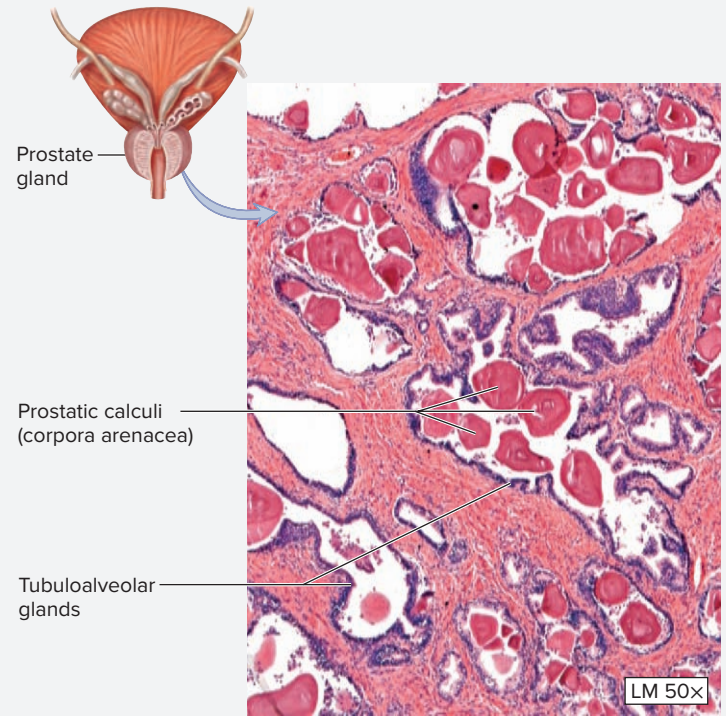
After observing the slide of the seminal vesicle, go back and observe the slide of the uterine tube on another microscope placed next to the microscope being used to view the seminal vesicle. Observe the slides under each microscope until specific

differences are noted between the two. Write down any and all differences that exist so as to definitively distinguish the two. One general guideline is that the mucosa of the uterine tube often appears *more* folded than that of the seminal vesicle, and there is very little open “lumen” (empty space between mucosal folds) to speak of in the uterine tube. Also, the muscular wall of the uterine tube often appears *thinner* than the muscular wall of the seminal vesicle.

**EXERCISE 23.9 Histology of the Prostate Gland**

The **prostate** gland is an accessory reproductive gland located immediately inferior to the urinary bladder. Like the seminal vesicles, the prostate produces substances that will become part of semen and that are important for proper sperm function.

1. Obtain a slide demonstrating the prostate gland and place it on the microscope stage. Bring the tissue sample into focus on low power and identify the prostatic urethra and the prostate gland itself (**figure 23.10**). Move the microscope stage so a part of the gland relatively far away from the urethra is at the center of the field of view. Then change to high power.
2. Identify the listed structure on the slide of the prostate, using table 23.9 and figure 23.10 as guides:
  - tubuloalveolar glands
3. As men age, calcifications often form in the prostate. Such calcifications are called **prostatic calculi** (corpora arenacea) (figure 23.10). Scan the slide and see if any of these are present in the specimen.



**Figure 23.10 The Prostate Gland.** Note the many prostatic calculi (corpora arenacea) seen at medium magnification.

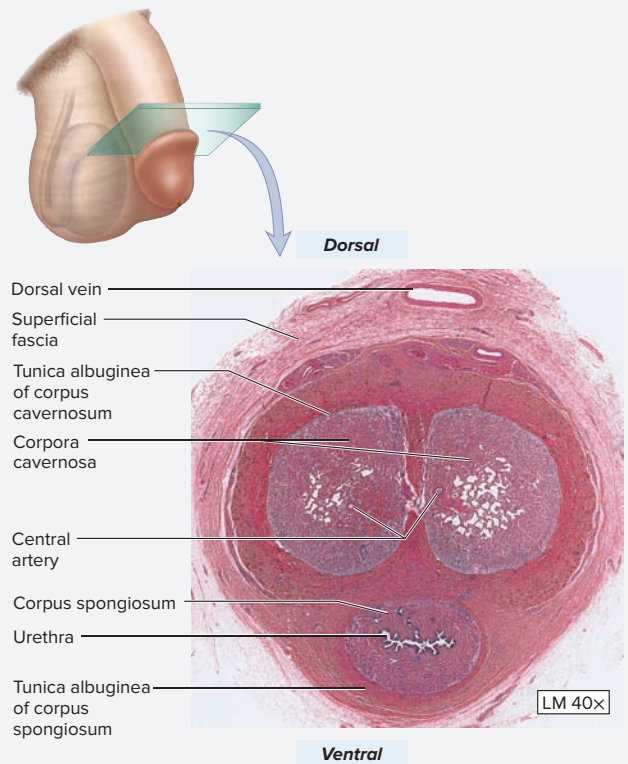
© McGraw-Hill Education/Al Telser

**EXERCISE 23.10 Histology of the Penis**

The **penis** is the male copulatory organ and is homologous to the female clitoris. It is composed of three erectile bodies, the paired **corpora cavernosa** and the single **corpus spongiosum**, which contains the male urethra (**figure 23.11**). In the center of each corpus cavernosum is a central artery that supplies blood to the penis. The erectile tissues of the corpus cavernosa are the equivalent of the deep venous drainage accompanying the central arteries. During an erection, the veins draining the penis become constricted and venous blood fills up the erectile tissues. This creates a hydrostatic pressure that keeps the penis erect as long as the venous flow out of the penis continues to be restricted.

1. Obtain a slide demonstrating a cross section of the penis and place it on the microscope stage. Observe at low power.
2. Identify the listed structures on the slide of the penis, using figure 23.11 as a guide:
 

<input type="checkbox"/> central artery	<input type="checkbox"/> superficial fascia
<input type="checkbox"/> corpus cavernosum	<input type="checkbox"/> urethra
<input type="checkbox"/> corpus spongiosum	<input type="checkbox"/> ventral surface
<input type="checkbox"/> dorsal surface	
<input type="checkbox"/> dorsal vein	



**Figure 23.11 Cross Section Through the Shaft of the Penis.** The penis contains two paired corpora cavernosa dorsally, and a single corpus spongiosum ventrally. Note the male urethra in the center of the corpus spongiosum.

© McGraw-Hill Education/Christine Eckel, photographer

(continued on next page)

(continued from previous page)

3. Sketch a cross section of the penis as seen through the microscope in the space provided. Label the structures listed in step 2 in the drawing.



4. *Optional Activity:* **AP|R Reproductive System**—Watch the “Male reproductive system overview” animation to review the male reproductive structures and their relationships.

### WHAT DO YOU THINK?

- 5 The homologue to the male penis is the female clitoris. The clitoris consists of two paired erectile tissues, which are corpora cavernosa. However, the clitoris does not contain a corpus spongiosum. Thus, what structure is “missing” from the clitoris as compared to the penis?

## Gross Anatomy

### Female Reproductive System

The internal detail, wall structures, and functions of most of the female reproductive organs were covered in the histology section of this chapter. The focus of the exercises in this section of the chapter involve making observations of the gross structure of the reproductive organs to gain an

appreciation of the organs’ locations within the female pelvic cavity, and their relationships with each other. Additional exercises guide the student in observing the numerous suspensory ligaments that anchor the ovaries, uterine tubes, and uterus in place within the pelvic cavity. A final exercise covers the gross anatomy of the female breast.

### EXERCISE 23.11 Gross Anatomy of the Ovary, Uterine Tubes, Uterus, and Suspensory Ligaments

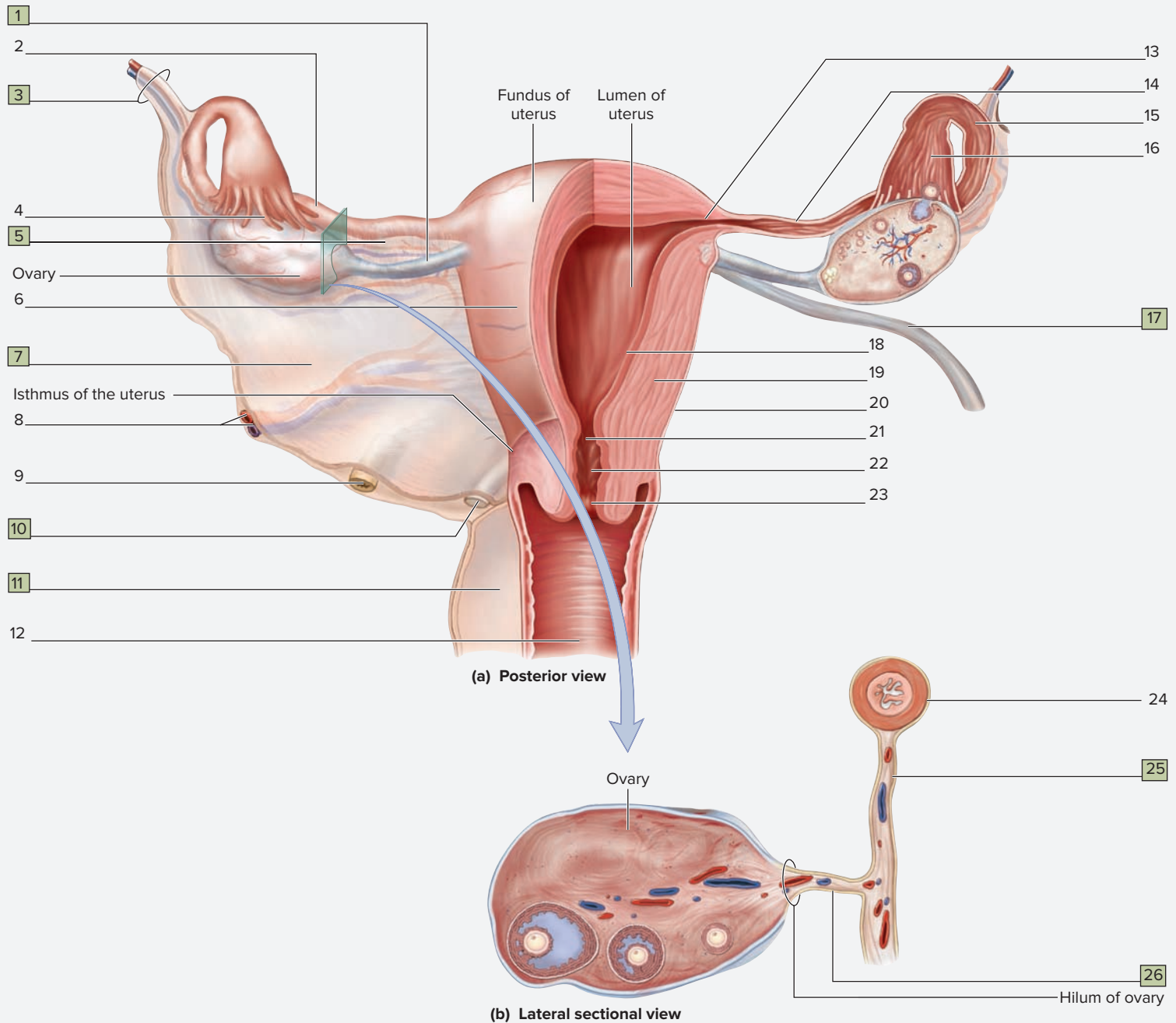
The ovary, uterine tubes, and uterus are all contained within the pelvic cavity of the female and are held in place by a number of suspensory ligaments. Most of the supporting ligaments of the female reproductive structures form from folds of the peritoneum as it drapes over the structures. **Table 23.10** summarizes the structure, function, and location of the suspensory ligaments.

1. Observe a female human cadaver or classroom models of the female pelvis and female reproductive organs. Also observe a classroom model demonstrating a midsagittal section through a female pelvis.
2. Identify the structures listed in **figures 23.12** and **23.13** on the cadaver or on classroom models, using table 23.10 and the textbook as guides. Then label them in figures 23.12 and 23.13.
3. *Optional Activity:* **AP|R Reproductive System**—In the Quiz section, select the “Structures: Female” option to test yourself on gross anatomy of female structures.

<b>Table 23.10</b>		
<b>Suspensory Ligaments of the Ovary, Uterine Tubes, and Uterus</b>		
<b>Suspensory Ligament</b>	<b>Description and Function</b>	<b>Word Origins</b>
<i>Broad Ligament</i>	Fold of peritoneum draped over the superior surface of the uterus. Portions of the broad ligament form the mesovarium and the mesosalpinx.	<i>broad</i> , wide + <i>ligamentum</i> , a bandage
<i>Mesosalpinx</i>	The mesentery of the uterine tube, which is formed as a fold of the most superior part of the broad ligament.	<i>meso-</i> , a mesentery-like structure + <i>salpinx</i> , trumpet (tube)
<i>Mesovarium</i>	The mesentery of the ovary, which is formed as a posterior extension of the broad ligament.	<i>meso-</i> , a mesentery-like structure + <i>ovarium</i> , ovary
<i>Ovarian Ligament</i>	Ligament contained within folds of the broad ligament. It extends from the medial part of the ovary to the superolateral surface of the body of the uterus.	<i>ovarium</i> , ovary + <i>ligamentum</i> , bandage
<i>Round Ligament of the Uterus</i>	Ligament attached to the superolateral surface of the body of the uterus. It extends laterally to the deep inguinal ring, passes through the inguinal canal, and attaches to the skin of the labia majora.	<i>ligamentum</i> , a bandage + <i>uterus</i> , <i>utero-</i> , uterus
<i>Suspensory Ligament of the Ovary</i>	A fold of peritoneum draping over the ovarian artery and vein superolateral to the ovary. Anchors the ovary to the lateral body wall.	<i>suspensio</i> , to hang up + <i>ligamentum</i> , a bandage
<i>Transverse Cervical (Cardinal) Ligament</i>	Ligament extending laterally from the cervix and vagina, connecting them to the pelvic wall.	<i>transverse</i> , across + <i>cervix</i> , neck + <i>ligamentum</i> , a bandage
<i>Uterosacral Ligaments</i>	Ligament connecting the inferior part of the uterus to the sacrum posteriorly.	<i>utero-</i> , uterus + <i>sacral</i> , the sacrum

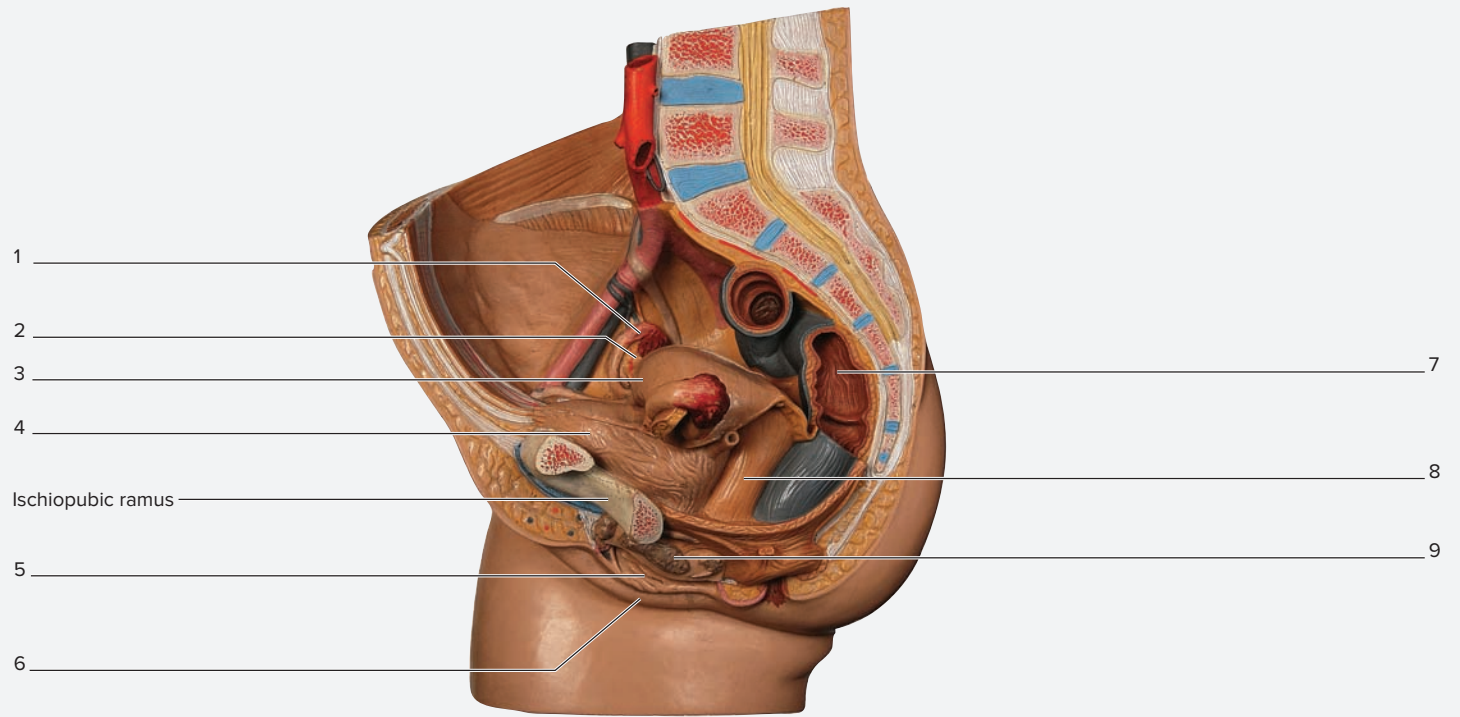
(continued on next page)

(continued from previous page)

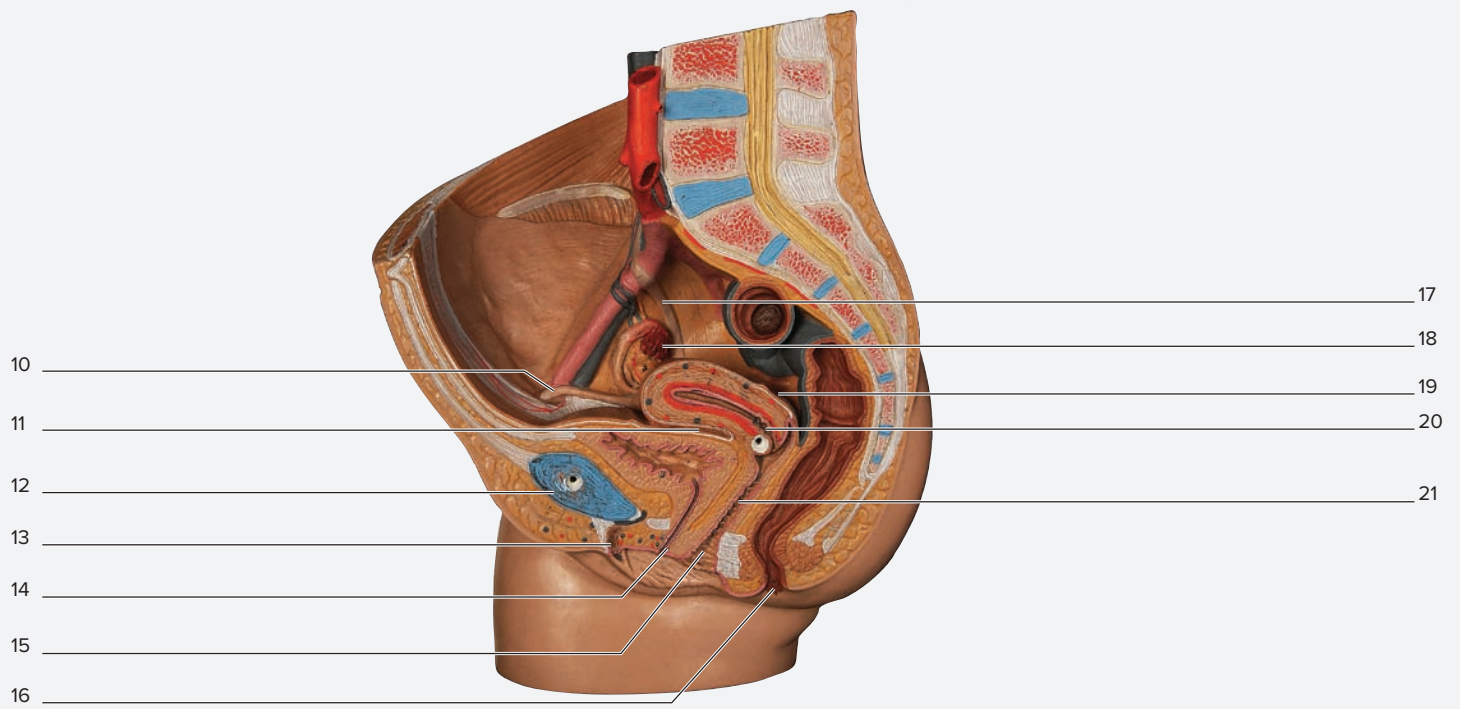


**Figure 23.12** Suspensory Ligaments of the Ovary, Uterine Tubes, and Uterus as Seen from a Posterior View. Numbers indicating suspensory ligaments are highlighted in green. Numbers indicating reproductive and other associated structures have no highlight. (a) Posterior view. (b) Lateral view. Use the terms listed to fill in the numbered labels in the figure. Some answers may be used more than once.

- |   |   |   |
|---|---|---|
| <input type="checkbox"/> ampulla of uterine tube      | <input type="checkbox"/> isthmus of uterine tube          | <input type="checkbox"/> uterine blood vessels        |
| <input type="checkbox"/> body of uterus               | <input type="checkbox"/> mesosalpinx                      | <input type="checkbox"/> uterine part of uterine tube |
| <input type="checkbox"/> broad ligament               | <input type="checkbox"/> mesovarium                       | <input type="checkbox"/> uterine tube                 |
| <input type="checkbox"/> cervical canal               | <input type="checkbox"/> myometrium                       | <input type="checkbox"/> uterosacral ligament         |
| <input type="checkbox"/> endometrium                  | <input type="checkbox"/> ovarian ligament                 | <input type="checkbox"/> vagina                       |
| <input type="checkbox"/> external os                  | <input type="checkbox"/> perimetrium                      |   |
| <input type="checkbox"/> fimbria                      | <input type="checkbox"/> round ligament of the uterus     |   |
| <input type="checkbox"/> infundibulum of uterine tube | <input type="checkbox"/> suspensory ligament of the ovary |   |
| <input type="checkbox"/> internal os                  | <input type="checkbox"/> transverse cervical ligament     |   |



(a) Midsagittal view



(b) Midsagittal view

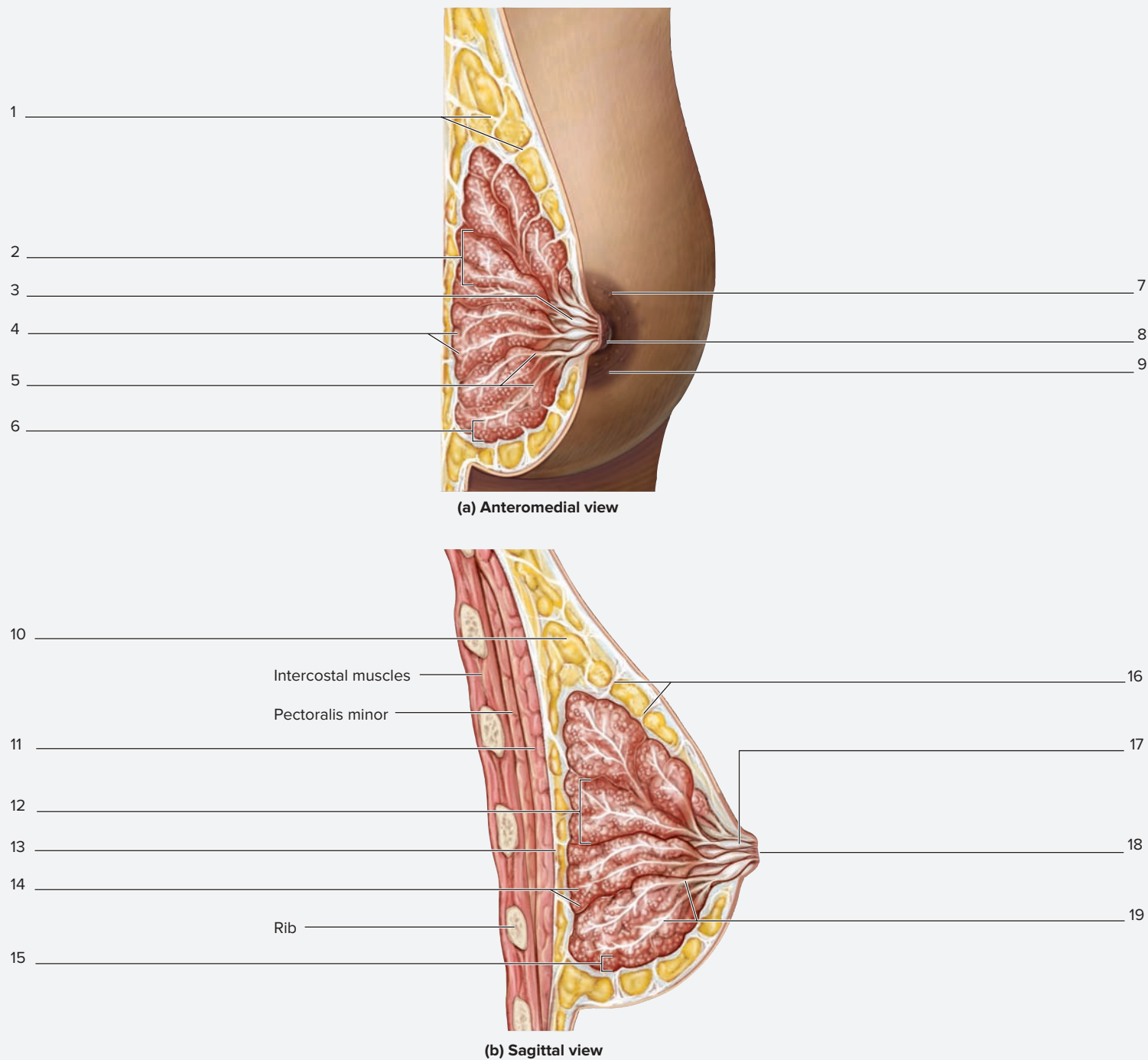
**Figure 23.13 Classroom Model of the Female Pelvic Cavity.** (a) Midsagittal view with pelvic structures intact. (b) Midsagittal view. Use the terms listed to fill in the numbered labels in the figure. Some answers may be used more than once.

- |  |  |   |  |
|--|--|---|--|
| <input type="checkbox"/> anus                      | <input type="checkbox"/> fimbria of uterine tube | <input type="checkbox"/> rectouterine pouch           | <input type="checkbox"/> uterine tube        |
| <input type="checkbox"/> bulb of the vestibule     | <input type="checkbox"/> labia majora            | <input type="checkbox"/> rectum                       | <input type="checkbox"/> uterus              |
| <input type="checkbox"/> cervix of uterus          | <input type="checkbox"/> labia minora            | <input type="checkbox"/> round ligament of the uterus | <input type="checkbox"/> vagina              |
| <input type="checkbox"/> clitoris                  | <input type="checkbox"/> ovary                   | <input type="checkbox"/> ureter                       | <input type="checkbox"/> vaginal orifice     |
| <input type="checkbox"/> external urethral orifice | <input type="checkbox"/> pubic symphysis         | <input type="checkbox"/> urinary bladder              | <input type="checkbox"/> vesicouterine pouch |

**EXERCISE 23.12** Gross Anatomy of the Female Breast

The female breast consists largely of fatty tissue and suspensory ligaments. Imbedded within are numerous modified sweat glands, the **mammary glands** (*mamma*, breast), which are compound tubuloalveolar exocrine glands. These glands enlarge greatly during pregnancy, enabling them to produce milk to provide nourishment for the new baby. **Table 23.11** describes the structures that compose the female breast.

1. Observe the breast of a prosected female human cadaver or a classroom model of the female breast.
2. Identify the structures listed in **figure 23.14** on the cadaver or the classroom model of the female breast, using table 23.11 and the textbook as guides. Then label them in figure 23.14.



**Figure 23.14** The Female Breast. (a) Anterior view. (b) Sagittal view. Use the terms listed to fill in the numbered labels in the figure. Some answers may be used more than once.

- |   |  |  |  |
|---|--|--|--|
| <input type="checkbox"/> adipose tissue | <input type="checkbox"/> areolar gland     | <input type="checkbox"/> lactiferous sinus | <input type="checkbox"/> nipple                  |
| <input type="checkbox"/> alveoli        | <input type="checkbox"/> deep fascia       | <input type="checkbox"/> lobe              | <input type="checkbox"/> pectoralis major muscle |
| <input type="checkbox"/> areola         | <input type="checkbox"/> lactiferous ducts | <input type="checkbox"/> lobule            | <input type="checkbox"/> suspensory ligaments    |

## Clinical View | Breast Cancer and Breast Self Examination (BSE)

### Incidence

In females, breast cancer is the second most commonly diagnosed cancer after skin cancer, and the second most common cause of death from cancer after lung cancer. Due to increased screening for breast cancers, currently only about 20% of patients diagnosed with breast cancer are likely to die from breast cancer. Luckily, breast cancer is a highly curable disease if caught early and there are several screening mechanisms that can be used to identify early lesion: clinical breast exam (CBE), mammography, and breast self exam (BSE). Of these, breast self exam is one of the most common ways that breast cancers are first noticed.

### What Is Breast Cancer?

The most common forms of breast cancers are carcinomas, which are tumors that originate in epithelial tissues. In the breast, the mammary glands and ducts consist of modified epithelial tissue, and most breast cancers originate in these tissues. The most common types of breast cancer are ductal carcinoma in situ (DCIS) and lobular carcinoma in situ (LCIS), which are tumors that originate in cells lining the ducts (DCIS) or in the glands themselves (LCIS). These tumors remain limited to the epithelial tissue (*in situ* means a tumor has not crossed the basement membrane of the epithelium). More serious forms of cancer are invasive carcinomas, which are tumors that have spread beyond the basement membrane of the epithelial tissues.

### Screening

#### Clinical Breast Exam (CBE)

All women of reproductive age are encouraged to make annual visits to their gynecologist for a clinical breast exam and a pap smear to test for early cervical changes that are risk factors for cervical cancer. The physician performing the CBE is palpating for abnormal lumps. However, they can also help teach a woman how to perform breast self exam (BSE) so she can monitor the condition of her breasts monthly instead of just during yearly visits. The vast majority of breast cancers are discovered by the patient herself.

#### Mammography

A mammogram is an x-ray of the breast that is used to look for areas of extra density or calcifications, which can be early signs of breast cancer. Most women are advised to start having mammograms at age 40, but those with a family history of the disease are often advised to have their first mammogram at age 35. Mammography is good at locating very small tumors (especially DCIS), which may not be palpable on self examinations or clinical examinations.

### Breast Self Exam (BSE)

Women should perform a breast self exam at least once a month to look for any unusual bumps, lumps, or thickening of breast tissue. Upon palpation, a typical breast feels a bit lumpy, with some firmer areas and some softer areas. The firmer areas can be thickenings of the suspensory ligaments, or fibrocystic changes to the breast. The softer areas are typically just adipose tissue. There are a number of benign (noncancerous) changes to the breast that can make breasts feel “lumpy.” Specifically, fibrocystic changes in the breast consist of fluid-filled cysts and are often surrounded by dense fibrous tissue. This tissue, though often large and dense, is typically mobile (moves around easily), and often mirrors itself on the opposite breast. That is, if fibrocystic changes are discovered in the lower right quadrant of the right breast, they are also likely to be found in the lower right quadrant of the left breast. On the contrary, breast cancers tend to feel much harder, like a kernel of unpopped popcorn. Breast cancers are also immobile (they do not move when they are palpated). Breast tumors are generally painless and sometimes cause dimpling of the skin overlying the tumor.

The following are three procedures for performing a breast self exam:

1. In the shower: Use soapy hands to palpate the breast while raising the arm on the same side of the breast you are palpating. Starting at the periphery of the breast, use two or three fingers to make small circles that progressively move toward the nipple. Squeeze the nipple to look for discharge. Be sure to palpate all the way up into the axilla, as the majority of tumors arise in the outer/upper quadrant toward the axillary region of the breast.
2. Lying down: Use the same procedure as in the shower. It is good to do an exam lying down because it makes the breasts lie flat, which may make it easier to feel certain lumps.
3. Standing in front of mirror: Place your hands on your hips, lean your elbows forward (anterior), and look for any indentations in the skin of the breast or “orange-peel”-looking skin, which can be indicative of underlying tumor.

If you discover an unusual lump, make an appointment with a gynecologist as soon as possible to discuss your findings from the BSE. The physician will then help determine if what was palpated was something benign or something that needs further exploration. Remember, always, that breast cancer is *highly curable* when caught early.

(continued on next page)



*(continued from previous page)*

Table 23. 11 The Female Breast		
Structure	Description and Function	Word Origins
<i>Alveoli</i>	Secretory units of the mammary glands, which produce milk.	<i>alveolus</i> , a concave vessel, a bowl
<i>Areola</i>	The pigmented area of skin surrounding the nipple.	<i>areola</i> , area
<i>Areolar Glands</i>	Sebaceous glands deep to the skin of the areola; produce sebum, which keeps the skin of the areola moist, particularly during lactation.	<i>areolar</i> , relating to the areola of the breast
<i>Lactiferous Duct</i>	Ducts that form from the confluence of small ducts draining milk from the alveoli and lobules.	<i>lacto-</i> , milk + <i>ductus</i> , to lead
<i>Lactiferous Sinus</i>	10–20 large channels that form from the confluence of several lactiferous ducts; the spaces where milk is stored prior to release from the nipple.	<i>lacto-</i> , milk + <i>sinus</i> , cavity
<i>Lobes</i>	Large subdivisions of the mammary glands.	<i>lobos</i> , lobe
<i>Lobules</i>	Smaller subdivisions of the mammary glands, which contain the alveoli.	<i>lobulus</i> , a small lobe
<i>Nipple</i>	A cylindrical projection in the center of the breast that contains the openings of the lactiferous ducts.	<i>neb</i> , beak or nose
<i>Suspensory Ligaments</i>	Bands of connective tissue that anchor the breast skin and tissue to the deep fascia overlying the pectoralis major muscle.	<i>suspensio</i> , to hang up + <i>ligamentum</i> , a band

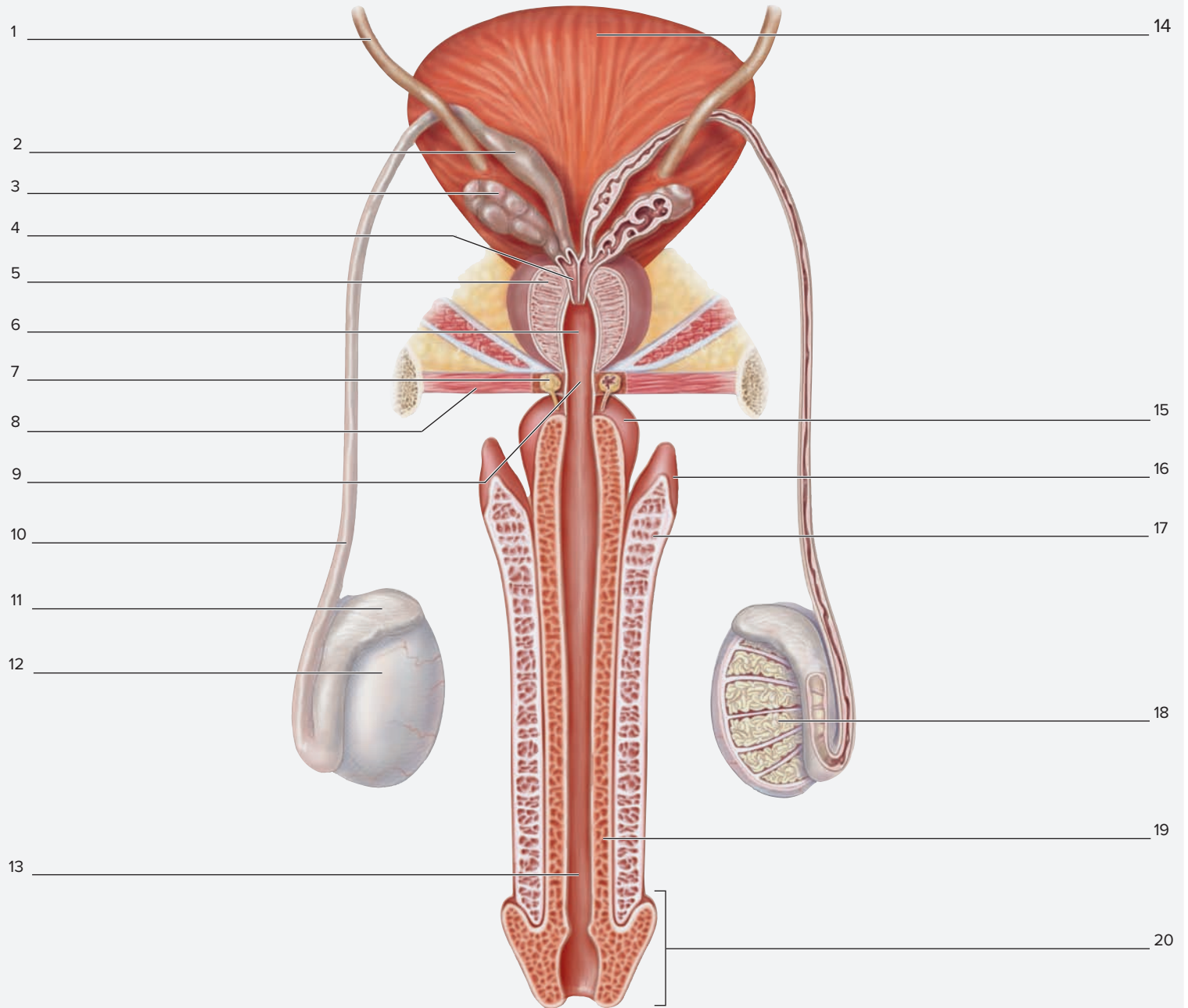
## Male Reproductive System

The **testes**, the primary male reproductive organs, function in the production of sperm and testosterone. Sperm produced in the testes are stored in the **epididymis** and transported via the **ductus deferens** to the male urethra during ejaculation. The **seminal vesicles** and **prostate gland** are accessory reproductive glands that produce substances that nourish

and protect the sperm and also compose the vast majority of semen. The **bulbourethral glands** are small glands located within the urogenital diaphragm that produce a mucus-like substance during sexual arousal that neutralizes the acidity of the male urethra and provides lubrication to ease the passage of semen during ejaculation.

**EXERCISE 23.13** Gross Anatomy of the Scrotum, Testis, Spermatic Cord, and Penis

1. Observe a prosected male human cadaver or classroom models of the male reproductive organs.
2. Identify the structures listed in **figures 23.15** and **23.16** on the cadaver or on classroom models, using the textbook as a guide. Then label them in figures 23.15 and 23.16.
3. *Optional Activity:* **AP|R Reproductive System**—In the Quiz section, select the “Structures: Male” option to test your knowledge of male reproductive gross anatomy.

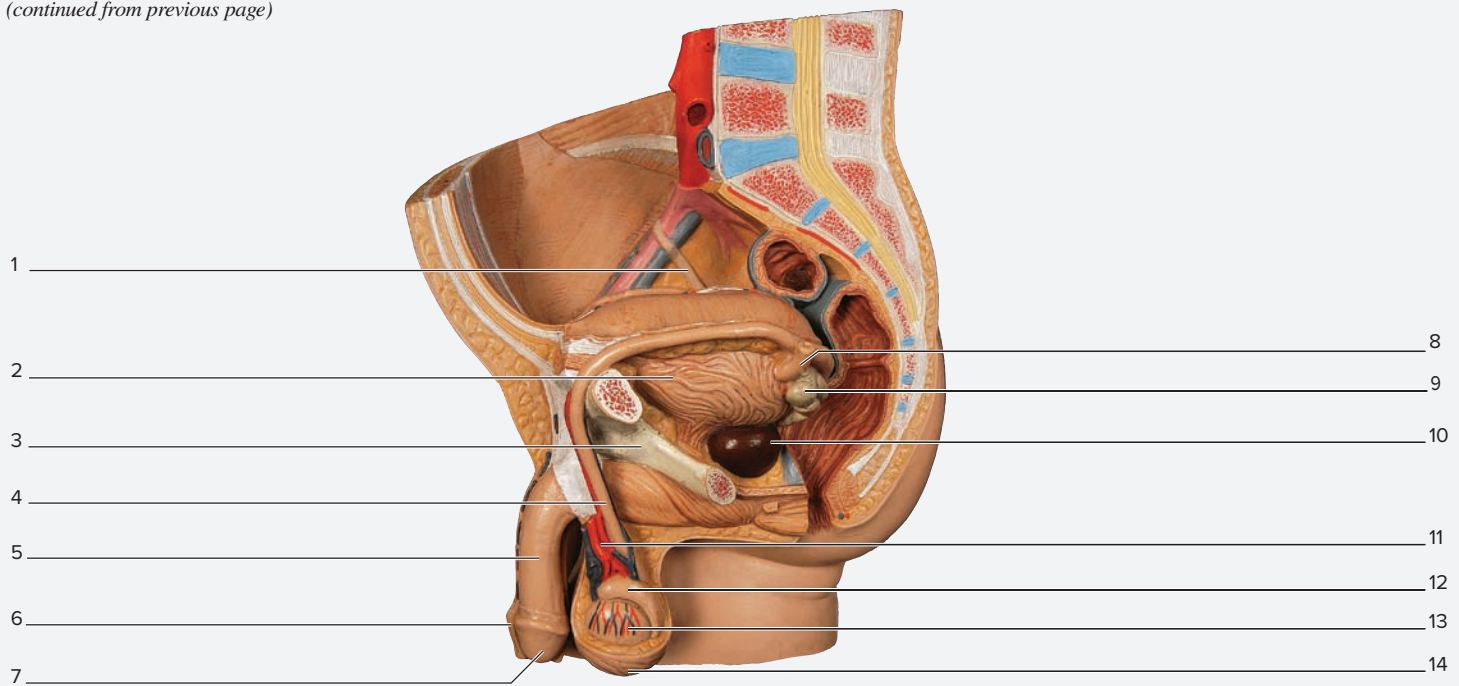


**Figure 23.15** Male Reproductive Tract Structures. Posterior view. Use the terms listed to fill in the numbered labels in the figure.

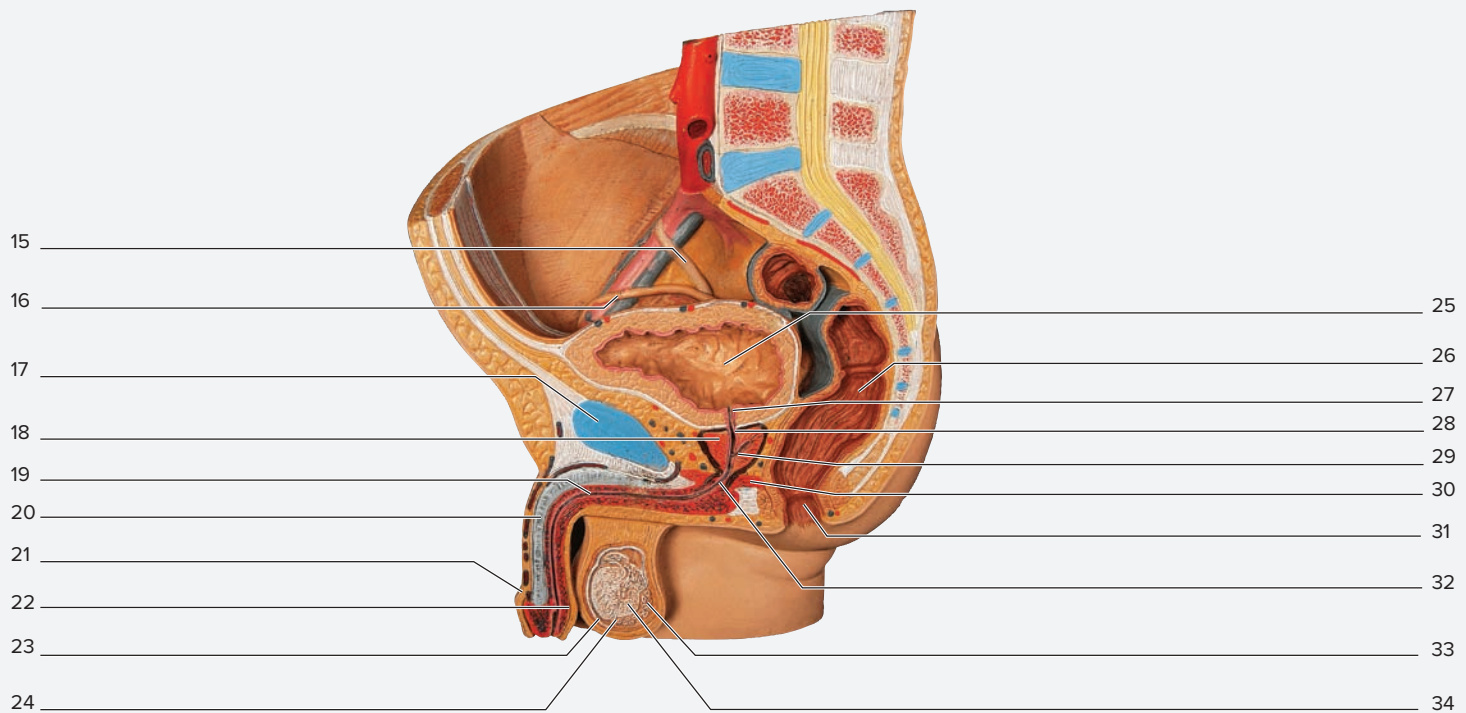
- |   |   |   |   |
|---|---|---|---|
| <input type="checkbox"/> ampulla of ductus deferens | <input type="checkbox"/> ductus deferens    | <input type="checkbox"/> prostate gland       | <input type="checkbox"/> urinary bladder      |
| <input type="checkbox"/> bulb of penis              | <input type="checkbox"/> ejaculatory duct   | <input type="checkbox"/> prostatic urethra    | <input type="checkbox"/> urogenital diaphragm |
| <input type="checkbox"/> bulbourethral gland        | <input type="checkbox"/> epididymis         | <input type="checkbox"/> seminal vesicle      |   |
| <input type="checkbox"/> corpus cavernosum          | <input type="checkbox"/> glans penis        | <input type="checkbox"/> seminiferous tubules |   |
| <input type="checkbox"/> corpus spongiosum          | <input type="checkbox"/> membranous urethra | <input type="checkbox"/> testis               |   |
| <input type="checkbox"/> crus of penis              | <input type="checkbox"/> penile urethra     | <input type="checkbox"/> ureter               |   |

(continued on next page)

(continued from previous page)



(a) Midsagittal view



(b) Midsagittal view

**Figure 23.16 Classroom Model of the Male Pelvic Cavity.** (a) Midsagittal view with pelvic structures intact. (b) Midsagittal view. Use the terms listed to fill in the numbered labels in the figure. Some answers may be used more than once.

- |  |   |   |   |
|--|---|---|---|
| <input type="checkbox"/> anus                        | <input type="checkbox"/> ischiopubic ramus  | <input type="checkbox"/> pubic symphysis            | <input type="checkbox"/> testis                     |
| <input type="checkbox"/> corpus cavernosum           | <input type="checkbox"/> membranous urethra | <input type="checkbox"/> rectum                     | <input type="checkbox"/> tunica albuginea of testis |
| <input type="checkbox"/> ductus deferens             | <input type="checkbox"/> penile urethra     | <input type="checkbox"/> scrotum                    | <input type="checkbox"/> tunica vaginalis of testis |
| <input type="checkbox"/> ejaculatory duct            | <input type="checkbox"/> penis              | <input type="checkbox"/> seminal vesicle            | <input type="checkbox"/> ureter                     |
| <input type="checkbox"/> epididymis                  | <input type="checkbox"/> prepuce            | <input type="checkbox"/> seminiferous tubules       | <input type="checkbox"/> urinary bladder            |
| <input type="checkbox"/> glans penis                 | <input type="checkbox"/> prostate gland     | <input type="checkbox"/> testicular artery and vein | <input type="checkbox"/> urogenital diaphragm       |
| <input type="checkbox"/> internal urethral sphincter | <input type="checkbox"/> prostatic urethra  |   |   |

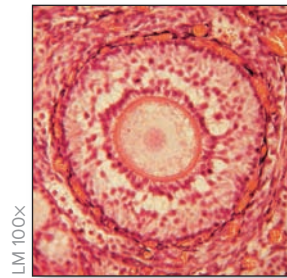
## POST-LABORATORY WORKSHEET

The ❶ corresponds to the Learning Objective(s) listed in the chapter opener outline.

### Do You Know the Basics?

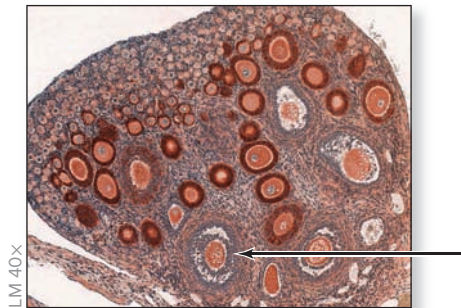
#### Exercise 23.1: Histology of the Ovary

- The germinal epithelium is composed of which of the following types of epithelial tissue? (Circle one.) ❶
  - simple columnar epithelium
  - simple cuboidal epithelium
  - simple squamous epithelium
  - transitional epithelium
- Identify the structure shown in the photomicrograph. (Circle one.) ❷
  - primary follicle
  - primordial follicle
  - secondary follicle
  - vesicular follicle



© Christine Eckel

- The arrow in this figure is pointing to a \_\_\_\_\_ (primary/secondary) follicle, which contains a \_\_\_\_\_ (primary/secondary) oocyte. ❸



© McGraw-Hill Education/Christine Eckel, photographer

#### Exercise 23.2: Histology of the Uterine Tubes

- Place the following layers that compose the wall of the uterine tube in order, from outermost to innermost. ❸ ❹
  - \_\_\_\_\_ a. mucosa
  - \_\_\_\_\_ b. muscularis
  - \_\_\_\_\_ c. serosa
- The uterine tube is lined with simple \_\_\_\_\_ (cuboidal/columnar) epithelium. ❺

#### Exercise 23.3: Histology of the Uterine Wall

- The two layers of the uterine endometrium are the functional layer and the basal layer. The \_\_\_\_\_ (functional/basal) layer is shed during menstruation. ❻
- The myometrium is composed of two layers of smooth muscle. \_\_\_\_\_ (True/False) ❼

**Exercise 23.4: Histology of the Vaginal Wall**

8. The wall of the vagina is composed of which of the following layers? (Check all that apply.) **8**
- \_\_\_ a. adventitia  
\_\_\_ b. mucosa  
\_\_\_ c. muscularis  
\_\_\_ d. submucosa
9. The innermost lining of the vagina is lined with which of the following epithelial tissues? (Circle one.) **9**
- a. keratinized stratified squamous epithelium  
b. nonkeratinized stratified squamous epithelium  
c. simple columnar epithelium  
d. simple cuboidal epithelium  
e. simple squamous epithelium

**Exercise 23.5: Histology of the Seminiferous Tubules**

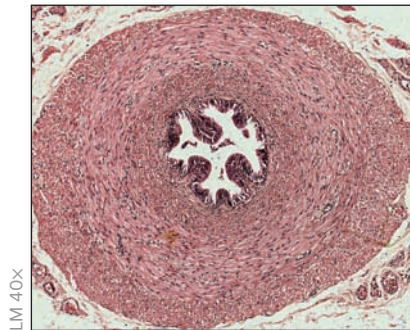
10. A cross section of a seminiferous tubule demonstrates a circular structure that contains layers of developing sperm. \_\_\_\_\_ (True/False) **10**
11. Spermatogonia are located near the \_\_\_\_\_ (basement membrane/lumen) of the seminiferous tubules. **11**
12. Sustentacular cells, located within seminiferous tubules, produce \_\_\_\_\_ (androgen-binding protein/testosterone), whereas interstitial (Leydig) cells, located in between seminiferous tubules, produce \_\_\_\_\_ (androgen-binding protein/testosterone). **12**

**Exercise 23.6: Histology of the Epididymis**

13. Upon viewing the epididymis through a microscope, thousands of spermatazoa are visible in the lumen of the tube. \_\_\_\_\_ (True/False) **13**
14. The epididymis is lined with \_\_\_\_\_ (simple/pseudostratified) columnar epithelium with stereocilia. **14**
15. Which of the following is a function of stereocilia within the epididymis? (Check all that apply.) **15**
- \_\_\_ a. enhance sperm maturation  
\_\_\_ b. increase surface area  
\_\_\_ c. propel sperm  
\_\_\_ d. secretion and absorption  
\_\_\_ e. sperm production

**Exercise 23.7: Histology of the Ductus Deferens**

16. Identify the structure shown in this following photomicrograph. (Circle one.) **16**
- a. ductus deferens  
b. epididymis  
c. penis  
d. prostate gland



© Christine Eckel

17. The ductus deferens contains a mucosa and layers of smooth muscle. The innermost smooth muscle layer is \_\_\_\_\_ (circular/longitudinal) muscle, whereas the outermost smooth muscle layer is \_\_\_\_\_ (circular/longitudinal) muscle. **17**
18. The ductus deferens is lined with pseudostratified ciliated columnar epithelium. \_\_\_\_\_ (True/False) **18**

**Exercise 23.8: Histology of the Seminal Vesicles**

19. Seminal vesicles release substances, including fructose, which nourish sperm. \_\_\_\_\_ (True/False) 19
20. Seminal vesicles are lined with stratified cuboidal epithelium. \_\_\_\_\_ (True/False) 20

**Exercise 23.9: Histology of the Prostate Gland**

21. Which of the following are distinguishing features of the prostate gland of an aging male when viewed through a microscope? (Check all that apply.) 21 22
- \_\_\_\_\_ a. cilia
  - \_\_\_\_\_ b. mucosal folds
  - \_\_\_\_\_ c. muscular wall
  - \_\_\_\_\_ d. prostatic calculi
  - \_\_\_\_\_ e. tubuloalveolar glands

**Exercise 23.10: Histology of the Penis**

22. The urethra is surrounded by which structure in the penis? (Circle one.) 23
- a. central artery
  - b. corpora cavernosa
  - c. corpus spongiosum
  - d. dorsal vein
23. When viewing the cross section of the penis through a microscope, there are three erectile bodies, paired corpora cavernosa, and a single corpus spongiosum. \_\_\_\_\_ (True/False) 24

**Exercise 23.11: Gross Anatomy of the Ovary, Uterine Tubes, Uterus, and Supporting Ligaments**

24. Place the following terms in the correct order to describe the pathway that an ovum takes as it travels from the ovary to the uterus. 25
- \_\_\_\_\_ a. ampulla of uterine tube
  - \_\_\_\_\_ b. infundibulum of uterine tube
  - \_\_\_\_\_ c. isthmus of uterine tube
  - \_\_\_\_\_ d. ovarian cortex
  - \_\_\_\_\_ e. uterine part of uterine tube
  - \_\_\_\_\_ f. uterus
25. Which of the following structures travels through the inguinal canal in females? (Circle one.) 26
- a. broad ligament
  - b. ovarian ligament
  - c. round ligament of the uterus
  - d. suspensory ligament of the ovary
  - e. uterosacral ligament
26. The peritoneal cavity is considered an \_\_\_\_\_ (open/closed) cavity in the female because the uterine tube is \_\_\_\_\_ (open/closed) at its distal end (the infundibulum). 27

**Exercise 23.12: Gross Anatomy of the Female Breast**

27. Which of the following are the secretory units of the mammary glands, which produce milk? (Circle one.) 28
- a. alveoli
  - b. areolar glands
  - c. lactiferous sinuses
  - d. lobules
  - e. nipples

**Exercise 23.13: Gross Anatomy of the Scrotum, Testis, Spermatic Cord, and Penis**

28. Match the description listed in column A with the associated structure listed in column B. 29 32

**Column A**

- \_\_\_\_\_ 1. located inferior to the urinary bladder
- \_\_\_\_\_ 2. produces a mucus-like substance that neutralizes acidity of the urethra
- \_\_\_\_\_ 3. produces fructose, an important component of semen
- \_\_\_\_\_ 4. site of sperm maturation
- \_\_\_\_\_ 5. site of sperm production

**Column B**

- a. bulbourethral gland
- b. epididymis
- c. prostate gland
- d. seminal vesicles
- e. testes

29. Which of the following is the portion of the male urethra that passes through erectile tissue? (Circle one.) 30

- a. membranous urethra
- b. prostatic urethra
- c. spongy urethra

30. Which of the following are considered accessory reproductive structures that contribute substances to semen (other than sperm)? (Check all that apply.) 31 32

- \_\_\_\_\_ a. bulbourethral gland
- \_\_\_\_\_ b. epididymis
- \_\_\_\_\_ c. prostate gland
- \_\_\_\_\_ d. seminal vesicles
- \_\_\_\_\_ e. testes

31. The spermatic cord is composed of the testicular artery and nerve, the ductus deferens, lymphatic vessels, and the pampiniform plexus of veins.

\_\_\_\_\_ (True/False) 33

32. Place the following structures in the order in which a sperm travels through the male reproductive tract during ejaculation. 34

- \_\_\_\_\_ a. ductus deferens
- \_\_\_\_\_ b. epididymis
- \_\_\_\_\_ c. membranous urethra
- \_\_\_\_\_ d. prostatic urethra
- \_\_\_\_\_ e. spongy urethra

**Can You Apply What You've Learned?**

33. You are a nurse and your job is to insert a catheter into the urethra of a female patient.

- a. Where will you look for the opening to the female urethra (be specific)?

\_\_\_\_\_

- b. Approximately how long must the catheter be in order to reach into the bladder of the female?

\_\_\_\_\_

# The Brain and Cranial Nerves

# 24

## OUTLINE AND LEARNING OBJECTIVES

### Gross Anatomy 532

#### The Meninges 532

##### EXERCISE 24.1: CRANIAL MENINGES 532

- 1 Identify *dura mater*, *arachnoid mater*, *pia mater*, *cranial dural septa*, and *dural venous sinuses*
- 2 Describe the pathway fluid takes as it flows through the *dural venous sinuses*

#### Ventricles of the Brain 536

##### EXERCISE 24.2: BRAIN VENTRICLES 536

- 3 Identify the components of the brain ventricular system on a model of the brain ventricles
- 4 Correlate each ventricular space with the secondary brain vesicle from which it developed

##### EXERCISE 24.3: CIRCULATION OF CEREBROSPINAL FLUID (CSF) 537

- 5 Trace the flow of cerebrospinal fluid (CSF) from its site of production in the *choroid plexus* to its site of drainage in the *arachnoid villi*

#### The Human Brain 539

##### EXERCISE 24.4: SUPERIOR VIEW OF THE HUMAN BRAIN 541

- 6 Identify structures visible in a superior view of the human brain and describe their functions

##### EXERCISE 24.5: LATERAL VIEW OF THE HUMAN BRAIN 542

- 7 Identify structures visible in a lateral view of the human brain and describe their functions

##### EXERCISE 24.6: INFERIOR VIEW OF THE HUMAN BRAIN 543

- 8 Identify structures visible in an inferior view of the human brain and describe their functions

##### EXERCISE 24.7: MIDSAGITTAL VIEW OF THE HUMAN BRAIN 544

- 9 Identify structures visible in a midsagittal view of the human brain and describe their functions

#### Cranial Nerves 545

##### EXERCISE 24.8: IDENTIFICATION OF CRANIAL NERVES ON A BRAIN OR BRAINSTEM MODEL 545

- 10 List the names, numbers, and general functions (motor, sensory, or mixed) of each of the cranial nerves
- 11 Identify the cranial nerves on a human brain or model of a human brain

#### Testing Cranial Nerve Functions 547

##### EXERCISE 24.9: TESTING SPECIFIC FUNCTIONS OF THE CRANIAL NERVES 549

- 12 Perform common tests of cranial nerve function

#### The Sheep Brain 556

##### EXERCISE 24.10: SHEEP BRAIN DISSECTION 557

- 13 Associate the structures of a sheep brain with those of a human brain, noting structures that differ greatly from each other in size and function

## INTRODUCTION

Recall a time when solving word problems in math class was difficult. At the time someone may have said, “Come on, use your gray matter!”—meaning “Use your brain! Think!” Having completed the exercises in chapter 14, it is now clear that the brain consists not only of gray matter (dendrites and cell bodies of neurons), but also of white matter (fiber tracts). The activities in this chapter showcase specific parts of the brain that are composed of gray and white matter.

To help make sense of the structures observed in this laboratory session, the tables in this chapter list the names of the structures along with brief summaries of associated functions and information about the derivation of the names of the structures. Keep in mind that brain structures were named well before their functions were known. Most of the names do not relate to function; instead, they derive from the general appearance of the structure. For instance, “mammillary bodies” have little or nothing to do with the female reproductive system, but to early anatomists they appeared to be “little breasts” on the inferior surface of the brain. The area known as the thalamus apparently looked like a “bed” or “bedroom.” In reality, the thalamus has very little, if anything, to do with the bedroom or sleep.

When learning the structures of the brain, try to imagine how and why each structure was given its name. This will make it easier to recall the names of structures.



In addition, pay attention to the function(s) of each structure identified. Knowledge of function is even more important than knowledge of structure, because when an area of the brain is damaged, there will be deficiencies directly related to the functions of that area of the brain. The same holds true for the cranial nerves, which transmit information between the brain and structures of the head, neck, and thoracic and abdominal viscera.

This laboratory session involves first examining the protective coverings of the brain—the meninges—then observing the ventricular system of the human brain and relating the development of ventricular structures to the development of the brain. These exercises will be followed with the study of preserved human brains or models of the human brain, and dissection of a representative mammalian brain: the sheep brain.

What follows is an investigation of the *cranial nerves*, which are nerves that arise from the brain (as contrasted with *spinal nerves*, which arise from the spinal cord). The cranial nerve exercises in this laboratory session are organized so that if completed in the proper sequence, knowledge of the

cranial nerves will become increasingly detailed. The first exercises establish a base knowledge about the locations and names of the nerves. Subsequent exercises build on that base knowledge, exploring the detailed functions, locations, and common disorders of the cranial nerves.

#### List of Reference Tables

Table 24.1	Meninges, Dural Septa, and Dural Venous Sinuses	p. 533
Table 24.2	Ventricles of the Brain	p. 537
Table 24.3	Brain Structures Visible in Superficial Views of Whole or Sagittally Sectioned Brains	p. 539
Table 24.4	Names of Cranial Nerves	p. 545
Table 24.5	Modalities Within Cranial Nerves	p. 547
Table 24.6	Detailed Functions and Divisions of the Cranial Nerves	p. 547
Table 24.7	Common Disorders of the Cranial Nerves	p. 549

These Pre-laboratory Worksheet questions may be assigned by instructors through their **connect** course.

## PRE-LABORATORY WORKSHEET

1. A fold of brain tissue is known as a \_\_\_\_\_ (gyrus/sulcus), whereas a groove between folds of brain tissue is known as a \_\_\_\_\_ (gyrus/sulcus).

2. Number the three meninges that cover the brain and spinal cord in order, from superficial (1) to deep (3).

\_\_\_\_\_ a. arachnoid mater    \_\_\_\_\_ b. dura mater    \_\_\_\_\_ c. pia mater

3. Match the ventricular structure listed in column A with the corresponding associated adult brain structure listed in column B.

### Column A

- \_\_\_\_\_ 1. cerebral aqueduct
- \_\_\_\_\_ 2. fourth ventricle
- \_\_\_\_\_ 3. lateral ventricle
- \_\_\_\_\_ 4. third ventricle

### Column B

- a. cerebral hemispheres
- b. diencephalon
- c. midbrain
- d. pons

4. Dural venous sinuses carry only venous blood \_\_\_\_\_. (True/False)

5. Match the description listed in column A with the corresponding brain structure listed in column B.

### Column A

- \_\_\_\_\_ 1. deep, horizontal groove between the frontal, parietal, and temporal lobes
- \_\_\_\_\_ 2. fold of brain tissue that serves as the primary somatic motor area of the brain
- \_\_\_\_\_ 3. fold of brain tissue that serves as the primary somatic sensory area of the brain
- \_\_\_\_\_ 4. separates the cerebral hemispheres from the cerebellar hemispheres
- \_\_\_\_\_ 5. separates the frontal lobe from the parietal lobe of the brain

### Column B

- a. central sulcus
- b. lateral sulcus
- c. postcentral gyrus
- d. precentral gyrus
- e. transverse fissure

6. Number the three parts of the brainstem in order, from superior (1) to inferior (3).

\_\_\_\_\_ a. medulla oblongata    \_\_\_\_\_ b. midbrain    \_\_\_\_\_ c. pons

7. Match the function listed in column A with the corresponding lobe of the brain listed in column B.

### Column A

- \_\_\_\_\_ 1. controls conscious movement of skeletal muscle
- \_\_\_\_\_ 2. primary auditory and auditory association area
- \_\_\_\_\_ 3. primary visual area
- \_\_\_\_\_ 4. receives sensory input from the skin and proprioceptors

### Column B

- a. frontal lobe
- b. occipital lobe
- c. parietal lobe
- d. temporal lobe

8. A cranial nerve is a \_\_\_\_\_ (central/peripheral) nervous system structure that originates from the brain.

9. Which of the following structures are innervated by visceral motor neurons? (Check all that apply.)

\_\_\_\_\_ a. cardiac muscle    \_\_\_\_\_ b. glands    \_\_\_\_\_ c. skeletal muscle    \_\_\_\_\_ d. smooth muscle

10. Which of the following cranial nerve(s) is/are involved with voluntary eye movement? (Check all that apply.)

\_\_\_\_\_ a. abducens (CN VI)    \_\_\_\_\_ b. oculomotor (CN III)    \_\_\_\_\_ c. optic (CN II)    \_\_\_\_\_ d. trochlear (CN IV)

## Gross Anatomy

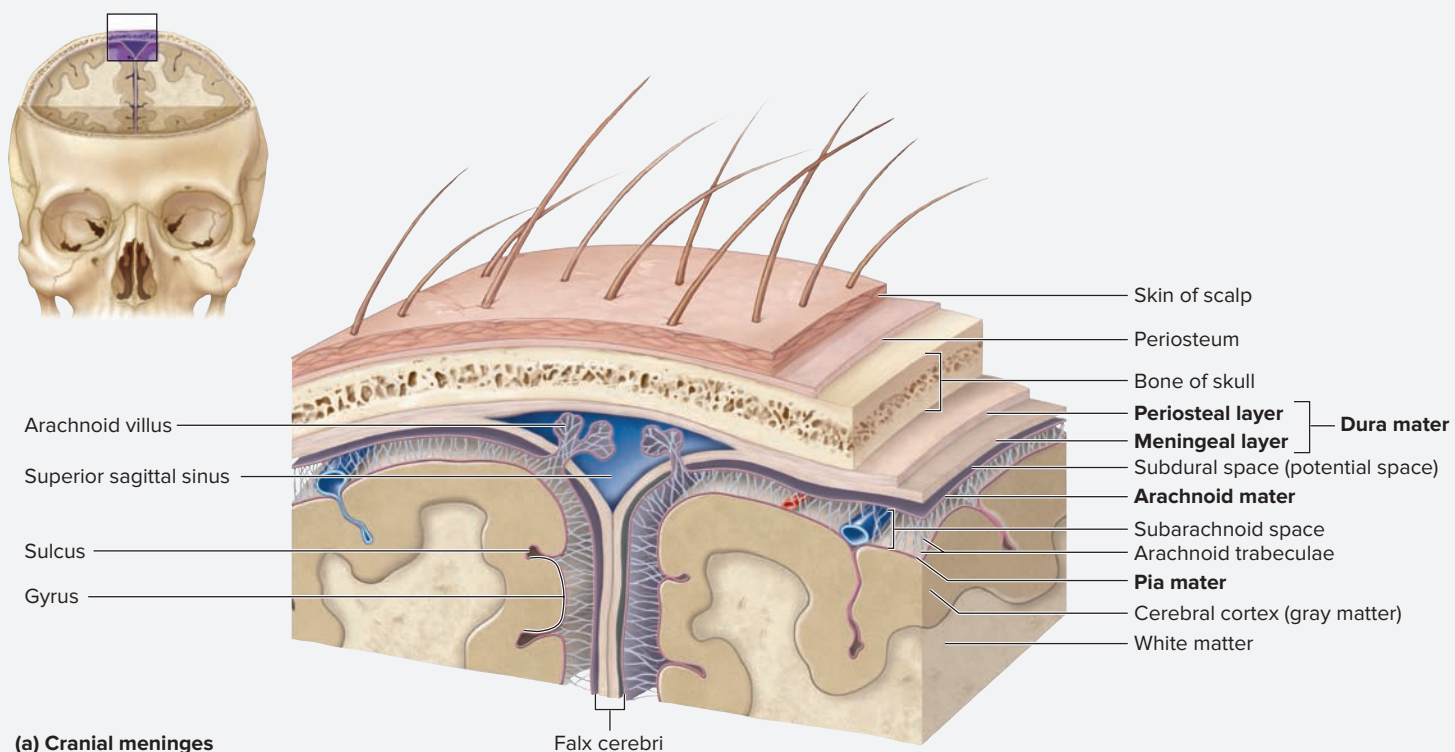
### The Meninges

The **meninges** are connective tissue coverings of the brain and spinal cord and consist of the dura mater, arachnoid mater, and pia mater. These coverings perform many functions and their structure varies slightly

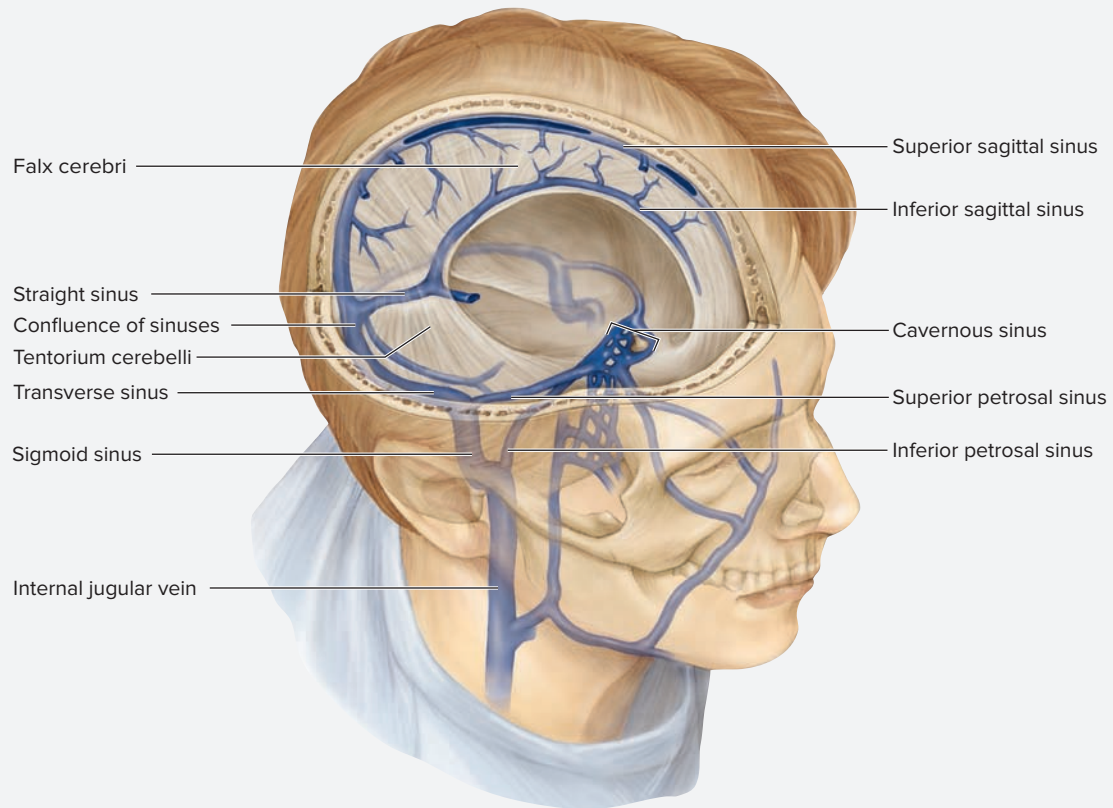
depending on whether they are covering the brain or the spinal cord. Exercise 24.1 explores meningeal structures as they apply to the brain, and exercises in chapter 16 consider meningeal structures as they apply to the spinal cord.

#### EXERCISE 24.1 Cranial Meninges

1. Obtain a model of the dura mater of the brain or a cadaveric specimen of the head with intact dural structures.
2. Identify meningeal structures listed in **figure 24.1** on a model or cadaveric specimen, using **table 24.1** and the textbook as guides. Then label them in **figure 24.2**.
  - a. Observe the dura mater (figure 24.1). The **dura mater** (*dura*, hard, + *mater*, mother) is composed of two layers: the outer **periosteal layer** (which is simply the periosteum that lines the internal portion of the cranial bones), and the inner **meningeal layer**. The meningeal layer folds inward to form cranial dural septae and dural venous sinuses (figure 24.1*b*). **Cranial dural septae** are partitions that stabilize and support the brain. **Dural venous sinuses** are modified veins that transport venous blood from the brain to the internal jugular vein. The largest dural venous sinus is the **superior sagittal sinus**. Eventually all sinuses drain into the **sigmoid** (*sigmoid*, S-shaped) **sinus**, which drains into the **internal jugular vein**. Table 24.1 includes a list of dural venous sinuses and describes their general locations.
  - b. If a cadaveric specimen is available, locate the superior sagittal sinus and note the small granular structures located in and around the sinus. These structures are called **arachnoid villi (granulations)** and serve as sites for absorption of cerebrospinal fluid from the subarachnoid space into the dural venous sinuses.
  - c. Obtain a human brain with the arachnoid mater and pia mater intact. If one is not available, this activity will be completed when performing the sheep brain dissection. On the human brain, note the thin, transparent covering that lies over the surface of the brain and does not follow the sulci (shallow grooves). This is the **arachnoid mater** (*arachnoid*, shaped like a spiderweb). Deep to the arachnoid mater is the finest, thinnest meningeal layer, the **pia mater** (*pia*, soft or tender). The pia mater is in direct contact with the neural tissue of the brain and follows all of the contours (gyri and sulci) on its surface. The space between the arachnoid mater and the pia mater is the **subarachnoid space**. What fluid is normally found in the subarachnoid space? \_\_\_\_\_



**Figure 24.1** The Meninges. (a) Coronal section through the superior sagittal sinus. (b) Dural venous sinuses and cranial dural septa.



(b) Dural venous sinuses

**Figure 24.1** The Meninges (*continued*). (a) Coronal section through the superior sagittal sinus. (b) Dural venous sinuses and cranial dural septa.

Table 24.1 Meninges, Dural Septa, and Dural Venous Sinuses		
Structure	Description and Function	Word Origins
<b>Meningeal Layer</b>		
<i>Dura Mater</i>	Very tough, durable membrane composed of dense irregular connective tissue that protects CNS structures within the cranial cavity and vertebral canal; composed of two layers.	<i>durus</i> , hard + <i>mater</i> , mother
<i>Periosteal Layer</i>	Outer layer of dura mater that composes the inner periosteum of the cranial bones and anchors the dura mater tightly to the cranial bones (not present within the vertebral canal). In most places within the cranial cavity it is anchored to, or continuous with, the meningeal layer.	<i>periosteal</i> , relating to the periosteum
<i>Meningeal Layer</i>	Inner layer of dura mater that forms cranial dural septa and dural venous sinuses within the cranial cavity.	<i>meninx</i> , membrane
<i>Arachnoid Mater</i>	Thin, loose connective tissue membrane that lies adjacent to the dura mater; contains numerous web-like extensions called arachnoid trabeculae, which are composed of collagen and elastic fibers that anchor it to the pia mater; forms a space (the subarachnoid space) for cerebrospinal fluid (CSF) to circulate around the brain and spinal cord.	<i>arachno-</i> , spider cobweb + <i>eidōs</i> , resemblance + <i>mater</i> , mother
<i>Pia Mater</i>	A thin, highly vascular, areolar connective tissue membrane in direct contact with the brain and spinal cord. It follows all the surface contours (gyri and sulci) of the brain and is generally inseparable from brain tissue.	<i>pia</i> , soft or tender + <i>mater</i> , mother
<b>Cranial Dural Septa</b>	Folds of the meningeal layer that extend inward to form partitions within the cranial cavity that stabilize and support the brain.	<i>durus</i> , hard + <i>septa</i> , fold
<i>Diaphragma Sellae</i>	Forms a “roof” over the sella turcica of the sphenoid bone and contains a hole for the passage of the infundibulum.	<i>diaphragm</i> , diaphragm + <i>sella</i> , saddle

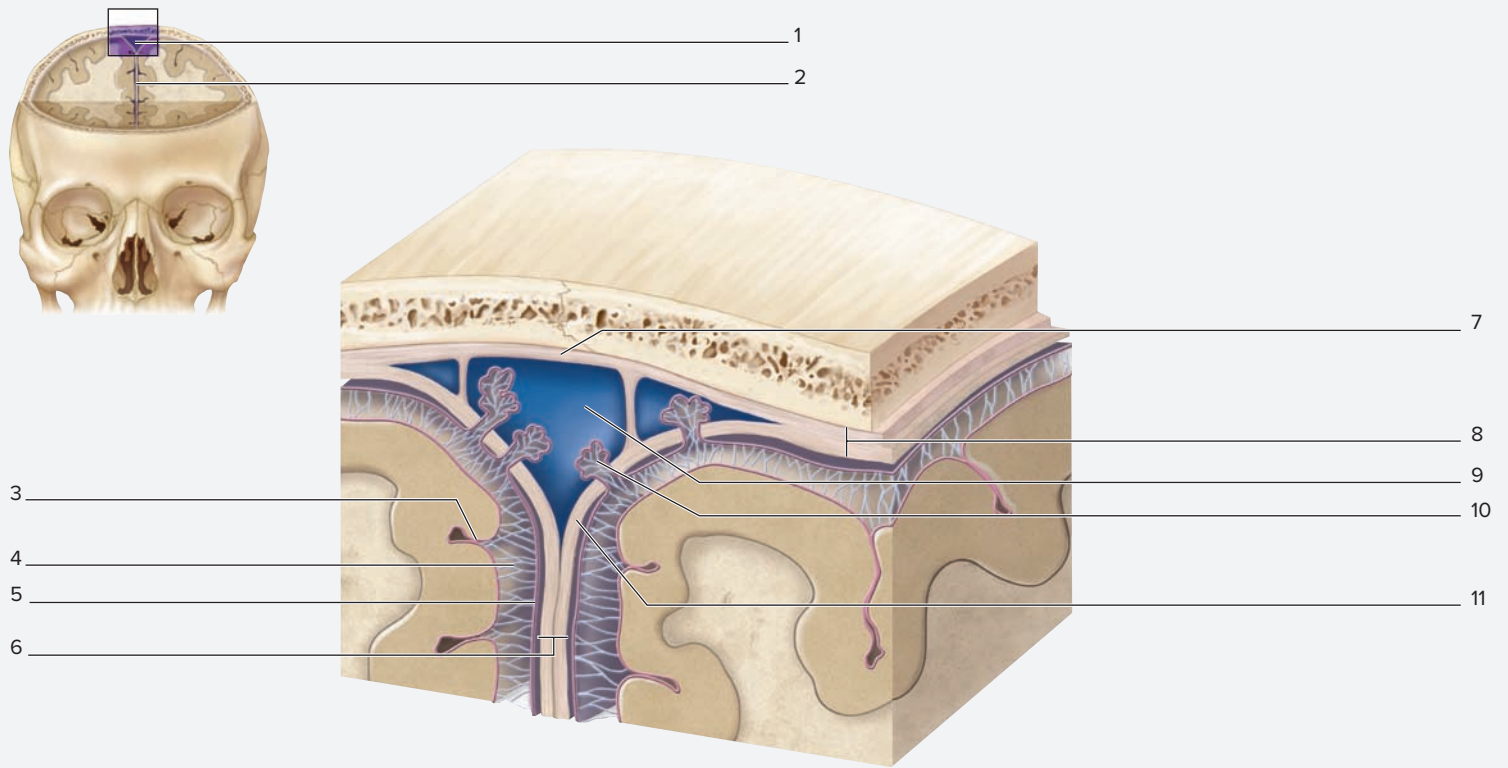
(continued on next page)

(continued from previous page)

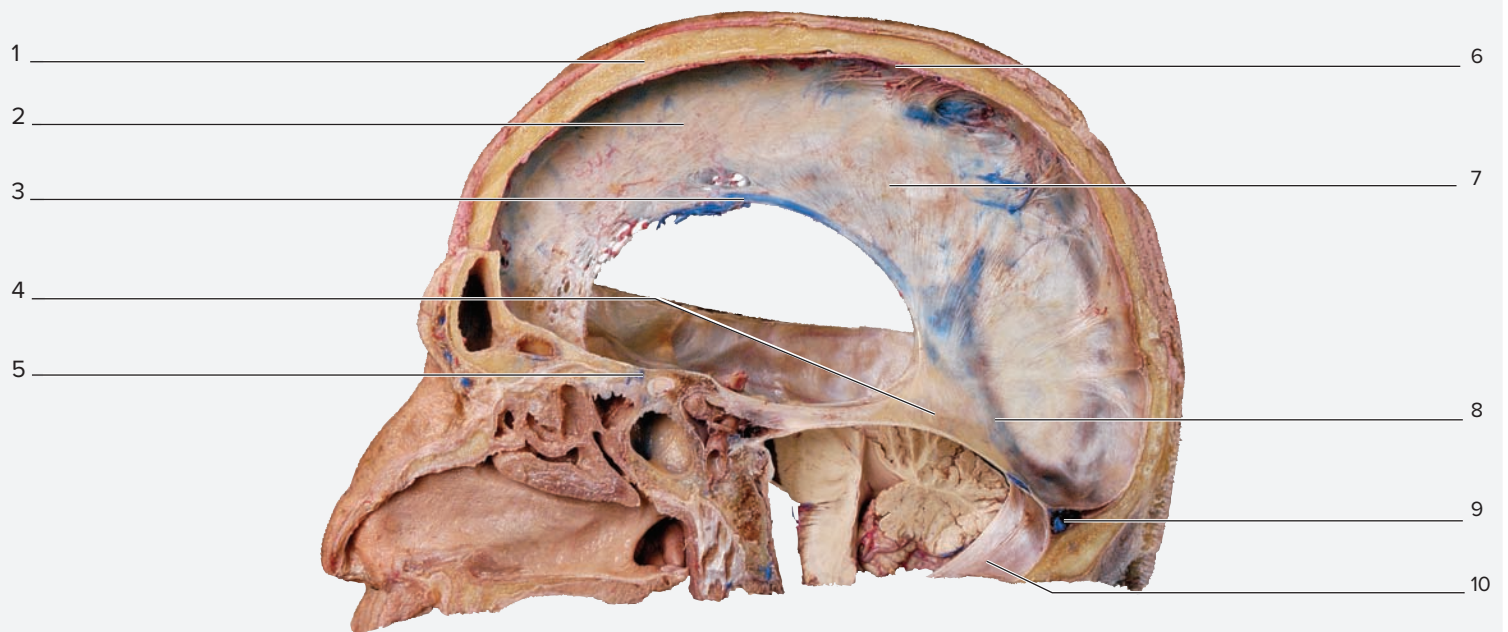
<b>Table 24.1</b>		
<b>Meninges, Dural Septa, and Dural Venous Sinuses (continued)</b>		
<b>Structure</b>	<b>Description and Function</b>	<b>Word Origins</b>
<i>Falx Cerebelli</i>	Located between the two cerebellar hemispheres.	<i>falx</i> , sickle + <i>cerebelli</i> , relating to the cerebellum
<i>Falx Cerebri</i>	Located between the two cerebral hemispheres, within the longitudinal fissure of the brain; anchored anteriorly to the crista galli of the ethmoid bone.	<i>falx</i> , sickle + <i>cerebri</i> , relating to the cerebrum
<i>Tentorium Cerebelli</i>	Drapes across the cerebellar hemispheres horizontally within the transverse fissure of the brain between the cerebellum and the cerebrum.	<i>tentorium</i> , a tent + <i>cerebelli</i> , relating to the cerebellum
<b>Dural Venous Sinuses</b>	Spaces formed between meningeal and periosteal layers of the dura mater within the cranial cavity; site of CSF reabsorption from the subarachnoid space and venous blood transport from the brain to the internal jugular vein.	<i>durus</i> , hard + <i>vena</i> , a blood vessel + <i>sinus</i> , a channel
<i>Inferior Sagittal Sinus</i>	Located within the inferior part of the falx cerebri; drains into the straight sinus.	<i>inferior</i> , below + <i>sagitta</i> , an arrow (relating to the sagittal plane) + <i>sinus</i> , a channel
<i>Occipital Sinus</i>	Smallest sinus within the cranial cavity; located in the margin of the tentorium cerebelli; drains into the confluence of sinuses.	<i>occipital</i> , inner surface of occipital bone + <i>sinus</i> , a channel
<i>Sigmoid Sinuses</i>	Located in the posterior cranial fossa just posterior to the petrous part of the temporal bone and extending into the jugular foramen. Transports venous blood from the transverse sinuses to the internal jugular vein.	<i>sigmoid</i> , shaped like an S + <i>sinus</i> , a channel
<i>Confluence of Sinuses</i>	Located within the posterior cranial cavity deep to the external occipital protuberance. Transmits venous blood from the superior sagittal sinus and the straight sinus to the transverse sinuses.	<i>confluens</i> , to flow together + <i>sinus</i> , a channel
<i>Straight Sinus</i>	Located at the junction between the falx cerebri, falx cerebelli, and tentorium cerebelli. Transmits venous blood from the inferior sagittal sinus to the confluence of sinuses.	straight + <i>sinus</i> , a channel
<i>Superior Sagittal Sinus</i>	Largest sinus within the cranial cavity; located within the superior portion of the falx cerebri. Transports venous blood from the subarachnoid space and the brain (respectively) to the confluence of sinuses.	<i>superior</i> , above + <i>sagitta</i> , an arrow (relating to the sagittal plane) + <i>sinus</i> , a channel
<i>Transverse Sinuses</i>	Located posterior to the tentorium cerebelli. Runs from the confluence of sinuses, along the posterior aspect of the occipital bone, to the posterior cranial fossa just posterior to the petrous part of the temporal bone. Transports venous blood from the confluence of sinuses to the sigmoid sinuses.	<i>transversus</i> , across + <i>sinus</i> , a channel
<b>Meningeal Spaces</b>		
<i>Epidural Space</i>	Space between the dura mater and the walls of the vertebral canal (there is no epidural space within the cranial cavity).	<i>epi</i> , above + <i>dura</i> , relating to the dura mater
<i>Subarachnoid Space</i>	Space between the arachnoid mater and the pia mater where CSF flows as it circulates around the brain and spinal cord. Blood vessels are located within this space.	<i>sub</i> , under + <i>arachnoid</i> , relating to the arachnoid mater
<i>Subdural Space</i>	Potential space between the dura mater and the arachnoid mater. In a healthy individual, this space does not exist, but traumatic injury may cause bleeding into the subdural space (subdural hematoma).	<i>sub</i> , under + <i>dural</i> , relating to the dura mater

3. *Optional Activity:* **AP|R 7: Nervous System**—Watch the “Meninges” and “Dural Sinus Blood Flow” animations to

reinforce your understanding of these structures and their relationships.



(a) Coronal section



(b) Midsagittal section

**Figure 24.2 Meningeal Structures.** Use the terms listed to fill in the numbered labels in the figure. Some answers may be used more than once.

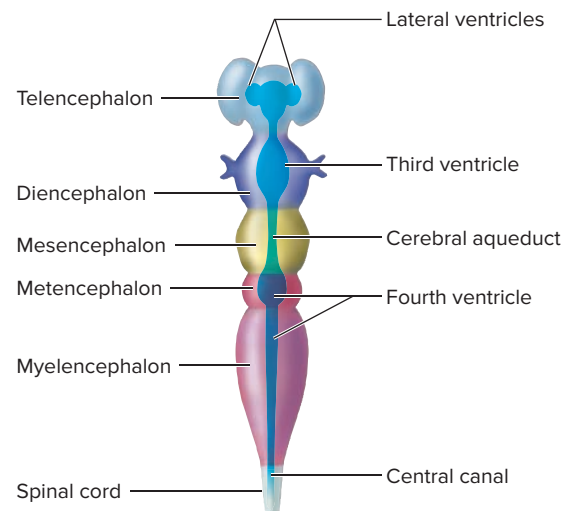
- |  |  |  |  |
|--|--|--|--|
| <input type="checkbox"/> arachnoid mater       | <input type="checkbox"/> dura mater                    | <input type="checkbox"/> falx cerebri            | <input type="checkbox"/> subarachnoid space      |
| <input type="checkbox"/> arachnoid villi       | <input type="checkbox"/> dura mater (meningeal layer)  | <input type="checkbox"/> inferior sagittal sinus | <input type="checkbox"/> superior sagittal sinus |
| <input type="checkbox"/> confluence of sinuses | <input type="checkbox"/> dura mater (periosteal layer) | <input type="checkbox"/> pia mater               | <input type="checkbox"/> tentorium cerebelli     |
| <input type="checkbox"/> diaphragma sellae     | <input type="checkbox"/> falx cerebelli                | <input type="checkbox"/> straight sinus          |  |

## Ventricles of the Brain

The **ventricles** are fluid-filled spaces within the central nervous system that are complex in shape. Exercise 24.2 involves viewing a *cast* of the ventricles, which is produced by filling the ventricular spaces with plastic, allowing the plastic to harden, and then removing the brain tissue so only the cast is left. A cast allows one to visualize the three-dimensional structure of the ventricles without the brain literally “getting in the way.” If casts of the brain ventricles are not available, this exercise can be performed using **table 24.2** and figures in the textbook.

The central nervous system initially develops as a neural tube. As it grows, the neural tube begins to change size and shape. The cephalic end develops into the brain, while the rest develops into the spinal cord. Both the brain and the spinal cord contain fluid-filled spaces inside. The pattern of growth of the neural tissue surrounding the neural tube changes the size and shape of the fluid-filled spaces within. Thus, because the spinal cord remains mostly a tubular structure as it grows, the fluid-filled space inside, the **central canal**, remains tubular. On the other hand, because the cephalic (brain) end of the neural tube undergoes extensive folding as it grows, the fluid-filled spaces within develop into irregular shapes. These shapes tell a story about how the parts of the brain developed.

The cephalic end of the neural tube first develops into three **primary vesicles** (prosencephalon, mesencephalon, and rhombencephalon) and then into five **secondary vesicles** (telencephalon, diencephalon, mesencephalon, metencephalon, and myelencephalon). **Figure 24.3** lists the secondary vesicles of the brain and the parts of the ventricular system that develop from each of them. For instance, the telencephalon



**Figure 24.3** Secondary Brain Vesicles and Associated Ventricular Structures of the Brain.


undergoes extensive growth as it develops into the cerebral hemispheres. This growth results in the horseshoe-shaped structure of the **lateral ventricles** in the adult brain. On the other hand, the mesencephalon does not undergo such extensive growth as it develops into the midbrain. Hence the fluid-filled space inside, the **cerebral aqueduct**, remains tubular in shape within the adult brain.

### EXERCISE 24.2 Brain Ventricles

1. Obtain a cast of the **ventricles of the brain** (**figure 24.4**).
2. Identify the ventricles of the brain listed in figure 24.4 on the cast of the ventricles, using table 24.2 and the textbook as guides. Then label them in figure 24.4. When identifying each of the ventricles, relate each ventricle to the **secondary brain vesicle** from which it developed (table 24.2 and figure 24.3).

#### Learning Strategy

When observing whole brains or brain models in the laboratory, always begin by locating the ventricular spaces and associating each ventricular space with a secondary brain vesicle (table 24.2). Next, identify the adult brain structures that surround the ventricular spaces. Finally, correlate each adult brain structure to the secondary brain vesicle from which it formed. For example, the lateral ventricles (ventricular space), which are part of the telencephalon (secondary brain vesicle), are surrounded by the cerebral hemispheres (adult brain structures). Thus, the cerebral hemispheres (brain structure) are derived from the telencephalon (secondary brain vesicle).



**Figure 24.4** Cast of the Ventricles of the Brain. Use the terms listed to fill in the numbered labels in the figure.

- cerebral aqueduct
- interventricular foramen
- third ventricle
- fourth ventricle
- lateral ventricles

Model # VH410 [1001262] © 3B Scientific GmbH, Germany, 2013 www.3bscientific.com/Photo by Christine Eckel, Ph.D.

Table 24.2 Ventricles of the Brain			
Structure	Location and Description	Secondary Brain Vesicle Derivative	Word Origins
<i>Lateral Ventricles</i>	Horseshoe-shaped ventricles within the cerebral hemispheres containing anterior and posterior horns whose shape follows the developmental shape of the cerebral hemispheres.	Telencephalon	<i>latus</i> , to the side + <i>ventriculus</i> , belly
<i>Third Ventricle</i>	Narrow, quadrilateral-shaped ventricle located in the midsagittal plane inferior to the corpus callosum and medial to the thalamic nuclei; surrounded by structures of the diencephalon.	Diencephalon	<i>ventriculus</i> , belly
<i>Cerebral Aqueduct</i>	Narrow channel that lies in the midbrain between the cerebral peduncles and the tectal plate (corpora quadrigemina).	Mesencephalon	<i>aquaeductus</i> , a canal
<i>Fourth Ventricle</i>	Diamond-shaped ventricle located anterior to the cerebellum and posterior to the pons.	Metencephalon (superior part) Myelencephalon (inferior part)	<i>ventriculus</i> , belly

**EXERCISE 24.3** Circulation of Cerebrospinal Fluid (CSF)

**Cerebrospinal fluid (CSF)** is a clear, colorless fluid produced from blood plasma, which is filtered by the choroid plexus within each brain ventricle. Approximately 500 mL of CSF is produced each day. Following its production within the lateral ventricles, CSF moves through the following structures: the interventricular foramen, the third ventricle, the cerebral aqueduct, and the fourth ventricle. CSF exits the fourth ventricle through the median and lateral apertures to enter the subarachnoid space, which surrounds both the brain and the spinal cord. CSF is returned to the blood

through arachnoid villi within the dural venous sinuses. CSF provides buoyancy to the brain, protecting both the brain and the spinal cord from sudden movements. CSF also provides environmental stability for cells in both the brain and the spinal cord by maintaining extracellular fluid composition within narrow limits.

- Using table 24.2, figure 24.4, and the textbook as guides, label the structures involved in CSF production and circulation in **figure 24.5**.

(continued on next page)



(continued from previous page)

2. Trace the flow of CSF from the choroid plexus within the ventricles to the arachnoid villi. Use the terms listed in column A to complete the pathway for CSF circulation in column B, in the spaces provided.

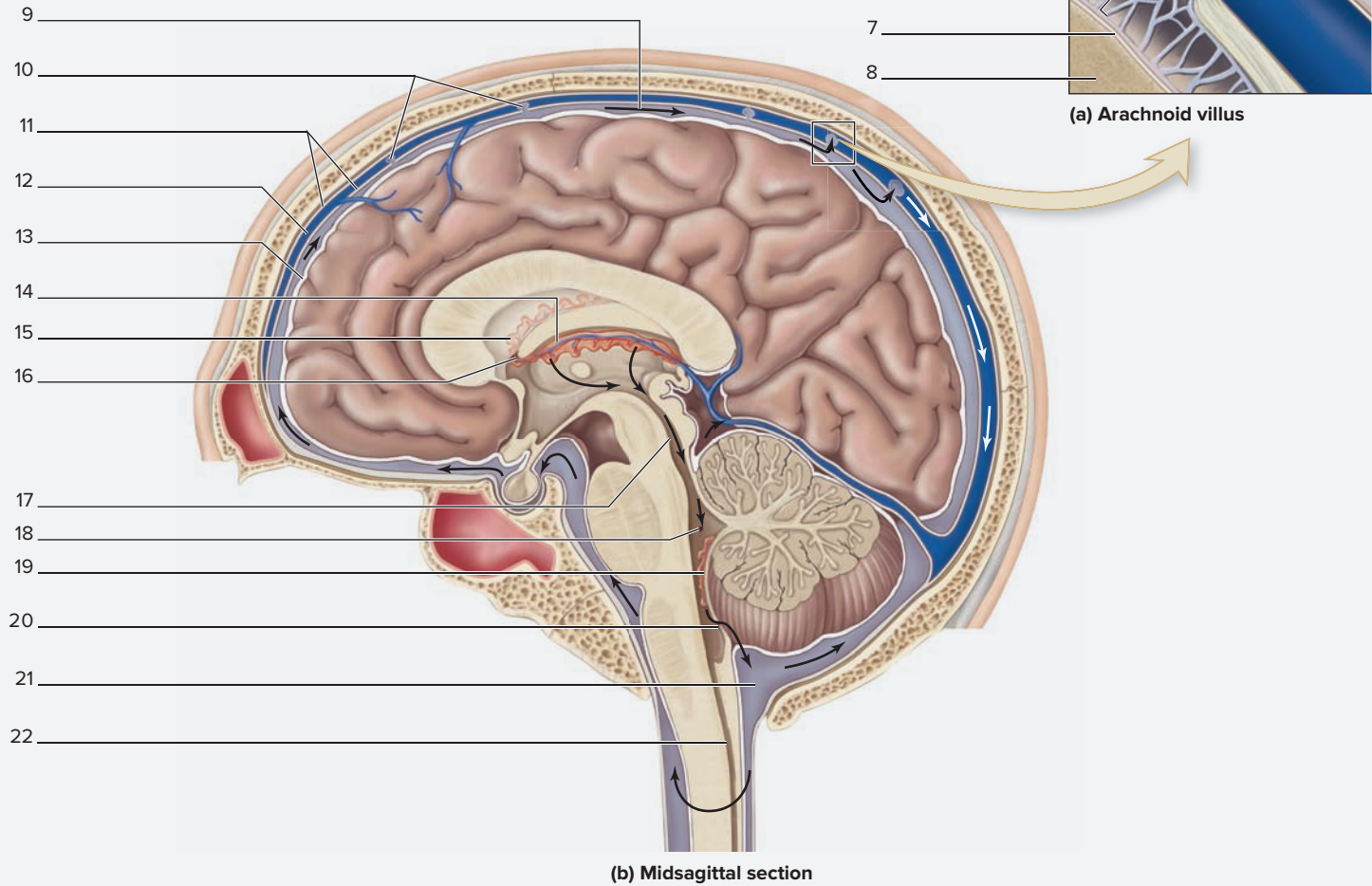
**Column A**

- cerebral aqueduct
- fourth ventricle
- interventricular foramen
- median and lateral apertures
- subarachnoid space
- third ventricle

**Column B**

1. lateral ventricles
2. \_\_\_\_\_
3. \_\_\_\_\_
4. \_\_\_\_\_
5. \_\_\_\_\_
6. \_\_\_\_\_
7. \_\_\_\_\_
8. arachnoid villi

3. **Optional Activity: AP|R 7: Nervous System**—View the “Brain Ventricles” and “CSF Flow” animations to see how cerebrospinal fluid flows through the brain ventricles.



**Figure 24.5 Cerebrospinal Fluid (CSF) Production and Circulation.** Note that arrows show the directional flow of CSF. Use the terms listed to fill in the numbered labels in the figure. Some terms may be used more than once.

- |  |  |   |  |
|--|--|---|--|
| <input type="checkbox"/> arachnoid mater   | <input type="checkbox"/> cerebral cortex                     | <input type="checkbox"/> CSF flow                 | <input type="checkbox"/> meningeal dura          |
| <input type="checkbox"/> arachnoid villi   | <input type="checkbox"/> choroid plexus of fourth ventricle  | <input type="checkbox"/> dura mater               | <input type="checkbox"/> periosteal dura         |
| <input type="checkbox"/> arachnoid villus  | <input type="checkbox"/> choroid plexus of lateral ventricle | <input type="checkbox"/> interventricular foramen | <input type="checkbox"/> pia mater               |
| <input type="checkbox"/> central canal     | <input type="checkbox"/> choroid plexus of third ventricle   | <input type="checkbox"/> lateral aperture         | <input type="checkbox"/> subarachnoid space      |
| <input type="checkbox"/> cerebral aqueduct |  | <input type="checkbox"/> median aperture          | <input type="checkbox"/> superior sagittal sinus |

## The Human Brain

The next series of exercises involves identifying structures that are visible in four views of the human brain: superior, lateral, inferior, and midsagittal. **Table 24.3** lists the primary brain structures, the views in which each is visible, and a description of its function.

When identifying parts of the brain, follow these steps to make things easier:

- Name the structures in a logical order, such as the order in which the structures appear from anterior to posterior. Learning the structures in an orderly fashion will allow for improved information recall later on.

- Do not think of brain regions as isolated structures. The structures are easier to identify within the context of their surroundings. Think about this the next time you are traveling to your anatomy & physiology class—would you know how to get to the classroom if all of the buildings on campus (with the exception of the one to which you are traveling) were suddenly moved around?
- Always associate a function with each structure identified. Use table 24.3 as a reference.

Table 24.3 Brain Structures Visible in Superficial Views of Whole or Sagittally Sectioned Brains				
Brain Structure	Description	Function(s)	Word Origins	Views Where Visible
<b>CEREBRUM</b>				
<i>Frontal Lobe</i>	Lies deep to the frontal bone.	Controls conscious movement of skeletal muscle; contains Broca's area, which controls motor speech. Controls conjugate eye movement (the ability to move the eyes together). Higher-level functions include judgment and foresight (the ability to think before acting).	<i>frontal</i> , in the front + <i>lobos</i> , lobe	Superior, lateral, inferior, and midsagittal
<i>Precentral Gyrus</i>	Fold of brain tissue located immediately anterior to the central sulcus.	Primary somatic motor area of the brain. Neurons from this gyrus are somatic motor neurons that initiate motor signals to control voluntary muscle activity.	<i>pre-</i> , before + <i>central</i> , relating to the central sulcus + <i>gyros</i> , circle	Superior, lateral, and midsagittal
<i>Occipital Lobe</i>	Lies deep to the occipital bone.	Primary visual area (the first area of the cerebral cortex where visual information synapses, after the thalamus). Visual association area (the ability to interpret visual information).	<i>occiput</i> , the back of the head + <i>lobos</i> , lobe	Superior, lateral, and midsagittal
<i>Parietal Lobe</i>	Lies deep to the parietal bone.	Receives sensory input from the skin and proprioceptors. Higher-level functions include logical reasoning (math, problem solving).	<i>parietal</i> , a wall + <i>lobos</i> , lobe	Superior, lateral, and midsagittal
<i>Postcentral Gyrus</i>	Fold of brain tissue located immediately posterior to the central sulcus.	Primary somatic sensory area of the brain. Sensory information that comes in from the body travels to this area of the cerebral cortex.	<i>post</i> , after + <i>central</i> , relating to the central sulcus + <i>gyros</i> , circle	Superior, lateral, and midsagittal
<i>Septum Pellucidum</i>	A thin membrane located between the corpus callosum (above) and fornix (below).	Contains neurons and glial cells, and forms a thin connection between the corpus callosum above and the fornix below; also forms a thin wall between the two anterior horns of the lateral ventricles.	<i>saeptum</i> , a partition + <i>pellucidus</i> , allowing the passage of light	Midsagittal
<i>Temporal Lobe</i>	Lies deep to the temporal bone.	Primary auditory and auditory association area of the brain; conscious perception of smell.	<i>tempus</i> , time	Lateral
<b>DIENCEPHALON</b>				
<i>Epithalamus</i>	A small projection extending posteriorly from the superior portion of the third ventricle.	Contains the pineal body (pineal gland) along with other structures.	<i>epi-</i> , above + <i>thalamos</i> , a bed or bedroom	Midsagittal
<i>Pineal Body (Gland)</i>	Small gland found within the epithalamus. It is not possible to establish the difference between the epithalamus and the pineal gland on gross observation alone.	Secretes the hormone melatonin from its precursor molecule, serotonin, in response to <i>decreased</i> light levels. Melatonin has an effect on circadian rhythms. May also play a role in establishing the onset of puberty.	<i>pineal</i> , shaped like a pinecone	Midsagittal
<i>Hypothalamus</i>	Located deep to the walls of the inferior part of the third ventricle.	Regulates body temperature, metabolism (hunger/thirst), sleep, sex, and emotional control (limbic system functions). It is also a "master" endocrine gland, controlling hormone secretion from the pituitary gland.	<i>thalamos</i> , a bed or bedroom	Midsagittal
<i>Mammillary Bodies</i>	Two small bump-like ("breast-shaped") structures of the hypothalamus located immediately posterior to the infundibulum.	Involved in short-term memory processing; part of the limbic system (the emotional brain). Also involved with suckling and chewing reflexes.	<i>mammillary</i> , shaped like a breast	Inferior and midsagittal
<i>Thalamus</i>	Paired nuclei located deep to the lateral walls of the third ventricle. A pin pierced through the lateral wall of the third ventricle adjacent to the intermediate mass will pass into the thalamic nuclei.	Primary relay center for all sensory information coming into the brain (except olfaction).	<i>thalamos</i> , a bed or bedroom	Midsagittal
<i>Intermediate Mass (Interthalamic Adhesion)</i>	A fiber tract that crosses the third ventricle. The cut end of this structure is visible in a midsagittal section of the brain in the middle of the third ventricle.	A fiber tract that connects the two thalamic nuclei to each other. It is absent in about 20% of human brains.	<i>intermediate</i> , in the middle + <i>mass</i> , a mass	Midsagittal

<b>Table 24.3 Brain Structures Visible in Superficial Views of Whole or Sagittally Sectioned Brains (continued)</b>				
<b>Brain Structure</b>	<b>Description</b>	<b>Function(s)</b>	<b>Word Origins</b>	<b>Views Where Visible</b>
<b>BRAINSTEM</b>				
<i>Medulla Oblongata</i>	The most inferior aspect of the brainstem, forming the transition zone between the brain and spinal cord.	Contains the centers for regulation of respiration and cardiac function, and contains nuclei of the <i>reticular activating system</i> , which is a group of nuclei that are important in regulating wakefulness and selective attention.	<i>medius</i> , middle + <i>oblongus</i> , rather long	Lateral, inferior, and midsagittal
<i>Midbrain (Mesencephalon)</i>	Found superior to the pons.	Contains external structures, inferior and superior colliculi, which are responsible for auditory and visual processing. Internal structures include substantia nigra (movement and emotional responses) and tegmentum (integrate motor information from cerebrum and cerebellum).	<i>mesos</i> , middle + <i>enkephalos</i> , brain	Lateral, inferior, and midsagittal
<i>Tectal Plate (Corpora Quadrigemina)</i>	Consists of four twin bodies, the superior and inferior colliculi.	Control center for visual and auditory reflexes.	<i>corpus</i> , body + <i>quad</i> , four + <i>geminus</i> , twin	Midsagittal
<i>Inferior Colliculus</i>	A pair of oval projections that make up the inferior part of the tectal plate (corpora quadrigemina).	Controls <i>auditory reflexes</i> , such as the sudden turning of the head toward the source of a very loud sound.	<i>inferior</i> , lower + <i>colliculus</i> , a mound or hill	Midsagittal
<i>Superior Colliculus</i>	A pair of rounded projections that make up superior part of the corpora quadrigemina (tectal plate).	Controls visual reflexes, such as the sudden turning of the head toward the source of a flashing light.	<i>superus</i> , above + <i>colliculus</i> , a mound or hill	Midsagittal
<i>Pons</i>	Appears as a large mass just superior to the medulla oblongata.	A “bridge” of nerve tracts that connect the cerebral hemispheres to the cerebellar hemispheres. Contains centers for control of respiration.	<i>pons</i> , bridge	Lateral, inferior, and midsagittal
<b>CEREBELLUM</b>				
<i>Cerebellum</i>	The second largest part of the brain.	Regulation of muscle tone (a low-level muscle contraction), coordination of motor activity, and maintenance of balance and equilibrium.	<i>cerebellum</i> , little brain	Lateral, inferior, and midsagittal
<b>LIMBIC SYSTEM</b>				
<i>Cingulate Gyrus</i>	A gyrus located just superior to the corpus callosum.	This area of the brain is not well understood. It is predominantly motor and may play a role in the limbic system (such as controlling motor functions with a strong emotional component).	<i>cingo</i> , to surround + <i>gyros</i> , circle	Midsagittal
<i>Fornix</i>	An arching fiber tract located inferior to the septum pellucidum.	Connects limbic system structures to each other.	<i>fornix</i> , arch	Midsagittal
<i>Olfactory Bulbs</i>	Swellings connected to the anterior end of the olfactory tracts that lie on the inferior surface of the frontal lobes of the brain lateral to the longitudinal fissure.	Location where cranial nerve I (CN I), the olfactory nerves, first synapse after passing through the cribriform plate of the ethmoid bone.	<i>olfactus</i> , to smell + <i>bulbus</i> , a globular structure	Inferior
<i>Olfactory Tracts</i>	Nerve fibers that extend from the olfactory bulbs posteriorly to the junction where the frontal lobes meet the optic chiasm.	Carry the axons of neurons from the olfactory bulbs toward structures in other areas of the brain involved with olfaction.	<i>olfactus</i> , to smell + <i>tractus</i> , a drawing out	Inferior
<b>FISSURES/SULCI</b>				
<i>Central Sulcus</i>	A deep groove that extends along the coronal plane.	Separates the frontal lobe from the parietal lobe.	<i>central</i> , in the center + <i>sulcus</i> , a furrow	Superior, lateral, and midsagittal
<i>Lateral Sulcus</i>	A horizontal groove between the frontal/parietal lobes and the temporal lobe.	Separates the frontal and parietal lobes from the temporal lobe.	<i>latus</i> , the side + <i>sulcus</i> , a furrow	Lateral
<i>Longitudinal Fissure</i>	A deep fissure between the two cerebral hemispheres.	Separates the two cerebral hemispheres; the falx cerebri occupies this fissure in a living human.	<i>longus</i> , long + <i>fissure</i> , a deep furrow	Superior and inferior
<i>Parieto-occipital Sulcus</i>	Small groove that runs along the coronal plane.	Separates the parietal lobe from the occipital lobe.	<i>parieto-occipital</i> , between the parietal and occipital lobes + <i>sulcus</i> , a furrow	Superior, lateral, and midsagittal
<i>Transverse Fissure</i>	A deep fissure between the cerebrum and the cerebellum.	Separates the cerebral hemispheres from the cerebellar hemispheres. The tentorium cerebelli lies in this fissure.	<i>transversus</i> , across + <i>fissure</i> , a deep furrow	Lateral
<b>FIBERS/TRACTS</b>				
<i>Cerebral Peduncles</i>	Tracts located between the midbrain and the pons.	The fibers connect the forebrain (cerebral hemispheres and diencephalon) to the hindbrain (medulla oblongata, pons, and cerebellum).	<i>cerebrum</i> , brain + <i>pedunculus</i> , a little foot	Inferior, midsagittal
<i>Corpus Callosum</i>	A fiber tract located superior to the lateral ventricles.	Contains axons that connect the two cerebral hemispheres.	<i>corpus</i> , body + <i>callosus</i> , thick-skinned	Midsagittal
<i>Infundibulum</i>	A funnel-shaped inferior extension of the brain located immediately posterior to the optic chiasm.	Consists of tracts that connect the hypothalamus to the posterior pituitary (pars nervosa).	<i>infundibulum</i> , a funnel	Inferior and midsagittal

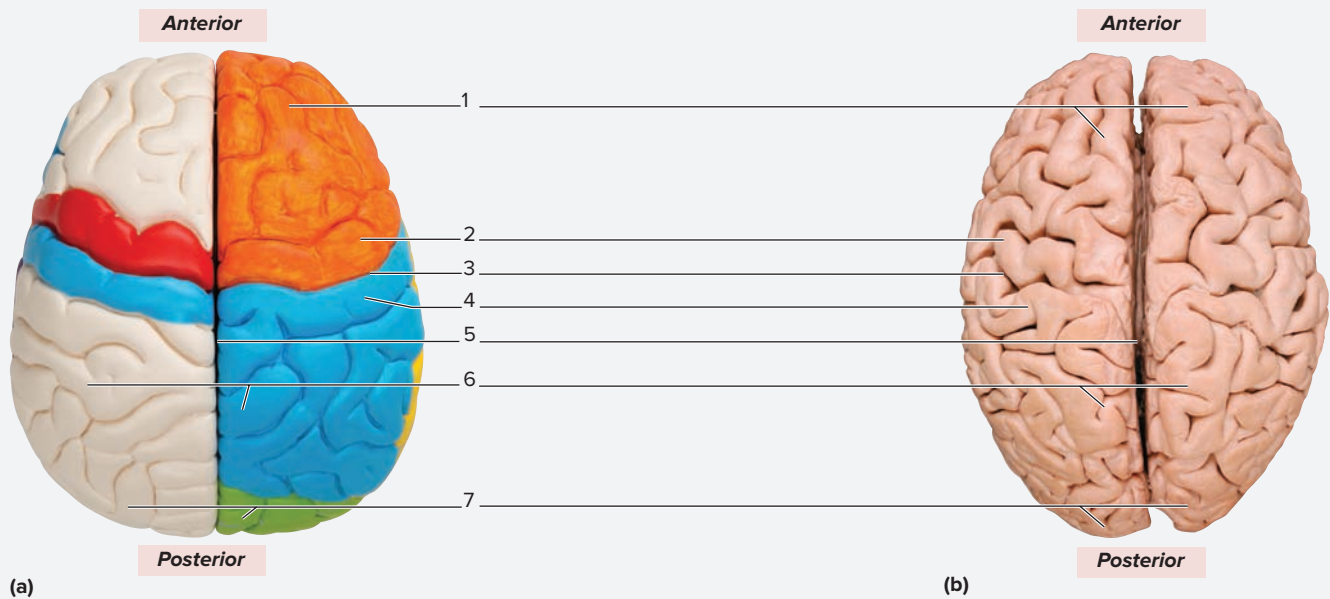
Table 24.3 Brain Structures Visible in Superficial Views of Whole or Sagittally Sectioned Brains (continued)				
Brain Structure	Description	Function(s)	Word Origins	Views Where Visible
<b>FIBERS/TRACTS (CONTINUED)</b>				
<i>Optic Chiasm</i>	The X-shaped structure formed where the two optic nerves join, with most fibers crossing to the opposite side; located just anterior to the infundibulum.	Location where fibers from both optic nerves cross over and travel in the optic tract on the opposite side. Not all fibers from the optic nerves cross over.	<i>optikos</i> , relating to the eye or vision + <i>chiasma</i> , two crossing lines	Inferior and midsagittal
<i>Optic Nerves</i>	Anterior to the optic chiasm.	Sensory neurons carrying visual information from the retina to the optic chiasm, where most fibers cross to the opposite side.	<i>optikos</i> , relating to the eye or vision + <i>nevus</i> , a white, cord-like structure	Inferior
<i>Optic Tracts</i>	Posterior to the optic chiasm.	Sensory neurons carrying visual information from the optic chiasm to the lateral geniculate nucleus of the thalamus.	<i>optikos</i> , relating to the eye or vision + <i>tractus</i> , a drawing out	Inferior

**EXERCISE 24.4 Superior View of the Human Brain**

- Obtain a human brain or models of a human brain and observe the superior surface.
  - Numerous grooves are associated with the brain surface. A large groove is a fissure, whereas a small groove is a sulcus. The most prominent feature in this view is the **longitudinal fissure**, which is a deep groove that separates the two cerebral hemispheres from each other. Observe the many sulci on the brain surface. One major sulcus to identify is the **central sulcus**. Identification of the central sulcus is difficult, though not impossible, on a real human brain. The following are two features to look for:
    - The **precentral gyrus** and the **postcentral gyrus** (two raised areas approximately in the middle of the brain's

superior surface) should become continuous with each other on the lateral aspect of the central sulcus just above the lateral sulcus (a groove that separates the temporal lobe from the frontal and parietal lobes). This means the central sulcus will not enter the lateral sulcus.

- The central sulcus will dip down into the longitudinal fissure.
  - Three of the five lobes of the cerebrum are visible on the superior surface view.
- Identify the structures listed in **figure 24.6** on the superior view of the brain, using table 24.3 and the textbook as guides. Then label them in figure 24.6.

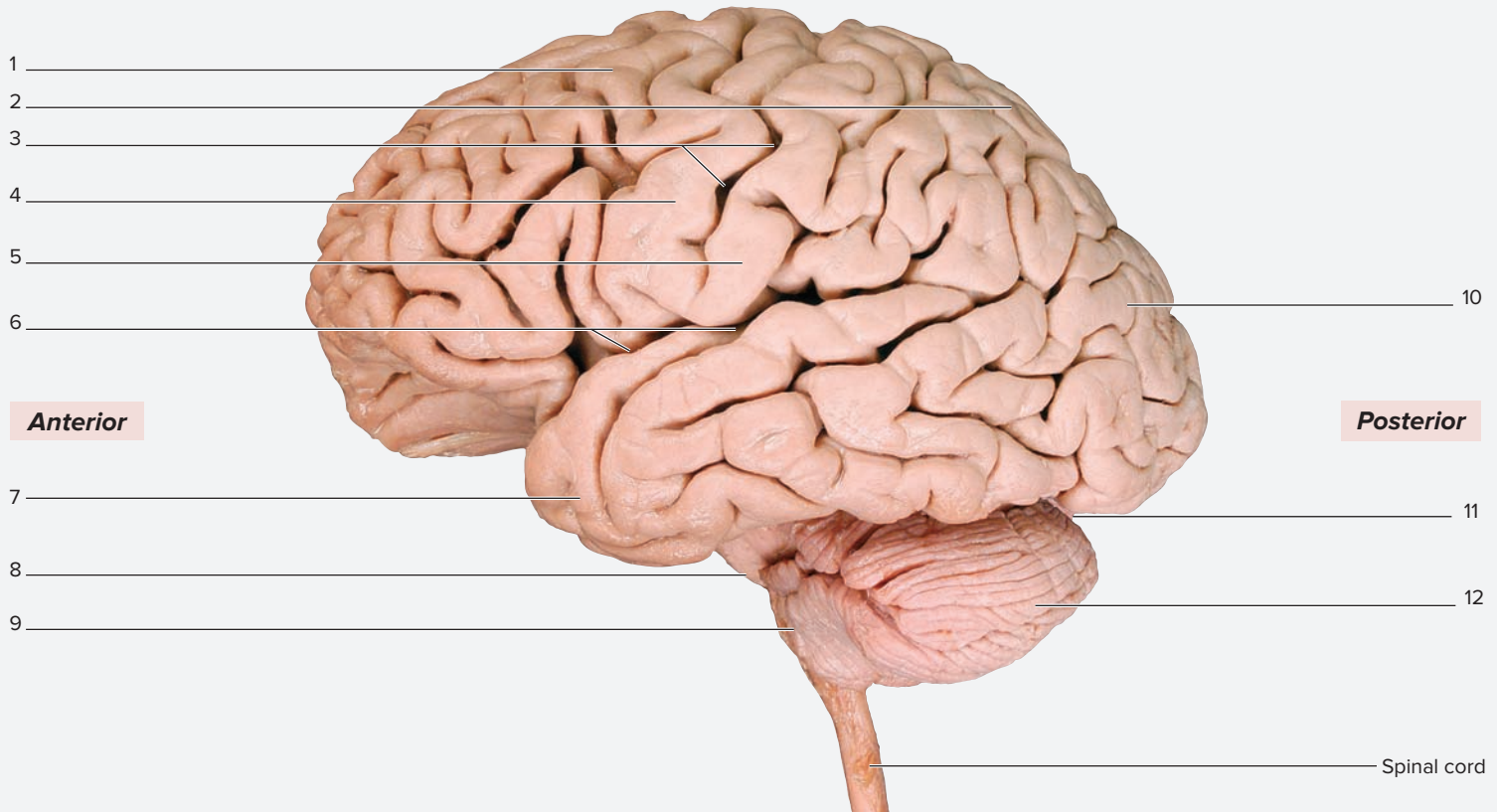

**Figure 24.6 Superior View of the Brain.** (a) Classroom model of the brain. (b) Preserved human brain. Use the terms listed to fill in the numbered labels in the figure.

- |   |   |  |   |
|---|---|--|---|
| <input type="checkbox"/> central sulcus | <input type="checkbox"/> longitudinal fissure | <input type="checkbox"/> parietal lobe     | <input type="checkbox"/> precentral gyrus |
| <input type="checkbox"/> frontal lobe   | <input type="checkbox"/> occipital lobe       | <input type="checkbox"/> postcentral gyrus |   |

**EXERCISE 24.5** Lateral View of the Human Brain

- Obtain a human brain or models of a human brain and observe the lateral surface.
  - As with the superior view, the central sulcus should be visible by identifying the location where the pre- and postcentral gyri become continuous with each other just above the lateral sulcus.
- Identify the structures listed in **figure 24.7** on the lateral view of the brain, using table 24.3 and the textbook as guides. Then label them in figure 24.7.
- Optional Activity:* **AP|R 7: Nervous System**—Watch the “Divisions of Brain” animation for an overview of the regions of the brain and their general functions.



**Figure 24.7** Lateral View of the Brain. Use the terms listed to fill in the numbered labels in the figure.

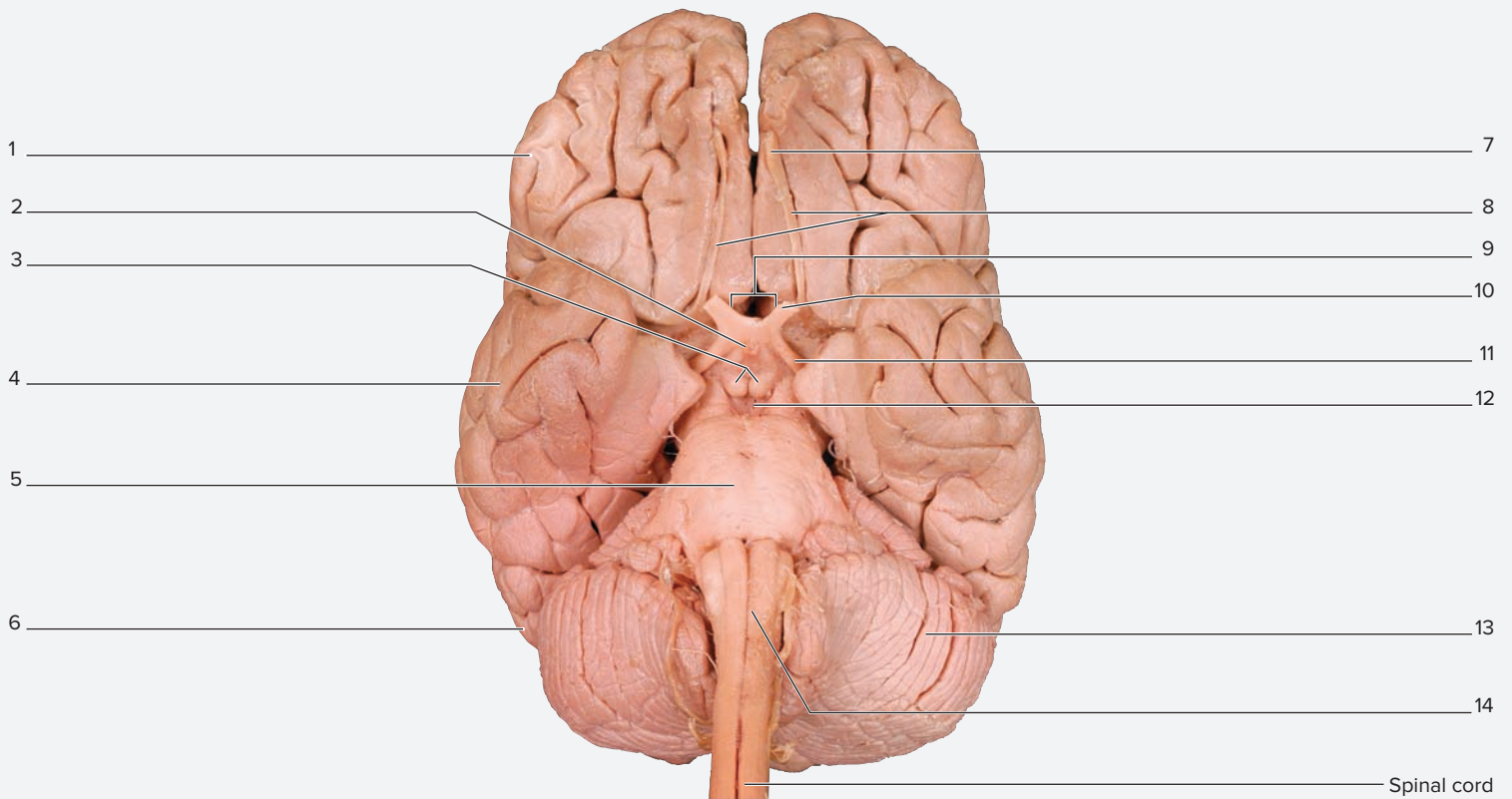- |   |  |   |
|---|--|---|
| <input type="checkbox"/> central sulcus | <input type="checkbox"/> medulla oblongata | <input type="checkbox"/> postcentral gyrus  |
| <input type="checkbox"/> cerebellum     | <input type="checkbox"/> occipital lobe    | <input type="checkbox"/> precentral gyrus   |
| <input type="checkbox"/> frontal lobe   | <input type="checkbox"/> parietal lobe     | <input type="checkbox"/> temporal lobe      |
| <input type="checkbox"/> lateral sulcus | <input type="checkbox"/> pons              | <input type="checkbox"/> transverse fissure |

**EXERCISE 24.6 Inferior View of the Human Brain**

- Obtain a human brain or models of a human brain and observe the inferior surface. This view is considerably more complicated than the superior or lateral views because of the cranial nerves that arise from the brain. Cranial nerve identification is covered later in this chapter.
  - Both the brainstem and the cerebellum are visible from this view.
  - Prominent features associated with the cerebrum are the **optic chiasm** and the **optic tracts**, which extend from it into the brain.
  - The **mammillary bodies** are two small projections posterior to the optic chiasm.
  - One of the more problematic structures to identify in this view on a real brain is the infundibulum. When

a brain is removed from the cranium, the pituitary gland almost always gets removed from the brain. The only structure left connected to the brain is the stalk of tissue that connects the pituitary gland to the hypothalamus, which is the **infundibulum**, or **pituitary stalk**. Observation of a model of the brain shows the pituitary gland to be intact. The infundibulum can be identified as a small strand of tissue that is located directly posterior to the optic chiasm and directly anterior to the mammillary bodies.

- Identify the structures listed in **figure 24.8** on the inferior view of the brain, using table 24.3 and the textbook as guides. Then label them in figure 24.8.



**Figure 24.8 Inferior View of the Brain.** Use the terms listed to fill in the numbered labels in the figure.

- |  |  |  |  |
|--|--|--|--|
| <input type="checkbox"/> cerebellum        | <input type="checkbox"/> medulla oblongata | <input type="checkbox"/> olfactory tract | <input type="checkbox"/> pons          |
| <input type="checkbox"/> frontal lobe      | <input type="checkbox"/> midbrain          | <input type="checkbox"/> optic chiasm    | <input type="checkbox"/> temporal lobe |
| <input type="checkbox"/> infundibulum      | <input type="checkbox"/> occipital lobe    | <input type="checkbox"/> optic nerve     |  |
| <input type="checkbox"/> mammillary bodies | <input type="checkbox"/> olfactory bulb    | <input type="checkbox"/> optic tract     |  |

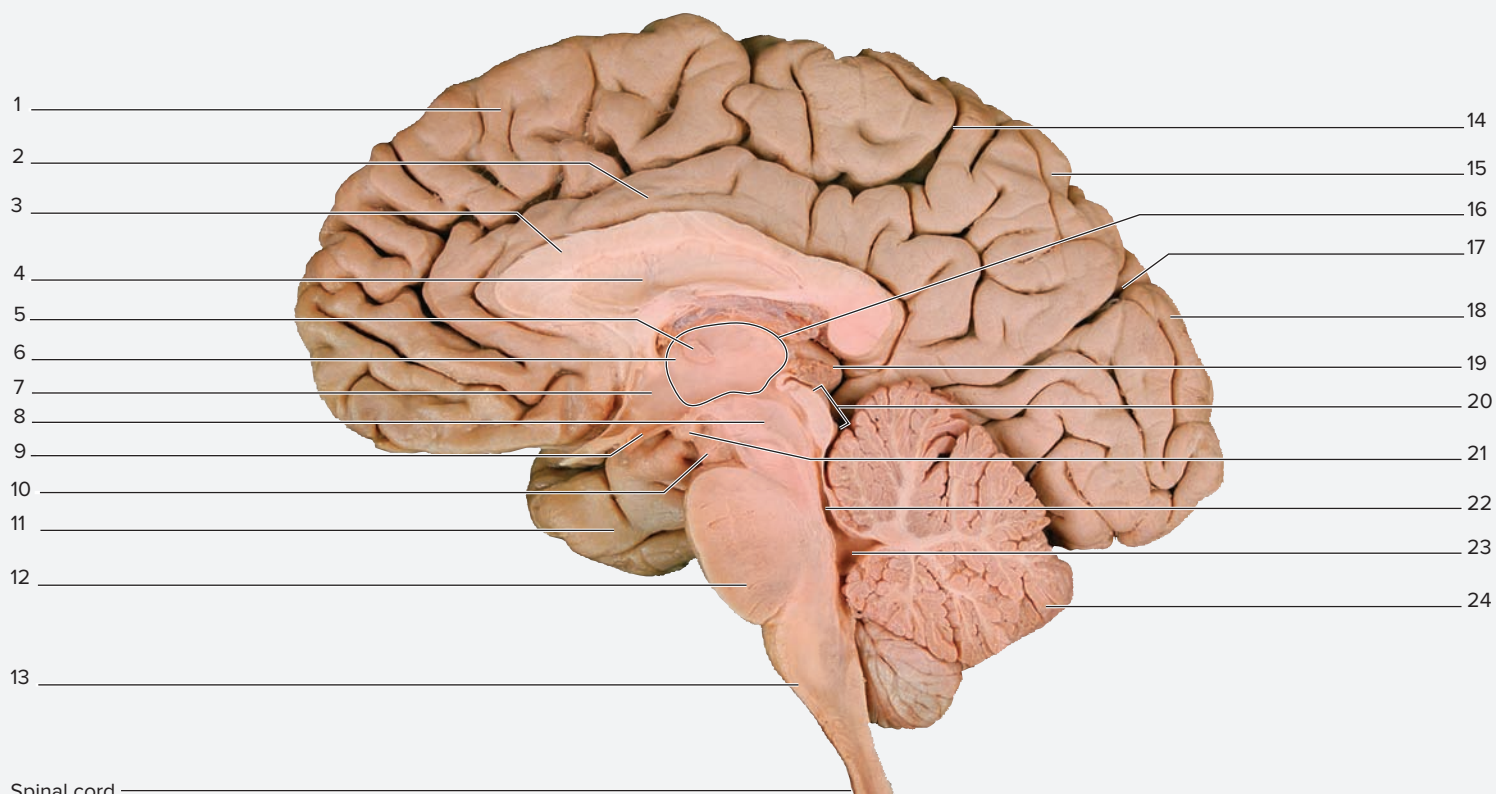
**EXERCISE 24.7** Midsagittal View of the Human Brain

1. Obtain a human brain or brain model that has been sectioned along the midsagittal plane and observe its medial surface (figure 24.9).

■ In the very center of view, notice the **third ventricle**. The third ventricle is the central depressed area that appears to have a cut nerve in the center. The “cut nerve” isn’t really a nerve, but it is similar. It is a fiber tract called the **interthalamic adhesion** (or **intermediate mass**), which connects the two thalamic nuclei to each other. Use the interthalamic adhesion, the thalamus, and the third ventricle as reference points for identification of other structures in this view.

■ Many of the structures that are located around the third ventricle of the brain belong to a system called the **limbic system** (*limbus*, border), so named because structures of the limbic system are located at the border of the third ventricle and the brainstem. The limbic system is referred to as the “emotional brain” because its structures play a role in our emotions.

2. Identify the structures listed in figure 24.9 on the midsagittal view of the brain, using table 24.3 and the textbook as guides. Then label them in figure 24.9.



Spinal cord

**Figure 24.9** Midsagittal View of the Brain. Use the terms listed to fill in the numbered labels in the figure.

- |  |   |  |  |
|--|---|--|--|
| <input type="checkbox"/> central sulcus    | <input type="checkbox"/> frontal lobe           | <input type="checkbox"/> occipital lobe                      | <input type="checkbox"/> temporal lobe   |
| <input type="checkbox"/> cerebellum        | <input type="checkbox"/> hypothalamus           | <input type="checkbox"/> parietal lobe                       | <input type="checkbox"/> thalamus        |
| <input type="checkbox"/> cerebral aqueduct | <input type="checkbox"/> infundibulum           | <input type="checkbox"/> parieto-occipital sulcus            | <input type="checkbox"/> third ventricle |
| <input type="checkbox"/> cerebral peduncle | <input type="checkbox"/> interthalamic adhesion | <input type="checkbox"/> pineal body (gland)                 |  |
| <input type="checkbox"/> cingulate gyrus   | <input type="checkbox"/> mammillary body        | <input type="checkbox"/> pons                                |  |
| <input type="checkbox"/> corpus callosum   | <input type="checkbox"/> medulla oblongata      | <input type="checkbox"/> septum pellucidum                   |  |
| <input type="checkbox"/> fourth ventricle  | <input type="checkbox"/> midbrain               | <input type="checkbox"/> tectal plate (corpora quadrigemina) |  |

## Cranial Nerves

An inferior view of the brain allows for visualization of the cranial nerves at the location where they arise from the brain. Cranial nerves are numbered, starting from the anterior (rostral) part of the brain and moving posterior (caudal), using Roman numerals I through XII (table 24.4). Figure 24.10 shows the inferior surface of the brain and the cranial nerves. The olfactory bulbs (where the olfactory nerves (CN I) synapse) and the

optic nerves (CN II) are very large, easily identifiable structures located on the inferior surface of the frontal lobes of the cerebrum. The remainder of the cranial nerves (CN III through CN XII) are generally smaller and are located closer together in the region of the midbrain, pons, and medulla that form the brainstem, thus making their identification a little more challenging. Exercise 24.7 will involve identifying the cranial nerves on a brain or on a model of the brain.

Nerve Number	Name	Foramina of Exit	Word Origins
I	Olfactory	Olfactory foramina in the cribriform plate of the ethmoid bone	<i>olfacio</i> , to smell
II	Optic	Optic canal	<i>optikos</i> , relating to the eye or vision
III	Oculomotor	Superior orbital fissure	<i>oculo-</i> , the eye + <i>motorius</i> , moving
IV	Trochlear	Superior orbital fissure	<i>trochileia</i> , a pulley
V	Trigeminal	Superior orbital fissure (V <sub>1</sub> —ophthalmic) Foramen rotundum (V <sub>2</sub> —maxillary) Foramen ovale (V <sub>3</sub> —mandibular)	<i>tri-</i> , three + <i>geminus</i> , twins
VI	Abducens	Superior orbital fissure	<i>abductio-</i> , to move away from the median plane
VII	Facial	Internal acoustic meatus (exits via the stylomastoid foramen)	<i>facialis</i> , relating to the face
VIII	Vestibulocochlear	Internal acoustic meatus	<i>vestibulum</i> , entrance + <i>cochlea</i> , snail shell
IX	Glossopharyngeal	Jugular foramen	<i>glossus</i> , tongue + <i>pharyngeus</i> , pharynx
X	Vagus	Jugular foramen	<i>vagus</i> , wanderer
XI	Accessory	Jugular foramen (accessory division) Foramen magnum (spinal division)	<i>spina</i> , spine + <i>accessory</i> , an extra structure
XII	Hypoglossal	Hypoglossal canal	<i>hypo</i> , beneath + <i>glossus</i> , tongue

### EXERCISE 24.8 Identification of Cranial Nerves on a Brain or Brainstem Model

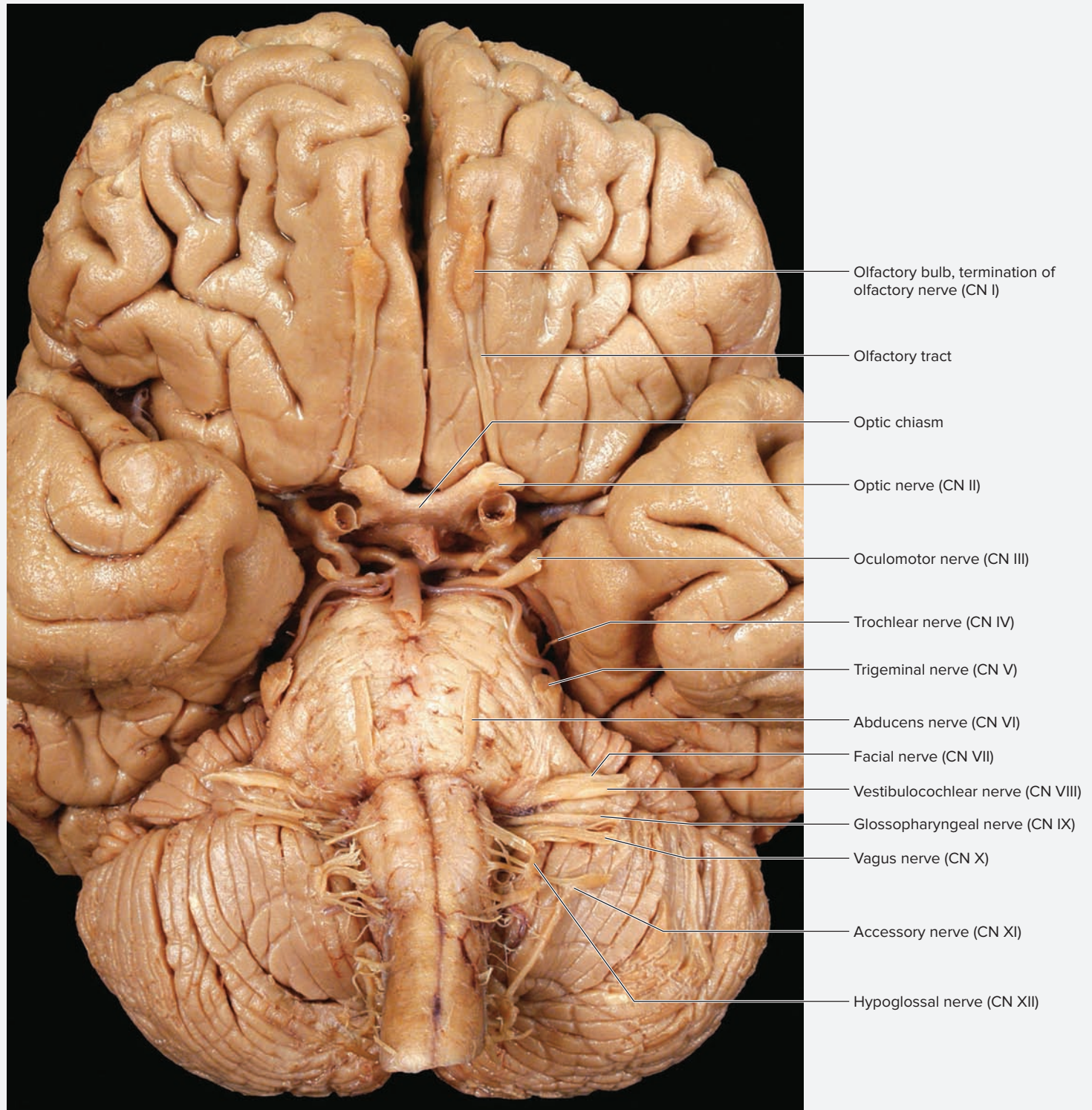
1. Obtain a human brain or a model of a human brain or brainstem.
2. Turn the brain over and observe its inferior surface (figure 24.10). Note all of the small nerves exiting the brain from various locations. These are the cranial nerves.
3. Identify the 12 cranial nerves on the inferior surface of the brain, using table 24.4 and figure 24.10 as guides.
4. Complete the chart for cranial nerves III through XII by listing the specific nerves that extend from each of the three areas of the brainstem. Use figure 24.10 as a guide. Keep in mind that knowledge of the general area where a specific nerve emerges can be helpful in identifying the nerves, even if by process of elimination.

Point of Exit	Cranial Nerve
<i>Midbrain</i>	
<i>Pons</i>	
<i>Medulla Oblongata</i>	

(continued on next page)



(continued from previous page)



**Figure 24.10** Cranial Nerves on the Inferior Surface of the Brain.

© McGraw-Hill Education/Photo and Dissection by Christine Eckel

5. **Mnemonic devices**, simple phrases or plays on words that aid in memory recall, make remembering long strings of anatomical names easier. One popular technique is to associate a word with the first letter of the corresponding word you want to remember. A mnemonic that will help you recall the names of the cranial nerves in numerical order is
- Oh Once One Takes The Anatomy Final, Very Good Vacations Are Heavenly.

Mnemonics work best when they mean something to you. Develop your own mnemonic for remembering the cranial nerves. \_\_\_\_\_

6. **Optional Activity: AP|R 7: Nervous System**—Visit the quiz area for cranial nerve location, composition, and related foramina.

### Testing Cranial Nerve Functions

Cranial nerves carry different types of information from the brain to or from the target organ(s) for each nerve. **Sensory** (afferent) information travels from the target organ to the brain, whereas **motor** (efferent) information travels from the brain to the target organ.

The types of information carried by cranial nerves are classified in **table 24.5**. Note that sensory may be somatic, sensory, or special. Motor may be somatic or visceral. Some cranial nerves also have both motor and sensory function.

**Table 24.6** lists the type of information carried by each cranial nerve and lists the specific functions of each cranial nerve.

Table 24.5	Modalities Within Cranial Nerves
<i>Somatic Motor</i>	Motor output to skeletal muscle
<i>Somatic Sensory</i>	Sensation from cutaneous touch, pain, temperature, position, and pressure receptors
<i>Special Sensory</i>	Somatic sensation from special sensory organs such as the eye and ear
<i>Visceral Motor</i>	Motor output to cardiac muscle, smooth muscle, and glands
<i>Visceral Sensory</i>	Sensation from sensory receptors within visceral organs (e.g., stretch receptors in bladder wall)

#### Learning Strategy

When observing a real brain instead of a model, the trochlear nerve (CN IV) may not be visible. It is very small, and often detaches from the brain when the brain is removed from the skull. If this is the case, make sure to identify the trochlear nerve on a model of the human brain. This nerve is unique because it is the only cranial nerve that originates from the posterior part of the brainstem, rather than the anterior or medial part.

#### Learning Strategy

A mnemonic device to remember if a cranial nerve is sensory (S), motor (M), or both (B) is this mnemonic device: **Some Say Marry Money But My Brother Says Big Brains Matter More.**

Table 24.6 Detailed Functions and Divisions of the Cranial Nerves			
Nerve Number	Name	Type of Nerve	Functions
<b>I</b>	Olfactory	Special sensory	Sensory nerve of smell
<b>II</b>	Optic	Special sensory	Sensory nerve of vision
<b>III</b>	Oculomotor	Somatic motor	Motor to levator palpebrae superioris (raises the upper eyelid) and all extrinsic eye muscles except for the superior oblique and the lateral rectus
		Visceral motor (parasympathetic)	Motor to the ciliary body and iris (pupillary sphincter muscles) of the eye
<b>IV</b>	Trochlear	Somatic motor	Motor to superior oblique extrinsic muscle of the eye
<b>V</b>	Trigeminal	Mixed	Sensation from the cornea, scalp, forehead, face, and teeth; motor to the muscles of mastication (chewing)
<b>V<sub>1</sub></b>	Ophthalmic branch	Somatic sensory	Sensory from the cornea, scalp, and forehead
<b>V<sub>2</sub></b>	Maxillary branch	Somatic sensory	Sensory from the face, cheeks, and maxillary (upper) teeth

<b>Table 24.6</b> Detailed Functions and Divisions of the Cranial Nerves ( <i>continued</i> )			
<b>Nerve Number</b>	<b>Name</b>	<b>Type of Nerve</b>	<b>Functions</b>
<b>V<sub>3</sub></b>	Mandibular branch	Somatic motor	Motor to the muscles of mastication
		Somatic sensory	Sensory from the chin, mandibular (lower) teeth, and tongue
<b>VI</b>	Abducens	Somatic motor	Motor to the lateral rectus extrinsic muscle of the eye
<b>VII</b>	Facial	Mixed	Sensory for taste from the anterior two-thirds of the tongue; motor to facial muscles, lacrimal glands, and salivary gland.
		Somatic motor	Motor to the muscles of facial expression
		Special sensory	Sensory for taste from the anterior two-thirds of the tongue
		Visceral motor (parasympathetic)	Motor to the lacrimal glands, and the submandibular and sublingual salivary glands
<b>VIII</b>	Vestibulocochlear	Special sensory	Sensory nerve of hearing and balance
<b>IX</b>	Glossopharyngeal	Mixed	Sensory for taste from the posterior one-third of the tongue, sensation from the ear and pharynx, motor to the stylopharyngeus muscle and the parotid salivary gland
		Somatic motor	Motor to the stylopharyngeus muscle
		Somatic sensory	Cutaneous sensation from the external ear; general sensation from posterior one-third of the tongue
		Special sensory	Sensory for taste from the posterior one-third of the tongue
		Visceral motor (parasympathetic)	Motor to the parotid salivary gland
		Visceral sensory	Sensory from the carotid sinus and carotid body, mastoid air cells, pharynx, middle ear, and tympanic cavity
<b>X</b>	Vagus	Mixed	Motor to the pharynx and thoracic and abdominal viscera, sensation from the pharynx and ear, and sense of taste from the pharynx and epiglottis (portion of larynx)
		Somatic motor	Motor to muscles of the pharynx, larynx, and palate (except stylopharyngeus and tensor veli palatini)
		Somatic sensory	Sensory from the external acoustic meatus, tympanic membrane, dura mater of the posterior cranial fossa, and auricle of the ear
		Special sensory	Sensory fibers for taste from the palate and epiglottis
		Visceral motor (parasympathetic)	Motor to glands of the pharynx and larynx, and smooth muscle of the heart, lungs, and abdominal viscera
		Visceral sensory	Sensory from the pharynx, larynx, bronchi, aorta, and abdominal viscera
<b>XI</b>	Accessory	Somatic motor	Motor to the trapezius and sternocleidomastoid muscles
<b>XII</b>	Hypoglossal	Somatic motor	Motor to the intrinsic and extrinsic muscles of the tongue

**EXERCISE 24.9** Testing Specific Functions of the Cranial Nerves

Neurological tests similar to some of those described in this exercise are performed by physicians when testing for damage to one or more cranial nerves. These tests can indicate if a cranial nerve is damaged. However, they are not infallible. For instance, an inability to hear could indicate damage to the vestibulocochlear nerve. However, the damage could also reside

in the auditory cortex of the brain. Each of the tests described here was chosen because it is both easy and quick to perform. **Table 24.7** lists the common disorders of the cranial nerves along with potential signs and symptoms, and causes of the disorders.

Nerve Number	Name	Signs and Symptoms of Damage	Potential Cause of the Disorder
<b>I</b>	Olfactory	Inability to smell (anosmia)	A fracture of the cribriform plate of the ethmoid can damage the olfactory nerves.
<b>II</b>	Optic	Blindness on the affected side (hemianopia)	Intracranial tumor or stroke that damages the nerve or tract prevents visual information from reaching the brain.
<b>III</b>	Oculomotor	Pupil dilation (mydriasis). Eye deviates down and out (strabismus) from muscle paralysis resulting in double vision (diplopia). Eyelid droops (ptosis).	Increased intracranial pressure is a common cause of compression of the nerve. The parasympathetic fibers that innervate the pupillary sphincter muscle are located on the surface of the nerve, so pupil dilation is often the first sign of nerve damage or increased intracranial pressure. Nerve damage results in paralysis of all extraocular muscles except the superior oblique and lateral rectus muscles. Paralysis of the levator palpebrae superioris muscle causes ptosis.
<b>IV</b>	Trochlear	Difficulty turning the eye inferior and lateral, which leads to double vision (diplopia)	Nerve damage results in paralysis of the superior oblique muscle.
<b>V</b>	Trigeminal	Trigeminal neuralgia (tic douloureux), a sudden, intense pain along the course of one of the divisions of the nerve	Pressure on the nerve from the artery that courses alongside it stimulates sensory fibers within the nerve. Pain is often triggered by touching structures inside the mouth.
<b>VI</b>	Abducens	Eye deviates medially (adducts), causing double vision (diplopia).	Any disorder that increases intracranial pressure (for example, a stroke) can cause this nerve to be crushed against the clivus (sloped portion) of the sphenoid bone.
<b>VII</b>	Facial	Bell palsy—paralysis of the muscles of facial expression on the side of the face with the affected nerve. Loss of taste sensation on the anterior two-thirds of the tongue (ageusia). Decreased salivation (hyoptyalism).	A viral infection that causes inflammation of the facial nerve is the most likely source. This problem often resolves itself within a couple of months.
<b>VIII</b>	Vestibulocochlear	Loss of balance and equilibrium, nausea, vomiting, and dizziness or inability to hear (anacusis)	Acoustic neuroma—a tumor originating in neurolemmocytes within the internal acoustic meatus—causes compression of the nerve.
<b>IX</b>	Glossopharyngeal	Difficulty swallowing (dysphagia). Loss of taste sensation on the posterior one-third of the tongue (ageusia). Decreased salivation (hyoptyalism).	Nerve damage interrupts the sensory component of the swallowing reflex.
<b>X</b>	Vagus	Difficulty swallowing (dysphagia) or hoarseness (dysphonia)	Nerve damage interrupts the motor component of the swallowing reflex. Hoarseness results from paralysis of the muscles of the larynx.
<b>XI</b>	Accessory	Difficulty elevating the scapula or rotating the head	Nerve damage results in paralysis of the sternocleidomastoid and/or trapezius muscles.
<b>XII</b>	Hypoglossal	When sticking out the tongue, it moves in the direction of the damaged nerve.	Compression of nerve from increased intracranial pressure.

(continued on next page)

(continued from previous page)

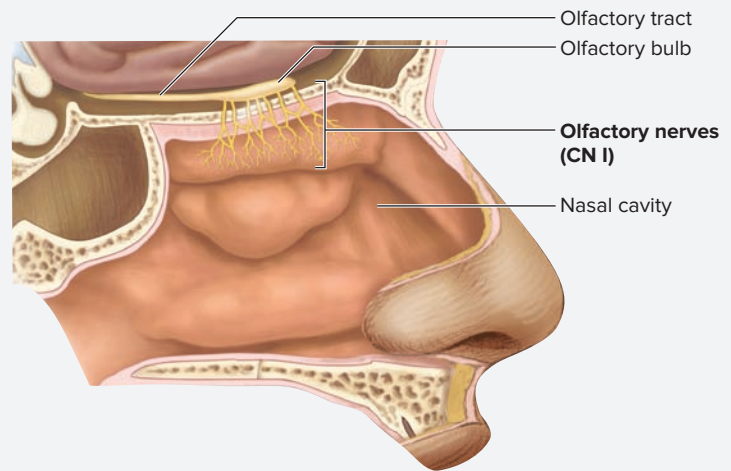
### EXERCISE 24.9A: Olfactory (CN I)

The olfactory nerves (**figure 24.11**) are unique as cranial nerves in that there are more than two of them (the rest of the cranial nerves are paired—a right and left for each), and they are constantly being replaced. The nerves lie within the nasal epithelium, and their axons project through the **olfactory foramina** within the cribriform plate of the ethmoid bone (table 24.4). The olfactory neurons then synapse with neurons within the **olfactory bulbs** and the signals are sent to the brain via the **olfactory tracts**.

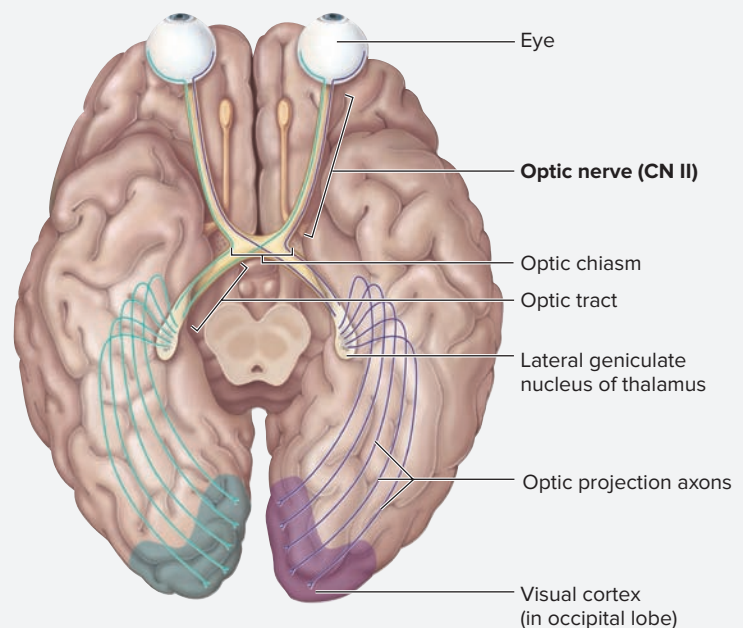
1. Obtain vials of peppermint, lemon, and vanilla oils.
2. While the subject's eyes are closed, pass an open vial of peppermint oil just under a laboratory partner's nose. Was the subject able to identify the smell?
3. Repeat this process with the vials of lemon and vanilla oils. Allow some time between applications of the different oils. Damage to the olfactory nerves results in an inability to identify odors. Excessive smoking or inflammation of the nasal mucosa as a result of a viral infection can inhibit the sense of smell, and the sense of smell also declines with age.

### EXERCISE 24.9B: Optic (CN II)

Each of the optic nerves (**figure 24.12**) begins as axons of ganglion cells located within the **retina** of the eye. Different parts of the retina correspond to different portions of the visual field. The axons of these nerves exit the eye at the optic disc, or “blind spot,” of the eye, at which point they become the **optic nerve**, which then travels posteriorly toward the diencephalon. Anterior to the infundibulum, most of the fibers cross over at the prominent **optic chiasm** (*chiasma*, a crossing of two lines) to the other side of the brain. The fibers then continue to travel posteriorly to reach the visual cortex in the occipital lobe of the brain. Figure 24.12 demonstrates the pattern of flow of visual information from the retina to the brain. When damage to the retina or optic nerve is suspected, visual field tests are performed to discover the location of the damage. These tests of visual function are beyond the scope of this course and will not be performed in this laboratory session.



**Figure 24.11** Location of the Olfactory Nerves (CN I).



**Figure 24.12** The Optic Nerve (CN II).

**EXERCISE 24.9C: Oculomotor (CN III)**

The oculomotor nerves (**figure 24.13**) send motor fibers to the majority of the extrinsic eye muscles as well as to the muscles that control pupil diameter and ciliary muscles involved in focusing (tables 24.6 and 24.7).

1. Obtain a small flashlight. Look into one of a laboratory partner's eyes and observe the size of the pupil. While looking into the subject's eye, gently shine the light into the eye (if it is a bright light, just bring it near the eye so that

more light enters the eye—the goal here is not to blind the individual with the light).

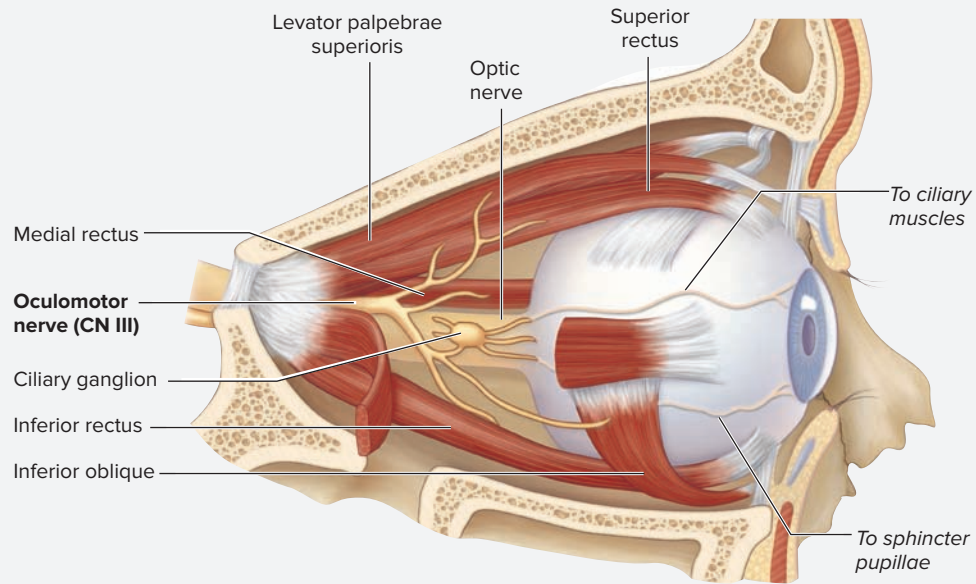
Was there a change in pupil diameter? \_\_\_\_\_

If so, what happened? \_\_\_\_\_

2. Repeat the above activity, but this time observe the pupil of the other eye.

Was there a change in pupil diameter? \_\_\_\_\_

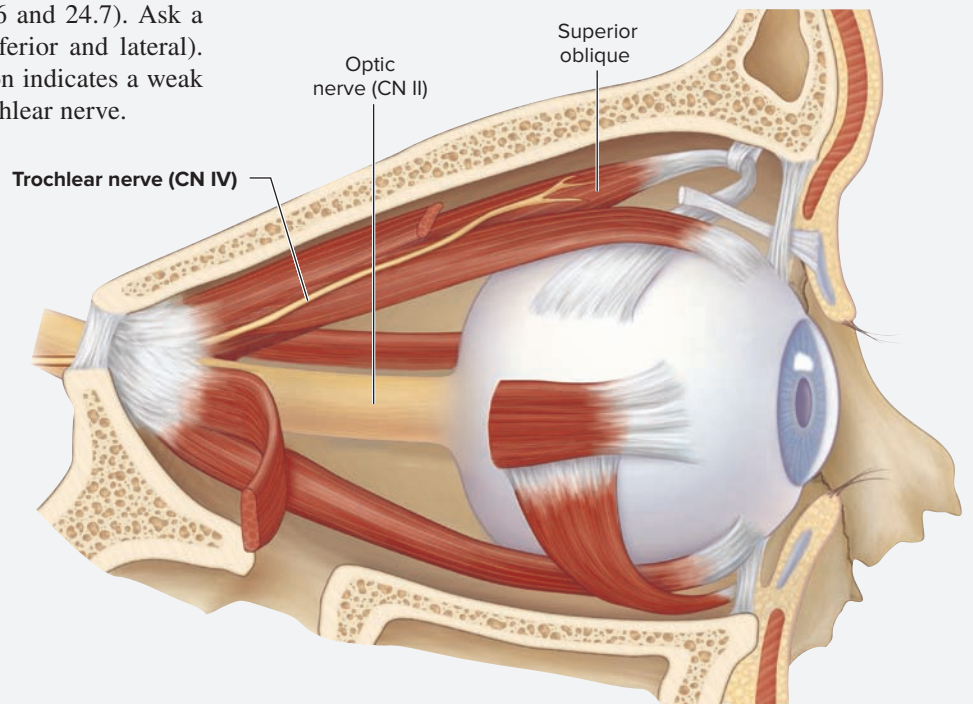
If so, what happened? \_\_\_\_\_



**Figure 24.13** The Oculomotor Nerve (CN III).

**EXERCISE 24.9D: Trochlear (CN IV)**

The trochlear nerve (**figure 24.14**) controls only one extraocular eye muscle—the superior oblique (tables 24.6 and 24.7). Ask a laboratory partner to look down and out (inferior and lateral). Weakness or an inability to perform this action indicates a weak superior oblique muscle or damage to the trochlear nerve.



**Figure 24.14** The Trochlear Nerve (CN IV).

(continued on next page)

(continued from previous page)

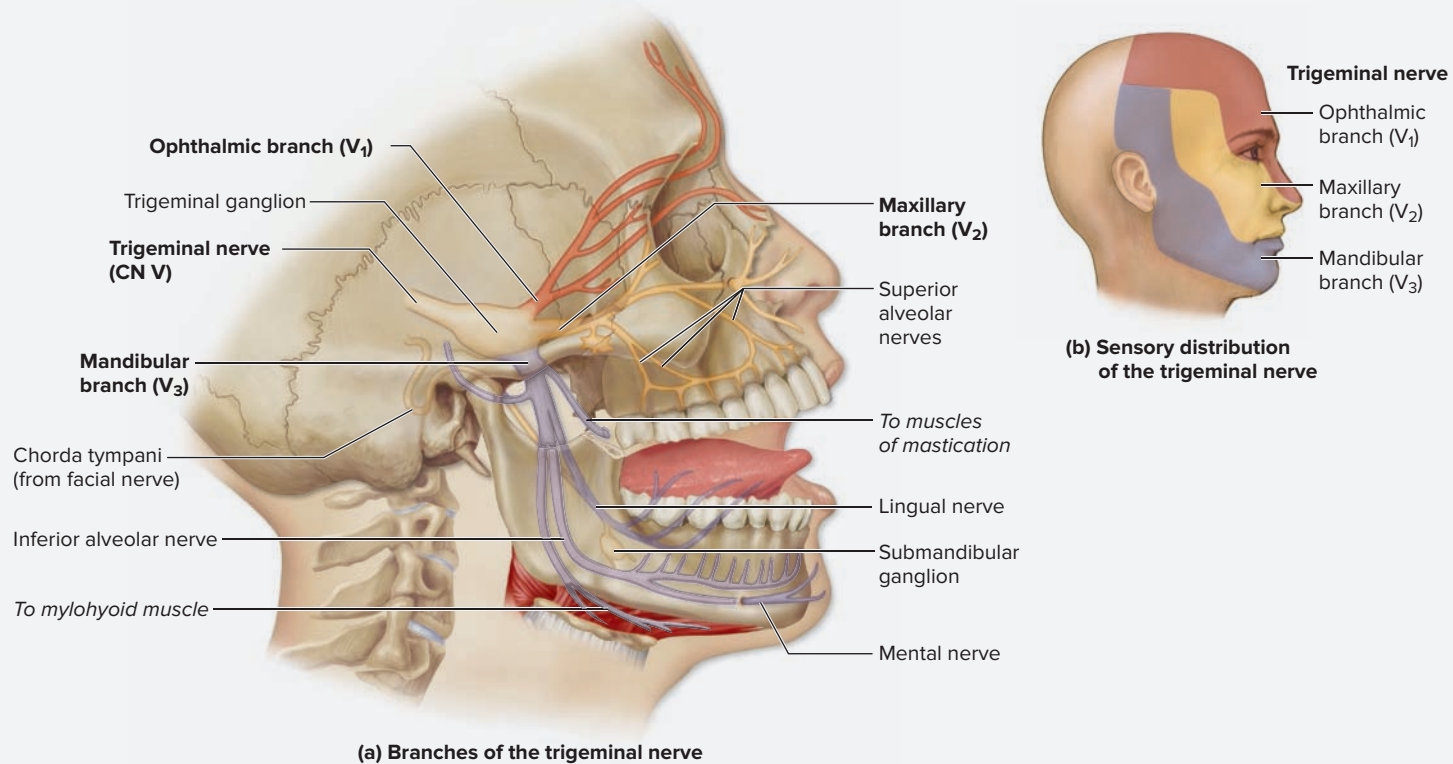
### EXERCISE 24.9E: Trigeminal (CN V)

The trigeminal nerve (**figure 24.15**) is the largest and most complex of the cranial nerves. It has three branches: the ophthalmic, maxillary, and mandibular branches, which are named  $V_1$ ,  $V_2$ , and  $V_3$ , respectively. It is the predominant nerve carrying sensory information from the face, but it also carries motor output to the muscles of mastication.

1. Obtain a feather and a cotton ball.
2. With the subject's eyes closed, proceed to gently touch the subject's face with the feather in the sensory distribution areas of the trigeminal nerve shown in **figure 24.15b**. An inability to feel this sensation in one or more

locations indicates damage to a branch of the trigeminal nerve.

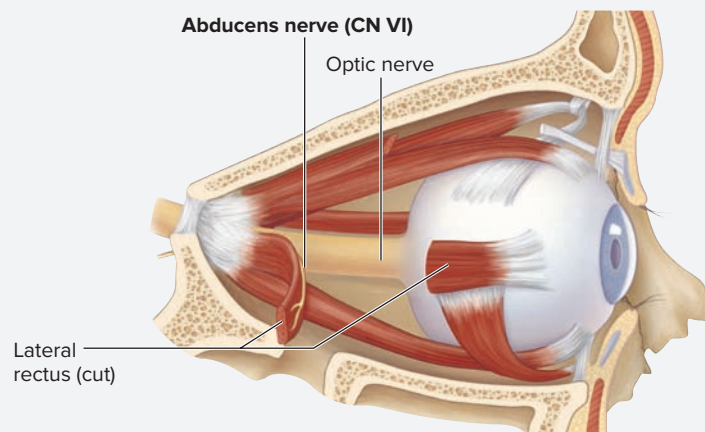
3. While the subject's eyes are open, have the individual look up and away. *Very gently and lightly* touch a few strands of the fibers from the cotton ball to the subject's cornea. This is a test for the *corneal reflex*, whose sensory component is carried by a branch of the trigeminal nerve. Touching the cornea with the cotton should cause the subject to blink. An absent corneal reflex indicates damage to the ophthalmic branch ( $V_1$ ) of the trigeminal nerve (contact lens wearers may also have a diminished or absent corneal reflex).



**Figure 24.15** The Trigeminal Nerve (CN V).

### EXERCISE 24.9F: Abducens (CN VI)

The abducens nerve (**figure 24.16**) controls only one extrinsic eye muscle—the lateral rectus (tables 24.6 and 24.7). Ask a laboratory partner to look laterally to the right. Weakness or an inability to do so indicates a weak lateral rectus muscle in the right eye or damage to the right abducens nerve.

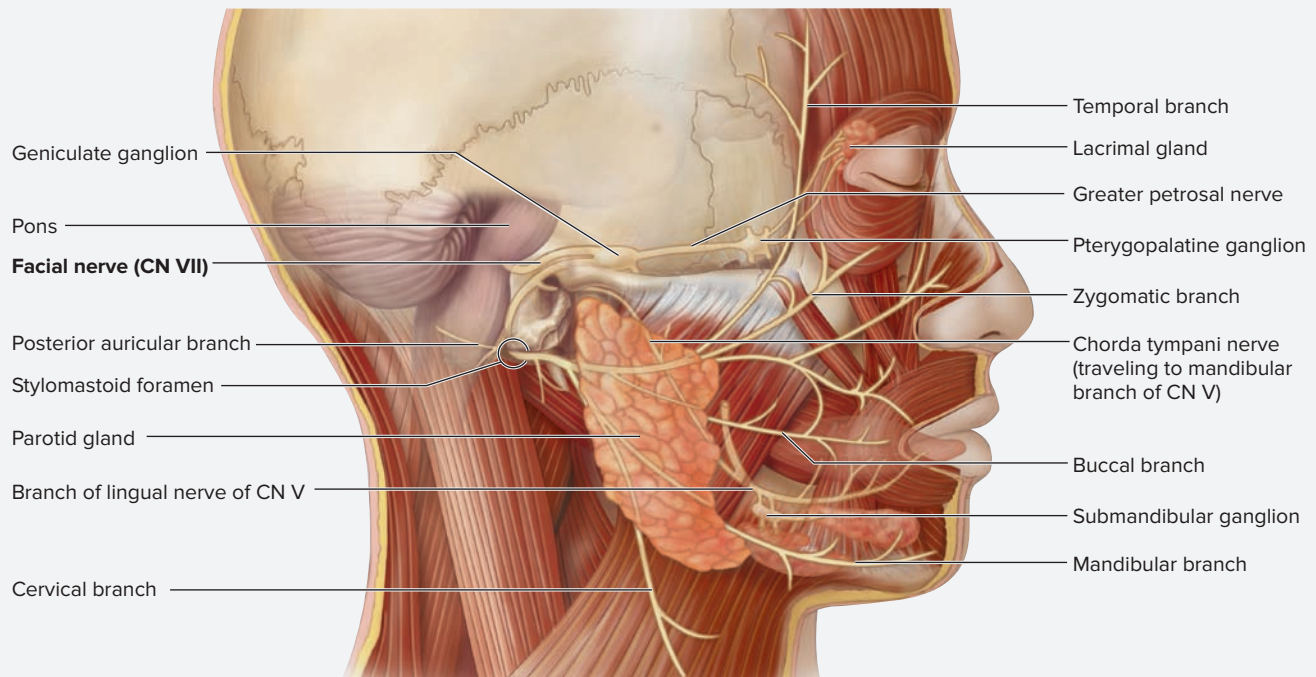


**Figure 24.16** The Abducens Nerve (CN VI).

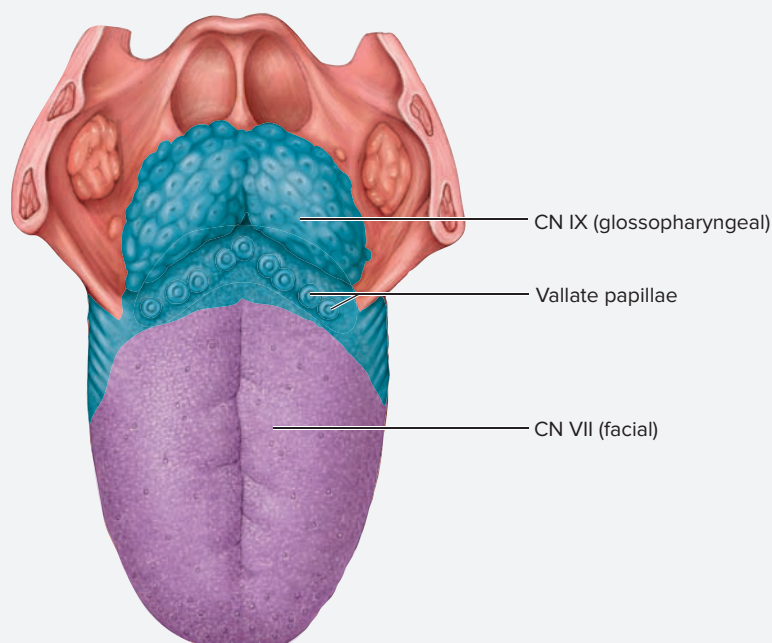
**EXERCISE 24.9G: Facial (CN VII)**

The facial nerve (**figure 24.17**) has several functions. Two major functions are to carry motor output to the muscles of facial expression and to carry sensory information to the brain from taste buds on the anterior two-thirds of the tongue (**figure 24.18**).

1. Obtain vials of salt and sugar, and a cup of drinking water.
2. While a subject has eyes closed, place a few grains of salt on the protruded tongue. Was the individual able to positively identify the taste as salty?
3. Have the subject take a drink of water to refresh the taste buds before performing the next test. Repeat step 2, but this time place a few grains of sugar on the tip of the tongue. Was the individual able to positively identify the taste as sweet? An inability to identify the salty or sweet tastes may indicate damage to the facial nerve.
4. Ask the subject to demonstrate facial expressions, such as surprise, happiness, sadness, and confusion. An inability to express these emotions facially may indicate paralysis of the muscles of facial expression, a common consequence of damage to the facial nerve.



**Figure 24.17** The Facial Nerve (CN VII).



**Figure 24.18** Innervation of the Taste Buds of the Tongue.

(continued on next page)

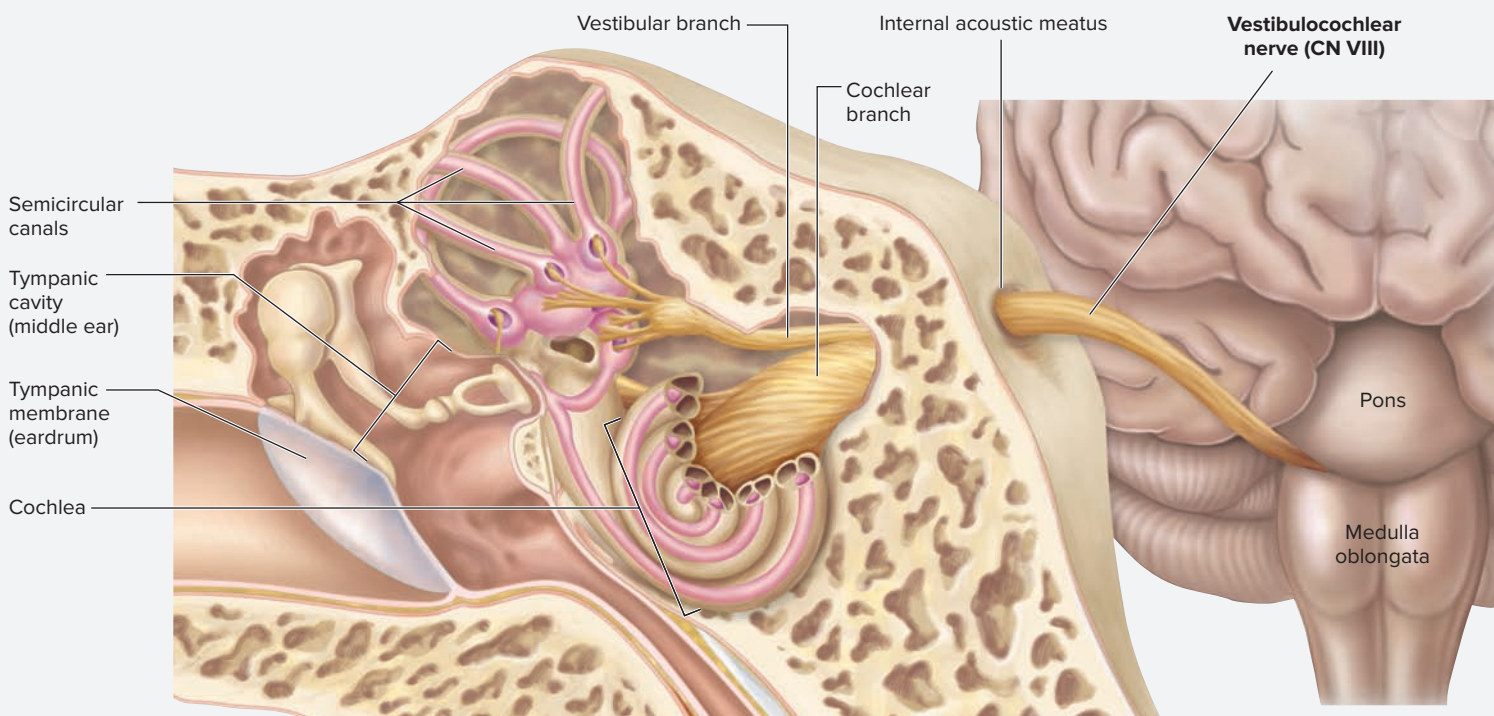


(continued from previous page)

### EXERCISE 24.9H: Vestibulocochlear (CN VIII)

The vestibulocochlear nerve (**figure 24.19**) is two nerves: the **vestibular nerve**, which transmits nerve signals from the vestibule and semicircular canals to the brain regarding balance and equilibrium and the **cochlear nerve**, which transmits nerve signals from the cochlea to the brain regarding sound. Both nerves enter the petrous part of the temporal bone through the **internal auditory canal**. **Figure 24.19** demonstrates the special sensory structures that are innervated by the vestibulocochlear nerve.

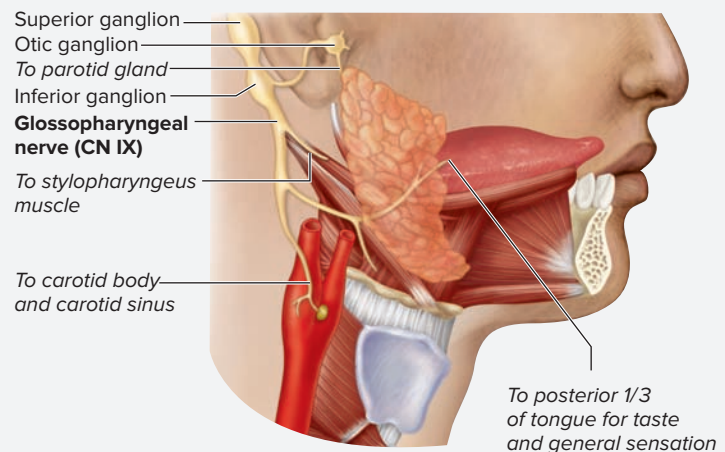
1. Obtain a tuning fork.
2. With the subject's eyes closed, gently strike the "fork" end of the tuning fork on the table, and then hold it near the individual's ear. Is the subject able to detect the sound? An inability to hear the vibrations caused by the tuning fork can indicate damage to the vestibulocochlear nerve.



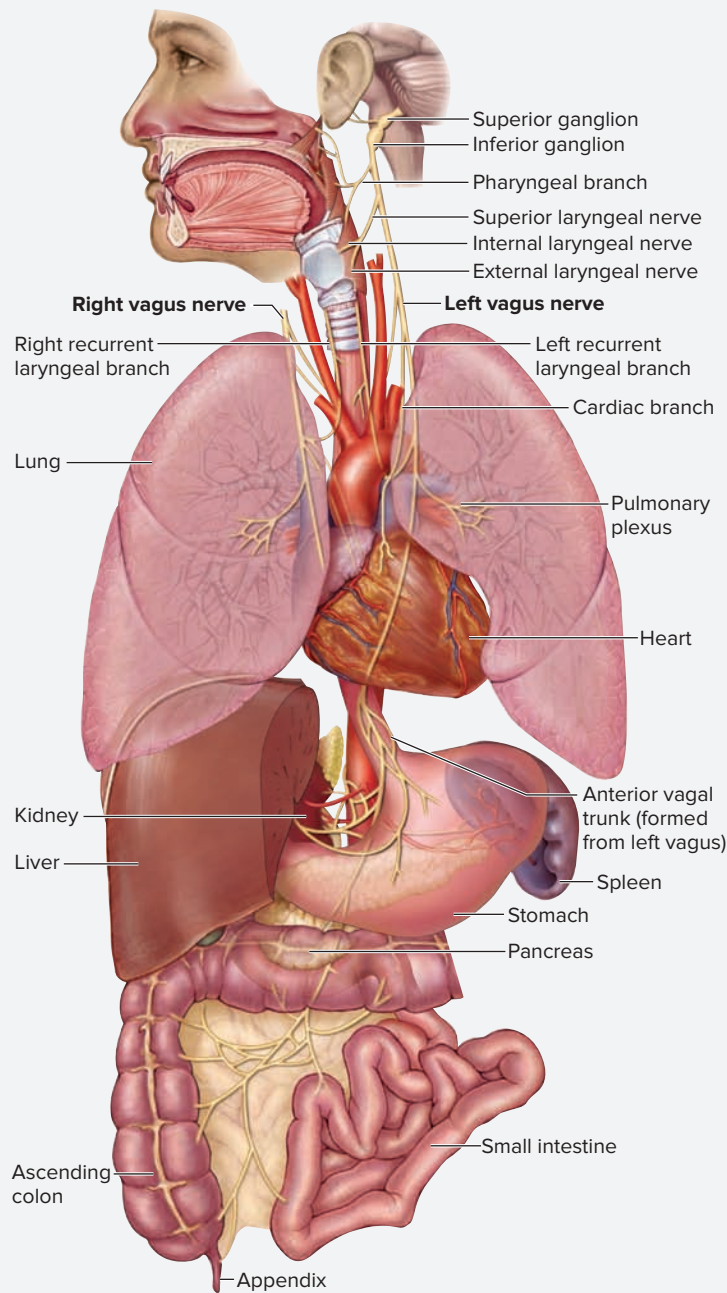
**Figure 24.19** The Vestibulocochlear Nerve (CN VIII).

### EXERCISE 24.9I: Glossopharyngeal (CN IX) and Vagus (CN X)

The glossopharyngeal and vagus nerves (**figures 24.20 and 24.21**, tables 24.6 and 24.7) both carry sensory and motor information to and from the soft palate, pharynx, and larynx as part of the coughing and gagging reflexes. In addition, the glossopharyngeal nerve carries sensory information from the taste buds on the posterior one-third of the tongue (see **figure 24.18**). The vagus nerve is unique as a cranial nerve because it innervates many structures within the thoracic and abdominal cavities. It is the predominant pathway for parasympathetic information to travel from the brain to the visceral organs of the body. Though tests for the functioning of the glossopharyngeal and vagus nerves are not easy to perform, try to observe at least some of the functions of these nerves with this exercise.



**Figure 24.20** The Glossopharyngeal Nerve (CN IX).



**Figure 24.21** The Vagus Nerve (CN X).

1. Have a subject, with the mouth open, say “Ah” while observing the soft palate and uvula.
2. Unilateral drooping of the soft palate or deviation of the uvula to one side may indicate damage to either the glossopharyngeal or the vagus nerve. The glossopharyngeal nerve carries sensory information from the pharynx to the brain, while the vagus nerve carries motor information back out to the muscles that raise the palate and that are used in swallowing.
3. Another test for the functioning of these two nerves is to test for the gag reflex. This will not be attempted in the lab because inexperienced testing of this reflex could cause choking or, in some cases, vomiting.

*(continued on next page)*

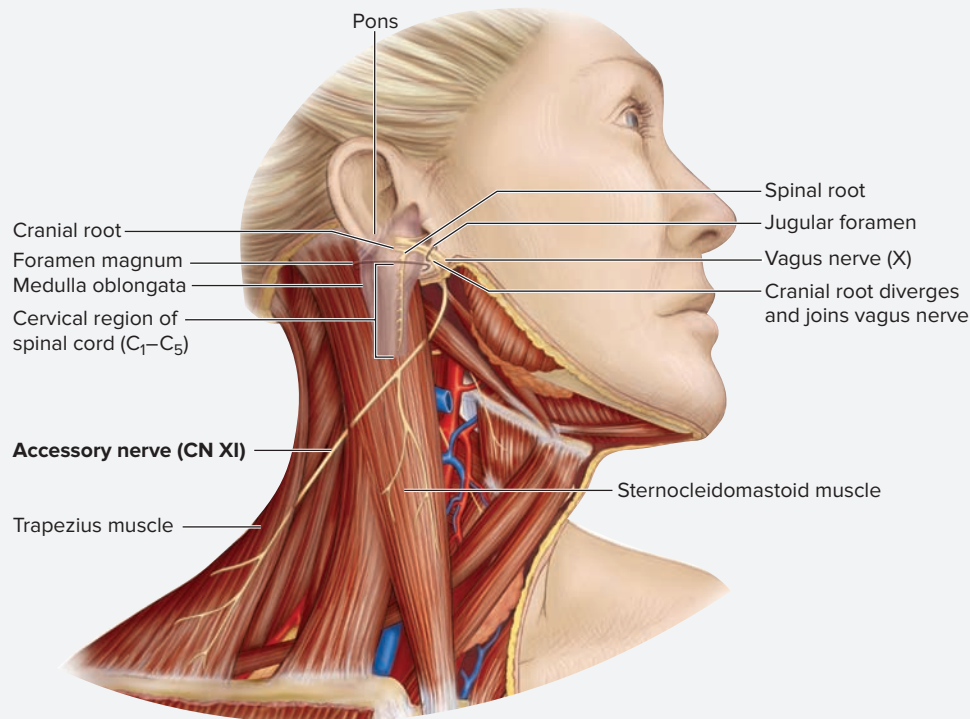
(continued from previous page)

### EXERCISE 24.9J: Accessory (CN XI)

The accessory nerve (**figure 24.22**) carries motor information to the trapezius and sternocleidomastoid muscles (tables 24.5 and 24.6).

1. Have a subject elevate the scapula (“shrug” the shoulders) to test the function of the trapezius muscle.

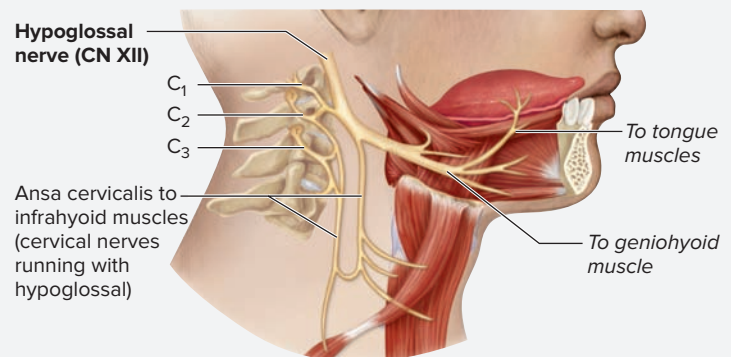
2. Next, have the subject rotate the head first to the right and then to the left to test the function of the sternocleidomastoid muscle. Damage to the accessory nerve would cause both of these actions to be weak or impossible due to paralysis of the muscles.



**Figure 24.22** The Accessory Nerve (CN XI).

### EXERCISE 24.9K: Hypoglossal (CN XII)

The hypoglossal nerve (**figure 24.23**) innervates intrinsic and extrinsic muscles of the tongue (tables 24.6 and 24.7). Have the subject stick out the tongue. The tongue should protrude straight out. If the hypoglossal nerve is damaged, the tongue will deviate to the side of the damaged nerve.




**Figure 24.23** The Hypoglossal Nerve (CN XII).

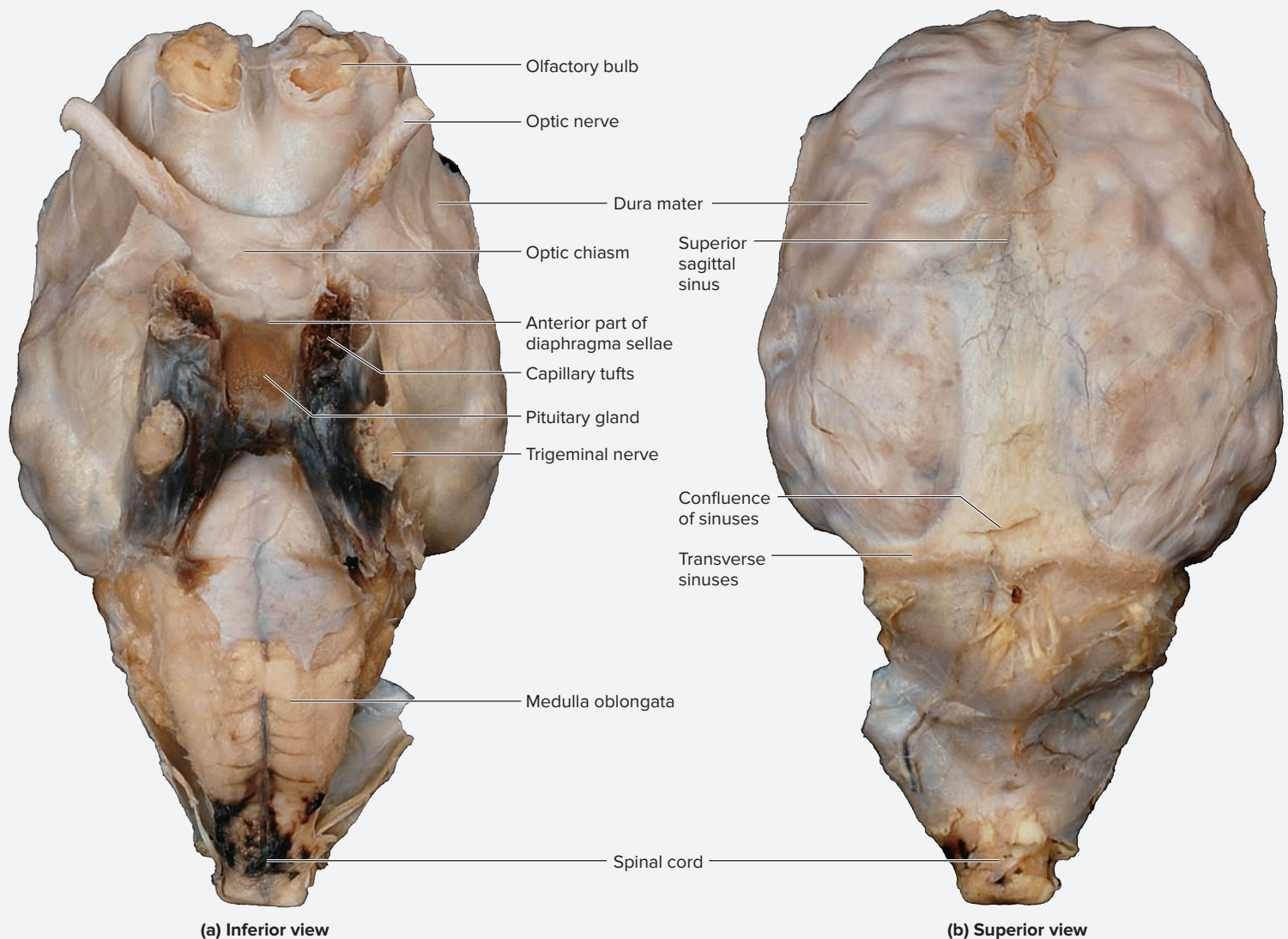
## The Sheep Brain

The following exercises involve identifying on a sheep brain many of the same structures identified on a human brain. Sheep brains share many similarities with human brains, and are readily available for laboratory studies. The experience of dissecting a real brain (as opposed to observing a plastic model of a brain) will give an appreciation for the true appearance and texture of the brain and its associ-

ated structures. Note that the brain tissue itself is relatively delicate. Even so, the tissue is much more solid than it would be if observing a fresh brain because it has been fixed with chemicals. Living brain tissues are *extremely* delicate, and have the consistency of firm gelatin. These dissection exercises involve identifying both brain structures *and* cranial nerves on the sheep brain.

**EXERCISE 24.10 Sheep Brain Dissection****EXERCISE 24.10A: Dura Mater**

-  Obtain a sheep brain, dissecting tray, and dissecting tools (forceps, scissors, a scalpel, and gloves). Place the sheep brain in the dissecting tray and take turns with a laboratory partner(s) observing its gross structure. This exercise requires a sheep brain with dura mater intact. If the dura mater is missing, proceed to the section “Inferior View of the Sheep Brain” (p. 559). Otherwise begin here.
- Using hands or blunt forceps, feel the toughness of the dura mater. Notice how it surrounds the entire brain. What type of tissue is the dura mater composed of?  
\_\_\_\_\_
- Observe the dura mater on the superior surface of the brain (**figure 24.24b**), and locate the following structures:
  - confluence of sinuses       transverse sinuses
  - superior sagittal sinus
- Rotate the brain so it is resting on its superior surface and the inferior surface is visible (**figure 24.24a**). Notice the relatively large **pituitary gland** projecting inferior to the dura mater. The goal in this part of the dissection will be to cut away the dura mater without disconnecting the pituitary from the rest of the brain. Notice the capillary tufts found just posterior and lateral to the pituitary gland. Just lateral to these capillaries on both sides are the large **trigeminal nerves** (CN V). Using a blunt probe, feel the dura mater surrounding the base of the pituitary gland. This dural membrane is the **diaphragma sellae**, which lies between the pituitary and the rest of the brain (except where the pituitary stalk exits the sella turcica of the sphenoid bone).
- To free the connections between the dura and the rest of the brain without breaking off the pituitary gland, first cut around the trigeminal nerves and capillary tufts. **Figure 24.25a** shows where to make the initial incision. Cut *around* (lateral to) the optic chiasm, diaphragma sellae, pituitary gland, and trigeminal nerves to make a complete circle, which will free the dura mater from its attachments.

**Figure 24.24** Anatomical Landmarks of the Sheep Brain.

© Christine Eckel

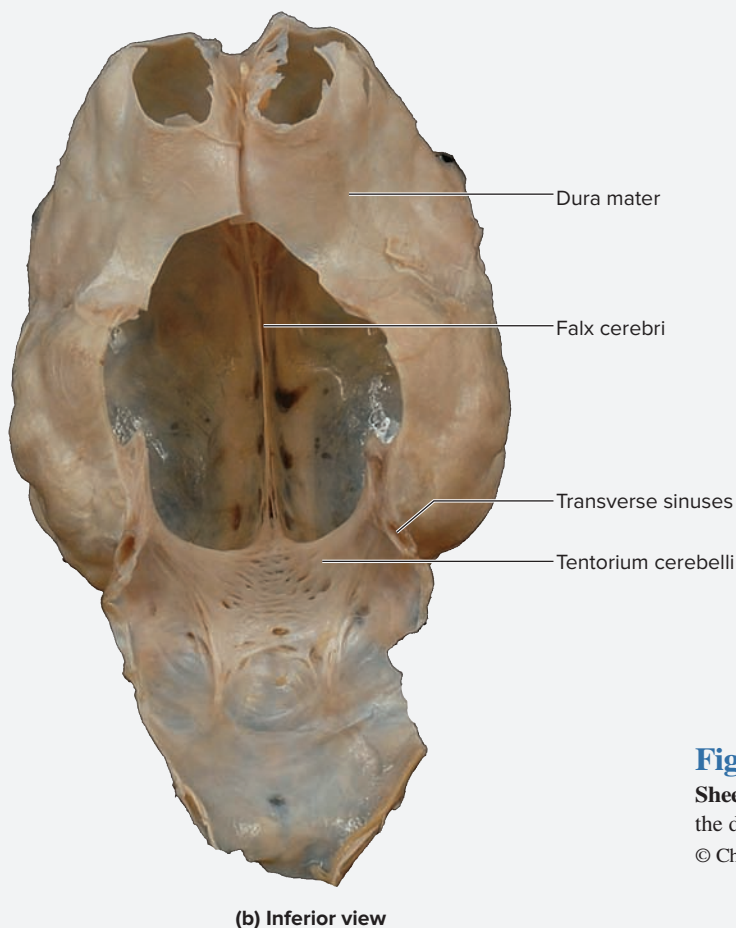
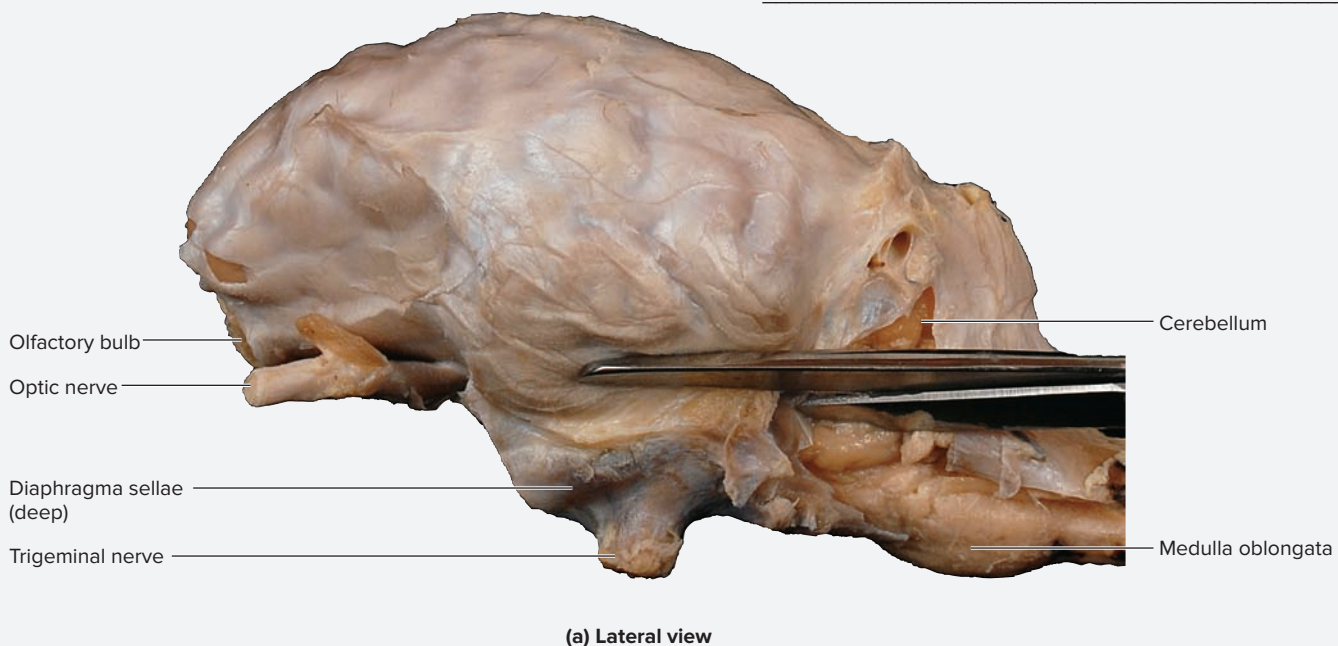
(continued on next page)

(continued from previous page)

6. Next, make an anterior cut in the dura mater along the midsagittal plane between the olfactory bulbs and olfactory tracts (figure 24.25b). Once the dura mater has been freed from its connections to the diaphragma sellae, gently pull the dura away from the brain. Pull in a posterior, superior direction so the falx cerebri and tentorium cerebelli slip out of their respective fissures without damaging the delicate brain tissues. When pulling the dura mater away from

the brain, gently tease away any remaining connections. Figure 24.25b shows what the dura mater should look like after it has been cut away and removed from the brain.

7. Once the dura mater is completely freed from the brain, observe it closely and compare the dural septa and sinuses in the sheep brain to those identified in the human brain. What dural septa is missing in a sheep brain that is present in a human brain?



**Figure 24.25** Incisions to Remove the Dura Mater from the Sheep Brain. (a) Initial incision in the dura mater. (b) Appearance of the dura mater after it has been cut away from the brain.

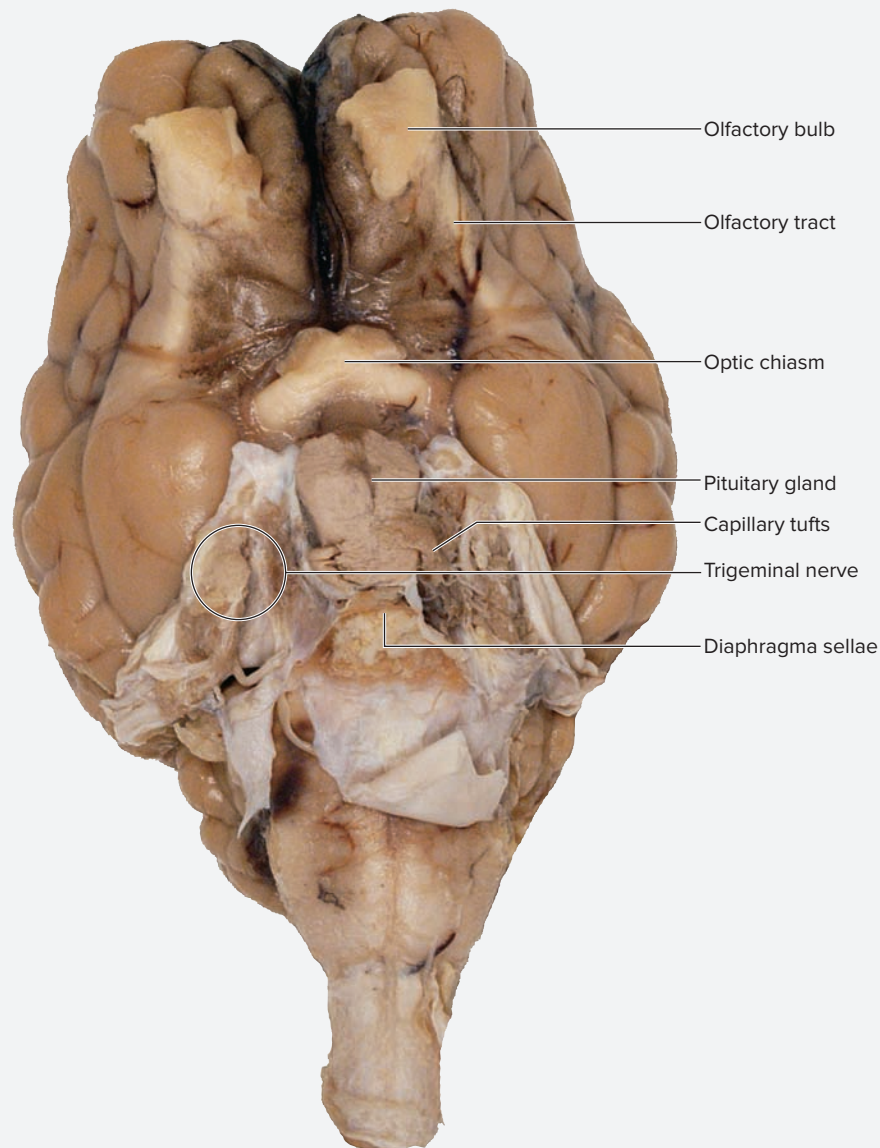
© Christine Eckel

**EXERCISE 24.10B: Inferior View of the Sheep Brain**

1. Obtain a sheep brain without the dura mater intact, or use the brain from which the dura mater has been removed. Place it in the dissecting pan on its superior surface so the inferior surface is visible (**figure 24.26**).
2. When sheep brains are collected by a commercial vendor for use in the laboratory, the dura mater is first separated from the cranial bones. In such specimens, most of the dura mater has been dissected away from the cranium and the only part remaining is the diaphragma sellae, a membrane between the sella turcica and the rest of the brain (see **figure 24.25a**). Surrounding the diaphragma sellae are some capillary tufts and large cranial nerves, the **trigeminal nerves** (CN V).
3. Identify the following on the sheep brain, using **figure 24.26** as a guide:

- |  |   |
|--|---|
| <input type="checkbox"/> capillary tufts   | <input type="checkbox"/> optic chiasm             |
| <input type="checkbox"/> diaphragma sellae | <input type="checkbox"/> pituitary gland          |
| <input type="checkbox"/> olfactory bulb    | <input type="checkbox"/> trigeminal nerves (CN V) |
| <input type="checkbox"/> olfactory tract   |   |

4. Next, dissect the diaphragma sellae and the capillary tufts away from the pituitary gland without damaging the cranial nerves, without detaching the pituitary from the infundibulum, and without detaching the trigeminal nerves from the brain. Dissect carefully, because it is very easy to accidentally detach these structures from the brain if there is too much tension on the diaphragma sellae while attempting its removal.
5. Gently lift the dura mater posterior to the pituitary gland to see the small nerves that enter the dura mater on its deep surface (**figure 24.27**).
6. Using scissors or a scalpel, detach the nerves where they enter the dura mater. Cut the nerves where they attach to the dura (not where they attach to the brain!) and then cut the dura and bony material away, removing as much of it as possible while keeping the pituitary intact. Be careful, because the connection between the pituitary and the rest of the brain is delicate.



**Figure 24.26** Inferior View of the Sheep Brain. The dura mater surrounding the pituitary gland has not yet been removed.

© Christine Eckel

(continued on next page)

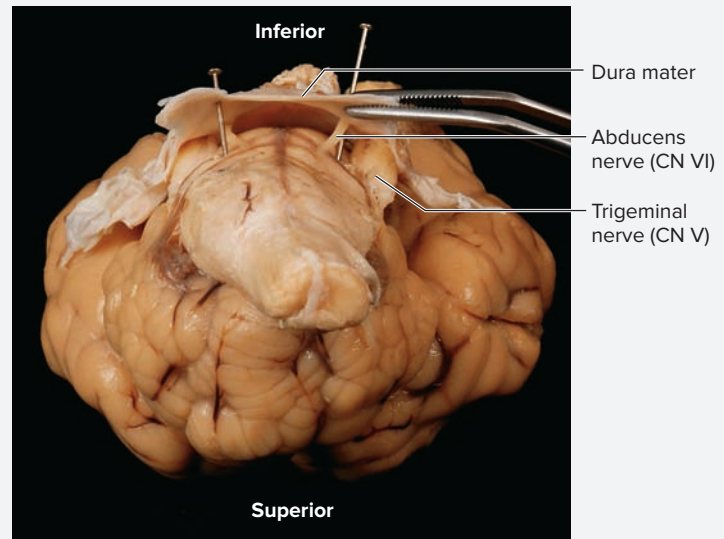
(continued from previous page)

7. Identify the following structures in the inferior view of the sheep brain, using **figure 24.28a** as a guide:

- |   |  |
|---|--|
| <input type="checkbox"/> cerebellum           | <input type="checkbox"/> optic chiasm        |
| <input type="checkbox"/> cerebral peduncle    | <input type="checkbox"/> optic nerve (CN II) |
| <input type="checkbox"/> frontal lobe         | <input type="checkbox"/> pituitary gland     |
| <input type="checkbox"/> longitudinal fissure | <input type="checkbox"/> pons                |
| <input type="checkbox"/> medulla oblongata    | <input type="checkbox"/> spinal cord         |
| <input type="checkbox"/> olfactory bulb       | <input type="checkbox"/> temporal lobe       |
| <input type="checkbox"/> olfactory tract      | <input type="checkbox"/> transverse fissure  |

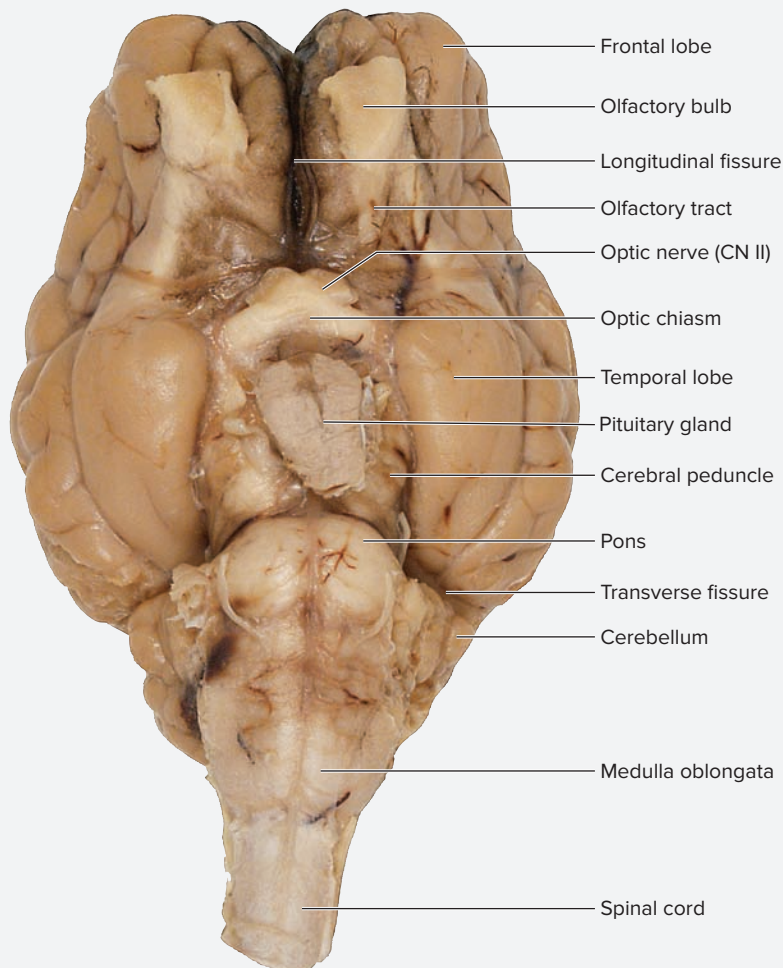
8. Gently lift the pituitary to observe the **mammillary body** (figure 24.28b). Note that the sheep brain has only a single mammillary body, whereas the human brain has two.

9. Finally, attempt to identify the cranial nerves listed in figure 24.28b. Identification of cranial nerves IX (glossopharyngeal nerve) through XII (hypoglossal nerve) may not be possible because these nerves are very small and may have been damaged or torn off the brain as the dura mater was removed from the brain, or as the brain was removed from the cranium.



**Figure 24.27** Cranial Nerves Entering the Dura Mater. The abducens and trigeminal nerves can be seen exiting the inferior surface of the sheep brain and piercing the dura mater.

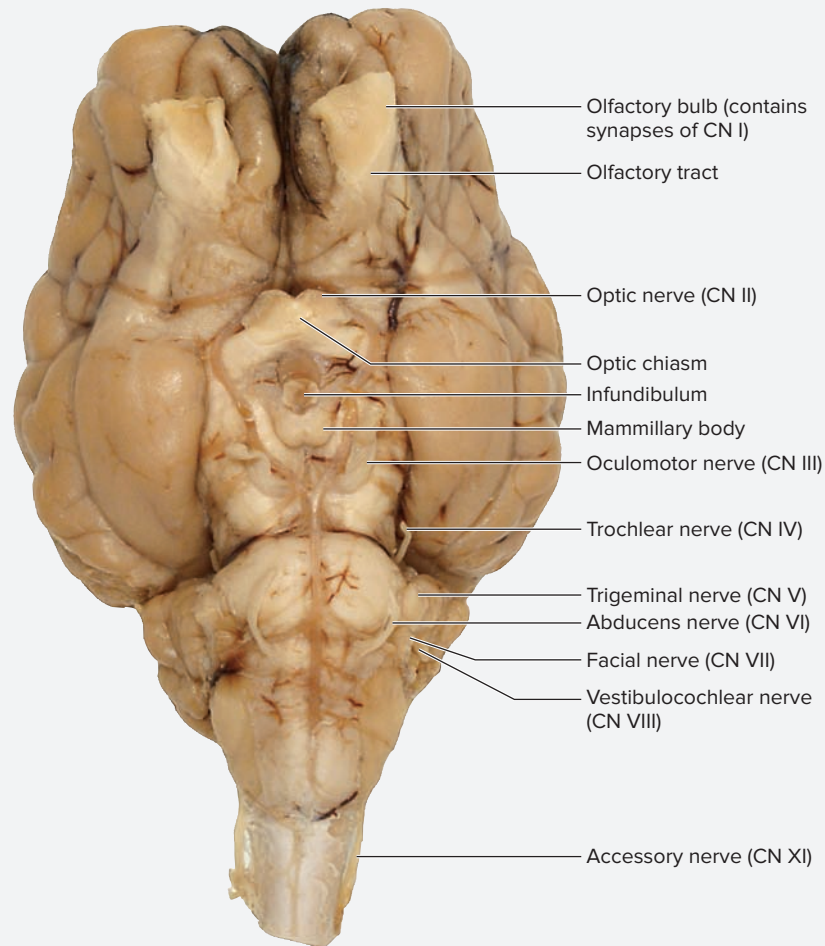
© Christine Eckel



(a) Inferior view, pituitary gland intact; dura mater removed

**Figure 24.28** Inferior Views of the Sheep Brain.

© Christine Eckel



(b) Inferior view, pituitary gland removed

**Figure 24.28** Inferior Views of the Sheep Brain (*continued*).

© Christine Eckel

**EXERCISE 24.10C: Superior View of the Sheep Brain**

1. Place the brain in the dissecting tray with the inferior side facing down (**figure 24.29a**). Note the thin, transparent **arachnoid mater** that covers the entire surface of the brain without dipping into the **sulci** (grooves) between the **gyri** (folds) of the brain. Note the numerous **blood vessels** that lie between the arachnoid mater and the **pia mater**. The space occupied by the blood vessels is also a space where cerebrospinal fluid flows in the living animal. What is the name of this space?

2. Identify the following structures in the superior view of the sheep brain, using figure 24.29a as a guide:

- |  |   |
|--|---|
| <input type="checkbox"/> arachnoid mater | <input type="checkbox"/> longitudinal fissure |
| <input type="checkbox"/> blood vessels   | <input type="checkbox"/> spinal cord          |
| <input type="checkbox"/> cerebellum      | <input type="checkbox"/> sulcus               |
| <input type="checkbox"/> cerebrum        | <input type="checkbox"/> transverse fissure   |
| <input type="checkbox"/> gyrus           |   |

3. Pick up the brain and gently pull the cerebellum away from the cerebrum so the transverse fissure is visible. Identify the following structures, using figure 24.29a as a guide:

- |  |  |
|--|--|
| <input type="checkbox"/> cerebellum          | <input type="checkbox"/> pineal gland        |
| <input type="checkbox"/> cerebrum            | <input type="checkbox"/> superior colliculus |
| <input type="checkbox"/> inferior colliculus |  |

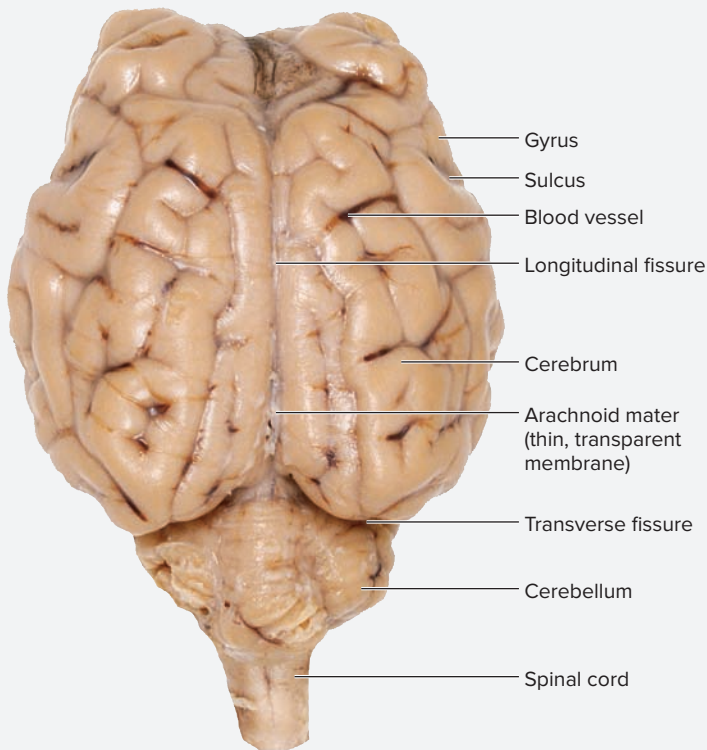
**EXERCISE 24.10D: Midsagittal and Coronal Sections of the Sheep Brain**

- Some lab members may perform a midsagittal section of the sheep brain; others will perform a coronal section. Ask the instructor which section to make before initiating a cut. Be sure to observe a brain that has been cut along a midsagittal plane and a brain cut along a coronal plane.
- Midsagittal Section:** Place the sheep brain in a dissecting tray with its superior surface facing up. Using a scalpel, cut the brain in half along the midsagittal plane. Start a cut

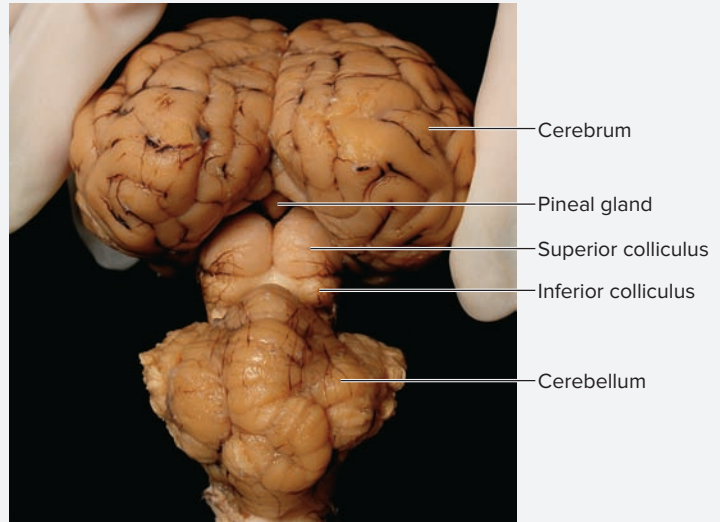
(continued on next page)



(continued from previous page)



(a) Superior view



(b) Posterior view

**Figure 24.29** Superior and Posterior Views of the Sheep Brain.

(a) Superior view of the sheep brain. (b) Posterior view; cerebral hemispheres are pulled away from the cerebellum to reveal deeper structures.

© Christine Eckel

on the anterior end of the brain by placing the scalpel blade within the longitudinal fissure. What is the first structure the scalpel blade will cut through?

3. Once the brain has been cut in half, observe its medial surface. Identify the following structures on the sheep brain, using **figure 24.30** as a guide:

- |   |  |
|---|--|
| <input type="checkbox"/> central canal (of spinal cord) | <input type="checkbox"/> medulla oblongata   |
| <input type="checkbox"/> cerebellum                     | <input type="checkbox"/> optic chiasm        |
| <input type="checkbox"/> cerebral aqueduct              | <input type="checkbox"/> pineal gland        |
| <input type="checkbox"/> cerebral peduncle              | <input type="checkbox"/> pituitary gland     |
| <input type="checkbox"/> cerebrum                       | <input type="checkbox"/> pons                |
| <input type="checkbox"/> corpus callosum                | <input type="checkbox"/> spinal cord         |
| <input type="checkbox"/> fornix                         | <input type="checkbox"/> superior colliculus |
| <input type="checkbox"/> fourth ventricle               | <input type="checkbox"/> thalamus            |
| <input type="checkbox"/> mammillary body                |  |

4. **Coronal Section:** Place the sheep brain in a dissecting tray with the superior surface down, and identify the pituitary gland (or the pituitary stalk if the pituitary gland has been removed). Using a scalpel, cut the brain in half along a coronal plane that travels through the pituitary gland and continues toward the cerebral hemispheres.

5. Once the brain has been cut in half, observe the cut surface. Identify the following structures on the sheep brain, using **figure 24.31** as a guide:

- |  |   |
|--|---|
| <input type="checkbox"/> cerebral cortex   | <input type="checkbox"/> internal capsule     |
| <input type="checkbox"/> cerebral peduncle | <input type="checkbox"/> lateral ventricle    |
| <input type="checkbox"/> choroid plexus    | <input type="checkbox"/> longitudinal fissure |
| <input type="checkbox"/> corona radiata    | <input type="checkbox"/> pons                 |
| <input type="checkbox"/> corpus callosum   | <input type="checkbox"/> thalamus             |
| <input type="checkbox"/> fornix            | <input type="checkbox"/> third ventricle      |
| <input type="checkbox"/> hypothalamus      |   |

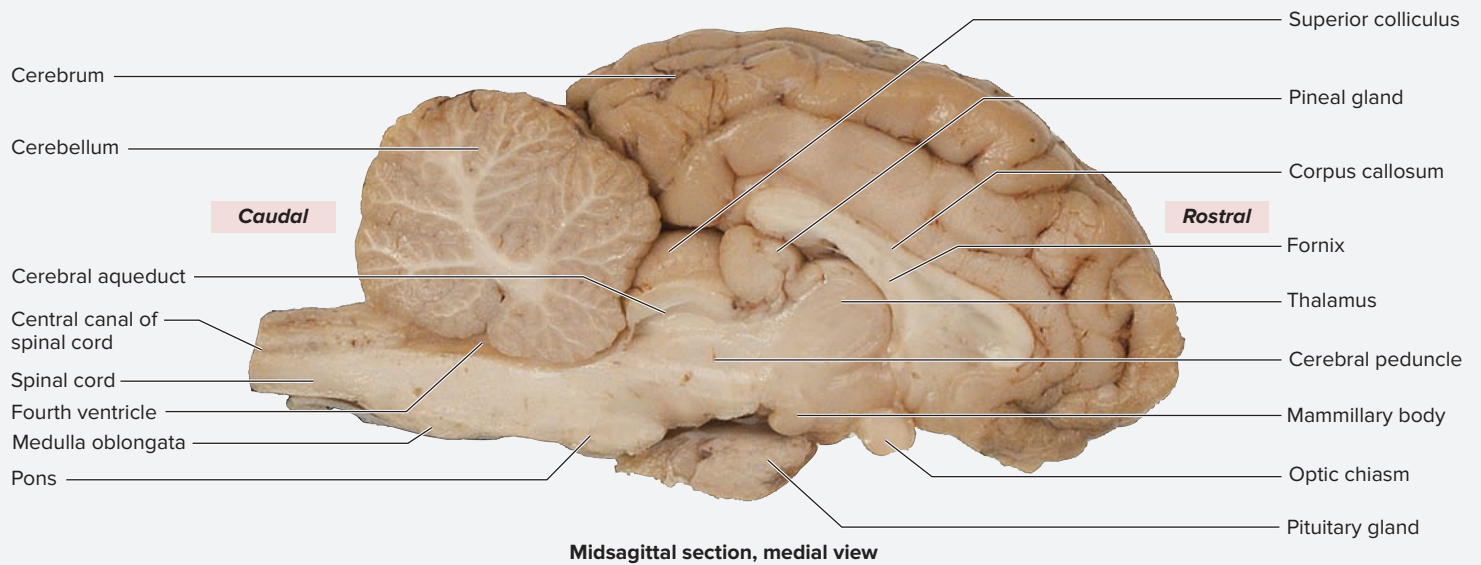
6. The **corpus callosum**, **fornix**, **internal capsule**, **corona radiata**, and **cerebral peduncles** are all fiber tracts. Recall from chapter 14 that a tract is a bundle of myelinated axons. What is the function of these fiber tracts? \_\_\_\_\_

7. Using forceps, open the lateral ventricles a bit to find the **choroid plexus** in the wall of the ventricle. Upon gross observation, the choroid plexus kind of looks like “junk” inside the ventricle, but it is really a tuft of capillaries covered by ependymal cells.

What two structures make up the choroid plexus?

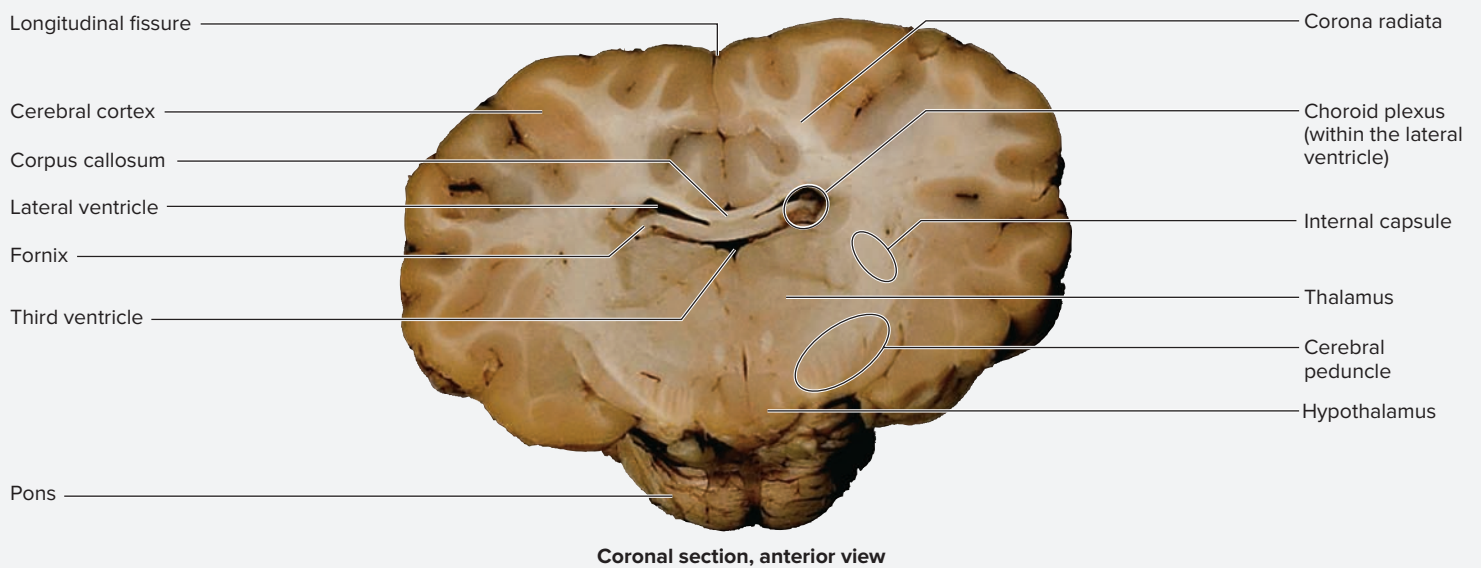
\_\_\_\_\_

\_\_\_\_\_



**Figure 24.30** Midsagittal View of the Sheep Brain.

© McGraw-Hill Education/Photo and Dissection by Christine Eckel



**Figure 24.31** Coronal Section Through the Sheep Brain.

© Christine Eckel

What is the function of the choroid plexus?

---



---

8. When the dissection has been completed, collect all the organic material from the dissecting pan and dispose of

it in the proper containers (ask the laboratory instructor what these are). Dispose of the scalpel blades in the sharps container, and throw used paper towels and gloves into the garbage. Clean all dissecting tools and the dissecting pan and return them to the proper storage area, and disinfect the laboratory workstation.

*This page intentionally left blank*

The ❶ corresponds to the Learning Objective listed in the chapter opener outline.

## Do You Know the Basics?

### Exercise 24.1: Cranial Meninges

1. Match the description listed in column A with the corresponding cranial dural septum listed in column B. ❶

#### Column A

- \_\_\_\_\_ 1. diaphragma sellae
- \_\_\_\_\_ 2. falx cerebelli
- \_\_\_\_\_ 3. falx cerebri
- \_\_\_\_\_ 4. tentorium cerebelli

#### Column B

- a. drapes across the cerebellar hemispheres horizontally within the transverse fissure
- b. located between the two cerebellar hemispheres
- c. located between the two cerebral hemispheres
- d. superior to the sella turcica of the sphenoid bone

2. The dura mater is composed of which type of connective tissue? (Circle one.) ❶

- a. areolar
- b. dense irregular
- c. dense regular
- d. reticular

3. Place the following structures through which CSF and venous blood flow in the correct order as they drain from the subarachnoid space into the internal jugular vein. ❷

- \_\_\_\_\_ a. confluence of sinuses
- \_\_\_\_\_ b. sigmoid sinuses
- \_\_\_\_\_ c. superior sagittal sinus
- \_\_\_\_\_ d. transverse sinuses

### Exercise 24.2: Brain Ventricles

4. Match the description listed in column A with the appropriate structure listed in column B. ❸

#### Column A

- \_\_\_\_\_ 1. capillaries that aid in production of CSF
- \_\_\_\_\_ 2. a channel located between the third and fourth ventricles
- \_\_\_\_\_ 3. a hole between the lateral ventricle and the third ventricle
- \_\_\_\_\_ 4. a membrane that separates the two lateral ventricles
- \_\_\_\_\_ 5. the two most superior ventricles
- \_\_\_\_\_ 6. the ventricle located between the brainstem and cerebellum
- \_\_\_\_\_ 7. the ventricle surrounded by the diencephalon

#### Column B

- a. cerebral aqueduct
- b. choroid plexus
- c. fourth ventricle
- d. interventricular foramen
- e. lateral ventricle
- f. septum pellucidum
- g. third ventricle

5. Match the ventricular space listed in column A with the secondary brain vesicle from which it developed listed in column B. ❹

#### Column A

- \_\_\_\_\_ 1. cerebral aqueduct
- \_\_\_\_\_ 2. fourth ventricle
- \_\_\_\_\_ 3. lateral ventricles
- \_\_\_\_\_ 4. third ventricle

#### Column B

- a. diencephalon
- b. mesencephalon
- c. myelencephalon
- d. telencephalon

**Exercise 24.3: Circulation of Cerebrospinal Fluid (CSF)**

6. Place the following structures through which CSF flows in the correct order as CSF flows through the ventricular system of the brain. **5**

- \_\_\_ a. cerebral aqueduct
- \_\_\_ b. fourth ventricle
- \_\_\_ c. interventricular foramen
- \_\_\_ d. lateral ventricles
- \_\_\_ e. third ventricle

**Exercise 24.4: Superior View of the Human Brain**

7. Match the description listed in column A with the appropriate structure listed in column B. **6**

**Column A**

- \_\_\_ 1. a fiber tract that connects the right and left cerebral hemispheres
- \_\_\_ 2. a groove between the frontal lobe and the remaining lobes
- \_\_\_ 3. a groove between the right and left cerebral hemispheres
- \_\_\_ 4. a groove between the temporal and parietal lobes
- \_\_\_ 5. a groove that separates the cerebrum from the cerebellum
- \_\_\_ 6. the most anterior lobe of the brain
- \_\_\_ 7. the most lateral lobe(s) of the brain
- \_\_\_ 8. the most superior lobe(s) of the brain
- \_\_\_ 9. ridges of brain tissue
- \_\_\_ 10. shallow grooves on the surface of the brain

**Column B**

- a. central sulcus
- b. corpus callosum
- c. frontal lobe
- d. gyri
- e. lateral sulcus
- f. longitudinal fissure
- g. parietal lobe
- h. sulci
- i. temporal lobe
- j. transverse fissure

**Exercise 24.5: Lateral View of the Human Brain**

8. Which of the following are major lobes visible on the surface of the cerebrum? (Check all that apply.) **7**

- \_\_\_ a. frontal    \_\_\_ b. insula    \_\_\_ c. occipital    \_\_\_ d. parietal    \_\_\_ e. temporal

**Exercise 24.6: Inferior View of the Human Brain**

9. Which of the following brain structures are visible on the inferior surface of the brain? (Check all that apply.) **8**

- \_\_\_ a. brainstem    \_\_\_ b. cerebellum    \_\_\_ c. frontal lobe    \_\_\_ d. parietal lobe    \_\_\_ e. temporal lobe

**Exercise 24.7: Midsagittal View of the Human Brain**

10. Match the description listed in column A with the corresponding structure listed in column B. **9**

**Column A**

- \_\_\_ 1. controls hormone secretion from the pituitary gland
- \_\_\_ 2. fiber tract that connects the left cerebral hemisphere to the right cerebral hemisphere
- \_\_\_ 3. involved in suckling reflex and chewing
- \_\_\_ 4. primary relay center for sensory information coming into the brain
- \_\_\_ 5. secretes the hormone melatonin from its precursor molecule, serotonin

**Column B**

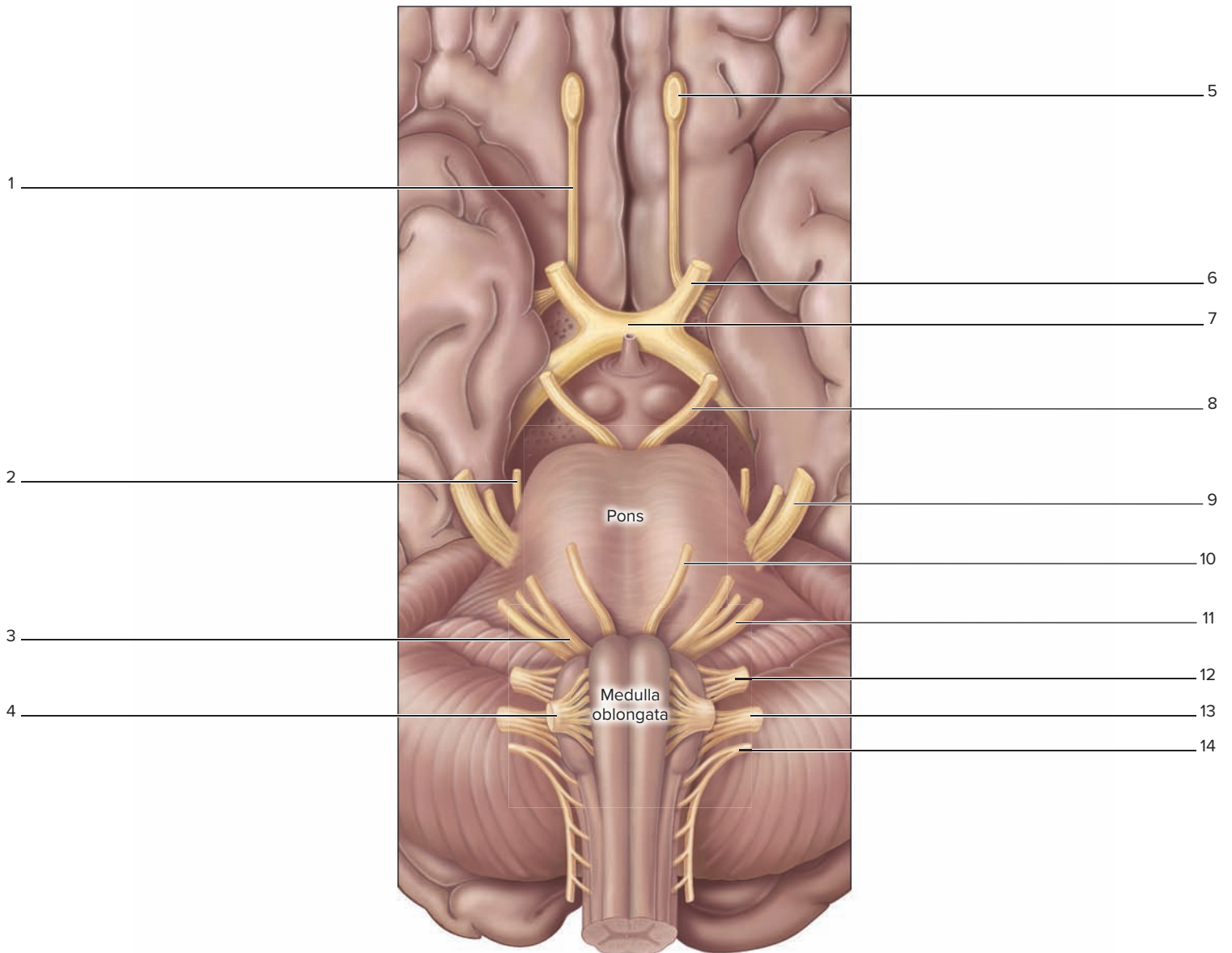
- a. corpus callosum
- b. hypothalamus
- c. mammillary bodies
- d. pineal body (gland)
- e. thalamus

**Exercise 24.8: Identification of Cranial Nerves on a Brain or Brainstem Model**

11. Complete the table by listing the cranial nerves that extend from the three regions of the brainstem. 10

Region of Brainstem	Cranial Nerves Extending from This Region of Brainstem
<i>Medulla Oblongata</i>	
<i>Pons</i>	
<i>Midbrain</i>	

12. Write the names of the numbered structures shown on the illustration of the inferior brain in the spaces provided. 11



**Exercise 24.9: Testing Specific Functions of the Cranial Nerves**

13. Match the disorder listed in column A with the cranial nerve associated with that disorder listed in column B. Some answers may be used more than once. 12

**Column A**

- \_\_\_ 1. blindness
- \_\_\_ 2. corneal reflex is absent (2 answers)
- \_\_\_ 3. difficulty turning the eye inferior and lateral
- \_\_\_ 4. inability to laterally rotate the eye
- \_\_\_ 5. inability to maintain balance and equilibrium
- \_\_\_ 6. inability to pucker the lips
- \_\_\_ 7. inability to smell
- \_\_\_ 8. inability to taste bitter (sensed by posterior taste buds of the tongue)
- \_\_\_ 9. pupillary reflexes are absent (2 answers)
- \_\_\_ 10. soft palate droops on one side (2 answers)
- \_\_\_ 11. tongue deviates to one side when it is stuck out of the mouth
- \_\_\_ 12. weakness in elevation of the scapula

**Column B**

- a. abducens
- b. accessory (spinal accessory)
- c. facial
- d. glossopharyngeal
- e. hypoglossal
- f. oculomotor
- g. olfactory
- h. optic
- i. trigeminal
- j. trochlear
- k. vagus
- l. vestibulocochlear

14. Three of the 12 cranial nerves carry somatic motor fibers to extrinsic muscles of the eye. Complete the table by listing the nerves that carry somatic motor fibers to the extrinsic eye muscles, and then name the muscle(s) innervated by each nerve. 12

Cranial Nerve	Muscles Innervated by the Nerve

15. Several cranial nerves innervate structures of the tongue. Complete the table by listing the nerves that innervate structures of the tongue, and then list the functions of each nerve. 12

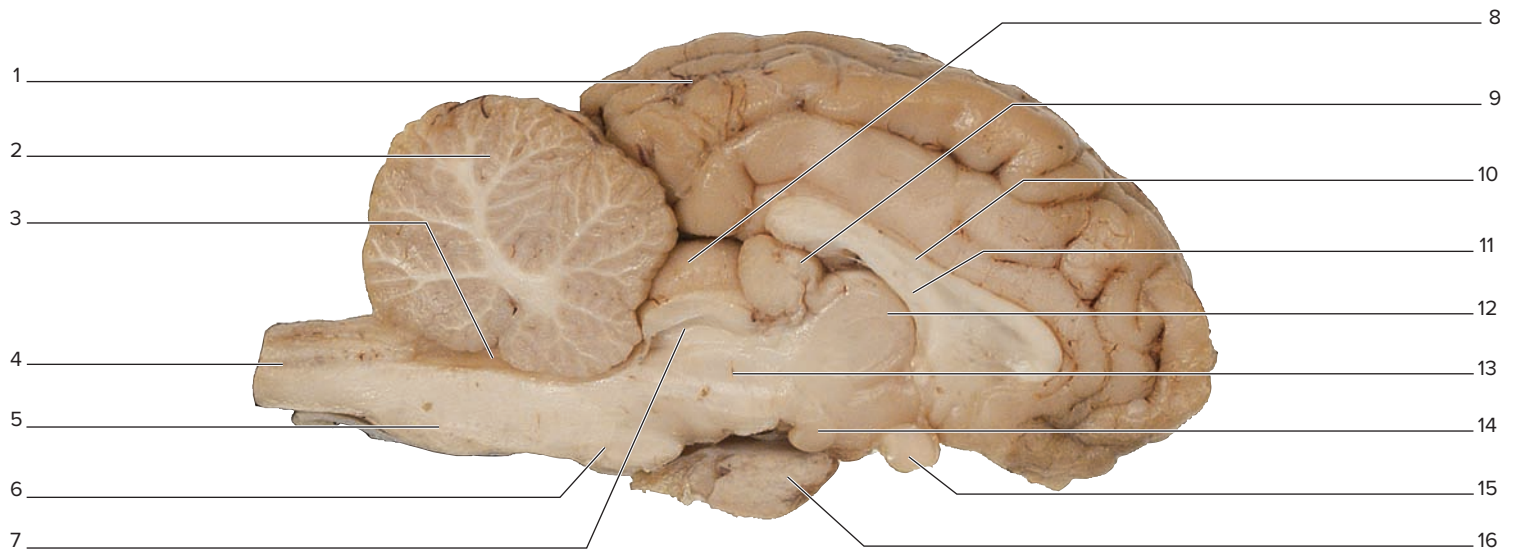
Cranial Nerve	Tongue Structures Innervated by the Nerve

16. Four of the 12 cranial nerves carry parasympathetic motor output. Complete the table by listing the nerves that carry parasympathetic motor output, and then give the parasympathetic function(s) of each nerve. 12

Cranial Nerve	Parasympathetic Motor Function(s) of the Nerve

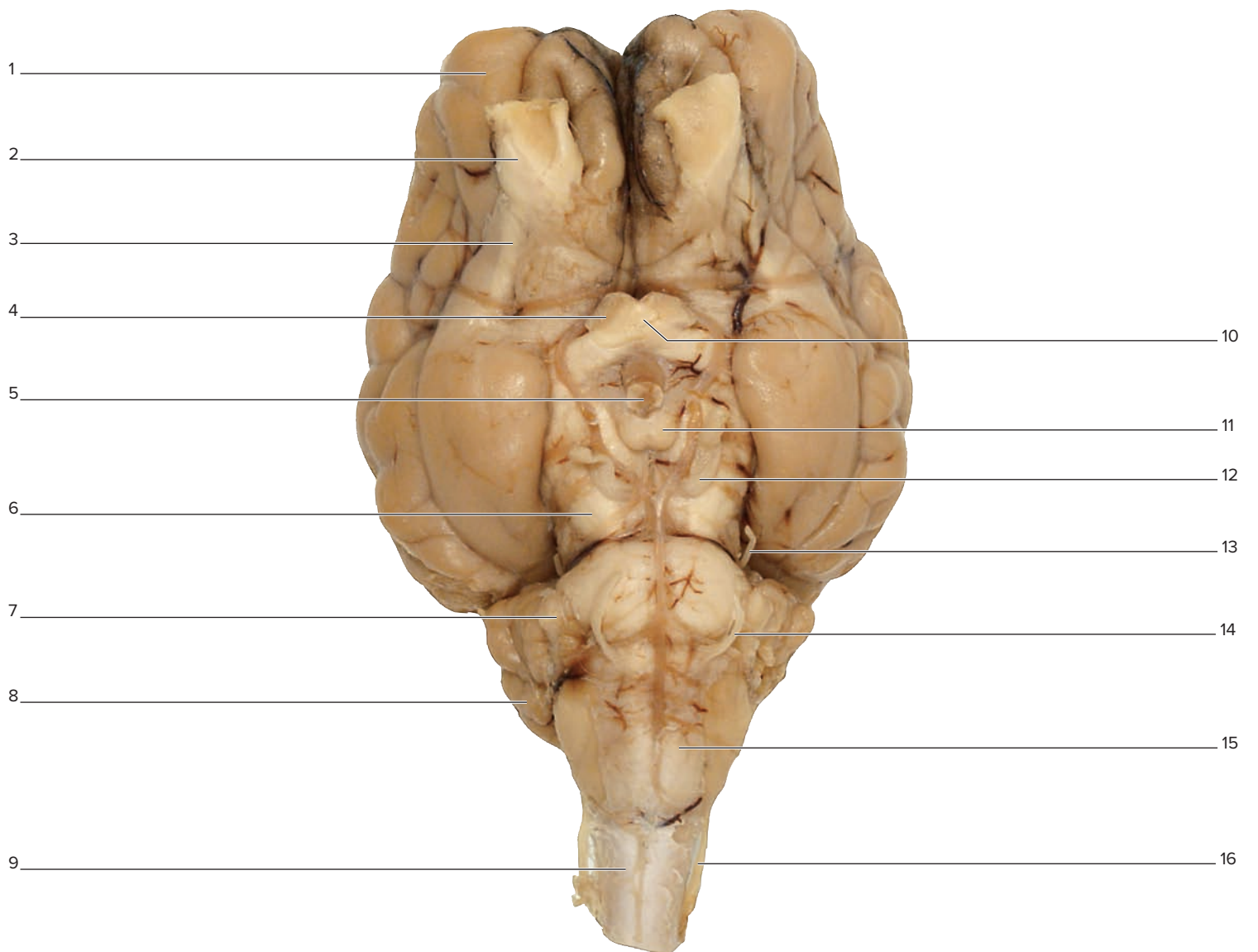**Exercise 24.10: Sheep Brain Dissection**

17. Label the following figure of a midsagittal section of a sheep brain. 13



© McGraw-Hill Education/Photo and Dissection by Christine Eckel

18. Label the following figure of the inferior view of a sheep brain. 13



© Christine Eckel



**Can You Apply What You've Learned?**

19. Match the following brain structures with the main region of the brain they are associated with by placing checks in the appropriate columns.

Area of the Brain	Brainstem	Cerebellum	Cerebrum	Diencephalon
<i>Arbor Vitae</i>				
<i>Cerebellar Cortex</i>				
<i>Cerebral Cortex</i>				
<i>Corpus Callosum</i>				
<i>Fourth Ventricle</i>				
<i>Hypothalamus</i>				
<i>Intermediate Mass</i>				
<i>Lateral Ventricles</i>				
<i>Medulla Oblongata</i>				
<i>Midbrain</i>				
<i>Pineal Gland</i>				
<i>Pons</i>				
<i>Tectal Plate</i>				
<i>Thalamus</i>				
<i>Third Ventricle</i>				
<i>Vermis</i>				

20. Describe the structural relationship between the optic nerves, optic chiasm, optic tract, hypothalamus, infundibulum, pituitary gland, and mammillary bodies.

---



---



---



---

21. You should have noticed that the tectal plate (corpora quadrigemina) is much larger in the sheep brain, relative to total brain size, than in the human brain. Using this information, answer the following questions:

a. What is the function of the superior colliculus?

---



---

b. What is the function of the inferior colliculus?

---



---

- c. What does the difference in size between the superior and inferior colliculi tell you about the influence this region of the brain has on the overall functioning of a sheep versus a human? (That is, compare how much influence this area of the brain has on control over body functions.)
- 

22. Compare and contrast structures of the human brain and those of the sheep brain. Complete the table with information about the relative size of the structure compared to the size of the entire brain. Then, based on function, explain why the structure might be more important for survival of the human or the sheep.

Brain Structure	Human Brain	Sheep Brain
<i>Frontal Lobe</i>		
<i>Inferior Colliculi</i>		
<i>Mammillary Bodies</i>		
<i>Medulla Oblongata</i>		
<i>Olfactory Bulbs</i>		
<i>Pineal Body (Gland)</i>		
<i>Superior Colliculi</i>		

23. What would be the effect of severing the corpus callosum?
- 

24. If the passage of fluid is blocked at the confluence of sinuses, into which sinuses will fluid back up?
- 

25. An **acoustic neuroma** is a tumor that arises from neurolemmocytes (Schwann cells) surrounding the vestibular portion of the vestibulocochlear nerve (CN VIII). The tumor is benign, but generally grows within the confined space of the petrous part of the temporal bone, thus compressing the nerve and creating problems with balance and hearing loss. What nerve other than CN VIII would you expect to be affected by this tumor (due to its close proximity)?
- 

26. When a light is shined into a patient's right eye, an examiner expects to see a change in pupil diameter in both eyes. The response, called the *consensual light reflex*, is used to test the function of two cranial nerves. The reflex involves one cranial nerve sending the afferent (sensory) signal toward the brain, and another cranial nerve sending the efferent (motor) signal out to the pupil.
- a. Which cranial nerve carries the afferent (sensory) signal to the brain? \_\_\_\_\_
- b. Which cranial nerve carries the efferent (motor) signal from the brain? \_\_\_\_\_

*This page intentionally left blank*

# The Spinal Cord and Spinal Nerves

# 25

## INTRODUCTION

When hearing that someone has fractured a vertebra in an accident, people most likely think of the worst-case scenario: “They are going to be paralyzed!” Though paralysis is common when the spinal cord is severed from damage at the fracture site itself, the amount of paralysis and subsequent loss of function is highly dependent upon what part of the spinal cord is injured.

The spinal cord transmits nerve signals between the body and the brain. An understanding of where nerve signals enter and exit the spinal cord is important for understanding the degree of paralysis that might result from trauma. For example, the most common vertebral fractures occur in the lower lumbar region (L<sub>3</sub>–L<sub>5</sub>). A fracture here cannot sever the spinal cord and rarely results in paralysis. The exercises in this chapter cover concepts that will explain why this is the case. In contrast, a fracture high in the vertebral column, such as between the atlas (C<sub>1</sub>) and axis (C<sub>2</sub>), is commonly fatal. Not because of paralysis or loss of sensation from the limbs, but because the nerve that controls the diaphragm (the phrenic nerve) can no longer stimulate the muscle to contract, and breathing ceases.

Injury to a spinal nerve or the peripheral nerves that branch from them are most often the result of peripheral

## OUTLINE AND LEARNING OBJECTIVES

### Histology 576

#### Spinal Cord Organization 576

##### EXERCISE 25.1: HISTOLOGICAL CROSS SECTIONS OF THE SPINAL CORD 576

- 1 Describe the organization of gray matter and white matter in the spinal cord
- 2 Identify spinal cord structures as seen in cross section when viewed with the microscope
- 3 Identify the cervical, thoracic, lumbar, and sacral parts of the spinal cord in histological cross section

### Gross Anatomy 579

#### The Spinal Cord 579

##### EXERCISE 25.2: GROSS ANATOMY OF THE SPINAL CORD 580

- 4 Compare and contrast the arrangement of the meninges covering the spinal cord and the brain
- 5 Identify the gross anatomical structures of the spinal cord on classroom models

#### Peripheral Nerves 582

##### EXERCISE 25.3: THE CERVICAL PLEXUS 582

- 6 Identify the phrenic nerve and describe its function

##### EXERCISE 25.4: THE BRACHIAL PLEXUS 583

- 7 Describe the organizational scheme of the brachial plexus
- 8 Identify the major nerves of the brachial plexus
- 9 Identify the nerves that innervate each compartment of the upper limb

##### EXERCISE 25.5: THE LUMBAR AND SACRAL PLEXUSES 586

- 10 Identify the major nerves of the lumbar plexus
- 11 Identify the nerves of the lumbar plexus that innervate each compartment of the lower limb
- 12 Identify the major nerves of the sacral plexus
- 13 Identify the nerves of the sacral plexus that innervate each compartment of the lower limb



nerve compression or irritation. Some familiar examples are *carpal tunnel syndrome*, which causes pain, weakness, or numbness in the hand, and *sciatica*, a condition in which pain or numbness occurs in the lower back, and may radiate to the buttock, posterior thigh, leg, and foot. Understanding these clinical conditions requires an appreciation for the organization of the spinal cord and spinal nerves.

The exercises in this chapter explore the structure and function of the spinal cord and spinal nerves, with a focus on major nerves of the body and the structures they serve.

Note that it may be necessary to look at more than one model to see all of the anatomic structures of the spinal cord and spinal nerves. For example, observing all the parts of the brachial plexus may require both

observing a model of the head, neck, and thorax and then viewing a model of the upper limb. As far as the spinal cord is concerned, understanding the cross-sectional anatomy of the spinal cord is critical for understanding the links between the central and peripheral nervous systems.

#### List of Reference Tables

Table 25.1	Regional Characteristics of the Spinal Cord	p. 578
Table 25.2	Histology of the Spinal Cord in Cross Section	p. 578
Table 25.3	Gross Anatomy of the Spinal Cord	p. 579
Table 25.4	Organization of the Brachial Plexus	p. 583
Table 25.5	Major Nerves of the Brachial Plexus	p. 585
Table 25.6	Major Nerves of the Lumbar Plexus	p. 587
Table 25.7	Major Nerves of the Sacral Plexus	p. 587

# Chapter 25: The Spinal Cord and Spinal Nerves

Name: \_\_\_\_\_

Date: \_\_\_\_\_ Section: \_\_\_\_\_

These Pre-laboratory Worksheet questions may be assigned by instructors through their **connect** course.

## PRE-LABORATORY WORKSHEET

1. Which of the following meningeal layers are found in both the brain and the spinal cord? (Check all that apply.)

- \_\_\_\_\_ a. arachnoid mater      \_\_\_\_\_ b. dura mater      \_\_\_\_\_ c. pia mater

2. Cerebrospinal fluid bathes the spinal cord by circulating within which of the following? (Check all that apply.)

- \_\_\_\_\_ a. central canal  
\_\_\_\_\_ b. epidural space  
\_\_\_\_\_ c. subarachnoid space  
\_\_\_\_\_ d. subdural space

3. Myelinated axons are found in the \_\_\_\_\_ (gray/white) matter of the spinal cord.

4. Both cranial and spinal nerves are part of the peripheral nervous system. \_\_\_\_\_ (True/False)

5. Which of the following sections of the spinal cord does not form a nerve plexus? (Circle one.)

- a. cervical      b. lumbar      c. sacral      d. thoracic

6. Match the common action listed in column A with the corresponding muscle compartment listed in column B.

### Column A

- \_\_\_\_\_ 1. adduction of the thigh  
\_\_\_\_\_ 2. dorsiflexion and inversion of the ankle  
\_\_\_\_\_ 3. eversion of the ankle  
\_\_\_\_\_ 4. extension of the hip, flexion of the knee  
\_\_\_\_\_ 5. extension of the knee, flexion of the hip  
\_\_\_\_\_ 6. plantar flexion and inversion of the ankle

### Column B

- a. anterior compartment of leg  
b. anterior compartment of thigh  
c. lateral compartment of leg  
d. medial compartment of thigh  
e. posterior compartment of leg  
f. posterior compartment of thigh

7. Which of the following plexuses is composed of rami, trunks, divisions, and cords? (Circle one.)

- a. brachial      b. cervical      c. lumbar      d. sacral

8. Match the nerve listed in column A with the corresponding plexus the nerve arises from listed in column B.

### Column A

- \_\_\_\_\_ 1. femoral nerve  
\_\_\_\_\_ 2. median nerve  
\_\_\_\_\_ 3. phrenic nerve  
\_\_\_\_\_ 4. tibial nerve

### Column B

- a. brachial plexus  
b. cervical plexus  
c. lumbar plexus  
d. sacral plexus

9. Somatic motor neurons are found in the \_\_\_\_\_ (anterior/posterior) horn of the spinal cord.

10. Somatic sensory neurons are structurally classified as \_\_\_\_\_ (bipolar/multipolar/unipolar) neurons.

11. Somatic motor neurons are structurally classified as \_\_\_\_\_ (bipolar/multipolar/unipolar) neurons.

## Histology

### Spinal Cord Organization

Recall that the brain consists of an outer cortex of gray matter and an inner core of white matter (with some nuclei of gray matter as well). The spinal cord is organized just the opposite, with an outer cortex of white matter surrounding an inner core of gray matter. The gray matter of the spinal cord is organized into horns, so named because of their appearance. **Posterior horns** contain axons from somatic sensory neurons that enter the spinal cord through the posterior roots as well as the cell bodies of interneurons (association neurons). **Anterior horns** contain dendrites and cell bodies of somatic motor neurons, whose axons exit the spinal cord through the anterior roots. **Lateral horns**, located only in the thoracic region and first 2 lumbar segments of the spinal cord, contain dendrites and cell bodies of visceral motor neurons, whose axons exit the spinal cord through the anterior roots and extend to visceral effectors (smooth muscle, cardiac muscle, and glands).

The **gray commissure** is a horizontal bar of gray matter that surrounds the narrow central canal. The white matter on each side of the spinal cord is partitioned into three **funiculi** (*funis*, cord) and are identified based on their anatomic position: posterior funiculus, lateral funiculus, and anterior funiculus. Each funiculus is composed of myelinated axons that transmit nerve signals between the brain and the body. The anterior funiculi are interconnected by the **white commissure**.

The spinal cord varies in diameter in different regions. It is the largest in the cervical (called the **cervical enlargement**) and lumbar region (called the **lumbar enlargement**). These enlargements exist because of the increased number of neuron cell bodies in these regions that make the additional connections to the upper and lower limbs, respectively. Make note of similarities and differences between the organization of gray matter and white matter in the spinal cord as compared to the brain.


### EXERCISE 25.1 Histological Cross Sections of the Spinal Cord

1. Obtain histology slides containing cross sections of the spinal cord (**figure 25.1**).
2. Begin by observing each slide with the naked eye and attempt to identify the different regions of the spinal cord (cervical, thoracic, lumbar, and sacral) based on cross-sectional area and relative amounts of gray vs. white matter. **Table 25.1** compares the general characteristics of tissue sections from each spinal cord region, and **table 25.2** summarizes the features observed in a typical spinal cord cross section.
3. Place the slide on the microscope stage and bring the tissue sample into focus on low power.
4. Identify the listed structures on the histology slide of the spinal cord, using figure 25.1, tables 25.1 and 25.2 and the textbook as guides:
5. Sketch a cross section of each spinal cord region in the spaces provided, making note of the major differences between the regions.

*Cervical*




*Thoracic*



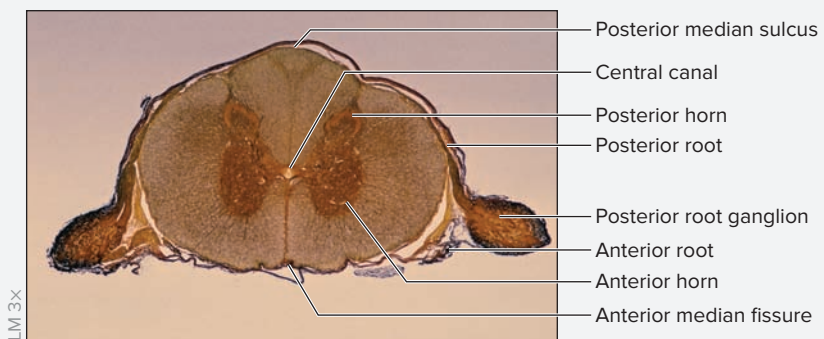
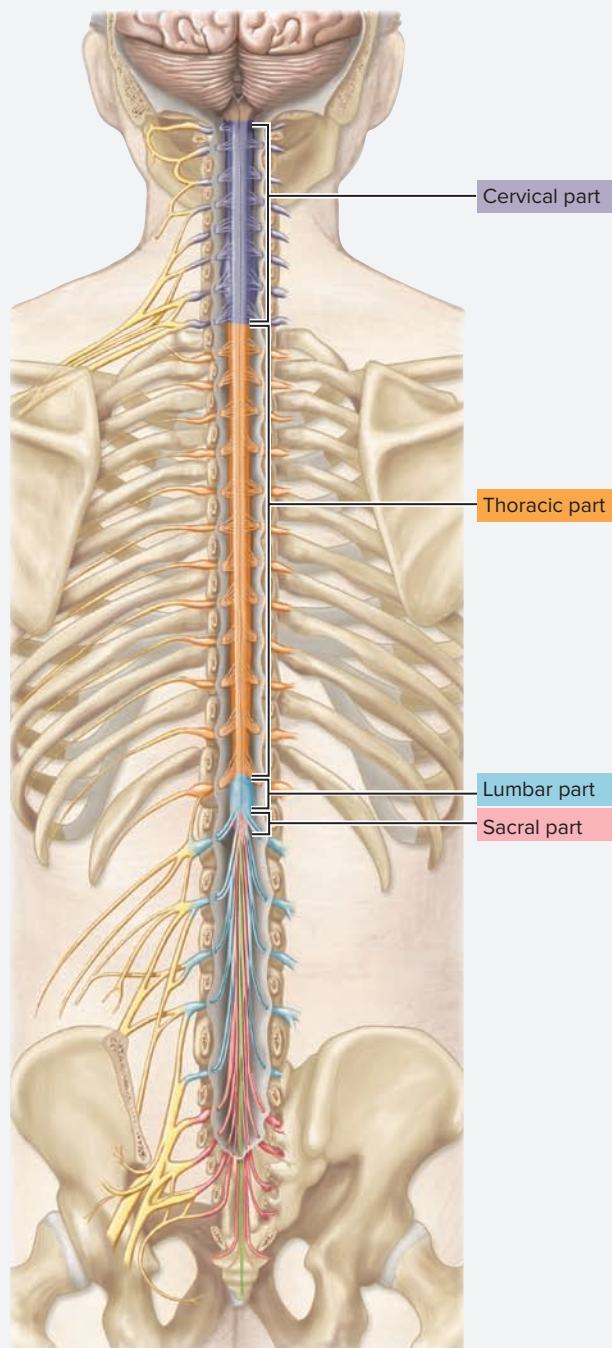
*Lumbar*



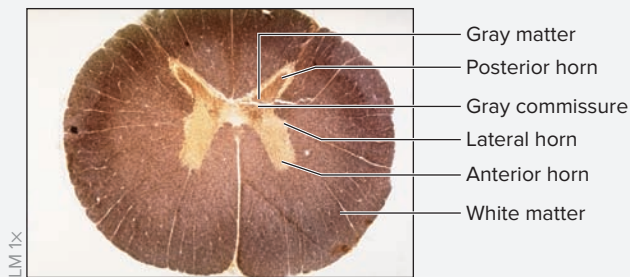*Sacral*



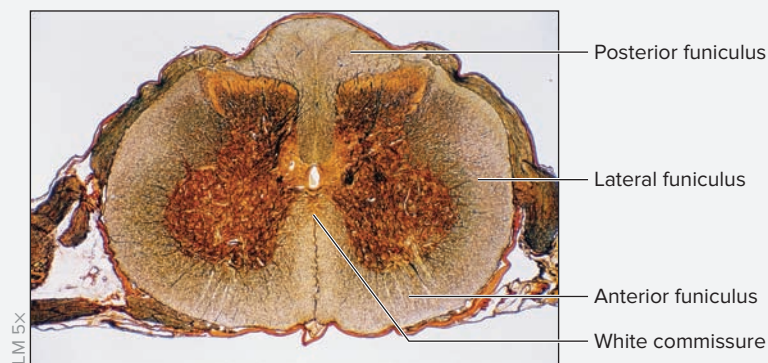- |  |  |
|--|--|
| <input type="checkbox"/> anterior funiculus          | <input type="checkbox"/> posterior funiculus     |
| <input type="checkbox"/> anterior horn               | <input type="checkbox"/> posterior horn          |
| <input type="checkbox"/> anterior median fissure     | <input type="checkbox"/> posterior median sulcus |
| <input type="checkbox"/> anterior root               | <input type="checkbox"/> posterior root          |
| <input type="checkbox"/> central canal               | <input type="checkbox"/> posterior root ganglion |
| <input type="checkbox"/> gray commissure             | <input type="checkbox"/> white commissure        |
| <input type="checkbox"/> gray matter                 | <input type="checkbox"/> white matter            |
| <input type="checkbox"/> lateral funiculus           |  |
| <input type="checkbox"/> lateral horn                |  |
| <input type="checkbox"/> nerve roots of cauda equina |  |



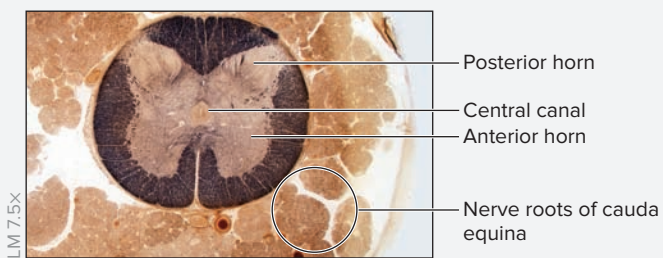
(a) Cervical



(b) Thoracic



(c) Lumbar



(d) Sacral

**Figure 25.1** Regional Histology of the Spinal Cord in Cross Section.

(a, c) © Ed Reschke; (b) © Lester V. Bergman/Corbis (d) © McGraw-Hill Education/Al Telser

### Learning Strategy

One way to correctly distinguish anterior from posterior horns is to remember that *posterior* horns reach all the way to the *back*. That is, in the posterior horns the gray matter extends all the way to the edge of the spinal cord, whereas in the anterior horns the gray matter does not extend to the edge of the spinal cord.

(continued on next page)



(continued from previous page)

Region of the Spinal Cord	Relative Size	Predominant Tissue	Word Origins
<i>Cervical</i>	Relatively large cross-sectional area due to an abundance of nerves entering and exiting from the cervical and brachial plexuses.	White matter	<i>cervix</i> , neck
<i>Thoracic</i>	Relatively small cross-sectional area. A distinguishing feature is the presence of lateral horns, which contain the cell bodies of sympathetic motor neurons.	White matter	<i>thorax</i> , chest
<i>Lumbar</i>	The largest cross-sectional area, due to an abundance of nerves entering and exiting from the lumbar and sacral plexuses. The anterior horns are large.	Gray matter	<i>lumbus</i> , loin
<i>Sacral</i>	The smallest cross-sectional area. Cross-sections of numerous nerve roots surrounding the spinal cord are usually visible if the section goes through both the spinal cord and the roots of the cauda equina, which run adjacent to the spinal cord.	Gray matter	<i>sacer</i> , sacred

Structure	Description	Word Origins
<b>WHITE MATTER</b>	Outer portion of the spinal cord consisting of bundles of myelinated axons organized into tracts.	literally, a substance that appears white in color
<i>Anterior Funiculus</i>	Tracts of white matter that occupy the anterior region of the spinal cord between the anterior gray horn and the anterior median fissure.	<i>anterior</i> , the front, + <i>funis</i> , cord
<i>Lateral Funiculus</i>	Tracts of white matter that occupy each lateral side of the spinal cord.	<i>latus</i> , to the side, + <i>funis</i> , cord
<i>Posterior Funiculus</i>	Tracts of white matter that occupy the posterior region of the spinal cord between the posterior gray horn and the posterior median sulcus.	<i>posterior</i> , the back, + <i>funis</i> , cord
<i>White Commissure</i>	White matter that interconnects the anterior funiculi.	<i>commissura</i> , a seam
<b>GRAY MATTER</b>	Butterfly-shaped inner region of the spinal cord. It contains cell bodies of motor neurons or interneurons, depending upon the location.	literally, a substance that appears gray in color
<i>Anterior Horns</i>	Gray matter on the anterolateral part of the spinal cord that primarily houses the cell bodies of somatic motor neurons (neurons that extend to skeletal muscle).	<i>anterior</i> , the front, + <i>horn</i> , resembling a horn in shape
<i>Lateral Horns</i>	Small lateral extensions of gray matter found in the T <sub>1</sub> –L <sub>2</sub> region of the spinal cord, and containing cell bodies of visceral motor neurons (neurons that extend to smooth muscle, cardiac muscle, and glands).	<i>latus</i> , to the side, + <i>horn</i> , resembling a horn in shape
<i>Posterior Horns</i>	Gray matter on the posterolateral part of the spinal cord that primarily houses the axons of sensory neurons and the cell bodies of interneurons (neurons contained completely within the central nervous system).	<i>posterior</i> , the back, + <i>horn</i> , resembling a horn in shape
<i>Gray Commissure</i>	A horizontal bar of gray matter that surrounds the central canal.	<i>commissura</i> , a seam
<b>OTHER</b>		
<i>Anterior Median Fissure</i>	Deep groove on the anterior surface of the spinal cord.	<i>anterior</i> , the front, + <i>median</i> , the middle, + <i>fissure</i> , a deep furrow
<i>Central Canal</i>	Small channel within the gray commissure of the spinal cord that is continuous with the ventricles of the brain; appears as a hole in a microscopic slide of the spinal cord.	<i>central</i> , in the center, + <i>canalis</i> , a duct or channel
<i>Posterior Median Sulcus</i>	Shallow groove located on the posterior surface of the spinal cord.	<i>posterior</i> , the back, + <i>median</i> , the middle, + <i>sulcus</i> , a furrow

## Gross Anatomy

### The Spinal Cord

The spinal cord, part of the central nervous system, is surrounded by the same three meninges that surround the brain: the dura mater, arachnoid mater, and pia mater (figures 25.2 and 25.3). The dura mater surrounding the spinal cord consists of only a single layer of tissue, whereas the dura mater surrounding the brain consists of two layers (periosteal dura and meningeal dura). In addition, there are two structures that help stabilize the spinal cord within the vertebral canal: the denticulate ligaments and

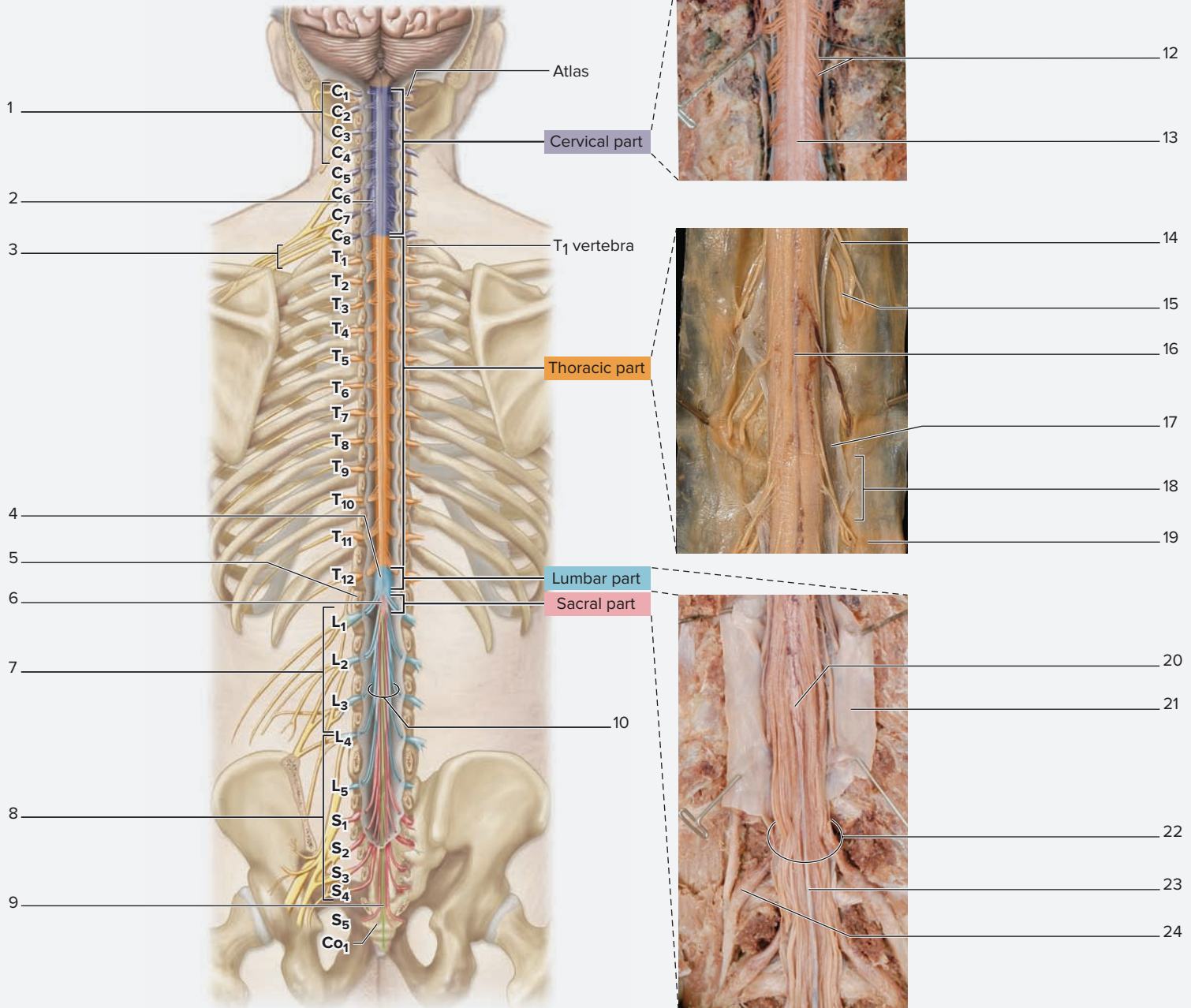
the filum terminale. **Denticulate ligaments** are extensions of the pia mater that anchor the spinal cord to the arachnoid mater and dura mater at regular intervals all along the length of the spinal cord. The **filum terminale** is an extension of the pia mater at the caudal end of the spinal cord that anchors it inferiorly to the coccyx. **Table 25.3** lists some of the key features of the spinal cord that you will identify upon gross observation, and describes their functions.

Structure	Description	Word Origins
<i>Anterior (Motor) Root*</i>	A nerve root exiting the ventrolateral surface of the spinal cord that contains axons of somatic motor neurons and visceral motor neurons.	<i>anterior</i> , the front, + <i>root</i> , the beginning part
<i>Cauda Equina</i>	A collection of anterior and posterior roots that extend inferiorly from the lumbar and sacral parts of the spinal cord and lie within the vertebral canal. It is named for the fact that the bundle of nerve roots resembles a horse's tail.	<i>cauda</i> , tail, + <i>equinus</i> , horse
<i>Conus Medullaris</i>	The cone-shaped distal tip of the spinal cord.	<i>konos</i> , cone, + <i>medius</i> , middle
<i>Denticulate Ligaments</i>	Extensions of the pia mater located between anterior and posterior roots. These "ligaments" anchor the spinal cord to the arachnoid and dura mater at intervals between the locations where anterior and posterior roots pierce the dura mater.	<i>denticulus</i> , a small tooth, + <i>ligamentum</i> , a bandage
<i>Filum Terminale</i>	An extension of pia mater that extends beyond the distal end of the spinal cord. It begins at the conus medullaris and attaches to the distal end of the dura mater at the coccyx.	<i>filum</i> , thread, + <i>terminatio</i> , ending
<i>Posterior (Sensory) Root*</i>	A nerve root exiting the posterolateral surface of the spinal cord that contains axons of somatic sensory neurons.	<i>posterior</i> , the back, + <i>root</i> , the beginning part
<i>Posterior Root Ganglion*</i>	A swelling on the posterior root that contains cell bodies of somatic sensory neurons and satellite cells (glial cells).	<i>posterior</i> , the back, + <i>root</i> , the beginning part, + <i>ganglion</i> , a swelling
<i>Rootlets (Radicular Fila)</i>	Small branches of nerve fibers coming off of the spinal cord that come together to form the anterior and posterior roots.	<i>radicula</i> , a spinal nerve root, + <i>filum</i> , thread

\*The anterior root is also known as the ventral root. The posterior root is also known as the dorsal root.

**EXERCISE 25.2** Gross Anatomy of the Spinal Cord

1. Observe a whole spinal cord from a cadaver (meninges intact) or a model of the spinal cord.
2. Identify the structures listed in figure 25.2 on a human spinal cord or a model of the spinal cord, using table 25.3 and the textbook as guides. Then label them in figure 25.2.



**Figure 25.2** Regional Gross Anatomy of the Spinal Cord. Use the terms listed to fill in the numbered labels in the figure. Some answers may be used more than once.

- |   |   |  |  |
|---|---|--|--|
| <input type="checkbox"/> anterior roots       | <input type="checkbox"/> cervical plexus      | <input type="checkbox"/> L <sub>1</sub> vertebra | <input type="checkbox"/> posterior root ganglion |
| <input type="checkbox"/> brachial plexus      | <input type="checkbox"/> conus medullaris     | <input type="checkbox"/> lumbar plexus           | <input type="checkbox"/> posterior rootlets      |
| <input type="checkbox"/> brain (cerebellum)   | <input type="checkbox"/> denticulate ligament | <input type="checkbox"/> lumbosacral enlargement | <input type="checkbox"/> posterior roots         |
| <input type="checkbox"/> cauda                | <input type="checkbox"/> dura mater           | <input type="checkbox"/> pia mater               | <input type="checkbox"/> sacral plexus           |
| <input type="checkbox"/> cervical enlargement | <input type="checkbox"/> filum terminale      | <input type="checkbox"/> posterior median sulcus |  |

3. Observe a model of a cross section of the spinal cord.
  4. Identify the structures listed in figure 25.3 on the spinal cord model, using tables 25.2 and 25.3 and the textbook as guides. Then label them in figure 25.3.
  5. Describe key features on the anterior and posterior surface of the spinal cord (as seen in cross section) that distinguish the anterior surface from the posterior surface in the spaces provided.
6. *Optional Activity: AP|R Nervous System*—Watch the “Typical Spinal Nerve” animation to help you visualize how spinal nerves relate to the spinal cord.

**WHAT DO YOU THINK?**

- 1 If a posterior root is severed, what loss of function will result?

---



---



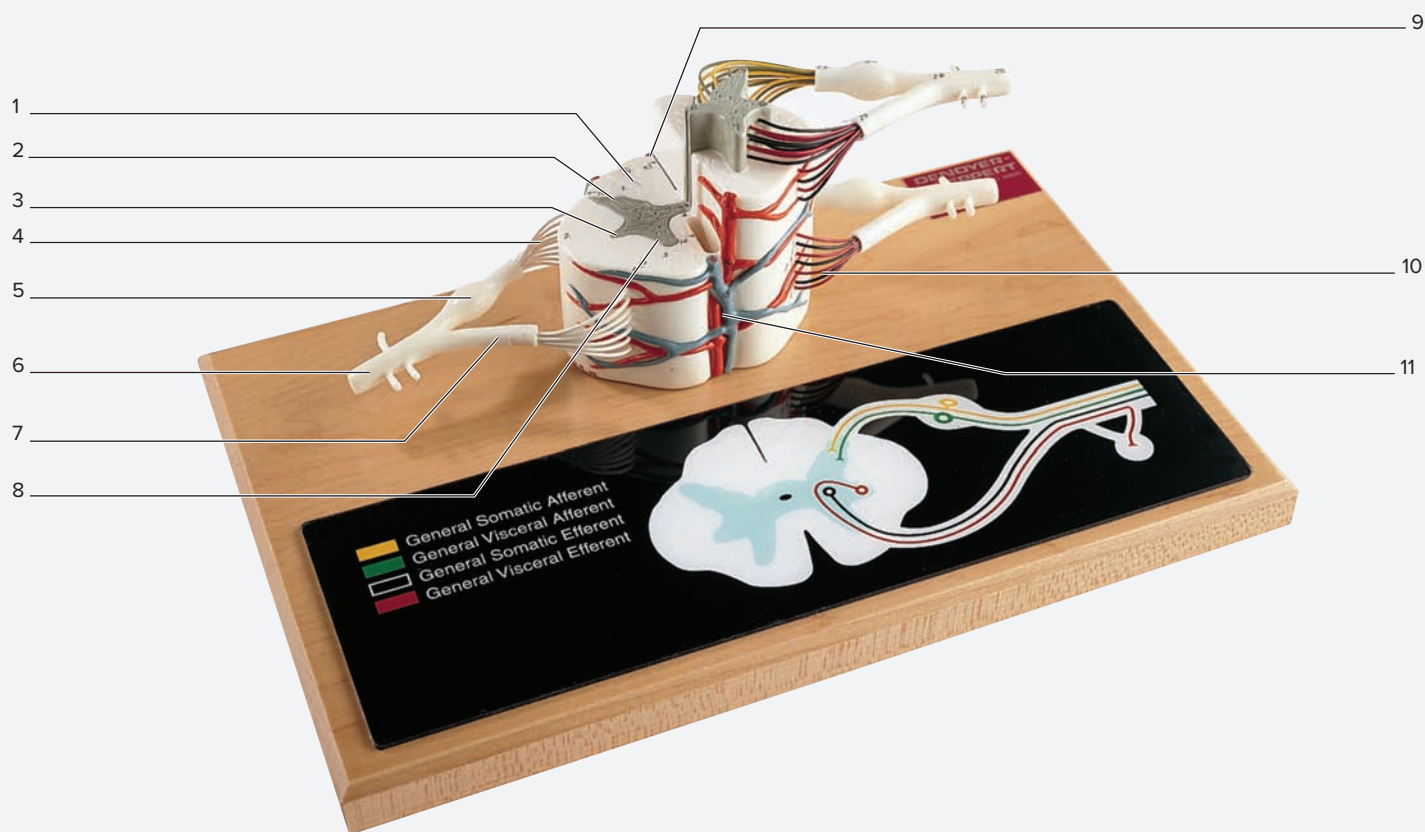
---



---



---



**Figure 25.3 Model of a Spinal Cord in Cross Section.** Use the terms listed to fill in the numbered labels in the figure.

- |  |  |  |   |
|--|--|--|---|
| <input type="checkbox"/> anterior horn           | <input type="checkbox"/> anterior rootlets   | <input type="checkbox"/> posterior horn          | <input type="checkbox"/> posterior rootlets |
| <input type="checkbox"/> anterior median fissure | <input type="checkbox"/> lateral horn        | <input type="checkbox"/> posterior median sulcus | <input type="checkbox"/> spinal nerve       |
| <input type="checkbox"/> anterior root           | <input type="checkbox"/> posterior funiculus | <input type="checkbox"/> posterior root ganglion |   |

## Peripheral Nerves

The peripheral nervous system consists of cranial nerves and spinal nerves. The structure and function of the cranial nerves was covered in chapter 24. The exercises in this chapter involve investigations into the structure and function of the **spinal nerves**. After spinal nerves exit the vertebral canal through intervertebral foramina, they immediately branch into posterior and anterior **rami**. The **posterior rami** innervate skin and muscles of the back that move the vertebral column (this excludes muscles located on the back that move the pectoral girdle and upper limb). In comparison, the structures innervated by the anterior rami depend upon

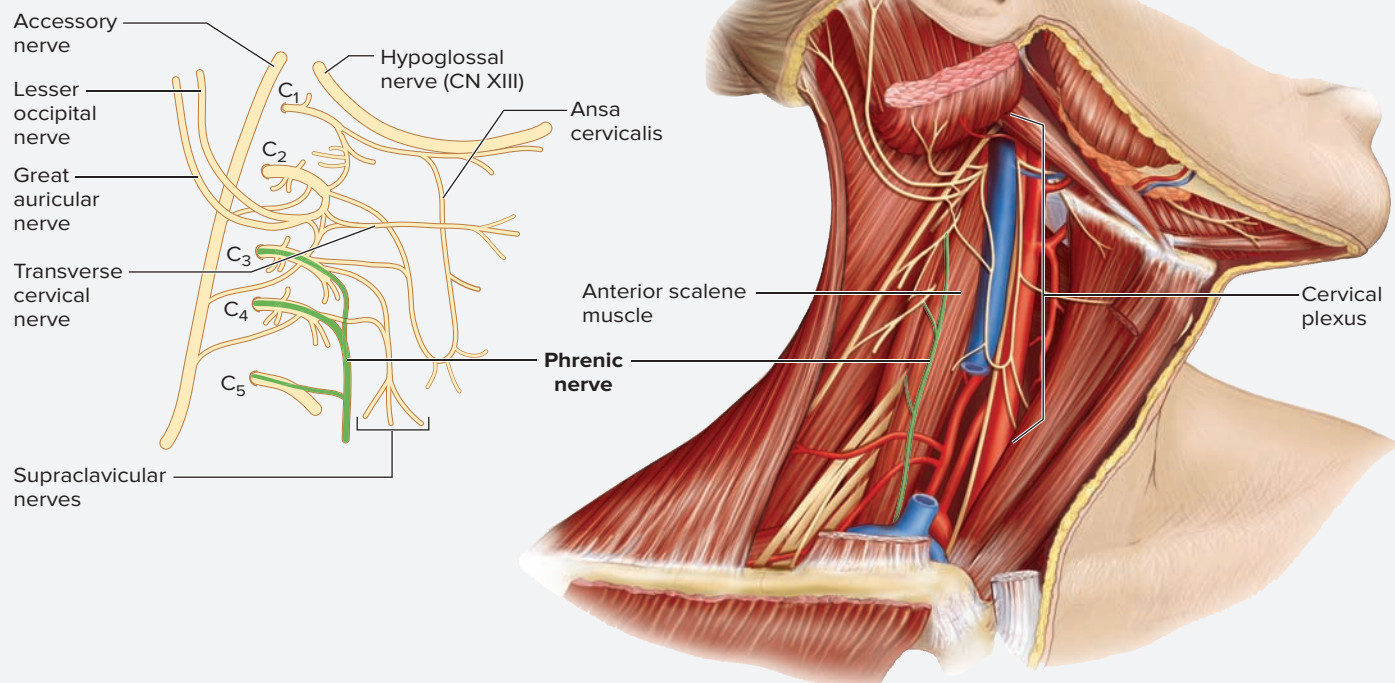
the location at which these rami extend from the vertebral column. In the thoracic region of the vertebral column, the **anterior rami** become **intercostal nerves** that supply skin, bone, and muscle of the thoracic cage. The anterior rami form complex networks called **plexuses** (*plexus*, a braid), which then branch to form peripheral nerves that innervate skin, muscle, and bones of the limbs in the cervical, lumbar, and sacral regions of the vertebral column. There are four major nerve plexuses: cervical, brachial, lumbar, and sacral. The laboratory exercises in this chapter guide the student in investigating each of these plexuses and exploring the major peripheral nerves that arise from each plexus.

### EXERCISE 25.3 The Cervical Plexus

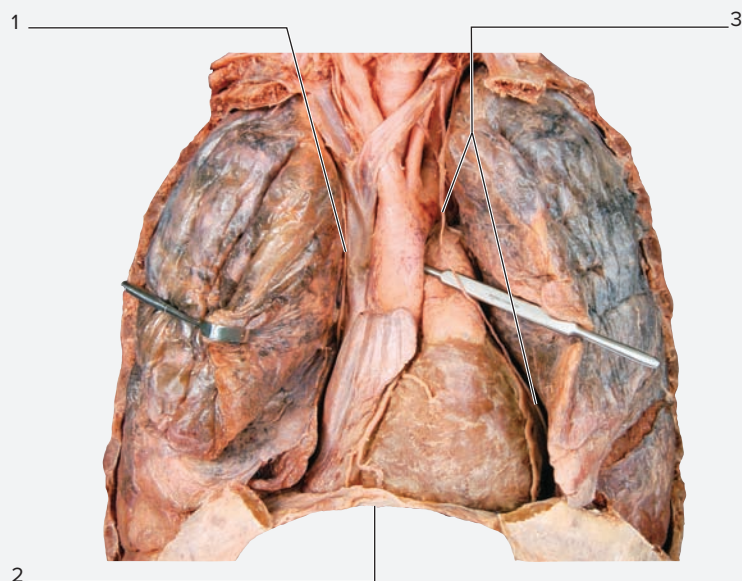
The cervical plexus arises from the anterior rami of spinal nerves C<sub>1</sub>–C<sub>4</sub>. Most of the nerves arising from the cervical plexus carry sensory information from skin on the lateral side of the neck and portions of the head and shoulders. Some nerves also carry motor information to anterior neck muscles. Perhaps the single most important nerve arising from the cervical plexus is the **phrenic nerve**, which innervates the diaphragm (*phrenic*, relating to the diaphragm or mind—historically the diaphragm was thought to be the seat of the mind). The phrenic nerves can be seen on the inferior part of the anterior scalene muscles, but they are difficult to identify in this location (**figure 25.4**). The nerves are most easily identified within the thoracic cavity (**figure 25.5**). Here they travel within the mediastinum, between the pleural and pericardial cavities. If

the heart or lungs have been removed from the cadaver, the phrenic nerves will be easy to identify (if they are still intact). If a model of the thorax is used to identify the phrenic nerves, look at the location where the pleural and pericardial cavities meet to locate the phrenic nerves.

1. Observe a prosected human cadaver or a model of the head, neck, and thorax demonstrating nerves of the cervical plexus.
2. Using your textbook as a guide, identify the structures listed in figure 25.5 on a human cadaver or a human torso model, using the textbook as a guide. Then label them in figure 25.5.



**Figure 25.4** The Cervical Plexus and Phrenic Nerve in the Posterior Triangle of the Neck.



**Figure 25.5** The Phrenic Nerves in the Thoracic Cavity. Use the terms listed to fill in the numbered labels in the figure.

- diaphragm                       right phrenic nerve
- left phrenic nerve

© McGraw-Hill Education/Photo and Dissection by Christine Eckel

### Learning Strategy

The phrenic nerve arises from the anterior rami of spinal nerves C<sub>3</sub>–C<sub>5</sub>, with the majority of fibers coming from C<sub>4</sub>. A handy way to remember this is, “C<sub>3</sub>, C<sub>4</sub>, and C<sub>5</sub> keep the body alive.” If the phrenic nerves are unable to stimulate the diaphragm, breathing will cease and death will follow.

### WHAT DO YOU THINK?

- 2 As relates to spinal cord injuries, what is an advantage of having the phrenic nerve arise from the cervical plexus instead of arising from the thoracic part of the spinal cord (even though the thoracic spinal cord is closer in physical location to the diaphragm)?

## EXERCISE 25.4 The Brachial Plexus

The **brachial plexus** arises from the anterior rami of spinal nerves C<sub>5</sub>–T<sub>1</sub>. The overall organization of the brachial plexus is complex, but follows an organized pattern. The branching pattern of the brachial plexus will be explored in detail in this laboratory exercise. However, note that the branching pattern of the brachial plexus is unique to the brachial plexus. Other plexuses (cervical, lumbar, and sacral) have their own branching patterns, which will not be explored in detail in this chapter.

1. Observe a prosected human cadaver or a model of the axilla and upper limb demonstrating nerves of the brachial plexus. The organization of the brachial plexus is summarized in **table 25.4**.
2. The focus of this exercise is on identification of the **trunks**, **cords** and **branches** of the brachial plexus. The brachial plexus starts out as three trunks, which pass between the anterior and middle scalene muscles of the neck. The **superior trunk** forms from the anterior rami of C<sub>5</sub> and C<sub>6</sub>, the **middle trunk** is a continuation of the anterior ramus of C<sub>7</sub>, and the **inferior trunk** forms from the anterior rami of C<sub>8</sub> and T<sub>1</sub>. Each trunk divides into two **divisions**: one anterior and one posterior. All posterior divisions come together to form the **posterior cord**, and all anterior divisions come together to form the **medial cord** and **lateral cords**. The cords are named for their location relative to the axillary artery.

Structure	Description	Number	Names
<b>Rami</b>	These are the anterior rami of cervical spinal nerves. The rami combine to form trunks as they pass between the anterior and medial scalene muscles of the neck.	5	C <sub>5</sub> , C <sub>6</sub> , C <sub>7</sub> , C <sub>8</sub> , T <sub>1</sub>
<b>Trunks</b>	Located between the anterior and middle scalene muscles of the neck.	3	Superior, middle, inferior
<b>Divisions</b>	Each trunk divides into an anterior and posterior division. The posterior divisions of each trunk come together to form the posterior cord. The anterior divisions of each trunk come together to form the medial and lateral cords.	6	Anterior and posterior division (for each trunk)
<b>Cords</b>	Located in the axilla and named for their location relative to the axillary artery.	3	Medial, lateral, and posterior
<b>Branches (Terminal Nerves)</b>	Each terminal nerve innervates a compartment of the arm or forearm, with the exception of the median and ulnar nerves, which both innervate the anterior compartment of the forearm.	5	Axillary, radial, musculocutaneous, median, ulnar

(continued on next page)

(continued from previous page)

- The best way to identify the terminal **branches** that arise from the medial and lateral cords of the brachial plexus (the musculocutaneous, median, and ulnar nerves) is to first locate the medial and lateral cords around the axillary artery and then spread apart the terminal branches that arise from the cords. Notice that the connections between the cords and branches appear to form a letter ‘M’ (**figure 25.6**).

### Learning Strategy

The segments of the brachial plexus, from proximal to distal, are **R**ami, **T**runks, **D**ivisions, **C**ords, and **B**ranches. A mnemonic for remembering this is, “**R**eally **T**ired, **D**rink **C**offee—**B**lack.” Another mnemonic is, “**R**andy **T**ravis **D**rinks **C**old **B**eer.”







- The Posterior Cord:** There are only two major nerves that arise from the posterior cord (**table 25.5**): the **axillary nerve**, which remains in the axillary region to innervate the deltoid and teres minor muscles; and the **radial nerve**, a large nerve that continues to travel posteriorly along the arm and forearm to innervate skin and muscle along the way (thus, a nerve from the *posterior* cord innervates all structures in the *posterior* compartments of the arm and forearm, including the triceps brachii muscle).
- The Medial and Lateral Cords:** The medial and lateral cords form three main terminal nerves: the musculocutaneous,

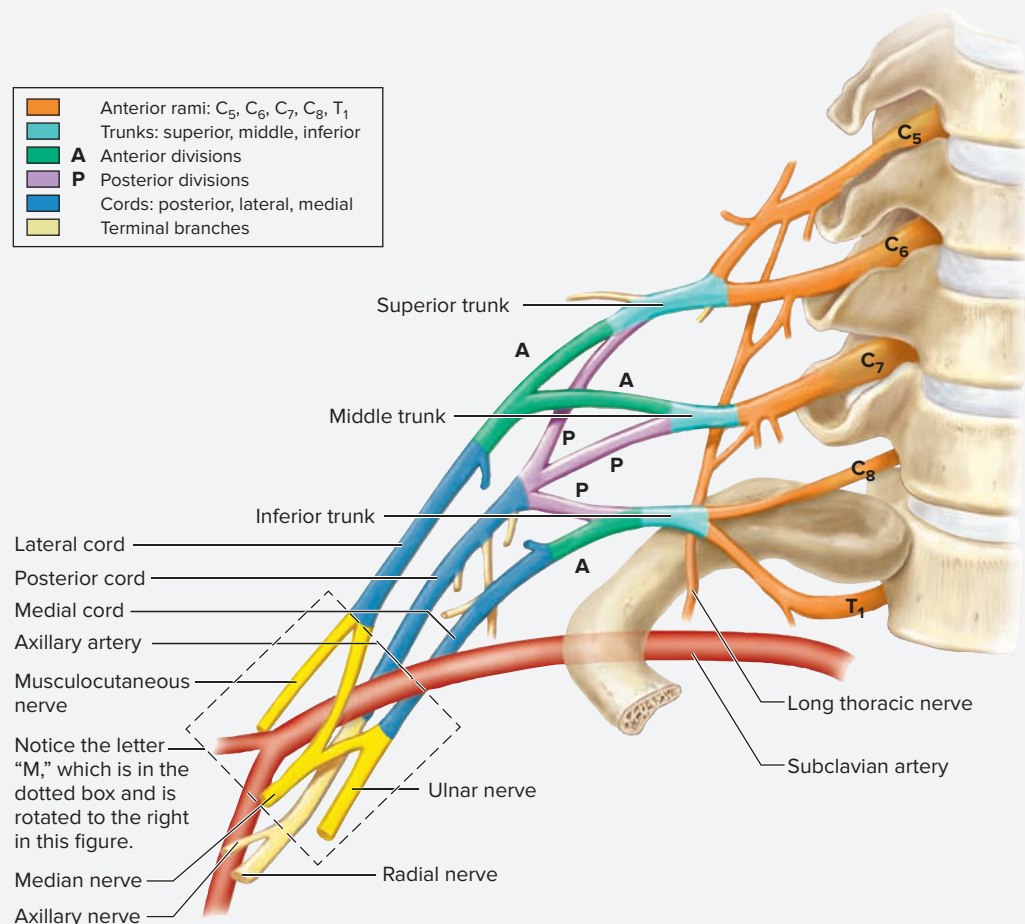
median, and ulnar nerves. The **musculocutaneous nerve** extends from the lateral cord and innervates muscles of the anterior compartment of the arm (biceps brachii, coracobrachialis, and brachialis). It is most easily identified where it pierces through the coracobrachialis muscle. The **ulnar nerve** extends from the medial cord and innervates muscles on the ulnar surface of the forearm along with most intrinsic muscles of the hand. The ulnar nerve is most easily identified where it passes superficially behind the medial epicondyle of the humerus. In this location it is vulnerable to injury. When it is struck, as when the elbow is accidentally banged against a counter, or other surface, a tingling sensation is often felt along the course of the nerve. For this reason, this region of the elbow supplied by the ulnar nerve is commonly referred to as the “funny bone.” The **median nerve** extends from branches of both medial and lateral cords. The median nerve is most easily identified in the distal, anterior compartment of the wrist, where it passes through the **carpal tunnel** into the hand. If observing the brachial plexus on a cadaver, try to pass a blunt probe through the carpal tunnel alongside the median nerve. The median nerve is easily irritated by repetitive motions of the wrist because its passage through the carpal tunnel is very narrow. As the flexor muscles of the forearm contract, their tendons can rub against the median nerve, causing inflammation that results in **carpal tunnel syndrome**.

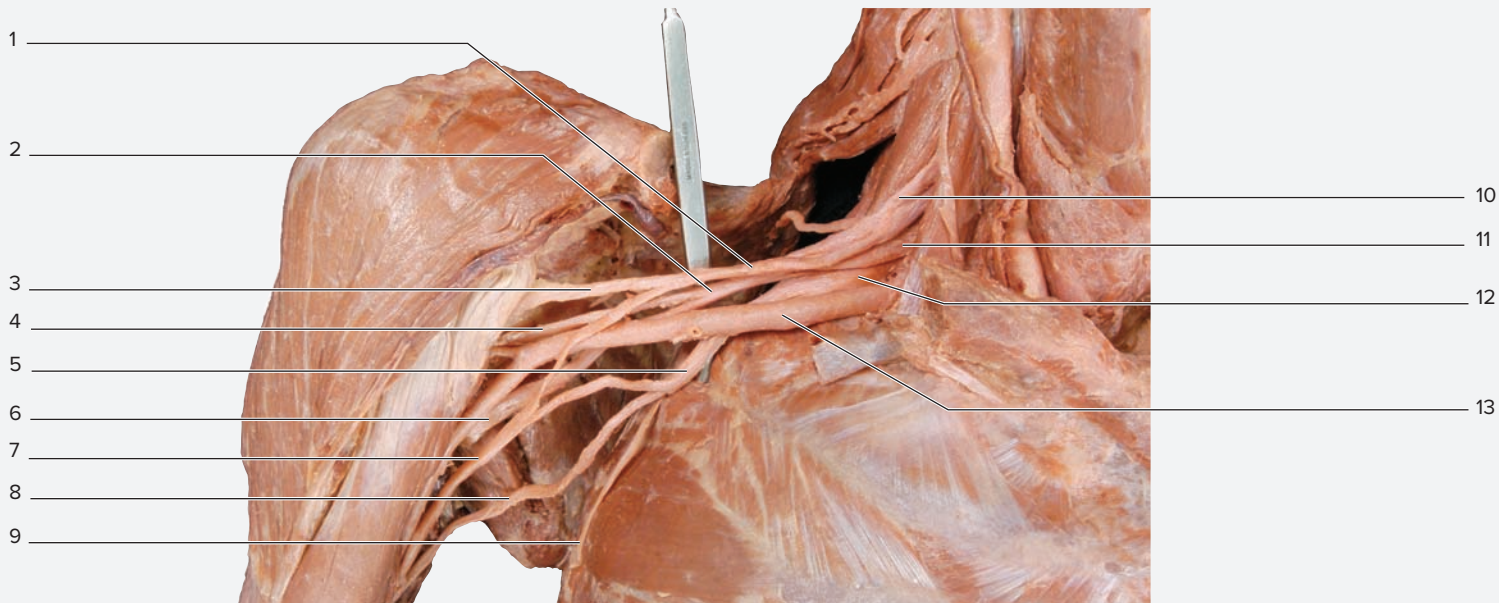
- Identify the structures of the brachial plexus listed in **figure 25.7** on a human cadaver or on models of the upper limb, using tables 25.4 and 25.5, and the textbook as guides. Then label them in figure 25.7.

### Figure 25.6 Organizational Scheme of the Brachial Plexus

Notice that the terminal branches of the medial and lateral cords come together to form the letter “M” (dotted box), which is rotated to the right in this figure.

	Anterior rami: C <sub>5</sub> , C <sub>6</sub> , C <sub>7</sub> , C <sub>8</sub> , T <sub>1</sub>
	Trunks: superior, middle, inferior
	<b>A</b> Anterior divisions
	<b>P</b> Posterior divisions
	Cords: posterior, lateral, medial
	Terminal branches





Right axilla, anterior view

**Figure 25.7 Major Nerves of the Brachial Plexus.** Use the terms listed to fill in the numbered labels in the figure. Some answers may be used more than once.

- axillary artery
- axillary nerve
- inferior trunk
- lateral cord
- long thoracic nerve
- medial cord
- median nerve
- middle trunk
- musculocutaneous nerve
- posterior cord
- radial nerve
- superior trunk
- ulnar nerve

© McGraw-Hill Education/Photo and Dissection by Christine Eckel

Table 25.5 Major Nerves of the Brachial Plexus				
Nerve	Description	Motor Innervation	Sensory Innervation	Word Origins
<b>Axillary</b> (C <sub>5</sub> -C <sub>6</sub> )	Arises from the posterior cord and runs around the surgical neck of the humerus en route to the shoulder. It can be easily injured when the surgical neck of the humerus is fractured.	Deltoid and teres minor	Skin on the dorsolateral aspect of the shoulder	<i>axilla</i> , the armpit
<b>Long thoracic</b> (C <sub>5</sub> -C <sub>7</sub> )	Arises from the roots of C <sub>5</sub> , C <sub>6</sub> , and C <sub>7</sub> and runs superficial to the serratus anterior muscle, which predisposes it to injury.	Serratus anterior	None	<i>longus</i> , long, + <i>thoracis</i> , relating to the thorax
<b>Median</b> (C <sub>5</sub> -T <sub>1</sub> )	Arises from both the medial and lateral cords. Runs along the anteriomedial aspect of the arm, passes deep to the bicipital aponeurosis in the cubital fossa, then enters the forearm. After passing through the forearm, it courses deep to the flexor retinaculum through the carpal tunnel and into the hand. The tight passage through the carpal tunnel predisposes the nerve to injury (carpal tunnel syndrome).	Anterior compartment of the forearm except for the flexor carpi ulnaris and ulnar half of the flexor digitorum profundus	Skin of the lateral three and one-half digits on the palmar surface of the hand (and the distal aspect of the same digits on the dorsal surface), skin of the medial palm proximal to its innervation of the digits	<i>median</i> , in the middle
<b>Musculocutaneous</b> (C <sub>5</sub> -C <sub>7</sub> )	Arises from both the medial and lateral cords of the brachial plexus. It pierces through the coracobrachialis muscle and then runs between the brachialis and biceps brachii muscles.	Anterior compartment of the arm; biceps brachii, brachialis, and coracobrachialis	Skin overlying the lateral surface of the forearm	<i>musculus</i> , a mouse (muscle), + <i>cutaneous</i> , relating to the skin
<b>Radial</b> (C <sub>5</sub> -T <sub>1</sub> )	Arises from the posterior cord and runs deep within the posterior compartment of the arm adjacent to the humerus.	Posterior (extensor) compartments of the arm and forearm	Skin overlying the posterior compartments of the arm and forearm and the dorsum of the hand (except the tips of the fingers and the entire fifth digit)	<i>radialis</i> , relating to the radius
<b>Ulnar</b> (C <sub>8</sub> -T <sub>1</sub> )	Arises from the medial cord. Runs along the medial aspect of the arm before becoming superficial immediately posterior to the medial epicondyle of the humerus (where it is easily injured).	Flexor carpi ulnaris and ulnar half of flexor digitorum profundus, as well as most intrinsic hand muscles	Skin of the medial one and one-half digits on the palmar surface of the hand, skin of the lateral surface of the hand on both palmar and dorsal surfaces	<i>ulnar</i> , relating to the ulna

(continued on next page)



(continued from previous page)

7. Sketch the brachial plexus in the space provided.



### Clinical View | Additional Nerves of the Brachial Plexus

The **long thoracic nerve** arises from the anterior rami of  $C_5$ – $C_7$  and innervates the **serratus anterior muscle**. Unlike most nerves, which lie deep to the muscles they innervate, the long thoracic nerve lies superficial to the serratus anterior muscle, which makes it susceptible to injury. Injury can result in paralysis of the serratus anterior muscle. Recall the discussion in chapter 13 that described how to diagnose a paralyzed or nonfunctional serratus anterior muscle. Summarize the procedure in the space provided.

### Learning Strategy



Recall from basic anatomic terminology that the term *medial* is a direction (towards the midline), and the term *median* is a location (in the middle). As concerns the brachial plexus, the

*cord* of the brachial plexus is *medial*, as in located medial to the axillary artery; the *nerve* of the brachial plexus is *median*, as in located in the middle (of the branches that form from medial and lateral cords).

## EXERCISE 25.5 The Lumbar and Sacral Plexuses

1. Observe a prosected human cadaver or a model of the abdomen and lower limb demonstrating nerves of the lumbar plexus. The purpose of this exercise is to identify the major nerves that arise from the lumbar plexus, which arise from the anterior rami of spinal nerves  $L_1$ – $L_4$  (table 25.6), and the major nerves that arise from the sacral plexus, which arise from the anterior rami of spinal nerves  $L_4$ – $S_4$  (table 25.7).
2. *Nerves of the Lower Limb Arising from the Lumbar Plexus:* It will be easiest to learn the nerves of the lower limb when relating each nerve to a single compartment. Recall the limb compartments from chapter 13; there are three compartments of the thigh (anterior, posterior, and medial) and three compartments of the leg (anterior, posterior, and lateral). Each compartment, for the most part, receives innervation from a single nerve from either the lumbar or the sacral plexus. First associate one nerve with one compartment. Then, learn the “exceptions” to the rules. The general rules for the lumbar plexus are as follows:

Compartment	Nerve
Anterior thigh	Femoral nerve
Medial thigh	Obturator nerve

3. *Lumbar Plexus:* Identify the nerves and muscles listed in figure 25.8 in the lower limb of a human cadaver or a model of the lower limb, using table 25.6 and the textbook as guides. Then label them in figure 25.8.
4. *Sacral Plexus:* Identify the nerves and muscles listed in figure 25.9a in the lower limb of a human cadaver or a model of the lower limb, using table 25.7 and the textbook as guides.

### Learning Strategy



The word *pudendal* means “that which is shameful.” Remembering this will make it easy to remember the structures the pudendal nerve innervates. It innervates all of the body’s “shameful” structures—namely, the external genitalia. In addition, its fibers control the contraction of the external sphincters surrounding the anus and urethra. Wouldn’t it be “shameful” if this nerve were damaged? A very minimal anesthetic given during childbirth is a **pudendal nerve block**. It blocks sensation from the birth canal (vagina), but the mother still receives sensations from the contracting uterus.

Table 25.6 Major Nerves of the Lumbar Plexus				
Nerve	Description	Motor Innervation	Sensory Innervation	Word Origins
<b>Femoral</b> (L <sub>2</sub> -L <sub>4</sub> )	Runs along the lateral border of the psoas major muscle, travels under the inguinal ligament into the femoral triangle to innervate the anterior compartment of the thigh.	Anterior compartment of the thigh	Skin of the anterior thigh and leg	<i>femoral</i> , relating to the femur or thigh
<b>Obturator</b> (L <sub>2</sub> -L <sub>4</sub> )	Runs along the medial border of the psoas major muscle, travels through the obturator foramen into the medial compartment of the thigh.	Medial compartment of the thigh	Skin on the medial surface of the thigh	<i>obturatus</i> , to occlude or stop up

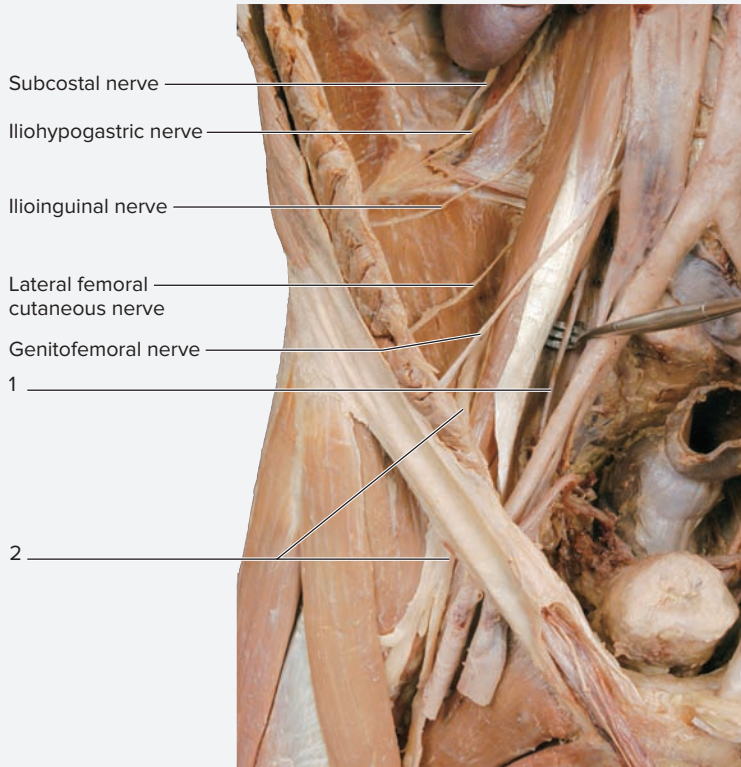
Table 25.7 Major Nerves of the Sacral Plexus				
Nerve	Description	Motor Innervation	Sensory Innervation	Word Origins
<b>Common Fibular</b> (L <sub>4</sub> -S <sub>2</sub> )	Begins at the bifurcation of the sciatic nerve proximal to the popliteal fossa, passes superficially near the head of the fibula, wraps around the neck of the fibula, and then divides into superficial and deep branches, which innervate the lateral and anterior compartments of the leg, respectively.	Biceps femoris muscle, short head	Skin on the proximal posterolateral surface of the leg	<i>fibular</i> , relating to the fibula
<b>Deep Fibular</b> (L <sub>4</sub> -S <sub>1</sub> )	Arises from the common fibular nerve at the neck of the fibula, passes through the extensor digitorum longus muscle into the anterior compartment of the leg.	Anterior compartment of the leg, dorsal musculature of the foot	Skin on the first interdigital cleft of the foot	<i>deep</i> , situated at a deeper level than a corresponding structure, + <i>fibular</i> , relating to the fibula
<b>Inferior Gluteal</b> (L <sub>5</sub> -S <sub>2</sub> )	Exits the pelvis through the greater sciatic foramen inferior to the piriformis.	Gluteus maximus	NA	<i>inferior</i> , lower, + <i>gloutos</i> , the buttock
<b>Posterior Femoral Cutaneous</b> (S <sub>1</sub> -S <sub>2</sub> )	Exits pelvis through the greater sciatic foramen inferior to the piriformis, just medial to the sciatic nerve.	NA	Skin on the posterior thigh	<i>posterior</i> , behind, + <i>femur</i> , the thigh, + <i>cutis</i> , the skin
<b>Pudendal</b> (S <sub>2</sub> -S <sub>4</sub> )	Exits the pelvis through the greater sciatic foramen inferior to the piriformis muscle, then travels through the lesser sciatic foramen to enter the perineum.	Perineal muscles, external anal sphincter, and external urethral sphincter	External genitalia in both males and females	<i>pudendal</i> , that which is shameful
<b>Sciatic</b> (L <sub>4</sub> -S <sub>3</sub> )	Exits the pelvis through the greater sciatic foramen inferior to the piriformis muscle, then enters the posterior compartment of the thigh through a groove between the ischial tuberosity and the greater trochanter of the femur.	Posterior compartment of the thigh (the tibial division of the sciatic is responsible for innervation of all posterior compartment thigh muscles except for the short head of the biceps femoris)	NA	<i>sciaticus</i> , the hip joint
<b>Superficial Fibular</b> (L <sub>5</sub> -S <sub>2</sub> )	Arises from the common fibular nerve at the neck of the fibula and descends within the lateral compartment of the leg.	Lateral compartment of the leg	Skin on the distal, lateral surface of the leg and the dorsal surface of the foot	<i>superficialis</i> , the surface, + <i>fibular</i> , relating to the fibula
<b>Superior Gluteal</b> (L <sub>4</sub> -S <sub>1</sub> )	Exits the pelvis through the greater sciatic foramen superior to the piriformis.	Gluteus medius, gluteus minimus, and tensor fascia latae muscles	NA	<i>superus</i> , above, + <i>gloutos</i> , the buttock
<b>Tibial (S)</b> (L <sub>4</sub> -S <sub>2</sub> )	Begins at the bifurcation of the sciatic nerve proximal to the popliteal fossa, runs along the tibialis posterior muscle, and then branches into two plantar nerves at the ankle.	Posterior compartment of the leg, plantar musculature of the foot	NA	<i>tibial</i> , relating to the tibia

5. *Nerves of the Sacral Plexus Within the Gluteal Region:* The **gluteal nerves** (superior and inferior) are named for their exit location relative to the piriformis muscle of the deep buttock (figure 25.9b). The **superior gluteal nerve** arises superior to the piriformis, while the **inferior gluteal nerve** arises inferior to the piriformis. A small

yet important nerve that also arises in this region is the **pudendal nerve** (*pudendal*, that which is shameful). The **sciatic nerve** arises inferior to the piriformis muscle and travels into the posterior compartment of the thigh, passing close to the ischial tuberosity. The sciatic nerve is the *largest nerve in the body* because it is actually two

(continued on next page)

(continued from previous page)



Right pelvic region, anterior view

**Figure 25.8 Right Pelvic Region, Anterior View.** Nerves of the Lumbar Plexus. Deep dissection of the pelvis and anterior thigh. Use the terms to fill in the numbered labels in the figure.

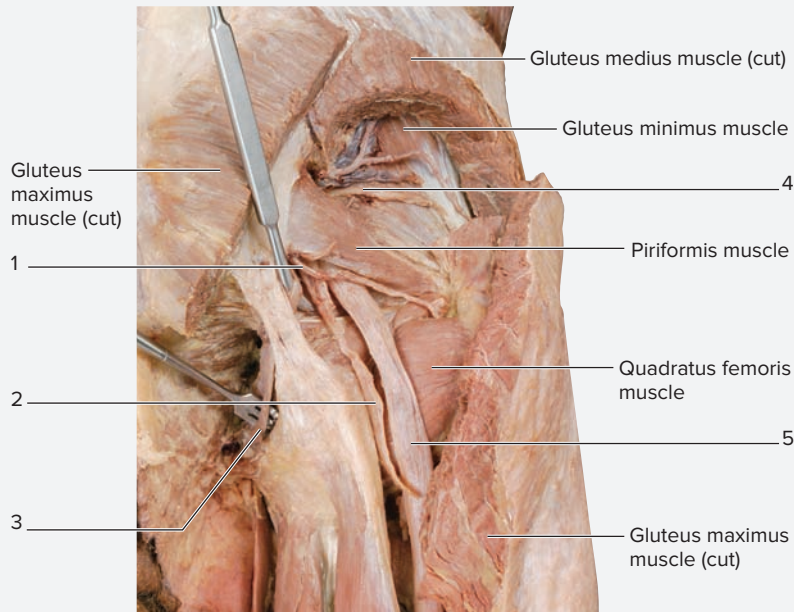
- femoral nerve
- obturator nerve

© McGraw-Hill Education/Photo and Dissection by Christine Eckel

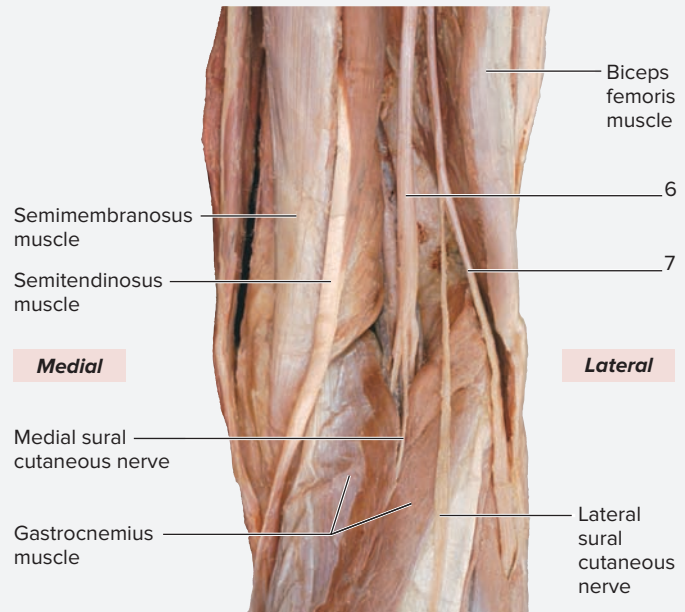
nerves, the **common fibular nerve** and the **tibial nerve**, bundled together in a common connective tissue sheath. Most commonly the two nerves separate from each other just proximal to the popliteal fossa of the knee. It is the **tibial division** of the sciatic nerve that is responsible for innervating the posterior compartment of the thigh. The general rules for the sacral plexus are as follows:

Compartment	Nerve
Anterior leg	Deep fibular nerve
Lateral leg	Superficial fibular nerve
Posterior leg	Tibial nerve
Posterior thigh	Sciatic nerve (tibial division)

6. Identify the nerves and muscles in the gluteal region listed in figure 25.9b on a human cadaver or a model of the gluteal region, using table 25.7 and the textbook as guides. Then label them in figure 25.9b.



(a) Right lower limb, posterior view (gluteal region)



(b) Right lower limb, posterior view (popliteal region)

**Figure 25.9 Nerves of the Sacral Plexus Within the Gluteal and Popliteal Regions.** Use the terms listed to fill in the numbered labels in the figure.

- common fibular nerve
- pudendal nerve
- tibial nerve
- inferior gluteal nerve
- sciatic nerve
- posterior femoral cutaneous nerve
- superior gluteal nerve

© McGraw-Hill Education/Photos and Dissections by Christine Eckel

# Chapter 25: The Spinal Cord and Spinal Nerves

Name: \_\_\_\_\_

Date: \_\_\_\_\_ Section: \_\_\_\_\_

## POST-LABORATORY WORKSHEET

The 1 corresponds to the Learning Objective(s) listed in the chapter opener outline.

### Do You Know the Basics?

#### Exercise 25.1: Histological Cross Sections of the Spinal Cord

1. The outer cortex of the spinal cord consists of \_\_\_\_\_ (gray/white) matter, whereas the inner medulla of the spinal cord consists of \_\_\_\_\_ (gray/white) matter. 1
2. Match the type of neuron listed in column A with the corresponding part of the spinal cord where the soma of the neuron may be found, listed in column B. 2

##### Column A

- \_\_\_\_\_ 1. interneuron
- \_\_\_\_\_ 2. somatic motor neuron
- \_\_\_\_\_ 3. somatic sensory neuron
- \_\_\_\_\_ 4. sympathetic motor neuron

##### Column B

- a. anterior gray horn
- b. lateral gray horn
- c. posterior gray horn
- d. posterior root ganglion

3. The \_\_\_\_\_ (cervical/lumbar) enlargement of the spinal cord is associated with the upper limbs, whereas the \_\_\_\_\_ (cervical/lumbar) enlargement is associated with the lower limbs. 3

#### Exercise 25.2: Gross Anatomy of the Spinal Cord

4. White matter is located \_\_\_\_\_ (centrally/peripherally) within the brain, and \_\_\_\_\_ (centrally/peripherally) within the spinal cord. 4
5. Which of the following is a structure that consists of posterior and anterior roots extending from the inferior end of the spinal cord into the lower vertebral canal and the sacral canal? (Circle one.) 5
  - a. cauda equina
  - b. conus medullaris
  - c. filum terminale
  - d. posterior root ganglion

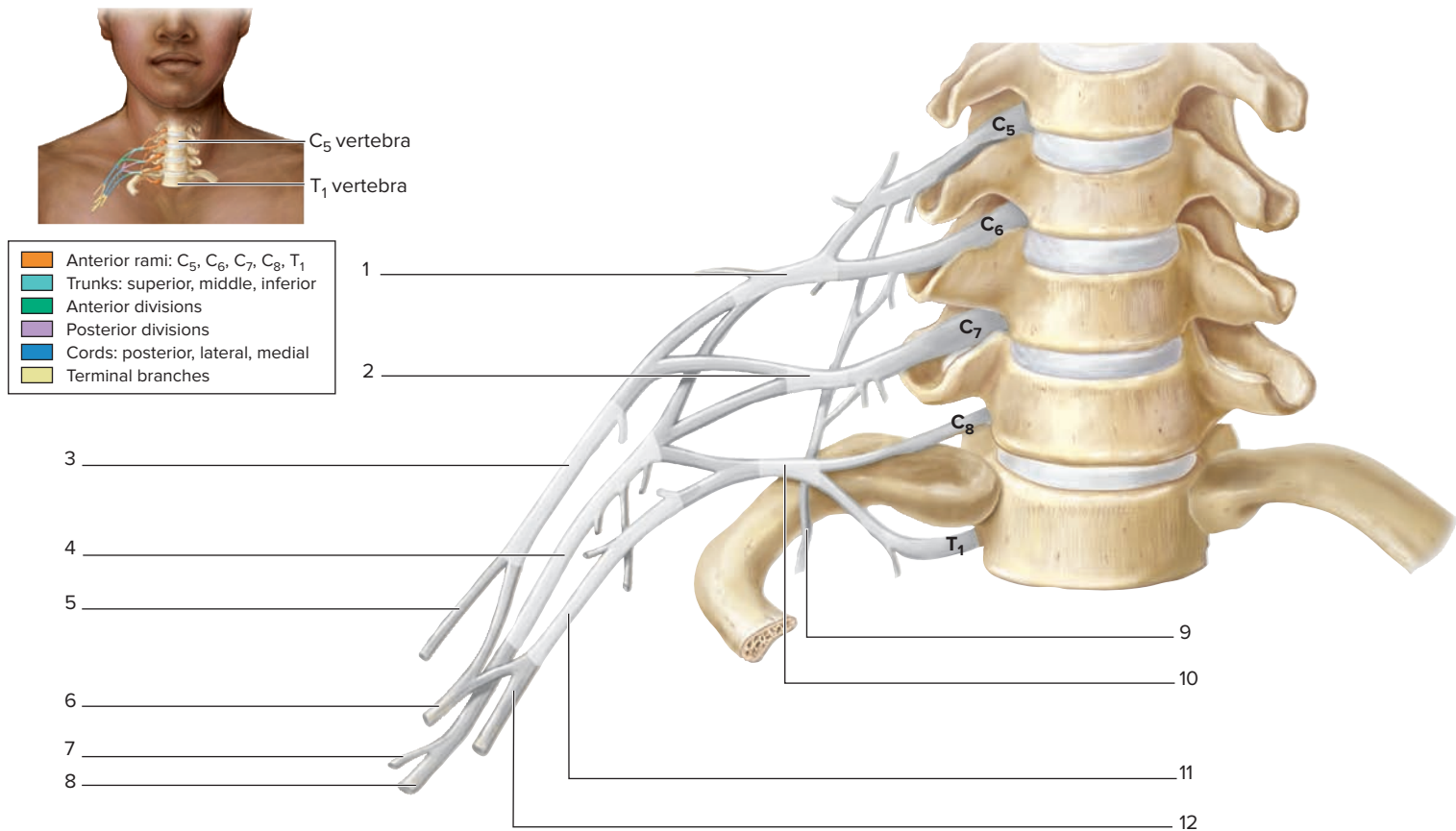
#### Exercise 25.3: The Cervical Plexus

6. The cervical plexus is formed from the anterior rami of these spinal nerves. (Circle one.) 6
  - a. C<sub>1</sub>–C<sub>3</sub>
  - b. C<sub>1</sub>–C<sub>4</sub>
  - c. C<sub>1</sub>–C<sub>5</sub>
  - d. C<sub>1</sub>–C<sub>6</sub>
  - e. C<sub>1</sub>–C<sub>7</sub>

#### Exercise 25.4: The Brachial Plexus

7. Rank the levels of organization of the brachial plexus in order, beginning with anterior rami and ending with branches. 7
  - \_\_\_\_\_ a. branches
  - \_\_\_\_\_ b. cords
  - \_\_\_\_\_ c. divisions
  - \_\_\_\_\_ d. roots (anterior rami)
  - \_\_\_\_\_ e. trunks
8. The ulnar nerve forms from the \_\_\_\_\_ (medial/lateral) cord of the brachial plexus. 8

9. Using colored pencils, color in the segments of the brachial plexus in the illustration as per the colors in the key. Then label the nerves indicated by the leader lines. 9



10. Match the region or compartment of the upper limb listed in column A with the nerve that innervates the majority of muscles in that region/compartment listed in column B. (Answer choices may be used more than once.) 9

**Column A**

- \_\_\_\_\_ 1. anterior arm (e.g., biceps brachii)
- \_\_\_\_\_ 2. anterior forearm (medial aspect and intrinsic muscles of the hand)
- \_\_\_\_\_ 3. most of the anterior forearm (lateral aspect)
- \_\_\_\_\_ 4. posterior arm (e.g., triceps brachii muscle)
- \_\_\_\_\_ 5. posterior forearm
- \_\_\_\_\_ 6. shoulder (e.g., deltoid muscle)

**Column B**

- a. axillary nerve
- b. median nerve
- c. musculocutaneous nerve
- d. radial nerve
- e. ulnar nerve

**Exercise 25.5: The Lumbar and Sacral Plexuses**

- 11. Identify a nerve that arises from the lumbar plexus. \_\_\_\_\_ 10
- 12. The femoral nerve innervates the \_\_\_\_\_ (anterior/medial/posterior) thigh, whereas the obturator nerve innervates the \_\_\_\_\_ (anterior/medial/posterior) thigh. 11
- 13. Identify a nerve that arises from the sacral plexus. \_\_\_\_\_ 12 13

### Can You Apply What You've Learned

14. Compare and contrast the features of the brain and spinal cord by filling in the following table.

Structure	Unique Features Within the Brain	Unique Features Within the Spinal Cord
Dura mater		
Arachnoid mater		
Pia mater		
Central space (for example, ventricles)		
Location of gray matter		
Location of white matter		

15. Fill in the table below with features of the main nerve plexuses.

Plexus	Formed from Anterior Rami of These Spinal Nerves	Major Nerves Formed from the Plexus
Cervical		
Brachial		
Lumbosacral		

16. Fill in the following table with the nerve that innervates each compartment or listed structure.

Location and/or Muscles	Nerve
Anterior compartment of the arm	
Anterior compartment of the forearm	
Anterior compartment of the leg	
Anterior compartment of the thigh	
Deltoid and teres minor muscles	
External genitalia, external anal, and urethral sphincter muscles	
Gluteus maximus muscle	
Gluteus medius, gluteus minimus, and tensor fascia lata muscles	
Lateral compartment of the leg	
Medial compartment of the thigh	
Medial forearm and most intrinsic hand muscles	
Posterior compartment of the arm	
Posterior compartment of the forearm	
Posterior compartment of the leg	
Posterior compartment of the thigh	
Serratus anterior muscle	

*This page intentionally left blank*

# The Autonomic Nervous System

# 26

## OUTLINE AND LEARNING OBJECTIVES

### Gross Anatomy 595

#### Autonomic Nervous System 595

##### EXERCISE 26.1: PARASYMPATHETIC DIVISION 596

- 1 Identify the major anatomical components of the parasympathetic division of the ANS

##### EXERCISE 26.2: SYMPATHETIC DIVISION 598

- 2 Identify the major anatomical components of the sympathetic division of the ANS

## INTRODUCTION

Why is it that heart rate increases and sweat glands increase secretions during stressful or frightening conditions? How is it that salivation begins at the sight, smell, or even thought of something tasty? The answer is the **autonomic nervous system (ANS)**. The human **nervous system** is divided into two major functional components: the somatic nervous system and the autonomic nervous system. The **somatic nervous system (SNS)** can be thought of as the “voluntary” division—it involves sensations that are usually conscious. This includes sensory input from the five special senses (touch, taste, hearing, vision, and smell) and proprioceptors within joints, tendons, and muscles. The motor output of the SNS goes to skeletal (voluntary) muscle tissue. In contrast, the ANS can be thought of as the “involuntary” division—it involves sensory stimuli that the body is typically unaware of (such as blood pressure or oxygen levels in the blood). The motor output of the ANS goes to cardiac muscle, smooth muscle, and glands. The ANS is composed of two divisions: the **parasympathetic division**, which controls “rest-and-digest” activities, and the **sympathetic division**, which controls the “fight-or-flight” response.

The exercises within this chapter involve observing the gross anatomical organization of the parasympathetic and sympathetic divisions of the ANS. Use knowledge from the previous chapters on the nervous system when completing these relatively condensed but very important laboratory exercises.

### List of Reference Table

Table 26.1	Comparison of Parasympathetic and Sympathetic Divisions	p. 596
------------	---	--------



These Pre-laboratory Worksheet questions may be assigned by instructors through their **connect** course.

## PRE-LABORATORY WORKSHEET

- The \_\_\_\_\_ (parasympathetic/sympathetic) division of the autonomic nervous system (ANS) controls “rest-and-digest” activities, whereas the \_\_\_\_\_ (parasympathetic/sympathetic) division of the ANS controls the “flight-or-fight” response.
- The parasympathetic division of the ANS is always inhibitory to cardiac muscle, smooth muscle, and glands. \_\_\_\_\_ (True/False)
- Which of the following statement(s) is/are accurate about the sympathetic division of the ANS? (Check all that apply.)
  - \_\_\_\_\_ a. The adrenal medulla acts as a modified ganglion.
  - \_\_\_\_\_ b. Ganglia are located at or within target organs.
  - \_\_\_\_\_ c. Preganglionic axons are short, whereas postganglionic axons are long.
  - \_\_\_\_\_ d. Preganglionic neuron cell bodies are located in the brainstem and sacral region of the spinal cord.
  - \_\_\_\_\_ e. Preganglionic neuron cell bodies are located in the lateral horns of the thoracic and lumbar regions of the spinal cord.
- The division of the ANS also known as the *craniosacral* division is the \_\_\_\_\_ (parasympathetic/sympathetic) division. The division of the ANS also known as the *thoracolumbar* division is the \_\_\_\_\_ (parasympathetic/sympathetic) division.
- Which of the following statements describes an action performed by the parasympathetic division of the ANS? (Check all that apply.)
  - \_\_\_\_\_ a. increased gastrointestinal (GI) motility
  - \_\_\_\_\_ b. increased heart rate
  - \_\_\_\_\_ c. increased salivation
  - \_\_\_\_\_ d. pupillary constriction
- Match the feature listed in column A with the corresponding division of the ANS listed in column B. (Answers will be used more than once.)
 

<b>Column A</b>	<b>Column B</b>
_____ 1. cell bodies of preganglionic neurons located in the lateral horns of the T <sub>1</sub> –L <sub>2</sub> segments of the spinal cord	a. parasympathetic
_____ 2. extensive divergence of axons	b. sympathetic
_____ 3. long preganglionic axons	
_____ 4. paravertebral ganglia located on either side of vertebral column	
_____ 5. preganglionic neurons located in the brainstem and lateral gray matter of the S <sub>2</sub> –S <sub>4</sub> segments of the spinal cord	
_____ 6. prevertebral ganglia located anterior to vertebral column and descending aorta	
_____ 7. terminal ganglia located close to target organs	
- Activation of the sympathetic division of the ANS will cause the pupils of the eye to \_\_\_\_\_ (constrict/dilate).
- Identify the structure(s) that is/are innervated by autonomic motor neurons. (Check all that apply.)
  - \_\_\_\_\_ a. cardiac muscle
  - \_\_\_\_\_ b. glands
  - \_\_\_\_\_ c. skeletal muscle
  - \_\_\_\_\_ d. smooth muscle

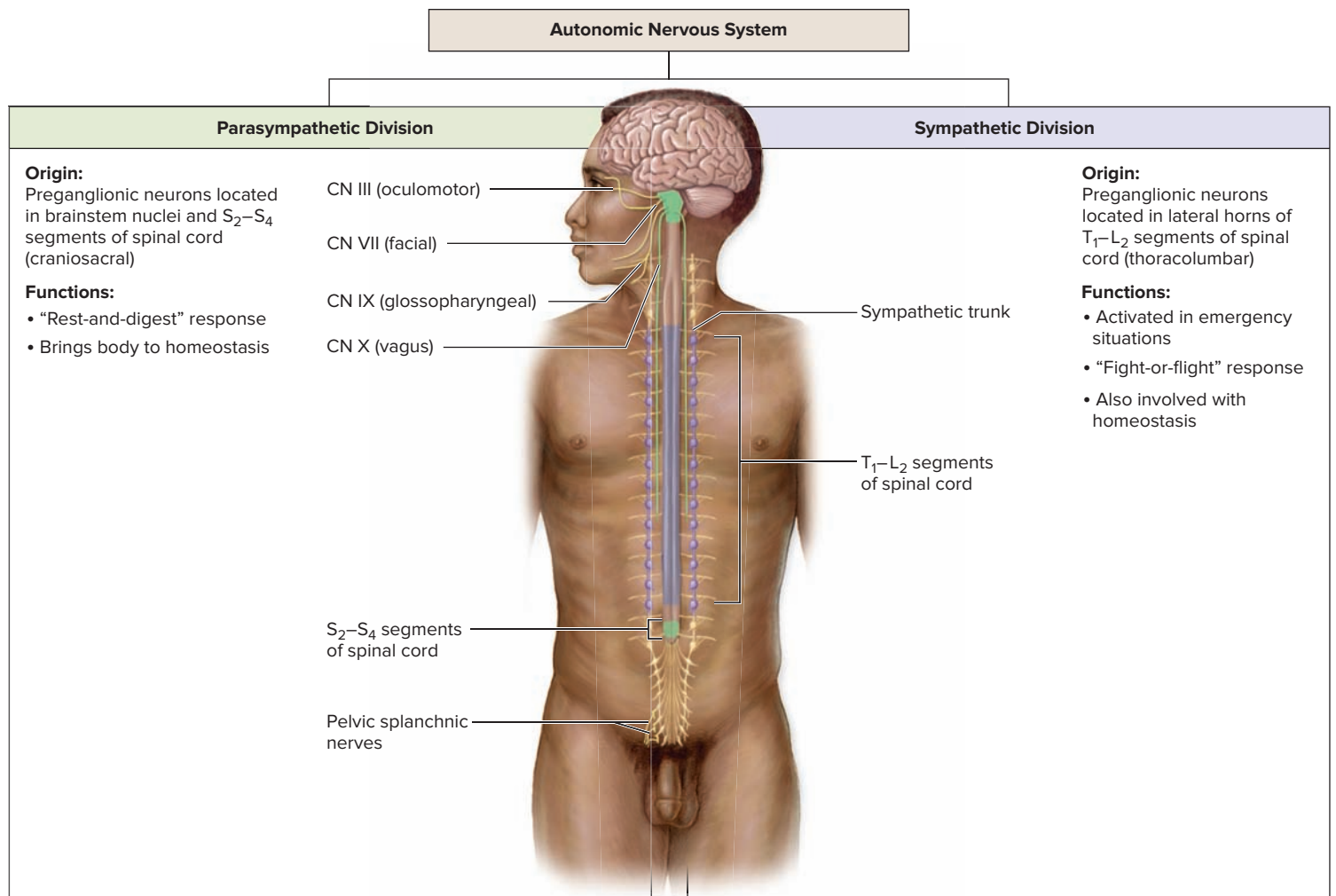
## Gross Anatomy

### Autonomic Nervous System

The autonomic nervous system regulates cardiac muscle, smooth muscle, and glands. Because of the involuntary nature of the ANS, most visceral effectors are dually innervated by the ANS. This means that effector organs (e.g., heart, gastrointestinal tract) receive innervation from both divisions of the ANS. These two divisions are the parasympathetic (craniosacral) division, which functions to control “rest-and-digest” functions, and the sympathetic (thoracolumbar) division, which is activated in emergency situations and during the “fight-or-flight” response (**figure 26.1**).

The term “parasympathetic” refers to the fact that the nerve fibers of this division originate from the CNS adjacent to where the nerve fibers of the sympathetic division originate (*para*, alongside). Recall from chapter 25 that cell bodies of autonomic (sympathetic) motor neurons are located in the lateral horns of the thoracic and lumbar regions of the spinal cord. The cell bodies of the parasympathetic division arise from portions of the CNS that are superior and inferior to the regions that give rise to the

sympathetic division. Specifically, cell bodies of neurons that compose the parasympathetic division arise from the brain (with axons that travel within cranial nerves III, VII, IX, and X) and also from lateral horns within the sacral region of the spinal cord. This is the origin of the alternate terms *craniosacral* for the parasympathetic division and *thoracolumbar* for the sympathetic division. In addition to the difference in the locations of preganglionic neuron cell bodies, there is a difference in the location of the ganglia for each of the divisions. Parasympathetic ganglia are located either close to the effector (these are called **terminal ganglia**), or within the wall of the target organs (these are called **intramural ganglia**) (**table 26.1**). Sympathetic ganglia are located in either the **sympathetic trunk ganglia** (also called paravertebral ganglia) or the **prevertebral ganglia**. The following exercise examines the gross anatomy of each division of the ANS, and involves noting locations of preganglionic and postganglionic neurons and tracing the pathway of motor output to target organs of the ANS throughout the body.



**Figure 26.1** Comparison of the Parasympathetic and Sympathetic Divisions of the ANS.

## Learning Strategy



When learning the two divisions of the ANS, remember “rest-and-digest” for the parasympathetic division and “fight-or-flight” for the sympathetic division. Based on these descriptions, many assume that the parasympathetic division is always inhibitory and that the sympathetic division is always excitatory. However, that is not the case. For example, while the parasympathetic division is inhibitory to pacemaker cells of the heart, causing heart rate to decrease, it is stimulatory to smooth muscle in the digestive

tract, promoting digestion and motility of the GI tract. Likewise, while the sympathetic division is stimulatory to pacemaker cells of the heart, causing heart rate to increase, it is inhibitory to smooth muscle surrounding the bronchioles (small airways), which causes dilation of the airways. Rather than simply associating “inhibition” or “excitation” with each division, think about what makes sense in light of the type of response being elicited and remember that the actions of autonomic nerves can be inhibitory or excitatory for either division of the ANS.

Feature	Parasympathetic Division	Sympathetic Division
<i>Divergence of Axons</i>	Few (1 axon innervates < 4 ganglionic cell bodies)	Extensive (1 axon innervates > 20 ganglionic cell bodies)
<i>Function</i>	Conserves energy and replenishes energy stores; maintains homeostasis; “rest-and-digest” division	Prepares body to cope with emergencies and intensive muscle activity; “fight-or-flight” division
<i>Length of Postganglionic Axon</i>	Short	Long
<i>Length of Preganglionic Axon</i>	Long	Short
<i>Location of Ganglia</i>	Terminal ganglia located close to the target organ; intramural ganglia located within wall of target organ	Sympathetic trunk (paravertebral) ganglia located on either side of vertebral column; prevertebral (collateral) ganglia located anterior to vertebral column and descending aorta
<i>Location of Ganglionic Neuron Cell Bodies</i>	Terminal or intramural ganglion	Sympathetic trunk ganglion (paravertebral) or prevertebral ganglion
<i>Location of Preganglionic Neuron Cell Bodies</i>	Brainstem and lateral gray matter in S <sub>2</sub> –S <sub>4</sub> segments of spinal cord	Lateral horns in T <sub>1</sub> –L <sub>2</sub> segments of spinal cord
<i>Rami Communicantes</i>	None	White rami attach to T <sub>1</sub> –L <sub>2</sub> spinal nerves; gray rami attach to all spinal nerves

### EXERCISE 26.1 Parasympathetic Division

- Observe **figure 26.2**, which is an overview of the parasympathetic pathways. Identify the structures listed in figure 26.2, using the textbook as a guide.
- List the structures that are innervated by parasympathetic fibers in the spaces provided.
  - Structures innervated by parasympathetic fibers that travel within cranial nerves:
 

CN III (oculomotor) \_\_\_\_\_

CN VII (facial) \_\_\_\_\_

CN IX (glossopharyngeal) \_\_\_\_\_

CN X (vagus) \_\_\_\_\_

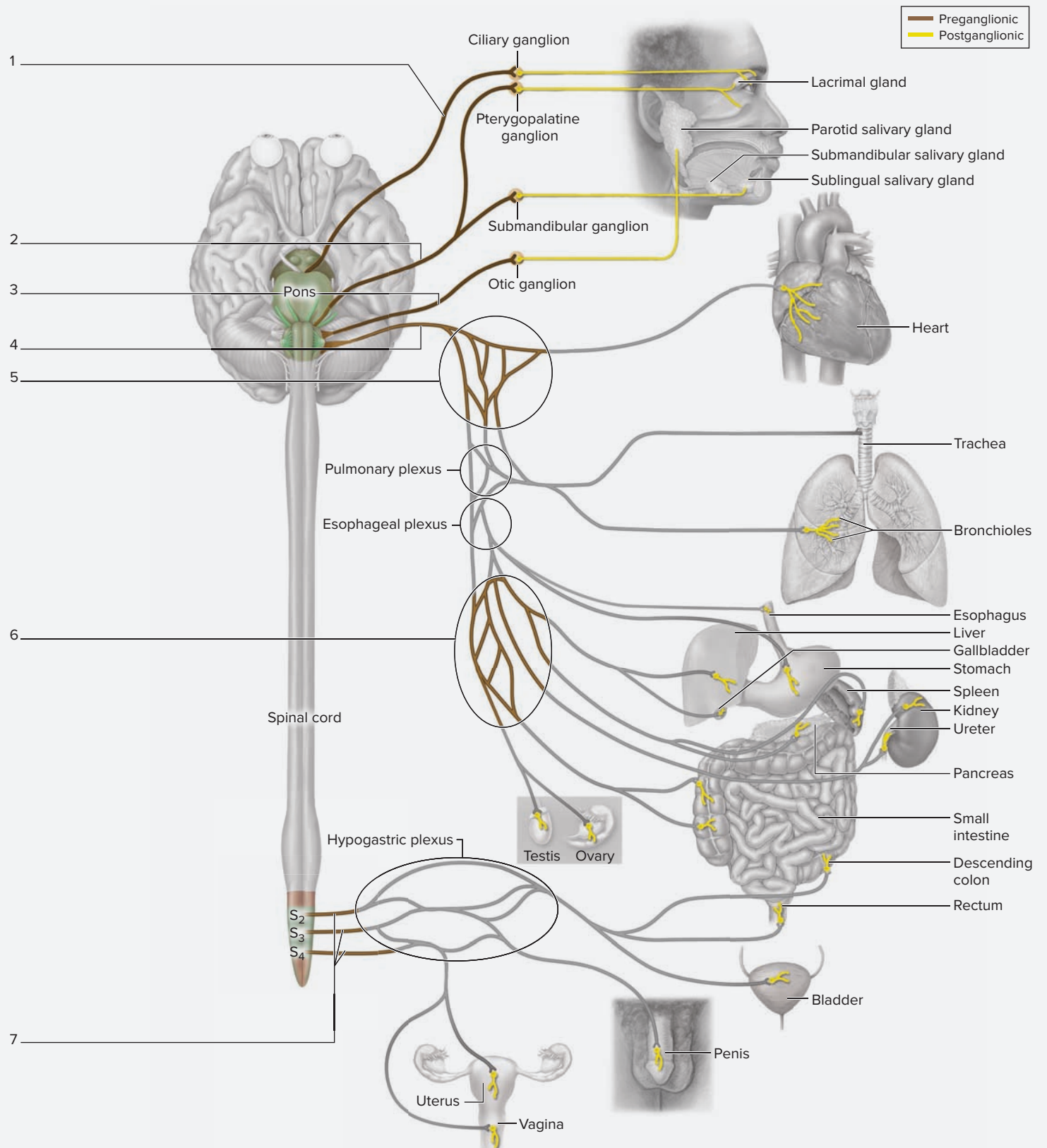
\_\_\_\_\_

\_\_\_\_\_

- Structures innervated by parasympathetic fibers that originate in the sacral region of the spinal cord:

\_\_\_\_\_

\_\_\_\_\_



**Figure 26.2 Overview of the Parasympathetic Division of the ANS.** The parasympathetic division of the ANS controls functions involved with “resting and digesting.” Use the terms listed to fill in the numbered labels in the figure.

- |  |   |  |   |
|--|---|--|---|
| <input type="checkbox"/> abdominal aortic plexus | <input type="checkbox"/> facial nerve (CN VII)          | <input type="checkbox"/> oculomotor nerve (CN III) | <input type="checkbox"/> vagus nerve (CN X) |
| <input type="checkbox"/> cardiac plexus          | <input type="checkbox"/> glossopharyngeal nerve (CN IX) | <input type="checkbox"/> pelvic splanchnic nerves  |   |

## Learning Strategy



A “big picture” way of remembering where parasympathetic innervation of visceral organs arises is to learn a couple of basic rules:

1. Specialized structures within the head (e.g., salivary glands) receive parasympathetic innervation through cranial nerves III, VII, IX, and X.
2. Nearly all thoracic and abdominal viscera receive parasympathetic innervation via the vagus nerve (CN X). Recall from chapter 24 that vagus means “wanderer” (because it wanders throughout the body). The vagus nerve is the only cranial nerve to innervate structures below the head.

3. Viscera within the pelvis are innervated by fibers that arise from the sacral spinal cord (e.g., structures of both the reproductive and urinary systems).

Clinically, this means that someone who has been paralyzed from the neck down will still have parasympathetic innervation of the majority of the vital viscera (e.g., heart, small intestine). However, the individual will lose function of involuntary sphincters such as those that control the flow of urine from the urinary bladder.

## EXERCISE 26.2 Sympathetic Division

The pathways for sympathetic fibers are more complex than those for parasympathetic fibers. One reason for this is that in order for the sympathetic response to have widespread and immediate effects, it must activate organs throughout the entire body in unison to initiate the “fight-or-flight” response. There are three separate pathways for preganglionic fibers to reach these ganglia from the spinal cord, with additional nerve fibers that extend to the **adrenal medulla**. This exercise involves tracing these pathways and considering the response of each organ that is innervated by each pathway.

1. Identify the structures listed in **figure 26.3**, using the textbook as a guide.
2. Think about the most likely “fight-or-flight” response initiated by the sympathetic division, using table 26.1 as a guide. Then, for each of the following organs, first identify the pathway for nerve signals to reach the organ, then name the specific effect created by the nervous stimulation.

### Heart (both rate and strength of contraction):

Pathway: \_\_\_\_\_

Response: \_\_\_\_\_

### Small intestine:

Pathway: \_\_\_\_\_

Response: \_\_\_\_\_

### Blood vessels within skeletal muscle:

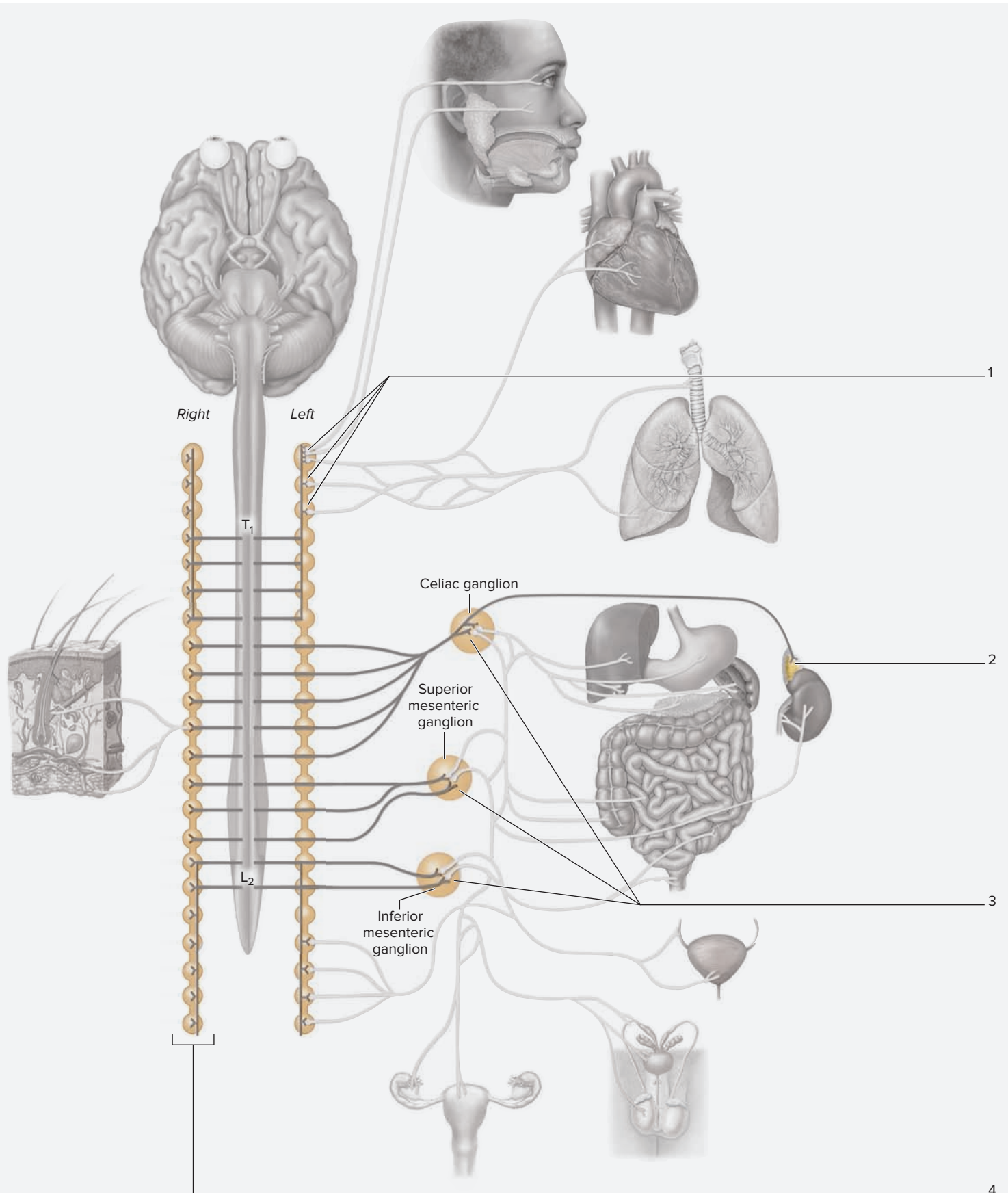
Pathway: \_\_\_\_\_

Response: \_\_\_\_\_

### Adrenal medulla:

Pathway: \_\_\_\_\_

Response: \_\_\_\_\_



**Figure 26.3 Overview of the Sympathetic Division of the ANS.** The sympathetic division of the ANS controls the “fight-or-flight” response. Use the terms listed to fill in the numbered labels in the figure.

- adrenal medulla
- prevertebral ganglia

- sympathetic trunk
- sympathetic trunk ganglia (paravertebral)

*This page intentionally left blank*

The ❶ corresponds to the Learning Objective listed in the chapter opener outline.

## Do You Know the Basics?

### Exercise 26.1: Parasympathetic Division

1. The parasympathetic division of the ANS is also called the \_\_\_\_\_ (craniosacral/thoracolumbar) division because of its anatomical location. ❶
2. Identify the cranial nerves that carry parasympathetic information. (Check all that apply.) ❶
  - \_\_\_\_\_ a. facial (CN VII)
  - \_\_\_\_\_ b. glossopharyngeal (CN IX)
  - \_\_\_\_\_ c. oculomotor (CN III)
  - \_\_\_\_\_ d. optic (CN II)
  - \_\_\_\_\_ e. vagus (CN X)

### Exercise 26.2: Sympathetic Division

3. The sympathetic division of the ANS is also called the \_\_\_\_\_ (craniosacral/thoracolumbar) division because of its anatomical location. ❷
4. The major sympathetic ganglia that lie on top of the unpaired abdominal blood vessels (celiac trunk, superior mesenteric artery, inferior mesenteric artery) are also known as \_\_\_\_\_ (paravertebral/prevertebral) ganglia because of their anatomic location relative to the vertebral column. ❷

## Can You Apply What You've Learned?

5. Match each of the effectors listed in column A with the cranial nerve that innervates the effector listed in column B.

#### Column A

- \_\_\_\_\_ 1. bronchioles
- \_\_\_\_\_ 2. ciliary muscles and iris of eye
- \_\_\_\_\_ 3. heart
- \_\_\_\_\_ 4. kidneys
- \_\_\_\_\_ 5. lacrimal gland
- \_\_\_\_\_ 6. salivary gland (parotid)
- \_\_\_\_\_ 7. salivary glands (under tongue)
- \_\_\_\_\_ 8. stomach and other digestive organs

#### Column B

- a. facial (CN VII)
- b. glossopharyngeal (CN IX)
- c. oculomotor (CN III)
- d. vagus (CN X)



*This page intentionally left blank*

# The Cardiovascular System: Blood

# 27

## OUTLINE AND LEARNING OBJECTIVES

### Histology 606

#### EXERCISE 27.1: IDENTIFICATION OF FORMED ELEMENTS ON A BLOOD SMEAR 607

- 1 Identify the following formed elements on a human blood smear slide: erythrocytes, platelets, eosinophils, basophils, neutrophils, monocytes, and lymphocytes
- 2 Describe the functions of the formed elements of the blood

#### EXERCISE 27.2: IDENTIFICATION OF MEGAKARYOCYTES ON A BONE MARROW SLIDE 610

- 3 Identify megakaryocytes on a slide of red bone marrow
- 4 Explain the process of platelet formation

### Gross Anatomy 611

#### EXERCISE 27.3: IDENTIFICATION OF FORMED ELEMENTS OF THE BLOOD ON CLASSROOM MODELS OR CHARTS 611

- 5 Identify the following formed elements on classroom models of blood cells: erythrocytes, platelets, eosinophils, basophils, neutrophils, monocytes, and lymphocytes

## INTRODUCTION

**B**lood is a bodily fluid that has fascinated humans for centuries. Its rich red color adds to both its beauty and its mystery. For some, the sight of blood is quite disturbing because it usually indicates that something is very wrong! It's no wonder that for centuries humans have been fascinated by this most colorful bodily fluid. Early Greek physicians believed that blood was one of the four bodily "humors" (*humor*, a bodily fluid). The other bodily fluids were phlegm, black bile, and yellow bile (**table 27.1**). Each of these humors was associated with an element: air, water, earth, or fire—and had particular characteristics: hot, cold, wet, or dry. Before putting any confidence in this idea, know that modern science recognizes over ninety-two naturally occurring elements, and earth, air, fire, and water are not among them! Greek physicians believed that a balance of the four humors was required for optimal health of both the body and the mind, and that disease was the result of an imbalance between the bodily fluids. It was this concept of disease that made bloodletting a popular treatment for disease. By draining some blood from a patient, the physician supposedly was putting the patient's humors back into balance. In those days, studying anatomy or medicine wasn't nearly as complicated as it is today. On the other hand, it is a wonderful thing not to have been a patient back then. This early concept of medicine remains today in descriptions of people's conditions, even though most are largely unaware that this is the case. An infant who cries all the time is referred to as being "colicky." Someone who is sad is described as feeling "melancholy." For comparison, a patient living in the year 400 B.C. who was feeling depressed would have been diagnosed as having an excess of "black bile." If the idea of

“black bile” isn’t enough to cause a good laugh, consider what early Greeks thought to be the source of phlegm: the brain. That thought may be humorous enough to transform one’s mood from melancholy to “sanguine,” or lively and optimistic. It is now time to tackle the current “sanguine” topic: blood. The exercises in this chapter explore the form and function of normal constituents of human blood. Knowledge of the normal appearance and abundance of the various types of blood cells provides a basis for recognizing when cells or amounts have become abnormal, and for understanding what that means.

Tables 27.2 and 27.3 summarize the characteristics of the formed elements

of blood. The structure and function of formed elements is the focus of this laboratory chapter. Exercises within this chapter involve identifying the formed elements of blood, exploring the functional relevance of each of the components, and learning how the different cell types play a critical role in both the cardiovascular and immune systems.

#### List of Reference Tables

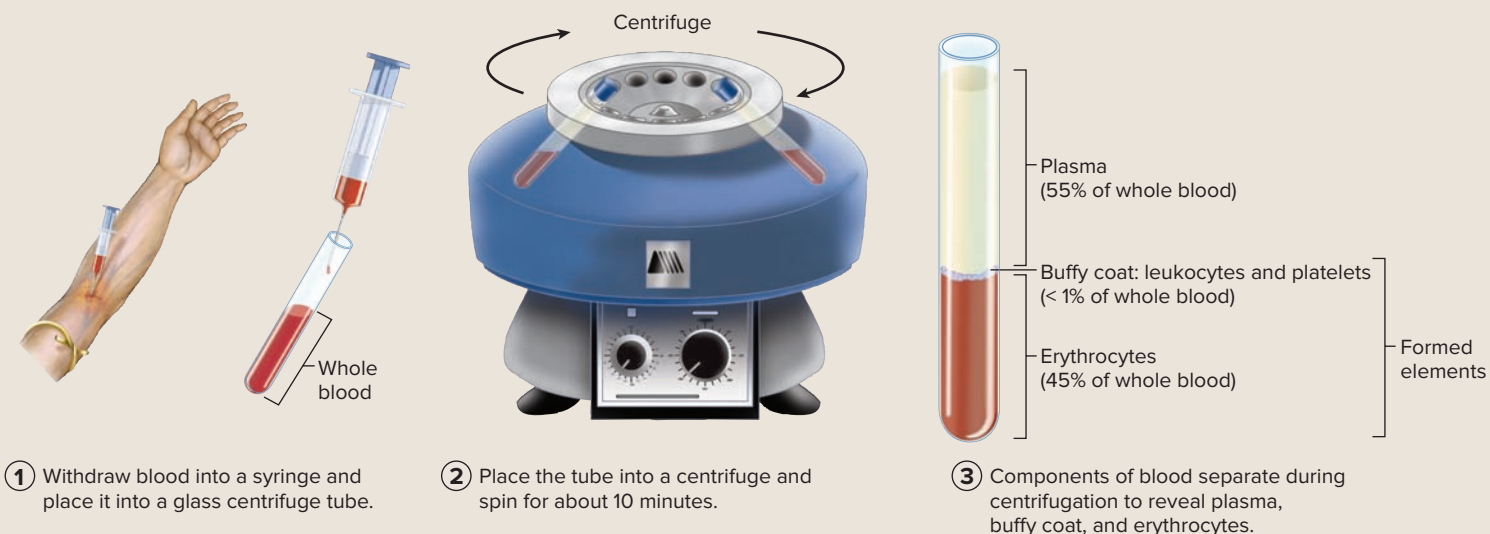
Table 27.1	The Four Greek Humors	p. 604
Table 27.2	Characteristics of the Formed Elements of Blood	p. 607
Table 27.3	Leukocyte Characteristics	p. 608

Table 27.1 The Four Greek Humors						
Bodily Fluid (Humor)	Element	Characteristics	Source	Mood	Mood Characteristics	Word Origins for Mood
Black Bile	Earth	Dry and cold	Spleen	Melancholy	Sad, depressed	<i>melas</i> , black + <i>chole</i> , bile
Blood	Air	Hot and wet	Heart	Sanguine	Lively and optimistic	<i>sanguis</i> , blood
Phlegm	Water	Cold and wet	Brain	Phlegmatic	Calm and unexcitable	<i>phlegma</i> , inflammation
Yellow Bile	Fire	Hot and dry	Liver	Choleric	Irritable	<i>chole</i> , bile

### Clinical View | Human Blood Samples for Laboratory Investigations

Blood is an amazing fluid with a beautiful red color due to the presence of hemoglobin within red blood cells. Hemoglobin is essential for the transport of oxygen throughout the body. Blood transports much more than just oxygen, however. It also transports nutrients, waste products, carbon dioxide, hormones, and heat. Proper circulation of blood to the tissues is essential for their survival. In medicine, a sample of a patient’s blood can yield important clues as to what diseases may be affecting the individual. For instance, a white blood cell count performed on a sample of the patient’s blood can determine whether the patient has a bacterial infection. An excess of neutrophils will confirm the suspicion that the patient has such an infection, whereas a normal abundance of neutrophils might be a clue that an infection is viral, rather than

bacterial, in nature. Figure 27.1 summarizes the steps involved in obtaining a sample of human blood for laboratory analysis. A blood sample is collected by a *phlebotomist* (*phleps*, vein + *tomē*, to cut) and placed in a test tube (figure 27.1, step 1). The test tube is then placed in a centrifuge, which spins the sample at high speed to separate the component parts (figure 27.1, step 2). Because the formed elements like erythrocytes and leukocytes are heavy, they fall to the bottom of the test tube, while the blood plasma remains floating on the top (figure 27.1, step 3). Leukocytes and platelets form a thin layer called a *buffy coat*, which sits on top of the layer of erythrocytes. The iron present in the hemoglobin in erythrocytes makes erythrocytes heavier than leukocytes, which explains why erythrocytes lie in the layer below leukocytes in the test tube.



**Figure 27.1** Separation of a Whole Blood Sample by Centrifugation. Using a centrifuge to separate whole blood into plasma (~55%) and formed elements (~45%) is the first step in determining the composition of whole blood.

These Pre-laboratory Worksheet questions may be assigned by instructors through their **connect** course.

## PRE-LABORATORY WORKSHEET

1. Number the following components of whole blood in order of abundance, from most abundant (1) to least abundant (3).

- \_\_\_\_\_ buffy coat
- \_\_\_\_\_ erythrocytes
- \_\_\_\_\_ plasma

2. Basophils, eosinophils, and neutrophils belong to the category of leukocytes known as \_\_\_\_\_ (agranuloctyes/granulocytes).

3. Match the description of the leukocyte listed in column A with the type of leukocyte listed in column B.

**Column A**

- \_\_\_\_\_ 1. bilobed nucleus; blue cytoplasmic granules
- \_\_\_\_\_ 2. bilobed nucleus; red cytoplasmic granules
- \_\_\_\_\_ 3. large, horseshoe-shaped nucleus; much larger than an erythrocyte
- \_\_\_\_\_ 4. multilobed nucleus; lavender cytoplasmic granules
- \_\_\_\_\_ 5. round nucleus surrounded by pale blue cytoplasm; similar in size to an erythrocyte

**Column B**

- a. basophil
- b. eosinophil
- c. lymphocyte
- d. monocyte
- e. neutrophil

4. Which of the following cells is responsible for producing platelets? (Circle one.)

- a. basophils
- b. erythrocytes
- c. lymphocytes
- d. megakaryocytes
- e. neutrophils

5. Which of the following formed elements is responsible for transporting oxygen and carbon dioxide in the blood? (Circle one.)

- a. basophils
- b. erythrocytes
- c. lymphocytes
- d. megakaryocytes
- e. neutrophils

6. Which of the formed elements is responsible for initiating coagulation? (Circle one.)

- a. basophils
- b. erythrocytes
- c. megakaryocytes
- d. neutrophils
- e. platelets

7. A measure of the percentage of erythrocytes in whole blood is called erythropoiesis. \_\_\_\_\_ (True/False)

8. Which of the following is not one of the components that result from centrifuging a sample of blood? (Circle all that apply.)

- a. formed elements
- b. granulocytes
- c. lymphocytes
- d. plasma
- e. serum

## Histology

### CAUTION:



The exercises in this chapter may involve the use of human, animal, or artificial blood. Blood samples, whether human or animal, are considered biohazardous waste and should be handled with care. Be sure to take precautionary measures while handling blood samples by wearing

nitrile gloves and safety goggles. Handle sharp objects with caution. Biohazardous wastes and sharps must be disposed of in the proper containers immediately following their use. Please consult with the laboratory instructor for further instructions on laboratory policies and procedures for handling and disposing of these substances.

### Clinical View | Making a Human Blood Smear

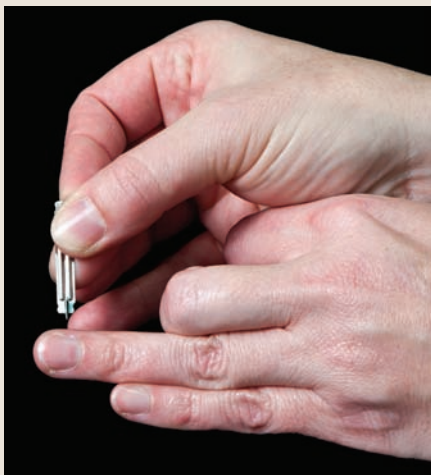Exercise 27.1 may require the use of a slide made from your own blood. To make a blood smear using your own blood, use the following procedure:

#### 1. Obtain the following:

- four glass slides
- lancet
- cotton balls
- alcohol prep pads
- vial of Wright's stain

Clean the slides with soap and water and let them dry. It takes two slides to make a blood smear, and the process may need to be repeated several times to obtain a good preparation. This is the reason for cleaning at least four slides, even though the actual smearing process involves only two.

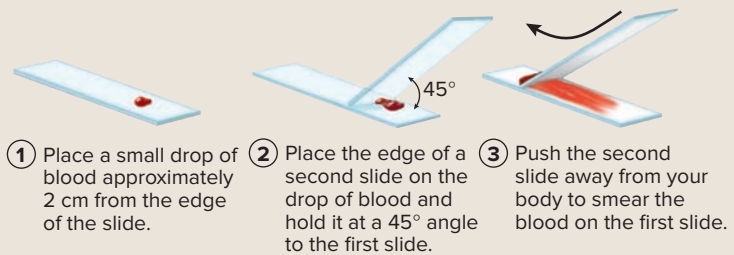
2. Using the alcohol prep pad, clean the side of the middle finger on the hand used the least (i.e., if you are right-handed, use the middle finger on your left hand).
3. Place the tip of the lancet on the clean finger, and pull the trigger so it pierces the skin. If using a lancet without a trigger (**figure 27.2**), poke the skin with a quick jab. Dispose of the lancet in a sharps container.



**Figure 27.2** Lancing Finger for Blood Sample.

© Christine Eckel

4. Squeeze the finger until a small drop of blood appears on the surface. Blot away the first drop of blood using the cotton ball and then squeeze the finger again until another drop appears.



**Figure 27.3** Preparation of a Blood Smear.

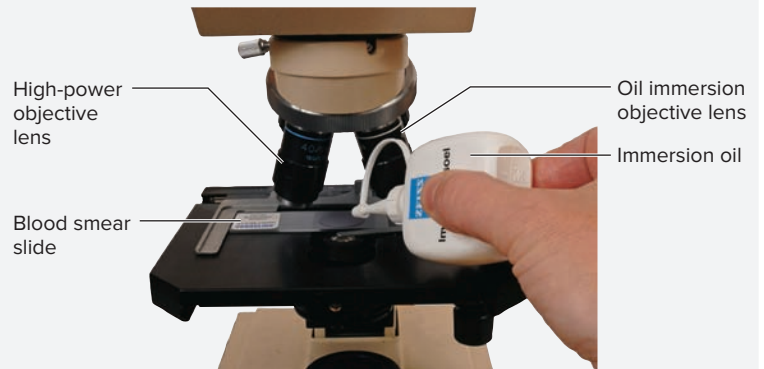
Gently touch the drop of blood to the top surface of the microscope slide about 2 cm from the edge of the slide (**figure 27.3**, step 1). Very little blood is needed to make the smear, so try not to squeeze the finger too hard.

5. Orient the slide so the end with the drop of blood on it is closest to you. Then place the edge of a second microscope slide on the drop of blood and hold it at a 45-degree angle to the slide with the drop of blood on it (**figure 27.3**, step 2).
6. Quickly push the second slide over the first slide (push away from your body) to smear the blood (**figure 27.3**, step 3). The goal is to obtain a very thin, transparent layer of blood on the slide. If the layer is too thick, the cells will be difficult to see because they will be too closely packed together. If the smear ends up uneven, or not well spread, start over with two new, clean slides. It might take a couple of tries to get a nice, even smear. Discard any slides that made contact with blood in a bowl containing a bleach solution. Allow the blood smear slide to air dry.
7. Place a couple of drops of Wright's stain on the blood smear slide. This means using enough stain to cover the smear, but not so much that it overflows the slide. Keep track of the number of drops used (number of drops = \_\_\_\_\_).
8. Let the slide stand for 3–4 minutes, until the smear begins to take on a blue/green color.
9. Add a volume of distilled water to the slide that is equal to the volume of Wright's stain used. Generally this means using the same number of drops of distilled water as drops of Wright's stain. Move the slide around and blow on it a little to mix the distilled water and stain on the slide.
10. Let the slide stand for 5–10 minutes. During this time, blow on the slide occasionally to keep the distilled water and stain mixed.
11. Rinse the slide with distilled water for 2–3 minutes, and then tilt the slide to allow the excess water to drip off of the slide. Allow the slide to air dry. Once the slide is dry it will be ready to examine.

**EXERCISE 27.1 Identification of Formed Elements on a Blood Smear**

1. Obtain a prepared slide of human blood or use the slide that was prepared using your own blood (see Clinical View: Making a Human Blood Smear). Place the slide on the microscope stage and observe at low power. Very little will be visible at this magnification, but, as always, it is important to progress from low to high power to continue keeping the sample in focus before progressing to use of the oil immersion objective.
2. Change from low to medium, then to high power, making sure to bring the slide into focus at each power. After the slide is in focus on high power, obtain a vial of immersion oil. Rotate the nosepiece (the part of the microscope that holds the objective lenses) so the high-power and oil immersion objectives lie on either side of the slide (**figure 27.4**). Place a drop of immersion oil over the center of the slide (where you see the light coming through the slide). Next, carefully rotate the nosepiece to bring the immersion objective into place over the slide. Bring the slide into focus.
3. Identify the listed formed elements on the prepared blood slide using tables 27.2 and 27.3, and **figure 27.5**, as guides. Note that some elements will be much easier to locate than others, due to their relative abundance in whole blood.

- |                                       |                                      |
|---------------------------------------|--------------------------------------|
| <input type="checkbox"/> basophils    | <input type="checkbox"/> monocytes   |
| <input type="checkbox"/> eosinophils  | <input type="checkbox"/> neutrophils |
| <input type="checkbox"/> erythrocytes | <input type="checkbox"/> platelets   |
| <input type="checkbox"/> lymphocytes  |                                      |



**Figure 27.4** Orienting the Objective Lenses for Placement of a Drop of Immersion Oil on the Prepared Blood Slide.

© Christine Eckel

4. After locating each formed element, sketch it in the space provided. Use colored pencils to shade each structure the way it appears under the microscope. In addition, make note of the approximate diameter of each cell, using the diameter of an erythrocyte (7.5  $\mu\text{m}$ ) as a reference.

*Erythrocyte*



Diameter: \_\_\_\_\_  $\mu\text{m}$

**Learning Strategy**

Although lymphocytes usually have circular nuclei and monocytes usually have indented or “horseshoe-shaped” nuclei, sometimes monocytes can also have what look like circular nuclei. In these cases, they can appear very similar in structure to lymphocytes. To prevent misidentification of a monocyte as a lymphocyte, always consider the size of the cell in addition to the shape of the nucleus. A monocyte is going to be two to three times larger than an erythrocyte, whereas a lymphocyte will be much closer to the same size as an erythrocyte.

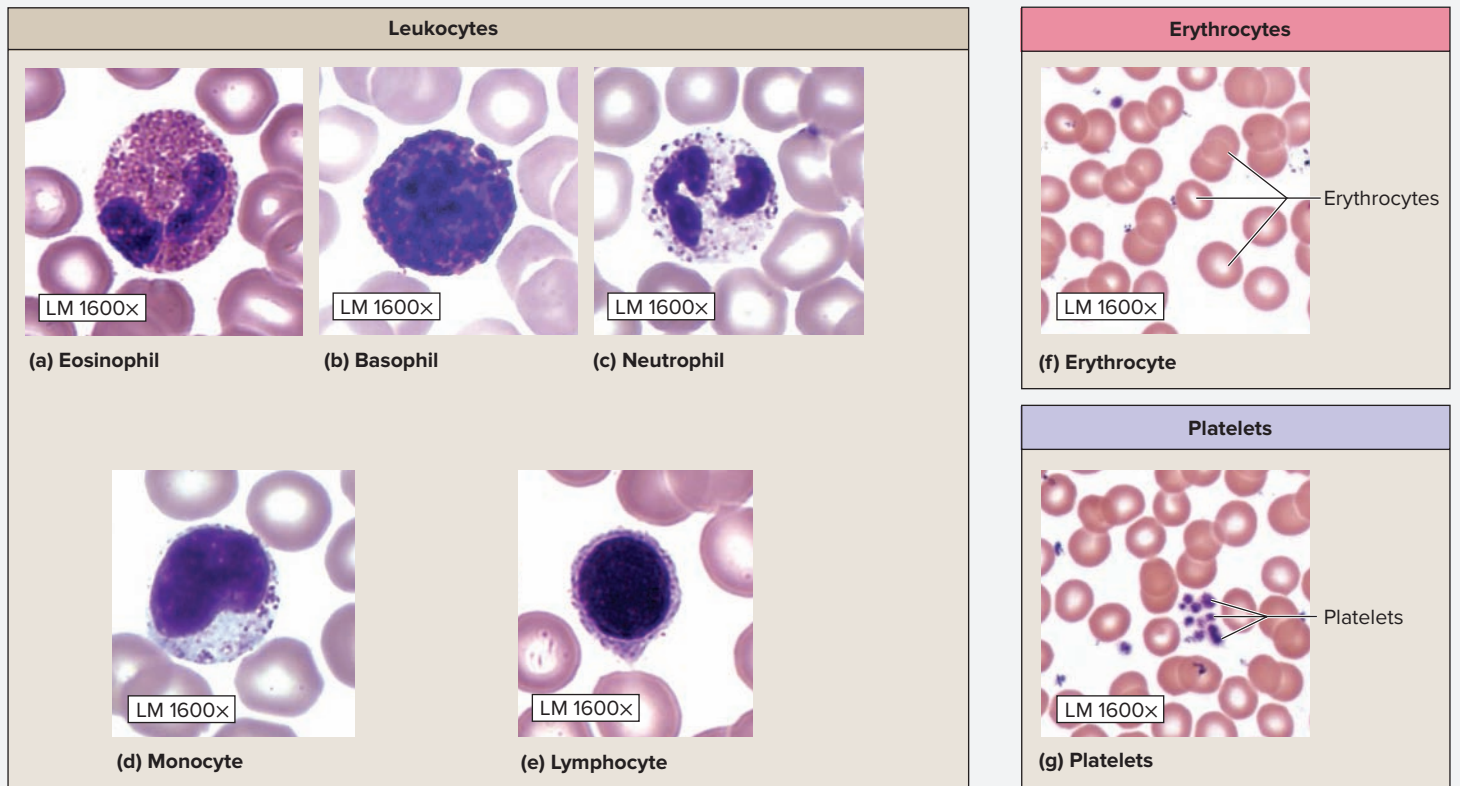
**Table 27.2** Characteristics of the Formed Elements of Blood

Formed Element	Description	Function	Size	Percentage of Formed Elements	Word Origins
<i>Erythrocytes (Red Blood Cells, RBCs)</i>	Very uniform in size and shape. Shaped like biconcave discs, lack a nucleus, and are orange to red in color due to their attraction for eosinophilic stains.	Transport oxygen and carbon dioxide, and participate in regulation of the pH of blood.	~7.5 $\mu\text{m}$	99%	<i>erythros</i> , red + <i>kytos</i> , a hollow (cell)
<i>Leukocytes (White Blood Cells, WBCs)</i>	Generally purple in color due to the basophilic staining properties of their nuclei. A summary of the characteristics of the various leukocytes is provided in table 27.3.	Protect the body from pathogens, fight infections, and remove dead or damaged tissues.	7–21 $\mu\text{m}$	< 1%	<i>leukos</i> , white + <i>kytos</i> , a hollow (cell)
<i>Platelets</i>	Small, purple-colored structures often mistaken for “junk” on the slide. They are cell fragments of megakaryocytes and are tiny compared to erythrocytes and leukocytes.	Play a role in hemostasis (blood clotting). When activated, the surfaces become spiny instead of smooth and they become very “sticky,” forming a platelet plug that helps stop bleeding from the blood vessel wall.	~2 $\mu\text{m}$	1%	<i>platys</i> , flat

(continued on next page)

(continued from previous page)


Table 27.3 Leukocyte Characteristics								
Leukocyte	Description	Function	Percentage of Leukocytes	Diameter Relative to That of an RBC	Nuclear Shape	Color of Cytoplasmic Granules	Common Conditions Causing an Increase in Abundance	Word Origins
AGRANULOCYTES								
<i>Lymphocytes</i>	Nearly the same size as an erythrocyte. Nuclei are very large and blue/purple in color, and are surrounded by a halo of pale blue cytoplasm.	Responsible for the specific immune response to infection. Each type of lymphocyte has a specific function in fighting pathogens.	20–25%	~1–2x	Large and round, nearly fills the entire cell	NA	Viral infections, autoimmune diseases	<i>lympho-</i> , referring to the lymphatic system + <i>kytos</i> , a hollow (cell)
<i>Monocytes</i>	Recognized by their enormous size, at least twice the size of an erythrocyte. Have a large, blue/purple nucleus that often has a small indentation in it, making it “horseshoe-shaped,” which helps distinguish it from a lymphocyte.	Monocytes are circulating cells. When they migrate out of the bloodstream, they become large, phagocytic cells called macrophages. They have little to no function in circulating blood.	3–8%	~2–3x	Large and horseshoe-shaped	NA	Bacterial infection	<i>monos</i> , single + <i>kytos</i> , a hollow (cell)
GRANULOCYTES								
<i>Neutrophils</i>	Have very light, lavender-colored cytoplasmic granules; the multi-lobed nucleus can be easily seen.	Important in fighting bacterial infections. They migrate out of the blood toward the site of infection, where they phagocytize bacteria and damaged tissues.	60–70%	~1.3x	Multilobed (~5 lobes)	Lavender (pale blue-purple)	Bacterial infection	<i>neutro-</i> , neutral + <i>philos</i> , to love
<i>Eosinophils</i>	Have orange to reddish cytoplasmic granules that are fairly light in color; the bluish-colored, bilobed nucleus can be seen easily.	Fight parasitic infections and mediate (neutralize) the effects of histamines. Phagocytize antigen-antibody complexes and allergens.	2–4%	~1.3x	Bilobed	Orange or red (eosinophilic)	Parasitic infections and allergic reactions	<i>acidus</i> , sour, referring to acidic dyes such as eosin + <i>philos</i> , to love
<i>Basophils</i>	Very rare and therefore difficult to locate on a blood smear. Cytoplasmic granules stain very dark blue, so the nucleus is generally not visible, though it is usually bilobed.	Release histamine and heparin, and are involved in the inflammatory response.	< 1%	~1.3x	Bilobed	Blue or purple (basophilic)	Tissue injury and allergic reactions	<i>baso-</i> , referring to basic dyes + <i>philos</i> , to love



**Figure 27.5** Formed Elements in the Blood.


© McGraw-Hill Education/AI Telser

*Platelet(s)*



\_\_\_\_\_ ×  
Diameter: \_\_\_\_\_ μm


*Neutrophil*



\_\_\_\_\_ ×  
Diameter: \_\_\_\_\_ μm

(continued on next page)



*(continued from previous page)****Eosinophil***

\_\_\_\_\_ ×  
Diameter: \_\_\_\_\_ μm

***Monocyte***

\_\_\_\_\_ ×  
Diameter: \_\_\_\_\_ μm

***Basophil***

\_\_\_\_\_ ×  
Diameter: \_\_\_\_\_ μm

***Lymphocyte***

\_\_\_\_\_ ×  
Diameter: \_\_\_\_\_ μm

5. After the exercise is completed, clean the microscope and slide thoroughly to remove all traces of oil from the instruments. To do this, rotate the nosepiece so the high-power and oil immersion lenses are on either side of the slide once again (figure 27.4). Use *lens paper* (do not use anything

else or it may damage the lenses!) and lens cleaning solution to carefully and thoroughly clean the oil from both the oil immersion objective and the blood smear slide. Blood smear slides prepared using your own blood should be disposed of by placing them in a bleach solution for disinfection.

### EXERCISE 27.2 Identification of Megakaryocytes on a Bone Marrow Slide

All the formed elements of the blood are produced in the red bone marrow through the process of **hemopoiesis** (*hemo-*, blood + *poiesis*, a making). Identifying the precursor cells of circulating blood cells is a complicated endeavor, which is generally undertaken only in upper-level histology courses. The goal of this laboratory exercise is to locate the

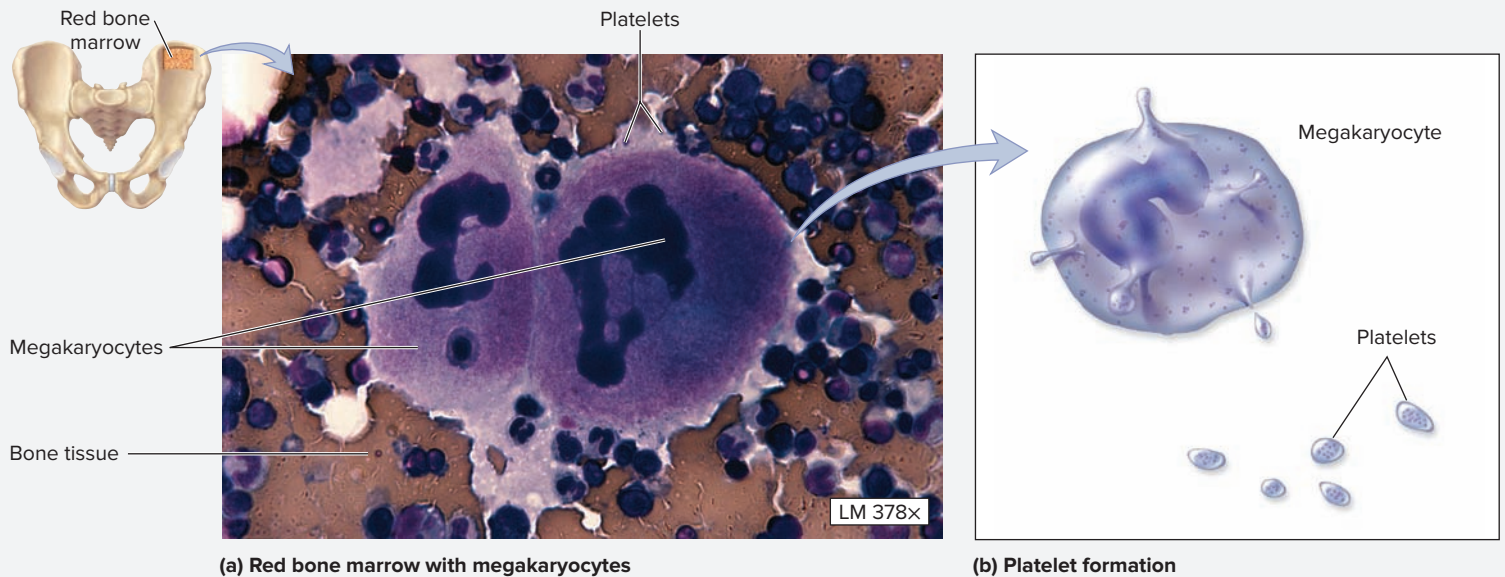
precursor cells of platelets (*megakaryocytes*) and investigate their structure and function. However, while engaging in the process of identifying megakaryocytes, try to obtain an appreciation for the general appearance of the precursor cells of erythrocytes and leukocytes that are visible on the slide.

1. Obtain a prepared slide of red bone marrow and place it on the microscope stage. Bring the slide into focus on high power. Identify the listed structures on the slide, using **figure 27.6** as a guide:

- bone tissue                       platelets  
 megakaryocytes                 red bone marrow

2. **Megakaryocytes** (*me-gas*, big + *karyo*, kernel (referring to the nucleus) + *kytos*, a hollow, cell) are extremely large cells with enormous nuclei. They are easily identifiable on prepared slides of bone marrow. Megakaryocytes remain within the bone marrow. However, their products, **platelets**, are continuously delivered to the bloodstream. Megakaryocytes produce platelets in a process that involves pinching off the cytoplasm of the megakaryocyte. Thus, a platelet is merely a fragment of the cytoplasm of a megakaryocyte enveloped by a portion of plasma membrane.

3. Sketch a megakaryocyte in the space provided. Indicate its relative size compared to the size of the developing blood cells observed on the bone marrow slide. Recall the diameter of an erythrocyte is 7.5  $\mu\text{m}$ .



**Figure 27.6** Bone Marrow Slide. Megakaryocytes in red bone marrow give rise to platelets.

(a) © Dr. Dorothea Zucker-Franklin/Phototake

## Gross Anatomy

### EXERCISE 27.3 Identification of Formed Elements of the Blood on Classroom Models or Charts

1. Observe classroom models or charts demonstrating blood cells. Identify each of the following blood cell types on the models or charts:
- basophils                       monocytes  
 eosinophils                   neutrophils  
 erythrocytes                   platelets  
 lymphocytes
2. *Optional Activity:* **AP|R Cardiovascular System**—Watch the “Hemopoiesis” animation to review the formation and characteristics of each of the formed elements.

*This page intentionally left blank*

The ❶ corresponds to the Learning Objective listed in the chapter opener outline.

## Do You Know the Basics?

### Exercise 27.1: Identification of Formed Elements on a Blood Smear

1. Which of the following is the most abundant type of leukocyte? (Circle one.) ❶
  - a. basophil
  - b. eosinophil
  - c. lymphocyte
  - d. monocyte
  - e. neutrophil
  
2. Which of the following is/are substances secreted by human basophils? (Check all that apply.) ❷
  - \_\_\_\_\_ a. antihistamine
  - \_\_\_\_\_ b. hemoglobin
  - \_\_\_\_\_ c. heparin
  - \_\_\_\_\_ d. histamine
  - \_\_\_\_\_ e. platelets
  
3. The formed element that composes less than 1% of leukocytes and releases histamine and heparin is \_\_\_\_\_. (Circle one.) ❷
  - a. basophils
  - b. lymphocytes
  - c. monocytes
  - d. neutrophils
  - e. platelets
  
4. A significant increase in the number of circulating neutrophils may indicate which of the following? (Check all that apply.) ❷
  - \_\_\_\_\_ a. allergic reaction
  - \_\_\_\_\_ b. bacterial infection
  - \_\_\_\_\_ c. parasitic infection
  - \_\_\_\_\_ d. viral infection

### Exercise 27.2: Identification of Megakaryocytes on a Bone Marrow Slide

5. Small cellular fragments that are involved in the process of hemostasis are platelets. \_\_\_\_\_ (True/False) ❸
6. Platelets are derived from monocytes, which reside in the bone marrow. \_\_\_\_\_ (True/False) ❸

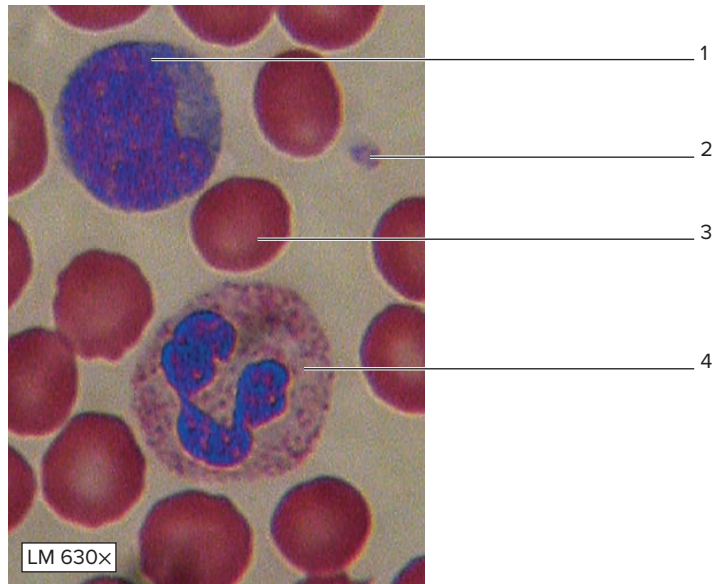
### Exercise 27.3: Identification of Formed Elements of the Blood on Classroom Models or Charts

7. A lymphocyte is a(n) \_\_\_\_\_ (granulocyte/agranulocyte) with a large, spherical nucleus surrounded by pale blue cytoplasm. ❶

**Can You Apply What You've Learned?**

8. The diameter of an erythrocyte is \_\_\_\_\_.

9. Label the formed elements of blood shown in the figure.



© Christine Eckel

10. The rarest type of leukocyte is \_\_\_\_\_.

11. An agranulocyte with a large, spherical nucleus surrounded by pale blue cytoplasm is a(n) \_\_\_\_\_.

12. A leukocyte that contains reddish-colored granules and a bilobed nucleus is a(n) \_\_\_\_\_.

13. A significant increase in the number of circulating neutrophils may indicate a(n) \_\_\_\_\_ infection.

14. Small cellular fragments that are involved in the process of hemostasis are \_\_\_\_\_.

15. The most abundant type of leukocyte is \_\_\_\_\_.

16. Lymphocytes are responsible for initiating the \_\_\_\_\_ immune response to infection.

17. A significant increase in the number of circulating eosinophils may indicate a(n) \_\_\_\_\_ infection.

18. Platelets are derived from \_\_\_\_\_, which reside in the bone marrow.

19. Formed elements that compose less than 1% of whole blood and are involved in defense against disease are \_\_\_\_\_.

20. A blood cell that is a precursor to tissue macrophages is a(n) \_\_\_\_\_.

# Index

Note: Page numbers followed by f and t refer to figures and tables, respectively.

## A

A bands, 208, 209f  
Abdominal cavity  
    *circulation to*, 383–387  
    *large intestine and*, 471f, 472f  
Abdominal wall  
    *circulation to*, 380–383  
    *muscles of*, 244–247  
Abdominopelvic regions and quadrants, 28  
Abducens nerve, 545t, 546f, 548t, 549t, 552  
Abductor pollicis longus, 264  
Accessory nerve, 545t, 546f, 548t, 549t, 556  
Accessory structures of eye, 314–315  
Acidophils, 330, 332f  
Acinar cells, 459, 460f  
Acromial process, 170  
Acromioclavicular joint, 170  
Actin, 208  
Actions  
    *of major muscle groups*, 218t  
    *naming skeletal muscles based on*, 216t  
Adductor hallucis muscle, 278, 280t  
Adductor longus muscle, 272  
Adenohypophysis, 330  
Adenoids, 408  
Adipose connective tissue, 68t, 69f, 99f  
Adrenal cortex, 335, 336f, 337t  
Adrenal glands, 335–337, 467f  
Adrenal medulla, 335, 336f, 337t, 598  
Adventitia layer  
    *respiratory passageways*, 426, 429t  
    *stomach*, 450  
    *ureters*, 485f  
    *urinary bladder*, 486f  
Afferent lymphatic vessels, 412, 413f, 414f  
Agonists, 233, 259  
Alveolar ducts, 432t  
Alveolar macrophages, 432f, 433t  
Alveolar processes, 133  
Alveolar sacs, 432t  
Alveolar Type I and Type II cells, 432f, 433t  
Alveoli, 431  
Amphiarthroses, 191, 192t  
Anaphase of cell cycle, 50t  
Anapomic planes and sections, 22–24  
Anastomosis, 387  
Anatomic position, 22  
Anatomic snuffbox, 264  
Anatomic terminology, 22  
Anatomy, 20. See also Gross anatomy  
Antagonists, 233  
Anterior (ventral), 25t  
Anterior arch, 145  
Anterior cavity of eye, 316t, 318  
Anterior chamber of eye, 316t, 318  
Anterior compartment  
    *arm*, 259  
    *forearm*, 261–263  
    *leg*, 275  
    *thigh*, 271–272  
Anterior horn cells, 288–289  
Anterior horns, 576, 577f, 578t  
Anterior muscles of pectoral girdle, 256  
Anterior neck, muscles of, 233–234  
Anterior pituitary, 330, 332f  
Anterior rami, 582, 583  
Anterior superior iliac spine, 184  
Anterior view of skull, 129, 130t  
Anulus fibrosus, 196  
Anus, 470  
Aorta, 352f, 353, 354f, 368  
Aortic semilunar valve, 353, 354f  
Apex of heart, 349, 349f  
Apocrine sweat glands, 94t, 97  
Aponeuroses, 244t, 245, 246, 247f  
Apoptosis, 410  
Appendicitis, 407  
Appendicular muscles  
    *hip*, 268–270  
    *lower limb*, 270–280  
    *overview*, 254  
    *pectoral girdle and glenohumeral joint*, 256–258  
    *upper limb*, 259–267  
Appendicular skeleton. See also Lower limb  
    *overview*, 116, 155–156  
    *pectoral girdle*, 159–162, 170  
    *pelvic girdle*, 171–174, 184  
    *upper limb*, 162–170  
Aqueous humor, 316t, 318  
Arachnoid mater, 532, 533t, 561  
Arachnoid villi, 532  
Architecture of skeletal muscles, 216–217  
Areolar connective tissue, 68t, 69f  
Arm  
    *compartments of*, 218t, 219f, 259–261  
    *of microscope*, 33t, 34f  
Arrector pili muscles, 99f  
Arterial arcades, 469  
Arterial supply to heart, 354t  
Arteries  
    *of kidney*, 488f  
    *to lower limb*, 393f  
    *overview*, 364  
    *of right upper limb*, 388f  
Arterioles, 364, 366t, 369–370, 375f, 488f  
Arthrology, 191  
Articular capsule, 197t  
Articular cartilage, 112, 192t, 197t  
Articular facet for dens, 145  
Articulating surfaces, 126t  
Articulations. See also specific joints  
    *cartilaginous*, 195–196  
    *fibrous*, 194–195  
    *functional categories of*, 191  
    *synovial*, 196–202  
Arytenoid cartilage, 435t, 436f  
Ascending colon, 470, 472f  
Ascending limb of nephron loop, 480t, 481f  
Astrocytes, 291–292  
Atlantoaxial joint, 137, 146  
Atlanto-occipital joint, 137, 145  
Atlas (C<sub>1</sub>), 145  
Auditory ossicles, 320t, 322  
Auditory tube, 321–322  
Auricles, 320t, 322, 356  
Autonomic nervous system  
    *divisions of*, 595  
    *overview*, 593

*parasympathetic division of*, 596–597  
    *sympathetic division of*, 596t, 598–599  
Avascular, 58  
Axial muscles  
    *abdominal wall*, 244–247  
    *head and neck*, 226–238  
    *overview*, 223  
    *respiration*, 242–244  
    *vertebral column*, 238–241  
Axial skeleton. See also Skull  
    *bone markings*, 126  
    *fetal skull*, 139–140  
    *overview*, 116, 124  
    *thoracic cage*, 148–150  
    *vertebral column*, 141–148  
Axillary nerve, 584, 585t  
Axillary skin, 97  
Axis (C<sub>2</sub>), 145, 146  
Axonal branches, 211  
Axon hillock, 287, 288t  
Axons, 80f, 287, 288t

## B

Ball-and-socket joint, 197, 198t  
Basal cells  
    *olfactory epithelium*, 427t  
    *trachea*, 428t, 429f  
Basal layer of uterine wall, 508  
Basal surface, 66  
Base  
    *of heart*, 349, 349f  
    *of microscope*, 33t, 34f  
Basement membrane, 58, 65f, 66  
Basilar membrane, 310, 311t, 322  
Basophils, 330, 332f, 608t, 609f  
Bicarbonate, 465  
Bifid, 144  
Bile, 465  
Biohazard bags, 7  
Biohazard waste, 7f, 606  
Bipennate architecture of skeletal muscles, 217t  
Bipolar neurons, 287  
Blade removers, 10  
Blood  
    *as fluid connective tissue*, 76f  
    *to kidneys*, 487–490  
    *overview*, 603–604  
    *samples for laboratory investigations*, 604  
Bloodborne antigens, 416  
Blood smears  
    *identification of formed elements on*, 607  
    *making*, 606  
Blood vessels. See also Systemic circulation  
    *arterioles*, 369–370  
    *capillaries*, 371–373  
    *characteristics of wall layers*, 366t  
    *elastic artery*, 368  
    *layers of wall*, 366t  
    *muscular artery*, 368–369  
    *overview*, 364  
    *tracing flow of blood through*, 374  
    *veins*, 370–371  
    *wall structure*, 367

## I-2 Index

- Blunt dissection techniques, 12–14  
Blunt probe, 4t  
Bodily “humors,” 603–604  
Body  
  *of nail, 98t*  
  *of pancreas, 466t*  
  *of sternum, 148t, 149*  
  *of stomach, 463t*  
  *of vertebra, 143*  
Body cavities and membranes, 27  
Bolus, 448  
Bone. See also Compact bone; specific bones  
  *classification of, based on shape, 111t, 112*  
  *decalcified, 107*  
  *long bone, structure of, 112–115*  
  *overview, 72*  
  *of skull, 139*  
Bone markings, 126  
Bone marrow, identification of megakaryocytes in, 610–611  
Bone tissue, 107–110  
Brachialis muscle, 259  
Brachial plexus, 583–586  
Brain, human. See also Cranial nerves  
  *circulation to, 377–380*  
  *inferior view of, 543*  
  *lateral view of, 542*  
  *midsagittal view of, 544*  
  *sections, 23f*  
  *superior view of, 541*  
  *ventricles of, 536–538*  
  *visible structures of, 539–541t*  
Brain, sheep, dissection of, 557–563  
Brainstem, 540t  
Branches of brachial plexus, 583, 584  
Breast cancer and breast self exam, 521  
Breasts, 520, 522t  
Bronchi, 428, 430–431, 440t  
Bronchial tree, 431f  
Bronchioles, 428, 430–431, 432  
Bronchopulmonary segments, 439  
Buffy coat, 604  
Bulb of hair, 95, 96f  
Bulbourethral glands, 512t, 522  
Bursae, 197t, 200t
- C**  
Cadavers, use of in anatomy laboratory, 2  
Calcaneus, 184, 279f  
Calcified cartilage, 110f  
Calcitonin, 333  
Calvaria, 127  
Calyces, 485t  
Canaliculi, 108  
Capillaries, 366t, 371–373  
Capillary beds, 364  
Capsule  
  *adrenal glands, 335, 336f*  
  *articular, 197t*  
  *lymph nodes, 412, 413f, 414f*  
  *spleen, 416t*  
Carcinoma, 77  
Cardiac impression, 439  
Cardiac muscle  
  *identification and classification of, 78f*  
  *identification of, 213*  
  *lookalikes, 81*  
  *overview, 77, 206, 208t, 346–347*  
Cardia region of stomach, 454t, 463t  
Cardiovascular system. See also Blood vessels;  
  Heart  
  *blood, 603–604, 606–611*  
  *overview, 343–344*  
Carina, 440  
Caring for compound microscopes, 33–34  
Carpals, 163t, 168  
Carpal tunnel, 584  
Carpal tunnel syndrome, 574, 584  
Carrying microscope, 33, 34f  
Cartilage, 72, 435t  
Cartilaginous joints, 192t, 195–196  
Catecholamine, 335  
Caudal, 25t  
Cecum, 470, 472f  
Cell bodies, 80f, 287, 288t  
Cellular, 58  
Cellular anatomy  
  *overview, 43–44*  
  *parts of prototypical cell, 48–49t*  
  *structure and function of prototypical cell, 46–49*  
Central artery, 415f, 416  
Central canals, 108, 536  
Central nervous system, glial cells of, 291–292  
Central sulcus, 540t, 541, 542  
Central tendon of diaphragm, 243  
Central vein, 458, 459f  
Centrifugation, separation of whole blood sample  
  by, 604f  
Centrioles, 48t, 51f  
Cerebellum, 290, 540t  
Cerebral aqueduct, 536, 537t  
Cerebral arterial circle, 377  
Cerebrospinal fluid, circulation of, 537–538  
Cerebrum, 289–290, 539t  
Cervical enlargement, 576  
Cervical part of spinal cord, 577f, 578t  
Cervical plexus, 582–583  
Cervical vertebrae, 141, 144f  
Chemicals, hazardous, 6–7  
Chief cells  
  *gastric pits and glands, 454t*  
  *parathyroid gland, 333, 334t*  
Chin, 131t  
Cholelithiasis, 468  
Choroid layer, 316t, 317  
Choroid plexus, 537, 562–563  
Chromatin, 48t  
Chromatophilic substance, 80f, 287, 288t, 289f  
Chromophobes, 330, 332f  
Chyme, 450, 455  
Cilia, 60t, 63f, 64f, 65, 66  
Ciliary body, 316t, 318  
Ciliated cells  
  *trachea, 428t, 429f*  
  *uterine tubes, 506, 507f*  
Circular architecture of skeletal muscles, 217t  
Circular folds, 455, 469  
Circular smooth muscle, 485  
Circulation. See also Blood vessels; Systemic  
  circulation  
  *of cerebrospinal fluid, 537–538*  
  *coronary, 353–356*  
Circulatory system and lymphatic system, 403  
Circumferential lamellae, 108  
Cirrhosis, 387  
Cisterna chyli, 417t  
Clavicle, 159t, 160, 162, 170  
Clavicular head, 234  
Clinical breast exam, 521  
Coarse adjustment knob of microscope, 33t, 34f  
Coccyx, 141, 147–148  
Cochlea, 310, 311t, 312, 320f, 321f  
Cochlear nerve, 554  
Collagen fibers, 67f, 70  
Collecting ducts, 481f, 483, 484f, 488f  
Colloid, 333  
Colon, 470  
Columnar cells, 60t, 62f, 63f, 64f, 65  
Common fibular nerve, 588  
Compact bone  
  *as component of long bone, 112, 113f*  
  *components of, 75f*  
  *in cow, 114f*  
  *ground and decalcified, 108–109*  
  *overview, 73t*  
Compartments, 218–219, 220f  
Compound microscopes  
  *caring for, 33–34*  
  *depth of field, 39*  
  *diameter of field of view, 37–38*  
  *focus and working distance, 35–36*  
  *loading slide, 35f*  
  *observing cellular anatomy with, 46–48*  
  *observing mitosis with, 51*  
  *orienting objective lenses for drop of immersion oil, 607f*  
  *parts of, 33t, 34f*  
  *troubleshooting, 35t*  
Concentric lamellae, 108  
Condenser of microscope, 33t, 34f  
Conducting zone, 426  
Condylar joint, 197–198  
Connective tissue  
  *adipose, 68t, 69t, 99f*  
  *areolar, 68t, 69t*  
  *covering skeletal muscle, 210–221*  
  *dense irregular, 68t, 71f, 93f, 99f*  
  *dense regular, 68t, 70f, 81, 214*  
  *elastic, 68t, 71, 72f*  
  *embryonic, identification of, 67*  
  *fibers, 67t*  
  *fluid, 66–67, 76*  
  *overview, 66–67*  
  *reticular, 68t, 69, 70f*  
  *supporting, 66, 72, 73t, 74–75*  
Connective tissue proper  
  *identification and classification of, 69–72*  
  *loose and dense, 68t*  
  *overview, 66, 67*  
Connective tissue (dermal) root sheath of hair  
  follicle, 95t, 96f  
Continuous capillaries, 371, 372f  
Contractile tissues, 77, 206, 208  
Convergent architecture of skeletal muscles, 217t  
Cords of brachial plexus, 583  
Coronal (frontal) plane, 22t, 27f  
Coronal section  
  *sheep brain, 562f, 563f*  
  *sheep heart, 357–358*  
  *superior sagittal sinus, 532f*  
Corona radiata, 562  
Coronary circulation, 353–356

- Coronary sinus, 351, 356  
 Coronoid process, 133  
 Corpora cavernosa, 515–516  
 Corpus albicans, 503f, 505f  
 Corpus callosum, 540t, 562  
 Corpus luteum, 503f, 505f  
 Corpus spongiosum, 515–516  
 Cortex  
   *of hair follicle, 95t, 96f*  
   *of lymph node, 412, 414f*  
   *of ovary, 502, 503f, 504f*  
 Cortical nephron, 481f  
 Corticomedullary junction, 480, 481f  
 Corticosteroids, 335  
 Cows  
   *bone dissection, 114–115*  
   *eye dissection, 317–319*  
 Cranial (cephalic), 25t  
 Cranial bones, 126  
 Cranial dural septae, 532  
 Cranial floor, superior view of, 137–138  
 Cranial meninges, 532–535  
 Cranial nerves  
   *abducens, 552*  
   *accessory, 556*  
   *common disorders of, 549t*  
   *facial, 553*  
   *functions and divisions of, 547–548t*  
   *glossopharyngeal, 554*  
   *hypoglossal, 556*  
   *on inferior surface of brain, 546f*  
   *modalities within, 547t*  
   *oculomotor, 551*  
   *olfactory, 550*  
   *optic, 550*  
   *overview, 545*  
   *of sheep, 560f*  
   *trigeminal, 230, 552*  
   *trochlear, 551*  
   *vagus, 555*  
   *vestibulocochlear, 554*  
 Cribriform, 132  
 Cribriform foramina, 306  
 Cruciate ligaments, 200  
 Crypts, 408  
 Cuboidal cells, 60t, 62f, 65  
 Cuboid bone, 396f  
 Cuticle layer of hair follicle, 95t, 96f  
 Cytoplasm, 44, 48t, 51f  
 Cytoskeleton, 48t
- D**  
 Decalcified bone, 107  
 Decalcified compact bone, 108  
 Deep, 25t  
 Deep fascia, 209f, 210  
 Deltoid, 170  
 Deltoid tuberosity, 170  
 Dendrites, 80f, 287, 288t  
 Dens, 146  
 Dense connective tissue, 68t  
 Dense irregular connective tissue, 68t, 71f, 93f, 99f  
 Dense regular connective tissue, 68t, 70f, 81, 214  
 Denticulate ligaments, 579  
 Depressions, 126t  
 Depth, naming skeletal muscles based on, 216t  
 Depth of field, 33t, 39  
 Dermal papillae, 91, 99f, 302
- Dermis  
   *axillary skin, 97*  
   *layers of, 92–93, 99f, 302*  
   *merocrine sweat glands and sensory receptors*  
     *in, 94, 95t*  
   *nails, 98*  
   *overview, 87*  
   *scalp, 95–96*  
 Descending colon, 472f  
 Descending limb of nephron loop, 480t, 481f  
 Desmosomes, 213  
 Desquamation, 90t  
 Detrusor muscle, 486  
 Development  
   *of oocytes, 502t*  
   *of ovarian follicles, 504t*  
   *of sperm, 509t*  
 Dialysis, 478  
 Diameter of field of view, measuring, 37  
 Diaphragm  
   *circulation and, 382f, 384f, 386f*  
   *hepatic portal system and, 385f*  
   *inspiration and, 424*  
   *as muscle of respiration, 242t, 243*  
 Diaphragmatic surface, 349, 349f  
 Diaphragm sellae, 533t, 557  
 Diaphysis, 112, 113f, 114f  
 Diarthrotic joints, 199  
 Diathroses, 191, 192t  
 Diencephalon, 539t  
 Digestive system  
   *duodenum and gallbladder, 465–468*  
   *large intestine, 457–458, 470–472*  
   *liver, 458–459, 465–468*  
   *oral cavity, pharynx, and esophagus, 461–463*  
   *overview, 446, 461f*  
   *pancreas, 459–460, 465–468*  
   *salivary glands, 448–450*  
   *small intestine, 455–456, 469–470*  
   *stomach, 450–454, 463–465*  
 Diopter adjustment ring of microscope, 33t, 34f  
 Directional terms, 25  
 Dissection  
   *cow bone, 114–115*  
   *cow eye, 317–319*  
   *instruments for, 4–5t*  
   *sheep brain, 557–563*  
 Dissection techniques  
   *blunt, 12–14*  
   *sharp, 7–12*  
 Distal, 25t, 27  
 Distal convoluted tubules, 481f, 482, 483f  
 Distal phalanx, 262  
 Divisions of brachial plexus, 583  
 Dorsal muscles of foot, 280t  
 Dorsum sellae, 137  
 Duct system of gallbladder, 466t  
 Ductus deferens, 512t, 513, 522  
 Duodenal glands, 455f, 456  
 Duodenum, 455f, 456, 465  
 Dural venous sinuses, 380, 532, 533f, 534t  
 Dura mater, 532, 533t, 557, 558f, 560f
- E**  
 Ear  
   *anatomy of, 319, 322*  
   *model of, 320f*  
   *structures of, 320–321t*  
 Edema, 403  
 Efferent lymphatic vessels, 412, 414f  
 Ejaculation, 513  
 Elastic artery, 366t, 368  
 Elastic cartilage, 73t, 75f, 76  
 Elastic connective tissue, 68t, 71, 72f  
 Elastic fibers, 67f, 70  
 Elastic tissues, 208  
 Encroaching fat, 469  
 Endocardium, 347, 350t  
 Endochondral bone development, 110  
 Endochondral ossification, 110  
 Endocrine glands, 328f, 337  
 Endocrine system  
   *adrenal glands, 335–337*  
   *anatomy of, 339*  
   *hypothalamus and pituitary gland, 330–332*  
   *overview, 327–328*  
   *pancreas, 337–338*  
   *pineal gland, 333*  
   *thyroid and parathyroid glands, 333–335*  
 Endometrium, 508  
 Endomysium, 209f, 210  
 Endoneurium, 295  
 Endoplasmic reticulum, 48t, 51f  
 Endothelium, 62, 347, 369f  
 Enteroendocrine cells, 454t  
 Eosinophils, 608t, 609f  
 Ependymal cells, 291, 292  
 Epicardium, 347, 350t  
 Epidermal ridges, 91, 93f, 99f  
 Epidermis  
   *layers of, 90–91, 99f, 302*  
   *overview, 87*  
   *as part of dermis, 93f*  
   *pigmented skin, 92*  
 Epididymis, 510f, 511–512, 522  
 Epigastric region, 28f  
 Epimysium, 209f, 210  
 Epineurium, 295  
 Epiphyseal plate, 110  
 Epiphyses, 112, 113f, 114f  
 Epithelial stem cells, 453  
 Epithelial tissue  
   *cell shapes, 60t*  
   *cell surface modifications and specialized*  
     *cells, 60t*  
   *flowchart for classification of, 59f*  
   *identification and classification of, 61–66*  
   *number of cell layers, 58t*  
 Eponychium of nail, 98t  
 Erector spinae, 238, 239t  
 Erythrocytes, 76, 369f, 424, 604, 607t, 609f  
 Esophagus, 461  
 Estrogen, 502  
 Ethanol, 6t  
 Ethmoid bone, 127t, 130t, 132  
 Exchange of fluids, 488  
 Excitable tissues, 77, 208  
 Exocrine glands, 337  
 Exocrine portion of pancreas, 459  
 Expiration, 424  
 Extensible tissues, 208  
 Extensor compartment, 259  
 Extensor pollicis brevis, 264, 265t  
 Extensor pollicis longus, 264, 265t  
 External acoustic meatus, 137, 320t, 322  
 External carotid arteries, 375



## I-4 Index

External ear, structures of, 320f  
External elastic lamina, 368, 369f  
External intercostal membrane, 242  
External intercostal muscles, 242, 424  
External jugular veins, 375  
External oblique muscles, 244–245, 247f  
External root sheath of hair follicle, 95t, 96f  
External urethral sphincter, 491  
Eye  
    *accessory structures of, 314t, 315f*  
    *of cow, dissection of, 317–319*  
    *extrinsic eye muscles, 229–230*  
    *internal structures of, 316t, 317f*  
    *muscles of, 227t*  
Eyepiece of microscope, 33t, 34f

**F**

Face of cadaver, 2  
Facets, 143–144  
Facial bones, 126–127  
Facial expression, muscles of, 226–229  
Facial nerves, 226, 545t, 546f, 548t, 549t, 553  
Fascicles, 208, 209f, 210  
Feces, 457  
Female pelvis, 172, 174f, 494f  
Female reproductive system  
    *breast, 520, 522t*  
    *ovary, 502–506, 516–519*  
    *suspensory ligaments, 517–519*  
    *uterine tubes, 506–507, 516–519*  
    *uterine wall, 508*  
    *uterus, 517–519*  
    *vaginal wall, 509*  
Femoral triangle, 271f, 272  
Femur, 127, 175t, 177–178, 184, 270  
Fenestrated capillaries, 371, 372f  
Fenestrations, 371  
Fetal circulation, 397–398  
Fetal skull, 139–140  
Fibrin, 76  
Fibrinogen, 76  
Fibrocartilage, 73t, 74f, 76, 196  
Fibrous capsule, 486  
Fibrous joints, 192t, 194–195  
Fibrous layer of articular capsule, 197t  
Fibrous pericardium, 349  
Fibula, 176t, 180, 184  
Fibularis brevis muscle, 275, 276t  
Fibularis longus muscle, 275, 276t  
Field of view, 33t, 37  
Filiform papillae, 304f, 305t  
Filtrate, 478  
Filtration membrane, 478  
Filum terminale, 579  
Fine adjustment knob of microscope, 33t, 34f  
Flat bones, 111t  
Flexion, 206  
Flexor compartment, 259  
Flexor digitorum profundus, 262, 264f  
Flexor digitorum superficialis, 262, 264f  
Flexor retinaculum, 262  
Fluid connective tissue, 66–67, 76  
Focusing microscope, 35–36  
Foliate papillae, 304, 305t  
Fontanels, 139  
Foot, intrinsic muscles of, 278–280  
Foramen, 127

Foramen lacerum, 136  
Foramen ovale, 350–351  
Forceps, 4t, 12  
Forearm, compartments of, 218t, 261–265  
Forehead, 130t  
Formalin, 6–7  
Fornix, 540t, 562  
Fossa ovalis, 350, 352  
Fourth ventricle, 537t  
Fovea centralis, 308t, 309, 316t  
Free nerve endings, 94, 95t, 99f, 302t, 312  
Frontal bone, 127t, 130t  
Functional layer of uterine wall, 508  
Fundic region of stomach, 453f, 454t, 463t  
Fungiform papillae, 304f, 305t  
Funiculi, 576, 577f, 578t

**G**

Gallbladder, 465–467, 468t  
Gallstones, 468  
Gametes, 500  
Ganglia, 287  
Ganglion, 293  
Gap junctions, 213  
Gastric glands, 452f, 453–454  
Gastric pits, 452f, 453–454  
Gastrocnemius muscle, 277, 278t  
Gastrointestinal (GI) tract, 446, 461f.  
    See also Digestive system  
General senses, 302  
Germinal center, 407, 413f, 414f  
Germinal epithelium, 502, 503f, 504f  
Glands  
    *adrenal, 335–337, 467f*  
    *apocrine sweat, 94t, 97*  
    *bulbourethral, 512t, 522*  
    *in dermis, 94t*  
    *duodenal, 455f, 456*  
    *endocrine, 328f, 337*  
    *exocrine, 337*  
    *gastric, 452f, 453–454*  
    *intestinal, 457*  
    *mammary, 520, 522t*  
    *merocrine sweat, 93f, 94, 99f*  
    *olfactory, 427t*  
    *parathyroid, 333–335*  
    *pineal, 333, 539t*  
    *pituitary, 330–332, 378f, 557*  
    *prostate, 512t, 515, 522*  
    *salivary, 448–450*  
    *sebaceous, 94t, 95, 97f, 99f*  
    *thyroid, 333–335*  
Glassy membrane of hair follicle, 95t, 96f  
Glenohumeral joint, 256, 257–258  
Glial cells, 79, 80f, 290f, 291–294  
Glomerular capsule, 481f, 482  
Glomerulus, 481f, 482, 487  
Glossopharyngeal nerve, 545t, 546f, 548t, 549t, 554  
Gluteal nerves, 587  
Gluteal region, sacral plexus, 588f  
Gluteus maximus, 270  
Glycerine, 6t  
Goblet cells  
    *epithelial tissues, 60t, 62, 66*  
    *trachea, 428t, 429f*  
Golgi apparatus, 48t, 51f

Gomphoses, 194  
Gonads, 500  
Gracilis muscle, 273  
Gray commissure, 576, 577f, 578t  
Gray matter, 287  
Greater trochanter of femur, 184  
Great saphenous vein, 371  
Gross anatomy  
    *abdominopelvic regions and quadrants, 28*  
    *anatomic planes and sections, 22–24*  
    *anatomic terminology and anatomic position, 22*  
    *body cavities and membranes, 27*  
    *directional terms, 25*  
    *language of, 19–20*  
    *overview, 1–2*  
    *regional terms, 26*  
Ground bone, 107  
Ground compact bone, 108  
Ground substance, 67f  
Gustation (taste), 304–306  
Gyri, 561

**H**

Hair cells, 310, 311t  
Hair follicles, 95–96, 99f  
Hallux, 176t, 183, 395f  
Hamstring muscles, 273  
Hand, intrinsic muscles of, 266–267  
Haustra, 470, 472f  
Hazardous chemicals, 6–7  
Hazardous waste, 7, 606  
Head. See also Head and neck, muscles of  
    *clavicular, 234*  
    *of fibula, 184, 276f*  
    *of mandible, 133*  
    *of microscope, 33t, 34f*  
    *muscles that move, 234–236*  
    *of pancreas, 466t*  
    *of skeletal muscles, 215t*  
Head and neck  
    *circulation to, 375–377*  
    *midsagittal section of, 433–434*  
Head and neck, muscles of  
    *anterior neck, 233–234*  
    *extrinsic eye, 229–230*  
    *facial expression, 226–229*  
    *mastication, 230–231*  
    *pharynx, 232–233*  
    *suboccipital region, 236–238*  
    *suprahyoid and infrahyoid, 234–236*  
    *tongue, 231–232*  
Hearing, 310–312  
Heart, human  
    *anatomy of, 349–353*  
    *arterial supply to, 354t*  
    *cardiac muscle, 346–347*  
    *coronary circulation, 353–356*  
    *layers of heart wall, 347, 350t*  
    *pericardial cavity, 348–349*  
    *specimens, obtaining, 359*  
    *venous drainage of, 356t*  
Heart, sheep  
    *coronal sections of, 357–358*  
    *sections through, 24f*  
    *superficial structures of, 356–357*  
    *transverse section of, 359*  
Hemopoiesis, 610

Hemopoietic tissue, 115  
 Hemorrhoids, 387  
 Hemostats, 4t, 9, 10f, 11  
 Hepatic cords, 458, 459f  
 Hepatic lobule, 458, 459f  
 Hepatic portal system, 383, 385f  
 Hepatic portal veins, 383  
 Hepatic sinusoids, 458  
 Hepatic veins, 383  
 Hepatocytes, 458, 459f  
 Hidden border of nail, 98t  
 Hilum of lymph node, 412, 413f, 416t  
 Hinge joint, 198t, 199  
 Hip, muscles of, 268–270  
 Hip abduction, 268, 270  
 Histology  
   *lookalikes in*, 81  
   *overview*, 1–2, 43, 55  
 Histopathology, 58–59  
 Homologues, 500  
 Humectants, 6  
 Humerus, 162t, 164–165, 170  
 Humors, Greek bodily, 603–604  
 Hyaline cartilage, 73t, 74f, 76, 195  
 Hyoid bone, 139  
 Hypertrophic cartilage, 110f  
 Hypogastric region, 28f  
 Hypoglossal nerve, 545t, 546f, 548t, 549t, 556  
 Hyponychium of nail, 98t  
 Hypophyseal fossa, 137  
 Hypothalamus, 330, 539t  
 Hypothenar eminence, 266  
 Hypothenar muscles, 266, 267t  
 Hypoxia, 353

**I**  
 I bands, 208, 209f  
 Ileum, 455f, 456, 469–470  
 Iliac crest, 184  
 Iliacus, 270  
 Iliocecal valve, 455f, 457  
 Iliopsoas muscle, 270, 271f  
 Ilium, 171  
 Immune system and lymphatic system, 403  
 Impressions on surface of lungs, 437–438  
 Inferior, 25t, 27  
 Inferior articular facets, 144  
 Inferior articular processes, 143  
 Inferior costal facets, 146  
 Inferior gluteal nerve, 587  
 Inferior mesenteric veins, 383, 384f  
 Inferior nasal conchae, 127t, 130t  
 Inferior trunk of brachial plexus, 583  
 Inferior vena cava, 350  
 Inferior view  
   *human brain*, 543f  
   *human skull*, 136  
   *sheep brain*, 559f, 560f, 561f  
 Infrahyoid muscles, 234–235  
 Infrapinatus muscle, 258  
 Infundibulum, 540t, 543  
 Inguinal canal, 244t, 246  
 Inguinal ligament, 245t, 246, 247f, 272, 393f, 395f  
 Inner ear, structures of, 321f  
 Inspiration, 424  
 Instruments for dissection, 4–5t  
 Integument, 87  
 Integument model, 99

Interatrial septum, 352  
 Intercalated disc, 213  
 Intercellular clefts, 371  
 Intercostal nerves, 582  
 Intermediate mass, 539t, 544  
 Internal acoustic meatus, 137  
 Internal auditory canal, 137, 554  
 Internal capsule, 562  
 Internal carotid arteries, 377  
 Internal elastic lamina, 368, 369f  
 Internal intercostal membrane, 242  
 Internal intercostal muscles, 242  
 Internal jugular veins, 377, 380, 532, 533f  
 Internal oblique muscles, 244t, 245, 247f  
 Internal root sheath of hair follicle, 95t, 96f  
 Internal structures of eye, 316–317  
 Internal urethral sphincter, 491  
 Interossei muscles, 266, 267t, 278, 280t  
 Interosseous membrane, 194  
 Interphase of cell cycle, 50t  
 Interstitial cells of testes, 510t  
 Interstitial lamellae, 108  
 Interthalamic adhesion, 539t, 544  
 Intervertebral discs, 196  
 Intervertebral foramen, 144  
 Intestinal glands, 457  
 Intramembranous ossification, 194  
 Intramural ganglia, 595  
 Iris diaphragm of microscope, 33t, 34f  
 Irregular bones, 111t  
 Ischemic, 353  
 Ischial tuberosities, 184, 274f  
 Ischium, 171, 172t  
 Isthmus, 333

**J**  
 Jejunum, 455f, 456, 469–470  
 Joints. See Articulations; specific joints  
 Juxtaglomerular apparatus, 482  
 Juxtamedullary nephron, 481f, 488f

**K**  
 Keratin, 90  
 Keratinization, 60t  
 Keratinocyte, 90  
 Kidney failure, 478  
 Kidneys  
   *blood supply to*, 487–490  
   *gross anatomy of*, 486–487  
   *overview*, 480–481  
   *renal cortex*, 482–483  
   *renal medulla*, 483–484  
   *urine-draining structures*, 490  
 Knee joints, 200–202

**L**  
 Laboratory equipment, 4–7  
 Lacrimal bone, 127t, 130t  
 Lacteals, 403  
 Lacunae, 108  
 Lambdoid suture, 135  
 Lamellated corpuscles, 93f, 94, 95t, 99f, 302t, 303  
 Laminae, 143  
 Lamina propria, 426, 427f, 428t, 429t  
 Lancing finger for blood sample, 606f  
 Language of anatomy, 19–20  
 Large bronchi, 430–431

Large intestine, 457–458, 470–472  
 Laryngeal elevators, 232t  
 Larynx, 428, 434f, 435, 440f  
 Lateral, 25t  
 Lateral compartment of leg, 275–276  
 Lateral cord of brachial plexus, 583, 584  
 Lateral epicondyle of femur, 184  
 Lateral horns, 576, 577f, 578t  
 Lateral malleolus, 184  
 Lateral mass, 146  
 Lateral sulcus, 540t, 542  
 Lateral ventricles, 536, 537t  
 Lateral view  
   *human brain*, 542f  
   *sheep brain*, 558f  
   *skull*, 134  
   *vertebral column*, 142f  
 Latissimus dorsi, 257, 258t  
 Left atrioventricular valve, 352, 354f  
 Left atrium, 352, 355f  
 Left coronary artery, 354  
 Left hypochondriac region, 28f  
 Left iliac region, 28f  
 Left lower quadrant, 28f  
 Left lumbar region, 28f  
 Left lung, 439f  
 Left upper quadrant, 28f  
 Left ventricles, 349f, 350, 352, 353f, 354f  
 Leg, compartments of, 218t, 275–278  
 Lens  
   *of eye*, 316t, 318, 319f  
   *of microscope, care of*, 33–34  
 Lesser trochanter of femur, 270  
 Lesser wing of sphenoid bone, 137  
 Leukocytes, 76, 604, 607t, 608t, 609f  
 Levator scapulae, 256  
 Ligaments of knee joints, 200t  
 Ligamentum arteriosum, 349f, 352f, 353  
 Light control of microscope, 33t, 34f  
 Limbic system, 540t, 544  
 Limbs, fascial compartments of, 218t, 219–220.  
   See also Lower limbs; Upper limbs  
 Linea alba, 245, 247f  
 Lingual tonsils, 408  
 Liver, 458–459, 465–468, 466t  
 Lobar bronchi, 440t  
 Lobes  
   *of lungs*, 439, 440f  
   *of thymus*, 410  
 Lobules  
   *hepatic*, 458, 459f  
   *of lungs*, 439  
   *of thymus*, 410, 411f  
 Locomotion, actions of gluteal muscles during, 270f  
 Long bones, 110, 111t, 112–115  
 Long head of biceps brachii, 259  
 Longissimus capitis, 236f, 237t  
 Longitudinal fissure, 540t, 541  
 Longitudinal smooth muscle, 485  
 Long thoracic nerve, 585t, 586  
 Loose connective tissue, 68t  
 Lower limbs. See also Foot, intrinsic muscles of; Leg, compartments of; Thigh, compartments of  
   *bones*, 175–176t  
   *circulation to*, 392–396  
   *femur*, 177–178

## I-6 Index

### Lower limbs. (*Continued*)

- fibula*, 180
  - metatarsals and phalanges*, 183
  - muscles of*, 270–280
  - overview*, 155
  - review*, 184
  - surface anatomy of*, 185
  - tarsals*, 181–182
  - tibia*, 179–180
- Lower respiratory tract, 428–430, 435–436
- Lumbar enlargement, 576
- Lumbar part of spinal cord, 577f, 578t
- Lumbar plexus, 586, 587t
- Lumbar vertebrae, 141, 147
- Lumbrical muscles, 266, 267t
- Lumen, 61
- Lungs, 431–433, 437–440
- Lunula of nail, 98t
- Lymph, 76f
- Lymphatic nodule, 407, 412, 413f, 414f
- Lymphatic system
- anatomy of*, 417–419
  - lymph nodes*, 412–414
  - musoca-associated lymphatic tissue*, 407–410
  - organs of*, 410–416
  - overview*, 403–404
  - Peyer patches*, 409
  - spleen*, 415–416
  - thymus*, 410–412
  - tonsils*, 408–409
  - vermiform appendix*, 410
  - vessels of*, 406
- Lymph nodes, 412–414
- Lymphocytes, 411f, 607, 608t, 609f
- Lysosomes, 48t, 51f

## M

- Macroglia, 291
- Magnification, determining, 35
- Main bronchi, 440t
- Male pelvis, 172, 174f, 493f
- Male reproductive system
- ductus deferens*, 513
  - epididymis*, 511–512
  - overview*, 522
  - penis*, 515–516, 523–524
  - prostate gland*, 515
  - scrotum, testis, and spermatic cord*, 523–524
  - seminal vesicles*, 514
  - semiferous tubules*, 509–511
- Male urinary system, 492f
- Mammary glands, 520, 522t
- Mamillary bodies, 539t, 543, 560
- Mammography, 521
- Mandible, 127t, 130–131t, 133
- Mandibular branch, 548t, 552f
- Mandibular condyle, 133
- Mandibular foramen, 133
- Manubrium, 148t, 149
- Masseter muscle, 230, 463f
- Mastication, muscles of, 230–231
- Mastoid process, 233
- Maxilla, 128t, 130t
- Maxillary branch, 548t, 552f
- McBurney's point, 407
- Measuring
- diameter of field of view*, 37
  - working distance*, 36f
- Mechanical stage controls of microscope, 33t, 34f
- Mechanical stage of microscope, 33t, 34f
- Medial, 25t, 586
- Medial compartment of thigh, 272–273
- Medial cord of brachial plexus, 583, 584
- Medial epicondyle
- femur*, 184
  - humerus*, 170
- Medial malleolus, 184
- Median, 586
- Median nerve, 584, 585t
- Mediastinum, 348, 437
- Medulla
- lymph node*, 412
  - ovary*, 502, 503f
- Medullary cavity, 112, 113f, 114f
- Medullary cords, 412, 413f, 414f
- Medullary sinuses, 412, 413f, 414f
- Megakaryocytes, 76, 610–611
- Meiosis, 500
- Meissner corpuscles, 93f, 94, 95t, 99f
- Melanin, 92
- Melanocytes, 92
- Melatonin, 333
- Membranous urethra, 493
- Meningeal layer, 532, 533t
- Meninges, cranial, 532–535
- Menisci
- knee joints*, 115, 200t
  - synovial joints*, 197t
- Menstrual cycle, 508t
- Mental foramen, 133
- Merocrine sweat glands, 93f, 94, 99f
- Mesenchymal cells, 67f
- Mesenchyme, 66
- Mesothelium, 62, 349
- Metacarpals, 163t, 169
- Metaphase of cell cycle, 50t
- Metaphyses, 112, 113f, 114f
- Metatarsals, 176t, 183, 184
- Microglia, 291
- Micrometer, 37
- Microtome, 59
- Microvilli, 60t, 62, 66, 455
- Micturition, 490
- Midclavicular line, 242, 244f
- Middle ear, structures of, 320–321f
- Middle phalanx, 262
- Midpalmar group of muscles, 266, 267t
- Midsagittal section
- female pelvis*, 494f
  - head and neck*, 433–434
  - male pelvis*, 493f
  - sheep brain*, 562f
- Midsagittal view
- human brain*, 544f
  - sheep brain*, 563f
- Midsagittal (median) plane, 22t, 27f
- Millimeter, 37
- Mitochondria, 48t, 51f
- Mitosis, 49, 50t, 51
- Mnemonic devices, 547
- Monocytes, 607, 608t, 609f
- Motor end plate, 211, 212f
- Motor information, 547
- Mouth, muscles of, 227t
- Movements of synovial joints, 199–200

### Mucosa

- olfactory*, 427–428
  - respiratory passageways*, 426
  - stomach*, 450, 451f, 452t
  - trachea*, 428t, 429t
  - ureters*, 485f
  - urinary bladder*, 486f
  - uterine tubes*, 506, 507f
  - vaginal epithelium*, 509f
- Mucosa-associated lymphatic tissue, 407–410
- Mucous cells, 448, 449t
- Mucous neck cells, 454t
- Multifidus muscles, 240
- Multipennate architecture of skeletal muscles, 217t
- Multipolar neurons, 287, 288–289
- Muscle fibers, 208, 209f
- Muscles. See also Appendicular muscles; Axial muscles; Cardiac muscle; Skeletal muscles; Smooth muscle
- of larynx*, 436f
  - stepwise approach to learning*, 226
- Muscle tissue, 77–79
- Muscular artery, 366t, 368–369
- Muscularis layer
- stomach*, 450, 451f, 452t
  - urinary bladder*, 486f
  - uterine tubes*, 507f
  - vaginal epithelium*, 509f
- Musculocutaneous nerve, 584, 585t
- Musculoskeletal system, 218–220
- Myelin sheath, 293
- Myocardial infarction, 353
- Myocardium, 347, 350t
- Myofibrils, 208, 209f
- Myofilaments, 208, 209f
- Myosin, 208

## N

- Nails, structure of, 98
- Nasal bone, 128t, 130t, 132
- Nasal cavity, 130t, 132, 434f
- Nasal septum, 130t, 132
- Neck. See also Head and neck
- anterior, muscles of*, 233–234
  - muscles of*, 227t
  - muscles that move*, 234–236, 237t
  - posterior triangle of*, 582f
- Necrotic tissues, 353
- Needles, dissecting, 4t
- Nephron loop, 480t, 481f, 483, 484f, 488f
- Nephrons, 478
- Nerves, 287
- Nervous system
- autonomic*, 593, 595–599
  - general senses*, 302–303, 312–313
  - sensory receptors and organs*, 300
  - somatic*, 593
  - special senses*, 304–312, 314–322
- Nervous tissue
- glial cells*, 291–294
  - gray and white matter*, 287
  - identification and classification of*, 79–80
  - neurons*, 287–290
  - overview*, 285
  - peripheral nerves*, 295
- Neural tunic, 308, 309f
- Neurofibril nodes, 293
- Neuroglia, 291

- Neurohypophysis, 330  
 Neurolemmocytes, 291, 293  
 Neuromuscular junction, 211, 212f  
 Neurons, 79, 80f, 287–290  
 Neutrophils, 608t, 609f  
 Nissl stain, 289  
 Nodes of Ranvier, 293  
 Nose, 130t, 227t  
 Nosepiece of microscope, 33t, 34f  
 Nuclear envelope, 51f  
 Nuclear pore, 51f  
 Nuclei, 287  
 Nucleolus, 44, 49t, 51f  
 Nucleus, 44, 49t, 51f  
 Nucleus pulposus, 196  
 Nutrient artery, 114
- O**
- Objective lens of microscope, 33t, 34f  
 Oblique muscles of eye, 229t  
 Oblique plane, 22t  
 Occipital bone, 128t  
 Occipital condyles, 145  
 Occipital lobe, 308, 539t  
 Ocular lens of microscope, 33t  
 Oculomotor nerve, 545t, 546f, 547t, 549t, 551  
 Odontoid process, 146  
 Olecranon, 170  
 Olfaction (smell), 306–307  
 Olfactory bulbs, 306, 307t, 540t, 546f, 550  
 Olfactory epithelium, 306, 307t, 427  
 Olfactory foramina, 550  
 Olfactory glands, 427t  
 Olfactory mucosa, 427–428  
 Olfactory nerves, 306, 545t, 547t, 549t, 550  
 Olfactory receptor cells  
   *as neurons*, 306  
   *of olfactory epithelium*, 307t, 427t  
 Olfactory tract, 306, 307t, 540t, 546f, 550  
 Omental appendages, 470, 472f  
 Oocytes, 502  
 Openings and spaces, 126t  
 Open scissors technique, 12–13  
 Ophthalmic branch, 547t, 552f  
 Opposition (movement of thumb), 266  
 Optic chiasm, 541t, 543, 546f, 550  
 Optic disc, 309, 316t, 318  
 Optic nerve  
   *common disorders of*, 549t  
   *function of*, 547t  
   *location of*, 546f  
   *overview*, 545t, 550  
   *retina and*, 308  
   *as visible in superficial views*, 541t  
 Optic tracts, 543  
 Oral cavity, 130t, 461–463  
 Orbicularis oris, 227t, 231f  
 Orbit, 130t, 131  
 Oropharynx, 461  
 Os coxae, 116, 171, 172, 173f  
 Ossification, 110f  
 Osteoblasts, 107t, 109  
 Osteoclasts, 107t, 109  
 Osteocytes, 107t, 109f  
 Osteoprogenitor cells, 107t, 108  
 Oval window, 319, 320f, 321f, 322
- Ovarian follicles, 502  
 Ovaries, 500, 502–506, 516–519  
 Oxyphil cells, 333, 334t
- P**
- Palate muscles, 232t  
 Palatine bone, 128t, 130t, 132  
 Palatine processes of maxillary bones, 132  
 Palatine tonsils, 408  
 Palmar aponeurosis, 262  
 Pancreas  
   *in digestive system*, 459–460, 465–468  
   *in endocrine system*, 337–338, 338f  
   *hepatic portal system and*, 385f  
   *structures of*, 466t  
 Pancreatic acini, 337, 338f, 459, 460f  
 Pancreatic duct, 460f  
 Pancreatic islets, 337, 338t, 460f  
 Pancreatic juice, 460, 465  
 Papillary layer of dermis, 92, 93f, 95, 99f  
 Papillary muscles, 350f, 351, 352f  
 Parafollicular cells, 333, 334t  
 Parallel architecture of skeletal muscles, 216, 217t  
 Paranasal sinuses, 434f  
 Parasympathetic division of autonomic nervous system, 593, 595–598  
 Parathyroid glands, 333–335  
 Parathyroid hormone, 333  
 Parietal bone, 128t  
 Parietal cells, 454t  
 Parietal layer  
   *pericardial cavity*, 348  
   *renal cortex*, 482  
 Parietal pericardium, 356  
 Parietal pleura, 424, 437  
 Parotid salivary gland, 448f, 449t  
 Patella, 184, 276f  
 Patellofemoral joints, 200  
 Pectinate muscle, 350  
 Pectoral girdle, 116, 155, 159–162, 170, 256–257  
 Pectoralis major, 257–258  
 Pedicles, 143  
 Peduncles, 540t, 562  
 Pelvic girdle, 116, 155, 184  
 Penis, 515–516  
 Pennate architecture of skeletal muscles, 216, 217t  
 Perforating canals, 108  
 Pericardial cavity, 348–349  
 Pericardial fluid, 349  
 Pericardial sac, 348  
 Perilymph, 322  
 Perimysium, 209f, 210  
 Perinephric fat, 486  
 Perineum, 246  
 Perineurium, 295  
 Periodontal membrane, 194  
 Periosteal layer, 532, 533t  
 Periosteum, 108  
 Peripheral nerves, 295, 582–588  
 Peritrabecular space, 414t  
 Peritubular capillaries, 487, 488f  
 Peroxisomes, 49t  
 Perpendicular plate of ethmoid bone, 132  
 Petrous part of temporal bone, 137  
 Peyer patches, 409, 456  
 Phalanges, 163t, 169, 176t, 183, 184  
 Pharyngeal constrictors, 232t  
 Pharyngeal tonsils, 408
- Pharynx, 232–233, 434f, 462–463  
 Phenol, 6–7  
 Phlebotomists, 604  
 Phrenic nerve, 582, 583f  
 Pia mater, 532, 533t, 561  
 Pigmented skin, 92  
 Pineal body (gland), 333, 539t  
 Pinealocytes, 333  
 Pineal sand, 333  
 Pins, dissecting, 4t  
 Piriformis muscle, 270  
 Pituitary gland, 330–332, 378f, 557  
 Pituitary stalk, 543  
 Pivot joint, 198t, 199  
 Plane joint, 198t, 199  
 Planes, 22  
 Plantar aponeurosis muscle, 278  
 Plantaris muscle, 277, 278t  
 Plantar muscles of foot, 280t  
 Plasma, 76  
 Plasma membrane, 44, 49t, 51f  
 Platelets, 76, 604, 607t, 609f, 611  
 Plate of ethmoid bone, 132  
 Pleura, 437  
 Pleural cavities, 437  
 Plexuses, 582  
 Podocytes, 482  
 Pointed scissors, 12  
 Polarity, 58  
 Pollex, 169, 266  
 Popliteal region, sacral plexus, 588f  
 Portal triads, 458, 459f  
 Portal veins, 383  
 Position, naming skeletal muscles based on, 215–216t  
 Postcapillary venules, 366t  
 Postcentral gyrus, 539t, 541  
 Posterior (dorsal), 25t  
 Posterior arch, 145  
 Posterior chamber of eye, 316t, 318  
 Posterior clinoid processes, 137  
 Posterior compartment  
   *arm*, 259–261  
   *forearm*, 264–265  
   *leg*, 277–278  
   *thigh*, 273–274  
 Posterior cord of brachial plexus, 583, 584  
 Posterior horns, 576, 577f, 578t  
 Posterior muscles of pectoral girdle, 256–257  
 Posterior pituitary, 330, 332f  
 Posterior rami, 582  
 Posterior root ganglia, 293, 294f  
 Posterior tubercle, 145  
 Posterior view  
   *human skull*, 135  
   *sheep brain*, 562f  
 Power switch of microscope, 33t, 34f  
 Precentral gyrus, 539t, 541  
 Preservatives, 6  
 Prevertebral ganglia, 595  
 Primary curvatures, 142  
 Primary follicles, 503f, 504t  
 Primary vesicles, 536  
 Prime movers, 233, 259  
 Primordial follicles, 503f, 504t  
 Progesterone, 502  
 Projections for tendon and ligament attachment, 126t

## I-8 Index

Proliferating cartilage, 110f  
Prophase of cell cycle, 50t  
Prostate gland, 512t, 515, 522  
Prostatic calculi, 515  
Prostatic urethra, 493  
Protective equipment, 6  
Prototypical cell, 46–49, 51  
Proximal, 25t, 27  
Proximal convoluted tubules, 481f, 482, 483f  
Pseudostratified columnar epithelium, 64f  
Pseudostratified epithelium, 58t  
Psoas major, 270  
Pubic symphysis, 196, 273f  
Pubis, 171, 172t  
Pudendal nerve, 587  
Pudendal nerve block, 586  
Pulmonary circuit, 374–375  
Pulmonary semilunar valve, 351, 354f  
Pulmonary trunk, 349f, 350f, 351, 354f  
Pulmonary veins, 352  
Purkinje cells of cerebellum, 290  
Pyloric region of stomach, 453f, 454t, 463t  
Pyramidal cells of cerebrum, 289–290

## Q

Quadrants, 28  
Quadriceps femoris muscles, 271t

## R

Radial nerve, 584, 585t  
Radius, 163t, 166, 170  
Rami, 582  
Reabsorption, 478, 488  
Rectum, 470, 472f  
Rectus abdominis muscle, 244t, 245, 247f  
Rectus muscles of eye, 229t  
Rectus sheath, 245, 246  
Red bone marrow, 115  
Red pulp, 415, 416t  
Regional terms, 26  
Regions, 28  
Removing scalpel blades from scalpel blade handles, 10  
Renal corpuscles, 481f, 482, 483f  
Renal cortex, 480, 481f, 482–483, 488f  
Renal fascia, 486  
Renal medulla, 480, 481f, 483–484, 488f  
Reproductive system  
  *female*, 502–509, 516–522  
  *male*, 509–516, 522–524  
  *overview*, 500  
Respiration, muscles of, 242–244  
Respiratory membrane, 432  
Respiratory system  
  *lower respiratory tract*, 428–430, 435–436  
  *lungs*, 431–433, 437–440  
  *overview*, 424  
  *pleural cavities*, 437  
  *upper respiratory tract*, 426, 433–434  
Respiratory zone, 426, 432t  
Resting cartilage, 110f  
Reticular connective tissue, 68t, 69, 70f  
Reticular fibers, 67f, 70  
Reticular layer of dermis, 92, 93f, 99f  
Reticuloendothelial cells, 458  
Retina, 308–309, 316t, 317, 550  
Retroperitoneal, 485

Rhomboids, 256  
Ribosomes, 49t, 51f  
Ribs, 148t, 149–150  
Right atrioventricular valve, 351  
Right atrium, 349f, 350, 355f  
Right coronary artery, 354  
Right hypochondriac region, 28f  
Right iliac region, 28f  
Right lower quadrant, 28f  
Right lumbar region, 28f  
Right lung, 438f  
Right lymphatic duct, 417t  
Right upper quadrant, 28f  
Right ventricles, 349f, 350, 351f, 353f, 354f  
Root of hair, 95  
Rotator cuff muscles, 258  
Rotatores, 240  
Rough endoplasmic reticulum, 289  
Round ligament of uterus, 246  
Round window, 310

## S

Sacral part of spinal cord, 577f, 578t  
Sacral plexus, 586, 587t, 588f  
Sacrotuberous ligament, 270  
Sacrum, 141, 147–148  
Saddle joint, 198t, 199  
Sagittal (parasagittal) plane, 22t  
Sagittal section of human brain, 539–541t  
Sagittal suture, 135  
Saliva, 448  
Salivary amylase, 448  
Salivary glands, 448–450  
Sarcolemma, 208  
Sarcoma, 77  
Sarcomeres, 208, 209f  
Sartorius muscle, 272  
Satellite cells, 210, 291, 293–294  
Scala tympani, 310, 311t  
Scala vestibuli, 310, 311t  
Scalene tubercle, 150  
Scalp, 95, 227t  
Scalpel blade handles, 5t, 8–10  
Scalpel blades, 5t, 8–10  
Scalpels, 5t, 8, 11–12  
Scapula, 159t, 160, 161f, 162, 170  
Scapular line, 242, 244f  
Sciatica, 574  
Sciatic nerve, 270, 587–588  
Scissors, dissecting, 5t, 12–13  
Sclera, 229, 317, 318f  
Sebaceous glands, 94t, 95, 97f, 99f  
Sebum, 95  
Secondary brain vesicle, 536  
Secondary curvatures, 142  
Secondary follicles, 503f, 504t  
Secondary vesicles, 536  
Secretion, 478, 488  
Secretory cells, 506, 507f  
Sectional anatomy, 22  
Sectioning specimens, 24  
Sections, 22  
Segmental bronchi, 440t  
Selection, process of, 410  
Self breast exam, 521  
Sella turcica, 137, 138f  
Semen, 514  
Semimembranosus muscle, 274  
Seminal vesicles, 512t, 514, 522  
Seminiferous tubules, 509–510  
Semispinalis muscles, 240  
Semitendinosus muscle, 274  
Sensory information, 547  
Sensory receptors  
  *in dermis*, 94, 95t, 302–303  
  *nervous system and*, 300  
  *in skin*, 312, 313f  
Septae, 410, 411f  
Serosa layer  
  *stomach*, 450, 451f, 452t  
  *uterine tubes*, 507f  
Serosus cells, 448, 449t  
Serosus pericardium, 349  
Serratus anterior muscle, 586  
Sexes, 500  
Shaft of hair, 95, 99f  
Shape  
  *of cells, classification of epithelial tissue based on*, 60t  
  *classification of bone based on*, 111t, 112  
  *naming skeletal muscles based on*, 215t  
Sharp dissection techniques, 7–12  
Sharps containers, 7, 606  
Sheep brain, dissection of, 557–563  
Sheep heart  
  *coronal sections of*, 357–358  
  *sections through*, 24f  
  *superficial structures of*, 356–357  
  *transverse section of*, 359  
Short bones, 111t  
Short head of biceps brachii, 259  
Shunts, 397  
Sigmoid colon, 470, 472f  
Sigmoid sinus, 532, 533f, 534t  
Simple columnar epithelium, 62f  
Simple columnar epithelium with cilia, 63f  
Simple cuboidal epithelium, 62f  
Simple epithelium, 58t, 61  
Simple squamous epithelium, 61f  
Sinusoidal capillaries, 371, 373f  
Size  
  *naming skeletal muscles based on*, 215t  
  *of specimens, estimating*, 38  
Skeletal muscles  
  *architecture of*, 216–217  
  *connective tissue coverings of*, 210–211  
  *histology of*, 210  
  *identification and classification of*, 78f  
  *lookalikes*, 81  
  *naming*, 215–216  
  *neuromuscular junction*, 211, 212f  
  *overview*, 77, 206, 208  
  *structural organization of*, 209f  
Skeletal system. See also Appendicular skeleton;  
  Axial skeleton  
  *bone tissue*, 107–110  
  *classification of bone based on shape*, 111t, 112  
  *human skeleton*, 116–117  
  *overview*, 105  
Skin. See also Dermis; Epidermis  
  *overview*, 87  
  *sensory receptors in*, 302–303, 312, 313f  
  *thick*, 90, 91, 99f  
  *thin*, 90, 99f

- Skull  
*anterior view of, 129, 130–131t*  
*bones and bony landmarks, 127–129t*  
*bones associated with, 139*  
*fetal, 139–140*  
*inferior view of, 136*  
*lateral view of, 134*  
*mandible, 133*  
*nasal cavity, 132*  
*orbit, 131*  
*overview, 126–127*  
*posterior view of, 135*  
*superior view of, 135*  
*superior view of cranial floor, 137–138*
- Slides  
*blood smear, preparing, 606*  
*handling, 34*  
*histology, 58–59*  
*loading into compound microscopes, 35f*  
*wet mount, preparing, 46–47*
- Small bronchi, 430–431
- Small intestine, 455–456, 469–470
- Smell (olfaction), 306–307
- Smooth muscle  
*histology, 79f*  
*lookalikes, 81*  
*overview, 77, 206, 208t, 213–214*  
*of ureters, 485*
- Soleus muscle, 277, 278t
- Somatic nervous system, 593
- Somatic sensory receptors, 302
- Special senses, 302
- Specimens  
*animal hearts, 359*  
*estimating size of, 38*  
*sectioning, 24*
- Spermatic cord, 246, 247f
- Spermatogenesis, 509
- Spermatogonia, 509, 510f
- Sphenoid bone, 128t, 130t, 137
- Spinal cord  
*components of, 576–578*  
*gross anatomy of, 579–581*  
*overview, 573–574*
- Spinal nerves, 582
- Spine of scapula, 170
- Spinous processes, 143
- Spiral organ, 310, 311f, 321t
- Spleen, 385f, 415–416, 467f
- Splenic artery, 415
- Splenic sinusoids, 416t
- Splenic veins, 383, 415
- Splenius capitis, 236f, 237t
- Splenius muscles, 239t
- Spondylolisthesis, 143
- Spongy bone, 109, 112, 113f
- Spongy urethra, 493
- Squamous cells, 60t, 61, 63, 64f
- Squamous part, 137
- Staining samples, 59, 70
- Stapedius muscle, 321t, 322
- Stereocilia, 511
- Sternal angle, 149
- Sternal head, 233
- Sternoclavicular joint, 160, 170
- Sternocleidomastoid muscle, 233, 237t
- Sternum, 148t, 149
- Stomach, 450–454, 463–465
- Storing microscope, 34
- Stratified columnar epithelium, 65
- Stratified cuboidal epithelium, 65
- Stratified epithelium, 58t, 61
- Stratified squamous epithelium, 63, 64f
- Stratum basale, 90t, 91f, 92f, 99f
- Stratum corneum, 90t, 91f, 99f
- Stratum granulosum, 90t, 91f, 99f
- Stratum lucidum, 90t, 91f, 99f
- Stratum spinosum, 90t, 91f, 92f, 99f
- Styloid process  
*radius, 170*  
*ulna, 170*
- Subarachnoid space, 532, 534t
- Subcapsular space, 414t
- Subcutaneous layer of dermis, 93f, 99f
- Sublingual salivary gland, 448f, 449t
- Submandibular salivary gland, 448f, 449t
- Submucosa  
*respiratory passageways, 426*  
*stomach, 450, 451f, 452t*  
*trachea, 428–429t*  
*urinary bladder, 486f*
- Suboccipital muscles, 237–238
- Suboccipital nerve, 137
- Suboccipital triangle, 137, 238f
- Subscapularis muscle, 258
- Substage lamp of microscope, 33t, 34f
- Sulci, 561
- Superficial, 25t
- Superficial inguinal ring, 246, 247f
- Superficial structures of sheep heart, 356–357
- Superficial view of human brain,  
 539–541t
- Superior, 25t, 27
- Superior articular facets, 144, 145
- Superior articular processes, 143
- Superior costal facets, 146
- Superior gluteal nerve, 587
- Superior mesenteric veins, 383, 384f
- Superior sagittal sinus, 532, 533f, 534t
- Superior trunk of brachial plexus, 583
- Superior vena cava, 349f, 350, 377f, 379f
- Superior view  
*cranial floor, 137–138*  
*human brain, 541f*  
*sheep brain, 562f*  
*skull, 135*
- Supinators, 259
- Supporting cells of olfactory  
 epithelium, 427t
- Supporting connective tissue, 66, 72, 73t, 74–75
- Suprahyoid muscles, 234–235
- Supraspinatus muscle, 258
- Suprasternal notch, 149
- Surface mucous cells, 454t
- Suspensory ligament  
*eye, 316t, 318*  
*ovary, uterine tubes, and uterus, 517t, 518–519f*
- Sustentacular cells of testes, 510t, 511
- Sutures, 194
- Sympathetic division of autonomic nervous system,  
 593, 595–596, 598–599
- Sympathetic trunk ganglia, 595
- Symphysis, 195t, 196
- Synaptic cleft, 211, 212f
- Synaptic knob, 211, 212f
- Synarthroses, 191, 192t
- Synchondrosis, 195–196
- Syndesmoses, 194
- Synergists, 233, 256, 259
- Synovial cavity, 197t
- Synovial fluid, 197t
- Synovial joints  
*classification of, 197–199*  
*knee, 200–202*  
*movements, 199–200*  
*overview, 192t, 196*  
*structure of, 197*
- Synovial membrane, 197t
- Systemic circulation  
*abdominal cavity, 383–387*  
*brain, 377–380*  
*head and neck, 375–377*  
*lower limbs, 392–396*  
*thoracic and abdominal walls,  
 380–383*  
*upper limbs, 387–391*
- T**
- Tactile cells, 94, 95t
- Tactile corpuscles, 93f, 94, 95t, 99f,  
 302–303t
- Tactile discs, 302t, 312
- Tapetum lucidum, 316t, 318
- Tarsals, 176t, 181–182
- Taste (gustation), 304–306
- Taste buds, 304, 305t, 553f
- Tectorial membrane, 310, 311t
- Telophase of cell cycle, 50t
- Temporal bone, 128t, 137
- Temporalis muscle, 230
- Temporal lobe, 310, 539t
- Temporomandibular joint, 133
- Tendinous cords, 351, 352f
- Tendinous intersections, 246, 247f
- Tendon of knee joint, 200t
- Tendon sheaths, 197t
- Tensor fasciae latae, 270
- Tensor tympani muscle, 321t, 322
- Teres minor muscle, 258
- Terminal ganglia, 595
- Testes, 500, 509, 510f, 522
- Testosterone, 509
- Thalamus, 308, 310, 539t
- Thenar eminence, 266
- Thenar muscles, 266, 267t
- Thick skin, 90, 91, 99f, 302t
- Thigh, compartments of, 218t, 220f,  
 271–274
- Thin skin, 90, 99f
- Third ventricle, 537t, 544
- Thoracic cage, 148–150
- Thoracic cavity, 348, 583f
- Thoracic duct, 417t
- Thoracic part of spinal cord, 577f, 578t
- Thoracic vertebrae, 141, 143, 146
- Thoracic wall, circulation to, 380–383
- Thymic corpuscles, 411
- Thymosin, 410
- Thymus, 410–412
- Thyroglobulins, 333
- Thyroid follicles, 333
- Thyroid gland, 333–335
- Thyroid hormone, 333
- Tibia, 176t, 179–180
- Tibial division, 588
- Tibial nerve, 588

## I-10 Index

Tibial tuberosity, 184  
Tibiofemoral joints, 200  
Tissue forceps, 11  
Tissues. See also Connective tissue; Epithelial tissue  
    *bone*, 107–110  
    *contractile*, 77, 206, 208  
    *elastic*, 208  
    *excitable*, 77, 208  
    *extensible*, 208  
    *hemopoietic*, 115  
    *mucosa-associated lymphatic*, 407–410  
    *muscle*, 77–79  
    *necrotic*, 353  
    *nervous*, 79–80, 285, 287–295  
    *overview*, 43, 55  
    *protecting with probe when dissecting with scalpel*, 11f  
Tongue  
    *dorsal surface of*, 304f  
    *innervation of taste buds of*, 553f  
    *muscles that move*, 231–232  
    *papillae of*, 305t  
Tonsils, 408–409  
Trabeculae  
    *lymph nodes*, 412, 413f, 414f  
    *spleen*, 416t  
    *spongy bone*, 109f, 115  
    *thymus*, 411f  
Trabeculae carneae, 350f, 351, 352f  
Trabecular arteries, 416  
Trachea, 426f, 428–430  
Tracheal cartilages, 428t, 429f  
Tracts, 287, 562  
Transitional cells, 60t, 65, 66f  
Transitional epithelium, 485, 486  
Transverse colon, 470, 472f  
Transverse foramen, 145  
Transverse (horizontal) plane, 22t  
Transverse processes, 143  
Transverse section  
    *human heart*, 353f  
    *sheep heart*, 359f  
Transversospinalis muscles, 239–240t, 241f  
Transversus abdominis muscle, 244t, 245, 247f  
Transversus thoracis muscle, 242  
Trapezius, 256  
Trays, dissecting, 4t  
Triceps surae muscles, 277  
Trigeminal nerves  
    *human*, 230, 545t, 546f, 547t, 549t, 552  
    *sheep*, 557, 559  
Trigone, 491  
Trochlear nerve, 545t, 546f, 547, 547t, 549t, 551  
Troubleshooting compound microscopes, 35t  
Trunks of brachial plexus, 583, 584f  
Tubercle of rib, 146  
Tuberculum sellae, 137  
Tubular fluid, 490  
Tumors, 77, 291  
Tunica albuginea, 502, 503f, 504f, 510f  
Tunica externa, 366t, 367f, 368f, 369f, 370f  
Tunica intima, 366t, 367f, 368f, 369f, 370f  
Tunica media, 366t, 367f, 368f, 369f, 370f  
Tympanic membrane, 319, 320f, 321f, 322

## U

Ulna, 163t, 166–167, 170  
Ulnar nerve, 170, 584, 585t  
Ultrafiltration, 478  
Umbilical region, 28f  
Umbilicus, 28, 247f  
Unipennate architecture of skeletal muscles, 217t  
Unipolar neurons, 287  
Upper limbs. See also Arm; Forearm,  
    compartments of; Hand, intrinsic muscles of  
    *bones of*, 162–168  
    *circulation to*, 387–391  
    *muscles of*, 259–267  
    *overview*, 155  
Upper respiratory tract, 426–428, 433–434  
Urea, 478  
Ureters, 478, 485, 490–491  
Urethra, 478, 485t, 491–494  
Urinary bladder, 478, 485t, 486, 491–494  
Urinary system  
    *kidneys*, 480–484, 486–490  
    *overview*, 478  
    *urinary tract*, 484–486, 490–494  
Urine, 478, 490  
Urogenital diaphragm, 491  
Uterine tubes, 506–507, 514, 516–519  
Uterus, 246, 508, 516–519

## V

Vagina, 509  
Vaginal epithelium, 509f  
Vagus nerve, 545t, 546f, 548t, 549t, 555  
Vallate papillae, 304, 305t, 553f  
Valve cusps, 406  
Varicose veins, 371  
Varicosities, 387  
Vasa recta, 469, 483, 484f, 487, 488f  
Vasa vasorum, 368, 370f  
Veins  
    *great saphenous and varicose*, 371  
    *kidney*, 488f  
    *lower limb*, 394f  
    *overview*, 364, 366t, 370  
    *right upper limb*, 389f  
Venous drainage of heart, 356t  
Ventricles of brain, 536–537  
Venules, 364, 366t, 369f, 375f  
Vermiform appendix, 410, 472f  
Vertebral arch, 143  
Vertebral arteries, 137, 145, 238f, 377  
Vertebral column  
    *characteristics of vertebrae*, 144–148  
    *muscles of*, 238–241  
    *overview*, 141  
    *regions and curvatures*, 142  
    *structure of vertebrae*, 143–144  
Vertebral foramen, 143  
Vesicular follicle, 502, 503f, 504f, 505f, 505t  
Vestibular nerve, 554  
Vestibulocochlear nerve  
    *cochlear branch of*, 310, 311t  
    *common disorders of*, 549t  
    *function of*, 548t  
    *inner ear and*, 321f  
    *location of*, 546f  
    *overview*, 545t, 554

Villi, 455  
Visceral layer  
    *pericardial cavity*, 348  
    *pericardium*, 349  
    *renal cortex*, 482  
Visceral pericardium, 356, 357f  
Visceral pleura, 437  
Visceral sensory receptors, 302  
Vision, 308–309. See also Eye; Retina  
Vitreous humor, 316t, 317  
Vocal folds, 435  
Vomer bone, 128t, 130t, 132

## W

Waste, disposal of, 7, 606  
Wet mount, preparing, 46–47  
White commissure, 576, 577f, 578t  
White matter, 287, 290  
White pulp, 415, 416t  
Working distance, 33t, 35, 36  
Worksheets  
    *Appendicular Muscles*, 255, 281–284  
    *Articulations*, 193, 203–204  
    *Autonomic Nervous System*, 594, 601  
    *Axial Muscles*, 225, 249–251  
    *Brain and Cranial Nerves*, 531  
    *Cardiovascular System: Blood*, 605, 613–614  
    *Cardiovascular System: Heart*, 345, 361–362  
    *Cellular Anatomy*, 45, 53  
    *Digestive System*, 447, 473–476  
    *Do You Know the Basics?*, 3, 15–17  
    *Endocrine System*, 329, 341–342  
    *General and Special Senses*, 301, 323–325  
    *Histology*, 57, 83–86  
    *Integument*, 89, 101–104  
    *Lymphatic System*, 405, 421–422  
    *Microscope*, 32, 41–42  
    *Muscle Tissue and Muscular System*, 207, 221–222  
    *Nervous Tissues*, 286, 297–298  
    *Orientation to the Human Body*, 21, 29–30  
    *Reproductive System*, 501, 525–528  
    *Respiratory System*, 425, 441–443  
    *Skeletal System: Appendicular Skeleton*, 157–158, 187–190  
    *Skeletal System: Axial Skeleton*, 125, 151–154  
    *Skeletal System: Bone Structure and Function*, 106, 119–121  
    *Spinal Cord and Spinal Nerves*, 575, 589–592  
    *Urinary System*, 479, 495–498  
    *Vessels and Circulation*, 365, 399–402  
Workspace for microscope, 33

## X

Xiphoid process, 148t, 149

## Y

Yellow bone marrow, 112, 114f

## Z

Z discs, 208, 209f  
Zygomatic arch, 134  
Zygomatic bone, 129t, 130t  
Zygotes, 500

This appendix includes answers to the What Do You Think? questions, labeling exercises, table completion activities, and calculation questions found in each chapter. Answers to in-exercise questions prompting students to record their personal observations and drawings are not provided due to their variability.

## Chapter 1

### What Do You Think?

- Hemostats are used to pinch off blood vessels by squeezing them closed.

### Chapter Activities

#### Exercise 1.1

- |                              |                       |
|------------------------------|-----------------------|
| 1. forceps                   | 7. scissors (pointed) |
| 2. scalpel blades            | 8. dissecting pins    |
| 3. scalpel (disposable)      | 9. blunt probe        |
| 4. scalpel blade handle (#3) | 10. dissecting needle |
| 5. scalpel blade handle (#4) | 11. blunt probe       |
| 6. scissors (curved)         | 12. hemostat          |

#### Exercise 1.2

- |      |      |      |      |
|------|------|------|------|
| 1. A | 3. A | 5. B | 7. A |
| 2. B | 4. A | 6. B |      |

## Chapter 2

### Chapter Activities

#### Figure 2.2 Sections Through a Human Brain

- |                         |                               |
|-------------------------|-------------------------------|
| 1. coronal (frontal)    | 3. transverse (horizontal)    |
| 2. midsagittal (median) | 4. sagittal (or parasagittal) |

#### Figure 2.4 Posterior View of an Individual with Three Reference Locations Marked

- thoracic
- antebrachial
- femoral

#### Figure 2.5 Regional Terms

- |                           |                               |
|---------------------------|-------------------------------|
| 1. oral (mouth)           | 14. mammary (breast)          |
| 2. cervical (neck)        | 15. pelvic                    |
| 3. axillary (armpit)      | 16. inguinal (groin)          |
| 4. brachial (arm)         | 17. tarsal (ankle)            |
| 5. antebrachial (forearm) | 18. otic (ear)                |
| 6. carpal (wrist)         | 19. vertebral (spinal column) |
| 7. digital (finger)       | 20. sacral                    |
| 8. femoral (thigh)        | 21. sural (posterior leg)     |
| 9. crural (leg)           | 22. calcaneal (heel)          |
| 10. frontal (forehead)    | 23. occipital (back of head)  |
| 11. orbital (eye)         | 24. lumbar (lower back)       |
| 12. buccal (cheek)        | 25. perineal                  |
| 13. mental (chin)         | 26. popliteal (back of knee)  |

#### Figure 2.6 Body Cavities

- |                          |                           |
|--------------------------|---------------------------|
| 1. posterior aspect      | 9. pelvic cavity          |
| 2. ventral cavity        | 10. thoracic cavity       |
| 3. cranial cavity        | 11. abdominopelvic cavity |
| 4. vertebral canal       | 12. mediastinum           |
| 5. thoracic cavity       | 13. pleural cavity        |
| 6. abdominopelvic cavity | 14. pericardial cavity    |
| 7. diaphragm             | 15. abdominal cavity      |
| 8. abdominal cavity      | 16. pelvic cavity         |

### Exercise 2.5, #2

Organ	Quadrant(s)	Region(s)
Left kidney	left upper	left hypochondriac, left lumbar
Liver	right upper, left upper	right hypochondriac, right lumbar, epigastric
Pancreas	right and left upper	epigastric, left hypochondriac
Small intestine	right and left lower	umbilical, hypogastric, right and left lumbar and right and left iliac
Spleen	left upper	left hypochondriac
Stomach	right and left upper	epigastric, left hypochondriac
Urinary bladder	right and left lower	hypogastric

## Chapter 3

### What Do You Think?

- As total magnification increases, working distance decreases. In a practical sense, this means you have less room to move the stage without having the objective lens run into the slide. With this in mind, remember you should *never* use the coarse adjustment knob with the high-power objective in place because you can easily crack or break the slide or the objective lens.
- You can answer this question using common sense and get pretty close to the correct answer, or you can be more specific and calculate the diameters of the field of view at both magnifications, estimate cell diameter at 200 $\times$  total magnification, and then calculate the number of cells that could fit within the field of view at 500 $\times$  total magnification (see calculations below):

Diameter of the field of view at 200 $\times$ : 0.6 mm  
 Total magnification at starting power: 200 $\times$   
 Diameter of field of view at 500 $\times$ : *unknown*  
 Total magnification at higher power: 500 $\times$

Calculation:  $0.6 \text{ mm} * 200\times = \textit{unknown} * 500\times$   
 $120 = \textit{unknown} * 500\times$   
 $120/500 = 0.24 \text{ mm}$  diameter of field of view at 500 $\times$  total magnification  
 Four cells wide =  $0.6 \text{ mm}/4 \text{ cells} = .15 \text{ mm/cell}$  at 200 $\times$  (diameter of one cell)

*Final answer:* Field of view at 500 $\times$  is **0.24 mm**, so approximately **1.6 cells** could be seen ( $[0.24 \text{ mm diameter} / (0.15 \text{ mm/cell})] = 1.6 \text{ cells}$ ).

### Chapter Activities

#### Figure 3.5

- For this question, use the same procedure described for What Do You Think? question 2 (see above). You are given that for 40 $\times$  the diameter of field is 4.8 mm. This is magnification 1 and diameter 1, respectively. Calculate for figure 3.5(b) and 3.5(c).

Figure 3.5(b) magnification 1 \* diameter 1 = magnification 2 \* unknown diameter of field  
 $40 * 4.8 = 200 * \textit{unknown diameter of field}$   
 $192/200 = \textit{unknown diameter of field}$   
 Diameter of field = 0.96 mm

Figure 3.5(c) magnification 1 \* diameter 1 = magnification 2 \* unknown diameter of field  
 $40 * 4.8 = 500 * \textit{unknown diameter of field}$   
 $192/500 = \textit{unknown diameter of field}$   
 Diameter of field = 0.38 mm

- Now you need to decide how many "specimens" would fit side-by-side at the widest part of the field of view, which looks like about 25 for figure 3.5a, about 5 for figure 3.5b, and about 2 for figure 3.5c. Finally, divide the diameter of the field (4.8 mm, 0.96 mm, and 0.38 mm) by the number of objects (25, 5, and 2) to get the diameter of one object:  $4.8/25 = 0.19 \text{ mm}$ ;  $0.96/5 = 0.19 \text{ mm}$ ; and  $0.38/2 = 0.19 \text{ mm}$ . Notice that your results for diameter of the object should be the same, even though the magnifications are different.
- Yes, it is possible. In fact, we just did this in question #2. You calculated the field of view as 0.38 mm, and the specimen reaches about halfway across the field, thus 0.19 mm.



## Chapter 4

### What Do You Think?

1. Rough endoplasmic reticulum (ER) functions to **synthesize proteins destined for the plasma membrane** of the cell. Nerve cells have a lot of protein channels in their cell membranes, which are used to transport ions such as Na<sup>+</sup> and K<sup>+</sup> in and out of the cell as they generate electrical signals. Thus, nerve cells have an abundance of rough ER, which is used in the synthesis of these protein channels.
2. Microtubules are necessary for forming the mitotic spindle and moving chromosomes during mitosis. A drug that interferes with the lengthening or shortening of microtubules will interfere with prophase, metaphase, anaphase, and telophase of mitosis. Thus, **mitosis will fail to occur**. This is advantageous for a chemotherapy drug because the objective is to stop the tumor cells from dividing and multiplying to slow or halt the growth of the tumor.

## Chapter 5

### What Do You Think?

1. The function of the uterine tube is to transport an ovum (egg) from the ovary to the uterus in the female reproductive tract (see chapter 23 for more information on this). Thus, the function of the cilia is to **propel the ovum toward the uterus** within the uterine tube.
2. Cuboidal and columnar cells contain many more **mitochondria** and **rough endoplasmic reticulum** than squamous cells. Mitochondria, the site of cellular respiration, produce most of the ATP in the cell. Rough endoplasmic reticulum functions to synthesize the carrier proteins—or “pumps”—that are used for membrane transport. To transport substances across an epithelial lining, the pumps use a lot of energy in the form of ATP. Because squamous cells are so thin, they generally allow substances to be transported via diffusion or pinocytosis rather than active transport. Simple diffusion does not require energy input, so the cell does not have the same energy needs or requirements for pumps. Thus, it does not need as many mitochondria or as much rough endoplasmic reticulum.
3. Most brain tumors arise from **glial cells** and are referred to as **gliomas**. Because glial cells retain the capacity for cell division and are constantly being replaced, they are more likely to experience damage to their DNA, which is the first step involved in the transformation of normal cells into cancerous cells (which subsequently form tumors).

## Chapter 6

### What Do You Think?

1. The layer of the epidermis that represents the transition from living to dead epithelial cells is the **stratum granulosum**. Keratinocytes begin to die within this layer because the epidermis lacks a blood supply and the keratinocytes **are too far away from their blood supply** (which is in the dermis) to receive adequate nutrients for survival.
2. The keratinocytes closest to the stratum basale are constantly undergoing cell division, or **mitosis**. These keratinocytes concentrate melanin granules just apical to their nuclei so the melanin can absorb UV radiation and prevent it from hitting the nuclei of the cells. UV radiation can cause errors to occur in DNA replication. When errors of DNA replication accumulate over time, it causes the cells to become abnormal and/or cancerous. For this reason, cells that are actively undergoing mitosis are most in need of the protection provided by melanin.
3. **Thick skin has more dermal papillae and epidermal ridges** than thin skin, and the epidermal/dermal layer is thrown into deep folds. In thin skin, the epidermal/dermal junction is flatter, and there are fewer dermal papillae and epidermal ridges. This is because **thick skin**, which is found on the palms of the hands and soles of the feet, **experiences far greater frictional forces** than thin skin. The greater number of epidermal ridges **helps keep the epidermis and dermis from separating**. This is why it is more difficult to develop a *blister* (an accumulation of fluid between the epidermis and dermis) in thick skin than in thin skin.
4. Placing a high concentration of tactile corpuscles on the surface of the skin allows us to sense very fine fluctuations in vibration, pressure, and texture. There are a great deal more sensory receptors on the skin of your hand than on your back, which is why you can discriminate objects much better with your hands than your back.

## Chapter 7

### What Do You Think?

1. When a bone fractures and subsequently undergoes the process of repair, **osteoblast** cells are involved in laying down new bone matrix and **osteoclast** cells are involved in remodeling the new bone that is formed as the repair process continues.

2. The medullary cavity of an adult long bone is filled with adipose connective tissue because, as ossification of the bone occurs, red bone marrow is converted into yellow bone marrow (adipose connective tissue). **The adipose tissue fills up what is a potentially large, open space within the bone** that, if left open, would make it easy for any infection within the bone to spread easily.
3. Because the **collagen fibers of the knee ligaments are continuous with the collagen fibers within the fibrocartilage of the meniscus**, most individuals who tear knee ligaments also have a torn meniscus. This is particularly true of tears to the anterior cruciate ligament, which are often associated with tears to the medial or lateral meniscus (or both).

## Chapter Activities

### Figure 7.10(a) The Human Skeleton

- |             |                 |                 |
|-------------|-----------------|-----------------|
| 1. cranium  | 10. sacrum      | 19. femur       |
| 2. mandible | 11. coccyx      | 20. patella     |
| 3. clavicle | 12. ischium     | 21. fibula      |
| 4. scapula  | 13. radius      | 22. tibia       |
| 5. sternum  | 14. ulna        | 23. tarsals     |
| 6. humerus  | 15. pubis       | 24. metatarsals |
| 7. rib      | 16. carpals     | 25. phalanges   |
| 8. vertebra | 17. metacarpals |                 |
| 9. ilium    | 18. phalanges   |                 |

### Figure 7.10(b) Posterior View

- |             |                 |                 |
|-------------|-----------------|-----------------|
| 1. skull    | 9. sacrum       | 17. femur       |
| 2. mandible | 10. coccyx      | 18. fibula      |
| 3. scapula  | 11. radius      | 19. tibia       |
| 4. humerus  | 12. ulna        | 20. tarsals     |
| 5. rib      | 13. pubis       | 21. metatarsals |
| 6. vertebra | 14. carpals     | 22. phalanges   |
| 7. ilium    | 15. metacarpals |                 |
| 8. ischium  | 16. phalanges   |                 |

## Chapter 8

### What Do You Think?

1. Fontanels are present after the birth of the infant **so the cranial cavity can continue to expand** to allow for the massive growth that occurs in the brain.
2. The bifid spinous processes of a superior cervical vertebra allow it to *fit over* the spinous process of the cervical vertebra below it. This **increases the range of motion in extension** of the neck.
3. The superior and inferior articular processes of the atlas are **oriented in the horizontal plane** instead of vertically. This allows for the gliding, fore-aft “yes” movement allowed at the atlanto-occipital joint, and the rotational “no” movement allowed at the atlantoaxial joint.
4. Little to no lateral rotation is allowed in the lumbar region because the function of the lumbar region of the vertebral column is to **provide solid support for the rest of the vertebral column**, which lies above it.
5. Laminectomy is surgery that creates space by removing the lamina—the back part of the vertebra that covers your vertebral canal. Also known as decompression surgery, laminectomy enlarges the vertebral canal to relieve pressure on the spinal cord or nerves.
6. Whenever needles are inserted into the thoracic cavity they are always placed along the superior border of a rib **so as not to injure the intercostal nerve, artery, and vein**, which run in the costal groove on the inferior surface of a rib.

## Chapter Activities

### Figure 8.1 Anterior View of the Skull

- |                                 |                              |                                    |
|---------------------------------|------------------------------|------------------------------------|
| 1. frontal bone                 | 9. infraorbital foramen      | 17. perpendicular plate of ethmoid |
| 2. parietal bone                | 10. maxilla                  | 18. vomer                          |
| 3. glabella                     | 11. superciliary arch        | 19. inferior nasal concha          |
| 4. supraorbital foramen (notch) | 12. supraorbital margin      | 20. alveolar processes             |
| 5. superior orbital fissure     | 13. sphenoid bone            | 21. mandible                       |
| 6. lacrimal bone                | 14. temporal bone            | 22. mental foramen                 |
| 7. nasal bone                   | 15. optic foramen (canal)    | 23. mental protuberance            |
| 8. zygomatic bone               | 16. inferior orbital fissure |                                    |

**Figure 8.2 The Orbit**

- nasal bone
- supraorbital foramen
- ethmoid bone
- frontal bone
- zygomatic process of frontal bone
- optic foramen
- superior orbital fissure
- lacrimal bone
- inferior orbital fissure
- zygomatic bone
- infraorbital foramen
- maxilla

**Figure 8.3 The Nasal Cavity**

- frontal sinus
- nasal bone
- superior nasal concha
- middle nasal concha
- lacrimal bone
- inferior nasal concha
- maxilla
- palatine process of maxilla
- crista galli
- cribriform plate of ethmoid
- sella turcica
- sphenoid sinus
- palatine bone
- sphenoid bone
- horizontal plate of palatine bone
- perpendicular plate of ethmoid bone
- vomer

**Figure 8.4 The Mandible**

- mandibular condyle
- coronoid process
- mandibular foramen
- condylar process (mandibular condyle)
- mandibular notch
- mylohyoid line
- ramus
- alveolar process
- mental foramen
- angle
- body
- mental protuberance

**Figure 8.5 Lateral View of the Skull**

- parietal eminence
- parietal bone
- inferior temporal line
- squamosal suture
- lambdoid suture
- squamous part of temporal bone
- occipital bone
- external acoustic meatus
- mastoid process of temporal bone
- styloid process of temporal bone
- head of mandible
- zygomatic process of temporal bone
- temporal process of zygomatic bone
- body of mandible
- coronal suture
- frontal bone
- superior temporal line
- pterion
- greater wing of sphenoid bone
- nasal bone
- lacrimal bone
- ethmoid bone
- lacrimal groove
- zygomatic bone
- maxilla
- mental foramen
- mental protuberance

**Figure 8.6 Posterior View of the Skull**

- sagittal suture
- parietal foramina
- parietal bone
- parietal eminence
- lambdoid suture
- sutural (wormian) bone
- occipital bone
- temporal bone
- external occipital protuberance
- mastoid process

**Figure 8.7 Superior View of the Skull**

- frontal bone
- coronal suture
- sagittal suture
- parietal bone
- parietal foramina
- lambdoid suture
- sutural (wormian) bone
- occipital bone

**Figure 8.8 Inferior View of the Skull**

- maxilla
- palatine bone
- vomer
- sphenoid bone
- foramen ovale
- foramen spinosum
- foramen lacerum
- jugular foramen
- carotid canal
- inferior nuchal line
- superior nuchal line
- incisive foramen
- temporal process of zygomatic bone
- zygomatic process of temporal bone
- mandibular fossa
- styloid process
- temporal bone
- mastoid process
- occipital condyle
- hypoglossal canal
- basilar region of occipital bone
- foramen magnum
- external occipital crest
- occipital bone
- external occipital protuberance

**Figure 8.9 Cranial Fossae**

- anterior cranial fossa
- middle cranial fossa
- posterior cranial fossa

**Figure 8.11 Superior View of the Cranial Floor**

- frontal sinus
- frontal bone
- optic canal (foramen)
- lesser wing of sphenoid
- foramen rotundum
- greater wing of sphenoid
- temporal bone
- petrous part of temporal bone
- parietal bone
- internal auditory meatus
- foramen magnum
- occipital bone
- internal occipital protuberance
- frontal crest
- crista galli
- cribriform plate of the ethmoid
- sella turcica
- foramen lacerum
- foramen ovale
- foramen spinosum
- jugular foramen
- hypoglossal canal
- groove for sigmoid sinus
- basilar part of occipital bone
- groove for transverse sinus
- internal occipital crest
- anterior clinoid process
- hypophyseal fossa
- posterior clinoid process

**Figure 8.12 The Hyoid Bone**

- greater cornu
- lesser cornu
- body

**Figure 8.13 The Fetal Skull**

- frontal bone
- parietal bone
- sphenoidal fontanel
- sphenoid bone
- mandible
- temporal bone
- mastoid fontanel
- occipital bone
- frontal bone
- anterior fontanel
- parietal bone

**Figure 8.14 Lateral View of the Vertebral Column**

- cervical vertebrae  
Number of vertebrae: 7
- thoracic vertebrae  
Number of vertebrae: 12
- lumbar vertebrae  
Number of vertebrae: 5
- sacral vertebrae/sacrum  
Number of vertebrae: 5
- coccygeal vertebrae  
Number of vertebrae: 4
- cervical curvature
- thoracic curvature
- lumbar curvature
- sacral curvature

**Figure 8.15 A Typical Vertebra**

- lamina
- transverse process (costal facet)
- superior articular process
- body
- spinous process
- vertebral arch
- transverse process
- pedicle
- vertebral (spinal) foramen
- transverse process (costal facet)
- superior articular process
- body
- inferior articular process

**Figure 8.16 Cervical Vertebra**

- body
- transverse process
- superior articular process (and facet)
- transverse foramen
- pedicle
- vertebral (spinal) foramen
- lamina
- spinous process (bifid)
- spinous process
- superior articular process
- transverse foramen
- body
- inferior articular process (and facet)

**Figure 8.17 The Atlas (C1)**

- anterior tubercle
- anterior arch
- superior articular facet
- transverse process
- transverse foramen
- posterior tubercle
- posterior arch
- articular facet for dens
- vertebral foramen
- groove for vertebral artery

**Figure 8.18 The Axis (C2)**

- dens (odontoid process)
- superior articular process
- transverse foramen
- transverse process
- pedicle
- vertebral (spinal) foramen
- lamina
- spinous process

**Figure 8.19 Thoracic Vertebra**

- |                               |                                |
|-------------------------------|--------------------------------|
| 1. body                       | 9. lamina                      |
| 2. vertebral (spinal) foramen | 10. costal facet               |
| 3. superior articular process | 11. spinous process            |
| 4. spinous process            | 12. inferior articular process |
| 5. superior costal facet      | 13. superior articular process |
| 6. pedicle                    | 14. superior costal facet      |
| 7. costal facet               | 15. body                       |
| 8. transverse process         | 16. inferior costal facet      |

**Figure 8.20 Lumbar Vertebra**

- |                               |                                |
|-------------------------------|--------------------------------|
| 1. body                       | 7. lamina                      |
| 2. vertebral (spinal) foramen | 8. superior articular facet    |
| 3. superior articular process | 9. transverse process          |
| 4. spinous process            | 10. spinous process            |
| 5. pedicle                    | 11. inferior articular process |
| 6. transverse process         | 12. body                       |

**Figure 8.21 Sacrum and Coccyx**

- |                               |                               |
|-------------------------------|-------------------------------|
| 1. superior articular process | 9. superior articular facet   |
| 2. ala                        | 10. median sacral crest       |
| 3. sacral promontory          | 11. auricular surface         |
| 4. anterior sacral foramina   | 12. posterior sacral foramina |
| 5. transverse lines (ridges)  | 13. sacral hiatus             |
| 6. coccygeal cornu            | 14. coccygeal cornu           |
| 7. coccyx                     | 15. coccyx                    |
| 8. sacral canal               |                               |

**Figure 8.22 The Sternum**

- |                       |                    |
|-----------------------|--------------------|
| 1. suprasternal notch | 4. body            |
| 2. manubrium          | 5. xiphoid process |
| 3. sternal angle      | 6. second rib      |

**Figure 8.23 A Typical Rib**

- |                             |  |
|-----------------------------|--|
| 1. superior articular facet | 8. shaft                                   |
| 2. inferior articular facet | 9. head                                    |
| 3. shaft                    | 10. neck                                   |
| 4. intervertebral foramen   | 11. tubercle                               |
| 5. head                     | 12. articular facet for transverse process |
| 6. tubercle                 | 13. angle                                  |
| 7. angle                    | 14. costal groove                          |

**Figure 8.24 The First Rib**

- |                                 |             |
|---------------------------------|-------------|
| 1. shaft                        | 4. head     |
| 2. groove for subclavian vein   | 5. neck     |
| 3. groove for subclavian artery | 6. tubercle |

**Chapter 9**

**What Do You Think?**

- The **surgical neck** of the humerus is more likely to fracture in an accident, particularly in younger individuals. The surgical neck is so named *because* of the propensity of this portion of the humerus to fracture over that of the “regular,” or anatomical, neck. The joint between the scapula and humerus is the **glenohumeral joint**.
- It is functionally important that the bones of the os coxae are fused together, rather than remaining as independent bones so that they can **provide solid support between the lower limb and the axial skeleton**, because the weight of the entire body must be supported by the lower limb when standing.
- A fracture to the **tibia**, a bone that must support the weight of the entire body, would result in the greatest loss of function of the lower limb. Because the fibula is not a weight-bearing bone, fractures of the fibula create fewer functional problems than fractures of the tibia.

**Chapter Activities**

**Figure 9.1 The Clavicle**

- |                 |                      |
|-----------------|----------------------|
| 1. acromial end | 4. conoid tubercle   |
| 2. sternal end  | 5. sternal end       |
| 3. acromial end | 6. costal tuberosity |

**Figure 9.2 The Right Scapula**

- |                     |                        |
|---------------------|------------------------|
| 1. acromion         | 6. suprascapular notch |
| 2. coracoid process | 7. spine               |
| 3. glenoid cavity   | 8. superior border     |
| 4. lateral border   | 9. superior angle      |
| 5. inferior angle   | 10. subscapular fossa  |

- |                           |                         |
|---------------------------|-------------------------|
| 11. medial border         | 22. coracoid process    |
| 12. acromion              | 23. suprascapular notch |
| 13. spine                 | 24. superior border     |
| 14. glenoid cavity        | 25. suprascapular fossa |
| 15. infraglenoid tubercle | 26. spine               |
| 16. lateral border        | 27. infraspinous fossa  |
| 17. superior angle        | 28. medial border       |
| 18. supraglenoid tubercle | 29. acromion            |
| 19. coracoid process      | 30. glenoid cavity      |
| 20. subscapular fossa     | 31. lateral border      |
| 21. inferior angle        | 32. inferior angle      |

**Figure 9.3 The Right Humerus**

- |                           |                        |
|---------------------------|------------------------|
| 1. anatomical neck        | 18. surgical neck      |
| 2. greater tubercle       | 19. deltoid tuberosity |
| 3. lesser tubercle        | 20. medial epicondyle  |
| 4. intertubercular sulcus | 21. olecranon fossa    |
| 5. surgical neck          | 22. lateral epicondyle |
| 6. deltoid tuberosity     | 23. trochlea           |
| 7. shaft                  | 24. lateral epicondyle |
| 8. coronoid fossa         | 25. medial epicondyle  |
| 9. radial fossa           | 26. capitulum          |
| 10. lateral epicondyle    | 27. trochlea           |
| 11. capitulum             | 28. ulna               |
| 12. trochlea              | 29. radius             |
| 13. head                  | 30. humerus            |
| 14. medial epicondyle     | 31. medial epicondyle  |
| 15. head                  | 32. lateral epicondyle |
| 16. greater tubercle      | 33. radius             |
| 17. anatomical neck       | 34. ulna               |

**Figure 9.4 The Radius**

- |                      |                              |
|----------------------|------------------------------|
| 1. head              | 4. shaft                     |
| 2. neck              | 5. styloid process of radius |
| 3. radial tuberosity | 6. ulnar notch               |

**Figure 9.5 The Ulna**

- |                       |                            |
|-----------------------|----------------------------|
| 1. trochlear notch    | 5. shaft of ulna           |
| 2. coronoid process   | 6. styloid process of ulna |
| 3. radial notch       | 7. olecranon               |
| 4. tuberosity of ulna | 8. coronoid process        |

**Exercise 9.2D, #3**

Carpal Bone	Word Origin	Bone Shape/Appearance
<i>Scaphoid</i>	<i>skaphe</i> , boat	shaped like a boat
<i>Lunate</i>	<i>luna</i> , moon	moon-shaped
<i>Triquetrum</i>	<i>triquetrus</i> , 3-cornered	triangular
<i>Pisiform</i>	<i>pisum</i> , pea	pea-shaped
<i>Hamate</i>	<i>hamus</i> , a hook	hook-shaped
<i>Capitate</i>	<i>caput</i> , head	head-shaped
<i>Trapezium</i>	<i>trapezion</i> , a table	table-shaped
<i>Trapezoid</i>	<i>trapezion</i> , a table	table-shaped

**Figure 9.7 The Metacarpals and Phalanges**

- |                               |                           |
|-------------------------------|---------------------------|
| 1. phalanges                  | 9. metacarpal V           |
| 2. metacarpals                | 10. metacarpal IV         |
| 3. carpals                    | 11. metacarpal III        |
| 4. distal phalanx             | 12. pollex (metacarpal I) |
| 5. middle phalanx             | 13. metacarpal II         |
| 6. proximal phalanx           | 14. head                  |
| 7. distal phalanx of pollex   | 15. body                  |
| 8. proximal phalanx of pollex | 16. base                  |

**Figure 9.8 Surface Anatomy of Upper Limb**

- |                       |                               |
|-----------------------|-------------------------------|
| 1. clavicle           | 6. styloid process of ulna    |
| 2. acromion           | 7. olecranon                  |
| 3. deltoid tuberosity | 8. styloid process of radius  |
| 4. medial epicondyle  | 9. spine of scapula           |
| 5. suprasternal notch | 10. medial boarder of scapula |

**Figure 9.9 The Right Os Coxae**

- |                           |                                   |
|---------------------------|-----------------------------------|
| 1. ala                    | 4. posterior superior iliac spine |
| 2. anterior gluteal line  | 5. posterior inferior iliac spine |
| 3. posterior gluteal line | 6. greater sciatic notch          |

7. ischial body
8. ischial spine
9. lesser sciatic notch
10. ischial tuberosity
11. iliac crest
12. anterior superior iliac spine
13. inferior gluteal line
14. anterior inferior iliac spine
15. lunate surface
16. acetabulum
17. superior pubic ramus
18. pubic crest
19. pubic tubercle
20. inferior pubic ramus
21. obturator foramen
22. ramus of ischium
23. iliac fossa
24. anterior superior iliac spine
25. anterior inferior iliac spine
26. arcuate line
27. pectineal line
28. superior pubic ramus
29. pubic tubercle
30. symphyseal surface of pubic bone
31. obturator foramen
32. inferior pubic ramus
33. iliac crest
34. posterior superior iliac spine
35. auricular surface
36. posterior inferior iliac spine
37. greater sciatic notch
38. ischial spine
39. lesser sciatic notch
40. body of ischium
41. ischial tuberosity
42. ramus of ischium

**Figure 9.11 The Right Femur**

1. head
2. greater trochanter
3. fovea
4. neck
5. intertrochanteric crest
6. lesser trochanter
7. shaft
8. head
9. shaft
10. patellar surface
11. intercondylar notch
12. lateral condyle
13. medial condyle
14. head
15. greater trochanter
16. neck
17. intertrochanteric line
18. lesser trochanter
19. shaft
20. adductor tubercle
21. lateral epicondyle
22. medial epicondyle
23. patellar surface
24. lateral condyle
25. medial condyle
26. head
27. fovea
28. greater trochanter
29. neck
30. intertrochanteric crest
31. lesser trochanter
32. pectineal line
33. gluteal tuberosity
34. linea aspera
35. medial supracondylar line
36. lateral supracondylar line
37. lateral epicondyle
38. popliteal surface
39. adductor tubercle
40. medial epicondyle
41. medial condyle
42. intercondylar notch
43. lateral condyle

**Figure 9.12 The Tibia**

1. lateral condyle
2. intercondylar eminence
3. medial condyle
4. tibial tuberosity
5. anterior border
6. medial malleolus
7. medial condyle
8. intercondylar eminence
9. lateral condyle
10. fibular articular facet
11. medial malleolus

**Figure 9.13 The Right Fibula**

1. head
2. neck
3. shaft
4. lateral malleolus

**Figure 9.14 The Tarsals**

1. phalanges
2. metatarsals
3. medial cuneiform
4. navicular
5. intermediate cuneiform
6. lateral cuneiform
7. cuboid
8. talus
9. calcaneus

**Exercise 9.5D, #5**

Tarsal Bone	Word Origin	Bone Shape/Appearance
<i>Talus</i>	<i>talus</i> , ankle	convex, triangular
<i>Calcaneus</i>	<i>calcaneous</i> , heel	elongated
<i>Navicular</i>	<i>navis</i> , ship	shaped like a boat
<i>Medial Cuneiform</i>	<i>cuneus</i> , wedge	wedge-shaped
<i>Intermediate Cuneiform</i>	<i>cuneus</i> , wedge	wedge-shaped
<i>Lateral Cuneiform</i>	<i>cuneus</i> , wedge	wedge-shaped
<i>Cuboid</i>	<i>kybos</i> , cube	cube-shaped

**Figure 9.15 The Metatarsals and Phalanges**

1. lateral cuneiform
2. cuboid
3. distal phalanx
4. middle phalanx
5. proximal phalanx
6. hallux (metatarsal I)/head
7. shaft
8. base
9. medial cuneiform
10. intermediate cuneiform
11. navicular
12. talus
13. calcaneus

**Figure 9.16 Surface Anatomy of Lower Limb**

1. iliac crest
2. anterior superior iliac spine
3. iliac crest
4. sacrum
5. greater trochanter of femur
6. ischial tuberosity
7. lateral condyle of femur
8. head of fibula
9. lateral malleolus
10. medial condyle of femur
11. patella
12. tibial tuberosity
13. shaft of tibia
14. medial malleolus
15. calcaneus
16. metatarsals
17. phalanges

**Chapter 10****What Do You Think?**

1. The ACL is commonly ruptured during contact sports because **it is relatively weak compared to other knee ligaments**. In addition, contact sports like football often cause a player to be hit from behind. If the player who is hit doesn't contract his muscles to protect the knee joint, the resulting movement of the femur with respect to the tibia can cause the ACL to tear.
2. Rupture of the tibial collateral ligament often coincides with a tear of the medial meniscus because **connective tissue fibers that compose the tibial collateral ligament are attached to the bundles of collagen fibers that compose the medial meniscus**.

**Chapter Activities****Figure 10.1 Fibrous Joints**

1. syndesmosis
2. gomphosis
3. suture

**Figure 10.2 Cartilaginous Joints**

1. synchondrosis
2. symphysis
3. synchondrosis
4. symphysis

**Figure 10.3 General Structure of Synovial Joints**

1. periosteum
2. yellow bone marrow
3. fibrous layer of articular capsule
4. synovial membrane
5. synovial (joint) cavity
6. articular capsule
7. articular cartilage
8. ligament

**Figure 10.4 Structural Classifications of Synovial Joints**

1. saddle
2. hinge
3. plane
4. ball-and-socket
5. condylar
6. pivot

**Figure 10.5 A Representative Synovial Joint: Right Knee Joint**

1. posterior cruciate ligament
2. lateral condyle of femur
3. lateral meniscus
4. fibular collateral ligament
5. anterior cruciate ligament
6. fibula
7. medial condyle of femur
8. medial meniscus
9. tibial collateral ligament
10. tibia
11. anterior cruciate ligament
12. medial condyle of femur
13. medial meniscus
14. posterior cruciate ligament
15. tibial collateral ligament
16. tibia
17. femur
18. lateral condyle of femur
19. fibular collateral ligament
20. lateral meniscus
21. fibula
22. femur
23. quadriceps femoris tendon
24. suprapatellar bursa
25. patella
26. prepatellar bursa
27. articular cartilage
28. patellar ligament
29. infrapatellar bursa
30. meniscus
31. tibia

## Chapter 11

### What Do You Think?

1. **quadriceps longus** (*quadriceps* = four heads; *longus* = long)
2. The muscles in the posterior compartment will have the opposite action as those in the anterior compartment (they are *antagonists*). Therefore, the common action will be **extension**.

### Chapter Activities

Figure 11.7 Muscles of the Human Body

Muscle Number	Muscle Name	Muscle Architecture
1	orbicularis oculi	circular
2	deltoid	multipennate
3	pectoralis major	convergent
4	sartorius	parallel
5	rectus femoris	bipennate
6	trapezius	convergent
7	triceps brachii	bipennate
8	extensor digitorum	parallel
9	gastrocnemius	bipennate (individual heads) multipennate (entire muscle)

## Chapter 12

### What Do You Think?

1. The vertebral artery travels through the **transverse foramina of the cervical vertebrae** en route to the posterior region of the neck. When it reaches the atlas, it bends medially and runs in the **groove for the vertebral artery** on the superior surface of the atlas.
2. In a male, contents of the spermatic cord pass through the inguinal canal. In a female, only a small ligament, the round ligament of the uterus, passes through. Because the **round ligament of the uterus is much smaller than the combined contents of the spermatic cord, the defect in the abdominal wall is smaller in a female than in a male**. Thus, indirect inguinal hernias are more common in males than in females.

### Chapter Activities

Figure 12.1 Muscles of Facial Expression

- |                                       |  |
|---------------------------------------|--|
| 1. epicranii (occipitofrontalis)      | 17. orbicularis oris                   |
| 2. epicranial aponeurosis             | 18. mentalis                           |
| 3. frontal belly of occipitofrontalis | 19. epicranial aponeurosis             |
| 4. procerus                           | 20. frontal belly of occipitofrontalis |
| 5. orbicularis oculi                  | 21. epicranii (occipitofrontalis)      |
| 6. levator labii superioris           | 22. levator palpebrae superioris       |
| 7. zygomaticus minor                  | 23. buccinator                         |
| 8. zygomaticus major                  | 24. orbicularis oculi                  |
| 9. depressor anguli oris              | 25. levator labii superioris           |
| 10. depressor labii inferioris        | 26. zygomaticus minor                  |
| 11. platysma                          | 27. zygomaticus major                  |
| 12. corrugator supercilia             | 28. orbicularis oris                   |
| 13. levator palpebrae superioris      | 29. levator anguli oris                |
| 14. nasalis                           | 30. depressor labii inferioris         |
| 15. levator anguli oris               | 31. depressor anguli oris              |
| 16. masseter                          | 32. platysma                           |

Figure 12.2 Extrinsic Eye Muscles

- |                     |                     |
|---------------------|---------------------|
| 1. superior rectus  | 5. superior oblique |
| 2. lateral rectus   | 6. medial rectus    |
| 3. inferior oblique | 7. lateral rectus   |
| 4. inferior rectus  | 8. inferior oblique |

Figure 12.3 Muscles of Mastication

- |               |                      |
|---------------|----------------------|
| 1. temporalis | 4. lateral pterygoid |
| 2. masseter   | 5. medial pterygoid  |
| 3. temporalis |                      |

Figure 12.4 Muscles That Move the Tongue

- |                  |                 |
|------------------|-----------------|
| 1. palatoglossus | 3. hyoglossus   |
| 2. styloglossus  | 4. genioglossus |

Figure 12.5 Muscles of the Pharynx

- |                          |                         |
|--------------------------|-------------------------|
| 1. tensor veli palatini  | 4. stylopharyngeus      |
| 2. levator veli palatini | 5. middle constrictor   |
| 3. superior constrictor  | 6. inferior constrictor |

### Clinical Connection: Understanding Actions of Agonists, Synergists, and Antagonists (p. 233)

The right sternocleidomastoid rotates the neck to the left.

The right splenius capitis rotates the neck to the right.

In summary: to rotate your neck to the right, you use the sternal head of the sternocleidomastoid on the left side of the neck, and the splenius capitis muscle on the right side of the neck.

Figure 12.6a Muscles of the Head and Neck

- |                                |                        |
|--------------------------------|------------------------|
| 1. mylohyoid                   | 6. sternohyoid         |
| 2. stylohyoid                  | 7. sternocleidomastoid |
| 3. digastric (anterior belly)  | 8. thyrohyoid          |
| 4. digastric (posterior belly) | 9. sternothyroid       |
| 5. omohyoid                    | 10. scalenes           |

Figure 12.6b, c Muscles of the Head and Neck

- |                                   |                                    |
|-----------------------------------|------------------------------------|
| 1. semispinalis capitis           | 14. sternocleidomastoid            |
| 2. sternocleidomastoid            | 15. splenius capitis               |
| 3. splenius capitis               | 16. levator scapulae               |
| 4. levator scapulae               | 17. splenius cervicis              |
| 5. splenius cervicis              | 18. rectus capitis posterior minor |
| 6. rectus capitis posterior minor | 19. rectus capitis posterior major |
| 7. rectus capitis posterior major | 20. obliquus capitis superior      |
| 8. obliquus capitis superior      | 21. obliquus capitis inferior      |
| 9. obliquus capitis inferior      | 22. longissimus capitis            |
| 10. longissimus capitis           | 23. splenius capitis               |
| 11. semispinalis capitis          | 24. semispinalis capitis           |
| 12. splenius capitis              | 25. splenius capitis               |
| 13. semispinalis capitis          |                                    |

Figure 12.7 Suboccipital Muscles

- |                                   |                              |
|-----------------------------------|------------------------------|
| 1. rectus capitis posterior minor | 3. obliquus capitis superior |
| 2. rectus capitis posterior major | 4. obliquus capitis inferior |

Figure 12.8 Muscles of the Vertebral Column

- |                          |                          |
|--------------------------|--------------------------|
| 1. splenius capitis      | 7. semispinalis thoracis |
| 2. splenius cervicis     | 8. multifidus            |
| 3. iliocostalis          | 9. quadratus lumborum    |
| 4. longissimus           | 10. intertransversarii   |
| 5. spinalis              | 11. rotatores            |
| 6. semispinalis cervicis | 12. interspinales        |

Figure 12.9 Muscles of Respiration

- |                          |                          |
|--------------------------|--------------------------|
| 1. external intercostals | 5. internal intercostals |
| 2. internal intercostals | 6. external intercostals |
| 3. transverse thoracis   | 7. diaphragm             |
| 4. diaphragm             |                          |

Figure 12.11 Muscles of Abdominal Wall

- |                            |                     |
|----------------------------|---------------------|
| 1. tendinous intersections | 4. internal oblique |
| 2. rectus abdominis        | 5. external oblique |
| 3. transverse abdominis    |                     |

## Chapter 13

### Chapter Activities

Figure 13.1 Muscles that Move the Pectoral Girdle and Glenohumeral Joint

- |   |                       |
|---|-----------------------|
| 1. trapezius                            | 12. rhomboid minor    |
| 2. deltoid                              | 13. rhomboid major    |
| 3. pectoralis major                     | 14. deltoid           |
| 4. biceps brachii (long head)           | 15. rhomboid major    |
| 5. biceps brachii (short head)          | 16. latissimus dorsi  |
| 6. subscapularis                        | 17. levator scapulae  |
| 7. tendon of biceps brachii (long head) | 18. supraspinatus     |
| 8. coracobrachialis                     | 19. infraspinatus     |
| 9. pectoralis minor                     | 20. teres minor       |
| 10. serratus anterior                   | 21. teres major       |
| 11. trapezius                           | 22. serratus anterior |

**Figure 13.2 Anterior (Flexor) Compartment of the Arm**

- |  |                     |
|--|---------------------|
| 1. coracobrachialis                          | 5. coracobrachialis |
| 2. biceps brachii (short head)               | 6. brachialis       |
| 3. biceps brachii (long head)                |                     |
| 4. tendon of the long head of biceps brachii |                     |

**Figure 13.3 Posterior (Extensor) Compartment of the Arm**

1. lateral head of triceps brachii
2. long head of triceps brachii
3. olecranon process of ulna

**Figure 13.5 Anterior (Flexor) Compartment of the Forearm**

- |                                 |                                   |
|---------------------------------|-----------------------------------|
| 1. medial epicondyle of humerus | 8. flexor digitorum superficialis |
| 2. common flexor tendon         | 9. flexor retinaculum             |
| 3. pronator teres               | 10. palmar aponeurosis            |
| 4. flexor carpi radialis        | 11. supinator                     |
| 5. palmaris longus              | 12. flexor pollicis longus        |
| 6. brachioradialis              | 13. pronator quadratus            |
| 7. flexor carpi ulnaris         | 14. flexor digitorum profundus    |

**Figure 13.7 Posterior (Extensor) Compartment of the Forearm**

- |                                   |                               |
|-----------------------------------|-------------------------------|
| 1. anconeus                       | 10. abductor pollicis longus  |
| 2. extensor carpi ulnaris         | 11. extensor pollicis brevis  |
| 3. extensor digiti minimi         | 12. olecranon process of ulna |
| 4. extensor retinaculum           | 13. dorsal interossei         |
| 5. extensor digitorum tendons     | 14. abductor pollicis longus  |
| 6. brachioradialis                | 15. extensor pollicis brevis  |
| 7. extensor carpi radialis longus | 16. extensor pollicis longus  |
| 8. extensor carpi radialis brevis | 17. extensor indicis          |
| 9. extensor digitorum             | 18. supinator                 |

**Figure 13.8 Intrinsic Muscles of the Hand**

- |                                |                             |
|--------------------------------|-----------------------------|
| 1. lumbricals                  | 6. adductor pollicis        |
| 2. flexor digiti minimi brevis | 7. flexor pollicis brevis   |
| 3. abductor digiti minimi      | 8. abductor pollicis brevis |
| 4. first dorsal interosseous   | 9. thenar group             |
| 5. lateral lumbrical           | 10. hypothenar group        |

**Figure 13.9 Muscles that Act About the Hip Joint/Thigh**

- |                       |                          |
|-----------------------|--------------------------|
| 1. gluteus maximus    | 9. quadratus femoris     |
| 2. piriformis         | 10. iliacus              |
| 3. superior gemellus  | 11. psoas major          |
| 4. obturator internus | 12. iliopsoas            |
| 5. inferior gemellus  | 13. tensor fasciae latae |
| 6. gluteus medius     | 14. iliotibial tract     |
| 7. gluteus minimus    | 15. psoas minor          |
| 8. gluteus medius     |                          |

**Figure 13.11 Anterior Compartment of the Thigh**

- |                         |                       |
|-------------------------|-----------------------|
| 1. inguinal ligament    | 7. adductor longus    |
| 2. tensor fasciae latae | 8. gracilis           |
| 3. iliotibial tract     | 9. sartorius          |
| 4. rectus femoris       | 10. vastus medialis   |
| 5. vastus lateralis     | 11. quadriceps tendon |
| 6. pectineus            | 12. patella           |

**Figure 13.12 Medial Compartment of the Thigh**

- |                    |                    |
|--------------------|--------------------|
| 1. pectineus       | 3. adductor longus |
| 2. adductor brevis | 4. gracilis        |

**Figure 13.13 Posterior Compartment of the Thigh**

- |                               |                     |
|-------------------------------|---------------------|
| 1. semimembranosus            | 5. gluteus maximus  |
| 2. semitendinosus             | 6. adductor magnus  |
| 3. biceps femoris, long head  | 7. iliotibial tract |
| 4. biceps femoris, short head |                     |

**Figure 13.14 Anterior Compartment of the Leg**

- |                              |                             |
|------------------------------|-----------------------------|
| 1. extensor digitorum longus | 3. fibularis tertius tendon |
| 2. extensor hallucis longus  | 4. tibialis anterior        |

**Figure 13.15 Lateral View of the Leg**

- |                     |                              |
|---------------------|------------------------------|
| 1. gastrocnemius    | 5. fibularis tertius         |
| 2. soleus           | 6. extensor digitorum brevis |
| 3. fibularis longus | 7. fibularis tertius tendon  |
| 4. fibularis brevis | 8. tibialis anterior         |

- |                              |                                       |
|------------------------------|---------------------------------------|
| 9. extensor digitorum longus | 12. extensor hallucis longus tendon   |
| 10. extensor hallucis longus | 13. extensor digitorum longus tendons |
| 11. extensor hallucis brevis |                                       |

**Figure 13.16 Right Leg, Deep Posterior View**

- |                       |                            |
|-----------------------|----------------------------|
| 1. plantaris          | 4. flexor digitorum longus |
| 2. popliteus          | 5. flexor hallucis longus  |
| 3. tibialis posterior | 6. calcaneal tendon        |

**Figure 13.17 Intrinsic Muscles of the Foot**

- |                                       |                                 |
|---------------------------------------|---------------------------------|
| 1. flexor digitorum brevis            | 8. adductor hallucis            |
| 2. abductor hallucis                  | 9. flexor hallucis brevis       |
| 3. abductor digiti minimi             | 10. flexor digiti minimi brevis |
| 4. lumbricals                         | 11. quadratus plantae           |
| 5. tendon of flexor hallucis longus   | 12. abductor digiti minimi      |
| 6. tendons of flexor digitorum longus | 13. abductor hallucis           |
| 7. quadratus plantae                  | 14. plantar interossei          |
|                                       | 15. dorsal interossei           |

**Chapter 14****What Do You Think?**

1. **Gray matter** is more involved in integration of information because it contains the cell bodies and dendrites of neurons. Synapses are abundant in such areas, and each synapse involves the transfer of information from one neuron to the next. White matter, on the other hand, consists of myelinated axons, which are involved with the transmission of information long distances from one area of the nervous system to another.
2. Glial cells in the central nervous system called oligodendrocytes insulates axons by producing the myelin sheath. Inflammation and demyelination occur during an “attack” but the oligodendrocytes have the ability to recover and repair. The recovery of the oligodendrocytes presents as recovery of nerve function.
3. The compression of a peripheral nerve that compresses blood vessels within the nerve will **cut off the nerve’s blood supply** and cause the axons to fail to send signals properly. This will result in nerve damage if blood flow is not restored soon. The lack of blood flow causes the area served by the nerve to become weak and go numb. Restoration of blood flow is associated with a prickly sensation along the sensory distribution of the nerve.

**Chapter 15****What Do You Think?**

1. Tactile corpuscles are sensitive to **light touch**. They are located relatively close to the surface of the skin so they can be sensitive to small disturbances occurring on the surface of the skin. If tactile corpuscles were located deeper within the dermis, it would take a stronger stimulus, such as deep pressure, to stimulate the receptors adequately.
2. Lamellated corpuscles are sensitive to **deep pressure and high frequency vibration**. They are located deep within the dermis of the skin. This location requires relatively strong pressure to stimulate the sensory receptor.
3. The optic disc is where the axons of ganglion cells exit the retina. There are **no photoreceptor cells (rods and cones) in this location**, which is why it is called the “blind spot” of the eye. Without photoreceptors, no light information can be sensed by the retina when light waves hit the optic disc.
4. A detached retina occurs because **there is no connective tissue to hold the retina in place**. The only thing holding the retina in place is the **fluid pressure of the vitreous humor** in the posterior cavity (vitreous chamber) of the eye.

**Chapter Activities****Figure 15.11 Accessory Structures of the Eye**

- |                      |                    |
|----------------------|--------------------|
| 1. eyelashes         | 5. pupil           |
| 2. lacrimal caruncle | 6. sclera          |
| 3. eyebrow           | 7. iris            |
| 4. superior eyelid   | 8. inferior eyelid |

**Chapter 16****What Do You Think?**

1. Individuals with pituitary gland tumors often experience visual disorders because of the **close proximity of the pituitary gland to the optic chiasm**. The optic chiasm, where fibers from the two optic nerves cross over to the opposite side of the brain, is located directly anterior to the infundibulum. The pituitary gland is located within the sella turcica of the sphenoid bone, directly inferior to the infundibulum. As a pituitary tumor grows, the bone tissue of the sella turcica somewhat limits the inferior movement of the tumor. Instead, the tumor tends to project superiorly where it begins to put pressure on the optic chiasm and the optic tracts, which lie next to the infundibulum. The pressure on these nerves is responsible for the visual disturbances.

## Chapter Activities

**Figure 16.9 Labeling Major Endocrine Glands of the Body**

- |                       |                               |
|-----------------------|-------------------------------|
| 1. parathyroid glands | 9. pituitary gland            |
| 2. thyroid gland      | 10. pancreas                  |
| 3. thymus             | 11. ovaries                   |
| 4. adrenal cortex     | 12. hypothalamus              |
| 5. adrenal medulla    | 13. anterior pituitary gland  |
| 6. testes             | 14. pineal gland              |
| 7. pineal gland       | 15. posterior pituitary gland |
| 8. hypothalamus       |                               |

## Chapter 17

### What Do You Think?

- The left atrium should have a thicker wall than the right atrium. Just as the left ventricle, the left atrium must pump blood at higher pressures than the right side of the heart.
- The **volume of blood pumped by the two ventricles must be the same** because ours is a closed circulatory system and all blood pumped to the pulmonary circuit returns to the systemic circuit and vice versa. If the volumes pumped by the two ventricles were different, then blood would back up in the circuit behind the ventricle that was pumping a lower volume. For instance, if the left ventricle pumped a lower volume of blood than the right ventricle, blood would back up in the pulmonary circuit, causing congestion within the lungs. This condition often occurs when an individual suffers from left-sided heart failure. If the right ventricle pumped a lower volume of blood than the left ventricle, blood would back up in the systemic circuit, causing congestion in the peripheral tissues, which is often seen as edema (swelling) of the extremities. This condition occurs when an individual suffers from right-sided heart failure.

## Chapter Activities

**Figure 17.1 Cardiac Muscle Tissue**

- |                      |                        |
|----------------------|------------------------|
| 1. striations        | 3. nucleus             |
| 2. intercalated disc | 4. cardiac muscle cell |

**Figure 17.3 Location of Heart Within the Thoracic Cavity**

- |                |              |
|----------------|--------------|
| 1. right lung  | 4. left lung |
| 2. diaphragm   | 5. heart     |
| 3. mediastinum |              |

**Figure 17.4 The Pericardial Sac**

- |  |  |
|--|--|
| 1. fibrous pericardium                               | 7. myocardium  |
| 2. parietal layer of serous pericardium              | 8. endocardium                                       |
| 3. pericardial cavity                                | 9. visceral layer of serous pericardium (epicardium) |
| 4. visceral layer of serous pericardium (epicardium) | 10. parietal layer of serous pericardium             |
| 5. myocardium  | 11. diaphragm  |
| 6. pericardial cavity                                |  |

**Figure 17.12 Circulation to and from the Heart Wall**

- |                          |                                      |
|--------------------------|--------------------------------------|
| 1. right coronary artery | 6. anterior interventricular artery  |
| 2. marginal artery       | 7. coronary sinus                    |
| 3. left coronary artery  | 8. right coronary artery             |
| 4. circumflex artery     | 9. posterior interventricular artery |
| 5. great cardiac vein    | 10. middle cardiac vein              |

## Chapter 18

### What Do You Think?

- Large blood vessels have thick walls composed of many cells (particularly smooth muscle cells), which need oxygen and nutrients just like any other cells of the body. The blood vessel walls are thick enough that they must have their own blood vessels, the vasa vasorum, to supply the tissues with oxygen and nutrient-rich blood because **the blood flowing within the lumen of the vessel is not adequate to supply these tissues**. In addition, blood flowing within the lumen of the vessels is generally flowing at high velocity, which is disadvantageous when it comes to exchange of substances between the blood and the tissues.
- An increase in carbon dioxide in the tissues of smooth muscle results in the local vasodilation in order to supply the region with adequate blood supply and glucose, as well as an avenue for the removal of metabolic wastes. In the case of a highly metabolically active organ, like the brain, vasodilation is necessary for the survival of the organ under conditions of hypoxia (low oxygen and high carbon dioxide). Elevated oxygen levels are associated with vasoconstriction, owing to the toxic nature of oxygen on tissues of the body. Vasoconstriction allows for the high oxygen concentration in the blood to be dispersed throughout the body, avoiding any injury to local tissue.

- The blood-brain barrier is composed of astrocytes and **continuous capillaries**. Continuous capillaries form the tightest barrier between the blood and the tissues because substances to be exchanged between the blood and the tissues are forced to pass through an endothelial cell to do so, giving the endothelial cells control over which substances pass through and which do not.
- The blood-cerebrospinal fluid barrier of the choroid plexus is composed of ependymal cells and **fenestrated capillaries**. Fenestrated capillaries have small holes (fenestrations) in the endothelial cells, which makes them more “leaky” than non-fenestrated endothelial cells. This “leakiness” in the capillaries of the choroid plexus allows fluid to escape from the blood and enter the ventricles of the brain as cerebrospinal fluid (CSF).
- Continuous capillaries form the tightest barrier between blood and tissues. Because of this, **the blood-brain barrier is a more complete barrier between the blood and the tissues** than is the blood-cerebrospinal fluid barrier.
- The right parietal lobe of the brain functions in logical reasoning and stereognosis (the ability to recognize by touch). Thus, a stroke of the middle cerebral artery that results in damage to the right parietal lobe of the brain would result in neurological deficits such as **difficulties with problem-solving (particularly math problems) and an inability to recognize objects based on touch (as when trying to identify an object placed inside a paper bag)**.
- The liver contains sinusoidal capillaries. Sinusoidal capillaries allow maximum exchange between the blood and the tissues. Because the liver’s main functions involve processing of the blood, it is advantageous to **allow maximum exchange between the hepatocytes of the liver and the substances within the blood**, which is what sinusoidal capillaries are specialized for.

## Chapter Activities

### Exercise 18.7, #4

right ventricle → pulmonary semilunar valve → pulmonary trunk → pulmonary arteries → lungs → pulmonary veins → left atrium

**Figure 18.6 Pulmonary Circulation**

- |                               |                               |
|-------------------------------|-------------------------------|
| 1. right pulmonary artery     | 9. aorta                      |
| 2. right pulmonary vein       | 10. pulmonary trunk           |
| 3. right atrium               | 11. pulmonary semilunar valve |
| 4. right AV valve             | 12. left atrium               |
| 5. right ventricle            | 13. left AV valve             |
| 6. branch of pulmonary artery | 14. left ventricle            |
| 7. branch of pulmonary vein   | 15. aortic semilunar valve    |
| 8. pulmonary capillaries      |                               |

**Figure 18.7 Circulation to the Head and Neck**

#### (a) Arterial supply

- |                                |                               |
|--------------------------------|-------------------------------|
| 1. internal carotid artery     | 9. posterior auricular artery |
| 2. external carotid artery     | 10. occipital artery          |
| 3. carotid sinus               | 11. maxillary artery          |
| 4. common carotid artery       | 12. facial artery             |
| 5. vertebral artery            | 13. superior laryngeal artery |
| 6. thyrocervical trunk         | 14. superior thyroid artery   |
| 7. subclavian artery           | 15. brachiocephalic trunk     |
| 8. superficial temporal artery |                               |

#### (b) Venous drainage

- |                               |                             |
|-------------------------------|-----------------------------|
| 1. vertebral vein             | 7. posterior auricular vein |
| 2. external jugular vein      | 8. maxillary vein           |
| 3. internal jugular vein      | 9. pharyngeal vein          |
| 4. subclavian vein            | 10. facial vein             |
| 5. right brachiocephalic vein | 11. lingual vein            |
| 6. superficial temporal vein  | 12. superior thyroid vein   |

**Figure 18.8 Circulation from the Aortic Arch to the Anterior Part of the Right Parietal Bone and Back to the Superior Vena Cava**

- |                                      |                                    |
|--------------------------------------|------------------------------------|
| 1. right brachiocephalic trunk       | 5. right superficial temporal vein |
| 2. right common carotid artery       | 6. right internal jugular vein     |
| 3. right external carotid artery     | 7. right brachiocephalic vein      |
| 4. right superficial temporal artery |                                    |

**Figure 18.9 Circulation to the Brain**

#### (a) Arterial Supply

- |                                  |                                   |
|----------------------------------|-----------------------------------|
| 1. middle cerebral artery        | 6. internal carotid artery        |
| 2. internal carotid artery       | 7. posterior communicating artery |
| 3. posterior cerebral artery     | 8. posterior cerebral artery      |
| 4. anterior communicating artery | 9. basilar artery                 |
| 5. anterior cerebral artery      | 10. vertebral artery              |

**(b) Venous Drainage**

- |                            |                            |
|----------------------------|----------------------------|
| 1. straight sinus          | 6. inferior sagittal sinus |
| 2. transverse sinus        | 7. cavernous sinus         |
| 3. sigmoid sinus           | 8. superior petrosal sinus |
| 4. internal jugular vein   | 9. inferior petrosal sinus |
| 5. superior sagittal sinus |                            |

**Figure 18.10 Circulation from the Aortic Arch to the Right Parietal Lobe of the Brain and Back to the Right Brachiocephalic Vein**

- |   |  |
|---|--|
| 1. right brachiocephalic artery           | e. Alternate 6: posterior communicating artery |
| 2. right common carotid artery            | 5. superior sagittal sinus                     |
| a. Alternate 2: right subclavian artery   | 6. transverse sinus                            |
| 3. right internal carotid artery          | 7. sigmoid sinus                               |
| b. Alternate 3: right vertebral artery    | 8. internal jugular vein                       |
| 4. middle cerebral artery                 | 9. right brachiocephalic vein                  |
| c. Alternate 4: basilar artery            |  |
| d. Alternate 5: posterior cerebral artery |  |

**Figure 18.11 Circulation to the Thoracic and Abdominal Walls****(a) Arterial Supply**

- |                                     |                                     |
|-------------------------------------|-------------------------------------|
| 1. right common carotid artery      | 15. left common carotid artery      |
| 2. vertebral artery                 | 16. left subclavian artery          |
| 3. right subclavian artery          | 17. aortic arch                     |
| 4. brachiocephalic trunk            | 18. descending thoracic aorta       |
| 5. internal thoracic artery         | 19. left gastric artery             |
| 6. anterior intercostal arteries    | 20. celiac trunk                    |
| 7. posterior intercostal arteries   | 21. left superior suprarenal artery |
| 8. superior epigastric artery       | 22. left renal artery               |
| 9. right inferior suprarenal artery | 23. superior mesenteric artery      |
| 10. right renal artery              | 24. left gonadal artery             |
| 11. descending abdominal aorta      | 25. left common iliac artery        |
| 12. right gonadal artery            | 26. left internal iliac artery      |
| 13. inferior mesenteric artery      | 27. left external iliac artery      |
| 14. inferior epigastric artery      | 28. left femoral artery             |

**(b) Venous Drainage**

- |                                     |                                     |
|-------------------------------------|-------------------------------------|
| 1. right subclavian vein            | 15. right inferior epigastric vein  |
| 2. right brachiocephalic vein       | 16. left subclavian vein            |
| 3. superior vena cava               | 17. left brachiocephalic vein       |
| 4. anterior intercostal veins       | 18. accessory hemiazygos vein       |
| 5. azygos vein                      | 19. left posterior intercostal vein |
| 6. internal thoracic vein           | 20. hemiazygos vein                 |
| 7. right posterior intercostal vein | 21. left suprarenal vein            |
| 8. inferior vena cava               | 22. left renal vein                 |
| 9. hepatic veins                    | 23. left gonadal vein               |
| 10. right superior epigastric vein  | 24. left common iliac vein          |
| 11. right suprarenal vein           | 25. left external iliac vein        |
| 12. right renal vein                | 26. left internal iliac vein        |
| 13. right gonadal vein              | 27. left femoral vein               |
| 14. right lumbar veins              | 28. inferior vena cava              |

**Figure 18.12 Circulation from the Left Ventricle of the Heart to the Right Kidney and Back to the Right Atrium of the Heart**

- |                              |                       |
|------------------------------|-----------------------|
| 1. ascending aorta           | 5. right renal artery |
| 2. aortic arch               | 6. right renal vein   |
| 3. descending thoracic aorta | 7. inferior vena cava |
| 4. abdominal aorta           |                       |

**Figure 18.13 Arterial Supply to Abdominal Organs****(a) Arterial Supply to the Stomach, Spleen, Pancreas, Duodenum, and Liver**

- |                          |   |
|--------------------------|---|
| 1. celiac trunk          | 8. right gastroepiploic artery                      |
| 2. common hepatic artery | 9. inferior vena cava (not part of arterial supply) |
| 3. hepatic artery proper | 10. left gastric artery                             |
| 4. left hepatic artery   | 11. splenic artery                                  |
| 5. right hepatic artery  | 12. left gastroepiploic artery                      |
| 6. gastroduodenal artery | 13. descending abdominal aorta                      |
| 7. right gastric artery  |   |

**(b) Arterial Supply to the Small and Large Intestines**

- |                               |                               |
|-------------------------------|-------------------------------|
| 1. middle colic artery        | 7. descending abdominal aorta |
| 2. right colic artery         | 8. inferior mesenteric artery |
| 3. ileocolic artery           | 9. sigmoid arteries           |
| 4. celiac trunk               | 10. left common iliac artery  |
| 5. superior mesenteric artery | 11. superior rectal artery    |
| 6. left colic artery          |                               |

**Figure 18.14 The Hepatic Portal System**

- |                              |                             |
|------------------------------|-----------------------------|
| 1. inferior vena cava        | 6. intestinal veins         |
| 2. hepatic veins             | 7. gastric veins            |
| 3. hepatic portal vein       | 8. splenic vein             |
| 4. right gastroepiploic vein | 9. inferior mesenteric vein |
| 5. superior mesenteric vein  |                             |

**Figure 18.15 Circulation from the Abdominal Aorta to the Spleen and Back to the Right Atrium of the Heart**

- |                    |                        |
|--------------------|------------------------|
| 1. abdominal aorta | 5. hepatic portal vein |
| 2. celiac trunk    | 6. hepatic veins       |
| 3. splenic artery  | 7. inferior vena cava  |
| 4. splenic vein    |                        |

**Figure 18.16 Circulation from the Abdominal Aorta to the Duodenum and Back to the Right Atrium of the Heart**

- |                          |                             |
|--------------------------|-----------------------------|
| 1. abdominal aorta       | 5. superior mesenteric vein |
| 2. celiac trunk          | 6. hepatic portal vein      |
| 3. common hepatic artery | 7. hepatic veins            |
| 4. gastroduodenal artery | 8. inferior vena cava       |

**Figure 18.17 Circulation from the Abdominal Aorta to the Sigmoid Colon and Back to the Right Atrium of the Heart**

- |                               |                        |
|-------------------------------|------------------------|
| 1. abdominal aorta            | 5. splenic vein        |
| 2. inferior mesenteric artery | 6. hepatic portal vein |
| 3. sigmoid arteries           | 7. hepatic veins       |
| 4. inferior mesenteric vein   | 8. inferior vena cava  |

**Figure 18.18 Circulation to the Upper Limb****(a) Arterial Supply**

- |                           |                            |
|---------------------------|----------------------------|
| 1. brachiocephalic artery | 6. ulnar artery            |
| 2. subclavian artery      | 7. radial artery           |
| 3. axillary artery        | 8. deep palmar arch        |
| 4. deep brachial artery   | 9. superficial palmar arch |
| 5. brachial artery        | 10. digital arteries       |

**(b) Venous Drainage**

- |                        |                                    |
|------------------------|------------------------------------|
| 1. subclavian vein     | 8. cephalic vein                   |
| 2. axillary vein       | 9. deep palmar venous arch         |
| 3. cephalic vein       | 10. superficial palmar venous arch |
| 4. basilic vein        | 11. dorsal venous network          |
| 5. brachial veins      | 12. digital veins                  |
| 6. median cubital vein | 13. ulnar veins                    |
| 7. radial veins        |                                    |

**Figure 18.19 Circulation from the Aortic Arch to the Anterior Surface of the Index Finger and Back along a Superficial Route to the Superior Vena Cava**

- |                                   |                                      |
|-----------------------------------|--------------------------------------|
| 1. brachiocephalic trunk (artery) | 9. superficial palmar venous arch    |
| 2. subclavian artery              | 10. cephalic vein                    |
| 3. axillary artery                | a. Alternate 11: median cubital vein |
| 4. brachial artery                | b. Alternate 12: basilic vein        |
| 5. radial artery                  | c. Alternate 13: axillary vein       |
| 6. superficial palmar arch        | 11. subclavian vein                  |
| 7. digital artery                 | 12. brachiocephalic vein             |
| 8. digital vein                   | 13. superior vena cava               |

**Figure 18.20 Circulation from the Aortic Arch to the Capitate Bone of the Wrist and Back along a Deep Route to the Superior Vena Cava**

- |                            |                          |
|----------------------------|--------------------------|
| 1. brachiocephalic artery  | 8. ulnar veins           |
| 2. subclavian artery       | 9. brachial vein         |
| 3. axillary artery         | 10. axillary vein        |
| 4. brachial artery         | 11. subclavian vein      |
| 5. ulnar artery            | 12. brachiocephalic vein |
| 6. deep palmar arch        | 13. superior vena cava   |
| 7. deep palmar venous arch |                          |



**Figure 18.21 Circulation to the Lower Limb**

**(a) Arterial Supply**

- |                           |                             |
|---------------------------|-----------------------------|
| 1. common iliac artery    | 9. dorsalis pedis artery    |
| 2. internal iliac artery  | 10. popliteal artery        |
| 3. external iliac artery  | 11. posterior tibial artery |
| 4. obturator artery       | 12. lateral plantar artery  |
| 5. femoral artery         | 13. medial plantar artery   |
| 6. deep femoral artery    | 14. plantar arch            |
| 7. anterior tibial artery | 15. digital arteries        |
| 8. fibular artery         |                             |

**(b) Venous Drainage**

- |                          |                           |
|--------------------------|---------------------------|
| 1. common iliac vein     | 9. dorsal venous arch     |
| 2. external iliac vein   | 10. popliteal vein        |
| 3. internal iliac vein   | 11. small saphenous vein  |
| 4. deep femoral vein     | 12. posterior tibial vein |
| 5. femoral vein          | 13. lateral plantar vein  |
| 6. great saphenous vein  | 14. medial plantar vein   |
| 7. anterior tibial veins | 15. digital veins         |
| 8. fibular veins         |                           |

**Figure 18.22 Circulation from the Abdominal Aorta to the Dorsal Surface of the Big Toe and Back along a Superficial Route to the Inferior Vena Cava**

- |                           |                          |
|---------------------------|--------------------------|
| 1. abdominal aorta        | 9. digital vein          |
| 2. common iliac artery    | 10. dorsal venous arch   |
| 3. external iliac artery  | 11. great saphenous vein |
| 4. femoral artery         | 12. femoral vein         |
| 5. popliteal artery       | 13. external iliac vein  |
| 6. anterior tibial artery | 14. common iliac vein    |
| 7. dorsalis pedis artery  | 15. inferior vena cava   |
| 8. digital artery         |                          |

**Figure 18.23 Circulation from the Abdominal Aorta to the Cuboid Bone of the Foot and Back along a Deep Route to the Inferior Vena Cava**

- |                            |                          |
|----------------------------|--------------------------|
| 1. abdominal aorta         | 8. lateral plantar vein  |
| 2. common iliac artery     | 9. posterior tibial vein |
| 3. external iliac artery   | 10. popliteal vein       |
| 4. femoral artery          | 11. femoral vein         |
| 5. popliteal artery        | 12. external iliac vein  |
| 6. posterior tibial artery | 13. common iliac vein    |
| 7. lateral plantar artery  | 14. inferior vena cava   |

**Exercise 18.14, #2**

Left ventricle → aorta → common iliac arteries → internal iliac arteries → umbilical arteries → placenta → umbilical vein → ductus venosus → inferior vena cava → right atrium

**Exercise 18.4, #3**

Table 18.4 Fetal Cardiovascular Structures and Associated Postnatal Structures		
Fetal Cardiovascular Structure	Postnatal Structure	Function of Fetal Structure
<i>Ductus arteriosus</i>	Ligamentum arteriosum	Shunt blood from the pulmonary trunk to the aorta, thereby bypassing the pulmonary circuit and nonfunctional lungs.
<i>Ductus venosus</i>	Ligamentum venosum	Carry oxygenated blood from umbilical vein to the inferior vena cava.
<i>Foramen ovale</i>	Fossa ovalis	Shunt blood from the right atrium to the left atrium, thereby bypassing the nonfunctional lungs.
<i>Umbilical arteries</i>	Medial umbilical ligaments	Carry deoxygenated blood from the fetus to the placenta so it can obtain oxygen from the mother's blood.
<i>Umbilical vein</i>	Round ligament of the liver (ligamentum teres)	Carry oxygenated blood from the placenta to the fetal circulation.

**Figure 18.24 Fetal Circulation**

- |                       |                                |
|-----------------------|--------------------------------|
| 1. superior vena cava | 11. pulmonary veins            |
| 2. right lung         | 12. foramen ovale              |
| 3. right atrium       | 13. right ventricle            |
| 4. liver              | 14. heart                      |
| 5. ductus venosus     | 15. descending abdominal aorta |
| 6. inferior vena cava | 16. common iliac artery        |
| 7. umbilical vein     | 17. umbilical arteries         |
| 8. aortic arch        | 18. umbilical cord             |
| 9. ductus arteriosus  | 19. placenta                   |
| 10. pulmonary artery  |                                |

**Chapter 19**

**What Do You Think?**

- The small intestine functions to absorb nutrients from the food we eat. Unfortunately, our mouths are not only a large entryway into the body for food and drink, but also for microorganisms and pathogens. In addition, the epithelium of the small intestine is thin relative to the epithelium of our skin. Thus, **an abundance of lymphatic nodules within the walls of the small intestine provides a robust “second-line defense” against pathogens that might enter our bodies through the wall of the small intestine.**

**Chapter Activities**

**Figure 19.11 Major Lymph Vessels of the Body**

- |                         |                   |
|-------------------------|-------------------|
| 1. right lymphatic duct | 3. lymph nodes    |
| 2. thoracic duct        | 4. cisterna chyli |

**Figure 19.12 Mucosa-Associated Lymphatic Tissue (MALT)**

- |                       |                       |
|-----------------------|-----------------------|
| 1. pharyngeal tonsils | 3. lingual tonsils    |
| 2. palatine tonsils   | 4. vermiform appendix |

**Figure 19.13 Lymph Node and Its Components**

- |                               |                                |
|-------------------------------|--------------------------------|
| 1. lymphatic nodule           | 7. trabeculae                  |
| 2. afferent lymphatic vessels | 8. lymphatic nodules           |
| 3. capsule                    | 9. peritrabecular space        |
| 4. medullary sinuses          | 10. subcapsular space          |
| 5. medullary cords            | 11. hilum                      |
| 6. medulla                    | 12. efferent lymphatic vessels |

**Figure 19.14 Gross Anatomy of the Spleen**

- |                        |                 |
|------------------------|-----------------|
| 1. splenic artery      | 3. spleen       |
| 2. hilum of the spleen | 4. splenic vein |

**Chapter 20**

**Chapter Activities**

**Figure 20.7 The Upper Respiratory Tract: Midsagittal View**

- |                          |                     |
|--------------------------|---------------------|
| 1. ethmoidal sinuses     | 9. sphenoidal sinus |
| 2. superior nasal concha | 10. superior meatus |
| 3. middle nasal concha   | 11. middle meatus   |
| 4. inferior nasal concha | 12. inferior meatus |
| 5. vestibule             | 13. nasopharynx     |
| 6. epiglottis            | 14. oropharynx      |
| 7. thyroid cartilage     | 15. laryngopharynx  |
| 8. cricoid cartilage     | 16. lumen of larynx |

**Figure 20.8 Classroom Model of the Larynx**

- |                           |                             |
|---------------------------|-----------------------------|
| 1. epiglottis             | 13. cricoid cartilage       |
| 2. hyoid bone             | 14. trachealis muscle       |
| 3. thyrohyoid membrane    | 15. tracheal C-Ring/trachea |
| 4. thyroid cartilage      | 16. epiglottis              |
| 5. laryngeal prominence   | 17. corniculate cartilage   |
| 6. tracheal “C” ring      | 18. vestibular ligament     |
| 7. epiglottis             | 19. vocal cords             |
| 8. hyoid bone             | 20. cricoid cartilage       |
| 9. thyrohyoid membrane    | 21. hyoid bone              |
| 10. cuneiform cartilage   | 22. thyrohyoid membrane     |
| 11. corniculate cartilage | 23. thyroid cartilage       |
| 12. thyroid cartilage     |                             |

**Figure 20.9 The Pleural Cavities**

- |                |                    |
|----------------|--------------------|
| 1. left lung   | 5. visceral pleura |
| 2. right lung  | 6. parietal pleura |
| 3. mediastinum | 7. pleural cavity  |
| 4. diaphragm   |                    |

**Figure 20.10 The Right Lung**

- |                       |                        |
|-----------------------|------------------------|
| 1. superior lobe      | 10. apex               |
| 2. horizontal fissure | 11. superior lobe      |
| 3. oblique fissure    | 12. oblique fissure    |
| 4. middle lobe        | 13. pulmonary arteries |
| 5. inferior lobe      | 14. primary bronchi    |
| 6. base               | 15. pulmonary veins    |
| 7. horizontal fissure | 16. inferior lobe      |
| 8. middle lobe        | 17. base               |
| 9. oblique fissure    |                        |

**Figure 20.11 The Left Lung**

- |                       |                        |
|-----------------------|------------------------|
| 1. apex               | 9. primary bronchi     |
| 2. superior lobe      | 10. pulmonary veins    |
| 3. oblique fissure    | 11. inferior lobe      |
| 4. cardiac notch      | 12. base               |
| 5. inferior lobe      | 13. oblique fissure    |
| 6. base               | 14. cardiac impression |
| 7. superior lobe      | 15. cardiac notch      |
| 8. pulmonary arteries | 16. oblique fissure    |

**Figure 20.12 The Bronchial Tree**

- |                            |                                |
|----------------------------|--------------------------------|
| 1. right primary bronchus  | 5. left primary bronchus       |
| 2. right tertiary bronchi  | 6. left tertiary bronchi       |
| 3. right secondary bronchi | 7. left secondary bronchi      |
| 4. trachea                 | 8. carina (internal structure) |

## Chapter 21

### What Do You Think?

- The epithelium of the large intestine has many **goblet cells**, which produce mucus. **Mucus is important for lubricating the large intestine to ease the passage of the feces as they solidify within the large intestine.**

### Chapter Activities

**Figure 21.10 Overview of the Digestive System**

- |                    |                     |
|--------------------|---------------------|
| 1. teeth           | 8. liver            |
| 2. tongue          | 9. gallbladder      |
| 3. salivary glands | 10. pancreas        |
| 4. oral cavity     | 11. small intestine |
| 5. pharynx         | 12. large intestine |
| 6. esophagus       | 13. rectum          |
| 7. stomach         | 14. anal canal      |

**Figure 21.11 Upper Digestive Tract****(a) Anterior View of the Oral Cavity**

- |  |                              |
|--|------------------------------|
| 1. upper lip (superior lip)                  | 10. soft palate              |
| 2. superior labial frenulum                  | 11. uvula                    |
| 3. glossopalatine arch                       | 12. fauces                   |
| 4. pharyngopalatine arch                     | 13. tongue                   |
| 5. palatine tonsil                           | 14. lingual frenulum         |
| 6. sublingual duct orifice                   | 15. teeth                    |
| 7. submandibular duct orifice                | 16. gingivae                 |
| 8. inferior labial frenulum                  | 17. lower lip (inferior lip) |
| 9. transverse palatine folds/<br>hard palate |                              |

**(b) Midsagittal View of the Oral Cavity and Pharynx**

- |                       |                    |
|-----------------------|--------------------|
| 1. hard palate        | 8. palatine tonsil |
| 2. oral cavity        | 9. oropharynx      |
| 3. tongue             | 10. lingual tonsil |
| 4. vestibule          | 11. epiglottis     |
| 5. soft palate        | 12. laryngopharynx |
| 6. palatoglossal arch | 13. esophagus      |
| 7. uvula              |                    |

**(c) Salivary Glands**

- |                           |                                 |
|---------------------------|---------------------------------|
| 1. parotid salivary gland | 5. sublingual salivary gland    |
| 2. parotid duct           | 6. submandibular salivary gland |
| 3. sublingual ducts       |                                 |
| 4. submandibular duct     |                                 |

**Figure 21.12 Classroom Model of the Stomach**

- |  |   |
|--|---|
| 1. lesser curvature                        | 8. greater curvature                        |
| 2. pyloric sphincter                       | 9. pyloric sphincter                        |
| 3. pylorus                                 | 10. pylorus                                 |
| 4. esophagus                               | 11. fundus                                  |
| 5. cardia of stomach                       | 12. cardia                                  |
| 6. inferior esophageal (cardiac) sphincter | 13. inferior esophageal (cardiac) sphincter |
| 7. body of stomach                         | 14. gastric folds (rugae)                   |

**Figure 21.13 Classroom Model of the Duodenum, Gallbladder, Liver, and Pancreas**

- |                              |                                 |
|------------------------------|---------------------------------|
| 1. gallbladder               | 8. left and right hepatic ducts |
| 2. duodenum                  | 9. cystic duct                  |
| 3. accessory pancreatic duct | 10. common hepatic duct         |
| 4. minor duodenal papilla    | 11. tail of pancreas            |
| 5. common bile duct          | 12. body of pancreas            |
| 6. major duodenal papilla    | 13. main pancreatic duct        |
| 7. head of pancreas          | 14. hepatopancreatic ampulla    |

**Figure 21.14 Classroom Model of the Liver**

- |                          |                           |
|--------------------------|---------------------------|
| 1. gallbladder           | 9. quadrate lobe of liver |
| 2. right lobe of liver   | 10. falciform ligament    |
| 3. common hepatic duct   | 11. right hepatic duct    |
| 4. cystic duct           | 12. left hepatic duct     |
| 5. common bile duct      | 13. left lobe of liver    |
| 6. hepatic portal vein   | 14. caudate lobe of liver |
| 7. hepatic artery proper | 15. porta hepatis         |
| 8. inferior vena cava    |                           |

**Figure 21.17 Classroom Model of the Abdominal Cavity and Large Intestine**

- |                                  |  |
|----------------------------------|--|
| 1. right lobe of liver           | 16. esophagus                              |
| 2. falciform ligament            | 17. duodenum                               |
| 3. pylorus of stomach            | 18. right colic (hepatic) flexure of colon |
| 4. gallbladder                   | 19. ascending colon                        |
| 5. greater curvature of stomach  | 20. taenia coli                            |
| 6. ascending colon               | 21. cecum                                  |
| 7. ileum of small intestine      | 22. tail of pancreas                       |
| 8. esophagus                     | 23. body of pancreas                       |
| 9. left lobe of liver            | 24. left colic (splenic) flexure of colon  |
| 10. body of stomach              | 25. transverse colon                       |
| 11. left colic (splenic) flexure | 26. descending colon                       |
| 12. transverse colon             | 27. rectum                                 |
| 13. taenia coli                  | 28. sigmoid colon                          |
| 14. jejunum of small intestine   |  |
| 15. sigmoid colon                |  |

## Chapter 22

### What Do You Think?

- To answer this question, first think of what would happen if gravity alone were the force that moved urine from the kidneys to the urinary bladder. What would happen to the flow of urine when you were lying down or doing a handstand? You guessed it; urine would no longer flow from the kidney to the urinary bladder. Thus, muscular contractions are necessary to actively propel urine from the kidney to the urinary bladder.

### Chapter Activities

**Figure 22.7 Coronal Section Through the Right Kidney**

- |                    |                 |
|--------------------|-----------------|
| 1. fibrous capsule | 7. minor calyx  |
| 2. renal cortex    | 8. renal pelvis |
| 3. renal medulla   | 9. major calyx  |
| 4. renal papilla   | 10. renal sinus |
| 5. renal column    | 11. ureter      |
| 6. renal pyramid   | 12. renal lobe  |

**Figure 22.9 Models of the Kidney Demonstrating the Blood Supply to the Kidney**

- |   |   |
|---|---|
| <p><b>(a) Coronal Section</b></p> <ol style="list-style-type: none"> <li>peritubular capillaries</li> <li>interlobular vein</li> <li>interlobular artery</li> <li>interlobar vein</li> <li>interlobar artery</li> <li>vasa recta</li> <li>renal artery</li> <li>renal vein</li> <li>segmental artery</li> <li>glomerulus</li> <li>afferent arteriole</li> <li>arcuate vein</li> <li>arcuate artery</li> </ol> | <p><b>(b) Close-up of the Renal Cortex and Renal Medulla</b></p> <ol style="list-style-type: none"> <li>efferent arteriole</li> <li>afferent arteriole</li> <li>glomerulus</li> <li>interlobular artery</li> <li>interlobular vein</li> <li>peritubular capillaries</li> <li>arcuate artery</li> <li>arcuate vein</li> <li>vasa recta</li> <li>interlobar artery</li> </ol> |
|---|---|

**Exercise 22.6, #4**

Abdominal aorta → renal artery → segmental artery → interlobar artery → arcuate artery → interlobular artery → afferent arteriole → glomerulus → efferent arteriole → peritubular capillaries or vasa recta → interlobular vein → arcuate vein → interlobar vein → renal vein → inferior vena cava

**Figure 22.10 Location of the Ureters Within the Abdominopelvic Cavity**

- |                 |                       |
|-----------------|-----------------------|
| 1. right kidney | 3. psoas major muscle |
| 2. ureter       | 4. urinary bladder    |

**Figure 22.11 Classroom Model of Male Urinary System Structures**

- |                              |                    |
|------------------------------|--------------------|
| 1. renal cortex              | 7. urinary bladder |
| 2. renal (medullary) pyramid | 8. left kidney     |
| 3. minor calyx               | 9. renal artery    |
| 4. renal papilla             | 10. renal vein     |
| 5. major calyx               | 11. ureter         |
| 6. renal pelvis              |                    |

**Figure 22.12 Classroom Model of a Midsagittal Section Through the Male Pelvis**

- |                       |                                 |
|-----------------------|---------------------------------|
| 1. urinary bladder    | 5. ureter                       |
| 2. prostatic urethra  | 6. muscularis (detrusor muscle) |
| 3. membranous urethra | 7. internal urethral sphincter  |
| 4. spongy urethra     | 8. external urethral sphincter  |

**Figure 22.13 Classroom Model of a Midsagittal Section Through the Female Pelvis**

- |                    |                                |
|--------------------|--------------------------------|
| 1. urinary bladder | 4. detrusor muscle             |
| 2. urethra         | 5. internal urethral sphincter |
| 3. ureter          | 6. external urethral sphincter |

## Chapter 23

### What Do You Think?

- A vesicular follicle is distinguished from a secondary follicle by the **presence of a single antrum**. Thus, if the antrum is divided into more than one region, the follicle is a secondary follicle, not a vesicular follicle.
- The corpus luteum is present during the **luteal phase** of the ovarian cycle. Hence the name of the phase (corpus luteum; luteal phase).
- The corpus luteum **secreted the hormones estrogen and progesterone**, which prepare the uterine lining for implantation of a fertilized egg, should fertilization occur.
- The ductus deferens is a muscular tube that functions to propel sperm toward the urethra during ejaculation. **Because sperm are only propelled through the ductus deferens during ejaculation, at other times the lumen of the ductus deferens will not have many, if any, sperm within its lumen.** On contrast, sperm are commonly visible inside the lumen of the epididymis when viewed histologically because the epididymis is the site for storage and maturation of sperm before ejaculation.
- The clitoris has no corpus spongiosum, which is the erectile tissue that surrounds the urethra in the male. Thus, the **clitoris also has no urethra**. The corpus spongiosum in the female surrounds the labia minora, and the female urethral opening is located posterior to the clitoris and within the folds of the labia minora. Thus, while the female urethra is surrounded by the corpus spongiosum (just as in the male), neither the corpus spongiosum nor the urethra are part of the clitoris.

## Chapter Activities

**Figure 23.12 Suspensory Ligaments of the Ovary, Uterine Tubes, and Uterus as Seen from a Posterior View**

- |                                     |                                  |
|-------------------------------------|----------------------------------|
| 1. ovarian ligament                 | 14. isthmus of uterine tube      |
| 2. uterine tube                     | 15. ampulla of uterine tube      |
| 3. suspensory ligament of the ovary | 16. infundibulum of uterine tube |
| 4. fimbria                          | 17. round ligament of the uterus |
| 5. mesosalpinx                      | 18. endometrium                  |
| 6. body of uterus                   | 19. myometrium                   |
| 7. broad ligament                   | 20. perimetrium                  |
| 8. uterine blood vessels            | 21. internal os                  |
| 9. ureter                           | 22. cervical canal               |
| 10. uterosacral ligament            | 23. external os                  |
| 11. transverse cervical ligament    | 24. uterine tube                 |
| 12. vagina                          | 25. mesosalpinx                  |
| 13. uterine part of uterine tube    | 26. mesovarium                   |

**Figure 23.13 Classroom Model of the Female Pelvic Cavity**

- |                                  |                               |
|----------------------------------|-------------------------------|
| 1. uterine tube                  | 12. pubic symphysis           |
| 2. ovary                         | 13. clitoris                  |
| 3. uterus                        | 14. external urethral orifice |
| 4. urinary bladder               | 15. vaginal orifice           |
| 5. labia minora                  | 16. anus                      |
| 6. labia majora                  | 17. ureter                    |
| 7. rectum                        | 18. fimbria of uterine tube   |
| 8. vagina                        | 19. rectouterine pouch        |
| 9. bulb of vestibule             | 20. cervix of uterus          |
| 10. round ligament of the uterus | 21. vagina                    |
| 11. vesicouterine pouch          |                               |

**Figure 23.14 The Female Breast**

- |                         |                             |
|-------------------------|-----------------------------|
| 1. suspensory ligaments | 11. pectoralis major muscle |
| 2. lobe                 | 12. lobe                    |
| 3. lactiferous sinus    | 13. deep fascia             |
| 4. alveoli              | 14. alveoli                 |
| 5. lactiferous ducts    | 15. lobule                  |
| 6. lobule               | 16. suspensory ligaments    |
| 7. areolar gland        | 17. lactiferous sinus       |
| 8. nipple               | 18. nipple                  |
| 9. areola               | 19. lactiferous ducts       |
| 10. adipose tissue      |                             |

**Figure 23.15 Male Reproductive Tract Structures**

- |                               |                          |
|-------------------------------|--------------------------|
| 1. ureter                     | 11. epididymis           |
| 2. ampulla of ductus deferens | 12. testis               |
| 3. seminal vesicle            | 13. penile urethra       |
| 4. ejaculatory duct           | 14. urinary bladder      |
| 5. prostate gland             | 15. bulb of penis        |
| 6. prostatic urethra          | 16. crus of penis        |
| 7. bulbourethral gland        | 17. corpus cavernosum    |
| 8. urogenital diaphragm       | 18. seminiferous tubules |
| 9. membranous urethra         | 19. corpus spongiosum    |
| 10. ductus deferens           | 20. glans penis          |

**Figure 23.16 Classroom Model of the Male Pelvic Cavity**

- |                                |                                 |
|--------------------------------|---------------------------------|
| 1. ureter                      | 18. prostate gland              |
| 2. urinary bladder             | 19. spongy (penile) urethra     |
| 3. ischiopubic ramus           | 20. corpus cavernosum           |
| 4. ductus deferens             | 21. prepuce                     |
| 5. penis                       | 22. tunica vaginalis of testis  |
| 6. prepuce                     | 23. tunica albuginea of testis  |
| 7. glans penis                 | 24. tunica vaginalis of testis  |
| 8. ductus deferens (ampulla)   | 25. urinary bladder             |
| 9. seminal vesicle             | 26. rectum                      |
| 10. prostate gland             | 27. internal urethral sphincter |
| 11. testicular artery and vein | 28. prostatic urethra           |
| 12. epididymis                 | 29. ejaculatory duct            |
| 13. testis                     | 30. urogenital diaphragm        |
| 14. scrotum                    | 31. anus                        |
| 15. ureter                     | 32. membranous urethra          |
| 16. ductus deferens            | 33. epididymis                  |
| 17. pubic symphysis            | 34. seminiferous tubules        |

## Chapter 24

### Chapter Activities

#### Figure 24.2 Meningeal Structures

- |   |   |
|---|---|
| <p>24.2a</p> <ol style="list-style-type: none"> <li>superior sagittal sinus</li> <li>falx cerebri</li> <li>pia mater</li> <li>subarachnoid space</li> <li>arachnoid mater</li> <li>falx cerebri</li> <li>periosteal dura</li> <li>dura mater</li> <li>superior sagittal sinus</li> <li>arachnoid villi</li> <li>meningeal dura</li> </ol> | <p>24.2b</p> <ol style="list-style-type: none"> <li>superior sagittal sinus</li> <li>falx cerebri</li> <li>pia mater</li> <li>subarachnoid space</li> <li>arachnoid mater</li> <li>falx cerebri</li> <li>dura mater, periosteal layer</li> <li>straight sinus</li> <li>confluence of sinuses</li> <li>falx cerebelli</li> </ol> |
|---|---|

#### Figure 24.4 Cast of the Ventricles of the Brain

- lateral ventricles
- interventricular foramen
- third ventricle
- cerebral aqueduct
- fourth ventricle

#### Exercise 24.3, #2 Column B

- lateral ventricles
- interventricular foramen
- third ventricle
- cerebral aqueduct
- fourth ventricle
- median and lateral apertures
- subarachnoid space
- arachnoid villi

#### Figure 24.5 Cerebrospinal Fluid (CSF) Production and Circulation

- periosteal dura
- arachnoid villus
- superior sagittal sinus
- meningeal dura
- arachnoid mater
- subarachnoid space
- pia mater
- cerebral cortex
- subarachnoid space
- arachnoid granulations
- dura mater
- superior sagittal sinus
- pia mater
- choroid plexus of third ventricle
- choroid plexus of lateral ventricle
- interventricular foramen
- cerebral aqueduct
- lateral aperture
- choroid plexus of fourth ventricle
- median aperture
- subarachnoid space
- central canal

#### Figure 24.6 Superior View of the Brain

- frontal lobes
- precentral gyrus
- central sulcus
- postcentral gyrus
- longitudinal fissure
- parietal lobe
- occipital lobes

#### Figure 24.7 Lateral View of the Brain

- frontal lobe
- parietal lobe
- central sulcus
- precentral gyrus
- postcentral gyrus
- lateral fissure
- temporal lobe
- pons
- medulla oblongata
- occipital lobe
- transverse fissure
- cerebellum

#### Figure 24.8 Inferior View of the Brain

- frontal lobe
- infundibulum
- mammillary bodies
- temporal lobe
- pons
- occipital lobe
- olfactory bulb
- olfactory tract
- optic chiasm
- optic nerve
- optic tract
- midbrain
- cerebellum
- medulla oblongata
- spinal cord

#### Figure 24.9 Midsagittal View of the Brain

- frontal lobe
- cingulate gyrus
- corpus callosum
- septum pellucidum
- interthalamic adhesion
- thalamus
- hypothalamus
- tegmentum
- mesencephalon
- cerebral peduncle
- temporal lobe
- pons
- medulla oblongata
- central sulcus
- parietal lobe
- thalamus

- parieto-occipital sulcus
- occipital lobe
- pineal body (gland)
- tectal plate (corpora quadrigemina)
- mammillary body
- cerebral aqueduct
- fourth ventricle
- cerebellum

### Chapter Activities

#### Exercise 24.8, #4

Point of Exit	Cranial Nerve
Midbrain	III, IV
Pons	V, VI, VII, part of VIII
Medulla oblongata	part of VIII, IX, X, XI, XII

## Chapter 25

### What Do You Think?

- If a posterior root was severed there would be a **loss of sensation** from the area of the body served by the spinal nerve that posterior root contributed to. There would be no loss of motor function because all motor nerves run in the anterior root.
- Because the phrenic nerve arises from the cervical plexus instead of arising from of the thoracic region of the spinal cord, **the innervation to the diaphragm will remain intact in the event of a spinal cord injury below C5**. This is hugely advantageous because while injuries to the lower cervical or upper thoracic region of the spinal cord will cause paralysis of upper limb muscles (not life-threatening), they will not cause an individual to stop breathing, which would be life-threatening.

### Chapter Activities

#### Figure 25.2 Regional Gross Anatomy of the Spinal Cord

- cervical plexus
- posterior rootlets
- brachial plexus
- lumbosacral enlargement
- L1 vertebra
- conus medullaris
- lumbar plexus
- sacral plexus
- filum terminal
- cauda equina
- brain (cerebellum)
- posterior rootlets
- posterior median sulcus
- posterior roots
- anterior roots
- posterior median sulcus
- pia mater
- denticulate ligament
- dura mater
- conus medullaris
- dura mater
- cauda equina
- filum terminale
- posterior root ganglion

#### Figure 25.3 Model of a Spinal Cord in Cross Section

- posterior funiculus
- posterior horn
- lateral horn
- posterior rootlets
- posterior root ganglion
- spinal nerve
- anterior root
- anterior horn
- posterior median sulcus
- anterior rootlets
- anterior median fissure

#### Figure 25.5 The Phrenic Nerves in the Thoracic Cavity

- right phrenic nerve
- diaphragm
- left phrenic nerve

#### Figure 25.7 Major Nerves of the Brachial Plexus

- lateral cord
- posterior cord
- musculocutaneous nerve
- axillary nerve
- medial cord
- radial nerve
- median nerve
- ulnar nerve
- long thoracic nerve
- superior trunk
- middle trunk
- inferior trunk
- axillary artery

#### Figure 25.8 Right Pelvic Region, Anterior View

- obturator nerve
- femoral nerve

#### Figure 25.9 Nerves of the Sacral Plexus Within the Gluteal and Popliteal Regions

- inferior gluteal nerve
- posterior femoral cutaneous nerve
- puddendal nerve
- superior gluteal nerve
- sciatic nerve
- tibial nerve
- common fibular nerve

## Chapter 26

### Chapter Activities

---

#### Figure 26.2 Overview of the Parasympathetic Division of the ANS

1. oculomotor nerve (CN III)
2. facial nerve (CN VII)
3. glossopharyngeal nerve (CN IX)
4. vagus nerve (CN X)
5. cardiac plexus
6. abdominal aortic plexus
7. pelvic splanchnic nerves

#### Figure 26.3 Overview of the Sympathetic Division of the ANS

1. sympathetic trunk ganglia (paravertebral)
2. adrenal medulla
3. prevertebral ganglia
4. sympathetic ganglia