

Henryk Dancygier

Clinical Hepatology

Principles and Practice of
Hepatobiliary Diseases
Volume 1

Foreword by
Scott L. Friedman

 Springer

Clinical Hepatology

Henryk Dancygier

Clinical Hepatology

Principles and Practice
of Hepatobiliary Diseases

Volume 1

With Contributions by

H.-D. Allescher · U. Beuers · H. Blum · R. S. Brown, Jr · E. Cay · H. Dancygier
S. Dasarathy · C. F. Dietrich · M. Doss · A. Dragan · S. M. Erturk · S. A. Fink
L. S. Friedman · G. Gerken · D. Häussinger · P. Hilgard · M. A. Kern · A. Koch
J. H. Lefkowitz · U. Leuschner · T. Longerich · A. J. McCullough · U. Merle
J. Mössner · S. Mueller · A. Niedenthal · C. Niederau · B. Riemann · J. N. Rogart
P. Ros · C. Sarrazin · P. Schirmacher · O. Schober · H. K. Seitz · S. H. Sigal
F. Stenschke · U. Stölzel · C. P. Strassburg · W. Stremmel · S. Susser · C. Trautwein
M. Tröltzsch · I. S. Weisberg · M. Wiedman · C. Wittekind · H. Witzigmann
P. S. Yachimski · S. Zeuzem

Foreword by Scott L. Friedman

 Springer

Henryk Dancygier, MD
Professor of Medicine
Chair, Department of Medicine II
Klinikum Offenbach, Goethe University Frankfurt/Main
Starkenburgring 66
63069 Offenbach, Germany
email: hdancygier@klinikum-offenbach.de

Adjunct Professor of Medicine
Department of Medicine, Division of Liver Diseases
Mount Sinai School of Medicine
New York, NY, USA
email: henryk.dancygier@mssm.edu

ISBN: 978-3-540-93841-5 e-ISBN: 978-3-540-93842-2

DOI: 10.1007/978-3-540-93842-2

Springer Heidelberg Dordrecht London New York

Library of Congress Control Number: 2009929701

© Springer-Verlag Berlin Heidelberg 2010

This work is subject to copyright. All rights are reserved, whether the whole or part of the material is concerned, specifically the rights of translation, reprinting, reuse of illustrations, recitation, broadcasting, reproduction on microfilm or in any other way, and storage in data banks. Duplication of this publication or parts thereof is permitted only under the provisions of the German Copyright Law of September 9, 1965, in its current version, and permission for use must always be obtained from Springer. Violations are liable to prosecution under the German Copyright Law.

The use of general descriptive names, registered names, trademarks, etc. in this publication does not imply, even in the absence of a specific statement, that such names are exempt from the relevant protective laws and regulations and therefore free for general use.

Product liability: The publishers cannot guarantee the accuracy of any information about dosage and application contained in this book. In every individual case the user must check such information by consulting the relevant literature.

Cover design: eStudioCalamar, Figueres/Berlin

Printed on acid-free paper

Springer is part & Springer Science + Business Media (www.springer.com)

Dedication

Dedicated to Dr. Herbert Falk (1924–2008).

A humanist of great generosity, supporter of scientific advancement and the always visible, but never dominant magnanimous patron of global medical education.

Foreword

Modern hepatology would be unrecognizable to those clinicians and pathologists, who founded the field only a generation ago. From a discipline that was largely observational – with few diagnostic tests and even fewer therapies – has emerged an exciting area that is among the most rapidly changing in all of medicine, and which now offers remarkable new tools and treatments. This textbook edited by Professor Dancygier beautifully captures this dynamism of hepatology, and in doing so provides a remarkably complete opus. The work is beautifully laid out exactly as a clinician would think, weaving in the science underlying clinical hepatology with precision and clarity. Standardized and gorgeous drawings, comprehensive tables, and a very consistent style are among its most valuable assets – quite simply, this book is fun to read!

While thoroughly modern, this work still proudly draws upon the roots of our specialty. A strong emphasis on pathology, patterns of injury, clinical presentations of disease, and approaches to clinical problems harken back to hepatology's earliest treatises. The book is particularly reminiscent of early editions of Dame Sheila Sherlock's classic single-author textbook, the fifth edition of which I read cover-to-cover while spending 3 months at the Royal Free Hospital as a medical student in 1977; a signed copy sits proudly on my shelf to this day, and I suspect that many will come to value Professor Dancygier's book for many of its similar virtues. The highly personal stamp of Professor Dancygier infuses this book with cohesion, and conveys the wonders of clinical hepatology. Underscoring another enduring feature of our specialty is the book's transatlantic flavor, with authors from throughout Germany and the USA. This connection between our two countries is also personal – Professor Dancygier's invitation for me to speak at a conference in Munich in 1989 was my first international meeting, and I am proud that our professional association and friendship continue to this day as a result of that first meeting 20 years ago.

I am delighted to be associated with *Clinical Hepatology*. Thus, it is a great personal privilege to introduce this unique and valuable textbook, which is sure to appeal to practitioners of today and ignite a spark of enthusiasm among the hepatologists of tomorrow.

Scott L. Friedman, M.D.
President, American Association for the Study of Liver Diseases
Fishberg Professor and Chief, Division of Liver Diseases
The Mount Sinai School of Medicine

Preface

Clinical hepatology is thriving. Hepatology has evolved from a pure diagnostic art to a science in which new treatment options are emerging at a quick pace. At this exciting time, based on the gratifying success of the German Edition of 2003, Springer Publishers have asked me to prepare a US-American/International edition. Gravely miscalculating the amount of labor, I gladly accepted this challenge.

The present book is not merely an updated version of the German edition but a completely new work with new US-American authors, a transatlantic endeavor. In common with its German predecessor, however, it not only aims to provide knowledge in hepatology but also to promote an understanding of liver diseases, and to create joy in dealing with clinical hepatological problems. It is intended for everybody caring for adult patients with hepatobiliary problems, particularly gastroenterologists/hepatologists, internists and clinical pathologists.

My aim was not to provide an encyclopedic behemoth. Instead, I intended to create a comprehensive, up-to-date (references until early 2009 are included), practical and readable book that outlines the current standards of diagnosis and treatment in hepatology and its associated biliary disorders. By elaborating on concepts in hepatology, disease mechanisms, common clinical problems and rare diseases alike it tries to serve the needs not only of the novice in hepatology, but also of the experienced practicing clinician. Ultimately, the success of the book will be determined by its ability to provide answers to clinically relevant questions and to guide clinical decisions.

The competent clinical hepatologist, like hardly any other clinician, has to integrate histopathological, biochemical, immunological, instrumental and clinical skills. The organization of the text follows this principle. It is divided into 3 main parts with 30 sections covering Basic Principles, Clinical Methods, and Hepatobiliary Diseases. Starting from basic concepts the field of clinical hepatology gradually unfolds. Unlike other Hepatology Textbooks I preferred not to include a “stand alone” chapter on liver pathology. Instead hepatopathology has been integrated throughout the entire text as it represents an integral part of clinical hepatology. The first five sections integrate structure and function of the liver and basically provide a general pathology of the liver. The clinical chapters are stringently organized and uniformly structured to enable rapid retrieval of the desired information. In order to enhance readability I have accepted some redundancy, especially in chapters dealing with hepatocellular transporters.

I am indebted to my coauthors, all renowned experts in hepatology. Without their help the creation of a textbook of this volume would not have been possible. My

special thanks go to a young gastroenterologist from Yale, Jason Rogart. He not only served as a proof reader for the contributions by authors whose native language is not English, but also as an author of several chapters and as an editorial assistant. My thanks go also to Ms. Annette Hinze, Meike Stoeck, and Mr. Claus-Dieter Bachem from Springer Publishers who skillfully supported the development of the Textbook. Last but not least I thank my wife Hellena for her endurance and unwavering support. After immersing into the project and resurfacing after finishing the last chapter she was still there.

Offenbach, May 2009

Henryk Dancygier

Volume 1

A. Basic Principles

Part I Structure and Function of the Liver

Part II Pathophysiology and Morphology of Liver Injury

B. Clinical Methods

Part III Evaluation of the Patient with Hepatobiliary Disease

Volume 2

C. Hepatobiliary Diseases

Part IV Diseases of the Liver

Part V Diseases of the Gallbladder and Extrahepatic Bile Ducts

Contents of Volume 1

A. Basic Principles

Part I Structure and Function of the Liver	3
Section I Embryology, Anatomy, and Histology	5
1 Embryonic Development	7
Henryk Dancygier	
2 Gross Anatomy	11
Henryk Dancygier	
3 Microscopic Anatomy	15
Henryk Dancygier	
Section II Fundamentals of Hepatic Physiology and Biochemistry	53
4 Hepatic Circulation	55
Henryk Dancygier	
5 Hepatocellular Transport	61
Henryk Dancygier	
6 Hepatic Metabolism	75
Henryk Dancygier, Uta Merle, Wolfgang Stremmel, and Claus Niederau	
7 Formation and Secretion of Bile and Bilirubin Metabolism	103
Ulrich Leuschner	
8 Hepatic Biotransformation	127
Henryk Dancygier	
9 Functional Heterogeneity and Metabolic Zonation	131
Henryk Dancygier	
10 Liver Cell Hydration and Cell Function	137
Dieter Häussinger	
11 The Liver as an Immune Organ	141
Henryk Dancygier	

12	Aging and the Liver	153
	Henryk Dancygier	
13	Hepatic Regeneration	157
	Henryk Dancygier	
Part II Pathophysiology and Morphology of Liver Injury		169
Section III Causes and Mechanisms of Liver Injury		171
14	Free Radicals, Reactive Oxygen Species, Oxidative and Endoplasmic Reticulum Stress	173
	Henryk Dancygier and Peter Schirmacher	
15	Hypoxic Liver Injury	181
	Henryk Dancygier and Peter Schirmacher	
16	Reperfusion Injury	185
	Henryk Dancygier and Peter Schirmacher	
17	Drug-Induced and Toxic Liver Injury	189
	Henryk Dancygier and Peter Schirmacher	
18	Immune Mediated Liver Injury	191
	Henryk Dancygier and Peter Schirmacher	
19	Endotoxin Mediated Liver Injury	197
	Henryk Dancygier and Peter Schirmacher	
20	Cholestasis-Induced Liver Injury	199
	Henryk Dancygier and Peter Schirmacher	
21	Metal-Induced Liver Injury	201
	Henryk Dancygier and Peter Schirmacher	
22	Radiation-Induced Liver Damage	203
	Henryk Dancygier and Peter Schirmacher	
Section IV Morphologic Patterns of Liver Injury		205
23	Liver Cell Degeneration and Cell Death	207
	Henryk Dancygier and Peter Schirmacher	
24	Cellular Adaptation, Intracellular Inclusions and Deposits	219
	Henryk Dancygier and Peter Schirmacher	
25	Necroinflammatory Reaction	235
	Henryk Dancygier and Peter Schirmacher	
26	Cholestatic Reaction	241
	Henryk Dancygier and Peter Schirmacher	
27	Granulomatous Reaction	247
	Henryk Dancygier and Peter Schirmacher	
28	Fibrogenic Reaction	251
	Henryk Dancygier and Peter Schirmacher	

Section V Scoring Systems in Hepatology	269
29 Histopathological Scoring Systems	271
Thomas Longerich and Peter Schirmacher	
30 Clinical Scoring Systems	289
Henryk Dancygier	

B. Clinical Methods

Part III Evaluation of the Patient with Hepatobiliary Disease	297
Section VI History and Physical Examination	299
31 History	301
Henryk Dancygier and Jason N. Rogart	
32 Symptoms	305
Henryk Dancygier and Jason N. Rogart	
33 Physical Examination	309
Henryk Dancygier and Jason N. Rogart	
Section VII Laboratory Testing	317
34 Basic Laboratory Parameters	319
Henryk Dancygier	
35 Tests of Liver Function	333
Henryk Dancygier	
36 Autoantibodies	345
Henryk Dancygier	
Section VIII Hepatobiliary Imaging and Manometric Studies	357
37 Ultrasonography	359
Christoph F. Dietrich	
38 Computed Tomography and Magnetic Resonance Imaging	405
Sukru M. Erturk, Esra Cay, and Pablo R. Ros	
39 Nuclear Imaging	425
Burkhard Riemann and Otmar Schober	
40 Endoscopic Retrograde and Percutaneous Transhepatic Cholangiography	437
Frank Stenschke, Henryk Dancygier, and Jason N. Rogart	
41 Cholangioscopy	449
Jason N. Rogart and Frank Stenschke	

42	Endoscopic Ultrasonography	455
	Andreas Niedenthal, Henryk Dancygier, and Jason N. Rogart	
43	Percutaneous Liver Biopsy	463
	Christian P. Strassburg	
44	Transvenous Liver Biopsy	473
	Ilan S. Weisberg, Samuel H. Sigal, and Robert S. Brown, Jr.	
45	Laparoscopy	485
	Philip Hilgard and Guido Gerken	
46	Measurement of Portal Pressure	511
	Henryk Dancygier	
47	Sphincter of Oddi Manometry	519
	Hans-Dieter Allescher	
	Section IX Approaches to Common Hepatobiliary Problems	525
48	Approach to the Patient with Upper Abdominal Pain	527
	Henryk Dancygier and Jason N. Rogart	
49	Approach to the Patient with Abnormal Liver Enzymes	533
	Henryk Dancygier and Jason N. Rogart	
50	Approach to the Patient with Hepatomegaly	549
	Henryk Dancygier and Jason N. Rogart	
51	Approach to the Patient with Focal Liver Lesions	553
	Henryk Dancygier and Jason N. Rogart	
52	Approach to the Patient with Cholestasis and Jaundice	559
	Henryk Dancygier and Jason N. Rogart	
53	Approach to the Patient with Portal Hypertension	593
	Henryk Dancygier and Jason N. Rogart	
54	Approach to the Patient with Ascites	603
	Henryk Dancygier and Jason N. Rogart	
	Subject Index	S1

Contents of Volume 2

C. Hepatobiliary Diseases

Part IV Diseases of the Liver	617
Section X Developmental Anomalies	619
55 Malformations and Malpositions of the Liver	621
Henryk Dancygier	
56 Bile Duct Anomalies	625
Henryk Dancygier	
57 Liver Cysts and Polycystic Liver Disease	631
Henryk Dancygier	
58 Vascular Anomalies	637
Henryk Dancygier	
Section XI Circulatory and Vascular Disorders	639
59 Hepatic Veins	641
Henryk Dancygier	
60 Sinusoids	649
Henryk Dancygier	
61 Portal Vein	657
Henryk Dancygier	
62 Hepatic Arteries	663
Henryk Dancygier	

Section XII Infectious Liver Diseases	669
63 Viral Infections by Hepatotropic Viruses	671
Simone Susser, Anette Dragan, Stefan Zeuzem, Christoph Sarrazin, Jay H. Lefkowitz, Henryk Dancygier	
64 Viral Infections by Nonhepatotropic Viruses	823
Henryk Dancygier	
65 Bacterial Liver Abscess and Other Bacterial Infections	831
Henryk Dancygier	
66 Amebic Liver Abscess and Other Protozoal Diseases	843
Henryk Dancygier	
67 Helminthic Infections	849
Henryk Dancygier	
68 Fungal Infections	859
Henryk Dancygier	
Section XIII Hepatobiliary Diseases in HIV-Infected Patients	863
69 Infections	865
Henryk Dancygier	
70 Neoplastic Diseases	873
Henryk Dancygier	
71 Drug-Induced Liver Injury	875
Henryk Dancygier	
Section XIV Autoimmune Liver Diseases	879
72 Autoimmune Hepatitis	881
Henryk Dancygier	
73 Primary Biliary Cirrhosis	895
Henryk Dancygier	
74 Autoimmune Cholangitis	909
Henryk Dancygier	
75 Primary Sclerosing Cholangitis	911
Henryk Dancygier	
76 Biliary Ductopenia (Vanishing Bile Duct Syndrome)	921
Henryk Dancygier	
77 Autoimmune Overlap Syndromes	925
Henryk Dancygier	
Section XV Acute Liver Failure	929
78 Acute Liver Failure	931
Alexander Koch and Christian Trautwein	

Section XVI Liver Cirrhosis and Sequelae	947
79 Liver Cirrhosis	949
Henryk Dancygier	
80 Complications of Liver Cirrhosis	967
Henryk Dancygier	
Section XVII Genetic and Metabolic Liver Disorders	1033
81 Wilson's Disease	1035
Uta Merle and Wolfgang Stremmel	
82 Hereditary Hemochromatosis and Iron Overload	1045
Claus Niederau	
83 α_1-Antitrypsin Deficiency	1071
Henryk Dancygier	
84 Porphyrias	1077
Ulrich Stölzel and Manfred O. Doss	
85 Inherited Syndromes of Intrahepatic Cholestasis	1093
Henryk Dancygier	
86 Cystic Fibrosis	1101
Henryk Dancygier	
87 Amyloidosis	1105
Henryk Dancygier	
88 Alcoholic Liver Disease	1111
Helmut Karl Seitz and Sebastian Mueller	
89 Nonalcoholic Fatty Liver Disease	1153
Henryk Dancygier	
90 Other Metabolic Diseases: Tabellary Overview	1181
Henryk Dancygier	
91 Malnutrition and Nutrition in Liver Disease	1187
Srinivasan Dasarathy and Arthur J. McCullough	
Section XVIII Drug-Induced and Toxic Liver Disease	1209
92 Hepatic Drug Metabolism and Drug Toxicity	1211
Henryk Dancygier and Christian P. Strassburg	
93 Drug- and Toxin-Induced Liver Injury	1223
Henryk Dancygier	

Section XIX Granulomatous Liver Disease	1233
94 Hepatic Granulomas	1235
Henryk Dancygier	
95 Sarcoidosis of the Liver	1239
Henryk Dancygier	
Section XX Interaction Between the Liver and Other Organ Systems ...	1243
96 Effects of Chronic Liver Disease on Other Organs: Tabellary Overview	1245
Henryk Dancygier	
97 Hepatic Involvement in Extrahepatic Disease: Tabellary Overview	1247
Henryk Dancygier	
Section XXI Pregnancy-Specific Liver Diseases	1255
98 Intrahepatic Cholestasis of Pregnancy	1257
Henryk Dancygier	
99 Acute Fatty Liver of Pregnancy	1263
Henryk Dancygier	
100 The Liver in Toxemia of Pregnancy	1267
Henryk Dancygier	
Section XXII Primary Tumors of the Liver and Intrahepatic Bile Ducts	1271
101 Benign Tumors	1273
Henryk Dancygier	
102 Malignant Tumors	1305
Henryk Dancygier	
Section XXIII Liver Transplantation and Surgery in Liver Disease	1351
103 Liver Transplantation: Indications, Preoperative Evaluation and Posttransplantation Management	1353
Scott A. Fink and Robert S. Brown, Jr.	
104 Risk of Surgery in Patients with Liver Disease	1383
Patrick S. Yachimski and Lawrence S. Friedman	
Section XXIV Gene Therapy	1401
105 A Look to the Future: Gene Therapy in Liver Diseases	1403
Hubert E. Blum	

Part V Diseases of the Gallbladder and Extrahepatic Bile Ducts	1413
Section XXV Anatomy, Histology and Physiology	1415
106 Gross and Microscopic Anatomy	1417
Ulrich Beuers and Henryk Dancygier	
107 Physiology of the Gallbladder and the Extrahepatic Bile Ducts	1423
Ulrich Beuers	
Section XXVI Developmental Anomalies	1427
108 Anomalies of the Gallbladder and the Cystic Duct	1429
Michael A. Kern and Peter Schirmacher	
109 Anomalies of the Extrahepatic Bile Ducts	1433
Michael A. Kern and Peter Schirmacher	
110 Benign Strictures of the Extrahepatic Bile Ducts	1437
Michael A. Kern and Peter Schirmacher	
Section XXVII Motility Disorders	1439
111 Motility Disorders of the Bile Ducts and Postcholecystectomy Syndrome	1441
Hans-Dieter Allescher	
Section XXVIII Gallstones	1457
112 Gallbladder Stones	1459
Ulrich Leuschner	
113 Bile Duct Stones	1481
Ulrich Leuschner and Jason N. Rogart	
Section XXIX Infectious Disorders	1491
114 Biliary Infections	1493
Ulrich Beuers	
Section XXX Tumors of the Gallbladder and Extrahepatic Bile Ducts	1503
115 Benign Tumors	1505
Marcus Wiedmann, Christian Wittekind, Michael Tröltzsch, and Joachim Mössner	
116 Malignant Tumors	1519
Marcus Wiedmann, Helmut Witzigmann, and Joachim Mössner	
Subject Index	1567

Contributors

Numbers in brackets refer to the chapters written or co-written by the contributor.

Hans-Dieter Allescher, MD

Professor of Medicine, Zentrum Innere Medizin,
Klinikum Garmisch-Partenkirchen, Ludwig-Maximilians Universität München,
Auenstr. 6, 82467 Garmisch-Partenkirchen,
Germany
[47, 111]

Ulrich Beuers, MD

Professor of Gastroenterology and Hepatology,
Department of Gastroenterology and Hepatology, G4-213,
Academic Medical Center, University of Amsterdam,
P.O. Box 22700, 1100 DE Amsterdam,
The Netherlands
[106, 107, 114]

Hubert E. Blum, MD

University Professor of Medicine, Department of Medicine II,
University Hospital, Hugstetter Strasse 55, 79106 Freiburg,
Germany
[105]

Robert S. Brown, Jr, MD

Associate Professor of Medicine, Presbyterian Hospital 14,
Room 202, Division of Digestive and Liver Diseases,
Columbia University, 622 West 168th St,
New York, NY 10032,
USA
[44, 103]

Esra Cay, MD

Department of Radiology, Sisli Etfal Training and Research Hospital,
Etfal Sokak, Istanbul,
Turkey
[38]

Henryk Dancygier, MD

Professor of Medicine, Department of Medicine II, Klinikum Offenbach,
Goethe University Frankfurt, Starkenburgring 66, 63069 Offenbach,
Germany
[1-6, 8, 9, 11-28, 30-36, 40, 42, 46, 48-62, 63.3, 64-77, 79, 80,
83, 85-87, 89, 90, 92-102, 106]

Srinivasan Dasarathy, MD

Cleveland Clinic, Department of Gastroenterology,
Mail Code NC22, 9500 Euclid Avenue, Cleveland, OH 44195,
USA
[91]

Christoph F. Dietrich, MD

Professor of Medicine, Caritas-Krankenhaus,
Department of Medicine 2, Uhlandstr. 7, 97980 Bad Mergentheim,
Germany
[37]

Manfred O. Doss, MD

Professor of Medicine, Consultation Porphyria,
Gabelsberger Str. 2535037 Marburg,
Germany
[84]

Anette Dragan

Certified Biologist, Department of Medicine 1,
University Hospital, Goethe University Frankfurt,
Theodor Stern Kai 7, 60596 Frankfurt am Main,
Germany
[63.1]

Sukru M. Erturk, MD

Department of Radiology,
Sisli Etfal Training and Research Hospital Etfal Sokak, Istanbul,
Turkey
[38]

Scott A. Fink, MD

Assistant Professor of Clinical Medicine Presbyterian Hospital 14,
Division of Digestive and Liver Diseases, Columbia University 622, West 168th Street,
New York, NY 11032,
USA
[103]

Lawrence S. Friedman, MD

Professor of Medicine, Harvard Medical School and Tufts University School of Medicine,
Department of Medicine, Newton-Wellesley Hospital,
Department of Medicine, Massachusetts General Hospital,
Boston, MA, 2014 Washington Street, Newton, MA 02462,
USA
[104]

Guido Gerken, MD

University Professor of Medicine,
Universitätsklinik Essen, Klinik für Gastroenterologie und Hepatologie,
Zentrum für Innere Medizin, Hufelandstr. 55, 45122 Essen,
Germany
[45]

Dieter Häussinger, MD

University Professor of Medicine,
Department of Gastroenterology and Infectious Diseases,
Heinrich Heine University, Moorenstrasse 5, 40225 Düsseldorf,
Germany
[10]

Philip Hilgard, MD

Professor of Medicine, Universitätsklinik Essen, Klinik für Gastroenterologie und Hepatologie,
Zentrum für Innere Medizin, Hufelandstr. 55, 45122 Essen,
Germany
[45]

Michael A. Kern, MD

Institute of Pathology, University of Heidelberg, Im Neuenheimer Feld 220,
69120 Heidelberg,
Germany
[108–110]

Alexander Koch, MD

University Hospital Aachen, Aachen University (RWTH),
Department of Internal Medicine III, Pauwelsstrasse 30,
52074 Aachen,
Germany
[78]

Jay H. Lefkowitz, MD

Professor of Clinical Pathology,
Presbyterian Hospital 15W-1574, Department of Pathology,
Columbia University, 630 West 168th Street,
New York, NY 10032,
USA
[63.2]

Ulrich Leuschner, MD

Professor of Medicine, Center of Internal Medicine University Hospital,
Goethe University Frankfurt, Theodor Stern Kai 7, 60596 Frankfurt am Main,
Germany
[7, 112, 113]

Thomas Longerich, MD

Institute of Pathology, University of Heidelberg, Im Neuenheimer Feld 220,
69120 Heidelberg,
Germany
[29]

Arthur J. McCullough, MD

Professor of Medicine, Department of Medicine, Cleveland Clinic,
MetroHealth Medical Center, 9500 Euclid Avenue Cleveland, OH 44195,
USA
[91]

Uta Merle, MD

University Hospital Heidelberg, Department of Gastroenterology and Hepatology,
Im Neuenheimer Feld 410, 69120 Heidelberg,
Germany
[6, 81]

Joachim Mössner, MD

University Professor of Medicine,
Department of Medicine. Gastroenterology and Hepatology,
University of Leipzig, Philipp-Rosenthal-Str. 27, 04103 Leipzig,
Germany
[115, 116]

Sebastian Mueller, MD

Center of Alcohol Research, Liver Disease and Nutrition, University of Heidelberg,
and Department of Medicine, Salem Medical Center, Zeppelinstr. 11–33,
69121 Heidelberg,
Germany
[88]

Andreas Niedenthal, MD

Department of Medicine II, Klinikum Offenbach,
Goethe University Frankfurt, Starkenburgring 66, 63069 Offenbach,
Germany
[42]

Claus Niederau, MD

Professor of Medicine, Katholische Kliniken Oberhausen gGmbH,
St. Josef-Hospital, Department of Internal Medicine,
University Duisburg-Essen, Mülheimer Str. 83, 46045 Oberhausen,
Germany
[6, 82]

Burkhard Riemann, MD

Professor of Radiology,
Department of Nuclear Medicine, Westfälische Wilhelms-Universität,
Albert-Schweitzer-Strasse 33, 48149 Münster,
Germany
[39]

Jason N. Rogart, MD

Assistant Professor of Medicine, Division of Gastroenterology and Hepatology,
Department of Internal Medicine, UMDNJ-Robert Wood Johnson Medical School,
One Robert Wood Johnson Place-MEB 478, New Brunswick, NY 08903,
USA
[31–33, 40–42, 48–54, 113]

Pablo R. Ros, MD

Professor of Radiology, Brigham and Women's Hospital Department of Radiology,
Harvard Medical School, 75 Francis Street, Boston, MA 02115,
USA
[38]

Christoph Sarrazin, MD

Professor of Medicine, Department of Medicine 1, University Hospital,
Goethe University Frankfurt, Theodor Stern Kai 7,
60596 Frankfurt am Main,
Germany
[63.1]

Peter Schirmacher, MD

University Professor of Pathology, Institute of Pathology, University of Heidelberg,
Im Neuenheimer Feld 220, 69120 Heidelberg,
Germany
[14–29, 108–110]

Otmar Schober, MD

University Professor of Radiology,
Department of Nuclear Medicine, Westfälische Wilhelms-Universität,
Albert-Schweitzer-Strasse 33, 48149 Münster,
Germany
[39]

Helmut K. Seitz, MD

Professor of Medicine, Gastroenterology and Alcohol Research,
Center of Alcohol Research, Liver Disease and Nutrition,
University of Heidelberg, and Department of Medicine,
Salem Medical Center, Zeppelinstr. 11–33, 69121 Heidelberg,
Germany
[88]

Samuel H. Sigal, MD

Division of Gastroenterology and Hepatology,
New York Weill Cornell Medical Center, New York, NY,
USA
[44]

Frank Stenschke, MD

Department of Medicine II, Klinikum Offenbach,
Goethe University Frankfurt, Starkenburgring 66,
63069 Offenbach,
Germany
[40, 41]

Ulrich Stölzel, MD

Professor of Medicine, Department of Internal Medicine II,
Porphyria Center Saxony, Klinikum Chemnitz gGmbH,
Krankenhaus Flemmingstrasse, Flemmingstrasse 2,
09116 Chemnitz,
Germany
[84]

Christian P. Strassburg, MD

Professor of Medicine, Department of Gastroenterology,
Hepatology and Endocrinology, University Hannover Medical School,
Carl-Neuberg-Str. 1, 30625 Hannover,
Germany
[43, 92]

Wolfgang Stremmel, MD

University Professor of Medicine,
University Hospital Heidelberg, Department of Gastroenterology and Hepatology,
Im Neuenheimer Feld 410, 69120 Heidelberg,
Germany
[6, 81]

Simone Susser, PhD

Certified Biologist, Department of Medicine 1 University Hospital,
Goethe University Frankfurt, Theodor Stern Kai 7, 60590 Frankfurt am Main,
Germany
[63.1]

Christian Trautwein, MD

University Professor of Medicine,
University Hospital Aachen, Aachen University (RWTH),
Department of Internal Medicine III,
Pauwelsstrasse 3052074 Aachen,
Germany
[78]

Michael Tröltzsch, MD

Department of Internal Medicine II,
University of Leipzig, Philipp-Rosenthal-Str. 27,
04103 Leipzig,
Germany
[115]

Ilan S. Weisberg, MD

Division of Gastroenterology and Hepatology,
New York Weill Cornell Medical Center,
New York, NY,
USA
[44]

Marcus Wiedmann, MD

Assistant Professor of Medicine,
Department of Medicine I, St. Marien-Krankenhaus,
Gallwitzallee 123–143, 12249 Berlin,
Germany
[115, 116]

Christian Wittekind, MD

University Professor of Pathology, Institute of Pathology,
University of Leipzig, Liebig-Str. 26, 04103 Leipzig,
Germany
[115]

Helmut Witzigmann, MD

Professor of Surgery, Department of Surgery, Hospital Dresden-Friedrichsstadt,
Friedrichstr. 41, 01067 Dresden,
Germany
[116]

Patrick S. Yachinski, MD, MPH

Harvard Medical School, Gastrointestinal Unit,
Massachusetts General Hospital and Division of Gastroenterology,
Brigham and Women's Hospital, Boston, MA
USA
[104]

Stefan Zeuzem, MD

University Professor of Medicine, Department of Medicine 1,
University Hospital, Goethe University Frankfurt, Theodor Stern Kai 7,
60590 Frankfurt am Main,
Germany
[63.1]

Chapter Outline

General Development	7
Molecular Control of Liver Development.....	9
References	10

General Development

The embryonic development of the liver starts by a process termed *liver specification* in which lateral plate mesoderm factors induce adjacent endoderm to initiate hepatic development. The anatomical result of this process is seen by the 3rd week of gestation – the embryo attains a size of 2–2.5 mm by an outgrowth of endodermal cells from the ventral wall of the foregut, and forms the *liver bud*. The liver bud and surrounding structures further differentiate to create the *hepatic diverticulum* [2, 3, 10, 11]. Already at this very early stage α -fetoprotein and albumin messenger RNA is expressed, indicating the commitment of this part of the ventral foregut to the lineage of liver cells, termed *hepatoblasts*. The hepatoblast, which derives from the definitive endoderm, is the common precursor from which hepatocytes and bile duct cells originate (Fig. 1.1). The early hepatic anlage is composed of two

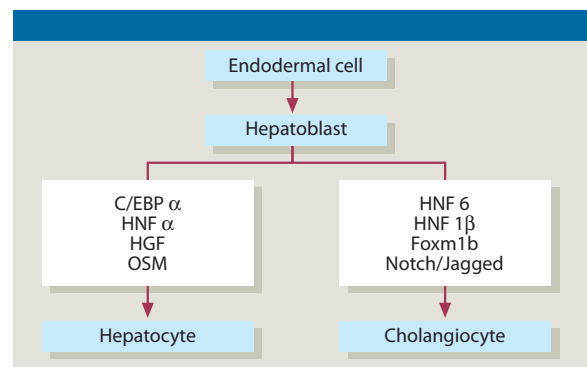


Fig. 1.1 Cell lineages in the developing liver and molecules that participate in determining the fate of the hepatoblast (Modified from [2, 14])

C/EBP α =CCAAT/enhancer binding protein; HNF=hepatocyte nuclear factor; HGF=hepatocyte growth factor; OSM=oncostatin M; Fox=transcription factor

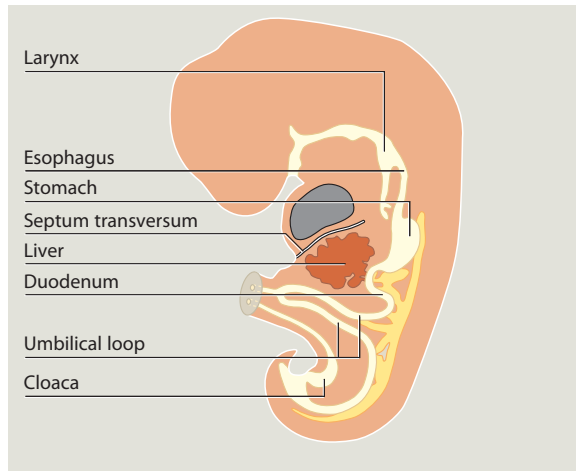


Fig. 1.2 Human embryo 5 mm in size. The liver cell cords penetrate into the septum transversum (Modified from [10])

neighbouring diverticular areas (Fig. 1.2). The cranial part of the hepatic diverticulum gives rise to the liver and the intrahepatic bile ducts, while the gallbladder, the cystic duct and main common bile duct arise from the caudad portion. At an embryonic size of 3.5 mm, the basement membrane surrounding the liver bud and hepatic diverticulum is lost, and cells delaminate and invade the surrounding *septum transversum* mesenchyme as cords of hepatoblasts. The cells undergoing this phase of hepatic development express a number of proteins, including transcription factor HNF4 α which identifies migrating hepatic cells, and three zinc finger factors, Gata 4–6, which identify the septum transversum mesenchyme [14]. In the septum transversum the invading hepatoblasts form sheets and cords along the sinusoidal vascular channels derived from the vitelline veins emanating from the yolk sac. The vitelline (or omphalomesenteric) veins fuse to form the portal vein. Its tributaries ramify within the liver along mesenchymal channels termed portal tracts. The development of the hepatic vasculature occurs by a combination of angiogenesis and vasculogenesis [14]. Angioblasts or endothelial cells surround the liver bud and separate it from the septum transversum. Sinusoids develop through vasculogenesis of vessels that originate within the mesenchyme of the septum transversum. Thus, the basic architecture of the liver parenchyma, cell cords and plates alternating with developing hepatic sinusoids is established. The hepatic vasculature develops in concert with the hepatoblasts and the vascular

channels serve as stents for proliferating hepatoblasts. The mesenchymal component contributes a significant part to the morphogenesis of the liver. During this developmental stage the liver cell plates are five to six cells thick. After birth most liver cell plates return to a thickness of two to three cells (*muralium duplex*), and after the age of 5 years the majority of liver cell plates is composed of one cellular layer (*muralium simplex*).

The ingrowth of hepatoblasts into the septum transversum, divides the ventral mesentery into two thin membranes. The *lesser omentum* is situated between the liver and the foregut and the *falciform ligament* extends between the liver and the ventral abdominal wall. The main common bile duct, hepatic artery, and portal vein run at the lower free edge of the lesser omentum. The mesenchymal tissue of the septum transversum forms the stroma, the capsule and the mesothelium of the liver. The mesoderm on the liver surface gives rise to the peritoneal layer that envelops the entire liver (*hepatic capsule*), except for the area of attachment between the liver and the diaphragm (*area nuda*).

By the 6th week of gestation the embryo is 1 cm long and the liver has two lobes. As a result of its rapid growth the organ extends inferiorly into the abdominal cavity.

The embryonic liver is a *hematopoietic organ*. At 8–10 weeks of gestation hepatic hematopoiesis begins, reaches its maximum toward the 6th or 7th month, and ceases completely during the 1st week after birth. Pluripotent hematopoietic stem cells, however, probably persist throughout the entire adult life (see Chapter 3). The hematopoietic cells reside outside the vessels in close contact with parenchymal cells. There also appears to be a close functional relationship between hematopoietic cells and the developing hepatic parenchyma, which is governed by cytokine signaling. Differentiation of the hematopoietic cells is influenced by the hepatocytes, and differentiation of the parenchyma contributes to the attenuation of the fetal liver as a hematopoietic organ.

The presence of *hepatic stellate cells (Ito cells)*, which appear to originate from the septum transversum mesenchymal cells, is noted from week 6 to 8 of gestation. *Kupffer cells* appear from week 8 to 12 of embryonic development and are believed to develop from bone marrow-derived monocytes in adults. However, their presence in the fetal liver precedes bone marrow development, and they may originate from the yolk sac [4].

A minor portion of primitive hepatoblasts commits itself to the *bile duct cell lineage*. Already in the 6th

week of gestation the first bile canaliculi arise between neighbouring parenchymal cells. The *intrahepatic bile duct system* develops in close association with the portal venous system, from hepatoblasts in contact with periportal mesenchyme. This mesenchyme has an important role for the induction of biliary differentiation of hepatoblasts. In the primordial portal tracts the portal vein ramifications are surrounded by a single circumferential layer of biliary epithelial cells, termed the *ductal plate*. Mesenchymal cells interpose between the ductal plate and the remaining parenchymal hepatoblasts, which differentiate into hepatocytes. Starting from ductal plate cells, the formation of the intrahepatic bile duct system is initiated between week 6 and 9 of gestation. Initially the ductal plate begins to reduplicate and lumina form between the two cell layers of the ductal plate. Its final design is accomplished by gradual remodeling into tubular structures incorporated into the mesenchyme to form the *terminal bile ducts* with a circular cross-section. Ductal plate cells in excess are being resorbed. Abutting and within the parenchyma are ductular structures half-lined by hepatocytes and half-lined by biliary epithelial cells, the *canals of Hering*. The remodeling of the ductal plate starts near the hilum of liver, and gradually extends toward the periphery. Hepatocellular bile formation begins around the 12th week. The immature intrahepatic biliary system maintains patency and continuity with the extrahepatic biliary tree, with no evidence of a solid phase of development, allowing for patent bile passage into the duodenum throughout gestation [1]. Maturation of the intrahepatic bile ducts is not fully achieved until the first postnatal weeks. Ductal plate malformations constitute a basic structural component of congenital diseases of the intrahepatic bile ducts. The development of the liver parenchyma and of the intrahepatic bile ducts is accompanied by the expression of characteristic cyokeratin profiles. *Cholangiocytes express cyokeratin types 7, 8, 18 and 19, while hepatocytes express cytokines 8 and 18* [12].

Molecular Control of Liver Development

Liver development is a highly complex process that requires extensive differentiation and organization of parenchymal and nonparenchymal cell types, extracellular

matrix, the development of hepatic vasculature and of the biliary tract. We are only now beginning to understand the pathways required to initiate hepatogenesis and to unravel the factors that regulate the interaction between parenchymal and nonparenchymal cells. There is mounting evidence that nonparenchymal cells have a direct impact on the development of hepatocytes. The mesenchymal component of the liver, which derives from the septum transversum mesenchyme is a critical source of mitogenic activity for hepatoblasts. Differential gene expression, transcription factors and signaling molecules are of prime importance for the induction and continuation of hepatogenesis and the list of the molecules that contribute to the onset of liver development has expanded significantly over the last decade and continues to grow [5–8]. Among the signaling molecules, the presence and the local concentration of fibroblast growth factors (FGF) 1 and 2 are essential for induction of hepatic fate. In addition to acting during the onset of hepatic development, FGFs also function during later stages of hepatogenesis. Specific FGFs act at multiple and distinct stages of hepatic development [5]. In concert with FGFs, signals by bone morphogenetic proteins (members of the transforming growth factor β superfamily) induce hepatic development within the ventral endoderm. β -catenin, a key component of the Wnt signaling pathway seems to be crucial for hepatoblast proliferation and liver growth [8]. T cell immunoglobulin and mucin domain 2 (Tim2) has been shown to regulate immune responses. It is specifically expressed on immature hepatocytes in the fetal liver, and recent evidence suggests that Tim2 is involved in the differentiation of fetal hepatocytes [13].

Many of the genes implicated in endoderm formation, such as FoxA and Gata 4/5/6 also prime the endoderm, making it “competent” to activate hepatic genes [7]. The response of the endoderm to these inductive stimuli is to initiate a program of hepatic gene expression, with specific transcription factors contributing to the onset of hepatic differentiation. α -fetoprotein and albumin genes are expressed early in hepatogenesis. Albumin is one of the earliest liver markers to be expressed in the hepatic endoderm and, furthermore, albumin mRNA expression is restricted to the developing liver. Several transcription factors have been identified that are essential for expression of the complete repertoire of proteins that define hepatocyte function. Hepatic nuclear factor 4 α (HNF4 α) appears to be particularly

potent in controlling hepatocyte differentiation and seems to play a fundamental role in transforming the fetal liver into an epithelial parenchyma during embryogenesis [9]. In addition to controlling hepatocyte differentiation, HNF4 α is also required to maintain a differentiated hepatocyte phenotype and is crucial for establishing normal liver architecture during development.

References

1. Crawford JM (2002) Development of the intrahepatic biliary tree. *Semin Liver Dis* 22: 213–26
2. Desmet VJ, van Eyken P, Roskams T (1999) Embryology of the liver and intrahepatic biliary tract. In: Bircher J, Benhamou JP, McIntyre N, Rizzetto M, Rodes J (eds) *Oxford textbook of clinical hepatology*, 2nd edn. Oxford University Press, Oxford, pp 51–61
3. Du Bois AM (1963) The embryonic liver. In: Rouiller C (ed.) *The liver*, Academic Press, New York, pp 1–39
4. Enzan H, Hara H, Yamashira Y, et al (1983) Fine structure of hepatic sinusoids and their development in human embryos and fetuses. *Acta Pathol Jpn* 33: 447–66
5. Jung J, Zheng M, Goldfarb M, et al (1999) Initiation of mammalian liver development from endoderm by fibroblast growth factors. *Science* 284: 1998–2003
6. Lemaigre F, Zaret KS (2004) Liver development update: new embryo models, cell lineage control, and morphogenesis. *Curr Opin Genet Dev* 14: 582–90
7. McLin VA, Zorn AM (2006) Molecular control of liver development. *Clin Liver Dis* 10: 1–25
8. Ober EA, Verkade H, Field HA, et al (2006) Mesodermal Wnt2b signaling positively regulates liver specification. *Nature* 442: 688–91
9. Parviz F, Matullo C, Garrison WD, et al (2003) Hepatocyte nuclear factor 4 α controls the development of a hepatic epithelium and liver morphogenesis. *Nat Genet* 34: 292–6
10. Sadler TW (1998) *Medizinische Embryologie. Die normale menschliche Entwicklung und ihre Fehlbildungen*. 9. Auflage, Georg Thieme Verlag, Stuttgart/New York
11. Starck D (1975) *Embryologie. Ein Lehrbuch auf allgemein biologischer Grundlage*. 3. Auflage, Georg Thieme Verlag, Stuttgart
12. Van Eyken P, Sciort R, Callea F, et al (1988) The development of the intrahepatic bile ducts in man: a keratin-immunohistochemical study. *Hepatology* 8: 1586–95
13. Watanabe N, Tanaka M, Suzuki K, et al (2007) Tim2 is expressed in mouse fetal hepatocytes and regulates their differentiation. *Hepatology* 45: 1240–9
14. Zhao R, Duncan SA (2005) Embryonic development of the liver. *Hepatology* 41: 956–67

Chapter Outline

Descriptive Anatomy.....	11
Functional Anatomy	13
References.....	14

The present review of gross anatomy of the liver begins with a short discussion of the traditional descriptive anatomy, helpful in the physical examination of the patient [4, 5]. Modern approaches to liver anatomy emphasize functional aspects. Therefore the outline on descriptive anatomy is followed by a review on functional anatomy [1–3].

The functional approach is based on the concept of liver units, *segments*, which are each composed of an autonomous blood supply and biliary drainage. The knowledge of these functional segments is particularly important when dissecting small space occupying lesions or when removing segments of the liver for transplantation. Modern imaging modalities, such as ultrasound, computed tomography and magnetic resonance imaging are capable of non-invasively visualizing these segments.

Descriptive Anatomy

The exsanguinated normal liver of a healthy adult weighs approximately 1.3–1.5 kg. It accounts for about 2% of body weight in adults, and 5% of body weight in children. The soft, parenchymal organ is situated in the right upper quadrant of the abdominal cavity. It lies directly beneath the diaphragm in the right hypochondriac region and is protected by the rib cage. The lateral aspect of the left liver lobe reaches the left hypochondriac region. During expiration the upper edge of the right liver lobe corresponds to the fourth intercostal space. The lower (anterior) liver margin courses obliquely upwards and crosses the right costal arch at the level of the 9th costal cartilage. The left liver lobe abuts the liver area of the anterior abdominal wall directly beneath the xiphoid process of the sternum.

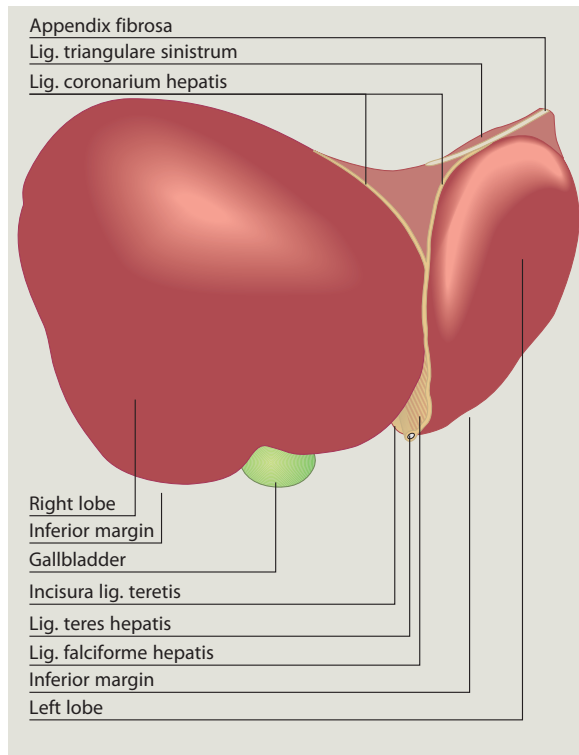


Fig. 2.1 Diaphragmatic surface of the liver

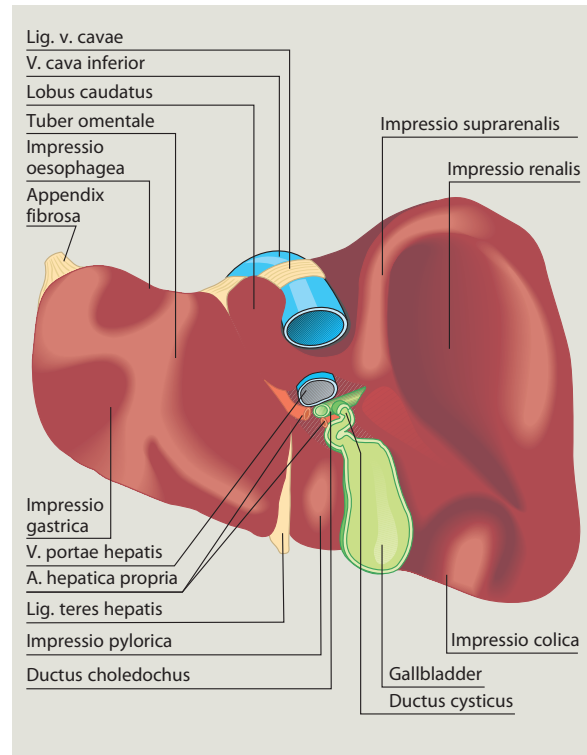


Fig. 2.2 Visceral surface of the liver

The diaphragmatic surface of the liver (*facies diaphragmatica*) (Fig. 2.1) is convex, and its cranial part shows a shallow impression (*impressio cardiaca*) that corresponds to the diaphragmatic cardiac saddle. Strong diaphragmatic muscle fibers may cause depressions of the cranial liver surface, called diaphragmatic grooves. The slightly concave inferior, visceral surface of the liver (*facies visceralis*) (Fig. 2.2) is in contact with the stomach, duodenum, colon, right kidney and right adrenal gland, which create flat impressions of the inferior surface. In the sagittal plane the liver has a cuneiform aspect with a sharp lower margin, *margo inferior*. The posterior aspect of the diaphragmatic liver surface is rounded and merges without a sharp boundary with the visceral hepatic surface. A tongue-shaped inferior extension of the lateral aspect of the right liver lobe is termed *Riedel's lobe*.

The entire surface of the liver is covered by a thin connective tissue capsule, *Glisson's capsule*, which lies just beneath a layer of flat peritoneal mesothelial cells. Extensions of the capsular fibrous tissue are continuous with the connective tissue within the liver. Most of the liver surface is covered by peritoneum, except for the

site of attachment of the gallbladder, the *fossa vesicae felleae*, and a small area on the posterior surface, *area nuda*, that adheres firmly to the diaphragm.

A peritoneal fold forms the falciform ligament, *ligamentum falciforme*, that divides the diaphragmatic surface of the liver into a right and left half, but not into different functional segments. The falciform ligament connects the liver to the diaphragm and to the anterior abdominal wall. At the site of the attachment of the liver to the diaphragm, *area nuda*, it branches into the right and left coronary ligament, *ligamentum coronarium hepatis dextrum et sinistrum*. The left coronary ligament is a thin, very short mesenteric plate, that ends with a free margin, the left triangular ligament (*ligamentum triangulare sinistrum*). It connects the connective tissue of the posterior margin of the left liver lobe to the diaphragm. The right coronary ligament merges its anterior fold with the parietal peritoneum of the diaphragm, with its posterior fold with the hepatorenal ligament (*ligamentum hepatorenale*). The free margin of the right coronary ligament is called the right triangular ligament (*ligamentum triangulare dextrum*). During embryonic development the falciform ligament

contains the umbilical vein. After birth the vein atrophies, leaving behind the *ligamentum teres*, which runs along the free inferior border of the falciform ligament to the inferior surface of the liver. Here, at the boundary between the right and left liver lobe, it causes a compression of the liver, the *incisura ligamenti teretis*. In portal hypertensive states the umbilical vein may become recanalized again. The incisura continues on the visceral face of the liver as a fissure, the *fissura umbilicalis*, that in its posterior segment contains the venous ligament, *ligamentum venosum*, with the obliterated venous duct (*ductus venosus*).

Anteriorly on the inferior surface of the right liver lobe, the quadrangular quadrate lobe (*lobus quadratus*) is found. It is demarcated medially by the fissure of the ligamentum teres, laterally by the gall bladder area and posteriorly by the porta hepatis. The medial posterior part of the right liver lobe, the *lobus caudatus*, is separated from the quadrate lobe by the porta hepatis. The *porta hepatis* on the visceral liver surface is the area where the portal vein and the hepatic artery enter and the bile ducts leave the liver. The hepatoduodenal ligament connects the duodenum to the porta hepatis and contains the common hepatic, the cystic, and the main common bile duct, the hepatic artery with its right and left branches, the portal vein, lymphatics and nerves. In the hepatoduodenal ligament the main common bile duct is usually found anteriorly and to

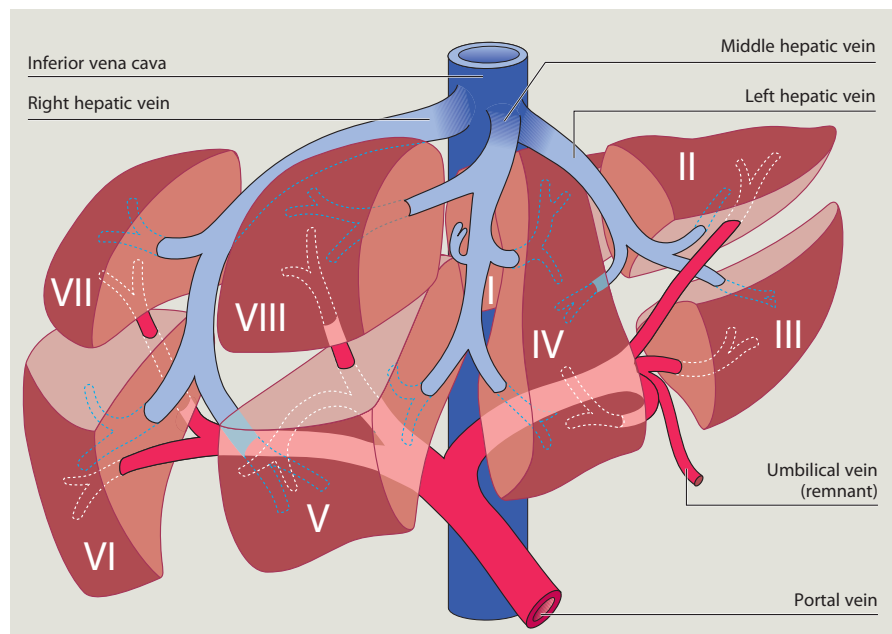
the right, the portal vein medially, and the hepatic artery dorsally and to the left. Many anatomical variants, however, do occur.

Functional Anatomy

The three main hepatic vein branches divide the liver into four sectors, each of which is supplied by a portal vein branch. The liver is further sub-divided into eight segments according to the course of portal and hepatic vein branches. Hepatic veins and portal vein branches are intertwined like the digits of two hands (Fig. 2.3).

An imaginary plane through the middle hepatic vein divides the liver into a *right and left part* (not identical to the right and left lobe described above). The right and left part of liver are completely independent units, receiving separate arterial and venous blood supplies and biliary drainage. The right and left hepatic vein sub-divide each part into an *anterior and a posterior sector*. With its right and left main branch, the portal vein supplies the right and left part of the liver, respectively. Each main portal vein branch further divides to supply the anterior and posterior sectors of the right and left part of the liver. With one exception (see below) in each sector, a further vascular

Fig. 2.3 Segmental anatomy of the liver. Hepatic veins (blue) and large portal vein branches (red) are interdigitating. Each of the four sectors, sub-divided by the main branches of the hepatic vein is supplied by a portal venous branch. Further ramifications of the portal triad subdivide the sectors into eight independent segments, each with its own blood supply and biliary drainage



subdivision supplies two *segments*. Each segment possesses its own vascular supply and biliary drainage.

In Fig. 2.3 the segmental anatomy of the liver is depicted. The *right liver* is made up of the right-posterior sector with segments 6 (inferior) and 7 (superior), and the right-anterior sector with segments 5 (inferior) and 8 (superior). The *left liver* consists of the left-anterior sector with segments 4 (medial) and 3 (lateral), which are separated by the umbilical fissure. The left-posterior sector is the sole sector having one segment only (segment 2).

Segment 1 is the *caudate lobe*. It has a unique position, receiving its portal venous blood from the right and left portal vein branches, and having its venous outflow drain directly to the retrohepatic inferior vena cava, thus bypassing the hepatic veins. This exceptional anatomical position of the caudate lobe attains clinical

significance in hepatic venous outflow tract disorders, such as Budd-Chiari syndrome (see Chapter 59).

References

1. Bismuth H (1982) Surgical anatomy and anatomical surgery of the liver. *World J Surg* 6: 3–9
2. Bismuth H, Majno PE, Kunstlinger F (1999) Macroscopic anatomy of the liver. In: Bircher J, Benhamou JP, McIntyre N, Rizzetto M, Rodes J (eds) *Oxford Textbook of Clinical Hepatology*, 2nd edn. Oxford University Press, Oxford, pp 3–11
3. Couinaud C (1957) *Le foie. Etudes anatomiques et chirurgicales*. Masson, Paris
4. Schiebler TH, Schmidt W, Zilles K (1999) *Anatomie*. 8. Auflage. Springer Verlag, Berlin/Heidelberg/New York
5. Starck D, Frick H (1967) *Repetitorium anatomicum*. 11. Auflage. Georg Thieme Verlag, Stuttgart

Chapter Outline

Structural Organization	15
Liver Lobule and Liver Acinus	15
Intrahepatic Bile Ducts	19
Intrahepatic Blood Vessels	21
Lymphatics	21
Nerves	22
Cell Types	22
Hepatocytes	23
Sinusoidal Endothelial Cells	32
Kupffer Cells.....	34
Hepatic Stellate Cells.....	36
Pit Cells (Liver Associated Lymphocytes).....	39
Biliary Epithelial Cells (Cholangiocytes)	40
Hepatic Stem Cells.....	40
Extracellular Matrix	42
Collagens.....	42
Elastin	44
Proteoglycans	45
Adhesive Glycoproteins.....	46
Cell–Matrix Communication	47
References	47

Structural Organization

The liver is the largest solid organ and the largest exocrine gland of the human body. It plays a central role in the metabolism of endogenous compounds and in the degradation and elimination of exogenous substances. The organ is composed of parenchymal and mesenchymal cells, the bile duct system, blood and lymph vessels, nerves and the extracellular matrix. [Table 3.1](#) shows the numerical distribution of different cell types in the human liver and [Table 3.2](#) shows the morphometric composition of the liver lobule.

The structural organization of the liver mirrors its functional diversity [22]. The debate regarding the functional hepatic unit has generated many models, but so far there is no final consensus. If such a unit is thought to represent the smallest entity, capable of exerting all hepatic functions autonomously, many investigations have shown that such a structural–functional unit arguably does not exist. The liver is a “continuum indivisibilis”; all attempts to describe separate entities are artificial. Nevertheless they are justified, since they further the understanding of pathophysiologic processes.

Liver Lobule and Liver Acinus

Small histological structures of the mammalian liver, *lobuli*, were first described by Wepfer (1664) and Malpighi (1666). In 1833 Kiernan defined the *classic liver lobule* [15]. In 1906 Mall described the “portal liver lobule” as the basic histologic structure, with the portal vein situated at its center and the terminal venules in its periphery [18]. The portal area is also found at the center of Brissaud’s and Sabourin’s “biliary liver lobule” [4]. Both latter concepts currently are of historical interest only.

Table 3.1 Quantitative distribution of the number of different cells in the liver

Cell type	Cell number (%)
Hepatocytes	60
Kupffer cells	15–25
Endothelial sinusoidal cells	10–20
Stellate (Ito) and pit cells	<5

Table 3.2 Morphometric composition of the liver lobule

Cell type/compartiment	Volume density (%)
Hepatocytes	78
Nonhepatocytes	6.3
Sinusoidal endothelial cells	2.8
Kupffer cells	2.1
Stellate (Ito) cells	1.4
Extracellular space	16

In 1949 Elias viewed the liver as a continuous system (“muralium”) of anastomosing plates (“laminae hepatis”) and sinusoidal spaces (“labyrinthus hepatis”) (Fig. 3.1) [9]. In the following years this idea gave way to an angioarchitectonic perception of the liver, according to which circumscribed parenchymal areas with their attendant blood supply and biliary drainage are arranged in an orderly fashion. The classic liver lobule was further subdivided into smaller units, known as *hepatic microcirculatory units*. Rappaport described the *liver acinus* with the terminal portal venule as its axial vessel [20]. The core structure of the *primary liver lobule* according to Matsumoto is the angular portal area

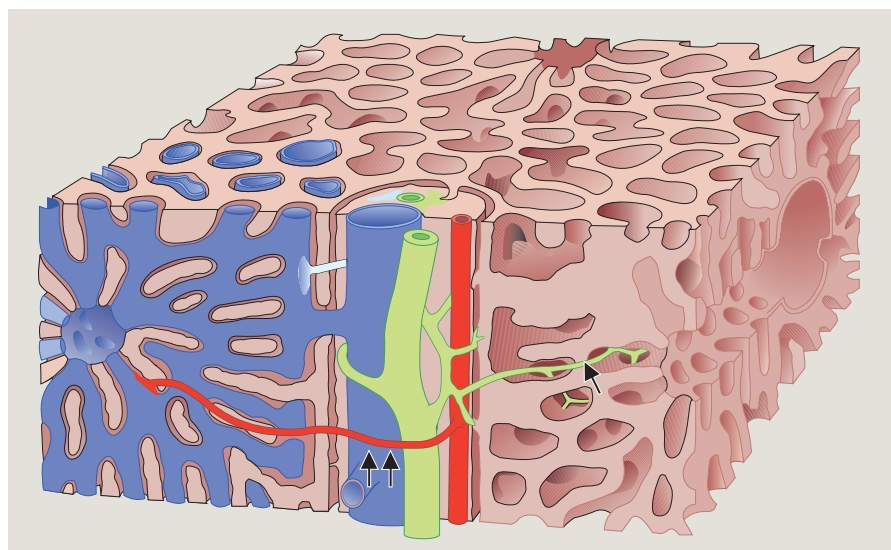
with its septal branchings (see below) [19]. Bloch interpreted the functional hepatic unit as the “*single sinusoid unit*,” in which the main component is represented by a sinusoid with its adjacent liver cell plates [3].

Recently, by observing sequential hepatic cryosections, the lobular concept has been extended and the hypothesis of a “*modular microarchitecture*” of the human liver has been formulated. According to this model 14 primary modules constitute a secondary module. A secondary module has a height of 1.9mm, a surface area of 14.7mm², and a volume of 5.1mm³. It is subdivided into primary modules by portal tracts and vascular septa, and by a common draining central venular tree. Primary modules are polyhedral, with seven to nine facets, having heights from 0.3 to 0.9mm, surface areas from 1.7 to 5.0mm², and volumes from 0.1 to 0.9mm³ [26].

Liver Lobule

The classic liver lobule was described by Kiernan in 1833 and maintains its validity until today. It is polygonal, usually hexagonal in cross-section, and measures approximately 0.7 × 2 mm (Fig. 3.2). The *central vein*, a terminal tributary of the hepatic vein is located at its center, and the *portal tracts* are found at its angles. Embedded in the connective tissue stroma of the portal tracts are the branches of the portal vein and hepatic artery, the bile ducts, lymphatics and nerves. Slender periportal fibrous septa (*interlobular septa*) demarcate

Fig. 3.1 Microscopic anatomy of the normal human liver (According to Elias) [9] The liver consists of a system of anastomosing hepatic plates and sinusoidal spaces. A network of hypothetical intralobular cholangioles (arrow) opens into the portal bile ducts (green). An intralobular artery (red) (two arrows) deriving from a portal branch of the hepatic artery bypasses the parenchyma and communicates directly with the sinusoids



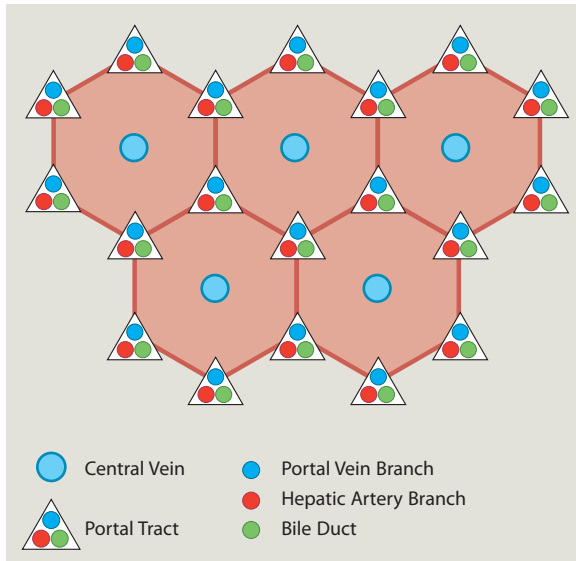


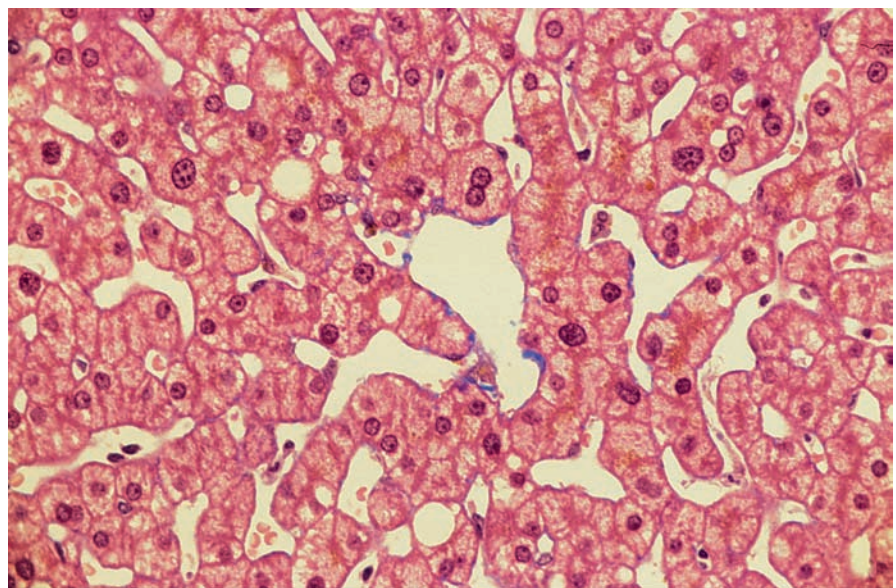
Fig. 3.2 Schematic diagram of liver lobules according to Kiernan. At the center of the classic lobule is the central vein, and at its corners are the portal tracts which contain branches of the hepatic artery, portal vein and bile ducts

individual liver lobules. Branching and anastomosing cords of hepatocytes extend between the central vein and the portal areas. In the adult liver the liver cell plates (*Remak's plates*) are one to two cells thick (Fig. 3.3). In newborns and infants the liver cell plates are thicker and consist of two or more cell layers. On average

approximately 24 hepatocytes are found between the portal tract and the central vein. Immediately abutting on the portal tract is a continuous concentric layer of hepatocytes, disrupted only by short links between the portal vessels and the sinusoids. This circumferential cellular layer represents the limiting plate (*interface*) between the lobular parenchyma and the portal tract.

The liver cell plates are separated by vascular channels, the *sinusoids*, which converge toward the central vein. Their lumen accounts for approximately 10% of the lobular parenchyma. The three-dimensional pattern of this meshwork of sinusoids and hepatocytes is comparable to a sponge. The air corresponds to the sinusoids and the spongy material represents the cords of hepatocytes. The sinusoids are lined by *sinusoidal endothelial cells* which, in contrast to endothelial cells of other organs, have fenestrated membranes like a sieve and form a loose cellular network. They lack a basement membrane, which facilitates the exchange of substances between the sinusoidal lumen, the space of Disse, and the hepatocytes. Periportal sinusoids are narrower and more convoluted compared to the straightened centrilobular sinusoids. The subendothelial space between the sinusoidal endothelium and the sinusoidal surface of the hepatocytes constitutes the *space of Disse*. It is 0.2–0.5 μm wide, amounts to approximately 2–4% of liver parenchyma, and contains components of the extracellular matrix. Matrix proteins are of vital significance for both sinusoidal cells and hepatocytes.

Fig. 3.3 Histological image of a normal liver (Masson Trichrome staining). The liver plates are mostly one cell thick, surrounded by sinusoids, and converge toward the central vein



A three-dimensional reticulin fiber framework spans the space of Disse. These fibers support the parenchyma, help to maintain sinusoidal patency, and serve as a guiding splint for proliferating and regenerating hepatocytes. Hepatocyte microvilli protrude through endothelial fenestrations into the space of Disse, and may establish direct contact between hepatocytes and the sinusoidal lumen [29]. In addition to endothelial cells, parietal macrophages known as *Kupffer cells* are present in the sinusoids. They are capable of phagocytosing foreign material and are endowed with antigen presentation capabilities. Also residing in the space of Disse, situated along the outer surface of endothelial cells and in between hepatocytes, are the vitamin A storing *hepatic stellate (Ito) cells*. After exposure to appropriate stimuli, hepatic stellate cells may transform into myofibroblasts and play an important role in fibrogenesis and in inflammatory processes. After immunologic stimuli such as interleukin-2, so-called *pit cells* may be found in the sinusoidal lumen, and occasionally in the space of Disse. These cells are liver-associated large granulated lymphocytes, which correspond to natural killer cells.

Liver Acinus

Based on the knowledge of hepatic microcirculation, Rappaport's concept of the liver acinus as the functional liver unit has proved extremely helpful for understanding structural – functional interrelationships. This concept assumes that hepatic parenchymal cells are grouped in a concentric fashion around afferent (perilobular) vessels. At the center of the acinus are terminal afferent vessels in the portal tract, i.e. the terminal branch of the portal vein and of the hepatic artery, respectively (Fig. 3.4). Two *terminal hepatic venules* (corresponding to the central veins of the classic lobule; Table 3.3) are found at its peripheral edge. Thus the liver acinus encompasses neighbouring segments of the classic lobule. Each terminal hepatic venule drains the blood of several acini.

Table 3.3 Comparison of roughly corresponding terms of the classic lobule (Kiernan) and the liver acinus (Rappaport)

Classic lobule	Liver acinus
Central (centrilobular) vein	Terminal hepatic venule
Centrilobular (lobular center)	Zone 3 ($O_2 \downarrow$; Cyt-P450 \uparrow)
Midlobular	Zone 2
Periportal (lobular periphery)	Zone 1 ($O_2 \uparrow$; Cyt-P450 \downarrow)

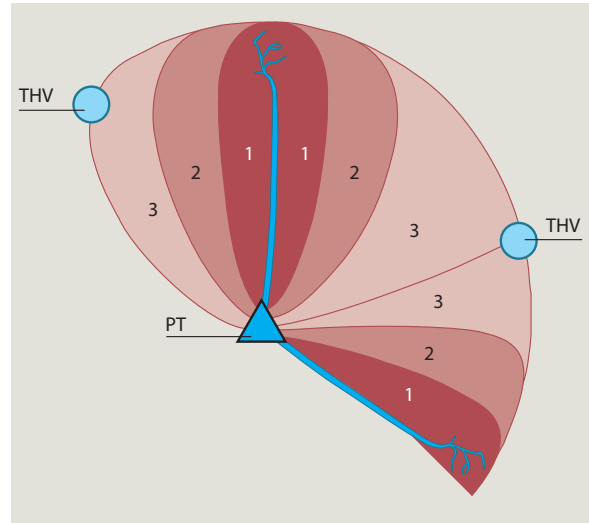
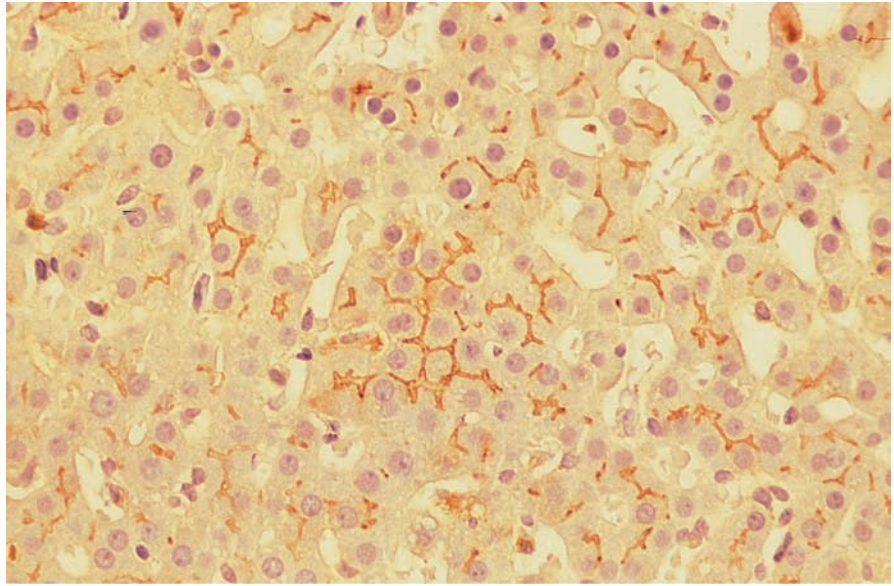


Fig. 3.4 Liver acinus according to Rappaport. The liver acini cling like grapes to the portal tract. The axial vessel is the terminal portal venule in the portal tract (PT). At the periphery of an acinus the terminal hepatic venule (THV) is found. Zones 1, 2 and 3 contain blood increasingly depleted in oxygen and nutrients. Zone 3 corresponds to the microcirculatory periphery

The liver acini are arranged in a trefoil pattern around the portal tract. The acini may further be assembled hierarchically. At least three simple acini form a *complex acinus* that in turn is the starting point for the construction of *acinar conglomerates*. In the simple acinus three zones are distinguished, which contain blood that is increasingly depleted in oxygen and exogenous substances. Zone 1 (periportal) is the zone nearest to the axis vessels. It contains blood with the highest oxygen concentration, and also the highest levels of insulin, glucagon, amino acids and other substances originating in the intestinal circulation. Perivenular zone 3 (centrilobular) corresponds to the microcirculatory periphery and has the lowest concentrations of oxygen and nutrients. Zone 2, by definition, occupies an intermediate position. Accordant to the acinar concentration gradient, zone 1 hepatocytes differ morphologically from liver cells in zone 3 (see Chapter 9). However interesting the idea of the acinus as the functional microcirculatory unit might be, and however attractive the concept of the acinus for the understanding of pathophysiological processes might seem, it must not be overlooked that its real existence is still unproven.

The microcirculatory angioarchitectonic concept is supported by studies of Matsumoto that emphasize the importance of “*vascular septa*” inside the liver

Fig. 3.5 Immunohistochemical visualization of bile canaliculi with polyclonal anti-carcinoembryonic antigen (CEA) antibodies



parenchyma as a framework for lobular architecture. The terminal branches of the portal vein are regarded as vascular septa. They are devoid of surrounding connective tissue, run perpendicular to the terminal hepatic venules, and discharge their contents into the sinusoids [19]. According to Matsumoto each primary lobule is a cuneiform structure consisting of a portal and a septal zone delimited by vascular septa. The sinusoids neighbouring the portal zone form a “transverse inflow front” that has major significance for the perfusion of the lobule. Thereafter the sinusoids run straight to the terminal hepatic venule. Ekataksin described tiny branches of the portal venules, “inlet venules” that establish a link to the sinusoids [6, 7].

Intrahepatic Bile Ducts

Bile produced by the hepatocytes flows within a three-dimensional lobular network of anastomosing bile canaliculi. The fluid reaches the duodenum through a system of communicating ducts whose diameter increases gradually from the liver to the duodenum. The smallest units are the *bile canaliculi* which are formed by apical microvillous processes of two or three adjacent hepatocytes. They may be well-visualized on light microscopy by immunohistochemistry using polyclonal antibodies against carcinoembryonic antigen (CEA) (Figs. 3.5 and 3.6) [12]. The pericanalicular cytoplasm

represents a specialized region of the hepatocyte that is responsible for the shape of the canaliculi. Actin filaments located in the pericanalicular ectoplasm radiate into the microvilli, suggesting that bile canaliculi are contractile structures that can actively “pump”, and thereby support bile transport. The canalicular bile drains into the *periportal cholangioles*, also called *bile ductules*, via the *canals of Hering*, which are located at the interface between the portal tract and lobular parenchyma. The *canals of Hering* are biliary canals partially lined by cholangiocytes and by hepatocytes (not by cells of intermediate morphology, which are not identified in normal livers) [21]. They are situated at the peripheral edge of the portal tracts, and may penetrate for a short distance through the limiting plate into the periportal lobular parenchyma. They represent the anatomic and physiological link between the intralobular canalicular system and the portal biliary tree, and are linked to the interlobular (terminal) bile ducts by the *bile ductules*. Bile ductules are lined entirely by cholangiocytes but do not have a basement membrane. They may traverse the limiting plate and possess an intralobular as well as intraportal segment, where they span the portal tract mesenchyme and merge the terminal bile ducts. Recent data suggest that the bile ductules traverse the boundaries of the portal tract into the lobule as ductular-vascular units which are accompanied by extensions of the portal vein that follow the vascular septa [13]. The canals of Hering and the bile ductuli thus represent short links between the bile canaliculi and the terminal bile ducts in

Fig. 3.6 Bile canaliculi (in the center and left corner) are formed by invaginations of the cell membrane of two or three adjacent hepatocytes. They have microvilli, but do not possess a basement membrane. Therefore they are not bile “capillaries.” Bile canaliculi are lined by electron dense tight junctions. EM $\times 8,000$

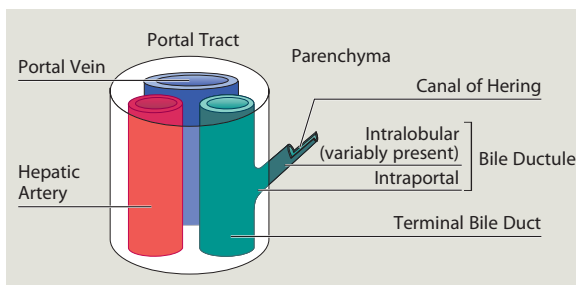



Fig. 3.7 Schematic diagram of the linkage between lobular bile canaliculi and terminal bile ducts in the portal tracts. The bile ductuli may have only an interlobular (portal) portion, in which case the canals of Hering extend through the limiting plate (Adapted from [21])

the portal tracts (Fig. 3.7). The interface of hepatocytes and the biliary tree does not reside at the limiting plate, but rather along an array of sites that project star-like from the portal tracts, along the bile ductuli and the canals of Hering [21]. The *terminal (interlobular) bile ducts* measure 15–20 μm in diameter and are the smallest branches of the portal tract-based biliary

system. The interlobular bile ducts have a basement membrane and are embedded in the connective tissue stroma of the portal tract whose collagen and elastic fibers are often arranged in loose periductal concentric bundles. One or two interlobular bile ducts accompany the terminal hepatic arteriole. They are surrounded by a peribiliary capillary plexus derived from hepatic artery and portal vein branches. The interlobular bile ducts anastomose with each other and empty into the *conducting (septal) bile ducts* that measure $>100\mu\text{m}$ in diameter. These conducting ducts are often embedded in a dense concentric collagenous stroma containing arteriolar plexuses and nerves. The septal bile ducts join to form the large *segmental bile ducts* (0.4–0.8 mm in diameter), and these unite toward the liver hilum to form the large *intrahepatic hilar bile ducts*. Some septal and segmental ducts possess *peribiliary glands* that communicate with the bile duct lumina. The intramural mucous glands drain directly into the bile duct lumen, while the extramural seromucinous glands communicate with the bile duct lumen through an excretory duct [25]. At the hepatic hilum

the intrahepatic bile ducts exit the liver as the left and right *hepatic duct*.

Computer-assisted measurements estimate the volume of the macroscopically visible bile duct system to be 14–24 cm³, and the inner surface area to be 336–575 cm² [17].

Intrahepatic Blood Vessels

The liver receives a dual blood supply from the hepatic artery and the portal vein. Twenty-five percent of flow volume is from the well-oxygenated blood of the *hepatic artery*, and the other 75% is from the oxygen-depleted blood of the *portal vein*. Portal venous blood, however, is rich in nutrients and other substances derived from the intestine and visceral organs. The large and medium sized branches of the hepatic artery are vessels with a well-developed internal elastic lamina, a muscle layer two to three cells thick, and numerous non-myelinated nerve fibers within the adventitia. These vessels propagate in the liver as *interlobar* and then as *interlobular arteries*, and finally reach the portal tracts where they fan out as *terminal hepatic arterioles*. The latter do not have an internal elastic lamina and the intima is surrounded by one smooth muscle layer. Ekataksin and Wake do not regard the hepatic artery as an artery that is primarily devoted to supplying the hepatic parenchyma, but rather view it as a stromal artery of the portal tracts [6]. According to Elias and Ekataksin, isolated branches of the hepatic artery may even bypass the hepatic parenchyma and drain directly into the sinusoids (Fig. 3.1) [8, 9].

The hepatic artery primarily supplies the following five compartments:

- Peribiliary vascular plexuses (with 50–70% this is the largest arteriolar compartment)
- Portal tract stroma
- Vasa vasorum of portal vein branches
- Vasa vasorum of hepatic veins
- Liver capsule

Hepatic arterial blood flows out through the portal veins, the sinusoids and lymphatics, and can even bypass the lobular parenchyma and drain directly into the sublobular veins.

The *portal vein* enters the liver at the porta hepatis with its main right and left branches, and divides

thereafter into the interlobar and then interlobular veins. These branches correspond to the liver segments (see Chapter 2) and run in a fibrous sheath together with branches of the hepatic artery and bile duct. Of all the vessels contained within the portal tract, the portal vein has the widest lumen and thinnest wall with little smooth muscle. The smallest portal vein branches in the portal tracts are called *terminal portal venules* or perilobular veins. These small vessels lack smooth muscle fibers and discharge their blood into the periportal sinusoids. The branches of the hepatic artery run in close proximity to those of the portal vein, occasionally winding spirally around the latter. In histologic sections this can give the impression that a portal vein branch is surrounded by several separate hepatic arterial branches. In the portal tracts complex *peribiliary capillary plexuses* and *arteriportal anastomoses* are found, the latter representing shunts between portal arterial and portal venous blood [24]. The arterial blood drains through these shunts first into the small branches of the portal vein and then into the sinusoids. Here it mixes with the portal venous blood and flows along a sinusoidal pressure gradient into the *terminal hepatic venule* (centrilobular vein). Unlike the sinusoidal endothelium, the endothelium of the terminal hepatic venules is not fenestrated. The centrilobular veins unite to form the *sublobular veins* which merge to form the *collecting veins*. The latter transport the blood of individual liver segments to the *hepatic veins*, which in turn drain into the inferior vena cava.

Lymphatics

The lymphatic system of the liver originates in the space of Disse. From here the lymph flows to the *space of Mall* that is situated in direct proximity to the portal tract, between the peripheral edge of the portal connective tissue and the first plate of periportal hepatocytes. From the space of Mall the lymph enters the portal capillary lymphatics and then leaves the liver through increasingly wider lymph vessels and three groups of lymph nodes: the *portal (hilar)*, *central* (situated in the region of the hepatic veins orifices) and *parietal (capsular) lymph nodes*. The hepatic lymph reaches the systemic circulation via the cisterna chyli and the thoracic duct. Lymphatics are present in all portal tracts, usually in close proximity to the hepatic artery [28].

They surround arteries and veins and follow them to their smallest branches. Only a small part of the hepatic lymph originates from the peribiliary capillary plexuses. Intramural lymphatics are present in the larger branches of the portal and hepatic veins. This intrahepatic lymphatic network communicates through a loose subcapsular plexus with capsular lymph vessels.

The lymphatic system of the gallbladder is arranged on three intercommunicating levels – mucosal, muscular and subserosal. Links to the hepatic lymph system exist.

Nerves

The liver contains a widely ramified network of adrenergic (sympathetic), cholinergic (parasympathetic), and peptidergic nerve fibers [2, 5, 10, 27]. The hepatic nerves influence the metabolism of hepatocytes, hemodynamics of the liver, and bile duct motility [16].

Parasympathetic fibers run with the vagus nerves. The efferent sympathetic innervation originates at the spinal level T5–T9, and the postganglionic fibers emanate from the celiac ganglion. At the hilum of the liver the nerves of the autonomous nervous system form plexuses surrounding the hepatic artery and the portal vein with bile duct. They enter the liver mostly as non-myelinated fibers and course with the hepatic artery branches and bile ducts into their smallest ramifications. Here, in the small portal tracts, they innervate the vascular and biliary structures. A fine neural network in the perisinusoidal space is in direct contact with hepatocytes and hepatic stellate (Ito) cells. The arteries are primarily sympathetically innervated, while the liver parenchyma and bile ducts possess both a sympathetic and parasympathetic innervation.

Peptidergic transmitters are mostly associated with adrenergic nerve fibers [1]. Vasoactive intestinal polypeptide, somatostatin, gastrin/C-terminal cholecystokinin, neurotensin, neuropeptide Y, substance P, glucagon, glucagon-like peptide, serotonin and galanin have all been found in the human liver [5]. However, the physiologic significance of the peptidergic innervation is unknown. Differences between species make interpretation difficult.

Afferent sensory fibers originating in the liver and the extrahepatic bile ducts run with the vagus and splanchnic nerves and the right phrenic nerve. They serve as osmo-, iono-, chemo- and metabolic receptors (e.g. glucose sensor) and as baro- and nociceptors.

Afferent nerves affect glucose homeostasis and modulate the hepatic actions of insulin. Stimulation of sympathetic nerves induces glycogenolysis and the release of glucose, and inhibits glycogen synthesis. Stimulation of parasympathetic nerves has opposite effects [11, 14]. Signal propagation via gap junctions between hepatocytes seems to be of utmost importance to the transduction of neurally mediated metabolic effects [23].

Hepatic baroreceptors appear to be involved in the “hepatorenal reflex” (see Chapter 54). However, as is apparent in the transplanted denervated liver, hepatic innervation is not essential for organ function.

Cell Types

The main parenchymal cell of the liver is the hepatocyte. Approximately every third cell in the liver is a sinusoidal cell or a cell associated with the sinusoids, excluding cells circulating in the sinusoids and residing in the connective tissue stroma of the portal tracts. Among these cells are the sinusoidal endothelial cells, Kupffer cells, hepatic stellate (Ito) cells, and the so-called pit cells (large granulated lymphocytes).

In [Table 3.4](#) the volumetric composition of sinusoidal cells is reported [77]. Although these cells amount to only 6% of the lobular parenchymal volume, they account for 35% of the collective cell number. 26% of all plasma membranes in the liver are allotted to sinusoidal cells. The coordinated interaction between parenchymal and nonparenchymal cells is essential for the functioning of the individual hepatocyte and of the entire organ. The generous equipment of nonparenchymal cells with cellular organelles is evidence for their substantial contribution in this regard. While only 1.2% of mitochondrial volume densities of the entire liver fall upon non-hepatocytes, non-hepatocytic cells are relatively well-endowed with lysosomal enzymes. Non-hepatocytes contain 43% of the volume of all liver lysosomes, with Kupffer cells possessing 22%. Sinusoidal endothelial cells, Kupffer cells and pit cells are in direct, close contact with sinusoidal blood. On the other hand, the contact of perisinusoidal

Table 3.4 Volumetric composition of sinusoidal cells

Cell type	Volume density (%)
Sinusoidal endothelial cells	44
Kupffer cells	33
Stellate cells	20
Pit cells	3

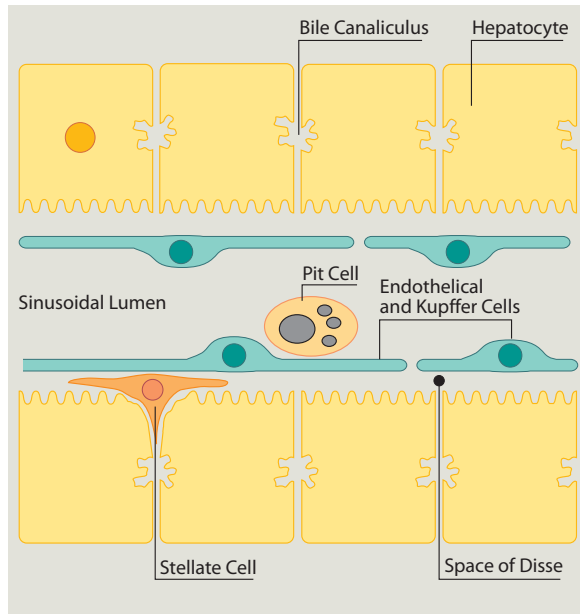


Fig. 3.8 Schematic representation of various cell types and their location in the human liver

stellate cells and of hepatocytes with blood occurs primarily in the space of Disse (Fig. 3.8).

In addition to the aforementioned cells the intrahepatic biliary epithelial cells (cholangiocytes) are also considered among the organotypic cells of the liver.

Recently new discoveries in stem cell biology and regenerative medicine have focused the interest on hepatic stem cells.

Table 3.5 Volumetric composition of the average hepatocyte^a

Compartment/organelles	Volume density (%)
Hyaloplasm	54.9
Lysosomes	2
Peroxisomes	1.3
Mitochondria	19
Endoplasmic reticulum	
rough	13
smooth	7.7
Lipid inclusions	0.3–2.1

^aIn relation to the cytoplasm; 7.3% fall upon the nucleus

Hepatocytes

The hepatocyte is a polygonal, polar, epithelial cell, 20–40 μm in size. Approximately 80% of parenchymal volume and 60–70% of the entire cell number in the liver is made up of hepatocytes (Tables 3.1 and 3.2). In Table 3.5 the volumetric composition of an average hepatocyte, related to its cytoplasm, is given.

The liver cell is surrounded by a plasma membrane that exhibits different, specialized domains. The smooth endoplasmic reticulum gives the cytoplasm a faint eosinophilic appearance, and the RNA of the rough endoplasmic reticulum often causes a basophilic stippling of the cytoplasm (Fig. 3.9). In addition to the nucleus, the organelles (these amount to 50% of the cell volume) and the cytoskeleton, glycogen inclusions, crystalline structures composed of phospholipids and proteins, and lipid droplets are

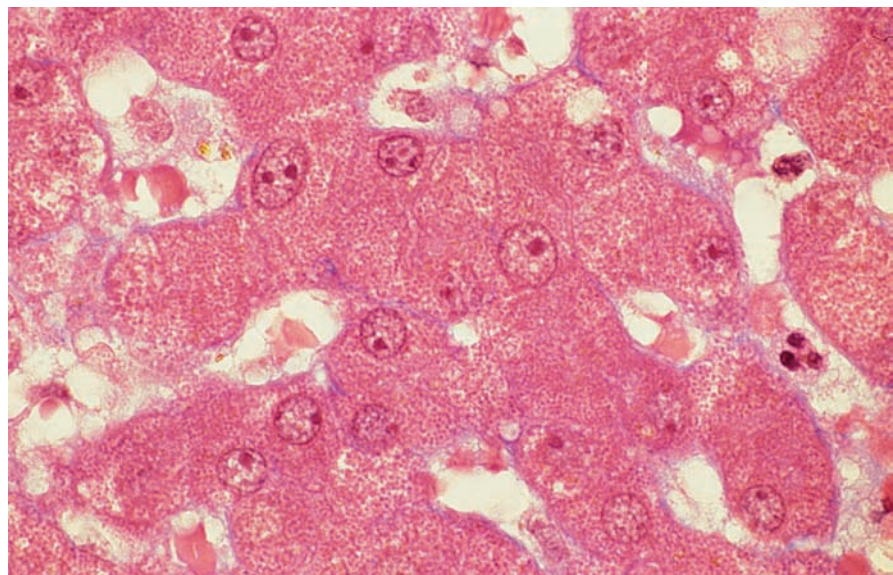


Fig. 3.9 Normal liver cells. On high magnification cytoplasmic stippling is discernible by light microscopy (Masson Trichrome stain; $\times 1,000$)

Fig. 3.10 Electron microscopy of normal hepatocytes. Their polygonal shape, the round nucleus, and the ample endowment with cell organelles are well-visualized ($\times 4,000$)

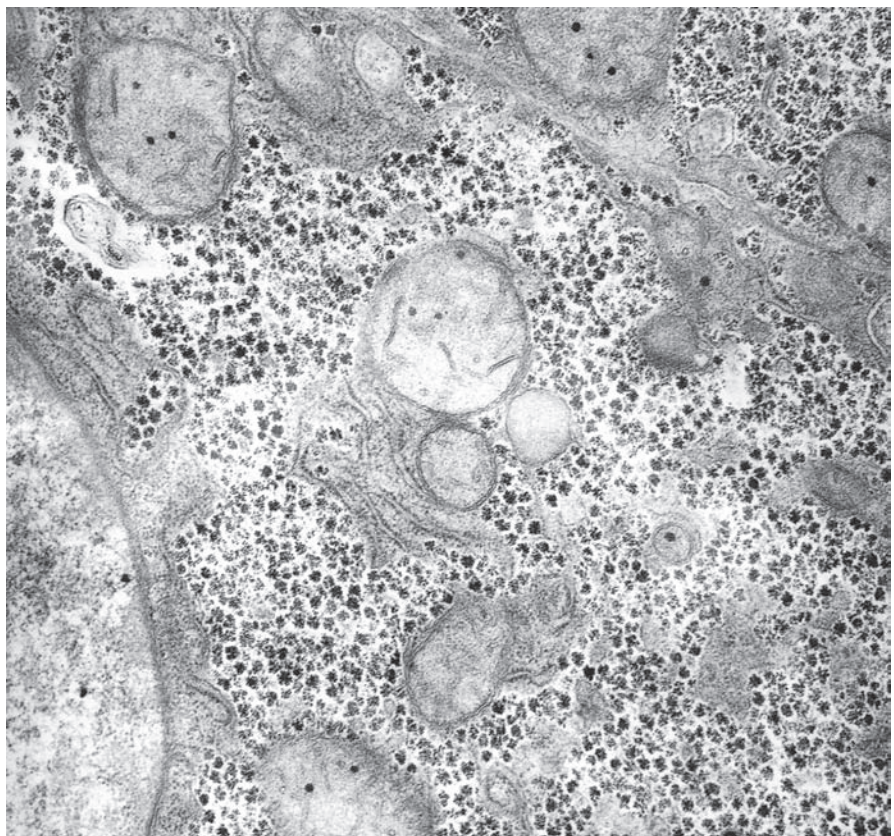
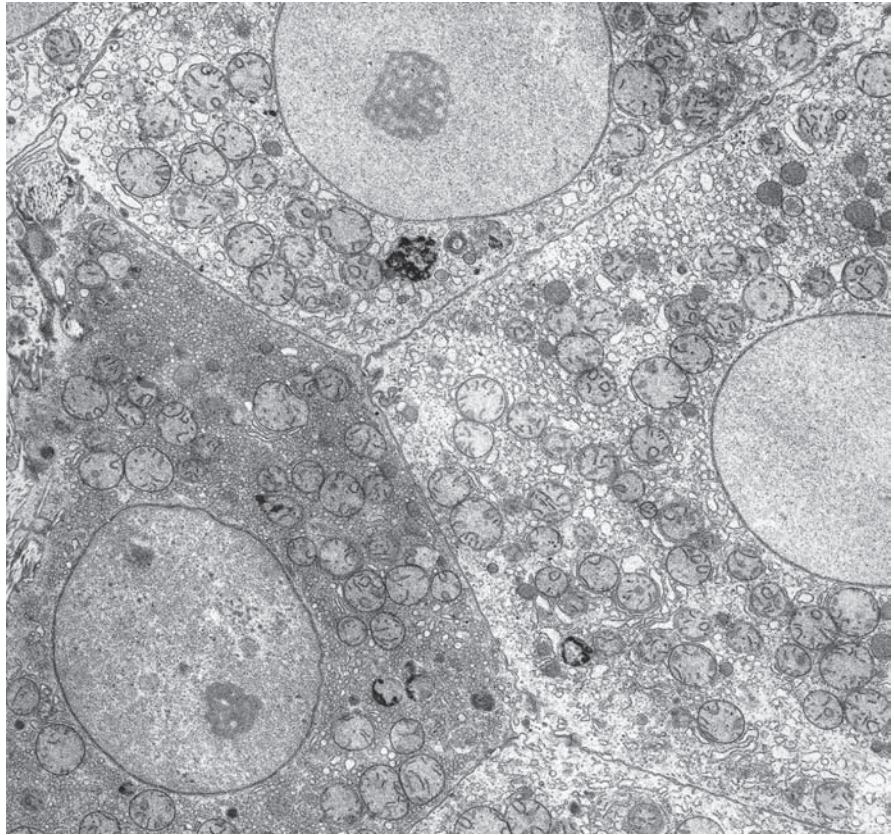


Fig. 3.11 Rosette-like cytoplasmic glycogen inclusions

all found inside the cell (Fig. 3.10). These inclusions, rather than representing pathologic cellular processes, may also be found in normal hepatocytes. Glycogen is deposited in electron dense particles measuring 15–30 nm (β -particles). β -particles may coalesce to form larger rosette like aggregates (α -particles) (Fig. 3.11). In the perivenular hepatocytes the glycogen granules are scattered between the tubules of the endoplasmic reticulum, while in the periportal liver cells the glycogen aggregates are more densely packed. 0.3–2.1% of the cell volume is occupied by small lipid droplets. With increasing age small lipofuscin granules may often be encountered at the biliary (apical) surface of the cell, especially in perivenular hepatocytes.

Plasma Membrane

The hepatocellular plasma membrane is a highly complex structure that forms a selective barrier, thereby maintaining the composition of the internal cellular milieu. Morphologically and functionally it may be divided into three specialized segments (*domains*). The following domains are distinguished:

- Sinusoidal (basolateral)
- Intercellular (lateral)
- Canalicular

These membrane sections differ biochemically, they vary in their fluidity, in enzyme and receptor composition, and in the integrated transport systems. In man 83% of the entire hepatocyte surface falls upon the lateral and basolateral membranes. Transport across the membrane at the sinusoidal surface is bidirectional, while at the canalicular surface substrate flow is unidirectional from the hepatocyte to the canalicular lumen [81].

Sinusoidal Membrane

The sinusoidal membrane exhibits many 0.5 μ m long microvilli that project into the space of Disse. Single microvilli protrude through the fenestrations of the sinusoidal endothelial cells into the sinusoidal lumen, thus establishing a direct contact between the hepatocyte and the sinusoidal blood. On the sinusoidal surface of liver cells many impressions (coated pits), with

clathrin-coated vesicles lying immediately beneath them, may be visualized

Canalicular Membrane

The canalicular membrane is found at the apical (biliary) pole of the hepatocyte. It corresponds to approximately 15% of the hepatocyte membrane surface. Foldings of the cell membrane at the apical pole of two to three neighbouring hepatocytes demarcate a highly specialized space, the bile canaliculus. In the three-dimensional reconstruction the canaliculi surround the waist of the hepatocytes in a belt-like fashion. The pericanalicular ectoplasm represents a narrow cytoplasmic zone devoid of cell organelles, but containing contractile microfilaments. The canalicular surface is isolated from the remainder of the lateral membrane by tight junctions, desmosomes and gap junctions (Fig. 3.12).

Lateral Membrane

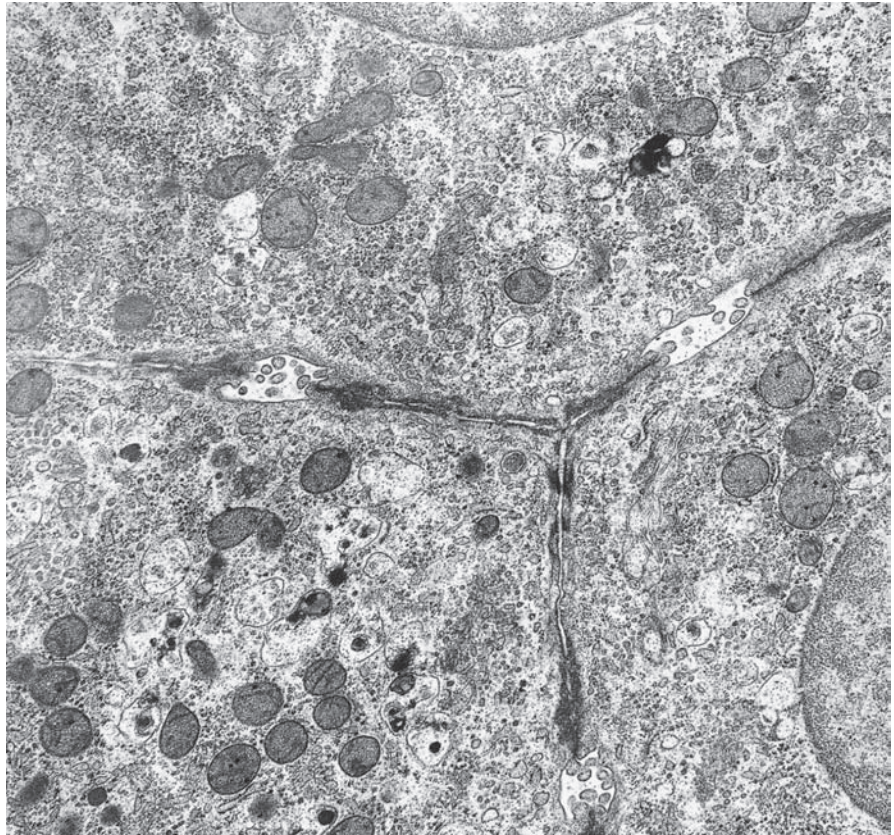
The lateral membrane extends from the bile canaliculus to the edge of the sinusoidal surface. It represents the contact area between adjacent hepatocytes and serves the intercellular communication between neighbouring liver cells.

Tight junctions (*zonulae occludentes*) extend in a band-like fashion around the bile canaliculi (Fig. 3.12). In these segments the normal intercellular space disappears and the hydrophilic phosphoglyceride heads of the outer surfaces of two adjacent plasma membranes are aligned with each other. They act as physical permeability barriers and prevent macromolecules from crossing from the bile canaliculus to the intercellular space and vice versa. However, water and electrolytes can permeate this barrier and move from the blood to the bile canalicular lumen, bypassing the cell interior of the hepatocyte.

Desmosomes are cytoskeletal links between adjacent hepatocytes. Their main constituents are integral plasma proteins, the *cadherins*. Through their extracellular domain they establish a cell-to-cell contact, while their intracellular segments remain anchored to the cytoskeleton. Desmosomes are scattered irregularly across the lateral hepatocyte membrane and function also as mechanical stabilizers of the hepatocytes in the liver tissue.

Gap junctions enable the communication between the cytoplasm of two neighbouring hepatocytes. They

Fig. 3.12 Canalicular membrane with tight junctions (zonulae occludentes) at the apical (biliary) pole of hepatocytes. Three canaliculi are displayed



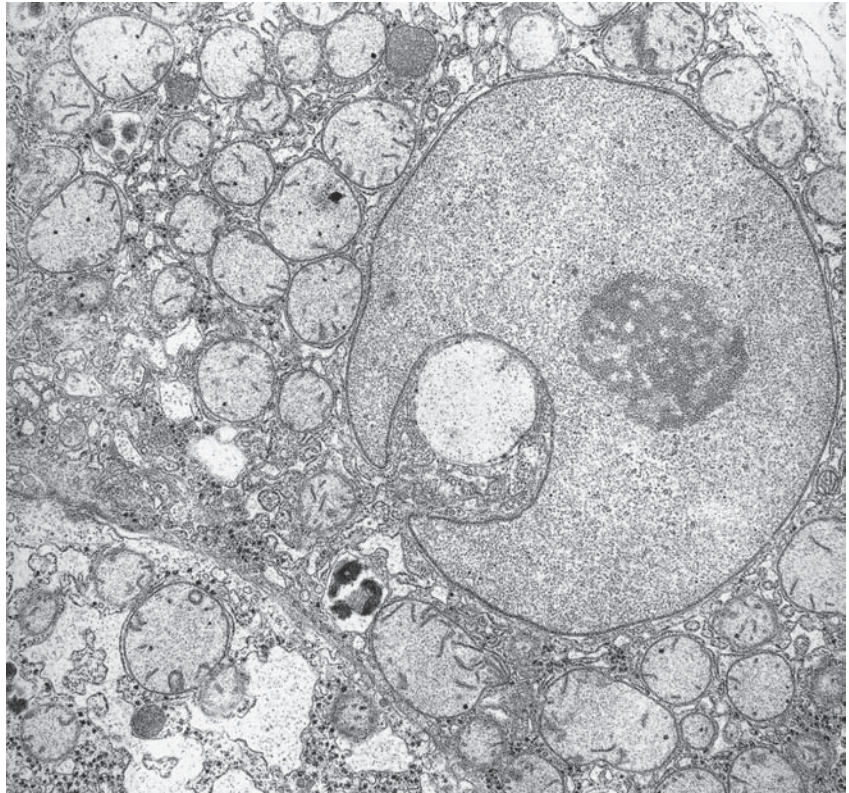
represent intercellular channels formed by *connexins*. Each cell forms a semi-channel made up of six connexin molecules. Both semi-channels are aligned to make a hexagonal structure with a stable pore, thus creating a patent, non-selective channel for electrical and chemical cell-to-cell communication between contiguous cells.

Nucleus

The hepatocyte nucleus comprises 5–10% of the cell volume. It is round and contains one or several nucleoli (Fig. 3.9). These are regions of dense RNA-containing granules and fibrils embedded in a protein matrix. The nuclear contents are kept separate from the cytoplasm by a nuclear membrane. This double-membrane contains pores which allow macromolecules to cross in a two-way process. The outer sheet of the nuclear membrane is studded with ribosomes. The space between the inner and outer membrane (*perinuclear space*) is in straight continuity with the

rough endoplasmic reticulum. The inner membrane (*lamina nuclearis*) consists mainly of a scaffold-like network of protein filaments. Translocation of proteins between the nucleus and the cytoplasm proceeds along *nuclear pore complexes* which have a diameter of 25 nm. These allow for the bidirectional transport of proteins, DNA- and RNA-containing ribonucleoproteins and viruses [91]. For the most part the chromatin in the nucleoplasm is *euchromatin* which is less dense and contains most of the active genes. *Heterochromatin* is more condensed and appears darker. It is found in small aggregates along the inner nuclear membrane and around the nucleolus. Approximately 25% of hepatocytes have two nuclei. The volume of the nuclei can be allotted to different classes in a ratio of 1:2:4:8 with a corresponding increase in ploidy and DNA-content [55]. The nuclear volume is proportional to the ploidy. The mitotic rate of the adult liver is very low, with a mitotic index of $1:10^4$ to $2.2:10^3$ cells. Nuclear inclusions, e.g. isolated glycogen particles or lipid droplets are observed quite frequently. They are formed by cytoplasmic

Fig. 3.13 Nuclear inclusions containing cytoplasmic material may originate from invagination and subsequent separation of the nuclear membrane



material invaginating through the nuclear membrane (Fig. 3.13).

Endoplasmic Reticulum

The endoplasmic reticulum (ER) is a system of interconnected, membrane-bound tubules, flat cisternae and vesicles (Fig. 3.14). It amounts to 15–20% of the cell volume. It has a surface of approximately $63,000\ \mu\text{m}^2$ per hepatocyte which is approximately 38 times the surface area of the plasma membrane. 40% of ER is *smooth ER* composed mainly of small vesicles of varying density and different lumina. The ER communicates with and is involved in packaging and delivery of proteins to the Golgi apparatus. It is distributed differently in various parts of the liver lobule and acinus. Its surface density in zone 3 hepatocytes (perivenular; centrilobular) is twice as high as in zone 1 hepatocytes (periportal; lobular periphery). In close association with the ER membranes plenty of glycogen can often be visualized. Sixty percent of ER belongs to the *rough ER* which is studded with ribosomes, is in continuity with the outer nuclear membrane, and is actively involved in protein synthesis.

The *functions of the ER* are manifold. Among them are

- Protein synthesis, protein translocation and transport to the Golgi apparatus
- Metabolism of fatty acids, phospholipids, triglycerides
- Synthesis and metabolism of cholesterol and bile acids
- Biotransformation of xenobiotics, e.g. drugs and endogenous substances, e.g. steroids by the monooxygenase system
- Glucuronidation
- Vitamin C synthesis
- Degradation of heme

The induction of enzyme systems located in the ER membranes and metabolic stress may lead to a reversible proliferation of ER membranes.

Golgi Apparatus

Discovered by Camillo Golgi in 1898 as the “internal reticular apparatus,” this structure today bears his name and plays a leading role in intracellular transport [63].

Fig. 3.14 Multiple endoplasmic reticulum vesicles with glycogen rosettes in-between. *Upper right corner: section through nucleus*

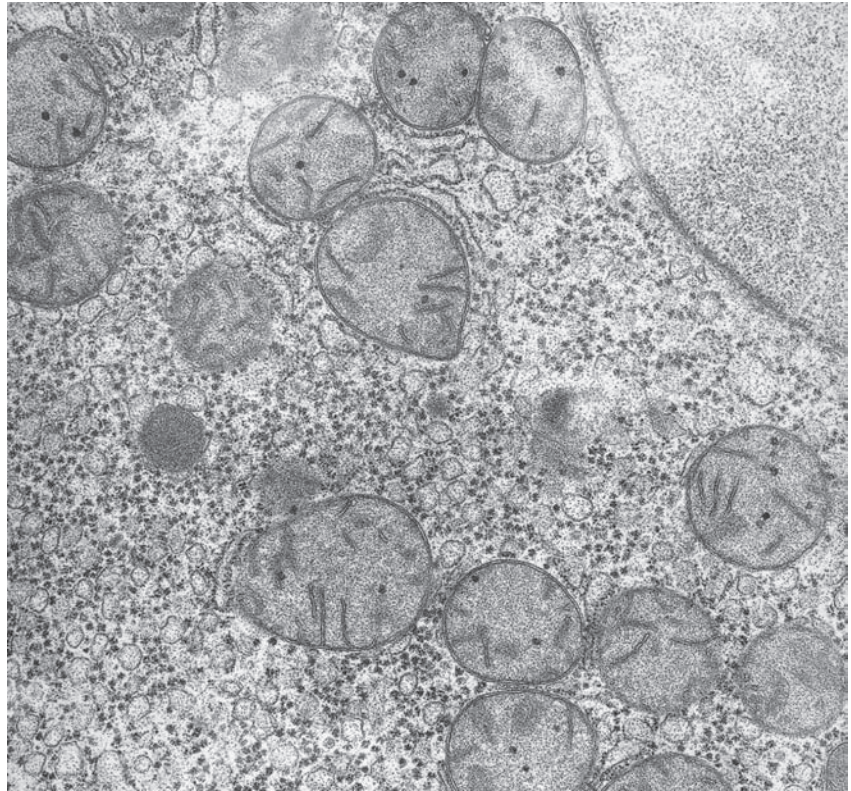
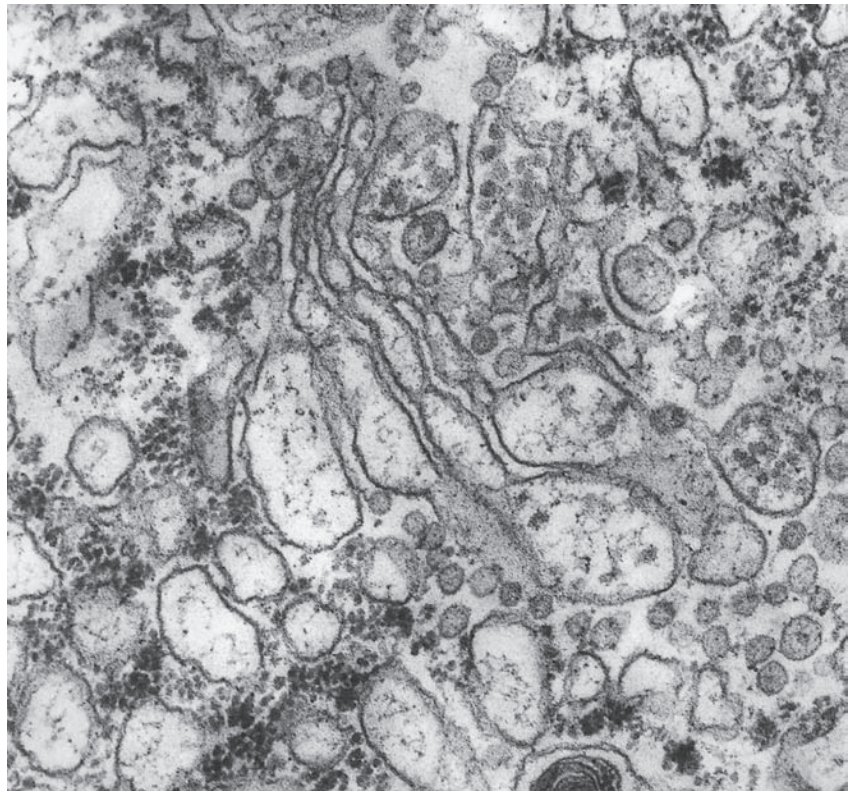


Fig. 3.15 Golgi complex. Note the stack of flattened membranous sacs (cisternae) surrounded by small vesicles



The Golgi apparatus is a three-dimensional structure of flattened membranous stacks that are now called *cisternae* and are surrounded by membranous tubules or vesicles (Fig. 3.15). It is a specialized region of the ER comprising approximately 6% of the ER membrane surface and 4% of the cell volume. A Golgi complex represents a dynamic steady-state system of ER-derived membranes. It consists of four to six parallel flat cisternae with budding small vesicles at their bulbous ends. Their convex area is termed *cis*-, the concave area *trans*-side. The Golgi complex is primarily localized near the nucleus, not far from the bile canaliculus. In each hepatocyte, up to 50 Golgi complexes communicate with each other.

The Golgi apparatus performs various important functions in the cell. It serves not only as the final assembly line but also as the delivery center in the cell. Most of the proteins synthesized in a cell are either bound for secretion (e.g. digestive enzymes, hormones, plasma proteins) by the regulated pathway, are house-keeping membrane proteins delivered by the constitutive pathway or are lysosomal enzymes. The Golgi stack receives proteins from the endoplasmic reticulum and transfers them to different compartments of the stack. During passage through the stack, the peptide

sequences or sugar chains of the proteins are modified. The modified proteins enter the *trans*-Golgi network for sorting and delivery to the appropriate targets. Presently there are two models for intra-Golgi transport. In the *vesicular transport model*, transport vesicles carry cargo proteins through the Golgi stack and also transport materials in a backward direction in protein coated vesicles. In the *cisternal maturation model*, proteins are transported within the cisternae, and membranous vesicles carry back resident proteins only in a retrograde direction. The cisterna itself migrates through the stack from a *cis* to *trans* direction [111].

The *functions of the Golgi apparatus* encompass

- Secretion of lipoproteins
- Glycosylation of secretory proteins
- Synthesis and recycling of glycoprotein membrane receptors
- Bile acid synthesis

Lysosomes

Lysosomes are polymorphic, electron dense bodies bound by a single membrane (Fig. 3.16) [37]. Each

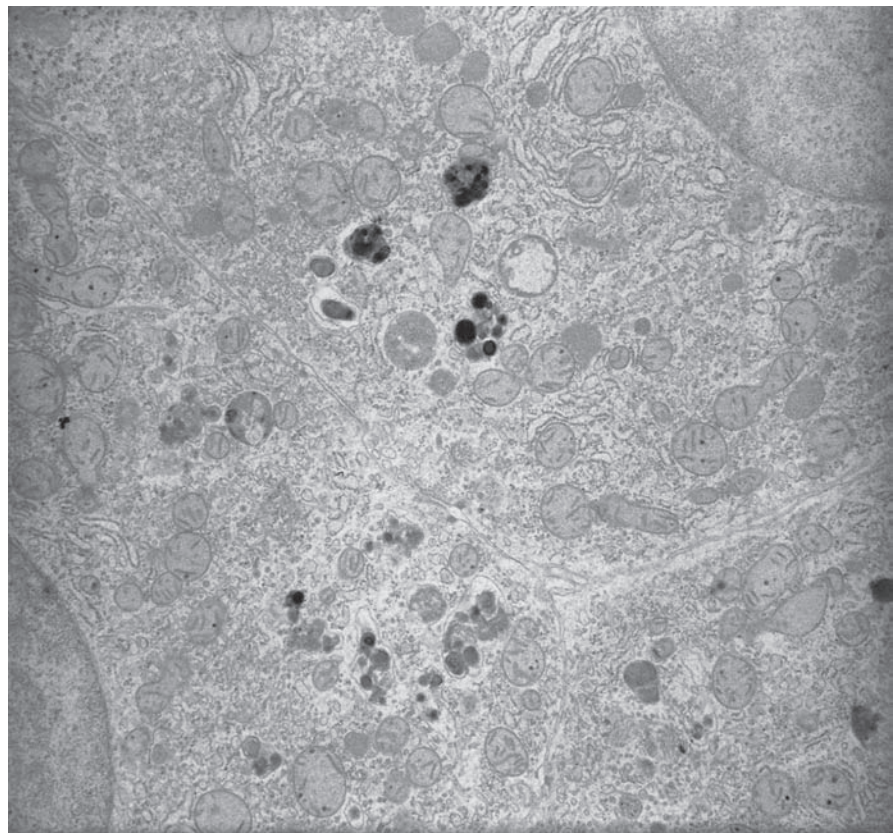


Fig. 3.16 Section through three hepatocytes. The lysosomes appear as polymorph, membrane bound, electron dense bodies

hepatocyte contains about 300 lysosomes. They contain lytic enzymes such as acid hydrolases (e.g. acid phosphatase, aryl sulphatase, esterase, β -glucuronidase) which are involved in digestion of ingested macromolecules and turnover of intracellular components. Histochemically, lysosomes may be identified by demonstrating acid phosphatase. Lysosomes are part of the GERL-compartment (see Chapter 5).

Lysosomes are involved in auto- and heterophagia. Their **main functions** are

- Incorporation and digestion of cytoplasmic components and cell organelles by primary lysosomes that develop into secondary lysosomes (storage stage; autophagic vacuoles)
- Storage of pigments, e.g. lipofuscin. These can stay for a long time inside the hepatocyte giving rise to so-called *residual bodies*. They are mainly found near the biliary pole of the cell
- Storage of exogenous substances, e.g. iron as ferritin
- Uptake of clathrin-coated vesicles after receptor mediated endocytosis forming *endosomes*. Insulin, low density lipoproteins, transferrin, immune globulin A, and asialo-glycoproteins are internalized in this manner (see Chapter 5). Fusion of endosomes leads to the formation of *multivesicular bodies*. Their contents may be catabolized by the cell or be transported to the basolateral or apical membrane where they are excreted by exocytosis into the extracellular space

Peroxisomes

Peroxisomes (microbodies) are round-oval, membrane-bound bodies measuring 0.2–1 μm in diameter [96, 106]. In humans their homogenous matrix contains crystalloid inclusions. There are approximately 500–600 peroxisomes per hepatocyte and they account for 1.3% of cytoplasmic volume. Peroxisomes contain more than 40 enzymes, among them oxidases which use molecular oxygen and generate toxic hydrogen peroxide that is hydrolysed by peroxisomal catalase. The activity of the peroxisomes consumes 20% of O_2 -requirement of the cell. Unlike mitochondria, however, peroxisomes cannot store energy, but dissipate ATP as heat.

Peroxisomes participate in many cellular **metabolic functions**, such as

- Respiration
- β -oxidation of long-chained fatty acids

- Purin metabolism
- Metabolism of ethanol
- Gluconeogenesis
- Side chain oxidation of cholesterol
- Bile acid synthesis

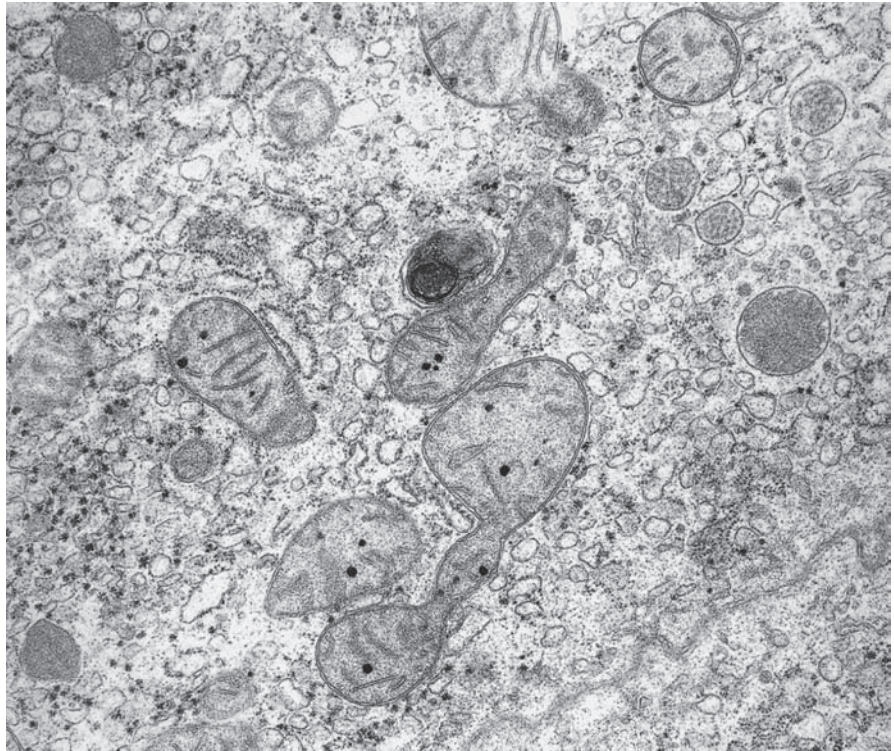
Cell nuclear receptors belonging to the nuclear receptor superfamily, the *peroxisome proliferator activated receptors (PPARs)*, cause proliferation of peroxisomes when activated by a number of synthetic compounds, e.g. thiazolidinediones.

Mitochondria

Mitochondria are complex cell organelles, characterized by a great variety in shape (Fig. 3.17) [90]. They measure approximately 0.5 \times 0.5–1 μm but occasionally may attain a size of 4 μm . Each hepatocyte contains approximately 1,000 mitochondria. Their shape is subject to changes and they can move inside the cell. Both their number and their size vary according to their zonal localization. Mitochondria in perivenular zone 3 are smaller and more numerous than their counterparts in periportal zone 1. 20% of cytoplasmic volume of zone 3 hepatocytes falls upon mitochondria, while this fraction in zone 1 hepatocytes amounts to 13%. Mitochondria are bounded by a double membrane, separated by a slim intermembranous space. The outer membrane is permeable to substances with a molecular weight of up to 2 kDa. The inner membrane is highly folded to form shelves (*cristae*) which increase its surface area to nearly 30% of the total surface area of the cell membrane! The membrane encloses a central matrix space that contains electron dense granules. These granules are composed of circular DNA, small amounts of RNA and Ca^{++} . They contain the second genetic system (mitochondrial genome; “25th chromosome”) [49]. Thus, mitochondria are able to produce some of their own proteins. Thirteen respiratory chain polypeptides are synthesized within the mitochondria. Overall the mitochondrial DNA codes for 37 genes. Ninety-nine percent of mitochondrial proteins, however, are the products of nuclear genes and are imported from the cytoplasm.

Mitochondria multiply by division, their half time being approximately 10 days. They contain many enzyme systems that can be allocated to the cristae or to the matrix.

Fig. 3.17 Normal hepatocyte with morphologically diverse mitochondria. The mitochondria show electron-dense granules containing DNA. Adjacent are membranous vesicles of the endoplasmic reticulum, and in the right upper part of the figure primary lysosomes (multivesicular bodies) are seen



- Respiratory chain enzymes are located on the cristae. The respiratory chain is built up of four protein complexes and ATP-synthase. The major part of energy stored and available as ATP is provided by oxidative phosphorylation.

The *matrix* contains

- Components of the tricarboxylic acid cycle
- Enzymes for β -oxidation of fatty acids
- Urea cycle enzymes
- Components of steroid metabolism
- Enzymes of heme-biosynthesis
- DNA and RNA

Nonspecific crystalline phospholipid and protein inclusions are not necessarily the expression of a pathologic process, they often can be found in mitochondria in healthy livers.

Cytoskeleton

While the plasma membrane represents the outer border of the cell, the cytoskeleton, whose fibers span as a three-dimensional internal scaffolding, maintains the

dynamic structure of the hepatocyte [54, 73]. The cytoskeleton permits the hepatocyte to change its shape and its organelles, and inclusions to move. The cytoskeleton is of importance in

- Maintaining cell shape by helping the cell resist external pressure
- Internal organization of the cell
- Intracellular organelle movements
- Transport processes
- Cell polarity
- Cell division

The most important components of the cytoskeleton are polymeric proteins, which often form long, helical structures. The cytoskeleton is made up primarily of

- Microfilaments
- Intermediate filaments
- Microtubules

Filaments and microtubules form the cytomatrix of the hepatocyte as a *microtrabecular network*. Specialized proteins anchor these structures, tie them together and affix them to the plasma membrane and to the cell organelles. The individual components of this network are dynamic structures that adapt to the functional

requirements of the cell and allow proteins and organelles to move from one part of the cell to another propelled by molecular motors (see below).

Microfilaments

Microfilaments are long fibers, 4–7 nm in diameter. They are made up of free cytoplasmic globular (G) actin molecules that polymerize to form filamentous (F) actin. G- and F-actin are in equilibrium with each other. The double-stranded molecules aggregate to bundles that traverse the cell as a three-dimensional mesh. Microfilaments may be visualized immunocytochemically by antibodies to actin. Microfilaments are involved in the formation of desmosomes. They are part of the contractile apparatus of the hepatocyte and are found predominantly at the cellular periphery beneath the plasma membrane and in the pericanalicular ectoplasm. From here they radiate into the canalicular microvilli, reach their tips, and control their motility.

Intermediate Filaments

Intermediate filaments are dynamic and motile elements of cellular architecture and participate in signal transduction [66, 67]. They are long polymeric proteins made up of monomeric subunits. Some of these filaments link the nuclear membrane to the cell membrane. They are a heterogeneous group of protein fibers, differing in composition and antigenicity with a diameter of 8–10 nm [123]. Five immunologically distinct groups, with a cell specific distribution are distinguished: cytokeratins, desmin, vimentin, acidic fibrillary glial protein and neurofilaments. These cell specific variations are formed during embryonic development.

Cytokeratins are intermediate filaments of epithelial cells and may be demonstrated in hepatocytes, and particularly in biliary epithelial cells [118]. Originating from the perinuclear region they span to the periphery of the cell. Here they interact with desmosomes on the lateral hepatocyte membrane thereby imparting stability to the liver cell texture. Their number, length and position are variable. Based on their molecular weight at least 20 different cytokeratin-subtypes may be distinguished [82, 83] All cytokeratin polypeptides are coded for by different genes. They can be grouped into acidic type I- and neutral to basic type II-cytokeratins. *Human*

hepatocytes contain cytokeratins 8 and 18, while biliary epithelial cells additionally express types 7 and 19. The different liver cytokeratin-subtypes may be nicely visualized by immunohistochemistry. The demonstration of different cytokeratin expression profiles in hepatocytes and biliary epithelial cells attains clinical significance in the histogenetic allocation of liver tumors.

Microtubules

Microtubules are a family of relatively stiff hollow structures with a cavity 15–20 nm in diameter surrounded by 5 nm walls. They are built up of two globular proteins, α - and β -tubulin. The α and β subunits form heterodimers which aggregate to form protofilaments that assemble to long tube-like microfilaments made up of stacked rings, with each ring containing 13 subunits. Free and polymerized tubulins are in a dynamic equilibrium. Microtubules may be visualized during light microscopy by using antibodies against tubulin. They form a dense cytoplasmic network of intertwined filaments that tend to concentrate near the sinusoidal membrane and the Golgi apparatus. Microtubules are part of the mitotic apparatus of the cell forming the spindle, which moves the chromosomes in mitosis. They provide the tracks along which intracellular vesicles, secretory granules and organelles move, although they are not in direct contact with the organelles. Microtubule-associated proteins (MAPs) stabilize the microtubules and mediate their interactions with other components of the cytoskeleton. The MAPs *kinesin* and *dynein* serve as motor proteins that catalyze the transport along a microtubule [101]. Kinesin possesses ATPase-activity and is involved in the movement of organelles towards the periphery of the cell, while dynein supports the transport in the opposite direction. The actions of these two MAPs have been characterized in neurons, but it is reasonable to assume that they exert comparable functions in the hepatocyte as well.

Sinusoidal Endothelial Cells

Sinusoidal endothelial cells (SEC) are flat cells spread along, and lining, the widely ramified network of sinusoids that converge towards the central vein of the

lobule. In contrast to endothelial cells of other blood vessels they lack a basement membrane. They are situated on a smooth layer of extracellular matrix that primarily contains collagen IV. Their nucleus bulges out the cell body and their slender cellular processes establish a loose contact with neighbouring endothelial cells. SEC membranes are highly folded, the cells contain vesicles and vacuoles, and they are in contact with the microvilli of the hepatocytes. Nonspecific esterase serves as a marker of SEC and SEC react with the monoclonal antibody MS-1 [38, 47, 122].

Pores (*fenestrae*) 100–150 nm in diameter are typical of SEC and transform the sinusoidal endothelium into a “sieve plate.” This endothelial sieve provides for direct communication between the sinusoidal lumen and the space of Disse, so that, for example, T lymphocytes may interact with hepatocytes through SEC-fenestrations [124, 128]. 6–8% of SEC surface falls upon the fenestrations. The endothelial fenestrae of periportal (zone 1) located SEC are somewhat larger than those of centrilobular (zone 3) SEC. However, the fenestrae in zone 3 outnumber those in zone 1, resulting in the “porosity” of centrilobular sinusoids being somewhat greater than that of periportal sinusoids. The endothelial fenestrations are dynamic structures, with the ability to change their diameter. This ability to contract and dilate is accomplished by both cytoskeletal actin and myosin filaments, and by actin binding proteins [45, 105]. Both $\text{Ca}^{++}\text{Mg}^{++}$ -ATPase and Ca^{++} pump-ATPase are present on the endothelial fenestrated plasma membrane and may be involved in the regulation of intracytoplasmic Ca^{++} concentration [129].

If under pathologic conditions sinusoids become capillarized, they lose their fenestrations, acquire a basement membrane-like layer and express factor VIII associated antigen and the CD34 molecule.

In addition to shielding mechanically the sinusoidal lumen from the space of Disse, SEC exert many *functions*, such as

- Scavenger and transport functions
- Barrier functions
- Synthesis and secretion of cytokines and growth factors
- Modulation of sinusoidal circulation

By means of specific *surface receptors* SEC may incorporate soluble material from the blood for intracellular lysosomal degradation or for selective transport to the hepatocytes. The uptake occurs after specific binding

Table 3.6 Sinusoidal endothelial receptors and corresponding ligands

Receptor	Ligand
Mannose/ N-acetylglucosamine receptor	Lysosomal enzymes
	Tissue plasminogen activator
	Salivary amylase
Fc receptor	Immune complexes
	Immune complexes
Hyaluronic acid receptor	Hyaluronic acid
	Chondroitin sulfate
Collagen receptor	Denatured collagens
Laminin receptor	Laminin/nidogen
Scavenger receptor	Polyanionic proteins
	Acetylated LDL
	Collagen-propeptide

Source: Adapted from [104]

of the ligand to its membrane receptor as receptor-mediated endocytosis or via coated pits and clathrin-coated vesicles (Table 3.6). SEC express fibronectin, hyaluronic acid, mannose and scavenger receptors, and the CD4 molecule on their surface. By clearing constituents of the extracellular matrix, such as degradation products of collagen, glycosaminoglycans, chondroitin sulfate, heparin and dermatan sulfate, they play a role in the metabolism of the extracellular matrix. Increased serum concentrations of extracellular matrix components in chronic liver diseases are therefore not necessarily due to increased synthesis of these components but can be caused by their diminished endothelial clearance. The *scavenger receptor* binds a multitude of substances involved in lipid metabolism, such as modified LDL and HDL [104]. The *mannose/N-acetylglucosamine receptor* binds, for example, lysosomal enzymes, microorganisms (bacteria, fungi, parasites) and tissue plasminogen activator (t-PA). SEC express an *Fc-receptor* for immune globulin G and *receptors for adhesion molecules ICAM-1* and *VCAM-1*. They appear to participate in the immune defense of hepatic infections and in inflammatory liver processes. Large protein molecules such as ceruloplasmin, transferrin, transcobalamin cross the SEC by *receptor mediated transcytosis*. During their endothelial passage they are chemically modified and bind thereafter to the galactose receptor on the sinusoidal membrane of the hepatocyte.

Extracellular fluid is taken up by pinocytosis in drop-shaped membrane bound vesicles.

Under normal circumstances SEC are not capable of phagocytosing foreign material. However, if the

function of liver macrophages (Kupffer cells) is impaired or if Kupffer cells are “exhausted,” SEC become phagocytotically competent and engulf foreign particles in large membranous vesicles with their cytoplasmic processes.

The sinusoidal endothelium represents a *selective barrier* for animate and inanimate particles on their way from the sinusoidal blood to the hepatocyte and backwards. The endothelial fenestrae are variable in their size and are selectively permeable. Increasing sinusoidal pressure experimentally leads to an increase in their diameter. Norepinephrine and serotonin (5HT₂-receptors on SEC membrane) increase actin-activated myosin ATPase activity which initiates contraction of cytoskeletal actin filaments and of fenestrae. The mechanism for the relaxation of fenestrae involves a decrease in the cytosolic-free calcium concentration and an inactivation of myosin light chain kinase. Under these conditions myosin light chain phosphatase dephosphorylates the myosin light chain and ultimately causes relaxation of fenestrae [45].

The endothelial sieve is permeable to large protein molecules, but is impermeable to blood cells. Chylomicrons can cross the endothelial fenestrae only after having been transformed into chylomicron remnants. Very low density lipoproteins secreted by the hepatocytes into the space of Disse reach the sinusoidal blood through the endothelial fenestrae. In addition to their defensive functions and clearance activities SEC are *secretory cells*. They secrete many substances with autocrine and paracrine effects (Table 3.7). Therefore they presumably also have an impact on the inflammatory reaction, growth of liver cells, liver regeneration and microcirculation.

Kupffer Cells

Kupffer cells are liver specific macrophages. As part of the mononuclear phagocyte system they constitute 80–90% of all tissue macrophages present in the body [41]. Their embryonic origin is from a stem cell in the bone marrow or in the liver. Their life span averages several months and they are replenished by transformation of circulating monocytes that migrate to the liver, and by limited self-renewal through division of resident Kupffer cells. Their mitotic index and proliferation rate are low [121].

Table 3.7 Secretory products of sinusoidal endothelial cells (selection)

Cytokines
TNF- α
Interleukin-1
Interleukin-6
Interferon
Growth factors
Hepatocyte growth factor (HGF)
Insulin like growth factor II
Transforming growth factor β
Fibroblast growth factor
Matrix components
Collagens III and IV
Thrombospondin
Laminin
Fibronectin
Undulin
Vasoactive substances
Endothelin
Nitric oxide
Plasminogen activator 1-inhibitor
Von Willebrand factor
Prostaglandins^a
Prostaglandin D ₂

^aMarkedly less than Kupffer cells

Kupffer cells reside within the lumen of the liver sinusoids. They are polymorph cells with membranous folds, plump microvilli and star-like cytoplasmic processes. With the help of these pseudopodia they adhere to the sinusoidal endothelial cells.

They are not evenly distributed throughout the liver, but show differences in population density, cytologic characteristics and physiologic functions in different zones of the hepatic acinus. Forty-three percent of Kupffer cells are found in the periportal zone 1, 32% in zone 2, and 25% in the perivenous zone 3. Compared to hepatocytes they are relatively rich in lysosomes. Kupffer cells located in zone 1 contain more lysosomes per cell than centrilobular Kupffer cells. The cellular hallmarks of Kupffer cells are the endogenous peroxidase activity localized in the nuclear membrane and in the endoplasmic reticulum, the expression of MHC class II antigens and of many surface receptors (Table 3.8) as well as the phagocytosis of latex particles.

The most important *Kupffer cell function* is the uptake, processing and presentation of antigenic material. As macrophages they are capable of phagocytosing foreign material, of producing cytokines and of

Table 3.8 Kupffer cells receptors and corresponding ligands

Receptor	Ligand/function
Galactose/fucose receptor	High activity for ligands expressing galactose <u>Examples</u> Erythrocytes Low density lipoproteins Fibrinogen Aggregated IgA Carcinoma antigens
Mannose/ N-acetylglucosamine receptor	Mannose expressing ligands or lysosomal enzymes <u>Example</u> Microorganisms
Lipoprotein receptors	Clearance of lipoproteins <u>Examples</u> <i>LDL-receptor</i> clears LDL-cholesterol <i>Scavenger receptor</i> clears LDL, VLDL, Lipoprotein a
Fc receptor	Binding of Fc-portions of IgG- and IgA-containing immune complexes
Complement receptors	Removal of complexes that are laden with complement, e.g. bacteria, thrombocytes
Fibronectin receptors	Phagocytosis of material opsonized with fibronectin
CEA receptor	Clearance of circulating CEA
Lipopolysaccharide receptor	Binding of endotoxin with subsequent Kupffer cell activation. Significant in septicemia
Cytokine receptors	TNF- α , IL-1, IL-2, TGF- β

Source: Adapted from [72]

fending off tumor cells. Through assumed paracrine effects they impact the function of hepatocytes, sinusoidal endothelial cells and hepatic stellate cells. Their shape and topographic distribution within the lobule are adapted to these functions. The numerous cellular pseudopodial processes confer a large contact area and their numerical preponderance in the periportal zone corresponds to the region of the most intense initial antigen affluence. While periportal Kupffer cells are more active phagocytes, their perivenous counterparts secrete relatively more cytokines [51]. Kupffer cells are constantly exposed to gut-derived bacteria, microbial debris and bacterial endotoxin. In the normal liver they clear approximately 90% of bacteria transported by the sinusoidal blood. The mechanism by which Kupffer cells clear viruses is not well understood. During acute

viral hepatitis Kupffer cells proliferate markedly. The human immune deficiency virus (HIV) can be taken up by CD4 receptors on Kupffer cells. Kupffer cells take up endotoxins by a receptor-independent mechanism and may transfer them to hepatocytes for further degradation. Upon activation Kupffer cells release various products, including cytokines, prostanoids, nitric oxide and reactive oxygen species, and may acquire cytotoxic features. Morphologic evidence of this activation is an increase in size and an augmentation of membrane folds, associated with an increased extension of their cytoplasmic processes. Kupffer cells are intimately involved in the liver's response to infection, toxins, ischemia, resection and other stresses [41]. In septicemia and in infectious diseases Kupffer cells secrete IL-1, IL-6, TNF- α , TGF- β , IFN- α , IFN- β and prostaglandin E₂ [43]. Cytokines, such as IL-1, IL-6, TNF- α , have an important role in the acute phase response and induce hepatocytes to synthesize acute phase proteins, e.g. C-reactive protein, fibrinogen, etc. Thus Kupffer cells play an important role in innate and acquired immunity and endotoxin-mediated Kupffer cell activation as well as cytotoxic mechanisms induced by Kupffer cells appear to be key mechanisms in the pathogenesis of various liver diseases.

In addition to their phagocytotic and endocytotic abilities, Kupffer cells are assumed to exert paracrine effects on hepatocytes, sinusoidal endothelial cells and stellate cells by secreting eicosanoids, growth factors and cytokines. Kupffer cells are responsible for 65% of hepatic eicosanoid production. Twenty-three percent fall upon sinusoidal endothelial cells and 12% on hepatocytes. The main product is prostaglandin D₂ that possibly stimulates the hepatocyte to increase glucose release into the blood. Kupffer cells also produce more thromboxane B₂, PGF_{2 α} and leukotrienes than sinusoidal endothelial cells. However, like endothelial cells they do not produce potent leukotrienes, such as LTB₄ or LTC₄. Interferon, TNF- α , platelet activating factor (PAF) stimulate the production of eicosanoids by Kupffer cells.

The production of hepatocyte growth factor by Kupffer cells suggests that they may affect growth and proliferation of hepatocytes, e.g. after liver injury or hepatic resection.

In addition to the aforementioned substances Kupffer cells may produce erythropoietin, insulin-like growth factor, proteoglycans, apoprotein E, nitric oxide and superoxide anion.

Hepatic Stellate Cells

(Synonyms: Ito cells, fat storing cells, lipocytes, pericytes)

In 1876 von Kupffer described for the first time “stellate cells” at the edge of the sinusoids and erroneously ascribed to them the function of phagocytosing endothelial cells. In 1882 Disse localized these “stellate cells” described by von Kupffer in the subendothelial, perisinusoidal space that today bears his name. Only in 1951 did Ito realize that the “stellate cells” described originally by von Kupffer and the resident liver macrophages represent two distinct cell populations [68]. Wake reported in 1971 that the “stellate cells” described by Ito correspond to the “stellate cells” described originally by von Kupffer [120]. Today the intrasinusoidal liver macrophages are called Kupffer cells. They are not identical to the perisinusoidal cells described originally by von Kupffer, which he wrongly assumed to be located inside the sinusoids. The perisinusoidal cell type differs in location, appearance and function from Kupffer cells. Many synonyms (see above) are in use today to name these perisinusoidal cells. In recent years the term “hepatic stellate cells” (HSC) has prevailed and will be used in this book interchangeably with “Ito cells”.

The origin of HSC is controversial and the debate whether they are of mesodermal, endodermal or neuroectodermal origin is ongoing [60]. Initially it appeared

that HSC originated from the mesenchymal cell of the septum transversum (see Chapter 1). However, there is some evidence that in the adult human liver HSC may derive from the bone marrow [36, 109]. Furthermore, relatively recent work has shown HSC to express glial fibrillary acidic protein and nestin, suggesting a neuroectodermal origin [84].

Every third to fourth non-parenchymal cell in the liver is an HSC. The volume density of HSC relating to non-parenchymal cells is 20%. HSC reside in the space of Disse between the basolateral membrane of the hepatocyte and the extraluminal side of the sinusoidal endothelial cells. Their long, dendritically ramified cytoplasmic processes entangle the sinusoids (hence their denomination as “pericytes”) and extend also into the interhepatocellular space. The close morphologic relation of HSC with sinusoidal epithelial cells, hepatocytes and nerve fibers lets one assume a mutual autocrine, paracrine and neural impact [42]. An intralobular heterogeneity is evidenced by the fact that more HSC are present in the periportal region than at the center of the lobule, and that zone 1 HSC are smaller and have shorter cell processes than HSC in zone 3.

In the normal liver HSC are difficult to recognize in sections stained conventionally with hematoxylin-eosin. They become readily visible as fat storing cells (lipocytes) by combining gold or silver impregnation with fat stains (Fig. 3.18). Their most striking characteristic in the normal liver is the storage of

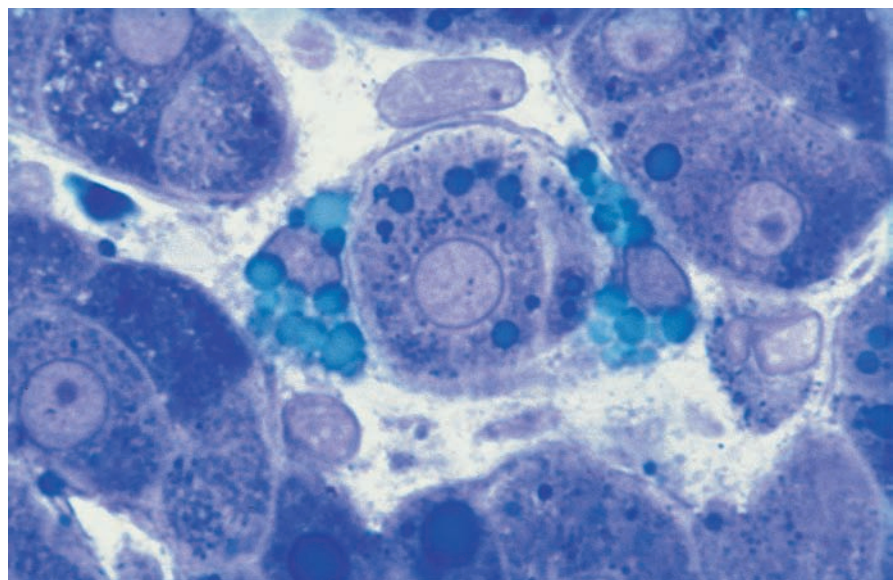
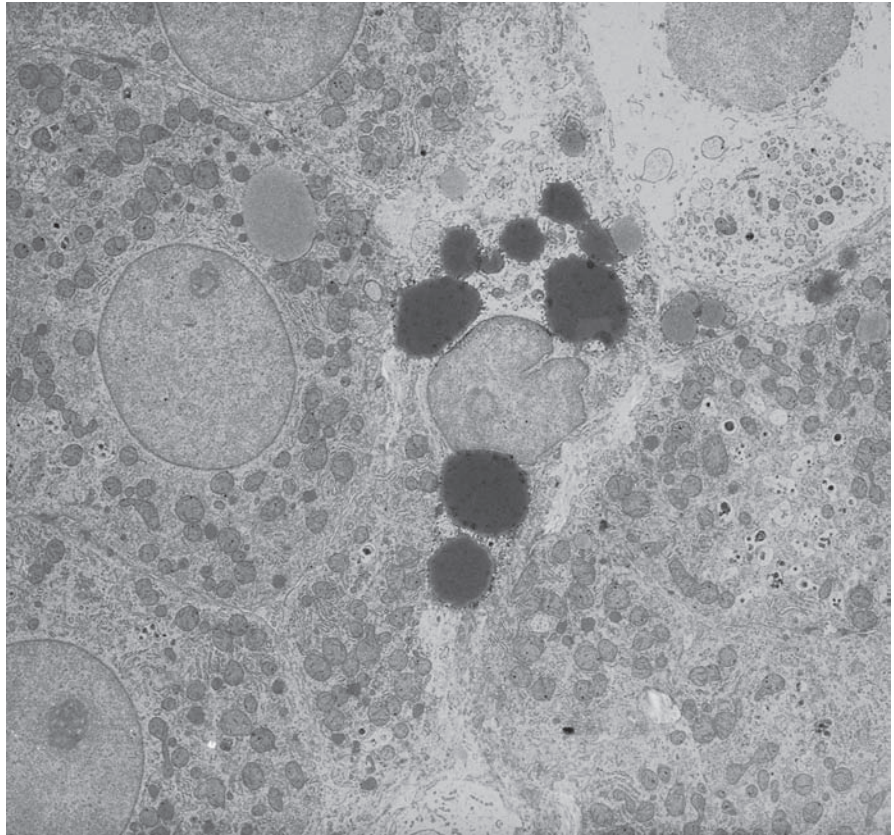


Fig. 3.18 Two stellate cells containing greenish cytoplasmic fat vacuoles. (Toluidine Blue stained semithin section)

Fig. 3.19 Fat storing stellate (Ito) cell in-between two hepatocytes in the space of Disse



vitamin A which upon excitation with UV-light with a wavelength of 328nm imparts a short-lived autofluorescence. This vitamin A autofluorescence is an endogenous marker of unfixed HSC. Due to its transient nature and the strong nonspecific fluorescence of surrounding structures, this feature of HSC can hardly be exploited for scientific investigations. In vitamin A intoxication this fluorescence is particularly prominent. In addition to retinoids HSC also store collagen and other extracellular matrix components. Immunocytochemical labelling with antibodies against cytoskeletal markers – desmin, vimentin, α -smooth muscle actin (α -SMA) – is nowadays the most common light microscopic method for visualizing HSC. The results, however, depend on the species examined and on the lobular localization of HSC. Desmin is not present in all HSC. Vimentin is found in all HSC but also in many other mesenchymal cells which curtails considerably its identification as a selective marker for HSC. Furthermore, resting and inactive HSC, i.e. those present in normal liver tissue and activated HSC, i.e. those stimulated by liver

injury exhibit different immunocytochemical characteristics. A very valuable marker, especially of activated HSC by liver injury, is α -SMA [100].

A characteristic electron microscopic feature of HSC is their cytoplasmic fat vacuoles (Fig. 3.19). These vacuoles contain primarily vitamin A as retinol, esterified with a long chain fatty acid, and small amounts of triglycerides, phospholipids, cholesterol and free fatty acids. The rough endoplasmic reticulum is well-developed and, together with the Golgi apparatus, increases markedly after cell activation. Thus, the *phenotype of the HSC depends on its functional state*. The resting HSC is small and densely packed with lipid storing vacuoles. Upon activation the cell enlarges, its processes become longer, the vacuoles decrease in number, the protein secretory apparatus becomes prominent, and many cytoskeletal markers are expressed. The morphologic structure and the abundance of its secretory products give rise to the diversity and complexity of HSC [92]. Research in the last 15–20 years has markedly increased our knowledge of HSC and has shown that, despite their relative

rarity, HSC have an important significance in liver metabolism and in the hepatic response to injury.

HSC exert *functions* in

- Vitamin A and lipid metabolism
- Regulation of sinusoidal blood flow
- Assembly and degradation of extracellular matrix
- Development of liver fibrosis [65, 71, 87, 98]

Furthermore, HSC have an impact on growth and proliferation of hepatocytes, and participate in the inflammatory reaction and in the immune function of the liver [39, 119].

Ninety-five percent of vitamin A in the body is stored in the liver. Orally administered vitamin A is esterified in intestinal epithelial cells, transported in chylomicron remnants to the liver, and taken up initially via receptor-mediated endocytosis by hepatocytes, where it is hydrolyzed to retinol. Though a small portion of retinol remains in the hepatocyte, a major part is transported from the hepatocyte to the HSC. Here again vitamin A is esterified and stored primarily as retinyl-palmitate. Small amounts of retinoids bound to retinoid-binding protein can be taken up by HSC directly from the circulation without involving chylomicron remnants. Direct delivery of retinol into serum by HSC also appears possible. In addition to retinoids, HSC also contain small amounts of triglycerides, phospholipids, cholesterol and free fatty acids.

HSC secrete apolipoprotein E and probably other lipoproteins. However, their exact role in lipoprotein metabolism is not yet defined.

In every acute and chronic liver injury HSC are activated [65]. The activation process is characterized by phenotypical changes (see Chapter 28). The cell transforms from a resting, vitamin A storing HSC to an active, proliferating, myofibroblast-like, contractile, mobile and fibrogenic cell. HSC increase in size, their vitamin A content diminishes and the protein secretory apparatus becomes prominent. Cytoskeletal markers of smooth muscle and fibroblasts – desmin, actin, vimentin – are expressed. The most intense activation and proliferation takes place in the regions of maximal liver injury.

These phenotypic alterations are preceded by an increase in gene expression, not yet entirely understood in its complexity. Gene transcription initiates within a few minutes after liver injury and requires the coordinated activity of several key transcriptional regulators of the HSC genome, e.g. nuclear factor κ B, Jun

family proteins and the peroxisome proliferator activated receptor γ to name just a few [79].

An intact intercellular communication between HSC and Kupffer cells, hepatocytes, thrombocytes, sinusoidal endothelial and inflammatory cells is required for coordinated HSC-activation. Autocrine and paracrine factors sensitize HSC to the action of mediators secreted by these cells. The activation process is accompanied by the synthesis of components of the extracellular matrix and by its continuous remodeling.

The expression of contractile elements (actin microfilaments) and of membrane receptors for vasoactive substances by activated HSC points toward their muscle cell-like features. Activated HSC express the renin-angiotensin system and contract after contact with endothelin-1, angiotensin II, thrombin, substance P, thromboxane A_2 and arginin-vasopressin [39, 40, 89]. Endothelin-1 appears to be the most important contractile stimulus in vivo and its physiologic counterpart, nitric oxide, is also produced by HSC [78, 88]. TGF- β 1 downregulates endothelin receptors favoring relaxation of HSC; on the other hand, TGF- β 1 itself may directly induce contraction of activated HSC [58, 70]. The presence of thrombospondin 1 seems to be a prerequisite for effective signal transduction by active TGF- β 1 in HSC [46]. To complicate things further, human HSC have been shown to secrete the vasodilator peptide adrenomedullin [62]. Thus, the complex interplay between HSC and sinusoidal endothelial cells and the physiological significance of various mediators are still poorly understood. However, the contractile features and the close proximity of HSC to nerve fibers and sinusoids gave way to the concept that HSC may acquire myofibroblast-like features and act as tissue-specific pericytes [87]. By contracting, HSC may change the luminal diameter of the sinusoids and thereby modulate sinusoidal blood flow. Thus HSC seem to have a role in microcirculation and in the pathophysiology of portal hypertension [94]. In addition to affecting sinusoidal blood flow there is emerging evidence that HSC participate in angiogenesis and in sinusoidal remodeling [74].

Recent investigations suggest that HSC do not represent a homogenous cell population, but rather are made up of morphologically and functionally diverse subpopulations. Liver myofibroblasts and HSC might even represent two different cell populations [93].

HSC are the most important cellular sources of extracellular matrix, both in the normal and in the

Table 3.9 Molecules of extracellular matrix and compounds regulating matrix degradation produced by hepatic stellate cells

Molecules of extracellular matrix	
Collagens:	Type I, III, IV, V, VI, XIV
Proteoglycans:	Heparan, dermatan- and chondroitin-sulfate, perlecan, syndecan-1, biglycan, decorin
Glycoproteins:	Fibronectin, laminin, merosin, tenascin, nidogen/entactin, undulin, hyaluronic acid, synemin [88]
Matrix proteinases and their inhibitors	
Matrix proteinases:	Matrix metalloproteinase 2 (type IV collagenase), stromelysin-1, matrix metalloproteinase 1 (interstitial collagenase), membrane-type matrix metalloproteinase
MMP ^a -regulators:	TIMP ^b -1, TIMP-2, uroplasinogen activator, plasminogen activator-inhibitor-1, uroplasinogen activator-receptor, C1 esterase-inhibitor, α_2 -macroglobulin

^aMatrix-metalloproteinase

^bTissue inhibitor of metalloproteinase

Source: Adapted from [57]

injured liver (Table 3.9). Resting HSC secrete a basement membrane like matrix consisting of non-fibrillar collagens (type IV and VI), while activated HSC produce an interstitial matrix rich in fibrillar collagens (type I and III), thereby contributing essentially to the pathogenesis of liver fibrosis which may develop after liver injury.

Recent work shows that activated HSC express leptin which is profibrogenic and which upregulates proinflammatory and proangiogenic cytokines in human HSC [30, 48]. By synthesizing matrix-proteases HSC are not only involved in the build-up of extracellular matrix, but also in its degradation. Expression of insulin-like growth factor I by activated stellate cells reduces fibrogenesis and enhances regeneration after liver injury [99].

The multitude of factors produced by HSC (Table 3.10) suggest that HSC also have an effect on hepatocellular proliferation and regeneration, and that they participate in the recruitment of mononuclear and neutrophil inflammatory cell infiltrates as well as in the acute phase reaction. Activated HSC may play a role in the immune function of the liver by expressing molecules for antigen presentation, internalizing macromolecules, and

Table 3.10 Cytokines, growth factors, inflammatory mediators and receptors associated with hepatic stellate cells

Mediators and growth factors	
Prostanoids:	PGF2 α , PGD2, PGI2, PGE2; LTC4, LTB4
Leukocyte mediators:	Macrophage colony stimulating factor (M-CSF), monocyte chemoattractant peptide-1 (MCP-1), platelet-activating factor (PAF)
Acute-phase-components:	α_2 -macroglobulin, interleukin-6
Mitogens:	Hepatocyte growth factor (HGF), epidermal growth factor (EGF), platelet derived growth factor (PDGF), stem cell factor, insulin-like growth factor I and II, acidic fibroblast growth factor
Vasoactive mediators:	Endothelin-1 (ET-1), nitric oxide (NO), adrenomedullin
Fibrogenic substances:	Transforming growth factor β (TGF- β)-1, -2, -3, leptin
Receptors	
Cytokines:	PDGF-r ¹ , TGF- β -r I, II and III, ET-r, EGF-r
Other:	Ferritin-r, thrombin-r, mannose-6-phosphate-r, uroplasinogen-r

¹r = receptor

Source: Adapted from [57]

modulating T-lymphocyte proliferation [119].

High glucose concentrations and oxidative stress stimulate HSC to proliferate [59, 108]. Hepatic stellate cell death can be induced by activated Kupffer cells by a caspase 9- and receptor-interacting protein-dependent mechanism involving expression by HSC of the TRAIL receptor-2/death receptor-5 and undergoing TRAIL-mediated apoptosis [56, 110]. HSC apoptosis may also be induced by proteasome inhibition, and HSC necrosis by the endogenous cannabinoid anandamide [34, 102]. Stimulation of HSC death may offer a potential future therapeutic strategy inhibiting liver fibrosis.

Pit Cells (Liver Associated Lymphocytes)

Pit cells were described for the first time by E. Wisse in 1976 [127]. They are liver associated lymphocytes and number approximately 10% of Kupffer cells. Due to their electron-dense cytoplasmic granules these rare non-parenchymal cells were originally thought to

represent endocrine cells. Nowadays they are counted among the large granulated lymphocytes (LGL).

The liver associated lymphocytes are polarly structured intrasinusoidal cells. The nucleus is situated eccentrically. Electron dense membranous granules are found in the center of the cell, measure 0.2–0.5 μm in diameter, and contain acid phosphatase. The vast majority of granules are round though some are rod-shaped. Parallel tubular structures are associated with the granules. Pit cells are attached to the luminal side of sinus endothelia and normally they are not present in the space of Disse. Their cytoplasmic processes are in contact with Kupffer cells and, through the endothelial sieve, with the microvilli of hepatocytes. They can form pseudopodia and are probably able to move actively along the sinusoidal wall. In viral and neoplastic diseases, under the influence of interleukin-2 they occasionally can migrate into the space of Disse [44, 72].

The liver associated lymphocytes probably originate from the bone marrow and reach the liver via the blood stream. However, they should not be confused with circulating peripheral LGL caught up accidentally in the sinusoidal network. *Pit cells are a liver specific population of LGL.* They reach their position by a targeted process, guided by adhesion molecules on sinusoidal endothelial and Kupffer cells.

Diverse pit cell subpopulations are found in the liver. This heterogeneity relates to phenotypic markers (different size and number of granules), immune phenotypic features (different surface markers) and functional characteristics (cytotoxic activity). Compared to blood-LGL, liver associated LGL display a higher grade of activation and a stronger cytotoxic activity. Pit cells are ascribed the features of natural killer (NK) cells, i.e. they kill their target cells “spontaneously” without the need of prior immunization. In contrast to cytotoxic T cells, lysis of target cells by NK cells is not MHC-restricted but occurs by an antibody dependent (ADCC) mechanism. Exocytosis of their granules is important in this process.

Liver associated lymphocytes probably exert antiviral and antitumoral functions. They help to eliminate the viruses via their cytotoxicity against virally infected cells. Their strategic location in the “first defense line” helps them to play an active role in immunologic tumor surveillance and in impeding the engraftment of metastatic tumor cells [126]. To what extent they may influence growth and differentiation of hepatocytes is presently still unknown.

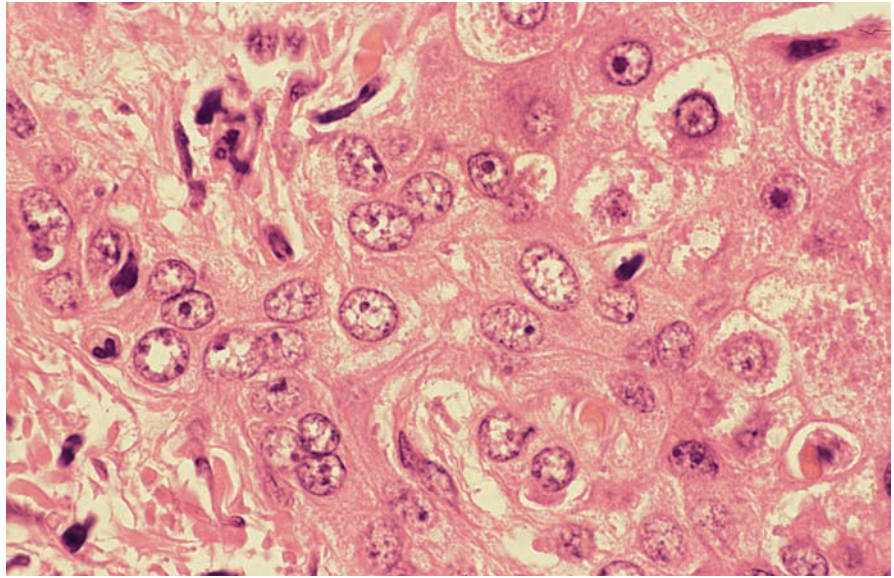
Biliary Epithelial Cells (Cholangiocytes)

Biliary epithelial cells make up approximately 3–5% of all cells in the liver. They do not represent a homogeneous cell population, but exhibit conspicuous morphological and functional heterogeneity along the course of the bile ducts towards the hilum of the liver [69, 80]. The cells of the *bile ductuli*, lying at the periphery of the portal tracts at the interface between the portal tract and the lobular parenchyma, have a relatively large nucleus and a scant cytoplasm. The *interlobular (terminal) bile ducts* are within the portal tracts and show a flat cuboidal epithelium. The nucleus is small, the cytoplasm faintly eosinophilic, not staining with Alcian blue or PAS. The *septal bile ducts* possess a simple, mucous secreting high cuboidal epithelium. The round-oval nucleus is located basally, and the cytoplasm is clear. The apical cell portion stains with PAS, and PAS-positive granules are found in a supranuclear position. Due to the acidic carboxyl-groups of mucopolysaccharides, their cytoplasm stains with Alcian blue [52, 113]. Despite the same embryonic precursors biliary epithelial cells and hepatocytes differ phenotypically and functionally [33, 103]. Cholangiocytes contain fewer mitochondria and endoplasmic reticulum than hepatocytes. They lack cytochrome P450. Their filamentous cytoskeleton is more pronounced. The plasma membrane has an apical pole with short, coarse microvilli. Their basolateral segments are in contact with adjacent biliary cells and rest on a basement membrane. With the exception of the bile canaliculi, all bile ducts have a basement membrane. Due to the mucopolysaccharides present, the basement membrane stains well and is readily visible as a delicate reddish strip on PAS and PAS-diastase staining. Cytokeratins 7 and 19, epithelial membrane antigen, carcinoembryonic antigen, carboanhydrase and γ -glutamyl-transpeptidase serve as markers for bile duct epithelia. A prominent Golgi apparatus, many cytoplasmic membranous vacuoles, and a rich vascularization are features that suggest an active role of bile duct epithelia in bile formation.

Hepatic Stem Cells

The concept of a hepatic stem cell was expressed for the first time by Wilson and Leduc in 1958 [125]. Stem

Fig. 3.20 Small cells with round to oval nuclei and scant cytoplasm are seen between the portal tract (left lower corner) and periportal hepatocytes (right upper corner). They demarcate the canals of Hering and are thought to have stem cell potential



cells are undifferentiated cells, capable of proliferating and of differentiating into a functionally distinct progeny. There is widespread agreement at this time that a cell population with stem cell potential resides in the liver [31, 107]. The liver can therefore be considered as an organ with facultative stem cells, which are called upon during injury states during which the hepatocytes and cholangiocytes themselves can no longer effectively regenerate [64]. Hematopoietic stem cells, embryonic stem cells, multipotent progenitor cells and monocytes have been reported to give rise to hepatocyte-like cells in vitro [116]. Recently it has been shown that mesenchymal stem cells derived from human bone marrow may serve as a source for the propagation of hepatocyte-like cells [35]. However, the question that has not been solved yet is whether liver stem cells in vivo originate in the bone marrow, in the blood or in other organs, or whether they reside in the liver from the onset of embryonic development until adult life [32, 36, 50, 61, 75, 86, 97, 109, 114, 115].

Specific cell surface markers for human hepatic stem cells are not available presently. Even the most basic parameters of liver stem cells such as their size and morphology are not yet known. There is some evidence however, that they are morphologically heterogeneous, displaying both hepatocyte-like and biliary-like epithelial phenotypes [76, 85].

Tissue maintenance in the liver is not driven by stem cells but rather by division of mature hepatocytes

and bile duct epithelial cells. However, quiescent hepatic cells with stem cell potential may become activated after certain stimuli to proliferate and differentiate into hepatocytes or cholangiocytes. The *oval cells* – oval nucleus, scant cytoplasm – localized in the canals of Hering (i.e. in the transition zone between periportal hepatocytes and the cholangiocytes of the smallest terminal bile ducts) are regarded as cells with stem cell potential (Fig. 3.20) [53, 95]. The precise origin of oval cells is unknown. It is assumed that they may correspond to bile duct cells of the embryonic ductal plate. Importantly, *oval cells are not liver stem cells*, but the bi-potential offspring of stem cells, analogous to what are called committed progenitors in the hematopoietic system [64]. In the human liver facultative stem cells are also believed to reside in the periductal regions of the portal tracts. Oval cells are activated to proliferate and differentiate by liver injury, especially if liver damage is combined with an inability of hepatocytes to proliferate. This is most often the case after massive hepatic necrosis, during carcinogenesis, or in each situation where liver cell proliferation is inhibited or slowed down by a noxious agent, e.g. DNA-damaging agent. Ductular reaction (see Chapter 20) might emanate from proliferating oval cells [112]. In animal experiments hepatocytes themselves could function as facultative stem cells and rescue the biliary epithelium during repair from injury, when its proliferative capacity was compromised.

Extracellular Matrix

The fibrous extracellular matrix (ECM) of the liver is primarily found in the liver capsule, portal tracts, space of Disse and in the perivenous areas. The ECM is not an inert filling material, but rather it represents a dynamic accumulation of complex macromolecules. Together with the cellular elements discussed above, components of the ECM perform important tasks within the overall function of the liver [138, 142, 143]. In close association with parenchymal and non-parenchymal cells the ECM participates in mechanical support to the liver, physiologic metabolic activities, signal transduction and cell differentiation, and plays an important active part in liver injury.

Cell surface membrane receptors for different matrix components mediate bidirectional contacts between hepatocytes and the ECM. The ECM may affect cellular gene expression and its products in turn act on the matrix.

The main producers of ECM in the human liver are the hepatic stellate cells. The ECM of the normal organ differs quantitatively and qualitatively from that of a diseased liver. *In all forms of liver injury activated hepatic stellate cells play a central role in remodeling of the ECM.* In performing this task they are influenced by mediators secreted by sinusoidal endothelial cells, Kupffer cells and hepatocytes, and probably by circulating lymphocytes and neutrophil granulocytes as well. The complex interplay of autocrine and paracrine growth factors, and of cytokines, in remodeling of the ECM is still poorly understood (see Chapter 28).

The following substances are *matrix components*:

- Collagens
- Elastin
- Glycosaminoglycans and proteoglycans
- Adhesive glycoproteins

These substances are macromolecules that participate in the assembly of basement membranes of blood vessels and bile ducts. They are also found in the portal fibrous stroma, loosely arranged in the space of Disse and in perineural tissue.

Collagens and elastin confer tensile strength to the ECM, whereas proteoglycans are responsible for its gel-like character. Adhesive glycoproteins form bridges between cells and the fiber proteins of the ECM. The great variation within individual families

of macromolecules and the different combination of single macromolecules in composing the matrix, confers an extreme diversity on the ECM.

Collagens

Compared to the collagen content of skin and tendons, the normal liver contains relatively little collagen, approximately 4 g/100 g dry weight liver tissue. Today we are cognisant of more than 90 genes that code for 19 different collagens. 90% of all collagen types in the body are collagen types I, II and III. *The predominant collagen types found in the liver are types I, III, IV, V and VI.*

Collagen Structure

The assembly of collagen molecules takes place according to a uniform principle. Chemical composition, diameter of microfibrils, and fibril arrangement, however, show tissue specific differences. Three helical polypeptide α -chains wind around each other to form a *triple helix*. Triple helices assemble to form *microfibrils* that cross-link and are stabilized by covalent bonds. Microfibrils aggregate to form *collagen fibrils* that may further grow into larger rope-like collagenous structures referred to as *collagen bundles* (Fig. 3.21) [138, 139].

Native collagen fibrils are readily identified in electron micrographs by their cross-striated appearance (*banded fibril*). They exhibit a marked axial periodicity. Each period consists of a light and a dark band. One can also discern 10–13 fine dark cross-striations within each period. The packaging of collagen molecules into fibrils and the “staggered arrangement” of basic collagen elements gives rise to the cross-striated appearance that is characteristic of collagen in electron micrographs.

The entire collagen molecule, however, is not made up of triple helices. Straight segments and globular domains are found as well. For steric reasons, every third amino acid in the triple helix must be glycine. Compared to other proteins proline and hydroxyproline are overrepresented in collagen, together comprising approximately 25% of all amino acid residues in collagen.

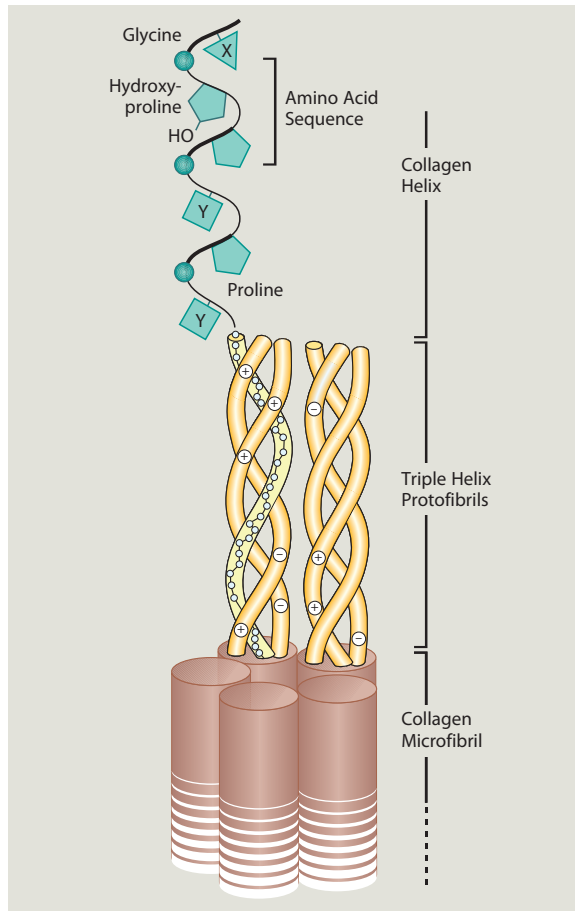


Fig. 3.21 Helical structures of fibrillary collagen. The spiraling polypeptide chains are composed of interconnected subunits (From [138]. With permission)

Collagen Biosynthesis

Hepatic collagen is synthesized by hepatic stellate cells. First *pre-procollagen* is formed, which after loss of a signal peptide gives rise to *procollagen*. Procollagen is taken up by the Golgi apparatus, where it undergoes many posttranslational modifications, is packed into vesicles and extruded into the extracellular space. *Only hydroxylated procollagen molecules are released by the Ito cells into the space of Disse*. The intracellular post-translational hydroxylation of approximately 50% of prolyl residues and 10–80% of lysyl residues is the prerequisite for the aggregation of α -chains to form a triple helix. In addition to hydroxylation, posttranslational glycosylations of the procollagen molecule occur in the hepatic stellate cells. *Procollagen matures to collagen in the extracellular space*. The formation of a stable

quaternary structure necessitates further modifications of procollagen, such as the separation of a registry peptide (a segment of 150 amino acids on the N-terminus of procollagen), the action of extracellular procollagen-proteinases, and lysin oxidase activity. These lead to cross-linking of collagen and the formation of mature and stable collagen fibres [132].

Collagen Types

The individual collagen types differ predominantly in protein content, degree of hydroxylation, glycosylation, and the extent of cross-linking. Collagen types I and II form large fibrils, whereas collagen types V and VI generate small ones. Collagen type IV forms a net-like structure.

Collagen Types I and III

Collagen types I and III each amount to approximately 40% of total collagen of the normal liver. In the cirrhotic liver collagen type I becomes the most important collagen quantitatively, as its relative proportion rises to 60–70% [140]. The reticulin framework of the liver, readily identified with special stains by light microscopy, does not have a chemically uniform composition; rather, it is composed of a mixture of the collagens type I and III with the corresponding glycoproteins.

Collagen Type IV

Collagen type IV belongs to the lattice forming collagens. One percent of liver collagen is collagen type IV and it is encountered in basement membranes, portal tracts, and the space of Disse. The triple helices of collagen type IV are disrupted by 20 non-helical segments. These sections are characterized by increased flexibility. The fibrils of type IV collagen cannot aggregate side to side. They form monomers and dimers that associate to form a tetrameric network.

Collagen Type V

The pericellular collagen type V is found in the center of larger fibrils. Two percent of liver collagen is collagen type V.

Collagen Type VI

With 0.1% of total liver collagen, type VI is the most uncommon collagen in the liver. It is found in the portal tract stroma and in the space of Disse. It forms microfibrils which form loose links between the collagen bundles of the larger fibrillary collagen types I and III. Its filaments are generated by antiparallel arrangement of monomers, side-to-side association of dimers, and end-to-end interaction of tetramers. It differs from other collagens by being primarily composed of globular domains, with only a small central region showing a triple helical structure. The globular domains are responsible for its interactions with collagen types I and III, other matrix proteins, and integrin membrane receptors, respectively.

Collagen Type XVIII

The non-fibrillary collagen type XVIII of the human liver is found in the perisinusoidal space and in the basement membranes. It is synthesized by hepatocytes in the normal liver and by activated hepatic stellate cells in the fibrotic liver [137].

Collagen Degradation

The half life of liver collagen is approximately 30 days. The degradation of collagen occurs in the extracellular space by *matrix-metalloproteinases* (MMP) that are specific for individual collagen types [130, 136]. A small proportion of collagen is degraded inside the cell by lysosomal cathepsins before being secreted, or after secretion and subsequent phagocytosis.

The *extended MMP-family* consists of at least 15 enzymes with varying substrate specificities, eight of which are present in the liver. According to their substrate profile MMPs are divided into three groups.

- Collagenases degrade interstitial collagens
- Gelatinases degrade gelatins and basement membrane collagens
- Stromelysins have a broad spectrum of activity

MMP 1 (interstitial collagenase) and MMP 8 (granulocyte collagenase) catabolize collagen types I, II, III, VII, VIII and X, denatured collagen and the central protein of the proteoglycans. MMP 3, 7 and 10,

called stromelysins, degrade proteoglycans, laminin, fibronectin and the collagens IV, V, IX and X.

MMPs are active exclusively in the extracellular space where they are secreted as inactive proenzymes. The activity of MMPs is affected by their gene expression and by activators and inhibitors in the extracellular space. Gene transcription is upregulated by EGF, FGF, IL-1, TGF- α , TNF- α and PDGF. TGF- β , IL-4 and glucocorticoids downregulate gene expression, except for MMP 2, whose gene expression is upregulated by TGF- β as well. Proteinases, such as plasmin and trypsin activate MMP proenzymes by proteolysis.

α_2 -macroglobulin and tissue inhibitors of metalloproteinases (TIMPs) inhibit the activity of MMPs. Hepatic stellate cells, and to a lesser extent also Kupffer cells, produce both MMPs and TIMPs and provide for a dynamic equilibrium of the extracellular matrix. Assembly and degradation of ECM components can therefore proceed side by side in a coordinate fashion.

Hydroxyproline accumulating during degradation of collagen cannot be reused for collagen synthesis. Seventy-five percent is oxidized in the liver to CO₂ and water. The remainder is excreted unchanged in the urine. The urinary excretion of hydroxyproline serves as a rough indicator for the turnover of collagen.

Elastin

Second to collagen, elastin is the major fibrous protein in the ECM. It provides tissues with elasticity. Elastin can assume one of several relaxed, random-coiled orientations. As a tissue is stretched the elastin molecule is elongated. When the stretching force is released elastin spontaneously retracts to its starting position. Thus the entire elastin network recoils like a rubber band.

In the liver elastin is found principally in the blood vessels and in peribiliary areas, as well as in small amounts in the portal tract stroma and in the liver capsule. Fibroblasts secrete *pro-* or *tropoelastin* into the extracellular space where it is converted to elastin. Once in the extracellular space, elastin molecules are covalently cross-linked to one another. They associate with collagen and glycoproteins to form an extensive network of elastic fibers. The cross-linking of elastin molecules to one another and with fibrillary collagen is catalyzed by lysin oxidase and gives rise to intramolecular desmosin cross-links.

Unlike the many different genetic types of collagen there is only one genetic type of elastin. The elastin gene is influenced by IGF-1, TNF- α and IL-1. The degradation is accomplished by elastase or by MMPs. α_1 -antitrypsin is a specific inhibitor of elastase.

Proteoglycans

Proteoglycans are complex macromolecules that are formed by the addition of numerous repeating *disaccharide glycosaminoglycan chains* to a *core protein*. Their aspect is reminiscent of a bottle brush (Fig. 3.22).

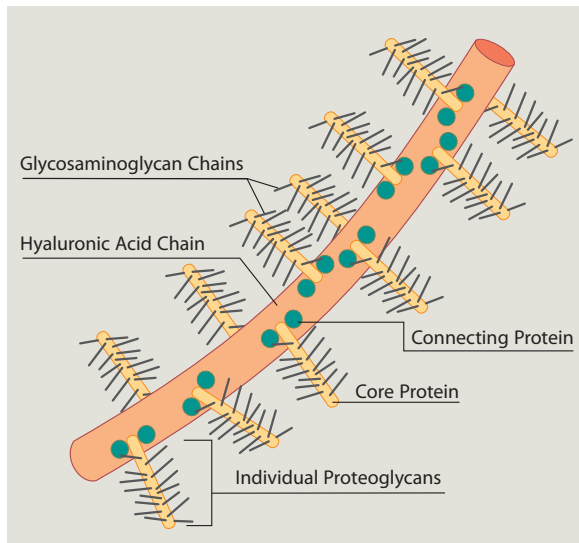


Fig. 3.22 Schematic representation of a proteoglycan with a core protein and numerous carbohydrate side chains

They can be further organized by the noncovalent attachment of several proteoglycan monomers to a large chain of hyaluronic acid molecules. This association is mediated by link proteins. *Proteoglycans are quantitatively the most important components of ECM.* They form a hydrated gel that represents the ground substance of the ECM [141].

Up to 90% of the proteoglycan molecule mass can be taken up by the carbohydrate moiety. The linkage between carbohydrates and backbone protein is accomplished by a trisaccharide consisting of two galactose molecules and one xylose molecule. This trisaccharide links the glycan chain to the hydroxyl group of a serine or threonyl residue of the core protein.

Based on their sugar moiety, glycosaminoglycans are subdivided into several major groups: hyaluronic acid, chondroitin sulfate, dermatan sulfate, heparin and heparan sulfate, and keratan sulfate (Table 3.11). Proteoglycans are characterized by an extraordinary diversity, due to different structures of the core protein, different numbers of side chains, and varying degrees of sulfation (Table 3.12).

Table 3.12 Selected proteoglycans and their preferred distribution

Proteoglycan	Distribution
Betaglycan	Cell membrane
Biglycan	ECM
Decorin	ECM
Fibromodulin	ECM
Aggrecan	ECM
Heparan sulfate-proteoglycan	Endothelial cells
Perlecan	Basement membrane
Syndecan	Epithelial cells
Thrombomodulin	Endothelial cells
Versican	Endothelial cells

Table 3.11 Glycosaminoglycans

Glycosaminoglycan	Disaccharide	Distribution
Hyaluronic acid	Glucuronic acid and N-acetylglucosamine	Skin, numerous connective tissues, vitreous body, and synovial fluid
Chondroitin sulfate	Glucuronic acid and N-acetylgalactosamine	Cartilage, cornea, arteries, skin, and bones
Dermatan sulfate	Either glucuronic or iduronic acid and N-acetylgalactosamine	Skin, heart, heart valves, and blood vessels
Keratan sulfate	Galactose and N-acetylglucosamine	Cartilage, vertebral disks, and cornea
Heparin	Either glucuronic or iduronic acid and N-acetylglucosamine	Lungs, liver, skin, and highly concentrated in mast cell granules
Heparan sulfate	Either glucuronic or iduronic acid and N-acetylglucosamine	Lungs, arteries, basement membranes, and cell surfaces

Source: Adapted from [132]

Hyaluronic acid, a constituent of virtually all connective tissues, is the largest glycosaminoglycan and the only one that is neither sulfated nor bound to a protein. It is synthesized in the cytoplasm by hyaluronic acid synthase. EGF, PDGF, IGF-1 and TGF- β stimulate the synthesis of hyaluronic acid. ICAM-1 appears to be the most important hyaluronic acid receptor on the surface of sinusoidal endothelial cells. It mediates clearance of circulating hyaluronic acid.

Proteoglycans are intertwined with one another and interact with collagen fibrils, forming large *supramolecular compounds*. By means of hyaluronic acid they may bind to the CD44-receptor (= hyaluronic acid receptor) on the cell membrane. In the liver CD44 is expressed on portal and perisinusoidal mesenchymal cells, cholangiocytes and Kupffer cells.

The main features of proteoglycans are their *hydrophilia* and their *ability to bind cations* which is due to their highly negative charge. This causes water to be drawn into the matrix, and turgor pressure to be built up. Proteoglycans form a permeability barrier and regulate the transport of small molecules through the ECM. Through interactions with growth factors (TGF- β , EGF, FGF, PDGF) and cytokines (IL-1, IL-6) they influence the intercellular signal transduction.

Through binding to secreted proteases and to their inhibitors they modulate the enzyme activities of the ECM, which is particularly important in remodeling of the ECM in liver injury.

Activated hepatic stellate cells are the major producers of proteoglycans. They are degraded by lysosomal hydrolases. Proteoglycans are not only found in the ECM, but they may also be expressed on the plasma membrane of cells, where some of them, e.g. the *syndecans*, function as fibronectin and collagen receptors. The cytoplasmic tails of these proteoglycan receptors can interact with the actin cytoskeleton, thus providing a link between the ECM and the cell interior.

Adhesive Glycoproteins

Adhesive glycoproteins or *nectins* form the “glue that holds ECM together”. Adhesive proteins are multifunctional proteins that contain specialized domains. They bind to cell surfaces, interact with collagen and proteoglycans, and thus mediate the contact between ECM, hepatocytes and non-parenchymal cells.

Fibronectin

Fibronectin is a large glycoprotein that is secreted as a dimer. Alternate splicing of its single gene product gives rise to approximately 20 different, tissue-specific multidomain fibronectin isomers. They possess binding sites for fibrin, heparin, bacteria and denatured collagen. By means of the RGD tripeptide sequence (see below) they bind to the fibronectin receptor on the cell surface that belongs to the integrin family.

The interaction and cross-linking of fibronectin with other components of the ECM occurs through the activity of tissue transglutaminase, an enzyme bound to fibronectin. In liver injury it is released from hepatocytes, sinusoidal endothelial cells and hepatic stellate cells.

Fibronectin facilitates adhesion of cells to the ECM through binding to its integrin receptor, enabling the communication between the cellular exterior and interior. It also mediates cell migration through the ECM. Fibronectin can also be demonstrated in the serum.

Tenascin

In the normal liver tenascin C is found exclusively in the perisinusoidal space. It is formed by activated hepatic stellate cells. In liver injury accompanied by portal fibrosis and ductular proliferation it is also expressed in the portal tracts. Among other functions, tenascin facilitates cell migration and cell division.

Undulin

Undulin is a widespread glycoprotein present in uniformly undulated fibers. It has a high affinity for collagen types I and III. Its function is unknown. It possibly participates in the supramolecular organization of collagen fibers.

Laminin

The extended family of laminins has a fundamental part in the assembly of the basal lamina. Laminins are large, elongated crucifix-shaped glycoproteins. Their protein moiety is composed of three polypeptide chains – A, B1 and B2 – that are disulfides bonded to one

another. They possess EGF-like domains and binding sites for other ECM components and for membrane receptors (integrins). Laminins bind to collagen type IV, fibronectin, heparan sulfate, perlecan, nidogen, and through the RGD epitope to the surface of many cells. In the normal basal lamina the EGF-like domains are masked. In inflammatory endothelial injury laminins become demasked and assume an active part in the inflammatory reaction [131].

Nidogen

Nidogen, also called *entactin*, is a short cell attachment glycoprotein that cross-links each laminin to type IV collagen and to other matrix proteins, thereby facilitating cell–matrix interactions. It contains an RGD motif.

Cell–Matrix Communication

The individual components of ECM are closely intertwined with one another and maintain relationships with hepatocytes, sinusoidal and perisinusoidal cells. This bidirectional communication is accomplished by heterodimeric receptors on the cell membrane that transmit and integrate signals from the ECM to the cytoskeleton and vice versa. Therefore, these receptors are called integrins.

Integrins

Integrins are adhesion molecules that confer mechanical stability to the interaction between cells and their environment. They also function as cellular sensors and signal molecules [134, 135]. Integrins are transmembrane glycoproteins which have a large extracellular domain, a transmembrane segment and, with the exception of the long β 4-chain, a short cytoplasmic domain. They possess two noncovalently associated subunits, α and β . There are nine different β polypeptide chains and at least 16 α subunits that can associate with different β chains, which leads to a wide variability of integrin ligand specificity. The integrin family is comprised of at least 20 different members with different specificities. Some integrins are found on numerous cell types, while others are cell-specific. Some integrins

bind to only one ECM component, e.g. to fibronectin, laminin or collagen, while others bind to several different but related matrix molecules. Many matrix proteins are ligands for different integrins. Thus eight integrin isoforms may interact with fibronectin. The *RGD (Arg-Gly-Asp) motif* and the presence of divalent cations – Ca^{2+} or Mg^{2+} – are of major importance in binding a ligand to an integrin. With their intracellular carboxy-terminal segments most integrins are in contact with actin-binding proteins of the cytoskeleton (talin, α -actinin, vinculin). Analogous to the hormone-receptor-effects, binding of a ligand to an integrin is followed by phosphorylation of the cytoplasmic portion of the integrin and by signal transduction [135]. By this means, signals from the ECM can influence intracellular tension and motility of the cytoskeleton. On the other hand intracellular actin filaments may alter the arrangement of secreted fibronectin molecules, thereby modifying the features of the ECM.

References

Structural Organization

1. Akiyoshi H, Gonda T, Terada T (1998) A comparative histochemical and immunohistochemical study of aminergic, cholinergic and peptidergic innervation in rat, hamster, guinea pig, dog and human livers. *Liver* 18: 352–9
2. Bioulac-Sage P, Lafon ME, Saric J, et al (1990) Nerves and perisinusoidal cells in human liver. *J Hepatol* 10: 105–12
3. Bloch EH (1970) The termination of hepatic arterioles and functional unit of the liver as determined by microscopy of the living organ. *Ann N Y Acad Sci* 170: 78–87
4. Brissaud E, Sabourin C (1888) Sur la constitution lobulaire du foie et les voies de la circulation sanguine intra-hepatique. *C R Soc Biol Annee* 8: 757–76
5. Ding WG, Fujimura M, Mori A, et al (1991) Light and electron microscopy of neuropeptide Y-containing nerves in human liver, gallbladder and pancreas. *Gastroenterology* 101: 1054–8
6. Ekataksin W, Wake K (1997) New concepts in biliary and vascular anatomy of the liver. *Prog Liver Dis* 15: 1–30
7. Ekataksin W, Kaneda K (1999) Liver microvascular architecture: an insight into the pathophysiology of portal hypertension. *Semin Liver Dis* 19: 359–82
8. Ekataksin W (2000) The isolated artery: an intrahepatic arterial pathway that can bypass the lobular parenchyma in mammalian livers. *Hepatology* 31: 269–79
9. Elias H (1949) A re-examination of the structure of the mammalian liver II: the hepatic lobule and its relation to the vascular and biliary systems. *Am J Anat* 85: 379–456
10. Forssmann WG, Ito S (1977) Hepatocyte innervation in primates. *J Cell Biol* 74: 299–313

11. Gardemann A, Puschell GP, Jungermann K (1992) Nervous control of liver metabolism and hemodynamics. *Eur J Biochem* 207: 399–411
12. Gerber MA, Thung SN (1978) Carcinoembryonic antigen in normal and diseased liver tissue. *Am J Pathol* 92: 671–80
13. Gouw ASH, van den Heuvel MC, Boot M, et al (2006) Dynamics of the vascular profile of the finer branches of the biliary tree in normal and diseased human livers. *J Hepatol* 45: 393–400
14. Jungermann K, Gardemann A, Beuers U, et al (1987) Regulation of liver metabolism by the hepatic nerves. *Adv Enzyme Regul* 26: 63–88
15. Kiernan F (1833) The anatomy and physiology of the liver. *Philos Trans R Soc Lond* 123: 711–70
16. Lauth WW (1980) Hepatic nerves: a review of their functions and effects. *Can J Physiol Pharmacol* 56: 679–82
17. Ludwig J, Ritman EL, LaRusso NF, et al (1998) Anatomy of the human biliary system studied by quantitative computer-aided three dimensional imaging techniques. *Hepatology* 27: 893–9
18. Mall FP (1906) A study of the structural unit of the liver. *Am J Anat* 5: 227–308
19. Matsumoto T, Komori R, Magara T, et al (1979) A study of the normal structure of the human liver, with special reference to its angioarchitecture. *Jikeikai Med J* 26: 1–40
20. Rappaport AM, Borowy ZJ, Longheed WM, et al (1954) Subdivision of hexagonal liver lobules into a structural and functional unit; role in hepatic physiology and pathology. *Anat Res* 119: 11
21. Roskams TA, Theise ND, Balabaud C, et al (2004) Nomenclature of the finer branches of the biliary tree: canals, ductules, and ductular reactions in human livers. *Hepatology* 39: 1739–45
22. Saxena R, Theise ND, Crawford JM (1999) Microanatomy of the human liver-exploring the hidden interfaces. *Hepatology* 30: 1339–46
23. Seseke FG, Gardemann A, Jungermann K (1992) Signal propagation via gap junctions, a key step in the regulation of liver metabolism by the sympathetic hepatic nerves. *FEBS Lett* 301: 265–70
24. Takasaki S, Hano H (2001) Three-dimensional observations of the human hepatic artery (arterial system in the liver). *J Hepatol* 34: 455–66
25. Tarada T, Nakanuma Y, Ohta G (1987) Glandular elements around the intrahepatic bile ducts in man: their morphology and distribution in normal livers. *Liver* 7: 1–8
26. Teutsch HF (2005) The modular microarchitecture of human liver. *Hepatology* 42: 317–25
27. Tiniakos DG, Lee JA, Burt AD (1996) Innervation of the liver: morphology and function. *Liver* 16: 151–60
28. Trutmann M, Sasse D (1994) The lymphatics of the liver. *Anat Embryol* 190: 201–9
29. Warren A, Le Couteur DG, Fraser R, et al (2006) T lymphocytes interact with hepatocytes through fenestrations in murine liver sinusoidal endothelial cells. *Hepatology* 44: 1182–90
30. Aleffi S, Petrai I, Bertolani C, et al (2005) Upregulation of proinflammatory and proangiogenic cytokines by leptin in human hepatic stellate cells. *Hepatology* 42: 1339–48
31. Alison M, Sarraf C (1998) Hepatic stem cells. *J Hepatol* 29: 676–82
32. Alison M, Poulson R, Jeffrey R, et al (2000) Hepatocytes from non-hepatic cells. *Nature* 406: 257
33. Alpini G, Prall RT, LaRusso NF (2001). The pathobiology of biliary epithelia. In: Arias IM (ed), *The liver: biology and pathobiology*, 4th edn. Raven Press, New York, pp 421–35
34. Anan A, Baskin-Bey ES, Bronk SF, et al (2006) Proteasome inhibition induces hepatic stellate cell apoptosis. *Hepatology* 43: 335–44
35. Aurich I, Mueller LP, Aurich H, et al (2007) Functional integration of hepatocytes derived from human mesenchymal stem cells into mouse livers. *Gut* 56: 405–15
36. Baba S, Fujii H, Hirose T, et al (2004) Commitment of bone marrow cells to hepatic stellate cells in mouse. *J Hepatol* 40: 255–60
37. Bainton DF (1981) The discovery of lysosomes. *J Cell Biol* 91: 66s–76s
38. Balabaud C, Boulard A, Quinton A, et al (1988). Light and transmission electron microscopy of sinusoids in human liver. In: Bioulac-Sage P, Balabaud C (eds) *Sinusoids in human liver: health and disease*. Rijswijk: Kupffer Cell Foundation
39. Bataller R, Nicolas JP, Gines P, et al (1997) Arginine vasopressin induces contraction and stimulates growth of cultured human hepatic stellate cells. *Gastroenterology* 113: 615–24
40. Bataller R, Sancho-Bru P, Ginés P, et al (2003) Activated human hepatic stellate cells express the renin-angiotensin system and synthesize angiotensin II. *Gastroenterology* 125: 117–25
41. Bilzer M, Roggel F, Gerbes AL, et al (2006) Role of Kupffer cells in host defense and liver disease. *Liver Int* 26: 1175–86
42. Bioulac-Sage P, Lafon ME, Saric J, et al (1990) Nerves and perisinusoidal cells in human liver. *J Hepatol* 10: 105–112
43. Bode JG, Peters-Regehr T, Schliess F, et al (1998) Activation of mitogen-activated kinases and IL-6 release in response to lipopolysaccharides in Kupffer cells is modulated by anisoosmolarity. *J Hepatol* 28: 795–802
44. Bouwens L, Wisse E (1992) Pit cells in the liver. *Liver* 12: 3–9
45. Braet F (2004) How molecular microscopy revealed new insights into the dynamics of hepatic endothelial fenestrae in the past decade. *Liver Int* 24: 532–9
46. Breitkopf K, Sawitza I, Westhoff JH, et al (2005) Thrombospondin 1 acts as a strong promoter of transforming growth factor beta effects via two distinct mechanisms in hepatic stellate cells. *Gut* 54: 673–81
47. Burt AD, Le Bail B, Balabaud C, et al (1993) Morphologic investigation of sinusoidal cells. *Semin Liver Dis* 13: 21–38
48. Cao Q, Mak KM, Lieber CS (2007) Leptin represses matrix metalloproteinase-1 gene expression in LX2 human hepatic stellate cells. *J Hepatol* 46: 124–33
49. Chinnery PF (2003) Searching for nuclear-mitochondrial genes. *Trends Genet* 19: 60–2
50. Crosby HA, Strain AJ (2001) Adult liver stem cells: bone marrow, blood, or liver derived? *Gut* 48: 153–54
51. Decker K (1990) Biologically active products of stimulated liver macrophages (Kupffer cells). *Eur J Biochem* 192: 245–61
52. Desmet VJ (1985) Intrahepatic bile ducts under the lens. *J Hepatol* 1: 545–59
53. Falkowski O, An HJ, Ianus IA, et al (2003) Regeneration of hepatocyte ‘buds’ in cirrhosis from intrabiliary stem cells. *J Hepatol* 39: 357–64

Cell Types

54. Feldmann G (1989) The cytoskeleton of the hepatocyte. Structure and functions. *J Hepatol* 8: 380–6
55. Feldmann G (1992) Liver ploidy. *J Hepatol* 16: 7–10
56. Fischer R, Cariers A, Reinehr R, et al (2002) Caspase-9 dependent killing of hepatic stellate cells by activated Kupffer cells. *Gastroenterology* 123: 845–61
57. Friedman SL (1996). Hepatic stellate cells. In: Boyer JL, Ockner RK (eds) *Progress in liver diseases*, Vol. XIV. W.B. Saunders, Philadelphia, PA, pp 101–30
58. Gabriel A, Kuddus RH, Rao AS, et al (1999) Down-regulation of endothelin receptors by transforming growth factor b1 in hepatic stellate cells. *J Hepatol* 30: 440–50
59. Galli A, Svegliati-Baroni G, Ceni E, et al (2005) Oxidative stress stimulates proliferation and invasiveness of hepatic stellate cells via a MMP2-mediated mechanism. *Hepatology* 41: 1074–84
60. Geerts A (2004) On the origin of stellate cells: mesodermal, endodermal or neuro-ectodermal? *J Hepatol* 40: 331–4
61. Gehling UM, Willems M, Dandri M, et al (2005) Partial hepatectomy induces mobilization of a unique population of haematopoietic progenitor cells in human healthy liver donors. *J Hepatol* 43: 845–53
62. Görbig MN, Ginés P, Bataller R, et al (2001) Human hepatic stellate cells secrete adrenomedullin: potential autocrine factor in the regulation of cell contractility. *J Hepatol* 34: 222–9
63. Golgi C (1898) Sur la structure des cellules nerveuses. *Arch Ital Biol* 30: 60–71
64. Grompe M (2005) The origin of hepatocytes. *Gastroenterology* 128: 2158–60
65. Hautekeer ML, Geerts A (1997) The hepatic stellate (Ito) cell: its role in human liver disease. *Virchows Arch* 430: 195–207
66. Helfand BT, Chang L, Goldman RD (2004) Intermediate filaments are dynamic and motile elements of cellular architecture. *J Cell Sci* 117: 133–41
67. Helfand BT, Chou YH, Shumaker DK, et al (2005) Intermediate filament proteins participate in signal transduction. *Trends Cell Biol* 15: 568–70
68. Ito T (1951) Cytological studies on stellate cells of Kupffer and fat storing cells in the capillary wall of human liver. *Acta Anat Nippon* 26: 2
69. Kanno N, LeSage G, Glaser SS, et al (2000) Functional heterogeneity of the intrahepatic biliary epithelium. *Hepatology* 31: 555–61
70. Kharbanda KK, Rogers DD, Wyatt TA, et al (2004) Transforming growth factor-beta induces contraction of activated hepatic stellate cells. *J Hepatol* 41: 60–6
71. Knittel T, Kobold D, Saile B, et al (1999) Rat liver myofibroblasts and hepatic stellate cells: different cell populations of the fibroblast lineage with fibrogenic potential. *Gastroenterology* 117: 1205–21
72. Kuiper J, Brouwer A, Knook DL, et al (1994). Kupffer and sinusoidal endothelial cells. In: Arias IM (ed) *The liver: biology and pathobiology*, 3rd edn. Raven, New York, pp 791–818
73. Lazarides E (1980) Intermediate filaments as mechanical integrators of cellular space. *Nature* 283: 249–56
74. Lee JS, Semela D, Iredale J, et al (2007) Sinusoidal remodeling and angiogenesis: a new function for the liver-specific pericyte? *Hepatology* 45: 817–25
75. Lee K-D, Kwang-Chun Kuo T, Whang-Peng J, et al (2004) In vitro hepatic differentiation of human mesenchymal stem cells. *Hepatology* 40: 1275–84
76. Liu C, Schreiter T, Dirsch O, et al (2004) Presence of markers for liver progenitor cells in human-derived intrahepatic biliary epithelial cells. *Liver Int* 24: 669–78
77. Loud AV (1968) A quantitative stereological description of the ultrastructure of normal rat liver parenchymal cells. *J Cell Biol* 37: 27–46
78. Mallat A, Lotersztajn S (1996) Multiple hepatic functions of endothelin-1 : physiopathological relevance. *J Hepatol* 25: 405–13
79. Mann DA, Smart DE (2002) Transcriptional regulation of hepatic stellate cell activation. *Gut* 50: 891–6
80. Marziani M, Glaser SS, Heather F, et al (2002) Functional heterogeneity of cholangiocytes. *Semin Liver Dis* 22: 227–40
81. Meier PY (1988) Transport polarity of hepatocytes. *Semin Liver Dis* 8: 293–307
82. Moll R, Franke WW, Schiller DL, et al (1982) The catalog of human cytokeratins: patterns of expression in normal epithelia, tumors and cultured cells. *Cell* 31: 11–24
83. Moll R, Schiller DL, Franke WW (1990) Identification of protein IT of the intestinal cytoskeleton as a novel type I cytokeratin with unusual properties and expression patterns. *J Cell Biol* 111: 567–80
84. Niki T, Pekny M, Hellemans K, et al (1999) Class VI intermediate filament protein nestin is induced during activation of rat hepatic stellate cells. *Hepatology* 29: 520–7
85. Parent R, Marion MJ, Furio L, et al (2004) Origin and characterization of a human bipotent liver progenitor cell line. *Gastroenterology* 126: 1147–56
86. Petersen BE, Bowen WC, Patrene KD, et al (1999) Bone marrow as a potential source of hepatic oval cells. *Science* 284: 1168–70
87. Pinzani M (1995) Hepatic stellate (Ito) cells: expanding roles for a liver-specific pericyte. *J Hepatol* 22: 700–6
88. Pinzani M, Milani S, De Franco R, et al (1996) Endothelin-1 is overexpressed in cirrhotic liver and exerts multiple effects on activated human hepatic stellate cells. *Gastroenterology* 110: 534–48
89. Pinzani M, Marra F, Carloni V (1998) Signal transduction in hepatic stellate cells. *Liver* 18: 2–13
90. Pon LA, Schon EA (2001) *Mitochondria*. Academic, New York
91. Radu A, Blobel G, Moore SM (1995) Identification of a protein complex that is required for nuclear protein import and mediates docking of import substrate to distinct nucleoproteins. *Proc Natl Acad Sci USA* 92: 1769–73
92. Ramadori G (1991) The stellate cell (Ito-cell, fat-storing cell, lipocyte, perisinusoidal cell) of the liver. New insights into pathophysiology of an intriguing cell. *Virchows Arch B Cell Pathol* 61: 147–58
93. Ramadori G, Saile B (2002) Mesenchymal cells in the liver – one cell type or two? *Liver* 22: 283–94
94. Reynaert H, Thompson MG, Thomas T, et al (2002) Hepatic stellate cells: role in microcirculation and pathophysiology of portal hypertension. *Gut* 50: 571–81
95. Roskams T, DeVos R, van Eyken P, et al (1998) Hepatic OV-6 expression in human liver disease and rat experiments: evidence for hepatic progenitor cells in man. *J Hepatol* 29: 455–63
96. Rouiller C, Bernard W (1956) “Microbodies” and the problem of mitochondrial regeneration in liver cells. *J Biophys Biochem Cytol Suppl.* 2: 355–8
97. Ruhnke M, Ungefroren H, Nussler A, et al (2005) Differentiation of in vitro-modified human peripheral blood monocytes into hepatocyte-like and pancreatic islet-like cells. *Gastroenterology* 128: 1774–86
98. Sakaida I, Nagatomi A, Hironaka K, et al (1999) Quantitative analysis of liver fibrosis and stellate cell changes in patients

- with chronic hepatitis C after interferon therapy. *Am J Gastroenterol* 94: 489–96
99. Sanz S, Pucilowska JB, Liu S, et al (2005) Expression of insulin-like growth factor I by activated hepatic stellate cells reduces fibrogenesis and enhances regeneration after liver injury. *Gut* 54: 134–41
 100. Schmitt-Gräff A, Krüger S, Borchard F, et al (1991) Modulation of alpha smooth muscle actin and desmin expression in perisinusoidal cells of normal and diseased human livers. *Am J Pathol* 138: 1233–42
 101. Schroer TA, Sheetz MP (1991) Functions of microtubule-based motors. *Ann Rev Physiol* 53: 629–52
 102. Siegmund SV, Uchinami H, Osawa Y, et al (2005) Anandamide induces necrosis in primary hepatic stellate cells. *Hepatology* 41: 1085–95
 103. Sirica AE (1992). Biology of biliary epithelial cells. In: Boyer JL, Ockner RK (eds) *Progress in liver diseases*, Vol X. W.B. Saunders, Philadelphia, PA, pp 63–87
 104. Smedsrod B, Pertoft H, Gustafson S, et al (1990) Scavenger functions of the liver endothelial cell. *Biochem J* 266: 313–27
 105. Smedsrod B, DeBleaser PJ, Braet F, et al (1994) Cell biology of liver endothelial and Kupffer cells. *Gut* 35: 1509–16
 106. Sternlieb J, Quintara N (1977) The peroxisomes of human hepatocytes. *Lab Invest* 36: 140–9
 107. Strain AJ, Crosby HA (2000) Hepatic stem cells. *Gut* 46: 743–45
 108. Sugimoto R, Enjoji M, Kohjima M, et al (2005) High glucose stimulates hepatic stellate cells to proliferate and to produce collagen through free radical production and activation of mitogen-activated protein kinase. *Liver Int* 25: 1018–26
 109. Suskind DL, Muench MO (2004) Searching for common stem cells of the hepatic and hematopoietic systems in the human fetal liver: CD34(+) cytokeratin 7/8(+) cells express markers for stellate cells. *J Hepatol* 40: 261–8
 110. Taimr P, Higuchi H, Kocova E, et al (2003) Activated stellate cells express the TRAIL receptor-2/death receptor-5 and undergo TRAIL-mediated apoptosis. *Hepatology* 37: 87–95
 111. Tamaki H, Yamashina S (2002) The stack of the Golgi apparatus. *Arch Histol Cytol* 65: 209–18
 112. Tan J, Hytiroglu P, Wiczorek R, et al (2002) Immunohistochemical evidence for hepatic progenitor cells in liver diseases. *Liver* 22: 365–73
 113. Tavoloni N (1987) The intrahepatic biliary epithelium: an area of growing interest in hepatology. *Semin Liver Dis* 7: 280–92
 114. Theise ND, Badve S, Saxena R, et al (2000) Derivation of hepatocytes from bone marrow cells in mice after radiation-induced myeloablation. *Hepatology* 31: 235–40
 115. Theise ND, Nimmakayalu M, Gardner R, et al (2000) Liver from bone marrow in humans. *Hepatology* 32: 11–6
 116. Thorgeirsson SS, Grisham JW (2006) Hematopoietic cells as hepatocyte stem cells: a critical review of the evidence. *Hepatology* 43: 2–8
 117. Uyama N, Zhao L, Van Rossen E, et al (2006) Hepatic stellate cells express synemin, a protein bridging intermediate filaments to focal adhesions. *Gut* 55: 1276–89
 118. Van Eyken P, Desmet VJ (1993) Cytokeratins and the liver. *Liver* 13: 113–22
 119. Vinas O, Bataller R, Sancho-Bru P, et al (2003) Human hepatic stellate cells show features of antigen-presenting cells and stimulate lymphocyte proliferation. *Hepatology* 38: 919–29
 120. Wake K (1971) “Sternzellen” in the liver: perisinusoidal cells with special reference to storage of vitamin A. *Am J Anat* 132: 429–62
 121. Wake K, Decker K, Kim A, et al (1989) Cell biology and kinetics of Kupffer cells in the liver. *Int Rev Cytol* 118: 173–229
 122. Wake K (1995). Structure of the sinusoidal wall in the liver. In: Wisse E, Knook DL, Wake K (eds) *Cells of the hepatic sinusoid*. Kupffer Cell Foundation, Leiden, pp 241–6
 123. Wang E, Fischmann D, Liem PKH, et al (1985) Intermediate filaments. *Ann NY Acad Sci* 455: 32–56
 124. Warren A, Le Couteur DG, Fraser R, et al (2006) T lymphocytes interact with hepatocytes through fenestrations in murine liver sinusoidal endothelial cells. *Hepatology* 44: 1182–90
 125. Wilson JW, Leduc EH (1958) Role of cholangioles in restoration of the liver of the mouse after dietary injury. *J Pathol Bacteriol* 76: 441–9
 126. Winnock M, Barcina MG, Lukomska B, et al (1993) Liver-associated lymphocytes: role in tumor defense. *Semin Liver Dis* 13: 81–92
 127. Wisse E, van’t Noordende JM, van der Meulen J, et al (1976) The pit cell: description of a new type of cell occurring in rat liver sinusoids and peripheral blood. *Cell Tissue Res* 173: 423–35
 128. Wisse E, De Zanger RB, Charles K, et al (1985) The liver sieve: considerations concerning the structure and function of endothelial fenestrae, the sinusoidal wall and the space of Disse. *Hepatology* 5: 683–92
 129. Yokomori H, Oda M, Ogi M, et al (2000) Hepatic sinusoidal endothelial fenestrae express plasma membrane Ca⁺⁺ pump and Ca⁺⁺ Mg⁺⁺-ATPase. *Liver* 20: 458–64

Extracellular Matrix

130. Arthur MJP (1994). Matrix degradation in the liver. In: Surrenti C, Casini A, Milani S, Pinzani M (eds) *Fat-storing cells and liver fibrosis*. Kluwer, Dordrecht, pp 110–27
131. Beck K, Hunter I, Engel J (1990) Structure and function of laminin: anatomy of a multidomain glycoprotein. *FASEB J* 4: 148–60
132. Burgeson RE (1988) New collagens, new concepts. *Annu Rev Cell Biol* 4: 551–77
133. Goodman SR (1998) *Medical cell biology*, 2nd edn. Lippincott-Raven, Philadelphia, PA, pp 205
134. Hynes RO (1987) Integrins: a family of cell surface receptors. *Cell* 48: 549–54
135. Hynes RO (2002) Integrins: bidirectional, allosteric signaling machines. *Cell* 110: 673–87
136. Laurent GJ (1987) Dynamic state of collagen: pathways of collagen degradation in vivo and their possible role in regulation of collagen mass. *Am J Physiol* 252: C1–C9
137. Musso O, Rehn M, Saarela J, et al (1998) Collagen XVIII is localized in sinusoids and basement membrane zones and expressed by hepatocytes and activated stellate cells in fibrotic human liver. *Hepatology* 28: 98–107

138. Petrides PE (1998). Binde-und Stützgewebe. In: Löffler G, Petrides PE (eds) *Biochemie und pathobiochemie*, 6th edn. Auflage, Springer Verlag, Berlin, pp 733–59
139. Prockop DJ, Kivirikko KI, Tuderman L, et al (1979) The biosynthesis of collagen and its disorders. *N Engl J Med* 301: 13–23
140. Rojkind M, Giambone MA, Biempica L (1979) Collagen types in normal and cirrhotic liver. *Gastroenterology* 76: 710–9
141. Ruoslahti E (1988) Structure and biology of proteoglycans. *Annu Rev Cell Biol* 4: 229–55
142. Schuppan D (1990) Structure of the extracellular matrix in normal and fibrotic liver: collagens and glycoproteins. *Semin Liver Dis* 10: 1–10
143. Schuppan D, Gressner AM (1999). Function and metabolism of collagens and other extracellular matrix proteins. In: Bircher J, Benhamou JP, McIntyre N, Rizzetto M, Rodés J (eds) *Oxford textbook of clinical hepatology*, 2nd edn. Oxford University Press, New York, pp 381–407

Chapter Outline

Hepatic Blood Flow.....	55
Regulation of Hepatic Circulation.....	56
Autoregulation.....	57
References.....	59

Hepatic Blood Flow

The hepatic blood flow is approximately 1,800 mL/min in men and 1,500 mL/min in women. The liver receives a dual blood supply through the hepatic artery and the portal vein. Twenty five to thirty percent of blood flow is through the hepatic artery, and 70–75% is through the portal vein, which receives the entire splanchnic blood (25% from spleen and pancreas, 75% from the stomach and the intestines) (Fig. 4.1) [12]. Unlike the portal venous blood which flows exclusively into the sinusoids, the hepatic artery does not primarily feed the liver parenchyma. Instead it supplies predominantly other structures (see Chapter 3) and only thereafter hepatic arterial and portal venous blood mix in the sinusoids [5, 16, 20]. The hepatic

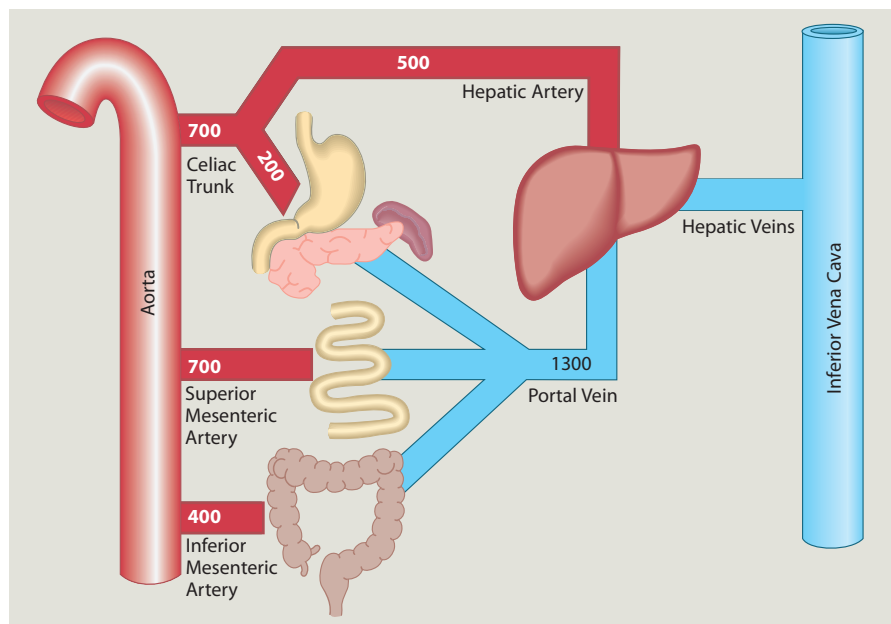


Fig. 4.1 The position of the liver in intestinal circulation. Schematic representation of flow rates (mL/min) and of the dual blood supply of the liver (Adapted from [18])

artery gives rise to peribiliary plexuses, to arterial branches of the interstitial portal tract tissue, to vessels of the hepatic capsule, as well as to the vasa vasorum of portal vein branches and of central, sublobular and large liver veins. The portal tract arterioles supply the walls of the portal vein branches and the bile ducts as well as the interstitial tissue of the portal tracts, forming a portal system of their own. Isolated arterioles may bypass the liver parenchyma and discharge directly into the central and/or liver veins. These vessels are called “bypass arteries”.

The hepatic arterial blood is rich in oxygen and poor in nutrients, while the portal venous blood is relatively oxygen deficient, but rich in nutrients and gut derived toxic substances. Arterial and venous blood mix to some extent in the portal tracts (arterio-portal anastomoses) but most mixing occurs in the sinusoids. In the liver acinus an oxygen gradient is present. Periportal (zone 1) hepatocytes receive highly oxygenated blood, while centrilobular (zone 3) hepatocytes are provided with blood having the lowest oxygen saturation. This explains why metabolism is predominantly aerobic in zone 1 and anaerobic in zone 3.

Under normal circumstances hepatic oxygen consumption is approximately 6 mL/min/100g liver tissue. The hemodynamic parameters of the healthy liver are reported in Table 4.1. The presinusoidal portal vascular resistance is relatively low, and greater than 70% of the portal pressure is transmitted to the sinusoids. In

the normal liver approximately two thirds of the fall in pressure occurs between the portal vein and the terminal hepatic venule (central vein), and one third between the latter and the inferior vena cava [3, 7]. The pressure gradient in the hepatic artery shows a significant presinusoidal drop along the multiple arterial ramifications between the hilum of the liver and the portal tracts.

The liver behaves like a “blood sponge”. The organ receives approximately 25% of cardiac output. Conditions characterized by an increased hepatic venous pressure, such as right sided heart failure or thrombotic occlusion of the liver veins, may lead to an increase in blood volume in the liver up to 60 mL/100g of liver tissue.

The hepatic blood flow depends on position and on the respiratory excursions. It is diminished in the upright compared to the supine position. Blood flow in the liver is diminished during sleep. During inspiration the venous blood flow in the liver decreases, while during expiration it increases. After food intake a marked increase in splanchnic perfusion is associated with a pronounced increase in liver perfusion. In old age liver perfusion is diminished [19].

Regulation of Hepatic Circulation

The regulatory mechanisms of liver blood flow in man are only partly known. Many animal experimental results are available that, however, are not transferable offhand to the human situation. It is important to understand that liver oxygen demand and hepatic metabolism are *not* essential determinants of hepatic arterial blood flow. The oxygen extraction of the normal liver is approximately 40%. An increased oxygen demand is not met by an increased blood flow, but is satisfied by an intensified O₂-extraction. A decrease in blood flow too leads to an increase in oxygen extraction of up to 95%.

Presumably regulation of hepatic blood flow is accomplished by

- Intrinsic autoregulation and by
- Extrinsic neural control [9]

Under physiologic conditions, both local and neural mechanisms act in concert. The intrinsic, local autoregulation seems to be more important than extrinsic, neural control.

Table 4.1 Hemodynamic parameters of the normal liver

Pressures (mmHg)	
Hepatic artery	100
Hepatic artery (portal tract)	30
Portal vein	5–8
Terminal portal venules	4, 8
Hepatic veins	1, 7
Inferior vena cava	1–2
Wedge hepatic venous pressure (WHVP)	5–8
Free hepatic venous pressure (FHVP)	1–2
Hepatic vein pressure gradient (WHVP-FHVP)	< 6
Flow rates and volumes (mL/min)	
Whole liver	1500
Hepatic artery	350
Portal vein	1150
Liver blood volume (mL)	500
Oxygen supply (%)	
through portal vein	50
through hepatic artery	50

Autoregulation

Compared to the kidneys and the brain, autoregulation of hepatic blood flow is less pronounced. Nonetheless, a pressure dependant autoregulation of blood flow in the hepatic artery exists. An increase in pressure will lead to a rise in resistance followed by a decrease of arterial flow, while a falling vascular resistance will cause a fall in pressure accompanied by a reactive increase of arterial flow.

The portal vessels represent a passive capacitance system. Blood flow in the portal vein is not governed by pressure dependent autoregulation. Instead it depends primarily on splanchnic inflow. However, changes in portal venous flow will affect blood flow in the hepatic artery. An increase in portal venous flow causes a rise in hepatic arterial resistance, while a decrease leads to hepatic arterial dilatation. Thus, a compromised portal venous flow may lead to a compensatory increase of arterial hepatic flow of up to 25–100%. Porto-caval anastomoses may lead to an increase of arterial flow up to 400%! Conversely, however, a diminished arterial blood flow cannot be compensated by an increase in portal venous flow.

Which are the components and mechanisms regulating blood flow in the sinusoids? We have to consider

- Neural factors
- Anatomic resistance elements and
- Vasoactive substances

Neural Factors

The smooth muscle fibers in the hepatic artery branches possess α -adrenergic vasoconstrictory receptors, β_2 -adrenergic vasodilatory receptors, and a subpopulation of vasodilating dopaminergic neurons. Stimulation of hepatic α -adrenergic receptors leads to contraction of arterial vessels with diminished hepatic blood flow. Stimulation of sympathetic nerves has no direct effect on portal venous flow. However, by increasing intrahepatic resistance adrenergic stimulation may contribute to portal hypertension. By constricting terminal portal venules and sinusoids, sympathetic stimulation may facilitate drainage of sinusoidal and hepatic venous blood into the systemic circulation [13].

Intrahepatic Resistance Elements

The sinusoidal blood originates mostly from the portal venous circulation and reaches the sinusoids through the portal venules. The portal vein branches in the portal tracts and the centrilobular terminal hepatic venules contain only very sparse smooth muscle fibers. The sinusoids of the healthy liver contain no smooth muscle fibers. They are kept open passively through the pressure of flowing blood. The regulation of vessel resistance is accomplished by sphincter-like mechanisms, and experimental studies favour the existence of intrahepatic resistance elements. These are situated at the level of arterio-portal anastomoses in the portal tracts, at the level of the smallest portal vein branches (preterminal portal venules), at the limiting plate between portal tract and lobular parenchyma, along the sinusoids, and in a postsinusoidal location. The morphology of these resistance elements is a matter of debate. *Myogenic "inlet" and "outlet" sphincters* located in the preterminal portal venules and at transition points between the sinusoids and the terminal hepatic venules are believed to regulate sinusoidal blood flow [10]. The *sinusoidal endothelial cells* themselves are able, to a certain degree, to influence the diameter of the sinusoids, thereby regulating sinusoidal resistance. Presumably these cells are contractile and, in addition, may exert certain sphincter-like functions through swelling.

During liver injury perisinusoidal *hepatic stellate cells* function as pericytes and acquire contractile features. They may thereby influence the diameter of sinusoidal lumina and regulate hepatic microcirculation [14]. Humoral mediators (see below) induce the contraction of human hepatic stellate cells.

Vasoactive Substances

Intrinsic, paracrine/autocrine acting vasoactive substances, such as:

- Endothelins
- Nitric oxide
- Carbon monoxide
- Adenosine and
- Others (substance P, angiotensin II, serotonin, norepinephrine, thrombin, prostacyclin)

are of importance in regulating vascular tone and liver blood flow.

Endothelins (ETs; ET-1, ET-2, ET-3). Endothelins are the most powerful vasoconstrictor peptides in mammals and are important regulators of hepatic microcirculation. These 21-amino-acid polypeptides derive from a large precursor molecule, *pre-pro-ET* that gives rise to the 39-amino-acid prohormone *big-ET*. Big-ET is cleaved to form ET-1 by endothelin – converting enzyme. The most important hepatic source of ETs are the sinusoidal endothelial cells. Two different endothelin receptors (ET_A and ET_B receptor) have been shown to be present in portal and in central veins, and on hepatic stellate and sinusoidal cells. After secretion by sinusoidal endothelial cells, ETs act in an autocrine/paracrine fashion primarily through ET_A receptors on the surface of target structures. ET-1 possesses the highest affinity for the ET_A receptor. The greatest receptor density is found on hepatic stellate cells which are the most important target structures for ETs in the liver. In addition, ETs act on the “inlet” sphincters of the preterminal portal venules. The signal is transduced through GTP-binding proteins and results in contraction of activated stellate cells (myofibroblast phenotype) and of “inlet” sphincters. The sole contraction of “inlet” sphincters could explain the finding of portal hypertension without concurrent narrowing of sinusoids. ET_B receptors (at least two types exist) seem to mediate both vasodilatation and contraction of stellate cells. In addition to their vasoconstricting effects ETs, together with other mitogens, enhance proliferation of stellate cells and smooth muscle cells [2, 4, 8, 21]. In liver injury activated stellate cells themselves, under the influence of transforming growth factor β , may produce ETs. It is assumed that this cellular mechanism contributes to the development of portal hypertension in liver cirrhosis.

Nitric oxide (NO). NO is the physiologic antagonist of ETs. The concentration of NO in the normal liver is low. It is synthesized and released by sinusoidal endothelial cells and leads, via cyclic GMP induced relaxation of stellate cells, to sinusoidal dilatation. NO is generated from L-arginine by the enzymatic action of NO-synthase (NOS) [11]. Three isoforms as well as a constitutive (eNOS) and an inducible form of NOS (iNOS) are known. In endothelial cells NO is synthesized constitutively. Transcription of eNOS-mRNA is enhanced by growth factors, such as transforming growth factor β , vascular endothelial growth factor and basic fibroblast growth factor. Mechanical factors (distension) and cell proliferation stimulate NO synthesis as well. Oxidized LDL and TNF α reduce the levels of eNOS-mRNA in

endothelial cells. In addition to constitutive NOS, each cell in the liver, under appropriate circumstances practically, is able to increase gene expression of inducible NOS. This is particularly true for the hepatocyte. TNF α , interleukin-1 β , and interferon γ induce the transcription of iNOS in hepatocytes and hepatic stellate cells. Exogenously administered NO is able to inhibit the ET-induced contraction of stellate cells and to induce already contracted cells to relax. Inadequate NO production disrupts the balance between vasoconstrictors and NO, and results in unopposed contraction of hepatic stellate cells and subsequent sinusoidal constriction, which leads to altered sinusoidal blood flow [17].

In addition to its key function of regulating sinusoidal blood flow and vascular tone, NO exhibits a wide variety of other actions, e.g. hepatoprotective and anti-apoptotic effects [15].

Carbon monoxide (CO). Newer investigations suggest that CO participates in regulating sinusoidal tone. CO is generated by the activity of heme oxygenase (HO). Two isoforms of HO exist, an inducible HO-1 and a constitutive HO-2. The constitutive form makes up the largest part of hepatic HO activity. The administration of HO inhibitors leads to sinusoidal constriction. It is assumed that like NO, CO too may lead to relaxation of hepatic stellate cells, thus acting as an endogenous modulator of sinusoidal perfusion.

Adenosine. As mentioned above, a reduction in portal venous flow leads to a compensatory increase in arterial blood flow. Adenosine presumably takes part in this *autoregulation of hepatic circulation* [6]. Independent of hepatic metabolism, constant amounts of adenosine accumulate and are removed from the space of Mall by portal venous blood (“washout” hypothesis). If portal venous flow is diminished the local concentration of adenosine will increase and will lead to dilatation of hepatic artery branches with subsequent increase of arterial blood flow. Therefore, blood flow in the hepatic artery is independent of liver metabolism but depends indirectly on the flow in the portal vein. This autoregulatory mechanism helps to keep the total liver blood flow constant.

Other substances. In addition to the main modulators of intrahepatic vascular tone – ETs and NO – other substances likely affect the constricting tone of hepatic stellate cells and sinusoids. Substance P, angiotensin II, serotonin, norepinephrine and thrombin cause stellate cells to contract [1]. Prostaglandin E₂ via cyclic AMP mediated signals inhibits the ET-induced contraction of stellate cells.

References

1. Bataller R, Gines P, Nicolas JM, et al (2000) Angiotensin II induces contraction and proliferation of human hepatic stellate cells. *Gastroenterology* 118: 1149–56
2. Bauer M, Bauer I, Sonin NV, et al (2000) Functional significance of endothelin B receptors in mediating sinusoidal and extrasinusoidal effects of endothelins in the intact rat liver. *Hepatology* 31: 937–47
3. Bohlen HG, Maas-Moreno R, Rothe CF (1991) Hepatic venular pressures of rats, dogs and rabbits. *Am J Physiol* 261: G539–47
4. Kaneda K, Ekataksin W, Sogawa M, et al (1998) Endothelin-1-induced vasoconstriction causes a significant increase in portal pressure of rat liver: Localized constrictive effect on the distal segment of preterminal portal venules as revealed by light and electron microscopy and serial reconstruction. *Hepatology* 27: 735–47
5. Lauth WW (1977) Hepatic vasculature: a conceptual review. *Gastroenterology* 73: 1163–9
6. Lauth WW, Legare DJ, D'Almeida MS (1985) Adenosine as putative regulator of hepatic arterial flow (the buffer response). *Am J Physiol* 248: H331–8
7. Maas-Moreno R, Rothe CF (1992) Contribution of the large hepatic veins to postsinusoidal vascular resistance. *Am J Physiol* 262: G14–22
8. Mallat A, Lotersztajn S (1996) Multiple hepatic functions of endothelin-1: physiopathological relevance. *J Hepatol* 25: 405–13
9. McCuskey RS, Reilly FD (1993) Hepatic microvasculature: dynamic structure and its regulation. *Semin Liver Dis* 13: 1–12
10. McCuskey RS (2000) Morphological mechanisms for regulating blood flow through hepatic sinusoids. *Liver* 20: 3–7
11. Moncada S, Higgs A (1993) The L-arginine-nitric oxide pathway. *N Engl J Med* 329: 2002–12
12. Myers JD (1947) The hepatic blood flow and splanchnic oxygen consumption in man: their estimation from urea production or bromsulphthalein excretion during catheterization of the hepatic veins. *J Clin Invest* 26: 1130–7
13. Richardson PDI, Withrington PG (1981) Liver blood flow. Intrinsic and nervous control of liver blood flow. *Gastroenterology* 81: 159–73
14. Rockey D (1997) The cellular pathogenesis of portal hypertension: stellate cell contractility, endothelin and nitric oxide. *Hepatology* 25: 2–5
15. Rockey DC, Shah V (2004) Nitric oxide biology and the liver: report of an AASLD research workshop. *Hepatology* 39: 250–7
16. Shah V, Garcia-Cardena G, Sessa WC, et al (1998) The hepatic circulation in health and disease: report of a single-topic symposium. *Hepatology* 27: 279–88
17. Shah V, Lyford G, Gores G, et al (2004) Nitric oxide in gastrointestinal health and disease. *Gastroenterology* 126: 903–13
18. Smith JJ, Kampine JP (1990) Circulation to special regions. In: Smith JJ, Kampine JP (ed) *Circulatory physiology – the essentials*. 3rd edn., Williams and Wilkins, Baltimore, MD, pp 205–329
19. Wynne HA, Cope LH, Mutch E, et al (1989) The effect of age upon liver volume and apparent liver blood flow in healthy man. *Hepatology* 9: 297–301
20. Yamamoto K, Sherman I, Phillips MJ, et al (1985) Three-dimensional observations of the hepatic arterial terminations in rat, hamster and human liver by scanning electron microscopy of microvascular casts. *Hepatology* 5: 452–6
21. Yanagisawa M (1994) The endothelin system. A new target for therapeutic intervention. *Circulation* 89: 1320–2

Chapter Outline

Basic Principles	61
Passive Transport	63
Active Transport.....	64
Vesicle Transport.....	65
Hepatocellular Transporters	66
Basolateral (sinusoidal) Transporters.....	66
Apical (canalicular) Transporters.....	69
Aquaporins	70
Regulation of Intracellular pH	70
Vesicle Transport of Hepatocellular Proteins	71
Receptor Mediated Endocytosis.....	72
Fate of Ligands and Receptors.....	73
References	74

Basic Principles

The regulated cellular uptake and excretion of endogenous and exogenous compounds are among the most important tasks of a liver cell. After uptake by, or synthesis within the cell, the compounds reach their destination by defined intracellular pathways. The site of destination may be within the cell, in different organelles, in the cell membrane or in the extracellular space. On their way the substances may be modified chemically or they may reach their target unchanged.

The hepatocyte is a structurally and functionally polarized cell (see Chapters 3 and 9). The basolateral (sinusoidal) domain of the plasma membrane accounts for approximately 85% of the cell surface, while the remaining 15% consists of the apical (canalicular) membrane domain. The basolateral membrane localizes transport systems, receptors, and ion channels involved in the exchange of solutes between the hepatocyte and the circulation. The apical membrane is exclusively responsible for the formation of canalicular bile, including the excretion of xenobiotics.

The directional transport of water, electrolytes, proteins, lipids and carbohydrates is indispensable for the maintenance of structure and function of the hepatocyte. [Table 5.1](#) summarizes the diverse cellular transport processes. In the first part of this chapter, general aspects of cellular transport processes are discussed. Specific hepatocellular transport systems are dealt with in the second part.

The most important compounds transported by the hepatocyte are proteins, bile salts, bilirubin, cholesterol, phospholipids, electrolytes and water. The transport across cell membranes is primarily accomplished by *ion channels*, *carrier proteins*, and *pumps*. In addition, *vesicle trafficking* by endo-, exo- and transcytosis takes

Table 5.1 Cellular transport processes

Passive Transport	Transport along an electrochemical gradient
• Simple diffusion	Does not require energy Does not require carrier/channels Is subject to competitive inhibition
• Facilitated diffusion	Channels (for ions and water) and carriers facilitate diffusion May require energy Competitive inhibition possible
Active Transport	Transport against an electrochemical gradient Requires energy (pumps) Is subject to competitive inhibition Pumps are substrate specific, may be activated and inactivated and show saturation kinetics
Vesicle Transport	Transport in membrane-enclosed vesicles
• Exocytosis	Extrusion of macromolecules from cytoplasmic secretory vacuoles into the extracellular space Exocytosis requires an external stimulus Exocytosis without the need for an external stimulus
- non constitutive (triggered) exocytosis	Exocytosis requires an external stimulus
- constitutive (untriggered) exocytosis	Exocytosis without the need for an external stimulus
• Endocytosis	Internalization of molecules in vesicles
- receptor mediated (adsorptive) endocytosis	Molecules bound to membrane receptors
- "fluid-phase" endocytosis (pinocytosis)	Molecules in solution, no membrane binding
• Transcytosis	Transfer of vesicles from one pole of the cell to the other without processing of vesicle contents
• Diacytosis	Part of the internalized intact ligand-receptor complex returns to the cell surface (retrocytosis)

place. Carrier-vesicles are the most important structures for the transport of proteins and lipids between various cellular compartments and organelles.

The hepatocellular membrane is composed of a largely fluid lipid double layer in which membrane proteins are "swimming". *Integral globular proteins* are embedded in the membrane in a mosaic fashion and extend through the entire cell membrane. Associated *peripheral proteins* stud the inside and the outside of the membrane. The lipid double layer is primarily composed of phospholipids. Their polar, hydrophilic heads are exposed to the exterior environment of the cell and to the cytoplasm, while their nonpolar, hydrophobic tails meet in the center of the membrane. In addition to phospholipids the cell membrane contains glycolipids and cholesterol. Carbohydrate chains on the outside of the membrane form the structural basis for *tissue specific receptors*.

The *plasma membrane of hepatocytes* is composed as follows:

- Proteins 44–46%
- Lipids 52–54%
- Carbohydrates 2–4%

and carries out many functions, such as:

- Mechanical and chemical protection
- Separation from and contact with neighbouring hepatocytes
- Contact and connection with the extracellular matrix
- Contact and interaction with nonhepatocytic cells
- Regulated transport of endogenous and exogenous substances
- Reception and transduction of signals from the extracellular space to the intracellular space and vice versa
- Enzymatic catalysis of chemical reactions
- Anchoring the cytoskeleton to maintain cellular and organelle structure as well as to enable intracellular movements

Due to the thermokinetic energy of solutes, the *transport of molecules* across cell membranes may be

- Passive

i.e. along an electrochemical gradient without requiring energy or

- Active

i.e. "uphill" against an electrochemical gradient and requiring energy.

Passive Transport

The simplest form of passive transport across the cell membrane is by *free diffusion*. Molecules move from areas of high concentration to areas of low concentration, or cations and anions move along an electrical gradient to negatively and positively charged areas, respectively. Movement continues until a concentration equilibrium or an electrical potential equilibrium is reached. The cell membrane is freely permeable to small molecules, such as water, urea, and ethanol, as well as for solved gases, oxygen, carbon dioxide and ammonia. The cell membrane is impermeable to larger molecules, such as glucose and other sugars, proteins and organic ions. Since, however, the cell requires these substances, different influx mechanisms for these compounds must exist and appropriate efflux mechanisms for many other substances must be available. The transport of these substances occurs by *facilitated diffusion* (Fig. 5.1). This is a form of a passive transport process mediated by *carrier proteins* by which substances are moved in the direction of their electrical or chemical gradient. Thus, carrier proteins are integral transmembrane proteins that facilitate the selective passage of substances.

In addition to carrier mediated facilitated diffusion, another passive transport process exists – diffusion through *channels* (Fig. 5.2). These are formed by trimeric channel proteins with central aqueous pores that allow diffusion of small molecules. *Ion channels* are relatively selective for certain ions, e.g. Na^+ , K^+ , Cl^- ,

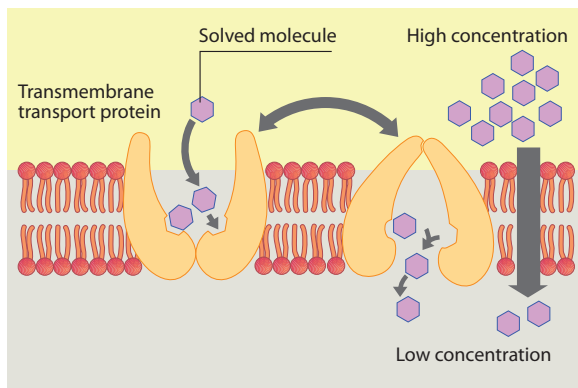


Fig. 5.1 Facilitated diffusion. The transport across the membrane occurs along an electrochemical concentration gradient and is facilitated by conformational alterations of the transport protein

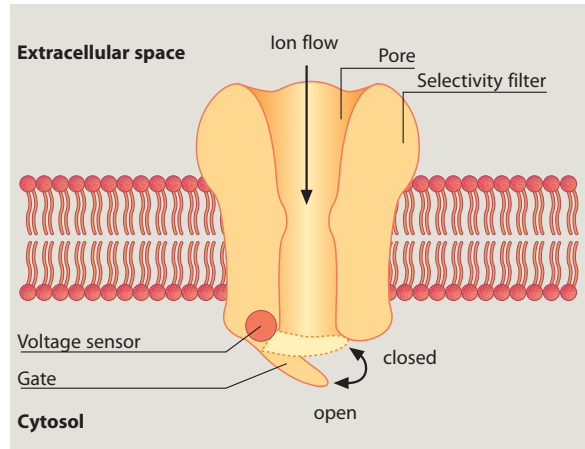


Fig. 5.2 Facilitated diffusion across channels. A channel protein forms a water-filled pore inside the plasma membrane that allows for the diffusion of certain ions. A selectivity filter discriminates between various ions, and a voltage sensor induces opening and closure of the pore (According to [12])

Ca^{++} . They are voltage or ligand-gated, such that alterations in membrane potential or ligand binding will lead to conformational changes, which are accompanied by changes in their permeability and in the rate at which they transport ions. *Water channels* are comprised of aquaporins [14].

Transport Proteins

Transport proteins are substrate specific, i.e. they transport only certain substances with high affinity. They can be activated by physical, chemical and hormonal stimuli. They can be selectively inhibited by substances that occupy the transport system. They display a saturation kinetic, i.e. transport performance decreases with increasing substrate concentration, because the maximal transport capacity is limited by the number of transport proteins.

In contrast to ion channels, carrier proteins bind the molecules that are to be transported. After binding, conformational changes of transport proteins occur that enable the passage of molecules through the membrane. Carriers have lower transport rates than channels, they are not gated, and often are able to transport two to three different substances in a fixed stoichiometric ratio (*cotransporter*) (Fig. 5.3). Carriers that bind more than one substance and transport the substances across the membrane together in

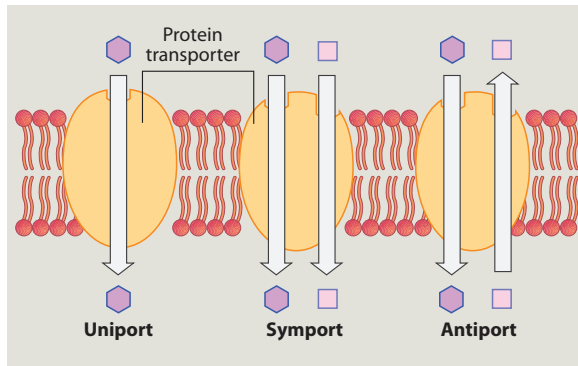


Fig. 5.3 Passive transport by carriers. Unidirectional transport of one substance (uniport), unidirectional transport of two different substances (symport), and transport of two different substances in opposite directions (antiport)

one direction are called **symports** (positive flow coupling). Transporters that exchange one substance for another are called **antiports** (negative flow coupling). **Uniports** are transport proteins that transport only one substance in one direction. They are not able to cotransport molecules. An example is the uniport for glucose transport. Glucose transport proteins (GLUT) are a family of structurally related membrane proteins that are expressed in a tissue and cell specific manner. GLUT2 is specific for β -cells of pancreatic islets of Langerhans and for hepatocytes. It is localized in the basolateral (sinusoidal) membrane of liver cells and binds glucose circulating in the sinusoidal blood. After glucose binding, GLUT2 undergoes a conformational change that enables the passage of sinusoidal glucose across the hepatocellular membrane into the liver cell. Hepatocytic GLUT2 has a relatively low affinity, but a high transport capacity, for glucose. The uptake of glucose into the hepatocyte is therefore directly correlated to the concentration of glucose in the sinusoidal blood.

Active Transport

Active transport is the transport of substances against their electrical and/or chemical gradient. It always requires energy which is provided almost exclusively by the hydrolysis of ATP to ADP and phosphate. The direct coupling of the hydrolysis of ATP to the transport process is referred to as

- Primary active transport

(Examples: $\text{Na}^+ - \text{K}^+$ ATPase; proton pumps).

If the active transport of Na^+ is coupled to the transport of other substances a

- Secondary active transport

is said to be present. (Examples: Na^+ -glucose symport of intestinal epithelial cells. A prerequisite for the transport is the presence of a Na^+ gradient which is achieved by the activity of $\text{Na}^+ - \text{K}^+$ ATPase).

According to their mechanism of action the ATPases responsible for primary active transport may be subdivided into three groups.

- P-ATPases

are phosphorylated by ATP during the catalysis cycle.

- V-ATPases

are found in many intracellular vesicles and catalyze the active transport of protons into these vesicles leading to a decrease of intravesicular pH. The acidic pH is important for the activation of lysosomal enzymes and for the release of receptors from secretory granules (see below).

- F-ATPases

are found in the mitochondrial membrane and exert their function in the synthesis of ATP.

Pumps

Pumps are a special type of carrier that mediate active transport. These transport proteins are ATPases that hydrolyze ATP on the inside of the cell membrane. The energy released during this reaction is used for active transport; therefore, these pumps are both enzymes and transporters. According to the substance transported, ion pumps, peptide pumps, and pumps for nonpolar compounds (drug pumps, MDR proteins) are distinguished.

An important **ion pump** is

- $\text{Na}^+ - \text{K}^+$ ATPase

which is present in all organs of the body, including in the hepatocyte. The energy derived from the hydrolysis of one molecule of ATP is used to extrude 3 Na^+ from the cell and to take 2 K^+ into the cell against a concentration

and an electrical gradient (*electrogenic pump* with a *coupling ratio of 3:2*). The pump functions as an anti-transport (Fig. 5.4). The Na^+/K^+ ATPase is a very active pump. The active transport of Na^+ and K^+ is one of the major energy-demanding processes in the body, accounting for a large part of the basal metabolism. Depending on the cell type and the activity level of the cell, 30–70% of cellular energy consumption is spent on this transport mechanism. This electrogenic pump, by maintaining the Na^+ and K^+ concentration gradient, creates important conditions for excitation processes, for the function of other transport processes (see below) and for the regulation of cell volume (see Chapter 10).

The superfamily of *ABC transporters* was originally discovered in bacteria and presently contains more than 50 members. A common structural element is an **ATP Binding Cassette** [13]. As a rule, ABC transporters have four domains. Two transmembrane domains delimit a pore through which substances pass across the plasma membrane. Two nucleotide binding domains on the cytoplasmic side of the membrane bind ATP and couple ATP hydrolysis to the transport process. A small subgroup of ABC transport proteins are *MDR gene products*, also called MDR P-glycoproteins. The denomination *MDR (multi drug resistance)* is derived from the fact that, in humans, some of these ATPases are overexpressed in malignant cells. By

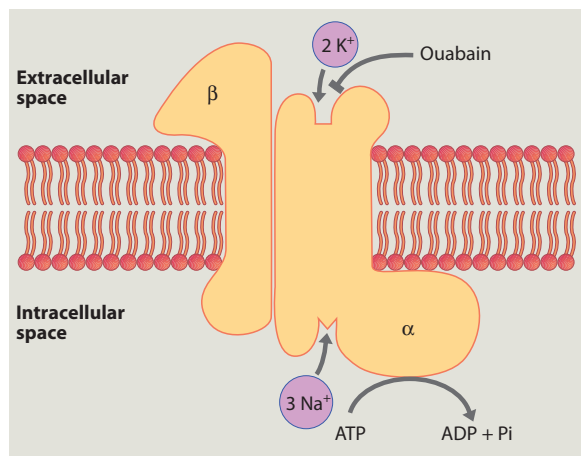


Fig. 5.4 Schematic representation of Na^+/K^+ ATPase. The pump consists of an α - and a β -subunit whose structure varies in different tissues. The intracellular domain of the α -subunit contains a binding site for Na^+ , phosphorylation and ATP. The extracellular domain has a binding site for K^+ and ouabain. Ouabain inhibits the Na^+/K^+ -ATPase

expulsion of chemotherapeutic agents from malignant cells, MDR transport proteins render these cells resistant to multiple cytostatic drugs. In hepatocytes ABC transporters (MDR transport proteins) are responsible for the transport of peptide fragments from the cytosol to the endoplasmic reticulum, and for extrusion of organic compounds through the canalicular membrane into the bile. The activity of these transporters depends on the energy released by hydrolysis of ATP. The *cystic fibrosis transmembrane conductance regulator (CFTR)* is also a member of the ABC family (see Chapters 52 and 86).

Vesicle Transport

As a rule macromolecules are transported within the hepatocytes in membrane-enclosed vacuoles. Uptake and secretion of substances are linked by the fusion of vesicle membranes with the cell membrane and with the membranes of cell organelles. Table 5.1 gives an overview of various forms of vesicle transport in the hepatocyte.

- **Exocytosis**

is the process by which macromolecules contained in cytoplasmic secretory vesicles are secreted into the extracellular space. The secretory vacuoles fuse with the cell membrane. The area of fusion then breaks down, leaving the contents of the vesicle outside the cell. Exocytosis is an energy consuming, Ca^{++} -dependent process. Exocytosis may be initiated by an exogenous stimulus, in which case it is called

- **Triggered or nonconstitutive exocytosis**

This form of exocytosis pertains less to the hepatocyte, but more to secretory active cells, such as pancreatic acinar cells and endocrine cells. Proteins from the Golgi apparatus initially enter secretory granules, where they are further processed before exocytosis. In

- **Non-triggered or constitutive exocytosis**

secretion of intracellular molecules does not require an exogenous stimulus. In the constitutive pathway proteins are promptly transported to the cell membrane in vesicles, with little or no processing or storage.

The intake of solutes is not visible under the microscope and is called

- **“Fluid-phase” endocytosis (pinocytosis)**

as opposed to

- **Receptor mediated (adsorptive) endocytosis**

in which a ligand binds to a membrane receptor, and this ligand-receptor complex is internalized into the cell in clathrin-coated vesicles.

To prevent an excessive increase of the cell surface, exocytosis nearly always is coupled to endocytosis (“*exocytosis coupled endocytosis*”).

- **Transcytosis**

describes the passage of vesicles from one pole of the cell to another pole, without processing the substances contained in the vesicles.

- **Dia-cytosis (retrocytosis)**

is a process by which part of the intact, internalized ligand-receptor complex recycles to the cell surface. It has to be distinguished from pure receptor recycling.

Cytoskeleton

A prerequisite for the directional vesicle traffic in the hepatocyte is the integrity of the microtubular cytoskeleton (see also Chapter 3). This microtubular web is composed of microfilaments which are formed by polymerized actin. They are indispensable for the structural and functional polarity of the hepatocyte. Microtubuli are found in the microvilli and they are especially abundant around the canaliculus, in the pericanalicular ectoplasm. In concert with cytoplasmic myosins, they maintain the structure and the contractility of the bile canaliculus. They are responsible for “anchoring” of the Golgi apparatus between the cell nucleus and the apical pole of the hepatocyte.

The transport of membrane-bound vesicles is target-oriented along the filamentous cytoskeletal structures (Fig. 5.5). **Motor proteins** move the vesicles in an energy-dependent, ATP-consuming process. The vesicles bind to the microtubular motor protein *kinesin* and to the cytoplasmic motor protein *dynein*, both belonging to the ATPases. Both motor proteins move the vesicles in an energy consuming, ATP-dependent process in opposing directions. The movement of vesicles requires further cytoplasmic factors, such as *spectrin*

and *dynactin*, a multiprotein-complex. Its main component is an actin isoform called actin-RPV (actin related protein of vertebrates).

Vesicle transport is influenced by many factors. Among them are secondary messengers (cAMP), Ca^{++} -influx into the cell, and protein kinase C. These factors seem to stimulate exocytosis and transcytosis. Osmotic stimuli (“hypotonic stress”) and alkalinization of the hepatocyte lead to stimulation of vesicle transport in the direction of the apical cell membrane.

Hepatocellular Transporters

(For cholangiocyte transporters see Chapter 52)

Liver cells contain many transport proteins that are integrated into their plasma membrane. These transporters reach various cell membrane domains by regulated vesicle trafficking from the Golgi apparatus (see below) [15]. Uptake of exogenous and endogenous substances occurs mostly at the hepatocyte’s basolateral domain, whereas their excretion predominantly occurs at the apical domain. To a lesser degree, substances may also be secreted through the basolateral membrane into the sinusoidal blood (“reflux”). Efflux of endogenous and exogenous (xenobiotics) cholephilic compounds occurs via transport proteins localized in the canalicular membrane.

After uptake through the sinusoidal liver cell membrane, bile acids and other organic and inorganic molecules are processed intracellularly. They are then transported through the hepatocyte and subsequently secreted across the canalicular membrane into the bile (see also Chapter 7). Any disturbance of these processes can lead to intracellular accumulation of potentially harmful substances [6, 11, 18, 26]. Transport proteins localized in the basolateral membrane and canalicular efflux transporters are depicted schematically in Fig. 5.6.

Basolateral (sinusoidal) Transporters

Most organic anions are transported in blood bound to albumin. After dissociation from albumin they are taken up by transport systems localized in the basolateral membrane of the hepatocyte. Bile acids belong to the most important anions. The *uptake of bile acids* is carried out by both Na^+ -dependent and Na^+ -independent

Fig. 5.5 Targeted vesicle transport (proteins, lipids) along microfilamentous structures of the cytoskeleton with the help of motor proteins (Modified according to [19])

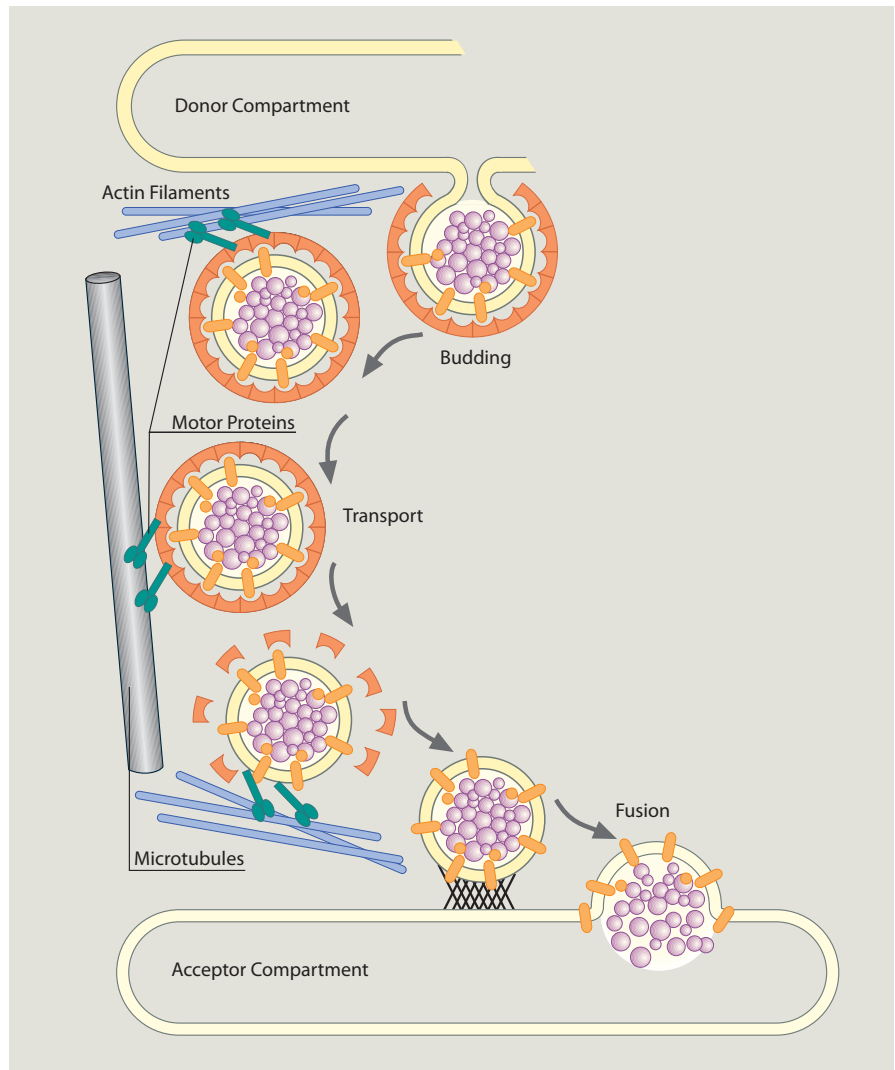
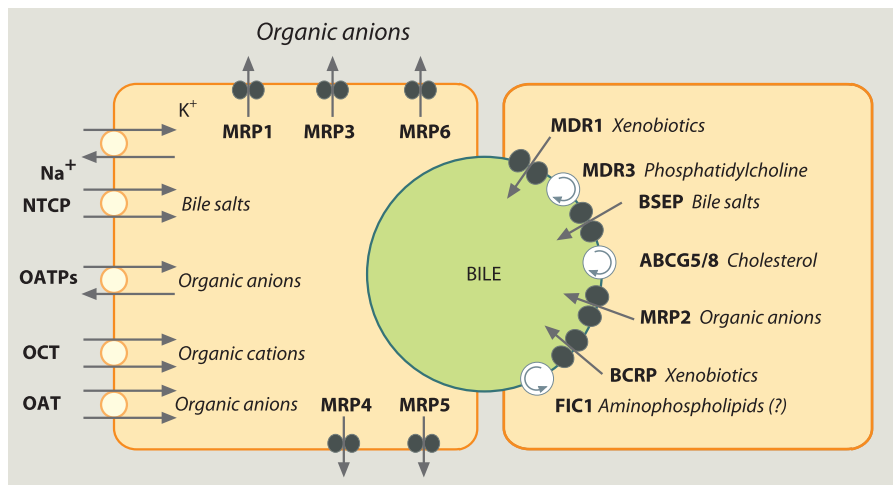


Fig. 5.6 Hepatocellular transport proteins at the basolateral (sinusoidal) and apical (canalicular) pole of hepatocytes involved in the uptake and efflux of endogenous and exogenous compounds. See text for abbreviations. (According to [20])



mechanisms [5, 25]. The Na^+ -dependent pathway is regarded as the most important mechanism of bile acid uptake. It is regulated by a Na^+ -gradient which is generated by the activity of Na^+ - K^+ -ATPase localized in the basolateral membrane. The Na^+ - K^+ -ATPase maintains the electrochemical gradient between the hepatocyte and its environment. By exchanging three intracellular Na^+ for two extracellular K^+ , a high extracellular Na^+ concentration and a high intracellular K^+ concentration is maintained. The resulting electrical gradient is -35 mV , with the cell interior being negative compared to the extracellular space. This potential difference enhances the intracellular uptake of positively charged particles and the efflux of negatively charged ions.

The *sodium-dependent pathway* is represented by the *sodium taurocholate cotransporting polypeptide (NTCP; Na-taurocholate cotransporter)*. The human NTCP is a glycoprotein of 349 amino acids with seven transmembrane domains. Its genomic DNA is localized on chromosome 14q24.1–24.2. The most important substrates of NTCP are conjugated bile acids (e.g. taurocholate and glycocholate, taurochenodeoxycholic acid and chenodeoxycholate). NTCP accounts for more than 80% of conjugated but less than 50% of unconjugated bile salt uptake. Certain sulfated steroids, such as estron-3-sulfate, dehydroepiandrosterone sulfate may also be transported by NTCP, albeit in much lower quantities.

The *sodium-independent uptake* of bile acids is mediated by different members of the superfamily of *organic anion transporting polypeptides (OATP)*. OATP transporters function as anion exchangers, which not only mediate the hepatocellular uptake, but also the excretion, of organic anions, such as bromosulphthalein (BSP) and taurocholate, across the basolateral membrane into the sinusoidal blood [10, 17, 27, 28].

In the human liver, the highest expressions are found for OATP1B1 and its 80% sequence homologue OATP1B3. OATP1B1, OATP1B3 and OATP1A2 exhibit overlapping transport activities for conjugated and unconjugated bile salts (the affinity of OATP for taurocholic acid is less than that of NTCP), BSP, neutral steroids, steroid sulfates (e.g. estron-3-sulfate) and glucuronides (e.g. estrogen-17 β -glucuronide). In addition, numerous drugs are substrates of OATPs, including fexofenadine, opioid peptides, cardiac glycosides, pravastatin, enalapril and methotrexate. The uptake of the hepatotoxins phalloidin and microcystin is mediated by OATP1B1 and OATP1B3, while the uptake of amanitin, the most dangerous natural

toxin capable of causing liver failure, seems to be exclusively mediated by OATP1B3 [21].

A second OATP of 691 amino acids – OATP2 – was identified in the basolateral membrane of human hepatocytes [7]. It shows a 44% homology with OATP1. The substrate specificity of OATP2 encompasses BSP, 17 β -glucuronosylestradiol, bilirubin-monoglucuronide, dehydroepiandrosterone-sulfate and taurocholate. Therefore, OATP2 like OATP1 seems to be important for the uptake of organic anions in the human liver, including BSP and bilirubin conjugates. However, the exact physiologic mechanisms of bilirubin and BSP uptake into the hepatocyte are still unknown. The existence of a bili-translocase, a BSP/bilirubin binding protein, has been postulated. However, their cDNA has not yet been identified.

In addition to the OATPs, the uptake and elimination by the hepatocyte of endogenous and exogenous organic anions and cations is carried out by sodium-independent systems belonging to the family of *organic anion and organic cation transporters (OAT and OCT)*. Until 2007 OAT2 was the only transporter of the OAT/OCT family believed to be liver-specific, whereas OCT1 is expressed in human liver as well as in kidneys, small intestine and colon. Recently a novel liver-specific OAT7, with a new class of substrates for organic anion transporters, has been described. It operates the exchange of sulfate conjugates for butyrate in hepatocytes [23].

OCT1 consists of 554 amino acids and is capable of transporting large and small organic cations [29]. However, the exact role of OAT2 and OCT1 in hepatic uptake of drugs and bile constituents remains to be established.

Basolateral transporters are subject to extensive transcriptional and posttranscriptional regulation. Disturbances of the regulatory mechanism play an important role in the pathophysiology of cholestasis [20]. Bacterial lipopolysaccharide, for example, downregulates NTCP-mRNA. The reduced activity of NTCP seems to play a key role in endotoxin (septicemia) associated cholestasis (see Chapter 52) [4].

To a lesser degree, organic anions and cations can enter the hepatocyte by carrier-independent mechanisms, such as passive diffusion or endocytosis. Highly lipophilic organic cations, for example, may diffuse passively through the hepatocyte membrane. Dopamine, choline, norepinephrine and serotonin belong to the endogenous organic cations.

In addition to uptake systems, the basolateral membrane also localizes transport proteins responsible for

the secretion of ions. These proteins belong to the family of *multidrug resistance-associated proteins (MRPs)*. MRPs are multispecific ATP-binding cassette (ABC) transporters involved in the efflux of organic anions. Six family members (MRP 1–6) are presently known, each displaying a tissue specific expression. With the exception of MRP2, which localizes on the canalicular membrane, all other MRPs are present in the basolateral membrane [21]. The genes for the individual proteins are on different chromosomes, and their physiological significance is still not completely understood.

MRP1 is expressed in the liver in very small quantities. The physiologic roles of MRP1 include the cellular efflux of glutathion-S-conjugates, leukotriene C₄, steroid conjugates (e.g. 17β-glucuronosyl-estradiol), and glucuronidated or sulfated bile acid conjugates. This “reflux” of organic anions across the basolateral membrane gains special importance in cholestasis.

MRP3 is strongly expressed in the liver, and transports sulfated and glucuronidated bile acids.

MRP4 and **MRP5** are heavily expressed in the liver. They mediate the transport of nucleoside analogs such as zidovudine, lamivudine, and stavudine (MRP4); cyclic adenosine and guanosine monophosphate; methotrexate and the purine analogs 6-mercaptopurine and 6-thioguanine; and, the endothelin ET_A-receptor antagonist BQ123.

The physiologic substrates of **MRP6** are yet unknown.

Apical (canalicular) Transporters

Many endogenous and exogenous hydrophobic substances become hydrophilic after conjugation with glucuronic acid, glutathione or sulfate, and thus suitable for biliary excretion. The rate limiting step (“bottle neck”) of hepatic transport for many substances is canalicular secretion. With the exception of FIC1, transport of bile constituents across the canalicular membrane and hepatic drug clearance is carried out by ATP dependent membrane proteins which belong to the ABC transporters. These include members of the family of multidrug resistance (MDR) P-glycoproteins (MDR1 and MDR3) and the bile salt export pump (BSEP).

In addition, the canalicular membrane localizes the multidrug resistance-associated protein (MRP2) and

the ABC half transporters breast cancer resistance protein (BCRP), as well as the cholesterol translocase/flippase ABCG5 and ABCG8.

The canalicular *excretion of bile acids* is carried out by at least two transport systems, the *multi-drug resistance associated protein 2 (MRP2)* and the *bile salt export pump (BSEP)*.

MRP2 has 1,545 aminoacids and mediates the canalicular transport of glucuronidated and sulfated bile salts. Because of its broad substrate specificity it was originally referred to as the canalicular, multispecific organic anion transporter (cMOAT). In addition to bile salts, MRP2 transports a wide spectrum of organic anions, including glucuronic acid conjugates (e.g. bilirubin diglucuronide), glutathione conjugates, leukotriene C₄, as well as cancer chemotherapeutic agents, uricosurics, and antibiotics. MRP2 is the main driving force for bile salt independent bile flow through canalicular excretion of reduced glutathione. A down-regulation of MRP2 was shown to occur in experimental intra- and extrahepatic cholestasis. Furthermore, experimental data suggest that activation of protein kinase C in cholestasis may lead to retargeting of canalicular MRP2 to the basolateral membrane [8].

BSEP constitutes the predominant bile salt efflux system and mediates the cellular excretion of conjugated bile salts such as taurine- or glycine conjugated cholate, chenodoxycholate, and deoxycholate. Its trafficking from the Golgi apparatus to the canalicular membrane is under control of certain kinases and may be enhanced by tauroursodeoxycholate [9].

The canalicular excretion of various organic cations is ATP-dependent and mediated by the *MDR 1* gene product. The MDR 1 gene codes for 1,279 amino acids and is located on chromosome 7. The endogenous substrate for MDR 1 is unknown, but it is thought to contribute to the canalicular excretion of drugs (e.g. chemotherapeutic and immunosuppressive agents, antiarrhythmic drugs, HIV protease inhibitors, antifungals) and xenobiotics into bile.

The **MDR 3** protein exhibits a 75% amino acid homology with MDR 1. It serves as an ATP-dependent phospholipid-translocase/flippase, translocating phosphatidylcholine from the inner to the outer leaflet of the canalicular membrane. MDR3 is important for the secretion of phospholipids into the bile, which, together with bile salts, forms mixed micelles that protect cholangiocytes from the detergent actions of bile salts.

BCRP has been shown to transport sulfated bile salt conjugates such as tauro lithocholate *in vitro*. Its physiologic role in canalicular secretion is unknown.

ABCG5 and **ABCG8** are involved in the hepatobiliary excretion of plant sterols and cholesterol.

Aquaporins

Aquaporins are a family of integral membrane water channel proteins that facilitate the rapid movement of water. In addition to water, they facilitate transmembrane transport of glycerol, urea, and, in special cases, CO₂, ammonia, nitrate, Cl⁻, carbamides, purines, pyrimidines, polyols, and arsenate. Among 13 aquaporins cloned in mammals, seven have been identified in the liver and biliary tree. Aquaporins are likely involved in canalicular and ductular bile secretion, gluconeogenesis, and microbial infection [16, 22].

Aquaporin 8, one of the main aquaporins in hepatocytes under non-stimulated conditions, is largely localized in intracellular vesicles. Upon stimulation by choleric substances it redistributes to the canalicular membrane, thereby increasing the apical cell surface permeability and facilitating osmotic water transport.

Aquaporin 9 is principally localized on the hepatocyte basolateral membrane and is highly permeable to glycerol and urea. Its exact role in the hepatocyte is unknown.

Regulation of Intracellular pH

The intracellular pH of the hepatocyte (pHi) results from the net balance of acid accumulated within the hepatocyte and acid excreted by the liver cell. It is kept within a narrow range by active transport processes. The maintenance of pHi is achieved by the activity of carriers that transport Na⁺, H⁺, Cl⁻ and HCO₃⁻ across the hepatocyte membrane. Among these transporters are the

- Na⁺/H⁺ -exchanger, the
- Na⁺/HCO₃⁻ -cotransporter in the basolateral membrane, and the
- HCO₃⁻/Cl⁻ -exchange pump in the canalicular membrane.

The Na⁺/H⁺ -exchanger leads to intracellular alkalization and the HCO₃⁻/Cl⁻-exchange pump leads to intracellular acidification, while the Na⁺/HCO₃⁻-cotransporter can bring about both.

The regulation of pHi within the hepatocyte is tightly associated with other cell functions. Glycolysis, accumulation and uptake of lactate and other acids, biliary excretion of HCO₃⁻, regulation of cell volume, intracellular concentrations of Ca⁺⁺ and cAMP, and membrane potential can all influence pHi [24]. The membrane potential and pHi are closely interrelated. Changes in pHi will lead to alterations of the membrane potential, while primary alterations of membrane potential difference will impact the pHi. The negative electrochemical gradient across the liver cell membrane enhances the influx of H⁺ and weak cationic acids, and the efflux of HCO₃⁻. A fall in pHi leads to depolarization of the hepatocyte membrane, while alkalization of the intracellular milieu causes hyperpolarization. The pH-induced alterations in potential difference are probably mediated by changes in the membrane permeability for K⁺. On the other hand, primary depolarization will lead to alkalization of the cell interior, while a hyperpolarization will cause acidification.

The activity of ion transporters is controlled by hormones and growth factors. [Table 5.2](#) summarizes the factors that influence the pHi of the hepatocyte.

The **Na⁺/H⁺-exchange** takes place at the basolateral membrane. It is electroneutral and is guided by the Na⁺-gradient. It leads to excretion of acid and is inversely correlated to the pHi. Insulin, arginine-vasopressin, epidermal growth factor, and activation of protein kinase C all stimulate the activity of hepatocellular Na⁺/H⁺ -exchange. The Na⁺/H⁺ -exchange is inhibited

Table 5.2 Factors affecting the intracellular pH of the hepatocyte (According to [24])

Factor	Intracellular pH
Metabolic inhibitors	↓
Hypoxia, anoxia	↓
Membrane potential difference	
Depolarization	↑
Hyperpolarization	↓
Temperature	inverse correlation
Metabolic acidosis	↓
Extracellular pH	direct correlation
Cellular volume increase	↑

by a decrease in extracellular Na^+ , by amiloride, cAMP and its analogs, as well as by a decreased intracellular Ca^{++} -concentration.

The $\text{Na}^+/\text{HCO}_3^-$ cotransport is electrogenic and Na^+ - and HCO_3^- -dependent. It localizes to the basolateral membrane and, by influx of HCO_3^- , it functions primarily as an acid extruder.

The $\text{HCO}_3^-/\text{Cl}^-$ -exchange pump is an electroneutral transporter localized in the canalicular membrane. It mediates the exchange of Cl^- for HCO_3^- , independent of Na^+ . By extruding HCO_3^- from the hepatocyte into the canalicular lumen, it contributes to the alkalization of bile and to the acidification of the hepatocyte interior. The activity of the $\text{HCO}_3^-/\text{Cl}^-$ -exchange pump is directly proportional to the pHi . The pump is stimulated by cAMP, glucagon, and protein kinase A agonists, and is inhibited by protein kinase C agonists.

Ion pumps are not distributed uniformly in the hepatic lobule. While Na^+/H^+ -exchange in periportal and perivenous hepatocytes is approximately equal, $\text{Na}^+/\text{HCO}_3^-$ -cotransport is more pronounced in periportal hepatocytes compared to perivenular liver cells. The $\text{HCO}_3^-/\text{Cl}^-$ -exchange pump is more active in perivenular cells.

Vesicle Transport of Hepatocellular Proteins

Protein synthesis takes place in the endoplasmic reticulum. Initially all proteins follow a common pathway from the endoplasmic reticulum to the Golgi apparatus. By pinching off and fusion of vesicles, secretory vesicles are transported through various compartments of the Golgi apparatus [2]. After this passage they reach their final cellular destination. The functions of a protein, and the cellular site where these functions are exerted, are genetically determined by defined amino acid sequences and by targeting signals. A target of a protein may be the basolateral or the canalicular membrane, where it may become incorporated into the membrane. Alternatively, proteins may be extruded by constitutive exocytosis into the blood or bile, or they may be directed to an intracellular address, e.g. the lysosomes (Fig. 5.7). If a protein is integrated into the membrane of the endoplasmic reticulum, it will finally be inserted into the plasma membrane. If, on the other

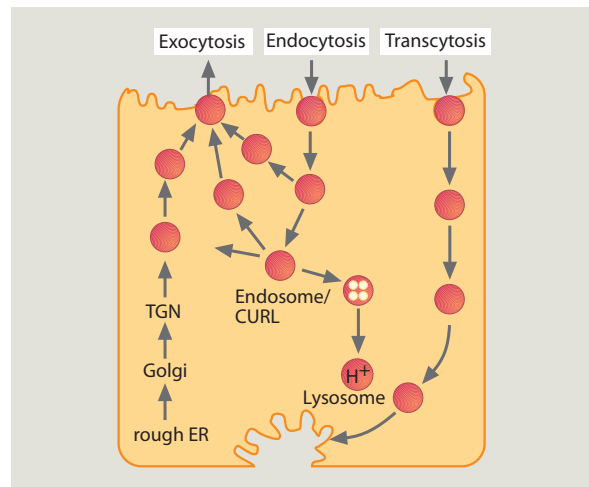


Fig. 5.7 Receptor mediated endocytosis and vesicular transport. Ligand molecules bind to specific surface receptors of the plasma membrane and are internalized in coated vesicles. The internalized vesicles reach endosomal sorting compartments in the peripheral cytoplasm. The acidification of the interior of the vesicles by proton pumps enhances the uncoupling of ligands from their receptors. The released ligands can be degraded by lysosomes, incorporated into the trans Golgi network (TGN), or recycled to the cell membrane to be secreted by exocytosis. *CURL* compartment of uncoupling receptor and ligand

hand, the protein is present in the lumen of the endoplasmic reticulum, it is destined for secretion. Present findings support the notion that *all* plasma membrane proteins – even those allotted for the apical domain – initially are transported to the basolateral membrane. Here proteins destined for the apical membrane are sorted out and, probably by transcytosis, are redirected to the canalicular membrane. The transcytosis of vesicles between various intracellular compartments occurs along the microtubular cytoskeleton.

The Golgi apparatus is a membrane system of stacked cisternae that are perforated in a netlike fashion at their outer margins, and surrounded by membranous tubules and vesicles. It takes up, processes and transports secretory products derived from the adjoining rough endoplasmic reticulum. The section of the Golgi apparatus next to the transitional element of the rough endoplasmic reticulum is called *cis-Golgi*, while the segment situated farthest away (the last Golgi transport station) is denoted *trans-Golgi-network* (*TGN*). The continuous and directed flow of vesicles occurs through budding and fusion of vesicles from one Golgi cistern to another, from *cis* to *trans*. From

the outermost margin of the TGN-cisternae vesicles pinch off as complete secretory products for exocytosis and as primary lysosomes.

The vesicular secretion in the Golgi apparatus is controlled by certain proteins. The lipid composition of the membrane and small GTPases, anchored to the cytosolic aspect of the membrane, are important for the assembly of coat protein complexes (coatomers). Coatomers surround the vesicles and are necessary for their addressing of consecutive cisterns.

Not all vesicles leaving the endoplasmic reticulum for cis-Golgi take the described pathway. The hepatocyte contains a salvage compartment in which proteins that have left the rough endoplasmic reticulum “by mistake” may be brought back again (“salvaged”) to the transitional element of the rough endoplasmic reticulum. These retrograde or shuttle-vesicles possess so called KDEL-receptors that are characterized by proteins with a specific amino acid sequence (lysine-aspartic acid-glutamic acid-leucin; retrieval-retention-sequence). Shuttle vesicles may originate from each part of the Golgi complex, not only from segments adjoining directly the rough endoplasmic reticulum.

During their passage through the Golgi apparatus the proteins are subject to many posttranslational modifications. On their way from cis to trans, glycosyl-transferases, for example, attach specific sugar residues to proteins of the vesicle membrane and to the vesicle contents. This process is called peripheral glycosylation.

Integral and peripheral membrane glycoproteins reach the basolateral cell surface through vesicles that have pinched off from the TGN. Proteins designed for the apical domain migrate by transcytosis from the basolateral to the canalicular membrane.

Membrane transporters (see above) reach the plasma membrane in specialized intracellular vesicles. Vesicle transport is tightly regulated. In response to appropriate stimuli transporters are integrated into the plasma membrane. They may be retrieved by endocytosis and remain for a period of time in vesicles (i.e. early endosomes) or undergo re-fusion after re-stimulation. Alternatively, they may move to a non-recycling compartment (i.e. late endosomes) where they ultimately will be degraded by lysosomes. Some transporters might be targeted for proteolysis through the ubiquitin-proteasome pathway [15].

What has been said about integral cell membrane proteins applies also to proteins that are designated for export. All proteins designed for secretion are first

transported to the plasma membrane. Lipoproteins, albumin, and transferrin reach the circulation by constitutive exocytosis. Other proteins such as polymeric IgA-receptor, however, are secreted into bile only after accessing the apical membrane by transcytosis from the sinusoidal pole.

Receptor Mediated Endocytosis

Receptor mediated adsorptive endocytosis is a cellular process by which different ligands bind to specific receptors on the cell surface, and then the ligand-receptor complexes are internalized in vesicles. Within the cell, endocytotic vesicles take different pathways [1, 3]. Examples of ligands that are taken up into hepatocytes by receptor mediated endocytosis are LDL, transferrin, asialoglycoproteins (ASGP), plasminogen activator-inhibitor complexes, hormones (insulin), epidermal growth factor (EGF), and certain lysosomal enzymes. Viruses and bacterial toxins can also gain access to the hepatocyte by this route. Protein secretion and receptor mediated endocytosis are not, as previously assumed, two sharply separated processes. Instead, as already suggested by the spatial closeness of endosomes (CURL; see below) and the TGN, the biosynthetic and the endocytotic pathways are closely interconnected.

The initial step in receptor mediated endocytosis is the accumulation of receptor proteins in indentations of the cell membrane, the *coated pits*, that account for approximately 2% of the cell surface. Receptors for different ligands are either diffusely distributed on the membrane (e.g. EGF, insulin, ASGP) or localized in coated pits (e.g. LDL, transferrin). Diffusely distributed cell surface receptor molecules, after contact with their respective ligand, redistribute and concentrate in circumscribed areas in the cell membrane. Thereafter, the ligand-receptor complexes move laterally in the cell membrane and concentrate in coated pits. On their outer surface, corresponding to the inner aspect of the cell membrane, these pits are coated with clathrin.

Ligands, such as LDL and transferrin react with previously locally concentrated receptor molecules. After reaching a critical size the ligand-receptor complexes within the coated pits further indentate and finally pinch off into the cell interior as coated vesicles. On their outside, coated pits and coated vesicles are covered by a polygonal web of specifically organized macromolecules. The most important coat-protein is

clathrin, which is a trimeric protein composed of light and heavy chains (triskelion). The triskelions assemble to form pentagonal and hexagonal subunits that create a cage – reminiscent of a leather soccer ball – around the vesicle (**clathrin coated vesicle**). In addition to clathrin, a second class of coat-proteins exists, the **adaptins**. Adaptins are barrel-shaped proteins located between the clathrin-web and the vesicle membrane. They are important for the assembly of clathrin, and probably mediate the binding of clathrin to the vesicle membrane. Furthermore, they are thought to be involved in the binding of receptor molecules.

Shortly after pinching off the plasma membrane, coated vesicles via an active ATP-dependent process lose their clathrin cover (uncoating), leaving behind “smooth”, membrane-bound vesicles containing receptor-ligand complexes (**receptosome**). These migrate to a peripheral cytoplasmic compartment adjoining the TGN, near the basolateral membrane and not far away from the original site of their endocytosis, and become **early endosomes**. Early endosomes are tubulovesicular organelles that contain endocytosed ligands during

the early uptake phase. The interior of these organelles becomes acidified by proton pumps integrated in their membranes. Acidification leads to the separation of receptor and ligand which takes place in the **compartment of uncoupling receptor and ligand (CURL)**. This uncoupling is pH-dependent, whereby different ligand-receptor complexes dissociate at different pH values. After separation, ligands and receptors accumulate in different parts of the tubulovesicle. Thereafter, the endosome separates in two vesicles, and ligand and receptor follow their individual fate.

Fate of Ligands and Receptors

Presently three endosomal fractions are distinguished. Early (**CURL**) and late (**multivesicular bodies**; prelysosomal structures) endosomes, as well as the endosomal **receptor-recycling compartment (RRC)**. The RRC is rich in recirculating receptors and contains only a few ligands. In the early endosomes sorting of ligands occurs,

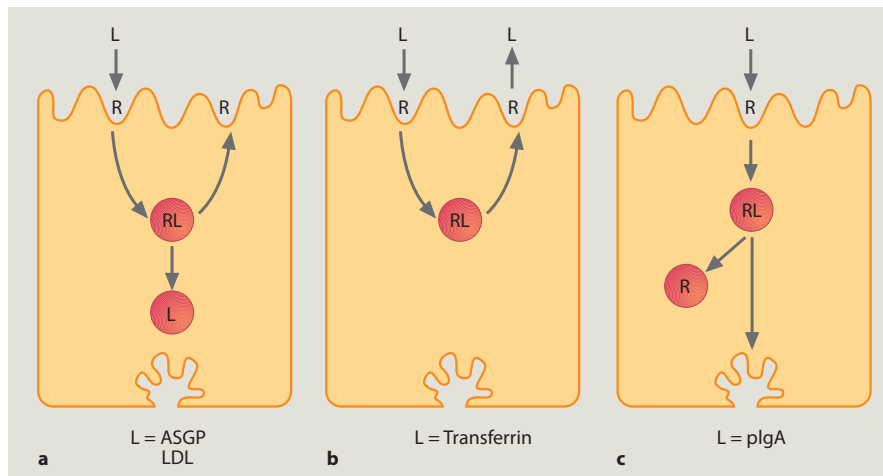


Fig. 5.8 Selected examples of intracellular sorting of receptor-ligands. **(a)** Asialoglycoprotein (ASGP), low density lipoprotein (LDL). *Receptor recycles, ligand is processed.* The ASGP-receptor has a high affinity for galactose residues of proteins. It recognizes ligands with terminal galactose-galactosamine residues. The ligand is degraded by lysosomes. The receptor returns to the cell surface and can be reused. Apolipoprotein B mediates the binding of LDL to the LDL-receptor. Cholesterol is released within the hepatocyte and suppresses the expression of new LDL-receptors. **(b)** Transferrin. *Recycling of receptor and ligand.* In the endosomes, iron dissociates from transferrin and is released intracellularly. The

remaining vesicles, containing receptor-bound apotransferrin, are transported to the sinusoidal membrane, where they fuse with the plasma membrane. Apotransferrin dissociates from its receptor and is secreted into the sinusoidal blood by exocytosis. **(c)** Polymeric IgA (pIgA). *Receptor is processed, ligand is transported.* The IgA-receptor is a transmembrane glycoprotein. The secretory component (SC) is part of the IgA receptor. pIgA and SC are transported for the most part by transcytosis to the apical membrane and are secreted into bile (possibly a small part is processed in the Golgi complex). The remaining part of the receptor does not recirculate, but is degraded by proteolysis (Adapted from [1])

according to their target site. This sorting process continues with repeated fusions and separations of membrane bound compartments. Certain molecules will return to the cell surface, e.g. receptor recycling, while others will be transported to late endosomes and lysosomes where they are degraded. Still others will traverse the hepatocyte by transcytosis and fuse with the canalicular membrane at the apical pole. While transport to the endosomes occurs rapidly within minutes, the transport to the Golgi system requires hours.

The different cellular pathways of some ligands and their hepatocellular membrane receptors is depicted and briefly described in Fig. 5.8.

References

- Bu G, Schwartz AL (1994) Receptor-mediated endocytosis. In: Arias IM, Boyer JL, Jakoby WB, Fausto N, Schachter D, Shafritz DA (eds). *The liver. Biology and pathobiology*. 3rd edn. Raven Press, New York, pp 259–74
- Crawford JM (1996) Role of vesicle-mediated transport pathways in hepatocellular bile secretion. *Semin Liv Dis* 16: 169–89
- Enrich C, Pol A, Calvo M, et al (1999) Dissection of the multifunctional “receptor-recycling” endocytic compartment of hepatocytes. *Hepatology* 30: 1115–20
- Green RM, Beier D, Gollan JL (1996) Regulation of hepatocyte bile salt transporters by endotoxin and inflammatory cytokines in rodents. *Gastroenterology* 111: 193–8
- Hagenbuch B, Meier PJ (1996) Sinusoidal (basolateral) bile salt uptake systems of hepatocytes. *Semin Liv Dis* 16: 129–36
- Kamisako T, Gabazza EC, Ishihara T, et al (1999) Molecular aspects of organic compound transport across the plasma membrane of hepatocytes. *J Gastroenterol Hepatol* 14: 405–12
- König J, Cui Y, Nies AT, et al (2000) A novel human organic anion transporting polypeptide localized to the basolateral hepatocyte membrane. *Am J Physiol* 278: G156–64
- Kubitz R, Huth C, Schmitt M, et al (2001) Protein kinase C – dependent distribution of the multidrug resistance protein 2 from the canalicular to the basolateral membrane in human HepG2 cells. *Hepatology* 34: 340–50
- Kubitz R, Sutfels G, Kuhlkamp T, et al (2004) Trafficking of the bile salt export pump from the Golgi to the canalicular membrane is regulated by the p38MAP kinase. *Gastroenterology* 126: 541–53
- Kullak-Ublick GA (1999) Regulation of organic anion and drug transporters of the sinusoidal membrane. *J Hepatol* 31: 563–73
- Kullak-Ublick GA, Stieger B, Meier PJ (2004) Enterohepatic bile salt transporters in normal physiology and liver disease. *Gastroenterology* 126: 322–42
- Löffler G, Petrides PE (1998) *Biochemie und Pathobiochemie*. 6. Auflage. Springer, Berlin
- Lomri N, Fitz JG, Scharschmidt BF (1996) Hepatocellular transport: role of ATP-binding cassette proteins. *Semin Liv Dis* 16: 201–10
- Marinelli RA, LaRusso NF (1997) Aquaporin water channels in liver: their significance in bile formation. *Hepatology* 26: 1081–4
- Marinelli RA, Tietz PS, LaRusso NF (2005) Regulated vesicle trafficking of membrane transporters in hepatic epithelia. *J Hepatology* 42: 592–603
- Masyuk AI, LaRusso NF (2006) Aquaporins in the hepatobiliary system. *Hepatology* 43: S75–81
- Meier PJ, Eckhardt U, Schroeder A, et al (1997) Substrate specificity of sinusoidal bile acid and organic anion uptake systems in rat and human liver. *Hepatology* 26: 1667–77
- Müller M, Jansen PLM (1998) The secretory function of the liver: new aspects of hepatobiliary transport. *J Hepatol* 28: 344–54
- Olkkonen VM, Ikonen E (2000) Genetic defects of intracellular-membrane transport. *N Engl J Med* 343: 1095–104
- Pauli-Magnus C, Meier PJ (2003) Pharmacogenetics of hepatocellular transporters. *Pharmacogenetics* 13: 189–98
- Pauli-Magnus C, Meier PJ (2006) Hepatobiliary transporters and drug-induced cholestasis. *Hepatology* 44: 778–87
- Portincasa P, Moschetta A, Mazzone A, et al (2003) Water handling and aquaporins in bile formation: recent advances and research trends. *J Hepatol* 39: 864–74
- Shin HJ, Anzai N, Enomoto A, et al (2007) Novel liver-specific organic anion transporter OAT7 that operates the exchange of sulfate conjugates for short chain fatty acid butyrate. *Hepatology* 45: 1046–55
- Strazzabosco M, Boyer JL (1996) Regulation of intracellular pH in the hepatocyte. Mechanisms and physiological implications. *J Hepatol* 24: 631–44
- Trauner M, Boyer JL (2003) Bile salt transporters: molecular characterization, function, and regulation. *Physiol Rev* 83: 633–71
- Wehner F, Kinne RKH, Petzinger E (1996) Second international Ringberg conference: “Cell biology and molecular basis of liver transport”. *Hepatology* 24: 259–67
- Wolkoff AW (1996) Hepatocellular sinusoidal membrane organic anion transport and transporters. *Semin Liver Dis* 16: 121–7
- Wolkoff AW, Suchy FJ, Moseley RH, et al (1998) Advances in hepatic transport: molecular mechanisms, genetic disorders, and treatment. A summary of the 1998 AASLD single topic conference. *Hepatology* 28: 1713–9
- Zhang L, Dresser MJ, Gray AT, et al (1997) Cloning and functional expression of a human liver organic cation transporter. *Mol Pharmacol* 51: 913–21

Hepatic Metabolism

6

Henryk Dancygier, Uta Merle, Wolfgang Stremmel, and Claus Niederau

Chapter Outline

Carbohydrates	76
Henryk Dancygier	
Uptake of Glucose	76
Release of Glucose	76
Bidirectional Glucose Transport	76
Glycolysis	76
Pentose Phosphate Pathway	77
Gluconeogenesis	77
Glycogen Metabolism	79
Regulation of Carbohydrate Metabolism	80
Key Reactions of Glycolysis and Gluconeogenesis..... 80	
Key Enzymes of Glycogen Metabolism..... 80	
Liver and Carbohydrate Homeostasis	80
Amino Acids and Proteins	82
Henryk Dancygier	
Nitrogen Compounds	83
Ammonia..... 84	
Urea Cycle..... 85	
Lipids	85
Henryk Dancygier	
Fatty Acid Degradation	86
Fatty Acid Synthesis	87
Cholesterol Synthesis	88

Synthesis of Complex Lipids	88
Liver and Lipid Homeostasis	89
Ketogenesis..... 89	
Cholesterol..... 89	
Lipoproteins..... 89	
Vitamin A	92
Henryk Dancygier	
Copper	92
Uta Merle and Wolfgang Stremmel	
Heme and Non-Heme Iron	93
Claus Niederau	
Regulation of Heme and Non-Heme Iron Metabolism and Absorption	94
Non-Heme Iron..... 94	
Heme Iron..... 98	
Influence of Non-Genetic Factors on Iron Absorption	99
References	99

The liver is the central metabolic organ of the body. The following paragraphs highlight important metabolic pathways. Our aim is to summarize fundamental hepatic metabolic processes in order to provide the clinician with a knowledge base for understanding the development and pathogenesis of metabolic liver diseases. A detailed description of biochemical pathways is not intended and is beyond the scope of this book. The interested reader is referred to textbooks of biochemistry.

Carbohydrates

Carbohydrates taken up with food are mostly polymers of the hexoses: glucose, galactose and fructose. The most important product of carbohydrate digestion and the most important monosaccharide circulating in blood is glucose. It is the major fuel for most tissues.

Uptake of Glucose

The uptake of glucose across the sinusoidal membrane into the hepatocyte depends on its concentration gradient and occurs by facilitated diffusion with the help of glucose transporter 2 (GLUT2). *Glucose uptake into the hepatocyte is not insulin dependent.* Within the hepatocyte glucose is phosphorylated by glucokinase to glucose 6-phosphate, which is an important intermediary compound at the junction of several metabolic pathways (see below). Under physiologic conditions, the phosphorylation of glucose to glucose 6-phosphate can be regarded as irreversible. The rapid conversion of glucose to glucose 6-phosphate keeps the intracellular concentration of free glucose low, thereby maintaining the glucose concentration gradient between the blood and the hepatocyte. *It is the activity of glucokinase that determines the rate of glucose uptake from the sinusoidal blood, whereas GLUT2 only facilitates glucose transport across the liver cell membrane.* GLUT2 and liver glucokinase have a low affinity but a high capacity for glucose, so that both are not saturated under physiological blood glucose concentrations. Therefore, the rate of glucose uptake and phosphorylation, i.e. the intracellular glucose concentration, depend on blood glucose levels, and the high- K_m glucokinase promotes increased hepatic utilization of glucose. In perivenular liver cells another glucose transporter (GLUT1) is present as well, having high affinity and low capacity for glucose transport.

Release of Glucose

The release of glucose from the hepatocyte into the sinusoidal blood occurs also by facilitated diffusion after glucose 6-phosphate has been dephosphorylated by glucose 6-phosphatase. Only cells equipped with

glucose 6-phosphatase are able to release glucose into the circulation. This enzyme is localized at the luminal side of the smooth endoplasmic reticulum membranes. In addition to parenchymal liver cells, only the intestinal epithelium and the renal cortex display glucose 6-phosphatase activity. Therefore, these organs are also able to release glucose into the blood.

Bidirectional Glucose Transport

The bidirectional glucose transport across the basolateral (sinusoidal) membrane is precisely regulated along the range of possible extreme glucose concentrations. The uptake of glucose induces glycolysis, simultaneously inhibiting hepatic production of glucose. On the other hand stimulation of glucose production enhances glucose export. *Hexose specific glucokinase is the key enzyme of glucose utilisation.* The high- K_m glucokinase is specific for the pancreatic β cell and for the hepatocyte. Glucokinase is not subject to end product inhibition. Rather, there exists a feedback regulation between glucokinase gene expression and the blood concentrations of glucose and insulin. Hyperglycemia and hyperinsulinemia stimulate, while glucagon inhibits the expression of glucokinase. Increased hepatic glucose uptake and utilization lower blood glucose concentration.

Glucose 6-phosphate is the pivotal compound of glucose metabolism. According to the needs of the organism the metabolism of glucose can follow several pathways: glycolysis, pentose phosphate pathway, glycogenolysis, gluconeogenesis and glycogen synthesis (Fig. 6.1).

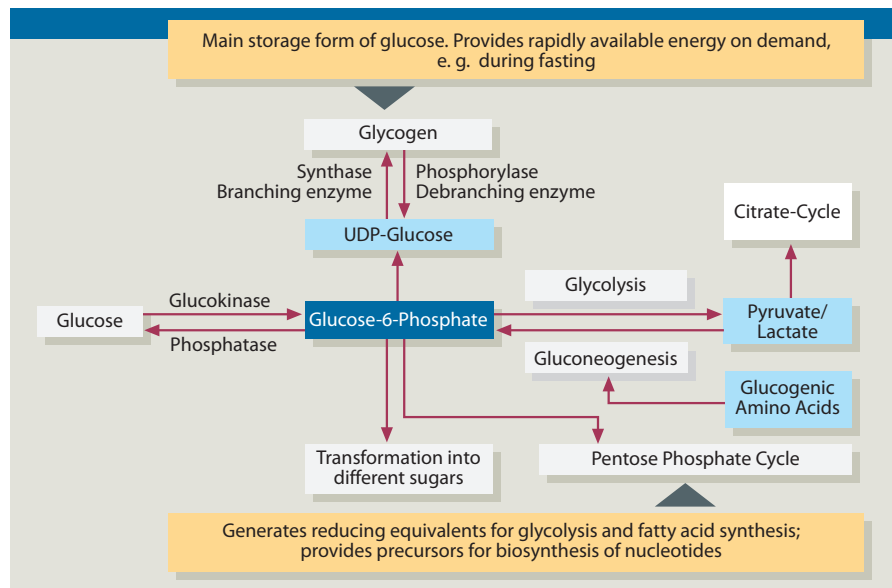
Fructose is found primarily in fruits and vegetables. In the liver it is converted to fructose 1-phosphate by fructokinase. This is then split into dihydroxyacetone phosphate and glyceraldehyde. Glyceraldehyde is converted to glyceraldehyde 3-phosphate, which is then metabolized by the glycolytic pathway. To a lesser degree fructose is reduced to glycerol.

Galactose, mainly present in dairy products, is also metabolized by glycolysis after being phosphorylated and epimerized to glucose 1-phosphate.

Glycolysis

Glycolysis is the major oxidative cytosolic pathway of glucose metabolism in which glucose (or glycogen) is converted to pyruvate and/or lactate (Fig. 6.2). It can

Fig. 6.1 Glucose 6-phosphate is the pivotal molecule of glucose metabolism



function either aerobically or anaerobically. Under *aerobic conditions* pyruvate, the cytosolic end product of glycolysis, enters the mitochondria and is oxidized to CO_2 and H_2O in the citric acid cycle (the common final metabolic pathway of carbohydrates, fatty acids, and some amino acids). The pairs of electrons produced in the citric acid cycle help to generate energy (ATP) during oxidative phosphorylation. Lactate is the end product of glycolysis under *anaerobic conditions*.

Beginning with glucose, three irreversible reactions occur during glycolysis that are regulated by three key enzymes, each catalyzing nonequilibrium reactions: hexokinase (glucokinase), phosphofructokinase I, and pyruvate kinase (Table 6.1). In addition, pentoses derived from the pentose phosphate pathway may enter glycolysis (Fig. 6.2).

The *energy balance* of glycolysis is as follows: if pyruvate/lactate derives from glycogen under anaerobic conditions, three molecules of ATP per one molecule of glucose 6-phosphate are generated. However, if pyruvate derives from one molecule of blood glucose the net gain is only two molecules of ATP, since one ATP molecule is consumed for the phosphorylation of glucose to glucose 6-phosphate. Under aerobic conditions two molecules of pyruvate, two ATP molecules and two molecules of $\text{NADH} + \text{H}^+$ are generated from one molecule of glucose. Under aerobic conditions the net energy gain is 19 times higher compared to anaerobic conditions. Thirty-eight molecules of ATP are generated from one molecule of blood glucose metabolized aerobically in glycolysis and then oxidized in the citric acid cycle.

Pentose Phosphate Pathway

The pentose phosphate pathway (hexose monophosphate shunt) is an alternative cytosolic route for the oxidation of glucose. Starting from glucose 6-phosphate, $\text{NADPH} + \text{H}^+$ is generated. This is required for the synthesis of fatty acids and isoprenoids. In addition, the hexose monophosphate shunt provides ribose 5-phosphate, a precursor for nucleotide synthesis. ATP is not produced in the pentose phosphate pathway. However, according to the energy needs, intermediate compounds, such as fructose 6-phosphate and glyceraldehyde 3-phosphate may be metabolized by glycolysis and generate energy (Fig. 6.2).

Gluconeogenesis

Gluconeogenesis is the process of converting noncarbohydrate precursors to glucose. The process is energy consuming. The major substrates for gluconeogenesis are lactate from skeletal muscle and erythrocytes, glucogenic amino acids from skeletal muscle and from the intestinal tract, and glycerol from adipose tissue. Fatty acids are not available for gluconeogenesis, since the acetyl residues that are generated during their β -oxidation are completely metabolized in the citric acid cycle. The liver is the major organ of gluconeogenesis (90%) and up to 250 g glucose are generated

Fig. 6.2 Glycolysis is the major cytoplasmic oxidative breakdown pathway of glucose. The key enzymes of glycolysis are glucokinase, phosphofructokinase and pyruvate kinase. Under aerobic conditions pyruvate enters the mitochondria and is metabolized in the citric acid cycle

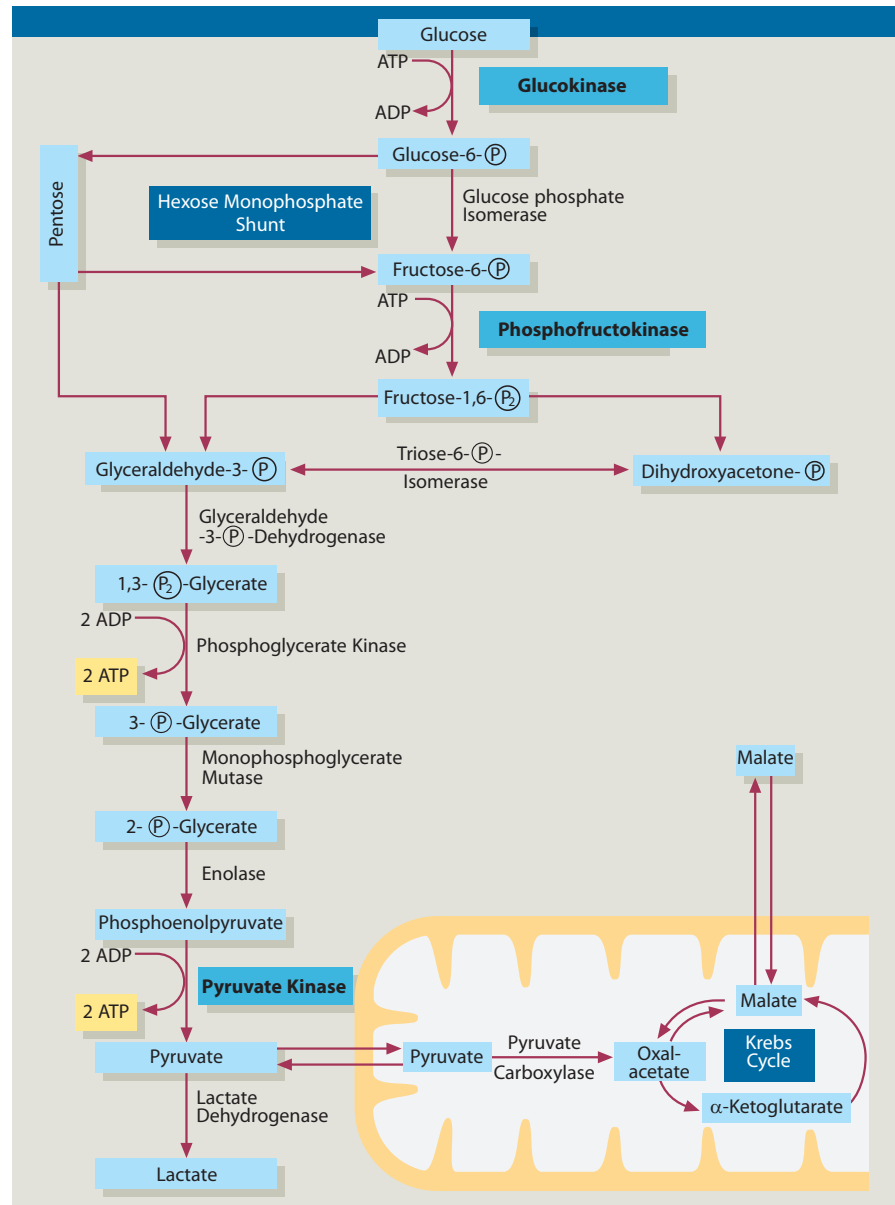


Table 6.1 Key enzymes and key reactions of glycolysis with the respective inducers and repressors

Enzyme	Reaction	Inducer	Repressor
Glucokinase	Glucose → glucose 6-phosphate	Insulin	AMP
Phosphofructokinase	Fructose 6-phosphate → fructose 1,6-biphosphate	Insulin, glucose, AMP, fructose 2,6-biphosphate	ATP
Pyruvate kinase	Phosphoenolpyruvate → pyruvate	Insulin, glucose	Glucagon, epinephrine

Source: From [7]. With permission

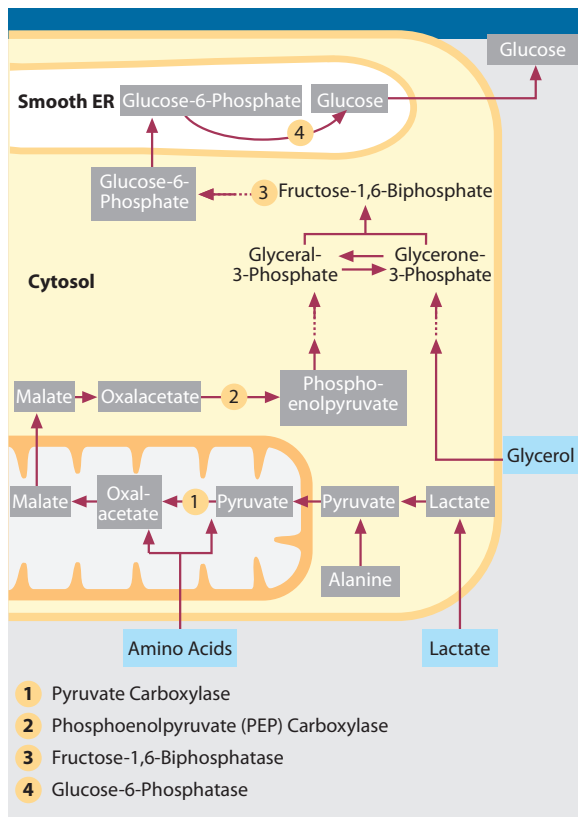


Fig. 6.3 The liver is the main organ for gluconeogenesis. The most important gluconeogenic amino acid is alanine. 1, 2 and 3 are key enzymes of gluconeogenesis

daily by this route. The renal tubular epithelia contribute approximately 10% to gluconeogenesis.

Gluconeogenesis takes place in the cytosol, mitochondria, and endoplasmic reticulum. Amino acids that are degraded in the citric acid cycle or that yield

pyruvate may be transformed to glucose (*gluconeogenic amino acids*). The amino acid contributing most to gluconeogenesis is alanine.

Cytoplasmic pyruvate crosses the mitochondrial membrane and is carboxylated in the mitochondrial matrix to oxalacetate (enzyme: pyruvate carboxylase), which is further reduced to malate. The mitochondrial membrane is impermeable to oxalacetate. Therefore, oxalacetate may exit the mitochondrion only by two indirect ways: (1) reduction to malate, and (2) transamination to aspartate. Malate then reaches the cytoplasm by specific transport systems localized in the inner mitochondrial membrane, while aspartate is transported to the cytoplasm in exchange for glutamate, where it is reconverted to oxalacetate by transamination.

In the cytoplasm oxalacetate is transformed to phosphoenolpyruvate. In a reversal of the glycolytic reaction chain, phosphoenolpyruvate is transformed to glucose 6-phosphate in an energy consuming process. Glucose 6-phosphate is transported to the smooth endoplasmic reticulum, where it is converted to glucose by the activity of glucose 6-phosphatase. Glucose enters the cytosol, crosses the sinusoidal membrane, and after traversing the space of Disse reaches the bloodstream (Fig. 6.3; Table 6.2).

Glycogen Metabolism

Glycogen is the hepatic storage form of glucose and is readily mobilized in the postprandial phase. Glycogen is a large, branched polymer of glucose, consisting of up to 50,000 carbohydrate residues. Seven to 10% of glucose molecules are localized terminally in the glycogen

Table 6.2 Key enzymes and key reactions of gluconeogenesis with the respective inducers and repressors

Enzyme	Reaction	Inducer	Repressor
Pyruvate carboxylase	Pyruvate → oxalacetate	cAMP, glucocorticoids, glucagon, epinephrine	Insulin
PEP carboxylase	Oxalacetate → PEP	cAMP, glucocorticoids, glucagon, epinephrine	Insulin
Fructose 1,6-bisphosphatase	Fructose 1,6-bisphosphate → fructose 6-phosphate	Glucocorticoids, glucagon, epinephrine	Insulin, AMP, fructose 2,6-bisphosphate
Glucose 6-phosphatase	Glucose 6-phosphate → glucose	Glucocorticoids, glucagon, epinephrine	Insulin

PEP phosphoenolpyruvate

Source: From [7]. With permission

macromolecule, thus representing starting points for synthetic or breakdown reactions. Glycogen synthesis and glycogen breakdown take place on the surface of insoluble glycogen particles.

The first step in glycogen synthesis is the transformation of glucose 6-phosphate to glucose 1-phosphate. Glucose 1-phosphate reacts with UTP to form *UDP-glucose (activated glucose)* which is the starting point of glycogen synthesis. Glycogen chain extension is catalysed by glycogen synthase, while branching of carbohydrate chains is accomplished by a *branching enzyme*. Branching enzyme breaks off a chain of approximately seven glucose units and rejoins them as an α -1,6 linkage to a free 6-OH group.

The major enzyme of glycogen breakdown is glycogen phosphorylase. It liberates one glucose 1-phosphate molecule, leaving the glycogen chain one residue shorter. Glycogen phosphorylase removes glucose residues from free chain ends until it is four residues from a branching point. Thereafter, three residues are moved by a transferase to an adjacent chain. The remaining single residue at the branching point is hydrolyzed by amylo 1,6-glucosidase (*debranching enzyme*) leaving a linear glucose chain for continued breakdown by glycogen phosphorylase. Glycogenolysis requires a coordinated interplay between phosphorylase and glucosidase.

The storage of glucose as glycogen is an energy efficient process. One ATP equivalent is used in generating UDP-glucose. Glucose 1-phosphate can be converted to glucose 6-phosphate by phosphoglucomutase, which can then enter the glycolytic pathway and generate energy.

Regulation of Carbohydrate Metabolism

The orderly course of the outlined reactions requires precise coordination and regulation. The following factors participate in this regulation

- Substrate concentrations
- End products
- Hormones
- Nerves
- Hydration of hepatocytes (see Chapter 10) and
- Metabolic zonation (see Chapter 9)

The regulation of carbohydrate metabolism remains functional in the transplanted and denervated liver. This shows that neural control of carbohydrate metabolism is of only minor importance.

Key Reactions of Glycolysis and Gluconeogenesis

The key reactions of glycolysis and gluconeogenesis with the respective regulators of key enzymes are reported in [Tables 6.1 and 6.2](#). ATP and citrate inhibit glycolysis by allosteric regulation of phosphofructokinase. Moreover, ATP also inhibits pyruvate kinase. Acetyl-CoA is also an inhibitor of pyruvate kinase and a stimulator of gluconeogenesis. *The phosphorylation of fructose 6-phosphate to fructose 1,6-biphosphate is a central control point of glycolysis and gluconeogenesis*. In contrast to fructose 1,6-biphosphate, fructose 2,6-biphosphate accumulates in only small amounts and has purely regulatory functions. It stimulates glycolysis by allosteric activation of phosphofructokinase and inhibits gluconeogenesis by inhibition of fructose 1,6-biphosphatase [10].

Key Enzymes of Glycogen Metabolism

The key enzymes of glycogen metabolism are glycogen synthase and glycogen phosphorylase. Insulin stimulates glycogen synthesis by inducing the expression of glycogen synthase. Epinephrine and glucagon inhibit glycogen synthesis by cAMP mediated interconversion of enzymes. Both enhance glycogenolysis by activating glycogen phosphorylase.

Liver and Carbohydrate Homeostasis

The liver functions as a glucostat and helps to maintain the concentration of blood glucose within narrow limits. If the concentration of glucose in the portal venous blood is high the liver takes up glucose; with a low portal venous glucose concentration hepatic glucose is released into the blood stream. The transport of glucose through the hepatocyte membrane is bidirectional, the liver cells being freely permeable to glucose. The glucose transporter localized in the membrane (GLUT2) is not regulated by insulin, i.e. the uptake of glucose into the hepatocyte depends on the glucose concentration gradient but is independent of insulin action.

Five percent of orally administered glucose is used by the liver for glycogen synthesis, while 30–40% are converted to fat. The remainder of ingested glucose is

metabolized in skeletal muscle and in other tissues. The brain and the erythrocytes especially depend on a supply of glucose as a source of energy.

The total amount of glycogen in the body amounts to approximately 400–500 g. A third of this amount is stored in the liver. Nearly the total remainder is found in skeletal muscle. The maximal storage capacity of the liver for glycogen is 65 g/kg liver tissue or 5–8% of liver weight. A person weighing 70 kg disposes of carbohydrate reserves of approximately 2,500 kcal. These are stored in approximately 400 g of muscle glycogen, 100–150 g of liver glycogen and 20 g of glucose in extracellular fluid. Compared to the energy stored as fat (>110,000 kcal!) the carbohydrate energy reserves are very small, but may be rapidly mobilized.

Liver glycogen primarily serves to maintain stable blood glucose levels in the interdigestive (postprandial) phase and during starvation. After fasting for 24 h the hepatic glycogen reserves are consumed. Muscle glycogen serves as an energy reserve for the muscle itself. Since skeletal muscles lack glucose 6-phosphatase, the muscle cell is not able to release glucose into the circulation and therefore, skeletal muscle does not participate directly in the regulation of blood glucose concentration. However, muscle glycogen is utilized indirectly to maintain blood glucose. In the fasting state, there is a considerable output of alanine from skeletal muscle that is exported to the liver, where it is a substrate for gluconeogenesis (see below).

During the *absorptive phase* increased amounts of glucose enter the portal venous circulation. More than 50% of glucose absorbed in the intestine is taken up by the liver and used either for glycogen and fatty acid synthesis or is degraded by oxidation. Glycogen is the storage form of glucose, while fatty acids can be used for the synthesis of triacylglycerols (triglycerides) that

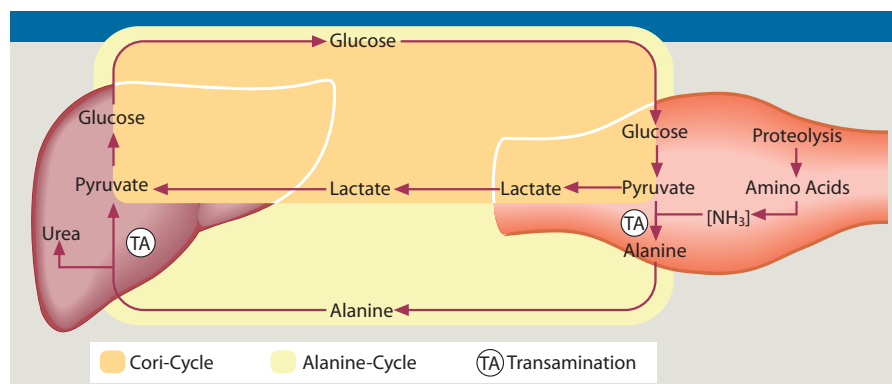
are either stored in the liver or packaged in very low density lipoproteins (VLDL) and released into the circulation.

During short fasting periods (*postabsorptive phase*) the liver releases glucose into the circulation by glycogenolysis (2/3) and gluconeogenesis (1/3), in particular to provide energy for the brain. Erythrocytes and the surrenal medulla are also dependent on glucose as a source of energy. In the fasting state the energy requirement of the brain is downregulated to 2 g of glucose/h. If during longer periods of starvation glucose supply ceases completely, the energy requirements of the brain are covered by gluconeogenesis and by alternative energy sources, such as ketone bodies. Amino acids from skeletal muscle, predominantly alanine, and glycerol from adipose tissue are the main substrates for gluconeogenesis. Ketogenesis during starvation is sustained by fatty acids that are released from adipose tissue and transported to the liver.

There is a close relationship between the carbohydrate metabolism of skeletal muscle and that of the liver (Fig. 6.4). During intense muscle work increased amounts of lactate are generated by anaerobic glycolysis. Lactate is released from the muscle to the circulation, is taken up by the liver and converted to glucose in an ATP consuming process (gluconeogenesis). Glucose diffuses back into the circulation and can be taken up by the muscle, providing it with fresh energy for contraction (*Cori cycle*).

Amino acids accumulated during degradation of muscle proteins are transformed by transamination to 2-oxoacids. Alanine is formed by transamination of pyruvate, which is derived from glycolysis of muscle glycogen. Alanine is exported to the liver where, after transamination back to pyruvate, it is a substrate for gluconeogenesis (*alanine cycle*). The ATP required for the hepatic synthesis of glucose from pyruvate is provided

Fig. 6.4 Cori and alanine cycles. The hepatic and muscular metabolism is closely interrelated



by the oxidation of fatty acids. By this route, glucose precursors (gluconeogenesis) and nitrogen (urea synthesis) are transported from skeletal muscle to the liver.

Amino Acids and Proteins

The liver plays a major role in the metabolism of amino acids and proteins. It is the main site of amino acid degradation (deamination) and of urea synthesis. The organ can selectively take up amino acids from the circulation, thereby contributing to their homeostasis and regulating their concentration in plasma. Unlike carbohydrates and lipids, amino acids and proteins cannot be stored in the liver, but must be metabolized (Fig. 6.5). Approximately 50% of proteins synthesized in the liver are secreted, i.e. they are designed for export. The remaining half is represented by structural liver cell proteins and by enzymes. By synthesizing and degrading structural, enzyme and export proteins, the liver contributes to their dynamic equilibrium [4, 5].

A person weighing 70 kg contains approximately 10 kg of protein that for the most part is localized in skeletal muscle. Approximately 400 g of protein is metabolized daily. Three hundred grams are degraded and newly synthesized (recycling), while the remainder is oxidized, transformed to glucose and replaced by oral intake. Fifty to 70 g of amino acids, peptides and proteins of endogenous origin are lost daily in the intestinal tract as protein containing enteric secretions, sloughed intestinal epithelia and to a lesser degree (about 2 g/day) as a proteinaceous exudate from plasma.

The daily oral protein intake of a balanced western diet is approximately 100 g. In the intestinal tract proteins are enzymatically hydrolyzed and absorbed as amino acids, di- and tripeptides. Only very small quantities of

oligopeptides and proteins may overcome the barrier of the intact intestinal epithelium. Free amino acids are absorbed, reach the liver by the portal venous route, and are efficiently extracted from the sinusoidal blood. Selective, mostly group-specific transport systems localized in the basolateral (sinusoidal) membrane take up the amino acids. The individual transport systems are expressed differently in various lobular zones. Hepatocytes are not able to take up dipeptides from plasma, but aminopeptidases localized in their cell membrane may selectively cleave alanine containing polypeptides.

The daily protein loss during fasting is 20–30 g and is mainly due to muscle catabolism. The amino acids released by skeletal muscle are taken up and metabolized by hepatocytes.

More than 90% of all plasma proteins, with the exception of immunoglobulins, are synthesized by the liver (Table 6.3). Albumin makes up 25% of the entire hepatic protein synthesis and accounts for 55–60% of all plasma proteins. The daily hepatic production of albumin is 12 g; if needed, this rate can be increased fourfold. In addition, the liver produces clotting factors, fibrinolytic proteins, protease inhibitors, transport proteins and prohormones, such as angiotensinogen or kininogen. Nearly all proteins are synthesized by the hepatocytes, each liver cell being able to synthesize the entire spectrum of proteins. Exceptions are the von Willebrand factor which is synthesized by sinusoidal endothelial cells, the retinol binding protein which is produced by hepatic stellate cells, and α_1 -antitrypsin which is generated by Kupffer cells.

The liver is of major importance for the clearance of plasma proteins. With the exception of albumin and C-reactive protein all proteins that are synthesized by the liver are glycosylated. Their uptake into the hepatocyte occurs by receptor mediated endocytosis (see Chapter 5). Cleavage of terminal N-acetyl-neuraminic acid residues exposes galactose-units of proteins. The asialoglycoprotein receptor (ASGPR) in the cell membrane has a high affinity for these galactose residues, and most proteins are taken up by the ASGPR. The process is highly effective, as an individual hepatocyte is able to internalize five million ASGPR molecules per hour. Hepatocytic and extracellular proteins (e.g., insulin-receptor complex or chylomicron remnants after internalization together with apolipoprotein B and E receptors) are metabolized within the hepatocyte to amino acids that replenish the pool of amino acids in the liver cell. The degradation occurs both in

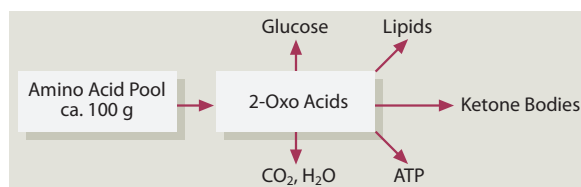


Fig. 6.5 Amino acids are not stored. They are utilized for (1) synthetic processes, (2) are transformed into other compounds, or (3) they are degraded in the citric acid cycle

Table 6.3 Selection of proteins synthesized and secreted by the liver

Protein	Function
Acute phase proteins (selection)	Local inflammatory reaction
C-reactive protein	
Serum amyloid A	
Fibrinogen	
Haptoglobin	
Ceruloplasmin	
α 1-Macroglobulin	
α 1-Antitrypsin	
Albumin	Carrier protein; osmotic regulator
Apoproteins (VLDL, HDL)	Binding and transport of lipids
α 1-Acidic glycoprotein (orosomucoid)	Unknown. Of significance in inflammation? Binds synthetic estrogens
α 1-Antitrypsin	Inhibitor of trypsin and general protease inhibitor
α 1-Fetoprotein	Unknown; carrier protein?
α 2-Macroglobulin	Inhibits endoproteases in serum; acute phase reactant
Antithrombin III	Protease inhibitor of intrinsic system of blood coagulation
Ceruloplasmin	Cu carrier protein; acute phase reactant
Fibrinogen	Hemostasis; fibrin precursor; acute phase reactant
Haptoglobin	Binds hemoglobin
Hemopexin	Binds heme
Clotting factors	All except Factor VIII
Complement factors	Inflammation; defense against infections
Plasminogen	Anticoagulatory activity
Protease inhibitors (selection)	Regulate proteolytic cascades, e.g. in inflammation, during coagulation and complement activation
α 1-Antitrypsin	
α 1-Antichymotrypsin	
α 2-Antiplasmin	
Antithrombin III	
C1-inhibitor	
Protein C and S	Anticoagulatory activity
Retinol binding protein	Binds vitamin A
Sex hormone binding globulin	Binds testosterone, estradiol
Thyroxine binding globulin	Binds thyroxine
Thyroxine binding prealbumin	Binds thyroxine
Transcalferrin	Binds vitamin D
Transcortin	Binds corticosteroids
Transferrin	Fe transport protein

the lysosomes and in the cytosol. The lysosomal pathway involves lysosomal proteases and does not require ATP. The process is selective, i.e. proteins characterized by specific polypeptide motifs are degraded preferentially [8]. Protein degradation in the cytosol involves ubiquitin and is ATP dependent. Ubiquitin is a small protein that plays a key role in marking various proteins for subsequent degradation in proteasomes. It is particularly associated with disposal of misfolded proteins and regulatory enzymes. Ubiquitin can be cleaved from a target protein by deubiquitinating enzymes and the liberated ubiquitin can be reused.

The hepatic protein metabolism is subject to *hormonal regulation*. Protein degradation is stimulated by glucagon and by low blood concentrations of amino acids. Insulin and high levels of amino acids stimulate protein synthesis and inhibit catabolism of proteins. The hydration state of the liver cell modulates these effects (see Chapter 10). Corticosteroids, growth hormone and thyroid hormone stimulate albumin synthesis.

The liver is able to synthesize all the essential amino acids starting from pyruvate, and from intermediate products of the citric acid cycle, such as α -ketoglutarate (2-oxoglutarate) and oxalacetate. The majority of these syntheses are subject to end product inhibition.

Most amino acids are degraded in the liver. Exceptions are the branched chain amino acids leucine, isoleucine, and valine. They are used by the liver primarily for protein synthesis and are metabolized by muscle.

The amino acid carbon skeletons after transamination contribute to the citric acid cycle and to ketone body synthesis (Fig. 6.6). All amino acids that can generate pyruvate or citric acid cycle intermediates can contribute to gluconeogenesis (*glucogenic amino acids*). Amino acids that provide acetoacetyl- or acetyl-CoA are *ketogenic amino acids*. They serve the generation of energy.

Nitrogen Compounds

Amino acid nitrogen can be used for the synthesis of N-containing compounds or be excreted mainly as urea, and to a lesser degree as ammonium and uric acid. α -Amino acids are nitrogen donors for the synthesis of porphyrins, purines, pyrimidines, polyamines (spermin, spermidin), glutathione, nicotine-adenine-dinucleotide,

and guanosine monophosphate. Glutamine shows the highest blood levels of all amino acids and is an important donor of amino-groups for the above mentioned biosynthetic processes in the liver. Intestinal glutamine is used primarily as an energy provider, while in the kidney it serves both energy production and gluconeogenesis.

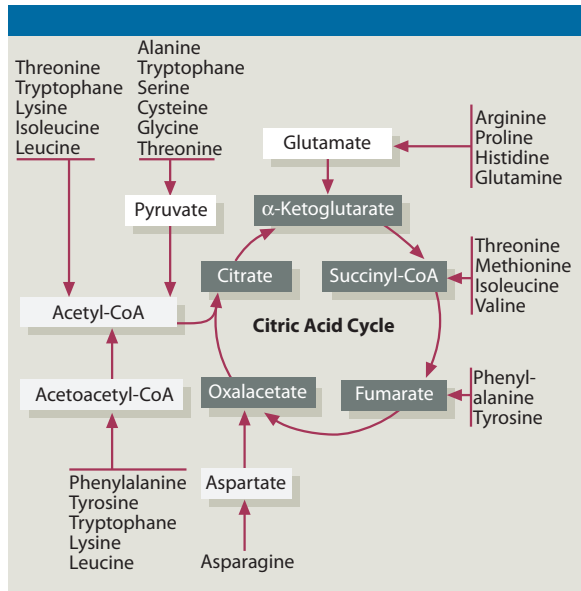


Fig. 6.6 The carbon skeleton of the amino acids is introduced via intermediates into the citric acid cycle (Adapted from [12])

Ammonia

Free ammonia, liberated by oxidative deamination, can be disposed of in three different ways (Fig. 6.7–6.9).

1. *Formation of glutamate* by transfer to a 2-oxo acid. This reaction is catalyzed enzymatically by glutamate dehydrogenase and represents the reversal of oxidative deamination.
2. *Formation of glutamine* by transfer to glutamate. This reaction is catalyzed by glutamine synthetase.
3. *Formation of urea*. This is the major pathway of nitrogen elimination. Approximately 80% of excess

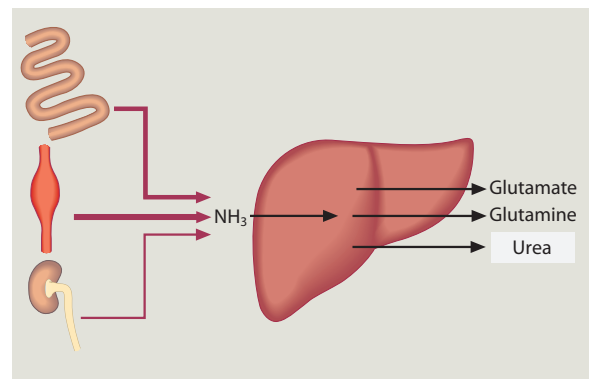


Fig. 6.7 Ammonia is primarily generated in skeletal muscle. Only small amounts are produced in the intestine and in the kidneys. Urea production in the liver is the major pathway of nitrogen elimination

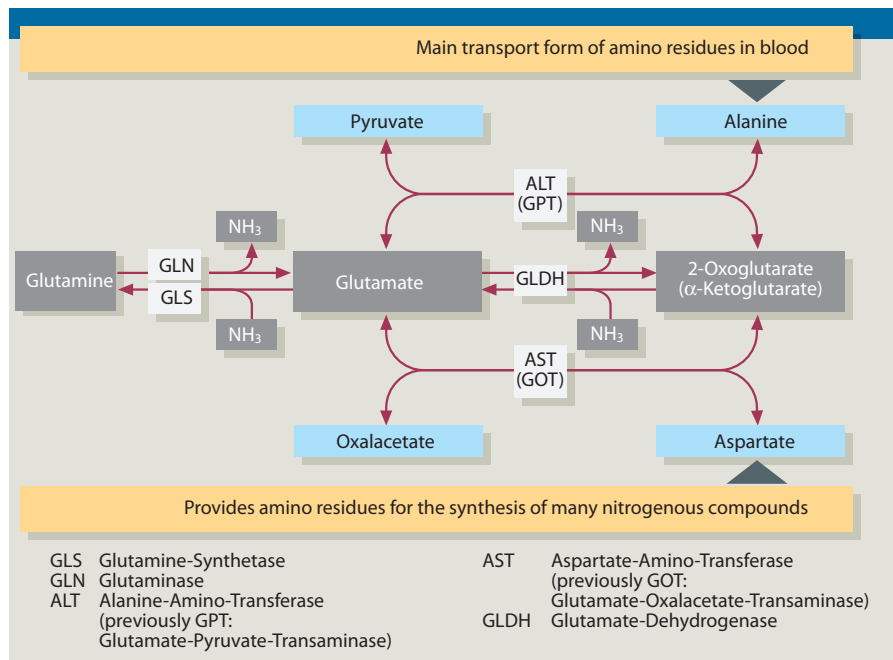


Fig. 6.8 Glutamate plays a central role in the metabolism of amino residues

nitrogen is excreted as urea, the remainder as free ammonium ions and creatine. Nitrogen, produced during oxidative deamination of amino acids, is transformed to urea in the urea cycle and excreted by the kidneys. On a balanced western diet the liver produces 20–30 g urea daily. On a protein rich diet hepatic urea production may triple.

Ammonia is not only produced by the hepatocyte during metabolism of amino acids, purines and pyrimidines. It may also derive from extrahepatic sources. Due to ammonia derived from intestinal glutamine and from protein metabolism by intestinal microorganisms, the ammonia levels in the portal vein are high (0.2–0.5 mmol/L). The liver is able to detoxify the inflowing ammonia by systems of urea and glutamine synthesis that are localized in different zones of the liver lobule (see Chapter 9).

Urea Cycle

In the urea cycle urea is derived from one free ammonium ion and one donated by aspartate. The urea cycle takes place in two cell compartments, partly in the

mitochondrial matrix and partly in the cytosol (Fig. 6.9). Its activity depends on the amino acid concentration in portal venous blood and correlates with the blood levels of nitrogen.

The key enzyme of the urea cycle is *carbamoyl-phosphate synthetase* which is activated allosterically by N-acetyl-glutamate. In the absence of N-acetyl-glutamate the enzyme is inactive. The concentration of N-acetyl-glutamate depends on the blood levels of glutamate. Glucocorticoids induce the urea cycle enzymes.

Urea synthesis is an energy consuming process. For one molecule of urea synthesized from one molecule of NH_3 and one amino residue of aspartate, one molecule of ATP is consumed. This calculation takes into account the energy produced by fumarate metabolism. Fumarate derives from the urea cycle, is further metabolized in the citric acid cycle, and is finally utilized in the respiratory chain. The energy expenditure is considerable, considering the amount of urea that is synthesized daily.

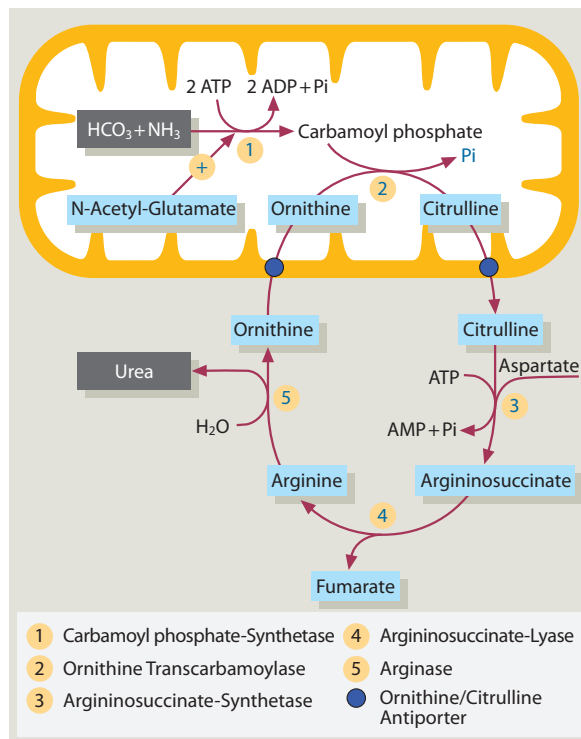


Fig. 6.9 Urea synthesis

Lipids

Lipids are a heterogeneous group of compounds. Acetyl-CoA (“activated acetic acid”) is the biosynthetic source of all lipids. Biologically, the most important lipids are

- Fatty acids
- Triglycerides (triacylglycerides, triacylglycerols, neutral fats)
- Phospho- and glycolipids and
- Steroids

Naturally occurring *fatty acids* always have an even number of carbon atoms, are not branched and may be saturated (no double bonds) or unsaturated (various number of double bonds). *Essential fatty acids* cannot be synthesized by the human organism and therefore, must be obtained from one’s diet. *Linoleic acid* (C18; two double bonds), *linolenic acid* (C18; three double bonds) and *arachidonic acid* (C20; four double bonds) are the polyunsaturated essential fatty acids. Essential fatty acids are required as precursors for the synthesis of eicosanoids (prostaglandins, prostacyclin, thromboxane, lipoxin, leukotrienes). Dietary fats very often contain palmitic, stearic, oleic and linoleic acid.

Triglycerides (the correct biochemical term is triacylglycerols. However, the term triglycerides is clinically time honored and will be used mainly throughout this

book) are glycerol esters with three fatty acids. Since they are electrically neutral, they are also called neutral fats. Triglycerides make up 98% of orally fed lipids. Due to their high caloric density of 9.5 kcal/g they represent the major energy reserve of man and are stored predominantly in adipocytes.

Phospholipids are complex esters and the main components of cell membranes. They include phosphatidylcholine (lecithin), phosphatidylethanolamine (cephalin), phosphatidylserine, and phosphatidylinositol. Sphingolipids, with sphingomyelin as the main representative, are found in large amounts in nervous tissue.

Glycolipids are present in all tissues and are found on the exterior of plasma membranes. Cerebrosides and gangliosides belong to this lipid class. A characteristic component of gangliosides is N-acetylneuraminic acid (sialic acid).

The major **steroids** are the sterols (cholesterol is the most important representative), the bile acids and the steroid hormones.

Fatty Acid Degradation

The free (nonesterified) fatty acid uptake by tissues is related directly to their plasma concentration, which in turn is determined by the rate of lipolysis in adipose tissue. After dissociation of the fatty acid–albumin complex at the plasma membrane, fatty acids bind to a *membrane fatty acid transport protein* that acts as a transmembrane cotransporter with Na^+ . On entering

the cytosol, free fatty acids are bound by intracellular *fatty acid-binding proteins*. Intracellular fatty acids may be used for lipid synthesis or be oxidized to generate energy. The oxidative metabolism of fatty acids starts with their activation (acetylation by acyl-CoA synthetase/fatty acid thiokinase). This reaction may occur both inside and outside the mitochondria. The major degradative pathway of fatty acids is β -oxidation that takes place in the mitochondrial matrix. It is an aerobic process, requiring the presence of oxygen; it is tightly interrelated with the citric acid cycle and the respiratory chain.

β -oxidation is a cyclic reaction in which two carbon subunits, in the form of acetyl-CoA, are repeatedly removed until the fatty acid carbon chain is completely degraded. The complete breakdown of long chain fatty acids requires several rounds of β -oxidation. The resulting acetyl-CoA can enter the citric acid cycle or be used for various biosynthetic processes (Fig. 6.10).

The mitochondrial membrane is permeable to short (C4–C5) and medium chain (C6–C12) fatty acids. However, the inner mitochondrial membrane is impermeable to long chain (>C12) fatty acids. Therefore, long chain fatty acids cross the mitochondrial membrane with the help of a group-specific transport system and penetrate the inner mitochondrial membrane in the form of carnitine derivatives. First, activated fatty acids are esterified with carnitine (carnitine acyl transferase I) in the cytoplasm. Thereafter, acyl carnitine crosses the mitochondrial membrane and is transported by carnitine translocase into the mitochondrial matrix in exchange for free

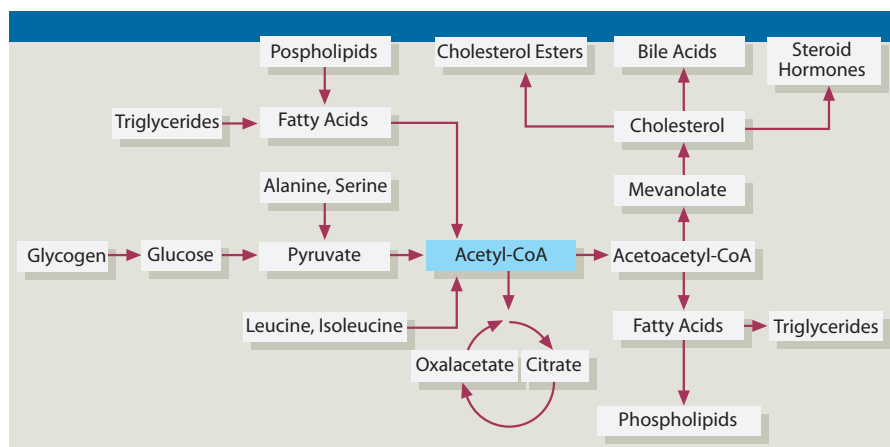


Fig. 6.10 Acetyl-CoA is the central molecule of intermediary metabolism

carnitine (*carnitine shuttle*). This process is inhibited by malonyl-CoA, thus preventing simultaneous fatty acid breakdown and synthesis (see below). Once inside the mitochondrial matrix the ester bond is hydrolyzed (carnitine acyl transferase II) and the activated fatty acid and carnitine are released. The activated fatty acid is ready for β -oxidation and the free carnitine is available for further exchange with and transport of fatty acids.

β -Oxidation of fatty acids is an energy producing process. The only energy consuming step is initial fatty acid activation by acyl-CoA synthetase/fatty acid thiokinase. The complete oxidation of one molecule of a C₆-fatty acid to CO₂ and water in the citric acid cycle and the respiratory chain yields 44 molecules of ATP (during glycolysis, one molecule glucose yields 32 molecules of ATP).

In addition to the major pathway of fatty acid breakdown outlined above, there exist alternative pathways for degradation of unsaturated fatty acids and for fatty acids with an odd number of carbon atoms, such as α - and ω -oxidation and *fatty acid breakdown in peroxisomes*. Under physiologic conditions these pathways play a minor quantitative role. However, their defects lead to rare and serious diseases, such as Refsum syndrome and Zellweger syndrome.

Fatty Acid Synthesis

Some long chain fatty acids may be synthesized from short chain fatty acids in the mitochondria in a process that corresponds to a reversal of β -oxidation. The majority of fatty acids, however, are synthesized *de novo* in a process separated from mitochondrial β -oxidation. Fatty acid synthesis starts from acetyl-CoA and takes place in the cytoplasm, predominantly in the smooth endoplasmic reticulum. *The most important provider of carbon atoms for fatty acids is glucose*. In the setting of energy excess, glucose is converted to fatty acids via the conversion of glucose to pyruvate, which enters the citric acid cycle in the mitochondria. Citrate formed in the Krebs cycle is shuttled to the cytosol where it is converted to acetyl-CoA by ATP citrate lyase [2]. *Acetyl-CoA carboxylase 1 (ACC1)*, the key enzyme of fatty acid synthesis, then catalyzes the carboxylation of acetyl-CoA to malonyl-CoA. Malonyl-CoA is used by

fatty acid synthase as the substrate for chain elongation. Malonyl-CoA condenses with an acyl residue of an acyl-carrier protein to form a β -ketoacid derivative. The acyl-carrier protein is part of the multienzyme complex of fatty acid synthase. Thus, the fatty chain grows by the attachment of acyl residues. With each cycle the fatty acid is elongated by two carbon subunits.

The human organism is capable of only synthesizing fatty acids up to a maximal chain length of 16 carbon atoms (palmitic acid; 16:0). Through further, separate reactions palmitate may be transformed to unsaturated fatty acids with longer carbon chains.

In adipose tissue and in the liver triglycerides are formed from fatty acids and glycerol. The major lipogenic hormone is insulin. Insulin's ability to activate lipogenesis is transcriptionally mediated by the membrane-bound transcription factor, *sterol regulatory element-binding protein-1c (SREBP-1c)*. SREBPs are a family of proteins that regulate the transcription of a range of genes involved in the cellular uptake and metabolism of lipids [1]. SREBP-1c is one of three SREBP isoforms that belong to the basic helix-loop-helix-leucine zipper family of transcription factors. SREBP-1c also activates acetyl-CoA carboxylase 2, an isoform of ACC that produces malonyl-CoA at the mitochondrial membrane. Increases in malonyl-CoA result in decreased oxidation of fatty acids due to inhibition of carnitine palmitoyl transferase-1, which shuttles fatty acids into mitochondria [2, 3]. By this mechanism simultaneous cytosolic fatty acid synthesis and mitochondrial fatty acid breakdown are prevented.

Carbohydrate (glucose)-mediated stimulation of lipogenesis is transcriptionally mediated by a second transcription factor, designated *carbohydrate response element binding protein (ChREBP)*. Glucose stimulates ChREBP to bind to an E-box motif in the promoter of liver-type pyruvate kinase (L-PK), a key regulatory enzyme in glycolysis. L-PK catalyzes the conversion of phosphoenolpyruvate to pyruvate, which enters the Krebs cycle to generate citrate, the principal source of acetyl-CoA used for fatty acid synthesis (Fig. 6.11) [2]. Recent data indicate that endogenous cannabinoids and cannabinoid agonists acting at specific hepatic cannabinoid receptors (CB) stimulate fatty acid synthesis and contribute to diet-induced obesity. Activation of CB increases the hepatic gene expression of the lipogenic transcription factor SREBP-1c and its targets acetyl-CoA carboxylase 1 and fatty acid synthase [9].

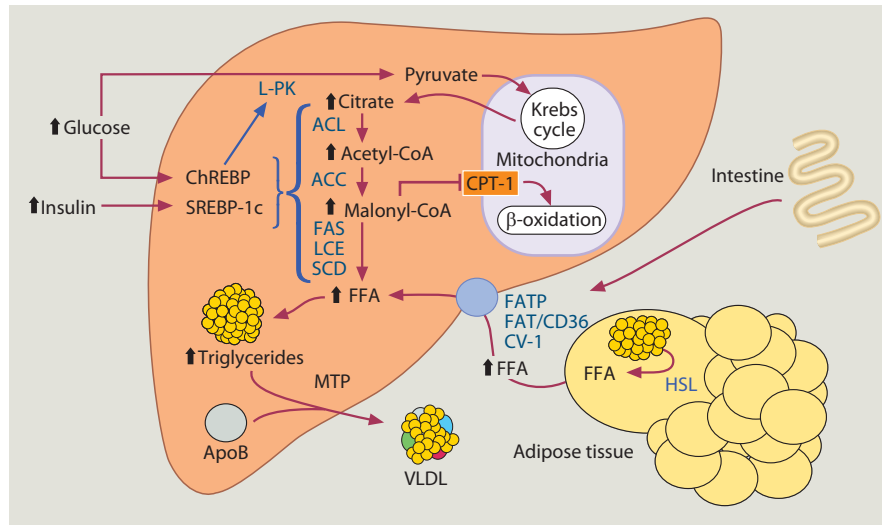


Fig. 6.11 Hepatic metabolism of free fatty acids and triglycerides. Hepatic triglycerides are either supplied by diet or are synthesized de novo in the liver. Dietary triglycerides are transported via chylomicrons from the intestine to the liver. Hepatic fatty acids derive either from dietary triglycerides, from lipolysis of triglycerides in adipose tissue, or from de novo synthesis from carbohydrates (mainly glucose). Fatty acid transport proteins, fatty acid translocase, caveolin-1 and fatty acid binding protein are involved particularly in the uptake of long chain fatty acids. The activity of hormone sensitive lipase (inhibited by insulin; stimulated in insulin resistant states) results in triglyceride lipolysis in adipose tissue and flux of free fatty acids to the liver. Free fatty acids can either be oxidized in the mitochondria or esterified to produce triglycerides for storage or incorporation into VLDL particles. Packaging of triglycerides into VLDL is supported by microsomal triglyceride transfer protein.

Hyperinsulinemia induces sterol regulatory element-binding protein-1c expression, leading to the transcriptional activation of all lipogenic genes. Hyperglycemia activates carbohydrate

response element-binding protein which transcriptionally activates liver-type pyruvate kinase and all lipogenic enzymes. Both transcription factors (ChREBP and SREBP-1c) synergistically activate the enzymes necessary for the conversion of excess glucose to fatty acids. Increased production of malonyl-CoA inhibits carnitine palmitoyl transferase-1, the protein responsible for fatty acid transport into the mitochondria, thereby preventing the simultaneous cytosolic synthesis of fatty acids, and their mitochondrial oxidation (Adapted from [2])

ACC acetyl-CoA carboxylase, ACL ATP citrate lyase, ApoB apolipoprotein B, ChREBP carbohydrate response element-binding protein, CPT-1 carnitine palmitoyl transferase-1, CV-1 caveolin-1, FAS fatty acid synthase, FAT/CD 36 fatty acid translocase, FATP fatty acid transport protein, FFA free fatty acids, HSL hormone sensitive lipase, LCE long chain fatty acid elongase, L-PK liver-type pyruvate kinase, MTP microsomal triglyceride transfer protein, SCD stearyl-CoA desaturase, SREBP-1c sterol regulatory element-binding protein-1c

Cholesterol Synthesis

Cholesterol is derived about equally from the diet and from biosynthesis. The synthesis of cholesterol occurs in the smooth endoplasmic reticulum. In a long reaction chain, starting with C_2 -units, the C_{27} -sterol is formed. Acetyl-CoA is the source of all carbon atoms in cholesterol. The synthesis proceeds with the formation of acetoacetyl-CoA, 3-hydroxy-3-methylglutaryl-CoA (3-HMG-CoA) and mevalonate. The *key enzyme of cholesterol synthesis is HMG-CoA reductase* which catalyzes the formation of mevalonate from 3-HMG-CoA. Free cholesterol and glucagon inhibit the activity of HMG-CoA reductase. Insulin and thyroxin stimulate the enzyme. Decreased intracellular cholesterol concentration and pharmacologic inhibition of HMG-CoA

reductase (statins) lead to an increase of LDL-receptors in the hepatocyte membrane (see below).

Synthesis of Complex Lipids

The synthesis of complex lipids occurs for the most part in the membrane system of the smooth endoplasmic reticulum. It starts with glycerol 3-phosphate, that is formed from dihydroxyacetone 3-phosphate (an intermediate of glycolysis) or by phosphorylation of glycerol. Glycerol 3-phosphate is esterified with long chain and unsaturated fatty acids and gives rise to phosphatidic acid, which is 1,2-diacylglycerol 3-phosphate, a key intermediate in the formation of all other phosphoglycerides.

Liver and Lipid Homeostasis

The liver has a major role in lipid metabolism. The formation of ketone bodies and the transformation of cholesterol into bile acids are functions specific to the liver (see Chapter 7). Most plasma lipoproteins, with their respective apoproteins are synthesized by the liver. The liver has a decisive share in the formation of fatty acids, triglycerides and cholesterol (esters).

Ketogenesis

Ketogenesis is an important metabolic task of the liver; its extent depends on the supply of fatty acids and on glucose metabolism. The ketone bodies (*acetoacetate*, *3-hydroxybutyrate*, and *acetone*) are formed in hepatic mitochondria when fatty acids are oxidized at a high rate and when the production of acetyl-CoA exceeds the energy needs of the hepatocyte. The starting point of their biosynthesis is the intramitochondrial condensation of two molecules of acetyl-CoA to form acetoacetyl-CoA. If too much acetyl-CoA is produced or, if the citric acid cycle is not able to cope with the acetyl-CoA because of a reduced glucose metabolism, acetyl-CoA accumulates and forms acetoacetyl-CoA. Acetoacetyl-CoA is the starting material for ketogenesis. The pathway of ketogenesis involves synthesis and breakdown of 3-hydroxy-3-methylglutaryl-CoA (HMG-CoA) by two key enzymes, *HMG-CoA synthase* and *HMG-CoA lyase*, the latter causing acetyl-CoA to split off from the HMG-CoA molecule, leaving free acetoacetate. The ketone bodies are interrelated and acetoacetate can give rise to 3-hydroxybutyrate and acetone.

Ketogenesis is regulated by (1) control of free fatty acid mobilization from adipose tissue; by (2) the activity of carnitine palmitoyltransferase I in liver, which determines the transport of fatty acids from the cytoplasm to the mitochondria, thereby determining the fraction of fatty acids that is oxidized and, by (3) the partition of acetyl-CoA between the pathway of ketogenesis and the citric acid cycle.

Ketone bodies are formed during starvation, in patients with diabetes mellitus, and in persons on a diet rich in fats but deficient in carbohydrates. The liver generates ketone bodies, but is not able to metabolize them. They are released into the sinusoidal blood and

are important fuels for extrahepatic tissues. Acetone is exhaled, and 3-hydroxybutyrate and acetoacetate serve as energy sources for the nervous tissue, the heart muscle and the renal cortex. If hepatic production of ketone bodies exceeds their extrahepatic consumption, ketonemia and possibly ketonuria develop. The ensuing metabolic acidosis, electrolyte disturbances, and disturbances of consciousness can be severe clinical sequelae.

Cholesterol

Cholesterol is the starting material for the synthesis of bile acids and steroid hormones, and is an essential component of cell membranes. Seventy to 80% of serum cholesterol is esterified with fatty acids, approximately half of it with linoleic acid. Cholesterol introduced with diet (especially egg yolk and animal fat) is integrated in intestinal epithelia into chylomicrons and transported via the lymphatic system and the circulation to the tissues. In adipose tissue and in skeletal muscle triglycerides are released from chylomicrons. The remaining cholesterol is transported in chylomicron remnants to the liver, where it is taken up by the hepatocyte LDL receptor and the LDL receptor related protein. However, the liver does not depend entirely on exogenous cholesterol. Like intestinal tissue the organ is able to synthesize significant amounts of cholesterol. The daily allowance of roughly 1 g, if needed, can be covered completely by endogenous synthesis that occurs to approximately 50% in the liver. Both free cholesterol and cholesterol used for bile acid synthesis are excreted by the canalicular route into the bile. The daily biliary cholesterol excretion amounts to approximately 1 g.

The metabolism of bile acids is discussed in Chapter 7.

Lipoproteins

Uptake by specific receptors of chylomicron remnants, of intermediate (IDL) and low density lipoproteins (LDL), synthesis and secretion of VLDL and apoproteins are among the most important functions of the liver in lipoprotein metabolism.

Most lipids do not circulate freely in plasma, but are bound to albumin or are embedded in variously large

Table 6.4 Human lipoproteins

Lipoprotein	Size (nm)	Composition (%)					Function
		PR	CH	CHE	TG	PH	
Chylomicrons	75–1,000	2	2	3	90	3	Transport of exogenous TG
VLDL	30–80	8	4	16	55	17	Transport of endogenous TG
IDL	25–40	10	5	25	40	20	Degradation product of HDL and VLDL
LDL	20	20	7	46	6	21	Transport of CH and CHE
HDL	7.5–10	50	4	16	5	25	Substrate of LCAT; Transport of CHE

VLDL very low density lipoproteins, *IDL* intermediate density lipoproteins, *LDL* low density lipoproteins, *HDL* high density lipoproteins, *PR* proteins, *CH* free cholesterol, *CHE* cholesteryl ester, *TG* triglycerides (triacylglyceroles), *PH* phospholipids, *LCAT* lecithin cholesterol acyl-transferase

lipoprotein complexes. Only short chain fatty acids are really soluble in plasma; the long chain fatty acids are bound as “free” fatty acids to albumin. Cholesterol, triglycerides and phospholipids are transported in lipoprotein complexes. Lipoproteins are spherical particles. Their core of non-polar lipids (triglycerides, cholesteryl esters) is surrounded by an envelope of polar lipids (phospholipids, nonesterified cholesterol) and proteins (apolipoproteins). Lipoproteins are subdivided into six classes according to their size and lipid content (Table 6.4). Their density is inversely correlated with their fat content and directly proportional to their protein content. The various lipoprotein classes are closely related to each other and their complex metabolism is outlined in a simplified way in Figs. 6.12–6.14).

Apolipoproteins are an integral part of lipoprotein structure and they exert important metabolic functions.

They are required for the assembly of lipoproteins, they activate enzymes involved in lipoprotein metabolism, and they act as recognition molecules of membrane receptors that mediate the intracellular uptake of lipoproteins.

Exogenous pathway. This term describes the transport of dietary lipids from the intestine to other tissues. *Chylomicrons* and their *remnants* represent the transport system for exogenously administered fats. Newly synthesized triglycerides in the enterocyte combine with dietary cholesterol and ApoB48, which is synthesized in the intestine, to form chylomicrons. This reaction is supported by *microsomal transfer protein*. Chylomicrons are secreted into intestinal lymph and reach the circulation via the thoracic duct. In the capillaries, especially those of adipose tissue and skeletal muscle, chylomicrons bind to *lipoprotein lipase* (LPL) of capillary endothelial cells. The enzyme is anchored

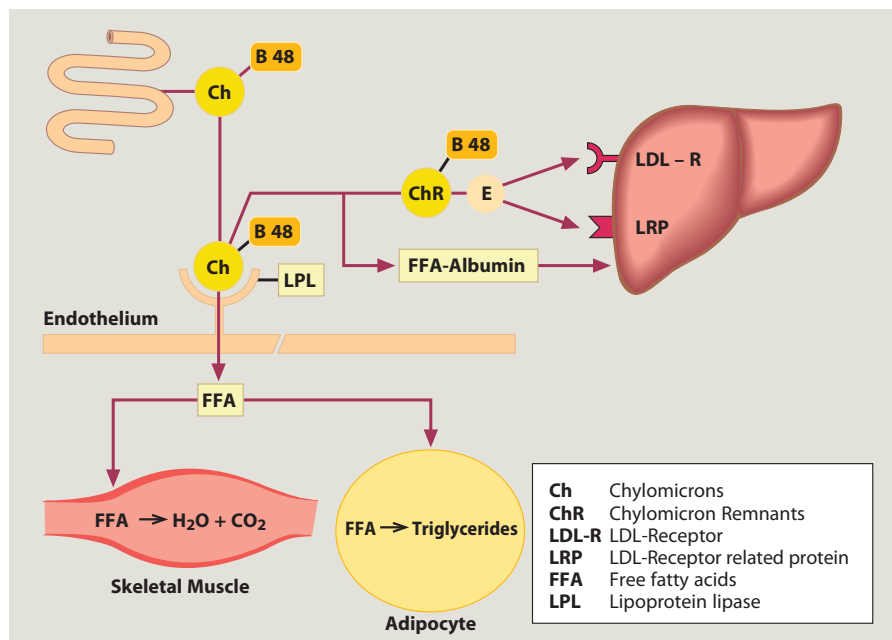


Fig. 6.12 Exogenous pathway of lipoproteins

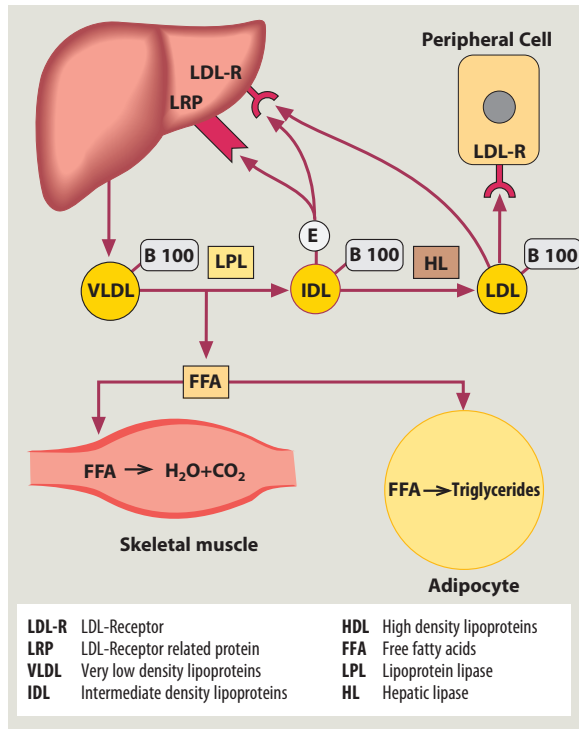


Fig. 6.13 Endogenous pathway of lipoproteins

to the luminal surface of capillary endothelium in most tissues and organs by a heparin-like glycosaminoglycan. It can be displaced by heparin from this bond. LPL catalyzes the hydrolysis of triglycerides in the core of chylomicrons and VLDL, releasing fatty acids and monoacylglycerol in the circulation. The free fatty acids are then taken up by the tissues for oxidation (muscle) or for storage in triglycerides (adipose tissue). Some free fatty acids bind to albumin and return to the liver, where they are oxidized to CO_2 and H_2O or are utilized for the synthesis of triglycerides.

The lipolysis within adipocytes of stored triglycerides is catalyzed by *hormone sensitive lipase*. The enzyme is activated by protein kinase A and by cyclic AMP. Thereafter, fatty acids are released into the circulation. Glucagon, catecholamines, ACTH, TSH, thyroxine, growth hormones and corticosteroids stimulate hormone sensitive lipase, while insulin and prostaglandin E inhibit the activity of the enzyme.

The action of capillary LPL generates, from chylomicrons rich in triglycerides, chylomicron remnants that are largely devoid of triglycerides but enriched in cholesterol. The latter remain in the circulation and are taken up into hepatocytes by the LDL receptor (LDL-R)

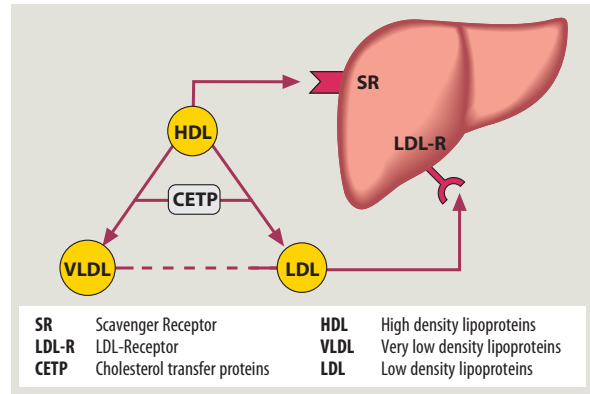


Fig. 6.14 High density lipoproteins (HDL) transport cholesterol from peripheral tissues to the liver

and the LDL receptor related protein (LRP) (Fig. 6.12). To state it in a simplistic way, dietary triglycerides are primarily bound for adipose tissue and skeletal muscle, while the liver is the target of dietary cholesterol. After a carbohydrate rich meal the liver transforms carbohydrates into fatty acids. These are esterified with glycerol to form triglycerides that are incorporated into nascent VLDL and secreted into the circulation.

Endogenous pathway. The endogenous pathway describes the transport between tissues of lipids generated inside the body. Endogenous lipids are transported in VLDL, IDL, LDL and HDL.

Very low density lipoproteins (VLDL) are formed from hepatic triglycerides, cholesterol and apo B-100. *Microsomal triglyceride transfer protein* is essential for transferring the bulk of triglycerides into the lumen of the endoplasmic reticulum for VLDL assembly and is required for the secretion of apo B-100 from the liver [11]. Triglycerides that have been synthesized in the liver are packaged in VLDL particles for transportation to extrahepatic tissues. **Intermediate density lipoproteins (IDL)** are formed by the hydrolyzing action of capillary lipoprotein lipase on VLDL, especially in adipose tissue and muscle. IDL can be regarded as VLDL remnants. IDL are taken up only to a minor degree via ApoE by the hepatocytic LDL-R and LRP. For the most part they are converted to LDL by *hepatic lipase* that is bound to the sinusoidal endothelium. Thereafter, LDL transport cholesterol (LDL-cholesterol) to the hepatocytes or to extrahepatic tissues (Fig. 6.13).

Low density lipoproteins (LDL) are cholesterol rich lipoproteins. They are the major transport form of cholesterol

to the tissues. Their receptor mediated endocytosis occurs after binding of Apo B-100 to the LDL-R that is present in most tissues. Approximately 70–80% of circulating LDL is cleared by the liver. The remainder 20–30% is cleared by LDL receptors on nonhepatic cells, especially on macrophages (scavenger receptor).

The number of LDL receptors expressed by the liver is an important regulatory element of serum cholesterol concentration. LDL/LDL-R vesicles are internalized into the cytoplasm, cholesterol is released after lysosomal degradation of vesicle contents, and LDL-R is redirected to the sinusoidal hepatocyte membrane. Free intracellular cholesterol suppresses both its own synthesis and the synthesis of LDL-R. Cholesterol and its metabolites repress transcription of the HMG-CoA reductase via activation of a membrane-bound transcription factor, *sterol regulatory element-binding protein (SREBP)*. Genetic defects of hepatic LDL-R lead to severe familial hypercholesterolemias [6].

High density lipoproteins (HDL) transport surplus cholesterol from extrahepatic tissues to the liver (“reverse cholesterol transport”), where it is excreted in bile. Free cholesterol is esterified in HDL by the activity of circulating *lecithin:cholesterol acyltransferase (LCAT)*. LCAT is synthesized in the liver and secreted into the circulation. The cholesteryl esters contained in HDL may reach the liver by at least two ways. (1) Transfer of cholesteryl esters to LDL and VLDL by *cholesteryl ester transfer proteins (CETP)* in exchange for triglycerides, and subsequent uptake of LDL into hepatocytes by the LDL-R (VLDL may be transformed to LDL). The remaining triglyceride-rich HDL are hydrolyzed by hepatic lipase. (2) Selective and direct uptake of cholesteryl esters into the liver by a scavenger receptor (Fig. 6.14).

Vitamin A

Vitamin A affects many physiological processes, such as vision, fertility, embryo- and morphogenesis, growth and differentiation. The three basic forms of vitamin A (synonym: retinoids) are retinol, retinaldehyde and retinoic acid. Retinaldehyde is part of the of the pigment rhodopsin and is required for normal vision. Retinol serves in the synthesis of glycoproteins and retinoic acid is an important growth and differentiation factor.

By interacting with nuclear receptors that belong to the superfamily of steroid-thyroid-receptors, vitamin A leads to changes in gene transcription and gene expression. Two types of retinoic acid receptors are distinguished, each having several subtypes: the retinoic acid receptor (RAR) and the retinoate X receptor (RXR).

The daily allowance of vitamin A for an adult is approximately 1 mg. Retinol is found in milk, liver and egg yolk. β -Carotenes have provitamin A activity. They are primarily supplied by fruits and vegetables (especially carrots). In man, carotenoids are transformed to vitamin A by a specific dioxygenase that is present in the intestinal mucosa and in the liver. Dietary vitamin A is transported in chylomicrons and reaches the liver in chylomicron remnants. The liver stores approximately 90% of vitamin A reserves (predominantly in stellate cells and in hepatocytes) and secretes vitamin A in the form of retinol. Circulating vitamin A is bound to the retinol-binding protein (RBP) which interacts with transthyretin. The synthesis and secretion of RBP occur in the hepatocytes. Retinoic acid is primarily transported bound to albumin. Vitamin A is taken up from the sinusoidal blood by the hepatocytes in the form of retinyl ester. After internalization it is hydrolyzed to retinol. Retinol may be (1) passed on to Ito cells for storage, (2) released into the sinusoidal circulation for the supply of other organs, or (3) reesterified in the hepatocytes and stored there. Seventy percent of hepatic retinoids are stored inside the cytoplasmic fat vacuoles of hepatic stellate cells, mostly as retinyl palmitate.

Copper

Copper is an essential trace element important for metabolism. It is a component of numerous cuproenzymes that are required for cellular respiration, iron metabolism, free radical detoxification, and synthesis of hemoglobin, elastin, and collagen.

On average, approximately 30–50% of dietary copper (~1.5–3 mg) is absorbed in the stomach and duodenum. After mucosal translocation copper is bound to albumin and transported via the portal vein to the liver, the main organ responsible for copper homeostasis. The high affinity copper transporter, hCtr1, is responsible for the uptake of copper

into hepatocytes [22]. Metallothioneins, a group of cysteine-rich intracellular proteins capable of binding metal ions, including copper, cadmium and zinc, have a critical role in protecting intracellular proteins from copper toxicity [18]. Metallochaperons transfer copper to the site of synthesis of copper-containing proteins [14, 16]. A specific copper chaperone, ATOX1, delivers copper to the Wilson's disease protein ATP7B by direct protein-protein interaction. ATP7B was identified in 1993 and codes for a transmembrane protein which functions as a copper-dependent P-type ATPase [13, 20]. The Wilson's disease protein contains eight transmembrane segments, six copper-binding regions, an ATP-binding domain, a transmembrane copper channel, a phosphorylation region, and a transduction domain responsible for the conversion of energy of ATP hydrolysis to copper transport across the trans-Golgi network membrane. The proper function of ATP7B in copper homeostasis depends on its intracellular localization: at low copper levels, the transporter is located in the trans-Golgi network and transports copper for incorporation into apo-ceruloplasmin to form holo-ceruloplasmin under physiologic conditions. Excess copper results in intracellular trafficking of ATP7B from the trans-Golgi network to a post-Golgi vesicular compartment [19]. At this site ATP7B may take over an excretory role in promoting biliary copper excretion. As *biliary excretion is the only mechanism for copper elimination*, the amount of copper excreted in the bile is directly proportional to the size of the hepatic copper pool.

Mutations of ATP7B can interrupt its normal cellular processing and result in Wilson's disease, characterized by impaired holo-ceruloplasmin synthesis and reduced biliary copper excretion leading to copper overload (see Chapter 81). Due to the lack of entry into the trans-Golgi network, copper accumulates in the cytosol. The fate it takes from there is unknown. In early phases of the disorder excess copper can be trapped by metallothionein. After a certain concentration has been reached it is assumed to be redistributed into lysosomes for deposition. This results in histological rhodanine-positive staining. Copper mediated free radical induced membrane injury may be one mechanism of hepatocellular damage (necrosis). In addition, induction of apoptosis is discussed as another mechanism responsible for disease progression. Cell death triggers release of excess copper into the bloodstream and uptake in other susceptible

organs. Alternatively, copper accumulates in those organs due to the same molecular mechanisms that operate in hepatocytes. The cellular physiology and pathophysiology of copper metabolism is poorly understood. The same is true for the different phenotypic courses of the disease, which might be due to modifying intracellular pathways.

The α_2 -globulin *ceruloplasmin* is an acute phase reactant that is synthesized in hepatocytes and secreted into the plasma following the incorporation of six atoms of copper late in the secretory pathway. Ninety-five percent of circulating copper is bound to ceruloplasmin. Therefore, serum ceruloplasmin concentration is a useful indicator of hepatic copper metabolism.

Ceruloplasmin transports copper, but plays an important role in iron metabolism and is required for normal iron homeostasis. It is an essential ferroxidase that reoxidizes iron. Compared to non-enzymatic reactions, the oxidation catalyzed by ceruloplasmin has the advantage of not generating oxygen radicals or H_2O_2 . In addition, ceruloplasmin facilitates the transfer of iron to transferrin [21].

Aceruloplasminemia is a rare autosomal recessive disease associated with mutation(s) in the ceruloplasmin gene. Patients with aceruloplasminemia have a normal copper homeostasis but show a marked iron overload in the liver (hepatocytes and Kupffer cells) and in the brain. The amount of iron deposition may equal that observed in genetic hemochromatosis. Aceruloplasminemia should therefore be considered in the differential diagnosis of unexplained iron overload, which is associated with a lack of ceruloplasmin or a decrease in the serum ceruloplasmin level [15, 17].

Heme and Non-Heme Iron

Iron is an essential element for microbes, plants, and mammals; it is a key component of most redox enzymes and of oxygen storage and transporting proteins including hemoglobin and myoglobin [51]. Iron is recycled from hemoglobin of aging red blood cells (approximately 20 mg/day) and mainly directed to new red blood cells. Intestinal iron absorption and iron losses are finely balanced under physiological conditions [24, 51]. Usually, the diet contains enough iron necessary to replace the small daily losses of 1–2 mg/day. Thus, approximately 10% of the total daily intake (10–20 mg) are finally

absorbed from the small intestine (1–2 mg). Humans and other mammals, however, do not have mechanisms to excrete excess iron. Thus, intestinal iron absorption is regulated by tight feedback mechanisms. Additionally, iron concentrations in most biological fluids are regulated to avoid iron excess which may generate reactive oxygen radicals.

Iron is absorbed from the small intestine as either inorganic iron (primarily from non-animal sources) or as heme (primarily from hemoglobin and myoglobin). In the last decade the regulation for absorption of non-heme iron has been elucidated in detail [24, 78]. Intestinal iron absorption is downregulated when iron stores increase and upregulated when iron stores are reduced. This regulation is finely tuned by several carriers and regulators recently identified (Figs. 6.15 and 6.16). It has also become increasingly evident that some of them interact with the HFE gene product in regulation of iron absorption [51]. Until recently it has been thought that regulation of iron homeostasis is regulated only by uptake and release of non-heme iron. The uptake of heme iron and its role for maintaining balanced iron stores has been unclear up to recently. Only recent studies identified a heme carrier protein 1 (HCP1) which functions to transport heme into cells [88].

The following review deals with the regulation of heme and non-heme iron metabolism and absorption, with special emphasis on potential dysregulations which lead to iron overload. The specific mutations of regulators and carriers of iron metabolism causing iron overload are described in more detail in the chapter about hemochromatosis (Chapter 82).

Regulation of Heme and Non-Heme Iron Metabolism and Absorption

Non-Heme Iron

Dietary non-heme iron is mainly present as oxidized, ferric iron (Fe III) which has to be reduced to ferrous (Fe II) iron in order to be taken up by duodenal enterocytes. Only some years ago the intestinal reductase, termed Dcytb (duodenal cytochrome B), has been identified [63]. After iron has been reduced, it is taken up by the enterocyte via the divalent metal transporter

1 (DMT1, also called Nramp2), which was isolated independently by two groups in 1997 [35, 48]. DMT1 is also expressed in the endosome where it can import both dietary and transferrin-bound iron [45, 47, 93]. After its uptake, iron can either be stored via ferritin or it can be exported at the basolateral membrane by the *iron exporter ferroportin 1* (also named IRG1 or MTP1). This carrier was independently identified by three groups [23, 32, 62]. Ferroportin, which is also expressed in hepatocytes and reticuloendothelial cells, transports Fe II across the basolateral membrane; thereafter, Fe II must be oxidized to Fe III before it can bind to circulating transferrin. The basolateral oxidase has also been identified and named *hephaestin* (Fig. 6.15) [96]. The basolateral uptake of transferrin-bound iron has been characterized in detail [49]. Transferrin 1 receptors exist on cell surfaces as homodimers joined by disulfide bridges. Diferric transferrin binds to the transferrin 1 receptor and the entire complex subsequently undergoes endocytosis. At the acidic pH of the endosome, Fe III is released from transferrin, and the apo-transferrin/transferrin 1 receptor complex recycles to the cell surface. At the slightly basic pH of the extracellular fluid, the apo-transferrin dissociates from transferrin 1 receptor, and the entire process begins again. The endosomal Fe III released from transferrin must be reduced to Fe II prior to transport across the endosomal membrane. DMT1 is likely also the endosomal transporter since it is expressed in a variety of tissues and sorted to endosomes [45, 93].

The proteins involved in these processes of iron uptake are finely regulated. In animal models of dietary iron deficiency, the duodenal expression of Dcytb, DMT1, ferroportin 1, and transferrin 1 receptor is increased in comparison to animals fed sufficient iron [32, 37, 62, 63, 93, 101]. Only hephaestin expression does not change in rat models of iron deficiency or loading [41]. Regulation of iron metabolism may vary among different cells and tissues because they have different needs. A fine regulation is necessary for duodenal mucosa and tissue macrophages to guarantee an adequate response to signals coming from blood-forming tissues. Similar mechanisms may be present in hepatocytes which store the iron. In many cells, iron-regulatory proteins (IRPs) interact with specific structural elements in mRNA transcripts, called iron-regulatory elements (IREs) [86]. The binding of IRPs to IREs increases when cellular iron is reduced resulting in increases in mRNA stability and abundance for transcripts with IREs in the 3' UTR such

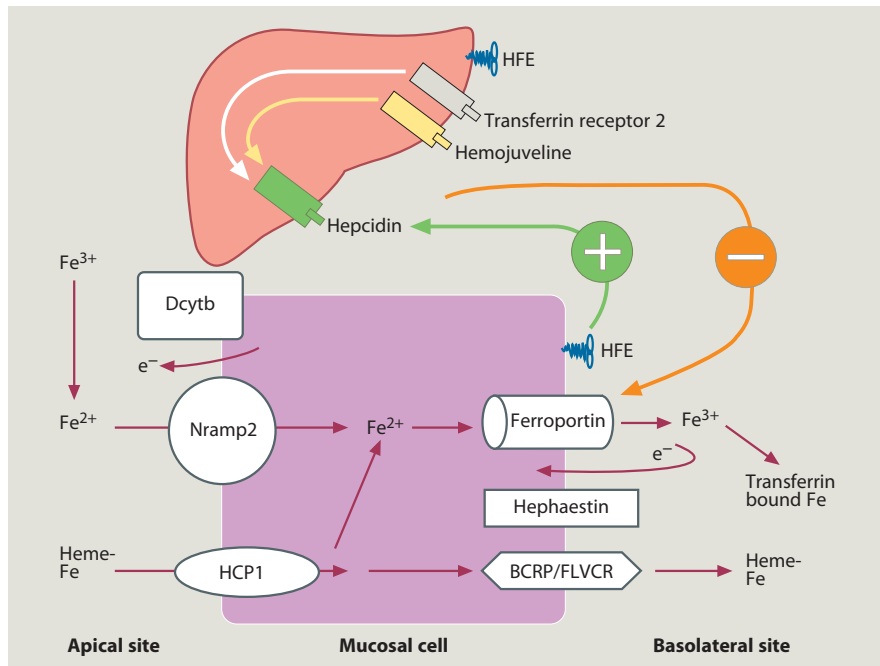


Fig. 6.15 Regulation of intestinal iron absorption. Dietary non-heme iron is mainly present as oxidized, ferric iron (Fe III) which is reduced to ferrous (Fe II) iron by the intestinal reductase Dcytb (duodenal cytochrome B). Iron absorption requires the transfer of iron across both the apical and basolateral membranes of duodenal enterocytes. The divalent metal transporter 1 (DMT1), located on the apical brush-border membrane, mediates the uptake of reduced, non-heme iron. A portion of this iron is retained within the cell for use or for storage via ferritin; the remainder is transferred to the circulation by basolateral exporter ferroportin. Released iron (Fe II) is then oxidized to Fe III in order to bind to plasma transferrin by the basolateral oxidase hephaestin. The absorption of heme iron is mediated by HCP 1 (heme carrier pro-

tein 1) which is expressed on the apical membrane. Iron released from heme probably has the same intracellular fate as absorbed non-heme iron. The existence of two mammalian heme exporters, Bcrp and FLVCR, suggests that heme may transit the enterocyte intact to be exported into the circulation. Hepcidin has been shown to downregulate the basolateral iron carrier ferroportin. It has also been demonstrated that hepcidin itself is upregulated by HFE. Thus, a HFE mutation may reduce the upregulation of hepcidin which then cannot downregulate ferroportin; the increase in ferroportin expression finally causes an increase in intestinal iron uptake. There may be further interactions between HFE, transferrin receptor 2, Nramp2, Dcytb, ferroportin, hephaestin and hepcidin, all of which are currently studied

as transferrin 1 receptor. Also, binding of IRPs to IREs in the 5' UTR of mRNA can inhibit translation which occurs in transcripts encoding the ferritin H chain. Ferritin iron in villus cells is increased in mice homozygous for a disruption of IRP2 [56]. In duodenal mucosa of patients with HFE hemochromatosis IRP binding activity is increased whereas ferritin is decreased [76]. DMT1 mRNA transcripts are a heterogeneous population with at least two species. One DMT1 mRNA species contains an IRE in the 3' UTR while the other does not. These two species also differ in their amino acid coding sequence for the carboxyl terminus [36, 47, 58]. Ferroportin 1 mRNA transcripts also contain a functional IRE, but this IRE is located in the 5' UTR [23, 62]. In duodenal mucosa mRNA transcripts increase for DMT1 and ferroportin 1 when there is iron deficiency.

This increase may be explained by IRE/IRP interaction in the case of DMT1, but not for ferroportin. IRP binding to the 3' IREs in DMT1 may result in stabilization of the mRNA and its corresponding increase; however, IRP binding to the 5' IRE of ferroportin should inhibit translation without having an effect on messenger levels. In addition Dcytb mRNAs, which have no IRE, also increase in iron deficiency; therefore, other regulatory, transcriptional mechanisms are involved.

Recent studies have elucidated a variety of mechanisms that regulate the expression of genes involved in the intestinal absorption of iron. Dysfunction of HFE function has a major impact on some of these mechanisms. In general all recent data suggest that reduced HFE function results in increased iron uptake from intestinal mucosa. In mouse models of and in patients

with genetic hemochromatosis reduction of HFE function is associated with an increase in the expression of DMT1 and ferroportin at the mRNA and protein levels of duodenal mucosa [37, 46, 101]. One study suggests the IRE-form of DMT1 may be specifically upregulated in the duodenum of the HFE $-/-$ mouse [37]. Another group also showed that DMT1 is upregulated in the hpx mouse and the mk mouse, but there was no change in the HFE $-/-$ mouse [29]. The explanation for this discrepancy is unclear. Additionally, the level of ferritin was found to be low in the duodenum of patients with hemochromatosis [76]. Later studies then showed that loss of HFE function mainly affects ferroportin and not DMT1 function.

Although HFE is widely expressed in many tissues, it is especially prominent in crypt cells of the duodenum [74, 97]. Crypt cells mature and become absorptive enterocytes as they migrate towards the tip of the villus. While HFE is strongly expressed in crypt cells, it is only weakly expressed in the villus. On the other hand, Dcytb, DMT1, and ferroportin are expressed predominantly in the villus and not in crypt cells [32, 45, 63]. These observations have suggested a model in which signals from blood-forming tissues and sites of iron storage are transmitted to the crypt cells of the duodenum; these signals may then “set” the level of expression of iron uptake systems in the mature villus cells. HFE has been thought to participate in this process by interacting with the transferrin 1 receptor. HFE is associated with transferrin receptor 1 in many tissues. Recombinant HFE and transferrin receptor 1 show nanomolar binding affinity at the pH of extracellular fluid [34, 57, 75, 97]. This interaction may be important because diferric transferrin also binds to transferrin receptor 1 with nanomolar affinity; such binding affinity is markedly reduced in the presence of HFE. Some authors have reported that overexpression of HFE in cultured HeLa cells results in reduction of iron uptake and of ferritin suggesting that interaction of HFE with transferrin receptor 1 downregulates iron uptake [29, 84, 87]. There are, however, many limitations with these studies [65].

Although recent studies have identified the luminal iron carrier Nramp2 and the iron reductase Dcytb, as well as the basolateral iron exporter ferroportin 1 and the iron oxidase hephaestin, none of these genes are altered in type 1 HFE hemochromatosis [38, 40, 77, 92]. On the other hand, later studies showed that mutations in some of the proteins are responsible for rare types of genetic hemochromatosis (types 2–4). Thus, it

remained unclear how HFE gene mutations finally caused increased iron absorption and iron overload. More recently, two further proteins were shown to act as important iron regulators, *transferrin receptor 2* and *hepcidin*. Mutations in transferrin receptor 2 gene may lead to the rare type 3 hemochromatosis. The most recent studies indicate that hepcidin is the key regulator of iron metabolism [27, 31, 68]. Hepcidin was first found in the urine and though to have antimicrobial effects. Later it was shown that the 25-amino-acid peptide hepcidin is predominantly synthesized by liver, secreted into plasma, and excreted into urine [54, 73, 80]. Hepcidin has been shown to downregulate the basolateral iron carrier ferroportin. It has also been demonstrated that hepcidin itself is upregulated by HFE. Thus, a HFE mutation may reduce the upregulation of hepcidin which then cannot downregulate ferroportin; the increase in ferroportin finally causes an increase in intestinal iron uptake (Fig. 6.15). There may be further interactions between HFE, transferrin receptor 2, Nramp2, Dcytb, ferroportin, hephaestin and hepcidin, all of which are currently being studied.

Decreased expression of hepcidin is the key mechanism for most forms of iron overload; conversely, increased hepcidin results in iron-deficiency anemia [39]. In hemochromatosis type 2 the decrease in hepcidin is due to mutations in the gene which encodes hemojuvelin (HJV). HJV is a co-receptor of the bone morphogenetic protein (BMP); HJV mutants may result in dysfunction of BMP signaling. Recent studies suggest that BMPs are autocrine hormones that induce hepcidin expression [27]. Hepcidin inhibits export of iron from enterocytes, macrophages and hepatocytes by reduction of ferroportin. Hepcidin expression is increased in iron overload and decreased in anaemia and hypoxia. Hepcidin is markedly induced during infections and inflammation, causing iron to be stored by macrophages, hepatocytes and enterocytes. The corresponding decrease in plasma iron may contribute to the anaemia associated with infection and inflammation. These alterations in iron metabolism probably also have a role in host defense by limiting the availability of iron to invading microorganisms. On the other hand hepcidin deficiency due to its dysregulation or mutations in the hepcidin gene itself are probably the cause of most forms of iron overload including genetic haemochromatosis. Hepcidin is a negative regulator of iron entry into plasma and acts by binding to the iron exporter ferroportin in small intestinal cells

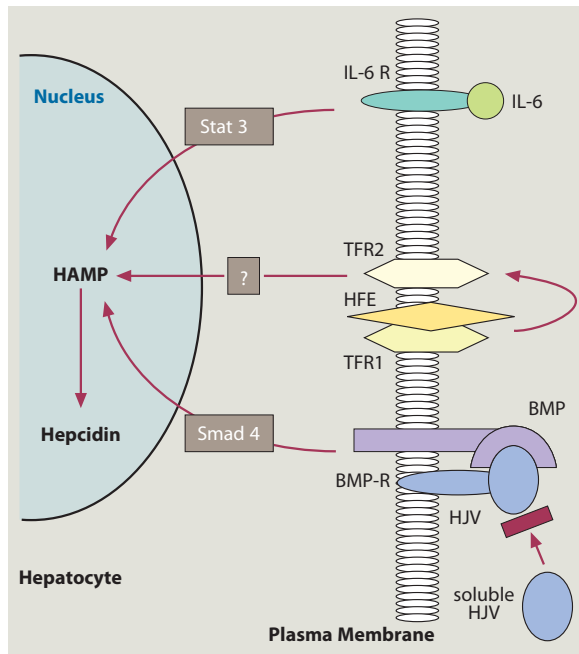


Fig. 6.16 Transcriptional regulation of hepcidin (Modified from [25, 27, 31, 66]). Hepcidin transcription depends upon signaling via BMP receptors (BMP-Rs) and downstream Smads. Binding of BMP to cell surface HJV generates phosphorylated RSmads which dimerize with Smad4. The RSmad/Smad4 heterodimer translocates into the nucleus to activate transcription of the HAMP gene which encodes hepcidin. Soluble HJV binding to BMP prevents the formation of the cell surface BMP-HJV complex and inhibits activation of BMP receptors. Inflammatory cytokines such as IL-6 activate Stat3 which also binds to the HAMP promoter. Stat3 activation requires the presence of Smad4 since deletion of the Smad4 gene prevents IL-6 induction of hepcidin. Smad4 is downstream of transferrin receptor 2 and HFE suggesting that the signal provided by these proteins also activates the HAMP promoter or that these membrane proteins affect BMP receptor signal transmission

and macrophages. Binding of hepcidin induces ferroportin internalization and degradation [67]. The loss of ferroportin from the cell surface prevents iron entry into plasma. Decreased iron entry into plasma results in low transferrin saturation, and less iron is delivered to the developing erythroblast. Also, decreased expression of hepcidin leads to increased cell surface ferroportin and increased iron absorption. Inflammation may increase hepcidin expression and secretion by the liver. Increased levels of circulating hepcidin then lead to internalization and degradation of the iron exporter ferroportin. The reduction of ferroportin results in iron loading of macrophages, reduction of plasma iron and transferrin-bound iron, and decrease of erythropoiesis.

The final consequence of inflammation-induced increase in circulating hepcidin is the anemia of chronic disease. Thus, hepcidin regulates iron import into plasma, transferrin saturation, and erythropoiesis. Iron overload results from decreased hepcidin causing increased iron import into plasma, high transferrin saturation, and iron excess in the liver. Circulating hepcidin is regulated by cytokines, plasma iron, anaemia, and hypoxia. Its dysregulation results in iron overload or deficiency.

A decrease in hepcidin expression results in iron overload in many organs. In most genetic forms of hemochromatosis there is a decreased hepcidin expression which can be associated with mutations of type 1 hemochromatosis gene (HFE), hemochromatosis type 2 genes (hemojuvelin), transferrin receptor 2 gene, and hepcidin antimicrobial peptide gene (HAMP). Mutations in HAMP, which encodes hepcidin, result in iron overload disease directly by affecting the iron carrier ferroportin and thereby increasing iron absorption. It has been unclear how mutations in transferrin receptor 2, HFE, and hemojuvelin genes may affect expression of hepcidin. Only recently it has been elucidated how hemojuvelin (HJV) alters the expression of hepcidin [27]. IL-6, and probably also other proinflammatory cytokines, may induce transcription of HAMP in hepatocytes (Fig. 6.16). This induction involves the activation of Stat3 and binding of Stat3 to a regulatory element in the HAMP promoter [27, 79, 95, 99]. It is accepted that hepcidin transcription is regulated via BMP receptors (BMP-Rs) and downstream Smads. BMPs may act as autocrine or paracrine hormones [31]. BMP may bind to HJV at the cell surface to activate BMP receptors and further downstream to generation of a RSmad/Smad4 heterodimer (Fig. 6.16) [27, 98]. This heterodimer translocates into the nucleus and activates the transcription of the HAMP gene. Administration of soluble HJV inhibits hepcidin expression in vitro and in vivo, ultimately increasing hepatic iron [27, 59]. Administration of soluble HJV reduced hepcidin in the liver as well as phosphorylated Rsmads, suggesting that HJV acts via BMP signaling. It has also been shown that soluble HJV reduces hepcidin expression in response to IL-6 [27]. Thus, recombinant HJV may be used as a drug for treatment of anemia of chronic disease which is usually associated with high hepcidin expression. IL-6 leads to intracellular activation of Stat3 that may bind to the HAMP promoter. Stat3 activation also requires the presence of Smad4, as deletion of the Smad4 gene prevents

IL-6 induction of hepcidin. Smad4 is located downstream of transferrin receptor 2 and HFE (Fig. 6.16). The signals of these proteins can activate the HAMP promoter and affect BMP receptor signal transmission [27]. BMPs are members of the TGF- β family which regulate cell proliferation and differentiation by a specific intracellular pathway; this pathway involves serine/threonine kinase receptors, formation of a BMP receptor complex, and finally phosphorylation of Rsmads [60]. Liver-specific inactivation of Smad4 results in loss of hepcidin synthesis and iron overload similar to the phenotype seen in hepcidin-knockout mice [59]. Babbitt et al also showed that mice with a deletion in the Smad4 gene were unable to synthesize hepcidin in response to inflammatory stimuli or to iron load [27]. These data suggest that the BMP/Smad4 pathway is critical to hepcidin expression.

HJV acts as a BMP co-receptor *in vitro* leading to activation of the BMP-receptor complex [26]. Mutations in the gene encoding HJV lead to early-onset iron overload disease [72]. This form of juvenile haemochromatosis is associated with a decrease in hepcidin expression and iron overload similar to that associated with HAMP mutations in patients. HJV is a surface protein expressed predominantly in hepatocytes and skeletal muscle. HJV has some homology with proteins involved in neural guidance including RBMCA, RGMCB, and DRAGON, all of which bind BMPs and enhance BMP-mediated signaling [72]. The function of HJV as a BMP co-receptor may be required for affecting hepcidin expression and thus iron homeostasis. Several recent studies suggest that BMPs are critical for expression of hepcidin and IL-6 induction [27, 98]. It has also been hypothesized that expression of BMPs is regulated in hepatocytes [31]. It has been speculated that Stat3 and Smad signaling may interact at the level of the HAMP/hepcidin promoter or that Stat3 might regulate BMP expression in hepatocytes [31, 42].

The mechanisms by which HFE and transferrin receptor 2 interact with the BMP/Smad4 system still need to be elucidated in further detail. Addition of BMPs to hepatocytes cultured from mice with deletions in the HFE or transferrin receptor 2 genes showed induction of hepcidin to levels that were similar to those in wild-type hepatocytes [94]. Thus, HFE and transferrin receptor 2 might work upstream of BMP. HFE and transferrin receptor 2 may interact and thereby provide a downstream signal that affects hepcidin expression [44]. It remains unknown whether the HFE/transferrin

receptor 2 complex interacts with the cell surface BMP/HJV/BMP receptor complex or whether intracellular signals provided by the HFE/transferrin receptor 2 complex act on the HAMP/hepcidin promoter.

Heme Iron

Recent evidence suggests that heme attaches to the apical brush border of the enterocyte and enters the cell intact via HCP1 (heme carrier protein 1) which has been identified as the apical heme carrier (Fig. 6.15) [25]. In support of its role in the absorption of heme iron, it was shown that forced expression of HCP1 in cultured cells promotes the uptake of both heme (in the form of iron protoporphyrin) and a similar molecule, zinc protoporphyrin, but not non-heme iron [88].

Little is known as yet how iron is liberated from the protoporphyrin ring inside the cell. At some point, iron must be freed from the protoporphyrin ring, although it is not certain when or where this occurs. It has been speculated that heme oxygenase may be involved since the enzyme can cleave heme to free iron [25]. However, it is doubtful whether the small amounts of heme oxygenase in enterocytes can fully do this job [82]. Regardless, iron liberated from heme is likely to enter the same intracellular pathway as inorganic iron. Thus, heme iron may finally leave the cell via the iron exporter ferroportin [25, 51]. A part of heme may be exported as an intact molecule by one of the recently discovered heme exporters, Bcrp and FLVCR (Fig. 6.15) [55, 81].

Mutations of genes altering the uptake or release of heme-iron may not cause iron overload or deficiency because iron homeostasis is predominantly regulated by uptake of non-heme iron [25, 51]. Thus, it has been speculated that absorption of heme is not necessary for survival and that mutations in the HCP1 gene may therefore be more common than the disease-causing mutations reported in genes for DMT1 and ferroportin [25]. On the other hand, genetic variability in the uptake of heme iron might explain the variability of disease penetrance in patients with HFE hemochromatosis. It has become increasingly clear that clinically relevant iron overload develops in only a part of homozygotes for the C282Y HFE mutation. This incomplete penetrance may be explained by the influence of modifier genes such as the HCP1 gene. Similar genetic modifiers may also affect the susceptibility to iron deficiency.

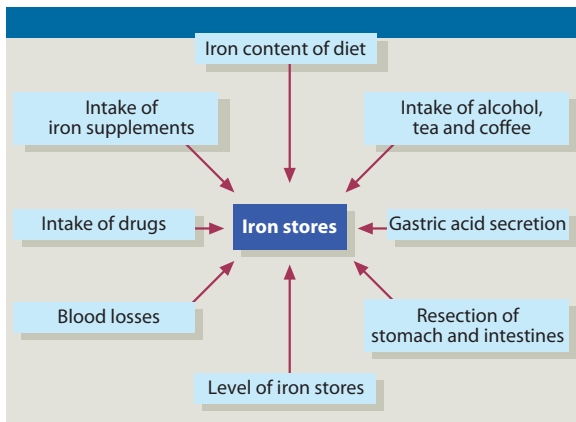


Fig. 6.17 Influence of various non-genetic factors on intestinal iron absorption. For further details see text

Influence of Non-Genetic Factors on Iron Absorption

Body iron stores are also affected by various non-genetic factors (Fig. 6.17). C282Y homozygous women develop clinical signs of iron overload 5–8 times less frequently and 10–15 years later than men due to their menstrual blood losses [69, 70]. Other blood losses also affect both the iron absorption as well the iron stores. It has been shown by many investigators that alcohol consumption increases intestinal iron absorption [33, 61]. Recent studies suggest that alcohol may increase iron absorption by down-regulation of hepcidin [50, 71]. In contrast to alcohol, tea and coffee decrease dietary non-heme iron uptake [66, 100]. Regular tea drinking with meals has been shown to reduce the frequency of phlebotomies required in the management of patients with haemochromatosis [53]. The uptake of non-heme iron is not only dependent on dietary content; the bioavailability of non-heme iron is also markedly affected by the composition of the meal [83]. Iron stores are often reduced in vegetarians [28]. Gastric and small intestinal resection as well as alterations in gastric acid secretion might reduce intestinal iron uptake. Recently it has been shown that proton pump inhibitors suppress absorption of dietary non-heme iron in patients with genetic hemochromatosis [52]. Similar effects have been shown for cimetidine many years ago [89]. Iron absorption tests showed that the reduction of intestinal iron absorption capacity is the

most probable cause of persistent anemia in patients with Roux-en-Y gastric bypass [64]. Accelerated small-intestinal transit is most likely responsible for the abnormalities of iron absorption following gastrectomy with Roux-en-Y or Billroth II anastomosis [85]. Blood transfusions as well as dietary iron supplementation, on the other hand, lead to an increase in body iron stores [43, 90]. Several drugs such are also known to alter intestinal iron absorption by various mechanisms. For example, ascorbic acid is a quite effective enhancer of the uptake of non-heme iron [91].

References

Carbohydrates, Amino Acids and Proteins, Lipids, Vitamin A

1. Brown MS, Goldstein JL (1997) The SREB pathway: regulation of cholesterol metabolism by proteolysis of a membrane-bound transcription factor. *Cell* 89: 331–40
2. Browning JD, Horton JD (2004) Molecular mediators of hepatic steatosis and liver injury. *J Clin Invest* 114: 147–52
3. Canbay A, Bechmann L, Gerken G (2007) Lipid metabolism in the liver. *Z Gastroenterol* 45: 35–41
4. Christensen HE (1990) Role of amino acid transport and countertransport in nutrition and metabolism. *Physiol Rev* 70: 43–77
5. Feldmann G, Scoazec JY, Racine L, et al (1992) Functional hepatocellular heterogeneity for the production of plasma proteins. *Enzyme* 46: 139–54
6. Goldstein JL, Kita T, Brown MS (1983) Defective lipoprotein receptors and atherosclerosis. Lessons from an animal counterpart of familial hypercholesterolemia. *N Engl J Med* 309: 288–96
7. Löffler G, Petrides PE (1998) *Biochemie und Pathobiochemie*. 6. Auflage. Springer Verlag, Berlin/Heidelberg/New York
8. Mortimore GE, Pösö AR (1987) Intracellular protein catabolism and its control during nutrient deprivation and supply. *Annu Rev Nutr* 7: 539–64
9. Osei-Hyiaman D, DePetrillo M, Pacher P, et al (2005) Endocannabinoid activation at hepatic CB1 receptors stimulates fatty acid synthesis and contributes to diet-induced obesity. *J Clin Invest* 115: 1298–305
10. Pilakis SJ, Granner DK (1992) Molecular physiology of the regulation of hepatic gluconeogenesis and glycolysis. *Annu Rev Physiol* 54: 885–909
11. Raabe M, Veniant MM, Sullivan MA, et al (1999) Analysis of the role of microsomal triglyceride transfer protein in the liver of tissue-specific knockout mice. *J Clin Invest* 103: 1287–98
12. Rehner G, Daniel H (1999) *Biochemie der Ernährung*. Spektrum Akademischer Verlag, Heidelberg

Copper

13. Bull PC, Thomas GR, Rommens JM, et al (1993) The Wilson disease gene is a putative copper transporting P-type atpase similar to the Menkes gene. *Nat Genet* 5: 327–37
14. Hamza I, Schaefer M, Klomp LW, et al (1999) Interaction of the copper chaperone HAH1 with the Wilson disease protein is essential for copper homeostasis. *Proc Natl Acad Sci USA* 96: 13363–8
15. Hellmann JD (2002) Ceruloplasmin metabolism and function. *Ann Rev Nutr* 22: 439–58
16. Huffman DL, O'Halloran TV (2001) Function, structure, and mechanism of intracellular copper trafficking proteins. *Annu Rev Biochem* 70: 677–701
17. Kono S, Suzuki H, Takahashi K, et al (2006) Hepatic iron overload with a decreased serum ceruloplasmin level in a novel clinical type of aceruloplasminemia. *Gastroenterology* 131: 240–5
18. Palmiter RD (1998) The elusive function of metallothioneins. *Proc Natl Acad Sci USA* 95: 8428–30
19. Schaefer M, Roelofsen H, Wolters H, et al (1999) Localization of the Wilson's disease protein in human liver. *Gastroenterology* 117: 1380–5
20. Tanzi RE, Petrukhin K, Chernov I, et al (1993) The Wilson disease gene is a copper transporting atpase with homology to the Menkes disease gene. *Nat Genet* 5: 344–50
21. Tao TY, Gitlin JD (2003) Hepatic copper metabolism: insights from genetic disease. *Hepatology* 37: 1241–7
22. Zhou B, Gitschier J (1997) hctrl: a human gene for copper uptake identified by complementation in yeast. *Proc Natl Acad Sci USA* 94: 7481–6
23. Donovan A, Brownlie A, Zhou Y, et al (2000) Positional cloning of zebrafish ferroportin1 identifies a conserved vertebrate iron exporter. *Nature* 403: 776–81
24. Duane P, Raja KB, Simpson RJ, et al (1992) Intestinal iron absorption in chronic alcoholics. *Alcohol* 27: 539–44
25. Feder JN, Penny DM, Irrinki A, et al (1998) The hemochromatosis gene product complexes with the transferrin receptor and lowers its affinity for ligand binding. *Proc Natl Acad Sci USA* 95: 1472–7
26. Fleming MD, Trenor CC 3rd, Su MA, et al (1997) Microcytic anaemia mice have a mutation in Nramp2, a candidate iron transporter gene. *Nat Genet* 16: 383–6
27. Fleming MD, Romano MA, Su MA, et al (1998) Nramp2 is mutated in the anemic Belgrade (b) rat: evidence of a role for Nramp2 in endosomal iron transport. *Proc Natl Acad Sci USA* 95: 1148–53
28. Fleming RE, Migas MC, Zhou X, et al (1999) Mechanism of increased iron absorption in murine model of hereditary hemochromatosis: increased duodenal expression of the iron transporter DMT1. *Proc Natl Acad Sci USA* 96: 3143–8
29. Fleming RE, Sly WS (2002) Mechanisms of iron accumulation in hereditary hemochromatosis. *Annu Rev Physiol* 4: 663–80
30. Fleming RE (2005) Advances in understanding the molecular basis for the regulation of dietary iron absorption. *Curr Opin Gastroenterol* 21: 201–16
31. Fletcher LM, Halliday JW (2002) Haemochromatosis: Understanding the mechanism of disease and implications for diagnosis and patient management following the recent cloning of novel genes involved in iron metabolism. *J Intern Med* 251: 81–92
32. Frazer DM, Vulpe CD, McKie AT, et al (2001) Cloning and gastrointestinal expression of rat hephaestin: relationship to other iron transport proteins. *Am J Physiol Gastrointest Liver Physiol* 281: G931–9
33. Fukuda S, Abematsu M, Mori H (2007) Potentiation of astroglialogenesis by STAT3-mediated activation of BMP-Smad signaling in neural stem cells. *Mol Cell Biol* 27: 4931–7
34. Gordeuk VR, Caleffi A, Corradini E, et al (2003) Iron overload in Africans and African-Americans and a common mutation in the SCL40A1 (ferroportin 1) gene. *Blood Cells Mol Dis* 31: 299–304
35. Goswami T, Andrews NC (2006) Hereditary hemochromatosis protein, HFE, interaction with transferrin receptor 2 suggests a molecular mechanism for mammalian iron sensing. *J Biol Chem* 281: 28494–8
36. Griffiths WJ, Kelly AL, Smith SJ, et al (2000) Localization of iron transport and regulatory proteins in human cells. *QJM* 93: 575–87
37. Griffiths WJ, Sly WS, Cox TM (2001) Intestinal iron uptake determined by divalent metal transporter is enhanced in HFE-deficient mice with hemochromatosis. *Gastroenterology* 120: 1420–9
38. Gruenheid S, Cellier M, Vidal S (1995) Identification and characterization of a second mouse Nramp gene. *Genomics* 25: 514–25
39. Gunshin H, Mackenzie B, Berger UV, et al (1997) Cloning and characterization of a mammalian proton-coupled metal-ion transporter. *Nature* 388: 482–8
40. Harford JB, Klausner RD (1990) Coordinate post-transcriptional regulation of ferritin and transferrin receptor expres-

Heme and Non-Heme Iron

23. Abboud S, Haile DJ (2000) A novel mammalian iron-regulated protein involved in intracellular iron metabolism. *J Biol Chem* 275: 19906–12
24. Andrews NC (1999) Disorders of iron metabolism. *N Engl J Med* 341: 1986–95
25. Andrews NC (2005) Understanding heme transport. *N Engl J Med* 353: 2508–9
26. Babitt JL, Huang FW, Wrighting DM, et al (2006) Bone morphogenetic protein signaling by hemojuvelin regulates hepcidin expression. *Nat Genet* 38: 531–9
27. Babitt JL, Huang FW, Xia Y, et al (2007) Modulation of bone morphogenetic protein signaling in vivo regulates systemic iron balance. *J Clin Invest* 117: 1933–9
28. Ball MJ, Bartlett MA (1999) Dietary intake and iron status of Australian vegetarian women. *Am J Clin Nutr* 70: 353–8
29. Canonne-Hergaux F, Levy JE, Fleming MD, et al (2001) Expression of the DMT1 (NRAMP2/DCT1) iron transporter in mice with genetic iron overload disorders. *Blood* 97: 1138–40
30. Corsi B, Levi S, Cozzi A, et al (1999) Overexpression of the hereditary hemochromatosis protein, HFE, in hela cells induces an iron-deficient phenotype. *FEBS Lett* 460: 149–52
31. De Domenico I, Diane M, Ward D, et al (2007) Hepcidin regulation: ironing out the details. *J Clin Invest* 117: 1755–58

- sion: the role of regulated RNA-protein interaction. *Enzyme* 44: 28–41
50. Harrison-Findik DD, Schafer D, Klein E, et al (2006) Alcohol metabolism-mediated oxidative stress down-regulates hepcidin transcription and leads to increased duodenal iron transporter expression. *J Biol Chem* 281: 22974–82
51. Hentze MW, Muckenthaler MU, Andrews NC (2004) Balancing acts: molecular control of mammalian iron metabolism. *Cell* 117: 285–97
52. Hutchinson C, Geissler C, Powell J, et al (2007) Proton pump inhibitors suppress absorption of dietary non-haem iron in hereditary haemochromatosis. *Gut* 56: 1291–5
53. Kaltwasser JP, Werner E, Schalk K, et al (1998) Clinical trial on the effect of regular tea drinking on iron accumulation in genetic haemochromatosis. *Gut* 43: 699–704
54. Krause A, Neitz S, Magert HJ et al (2000) LEAP-1, a novel highly disulfide-bonded human peptide, exhibits antimicrobial activity. *FEBS Lett* 480: 147–50
55. Krishnamurthy P, Ross DD, Nakanishi T, et al (2004) The stem cell marker Bcrp/ABCG2 enhances hypoxic cell survival through interactions with heme. *J Biol Chem* 279: 24218–25
56. LaVaute T, Smith S, Cooperman S, et al (2001) Targeted deletion of the gene encoding iron regulatory protein-2 causes misregulation of iron metabolism and neurodegenerative disease in mice. *Nat Genet* 27: 209–14
57. Lebron JA, Bennett MJ, Vaughn DE, et al (1998) Crystal structure of the hemochromatosis protein HFE and characterization of its interaction with transferrin receptor. *Cell* 93: 111–23
58. Lee PL, Gelbart T, West C, et al (1998) The human Nramp2 gene: characterization of the gene structure, alternative splicing, promoter region and polymorphisms. *Blood Cells Mol Dis* 24: 199–215
59. Lin L, Goldberg YP, Ganz T (2005) Competitive regulation of hepcidin mRNA by soluble and cell-associated hemojuvelin. *Blood* 106: 2884–9
60. Massague J, Seoane J, Wotton D (2005) Smad transcription factors. *Genes Dev* 19: 2783–10
61. Mazzanti R, Srail KS, Debnam ES, et al (1987) The effect of chronic ethanol consumption on iron absorption in rats. *Alcohol* 22: 47–52
62. McKie AT, Marciani P, Rolfs A, et al (2000) A novel duodenal iron-regulated transporter, IREG1, implicated in the basolateral transfer of iron to the circulation. *Mol Cell* 5: 299–309
63. McKie AT, Barrow D, Latunde-Dada GO, et al (2001) An iron-regulated ferric reductase associated with the absorption of dietary iron. *Science* 291: 1755–9
64. Mizón C, Ruz M, Csendes A, et al (2007) Persistent anemia after Roux-en-Y gastric bypass. *Nutrition* 23: 277–80
65. Montosi G, Paglia P, Garuti C, et al (2000) Wild-type HFE protein normalizes transferrin iron accumulation in macrophages from subjects with hereditary hemochromatosis. *Blood* 96: 1125–9
66. Nelson M, Poulter J (2004) Impact of tea drinking on iron status in the UK: a review. *J Hum Nutr Diet* 17: 43–54
67. Nemeth E, Tuttle MS, Powelson J, et al (2004) Hepcidin regulates cellular iron efflux by binding to ferroportin and inducing its internalization. *Science* 306: 2090–3
68. Nemeth E, Ganz T (2006) Regulation of iron metabolism by hepcidin. *Annu Rev Nutr* 26: 323–42
69. Niederau C, Fischer R, Sonnenberg A, et al (1985) Survival and causes of death in cirrhotic and noncirrhotic patients with primary haemochromatosis. *New Engl J Med* 313: 1256–62
70. Niederau C, Fischer R, Pürschel A, et al (1996) Long-term survival in patients with hereditary hemochromatosis. *Gastroenterology* 110: 1107–19
71. Ohtake T, Saito H, Hosoki Y, et al (2007) Hepcidin is down-regulated in alcohol loading. *Alcohol Clin Exp Res* 31: S2–8
72. Papanikolaou G, Samuels ME, Ludwig EH, et al (2004) Mutations in HFE2 cause iron overload in chromosome 1q-linked juvenile hemochromatosis. *Nat Genet* 36: 77–82
73. Park CH, Valore EV, Waring AJ, et al (2001) Hepcidin, a urinary antimicrobial peptide synthesized in the liver. *J Biol Chem* 276: 7806–10
74. Parkkila S, Waheed A, Britton RS, et al (1997) Immunohistochemistry of HLA-H, the protein defective in patients with hereditary hemochromatosis, reveals unique pattern of expression in gastrointestinal tract. *Proc Natl Acad Sci USA* 94: 2534–9
75. Parkkila S, Waheed A, Britton RS, et al (1997) Association of the transferrin receptor in human placenta with HFE, the protein defective in hereditary hemochromatosis. *Proc Natl Acad Sci USA* 94: 13198–202
76. Pietrangelo A, Casalgrandi G, Quaglino D, et al (1995) Duodenal ferritin synthesis in genetic hemochromatosis. *Gastroenterology* 108: 208–17
77. Pietrangelo A (2002) Physiology of iron transport and the hemochromatosis gene. *Am J Physiol Gastrointest Liver Physiol* 282: G403–14
78. Pietrangelo A (2004) Hereditary hemochromatosis – a new look at an old disease. *N Engl J Med* 350: 2383–97
79. Pietrangelo A, Dierssen U, Valli L, et al (2007) STAT3 is required for IL-6-gp130-dependent activation of hepcidin in vivo. *Gastroenterology* 132: 294–300
80. Pigeon C, Ilyin G, Courselaud B et al (2001) A new mouse liver-specific gene, encoding a protein homologous to human antimicrobial peptide hepcidin, is overexpressed during iron overload. *J Biol Chem* 276: 7811–9
81. Quigley JG, Yang Z, Worthington MT, et al (2004) Identification of a human heme exporter that is essential for erythropoiesis. *Cell* 118: 757–66
82. Raffin SB, Woo CH, Roost KT, et al (1974) Intestinal absorption of hemoglobin iron-heme cleavage by mucosal heme oxygenase. *J Clin Invest* 54: 1344–52
83. Reddy MB, Hurrell RF, Cook JD (2000) Estimation of non-heme-iron bioavailability from meal composition. *Am J Clin Nutr* 71: 937–43
84. Riedel HD, Muckenthaler MU, Gehrke SG, et al (1999) HFE downregulates iron uptake from transferrin and induces iron-regulatory protein activity in stably transfected cells. *Blood* 94: 3915–21
85. Rieu PN, Jansen JB, Joosten HJ, et al (1990) Effect of gastrectomy with either Roux-en-Y or Billroth II anastomosis on small-intestinal function. *Scand J Gastroenterol* 25: 185–92
86. Rouault T, Klausner R (1997) Regulation of iron metabolism in eukaryotes. *Curr Top Cell Regul* 35: 1–19
87. Roy CN, Penny DM, Feder JN, et al (1999) The hereditary hemochromatosis protein, HFE, specifically regulates transferrin-mediated iron uptake in hela cells. *J Biol Chem* 274: 9022–8

88. Shayeghi M, Latunde-Dada GO, Oakhill JS, et al (2005) Identification of an intestinal heme transporter. *Cell* 122: 789–801
89. Skikne BS, Lynch SR, Cook JD (1981) Role of gastric acid in food iron absorption. *Gastroenterology* 81: 1068–71
90. Telfer PT, Prestcott E, Holden S, et al (2000) Hepatic iron concentration combined with long-term monitoring of serum ferritin to predict complications of iron overload in thalassaemia major. *Br J Haematol* 110: 971–7
91. Teucher B, Olivares M, Cori H (2004) Enhancers of iron absorption: ascorbic acid and other organic acids. *Int J Vitam Nutr Res* 74: 403–19
92. Townsend A, Drakesmith H (2002) Role of HFE in iron metabolism, hereditary haemochromatosis, anaemia of chronic disease, and secondary iron overload. *Lancet* 359: 786–90
93. Trinder D, Oates PS, Thomas C, et al (2000) Localisation of divalent metal transporter 1 (DMT1) to the microvillus membrane of rat duodenal enterocytes in iron deficiency, but to hepatocytes in iron overload. *Gut* 46: 270–6
94. Truksa J, Peng H, Lee P, et al (2006) Bone morphogenetic proteins 2, 4, and 9 stimulate murine hepcidin 1 expression independently of HFE, transferrin receptor 2 (Tfr2), and IL-6. *Proc Natl Acad Sci USA* 103: 10289–93
95. Verga Falzacappa MV, Vujic Spasic M, Kessler R, et al (2007) STAT3 mediates hepatic hepcidin expression and its inflammatory stimulation. *Blood* 109: 353–8
96. Vulpe CD, Kuo YM, Murphy TL, et al (1999) Hephaestin, a ceruloplasmin homologue implicated in intestinal iron transport, is defective in the sla mouse. *Nat Genet* 21: 195–9
97. Waheed A, Parkkila S, Saarnio J, et al (1999) Association of HFE protein with transferrin receptor in crypt enterocytes of human duodenum. *Proc Natl Acad Sci USA* 96: 1579–84
98. Wang RH, Li C, Xu X, et al (2005) A role of SMAD4 in iron metabolism through the positive regulation of hepcidin expression. *Cell Metab* 2: 399–409
99. Wrighting DM, Andrews NC (2006) Interleukin-6 induces hepcidin expression through STAT3. *Blood* 108: 3204–9
100. Zijp IM, Korver O, Tijburg LB (2000) Effect of tea and other dietary factors on iron absorption. *Crit Rev Food Sci Nutr* 40: 371–98
101. Zoller H, Koch RO, Theurl I, Obrist P, et al (2001) Expression of the duodenal iron transporters divalent-metal transporter 1 and ferroportin 1 in iron deficiency and iron overload. *Gastroenterology* 120: 1412–9

Formation and Secretion of Bile and Bilirubin Metabolism

7

Ulrich Leuschner

Chapter Outline

Bile Composition	103
Liver Bile	104
Bile Formation in the Hepatocyte	104
Bile Formation in the Bile Ducts	104
Gallbladder Bile	105
Bile Lipids and Bilirubin	105
Cholesterol	105
Bile Acids and Bile Salts	107
Bile Acid Synthesis	107
Secondary and Tertiary Bile Acids	108
Phospholipids	109
Bilirubin	110
Bilirubin Synthesis	110
Transport and Uptake into Hepatocytes	110
Glucuronidation	111
Excretion into Bile	112
Bilirubin in the Intestine	112
Bile Secretion	112
Bile Acid Dependent Bile Secretion	112
Bile Acid Independent Bile Secretion	114
Influence of the Cell Structure on Bile Secretion	115
Functional Regulation of Bile Secretion	115
Enterohepatic Circulation of Bile Acids	116
Bile Acid Uptake into the Hepatocyte	117
Na ⁺ -Dependent Bile Acid Reabsorption	118
Na ⁺ -Independent Bile Acid Reabsorption	118
Transcellular Bile Acid Transport	118
Pathological Alterations of Bile Acid Metabolism	119
Lithogenic Bile	119

Cholestasis	122
Bile Acid Metabolism During Extrahepatic Cholestasis	122
Bile Acid Metabolism During Intrahepatic Cholestasis	122
Cholestasis Caused by Toxic Bile Acids	123
Genetic Disturbances of Bile Acid Metabolism	124
References	124

Man produces 500–800 ml bile daily. Bile is produced by hepatocytes and is modified in the biliary tree. We distinguish between the yellow-golden liver bile and the more yellow-brown gallbladder bile. The colour of the bile originates from bilirubin and bilirubin metabolites. Liver- and gallbladder bile are isotonic because the tight junctions between bile duct epithelial cells are freely permeable to water. Bile is a micelle and lipid rich watery fluid. In contrast, the so called “chalk-milk bile” is pasteous and partly crumbly. In gallbladder hydrops, gallbladder bile is a watery clear fluid. This means that bile may change its consistency from a watery fluid to a solid mass. Cholesterol, phospholipids, bilirubin, electrolytes, proteins and several drugs are excreted with the bile.

Bile Composition

Liver- (or hepatocyte) and gallbladder bile differ to a lesser extent in their different components than in their concentration. In this chapter, the composition of bile will first be reviewed, followed by how it is produced under the influence of the liver, the bile ducts and the gallbladder. The bile lipids (cholesterol, bile acids, phospholipids) and bilirubin, the most important components of bile, will also be discussed.

Liver Bile

Primary bile is also called hepatocyte or canalicular bile. Sixty to 70% of the daily produced amounts of bile are primary or hepatocellular bile. The watery bile is a lipid-rich secretion and excretion of the liver (Table 7.1). Secreted are water soluble compounds, which can also be excreted via the kidneys. Water insoluble substances which cannot be excreted by the kidneys are also excreted in bile.

The functions of human bile encompass

- Secretion of cholesterol into bile
- Secretion of other metabolites such as bilirubin, drugs
- Excretion of heavy metals
- Emulgation of lipids in the gut
- Emulgation of fat soluble vitamins
- Neutralization of gastric juice
- Activation of pancreatic enzymes
- Stimulation of gut motility

An overview of the composition of human bile is given in Table 7.2.

Table 7.1 Biliary substances secreted and excreted by the bile producing system

Substances secreted	Substances excreted
Bile salts	Cholesterol
Phospholipids	Bilirubin
Glutathione	Bile salts
Immunoglobulins A, M	Lipophilic drugs
Mucus	Metals (iron, manganese, copper, zinc, magnesium, lead)

Table 7.2 Composition of human bile

Substance	Liver bile	Gallbladder bile
Water	90–95%	82%
Solid compounds	5–10%	18%
Free cholesterol	80–200 mg/dL	300–1000 mg/dL
Phospholipids	150–800 mg/dL	200–900 mg/dL
Bile salts	3–45 mM	40–400 mM
Bilirubin	1–2 mM	3–7 mM
Na ⁺	140–170 mM	150–264 mM
K ⁺	2.7–6.7 mM	8.2–19.6 mM
HCO ₃ ⁻	12–55 mM	19 mM
Ca ⁺⁺	2.5–6.4 mM	3.1–17.4 mM
Protein (total)	2–20 mg/dL	-
Glutathione (total)	0–5 mM	-
pH	6.2–8.5	5.6–8.0
Specific weight	0.995–1.008	1.008–1.034

From the 18% of solid bile compounds (82–95% of bile are water), 65–70% are bile acids, 4% cholesterol and 20–23% phospholipids. Bile salts, phospholipids and cholesterol are called bile lipids. Bilirubin represents 0.3% and protein only 4–5% of the solid compounds. The most important biliary bile acids are cholic acid (ca. 40% of all biliary bile acids), chenodeoxycholic acid (40%), deoxycholic acid (10–15%) and ursodeoxycholic acid (2–5%). There are some other bile acids of lesser importance. Due to the pH of bile, bile acids exist as Na⁺/K⁺-salts and are completely conjugated with the amino acids taurin and glycine. Although in a strict way bile acids exist as bile salts, the two terms are used interchangeably.

Phospholipids in 98% are phosphatidylcholin (lecithin), 2% are sphingomyelins, cephalins and lysolecithin. Most of the proteins secreted into bile are so-called secretion products, such as immunoglobulin IgA, IgM and, in rather small concentrations, also IgG. This applies also to the liver enzymes aspartate aminotransferase (AST), alanine aminotransferase (ALT) and alkaline phosphatase (ALP), the latter being located at the canalicular membrane of the hepatocyte, and 5-nucleotidase. Glycoproteins play an important role as nucleation factors during the development of gallstones, although the role of glycoproteins is not yet clearly understood. Besides these compounds several electrolytes, metals and water soluble vitamins are excreted. Bilirubin excreted in small concentrations gives bile its colour.

Bile Formation in the Hepatocyte

The most important compounds in bile are bile acids, synthesized from cholesterol (see below).

Bile Formation in the Bile Ducts

Ductular bile production in man is only 20–30% of total bile production. In the bile ducts primary bile is diluted by the secretion of about 150 ml H₂O/24h. Bile duct endothelial cells reabsorb glucose actively by a transport system, while amino acids, some side chain-shortened bile acids and the weak unconjugated ursodeoxycholic acid (UDCA) are reabsorbed by passive diffusion.

UDCA in primary bile is anionic, unprotonated. While passing along the bile ductular epithelial cells it becomes protonated. As a neutral, protonated bile acid UDCA is reabsorbed by the epithelial cells and transported to the liver via blood stream (cholehepatic shunt). For each mole of UDCA, one mole of HCO_3^- originates from H_2CO_3 . The gastrointestinal hormone secretin also increases the concentration of HCO_3^- of primary bile. HCO_3^- has strong choleric properties by stimulating water secretion in bile duct cells. It is unclear whether during this process Na^+/H^+ - and $\text{Na}^+/\text{HCO}_3^-$ -cotransporters play a role. Because of its influence on the formation of HCO_3^- UDCA is called a hypercholeric bile acid. Since we are not able to puncture small bile ducts and bile canaliculi under physiological and pathological conditions data on composition of intrahepatic bile are uncertain.

Gallbladder Bile

Gallbladder bile is concentrated and chemically altered liver bile (Table 7.2). The most important changes occur during the development of cholesterol gallbladder stones: after an initial hypersecretion of cholesterol the composition of liver bile changes by the secretion of bile acids, phospholipids, nucleation and antinucleation factors and an augmented production of mucus from the gallbladder wall (mucines), glycoproteins and mucopolysaccharides. Enzymes of mucosal cells and bacteria further change gallbladder bile composition (see Chapter 112). Gallbladder tone and motility are further factors influencing bile composition.

While bile is diluted in bile canaliculi by the secretion of water, in the gallbladder it is concentrated to a far greater extent. *In vitro* gallbladder mucosa is able to reabsorb 0.5–2.9 ml $\text{H}_2\text{O}/\text{h}$, *in vivo* three times as much. Therefore gallbladder bile is 5–10-fold more concentrated than bile duct bile. The uptake of water by the mucosal cell occurs by passive diffusion after NaCl has been reabsorbed actively. Na^+ and Cl^- are bound to an apical membrane transporting system and are exchanged against H^+ and HCO_3^- . Cl^- is excreted by a chloride channel, while Na^+ is excreted at the basolateral side of the cell by Na^+/K^+ -ATPase.

Cholesterol probably is reabsorbed in negligible amounts, bilirubin probably only in the unconjugated form. In animal experiments only 10–15% of phos-

pholipids of a 0.1–1.0mM phosphatid solution is reabsorbed by gallbladder mucosal cells, while the extent of phospholipid reabsorption in man is unknown.

As shown in Table 7.2, gallbladder bile has a lower pH than liver bile. Up to now it is still hypothetical how gallbladder bile becomes more acidic. It has been discussed, for example, that H^+ -ions are exchanged for Na^+ -ions. The role of HCO_3^- during this process is unknown. All changes which occur in the gallbladder seem only to depend on the time period during which bile remains in the gallbladder. This is true for bile composition and for alterations of its physicochemical properties.

Bile Lipids and Bilirubin

Cholesterol

Bile lipids primarily consist of cholesterol, bile salts and phospholipids. Important bile lipids are bile acids, due to their most important physiological and pathophysiological properties. Bile acids are synthesized in hepatocytes from cholesterol.

Cholesterol consists of a steroid ring system with an aliphatic side chain (Fig. 7.1). Cholesterol is synthesized in all human tissues, but predominantly in the liver (80–90%), followed by the intestinal tract, the skin and muscles. Synthesis of cholesterol starts from acetyl-coenzyme A. The key enzyme of cholesterol synthesis is the β -hydroxy- β -methylglutaryl

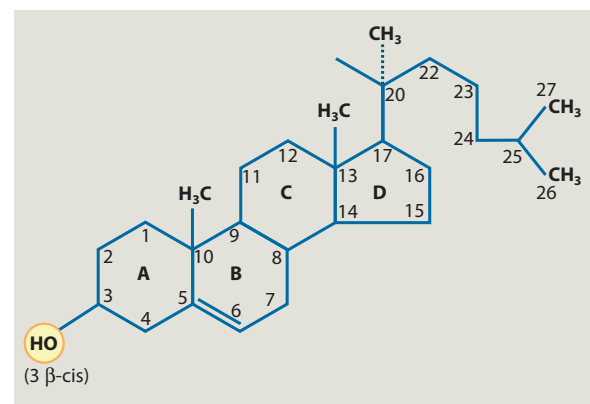


Fig. 7.1 Cholesterol

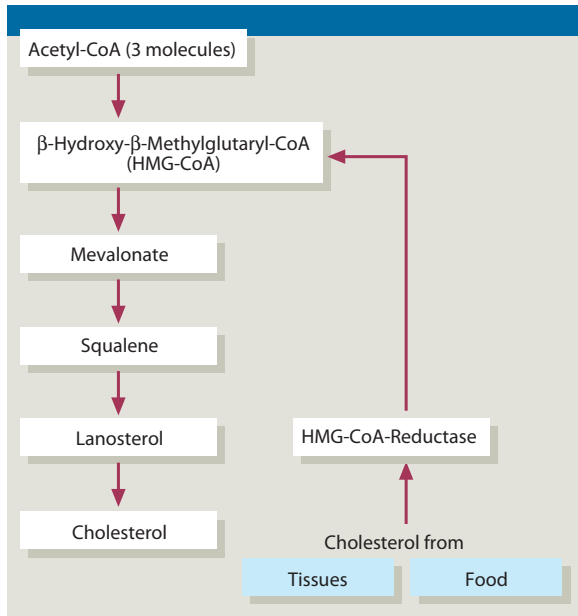


Fig. 7.2 Biosynthesis of cholesterol and impact of tissue and food cholesterol on HMG-CoA-reductase

coenzyme-A-reductase (HMG-CoA-reductase; Fig. 7.2). The activity of this enzyme depends on cholesterol uptake from the food and cholesterol concentration in peripheral tissues. Cholesterol is transported to the liver bound to the lipoproteins LDL and HDL, to smaller amounts also in chylomicrone- and VLDL-remnants. For the uptake of free or esterified cholesterol by the hepatocyte, apo-B/E-receptors are located on the liver cell membrane [2]. After internalisation of the cholesterol a cholesterol vesicle develops, which fuses with lysosomes. The cholesterol ester is split by lysosomal lipases. Free cholesterol migrates to the cytoplasm of the cell and by inhibiting the HMG-CoA-reductase it down-regulates intracellular cholesterol synthesis (negative feed-back-mechanism), inhibits the synthesis of LDL-receptors (apo-B/E = inhibits further reabsorption of cholesterol), and stimulates its esterification with saturated fatty acids (acyl-CoA-cholesterol-acyl-transferase: ACAT) (Fig. 7.3).

The following possibilities exist for absorbed and newly synthesized cholesterol: (1) after reesterification of free cholesterol under the influence of ACAT, VLDL-lipoproteins are formed, which can be secreted into blood; (2) cholesterol esters can be stored in intracellular membranes or in small lipid droplets in the

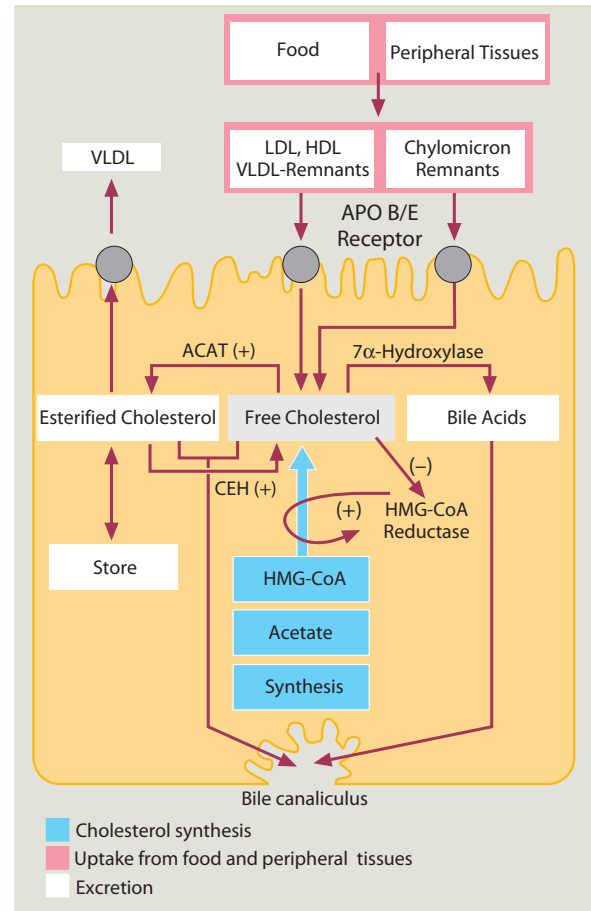


Fig. 7.3 Metabolism of cholesterol in the hepatocyte

cytoplasm, from where they can be rebuilt by cholesterol ester-hydrolase (CEH) to free cholesterol, and finally, (3) cholesterol can be used for the synthesis of bile acids and be excreted into bile (Fig. 7.3). Under pathological conditions (hypersecretion of cholesterol) a smaller amount can also be excreted into bile as free, non-esterified cholesterol or as cholesterol ester, where it is transformed into phospholipid-cholesterol vesicles or so-called liquid crystals. Cholesterol, which enters the intestine and is not reabsorbed is reduced by bacteria to 5α -cholestan- 3β -ol and 5β -cholestan- 3β -ol, and is excreted with the stool.

The mechanism by which cholesterol is secreted into bile is not well understood. There is a tight connection with the excretion of bile acids and phospholipids, but transporters for cholesterol secretion have not yet been clearly identified [24].

Bile Acids and Bile Salts

Bile Acid Synthesis

The most important step by which the organism rids itself of cholesterol, is by the degradation of cholesterol into bile acids. The end point of this procedure is the so-called primary bile acids. These are cholic acid (CA) (3α , 7α , 12α -trihydroxycholanolic acid) and chenodeoxycholic acid (CDCA) (3α , 7α -dihydroxycholanolic acid) (Fig. 7.4). Because of their detergent properties bile acids may be toxic, and

perturbations in transport or secretion can result in a variety of pathologic alterations. Therefore, intracellular concentrations of bile acids must be tightly regulated.

The most important step during degradation of cholesterol to bile acid is hydroxylation of the steroid ring system in the position C_7 . This step is catalysed by the mixed functional cytochrome-P450-containing oxidase [(CYP)7A1] cholesterol- 7α -hydroxylase, which is the rate limiting enzyme in bile acid synthesis. Its activity is regulated by bile acids reabsorbed from the portal blood (negative feed-back-mechanism). 7α -Hydroxylase activity can increase tenfold.

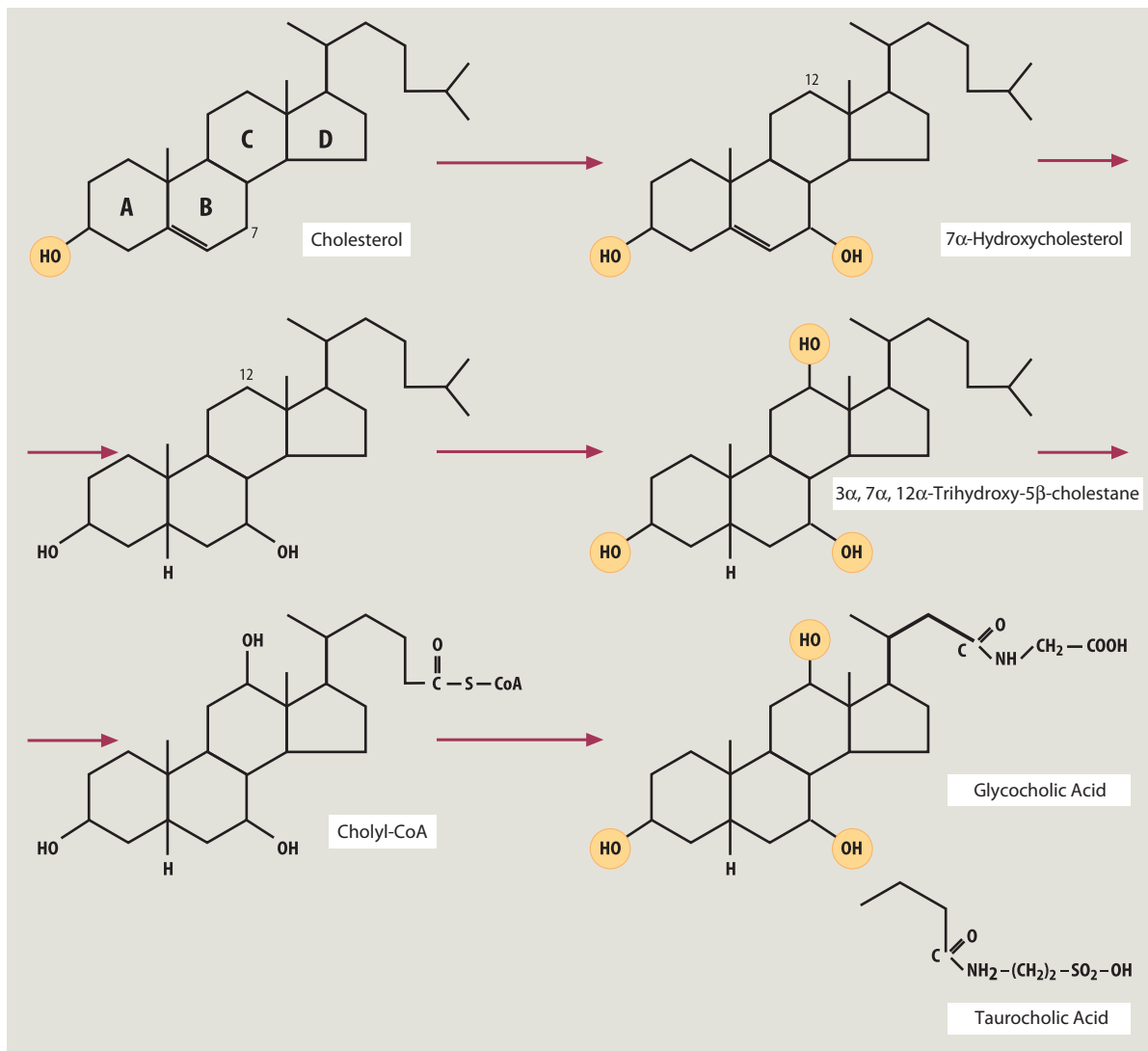


Fig. 7.4 Bile acid synthesis

It has become apparent that various members of a nuclear receptor superfamily of activated transcription factors are key regulators of CYP 7A1. Endogenous bile acids are ligands for the farnesoid X receptor (FXR), which is highly expressed in the liver, the gut and the kidneys [4]. A strong activator of FXR is CA, while LCA (lithocholic acid) and DCA (deoxycholic acid) are less effective. FXR regulates genes, involved in bile acid homeostasis in the liver and the intestine (see enterohepatic circulation of bile acids). Bile acid activated FXR encodes genes suppressing CYP 7A1, which is an important adaptive response to prevent accumulation of potentially toxic bile acids. In addition, FXR and another nuclear receptor, pregnancy X receptor (PXR), stimulate the excretion of bile acids by bile acid transporters. FXR seems to be highly important in bile acid homeostasis, because additional target genes for FXR are the genes for the expression of the multi-drug resistance-associated protein 2 (MRP2) and the bile salt export pump (BSEP), both located at the canalicular membrane of the hepatocyte (Fig. 7.11, Table 7.5).

The further introduction of a hydroxyl group at C₁₂ of the steroid ring C and reduction of the side chain with introduction of a carboxyl group finally leads to the quantitatively most important human bile acid cholic acid (CA). Every further imported OH-group makes the apolar cholesterol molecule more polar and, by this, more hydrophilic and water soluble.

Bile acid synthesis from cholesterol follows two different ways. While during synthesis of cholic acid first ring hydroxylation occurs followed by shortening of the side chain, during synthesis of chenodeoxycholic acid ring changes and reduction of the side chain occur simultaneously.

Less water soluble bile acids are conjugated with one of the two amino acids glycine or taurine by which they become more polar and therefore more hydrophilic in a wide pH and concentration range (Fig. 7.4). In man, glycine conjugates predominate in a ratio of 3:1. Conjugated bile acids precipitate by calcium ions to a lesser extent than unconjugated compounds and they are unable to penetrate cell membranes by passive diffusion. Therefore, active transport systems are necessary for the uptake. Since conjugation of bile acids is very efficient in the hepatocyte, most bile acids exist in the conjugated form.

7 α -hydroxylation of the steroid ring system occurs in the endoplasmic reticulum, 12 α -hydroxylation and side chain shortening in the mitochondria, and the conjugation with glycine or taurine in the cytoplasm of the liver cell.

Secondary and Tertiary Bile Acids

Secondary bile acids develop under the influence of intestinal bacteria proximal to the valve of Bauhin, in the terminal ileum, but mainly in the cecum and in the colon. Here bile acids are first deconjugated and subsequently dehydroxylated at C7 of the steroid ring system. Subsequently, dehydroxylated deoxycholic (DCA) acid is formed from cholic acid, and monohydroxylated lithocholic (LCA) acid from chenodeoxycholic acid. If after dehydroxylation of CDCA oxidation at C7 occurs, the secondary 7-ketolithocholic acid develops (Fig. 7.5). Some other bacterial degradation products of bile acids have been described, the role of which is unknown.

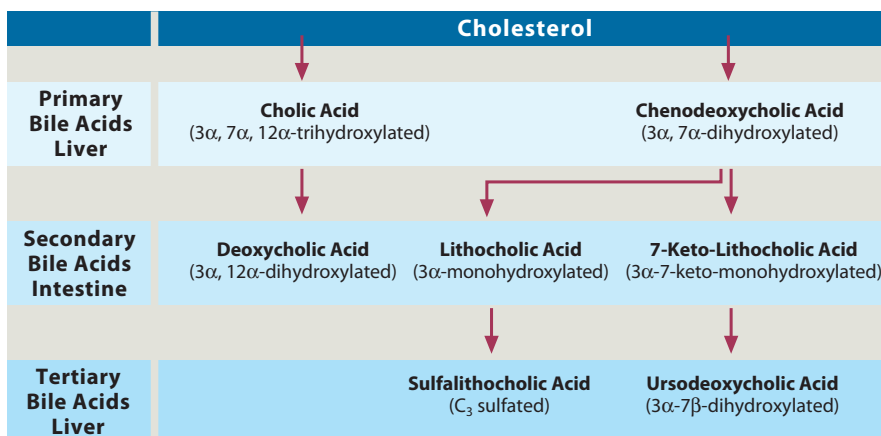


Fig. 7.5 Formation of primary, secondary and tertiary bile acids in the liver and intestine

Tertiary bile acids develop from secondary bile acids, after they have been reabsorbed in the intestine and returned to the liver. Ursodeoxycholic acid (UDCA: 3 α , 7 β -dehydroxycholcholic acid) develops from 7-keto-lithocholic acid mostly in the intestine, but also in the liver. Sulfolithocholic acid is created from lithocholic acid. UDCA is therefore the 7 β -epimer of CDCA.

Besides the described conjugation of bile acids with the amino acids glycine and taurine at the carboxyl group of the side chain, bile acids can also be sulfated, glucuronidated, glycosylated and bound to N-acetylglucosamine. Sulfated and glucuronidated bile acids, such as lithocholic acid are less water soluble and more toxic. On the other hand water soluble bile acids are less toxic or nontoxic and can be excreted via the bile or by the kidneys. These different steps of synthesis are not restricted to the liver, as they have also been found to a lesser extent in the intestine and kidneys. All compounds mentioned here can be found in human bile, although in different and only small concentrations.

Bile acids play an important role in the human organism. Cholic acid and chenodeoxycholic acid are able to form micelles and therefore are of utmost importance for intestinal reabsorption of fat soluble and water insoluble compounds (Table 7.3). Chenodeoxycholic acid forms micelles, UDCA predominantly forms so called liquid

crystals with cholesterol. Through this mechanism, these two bile acids are able to keep the water insoluble cholesterol soluble and are able to dissolve cholesterol from cholesterol gallstones. Bile acids stimulate pancreatic enzymes and influence intestinal motility. UDCA is also used for the treatment of primary biliary liver diseases as well as after liver transplantation (Table 7.4). A lack of bile acids induces the development of gallbladder stones, and can induce diarrhea, steatorrhea, vitamin deficiency and the development of oxalate kidney stones.

Phospholipids

Like cholesterol, phospholipids are present in all human tissues, where they play an important role in the structure and composition of biomembranes. They contain a hydrophilic phosphoryl-choline-headgroup, a middle piece of glycerol and two hydrophobic, aliphatic side chains (Fig. 7.6). 98% of phospholipids are phosphatidyl choline (lecithin), which has developed from diacylglycerine by methylation with methionine. Phospholipids, which occur only in smaller concentrations in bile are sphingomyelins, cephalines and lysolecithin, a bacterial degradation product of lecithin.

Table 7.3 Physiological significance of bile acids in humans

Bile acid	Function, significance
Cholic acid (CA)	Micelle formation; dissolves lipophilic compounds in the watery milieu of bile and intestine, facilitates reabsorption, has choleric properties
Chenodeoxycholic acid (CDCA)	Micelle formation like CA, inhibits cholesterol synthesis, has choleric properties, inhibits 7 α -hydroxylase
Ursodeoxycholic acid (UDCA)	Forms liquid crystals with cholesterol and phospholipids, inhibits cholesterol reabsorption in the gut, has choleric properties
Deoxycholic acid (DCA)	Augments water secretion through tight junctions (diarrhea), cytotoxic, damages phospholipid membranes
Lithocholic acid (LCA)	Cytotoxic, induces cholestasis, damages phospholipid membranes

Table 7.4 Bile acids as drugs

Bile acid	Conditions in which bile acid is used as a drug
Chenodeoxycholic acid (CDCA)	Cholesterol gallbladder stones Hereditary abnormalities of bile acid synthesis Cerebrotendinous xanthomatosis
Ursodeoxycholic acid (UDCA)	Primary biliary cirrhosis Primary sclerosis cholangitis Overlap syndromes After liver transplantation Cystic fibrosis Cholestasis of pregnancy Cholesterol gallbladder stones

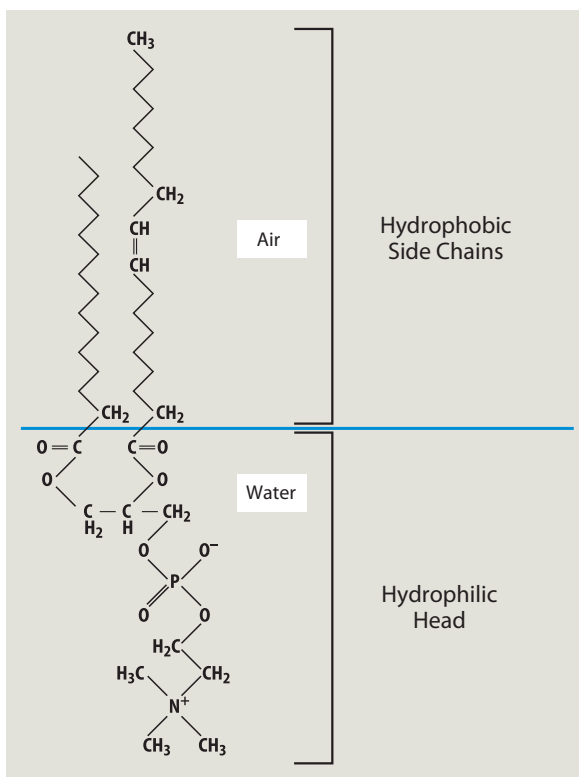


Fig. 7.6 Structural formula of phosphatidylcholine

Bilirubin

Bilirubin is the main degradation product of heme metabolism. Sixty-five to 75% of bilirubin originates from hemoglobin of erythrocytes, 25–35% from the degradation of other heme proteins, such as myoglobin, cytochrome, tryptophane, pyrrolases, from peroxidases and catalases [1]. Bilirubin is synthesized in the reticulo-endothelial system (RES) of spleen, bone marrow and the liver. Man produces approximately 250–350 mg bilirubin daily.

Bilirubin Synthesis

The first step in bilirubin synthesis is the degradation of heme to biliverdin. Heme, containing four pyrrole rings is split at the α -methylene bond with the participation of three molecules O₂ and NADPH (Fig. 7.7). To a lesser extent the ring can also be disrupted at the

β -, γ - and δ -bond. After liberation of iron a linear tetrapyrrole develops, the so-called biliverdin. Cleavage of the ring structure occurs at the inner side of membranes of the endoplasmic reticulum by a microsomal heme oxidase. The cytosolic and ubiquitous occurring biliverdin reductase catalyses the development from α -biliverdin to IX α -bilirubin. Like heme-oxygenase, biliverdin reductase is stereospecific and therefore mainly forms IX α -bilirubin and to a lesser extent β -, γ - and δ -isomers. Both enzymes develop their maximal activity in the spleen, followed by the liver and kidneys.

Transport and Uptake into Hepatocytes

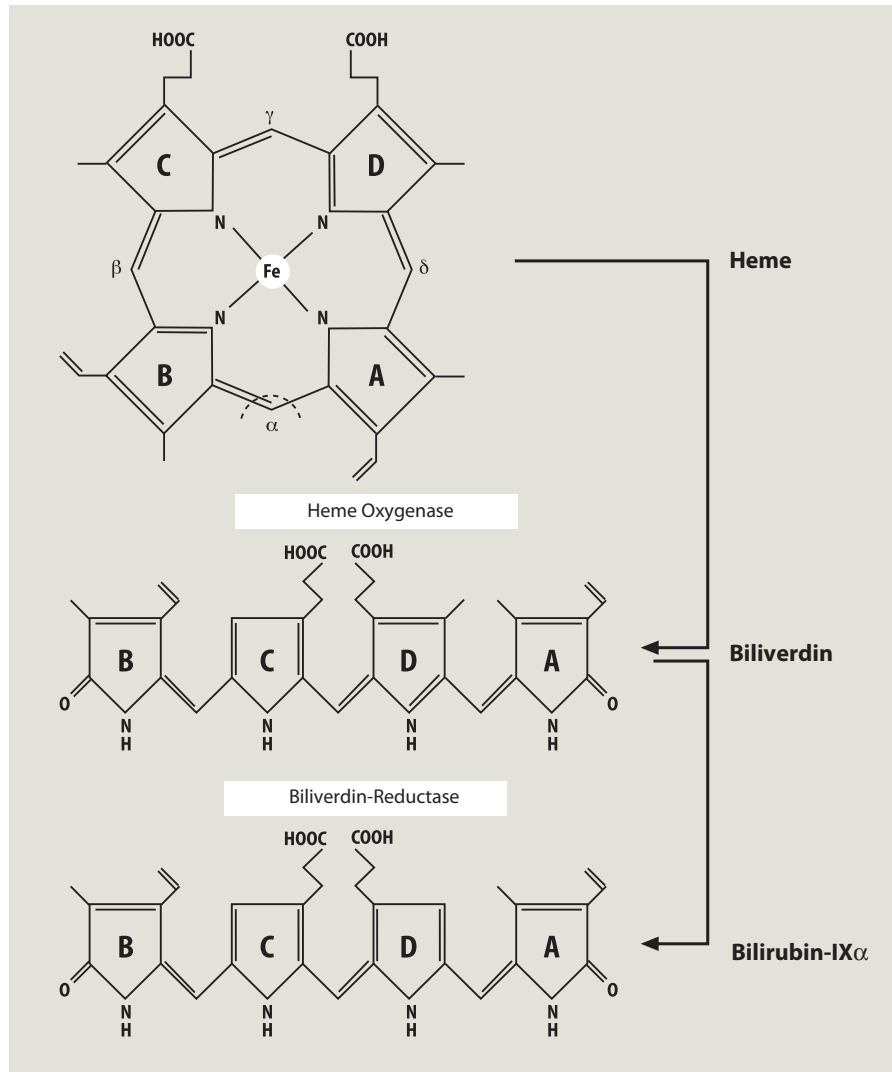
Unconjugated bilirubin is poorly water soluble. Therefore, for the transport to the liver it is reversibly bound to albumin in the blood, and by this its concentration is 1,000-fold higher than in water. Less than 1% of total serum bilirubin occurs as free bilirubin.

Uptake of bilirubin into the hepatocyte occurs via a membrane bound transporter that has a rather high transport capacity (Fig. 7.11). Up to now at the sinusoidal cell membrane three different bilirubin binding proteins have been isolated. It is not well known which of them is the most important transporter. One of these proteins today is called *bilitranslocase*, its molecular weight ranging from 35 to 37 kDa.

The rapid uptake of bilirubin into the hepatocyte is transporter mediated, Na⁺-independent, and has a saturation kinetics. The transporter can be competitively inhibited by bromosulphthalein and indocyanine green, but not by bile acids. Therefore the bilirubin transporter probably differs from that of bile acids. Although the bilirubin transporters seem to function bidirectionally the main flow of bilirubin is directed to the cell organelles and bile canaliculi. The mechanism which drives this stream toward bile canalicular membranes is not known. The secretion of bilirubin into bile is not as rapid as the uptake and presents the rate limiting step. A smaller amount of bilirubin probably is excreted by vesicles formed by membrane phospholipids. But this mechanism of transport plays a minor role [26].

The intracellular transport of bilirubin is mediated by two *carrier proteins*, which are called Y- and Z-protein. More important is the Y-protein (ligandin),

Fig. 7.7 Bilirubin synthesis from heme in the cells of the reticulo-endothelial system



which is glutathione-S-transferase B, a subunit of glutathione transferase. Z-protein is a transporter in reserve, since it is only activated by higher bilirubinate concentrations.

Glucuronidation

In the smooth and rough endoplasmic reticulum of the hepatocytes glucuronidation of bilirubin occurs at the carboxyl residue of the propionic acid groups (Fig. 7.8). By this the apolar, water insoluble IX α -bilirubin is converted to the water soluble mono- and also

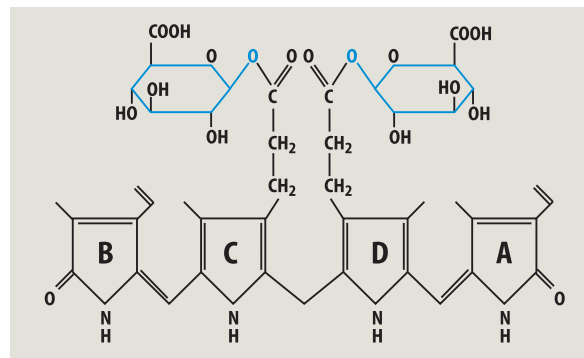


Fig. 7.8 Bilirubin-diglucuronide conjugation in the hepatocyte

diglucuronidated form. Glucuronic acid is a sugar, which per se would make the bilirubin molecule water soluble due to its polar groups, but more important seems to be the blocking of the carboxyl groups of the bilirubin rings C and D. If these two groups remain unesterified, then internal hydrogen bonds will develop with the nitro groups of the pyrrole rings A and B. Between the two dipyrrole rings (A, D and B, C) an angle of 98° exists, which stiffens the molecule and by blocking the polar groups makes it water insoluble (ridge-tile form) (Fig. 7.9).

Glucuronidation is catalyzed by uridindiphosphate glucuronyl-transferase (UDPGT). At first a monoglucuronide develops, and later a diglucuronide. In man two isoenzymes of the UDPG-family are responsible for glucuronidation. The same enzymes are also responsible for the glucuronidation of steroid hormones, bile acids and carcinogenic substances. UDPGT is located in the endoplasmic reticulum and to a smaller extent in the Golgi apparatus of the hepatocyte [25]. In man UDPGT is found only in the liver, though in some animals it is also present in the intestine, in the kidney and in the suprarenal gland. The enzymes as well as the binding sites for bilirubin are located on the luminal side of the endoplasmic reticulum. Since the enzyme is only fully active when bound to the membranes, membrane lipids or proteins seem to be important for its function. Deconjugating glucuronidases are also found in the endoplasmic reticulum, but their activity is weak.

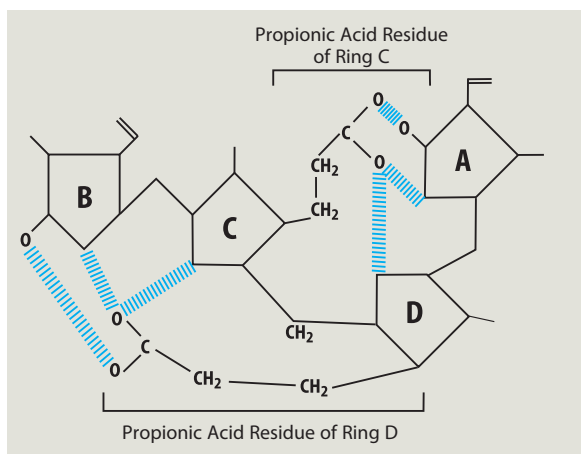


Fig. 7.9 Angulated form of bilirubin IX α . Rings D and A are twisted around the central methylene (CH₂) residue in such a way that the carboxyl residue of ring D gets in contact with ring B (“ridge-tile form”)

Excretion into Bile

Excretion of bilirubin is the rate limiting step in bilirubin metabolism. Bilirubin concentration in bile is approximately 100-fold higher than in the liver cell. Excretion of bilirubin runs against a high concentration gradient and therefore necessitates an active transport system. As transporter the ATP-dependent MRP2 or cMRP (canalicular multidrug resistance protein; cMOAT: canalicular multispecific organic anion transporter) is being discussed (see below), which in addition to conjugated bilirubin also excretes leukotrienes and some drugs (Fig. 7.11). Less than 5% is excreted by exocytosis, which also plays a minor role in the excretion of bile acids and cholesterol. Exocytosis may become a more prominent when there is a surplus of substances which need to be excreted.

In bile 20–40% of bilirubin is mono- and 60–80% is diglucuronide, while only 0.5–2% is unconjugated. Bilirubin does not possess choleric properties. Together with bile acids, cholesterol and phospholipids it is transported in mixed micelles and vesicles (see below) [27].

Bilirubin in the Intestine

Near the cecal valve and in the colon bilirubin diglucuronides are deconjugated by bacterial diglucuronidases. Through this mechanism bilirubin becomes apolar and water insoluble.

Unconjugated bilirubin is degraded by bacterial reductases to urobilinogen, which is reabsorbed in the intestine to less than 1%. It is primarily eliminated by the liver (enterohepatic circulation), while the remainder enters the systemic circulation and is excreted by the kidneys. The unreabsorbed urobilinogen (99%) is further degraded to urobilin and stercobilin and excreted with the stool. These last degradation products of bilirubin are colourless, so it is most likely the dipyrroles and bilirubin polymers which give stool its characteristic colour. These are the same compounds which impart the colour to the brown calcium-bilirubinate stones of the biliary tree and the black pigment stones of the gallbladder (Fig. 7.10).

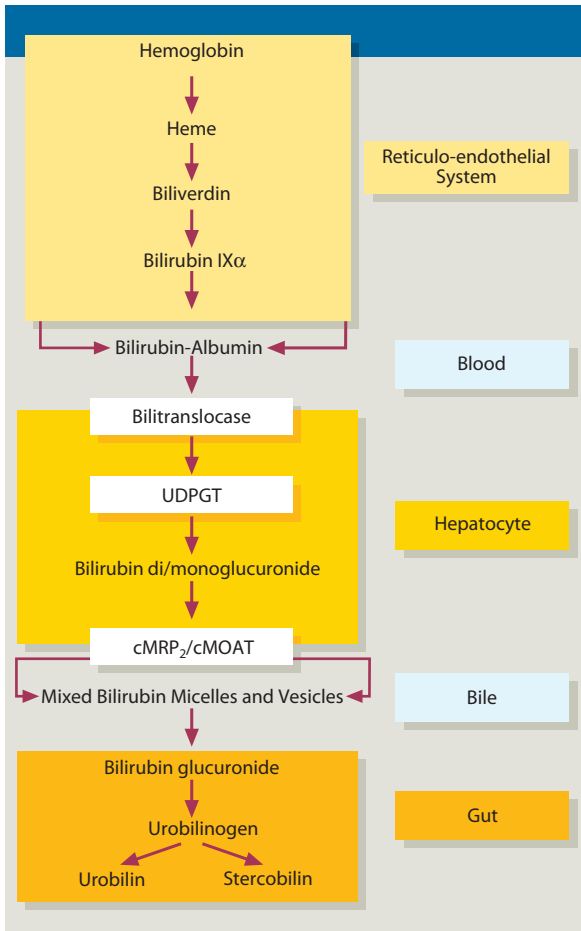


Fig. 7.10 Metabolism of bilirubin

Bile Secretion

Bile acids are essential to bile secretion [9]. One has to differentiate between bile acid dependent and bile acid independent bile flow. Additionally, bile acid secretion together with lysosomal enzymes, immunoglobulin A and some other lipophilic substances in vesicles (exocytosis) exists, but obviously plays a minor role [21]. This vesicular transport is directed from the endoplasmic reticulum to the Golgi apparatus and further to the canalicular hepatocyte membrane, within which the vesicles melt and release their content into bile.

Bile Acid Dependent Bile Secretion

Bile acid concentration in the hepatocyte is approximately 5 μM, while in bile it is more than 1,000 μM. Therefore an active transporter system must exist, which pumps bile acids against a high concentration gradient into the bile canaliculi. Up to now two bile acid transporters have been described. The first is the MRP₂-transporter, which is also called cMRP (canalicular multidrug resistance protein) or cMOAT (canalicular multispecific organic anion transporter) [13]. This transporter enables the transmembraneous passage of lipophilic compounds as glutathione conjugate, as glucuronate or sulfate. It also transports sulfated tauro-lithocholic acid (Fig. 7.11). Probably this transporter

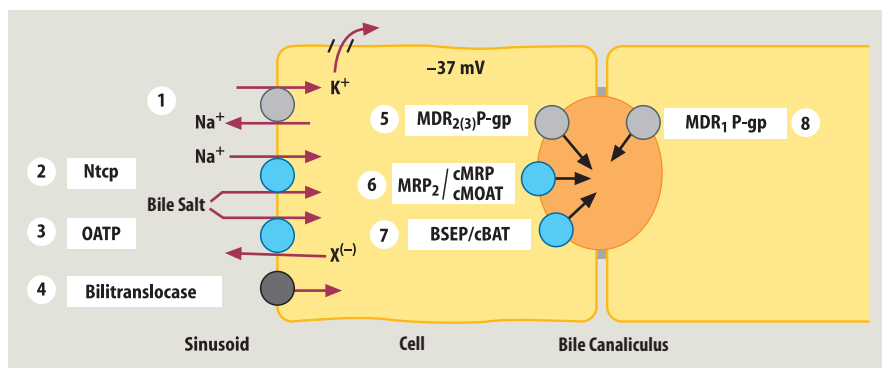


Fig. 7.11 Transport systems on the basolateral (sinusoidal) and canalicular hepatocyte membrane. (1) Na⁺/K⁺ pump, (2) Ntcp: sodium dependent bile acid cotransporter, (3) OATP: sodium independent transporter of bile acids, bromosulphophthalein, estrogen conjugates, ajmalin, and other organic anions, (4) Bilirubin transporter: one of several bilirubin transporters, (5) MDR₂₍₃₎

P-gp: transporter of phosphatidylcholine (lecithin), (6) MRP₂: glutathione, glucuronate, and sulfate transporter, including transport of sulfated lithocholic acid and glucurosonyl-hyodeoxycholic acid, (7) BSEP: bile salt export pump, transporter of monoanionic bile salts, (8) MDR₁P-gp: transporter of lipophilic cations, such as glucosyl-ceramide.

Table 7.5 Molecular mechanisms of bile formation and secretion

Absorption at the basolateral hepatocyte membrane
NTCP: sodium-taurocholate cotransporter: conjugated bile acids, sulfated steroids, sodium
OATP2: organic anion transporting polypeptide: unconjugated bile acids, bilirubin, other organic anions (belongs to the sodium-independent superfamily of organic anion transporters)
Secretion at the canalicular membrane (ATP-dependent export pumps, or ATP-binding-cassette-transport proteins, or superfamily of the ABC-transporter)
BSEP: bile salt export pump: conjugated bile salts, C, CDC, DC
MRP ₂ : multidrug resistance associated protein 2: bilirubin-diglucuronide, glutathione, divalent bile acid conjugates, and other conjugated organic anions
MDR ₃ : multidrug resistance P-glycoprotein 3: flippase, flips PLP from the inner to the outer canalicular membrane
AE2: chloride–bicarbonate anion exchanger: in the apical membrane of hepatocytes and bile duct epithelial cells
CFTR: cystic fibrosis transmembrane conductance regulator: chloride channel

is most responsible for the bile acid independent fraction of choleresis. The second bile acid transporter is the BSEP (bile salt export pump) or cBAT (canalicular bile acid transporter). BSEP transports mono-anionic bile acids, for instance taurocholic acid (TCA). Other substrates than bile acids have not yet been described for this transporter, therefore it is mainly responsible for the bile acid dependent bile flow (Table 7.5).

There is also a membrane located transporter system for phospholipids, the so-called MDR-2(3)-P-glycoprotein, which especially transports phosphatidylcholine (lecithin) [6]. The MRP₂-transporter also transports conjugated bilirubin, leukotrienes, cytostatics and ceftriaxone. For further transporter systems see Table 7.5 and Fig. 7.11.

All three transporters mentioned are ATP-dependent. Since the hydrolytic cleavage of ATP occurs by the transporter itself, it is also called transport-ATPase. The group of ATP-dependent transporters is also called ABC-proteins (ATP-binding-cassette). Some other transporters and ion channels, for instance for chloride, are important for bile secretion.

Bile secretion is favoured by the negative membrane potential of -37 mV , which is maintained by the Na^+/K^+ -pump and K^+ -excretion through K^+ -channels. In contrast to bile acid transporters which enable a 100-fold increase of concentration in the bile canaliculus, the negative membrane potential increases concentration by only threefold.

Bile acid dependent bile secretion mainly occurs in the periphery of the liver lobule which explains the high first-pass clearance of bile acids in this zone. Consequently, the more centrally located hepatocytes are deprived from bile acids, reducing bile acid dependent secretion in this area. Because these hepatocytes

also have the full set of transporters, however, under pathologic conditions they can take on task of periportal hepatocytes.

Bile flow is directly correlated with bile acid secretion. So-called hypercholeric bile acids, such as ursodeoxycholic acid, stimulate flow much stronger than would be expected according to their osmotic properties. This supports the notion that HCO_3^- formation and secretion into bile ducts plays an important additional role (see paragraph on “Bile Formation in the Bile Ducts”). This also means that choleresis induced by hypercholeric bile acids not only derives from hepatocytes but also from bile duct epithelial cells.

Bile Acid Independent Bile Secretion

Animal experiments have shown that complete deprivation of bile acids does not completely arrest bile flow, which means that bile acids are not the only driving force behind choleresis. Other substances secreted into the canaliculus must therefore also have choleric properties (Fig. 7.12). The most important compounds are glutathione (as disulphide and in conjugated form) as well as bicarbonate.

Glutathione is synthesized in the hepatocyte and can be excreted via the negative membrane potential of -37 mV or by the MRP₂ ATP dependent transporter. In the bile canaliculus glutathione is hydrolyzed by ectoenzymes (e.g. γGT) to its amino acid compounds and γ -glutamyl conjugates. These compounds have strong choleric properties.

The influence of HCO_3^- on bile salt independent choleresis is less well documented. Because in animal

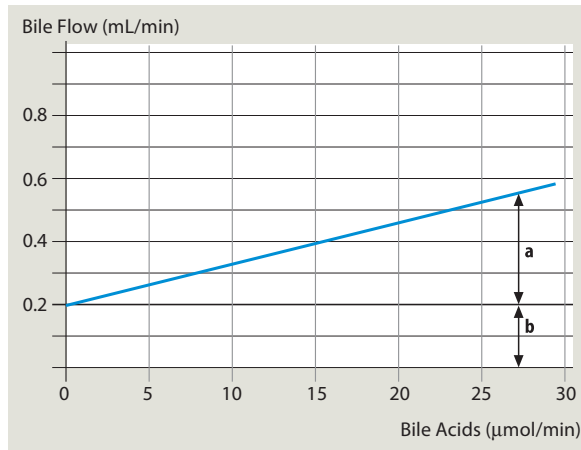


Fig. 7.12 Bile acid dependent and independent bile flow. (a) Excretion of bile acids increases commensurate to increasing bile acid secretion (bile acid dependent cholestasis). (b) Bile also flows at a rate of 0.2 mL/min without bile acid excretion (bile acid independent cholestasis)

experiments a lack of bicarbonate reduces cholestasis by 50%, however, it is believed that HCO_3^- must have an effect. It has been shown, for example, that an alkaline intracellular milieu and the presence of cAMP stimulate HCO_3^- secretion (Cl^- -exchange against HCO_3^-) at the membrane, which subsequently stimulates cholestasis. In order to maintain an isotonic and electroneutral milieu, water, cations and other water soluble substances follow the secreted osmotic compounds. Calcium is also an important substance which is found in bile in only millimolar concentrations. The role of calcium during cholestasis, however, is also poorly understood.

Ectoenzymes (γ -glutamyltransferase, dipeptidases, 5-nucleotidase, ecto-ATPase) located at the canalicular side of the cell membrane degrade several other secreted substances, thereby increasing the number of osmotic particles, which in turn increase cholestasis as well.

Influence of the Cell Structure on Bile Secretion

The cytoskeletal microtubules are made up of thick myosin filaments, keratin filaments and thin actin fibres (see Chapter 3). All of these structures participate in bile formation [14, 18]. Microfilaments form a pericanalicular network and extend into the tips of canalicular microvilli. By contracting, they gather the

canaliculus like a collar. In this situation microvilli are slim and fill the complete lumen of the bile canaliculus. When these slim filaments are damaged, for example by the toxic bile acids deoxycholic acid or lithocholic acid or by other toxins such as cytochalasin B or phalloidin, the size of the microvilli is reduced and a more amorphous, granular deposit in the pericanalicular area develops, which is referred to as ectoplasm. The bile canaliculus widens and remains dilated when microvilli are completely destroyed and cholestasis develops. Microfilaments probably participate also in the secretion of proteins and lipoproteins.

Under special conditions structures between neighbouring hepatocytes render possible the permeation of bile components through the intercellular space into the space of Disse. Between two hepatocytes three different types of connections exist: the tight junctions (zonulae occludentes), the adhering junctions (two subtypes: zonulae adherentes and desmosomes) and the so-called gap junctions (protein channels). The tight junctions seal the bile canaliculi against the intercellular space and the space of Disse. The extent of isolation depends on the protein fibers connecting the two cell membranes. The zonulae adherentes represent adhesion proteins, which connect the cell with the extrahepatic matrix. The desmosomes rivet two cells by round or oval structures at the inner side of two neighbouring cell membranes. Gap junctions are connecting channels between cells which enable the exchange of ions and macromolecules. With respect to the permeability tight junctions can be influenced.

Thus, for instance, the more apolar chenodeoxycholic acid and deoxycholic acid increase water secretion through the intercellular spaces into the gut and loosen the tight junctions between hepatocytes. Many other compounds are also able to loosen sealing between liver cells.

Functional Regulation of Bile Secretion

Regulation of bile secretion is not well understood. Morphological, chemical, physical and neurohormonal factors are involved [20].

Bile secretion is a directed active transport of osmotic compounds through the hepatocyte into bile canaliculi followed by transport of water and electrolytes trans- and paracellularly. Afterwards, continued

bile formation prevents back diffusion of primary bile into the hepatocyte or into the intercellular space, the sinusoids and general circulation.

Bile flow is not only regulated by cell structures, as mentioned above, but also by the already described transporter systems, by cyclic adenosine monophosphate (cAMP), by protein kinase C, calcium ions, the grade of hydration of the cell, and by neuropeptides and hormones.

Back diffusion of biliary substances into the hepatocyte is difficult to differentiate from retained substances. The transporter systems shown in Fig. 7.11 are not known to exert a bidirectional activity, but this also cannot be excluded.

cAMP increases bile acid dependent and independent bile flow, vesicular excretion of bile acids, and influences the microtubular system. cAMP probably also increases bile acid uptake at the basolateral cell membrane. Calcium ions inhibit choleresis and increase the permeability of tight junctions, which makes fluid exchange between bile canaliculus and the space of Disse possible. Since the more apolar monohydroxylated bile acids increase cytosolic calcium concentrations by liberating

calcium from the intracellular depots and an augmented uptake into the cell, it favours cholestasis. Protein kinase C is involved in all three transport mechanisms of bile acids: it inhibits the sinusoidal uptake, the canalicular secretion, and exocytosis. Under the influence of calcium, protein kinase C probably stimulates exocytosis.

Swelling of the hepatocyte increases bile secretion, while cell shrinking reduces it. Vagal activity stimulates choleresis via ductular HCO_3^- secretion, and, via the same mechanism, secretin increases and somatostatin inhibits bile flow.

Enterohepatic Circulation of Bile Acids

Enterohepatic circulation denotes the cycle by which bile is first secreted by the hepatocyte into the bile canaliculi, transported through the bile ducts, reabsorbed in the intestinal tract, transferred by portal venous blood to the liver, taken up and metabolized by hepatocytes, and then secreted once again (Fig. 7.13). The term bile acid pool is used to refer to the total

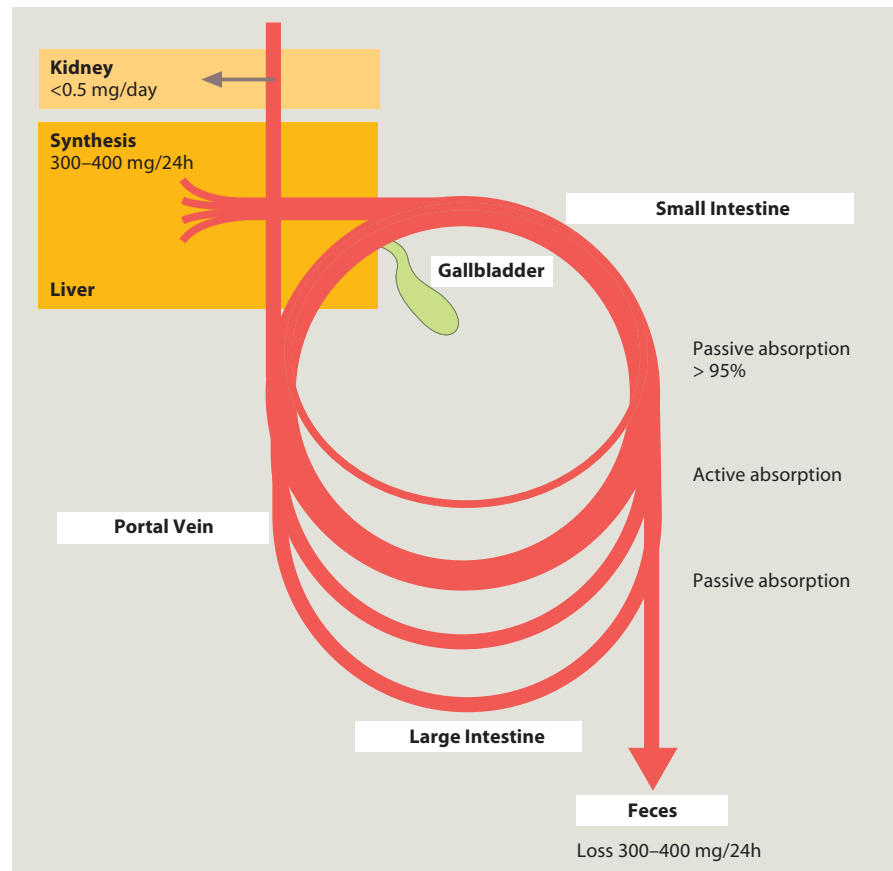


Fig. 7.13 Enterohepatic circulation of bile acids

amount of bile acids in the organism. In a healthy person the bile acid pool amounts to 4 g, the greatest part of which during fasting is located in the gallbladder. The half-life time of circulating bile acids is 2–3 days.

The system described above has two pumps. One of these pumps is located at the sinusoidal and canalicular hepatocyte membrane, and the other at the luminal and vascular side of enterocyte. There are two reservoirs: one is in the gallbladder and the other in the upper small intestine [10]. During meals the gallbladder contracts approximately two times (or sometimes continuously during an opulent meal) while the sphincter of Oddi relaxes. Therefore bile rapidly enters the intestine and rapid bile acid circulation is possible. After a meal, the gallbladder relaxes, the sphincter of Oddi's basal pressure is restored, and bile is collected and stored in the gallbladder. Under physiological conditions approximately 50% of bile bypasses the gallbladder without entering the organ.

Bile acids are reabsorbed in the jejunum only in small amounts, mainly passively. Active transport in the jejunum is weak and predominately seen for conjugated dihydroxy bile acids. Conjugated bile acids are unable to be reabsorbed due to their molecular size.

In the terminal ileum more than 90% of circulating bile acids are reabsorbed and only 10% pass into the colon. The actively reabsorbed bile acids are predominately conjugated bile acids. The bile acid transporter is a sodium dependent co-transporter, located in the apical cell membrane of the enterocyte. Although the IBAT (ileal bile acid transporter) or apical membrane sodium dependent bile acid transporter (ASBT) has already been cloned we do not know much about this system. Similar to the uptake of bile acids in the liver, active bile acid reabsorption in the intestine shows saturation kinetics and therefore can be inhibited competitively in a sodium dependent manner. At the basolateral domain of the enterocytes bile acids are extruded into portal blood by the organic solute transporter OST- α /OST- β . Recently it has been shown that bile acids bind to the nuclear bile acid receptor farnesoid X receptor (FXR) encoding the human genes of OST- α / OST- β [3, 7, 15, 19]. Bound to FXR, they repress the transcription of the gene encoding cholesterol 7 α -hydroxylase, the rate limiting enzyme in bile acid synthesis [4]. Simultaneously they activate the gene encoding intestinal bile acid binding protein (IBABP), which is an intracellular bile acid transporter. Thus bile acids may adjust the rate of their own efflux.

Free, unconjugated bile acids are not only reabsorbed in the jejunum and ileum, but all throughout the

intestinal tract by passive diffusion. Polarity of bile acids, depending on the pH of the intestinal content, is the most important aspect during this process. Furthermore, oxo derivatives and some bacterial degradation products of bile acids are reabsorbed in smaller amounts, which are of no significance because they are reconstructed to the original compound in the liver.

Bile acids which entered the area around the cecal valve or the cecum and the distal part of the colon are completely deconjugated, while dehydroxylation is possible only by bacteria of the colon. Dehydroxylation at C7 of the steroid ring system of cholic acid leads to the formation of deoxycholic acid (3 α ,12 α -dihydroxycholic acid, DCA) and of chenodeoxycholic acid to lithocholic acid (3 α -monohydroxycholic acid, LCA). Since both bile acids have lost their hydroxyl group and become more apolar (and therefore more lipophilic), they are more toxic than their precursors. Approximately half of deoxycholic acid is reabsorbed passively in the colon, the fraction of absorbed lithocholic acid being less. Sulfated and glucuronidated bile acids are not reabsorbed in the intestine, but rather they are excreted via the stool (detoxification). The daily loss of bile acids with the stool amounts to approximately 300–500 mg; this amount is fully resynthesized in the liver.

After reabsorption from the intestine, bile acids are nearly completely bound to albumin in the portal blood and re-transported to the liver. Fewer than 10% are bound to lipoproteins, especially to HDL, and less so to LDL. The distribution depends on the hydrophilicity. Hydrophobic bile acids more often bind to albumin; as they become even more hydrophilic, they bind more to lipoproteins. Ninety-eight percent of the less water soluble dihydroxylated bile acids are bound to albumin, whereas this is the case for only 70–75% of the more hydrophilic trihydroxylated bile acids and UDCA. Bile acid concentration in the portal tract (20 μ M) is six to ten times greater than in the general circulation.

Bile Acid Uptake into the Hepatocyte

While bile acid synthesis occurs mainly in the center of the liver lobule, bile acid uptake from the portal blood mainly occurs in the lobular periphery. The maximal velocity of bile acid uptake is high and it is not the rate limiting factor for bile acid transport from the sinusoidal blood into the bile canaliculi. The first-pass-clearance for cholic acid is approximately 90%, and 75–89% for chenodeoxycholic acid, deoxycholic and ursodeoxycholic

acid. First-pass clearance for lithocholic acid is only 40–50%. Bile acid secretion at the canalicular side is the rate-limiting step for this process.

Only a small amount of bile acids enters the systemic circulation. Plasma concentration of bile acids in the fasting period is therefore only 3–4 μM , and after a meal is 6–12 μM . Since trihydroxylated and conjugated bile acids are reabsorbed from the portal blood by the hepatocyte more rapidly, in the systemic circulation we therefore find predominately dihydroxylated and unconjugated bile acids. Bile acids bound to albumin in the systemic circulation can to a lesser extent also be excreted by the kidneys. Urine concentrations of bile acids, however, are rather low because most of the bile acids are reabsorbed in the renal proximal tubules by the bile acid transporter IBAT (same name as in the intestine).

The sinusoidal uptake of bile acids into the hepatocytes occurs by Na^+ -dependent (ASBT, NTCP) and Na^+ -independent mechanisms (OATP2) [8, 23]. Both transporters have already been cloned in rat and in man. In addition to a transporter dependent uptake for unconjugated bile acids a passive, nonionic diffusion exists, but plays a minor role and probably is important only for ursodeoxycholic acid and cholic acid.

Na^+ -Dependent Bile Acid Reabsorption

Conjugated, and to a smaller extent unconjugated bile acids are predominantly reabsorbed by a Na^+ -dependent transporting system in the hepatocyte. This ASBT-, NTCP-system (Na^+ -taurocholate cotransporting polypeptide)

is located at the basolateral membrane of the hepatocyte (Figs. 7.11 and 7.14). The uptake of Na^+ is associated with the uptake of one molecule of a bile acid. The driving force is an intracellular Na^+ -deficit, which is maintained by Na^+/K^+ -ATPase. Three sodium ions are pumped out of the cell and two potassium ions are taken up.

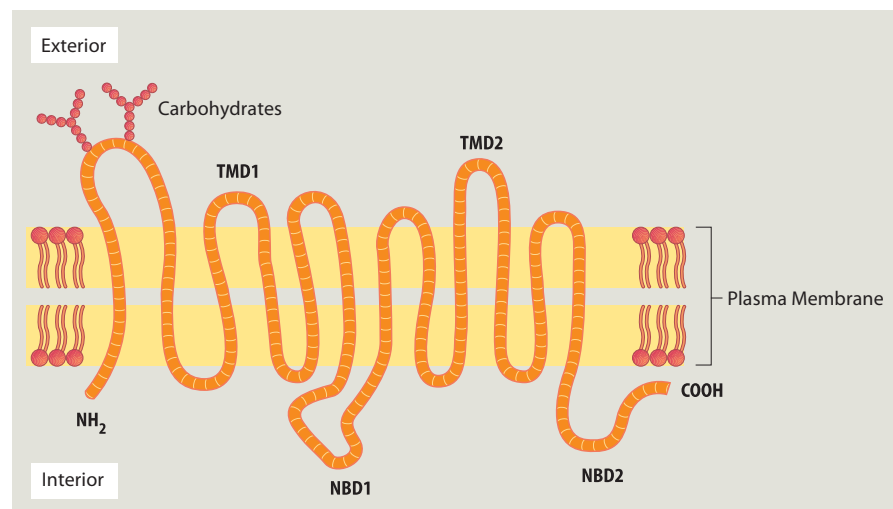
Na^+ -Independent Bile Acid Reabsorption

The sodium independent bile acid transport into the hepatocyte in part is performed by the organic anion transporting polypeptide (OATP2). OATP2 transports a great number of amphiphatic, organic substances, such as bile acids, bromosulphthalein, estrogen conjugates, ouabain and ajmalin. The transporter probably represents something like a sinusoidal “overflow system” because it is also able to transport several organic substances from the hepatocyte into the space of Disse (bidirectional transporter). This mechanism would prevent accumulation of toxic substances in the hepatocyte.

Transcellular Bile Acid Transport

The transcellular bile acid transport depends on bile acid supply. Under physiological conditions this mainly occurs by means of binding proteins, in the case of a surplus of substrate also in vesicles. This means that bile acids within the hepatocyte do not exist

Fig. 7.14 Schematic representation of an ATP-cassette transporter. NBD: nucleotide-binding domains (bind ATP, regulate function), TMD: transmembrane domains (substrate specific)



as free molecules. Up to now three transport proteins have been identified. The most important seems to be the Y-binding-protein. It belongs to the family of polypeptides, which also bind steroid hormones (estrogens), hormones of the thyroid gland and heme. Also, the hepatic fatty acid binding protein (H-FABP) is able to transport bile acids, but probably plays a minor role. Subunits of the glutathione-S-transferase also bind to bile acids as well as to bilirubin and other organic anions, but are also of minor importance.

In addition to the protein mediated transcellular bile acid transport a vesicular transport exists. If there is a surplus of bile acids small vesicles form at the sinusoidal membrane of the hepatocyte, migrate to the endoplasmic reticulum, the Golgi apparatus, and from there to the bile canaliculus. ATP provides the energy for bile acid transport. The migration of bile acid containing vesicles to the lateral cell membranes has not been observed. Investigations with radioactive bile acids have demonstrated that the transcellular transport from the sinusoid to the canaliculus can occur in seconds to minutes.

Bile acids, reabsorbed from the portal blood are rehydroxylated and reconstituted in the hepatocyte. Deoxycholic acid (DCA), the degradation product of cholic acid, and lithocholic acid (LCA), the degradation product of chenodeoxycholic acid, are handled in a different way. DCA is conjugated with glycine or taurine and then again circulates together with primary bile acids, while the toxic LCA is also reconstituted, but in addition is sulfated at C3 of the steroid ring system. After secretion into the intestine it is not reabsorbed, but rather is excreted via the stool (detoxification).

Pathological Alterations of Bile Acid Metabolism

Lithogenic Bile

Due to their molecular structure bile acids are amphiphilic, which means they are water soluble and insoluble simultaneously. Bile acid molecules have a hydrophobic “back” and a hydrophilic lower side (Fig. 7.15). Bile acids are surface active. In water they spread on the surface with the hydrophilic groups of the molecules stretching into the water and the hydrophobic part into air (Fig. 7.16). With the addition of more bile acids (up to a concentration of 1–5 mM),

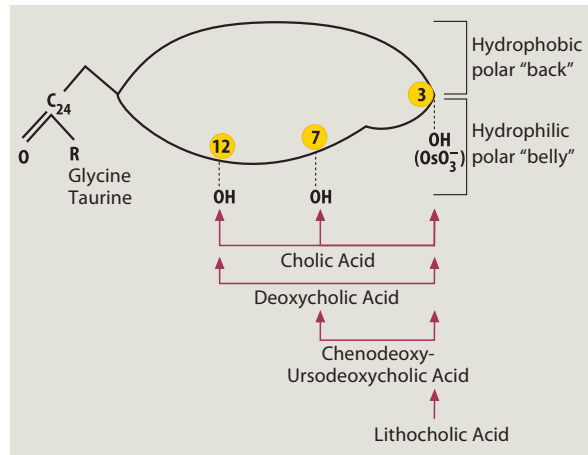


Fig. 7.15 Spatial representation of the physiologic bile acids of man accounting for the hydrophobic and hydrophilic part of the molecule

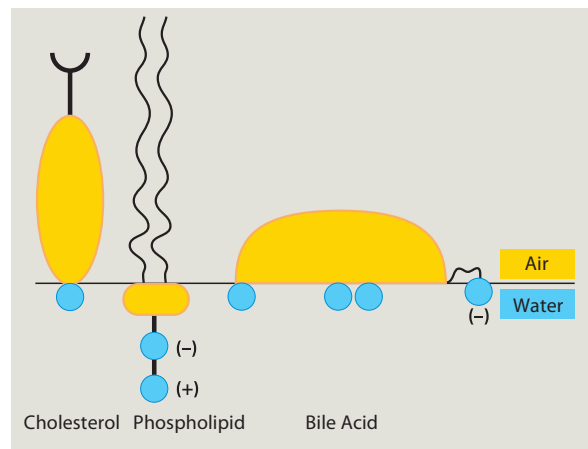
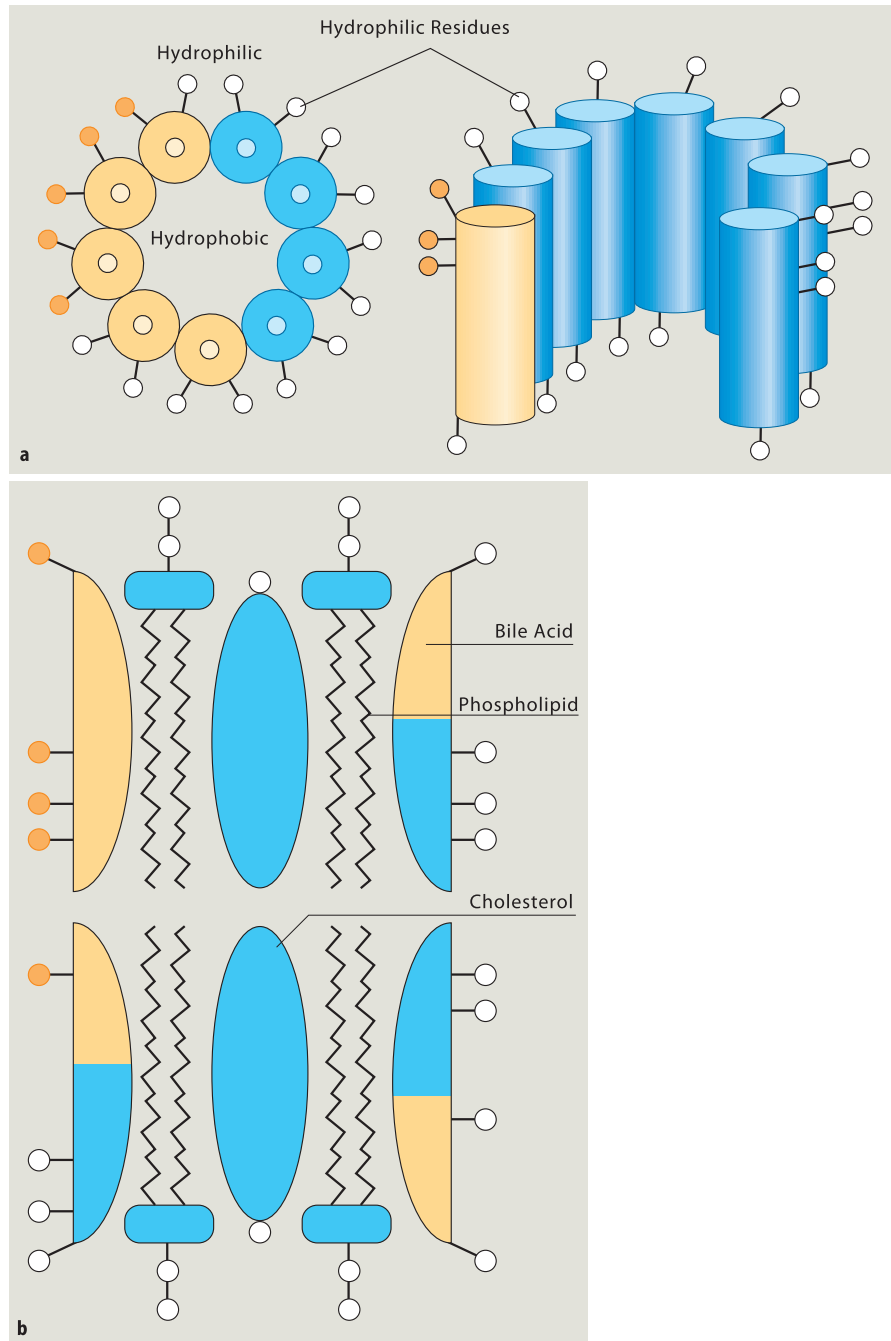


Fig. 7.16 Alignment of bile lipids at the water–air interface

micelles are formed, which are cylinder-shaped molecular aggregates invading the watery milieu (Fig. 7.17). This concentration of bile acids is called the *critical micellar concentration* (CMC). Simple bile acid micelles consist exclusively of bile acids, in which the hydrophilic parts (hydroxyl-, phosphate groups) stretch into the water and the hydrophobic part of the molecules, mainly the steroid ring systems, into the interior of the micelle. In the hydrophobic interior they are able to transport cholesterol or other hydrophobic compounds, such as fat soluble vitamins or monoglycerides. Simple bile acid–cholesterol–micelles have a size of 2–3 nm and are thermostable. Excellent micelle-forming bile acids are cholic acid and chenodeoxycholic

Fig. 7.17 (a) Longitudinal and transverse section through a bile acid micelle. (b) Mixed bile acid, phospholipid, cholesterol micelle

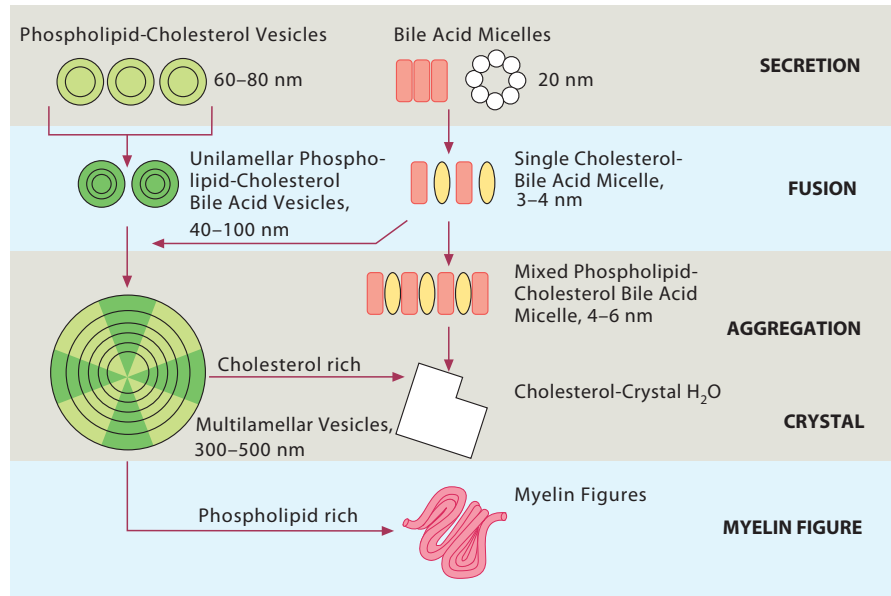


acid, and to a much lesser extent deoxycholic acid, ursodeoxycholic acid and lithocholic acid.

Cholesterol is nearly water insoluble; nonetheless, its concentration in bile is approximately 10 million times higher than in water due to the fact that it is incorporated into several transport systems, such as micelles. While biliary phospholipids are excreted into the bile

canaliculus by means of the MDR-2 (3)-P-glycoprotein-transporter, the excretory mechanism for cholesterol is unclear. At the canalicular cell membrane cholesterol together with phospholipids forms vesicles measuring 60–80 nm in size, located in the lumen of the bile capillary (Fig. 7.18). These vesicles are integrated into bile acid micelles. Twenty to 130 bile acid molecules are

Fig. 7.18 Biliary transport of cholesterol in vesicles, micelles and liquid crystals



required to dissolve one molecule of cholesterol. Micellar dissolution capacity of bile acid micelles is increased two to threefold by incorporation of phospholipids. This type of micelle is called a *mixed micelle* (bile acid–phospholipid–cholesterol–micelle), which has a size of 4–6 nm. Micellar solutions of cholesterol are thermodynamically stable, which means that cholesterol remains dissolved.

Unilamellar vesicles, consisting only of phospholipids and cholesterol, are formed when the concentration of cholesterol in bile increases to a point that the capacity of bile acid micelles to dissolve cholesterol becomes overwhelmed (Fig. 7.19). This surplus of cholesterol can result from an increase in hepatic synthesis (HMG-CoA reductase), an increased activity of transporters, or a reduced excretion of bile acids into bile. Unilamellar vesicles have a high transport capacity for water insoluble compounds. The size of unilamellar vesicles is 40–100 nm. These mixed vesicles are more thermodynamically unstable when compared to micelles. If bile acid concentration increases again, cholesterol can migrate from the vesicles back into the more stable micelles [5]. Immediately after secretion of the different components into bile there is no thermodynamic equilibrium. Due to the uptake of water by the gallbladder mucosa, equilibrium is reached only after hours or even days.

When unilamellar vesicles fuse or aggregate, multilamellar vesicles are formed which are also called *liquid crystals* or *liposomes*. These liposomes are thermodynamically unstable. From the 500 nm liposomes

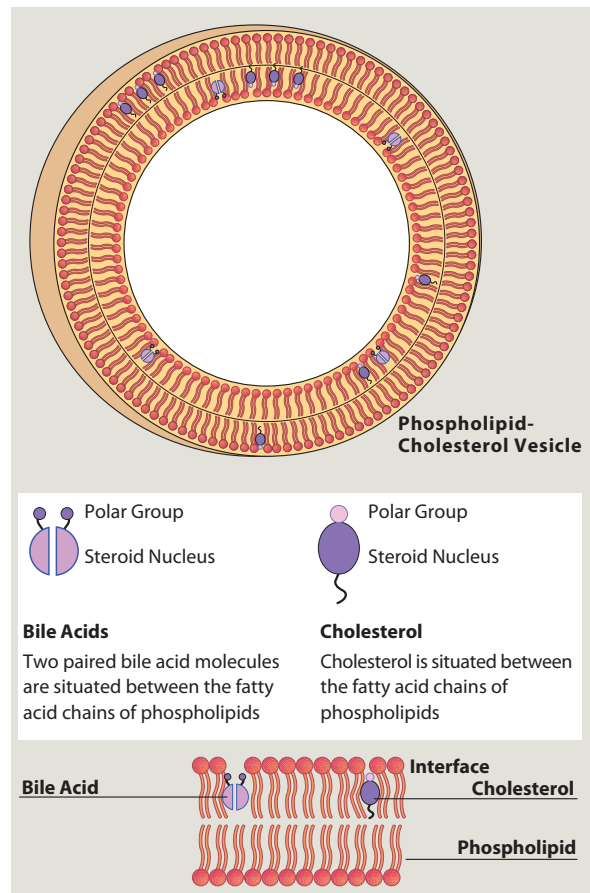


Fig. 7.19 Unilamellar phospholipid vesicle with high transport capacity for phospholipids and cholesterol

cholesterol crystals can develop which can grow by apposition of cholesterol to larger crystals [11, 21]. This additional cholesterol originates from oversaturated unilamellar vesicles or from oversaturated mixed micelles (Fig. 7.18). Phospholipids liberated from vesicles during the process of fusion are taken up by micelles. If phospholipids dominate in these micelles, so-called *myelin figures* develop.

Bile supersaturated in cholesterol is the predisposition for the development of cholesterol gallbladder stones (see Chapter 112) [22].

Cholestasis

The term “cholestasis” can be used as a symptom, sign, or description of a pathophysiologic process, but it should not be used as a final diagnosis as it lacks specificity. It may have extra- or intrahepatic causes (see Chapters 26 and 52).

Bile Acid Metabolism During Extrahepatic Cholestasis

During cholestasis bile acids accumulate in the hepatocyte and enter the sinusoids via the intercellular space. Therefore serum concentrations of bile acids increase multifold. Intracellularly, C3-sulfated bile acids are

increased, especially sulfates of the amidated chenodeoxycholic acid. Sulfated bile acids are excreted by the kidneys. To a smaller extent during cholestasis, C₆-hydroxylated bile acids also are created, such as hyocholic acid (3 α , 6 α , 7 α trihydroxy-cholic acid, CMC 6mM).

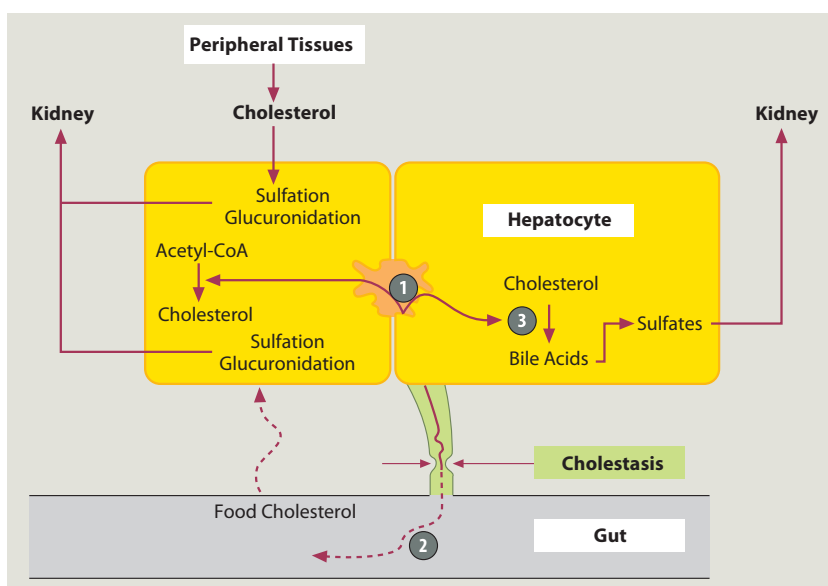
Intracellular accumulation of bile acids is associated with the reduction of bile acid synthesis (negative feedback of the 7 α -hydroxylase) and by negative feedback of the HMG-CoA-reductase. Because of the decrease in bile acid concentrations in the small intestine, the uptake of dietary cholesterol is also reduced. Now the only source for cholesterol originates from peripheral tissues. In the case of complete cholestasis, excretion of cholesterol occurs after sulfation and glucuronidation, via the kidneys (Fig. 7.20).

Since secretion of bile acids into bile capillaries also influences secretion of phospholipids, cholestasis also influences phospholipid metabolism. Excretion of phospholipids during cholestasis most likely occurs by exocytosis into the sinusoids. If these vesicles include albumin and lipoprotein, they are called lipoprotein X.

Bile Acid Metabolism During Intrahepatic Cholestasis

In parenchymal liver disease bile acid metabolism can be disturbed; nevertheless, excretion into bile remains an important mechanism. In most liver diseases bile

Fig. 7.20 Metabolism of cholesterol and bilirubin in cholestasis. *Cholesterol metabolism*: retained bile acids inhibit HMG-CoA-reductase (1) with consequent decrease in cholesterol synthesis. Intestinal cholesterol absorption is diminished due to a deficiency of bile acids in the gut lumen (2). Cholesterol is excreted via the kidneys. *Bile acid metabolism*: retained bile acids inhibit 7 α -hydroxylase (3). Bile acids are excreted via the kidneys.



acid synthesis is likely reduced and renal excretion increased. In patients with liver cirrhosis the C_{12} -hydroxylation seems to be disturbed, as suggested by the reduction of cholic acid synthesis. In patients with an acute liver dystrophy, bile acid uptake, the conjugation with glycine or taurine, biliary secretion, as well as neogenesis from cholesterol are all nearly absent. In these cases, the most important steps of biotransformation of cholesterol are likely blocked: i.e. conjugation, hydroxylation and oxydoreduction.

Cholestasis Caused by Toxic Bile Acids

Monohydroxylated bile acids such as lithocholic acid (LCA), which develops from chenodeoxycholic acid by bacterial degradation in the intestine, have cholestatic properties [12]. Three aspects have been described: (1) tauroolithocholic acid and LCA are like other apolar bile acids, which are less water soluble and precipitate in bile canaliculi or smaller bile ducts, (2) LCA influences the bile acid independent bile flow, and (3) as a hydrophobic and strongly lipophilic bile acid LCA dissolves phospholipids and cholesterol from biomembranes (Fig. 7.21) [16]. Through these processes, not only membrane structure but also membrane functions are being disturbed. But since similar effects could be demonstrated in animal experiments with water soluble derivatives of monohydroxylated bile acids, the hydrophilic/lipophilic-hypothesis probably is not the only explanation for the cholestatic effect of apolar bile acids. Calcium homeostasis, for example, has also been investigated because of the high affinity that cholestatic bile acids have for calcium. Lithocholic acid and tauroolithocholic acid, for instance, increase the cytosolic calcium concentration by liberation of Ca^{++} from cell depots and by increasing the influx from the pericellular space. Calcium is able to reduce bile secretion.

Cholestasis is accompanied by a decrease in the Na^+/K^+ -ATPase-activity on the sinusoidal cell membrane of the hepatocyte, while the Mg^{+} -ATPase of the canalicular membrane is not affected. Simultaneous application of cholestatic monohydroxy bile acids and choleric di- or trihydroxy bile acids, especially of ursodeoxycholic acid, prevents cholestasis and prevents inhibition of enzyme activity. Therefore UDCA

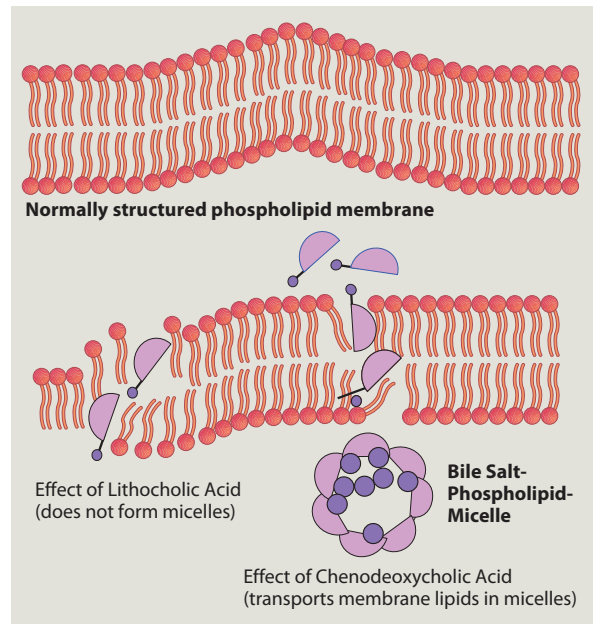


Fig. 7.21 Bile acid-induced membrane injury

is used for the treatment of primary biliary liver diseases, although the true effect of UDCA in biliary diseases is complex and not well understood.

Cholestatic monohydroxy bile acids may also be synthesized in the liver. In the case of a less functioning endoplasmic reticulum, in which usually biosynthesis of bile acids starts with 7α -hydroxylation of the steroid ring system, shortening of the aliphatic side chain can occur in the mitochondria. 3β -hydroxy- δ 5-cholenic acid is formed, which in turn develops into lithocholic acid and allolithocholic acid. 3β -OH- δ 5-cholenic acid and allolithocholic acid are as toxic as enteral LCA. This metabolic pathway usually is restricted to the period of fetal development. However, it becomes reactivated in adults in cholestasis.

One of the most important questions regarding cholestatic bile acids remains unanswered: do they, *in vivo*, truly reach toxic concentrations? [17] One factor that may have an important impact is time, i.e. the duration of exposure to varying levels of toxic bile acids. For example, low toxic bile acid concentrations over a longer period may have similar effects to higher concentrations during a short period. Additionally, it remains to be determined whether toxic bile acids in

lower concentrations are able to “aggravate” toxic effects of other hepatotoxic compounds.

Genetic Disturbances of Bile Acid Metabolism

Hereditary disturbances of bile acid metabolism influence bile acid transport, biosynthesis and biotransformation (see also Chapter 85). At present, convincing data concerning genetic alterations of bile acid uptake at the sinusoidal cell membrane, the transcellular transport and the passage through the intestine are not available. In the autosomal recessive Byler’s disease (progressive familial intrahepatic cholestasis; PFIC 1–3), we find, for instance, high concentrations of hepatocellular and serum bile acids but biliary concentrations are rather low. This observation suggests that canalicular dysfunction may play a prominent role. By electron microscopy, for example, alterations of the microtubuli and bile duct degeneration have been detected. Dysfunction of BSEP or of MRP₂-transporter may also be present, as has also been described in primary biliary liver diseases. For clinical findings and symptoms of hereditary intrahepatic cholestasis syndromes see Table 85.1.

If one considers that 10 different enzymes are involved in the synthesis of bile acids from cholesterol, one would expect disturbances of bile acid synthesis to be more prevalent. Enzyme defects of bile acid synthesis probably are responsible for approximately 2–5% of cholestatic liver diseases during childhood. Most of these diseases are associated with a deprivation of primary bile acids in bile and a simultaneous increase of atypical compounds. Clinically, cholestasis develops accompanied by an increase of serum bilirubin and malabsorption for fat and fat soluble vitamins. γ -glutamyl transpeptidase level in serum, however, is normal. Treatment exists in the form of primary bile acids, such as cholic acid or chenodeoxycholic acid, occasionally administered in combination with ursodeoxycholic acid.

Disturbance of bile acid synthesis could occur at the steroid ring system, at the side chain, and theoretically also during biotransformation. A deficit of trihydroxycholestanic acid-CoA-oxidase and of the bile acid-CoA-ligase has also been observed. The observation that no alterations in the processes of glucuronidation and sulfation (“biotransformation”) have been identified suggests that these are basic phylogenetic functions of the hepatocyte.

References

1. Bissel DM (1986) Heme catabolism and bilirubin formation. In: Ostrow JD (ed) *Bile pigments and jaundice*. Marcel Dekker, New York, pp 133–56
2. Brown MS, Goldstein JL (1986) A receptor-mediated pathway for cholesterol homeostasis. *Science* 232: 34–47
3. Chawla A, Repa JJ, Evans RM, et al (2001) Nuclear receptors and lipid physiology: opening the X-files. *Science* 294: 1866–70
4. Chiang JY, Kimmel R, Weinberger C, et al (2000) Farnesoid X receptor responds to bile acids and represses cholesterol 7 α -hydroxylase gene (CYP7A1) transcription. *J Biol Chem* 275: 10918–24
5. Carey MC, Cohen DE (1987) Biliary transport of cholesterol in vesicles, micelles and liquid crystals. In: Paumgartner G, Stiehl A, Gerok W (eds) *Bile acids and the liver*. MTP Press, Lancaster, pp 287–300
6. Cohen DE, Leonard MR, Carey MC (1994) In vitro evidence that phospholipid secretion into bile may be coordinated intracellularly by the combined actions of bile salts and the specific phosphatidylcholine transfer protein of liver. *Biochemistry* 33: 9975–80
7. Goodwin B, Kliewer SA (2002) Nuclear receptors. I. Nuclear receptors and bile acid homeostasis. *Am J Physiol Gastrointest Liver Physiol* 282: G926–31
8. Hagenbuch B, Meier PJ (1996) Sinusoidal (basolateral) bile salt uptake systems of hepatocytes. *Semin Liver Dis* 16: 129–36
9. Hofmann AF (1990) Bile acid secretion, bile flow and biliary lipid secretion in humans. *Hepatology* 12: 17S–22S
10. Hofmann AF (1999) The continuing importance of bile acids in liver and intestinal disease. *Arch Intern Med* 159: 2647–5
11. Holan KR, Holzbach RT, Hermann RE, et al (1997) Nucleation time: a key factor in the pathogenesis of cholesterol gallstone disease. *Gastroenterology* 77: 611–7
12. Kakis G, Yousef IM (1980) Mechanism of cholic acid protection in lithocholate-induced intrahepatic cholestasis in rats. *Gastroenterology* 78: 1402–11
13. Keppler D, König J, Leier I, et al (1997) ATP-dependent transport of dianionic bile salts by the canalicular isoform of the multidrug resistance protein (MRP2/cMRP/cMOAT). In: Paumgartner G, Stiehl A, Gerok W (eds) *Bile acids in hepatobiliary diseases*. Kluwer, Dordrecht/Boston, MA, pp 129–36
14. Kunze D, Rüstow B (1993) Pathobiochemical aspects of cytoskeleton components. *Eur J Clin Chem Clin Biochem* 31: 477–89
15. Landrier JF, Eloranta JJ, Vavricka SR, et al (2006) The nuclear receptor for bile acids, FXR, transactivates human organic solute transporter-alpha and -beta genes. *Am J Physiol Gastrointest Liver Physiol* 290: G476–85
16. Leuschner U, Güldütuna S, Bhatti S, et al (1995) Cytotoxicity and membrane protection by bile acids. In: Meyer zum Büschenfelde KH, Paumgartner G, Schölmerich J (eds) *Perspectives in gastroenterology. Current facts and future trends*. Urban & Schwarzenberg, München, pp 153–64
17. Leuschner U, Schneider M, Loos R, et al (1977) Morphologic investigations on the toxicity of orally applied CDCA in the liver, gastrointestinal tract, kidney and adrenal gland of the rat. *Res Exp Med* 171: 41–55

18. Luna LJ, Hitt AL (1992) Cytoskeleton-plasma membrane interactions. *Science* 258: 955–64
19. Makishima M, Okamoto AY, Repa JJ, et al (1999) Identification of a nuclear receptor for bile acids. *Science* 284: 1362–5
20. Nathanson MH, Boyer JL (1991) Mechanisms and regulation of bile secretion. *Hepatology* 14: 551–65
21. Nies AT, Gatmaitan Z, Arias IM (1996) ATP-dependent phosphatidylcholine translocation in rat liver canalicular plasma membrane vesicles. *J Lipid Res* 37: 1125–36
22. Paumgartner G, Sauerbruch T (1991) Gallstone pathogenesis. *Lancet* 338: 1117–21
23. Stremmel W, Tiribelli C, Vylka K (1993) The multiplicity of sinusoidal membrane carrier systems of organic anions. In: Tavoloni N, Berk PD (eds) *Hepatic transport and bile secretion*. Raven, New York, pp 225–34
24. Turley SD, Dietschy JM (1988) The metabolism and excretion of cholesterol by the liver. In: Arias IM, Jacoby WB, Popper H, et al (eds) *The liver. Biology and pathology*. Raven, New York, pp 617–41
25. Vanstapel F, Blanckaert N (1988) Topology and regulation of bilirubin UDP-glucuronyltransferase in sealed native microsomes from rat liver. *Arch Biochem Biophys* 63: 216–25
26. Whitmer DI, Hauser SC, Gollan JL (1984) Mechanisms of formation, hepatic transport, and metabolism of bile pigments. In: Okuda K, Nakayama F, Wong J (eds) *Intrahepatic calculi*. Riess, New York, pp 29–52
27. Zucker SD, Storch J, Zeidel ML, et al (1992) Mechanism of the spontaneous transfer of unconjugated bilirubin between small unilamellar phosphatidylcholine vesicles. *Biochemistry* 31: 3184–92

Chapter Outline

Phase I Reactions	127
Phase II Reactions	128
Cytochrome P450 System	128
References	130

Exogenous compounds (xenobiotics) must be metabolized before they can be excreted. The biochemical transformation of xenobiotics, such as alcohol, nicotine and drugs is a prime activity of the liver. In addition to the liver, biotransformation processes occur in plasma, in the lungs, in the gastrointestinal tract and in the skin. Because of their poor solubility in water, lipophilic substances are reabsorbed in the renal tubules and are excreted only slowly by the kidneys. The elimination velocity of lipophilic compounds depends on their transformation to water soluble substances. *Hepatic biotransformation increases the polarity of xenobiotics, thereby increasing their solubility in water and enhancing their biliary and renal excretion.*

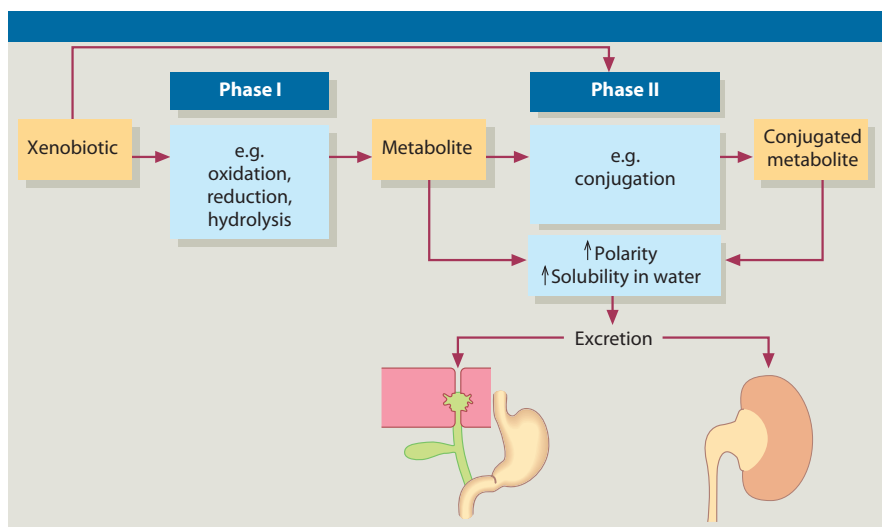
The processes of hepatic biotransformation may be divided in

- Phase I and
- Phase II reactions (Fig. 8.1 and Table 8.1)

Phase I Reactions

Phase I reactions are nonsynthetic processes, such as oxidation, reduction and hydrolysis [6]. They increase the polarity of xenobiotics. *Oxidative processes are by far the most important reactions of biotransformation.* The oxidations are catalyzed by oxidases and by mono- and dioxygenases. Oxidases remove H⁺ or electrons. Monooxygenases introduce one oxygen atom from an O₂ molecule into the xenobiotic, while the remaining oxygen is reduced to water. Dioxygenases transfer both atoms of an oxygen molecule to the foreign substance. Microsomal monooxygenases (see below) are of major importance for the oxidation of drugs.

Fig. 8.1 Biotransformation increases the polarity and water solubility of foreign compounds, thereby enhancing their biliary and renal excretion



Phase II Reactions

Phase II reactions are synthetic processes that are mostly performed by specific transferases. As a rule these reactions generate water soluble polar metabolites that are secreted by active, nonselective biliary and renal transport systems. *Conjugation reactions* prepare foreign substances or their phase I metabolites for excretion. Conjugation occurs with activated glucuronic acid (glucuronidation), activated acetic acid (acetylation), active sulfate (sulfation), amino acids, methyl residues (methylation), and glutathione. Glutathione conjugates are subjected to further metabolism before excretion. The resulting compound is mercapturic acid, a conjugate of acetylcysteine, and its derivatives, which is then excreted in the urine.

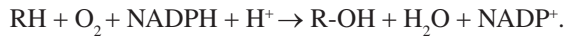
Table 8.1 Important biotransformation reactions (Adapted from [6])

Phase-I-Reactions	Phase-II-Reactions
Hydroxylation	Glucuronidation
N,O-S-Deacylation	Glycosylation
Dehalogenation	Sulfation
Alcohol Oxidation	Methylation
N,S-Oxidation	Acetylation
Aminoxidation	Condensation
Hydration	Conjugation with glutathione, amino acids, fatty acids
Reduction	
Hydrolysis	
Isomerisation	
Epoxide Formation	
Desulfation	

Generally phase II reactions reduce the toxicity of xenobiotics (*bioinactivation, detoxification*). However, the generation of toxic intermediary metabolic products during biotransformation (*bioactivation, "toxication"*) is also a well known phenomenon [6].

Cytochrome P450 System

Although xenobiotics may be metabolized in various cell compartments, e.g. cytosol and mitochondria, the majority of foreign compounds are degraded by enzymes that are localized in the membrane system of the smooth endoplasmic reticulum. After ultracentrifugation this membrane compartment corresponds to the microsomal fraction. These microsomal oxidizing enzymes are also called *mixed function oxidases* or *monooxygenases*. The microsomal enzymes catalyze conjugation reactions and most oxidations. Reductions and hydrolytic reactions occur both within and outside the microsomal fraction. The main component of the monooxygenase system is a hemoprotein called *cytochrome P450* (*CYP450*) [8, 9]. The term CYP450 derives from its ability to absorb light with a wavelength of 450nm in the presence of carbon monoxide [3]. The system was first described in 1975 by Estabrook in the surreal cortex and only then was also found to be present in the liver [4]. CYP450 serves as a terminal oxidase and uses equivalent amounts of molecular oxygen, NADPH and xenobiotic according to the following reaction:



First the xenobiotic R combines with oxidized (Fe^{3+}) CYP450 to form a binary complex. After transfer of electrons the ternary complex disintegrates, giving rise to the hydroxylated foreign compound and water, as well as regenerating CYP450.

A simplified scheme of the oxidative cycle is presented in Fig. 8.2. The oxidative cycle starts by binding of the foreign substrate to CYP450. Mediated by a flow system of electrons, water is formed and the foreign substrate is oxidized. Reduced NADP serves as the donor of electrons, whereas cytochrome c-reductase functions as an electron acceptor. One electron is used for the reduction of one oxygen atom to water, while the second oxygen atom oxidizes the xenobiotic. Since, during this reaction electrons are transferred onto molecular oxygen, occasionally, in the course of biotransformation, reactive oxygen species (O_2^- , H_2O_2 , R-OOH) are released that may expose the hepatocyte to potentially dangerous oxidative stress. CYP450 has been visualized immunocytochemically in the human liver and found to be differently expressed in various lobular

zones [1]. The centrilobular zone 3 displays the strongest CYP450-immunoreactivity, while it is less intense in zone 2. Periportal hepatocytes (zone 1) do not exhibit any CYP450-immunoreactivity at all. Thus, the zonal toxicity of xenobiotics that are metabolized by CYP450 to hepatotoxins becomes understandable, as exemplified by the centrilobular liver injury produced by CCl_4 and bromobenzole. Biliary epithelia, sinusoidal endothelial cells and Kupffer cells do not contain CYP450.

At least 20 CYP450 isoenzymes have been characterized in the human liver [7]. In addition to the microsomes, they are also present in the nuclear membrane, where they may play a role in carcinogenesis. The CYP450 isoenzymes are divided into families and subfamilies. Presently, 9 genetic families with more than 70 genes are known [5]. Their differences with regard to their activities and substrate specificities are in part genetically determined (*genetic polymorphism*). Different compounds may inhibit or induce individual isoenzymes (Table 8.2) [2, 7, 10].

These characteristics of the microsomal oxygenase system have important clinical implications for

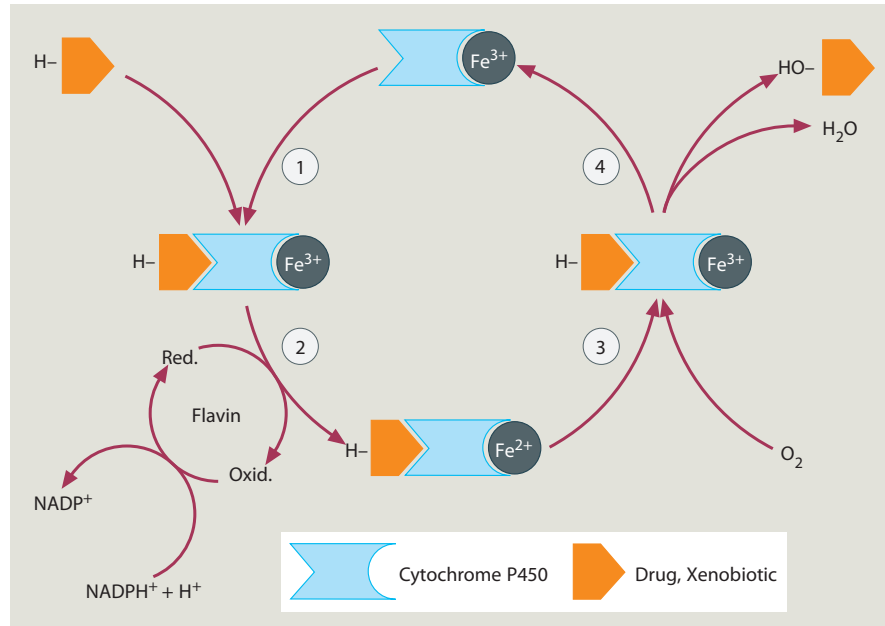


Fig. 8.2 Cytochrome P450 dependent redox-cycle. In the *first step* (1) the oxidized form (Fe^{3+}) of the enzyme combines with the reduced substrate (drug). In the rate limiting *second step* (2) the cytochrome complex is reduced by NADPH-cytochrome P450 reductase to Fe^{2+} . NADPH serves as a donor of electrons. In the

third step (3) the reduced cytochrome-drug complex reacts with molecular oxygen and forms a ternary intermediary complex. In this complex, iron is present again in its oxidized form (Fe^{3+}). In the *fourth step* (4) the ternary complex disintegrates releasing oxidized cytochrome, oxidized substrate (drug, toxin) and water

Table 8.2 Characteristic features of selected hepatic cytochrome P450 isoenzymes of man

Cytochrome P450 Family	Substrate (Selection)	Inducers (Selection)	Inhibitors (Selection)	Genetic Polymorphism
I	Caffeine	Nicotine	Chinolones	No
	Phenacetin	Paracetamol		
	Theophyllin	Omeprazole		
II C	Phenytoin	Not known	Ketoconazole	Yes
	Warfarin		Cimetidine	
	Diazepam			
	Hexobarbital			
	Omeprazole			
	Proguanil			
	Tolbutamide			
II D	Debrisoquin	Not known	Quinidine	Yes
	Dextromethorphan			
	Codeine			
	Many β -adrenergic blockers			
II E₁	Imipramine			
	Paracetamol	Phenobarbital	Disulfiram	Yes
	Ethanol	Ethanol		
III		Isoniazid		
	Cyclosporin A	Anti seizure drugs:	Ketoconazole	No
	Erythromycin		Macrolides	
	Ketoconazole	Phenytoin		
	Nifedipine	Carbamazepine		
	Lidocaine	Rifampicin		
	Estrogens	Glucocorticoids		
Midazolam				

medical drug treatment and for the interaction of drugs. If a patient receives a drug that is an enzyme inducer concomitantly with a drug that is metabolized by the CYP450 system, the dosage of the latter should be increased to achieve therapeutic plasma levels. After stopping the enzyme inducer, the dosage should be readjusted (reduced), in order to avoid overdosing. Enzyme inducers increase the effect of drugs that are metabolized preferentially by CYP450 and whose metabolic products are pharmacologically more potent than the original substance. If two drugs that are metabolized by microsomes are taken concomitantly, one substance can inhibit the metabolism of the other. If the doses are not adjusted overdose may ensue (see Section XVIII).

References

- Barnes TS, Shaw PM, Burke MD, et al (1986) Monoclonal antibodies against human cytochrome P-450. *Biochem Soc Trans* 14: 621–6
- Ernster L, Orrenius S (1965) Substrate induced synthesis of hydroxylating enzyme system of liver microsomes. *Fed Proc* 24:1190–9
- Estabrook RW, Cooper DY, Rosenthal O (1963) The light reversible carbon monoxide inhibition of the steroid C21-hydroxylase system of the adrenal cortex. *Biochem Zschr* 338: 741–6
- Estabrook RW, Martinez-Zedilio G, Young S, et al (1975) The interaction of steroids with liver microsomal cytochrome P-450 – a general hypothesis. *J Steroid Biochem* 6: 419–25
- Gonzalez FJ (1990) Molecular genetics of the P-450 superfamily. *Pharmacol Ther* 45:1–38
- Häussinger D (1996) Physiological functions of the liver. In: Greger R, Windhorst U (eds.) *Comprehensive physiology. From cellular mechanism to integration*. Springer, Publisher Heidelberg, New York, pp 1369–91
- Lipp HP, Schuler U (1995) Die menschlichen Cytochrom-P-450-Isoenzyme. *Arzneimitteltherapie* 13: 272–80
- Okey AB (1990) Enzyme induction in the cytochrome P-450 system. *Pharmacol Ther* 45: 241–98
- Omura T, Sato R, Cooper DY, et al (1965) Function of cytochrome P-450 of microsomes. *Fed Proc* 24: 1181–9
- Remmer H, Merkar HJ (1965) Effect of drugs on the formation of smooth endoplasmic reticulum and drug metabolizing enzymes. *Ann NY Acad Sci* 123: 79–83

Chapter Outline

Parenchymal Cells	131
Glucose Metabolism	133
Detoxification of Ammonium	134
Systemic pH-Regulation	135
Bile Acid Extraction.....	135
Intrahepatic Biliary Epithelial Cells	136
Nonparenchymal Cells	136
References	136

Parenchymal Cells

Along its course from the portal area to the terminal hepatic venule the sinusoidal blood encounters various populations of hepatocytes. The functional specialization of different hepatocyte populations is reflected by their different metabolic activities which lead to changes in the composition of the sinusoidal blood. Blood in the periportal sinusoids is rich in oxygen and nutrients, while blood flowing in the perivenous sinusoids is already “skimmed”. The partial pressure of oxygen falls by approximately 50% from the periportal to perivenous zone. Also, the anatomic arrangement of the sinusoids varies in different lobular zones. While the periportal sinusoids run obliquely and partly parallel to the limiting plate, amply anastomosing with each other, the centrilobular sinusoids are “stretched” and straighter, radiating toward the terminal hepatic venule. This different arrangement is reflected by the higher ratio of surface to volume density in the periportal compared to the centrilobular sinusoids. Analogous to the sinusoids, the hepatocytes are also arranged differently in various lobular domains. In the periportal zone the liver cell trabeculae are more difficult to discern. Across a span of 6–8 liver cells the periportal hepatocytes appear relatively disordered, whereas they are arranged in one cell thick trabeculae towards the terminal hepatic venule.

The relative uniformity of hepatocytes at the light microscopic level is opposed by their **structural heterogeneity** at the electron microscopic level and their **functional heterogeneity** at the metabolic level. Periportal hepatocytes are smaller than their perivenous counterparts. The volume density of mitochondria and the surface of their cristae are higher in zone 1 hepatocytes than in perivenous liver cells. Zone 1 hepatocytes contain more Golgi membranes and are richer in glycogen than zone 3 hepatocytes. On the other hand, liver cells

in zone 3 have more smooth endoplasmic reticulum and more lysosomes than periportal hepatocytes.

These differences in the content of organelles are associated with different concentrations, activities and amounts of enzymes, as well as different transport systems and membrane receptors present in hepatocytes [8, 9]. Gradients of opposing signaling molecules along the portocentral axis determine the pattern of enzymes and other proteins expressed in periportal and pericentral hepatocytes [7]. This heterogeneity causes different metabolic pathways to be distributed in different zones of the liver acinus, i.e. *metabolic zonation*. The metabolic zonation represents an important regulatory principle that avoids futile metabolic cycles and is not completely developed until the age of approximately six years. Although we do not comprehend completely the origin and causes of metabolic zonation, its knowledge is important to understand processes in liver physiology and pathophysiology [1, 3, 6]. In most cases metabolic zonation is not strict, i.e. various metabolic zones are not sharply demarcated, but rather merge dynamically. However, while the expression of some enzymes and transport systems is restricted to relatively few perivenous hepatocytes (e.g. glutamine synthase, ornithine aminotransferase and glucose transporter 1 [GLUT1]), the vast majority of metabolic

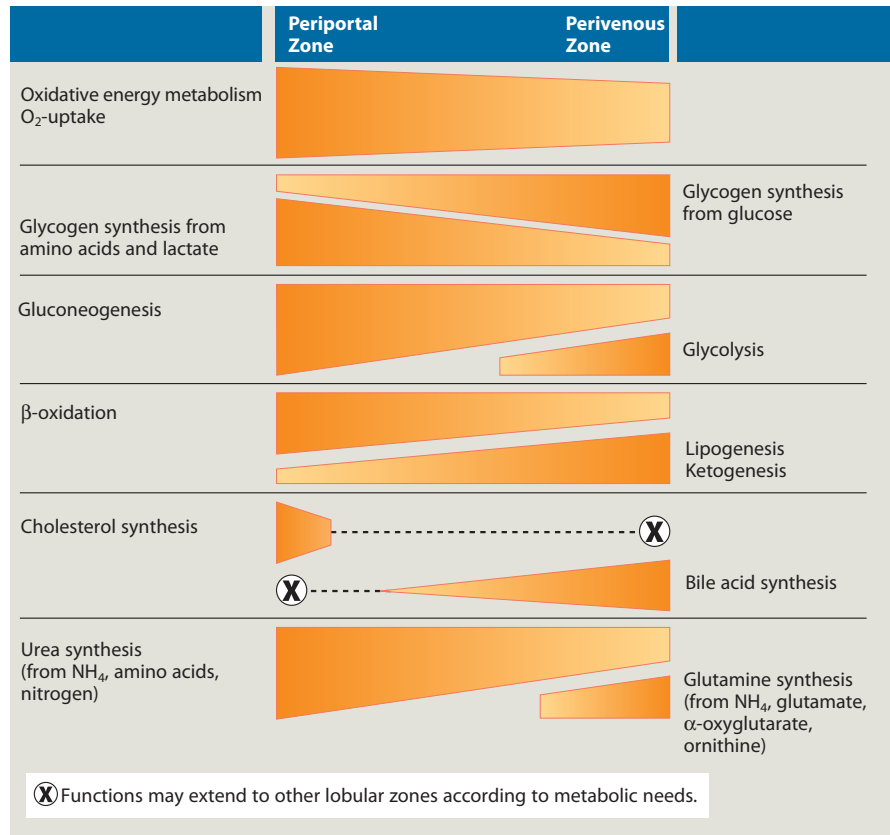
compartments display acinary gradients. The enzymes of biotransformation are expressed predominantly in perivenous hepatocytes, while glutathione peroxidase is more strongly expressed in periportal liver cells. This different expression of glutathione peroxidase is one possible reason that toxic liver injury by free radicals is more pronounced in centrilobular than in periportal areas. The oxidative iron metabolism is most intense in periportal hepatocytes, where O_2 -tension is highest and gluconeogenesis takes place. Corresponding to the zonal expression of enzymes (Table 9.1), hepatic metabolic pathways also show a zonation (Fig. 9.1 and Table 9.2). This zonation is not a static phenomenon, but rather adapts dynamically to the actual metabolic needs. Specific metabolic requirements may lead to an expansion of certain metabolic zones at the expense of others [11, 12].

What causes metabolism to segregate in acinar zones is poorly understood. Experimentally, flow reversal from the terminal hepatic venule to the portal area leads to a partial redistribution of enzymes. This supports the notion that the position of the hepatocyte in the micro-circulatory unit is important for the development of its metabolic capabilities. It is assumed that oxygen, as an acceptor of electrons in energy metabolism, plays a decisive role in the regulation of metabolic zonation. In

Table 9.1 Zonation of enzymes and transport systems in the liver lobule (Adapted from [6])

Periportal	Perivenous
Glucose-6-phosphatase	Glucokinase
Phosphoenolpyruvate carboxykinase	Hexokinase
Fructose-1,6-biphosphatase	Glucose-6-phosphate dehydrogenase
β -Hydroxybutyryl-CoA dehydrogenase	Pyruvate kinase
3-Hydroxy-3-methylglutaryl-CoA Reductase	Isocitrate dehydrogenase
Succinate dehydrogenase	Malic enzyme
Malate dehydrogenase	Citrate lyase
Cytochrome oxidase	Fatty acid synthase
Alanine aminotransferase	Acetyl-CoA carboxylase
Aspartate aminotransferase	β -Hydroxybutyrate dehydrogenase
Tyrosine aminotransferase	Alcohol dehydrogenase
Carbamoyl phosphate synthase	7 α -Hydroxylase
Ornithine-carbamoyl transferase	Glutamate dehydrogenase
Arginine-succinate synthase	Glutamine synthase
Arginase	Ornithine aminotransferase
Glutaminase	Uptake of glutamate, aspartate and dicarboxylate
γ -Glutamyl transpeptidase	Glucose-transporter (GLUT1)
Uptake of alanine, proline and serine	Cytochrome P450
Glucose-transporter (GLUT2)	Glutathione-S-transferases
Cathepsin B, H	UDP-Glucuronosyl transferases
Glutathione peroxidase	NADPH-Cytochrome P450 reductase
D-Amino acid oxidase	
Monoamine oxidase	

Fig. 9.1 Schematic representation of metabolic gradients in the liver lobule (Adapted from [3])



addition, hormones such as insulin and glucagon, varying substrate gradients (amino acids), local mediators and signaling molecules (eicosanoids, cytokines), the extracellular matrix and neural mechanisms all play a yet not well-defined role in the generation of metabolic gradients. In the final analysis, *different gene expression* in hepatocytes within the liver lobule is responsible for liver cell heterogeneity [2, 7]. Changes in the acinar microenvironment, such as different concentrations

of substrates, hormones and varying oxygen tensions in different parts of the sinusoids, may activate or repress genes. Thus, the gene for 3-hydroxy-3-methyl glutaryl CoA-reductase, the rate limiting enzyme of cholesterol synthesis, is expressed in only a few periportal hepatocytes. The expression of the key enzyme of bile acid synthesis, cholesterol 7 α -hydroxylase, as well as that of glutamine synthase and GLUT1, is restricted to a few centrilobular hepatocytes. Gene expression is subject to circadian rhythms and is mostly controlled transcriptionally by certain regulatory proteins. The regulation for GLUT1 occurs posttranscriptionally. Recent evidence suggests that the phenomenon of zonal expression of glutamine synthase is caused by a protein that interacts with the silencer element in the first intron and not by a differential expression of enhancer-binding proteins [2].

Table 9.2 Zonation of different metabolic pathways in the liver lobule (Adapted from [6])

Periportal	Perivenous
Gluconeogenesis	Glycolysis
Glycogen synthesis from amino acids and lactate	Glycogen synthesis from glucose
Oxidative energy metabolism	Fatty acid synthesis
Fatty acid oxidation	Glutamine synthesis
Ketogenesis	Transamination of ornithine
Cholesterol synthesis	Biotransformation
Uptake and degradation of amino acids (except for uptake of aspartate and glutamate)	Uptake of dicarboxylate
Urea synthesis	

Glucose Metabolism

The control of glucose homeostasis occurs through reciprocal regulation in periportal and perivenous hepatocytes. Periportal hepatocytes synthesize glucose from

gluconeogenic precursors, such as lactate, pyruvate and alanine. Perivenous hepatocytes utilize glucose for glycolysis and glycogen synthesis.

Absorptive Phase

During intestinal absorption (*net hepatic uptake of glucose*) glucose is taken up by perivenous hepatocytes. Here glucose is either metabolized via glycolysis to lactate that is then released from the liver, or used for glycogen synthesis. Periportal liver cells take up lactate and alanine, use it for gluconeogenesis, and also synthesize glycogen. Thus, glycogen synthesis occurs throughout the entire liver lobule. However, while in periportal hepatocytes glycogen is generated from gluconeogenic precursors, in other words, from newly synthesized glucose, glycogen in perivenous hepatocytes predominantly derives from preformed blood glucose.

Postabsorptive Phase

The postabsorptive phase (*net hepatic release of glucose*) is characterized by increased glycogenolysis and gluconeogenesis, and subsequent glucose release from periportal hepatocytes (Fig. 9.2). Prolonged starvation enhances the release of hepatic glucose and the periportal metabolic zone extends towards the center of the lobule. Thus, metabolic changes during the absorptive and postabsorptive phase are not a consequence of alterations in activity of the individual hepatocyte, but rather reflect shifting of metabolic processes in different acinar zones.

Detoxification of Ammonium

The concentration of NH_4 is high in the periportal sinusoidal blood and decreases towards the center of the lobule. Hepatic ammonium detoxification is carried out by two serially operating systems – *periportal urea synthesis* and *perivenous glutamine synthesis* (Fig. 9.3). Periportal hepatocytes dispose of a high capacity and low affinity NH_4 -uptake system, while perivenous hepatocytes take up NH_4 with high affinity, but have a low NH_4 -uptake capacity. NH_4 is detoxified in the periportal

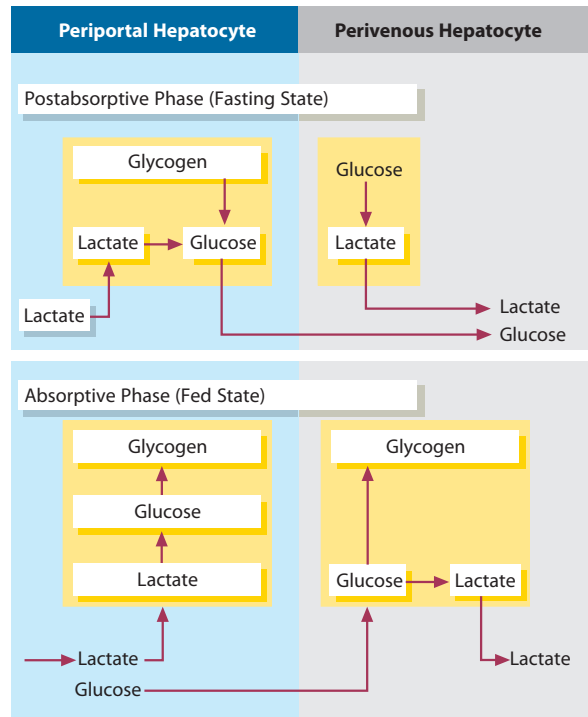
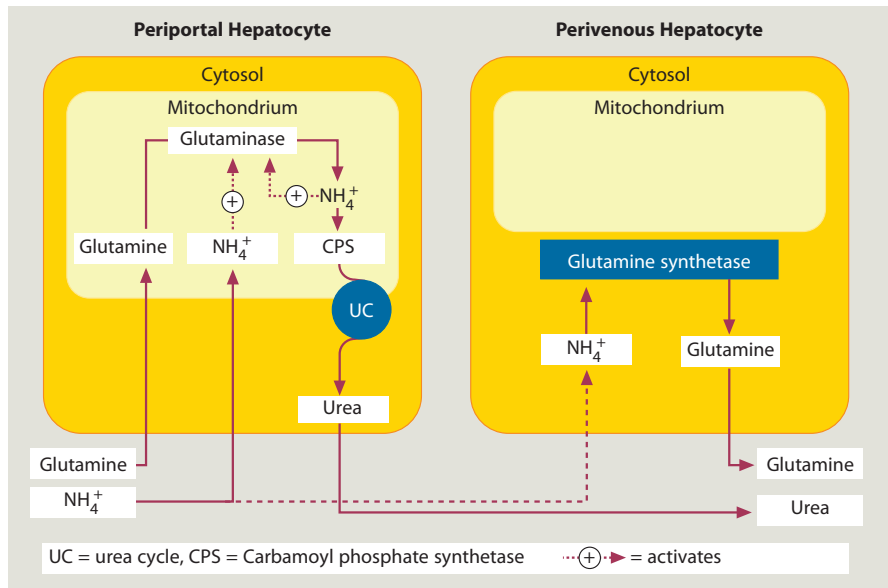


Fig. 9.2 Zonation of glucose metabolism in the absorptive and postabsorptive phase. In the *postabsorptive phase*, between meals, initially glycogen in the periportal zone is metabolized to glucose. Thereafter, it is metabolized to lactate in the perivenous zone. Lactate is released, it recirculates, is taken up by periportal hepatocytes and is used for gluconeogenesis. In the *absorptive phase* glucose bypasses the periportal hepatocytes, is taken up by perivenous liver cells and is used for glycogen synthesis. If the glycogen stores of perivenous liver cells are replete, glucose is metabolized to lactate that is then released into the circulation, recirculates and is taken up by periportal hepatocytes. Here it is converted to glycogen via prior gluconeogenesis

hepatocytes primarily by mitochondrial urea synthesis. Here the uptake of glutamine and its breakdown by glutaminase also occurs. Extracellular and intracellular NH_4 activate glutaminase. In the reaction catalyzed by glutaminase additional ammonium is provided for the urea cycle (carbamoyl phosphate synthase). Thus glutaminase supports the synthesis of urea.

Approximately 80% of NH_4 in the portal blood is metabolized to urea. Ammonium that evades periportal urea synthesis is intercepted by perivenous hepatocytes (scavenger cells) and is detoxified by the cytosolic synthesis of glutamine. While most enzymes display acinar concentration and activity gradients (see above), glutamine synthase and ornithine aminotransferase are localized strictly in a small population of perivenous

Fig. 9.3 The elimination of ammonium occurs by two serial systems: the periportal synthesis of urea (low affinity/high capacity) and the perivenous synthesis of glutamine (high affinity/low capacity). This “division of work” results from differential expression of enzymes and transport systems. Periportal hepatocytes contain urea cycle enzymes and glutaminase, but no glutamine synthase. This enzyme is present only in a small group of perivenous hepatocytes (scavenger cells) that are nearly completely devoid of enzymes of the urea cycle

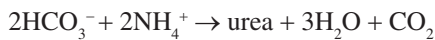


hepatocytes, directly adjoining the terminal hepatic venule. Glutamate and aspartate are taken up nearly exclusively by perivenous hepatocytes.

In the healthy liver periportal glutaminase and perivenous glutamine synthase work in concert. On the balance, glutamine is not consumed during detoxification of ammonium. Periportal glutamine breakdown with concomitant perivenous glutamine synthesis is termed the *intercellular glutamine cycle*.

Systemic pH-Regulation

The periportal urea synthesis does not only serve to detoxify ammonium, but is integrated as well in the systemic acid-base regulation [4, 5]. During urea synthesis a strong base (HCO_3^-) is neutralized by a weak acid (NH_4^+):



i.e. ***HCO₃⁻ is eliminated by the synthesis of urea.*** In metabolic alkalosis the synthesis of urea is intensified, while in metabolic acidosis it is downregulated. The elimination of HCO_3^- in the liver occurs via the urea cycle. The homeostasis of HCO_3^- is regulated by the strong dependency of glutaminase activity on the extracellular pH. In metabolic acidosis periportal

uptake of glutamine and synthesis of urea decrease, while perivenous synthesis of glutamine increases. The inhibition of the urea cycle in metabolic acidosis is explained by a marked pH-dependent decrease of glutaminase activity. Already a small decrease in pH will cause a profound reduction of the activity of this enzyme. Ammonium intoxication in metabolic acidosis is prevented by the perivenous elimination of ammonium that is mediated by glutamine synthesis.

Bile Acid Extraction

The extraction of bile acids from the sinusoidal blood resembles the elimination of ammonium (see Chapters 5 and 7). The uptake of bile acids from the sinusoids occurs by a transport system that, in the periportal area has a low affinity and high capacity for bile acids, while the reverse is true for the perivenous zone. This alignment of bile acid transporters provides for an effective extraction of bile acids from sinusoidal blood despite their diminishing concentrations from the portal to the perivenous zone. Under physiologic conditions most of the bile acids are already extracted by periportal hepatocytes. In cholestasis, periportal hepatocytes are exposed to increased amounts of bile acids. As a consequence, extraction of bile acids by perivenous hepatocytes increases accordingly.

The described functional heterogeneity does not only apply to hepatocytes, but also to the intrahepatic biliary epithelia and the nonparenchymal cells.

Intrahepatic Biliary Epithelial Cells

The intrahepatic bile ducts are lined by cholangiocytes. Their absorptive and secretory activities modify the bile flowing from the liver to the duodenum. The diameter of the bile ducts decreases continuously from the hepatic hilum to the bile canaliculi: hepatic ducts (800 μm), segmental bile ducts (400–800 μm), septal ducts (100–400 μm), interlobular ducts (15–100 μm) and bile ductuli (cholangioles; <15 μm). The absorptive and secretory processes display functional gradients along the biliary tree as is evidenced by, for example, the different ability of cholangiocytes to respond to secretin and somatostatin, and by the different expression of enzymes and membrane receptors [10]. Lipase, pancreatic α -amylase, and trypsin are expressed by the large intrahepatic bile ducts, the septal ducts and the peribiliary glands. Lewis blood group antigens are expressed by septal ducts. The antiapoptotic protein Bcl-2 is present in ductular cholangiocytes and in epithelial cells of the interlobular bile ducts, while the $\text{Cl}^-/\text{HCO}_3^-$ -exchanger (which plays a major role in ductal bile secretion) as well as secretin and somatostatin receptors are primarily expressed by larger bile ducts. The heterogeneity of cholangiocytes is also evidenced by different reaction patterns of various bile duct segments to immunologic, toxic and mechanic stimuli (see Chapter 52 and Section XIV).

Nonparenchymal Cells

Centrilobular *sinusoidal endothelial cells* are more “porous”, i.e. they have more fenestrae than periportal endothelial cells, while the endocytotic activity of the

latter is more pronounced. Periportal *Kupffer cells* are larger, more numerous, contain more lysosomes and are more active phagocytotically than Kupffer cells located in the perivenous zone. On the other hand, the cytotoxic activity of centrally located Kupffer cells is superior to that of periportal Kupffer cells. Periportal *stellate cells* are more numerous, contain more fat drops, produce more extracellular matrix and store more vitamin A compared to their centrilobular counterparts. The *pit cells* too are more numerous, and their ability to lyse tumor cells is more pronounced in the periportal zone.

References

1. Bouwens L, De Bieser P, Vanderkerken K, et al (1992) Liver cell heterogeneity: functions of non-parenchymal cells. *Enzyme* 46: 155–68
2. Gaunitz F, Deichsel D, Heise K, et al (2005) An intronic silencer element is responsible for specific zonal expression of glutamine synthase in the rat liver. *Hepatology* 41: 1225–32
3. Gebhardt R (1992) Metabolic zonation of the liver: regulation and implications for liver function. *Pharmac Ther* 53: 275–354
4. Häussinger D, Gerok W, Sies H (1986) The effect of urea synthesis on extracellular pH in isolated perfused rat liver. *Biochem J* 236: 261–5
5. Häussinger D (1992) Liver and systemic pH-regulation. *Z Gastroenterol* 30: 147–50
6. Häussinger D (1996) Zonal metabolism in the liver. In: Greger R, Windhorst U (eds), *Comprehensive human physiology*, Springer, Berlin, pp 1393–402
7. Hailfinger S, Jaworski M, Braeuninger A, et al (2006) Zonal gene expression in murine liver: lessons from tumors. *Hepatology* 43: 407–14
8. Jungermann K, Katz N (1989) Functional specialization of different hepatocyte populations. *Physiol Rev* 69: 708–64
9. Jungermann K, Kietzmann T (2000) Oxygen: modulator of metabolic zonation and disease of the liver. *Hepatology* 31: 255–60
10. Kanno N, LeSage G, Glase S, et al (2000) Functional heterogeneity of the intrahepatic biliary epithelium. *Hepatology* 31: 555–61
11. Lamers WH, Hilberts A, Furt E, et al (1989) Hepatic enzymic zonation: a reevaluation of the concept of the liver acinus. *Hepatology* 10: 72–6
12. Traber PG, Chianale J, Gumucio JJ (1988) Physiologic significance and regulation of hepatocellular heterogeneity. *Gastroenterology* 95: 1130–43

Chapter Outline

Dynamics of Hepatocellular Hydration	138
Cell Hydration and Signal Transduction	138
Regulation of Cell Function by the Hepatocellular Hydration State	138
Protein Turnover	138
Bile Formation	139
Carbohydrate Metabolism	139
Function of Nonparenchymal Cells	140
Gene Expression, Cytoprotection and Virus Replication	140
References	140

Cell volume is an independent factor that regulates physiologic cell functions. It is increasingly evident that nutrients, hormones, oxidative stress, solute transport, and other osmotic stimuli may exert their effects on liver metabolism and membrane transport using cell volume as an intermediary signal [1–6]. The terms *cell volume* and *cellular hydration* are used interchangeably, since short-term changes of cell volume are practically always caused by shifts in the cellular water content (cellular hydration). The water content of a liver cell is a dynamic parameter that may change within minutes under the influence of nutrients, hormones and inflammatory mediators. Physiologic alterations in cell hydration are generally small (up to $\pm 15\%$ of the baseline value), with effective volume regulatory mechanisms counteracting changes that exceed this physiologic range. However, there is increasing evidence that even small changes in the volume setpoint above or below the starting value constitute an independent signal for cell function and initiate signaling cascades that involve changes in cellular kinases, protein activity, and gene expression [7, 8]. The intracellular signal transduction cascades that are activated by changes in hydration are very complex and only partly understood. The same applies to the cellular structures which can sense the changes in hydration; however, in liver the integrin system serves as an osmosensor as does the endosomal compartment. The concept that hepatocyte volume serves as a signal regulating liver cell and organ function provides a new conceptual framework for modulation of liver metabolism and bile formation through effects on volume-sensitive signaling and ion channels [1, 6]. Furthermore, changes in cellular hydration are not only to be regarded as a physiologic control mechanism, but also may play a role in the pathogenesis of many diseases.

Dynamics of Hepatocellular Hydration

Almost all changes in cell hydration result from osmotic water movements across the cell membrane. The membrane is freely permeable to water. Osmotically effective concentration gradients across the cell membrane are generated either by changes in extracellular osmolarity or by altered activity of membrane bound transport systems for ions or substrates. Thus, a rise in extracellular osmolarity will lead to an osmotic flow of water out of the cell (cell shrinkage) while a hypoosmotic exposure will cause cell swelling. Although rapidly effective volume regulatory mechanisms prevent excessive changes in cell volume, they are not able to counteract these volume deviations completely and to restore the resting cell volume. The degree of the resulting deviation correlates with functional cell changes. Pathophysiologically relevant changes in extracellular osmolarity occur, for example, in hypernatremic states due to water loss or in hyponatremia caused by oversecretion of antidiuretic hormone. Under physiologic conditions, however, extracellular osmolarity is subject to only minor fluctuations, and changes in liver cell hydration are caused primarily by alterations in activity of membrane bound ion and substrate transport systems. Thus, the concentration-dependent and mostly Na^+ -dependent uptake of amino acids into the hepatocyte increases its hydration, while oxidative stress, glucagon and urea lead to the opening of K^+ -channels in the cell membrane with consequent K^+ (and Cl^-) efflux resulting in cell shrinkage. Insulin and growth factors activate the Na^+/H^+ exchanger, the Na^+/K^+ ATPase and the $\text{Na}^+-\text{K}^+-2\text{Cl}^-$ cotransporter and increase cell hydration by intracellular accumulation of Na^+ , K^+ and Cl^- [3]. The latter transport system is also activated by acetaldehyde, which is the reason that ethanol causes cell swelling. The stimulation of α -adrenergic liver nerves leads also to cell swelling. Thus, a neural regulation of hepatocellular hydration might be assumed as well. Furthermore, adenosine, extracellular ATP, vasopressin and serotonin cause cell shrinkage, while bradykinin leads to cell swelling.

Cell Hydration and Signal Transduction

Changes in liver cell hydration activate various intracellular signal transduction cascades (*osmosignaling*), primarily of mitogen-activated protein kinases (MAP-kinases) of the Erk-, JNK- and p38^{MAPK} -family. In

addition, protein phosphatases such as MKP-1 are induced. MAP-kinases are pivotal regulatory elements. Not only do they mediate the effects of growth hormones, but they are also responsible for the dependence of diverse cell functions on hydration. Thus, there is ample evidence that changes in cell volume directly influence a broad range of processes including kinase activation, gene expression, and membrane transport. However, the mechanism by which the liver cell senses a volume change and the way in which this information activates signal transduction elements is still poorly understood. Nonetheless, the *hepatic integrin system was identified as a sensor of hepatocyte swelling* that activates the MAP kinase cascade. *Cell shrinkage, conversely, is sensed by the endosomal compartment*, with subsequent activation of NADPH oxidases. The resulting formation of reactive oxygen species triggers a variety of other protein-kinase systems [9].

Regulation of Cell Function by the Hepatocellular Hydration State

An altered nutrient and hormonal supply will physiologically lead to dynamic changes in cell hydration that, within minutes, will cause dramatic adjustments of cell function. Therefore, *shifts in cell volume represent a metabolic regulatory principle* which allows for a rapid adaptation of cell function to an altered substrate supply or to changed hormonal influences [2]. Changes in cell volume have substantial effects on signal transduction, membrane transport, and nuclear transcriptional events. In general, cell swelling represents an anabolic signal, stimulating protein and glycogen synthesis, while simultaneously inhibiting proteolysis and glycogenolysis. Cell shrinkage has the opposite effects, leading to catabolic changes in protein and glycogen processing (Table 10.1). The function of nonparenchymal cells in the liver is also regulated by their state of hydration.

Protein Turnover

The hydration state is an essential parameter that determines the breakdown of proteins in the hepatocyte [4]. If the water content of a liver cell increases by approximately 1%, proteolysis diminishes by approximately 2%. This occurs irrespective of the mechanism that brings about the changes in hydration. The antiproteolytic

Table 10.1 Adaptation of metabolic liver functions in response to cell swelling such as occurs during cumulative substrate uptake or under the influence of hormones such as insulin (With permission from [5])

Stimulation of	Inhibition of
Protein synthesis	Proteolysis
Glycogen synthesis	Glycogenolysis
Amino acid uptake	
Amino acid catabolism	
Pentose phosphate shunt	
Release of reduced glutathione into the sinusoidal space	Release of oxidized glutathione into bile
Bile acid secretion	
	Acidification of endocytotic vesicles
	Viral replication
mRNA induction for β -actin, tubulin, c-jun	mRNA induction for PEPCK ^a , tyrosine aminotransferase

^a PEPCK Phosphoenolpyruvate carboxykinase

action of insulin and of some amino acids, such as glutamine, alanine and glycine, is nearly exclusively mediated by insulin and amino acid induced cell swelling, whereas glucagon stimulated proteolysis is explained by hormone induced cell shrinkage. The ethanol induced cell swelling also inhibits protein breakdown and thus contributes to the intracellular accumulation of proteins seen in an alcoholic fatty liver. Inhibition of proteolysis by cell swelling is mediated by activation of p38^{MAPK} with subsequent inhibition of the formation of autophagic vacuoles. Swelling of liver cells not only inhibits proteolysis, but simultaneously increases hepatic protein synthesis. The opposite changes are induced by cell shrinkage. Thus *cell swelling is a protein anabolic signal, whereas cell shrinkage acts as a protein catabolic signal*. Since this probably applies not only to liver cells, but also to skeletal muscle cells, this concept could potentially be used for understanding new aspects of protein catabolic states in general. Independent of the underlying disease, there is in fact a close relationship between the hydration state of the skeletal muscle cell and the magnitude of protein catabolism in severely ill patients. It is possible that the decrease in hydration of skeletal muscle and liver cells represents the common final pathway that leads to protein breakdown in a multitude of diseases. The pathogenetic mechanisms underlying cell shrinkage may be multifactorial, heterogeneous, and disease specific (e.g. oxidative stress, inflammatory mediators, toxins, hormonal stress response, etc.). The successful treatment of protein catabolic states by intravenous

infusion of amino acids is probably due to an increase in cellular hydration.

Bile Formation

Bile formation is an osmotically driven process. Substances destined for biliary secretion are taken up by transport systems located in the sinusoidal membrane of the hepatocyte and are then secreted into the bile canaliculus by specific transport ATPases (see Chapters 5 and 7). Canalicular bile secretion is the rate limiting step and is carefully regulated by the hydration state of the liver. An increase in cellular water content by only 10%, doubles the secretory capacity for bile acids within minutes, while cell shrinkage diminishes bile acid secretion. The endowment of the canalicular membrane with secretory transport ATPases probably depends on cell hydration. These transport molecules are only partially integrated into the canalicular membrane and are for the most part contained in vesicles in the pericanalicular ectoplasm. It is assumed that cell swelling, with the help of the microtubular apparatus, results in the incorporation of these transporter vesicles into the canalicular membrane, thus augmenting its transport capacity (cholesteris). Cell shrinkage, but also endotoxin, may lead to a rapid disintegration of transporters with subsequent cholestasis. The dependency of biliary excretion on hydration is mediated by mitogen activated protein kinases of the Erk and p38 family. Their activation by cell swelling is the decisive trigger for the rapid increase in bile acid secretory capacity. Interestingly, the Erk and p38 kinases are activated by tauroursodeoxycholic acid also in an integrin-dependent way. This may be one explanation for the beneficial effect of ursodeoxycholic acid in some cholestatic diseases, such as primary biliary cirrhosis.

Carbohydrate Metabolism

Cell swelling stimulates glycogen synthesis and the pentose phosphate shunt, simultaneously inhibiting glycogen breakdown. Cell shrinkage increases glycogenolysis and leads to the induction of phosphoenolpyruvate carboxykinase, a key enzyme of gluconeogenesis. Therefore, a decrease in cellular hydration that is often observed during starvation, can be regarded as a homeostatic response of glucose metabolism. Cell shrinkage

not only increases proteolysis with release of amino acids, but also simultaneously stimulates gluconeogenesis from these amino acids. Furthermore, there is evidence that cellular dehydration contributes to insulin resistance. Cell shrinkage leads to the induction of MAP-kinase-phosphatase-1 that inactivates important components of the insulin activated signal transduction at the postreceptor level. This could explain the well known clinical observation that hyperosmotic states are associated with insulin resistance.

Function of Nonparenchymal Cells

The function of nonparenchymal cells in the liver is also subject to control by the hydration state. Thus, a decrease in hydration of *Kupffer cells* leads to a potentiation of endotoxin mediated induction of cyclooxygenase-2 (Cox-2) and up to a tenfold increase of prostanoid production. Similarly, hydration affects the induction of Cox-2 in *sinusoidal endothelial cells*. The hydration state also regulates phagocytosis and cytokine production by Kupffer cells. Osmolytes, such as betain and taurine may modulate these immunologic functions of nonparenchymal cells. In the context of activation and transformation of *hepatic stellate cells* to myofibroblasts osmolyte transporters are intensely expressed. The significance of this finding, however, is unclear but may relate to the recent discovery that hepatic stellate cells are a progenitor cell compartment in the liver which can differentiate not only into myofibroblasts, but also to endothelial cells and hepatocytes.

Gene Expression, Cytoprotection and Virus Replication

The list of genes that are regulated by the hydration state is long. Here, only the hydration dependent expression of osmolyte transporters that are found in all types of liver cells is highlighted. It should be remembered, however, that osmolytes used by different liver cells differ. Osmolytes are organic compounds, such as taurine, betain and myoinositol, that are rapidly released by cells upon cell swelling. Due to the osmosensitive induction of their transporters, they accumulate intracellularly during cell shrinkage. These osmolytes do not

only serve to regulate cell volume, but they also stabilize protein structures, which explains their cytoprotective effect. Accordingly, taurine transporter knockout mice develop liver injury. The extent of liver injury by various agents is considerably enhanced in poorly hydrated cells, whereas the tolerance to liver damage is improved in well hydrated cells and/or in the presence of osmolytes. The addition of taurine and betain may also avert to a large extent ischemia-reperfusion injury of the liver. On the one hand this is explained by the inhibition of prostanoid formation by Kupffer cells, but is also due to an improved heat shock response.

The cellular state of hydration does not only regulate the expression of cellular genes, but also affects virus replication. In animal models (duck hepatitis B) it was shown that cell shrinkage enhances virus replication, while it is inhibited by cell swelling. Interestingly, the effect of cell volume on viral and host protein synthesis is reciprocal: cell shrinkage inhibits protein synthesis in host cells, but simultaneously increases synthesis of viral proteins. The opposite occurs in cell swelling. The cause for the dependence of virus replication on the hydration state is unclear. Cell volume may regulate the formation and activation of transcription factors by the host which bind to regulatory elements of the viral genome.

References

1. Dunkelberg JC, Feranchak AP, Fitz JG (2001) Liver cell volume regulation: size matters. *Hepatology* 33: 1349–52
2. Häussinger D, Lang F (1991) Cell volume in the regulation of hepatic function: a mechanism for metabolic control. *Biochim Biophys Acta* 1071: 331–50
3. Häussinger D, Lang F (1992) Cell volume and hormone action. *Trends Pharmacol Sci* 13: 371–3
4. Häussinger D, Roth E, Lang F, et al (1993) Cellular hydration state: an important determinant of protein catabolism in health and disease. *Lancet* 341: 1330–2
5. Häussinger D (1996) Physiological functions of the liver. In: Greger R, Windhorst U (eds) *Comprehensive physiology. From cellular mechanisms to integration*. Springer, Berlin, pp 1369–91
6. Häussinger D, Kubitz R, Reinehr R, et al (2004) From experimental to clinical hepatology. *Mol Aspects Med* 25: 221–360
7. Häussinger D, Sies H (2007) Osmosensing and osmosignaling. *Meth Enzymol* 428: 77–107
8. Lang F, Busch GL, Ritter M, et al (1998) Functional significance of cell volume regulatory mechanisms. *Physiol Rev* 78: 247–306
9. Schliess F, Görg B, Häussinger D (2006) Pathogenetic interplay between osmotic and oxidative stress: the hepatic encephalopathy paradigm. *Biol Chem* 387: 1363–70

Chapter Outline

Kupffer Cells	142
Intrahepatic Lymphocytes	142
T Lymphocytes.....	143
Natural Killer T (NK T) Cells.....	144
Natural Killer (NK) Cells.....	144
Dendritic Cells	145
Hepatocytes	145
Sinusoidal Endothelial Cells	146
Hepatic Stellate Cells	146
Biliary Epithelial Cells	146
Biliary Immunoglobulins	147
Cytokines and the Liver	148
Immunologic Tolerance	148
Intrahepatic Immune Responses	149
Liver and the Acute Phase Reaction	150
References	151

The liver accommodates a variety of cell populations, some of which are primarily engaged in immune activities. The intrahepatic immunologic processes result from a complex interplay between parenchymal and nonparenchymal cells [18, 19, 22, 26]. The knowledge of the characteristic liver architecture, the distinct hepatic circulation, and the specific cellular composition of the organ form the basis for understanding the immunological role of the liver.

Immunologically important molecules, such as complement factors and acute phase proteins are synthesized in the liver. The liver harbors a large fraction of the reticuloendothelial system of the human body, thereby participating in nonspecific immune defense reactions. If antigens expressed on hepatocytes are the targets of an immune reaction, the liver itself becomes the center of the “immunologic battle” (see Chapter 18). On the other hand, primary nonhepatic immunologic disorders, such as the collagen vascular diseases, may secondarily affect the liver.

The morphology of the liver and of its cellular elements is discussed extensively in Chapters 2 and 3. The liver is situated strategically between the splanchnic area and the systemic circulation. Its dual blood supply from the portal vein and the hepatic artery leads to a continuous exposure to intestinal, pancreatic, splenic and systemic antigens. Gut microorganisms, after overcoming the intestinal barrier, gain access to the liver via the portal circulation and may elicit intrahepatic immune reactions. This early antigenic contact suggests that the liver must accommodate the components of the innate immune system in order to avert gut derived infectious, toxic and carcinogenic injuries. The composition of immunocompetent cells in the liver corroborates the assumption that innate, nonspecific immune reactions belong to the most important immunologic tasks of the organ.

Kupffer Cells

Kupffer cells and lymphocytes account for the bulk of immune cells in the liver. Kupffer cells are resident macrophages and account for approximately 80% of all tissue associated macrophages in the human body. Thus, the liver houses a substantial fraction of the monocytic phagocyte system and plays a pivotal role in the defense against animate infectious agents and inanimate particles. Kupffer cells constitute the first line of defense against gut derived antigens. They are able to phagocytose senescent erythrocytes, fragmented cells and infectious agents. They interact with endotoxins and tumor cells, and are capable of eliminating antigen-antibody complexes, presenting antigens, and synthesizing proinflammatory cytokines. Phagocytosis by Kupffer cells occurs either as immune or nonimmune phagocytosis. In *immune phagocytosis* IgM laden particles and antigen-antibody complexes are taken up by Fc- and C₃-complement receptors. *Nonimmune phagocytosis* is mediated by opsonins or by lectin receptors on the surface of Kupffer cells that bind the particles to be phagocytosed. Fibronectin is an opsonin produced by hepatocytes.

Various bacterial stimuli, such as lipopolysaccharide and bacterial superantigens induce Kupffer cells to secrete autocrine and paracrine inflammatory

mediators. After contact with lipopolysaccharide, amongst other substances, Kupffer cells produce interleukins (IL) 1, 6, 10 and 12. With the exception of IL-10 these cytokines stimulate natural killer (NK) and NK T cells (see below) to synthesize interferon- γ , thereby acquiring cytotoxic features against tumor cells and infected cells. IL-10 is an immune regulatory molecule that diminishes CD4⁺ T cell activation by antigen presenting sinusoidal endothelial cells and by Kupffer cells. This effect is mediated by down-regulating receptor-mediated antigen uptake and reducing the expression of both MHC class II and the costimulatory molecules CD80 and CD86. Prostanoids produced by Kupffer cells enhance this effect [25].

Therefore, Kupffer cells are an integral part of immunologic feedback loops of interacting cells and their mediators. The immunologic reaction chain generated in this way ultimately results in the activation of the non-specific defense system, the generation of cytotoxic cells, and the production of immunoglobulins (Fig. 11.1).

Intrahepatic Lymphocytes

The normal liver houses approximately 10¹⁰ lymphocytes. They are located predominantly in the portal tracts and the periportal areas, but are also scattered throughout the parenchyma. Lymphocytes residing in the liver are regarded as liver specific lymphocytes; surprisingly little is known about their functions. They differ phenotypically and functionally from lymphoid cells in the peripheral circulation (Table 11.1). *Conventional*

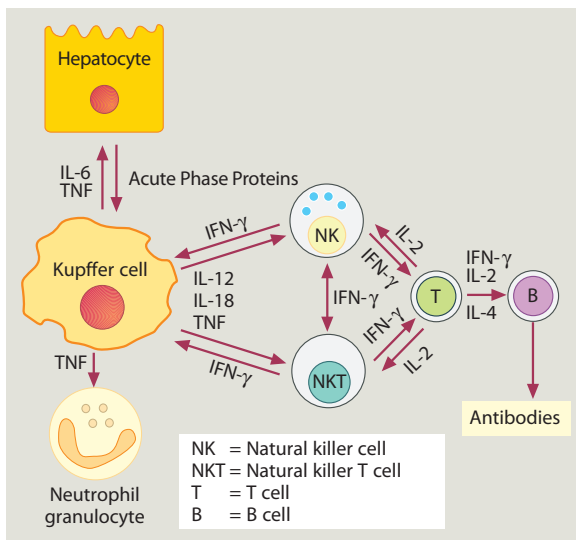


Fig. 11.1 Simplified diagram of the interactions between hepatocytes, Kupffer cells and lymphocytes in hepatic inflammatory reactions

Table 11.1 Distribution of phenotypical markers on normal blood and intrahepatic T lymphocytes in man (Adapted from [6])

T-Cell-Phenotype	Blood (%)	Liver (%)
CD4	60	22
CD8	38	72
CD4 ⁺ CD8 ⁺	1,3	5,5
CD4 ⁺ CD8 ⁻	5	14,5
CD8 α^+ β^-	<1	15,4
$\alpha\beta$ TCR	96	85
$\gamma\delta$ TCR	3,5	15
V α 24 TCR	<1	4,6
CD56	2	32

*Mean values of the percental frequency. The interindividual variation is extremely large.

T cells comprise CD8⁺ and CD4⁺ T cells. *Unconventional T cells* are categorized into two major populations, those that express NK cell markers (NK T cells) and those that do not express NK cell markers ($\gamma\delta$ T cells). The bulk of intrahepatic lymphocytes are T cells (CD8⁺ T cells outnumber CD4⁺ T cells) and natural killer (NK) cells (94%), with B cells making up a much smaller percentage (6%). NK T cells account for up to 30% of the total number of T cells in the liver (Fig. 11.2) [3, 4, 22, 32].

Intrahepatic lymphocytes exhibit a high degree of activation and spontaneous cytotoxicity. This fact, together with the strong expression of molecules mediating apoptosis, support the assumption that intrahepatic lymphocytes participate in immunologic surveillance. Furthermore, the hepatic immune system is involved in the induction of peripheral tolerance.

The apoptosis of activated T cells, especially of CD8⁺ lymphocytes, occurs preferentially in the liver. The capture of apoptotic T cells from the sinusoidal blood is an active receptor-binding-process mediated by sinusoidal endothelial cells (SEC). The specific architecture of the liver, with fenestrated SEC, a large number of resident macrophages combined with an excellent blood supply receiving a large fraction of cardiac output, support the apoptotic clearance function of the organ. Whether T cells bound for intrahepatic apoptosis have been primed in the periphery, merely accumulate in the liver

“to die”, or whether they receive the apoptotic signal in the liver, is not known.

T Lymphocytes

T lymphocytes are pivotal components of adapted immunity. With their surface receptors they recognize peptides presented in association with MHC class I (CD8⁺ cytotoxic T cells) or class II molecules (CD4⁺ helper T cells) (MHC restriction). After reacting with their target cells, the T cells expand clonally.

Hepatic T lymphocytes are a heterogeneous cell population; compared to the classical T cells, they exhibit additional functional characteristics. They are transported to the liver by the circulation, become resident lymphocytes and probably mature inside the liver. Hematopoietic stem cells have also been described in the human liver.

The liver contains both *conventional T lymphocytes* that present antigen in the classic way, i.e. in conjunction with MHC class I or II antigens, and *unconventional, alternative T cells*. The latter express only small amounts of CD3. They are distinguished by a limited variability of antigen receptors, by more non-specific mechanisms of antigen recognition, and by a lack of MHC restriction. The bulk of alternative T cells display NK-like cytotoxic activities and belong to the *natural killer T cells* (NK T; CD 56 lymphocytes; see below).

The vast majority of hepatic T cells (Th1/Tc1) secrete inflammatory cytokines, including interferon- γ , TNF- α , and interleukin-2. Approximately 5% have a Th2/Tc2 cytokine secretory profile, but they produce only interleukin-4 and no interleukin-5. Most interleukin-4 producing T cells in the liver secrete also interferon- γ . Thus, they resemble more Th0 than conventional Th2 cells. Th0 lymphocytes rank among the undifferentiated cells and are believed to exert immune regulatory functions.

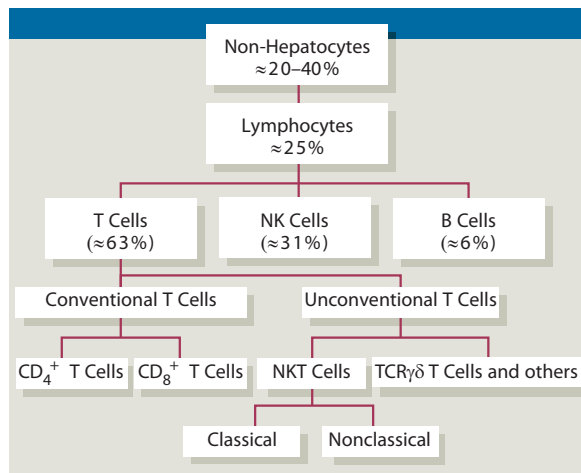


Fig. 11.2 Composition of intrahepatic lymphocyte populations in the healthy liver. Numbers indicate the estimated frequency of each population relative to the total number of nonparenchymal cells. Non-hepatocytes comprise 20–40% of the total cell number found in the liver (Adapted from [22])

$\alpha\beta$ -T Cell Receptor Lymphocytes

Eighty-five percent of hepatic T cells express the $\alpha\beta$ -T cell receptor (TCR). Approximately half of $\alpha\beta$ -TCR expressing cells are conventional T cells. Together with CD4 or CD8 cells they express large amounts of CD3. The result is a mixed population of CD8⁺CD4⁻, CD4⁺CD8⁻, CD4⁻CD8⁻ (double negative) and CD4⁺CD8⁺

(double positive) cells that do not express NK cell markers. Sixty to 90% of hepatic T cells are CD8⁺. Conventional CD4⁺CD8⁻ and CD8⁺CD4⁻ $\alpha\beta$ -T cells account for less than 40% of the hepatic CD3⁺ cell population. The intrahepatic pool of double negative cells is particularly vast. In addition, the liver contains T cells that express the CD8 α -chain but not the CD8 β -chain (CD8 $\alpha^+\beta^-$ cells).

$\gamma\delta$ -T Cell Receptor Lymphocytes

While fewer than 5% of peripheral T cells express the $\gamma\delta$ -TCR, 15–35% of intrahepatic T cells express this receptor. Thus, in addition to the small intestine, skin, lungs and the pregnant uterus, the liver is the organ with the highest $\gamma\delta$ -T cell density in the body. The $\gamma\delta$ -TCR recognizes a limited range of antigens, such as bacterial and viral nonpeptidic antigens and stress inducible proteins [31]. However, the exact target antigens and functions of hepatic $\gamma\delta$ -T cells are unknown. Particularly important is the fact that antigen recognition by $\gamma\delta$ -T cells is not MHC restricted. This feature, combined with their relatively large number in the liver, suggests that $\gamma\delta$ -T cells are important in eliminating infectious agents, virally infected cells, and tumor cells. Furthermore, this indicates that nonspecific innate immunity plays a major role in the immunologic functioning of the liver.

Natural Killer T (NK T) Cells

The liver is selectively enriched for cells representative of innate immunity, including natural killer T (NK T) cells [9]. The NK activity is not only limited to conventional CD3⁻CD56⁻-cells (see below). The majority of lymphocytes with T cell receptors of limited variability also express NK-activating and inhibiting receptors; they are designated as NK T cells. The population of classical NK T cells arises in the thymus, displays a very restricted T cell repertoire, and recognizes antigen in the context of the MHC class I molecule CD1. On average, 32% of all hepatic CD3⁺ cells are NK T cells (CD3⁺CD56⁺), compared to only 2% in the peripheral blood. 60% of human hepatic NK T cells express the $\gamma\delta$ -TCR (nonclassical NK T cells);

they probably recognize CD1 associated with glycolipids. Interestingly, hepatocytes express CD1, which hints to a possible interaction between NK T cells and liver cells. Activated Kupffer cells seem to be necessary for the functional maturation of NK T cells. The cytotoxic activities of human hepatic NK T cells are stimulated by interleukins 2, 12 and 15. After being activated, NK T cells secrete many cytokines, including interferon- γ , TNF- α , interleukin 2 and 4.

The exact functions of NK T cells are not yet known. It is speculated that NK T cells might represent an evolutionary and functional link between the innate nonspecific immune system and the acquired specific immune system. By secreting cytokines they are believed to influence the local immunologic microenvironment of the liver [9].

A subgroup of NK T cells express a non-variable TCR with a V α 24J α Q α -chain and a limited number of β -chains (V β 8 or V β 11). These are the V α 24J α Q⁺ T lymphocytes. They account for up to 4% of hepatic T cells, but fewer than 0.2% of peripheral T cells. Synthetic protozoal α -galactosylceramide and glycosyl phosphatidylinositols are potent stimulators of these cells. After pharmacologic stimulation or reaction with anti CD3, as many as 12% of these cells may simultaneously secrete interferon- γ and interleukin 4. These cells are possibly early regulators of specific hepatic immune responses and may play a role in the pathogenesis of immunologically mediated liver diseases.

Natural Killer (NK) Cells

NK cells are important components of innate immunity and possess potent cytolytic activity against virus-infected and tumor cells. They exhibit spontaneous cytotoxicity and have no T cell markers (CD3⁻, CD56⁺). NK cells account for approximately 30% of intrahepatic lymphocytes. They contain large cytoplasmic granules (*large granulated lymphocytes*; *pit cells*) and mediate antibody dependent cytotoxicity (ADCC). NK cells presumably play a role in tumor cell lysis and in the defense against viruses, intracellular bacteria and parasites. In patients with malignant liver tumors, their number may increase significantly and account for up to 90% of all intrahepatic lymphocytes. NK cells have receptors for the Fc portion of immunoglobulins. They do not express antigen specific receptors, but are able

to recognize changes in the expression of membrane glycoproteins of target cells. Human NK cells are activated by binding to antibody laden target cells and by cytokines (interferon- γ , interleukins 2, 12 and 15). Binding occurs through the surface molecule CD16 (IgG Fc-receptor) which mediates ADCC. Complex interactions between HLA class I molecules and killer immunoglobulin-like receptors (KIRs) activate or inhibit NK cells.

Dendritic Cells

The liver contains several types of antigen presenting cells, including sinusoidal endothelial cells and Kupffer cells. In certain situations hepatocytes have also been reported to acquire antigen presenting skills. However, the professional antigen presenting cell is the dendritic cell (DC). DCs are very efficient in capturing, processing, and presenting antigen to naïve T cells. However, compared with bone marrow derived or splenic DC, they stimulate naïve allogeneic T cells only poorly. The unique cytokine microenvironment in the liver (rich in IL-10 and TGF- β) may render resident DCs tolerogenic (see below “Immunologic Tolerance”).

Resident hepatic DCs are derived from bone marrow and represent a major component of innate immunity. Compared with lymphoid tissue only few DCs are found in the normal liver where they predominantly reside around the portal tracts [21]. During inflammation, DCs are recruited into the liver sinusoids and

populate periportal and pericentral areas. Once activated, they migrate via the space of Disse to the lymphatics in the portal tracts and, ultimately, to extrahepatic lymph nodes.

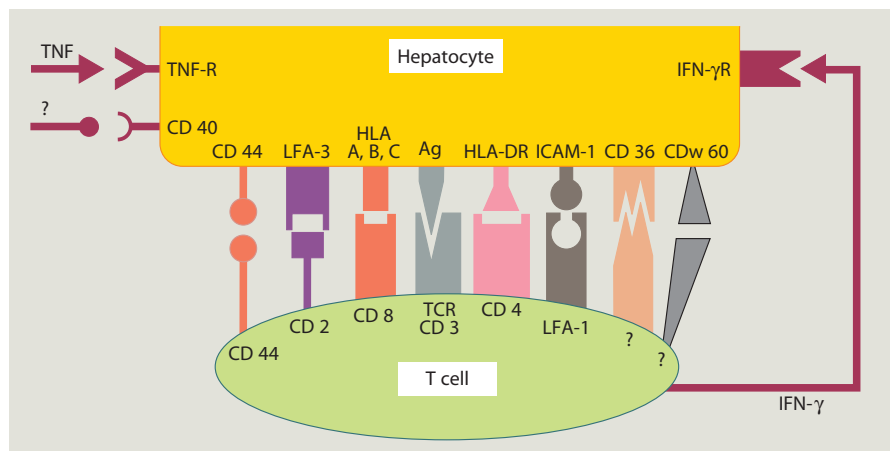
Two principal subsets of DCs, deriving from a common precursor, are recognized: the myeloid (MDC) and lymphoid (plasmacytoid, PDC) DC. Upon stimulation DCs produce inflammatory cytokines, such as IL-12 and TNF- α . PDC and MDC are distinct in their toll-like receptor (TLR) expression and cytokine secretion profile (Table 11.3).

Hepatocytes

Hepatocytes produce complement components and acute phase proteins. Immune activated hepatocytes express numerous surface markers, receptors for immune mediators and adhesion molecules (Fig. 11.3). Under certain conditions hepatocytes may serve as antigen presenting cells and react directly with lymphocytes.

Hepatocytes participate in the metabolism of secretory IgA. They can take up IgA from the sinusoidal circulation, transport it intracellularly, and secrete it across the canalicular membrane into bile (see Chapter 5). In contrast to the rat, in man this “enterohepatic circulation” of polymeric IgA (pIgA) is of only minor importance. The pIgA in human bile originates mostly from plasma cells located in the walls of the bile ducts and is secreted into bile across the biliary epithelial cells.

Fig. 11.3 The immunologically activated hepatocyte expresses numerous surface molecules which enable the liver cells to react with T lymphocytes



Sinusoidal Endothelial Cells

The sinusoidal endothelial cells (SEC) are crucial elements in liver immunity. They form a sieve-like, fenestrated endothelium and participate actively in the immunologic processes in the liver. Uptake of antigens by SEC occurs at the mannose receptor, and SEC contribute to the clearance of antigens from the circulation by receptor mediated endocytosis. SEC produce cytokines, including IL-1; they express adhesion molecules for T cells, B cells and neutrophil granulocytes. All surface markers required for antigen presentation are expressed by SEC (MHC class I and II as well as the costimulatory molecules CD80, CD86, CD40, CD54). SEC are therefore able to take up and present antigens as well as to activate T cells. CD4⁺-activation by SEC, however, is less efficient than by “professional” antigen presenting cells from the bone marrow. IL-10 produced by Kupffer cells and prostaglandin E₂ formed constitutively by SEC downregulate antigen presentation by SEC and contribute to the tolerogenic intrahepatic microenvironment.

Antigen uptake does not only occur on the luminal side of the sinusoids; antigens originating in hepatocytes may also be taken up and processed by SEC, and then presented to T cells. This pathway is important both for the immunologic surveillance of leukocytes that cross the liver as well as for the recruitment of liver specific T cells.

SEC express markers involved in recognition and apoptosis, and may contribute to immunologic tolerance by inducing apoptosis of activated T cells (see below) [13].

The sinusoidal endothelium does not have a basement membrane. Its continuity is interrupted by dynamic fenestrations, which may actively change their diameter. This feature may allow antigens and cellular components circulating in the sinusoidal blood to interact directly through SEC fenestrations with the basolateral (sinusoidal) membranes of liver cells; thus, direct contact between circulating lymphocytes and hepatocytes can be established. This is further supported by the presence on T cells and on hepatocytes of complementary adhesion molecules, such as leukocyte function antigen (LFA)-1 and intracellular adhesion molecule (ICAM)-1, respectively. Recently, at the ultrastructural level, a direct interaction between T lymphocytes and hepatocytes through SEC fenestrations has been demonstrated *in vivo*. This

mechanism of interaction between immune cells and hepatocytes may have implications for the pathogenesis of viral hepatitis in which hepatocytes may represent the main antigen-presenting cell, and for the development of immune tolerance as naïve T lymphocytes pass through the liver [30]. Paracrine interactions between SEC and hepatocytes may regulate lymphocyte traffic through SEC and amplify lymphocyte recruitment through the sinusoids by regulating the expression and function of endothelial adhesion molecules [8].

Hepatic Stellate Cells

Hepatic stellate cells (HSC) are localized in the perisinusoidal space of Disse and have a stellate appearance. After hepatocellular injury, they transform into myofibroblasts and play an important role in fibrogenesis and chronic hepatic inflammation (see Chapters 3 and 28). HSC regulate leukocyte trafficking by secreting monocyte chemoattractant protein-1. They also interact actively through cytokines and growth factors with Kupffer cells, platelets, endothelial cells, and hepatocytes [26]. Leptin promotes the production of proinflammatory cytokines by stellate cells, which may be important in the pathogenesis of certain forms of non-alcoholic fatty liver disease [1].

Biliary Epithelial Cells

Biliary epithelium accounts for less than 5% of total liver mass. Cholangiocytes may both actively contribute to intrahepatic immune regulation and become passively involved in immune mediated bile duct injury [23]. Biliary epithelial cells are the target of immune reactions in primary biliary cirrhosis, primary sclerosing cholangitis, autoimmune cholangitis, chronic graft versus host disease, in transplant rejection and in the vanishing bile duct syndrome.

Bile ducts are not merely passive bile draining channels. They are dynamic structures, composed of different cell populations that, through secretory and absorptive processes, modify the composition of bile. Bile transports immunoglobulins into the intestine. Cholangiocytes secrete cytokines, express adhesion molecules, and under certain circumstances also antigens which may become the target

Fig. 11.4 Immunological expression and secretion profile of biliary epithelial cells

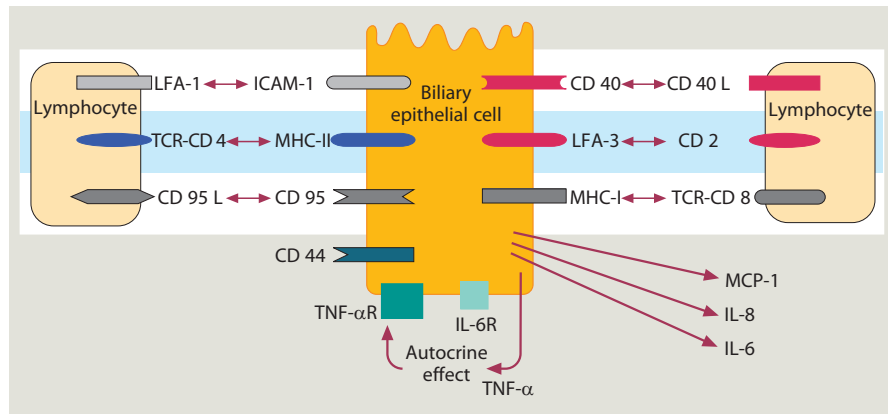


Table 11.2 Effect of cytokines on the expression of surface markers by normal biliary epithelial cells (Adapted from [23]; some results were obtained in cultured biliary epithelial cell lines)

	ICAM-1 Expression	HLA-I Expression	HLA-II Expression	LFA-3 Expression	CD40 Expression
Unstimulated	Low	Low	Not present	Low	Low
TNF-α	↑	↔	↔	↔	↑
IFN-γ	↑	↑	↑	↔	↑
IL-1	↑	↑	↑	?	?
TGF-β	↓	↓	↓	↑	↔

↑ Increase, ↓ Decrease, ↔ no effect, ? no data available

of immunological reactions. After being stimulated by cytokines, biliary epithelial cells may acquire antigen presenting functions and become actively involved in intrahepatic immune reactions.

Under physiological conditions, lymphocytes are already found in the bile ducts. CD8⁺ cells are present predominantly within the epithelium, while CD4⁺ lymphocytes predominate in the subepithelial fibromuscular layers. The interaction between cholangiocytes and lymphocytes may be established through adhesion molecules. Alternatively, T cell recognition can occur via CD40 and LFA-3 (alternative pathway).

Proinflammatory cytokines (TNF-α, IL-6) affect the expression of surface receptors on biliary epithelial cells (Fig. 11.4, Table 11.2). Inactive bile duct cells express ICAM-1, LFA-3 and HLA class I molecules. In the normal liver, biliary epithelia do not express HLA class II antigens. However, after stimulation by interferon-γ and IL-1, cholangiocytes may be activated *in vitro* to express HLA class II antigens. Aberrant HLA class II expression on biliary epithelia may be seen in transplant rejection, in graft versus host disease and in primary biliary cirrhosis. This indicates that

under the influence of proinflammatory cytokines, biliary epithelial cells can assume antigen presenting features, react directly with CD4⁺ cells and play an active role in the immune reaction.

Biliary epithelia themselves may also produce cytokines. After being stimulated by TNF-α and IL-6 they produce IL-8 and monocyte chemoattractant protein (MCP)-1, thereby attracting neutrophil granulocytes and lymphocytes to the portal areas. Thus, bile duct epithelia are not only the targets of immunological reactions; in inflammatory processes they become partners in the cytokine-network and engage actively in the immune reaction, generating and perpetuating the inflammatory process in the portal tract.

Biliary Immunoglobulins

IgG, monomeric IgA, and polymeric IgA are found in human bile. It is assumed that biliary immunoglobulins derive partly from the blood; a large fraction is produced locally by intramural plasma cells and is then

secreted across the epithelium into the bile duct lumen. Polymeric immunoglobulin receptor and the secretory component have been localized in the basolateral membrane of biliary epithelial cells. Plasma cell derived IgA binds to these structures; it traverses the cholangiocyte by transcytosis and is then secreted into bile. There is no exchange of IgA between neighbouring epithelial cells. Another source of dimeric biliary IgA are gut associated plasma cells localized in the lamina propria of the small intestine. Dimeric IgA reaches the liver by the portal venous circulation and is extracted from the sinusoidal circulation by hepatocytes. Liver cells express the receptor for dimeric IgA (secretory component) in their basolateral membrane. The ligand-receptor (dimeric IgA-secretory component) complex crosses the hepatocyte and is secreted across the canalicular membrane into the bile (see Chapter 5). However, under physiologic conditions in man this pathway is of minor importance. The functions of biliary immunoglobulins are not clear. It is assumed that they protect biliary epithelia from infectious agents by enhancing biliary excretion of these organisms complexed with IgA.

Cytokines and the Liver

All cells residing in the liver are capable of producing cytokines. Cytokines participate in the physiologic immune homeostasis, and influence immune and inflammatory processes by paracrine and autocrine mechanisms. However, due to methodological difficulties in exploring their functions, it is very difficult to assess their physiologic roles and pathophysiologic effects. Our knowledge is mainly based on animal experiments, and on data derived from isolated cells or cell cultures. The local physiologic levels of cytokines in the human liver are also unknown. Their effects in the hepatic microenvironment not only depend on their concentration, but are also affected by the presence of other mediators and cells; *i.e., one and the same cytokine under different conditions may exert different functions*. Presently, reliable conclusions regarding the *in vivo* physiologic and pathophysiologic actions of cytokines in the human liver are not possible.

Cytokines are not only important in immunologic processes and inflammatory reactions (e.g., infections, sepsis and multiorgan failure), but they also play roles in ischemic and reperfusion liver injury, liver regeneration, and

the formation of extracellular matrix by HSC. Tumor growth factor (TGF)- α , epidermal growth factor, and fibroblast growth factor stimulate, whereas TGF- β inhibits hepatic regeneration (see Chapter 13) [12, 20, 27].

Normal metabolic pathways in the liver, such as gluconeogenesis, lipid and protein metabolism, are also affected by cytokines. As mentioned previously, it is not currently possible to decide which metabolic effects of cytokines in man are actually of physiological significance. Therefore, the following statements simply enumerate experimental results of individual metabolic effects of cytokines, without attempting to provide an integrated picture of cytokine action on metabolism.

- IL-6 and insulin like growth factor (IGF)-1 stimulate glucose transport into the cell
- IL-1 diminishes the activity of phosphoenolpyruvate carboxykinase, thereby inhibiting gluconeogenesis
- Interferon- α , TNF- α , IL-1 and IL-6 stimulate fatty acid synthesis
- IL-1 and TNF- α stimulate the uptake of amino acids by hepatocytes
- TNF- α increases the activity of key enzymes of hepatic cholesterol synthesis (HMG CoA-reductase)
- TNF- α stimulates lipid synthesis and secretion as well as the expression of hepatocyte LDL-receptors
- TNF- α diminishes the activity of hepatic and plas-matic lecithin-cholesterol acyl transferase
- TNF- α and IL-1 β inhibit the activity of bile acid transporters in the canalicular membrane
- IL-1 induces the expression of cytochrome P450 2E1 and of glutathione S-transferase. By contrast, IL-2, TNF- α , IL-1 β and IL-6 inhibit the induction of certain cytochrome P450 isoforms
- Cytokines and growth factors, particularly insulin like growth factor (IGF)2 and TGF- α , play a role in hepatocarcinogenesis
- IL-10 and TGF- β generate a tolerogenic hepatic microenvironment, contributing to the promotion of immunologic tolerance

Immunologic Tolerance

There is clear experimental and clinical evidence that the liver has an ability to induce immunologic tolerance [2]. The liver may reduce the immunogenicity of transplantation antigens. Patients with liver transplants

tolerate grafts of other organs (e.g. kidneys and skin) better than patients without a liver transplant. The mechanisms leading to hepatic induction of tolerance are not well understood. Generation of specific suppressor cells, trapping, apoptosis and phagocytosis of activated T cells, and clonal deletion of autoreactive cells are among the factors discussed [12]. Sinusoidal endothelial cells express markers involved in recognition, sequestration and apoptosis. Recently a role for liver sinusoidal endothelial cells in tolerance induction has been proposed by inducing apoptosis in activated T cells [13].

Hepatic dendritic cells are believed to play a role in the induction of immune tolerance. An important factor contributing to the promotion of tolerance is the unique hepatic “tolerogenic microenvironment” furthered by IL-10 and TGF- β [7, 15–17]. Kupffer cells and SEC constitutively express the anti-inflammatory cytokines IL-10 and TGF- β , while hepatocytes secrete IL-10 in response to autocrine and paracrine TGF- β . These cytokines confer tolerogenicity on DCs and on other antigen presenting cells by inhibiting their maturation and T cell stimulatory function. In contrast to lipopolysaccharide-stimulated splenic DCs, endotoxin-activated hepatic DCs induce alloantigen-specific T cell hyporesponsiveness [5].

The liver participates in the *induction of oral tolerance*. It is continuously flooded with oral antigens that, after intestinal uptake, reach the organ by the portal venous route. Three major mechanisms are thought to be involved in the generation of oral tolerance by the liver. (1) oral antigens are cleared by the hepatic scavenger cell population; (2) hepatic DCs take up oral antigens, present them in association with MHC class II molecules to CD4 T cells which give rise to regulatory CD4 T cells, which in turn eliminate other antigen-specific T cells; and (3) SEC take up oral antigens, present them to CD8 T cells, and induce immune tolerance in these CD8 T cells [15].

Intrahepatic Immune Responses

The induction of a specific hepatic immune response is a complex process, with different pathogens being able to induce different immune responses. CD8⁺ cytotoxic T cells are the effector cells of adaptive immunity against *Listeria monocytogenes*. Formation of granulomas in

experimental *Schistosomiasis* is mediated by CD4⁺ cells. The severity of the illness is influenced by the cytokine profile and by the interaction between Th1- and Th2-cytokines.

Pattern recognition receptors (PRR) are germline encoded, constitutively expressed molecules that recognize pathogen-associated molecular patterns. They function as sensors of microbial danger signals enabling the host to initiate an immune response [28]. PRR are present not only in immune cells resident in the liver but also in liver parenchymal cells. *Toll-like receptors* (TLR) are PRR that recognize microbes either on the cell surface or on lysosomal/endosomal membranes, while pathogens that invade the cytosol are detected by cytoplasmic PRR. PRR may also recognize damage-associated molecules and may induce inflammatory responses in the absence of microbes. At present, ten TLR have been discovered in humans. Some are expressed on the cell membrane, while others are found in the endosomal compartment. The surface expressed TLR recognize infectious organisms or their components, while intracellular TLR sense nucleic acids derived from viruses or the host. Ligand recognition by TLR triggers a complex signaling cascade that culminates in activation of proinflammatory cytokines, costimulatory molecules, or type I interferons [24]. The liver accommodates a network of parenchymal and non-parenchymal cells, including immune cells that express various TLR (Table 11.3).

Gut derived *bacterial lipopolysaccharide* (LPS, endotoxin), a component of the wall of Gram negative and certain Gram positive bacteria, continuously reaches the liver by the portal venous circulation. TLR4 is a

Table 11.3 Expression of Toll-like receptors (TLR) by cell populations resident in the liver (Adapted from [28])

Cell type	TLR-expression
Hepatocyte	TLR 1–9
Kupffer cell	TLR 2, 4
Stellate cell	TLR 2, 3, 4
Sinusoidal endothelial cell	TLR 4
Biliary epithelial cell	TLR 2, 3, 4, 5
Dendritic cells	
Myeloid	TLR 1–9
plasmacytoid	TLR 7, 9
T-lymphocytes, NK cells	TLR 1, 2, 4, 5 and 9
B cells	TLR 1, 6, 7, 9 and 10

surface expressed TLR and is the major component of the LPS recognition receptor complex. While LPS in extrahepatic tissues normally leads to an immune activation, it does not cause inflammation in the liver. By downregulating of MHC class II, CD80 and CD86 surface molecules and by impairing intracellular antigen processing, LPS diminishes antigen presentation by SEC and by Kupffer cells. The receptor mediated antigen uptake is not affected by LPS. TGF- β , an immunosuppressive cytokine that is secreted by Kupffer cells, and SEC already under physiological conditions might add to the immunosuppressive effect of LPS.

In *viral hepatitis* T cells attack hepatocytes expressing viral peptides on their surface. The T cell response triggers a necroinflammatory process that may either terminate with the elimination of the virus and virus-laden hepatocytes or, if inadequate, may lead to viral persistence. The intensity of the T cell response is crucial for successful virus elimination and determines whether or not acute viral infection will become chronic. It is possible that the “tolerogenic environment” in the liver contributes to viral persistence and to the development of chronic hepatitis. In chronic hepatitis C the number of $\gamma\delta$ -T cell receptor lymphocytes and NK cells is also increased. Their significance in the pathogenesis of chronic hepatitis C is unknown.

In the early phase of hepatitis B, it is possible that the production of interferon- γ by non CD3 cells is a co-determinant, deciding whether the virus will be eliminated or persist.

In *autoimmune hepatitis* and *cholangitides*, autoantigens in association with HLA class II molecules presumably are the targets of the immune reaction [14].

Liver and the Acute Phase Reaction

The acute phase reaction is an important systemic reaction to tissue injury and a response to acute and chronic infections. The reaction is rapid and generates the first non-specific line of defense against foreign invaders. Through this reaction the organism gains time to mount a specific humoral and cellular immune response. Mediators of the acute phase reaction are *acute phase proteins*; they are synthesized mainly in the liver (Table 11.4). By definition, acute phase proteins are proteins whose plasma levels in acute

Table 11.4 Acute phase proteins synthesized by the human liver (selection)

Positive Acute-Phase-Proteins ($\geq 25\%$ increase in plasma levels)
C-reactive protein
Serum-amyloid A
α_1 -proteinase inhibitor
α_1 -acidic glycoprotein
α_1 -antichymotrypsin
Fibrinogen
Haptoglobin
Ceruloplasmin
C ₃ -complement-component
α_2 -antiplasmin
C ₁ -inactivator
Negative Acute-Phase-Proteins (< 25% decrease in plasma levels)
Albumin
Transferrin
α -fetoprotein
Insulin-like growth factor I
Thyroxine-binding globulin

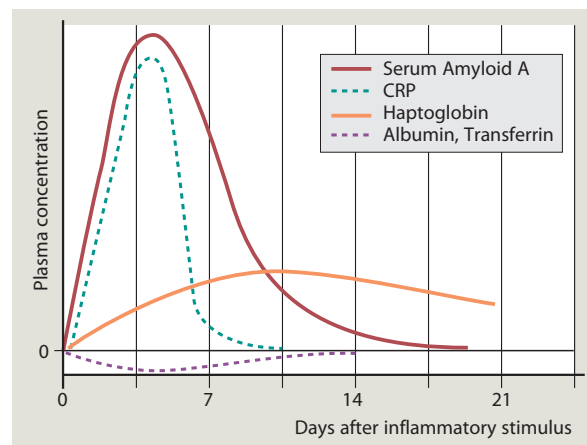


Fig. 11.5 Changes in plasma concentrations of selected acute phase proteins after an inflammatory stimulus

inflammatory diseases increase (*positive acute phase proteins*) or decrease (*negative acute phase proteins*) by at least 25% from baseline. The changes in concentration of these proteins are primarily due to alterations in their hepatocellular synthesis and secretion. The individual acute phase proteins differ both in the magnitude of concentration increase and in the time course of concentration changes (Fig. 11.5). Thus, for example, the concentration of ceruloplasmin increases by

approximately 50%, while the plasma levels of C-reactive protein and serum amyloid A may rise up to 1,000-fold in an acute inflammatory process.

The synthesis of acute phase proteins is induced by extracellular signaling molecules. Cytokines, which are released by activated macrophages, monocytes, fibroblasts and endothelial cells, and include IL-1, IL-6, TNF- α , IFN- γ , and TGF- β , stimulate the synthesis of acute phase proteins by hepatocytes. After binding of cytokines to hepatocytic membrane surface receptors, signals are transduced into the cell interior, impacting expression and regulation of specific genes primarily at the transcriptional level. Posttranscriptional and posttranslational mechanisms, however, also participate in the synthesis of acute phase proteins. Since IL-6 is involved in all actions of hepatic acute phase genes, it is regarded as the major regulator of the acute phase response. IL-6 binds to specific receptors on the hepatocyte membrane and enhances the transcription of genes that code for the acute phase reactants. Simultaneously, IL-6 diminishes the transcription of prealbumin and albumin-mRNA. Glucocorticoids usually enhance the stimulatory effects of cytokines on the synthesis of acute phase proteins.

Proinflammatory cytokines (IL-1, IL-6, TNF- α) also exert numerous other effects on hepatocytes. They increase, for example, the synthesis of the metal binding protein, metallothionein, thus enhancing zinc binding and leading to a decrease of plasma zinc levels. They stimulate the activities of inducible NO synthase, microsomal heme oxygenase, manganese superoxide dismutase, and tissue inhibitor of metalloproteinase (TIMP)-1 [10, 11, 29].

References

- Aleffi S, Petrai I, Bertolani C, et al (2005) Upregulation of proinflammatory and proangiogenic cytokines by leptin in human hepatic stellate cells. *Hepatology* 42: 1339–48
- Bertolino P, Klimpel G, Lemon SM (2000) Hepatic inflammation and immunity: a summary of a conference on the function of the immune system within the liver. *Hepatology* 31: 1374–8
- Crispe IN, Mehal WZ (1996) Strange brew: T cells in the liver. *Immunol Today* 17: 522–5
- Crosbie OM, Reynolds M, McEntee G, et al (1999) In vitro evidence for the presence of hematopoietic stem cells in the adult human liver. *Hepatology* 29: 1193–8
- De Creus A, Abe M, Lau AH, et al (2005) Low TLR4 expression by liver dendritic cells correlates with reduced capacity to activate allogeneic T cells in response to endotoxin. *J Immunol* 174: 2037–45
- Doherty DG, O'Farrelly C (2000) Innate and adaptive lymphoid cells in the human liver. *Immunol Rev* 174: 5–20
- Doherty DG, O'Farrelly C (2001) Dendritic cells: regulators of hepatic immunity or tolerance? *J Hepatology* 34: 156–60
- Edwards S, Lalor PF, Nash GB, et al (2005) Lymphocyte traffic through sinusoidal endothelial cells is regulated by hepatocytes. *Hepatology* 41: 451–9
- Exley MA, Koziel MJ (2004) To be or not to be NKT: natural killer T cells in the liver. *Hepatology* 40: 1033–40
- Gabay C, Kushner I (1999) Acute-phase proteins and other systemic responses to inflammation. *N Engl J Med* 340: 448–54
- Heinrich PC, Castell JV, Andus T (1990) Interleukin-6 and the acute phase response. *Biochem J* 265: 621–36
- Jonsson JR, Edwards-Smith CJ, Catania SC, et al (2000) Expression of cytokines and factors modulating apoptosis by human sinusoidal leukocytes. *J Hepatol* 32: 392–8
- Karrar A, Broome U, Uzunel M, et al (2007) Human liver sinusoidal endothelial cells induce apoptosis in activated T cells: a role in tolerance induction. *Gut* 243–52
- Kita H, Mackay IR, van de Water J, et al (2001) The lymphoid liver: considerations on pathways to autoimmune injury. *Gastroenterology* 120: 1485–501
- Knolle PA (2006) Involvement of the liver in the induction of CD8 T cell tolerance towards oral antigen. *Z Gastroenterol* 44: 51–6
- Lau AH, de Creus A, Thomson AW (2003) Liver tolerance mediated by antigen presenting cells: fact or fiction? *Gut* 52: 1075–8
- Lau AH, Thomson (2003) Dendritic cells and immune regulation in the liver. *Gut* 52: 307–14
- Mehal WZ, Azzaroli F, Crispe N (2001) Immunology of the healthy liver: old questions and new insights. *Gastroenterology* 120: 250–60
- Peters M, Vierling J, Gershwin ME, et al (1991) Immunology and the liver. *Hepatology* 13: 977–94
- Peters M (1996) Actions of cytokines on the immune response and viral interactions: an overview. *Hepatology* 23: 909–16
- Prickett TC, McKenzie JL, Hart DN (1988) Characterisation of interstitial dendritic cells in human liver. *Transplantation* 46: 754–61
- Recanelli V, Rehermann B (2006) The liver as an immunological organ. *Hepatology* 43: S54–62
- Reynoso-Paz S, Coppel RL, Mackay IR, et al (1999) The immunobiology of bile and biliary epithelium. *Hepatology* 30: 351–7
- Schwabe RF, Seki E, Brenner DA (2006) Toll-like receptor signaling in the liver. *Gastroenterology* 130: 1886–900
- Seki S, Habu Y, Kawamura T, et al (2000) The liver as a crucial organ in the first line of host defense: the roles of Kupffer cells, natural killer (NK) cells and NK1.1 Ag⁺ T cells in T helper 1 immune responses. *Immunol Rev* 174: 35–46
- Selmi C, Mackay IR, Gershwin ME (2007) The immunological milieu of the liver. *Semin Liv Dis* 27: 129–39
- Simpson KJ, Lukacs NW, Colletti L, et al (1997) Cytokines and the liver. *J Hepatol* 27: 1120–32
- Szabo G, Dolgianuc A, Mandrekar P (2006) Pattern recognition receptors: a contemporary view on liver diseases. *Hepatology* 44: 287–98

29. Trautwein C, Böker K, Manns MP (1994) Hepatocyte and immune system: acute phase reaction as a contribution to early defence mechanisms. *Gut* 35: 1163–6
30. Warren A, Le Couteur DG, Fraser R, et al (2006) T lymphocytes interact with hepatocytes through fenestrations in murine liver sinusoidal endothelial cells. *Hepatology* 44: 1182–90
31. Welsh RM, Lin MY, Lohman BL, et al (1997) Alpha beta and gamma delta T-cell networks and their roles in natural resistance to viral infections. *Immunol Rev* 159: 79–93
32. Winnock M, Garcia Barcina M, Lukomska M, et al (1995) Human liver-associated lymphocytes: an overview. *J Gastroenterol Hepatol* 10: S43–6

Chapter Outline

Endogenous Factors	153
Exogenous Factors	153
Liver Diseases in the Aged.....	155
References	155

Aging of cells and organs is a multifactorial, genetically controlled, physiological process that is affected by environmental factors. Aging of a cell begins with the moment of its creation. The process is associated with proliferation, differentiation, maturation and with progressive decline of physiologic performance. The functional deficit ends with death.

Endogenous Factors

To this day it is not clear whether the endogenous genetic program consists of activation of age-specific genes or whether it is determined by the loss of growth regulatory genes. An attractive aging hypothesis assumes genetic defects by shortening of telomeres. Telomeres are structures at the end of chromosomes. Human telomeres have a variable number of repeats of the sequence 5'-TTAGGG-3', which can extend for several kilobases. They stabilize the terminal chromosomal segments, anchor them to the nuclear matrix, and regulate the ability of the cell to proliferate. The enzyme responsible for their synthesis is the telomerase. The proliferation of human cells is accompanied by a progressive loss of telomerase activity. The loss of DNA at the chromosomal ends leads to a shortening of telomeres with deletion of important genes, and terminates in the inability of the cell to divide. The decrease of hepatic telomerase activity in old age might affect the ability of liver cells to proliferate and to regenerate, and to respond to injurious stimuli [3].

Exogenous Factors

The genetic factors are accompanied by exogenous influences of daily life, such as the lifelong summation of damaging factors. Oxidative stress by accumulating

free radicals causes structural and functional damage to membranes and cells (see Chapter 14). The accumulation of lipofuscin (“wear and tear pigment”) in senescent hepatocytes is the visible expression of lipid peroxidation. Free radicals also damage nucleic acids and enzymes. If the extent of DNA strand breaks exceeds the ability of the cell to repair the injury, the resultant damage will lead to a shortening of cell survival.

The primary structure of proteins does not alter in old age, but the number of posttranslational modifications increases. Nonenzymatic glycosylation of proteins results in the formation of advanced glycosylation end products (AGE) that may crosslink proteins and impair their function. The generation of AGE is well documented in diabetes mellitus; its significance for the liver, however, is unknown.

Age related changes in the formation of heat shock proteins (HSP), including the loss of HSP70, may impact defense mechanisms and thereby contribute to reduced cell survival.

With increasing age oxidative phosphorylation in mitochondria, the synthesis of DNA and RNA, and the levels of structural, enzymatic and receptor proteins diminish. The ability of the aging cell to react to injurious insults and to repair damaged DNA is impaired.

Little is known about the normal life span of human liver cells, since most data are derived from animal experiments. In prior autoradiographic studies, the fraction of H^3 -thymidine labelled hepatocyte nuclei was determined. Since thymidine is a component of DNA, the quantification over an extended period of time of these liver cell nuclei allowed for the calculation of the life span of labelled cells. The life span of normal rat hepatocytes, defined as the time to cell division or cell death, varies between 191 and 453 days [12]. In cirrhotic rat livers the life span of hepatocytes is reduced to approximately 26 days. Understandably, analogous data in man are lacking. Nevertheless, animal experiments suggest that the life span of the hepatocytes of a chronically diseased liver is shortened compared to hepatocytes of a healthy organ.

A liver cell does not show its age. Nevertheless, the progressive aging process is associated with structural changes. The portal tracts in aged livers are larger than in those of young adults, and the vessels contain more collagen. Scanning and transmission electron-microscopic examination reveals that aging is associated with pseudocapillarization of the sinusoidal endothelium, indicated by defenestration with reduced

porosity, thickening of the endothelium, and infrequent development of a basal lamina. Collagen deposits are found in the space of Disse. Immunohistochemistry studies show strong expression of collagen IV, moderate expression of factor VIII-related antigen, and weak expression of collagen I along the sinusoids of livers from old rats [9]. Thus, aging in the liver is associated with changes in the sinusoidal endothelium and the space of Disse that lead to a loss of permeability of the liver sieve and may restrict the availability of oxygen and other substrates [10]. In addition, pseudocapillarization of the hepatic sinusoidal endothelium may impair hepatic lipoprotein metabolism and impede lipoprotein transfer from the bloodstream to the hepatocyte, thus reducing hepatic clearance of lipoproteins [6]. Moreover, the composition of biologic membranes changes with increasing age. The cholesterol content increases, while the level of phospholipids and linolic acid diminishes.

With advancing age increased lysosomal deposition of lipofuscin is observed, along with a decrease of the smooth endoplasmic reticulum, the Golgi apparatus, and the ribosomes. The cell nucleus enlarges and its DNA content increases [4].

Mitochondrial damage may play a key role in liver aging. Age is associated with a decrease in mitochondrial membrane potential, an increase in mitochondrial size, and an increase in mitochondrial peroxide generation. A correlation has been shown between age-associated impairment of cell metabolism and specific changes in mitochondrial function (e.g. impairment of the mitochondrial malate transporter) and morphology [13].

Conventional liver tests, such as serum bilirubin, aminotransferases or alkaline phosphatase do not show age specific changes. Other morphological and functional liver parameters, however, do show alterations with advancing age (Table 12.1). Between the

Table 12.1 Age-related morphological and functional changes of the liver (According to [15])

Morphology	
	Reduction in liver weight
	Reduction in number of liver cells
	Increase in liver cell size
	Reduction in number of mitochondria
Function	
	Reduction in liver blood flow
	Reduction in proliferative capacity of hepatocytes
	Altered pharmacokinetics

5th and 7th decade the liver weight decreases by approximately 30–50%, and liver size decreases by 18–25%. In persons over 65 years of age liver blood flow is reduced by 30–50%, while liver perfusion (blood flow per volume unit) decreases by only 11% [2, 8]. Concurrent with the reduction in liver volume and liver blood flow, metabolic activities and dynamic liver function tests, such as galactose-elimination, aminopyrine-demethylation and caffeine clearance, are reduced. Hepatic nitrogen clearance in aging man may diminish up to 50% [5, 11, 16].

Hepatic drug metabolism in aged people is impaired only to a minor degree [17]. The reduction in liver volume, liver blood flow and perfusion may at least partly account for this decline in hepatic drug clearance. In animal experiments both the basal activity and the inducibility of the microsomal cytochrome P450 system is reduced in older animals. Reduction of biotransformation phase I reactions in the elderly may lead to high peak blood concentrations of various drugs. Phase II reactions, including conjugation, formation of mercaptan and acetate are not impaired in advanced age [1, 14, 18].

Liver Diseases in the Aged

There are no age specific liver diseases, but age can affect the course and prognosis of some liver disorders [7].

Hepatitis A often runs a more severe course in old than in young patients. The seroconversion rate after hepatitis A vaccination, both in the young and elderly is greater than 90%. Therefore, nonimmune older people, when travelling to Hepatitis A endemic areas should also be vaccinated.

Acute liver failure has a worse prognosis in older people.

Chronic viral hepatitis do not have a different clinical course in the old compared to the young. However, the rate of chronic virus carriers after infection with the *hepatitis B virus* is higher in old people. This is probably caused by a reduced immune response in the elderly with subsequent impaired virus elimination. The response to vaccination against hepatitis B is also reduced in older age. The prevalence of *chronic hepatitis C* seems to increase with age. In southern Italy, for example, approximately 42% of people over 60 years are anti HCV positive, compared

to 11% of those younger than 35 years. These impressive figures, however, were not reproduced in other regions in Europe or in the USA. Side effects of interferon therapy do not occur more often, nor are they more pronounced in the elderly. Nevertheless, treatment in old age with interferon generally is not warranted, since untreated chronic hepatitis C will lead to a reduced life expectancy in only 4% of this patient population.

While in the past the upper age limit for organ donation for *liver transplant* was 50 years, nowadays even an age of over 60 years per se does not represent a contraindication for organ donation. Although the liver from an older donor may be more susceptible to ischemic injury, there is no evidence that this impacts long-term prognosis. At present, liver transplants are also performed successfully in older recipients. The post-operative complications in older patients are comparable to those of younger people.

References

1. Barber DJ, Fairhurst S, Horton AA (1983) Effect of old age on paracetamol induced lipid peroxidation in rat liver. *Toxicol Lett* 15: 283–7
2. Boyd WP (1933) Normal variability in weight of the adult human liver and spleen. *Arch Pathol* 16: 350–72
3. Cotran RS, Kumar V, Robbins SL (1999) Cellular aging. In: Robbins (ed), *Pathologic basis of disease*. 6th edn. WB Saunders, Philadelphia, PA, pp 45–8
4. David H, Peinke P (1988) Liver morphology with aging. In: Bianchi L (ed), *Aging in liver and gastrointestinal tract*. MTP, Lancaster, pp 143–59
5. Fabbri AA, Marchesini A, Bianchi G, et al (1994) Hepatic nitrogen clearance in ageing man. *Liver* 14: 288–92
6. Hilmer SN, Cogger VC, Fraser R, et al. (2005) Age-related changes in the hepatic sinusoidal endothelium impede lipoprotein transfer in the rat. *Hepatology* 42: 1349–54
7. James OFW (1997) Parenchymal liver disease in the elderly. *Gut* 41: 430–2
8. Kitani K (1990) Aging and the liver. In: Popper H, Schaffner F (eds) *Progress in liver disease*, vol. 9, W.B. Saunders, Philadelphia, PA, pp 603–23
9. Le Couteur DG, Cogger VC, Markus AMA, et al (2001) Pseudocapillarization and associated energy limitation in the aged rat liver. *Hepatology* 33: 537–43
10. Le Couteur DG, Fraser R, Cogger VA, et al (2002) Hepatic pseudocapillarisation and atherosclerosis in ageing. *Lancet* 359: 1612–5
11. Liu Y, Guyton KZ, Gorospe M, et al (1996) Age-related decline in mitogen activated protein kinase activity in epidermal growth factor-stimulated rat hepatocytes. *J Biochem* 271: 3604–7

12. MacDonald RA (1971) "Lifespan" of liver cells. *Arch Intern Med* 107: 335–43
13. Sastre J, Pallardo FV, Pla R, et al (1996) Aging of the liver: age-associated mitochondrial damage in intact hepatocytes. *Hepatology* 24: 1199–205
14. Vestal RE (1989) Aging and determinants of hepatic drug clearance. *Hepatology* 9: 331–4
15. Weik C, Strohmeyer G (1999) Hepatobiliäre Erkrankungen im Alter. *Dtsch med Wschr* 124: 466–71
16. Wood AJJ, Vestal RE, Wilkinson GR, et al (1979) Effect of aging and cigarette smoking on antipyrine and indocyanine green elimination. *Clin Pharmacol Ther* 26: 16–20
17. Woodhouse KW, James OFW (1990) Hepatic drug metabolism and ageing. *Br Med Bull* 46: 22–35
18. Wynne HA, Cope LH, Mutch E, et al (1989) The effect of age upon liver volume and apparent liver blood flow in healthy man. *Hepatology* 9: 297–301

Chapter Outline

Definition.....	158
Morphology of Liver Regeneration.....	158
Hepatic Stem Cells.....	159
Extracellular Matrix.....	159
Angiogenesis.....	160
Regulators of Hepatic Growth.....	160
Hormones and Neurotransmitters.....	160
Growth Factors and Cytokines.....	161
Neural Factors.....	163
Nutrients.....	163
Cell Cycle and Cell Proliferation.....	163
Molecular Mechanisms of Liver Regeneration.....	164
Alternate Pathways in Liver Regeneration.....	167
Termination of Liver Regeneration.....	167
References.....	167

For nearly 100 years the mechanisms by which viable, functioning parenchyma replaces lost or non-functional liver tissue are the subject of intense research, utilizing increasingly more sophisticated techniques. Initial morphological methods were complemented by biochemical techniques in the ensuing decades. Presently, combined genetic and molecular investigations represent the state of the art [5].

Loss of liver tissue is the most potent stimulus for hepatic regeneration. The development of two-thirds partial hepatectomy (PHx) in the rat liver by Higgins and Anderson in 1931 represented a methodological milestone in the exploration of liver regeneration [24]. Until today this simple and reproducible technique serves as the basis for most investigations dealing with liver regeneration.

The most basic parameter of hepatic regeneration is *liver weight*. However, restoration of liver weight after loss of liver tissue is a very crude parameter, also influenced by hepatocellular deposits that are not related to liver regeneration. Conclusions regarding mechanisms of liver regeneration cannot be drawn from changes in liver weight. *Cell proliferation* may be determined, for example, by calculating the fraction of cells undergoing mitosis or proliferating in relation to quiescent cells. Determining mitotic indexes by counting mitotic cells is time consuming and cumbersome. Determining the incorporation of tritiated thymidine into DNA requires the application of radioactive material and understandably cannot be performed in man. Immunocytochemical labeling of nuclear antigens with proliferation markers, such as Ki-67 or proliferating cell nuclear antigen (PCNA), is relatively simple. The quantitative analysis, however, is time consuming. Quantification of tissue proteins and enzymes (e.g. putrescine, ornithine decarboxylase, thymidine kinase) is affected by the nutritional status and is not precise. The plasma levels of

thymidine kinase, ornithine decarboxylase, fibronectin and α -fetoprotein can be determined quite easily; however, the significance of these compounds for assessing liver regeneration is not clear.

The study of changes in *biochemical properties* combined with the investigation of varying *gene expression patterns* are modern techniques applied in the exploration of liver regeneration. When used in isolated cells or cell cultures, these techniques are demanding and require elaborate DNA technologies. However sophisticated, no single method can claim to be the gold standard in investigating liver regeneration.

Hepatic regeneration is an extremely complex process. It involves a network of autocrine, paracrine and endocrine signals. The complete morphological and functional restoration of the liver requires a finely tuned interaction between parenchymal and nonparenchymal cells, components of the extracellular matrix, and a tight coordination of factors stimulating and inhibiting cell proliferation. Growth initiating signals stimulate, via hepatic receptors, action cascades of secondary messengers, protein kinases, proto-oncogenes and clusters of genes important for cell growth. Despite decade long efforts, however, the physiologic regulators of liver regeneration are unknown up to this day. The vast majority of hitherto available data was obtained from animal experiments. These findings, as well as data from research on isolated human cells or cell cultures, cannot be simply extrapolated to the human situation *in vivo*; despite this fact, no sharp distinction will be made in this chapter between animal and human data in order to provide a framework of understanding for the basic concepts involved in liver regeneration.

Definition

Physiologic liver regeneration denotes the full morphological and functional preservation of hepatic tissue by replacement of physiologically dying parenchymal and nonparenchymal cells. The liver belongs to the stable tissues and has a low mitotic rate; therefore, in conventional sections this physiologic cell replacement is not easily recognized. The healing of liver defects caused by cell injury or cell loss is called *pathologic* or *reparative regeneration*. If the cell defect is compensated by hyperplasia of cells identical to those lost, regeneration is *complete*; if the defect is replenished by surrogate

tissue an *incomplete regeneration* is present. Thus, the complete physiologic regeneration implies a compensatory hyperplasia with complete restoration of the normal histological architecture and organ-specific functions.

Morphology of Liver Regeneration

Morphologic signs of hepatic regeneration include an increased cell proliferation (hyperplasia) and mitotic rate. This is evidenced by thickening of liver cell plates with widespread double-cell plates which makes sinusoids more difficult to discern. The hepatocyte nuclei show an increased variation in size, and the fraction of bi- and polynucleated hepatocytes is augmented. Proliferating hepatocytes have a clear cytoplasm and contain less pigment (lipofuscin, siderin) even near terminal venules. Accumulation of lipid droplets in hepatocytes is seen in the first 48 h after PHx. This is associated with an increase in fatty acid and lipid synthesizing enzymes. Pseudoglandular structures (rosettes) are formed by grouping of several liver cells around a central lumen. Inflammatory cellular infiltrates are absent; Kupffer cell reaction is lacking or minimal.

Cholangiocytes also proliferate after PHx, metabolic-toxic, immunologic or mechanical injury. Cholangiocyte proliferation occurs as a *ductular reaction* or as a *proliferation of portal bile ducts* (see Chapters 20 and 26) [52]. The ductular reaction is observed primarily as a regenerative phenomenon when there is extensive loss of liver parenchyma or in the context of hepatocarcinogenesis. Proliferation of portal bile ducts is seen in mechanical bile duct obstruction and in chronic cholestatic diseases, such as primary biliary cirrhosis and primary sclerosing cholangitis.

Ductular hepatocytes are small cells with oval nuclei and prominent nucleoli (Fig. 3.20). They delimit an ill defined lumen and do not reside on a basement membrane. They are localized at the interface between the portal tract and the lobular parenchyma, and extend into necrotic parenchymal areas. They are believed to correspond to rat oval cells and are ascribed stem cell potential, i.e. they have the ability to transform into hepatocytes or biliary epithelial cells (see below) [15, 40].

Ductular cell proliferation has to be distinguished from *proliferation of portal bile ductules*. Bile ductules consist of small epithelial cells with round to oval nuclei; they reside on a basement membrane and

Table 13.1 Regulation of cholangiocyte proliferation

	Stimulation	Inhibition
Cytokines/growth factors	IL-1 α , IL-6, TGF- α , TNF- α , EGF HGF, IGF-1	TGF- β
Hormones/neuropeptides	Estrogens, acetylcholine, PTHrP	Somatostatin, Gastrin
Bile acids	LCA, TCA, TLCA	UDCA, TUDCA

LCA Lithocholic acid, TLCA taurolithocholic acid, TCA taurocholic acid, UDCA ursodeoxycholic acid, TUDCA tauroursodeoxycholic acid, PTHrP parathyroid hormone related peptide. See text for further abbreviations

Source: Adapted from [4]

delineate a central lumen. Proliferating bile ductules characteristically are found inside, albeit at the periphery of the portal tract, bordering periportal liver parenchyma; they are accompanied by a cellular inflammatory infiltrate of neutrophil granulocytes.

Proliferating cholangiocytes acquire phenotypic characteristics of neuroendocrine cells. They express neuroendocrine markers, such as S-100 and chromogranin A. They express parathyroid hormone related peptide, an incomplete mitogen that requires epidermal growth factor and transforming growth factor β to stimulate cell division. Furthermore, their response to hormones, neuropeptides and transmitter substances, such as secretin, somatostatin and acetylcholine is increased. A selection of regulators of cholangiocyte proliferation are reported in Table 13.1.

Hepatic Stem Cells (See Chapter 3)

Under normal conditions, there is no standing population of liver stem cells. When liver tissue is lost and hepatocyte proliferation is downregulated or arrested, the biliary compartment can generate oval cells (in rodents) (“ductular hepatocytes” in humans). Thus, the biliary tree harbors facultative stem cells for hepatocytes [17, 31, 51]. The opposite may also be true, i.e. hepatocytes may transform to biliary epithelial cells. This mechanism seems to be important in the repair of bile duct injury in situations where cholangiocytes cannot compensate for biliary injury [30]. Whether hepatic stem cells originate only in the liver or derive also from bone marrow hematopoietic progenitor cells which secondarily populate the liver is a matter of debate [2, 3, 13, 19, 22, 23, 35, 38, 43, 48, 49].

However, both pathways are not mutually exclusive. Recent findings also indicate that hepatic stellate cells represent a progenitor cell compartment, which can differentiate not only into myofibroblasts, but also into endothelial cells and hepatocytes.

Extracellular Matrix

The extracellular matrix plays a major role in the regulation of hepatocyte proliferation. It impacts the expression of key elements of cell-cycle control, such as cyclin A and D1 and cyclin dependent kinase inhibitors p21 and p27 (see below) [33]. Moreover, hepatocyte growth factor (HGF) is produced by extracellular matrix cells.

Liver regeneration is associated with orderly remodeling of the extracellular matrix, which is the prerequisite for undisturbed liver cell proliferation. Remodeling of the extracellular matrix proceeds through two major pathways. The first pathway is associated with *activation of urokinase*, which causes enhanced transformation of plasminogen to plasmin. Plasmin activates a variety of matrix related metalloproteinases (MMP) [31]. The concentrations of inactive MMP (pro MMP-2 and pro MMP-9) rise 30 minutes after PHx. Activation of MMP9 is seen at 2–4 h after PHx and MMP9 protein can be demonstrated by immunocytochemistry in periportal hepatocytes, from where it gradually expands through the midzonal to the pericentral areas of the lobule. In addition, urokinase may release and activate HGF (see below). Both HGF and epidermal growth factor bind to the extracellular matrix in the periportal areas. The second pathway is mediated through a family of *membrane bound metalloproteinases* (MT MMP). Twelve to 48 h after PHx, MT1 MMP, acting together with tissue inhibitor of metalloproteinase 2 (TIMP2), activates MMP2. The levels of TIMP1 are increased at 6–18 h after PHx. These data suggest that TIMP regulate the activities of MMP2 and MMP9, which are important factors in hepatic regeneration and probably contribute to the priming of hepatocytes after PHx [25]. MMP9 affects matrix remodeling, as well as cytokine, growth factor, and caspase expression [36].

Changes in several extracellular matrix proteins are seen soon after PHx, including fibronectin, laminin, entactin. TGF- β , a mitoinhibitory cytokine, binds to decorin, an extracellular matrix protein attached to the plasma membrane.

Angiogenesis

Restoration of normal liver histology requires the formation of a vascular network. Angiogenesis is very precisely regulated after PHx and proliferation of the sinusoidal endothelial cells peaks 2–3 days after PHx. Replicating endothelial cells invade the poorly vascularised hepatocyte clusters, permeate them and form new sinusoids. A wide variety of angiogenic factors (including vascular endothelial growth factor [VEGF], angiopoietins 1 and 2) produced by regenerating hepatocytes, stimulate proliferation of endothelial cells. In addition to their mitogenic effects, growth factors, such as TGF- α , FGF1, FGF2 and HGF (see below) also have angiogenic effects. Recent studies have shown a positive feedback proliferative loop between hepatocytes and endothelial cells. Proliferating hepatocytes produce VEGF which, in addition to its angiogenic action stimulates the production of HGF in endothelial cells [31]. A proliferative response of the finer branches of the biliary tree might induce biliary vascularization after biliary injury, which seems to be a prerequisite for bile duct regeneration [50].

Regulators of Hepatic Growth

Hepatic growth regulators can be divided into three groups:

- Complete liver cell mitogens
- Comitogenic growth factors
- Growth inhibitors

Complete mitogens are substances that directly stimulate DNA synthesis and mitosis of cultured hepatocytes in a serum free medium. Epidermal growth factor (EGF), transforming growth factor- α (TGF- α), hepatocyte growth factor (HGF) and fibroblast growth factor (FGF) are complete mitogens.

Comitogens have no direct proliferative effect on cultured hepatocytes, but they enhance the stimulatory effects of complete mitogens and reduce the inhibitory effects of growth inhibitors. Insulin, glucagon, growth hormones, insulin-like growth factors, adrenal cortical, thyroid and parathyroid hormones as well as Ca⁺⁺, vitamin D, prostaglandins, estrogens and certain

cytokines (e.g. TNF- α , IL-1 and IL-6) are among the comitogenic compounds [16, 18, 21, 29].

TGF- β , hepatic proliferation inhibitor, and certain interleukins rank among the *inhibitors of hepatic regeneration*.

Hormones and Neurotransmitters

Insulin and glucagon. In the intact liver insulin and glucagon do not stimulate DNA synthesis significantly. During liver regeneration, however, hepatic extraction of insulin and glucagon from the portal venous circulation increases and the infusion of insulin and glucagon after PHx nearly doubles DNA synthesis. The ratio of insulin to glucagon levels (\uparrow insulin, $\uparrow\uparrow\uparrow$ glucagon) in the portal venous circulation appears to be of major importance in stimulating hepatic regeneration. In addition, insulin has a synergistic effect on the EGF-stimulated liver cell proliferation.

Thyroid hormones. T3 and T4 stimulate hypertrophy and hyperplasia of liver cells. In hypothyroid animals the regenerative activity after PHx is diminished. Addition of T3 enhances the regenerative capacity of the liver following PHx [27]. However, the contribution of thyroid hormones to liver regeneration under physiologic conditions *in vivo* is poorly understood and probably of secondary importance.

Calcitonin. Calcitonin stimulates liver cell proliferation *in vitro*.

ACTH and adrenal cortical hormones. ACTH and glucocorticoids cause hepatomegaly by inducing hypertrophy of hepatocytes. The impact of glucocorticoids on liver cell growth is dose dependent and is influenced by the culture conditions, so that presently their physiologic effects on the liver cannot be assessed. In pharmacologic doses glucocorticoids slow down liver cell proliferation after PHx.

Catecholamines. Catecholamines probably are physiologic regulators of the early phase of liver regeneration. Norepinephrine and epinephrine levels in plasma rise sharply within 30 min after PHx. Norepinephrine – the neurotransmitter of the sympathetic nervous system and product of the medullary cells of the adrenal glands – exercises its effects through the α -1 adrenergic receptor. Norepinephrine synergizes and increases the mitogenic effects of HGF and EGF and partially counteracts the mitoinhibitory activity of TGF- β , thus stimulating the

initiation of DNA synthesis within hepatocytes. In addition, norepinephrine induces stellate cells to produce extracellular matrix, which impacts liver regeneration.

Serotonin. Recent animal experiments show that thrombocytopenia, or impaired platelet activity (platelets are major carriers of serotonin in the blood) result in the failure to initiate liver cell proliferation. This failure of regeneration can be rescued by reloading serotonin-free platelets with a serotonin precursor molecule. These results suggest that platelet-derived serotonin is involved in the initiation of liver regeneration [26].

Parathyroid hormone and calcium. In the early phase of liver regeneration the secretion of parathyroid hormone and calcitonin is increased. The intracellular concentration of the Ca⁺⁺-binding protein calmodulin is increased. The extracellular Ca⁺⁺ concentration appears to be important for entry of hepatocytes into the S-phase of the cell cycle.

Prolactin. Immediately after PHx prolactin levels in serum transiently surge. Repeated injections of prolactin cause a slight stimulation of hepatic DNA synthesis. Again, the physiologic significance of these findings is unclear.

Vasopressin, estrogens and androgens. The significance of these hormones for the regeneration of the human liver is unknown; however, they probably do not have a significant physiologic role.

Growth hormone. Growth hormone stimulates liver cell regeneration, especially when given a few hours prior to PHx; however, the physiologic significance of growth hormone on hepatic regeneration is uncertain.

Growth Factors and Cytokines

Hepatocyte Growth Factor (HGF). HGF was originally identified in plasma from patients with fulminant hepatic failure and was cloned in 1989 [8, 32, 34]. HGF is a heterodimer, consisting of a large α - and a small β -subunit. There is extensive amino acid sequence homology with plasminogen. HGF is produced in an inactive form and is then activated by numerous proteinases, including urokinase plasminogen-activator, plasmin and cathepsins. The main source of HGF is the liver, but it is also synthesized in the lungs and kidneys. Hepatic HGF is produced by nonparenchymal cells of the extracellular matrix and is localized in the extracellular matrix, bound to matrix proteins.

HGF is a multifunctional cytokine. It is the *most potent hepatocyte mitogen* but also enhances proliferation of many other cell types. Infusion of HGF into the liver of experimental animals causes massive hepatic enlargement. Scatter factor, a cytokine that induces cell motility, was found to be identical to HGF. Based on this discovery HGF is also sometimes referred to as HGF/SF [31]. During morphogenesis, binding of HGF to its receptor induces mitogenic and motogenic effects.

HGF acts after binding to its cell surface receptor, which is the product of the proto-oncogene *c-met*, a transmembrane receptor kinase. The HGF receptor is activated by tyrosine phosphorylation within 30–60 min after PHx. HGF mRNA increases in the regenerating liver, starting at 3 h after PHx with peak levels reached by 24 h. HGF concentration rises 20-fold in the plasma shortly after PHx and elevated activity persists for more than 48 h. The HGF rise in peripheral blood is probably related to the release and activation of HGF from the rapidly remodeling hepatic extracellular matrix stores. In addition to its mitogenic effects, HGF has been shown to upregulate the expression of several anti-apoptotic proteins associated with signal transduction, such as Bcl X.

Thus, the available evidence suggests that HGF appears to be of key importance to liver regeneration, and the effects of HGF and epidermal growth factor are synergistic. Together they provide the strongest mitogenic stimulus known for hepatocytes [7].

Epidermal Growth Factor (EGF). EGF is a potent mitogen for epithelial and mesenchymal cells [28]. It is a direct mitogen for hepatocytes and stimulates DNA synthesis by directly interacting with nuclear structures. Infusion of EGF into the portal vein causes DNA synthesis in periportal hepatocytes. EGF enhances the proliferative effects of TGF- α and HGF. Insulin stimulates the proliferative effects of EGF on hepatocytes. Plasma levels of EGF are not increased following PHx; however, there is enhanced tyrosine phosphorylation (activation) of the EGF receptor within 30–60 min after PHx. The physiological significance of EGF is not clear. EGF might be a primary regulator of liver growth and contribute (possibly together with insulin) to the mitogenic signaling events during the early stages of liver regeneration. Amphiregulin, a member of the EGF family whose expression is not detectable in the healthy liver, may contribute to the initial phases of liver regeneration after PHx [6].

Transforming Growth Factor alpha (TGF- α). TGF- α shows a 30–40% amino sequence homology with EGF and acts through binding to the EGF receptor. Its effects are analogous to those of EGF, and TGF- α has strong mitogenic effects on all hepatic cell types. Direct infusion of TGF- α to the hepatic circulation stimulates DNA synthesis in hepatocytes and proliferation of liver cells. TGF- α mRNA increases in hepatocytes starting at 3–5 h after PHx and peaks at 24 h. TGF- α reaches its peak concentration 24–48 h after PHx.

Despite these data the physiologic significance of TGF- α in liver regeneration is still controversial. Data suggesting a key role are opposed by findings showing TGF- α deficient mice to have normal liver regeneration, suggesting that the role of TGF- α in liver regeneration may not be crucial or may be compensated by other EGF receptor ligands [31]. TGF- α produced in hepatocytes may be involved in the generation of mitogenic signals for the adjacent cells expressing the EGF receptor, including HSC and sinusoidal endothelial cells. It could function as an autocrine regulator, enhancing liver regeneration after the process has been initiated by other signals.

Transforming Growth Factor beta (TGF- β). The TGF- β family comprises three members (TGF- β 1–3). TGF- β 1 is a potent growth inhibitory and profibrogenic cytokine produced primarily by Kupffer cells and to a minor degree by sinusoidal endothelial and stellate cells. It inhibits proliferation of hepatocytes and counteracts the effects of mitogens, such as HGF and EGF [42]. Norepinephrine decreases the mitoinhibitory effects of TGF- β 1 (see above). TGF- β 1 is present in the extracellular matrix in its latent form, bound to the plasma membrane protein decorin. The active form of TGF- β 1 is generated by the proteolytic action of plasmin (generated by activation of plasminogen by urokinase) on TGF- β 1.

TGF- β 1 mRNA increases in the liver beginning at 3 hours and peaking from 24 to 72 h after PHx. TGF- β 1 increases rapidly in plasma after PHx in the same pattern as HGF [14]. Active TGF- β 1 circulating in plasma is rapidly inactivated by binding to the plasma protein α_2 -macroglobulin. During liver regeneration TGF- β 1 immunoreactivity is initially seen in periportal hepatocytes and then progresses as a wave towards the pericentral area of the lobule; the periportal hepatocytes then become TGF- β 1 negative again.

In addition to its mitoinhibitory effects on hepatocytes, TGF- β 1 has strong mitogenic effects, stimulating hepatocyte migration across barriers, TGF- β 1 also affects production and remodeling of extracellular

matrix, which is crucial for liver regeneration to proceed orderly.

The precise physiologic role of TGF- β 1 in liver regeneration is not known. It is believed that, by affecting the balance between mitogens (HGF, EGF) and mitoinhibitors (TGF- β 1, activin), TGF- β 1 may be involved in termination of liver regeneration, after liver mass has been restored.

Fibroblast Growth Factors (FGF). The family of FGF encompasses 23 members that are mitogenic for several cell types, including hepatocytes. Acidic and basic FGF (FGF1 and FGF2) stimulate hepatocyte proliferation in the regenerating liver. The effects of FGF are mediated through four FGF receptors, which constitute transmembrane tyrosine kinases. After PHx, FGF is secreted by parenchymal and nonparenchymal cells. The peak levels of acidic FGF mRNA correspond roughly to the maximal DNA synthesis and remain elevated for 7 days. The role of FGF in regeneration is not clear. Acidic FGF might function as a signal that maintains the early phases of regeneration and also contributes to the termination of cell proliferation.

Insulin-like Growth Factors (IGF). IGF are produced in the liver as a result of growth hormone action on the hepatocyte. While the normal, quiescent liver does not express IGF-receptors, the regenerating liver probably does. The data regarding enhancement of regeneration by IGF are conflicting.

Tumor necrosis factor alpha (TNF- α). TNF- α is an important hepatotrophic cytokine [41]. It is produced mainly by resident hepatic macrophages (Kupffer cells). In animal experiments exogenously administered TNF- α stimulates hepatic DNA synthesis and accelerates liver weight gain after PHx. Anti TNF- α antibodies inhibit these effects, which are also absent in TNF- α receptor knockout mice [1]. TNF- α is one of the earliest cytokines that are induced after PHx and might trigger liver regeneration. TNF- α stimulates the production of IL-6 in hepatocytes, as well as in Kupffer cells, and augments the mitogenic effects of HGF and TGF- α . These effects are mediated by activation of intracellular signals and transcription factors, such as STAT3 and NF- κ B (Fig. 13.1). *TNF- α mediated activation of NF κ B is a key event in liver regeneration.* Indeed, the pro-mitogenic activity of TNF- α depends on whether TNF- α induces activation of NF κ B. NF κ B travels to the nucleus and affects transcription of several genes associated with cell replication. Our current understanding is that TNF- α is a mitogenic factor that “primes” hepatocytes and enhances their sensitivity to direct mitogens, such as HGF and TGF- α .

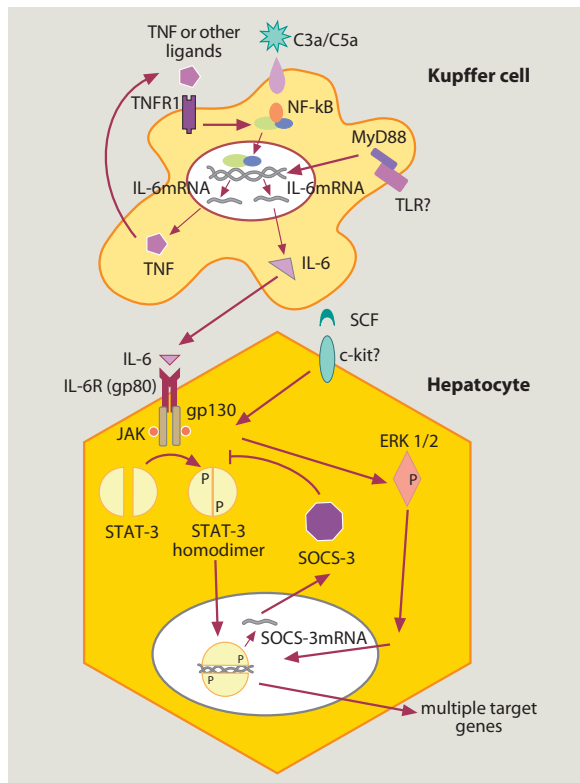


Fig. 13.1 Cytokine pathways activated during liver regeneration. See text for abbreviations (Adapted from [20])

Interleukin 6 (IL-6). IL-6 is a pleiotropic, multifunctional cytokine produced by Kupffer cells. It is associated with induction of the “acute phase response”, in which hepatocytes produce a spectrum of proteins in response to systemic acute inflammation or infection (see Chapter 11). The role of IL-6 in liver regeneration is not clearly defined; however, it is the strongest inducer of STAT3 in hepatocytes [46]. IL-6 deficient mice show a markedly reduced hepatocyte proliferation after loss of hepatic parenchyma [12]. The proliferation rate is nearly normalized by prior administration of IL-6 [37]. The DNA synthesis of nonparenchymal cells is not affected by lack of IL-6; however, IL-6 is a direct mitogen for biliary epithelial cells. IL-6 is required for the expression of certain early genes after PHx. After binding to its receptor on the hepatocyte surface (gp80/gp130 complex), signal transduction occurs by activation of a tyrosine kinase of the Janus kinase family (JAK) and phosphorylation (activation) of cytoplasmic STAT (signal transducer and activator of transcription) Protein 3. Activated cytoplasmic STAT3 enters into the cell nucleus, binds to and transactivates promoter genes (Fig. 13.1) (see below) [44].

Interleukin 15 (IL-15). IL-15 inhibits apoptosis and increases cellular proliferation and differentiation. Recently IL-15 has been shown to increase hepatic regenerative activity [45].

Stem Cell Factor (SCF). SCF is a ligand of the receptor c-Kit. Hepatocyte proliferation after PHx is decreased in SCF deficient mice, and administration of SCF to IL-6 deficient mice enhances hepatocyte proliferation [39].

Neural Factors

A marked increase of adrenergic nerves in the portal tracts may be observed in the regenerating liver and neurotransmitters may affect the proliferation of hepatocytes and cholangiocytes (see above). Sympathectomy, on the other hand, reduces DNA synthesis in the regenerating liver. Whether these observations reflect a physiologic role of neurotransmitters in hepatic regeneration is not known.

Nutrients

Starvation for 48 h prior to PHx slows down hepatocyte proliferation and reduces liver regeneration, although it does not halt the process completely. Overfeeding also retards hepatic regeneration. Therefore, an adequate and balanced supply of nutrients is necessary for liver regeneration to proceed optimally.

Cell Cycle and Cell Proliferation

Cell growth, division, differentiation, maturation and death are closely related events in the live cycle a cell. In the adult liver more than 99% of hepatocytes are in the *resting phase* G_0 . After being activated the cell enters into the G_1 -*phase*, in which, after intracellular signal transduction certain genes are transcribed and the synthesis of specific proteins is induced. If the process continues, the cell reaches the *restriction point* in the late G_1 -*phase*. From this “point of no return” the full cell cycle has to be completed. The restriction point probably corresponds to the genetically determined start of DNA polymerase synthesis. The subsequent

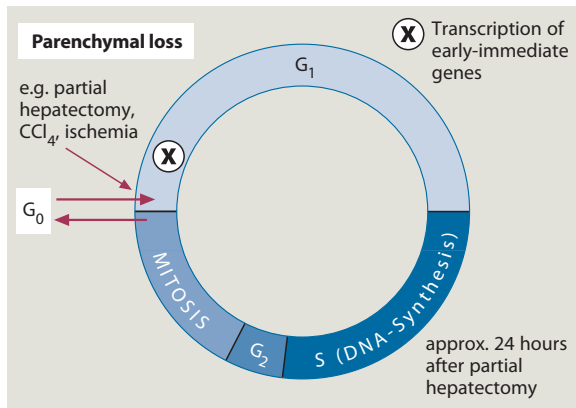


Fig. 13.2 Cell cycle. In the adult liver nearly all cells are in the resting phase G_0 . After partial hepatectomy (PHx) all hepatocytes undergo at least one division, with most liver cells dividing several times. Accompanied by the de novo transcription of immediate early genes, the cells rapidly enter into the G_1 -phase. The peak of DNA synthesis occurs 24 h after PHx, and is swiftly followed by the G_2 -phase and mitosis (M-phase). As soon as the critical liver cell mass is restored, the hepatocytes return to the G_0 -phase

S-phase is characterized by the replication of DNA. After a short G_2 -phase the cell divides mitotically in the *M-phase* (Fig. 13.2). For the cell cycle to proceed undisturbed, the cell must pass control points in each phase. In human tissue the duration of the S-, G_2 - and M-phase is relatively constant. The differences in the length of the cell cycle between various tissues are mainly due to the varying length of the G_1 -phase which may last for days or even years.

The liver belongs to the stable, postmitotic tissues. Hepatocytes are long-living cells which under physiologic conditions rarely divide, and whose mitotic rate is low. The turnover of liver cells is very slow; it amounts to 150–400 days. Pulse chase studies with tritiated thymidine show that [3 H] thymidine is incorporated into the DNA of periportal hepatocytes, whose replication rate is higher than that of perivenular liver cells. Cell kinetic investigations of the rat liver have originated the idea that during development hepatocytes migrate along the liver plates from their place of origin in the periportal zone towards the central vein [53]. During this process they mature, differentiate and grow old. However attractive, this hypothesis of the “streaming liver” has not been substantiated and still is controversial [9]. Indeed, it seems more probable that during development hepatocytes remain in one place and do not “flow” through the lobule. Hepatocytes after PHx divide only once or twice; this observation suggests that their proliferative capacity is low. The clonal growth of transplanted hepatocytes,

however, testifies to their high replication potential, comparable to that of progenitor cells in proliferating tissues.

Changes in functional liver mass elicit adaptive processes. After mechanical, toxic-metabolic, infectious or immunological cell injury or increased functional stress, liver cell metabolism favors proliferation and increased cell division. *The most potent stimulus for liver regeneration is partial hepatic resection*. Six to 10 days after PHx in the rat the liver cell mass is completely restored. Another impressive example of liver regeneration caused by a functional deficit is the transplantation of a small donor liver into a large recipient (“small for size” graft). The sensor for growth regulation is not the liver mass per se, but the *ratio of liver mass to body mass*. The regulation of liver mass works also the other way around. A “large for size” graft shrinks after transplantation. In this case liver mass is probably restored to normal by apoptosis.

Molecular Mechanisms of Liver Regeneration

Liver regeneration is a genetically controlled and regulated process and involves the activation of cytokine, growth factor and metabolic networks (Fig. 13.3) [20]. After experimental PHx a generalized, synchronized proliferative response of the remaining liver tissue ensues. This response initiates in the periportal zones and during the course of the regenerative process engages the entire lobule. In Fig. 13.4 the time course

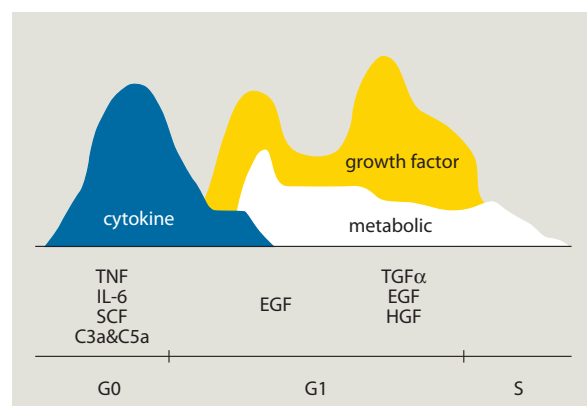
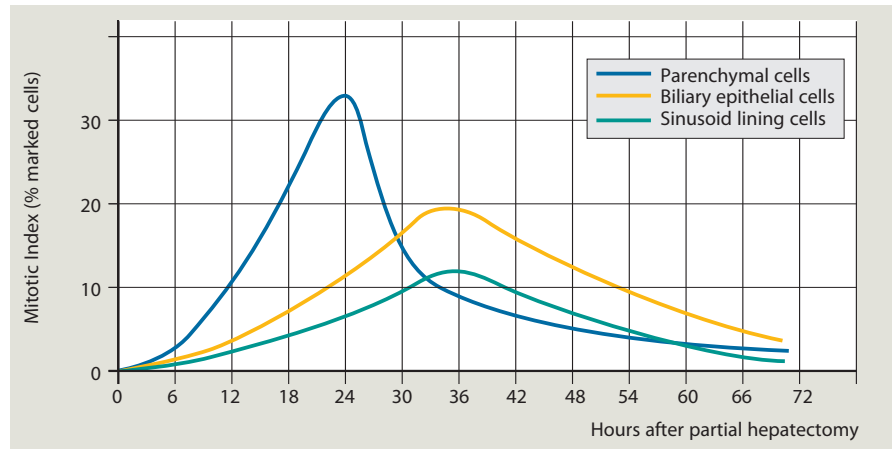


Fig. 13.3 Cytokine, growth factor, and metabolic activation profiles during liver regeneration. Networks are only transiently activated after PHx. Representative molecules that participate in each network are shown. See text for abbreviations (Adapted from [20])

Fig. 13.4 Time course of mitotic activity of parenchymal and nonparenchymal cells of rat liver after PHx (Adapted from [10])



of mitotic indexes of various rat liver cell populations after PHx is shown.

Hepatic regeneration proceeds in several steps. The *preproliferative phase* begins immediately after PHx and is characterized by an additional functional burden on the remaining parenchyma. Preparation for mitosis occurs in this phase. The *proliferative phase*, with the first mitotic wave, follows DNA synthesis after an interval of 6 to 8 hours. New mitotic waves occur in regular intervals, but are lower than the initial mitotic wave. The *restitution phase*, characterized by functional and morphological restoration of liver architecture, heralds the termination of the regenerative process.

In this multistep process the entry of quiescent hepatocytes into the cell cycle (G_0/G_1 transition; *priming phase*) and the progression beyond the restriction point (transition of the late G_1 -phase into the S-phase of DNA synthesis and cell division) seem to be of critical importance.

Before hepatocytes are able to replicate and respond to growth factors, they first must achieve “replicative competence” (priming). In this lag-phase after PHx, known already for a long time, hepatocytes initially express growth associated proto-oncogenes at the mRNA level. This preparatory phase at the transition from the G_0 to the G_1 -phase is associated with the expression of predominantly three proto-oncogens: *c-fos*, *c-jun* and *c-myc*. These are expressed within a few minutes after PHx and are therefore called *immediate early genes*. Their expression is reversible and they do not require protein synthesis to be activated. Thus far, more than 70 immediate early genes have been identified. By expressing proto-oncogenes during

the early G_1 -phase, hepatocytes acquire the ability to respond to growth factors. The proteins coded for by the immediate early genes serve as transactivators of other genes that are responsible for the progression of hepatocytes in the cell cycle.

Transcription factors are proteins that bind to specific genes and enhance their transactivation. One transcription factor may activate several genes; on the other hand one gene may bind several transcription factors. *NFκB* (nuclear factor for the kappa chain of B cells) and *STAT* (signal transducer and activator of transcription) Protein 3 are two preformed transcription factor-complexes that are activated during the primary response to PHx. Their activation in the cytoplasm is followed by translocation into the nucleus, where they bind to DNA and modulate several promoters. *NFκB* has numerous target genes, including proto-oncogenes such as *c-myc*. *STAT3* in its inactive form is also present in the cytoplasm; after activation, it translocates into the nucleus and binds to the promoter region of immediate early genes.

The second phase of gene expression after PHx is characterized by the expression of *delayed early genes* and cell cycle genes. *Bcl-x* belongs to the delayed early genes and is an important antiapoptotic liver gene. *p53*, *mdm2*, *p21*, cyclins and cyclin-dependent kinases (cdks) belong to the cell cycle genes (Fig. 13.5). Cyclin D1 is the major marker of cell cycle progression. Its induction denotes crossing of the restriction point and the entry into the S-phase.

Cell cycle repressors (*TGF-β1*, *activin*, *p21*, *p53*) are also activated after PHx. The interplay between activators and repressors probably determine the timing of termination of regeneration.

Fig. 13.5 Time course of gene activation in the regenerating liver after PHx (Adapted from [18]. With kind permission)

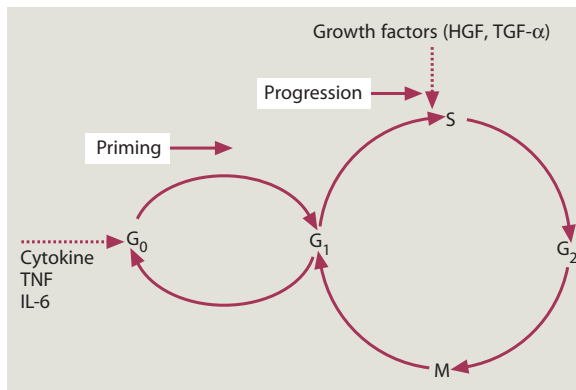
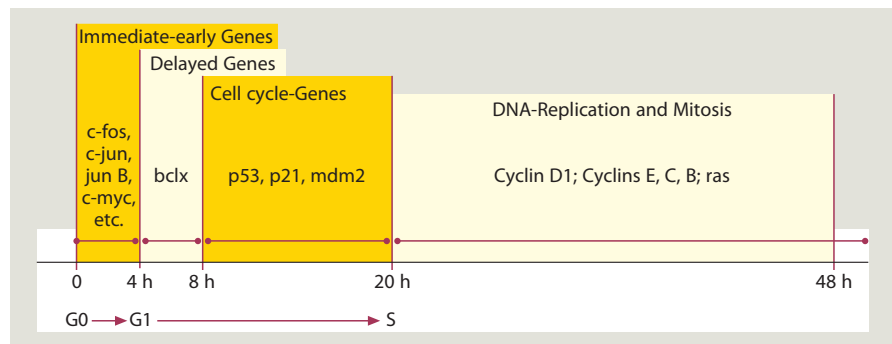


Fig. 13.6 Multi-step model of liver regeneration according to N. Fausto [18]. Liver regeneration can be subdivided in two phases: priming and progression through the cell cycle. Priming is a reversible process, initiated by cytokines, nutrients and hormones. During priming the cells acquire replicative competence, i.e. the ability to proliferate upon stimulation by growth factors. Hepatocytes depend on growth factors, in order to pass beyond the restriction point in the G₁-phase. The expression of cyclin D1 denotes the transition point G₁/S. Beyond this transition point DNA synthesis occurs independent of growth factors

The expression of early and delayed genes of liver regeneration per se does not lead to the replication of DNA. This does not occur until the cells have entered the cell cycle and crossed the restriction point. The progression through the cell cycle is accomplished by growth factors, such as HGF and TGF- α . HGF and TGF- α stimulate DNA synthesis of hepatocytes *after* these have passed the restriction point (Fig. 13.6).

The search for factors which initiate and terminate liver regeneration and maintain the constancy of liver mass, belongs to the most fascinating areas of current liver research. TGF- α and IL-6 are the major components of early signal transduction that initiate liver regeneration. TGF- α enhances priming of hepatocytes

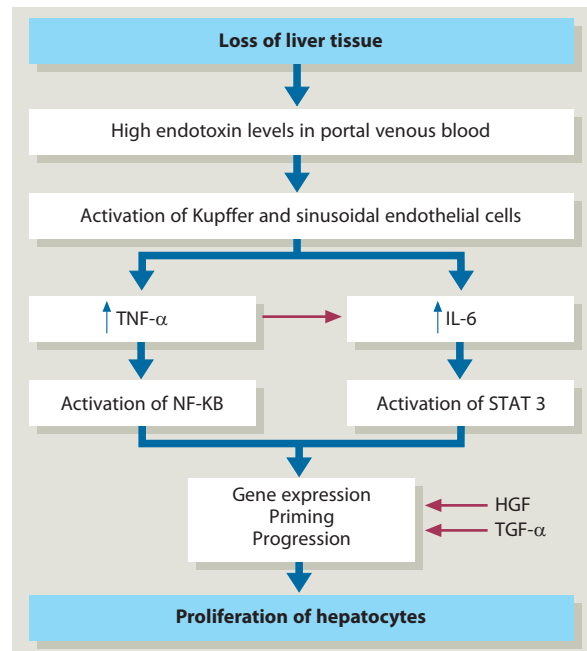


Fig. 13.7 Simplified overview of the mechanisms leading from loss of liver tissue to hepatocyte proliferation

and stimulates the production and secretion of IL-6 by Kupffer cells. IL-6 binds to the soluble IL-6 receptor (sIL-6R). The complex of IL-6/sIL-6R binds to hepatocyte surface receptors and initiates an intracellular signal cascade that leads to activation (phosphorylation) of STAT3 (Fig. 13.1). TNF- α can also activate NF κ B. While TNF- α and IL-6 control priming, progression through the cell cycle is regulated by growth factors, such as HGF and TGF- α (Fig. 13.6). Figure 13.7 outlines a simplified scheme of the pathways leading from loss of liver tissue to hepatocyte proliferation.

Alternate Pathways in Liver Regeneration

The liver has several possible mechanisms to restore lost tissue after sustaining injury. These depend on the noxious agent, the nature of the underlying liver disease, and the number of hepatocytes lost. Physiologic liver regeneration involves proliferation of hepatocytes. After PHx the missing liver cell mass is replaced primarily by the replication of adult hepatocytes. When hepatocyte proliferation is suppressed, a new population of cells emerges from the periportal regions. These precursor cells derive from cells associated with the biliary epithelium; because of their shape, they have been called *oval cells* (Fig. 3.20). Oval cells emerge as small cells from around the portal tracts, infiltrate the lobular areas, become hepatocytes, and eventually restore hepatic mass. Thus, when hepatocyte proliferation is arrested or when hepatocytes cannot regenerate fast enough to replenish lost cells (e.g., in fulminant hepatitis) the biliary epithelial cells become facultative stem cells for hepatocytes. That is, the biliary compartment generates “ductular hepatocytes”, the human equivalent of oval cells which may rescue the liver. Extensive parenchymal necrosis, however, leads to activation of hepatic precursors derived from embryonic stem cells which, in addition to oval cells, may contribute to the regeneration of the injured liver [23].

On the molecular level, an alternate pathway to liver regeneration is by activation of the ras-dependent, mitogen-activated protein kinase (MAPK) cascade, which leads to activation of regulatory proteins that stimulate DNA synthesis.

Termination of Liver Regeneration

The termination of liver regeneration is characterized by a decrease in hepatocyte proliferation, accompanied by hyperplasia of Kupffer, HSC and sinusoidal endothelial cells. The proportionality between liver weight and body weight seems to be the crucial signal in terminating liver regeneration. The precise mechanisms underlying this signal, however, are poorly understood. The most well-known hepatocyte antiproliferative factors within the liver are *TGF-β* and *activin*. *TGF-β* has mitoinhibitory and profibrogenic effects. Upregulated expression of

TGF-β leads to liver fibrosis and apoptosis. The enhanced deposition of new extracellular matrix may also contribute to the reduction of hepatocyte proliferation. *Activin* is a member of the *TGF-β* family with similar effects on apoptosis and mitosis. Suppressors of cytokine signaling (SOCS) are important negative regulators of cytokine signaling and prevent the activation of STAT proteins (Fig. 13.1). Downregulation of activated STAT3 terminates the IL-6 stimulatory signals and may thus contribute to termination of liver regeneration [11, 46, 47].

References

1. Akerman P, Cote P, Yang SQ, et al (1992) Antibodies to tumor necrosis factor- α inhibit liver regeneration after partial hepatectomy. *Am J Physiol* 263: G579–85
2. Alison M, Sarraf C (1998) Hepatic stem cells. *J Hepatol* 29: 676–82
3. Alison M, Poulson R, Jeffrey R, et al (2000) Hepatocytes from non-hepatic cells. *Nature* 406: 257
4. Alvaro D, Gigliozzi A, Attili AF (2000) Regulation and deregulation of cholangiocyte proliferation. *J Hepatol* 33: 333–40
5. Assy N, Minuk GY (1997) Liver regeneration: methods for monitoring and their applications. *J Hepatol* 26: 945–52
6. Berasain C, Garcia-Trevijano ER, Castillo J, et al (2005) Amphiregulin: an early trigger of liver regeneration in mice. *Gastroenterology* 128: 424–32
7. Block GD, Locker J, Bowen WC, et al (1996) Population expansion, clonal growth, and specific differentiation patterns in primary cultures of hepatocytes induced by HGF/SF, EGF and TGF α in a chemically defined (HGM) medium. *J Cell Biol* 132: 1133–49
8. Bottaro DP, Rubin JS, Faletto DL, et al (1991) Identification of the hepatocyte growth factor receptor as the *c-met* proto-oncogene product. *Science* 251: 802–4
9. Bralet MP, Branchereau S, Brechot C, et al (1994) Cell lineage study in the liver using retroviral mediated gene transfer. Evidence against the streaming of hepatocytes in the normal liver. *Am J Pathol* 144: 896–905
10. Bucher NLR, Strain AJ (1992) Regulatory mechanisms in hepatic regeneration. In: Millward-Sadler GH, Wright R, Arthur MJP (eds) *Wright's liver and biliary diseases. Pathophysiology, diagnosis and management*, 3rd edn. W.B. Saunders, Philadelphia, PA, pp 258–74
11. Campbell JS, Prichard L, Schaper F, et al (2001) Expression of suppressors of cytokine signaling during liver regeneration. *J Clin Invest* 107: 1285–92
12. Cressman DE, Greenbaum LE, DeAngelis RA, et al (1996) Liver failure and defective regeneration in interleukin-6-deficient mice. *Science* 274: 1379–83
13. Crosby HA, Strain AJ (2001) Adult liver stem cells: bone marrow, blood, or liver derived? *Gut* 48: 153–54
14. Date M, Matsuzaki K, Matsushita M, et al (2000) Modulation of transforming growth factor β function in hepatocytes and hepatic stellate cells in rat liver injury. *Gut* 46: 719–24

15. De Vos R, Desmet V (1992) Ultrastructural characteristics of novel epithelial cell types identified in human pathologic liver specimens with chronic ductular reaction. *Am J Pathol* 140: 1441–50
16. Diehl AM (2000) Cytokine regulation of liver injury and repair. *Immunol Rev* 174: 160–71
17. Falkowski O, An HJ, Ianus IA, et al (2003) Regeneration of hepatocyte “buds” in cirrhosis from intrabiliary stem cells. *J Hepatol* 39: 357–64
18. Fausto N (2000) Liver regeneration. *J Hepatol* 32(Suppl. 1): 19–31
19. Fausto N (2004) Liver regeneration and repair: hepatocytes, progenitor cells, and stem cells. *Hepatology* 39: 1477–87
20. Fausto N, Campbell JS, Riehle KJ (2006) Liver regeneration. *Hepatology* 43: S45–53
21. Fausto N, Mead JE (1989) Regulation of liver growth: protooncogenes and transforming growth factors. *Lab Invest* 60: 4–13
22. Gehling UM, Willems M, Dandri M, et al (2005) Partial hepatectomy induces mobilization of a unique population of haematopoietic progenitor cells in human healthy liver donors. *J Hepatol* 43: 845–53
23. Heo J, Factor VM, Uren T, et al (2006) Hepatic precursors derived from murine embryonic stem cells contribute to regeneration of injured liver. *Hepatology* 44: 1478–86
24. Higgins GM, Anderson RM (1931) Experimental pathology of the liver. I. Restoration of the liver of the white rat following partial surgical removal. *Arch Pathol* 12: 186–202
25. Kim TH, Mars WM, Stolz DB, et al (2000) Expression and activation of pro-MMP-2 and pro-MMP-9 during rat liver regeneration. *Hepatology* 30: 75–82
26. Lesurtel M, Graf R, Aleil B, et al (2006) Platelet-derived serotonin mediates liver regeneration. *Science* 312: 104–7
27. Malik R, Mellor N, Selden C, et al (2003) Triiodothyronine enhances the regenerative capacity of the liver following partial hepatectomy. *Hepatology* 37: 79–86
28. Marti U, Burwen SJ, Jones AL (1989) Biological effects of epidermal growth factor, with emphasis on the gastrointestinal tract and liver: an update. *Hepatology* 9: 126–38
29. Michalopoulos GK (1990) Liver regeneration: molecular mechanisms of growth control. *FASEB J* 4: 176–87
30. Michalopoulos GK, Bowen WC, Mule K, et al (2002) Hepatocytes undergo phenotypic transformation to biliary epithelium in organoid cultures. *Hepatology* 36: 278–83
31. Michalopoulos GK, DeFrances M (2005) Liver regeneration. *Adv Biochem Eng Biotechnol* 93: 101–34
32. Miyazawa K, Tsubouchi H, Naka D, et al (1989) Molecular cloning and sequence analysis of cDNA for human hepatocyte growth factor. *Biochem Biophys Res Commun* 163: 967–73
33. Nagaki M, Sugiyama A, Naiki T, et al (2000) Control of cyclins, cyclin-dependent kinase inhibitors, p21 and p27, and cell cycle progression in rat hepatocytes by extracellular matrix. *J Hepatol* 32: 488–96
34. Nakamura T, Nishizawa T, Hagiya M, et al (1989) Molecular cloning and expression of human hepatocyte growth factor. *Nature* 342: 440–43
35. Oh SH, Witek RP, Bae SH, et al (2007) Bone marrow-derived hepatic oval cells differentiate into hepatocytes in 2-acetylaminofluorene/partial hepatectomy-induced liver regeneration. *Gastroenterology* 132: 1077–87
36. Olle EW, Ren X, McClintock SD, et al (2006) Matrix metalloproteinase-9 is an important factor in regeneration after partial hepatectomy in mice. *Hepatology* 44: 540–9
37. Peters M, Blinn G, Jostock T, et al (2000) Combined interleukin 6 and soluble interleukin 6 receptor accelerates murine liver regeneration. *Gastroenterology* 119: 1663–71
38. Petersen BE, Bowen WC, Patrene KD, et al (1999) Bone marrow as a potential source of hepatic oval cells. *Science* 284: 1168–70
39. Ren X, Hogaboam C, Carpenter, et al (2003) Stem cell factor restores hepatocyte proliferation in IL-6 knockout mice following 70% hepatectomy. *J Clin Invest* 112: 1407–18
40. Roskams T, De Vos R, van Eyken P, et al (1998) Hepatic OV-6 expression in human liver disease and rat experiments: evidence for hepatic progenitor cells in man. *J Hepatol* 29: 455–63
41. Simpson KJ, Lukas NW, Colletti L, et al (1997) Cytokines and the liver. *J Hepatol* 27: 1120–32
42. Strain AJ (1988) Transforming growth factor- β and inhibition of hepatocellular proliferation. *Scand J Gastroenterol* 23(Suppl. 151): 37–45
43. Strain AJ, Crosby HA (2000) Hepatic stem cells. *Gut* 46: 743–45
44. Streetz KL, Luedde T, Manns MP, et al (2000) Interleukin 6 and liver regeneration. *Gut* 47: 309–12
45. Suzuki A, McCall S, Choi SS, et al (2006) Interleukin-15 increases hepatic regenerative activity. *J Hepatol* 45: 410–8
46. Taub R (2003) Hepatoprotection via the IL-6/Stat3 pathway. *J Clin Invest* 112: 978–80
47. Taub R (2004) Liver regeneration: from myth to mechanism. *Nature Reviews* 5: 836–47
48. Theise ND, Badve S, Saxena R, et al (2000) Derivation of hepatocytes from bone marrow cells in mice after radiation-induced myeloablation. *Hepatology* 31: 235–40
49. Theise ND, Nimmakayalu M, Gardner R, et al (2000) Liver from bone marrow in humans. *Hepatology* 32: 11–6
50. Van den Heuvel MC, Gouw ASH, Boot M, et al (2006) The finest branches of the biliary tree might induce biliary vascularisation necessary for biliary regeneration. *J Hepatol* 44: 947–55
51. Vig P, Russo FP, Edwards RJ, et al (2006) The sources of parenchymal regeneration after chronic hepatocellular liver injury in mice. *Hepatology* 43: 316–24
52. Wilson JW, Leduc EH (1958) Role of cholangioles in restoration of the liver of the mouse after dietary injury. *J Pathol Bacteriol* 76: 441–49
53. Zajjcek G, Oren J, Weinreb M (1985) The streaming liver. *Liver* 5: 295–300

Free Radicals, Reactive Oxygen Species, Oxidative and Endoplasmic Reticulum Stress

14

Henryk Dancygier and Peter Schirmacher

Chapter Outline

Free Radicals and Reactive Oxygen Species.....	174
Lipid Peroxidation	175
Modification of Proteins	176
Endoplasmic Reticulum Stress	176
Modification of DNA	176
Damage to Carbohydrates.....	176
Oxidative Liver Damage.....	176
Defense Mechanisms Against Endoplasmic Reticulum Stress and Oxidative Stress	177
Unfolded Protein Response.....	177
Antioxidants	178
Enzymes	179
References	180

The structure and function of an organ are intrinsically linked to each other. The liver, as the central metabolic organ of the body constantly encounters exogenous and endogenous injurious agents. The most important etiologic principles and causes of liver injury are

- Nutritional and metabolic factors
- Drugs and toxins
- Infectious agents
- Endotoxins
- Immunological disturbances (e.g. specific and non-specific primary autoimmune disorders of the liver; primary nonhepatic immune reactions occurring, for example, in systemic infections and in drug-induced and toxic reactions with secondary involvement of the liver)
- Genetic disorders (e.g. storage diseases [proteins, carbohydrates], cystic fibrosis, α_1 -antitrypsin deficiency)
- Hypoxia (e.g. ischemia, reperfusion damage)
- Cholestasis (e.g. primary biliary cirrhosis, primary sclerosing cholangitis, cholangitis in bile duct obstruction)
- Metal induced damage (e.g. iron, copper)
- Physical injuries (e.g. mechanical trauma, ionizing radiation)

Often several overlapping causes/mechanisms contribute to liver damage. Though primary biliary cirrhosis, for example, is primarily an immunologically mediated disorder, cholestatic pathogenetic mechanisms add to liver injury during the long course of the disease.

There remains, however, a small group of patients in whom, despite all diagnostic efforts, the cause of liver damage remains unknown. The prevalence and the clinical significance of individual injurious factors are quite variable. Thus, while traumatic and radiation

induced liver injuries play only a minor role in clinical hepatology, all other liver disorders listed above are encountered regularly, albeit with varying frequency.

The sensitivity to different noxious stimuli as well as the individual thresholds and reaction patterns to injury vary in different organs and cell types. Thus, while brain tissue and cardiac muscle are very sensitive to hypoxia, normal liver, due to its dual arterial and portal venous blood supply is less susceptible to hypoxic injury with the exception of advanced liver disease such as cirrhosis. In clinical practice, liver damage is most often caused by infectious agents, drugs, and toxins, and is frequently mediated by immunologic mechanisms.

The activity of hepatocytes undulates around a physiological level. If a cell becomes injured, its activity level is altered. Depending on the nature and severity of the injury as well as the reaction pattern of the cell, a new activity level is reached which may even be higher than the original one, a process called adaptation.

The damaging process is a continuum of biochemical and morphological reactions. In its early phases the damage is principally reversible. If a “point of no return” is reached, the damage proceeds irreversibly. It is impossible to draw a sharp division line between the reversible and irreversible lesion. While simple cell swelling and ballooning is still reversible, the massive influx of Ca^{++} denotes a severe membrane injury and heralds the irreversibility of the damaging process.

The exact pathophysiological mechanisms leading to liver damage are not understood in all their details. Initially the various noxae proceed along different pathogenic pathways; but ultimately common pathways result in disordered energy supply, loss of membrane function, necrosis, apoptosis, and autophagy.

Reactive oxygen species and free radicals leading to ATP depletion and oxidative stress are a frequent cause of hepatocellular injury. The damage of membrane integrity leads to a functional impairment of ion transport systems localized in the membrane. Disturbed membrane permeability ultimately results in an uncontrolled flow of ions and water, and in the breakdown of intracellular Ca^{++} -homeostasis, which plays a major role in the development of cell death [6]. The pathogenetic factors contributing to cell death are numerous and their actions are intertwined. Therefore it is hardly possible to determine the pathogenetic significance of an individual factor per se in the progression from cell damage to cell death. Table 14.1 summarizes important pathogenetic mechanisms, which lead to cell injury and death.

Table 14.1 Basic pathogenetic mechanisms leading to cell injury and cell death

Mechanism	Consequences
ATP loss	Cell swelling, diminished protein synthesis, inhibition of energy dependent membrane transport systems, reduced lipogenesis. Contributes to the loss of integrity of plasma membranes
Oxidative stress	Destroys cell membranes and cell integrity
Loss of Ca^{++}-homeostasis	Low cytosolic Ca^{++} concentration rises after (ischemic or toxic) injury. High intracellular Ca^{++} levels damage organelles and plasma membranes

Free Radicals and Reactive Oxygen Species

Free radicals are molecules whose atoms carry an unpaired electron on the outer shell. This condition makes the molecule unstable and highly reactive, i.e. it can transfer one electron to other molecules or receive one from them. Free radicals (ROO^{\cdot} , RO^{\cdot} , OH^{\cdot}) produced during peroxide formation can cause deleterious effects. Oxygen itself, but mainly its highly reactive radicals bind to proteins, lipids and carbohydrates. They are capable of oxidizing and damaging nearly all molecular components of the cell. *The most reactive biological free radical is the hydroxyl radical (OH^{\cdot}).*

Once initiated, these potentially deleterious free radical chain reactions are very difficult to counteract, and not infrequently result in cell death.

Nitric oxide (NO) is an unstable free radical produced by constitutive endothelial NO synthase and by inducible NO synthase. The latter is upregulated by lipopolysaccharide (LPS) and cytokines in both parenchymal and nonparenchymal liver cells. NO plays a major role in maintaining liver perfusion, and inducible NO protects against apoptosis induced by LPS and $\text{TNF-}\alpha$. However, NO may also exert toxic effects. By reacting with O_2 potent peroxynitrite species are generated that contribute to liver cell necrosis in ischemia-reperfusion injury and shock [3, 8].

Free radicals are generated by

- Normal, usually oxidative metabolic processes. O_2 -molecules with unpaired electrons, for example, are formed regularly in the mitochondrial respiratory

chain. Since mitochondrial electron transport uses approximately 90% of the cellular oxygen demand, mitochondria represent the largest source of reactive oxygen species

- Absorption of external energy sources, e.g. UV-light, ultrasound, ionizing radiation
- Enzymatic metabolism of exogenous and endogenous substances. Thus free radicals may be generated during the degradation of drugs and chemical compounds by mixed function oxidases localized in the endoplasmic reticulum. Superoxide anion is generated as a by-product by the activity of xanthine oxidase during the metabolism of purines to uric acid. The membrane associated NADPH oxidase in inflammatory cells during phagocytosis produces highly reactive oxidative substances, which may damage not only the infectious pathogens but also neighbouring cells, including hepatocytes (see below).

Figure 14.1 presents an overview of the generation of reactive oxygen metabolites. In Table 14.2 biologically active free radicals are listed.

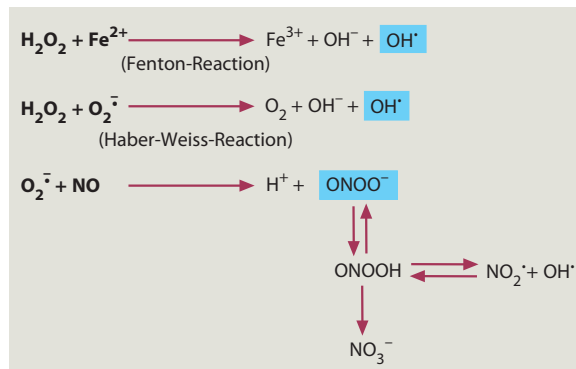


Fig. 14.1 Generation of reactive oxygen metabolites

Table 14.2 Biologically active free radicals

Radical species	Name of radical	Comments
$\text{O}_2^{\bullet -}$	Superoxide	Formed by (1) direct auto-oxidation in mitochondria or (2) enzymatically in the cytosol (xanthine oxidase, cytochrome P450). Also generated by physical factors (UV-radiation, high intensity ultrasound, ionizing radiation)
HO_2^\bullet	Perhydroxyl	Protonated form of $\text{O}_2^{\bullet -}$
H_2O_2	Hydrogen peroxide	Generated by superoxide dismutase or by peroxisomal oxidases
HO^\bullet	Hydroxyl	Most potent free oxygen radical. Generated by hydrolysis of water, ionizing radiation, or metals (Fe, Cu)
ROO^\bullet	R-dioxy	Organic radical. Formed as alkyl-dioxy-radical during lipid oxidation
ROOH	R-hydroperoxide	Protonated form of dioxy-radicals (e.g. lipid peroxide)

Source: Adapted from [9]

The major pathogenetic mechanisms by which free radicals cause cell damage at the molecular level are

- Lipid peroxidation
- Modification of proteins
- Modification of DNA, and possibly
- Damage to carbohydrates

Lipid Peroxidation

Lipid peroxidation (auto-oxidation) is a source of free radicals and is the key event of hepatocellular damage mediated by oxidative stress (see below). Phospholipids containing unsaturated fatty acids are essential components of biological membranes and are exquisitely sensitive to oxidative stress. The “oxidative assault” modifies unsaturated fatty acids and ignites lipid peroxidation, a self-perpetuating chain reaction (autocatalytic process) in the course of which further reactive lipid radicals are generated (Fig. 14.2).

Lipid peroxidation impacts mainly polyunsaturated fatty acids; the extraction of hydrogen with subsequent generation of a radical occurs particularly easily at double bonds interrupted by methylene residues. By reacting with oxygen the radical becomes an alkyl-dioxy-radical and in turn catalyzes the extraction of hydrogen from another fatty acid molecule. This auto-catalytic reaction generates new lipid radicals and increasing numbers of lipid peroxides, which may react with numerous molecular components of the cell. These processes strongly modify the features of lipids and other cellular components with deleterious effects on cell functions. Peroxidation is also catalyzed in vivo by heme compounds and by lipoxigenases found in platelets and leukocytes.

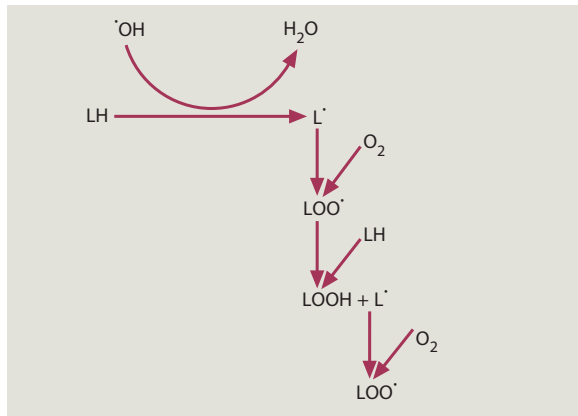


Fig. 14.2 Polyunsaturated fatty acids (LH) contained in membrane phospholipids are especially sensitive to auto-oxidation by reactive oxygen species. These extract a hydrogen atom from a carbon atom situated next to a double bond, thereby generating lipid radicals ($L\cdot$). By the subsequent attachment of oxygen, unstable lipid peroxyl radicals ($LOO\cdot$) are formed. These disintegrate and generate by-products, such as malondialdehyde. Thus, lipid peroxidation is a self-perpetuating chain reaction providing a continuous supply of free radicals that initiate further peroxidation (Adapted from [6])

Malondialdehyde and *4-hydroxynonenal* are important aldehyde by-products generated during peroxidation and are regarded as markers of lipid peroxidation [12].

Modification of Proteins

The reaction of free oxygen radicals with proteins leads to alterations of their biological activities. Methionine, histidine and tryptophan residues as well as the thiol-groups of cysteine are particularly prone to damage by reactive oxygen species. Cross-linking of proteins at sulfhydryl-groups leads to a loss of activity of key enzymes.

Endoplasmic Reticulum Stress

Unfolded proteins affecting endoplasmic reticulum (ER) homeostasis cause ER stress. These disturbances of normal ER functions lead to an evolutionary conserved cell reaction, the *unfolded protein response* (see below), which is aimed initially at compensating for damage. However, acute or prolonged ER stress may trigger cell death. Cell death mechanisms induced by ER stress are highly complex. Multiple potential participants have

been described but there is little clarity about the dominant death effectors in a particular cellular context, and the exact pathogenesis of ER stress induced cell death still remains enigmatic. ER stress seems to play a major role in hypoxia and ischemia-reperfusion injury of the liver [14, 15].

Modification of DNA

The oxidative stress caused by free radicals may also damage the DNA. The bases and deoxyribose of both the nuclear and the mitochondrial DNA may be altered with consequent DNA strand breaks and mismatching of modified bases. New base pairs may be mutagenic.

Damage to Carbohydrates

Damage to carbohydrate by oxidative stress is, in comparison, less well understood. In regard to the mechanisms of hepatocellular damage described above, the carbohydrate pathway seems to be of minor importance. However, the oxidative modification of hyaluronic acid and of proteoglycans can damage the extracellular matrix. The resulting impairment of substance exchange and of the free communication between parenchymal and nonparenchymal liver cells may contribute to the development and perpetuation of hepatocellular injury.

Oxidative Liver Damage

Oxidative stress is a common pathogenetic mechanism of various forms liver damage. It may affect all molecules and the hepatocyte in many different ways. *Oxidative stress develops whenever the generation of reactive oxygen species (ROS) and free radicals exceeds the antioxidant defense mechanisms.* The spectrum of cell reactions to oxidative stress depends on the intensity of the stress and on the sensitivity of the cell. Cells may remain unaffected, become transiently functionally impaired, or may die (apoptosis or necrosis) [7].

Hepatic parenchymal and nonparenchymal cells contribute to the generation of ROS and to ROS-induced liver injury. Kupffer cells, infiltrating inflammatory cells and vascular endothelia play a major role. The products

of lipid peroxidation damage cells (see above); in addition, they serve as signaling molecules and chemotactic factors for neutrophil granulocytes, stimulate the synthesis of chemokines, and induce fibrogenesis by enhancing collagen gene expression in activated stellate cells.

Oxidative stress oxidizes mitochondrial NAD(P)H and promotes the generation of ROS in mitochondria. Both increase the concentration of free mitochondrial Ca⁺⁺ and activate mitochondrial serine proteases (calpains) leading to increased permeability of the mitochondrial membranes. Cytosolic calpains degrade cytoskeletal proteins, thereby enhancing hepatocyte membrane bleb-formation. Oxidative stress may also damage hepatic sinusoidal endothelial cells thus affecting the “liver sieve” with far reaching functional consequences for the entire organ [2].

In addition to the direct ROS-induced injury of hepatocytes, ROS may contribute to liver cell damage indirectly, by enhancing the expression of proinflammatory genes [1, 4, 5]. The expression of TNF- α , IL-1, IL-8 and cellular adhesion molecules are regulated by the transcription factor NF κ B and in some cases by the activating protein-1 (AP-1). ROS may lead to the activation of NF- κ B and AP-1. In turn TNF- α released by Kupffer cells may stimulate hepatocytes to produce ROS, thereby perpetuating the ROS-induced injury in a vicious circle-like pattern. Figure 14.3 summarizes the cell damage induced by oxidative stress.

Defense Mechanisms Against Endoplasmic Reticulum Stress and Oxidative Stress

Free radicals constantly accumulate even during the physiologic metabolism of the cell. In turn, the organism has developed strategies against ER stress and defense mechanisms to prevent oxidative injuries, to trap and eliminate free radicals and to repair the resulting damage.

The rapid upregulation of *survival genes* that control the permeability of mitochondrial membranes, represents an early cellular defense mechanism which may prevent the release of ROS generated in mitochondria.

Unfolded Protein Response

An early response to ER stress and oxidative stress is the activation of the unfolded protein response, which induces profound changes in cellular metabolism including general translation attenuation, transcriptional upregulation of chaperone genes, and activation of ER-associated degradation [14, 15].

Chaperones are proteins that support post-translational modification of proteins. They act upon unfolded or denatured proteins and promote their proper folding. Thus, chaperones have the potential to prevent the damage caused by misfolding. In addition, chaperones are involved in transport across membranes, for example into the mitochondria and endoplasmic reticulum, and they also assist in protein degradation. Many chaperones are heat shock proteins. *Chaperonins* are protein complexes that assist the folding of polypeptides into their functional protein state. They belong to the large class of molecular chaperones.

Heat shock proteins (Hsp) are a group of intracellular, non-secreted proteins whose expression is increased whenever cells are exposed to different kinds of stress conditions. Therefore Hsp are also called stress proteins, and are categorized according to their molecular weight; Hsp70 and Hsp90 each define families of chaperones. Increased synthesis of Hsp is part of the early cellular response to oxidative and ER stress, and is transcriptionally regulated. Hsp exert many functions. They are molecular chaperones for protein

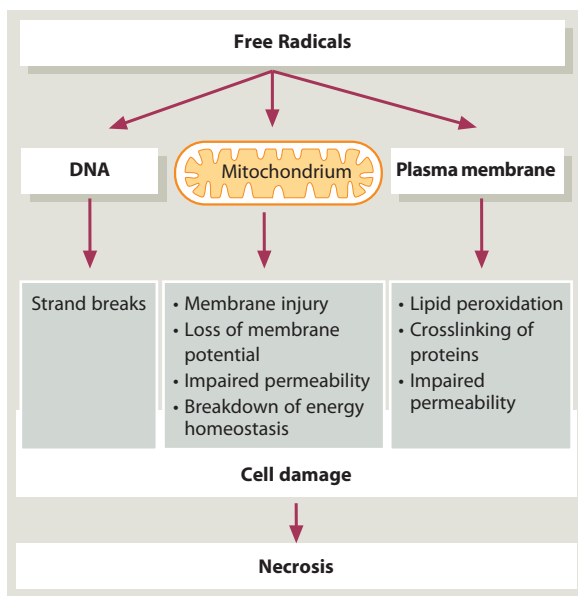


Fig. 14.3 Mechanisms of cell injury induced by oxidative stress

molecules and they help to stabilize partially unfolded proteins and to transport proteins across membranes within the cell. They play a major role in the prevention and development of cell death. Increased expression of Hsp70 in the cell decreases the susceptibility towards apoptosis. Synthesis of *uncoupling protein-2* (another Hsp) inhibits the formation of ROS during mitochondrial respiration [11, 13].

Ubiquitin (also a Hsp) is a highly conserved, small regulatory protein (76 amino acids) that is present in all eukaryotic cells. It is used by cells to label old, damaged, or misfolded proteins (*ubiquitination*) for proteolysis, by the covalent attachment of one or more (polyubiquitination) ubiquitin monomers. The (poly) ubiquitinated protein then moves to a proteasome, a barrel-shaped structure, where the proteolysis occurs.

Antioxidants

Antioxidant substances in low concentrations delay or inhibit the oxidation of a substrate and are used for the detoxication of ROS. The antioxidant mechanism may be *enzymatic* or *nonenzymatic* (Table 14.3).

Table 14.3 Defense mechanisms against oxidative stress

System	Compound
Nonenzymatic	α -Tocopherol (vitamin E)
	Ascorbic acid (vitamin C)
	β -Carotene
	Glutathione
	Uric acid
	Ceruloplasmin
	Transferrin
	Ferritin
	N-acetyl-cysteine
	Enzymatic
Glutathione peroxidases	
Catalase	
Auxiliary enzymatic mechanisms	Conjugating enzymes
	Glutathione-S-transferase
	Glucuronyl transferases
	Regeneration of glutathione
	Glutathione reductase
	Repair systems
	DNA-repair
Degradation of oxidative proteins and lipids	

Source: Adapted from [9]

Antioxidants act as scavengers of free radicals and fall into two classes: (1) *preventive antioxidants*, which reduce the rate of chain initiation; and (2) *chain-breaking antioxidants*, which interfere with chain propagation.

Vitamin E

The lipid soluble α -tocopherol (vitamin E) is a chain-breaking, free-radical trapping, nonenzymatic, naturally occurring antioxidant in cell membranes and plasma lipoproteins. Vitamin E acts in the lipid phase to trap ROO^{\bullet} radicals formed by peroxidation of polyunsaturated fatty acids. It disrupts the auto-catalytic lipid peroxidation chain. The tocopheroxyl radical product is relatively unreactive, and is reduced back to tocopherol by reaction with Vitamin C (Fig. 14.4).

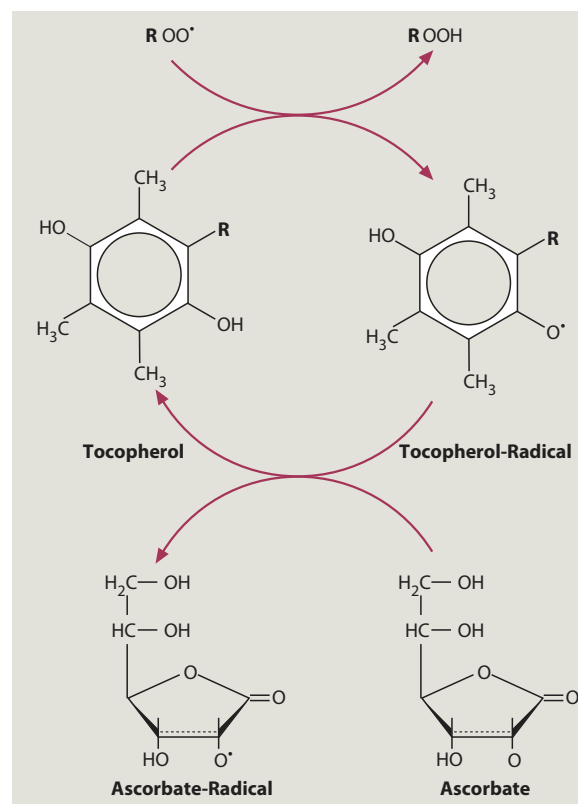


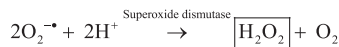
Fig. 14.4 Interaction between vitamins C and E in the nonenzymatic defense against lipid peroxidation (Adapted from [9])

Enzymes

The most important enzyme systems for eliminating ROS and repairing ROS-induced damage are

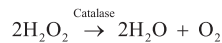
- Superoxide dismutase
- Catalase
- Glutathione peroxidase, and the
- DNA-repair enzymes

The potential toxicity of oxygen is due to its conversion to a *superoxide anion free radical* ($O_2^{\cdot-}$) by transfer of a single electron to O_2 . Superoxide is formed when reduced flavins, which are present, for example, in enzymes, such as xanthine oxidase, are reoxidized univalently by molecular oxygen. *Superoxide dismutase* is the main chain-breaking antioxidant and is the enzyme responsible for superoxide radical removal according to the following reaction



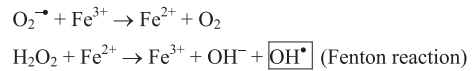
In this reaction, superoxide acts as both oxidant and reductant. Thus superoxide dismutase, which occurs in all major aerobic tissues, protects the organism against the deleterious effects of superoxide.

Catalase is a preventive antioxidant and metabolizes H_2O_2 , generated in the above reaction, to water and oxygen

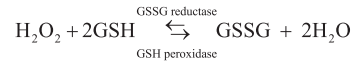


The antioxidant enzyme systems are localized in close proximity to the sites of oxidant formation. Catalase is present in peroxisomes, while Mn-superoxide dismutase is found in the mitochondria and Cu-Zn-superoxide dismutase is localized in the cytosol.

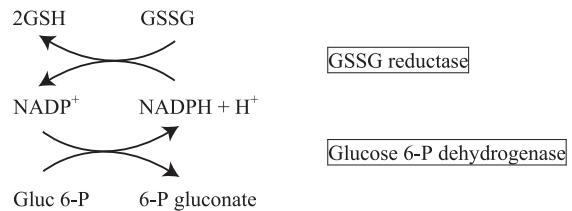
These enzyme systems act in close coordination with iron and copper binding proteins, in order to prevent the formation of free radicals. Iron plays a major role in the generation of hydroxyl radicals (Fig. 14.1). The intracellular binding of trivalent iron to ferritin and its tightly regulated release make sure that under physiologic conditions only a few hydroxyl radicals are formed. On the other hand, excessive iron uptake or the unregulated release of iron from its intracellular stores – especially in the presence of superoxide radical – leads to increased hydroxyl radical levels:



Another important enzymatic defense mechanism against H_2O_2 and hydroxyl radicals is *reduced glutathione* (GSH) with the enzymes *GSH peroxidase* and *GSSG (oxidized glutathione) reductase*:



GSH peroxidase is a preventive antioxidant and its activity is regulated by selenium which is an essential component of GSH peroxidase. The oxidation of GSH can also occur due to toxic metabolites, chemicals, and drugs. GSH is a free radical scavenger and an important substance in the cellular detoxication process. Under physiologic conditions, consumed GSH is reconstituted by GSSG reductase with NADPH as a cofactor. The most important system for regenerating NADPH/ H^+ is the glucose 6-phosphate dehydrogenase:

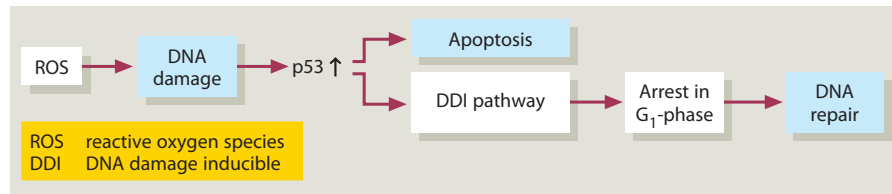


Low intracellular GSH levels make the cell vulnerable to oxidative stress. A reduction of GSH can occur by several mechanisms. The activity of GSH synthase may be reduced whenever important cofactors (selenium) or amino acid precursors (cysteine) are lacking. When large amounts of ROS or toxic products derived from drug metabolism are generated (e.g. in acetaminophen overdose), oxidation of GSH may exceed the reduction of GSSG. The accumulation of GSSG is enhanced especially in situations with reduced supply of NADPH, such as in glucose 6-phosphate dehydrogenase deficiency. Excess GSSG is transported out of the cell by a membrane-associated ATPase.

Free radicals that are generated during cytochrome P450 mediated metabolism of xenobiotics may interact with sulfhydryl groups of proteins generating protein-thiols, which form disulfides with GSSG.

Reactive intermediates can also react with and inactivate GSH. An important cellular defense mechanism

Fig. 14.5 p53 plays a major role in the reaction to ROS induced liver injury



against inactivation of GSH is the enzymatic formation of S-conjugates with GSH. Glutathion S-transferases catalyze the formation of thioethers from glutathione and reactive compounds. By this detoxication route S-conjugates are removed from the body.

The knowledge of these hepatocellular defense mechanisms is not only of theoretical importance. It becomes clinically important in certain intoxications, such as acetaminophen toxicity or mushroom intoxication with *Amanita phalloides*. High therapeutic doses of N-acetyl cysteine replenish the GSH stores, thereby improving the detoxicating function of the liver and the prognosis of the patient. In addition N-acetyl-cysteine may have protective effects by modulating inducible NO synthase gene expression and NF- κ B activity in hepatocytes [10].

If the antioxidant defense mechanisms are not sufficient to prevent injury, the hepatocyte has means at its disposal to reduce the intensity of damage that has already occurred by removing or repairing oxidatively altered molecules. Most effective in this regard are the *enzymes of DNA repair*. Damaged DNA fragments are initially identified by specific proteins and then are excised by *DNA-glycosylases* and the *AP (apurinic and apyrimidinic) endonuclease*. The gap is first filled with bases complementary to the undamaged DNA strand (*DNA polymerase*) and finally closed (*DNA ligase*) [9]. In order to enable the cell to activate these repair mechanisms, the oxidatively damaged DNA must first be prevented from replicating. The nuclear phosphoprotein p53 plays a major role in this process. It most likely acts as a transcription factor and controls genes that regulate cell proliferation. The half life of p53 increases and its concentration in the cell nucleus rises after oxidative DNA damage. Accumulation of p53 can elicit programmed cell death (apoptosis) and it can activate the DNA damage inducible (DDI) pathway. While the former mechanism allows for removing cells with damaged DNA, the latter pathway leads to a transient proliferation arrest in the G₁ phase and provides the organism with time to repair the damaged DNA (Fig. 14.5).

The repair of damaged plasma and organelle membranes is accomplished by substituting membrane lipids

with phosphoglycerides synthesized in the endoplasmic reticulum; these reach the site of membrane injury with the assistance of specific enzymes and lipid transfer proteins.

References

1. Adamson GM, Billings RE (1992) Tumor necrosis factor induced oxidative stress in isolated mouse hepatocytes. *Arch Biochem Biophys* 294: 223–9
2. Cogger VC, Muller M, Fraser R, et al (2004) The effects of oxidative stress on the liver sieve. *J Hepatol* 41: 370–6
3. Diehl AM (2000) Cytokine regulation of liver injury and repair. *Immunol Rev* 174: 160–71
4. Jaeschke H (2000) Reactive oxygen and mechanisms of inflammatory liver injury. *J Gastroenterol Hepatol* 15: 718–24
5. Jones BE, Lo CR, Liu H, et al (2000) Role of caspases and NF- κ B signaling in hydrogen peroxide- and superoxide-induced hepatocyte apoptosis. *Am J Physiol* 278: G693–9
6. Kane AB (1996) Mechanisms of cell and tissue injury. In: Sirica AE (ed) *Cellular and molecular pathogenesis*. Lippincott-Raven, Philadelphia, PA, pp 1–22
7. Kaplowitz N, Tsukamoto H (1996) Oxidative stress and liver disease. In Boyer JL, Ockner RK (eds) *Progress in liver disease*, Vol XIV. W.B. Saunders, Philadelphia, PA, pp 131–59
8. Kaplowitz N (2000) Mechanism of liver cell injury. *J Hepatol* 32(Suppl 1) 39–47
9. Löffler G (1998) Replikation und Gentechnik. In: Löffler G, Petrides PE (eds), *Biochemie und Pathobiochemie*, 6. Auflage. Springer Verlag, Berlin, pp 205–37
10. Majno PL, Medina J, Zubia I, et al (2004) N-Acetyl-cysteine modulates inducible nitric oxide synthase gene expression in human hepatocytes. *Hepatology* 40: 632–7
11. Mattiasson G, Sullivan PG (2006) The emerging functions of UCP2 in health, disease, and therapeutics. *Antioxid Redox Signal* 8: 1–38
12. Paradis V, Kollinger M, Fabre M, et al (1997) In situ detection of lipid peroxidation by-products in chronic liver diseases. *Hepatology* 26: 135–42
13. Sluse FE, Jarmuszkiewicz W, Navet R, et al (2006) Mitochondrial UCPs: new insights into regulation and impact. *Biochim Biophys Acta* 1757: 480–5
14. Xu C, Bailly-Maitre B, Reed J (2005) Endoplasmic reticulum stress: cell life and death decisions. *J Clin Invest* 115: 2656–64
15. Zhao L, Ackerman SL (2006) Endoplasmic reticulum stress in health and disease. *Curr Opin Cell Biol* 18: 444–52

Chapter Outline

Hepatocellular Ischemia	181
References	183

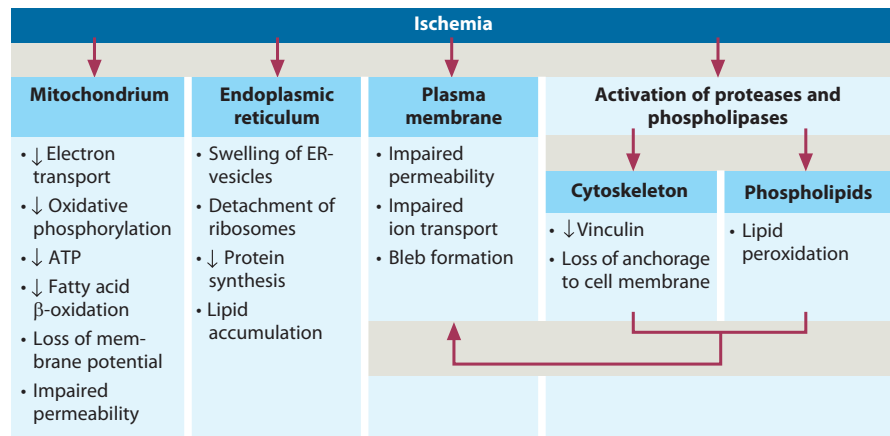
Hepatocellular Ischemia

The dual blood supply of the liver from the hepatic artery and the portal vein renders the organ highly tolerant to ischemia, if only one vascular system is affected. Therefore, ischemic-hypoxic liver injuries are, clinically, relatively rare by comparison, although by no means insignificant. Most hepatocytes remain viable after 24–48 h of cold preservation and can be transplanted successfully. Shock, congestive right heart failure, obstruction of the hepatic venous outflow by thrombosis, membranes or tumors may lead to extensive centrilobular (zone 3) parenchymal injury. However only shock with multiorgan dysfunction is characterized predominantly by liver ischemia, while in the latter conditions pathogenesis involves both congestive and hypoxic factors. Local compression of vessels by intrahepatic tumors leads to hypoxic changes in adjacent hepatocytes. Therapeutic embolization of tumor feeding vessels tries to take advantage of anoxia by inducing ischemic tumor necrosis. Hypoxia, through hypoxia-inducible transcription factors, is a key stimulus for angiogenesis, which is a key event in chronic liver diseases [3]. Chronic intermittent hypoxia, such as can be observed, for example, during obstructive sleep apnea, leads to mild liver injury via oxidative stress and excessive glycogen accumulation in hepatocytes [4].

In this and the following chapter the basic events and pathophysiological mechanisms occurring at the cellular level during ischemia and ischemia/reperfusion injury will be discussed. The clinical aspects of hypoxic liver diseases, including “hypoxic hepatitis” and acute and chronic venous congestion are discussed in Chapter 34 and in Section XI.

Hepatocellular ischemia initially activates adaptation processes in liver cells, such as enhanced gene and protein expression. Induction of heat shock proteins,

Fig. 15.1 Cellular alterations in ischemic injury



glucose-regulated and hypoxia-associated proteins, expression of fibronectin, increased activity of glucose 6-phosphate dehydrogenase, expression of immediate early genes (*c-fos*, *c-myc*, *c-jun*), activation of transcription factors (e.g. NF-κB), and induction of proteases and protease inhibitors are all observed during the early phases of hepatic ischemia.

The pathophysiologic basis for hypoxic cell damage is the impairment of the cellular energy supply, with initial sublethal changes, such as cell swelling and fatty change. The first hypoxic lesions are observed in the centrilobular areas approximately 2 h after ischemia begins. The early metabolic changes are fully reversible upon restoration of normal blood supply. After normothermic ischemia of 3 h duration the injuries become irreversible. While hydroptic cell swelling is a reversible phenomenon, the massive intracellular influx of Ca^{++} indicates severe and irreversible membrane damage. The process of Ca^{++} influx is pivotal in the transition from a reversible to a non-reversible hepatocellular injury. Despite numerous investigations, however, the detailed biochemical events that characterize the transition from a reversible lesion to irreversible hypoxic damage, are not yet precisely defined. **Figure 15.1** and **Table 15.1** summarize the events that occur during ischemic cell damage. During oxygen deficiency, oxidative phosphorylation diminishes in favor of increased anaerobic glycolysis, with subsequent accumulation of lactate and a decrease of intracellular pH. If hypoxia persists, mitochondrial electron transport becomes impaired and intracellular ATP levels fall. The decrease in cellular energy reserves causes homeostatic mechanisms to fail. Membranous ion transport systems are damaged, the selective

Table 15.1 Evolution of ischemic liver cell death

• Oxygen deficiency	
• Mitochondrial ATP depletion	
• Impairment/failure of membrane associated ATP-dependent ion pumps	
• Influx of Na^+ and H_2O into the cell	
• Cell swelling (ballooning)	
• Adjustment of metabolism to anaerobic glycolysis	
• Activation of heat shock proteins	
• Fall of intracellular pH	
• <i>Influx of calcium into the cell (key event in transition from reversible to irreversible cell damage)</i>	
• Calcium activates	
Phospholipases:	Loss of membrane phospholipids; formation of lysophosphatides and fatty acids. Continuous membrane damage (vicious cycle)
Proteases:	Injury of the cytoskeleton and damage of membrane proteins Formation of “blebs”
ATPase:	Continuing loss of ATP (vicious cycle)
Endonucleases:	Clumping of nuclear chromatin
• Begin of protein denaturation	
• Damage of all cellular membrane systems	
• Swelling of the vesicles of the endoplasmic reticulum and of other cell organelles	
• Cell death	

Source: Adapted from [1]

membrane permeability and the membrane potential cannot be sustained anymore, and cell volume regulation is impaired. K^+ efflux into the extracellular space increases and Ca^{++} accumulates within the cell. Cytosolic Ca^{++} activates proteases and phospholipases which in turn perpetuate cell injury by damaging membranes and the cytoskeleton. Increased influx of

extracellular water leads to cell and organelle swelling (ballooning). Vacuoles are formed and blebs detach from the cell membrane [1].

In addition to hepatocytes, sinusoidal endothelial cells (SEC) and Kupffer cells (KC) are also affected by hypoxic liver damage. Activated SEC and KC generate reactive oxygen species (ROS), chemokines and proinflammatory cytokines. TNF- α and interleukin-1 secreted by KC recruit and activate CD4⁺ T lymphocytes to secrete cytokines, which in turn amplify KC activation [2]. Chemokines promote neutrophil activation and infiltration, thereby contributing to the progression of parenchymal injury by releasing ROS and proteases. Additionally, swelling of SEC and KC in association with an imbalance between nitric oxide (vasodilation) and endothelins (vasoconstriction) in favor of the latter, narrows the sinusoidal lumen and contributes to microcirculatory dysfunction.

Thus, during hypoxic-ischemic liver injury ROS and free radicals are also released, and contribute to liver damage. Pathophysiologic mechanisms of ischemia and of oxidative stress (see Chapter 14) are intertwined and act in concert.

References

1. Kumar V, Abbas AK, Fausto N (2005) Cellular adaptations, cell injury, and cell death. In: Kumar V, Abbas AK, Fausto N (eds) Robbins and Cotran pathologic basis of disease, 7th edn. Elsevier Saunders, Philadelphia, PA, pp 3–46
2. Massip-Salcedo M, Roselló-Catafau J, Prieto J, et al (2007) The response of the hepatocyte to ischemia. *Liver Int* 27: 6–16
3. Pugh CW, Ratcliffe P (2003) Regulation of angiogenesis by hypoxia: role of the HIF system. *Nat Med* 9: 677–84
4. Savransky V, Nanayakkara A, Vivero A, et al (2007) Chronic intermittent hypoxia predisposes to liver injury. *Hepatology* 45: 1007–13

Chapter Outline

Ischemia-Reperfusion Injury	185
References	187

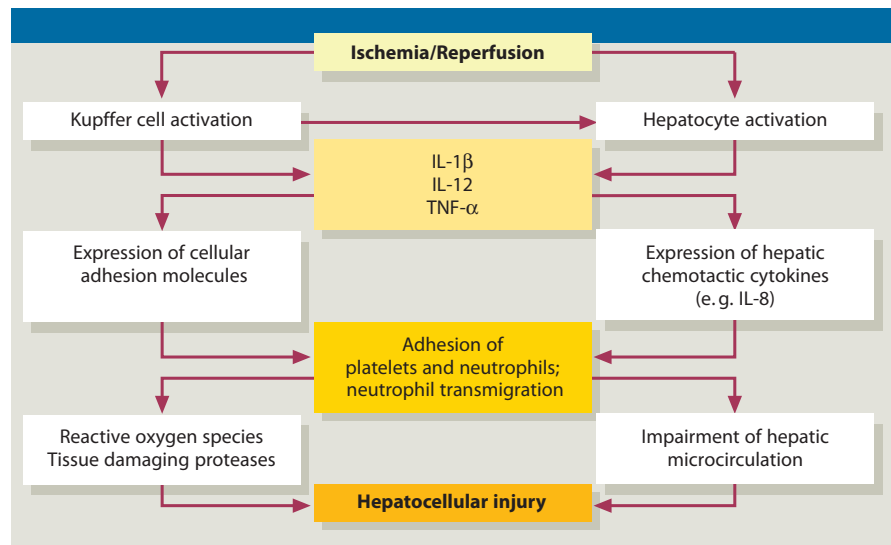
Ischemia-Reperfusion Injury

Ischemia-reperfusion injury is a phenomenon whereby cellular damage in a hypoxic organ is accentuated following the restoration of oxygen delivery. A clinical example is the reperfusion of a transplanted liver that was exposed to “warm” and “cold” ischemia prior to transplantation. This form of injury was first recognized as a clinically important pathological phenomenon during studies of experimental liver transplantation in 1975 [9]. However, it was not until the mid-1980s that the term “reperfusion injury” was generally used in the literature.

Hepatic ischemia-reperfusion injury can be categorized into *warm* and *cold-storage reperfusion injury*. While sinusoidal endothelial cells are most susceptible to cold ischemia, hepatocytes are the main target of warm ischemia. Warm reperfusion injury is more clinically relevant in hepatic surgery than damage induced by cold ischemia. Fatty livers, ischemically damaged livers from patients in hypovolemic shock, and livers from donors who were treated for prolonged periods in intensive care units are particularly prone to the development of reperfusion injury after transplantation. The consequences may be catastrophic, resulting in primary graft dysfunction or nonfunction, as well as shortened graft and patient survival times (see Chapter 103).

Although the molecular mechanisms of ischemia-reperfusion damage are incompletely understood, a pathophysiological scenario set against the background of hepatic microcirculatory failure emerges, consisting of a complex interaction of *cytokines*, *chemokines* and *proinflammatory mediators*, as well as the generation of oxygen-dependent free radicals. (Fig. 16.1) [5, 7, 8]. Hepatocytes, sinusoidal endothelial cells, Kupffer cells, and neutrophil granulocytes, all contribute to the

Fig. 16.1 Pathogenetic concepts of ischemia-reperfusion injury of the liver



development of reperfusion injury. Hepatic ischemia stimulates Kupffer cells to secrete TNF- α , interferon- γ , platelet activating factor, IL-1, and IL-12. The central mediator of the hepatic response to ischemia-reperfusion is TNF- α . These cytokines not only act locally by stimulating adjacent hepatocytes to secrete further cytokines, but also exert functional effects on distant organs, e.g. the lungs. TNF- α induces the expression of adhesion molecules by vascular endothelia and enhances the chemotaxis of neutrophils, e.g. by IL-8 and its homologues (secreted by activated sinusoidal endothelial cells). Recent experimental data show that ceramide generated from increased activity of acidic sphingomyelinase after reperfusion may play an important role in ischemia-reperfusion injury by inducing intracellular factors of apoptosis and participating in TNF- α signaling [4].

The inflammatory reaction is accompanied by a *dysfunction of the hepatic microcirculation*. Sinusoidal endothelial cell activation results in upregulation of selectins, adhesion molecules (e.g. ICAM-1) and chemokines (e.g. IL-8) with consequent enhanced adhesion of platelets and neutrophils. Fibrinogen mediated interaction between thrombocytes and endothelial cells induces apoptosis of sinusoidal endothelial cells which, together with the activation of the complement system and of procoagulant factors, plays a major pathophysiological role in the development of hepatic microcirculatory failure [6]. Furthermore, an imbalance between vasoconstrictors (endothelins) and vasodilators (nitric oxide) in favor of the former impairs sinusoidal blood flow.

The most important source of *reactive oxygen species* and tissue-damaging proteases in reperfusion injury are activated neutrophils and Kupffer cells. The enzymes *xanthine oxidase* and *NADPH oxidase* are of special pathogenetic importance. Xanthine oxidase is found in hepatocytes and in endothelial cells, NADPH oxidase is present in Kupffer cells and in activated granulocytes. *Xanthine oxidase seems to be the principal source of postischemic oxidant stress to the liver*. After reperfusion molecular oxygen reacts with hypoxanthine (derived from ATP under conditions of oxygen deficiency) and with xanthine oxidase, forming highly toxic oxygen metabolites, superoxides, H₂O₂, and hydroxyl radicals, which damage the liver (see Chapter 14). Inhibitors of xanthine oxidase, such as allopurinol and antibiotics (in animal experiments), are capable of alleviating the reperfusion damage [1, 3]. The protective effect of allopurinol may involve preserving mitochondrial integrity in addition to inhibiting xanthine oxidase.

Histologically, ischemia-reperfusion injury manifests by neutrophilic infiltration of liver parenchyma (with granulocyte “sticking”), ballooning of hepatocytes, and liver cell death (occurring both by apoptosis and necrosis), which mainly affects centrilobular and midzonal hepatocytes. Cholestasis is usually present, and in severe cases cholangiolar cholestasis similar to that seen in sepsis may occur. The hepatocellular injury is accompanied by damage to endothelial and hepatic stellate cells. Macrovesicular steatosis is generally considered a pre-existing donor lesion. In animal experiments the preoperative dietary administration of omega-3 fatty acids protected macrosteatotic livers against reperfusion injury [2].

References

1. Bilzer M, Gerbes AL (2000) Preservation injury of the liver: mechanisms and novel therapeutic strategies. *J Hepatol* 32: 508–15
2. El-Badry AM, Moritz W, Contaldo C, et al (2007) Prevention of reperfusion injury and microcirculatory failure in macrosteatotic mouse liver by omega-3 fatty acids. *Hepatology* 45: 855–63
3. Lentsch AB, Kato A, Yoshidome H, et al (2000) Inflammatory mechanisms and therapeutic strategies for warm hepatic ischemia-reperfusion injury. *Hepatology* 32: 169–73
4. Llacuna L, Mari M, Garcia-Ruiz C, et al (2006) Critical role of acidic sphingomyelinase in murine hepatic ischemia-reperfusion injury. *Hepatology* 44: 561–72
5. Massip-Salcedo M, Roselló-Catafau J, Prieto J, et al (2007) The response of the hepatocyte to ischemia. *Liver Int* 27: 6–16
6. Sindram D, Porte RJ, Hoffman MR, et al (2000) Platelets induce sinusoidal endothelial cell apoptosis upon reperfusion of the cold ischemic rat liver. *Gastroenterology* 118: 183–91
7. Straatsburg IH, Boermeester MA, Wolbink GJ, et al (2000) Complement activation induced by ischemia-reperfusion in humans: a study in patients undergoing partial hepatectomy. *J Hepatol* 32: 783–91
8. Teoh NC, Farrell GC (2003) Hepatic ischemia-reperfusion injury: pathogenetic mechanism and basis for hepatoprotection. *J Gastroenterol Hepatol* 18: 891–902
9. Toledo-Pereyra LH, Simmons RL, Najarian JS (1975) Protection of the ischemic liver by donor pretreatment before transplantation. *Am J Surg* 129: 513–7

Chapter Outline

General Principles.....	189
References.....	190

General Principles

Drugs may damage the liver by two different mechanisms. The first mechanism is *toxicity* (see also Chapter 8 and Section XVIII). It is

- Dose dependent
- Predictable
- Reproducible

Hepatotoxins are either *directly* hepatotoxic or they damage the liver *indirectly* by reactive metabolites that are generated during their metabolism.

This direct or metabolically-mediated indirect liver toxicity is in contrast to a much larger group of drugs in which liver damage is due to *idiosyncrasy*. This type of liver injury is

- Dose independent
- Unpredictable
- Not reproducible (except in the same person)

The idiosyncratic mechanisms of liver injury are not completely understood. Both allergic and toxic factors play a role. In *hypersensitivity reactions* drugs or their metabolic products act as allergens and alter the antigenicity of the hepatocyte membrane. In course of the ensuing immunological reactions the liver is damaged [1–3]. In “*idiosyncratic toxicity*” altered metabolism by allelic variation and polymorphisms of enzymes are thought to be involved.

Classic examples of *toxic liver damage* are the intoxications with *Amanita phalloides* and carbon tetrachloride. Two toxins of *A. phalloides* – phalloidin and amanitin – attack the liver directly. Phalloidin damages the membranes of the smooth endoplasmic reticulum, the cell membrane and the cytoskeleton by inhibiting the polymerisation of actin. Amanitin inhibits the synthesis of RNA and proteins.

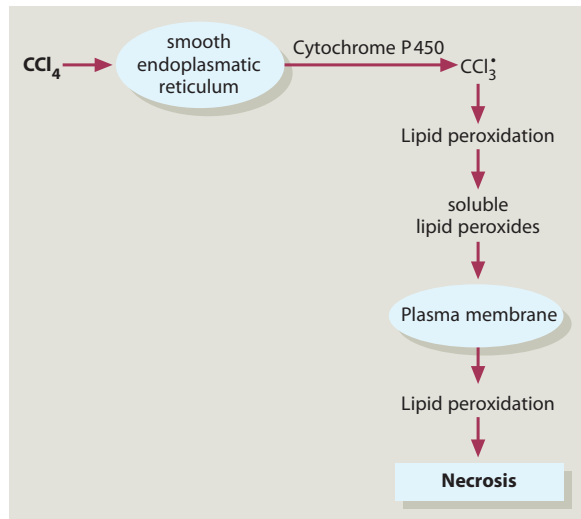


Fig. 17.1 Pathogenesis of CCl_4 -induced liver damage

Carbon tetrachloride (CCl_4) is exemplary of substances that damage the hepatocyte indirectly via reactive degradation products. **Figure 17.1** shows the mechanism of CCl_4 -induced liver damage. The crucial pathogenetic step is the formation of the unstable,

highly reactive trichloromethyl-radical (CCl_3^\bullet), which damages the liver by mixed function oxidases (cytochrome P450) localized in the endoplasmic reticulum. The stronger the enzymatic activity and the enzyme induction, the more intense is the “toxication” of CCl_4 and the more extensive is the liver damage. Severe intoxications cause extensive centrilobular parenchymal necroses and acute liver failure (acute liver dystrophy). In less severe cases (e.g., after short and low dose exposure to CCl_4) the necrotic areas are generally smaller; also, perinecrotic hepatocytes show sublethal fatty changes with small and medium sized fat droplets, caused by impaired synthesis of lipoproteins and triglyceride secretion. These changes are reversible.

References

1. Farrell GC (1994) Drug-induced liver disease. Churchill Livingstone, Edinburgh, pp. 414–30
2. Kaplowitz N, DeLeve LD (eds) (2003) Drug-induced liver disease. Marcel Dekker, New York
3. Zimmerman HJ (1999) Hepatotoxicity. The adverse effects of drugs and other chemicals on the liver, 2nd edn. Lippincott Williams & Wilkins, Philadelphia, PA

Chapter Outline

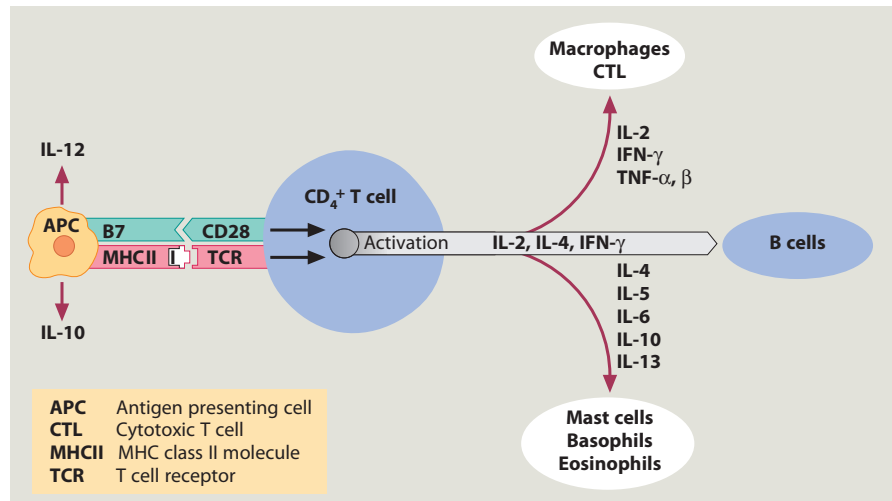
Antiviral Immune Reactions	192
Cytotoxic T Lymphocytes	193
Natural Killer (NK) Cells.....	194
Intracellular Virus Inactivation.....	194
Autoimmune Reactions	194
Autoimmune Hepatitis	195
Primary Biliary Cirrhosis.....	195
References	196

Immune mediated cell and tissue damage occurs during immune responses aimed at eliminating foreign or attacking self-antigens. Hepatocytes, biliary epithelial, and endothelial cells are the favored targets of an immunologic attack, which primarily occurs in

- Infections (viral, bacterial, protozoal)
- Drug-induced liver damage
- Autoimmune hepatobiliary diseases, and
- Liver transplant rejection

Infectious and immune pathogenetic mechanisms are often intertwined and in most cases cannot be sharply separated. Infectious organisms may be cytopathic and damage or kill the cell directly. However, infectious pathogens do not usually cause liver injury by themselves, but rather set in motion a series of events during which liver cells are damaged. Bacteria, for example, are phagocytosed by macrophages which subsequently release proinflammatory mediators, including interleukin-1 and TNF- α , which in turn damage vascular endothelia, increase vessel permeability and promote inflammation. Macrophages use MHC class II molecules on their surface to present bacterial components to T helper cells; these produce proinflammatory cytokines which stimulate B cells to proliferate and to secrete antibodies (Fig. 18.1). Cytokines released during antigen specific immune reactions may injure cells and recruit components of innate immunity that damage adjacent structures. Pathogens may also activate complement, either by the classic or alternative pathway. Chemotactins (C3a, C5a) attract neutrophils; infiltrating neutrophils upregulate the expression of endothelial adhesion molecules (e.g. ICAM-1), increase vascular permeability and damage vessels. All of these processes together promote local inflammatory reactions with subsequent injury of parenchymal and nonparenchymal cells.

Fig. 18.1 The interaction between antigen presenting cells and CD4⁺ T lymphocytes leads to the release of cytokines and stimulates other cells to participate in the immune and inflammatory reaction (Adapted from [10])



The natural defenses against viruses encompass the specific cellular T cell and the antibody-mediated humoral B cell responses as well as nonspecific immune mechanisms, with interferons playing a major role. In hepatic infections with non-cytopathic viruses, the immune system tries to recognize infected cells, to eliminate the virus, and to contain the infection. A rapid and efficient cytotoxic immune response causes lysis of infected hepatocytes and eliminates the virus. This process is associated clinically with acute hepatitis followed by viral clearance and healing. If the immune response is not successful viral persistence ensues. The clinical result is chronic hepatitis with smoldering necro-inflammatory and regenerative processes occurring side by side.

Hepatitis B virus (HBV) is a hepatotropic virus that is not directly cytopathic to liver cells. Liver injury in viral hepatitis is not caused by HBV itself, but instead by the immune response to the virus. In acute hepatitis B the cytotoxic T cell response against HBV is strong, multispecific and polyclonal. In the vast majority of patients this strong immune reaction leads to viral clearance. On the other hand, patients with chronic HBV infection display only a weak to moderate cytotoxic T cell response with incomplete lysis of infected hepatocytes and incomplete elimination of HBV. Persistence of HBV infection may support a mild but chronic hepatocellular damage that manifests clinically as chronic hepatitis (see Chapter 63).

Like viral liver diseases, many drug-induced liver reactions are largely immune mediated (see Chapters

17 and 92). The drug may be enzymatically transformed to reactive metabolites, which bind to self-constituents, most frequently the metabolizing enzyme, thus forming neoantigens. These neoantigens are the point of attack for cytotoxic immune mechanisms.

Lymphocyte mediated cytotoxicity and *non-cytotoxic antiviral strategies* represent exemplary immune mechanisms of liver cell damage and will be discussed briefly in the following paragraphs. The immunopathologic processes occurring in the various types of viral hepatitis and in immune mediated hepatobiliary diseases are treated separately in the respective clinical sections.

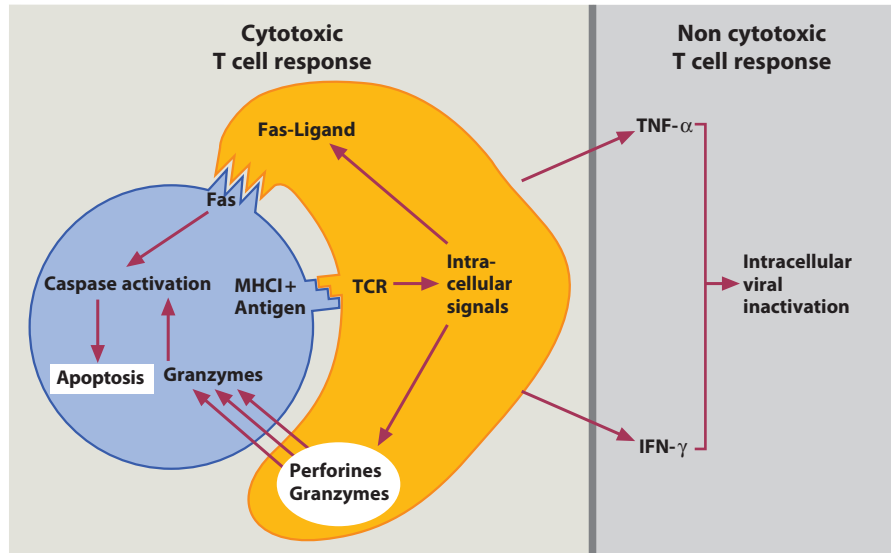
Antiviral Immune Reactions

Cytotoxic T lymphocytes (CTL) and natural killer (NK) cells are the most important immune cells in the defense of viral infections. These effector cells act by various mechanisms, including exocytosis, granule-associated cytoplasmic proteins (perforins and granzymes), expression of Fas-ligand, TRAIL (*Tumor necrosis factor-Related Apoptosis-Inducing Ligand*) and by the secretion of cytokines (interferon- γ and TNF- α) [6].

The actions of CTL and NK cells lead to

- Cell death (necrosis or apoptosis) of their target cells or to
- Intracellular virus inactivation

Fig. 18.2 The cytotoxic T cell can induce apoptosis of its target cell either via the Fas-dependent pathway, or by direct activation of caspase by granzymes. TNF- α and interferon- γ are important mediators of the non-cytotoxic T cell response



Cytotoxic T Lymphocytes

Specific CTL (mainly CD8⁺ cells) are effector cells of cytolytic reactions and play a major role in virus elimination. They can identify and lyse virally infected cells with the help of T helper lymphocytes (mainly CD4⁺ cells) and macrophages. CD8⁺ cells recognize viral antigens only if these are presented in association with MHC class I antigens on the surface of virally infected cells. CTL reveal their cytotoxic potential after reacting via their T cell receptor with the complex of MHC molecule and viral antigen (Fig. 18.2). Thus, the interaction between lymphocytes and their target cells is *antigen specific* and *MHC restricted*. After recognizing and establishing contact with target cells, the activated cytotoxic T cells initiate their lysis. The destruction of the target cell is mediated (1) by the release of soluble mediators stored in lysosomal granules (perforins, granzymes), and (2) by the expression of the Fas-ligand on the cell membrane of lymphocytes, which serves as an apoptotic signal. After the cytolytic attack the target cell perishes by necrosis (disintegration of membranes and organelles) or by apoptosis (chromatin condensation, DNA fragmentation, formation of membrane blebs) (see Chapter 23).

Perforin, also called cytolyisin, is a 70kDa glycoprotein that is synthesized exclusively by activated cytolytic lymphocytes. It gets its name from the ability to generate pores in cell membranes. In the presence of Ca⁺⁺ conformationally altered perforin monomers bind

to the plasma membrane of a target cell. Once inserted into the cell membrane, perforin molecules aggregate to homopolymers and generate pores with a diameter of 5–20 nm. These serve as nonselective ion channels, increase membrane permeability and impair cellular volume control, thus leading to colloid-osmotic lysis of the cell. Thereafter the cytotoxic T lymphocyte detaches from its target cell and is ready to attack other cells [9].

Granzymes are lysosomal proteases. Although not cytolytic by themselves, they indirectly participate in cell death in concert with perforin. While perforin by itself leads to osmotic-lytic cell necrosis, the coordinated action of perforin and granzymes induces apoptosis. Granzymes penetrate into the cell by the path created by perforin and trigger apoptosis by disrupting DNA binding nuclear proteins, activating caspases and other cytosolic proteins.

The induction of apoptosis can also occur by another mechanism, the *Fas-dependent cell death*. After contact with its target cell, the cytotoxic T lymphocyte expresses Fas-ligand on its surface which binds to the Fas (APO-1)-receptor on the target cell. Hepatocytes constitutively express Fas-receptors, and their expression is further enhanced by inflammatory stimuli. Fas (APO-1) is a 43 kDa protein belonging to the superfamily of TNF- and NGF (nerve growth factor)-receptors. The interaction between Fas-ligand and Fas (APO-1) can induce apoptosis of the Fas (APO-1)-expressing cell. Although these processes are not yet

completely understood, proteases seem to be important for the transduction of signals leading to apoptosis. The Fas-dependent cell death amounts to approximately one third of the total cytolytic activity of cytotoxic CD8⁺ T lymphocytes. It also contributes to cell death by CD4⁺ cytotoxic T lymphocytes, NK cells and lymphokine-activated killer cells.

In addition to the Fas-ligand pathway cytotoxic lymphocytes dispose of a further apoptosis inducing mechanism (independent of granules), *TRAIL*. Its significance in the liver still is unclear. *TRAIL*, also called APO-2L, belongs to the rapidly growing TNF-superfamily that presently encompasses at least 15 members. *TRAIL* is a membrane protein that is expressed on the surface of activated T, B, NK, dendritic cells and monocytes. In its biologically active form it exists as a homotrimer and shows amino acid sequence homologies with the Fas-ligand. Like the Fas-ligand and other members of the TNF-family, *TRAIL* can also induce apoptotic cell death in cells expressing the respective TNF-receptors. Interferon- γ potentiates *TRAIL*-induced apoptosis of virally infected cells.

Natural Killer (NK) Cells

In addition to cytotoxic T lymphocytes NK cells may eliminate virus laden cells. NK cells probably act in the early phases, while cytotoxic T cells operate during the later course of viral infection. NK cells do not express classic T or B cell markers. Unlike cytotoxic T lymphocytes, target cell recognition by NK cells is not MHC restricted. They express Fc-receptors for immunoglobulins on their surface, which bind to the antibody laden target cell. Thus, immunoglobulins serve as a bridge between NK and target cells. Cell lysis by NK cells is therefore called *antibody dependent cellular cytotoxicity (ADCC)*.

Intracellular Virus Inactivation

In addition to the cytotoxic T cell response, intracellular virus inactivation is a non-cytotoxic and non-cytolytic antiviral mechanism of CTL [18]. Activated CTL secrete interferon- γ and TNF- α that inactivate intracellular virus without killing the target cell

(Fig. 18.2). Both cytokines are capable of inhibiting viral gene expression and replication without damaging the infected cells. Viral DNA and RNA are cleared from the liver and from the serum without any demonstrable hepatic inflammatory reaction. This antiviral mechanism is thus mediated by cytokines secreted by CTL, i.e. interferon- γ and TNF- α . In addition interferon- γ activates macrophages, which, supported by TNF- α , enhance the process of virus inactivation.

The phenomenon of intracellular virus inactivation may also be observed in simultaneous infections with different viruses. Thus, CTL specific for cytomegalovirus or adenovirus by secreting cytokines may cause intracellular inactivation of, for example, hepatitis B virus. This phenomenon is called *viral cross talk* [17].

Autoimmune Reactions

The causes of autoimmune diseases and the exact mechanisms that lead to loss of immunological specificity and of self-tolerance are unknown. Among others, the release of sequestered antigens, molecular mimicry, altered self-antigens, polyclonal activation of autoimmunoreactive cells and genetic factors are discussed [2, 8].

Usually B and T cells with antigen receptors for self-antigens are eliminated by apoptosis or clonal anergy during ontogenesis. If autoreactive B or T cells escape these regulatory mechanisms, reactive lymphocytes may account for the body's attack on itself. This loss of B and/or T cell tolerance with aberrant self-recognition is a further mechanism that is believed to be responsible for the development of autoimmune diseases with genetic predisposition playing a major role [15, 16].

The pathogenetic effector mechanisms that ultimately lead to autoimmune liver cell damage correspond largely to the cytotoxic immune reactions described above.

Among the classic hepatobiliary autoimmune diseases are *autoimmune hepatitis* and *primary biliary cirrhosis* (see Section XIV). However, autoimmune reactions in the liver may also participate in the pathogenesis of primary sclerosing and autoimmune cholangitis, the vanishing bile duct syndrome, overlap syndromes, as well as numerous viral diseases, drug-induced liver injury or the autoimmune polyendocrine syndrome.

Autoimmune Hepatitis

Most patients with autoimmune hepatitis (AIH) show circulating antibodies that are directed, among others, against the asialoglycoprotein-receptor (ASGPR), various cytochrome P450 enzymes, UDP-glucuronyl transferases and other soluble nuclear and cytosolic antigens (e.g. ANA, SMA, LKM, SLA/LP (see Chapters 36 and 72)). The different autoantibody patterns define individuals with distinctive clinical phenotypes of AIH. Despite the diagnostic importance of the autoantibody profile, the immunopathogenetic significance of the various autoantibodies in causing liver damage in AIH is poorly understood. Most diagnostically relevant autoantibodies do not injure the liver and up to 10% of patients with AIH do not have demonstrable circulating autoantibodies, although most of these patients have elevated IgG levels in plasma. SLA/LP is the only one disease-specific autoantigen, but seems to be relevant in only about 20% of patients [4].

The exact pathogenesis of AIH is still unsolved. The development of immunologically mediated liver injury in AIH occurs against the background of predisposing genetic factors. Humans with HLA B8, DR3, DR4 and DR 52a have a higher risk to develop AIH. Loci that code for complement, immunoglobulins and the T cell receptor may enhance genetic predisposition.

Various hypotheses for the development of AIH have been advanced: (1) dysregulation of T cells with subsequently increased antigen-induced antibody production by B cells; (2) abnormal T cell response against the ASGPR; (3) initiation of a T cell response by viral infections, such as hepatitis A, Epstein-Barr and rubella virus; (4) decreased numbers of regulatory T cells; (5) triggering of an autoimmune reaction by molecular mimicry between B cell epitopes on cytochrome P450 IID6 and an early protein of herpes simplex virus 1. None of these hypotheses can be considered proven at present.

The inflammatory cell infiltrate in AIH contains plasma cells, but CD4⁺ and CD8⁺ T cells predominate. CD8⁺ T cells isolated from portal tracts of patients with AIH are cytotoxic against syngeneic hepatocytes. T cells infiltrating the liver in AIH have a restricted repertoire of T cell-receptor V β -chains and they express large amounts of the antiapoptotic protein Bcl-2. This suggests that they are part of a long-lived antigen driven immune response.

An increased expression of soluble Fas may be found in the serum of patients with AIH, and Fas polymorphisms influence the susceptibility to AIH [5]. Altered modulation of ligands for programmed cell death has been demonstrated in the liver of patients with AIH [11]. Thus, the apoptotic pathway performed by as yet ill-characterized CTL may represent a further interesting pathogenetic model in AIH.

Primary Biliary Cirrhosis

Primary biliary cirrhosis (PBC) is characterized by a progressive inflammatory destruction of interlobular and septal bile ducts (see Chapter 73). Bile duct destruction is accompanied by T cell infiltrates and enhanced expression of MHC class II and adhesion molecules. More than 90% of patients with PBC have circulating antimitochondrial antibodies (AMA) that are directed against the E2 component of the mitochondrial pyruvate dehydrogenase complex (PDC-E2). Approximately 50% of patients also exhibit antibodies against various nuclear antigens.

Autoreactive T cells and autoantibodies play a major role in biliary epithelial cell injury. A molecule related antigenically to PDC-E2 is expressed on the surface of biliary epithelial cells from patients with PBC. This molecular resemblance might explain the selective damage of biliary epithelia in PBC. PDC-E2 reactive T cells have been demonstrated in the liver and in the peripheral blood from patients with PBC [12]. These T cells exhibit a restricted repertoire of T cell-receptor V β -chains, which suggests that, like in AIH, they are part of a long-lived antigen regulated immune response.

Interesting data indicate that infectious agents are possibly involved in the immune pathogenesis of PBC [7]. Chlamydia pneumoniae antigen and RNA, for example, have recently been demonstrated in liver tissue of patients with PBC suggesting that C. pneumoniae antigen may trigger an immune response based on molecular mimicry [1]. Similarly human β -retrovirus, *Novosphingobium aromaticovorans* (an ubiquitous xenobiotic metabolizing bacterium), *Escherichia coli*, and *Paracoccus denitrificans* have all been implicated in PBC, although their pathogenetic significance has never been proven [3, 13, 14, 19].

References

1. Abdulkarim AS, Petrovic LM, Kim WR, et al (2004) Primary biliary cirrhosis: an infectious disease caused by *Chlamydia pneumoniae*? *J Hepatol* 40: 380–4
2. Bogdanos DP, Choudhuri K, Vergani D, et al (2001) Molecular mimicry and autoimmune liver disease: virtuous intentions, malign consequences. *Liver* 21: 225–32
3. Burroughs AK, Butler P, Sternberg MJ, et al (1992) Molecular mimicry in liver disease. *Nature* 358: 377–8
4. Herkel J, Schuchmann M, Tiegs, et al (2005) Immune-mediated liver injury. *J Hepatol* 42: 920–3
5. Hiraide A, Imazeki F, Yokosuka O, et al (2005) Fas polymorphisms influence susceptibility to autoimmune hepatitis. *Am J Gastroenterol* 100: 1322–9
6. Hoskin DW (2000) TRAIL: a newly described effector mechanism of cytotoxic lymphocytes. *Mod Asp Immunobiol* 1: 136–9
7. Jones DEJ, Palmer JM, Burt AD, et al (2002) Bacterial motif DNA as an adjuvant for the breakdown of immune self-tolerance to pyruvate dehydrogenase complex. *Hepatology* 36: 679–86
8. Kamradt T, Mitchison NA (2001) Tolerance and autoimmunity. *N Engl J Med* 344: 655–64
9. Liu CC, Young LHY, Young JDE (1996) Lymphocyte-mediated cytolysis and disease. *N Engl J Med* 335: 1651–9
10. Mabee CL, Thiele DL (2000) Mechanisms of autoimmune liver disease. *Clin Liver Dis* 4: 431–45
11. Matak N, Kikuchi K, Kawai T, et al (2007) Expression of PD-1, PD-L1, and PD-L2 in the liver in autoimmune liver diseases. *Am J Gastroenterol* 102: 302–12
12. Pingel S, Arenz M, Meyer zum Büschenfelde KH, et al (2002) Pyruvate dehydrogenase specific T cells in primary biliary cirrhosis show restricted antigen recognition sites. *Liver* 22: 308–316
13. Sayers TJ, Baum H (1976) Possible cross-reactivity of human anti-mitochondrial antibodies with membrane vesicles of *Paracoccus denitrificans*. *Biochem Soc Trans* 4: 138–9
14. Selmi C, Balkwill DL, Invernizzi P, et al (2003) Patients with primary biliary cirrhosis react against a ubiquitous xenobiotic metabolizing bacterium. *Hepatology* 38: 1250–7
15. Theofilopoulos AN (1995) The basis of autoimmunity: part I. Mechanisms of aberrant self-recognition. *Immunol Today* 16: 90–8
16. Theofilopoulos AN (1995) The basis of autoimmunity: part II. Genetic predisposition. *Immunol Today* 16: 150–8
17. Wedemeyer H, Mizukoshi E, Davis AR, et al (2001) Cross-reactivity between hepatitis C virus and influenza A virus determinant-specific cytotoxic T cells. *J Virol* 75: 11392–4000
18. Thimme R, Blum HE (1998) T-Zell-Antwort gegen Viren. Eine neue nicht-zytotoxische antivirale Strategie. *Dtsch med Wschr* 123: 1007–8
19. Xu L, Sakalian M, Shen Z, et al (2004) Cloning the human betaretrovirus proviral genome from patients with primary biliary cirrhosis. *Hepatology* 39: 151–6

Chapter Outline

Endotoxin-Induced Inflammation	197
Endotoxin-Induced Cholestasis	197
References	198

The liver continuously encounters gut-derived bacterial products via the portal venous circulation, including endotoxin. Fifty percent of bacterial lipopolysaccharide is cleared by Kupffer cells, 20% by sinusoidal endothelial cells and 30% by hepatocytes. Endotoxin plays a major role in liver damage in septicemia, intestinal bacterial overgrowth, and in alcoholic and cholestatic liver diseases [6]. It impacts gene expression of parenchymal and nonparenchymal cells and impairs numerous hepatocellular transport processes [1].

Endotoxin-Induced Inflammation

The effects of endotoxin on liver cells are most likely mediated by cytokines released by Kupffer cells and infiltrating inflammatory cells. One of the earliest events in endotoxin-induced liver damage is the induction of TNF- α production in Kupffer cells [2]. Endotoxin stimulates the synthesis of TNF- α mRNA by enhancing the translocation of NF κ B into the cell nucleus. TNF- α sets in motion a cascade of proinflammatory cytokines whose concerted action damages hepatocytes, recruits inflammatory cells and initiates repair processes, including fibrogenesis (Fig. 19.1).

In addition to its stimulatory effects on Kupffer and inflammatory cells, endotoxin itself damages the cell membrane, increases the permeability for Ca⁺⁺, generates oxygen-derived free radicals, and enhances lipid peroxidation [5].

Endotoxin-Induced Cholestasis

Endotoxin reduces the expression of the basolateral Na⁺-taurocholate-cotransport-protein (NTCP) and inhibits the enzymatic activity of Na⁺/K⁺-ATPase. The

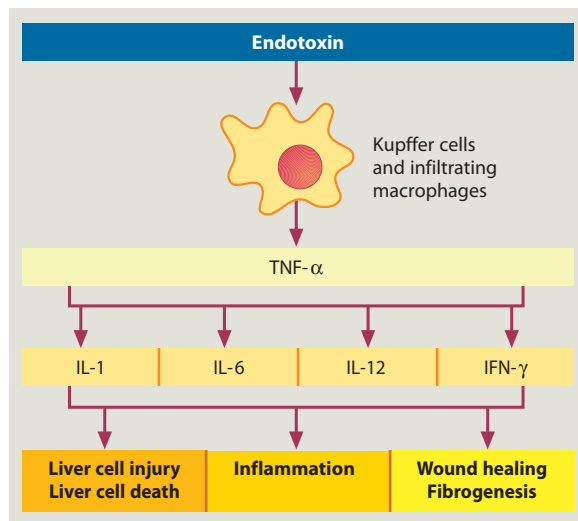


Fig. 19.1 Pathogenesis of endotoxin induced liver injury

latter can also be inhibited by interleukin-6. The reduction in NTCP mRNA is mediated by TNF- α and interleukin-1, while the decline in enzyme activity might be related to endotoxin induced changes of membrane fluidity [1]. The end result of endotoxin effects is a reduced Na⁺-dependent uptake of taurocholic acid at the basolateral membrane, a diminished uptake of bilirubin, as well as a decrease in the bile acid dependent and independent bile flow, i.e. cholestasis.

In addition to their effects on hepatocytes, endotoxin and cytokines may affect biliary epithelial cells. Endotoxin has been shown to stimulate cholangiocyte proliferation by the release of interleukin-6 from cholangiocytes, and to enhance the development of cholestasis and cholangitis by damaging bile duct epithelial cells [3, 4].

References

1. Green RM, Beier D, Gollan JL (1996) Regulation of hepatocyte bile salt transporters by endotoxin and inflammatory cytokines in rodents. *Gastroenterology* 111: 193–8
2. Jirillo E, Caccavo, Magrone, T, et al (2002) The role of the liver in the response to LPS: experimental and clinical findings. *J Endotoxin Res* 8: 319–27
3. Kimmings AN, van Deventer SJH, Obertop H, et al (2000) Endotoxin, cytokines, and endotoxin binding proteins in obstructive jaundice and after preoperative biliary drainage. *Gut* 46: 725–31
4. Park J, Gores G, Patel T (1999) Lipopolysaccharide induces cholangiocyte proliferation via and interleukin-6-mediated activation of p44/p42 mitogen-activated protein kinase. *Hepatology* 29: 1037–43
5. Sakaguchi S, Furusawa S (2006) Oxidative stress and septic shock: metabolic aspects of oxygen-derived free radicals generated in the liver during endotoxemia. *FEMS Immunol Med Microbiol* 47: 167–77
6. Siegmund SV, Dooley S, Brenner DA (2005) Molecular mechanisms of alcohol-induced hepatic fibrosis. *Dig Dis* 23: 264–74

Chapter Outline

General Principles.....	199
References.....	200

General Principles

Cholestasis denotes disrupted/slowed bile flow or impaired bile formation. It always results in or is caused by hepatobiliary dysfunction, and leads to retention of biliary constituents. During severe cholestasis of long duration, cholestasis itself damages the liver and further contributes to reduction of bile flow, thus creating a vicious circle.

Cholestasis-induced liver injury is multifactorial. The detergent properties of retained bile acids and the hepatocellular accumulation of copper (normally excreted through the bile) are pathogenetically relevant events because they damage membranes and injure the microtubular cytoskeleton. In addition, bile acids activate programmed cell death pathways [1]. They enhance the cytosolic transport of Fas to the cell surface and induce apoptosis of liver cells via a Fas dependent, Fas ligand independent mechanism [2, 3].

Cholestasis and endotoxin-induced liver damage are pathophysiologically interrelated, and the pathogenetic mechanisms of endotoxin-induced liver damage (see Chapter 19) also contribute to cholestasis induced hepatocellular injury. Thus, obstructive cholestasis with bacterial cholangitis, for example, may be accompanied by endotoxemia which in turn would support and aggravate cholestatic liver injury.

The histology of cholestatic reaction and the clinical aspects of cholestasis are discussed in Chapters 26 and 52, respectively.

References

1. Grambihler A, Higuchi H, Bronk SF, et al (2003) cFLIPL-L inhibits p38 MAPK activation: an additional anti-apoptotic mechanism in bile acid-mediated apoptosis. *J Biol Chem* 278: 26831–7
2. Miyoshi H, Rust C, Roberts PJ, et al (1999) Hepatocyte apoptosis after bile duct ligation in the mouse involves Fas. *Gastroenterology* 117: 669–77
3. Sodeman T, Bronk SF, Roberts PJ, et al (2000) Bile salts mediate hepatocyte apoptosis by increasing cell surface trafficking of Fas. *Am J Physiol* 278: G992–9

Chapter Outline

Iron and Copper-Induced Liver Injury	201
References	202

The most relevant hepatotoxic metals are *iron* and *copper*. Chronic, heavy overload of the liver with these metals leads to cell damage, progressive fibrosis and ultimately to liver cirrhosis and its complications (see Section XVI) [1, 4].

Iron and Copper-Induced Liver Injury

Hepatic *iron overload* most often is due to increased and uncontrolled intestinal absorption (e.g. genetic hemochromatosis [see Chapters 6 and 82]), parenteral iron administration (e.g. repeated blood transfusions), or chronic hemolysis. Secondary iron overload, however, may be observed in many cirrhotic livers of varying etiologies, particularly in those of non-biliary origin [5]. The mechanism of hemosiderosis is not well understood, but it may contribute to the progression of liver cirrhosis. The excess iron that reaches the hepatocyte is stored in the cytosol and in the lysosomes as ferritin or as lysosomal hemosiderin. In secondary iron overload states, iron is first taken up by Kupffer cells, and possibly also by endothelial and hepatic stellate cells, and only thereafter by hepatocytes. This is in contrast to genetic hemochromatosis, where iron storage occurs primarily in hepatocytes. Only after hepatocellular storage capacity is exceeded, iron is deposited in Kupffer cells and in cholangiocytes. Small foci of iron-containing Kupffer cells testify to prior liver cell death.

In addition to its direct hepatotoxic effects, iron seems to play a pathogenetic role as a cofactor in non-hemochromatotic liver diseases, such as alcoholic liver injury, nonalcoholic steatohepatitis, chronic viral hepatitis (mainly hepatitis C), porphyria cutanea tarda and α_1 -antitrypsin deficiency [2, 3].

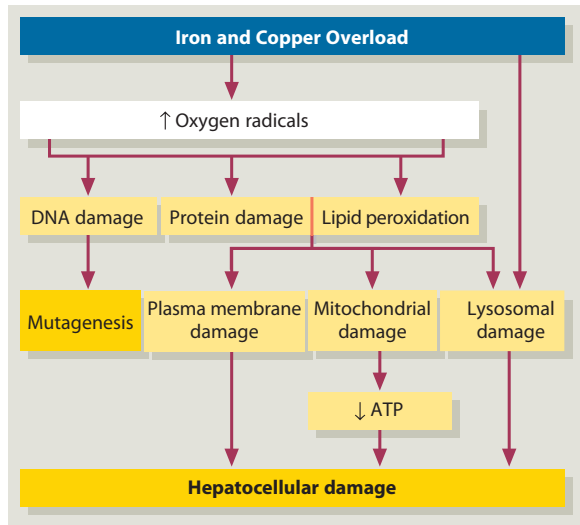


Fig. 21.1 Pathogenic model of iron- and copper-induced liver injury

In the hepatocyte copper is incorporated into Cu-containing enzymes or ceruloplasmin which is then secreted into the circulation. Intracytoplasmic copper is bound to metallothionein and excreted in bile (see Chapter 6). Genetically determined *copper overload* is seen in Wilson's disease (Chapter 81). Conditions characterized by impaired biliary secretion, such as chronic cholestatic liver diseases, are also associated with copper overload.

The toxicity of iron and copper is believed to involve two non-mutually exclusive mechanisms: (1) oxidative stress, with metal-catalyzed production of reactive oxygen species causing oxidative damage to lipids, proteins and nucleic acids, and (2) direct metal-induced organelle injury.

The increased risk of hepatocellular carcinoma in patients with genetic hemochromatosis is believed to be due to iron-induced oxidative DNA damage, as well as to proliferative stimuli in regenerative nodules.

Under physiologic conditions lysosomes are responsible for the homeostasis of normal iron and copper

levels, i.e. for their storage and biliary excretion. Excessive accumulation of iron or copper leads to functional impairment of lysosomes and to damage of their membranes with subsequent release of hydrolytic enzymes and stored metals. These substances damage the hepatocyte by the enzymatic pathway and by the mechanism described above.

In addition to lysosomes, other cell organelles, primarily mitochondria, can be damaged by excessive metal overload. Impairment of the cytochrome oxidase complex (the common final pathway for electrons and hydrogen ions that leads to the generation of water and energy [ATP]) seems to be particularly relevant in this regard.

Figure 21.1 summarizes the pathogenetic mechanisms of iron- and copper-induced hepatotoxicity. Oxidative stress and both lysosomal and mitochondrial dysfunction result in hepatocellular damage. Furthermore, within the context of metal-induced chronic liver injury, Kupffer cells are activated and secrete proinflammatory and profibrogenic cytokines (mainly TNF- α and TGF- β). Activated hepatic stellate cells enhance remodeling of the extracellular matrix (Chapter 28).

References

1. Bonkovsky HL, Ponka P, Bacon BR, et al (1996) An update on iron metabolism: summary of the fifth international conference on disorders of iron metabolism. *Hepatology* 24: 718–29
2. Bonkovsky HL, Lambrecht RW (2000) Iron-induced liver injury. *Clin Liver Dis* 4: 409–29
3. Bonkovsky HL, Lambrecht RW, Shan Y (2003) Iron as a comorbid factor in nonhemochromatotic liver disease. *Alcohol* 30: 137–44
4. Britton RS (1996) Metal-induced hepatotoxicity. *Semin Liver Dis* 16: 3–12
5. Ludwig J, Hashimoto E, Porayko MK, et al (1997) Hem siderosis in cirrhosis: a study of 447 native livers. *Gastroenterology* 112: 882–8

Chapter Outline

General Principles.....	203
References.....	204

General Principles

Radiation-induced liver injury is rare. It may occur after radiotherapy with at least 30 Gy, such as may be seen in patients with lung cancer, metastatic ovarian carcinoma, or malignant abdominal lymphomas. Even after localized liver radiation with 1,500 Rad, liver weight is restored after partial hepatectomy. This, however, is not accomplished through hepatocyte proliferation. Instead, hepatocytes increase their size and liver mass is restored by cellular hypertrophy [4]. After hepatic radiation, activation and proliferation of hepatic stellate cells is observed as an early event followed by portal and severe sinusoidal fibrosis [6]. Radiation probably also damages sinusoidal and central vein endothelial cells, and may manifest clinically as *sinusoidal obstruction syndrome* (formerly called veno-occlusive disease) (see Chapter 60) [5].

Radiation-induced bile duct strictures are a very rare cause of *obstructive jaundice* and symptoms of biliary obstruction typically occur after a very long (10 years and more) symptom-free period [1, 2]. The pathogenesis of radiation-induced bile duct injury probably involves progressive obliterative vasculitis causing ischemia, various degrees of biliary epithelial atrophy, and/or ulcerative changes and fibrosis.

In 1928 colloidal *thorium dioxide* was introduced as an angiographic contrast medium (Thorotrast); it was distributed worldwide in the 1930s and 1940s. After intraarterial administration this colloid is taken up by cells of the reticuloendothelial system, mainly in liver and spleen, and accumulates in lysosomes. Thorium dioxide emits α -radiation and its biologic half-life amounts to 200–400 years! In the liver thorotrast is first taken up by Kupffer cells; during the ensuing years it drains into the portal tracts and is stored

in portal tract macrophages. The chronic continuous low dose radiation by thorium dioxide induces hepatic fibrosis, accompanied by only a scant inflammatory reaction, and may ultimately result in presinusoidal portal hypertension.

A far more serious consequence of Thorotrast application is the induction of hepatic *angiosarcomas* (see Chapter 102) (more rarely hepatocellular and cholangiocellular carcinomas) which were reported for the first time in 1947 and led to the withdrawal of Thorotrast from the market [3]. Due to its long half-life and to the long latency period (up to several decades) of sarcoma development, Thorotrast-induced hepatic angiosarcomas were rarely seen until a few years ago.

References

1. Cherqui D, Palazzo L, Piedbois P, et al (1994) Common bile duct stricture as a late complication of upper abdominal radiotherapy. *J Hepatol* 20: 693–7
2. Geubel AP, Sempoux C, Rahier J (2003) Bile duct disorders. *Clin Liver Dis* 7: 295–309
3. MacMahon HE, Murphy AS, Bate MI (1947) Endothelial-cell sarcoma of liver following Thorotrast injections. *Am J Pathol* 23: 585–613
4. Michalopoulos GK, DeFrances MC (1997) Liver regeneration. *Science* 276: 60–6
5. Reed GB, Cox AJ (1966) The human liver after radiation injury: a form of veno-occlusive disease. *Am J Pathol* 48: 597–611
6. Sempoux C, Horsmans Y, Geubel AP, et al (1997) Severe radiation induced liver disease following localized radiation therapy for biliopancreatic carcinoma: activation of hepatic stellate cells as an early event. *Hepatology* 26: 128–34

Chapter Outline

Degenerative Cell Changes	207
Hydropic Cell Swelling.....	207
Hypoxic Vacuoles.....	208
Cytoplasmic Deposits	208
Feathery Degeneration	209
Cell Death	209
Necrosis.....	209
Apoptosis	213
References	218

Degenerative Cell Changes

Hydropic Cell Swelling

(Synonyms: ballooning, ballooning degeneration, toxic cell swelling, vacuolar degeneration, hydropic change). Ballooning denotes a severe, but reversible hepatocellular change. This injury initially is not lethal but may become a precursor of lytic necrosis if the injurious insult continues. Ballooning degeneration is observed in viral, toxic (alcohol), and ischemic liver damage, mainly in centrilobular (zone 3) hepatocytes.

Hydropic cell swelling represents an osmotic cell edema due to impaired hepatocellular energy homeostasis and altered permeability of the cell membrane; these alterations affect ion pumps localized in the membrane with subsequent influx of sodium and water. The swollen, ballooned hepatocytes are rounded, with cytoplasm that appears clear and stringy (Fig. 23.1). Large segments of the hepatocyte are occupied by clear spaces, the organelles are rarified and irregularly clumped. Peribiliary basophilia, which describes the accumulation of rough endoplasmic reticulum at the apical (biliary) pole of the hepatocyte, is a phenomenon due to cell hydration rather than a distinct feature of hydropic cell swelling (Fig. 23.2). Small, clear cytoplasmic vacuoles represent distended segments pinched-off from the endoplasmic reticulum (vacuolar degeneration). Swelling of mitochondria with rarefaction of their cristae, intramitochondrial accumulation of amorphous material rich in phospholipids, myelin figures, loss of intercellular contacts, and disaggregation of granular and fibrillary nucleolar elements are further alterations that may be seen by electron microscopy in hydropic cell swelling.

Fig. 23.1 Ballooned hepatocytes. Some hepatocytes also contain fat vacuoles and intranuclear inclusions. Hematoxylin-Eosin

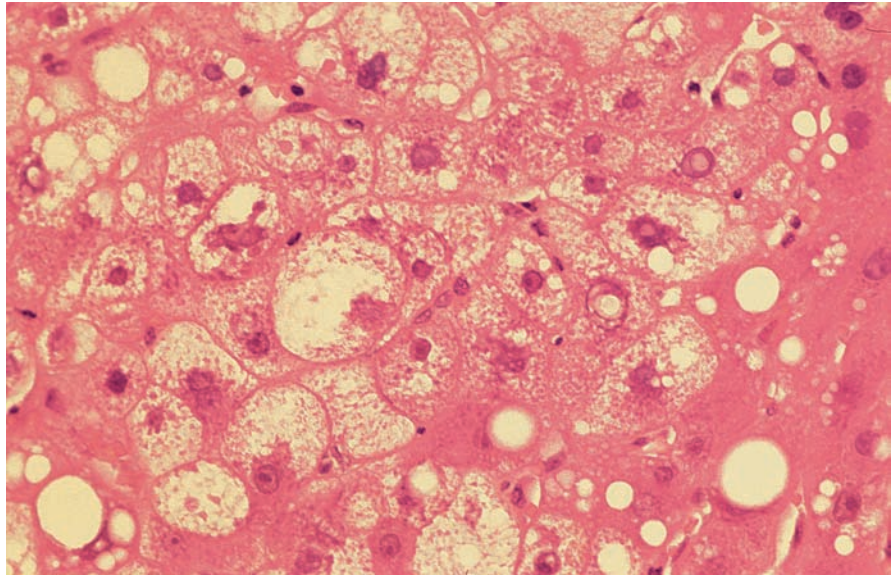
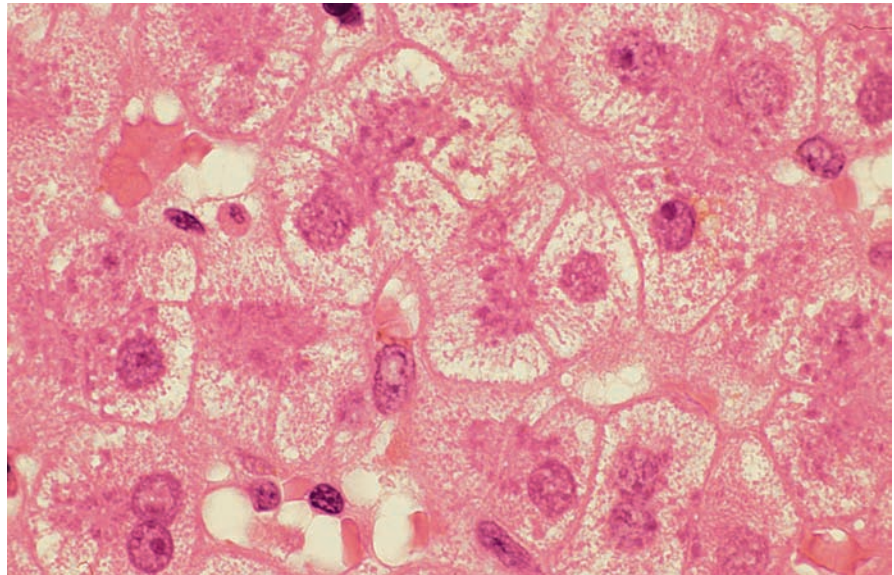


Fig. 23.2 Peribiliary basophilia in hydroppically swollen hepatocytes. Hematoxylin-Eosin



Hypoxic Vacuoles

Hypoxic vacuoles represent ischemic lesions and are caused by invagination of the liver cell membrane. On light microscopy they appear as pale vacuoles, mainly localized in perivenular hepatocytes and contain fibrinogen, albumin and other plasma proteins. The membranes limiting the vacuoles are not derived from the

endoplasmic reticulum and differ thereby from the cytoplasmic vacuoles present in α_1 -antitrypsin deficiency and fibrinogen storage disease.

Cytoplasmic Deposits

See Chapter 24.

Feathery Degeneration

(Synonym: pseudoxanthomatous degeneration). Feathery degeneration denotes a cytoplasmic alteration caused by the detergent action of retained toxic bile acids (*cholate stasis*) that imparts a diffuse, foamy, reticular (“feathery”) appearance to the swollen hepatocyte (Fig. 23.3). On electron microscopy damaged smooth endoplasmic membranes with dilated vesicles containing whorl-like membranous material can be observed. Feathery degeneration affects single cells or small groups of hepatocytes, mostly in the periportal parenchyma which otherwise appears unremarkable, and occurs mostly in cholestasis of longer duration.

Cell Death

Cell death either occurs as a programmed, physiologic event in the framework of normal organ homeostasis, or it is caused by a traumatic, pathologic incident. The characteristic morphological changes of cell death occur several hours after transition from the reversible to the irreversible phase of injury. This transition cannot be precisely identified by light microscopy. The denaturation of proteins begins while the cell is still alive and continues after its death. During the processes leading to cell death numerous degradative enzymatic reactions occur. However, it is difficult to

tell apart those reactions that are causally related to cell death from biochemical epiphenomena [4, 16].

Cell death manifests itself as

- Necrosis or
- Apoptosis

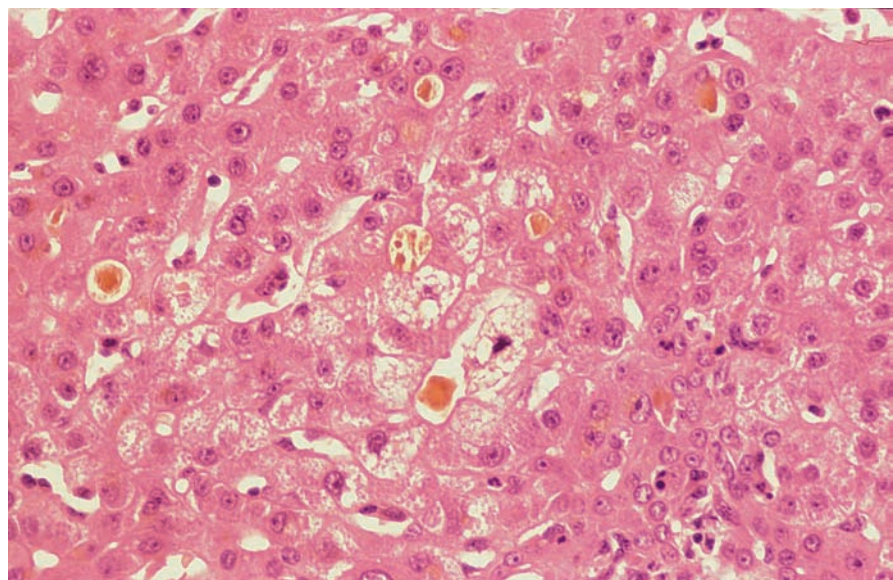
While necrosis represents an unplanned accident by which innocent cells die in a hostile environment, in apoptosis the cell exerts its own death. The structural hallmark of necrosis is loss of plasma membrane integrity with release of cell contents into the extracellular space eliciting an inflammatory reaction. Apoptotic cell death (*programmed cell death*) leaves the plasma membrane essentially intact, and leads to the fragmentation of the nucleus as well as the cell - generating membrane-bound structures that once contained intact viable organelles. Apoptotic bodies are extruded from surrounding viable lobular hepatocytes and may remain in liver tissue for extended periods of time. Phosphatidylserines generated during the apoptotic process activate macrophages and phagocytosis, but a true inflammatory reaction is missing.

Both processes, necrosis and apoptosis, often occur together and mixed forms of cell death also exist.

Necrosis

Necrosis refers to changes that become visible *following* cell death. The processes leading to necrosis initially

Fig. 23.3 Cholestasis with bile plugs in dilated biliary canaliculi. Some hepatocytes show feathery degeneration. Hematoxylin-Eosin



are still reversible. Prenecrotic changes are characterized by swelling of cell organelles, lytic nuclear changes, and the formation of organelle-free plasma membrane blebs. The blebs may pinch-off from the plasma membrane, thereby restoring its integrity. The blebs may also rupture, releasing cytosolic enzymes into the extracellular space. Bleb-formation is caused by deranged interactions between the cytoskeleton and the plasma membrane, but is not due to osmotic cell swelling.

Numerous theories have been advanced regarding necrotic cell death. At present, mitochondrial damage is viewed as the pivotal pathogenetic event leading to necrosis. Mitochondrial injury is followed by impairment of oxidative phosphorylation, ATP-depletion, loss of energy homeostasis and an increase in permeability of the plasma membrane. An increased influx of Ca^{++} activates degradative hydrolases, including proteases, phospholipases and endonucleases that further damage the plasma membrane. In the presence of oxygen, reactive oxygen species are generated that promote lipid peroxidation thus further damaging the plasma membrane and interrupting the association between the cytoskeleton and the cell membrane. Ultimately these processes result in loss of membrane integrity [26].

Necrosis manifests itself on light microscopy as

- Lytic necrosis, and
- Coagulative necrosis

The precursor of *acidophilic necrosis* is acidophilic degeneration with cell shrinkage as a result of dehydration and loss of glycogen (Fig. 23.4). When denaturation, and

not hydropic swelling, is the leading process *coagulative necrosis* develops. The outline of the coagulated, eosinophilic hepatocytes remains preserved for some days. The dead cells are then fragmented and removed by phagocytosis of the cellular debris. The increased eosinophilia is caused by the loss of normal basophilia (due to ribosomal RNA), combined with cellular dehydration and by the increased binding of eosin to denatured cytoplasmic proteins.

The precursor of *lytic necrosis* is hydropic cell swelling (ballooning) (see above). This type of necrosis develops rapidly; necrotic cells “drop out” and leave behind gaps in the trabecular parenchymal texture. Lytic necrosis elicits an inflammatory reaction, predominantly with mononuclear cells. Macrophages containing phagocytosed hepatocytic debris (iron containing groups of Kupffer cells, ceroid storing macrophages) and lymphocytes mark the site of previous necrosis (Fig. 23.5).

According to the extent of hepatocyte necrosis and its distribution within the liver acinus, various *patterns of necrosis* are distinguished.

Single Cell Necrosis

Single cell necrosis occurs either as disseminated or focal (spotty) necrosis of individual cells or of very small groups of hepatocytes (<10 cells). The reticular framework remains intact. Dead hepatocytes drop out and are rapidly removed, leaving behind gaps in the

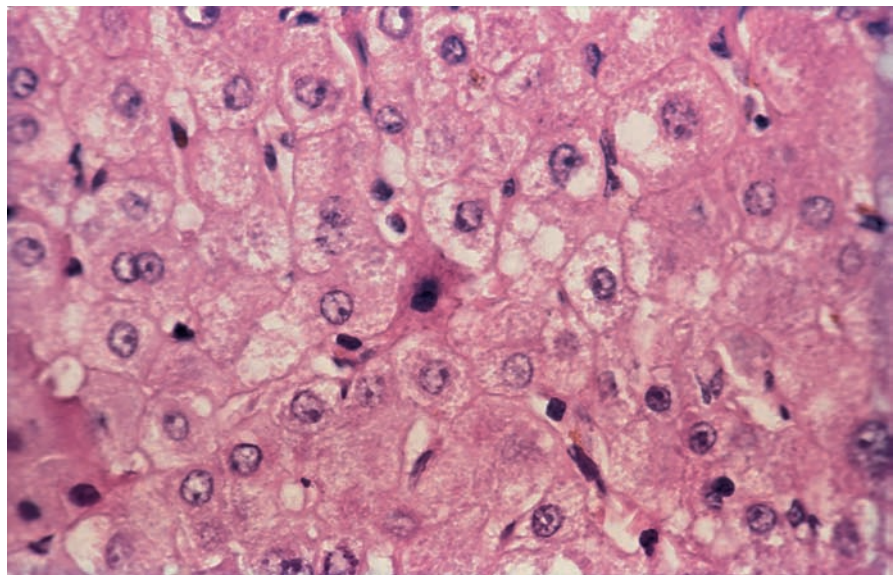


Fig. 23.4 Shrunken, dehydrated, acidophilic hepatocyte (acidophilic degeneration). Hematoxylin-Eosin

Fig. 23.5 Clusters of ceroid-storing macrophages mark the site of previous hepatocyte death. PAS-Diastase

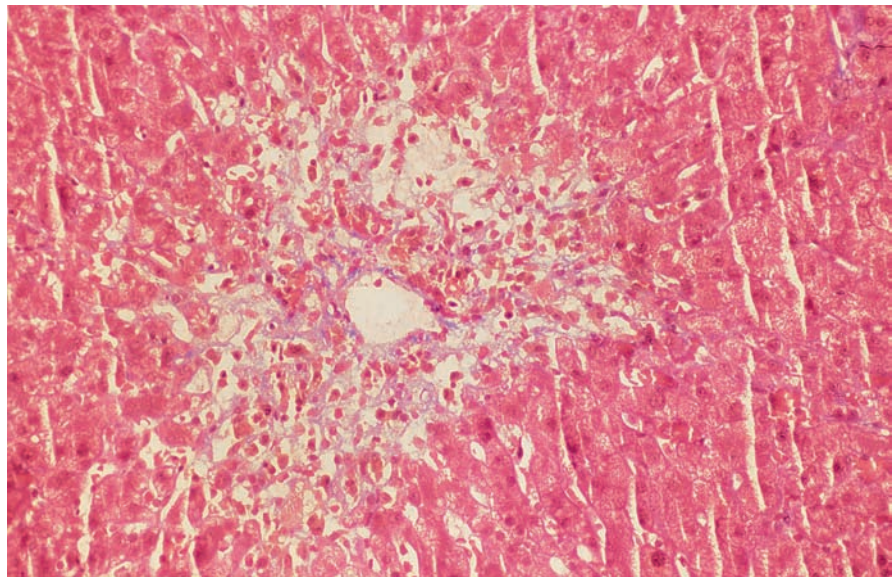
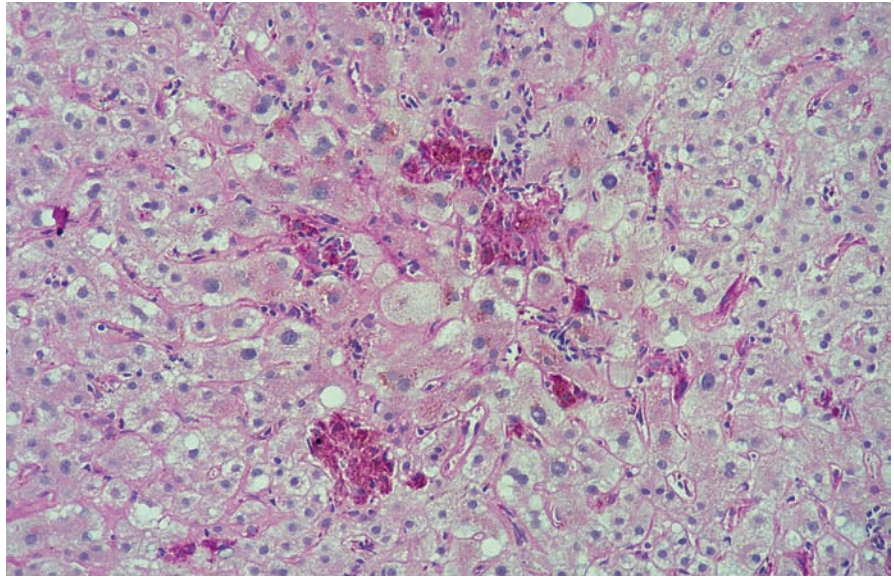


Fig. 23.6 Centrilobular (perivenular) parenchymal necrosis. Hematoxylin-Eosin

liver cell-plates and a focal mononuclear inflammatory infiltrate. Thus, focal necrosis is more often indirectly recognized by these reactive changes than by the necrotic cell itself. Spotty necrosis is a nonspecific finding. It is mainly observed in acute hepatitis.

Necrosis of Cell Groups and Confluent Necrosis

In contrast to focal, spotty necrosis this term denotes the death of larger groups of contiguous hepatocytes.

Necrotic cell groups may be distributed haphazardly within the lobule and/or they may merge to form confluent necrosis. If clusters of hepatocytes in a defined acinar zone are affected, the process is called *zonal necrosis*. According to the zone affected, necroses are designated as periportal, centrilobular (perivenular), midacinar, etc. (Fig. 23.6). If the entire liver lobule is necrotic a *massive (panlobular) necrosis* is present. Confluent necrosis refers to coalescing group necroses. *Submassive necrosis* denotes confluent necroses within a lobule, while in *multilobular necrosis* substantial

necrotic areas of several lobules merge forming necrotic bridges between vascular structures. Confluent zonal necrosis occurs in hypoxic/ischemic conditions, such as shock, heart failure, heat stroke and in viral and drug-induced liver injury (e.g. acetaminophen, nonsteroidal antiinflammatory drugs).

Bridging necrosis describes extensive confluent necrosis between neighboring vascular structures. These “bridges” may be contained within one acinus or they may span from one acinar zone to a neighboring acinus. Bridging necrosis is particularly well appreciated in reticulin stains that visualize reticulin fiber collapse (Fig. 23.7). *Veno-venous necrosis* connects the central veins of neighboring lobules corresponding to the microcirculatory periphery of a complex acinus. This type of bridging is observed in circulatory failure and venous outflow obstruction. *Porto-venous necrosis* links the portal tract and the central vein and corresponds to the microcirculatory periphery of a simple acinus. It occurs in acute viral hepatitis and in flares of chronic hepatitis. *Porto-portal necrosis* spans the portal tracts of neighboring lobules and is seen in chronic hepatitis and in biliary tract disease.

Piecemeal Necrosis

Piecemeal necrosis is a time honoured denomination for hepatocellular necrosis or apoptosis mediated by

cytotoxic T lymphocytes at the interface between portal tracts or fibrous septa and lobular parenchyma. It is part of the chronic inflammation at the parenchymal-connective tissue interface which erodes the limiting plate (*interface hepatitis*) (Fig. 23.8). The portal-parenchymal interface becomes blurred with mesenchymal cells and extracellular matrix expanding at the expense of the periportal parenchyma. In severe interface hepatitis clear, hydropically swollen hepatocytes, grouped around a small central lumen (*liver cell rosettes*) are observed in the vicinity of piecemeal necroses. They are believed to be represent liver cell regeneration. Piecemeal necroses mainly occur in chronic hepatitis with at least moderate inflammatory activity.

Surgical “Necrosis”

Surgical “necroses” describe clusters of neutrophils within the sinusoids in biopsies obtained intraoperatively during laparotomy (Fig. 23.9). They are typically found in the subcapsular parenchyma and near the central vein. The extent of these alterations increases with the duration of the operation and with the extent of manipulation of the liver by the surgeon. The clusters of neutrophils are a nonspecific finding that are probably due to altered cell distribution during laparotomy and do not represent a true inflammation. They are therefore not clinically relevant. Rarely, mechanical trauma by the hand of the surgeon may cause a

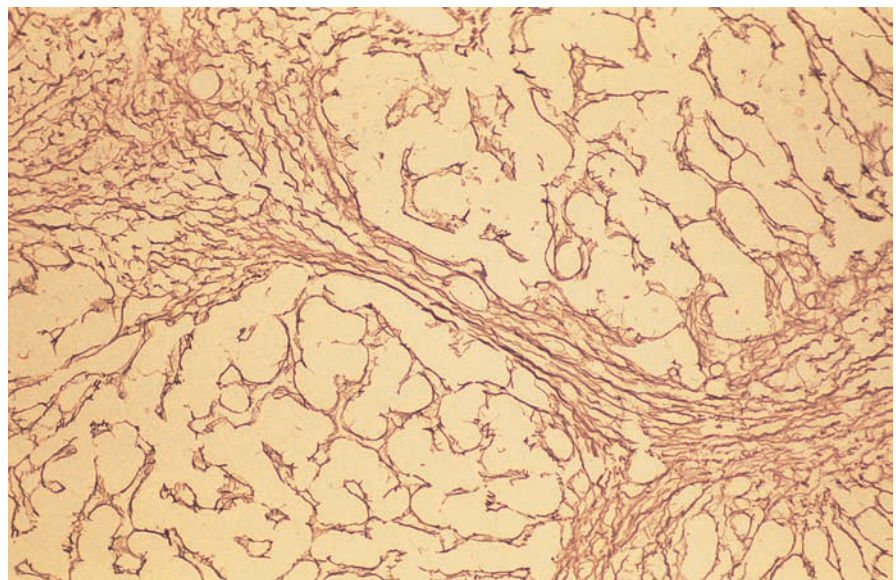


Fig. 23.7 Bridging necrosis. The collapse of reticulin fibers marks extensive confluent necrosis linking neighboring portal tracts. Gomori reticulin stain

Fig. 23.8 Cellular inflammatory infiltrate at the interface between portal tract and lobular parenchyma (interface hepatitis). Single lymphocytes erode the limiting plate and cause hepatocellular death (piecemeal necrosis). Hematoxylin-Eosin

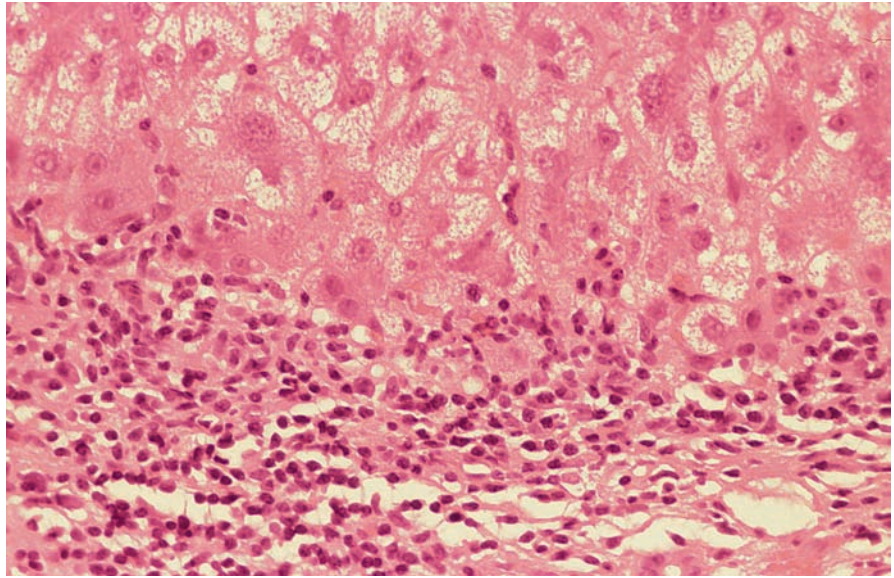
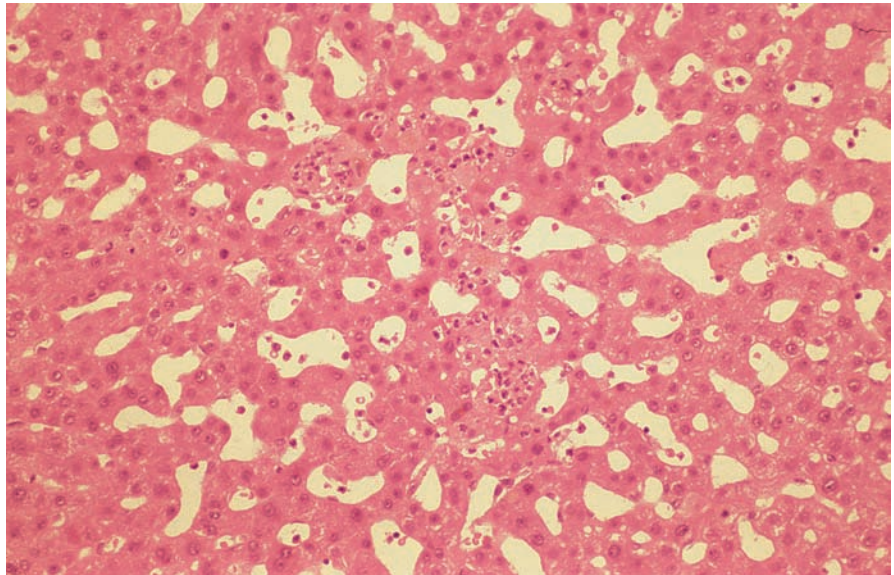


Fig. 23.9 Surgical “necrosis”. Clusters of neutrophilic granulocytes accumulate in the sinusoids in the course of intraabdominal operations. Hematoxylin-Eosin



localized hepatocellular ischemia with focal liver cell necrosis and subsequent reactive inflammation.

Apoptosis

In the early 1970s Kerr recognized and described apoptosis as a discrete form of cell death and a basic biological phenomenon necessary for the preservation of

life [14, 15]. Apoptosis is a physiological, genetically programmed, active process that requires a functioning system of protein synthesis. It leads to shrinkage and fragmentation of single or small cluster of cells. The apoptotic cell is rapidly cleared, before its contents have leaked out.

Apoptosis is responsible for the maintenance of normal cell homeostasis in all organs, for the balance between the generation of new cells and cell loss. Aged, damaged or abnormal cells that threaten to

impair normal organ function are cleared by apoptosis. Apoptosis occurs during embryogenesis, organ growth and atrophy, in toxic injuries, viral infections, immune reactions and in tumorigenesis [6, 8, 11, 31].

Morphology

Apoptosis leads to morphological changes of the cell nucleus and the cytoplasm. The nuclear chromatin condenses at the nuclear membrane; at first the nucleus becomes pyknotic and disintegrates thereafter into small dense chromatin fragments. The DNA becomes fragmented. The cytoplasm too condenses giving rise to round or oval apoptotic cells with an intensely eosinophilic cytoplasm containing dense nuclear fragments. The cell continues to shrink, forms blebs, and finally disintegrates into small fragments that are surrounded by an intact cell membrane. These membrane bound *apoptotic bodies* initially contain still largely intact cell organelles. They express phosphatidyl serine and adhesive glycoproteins (e.g. thrombospondin) on their outer surface which serve as recognition molecules for macrophages that engulf apoptotic cell fragments. During this process no intracellular material leaks out into the extracellular space and an inflammatory reaction, such as in necrosis, is missing. In contradiction to necrosis that may include clusters of cells, segments of organs and even entire organs, apoptosis affects single cells that are extruded from the surrounding tissue. The differences between apoptosis and necrosis are summarized in [Table 23.1](#).

Apoptosis of hepatocytes generates round, eosinophilic structures known as *acidophilic bodies*, previously called “Councilman bodies” (first described by Councilman in yellow fever) ([Fig. 23.10](#)). Usually the remnants of the pyknotic nucleus are still discernible. Some acidophilic bodies represent shrunken remnants of the entire hepatocyte, while others correspond to hepatocellular fragments. The acidophilic bodies are phagocytosed by Kupffer cells or invading macrophages. Thus, the contents of apoptotic bodies are not released into the surrounding tissue.

Molecular Mechanisms

Apoptosis can be induced by a variety of external stimuli. The interaction of ligands with specific surface receptors (“death receptors”) activates intracellular signaling cascades that culminate in cell death [5]. Numerous mechanisms are capable of activating death receptors or initiating apoptosis by intracellular mechanisms ([Fig. 23.11](#)) [7].

Apoptosis can be initiated through an extrinsic or an intrinsic pathway depending on the initial site of activation of the cell death process ([Fig. 23.12](#)) [28]. The *ligand/receptor-interaction* activates the caspase (cysteine aspartate protease) family of enzymes which are the most important effectors of apoptosis. Crucial to their catalytic activity is the presence of a cysteine residue in the active center of the molecule. The effector caspases cleave proteins whose functional loss induces apoptosis. Members of the TNF- and TNF/

Table 23.1 Differences between necrosis and apoptosis

Feature	Apoptosis	Necrosis
Regulation	Genetically regulated and programmed; active, energy consuming process	Not genetically regulated; passive, “accidental” cell death
Triggered by	Physiologic or pathologic stimuli	Pathologic stimuli
Morphology	Death of single cells or very small clusters of cells; the tissue architecture remains intact	Death of single cells, large groups of cells, organ segments and even entire organs
Blebs	Yes; organelles within blebs	Yes; no organelles within blebs
Plasma membrane	Remains intact	Integrity is lost
Organelles	Integrity is preserved initially	Integrity is lost
Nucleus	Chromatin condenses at the nuclear membrane; fragmentation of the nucleus (pyknosis, karyorrhexis); internucleosomal DNA-degradation (“DNA-ladder”)	Formation of chromatin clumps; nucleus disintegrates (karyolysis); accidental DNA cleavage
Final result	Apoptotic body	Cell disintegration
Reaction	Phagocytosis by macrophages or neighboring cells; no inflammatory reaction	Inflammatory reaction; regeneration of tissue or fibrosis (scar)

Fig. 23.10 An apoptotic cell with fragmented, pyknotic nuclear remnants is cleared from liver cell trabeculae. An inflammatory reaction is lacking. Hematoxylin-Eosin

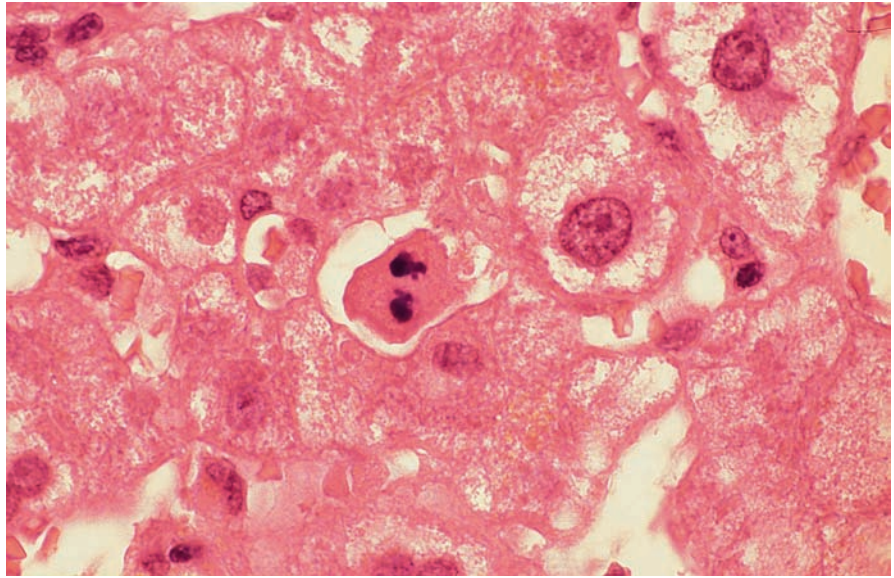
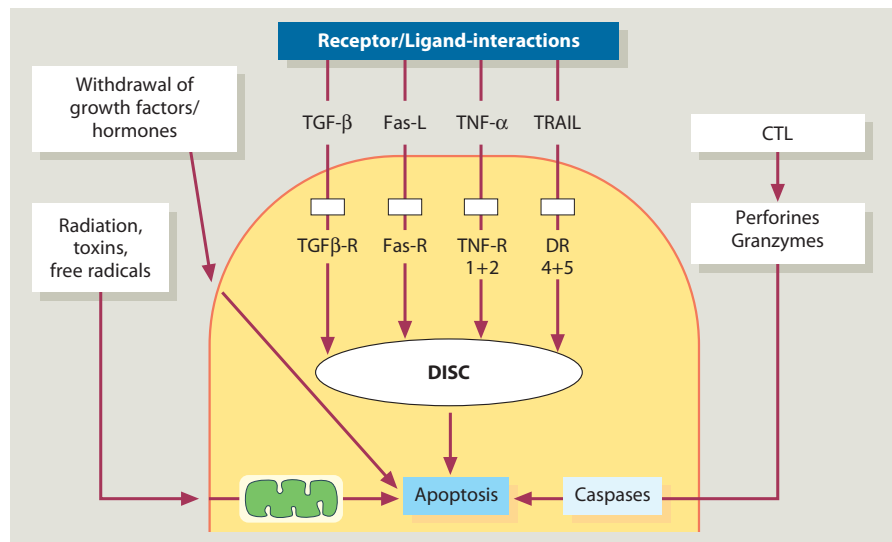


Fig. 23.11 Apoptosis can be initiated by various stimuli. Some stimuli, such as granzymes from cytotoxic lymphocytes (CTL) directly activate caspases. Some ligands induce apoptosis after interacting with their specific receptors via the formation of DISC. Free radicals and toxins may activate caspases by damaging mitochondria and releasing cytochrome c. For abbreviations see text



NGF (nerve growth factor)-receptor family, with FAS (Apo-1; CD 95) being an important member of this family, play a central role in ligand-induced apoptosis.

Fas-induced apoptosis is currently the best characterized apoptotic pathway and is illustrated in a simplified scheme in Fig. 23.12. The reaction of Fas with its ligand or with antibodies against Fas leads to trimerization of Fas. This is followed by recruitment of the intracellular adapter-molecule *FADD* (Fas-Associated Death Domain) to the receptor with subsequent activation of apoptosis-inducing cascades [23].

The multiprotein-aggregate of Fas-receptor, cytosolic linker proteins (FADD) and pro-caspase 8 forms the so-called **Death Inducing Signaling Complex (DISC)**. High local concentrations of procaspase 8 in DISC undergoes autoproteolytic cleavage, releasing activated caspase 8. Active caspase 8 cleaves and activates bid (a member of the Bcl-2 family) that in turn activates proapoptotic Bcl-2 family members, such as Bax and Bak. These are integrated into the mitochondrial membrane and lead to the release of mitochondrial proteins including cytochrome c. Following its

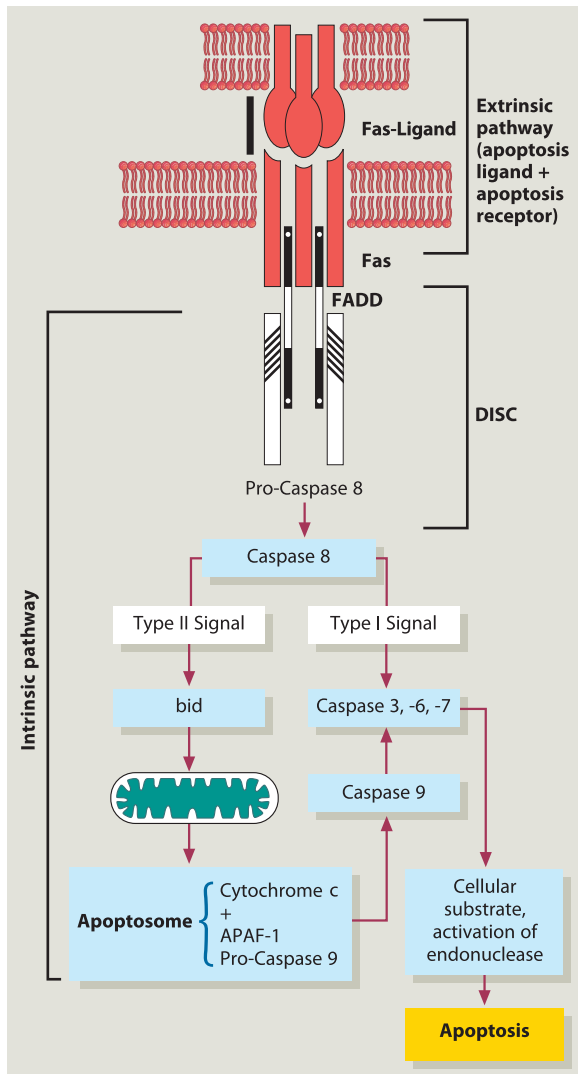


Fig. 23.12 Fas (Apo-1; CD 95) induced apoptosis. See text for details

release from the mitochondria, cytochrome c triggers the formation of the *apoptosome*, a complex including apoptosis protease-activating factor-1 (APAF-1) and procaspase 9. The formation of the apoptosome leads to cleavage and activation of caspase 9, which in turn activates caspase 3.

Depending on whether or not mitochondrial proteins are involved, at least two pathways (type I and II) of Fas-induced apoptosis may be distinguished. In type I apoptosis, high local caspase 8 concentrations at the level of DISC are recruited that can directly activate caspase 3. If concentrations of caspase 8 in DISC are

low, activation of caspase 3 is accomplished by mitochondrial cytochrome c, which represents the type II pathway.

Thus, activated caspase 3 is a central effector protein of apoptosis. It cleaves and activates other caspases that attack cellular substrates and finally leads to the structural breakdown of the cell. Caspase 3 also activates a nuclease that catalyzes the internucleosomal cleavage of DNA and is therefore called DNA fragmentation factor. A special form of DNA degradation is accomplished by non-lysosomal endonuclease [2]. Activated non-lysosomal endonuclease transforms the double stranded DNA into oligo-nucleosomal fragments of defined size which leads to a ladder-like appearance of the DNA degradation products after gel electrophoresis. This type of DNA fragmentation is a characteristic phenomenon of apoptosis, although not always demonstrable. Of importance for apoptosis is also the activation of transglutaminases that lead to crosslinking of proteins.

TNF-Related Apoptosis-Inducing-Ligand (TRAIL), TNF- α . In addition to Fas there exist other death receptors that mediate apoptosis of liver cells. TRAIL and TNF- α may induce apoptosis via specific receptors, thereby assuming an important role in the pathogenesis of many liver lesions.

TRAIL is a multifunctional cytokine that exhibits a high amino acid homology with Fas-ligand. In humans there are two death-inducing receptors for TRAIL (TRAIL-R). The signaling induced by these receptors can lead to apoptosis but may also result in activation of survival signals mediated by the nuclear factor (NF)- κ B (Fig. 23.13). TRAIL is important in the homeostasis of the immune system. The TRAIL/TRAIL-R system impacts infectious and autoimmune reactions and seems to play a role in tumorigenesis and in immune mediated liver injury. It has gained much attention due to its high anti-tumor potential [1, 27]. Recently it has been shown that free fatty acids sensitize hepatocytes to TRAIL mediated cytotoxicity, which may be relevant to the pathogenesis of nonalcoholic fatty liver disease [17].

TGF- β is a potent inducer of apoptosis and may play a role in the reversal of liver cell hyperplasias and in hepatocarcinogenesis. TRAIL has been shown to mediate TGF- β -induced apoptosis in hepatoma cells [10].

TNF- α induced apoptosis may be pathogenetically relevant in endotoxin mediated liver injury and in alcoholic and nonalcoholic steatohepatitis. In addition to the caspase 8/Bid mediated mechanism of

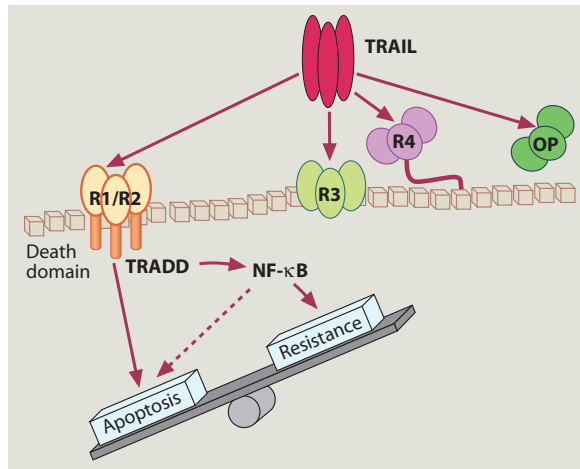


Fig. 23.13 TRAIL receptor signaling. Schematic diagram showing the major intracellular signaling pathways activated following TRAIL ligation to its membrane-bound receptors. R1 and R2 are the dominant receptors in initiating TRAIL-induced apoptosis, while the activation of NF- κ B may induce the expression of both antiapoptotic and proapoptotic signals. (Adapted from [9])

apoptosis discussed above, TNF- α induced apoptosis is mainly dependent on the release and activation of cathepsin B (a cysteine protease) from lysosomal vesicles. Cathepsin B exerts a proapoptotic effect by releasing cytochrome c from mitochondria.

Regulation of Apoptosis

Apoptosis can be stimulated or inhibited by various proteins at different levels of the signaling cascade, and the ratio between pro- and antiapoptotic factors probably determines the pathway. Among the most important regulatory proteins are Bcl-2 (Bcl = B cell lymphoma) and the family of Bcl-2 related proteins, such as Bcl-x, Bax, Mcl-1, A1 (Table 23.2). *The proto-oncogene Bcl-2*

Table 23.2 Bcl-2 gene family: promoters and suppressors of apoptosis

Antiapoptotic	Proapoptotic
Bcl-2	Bax
Bcl-x _L	Bcl-x _s
Bcl-w	Bak
Mcl-1	Bag
Bfl-1	Bid
Brag-1	Bik
A1	Hrk
	Bad

inhibits apoptosis. Bcl-2 inhibits the endonuclease mediated degradation of DNA and blocks the release of mitochondrial cytochrome c. It prolongs cell survival without stimulating cell proliferation. Bcl-2 itself probably is regulated by the tumor suppressor gene p53. p53 (“guardian of the genome”) causes arrest of cell cycle in the G₁-phase and enhances apoptosis. An upregulation of p53 leads to a decrease of Bcl-2 and to an increase of Bax thus increasing apoptotic activity [29].

The phosphorylation status of Bid determines the apoptotic threshold of hepatocytes. Sustained phosphorylation of bid confers resistance to Fas induced apoptosis [30].

Other inhibitors of apoptosis are members of the inhibitor of apoptosis gene (IAP) family, including survivin. It plays a role in hepatic tumorigenesis by inhibiting apoptosis, thus enabling abnormal neoplastic cells to survive [24].

Recent animal experimental data provide evidence that norepinephrine released from the hepatic sympathetic nerves plays a role in protecting the liver from Fas-mediated fulminant hepatitis, possibly via mechanisms including antiapoptotic proteins and interleukin 6 [3].

Apoptosis in Liver Diseases

Apoptosis as a fundamental biological phenomenon has significant impact on liver function. Disproportional activation of apoptosis will lead to cell and organ dysfunction with atrophy, while inhibiting apoptosis will favor the development of liver cell hyperplasia, and hepatocellular or cholangiocellular carcinogenesis [13, 19–22].

Many hepatic cells express Fas and thus are susceptible to Fas-mediated death, and apoptosis is assumed to play an important pathogenetic role in many liver diseases. Thus, understanding the molecular mechanisms of apoptosis will probably allow for the development of new therapeutic opportunities in the future.

In viral hepatitis, in graft rejection, and in autoimmune liver diseases apoptosis is mediated mainly by infiltrating or resident lymphocytes. Many hepatotoxic substances induce apoptosis by releasing mitochondrial cytochrome c. Drug-induced idiosyncratic liver injury may also employ hepatocellular apoptosis. Recent data argue for apoptotic cell death to be pathogenetically important in alcoholic hepatitis [18, 32].

Apoptosis may also affect cholangiocytes and thus contribute to the development of cholestatic liver diseases and ductopenic cholangiopathies. Certain bile

acids, such as chenodeoxycholic acid and deoxycholic acid induce apoptosis of hepatocytes by ligand-independent oligomerization of Fas-receptor with subsequent recruitment of FADD. Ursodeoxycholic acid may inhibit apoptosis by inhibiting mitochondrial depolarization; this mechanism may be responsible for the favorable effect of ursodeoxycholic acid on the course of some cholestatic liver diseases [25].

Intracellular copper in Wilson's disease may activate the Fas-system and thereby possibly contribute to hepatocyte death. A similar mechanism might contribute to iron-induced cell death in genetic hemochromatosis.

Apoptosis of activated stellate cells inhibits inflammation and fibrosis and, within limits, may also reverse hepatic fibrosis in its early stages [12].

References

1. Abe K, Kurakin A, Mohseni-Maybodi M, et al (2000) The complexity of TNF-related apoptosis-inducing ligand. *Ann N Y Acad Sci* 926: 52–63
2. Arends MJ, Morris RG, Wyllie AH (1990) Apoptosis. The role of the endonuclease. *Am J Pathol* 136: 593–608
3. Chida Y, Sudo N, Takaki A, et al (2005) The hepatic sympathetic nerves play a critical role in preventing Fas induced liver injury in mice. *Gut* 54: 994–1002
4. Farber JL (1992) The biochemistry of cell death. *J Toxicol Pathol* 5: 1–9
5. Faubion WA, Gores GJ (1998) Death receptors in liver biology and pathobiology. *Hepatology* 29: 1–4
6. Feldmann G (1997) Liver apoptosis. *J Hepatol* 26(Suppl. 2): 1–11
7. Fesus L, Davies JA, Piacentini M (1991) Apoptosis: molecular mechanisms in programmed cell death. *Eur J Cell Biol* 56: 170–7
8. Galle PR (1997) Apoptosis in liver disease. *J Hepatol* 27: 405–12
9. Herr I, Schemmer P, Büchler MW (2007) On the TRAIL to therapeutic interventions in liver disease. *Hepatology* 46: 266–74
10. Herzer K, Ganten TM, Schulze-Bergkamen H, et al (2005) Transforming growth factor beta can mediate apoptosis via the expression of TRAIL in human hepatome cells. *Hepatology* 42: 183–92
11. Hockenbery D (1995) Defining apoptosis. *Am J Pathol* 146: 16–9
12. Iredale JP, Benyon RC, Pickering J, et al (1998) Mechanisms of spontaneous resolution of rat liver fibrosis. Hepatic stellate cell apoptosis and reduced hepatic expression of metalloproteinase inhibitors. *J Clin Invest* 102: 538–49
13. Kaplowitz N (2000) Cell death at the millennium: implications for liver diseases. *Clin Liver Dis* 4: 1–23
14. Kerr JFR (1971) Shrinkage necrosis: a distinct mode of cellular death. *J Pathol* 105: 13–20
15. Kerr JFR, Wyllie AH, Currie AR (1972) Apoptosis: a basic biological phenomenon with wide-ranging implications in tissue kinetics. *Br J Cancer* 26: 239–57
16. Majno G, Joris J (1995) Apoptosis, oncosis, and necrosis. An overview of cell death. *Am J Pathol* 146: 3–15
17. Malhi H, Barreyro FJ, Isomoto H, et al (2007) Free fatty acids sensitise hepatocytes to TRAIL mediated cytotoxicity. *Gut* 56: 1124–31
18. Natori S, Rust C, Stadheim LM, et al (2001) Hepatocyte apoptosis is a pathologic feature of human alcoholic hepatitis. *J Hepatol* 34: 248–53
19. Patel T, Gores GJ (1995) Apoptosis and hepatobiliary disease. *Hepatology* 21: 1725–41
20. Patel T, Roberts LR, Jones BA, et al (1998) Dysregulation of apoptosis as a mechanism of liver disease: an overview. *Semin Liver Dis* 18: 105–14
21. Patel T, Steer CJ, Gores GJ (1999) Apoptosis and the liver: a mechanism of disease, growth regulation, and carcinogenesis. *Hepatology* 30: 811–5
22. Patel T (2000) Apoptosis in hepatic pathophysiology. *Clin Liver Dis* 4: 295–317
23. Pinkoski MJ, Brunner T, Green DR, et al (2000) Fas and Fas ligand in gut and liver. *Am J Physiol Gastrointest Liver Physiol* 278: G354–66
24. Pitot HC (1998) Hepatocyte death in hepatocarcinogenesis. *Hepatology* 28: 1–5
25. Rodrigues CMP, Fan G, Ma X, et al (1998) A novel role for ursodeoxycholic acid in inhibiting apoptosis by modulating mitochondrial membrane perturbation. *J Clin Invest* 101: 2790–9
26. Rosser BG, Gores GJ (1995) Liver cell necrosis: cellular mechanisms and clinical implications. *Gastroenterology* 108: 252–75
27. Schaefer U, Voloshanenko O, Willen D, et al (2007) TRAIL: a multifunctional cytokine. *Front Biosci* 12: 3813–24
28. Schattenberg JM, Galle PR, Schuchmann M (2006) Apoptosis in liver disease. *Liver Int* 26: 904–11
29. Schmitz I, Kirchhoff S, Krammer PH (2000) Regulation of death receptor-mediated apoptosis pathways. *Int J Biochem Cell Biol* 32: 1123–36
30. Vogel A, Aslan JE, Willenbring H, et al (2006) Sustained phosphorylation of bid is a marker for resistance to fas-induced apoptosis during chronic liver diseases. *Gastroenterology* 130: 104–19
31. Wyllie AH, Kerr JF, Currie AR (1980) Cell death: the significance of apoptosis. *Int Rev Cytol* 68: 251–306
32. Ziolk M, Tepper M, Lohez M, et al (2001) Clinical and biological relevance of hepatocyte apoptosis in alcoholic hepatitis. *J Hepatol* 34: 254–60

Chapter Outline

Cytoplasmic Changes	219
Ground-Glass Hepatocytes	219
Lafora Bodies	222
Oncocytic Change	222
Megamitochondria	222
Intracytoplasmic Inclusions and Deposits.....	224
Nuclear Changes	232
Nuclear Swelling.....	232
Nuclear Inclusions	232
References	234

In order to survive, the cell must be able to adapt. Adaptation is associated with alterations of organelles which often are visible by light microscopy. The intracellular accumulation of substances may reflect adaptive mechanisms or be a manifestation of metabolic derangement. Storage of substances may be innocuous or may contribute to cell injury. In this chapter important hepatocellular adaptation phenomena, intracellular inclusions and deposits, are outlined according to their localization in the cytoplasm or nucleus.

Cytoplasmic Changes

Ground-Glass Hepatocytes

The increase of smooth endoplasmic reticulum membranes imparts the cytoplasm a weakly eosinophilic, finely granular to homogenous ground-glass appearance (Fig. 24.1). Ground-glass hepatocytes are found in hepatitis B virus infection, in which an excess of HBV surface antigens are present in proliferated endoplasmic reticulum vesicles. These HBsAg-positive ground-glass cells have to be differentiated from so-called induced cells, from hepatocytes containing Lafora bodies, liver cells with inclusions in type IV glycogenosis, polyglucosan-like hepatocellular inclusions, fibrinogen inclusions, and from morphologically similar inclusions of unknown origin (see below). Furthermore, hepatocytes with an oncocytic change due to marked mitochondrial hyperplasia may have a ground-glass-like appearance.

In *HBsAg-positive ground-glass cells* the nucleus is often displaced to the cell periphery. The eosinophilic inclusion usually is surrounded by an “empty” halo, which probably reflects a fixation or embedding artifact (retraction rim; see Fig. 63.34a). On electron

Fig. 24.1 Clusters of HBsAg positive hepatocytes with a homogeneous, ground-glass cytoplasm. Hematoxylin-Eosin

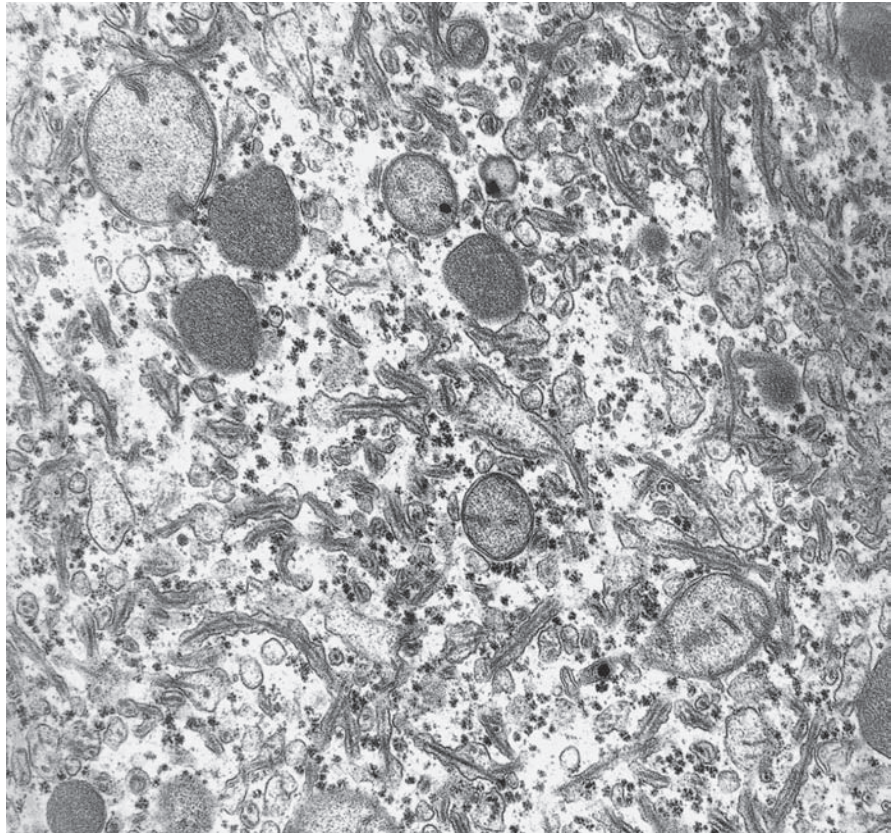
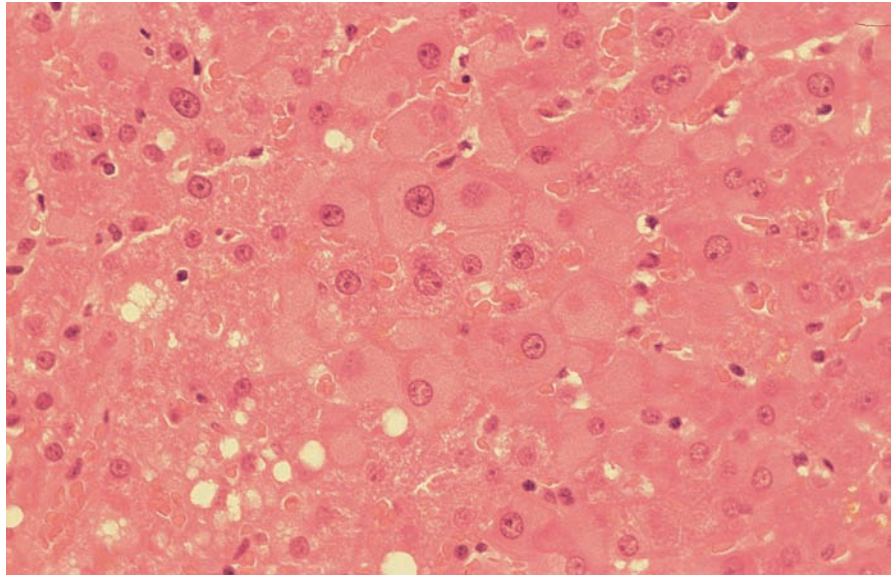


Fig. 24.2 Filamentous, HBsAg containing material in smooth endoplasmic reticulum vesicles. EM ($\times 8,000$)

microscopy HBsAg is found in the cisterns of the smooth endoplasmic reticulum (Fig. 24.2). On light microscopy the material can be highlighted by staining with orcein or by immunohistochemistry using

antibodies against HBsAg (Fig. 24.3). Usually, HBsAg-positive ground-glass cells are haphazardly scattered in small clusters throughout the lobule, but their number may vary greatly.

Fig. 24.3 Immunocytochemical demonstration of HBsAg containing hepatocytes. Selective staining of cytoplasm. Avidin-Biotin-Complex Peroxidase stain

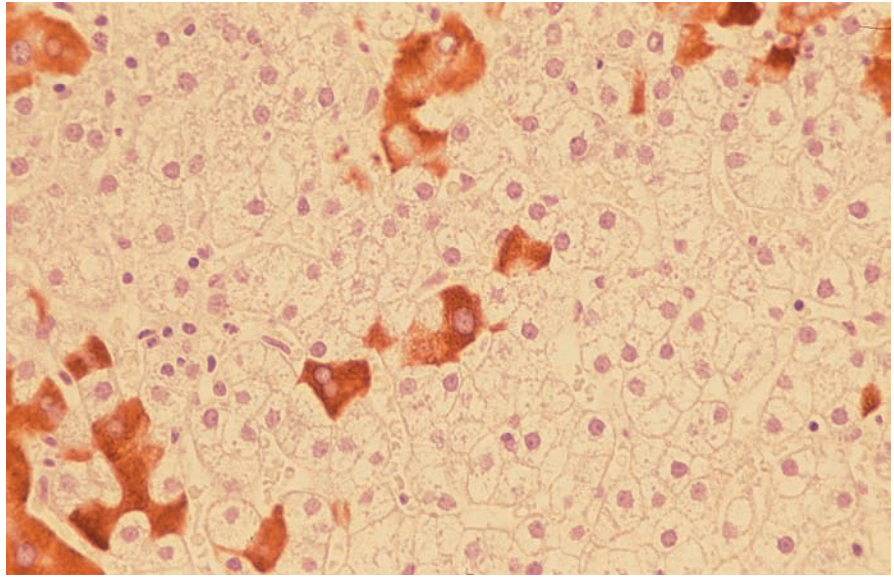
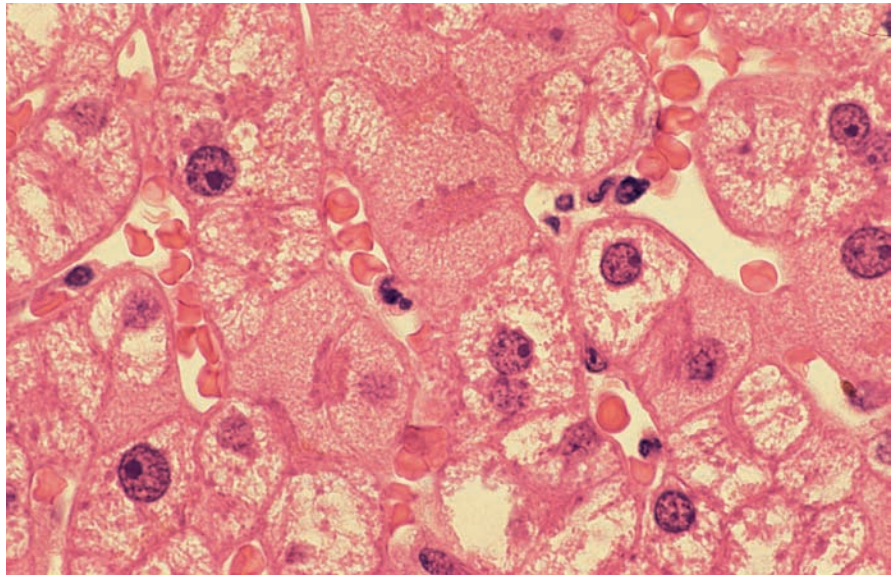


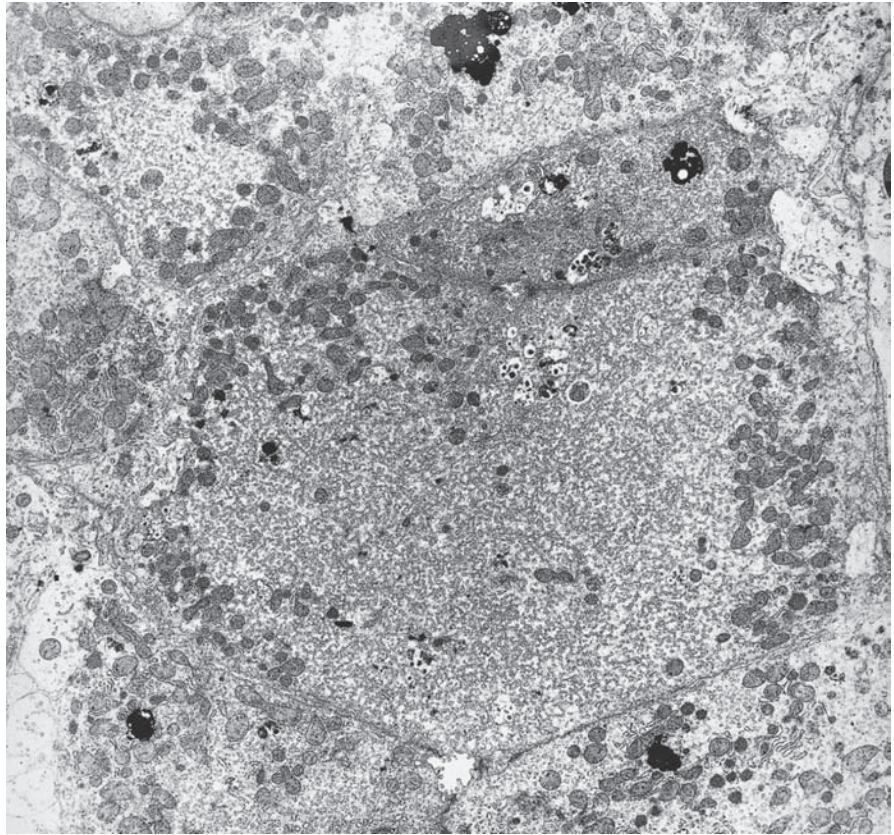
Fig. 24.4 Metabolically induced hepatocytes with peribiliary basophilia. Hematoxylin-Eosin



Induction of enzymes localized in the membranes of the smooth endoplasmic reticulum (SER) by chemicals (drugs) leads to proliferation and hypertrophy of these membranes and to the appearance of “*induced hepatocytes*”. These changes are triggered, for example by alcohol and many drugs, including barbiturates, diphenylhydantoin, benzodiazepines, methotrexate, cyclophosphamide and rifampicin. Induced hepatocytes have a homogeneous, faintly eosinophilic, loosely honeycombed cytoplasm with peribiliary basophilia (Fig. 24.4). A peripheral clear halo, like the one observed in HBsAg-positive ground-

glass cells usually is lacking. The markedly increased SER-membranes may displace other cell organelles to the cell periphery (Fig. 24.5). Unlike HBsAg-positive ground-glass cells which are scattered haphazardly within the lobule, metabolic induction primarily affects centrilobular hepatocytes. These changes are reversible after cessation of the inducing biotransforming stimulus. The cell regains its original appearance. However, cytoplasmic *hyalin droplets*, representing a surplus of densely eosinophilic, degraded SER-membranes may reflect remnants of induced membranes.

Fig. 24.5 Metabolically induced hepatocyte. Smooth endoplasmic reticulum vesicles are hyperplastic and displace the other organelles to the cell periphery. EM ($\times 3,000$)



Lafora Bodies

Lafora bodies occur in myoclonus epilepsy. On hematoxylin-eosin staining Lafora bodies are single, relatively large, sharply delineated, round-oval, weakly eosinophilic, homogeneous or finely granular intracytoplasmic inclusions. They probably contain acidic mucopolysaccharides, are often surrounded by a clear halo (probably a fixation artifact) and displace the nucleus to the cell periphery. Lafora bodies are present predominantly in periportal hepatocytes. They morphologically resemble ground-glass hepatocytes seen in chronic HBV infection. Similar eosinophilic inclusions (“Pseudo-Lafora” bodies) may be seen, for example in cyanamide aversion therapy for alcohol abuse and in isoniazide induced hepatitis.

Oncocytic Change

The oncocytic change of a liver cell is an adaptation phenomenon to mitochondrial strain resulting in the

accumulation of large numbers of closely-packed mitochondria (“mitochondriosis”). The hepatocytes are swollen with a granular, eosinophilic cytoplasm. Oncocytic (oxyphilic) hepatocytes often occur in clusters and should not be confused with ground-glass hepatocytes.

Megamitochondria

Giant mitochondria display a great variety of shapes and may already be identified by light microscopy as round to oval, eosinophilic, cytoplasmic inclusions (Fig. 24.6). On electron microscopy intramitochondrial inclusions are often present (Fig. 24.7). These changes are a nonspecific reaction to toxic liver injury and are found particularly often in alcoholic liver disease. Upon abstinence from alcohol these alterations may reverse. Other diseases in which megamitochondria may be present are nonalcoholic steatohepatitis, cryptogenic cirrhosis (with nonalcoholic fatty liver disease being its precursor in many cases) and systemic

Fig. 24.6 Macrovesicular steatosis of several hepatocytes. One ballooned hepatocyte contains several round weakly eosinophilic inclusions that correspond to megamitochondria. Hematoxylin-Eosin

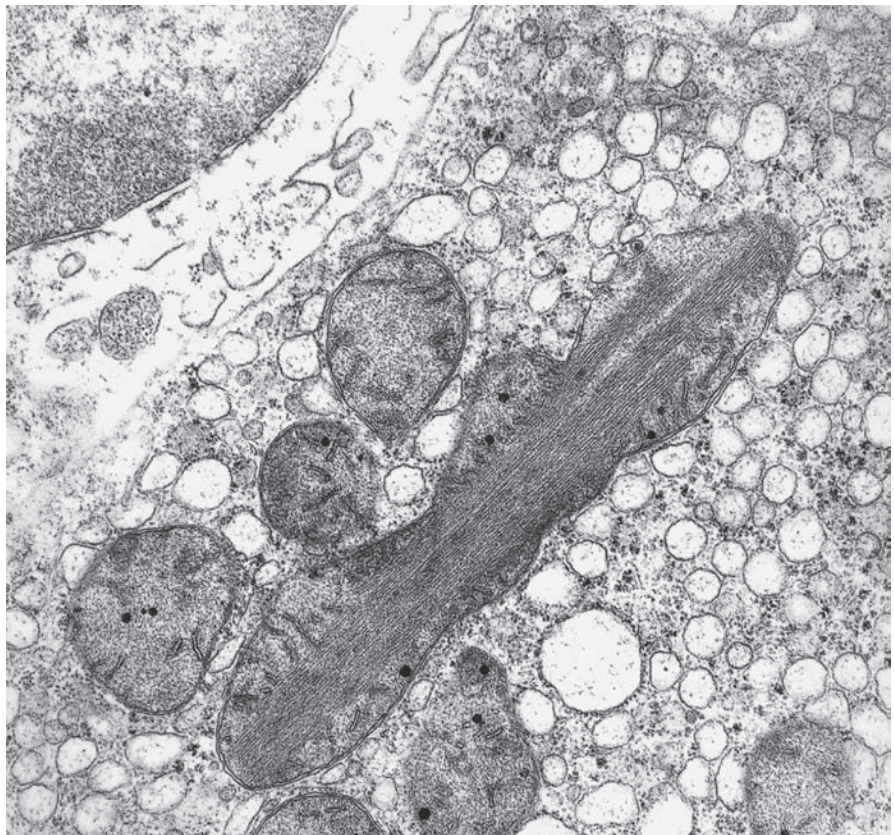
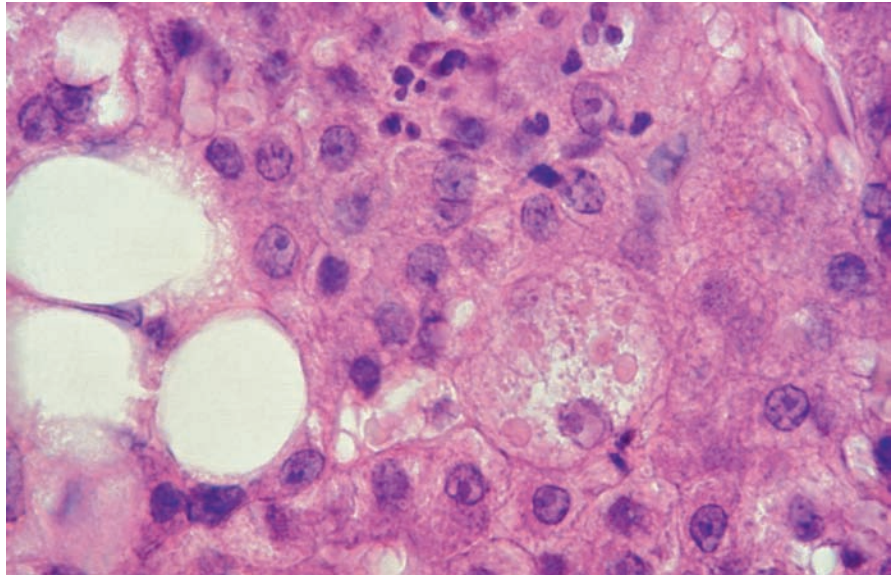


Fig. 24.7 Long, giant mitochondrion containing crystalloid inclusions. The vesicles of the smooth endoplasmic reticulum are dilated. Both changes are nonspecific manifestations of cell injury. EM ($\times 8,000$)

sclerosis. However, they also may occur in the absence of an obvious liver disease. Giant mitochondria should be distinguished from eosinophilic inclusions in α_1 -antitrypsin deficiency. Unlike the globules in α_1 -antitrypsin deficiency, megamitochondria are PAS-negative (see Chapter 83).

Intracytoplasmic Inclusions and Deposits

In addition to the changes described above, hepatocytes, Kupffer cells and stellate cells may show cytoplasmic deposits of

- Lipids
- Carbohydrates
- Proteins
- Metals
- Pigments
- Porphyrin crystals
- Foreign bodies
- Erythrocytes and
- Infectious agents

Lipids

Triglycerides. The increased deposition of intracellular triglycerides is the most common pathologic alteration of the liver. A fatty liver is nearly always caused by increased storage of triglycerides (neutral fats) in hepatocytes. In a healthy liver fat accounts for only up to 5% of its dry weight. If more than 5% of hepatocytes contain fat *hepatic steatosis* and if more than half of all hepatocytes are steatotic, then marked *fatty liver* is said to be present.

Fatty liver is the expression of an impaired lipid metabolism and corresponds to a sublethal liver injury. Steatosis develops if import or synthesis of triglycerides exceeds their degradation or export from the hepatocyte (see Chapter 89). Thus, the causes of steatosis are manifold. Frequent etiologies of hepatic steatosis are the excessive nutritional supply of exogenous triglycerides (obesity), toxins (alcohol) and hypoxia (impairment of mitochondrial fatty acid β -oxidation), as well as under- and malnutrition with inhibition of protein synthesis and subsequent impairment of lipoprotein synthesis.

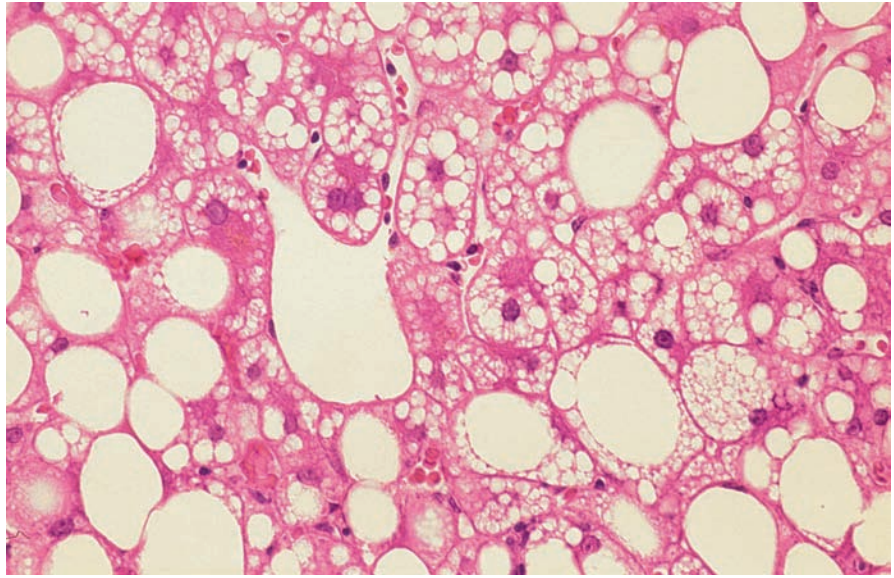
While formerly it was assumed that fat does not injure hepatocytes, nowadays there is increasing evidence that steatosis is not always an innocuous morphologic change, but can aggravate and perpetuate liver damage (*steatohepatitis*) by itself. Fatty livers are more susceptible to injury by reactive oxygen species, and to endotoxin-induced and hypoxic liver damage.

In paraffin-embedded tissue, fat deposits appear as empty vacuoles. These vacuoles may be randomly distributed throughout the lobule, but more often are zonally accentuated. In frozen sections the neutral fat may be stained with special stains, such as Sirius red and Sudan black. According to the size of the fat vacuoles *microvesicular* and *macrovesicular steatosis* are distinguished; both can also coexist. In macrovesicular steatosis the fat vacuole occupies nearly the entire cytoplasm, displacing the nucleus to the periphery of the hepatocyte. In microvesicular steatosis numerous small fat vacuoles and droplets fill the cytoplasm, leaving the nucleus in its central position (Fig. 24.8). Macrovesicular steatosis is much more common than microvesicular and mixed types are frequent. While pure macrovesicular steatosis probably represents mainly a storage phenomenon, microvesicular steatosis is more serious, indicating severe cell injury with impaired energy homeostasis and deranged mitochondrial β -oxidation. Large “fat cysts” may form if fat laden hepatocytes rupture. *Lipogranulomas* represent fat vacuoles surrounded by histiocytes (see Chapter 27).

The main causes of macrovesicular steatosis are obesity, type 2 diabetes mellitus, and alcoholic liver disease (see Chapters 88 and 89). Microvesicular steatosis is seen in tetracycline intoxication, idiosyncratic reactions to valproic acid, acute fatty liver of pregnancy, Reye’s syndrome and in Jamaican vomiting disease. A pure microvesicular fatty liver involving nearly all hepatocytes occurs very rarely in alcoholic hepatitis and has been called *acute alcoholic foamy degeneration*. Another rare form of microvesicular steatosis is seen in the Amazonas basin in chronic hepatitis B virus carriers with hepatitis D virus superinfection (Labrea fever). The hepatocytes in these cases are called *Morula cells*.

Cholesterol. Cholesterol accumulates with triglycerides in hepatocytes and/or Kupffer cells in Tangier disease, familial hypercholesterolemia, Nieman-Pick type C disease, Wolman’s disease, and cholesteryl

Fig. 24.8 Macro- and microvesicular steatosis. In macrovesicular steatosis the nucleus is displaced to the cell margin and may not be visible in the section plane. In hepatocytes showing microvesicular steatosis the nucleus remains in its central position. Hematoxylin-Eosin



ester storage disease [4]. On polarizing microscopy cholesterol crystals appear as birefringent, needle-shaped structures. In cholesterol ester storage disease and in Wolman's disease cholesterol deposits are present in lysosomes, while in familial high density lipoprotein deficiency (Tangier disease) cholesteryl esters lie freely in the cytoplasm.

Phospholipids. Hepatocellular phospholipidoses may occur in drug-induced liver injury; they are especially common during amiodarone therapy [10, 13]. On light microscopy phospholipids are difficult to appreciate, but appear as small clear droplets with fine eosinophilic granules. The swollen hepatocytes and Kupffer cells contain small vacuoles and may appear foamy. On electron microscopy phospholipids form myelin-like figures ("fingerprints"). Myelin figures represent large lysosomes containing concentric layers of membranous material.

Glucocerebrosides. Gaucher's disease is an inborn error of metabolism (deficiency of acid β -glucosidase [glucocerebrosidase]) resulting in abnormal lysosomal accumulation of glucocerebrosides in the reticuloendothelial system. In the liver, Kupffer cells and portal macrophages are primarily affected. These cells enlarge and their abundant pale cytoplasm contains a faintly striated material, reminiscent of folded paper (*Gaucher cells*). Gaucher cells are best seen on PAS-diastase and Masson trichrome stains. Identical cells may be observed in chronic myelogenous leukemia due to increased leukocyte turnover with overproduction of cerebroside.

Pseudo-Gaucher cells occur in multiple myeloma and in malignant lymphomas. On light microscopy they cannot be distinguished from Gaucher cells. However, on electron microscopy they do not contain cerebroside, but rather crystalline immunoglobulins.

Rare inherited lipid storage diseases are summarized in Chapter 90.

Carbohydrates

Glycogen. The abnormal accumulation of glycogen confers a plant cell-like appearance to the hepatocytes. The liver cells appear enlarged and clear with accentuated cell borders, and may compress the sinusoids. The accentuation of cell membranes combined with sinusoidal compression leads to a mosaic pattern in liver sections. The cytoplasmic storage of glycogen is often accompanied by accumulation of nuclear glycogen.

In *glycogenosis type IV (Andersen's disease; amylopectinosis)* branching enzyme is lacking which results in hepatic storage of a poorly branched abnormal glycogen. The cytoplasmic inclusions are large, PAS-positive and diastase resistant (in contrast to normally branched glycogen). They may resemble ground-glass inclusions or Lafora bodies. Periportal and periseptal hepatocytes are predominantly affected.

In *glycogenosis type II* hepatocytes are only moderately enlarged. Their cytoplasm contains small, PAS-positive vacuoles that correspond to lysosomal glycogen particles.

In poorly controlled diabetes mellitus massive accumulation of glycogen in hepatocytes (resembling glycogenesis type I) may lead to hepatomegaly (*Mauriac syndrome*).

Focal accumulations of glycogen may be present in hepatocellular adenomas, carcinomas and premalignant foci.

Ground-glass type, PAS-positive inclusions containing *abnormal glycogen* (closely resembling *polyglucosan bodies*) may be found in various conditions, such as after liver and hematopoietic stem cell transplantation, diabetes mellitus, or extensive small and large bowel disease. The pathogenesis is not well understood [9].

Proteins

α_1 -antitrypsin. Cytoplasmic accumulation of altered proteinase inhibitor variants in hepatocytes is found in patients with α_1 -antitrypsin deficiency (see Chapter 83). The round, eosinophilic inclusions of various size are present in the endoplasmic reticulum and are localized predominantly in periportal hepatocytes. The inclusions stain with PAS, are diastase resistant and may also be visualized by immunohistochemistry using antibodies against α_1 -antitrypsin (Figs. 83.1 and 83.2). They must be differentiated from autophagic vacuoles and giant mitochondria; both do not stain with PAS.

Fibrinogen. Globular, eosinophilic fibrinogen deposits may resemble inclusions in α_1 -antitrypsin deficiency. However, they are negative on PAS-staining. If they enlarge they may fill the entire hepatocyte cytoplasm leading to a ground-glass appearance. On electron microscopy fibrinogen appears as fluffy or granular material within dilated cisterns of the rough endoplasmic reticulum [1]. Fibrinogen containing inclusions are found in *fibrinogen storage disease*.

Albumin and other plasma proteins may be contained in hypoxic vacuoles that develop by invagination of the cell membrane in ischemic conditions. Centrilobular hepatocytes are primarily affected. On light microscopy they may be visible as pale cytoplasmic vacuoles of various size.

Immunoglobulins. In patients with hypergammaglobulinemia small, granular, eosinophilic, diastase PAS-positive inclusions (containing immunoglobulins) are occasionally seen in sinusoidal endothelial cells [5, 6]. *Pseudo-Gaucher cells* are immunoglobulin containing

Table 24.1 Prevalence of Mallory-Denk bodies [7]

Disease	Mean prevalence (%)
Indian childhood cirrhosis	73
Alcoholic hepatitis	65
Alcoholic cirrhosis	51
Wilson's disease	25
Primary biliary cirrhosis	24
Nonalcoholic steatohepatitis	10–20
Hepatocellular carcinoma	23
Chronic obstructive cholestasis	2
A- β -lipoproteinemia	Sporadic
Von Gierke's disease	Sporadic
Focal nodular hyperplasia	Sporadic

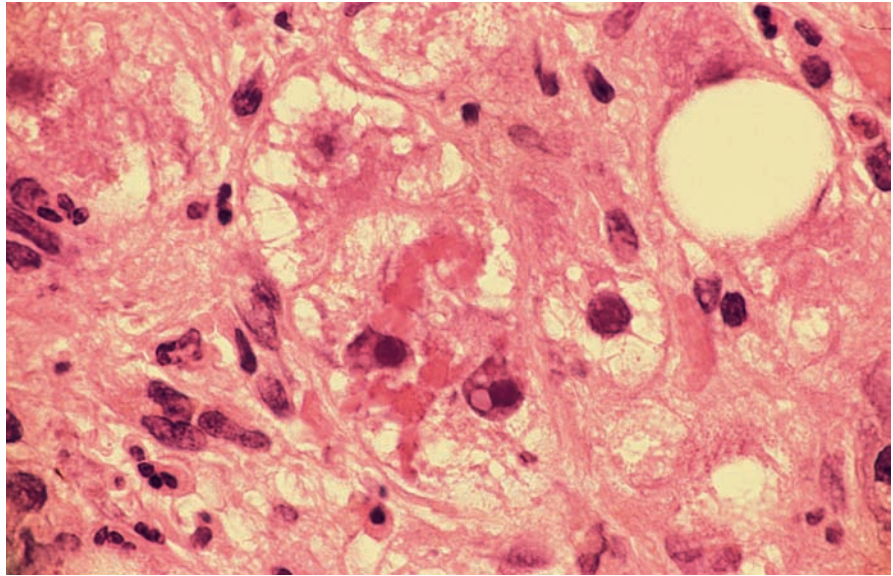
Kupffer cells and portal macrophages resembling Gaucher cells. They can be present in patients with multiple myeloma and malignant lymphoma.

Globular amyloid, which is localized extracellularly, may rarely mimic an intracellular inclusion and simulate HBsAg negative ground-glass cells.

Mallory-Denk bodies (MDBs) were described for the first time in 1911 by Mallory in alcoholic liver cirrhosis [11]. In Western countries MDBs are characteristic but not specific for alcoholic liver disease. They can be found in numerous other diseases, but never occur in a healthy liver (Table 24.1). Prolonged cholestasis of diverse origin can lead to the formation of MDBs in liver cells. MDBs have been observed in drug-induced liver injury, for example in patients treated with amiodarone, diltiazem or nifedipine. MDBs are densely eosinophilic, branched or rope-like cytoplasmic inclusions that are generally present in ballooned hepatocytes, rarely in biliary epithelial cells (Fig. 24.9). In some cases the underlying illness may be inferred from their lobular distribution. In alcoholic hepatitis centrilobular hepatocytes are mainly affected, while drug-induced MDBs are more scattered throughout the entire lobule and MDBs in prolonged cholestatic states are found predominantly in periportal and periseptal liver cells.

MDBs contain aggregated, hyperphosphorylated intermediate filaments (cytokeratin), ubiquitin, heat shock proteins, and protein p62, and can be easily identified in hematoxylin-eosin stained sections [2, 15]. If they are small they can be detected by immunohistochemistry using anti-ubiquitin and anti-cytokeratin antibodies (Fig 29.4d). All MDBs contain cytokeratins 8 and 18, and a significant percentage also cytokeratins 19 and/or 20. However, the normal ratio of 1:1 between CK 8 and CK 18 is shifted in favor of CK 8. Ultrastructurally three

Fig. 24.9 In the lower center of the figure two hepatocytes containing alcoholic hyalin (Mallory-Denk bodies) are visible. The remaining hepatocytes show signs of marked injury. Hematoxylin-Eosin



main types, according to the alignment of intermediary filaments, are distinguished. (1) MDBs with parallel filaments, (2) MDBs with irregularly arranged filaments, and (3) MDBs without filamentous structures, exhibiting a more granular-amorphous aspect. The latter two types prevail [7, 14].

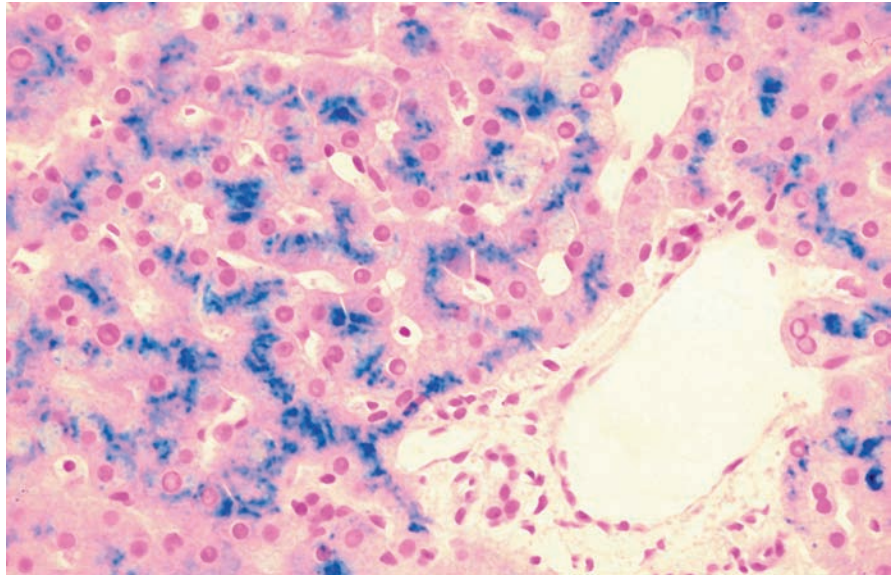
The exact pathogenesis of MDBs is still not entirely understood. It is not clear whether they are only the morphologic manifestation of cell injury, i.e. simply a disease-associated type of inclusion, or whether they represent a protective mechanism of the hepatocyte against further damage [8, 15, 16]. Both possibilities are not mutually exclusive. The high proportion of ubiquitin and of other noncytokeratin components, such as stress proteins, α B crystallin and heat shock protein (Hsp)70, together with protein p62 suggest that these proteins may allow hepatocytes to dispose of potentially harmful proteins in a biologically inert manner [15]. p62 is encoded by an immediate-early response gene that rapidly responds to a variety of extracellular signals involved in cell proliferation, differentiation, and particularly oxidative stress. These proteins play a major role in the proteasomal degradation of proteins and in the control of protein folding. The association of Hsp70, ubiquitin and p62 with MDBs argues for an impaired proteasome function [12]. Furthermore, it could be demonstrated experimentally that the lack of cytokeratin 8 gene might enhance liver injury. The pathophysiologic significance of MDBs in the development of liver diseases is not known and they are not relevant prognostically.

Metals

Iron. Ferritin is the major storage form of iron within the hepatocyte. In iron overload it is partially degraded to hemosiderin, and hemosiderin granules correspond to denatured and aggregated ferritin micelles.

Hemosiderin is a granular, iron-containing, golden-brown pigment. The granules represent hemosiderin laden autophagosomes. In marked iron overload the ferritin/hemosiderin granules are not only confined to lysosomes but are freely scattered within the cytoplasm. Hemosiderin can be identified by light microscopy, but in hematoxylin-eosin stained sections the granules occasionally are difficult to distinguish from lipofuscin granules (hemosiderin is preferentially located in periportal and lipofuscin in centrilobular hepatocytes). With the specific Prussian blue stain hemosiderin is demonstrable as blue granules in hepatocytes, Kupffer cells, and endothelial cells (*siderosis*) (Fig. 24.10 and 29.6). In genetic hemochromatosis it may also accumulate in cholangiocytes. In secondary iron overload states, such as hemolytic disorders and multiple blood transfusions, hemosiderin accumulates primarily in Kupffer cells, portal macrophages, and to a lesser extent in liver cells. Predominant Kupffer cell siderosis also may be caused by enhanced phagocytosis of erythrocytes, e.g. in sickle cell anemia. Secondary Kupffer cell siderosis is due to increased uptake of iron from necrotic liver cells. Clusters of hemosiderin-containing Kupffer cells may represent residues of necrotic hepatocytes (“residual nodules”). For reasons not completely

Fig. 24.10 Hepatocellular siderosis. Prussian blue



understood, patients with insulin-resistance states may show a mild to moderate hepatic iron overload.

Copper. An increased hepatocellular deposition of copper occurs in cholestatic liver diseases (copper is a sensitive morphological marker of cholestasis), in Wilson's disease, and in Indian childhood cirrhosis. Cytochemically demonstrable copper is usually confined to periportal hepatocytes. In the early stages of Wilson's disease copper is diffusely distributed in the cytoplasm of liver cells, while in patients with advanced Wilson's disease copper is confined to lysosomes and is best demonstrated by the rhodanine stain. Even excessive accumulations of copper are not visible in routine hematoxylin-eosin stained sections. Cytoplasmic copper granules are best visualized with rhodanine or with orcein. Rhodanine reacts with the copper itself (Fig. 26.4), while orcein and Victoria blue stain copper-binding protein (metallothionein). Large lipofuscin granules in Kupffer cells and macrophages also stain with orcein; however, unlike copper granules lipofuscin granules are already visible in hematoxylin-eosin stained sections.

Pigments

Pigments are colored compounds that originate in the organism (*endogenous pigments*) or are administered to the patient (*exogenous pigments*).

Lipofuscin is a yellow-brown (fuscus = brown), fine granular pigment. It is easily demonstrable on light microscopy with routine stains (hematoxylin-eosin,

PAS-diastase, negative on Prussian blue). Under ultraviolet light it displays a yellow-orange autofluorescence. Lipofuscin is formed by autophagy and is localized in lysosomes (Fig. 24.11). Lipofuscin is not one chemically defined molecule, but rather a degradation product of intracellular lipids that consists of lipid polymers and phospholipid-protein complexes. It is generated by lipid peroxidation of polyunsaturated fatty acids from organelle membranes and is considered a morphologic manifestation of previous injury by free radicals of intracellular membrane systems ("*wear and tear*" pigment). Lipofuscin itself is assumed to not impair cell function.

Lipofuscin occurs predominantly in perivenular hepatocytes and is concentrated at the apical (biliary) pole of the hepatocytes. It is found in older age (brown liver atrophy), malnutrition, cachexia, toxic injury, analgesics abuse and in vitamin E deficiency. Centrilobular lipofuscin, even in large quantities, has no diagnostic or prognostic significance. Panlobular lipofuscin occurs after long term use of phenacetin, amidopyrin, acetylsalicylic acid or psychopharmacological drugs. Lipofuscin may accumulate in Kupffer cells and portal macrophages in inherited diseases, such as chronic granulomatous disease, ceroid lipofuscinosis, Hermansky-Pudlak syndrome, Niemann-Pick disease type C, Fabry's disease, and cholesterol ester storage disease [4].

Dubin-Johnson pigment is composed of coarse, dark brown pigment granules, seen throughout the lobule, although more heavily concentrated in centrilobular hepatocytes. It is localized in lysosomes, resembles

Fig. 24.11 Lipofuscin is a lysosomal pigment. Lysosomes are discernible as irregularly shaped, electron dense bodies. Additionally (as a morphologic manifestation of cholestasis), in the left lower and in the right upper corner of the figure dilated bile canaliculi with completely flattened microvilli, containing amorphous biliary material, are seen. EM ($\times 3,000$)

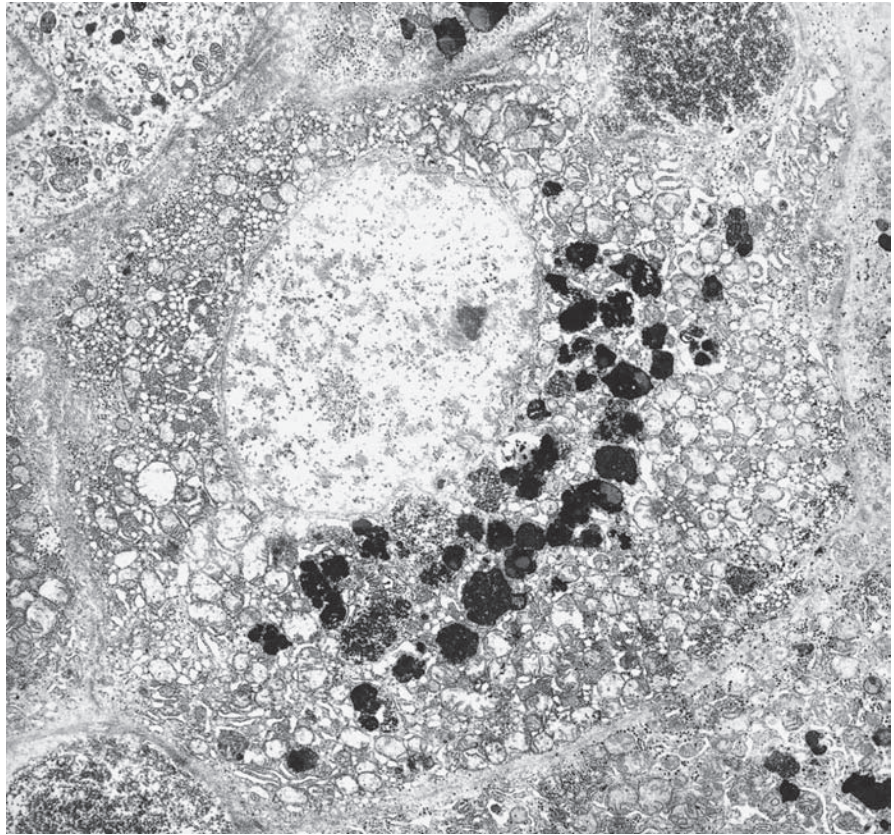
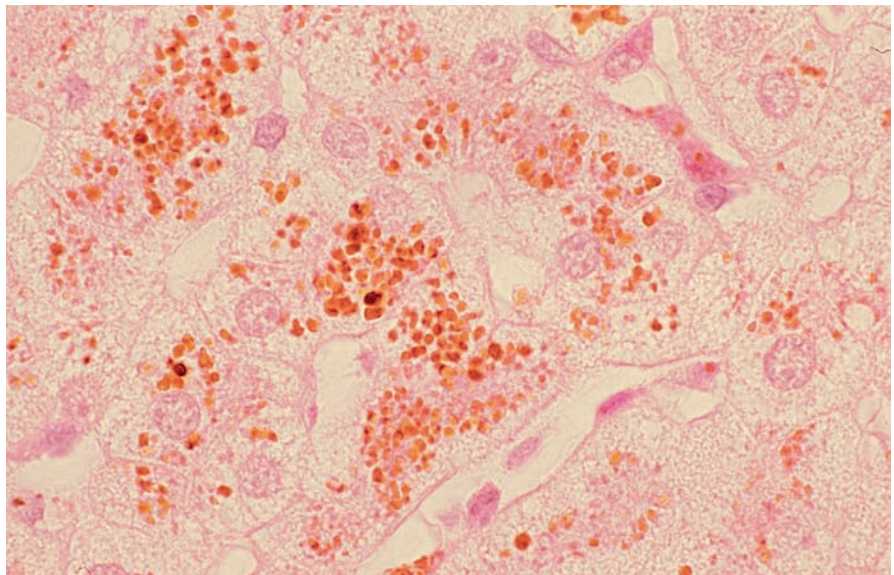


Fig. 24.12 Hepatocytes with coarse, golden-brown cytoplasmic pigment in Dubin-Johnson syndrome. PAS-diastase

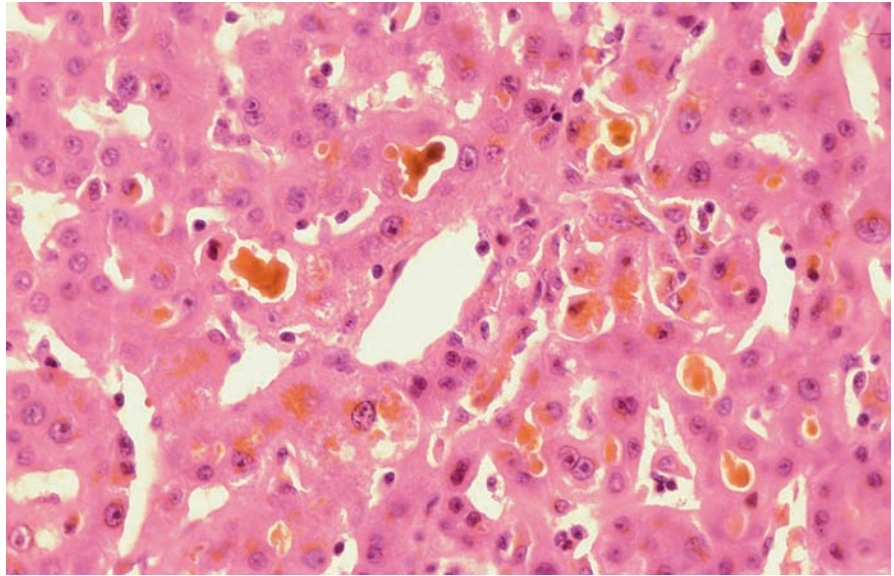


lipofuscin, and shares some histochemical and ultrastructural properties with melanin (Fig. 24.12).

Ceroid pigment is a coarse, brown pigment (in hematoxylin-eosin stains) in hypertrophied Kupffer cells and macrophages (“ceroid macrophages”). It is

diastase resistant, and is particularly well discernible in PAS-stained liver sections pretreated with diastase (Fig. 23.5). It contains oxidized lipids and is biochemically similar to lipofuscin. Unlike lipofuscin (endogenous lipids/autophagy), ceroid is formed by

Fig. 24.13 Cholestasis. Bile plugs imbued with bilirubin are seen in dilated bile canaliculi; bile droplets in the cytoplasm of hepatocytes and Kupffer cells. Hematoxylin-Eosin



phagocytosis of lipids of perished hepatocytes (exogenous lipids/heterophagy). Ceroid is an acid fast lipopigment and its presence is indicative of previous liver cell death. It is encountered in the resolution phase of acute viral hepatitis or after drug- and toxin-induced hepatocyte necrosis. Ceroid-storing macrophages mostly are scattered in small clusters throughout the lobule; with time they move towards the portal tracts.

Bilirubin. The yellow-greenish, amorphous bile pigment occurs in cholestatic liver diseases in bile canaliculi and ductules, hepatocytes and Kupffer cells (Fig. 24.13). In contrast to the natural bile pigment, bilirubin, as seen by light microscopy in cholestasis, is altered chemically. The porphyrin ring is broken up and no longer contained iron.

Protoporphyrin crystals are seen in erythropoietic protoporphyria as coarse, darkly stained, red-brown deposits in hepatocytes, bile canaliculi and ductules, Kupffer cells and portal macrophages. By polarizing microscopy, the protoporphyrin displays brilliant red birefringence, with the canalicular casts having a Maltese-cross appearance. Deposits of protoporphyrin cause cell damage and lead to hepatocellular degeneration, liver cell necrosis, portal fibrosis and chronic inflammation.

Uroporphyrin crystals occur in porphyria cutanea tarda as needle-shaped inclusions in hepatocytes. Provided they have not been dissolved out in formalin-fixed, paraffin-embedded sections, they may be visualized best in liver cell cytoplasm in unstained sections viewed by polarized light. The ferric ferricyanide

method accentuates their shape [3]. Both protoporphyrin and uroporphyrin exhibit red autofluorescence when excited by ultraviolet light (see Chapter 84).

Malarial pigment is a black pigment that derives from hemoglobin. Plasmodial organisms digest heme and protect themselves from toxic heme-products by polymerizing these compounds to hemozoin. Malarial pigment consists of hemozoin and plasmodial degradation products. Whenever parasitized erythrocytes die, malarial pigment is taken up by Kupffer cells and splenic macrophages, and becomes visible as dark granules (Fig. 24.14).

Schistosomal pigment is also a hemozoin pigment (product of host hemoglobin catabolism by adult worms) and on light microscopy is indistinguishable from malarial pigment. It appears as dark brown-black, iron- and melanin-containing, PAS-negative granules in Kupffer cells, in portal tract macrophages, and in granuloma macrophages.

Anthracotic pigment is found occasionally in liver macrophages in coal mine workers (Fig. 24.15).

Melanin may be found in melanoma metastases.

Foreign Bodies

Foreign bodies are phagocytosed by Kupffer cells and portal macrophages. Talc cellulose may be found in intravenous drug users. Polyvinylpyrrolidone can be seen after administration of so called plasma expanders,

Fig. 24.14 Brown-black malarial pigment in Kupffer cells in *Malaria tropica*. Hematoxylin-Eosin

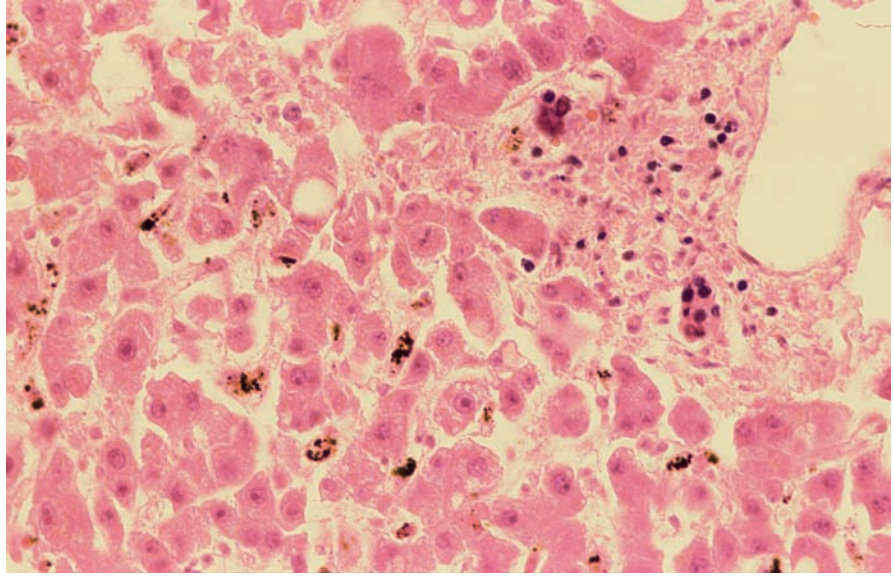
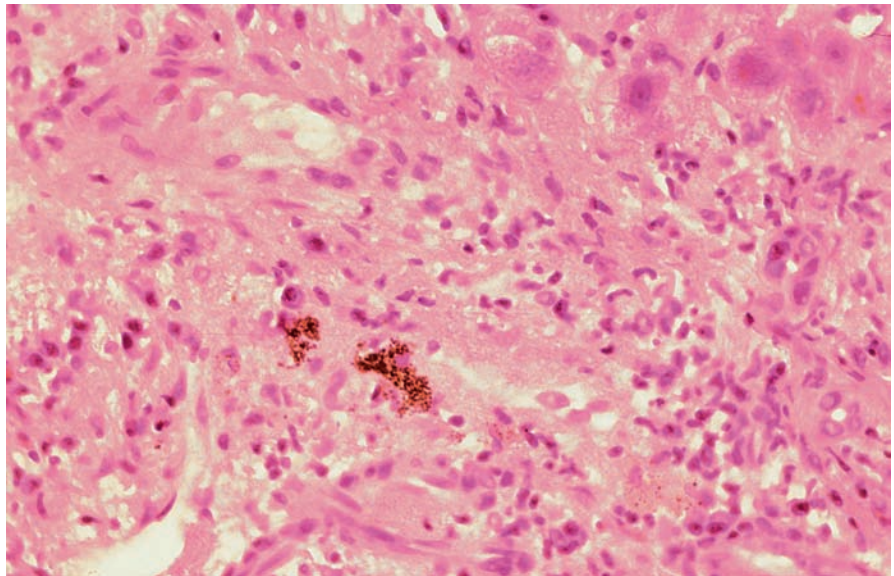


Fig. 24.15 Brown-black anthracotic pigment in portal macrophages. Hematoxylin-Eosin



silicone after implantation of artificial heart valves or breast implants, and thorotrast (ionizing contrast agent) after intravascular administration (even dating back decades).

Erythrocytes

Erythrophagocytosis by hepatocytes may be seen occasionally in single cases of hepatocellular carcinoma, in precirrhotic Wilson's disease and in alcoholic hepatitis. The phagocytosed erythrocytes must be differentiated from megamitochondria.

Erythrophagocytosis by Kupffer cells may be observed in sickle cell anemia, leptospirosis, *Plasmodium falciparum* malaria, and in hemophagocytosis syndrome.

Infectious Agents

Kupffer cells and portal macrophages phagocytose infectious agents as part of their defensive activities in infections. Thus, *Leishmania donovani* can be visualized in the liver in cases of visceral leishmaniasis, *Plasmodium falciparum* in malaria, and *Toxoplasma*

gondii (although very rarely) in toxoplasmosis. Occasionally the occurrence in the liver of *Cryptococcus neoformans* and *Histoplasma capsulatum* has been reported. In the context of immune deficiencies, atypical mycobacteria may be visualized in clusters of hepatic macrophages (Fig. 65.3).

Nuclear Changes

The normal hepatocyte is a cell with a single nucleus and a diploid chromosome set. Binucleated hepatocytes with two diploid genomes and rarely cells with tetraploid and octoploid chromosome sets also occur. The proportion of large and binucleated hepatocytes increases with advancing age. Disease processes characterized by hepatocyte death, such as viral hepatitis or liver cirrhosis of viral origin, may also lead to an increase in the number of large multinucleated hepatocytes. This is interpreted as an incomplete attempt at regeneration. Multinucleated giant cells can also form by syncytial fusion of several hepatocytes; this process is observed in so-called giant cell hepatitis of the newborn (probably a nonspecific reaction to viral infections) and in cholestatic diseases, such as inborn bile duct atresia and hypoplasias. In adults, giant cells occur less frequently, and they are mostly seen in severe acute viral infections and in drug and toxin-induced liver injury.

Nuclear Swelling

Simple nuclear swelling reflects an increased fluid and protein content and has been interpreted as a sign of enhanced nuclear activity.

Nuclear Inclusions

Nuclear (pseudo)inclusions generally contain proteins and glycogen, and only occasionally lipids. They are formed by invagination of the nuclear membrane which initially remains connected to the cytoplasm by a “plasma bridge” but then pinches off and lies inside the nucleus, completely surrounded by the nuclear membrane (Fig. 3.13). During further development they may lose their nuclear envelope and shine as bright red “hyalin” nuclear inclusion bodies.

Glycogen

Glycogen inclusions consist of monoparticulate glycogen. They enlarge the nucleus and push the chromatin to the nuclear periphery. In routinely formalin-fixed, paraffin-embedded and hematoxylin-eosin stained sections the glycogen is lost and the nuclei appear optically empty (“Lochkerne”) (Fig. 24.16).

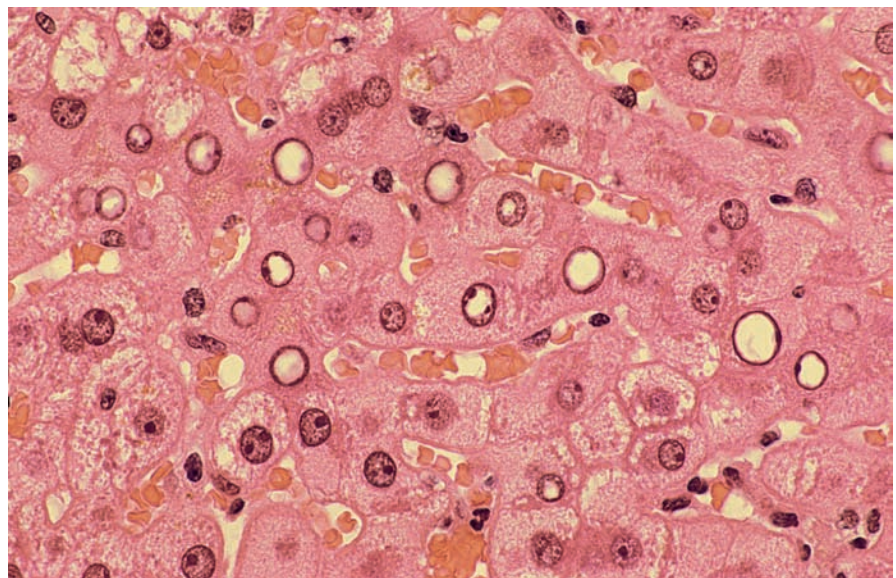


Fig. 24.16 “Empty” glycogenated nuclei. A ring of condensed chromatin is present at the periphery of the nucleus. Hematoxylin-Eosin

Glycogenated nuclei do not have a diagnostic significance of their own. They are encountered in children and in numerous diseases, including diabetes mellitus, metabolic syndrome, nonalcoholic fatty liver disease, Wilson's disease, glycogenosis type I and III, glycogen rich hepatocellular carcinomas, and tuberculosis. They may also be present in seemingly healthy individuals.

Lipids

Cytoplasmic lipids invaginated into the nucleus may also appear as optically empty nuclear vacuoles.

Viral Inclusions

While the nuclear inclusions described above do not have a significant diagnostic relevance, viral nuclear inclusions may be of considerable diagnostic importance.

Cytomegalovirus (CMV). Inclusions containing CMV occur relatively rarely in the liver. They are basophilic and are surrounded by a halo. The cytoplasm of the enlarged (cytomegalic) cells is strongly basophilic. These nuclear inclusions may be found in all cell types in the liver, however, most frequently they are seen in hepatocytes and biliary epithelial cells. CMV antigens may be visualized by immunocytochemistry.

Herpes Simplex Virus (HSV). Hepatic HSV inclusions are found in disseminated disease with hepatocellular necroses, predominantly in hepatocytes bordering the necrotic areas, but sporadically also in dead hepatocytes. They occur in two forms. *Cowdry type A* inclusions are eosinophilic, round or irregular. They may be surrounded by a halo; the nuclear chromatin is displaced to the periphery, and the nuclear membrane rapidly fragments. The more frequent *Cowdry type B* inclusions impart the nucleus a homogeneous eosinophilic aspect. The nucleolus and the chromatin granules are ill defined. HSV antigens may be visualized by immunocytochemistry.

Varicella Zoster Virus. The inclusions are analogous to those in HSV infection.

Hepatitis B core Particles. While in chronic viral hepatitis B, HBsAg-containing material is found in the cytoplasm, HBcAg-particles may be found in the nucleus of hepatocytes in highly replicative HBV-infection (e.g. immunosuppressed host). They may impart the nucleus with a weakly eosinophilic, finely granular, sand-like aspect, in which case they are called "*sanded nuclei*" (see Fig. 63.34a). While it is difficult to see HBcAg containing nuclei in hematoxylin-eosin stained sections, they are easily identified by immunocytochemistry using antibodies directed against HBcAg (Fig 24.17). Sanded nuclei are rare compared to HBsAg-positive ground-glass hepatocytes.

Yellow Fever. Eosinophilic intranuclear inclusions (*Torres bodies*) are rarely seen in this flaviviral infection.

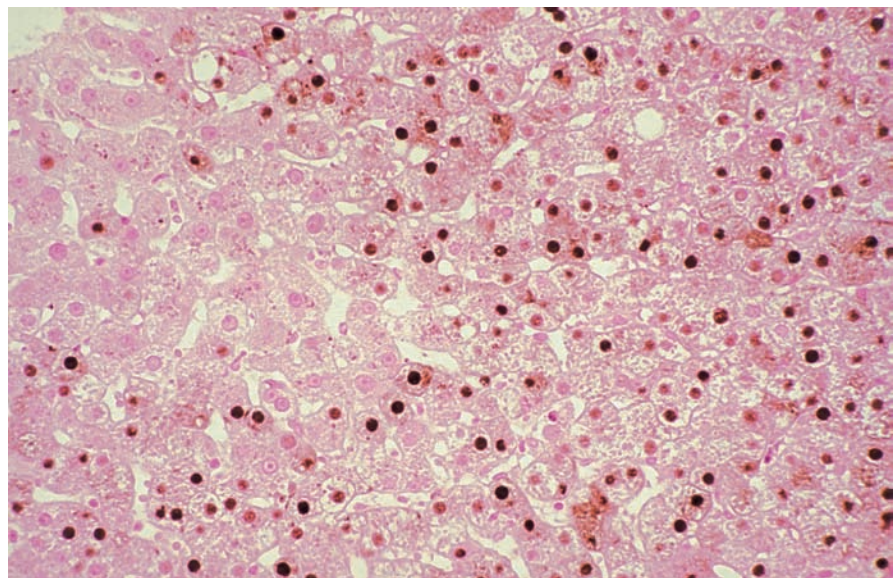


Fig. 24.17 Immunocytochemical demonstration of HBcAg containing hepatocyte nuclei (not identical with sanded nuclei). Avidin-Biotin-Complex Peroxidase stain

References

1. Callea F, deVos R, Togni R, et al (1986) Fibrinogen inclusions in liver cells: a new type of ground-glass hepatocyte. Immune light an electron microscopic characterization. *Histopathology* 10: 65–73
2. Denk H, Stumptner C, Zatloukal K (2000) Mallory bodies revisited. *J Hepatol* 32: 689–702
3. Fakan F, Chlumská A (1987) Demonstration of needle-shaped hepatic inclusions in porphyria cutanea tarda using the ferric ferricyanide reduction test. *Virchows Archiv A* 411: 365–8
4. Ishak KG (2002) Inherited metabolic diseases of the liver. *Clin Liver Dis* 6: 455–79
5. Iwamura S, Enzan H, Saibara T, et al (1994) Appearance of sinusoidal inclusion-containing endothelial cells in liver disease. *Hepatology* 20: 604–10
6. Iwamura S, Enzan H, Saibara T, et al (1995) Hepatic sinusoidal endothelial cells can store and metabolize serum immunoglobulin. *Hepatology* 22: 1456–61
7. Jensen K, Gluud C (1994) The Mallory body: morphological, clinical and experimental studies (part 1 of a literature survey). *Hepatology* 20: 1061–77
8. Jensen K, Gluud C (1994) The Mallory body: theories on development and pathological significance (part 2 of a literature survey). *Hepatology* 20: 1330–42
9. Lefkowitz JH, Lobritto SJ, Brown RS, et al (2006) Ground-glass, polyglucosan-like hepatocellular inclusions: a “new” diagnostic entity. *Gastroenterology* 131: 713–8
10. Lewis JH, Mullick FG, Ishak KG, et al (1990) Histopathologic analysis of suspected amiodarone hepatotoxicity. *Hum Pathol* 21: 59–67
11. Mallory FB (1911) Cirrhosis of the liver. Five different types of lesions from which it may arise. *Bull John Hopkins Hosp* 22: 69–75
12. McPaul LW, Wang J, Hol EM, et al (2002) Molecular misreading of the ubiquitin B gene and hepatic Mallory body formation. *Gastroenterology* 122: 1878–85
13. Poucell S, Ireton J, Valencia-Mayoral P, et al (1984) Amiodarone-associated phospholipidosis and fibrosis of the liver. Light, immunohistochemical, and electron microscopic studies. *Gastroenterology* 86: 926–36
14. Schirmacher P, Dienes HP, Moll R (1998) De novo expression of nonhepatocellular cytokeratins in Mallory body formation. *Virchows Arch* 432: 143–52
15. Stumptner C, Fuchsichler A, Heid H, et al (2002) Mallory body – a disease-associated type of sequestosome. *Hepatology* 35: 1053–62
16. Zatloukal K, Stumptner C, Lehner M, et al (2000) Cytokeratin 8 protects from hepatotoxicity, and its ratio to cytokeratin 18 determines the ability of hepatocytes to form Mallory bodies. *Am J Pathol* 156: 1263–74

Chapter Outline

Liver Cell Injury	236
Inflammatory Reactions	236
References	239

Necroinflammatory reactions are primarily due to infectious (notably viral), immunological, and drug- and toxin-induced liver diseases. They also may represent a significant component of circulatory (hypoxic), metabolic, and cholestatic diseases. Necroinflammatory lesions are characterized morphologically by a variable interplay between hepatocellular degeneration, liver cell death and inflammatory reaction. Thus, the morphological components of a hepatic reaction are liver cell injury/death (apoptosis and/or necrosis), inflammatory cell infiltrate, and signs of regeneration and fibrosis (if the inflammatory process persists long enough) [1].

According to the time course acute and chronic hepatitis are distinguished.

Morphologically, no sharp division can be made between acute and chronic necroinflammatory reactions. However, accentuation of the inflammatory infiltrate at the portal tracts, even with the evolution of portal lymph follicles, interface activity, and portal-septal fibrosis are clues to the chronicity of the inflammatory process. Nevertheless, chronic hepatitis may also display a marked lobular inflammatory activity, and portal inflammatory infiltrates may persist following clinical recovery of acute hepatitis B. Clinically, *each necroinflammatory process that lasts longer than 6 months is called chronic*.

In the present chapter a short overview of the essential morphological features that characterize a necroinflammatory reaction is given in order to provide the clinician with an understanding of this basic morphological process. The detailed description of diseases associated with necroinflammatory reactions and their respective pathogenetic pathways are found in the clinical chapters.

Liver Cell Injury (See Chapter 23)

Acute and chronic viral hepatitis are the classic examples of necroinflammatory reactions. Liver cell changes range from cell swelling to cell death. The predominant form of necrosis in acute viral hepatitis is *lytic liver cell necrosis* that is preceded by ballooning degeneration. Cell death mostly occurs as focal, spotty necrosis predominantly in perivenular areas. Occasionally clusters of cells are affected and in severe cases confluent, bridging necrosis develops. Necrotic hepatocytes are rapidly cleared from the liver cell plates, which explains why lytically necrotic hepatocytes are underrepresented in liver biopsies. Focal accumulations of lymphocytes and scavenger macrophages point to previous lytic necroses. The simultaneous occurrence of cell injury, cell death, inflammatory infiltrates, scavenging phenomena and regenerative processes create a disordered appearance at low magnification due to the disruption of the usual architecture of liver-cell plate structure.

Hepatocytes undergoing *apoptosis* become densely eosinophilic (acidophilic bodies). They round up, detach from surrounding hepatocytes, and finally are phagocytosed and degraded by macrophages.

So-called *piecemeal necrosis* is not a discrete form of necrosis, but is typical of interface hepatitis, a hallmark of chronic inflammation.

Inflammatory Reactions

Hepatitis A and B virus-triggered liver injury is mediated mainly by the host's immune response to viral proteins expressed by infected hepatocytes and, to a lesser extent, by direct cytopathic effects of the virus. Cytotoxic T lymphocytes kill virus-infected hepatocytes by Fas dependent apoptosis. Activation of intrahepatic caspases may occur in fulminant hepatitis B and confirms a pivotal role of apoptotic pathways in the pathogenesis of fulminant hepatitis B [3].

Inflammatory cell infiltrates in viral hepatitis occur both within the lobules and the portal tracts. According to the most prevalent localization of the cellular infiltrate, the inflammation may be designated as portal, interface, or lobular hepatitis. The predominant cells are lymphocytes, macrophages and plasma cells. The composition of the inflammatory infiltrate depends mainly on the stage of the disease. At the peak of acute necrotizing viral hepatitis lymphocytes and macrophages are prominent. There is diffuse hyperplasia of Kupffer cells (Fig. 25.1). With ongoing inflammation this balance shifts in favor of macrophages, and in the late phases of the disease phagocytosing macrophages (scavenger cells) point to the resolution of the necroinflammatory process. Clusters of ceroid storing and hemosiderin laden Kupffer cells ("residual nodules")

Fig. 25.1 Acute viral hepatitis. The entire lobule is involved and in disarray. Sinusoidal lining cells (mainly Kupffer cells) are activated. There is diffuse inflammatory cell infiltration, predominantly by lymphocytes, monocytes and macrophages. Several injured multinucleated hepatocytes are seen. Hematoxylin-Eosin

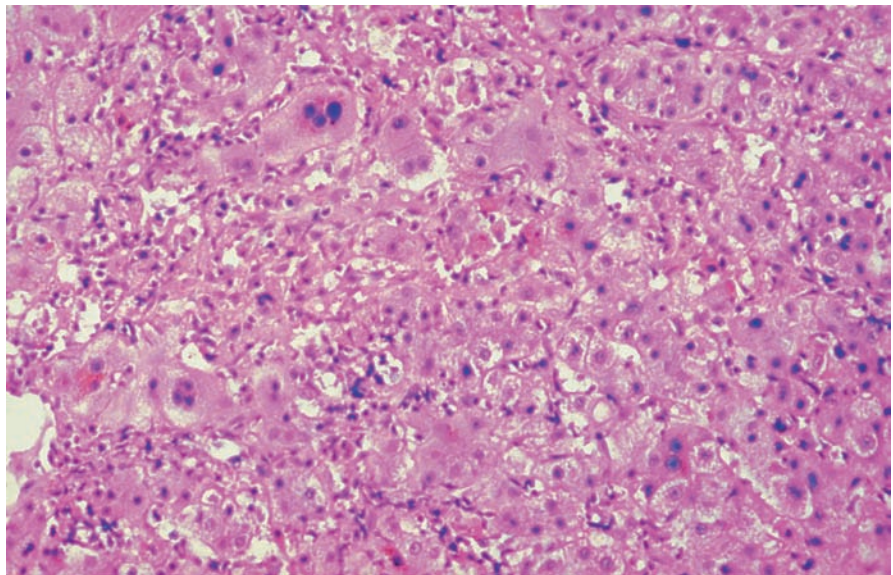


Fig. 25.2 Chronic hepatitis C with low inflammatory activity. The inflammatory infiltrate is confined to the portal tract which appears rounded. The limiting plate is intact. Several small intralobular inflammatory foci are also seen. Hematoxylin-Eosin

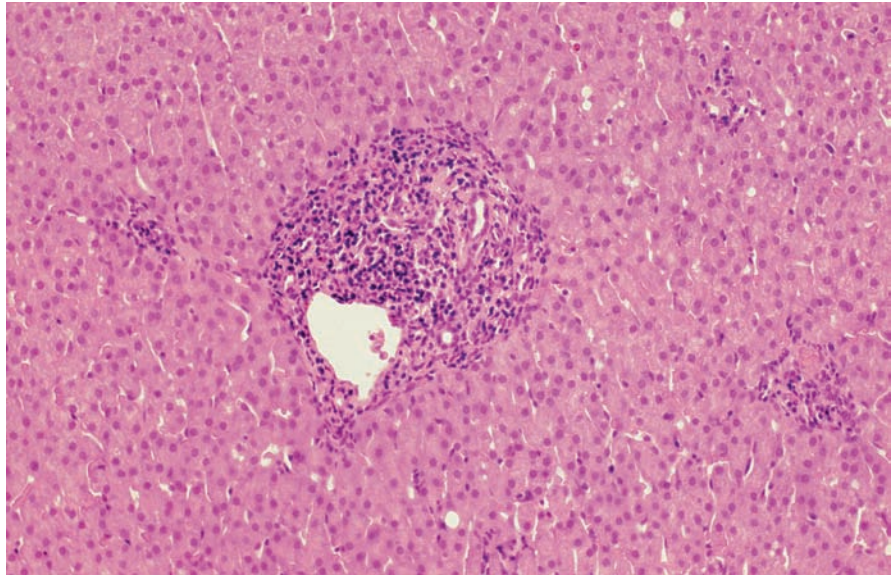
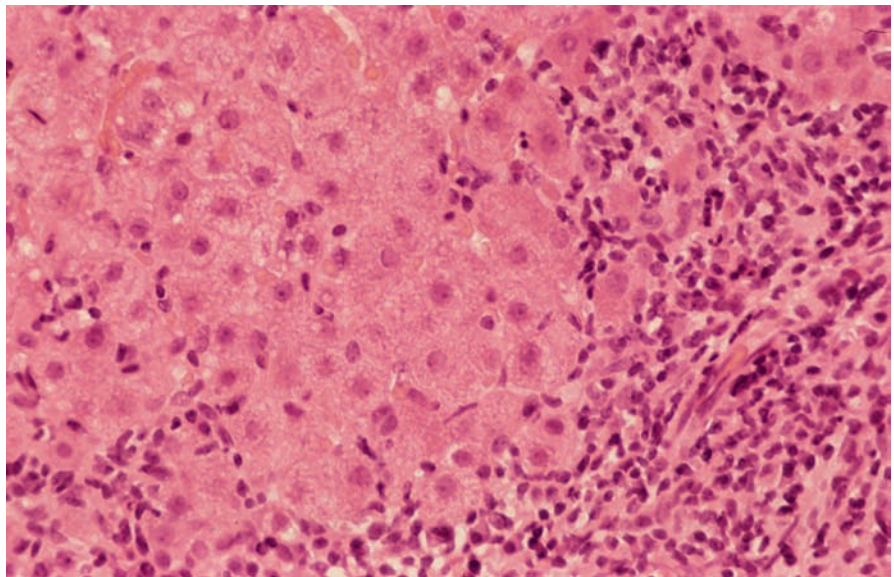


Fig. 25.3 Chronic hepatitis with marked inflammatory activity. The inflammatory infiltrate extends from the portal tract to the adjoining lobular parenchyma. Lymphocytes attack individual hepatocytes and induce their death (“piecemeal necrosis”). Hematoxylin-Eosin



attest to previous hepatocellular necroses and cell drop-outs (Fig. 23.5). Cellular degradation products are in part drained to the portal tracts, where macrophages containing cell debris can be demonstrated.

Neutrophilic granulocytes usually do not contribute to the typical picture of acute viral hepatitis. However, they are encountered in cases of confluent necrosis with marked ductular proliferation and in cholestasis.

In *chronic viral and autoimmune hepatitis* lymphocytes are prominent in the inflammatory infiltrate, with

a varying degree of plasma cells in autoimmune hepatitis (note: in acute viral hepatitis plasma cells may also be prominent). The inflammatory infiltrate is localized predominantly in the portal/periportal areas (Fig. 25.2). The interface activity characterizes the active, ongoing inflammatory process (Fig. 25.3). Depending on the degree of the inflammatory activity, however, cellular inflammatory infiltrates may also be present within the lobule. With ongoing inflammation the inflammatory process is accompanied by progressive fibrosis.

Fig. 25.4 Hepatic liver cell rosettes in chronic hepatitis with marked inflammatory activity and fibrosis. Small groups of swollen liver cells are arranged in a gland-like pattern and are surrounded by fine fibrous strands. Masson Trichrome

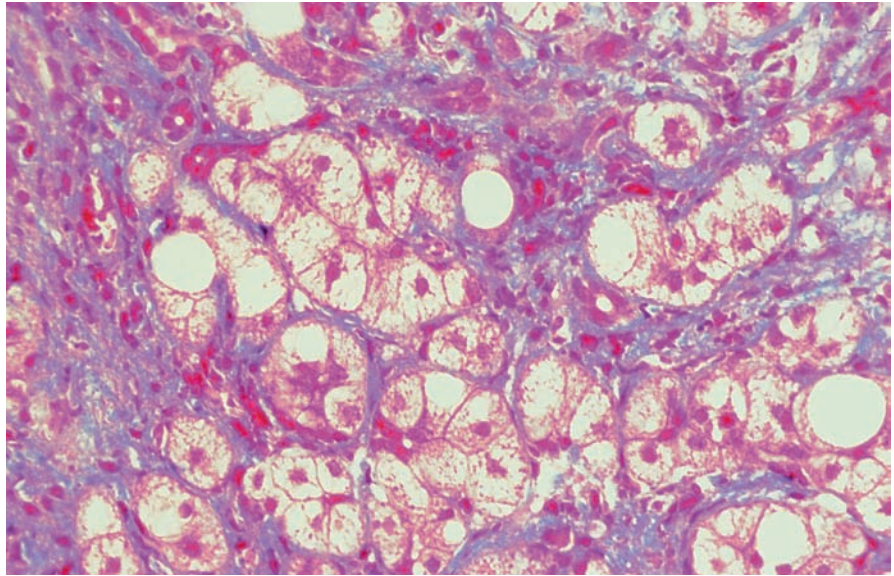
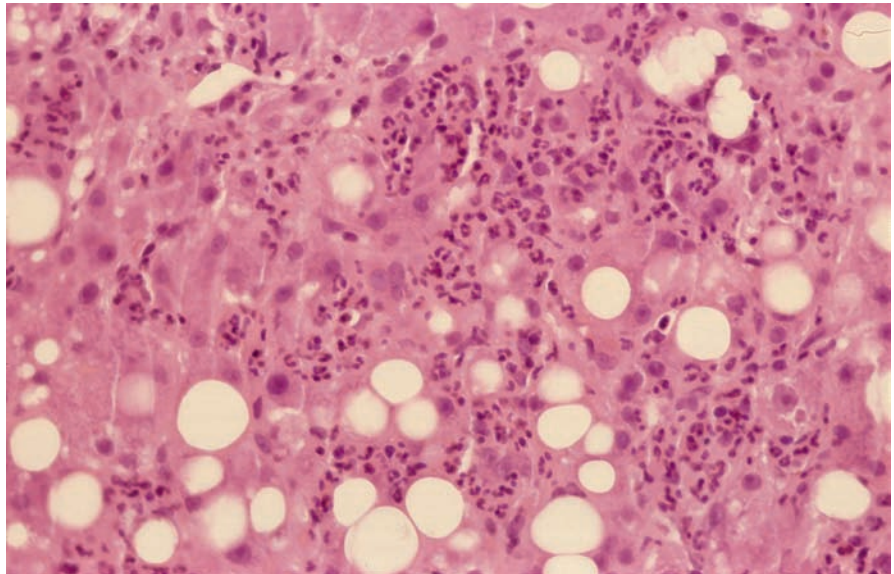


Fig. 25.5 Florid alcoholic hepatitis. Many hepatocytes are steatotic (facultative lesion). The inflammatory infiltrate consists largely of neutrophilic granulocytes (obligatory lesion). Hematoxylin-Eosin



In marked chronic necroinflammatory reactions (e.g., with panlobular inflammation and bridging necroses), small groups of injured hepatocytes are often arranged in a gland-like pattern forming *hepatic liver cell rosettes* (Fig. 25.4). This phenomenon is possibly a manifestation of a hyperplastic-regenerative activity of individual hepatocytes. In contrast to cholestatic liver cell rosettes (see Chapter 26), hepatic rosettes are typically surrounded by fibrosis.

Mild degenerative lesions of portal bile ducts may be encountered in chronic hepatitis. The biliary epithelium may display some vacuoles and, occasionally,

some lymphocytes may invade the bile duct. However, in contrast to bile duct lesions in primary biliary cirrhosis, the basement membrane in hepatic bile duct injury remains intact. Thus the hepatic bile duct lesion is not destructive and is reversible [2].

Necroinflammatory lesions are also the hallmark of *alcoholic hepatitis*. However, in alcoholic liver disease the degenerating and dying liver cells are surrounded predominantly by neutrophilic granulocytes, which in marked acute inflammation may form cell clusters that may even resemble microabscesses (Fig. 25.5). Steatosis, Mallory-Denk bodies and “chicken wire” fibrosis are

characteristic but nonspecific features of alcoholic hepatitis; they count among the facultative, non obligatory lesions. *Nonalcoholic steatohepatitis* causes a comparable histological picture in patients without relevant alcohol consumption (≤ 20 g ethanol/day). These lesions are the hepatic manifestation of the metabolic syndrome and occur most commonly in patients with insulin resistance, diabetes mellitus type 2, visceral obesity, hyperlipidemia and hypertension (see Chapter 89).

Inherited metabolic diseases of the liver, especially Wilson's disease, may also show chronic necroinflammation.

References

1. Bianchi L (1986) Necroinflammatory liver diseases. *Semin Liver Dis* 6: 185–98
2. Christoffersen P, Dietrichseon O, Faber V, et al (1972) The occurrence and significance of abnormal bile duct epithelium in chronic aggressive hepatitis. *Acta Pathol Microbiol Scand (A)* 80: 294–302
3. Leifeld L, Nattermann J, Fielenbach M, et al (2006) Intrahepatic activation of caspases in human fulminant hepatic failure. *Liver Int* 26: 872–9

Chapter Outline

Hepatic Histopathology in Biliary Obstruction	241
Ductular Reaction	245
References	246

The term cholestasis has a different connotation for the pathologist, the clinical hepatologist and the basic scientist. The term was coined by Popper and Szanto in 1956 to describe the histopathological findings of bilirubin pigment stagnation in the hepatocytes and bile ducts [9]. Nowadays, to the pathologist cholestasis is more than mere bilirubinostasis and encompasses the visible manifestation of the broad array of pathophysiological derangements in hepatocellular uptake, transcellular transport, canalicular secretion, and flow of biliary constituents [7]. Thus, the morphological consequences of cholestasis may be due not only to impaired bile flow but also to intrinsic hepatocellular dysfunction. The causes of cholestasis are manifold and its differential diagnosis may be a clinical challenge requiring the deliberate use of laboratory parameters and advanced imaging techniques (see Chapter 52).

In this chapter the morphology of the cholestatic reaction is outlined. The term *cholestatic reaction* denotes the entirety of morphological changes seen in *cholestasis*. This reaction encompasses a wide spectrum of intraacinar and portal changes, and varies with the cause and duration (acute or chronic) of the cholestatic process [5, 7].

Hepatic Histopathology in Biliary Obstruction

The prototype and most simple example of cholestasis is impaired bile flow resulting from mechanical obstruction of a bile duct. The histopathological evaluation of the cholestatic reaction in bile duct obstruction has to take into account the time factor and the localization of the alterations. It is neither possible to assess exactly the chronicity of the process nor to determine

the anatomic level of the obstructing lesion from the hepatic histopathological changes alone.

In the *early stages*, during the first few days after bile duct obstruction, the periductal, portal edema is prominent, while inflammatory cell infiltrates are sparse or are still completely absent. In the following few weeks, periductal edema persists and the portal tracts widen; the interlobular bile ducts proliferate and dilate, and an inflammatory infiltrate, consisting mainly of neutrophilic granulocytes becomes prominent (Figs. 26.1 and 26.2). Neutrophils surround the proliferated bile

ducts at the edge of the portal tracts. Bile plugs may be present in their dilated lumina. Within the lobule (initially affecting predominantly the perivenular area, later involving the entire lobule), intracytoplasmic bile is visible within the hepatocytes (*bilirubinostasis*) and Kupffer cells (bilirubin phagocytosis) and bile plugs (“bile thrombi”) are seen in dilated canaliculi (*canalicular bilirubinostasis*) (Fig. 24.13). The hepatocytes may group in a pseudoglandular pattern, i.e. several hepatocytes group around a central lumen that may contain inspissated bile (*cholestatic liver cell rosettes*).

Fig. 26.1 Acute cholangitis. The portal tract is enlarged and there is a proliferation of interlobular bile ducts. Some are dilated and irregularly shaped, and accompanied by neutrophilic cell infiltrates. Hematoxylin-Eosin

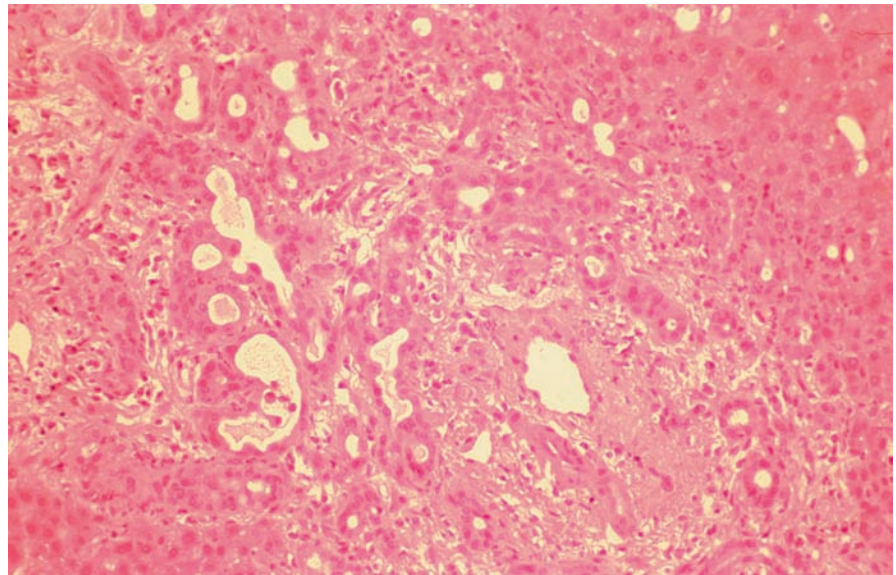
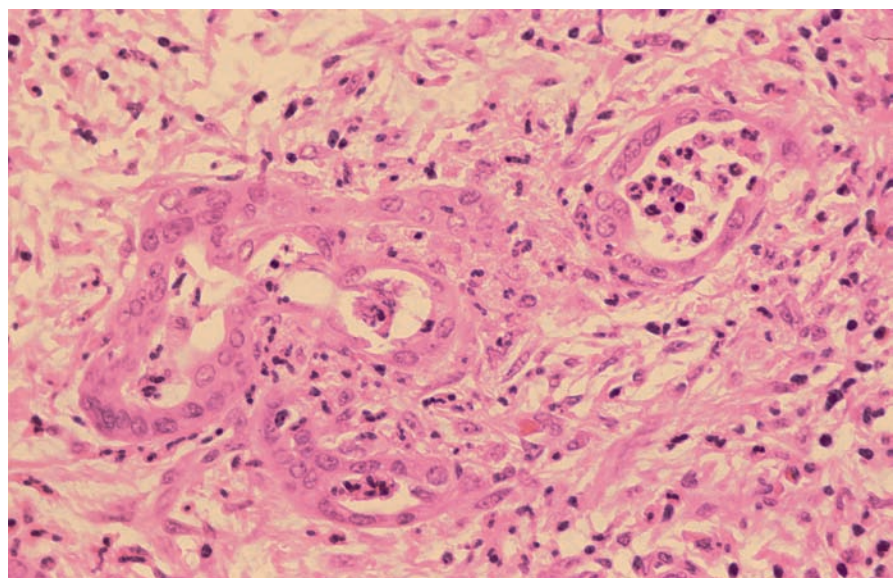


Fig. 26.2 Acute cholangitis. Neutrophilic granulocytes invade the wall and the lumen of portal bile ducts. The biliary epithelium is damaged. Focally (*right upper corner*), the bile duct is disrupted. Hematoxylin-Eosin



Hydropically swollen and pale hepatocytes with a rarified, clear, reticular cytoplasm (mostly periportal, less frequently lying separately or in small clusters), scattered in the parenchyma represent *cholate stasis* due to bile acid retention (*feathery degeneration*; Figs. 26.3 and 23.3). In approximately 2% of cases of longer standing biliary obstruction Mallory-Denk bodies are found in periportal hepatocytes. In cholestatic areas liver cell necroses of various degrees may be found. Their bile contents and their PAS-positive, diastase-resistant remnants are phagocytosed by macrophages and hypertrophied Kupffer cells.

If the mechanical obstruction lasts longer than 1 month, *bile lakes* may form, predominantly in the periportal areas. They represent extravasates of bile into the parenchyma. They are surrounded by hepatocytes showing pseudoxanthomatous degeneration, by histiocytes and more rarely by foreign giant cells. *Bile infarcts* (*Charcot-Gombault infarcts*) are relatively sharply circumscribed, mostly periportally localized areas of hepatocellular coagulation necrosis; the necrotic hepatocytes, in places surrounded by free bile, lie in a fibrin rich stroma and are strongly imbued with bile. Bile lakes and bile infarcts most frequently occur in acute mechanical obstruction of a large bile duct. However, nowadays, in the era of rapid clinical-morphological diagnosis (transcutaneous and endoscopic ultrasound, computed tomography, magnetic resonance imaging) and (endoscopic) therapy of biliary obstruction, such lesions are only very rarely encountered in liver biopsies.

In the *chronic stages* of biliary obstruction the acute inflammatory reaction abates and fibrotic changes become prominent. The portal tracts are fibrotic and enlarged, typically with a concentric periductal fibrosis and a periductal mononuclear cell infiltrate that varies in density. At this stage bile plugs are hardly seen. Not only hepatocytes but also the biliary epithelial cells suffer from chronic obstructive cholestasis. The epithelium becomes stratified with hyperchromatic and polymorphic nuclei, and nuclear and cytoplasmic vacuolization can be seen. As a manifestation of longstanding cholestasis, zone 1 (periportal) hepatocytes are pale and swollen, with a finely granular cytoplasm (*cholate stasis*). They contain copper (rhodanin stain), copper-binding protein (metallothionein; orcein stain), bilirubin granules and occasionally Mallory-Denk bodies (Fig. 26.4). *Cholestatic liver cell rosettes* (pseudoglandular transformation of liver cells) are not confined to mechanical cholestasis but may be found in longstanding cholestasis of any etiology. Rosette forming or periportal hepatocytes may express cytokeratins (e.g. CK 7) otherwise typical of bile ducts.

Pericholangiolar fibrosis is the pacemaker for the formation of fibrous septa in chronic cholestatic liver diseases. However, despite increasing biliary fibrosis the basic lobular architecture, i.e. the relationship between portal tracts and central veins, remains conserved. In long-term bile duct obstruction a *secondary biliary cirrhosis* may develop, with a map-like pattern

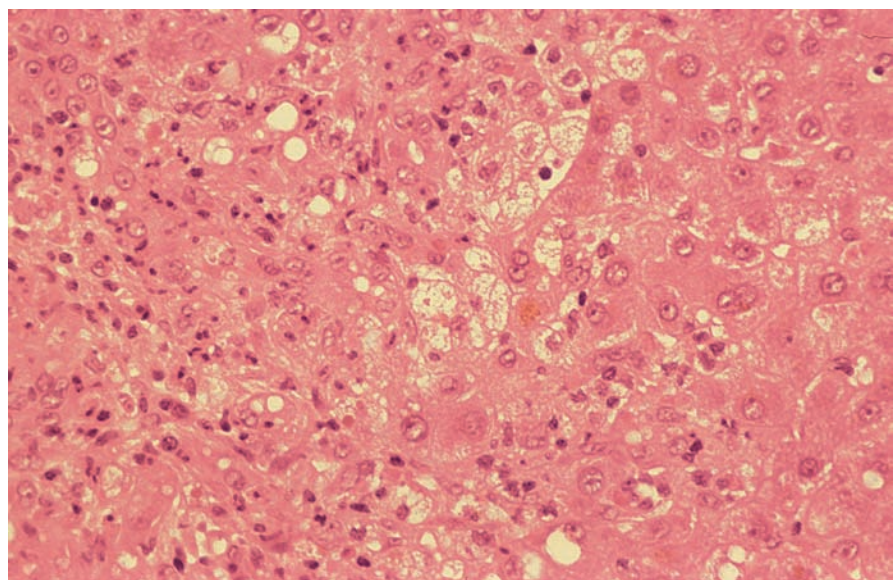
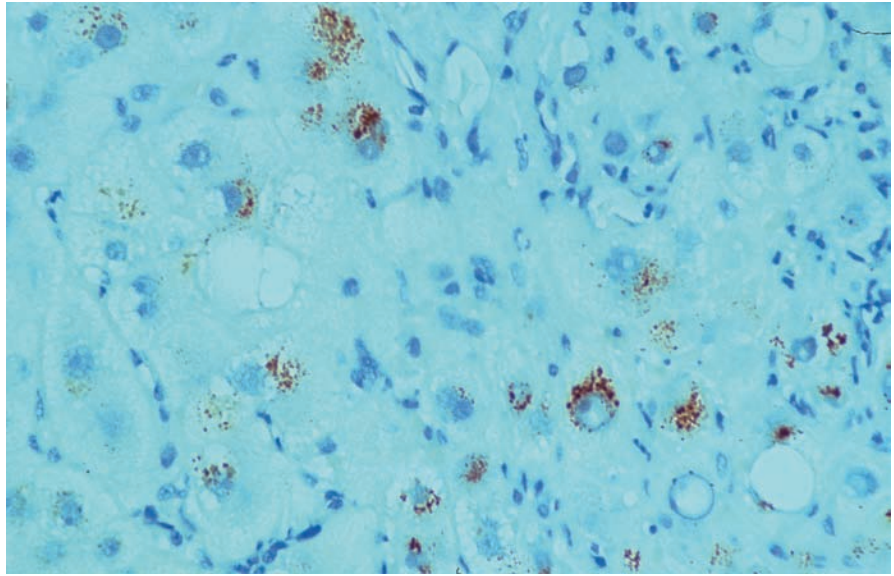


Fig. 26.3 Cholestasis. In the center of the figure a group of hepatocytes with clear, reticular cytoplasm are seen (*cholate stasis*; *feathery degeneration*). Hematoxylin-Eosin

Fig. 26.4 Copper storing hepatocytes in cholestasis. Rhodanin stain



of fibrous septa and small, round regenerating nodules, resembling a mosaic-like puzzle. A fine edematous halo is seen around the fibrous septa and in the periphery of parenchymatous nodules.

Hyperlipidemia often accompanies chronic cholestasis, and fat-laden histiocytes (xanthoma cells) may lie singly or, more often, in small groups in the acini or in the portal tracts.

The cholestatic changes in mechanical bile duct obstruction differ from alterations seen in primary sclerosing cholangitis, primary biliary cirrhosis and other diseases of the small bile ducts. However, nowadays, in addition to histopathological findings the differential diagnosis of these conditions is based on serological and endoscopic-radiological techniques (see Section XIV).

The liver contains putative stem cell precursors probably representing cells lining the canals of Hering (see Chapter 3), which may proliferate after massive hepatic necrosis and are capable of differentiating into hepatocytes and biliary cells. This cholangiolar proliferation is part of the ductular reaction (see below) and should be differentiated from the proliferation of interlobular bile ducts that may also occur in mechanical bile duct obstruction.

In *acute, ascending, suppurative bacterial cholangitis* neutrophilic granulocytes are numerous and neutrophils invade the wall and the lumen of interlobular bile ducts (see Fig. 26.2). The interlobular bile ducts may rupture and give rise to small abscesses within the

portal tracts. In addition, centrilobular signs of cholestasis are usually also present.

A ductular proliferation with dilated, bile-containing cholangioles, surrounded or infiltrated by neutrophils, is highly characteristic of *septicemia* (“*cholangitis lenta*”), provided bile duct obstruction has been excluded [6].

Drug-induced cholestatic liver injury may manifest as a bland, hepatocellular or canalicular cholestasis without an inflammatory cell infiltrate, or as a cholangiodestructive reaction (cholangiofibrosis, ductopenia).

Hepatitis A virus infection quite often may be associated with cholestasis. Canalicular dilatation is modest and the hepatocellular changes of acute viral hepatitis are distributed across the entire lobule and not limited to the cholestatic areas. The inflammatory portal infiltrate contains predominantly lymphocytes. While in mechanical bile duct obstruction liver cell plates remain intact, in acute viral hepatitis lobular architecture is in disarray, due to cell swelling, liver cell drop-out and regeneration.

Portal bile duct lesions, described mostly in *chronic viral hepatitis C* (“Poulsen-Christoffersen lesion”; stratification of biliary epithelium, vacuolation of cholangiocytes and mononuclear cell infiltration), are of questionable significance. They have never been linked to viral pathogenesis, and probably are clinically irrelevant. Significant bile duct lesions in viral hepatitis always represents comorbidity.

Small duct primary sclerosing cholangitis (formerly called *pericholangitis*) is a variant of primary sclerosing cholangitis (PSC) in patients with chronic cholestasis and hepatic histology compatible with PSC but normal findings on endoscopic or magnetic resonance cholangiography. Most cases of PSC occur in the setting of underlying inflammatory bowel disease.

Ductular Reaction

The term ductular reaction was coined by Popper et al. in 1957 [10]. Ductular reaction is a reaction of ductular phenotype, possibly but not necessarily of ductular origin [13]. It occurs in nearly all cases of extrahepatic cholestasis. However, it is not specific for cholestasis and is also seen in many acute and chronic, non-cholestatic liver diseases, in hepatic tumorigenesis, in liver cirrhosis and in hepatic regeneration after extensive loss of liver parenchyma [1–3, 13].

The ductular reaction is characterized morphologically by

- Increased numbers of ductular profiles in a plane section of a portal tract
- A pericholangiolar inflammatory cellular infiltrate (predominantly neutrophils) and by
- Periductular fibrosis

It is most pronounced in periportal zone 1. The injury of periportal hepatocytes in ductular reaction has been called “biliary piecemeal necrosis,” but the use of this term is discouraged.

Ductular reaction has been termed “typical” or “atypical”. In “typical” ductular reaction, ductules allegedly have a recognizable lumen lined by cuboidal cells and are the result of proliferation of pre-existing ductules. This type of ductular reaction is seen in acute and complete extrahepatic bile duct obstruction. In contrast, “atypical” ductules are described as thin, elongated structures, lined by flattened cells, and lacking easily discernible lumina. This type of reaction has been described in regeneration after massive loss of hepatic parenchyma and in incomplete extrahepatic bile duct obstruction. It is believed to be related to metaplasia of hepatocytes and/or progenitor cell activation. However, distinction between these two types of ductular reaction is not easy, and their distinct existence has even been questioned, so that these terms are best avoided [12, 13].

The pathogenesis of ductular reaction is poorly understood. An increase in intraductal pressure and humoral factors are assumed to trigger ductular reaction. The extracellular matrix also plays a major role by modulating the bioavailability and the local concentrations of cytokines and growth factors. Periductal hemato-lymphoid cells and stromal cells are the sources of growth factors that stimulate biliary epithelial cells to express receptors for these factors.

The origin of ductular cells still is obscure. They may arise from (1) proliferating pre-existing cholangiocytes, (2) metaplasia of periportal hepatocytes, or (3) be the result of proliferation and differentiation of common progenitor cells (local and/or circulating, possibly bone marrow derived cells) [4, 13, 15–17]. However, these various mechanisms are not mutually exclusive.

Numerous cytokines and growth factors that are partly produced by the proliferating cholangiocytes themselves are involved in the ductular reaction [14]. Interleukin-6 (IL-6) and hepatocyte growth factor (HGF) stimulate proliferation of epithelial cells [8]. Periductal mesenchymal cells are an important source of HGF, while IL-6 is synthesized by inflammatory cells and by the biliary epithelial cells themselves. Reactive human ductules also express parathyroid hormone related peptide (PTHrP) that impacts on the proliferation of stem cells and is of importance in ductular reaction during hepatic regeneration after extensive liver cell necrosis [11].

The increase of ductular structures is accompanied by an inflammatory cellular infiltrate and by the development of a periductular fibrosis. The biliary epithelial cells are involved in recruiting inflammatory cells by secreting chemotaxins for neutrophils, interleukin-8 and monocyte chemoattractant protein 1. Conditions associated with endotoxin-mediated activation of Kupffer cells, for example septicemia or states with an impaired intestinal barrier function, lead to a ductular reaction by endotoxin-induced release of IL-1, IL-6 and TNF- α . An impressive example is cholestasis and ductular reaction seen in septicemia that, in analogy to endocarditis, has been termed “cholangitis lenta” (see above) [6].

By expressing and/or activating growth factors, including TGF- β , platelet derived growth factor- β (PDGF), and endothelin-1, biliary epithelial cells activate portal fibroblasts and stimulate fibrogenesis. PDGF attracts stellate cells that accumulate in the

neighborhood of proliferating ductules. TGF- β is a potent profibrogenic factor and stimulates stellate cells to produce extracellular matrix. Thus, ductular reaction might be a pacemaker for progressive biliary fibrosis in cholestatic liver diseases, such as primary biliary cirrhosis and primary sclerosing cholangitis.

The ductular reaction is reversible after the initiating cause has been eliminated. Even fibrous connective tissue may be degraded to a certain degree, and the surplus of ductular cells falls prey to apoptosis.

References

1. Burt AD, MacSween RNM (1993) Bile duct proliferation – its true significance? *Histopathology* 23: 599–602
2. Desmet V, Roskams T, van Eyken P (1995) Ductular reaction in the liver. *Path Res Pract* 191: 513–24
3. Falkowski O, An HJ, Ianus IA, et al (2003) Regeneration of hepatocyte “buds” in cirrhosis from intrabiliary stem cells. *J Hepatol* 39: 357–64
4. Golding M, Sarraf C, Lalani EN, et al (1996) Reactive biliary epithelium: the product of a pluripotential stem cell compartment? *Hum Pathol* 27: 872–84
5. Green RM, Crawford JM (1995) Hepatocellular cholestasis: pathobiology and histological outcome. *Semin Liver Dis* 15: 360–71
6. Lefkowitz JH (1982) Bile ductular cholestasis: an ominous histopathologic sign related to sepsis and “cholangitis lenta”. *Hum Pathol* 13: 19–24
7. Li MK, Crawford JM (2004) The pathology of cholestasis. *Semin Liver Dis* 24: 21–42
8. Liu Z, Sakamoto T, Ezure T, et al (1998) Interleukin-6, hepatocyte growth factor and their receptors in biliary epithelial cells during a type I ductular reaction in mice: interactions between the periductal inflammatory and stromal cells and the biliary epithelium. *Hepatology* 28: 1260–8
9. Popper H, Szanto PB (1956) Intrahepatic cholestasis (cholangiolitis). *Gastroenterology* 31: 683–700
10. Popper H, Kent G, Stein R (1957) Ductular reaction in the liver in hepatic injury. *J Mt Sinai Hosp* 24: 551–6
11. Roskams T, Campos RV, Drucker DJ, et al (1993) Reactive human bile ductules express parathyroid hormone-related peptide. *Histopathology* 23: 11–9
12. Roskams T, Desmet V (1998) Ductular reactions and its diagnostic significance. *Semin Diagn Pathol* 15: 259–69
13. Roskams TA, Theise ND, Balabaud C, et al (2004) Nomenclature of the finer branches of the biliary tree: canals, ductules, and ductular reactions in human livers. *Hepatology* 39: 1739–45
14. Saito JM, Maher JJ (2000) Bile duct ligation in rats induces biliary expression of cytokine-induced neutrophil chemoattractant. *Gastroenterology* 118: 1157–68
15. Sirica AE (1995) Ductular hepatocytes. *Histol Histopathol* 10: 433–56
16. Tan J, Hytiroglu P, Wiczorek R et al (2002) Immunohistochemical evidence for hepatic progenitor cells in liver diseases. *Liver* 22: 365–373
17. Van Eyken P, Desmet VJ (1993) Cytokeratins and the liver. *Liver* 13: 113–22

Chapter Outline

Granuloma Types	247
Foreign Body Granulomas	247
Immune Granulomas.....	247
Granulomatous Hepatitis	248
References	249

The granulomatous reaction is a distinctive pattern of chronic inflammation characterized by nodular aggregation of inflammatory cells, predominantly activated macrophages, which often are transformed into epithelium-like (epithelioid) cells. Other cellular components that may be present in granulomas are lymphocytes, plasma cells, fibroblasts and multinucleate giant cells of Langhans or foreign body type. Granulomas are found in approximately 2.5–9% of all liver biopsies (see Section XIX).

Granuloma Types

There are two types of granulomas, which differ in their pathogenesis

- Foreign body granulomas and
- Immune granulomas

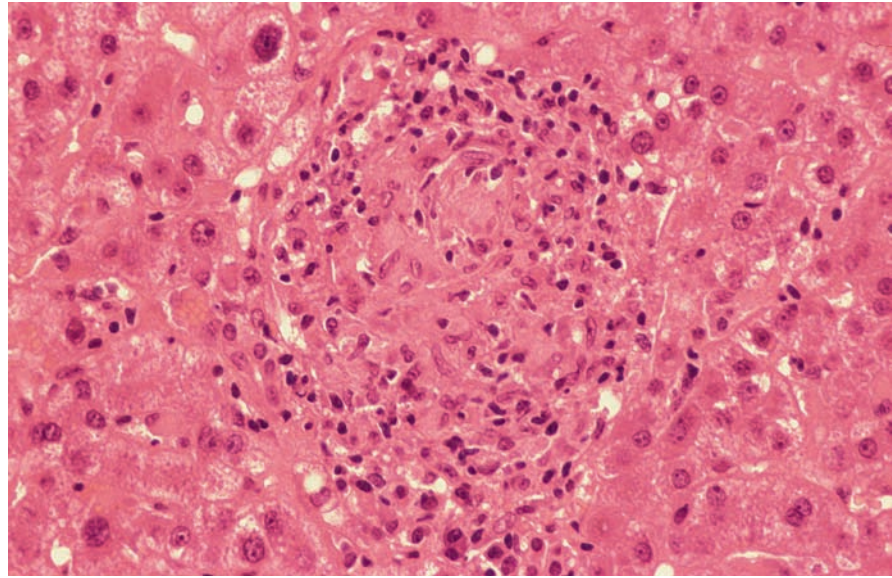
Foreign Body Granulomas

Foreign body granulomas are elicited by relatively inert foreign material, such as talc, starch, silicone or fat. Lipo- and mineral oil granulomas also are among foreign body granulomas (see below).

Immune Granulomas

Immune granulomas form in the context of a cell-mediated immune response elicited by insoluble antigens, typically microbes. During this antigenic stimulation

Fig. 27.1 Epithelioid granuloma. Hematoxylin-Eosin



macrophages may transform to epithelium-like (epithelioid) cells forming an *epithelioid granuloma* (Fig. 27.1). A *lymphohistiocytic granuloma* is a focal accumulation of non-transformed histio- and lymphocytes. Macrophages in granulomas derive both from circulating monocytes attracted by chemotaxis, and from local, resident macrophages recruited by T cell derived growth factors. CD4⁺ T cells accumulate in the center of epithelioid granulomas, while the majority of CD8⁺ T cells are found at its periphery. T cells produce cytokines, such as IL-2, which activates other T cells, perpetuating the response, and IFN- γ , which is important in activating macrophages and transforming them into epithelioid cells and multinucleate giant cells. Epithelioid cells also produce large amounts of cytokines.

Compared to foreign body granulomas, the cell turnover in immune granulomas is very high. Thus, immune granulomas are dynamic structures, whose morphologic characteristics vary with time. This fact explains the common observation of finding granulomas of different developmental stages in one liver biopsy. The fate of granulomas varies. They can vanish completely, without leaving a trace. This is observed in granulomatous hypersensitivity reactions to drugs. Alternatively, they can persist, which suggests the persistence of the eliciting immunological stimulus. Or they can heal by scar formation, which is typical, for example, of sarcoidosis (see Chapter 95) [4].

Granulomatous Hepatitis

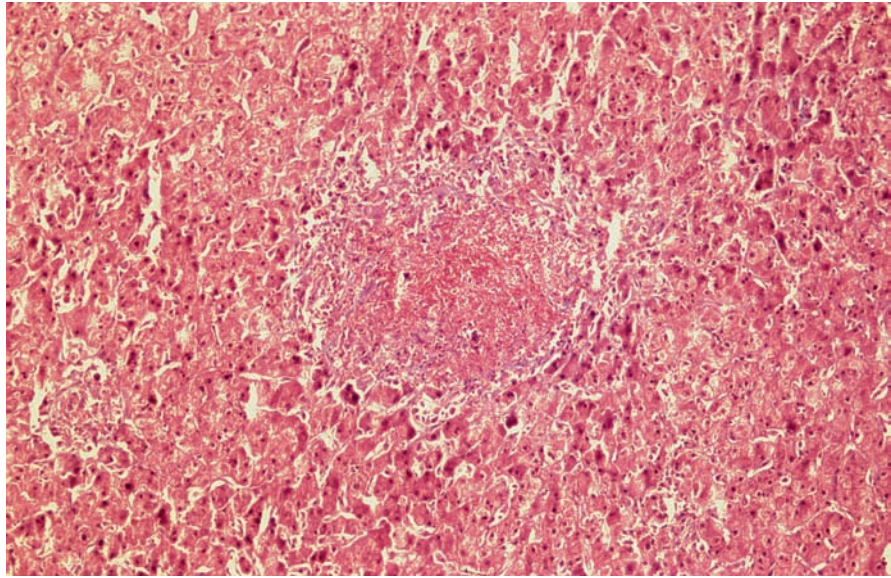
The term granulomatous hepatitis describes relevant necroinflammation coupled with a significant granulomatous component. The granulomas may be the sole manifestation of inflammation, or they may be accompanied by other signs of hepatitis [3]. The etiology of a granuloma cannot be inferred from its histological appearance. In individual cases, however, its features and location may give some clues as to its manifold etiologies (Table 27.1).

Table 27.1 Localization of hepatic granulomas

Typical localization	Examples
Subcapsular	Suture or talc granuloma, healed miliary tuberculosis, histoplasmosis
Diffuse	
Portal and intralobular	Sarcoidosis, infectious granulomas, drug-induced granulomas, tuberculosis
Portal and perivenular	Mineral oil granulomas
Portal, periductal	Primary biliary cirrhosis
Portal, arterial	Granulomatous arteritis, e.g. polyarteritis nodosa, Wegener's disease, phenytoin-induced
Liver hilum (\pm intrahepatic)	Lymphadenopathy in tuberculosis or sarcoidosis

Source: Adapted from [1]

Fig. 27.2 Miliary tuberculosis. Caseating granuloma. Masson Trichrom



The prototype of an immune granuloma is that caused by *Mycobacterium tuberculosis*. It may be non-caseating or caseating, with central amorphous debris and loss of all cellular details (caseating necrosis) (Fig. 27.2). Acid fast bacilli can be demonstrated in approximately 80% of tuberculous granulomas using combined molecular and histochemical approaches.

In patients with AIDS, *Mycobacterium avium intracellulare* (MAI) infection may lead to focal accumulations of MAI-filled macrophages in the liver. They are PAS-positive and typically in Ziehl-Neelsen stained sections many acid fast rods (MAI) are visible (see Chapter 69).

Epithelioid *granulomas in sarcoidosis* are noncaseating. Sarcoid granulomas have a tendency to exhibit fibrosis and to coalesce to larger structures that may impinge portal tracts and compress bile ducts, thus even leading to cholestatic liver disease [4].

Fibrin ring granulomas are characteristic of Q-fever, but they may also be encountered in malignant lymphomas and in allopurinol hypersensitivity. A central, lipoid vacuole is surrounded by histiocytes, some lymphocytes, neutrophilic and occasionally eosinophilic granulocytes, and is encircled by a ring of fibrin. This aspect leads to the pictorial term “*doughnut granuloma*”.

Birefringent *foreign material* in granulomas, such as talc or starch, is often found in intravenous drug users. *Mineral oil granulomas* are special foreign body granulomas. Optically empty spaces (deposits of mineral oil) within the portal tracts or adjacent to the central veins are surrounded occasionally by vacuolated macrophages [2].

Lipogranulomas are accumulations of histiocytes and mononuclear cells surrounding a macrovesicular steatotic hepatocyte. They are one of the hallmarks of alcoholic and nonalcoholic steatohepatitis. Granuloma-like accumulations of enlarged Kupffer cells whose cytoplasm has a foamy appearance caused by phagocytosis of tiny neutral fat droplets from dead hepatocytes are called *lipohagic residual nodules*.

Granulomas containing many eosinophilic granulocytes suggest a *parasitic* or an *allergic etiology*, e.g. drugs. However, only the histological or immunocytochemical demonstration of the parasite itself or of its degradation products can prove the etiology. Schistosomiasis granulomas, for example, may contain schistosomal eggs. The histological aspect of a drug-induced granuloma does not allow conclusions regarding the causative drug.

References

1. Denk K, Scheuer PJ, Baptista A, et al (1994) Guidelines for the diagnosis and interpretation of hepatic granulomas. *Histopathology* 25: 209–18
2. Dincsoy H, Wessner RE, MacGee J (1982) Lipogranulomas in non-fatty human livers. A mineral oil induced environmental disease. *Am J Clin Pathol* 78: 35–41
3. Ferrell D (1990) Hepatic granulomas: a morphologic approach to diagnosis. *Surg Pathol* 3: 87–106
4. Valla DC, Benhamou JP (2000) Hepatic granulomas and hepatic sarcoidosis. *Clin Liver Dis* 4: 269–85

Chapter Outline

Definition	251
Epidemiology	251
Etiology	251
Pathogenesis	252
Hepatic Stellate Cells (Ito Cells).....	252
Cytokines and Peptides	253
Extracellular Matrix	255
Resolution of Liver Fibrosis	256
Histopathology	256
Portal and Periportal Fibrosis.....	256
Perisinusoidal and Pericellular Fibrosis.....	257
Centrilobular Fibrosis	258
Fibrous Septa	258
Diagnosis	258
Liver Biopsy.....	259
Cross-Sectional Imaging	261
Serum Biomarkers of Fibrogenesis.....	262
Therapeutic Approaches	263
References	266

Definition

Liver fibrosis is a wound repair response of the liver to chronic injury. Fibrogenesis is a dynamic, potentially reversible process, reflecting a balance between matrix synthesis, deposition, and degradation, ultimately resulting in the accumulation of a qualitatively altered extracellular matrix (ECM).

Epidemiology

Liver fibrosis is clinically significant because it is a prerequisite and the potential precursor of cirrhosis. Reliable data on the incidence and prevalence of fibrosis are not available because non-invasive diagnostic tests still lack a high sensitivity. If one considers that (1) the prevalence of liver cirrhosis in Western countries is approximately 1.1%, (2) liver cirrhosis is the most common cause of death among gastroenterological diseases, (3) up to 10% of cirrhotics are only diagnosed at autopsy, despite being preceded for years or decades by fibrosis, and (4) chronic hepatitis C has reached epidemic proportions, then it is fair to assume that hepatic fibrosis is quite prevalent in the general population.

Etiology

All liver injuries that may result in cirrhosis (see Chapter 79) are also causes of liver fibrosis. Clinically most relevant are alcoholic and nonalcoholic fatty liver disease, chronic viral hepatitis B (D) and C, metabolic

and genetic hepatopathies (e.g. genetic hemochromatosis, α_1 -antitrypsin deficiency, Wilson's disease), drug- and toxin-induced, autoimmune and biliary liver diseases, as well as chronic right-sided congestive heart failure. Additionally, rare forms of congenital hepatic fibrosis should also be considered.

Hepatoportal sclerosis, a rare idiopathic sclerosis of portal vein branches, may cause noncirrhotic portal hypertension. Ionizing radiation-induced liver fibrosis is very rare. Focal fibrosis as a manifestation of loss of parenchyma (scarring) is observed in local circulatory disturbances, healed abscesses, in parasitic liver diseases, after traumatic tissue damage or after fibrous obliteration of a cavernous hemangioma. Large, broad scars form after subacute liver dystrophy or in treatment-induced regression of tumors by systemic or local chemotherapy, chemoembolization, laser ablation, local cryotherapy or percutaneous alcohol injection.

Several etiologies have to be considered in fibrosis of a transplanted liver, including recurrent primary disease, biliary obstruction, ischemia, or immunosuppressive medications (e.g. centrilobular fibrosis due to azathioprine). Chronic rejection reaction causes ductopenia but usually does not lead to significant fibrosis.

Liver tumors may display various degrees of intratumoral fibrosis. Cavernous hemangioma of the liver may contain sclerosed areas. Focal nodular hyperplasia is characterized by a central fibrovascular core. Hepatocellular carcinoma may be surrounded by a fibrous capsule, and the sclerosing and fibrolamellar variants of hepatocellular carcinoma are characterized by dense fibrosis. Cholangiocellular lesions such as von Meyenburg complexes, or especially cholangiocarcinomas may have a marked fibrosis. Epithelioid hemangioendothelioma is characterized by an extensive fibrosis.

Pathogenesis

Fibrosis is a reaction pattern to injury. The chronic fibroproliferative reaction represents a healing response in chronic inflammation and in repair of tissue damage resulting in increased collagen deposition and scar formation. In the liver a *regional reparative fibrosis*

that is characteristic of healing of focal lesions caused by circumscribed loss of liver parenchyma, has to be differentiated from a *diffuse reactive fibrosis* that is observed within the context of chronically injurious agents and chronic inflammatory hepatic reactions. The latter pattern of fibrosis is important in clinical hepatology, since this form of fibrosis if untreated may progress to liver cirrhosis and its complications.

Every increase in hepatic connective tissue is preceded by an injury to the liver. In order for liver fibrosis to progress, the injurious stimulus must be chronic and continuous. A short lived, one-time insult (for example, in severe fulminant hepatitis or toxic liver injury) may cause broad fibrous bands that distort the regular parenchyma but usually does not result in progressive fibrosis. The causative injurious agent damages liver and endothelial cells and recruits inflammatory cells. These cells release cytokines and other mediators that in turn activate effector cells of fibrogenesis to produce and deposit extracellular matrix proteins. Oxidative stress also is likely to be involved in the progression of liver fibrosis during chronic liver disease of different etiologies [49].

Three important components in the pathogenesis of hepatic fibrosis merit special consideration:

- Hepatic stellate cells (HSC)
- Cytokines and peptides and the
- Extracellular matrix

Hepatic Stellate Cells (Ito Cells)

HSC are key effectors in the fibrogenic process (see Chapter 3). They are the main producers of extracellular matrix proteins and contribute significantly to maintaining the dynamic balance of the extracellular matrix (see below) [38]. Fibrogenesis by HSC is regulated by the concerted action of numerous endocrine, paracrine and autocrine factors, among them cytokines, peptides and the extracellular matrix itself. In addition to HSC, perivenular myofibroblasts, portal tract fibroblasts, cholangiocytes and sinusoidal epithelial cells may synthesize matrix proteins.

Hepatic fibrogenesis initiates with the activation of HSC by liver injury (Fig. 28.1). The initial HSC-activating stimuli derive from injured hepatocytes,

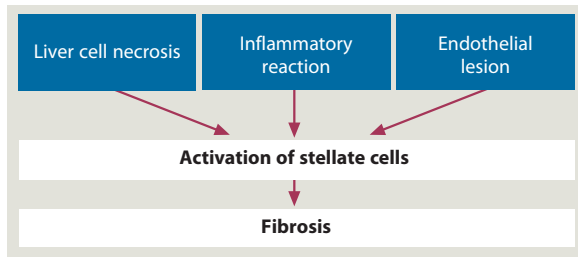


Fig. 28.1 Activation of hepatic stellate cells by various stimuli is pivotal in the pathogenesis of fibrosis

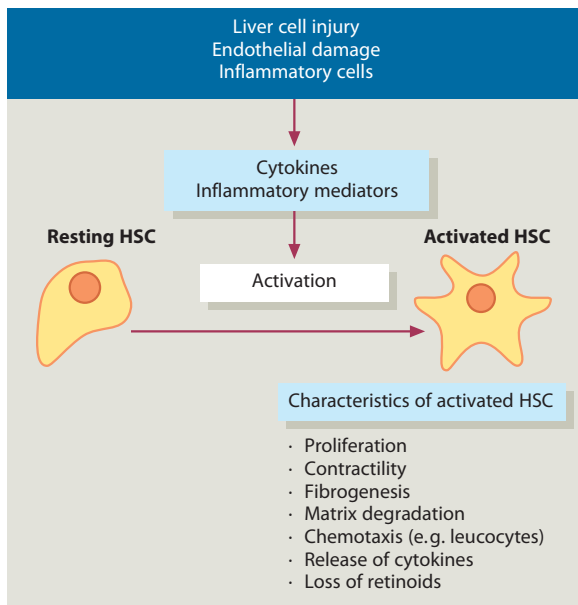


Fig. 28.2 Phenotypic characteristics of hepatic stellate cells

neighboring endothelial, Kupffer and inflammatory cells. During ongoing liver damage, HSC perpetuate their own activation by autocrine factors. These stimuli, in concert with the interaction of activated HSC and extracellular matrix cause HSC to transform into contractile myofibroblasts (Fig. 28.2). The activation process is complex and is associated with HSC-proliferation, increase in HSC-contractility, release of proinflammatory cytokines, and enhanced formation of both matrix degrading enzymes and their inhibitors. It finally results in the disorganized accumulation of extracellular matrix [20, 21]. Recent data suggest that not all myofibroblasts in the liver derive from transformed HSC. There is evidence, however, not undisputed that in liver diseases of diverse etiologies a significant proportion of hepatic

Table 28.1 Impact of cytokines and peptides on hepatic fibrogenesis

Substance	Relative fibrogenic effect
Profibrogenic	
Transforming growth factor- β	+++
Transforming growth factor- α	+
Interleukin-1	+
Interleukin-4	+
Insulin-like growth factor I and II	+
Interleukin-6	+
Platelet-derived-growth factor	++
Monocyte chemotactic factor-1	+
Fibroblast growth factor	+
Thrombin	+
Vascular endothelial growth factor	+
Endothelin-1	++
Leptin	++
Antifibrogenic	
Tumor necrosis factor- α	+
Interferon- γ	+++
Interleukin-10	++
Hepatocyte growth factor	++

Source: Adapted from [57]

myofibroblasts may be of bone marrow origin and contribute significantly to liver fibrosis and cirrhosis [17].

Cytokines and Peptides

Multiple cytokines and peptides are involved in fibrogenesis. Their actions are complex and most of them exert several paracrine and autocrine effects simultaneously, not only on fibrogenesis but also on inflammation, cell proliferation, and regeneration [22, 47]. The effects on fibrogenesis are outlined in Table 28.1.

Transforming Growth Factor- β 1 (TGF- β 1)

TGF- β 1 is the best characterized profibrogenic cytokine [3, 7, 8]. It is produced by Kupffer cells, endothelial cells, HSC and possibly also by hepatocytes. Hepatitis C virus nonstructural genes induce an increased expression of TGF- β 1 in infected hepatocytes [61].

Increased hepatic fibrogenesis is accompanied by an enhanced expression of TGF- β 1 mRNA and by a rise in serum levels of TGF- β 1 [42]. TGF- β 1 is secreted into the extracellular space in a biologically latent form and binds covalently to its propeptide, the 80kDa latency-associated peptide (LAP). Activation of TGF- β 1 occurs by proteolytic cleavage from LAP. In the liver this is probably mediated by the protease plasmin. The surface receptors for TGF- β 1 are serine-threonine kinases. Activation of TGF- β receptor type II leads to the phosphorylation of receptor associated proteins and to the formation of an intracellular trimolecular protein complex that translocates into the nucleus activating the transcription of TGF- β responsive genes.

The actions of TGF- β 1 are manifold. TGF- β 1 stimulates the synthesis of extracellular matrix components, such as collagens, non-collagenous glycoproteins and proteoglycans. An early alteration of the extracellular matrix during fibrogenesis is represented by the expression of a fibronectin splicing variant that may activate HSC. The expression of this fibronectin-isoform is regulated by TGF- β 1. TGF- β 1 inhibits matrix degradation by inhibiting the synthesis of matrix-degrading enzymes and by stimulating gene expression of plasminogen-activator-inhibitor and of tissue inhibitors of metalloproteinases-1 (TIMP-1) (Fig. 28.3). By modulating the expression of integrins, TGF- β 1 promotes cell adhesion to the extracellular matrix.

In addition to its profibrogenic effects, TGF- β 1 exerts strong immunosuppressive (inhibiting the differentiation of T cells in Th1 and Th2 cells) and anti-proliferative actions on epithelial cells, including hepatocytes (see Chapter 13).

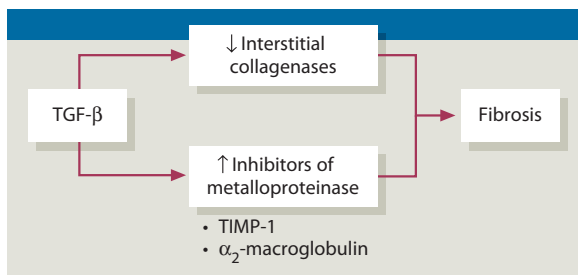


Fig. 28.3 TGF- β is a central regulator of fibrogenesis. The balance between the activity of matrix metalloproteinases and their tissue inhibitors determines the degree of fibrogenesis and fibrolysis

Transforming Growth Factor- α and Platelet-Derived Growth Factor

TGF- α and platelet-derived growth factor (PDGF) are among the most important profibrogenic cytokines that are produced in the damaged liver. TGF- α directly stimulates HSC to produce extracellular matrix proteins. PDGF is the most potent and best characterized HSC-proliferation stimulating factor. Activated HSC express PDGF-receptors that transmit their signal via phosphatidylinositol 3-kinase into the cell interior [40]. Thus, PDGF enhances fibrogenesis indirectly, by stimulating HSC activation and proliferation [9].

In addition, HSC also synthesize monocyte chemoattractant protein-1 (MCP-1), insulin like growth factor-1, and interleukin-6 that stimulate HSC-proliferation in an autocrine fashion, thereby enhancing fibrogenesis indirectly. Endothelial growth factor, fibroblast growth factor, endothelin-1 (ET-1), thrombin and TGF- α also stimulate HSC-proliferation.

PDGF and MCP-1 increase the migratory capacity of activated HSC, thereby enabling HSC to aggregate at the site of liver injury [25, 41]. Activation of HSC is also associated with an increase in their contractility. Augmented HSC-contractility probably contributes to the increased intrahepatic vascular resistance (HSC are also pericytes) and to the contraction of fibrous septa frequently observed in the end stage of chronic liver diseases.

Endothelin-1

ET-1 is a vasoactive peptide with numerous biologic actions (see Chapter 54). ET-1 is converted to its active form by proteolytic cleavage of a precursor peptide ("Big ET") by the endothelin converting enzyme-1 (ECE-1). TGF- β 1 stabilizes ECE-1 mRNA thereby stimulating the generation of active ET-1. ET is the most important autocrine stimulator of HSC-contractility. Nitric oxide, carbon monoxide and adrenomedullin cause HSC to relax. In the healthy liver sinusoidal endothelial cells are the main producers of ET. In chronic liver disease HSC take on this role. In addition ET-1 also stimulates the synthesis of extracellular matrix.

Hepatocyte growth factor and interleukin-10 are also produced by HSC, however, they rather inhibit fibrogenesis.

Leptin

Leptin, the *ob* gene product, is a multifunctional adipocyte hormone. It controls appetite, has immunomodulatory and profibrogenic activity, and is involved in wound healing. Recent data suggest that leptin is a mediator of hepatic fibrosis and might play a major role in obesity associated liver fibrosis [37].

Extracellular Matrix

An increase in ECM and ECM-remodeling are essential components of hepatic fibrogenesis, irrespective of the cause of liver injury. The ECM is a dynamic structure, and physiologically a constant balance between matrix assembly and matrix degradation exists (see Chapter 3). ECM proteins are degraded by a group of enzymes called *matrix-metalloproteinases* (MMPs). Among them are interstitial collagenases, gelatinases, and stromelysins. The activity of MMPs is regulated by specific activators and inhibitors. The plasminogen activator systems uroplasminogen (uPA) and tissue plasminogen (tPA) are among the most important activators of MMPs. Plasmin degrades the ECM both directly and via activation of MMPs.

Tissue inhibitors of matrix metalloproteinases (TIMPs) suppress the activity of MMPs [1]. TIMP-1 inhibits interstitial collagenase, whose expression by HSC increases markedly during fibrogenesis. The dynamic balance of ECM shifts towards fibrogenesis by diminishing the activity of MMPs, for instance by inhibiting its activators or stimulating its inhibitors (Fig. 28.3).

HSC may synthesize matrix degrading enzymes and plasminogen activators as well as produce TIMPs, thereby regulating ECM-remodeling. This process is characterized by a close interplay between HSC and ECM, in which the ECM modulates the activity of HSC, thus affecting fibrogenesis.

A recently described new family of proteins, *A Disintegrin and Metalloproteinase* (ADAMs), cleaves

transmembrane proteins. Activated HSC produce several ADAMs. Their biological significance is currently under investigation.

The interactions between cells and ECM are mediated by integrins, glycans, receptor tyrosine kinases or phosphatases and syndecans. The most important collagen-binding integrins $\alpha_1\beta_1$ and $\alpha_2\beta_1$ are expressed by HSC. They mediate the cross-linking of collagen types I, III and IV, the adhesion of HSC to collagen fibers and the HSC-induced contraction of collagen fiber networks. Basement membrane matrix integrity, cell-matrix interactions, and MMPs regulate HSC migration and play an important role in anchoring HSC, thus preventing them from spreading within the space of Disse and potentially elsewhere in the liver [68].

The expression of nearly all known matrix proteins is increased during fibrogenesis. The production of interstitial collagen types I, II and IV, proteoglycans, fibronectin, laminin, tenascin, and undulin is most pronounced [15]. To a lesser degree also changes in collagen type V, SPARC (secreted protein, acidic and rich in cysteine), vitronectin, nidogen (entactin), and elastin occur.

The early stage of fibrogenesis is characterized by the remodeling of subendothelial matrix. In this process the normal, low-density, basement membrane-like material of the subendothelial ECM is transformed into a matrix containing interstitial, fibrillary collagens. During the early phases of liver injury collagens type III and V and fibronectin accumulate in the space of Disse. In chronic liver injury collagen types I and IV, undulin, elastin and laminin are increasingly deposited. Most prominent is the increase in collagen type I and its ratio to collagen types III and V increases. Collagen VI induces the mesenchymal synthesis of DNA. In contrast, collagen XIV (undulin), which adheres to the surface of collagen fibers, inhibits cellular activity.

A new subfamily of receptor tyrosine kinases are the *discoidin domain receptors* (DDR). Unlike the receptor tyrosine kinases, signal transduction via DDRs is not initiated by growth factors, but by fibrillary collagens. Thus, the recent demonstration of DDR2 mRNA in activated HSC might explain a further mechanism of cell-matrix-interaction. Fibrillary collagen (especially type I), forming within the context of perisinusoidal fibrogenesis, perpetuates the activation of HSC, by binding to the DDR2 receptor.

Resolution of Liver Fibrosis

Liver fibrosis can be considered a bidirectional process. Although the dogma still holds true that cirrhosis is an irreversible end stage of liver disease, early stages of liver fibrosis may be reversible, either spontaneously or (more often) induced by treatment of the underlying disease. Even in a cirrhotic liver, matrix degradation can occur and fibrous tissue can regress to a significant degree [6, 14, 26, 28]. *Undisputed evidence for complete spontaneous or therapy-induced reversal of advanced cirrhosis does not exist.*

HSC, liver myofibroblasts, and inflammatory cells involved in the fibrotic process, including macrophages and Kupffer cells, secrete matrix degrading MMPs. They are expressed in the liver even in cirrhosis, but their activity is limited by powerful inhibitors, especially TIMP-1 and TIMP-2 [5]. When expression of TIMPs decreases, MMPs continue to be expressed, resulting in increased collagenase activity and consequent matrix degradation [46].

Factors regulating HSC-activation, survival and apoptosis play a pivotal role in matrix degradation and in the resolution of liver fibrosis. A key process in resolution of hepatic fibrosis is apoptosis of HSC [30, 31]. During matrix remodeling soluble factors important for HSC activation and survival are produced. When the injurious stimulus that leads to accumulation

and remodeling of extracellular matrix is withdrawn, the loss of these survival factors may cause activated HSC to undergo apoptosis. Apoptosis of HSC reduces the major cellular source of collagen and TIMPs. In Fig. 28.4 the role of HSC apoptosis in resolution of liver fibrosis is schematically depicted.

Histopathology

The hepatic connective tissue may extend into the interstitial and perivascular spaces giving rise to *different patterns of fibrosis*. The structural organisation of the liver is responsible for the organotypic fibrosis pattern. According to the localization portal/periportal, perisinusoidal, and perivenous fibrosis are differentiated. However, in fibrosis involving diffusely the entire organ, all acinar and portal zones are involved, albeit, each to a different degree. Therefore, often it is not warranted to draw a sharp distinction between the various localization patterns.

Portal and Periportal Fibrosis

Enlargement of portal tracts by portal and periportal fibrosis with fibrous spurs extending into the adjacent parenchyma is a frequent finding (Fig. 28.5). It occurs in biliary diseases, such as primary biliary cirrhosis, chronic ascending and primary sclerosing cholangitis. *Periductal fibrosis* with concentric layers (onion skin-like) of fibrous tissue surrounding the interlobular bile ducts is characteristic for sclerosing cholangitis, but not specific for its primary variant (Fig. 28.6). Furthermore, portal/periportal fibrosis of varying degrees is seen in cystic fibrosis, congenital fibrosis and hereditary cholestatic syndromes, in chronic hepatitis, as a residual lesion after acute hepatitis, in toxic liver injury (alcohol, methotrexate), in metabolic diseases and in so called hepatoportal sclerosis. In mechanical bile duct obstruction ductular cholangiocytes express TGF- β 1, MCP-1, and PDGF thereby attracting and activating portal fibroblasts and HSC. Thus ductular reaction (see Chapter 26) seen in obstructive cholestasis may be a pacemaker for portal fibrosis. On its own the histopathological demonstration of portal/periportal fibrosis is not very helpful diagnostically.

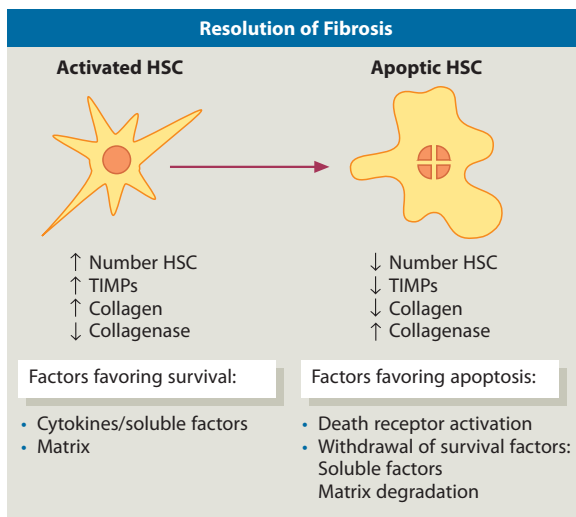


Fig. 28.4 Apoptosis of hepatic stellate cells is mediating regression of fibrosis (Adapted from [28]. With kind permission)

Fig. 28.5 Mild portal fibrosis. Slender fibrous septa extend into the adjacent lobular parenchyma. Masson Trichrome

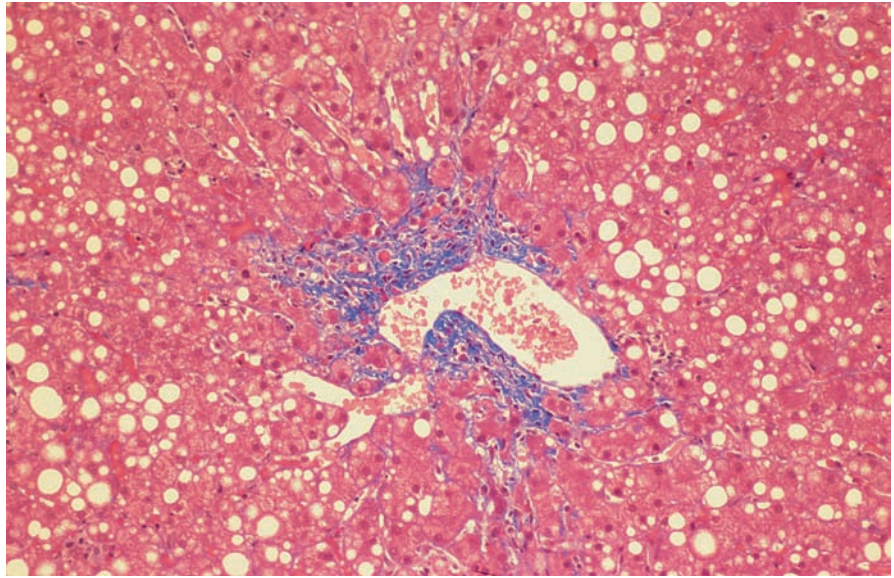
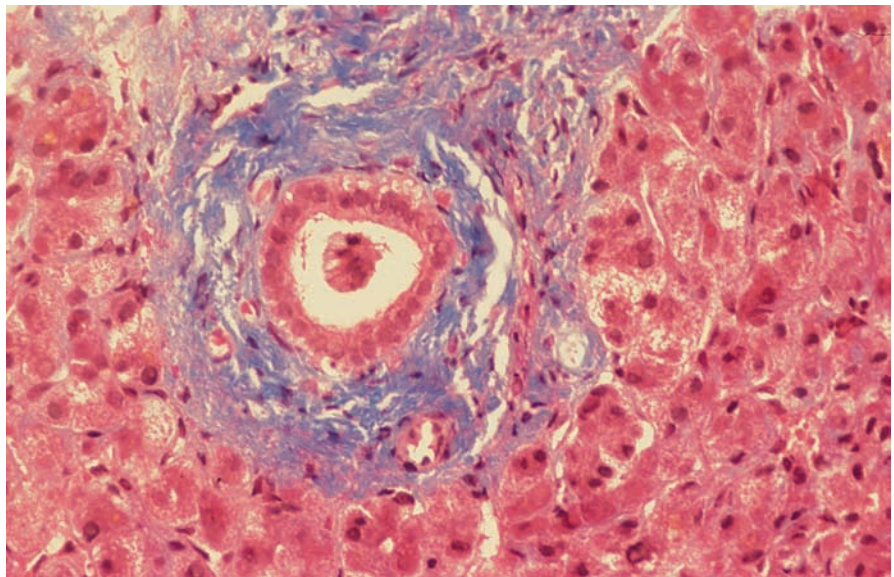


Fig. 28.6 Concentric periductal fibrosis. Masson Trichrome



Perisinusoidal and Pericellular Fibrosis

Slender fibrous extensions running along the sinusoids or encircling individual hepatocytes may involve diffusely the entire lobule or be limited to the periportal or centrilobular areas. Initially the cytoarchitecture is not affected. If the process progresses, however, fibrous deposits in the space of Disse lead to its collagenization, and the sinusoidal endothelial cells lose their fenestrations and form a basement membrane-like layer. This process

has been termed “*capillarization of hepatic sinusoids*” and it hampers the exchange of substances between the sinusoidal blood and the hepatocytes (Fig. 28.7) [60].

Centrilobular perisinusoidal fibrosis is seen in chronic right-sided heart failure and in Budd-Chiari syndrome. Complete portal vein thrombosis may lead to liver cell atrophy accompanied by sinusoidal fibrosis. Myeloproliferative diseases, chronic liver injury by vinyl chloride, arsenic and alcohol all cause sinusoidal fibrosis. Chronic alcohol abuse is clinically by far the

most important, with fibrosis often beginning in the center of the lobule (*perivenous sclerosis*; *central hyaline sclerosis*) and progressing in a chickenwire-like pattern to the midlobular areas (Fig. 28.8). Nonalcoholic fatty liver disease may cause the same pattern of liver fibrosis. Nowadays, congenital syphilis as a cause of perisinusoidal fibrosis is a rarity in Western countries.

Centrilobular Fibrosis

Centrilobular fibrosis is seen in chronic venous congestion, chronic alcohol abuse and as a residual change after perivenular loss of parenchyma in hepatitis or in drug or toxin-induced liver damage.

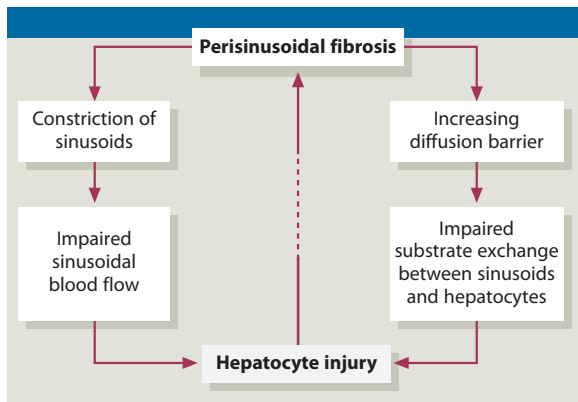


Fig. 28.7 Hepatocyte injury and perisinusoidal fibrosis form a vicious circle

Fibrous Septa

Progressive portal and centrilobular fibrosis may lead to the formation of fibrous septa (Fig. 28.9). These may link portal tracts (*portal–portal*), terminal hepatic venules and portal tracts (*portal–central*), and central veins of neighboring lobules (*central–central*). These bridging fibrous septa per se linking vascular structures must not be misconstrued as cirrhotic change. Fibrous septa may develop as part of an active inflammatory process (*active septa*) or they may traverse the parenchyma as cell-free scars (*passive septa*), for example, after ischemic damage or healed inflammation.

Collapse fibrosis denotes an increase in collagen synthesis and deposition, as a result of the localized collapse of the reticulin fiber network. It may be observed, for example, after bridging or panlobular necrosis. Table 28.2 outlines the various forms of hepatic deposition of connective tissue.

Diagnosis

Given the importance of fibrosis in staging chronic liver disease and predicting outcome, it is paramount to assess hepatic fibrosis prior to and during therapy. There are no clinical signs and symptoms suggestive of mild or moderate liver fibrosis. The diagnosis of liver fibrosis rests on *noninvasive* and *invasive morphological methods*, including ultrasound with

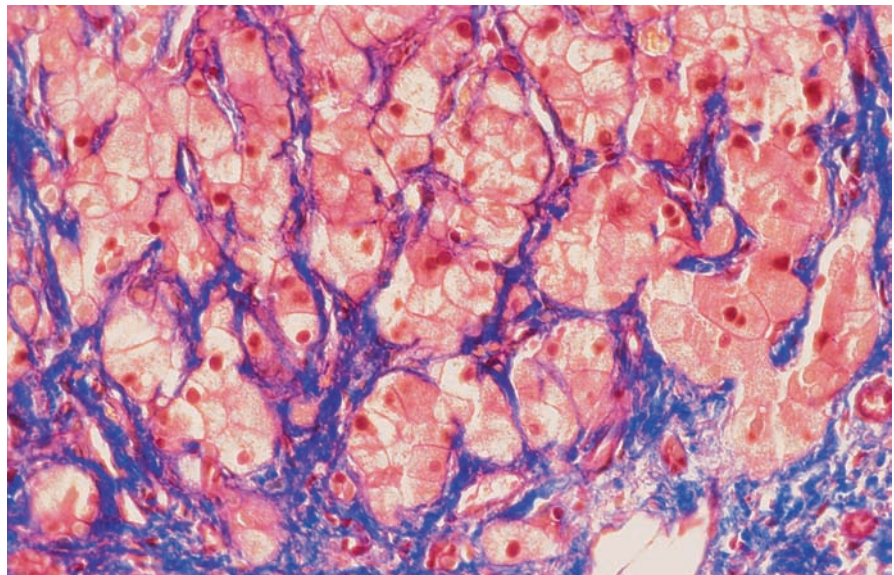
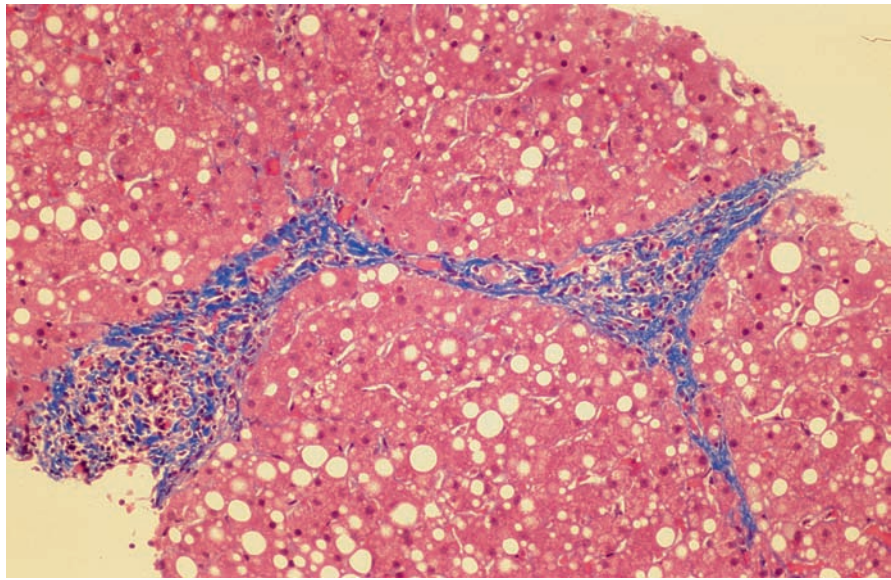


Fig. 28.8 Perisinusoidal fibrosis. Fine fibrous strands extend in a netlike pattern in the space of Disse and surround clusters of hepatocytes. Masson Trichrome

Fig. 28.9 Passive portal-portal fibrous septum. Masson Trichrome



transient elastography, CT, MRI, and histology. Even the most refined CT and MRI technologies are not able to reliably visualize early stages of fibrosis. Liver biopsy, although still the gold standard, is an invasive technique that has its limitations (see below) and is poorly accepted by patients. Therefore, in recent years noninvasive, direct and indirect serum parameters (biomarkers) of fibrosis have been intensively studied, in order to obviate the need for liver biopsy.

Liver Biopsy

Advantages of Liver Biopsy

Liver biopsy is considered the current *gold standard* in assessing the extent, distribution and progression of liver fibrosis. Stains for collagen fibers (e.g. van Gieson, modified Gomori's stain) provide baseline information that can be compared with future biopsies, thus allowing assessment of the progression or regression of liver fibrosis. Reticulin fibers are stained with silver techniques. They are not uniform chemically and are composed of collagen types I and III with associated glycoproteins.

Immunohistochemical analysis of biopsy specimen may yield insight into the pathogenesis of fibrosis and add important information. These techniques, however, are not routinely part of clinical-histopathological assessment of fibrosis. Applying mono- or polyclonal

antibodies, individual matrix proteins may be visualized. Tenascin is deposited early in fibrogenesis, and thus can be considered an indicator of immature, potentially reversible matrix tissue, while vitronectin is a marker of mature extracellular matrix. The synthesis of individual matrix molecules may be analyzed by in situ hybridization.

The activity of the fibrogenic process and its progression are difficult to assess in standard hematoxylin-eosin stained sections. Immunohistochemical assessment of HSC-activation may offer new perspectives in analyzing fibroblasts and the fibrogenic process in liver biopsies. α_1 -actin, neural cell adhesion molecule and nestin are regarded as markers of activated HSC. Actin-immunoreactive myofibroblasts are a morphological correlate of fibrogenic activity. Prion protein (PrP), a glycosylated surface protein has recently been described as new marker of HSC-activation [34]. It is normally expressed mainly in neurons and glia in the central nervous system, but also occurs in the stomach, spleen, kidney, leukocytes, macrophages and platelets. PrP-expression by HSC in chronic liver diseases, however, seems to correlate more with the grade of inflammation than with the stage of fibrosis.

Limitations of Liver Biopsy

Despite still being the gold standard in assessing hepatic fibrosis, liver biopsy has important limitations. Liver biopsy, whether performed by the percutaneous,

Table 28.2 Histologic patterns of hepatic fibrosis

Fibrosis pattern	Comments
Portal fibrosis	Fibrous enlargement of portal tracts
Periportal fibrosis	Fibrous portal extensions radiate into the neighboring parenchyma
Biliary fibrosis	Periportal fibrosis and portal-portal septa surround trefoil- and mosaic-like parenchymal nodules. Expression of advanced, but still reversible, chronic bile duct disease. In contrast to cirrhosis the basic lobular architecture and the vascular relationships are still preserved
Concentric periductal fibrosis	Biliary type fibrosis. Onionskin-like accumulation of connective tissue around the bile ducts. Occurs in various ductopenic syndromes, and as fibro-obliterative cholangitis in primary sclerosing cholangitis
Periductular fibrosis	Accompanies ductular reaction in chronic cholestatic liver diseases
Perivenular fibrosis	Fibrous thickening ($\geq 4 \mu\text{m}$) of at least two thirds of the circumference of the wall of the terminal hepatic venule (central vein)
Centrilobular fibrosis	Fibrous scarring around the terminal hepatic venule. In alcoholic liver disease it can appear as “sclerosing hyaline necrosis”
Pericellular or perisinusoidal fibrosis	Fibrous tissue strands surround single hepatocytes or groups of hepatocytes in a “chicken wire” like pattern. Seen in alcoholic and NASH-induced damage
Septal fibrosis	Increase in connective tissue forming variously broad fibrous septa
Fibrous septa	
Portal-portal septa	Link neighboring portal tracts. They form within the context of a marked ductular reaction in chronic cholestasis or subsequent to progressive “piecemeal necrosis” in chronic hepatitis
Central-central septa	Link neighboring central veins. They represent the scar stage of central-central bridging necrosis, i.e. of confluent parenchymal necroses in the microcirculatory periphery of a complex liver acinus
Portal-central septa	Link portal tracts with central veins. They form subsequent to portal-central bridging necrosis, i.e. of confluent parenchymal necroses in the microcirculatory periphery of a simple liver acinus
Active septa	Fibrous septa, ill delineated from adjacent parenchyma by infiltrating mononuclear cells. The inflammatory cells may further stimulate fibrogenesis
Passive septa	“Quiescent” fibrous strands without inflammatory cell infiltrates; sharply delineated from adjacent parenchyma. They represent the scarred healing stage, for example of extensive confluent parenchymal necrosis (postnecrotic collapse). Passive septa older than 6 months may contain elastic fibers
Primary collapse fibrosis	Postnecrotic collapse and fibrous scarring due to confluent parenchymal necrosis in a previously normal parenchyma. The topographic relationships between portal tracts and terminal hepatic venules remain largely preserved
Secondary collapse fibrosis	Postnecrotic collapse and fibrous scarring due to extensive necrosis in a previously injured parenchyma, e.g. in a cirrhotic liver. The normal topographic relationships between portal tracts and terminal hepatic venules generally are distorted
Pipestem-fibrosis	Originates from portal granulomas and occurs typically in schistosomiasis of the liver
Hepatoportal sclerosis	Corresponds to a phlebosclerosis of portal vein branches due to organized thrombi or portal hypertension. Usually associated with portal and periportal fibrosis

laparoscopic, or transjugular route, is an *invasive procedure* associated with a low, but significant rate of complications (Table 28.3; see Chapters 43–45). The liver is a large volume organ and needle biopsy samples only 1/50,000 of the liver and thus is subject to *sampling error*, particularly if fibrosis is non-homogeneously distributed, which is usually the case. Subcapsular tissue extending approximately 4–5 mm beneath the liver capsule contains an increased amount

of fibrous tissue. Thus, superficial biopsies may give the erroneous impression of liver fibrosis and should therefore be interpreted with caution. Diagnostic accuracy of biopsy increases with the number of biopsy samples. However, for obvious reasons it hardly can be expected from a patient to consent to more than two punctures during one examination or to repeated liver biopsies in short time intervals. *Single percutaneous biopsies may misclassify cirrhosis in 10–30% of cases*

Table 28.3 Advantages and limitations of liver biopsy in evaluating liver injury

Parameter	Value of liver biopsy
Diagnosis	Fibrosis stage, architectural distortion, necro-inflammatory activity, intracellular inclusions and deposits (e.g. fat, iron, pigments, etc.), differential diagnosis and comorbidity
Prognosis and guide to therapy	Established role
Posttransplant	Established role
Limitations	Sampling error (subcapsular biopsy, small size) <i>33% Sampling error for assessment of fibrosis stage</i>
Interobserver variation	10% for fibrosis stage, 40% for activity (METAVIR) (see Chapter 29)
Sample requirements	Diameter \geq 1.2 mm Length \geq (1.5)–2 cm
Adverse events	<i>Percutaneous liver biopsy:</i> Mortality 1–2/10,000 Morbidity 3/1,000 Localized pain 3/10
Contraindications	Inability to cooperate Severe comorbidity Coagulopathy (transjugular biopsy may be performed) Obesity (relative contraindication)

[48, 52]. Laparoscopic biopsy offers the advantage of direct macroscopic assessment of the liver surface, which can significantly help in the diagnosis of cirrhosis. In addition, several biopsies of different regions of the liver can be easily obtained, further increasing the diagnostic accuracy. This multi-puncture approach is to be recommended, since at laparoscopic biopsy a discordance of at least one fibrosis stage in one third of patients between right and left liver lobe may be present [56]. The approach to laparoscopic versus percutaneous liver biopsy differs between hepatologists in the United States and Europe, with diagnostic laparoscopy being performed relatively more frequently in Europe, especially in Germany. The authors believe that laparoscopic liver biopsy is superior to percutaneous biopsy in the diagnosis of liver fibrosis and cirrhosis.

Another factor affecting the diagnosis of liver fibrosis is the type and size of the biopsy needle. Compared to the Menghini needle, cutting-type instruments may increase the likelihood of obtaining more representative liver tissue, though at the expense of an increased rate of complications.

A further limitation of liver biopsy is the non-negligible *intra-* and *interobserver variation* among pathologists, and the dependency of the histopathological interpretation on the experience of the pathologist. Using the standardized scoring systems (e.g. METAVIR, Ishak; see Chapter 29), there is a concordance rate of $\geq 80\%$ between pathologists about

fibrosis if biopsy size reaches 25 mm (which is not the rule in percutaneous biopsy). The concordance rate is directly related to the length of the biopsy specimen and falls to 65% in biopsies 15 mm in length [4].

Despite all its limitations, liver biopsy is still the only method that allows for the staging of fibrosis and grading of necroinflammatory activity, for instance in chronic viral hepatitis, in alcoholic and nonalcoholic fatty liver disease, and therefore remains indispensable in the management of these patients. Hopefully, it will become possible to correlate histopathological findings with serological markers, thus providing a reflection of the dynamic state of fibrogenesis.

Cross-Sectional Imaging

Current radiological imaging modalities, such as computed tomography and magnetic resonance imaging lack sensitivity for fibrosis staging. They are not able to detect fibrosis at an early stage.

Ultrasonography. The accurate interpretation of ultrasonographic findings is highly dependent on the expertise of the examiner (which ideally should be a well trained gastroenterologist/hepatologist or radiologist rather than a technician). But even in experienced hands, early stages of fibrosis cannot be detected by ultrasound. Based on surface modularity (not on the direct demonstration of fibrosis!) and the presence

of splenomegaly, the diagnostic accuracy of ultrasound for the diagnosis of cirrhosis in a highly specialized academic center has been reported to reach 82–88%, and for bridging fibrosis 84% [2]. It can be assumed that the accuracy in daily clinical practice is much lower.

Transient elastography is a novel noninvasive technique that uses both ultrasound (5 MHz) and low-frequency (50 Hz) elastic waves, whose propagation velocity is directly related to tissue elasticity. It attempts to quantify fibrosis by measuring liver stiffness. The depth of measurement from the skin surface is 25–65 mm and ten validated measurements are acquired in each patient. Current devices measure liver stiffness of a tissue cylinder that is approximately 1 cm in diameter and 5 cm long. The technique is reported to have good reproducibility with low inter- and intraobserver variability, although steatosis and necroinflammatory activity may impact the correlation between liver stiffness and fibrosis, especially in its early stages.

Up to now mainly patients with chronic hepatitis C have been evaluated with transient elastography. In 106 patients with chronic hepatitis C, the areas under the receiver operating curves (AUROC) were determined for different fibrosis stages in liver biopsy according to the Metavir classification system (see Chapter 29). The AUROC were 0.88 in patients with significant fibrosis ($\geq F2$) and 0.99 in those with cirrhosis [59]. Similar results were obtained in 327 patients with chronic hepatitis C. The AUROC were 0.79, 0.91 and 0.97 for patients with significant fibrosis $F \geq 2$, $F \geq 3$ and F4 (cirrhosis), respectively. The AUROC values were higher for larger biopsies [70]. A study of 711 patients, 26 patients with NASH, demonstrated an AUROC of 0.8 for significant fibrosis and 0.96 for cirrhosis [19]. Transient elastography compared favorably in 183 patients with chronic hepatitis C in comparison with and combined with biochemical markers (Fibrotest and the aspartate transaminase to platelets ratio index [APRI]) [11]. In a review of currently available data on the efficacy of transient elastography the AUROC for F2 were 0.79–0.83, for F3 0.90–0.91 and for F4 0.91–0.97. The technique enables the diagnosis of cirrhosis regardless of its etiology, with positive and negative predictive values of 70–95% and 77–95%, respectively [44]. In a recent meta-analysis transient elastography has been reported to have good

diagnostic accuracy for the diagnosis of advanced fibrosis, but a high variation of results is found in earlier stages of fibrosis [23].

Measuring liver stiffness by transient elastography might also serve as a non-invasive tool for identifying patients with portal hypertension, since a correlation between liver stiffness as determined by transient elastography and the hepatic venous pressure gradient has been reported [66].

Serum Biomarkers of Fibrogenesis

Liver biopsy is an invasive technique that is flawed with some limitations in assessing liver fibrosis. A large number of serum and urinary markers of fibrosis have been evaluated in the past years, in order to find simple serologic parameters that reflect the dynamics of fibrogenesis, allowing to guide treatment decisions, and enabling to monitor the effect of antifibrotic therapies, especially in chronic viral hepatitis. The

Table 28.4 Biomarkers evaluated in relation to fibrogenesis

Indirect markers (do not reflect extracellular matrix metabolism)
Aminotransferases and γ GT
Prothrombin time
Platelets
Apolipoproteins
Cytokines involved in inflammation and fibrogenesis
TGF- β
TGF- α
IL-10
IL-2
IL-2 receptor
IL-12
Vascular endothelial growth factor
Leptin
Direct markers of ECM-remodeling and other markers
Procollagen peptides I and III
Type IV, VI, XIV collagen
Laminin
Tenascin
Fibronectin
Matrix metalloproteinase
Tissue inhibitor of metalloproteinases
YKL-40 (Chondrex; human cartilage protein)
Hyaluronic acid
Vitronectin

Source: Adapted from [50]

Table 28.5 Selection of clinical fibrosis scores and indices based on indirect markers of liver fibrosis

Score/index	Calculation	Interpretation
APRI index [67] ^a	AST level (/ULN) × 100 divided by platelets (10 ⁹ /L)	Index ≥ 1.5: marked fibrosis (Ishak ≥ 3) Index ≤ 0.5: exclusion of marked fibrosis (Ishak < 3)
Fibrotest [11]	4.467 × log [α ₂ macroglobulin (g/L)] – 1.357 × log [haptoglobin (g/L)] + 1.017 × log [γGT (IU/L)] + 0.281 × [age (years)] + 1.737 × log [bilirubin (μmol/L)] – 1.184 [apolipoprotein A1 (g/L)] + 0.301 × [gender (0 for female; 1 for male) – 5.540]	Score = 0.60–1.00: marked fibrosis (METAVIR F2, F3, F4) Score = 0–0.10: exclusion of marked fibrosis
Forns index [18]	7.811 – 3.131 × log (platelet count [10 ⁹ /L]) + 0.781 × log (γGT [IU/L]) + 3.467 × log (age) – 0.014 × (cholesterol [mg/dL])	Index ≥ 6.9: marked fibrosis (Scheuer stage 3, 4; METAVIR F3, F4) Index ≤ 4.21: exclusion of marked fibrosis
Pohl score [51]	AST/ALT (U/L) and platelet number/μL	AST/ALT > 1 and platelets < 150,000/μL: marked fibrosis (METAVIR F3, F4) AST/ALT < 1 and platelets > 150,000/μL: exclusion of marked fibrosis
Fibro index [35]	1.738 – 0.064 (platelets [× 10 ⁴ /mm ³]) + 0.005 (AST [IU/L]) + 0.463 (gamma globulin [g/dL])	Index ≤ 1.25: no or mild fibrosis (F0, F1) Index ≥ 2.25: marked fibrosis (F2, F3)

^aAPRI aspartate aminotransferase-to-platelet ratio index

The major strength of the APRI is the exclusion of significant HCV-related fibrosis [64]

ULN upper limit of normal

increased pathophysiologic understanding of fibrosis and the characterization of numerous molecular components of fibrogenesis has defined the ECM-components and growth factors in serum that are associated with liver fibrosis [55, 62]. [Tables 28.4 and 28.5](#) summarize selected biomarkers and scores evaluated in relation to fibrogenesis. [Table 28.6](#) summarizes direct markers of fibrosis, i.e. of substances that are involved in ECM remodeling. Searching for reliable serum biomarkers of liver fibrosis has led to the examination of numerous potential factors, but *no single substance can claim to be a marker of fibrogenesis*. Clinical validation of candidate markers causes serious problems. The proteins and peptides measured are heterogeneous and their occurrence is not restricted to the liver, i.e. they are neither specific for fibrosis nor for the liver. Since fibrosis usually progresses over many years, examination of serial serum samples of a large number of patients, correlating them with serial liver biopsies would ideally be necessary, in order to validate the clinical significance of biomarkers for liver fibrosis. For obvious reasons this goal can hardly be achieved.

Therefore, currently panels of parameters are determined and mathematical “fibrosis-indices” are generated in the hope to describe reliably the fibrogenic process. Since nearly all of these indices were

developed in patients with chronic hepatitis B and C, in alcoholic liver disease and in nonalcoholic fatty liver disease they will be discussed in the respective clinical chapters (Chapters 63, 88 and 89). Despite all efforts, their clinical impact still is limited.

Therapeutic Approaches

Untreated, progressive liver fibrosis leads to cirrhosis with its sequelae and ultimately to a reduced survival of the patient. Thus, the development of effective antifibrotic therapies in chronic liver diseases is of utmost clinical importance. There are convincing data from animal experiments and clinical observations in humans that liver fibrosis may potentially resolve. Iron depletion by venesection in genetic hemochromatosis, successful abstinence from alcohol in alcoholic liver disease, and biliary drainage in bile duct stenosis may lead to regression of hepatic fibrosis [16, 26]. Successful antiviral therapy of chronic hepatitis B and C leads to histologic improvements of fibrosis as does antiinflammatory and immunosuppressive therapy of autoimmune hepatitis [13, 54, 58, 63]. In these examples it is not the fibrotic process itself, but rather the underlying disease that is

Table 28.6 Direct serum biomarkers of fibrosis^a

Marker	Comment
Procollagen type III aminoterminal peptide	Procollagen type III aminoterminal peptide (PIIINP) is the most widely studied serum biomarker of fibrogenesis. Extracellular PIIINP is cleaved by a specific N-propeptidase from collagen type III molecule. Only a collagen type III molecule that has been processed in this way enables further growth of collagen fibrils. The release of PIIINP is therefore thought to correlate with the synthesis and deposition of fibrillary collagen. However, the significance of PIIINP in serum is curtailed by several factors. At least four molecular species of PIIINP are found in serum. Increased serum levels may also be caused by degradation of collagen fibrils. Serum levels of PIIINP do not only depend on its release from the fibrotic liver, but are also determined by its clearance from the sinusoidal blood by receptor-mediated endocytosis. Serum levels of PIIINP are significantly influenced by sinusoidal endothelial cell function. Thus, the sensitivity of PIIINP serum concentration in relation to hepatic fibrogenesis seems to be rather low.
Type IV collagen	Type IV procollagen is the major structural protein of hepatic basement membranes. Its C- and N-terminal propeptides, as well as its central triple helix can be measured in serum. Together with laminin, a noncollagenous basement membrane protein, increased serum levels of type IV procollagen apparently reflect increased turnover of basement membranes. In pilot studies serum levels correlated with the stage of fibrosis and the degree of portal hypertension.
Type VI collagen	Increased serum levels of proteolytically released fragments of type VI collagen potentially may help in differentiating between mild and severe hepatic fibrosis.
Type XIV collagen	Serum levels of type XIV collagen are increased already in the early stages of chronic liver diseases. However they do not discriminate between the various stages of fibrosis.
Laminin	Laminin is synthesized by hepatic stellate cells and deposited in the basement membranes in the liver. Serum levels of laminin are elevated particularly in patients with alcoholic liver disease and correlate with the severity of fibrosis and inflammatory activity [36]. For unknown reasons, in chronic hepatitis C serum levels of laminin are not always associated with the stage of fibrosis.
Tenascin	Tenascin is expressed exclusively by proliferating connective tissues and in the perisinusoidal space.
Hyaluronic acid	Hyaluronic acid is ubiquitous and is taken up by sinusoidal endothelial cells via receptor mediated endocytosis. Thus it can be regarded as a marker of liver perfusion and endothelial cell function. In this context serum levels of hyaluronic acid correlate with fibrosis and necroinflammatory activity in chronic liver disease. However, they are not direct markers of fibrogenesis.
Matrix metalloproteinases	Theoretically, matrix metalloproteinases would be ideal candidates for evaluating matrix degradation. However, their utility in clinical practice is not established, since their serum concentration depends on many regulatory factors still incompletely understood.
Tissue inhibitors of metalloproteinases	In chronic hepatitis C serum levels of tissue inhibitor of metalloproteinase-1 and 2 seem to be correlated with the stage of fibrosis and the grade of inflammation. These findings, however, lack specificity.
Transforming growth factor-β1	TGF-β1 is a central regulator of fibrogenesis. In patients with liver fibrosis elevated serum levels of TGF-β1 may be present. However, TGF-β1 is involved in many biological processes, and the changes in its serum concentration are neither specific for fibrogenesis nor do they correlate with the stage of fibrosis.
Serum protein profiling	Serum proteomic and glycomic fingerprinting is a promising diagnostic approach, in order to identify features predictive of fibrosis. This high through DNA sequencer based technique can measure serum protein expression, protein-protein or protein-glycan interactions, and enzymatic activity. Pilot studies with proteomics and protein glycomics (measuring N-glycan profiles) yield encouraging results demonstrating a correlation with METAVIR stage and other serum biomarkers of fibrosis [10, 53]. However, the technology is still evolving and not yet ready to be applied in clinical practice.

^aDespite intensive research their clinical relevance still is small

Table 28.7 Substances that have been used in patients with chronic liver disease or in an experimental setting aiming at reducing fibrogenesis

Substance	Comment
Corticosteroids	Corticosteroids inhibit collagen synthesis. However, they also suppress the expression of MMPs and TIMPs by as yet unknown mechanisms. The administration of corticosteroids solely with the intent to treat fibrosis is not warranted. In autoimmune hepatitis corticosteroids inhibit the inflammatory reaction, thereby reducing fibrogenesis [63]. They have no net effect on matrix synthesis by HSC. Their antifibrotic effects in chronic inflammatory liver diseases stem from their antiinflammatory actions.
Colchicine	Colchicine has many in vitro antifibrotic effects. It inhibits collagen synthesis and the polymerization of microtubuli, thereby inhibiting the efflux of collagen fibrils into the extracellular space. Colchicine can also stimulate the activities of MMPs. In addition, by inhibiting lipid peroxidation and reducing inflammatory reactions it exerts indirect antifibrotic effects. Despite these data, the clinical utility of colchicine as an antifibrotic agent in chronic liver diseases is not documented.
Ursodeoxycholic acid	Ursodeoxycholic acid (UDCA) is ascribed with many hepatoprotective effects, among others the stabilization of membranes. UDCA does not have a direct antifibrotic effect on the liver. The reported slowing of progression of liver fibrosis in patients with primary biliary cirrhosis is probably due, if anything, to a reduction in biliary inflammation.
Pentoxifylline	This derivative of methylxanthine inhibits in vitro the PDGF-mediated stimulation of fibroblast proliferation. It downregulates type I procollagen mRNA in the fibrotic liver, but has the opposite effect on the profibrogenic TIMP-1 mRNA. Therefore its overall antifibrotic effect is small. In addition pentoxifylline has antioxidative effects, thereby impacting fibrogenesis negatively.
Simvastatin	This lipid lowering inhibitor of HMG-CoA-reductase inhibits in vitro the cytokine- and serum-induced proliferation of HSC.
Sulfasalazine	Sulfasalazine is an inhibitor of κ B-kinase suppressor, and induces apoptosis of activated rat and human HSC [45]. In chronic human liver diseases its effects are not documented.
Prostaglandins Proline analogs	Prostaglandin E2 in animal experiments inhibits the expression of collagens, fibronectin and TGF- β . Proline analogs can be integrated into the nascent collagen molecule, thus impairing further collagen synthesis.
Silymarin	Silymarin, with its active component silibinin, has antifibrotic effects. Its clinical use, however, is not established.
Endothelin A receptor inhibitors	Inhibitors of endothelin A receptors can be administered orally and inhibit the deposition of collagen in the liver.
Interferons	Interferons have antifibrotic effects and can inhibit HSC-activation. Interestingly, in chronic viral hepatitis, interferon seems to exert its antifibrotic actions independent from its antiviral effects [12].
Prolyl hydroxylase inhibitors	Prolyl hydroxylase is essential for the formation of stable collagen triple helices. Therefore this enzyme represents an important target of antifibrotic therapy. HOE 77 and safronil are competitive inhibitors of prolyl hydroxylase. Both substances can inhibit HSC-activation in vitro.
Anti-transforming growth factor-β	TGF- β is a key regulator of fibrogenesis. In animal studies, antibodies directed against TGF- β or TGF-soluble receptor inhibited hepatic fibrosis [69].
Vitamin E	Antioxidative substances, including Vitamin E, so far have not shown clinically convincing antifibrotic effects.
Cannabinoids	Cannabinoid receptors CB2 are highly upregulated in the cirrhotic liver, predominantly in hepatic myofibroblasts and activated HSC. Their activation triggers antifibrogenic effects, namely, growth inhibition and apoptosis [32]. Thus selective agonists of CB2 receptors have the potential to become antifibrotic drugs.
Adiponectin	This peptide is produced by adipocytes and reduces proliferation and migration of activated HSC as well as TGF- β 1-induced collagen synthesis. These antifibrogenic characteristics have not been confirmed yet in man by pharmacological agonists of adiponectin receptors.
Leptin	This adipocyte-derived hormone is profibrogenic and is produced by activated hepatic myofibroblasts during injury-induced fibrogenesis. Liver fibrogenesis is reduced in leptin deficient mice. Thus, antagonists of leptin receptors are potential candidates as antifibrotic agents.
Thiazolidinediones	Thiazolidinediones inhibit the main fibrogenic properties of activated HSC via PPAR γ -dependent and independent mechanisms. They decrease fibrosis progression in several experimental models in vitro and in vivo, suggesting that these compounds may represent a promising approach for the treatment of liver fibrosis [24].
Gene therapy	Genetic therapeutic approaches are still in their infancy. An extrahepatic human neutrophil collagenase complementary DNA (<i>matrix metalloprotease-8</i>) cloned in an adenovirus vector ameliorated fibrosis in experimental rat liver cirrhosis [65]. Treatment of mice with an adenovirus encoding <i>adiponectin</i> reduced liver fibrogenesis [33]. Clinically relevant results in humans are currently not available.

treated, with fibrolysis occurring as a desired secondary event.

Characterization of molecular mechanisms of liver fibrogenesis and resolution has paved the way for novel approaches to therapeutic interventions based on direct interference with major pro- and antifibrogenic pathways. The goals of antifibrotic therapy may be achieved by

- Reducing fibrogenesis and/or
- Stimulating matrix degradation

In addition to eliminating the causative injury, fibrogenesis can be reduced by inhibiting or downregulating HSC activation or by antagonizing profibrogenic factors. It is well known that activated HSC can become quiescent cells again, although the exact mechanisms involved in this process are poorly understood. Activated HSC synthesize IL-10 that has antiinflammatory and antifibrotic activity. IL-10 may limit autocrine signaling of the formation of new extracellular matrix via negative feedback [43]. Hepatocyte growth factor has also a deactivating effect on HSC.

The selective *depletion of HSC* and the *induction of HSC apoptosis* are highly interesting potential therapeutic approaches (Fig. 28.4). The contact between HSC and ECM is a fundamental precondition for fibrogenesis. Loosening this contact acts as a potent proapoptotic signal. Thus matrix degradation may induce HSC apoptosis. Apoptosis of HSC is associated with diminished expression of TIMP-1. Blockade of macrophage infiltration inhibits activation of HSC and leads to suppression of liver fibrogenesis [29].

Enhanced matrix degradation can be achieved by increasing the activity of MMPs or by diminishing that of TIMPs.

In the past years a large number of candidate drugs have been validated in animal and cell culture studies, and clinical trials are currently underway. However, proof of effectiveness is still lacking in humans. One major difficulty is specific drug targeting to liver fibrogenic cells. To circumvent these problems, attempts are being made to link antifibrotic drugs to carriers that selectively bind to receptors specifically expressed and upregulated in liver fibrogenic cells [39]. Table 28.7 summarizes substances that have been used in patients with chronic liver disease or in experimental situations aiming at reducing fibrogenesis.

References

1. Arthur MJP, Mann DA, Iredale JP (1998) Tissue inhibitors of metalloproteinases, hepatic stellate cells and liver fibrosis. *J Gastroenterol Hepatol* 13(Suppl) S33–8
2. Aube C, Oberti E, Korali N, et al (1999) Ultrasonographic diagnosis of hepatic fibrosis or cirrhosis. *J Hepatol* 30: 472–8
3. Bedossa P, Peltier E, Terris B, et al (1995) Transforming growth factor-beta 1 (TGF- β 1) and TGF- β 1 receptors in normal, cirrhotic, and neoplastic human livers. *Hepatology* 21: 760–6
4. Bedossa P, Dargere D, Paradis V (2003) Sampling variability of liver fibrosis in chronic hepatitis C. *Hepatology* 38: 1449–57
5. Benyon RC, Iredale JP, Goddard S, et al (1996) Expression of tissue inhibitor of metalloproteinases-1 and -2 is increased in fibrotic human liver. *Gastroenterology* 110: 821–31
6. Benyon RC, Iredale JP (2000) Is liver fibrosis reversible? *Gut* 46: 443–6
7. Blobel GC, Schieman WP, Lodish HF (2000) Role of transforming growth factor β in human disease. *N Engl J Med* 342: 1350–8
8. Border WA, Noble NA (1994) Transforming growth factor (beta) in tissue fibrosis. *N Engl J Med* 331: 1286–92
9. Borkham-Kamphorst E, van Roeyen CR, Ostendorf T, et al (2007) Profibrogenic potential of PDGF-D in liver fibrosis. *J Hepatol* 46: 1064–74
10. Callewaert N, van Vlieberghe H, van Hecke A, et al (2004) Noninvasive diagnosis of liver cirrhosis using DNA sequencer-based total serum protein glycomics. *Nat Med* 10: 429–34
11. Castera L, Vergniol J, Foucher J, et al (2005) Prospective comparison of transient elastography, Fibrotest, APRI, and liver biopsy for the assessment of fibrosis in chronic hepatitis C. *Gastroenterology* 128: 343–50
12. Castilla A, Prieto J, Fausto N (1991) Transforming growth factors β 1 and α in chronic liver disease. Effects of interferon alpha therapy. *N Engl J Med* 324: 933–40
13. Dienstag JL, Goldin RD, Heathcote EJ, et al (2003) Histological outcome during long-term lamivudine therapy. *Gastroenterology* 124: 105–17
14. Dufour JF, DeLellis R, Kaplan MM (1997) Reversibility of hepatic fibrosis in autoimmune hepatitis. *Ann Intern Med* 127: 981–5
15. El-Karef A, Kaito M, Tanaka H, et al (2007) Expression of large tenascin-C splice variants by hepatic stellate cells/myofibroblasts in chronic hepatitis C. *J Hepatol* 46: 664–73
16. Falize L, Guillygomarc'h A, Perrin M, et al (2006) Reversibility of hepatic fibrosis in treated genetic hemochromatosis: a study of 36 cases. *Hepatology* 44: 472–7
17. Forbes SJ, Russo FP, Rey V, et al (2004) A significant proportion of myofibroblasts are of bone marrow origin in human liver fibrosis. *Gastroenterology* 126: 955–63
18. Forns X, Ampurdanes S, Llovet JM, et al (2002) Identification of chronic hepatitis C without hepatic fibrosis by a simple predictive model. *Hepatology* 36: 986–92
19. Foucher J, Chanteloup E, Verginot J, et al (2006) Diagnosis of cirrhosis by transient elastography (FibroScan): a prospective study. *Gut* 55: 403–8
20. Friedman SL (1993) The cellular basis of hepatic fibrosis. Mechanism and treatment strategies. *N Engl J Med* 328: 1828–35

21. Friedman SL (2000) Molecular regulation of hepatic fibrosis, an integrated cellular response to tissue injury. *J Biol Chem* 275: 2247–50
22. Friedman SL, Rockey DC, Bissell DM (2007) Hepatic fibrosis 2006: report of the third AASLD single topic conference. *Hepatology* 45: 242–9
23. Friedrich-Rust M, Ong MF, Martens S, et al (2008) Performance of transient elastography for the staging of liver fibrosis: a meta-analysis. *Gastroenterology* 134: 960–74
24. Galli A, Crabb DW, Ceni E, et al (2002) Antidiabetic thiazolidinediones inhibit collagen synthesis and hepatic stellate cell activation in vivo and in vitro. *Gastroenterology* 122: 1924–40
25. Grappone C, Pinzani M, Parola M, et al (1999) Expression of platelet-derived growth factor in newly formed cholangiocytes during experimental biliary fibrosis in rats. *J Hepatol* 31: 100–9
26. Hammel P, Couvelard A, O'Toole D, et al (2001) Regression of liver fibrosis after biliary drainage in patients with chronic pancreatitis and stenosis of the common bile duct. *N Engl J Med* 344: 418–23
27. Hayasaka A, Saisho H (1998) Serum markers as tools to monitor liver fibrosis. *Digestion* 59: 381–4
28. Henderson NC, Iredale JP (2007) Liver fibrosis: cellular mechanisms of progression and resolution. *Clin Sci* 112: 265–80
29. Imamura M, Ogawa T, Sasaguri Y, et al (2005) Suppression of macrophage infiltration inhibits activation of hepatic stellate cells and liver fibrogenesis in rats. *Gastroenterology* 128: 138–46
30. Iredale JP, Benyon RC, Pickering J, et al (1998) Mechanisms of spontaneous resolution of rat liver fibrosis. Hepatic stellate cell apoptosis and reduced hepatic expression of metalloproteinase inhibitors. *J Clin Invest* 102: 538–49
31. Issa R, Williams E, Trim N, et al (2001) Apoptosis of hepatic stellate cells: involvement in resolution of biliary fibrosis and regulation by soluble growth factors. *Gut* 48: 548–57
32. Julien B, Grenard P, Teixeira-Clerc F, et al (2005) Antifibrogenic role of the cannabinoid receptor CB2 in the liver. *Gastroenterology* 128: 742–55
33. Kamada Y, Tamura S, Kiso S, et al (2003) Enhanced carbon tetrachloride-induced liver fibrosis in mice lacking adiponectin. *Gastroenterology* 125: 1796–807
34. Kitada T, Seki S, Ikeda K, et al (2000) Clinicopathological characterization of p18: a novel marker of activated human hepatic stellate cells. *J Hepatol* 33: 751–7
35. Koda M, Matunaga Y, Kawakami M, et al (2007) FibroIndex, a practical index for predicting significant fibrosis in patients with chronic hepatitis C. *Hepatology* 45: 297–306
36. Korner T, Kropf J, Gressner AM (1996) Serum laminin and hyaluronan in liver cirrhosis: markers of progression with high prognostic value. *J Hepatol* 25: 684–8
37. Leclercq IA, Farrell GC, Schriemer R, et al (2002) Leptin is essential for the hepatic fibrogenic response to chronic liver injury. *J Hepatol* 37: 206–13
38. Li D, Friedman SL (1999) Liver fibrogenesis and the role of hepatic stellate cells: new insights and prospects for therapy. *J Gastroenterol Hepatol* 14: 618–33
39. Lotersztajn S, Julien B, Teixeira-Clerc F, et al (2005) Hepatic fibrosis: molecular mechanisms and drug targets. *Annu Rev Pharmacol Toxicol* 45: 605–28
40. Marra F, Gentilini A, Pinzani M, et al (1997) Phosphatidylinositol 3-kinase is required for platelet-derived growth factor's actions on hepatic stellate cells. *Gastroenterology* 112: 1297–306
41. Marra F, Romanelli RG, Giannini C, et al (1999) Monocyte chemoattractant protein-1 as a chemoattractant for human hepatic stellate cells. *Hepatology* 29: 140–8
42. Nagy P, Schaff Z, Lapis K (1991) Immunohistochemical detection of transforming growth factor- β_1 in fibrotic liver diseases. *Hepatology* 14: 269–73
43. Nelson DR, Lauwers GY, Lau JY, et al (2000) Interleukin 10 treatment reduces fibrosis in patients with chronic hepatitis C: a pilot trial of interferon nonresponders. *Gastroenterology* 118: 655–60
44. Nguyen-Khac E, Capron D (2006) Noninvasive diagnosis of liver fibrosis by ultrasonic transient elastography (Fibroscan). *Eur J Gastroenterol Hepatol* 18: 1321–5
45. Oakley F, Meso M, Iredale JP, et al (2005) Inhibition of inhibitor of κ B kinases stimulates hepatic stellate cell apoptosis and accelerated recovery from rat liver fibrosis. *Gastroenterology* 128: 108–20
46. Okazaki I, Watanabe T, Hozawa S, et al (2000) Molecular mechanisms of the reversibility of hepatic fibrosis: with special reference to the role of matrix metalloproteinases. *J Gastroenterol Hepatol* 15(Suppl) D26–32
47. Olaso E, Friedman SL (1998) Molecular regulation of hepatic fibrogenesis. *J Hepatol* 29: 836–47
48. Pagliaro L, Rinaldi F, Craxi A, et al (1983) Percutaneous blind biopsy versus laparoscopy with guided biopsy in diagnosis of cirrhosis: a prospective, randomized trial. *Dig Dis Sci* 28: 39–43
49. Parola M, Robino G (2001) Oxidative stress-related molecules and liver fibrosis. *J Hepatol* 35: 297–306
50. Patel K, Rockey DC (2006) Clinical utility of biomarkers of liver fibrosis. *Gastroenterol Hepatol* 2: 48–57
51. Pohl A, Behling C, Oliver D, et al (2001) Serum aminotransferase levels and platelet counts as predictors of degree of fibrosis in chronic hepatitis C virus infection. *Am J Gastroenterol* 96: 3142–6
52. Poniachik J, Bernstein DE, Reddy KR, et al (1996) The role of laparoscopy in the diagnosis of cirrhosis. *Gastrointest Endosc* 43: 568–71
53. Poon TC, Hui AY, Chan HL, et al (2005) Prediction of liver fibrosis in chronic hepatitis B infection by serum proteomic fingerprinting: a pilot study. *Clin Chem* 51: 328–35
54. Poynard T, McHutchison J, Manns M, et al (2002) Impact of pegylated interferon α -2b and ribavirin on liver fibrosis in patients with chronic hepatitis C. *Gastroenterology* 122: 1303–13
55. Ramadori G, Zöhrens G, Manns M, et al (1991) Serum hyaluronate and type III procollagen aminoterminal propeptide concentration in chronic liver disease. Relationship to cirrhosis and disease activity. *Eur J Clin Invest* 21: 323–30
56. Regev A, Berho M, Jeffers LJ, et al (2002) Sampling error and intraobserver variability in liver biopsy in patients with chronic HCV infection. *Am J Gastroenterol* 97: 2614–8
57. Rockey DC (2000) The cell and molecular biology of hepatic fibrogenesis: clinical and therapeutic implications. *Clin Liver Dis* 4: 319–55
58. Sakaida I, Nagatomi A, Hironaka K, et al (1999) Quantitative analysis of liver fibrosis and stellate cell changes in patients with chronic hepatitis C after interferon therapy. *Am J Gastroenterol* 94: 489–96

59. Sandrin L, Fourquet B, Hasquenoph JM, et al (2003) Transient elastography: a new noninvasive method for the assessment of liver fibrosis. *Ultrasound Med Biol* 29: 1705–13
60. Schaffner F, Popper H (1963) Capillarization of hepatic sinusoids in man. *Gastroenterology* 44: 239–42
61. Schulze-Krebs A, Preimel D, Popov Y, et al (2005) Hepatitis C virus-replicating hepatocytes induce fibrogenic activation of hepatic stellate cells. *Gastroenterology* 129: 246–58
62. Schuppan D, Jax C, Hahn EG (1999) Serummarker der Leberfibrose. *Dtsch med Wschr* 124: 1213–8
63. Schwarcz R, Glaumann H, Weiland O (1993) Survival and histological resolution of fibrosis in patients with autoimmune chronic active hepatitis. *J Hepatol* 18: 15–23
64. Shaheen AA, Myers RP (2007) Diagnostic accuracy of the aspartate aminotransferase-to-platelet ratio index for the prediction of hepatitis C-related fibrosis: a systematic review. *Hepatology* 46: 912–21
65. Siller-Lopez F, Sandoval A, Salgado S, et al (2004) Treatment with human metalloproteinase-8 gene delivery ameliorates experimental rat liver cirrhosis. *Gastroenterology* 126: 1122–33
66. Vizzutti F, Arena U, Romanelli RG, et al (2007) Liver stiffness measurement predicts severe portal hypertension in patients with HCV-related cirrhosis. *Hepatology* 45: 1290–7
67. Wai CT, Greenson JK, Fontana RJ, et al (2003) A simple noninvasive index can predict both significant fibrosis and cirrhosis in patients with chronic hepatitis C. *Hepatology* 38: 518–26
68. Yang C, Zeisberg M, Mosterman B, et al (2003) Liver fibrosis: insights into migration of hepatic stellate cells in response to extracellular matrix and growth factors. *Gastroenterology* 124: 147–59
69. Yata Y, Gotwals P, Kotliansky V, et al (2002) Dose-dependent inhibition of hepatic fibrosis in mice by a TGF- β soluble receptor: implications for antifibrotic therapy. *Hepatology* 35: 1022–30
70. Ziol M, Handra-Luca A, Kettaneh A, et al (2005) Noninvasive assessment of liver fibrosis by measurement of stiffness in patients with chronic hepatitis C. *Hepatology* 41: 48–54

Chapter Outline

Abbreviations	271
Chronic Hepatitis	272
Grading and Staging of Chronic Hepatitis	272
Autoimmune Hepatitis	276
Drug-Induced Liver Damage	277
Fatty Liver Disease/Steatohepatitis	277
Biliary Diseases	280
Hepatic Iron-Overload	282
Semiquantitative Scoring System for Evaluation of Hepatic Fibrosis	283
Rejection in Liver Transplant Pathology	284
Future Developments	285
References	286

Abbreviations

AFLD	Alcoholic fatty liver disease
AIH	Autoimmune hepatitis
AMA	Anti-mitochondrial antibodies
ANA	Anti-nuclear antibodies
Anti-LC1	Antibodies to liver cytosol type 1
Anti-LKM1	Antibodies to liver kidney microsome type 1
Anti-SLA/LP	Antibodies to soluble liver antigen/liver pancreas
Anti-SMA	Antibodies to smooth muscle antigen
AP	Serum alkaline phosphatase
ASH	Alcoholic steatohepatitis
ALT	Serum alanine aminotransferase
AST	Serum aspartate aminotransferase
CCC	Cholangiocellular carcinoma (cholangiocarcinoma)
CK	Cytokeratin
CMV	Cytomegalovirus
EBV	Epstein-Barr Virus
HBV	Hepatitis B Virus
HCC	Hepatocellular carcinoma
HCV	Hepatitis C Virus
HDV	Hepatitis D Virus
H & E	Hematoxylin and eosin
HII	Hepatic iron index
IgG	Immunoglobulin G
LIC	Liver iron content
MELD	Model for End-stage Liver Disease
mHAI	Modified histological activity index
MPF	Medium power field
NAFLD	Non-alcoholic fatty liver disease
NAS	NAFLD activity score
NASH	Non-alcoholic steatohepatitis
pANCA	Perinuclear anti-neutrophil cytoplasmic antibodies

PAS	Periodic Acid-Schiff
PBC	Primary biliary cirrhosis
PSC	Primary sclerosing cholangitis
RAI	Rejection activity index
SSS	Semiquantitative Scoring System

To achieve optimal histological interpretation of a liver biopsy specimen, several technical prerequisites from the clinical and the pathological side are required. Since there is a direct correlation between the size of the biopsy cylinder and the portal tracts included, the length of the biopsy should be at least 15 mm (diameter ≥ 1.2 mm), which generally guarantees at least ten interpretable portal tracts [16]. Fixation should be achieved immediately using adequate fixatives (e.g. 4% buffered formaldehyde solution). Additionally, all relevant clinical information and questions as well as serological parameters should be communicated, preferentially using standardized forms. It is recommended that liver biopsy assessment is completed on the basis of at least eight consecutive slices stained by appropriate methods (e.g. H & E, connective tissue stains [such as modified Gomori's stain], Prussian blue iron stain, and PAS, preferentially after diastase-digestion) [73]. Finally, liver biopsy interpretation requires a systematic evaluation of the various structures within the specimen (portal tracts, liver acinus, hepatic veins). If these prerequisites are fulfilled, liver biopsy represents the gold standard for the assessment of chronic liver disease [62].

Liver biopsy in chronic liver disease serves several purposes: establishment of a diagnosis, assessment of histological activity, evaluation of tissue architecture, clues to etiology and conflicting morbidity, as well as monitoring of therapy. Since liver biopsy, despite technical improvements, is not without risk for the patient, its indication must be justified in the proper clinical context [61]. Thus, the information obtained following liver biopsy should have an impact on the therapeutic decision [31].

Histopathological scoring systems have been developed for many entities including chronic hepatitis, fatty liver disease, chronic biliary diseases, iron-storage diseases, drug-induced liver damage (e.g. methotrexate-induced damage), as well as rejection in liver transplant pathology. The degree of architectural distortion and fibrosis (staging) is an important integrative denominator for disease progression, reversibility of liver damage, and functional hepatic reserve. Thus, disease staging is an especially important histological criterion to estimate prognosis and therapeutic options or indications. During

the last several years, many non-invasive tests have been introduced for the assessment of liver fibrosis, but until now all have failed to adequately differentiate early fibrotic stages [13, 51, 69]. Patients with earlier, but progressive fibrotic remodeling have an especially high need to be treated, and, therefore, liver biopsy is unsurpassed in its staging potential [22]. Nevertheless, the quantitative assessment of liver biopsy parameters is not without caveats. Generally, the subcapsular liver parenchyma shows more severe fibrotic changes compared to the central portion of the liver, which implies that the subcapsular 0.5 cm are not representative of disease stage. Therefore, a proper length of the biopsy cylinder (≥ 1.5 cm), as mentioned earlier, is important for representative staging, which should be based on adequate connective tissue stains [6]. The use of an additional reticulin staining component facilitates the analysis of the hepatic architecture and its distortion.

Additionally, the degree of the inflammatory activity (grading) is evaluated in chronic hepatitis. Of note, the grade of inflammation may vary over time and thus the inflammatory activity in a single biopsy represents only a "snapshot". Nevertheless, disease activity in chronic hepatitis, which does not necessarily correlate with serum enzyme concentrations, is the main determinant of disease progression and thus adds important information regarding prognosis and the urgency to treat [40].

Chronic Hepatitis

Whereas acute hepatitis is characterized qualitatively by primary acinar liver damage, chronic hepatitis *by definition* shows a predominance of portal inflammation. Interface hepatitis (in older terminology: piecemeal necrosis), acinar inflammation, and portal or septal fibrosis are frequent but optional features (see Chapters 25 and 28). In adults, chronic hepatitis is primarily typed according to the underlying etiology (Fig. 29.1) [19]. Thus, infections (HBV \pm HDV, HCV), drugs and toxins, autoimmunity, metabolic, and inherited diseases, and so-called "cryptogenic" origins are differentiated.

Grading and Staging of Chronic Hepatitis

The degree of necroinflammation (grading) may vary considerably inter-individually as well as during the

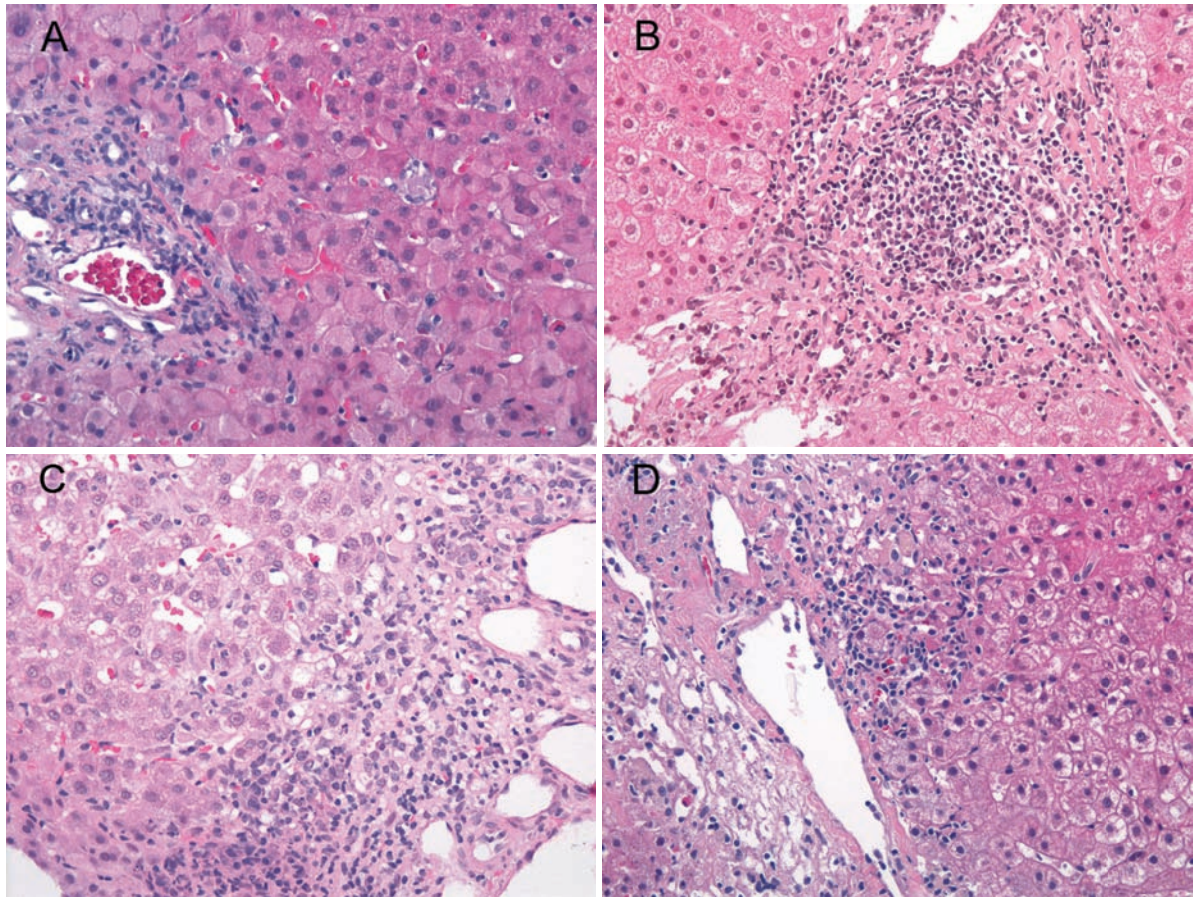


Fig. 29.1 The etiology of chronic hepatitis: (a) Chronic hepatitis B showing numerous ground-glass hepatocytes. (b) Formation of portal lymph follicles typically seen in chronic hepatitis C. (c) Autoimmune hepatitis with marked interface hepatitis, plasma

cell-rich portal infiltrate and pseudogland formation of periportal hepatocytes. (d) Drug-induced chronic hepatitis with sparse portal inflammatory infiltrate and intermingled eosinophils

course of chronic hepatitis in a given patient. Thus, the inflammatory activity seen in a liver biopsy specimen only represents a short-term picture that may even show some focal differences [76]. Nevertheless, inflammatory activity, especially the degree of interface hepatitis, has a high predictive value with respect to disease progression [28]. Several grading systems have been proposed to evaluate the degree of necroinflammatory activity; however, although grading itself is widely accepted, no uniform consensus for a certain system has yet been achieved. These include the scoring systems according Desmet et al., Batts and Ludwig, and the modified histological activity index (Table 29.1), which represents a further development of the so-called Knodell's score as well as the METAVIR score [5, 7, 19, 39, 44]. Desmet's score (Table 29.1, Fig. 29.2) is descriptive in terms of inflammatory activity and distinguishes four grades (minimal, mild, moderate,

severe = grades 1 to 4). Like the METAVIR score it has a good inter- and intra-observer reproducibility, a broad applicability, and – importantly – it can be derived from the more complex mHAI score [30]. Chronic hepatitis with minimal inflammatory activity (grade 1), in particular, shows mild portal infiltration, minimal acinar inflammation, and no interface hepatitis. Mild chronic hepatitis (grade 2) shows a more severe portal inflammation with focal interface hepatitis and single liver cell necrosis. In moderate chronic hepatitis (grade 3), moderate to severe portal inflammation with confluent interface hepatitis is seen. Additionally, group cell necroses without bridging may be observed. In severe chronic hepatitis (grade 4), there may be bridging or panacinar necrosis in addition to the features mentioned above. The use of the mHAI score, which is more complex and separately evaluates interface activity (none, focal, continuous, percentage

Table 29.1 Grading and staging of chronic viral hepatitis

Grading according to Desmet & Scheuer [19]				Ishak's modified histological activity index (mHAI) [39]		
Grade	Verbal	mHAI-Score	Histological features			
1	Minimal	1–3	Mild portal inflammation, none or minimal acinar inflammation/ few single cell necrosis, no interface hepatitis	Interface hepatitis	0	None
					1	Focal, few portal tracts
					2	Focal, majority of portal tracts
					3	Continuous < 50% of portal tracts
					4	Continuous < 50% of portal tracts
2	Mild	4–8	Mild to moderate portal inflammation, focal interface hepatitis, some single cell necrosis, no confluent necrosis	Confluent necroses	0	None
					1	Focal
					2	Few zone 3-necrosis
					3	Multiple zone 3-necrosis
					4	Zone 3- and few portocentral bridging necrosis
3	Moderate	9–12	Moderate to severe portal inflammation, confluent interface hepatitis, multiple single cell necrosis, some confluent necrosis, no bridging or panacinar necrosis		5	Zone 3- and multiple portocentral bridging necrosis
					6	Panacinar/multiacinar necrosis
				Single cell necroses	0	None
					1	1 focus/MPF (objective 10x)
					2	2–4 foci/MPF
					3	5–10 foci/MPF
					4	> 10 foci/MPF (objective 10x)
4	severe	13–18	Severe portal inflammation and interface hepatitis, severe acinar inflammation including confluent, bridging and panacinar necrosis	Portal inflammation	0	None
					1	Mild, few or all portal tracts
					2	Moderate, few or all portal tracts
					3	Moderate, all portal tracts
					4	Severe, all portal tracts

METAVIR-grading [7]		
Interface hepatitis	Acinar inflammatory foci	Score
0	0	A = 0
0	1	A = 1
1	0,1	
0,1	2	A = 2
2	0,1	
2	2	A = 3
3	0,1,2	

Interface hepatitis: 0 = no, 1 = mild, 2 = moderate, 3 = severe
 Acinar necrosis: 0 = no, 1 = mild, 2 = moderate, 3 = severe

Staging according to Desmet & Scheurer [19]			Semiquantitative Severity Score [14]		
Score	Verbal	Histological features	Criterion	Score	Verbal
0	No fibrosis	No portal fibrosis	Central vein	0	Normal or absence of vein (cirrhosis)
1	Mild fibrosis	Enlarged portal tracts without septa		1	Moderately thickened (stellate aspect of vein wall)
2	Moderate fibrosis	Incomplete portoportal septa, preserved architecture		2	Markedly thickened wall (annular aspect of vein wall with numerous fibrous extensions between hepatocytes)
3	Severe fibrosis	Portal fibrosis with septa and architectural distortion (differences in central vein – portal tract distances, no evidence of complete cirrhotic remodeling)	Perisinusoidal fibrosis	0	Normal
				1	Localised fibrosis
				2	Diffuse fibrosis
4	Cirrhosis	Probable or definite cirrhotic remodeling	Portal tract	0	Normal
				1	Enlarged without septa
				2	Enlarged with septa
				3	Cirrhosis
			Number of septa	0	None
				1	≤ 6 septa/10 mm
				2	> 6 septa/10 mm
				3	Nodular organisation
			Width of septa	0	Thin and/or incomplete
				1	Thick and loose connective matrix
				2	Very thick and dense connective matrix
				3	>2/3 biopsy area

METAVIR-staging [7]	
Stage	Histological feature
F0	No portal fibrosis
F1	Portal fibrosis without septa
F2	Portal fibrosis with few septa
F3	Portal fibrosis with numerous septa, no cirrhosis
F4	Cirrhosis

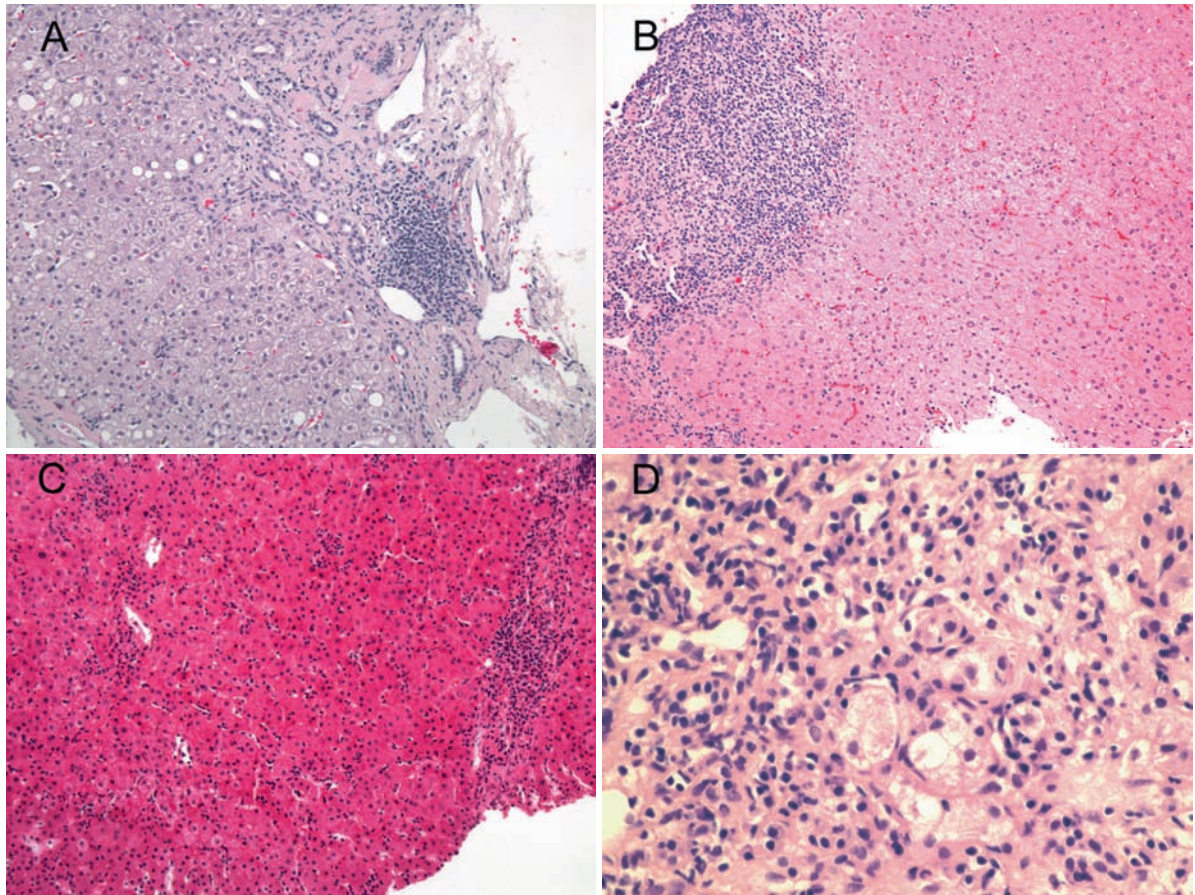


Fig. 29.2 Grading of chronic hepatitis: (a) Chronic hepatitis C with minimal inflammatory activity (grade 1) showing portal lymphocytic aggregates and an intact limiting plate towards the acinar parenchyma. Additionally, there is minimal macrovesicular steatosis. (b) In this case of chronic HBV-infection the portal tract is expanded by a comparably dense mononuclear inflammatory infiltrate showing focal interface activity (grade 2).

Additionally, there are some acinar single cell necroses. (c) Chronic hepatitis C showing a moderately dense portal inflammatory infiltrates, confluent interface activity and numerous cytolytic as well as some small group necroses within the acinar parenchyma (grade 3). (d) Chronic hepatitis with severe confluent interface hepatitis (grade 4)

of portal tracts), confluent necroses (none, perivenular, panacinar), single cell necroses, and density of the portal inflammatory infiltrate, is more precise, but is less practical to use in diagnostic routine compared to Desmet's scoring system. In contrast, the mHAI as the most detailed score is ideal for evaluation in clinical trials. The METAVIR score, which exhibits good reproducibility, has only been evaluated for chronic HCV infection and lacks exact definitions with respect to the single criteria applied. The density of the portal inflammatory infiltrate, which is a hallmark of chronic hepatitis, is neither reflected by the METAVIR score, nor by the scoring system according to Batts and Ludwig [5, 7]. Both scoring systems, in contrast to Desmet's score, have the drawback of some

inconsistency in creating cases of chronic hepatitis with no activity. Furthermore the specific relevance of the shows septa formation infiltrates for disease progression has not been thoroughly evaluated.

The evaluation of fibrosis and architectural distortion (staging) represents the most important histological criterion in terms of prognosis, therapeutic decision, and urgency to treat [49]. As in grading, several systems have been proposed for the staging of chronic hepatitis [5, 6, 19, 39]. The Desmet score (Table 29.1, Fig. 29.3), which was developed on the basis of Scheuer's score, distinguishes five separate descriptive stages (none, mild, moderate, severe fibrosis, and cirrhosis) [71]. The advantages of this system include its ease of use, clear definitions, and comparably small intra- and

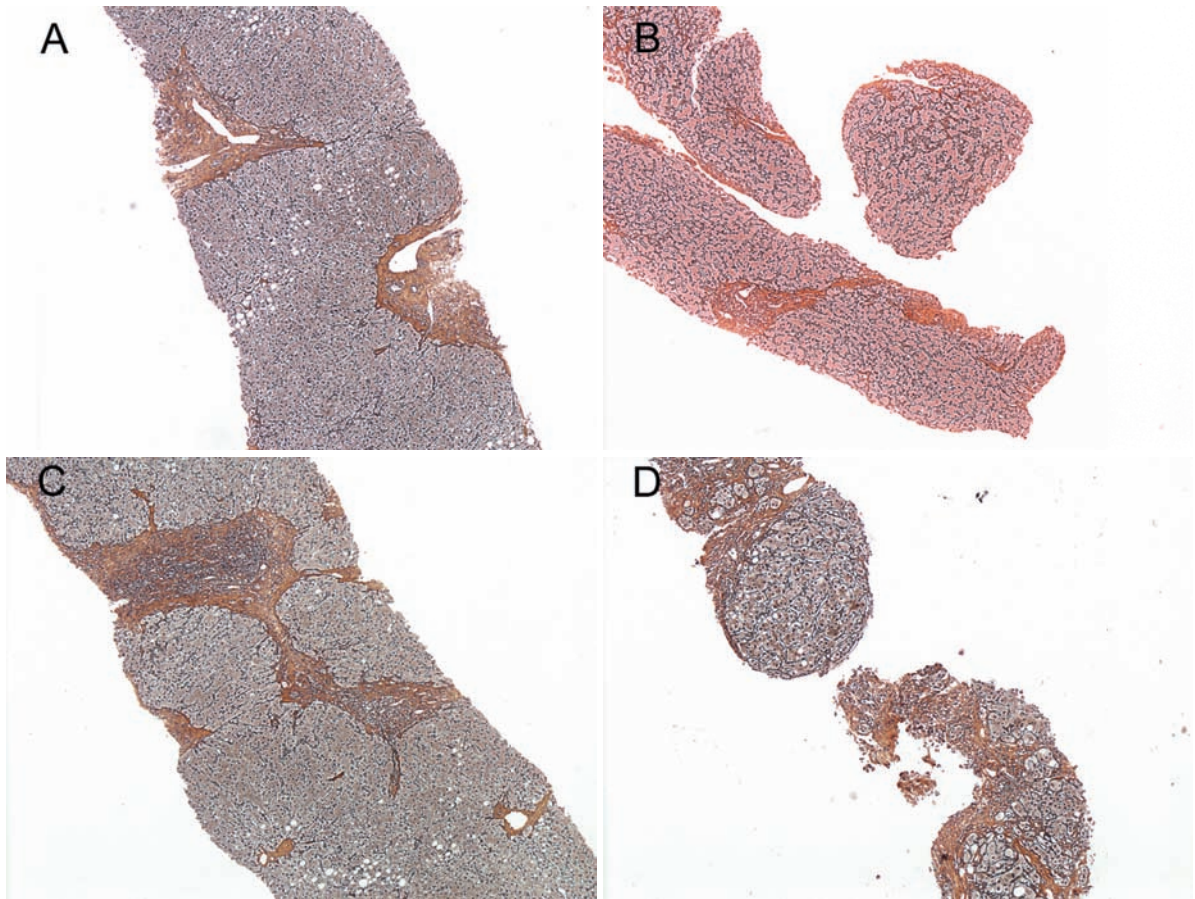


Fig. 29.3 Staging of chronic hepatitis (modified Gomori's stain): (a) Fibrotic expansion of the portal tract in this case of chronic hepatitis C (stage 1). (b) Portal fibrosis and septa formation (stage 2). (c) Portal and septal fibrosis leading to incomplete pseudolob-

uli and architectural distortion (stage 3). (d) Fragmented biopsy cylinder showing complete pseudolobuli. Note the rounded shape of the fragments indicative of cirrhotic remodelling (stage 4)

inter-observer variability [30]. Mild fibrosis (stage 1) shows enlargement of the shows septa formation tracts due to collagen deposition. Stage 2 additionally shows septa formation with preservation of the hepatic architecture. In stage 3, architectural distortion is evident as determined by the loss of hepatic venules and/or reduced porto-central distances. The distortion of the hepatic architecture by blood vessel carrying porto-central septa leads to a bypass of the liver parenchyma, which negatively influences the hepatic function. Finally, cirrhosis (stage 4) is determined by the formation of complete pseudolobules. Other staging systems (e.g. METAVIR, Batts and Ludwig) are comparable, but are not defined as precisely as Desmet's score. Scoring according to Ishak et al. differentiates seven stages and additionally separates fibrosis of some and of most portal tracts as well as a stage of incomplete cirrhosis, which does not provide additional information of diagnostic

relevance compared to the five stages in Desmet's score. Of note, progressive fibrosis stages are not well-differentiated by Desmet's score, which is a disadvantage of all qualitative scoring systems introduced thus far. Because antiviral therapy may lead to the regression of liver fibrosis, the use of the semiquantitative fibrosis score according to Chevallier et al. (Table 29.1) is recommended for clinical therapeutic trials [4, 14].

Autoimmune Hepatitis

Autoimmune hepatitis is regarded as a clinical syndrome defined by the combination of several clinical, serological, and histological features. Thus, a scoring system in which liver pathology represents a significant component has been developed that considers all

of these aspects (Table 29.2A, Fig. 29.1c) [2]. The correct typing of autoimmune hepatitis is of major clinical importance since this type of hepatitis usually rapidly progresses to cirrhosis if not treated immediately with immunosuppressive medication.

Recently, the International Autoimmune Hepatitis Group reached a consensus on simplified criteria for the diagnosis of AIH (Table 29.2B) [34a]. The histological demonstration of hepatitis is considered a prerequisite for application of this score. In contrast to previous scoring systems (Table 29.2A), which considered many individual histological features, the updated system defines three histological categories for grading of histology: atypical histology, histology compatible with AIH, and typical histology. Typical AIH histology is defined as lymphocytic/lymphoplasmocytic portal infiltrates with interface hepatitis, emperipolesis, and hepatic pseudorosette formation. To be considered typical, each of the three features of typical AIH histology has to be present. Compatible features are a picture of chronic hepatitis with lymphocytic infiltration without all the features considered typical. Histology is considered atypical when showing signs of other diseases, such as steatohepatitis.

Drug-Induced Liver Damage

Drug- and toxin-induced liver disease can produce all forms of acute, chronic, vascular and neoplastic liver diseases [41]. Scoring in drug-induced hepatitis is mainly limited to methotrexate toxicity [65]. The likelihood of methotrexate-induced liver damage in susceptible individuals is directly correlated with the duration of therapy and inversely correlated with the length of the interval between the doses [66]. Histological changes seen in methotrexate-induced liver damage are steatosis, ballooning degeneration, liver cell necrosis, prominence of hepatic stellate cells, (perisinusoidal) fibrosis and, finally, cirrhosis. Thus, the changes resemble those of alcoholic or non-alcoholic steatohepatitis. Portal inflammation is usually moderate and consists of lymphocytes, macrophages, and neutrophils [57]. Notably, conditions leading to fatty liver disease (e.g. chronic alcohol abuse, obesity, type 2 diabetes mellitus) have been shown to increase the likelihood of methotrexate-induced hepatotoxicity [56]. The frequency and interval of liver biopsies to survey methotrexate toxicity is based on the cumulative drug dose administered.

Classification of methotrexate toxicity is performed using the score described by Roenigk et al. (Table 29.3), which allows consistency in the evaluation of liver damage and prognosis [64].

Fatty Liver Disease/Steatohepatitis

Cytoplasmic fat accumulation is one of the most frequent pathological features seen in liver biopsies. The most common etiologies include chronic alcohol abuse, obesity, diabetes mellitus type 2 (metabolic syndrome), malnutrition, and a number of drugs and toxins. Additionally, hepatic steatosis can be observed in chronic hepatitis C (notably genotypes 2 and 3). Histologically, microvesicular, macrovesicular (displacement of the nucleus by a large fat droplet), and mixed-type steatosis can be differentiated. Intracellular fat accumulation may be focal, zonally restricted (frequently perivenular), or diffuse. Additionally, lipogranulomas, probably resulting from the rupture of fat-laden hepatocytes, can be observed. When significant necroinflammation is causally related to steatosis, the condition is named steatohepatitis. The factors determining the progression from simple steatosis to steatohepatitis with consecutive fibrosis are complex and not well understood, but seem to involve oxidative stress and lipid peroxidation (see Chapter 89). The histological features of steatohepatitis include: hepatocellular ballooning apoptosis, necrosis with neutrophilic infiltration, and the development of perisinusoidal and, preferentially, in the case of chronic alcohol-induced liver damage, perivenular fibrosis (Fig. 29.4). Alcoholic and non-alcoholic liver disease (diabetes mellitus, obesity, drugs) cannot be distinguished on morphological grounds alone, although the inflammatory lesions in NAFLD tend to be less severe and Mallory-Denk bodies tend to be absent or smaller [21, 43]. In contrast, so-called glycogenated nuclei are more prevalent in NAFLD (inset Fig. 29.4b). Nevertheless, there are some features observed in alcoholic steatohepatitis that have not yet been described in non-alcoholic fatty liver disease. These include sclerosing hyaline necrosis, cholangiolitis, and acute cholestasis. Sclerosing hyaline necrosis is characterized by extensive perivenular necrosis and consecutive fibrous tissue deposition, which may result in the occlusion of hepatic venules [23].

Since scoring systems are etiology-dependent, their application in steatohepatitis depends on the adequate communication of the relevant clinical and serological

Table 29.2A Classical scoring system for the diagnosis of autoimmune hepatitis (Modified from [2])

Category	Factor	Score	Category	Factor	Score
Gender	Female	+ 2	AMA	Positive	- 4
AP to AST or ALT ratio	< 1.5	+ 2	Viral markers	Positive	- 3
	1.5–3.0	0		Negative	+ 3
	> 3.0	- 2			
γ -globulin or IgG above normal	> 2.0	+ 3	Drugs	Yes	- 4
	1.5 to 2.0	+ 2	No	+ 1	
	1.0 to 1.5	+ 1	Alcohol	< 25 g/day	+ 2
	< 1.0	0		>> 60 g/day	- 2
ANA, SMA or LKM	> 1:80	3	Treatment response	Complete	+ 2
	1:80	2		Relapse	+ 3
	1:40	1			
	< 1:40	0			
Other liver-defined antibodies	Anti-SLA/LP, anti-actin, anti-LC1, pANCA	+ 2	Histological features	Interface hepatitis	+ 3
				Plasma cells	+ 1
				Rosettes	+ 1
				None of above	- 5
				Biliary changes	- 3
			Other features	- 3	

Pretreatment sum score: > 15 definite diagnosis, 10–15 probable diagnosis

Posttreatment sum score: > 17 definite diagnosis, 12–17 probable diagnosis

Table 29.2B Revised scoring system for the diagnosis of autoimmune hepatitis (Modified from [34a])

Variable	Cutoff	Points
ANA or SMA	$\geq 1:40$	1
ANA or SMA or LKM or SLA	$\geq 1:80$ $\geq 1:40$ positive	2*
IgG	>upper normal limit	1
	>1.1 times upper normal limit	2
Liver histology	Compatible with AIH	1
	Typical	2
Absence of viral hepatitis	Yes	2
		≥ 6 : probable AIH ≥ 7 : definite AIH

*Addition of points achieved for all autoantibodies (maximum, 2 points)

Table 29.3 Classification of hepatic methotrexate toxicity (According to [65])

Grade	Histologic features			
	Fat	Nuclear polymorphism	Fibrosis	Necroinflammation
I	\pm	\pm	0	\pm portal
II	++ - +++	++ - +++	0	++ - +++ portal
IIIa	\pm	\pm	Septal	\pm
IIIb	\pm	\pm	++ - +++	\pm
IV	nr	nr	Cirrhosis	nr

\pm = none or mild, + = present; ++ = moderate; +++ = severe, nr = not relevant

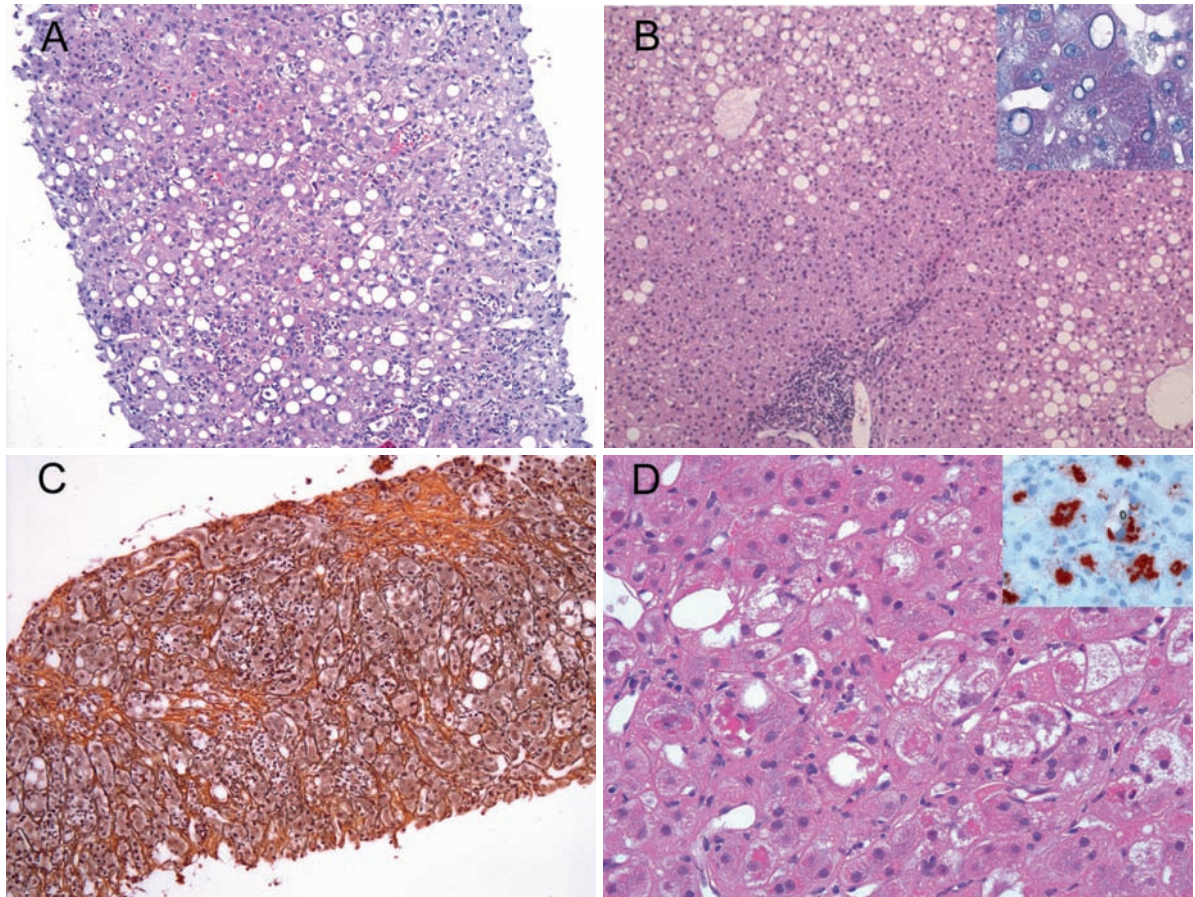


Fig. 29.4 Fatty liver disease/steatohepatitis: (a) Severe alcoholic steatohepatitis showing numerous single cell and group necroses and prominent neutrophilic infiltration. (b) In this case of non-alcoholic fatty liver disease there is mixed micro- and macrovesicular steatosis pronounced in acinar zone 3 and a few single cell necroses (inset: glycogenated nuclei, D-PAS). (c) Prominent

perisinusoidal fibrosis resulting from steatohepatitis (modified Gomori's stain). (d) Steatohepatitis in remission: Only mild inflammatory activity is seen and fatty change regressed. Note the persistence of ballooned hepatocytes and the intracytoplasmic accumulation of Mallory's hyaline (inset: ubiquitin immunohistochemistry depicting Mallory's hyaline)

information. Several studies have shown the impact of Mallory-Denk body formation, the presence of alcoholic hepatitis, and gender on the progression and prognosis of AFLD. In contrast to NAFLD, however, no widely accepted histopathological scoring system has been developed [15, 26, 58, 60, 77]. In contrast, several systems have been proposed for the grading and staging of non-alcoholic steatohepatitis [11, 43, 55]. Nowadays, the histological scoring system according to Kleiner et al. (NAS), which is based on the scoring system by Brunt and coworkers, is used most frequently. For the grading of NAFLD, the following parameters are evaluated: the amount and type of fat, the degree of hepatocellular ballooning, and the degree

of acinar inflammation (Table 29.4). A total score less than or equal to 2 is not suggestive of NASH, whereas a NAS of 5 or more establishes active NASH. NAS values of 3 and 4 are considered borderline.

The staging of steatohepatitis is based on the type and amount of fibrosis. Whereas perisinusoidal or perivenular fibrosis was initially considered stage 1, in the revised scoring system stage 1 is now subdivided into three substages (A to C), differentiating mild (A), moderate (B), or no perisinusoidal, but portal fibrosis (C) [11, 43, 55]. If both portal and perisinusoidal fibrosis are present, stage 2 is applied. In stage 3, bridging fibrosis is present, which may progress to liver cirrhosis (stage 4, Table 29.5).

Table 29.4 Non-alcoholic Fatty Liver Disease Activity Score (NAS) for the differentiation of fatty liver disease and steatohepatitis (Modified from [11, 43, 55])

Category	Criterion	Score
Steatosis	< 5%	0
	5–33%	1
	> 33–66%	2
	> 66%	3
Acinar inflammation	None	0
	< 2 foci/medium power field (MPF, 200x)	1
	2–4 foci/MPF	2
Hepatocellular ballooning	> 4 foci/MPF	3
	None	0
	Few hepatocytes	1
	Numerous/prominent ballooning	2

Sum score (NAS): 0 to 2 = not diagnostic of steatohepatitis, 3/4 = indefinite of steatohepatitis, ≥ 5 = steatohepatitis

Table 29.5 Staging of steatohepatitis (Modified from [11, 43, 55])

Stage	Fibrosis
0	None
1A	Mild, zone 3, perisinusoidal
1B	Moderate, zone 3, perisinusoidal
1C	Portal/periportal without perisinusoidal
2	Perisinusoidal and portal/periportal fibrosis
3	Bridging fibrosis
4	Cirrhosis

Biliary Diseases

Valid histopathological staging schemes exist for PBC and PSC. PBC represents a chronic, progressive liver disease selectively affecting the interlobular bile ducts. Several histological staging systems have been developed by Rubin et al., Scheuer, and Ludwig et al. [47, 67, 70]. These systems generally evaluate comparable histological parameters and use these criteria to distinguish three to four stages. The Scheuer score, which is the most widely accepted system, discriminates four stages (Table 29.6): Stage 1 is characterized by a florid duct lesion (Fig. 29.5a and c). This early portal biliary lesion of PBC consists of epithelial changes (swelling, cytoplasmic vacuolation with an irregular contour or eosinophilic shrinking with pyknotic nuclei) and a disruption of the basement membrane of small interlobular or septal bile ducts [67]. An inflammatory infiltrate is seen around affected ducts and may even result in lymph follicle formation. Another characteristic of florid duct

Table 29.6 Staging of chronic biliary disease according to Scheuer and Ludwig [47, 70]

Stage	Criteria
1	Portal hepatitis (florid duct lesion)
2	Ductular reaction and periportal hepatitis
3	Septal fibrosis
4	Cirrhosis

lesions in PBC are portal epithelioid cell granulomas either intimately associated or in close vicinity to damaged bile ducts [52]. Stage 2 encompasses periportal inflammation with a ductular reaction (stage 2, Fig. 29.5d). Especially in stage 2, the histological distinction from the AIH/PBC overlap syndrome may be difficult and in some cases even arbitrary. In stage 3, septal fibrosis with scarring and porto-portal bridging is observed (Fig. 29.5e). Stage 4 is defined by biliary-type fibrosis/cirrhosis (stage 4, Fig. 29.5f), which is characterized by porto-portal bridging fibrosis outlining the classical hepatic lobule, thus initially leaving the normal vascular relationship essentially intact. True cirrhosis may eventually develop in late-stage disease with portal-central bridging. Notably, due to the heterogeneous distribution of the disease, histological lesions characterizing different stages may coexist and be seen within the same liver biopsy specimen. Nevertheless, it has been shown that the use of a simple and reproducible staging system (e.g. Scheuer's score) has prognostic relevance since stage regression is infrequent [46]. Thus, liver biopsy is important in the assessment of prognosis, in the evaluation of disease progression (during therapy) and for the adequate timing of liver transplantation. Nevertheless, mathematical models such as the updated Mayo Clinic model (see Chapter 30), which are based on clinical and serological data, may be superior in predicting short-term survival in patients with advanced PBC. Whether a recently reported novel histopathological scoring system for the grading and staging of PBC is superior will have to be evaluated further [35]. In this scoring system, cholangitis as well as interface and acinar inflammation (similar to chronic hepatitis) are graded (Table 29.7). However, grading in this scheme has arbitrary aspects, since hepatocellular damage in PBC is weighted at least equivalently to the biliary damage, which does not reflect the natural course of classical PBC.

PSC is not a typical autoimmune liver disease and responds poorly to immunosuppressive therapy. The portal lesions in PSC, which may be seen in liver biopsies, are periductal edema and concentric, onion-

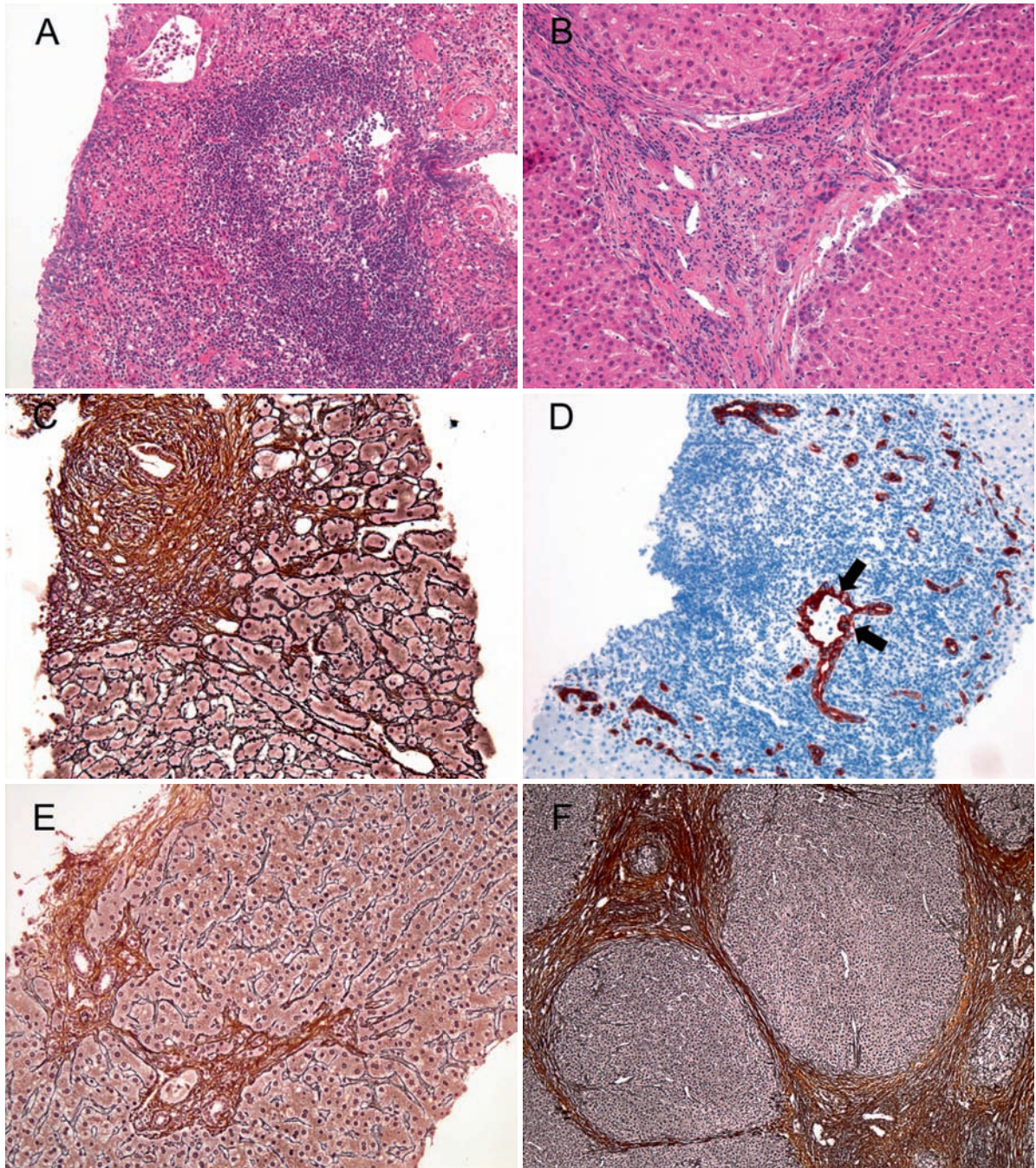


Fig. 29.5 Chronic biliary diseases: (a) Florid duct lesion in PBC. An epithelioid cell granuloma surrounds and destroys the portal bile duct. (b) PSC showing atrophic changes of the portal bile duct and a mild mononuclear infiltrate as well as a mild ductular reaction. (c) In this case of stage I PBC there is a fibrous expansion of the portal tract showing only minimal ductular reaction. (d) Stage II PBC with distortion of the portal bile duct

and a moderate ductular reaction close to the portal-acinar interface. Note few intraepithelial lymphocytes (arrows, cytokeratin 7 immunostain). (e) Porto-portal bridging fibrosis (stage III) in a case of PSC. (f) Biliary type fibrosis/cirrhosis in PSC with pseudolobules formed by porto-portal bridging fibrosis (stage IV). Note the inconspicuous central veins in the center of the nodules

Table 29.7 Grading and Staging of PBC according to Hiramatsu et al. [35]

Staging	0	1	2	3
Fibrosis (F)	Absent or limited to portal tracts	Periportal fibrosis (incomplete septa)	Bridging fibrosis with lobular distortion	Cirrhosis
Bile duct loss	Absent	< 1/3 of portal tracts	1/3 to 2/3 of portal tracts	> 2/3 of portal tracts
Chronic cholestasis (orcein-positive granules)	Absent	< 1/3 periportal hepatocytes	1/3 to 2/3 of periportal hepatocytes	> 2/3 of periportal hepatocytes
Grading	0	1	2	3
Cholangitis	Absent or ambiguous	< 1/3 of portal bile ducts	1/3 to 2/3 of bile ducts	> 2/3 of portal bile ducts
Interface hepatitis	Absent	Focal or mild	Moderate	Severe and extensive
Acinar inflammation	Absent	Mild and focal	Many and multiple, focal necroses	Zonal / bridging necroses

skin-like fibrosis with loose inflammatory infiltrates between the collagen sheets or loss of bile ducts in the terminal portal tracts [34]. Importantly, concentric periductal fibrosis is not absolutely specific for PSC, since it may be found to a certain extent in chronic biliary obstruction. The ductular epithelium may show atrophic changes (Fig. 29.5b) and sometimes disappears completely, leading to the formation of fibro-obliterative scars. Although ursodeoxycholic acid may ameliorate the symptoms, it has not been shown to significantly affect patient survival [45]. Thus, the disease is progressive and may lead to the need for liver transplantation. The staging of PSC has prognostic relevance for the optimal timing of liver transplantation. PSC primarily affects medium- to large-sized bile ducts (>100 µm in diameter), which are not necessarily present in liver biopsy specimens. Additionally, intra- and extrahepatic bile ducts are typically affected in PSC in a heterogeneous focal or segmental fashion. Thus, because PSC is a patchy rather than a diffuse liver disease, liver biopsy may not be representative of true disease stage and therefore has a lower predictive value for disease prognosis. Furthermore, it has been estimated that only 50% of the biopsies may show diagnostic lesions of PSC [3]. Thus, liver biopsy is not the preferred tool to establish the diagnosis of PSC, but it may help in excluding other liver diseases [12]. Scoring systems for PSC have not been vigorously tested for their reliability; mostly, the systems set forth by Ludwig et al. or Scheuer et al. which were originally developed for PBC are applied [47, 70].

Hepatic Iron-Overload

Iron is essential for many cell functions, but increased intracellular deposition may result in cell toxicity. Iron-induced cell damage has been attributed to increased oxidative stress and the production of reactive oxygen species (see Chapter 21). Siderosis is defined as demonstrably increased amounts of tissue iron. Hepatic siderosis may be either primary (e.g. hereditary hemochromatosis), or secondary due to either acquired iron overload (e.g. blood transfusion, hemolysis, hemodialysis) or, to a lesser extent, caused by chronic liver diseases (e.g. viral or alcoholic hepatitis). The qualitative distribution of stainable iron within certain cell types is relevant for the evaluation of the underlying cause. Whereas extensive hepatocellular iron storage indicates increased uptake via the digestive tract in hereditary forms of iron-storage diseases (e.g. hereditary hemochromatosis), combined hepatocellular and Kupffer cell siderosis (with additional hepatocellular damage with iron release and consecutive deposition in macrophages) can be observed in thalassemia as well as in hereditary hemochromatosis. Hemolysis or repeated erythrocyte transfusions primarily result in Kupffer cell siderosis and exclude untreated hereditary iron storage diseases [1, 42]. Histological grading of liver iron content based on semiquantitative assessment of tissue iron stains applies only to hepatocellular siderosis; it is performed as described in Table 29.8 (Fig. 29.6) and supports disease typing [72]. The grading system can be easily applied in routine practice. Additionally, a more complex scoring system has been developed, which

Table 29.8 Grading of hepatocellular siderosis

Score	Criterion
0	No or minimal siderosis (hardly visible, magnification 400x)
1	Mild siderosis (hardly visible, magnification 250x)
2	Moderate siderosis (easily visible hemosiderin granules, magnification 100x)
3	Severe siderosis (hemosiderin granules visible at magnification 25x)
4	Iron excess (easily visible hemosiderin granules at low power magnification)

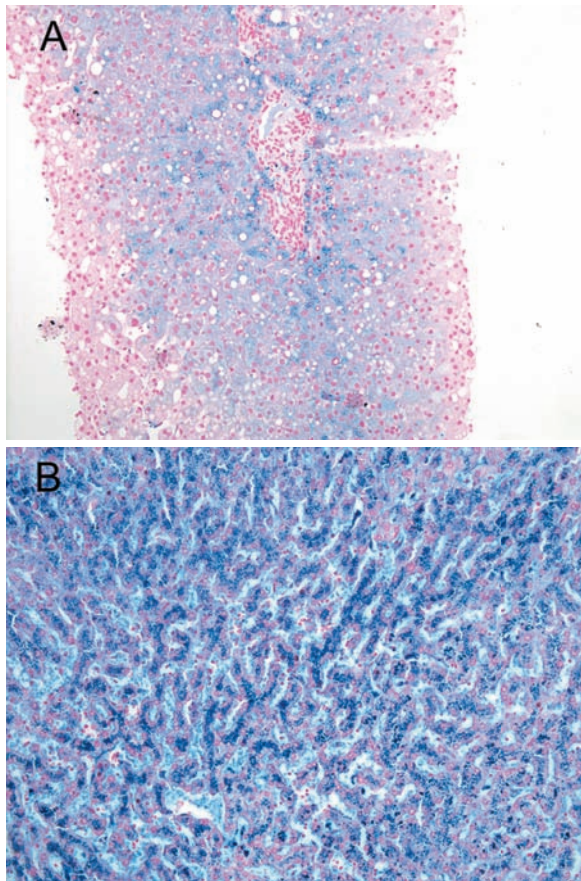


Fig. 29.6 Grading of hepatic siderosis. (a) Grade 1 hepatocellular siderosis with pronounced portal-central gradient. (b) Grade 4 siderosis (iron excess) with iron clumps predominantly in hepatocytes without an obvious portal-central iron gradient and only minor Kupffer cell siderosis

individually scores the iron content of hepatocytes, bile ducts, Kupffer cells and endothelial cells [20]. Although such a grading system is more accurate, it does not provide additional diagnostic information and its use is

Table 29.9 Staging of hereditary hemochromatosis

Stage	Description	Criteria
I	Iron overload, no fibrosis	Siderosis grade 3 to 4 Gradual decrease zone 1 to 3 No siderosis in Kupffer cells, portal macrophages, biliary epithelia No portal fibrosis
II	Fibrosis	Siderosis grade 3 to 4 Holly-like hepatocellular fibrosis Siderosis of portal macrophages, ductular reaction, eventually minimal lymphocytic infiltrates Possibly iron-free foci
III	Cirrhosis	Siderosis grade 4 Liver cirrhosis Siderosis of portal macrophages, biliary epithelia Sideronecrosis of iron-laden hepatocytes, consecutive Kupffer cell siderosis Eventually HCC (or CCC) development

restricted to experimental studies on iron storage diseases. Since tissue iron stains are largely quantitative, there is no need for liver iron content measurement by atomic absorption spectrometry.

The natural course of iron storage diseases leads to liver fibrosis and finally cirrhosis. Iron storage diseases are staged according to the degree of fibrosis (Table 29.9). Staging of these diseases is relevant since therapeutic phlebotomy can halt disease progression and may even result in regression of fibrosis. In addition, with only a handful of exceptions, HCC occurs only in patients with stage III disease [10, 24, 25, 29]. Thus, the staging of iron storage disease is relevant for prognosis and HCC surveillance.

Semiquantitative Scoring System for Evaluation of Hepatic Fibrosis

During chronic liver disease progressive fibrosis develops regardless of the underlying etiology [32]. Of note, there may be heterogeneity in the amount of fibrosis within a biopsy cylinder and, as mentioned earlier, the subcapsular liver parenchyma generally shows more

severe fibrotic changes compared to the central portion of the liver. Therefore, a proper length of the biopsy cylinder (≥ 1.5 cm) is important for the correct assessment of fibrotic remodeling [6]. Whereas most staging systems developed are qualitative on the one hand and evaluated only for certain diseases (e.g. chronic hepatitis, chronic biliary disease, see above) on the other hand, the Semiquantitative Scoring System (SSS) according to Chevallier et al. was developed for the quantification of fibrosis regardless of the underlying etiology [14]. It evaluates three sites of fibrous deposition (hepatic vein, portal tract, and perisinusoidal space), and additionally, if present, the width and number of septa (Table 29.1). Thus the scoring system combines localization and (semi)quantification of hepatic fibrosis. The SSS has been shown to have low inter- and intraobserver variability, indicating good reproducibility [14]. Morphometry is considered to be the gold standard of morphological measurements and thus quantification of fibrosis [50, 68]. To balance the number and width of fibrotic septa compared to the sites of fibrosis, and to achieve a good correlation with morphometric data, a formula was elaborated to calculate the overall score: $SSS = \text{perivenular fibrosis} + \text{perisinusoidal fibrosis} + \text{portal fibrosis} + 2 \times (\text{number} + \text{width of septa})$. Nevertheless, compared to morphometry there are some limitations. First, the evaluation of a certain extent of fibrosis for each site is subjective. Second, the semiquantitative score may be insufficient to detect small changes in fibrosis (e.g. following therapy of chronic viral hepatitis). Third, the definition of certain parameters in the SSS is somewhat imprecise (e.g. width of septa, Table 29.1). Additionally, it is not as practical to use on a daily basis compared with qualitative staging systems. Nevertheless, the SSS is superior to qualitative scoring systems, which cannot differentiate the amount of fiber deposition in cirrhosis, in discriminating progressive fibrotic changes subtle changes due to therapy. Thus, the use of the SSS is recommended for therapeutic studies, in which increase or regression of fibrosis will be evaluated.

Rejection in Liver Transplant Pathology

Rejection is an immunological reaction against alloantigens, which are presented by the graft cells. Three main types of rejection can be distinguished: hyperacute

(humoral), acute (cellular) and chronic (ductopenic or vascular) (see Chapter 103). Histopathological scoring is mainly applied to acute (cellular) rejection episodes, but not to hyperacute rejection. Additionally, an international working panel has offered recommendations for the histopathological staging and reporting of chronic liver allograft rejection [17].

Acute rejection, which frequently occurs episodically within the first month after transplantation, is the most common form of liver allograft damage [33, 54, 63]. Acute rejection is characterized by the histological triad of portal inflammation, bile duct damage, and endothelitis (International Working Party 1995) [38]. The portal infiltrate typically shows a mixed composition including lymphocytes, eosinophils, neutrophils, macrophages, and, with increased severity, large blastoid cells. Bile ducts are frequently infiltrated by inflammatory cells, show cytoplasmic vacuolisation, nuclear condensation, and focal disruption of the basement membrane. Endothelitis may vary from luminal lymphocyte adhesion to circumferential subendothelial infiltration with a disruption of the endothelial lining. Severe endothelitis of the central veins may result in venous occlusion and confluent perivenular necrosis, a condition which is associated with an increased risk for chronic rejection. Thus, the grading of acute rejection can have a prognostic impact [37, 75]. The severity of acute liver allograft rejection is graded worldwide according to the BANFF scheme (Table 29.10) [37].

Chronic liver allograft rejection occurs in 3–5% of patients and it is an important cause of late graft dysfunction [18, 59]. In contrast to the grading of acute rejection, histopathological scoring is applied in chronic rejection to discriminate an early, potentially reversible stage from late chronic rejection. Chronic rejection evolves from severe or persistent acute rejection and usually occurs within the first year following transplantation [8, 9, 27, 38]. Whereas the diagnosis of acute rejection is generally reserved for active necroinflammatory lesions, which are reversible by immunosuppression, chronic rejection is traditionally considered to involve irreversible damage of biliary structures and/or hepatic vessels [48]. The final diagnosis of chronic liver allograft rejection is based on the combination of clinical, radiological, serological, and histopathological findings. The minimal histological criteria for chronic allograft rejection are the presence of bile duct atrophy, affecting the majority of bile ducts, with or without bile duct loss, foam cell obliterative arteriopathy, or bile duct

Table 29.10 BANFF Grading Scheme for acute rejection (Modified from [37])

Component	Criteria	Score
Portal inflammation	Minority of portal tracts infiltrated by mostly lymphocytes, no portal tract expansion	1
	Expansion of $\geq 50\%$ of portal tracts by a mixed infiltrate including occasional eosinophils and blastoid cells	2
	Expanding of $\geq 50\%$ of portal tracts by a mixed infiltrate with numerous eosinophils and blasts and spill-over into the acinar parenchyma	3
Bile-duct damage/ inflammation	Minority of bile ducts surrounded by inflammatory cells plus degenerative alterations of cholangiocytes in some ducts	1
	$\geq 50\%$ of bile ducts inflamed plus degenerative changes of the epithelium in some ducts	2
	$\geq 50\%$ of bile ducts show degenerative changes or focal luminal disruption	3
Venous endothelial inflammation	$\leq 50\%$ of portal and/or hepatic venules show subendothelial inflammatory infiltration	1
	$\geq 50\%$ of portal and/or hepatic venules show subendothelial inflammatory infiltration	2
	Additional extension of perivenular inflammation with associated liver cell necrosis	3

The rejection activity index (RAI) is the sum of the scores of each category: RAI 3 = borderline, RAI 4/5 = mild, RAI 6/7 = moderate, RAI 8/9 = severe

loss in the majority of portal tracts. Since arteries with pathognomonic foam cell infiltrates are rarely seen in liver biopsies, the evaluation of damage and loss of bile ducts is the relevant diagnostic criterion. Nevertheless, there is a transition from acute to chronic rejection, where portal features of acute rejection resolve, but perivenular necroinflammation persists, which may therefore belong to early stage of chronic rejection [53, 74]. Early features of chronic biliary damage preceding loss of bile ducts include eosinophilic transformation of the biliary epithelial cytoplasm, uneven nuclear spacing, formation of syncytia, nuclear atypia, and disruption of the epithelial lining [17]. Since not all portal tracts regularly contain bile ducts, hepatic artery, and portal vein branches, the loss of bile duct or hepatic artery branches should be considered when less than 80% of the portal tracts contain these structures [16]. Importantly, these early changes of chronic rejection may be reversible after augmentation of immunosuppression [36, 74]. The recommendations for staging of chronic rejection differentiate the early stage of chronic rejection with ongoing inflammatory activity, which may be reversible with increased immunosuppression, from the late stage without necroinflammatory activity, which may require retransplantation. Nevertheless, they represent only working guidelines and the decision to continue with either increased immunosuppression or retransplantation should be based on the complete clinicopathological and serological data as well as the presence of comorbidities (e.g. bile duct or vascular strictures) [17]. The features of early and late chronic rejection are depicted in [Table 29.11](#). Early chronic rejection is

diagnosed if no more than one of the target structures shows late changes. A biopsy diagnosis of late chronic liver allograft rejection thus requires at least two late changes. The application of these recommendations results in a higher sensitivity for diagnosis of chronic rejection, as compared to the former classification (i.e., bile duct loss $> 50\%$), while keeping an acceptable specificity [48]. Nevertheless, the discrimination of early and late chronic liver allograft rejection is to some extent arbitrary since no histological feature reliably predicts the outcome of chronic rejection [74].

Future Developments

Further standardization and optimization of diagnostic and differentiated therapeutic approaches will lead to the development of generally accepted and more evidence-based histopathological scoring systems. Universally accepted scoring schemes, such as for the evaluation of acute rejection, will allow the promotion of histopathological evaluation in clinical studies. Systems that can be used for these purposes should fulfill some prerequisites. They must, for example, address all prognostically relevant histological criteria without being too complex to be applied during routine clinical practice. Simplicity and a precise definition of the diagnostic criteria will allow for further reduction in the intra- and inter-observer variability. This ultimately will allow for better comparability of independent clinical studies, which in turn will provide more uniform data to set a more quantitative basis for prognostic parameters

Table 29.11 Features of chronic liver allograft rejection (Modified from [17])

Structure	Early chronic rejection	Late chronic rejection
Small bile ducts (< 60 μm)	Degenerative changes of most ducts including eosinophilic transformation of the cytoplasm, increases in nuclear/cytoplasmic ratio, nuclear hyperchromasia; uneven nuclear spacing; loss of individual ductular cells Bile duct loss in < 50% of portal tracts	Degenerative changes in remaining bile ducts Loss in ≥50% of portal tracts
Terminal hepatic venules and zone 3 hepatocytes	Intimal/luminal inflammation Lytic zone 3 necrosis and inflammation Mild perivenular fibrosis	Focal obliteration Variable inflammation Severe (bridging) fibrosis
Portal tract hepatic arterioles	Occasional loss (< 25% of portal tracts)	Loss involving > 25% of portal tracts
Other	So-called transition hepatitis with spotty hepatocellular necrosis	Sinusoidal foam cell accumulation; marked cholestasis
Large perihilar hepatic artery branches	Intimal inflammation, focal foam cell deposition, no luminal narrowing	Luminal narrowing by subintimal foam cell aggregation Fibrointimal proliferation
Large perihilar bile ducts	Inflammatory damage and focal foam cell aggregates	Mural fibrosis

and differential therapeutic approaches. Nevertheless, qualitative assessment (e.g. Desmet score) may have some limitations in clinical studies since all qualitative scores are non-linear and somewhat overlapping [5, 19, 39]. Therefore, more complex and quantitative scoring systems, such as the mHAI for the evaluation of inflammatory activity in chronic hepatitis or Chevallier's semiquantitative severity score for the evaluation of tissue remodeling, may be superior in discriminating subtle changes achieved by therapy [5, 14, 19, 41].

References

1. Alla V, Bonkovsky HL (2005) Iron in nonhemochromatotic liver disorders. *Semin Liver Dis* 25: 461–72
2. Alvarez F, Berg PA, Bianchi FB, et al (1999) International Autoimmune Hepatitis Group Report: review of criteria for diagnosis of autoimmune hepatitis. *J Hepatol* 31: 929–38
3. Angulo P, Larson DR, Therneau TM, et al (1999) Time course of histological progression in primary sclerosing cholangitis. *Am J Gastroenterol* 94: 3310–3
4. Arima M, Terao H, Kashima K, et al (2004) Regression of liver fibrosis in cases of chronic liver disease type C: quantitative evaluation by using computed image analysis. *Intern Med* 43: 902–10
5. Batts KP, Ludwig J (1995) Chronic hepatitis. An update on terminology and reporting. *Am J Surg Pathol* 19: 1409–17
6. Bedossa P, Dargere D, Paradis V (2003) Sampling variability of liver fibrosis in chronic hepatitis C. *Hepatology* 38: 1449–57
7. Bedossa P, Poynard T (1996) An algorithm for the grading of activity in chronic hepatitis C. The METAVIR Cooperative Study Group. *Hepatology* 24: 289–93
8. Blakolmer K, Jain A, Ruppert K, et al (2002) Chronic liver allograft rejection in a population treated primarily with tacrolimus as baseline immunosuppression: long-term follow-up and evaluation of features for histopathological staging. *Transplantation* 69: 2330–6
9. Blakolmer K, Seaberg EC, Batts K, et al (1999) Analysis of the reversibility of chronic liver allograft rejection implications for a staging schema. *Am J Surg Pathol* 23: 1328–39
10. Blumberg RS, Chopra S, Ibrahim R, et al (1988) Primary hepatocellular carcinoma in idiopathic hemochromatosis after reversal of cirrhosis. *Gastroenterology* 95: 1399–402
11. Brunt EM, Janney CG, Di Bisceglie AM, et al (1999) Nonalcoholic steatohepatitis: a proposal for grading and staging the histological lesions. *Am J Gastroenterol* 94: 2467–74
12. Burak KW, Angulo P, Lindor KD (2003) Is there a role for liver biopsy in primary sclerosing cholangitis? *Am J Gastroenterol* 98: 1155–8
13. Castera L, Vergniol J, Foucher J, et al (2005) Prospective comparison of transient elastography, Fibrotest, APRI, and liver biopsy for the assessment of fibrosis in chronic hepatitis C. *Gastroenterology* 128: 343–50
14. Chevallier M, Guerret S, Chossegros P, et al (1994) A histological semiquantitative scoring system for evaluation of hepatic fibrosis in needle liver biopsy specimens: Comparison with morphometric studies. *Hepatology* 20: 349–55
15. Christoffersen P, Eghoje K (1973) Mallory bodies in liver biopsies from chronic alcoholics. A comparative morphological, biochemical, and clinical study of two groups of chronic alcoholics with and without Mallory bodies. *Scand J Gastroenterol* 8: 341–6

16. Crawford AR, Lin XZ, Crawford JM (1998) The normal adult human liver biopsy: a quantitative reference standard. *Hepatology* 28: 323–31
17. Demetris A, Adams D, Bellamy C, et al (2000) Update of the International Banff Schema for Liver Allograft Rejection: working recommendations for the histopathologic staging and reporting of chronic rejection. An International Panel. *Hepatology* 31: 792–9
18. Demetris AJ, Murase N, Lee RG, et al (1997) Chronic rejection. A general overview of histopathology and pathophysiology with emphasis on liver, heart and intestinal allografts. *Ann Transplant* 2: 27–44
19. Desmet VJ, Gerber M, Hoofnagle JH, et al (1994) Classification of chronic hepatitis: diagnosis, grading and staging. *Hepatology* 19: 1513–20
20. Deugnier YM, Turlin B, Powell LW, et al (1993) Differentiation between heterozygotes and homozygotes in genetic hemochromatosis by means of a histological hepatic iron index: a study of 192 cases. *Hepatology* 17: 30–4
21. Diehl AM, Goodman Z, Ishak KG (1988) Alcohollike liver disease in nonalcoholics. A clinical and histologic comparison with alcohol-induced liver injury. *Gastroenterology* 95: 1056–62
22. Dienstag JL (2002) The role of liver biopsy in chronic hepatitis C. *Hepatology* 36: S152–60
23. Edmondson HA, Peters RL, Reynolds TB, et al (1963) Sclerosing hyaline necrosis of the liver in the chronic alcoholic. A recognizable clinical syndrome. *Ann Intern Med* 59: 646–73
24. Falize L, Guillygomarc'h A, Perrin M, et al (2006) Reversibility of hepatic fibrosis in treated genetic hemochromatosis: a study of 36 cases. *Hepatology* 44: 472–7
25. Fellows IW, Stewart M, Jeffcoate WJ, et al (1988) Hepatocellular carcinoma in primary haemochromatosis in the absence of cirrhosis. *Gut* 29: 1603–6
26. Forrest EH, Evans CD, Stewart S, et al (2005) Analysis of factors predictive of mortality in alcoholic hepatitis and derivation and validation of the Glasgow alcoholic hepatitis score. *Gut* 54: 1174–9
27. Freese DK, Snover DC, Sharp HL, et al (1991) Chronic rejection after liver transplantation: a study of clinical, histopathological and immunological features. *Hepatology* 13: 882–91
28. Ghany MG, Kleiner DE, Alter H, et al (2003) Progression of fibrosis in chronic hepatitis C. *Gastroenterology* 124: 97–104
29. Goh J, Callagy G, McEntee G, et al (1999) Hepatocellular carcinoma arising in the absence of cirrhosis in genetic haemochromatosis: three case reports and review of literature. *Eur J Gastroenterol Hepatol* 11: 915–9
30. Goldin RD, Goldin JG, Burt AD, et al (1996) Intra-observer and inter-observer variation in the histopathological assessment of chronic viral hepatitis. *J Hepatol* 25: 649–54
31. Grant A, Neuberger J (1999). Guidelines on the use of liver biopsy in clinical practice. *British Society of Gastroenterology. Gut* 45(Suppl 4): IV1–IV11
32. Gressner AM (1991) Liver fibrosis: perspectives in pathobiochemical research and clinical outlook. *Eur J Clin Chem Clin Biochem* 29: 293–311
33. Gruttadauria S, Vasta F, Mandala L, et al (2005) Basiliximab in a triple-drug regimen with tacrolimus and steroids in liver transplantation. *Transplant Proc* 37: 2611–3
34. Harrison RF, Hubscher SG (1991) The spectrum of bile duct lesions in end-stage primary sclerosing cholangitis. *Histopathology* 19: 321–7
- 34a. Hennes EM, Zeniya M, Czaja AJ, et al (2008) Simplified criteria for the diagnosis of autoimmune hepatitis. *Hepatology* 48: 169–76
35. Hiramatsu K, Aoyama H, Zen Y, et al (2006) Proposal of a new staging and grading system of the liver for primary biliary cirrhosis. *Histopathology* 49: 466–78
36. Hubscher SG, Buckels JA, Elias E, et al (1991) Vanishing bile-duct syndrome following liver transplantation—is it reversible? *Transplantation* 51: 1004–10
37. International Panel (1997) Banff schema for grading liver allograft rejection: an international consensus document. *Hepatology* 25: 658–63
38. International Working Party (1995) Terminology for hepatic allograft rejection. *Hepatology* 22: 648–54
39. Ishak K, Baptista A, Bianchi L, et al (1995) Histological grading and staging of chronic hepatitis. *J Hepatol* 22: 696–9
40. Ishak KG (2000) Pathologic features of chronic hepatitis. A review and update. *Am J Clin Pathol* 113: 40–55
41. Ishak KG, Zimmerman HJ (1995) Morphologic spectrum of drug-induced hepatic disease. *Gastroenterol Clin North Am* 24: 759–86
42. Kaji K, Nakanuma Y, Sasaki M, et al (1995) Hemosiderin deposition in portal endothelial cells: a novel hepatic hemosiderosis frequent in chronic viral hepatitis B and C. *Hum Pathol* 26: 1080–5
43. Kleiner DE, Brunt EM, Van Natta M, et al (2005) Design and validation of a histological scoring system for nonalcoholic fatty liver disease. *Hepatology* 41: 1313–21
44. Knodell RG, Ishak KG, Black WC, et al (1981) Formulation and application of a numerical scoring system for assessing histological activity in asymptomatic chronic active hepatitis. *Hepatology* 1: 431–5
45. LaRusso NF, Shneider BL, Black D, et al (2006) Primary sclerosing cholangitis: summary of a workshop. *Hepatology* 44: 746–64
46. Locke GR, Therneau TM, Ludwig J, et al (1996) Time course of histological progression in primary biliary cirrhosis. *Hepatology* 23: 52–6
47. Ludwig J, Dickson ER, McDonald GS (1978) Staging of chronic nonsuppurative destructive cholangitis (syndrome of primary biliary cirrhosis). *Virchows Arch A Pathol Anat Histol* 379: 103–12
48. Ludwig J, Wiesner RH, Batts KP, et al (1987) The acute vanishing bile duct syndrome (acute irreversible rejection) after orthotopic liver transplantation. *Hepatology* 7: 476–83
49. Marcellin P, Asselah T, Boyer N (2002) Fibrosis and disease progression in hepatitis C. *Hepatology* 36: S47–56
50. Masseroli M, Caballero T, O'Valle F, et al (2000) Automatic quantification of liver fibrosis: design and validation of a new image analysis method: comparison with semi-quantitative indexes of fibrosis. *J Hepatol* 32: 453–64
51. Miele L, Forgione A, Gasbarrini G, et al (2007) Noninvasive assessment of fibrosis in non-alcoholic fatty liver disease (NAFLD) and non-alcoholic steatohepatitis (NASH). *Transl Res* 149: 114–25
52. Nakanuma Y, Ohta G (1983) Quantitation of hepatic granulomas and epithelioid cells in primary biliary cirrhosis. *Hepatology* 3: 423–7
53. Neil DA, Hubscher SG (2002) Histologic and biochemical changes during the evolution of chronic rejection of liver allografts. *Hepatology* 35: 639–51

54. Neuberger J (1999) Incidence, timing, and risk factors for acute and chronic rejection. *Liver Transpl Surg* 5: S30–6
55. Neuschwander-Tetri BA, Caldwell SH (2003) Nonalcoholic steatohepatitis: summary of an AASLD Single Topic Conference. *Hepatology* 37: 1202–19
56. Nyfors A, Poulsen H (1976) Liver biopsies from psoriatics related to methotrexate therapy. I. Findings in 123 consecutive non-methotrexate treated patients. *Acta Pathol Microbiol Scand [A]* 84: 253–61
57. Nyfors A, Poulsen H (1977) Morphogenesis of fibrosis and cirrhosis in methotrexate-treated patients with psoriasis. *Am J Surg Pathol* 1: 235–43
58. Orrego H, Blake JE, Blendis LM, et al (1987) Prognosis of alcoholic cirrhosis in the presence and absence of alcoholic hepatitis. *Gastroenterology* 92: 208–14
59. Pappo O, Ramos H, Starzl TE, et al (1995) Structural integrity and identification of causes of liver allograft dysfunction occurring more than 5 years after transplantation. *Am J Surg Pathol* 19: 192–206
60. Pares A, Caballeria J, Bruguera M, et al (1986) Histological course of alcoholic hepatitis. Influence of abstinence, sex and extent of hepatic damage. *J Hepatol* 2: 33–42
61. Piccinino F, Sagnelli E, Pasquale G, et al (1986) Complications following percutaneous liver biopsy. A multi-centre retrospective study on 68,276 biopsies. *J Hepatol* 2: 165–73
62. Pradat P, Alberti A, Poynard T, et al (2002) Predictive value of ALT levels for histologic findings in chronic hepatitis C: a European collaborative study. *Hepatology* 36: 973–7
63. Ringe B, Moritz M, Zeldin G, et al (2005) What is the best immunosuppression in living donor liver transplantation? *Transplant Proc* 37: 2169–71
64. Roenigk HH, Jr., Auerbach R, Maibach HI, et al (1982) Methotrexate guidelines – revised. *J Am Acad Dermatol* 6: 145–55
65. Roenigk HH, Jr., Auerbach R, Maibach HI, et al (1988) Methotrexate in psoriasis: revised guidelines. *J Am Acad Dermatol* 19: 145–56
66. Roenigk HH, Jr., Bergfeld WF, St Jacques R, et al (1971) Hepatotoxicity of methotrexate in the treatment of psoriasis. *Arch Dermatol* 103: 250–61
67. Rubin E, Schaffner F, Popper H (1965) Primary biliary cirrhosis. Chronic non-suppurative destructive cholangitis. *Am J Pathol* 46: 387–407
68. Rubio CA, Porwit A (1988) Quantitation of fibrosis in liver biopsies. *Anal Quant Cytol Histol* 10: 107–9
69. Sandrin L, Fourquet B, Hasquenoph JM, et al (2003) Transient elastography: a new noninvasive method for assessment of hepatic fibrosis. *Ultrasound Med Biol* 29: 1705–13
70. Scheuer P (1967) Primary biliary cirrhosis. *Proc R Soc Med* 60: 1257–60
71. Scheuer PJ (1991) Classification of chronic viral hepatitis: a need for reassessment. *J Hepatol* 13: 372–4
72. Scheuer PJ, Williams R, Muir AR (1962) Hepatic pathology in relatives of patients with haemochromatosis. *J Pathol Bacteriol* 84: 53–64
73. Schirmacher P, Fleig WE, Tannapfel A, et al (2004) Biopic diagnosis of chronic hepatitis. Results of an evidence-based consensus conference of the German Society of Pathology, of the German Society for Digestive and Metabolic Diseases and of Compensated Hepatitis (HepNet). *Pathology* 25: 337–48
74. Sebagh M, Blakolmer K, Falissard B, et al (2002) Accuracy of bile duct changes for the diagnosis of chronic liver allograft rejection: reliability of the 1999 Banff schema. *Hepatology* 35: 117–25
75. Sebagh M, Debette M, Samuel D, et al (1999) “Silent” presentation of veno-occlusive disease after liver transplantation as part of the process of cellular rejection with endothelial predilection. *Hepatology* 30: 1144–50
76. Siddique I, El-Naga HA, Madda JP, et al (2003) Sampling variability on percutaneous liver biopsy in patients with chronic hepatitis C virus infection. *Scand J Gastroenterol* 38: 427–32
77. Sorensen TI, Orholm M, Bentsen KD, et al (1984) Prospective evaluation of alcohol abuse and alcoholic liver injury in men as predictors of development of cirrhosis. *Lancet* 8397: 241–4

Chapter Outline

Child-Turcotte-Pugh Score.....	289
Model for End-Stage Liver Disease.....	290
Mayo Risk Score.....	291
Maddrey Index (Discriminant Function) and Lille Model.....	291
King's College Criteria.....	292
Hepatic Iron Index.....	292
Noninvasive Assessment of Liver Fibrosis.....	292
International Autoimmune Hepatitis Group Score.....	292
References.....	293

In the present chapter a short overview of selected clinical scoring systems in hepatology is presented. The reader will find a discussion of the various scoring models as they pertain to specific liver conditions in the respective clinical chapters.

The aim of prognostic models and scores is to objectively estimate disease severity, in order to help make decisions regarding specific medical interventions and assess the outcome of hepatic diseases. The two most commonly used models in the care of patients with liver disease are the *Child-Turcotte-Pugh score* and the *Model for End-Stage Liver Disease*. In addition, decision models have been developed for primary biliary cirrhosis and primary sclerosing cholangitis (*Mayo Risk Score*), acute liver failure (*King's College criteria*), alcoholic hepatitis (*Maddrey Index* and *Lille Model*), and hereditary hemochromatosis (*Hepatic Iron Index*). Multiple *models for the noninvasive assessment of liver fibrosis* are currently being evaluated.

Child-Turcotte-Pugh Score

The original Child-Turcotte-Pugh (CTP) staging system was derived empirically. It incorporated serum albumin, serum bilirubin, nutritional status, ascites, and hepatic encephalopathy [6]. The system was revised in 1973 and “nutritional status” was replaced by prolongation (in seconds) of prothrombin time [25]. The current CTP-system is based upon five parameters (Table 30.1). Points are assigned to each parameter, such that an overall score can be calculated (5–15). The patient with chronic liver disease can be placed into one of three classes (A: 5–6 points, B: 7–9 points, C: 10–15 points). *CTP class A is consistent with well-compensated cirrhosis, class B with decompensation*

Table 30.1 The Child-Turcotte-Pugh Scoring System [6, 25]

Parameter	Units	Points assigned		
		1	2	3
Serum bilirubin	μmol/L	< 34	34–51	> 51
	mg/dL	< 2	2–3	> 3
Serum albumin	g/dL	> 3.5	3.0–3.5	< 3
	g/L	> 35	30–35	< 30
Prothrombin time	Seconds over control	< 4	4–6	> 6
	INR	< 1.7	1.7–2.3	> 2.3
Ascites		Absent	Slight, easily controlled	Moderate to severe, poorly controlled
Hepatic encephalopathy		None	Minimal (grade 1–2)	Advanced (grade 3–4)

and a significant functional compromise, and class C denotes severely decompensated disease. CTP has proven to be a reliable staging system and a fairly good predictor of survival and the likelihood of major complications (e.g. variceal bleeding, spontaneous bacterial peritonitis) in patients with liver cirrhosis. Initially it was also used to list patients for liver transplantation. Because it is very practical and easy to calculate at the bedside, the CTP score is the most widely used scoring system in clinical practice for assessing the risk of mortality in patients with cirrhosis and portal hypertension [9]. The CTP classes correlate with 1- and 2-year patient survival (A: 100% and 85%, B: 80% and 60%, and C: 45% and 35%, respectively).

The CTP score, however, has several shortcomings. It includes, for example, subjective parameters such as the degree of ascites and encephalopathy. The CTP score was developed when ultrasound diagnosis of ascites was not available. Today, ultrasound allows for the detection of even 100–150 mL of ascites that cannot be detected on physical examination. Therefore small amounts of ascites and low-grade, subclinical encephalopathy are not recorded in the CTP-score. Furthermore, CTP score is limited in its discriminatory capacity by a “ceiling” and “floor” effect and cannot distinguish among patients within a single class.

Model for End-Stage Liver Disease

The Model for End-Stage Liver Disease (MELD) was developed to overcome the subjective interpretation inherent in the CTP score. It uses the patient’s laboratory values (serum bilirubin, serum creatinine, internationalized ratio for prothrombin time [INR]) according to the following formula

$$\text{MELD} = 3.8[\text{Ln serum bilirubin (mg/dL)}] + 11.2[\text{Ln INR}] + 9.6[\text{Ln serum creatinine (mg/dL)}] + 6.4$$

where Ln is the natural logarithm. For adults undergoing dialysis twice a week, the creatinine in the equation is set to 4 mg/100 mL. Several on-line calculators are available to calculate the MELD score (www.unos.org). The MELD score is continuous, with 34 levels ranging between 6 and 40.

MELD was developed initially in cirrhotic patients who underwent transjugular intrahepatic portosystemic shunt (TIPS) procedure, in order to predict early death following elective TIPS. The original MELD score included the etiology of liver disease (alcoholic, cholestatic, viral hepatitis, and “others”). However, the exclusion of etiology of liver disease did not significantly affect the c-statistics for 3 month survival. The MELD score performed well in predicting death within 3 months post-TIPS with a c-statistic of 0.87 for hospitalized patients, 0.80 for noncholestatic ambulatory patients, 0.87 for patients with primary biliary cirrhosis, and 0.78 for historical cirrhotic patients [14, 23]. When using the modified MELD score (i.e. excluding the etiology of liver disease), the best outcomes post-TIPS are seen in patients with a MELD score < 14. Elective TIPS should generally be avoided in patients with a MELD score > 24.

The MELD score is currently regarded by most as the best predictor of pretransplantation mortality; consequently, the major application of the revised MELD score is in prioritizing allocation of organs for liver transplantation (donor organs rarely become available unless the MELD score exceeds 20–30) [11]. However, there is still a debate as to whether the MELD score is superior to the CTP score to predict mortality in patients with cirrhosis on the liver transplantation waiting list

and after liver transplantation. Recently it has been reported that on the basis of the current literature, MELD score does not perform better than the CTP score for patients with cirrhosis on the waiting list and cannot predict post-liver transplantation mortality [7].

In addition to patients undergoing TIPS procedure and those waiting for a liver transplant, the initial application was broadened and MELD has been shown to be valuable across a wide spectrum of liver disease [26]. The MELD score has prognostic value in alcoholic hepatitis, hepatorenal syndrome, fulminant liver failure due to acetaminophen-induced liver injury, and sepsis in cirrhosis. It helps to guide decisions regarding surgical procedures in chronic liver disease patients, and in determining optimal treatment for patients with hepatocellular carcinoma who are not candidates for liver transplantation [1, 27, 28].

Despite the many advantages of the MELD score, there are approximately 15–20% of patients whose survival cannot be accurately predicted by the MELD score [15]. Sodium concentration is an independent prognostic factor in patients with cirrhosis and there is a linear increase in the risk of death as Na^+ decreases between 135 and 120 mEq/L. The incorporation of serum sodium and age to the original MELD formula has been shown to provide a more accurate survival prediction than MELD alone [5, 19, 21]. Although the MELD score uses only objective variables and eliminates the subjectivity inherent in the CTP scoring system, it is also affected by potential sources of error. Different methods of creatinine measurement significantly affect MELD scores [8]. Elevated bilirubin concentration interferes in a variety of ways with different assays of creatinine measurement, thus causing variability in MELD scores. This problem can be circumvented by using an enzymatic method to measure serum creatinine.

Mayo Risk Score

The Mayo Risk Score was developed as a prognostic score for patients with primary biliary cirrhosis (PBC) [10]. It predicts survival of patients with PBC which aids in the selection of patients for, and timing of, orthotopic liver transplantation. The score is based on the patient's age, total serum bilirubin and serum albumin concentrations, prothrombin time, and severity of edema.

The addition of histologic stage does not significantly improve the predictive power of the model. Thus it has the advantage of not requiring liver biopsy [10, 12]. The Mayo Risk Score has been modified to an abbreviated form by introducing cut-off levels for age, bilirubin, albumin and prothrombin time, maintaining nearly the same prognostic information as the original score [17]. However, since both versions of the Mayo Risk Score are based on baseline data only, long term prognostication in early stages of PBC is not very precise.

A new Mayo model to predict survival of patients with primary sclerosing cholangitis (PSC) was derived from the Mayo Risk Score. It includes more reproducible variables (age, bilirubin, albumin, aspartate aminotransferase, and history of variceal bleeding) and also obviates the need for a liver biopsy [16].

$$R = 0.03 (\text{age [y]}) + 0.54 \log_e (\text{bilirubin [mg/dL]}) + 0.54 \log_e (\text{aspartate aminotransferase [U/L]}) + 1.24 (\text{variceal bleeding [no = 0/yes = 1]}) - 0.84 (\text{albumin [g/dL]}).$$

The risk score was used to obtain survival estimates for up to 4 years of follow-up. Probability of survival at time t years is calculated as $S(t) = S_0(t)^{\exp(R-1.00)}$ [16].

Maddrey Index (Discriminant Function) and Lille Model

The Maddrey Index is used to estimate disease severity and mortality risk in patients with *alcoholic hepatitis* [22].

$$\text{Discriminant function} = 4.6 \times [\text{patient PT} - \text{control PT}] + \text{serum bilirubin [mg/dL]}$$

PT = prothrombin time

A value greater than 32 characterizes severe alcoholic hepatitis associated with a high short-term mortality, and has been used to determine the need for corticosteroid therapy [13].

A specific prognostic model (*Lille model*) was generated to identify patients with severe alcoholic hepatitis, who despite a discriminant function ≥ 32 will not respond to corticosteroids. The model combining six reproducible variables (age, renal insufficiency,

albumin, prothrombin time, bilirubin, and evolution of bilirubin at day 7) was highly predictive of death at 6 months. The area under the receiver operating characteristic curve of the Lille model was 0.89 ± 0.02 , higher than the Child-Pugh (0.62 ± 0.04 , $P < 0.00001$) or Maddrey scores (0.66 ± 0.04 , $P < 0.00001$). A Lille score above 0.45 allowed for early identification of patients with a marked decrease in 6 months survival despite corticosteroid therapy [20]. The Lille score is not widely used in clinical practice.

King's College Criteria

King's College Criteria define a statistical model developed for predicting outcome in patients with *acute liver failure* and allowing to propose recommendations for liver transplantation in fulminant hepatic failure (FHF) (Table 30.2) [24]. The King's College Criteria are particularly helpful in acetaminophen-induced acute liver failure. The positive and negative predictive values for mortality in those with acetaminophen-induced liver failure were 88% and 65%, respectively, and the corresponding values for patients with other causes of FHF were 79% and 50%, respectively [2].

Table 30.2 King's College criteria for liver transplantation in fulminant hepatic failure [24]

Acetaminophen-induced fulminant hepatic failure

Arterial pH < 7.3 (irrespective of the grade of encephalopathy)

OR

Grade III or IV encephalopathy AND

Prothrombin time > 100 s AND

Serum creatinine > 3.4 mg/dL (301 μ mol/L)

All other causes of fulminant hepatic failure

Prothrombin time > 100 s (irrespective of the grade of encephalopathy)

OR

Any **three** of the following variables (irrespective of the grade of encephalopathy)

1. Age < 10 years or > 40 years
2. Etiology: non-A, non-B hepatitis, halothane hepatitis, idiosyncratic drug reactions
3. Duration of jaundice before onset of encephalopathy > 7 days
4. Prothrombin time > 50 s
5. Serum bilirubin > 18 mg/dL (308 μ mol/L)

Hepatic Iron Index

The Hepatic Iron Index (HII) was developed prior to the availability of genetic testing, with the hope that it could help distinguish patients with hereditary hemochromatosis (HH) from those with other causes of hepatic iron overload. The HII is based on the assumption that in HH iron deposition progressively increases with age, while progressive iron deposition does not occur in other liver diseases with iron overload, such as porphyria cutanea tarda, alcoholic liver disease, or chronic viral hepatitis [3]. It is calculated according to the following formula

$$\text{HII} = \frac{\text{hepatic iron concentration } (\mu\text{M/g dry weight})}{\text{patient's age (years)}}$$

A HII ≥ 1.9 was thought to be a strong indicator of homozygous HH, while most persons with heterozygous HH and patients with mild iron overload due to other causes had a HII < 1.5 [18]. With the advent of genetic testing it was shown that HII is not as accurate as originally believed and 30–50% of patients who are C282Y homozygotes have no phenotypic expression and therefore would not have an elevated HII [4]. Thus, the value of HII has greatly diminished. It still may have some role in a clinical setting when serum iron studies are abnormal and genetic testing is negative.

Noninvasive Assessment of Liver Fibrosis

See Chapters 28 and 53.

International Autoimmune Hepatitis Group Score

See Chapters 29 and 72.

References

1. Alessandria C, Ozdogan O, Guevara M, et al (2005) MELD score and clinical type predict prognosis in hepatorenal syndrome: relevance to liver transplantation. *Hepatology* 41: 1282–9
2. Anand AC, Nightingale P, Neuberger JM (1997) Early indicators of prognosis in fulminant hepatic failure: an assessment of the King's criteria. *J Hepatol* 26: 62–8
3. Bassett ML, Halliday JW, Powell LW (1986) Value of hepatic iron measurements in early hemochromatosis and determination of the critical iron level associated with fibrosis. *Hepatology* 6: 24–9
4. Beutler E, Felitti VJ, Koziol JA, et al (2002) Penetrance of 845G → A (C282Y) HFE hereditary haemochromatosis mutation in the USA. *Lancet* 359: 211–8
5. Biggins SW, Kim WR, Terrault NA, et al (2006) Evidence-based incorporation of serum sodium concentration into MELD. *Gastroenterology* 130: 1652–60
6. Child III, CG, Turcotte, JG (1964) Surgery and portal hypertension. In: Child III CG (ed) *The liver and portal hypertension*, WB Saunders, Philadelphia, PA, p. 50
7. Cholongitas E, Marelli L, Shusang V, et al (2006) A systematic review of the performance of the Model for End-Stage Liver Disease (MELD) in the setting of liver transplantation. *Liver Transpl* 12: 1049–61
8. Cholongitas E, Marelli L, Kerry A, et al (2007) Different methods of creatinine measurement significantly affect MELD scores. *Liver Transpl* 13: 523–29
9. Christensen E, Schlichting P, Fauerholdt L, et al (1984) Prognostic value of Child-Turcotte criteria in medically treated cirrhosis. *Hepatology* 4: 430–5
10. Dickson ER, Grambsch PM, Fleming TR, et al (1989) Prognosis in primary biliary cirrhosis: model for decision making. *Hepatology* 10: 1–7
11. Freeman RB Jr, Wiesner RH, Harper A, et al (2002) The new liver allocation system: moving toward evidence-based transplantation policy. *Liver Transpl* 8: 851–8
12. Grambsch PM, Dickson ER, Kaplan M, et al (1989) Extramural cross-validation of the Mayo primary biliary cirrhosis survival model establishes its generalizability. *Hepatology* 10: 846–50
13. Imperiale TF, McCullough AJ (1990) Do corticosteroids reduce mortality from alcoholic hepatitis? A meta-analysis of the randomized trials. *Ann Intern Med* 113: 299–307
14. Kamath PS, Wiesner RH, Malinchoc M, et al (2001) A model to predict survival in patients with end-stage liver disease. *Hepatology* 33: 464–70
15. Kamath PS, Kim WR (2007) The Model for End-Stage Liver Disease (MELD). *Hepatology* 45: 797–805
16. Kim WR, Therneau TM, Wiesner RH, et al (2000) A revised natural history model for primary sclerosing cholangitis. *Mayo Clin Proc* 75: 688–94
17. Kim WR, Wiesner RH, Poterucha JJ, et al (2000) Adaptation of the Mayo primary biliary cirrhosis natural history model for application in liver transplant candidates. *Liver Transpl* 6: 489–94
18. Kowdley KV, Trainer TD, Saltzman JR, et al (1997) Utility of hepatic iron index in American patients with hereditary hemochromatosis: a multicenter study. *Gastroenterology* 113: 1270–7
19. Londoño MC, Cárdenas A, Guevara M, et al (2007) MELD score and serum sodium in the prediction of survival of patients with cirrhosis awaiting liver transplantation. *Gut* 56: 1283–90
20. Louvet A, Naveau S, Abdelnour M, et al (2007) The Lille model: a new tool for therapeutic strategy in patients with severe alcoholic hepatitis treated with steroids. *Hepatology* 45: 1348–54
21. Luca A, Angermayr B, Bertolini G, et al (2007) An integrated MELD model including serum sodium and age improves the prediction of early mortality in patients with cirrhosis. *Liver Transpl* 13: 1174–80
22. Maddrey WC, Boitnott JK, Bedine MS, et al (1978) Corticosteroid therapy of alcoholic hepatitis. *Gastroenterology* 75: 193–9
23. Malinchoc M, Kamath PS, Gordon FD, et al (2000) A model to predict poor survival in patients undergoing transjugular intrahepatic portosystemic shunts. *Hepatology* 31: 864–71
24. O'Grady JG, Alexander GJ, Hayllar KM (1989) Early indicators of prognosis in fulminant hepatic failure. *Gastroenterology* 97: 439–45
25. Pugh, RN, Murray-Lyon, IM, Dawson, JL, et al (1973) Transection of the oesophagus for bleeding oesophageal varices. *Br J Surg* 60: 646–9
26. Said A, Williams J, Holden J, et al (2004) Model for end stage liver disease score predicts mortality across a broad spectrum of liver disease. *J Hepatol* 40: 897–903
27. Schmidt LE, Larsen FS (2007) MELD score as a predictor of liver failure and death in patients with acetaminophen-induced liver injury. *Hepatology* 45: 789–96
28. Terra C, Guevara M, Torre A, et al (2005) Renal failure in patients with cirrhosis and sepsis unrelated to spontaneous bacterial peritonitis: value of MELD Score. *Gastroenterology* 129: 1944–53

Chapter Outline

Family History	301
Past and Present Medical History	302

The medical interview and physical examination remain the cornerstone of the diagnostic process despite the increasing use of advanced technology in medicine. In most patients these fundamental medical skills will allow the physician to formulate a correct presumptive diagnosis, properly select the appropriate diagnostic tests, and avoid unnecessary testing.

The directed hepatologic interview and physical examination serve mainly to answer the following questions:

- Is a hepatobiliary disease present?
- To which *disease category* does the disorder belong (Table 31.1)?
- Is the clinical syndrome primarily *hepatocellular* (necroinflammatory), *cholestatic*, or *mixed* (see Chapter 49)?
- Is the disease *active* or *not active*? Active disease should be *graded*: mild, moderate, or severe.
- At which point in its natural history and in which stage is the disease? Acute or chronic, early or late stage?
- Can a statement regarding *prognosis* be formulated?

Family History

The family history includes questions regarding icteric diseases, anemias, gallstones and tumors. In addition, a family history of genetic diseases such as Wilson's disease, hemochromatosis, α_1 -antitrypsin deficiency, familial cholestatic syndromes (e.g. familial intrahepatic cholestasis [FIC] or benign recurrent intrahepatic cholestasis [BRIC]) and Alagille's syndrome should be investigated as affected family members may be undiagnosed and only manifest systemic symptoms such as diabetes in hemochromatosis, or psychiatric illness in Wilson's disease.

Table 31.1 Categories of liver diseases*

Infectious
Viruses, bacteria, parasites, fungi, worms
Immune/autoimmune
Cholestatic, hepatocellular, mixed
Metabolic
Steatosis, steatohepatitis (alcoholic, nonalcoholic)
Amyloidosis, malnutrition and overfeeding, total parenteral nutrition
Genetic
Bilirubin metabolism, Wilson's disease, hemochromatosis, α_1 -antitrypsin deficiency, storage diseases, mitochondrial diseases, porphyrias, cystic fibrosis
Cholestatic
Granulomatous
Drug-induced and toxic
Circulatory and vascular
Tumorous
Neoplastic, hyperplastic, infectious, dysontogenetic (cyst)
Pregnancy associated
Reactive
Diseases of other organs/systemic diseases
Idiopathic

*Overlapping between various categories is common and many diseases may be assigned to more than one category.

Past and Present Medical History

As a central metabolic organ, the liver is affected by many physiological and, pathological factors, both exogenous and endogenous. Therefore, the hepatologic interview must encompass, in both a systematic and specific manner, potential *hepatotoxic factors*.

A patient's geographic and ethnic roots, as well as the travel history (schistosomiasis, endemic regions for viral hepatitis), for example, may yield important information. Sexual activities and preferences, multiple partners, and promiscuity may give important indications as to the nature of the underlying liver disease (e.g. viral hepatitis, gonococcal and chlamydial perihepatitis in women). Overt or surreptitious alcohol use must be investigated and quantified, as should the use of both prescribed and over-the-counter herbal supplements.

Answers to questions regarding past liver diseases, elevated "liver tests", past jaundice, physical performance status, concentration ability, or the capacity to cope with the daily workload may provide initial clues to the presence of a chronic liver disorder (hepatitis,

cirrhosis). Within this context, an increase in weight and/or in the circumference of the abdomen ("trousers/skirt or belt too tight") may hint at the development of ascites. A black, tarry stool in the presence of known liver disease suggests an advanced stage with upper gastrointestinal bleeding. Targeted questions should address bruising after minor trauma, and spontaneous gum or nasopharyngeal bleeding.

Often the circumstances under which a liver disease clinically presents provide the key to its cause. Was the onset abrupt or insidious? Is the patient in a postoperative state? Did the increase in serum liver enzymes occur within the context of total parenteral nutrition? Is the patient pregnant? Are there indications for systemic diseases or for disorders of other organs, e.g. septicemia or circulatory dysfunction? Does the patient currently or did she or he in the past suffer from a neoplastic condition? Did the patient recently develop diabetes mellitus or was he/she suffering from depression prior to the onset of jaundice, suggesting perhaps a diagnosis of pancreatic cancer with biliary obstruction?

A central aspect of the hepatologic history is devoted to the exploration (dating back a long time) of potential *exogenous risk factors*. This includes the search for occupational or hobby related exposure to hepatotoxic agents, contact with icteric patients or patients with hepatitis or viral carriers, travel to regions endemic for viral hepatitis. The patient should be asked about past surgical procedures, dental treatments, incidental needle stick injuries, intramuscular injections, transfusion of blood or blood products, intravenous drug use, tattooing, and contact with animals.

Exposure to *all* foreign compounds should be meticulously sought, as many patients are not aware of the hepatotoxic potential of many "harmless natural" substances. A detailed *medication and drug history is of the utmost importance*. Intravenous drug use predisposes to viral hepatitis and HIV-associated hepatobiliary diseases. Oral ingestion of ecstasy or nasal use of cocaine can also injure the liver. By far the most important hepatotoxin, however, is alcohol. The patient's drinking habits should be evaluated and an average daily alcohol intake (more than 20 g per day?) should be assessed. Questioning in this regard should be done in a respectful fashion and with empathy, so as to gain the trust of the patient and strengthen the doctor-patient relationship. During the first encounter with the physician, the patient often conceals his true alcohol drinking habits or underestimates the regular use of

small amounts of alcohol which does not seem noteworthy to report. In this case, the physician initially should not inquire too intensively and should not insist on a specific answer, but rather return to the point later after mutual trust has been established.

All remedies taken by the patient are regarded as potentially hepatotoxic xenobiotics. This also includes over-the-counter compounds, such as vitamins, dietary supplements, medicinal herbs, and homeopathic

compounds. Within this context it often proves useful to ask the patient to take his or her time to write down a list of *all* tablets, pills, liquids, etc. he or she has taken in the past weeks or months and to present this list at the next visit. Medications that have been discontinued should also be recorded, as the liver damage from some drugs may not become apparent until after the drug has been stopped (e.g., amiodarone or amoxicillin/clavulanic acid).

Chapter Outline

Fatigue	305
Neuropsychiatric Symptoms	306
Gastrointestinal Symptoms	306
Pain	306
Pruritus	307
Muscle Cramps	307
Fever	307
Sexual Dysfunction	307
Systemic Manifestations of Conditions Associated with Specific Liver Diseases	307
References	307

Patients with liver diseases are often asymptomatic and only attract attention by elevated liver enzymes found incidentally, for example, during a routine health maintenance examination. Though liver diseases have many causes, however, the spectrum of their clinical presentation is quite uniform. Therefore, it is generally not possible to make a definitive diagnosis based solely on symptoms. The constellation of symptoms, the time of onset, and their progression is more important for the classification of a liver disease than is an isolated symptom [3].

Fatigue

Fatigue is a nonspecific but common symptom of chronic liver disease that significantly impacts quality of life. In contrast to depression, fatigue of chronic liver disease is rarely fully pronounced in the morning hours, but rather increases during the day. The patient often needs to rest after physical and intellectual activities in order to regain energy to continue his or her daily program. Fatigue usually begins insidiously (initially not recognized by the patient), it is often intermittent, and its daily intensity fluctuates. Fatigue commonly occurs in acute and chronic hepatitis and liver cirrhosis, but may be especially pronounced in primary biliary cirrhosis where it typically progresses gradually over the years. The patient adjusts to these subtle changes in his or her well-being, and it commonly takes years before he or she seeks medical attention. Especially in slowly progressing chronic liver diseases, the physical and mental performance status may remain preserved for a long time and decline drastically only after overt cirrhosis has developed.

Neuropsychiatric Symptoms

Changes in mental status, such as impaired concentration and disturbances of the sleep–wake cycle (i.e., drowsy during daytime, and awake during the night) characterize the *portosystemic encephalopathy* of advanced liver disease (see Chapter 80). The intellectual performance of the patient declines, memory disturbances ensue, and mood fluctuations abound, with easy irritability and euphoria alternating with depression. Obtundation and ataxia can be seen in late stages. Subclinical mental alterations are often present in patients with liver cirrhosis and may be assessed with adequately designed psychometric tests. Early recognition of minimal hepatic encephalopathy is important, as there is recent evidence that treatment with lactulose improves cognitive functioning and health-related quality of life [4]

Gastrointestinal Symptoms

Anorexia with aversion to certain foods combined with *nausea* often occur in acute viral hepatitis and in icteric patients with hepatic failure or biliary obstruction. Smokers report an aversion to nicotine during the acute hepatic phase; the first “tasty cigarette” and an improved appetite are often the first indications of impending clinical improvement, even before elevated liver enzymes begin to decline toward normal. Nicotine aversion, however, is not thought to be specific for acute hepatitis, but occurs generally in many icteric patients.

Disturbances of taste are often present in acute hepatitis, combined with unpleasant olfactory sensations, especially involving meat and bitter or fatty foods [2]. *Nausea* in acute hepatitis mostly occurs before the appearance of jaundice and is generally not accompanied by vomiting. In acute biliary obstruction due to a stone, however, vomiting often occurs. The color of the vomit should be investigated: is it bilious, blood-tinged (source of bleeding proximal to the ligament of Treitz), or hematin-like brown-black (erosions of gastric mucosa, peptic ulcer)? Nausea and vomiting are not necessarily a manifestation of liver disease per se, but can be the direct consequence of acute alcohol consumption or may be drug-induced. *Diarrhea* is usually not part of the clinical spectrum of acute and chronic liver disease though the stools are often soft

and loose in many liver diseases, especially when accompanied by diabetes.

The *increase in abdominal girth* (“clothes and belt too tight”) may be caused by meteorism (swelling of the abdomen due to gas in the stomach or intestines) and/or be due to the development of ascites, and is an indication of an advanced stage of liver disease. Usually meteorism precedes the appearance of ascites (“first the wind and then the rain”). If the increase in abdominal girth is accompanied by *weight gain* and the development of ankle edema, this may be regarded as largely specific for fluid retention with ascites formation. An early sign of fluid retention is the appearance of nocturia, which is due to increased fluid resorption in the recumbent position. Marked, tense ascites causes diaphragmatic elevation with restricted diaphragmatic movement and may be accompanied by dyspnea and cardiac complaints. Other hepatic causes for dys- and tachypnea are cystic fibrosis and α_1 -antitrypsin deficiency. Extensive liver metastases, especially in slim patients, may also lead to an increase in abdominal girth, which, however, usually is accompanied by weight loss.

Protein-calorie malnutrition is typical for patients with advanced chronic liver disease. *Weight loss* may be due to anorexia with reduced food intake, or may be the consequence of a generalized wasting of muscle and adipose tissue in liver cirrhosis. Another cause of weight loss in patients with cirrhosis or primary sclerosing cholangitis is the development of hepatocellular carcinoma or cholangiocarcinoma.

Pain

Pain in the right upper quadrant in acute hepatic infections is due to acute stretching of the liver capsule, and is perceived as a noncharacteristic, dull pressure (“Organgefühl”). Intense pain is an indication of gallbladder disease, liver abscess, or of a rapidly developing acute venous outflow obstruction (e.g., Budd–Chiari), rather than due to diffuse parenchymal liver disease. If the diaphragm is involved in the pathological process, the pain may radiate to the right shoulder. Approximately 20% of patients with primary biliary cirrhosis complain of mild to moderate pain beneath the right costal margin (see Chapter 48).

Pruritus

Pruritus may occur in every hepatopathy, but is most often observed in chronic cholestatic liver diseases, drug-induced cholestasis, and early in the course of obstructive jaundice. It is most pronounced in the extremities, rarely occurs in the face, and nearly never is present in the genital region. Initially pruritus is most agonizing in the evening hours and during the night; later in the course of the disease, it is also present during the day and may be recognized easily on physical examination by extensive skin excoriations.

Muscle Cramps

Painful muscle cramps, mostly in the calves during the night, occur in patients with liver cirrhosis. Their incidence and intensity depend on the duration of liver cirrhosis, the degree of functional liver impairment, and the reduction of effective circulating volume [1].

Fever

Fever may occur in hepatocellular carcinoma, liver abscess, emerging portal vein thrombosis, cholangitis, and acute viral, alcoholic or drug-induced hepatitis. Shaking chills are not typical of acute viral hepatitis and suggest instead a diagnosis of ascending, suppurative cholangitis or hepatic abscess.

Sexual Dysfunction

Loss of libido and erectile dysfunction (ED), the latter especially in alcoholics, are seen regularly in patients with advanced cirrhosis, with females complaining less often than males. ED may be seen in as many as 85% of

patients with chronic liver disease, with older age and low serum albumin as independent risk factors [6]. Unfortunately, recent evidence suggests that sexual functioning in patients with end-stage liver disease does not significantly improve after liver transplantation [5].

Systemic Manifestations of Conditions Associated with Specific Liver Diseases

Certain liver diseases may have systemic manifestations that may produce symptoms that hint at a specific diagnosis. Behavioral problems or seizures, for example, can be initial manifestations of Wilson's disease. Arthralgias or symptoms related to diabetes such as polyuria and blurred vision may suggest hemochromatosis. Patient's with hepatitis C related cryoglobulinemia or those with porphyria cutanea tarda may complain of a skin rash. Pulmonary complaints can be seen in α_1 -antitrypsin deficiency.

References

1. Angeli P, Albino G, Carraro P, et al (1996) Cirrhosis and muscle cramps: evidence of a causal relationship. *Hepatology* 23: 264–73
2. Deems RO, Friedman MI, Friedman LS, et al (1993) Chemosensory function, food preferences and appetite in human liver disease. *Appetite* 20: 209–16
3. McIntyre N (1999) Symptoms and signs of liver disease. In: Bircher J, Banhamou J-P, McIntyre N, Rizzetto M, Rodés J (eds) *Textbook of clinical hepatology*, 2nd edn. Oxford University Press, Oxford, pp 479–99
4. Prasad S, Dhiman RK, Duseja A, et al (2007) Lactulose improves cognitive functions and health-related quality of life in patients with cirrhosis who have minimal hepatic encephalopathy. *Hepatology* 45: 549–59
5. Sorrell JH, Brown JR (2006) Sexual functioning in patients with end-stage liver disease before and after transplantation. *Liver Transpl* 12: 1473–7
6. Toda K, Miwa Y, Kuriyama S, et al (2005) Erectile dysfunction in patients with chronic viral liver disease: its relevance to protein malnutrition. *J Gastroenterol.* 40: 894–900

Chapter Outline

General Appearance of the Patient	309
Examination of the Liver	310
Examination of the Gallbladder	310
Examination of the Spleen	310
Ascites	312
Auscultation of the Abdomen	312
Skin and Mucous Membranes	312
Jaundice (Icterus)	312
Scratch Effects	313
Spider Teleangiectasia	313
Palmar Erythema	313
“Banknote” Skin	314
Glazed Tongue	314
Bleeding Signs	314
Palpable Purpura	314
Xanthelasma and Eruptive Xanthomas	314
Hyperpigmentation	314
Hypopigmentation	314
Papulous Acrodermatitis	314
Lichen Planus	314
Hair Growth	315
Nodular Panniculitis	315
Nail Changes	315
Neurologic-Psychiatric Changes	315
Other Changes	316
References	316

Physical examination is normal in the early stages of many chronic liver diseases. With further disease progression, however, physical signs appear which suggest the existence of a chronic liver disease. The physical examination of a patient with liver disease should place special emphasis on the

- General appearance of the patient
- Size and consistency of liver and spleen
- Presence or absence of ascites
- Skin and mucosa signs
- Nail changes, and
- Mental status

General Appearance of the Patient

The first inspection often yields a clear indication whether or not the patient has liver disease. Is the patient icteric? Are the lips dark red? Are cutaneous scratch signs present? Is the abdomen distended? Are dilated or teleangiectatic cutaneous vessels visible? Is there localized or generalized edema? Is there muscle wasting? Does the patient give off an offensive smell? Is the patient lethargic or confused? These are among the first questions that can be answered within a few seconds and give insightful information. In some chronic alcoholics, the typical red tumid face (*facies alcoholica*) allows an instant diagnosis of the underlying liver disease. Most patients with alcoholic liver disease, however, lack this distinctive feature.

Mild hypertelorism with deep-set eyes, a broad forehead, a flat nose and a small pointed chin should arouse the suspicion of *Alagille’s syndrome*.

Marked *ascites*, which in advanced cirrhosis is often associated with *scrotal edema*, is readily recognized on

inspection of the patient. When standing, the abdomen is distended, the umbilicus may be effaced or everted, and an *umbilical hernia* may be present. Hepatic *cachexia* with loss of adipose tissue, hollow cheeks, generalized muscle atrophy, and skinny extremities is in marked contrast to the prominently distended abdomen (Fig. 79.5). In decompensated cirrhosis, generalized edema may obscure signs of muscle wasting.

Engorged, meandering abdominal veins are a manifestation of portal hypertension and are often visible through the anterior abdominal wall. They should not be mistaken for the very rare *caput medusae*. This is formed by reopening of the umbilical vein and manifests itself as engorged veins forming a knot around the umbilicus, and by collateral veins radiating from the navel. The blood volume in a *caput medusae* (also that below the umbilicus) flows centrifugally from the umbilicus. The differential diagnosis includes obstruction of the inferior vena cava with formation of venous collateral vessels. However, in this case the entire venous blood (also that in the veins from below the navel) flows cephalad towards the superior vena cava.

Gynecomastia (noninflammatory enlargement of the male breast) may be seen in patients with advanced liver cirrhosis, hypogonadism, hyperthyroidism, estrogen producing tumors, and during treatment with medications such as aldosterone antagonists, antiandrogens, cimetidine, protease inhibitors, alkylating agents, and certain antipsychotic drugs [4]. The pathophysiology is not well understood. Increased estrogen levels or a disproportion between estrogens and testosterone may play a role in proliferation of breast tissue in some patients, but it is not always present [4, 7]. Gynecomastia is usually small and unilateral. On exam, a concentric mound of soft, elastic, or firm tissue can be palpated around the nipple–areolar complex; sometimes, it may be tender. Occasionally gynecomastia can develop bilaterally and reach dimensions of a normal female breast. Hard, asymmetric subareolar masses fixed to the skin or chest wall should arouse the suspicion of carcinoma, as should the presence of nipple bleeding or discharge, which should not be present in benign gynecomastia [4]. Changes in hormonal levels may also be reflected by concomitant loss of hair (e.g., shins) and decrease in testes size.

A sweetish, ammoniacal, musty breath in patients with severe parenchymal liver disease is called *fetor*

hepaticus. It has been likened to “a mixture of rotten eggs and garlic” [8, 14]. The compounds causing the odor are probably dimethylsulphide or dimethyldisulphide. The intensity of *fetor hepaticus* correlates with the severity of liver disease and with the degree of portal-systemic shunting, not with encephalopathy per se. Thus alert patients with severe portal-systemic shunting may also have the characteristic breath [24].

Examination of the Liver

The anterior surface of the liver is mostly covered by the chest wall and is inaccessible to palpation. Only a narrow strip of the left liver lobe abuts the abdominal wall (medial to the intersection of the right midclavicular line and the costal margin), and, with difficulty, is accessible to palpation.

The physical examination of the liver aims to determine size, tenderness, and consistency of the organ, as well as the presence or absence of irregularities or nodularities. When most patients take a deep breath, the lower edge of the normal liver strikes the palpating fingers in the right midclavicular line. The normal organ is nontender and the edge is smooth, regular, and soft.

The liver span, i.e. the distance between the upper border of the liver and its lower edge, usually is determined in the right midclavicular line. The span of the normal liver is approximately 9 ± 2 cm in women and 11 ± 2 cm in men. The upper border is determined by percussion, the lower edge by percussion or palpation. The determination of the lung–liver interface (i.e., where lung resonance changes to liver dullness) is performed by light percussion. If percussion is performed too heavily, the upper border of the liver is determined too high. However, if percussion is performed in the middle or posterior axillary line, or on the back, it must be heavy because of increased muscle thickness in these areas. In adults, liver dullness in the midclavicular line extends from the fifth intercostal space to directly beneath the right costal margin. The consistency of the liver parenchyma probably determines, in part, whether a liver is palpable.

The distance between the lower liver edge and the costal margin does not reflect the overall liver size; therefore, the finding of a palpable liver edge is an unreliable sign of hepatomegaly [14]. To evaluate for

hepatomegaly, in addition to palpation, the upper border of hepatic dullness must be percussed [5, 15, 16].

Compared to sonographic measurement, the clinician's assessment of liver size almost always underestimates the actual value [22, 23]. Clinicians place the upper border too low and the lower border too high [14, 20, 23]. Experienced clinicians, each examining the same patient, may differ in their estimate of the patient's liver span, on average, by 8 cm! [20]. Thus, the percussed liver span is very dependent on the clinician's technique, with a high inter-, but a low intraexaminer variability. One and the same examiner may therefore reliably judge changes of liver size throughout the course of an illness. Auscultation of the liver, while scratching the skin overlying the organ, the "hepatic scratch test", should not be employed, since the results are inconsistent and unreliable.

Chronic obstructive pulmonary disease (COPD), gas-filled intestinal loops, ascites, and obesity make physical examination of the liver difficult and may lead to false results. Depression of the diaphragm, for example, in COPD, may cause the liver to "fall" 1–2 cm beneath the costal arch and become palpable, without necessarily being enlarged. In skinny persons with a firm abdominal wall and strong abdominal muscles, palpation of the liver is difficult. Confusing the lower edge of the left liver lobe with the tendinous inscriptions of the rectus abdominis muscle is the most common error in palpating the left liver lobe. It can easily be avoided by observing the movement of the interested structures during respiration. The tendinous inscriptions do not move during respiration with respect to the skin. However, with deep inspiration and upward movement of the sternum and the costal margin, the inscriptions move cephalad, while the liver edge slides downwards.

An enlarged, soft liver is found in patients with steatosis, as well as those with both alcoholic and nonalcoholic steatohepatitis. The alcoholic micronodular cirrhotic liver is enlarged in its initial stages and cannot be reliably distinguished from fatty liver based solely on consistency. A liver with posthepatic (postnecrotic) cirrhosis is shrunken and macronodular, and is usually considerably smaller and harder than its alcoholic counterpart. A liver with metastases may be greatly enlarged; in the cachectic patient, its nodular surface and hard consistency may be easily appreciated by palpation. The liver is also enlarged in rapidly

developing venous outflow obstruction, such as occurs in Budd-Chiari syndrome, but in contrast to a metastatic liver it is tender on palpation.

In acute viral hepatitis palpation of the liver elicits a dull pain that is due to stretching of the capsule. If a liver abscess is situated near the capsule, pressure by palpation may also elicit pain. For abscesses embedded deep within the hepatic parenchyma, or to assess tenderness of a nonpalpable liver, pain may be elicited by short bilateral compression of the lower chest wall (only the right side should hurt).

A *pulsatile liver* has been described in tricuspid regurgitation with pulmonary hypertension, and in constrictive pericarditis.

Examination of the Gallbladder

The normal gallbladder is neither visible nor palpable under normal conditions. When the organ is enlarged (acute inflammation, hydrops, empyema, or tumor), however, it may be palpated.

Pain originating from the gallbladder localizes to the right upper quadrant and frequently radiates to the right flank, to the back, and occasionally to the right shoulder. Corresponding to Head's zones, skin hyperalgesia extends in a semibelt-like fashion from the midabdominal line to the spine.

When palpating the right upper quadrant, increased pain and respiratory splinting during deep inspiration is characteristic for acute cholecystitis (*Murphy's sign*). A palpable, solid, non-tender gallbladder in patients with obstructive jaundice is suggestive of a tumor in the head of the pancreas, and argues against stones in the common bile duct. This sign, first described by *Courvoisier*, is rarely encountered nowadays.

Examination of the Spleen

The spleen lies under the left diaphragm and extends obliquely with its long axis along the tenth rib, and along the midaxillary line from the ninth to the eleventh rib. Palpation and percussion are best performed in the supine or right oblique position. The extension of the area of splenic dullness (*Traube's space*) on palpation is approximately 7 cm. During deep inspiration

the spleen is separated from the chest wall by the lung. The normal-sized spleen is not palpable, while the descending margin of an enlarged spleen will touch the fingertips during inspiration. However, the determination of splenic size by palpation and percussion is quite imprecise and is subject to many confounding factors, such as COPD, meteorism, enlarged gastric air bubble, fluid in the stomach, feces in the colon, nonsplenic tumor in the left upper quadrant, and left sided pleural effusion [1].

The causes of splenomegaly are numerous and it is beyond the scope of this chapter to discuss them. Vascular, infectious, hematologic-oncologic, infiltrative and immune diseases must be considered. Within the context of chronic liver disease, an enlarged spleen usually is a manifestation of portal hypertension. The spleen is also enlarged in acute viral hepatitis, though it is not often palpated due to its soft consistency.

Ascites

The accumulation of large quantities of fluid within the peritoneal cavity leads to abdominal distension and to the effacement or eversion of the umbilicus. Abdominal swelling due to ascites should be differentiated from that seen in meteorism (gaseous distension) or in marked obesity. The characteristic signs of ascites are *bulging flanks* in the supine position, *tympany* at the top of the abdominal wall (gas-filled small intestinal loops float on top of the fluid), *shifting dullness* when the patient turns to one side, and a *fluid wave* that may be elicited by tapping the patient's flank with a hand.

The sensitivity and specificity of physical examination for the determination of ascites (equal clinical skills provided) depend primarily on the amount of peritoneal fluid present. The demonstration of shifting dullness is highly sensitive (up to 86%), while clear evidence of a fluid wave is highly specific (up to 82%) for the presence of ascites. However, eliciting these signs usually requires a minimum of 500 mL of ascites (by comparison, computed tomography and ultrasonography can detect as little as 100–150 mL). On the other hand, if shifting dullness is absent, ≥ 500 mL of ascites can be excluded with an accuracy of $>90\%$ [6, 10, 21, 27].

Auscultation of the Abdomen

The auscultation of the abdomen in liver disease plays only a minor role. Nevertheless it should not be omitted, since occasionally it may yield useful information. An extensive portal collateral circulation in cirrhosis may cause a continuous venous flow murmur above the falciform ligament, between the umbilicus and the epigastric angle [13]. A systolic bruit may be a clue to increased arterial flow, as may be seen, for example, in large hepatic malignancies (generally hepatocellular carcinoma) [9]. A respiratory-dependent hepatic friction rub may be associated with hepatic malignancy (metastasis or primary liver cancer) or a perihepatitis (gonorrheal, chlamydial). A transient friction rub occurs after liver biopsy and is caused by the adherence of a small clot to the puncture site; it has no clinical significance [11, 12].

Skin and Mucous Membranes

Due to a hyperdynamic circulation with increased cardiac output and decreased peripheral vascular resistance, most patients with liver cirrhosis have a warm and dry skin. In addition, many alterations of the skin may occur and serve as clues to an underlying liver disease, which are therefore called “*cutaneous signs of liver disease*”.

Jaundice (Icterus)

Jaundice is a yellowish discoloration of the skin and tissues caused by deposition of bile pigment. Bilirubin binds selectively to connective tissue. When serum bilirubin concentration exceeds 2.5 mg/dL icterus is usually first noted in the conjunctiva of the eyes, the white segment of the frenulum of the tongue, the gums, or even the tympanic membrane. In the eyes, most of the pigment is deposited in the conjunctiva, not the sclera. Therefore the traditional term “scleral icterus” may be a misnomer. When serum bilirubin exceeds 4 mg/dL, jaundice of the skin becomes apparent. Conjugated bilirubin binds to tissue proteins and is

only slowly degraded. This explains why the disappearance of jaundice and icterus often lags behind the resolution of elevated serum bilirubin concentrations. The recognition of scleral icterus is subject to significant inter-observer variation. Among other factors, it depends on the clinician's experience, the level of serum bilirubin, and on exogenous factors such as the illumination of the examination room. Approximately one third of examiners do not detect scleral icterus at the textbook threshold bilirubin value of 2.5 mg% [19, 25]. This proportion declines with rising bilirubin levels. Medical students, on the other hand, tend to make false positive interpretations, i.e. they tend to describe alleged scleral icterus with bilirubin values <1 mg%. Persons with excessive ingestion of carrots develop carotenemia and a yellowish discoloration of the skin that occasionally may be mistaken for jaundice. In contrast to jaundice, however, the conjunctivae are spared.

When evaluating a patient with jaundice (see Chapter 52), one should ask about changes in the color of the urine and feces. Dark urine with acholic, occasionally steatorrheic feces is typical for cholestatic jaundice. Usually the urine darkens before jaundice appears. Jaundice without darkening of the urine suggests elevated serum concentrations of indirect (unconjugated) bilirubin and should prompt one to consider hemolytic anemias and genetic errors of bilirubin metabolism (e.g., Gilbert-Meulengracht syndrome, Crigler-Najjar syndrome). Darkening of the urine is not always caused by bilirubinuria. A concentrated urine in dehydrated patients has a deep yellow to dark orange color. Marked hematuria confers the urine a Cola-like aspect, while myoglobinuria resulting from rhabdomyolysis can turn urine tea-colored.

Scratch Effects

Hepatobiliary jaundice often is accompanied by pruritus (see Chapter 31). Even if the patient does not explicitly mention pruritus, a careful examination of the skin may reveal scratch marks and give an idea not only about the presence of pruritus but also about its intensity. Pruritus and the resulting excoriations may also be present in patients without overt jaundice, as is often seen in

cholestatic liver diseases such as primary biliary cirrhosis, and sometimes in chronic hepatitis C.

Spider Telangiectasia

Spider angiomas (“*spider nevi*”) were first described by the English physician Erasmus Wilson in 1867. Spider nevi are not true nevi, but rather are reddish cutaneous lesions caused by dilated arterial blood vessels. They usually measure 3–15 mm in diameter. They consist of (1) a small central arteriole (“body” of the spider) which is often slightly elevated and occasionally pulsating, (2) multiple radiating capillary “legs”, and (3) a surrounding, ill-defined erythema, which may encompass the entire lesion or only its central portion [3]. After pressing on the lesion to induce blanching, it refills with blood starting from the center and then extending to the periphery. Spider nevi typically occur on the face and neck, followed by the shoulders, thorax, arms, and hands. They are rare below the umbilicus. In addition to liver cirrhosis, spider angiomas may occur during pregnancy (they typically appear between the second and fifth month and usually disappear within days after delivery), in hyperthyroidism, as a paraneoplastic sign, in malnutrition, and occasionally in persons without any underlying disease [2]. They must be distinguished from simple cutaneous telangiectasias or those associated with Osler-Weber-Rendu syndrome (hereditary hemorrhagic telangiectasia). Hormonal causes with an increased ratio of estradiol to testosterone have been postulated to contribute to their formation. However, the exact cause still remains poorly understood.

Palmar Erythema

Palmar erythema is a symmetric reddening, probably due to arterio-venous anastomoses, of the surfaces of the palms. It is most pronounced over the hypothenar and thenar eminences, as well as on the flexor surfaces of the distal phalanges. The erythema can also occur on the soles of the feet and on the toes. In addition to liver cirrhosis, palmar erythema may be seen in patients with rheumatoid arthritis, carcinomas, systemic lupus

erythematous, diabetes mellitus, hyperthyroidism, during pregnancy, and in healthy persons.

“Banknote” Skin

Some patients with liver cirrhosis have a very fine skin with the delicate, tortuous cutaneous vessels gleaming like fibers of a banknote. This sign is occasionally also seen in normal light-skinned individuals.

Glazed Tongue

A smooth, deeply red tongue, due to hyperemia and atrophy of the papillae is often seen in patients with liver cirrhosis of various etiologies. Also, the lips may assume a deep red color.

Bleeding Signs

Hematomas after minor trauma (bruises) and/or purpuric or petechial bleeding of the oral mucosa are manifestations of a complex disorder of coagulation (thrombocytopenia, deficiency of clotting factors) and capillary fragility. The latter may be enhanced by the chronic ingestion of corticosteroids.

Bleeding from the gums, nasopharyngeal space, esophageal or gastric varices, portal hypertensive gastropathy and enteropathy, or from peptic ulcers may manifest as hematemesis or melena.

Palpable Purpura

These non-blanching, purplish spots or patches are most often found on the lower extremities and suggest vasculitis in the context of cryoglobulinemia, especially in patients with chronic hepatitis C, but occasionally also with hepatitis B.

Xanthelasmas and Eruptive Xanthomas

These are caused by cutaneous cholesterol deposits in patients with hypercholesterolemia and long standing

cholestatic liver disease. Xanthelasmas, the most common type of xanthomas, occur in the periorbital areas (upper lids, inner canthus) and appear as soft, yellowish polygonal papules or plaques. Eruptive xanthomas appear suddenly and occur preferably on the extensor surfaces of the extremities and the buttocks. The initially reddish, dome-shaped papules may coalesce to form nodules and take on a yellow center with a red halo.

Hyperpigmentation

Hyperpigmentation of the skin is observed in primary biliary cirrhosis and in genetic hemochromatosis. In the latter the bronze color of the skin is due to melanin rather than iron deposits. Diffuse cutaneous hyperpigmentation is also present in the adult form of Gaucher’s disease. In porphyria cutanea tarda spotty hypopigmentation may also be seen in addition to hyperpigmentation.

Hypopigmentation

Symmetrically distributed, hypopigmented skin areas on the back on both sides of the spine (“*butterfly sign*”) may very rarely be encountered in icteric patients with chronic cholestatic, pruritic liver diseases [18, 26]. This change may be due to the fact that it is very difficult for the patient to reach, and therefore scratch, these areas.

Vitiligo may occur in primary biliary cirrhosis and in autoimmune hepatitis.

Papulous Acrodermatitis

It is also called *Giannotti–Crosti syndrome* and is an inflammatory skin disease characterized by a lichenoid-papulous exanthema on the hips and buttocks, followed by the arms and finally the face. It is caused by hepatitis B virus and occurs mostly in anicteric HBV infection in children (*Acrodermatitis papulosa eruptiva infantilis*).

Lichen Planus

This recurrent, pruritic, inflammatory eruption characterized by small, discrete, polygonal, planar, violaceous

papules and plaques is most commonly distributed symmetrically on the flexor surfaces of the wrists. It is associated predominantly with primary biliary cirrhosis, but may also occur with other liver diseases such as hepatitis C virus infection.

Hair Growth

Loss of hair is seen especially on the abdomen (“abdominal baldness”), in the pubic area and underarms, and on the shins. A *hypertrichosis*, often combined with blisters on sun exposed areas, is seen in patients with porphyria cutanea tarda and porphyria variegata. A cutaneous photo-sensitivity is also observed in the very rare hereditary coproporphyrinemia and in hepato-erythropoietic porphyria.

Nodular Panniculitis

A nodular panniculitis may be observed in α_1 -antitrypsin deficiency. It is characterized by painful, single or multiple subcutaneous nodules, usually on the lower extremities. The nodules may ulcerate and heal by scar formation.

Nail Changes

In patients with liver cirrhosis a variety of noncharacteristic nail changes may be observed. They are mostly a manifestation of chronic metabolic disturbances associated with malnutrition and deranged homeostasis of vitamins and trace elements. In the individual case, however, the pathophysiological mechanisms are poorly understood.

Beau's lines are transverse linear depressions in the nail plate parallel to the lunula (the crescent-shaped whitish area of the nail bed). They are caused by any condition severe enough to disrupt normal nail growth, and have been described in chronic liver disease and as a complication of immunosuppressive treatment for autoimmune hepatitis. The lines mark the slowed growth or the point of growth arrest of the nail. Since nails grow by 1 mm every 6–10 days the timing of the disease process may be calculated by measurement of the distance of the line from the lunula. Upon normalization of nail growth they grow out.

In *Terry nails* the proximal 80% of the nail bed is white, leaving a distal band of normal pink. The exact mechanism is unknown, though it is postulated that these changes result from a decrease in vascularity and increase in connective tissue in the nail bed.

In *Lindsay nails* (“*half and half nails*”) an increase in the size of the lunula to approximately 50% of the nail bed is observed. The proximal white portion of the nail bed is sharply separated from the distal pink-red part. They occur in hypoalbuminemic conditions.

Muehrcke lines are paired, white, arcuate bands in the nail bed parallel to the lunulae. They are seen in long-standing hypoalbuminemic (<2.0 g/dL) conditions, such as liver cirrhosis and nephrotic syndrome. They represent vascular abnormalities of the nail bed and transiently disappear when the nail is depressed. They do not move distally with nail growth (localized in nail bed, not in nail plate) and resolve when serum albumin is corrected.

Light *blue lunulae* are occasionally seen in patients with Wilson's disease. Their cause is unknown. A locally increased deposition of copper is not present.

Neurologic-Psychiatric Changes

Patients with advanced chronic liver disease or with massive acute parenchymal necrosis develop changes in their mental status and exhibit various neurologic-psychiatric signs.

Hepatic encephalopathy is a potentially reversible cerebral dysfunction occurring in acute liver failure and/or caused by portal-systemic shunting. Depending on its severity, different stages of encephalopathy are distinguished, ranging from subclinical changes to deep hepatic coma (see Chapters 78 and 80). The knowledge of *subclinical hepatic encephalopathy* is important, since these patients in everyday life appear to function normally, without evidence of neuropsychological problems. Formal neuropsychiatric testing, however, can detect subtle apraxias and other cerebral dysfunctions.

Asterixis is a sign of hepatic encephalopathy. It is a high amplitude flapping tremor (“liver flap”) that may be elicited in various ways. The most common maneuver is to have the patient dorsiflex his/her hands while holding his/her arms outstretched with fingers spread apart (“stop-sign”). Alternatively, if the patient can stick his or her tongue out straight and attempt to hold it still, a flap can be observed. In a less cooperative patient,

having the patient perform a tight hand grip may elicit the typical rhythmic contractions of asterixis. Asterixis is not a specific sign of liver disease and may also be observed in encephalopathy from hypercapnia, uremia or cardiac insufficiency. Unilateral asterixis indicates structural disease in the contralateral brain [17].

Other Changes

Dupuytren's contracture describes the painless local thickening and shortening of palmar aponeurosis from hyalinization of collagen fibers. It begins near the base of the digit and extends to form a plaque or band. It induces retraction and dimpling of the palmar skin and flexion contractures of the fingers. This type of contracture is typically seen in patients with alcoholic cirrhosis. However, it may also occur in persons without liver disease. The pathogenesis is poorly understood. Damage to the fascia by local overproduction of free radicals and oxidative stress is hypothesized.

Palpation of the testes is an integral part of physical examination. *Testicular atrophy* is encountered especially in patients with alcoholic cirrhosis.

Nontender, bilateral *parotid swelling* is occasionally seen in patients with liver cirrhosis. The overlying skin is not erythematous.

Kayser-Fleischer ring is a peripheral, golden-brown opacity in the cornea caused by copper deposition in Descemet's membrane. The ring is seen best on slit lamp examination and is a typical feature of Wilson's disease (see Chapter 81), although it very rarely may also be observed in patients with primary biliary cirrhosis.

Serum sickness with urticaria, angioedema, petechial bleeding, palpable purpura and erythema multiforme-like lesions is occasionally seen in the prodromal phase of hepatitis B. It is probably a manifestation of an immune-complex vasculitis mediated by circulating HBsAg containing immune-complexes.

References

- Barkun AN, Camus M, Green L, et al (1991) The bedside assessment of splenic enlargement. *Am J Med* 91: 512–8
- Bean WB (1943) Acquired palmar erythema and cutaneous vascular "spiders". *Am Heart J* 25: 463–77
- Bean WB (1945) The cutaneous arterial spider: a survey. *Medicine* 24: 243–331
- Braunstein GD (2007) Gynecomastia. *N Engl J Med* 357: 1229–37
- Castell DO, O'Brien KD, Muench H, et al (1969) Estimation of liver size by percussion in normal individuals. *Ann Intern Med* 70: 1183–9
- Cattau EL, Benjamin SB, Knuff TE, et al (1982) The accuracy of the physical examination in the diagnosis of suspected ascites. *JAMA* 247: 1164–6
- Cavanaugh J, Niewoehner CB, Nuttall FQ (1990) Gynecomastia and cirrhosis of the liver. *Arch Intern Med* 150: 563–5
- Challenger F, Walshe JM (1955) Foetor hepaticus. *Lancet* 1: 1239–41
- Clain D, Wartnaby K, Sherlock S (1966) Abdominal arterial murmurs in liver disease. *Lancet* 2: 516–9
- Cummings S, Papadakis M, Melnick J, et al (1985) The predictive value of physical examination for ascites. *West J Med* 142: 633–6
- Fenster F, Klatskin G (1961) Manifestations of metastatic tumors of the liver: a study of eighty-one patients subjected to needle biopsy. *Am J Med* 31: 238–48
- Fred HL, Brown GR (1962) The hepatic friction rub. *N Engl J Med* 266: 554–5
- McFadzean AJS, Gray J (1953) Hepatic venous hum in cirrhosis of liver. *Lancet* 2: 1128–30
- McGee S (2001) Evidence-based physical diagnosis. W.B. Saunders, Philadelphia, PA
- Meidl EJ, Ende J (1993) Evaluation of liver size by physical examination. *J Gen Intern Med* 8: 635–7
- Naylor CD (1994) Physical examination of the liver. *JAMA* 271: 1859–65
- Reinfeld H, Louis S (1983) Unilateral asterixis: clinical significance of the sign. *N Y State J Med* 83: 206–8
- Reynolds TB (1973) The "butterfly" sign in patients with chronic jaundice and pruritus. *Ann Intern Med* 78: 545–6
- Ruiz MA, Saab S, Rickman LS (1997) The clinical detection of scleral icterus: observation of multiple examiners. *Mil Med* 162: 560–3
- Sapira JD, Williamson DL (1979) How big is the normal liver? *Arch Intern Med* 139: 971–3
- Simel DL, Halvorsen RA, Feussner JR (1988) Quantitating bedside diagnosis: clinical evaluation of ascites. *J Gen Intern Med* 3: 423–8
- Skrainka B, Stahlhut J, Fulbeck CL, et al (1986) Measuring liver span: bedside examination versus ultrasound and scintiscan. *J Clin Gastroenterol* 8: 267–70
- Sullivan S, Krasner N, Williams R (1976) The clinical estimation of liver size: a comparison of techniques and an analysis of the source of error. *Brit Med J* 2: 1042–3
- Tangerman A, Meuwesse-Arends MT, Jansen JB (1994) Cause and composition of foetor hepaticus. *Lancet* 343: 483
- Theodossi A, Knill-Jones RP, Skene A (1981) Inter-observer variation of symptoms and signs in jaundice. *Liver* 1: 21–32
- Venencie PY, Cuny M, Samuel D, et al (1988) The "butterfly" sign in patients with primary biliary cirrhosis. *J Am Acad Dermatol* 19: 571–2
- Williams JW, Simel DL (1992) The rational clinical examination. Does this patient have ascites? How to divine fluid in the abdomen. *JAMA* 267: 2645–8

Chapter Outline

Enzymes	319
Aminotransferases.....	320
Glutamate Dehydrogenase.....	322
Lactate Dehydrogenase.....	323
Gamma-Glutamyl Transferase.....	323
Alkaline Phosphatase.....	324
5'-Nucleotidase.....	325
Leucin Aminopeptidase.....	326
Cholinesterase.....	326
Other Enzymes.....	327
Bile Acids	327
Albumin	327
γ-Globulins	328
Clotting Factors	328
Prothrombin Time.....	329
Partial Thromboplastin Time.....	329
Ammonia	329
Bilirubin	330
References	331

In addition to the patient's history and physical examination basic biochemical parameters help to differentiate and further characterize liver diseases. Changes in serum concentrations allow us to define patterns of liver injury and they may also give rough clues to the acinar localization of liver damage. Damaged and dying liver cells release their contents into the extracellular space and into the circulation, and *cell enzymes are sensitive indicators of cell injury*. Disturbances of bile flow are accompanied by increased activities of compounds that are localized in the biliary tree and/or are excreted in bile. The decline in global liver performance may be recognized by changes in substances synthesized and metabolized by the liver. In [Table 34.1](#) the parameters of various patterns of liver injury are listed. In addition to the information on individual laboratory parameters provided here, the reader is referred to Chapter 49 for discussion of the clinical approach to the patient with abnormal liver chemistries. For didactic reasons there is some overlap in both chapters.

Enzymes

Enzymes catalyze defined chemical reactions and have a high substrate and reaction specificity. In healthy persons their intracellular concentrations are up to 10,000-fold higher than their respective serum values. Elevations in serum enzyme levels are due to (1) cell injury (ranging from mild disturbance of permeability to irreversible cell damage), (2) increased synthesis and release of enzymes, and/or (3) decreased enzyme clearance. The interpretation of liver enzyme levels requires a thorough understanding of the structure and

Table 34.1 Parameters of hepatic patterns of injury

Injury pattern	Parameter
Hepatocellular (necroinflammatory) injury	Aminotransferases Glutamate dehydrogenase Lactate dehydrogenase Bile acids
Cholestatic injury	Alkaline phosphatase γ -Glutamyltransferase 5'-Nucleotidase Leucin aminopeptidase Lipoprotein-X Bile acids
Global decrease in liver synthesizing capacity	Albumin Coagulation factors Cholinesterase Bilirubin Ammonia
Fibrogenesis/fibrosis^a	P III-NP ^b P I-CP ^b Collagen type IV (7S-domain) Prolylhydroxylase
Immune- and inflammatory reaction	Acute phase proteins Total γ -globulins IgG, IgA, IgM Autoantibodies

^aSee Chapter 28

^bP III-NP Aminoterminal propeptide of procollagen type III, P I-CP carboxyterminal propeptide of procollagen type I

function of the liver, and can only be performed correctly within the clinical context of the patient, integrating historical data and physical findings.

In the context of certain liver enzyme patterns, knowing the cellular and acinar distribution of enzymes and the factors that impact their release will help localize the site of damage within the acinus and in some cases permit conclusions about the specific etiology of liver injury. Simplistically, *hepatitic (necroinflammatory)*, *cholestatic*, and *mixed patterns of liver injury* may be distinguished (see Chapter 49) [6, 7]. Generally, however, in addition to determining enzyme patterns in serum, further serologic, immunologic, and genetic examinations, as well as the use of imaging modalities is necessary, in order to determine the etiology, severity, course and prognosis of a liver disease.

Liver enzyme levels and their activity patterns in serum do not reflect liver function (possibly with the exception of cholinesterase). The liver function tests proper are discussed in Chapter 35.

Aminotransferases

Aminotransferases (transaminases) are enzymes that catalyze the conversion of α -ketoacids to amino acids by transfer of one amino residue.

Aspartate aminotransferase (AST) (old term glutamate-oxalacetate transaminase; GOT) catalyzes the transfer of the 2-amino residue of aspartate to 2-oxoglutarate, generating glutamate and oxalacetate. *Alanine aminotransferase (ALT)* (old term glutamate-pyruvate transaminase; GPT) catalyzes the transfer of the 2-amino residue of alanine to 2-oxoglutarate, forming glutamate and pyruvate.

AST and ALT are the most frequently used indicators of necroinflammatory liver diseases.

AST occurs in the liver, but is also present in skeletal and cardiac muscle, kidneys, brain, pancreas, intestines, leuko- and erythrocytes and in the lungs. An elevated AST nearly always originates from the liver, heart or skeletal muscle. Thus, *AST is not liver specific*, and elevations of serum levels also occur, among others, in muscle and heart diseases.

ALT is found nearly exclusively in the liver. Its specific hepatic activities are tenfold the respective activities in heart or skeletal muscle. Thus, for practical purposes *ALT may be regarded as largely liver specific*.

At the cellular level ALT is primarily stored in the cytosol of hepatocytes. AST is found in the mitochondria (70%) and in the cytoplasm (30%). In contradistinction to its cellular distribution, most of the serum AST in healthy persons represents the cytosolic AST-isoenzyme. AST and ALT activities in the liver are approximately 7,000- and 3,000-fold the serum activities, respectively. The half-life of total AST is 17 ± 5 h, that of ALT 47–50 h. The half-life of mitochondrial AST averages 87 h [2]. AST and ALT activities are significantly higher in males than in females.

Normal serum levels of aminotransferases reflect the physiologic cell turnover. Elevated serum levels are not due to increased enzyme synthesis, but are rather the manifestation of enhanced enzyme release caused by liver cell death or by liver injury with an increase in permeability of the hepatocellular membrane. ALT and AST are therefore regarded as sensitive indicators of hepatocellular damage. They lend themselves as basic diagnostic parameters to assess and follow liver disease. ALT is a relatively specific indicator of liver disease, with elevated serum levels

present in even minor cell injury. It can therefore be used to screen for liver damage. However, it has recently been pointed out that current standards for "normal" ALT levels might miss patients with subclinical liver disease, as is seen for example in chronic hepatitis C infection or nonalcoholic fatty liver disease; consequently, a revision of normal limits for ALT level has been suggested [5].

The diagnostic sensitivity of AST for liver disease is lower than that of ALT. However, *neither aminotransferase is diagnostically specific.*

The concomitant elevation of ALT and AST levels always suggest hepatocellular necrosis. The degree of aminotransferase levels depends on the amount released and the clearance of the enzymes. There is no strict correlation with the amount of parenchyma lost. However, the height of ALT levels can be used to roughly estimate the severity of liver parenchymal damage. ALT levels greater than 15- to 50-fold the upper limit of normal (ULN) indicate extensive hepatocellular death (viral, toxic, ischemic). AST elevations greater than 1,000 U/L can be seen within a few days of acute viral hepatitis or of toxic and hypoxic liver injury. Typically in acute viral hepatitis serum levels of ALT are higher than those of AST. The persistence of elevated aminotransferase levels in viral hepatitis for more than 6 months suggests the development of chronic illness. However, there is no correlation between the aminotransferase levels and the inflammatory activity, and the height of aminotransferase rise has no prognostic significance.

In cholelithiasis an early rise of AST occurs, generally $<5 \times$ ULN. If cholangitis supervenes, AST levels may exceed $10 \times$ ULN.

The ratio of AST/ALT (*De Ritis quotient*) may serve as a crude parameter for judging liver damage [1]. Repeat determinations of the quotient during follow-up allows a rough estimate of the degree and the progression of liver damage in individual patients. Values <1 suggest minor liver injury, while an increase to $>1-2$ occurs in severe chronic necroinflammatory liver diseases, such as for example in chronic viral hepatitis and in florid alcoholic hepatitis.

A normal ALT has a high negative predictive value and excludes clinically apparent liver disease with a probability of $>90\%$. Increased ALT levels, however, are not necessarily caused by liver disease. The predictive value of ALT depends on the prevalence of liver

disease in the population studied. Thus, assuming a prevalence of hepatobiliary disease of 8%, the positive predictive value of increased ALT levels for hepatic disease is only 31%. This means that approximately only every third patient with elevated ALT levels in serum will have a significant liver disease [10]. In fact, the elevated ALT levels in the remaining two thirds of patients are also hepatic in origin, but, especially if the increase is mild (up to $5 \times$ ULN), these elevations are short lived and transient, and represent mostly a harmless hepatic reaction to diseases of other organs, rather than a clinically relevant liver disease.

On the other hand, normal aminotransferase levels do not exclude chronic liver disease. Advanced ("burnt out") liver cirrhosis is associated with a marked *decrease* in ALT synthesis. Thus, low normal aminotransferase levels may be seen in long-standing liver cirrhosis. Fluctuating aminotransferase levels, with periods of normal values may be seen in chronic viral hepatitis C, despite ongoing necroinflammation.

Factors not associated with liver injury may affect aminotransferase levels. ALT shows 45% variation during the day, with highest levels in the afternoon, and lowest at night. The day to day variation is 10–30% with ALT and 5–10% with AST. AST levels are 15% higher in African-American men than in white men. Strenuous exercise leads to a threefold increase of AST. This effect is seen predominantly in men. Muscle injury is associated with a significant increase in AST and a moderate increase in ALT levels. Hemolysis and hemolytic anemia lead to a significant increase of AST and a moderate increase of ALT levels [2]. Age also has to be considered in interpreting ALT levels. Recently it has been suggested that the association between age and serum ALT activity is not a simple linear correlation, but rather an inverted U-like relation [3].

In patients treated with erythromycin or paraaminosalicylic acid high aminotransferase levels are measured. False low levels are seen in uremia.

AST and ALT may form *macroenzymes* by generating immune complexes with IgG and IgA. Their large size prevents cellular uptake and degradation, thus markedly prolonging their half-life. Typically, significant and stable elevations are seen for months and years without clinical evidence of disease. In one and the same patient macroenzymes affect either AST or ALT, with AST being more often affected.

Synopsis of ALT and AST:

- ALT is largely liver specific, while AST is also found in skeletal and cardiac muscle, kidneys, brain, pancreas, intestine, lungs, and white and red blood cells.
- ALT is present in the cytosol of hepatocytes; AST is found in the mitochondria (70%), and in the cytoplasm (30%).
- Elevated blood aminotransferase levels are due to their enhanced release from damaged or dead hepatocytes, and not to an increased enzyme synthesis.
- ALT and AST are the most frequently used indicators of necroinflammatory liver disease.
- The concomitant rise in ALT and AST suggests hepatocellular necrosis.
- A normal ALT excludes a clinically relevant liver disease with a probability of > 90%.
- The presently used values for upper limit of normal of ALT may be too high and miss patients with subclinical liver disease, especially in chronic hepatitis C and in nonalcoholic fatty liver disease.
- Factors not associated with liver injury may affect aminotransferase levels.

Glutamate Dehydrogenase

Glutamate dehydrogenase (GLDH) catalyzes the oxidative deamination of glutamate. The reaction catalyzed by GLDH is reversible and serves also in amino acid biosynthesis. The GLDH is a mitochondrial enzyme occurring predominantly, but not exclusively, in the liver. It is also present in the kidneys, brain, lungs and skeletal muscle. The specific activity of GLDH in the liver is tenfold that in the kidneys, brain, lungs and 80-fold that in skeletal muscle. Increased GLDH serum levels derive exclusively from the liver. Thus, for practical purposes *GLDH may be regarded as a liver specific enzyme*. The half-life of GLDH in the circulation is between 6 and 18 h.

In the liver GLDH is localized primarily in the mitochondrial matrix of centrilobular, perivenous hepatocytes (zone 3). Its concentration in zone 3 is 1.8 times higher than in periportal, zone 1 hepatocytes. GLDH is not suited as a screening test for

hepatobiliary diseases. Because of its localization, the enzyme is an *indicator of predominantly centrilobular parenchymal liver injury*. Compared with blood in acinar zone 1, sinusoidal blood in zone 3 is relatively deficient in oxygen. Therefore the centrilobular region is particularly prone to hypoxic and ischemic liver damage. The degree of increase in GLDH correlates directly with the extent of centrilobular parenchymal injury. Thus, serum levels of GLDH allow for a rough estimate of the severity of parenchymal damage. Elevated GLDH levels are found primarily in alcoholic hepatitis (early mitochondrial injury by ethanol) and in other toxic liver injuries that affect predominantly zone 3, as well as in circulatory disturbances with centrilobular hypoxia. Among the latter are the various forms of shock liver, ischemic “hepatitis” (not a true hepatitis, but rather a hepatosis), acute right cardiac congestion and acute obstruction of the hepatic venous outflow tract. Transient and short lived elevations of GLDH levels in serum are also seen in patients in the early stages of bile duct obstruction and in common bile duct stones passing through the papilla, because obstructive cholestasis initially causes “stress” to centrilobular hepatocytes. Thus, in a patient with known cholelithiasis and transient right upper quadrant pain, this early and transient rise in GLDH is diagnostically important and should prompt the imaging of the common bile duct.

In combination with the aminotransferases, the GLDH levels may yield differential diagnostic information. In liver injury with very high aminotransferase activities in serum, concomitantly high GLDH levels favor a diagnosis of toxic or hypoxic liver injury over acute viral hepatitis.

Synopsis of GLDH:

- Mitochondrial enzyme; localized predominantly in perivenous, centrilobular hepatocytes.
- Indicator of damage to centrilobular (zone 3) hepatocytes.
- Elevated levels occur in alcoholic, toxic, ischemic-hypoxic (cardiocirculatory shock, septicemia) liver injuries, in acute right heart congestion or in acute occlusion of the hepatic venous outflow.
- Passage of a bile duct stone through the papilla into the duodenum causes transient (2–3 days) elevations of GLDH levels.

Lactate Dehydrogenase

Lactate dehydrogenase (LDH) is a cytoplasmic enzyme that is present in all organs, predominantly, however, in the liver, erythrocytes, heart muscle and in the kidneys. It catalyzes the oxidation of lactate to pyruvate.

Total LDH consists of five isoenzymes, of which LDH-5 is the hepatic isoenzyme. The half-life of LDH-5 is 7–12 h, which means that unlike in myocardial infarction and hemolysis, increases of liver specific LDH are only short lived.

The total serum LDH levels rise already in minor tissue injury. Because of a lack of sensitivity and specificity, the clinical value of LDH and even its isoenzymes is very limited. Many drugs (androgens, amiodarone, allopurinol, anticonvulsive drugs, erythromycin, paracetamol, coumadin) may lead to an increase of LDH levels. Major elevations are observed in liver metastases and in hypoxic liver damage. The hepatic involvement in Epstein Barr virus infection, in contrast to other viral liver infections, is characterized by high activities of LDH in relation to the aminotransferase levels. In these cases the source of LDH is the lymphatic system (LDH-3 and 4).

Synopsis of LDH:

- Ubiquitous cytoplasmic enzyme.
- General indicator of tissue injury.
- Clinical usefulness in liver disease is very limited, even if hepatic isoenzyme LDH-5 is determined.
- High activities of LDH occur in Epstein Barr virus associated hepatitis (source: lymphatic system).

Gamma-Glutamyl Transferase

γ -Glutamyl transferase (γ -GT) (or transpeptidase) catalyzes the transfer of γ -glutamyl residues between peptides or from one peptide to an L-amino acid. It serves as an amino acid transferase. Its physiologic significance is not completely understood. γ -GT may play a physiologic role in the transmembrane transport of amino acids, in the γ -glutamyl cycle, and in the cleavage of glutathione and its conjugates.

γ -GT is not liver specific. It is present in decreasing quantities in the proximal renal tubule, liver, pancreas (ductules and acinar cells), and intestine. In the hepatocyte γ -GT is a membrane bound enzyme. It is present in the smooth endoplasmic reticulum and predominantly

on the canalicular membrane, and to a lesser degree on the sinusoidal membrane. Only approximately 10% is located in the cytosol. In cholangiocytes the enzyme is associated with the luminal cell membrane. γ -GT activity in serum derives primarily from liver.

In the serum multiple forms of γ -GT (practically all originate from the liver) are present. The major fraction of the enzyme is bound to lipoproteins, primarily HDL. A minor portion is water soluble. Clearance of γ -GT is primarily hepatic, by biliary excretion. The activity of the enzyme in bile is approximately ten times higher than in plasma. A small part is catabolized in the kidneys and excreted in urine. The half-life of γ -GT in humans is approximately 7–10 days; in alcoholic liver injury, the half-life increases to as much as 28 days, suggesting impaired clearance.

Because even minor cell injury causes release of γ -GT into the extracellular space, it is a *very sensitive indicator of liver injury that, however, lacks specificity*. Elevated γ -GT serum levels are not necessarily associated with a liver disease. In 22–30% of persons with an isolated (mild) increase of γ -GT no discrete hepatobiliary disease is present. If increased γ -GT activity is accompanied by a rise in other liver specific enzymes (ALT, GLDH), elevated γ -GT levels may be interpreted as a sign of liver damage. More important than the interpretation of isolated increases of γ -GT levels is the *high negative predictive value of the enzyme*, i.e. normal γ -GT levels in serum exclude a hepatobiliary disorder with a probability of >90% [10].

Increased serum γ -GT levels in liver disease are due to cell membrane injury with enhanced release of the enzyme, to detachment of membrane bound enzyme by the solubilizing action of bile acids, or to an increased synthesis induced by many drugs. Enzyme induction may occur through the use of, for example, ethanol, barbiturates, carbamazepine, cimetidine, furosemide, heparin, isotretinoin, methotrexate, oral contraceptives, phenytoin, and valproic acid.

Similar to alkaline phosphatase (AP) and 5'-nucleotidase, γ -GT is also increased in cholestatic liver diseases. However, an increased γ -GT level cannot differentiate between intra- and extrahepatic cholestasis. *An increased γ -GT level in the presence of increased AP concentrations in serum hints at the hepatic origin of AP.*

Mild increases (approximately 2–3 \times ULN) occur in enzyme induction by drugs, in nonalcoholic and alcoholic steatosis, or in venous congestion in right heart failure. Space occupying liver lesions may also lead to an increase in γ -GT activity.

Measuring isolated γ -GT levels has no clinical significance. Elevated γ -GT levels should be evaluated by repeat testing and a meaningful interpretation requires the comparison with other enzymatic indicators of liver injury.

In alcoholic liver disease elevation of γ -GT activity is a sensitive, but nonspecific parameter. *A decrease in enzyme activity during abstinence from alcohol is diagnostically more helpful than the presence of elevated γ -GT levels per se.* This pattern is a clear indicator of alcohol as the cause of an elevated γ -GT. In florid alcoholic hepatitis γ -GT levels may be 30–50-fold the ULN. In milder forms the ratio of γ -GT/AST is usually >6. An AST/ALT ratio >2 also supports the alcoholic etiology of liver injury.

In addition to liver injury extrahepatic factors may affect levels of γ -GT: a 10–15% day to day variation is observed; γ -GT activities decrease after meals; γ -GT levels are approximately double in African-Americans; smoking increases γ -GT (10% higher with 1 pack/day, approximately double with heavier smoking); beginning in the second trimester of pregnancy γ -GT levels start to decrease (in contrast to AP); and, false low values are measured in hemolysis [2].

Synopsis of γ -glutamyl transferase:

- Occurrence: kidneys, pancreas, liver, spleen, lungs.
- Liver: 90% membrane bound, predominantly in the canalicular membrane; 10% in the cytosol.
- Sensitive but nonspecific indicator of hepatobiliary injury. It is *the most overused enzyme in clinical hepatology.*
- Levels are increased in cholestatic diseases, space occupying liver lesions, venous congestion. Enzyme induction by many drugs and by ethanol.
- Elevated γ -GT levels are not specific for alcoholic liver injury. However, a decrease of previously elevated levels during abstinence from alcohol has differential diagnostic significance and adds to the specificity of the enzyme.
- Normal γ -GT levels exclude a hepatobiliary disease with a probability of >90% (high negative predictive value).
- Because of lack of specificity, γ -GT should be reserved for specific indications, such as determining the source of an increased alkaline phosphatase.

Alkaline Phosphatase

Alkaline phosphatase (AP) belongs to an enzyme family that hydrolyzes esters of phosphoric acid in an alkaline milieu. The total activity of AP in serum is the sum of the activities of several enzymes from different tissues. The AP in serum can be subdivided into genetically determined different isoenzymes and into many organ-specific, posttranslationally modified enzymatic forms: hepatic, osseous, small intestinal, renal and placental AP. The half-life is 3–7 days. Up to the age of 50 years the mean AP activity in serum is slightly higher in men than in women. In the seventh decade the AP activity rises in both genders, usually more pronounced in women. In healthy persons liver (>17 isoforms) and bone are the most important sources of AP, accounting for more than 80% of circulating AP. Less than 20% is intestinal AP. An increase in small intestinal AP is found in chronic renal insufficiency and in persons secreting blood group O and B erythrocyte antigens. In the latter group fatty meals may cause an excessive release of intestinal AP. *Therefore, measurement of AP values should be performed in the fasting state.*

AP is localized within the hepatocytes and in the canalicular membrane. Biliary obstruction, increased pressures in the biliary system, and elevated concentrations of bile acids all stimulate AP synthesis. Bile acids may modify AP synthesis at the translational level [4]. *The increase in serum AP levels seen in hepatobiliary disease results from enhanced release of newly formed canalicular AP.* Bile acids have membrane solubilizing features and increase the permeability of intercellular tight junctions, thereby increasing detachment of membrane bound AP and enhancing the passage of the enzyme into sinusoidal blood. Deranged biliary excretion, with increased retention and subsequent passage into the circulation, is of no pathophysiologic importance for the increase in serum AP levels.

Liver AP is an indicator of cholestasis and increased levels are found in all forms of cholestasis. The diagnostic sensitivity of AP in cholestatic liver disease is 80–100%. In these cases AP levels rise up to three to four times the ULN. A high molecular isoform of AP and an AP-lipoprotein X-complex are also found frequently in cholestasis. Currently, however, it is not necessary to measure lipoprotein X levels in the serum, as modern imaging tools have replaced its role in the clinical diagnosis of cholestasis. *Elevated AP levels in*

serum do not differentiate between intra- and extrahepatic cholestasis. Mild increases in AP activities are found in many different forms of liver injury, such as viral hepatitis, drug-induced, granulomatous and neoplastic liver disease.

AP levels not associated with hepatobiliary disease begin to rise in the second trimester of pregnancy (due to placental and bone isoenzymes; they return to normal 3–4 weeks after delivery), in adolescents during periods of growth, and in many bone diseases that are associated with increased osteoblastic activity (however, in multiple myeloma AP levels are characteristically normal). Generally a separation of AP into its isoenzymes is not necessary, because usually the clinical context suggests the organ of origin. If there is an increase in γ -GT activity associated with elevated AP levels, there is a high probability that the liver is the source of increased serum AP levels.

If AP levels are disproportionately high ($>1,000$ U/L) compared to the bilirubin concentration, granulomatous disorders (sarcoidosis, tuberculosis) or infiltrative lesions (tumors, abscess) should be considered. In primary biliary cirrhosis and in primary sclerosing cholangitis levels of AP and γ -GT are disproportionately high compared to aminotransferase concentrations. In these chronic cholestatic disorders the rise of AP and γ -GT is noted years earlier than that of serum bilirubin.

Elevated levels of liver AP may also be due to extrahepatic causes, such as hyperthyroidism or right heart failure. In approximately 10% of patients with malignant lymphoma as well as in hypernephroma serum levels of liver AP are increased, without hepatic infiltration by the tumor. The pathophysiology of this paraneoplastic increase in serum AP is not well understood. Stimulation of AP synthesis by substances produced by the tumors has been discussed. After successful tumor treatment AP levels return to normal again.

An AP isoenzyme termed “Regan”-isoenzyme, which is nearly identical to placental AP, may be found in serum of patients with adenocarcinomas, especially those originating in the ovaries, bronchial system, and kidneys. This isoenzyme can also be found in patients with malignant lymphomas and hepatocellular carcinoma.

Low total serum AP values may occur in hypothyroidism (can lead also to elevated AP levels), familial hypophosphatasia, pernicious anemia, zinc and magnesium deficiency, hemolytic crisis in Wilson’s disease (hemoglobin inhibits enzyme activity), adynamic bone disease in chronic hemodialysis, achondroplasia, hypo-

physeal dwarfism, malnutrition, chronic radiation illness, and occasionally in long-term use of oral contraceptives.

In interpreting AP activities, certain factors must be considered. Day to day variations of 5–10% occur. Food ingestion increases AP as much as 30 U/L in blood groups B and O due to an intestinal isoenzyme, and remains elevated up to 12 h. AP is 15% higher in African-American men, and 10% higher in African-American women. An increased body mass index may lead to 25% higher AP values. Hemoglobin inhibits enzyme activity and high bilirubin concentrations affect the photometric measurement. Hemolysis and hyperlipidemia may cause false low values. Oral contraceptives lower liver AP up to 10%, and fenofibrate and clofibrate up to 30%. Conversely, anticonvulsive medications lead to an increase of serum AP activities, in men up to 25% and in women up to 70%.

Synopsis of alkaline phosphatase:

- The total activity of serum AP represents the sum of the activities of several enzymes from different tissues (liver, bones, small intestine, placenta).
- If increased activity of AP is associated with a simultaneous rise in γ -GT, for practical clinical purposes it can be assumed that elevated AP levels are hepatic in origin.
- Liver AP is predominantly bound to the canalicular hepatocyte membrane.
- Liver AP is a sensitive indicator of cholestasis of various etiologies (sensitivity 80–100%), but AP levels do not discriminate between intra- and extrahepatic cholestasis.
- Increased AP serum levels in cholestatic liver disease are due to membrane detachment and release of newly synthesized enzyme, and not to “overflow” of biliary retained AP.
- Mild elevations of AP serum levels may be found in viral hepatitis, drug-induced, granulomatous and neoplastic liver disease.
- In interpreting serum AP levels, nonhepatic confounding factors have to be considered.

5'-Nucleotidase

5'-nucleotidase (5'-NT) catalyzes the hydrolysis of nucleotides, e.g. adenosine monophosphate. The

enzyme is present in many organs, including liver, brain, heart, blood vessels and the endocrine pancreas. In the hepatocytes it is primarily associated with the canalicular and sinusoidal membrane, but it is also found in the lysosomes and in other intracellular compartments. Its physiologic function is unknown.

Increased 5'-NT serum values occur predominantly in liver disease. They are not due to neosynthesis, but are caused by the release of preformed enzyme from its membrane-associated localization through the detergent action of bile acids.

Like alkaline phosphatase, 5'-NT is an indicator of cholestasis. However, it is less sensitive than AP, so that its initial determination in a patient with suspected cholestasis is not suggested. Instead, increased 5'-NT values in the presence of increased activity of total AP point at the liver as the source of AP activity. Normal 5'-NT concentrations accompanying increased AP activities, however, do not exclude a hepatobiliary disease. Serum levels of 5'-NT are closely correlated with those of γ -GT. Unlike γ -GT, 5'-NT is not induced by drugs or alcohol.

5'-NT has a high predictive value (86%) for the presence of hepatic metastases and its false positive rates (7%) are lower than those of γ -GT [8, 9].

Taken together, *the practical usefulness of 5'-NT is low, and compared to other enzymes it does not add essential information.*

Synopsis of 5'-nucleotidase:

- Indicator of cholestasis.
- Release from membranes probably due to detergent action of bile acids.
- Similar to AP. However, cannot substitute for AP.
- High positive predictive value for the presence of liver metastases.
- No induction of 5'-NT synthesis by drugs or ethanol.
- 5'-NT has very limited usefulness in clinical hepatology.

Leucin Aminopeptidase

The leucin aminopeptidase (LAP) cleaves aminoterminal amino acids from peptides. The enzyme is present

in nearly all human tissues. High activities are found in biliary epithelium. The LAP activities in serum probably originate from the liver.

The serum levels of LAP are elevated in intra- and extrahepatic cholestasis and increase during the last trimester of pregnancy. In contrast to AP activity, LAP is not affected by bone disease, and the serum levels do not differ in children and adults [9]. The sensitivity of LAP in cholestatic liver disease is not superior to that of AP, and measuring LAP levels has no advantage compared to other enzymatic indicators of cholestasis. Thus, LAP is only of minor practical value.

Synopsis of leucin aminopeptidase:

- LAP is an indicator of cholestasis.
- Information gained by LAP is not superior to AP.
- No increased activity of LAP in bone disease.
- LAP serum levels increase during pregnancy.

Cholinesterase

Cholinesterases (ChE) catalyze the hydrolysis of acetylcholine. ChE I ("true cholinesterase") occurs in erythrocytes, in the grey matter of the central nervous system, in sympathetic ganglia, at the myoneural junction, in lung and spleen, but not in plasma. ChE II is found in the liver (nonspecific ChE, "pseudo-ChE"). ChE II also occurs in plasma, the intestinal mucosa, pancreas, spleen, and in the white matter of the central nervous system. ChE in plasma is synthesized by the liver; its half-life in circulation is 10 days. Mutations of the ChE gene cause a marked genetic polymorphism.

ChE is an indicator of hepatic protein synthesis and is clinically used to evaluate the synthetic performance of the liver. The synthesis of ChE is coupled to albumin synthesis, i.e. with increasing synthesis of albumin ChE levels also rise, and vice versa. Day to day variations of 10% limit the usefulness of isolated ChE determinations. Repeat measurements are necessary to evaluate liver function. The decline of ChE activity during follow-up examinations suggests decreasing liver function, e.g. progressing fibrosis/cirrhosis. Decreased activity of ChE, however, may also be observed in primary and secondary liver tumors, in toxic liver injury, in acute liver failure, and in malnutrition states. *ChE has no diagnostic specificity.* Its clinical usefulness lies

in the long-term monitoring of liver disease, and its levels should be interpreted in the context of activities of aminotransferases, γ -GT, albumin and coagulation parameters.

Increased serum levels of ChE may be seen in obesity, hyperlipoproteinemia, alcoholic fatty liver, diabetes mellitus, and in the nephrotic syndrome. Hemolysis may simulate increased ChE levels.

Drugs such as estrogens, oral contraceptives, corticosteroids, diazepam, and propranolol inhibit the synthesis of ChE. Cyclophosphamide, by directly interacting with the enzyme, irreversibly inhibits its activity. This effect is abrogated after some weeks by new hepatic synthesis of ChE. However, the clinical significance of this interaction is of minor importance, since the inhibitory concentrations of cyclophosphamide exceed by far its therapeutic doses.

Synopsis of cholinesterase:

- ChE is a global indicator of hepatic protein synthesis.
- The decrease of serum ChE concentration in repeat follow-up examinations suggests declining liver function.
- ChE has no diagnostic specificity.
- Hepatic synthesis of ChE is coupled to albumin synthesis. When albumin synthesis increases, so does synthesis of ChE and vice versa.

Other Enzymes

Sorbitol dehydrogenase (SDH) occurs in the cytoplasm of liver cells. Increased serum SDH levels are a manifestation of hepatocellular injury and parallel those of aminotransferases.

Isocitrate dehydrogenase (IDH) is found in significant quantities in the liver, kidneys, skeletal and heart muscle. Increases in activities in serum correspond to those of aminotransferases.

Ornithine transcarbamylase (OTC) is a liver specific mitochondrial enzyme of the urea cycle. Increased serum levels are an expression of hepatocellular injury and correspond to aminotransferase activities.

Compared to ALT, AST and GLDH, the activities of SDH, IDH, OTC and of many other enzymes in evaluating hepatocellular injury do not yield additional

clinically relevant information. They are of no significance in clinical practice.

Bile Acids

The metabolism of bile acids (BA) is discussed in Chapter 7. In serum, BA are transported bound predominantly to albumin, and to a lesser degree (<10%) to lipoproteins. The major fraction of bile acids reaches the liver as taurine- or glycine conjugates. Depending on their structure and conjugation, between 62% and 95% of BA are taken up by the hepatocytes during their first sinusoidal passage (“first-pass-extraction”). The rate limiting step in BA transport (“bottle neck”) is canalicular BA secretion.

In serum both total BA concentrations as well as levels of individual BA and their conjugates can be measured. *In nearly all moderate and severe liver parenchymal injuries the concentration of BA in serum is increased.* BA are sensitive indicators of global liver function. However, due to their high extraction rate, their serum concentrations also depend on effective hepatic circulation. Increased BA concentrations in serum are encountered primarily in advanced liver disease, when levels of aminotransferases may be normal again. Increased BA levels in cirrhosis are interpreted as a manifestation of portal-systemic shunts combined with decreased hepatic clearance from the sinusoidal blood.

Elevated BA levels in serum – in the fasted state and/or 2 h postprandially – are sensitive, but nonspecific indicators of hepatobiliary dysfunction. However, compared to the combination of enzymes and to other parameters discussed in this chapter they do not provide clinically relevant additional information. Elevated BA levels do not discriminate between necroinflammatory and cholestatic liver lesions. Thus, *measurement of BA in serum is of little clinical importance.*

Albumin

Albumin is the major binding and transport protein in humans. It is produced exclusively in the liver. The daily rate of synthesis amounts to 15–17g, which is equivalent to 12–20% of the total hepatic protein

synthesizing capacity. The rate of production is dependent on several factors, including supply of amino acids, plasma oncotic pressure, levels of inhibitory cytokines (particularly interleukin-6), and the number of functioning hepatocytes [2]. The production rate can be doubled if necessary. The total albumin pool in plasma is exchanged daily with the extracellular space. The half-life of serum albumin is approximately 19–21 days. Lysosomal proteases degrade albumin predominantly in the liver, kidneys and skin, with capillary endothelial cells being essentially involved in albumin breakdown. Approximately 1 g of albumin is lost daily through the gut and 15 g via the kidneys.

In interpreting albumin levels one must keep in mind several factors. Compared to values in the upright position, albumin concentration in serum declines by approximately 15% after 30 min recumbency. Prolonged tourniquet use during collection, or specimen evaporation cause an increase in albumin concentration (hemoconcentration). An increase in the absolute amount of albumin in the body does not occur. Clinically, hyperalbuminemia typically is due to hemoconcentration, caused by dehydration.

The *serum albumin level is a parameter of hepatic synthesizing capacity*, but it is neither sensitive nor specific for liver function. Typically, in chronic hepatitis albumin gradually falls with progression to cirrhosis. Albumin concentrations are a marker of decompensation and prognosis in cirrhosis. Hypoalbuminemia in decompensated cirrhosis is not only due to reduced hepatic synthesis, but also to shifts of albumin into the “third space” (edema, ascites) with subsequent dilutional peripheral hypoalbuminemia.

In addition to chronic liver disease, the differential diagnosis of hypoalbuminemia includes protein loss (nephrotic syndrome, burns, protein losing enteropathy), decreased albumin synthesis (catabolic states; acute phase reaction; interleukin-1 and -6 and tumor necrosis factor- α downregulate the expression of the albumin gene; glucocorticoids), and decreased protein intake (malnutrition, very low protein diets). Pregnancy is also a common cause of hypoalbuminemia, while inborn errors of albumin synthesis, such as analbuminemia, are exceedingly rare.

The synthesis of cholinesterase is coupled to that of albumin. Thus, conditions characterized by loss of albumin with compensatory increase in albumin synthesis (nephrotic syndrome, protein losing enteropathy)

are associated with increased serum activities of cholinesterase.

γ -Globulins

Hyper- γ -globulinemia is a nonspecific manifestation of chronic inflammatory disorders, including chronic liver disease. Increased levels of γ -globulins indicate augmented and persistent antigenic stimulation. Hypergammaglobulinemia in chronic liver disease is polyclonal, heterogeneous, with immunoglobulins directed against numerous bacterial, viral or cellular antigens. In the context with other parameters of liver injury, immunoglobulin concentrations help to evaluate chronic liver inflammation. Their serum levels correlate with the severity and duration of the inflammatory process.

The quantitative measurement of individual immunoglobulin classes is of limited practical value. However, to a certain degree, different immunoglobulin patterns allow conclusions regarding the etiology of liver disease. An increase in the concentration of virus-specific IgM is typical for acute hepatitis. During follow-up, IgM-titer declines and is followed by a rise in IgG. In chronic viral hepatitis and in autoimmune hepatitis serum levels of IgG are increased. In LKM-1 positive autoimmune hepatitis, IgA levels are often decreased. A predominant increase in IgM is seen in immune-mediated chronic cholestatic diseases, such as primary biliary cirrhosis, while in chronic alcoholic liver disease IgA levels are elevated. The immunologic diagnosis of viral hepatitis and the diagnostic significance of circulating antibodies in autoimmune hepatobiliary disease are discussed in Chapters 36 and 63, and in Section XIV.

Clotting Factors

A decreased synthesis and secretion of clotting factors, due to restricted liver function, may cause complex coagulation disorders. The vitamin K dependent factors II, VII, IX, X and proteins C and S (inhibitors of hemostasis) are particularly affected. Individuals with vitamin K deficiency synthesize normal amounts, though they are inactive precursors of clotting factors termed “proteins induced by vitamin K absence/antagonists”

(PIVKA). Additionally, in severe parenchymal liver injury activities of factor V and antithrombin III are diminished, and polymerization of fibrinogen is impaired. Factor VIII is not produced by the hepatocyte, but rather by the endothelium.

Prothrombin Time

The prothrombin time (PT) screens for abnormalities in the extrinsic and common pathways of coagulation and encompasses the plasma factors II, V, VII, X and fibrinogen that are all produced by the liver. With the exception of factor V, all other factors determining PT are activated by a vitamin K dependent enzyme. Their half-life is short, and ranges from 12 h to 6 days. Since all factors contributing to PT are produced by the liver, *PT is a sensitive parameter in estimating global hepatic protein synthetic capacity*. However, PT is relatively insensitive to deficiency of any single clotting factor, and there is no significant increase until concentrations fall below 10% of normal.

In liver injury changes of PT occur rapidly, and they correlate with the degree of parenchymal liver damage. Repeat determinations of PT are helpful in follow-up of the patient and in estimating prognosis. *In acute liver injury PT is a much more sensitive parameter than albumin*. Factor VII has the shortest half-life of all PT determining factors. Therefore, in the initial phase of liver injury PT represents primarily the state of the prothrombin complex, especially of factor VII. However, in clinical practice it is not necessary to determine individual coagulation factors.

PT is prolonged in parenchymal liver damage with decreased synthesis of certain clotting factors (II, VII, and X), and in vitamin K deficient states, e.g. cholestasis-induced absorption disturbances, steatorrhea or diminished vitamin K ingestion. Further causes of a prolonged PT are disseminated intravascular coagulation, the administration of antibiotics and cholestyramine.

Partial Thromboplastin Time

The prolongation of partial thromboplastin time (decrease of the activities of factors II, IX, and X) may also be used as an indicator of severe liver disease.

Ammonia

Ammonia derives from endogenous protein metabolism. It is generated in all organs and is produced in the gut lumen by bacterial protein degradation (mainly glutamine). At physiologic pH-values 98% of ammonia is present as NH_4^+ , a weak acid. 70% of NH_4^+ is cleared by urea synthesis, which exclusively occurs in the liver, predominantly in periportal hepatocytes. 30% of NH_4^+ is eliminated via synthesis of glutamine localized in pericentral hepatocytes. Urea and glutamine are excreted in the urine.

Increased blood ammonia levels occur in severe liver disease that is associated with reduced functional hepatic mass and with considerable impairment of urea and glutamine synthesis (usually advanced cirrhosis with or without hepatic encephalopathy; acute liver failure). In these cases, gut derived ammonia that reaches the liver by the portal venous circulation cannot be detoxified. In portal hypertension, increased NH_4^+ serum levels are due to NH_4^+ containing blood bypassing the liver through portal-systemic shunts. However, *there is no good correlation between blood ammonia levels and the degree of hepatic encephalopathy*. Therefore, monitoring encephalopathic patients solely with plasma NH_4^+ is not advised.

Rare causes of increased blood concentrations of NH_4^+ are genetic disorders resulting in deficiency of urea cycle enzymes, their inhibition in metabolic diseases, and Reye's syndrome.

Hyperammonemia not due to liver disease is also rare. Valproic acid, glycine (in irrigation fluids used in prostate, endometrial resection), high dose chemotherapy for multiple myeloma with meningeal involvement, and occasionally diuretics may increase ammonia production.

Extrahepatic factors may affect blood ammonia levels. Specimens should have plasma separated from cells within 1 h of collection; in patients with liver disease, separation within 15 min is ideal. A delay in analysis increases ammonia levels due to cellular metabolism: 20% at 1 h and 100% by 2 h. Hemolysis (delay in analysis), strenuous muscle exercise (increases up to three-fold) and cigarette smoking (increases $10 \mu\text{mol/L}$ after one cigarette) within 1 h of collection of blood also cause elevations of ammonia values. Increased ammonia levels are seen in acute leukemia, blood transfusion, bone marrow transplantation, gastrointestinal bleeding or high protein intake [2].

Bilirubin

Bilirubin metabolism is discussed in Chapter 7, the clinical approach to the patient with cholestasis and jaundice in Chapter 52.

250–350 mg bilirubin which represents approximately 80–85% of the daily production of unconjugated bilirubin, are produced daily through physiologic degradation of senescent red blood cells. The remaining 15–20% result from breakdown of heme-containing proteins (myoglobin, cytochromes, catalases) and from maturation defects of erythrocytes in the bone marrow (ineffective erythropoiesis). Normal clearance is 5 mg/kg/day, or approximately 400 mg/day in adults. The half-life of unconjugated bilirubin is <5 min.

The bilirubin concentration in serum is the result of the balance between extrahepatic bilirubin formation, plasma transport (bound to albumin), its uptake, conjugation and transport across the hepatocyte, and its canalicular biliary excretion. The rate limiting step of bilirubin transport is canalicular secretion, while UDP-glucuronyltransferase can cope with large amounts of bilirubin, up to 20-fold the physiologic value, and remains preserved for long periods even in chronic advanced liver disease.

Bilirubin in serum can be subdivided into a *direct* reacting, water-soluble *conjugated form*, and an *indirect* reacting, lipid-soluble *non conjugated form*. Conjugated, water-soluble bilirubin is rapidly excreted into bile and is present only in minor amounts in the blood in normal individuals. More than 70% of bilirubin in serum is unconjugated. Men have slightly higher values than women. Differentiating bilirubin into a direct and indirect fraction should be performed with total bilirubin levels ≥ 5 mg%, since with lower total bilirubin values results are inaccurate.

Jaundice is a classic, but neither sensitive nor specific sign of liver disease. It becomes visible as scleral icterus with a bilirubin concentration ≥ 2.5 mg% (see Chapter 33). Hyperbilirubinemia may be prehepatic, intra- and posthepatic in origin. However, usually several pathogenetic mechanisms act in concert.

Increases in unconjugated bilirubin occur in hemolysis, increased ineffective erythropoiesis (megaloblastic anemias, thalassemias, porphyrias, after large volume bleeds), and during resorption of large hematomas or tissue injuries (lung infarction, muscle injuries). With normal liver function, total bilirubin concentration in

chronic hemolysis rarely exceeds 5 mg%. Conditions associated with impaired hepatic uptake or conjugation also lead to a predominantly unconjugated hyperbilirubinemia. Gilbert's syndrome, found in approximately 5% of the population, causes mild unconjugated hyperbilirubinemia (total bilirubin rarely exceeds 4–5 mg%) due to impaired UDP-glucuronyltransferase activity along with decreased organic ion uptake. Unconjugated bilirubin is bound to albumin and cannot pass through the glomerular basement membrane into the urine. Bilirubin excreted in urine is always conjugated, water-soluble. Bilirubinuria often precedes the appearance of jaundice.

Measuring *urobilinogen* excretion in urine is currently of little if any importance. Urobilinogens are bacterial breakdown products of bilirubin in the gut. Approximately 50–70% of enterally produced urobilinogen is resorbed and excreted by the kidneys. The remainder reaches the liver via the portal vein, is extracted by the hepatocytes and excreted in bile. If too much bilirubin is produced, the quantity of newly generated urobilinogen may exceed the uptake capacity of hepatocytes and is excreted by the kidneys. The *presence of urobilinogen in urine is evidence that bilirubin is present in the gut*, i.e. that the bile ducts are, at least partially or intermittently patent. In complete bile duct obstruction the enterohepatic circulation is interrupted, bilirubinuria is present, while urobilinogen is absent from urine. Modern hepatobiliary imaging techniques have significantly limited the relevance of urobilinogen measurements in urine.

Increases in conjugated bilirubin are highly specific for hepatobiliary disease. Deranged hepatobiliary excretion of bilirubin occurs in hepatocellular disease and in bile duct obstruction. Initially conjugated bilirubin may still reach the space of Disse through the tight junctions and drain with the lymph to the space of Mall (see Chapter 3). If this lymphatic drainage capacity is exceeded, bilirubin regurgitates into the blood and causes a predominantly conjugated hyperbilirubinemia. In stone-induced extrahepatic bile duct obstruction, serum bilirubin concentration usually is ≤ 6 mg% and only rarely exceeds 15 mg%, since obstruction generally is incomplete and intermittent. As long as renal function is intact and there is no concomitant hemolysis, in patients with parenchymal liver disease and impaired canalicular excretion, serum bilirubin rarely exceed 30 mg%. In primary biliary cirrhosis, in alcoholic

hepatitis and in acute liver failure the degree of bilirubin elevation correlates roughly with prognosis.

One fraction of conjugated bilirubin (*Delta bilirubin*, also sometimes termed biliprotein) in patients with cholestatic liver disease is bound to albumin. This complex is degraded only slowly, it is excreted by the kidneys and has a long half-life of 18 days (the same as albumin). The direct bilirubin assay measures the majority of Delta bilirubin and conjugated bilirubin.

In the acute phase of cholestatic disease 20–50% of total bilirubin is Delta bilirubin. While the patient improves clinically the Delta fraction may rise to 50–90%. The clinical observation of prolonged jaundice (continuing direct hyperbilirubinemia) in patients recovering from hepatitis or biliary obstruction, i.e. despite rapid decrease of bilirubinuria and clinical improvement, is explained by the formation of Delta bilirubin.

Factors affecting bilirubin besides liver injury are food ingestion (bilirubin increases an average of one-fold to twofold with fasting up to 48 h), ethnicity (33% lower in African-American men, 15% lower in African-American women), pregnancy (33% decrease by second trimester), and oral contraceptives (15% lower). Light can convert unconjugated bilirubin to a photoisomer that reacts directly; it also causes total bilirubin to decrease by 0.34 $\mu\text{mol/L/h}$ (0.02 mg/dL/h) [2].

References

1. De Ritis F, Coltori M, Giusti G (1972) Serum transaminase activities in liver disease. *Lancet* I: 685
2. Dufour DR (2000) Laboratory guidelines for screening, diagnosis and monitoring of hepatic injury, Vol 12. The National Academy of Clinical Biochemistry, Washington, DC
3. Elinav E, Ben-Dov IZ, Ackerman E, et al (2005) Correlation between serum alanine aminotransferase activity and age: an inverted U curve pattern. *Am J Gastroenterol* 100: 2201–4
4. Khan KN, Tsutsumi T, Nakata K, et al (1998) Regulation of alkaline phosphatase gene expression in human hepatoma cells by bile acids. *J Gastroenterol Hepatol* 13: 643–50
5. Prati D, Taioli E, Zanella A, et al (2002) Updated definitions of healthy ranges for serum alanine aminotransferase levels. *Ann Intern Med* 137: 1–9
6. Ravel R (1995) *Clinical laboratory medicine*, 6th edn. Mosby-Year Book, St. Louis
7. Reichling JJ, Kaplan MM (1988) Clinical use of serum enzymes in liver disease. *Dig Dis Sci* 33: 1601–14
8. Schmidt E, Schmidt FW (2000) Klinisch-chemische Untersuchungsmethoden. In: Schmidt E, Schmidt FW, Manns MP (Hrsg) *Lebererkrankungen. Pathophysiologie – Diagnostik – Therapie. Ein Zwischenbericht für Klinik und Praxis*. Wissenschaftliche Verlagsanstalt mbH, Stuttgart, pp 8–60
9. Thomas L (1998) *Labor und Diagnose. Indikation und Bewertung von Laborbefunden für die medizinische Diagnostik*. 5. Auflage. TH-Books Verlagsgesellschaft mbH, Frankfurt/Main
10. von Herbay A, Strohmeyer G (1994) Die erhöhte gamma-GT – Ursachen und Interpretationen. *Dtsch med Wschr* 119: 1041–4

Chapter Outline

Bromosulphthalein Test	335
Principle and Technique.....	335
Confounding Factors.....	335
Side Effects	335
Assessment.....	335
Indocyanine Green Test	336
Principle and Technique.....	336
Confounding Factors.....	336
Side Effects	336
Assessment.....	336
Sorbitol Clearance	337
Principle and Technique.....	337
Confounding Factors.....	337
Side Effects	337
Assessment.....	337
Galactose Elimination Capacit	337
Principle and Technique.....	337
Confounding Factors.....	338
Side Effects	338
Assessment.....	338
Monoethylglycinexylidide Test	338
Principle and Technique.....	338
Confounding Factors.....	339
Side Effects	339
Assessment.....	339
Caffeine Clearance	339
Principle and Technique.....	339
Confounding Factors.....	340
Side Effects	340
Assessment.....	340
Antipyrine Clearance	340

Principle and Technique.....	340
Confounding Factors.....	340
Side Effects	341
Assessment.....	341
Aminopyrine Breath Test	341
Principle and Technique.....	341
Confounding Factors.....	341
Side Effects	341
Assessment.....	342
References	342

The basic laboratory parameters discussed in the previous chapter are indispensable in the management of patients with liver disease. They provide information on liver injury but are not able to assess the functional capacity of the liver. Quantitative tests of liver function (Q-LFTs) measure the capacity of the liver to clear, transport, metabolize and excrete endogenous or exogenous substances, thus ideally providing information on the metabolic capacity of various hepatocellular compartments. Nowadays, Q-LFTs are very rarely applied in clinical practice and their use is restricted to a few specialized centers. Despite their minor role in clinical practice, overview on Q-LFTs is provided for the interested reader in this chapter.

Quantitative LFTs assess the ability of the liver to transport organic anions, clear endogenous and exogenous substances from the circulation, metabolize them intracellularly, and excrete them in bile. The hepatic turnover of a test substance depends on liver blood flow, its diffusion capacity between the sinusoidal blood and the hepatocyte, hepatocyte uptake at the basolateral membrane, the metabolic capacity of liver parenchyma

and the efficacy of canalicular transport systems. Thus, the “*functional liver cell mass*” encompasses the uptake of a test substance into the hepatocyte, its intracellular transport, storage and metabolic processing and possibly its biliary excretion. The extent of impairment in the turnover of a substance allows one to infer hepatic functional parameters.

When measuring the clearance of test or exogenous compounds that are eliminated nearly exclusively by the liver, compounds with *high* (blood flow dependent), *intermediate*, and *low* (capacity dependent) *hepatic clearance* are distinguished. In a healthy person (and with some reservations also in a patient with liver disease) substances with a high hepatic clearance allow for an estimation of liver blood flow. On the other hand, a

low hepatic clearance mirrors the enzymatic capacity to metabolize xenobiotics, and is also termed intrinsic clearance. The *microsomal function* of the liver is reflected by the capacity-dependent degradation of exogenous compounds by mixed function oxidases of the cytochrome P450 system, such as CYP1A2, CYP2C19_{MEPH}, CYP2E1, and CYP3A. The metabolism of foreign compounds by enzymes localized in the cytoplasm, such as galactokinase, represents the *cytosolic function*. Since substrate specificities, inducers and inhibitors of many enzymes are known, the metabolism of indicator substances may be regarded as a widely specific function test of the respective enzyme. In order to test the metabolizing activity of various enzymes, different test compounds are administered (“cocktail approach”)

Table 35.1 Quantitative tests of liver function (Adapted from [4])

Hepatic Extraction Rate	Test-substance	Dose and application	Metabolized by	Functional parameter measured	Confounding factors
HIGH (>70%)	Bromo – sulphthalein	5 mg/kg i.v.	∅	Excretory Capacity	Hypoalbuminemia Hyperbilirubinemia
	Indocyanine Green	0.5 (–5.0) mg/kg i.v.	∅		
	Sorbitol	50 mg/min 3 h i.v.	Sorbitol-Dehydrogenase	Liver Blood Flow	Sorbitol infusion Fructose intolerance Ethanol
	Galactose	50 mg/min 3 h i.v.	Galactokinase		
INTERMEDIATE (30–70%)	Galactose	0,5 g/kg 45% solution ≅ 30 g i.v. 2 μCi + 0,5 g/kg i.v.	Galactokinase	Cytosolic Metabolic Capacity	Ethanol
	Lidocaine/ MEGX	1 mg/kg (2%) i.v.	CYP3A4		*
LOW (<30%)	Caffeine	1–2–4 mg/kg or – 280 mg p.o.	CYP1A2 CYP2E1 CYP3A Xanthine-Oxidase Arylamin-N-acetyltransferase	Microsomal Metabolic Capacity	Age, Caffeine, Nicotine, Mexitil **
	Antipyrine	10–15 mg/kg p.o.	CYP1A2 CYP3A	(Functional Liver Cell Mass)	Many drugs
	Aminopyrine	1,5 μCi ≅ 1 mg i.v. 2 μCi in 50 mL p.o.	CYP1A2 CYP3A Amino-N-Demethylase Glutathione-dependent Dehydrogenase Folic acid dependent enzymes		Basal metabolic rate, Fever, Hyper- and Hypothyroidism, Hypothermia, Ethanol, Renal insufficiency, Glutathione and Folic acid deficiency, * and **

* Enzyme inducers: Barbiturates, Phenytoin, Rifamycin (CYP3A), and others,

** Enzyme inhibitors: Cimetidine, Allopurinol, Oral Contraceptives

or the metabolites of only one substance are investigated (“metabolic fingerprint”). Table 35.1 provides an overview of various quantitative LFTs.

Q-LFTs were developed to assess hepatic dysfunction quantitatively, thus enabling the clinician to evaluate loss of functional liver mass and to improve prognostication of liver disorders. These goals are met differently by various Q-LFTs. The tests depend on numerous endogenous and exogenous influences. They show a *marked interindividual variability*, but a relatively *stable intraindividual reproducibility*. Thus, repeat follow-up tests in individual patients are more informative than the comparison of mean values between groups of patients. All tests are limited by their *nonspecificity* [4–6, 10, 13, 15, 16, 24, 31–33].

Bromosulphthalein Test

The bromosulphthalein (BSP) test was described for the first time in 1913 and was introduced into clinical practice by Rosenthal and White in 1925 [26,27]. For decades this test has been the best evaluated and most often used Q-LFT. The BSP test is an indicator of hepatic blood flow and measures primarily the biliary excretory capacity.

Principle and Technique

BSP is a water-soluble anionic organic dye that binds completely to plasma proteins (predominantly albumin) and to α_1 -lipoproteins immediately after intravenous injection. BSP is cleared from the sinusoidal circulation by the organic anion transport system (OATP) that is localized in the sinusoidal hepatocyte membrane (see Chapters 5 and 7). Within the hepatocyte BSP is predominantly conjugated with glutathione and thereafter excreted in bile. Since the cellular uptake capacity for BSP by far exceeds its biliary excretion, BSP transiently accumulates within the hepatocyte, bound to proteins Y and Z. If storage and/or excretory capacity are impaired BSP regurgitates into plasma. In addition to uptake by the liver, small amounts of BSP are taken up by other organs (lymphatic system); BSP is subject to enterohepatic circulation and is excreted in the urine. The BSP-elimination rate from serum (approximately 50–80%) is dose dependent, and decreases with higher BSP-doses. After intravenous (i.v.) application of BSP 5 mg/kg body

weight, the concentration of the dye is measured photometrically either only once (45 min after i.v. application) or several times at predetermined intervals, and the extraction rate is calculated. Usually the retention of BSP is expressed as the percentage of the amount applied.

Confounding Factors

Hypoalbuminemic disorders, such as nephrotic syndrome, with decreased plasma protein binding lead to accelerated elimination of BSP. The displacement of BSP from its protein binding in plasma to the extracellular space by drugs may cause an apparent delay of its elimination. The interaction between bilirubin and BSP may be a cause of incorrect test results. Hyperbilirubinemia (>3 mg/dL) competitively inhibits BSP uptake by the hepatocyte and alters the absorption spectrum of BSP. High serum bilirubin levels displace BSP from its protein binding in plasma. In biliary obstruction, BSP concentrations in lymphatic tissue are approximately four times those measured in plasma.

Side Effects

Local irritation at the site of BSP application due to paravasal injection, acute thrombophlebitis, and gangrene of an extremity resulting from inadvertent intraarterial injection are among the potential side effects. Systemic allergic reactions with fatal anaphylactic shock have been described.

Assessment

Because of its high extraction rate BSP-clearance strongly depends on hepatic blood flow. Standard BSP-testing is an interesting parameter, especially in cholestatic liver disorders, to assess the excretory function of the hepatocytes. However, the results are non-specific, do not provide clues as to the etiology of jaundice, and have no prognostic significance. The BSP-test has lost its former clinical significance and, if at all, is currently used in the context of experimental hepatology. Because of occasionally fatal allergic reactions, the BSP-test has been withdrawn from the clinical market.

Indocyanine Green Test

The indocyanine green (ICG) elimination test serves to semiquantitatively evaluate liver blood flow. However, elimination rates also decrease in hepatic parenchymal injury.

Principle and Technique

ICG (tricarboyanine color) is an organic anion that after intravenous injection nearly completely binds to plasma proteins, predominantly albumin and α_1 -lipoproteins. It remains in the intravascular space, does not cross the placental barrier, and is taken up exclusively by the liver. ICG is subject to a high, dose-dependent hepatic elimination, is nearly completely (97%) secreted (practically unchanged) in bile, and is not reabsorbed in the intestine [23]. The transport capacity for ICG-uptake of systems localized in the sinusoidal liver cell membrane is $> 72 \mu\text{mol/kg}$ body weight, which far exceeds the excretory transport capacity. If the rate of intravenous ICG infusion exceeds its excretory capacity, ICG accumulates in the liver, in which case it exerts anticholeretic effects by inhibiting bile acid independent bile flow. Therefore, the test doses of ICG applied lag far behind the maximal excretory capacity of the liver. Once nearly complete hepatic extraction is achieved, *ICG clearance corresponds to the hepatic plasma flow*.

Since the solubility and stability of ICG in a watery solution is less than that of BSP, a fresh test solution must always be prepared before use. Addition of albumin enhances stability, but leads to a shift of the absorption spectrum from 780 to 805 nm.

In order to avoid lipemic turbidity of serum, the test is performed in the morning, after a fasting period of twelve hours with the patient in the recumbent position. An intravenous bolus (10–15 s) of a 0.5% solution (5 mg/mL) of 0.5 mg (0.64 μmol) ICG/kg body weight is applied (some authors advocate a dose of 5 mg [6.4 μmol] ICG/kg body weight). Thereafter eight blood samples are taken in three minutes intervals. To simplify the procedure, occasionally only one blood sample is taken 20 min after an i.v. ICG-bolus. Subsequently the extinction in serum at 805 nm (absorption maximum) is determined photometrically and compared to the value before ICG application and to the 0.5% standard. The distribution volume of ICG can be calculated dividing the dose

of ICG injected by the ICG-concentration in serum five minutes after application. Hepatic blood flow can be determined dividing ICG clearance by the ICG concentration in serum 5 min after its application. A simplified, noninvasive measurement of ICG-elimination is possible by dichromatic ear densitometry or finger spectrophotometry. An initial clearance rate of $< 16\%$ /min, a half-life of > 5 min or a retention in serum of $> 4\%$ after 20 min are considered pathologic.

With the common doses of ICG used, the transport system of liver cells for ICG is not saturated. Therefore slight reductions in functional liver cell mass are not detected by the ICG-test. With augmented ICG doses and increased impairment of liver cell function or reduction in liver cell mass, the extraction rate of ICG progressively decreases and ICG-clearance no longer depends on blood flow exclusively. In this case a continuous i.v. infusion of ICG is superior to bolus application. However, higher ICG-doses are associated with an increased rate of side effects.

Confounding Factors

Bilirubin and rifamycin inhibit ICG uptake by the hepatocyte. However, for clinical purposes competitive inhibition of ICG-elimination by bilirubin may be disregarded up to serum bilirubin levels of 3 mg/dL. Unlike BSP the ICG concentration in lymphatic tissues does not increase in biliary obstruction.

Side Effects

Side effects are rare with the ICG doses usually applied, although isolated anaphylactic reactions have been described. The inadvertent subcutaneous or paravasal injection of even larger amounts of ICG leads merely to swelling but does not cause tissue necrosis.

Assessment

ICG has replaced BSP in the evaluation of hepatic plasma flow even though it is less sensitive. The test, however, is not routinely used in clinical practice because of its high costs.

In patients with liver cirrhosis ICG-clearance correlates with the Child-Pugh classification, the BSP-elimination, the galactose elimination capacity, and with the results of the aminopyrine breath test. The intraindividual variation of the test is less than the interindividual variability, which underscores its potential value in serial follow-up evaluations of an individual patient. In patients after liver transplantation or partial hepatic resection, ICG clearance is a good indicator of liver function. It may help to predict transplant failure. In patients with primary biliary cirrhosis, together with other parameters, the ICG test may assist in estimating survival probability. However, the *ICG-test is not suited as a general prognostic parameter in chronic liver disorders.*

Sorbitol Clearance

Hepatic clearance of D-sorbitol may be used as a test evaluating functional liver plasma flow [21].

Principle and Technique

Sorbitol is metabolized in the liver to fructose, but is also eliminated unchanged by the kidneys. Hepatic sorbitol clearance can be calculated if renal sorbitol clearance is known, by subtracting it from the total sorbitol clearance. A 40% sorbitol solution is given by continuous intravenous infusion at a rate of 7.5 mL/h (corresponding to 50 mg of sorbitol/min) over 3 h. Blood and urine samples are collected 150, 160, 170, and 180 min after the start of infusion

Confounding Factors

Faulty test results, and possibly sorbitol intolerance, are to be expected in patients who recently received a sorbitol infusion, or in those with fructose intolerance.

Side Effects

Serious side effects of sorbitol infusion have not been described though possible sorbitol intolerance should be kept in mind.

Assessment

Using the relatively low dose described above, sorbitol is well suited to assess hepatic blood flow and is more cost-effective, as well as safer, than the ICG-test. Additionally, by measuring bioavailability sorbitol clearance can estimate the presence of intra- and extra-hepatic shunts. However, clinical studies evaluating the efficacy of sorbitol clearance are lacking; therefore, at present, a final comment on its clinical utility is not warranted. In addition, the considerable expenditure of time (180 min) may be a barrier to its routine clinical use.

Galactose Elimination Capacity

The galactose elimination capacity (GEC) was determined by Bauer in 1906 and is still used to *evaluate cytosolic metabolic liver function.*

Principle and Technique

Galactose is a monosaccharide that after intravenous application distributes in the extracellular space. It rapidly is taken up by the liver, and metabolized by cytosolic hepatocellular enzymes. It is first phosphorylated by galactokinase and subsequently epimerized to glucose 6-phosphate. *Phosphorylation is the rate limiting step in the elimination of galactose.* The metabolism of galactose is capacity dependent, and follows zero order elimination kinetics, i.e. a constant amount of galactose, independent of its initial concentration, is metabolized per time unit. In a healthy person, with plasma concentrations of ≥ 50 mg/dL, a maximum of 500 mg galactose/min can be metabolized. The elimination rate reflects functional liver cell mass; however, it does not only depend on hepatic function. The galactose molecule distributes in the extravascular space, it is eliminated in urine, and a small fraction is also metabolized extrahepatically. These complex conditions with renal and non-renal clearance are mirrored by the first part of the elimination curve. As soon as the galactose concentration in serum falls below a certain threshold (50 mg/dL), a change in elimination kinetics occurs (first order reaction kinetics), i.e. the turnover per time unit is no longer capacity dependent and constant, but rather proportional

to the galactose concentration present at each time point. GEC can also be used to estimate liver perfusion.

The test is performed in the fasting state, with the urinary bladder emptied, and the patient recumbent. Galactose (0.5 g/kg body weight) in a 45% solution (corresponding to approximately 30 g in 70 mL) is given as an intravenous bolus over 5 min. This dose leads to an initial saturation of the enzyme systems involved in galactose metabolism. Both oral and intravenous routes of galactose administration have been described, but the latter is too laborious and time consuming for routine use. Between 20 and 60 min after galactose administration galactose concentration in blood is determined in 5 min intervals, measuring urine output concomitantly. A simplified method for determining GEC has also been described, with blood samples taken 45 and 60 min after administration of galactose [3]. The individual measurements are plotted onto a coordinate system and the GEC in mg/min/kg body weight is determined graphically.

A methodological variant of the GEC-test is the ^{13}C - or ^{14}C -galactose-breath test. After intravenous injection of labelled galactose the amount of $^{13}\text{CO}_2$ or $^{14}\text{CO}_2$ exhaled correlates with the GEC.

Confounding Factors

Since galactose distributes in the extracellular fluid, its elimination kinetics are influenced by changes in the distribution volume. Ethanol inhibits the elimination of galactose. Therefore, the test person should abstain from alcohol for at least 24 h prior to performing the test. Interactions between galactose and drugs are not known to occur.

Side Effects

Since galactose is a physiologic substrate, the test is pharmacologically and clinically harmless. Side effects do not occur.

Assessment

The GEC is reliable in determining various degrees of loss of functional hepatic parenchyma in acute and

chronic liver disorders [11]. GEC correlates with the BSP-test, the elimination of tryptophan, the results of the aminopyrine breath test, and with certain restrictions, as well as with the Child-Pugh classification. It may aid in predicting survival of patients with cirrhosis and in acetaminophen-induced toxicity [17, 19, 25, 28, 29]. Due to its methodological complexity and personnel-intensity, combined with a lack of specificity, the determination of GEC is restricted to specialized centers and has not gained widespread use in clinical practice.

Monoethylglycinexylidide Test

Monoethylglycinexylidide (MEGX) is a metabolite of lidocaine. The MEGX-test measures the microsomal, cytochrome P450 dependent metabolism of lidocaine [20, 30].

Principle and Technique

The test is performed after a 12 h fasting period with the patient in the recumbent position. Lidocaine (2%), 1 mg/kg body weight, is given i.v. over 1–3 min. Lidocaine, which is chemically an aminoethylamide, is nearly exclusively metabolized in the liver via oxidative N-dealkylation (deethylation) by cytochrome P450 enzymes. The first metabolite formed during this process by the action of CYP4503A4 is MEGX. Its concentration in plasma is determined by automated MEGX-fluorescence-polarization-immunoassay (FPIA) in blood samples taken immediately prior to and 15, 30, and 60 min after lidocaine injection. The lower limit of detection of MEGX is 11 $\mu\text{g/L}$. The extraction rate of lidocaine is relatively high (approximately 70%). In patients with liver cirrhosis the distribution of lidocaine, practically, does not depend on hepatic blood flow, but is exclusively determined by the intrinsic clearance, i.e. by the metabolic capacity of the liver. Only 3% of lidocaine is excreted unchanged in urine within the first 24 h. MEGX is further metabolized to glycinexylidide and 4-hydroxy-2, 6-xylidine and is found only in minor quantities (approximately 4% of lidocaine dose) in the urine. MEGX concentration in the saliva correlates well with its serum concentration.

Confounding Factors

High serum bilirubin levels (>10 mg/dL) may interfere with FPIA. Therefore, the serum of such patients must be pretreated with a precipitating agent. There is no interaction between FPIA and the ICG test, so that both tests can be performed together. The lidocaine metabolizing cytochrome P4503A4 is subject to genetic polymorphism and may be induced or inhibited by many drugs and foreign compounds. Erythromycin, cyclosporine, nifedipine, barbiturates, phenytoin, dexamethasone, rifamycin and many others induce lidocaine metabolism and thereby increase the concentration of MEGX. In patients with liver disease downregulation of CYP4503A4 mRNA by cytokines and interferon α is of special significance.

Side Effects

Untoward effects of lidocaine injection occur in nearly all patients, but they are mild and transient. They include mild light-headedness, tiredness, dizziness, transient tinnitus, impaired vision and speech, dry mouth with dysgeusia, and paresthesias of lips, tongue and ear lobes. Serious cardiac arrhythmias and anaphylactic reactions have been observed rarely.

Assessment

Due to the high extraction of lidocaine and its metabolism, the *MEGX-test is considered a sensitive and specific indicator of metabolic liver function*. In healthy persons a rapid increase in MEGX concentration is usually observed immediately after injection of lidocaine. The maximal concentrations occur after 15 min. By contrast, in patients with liver disorders and impaired hepatic metabolic capacity this rise in concentration is considerably delayed and reaches its maximum only after four hours. Significantly decreased mean MEGX concentrations are seen in patients with liver cirrhosis, fatty livers with ballooning degeneration of hepatocytes and with hepatic involvement in sickle cell anemia [30]. The MEGX concentration is correlated inversely to the severity of liver disease. Concentrations of 50–90 $\mu\text{g/L}$

are discussed as cut-off values. The MEGX levels are usually higher in men than in women. They correlate with the height, body weight and body surface of the patient and decrease with age.

Compared to the ICG test and to the caffeine clearance (see below), the MEGX-test is more rapid, less complex and easier to perform. A significant decrease in MEGX formation in liver cirrhosis is a prognostic indicator of poor survival [1]. However, due to the marked interindividual variability repeat measurements in one patient are needed. The MEGX-test is helpful in assessing liver function prior to major operations and in evaluating donor liver suitability [8]. In chronic liver disease the MEGX-test is supposed to have a higher sensitivity than the aminopyrine breath test, since lidocaine degradation is significantly more impaired than the elimination of antipyrine [20]. Despite its advantages the MEGX-test has not gained acceptance in clinical practice, mainly because of the many side effects associated with lidocaine administration.

Caffeine Clearance

Caffeine (1, 3, 7-trimethylxanthine) is exclusively metabolized by the liver and can therefore be used to analyze microsomal metabolic liver function.

Principle and Technique

Caffeine is nearly completely absorbed and can therefore be administered both intravenously and orally. It is N-demethylated by the hepatic microsomal cytochrome P450 and P448 enzymes exclusively (Cyp1A2, CYP2E1, CYP3A, xanthine oxidase and the phase II-enzyme arylamine-N-acetyltransferase). CYP3A catalyzes the oxidation of caffeine to 1, 3, 7-trimethyl-uric acid. CYP2E1 and CYP1A2 are involved in the N1- and N7-demethylation, the latter enzyme with a clearly lower activity. The ratio of the metabolites paraxanthine and 1, 7-methyluracil to caffeine or of the three secondary metabolites (1-methyluracil, 1-methylxanthine, and 5-acetylamino-6-amino-3-methyluracil) to the concentration of 1, 7-methyluracil represents a direct measure of CYP1A2 activity. The activity of arylamine-N-acetyltransferase can be determined by measuring

the secondary metabolite 5-acetylamino-6-formylamino-3-methyluracil in several urine samples obtained within 12h after administration of caffeine.

Since caffeine clearance is dose dependent, serial measurements with a standardized caffeine dose should be performed [7]. Twenty-four hours after oral administration of 280mg (or according to some authors 1–5mg/kg body weight) of caffeine, the metabolites of caffeine are measured either in plasma or in saliva [9, 34]. The applied dose roughly corresponds to the amount of caffeine in a cup of coffee. The caffeine clearance can then be calculated from the area under the elimination curve. Salivary concentrations of caffeine correlate well with plasma concentrations, which makes this noninvasive test attractive in pediatric liver patients. The noninvasive ¹³C-caffeine breath test is also a valid indicator of plasma caffeine clearance and correlates reproducibly with hepatic function [22].

Confounding Factors

Caffeine clearance decreases with age, nicotine consumption, the concomitant use of drugs (cimetidine, oral contraceptives or mexitol), and is also influenced by the exogenous supply of caffeine. Cytochrome P448 (CYP1A1 and CYP1A2)-inducers, such as theophylline, phenacetin, acetaminophen and imipramine increase caffeine clearance.

Side Effects

In the doses used, caffeine is toxicologically innocuous.

Assessment

In chronic liver disease caffeine clearance is reduced (< 2mL/kg/min) [14]. Caffeine metabolism seems to be subject to “maturation” and to intraindividual variation [2]. Thus, in the first months of life a markedly prolonged half-life of caffeine is present (96h) that in the 9th month of life falls to adult values of 4–6h. Patients with a transjugular portal systemic shunt have a prolonged caffeine

clearance. Results of caffeine clearance correlate with galactose elimination capacity and with those of the aminopyrine breath test. The test is comparatively easy to perform. Like the aminopyrine breath test caffeine clearance is of limited value as a screening test for the detection of early stages of liver disease. Currently there are no evidence based data supporting the use of caffeine clearance as a prognostic parameter in liver disease. Compared to the Child-Pugh classification, caffeine clearance does not seem to add any significant additional prognostic information.

Antipyrene Clearance

Antipyrene (phenazone) was used as an analgesic and antipyretic, and like aminopyrine is metabolized by hepatic microsomes.

Principle and Technique

After oral administration antipyrene is rapidly and completely absorbed in the gastrointestinal tract. It is not bound to plasma proteins and is nearly completely metabolized in the liver by the cytochrome P450 oxygenases CYP1A2, CYP2C and CYP3A. Twenty-four hours after oral administration of antipyrene (10–15mg/kg body weight) its disappearance rate from serum or saliva is determined, or its metabolites in saliva are measured by gas chromatography. Due to its long half-life of 10h, several serum samples should be obtained, in order to increase the reliability of antipyrene clearance.

Confounding Factors

Since antipyrene is not bound to plasma proteins its metabolism is not influenced by plasma protein concentrations. However, antipyrene metabolism is relatively variable and decreases with age as well as in a low calorie diet, nicotine, coffee and alcohol consumption. Interactions with many drugs, e.g. the cytochrome P3A inducer rifamycin or the inhibitor diltiazem also affect test results.

Side Effects

Antipyrine, if at all, should be administered orally, since the safety of intravenous application is not well known, and isolated fatal incidents have been reported.

Assessment

The metabolism of antipyrine is impaired in chronic liver disease and correlates with the prothrombin time as well as with the serum albumin concentration and the histologic stage of liver injury, respectively.

In patients with acute liver injury, such as occurs in acute viral hepatitis or during the initial stage of obstructive jaundice, antipyrine clearance is only slightly reduced. In patients with compensated liver cirrhosis the test is only minimally abnormal. A disadvantage of the test is the long half-life of antipyrine, which in chronic liver disorders may even increase to > 35 h. In these cases several blood and/or saliva samples over a time period of at least 24 h should be examined. The prognostic value of antipyrine clearance is low. For these reasons there is no compelling reason to perform antipyrine clearance in clinical practice.

Aminopyrine Breath Test

The aminopyrine breath test (ABT) is the test most widely used and best evaluated for the quantitative assessment of liver function. The analgesic aminopyrine is rapidly absorbed, taken up by the liver with a low extraction rate, largely independent of hemodynamic influences, and demethylated by liver microsomes. Thus, aminopyrine exhibits many ideal characteristics of a substance used to evaluate a partial hepatic metabolic function.

Principle and Technique

After two basic blood samples have been taken, 1 mg of radioactively labeled [*N*-4-dimethylamine-]¹⁴C-aminoantipyrine, corresponding to a dose of 1.5 μ Ci,

is administered intravenously (for a non-radioactive alternative see below). It can also be taken orally in a dose of 2 μ Ci dissolved in 50 mL water. [*N*-4-dimethylamine-]¹⁴C-aminoantipyrine is taken up virtually exclusively by the liver and demethylated by amino-N-demethylase, a microsomal cytochrome P450 dependent oxidizing enzyme. The ¹⁴C-labeled methyl groups cleaved from the main molecule are oxidized to bicarbonate within the hepatocyte in several glutathion and folic acid dependent steps (generating formic acid as an intermediate), and finally exhaled as ¹⁴CO₂. The rate limiting step is the oxidation of formic acid to CO₂ by a folic acid dependent enzyme, which explains why test results are influenced by the redox equilibrium. The activity of ¹⁴CO₂ is determined in several breath samples over two hours. The exhaled amount is an indirect measure of the demethylation rate and correlates with the clearance of aminopyrine from plasma. A healthy person exhales, on average, 7.6% of the ¹⁴C administered. Data from a breath sample taken 2 h after administration of aminopyrine correlate with results obtained during a longer (8–24 h) sampling period. Thus, although the acquisition of data at several measuring points is desirable, for clinical purposes a one point determination at 2 h is sufficient.

Confounding Factors

Cytochrome P450 inducers (barbiturates, phenytoin or rifamycin), enzyme inhibitors (cimetidine, disulfiram, allopurinol), oral contraceptives as well as vitamin B₁₂, folic acid or glutathione deficiency may affect the results of ABT. Changes in the basal metabolic rate (fever, infections, hypothermia, hyper- or hypothyroidism), ethanol or renal insufficiency also falsify test results.

Side Effects

The risk of sensitization to aminopyrine is very low. However, in patients with chronic intake of the analgesic, isolated cases of agranulocytosis have been reported. The major disadvantage of ABT, however, is the exposure to a radioactive substance. In the dose mentioned, the ABT is associated with a radiation exposure of 0.5–2.5 mrem (depending also on liver function) and thus corresponds to the radiation dose of one or two chest

x-ray films. Alternatively, ABT can be performed with a non-radioactively labeled aminopyrine, using the ^{13}C -isotope ($[N$ -4-dimethylamine-] ^{13}C -aminopyrine). However, a prerequisite for the ^{13}C -ABT is the availability of an expensive mass-spectrometer.

Assessment

In liver cirrhosis a reduced N-demethylation rate is associated with a reduced liver cell mass. However, the ABT is not able to reflect exactly the degree of liver injury, and there exists a marked overlap between patients with chronic liver disease and healthy persons. Correlations between the results of ABT and reduced serum albumin and prothrombin levels, elevated serum bile acid levels, as well as those of the BSP-test and GEC have been described.

Though advanced chronic alcoholic liver disease and an acute alcoholic binge reduce aminopyrine metabolism, the other alcohol-induced induction of mixed function oxidases may cause demethylation rate to increase in the fasting state. Thus, the effects of ethanol on aminopyrine turnover are determined both by its action on microsomal enzymes and by the degree of alcohol-induced hepatocellular injury.

The ABT may be helpful in the prognostic evaluation of patients with liver cirrhosis, acetaminophen-induced liver toxicity, and prior to liver surgery [18]. Repeat testing in intervals of several months is superior to one time testing in evaluating progressive liver disease. The intravenous administration of aminopyrine is superior to the oral administration. The ABT may differentiate a subgroup of patients with liver cirrhosis with pharmacological induction of microsomal liver function in whom the GEC, the ICG test and the sorbitol clearance remain unchanged [12]. However, it is not clear whether identifying patients with advanced liver disease in whom a partial metabolic function is still inducible is of any clinical significance.

In conclusion, despite a solid theoretical basis and many publications in the last decades, quantitative tests of liver function are not widely used in clinical practice. Due to high methodological complexity, time and man power needs, the financial costs, and rare but occasionally severe side effects, the performance of

Q-LFTs is rather an exception than the rule. Their use is restricted to few hepatology centers, and to scientific and experimental questions.

References

1. Arrigoni A, Gindro T, Aimò G, et al (1994) Monoethylglycinexylidide test: a prognostic indicator of survival in cirrhosis. *Hepatology* 20: 383–7
2. Balogh A, Harder S, Vollandt R, et al (1992) Intra-individual variability of caffeine elimination in healthy subjects. *Int J Clin Pharmacol Ther Toxicol* 30: 383–7 Published erratum appears in *Int J Clin Pharmacol Ther Toxicol* (1993) 3: 208
3. Bergstrom M, Soderman C, Eriksson LS (1993) A simplified method to determine galactose elimination capacity in patients with liver disease. *Scand J Clin Lab Invest* 53: 667–70
4. Brockmüller J, Roots I (1994) Assessment of liver metabolic function. Clinical implications. *Clin Pharmacokinet* 27: 216–48
5. Brody DH, Leichter L (1979) Clearance tests of liver function. *Med Clin North Am* 63: 621–30
6. Caspary WF (1978) Atemanalytische Tests in der Leberfunktionsdiagnostik. *Z Gastroenterol* 16: 188–97
7. Cheng WS, Murphy TL, Smith MT, et al (1990) Dose-dependent pharmacokinetics of caffeine in humans: relevance as a test of quantitative liver function. *Clin Pharmacol Ther* 47: 516–24
8. Fairchild R, Solomon H, Contis J, et al (1996) Prognostic value of the monoethylglycinexylidide liver function test in assessing donor liver suitability. *Arch Surg* 131: 1099–102
9. Farinati F, Dalri L, Rossaro L, et al (1993) Serum and salivary caffeine clearance in cirrhosis. Any role in selection for surgery and timing for transplantation? *J Hepatol* 18: 135–6
10. Friedman LS, Martin P, Muñoz SJ (1996) Liver function tests and the objective evaluation of the patient with liver disease. In: Zakim D, Boyer T (ed) *Hepatology – A textbook of liver disease*. 3rd edn. W.B. Saunders, New York, pp. 791–833
11. Giannini EG, Fasoli A, Borro P, et al (2005) ^{13}C -galactose breath test and ^{13}C -aminopyrine breath test for the study of liver function in chronic liver disease. *Clin Gastroenterol Hepatol* 3: 279–285
12. Herold C, Ganslmayer M, Ocker M, et al (2003) Inducibility of microsomal liver function may differentiate cirrhotic patients with maintained compared with severely compromised liver reserve. *J Gastroenterol Hepatol* 18: 445–9
13. Jalan R, Hayes PC (1995) Quantitative tests of liver function. *Aliment Pharmacol Ther* 9: 263–70
14. Lewis FW, Rector WG Jr (1992) Caffeine clearance in cirrhosis. The value of simplified determinations of liver metabolic capacity. *J Hepatol* 14: 157–62
15. Lotterer E, Högel J, Gaus W, et al (1997) Quantitative liver function tests as surrogate markers for end-points in controlled clinical trials: a retrospective feasibility study. *Hepatology* 26: 1426–33
16. Maynard ND, Bihari DJ, Dalton RN, et al (1997) Liver function and splanchnic ischemia in critically ill patients. *Chest* 111: 180–7

17. Merkel C, Gatta A, Zoli M, et al (1991) Prognostic value of galactose elimination capacity, aminopyrine breath test, and ICG clearance in patients with cirrhosis. Comparison with the Pugh score. *Dig Dis Sci* 36: 1197–203
18. Merkel C, Bolognesi M, Bellon S, et al (1992) Aminopyrine breath test in the prognostic evaluation of patients with cirrhosis. *Gut* 33: 836–42
19. Merkel C, Marchesini G, Fabbri A, et al (1996) The course of galactose elimination capacity in patients with alcoholic cirrhosis: possible use as a surrogate marker for death. *Hepatology* 24: 820–3
20. Meyer-Wyss B, Renner E, Luo H, et al (1993) Assessment of lidocaine metabolite formation in comparison with other quantitative liver function tests. *J Hepatol* 19: 133–9
21. Molino G, Cavanna A, Avagnina P, et al (1987) Hepatic clearance of D-sorbitol. Noninvasive test for evaluating functional liver plasma flow. *Dig Dis Sci* 32: 753–8
22. Park GJH, Katelaris PH, Jones DB, et al (2003) Validity of the ¹³C-caffeine breath test as a noninvasive, quantitative test of liver function. *Hepatology* 38: 1227–36
23. Paumgartner G (1975) The handling of indocyanine green by the liver. *Schweiz Med Wschr* 105(Suppl): 1–30
24. Preisig R (1985) Fremdstoffen als Indikatoren der Leberfunktion. *Schweiz Med Wschr Suppl* 19: 36–42
25. Reichen J, Widmer T, Cotting J (1991) Accurate prediction of death by serial determination of galactose elimination capacity in primary biliary cirrhosis: a comparison with the Mayo model. *Hepatology* 14: 504–10
26. Rosenthal SM, White EC (1925) Clinical application of bromsulphthalein test for hepatic function. *JAMA* 84: 1112
27. Rowntree LG, Hurwitz SH, Bloomfield AL (1913) An experimental and clinical study of the value of phenoltetrachlorophthalein as a test of hepatic function. *Bull Johns Hopkins Hosp* 24: 327
28. Salerno F, Borroni G, Moser P, et al (1996) Prognostic value of the galactose test in predicting survival of patients with cirrhosis evaluated for liver transplantation. A prospective multicenter Italian study. *J Hepatol* 25: 474–80
29. Schmidt LE, Ott P, Tygstrup N (2004) Galactose elimination capacity as a prognostic marker in patients with severe acetaminophen-induced hepatotoxicity: 10 years' experience. *Clin Gastroenterol Hepatol* 2: 418–24
30. Shiffman ML, Luketic VA, Sanyal AJ, et al (1994) Hepatic lidocaine metabolism and liver histology in patients with chronic hepatitis and cirrhosis. *Hepatology* 19: 933–40
31. Stremmel W, Wojdat R, Groteguth R, et al (1992) Leberfunktionstests im klinischen Vergleich. *Z Gastroenterol* 30: 784–90
32. Tygstrup N (1990) Assessment of liver function: principles and practice. *J Gastroenterol Hepatol* 5: 468–82
33. Wahlländer A, Beuers U (1990) Prognostischer Wert von Leberfunktionstests – Klinik, laborchemische Parameter und quantitative Funktionstests. *Leber Magen Darm* 20:115–6, 119–23, 126–8
34. Wahlländer A, Mohr S, Paumgartner G (1990) Assessment of hepatic function. Comparison of caffeine clearance in serum and saliva during the day and at night. *J Hepatol* 10: 129–37

Chapter Outline

Antinuclear Antibodies (ANA)	345
Target Antigens	345
Immunofluorescence Reactivities	345
Occurrence and Significance.....	345
Smooth Muscle Antibodies (SMA)	349
Target Antigens	349
Immunofluorescence Reactivities	349
Occurrence and Significance.....	349
Antimitochondrial Antibodies (AMA)	350
Target Antigens	350
Immunofluorescence Reactivities	350
Occurrence and Significance.....	350
Antibodies Against Liver-Kidney-Microsomes (LKM)	351
Target Antigens	351
Immunofluorescence Reactivities	351
Occurrence and Significance.....	351
Antibodies Against Soluble Liver Antigen/Liver-Pancreas Antigen (SLA/LP)	352
Target Antigens	352
Detection Systems.....	352
Occurrence and Significance.....	352
Antibodies Against Liver Cytosol Type 1 (LC-1)	352
Target Antigens	352
Immunofluorescence Reactivities	352
Occurrence and Significance.....	353
Antibodies Against Asialoglycoprotein-Receptor (ASGPR)	353
Target Antigens	353
Detection Systems.....	353
Occurrence and Significance.....	353

Antineutrophil Cytoplasmic Antibodies (ANCA)	353
Target Antigens	353
Immunofluorescence Reactivities	354
Occurrence and Significance.....	354
References	354

Infectious, toxic, genetic, and metabolic liver diseases must be differentiated from autoimmune liver diseases, such as autoimmune hepatitis, primary biliary cirrhosis, primary sclerosing cholangitis and overlap syndromes. This is not only important from the pure diagnostic standpoint but it is also therapeutically significant. In each liver disorder of unknown cause the presence in serum of autoantibodies must be investigated. The presence of antibodies directed against self structures is part of the regulatory network of normal immunologic homeostasis and per se does not define a disease. Up to 15% of the B- and T-cell repertoire is believed to be autoreactive. Low titer IgM antibodies against nuclear antigens, various tissue components and rheumatoid factors may be found in healthy individuals. For unknown reasons the prevalence of many autoantibodies increases with age, with more than 40% of healthy persons older than 60 years displaying weakly positive titers of antinuclear antibodies.

The immunopathogenic potential of an autoantibody, among other factors, depends on its isotype, titer, its antigenic affinity and its ability to activate complement. In [Table 36.1](#) the characteristics of naturally occurring and pathologic antibodies are listed. Naturally occurring autoantibodies are more often found in females than males, they do not bind complement, have only a low antigenic affinity, usually are multivalent and are not associated with a disease. They may exert protective functions by binding remnants of dead cells and foreign

Table 36.1 Differences between naturally occurring and pathologic autoantibodies

Naturally occurring autoantibodies	Pathologic antibodies
Stem cell response	Induced by autoantigen
Probably preservation of self tolerance	Directed against target antigens
Multivalent (react with many epitopes)	Directed against one or few antigens
Often in women ≥ 60 years	Relatively independent of age and gender
IgM	IgG
Low titer	High titer
Low autoantigen-affinity	High autoantigen-affinity
No activation of complement	Activation of complement
No disease association	Points toward (auto)immune process
Associated with normal laboratory parameters	Associated with parameters of disease activity

antigens that resemble autoantigens, thereby averting the formation of autoreactive lymphocytes.

Classical autoimmune diseases are characterized by the presence of high autoantibody titers. These are produced by specific plasma cell clones of antigen-activated B lymphocytes. They have a high antigenic binding affinity, may inhibit the activity of autoantigens in vitro, and activate complement. The causes for the formation of pathologic autoantibodies are poorly understood. Recognition of autoantigens that were overlooked or masked during ontogenesis (cryptogenic epitopes), and formation of new antigens (neoepitopes) are among the most popular theories advanced to explain the appearance of antibodies reacting with self structures. However, the pathogenetic role of autoantibodies in the development of inflammatory liver disease is not clear, and their diagnostic significance can only be appreciated within the context of the clinical picture.

The basic and most frequently used *technique for the detection* (“screening”) of autoantibodies in serum is *indirect immunofluorescence microscopy*. Since most autoantibodies are not species specific and their target antigens have changed little during phylogenesis, indirect immunofluorescence is generally performed on a freshly removed rodent (usually rat) multi-organ substrate panel that should include kidney, liver and stomach. The localization and pattern of immunofluorescence (e.g. homogeneous, dotted, etc.), the staining of nucleoli, the reaction of mitotic cells, and the various reaction patterns in different tissues, allows for detection of

Table 36.2 Application of autoantibodies in hepatobiliary disease

Application	Autoantibody
Diagnosis of chronic hepatobiliary disease (<i>standard</i>)	ANA/anti-histone autoantibodies AMA/anti- PDH-E2-complex SMA Anti-LKM-1 p-ANCA Anti-SLA/LP
Assessment of response to treatment (<i>still needs evaluation</i>)	Anti-ds-DNA Anti-actin Anti-ASGPR Anti-LC-1
Identification of target autoantigens (<i>experimental</i>)	Cytochrome P450 2D6 antibodies UDP-glucuronyl transferase antibodies p-ANCA Anti-LC-1 Anti-SLA/LP

ANA, SMA, anti-LKM-1, AMA, as well as antibodies to liver cytosol type 1. Controls must include sera with known negative and positive reactivity for autoantibodies. According to the second antibody used (anti human IgG, IgM or IgA) the immunoglobulin class of the autoantibody may be determined. Immunofluorescence results are quantified by the highest dilution level (titer) at which a weak staining is just visible. A clinically significant level of positivity would start at the arbitrary dilution of 1/40 to 1/80. In contrast, for subjects up to the age of 18 years, any level of autoantibody reactivity in serum is infrequent, so that positivity at dilutions of 1/20 for ANA and SMA and even 1/10 for anti-LKM-1 is clinically relevant [30].

The molecular characterization of target antigens has permitted to develop ELISA and immunoblot techniques for the quantitative determination of autoantibodies directed against defined purified or recombinant standardized antigens [3, 5].

The quantitative analysis of circulating and hepatic *lymphocyte subpopulations* is relatively easy to perform but has not yet attained practical relevance in the diagnosis of autoimmune liver diseases. Therefore, in the following paragraphs only diagnostically relevant autoantibodies in hepatobiliary disease will be discussed (Table 36.2).

The spectrum of these autoantibodies encompasses

- Antinuclear antibodies (ANA)
- Anti smooth muscle antibodies (SMA)
- Antimitochondrial antibodies (AMA)
- Anti liver-kidney-microsomes (LKM) antibodies
- Anti soluble liver antigen (SLA/LP) antibodies

- Anti liver cytosol (LC-1) antibodies
- Anti asialo-glycoprotein-receptor (ASGPR) antibodies
- Anti neutrophil cytoplasm antibodies (ANCA)

The diagnostic efficacy of individual antibodies in liver disease varies. Currently ANA, SMA, AMA, LKM, SLA/LP and ANCA are the most important autoantibodies in the clinical evaluation of patients with autoimmune liver diseases [16].

Antinuclear Antibodies (ANA)

Target Antigens

Many biochemically different nuclear structures were identified as targets of ANA. They may be subdivided into water insoluble nucleotides (double [ds] or single stranded [ss] DNA, DNA-histone complexes), water soluble ribonucleoproteins (Sm, U1-snRNP, SS-A [Ro], SS-B [La]), nucleolar antigens (fibrillarin, RNA-polymerase, Pm-Scl), histones and non-histone proteins (Scl-70, PM-1), or may be classified according to their pattern of nuclear immunofluorescence [6, 26]. Cyclin A, a nuclear protein involved in cell cycle regulation and DNA-transcription has also been identified as a molecular target antigen in approximately 20% of patients with autoimmune hepatitis (AIH).

Immunofluorescence Reactivities

In clinical practice, primarily the demonstration of high-titer ANA with specificity against ds-/ss-DNA, Sm, U1-snRNP, SS-A (Ro), SS-B (La), centromeres and nucleolar antigens is diagnostically important. Indirect immunofluorescence microscopy using cryostat sections of cell culture lines (Hep-2 cells), rat and primate (monkey) liver and rat kidney is still the most widely used screening method. According to the immunofluorescence reaction patterns on different tissue sections ANA may be clearly distinguished from other autoantibodies, such as AMA, SMA, LKM, etc., and first conclusions as to the specificity of ANA, their target antigens and the underlying disorder may be drawn.

Thus, a *homogeneous nuclear fluorescence* on Hep-2 cells or hepatocytes (primate liver) favors an antibody reaction with DNA or histones. A simple and

highly specific method of detecting antibodies against ds-DNA is the demonstration by immunofluorescence microscopy of an antibody reaction with the ds-DNA containing kinetoplast of the flagellate *Crithidia luciliae*.

A *speckled fluorescence pattern* on Hep-2 cells or on liver sections, sparing the nucleoli indicates an antibody reaction with nucleoproteins (e.g. U1-sn-RNP, Sm, SS-A [Ro], SS-B [La]).

An intense *immunofluorescence of nucleoli or centromeres* is a clue to the presence of antibodies against nucleolar antigens such as RNA-polymerase I, U3-nRNP/fibrillarin, PM-Scl (PM-1) or against centromeres (Cenp A-C) (Table 36.3).

An immunofluorescence pattern denominated “*nuclear dots*” describes the presence of approximately 5–20 coarse fluorescence dots within the nucleus. The target antigen of these ANA is an intranuclear protein designated Sp-100 that exhibits sequence homologies with an MHC class I domain and with various regulatory proteins [24].

Generally the *ANA fluorescence pattern does not allow for conclusions on the clinical course or the prognosis of a disease*. By specifying the level of dilution, ANA may be quantified. Clinically relevant titers are present when a marked fluorescence of nuclear structures is seen on rat liver sections with serum dilutions of $\geq 1:80$. For the exact specification and quantification of ANA, diverse radioimmunological, immunoblot or ELISA-techniques on defined nuclear antigens are available (Table 36.3).

Occurrence and Significance

With the exception of antibodies against centromeres, the majority of ANA is neither organ nor species specific. The main significance of ANA in non-hepatological disease is in the diagnosis of systemic lupus erythematosus and of mixed connective tissue disease (Sharp syndrome). In autoimmune liver disease *ANA are found primarily (but not exclusively) in 40–70% of patients with classic type 1 AIH* (“lupoid hepatitis”) (Table 36.4). In more than 95% of these cases ANA are present in high titers (up to $> 1:16000$; median 1:320), they belong to the IgG class, and show a homogeneous or a speckled immunofluorescence pattern. They are often accompanied by other autoantibodies (SMA, ASGPR, in 40% by centromere antibodies and in 20% by antibodies to SS-A [Ro]) (Table 36.4). The presence of high-titer ds-DNA

Table 36.3 Antinuclear antibodies

IIF staining pattern	Target antigens	Other detection methods	Occurrence
Homogeneous	ds-DNA ss-DNA Histones	RIA, ELISA RIA, ELISA CBR	SLE, “lupoid” hepatitis, drug-induced LE, SS, RA, CAH, PBC, MG
Nuclear			
– Homogeneous	U3-nRNP (fibrillar)		Scl, healthy persons,
– Granular	RNA-polymerase I	CIE, IB	MCTD, PBC
– Homogeneous and Nucleoplasm	Pm-Scl (PM-1)	ELISA	Overlap-syndromes
– “Nuclear dots”	SP-100	ELISA, IB	Scl/myositis-overlap PBC
Speckled	U1-snRNP (70 kD)	CIE, IB, ELISA	SLE, MCTD, Scl, RA, PBC
	SM (To)	CIE, IB, ELISA	SLE
	SS-A (Ro), SS-B (La)	CIE, IB, ELISA	SLE, MCTD, Scl, SS, overlap-syndrome
	Scl-70	Double diffusion on agar	Scl
	PM-1	Double diffusion on agar	Polymyositis
Centromeres	CENP-A, B, C		CREST (limited Scl), MCTD, PBC
Centrosome	Neuron-specific enolase		Limited Scl
Cytoplasmic	SS-A (Ro), Jo-1, ribosomes, Golgi, mitochondria RF-ANA RANA	IIF on EBV-infected B cells	Among others SS, Jo-1-syndrome, MCTD, SLE, overlap-syndromes, PBC RA, SLE, MCTD, cryoglobulinemias RA

ANA = Antinuclear antibodies; CAH = Chronic active hepatitis;

CBR = Complement binding reaction;

CENP = Centromeric antigens;

CIE = Counter immuno-electrophoresis;

CREST = Calcinosis cutis, Raynaud phenomenon, esophageal motility disorder, sclerodactylia, teleangiectasias;

ds-DNA = Double stranded DNA;

EBV = Epstein-Barr virus;

ELISA = Enzyme linked immunosorbent assay;

IB = Immunoblot;

IIF = Indirect immunofluorescence microscopy;

MCTD = Mixed connective tissue disease;

MG = Myasthenia gravis;

PBC = Primary biliary cirrhosis;

PM = Polymyositis;

RA = Rheumatoid arthritis;

RANA = Rheumatoid arthritis associated nuclear antigen;

RF-ANA = Rheumafactor exhibiting cross reactivity with ANA;

RIA = Radioimmunoassay;

RNP = Ribonucleoprotein;

SCL = Systemic sclerosis;

SLE = Systemic lupus erythematosus;

snRNP = Small nuclear ribonucleoprotein;

SS = Sjögren’s syndrome;

SS-DNA = Single stranded DNA

antibodies in patients with ANA-positive autoimmune hepatitis is associated with a poor short term response to corticosteroid therapy. A speckled fluorescence pattern is usually found in younger patients with AIH and is associated with higher levels of AST in serum compared to cases with a homogeneous fluorescence pattern.

However, *there is no strict correlation between fluorescence patterns and outcome of treatment.*

Low-titer ANA, often IgM, with a homogeneous nuclear fluorescence are found in 20–40% of patients with rheumatoid arthritis, in vasculitis, myasthenia gravis, viral infections and in many healthy older persons.

Table 36.4 Autoantibody patterns in liver diseases

Disease	ANA	LKM	SMA ^a	SLA/LP ^b	AMA	ASGPR
Type 1 AIH	+++	∅	++	±	–	++
Type 2 AIH	–	+++ ^c	–	–	∅	++
Type 3 AIH	–	∅	±	+++	–	++
Primary biliary cirrhosis	+	∅	+	–	+++	±
Overlap PBC/AIH	++	∅	++	–	++	++
Tienylic acid-induced hepatitis	–	+++ ^d	–	–	∅	–
Chronic hepatitis B	±	∅	±	–	±	++
Chronic hepatitis C	–	±	–	–	–	–
Chronic hepatitis D	±	– ^e	±	–	±	++
Alcoholic liver disease	–	–	±	–	–	±
Healthy persons	–	∅	–	∅	–	∅

^a In most autoimmune liver diseases SMA have anti-actin activity; AIH with high titer SMA as the only autoantibody marker is sometimes called type 4 AIH.

^b SLA and LP antibodies are identical.

^c Anti-LKM-1, possibly also anti-LC-1 present.

^d Anti-LKM-2.

^e Anti-LKM-3.

∅ not detectable, – detectable in < 10% of cases, ± detectable in 10–30% of cases, + detectable in 30–50% of cases, ++ detectable in 50–90% of cases, +++ detectable in > 90% up to 100% of cases.

High-titer ANA with speckled fluorescence may occur in Sharp syndrome as well as in some cases of systemic lupus erythematosus, Sjögren syndrome, polymyositis, dermatomyositis, systemic sclerosis or in primary biliary cirrhosis (“nuclear dots” in 30–40% of cases), and rarely in primary sclerosing cholangitis.

Nucleolar or centromere type ANA occur predominantly in systemic sclerosis or in CREST-syndrome, more rarely in Sharp syndrome, systemic lupus erythematosus and in 10% of cases of primary biliary cirrhosis. In the latter a characteristic staining of the nuclear membrane often may be observed.

Thus, expression of ANA is nonspecific and may also vary within one and the same patient. ANA may disappear and reappear in a non predictable manner. They may be accompanied or replaced by SMA. *The positive predictive value of isolated high-titer ANA for the diagnosis of AIH is less than 5%.*

Smooth Muscle Antibodies (SMA)

Target Antigens

The target structures of SMA are the contractile elements of microfilaments, (actin, actomyosin, myosin, tubulin) and of intermediary filaments (vimentin, desmin, skeletin) which occur in the cytoskeleton of the

hepatocyte, but are also present in many myofibrils and connective tissue cells (mesenchyme). In liver disease the most important target antigen is actin [27]. Actin-like antigens are also components of many viruses, including paramyxoviruses (measles or herpes virus).

Immunofluorescence Reactivities

SMA stains the walls of the arterial vessels in the liver, kidney and stomach, the muscular layer of the stomach and, in addition, it stains the vascular axis with the interglandular fibers (“inter-parietal cell septa”) of the lamina propria of the gastric mucosa. The examination of the kidney is of importance since this allows visualization of the V (vessels), G (glomeruli) and T (tubules) pattern. The specificity of immunofluorescence results may be verified by ELISA or RIA using defined purified smooth muscle antigens.

Occurrence and Significance

The occurrence of low-titer SMA is nonspecific and is seen in infections, chronic inflammatory, malignant and autoimmune diseases. SMA are found in 70–80% of patients with different types of AIH. However, SMA may also be present in viral hepatitis (50–80%),

CMV- and EBV-infections, primary biliary cirrhosis, and primary sclerosing cholangitis (40–70%).

SMA are neither species nor organ specific. In contrast to other autoantibodies, the prevalence of SMA does not increase with age. SMA present in acute viral hepatitis, in collagen vascular diseases and in approximately 10% of healthy persons usually are low-titer IgM antibodies that do not bind complement and generally are not accompanied by ANA. In contrast, SMA in type 1 and 3 AIH typically are high-titer (median 1:160), complement binding IgG antibodies that as a rule are accompanied by ANA (type 1 AIH) and occasionally by antibodies to SLA/LP (type 3 AIH) (Table 36.4). There is a strong association (sensitivity 80%) between anti-actin reactivity and AIH-1, but some 20% of SMA positive patients with AIH-1 lack the actin-SMA pattern, such that the absence of anti-actin SMA does not exclude the diagnosis [4]. Since actin is closely associated with the hepatocellular membrane, anti-actin SMA may enhance the binding of immunoglobulins to the surface of liver cells and thereby contribute to antibody dependent cell-mediated cytotoxicity. This may explain the observation that the occurrence of anti-actin SMA in ANA positive patients with AIH seems to be associated with a worse prognosis.

SMA in primary biliary cirrhosis are also of the anti-actin type, and depending on the stage of disease IgM or IgG antibodies.

The extrahepatic diseases associated with SMA are primarily cardiomyopathies (48–56%), the postcardiotomy syndrome (80–100%) and Dressler's syndrome (40–70%). Generally in these cases autoantibodies against other muscle antigens, such as actomyosin, tropomyosin or sarcolemma are also present.

Anti-vimentin IgM antibodies may be found in nearly all serum, and are therefore considered to be the “naturally” occurring autoantibodies. Low-titer anti-vimentin IgG antibodies are produced in the wake of (nearly) each polyclonal immunoglobulin stimulation. High-titer IgM or IgG SMA are observed in systemic lupus erythematosus (50%), in chronic viral hepatitis with marked inflammatory activity (65%), in primary biliary cirrhosis (50%), in advanced alcoholic liver disease (30%), in rheumatoid arthritis (80%), and in infectious mononucleosis (100%). These high titers decrease only slowly. 3–25% of healthy blood donors have low-titer ($\leq 1:20$) SMA. Anti-desmin SMA (a specific marker of smooth muscle) are much more infrequent and occur practically only in rheumatoid arthritis.

Anitimitochondrial Antibodies (AMA)

Target Antigens

In patients with primary biliary cirrhosis (PBC) AMA recognize the highly conserved regions of 2-oxo-acid dehydrogenase enzymes (OADC), particularly the dihydrolipoamide acetyltransferase (E2 component) of the pyruvate dehydrogenase complex (PDC). Serum AMA react selectively with members of the 2-OADC family; these include PDC-E2, the E2 subunit of branched chain 2-oxo-acid dehydrogenase complex (BCOADC-E2), the E2 subunit of the oxoglutarate dehydrogenase complex (OGDC-E2), the dihydrolipoamide dehydrogenase (E3)-binding protein (E3BP), and the E1 α subunit of the pyruvate dehydrogenase complex (PDC-E1 α) [11].

Immunofluorescence Reactivities

Indirect immunofluorescence on rat kidney, rat stomach or human epithelial cells (Hep-2 cells) is still the most widely used screening assay for AMA. Typically a finely granular, speckled cytoplasmic fluorescence, giving the impression of a “starry sky”, is found. Although immunofluorescence patterns may give some clues as to the subtype of AMA, reliably subtyping AMA requires the application of techniques based on the isolation of defined autoantigens (ELISA, RIA, immunoblot).

Occurrence and Significance

AMA are the diagnostic hallmark of PBC. High titer ($> 1:100$), mostly IgG AMA, often in combination with ANA (“nuclear dots” or “centromere” type) are detected in up to 95% of affected individuals. Use of cloned mitochondrial antigens containing the major autoepitopes in an ELISA format can identify AMA in the sera of patients previously defined as AMA negative [11]. Immunoblotting has an overall sensitivity of more than 90% and a specificity of 98% in PBC.

Unspecified AMA have a high diagnostic sensitivity for PBC, but a low specificity. However, with

increasing AMA titers the probability of hepatobiliary disease increases, and high-titer AMA against dihydro-lipoamide acetyltransferase of the pyruvate dehydrogenase complex (anti PDH-E2) are regarded as nearly pathognomonic for PBC, with a diagnostic sensitivity of 98% and a specificity of up to 95%.

Despite their diagnostic importance, AMA do not seem to have a pathogenic role in PBC, and can occur in healthy relatives of PBC patients [2, 13]. AMA are often detectable for several years before the onset of overt clinical disease and their titer usually increases with the duration of the illness [15]. AMA titers, however, do not correlate with the severity or prognosis of PBC and usually persist after liver transplantation, even without any evidence of recurrent disease in the transplanted liver [14]. AMA are therefore not clinically useful during follow-up of patients with PBC [22].

Non PBC specific AMA can occur in chronic viral hepatitis, primary sclerosing cholangitis, granulomatous liver disease, drug-induced cholestatic liver injury and in hepatic involvement in malignant lymphoma.

AMA may also be found in nonhepatic autoimmune disorders, e.g. collagen vascular diseases.

So-called naturally occurring mitochondrial antibodies (NOMA) react with many secondary mitochondrial antigens and are detectable only with immunoblotting in slightly diluted sera [13]. The significance of these autoantibodies is not clear.

Antibodies Against Liver-Kidney-Microsomes (LKM)

Target Antigens

Autoantibodies against LKM are directed against lipoproteins localized in the membranes of the rough endoplasmic reticulum. They occur in proximal renal tubular epithelial cells, in hepatocytes and in epithelial cells of the duodenal and bronchial mucosa. LKM immunoreactivities are heterogeneous and associated with several immune-mediated liver diseases (see below). LKM autoantibodies may be subclassified as LKM-1, LKM-2, and LKM-3, mainly according to the disease setting in which they occur.

LKM-1 antibodies recognize a sequence of eight amino acids of cytochrome P450 isoform 2D6 (involved

in debrisoquin metabolism, formerly called db 1) and, in approximately 10% of cases, of cytochrome P450 1A2 (50kD) [17, 18]. They inhibit the enzymatic activity in vitro. LKM-2 antibodies are directed against cytochrome P450 2C9 that is involved in the metabolism of the diuretic ticrynafen, and the target antigens of LKM-3 antibodies are uridine diphosphate glucuronosyl transferases [21].

Immunofluorescence Reactivities

LKM antibodies can be demonstrated by indirect immunofluorescence using cryostat sections of rat liver and rat kidney. AMA can be confused with anti LKM-1 and the inadvisable use of renal tissue in isolation (as often done), or faulty orientation of the tissue, can result in erroneous interpretation. Examination of the three tissue substrates (liver, kidney, stomach) should allow a ready distinction between AMA and anti-LKM. Anti-LKM-1 stains the liver cell cytoplasm and the P3 portion of the renal tubules strongly and diffusely, but spares cells of the gastric glands. AMA give a fainter staining of liver cell cytoplasm but a stronger staining of all renal tubules, especially the smaller distal ones. In contrast to anti LKM-1, AMA also stain the gastric parietal cells and Hep-2 cells [30]. Subdividing LKM-antibodies by immunofluorescence is not possible. Western blotting (demonstration of 50kD band) and specific anti cytochrome P450 2D6 ELISAs are available for the demonstration of LKM-1 antibodies.

Occurrence and Significance

LKM antibodies occur relatively rarely. *Autoantibodies to LKM-1 are the main serological marker of type 2 AIH (Table 36.4)*. Their pathogenic role is still debated. Anti LKM-1 are often found in high titers (> 1:2000) in young patients, and mostly belong to the subclass IgG1. They frequently are associated with various extrahepatic syndromes. In addition to type 2 AIH, LKM antibodies may occur in chronic viral hepatitis C, drug-induced hepatitis, and hepatitis in AIRE (auto-immune regulator) deficiency, i.e. in type 1 autoimmune polyglandular syndrome. Patients with chronic

hepatitis C and LKM-1 autoantibodies respond to treatment with pegylated interferon and ribavirin. These patients have chronic viral hepatitis and not AIH, with LKM-1 antibodies representing an autoimmune epiphenomenon. The induction of LKM-1 antibodies in chronic hepatitis C seems to be due to a partial sequence homology (cross reaction) between the target antigen of anti-LKM, cytochrome P450 2D6, and two segments of HCV polyprotein. HCV-induced anti-LKM-1 are directed against a different epitope on cytochrome P450 2D6 than LKM-1 antibodies associated with type 2 AIH [34].

Up to now LKM-2 antibodies have only been observed in hepatitis induced by tienilic acid (ticrynafen).

LKM-3 antibodies may be present in 10% of patients with chronic hepatitis D. Exposure to halothane, phenytoin, penobarbital and carbamazepine has also been associated with the generation of LKM-3 antibodies. Dihydralazine-induced hepatitis may also be accompanied by LKM antibodies.

Antibodies Against Soluble Liver Antigen/Liver-Pancreas Antigen (SLA/LP)

Target Antigens

Anti-SLA and anti-LP were independently described, and were initially considered to be different. More recently, it has been shown that antibodies to SLA and LP are identical and are therefore called anti-SLA/LP. Cytosolic UGA-suppressor-tRNA associated protein is the target antigen of SLA/LP antibodies (in the past, it was thought to be cytokeratins or glutathione-S-transferases) [12, 31–33]. The highest concentrations of SLA/LP are found in liver and kidneys.

Detection Systems

Antibodies against SLA/LP are demonstrated by RIA or ELISA and cannot be visualized by immunofluorescence microscopy. Molecularly based diagnostic assay kits are available but not yet fully evaluated.

Occurrence and Significance

Anti-SLA/LP is a specific diagnostic marker of type 1 AIH but can also be detected in sera from patients with type 2 AIH and AIH/primary sclerosing cholangitis overlap syndrome by means of more sensitive techniques [11]. In patients with type 1 AIH, anti-SLA/LP occur in 17–30%, and in type 2 AIH in 8% of cases. In patients with overlap syndrome, anti-SLA/LP are found in approximately 15% of cases.

Occasionally anti-SLA/LP is found in patients with AIH who are negative for ANA, SMA or anti-LKM-1. The demonstration of anti SLA/LP in these patients is clinically valuable, because it testifies to the autoimmune nature of their disease that otherwise would have been misclassified as cryptogenic hepatitis. Autoantibodies against SLA/LP are not only diagnostically significant, but also allow for the assessment of the immunologic activity of the disease. Their detection at the time of diagnosis identifies patients with more severe disease and a likely adverse outcome. During clinical remission induced by immunosuppressive therapy, anti-SLA/LP levels fall, while their increase is an early indicator of a disease flare [20].

Antibodies Against Liver Cytosol Type 1 (LC-1)

Target Antigens

The molecular target of anti-LC-1 has been identified as formimino-transferase cyclodeaminase, an enzyme involved in folate metabolism.

Immunofluorescence Reactivities

Anti-LC-1 may be visualized by indirect immunofluorescence microscopy using rat hepatocytes. They cause a homogeneous cytoplasmic staining, with relative sparing of perivenular hepatocytes. Microscopical demonstration of anti-LC-1 is usually obscured by concurrent presence of anti-LKM-1. In the presence of anti-LKM-1, anti-LC-1

can be detected by immunodiffusion, counterimmunoelectrophoresis or Western blot as a reactivity with a 58–60kD protein using a human liver cytosolic fraction as substrate. Since the molecular target of anti-LC-1 has been defined, commercial kits have become available.

Occurrence and Significance

In approximately two thirds of cases anti-LC-1 are associated with anti-LKM-1; together with anti-LKM-1 they define type 2 AIH [1]. However, anti-LC-1 occur only in approximately 50% of patients with type 2 AIH (predominantly young patients under 20 years of age), and in 10% of patients anti-LC-1 are the only detectable markers of type 2 AIH [1]. In contrast to anti-LKM-1, anti-LC-1 does correlate with AIH severity, progression, or response to treatment.

Anti-LC-1 is found only occasionally in type 1 AIH and in patients with chronic HCV infection.

Antibodies Against Asialoglycoprotein-Receptor (ASGPR)

Target Antigens

The ASGPR is a liver specific transmembranous glycoprotein. It is also called liver-lectin, and is a galactose specific receptor responsible for the hepatocellular uptake and biliary excretion of many glycoproteins devoid of sialic acid. ASGPR is involved in the induction of T cell proliferation and activation of cytotoxic T cells by binding, presenting, and internalizing potential antigens. Therefore, antibodies against the ASGPR likely play a major role in the pathogenesis of immune-mediated liver disease.

Detection Systems

Antibodies against ASGPR are demonstrated by RIA, ELISA or Western blot. The performance of the tests is restricted to specialized laboratories, and commercial test assays are not yet available.

Occurrence and Significance

Antibodies against ASGPR of animal origin are found in most inflammatory liver diseases. They may occur in viral and non-viral liver disease, AIH, extrahepatic autoimmune disorders, alcoholic liver disease or in PBC, thus reflecting the inflammatory process itself rather than the cause of liver disease. However, high-titer (median 1:325) antibodies against human ASGPR are detected in 83–90% of patients with type 1 AIH, and may be useful to extend the diagnosis of AIH in patients without the usual classic autoantibodies (ANA, SMA) [7, 28]. While high-titer anti-ASGPR are relatively specific for AIH, low-titer anti-ASGPR do not rule out other liver diseases, such as viral hepatitis B. Interferon treatment of chronic hepatitis B may also lead to the transient appearance of low-titer anti-ASGPR [29].

The titer of anti-ASGPR correlates with the inflammatory activity, and may be useful to monitor treatment responses. In the active phase of AIH, IgG and IgM anti-ASGPR are present, while IgM antibodies regularly disappear during remission. The complete loss of IgG anti-ASGPR potentially indicates the time at which immunosuppressive treatment may be discontinued with a relatively low risk of relapse. Patients in whom anti-ASGPR is present at the end of treatment have a higher risk of relapse than patients in whom anti-ASGPR disappeared during therapy.

Antineutrophil Cytoplasmic Antibodies (ANCA)

Target Antigens

ANCA are directed at cytoplasmic components (enzymes of azurophilic or primary granules) of neutrophils and monocytes. Various target antigens have been identified. Proteinase 3 (PR3) is the target antigen for c-ANCA, characteristic of Wegener's granulomatosis. The target antigens for p-ANCA are myeloperoxidase (MPO), human leukocyte elastase (HLE), lysozyme (LZ), lactoferrin (LF), cathepsin G (CG), β -glucuronidase, and several others still poorly defined antigens [10]. MPO is considered the major antigen for pANCA in patients with polyarteritis nodosa, and focal necrotizing or extracapillary proliferative

glomerulonephritis. LF and particularly CG, as well as a cationic antimicrobial protein (CAP57) are discussed as potential target antigens for atypical pANCA often detected in primary sclerosing cholangitis (PSC). ANCA in PSC and in ulcerative colitis are believed to be directed at diverse antigens. ANCA occurring occasionally within the context of chronic viral hepatitis are poorly defined and also recognize different target antigens from that known in vasculitis (PR3, MPO, HLE).

Immunofluorescence Reactivities

Two different staining patterns may be seen by indirect immunofluorescence microscopy. *c*-ANCA are characterized by a diffuse granular, centrally accentuated *cytoplasmic staining*, sparing the cell nucleus. *p*-ANCA are defined by a *perinuclear staining* pattern. The perinuclear staining pattern, however, does not allow reliable conclusions as to the potential target antigen(s). The classical p-ANCA staining pattern is an artifact of ethanol fixation of neutrophils, caused by migration of strongly cationic cytoplasmic proteins (such as myeloperoxidase) to the negatively charged nuclear membrane; the cytoplasmic pattern is retained if neutrophils are fixed with crosslinking agents such as formaldehyde. However, p-ANCA in AIH ('atypical' p-ANCA) often differ from classical p-ANCA by retention of perinuclear staining on formaldehyde-fixed cells [30]. "Atypical" p-ANCA found in PSC, ulcerative colitis, and Crohn's disease may react with nuclear membrane components (perinuclear anti-neutrophil antibodies, *p*-ANNA).

The detection of ANCA is also possible by immunoperoxidase, ELISA and Western blot techniques, which should allow for molecular characterization of various target antigens.

Occurrence and Significance

In this section the significance of ANCA as related to hepatobiliary disease is discussed. A discussion of the diagnostic importance of ANCA in rheumatic, vasculitic and extrahepatic autoimmune diseases is beyond the scope of this chapter.

p-ANCA are detected by indirect immunofluorescence at high titer in up to 90% of patients with type 1

AIH [25]. Eighty percent of these autoantibodies belong to the IgG class and their pathogenic role (if any) in AIH is not clear [19]. Detection of atypical p-ANCA can act as an additional indicator of type 1 AIH, particularly in the absence of other autoantibodies. Most patients with type 2 AIH are p-ANCA negative.

Atypical p-ANCA are also detected in 65–85% of patients with PSC, irrespective of disease stage and the concomitant presence of chronic inflammatory bowel disease. p-ANCA in PSC belong predominantly to the IgG1 and IgG3 subclasses of immunoglobulins. They seem to occur significantly more often in PSC patients with bile duct complications. The sensitivity of p-ANCA for PSC is 65% and the specificity has been reported to be 100% [8, 9]. p-ANCA are also found in approximately 25% of healthy relatives of PSC-patients [23].

Atypical p-ANCA may also be found in up to 60–80% of patients with ulcerative colitis, and in approximately 10% of patients with Crohn's disease. They also occur, although much less frequently and in lower titers, in patients with primary biliary cirrhosis, chronic viral hepatitis, HIV-, Epstein-Barr virus, cytomegalovirus infections, as well as in approximately 7% of healthy blood donors.

References

1. Abuaf N, Johanet C, Chretien P, et al (1992) Characterization of the liver cytosol antigen type 1 reacting with autoantibodies in chronic active hepatitis. *Hepatology* 16: 892–8
2. Berg PA, Klein R (1992) Antimitochondrial antibodies in primary biliary cirrhosis and other disorders: definition and clinical relevance. *Dig Dis Sci* 10:85–101
3. Czaja AJ (1996) Autoimmune liver disease. In: Zakim D, Boyer TD (ed) *Hepatology – A textbook of liver disease*, 3rd edn. WB Saunders, Philadelphia/London/Toronto/Montreal/Sydney/Tokyo, pp 1259–92
4. Czaja AJ, Cassani F, Cataleta M, et al (1996) Frequency and significance of antibodies to actin in type 1 autoimmune hepatitis. *Hepatology* 24: 1068–73
5. Czaja AJ, Homburger HA (2001) Autoantibodies in liver disease. *Gastroenterology* 120: 239–49
6. Czaja AJ, Nishioka M, Morshed SA, et al (1994) Patterns of nuclear immunofluorescence and reactivities to recombinant nuclear antigens in autoimmune hepatitis. *Gastroenterology* 107: 200–7
7. Czaja AJ, Pfeifer KD, Decker RH, et al (1996) Frequency and significance of antibodies to asialoglycoprotein receptor in type 1 autoimmune hepatitis. *Dig Dis Sci* 4: 1733–40
8. Duerr RH, Targan SR, Landers CJ, et al (1991) Neutrophil cytoplasmic antibodies: a link between primary sclerosing cholangitis and ulcerative colitis. *Gastroenterology* 100: 1385–91

9. Gross WL, Hauschild S, Schmitt WH (1993) Immundiagnostische und immunpathogenetische Bedeutung von Anti-Neutrophilen-Zytoplasma-Antikörpern. *Dtsch med Wschr* 118: 191–9
10. Halbwachs-Mecarelli L, Nusbaum P, Noel LH, et al (1992) Antineutrophil cytoplasmic antibodies (ANCA) directed against cathepsin G in ulcerative colitis, Crohn's disease and primary sclerosing cholangitis. *Clin Exp Immunol* 90: 79–84
11. Invernizzi P, Lleo A, Podda M (2007) Interpreting serological tests in diagnosis of autoimmune liver disease. *Sem Liver Dis* 27: 161–72
12. Kernebeck T, Lohse AW, Grötzinger J, et al (2001) A bioinformatical approach suggests the function of the autoimmune hepatitis target antigen soluble liver antigen/liver pancreas. *Hepatology* 34: 230–3
13. Klein R, Berg PA (1990) Demonstration of “naturally occurring mitochondrial antibodies” in family members of patients with primary biliary cirrhosis. *Hepatology* 12: 335–41
14. Klein R, Huizenga JR, Gips CH, et al (1994) Antimitochondrial antibody profiles in patients with primary biliary cirrhosis before orthotopic liver transplantation and titres of antimitochondrial antibody-subtypes after transplantation. *J Hepatol* 20: 181–9
15. Klein R, Klöppel G, Garbe W, et al (1991) Antimitochondrial antibody profiles determined at early stages of primary biliary cirrhosis differentiate between a benign and a progressive course of the disease. A retrospective analysis of 76 patients over 6–18 years. *J Hepatol* 12: 21–7
16. Manns MP (1989) Autoantibodies and antigens in liver diseases—updated. *J Hepatol* 9: 272–80
17. Manns MP, Griffin KJ, Sullivan KF, et al (1991) LKM-1 autoantibodies recognize a short linear sequence in P450IID6, a cytochrome P-450 monooxygenase. *J Clin Invest* 88: 1370–8
18. Manns MP, Johnson EF, Griffin KJ, et al (1989) Major antigen of liver kidney microsomal autoantibodies in idiopathic autoimmune hepatitis is cytochrome P450db1. *J Clin Invest* 83: 1066–72
19. Mayet WJ, Orth T, Schwarting A, et al (1996) Die Bedeutung antineutrophiler zytoplasmatischer Antikörper (ANCA) in der Diagnostik und Immunpathogenese chronisch entzündlicher Lebererkrankungen. *Med Klin* 91: 384–8
20. McFarlane IG, Hegarty JE, McSorley CG, et al (1984) Antibodies to liver-specific protein predict outcome of treatment withdrawal in autoimmune chronic active hepatitis. *Lancet* 2: 954–6
21. Philipp T, Durazzo M, Trautwein C, et al (1994) Recognition of uridine diphosphate glucuronosyl transferases by LKM-3 antibodies in chronic hepatitis D. *Lancet* 344: 578–81
22. Poupon R, Poupon RE (1996) Primary Biliary Cirrhosis. In: Zakim D, Boyer TD (ed) *Hepatology: A textbook of liver disease*, 3rd edn. WB Saunders, Philadelphia/London/Toronto/Montral/Sydney/Tokyo, pp 1329–65
23. Seibold F, Slametschka D, Gregor M, et al (1994) Neutrophil autoantibodies: a genetic marker in primary sclerosing cholangitis and ulcerative colitis. *Gastroenterology* 107: 532–6
24. Szostecki C, Will H, Netter HJ, et al (1992) Autoantibodies to the nuclear Sp100 protein in primary biliary cirrhosis and associated diseases: epitope specificity and immunoglobulin class distribution. *Scand J Immunol* 36:555–64
25. Targan SR, Landers C, Vidrich A, et al (1995) High-titer antineutrophil cytoplasmic antibodies in type-1 autoimmune hepatitis. *Gastroenterology* 108: 1159–66
26. Thomas L (1992) Labor und diagnose: Indikation und Bewertung von Laborbefunden für die Medizinische Diagnostik. 4. überarb. Aufl. Autoantikörper gegen Organgewebe und Thrombozyten. Med. Verl.-Ges., Marburg
27. Toh BH (1979) Smooth muscle autoantibodies and autoantigens. *Clin Exp Immunol* 38: 621–8
28. Treichel U, McFarlane BM, Seki T, et al (1994) Demographics of anti-asialoglycoprotein receptor autoantibodies in autoimmune hepatitis. *Gastroenterology* 107: 799–804
29. Treichel U, Paietta E, Poralla T, et al (1994) Effects of cytokines on synthesis and function of the hepatic asialoglycoprotein receptor. *J Cell Physiol* 158: 527–34
30. Vergani D, Alvarez F, Bianchi FB, et al (2004) Liver autoimmune serology: a consensus statement from the committee for autoimmune serology of the International Autoimmune Hepatitis Group. *J Hepatol* 41: 677–83
31. Wachter B, Kyriatsoulis A, Lohse AW, et al (1990) Characterization of liver cytokeratin as a major target antigen of anti-SLA antibodies. *J Hepatol* 11: 232–9
32. Wesierska-Gadek J, Grimm R, Hitchman E, et al (1998) Members of the glutathione S-transferase gene family are antigens in autoimmune hepatitis. *Gastroenterology* 114: 329–35
33. Wies I, Brunner S, Henninger J, et al (2000) Identification of target antigen for SLA/LP autoantibodies in autoimmune hepatitis. *Lancet* 355: 1510–5
34. Yamamoto AM, Cresteil D, Homberg JC, et al (1993) Characterization of anti-liver-kidney microsome antibody (anti-LKM1) from hepatitis C virus-positive and -negative sera. *Gastroenterology* 104:1762–7

Chapter Outline

Introduction	359
Examination Technique, Anatomy and Artefacts	360
Diffuse Liver Disease	360
Hepatic Steatosis.....	360
Liver Cirrhosis	360
Perihepatic Lymphadenopathy.....	361
Acute Viral Hepatitis.....	361
Chronic Viral Hepatitis C.....	362
Primary Biliary Cirrhosis.....	362
Primary Sclerosing Cholangitis	363
Other Diseases	364
Doppler Ultrasound Techniques in the Evaluation of Liver Disease	364
Blood Supply of Hepatic Vessels	364
Color Doppler Imaging (CDI) for Analysis of Hepatic Vessel Flow Pattern	365
Vascular (Doppler) Indices	365
Examination of the Hepatic Artery in Patients with Diffuse Liver Disease.....	366
Examination of the Portal Vein in Patients with Diffuse Liver Disease.....	366
Examination of the Hepatic Veins in Patients with Diffuse Liver Disease.....	369
Focal Liver Lesions	371
Detection and Characterization of Liver Tumors.....	372
Differentiation of Benign and Malignant Lesions	374
Liver Tumor Characterization.....	376
Gallbladder Disease	391
Anatomy.....	392
Congenital Anomalies of the Gallbladder.....	392
Cholecystolithiasis	393
Cholecystitis.....	393
Gallbladder Polyps.....	395
Gallbladder Carcinoma	395
Extrahepatic Bile Ducts	395

Congenital Disorders	395
Cholelithiasis.....	396
Secondary Sclerosing Cholangitis	397
Cholangiocellular Carcinoma	397
Other Extrahepatic Bile Duct Tumors.....	398
References.....	399

Introduction

After obtaining the patient history and performing a physical examination, conventional B-mode and color Doppler imaging (CDI) are the imaging methods of choice in, for example, the evaluation of right upper quadrant pain, obstructive jaundice, the screening of metastatic diseases or for hepatocellular carcinoma in patients with liver cirrhosis, in patients with elevated liver enzymes and many other hepatobiliary diseases. In the hands of a hepatologist/gastroenterologist ultrasound has become a diagnostic tool equal in importance to endoscopy.

Primarily, ultrasound is the method of choice in the confirmation or exclusion of dilated bile ducts, cysts and calcifications. The overall importance of ultrasound in distinguishing different etiologies of diffuse liver diseases was regarded as relatively low. Nevertheless ultrasound is a very sensitive means of detecting complications of liver cirrhosis. Porto-systemic shunts and typical changes in the morphology of blood vessels can be diagnosed by color Doppler ultrasound and can be used as an indirect sign of advanced damage to liver parenchyma. Liver tumor detection and characterization has been dramatically improved by using contrast enhanced imaging techniques.

Examination Technique, Anatomy and Artefacts

Examination technique (segmental) anatomy and artefacts are not specific topics of this book chapter and the author refers the interested reader to respective ultrasound textbooks. The same is true for description of interventional techniques.

Diffuse Liver Disease

Criteria for analysing diffuse liver disease include evaluation of the liver parenchyma (echo texture, ultrasound attenuation), detection of lymph nodes in the hepatoduodenal ligament, identifying inflammatory liver disease or neoplastic infiltration, and vessel architecture. Color and pulsed wave Doppler imaging (CDI) is helpful in the analysis of hepatic vessel flow patterns. Ultrasound contrast agents (USCA) have improved the detection (exclusion) rate of focal liver lesions.

Hepatic Steatosis

Hepatic steatosis is the most common liver pathology. Sensitivity and specificity of the detection of hepatic steatosis by B-mode ultrasound examination may be very high in the hands of an expert investigator who consistently applies specific criteria [39, 44, 89, 136, 142, 154]. However, in clinical practice images will be interpreted by clinicians with varying levels of experience. In this regard, a recent observational study assessed the performance of grey scale ultrasound in the diagnosis of hepatic steatosis in patients with chronic HCV infection in a routine clinical setting (i.e., outside the context of a controlled study) and found no consistent correlation with steatosis on liver biopsies [74].

In transabdominal ultrasound hepatic steatosis is characterised by increased echogenicity, which is often compared to the spleen or kidney [124]. Supporting findings may be ultrasound attenuation (the decrease in amplitude or intensity as sound travels through a material. Attenuation is due to three factors: absorption, scattering, and beam divergence), decreased detail of intra-hepatic architecture and loss of definition of the hemi-diaphragm [88]. However, the performance

characteristics of conventional grey scale ultrasound vary considerably among studies, ranging from good to poor, also dependent on techniques used [18, 19, 124, 141]. One reason might be that concomitant liver pathology can complicate the diagnosis of steatosis on ultrasound. For example, echogenicity on ultrasound may be consistent with either steatosis or fibrosis and may not effectively differentiate between those two conditions [98]. The value of the so-called fibroscan is controversial and of limited value [56, 135]. Another drawback is the need for subjective interpretation of the images by the investigator, which accounts for high inter- and intra-observer variability [157]. In the majority of patients with hepatic steatosis distinctive hypoechoic areas in the liver hilum can be demonstrated by ultrasound examination [3]. It is believed that the presence of focal hypoechoic areas (FHA) within the liver hilum corresponds to parenchymal islands with normal fat content, that are surrounded and contrasted by bright echogenic parenchyma with fatty infiltration [140]. Of note, FHA are relatively specific for hepatic steatosis and can help to differentiate fatty from fibrotic liver disease [18]. Similar focal hypoechoic areas were demonstrated in patients with liver steatosis due to systemic corticosteroid therapy, even though the more important focal lesions in this condition are hyperechoic [39]. Pathogenetically areas of different fat content might be explained by a different arterial and portal venous blood supply in comparison to the surrounding liver parenchyma.

Liver Cirrhosis

The accuracy of ultrasound in the correct diagnosis of “liver cirrhosis” in patients with complications (ascites, splenomegaly, collaterals) is high whereas in the initial stages it may be overlooked in up to 30% of patients [44]. Sonographic signs of liver cirrhosis include inhomogeneous echotexture and irregular liver surface delineation and a variety of other possible findings also dependent on the etiology of diseases (see respective chapters).

Most sonographic signs show a good positive but only a moderate negative predictive value. A nodular liver surface (especially using high frequency transducers) has an excellent positive predictive value of theoretically up to 100% (sensitivity, specificity and accuracy were 0.58–0.88, 0.82–0.94 and 68–89%, respectively). A proportional enlargement of diameters

of the caudate lobe in relation to the right and left lobe, the proportional enlargement of the left lobe in relation to the right lobe and certain caudate lobe indexes alone had a sensitivity, specificity and accuracy of 43–95%, 95–100% and 67–93% but are of limited value in daily routine. Coarse liver parenchyma as a sign of liver cirrhosis has an accuracy of approximately 65%. An enlarged spleen shows a sensitivity, specificity and accuracy of 62–82%, 78–93% and 74%. The positive predictive value of the detection of signs of portal hypertension is excellent such as reversed portal flow and the detection of collateral vessels. The negative predictive value is worse. Overall, the accuracy is about 60%. In Doppler studies a rise in the arteriportal peak velocity ratio of more than 3.5 is predictive for cirrhosis. An enlarged portal vein diameter greater than 1.25 cm or a reduced portal vein flow velocity indicates cirrhosis with a sensitivity and specificity of about 80%. The congestion index, the ratio between cross sectional area and averaged mean velocity is reported to have an excellent sensitivity and specificity. The lack of a standard for Doppler measurements limits the feasibility.

Perihepatic Lymphadenopathy

Recent advances in ultrasound technology enables the visualisation not only of enlarged, but also of normal perihepatic lymph nodes within the hepato-duodenal ligament [21, 26, 36, 42, 45, 67, 76, 80, 83, 91, 102–106, 114, 158, 176, 177]. Two groups of lymph nodes can be detected regularly in anatomic examinations: dorsal in the hepato-duodenal ligament adjacent to the cystic duct (“cystic duct nodes”) and ventral in the hepato-duodenal ligament adjacent to the orifice of the foramen epiploicum. Improvement of sonographic techniques and the knowledge of the well defined anatomical sites of perihepatic lymph nodes between the inferior cava and portal vein next to the right renal artery have lead to improved identification of lymph nodes in the liver hilum by ultrasound.

The liver hilum should be examined in the left lateral position (15–30°) with the right hand above the head. Post mortem examinations and ultrasound studies in patients undergoing elective liver surgery have demonstrated the reliability of this sonographic method [36]. The reproducibility of the method was investigated by repeated ultrasound examinations of the lymph nodes in

the hepato-duodenal ligament in ten healthy subjects on 7 consecutive days. The mean coefficient of variation for intra-individual assessment of perihepatic total lymph node volume was 12% [36].

Acute Viral Hepatitis

Changes of the liver echo-texture (mainly hypo-echoic with pronounced portal vein walls) may be observed but findings are unspecific.

In contrast to the patients with chronic liver disease there is only limited ultrasound data on patients with acute hepatitis with confusing results, demonstrating perihepatic lymphadenopathy in only a few patients [91, 113, 166]. It should be considered that former studies were performed with technical equipment specifications that are not representative of technology available today. In patients with high levels of transaminases it is of importance to differentiate between viral and toxic causes since this knowledge is indicative for the management of these patients. In 40 patients with acute hepatitis, enlarged perihepatic lymph nodes could be identified by transabdominal ultrasound in all patients with adequate visualisation of the liver hilus (sensitivity of 100%) which was helpful to differentiate between toxic and viral genesis. In the same manner in chronic liver disease, perihepatic lymphadenopathy was present in 86% of viral, in 90% of autoimmune hepatitis, in 100% of primary sclerosing cholangitis, in 97% of primary biliary cirrhosis, but only in 6% of haemochromatosis, in 1% of fatty liver disease, and in 4% of cholecystolithiasis [14a].

Doppler techniques reveal a nonspecific hyperdynamic state in hepatic vessels with a higher diastolic arterial blood flow when compared to healthy subjects. Portal venous blood flow is increased and, perhaps due to oedema and narrowing of the hepatic veins, the flow pattern is often monophasic.

Gallbladder wall thickening is a short-life sonographic phenomenon of the early phase of acute hepatitis in about half of patients [100, 163]. Therefore the diagnostic value of gallbladder wall thickening in acute viral hepatitis is limited. Relative liver parenchymal hypo-echogenicity and pronounced peri-portal tracts are dependent on the examination technique and are therefore of limited value.

Chronic Viral Hepatitis C

Steatosis in Patients with Chronic Viral Hepatitis C

In patients with chronic viral hepatitis C infection not only the sequelae of liver cirrhosis but also hepatic steatosis is a frequent histological finding, occurring in more than 50% of cases [128]. The reliable assessment of steatosis seems to be of clinical relevance, as recent studies suggest that hepatic steatosis is an independent predictor of response to therapy. Rubbia-Brand et al. demonstrated that viral clearance was accompanied by the disappearance of steatosis following Interferon treatment [137]. The reason for the high frequency of steatosis in chronic HCV infection remains poorly understood. Even when the most common causes of steatosis are carefully excluded, a significant proportion of patients with chronic HCV infection have steatosis. The objective of a recent study was to compare the performance of two alternative ultrasound parameters, hepatic vein flow (HVF) pattern and the presence of focal hypoechoic areas (FHA) within the liver hilum, as non-invasive predictors for liver steatosis in patients with chronic hepatitis C virus (HCV) infection. In 122 consecutive patients with chronic HCV infection, the HVF pattern and presence of FHA within the liver hilum were assessed by Doppler and B-mode ultrasound. All patients underwent liver biopsy and the sonographic results were compared to a histological score of steatosis as gold standard. Associations of fatty infiltrations with clinical and sonographic features were evaluated by stepwise logistic regression analysis. Reduced HVF and FHA, but no standard clinical and laboratory parameters, strongly correlated with steatosis on histology ($p < 0.001$). Both sonographic parameters made excellent predictions for the subgroup of patients with severe steatosis, particularly when both tests were combined (sensitivity [SE] 95%, specificity [SP] 96%, positive predictive value [PPV] 93%, negative predictive value [NPV] 97% and accuracy 96%). However, sensitivity and accuracy of HVF pattern were markedly reduced when all degrees of steatosis were defined as *positive* (SE 71%, SP 76%, PPV 81%, NPV 64%, and accuracy 73%). In contrast, the dichotomous parameter FHA remained a powerful indicator even under the latter condition (SE 74%, SP 100%, PPV 100%, NPV 72%, and accuracy 84%).

Combination of both sonographic tests resulted in improved sensitivity (82%), but a significant loss of specificity (76%) and accuracy (80%) in the prediction of liver steatosis. Sonographic evaluation of reduced HVF and FHA within the liver hilum is easy to perform, reproducible and has a high value in the diagnosis of liver steatosis. However, the lack of sonographic evidence of steatosis cannot definitively exclude the presence of mild steatosis as shown on biopsy [44].

Perihepatic Lymphadenopathy

Adequate sonographic visualisation of the liver hilum presumed, lymph nodes are detectable within the hepato-duodenal ligament in almost all patients with chronic viral hepatitis C, chronic viral hepatitis B, and auto-immune liver disease, including primary biliary cirrhosis. Depending on the stage of the liver disease, enlarged lymph nodes are also found in primary sclerosing cholangitis and malignant diseases [21, 36, 76]. The total perihepatic lymph node volume changes according to the antiviral response and leads to progressive normalisation of the perihepatic lymph node volume in sustained virological responders. The decrease in the perihepatic lymph node volume is associated with an improvement in liver histology [42].

In contrast, patients with toxic hepatopathia, non-alcoholic or alcoholic fatty liver disease (steatohepatitis) (NASH, ASH), cholecystolithiasis, haemochromatosis and cystic fibrosis do not present with enlarged lymph nodes. The lymphadenopathy in advanced stages in patients with haemochromatosis and other diseases does not normally present as perihepatic lymphadenopathy. This might be explained by their advanced portal hypertension and latent inflammation. Mediastinal lymphadenopathy has also been described in patients with chronic viral hepatitis C using mediastinal ultrasound whereas abdominal lymph node locations are not significantly altered in patients with chronic virus hepatitis C infection [43, 46].

Primary Biliary Cirrhosis

The echo texture of the liver parenchyma in patients with primary biliary cirrhosis (PBC) in stages I and II are nonspecific. In stage IV typical signs of liver

cirrhosis are detectable. The liver parenchyma of patients with stage III PBC show advanced sono-morphological modifications like inhomogenous parenchyma but no safe signs of liver cirrhosis. Recently the relationship of the total perihepatic lymph node volume and histological staging, cholestatic and inflammatory parameters, and immunological features were investigated in patients with PBC. In these patients lymph nodes were detected in all 59 patients with adequate visualisation of the liver hilum. Compared to healthy controls the total lymph node volume was significantly increased (2.8 ± 2.0 ml) in patients with PBC [37, 99]. Lymph nodes were detectable in 67% of healthy controls with adequate visualisation of the liver hilum. The mean of total perihepatic lymph node volume in patients with primary biliary cirrhosis, stage I, stage II, and stage III increased progressively.

Primary Sclerosing Cholangitis

In asymptomatic patients, primary sclerosing cholangitis (PSC) is suspected when laboratory data gives evidence of cholestasis [76]. However neither the clinical symptoms, nor the biochemical evidence of cholestasis, are specific for PSC and they lack sensitivity, particularly in the early course of the disease [143].

In recent years, few studies investigated features of PSC by ultrasound examination [108, 121]. However, interpretation of these studies is limited due to selection of patients with previously known PSC status and the use of different diagnostic ultrasound criteria.

Majoie et al. prospectively examined 23 patients with confirmed PSC, and correlated ultrasound findings of the bile duct to ERC results. The ultrasound examination was able to confirm extra-hepatic duct disease in the majority of cases when a stenosis was present on ERC. However, the authors were unable to detect all 6 PSC patients with intra-hepatic duct disease by ultrasound, despite the presence of multiple strictures in ERC. Ultrasound is, therefore, useful for the detection and follow up of extra-hepatic bile duct lesions, but not that alterations of the intra-hepatic duct system which cannot be displayed. Consistent with these findings, in 5/17 (29%) of the patients the diameter of the common hepatic bile duct was enlarged (>6mm) and we observed mural thickening in 14/17 (82%) of

our PSC patients. It is important to mention, however, that mural thickening by itself is a rather unspecific marker for cholangitis. In contrast, *asymmetric* mural thickening, as a more specific sign of PSC, was only recorded in 7/17 (41%) of our PSC patients. As in the previously mentioned study, we were unable to detect intra-hepatic lesions of the bile duct.

In 2/17 (12%) of the patients with confirmed PSC, the hepatic echo texture revealed typical signs of fatty liver in ultrasound (echo rich texture, distal transducer signal attenuation, areas of focal sparing in the liver hilum), whereas in the remaining 15/17 (88%) patients the echo texture was segmentally altered (landscape-pattern, hypo- and hyperechoic). In 9/17 (53%) patients echo rich lesions were detected. Histopathological examination confirmed the presence of hemangioma in two of these. For the remaining seven patients, a histological sample was not obtained and the lesions were interpreted as focal fatty infiltration, as previously described. Criteria were the typical location in the liver hilum or the close proximity to the Ligamentum teres hepatis, as well as the presence of central feeding vessels. Two of 17 (12%) PSC patients presented with typical calcifications with shadowing, but no dilatation of the adjacent bile duct, as recently reported.

While hyperplasia of the perihepatic lymph nodes has been described in PSC patients following surgery or CT examination, its prevalence and cause in IBD patients remain largely obscure [47, 49, 87]. The purpose of a recently published study was to evaluate transabdominal ultrasound examination, as a simple and non-invasive diagnostic procedure for the diagnosis of PSC in patients with underlying IBD, as well as to compare the predictivity of our findings with currently used standard procedures [77, 76]. 310 patients with a previously well established diagnosis of IBD (152 male, 158 female, mean age (\pm SD) 38 ± 14 [range 18–78]) were prospectively evaluated by ultrasound for enlarged perihepatic lymph nodes as well as by serological testing for cholestasis indicating enzymes. When autoimmune or viral hepatitis were excluded, enlarged lymph nodes in ultrasound predicted PSC more accurately than conventional serum parameters alone (PPV 94% and 39%, respectively [$p < 0.001$]) and the ratio of the sensitivities increased by the factor 1.13 in favor of the sonographic examination. In patients with IBD, detection of enlarged perihepatic lymph nodes is a highly predictive indicator for the presence of PSC.

Other Diseases

Patients with autoimmune hepatitis (AIH) generally show perihepatic lymphadenopathy with lymph nodes sized >20mm. There are no other typical ultrasound features of the hepatobiliary tract in patients with AIH.

Changes of the liver parenchyma and echotexture in patients with sarcoidosis are unspecific. Perihepatic lymphadenopathy in these patients is sometimes impressive with lymph node sizes up to 60mm. Perihepatic lymphadenopathy is indicative of hepatic involvement. In patients with advanced disease, signs of liver cirrhosis and portal hypertension are common with respective flow changes of the hepatic vessels. Similarly to PBC, the flow pattern in the portal and hepatic veins is increased in contrast to other forms of liver cirrhosis.

In patients with cystic fibrosis the rate of adequate sonographic visualisation of the liver hilus, the lymph node detection rate and the perihepatic lymph node volumes were not significantly different. In none of the CF-patients and healthy controls were enlarged perihepatic lymph nodes detected. There were no typical sonographic findings of the liver echo texture. A micro-gallbladder as typical sign of CF was found in 18 of 72 (25%), whereas no patient had a micro-gallbladder in the control group. In 7 out of 18 (39%) patients with micro-gallbladder cholestasis indicating enzymes were elevated. The presence of micro-gallbladder was statistically not related to the level of cholestatic enzymes.

In patients with alcoholic steatohepatitis (ASH) and non-alcoholic steatohepatitis (NASH) attenuation of the ultrasound beam makes it more difficult to examine the liver hilum. Adequate visualisation is possible in only 80% of patients. In a series of 60 patients no enlarged perihepatic lymph nodes could be found.

Sonographic features in patients with frequently encountered toxic liver disease are nonspecific [116]. In a series of 100 patients no enlarged perihepatic lymph nodes could be found.

Changes of the liver parenchyma in patients with AIDS are dependent on the kind of opportunistic infections or neoplastic infiltration. Many causes have to be considered (e.g., bacillary angiomatosis) [13]. In a consecutive series 82/100 patients with AIDS showed enlarged perihepatic lymph nodes. Co-infection with the hepatitis B and C virus and mycobacteriosis are common. We found no significant correlation with viremia. Hepatobiliary infections as a cause of perihepatic lymphadenopathy have also to be considered, e.g., cytomegaly virus infection.

Enlarged perihepatic lymph nodes have been found in almost all patients with end-stage liver disease [49]. Ultrasound findings in end-stage Wilson's disease resemble liver cirrhosis caused by other aetiologies. In earlier stages multiple intrahepatic, mainly small (<20mm) hypoechoic nodules could be observed in 8/10 consecutive patients with Wilson's disease. Biopsy findings revealed prominent copper accumulation and in two patients additionally dysplastic nodules.

There are many liver diseases with specific and non-specific ultrasound changes which are not described here in the context of perhaps more common diseases in the western world. For example, patients with hepatobiliary schistosomiasis and portal hypertension show typical fibrotic strands as sequelae of fibrous portal venous obliteration.

Doppler Ultrasound Techniques in the Evaluation of Liver Disease

In general, clinical signs of vascular changes in the liver are nonspecific. They may consist of an uncharacteristic loss of appetite, epigastric pain, nausea and a distended abdomen with a sensation of pressure, for example. Usually, the cardinal symptoms of the underlying illness become distinct. Doppler ultrasound techniques are helpful in the evaluation of the hepatic artery, portal vein liver veins and respective diseases, e.g., portal hypertension, portal vein thrombosis, Budd–Chiari syndrome and many other circumstances.

Blood Supply of Hepatic Vessels

The liver is supplied with blood through two vascular systems with completely different haemodynamics. The disposal is managed by the hepatic vein system:

- Arterial flow (high pressure, low flow resistance)
- Portal-venous system (low pressure, low flow resistance)
- Venous outflow (low pressure and low flow resistance)

Vascular hepatopathies occur with abnormal vascular courses, aneurysms, stenoses and occlusions of these vessels.

Arterial Flow

A hypoperfusion in the arterial vascular system is not frequent and may be caused by congenital malformations as well as by acquired embolic, thrombotic, inflammatory, vascular-tumorous, vasculitic or arteriosclerotic-degenerative changes, or an (acute) heart insufficiency with forward failure and shock. Hyperperfusion is observed even less frequently and is caused by arteriovenous shunts which are of congenital, traumatic or septic-embolic origin, for example. Though rare, clinically relevant *congenital arterial vascular malformations* are of several types:

- Hypoplasia and aplasia of the common hepatic artery and/or its branches with atrophy of related liver segments
- Aneurysms of the common hepatic artery and its branches
- Atypical vascular courses (e.g., with impression of the hepatic choledochal duct)
- Arteriovenous and arterioportovenous shunts (e.g., occurrence of M. Osler)
- Abnormal hepatic vascular malformations occur more frequently in connection with vascular changes in other organs (heart, lungs, brain, and kidneys) which tend to determine the clinical course and prognosis to a greater extent

Portal Venous System

With impairments of the portal venous system, the signs of portal hypertension (splenomegalia with hypersplenism, ascites and collateral circulation) with continued liver function come to the fore. Its most important disorder is *portal vein thrombosis*.

Venous Outflow

With disorders of the venous outflow, first a (substantial) restriction of the liver function occurs and, second, signs of high portal vein pressure are detected. *Right-ventricular heart failure* is the most frequent venous outflow disorder. The increase in post hepatic resistance reduces the portal hepatic perfusion and may lead to a pendular or retrograde flow in the portal vein, especially in cases with an additional intrahepatic increase in resistance.

Color Doppler Imaging (CDI) for Analysis of Hepatic Vessel Flow Pattern

Modern ultrasound scanners increasingly provide Doppler technologies, which allow assessment of hepatic haemodynamics beyond conventional grey-scale imaging. CDI is accurate and well established in evaluating portal hypertension, portal vein thrombosis due to different causes, Budd–Chiari syndrome and other forms of veno-occlusive diseases. CDI is routinely used to evaluate patients prior to liver transplantation to determine portal vein patency and identify retrograde portal venous flow as a sign of portal hypertension as well as monitoring after liver transplantation [12, 151–153]. Both are important information for the transplant surgeon. CDI is also important to monitor flow direction and patency of spontaneous and artificial porto-systemic shunts, e.g., TIPSS. Patients after liver transplantation are monitored by analysing the hepatic artery. Stenosis and rejection are indicated by changes in the resistance flow pattern (e.g., *pulsus parvus et tardus*) [118, 119].

Chronic heart failure reveals tetra-phasic flow in the right liver vein and highly undulating flow patterns in the portal vein, reversing during intensified therapy. The flow pattern in the liver veins is helpful to characterise diffuse parenchymal liver disease [35].

Vascular (Doppler) Indices

Vascular indices, e.g., Doppler perfusion index (DPI), hepatic transit time and various ratios analysing different vessels have been used for liver tumor detection and characterization but are currently only used in the experimental setting. The Doppler perfusion index (DPI) is the ratio of hepatic arterial blood flow (normal below 20%) to the total liver blood flow (hepatic arterial and portal venous blood flow). DPI is reported to be elevated in the presence of intra-hepatic tumors as well as in patients with liver cirrhosis, and was used to screen patients with suspected metastases. The promising data could not be reproduced [97]. The portal vein congestive index (PVCi) is the ratio of cross sectional area of the extra-hepatic portal vein to time averaged mean velocity of blood flow in the portal vein [70, 71]. The PVCi is elevated in liver cirrhosis at an early stage with a constant portal vein blood flow

(cross sectional area multiplied by the time averaged mean velocity) which can be reached by an increased portal vein pressure with consecutive dilatation of the latter vessel.

Examination of the Hepatic Artery in Patients with Diffuse Liver Disease

Examination Technique

There is only limited data analysing hepatic arterial vessels in contrast to many studies examining the portal and hepatic veins in liver diseases. The reasons are obvious: anatomic variations of the coeliac trunk are common in up to 50% and, therefore, the examination technique is not standardised. Leen investigated the arterial flow in the common hepatic artery to determine hepatic arterial blood flow neglecting that the superior gastroduodenal artery takes up to 50% of blood flow away from the liver into the intestine. These impressive results of identifying occult liver metastases could never be reproduced by another group until now [97].

With high end ultrasound devices it is possible to detect arterial blood flow close to the main branch of the portal vein via the previously described intercostal approach. This measurement site represents the main arterial supply of the liver and is in the majority of patients the proper hepatic artery. Due to many variants in the hepatic arterial supply absolute parameters like velocities and flow volumes are problematic whereas the resistance and pulsatility indices represent the parenchymal influence distal to the measurement point. The indices can therefore represent hepatic parenchymal influence only with a certain degree of confidence.

Reproducibility of the Method

The interobserver variability analysing the hepatic arterial blood flow at the measurement point mentioned above for the resistance and pulsatility index is below 12% and much higher for the velocities (peak systolic, end diastolic, time averaged mean velocity) and the blood flow volume (about 30%, unpublished data).

Examination of the Portal Vein in Patients with Diffuse Liver Disease

Portal Venous Blood Flow

Different pathological flow patterns of the portal venous system have been described [63]. Marked pulsatile hepato-petal or hepato-fugal flow in the portal vein and/or its branches is seen under pathological conditions, tricuspid regurgitation, increased hepatic outflow resistance and liver diseases. Pathophysiologically tricuspid regurgitation is the predominantly suggested cause for the duplex Doppler ultrasound phenomena of pulsatile portal vein flow. Severe pulmonary hypertension may be responsible for a second important pathophysiological mechanism. Pulsatile flow in the portal vein has predominantly been found in patients with severe right heart failure, demonstrating right atrial pressure negatively correlated with portal vein pulsatility ratio. All patients with hepato-fugal flow were in the New York Heart Association (NYHA) Class III or IV. Pulsatile hepato-petal flow was found more often in patients with NYHA Class I or II [129]. Pericardial effusion, constrictive pericarditis, pericardial tumors and right atrial tumor and possible other causes leading to an increased right atrial pressure are responsible for a pressure-related hepatic venous outflow block with subsequent trans-sinusoidal hepato-portal shunting, similar to the mechanical outflow block that causes reversed pulsatile flow in liver cirrhosis [174]. In patients with chronic hepatitis C, dampened pulsatility in the portal vein has been associated with inflammation but not with other parameters of the histological activity index or intra-hepatic fat deposition. The intra-hepatic fat deposition is associated with a flattening of pulsatility [35].

Portal Hypertension

Color Doppler ultrasound is helpful in the detection of the presence and direction of blood flow in the portal venous system [71]. Color Doppler ultrasound examination is recommended in patients with suspected portal hypertension. Hepato-fugal flow in the portal vein is found in about 10% patients with liver cirrhosis. The prevalence was recently found to be 8.3% [58]. Prevalence does not differ in relation to the aetiology of

liver cirrhosis but is stage dependent and could be more often found in Child's B and C cirrhosis than Child's A cirrhosis [58]. Various haemodynamic patterns of portal venous blood flow exist. The clinical significance of this Doppler phenomenon is still unclear, but it may play a protective role against future risk of bleeding [58].

Portal Vein Pulsatility

The respiratory cycle modulates portal venous flow via intra-abdominal pressure. Portal vein pulsatility is characterised by the ratio between minimum and peak portal vein velocities. A pulsatility ratio >0.54 was found in over 90% of normal individuals [78]. The venous pulsatility index [(maximum frequency shift – minimum frequency shift)/maximum frequency shift] was 0.48 ± 0.31 (mean \pm standard deviation) in healthy adults. Additionally, a marked pulsatile hepato-petal flow in the portal vein has been described, particularly in thin subjects with a venous pulsatility index of >0.5 , with an inverse correlation to body mass [59]. Decreased pulsatility has been observed during deep inspiration and in obese subjects but also in the sitting position. Changes of portal vein pulsatility might be explained by changes in abdominal pressure and liver elasticity (compliance) [51, 59]. High abdominal pressure during deep inspiration may cause flow reversal in patients with right heart failure or liver disease also depending on the site. Reverse flow may be seen only in peripheral branches of the portal venous system [62] It is more confusing that a short time phase reversal of portal vein flow can be seen during deep inspiration using color Doppler ultrasound even in patients with the absence of cardiac and liver disease. Portal vein–hepatic vein shunts and portocaval shunts may also cause pulsatile portal flow [6, 66].

“Absent” Portal Venous Blood Flow

Very slow portal vein velocities of less than 2 cm/s are difficult to detect because this Doppler signal is lower than the threshold of the ultrasound equipment and additional respiratory modulation of the patients. A stagnant or portal venous “0” flow is mainly seen in patients with liver cirrhosis. In patients with stagnant portal vein flow the use of ultrasound contrast enhancing agents might be helpful in the exclusion of portal vein (appositional) thrombosis.

Retrograde Portal Venous Blood Flow

Reversed portal venous blood flow can be observed when intra-hepatic resistance is greater than the resistance of porto-systemic collaterals. An association has been found between portal venous flow patterns (e.g., abnormal flow direction) and the presence of mainly spontaneous porto-systemic shunts but also oesophageal varices and ascites [169]. The increase of intrahepatic resistance might be explained by structural abnormalities, e.g., hepatocyte enlargement, Disse space collagenisation and hepatic vein sclerosis [10]. Retrograde portal venous flow has been observed mainly in patients with portal hypertension. Different haemodynamic flow patterns of continuous flow in the portal vein, the splenic vein and the mesenteric vein have been described. Isolated or combined reversed flow in the portal vein and/or the mesenteric and splenic vein have also been described [58].

Respiration Dependent Hepatofugal Portal Flow

Respiration dependent hepato-fugal portal flow is a rare finding associated with periodic portal hypertension in patients with right heart insufficiency and/or liver disease. Thirteen patients with respiration dependent reversal of blood flow in the portal vein were identified over a period of 1 year. Its clinical significance is unclear. Its occurrence was predominantly associated with an increased venous pulsatility index due to tricuspid regurgitation or venous outflow obstruction [64].

Doppler Wave Form Changes in Patients with Severe Congestive Heart Failure

Twenty-one patients with congestive heart failure were examined with duplex ultrasound of the portal vein. The Doppler sonographic findings were compared with those of healthy subjects, patients with chronic liver disease and patients with Budd–Chiari syndrome. Increased pulsatility of the Doppler signals was demonstrated in 11 patients with severe congestive heart failure. Two patients with severe congestive heart failure showed decreasing pulsatility of portal Doppler signals in response to therapeutic procedures. Portal flow patterns suggestive of severe congestive heart failure include a monophasic forward flow with peak

velocity in ventricular diastole and gradual diminution of velocity throughout ventricular systole ($n = 5$), a reversed flow velocity in ventricular systole ($n = 3$), and vena cava-like biphasic forward velocity peaks during each cardiac cycle ($n = 2$). The time-velocity waveform shape of portal flow is, to a large degree, influenced by the mechanical events in the right side of the heart in severe congestive heart failure [78].

Portal Vein Examination Techniques and other Applications

Examination Technique

The portal vein diameter and flow pattern is measured via an intercostal approach at an angle close to 0° right before it parts into its right and left main branch. The biphasic FFT-Doppler spectrum of the portal vein should be documented during a 5–8 s suspended respiration at a mid respiration level to avoid influences of respiration and intrathoracic pressure. The sample gate is adjusted to the inner diameter of the vessel and Fast Fourier transformation (FFT) spectral analysis is recorded. The maximum (V_{\max}) and minimum (V_{\min}) velocity (cm/s) of an undulational circle are automatically or manually set. The difference of V_{\max} and V_{\min} are calculated as a parameter of biphasic oscillations as well as the portal vein resistance index ($(V_{\max} - V_{\min})/V_{\max}$) in analogy to the resistance index of arterial vessels.

Reproducibility of the Method

The reproducibility of the method was also investigated by repeated sonographic examinations of the portal vein flow in ten healthy subjects over 7 consecutive days. The mean coefficient of variation for intra-individual assessment of the flow velocity (V_{\max} and V_{\min}) was 12% and 10% respectively, which is well in accordance with other published data.

Portal Vein Thrombosis

An occlusion of the portal vein may have various causes and is the main reason for an increase in pre-hepatic portal vein pressure. Especially with inflammatory disorders *coagulation defects* with thrombocytosis and an increase

in fibrogen occur quite frequently. Periportal venous collaterals in the sense of a *cavernous transformation* may at least partially compensate the portovenous hepatic inflow. Also, the reduced portovenous blood supply may be compensated by an increased arterial perfusion so that the liver function usually appears only slightly impaired. On the other hand, portosystemic collaterals lead to a reduced “first-pass” effect of the liver. This is especially important when portal vein thrombosis is caused by cirrhosis with reduction of flow, since because of this, encephalopathy may become manifest and the liver-dependent medication metabolism may be disturbed.

Collateral circulation with the formation of oesophagus and fundus varices (hemorrhage of varices in about 70% of the patients), splenomegaly (40%) with anaemia (15%) and thrombocytopenia (5%) and a normal liver consistency are indications of thrombosis of the portal vein. Ascites (10%) is detected rather infrequently. There also may be in evidence a septic clinical picture with diffuse intravascular coagulation and haemorrhagic infarction of the small intestine. Unresolved fever may be caused by septic thrombosis of the portal vein (pyephebitis). In a patient with sufficient collateral circulation or only incomplete thrombosis, the pain is frequently uncharacteristic, so that in most cases only the manifestation of complications (gastrointestinal bleeding, hypersplenism syndrome) may lead to a diagnosis.

Color-coded duplex sonography is the method of choice and has a high degree of sensitivity (>90%). Contrast-enhanced computed tomography is an alternative, especially with obese patients. In general, magnetic resonance tomography and splenic portography are unnecessary. Before operations or interventions it may be desirable to do an angiography of the visceral vessels.

Ultrasound is specific for exclusion of infiltration of hepatic vessels (e.g., portal vein and hepatic veins). The detection by Doppler ultrasound of pulsatile flow in portal vein thrombi occurring in patients with cirrhosis is a moderately sensitive but highly specific sign for the diagnosis of malignant portal vein thrombus. However, continuous flow can be detected in benign (appositional) and malignant (neoplastic) portal vein thrombus and is thus not useful in differentiating between the two. Portal vein thrombosis is a common sign of tumor angiogenesis, especially in extensive tumor stages [48, 50]. To differentiate between benign and malignant portal and hepatic vein thrombosis it is useful to use color Doppler imaging or contrast enhanced techniques. Using color Doppler

imaging malignant infiltration can be assumed, if pulsatile flow is derived from inside of the thrombus. If this is not conclusive, contrast enhanced ultrasound is more sensitive in showing arterial enhancement of the thrombus. In 25 of 100 patients with histologically proven hepatocellular carcinoma portal vein thrombosis was diagnosed, of which 11 cases (44%) presented with pulsatile signals from the intra-luminal thrombus. Six patients had an occlusion of one or more liver veins with two of the six patients showing pulsatile signals from inside the thrombus indicating also tumor thrombus (see below) [81, 82].

CT examinations of 58 patients with cirrhosis and portal vein thrombosis (PVT) were recently retrospectively reviewed. Images were assessed for location, extent, enhancement, neovascularity and maximal diameter of PVT. The type of PVT was proven histologically in 42 patients and clinically in the remaining 16 patients. Using different threshold PVT diameters or the presence of PVT neovascularity, we calculated the sensitivity and specificity of CT for revealing malignant PVT. The mean diameters of malignant and benign portal vein thrombi were significantly different (23.4 vs 16 mm; $p = 0.0001$). Neovascularity was seen on CT scans in 43% (20/47) of patients with malignant PVT and in no patient with benign PVT. Identification of a main PVT diameter greater than or equal to 23 mm or PVT neovascularity resulted in a sensitivity and specificity for the CT characterization of malignant PVT of 86% and 100%, respectively [167].

Examination of the Hepatic Veins in Patients with Diffuse Liver Disease

The normal flow pattern in the right hepatic vein is triphasic [28, 120]. The FFT-Doppler ultrasound spectrum of the right hepatic vein 6–8 cm distal to the confluence of the hepatic veins can be classified into a triphasic waveform with a short reversed flow, a biphasic waveform with no reversed flow, but fluttering of more than 10% of the mean phasic amplitude, or a monophasic flat waveform with fluttering of less than 10% of the mean phasic amplitude. The maximum, medium, and minimum (reversed flow) velocity (cm/s) could be additionally recorded. Because of changes in the vessel diameter up to 2 mm per cycle during systole and diastole and different directions of the normal triphasic hepatic vein flow, it is not useful to calculate the

blood flow (ml/min) in the hepatic veins. It was previously shown that a non-triphasic hepatic vein flow (HVF) is mainly associated with the degree of fat deposition within the liver and less related to inflammatory parameters and the extend of liver fibrosis [35]. Recently a large scale study on patients with chronic HCV infection confirmed that hepatic steatosis can be excluded by normal liver haemodynamics, however, some operative characteristics (specificity and positive predictive values) were rated insufficient [142].

Non-triphasic HVF and FHA within the liver hilum are both parameters that can be easily measured and quantified by ultrasound. The recorded values are reproducible and less dependent on the investigators interpretation than conventional grey scale imaging.

Examination Technique

The right hepatic vein is identified via the intercostal approach and the sample gate is positioned 6–8 cm distal to the confluence of hepatic veins and adjusted according to the inner diameter of the vessel (typically 3–7 mm). Fast Fourier Transformation (FFT) spectral analysis is recorded for at least 5 s. The Doppler ultrasound spectrum can be recorded within a short breathing pause of 5–8 s without relevant intra-abdominal or intra-thoracic pressure related artefacts. To avoid artefacts due to different respiratory positions and different abdominal and intrathoracic pressures, the evaluation of the right hepatic vein via the tenth or eleventh intercostal space 6–8 cm distal to the confluence of the hepatic veins offers a standardised procedure and provides reproducible results with an acceptable insonation angle in all patients and healthy subjects. To establish the best position for evaluation of the flow pattern, the right hepatic vein was also evaluated 2 cm distal to the confluence of the hepatic veins. In all healthy subjects the flow pattern was triphasic 2 cm next to the confluence with the inferior vena cava. Therefore, the Doppler ultrasound spectrum 6–8 cm distal to the confluence of the hepatic veins may better reflect histological changes of the liver parenchyma.

Which Liver Vein should be examined?

The close anatomical relationship between the left liver lobe and the heart frequently leads to Doppler signal artefacts in any signal obtained from the left hepatic

vein. Because of these artefacts, which are mainly due to heart movements, the left hepatic vein cannot always be reliably evaluated. Adequate sonographic visualisation of the middle hepatic vein and evaluation of the FFT-spectrum is best accomplished during slight inspiration and via the subcostal route. In 35/135 patients however, evaluation of the middle hepatic vein was only possible during deep inspiration with respiration related artefacts of the Doppler ultrasound spectrum with an initial monophasic waveform changing to a bi- and triphasic waveform during the examination. The most reproducible Doppler ultrasound spectrum can be obtained from the right hepatic vein via the intercostal approach.

Reproducibility of the Method

The reproducibility of the method was investigated by repeated sonographic examinations of the flow pattern in the right hepatic vein in ten healthy subjects over 7 consecutive days. The mean coefficient of variation for intra-individual assessment of flow velocity was 13% for the hepato-fugal flow and 19% for the reversed flow. The flow pattern in the ten subjects investigated was always triphasic. The reproducibility for the middle hepatic vein was less favourable with a mean coefficient of variation for intra-individual assessment of the flow velocity of 25% for the hepato-fugal flow and of 76% for the reversed flow. In patients with no artefacts intra-individual differences in the flow pattern between the right and middle hepatic vein were not observed [35].

Hepatic Venous Outflow Obstruction (Budd–Chiari syndrome)

Budd–Chiari syndrome (BCS) is a rare cause of liver disease with or without portal hypertension. Approximately one third present with acute disease, while two thirds have chronic presentation [55]. Color Doppler imaging is helpful in the diagnosis. Pulsed Doppler ultrasound accurately detected the site of the block in 31 of 39 patients (79.4%) [156]. The obstruction was in the hepatic vein in 20 patients, in the inferior vena cava in 10, and in both in 41 patients. Aetiologically, four had pregnancy-related disease, four tumor-related, three hypercoagulable states, 18 inferior vena cava membranes and 42 were idiopathic. In patients with

newly diagnosed Budd–Chiari syndrome hepatocellular carcinoma has to be ruled out. The experience with contrast enhanced ultrasound is so far limited [130].

Veno-occlusive Disease

Duplex sonography of the portal vein system and the hepatic veins may show typical changes, but display only a relatively low sensitivity and specificity. Sonographic indications of veno-occlusive disease (VOD) are the detection of ascites, thickening of the gall bladder wall, increase of the resistance index in the hepatic artery (RI) to a level higher than 0.75, as well as retrograde flow in the portal vein and changes in the portal vein flow profile. Since most patients are severely ill, the prevalence of pathological sonographic findings is high so that these previous changes cannot be positively differentiated from the signs of VOD.

Veno-occlusive disease is a well recognised problem in patients with haematological disorders, especially after bone marrow and stem cell transplantation and ultrasound has proven to be useful in single centre experiences. Published data is sparse in patients with veno-occlusive disease [24, 35, 72, 75, 93, 94, 148, 164]. Ascites, thickening of the gallbladder wall and changes (mainly reversal) of portal flow are sonographic findings in veno-occlusive disease of the liver. The frequency and specificity of these findings and their relationship to the severity of this disease have only been studied in few patients. Sixty-five patients who had bone marrow transplantation were prospectively studied with serial B-scans and duplex color Doppler ultrasound. For all patients, assessment included liver size and texture, thickening of the gallbladder wall (greater than 10mm) and presence of ascites. Doppler flow velocity profiles were obtained from the portal vein, hepatic veins and inferior vena cava. The hepatic artery resistance index (RI) was calculated. Twenty volunteers were also studied to establish normal flow values. Nineteen patients had documented veno-occlusive disease, nine had hepatic graft vs host disease (GVHD) (five after proved venoocclusive disease), two had hepatitis, and 40 had no clinical or biochemical evidence of liver injury after bone marrow transplantation. Ascites ($n = 16$), thickening of the gallbladder wall ($n = 8$), hepatomegaly ($n = 8$), and altered liver texture ($n = 3$) were not distinguishing features of venoocclusive disease. Mean

hepatic artery RI was as follows (ranges are in parentheses): control group, 0.69 (0.58–0.76); veno-occlusive disease patients, 0.81 (0.75–0.87); GVHD patients, 0.69 (0.63–0.71); all other patients after bone marrow transplantation, 0.66 (0.61–0.71). The RI values in veno-occlusive disease were significantly elevated, but an incremental rise in RI with increasing severity of the disease was not seen. Abnormalities in portal vein flow were seen in only two patients: in one with fatal veno-occlusive disease, reversed portal flow developed, and in one with GVHD, portal vein thrombosis developed. Contrary to previous reports, no correlation between abnormalities in portal flow and veno-occlusive disease was seen. Flow velocities in the hepatic veins and the inferior vena cava were not significantly different from values in the volunteer group [75].

Color Doppler imaging was also helpful in the diagnosis of 12 patients with veno-occlusive disease in patients after bone marrow transplantation revealing low (<10 cm/s) or reversed portal venous flow, high resistance arterial flow pattern (resistance index > 0.85) and flattened monophasic flow pattern in the right liver vein of less than 8 cm/s.

Osler–Weber–Rendu Syndrome

Especially in the supply area of the superior mesenteric artery dense networks with corresponding malformations are found. The *liver involvement* (in 30–70% of the cases) could lead to liver cirrhosis, as a result of sclerosis which forms around the multiple vascular malformations. The cirrhosis as well as multiple portosystemic shunts caused by vascular malformations contributes to the development of an encephalopathy. The liver cirrhosis caused by the basic illness must be distinguished from the effects of the often multiple transfusions (post transfusion hepatitis).

Therapy

In the case of an arterio-venous shunt formation in the liver with systemic effects (which frequently occur at a later age), *the selective arterial embolisation* of the supplying vessels has proven successful. Due to the general state of health of the patient, surgery (ligature of the supplying vessel, partial resection of the liver) is not always possible.

Transjugular Intrahepatic Portosystemic Shunts

A high percentage of patients with transjugular intrahepatic portosystemic shunts (TIPSS) have post procedural shunt complications, including thrombosis of the stent, stenosis of the stent, or stenosis of the hepatic vein draining the stent. Doppler ultrasound is an excellent non-invasive screening technique for the detection of complications of TIPSS. Complications of TIPSS can be detected by using three criteria: (1) no flow for thrombosis, (2) a temporal change in peak stent velocity greater than 50 cm/s for stent and/or hepatic vein stenosis, and (3) reversed flow in the hepatic vein draining the stent for hepatic vein and, rarely, stent stenosis. After TIPSS, 45 patients were routinely evaluated with both Doppler ultrasound and angiography as gold standard. The sonographic protocol consisted of insonation of the stent, portal vein and hepatic vein to determine the presence of flow, peak velocity, and direction of flow. The angiograms were evaluated for stenoses of the stent or hepatic vein that caused an increase in the porto-systemic pressure gradient greater than 15 mmHg, increased intra-hepatic portal venous filling, retrograde filling of the draining hepatic vein, or opacification of varices. Adequate follow-up was obtained in 29 of the 45 patients. Sixteen of the 29 patients had shunt complications that consisted of one stent thrombosis, three stent stenoses, nine hepatic vein stenoses, and three concomitant stenoses of the stent and hepatic vein. Flow was not detected by ultrasound in the stent of the patient with thrombosis. There was a significant difference ($p = 0.003$) between the temporal change in peak stent velocity in patients with stenoses versus those without. Use of a change (increase or decrease) in peak stent velocity greater than 50 cm/s from the post-TIPSS baseline sonogram as the diagnostic criterion for the detection of shunt stenoses resulted in a 93% sensitivity and 77% specificity. Five patients with stenosis had reversed flow in the draining hepatic vein. Only one patient with a stenosis had a peak stent velocity less than 50 cm/s.

Focal Liver Lesions

The characterization of focal liver lesions by ultrasound is sufficient in typical cases. The use of ultrasound contrast media (signal enhancers) raises the rate of

Table 37.1 Classification of liver tumors and nodular lesions

Cell of origin	Benign liver tumor or nodular lesion (in parenthesis malignant transformation)	Abbreviation
Hepatocyte	Hepatocellular adenoma (→ hepatocellular carcinoma)	HCA (HCC)
	Focal nodular hyperplasia (→ fibrolamellar carcinoma)	FNH (FLHCC)
	Nodular regenerative hyperplasia	NRH
	Partial nodular transformation	PNT
	Macroregenerative nodule	MRN
Bile-duct epithelium	Bile-duct adenoma (→ combined hepatocellular and cholangiocarcinoma)	BDA (HCC/CCC)
	Bile-duct cystadenoma (→ cystadenocarcinoma)	BDCA (BDCACa)
	Bile-duct adenofibroma	BDAF
Mixed liver and bile duct cell	Mesenchymal hamartoma (→ angiosarcoma)	
Endothelial cell	Hemangioma	Haem
	Infantile haemangioendothelioma	

Source: Modified from Scheuer PJ, Lefkowitz JH (2000) Liver Biopsy Interpretation, 6th edn. W.B. Saunders, p. 191

differentiation and can avoid the uncritical and sequential application of radiological imaging (computed tomography [CT] or magnetic resonance imaging [MRI]). If in doubt about the nature of a lesion, a histological diagnosis remains indispensable.

Other focal liver lesions (Table 37.1) are characterised sonographically not only by analysis of differences in echogenicity from the surrounding liver tissue, but also by the detection of hyper- or hypovascularisation (color duplex ultrasound) and by changes occurring in inflow kinetics (enhancement) of contrast media. As a result of their double blood supply via both the portal vein and the hepatic artery, focal lesions in the liver often exhibit no sustained hyper- or hypoperfusion, but depending on the perfusion phase and the histology, present with a complex spatio-temporal picture of increased and reduced contrast enhancement. Certain lesions display a characteristic vascular picture (e.g., wheel-spoke phenomenon [FNH]) or a distinctive perfusion pattern (e.g., iris diaphragm phenomenon [Hemangioma]), allowing the lesions to be characterised. Unfortunately contrast enhancement does not always exhibit such typical and unique patterns. Multiple reviews and guidelines have been recently published as well as multicentre trials using contrast enhancing techniques [1, 16, 28, 34].

Detection and Characterization of Liver Tumors

Conventional B-scan ultrasound makes it possible to detect unequivocally the frequently occurring typical

liver cysts (criteria: round, anechoic, smoothly delimited, marginal shadows, amplification of the sound) and calcifications (echo-rich, sound shadows) by differences in echogenicity in comparison with the surrounding liver tissue. Detection and characterization of liver tumors on the other hand, still represents a challenge to the imaging methods despite all the advances in imaging techniques (ultrasound, CT and MRI scanning).

Focal lesions are detected and characterised ultrasonographically by an analysis of echogenicity differences from the surrounding liver tissue, but also by the detection of hyper- or hypovascularisation (color duplex ultrasound) and recently by the changes occurring in inflow kinetics of the contrast media. Circumscribed lesions of liver-foreign tissue (e.g., metastases) can sometimes also be detected by the absence of uptake of liver-specific contrast media (e.g., Levovist®). Such lesions appear in the post vascular late-phase image as storage defects, though this late-phase effect is neither absolutely specific nor absolutely sensitive.

As a result of their dual blood supply via the portal vein and the hepatic artery, focal lesions in the liver often exhibit no general hyper- or hypo perfusion but, depending on the flow phase and the histology, present a complex temporal and spatial picture of increased and reduced contrast. Certain lesions can give a characteristic vascular picture (e.g., the wheel-spoke phenomenon) or a distinctive perfusion pattern (e.g., halo contrasting or iris diaphragm phenomenon), allowing the lesions to be characterised, but the contrast patterns do not always take this typical form. Similar arterial, parenchymatous, and venous characteristics are exhibited by the spleen and by lymph nodes.

Ultrasound Contrast Agents

The use of contrast agents in X-ray, computerized and magnetic resonance tomography has been established for a long time ago and has increased the sensitivity and specificity of the examinations. The principle of contrast-enhanced ultrasound has now been known for over three decades, since Gramiak and Shah obtained strong ultrasound echo signals in blood following an injection of indocyanine green. The signals were due to the presence of air bubbles. By targeted production of such air or gas bubbles, attempts have subsequently been made to develop echogenic solutions enabling echo-poor or anechoic blood to be visualised sonographically for the purpose of improved vessel diagnostics.

The basic principle of ultrasonographic contrast agents is the provision of many small but strongly echogenic surfaces. This is ideally achieved by microbubbles of gas. All currently available ultrasonographic contrast media comprise a shell, in order to increase the stability of the microbubbles in blood and to obtain a standardised bubble size, and an included or adsorbed bubble of gas. Some of the products have a hard shell (e.g., galactose microparticles or denatured albumin), others a flexible outer membrane (e.g., a phospholipid membrane) which in an ultrasonic field begins to oscillate at fairly low sound pressures. As far as the gas itself is concerned, a distinction is drawn between products with bubbles of air (products of the first generation, such as Levovist® and Albunex®) and ones with bubbles of a sparingly soluble gas (second-generation products such as SonoVue® or Optison®) which provide longer contrast duration because the gas dissolves only in small amounts in the surrounding blood. The first ultrasound contrast agents as well as air bubbles in a shaken syringe were not able to pass the lung. So the use of these agents has been limited to imaging the right heart for the demonstration or exclusion of a shunt. The production of ultrasound contrast agents with a stable formula and a suitable size made it possible for them to be able to pass the capillary bed of the lung and enabled additional imaging of the arterial system of the whole body.

In principle, two different kinds of examinations are possible: (1) dynamic investigations in which the course of the contrast is visualised in the liver parenchyma during the arterial, capillary and portal-venous phase, and (2) investigations of the accumulation of the contrast medium within liver tissue.

The dynamic examinations are ideally carried out with low sound energies (mechanical index MI 0.1–0.3) in real-time imaging mode to enable the use of the flexible second-generation microbubbles (e.g., SonoVue®) so that the bubbles are not destroyed. Imaging of accumulation in the late phase requires a contrast medium with a tissue-specific affinity, so that at the end of the vascular phase it becomes enriched in some particular tissue, e.g., in the reticuloendothelial system of the liver and spleen. This effect has been described for Levovist® and Sonazoid® and it can be used diagnostically for uniform enhancement of healthy liver tissue in the liver-specific late phase (i.e., after the end of the vascular phase). Here, it is very important to ensure that the late-phase examination is not carried out too early, to avoid an overlap with the portal-venous phase.

The microbubbles of the ultrasonographic contrast agents have a size distribution in the range of 1–10 µm and can therefore freely pass through capillaries. The resonance frequency of microbubbles of this size fortunately lies in the range of sound frequencies used for diagnostic purposes, which permits the formation of harmonic responses. The sound waves are reflected from the microbubble surfaces or, strictly speaking, they are back-scattered with the same wavelength as the incident wave. The back-scattering is also referred to as linear behaviour of the microbubbles. The microbubbles of a sonographic contrast medium are very effective back-scatterers, increasing the signal intensity by more than 30 dB. This corresponds to a factor of 1,000 at the detected sound energy. With increasing sound pressure however, non-linear behaviour of the microbubbles increasingly comes to the foreground. The bubbles begin to oscillate, emitting harmonic oscillations. As the sound pressure rises further the microbubbles gradually become unstable, begin to break up, and finally are destroyed with short transient emission of a high-energy signal (SAE or stimulated acoustic emission). In principle, all sonographic contrast media behave in this way. The absolute magnitude of the sound energy at which the harmonic response or destruction of the microbubbles sets in is of course differs within different contrast enhancers.

During their oscillation, microbubbles give a non-linear response to the sound pressure. The reason is the compression of the microbubbles against the pressure of the enclosed gas occurs to a smaller extent than expansion, leading to asymmetric (non-linear) oscillation of the bubble diameters. This has given rise

to a number of techniques (for example, harmonic imaging, wide-band harmonic imaging (pulse or phase inversion methods), flash echo imaging, etc.), which will not be considered here in close detail.

The use of contrast agents in the liver is possible for different purposes:

- Detection of liver tumors [1, 4, 16]
- Characterization of liver tumors (benign versus malignant) [33, 173]
- Monitoring local ablative treatment [9, 17, 73]
- Imaging hepatic vessels [60]
- Describing diffuse liver disease by demonstrating intrahepatic microscopic shunts by measuring the hepatic transit time (time interval between appearance in the hepatic artery to the liver veins)

Liver Tumor Detection

It has been demonstrated that by resorting to contrast-enhanced phase or pulse inversion techniques the detection rate of metastases can be increased in comparison with conventional B-scan ultrasound. Comparative studies have shown that the detection rate is of the same order of magnitude as the detection rate for contrast-enhanced CT and MRI scans [34].

The aim of a recently published prospective multicentre study was to evaluate contrast-enhanced ultrasound (CEUS) using SonoVue® in the detection of liver metastases in patients with known extrahepatic primary tumors versus the combined gold standard comprising CT, MRI and clinical/histological data. One hundred and two patients were examined per protocol using SonoVue® with a low-mechanical-index technique and contrast-specific software with continuous scanning for at least 5 min. CEUS with SonoVue® increased significantly the number of focal liver lesions detected versus unenhanced ultrasound. In 31.4% of the patients, more lesions were found after contrast enhancement. The total numbers of lesions detected were comparable with CEUS [55], triple-phase spiral CT [61] and MRI with a liver-specific contrast agent [53] (Tables 37.2 and 37.3). Accuracy of detection of metastatic disease (i.e., at least one metastatic lesion) was significantly higher for CEUS (91.2%) than for unenhanced ultrasound (81.4%) and was similar to that of triple-phase spiral CT (89.2%). In 53 patients whose CEUS examination was negative, a follow-up

Table 37.2 Patients with correct diagnosis (existence of metastatic disease) with unenhanced ultrasound and contrast-enhanced ultrasound (CEUS)

		Contrast-enhanced ultrasound		
		Correct diagnosis		
		Yes	No	
Unenhanced ultrasound	Yes	82	1	83
Correct diagnosis	No	11	8	19
		93	9	102

Table 37.3 Patients with correct diagnosis (existence of metastatic disease) with contrast-enhanced ultrasound (CEUS) and triple-phase spiral CT

		Contrast-enhanced ultrasound		
		Correct diagnosis		
		Yes	No	
CT	Yes	83	8	91
Correct diagnosis	No	10	1	11
		93	9	102

examination 3–6 months later confirmed the absence of metastatic lesions in 50 patients (94.4%). Contrast-enhanced ultrasound in the portal venous and late phase following injection of SonoVue® considerably improves the detection of liver tumors compared with conventional B-mode ultrasound and is therefore a suitable method for the follow-up of patients with primary extrahepatic cancer.

Differentiation of Benign and Malignant Lesions

Characterization of a liver lesion begins once an abnormality is found. An imaging procedure that is used to detect liver masses should also enable the examiner to differentiate between benign and malignant lesions, since benign and malignant lesions have been reported to vary in their uptake during the portal venous and liver specific late phase after injection of Levovist®. Homogeneous parenchymal Levovist® uptake in the portal venous and liver specific late phase seems to be indicative of benign focal liver lesions [33, 160, 170–173]. The non-enhancing defects of malignant liver lesions, and also abscesses, might be explained by the lack of liver specific tissue, e.g., portal veins, sinusoids and reticulo-endothelial cells. The extent of late phase

Table 37.4 Demographic profile and tumor size of patients with histologically proven liver tumors, contrast-enhancement in 74 patients with histologically proven malignant liver tumors or lesions, and contrast-enhancement in 95 patients with histologically proven benign liver tumors or lesions [33]

Characteristics	
Demography	
No. (M/F)	80/94
Mean age (year) [†]	52 ± 15 (7–80)
	Mean size (mm) ^a
Benign liver lesions (<i>n</i> = 95)	41 ± 24 (8–130)
Focal nodular hyperplasia (<i>n</i> = 36)	51 ± 18 (20–110)
Hemangioma (<i>n</i> = 31)	37 ± 31 (8–130)
Adenoma (<i>n</i> = 10)	40 ± 20 (15–80)
Abscess (<i>n</i> = 5)	40 ± 24 (10–80)
Microhamartomas (<i>n</i> = 4)	12 ± 2 (9–15)
Focal steatosis (<i>n</i> = 4)	32 ± 5 (25–38)
Nodular regenerative hyperplasia (<i>n</i> = 1)	40
Hyper regenerative nodule (<i>n</i> = 1)	35
Focal biliary cirrhosis (<i>n</i> = 1)	25
Bacillary angiomatosis (<i>n</i> = 1)	50
Inflammatory pseudotumor (<i>n</i> = 1)	40
Malignant liver lesions (<i>n</i> = 79)	40 ± 21 (7–120)
Metastatic liver tumor (<i>n</i> = 37)	33 ± 12 (10–75)
Hepatocellular carcinoma (<i>n</i> = 33)	42 ± 24 (7–120)
Cholangiocellular carcinoma (<i>n</i> = 4)	59 ± 42 (40–100)
Lymphoma (<i>n</i> = 4)	44 ± 17 (17–60)
Haemangioendotheliosarcoma (<i>n</i> = 1)	100

[†]Mean ± standard deviation (range)

Table 37.5 Contrast-enhancement in 74 patients with histologically proven malignant liver tumors or lesions

Liver tumor	Hypoechoic contrast-enhancement
Malignant liver lesions (<i>n</i> = 79)	79/79
Metastatic liver tumor (<i>n</i> = 37)	37/37
Hepatocellular carcinoma (<i>n</i> = 33) ^a	33/33
Cholangiocellular carcinoma (<i>n</i> = 4)	4/4
Lymphoma (<i>n</i> = 4)	4/4
Haemangioendotheliosarcoma (<i>n</i> = 1)	1/1

^aHCC were variable and less impressive in 13 patients with a heterogeneous enhancing liver parenchyma during the liver specific late-phase, also indicating that HCC may also show some contrast up-take which may lead to misinterpretation. In those 13 patients repeated contrast examinations were necessary to determine the malignant nature of the lesion due to technical reasons

contrast uptake by a lesion is mainly determined by the degree of similarity of the lesion to normal liver parenchyma, resulting in false positive findings and misinterpretation in patients with abscesses, necrosis, scars, calcifications, cysts and thrombosis. As cysts and calcifications can be correctly diagnosed by conventional

Table 37.6 Contrast-enhancement in 95 patients with histologically proven benign liver tumors or lesions [33]

Liver tumor	Isoechoic contrast-enhancement
Benign liver lesions (<i>n</i> = 95)	88/95
Focal nodular hyperplasia (<i>n</i> = 36)	35/36
Hemangioma (<i>n</i> = 31)	31/31 ^a
Adenoma (<i>n</i> = 10)	10/10
Abscess (<i>n</i> = 5)	0/5
Microhamartomas (<i>n</i> = 4)	4/4
Focal steatosis (<i>n</i> = 4)	4/4
Focal biliary cirrhosis (<i>n</i> = 1)	1/1
Bacillary angiomatosis (<i>n</i> = 1)	1/1
Nodular regenerative hyperplasia (<i>n</i> = 1)	1/1
Regenerative nodule (<i>n</i> = 1)	1/1
Inflammatory pseudotumor (<i>n</i> = 1)	0/1

^aThe vascular-phase contrast-enhancement pattern of hemangiomas was variable. Characteristic was a progressive heterogeneous centripetal fill-in and considerable enhancement on liver specific late-phase imaging, revealing diminished contrast to the surrounding liver parenchyma in all patients

B-mode ultrasound, it is therefore mandatory to perform a baseline scan before using ultrasound contrast agents.

The results of a previously published study show that contrast enhanced phase inversion ultrasound may discriminate between benign liver specific tissue and non-liver specific tissue-mainly malignant focal liver lesions in the portal venous and liver specific late phase in almost all patients (Table 37.4–37.6) [33]. There were only a few false positive findings, mainly caused by abscesses and necrosis, and two liver tumors – one case of old focal nodular hyperplasia with mainly scar tissue, and one case of inflammatory pseudotumor of the liver, which was definitively diagnosed only by operation. The difficult diagnosis of the inflammatory pseudotumor of the liver is in accordance with current literature. In contrast, homogeneous uptake was found in focal nodular hyperplasia, in adenoma, in hemangioma, in focal steatosis, in hyperregenerative nodules and other benign liver tumors and nodules. Therefore, homogeneous parenchymal Levovist[®]-uptake in the portal venous and liver specific late phase seems to be indicative of benign focal liver lesions. In the mentioned study none of the lesions with homogeneous Levovist[®]-uptake in the portal venous and liver specific late phase turned out to be malignant (indicating no false negative finding).

This is in accordance with recently published studies, which mainly used imaging methods as the gold standard, but not histology in all patients [92, 159, 170–173].

In conclusion, contrast enhanced phase inversion ultrasound in the portal venous and liver specific late phase after injection of Levovist® and SonoVue® considerably improves the characterization of liver tumors compared with conventional B-mode ultrasound, leading to differentiation of benign and malignant liver lesions in most patients – if cysts and calcifications are excluded by conventional B-mode ultrasound [33, 173]. PIUS facilitates the clinical decision as to whether a sonographically detected liver lesion will need further investigation or not. From this point of view, this new technique might help to reduce unnecessary or invasive examinations in certain cases, such as invasive liver biopsy, CT scan and MRI.

Only a few false positive findings were observed, mainly due to abscesses or necrosis, and in two liver tumors – one case of old focal nodular hyperplasia with predominantly scar tissue, and one case of an inflammatory pseudo-tumor of the liver, which was definitively diagnosed only by surgical exploration. The difficulties in diagnosis of the inflammatory pseudo-tumor of the liver is in accordance with current literature [144].

Liver Tumor Characterization

Liver Cyst

Liver cysts are a common sonographic finding. They are readily diagnosed using conventional B-mode ultrasound. The typical cyst criteria are: echo-free, round-oval, well-defined borders with lateral shadowing and posterior echo enhancement. Very early echinococcosis might be confused with atypical liver cysts.

Blood vessels have to be excluded by color Doppler imaging, ruling out arterio-portal venous malformations with a cystic appearance.

Using contrast enhanced ultrasound, cysts show no contrast enhancement at all. As they may be confused with metastases in contrast enhanced ultrasound (CE-US), conventional B-mode ultrasound should precede CE-US. CE-US is helpful in recognising echinococcosis in all stages.

Hemangioma

Hepatic hemangiomas are known to be the most common benign liver tumors, with an incidence in autopsy

and imaging studies of up to 7%. As incidentally discovered hepatic tumors are more frequently detected with the increasing use of modern abdominal imaging techniques, reliable non-invasive characterization and differentiation of such liver tumors is highly important in the clinical routine.

Approximately 10% of patients with hemangiomas cannot be reliably diagnosed using imaging methods. In a series of 1,011 patients who underwent hepatic resection for liver tumors, 107 (11%) of these patients were asymptomatic individuals who presented with incidentalomas. Benign pathologies were found in 45 (42%) patients, including focal nodular hyperplasia ($n = 17$), hemangioma ($n = 12$), angiomyolipoma ($n = 5$), cirrhotic regenerative nodule ($n = 4$), hepatic adenoma ($n = 2$), and others ($n = 5$). One retrospective study of percutaneous biopsies of 38 patients (1–13.5 cm, with a mean of 3 cm) with suspected hemangioma using 20 gauge needles reported that it is safe and effective for establishing the diagnosis of hemangioma [8].

In a series of 25 consecutive patients who underwent surgery for giant hemangioma, CT and MR images were reviewed retrospectively and revealed similar results in accordance with our findings [23].

Conventional B-mode ultrasound. Most hemangiomas demonstrate typical sono-morphological features in conventional B-mode, as follows: less than 3 cm in diameter, lobulated with a well defined outline, located next to liver vessels, demonstrating an echo-rich texture and sometimes posterior acoustic enhancement due to blood filled capillaries (Tables 37.7 and 37.8).

Color Doppler imaging. Although hemangiomas are highly vascularised masses, from the histo-pathological point of view they consist essentially of a large number of capillary-sized vessels and so, even with the use of high-end machines, conventional color Doppler ultrasound often detects little or no blood flow inside the hemangioma due to the fact that the blood flow velocity in the capillary hemangioma is too slow. The supplying and draining vessels (“feedings vessels”) may be visualised (depending on the ultrasound systems performance).

Contrast-enhanced ultrasound. There are many reports in the literature in characterization of liver hemangioma but results were inconsistent so far. CEUS has markedly improved the correct diagnosis of hemangioma which is possible in about 95% of patients. Difficult differential diagnosis includes shunt hemangioma in the cirrhotic liver which might be confused with hepatocellular adenoma or carcinoma. A thrombosed hemangioma

Table 37.7 Typical hemangioma, diagnostic criteria

B-mode criteria	
Less than 3 cm in diameter	
Echo-rich structure	
Homogeneous interior	
Round or slightly oval shape	
Smooth outline	
Absence of any halo sign	
Possible detection of feeding and draining vessel	
Absence of any signs of invasive growth	
Dorsal through-enhancement	

Table 37.8 Sonographic findings in 200 patients with hemangioma examined by contrast enhanced ultrasound

Characteristics	
Mean size (cm)	3 ± 3 cm
Echogenicity	
Echo-rich	180 (90%)
Isoechoic or echo-poor	20 (10%)
Vascularity using color Doppler imaging	
No intra-lesional vessels	184 (92%)
Intra-lesional vessels (hypervascular)	16 (8%)
Peripheral nodular enhancement	
Using Levovist®	54 (27%)
Using SonoVue®	152 (76%)
Complete iris diaphragm phenomenon within 60s	20 (10%)
Complete iris diaphragm phenomenon within 3min ^a	

^aDepending on the technique and ultrasound machine used

might be confused with a metastasis by demonstrating contrast sparing in the portal venous phase.

Tumor enhancement characteristics differ depending on the contrast medium and technique used (intermittent scanning versus continuous real-time technique). Hemangioma characterization using Levovist® reveals arterial fill-in within 1 min in up to 10% of patients histologically demonstrating arterio-portal venous shunts (so-called “shunt hemangioma”).

Contrast enhancement using Levovist® showed peripheral nodular contrast-enhancement with gradual centripetal filling and are regarded as having a large, slowly enhancing blood volume in about 25% of patients. In contrast, the typical CE-US sign of hemangioma using SonoVue® is peripheral nodular contrast-enhancement which can be observed in more than 75%, focussing on the tumor periphery. Atypical features include small (<15mm) or huge hemangiomas (>4–7cm [depending on the literature published]), so called “shunt hemangiomas” with abundant arterio(porto-)venous shunts

(functionally described as high flow hemangiomas), sclerosing hemangiomas, and hemangiomas with regressive changes like calcifications, thrombosis and venoliths. Noticeably hemangiomas smaller than 10mm tend to lack the typical hemangioma contrast enhancement and are a particular challenge [38].

The kinetics are variable, and in the case of hemangiomas with abundant arterio-portal venous shunts the centripetal fill-in can last less than a minute or even only a few seconds. Therefore, imaging in the first 60s is of utmost importance in characterising hemangioma by CE-US, demonstrating superiority of SonoVue® in comparison to Levovist®.

Other methods. The best, though most expensive, imaging method for hemangiomas is MRI with a sensitivity and specificity between 85% and 95%. Bright signal intensity on T2-weighted images and similar enhancement pattern to enhanced CT are very specific and effective for accurate diagnosis. However, there are also atypical findings of hemangioma such as cystic hemangiomas or small hemangiomas with immediate homogeneous enhancement. In these cases, histologic confirmation via needle biopsy is required [20].

Atypical hemangioma behaviour includes the differential diagnosis of hemangioma versus hypervascular malignancy, hemangioma with arterioportal shunts, hemangioma in liver cirrhosis, hemangioma in fatty liver, small hypoattenuating hemangioma, atypical signal on T2-weighted MR imaging, attenuation relative to vascular pool [85].

Small hypoattenuating hemangiomas are detected more frequently with helical CT (the incidence being 8–16%), whereas they are easily overlooked on conventional CT because they tend to be isoattenuating on late phase images. Small hypoattenuating hemangiomas are particularly problematic in patients with underlying malignancy. If present, the “bright-dot” sign – tiny enhancing dots in the hemangioma that do not progress to the classic globular enhancement because of the small size of the lesion and the propensity for very slow fill-in – is helpful in diagnosing this type of hemangioma [84]. However, a number of hemangiomas have no discernible enhancement. One pathologic correlative study suggested that hemangiomas with a slow fill-in pattern have relatively large vascular spaces and that those with rapid enhancement have small vascular spaces and a large interstitium. Such a tendency has no relationship to the size of the tumor [182]. Therefore,

hemangiomas should be included in the differential diagnoses of small hypoattenuating lesions as well as hypervascular lesions. CEUS, which has the advantage of real-time dynamic assessment, could be of help in characterising such lesions.

Characterization of histologically proven hemangioma. Contrast enhanced ultrasound was recently assessed in patients with histologically confirmed hemangiomas with respect to contrast enhancing kinetics and tumor characteristics. In 58 patients with indeterminate hepatic lesions demonstrated with at least two imaging methods (ultrasound/computed tomography/magnetic resonance imaging), ultrasound guided liver biopsy revealed hemangioma. In all these patients a hepatic neoplasm had been suspected due to underlying malignant disease ($n = 41$), liver cirrhosis ($n = 15$) or growth of the lesion ($n = 2$). All patients underwent non-linear, low mechanical index real time contrast enhanced ultrasound scanning with bolus injections of SonoVue®. Peripheral nodular arterial enhancement was detected in 43 patients (74%), while the typical metastatic peripheral rim-like enhancement was not observed at all. Strong homogenous arterial enhancement was found in 9/58 (16%) of patients. In 6 patients (10%) the arterial contrast enhancement pattern could not be determined due to very small size of the lesions or fibrotic nodules. Forty-five (78%) of the hemangiomas showed homogenous centripetal filling within 180s (Table 37.9–37.11). In conclusion, contrast enhanced ultrasound demonstrates typical hemangioma imaging characteristics, i.e., peripheral nodular contrast enhancement and iris-diaphragm sign in a high percentage of patients with undetermined lesion. This technique may therefore improve

Table 37.9 Demographic characteristics and indications for biopsy in 58 histological proven hemangiomas

Characteristics	
Demography	
No (M/F)	58 (29/29)
Mean age (year)	56 ± 13 (24–77)
Indication for biopsy	
Underlying malignant disease	41/58 (81%)
Growing tumor ^a	2/58 (3%)
(Suspected) liver cirrhosis (HCV/PBC/CF ^b)	15/58 (19%) (10/4/1)

m male, *f* female, *HCV* hepatitis-C-virus infection, *PBC* primary biliary cirrhosis, *CF* cystic fibrosis

^aAn impressive growth pattern from less than 20 mm to more than 50 mm within 2 years was seen in a patient with a malignant ovarian tumor

Table 37.10 B-mode and color Doppler imaging characteristics of 58 histological proven lesions

Number of lesions	
One lesion	21/58 (36%)
Multiple lesions	37/58 (64%)
Size (mm)	35 ± 28 (6–130)
Echogenicity	
Hyperechoic	45/58 (78%)
Isoechoic	4/58 (7%)
Hypoechoic	9/58 (15%)
Halo	0/58 (0%)
Color Doppler imaging	
Feeding and draining vessels ^a	25/58 (43%)
Homogenous hypervascularity	4/58 (7%)

^aRepresenting the color Doppler imaging (CDI) sign of peripheral nodular contrast enhancement. In patients with liver cirrhosis the tumors were hyperechoic in 14 and isoechoic in one. In none of the patients CDI was helpful in identifying shunts since perfusion patterns can not be displayed

Table 37.11 Contrast enhancing pattern of 58 histologically proven lesions

Characteristics	
Contrast enhancement, arterial	
Peripheral nodular arterial enhancement	43/58 (74%)
Peripheral rim like enhancement	0/58 (0%)
Not determinable (e.g., due to size of the lesion, solitary fibrotic nodule)	6/58 (10%)
Strong homogenous arterial enhancement ^a	9/58 (16%)
Centripetal filling	
Complete (homogenous) fill-in < 180 s	45/58 (78%)
≤ 30 s	12 (21%)
> 30 s and ≤ 60 s	6 (10%)
> 60 s and ≤ 180 s	27 (47%)
Incomplete (inhomogenous, incomplete iris diaphragm sign, including one with non-enhancing solitary necrotic nodule)	13/58 (22%)
Sensitivity	
Peripheral nodular arterial enhancement	43/58 (74%)
Complete portal venous fill-in	45/58 (78%)
Combination of both	57/58 (98%)

^aIn two patients with liver cirrhosis shunt-hemangiomas were found

non-invasive functional characterization and differentiation of hemangioma.

Arterioportal shunts. Arterioportal shunts associated with a hepatic tumor have been reported primarily in patients with malignant tumors, especially in advanced hepatocellular carcinoma with portal vein invasion [122, 123, 149, 162]. However, arterioportal

shunts have been observed in hepatic hemangiomas not only using CEUS but also on multiphase helical CT and MRI in a significant percentage of hemangiomas (19–26%) which is in the same range [38]. One possible explanation for rapidly enhancing small hemangiomas is a hyperdynamic status with large arterial inflow, rapid tumoral enhancement, and consequently, large and rapid outflow, which seems to result in early opacification of the draining portal vein via shunts [86]. Shunt hemangiomas are typically surrounded by focal hypoechoic areas representing less fat content in comparison with the surrounding liver parenchyma. The metabolic changes are explained by a mainly arterial blood supply of the hypoechoic areas whereas blood supply of the surrounding liver parenchyma is mainly by portal venous vessels containing more lipids and insulin (Fig. 37.1).

Focal Nodular Hyperplasia

Focal nodular hyperplasia (FNH) and the important differential diagnosis of hepatocellular adenoma (HCA) are two benign, mostly incidentally discovered hepatic neoplasia, which occur predominantly in young and middle-aged women. Differentiation is essential because of different therapeutic approaches: HCA is an indication for surgery because of the risk of hemorrhage and potential malignant transformation; in contrast, FNH can be managed conservatively. However, until recently the non-invasive differentiation of especially atypical FNH from HCA and other benign or malignant neoplasia has remained challenging, with no satisfactory tests apart from histological examination of a liver biopsy sample. Histological features of FNH are controversially discussed in the literature. In contrast to a recent report in three patients demonstrating no portal veins most reports describe (arterio-portal venous) vascular abnormalities, but there are still some controversies [57, 95, 115, 175]. Scoazec et al. reported on the findings that the extra-cellular matrix is similar to that of portal tracts [145]. Kondo F et al. report that in FNH nodules, severe anomaly of portal tracts including portal veins and hepatic arterial branches are observed [95]. In addition, congenital absence of

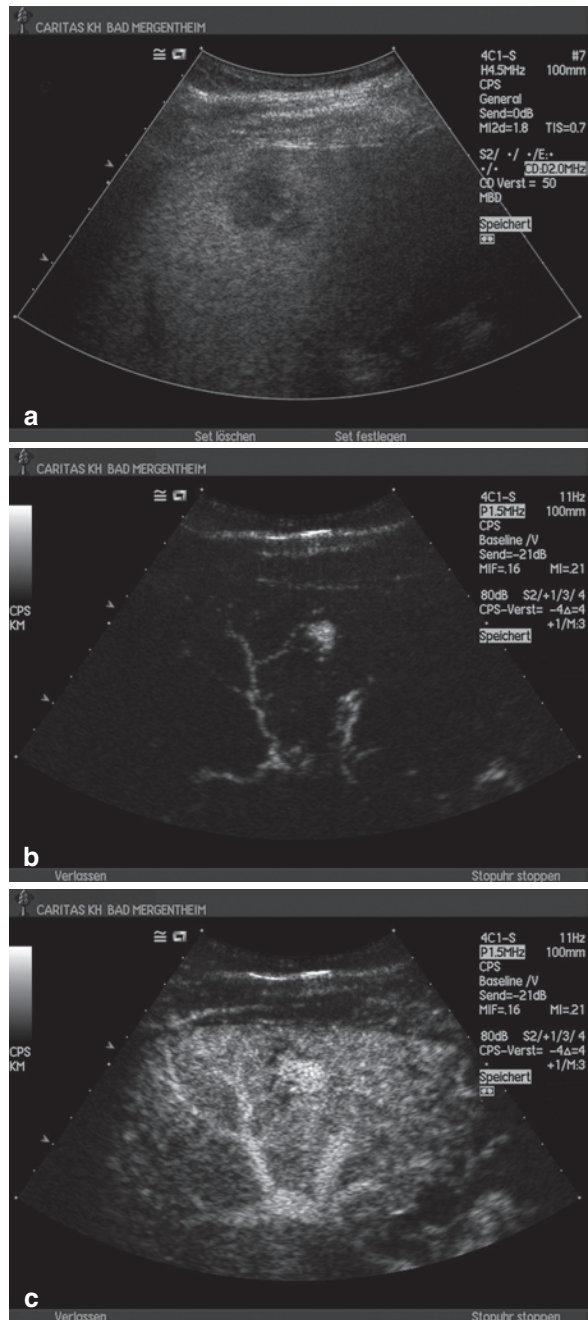


Fig. 37.1 Focal hypoechoic lesion subcapsular with inhomogeneous echogenicity (a). Color and Power Doppler imaging were not helpful. The real lesion is an hemangioma with peripherally located feeding vessels and arterio-portal venous shunts (shunt hemangioma) leading to regional focal fatty sparing. The typical contrast-enhanced ultrasound finding is centripetal fill-in within seconds (b, c).

portal veins has been reported in few patients, mainly children. The cited literature has been recently summarised [41].

Helical CT and MR imaging do provide some useful information in the diagnosis of FNH, especially when the lesion depicts typical features, such as a central scar and uniform hypervascularity. Typical features are only reported in about 50%. In a series of 305 FNH studied macroscopically, a central scar could be found only in about 50% [115].

Conventional B-mode ultrasound. FNH is typically an isoechoic tumor of variable size, with a central scar and calcifications (50–80%).

Color Doppler imaging. Typically, color Doppler imaging reveals a (arterially) hypervascularised tumor (>90%) with characteristic (para-) central arterial blood supply. In many patients, increased blood flow compared with the surrounding liver tissue can be detected even in color duplex mode, causing a so-called wheel-spoke phenomenon. This hyperperfusion that can be recognised in native imaging is by no means obligatory and is reported only in about 50–70% of patients. It could also be shown that inter-observer reliability in recognising the wheel-spoke appearance is very low.

Contrast-enhanced ultrasound. The examination of the hepatic arterial and portal venous/sinusoidal phase by contrast-enhanced phase inversion ultrasound allows for reliable differentiation between FNH and HCA. This important finding could be explained by the lack of portal veins in contrast to FNH which presents (atypical) portal veins in many but not all patients.

In a contrast enhanced examination, FNH typically appears as a hyper-perfused tumor-like lesion relative to the surrounding liver tissue in the early arterial phase. This hyper-perfusion is easily visible during continuous scanning with a low mechanical index, comparing the contrast enhancement of the lesion with the surrounding hepatic arteries. Depending on the patient's cardiac output, some 8–20s after injection of the echo-signal enhancer into the cubital vein there is a rapid take-up of the substance with demonstration of the arterial vascular pattern and enhancement from the centre outwards. During the portal venous phase FNH is isoechoic with the portal vein, and slightly hyperechoic in comparison to the surrounding liver parenchyma (Fig. 37.2).

Forty patients with histologically proven FNH ($n = 30$) or HCA ($n = 10$) were included in a prospective study evaluating tumor characteristics. The pattern of tumors was described as hypoechoic, isoechoic,

or hyperechoic when compared to the surrounding liver tissue, and tumor vascularity was classified as hypervascular, isovascular, or hypovascular by Power Doppler ultrasound. The internal vascular architecture was also recorded. Four grams of Levovist® (400 mg/ml) was given intravenously and the liver scanned using phase inversion ultrasound for the first 30s, followed by intermittent scanning. The following parameters for imaging after Levovist® were used: mechanical index 1.6, power 100%, gain 20 dB, and frame rate 10–14/s.

In all 40 patients enhancement of the hepatic artery and portal vein was observed. In 29 of 30 patients with FNH the contrast pattern revealed pronounced arterial and portal venous/sinusoidal enhancement. Only one patient with FNH lacked portal venous/sinusoidal enhancement, possibly due to extensive, histologically documented fibrosis. Using Levovist®, homogenous enhancement was detected during the hepatic arterial phase in all ten patients with HCA, preceding enhancement of normal liver parenchyma. In contrast to patients with FNH, no enhancement was seen in HCA during the hepatic portal venous/sinusoidal phase with isoechoic or slight hypoechoic appearance in the parenchymal and sinusoidal late phase. Sonographic findings of this study are summarised in Table 37.12. Some of the patients were also examined after intravenous application of 4.8 ml SonoVue® using phase inversion ultrasound. Comparing Levovist® and SonoVue® during the arterial and portal venous/sinusoidal phase, there was a better visualisation of hepatic vessels with SonoVue® in all patients examined.

Recently, a study was published using SonoVue® in characterization of histologically proven FNH ($n = 24$) or HCA ($n = 8$). In a pre-study phase in ten consecutive patients the onset of hepatic arterial enhancement was observed to commence between 8 and 22s after injection and the early onset of portal venous began between 12 and 30s after injection. Phase inversion ultrasound was used before biopsy using the following imaging parameters: mechanical index 0.2–0.3, power 3%, gain 52–60 dB, and frame rate 10–14/s. The liver was scanned continuously for up to 5 min. Using this approach, contrast enhancing tumor characteristics were evaluated during the hepatic arterial and early portal venous phase comparing the contrast enhancement to the enhancing hepatic artery and portal vein branches (Table 37.13) [41].

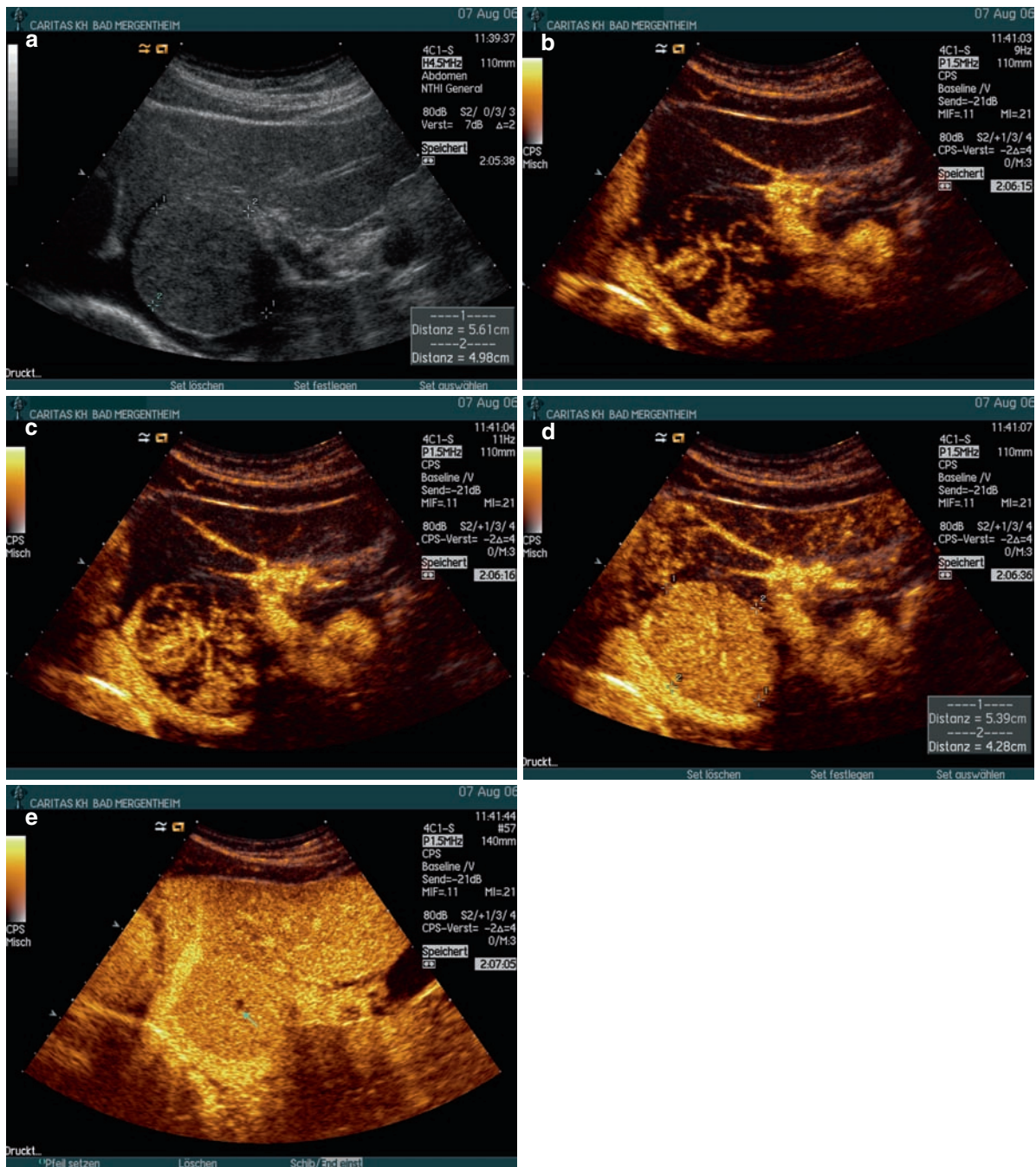


Fig. 37.2 FNH using B-mode often appears isoechoic in comparison to the surrounding liver parenchyma and can not be differentiated from malignant tumors like hepatocellular carcinoma (a, FNH of segment 1 (caudate lobe) in between markers). FNH in the arterial phase appears typically as a hypervascular and hyperperfused structure relative to the surrounding liver tissue

demonstrating the typical central artery in about 70% (b-d) [115]. During the portal venous phase FNH is isoechoic with the portal vein, and in more than 90% of lesions to some extent hypervascular in comparison with the parenchymatous environment. The typical central scar (in between markers) can be found in approximately 70% of patients proven in autopsy studies (e)

Table 37.12 Patient characteristics and sonographic findings in 40 patients with histologically proven FNH and hepatocellular adenoma examined with Levovist®

	FNH	HCA
Number	30	10
Male/Female	4/26	1/9
Age (years)	40 ± 12 (18–64)	41 ± 14 (23–70)
Size of lesion (mm)	52 ± 18 (26–110)	40 ± 20 (15–80)
Conventional B-mode ultrasound		
Echo texture		
Hypoechoic	10 ^a	3 ^a
Isoechoic	19	6
Hyperechoic	1	1 ^b
Central scar	14	2
Color/power Doppler imaging		
Hypervascular	29	8
Radial vascular architecture	10	0
Contrast-enhanced ultrasound		
Arterial phase enhancement	30	10
Portal venous phase enhancement	29	0

^aAll in a sonographically bright liver

^bIn a patient with glycogen storage disease

Table 37.13 Patient characteristics and sonographic findings in 32 patients with histologically proven FNH and hepatocellular adenoma examined with SonoVue® [41]

	FNH	HCA
Number	24	8
Male/Female	2/22	0/8
Age (years)	37 ± 10 (18–64)	37 ± 10 (23–47)
Size of lesion (mm)	55 ± 21 (26–110)	32 ± 15 (15–55)
Conventional B-mode ultrasound		
Echo texture		
Hypoechoic	7 ^a	4 ^a
Isoechoic	16	4
Hyperechoic	1	
Central scar	10	0
Color/power Doppler imaging		
Hypervascular	23	8
Radial vascular architecture	10	0
Contrast-enhanced ultrasound		
Arterial phase enhancement	24	8
(Early) Portal venous phase enhancement	23	0

^aAll in a sonographically bright liver

Hepatocellular Adenoma

Conventional B-mode ultrasound. In B-mode ultrasound of an otherwise normal liver, a hepatocellular adenoma (HCA), like FNH, is usually isoechoic with the surrounding liver tissue. Because of this lack of echogenicity, an adenoma can be very difficult to differentiate from the surrounding liver tissue. In a fatty liver, adenomas may be poorly echogenic, whereas in patients with storage diseases (e.g., glycogenosis or Niemann-Pick disease) adenomas may even give stronger echoes [65]. As in the case of FNH, a rounded contour or a vascular impression may indicate a tumor poorly discernible from liver parenchyma. There are no other typical criteria in B-mode ultrasound.

Color Doppler imaging. According to the available data there are still no standardised criteria for the differentiation of adenomas from other hepatic masses based on perfusion pattern. The typical wheel-spoke structure with a central vascular supply and a central scar seen in FNH is absent in adenoma – but calcifications are observed depending on size. Like FNH, an adenoma exhibits arterial hypervascularity (predominantly marginal). However, this vascular pattern can also be encountered in hepatocellular carcinomas and hyperperfused metastases, and is therefore not pathognomonic.

Contrast-enhanced ultrasound. Like FNH, an adenoma exhibits arterial hyperperfusion (but mainly in the margin). However, this vascular pattern can also be encountered in hepatocellular carcinomas and hyperperfused metastases and is therefore not pathognomonic.

Contrast enhanced phase inversion ultrasound was recently assessed in patients with histologically proven focal nodular hyperplasia or hepatocellular adenoma. It has to be taken into account that histologically no portal veins (and in addition, no bile ducts) are present in adenomas. CEUS demonstrated pronounced arterial and portal venous enhancement in all but one patient with FNH. In contrast, after homogeneous enhancement during hepatic arterial phase (8–25 s after the injection), no enhancement during hepatic portal venous phase was detected in any patient with HCA (Fig. 37.3) [41].

Differential diagnosis. Scintigraphic methods for adenoma and FNH diagnostics have also been established. Bile duct tracers bypass adenomas, because no bile ducts are present in an adenoma. A liver-cell adenoma therefore does not show up in hepatobiliary

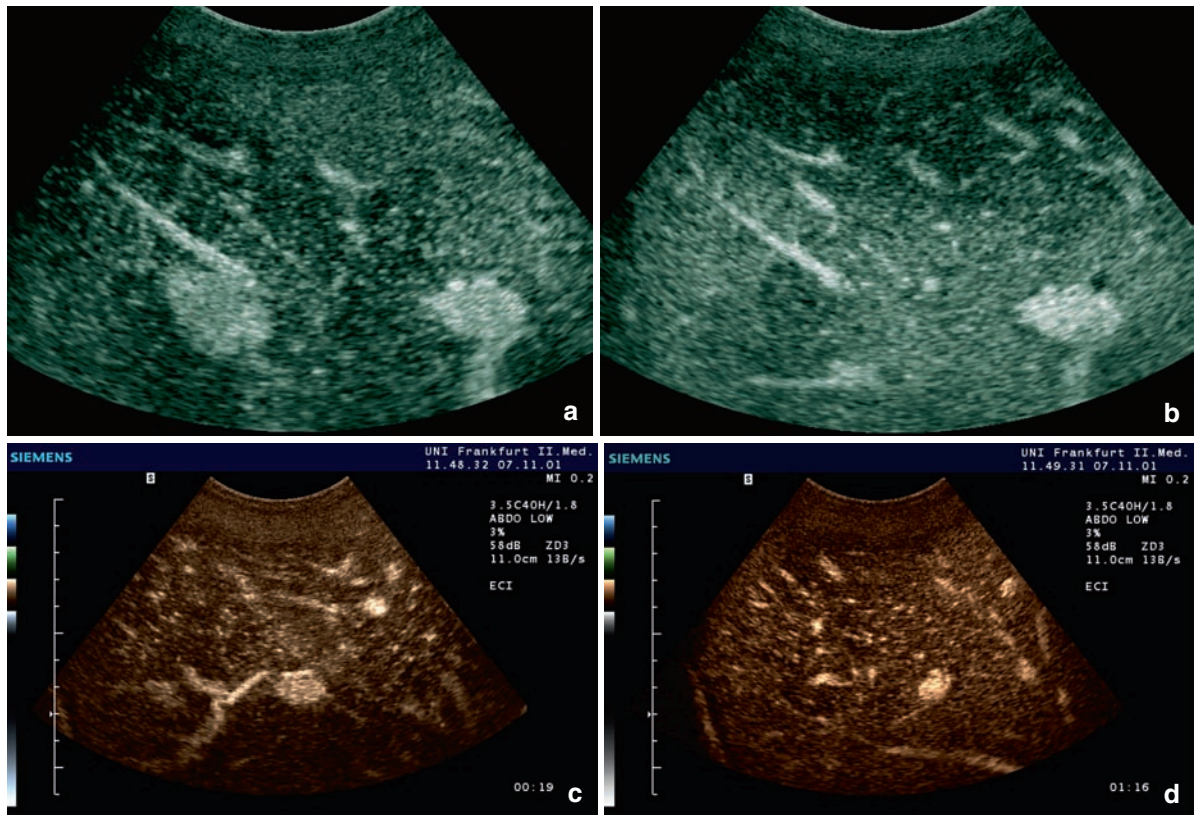


Fig. 37.3 (a–d) Contrast-enhanced phase inversion ultrasound (CE-PIUS) of a patient with hepatocellular adenoma using modified Photopic. CE-PIUS revealed only arterial phase enhancement for 10 s (10–20 s) after administration of SonoVue® (a). At the end of the arterial phase (<25 s after administration of SonoVue®) a slightly hypochoic liver tumor was detected by

contrast-enhanced phase inversion ultrasonography and no portal venous sinusoidal enhancement was observed (b). The same patient was examined after stem cell transplantation due to acute leukaemia. Tumor size decreased but enhancement characteristics did not change, as shown in (c, d)

sequence scintigraphy. False positive findings have been observed. An FNH with its abundant bile duct proliferation picks up bile duct tracers very quickly, however, and gives them up with a delay, so that an FNH can be well diagnosed scintigraphically provided it is of sufficient size: the nuclear-medicine techniques mentioned are only reliable from a tumor size of 3–4 cm.

Hepatocellular adenomas in (glycogen) storage diseases. Hepatic adenomas are frequently seen in adult patients with glycogen storage diseases (GSD 1), but their pathogenesis is not understood. Glucagon/insulin imbalance, cellular glycogen overload, and proto-oncogene activation have been suggested as possible mechanisms [7]. Prevention or even regression of hepatic adenomas during dietary therapy has been described by some, but not all authors [101, 125]

Bianchi reviewed 50 cases of hepatocellular adenoma and ten cases of hepatocellular carcinoma from the literature on patients with GSD 1 in 1993 [7]. In 5 of these 10 cases transition from hepatocellular adenoma into hepatocellular carcinoma seemed likely. The histology of adenomas corresponded to other adenomas, except for the appearance of Mallory bodies, which are known to occur in HCC and alcoholic cirrhosis. In another case series from the literature including 37 patients with GSD 1a 75% had at least one hepatic adenoma but only one patient was reported to have HCC [161]. Optimal treatment strategies for hepatic adenomatosis in general and in patients with GSD have not yet been developed [183]. Because the rate of malignant transformation appears to be relatively low some authors advocate watchful waiting with frequent sonographic controls [68, 101]. Matern et al. reviewed

the literature and the clinical experience of several liver transplant centers and described 25 liver transplantations in patients with different forms of GSD [109]. Nine of these were done in GSD 1 patients (7 with GSD 1a and 2 with GSD 1b) because of poor metabolic control and liver adenomas. All nine transplants were successful and the authors recommended liver transplantation for GSD 1 patients with liver malignancy or hepatic failure. A similar conclusion has been reached by Faivre et al. [53].

Focal Steatosis

Fatty infiltration was generally considered to be a diffuse process involving the entire liver. Since Brawer and Scott identified focal hepatic fatty infiltration at autopsy and in imaging studies in 1980, focal hepatic fatty infiltration has been widely discussed. Diffuse fatty changes of the liver were recognized on CT examination soon after the introduction of CT technology. Focal fatty changes of the liver were subsequently described as histological and radiological entities soon after. It is well known, that diffuse hepatic fatty infiltration may occur in association with several conditions like alcoholism, diabetes mellitus, obesity, intravenous hyperalimentation, malnutrition, pregnancy, Cushing's syndrome, Corticosteroid medication, hepatitis, porphyria, hepatotoxic drugs, congestive heart failure and many others like the Kwashiorkor syndrome, Wilson's disease or intestinal bypass.

Bright focal areas in the liver hilum occur in >40% of inflammatory bowel disease patients during medication with corticosteroids. In our experience, hyperechoic lesions may be observed 3 weeks after corticosteroid intake (more than 10 mg prednisolone/day), and usually resolve within 3 months after cessation of corticosteroid therapy. This phenomenon occurs in IBD-patients as frequently and as intensely as in patients with autoimmune disease and longstanding corticosteroid therapy. The histological nature of these corticosteroid derived lesions is not yet clear. Different amounts or types (large, small vacuoles) of fat deposition are likely, because a change of appearance over time can be observed. Hemangiomas may mimic such lesions, but not all bright lesions in the liver are hemangiomas. In 20 unselected corpses, four showed similar bright echogenic lesions in the liver hilum, but histology differed remarkably (two fibrous tissue, one fatty

infiltration and one hemangioma). It is well known that the vascular supply of the hilar region in liver segment IV differs from the perfusion of liver tissue adjacent to the gallbladder. This could give a possible explanation for different reactions of liver parenchyma to fatty infiltration. Although well documented, the underlying mechanism is still unknown. Changes in arterio-portal venous perfusion have been suggested. In patients with focal fatty lesions we observed centrally located arterial blood supply and direct venous drainage from and into the liver hilum; in contrast, portal venous perfusion varies [35, 39, 44].

Conventional B-mode ultrasound. Fatty infiltration may affect the liver diffusely or focally, but it does usually not cause any mass effect or displace vessels. Sonographically, hepatic fatty infiltration appears as segmental or lobular areas of brighter echogenicity, in contrast to the echogenicity of the normal liver parenchyma. A central, peri-hilar location in segment IV or V is typical – other locations are rarely involved.

An oval shaped hypoechoic lesion in the liver hilum is always related to fatty liver and could represent normal liver tissue surrounded by diffuse fatty infiltration of the liver. A hypoechoic lesion in the liver hilum without signs of expansion seem to be a relevant sign of fatty liver and should not be confused with mass lesions. The typical relationship to fatty liver, the typical location and shape are helpful in differential diagnosis.

Color Doppler imaging. In color Doppler ultrasound, both focal fatty degeneration and its focal absence appear normal; neither hyper- nor hypoperfusion is apparent, since we are dealing with normal liver tissue. Typically, central feeding and draining vessels (Fig. 37.4) may be detected in a high percentage of patients demonstrating the pathogenetic mechanism of different vascularisation of the liver hilum.

Contrast enhanced ultrasound. Focal fatty changes in the liver may simulate mass lesions, thus focal hepatic lesions might be mistaken for hepatic neoplasm at ultrasound. This is important to know, when it comes to a differential diagnosis, especially in patients with underlying malignant disease. Contrast enhanced ultrasound is helpful to rule out malignant infiltration. In the arterial and venous phase the supplying and draining vessels of the liver hilum can be imaged. In the enhanced echo signal sequence, different fatty degeneration regions are imaged like normal liver tissue in the capillary and portal venous phase. Therefore, in the portal venous phase these lesions are

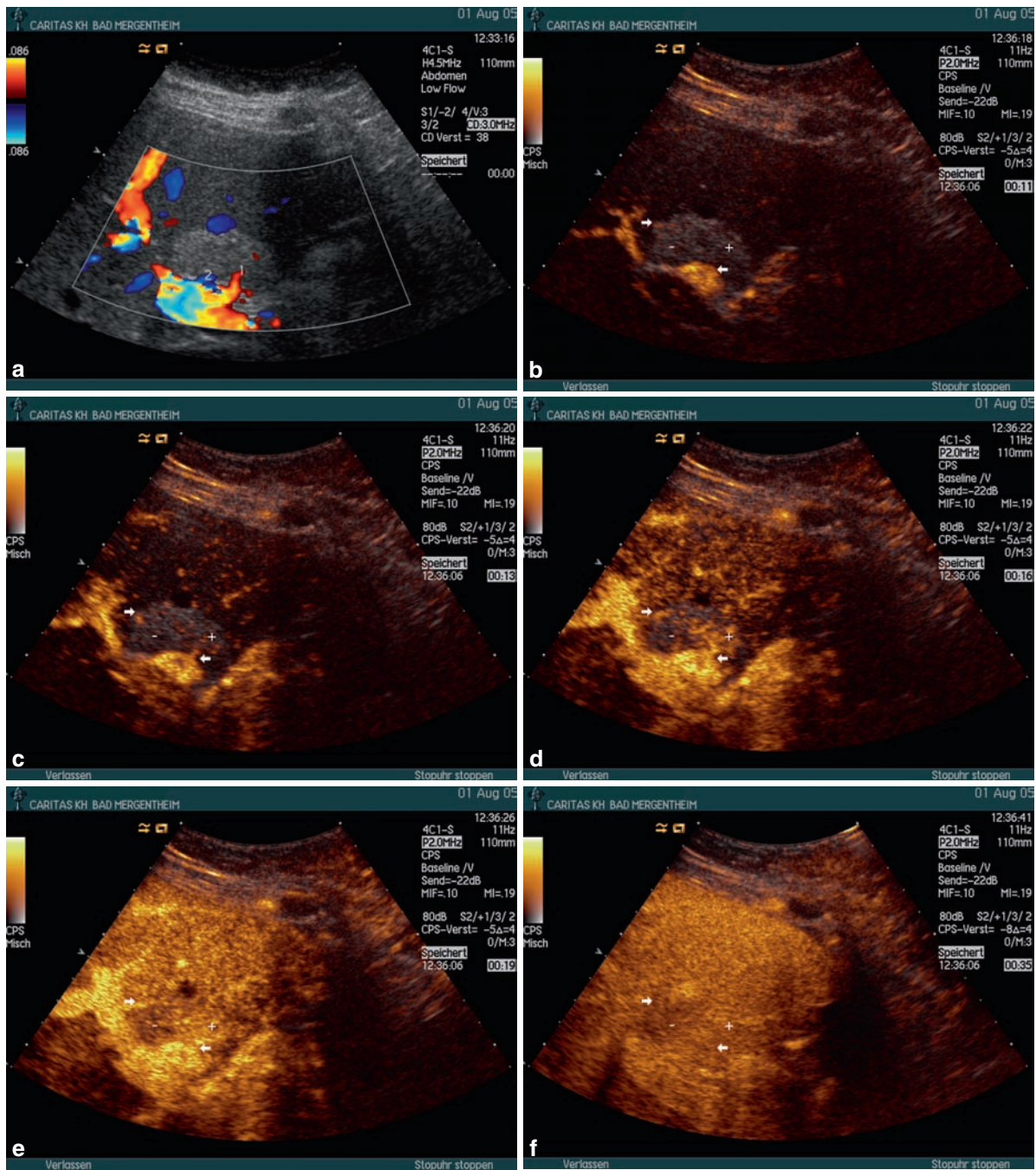


Fig. 37.4 (a-f) Focal hyperchoic lesion in the quadrante lobe adjacent to liver hilum, which was found to be fatty infiltration. Using conventional color Doppler ultrasound arterial and venous draining vessels are visualized (a). The contrast enhancement pattern is also displayed. Notice a hypoenhancing hypochoic part of the lesion (“-”) vessel supplied via the liver parenchyma (left upper part) and an arterial hyperenhancing hyperchoic

part, vessel supplied via the liver hilum (right lower part of the images). The arterial blood supply and venous drainage of that kind of lesions has been recently described [44]. See also Dietrich CF (2006) Characterization of benign focal liver lesions with contrast-enhanced ultrasound (CEUS). In: Lencioni R (ed) Enhancing the Role of Ultrasound with Contrast Agents. Springer-Verlag, pp 17–38

indistinguishable from background. Enhancement in the arterial phase might be slightly delayed in comparison to the surrounding liver parenchyma.

Benign Liver Lesions in Liver Cirrhosis

Benign liver lesions in liver cirrhosis have the same occurrence rate as in patients without parenchymal liver disease, with the exception of FNH which is difficult to prove in liver cirrhosis. Recently, 100 consecutive patients (80 male, 20 female, 62 ± 12 (31–90) years) with histologically proven hepatocellular carcinoma at time of diagnosis were investigated. Sonographic evaluation of the entire liver was possible in 88% of all cases. In 25 patients (25%) additional focal lesions were found (eight hepatocellular adenoma, eight atypical hemangioma, five regenerative nodules, four cysts larger than 10 mm). Apart from cysts, all additional liver tumors were histologically proven without severe complications (e.g., hemorrhage, severe pain, or perforation). Cirrhosis of the liver was confirmed in 91 of 100 patients (91%), while nine patients (9%) had no cirrhosis. Patients' characteristics are summarised in Table 37.14. Therefore, biopsy and histology is crucial before extended liver surgery [82]. The problem of hypovascular hepatocellular carcinoma has been recently addressed [11].

Hepatocellular Carcinoma

Conventional B-mode ultrasound. In B-mode ultrasound of an otherwise normal liver, a hepatocellular carcinoma (HCC), like FNH and adenoma, is usually iso- or slightly hypoechogenic compared to the surrounding liver tissue. Echogenicity depends on its size and on the surrounding liver tissue. Because of this lack of an echo difference, a hepatocellular carcinoma can be very difficult to identify in patients with liver cirrhosis. There are no other typical criteria in B-mode ultrasound in small hepatocellular carcinoma <30 mm.

Color Doppler imaging. The majority of hepatocellular carcinomas are already distinctly hyperperfused in the native color Doppler (about 80–90%). In such cases, confusion is possible with other hyperperfused liver tumors which, however, are rare or are rarely observed in a cirrhotic liver. From the differential diagnostic point of view it is then necessary to consider an FNH, an adenoma, or metastases of hyperperfused

Table 37.14 Patient characteristics of 100 patients with histologically proven hepatocellular carcinoma

Characteristics	n
Etiology or associated illness	
Viral hepatitis B/C	52
Alcohol consumption	25
Autoimmune hepatitis	2
Primary biliary cirrhosis	1
Primary sclerosing cholangitis	1
Haemochromatosis	7
Glycogenesis v. Gierke	1
Unknown origin	10
Liver cirrhosis	
Histologically proven	91
Child-Pugh Score A	44
Child-Pugh Score B	36
Child-Pugh Score C	11
Histologically not proven (excluded)	9
Patients with additional liver tumor	25
Adenoma	8
Hemangioma	8
Regenerative nodules	5
Cysts larger than 10 mm	4
Alpha-fetoprotein	
<15 ng/ml	31
>15 ng/ml	69

n = number of patients

tumors, e.g., a hypernephroma, mammary carcinoma, bronchial carcinoma, or carcinoids. Metastases of primary extrahepatic tumors are however rare in a cirrhotic liver. Color duplex ultrasound is important for distinguishing between bland portal vein thromboses and tumor thromboses due to a hepatocellular carcinoma. Thrombi due to tumors produce (arterial) blood flow signals, which are absent with purely coagulation thrombi. The results of a recent study focussing on the echogenicity and vascularity patterns of HCC are summarised in (Table 37.15).

Contrast-enhanced ultrasound. A clear improvement in the malignancy assessment of liver tumors in liver cirrhosis can be achieved by using echo-signal enhancers. An HCC typically exhibits hyperperfusion of the tumor compared with the surrounding liver tissue at a time when in the surrounding liver no contrast effect is as yet discernible. In the HCC a chaotic vascular pattern is typically observed, as a sign of neovascularisation of the tumor. Regeneration nodules may also exhibit additional arterial enrichment; by analysis of the portal venous phase it may be possible to differentiate these (isoechogenic) nodules from hepatocellular carcinomas (weakly echogenic contrasting).

Table 37.15 B-mode features of histologically proven hepatocellular carcinoma

Characteristics	N
Number and localisation	
Solitary lesion	43
Multiple lesions (≤ 3)	57
Size (mm)	6–260
Tumors > 30 mm	69
Tumors ≤ 30 mm	31
Tumors ≤ 10 mm	6
Echogenicity (compared to surrounding liver tissue)	
Hypoechoic	48
Hyperechoic	19
Isoechoic	8
Hyper- and hypoechoic in one lesion	25
Vascularity (compared to surrounding liver tissue)	
Hypervascular	65
Isovascular	22
Hypovascular	13
Vascular complications	
Portal vein thrombosis (PVT)	25
PVT and pulsatile flow	11
Budd–Chiari syndrome (BCS)	6
BCS and pulsatile flow	2

N = number of patients

Ultrasonographic recognition of hepatocellular carcinomas in liver cirrhosis can be difficult if the echo texture is very inhomogeneous. One possible approach is to examine the liver in the early arterial phase after the injection of a signal enhancer, with low mechanical index (mechanical index < 0.4 , high dynamic range, scan rate 10–15/s). Investigations aimed at finding out whether early detection of HCC in risk groups is possible by this method are currently in progress. Additionally, in the technique with high mechanical index (MI 1.2–1.6, 20 dB, scan rate 10–15/s) the use of Levovist® in the late phase (> 5 min) has been found to be helpful in improving detection in some patients.

CEUS has early proven to be effective in the screening of hepatocellular carcinoma at 6 months intervals. In a study of 164 patients with liver cirrhosis ultrasound identified hepatocellular carcinoma in 26 of 34 cases (76 %) while the lesion was still single and small (< 4 cm) [185].

Metastases

The liver is the parenchymatous organ in which metastases of extrahepatic tumors are encountered most often. In Europe and USA metastases of carcinomas

are the most common circumscribed malignant changes in the liver. The special features of portal vein circulation favour hematogenous metastasis to the liver.

Conventional B-mode ultrasound. The size of the metastases can be anywhere between only microscopically detectable (cellular) infiltration and giant masses measuring more than 20 cm and the echogenicity varies widely.

The differential diagnosis of masses suspected of being metastases is manifold. Ultrasonically directed puncture of the liver lesion, with optimisation of the coagulation situation and (cytological) histological and possibly microbiological investigation of the liver tissue, is diagnostically decisive. The differential diagnosis must take account of complications of the underlying disease and complications of therapy (e.g., neutropenia with bacterial and/or mycotic abscesses).

Color Doppler imaging. Metastases are as a rule poorly vascularised and their essential characteristic is a predominantly arterial blood supply (with little or no portal venous blood supply). Like the echogenicity, the vascularisation depends on the size, the biological behaviour, and nature of the primary tumor. Irregular vascularisation is often observed, with broken-off vessels and peripherally situated arterio(porto-)venous shunt formation. The metastases of neuroendocrine tumors (but also, e.g., metastases of hypernephroid carcinomas) may be more richly vascularised than other metastases. However, no conclusions are possible about the primary tumor on the basis of the vascularisation pattern observed.

Contrast enhanced ultrasound. Contrast enhanced ultrasound has markedly improved the detection rate of liver metastases. Liver metastases can be reliably diagnosed as hypoenhancing lesions during the liver specific portal venous sinusoidal phase. False negative findings are rarely encountered whereas false positive findings have to be ruled out by puncture and histological examination, e.g., abscess, necrosis fibrous tissue and others.

Metastases may be contrasted already in the arterial phase, even though early arterial enhancement (in less than 15 s) is not typical and often the only observation is a degree of signal enhancement with a marginal emphasis (“halo sign”, “rim sign”). Contrasting of the vessels proceeds from the periphery towards the centre, and the vascular pattern is irregular. In poorly vascularised metastases contrast enhanced color Doppler ultrasound also often reveals only small blood vessels situated at the edges (or within the lesion), and in many patients vascularisation cannot be imaged at all.

In the capillary phase after 20–40s a diffusely delimited (and for richly vascularised metastases maximal) signal intensification is observed more often, all non-vascularised regions such as necroses or calcifications being bypassed.

In the portal venous phase metastases are contrasted increasingly as signal “black spots” against the background of uniformly enhanced normal liver tissue (Fig. 37.5); potential problems are overexposure artefacts and blooming by contrast enhanced power Doppler ultrasound. In the late portal venous phase very small metastases stand out better, because the artefacts are then less pronounced than directly after the injection of the signal enhancer. Artefacts can be avoided by using a phase inversion technique.

Unlike the portal venous “black spot” effect of metastases, as a rule large hemangiomas show a decrease in the unenhanced signal area (the iris diaphragm phenomenon). This phenomenon has also been observed in metastases in rare cases. Any differential diagnosis must take into account complications of the underlying disease, and complications of therapy (e.g., neutropenia with bacterial and/or mycotic abscesses). Benign growths are found with the same frequency (5–20%) as in a healthy population (for example liver cysts, calcifications, hemangiomas, FNH, adenomas).

Neuroendocrine metastases. Forty-eight patients with histologically proven neuro-endocrine tumors (NET) and suspected liver metastases – as well as 50 consecutive patients with liver metastases of other origins – were included in a prospective study to evaluate tumor characteristics using B-mode, color Doppler (CDI), and contrast-enhanced ultrasound (CEUS) (Table 37.16).

Metastases of neuro-endocrine tumors are often small and hyperechoic and therefore mimic hemangioma and sometimes metastases of other origins (e.g., gastrointestinal). With increasing size of neuro-endocrine metastases, a combined echo rich and centrally echo poor texture is observed as a typical sonomorphological characteristic, due to frequent central necrosis, intra-tumoral hemorrhage, necrosis, fibrous tissue or calcifications. Therefore, visual diagnosis by B-mode ultrasound may be possible in about 50% of the cases. This observation is in contrast with the results of Rickes et al., who described no significant differences between the metastases of neuro-endocrine tumors and adenocarcinomas [132]. Rickes et al. found hepatic metastases of neuro-

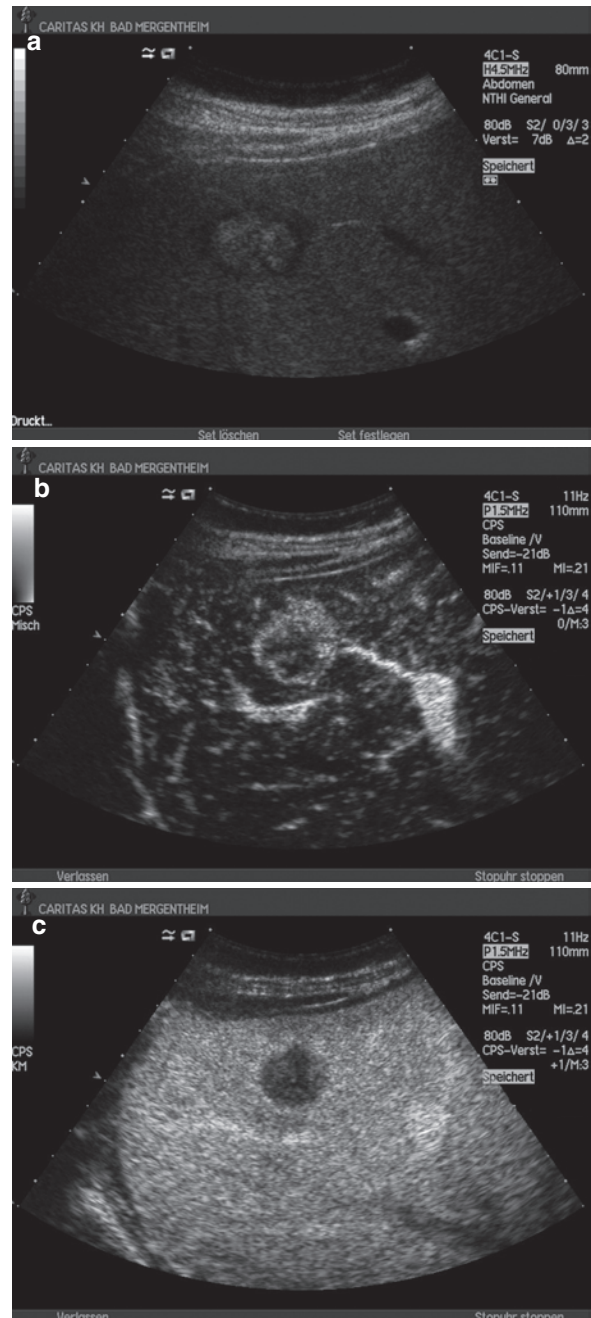


Fig. 37.5 (a–c) Metastases have a wide variety of B-mode appearance and can be confused with any kind of lesion. Color Doppler imaging is helpful in only few patients. Hypervascular metastases reveal the typical peripheral rim sign in the arterial phase (b) which can also be encountered in hepatocellular adenoma and hepatocellular carcinoma, and is therefore not pathognomonic. Metastases typically exhibit a sharp contrast to normal liver tissue in the liver specific portal venous (sinusoidal) phase (c)

Table 37.16 Patient characteristics and sonographic findings in patients with neuroendocrine tumors and metastases of other origin

	NET-METs	other METs	p-value
Number	44 ^b	50	
Male/female	21/23 (48%/52%)	29 /21 (58%/42%)	
Age in years ± SD (range)	57 ± 14 (33–76)	58 ± 11 (28–75)	
Size of lesion in mm ± SD (range)	37 ± 25 (10–120)	31 ± 11 (10–75)	
Conventional B-mode ultrasound			
Echo texture of the lesion			
Hypoechoic	9 (20%)	37 (74%)	<0.005
Isoechoic	0 (0%)	1 (2%)	0.22; n.s.
Hyperechoic	8 (18%)	8 (16%)	0.35; n.s.
Combined echorich and echopoor	27 (61%)	4 (8%)	<0.005
(centrally cystic)	(14 [32%])	(0 [0%])	<0.005
Normal echo texture (surrounding liver)	17 (39%)	42 (84%)	<0.005
Sonographic signs of fatty liver	26 (59%)	8 (16%)	<0.005
Sonographic signs of liver cirrhosis	1 (2%)	0 (0%)	0.14; n.s.
Color/power Doppler imaging			
Hypervascular ^a	29 (66%)	8 (16%)	<0.005
Isovascular ^a	15 (34%)	1 (2%)	<0.005
Hypovascular ^a	0 (0%)	41 (82%)	<0.005
Central artery, stellate sign	0 (0%)	0 (0%)	
Contrast-enhanced ultrasound			
Arterial phase enhancement	39 (89%)	9 (18%) ^c	<0.005
(combined hypervascular/isovascular)	(14 [32%])		
Portal-venous/sinusoidal phase enhancement	5 (11%) (isoechoic)	0 (0%)	0.08; n.s.

n.s. = not significant, SD = standard deviation

^aIn comparison to the surrounding liver parenchyma

^bPatients with histologically proven hemangiomas excluded

^cMainly at the peripheral margins

endocrine tumors using conventional B-mode as hypoechoic, well delineated lesions, which may present with lobulated margins as well as with an echogenic pattern. Hypoechoic or isoechoic metastases with a hypoechoic halo are also found [132]. Possible explanations may be differences in the inclusion criteria, or different types and sizes of neuro-endocrine tumor metastases. Echo rich metastases were observed in more differentiated tumors. In 4/48 patients with NET, liver biopsy revealed hemangiomas.

Neuro-endocrine metastases are often hypervascularised, with a strong arterial and capillary blood supply similar to shunt hemangioma, small hepatocellular adenoma or hypervascular tumors of other origin [111, 132] With CDI, neuro-endocrine metastases appeared hypervascular (66%) or isovascular (34%). Metastases of another origin were hypovascular in 82%. With CEUS, neuro-endocrine metastases showed increased arterial enhancement in 38 patients and hypoechoic appearance in the portal-venous phase in 39 patients. In liver metastases of another origin, the sensitivity for

malignancy due to a hypoechoic appearance during the portal-venous phase was 100%. In liver metastases of NET origin the sensitivity for malignancy was only 39/48 (82%) [111]. Due to the strong contrast enhancement via the hepatic artery, the wash-out may be prolonged compared to hypovascularised metastases. Recently, vessels have been detected in 46% and arteries with a low resistance were found in most of the cases. Peri-tumoral vessels have also been found in 50% [132].

In accordance with recently published data, and in the case of normal surrounding liver parenchyma, neuro-endocrine tumor metastases can be unmasked by a hypoenhancement in the portal-venous and late phase. Due to their hypervascularisation, the increased arterial flow of neuro-endocrine metastases causes a strong and prolonged arterial and capillary enhancement, partially overlapping the reduced portal-venous and sinusoidal flow in the lesion. Thus the lesion-to-liver contrast may be reduced and obscure the proper delineation of the lesion, especially in the early part of

the portal-venous phase. In cases with pathological surrounding liver parenchyma, e.g., liver cirrhosis or fatty liver disease, the differentiation of benign and malignant lesions might be worse. In the patient with liver cirrhosis, the lesion appeared isoechoic during the arterial and portal-venous phase and was, therefore, misdiagnosed as benign. In patients with fatty livers, the typical arterial enhancement of NET metastases was less pronounced but still present in most patients (24/26) perhaps due to attenuation effects.

Lymphoma

Conventional B-mode ultrasound. Unlike the often diffuse infiltration of the liver by extranodal Hodgkin's, and in particular non-Hodgkin's lymphomas (about 50%), circumscribed alterations can be detected relatively rarely by ultrasound (in less than 10–20% of the cases).

Circumscribed lymphomas can infiltrate the liver in small or large nodules or over an extended area, and also depending on their rate of growth, are often very hypoechoic than the surrounding liver tissue. In individual cases they may in fact give no echoes at all. Characteristically, amplification of the echo distal to the mass is then also observed. Depending on the regressive changes taking place (e.g., an inward flow of blood or necroses), on the other hand, echo-rich lymphomas are also not uncommon.

In our experience lymphoma infiltrations of the liver are accompanied by sonographically detectable (often only moderate, however) enlargement of the perihepatic lymph nodes (the normal lymph node size is up to 17 mm [median value plus two standard deviations]). From a differential diagnosis perspective, inflammatory liver conditions should be considered (e.g., viral hepatitis B or C, PBC, PSC), and also lymph node metastases.

Color Doppler imaging. The vascularisation of circumscribed lymphomas is often, though not always, more sparse than in healthy liver tissue. Broken-off vessels and arteriovenous shunts are typically observed, which in the duplex ultrasonographic spectral analysis can lead to the disappearance of the diastolic flow component.

Contrast enhanced ultrasound. In contrast to the variable arterial perfusion, characteristically lymphomas reveal reduced signal enhancement in the portal venous phase in comparison with surrounding liver tissue, due

to the absence of portal veins in the lymphoma region. By means of the phase inversion technique, lymphomas that are not delineable in the native examination can be detected in the capillary and portal venous phase.

By differentiation in the liver specific late phase, according to current research results, inflammatory lymph nodes can be distinguished from lymph nodes with malignant infiltration in the portal fissure, since the latter exhibit sharply demarcated (malignantly infiltrated) areas; however, this hypothesis still needs to be checked in prospective studies.

The conditions that should be considered as differential diagnoses are complications of the underlying lymphoma disease (e.g., extramedullary haematopoiesis, more frequent subcapsular hematomas in the presence of coagulation disturbances) and complications of therapy (e.g., neutropenia with bacterial and/or mycotic abscesses), but also haemophagocytosis syndrome.

Rare Entities

In many other focal liver lesions conventional B-mode ultrasound, color Doppler imaging and contrast enhanced ultrasound are helpful for characterization and diagnosis, e.g., abscesses, hematoma (trauma), bilioma, hamartoma (von Meyenburg complexes), granuloma, angiosarcoma of the liver, angiomyolipoma, nodular regenerative hyperplasia, bile duct adenoma (cholangiocellular adenoma), echinococcosis, granuloma, tuberculosis, sarcoidosis, sickle cell anaemia with liver infarct, bartonellosis, pseudoaneurysm of hepatic arteries, nodules in Wilson's disease, Peliosis, inflammatory pseudotumor of the liver, cholangiofibroma and some more entities which have been recently published [13, 14, 55, 134, 144] A variety of focal liver lesions will not be discussed in detail, e.g., echinokokkosis but descriptions are found elsewhere.[40] Contrast-enhanced endoscopic ultrasound techniques and real-time 3D reconstructions have been described as well [27, 32].

Abscess

The patient's medical history and physical examination (febrile temperature, signs of sepsis) are most helpful in differentiation from necrotic metastases.

Phlegmonous inflammation and abscesses demonstrate variable and sometimes confusing B-mode images changing over time. The initial phlegmonous

inflammation is often isoechoic in comparison to the surrounding liver parenchyma and is sometimes difficult to recognise. In older (chronic) abscesses hypervascularity of the nodule border might be confused with pseudotumor of the liver, even histologically. Small disseminate candida abscesses might be confused with lymphoma or circumscribed haemophagocytosis (especially in the young). Puncture and drainage (if necessary) are the diagnostic and therapeutic implications. Abscesses up to 5 cm might be drained by one procedure whereas larger abscesses need to be treated over days.

The initial phlegmonous inflammation is often hypervascular in comparison to the surrounding liver parenchyma but difficult to recognise. In older (chronic) abscesses hypervascularity of the nodule border is typical.

In typical cases CE-US shows sharply delineated hypervascularity demonstrating the pseudocapsule and no gas bubbles inside the lesion.

Hematoma

Hematoma can be clinically diagnosed in most cases. Spontaneously evolving and painful hematoma is typical of amyloidosis of the liver.

B-mode image depends on the stage of hematoma. The very early hematoma is hyperechoic, later stages are iso- or mostly hypoechoic. Therefore, change in morphology is typical for hematoma.

Color Doppler imaging demonstrates no flow pattern.

CE-US is helpful in defining circumscribe versus diffuse infiltrating hematoma. CE-US might be helpful in clinically uncertain cases with similar results as those shown for computed tomography.

Nodular Regenerative Hyperplasia

Nodular regenerative hyperplasia of the liver (NRH) is a rare pathological finding, typically associated with haematological or autoimmune disease. The main clinical symptom is portal hypertension without underlying liver cirrhosis. A retrospective study of 2,500 autopsies showed a prevalence of 2.6% for NRHL. Furthermore, in 10.2% of those autopsy cases, variable degrees of nodular transformation were found. NRHL itself consists of multiple hepatic nodules resulting from periportal hepatocyte regeneration with surrounding

atrophy. Typically, fibrous septa between the nodules are missing. The pathogenesis remains unknown, although some authors suggested that NRHL may be a secondary and non-specific tissue adaptation to heterogeneous perfusion. The pathogenesis of NRHL remains unknown. Histological assessment of the liver is necessary for diagnosis, because the nodular appearance of the hepatic surface may otherwise be difficult to differentiate from cirrhosis or hepatic metastases. The prognosis of NRHL depends on the development and severity of portal hypertension, which often requires only pharmacological treatment [55]. Development of NRHL without any underlying disease is typically characterised by liver failure and a poor clinical outcome.

Ultrasound typically shows multiple (unspecific) hepatic nodules, which are suggestive of multi-locular hepatocellular carcinoma or metastatic disease of the liver.

Signs of portal hypertension and the rarer Budd–Chiari syndrome should be carefully sought.

CE-US is helpful in defining circumscribed versus diffuse infiltrating nodular regenerative hyperplasia.

Inflammatory Pseudotumor

Inflammatory pseudotumor is a rare disease that can present with fever, abdominal pain, vomiting and weight loss indicating malignancy or abscess. The definitive diagnosis is often only achieved by surgery. Contrast enhanced ultrasound may reveal hypoechoic contrast enhancement falsely indicating malignant disease [144].

Gallbladder Disease

Ultrasound has become widely accepted for the diagnosis of gallbladder disease. Sensitivity for cholecystolithiasis is approximately 100%. Cholecystitis, including its acute and chronic complications, is also a domain of ultrasound techniques. Any obstruction of the bile ducts and its localisation is easily recognised. However, clarifying the etiology is a question far more difficult to answer. Ultrasound contrast agents have proven to be useful for clarification of biliary tumors. Gallbladder polyps are well detectable. Adenomas of more than 1 cm are an indication for surgery, the detection of a vessel at the base of the polyp by color Doppler ultrasound is helpful. Gallbladder

carcinomas, as a disease of old age with few early symptoms, are usually detected at a late stage when the liver is already infiltrated.

Anatomy

The gallbladder is a saccular structure (fundus, body, infundibulum [which is the portion of body that joins the neck] and neck) for bile storage in the gallbladder fossa of the posterior right hepatic lobe. The normal gallbladder size is reported to be 10 × 4 cm, but depends on volume of bile (normal 40–60 ml, measured by a rotating ellipsoid). Cholecystomegaly in patients with diabetes mellitus during long standing fasting periods may reveal gallbladder diameters up to 15 × 6 cm without clinical relevance, in contrast to clinically important hydrops manifested by right upper quadrant pain and fever. The normal wall thickness is 1–3 mm. The cystic artery, a branch of right hepatic artery, is the main arterial supply. The gallbladder volume can be determined before and after a test meal. Contraction of >40–60% is regarded as normal. Normal contraction is a requirement before gall stone treatment with, for example, ursodeoxycholic acid.

Congenital Anomalies of the Gallbladder

Congenital anomalies include a wide variety of abnormalities, sonographically rarely encountered in adult patients. If congenital abnormalities are found during routine ultrasound examination the findings are to be highlighted in the clinical context of being mainly without consequences.

Agnesia and Hypoplasia, Microgallbladder

Agnesia and numeric anomalies of the gallbladder have to be considered. Agnesia (absence) of gallbladder is rare and normally of no clinical significance. About 50% of agnesia cases are discovered at autopsy and it is associated with duodenal atresia and other congenital anomalies. Hypoplasia is associated with extrahepatic biliary atresia. Microgallbladder is defined as less than 2–3 cm long, 0.5–1.5 cm wide and regarded

as a typical finding of cystic fibrosis but is also associated with idiopathic neonatal hepatitis and alpha-1-antitrypsin disease [29].

Abnormal Position of the Gallbladder

Abnormal positions of the gallbladder are rare. Left sided (with or without situs inversus), intrahepatic (<5%), suprahepatic, lesser sac or abdominal wall and retroperitoneal have been described.

Other Congenital Anomalies of the Gallbladder

Variations of the gallbladder's shape are much more frequently encountered but clinically rarely of importance (e.g., “phrygian cap”). Phrygian cap is an inversion of the distal fundus into body, to which it may become adherent. Phrygian cap is either an anatomic variant or acquired abnormality and present in up to 5% of sonograms. Gallbladder diverticula and volvulus are also very rare [52].

Congenital anomalies of the gallbladder also include duplication, bilobed gallbladder due to longitudinal (more typical) or transverse septum (more common) and hypoplastic narrowing of biliary channels (true biliary atresia). Multiseptated gallbladder may be congenital or acquired and reveals three or more communicating compartments lined by columnar epithelium.

In adults cholecystolithiasis is often present. Heterotopia of the gallbladder, typically an incidentally finding, is also called ectopia or choristoma and is defined by normal tissue in an abnormal location. Liver parenchymal, pancreatic or gastric heterotopia have also been observed by ultrasound.

Hourglass gallbladder is divided by a central constriction and is regarded as a variant of transverse septated gallbladder. Pathogenetically hourglass gallbladder is usually acquired due to septum of inflamed fibrous tissue or adenomyomatous hyperplasia.

Aberrant bile ducts (ducts of Luschka) are rarely identified by ultrasound but are present in 10% of cholecystectomy specimens. They may be buried in the gallbladder wall and may communicate with intrahepatic bile ducts, larger accessory bile ducts or join with the cystic duct. Rokitansky-Aschoff sinuses are outpouchings of gallbladder mucosa that penetrate into the muscle wall (“acquired herniations”). Rokitansky-Aschoff

sinuses (pseudodiverticula) may show progressive occlusion of communication with the gallbladder leading to cysts. Solitary congenital diverticula have a wide range of size (from 5 mm up to 10 cm) presenting all three layers of gallbladder wall. Wandering gallbladder shows a long mesentery or no firm attachment to liver and is regarded at risk for torsion. The described findings are rarely encountered during routinely performed ultrasound but are important to know when it comes to a differential diagnosis.

Cholecystolithiasis

The term cholelithiasis describes the presence of gallstones in the biliary tract. Depending on the localisation of the concrement a further distinction between cholecystolithiasis and choledocholithiasis is used. In 15% of the patients a combination of both conditions has to be expected.

Cholecystolithiasis can be detected by transabdominal ultrasound with high sensitivity, whereas choledocholithiasis is more difficult to detect [22, 181]. The literature has been recently summarised [117]. Transabdominal ultrasound is the imaging method of choice for any kind of gallbladder stones. Numbers, size, echo texture, shadowing and mobility should be recorded. Sonographically determined diagnosis of stone origin is not possible so far. Non-calcified cholesterol-derived stones typically do not show shadowing and may “swim” in the gallbladder lumen in contrast to calcified stones [180]. So-called pigment stones, rarely found in Europe (<10%), demonstrate multiple complete shadowing [22]. Very small stones may be overlooked but routinely performing the examination in the left lateral decubitus and standing positions improves the detection rate to almost 100%. Mirizzi syndrome with stone impaction in the cystic duct may be more difficult to visualise.

Various amounts of sludge have been observed in fasting patients with or without motility disorders of the gallbladder. Other causes include critical illness (e.g., 25–47% of intensive care unit patients) total parenteral nutrition, stenosis in the extrahepatic bile duct and pregnancy [110, 112]. Differential diagnosis includes neoplasia, empyema and hemorrhage (clot).

Intrahepatic stones (hepaticolithiasis) are much more common in Asia than in Europe. Congenital anomalies and parasitoses are the leading causes.

Cholecystitis

Acute Cholecystitis

Acute cholecystitis can be divided into either gallstone associated (acute calculous cholecystitis) or acute acalculous cholecystitis. Fifty percent have bacterial infection (*Escherichia coli*, *Enterobacter*, *Enterococcus*, *Klebsiella*, *Clostridium*, *Peptostreptococcus*, *Bacteroides*). More than 10% perforate without treatment (cholecystectomy). Sonographic appearances are of an enlarged, distended gallbladder with a thickened wall. The thickened multiple layered wall is a constant finding and is caused by oedema, hemorrhage, ulcers and pus. Color Doppler imaging reveals hypervascularisation which represents the typically pathoanatomically described congested vessels (“angry red color”). Gallbladder wall thickening has also been described in acute and chronic active hepatitis and liver cirrhosis. In the latter, it represents varices [5, 44, 127].

Acute acalculous cholecystitis represents only 10% of cases. Patients are usually severely debilitated, due to severe trauma, sepsis, shock, burns, cancer, diabetes, multiple blood transfusions, surgery or cystic duct obstruction from various causes. The mortality is extremely high (10–50%). A rare form of acute acalculous cholecystitis is cocaine related acute cholecystitis.

Emphysematous cholecystitis is a rare form of acute cholecystitis associated with diabetes and peripheral atherosclerotic disease (Fig. 37.6).

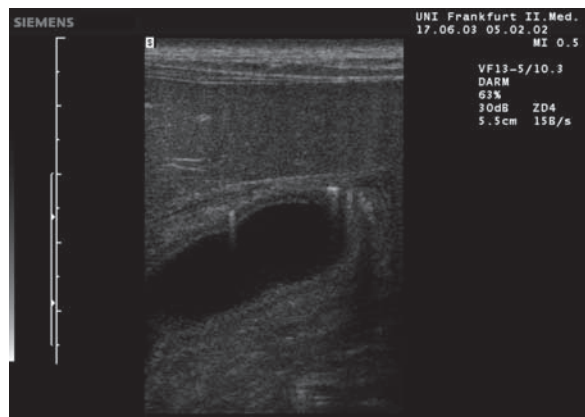


Fig. 37.6 Emphysematous cholecystitis is a rare form of acute cholecystitis associated with diabetes and peripheral atherosclerotic disease. Air bubbles are typically seen in the thickened gallbladder wall of seriously ill patients

Vascular compromise of the cystic artery has been described as the most important pathophysiological factor. Ultrasound reveals gas bubbles inside of the thickened gallbladder wall. Perforation is the typical complication.

Gall stone perforation by a large stone (mostly >25 mm) and stone passage into the bulb of duodenum (called Bouveret syndrome when gastric outlet obstruction results) can be easily recognised with transabdominal ultrasound identifying air bubbles tracking from the duodenal bulb into the lumen of the gallbladder [2, 15, 69].

Chronic Cholecystitis

Chronic cholecystitis is sonographically characterised by an irregular thickened gallbladder wall, mainly caused by intermittent obstruction of gallbladder neck/cystic duct by gallstones, often causing biliary colic. Ninety-five percent are associated with cholecystolithiasis. Bacteria are present in up to one third of patients, including similar organisms as in acute cholecystitis. There are many different forms of chronic cholecystitis which cannot be differentiated by ultrasound. Main complications are acute cholecystitis, choledocholithiasis, acute pancreatitis, gallstone ileus and biliary fistulas.

Diffuse lymphoplasmacytic acalculous cholecystitis is a relatively sensitive sign for primary sclerosing cholangitis. An association with lymphoplasmacytic sclerosing pancreatitis has also been described. Other forms are AIDS related, often acalculous, cholecystitis caused by opportunistic infections (cryptosporidia, CMV, microsporidia), eosinophilic cholecystitis in Churg–Strauss syndrome, follicular cholecystitis (also called lymphoid polyp). Granulomatous cholecystitis in patients with tuberculosis and xanthogranulomatous cholecystitis (due to rupture of Rokitansky-Aschoff sinuses with extravasation of bile or ulceration of gallbladder mucosa) are other rare forms which have been encountered. Gangrenous cholecystitis occurs in 15% of acute cholecystitis cases with mural infarction, with perforation occurring in more than 25%. Typically air can be found in the gallbladder (pneumobilia). *Clostridium perfringens* seems to be of pathophysiological importance.

Porcelain gallbladder is found in 0.5% of cholecystectomies. The association (>20%) with gallbladder

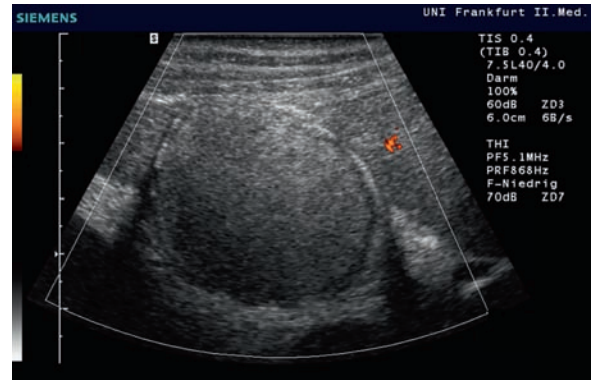


Fig. 37.7 Porcelain gallbladder is characterised by hyperchoic calcifications of the gallbladder wall

carcinoma is well known (Fig. 37.7) [90, 131, 150, 178, 179]. Sonographically, the calcified wall can easily be detected.

Miscellaneous Non-tumor Disorders

Miscellaneous non-neoplastic disorders are various. Adenomyomatous hyperplasia is also called adenomyomatosis or diverticular disease of gallbladder. Most commonly, ultrasound reveals only a thickened wall [79, 184]. Adenomyomatous hyperplasia (generalised, segmental or localised) is relatively common (up to 10% of cholecystectomy specimens) and usually asymptomatic. In the generalised form, diffuse wall thickening is found (up to >10mm) with intramural diverticula resembling cystic spaces within the wall. In the segmental form, focal thickening of the gallbladder wall can usually be recognised in the body, giving it an hourglass configuration. In the localised form the fundus shows nodules from 0.5 to 3 cm with grey-white cut surface containing multiple cysts. The latter may cause gallbladder inversion and is also called adenomyoma. Asymptomatic cholesterosis is mostly characterised by cholesterol infiltration (sonographically revealing comet tail artefacts) in an otherwise normal gallbladder wall. Cholesterosis is present in up to 20% of cholecystectomy specimens, usually found in adult multiparous women. Cholesterosis is associated with bile supersaturation with cholesterol, but not with increased serum cholesterol. Cholesterol infiltration is due to accumulation of cholesterol esters and triglycerides in subepithelial macrophages and gallbladder epithelium. Macroscopically focal or diffuse yellow, flat deposits

on mucosal surface are seen which may have speckled appearance (“strawberry gallbladder”). Association with cholesterol polyps is reported in 20%. Gallbladder varices as a cause of gallbladder thickening can be excluded using color Doppler imaging [168].

Gallbladder Polyps

Benign gallbladder tumors are divided into adenoma of gallbladder (typically demonstrating central vessels penetrating the polyp using color Doppler imaging) (Fig. 37.8), adenomyosis, cholesterol polyps (containing cholesterol deposits and therefore no or few vessels), hyperplastic/metaplastic polyps, granular cell tumor (often associated with similar lesions in extrahepatic bile ducts), inflammatory polyps and villous papilloma. Adenoma of the gallbladder are mainly single (90%), rarely multiple (10%) and contain by definition at least low grade dysplastic epithelium. An increased prevalence is found with familial adenomatous polyposis or Peutz–Jeghers syndrome. Invasive carcinoma has been rarely reported in lesions <10 mm. The treatment is total excision respective cholecystectomy. Adenomyosis is caused by hyperplasia of muscularis propria with intramural hyperplastic or cystically dilated glands mainly in the fundus. They represent 15–25% of benign polyps. Cholesterol polyps are the most common benign polyps (50–90%). Inflammatory polyps are associated with chronic cholecystitis. They

are described as 3–15 mm, usually sessile and single polyps, macroscopically red-grey-brown.

Growing gallbladder polyps or neoplasia >10 mm should be surgically removed due to potential malignant transformation.

Gallbladder Carcinoma

Carcinomas of the gallbladder can be easily recognised using transabdominal ultrasound whereas correct staging is much more difficult and underestimation possible. As with other tumors of the upper GI tract, a definite sonographic distinction between inflammatory and neoplastic alterations or changes in connective tissue is not possible. In some cases a sonographic diagnosis of adenomyomatosis, cholesterol polyps and other pathologies of the gallbladder can be made. Similar to findings in examination of the oesophagus, stomach and duodenum, inflammatory alterations can lead to narrowing of the bile duct that can mimic an invasive tumor of the ductal wall.

The use of ultrasound contrast agents can help in the differentiation of normal and infiltrated areas. In addition, lymph node infiltration might be microscopically not altering size, form, and echo texture of the lymph node.

Extrahepatic Bile Ducts

Sonographic differentiation of jaundice caused by obstructive and hepatocellular origin is possible in almost all patients analysing the diameter of the common hepatic bile duct (cbd, normal value ≤ 7 mm) but microlithiasis might be overlooked. The left lateral decubitus position is helpful for adequate visualisation of the liver hilum [30]. The papilla can be less reliably displayed using the transabdominal approach.

Congenital Disorders

Choledochal Cysts

Choledochal cysts are the most common cause of obstructive jaundice in infants and beyond infancy, but

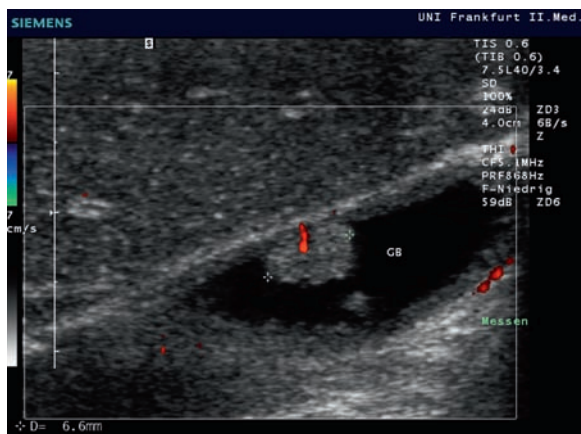


Fig. 37.8 Adenoma (6 mm) of the gallbladder typically demonstrating central vessels penetrating the polyp using color Doppler imaging

may be found at any age. Choledochal cysts (Todani Type I–V) are associated with other hepatobiliary tract abnormalities. They may rupture spontaneously. The choledochal cyst is actually not a cyst, but a dilatation of common bile duct which may secondarily obstruct other biliary ducts or the duodenum (Fig. 37.9). Type 1 is characterised by a segmental or diffuse fusiform dilatation of common bile duct (50–90%). Type 2: diverticulum of common bile duct. Type 3: dilation of intraduodenal common bile duct (choledochocele). Type 4: multiple cysts of extrahepatic bile ducts with (4A) or without (4B) cysts of intrahepatic ducts and Type 5: one or more cysts of intrahepatic ducts (Caroli's disease) [107, 133, 165]. It is of importance that 2–10% of the patients develop biliary tract carcinoma at a

mean age of 35 years. Carcinomas may develop within the wall of the cyst, within the gallbladder or bile ducts. The treatment of choice is the complete cyst removal with biliary reconstruction, usually with Roux-en-Y hepaticojejunostomy. The definitive role of ultrasound techniques is not yet fully determined, due mainly to limited experience. Magnetic resonance imaging (MRC) and endoscopic retrograde cholangiography are the diagnostic methods of choice.

Choledocholithiasis

Cholecystolithiasis can be detected by transabdominal ultrasound with high sensitivity (Table 37.17), whereas choledocholithiasis is more difficult to detect (Table 37.18). The literature has been recently summarised [31]. In contrast to the shadowing exhibited by gallbladder stones, primary choledocholithiasis often does not show shadowing. Even with the most modern equipment the sensitivity for choledocholithiasis is still largely dependent on the expertise of the examiner and ranges from 25% to 100%. Transabdominal examination in the left lateral decubitus position is helpful. Endosonography (94–100%) and miniprobe endosonography (extraductal [endoscopic] ultrasound [EDUS]) are more efficient. The EDUS diagnosis of choledocholithiasis was confirmed to be correct in 33 out of 34 patients (97%). As expected, EDUS failed to detect peripheral lesions [146]. Parasites have to be considered as well (e.g., *Ascaris*) [126, 138, 139].

Endoscopic retrograde cholangiopancreatography (ERCP) was considered the diagnostic gold standard with a reported success rate of 90–96%. The value of diagnostic ERCP might be grossly overestimated though, as the rate of correctly diagnosed choledocholithiasis

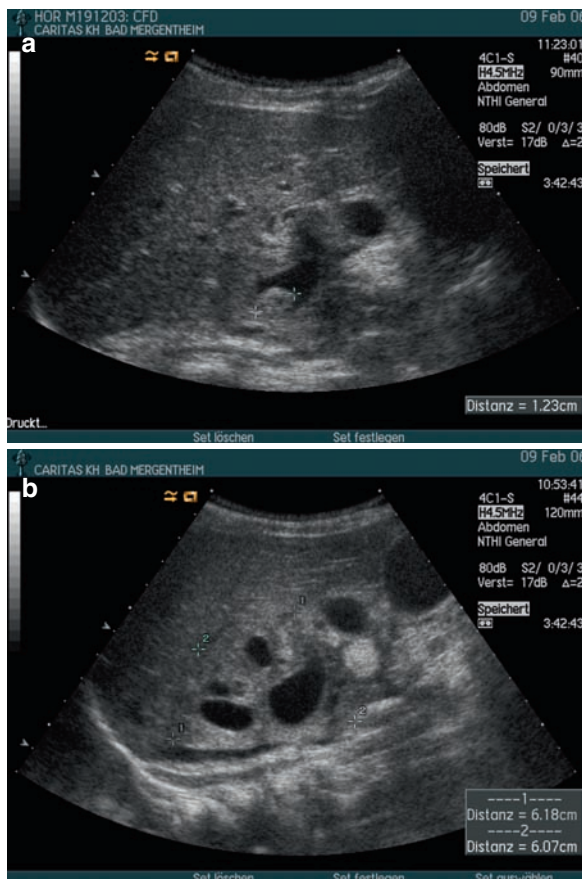


Fig. 37.9 (a, b) Choledochal cyst is not actually a cyst, but a dilatation of common bile duct which may secondarily obstruct other biliary ducts and the duodenum. Typically gallstones and sludge can be displayed (a, in between markers). Choledochocele may also demonstrate as a huge mass clinically accompanied by acute necrotic pancreatitis (b)

Table 37.17 Detection of cholecystolithiasis by transabdominal ultrasound – review of the literature [31]

Sensitivity (%)	Specificity (%)	Reference
98	94 – 98	[22]
70	100	[25]
97	92	[54]
91	99	[96]
98	nm	[147]
91	100	[155]
87	93	[61]

nm: Not mentioned

Table 37.18 Detection of choledocholithiasis by transabdominal ultrasound – review of the literature [31]

Patients (n)	Sensitivity (%)	Specificity (%)	NPV (%)	PPV (%)	Gold standard
62	25	100	56	100	ERCP with or without EST or IOC
52	80	94	nm	nm	ERCP/EST or surg. expl.
nm	38	100	nm	nm	No results
35	47	90	nm	nm	ERCP/EST
142	63	95	nm	nm	ERCP with or without EST or surg. expl.
36	50	100	74	100	ERCP/EST
50	100	97	92	100	ERCP/PTC
132	68	nm	nm	nm	ERCP/EST
29	38	100	nm	nm	ERCP

nm: Not mentioned; *NPV* negative predictive value; *PPV* positive predictive value; *ERCP* endoscopic retrograde cholangiopancreatography; *EST* endoscopic sphincterotomy; *Surg. expl.* surgical exploration; *IOC* intraoperative cholangiography; *PTC* percutaneous transhepatic cholangiography

seems to be much lower, especially since small gallstones (<3mm) with normal or even dilated bile ducts are easily overlooked even in ERCP. The combination of ERCP with EST (endoscopic sphincterotomy), including stone extraction using the dormia basket or balloon, is the therapeutic method of choice in choledocholithiasis, but it is an invasive technique with a significant risk of complication for the patient. The reported results using magnetic resonance imaging (MRCP) and computed tomography (CT) are less convincing especially in small stones without dilated common bile duct. The method of choice to exclude choledocholithiasis without sphincterotomy is endoscopic ultrasound.

Secondary Sclerosing Cholangitis

Decades ago secondary sclerosing cholangitis was much more common than primary sclerosing cholangitis. Typical causes are biliary obstruction (choledocholithiasis, post-operative, chronic pancreatitis, choledochal cyst and extrahepatic biliary atresia). Infections in immunodeficiency states have also to be considered as well as toxins, ischemia and malignancy. The most important complications of secondary sclerosing cholangitis, e.g., hepatic lobar atrophy, can be reduced and are rarely seen today due to improved diagnostics and therapy. Sonographic features are enlarged extrahepatic bile ducts with more or less symmetrical thickening of the wall in contrast to asymmetric thickening in primary sclerosing cholangitis.

Cholangiocellular Carcinoma

Cholangiocellular carcinomas (mainly adenocarcinoma) have been more frequently detected using transabdominal ultrasound. Carcinomas of the bile duct are much more common extrahepatically but can be found also intrahepatically. In the latter location they may be easily confused sonographically with hepatocellular carcinoma. Mixed forms have been observed. Sonographically dilated bile ducts proximal of the stenosis is the typical finding. Delineation of the tumor is more difficult. Contrast enhanced ultrasound has improved the detection and characterization of cholangiocellular carcinoma but prospective studies are lacking. Peritoneal metastases are common but difficult to visualise using imaging methods without laparoscopy.

Conventional B-mode ultrasound. Cholangiocellular carcinomas can occur along the bile duct as so-called Klatskin tumors (hilar CCC, more common), but they may also appear as primary solid tumors in the liver (peripheral CCC). For the peripheral type there are no typical ultrasonographic characteristics, and the diagnosis is usually made incidentally, within the framework of a biopsy of a mass found in the liver. Ultrasonographic examination shows a solid mass which can have any echogenicity and exhibits signs of a malignant growth. The liver metastases of a peripheral CCC are often situated like satellites around the primary focus.

Color Doppler imaging. The majority of circumscribed cholangiocellular carcinomas are slightly hyperperfused in the native color Doppler but color Doppler imaging findings vary widely.

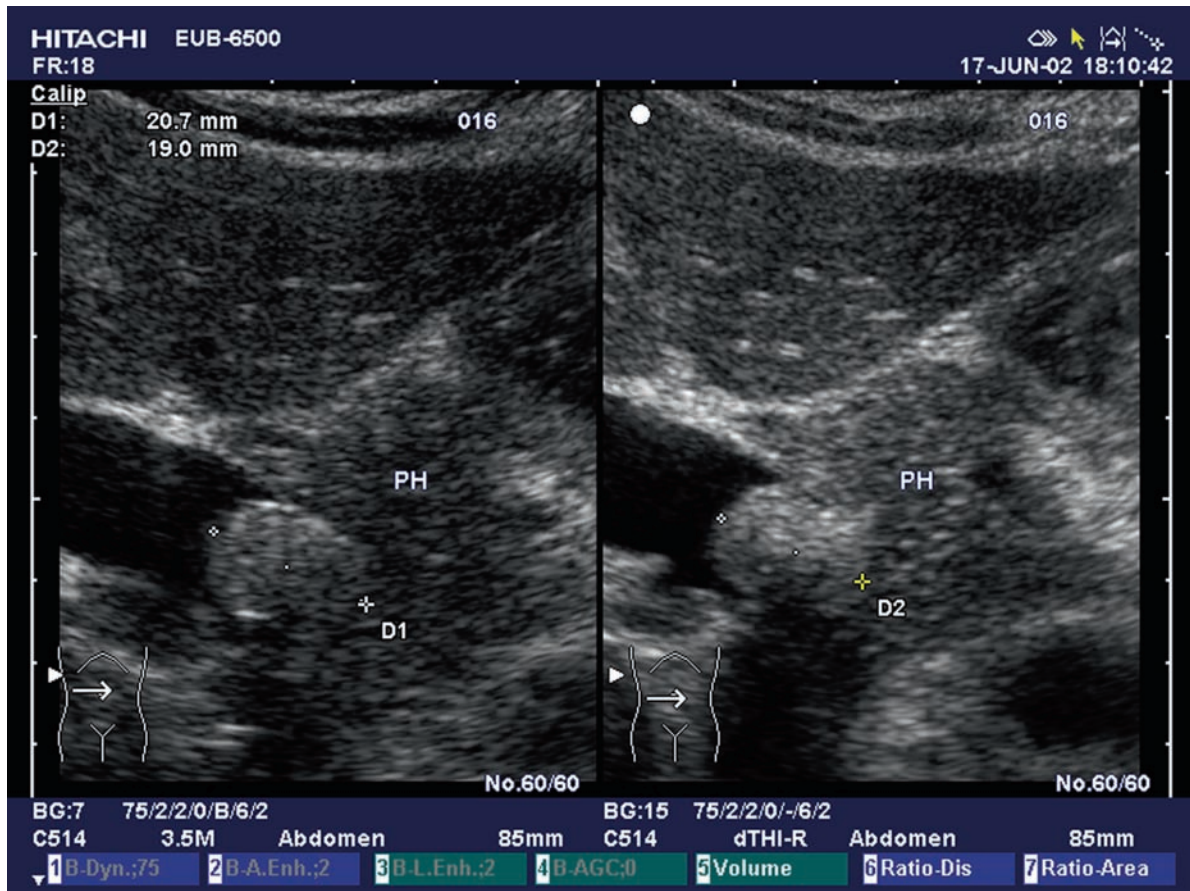


Fig. 37.10 Adenomas (in between markers) of the extrahepatic bile ducts are rarely encountered by ultrasound and represent only 10% of the incidence of carcinoma. PH: pancreatic head

Contrast enhanced ultrasound. In the arterial phase, the perfusion picture is variable, but mainly hyperperfused; in the late portal venous phase CCC are contrasted as punched-out defects. This behaviour is not always easy to demonstrate in the case of the Klatskin tumors, which often exhibit an appreciable pericholangitic component. As far as differential diagnoses are concerned, in the case of the hilar type of CCC, inflammatory bile duct alterations should be considered, for example cholangitis. Stratification of the bile ducts is then, however, preserved, and may actually be accentuated in the sonographic image.[13] For the detection of cholangiocellular carcinomas the examination technique in the liver specific late phase has also proved to be diagnostically useful in patients giving normal CT, MRI, and MRCP results, but so far there have been no conclusive studies on differential diagnosis of primary sclerosing cholangitis and cholangiocellular carcinomas.

Other Extrahepatic Bile Duct Tumors

Adenomas represent only 10% of the incidence of carcinoma and are much more common in the gallbladder than extrahepatic biliary tree (Fig. 37.10). Other forms of benign tumors are rare, e.g., carcinoid of the extrahepatic bile ducts.

Carcinoma of extrahepatic bile ducts represent as adenocarcinomas in up to 95% of extrahepatic bile duct malignancies (bile duct carcinoma, cholangiocarcinoma) (Fig. 37.11). Klatskin (hilar) tumors include 70% of tumors and arise at the confluence of right and left hepatic ducts at liver hilus. They are slow growing with infrequent distant metastases.

TNM staging for extrahepatic bile duct carcinoma applies to carcinomas arising above ampulla of Vater, including carcinomas in congenital choledochal cysts and intrapancreatic portion of common

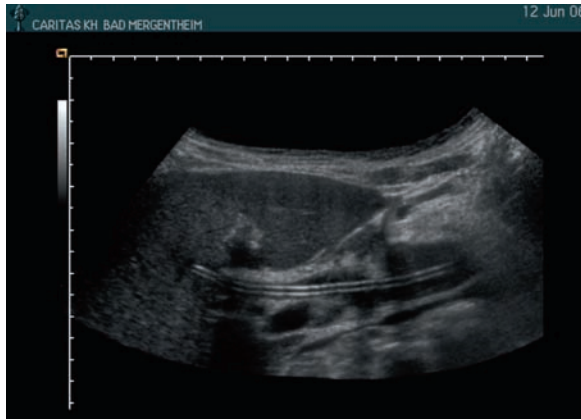


Fig. 37.11 Bile duct carcinoma are drained by stents which can be easily displayed by ultrasound. A stent is shown using panoramic imaging

bile duct. The classification excludes sarcomas and carcinoid tumors.

Features to report also from a surgical point of view are obstruction, bile duct wall thickness (as a sign of infection), stones, tumor location and size, depth of invasion, tumor extension to adjacent structures and regional lymph nodes.

References

- Albrecht T, Blomley MJ, Burns PN, et al (2003) Improved detection of hepatic metastases with pulse-inversion US during the liver-specific phase of SHU 508A: multicenter study. *Radiology* 227:361–70
- Ariche A, Czeiger D, Gortzak Y, et al (2000) Gastric outlet obstruction by gallstone: Bouveret syndrome. *Scand J Gastroenterol* 35:781–3
- Aubin B, Denys A, LaFortune M, et al (1995) Focal sparing of liver parenchyma in steatosis: role of the gallbladder and its vessels. *J Ultrasound Med* 1995; 14:77–80
- Bartolozzi C, Donati F, Cioni D, et al (2004) Detection of colorectal liver metastases: a prospective multicenter trial comparing unenhanced MRI, MnDPDP-enhanced MRI, and spiral CT. *Eur Radiol* 14:14–20
- Basar O, Kisacik B, Bozdogan E, et al (2005) An unusual cause of acalculous cholecystitis during pregnancy: hepatitis A virus. *Dig Dis Sci* 50:1532
- Bezzi M, Mitchell DG, Needleman L, et al (1988) Iatrogenic aneurysmal portal-hepatic venous fistula. Diagnosis by color Doppler imaging. *J Ultrasound Med* 7:457–61
- Bianchi L (1993) Glycogen storage disease I and hepatocellular tumors. *Eur J Pediatr* 152(Suppl 1):S63–S70
- Biecker E, Fischer HP, Strunk H, et al (2003) Benign hepatic tumors. *Z Gastroenterol* 41:191–200
- Bleicher RJ, Allegra DP, Nora DT, et al (2003) Radiofrequency ablation in 447 complex unresectable liver tumors: lessons learned. *Ann Surg Oncol* 10:52–8
- Blendis LM, Orrego H, Crossley IR, et al (1982) The role of hepatocyte enlargement in hepatic pressure in cirrhotic and noncirrhotic alcoholic liver disease. *Hepatology* 2:539–46
- Bolondi L, Gaiani S, Celli N, Golfieri R, Grigioni WF, Leoni S, et al (2005) Characterization of small nodules in cirrhosis by assessment of vascularity: the problem of hypovascular hepatocellular carcinoma. *Hepatology* 42(1): 27–34
- Boozari B, Gebel M, Bahr MJ, Manns MP, Strassburg CP, Bleck JS, et al (2005) Changes of duplex parameters and splenic size in liver transplant recipients during a long period of observation. *World J Gastroenterol* 11(43):6787–91
- Braden B, Helm B, Fabian T, Dietrich CF (2000) Bacillary angiomatosis of the liver, a suspected ultrasound diagnosis? *Z Gastroenterol* 38(9):785–9
- Braden B, Thalhammer A, Schwarz W, Dietrich CF (2002) Bleeding complications from hepatic mucoid aneurysmata: value of color duplex sonography after liver transplantation. *Liver Transpl* 8(7):636–8
- Braden B, Faust D, Ignee I, et al (2008) Clinical relevance of perihepatic lymphadenopathy in acute and chronic liver disease. *J Clin Gastroenterol* 42: 931–6
- Brennan GB, Rosenberg RD, Arora S (2004) Bouveret syndrome. *Radiographics* 24(4):1171–5
- Bryant TH, Blomley MJ, Albrecht T, Sidhu PS, Leen EL, Basilico R, et al (2004) Improved characterization of liver lesions with liver-phase uptake of liver-specific microbubbles: prospective multicenter study. *Radiology* 232(3): 799–809
- Buscarini E, Savoia A, Brambilla G, Menozzi F, Reduzzi L, Strobel D, et al (2005) Radiofrequency thermal ablation of liver tumors. *Eur Radiol* 15(5):884–94
- Caturelli E, Squillante MM, Andriulli A, Cedrone A, Cellerino C, Pompili M, et al (1992) Hypoechoic lesions in the ‘bright liver’: a reliable indicator of fatty change. A prospective study. *J Gastroenterol Hepatol* 7(5):469–72
- Celle G, Savarino V, Picciotto A, Magnolia MR, Scalabrini P, Dodero M (1988) Is hepatic ultrasonography a valid alternative tool to liver biopsy? Report on 507 cases studied with both techniques. *Dig Dis Sci* 33(4):467–71
- Choi BY, Nguyen MH (2005) The diagnosis and management of benign hepatic tumors. *J Clin Gastroenterol* 39(5):401–12
- Choi MS, Lee JH, Koh KC, Paik SW, Rhee PL, Kim JJ, et al (2001) Clinical significance of enlarged perihepatic lymph nodes in chronic hepatitis B. *J Clin Gastroenterol* 32(4):329–32
- Cooperberg PL, Burhenne HJ (1980) Real-time ultrasonography. Diagnostic technique of choice in calculous gallbladder disease. *N Engl J Med* 302(23):1277–9
- Coumbaras M, Wendum D, Monnier-Cholley L, Dahan H, Tubiana JM, Arrive L (2002) CT and MR imaging features of pathologically proven atypical giant hemangiomas of the liver. *AJR Am J Roentgenol* 179(6):1457–63
- Czauderna P, Katski K, Kowalczyk J, Kurylak A, Lopatka B, Skotnicka-Klonowicz G, et al (2000) Venooclusive liver disease (VOD) as a complication of Wilms’ tumor management in the series of consecutive 206 patients. *Eur J Pediatr Surg* 10(5):300–3

25. Di Nardo R, Urbano D, Drudi FM, Chianta GL, Tortora A, De Simone P, et al (1996) Ultrasonography in the preoperative assessment of candidates for laparoscopic cholecystectomy: examination technique and results. *Radiol Med (Torino)* 92(5):605–9
26. Dietrich C.F., Brunner V, Kappeser P, Teuber G, Caspary W, Zeuzem S (1998) Sonographic assessment of perihepatic lymph nodes for identification of primary sclerosing cholangitis in patients with inflammatory bowel disease. *Hepatology* 28:443A
27. Dietrich CF (2002) 3D real time contrast enhanced ultrasonography, a new technique. *Rofo* 174(2):160–3
28. Dietrich CF, Becker D (2002) Signalverstärkte Lebersonographie zur verbesserten Detektion und Charakterisierung von Lebererkrankungen. *Dt Aerzteblatt* 24:1666–72
29. Dietrich CF, Chichakli M, Hirche TO, Bargon J, Leitzmann P, Wagner TO, et al (2002) Sonographic findings of the hepatobiliary-pancreatic system in adult patients with cystic fibrosis. *J Ultrasound Med* 21(4):409–16
30. Dietrich CF, Gottschalk R, Herrmann G, Caspary WF, Zeuzem S (1997) Sonographic detection of lymph nodes in the hepatoduodenal ligament. *Dtsch Med Wochenschr* 122(42):1269–74
31. Dietrich CF, Gouder S, Hocke M, Schuessler G, Ignee A (2004) Endosonographie der Choledocholithiasis und ihrer Differentialdiagnosen. *Endoskopie Heute* 17:160–6
32. Dietrich CF, Ignee A, Frey H (2005) Contrast-enhanced endoscopic ultrasound with low mechanical index: a new technique. *Z Gastroenterol* 43(11):1219–23
33. Dietrich CF, Ignee A, Trojan J, Fellbaum C, Schuessler G (2004) Improved characterization of histologically proven liver tumors by contrast enhanced ultrasonography during the portal venous and specific late phase of SHU 508A. *Gut* 53(3):401–5
34. Dietrich CF, Kratzer W, Strobe D, Danse E, Fessl R, Bunk A, et al (2006) Assessment of metastatic liver disease in patients with primary extrahepatic tumors by contrast-enhanced sonography versus CT and MRI. *World J Gastroenterol* 12(11):1699–705
35. Dietrich CF, Lee JH, Gottschalk R, Herrmann G, Sarrazin C, Caspary WF, et al (1998) Hepatic and portal vein flow pattern in correlation with intrahepatic fat deposition and liver histology in patients with chronic hepatitis C. *AJR Am J Roentgenol* 171(2):437–43
36. Dietrich CF, Lee JH, Herrmann G, Teuber G, Roth WK, Caspary WF, et al (1997) Enlargement of perihepatic lymph nodes in relation to liver histology and viremia in patients with chronic hepatitis C. *Hepatology* 26(2):467–72
37. Dietrich CF, Leuschner MS, Zeuzem S, Herrmann G, Sarrazin C, Caspary WF, et al (1999) Peri-hepatic lymphadenopathy in primary biliary cirrhosis reflects progression of the disease. *Eur J Gastroenterol Hepatol* 11(7): 747–53
38. Dietrich CF, Mertens JC, Braden B, Schuessler G, Ott M, Ignee A (2007) Contrast-enhanced ultrasound of histologically proven liver hemangiomas. *Hepatology* 45(5): 1139–45
39. Dietrich CF, Schall H, Kirchner J, Seifert H, Herrmann G, Caspary WF, et al (1997) Sonographic detection of focal changes in the liver hilus in patients receiving corticosteroid therapy. *Z Gastroenterol* 35(12):1051–57
40. Dietrich CF, Schreiber-Dietrich D, Schuessler G, Ignee A (2007) Contrast enhanced ultrasound of the liver – state of the art. *Dtsch Med Wochenschr* 132(22):1225–31
41. Dietrich CF, Schuessler G, Trojan J, Fellbaum C, Ignee A (2005) Differentiation of focal nodular hyperplasia and hepatocellular adenoma by contrast-enhanced ultrasound. *Br J Radiol* 78(932):704–7
42. Dietrich CF, Stryjek-Kaminska D, Teuber G, Lee JH, Caspary WF, Zeuzem S (2000) Perihepatic lymph nodes as a marker of antiviral response in patients with chronic hepatitis C infection. *AJR Am J Roentgenol* 174(3):699–704
43. Dietrich CF, Viel K, Braden B, Caspary WF, Zeuzem S (2000) Mediastinal lymphadenopathy: an extrahepatic manifestation of chronic hepatitis C?. *Z Gastroenterol* 38(2):143–52
44. Dietrich CF, Wehrmann T, Zeuzem S, Braden B, Caspary WF, Lembcke B (1999) Analysis of hepatic echo patterns in chronic hepatitis C. *Ultraschall Med* 20(1):9–14
45. Dietrich CF, Zeuzem S (1999) Sonographic detection of perihepatic lymph nodes: technique and clinical value. *Z Gastroenterol* 37(2):141–51
46. Dietrich CF, Zeuzem S, Caspary WF, Wehrmann T (1998) Ultrasound lymph node imaging in the abdomen and retroperitoneum of healthy probands. *Ultraschall Med* 19(6):265–9
47. Dodd GD, III, Baron RL, Oliver JH, III, Federle MP (1999) End-stage primary sclerosing cholangitis: CT findings of hepatic morphology in 36 patients. *Radiology* 211(2):357–62
48. Dodd GD, III, Baron RL, Oliver JH, III, Federle MP (1999) Spectrum of imaging findings of the liver in end-stage cirrhosis: Part II, focal abnormalities. *AJR Am J Roentgenol* 173(5):1185–92
49. Dodd GD, III, Baron RL, Oliver JH, III, Federle MP, Baumgartel PB (1997) Enlarged abdominal lymph nodes in end-stage cirrhosis: CT-histopathologic correlation in 507 patients. *Radiology* 203(1):127–30
50. Dodd GD, III, Memel DS, Baron RL, Eichner L, Santiguada LA (1995) Portal vein thrombosis in patients with cirrhosis: does sonographic detection of intrathrombus flow allow differentiation of benign and malignant thrombus?. *AJR Am J Roentgenol* 165(3):573–77
51. Drye JC (1948) Intraperitoneal pressure in the human. *Surg Gynecol Obstet* 87:72–9
52. Erdogmus B, Yazici B, Safak AA, Ozdere BA (2004) Multiseptate gallbladder with acute acalculous cholecystitis. *J Clin Ultrasound* 32(8):423–4
53. Faivre L, Houssin D, Valayer J, Brouard J, Hadchouel M, Bernard O (1999) Long-term outcome of liver transplantation in patients with glycogen storage disease type Ia. *J Inher Metab Dis* 22(6):723–32
54. Fang R, Pilcher JA, Putnam AT, Smith T, Smith DL (1999) Accuracy of surgeon-performed gallbladder ultrasound. *Am J Surg* 178(6):475–9
55. Faust D, Fellbaum C, Zeuzem S, Dietrich CF (2003) Nodular regenerative hyperplasia of the liver: a rare differential diagnosis of cholestasis with response to ursodeoxycholic acid. *Z Gastroenterol* 41(3):255–8
56. Friedrich-Rust M, Ong MF, Herrmann E, Dries V, Samaras P, Zeuzem S, et al (2007) Real-time elastography for noninvasive assessment of liver fibrosis in chronic viral hepatitis. *AJR Am J Roentgenol* 188(3):758–64

57. Fukukura Y, Nakashima O, Kusaba A, Kage M, Kojiro M (1998) Angioarchitecture and blood circulation in focal nodular hyperplasia of the liver. *J Hepatol* 29(3):470–5
58. Gaiani S, Bolondi L, Li BS, Zironi G, Siringo S, Barbara L (1991) Prevalence of spontaneous hepatofugal portal flow in liver cirrhosis. Clinical and endoscopic correlation in 228 patients (see comments). *Gastroenterology* 100(1):160–7
59. Gallix BP, Taourel P, Dauzat M, Bruel JM, LaFortune M (1997) Flow pulsatility in the portal venous system: a study of Doppler sonography in healthy adults. *AJR Am J Roentgenol* 169(1):141–4
60. Gebel M, Caselitz M, Bowen-Davies PE, Weber S (1998) A multicenter, prospective, open label, randomized, controlled phase IIIb study of SH U 508 a (Levovist) for Doppler signal enhancement in the portal vascular system. *Ultraschall Med* 19(4):148–56
61. Goodman AJ, Neoptolemos JP, Carr-Locke DL, Finlay DB, Fossard DP (1985) Detection of gall stones after acute pancreatitis. *Gut* 26(2):125–32
62. Gorg C, Riera-Knorrenschild J, Dietrich J (2001) Doppler sonographic diagnosis of respiration-dependent reversed flow in the hilar splenic vein. *J Clin Ultrasound* 29(9):527–30
63. Gorg C, Riera-Knorrenschild J, Dietrich J (2002) Pictorial review: color Doppler ultrasound flow patterns in the portal venous system. *Br J Radiol* 75(899):919–29
64. Gorg C, Seifart U, Zugmaier G (2004) Color Doppler sonographic signs of respiration-dependent hepatofugal portal flow. *J Clin Ultrasound* 32(2):62–8
65. Gossmann J, Scheuermann EH, Frilling A, Geiger H, Dietrich CF (2001) Multiple adenomas and hepatocellular carcinoma in a renal transplant patient with glycogen storage disease type 1a (von Gierke disease). *Transplantation* 72(2):343–4
66. Grant EG, Tessler FN, Gomes AS, Holmes CL, Perrella RR, Duerinckx AJ, et al (1990) Color Doppler imaging of portosystemic shunts. *AJR Am J Roentgenol* 154(2):393–7
67. Grobmyer SR, Wang L, Gonen M, Fong Y, Klimstra D, D'angelica M, et al (2006) Perihepatic lymph node assessment in patients undergoing partial hepatectomy for malignancy. *Ann Surg* 244(2):260–4
68. Grossman H, Ram PC, Coleman RA, Gates G, Rosenberg ER, Bowie JD, et al (1981) Hepatic ultrasonography in type I glycogen storage disease (von Gierke disease). Detection of hepatic adenoma and carcinoma. *Radiology* 141(3):753–6
69. Gullino D, Giordano O, Cardino L, Chiarle S (1977) Complication of spontaneous internal biliary fistulae (experiences in 46 cases). *Minerva Chir* 32(19):1221–38
70. Haag K (1996) Current diagnosis of liver diseases: duplex ultrasonography. *Schweiz Rundsch Med Prax* 85(47):1524–8
71. Haag K, Rossle M, Ochs A, Huber M, Siegerstetter V, Olschewski M, et al (1999) Correlation of duplex sonography findings and portal pressure in 375 patients with portal hypertension. *AJR Am J Roentgenol* 172(3):631–5
72. Hagglund H, Ringden O, Ericzon BG, Duraj F, Ljungman P, Lonnqvist B, et al (1996) Treatment of hepatic venoocclusive disease with recombinant human tissue plasminogen activator or orthotopic liver transplantation after allogeneic bone marrow transplantation. *Transplantation* 62(8): 1076–80
73. Hansler J, Neureiter D, Wasserburger M, Janka R, Bernatik T, Schneider T, et al (2004) Percutaneous US-guided radiofrequency ablation with perfused needle applicators: improved survival with the VX2 tumor model in rabbits. *Radiology* 230(1):169–74
74. Hepburn MJ, Vos JA, Fillman EP, Lawitz EJ (2005) The accuracy of the report of hepatic steatosis on ultrasonography in patients infected with hepatitis C in a clinical setting: a retrospective observational study. *BMC Gastroenterol* 5:14
75. Herbetko J, Grigg AP, Buckley AR, Phillips GL (1992) Venooclusive liver disease after bone marrow transplantation: findings at duplex sonography. *AJR Am J Roentgenol* 158(5):1001–5
76. Hirche TO, Russler J, Braden B, Schuessler G, Zeuzem S, Wehrmann T, et al (2004) Sonographic detection of perihepatic lymphadenopathy is an indicator for primary sclerosing cholangitis in patients with inflammatory bowel disease. *Int J Colorectal Dis* 19(6):586–94
77. Hirche TO, Russler J, Schroder O, Schuessler G, Kappeser P, Caspary WF, et al (2002) The value of routinely performed ultrasonography in patients with Crohn disease. *Scand J Gastroenterol* 37(10):1178–83
78. Hosoki T, Arisawa J, Marukawa T, Tokunaga K, Kuroda C, Kozuka T, et al (1990) Portal blood flow in congestive heart failure: pulsed duplex sonographic findings. *Radiology* 174(3 Pt 1):733–6
79. Hwang JI, Chou YH, Tsay SH, Chiang JH, Chang CY, Boland GW, et al (1998) Radiologic and pathologic correlation of adenomyomatosis of the gallbladder. *Abdom Imaging* 23(1):73–7
80. Ierna D, D'Amico RA, Antoci S, Campanile E, Neri S (2000) Perihepatic lymphadenopathy in chronic hepatitis C: a complementary diagnostic element?. *J Gastroenterol Hepatol* 15(7):783–5
81. Ignee A, Gebel M, Caspary WF, Dietrich CF (2002) Doppler imaging of hepatic vessels - review. *Z Gastroenterol* 40(1): 21–32
82. Ignee A, Weiper D, Schuessler G, Teuber G, Faust D, Dietrich CF (2005) Sonographic characterization of hepatocellular carcinoma at time of diagnosis. *Z Gastroenterol* 43(3):289–94
83. Ishii H, Saito H (2000) Perihepatic lymphadenopathy in chronic liver diseases. *J Gastroenterol Hepatol* 15(7):695–6
84. Jang HJ, Choi BI, Kim TK, Yun EJ, Kim KW, Han JK, et al (1998) Atypical small hemangiomas of the liver: “bright dot” sign at two-phase spiral CT. *Radiology* 208(2):543–8
85. Jang HJ, Kim TK, Lim HK, Park SJ, Sim JS, Kim HY, et al (2003) Hepatic hemangioma: atypical appearances on CT, MR imaging, and sonography. *AJR Am J Roentgenol* 180(1):135–41
86. Jeong MG, Yu JS, Kim KW (2000) Hepatic cavernous hemangioma: temporal peritumoral enhancement during multiphase dynamic MR imaging. *Radiology* 216(3): 692–7
87. Johnson KJ, Olliff JF, Olliff SP (1998) The presence and significance of lymphadenopathy detected by CT in primary sclerosing cholangitis. *Br J Radiol* 71(852):1279–82
88. Joseph AE, Saverymuttu SH, al Sam S, Cook MG, Maxwell JD (1991) Comparison of liver histology with ultrasonography in assessing diffuse parenchymal liver disease. *Clin Radiol* 43(1):26–31

89. Joy D, Thava VR, Scott BB (2003) Diagnosis of fatty liver disease: is biopsy necessary?. *Eur J Gastroenterol Hepatol* 15(5):539–43
90. Kane RA, Jacobs R, Katz J, Costello P (1984) Porcelain gallbladder: ultrasound and CT appearance. *Radiology* 152(1):137–41
91. Kathrein H, Vogel W, Dietze B, Judmaier G (1989) Differential diagnostic importance of sonographically detected lymph node enlargement of the liver hilum in non-malignant liver diseases. *Ultraschall Med* 10(3):127–31
92. Kim TK, Jang HJ, Wilson SR (2005) Imaging diagnosis of hepatocellular carcinoma with differentiation from other pathology. *Clin Liver Dis* 9(2):253–79
93. Klein SA, Hermann S, Dietrich JW, Hoelzer D, Martin H (2002) Transplantation-related toxicity and acute intestinal graft-versus-host disease after conditioning regimens intensified with Rhenium 188-labeled anti-CD66 monoclonal antibodies. *Blood* 99(6):2270–1
94. Klein SA, Martin H, Schreiber-Dietrich D, Hermann S, Caspary WF, Hoelzer D, et al (2001) A new approach to evaluating intestinal acute graft-versus-host disease by transabdominal sonography and color Doppler imaging. *Br J Haematol* 115(4):929–34
95. Kondo F, Nagao T, Sato T, Tomizawa M, Kondo Y, Matsuzaki O, et al (1998) Etiological analysis of focal nodular hyperplasia of the liver, with emphasis on similar abnormal vasculatures to nodular regenerative hyperplasia and idiopathic portal hypertension. *Pathol Res Pract* 194(7):487–95
96. Krook PM, Allen FH, Bush WH, Jr., Malmer G, MacLean MD (1980) Comparison of real-time cholecystosonography and oral cholecystography. *Radiology* 135(1):145–8
97. Kruger S, Strobel D, Wehler M, Wein A, Hahn EG, Becker D (2000) Hepatic Doppler perfusion index – a sensitive screening method for detecting liver metastases?. *Ultraschall Med* 21(5):206–9
98. Kutcher R, Smith GS, Sen F, Gelman SF, Mitsudo S, Thung SN, et al (1998) Comparison of sonograms and liver histologic findings in patients with chronic hepatitis C virus infection. *J Ultrasound Med* 17(5):321–5
99. Leuschner M, Dietrich CF, You T, Seidl C, Raedle J, Herrmann G, et al (2000) Characterization of patients with primary biliary cirrhosis responding to long term ursodeoxycholic acid treatment. *Gut* 46(1):121–6
100. Levine J, Seidman E, Teele RL, Walker WA (1986) Gallbladder wall thickening in acute hepatitis. *J Pediatr Gastroenterol Nutr* 5(1):147–9
101. Limmer J, Fleig WE, Leupold D, Bittner R, Ditschuneit H, Beger HG (1988) Hepatocellular carcinoma in type I glycogen storage disease. *Hepatology* 8(3):531–7
102. Lyttkens K, Forsberg L, Hederstrom E (1990) Ultrasound examination of lymph nodes in the hepatoduodenal ligament. *Br J Radiol* 63(745):26–30
103. Lyttkens K, Hannesson P, Prytz H, Wallengren NO, Forsberg L (1996) Lymph nodes in the hepato-duodenal ligament. A comparison between ultrasound and low-field MR imaging. *Acta Radiol* 37(4):521–3
104. Lyttkens K, Prytz H, Forsberg L, Hagerstrand I (1995) Hepatic lymph nodes as follow-up factor in primary biliary cirrhosis. An ultrasound study. *Scand J Gastroenterol* 30(10):1036–40
105. Lyttkens K, Prytz H, Forsberg L, Hederstrom E, Hagerstrand I (1992) Ultrasound, hepatic lymph nodes and primary biliary cirrhosis. *J Hepatol* 15(1–2):136–9
106. Lyttkens K, Prytz H, Forsberg L, Hederstrom E, Hagerstrand I (1994) Ultrasound, hepatic lymph nodes and chronic active hepatitis. *J Hepatol* 21(4):578–81
107. Madjov R, Chervenkov P, Madjova V, Balev B (2005) Caroli's disease. Report of 5 cases and review of literature. *Hepatogastroenterology* 52(62):606–9
108. Majoie CB, Smits NJ, Phoa SS, Reeders JW, Jansen PL (1995) Primary sclerosing cholangitis: sonographic findings. *Abdom Imaging* 20(2):109–12
109. Matern D, Starzl TE, Arnaout W, Barnard J, Bynon JS, Dhawan A, et al (1999) Liver transplantation for glycogen storage disease types I, III, and IV. *Eur J Pediatr* 158(Suppl 2):S43–S48
110. Molenat F, Boussuges A, Valantin V, Sainty JM (1996) Gallbladder abnormalities in medical ICU patients: an ultrasonographic study. *Intensive Care Med* 22(4):356–8
111. Mork H, Ignee A, Schuessler G, Ott M, Dietrich CF (2007) Analysis of neuroendocrine tumor metastases in the liver using contrast enhanced ultrasonography. *Scand J Gastroenterol* 42(5):652–62
112. Murray FE, Stinchcombe SJ, Hawkey CJ (1992) Development of biliary sludge in patients on intensive care unit: results of a prospective ultrasonographic study. *Gut* 33(8):1123–5
113. Nardi P, Biagi P, Bocchini S (1990) Enlargement of the lymph nodes of the hilum hepatitis: a further ultrasonographic sign of acute viral hepatitis. *Radiol Med (Torino)* 79(3):212–4
114. Neri S, Ierna D, Mauceri B, Abate G, Cilio D, Bordonaro F, et al (2003) Can ultrasonographic findings of perihepatic lymphadenopathy promote investigations to detect possible presence of virus C infection in non-symptomatic subjects?. *Hepatol Res* 27(2):124–8
115. Nguyen BN, Flejou JF, Terris B, Belghiti J, Degott C (1999) Focal nodular hyperplasia of the liver: a comprehensive pathologic study of 305 lesions and recognition of new histologic forms. *Am J Surg Pathol* 23(12):1441–54
116. Nuernberg D, Ignee A, Dietrich CF (2006) Ultrasound in gastroenterology – liver and spleen. *Z Gastroenterol* 44(9):991–1000
117. Nuernberg D, Ignee A, Dietrich CF (2007) Ultrasound in gastroenterology. Biliopancreatic system. *Med Klin (Munich)* 102(2):112–6
118. Ochs A (2005) Transjugular intrahepatic portosystemic shunt. *Dig Dis* 23(1):56–64
119. Ochs A, Rossle M, Haag K, Hauenstein KH, Deibert P, Siegerstetter V, et al (1995) The transjugular intrahepatic portosystemic stent-shunt procedure for refractory ascites. *N Engl J Med* 332(18):1192–7
120. Oguzkurt L, Yildirim T, Torun D, Tercan F, Kizilkilic O, Niron EA (2005) Hepatic vein Doppler waveform in; 54(2):253–7
121. Oikarinen H, Paakko E, Suramo I, Paivansalo M, Tervonen O, Lehtola J, et al (2001) Imaging and estimation of the prognostic features of primary sclerosing cholangitis by ultrasonography and MR cholangiography. *Acta Radiol* 42(4):403–8
122. Oliver JH, III, Baron RL (1996) Helical biphasic contrast-enhanced CT of the liver: technique, indications, interpretation, and pitfalls. *Radiology* 201(1):1–14

123. Oliver JH, III, Baron RL, Federle MP, Jones BC, Sheng R (1997) Hypervascular liver metastases: do unenhanced and hepatic arterial phase CT images affect tumor detection?. *Radiology* 205(3):709–15
124. Osawa H, Mori Y (1996) Sonographic diagnosis of fatty liver using a histogram technique that compares liver and renal cortical echo amplitudes. *J Clin Ultrasound* (1):25–9
125. Parker P, Burr I, Slonim A, Ghishan FK, Greene H (1981) Regression of hepatic adenomas in type Ia glycogen storage disease with dietary therapy. *Gastroenterology* 81(3):534–6
126. Pirlich M, Schachschal G, Wermke W (2003) Image of the month. *Gastroenterology* 124(4):879, 1171
127. Piscaglia F, Vidili G, Ugolini G, Ramini R, Montroni I, De Iaco P, et al (2005) Fitz–Hugh–Curtis syndrome mimicking acute cholecystitis: value of new ultrasound findings in the differential diagnosis. *Ultraschall Med* 26(3):227–30
128. Ramalho F (2003) Hepatitis C virus infection and liver steatosis. *Antiviral Res* 60(2):125–7
129. Rengo C, Brevetti G, Sorrentino G, D’Amato T, Imperato M, Vitale DF, et al (1998) Portal vein pulsatility ratio provides a measure of right heart function in chronic heart failure. *Ultrasound Med Biol* 24(3):327–32
130. Rickes S, Csepregi A (2004) Images of interest. Hepatobiliary and pancreatic: Budd–Chiari syndrome. *J Gastroenterol Hepatol* 19(7):828
131. Rickes S, Ocran K (2002) Images in clinical medicine. Porcelain gallbladder. *N Engl J Med* 346(14):e4
132. Rickes S, Ocran KW, Gerstenhauer G, Neye H, Wermke W (2004) Evaluation of diagnostic criteria for liver metastases of adenocarcinomas and neuroendocrine tumors at conventional ultrasound, unenhanced power Doppler sonography and echo-enhanced ultrasound. *Dig Dis* 22(1):81–6
133. Rickes S, Unkrodt K, Ocran K, Neye H, Lochs H, Wermke W (2000) Evaluation of Doppler ultrasonography criteria for the differential diagnosis of pancreatic tumors. *Ultraschall Med* 21(6):253–8
134. Rickes S, Wermke T, Ocran K, Seitz G, Wermke W (2002) Contrast behaviour of a angiomyolipoma of the liver at echo-enhanced power-Doppler sonography. *Ultraschall Med* 23(5):338–40
135. Rigamonti C, Fraquelli M (2007) Do not trivialize the Fibroscan examination, value its accuracy. *J Hepatol* 46(6): 1149
136. Rinella ME, Alonso E, Rao S, Whittington P, Fryer J, Abecassis M, et al (2001) Body mass index as a predictor of hepatic steatosis in living liver donors. *Liver Transpl* 7(5): 409–14
137. Rubbia-Brandt L, Quadri R, Abid K, Giostra E, Male PJ, Mentha G, et al (2000) Hepatocyte steatosis is a cytopathic effect of hepatitis C virus genotype 3. *J Hepatol* 33(1): 106–15
138. Sandouk F, Anand BS, Graham DY (1997) The whirlpool jet technique for removal of pancreatic duct ascaris. *Gastrointest Endosc* 46(2):180–2
139. Sandouk F, Haffar S, Zada MM, Graham DY, Anand BS (1997) Pancreatic-biliary ascariasis: experience of 300 cases. *Am J Gastroenterol* 92(12):2264–7
140. Sauerbrei EE, Lopez M (1986) Pseudotumor of the quadrate lobe in hepatic sonography: a sign of generalized fatty infiltration. *AJR Am J Roentgenol* 147(5):923–7
141. Saverymuttu SH, Joseph AE, Maxwell JD (1986) Ultrasound scanning in the detection of hepatic fibrosis and steatosis. *Br Med J (Clin Res Ed)* 292(6512):13–5
142. Schneider AR, Teuber G, Kriener S, Caspary WF (2005) Noninvasive assessment of liver steatosis, fibrosis and inflammation in chronic hepatitis C virus infection. *Liver Int* 25(6):1150–5
143. Schruppf E, Elgio K, Fausa O, Gjone E, Kolmannskog F, Ritland S (1980) Sclerosing cholangitis in ulcerative colitis. *Scand J Gastroenterol* 15(6):689–97
144. Schuessler G, Fellbaum C, Fauth F, Jacobi V, Schmidt-Matthiesen A, Ignee A, et al (2006) The inflammatory pseudotumor – an unusual liver tumor. *Ultraschall Med* 27(3):273–9
145. Scoazec JY, Flejou JF, d’Errico A, Couvelard A, Kozyraki R, Fiorentino M, et al (1995) Focal nodular hyperplasia of the liver: composition of the extracellular matrix and expression of cell-cell and cell-matrix adhesion molecules. *Hum Pathol* 26(10):1114–25
146. Seifert H, Wehrmann T, Hilgers R, Gouder S, Braden B, Dietrich CF (2004) Catheter probe extraductal EUS reliably detects distal common bile duct abnormalities. *Gastrointest Endosc* 60(1):61–7
147. Seitz K, Hege-Blank U, Holzinger H (1987) 10 years of sonographic diagnosis of gallstones – what do surgical statistics tell us about its reliability?. *Ultraschall Med* 8(3):121–5
148. Sharafuddin MJ, Foshager MC, Steinbuch M, Weisdorf DJ, Hunter DW (1997) Sonographic findings in bone marrow transplant patients with symptomatic hepatic venoocclusive disease. *J Ultrasound Med* 16(9):575–86
149. Shimada M, Matsumata T, Ikeda Y, Urata K, Hayashi H, Shimizu M, et al (1994) Multiple hepatic hemangiomas with significant arteriportal venous shunting. *Cancer* 73(2): 304–7
150. Shimizu M, Miura J, Tanaka T, Itoh H, Saitoh Y (1989) Porcelain gallbladder: relation between its type by ultrasound and incidence of cancer. *J Clin Gastroenterol* 11(4):471–6
151. Sidhu PS, Ellis SM, Karani JB, Ryan SM (2002) Hepatic artery stenosis following liver transplantation: significance of the tardus parvus waveform and the role of microbubble contrast media in the detection of a focal stenosis. *Clin Radiol* 57(9):789–99
152. Sidhu PS, Marshall MM, Ryan SM, Ellis SM (2000) Clinical use of Levovist, an ultrasound contrast agent, in the imaging of liver transplantation: assessment of the pre- and post-transplant patient. *Eur Radiol* 10(7):1114–26
153. Sidhu PS, Shaw AS, Ellis SM, Karani JB, Ryan SM (2004) Microbubble ultrasound contrast in the assessment of hepatic artery patency following liver transplantation: role in reducing frequency of hepatic artery arteriography. *Eur Radiol* 14(1):21–30
154. Siegelman ES, Rosen MA (2001) Imaging of hepatic steatosis. *Semin Liver Dis* 21(1):71–80
155. Silidker MS, Cronan JJ, Scola FH, Moore MM, Schepps B, Thompson W, et al (1988) Ultrasound evaluation of cholelithiasis in the morbidly obese. *Gastrointest Radiol* 13(4): 345–6
156. Singh V, Sinha SK, Nain CK, Bambery P, Kaur U, Verma S, et al (2000) Budd–Chiari syndrome: our experience of 71 patients. *J Gastroenterol Hepatol* 15(5):550–4
157. Smith-Levitin M, Blickstein I, Albrecht-Shach AA, Goldman RD, Gurewitsch E, Streltsoff J, et al (1997)

- Quantitative assessment of gray-level perception: observers' accuracy is dependent on density differences. *Ultrasound Obstet Gynecol* 10(5):346–9
158. Soresi M, Bonfissuto G, Sesti R, Riili A, Di Giovanni G, Carroccio A, et al (2004) Perihepatic lymph nodes and antiviral response in chronic HCV-associated hepatitis. *Ultrasound Med Biol* 30(6):711–7
 159. Strobel D, Kleinecke C, Hansler J, Frieser M, Handl T, Hahn EG, et al (2005) Contrast-enhanced sonography for the characterization of hepatocellular carcinomas – correlation with histological differentiation. *Ultraschall Med* 26(4):270–6
 160. Strunk H, Borner N, Stuckmann G, Frohlich E, Hadizadeh D (2005) Contrast-enhanced “low MI real-time” phase-inversion sonography to differentiate between malignant and benign focal liver lesions. *Rofo* 177(10):1394–404
 161. Talente GM, Coleman RA, Alter C, Baker L, Brown BI, Cannon RA, et al (1994) Glycogen storage disease in adults. *Ann Intern Med* 120(3):218–26
 162. Taylor KJ, Ramos I, Morse SS, Fortune KL, Hammers L, Taylor CR (1987) Focal liver masses: differential diagnosis with pulsed Doppler US. *Radiology* 164(3):643–7
 163. Teehey SA, Baron RL, Bigler SA (1991) Sonography of the gallbladder: significance of striated (layered) thickening of the gallbladder wall. *AJR Am J Roentgenol* 156(5):945–7
 164. Teehey SA, Brink JA, Borson RA, Middleton WD (1995) Diagnosis of venoocclusive disease of the liver after bone marrow transplantation: value of duplex sonography. *AJR Am J Roentgenol* 164(6):1397–401
 165. Todani T, Watanabe Y, Toki A, Ogura K, Wang ZQ (1998) Co-existing biliary anomalies and anatomical variants in choledochal cyst. *Br J Surg* 85(6):760–3
 166. Toppet V, Souayah H, Delplace O, Alard S, Moreau J, Levy J, et al (1990) Lymph node enlargement as a sign of acute hepatitis A in children. *Pediatr Radiol* 20(4):249–52
 167. Tublin ME, Dodd GD, III, Baron RL (1997) Benign and malignant portal vein thrombosis: differentiation by CT characteristics. *AJR Am J Roentgenol* 168(3):719–23
 168. Venerito M, Monkmuller K, Malfertheiner P, Ricketts S (2006) Hepatobiliary and pancreatic: gallbladder varices. *J Gastroenterol Hepatol* 21(8):1348
 169. von Herbay A, Frieling T, Haussinger D (2000) Color Doppler sonographic evaluation of spontaneous portosystemic shunts and inversion of portal venous flow in patients with cirrhosis. *J Clin Ultrasound* 28(7):332–9
 170. von Herbay A, Vogt C, Haussinger D (2002) Late-phase pulse-inversion sonography using the contrast agent levovist: differentiation between benign and malignant focal lesions of the liver. *AJR Am J Roentgenol* 179(5):1273–79
 171. von Herbay A, Vogt C, Haussinger D (2002) Pulse inversion sonography in the early phase of the sonographic contrast agent Levovist: differentiation between benign and malignant focal liver lesions. *J Ultrasound Med* 21(11):1191–200
 172. von Herbay A, Vogt C, Haussinger D (2004) Differentiation between benign and malignant hepatic lesions: utility of color stimulated acoustic emission with the microbubble contrast agent Levovist. *J Ultrasound Med* 23(2):207–15
 173. von Herbay A, Vogt C, Willers R, Haussinger D (2004) Real-time imaging with the sonographic contrast agent SonoVue: differentiation between benign and malignant hepatic lesions. *J Ultrasound Med* 23(12):1557–68
 174. Wachsberg RH, Needleman L, Wilson DJ (1995) Portal vein pulsatility in normal and cirrhotic adults without cardiac disease. *J Clin Ultrasound* 23(1):3–15
 175. Wanless IR, Mawdsley C, Adams R (1985) On the pathogenesis of focal nodular hyperplasia of the liver. *Hepatology* 5(6):1194–200
 176. Watanabe T, Sassa T, Hiratsuka H, Hattori S, Abe A (2005) Clinical significance of enlarged perihepatic lymph node on ultrasonography. *Eur J Gastroenterol Hepatol* 17(2):185–90
 177. Wedemeyer H, Ockenga J, Frank H, Tillmann HL, Schuler A, Caselitz M, et al (1998) Perihepatic lymphadenopathy: a marker of response to interferon alpha in chronic hepatitis C. *Hepatogastroenterology* 45(22):1062–8
 178. Weiner PL, Lawson TL (1975) The radiology corner. Porcelain gallbladder. *Am J Gastroenterol* 64(3):224–7
 179. Welch NT, Fitzgibbons RJ, Jr., Hinder RA (1991) Beware of the porcelain gallbladder during laparoscopic cholecystectomy. *Surg Laparosc Endosc* 1(3):202–5
 180. Wermke W (1989) Ultrasonic diagnosis of gallstone diseases. *Z Gesamte Inn Med* 44(13):377–82
 181. Wermke W (1992) Ultrasonic diagnosis of bile duct calculi. A prospective study regarding the effects and the objective and subjective factors on accuracy in choledocholithiasis. *Ultraschall Med* 13(6):246–54
 182. Yamashita Y, Ogata I, Urata J, Takahashi M (1997) Cavemous hemangioma of the liver: pathologic correlation with dynamic CT findings. *Radiology* 203(1):121–5
 183. Yoshidome H, McMasters KM, Edwards MJ (1999) Management issues regarding hepatic adenomatosis. *Am Surg* 65(11):1070–6
 184. Yoshimitsu K, Honda H, Aibe H, Shinozaki K, Kuroiwa T, Irie H, et al (2001) Radiologic diagnosis of adenomyomatosis of the gallbladder: comparative study among MRI, helical CT, and transabdominal US. *J Comput Assist Tomogr* 25(6):843–50
 185. Zoli M, Magalotti D, Bianchi G, Gueli C, Marchesini G, Pisi E (1996) Efficacy of a surveillance program for early detection of hepatocellular carcinoma. *Cancer* 78(5):977–85

Chapter Outline

Computed Tomography	406
Magnetic Resonance Imaging	406
Frequently Encountered Hepatic Pathologies	407
Benign Tumors	407
Malignant Tumors	412
Focal Infections	417
Conclusion	421
References	421

Liver pathologies are common disease processes. Annually, thousands of patients are examined using different imaging modalities for the work-up of suspected or known liver diseases.

A primary objective in imaging the liver is to distinguish benign from malignant processes. One should correctly diagnose benign focal liver lesions such as cysts or hemangiomas to avoid unnecessary surgeries. It should be also noted that some other benign lesions such as focal nodular hyperplasias and hepatocellular adenomas may require surgical treatment. However, since the therapeutical approaches substantially differ, they need to be differentiated from primary or metastatic malignant focal lesions. Regarding the malignant lesions, it is important to early detect primary malignancies such as hepatocellular carcinomas since they may be treated using different approaches such as liver transplantation, chemoembolization, or alcohol ablation. Regarding the metastatic liver lesions, it is important to correctly determine the number and locations of the metastases, since these patients may be effectively treated with different techniques including segmental resection and radiofrequency ablation.

Hussain et al. summarizes the main goals of imaging as to assess (1) the number and size of the liver abnormalities, (2) the location of abnormalities relative to liver vessels, (3) the nature of lesions (benign versus malignant), (4) the origin (primary versus secondary) of abnormalities, (5) the liver parenchyma surrounding the lesions [28].

Today, different imaging modalities are used to investigate liver abnormalities. In fact, there is still no consensus concerning the optimal strategy for imaging the liver [27]. Imaging modalities often are applied based upon the availability and the experience of radiologists and gastroenterologists. In this chapter we will try to give information about computed tomography

and magnetic resonance imaging and radiologic appearances of various liver pathologies.

Computed Tomography

Hepatic computed tomography (CT) imaging in the 1970s and 1980s was limited by the slow speed and resulting long imaging time [14]. During the last 20 years, CT has undergone several major technological modifications [7]. The introduction of spiral (synonym: helical) CT in 1994 was a major advance in CT technology [7]. Initially, only single slice spiral CTs were available, whereas recently, 64-slice (multislice or multidetector row) spiral CTs have been developed. Today, with the use of multidetector CT technology, the entire liver can be imaged in more than one pass during a single breathhold [28]. Thus, it is possible to capture different phases of the contrast enhancement of the liver including the native unenhanced phase, the arterial phase, the portal venous phase and the hepatic venous phase [28]. These phases provide very valuable information about the vascular character of the liver lesions that can be used in the differential diagnosis. Based on the degree of enhancement during the arterial, portal venous, and hepatic venous phases, hepatic lesions can be characterized as hypervascular, hypovascular, or isovascular. Furthermore, multidetector CTs can now provide high-resolution images in any given imaging plane, a feature that was previously only available with MRI [14].

The major drawback of CT, on the other hand, is the ionizing radiation issue. In clinical practice, radiologists try to minimize the ionizing radiation dose and therefore the number of phases that are acquired with CT, for example, are often limited. This issue is even more crucial for relatively young patients. Second, CT scanning requires the use of iodinated contrast material, which can cause adverse reactions. Finally, the third limitation remains the lack of the ability to alter the intrinsic soft tissue contrast that is useful to detect and characterize liver lesions [28].

Magnetic Resonance Imaging

Magnetic resonance imaging (MRI) is an imaging modality with various advantages when compared with its counterparts. Whereas CT and ultrasound (US) rely

on a single factor (x-ray attenuation in the case of CT and sound reflection in the case of US), MRI relies on numerous factors including interactions at the molecular level [14]. MRI offers very important biological and pathological information about the T1- and T2-relaxation times of the tissues, fat and metal deposition within the tissues, hemorrhage, perfusion, vascular flow, molecular diffusion and susceptibility.

The two main advantages of MRI when compared with CT is the lack of ionizing radiation and the variety of the contrast agents. The three types of contrast agents commonly used in clinical practice are, (1) nonspecific extracellular gadolinium chelates that cause increased signal intensity in the tissues on T1-weighted images (such as Gd-DTPA), (2) hepatocyte-selective contrast agents that are specifically captured by hepatocytes and excreted by bile ducts (such as Gd-EOB-DTPA or Gd-BOPTA), (3) reticuloendothelial system (RES)-specific agents (superparamagnetic iron oxide particles [SPIOs]) that are specifically captured by organs containing RES such as liver (Kupffer cells). Regarding the gadolinium containing contrast agents, patients with heavily decreased renal function (glomerular filtration rate $< 30 \text{ mL/min/1.72 m}^2$) are at particular risk for developing nephrogenic systemic fibrosis (NSF), a rare but potentially deadly disease that seems to be linked to the prior administration of certain Gd-chelates [41]. Thus, in patients with chronic renal failure and with previous proinflammatory events, gadolinium chelates should be used with precaution and higher doses (0.2 mmol/kg of body weight and higher) should be avoided.

At the time of its very first introduction, magnetic resonance cholangiopancreatography (MRCP) was considered a promising technique with potential for detecting pathologies of biliary tract and pancreatic duct [17]. Since that time, MRCP has undergone a number of technical refinements. Today, in the initial diagnostic work-up of bilio-pancreatic disorders, MRCP has replaced the use of diagnostic endoscopic retrograde cholangiopancreatography (ERCP) in many institutions. Basically, the routine MR cholangiopancreatography (MRCP) sequence is composed of heavily T2-weighted images that are highly water sensitive [14]. On these images, bile is displayed as high in signal intensity and thus depiction of the biliary and pancreatic ducts is provided. Compared with ERCP, MRCP offers a number of advantages, such as non-invasiveness and short examination times [17]. MRCP does not expose patients to ionizing radiation or

iodinated contrast material unlike ERCP. It can be performed in patients in whom it is impossible to perform ERCP due to anatomical alterations from previous surgery [17]. Furthermore, combination of MRCP with dynamic contrast-enhanced magnetic resonance imaging and MR angiography optimizes the evaluation of abdominal organs, including the pancreas, liver, gallbladder and surrounding vascular structures. At present, this so called “all-in-one” imaging approach is presumably the most comprehensive and cost-effective imaging technique in the evaluation of bilio-pancreatic malignancies. Nevertheless, the major strength of ERCP is the access for therapeutic interventions it offers. Unlike ERCP, MRCP is a purely diagnostic technique.

Frequently Encountered Hepatic Pathologies

Benign Tumors

Hemangioma

On unenhanced CT scans, hemangiomas appear as low-density masses with well-defined, lobulated borders. Calcification is observed in 10–20% of cases [56]. After intravenous administration of contrast material, both arterial phase and portal venous phase CT scans show early, peripheral, globular enhancement of the lesion [22, 63]. Venous-phase CT shows centripetal enhancement that progresses to uniform filling that persists on delayed-phase images. Although small lesions often fill in completely, large tumors may not seldomly show central nonenhancing zones during venous and delayed phases, corresponding to scar tissue or cystic cavities [67]. Approximately 16% of all hemangiomas and 42% of small ones (<1 cm in diameter) show immediate homogenous enhancement at arterial phase CT imaging, and this can make their differentiation from HCCs difficult [37, 67].

On MRI, hemangiomas have long T1 and T2 values, so they have moderately low signal intensity on T1-weighted images and characteristically demonstrate marked hyperintensity on T2-weighted images, which may contain low-intensity areas correlating with zones of

fibrosis [46, 55, 57]. They maintain high signal intensity on longer TE (>120ms) T2-weighted sequences [45]. Nevertheless, the signal characteristics of hemangiomas may overlap with those of other malignant and benign lesions [36]. Therefore, suspected hemangiomas should be evaluated using a dynamic breath-hold sequence, in a manner similar to contrast-enhanced dynamic CT protocol (Figs. 38.1–38.3) [27].

Focal Nodular Hyperplasia

In unenhanced CT studies, focal nodular hyperplasia (FNH) usually appears as a homogeneous, hypodense mass. In a third of cases, a low-density central area is seen, corresponding to the scar [43, 59]. During the arterial phase of contrast-enhanced CT, FNH enhances rapidly and becomes hyperdense relative to normal liver. The low attenuation scar appears conspicuous against the hyperdense tissue and foci of enhancement may be seen within the scar representing arteries [9]. In the portal venous phase and later phases of enhancement the difference in attenuation between FNH and normal liver decreases and the FNH may become isointense with normal liver [8, 9, 11, 29]. Ten-minute delayed images can show increased contrast uptake in the scar relative to surrounding liver [22].

On unenhanced MR studies, FNH is an isointense tumor on T1-weighted images that becomes slightly hyperintense to isointense on T2-weighted images. The central scar is hypointense on T1-weighted images and hyperintense on T2-weighted images [39, 64]. However, there is overlap in the appearance of FNH and malignant lesions on unenhanced T1-weighted and T2-weighted images and further characterization using contrast-enhanced dynamic studies may be necessary. The enhancement characteristics of FNHs following the intravenous gadolinium are similar those encountered on CT (Fig. 38.4).

On T2-weighted images with superparamagnetic iron oxide administration, FNH shows loss of signal due to uptake of iron oxide particles by Kupffer cells within the lesion [39]. The degree of signal loss seen in FNH using SPIO is significantly greater than in other focal liver lesions such as metastases and hepatocellular adenoma [64]. The use of hepatobiliary agents might be also helpful in characterization of FNH. FNH contains hepatocytes which take up these agents, resulting in hyperintensity of the lesion relative to the liver on T1-weighted images [27].

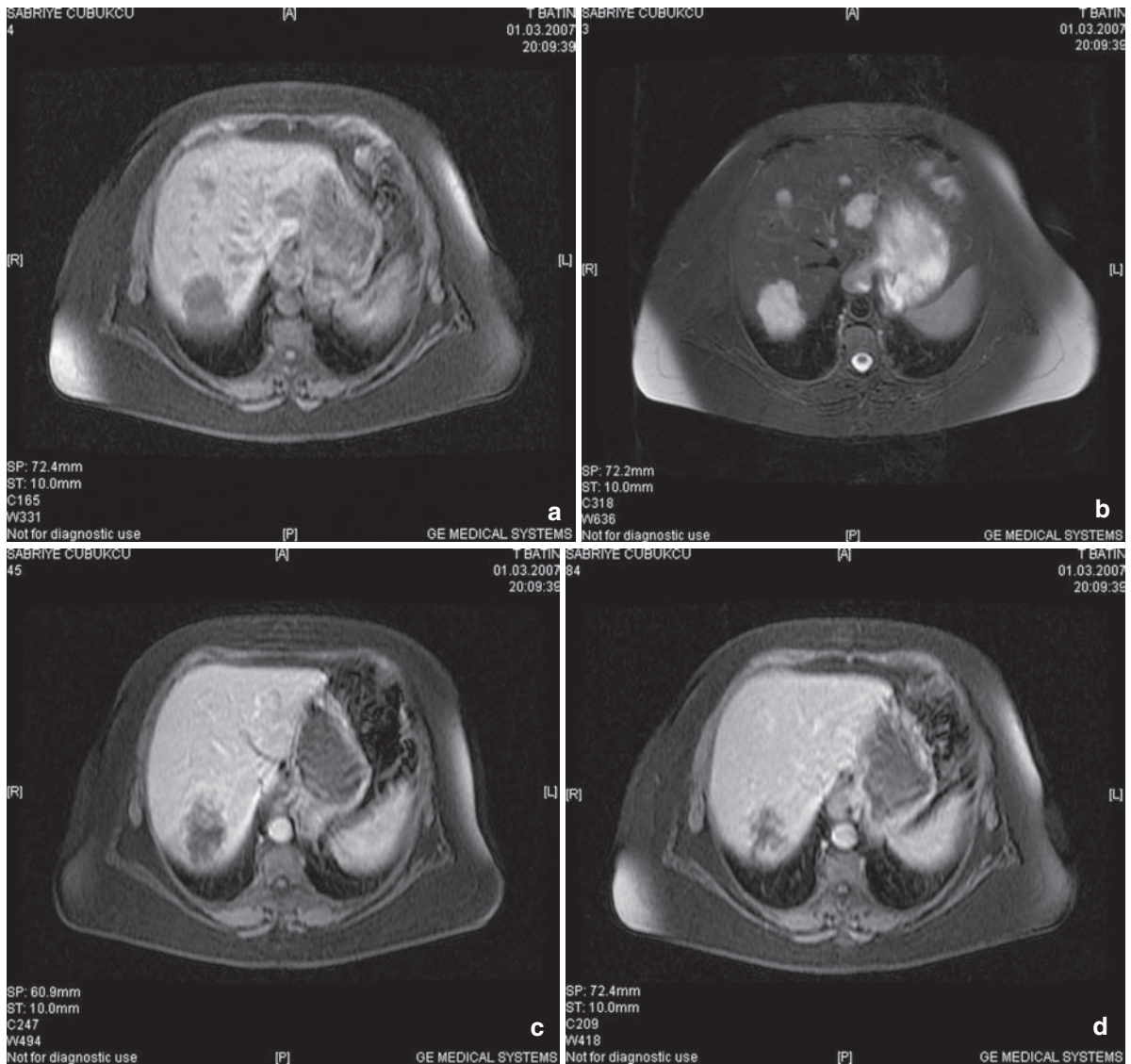


Fig. 38.1 MR images show multiple hemangiomas hypointense on T1-weighted (a), hyperintense on T2-weighted images (b). On the dynamic post-contrast T1-weighted images (c, d), whereas

the smaller lesions show complete fill-in, the largest lesion shows gradual nodular but incomplete fill-in

Hepatocellular Adenoma

Unenhanced CT usually demonstrates a hypodense mass due to the presence of fat and glycogen within the tumor [59]. However, hyperdense areas corresponding to fresh hemorrhage can be noted.

Contrast-enhanced dynamic CT imaging allows more accurate detection and characterization of HCA. After administration of intravenous contrast medium during dynamic scanning, small HCAs enhance

rapidly and are of increased attenuation relative to the liver [6]. The enhancement does not persist in adenomas because of arteriovenous shunting and the lesions become nearly isoattenuating to normal liver on portal venous and delayed scans [56]. A peripheral and centripetal enhancement pattern, reflecting the presence of the large subcapsular feeding vessels, may also be seen [23]. Larger HCAs may be more heterogeneous than smaller lesions and the CT appearance is non-specific [6].

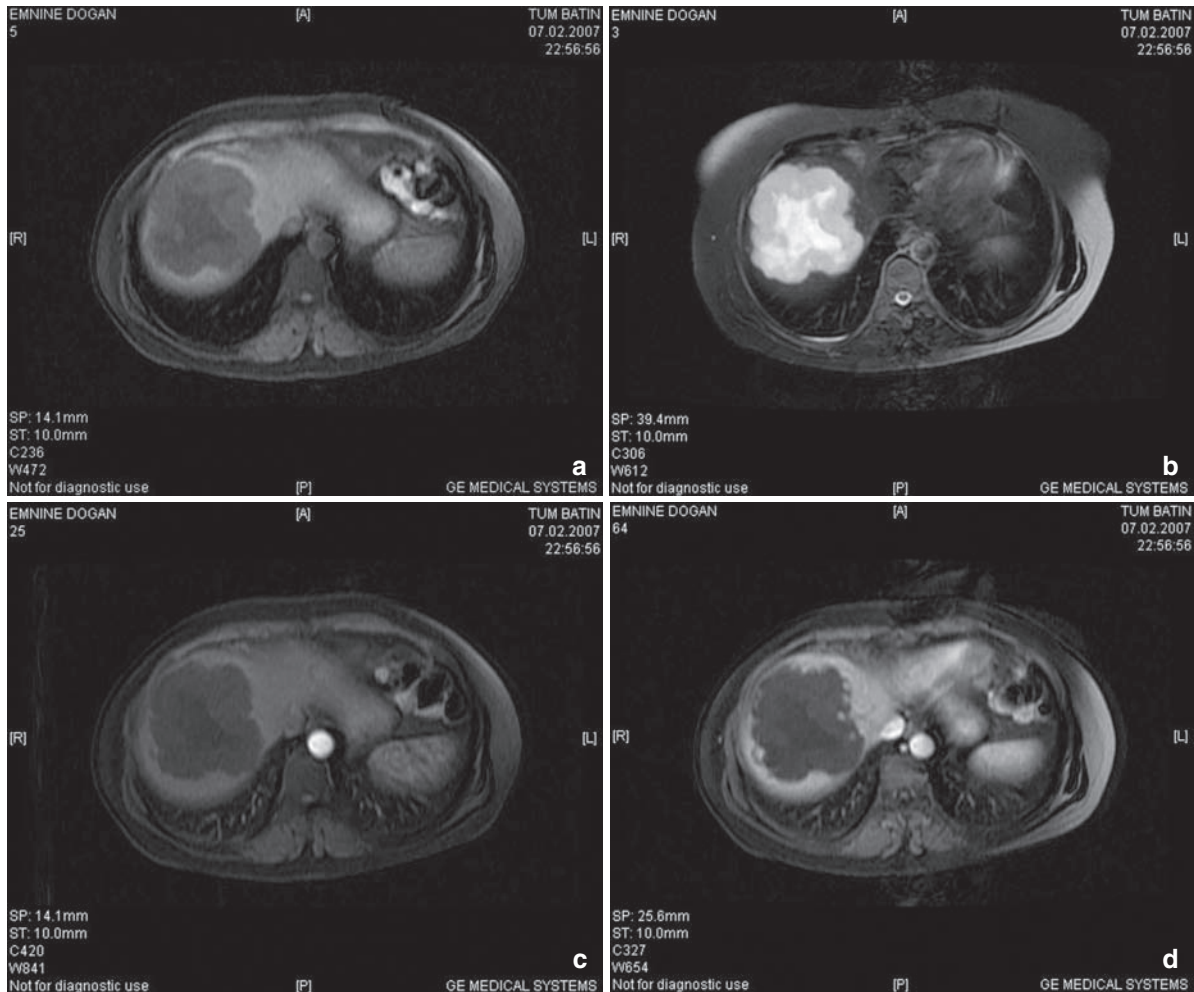


Fig. 38.2 MR images show a large hemangioma in the right lobe of the liver. The hemangioma is hypointense on T1-weighted (a) and hyperintense on T2-weighted images (b). On the dynamic

post-contrast T1-weighted images (c, d), the lesion shows gradual nodular peripheral incomplete enhancement

On MR studies, adenomas are heterogeneous in appearance. They contain areas of increased signal intensity on T1-weighted images resulting from the presence of fat and hemorrhage and low signal areas corresponding to necrosis [52]. It has been reported that hepatocellular adenomas are predominantly hyperintense relative to liver on T2-weighted images. But like on T1-weighted images, they contain areas of heterogeneous signal intensity reflecting the presence of hemorrhage and necrosis. One third of HCAs have a peripheral rim corresponding to a fibrous capsule [2]. In most cases the rim is of low signal intensity on both T1 and T2-weighted images [2]. Hepatic adenomas typically demonstrate decreased signal intensity on

out-of-phase T1 weighted gradient echo images or fat-suppressed T1 weighted images because of their fat content [45].

On contrast-enhanced dynamic studies, the adenomas show early enhancement during the arterial phase and a rapid wash-out. Hepatic adenomas show a more uniform and moderate enhancement on arterial phase images compared to intense homogenous and peripheral nodular enhancement patterns of focal nodular hyperplasias and hemangiomas, respectively (Fig. 38.5). Adenomas usually do not show uptake of SPIOs [23]. However, hepatocyte-specific contrast agents, such as Gd-EOB-DTPA are uptaken by adenomas because of the presence of hepatocytes.

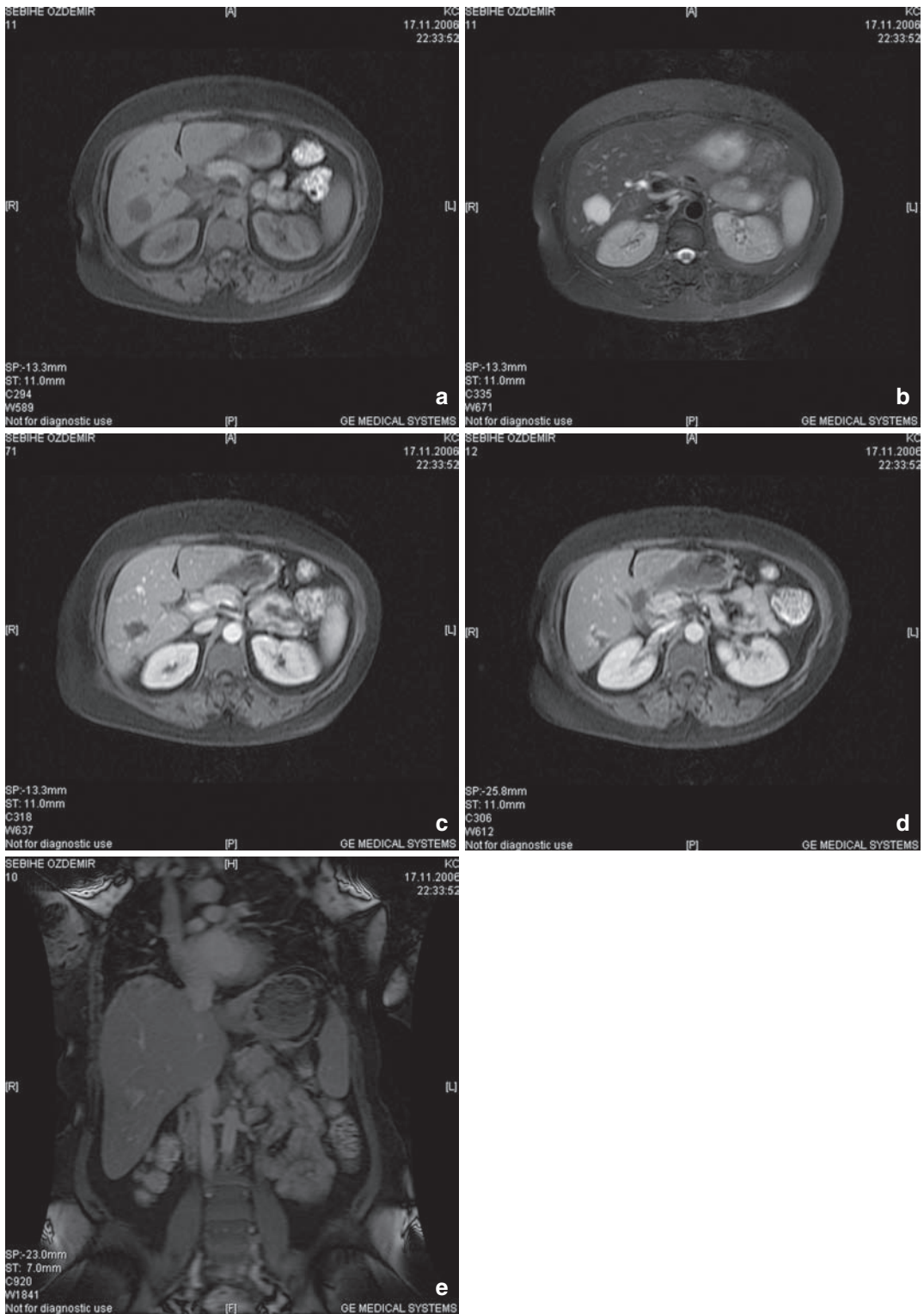


Fig. 38.3 MR images show a hemangioma in the right lobe of the liver. The hemangioma is hypointense on T1-weighted (a) and hyperintense on T2-weighted images (b). On the dynamic

post-contrast axial T1-weighted images (c, d), the lesion shows gradual nodular peripheral enhancement. On the delayed phase coronal T1-weighted image (e) there is complete fill-in

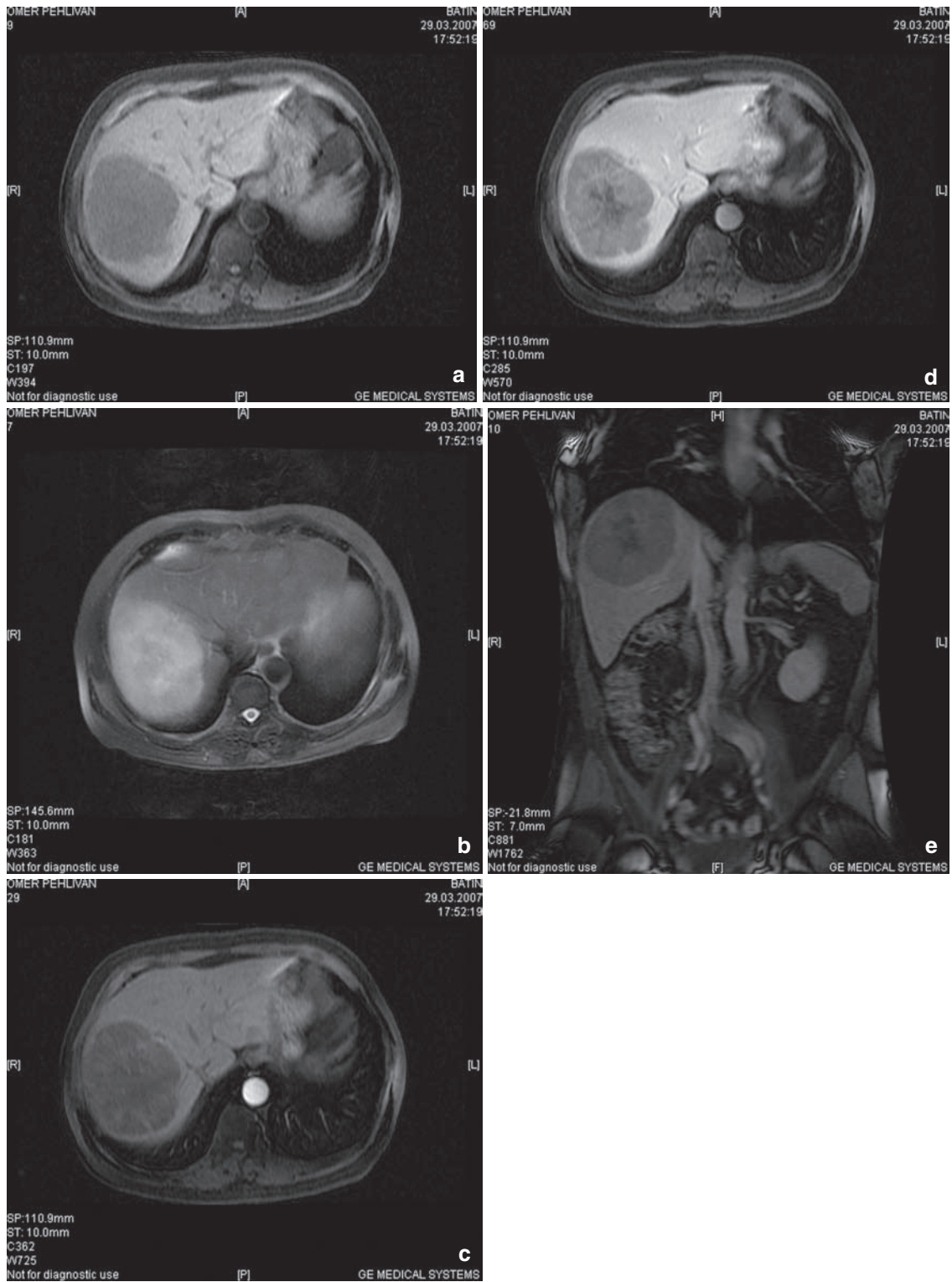


Fig. 38.4 MR images show a FNH in the right lobe of the liver. The lesion is hypointense on T1-weighted MR (a) and hyperintense on T2-weighted MR images (b). On the post-contrast

dynamic images, the lesion shows early enhancement in the arterial phase (c). On the venous phase (d) and delayed phase (e) images the central area of the lesion remains unenhanced

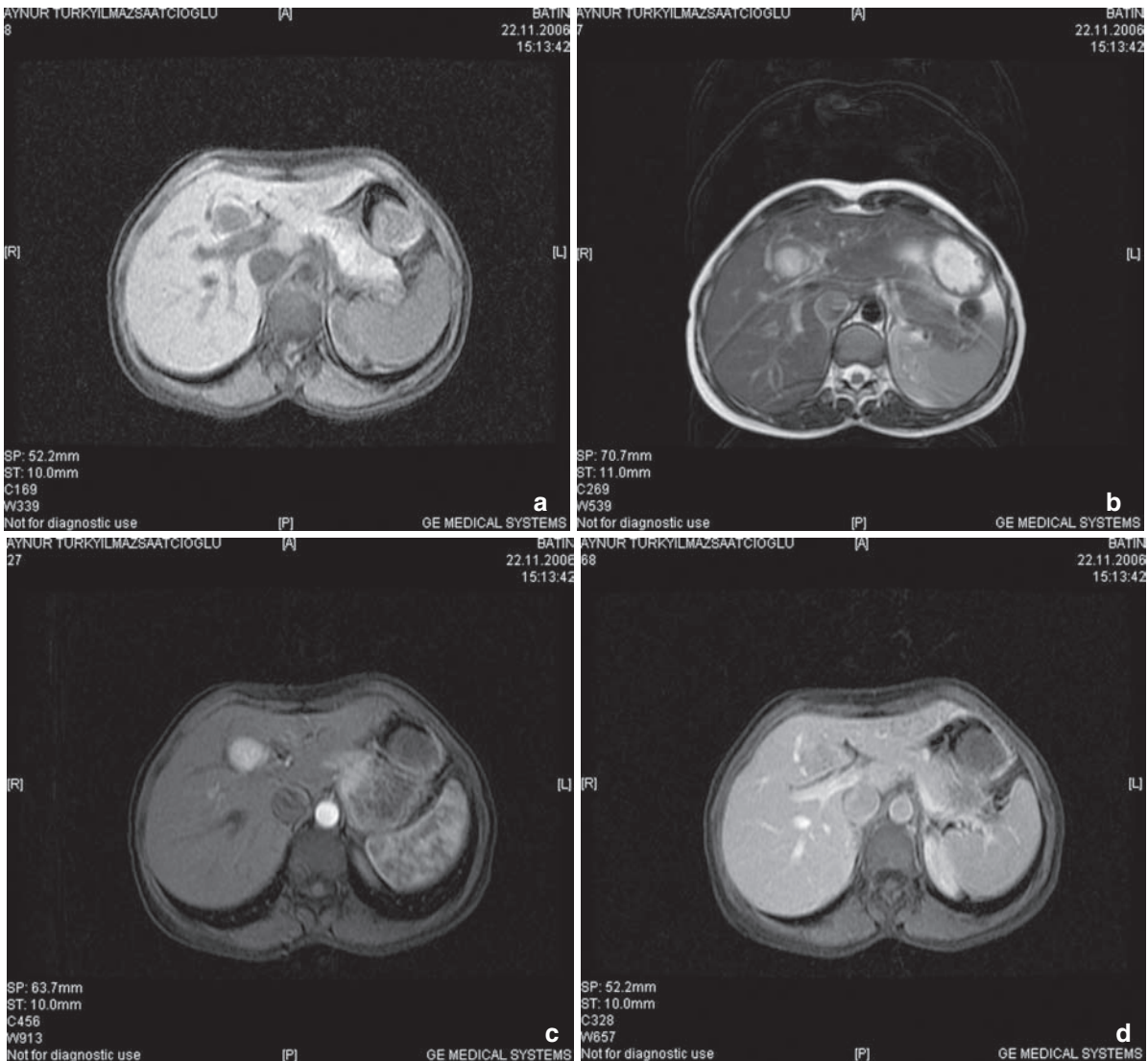


Fig. 38.5 Hepatic adenoma. T1 weighted MR image (a) shows an hypointense lesion located adjacent to the portal vein. The lesion is hyperintense on T2-weighted MR image (b) and shows strong

enhancement on the arterial phase post-contrast T1-weighted image (c). On the portal venous phase image (d), the lesion becomes isointense with the liver

Malignant Tumors

Hepatocellular Carcinoma

Unenhanced CT scans demonstrate a large, hypodense mass with central areas of lower attenuation that corresponds to the tumor necrosis frequently seen in hepatocellular carcinoma (HCC). Contrast-enhanced dynamic CT imaging is an efficient technique for determination of HCC and pre-operative staging of HCC [5, 33]. Dynamic study includes non-enhanced, hepatic arterial, portal

venous and delayed phase images. Since HCC derives its blood supply mainly from hepatic artery, the tumor demonstrates early enhancement during arterial phase and is relatively hypodense on the delayed phase images due to the early-washout of contrast medium by arterial blood. The capsule of encapsulated HCCs appears iso- or hypodense relative to the liver at the arterial phase of the enhancement, and enhances on delayed CT images.

An additional role for CT lies in the non-invasive evaluation of hepatic arterial anatomy in potential candidates for liver transplantation [65]. In the majority of

cases 3D CT arteriography was comparable to conventional arteriography and surgical findings in the delineation of the major hepatic arteries. The technique of 3D CT angiography is safe, convenient and less invasive than conventional arteriography [65].

On MR images, HCC has a variable appearance with low-intensity, isointensity, and high-intensity patterns seen on T1-weighted images, depending on the degree of fatty change, the presence of internal fibrosis, and dominant histologic pattern [21, 31, 47]. The capsule of encapsulated HCCs is visualized as a hypointense rim in T1-weighted images.

MR has also been used to differentiate small HCCs from regenerative nodules of cirrhosis. Cirrhotic nodules are usually of high signal intensity on T1-weighted images [42, 60, 66]. On T2-weighted images cirrhotic nodules are iso- or hypointense to the liver. The relative hypointensity is due to greater accumulation of iron within the nodule than in surrounding liver [42]. HCC arising within a siderotic nodule has a characteristic “nodule within a nodule” appearance on MR imaging. The HCC appears as a small focus of high signal intensity within the low signal intensity nodule [42].

Like in CT, during dynamic gadolinium enhanced imaging, HCC shows early enhancement in the arterial phase. In the portal phase, the tumor is usually isointense and in delayed phase, it becomes hypointense due to the contrast medium wash-out. HCCs larger than 1.5 cm in size tend to have a fibrous capsule that may be demonstrated as a hypointense band on delayed phase images (Figs. 38.6–38.9) [25]. MRI depicts vascular invasion, which is seen in 30–50% of patients, as a lack of signal void on multi-slice T1 weighted GRE and flow-compensated T2-weighted fast spin-echo images [30]. On gadolinium enhanced images, the tumor thrombus shows a typical early arterial enhancement.

Intrahepatic Cholangiocarcinoma

On unenhanced CT scans, this lesion usually manifests as a homogeneous, hypodense mass that shows early peripheral and delayed, persistent central enhancement after contrast agent injection [10, 12, 25, 32, 61]. Retraction of the overlying liver capsule is a feature suggestive of intrahepatic cholangiocarcinoma (ICAC) [61]. A central scar may be seen in 30% of cases. Small areas of necrosis, hemorrhage, mucin and calcification can also be present within the tumor. Biliary dilatation

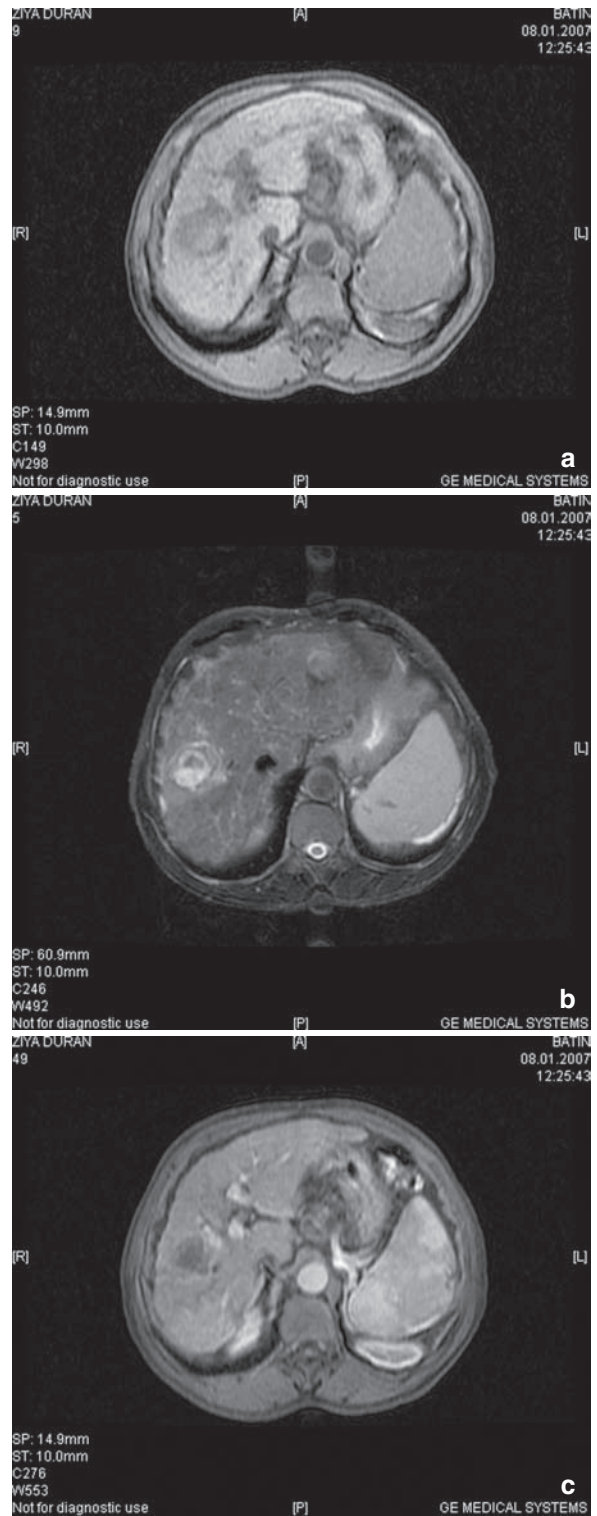


Fig. 38.6 Hepatocellular carcinoma. MR images show dysmorphic changes in the liver (due to cirrhosis) and a lesion in the right lobe of the liver. The lesion is hypointense on T1-weighted image (a), hyperintense on T2-weighted image (b) and shows early contrast enhancement during arterial phase image (c)

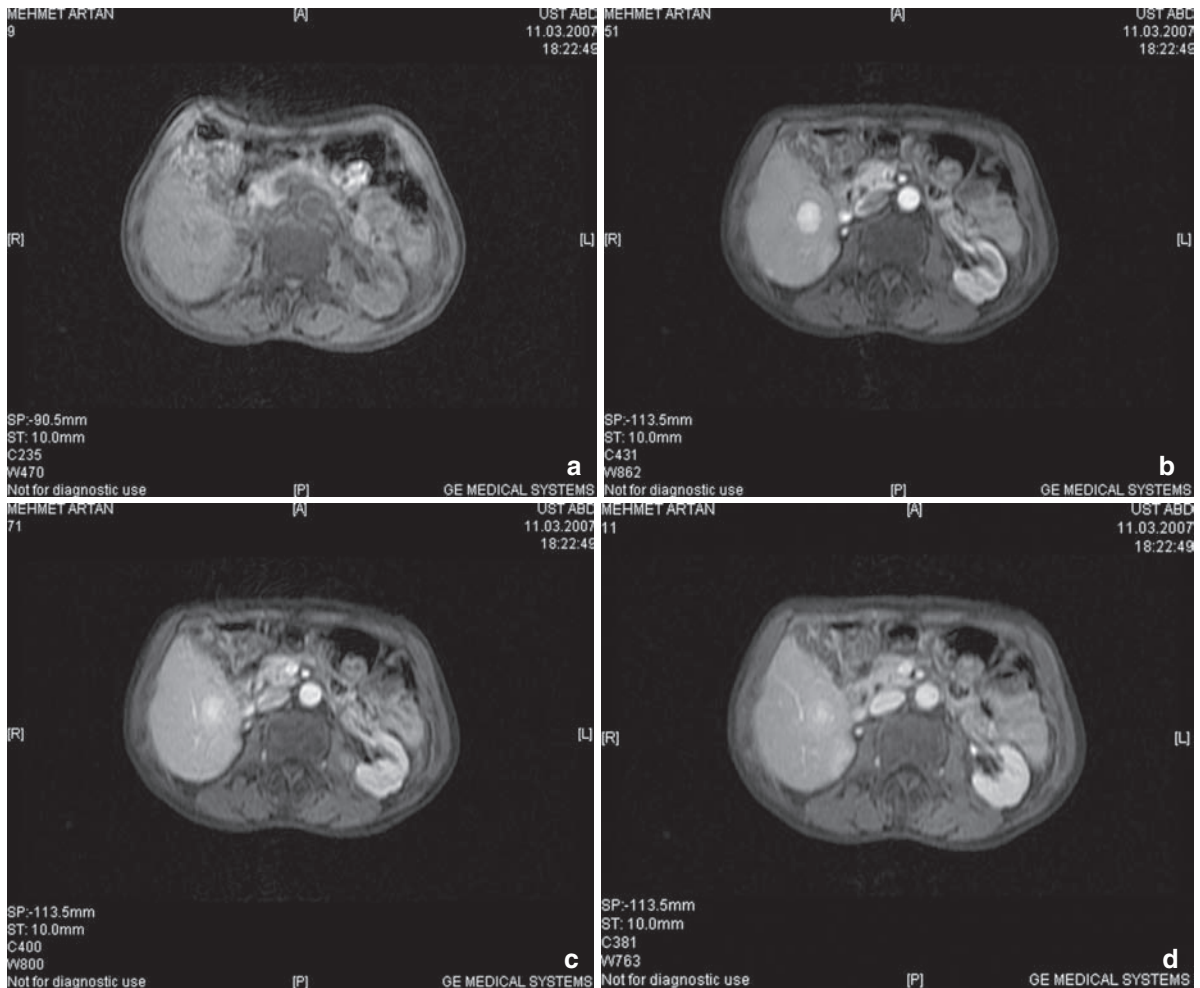


Fig. 38.7 Hepatocellular carcinoma. On T1-weighted pre-contrast image (a) a slightly hyperintense lesion is visible in the right hepatic lobe. The lesion strongly enhances in the arterial

phase (b) after gadolinium injection. On the portal venous phase image (c), the lesion is slightly hyperintense and on the delayed phase image (d) it becomes isointense to the liver

near to the tumor is another finding which can be detected in 20% of the cases.

On MR images, ICAC appears as a large mass of decreased signal intensity on T1WI and increased signal on T2-weighted images (Fig. 38.10) [1, 18]. A central area of hypointensity is seen in some cases on T2-weighted images and corresponds to the central scar. The pattern of enhancement on gadolinium-DTPA enhanced scans depends on the size of the lesion [1]. Whereas larger ICACs (>4cm) show peripheral enhancement which progresses centripetally and spares the central scar, smaller lesions (2–4cm) enhance homogeneously [1]. These patterns of enhancement may also be seen in hemangiomas. However, the degree of enhancement of hemangiomas is greater [1,

18]. In addition ICACs may have other features such as satellite nodules, invasion of the portal vein and dilatation of intrahepatic bile ducts distal to the lesion which are not associated with hemangiomas [18].

Metastases

On CT scans, metastases can be hyperdense, isodense, hypodense, hypodense with peripheral enhancement, cystic, complex, calcified, or diffusely infiltrating. The CT appearance depends on tumor size and vascularity, the degree of hemorrhage and necrosis, and the quality of the intravenous contrast bolus. Thus, individual metastatic lesions within the liver can have

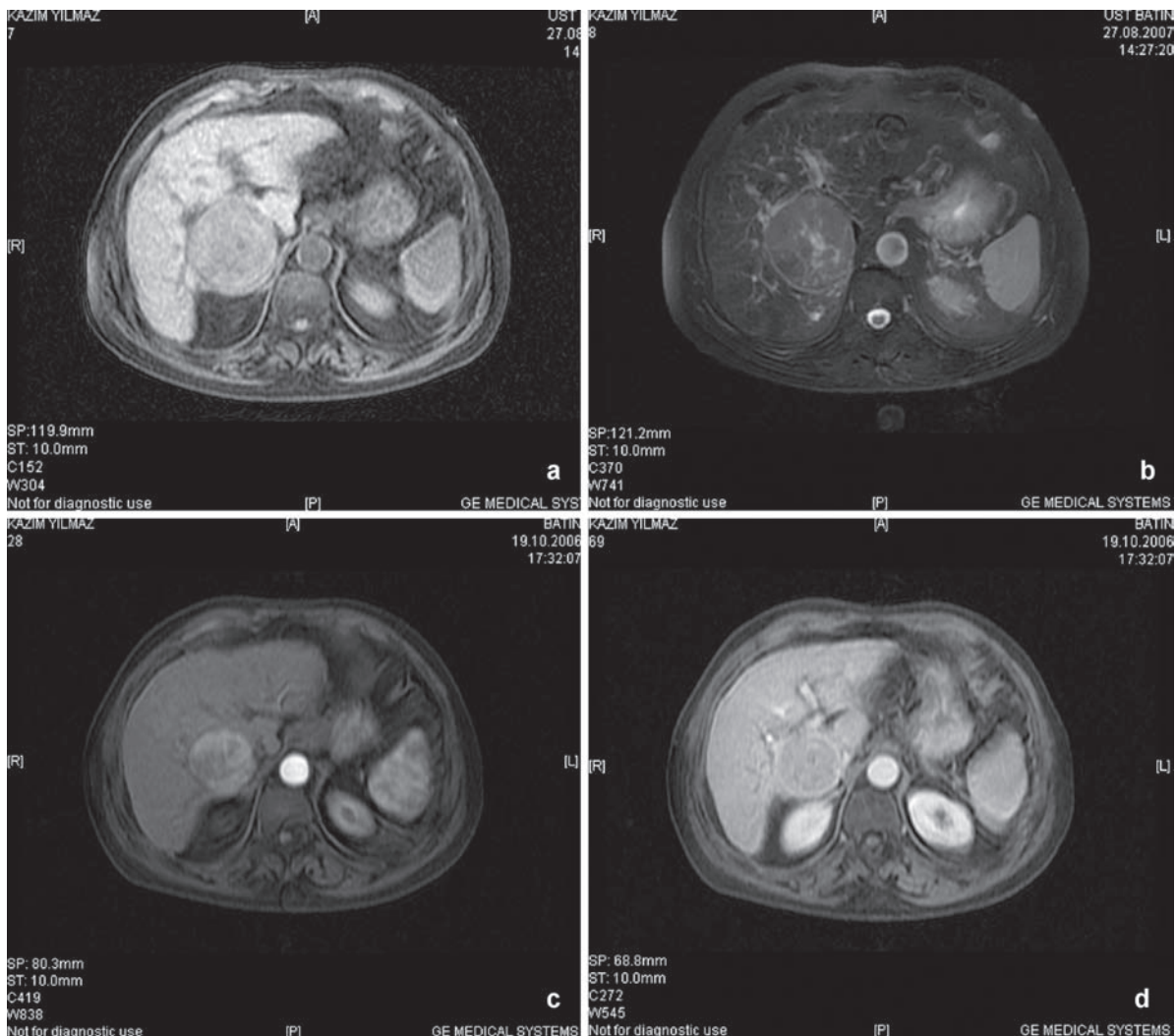


Fig. 38.8 Hepatocellular carcinoma. Axial T1-weighted (a) and T2-weighted (b) MR images show a well defined hyperintense lesion in the right lobe of the liver. Note the peripheral band of low signal intensity surrounding the lesion. Early- (c) and

delayed-phase (d) gadolinium-enhanced axial T1-weighted images show early homogeneous enhancement with washout and capsular enhancement

different CT findings and metastases from different cell types can appear identical [4, 19, 20, 26, 62].

Hypodense metastases are uncommon. These lesions are usually hypervascular and enhance rapidly and diffusely becoming isodense with normal liver. These lesions may be difficult to visualize on contrast-enhanced CT scans obtained during the portal venous phase of enhancement. Hypervascular lesions may occasionally be also seen as hypoattenuating lesions on PVP images [49]. Islet cell tumors are among the most common of the very hypervascular metastases, with breast carcinoma, carcinoid, melanoma, thyroid

carcinoma and renal cell carcinoma also resulting in hypervascular metastases [48].

The majority of metastases are hypodense with an attenuation between that of water and that of normal liver. These lesions are usually hypovascular, and intravenous contrast medium increases their conspicuity by increasing the density of normal liver. These lesions are best depicted during the portal phase of enhancement (60s after intravenous contrast) [6, 49]. Colon, lung, prostate, gastric and transitional-cell carcinoma are the most common tumors that appear as hypovascular liver metastases (Figs. 38.11–38.13) [53].

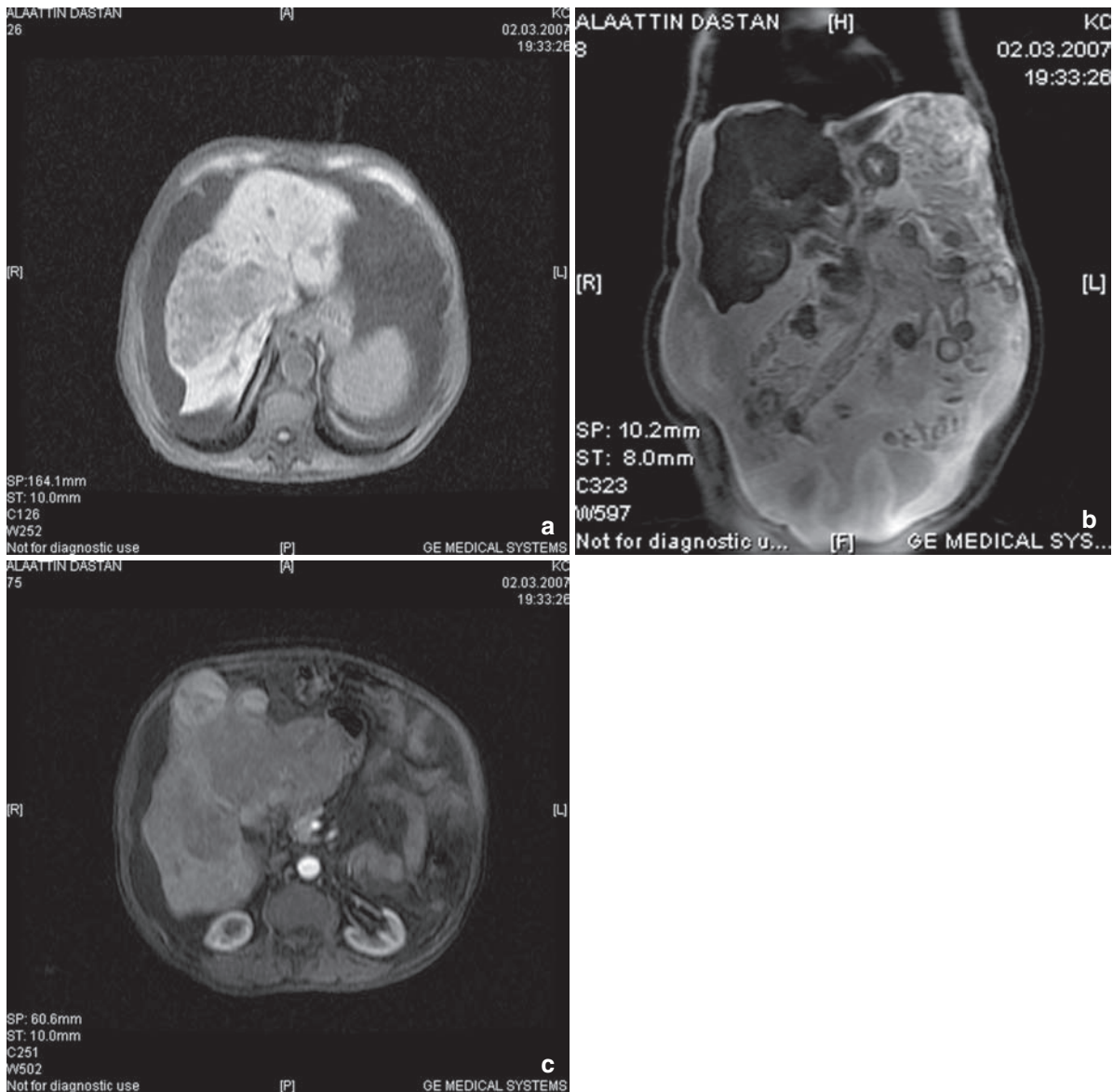


Fig. 38.9 Multifocal hepatocellular carcinoma. Axial T1-weighted (a) and coronal T2-weighted (b) MR images show dysmorphic changes of the liver and multiple lesions. The lesions show

different degrees of contrast enhancement on post-contrast T1-weighted axial MR image (c)

The T1 and T2 relaxation times of liver metastases vary considerably, depending on the primary tumor, the degree of necrosis, hemorrhage, and vascularity. Nevertheless, the T1 and T2 relaxation times of most liver metastases are longer than those of normal liver and shorter than those of simple cysts or hemangiomas. Therefore, liver metastases appear more hyperintense than the normal liver and more hypointense than the

cysts and hemangiomas on T2-weighted MR images (Figs. 38.14 and 38.15).

Several recent studies have evaluated the accuracy of SPIO-enhanced MRI in the detection of liver metastases using findings at intraoperative US and pathologic examination as the gold standard [24, 50, 58]. Using SPIO, metastatic lesions should appear unenhanced against a negatively enhanced liver. Gd-BOPTA

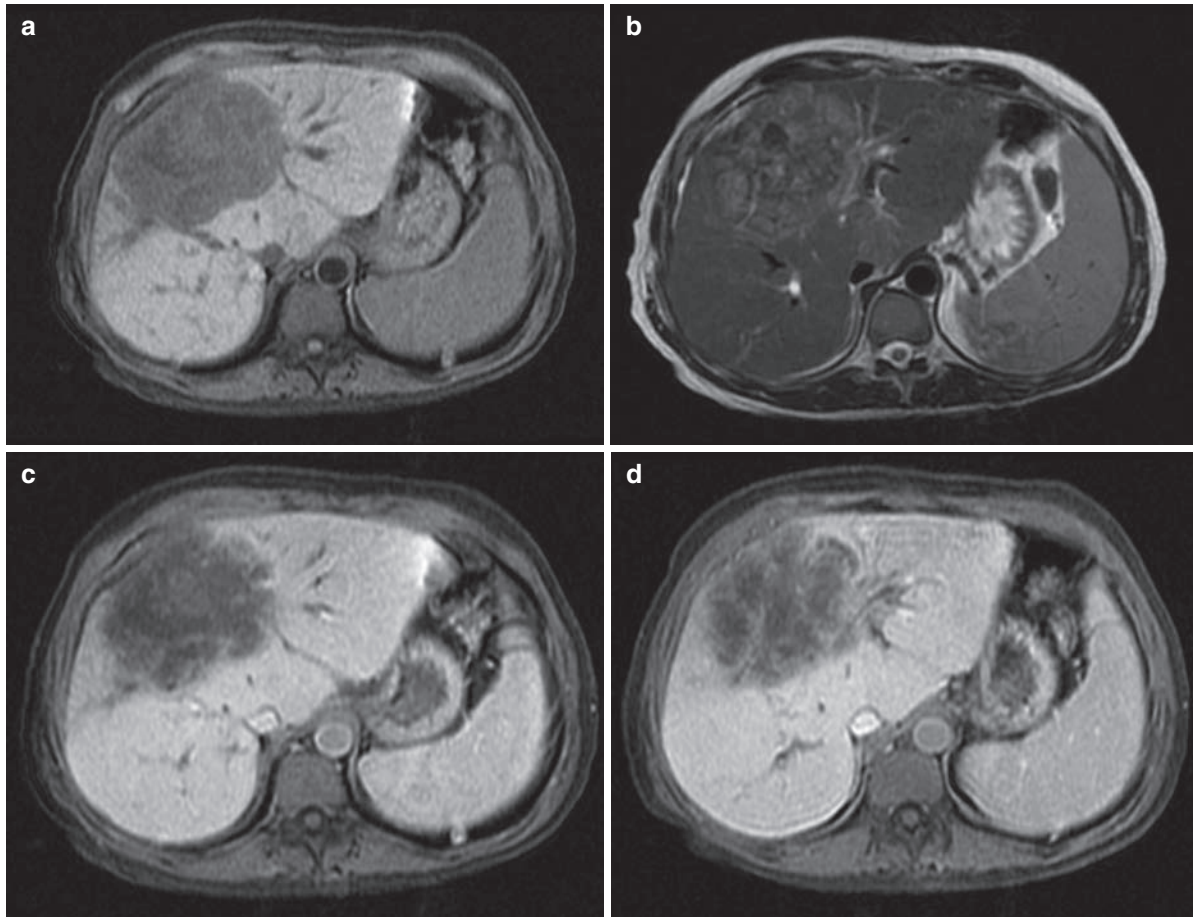


Fig. 38.10 Intrahepatic cholangiocarcinoma. Axial T1-weighted (a) and T2-weighted (b) MR images show a lesion in the right hepatic lobe. The lesion enhances heterogeneously and shows a peripheral rim-like enhancement on post-gadolinium images (c, d)

and Gd-EOB-DTPA are hepatobiliary positive contrast agents that show their enhancement effect on T1-weighted sequences. Using them, metastatic lesions should appear unenhanced against a positively enhanced liver. Although they have shown promising results in the detection of focal liver lesions, their exact role in the evaluation of patients with hepatic metastases and in differentiation of metastatic disease from primary disease has yet to be defined.

Focal Infections

Bacterial Hepatic Abscesses

Hepatic abscesses, like most other focal hepatic processes, prolong T1 and T2 relaxation times [40]. At MR

imaging, air within the abscess appears as a signal void and is therefore more difficult to differentiate from calcifications. However, the shape and location (air-fluid level) should enable the correct diagnosis. After administration of gadolinium-DTPA, abscesses typically show rim enhancement, which is secondary to increased capillary permeability in the surrounding liver parenchyma (the “double target” sign). Small lesions (<1 cm) may enhance homogeneously mimicking hemangiomas [40]. Abscess wall enhancement on dynamic postgadolinium images may be considered as a distinctive feature of pyogenic liver abscesses. Abscess wall shows a fast and intense enhancement that persists on portal venous and late-phase images. Some of the lesions may contain internal septations, which also reveal persistent enhancement on late phase images [3].

By virtue of its good spatial and contrast resolution, computed tomography (CT) is the single best method

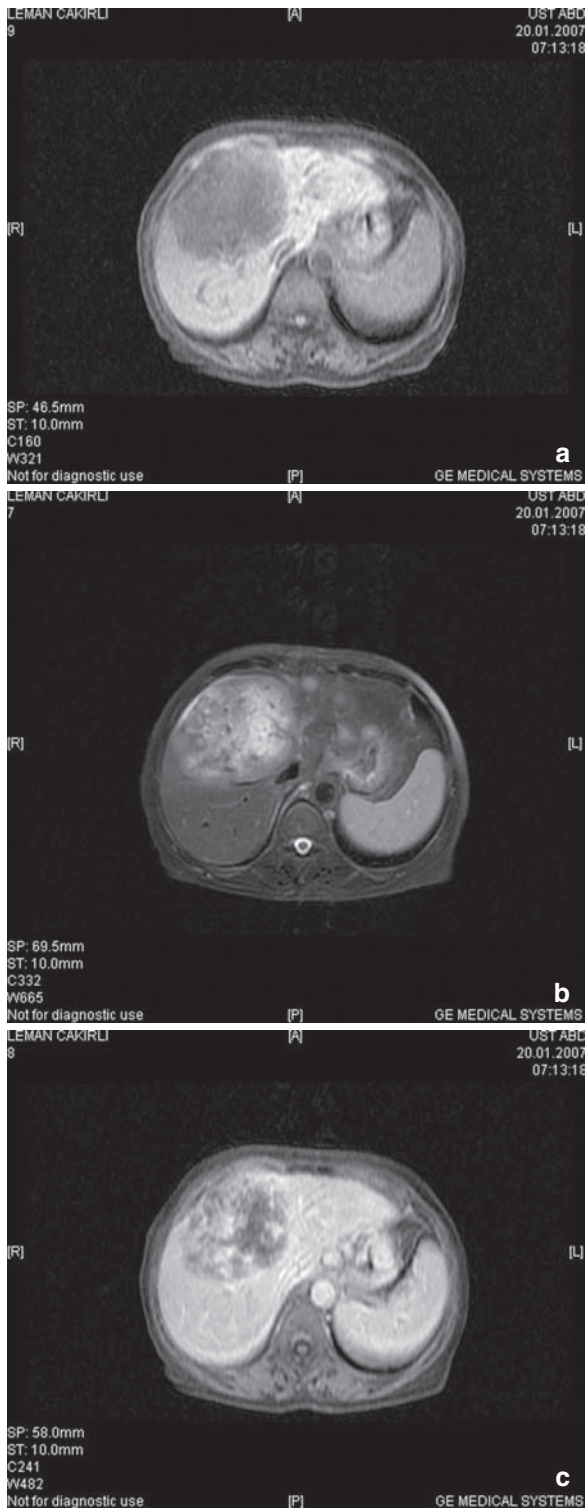


Fig. 38.11 Calcified liver metastases from malignant melanoma of the skin. Nonenhanced (a) and contrast-enhanced (b) CT images show calcified metastases in the right lobe of the liver

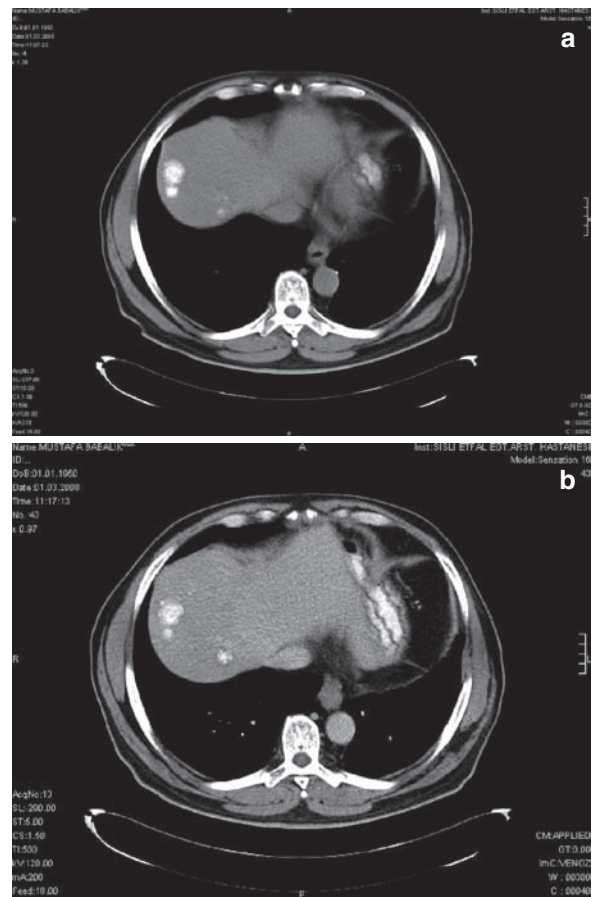


Fig. 38.12 Metastasis from gastric adenocarcinoma. The lesion is barely visible on the nonenhanced (a) CT image and becomes prominent on the contrast-enhanced CT image (b)

for detecting hepatic abscess, with a sensitivity as high as 97%. On CT scans, abscesses appear as generally rounded masses that are hypodense on both contrast and noncontrast scans. The presence of central gas, either as air bubbles or an air-fluid level, is a specific sign, but it is present in less than 20% of cases [15]. A large air-fluid or fluid-debris level is often associated with communication with the gut [34].

Amebic Abscesses

The CT appearance of amebic abscess is variable and nonspecific. The lesions are usually peripheral, round or oval areas of low attenuation (10–20 Hounsfield units). A peripheral rim of slightly higher attenuation can be seen on noncontrast scans and shows marked enhancement after administration of contrast material.

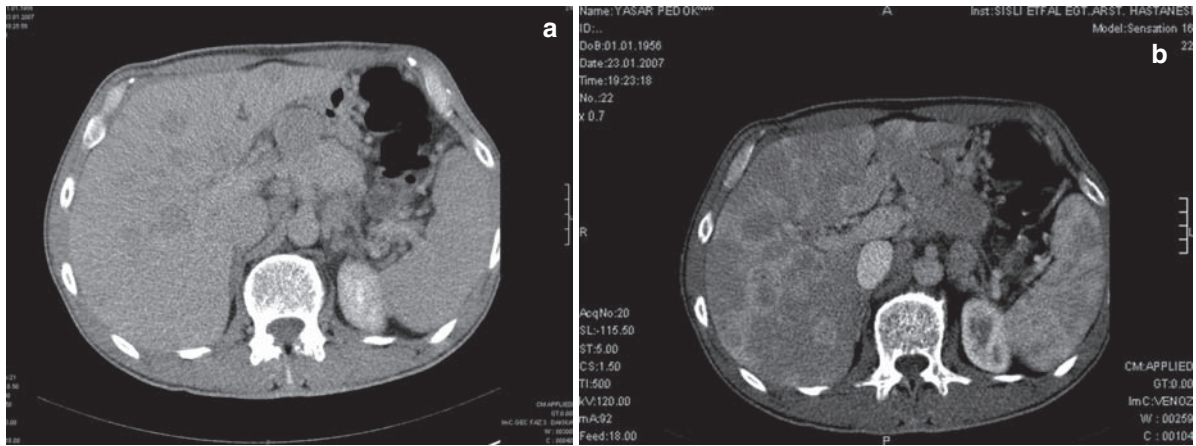


Fig. 38.13 Metastases from gastric adenocarcinoma. Both non-enhanced (a) and contrast-enhanced (b) CT images show multiple lesions within the liver. The non-enhancing central portions

of the lesions represent tumor necrosis. Note the presence of gastric wall thickening

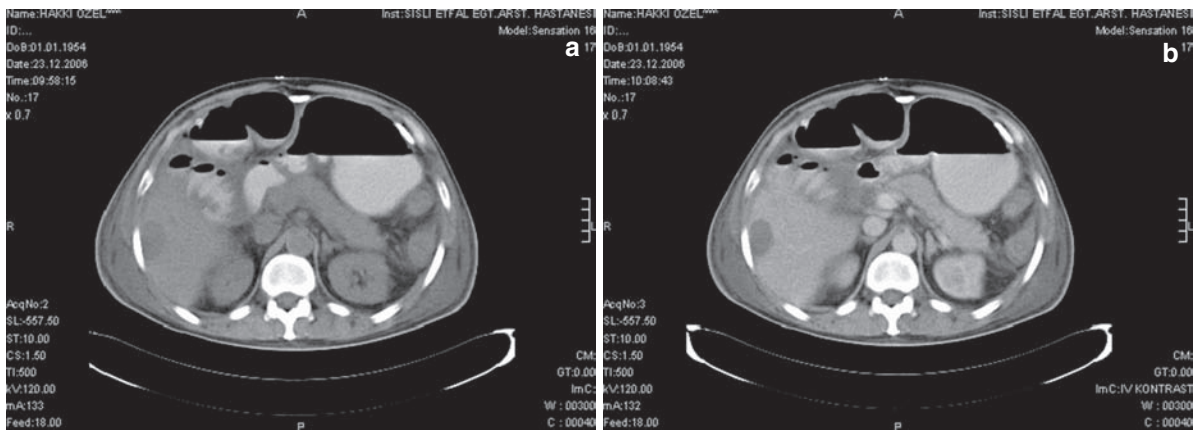


Fig. 38.14 Metastasis from adenocarcinoma of the colon. T1-weighted MR image (a) shows a large hypointense lesion in the right lobe of the liver. On the T2-weighted MR image (b), the

lesion appears hyperintense and some additional hyperintense lesions are also visible

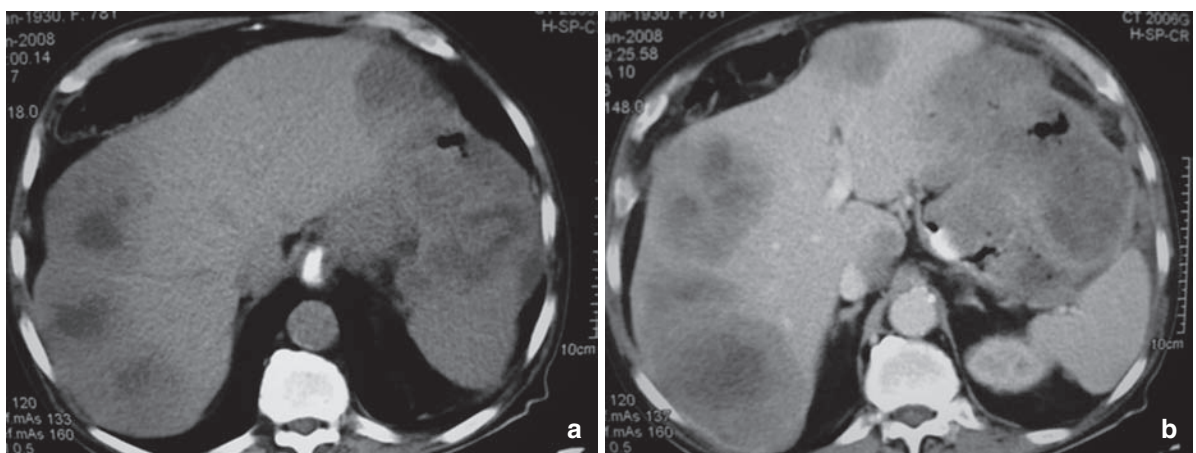


Fig. 38.15 Cystic metastasis from mucinous adenocarcinoma of the colon. The lesion is hypointense on T1-weighted image (a) and heterogeneously hyperintense on T2-weighted image (b)

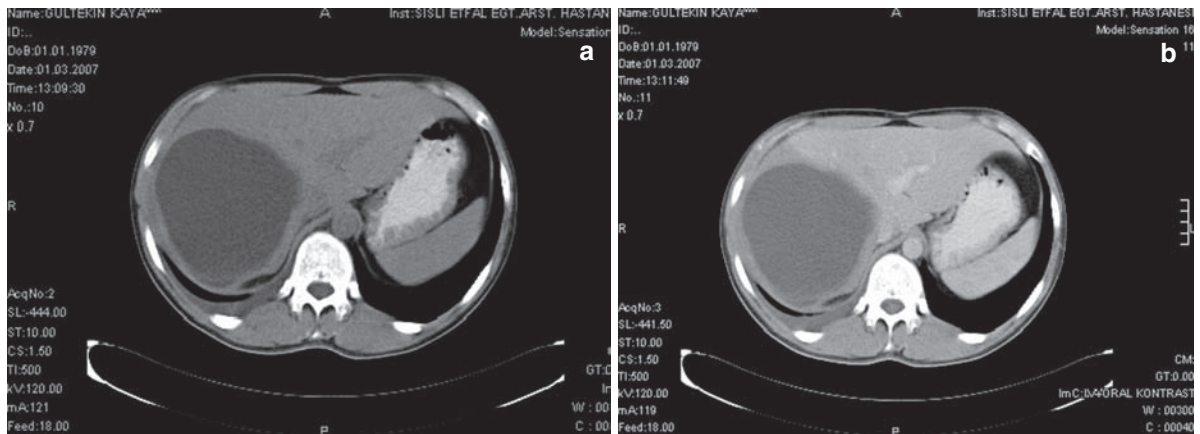


Fig. 38.16 Echinococcal cyst. Axial nonenhanced (a) and enhanced (b) CT images show a large cystic lesion in the right lobe of the liver. Note the presence of perilesional edema

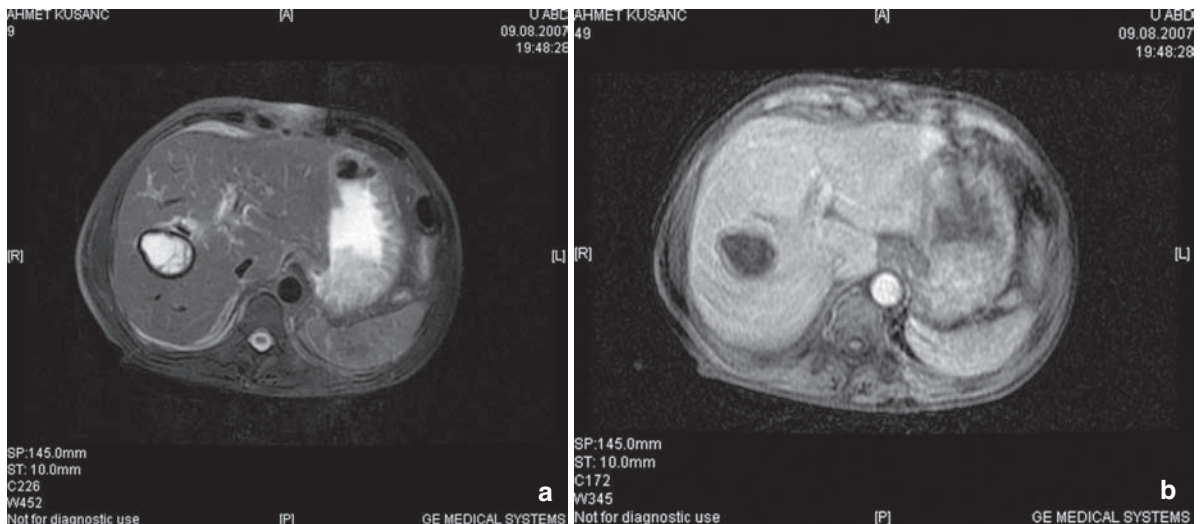


Fig. 38.17 Echinococcal cyst. Axial T2-weighted (a) and post-gadolinium T1-weighted (b) MR images show a cystic lesion in the right hepatic lobe that is surrounded by a hypointense rim and contains multiple septations

On MR imaging, amebic liver abscesses are spherical and usually solitary lesions with a hyperintense center on T2-weighted images and a hypointense center on T1-weighted images. The abscess wall is thick and on gadolinium enhanced images, the enhancement pattern is similar to that of pyogenic abscess [3, 44]. Diffuse central inhomogeneity is often seen on T2-weighted images. Edema in otherwise normal surrounding parenchyma may be appreciated on T2-weighted images [16, 54].

Hepatic Echinococcal Disease

On CT scans, hydatid disease appears as unilocular or multilocular, well-defined cysts with either thick or thin walls [3, 51]. Daughter cysts are usually seen as areas of lower attenuation than the mother cyst and are usually oriented in the periphery of the lesion. Daughter cysts can also float free in the lumen of the mother cyst, so altering the patient's position may change the position of these cysts, confirming the diagnosis of

echinococcal disease. Curvilinear ring-like calcification is also a common feature (Fig. 38.16) [38, 51].

On MR studies, the cyst component of echinococcal cysts is similar to that of other cysts, with long T1 and T2 relaxation times. However, because of its superb contrast resolution, MR imaging best demonstrates the pericyst, the matrix or hydatid sand (debris consisting of freed scolices), and the daughter cysts [44]. The pericyst usually has low signal intensity on T1- and T2-weighted images, because of its fibrous component. This rim and a multiloculated or multicystic appearance are distinctive features. The hydatid matrix appears hypointense on T1-weighted images and markedly hyperintense on T2-weighted images. When present, daughter cysts are hypointense relative to the matrix on both T1- and T2-weighted images [35]. Floating membranes have low signal intensities on T1- and T2-weighted images (Fig. 38.17).

Calcifications display low signal but are more difficult to identify on MR images than on CT [13].

Conclusion

In summary, both CT and MRI have essential roles in hepatic imaging. CT is an extremely valuable modality in the imaging of liver lesions. With the introduction of new technical developments, such as multidetector CT, the role of CT has become even more prominent. Today, liver lesions can be accurately detected and characterized via improved separation of liver enhancement phases and improved spatial resolution of the technique. MRI, on the other hand, seems to provide the overall most accurate detection and characterization of hepatic lesions. New MRI contrast agents further improve lesion detection and characterization. Furthermore, unlike CT, MRI does not carry the risks of patient irradiation.

References

- Adjei ON, Tamura S, Sugimura H, et al (1995) Contrast-enhanced MR imaging of intrahepatic cholangiocarcinoma. *Clin Radiol* 50: 6–10
- Arrive L, Flejou J-F, Vilgrain V, et al (1994) Hepatic adenoma: MR findings in 51 pathologically proved lesions. *Radiology* 193:507–12
- Balci NC, Sirvanci M (2002) MR imaging of infective liver lesions. *Magn Reson Imaging Clin N Am* 10: 121–35
- Baron RL, Freeny PC, Moss AA (1992) The liver. In: Moss AA, Gamsu G, Genant HK (eds) *Computed tomography of the whole body*, (2nd ed. WB Saunders, Philadelphia, PA, pp 735–822
- Baron RL, Oliver JH 3rd, Dodd GD 3rd, et al (1996) Hepatocellular carcinoma: Evaluation with biphasic, contrast-enhanced helical CT. *Radiology* 199: 505–11
- Bluemke DA, Soyer P, Fishman EK (1995) Helical (spiral) CT of the liver. *Radiol Clin North Am* 33: 863–86
- Braga L, Guller U, Semelka RC (2004) Modern hepatic imaging. *Surg Clin North Am* 84: 375–400
- Brancatelli G, Federle MP, Grazioli L, et al (2001) Focal nodular hyperplasia: CT findings with emphasis on multiphasic helical CT in 78 patients. *Radiology* 219: 61–8
- Buetow PC, Pantongrag-Brown L, Buck JL, et al (1996) Focal nodular hyperplasia of the liver: radiologic-pathologic correlation. *RadioGraphics* 16: 369–88
- Carr DH, Hadjis NS, Banks LM, et al (1985) Computed tomography of hilar cholangiocarcinoma: a new sign. *AJR* 145: 53–6
- Casarella WJ, Knowles DM, Wolff M, et al (1978) Focal nodular hyperplasia and liver cell adenoma: radiologic and pathologic differentiation. *AJR* 131: 393–402
- Choi BI, Han JK, Kim TK (1998) Diagnosis and staging of cholangiocarcinoma by computed tomography. In: Meyers MA (ed) *Neoplasms of the digestive tract: imaging, staging, and management*. Lippincott-Raven, Philadelphia, PA, pp503–16
- Claudon M, Bessieres M, Regent D, et al (1990) Alveolar echinococcosis of the liver: MR findings. *J Comput Assist Tomogr* 14: 608–614
- Cohen EI, Wilck EJ, Shapiro RS (2006) Hepatic imaging in the 21st century. *Semin Liver Dis* 26: 363–72
- Doyle DJ, Hanbidge AE, O'Malley ME (2006) Imaging of hepatic infections. *Clin Radiol* 61: 737–48
- Elizondo G, Weissleder R, Stark DD, et al (1987) Amebic liver abscess: diagnosis and treatment evaluation with MR imaging. *Radiology* 165: 795–800
- Erturk SM, Mortelé KJ, Oliva MR, et al (2005) State-of-the-art computed tomographic and magnetic resonance imaging of the gastrointestinal system. *Gastrointest Endosc Clin N Am* 15: 581–614
- Fan ZM, Yamashita Y, Harada M, et al (1993) Intrahepatic cholangiocarcinoma: Spin-echo and contrast-enhanced dynamic MR imaging. *AJR* 161: 313–7
- Foley WD, Jochem RJ (1991) Computed tomography: focal and diffuse disease. *Radiol Clin North Am* 29: 1213–33
- Friedman AC, Fishman EK, Radecki PD, et al (1987) Focal disease. In: Friedman AC (ed) *Radiology of the liver, biliary tract, pancreas and spleen*. Williams & Wilkins, Baltimore, MD, pp 151–264
- Fujita T, Honjo K, Ito K, et al (1997) High-resolution dynamic MR imaging of hepatocellular carcinoma with a phased-array body coil. *Radiographics* 17: 315–31
- Gibbs JF, Litwin AM, Kahlenberg MS (2004) Contemporary management of benign liver tumors. *Surg Clin North Am* 84: 463–80
- Grazioli L, Federle MP, Brancatelli G, et al (2001) Hepatic adenomas: imaging and pathologic findings. *Radiographics* 21: 877–92

24. Hagspiel KD, Neidl KFW, Eichenberger AC, et al (1995) Detection of liver metastases: Comparison of superparamagnetic iron oxide-enhanced and unenhanced MR imaging at 1.5T with dynamic CT, intraoperative US and percutaneous US. *Radiology* 196: 471–8
25. Harisinghani MG, Hahn PF (2002) Computed tomography and magnetic resonance imaging evaluation of liver cancer. *Gastroenterol Clin North Am* 31: 759–76
26. Heiken JP (1998) Liver. In: Lee JKT, Sagel SS, Stanley RJ, et al (eds) *Computed body tomography with MRI correlation*, 3rd edn. Lippincott-Raven, Philadelphia, PA, pp 701–78
27. Hussain SM, Semelka RC (2005) Hepatic imaging: comparison of modalities. *Radiol Clin North Am* 43: 929–47
28. Hussain SM, Semelka RC (2005) Liver masses. *Magn Reson Imaging Clin N Am* 13: 255–75
29. Hussain SM, Terkivatan T, Zondervan PE, et al (2004) Focal nodular hyperplasia: findings at state-of-the-art MR imaging, US, CT, and pathologic analysis. *24: 3–17*
30. Hussain SM, Zondervan PE, IJzermans JN, et al (2002) Benign versus malignant hepatic nodules: MR imaging findings with pathologic correlation. *Radiographics* 1023–36
31. Inoue E, Kuroda C, Fujita M, et al (1993) MR features of various histologic grades of small hepatocellular carcinoma. *J Comput Assist Tomogr* 17: 75–9
32. Itai Y, Araki T, Furui S, et al (1983) Computed tomography of primary intrahepatic biliary malignancy. *Radiology* 147: 485–90
33. Jang HJ, Lim JH, Lee SJ, et al (2000) Hepatocellular carcinoma: are combined CT during arterial portography and CT hepatic arteriography in addition to triple-phase helical CT all necessary for preoperative evaluation? *Radiology* 215: 373–80
34. Jeffrey RB, Tolentino CS, Chang FC, et al (1988) CT of small pyogenic hepatic abscesses: the cluster sign. *AJR* 151: 487–9
35. Kalovidouris A, Gouliamos A, Vlachos L, et al (1994) MRI of abdominal hydatid disease. *Abdom Imaging* 19: 489–94
36. Kamel IR, Bluemke DA (2003) MR imaging of liver tumors. *Radiol Clin North Am* 41: 51–65
37. Kim T, Federle MP, Baron RL, et al (2001) Discrimination of small hepatic hemangiomas from hypervascular malignant tumors smaller than 3 cm with three-phase helical CT. *Radiology* 219: 699–706
38. Lewall DB, Bailey TM, McCorrell SJ (1986) Echinococcal matrix: computed tomographic, sonographic, and pathologic correlation. *J Ultrasound Med* 5: 33–35
39. Mahfouz A-E, Hamm B, Taupitz M, et al (1993) Hypervascular liver lesions: differentiation of focal nodular hyperplasia from malignant tumors with dynamic gadolinium-enhanced MR imaging. *Radiology* 186: 133–8
40. Mendez RJ, Schiebler ML, Outwater EK, et al (1994) Hepatic abscesses: MR imaging findings. *Radiology* 190: 431–6
41. Michaely HJ, Attenberger UI, Kramer H, et al (2007) Abdominal and pelvic MR angiography. *Magn Reson Imaging Clin N Am* 15: 301–14
42. Mitchell DG (1992) Focal manifestations of diffuse liver disease at MR imaging. *Radiology* 185: 1–11
43. Morteale KJ, Praet M, Van Vlierberghe H, et al (2000) CT and MR imaging findings in focal nodular hyperplasia of the liver: radiologic-pathologic correlation. *Am J Roentgenol* 175: 687–92
44. Morteale KJ, Segatto E, Ros PR (2004) The infected liver: radiologic-pathologic correlation. *Radiographics* 24: 937–55
45. Motohara T, Semelka RC, Nagase L (2002) MR imaging of benign hepatic tumors. *Magn Reson Imaging Clin N Am* 10: 1–14
46. Ohtomo K, Itai Y, Yoshikawa K, et al (1987) Hepatic tumors: dynamic MR imaging. *Radiology* 163: 27–31
47. Ohtomo K, Matsuoka Y, Abe O, et al (1997) High-resolution MR imaging evaluation of hepatocellular carcinoma. *Abdom Imaging* 22: 182–6
48. Oliver JH 3rd, Baron RL, Federle MP, et al (1997) Hypervascular liver metastases: do unenhanced and hepatic arterial phase CT images affect tumor detection? *Radiology* 205: 709–15
49. Oliver JH III, Baron RL, Federle MP, et al (1996) Detecting hepatocellular carcinoma: value of unenhanced or arterial phase CT imaging or both used in conjunction with conventional portal venous phase contrast-enhanced CT imaging. *AJR* 167: 71–7
50. Oudkerk M, van den Heuvel AG, Wielopolski PA, et al (1997) Hepatic lesions: detection with ferumoxide-enhanced T1-weighted MR imaging. *Radiology* 203: 449–56
51. Pandolfo I, Blandino G, Scribano E, et al (1984) CT findings in hepatic involvement by echinococcus granulosus. *J Comput Assist Tomogr* 8: 839–45
52. Paulson EK, McClellan JS, Washington K, et al (1994) Hepatic adenoma: MR characteristics and correlation with pathologic findings. *AJR* 163: 113–6
53. Pedro MS, Semelka RC, Braga L (2002) MR imaging of hepatic metastases. *Magn Reson Imaging Clin N Am* 10: 15–29
54. Ralls PW, Henley DS, Colletti PM, et al (1987) Amebic liver abscess: MR imaging. *Radiology* 165: 801–4
55. Ros PR, Lubbers PR, Olmsted WW, et al (1987) Hemangioma of the liver: magnetic resonance-gross morphologic correlation. *AJR* 149: 1167–70
56. Ros PR (1990) Computed tomography-pathologic correlations in hepatic tumors. In: Ferrucci JT, Mathieu DG (eds) *Advances in hepatobiliary radiology*. CV Mosby, St. Louis, pp 75–108
57. Semelka RC (1997) Liver. In: Semelka RC, Ascher SM, Reinhold C (eds) *MRI of the abdomen and pelvis*. Wiley-Liss, New York, pp 19–136
58. Seneterre E, Taourel P, Bouvier Y, et al (1996) Detection of hepatic metastases. Ferumoxides-enhanced MR imaging versus unenhanced MR imaging and CT during arterial portography. *Radiology* 200: 785–92
59. Shamsi K, De Schepper A, Degryse H, et al (1993) Focal nodular hyperplasia of the liver: radiologic findings. *Abdom Imaging* 18: 32–8
60. Shimamoto K, Sakuma S, Ishigaki T, et al (1992) Hepatocellular carcinoma: evaluation with color Doppler US and MR imaging. *Radiology* 182:149–53
61. Soyer P, Bluemke DA, Reichle R, et al (1995) Imaging of cholangiocarcinoma: I. peripheral cholangiocarcinoma. *AJR* 165: 1427–31
62. Stephens DH (1988) The liver. In: Haaga JR, Alfydi RJ (eds) *Computed tomography of the whole body*. CV Mosby, St. Louis, pp 792–853
63. Vilgrain V, Boulous L, Vullierme MP, et al (2000) Imaging of atypical hemangiomas of the liver with pathologic correlation. *Radiographics* 20: 379–97
64. Vilgrain V, Flejou J-F, Arrive L, et al (1992) Focal nodular hyperplasia of the liver: MR imaging and pathologic correlation. *Radiology* 184: 699–703

65. Winter TC III, Freeny PC, Nghiem HV, et al (1997) Hepatic arterial anatomy. In: Fujita T, Honjo K, Ito K, et al (eds) High-resolution dynamic MR imaging of hepatocellular carcinoma with a phased-array body coil. *Radiographics* 17: 315–31
66. Yamamoto H, Yamashita Y, Yoshimatsu S, et al (1995) Hepatocellular carcinoma in cirrhotic livers: detection with unenhanced and iron-oxide enhanced MR imaging. *Radiology* 195: 106–12
67. Yamashita Y, Ogata I, Urata J, et al (1997) Cavernous hemangioma of the liver: pathologic correlation with dynamic CT findings. *Radiology* 203: 121–5

Chapter Outline

Static Liver/Spleen-, Colloidal Scintigraphy	425
Principle of Investigation and Pathophysiology.....	425
Acquisition Technology	426
Interpretation.....	426
Blood Pool and Perfusion Scintigraphy	426
Principle of Investigation and Pathophysiology.....	426
Acquisition Technology	426
Interpretation.....	427
Hepatobiliary Scintigraphy	427
Principle of Investigation and Pathophysiology.....	427
Acquisition Technology	427
Interpretation.....	428
Focal Liver Lesions.....	429
¹⁸F-FDG-PET/ -CT	432
Focal Liver Lesions.....	433
References	435

Nuclear medicine imaging procedures supplement primarily morphologic techniques by providing functional, metabolic and molecular information. This chapter focuses on the different scintigraphic procedures and their indications in liver diagnostics. Their clinical impact has changed by the establishment of ultrasound, computed tomography (CT) and magnetic resonance imaging (MRI) (see Chapters 37 and 38) [53]. The detection of intrahepatic lesions is no longer the principle aim of nuclear medicine procedures, unless the patients cannot be examined using morphologic techniques (adiposity, contraindications for application of contrast media, cardiac pacemaker, metal parts in situ). The priority of scintigraphic procedures is the differential diagnostics with regard to the distinction and originality of the detected lesions. Different tracer principles and acquisition techniques are applied, adapted to the respective assumed diagnosis.

Static Liver/Spleen-, Colloidal Scintigraphy

Principle of Investigation and Pathophysiology

Approximately 65% of the cells of the liver parenchyma are hepatocytes, 15% Kupffer cells, and the remaining 20% comprise endothelial and stellate cells (Ito cells) as well as epithelial cells of the bile ducts. As part of the reticuloendothelial system (RES), the Kupffer cells possess the ability of phagocytosis, e.g. of colloidal particles [17]. ^{99m}Tc-labelled colloidal particles are also stored by the cells of the RES in the spleen and bone marrow. The relative distribution of

the colloids between these three organ systems is influenced by their particle size. Particles with a size of 200–1,000 nm, like sulphur colloids, preferentially accumulate in the liver. Accordingly, 85% of the sulphur colloid is taken up by the liver, 10% by the spleen and 5% by the bone marrow [44].

Hepatic diseases, which lead to a destruction of the RES, cause diffuse reductions in tracer accumulation or focal defects in the colloidal scintigraphy. Therefore, these reductions in tracer uptake are non-specific and allow no conclusion with respect to the etiology of the underlying disease. Instead, this technique yields some quantitative data on regional and global function.

Acquisition Technology

Planar images of the liver are acquired 20–30 min after intravenous injection of 100–200 MBq ^{99m}Tc -sulphur- or albumin colloid [45]. Additionally, a single photon emission computed tomography (SPECT) should be performed, particularly in order to increase the detection rate of central photopenic defects in the liver. A functional test of perivenous shunts can be accomplished after injection of 150 MBq of ^{99m}Tc -labelled macro-aggregated albumin particles into the ascites.

Interpretation

Organ size and shape can be judged using colloidal scintigraphy. The liver spleen quotient can be calculated on the basis of the geometrical mean, the volumes of the functional liver tissue can be determined, and the extent and homogeneity of the liver uptake can be estimated. In particular, the liver parenchyma is screened for photopenic defects [16]. A diffuse reduction in the hepatic uptake or a shift of the activity maximum to the relatively enlarged left liver lobe with a concomitant increase in the bone marrow is found in patients with liver cirrhosis. An increase in lienal tracer accumulation with a reduction in the liver/spleen ratio occurs during the development of portal hypertension. This so-called “colloidal shift” is a typical pattern in hepatic failure. In the case of Budd Chiari syndrome the tracer accumulation in projection of the lobus caudatus is normal, whereas it is diffusely reduced in the remaining liver

parenchyma. If only the lobus quadratus shows an inconspicuous uptake an obstruction of the superior vena cava can be diagnosed. A physiological hepatic colloid distribution is found in hepatic diseases without involvement of the reticuloendothelial system (e.g. virus hepatitis). Large mass lesions usually cause a destruction and/or a displacement of the liver parenchyma. Therefore, metastases, hepatocellular carcinomas, cysts and abscesses present with nonspecific uptake defects. Focal nodular hyperplasia belongs to liver tumors with normal or even enhanced phagocytotic activity. A pulmonary activity accumulation is found in the functional tests of peritoneovenous shunts and in hepatopulmonary syndrome because the labelled macro-aggregated albumin particles (^{99m}Tc -MAA) enter the pulmonary circulation via the venous blood pool.

Blood Pool and Perfusion Scintigraphy

Principle of Investigation and Pathophysiology

The blood pool can be imaged by intravenous injection of ^{99m}Tc -labelled autologous erythrocytes [55]. The erythrocytes can be labelled *in vivo*, *in vitro* or combined *in vivo/in vitro* using a commercially available kit. The hepatic blood circulation can be examined with ^{99m}Tc -DTPA [45].

Acquisition Technology

A triple-phase scintigraphy with a fast sequence for the perfusion phase followed by early and late static acquisitions in several projections is performed after bolus injection of 750 MBq ^{99m}Tc -labelled autologous erythrocytes. Blood pool scintigraphy is indicated especially in suspicion of a liver hemangioma [27]. Due to the cavernous transformation a decreased or normal blood flow can be found, while the blood pool activity and the contrast to the normal liver parenchyma increase over time. Because of the slight stasis this so-called “fill in” is faster in small than in large hemangiomas. Late images are obligatory due to the slow “fill in” and SPECT should be performed approximately 2 h post-infusion.

After intravenous bolus injection (0.5 mL) of 400 MBq ^{99m}Tc -DTPA time activity curves are acquired over the liver and a purely arterially perfused organ such as the spleen or kidney for determination of the hepatic perfusion. The dual blood supply of the liver results in a biphasic time activity curve with a 1st activity increase by the arterial and a 2nd peak by the portal venous perfusion. The areas under the curves can be evaluated quantitatively and correspond to the perfusion rates of the arterial and portovenous phases.

Interpretation

Hemangiomas show the typical “fill in” phenomenon in the blood pool scintigraphy [32]. The perfusion scintigraphy is the only non-invasive procedure to assess the relative proportions of the arterial and portovenous blood perfusion of the liver. Normal values of the arterial fraction amount to 20–40% of the total perfusion. In portal hypertension due to liver cirrhosis the arterial fraction is increased to about 60%. However, depending on the degree of decompensation, values of up to 90–100% may also be found. The liver scintigraphy can be helpful for the evaluation of the blood perfusion after a hepatic trauma and partial liver resection as well as for follow-up examinations after liver transplantation and implantation of transjugular intrahepatic portosystemic shunts (TIPS) [31, 47]. Intrahepatic metastases are supplied via branches of the *arteria hepatica*. Therefore, a progressive metastatic spread leads to a relative increase in the arterial perfusion of the liver. The time activity curve over the hepatic lesion shows a clearly reduced or missing portovenous perfusion.

Hepatobiliary Scintigraphy

Principle of Investigation and Pathophysiology

The scintigraphy with ^{99m}Tc -labelled iminodiacetate derivatives (IDA, HIDA, DISIDA, Lidocain) permits the evaluation of the regional and global hepatobiliary function and the bile duct system [34]. These compounds

are taken up by the hepatocytes via an active transport mechanism and are excreted via the bile ducts without conjugation. The IDA derivatives are not absorbed in the intestine. Bilirubin competes with their specific uptake into the hepatocytes. Therefore, high bilirubin serum levels do not prevent the hepatobiliary scintigraphy. However, they require the application of higher activities and a prolonged data acquisition. The renal elimination becomes more important with high bilirubin serum levels.

Hepatobiliary scintigraphy is the only imaging procedure that allows the non-invasive investigation of the regional and global liver function. Intrahepatic lesions can destroy or displace liver parenchyma. Therefore, they lead to nonspecific photopenic defects in analogy to the colloidal scintigraphy. On the other hand, hepatic tumors like the hemangioma, FNH or HCC can present with increased uptake to variable degrees in the different phases of hepatobiliary scintigraphy [42]. The rapid kinetics of the radiopharmaceutical leads to contrast differences between the liver parenchyma and the bile ducts, which are helpful for the evaluation of the metabolic “trapping” in these liver tumors.

Apart from focal hepatic lesions, the hepatobiliary scintigraphy offers the possibility to detect impairments in global liver function often before the corresponding changes in the laboratory constellation occur. In addition, this investigation can be helpful for the evaluation of the rejection of liver transplants.

Acquisition Technology

According to the bilirubin serum level 75–370 MBq ^{99m}Tc -labelled iminodiacetate derivatives are injected intravenously (adults <5 mg/dL: 75–100 MBq, 5–10 mg/dL: 200 MBq, > 10 mg/dL: 370 MBq; infants and babies approx. 20 MBq in accordance with the recommendations of the EANM Paediatrics Committee) [29]. The patients should be instructed to fast for 4–24 h.

Depending upon the localization of the hepatic lesion ventral or dorsal images are acquired. An additional SPECT image in the late phase is useful.

If necessary a stimulating meal (baby’s milk) can be given, in order to induce the emptying of the bile ducts and the gallbladder. If no activity can be detected in the small intestine after 3 h, delayed images should be acquired up to 24 h post-infusion (p.i.)

Interpretation

The normal transport kinetics of the radiopharmaceutical shows a peak accumulation in the liver parenchyma at 10 ± 3 min, with a time of appearance in the ductus choledochus at 10 ± 4 min, in the gallbladder at 15 ± 5 min and in the duodenum at 20 ± 8 min p.i. [45]. Almost no activity should remain in the liver parenchyma 60 min p.i. In impaired liver parenchyma the activity accumulation is reduced and its elimination is delayed.

The occlusive jaundice is characterized by a lack of activity excretion into the intestine, whereas in parenchymal jaundice the radiopharmaceutical is excreted into the intestine [10]. The hepatobiliary scintigraphy can be helpful in patients with an early occlusive jaundice before the sonographic visualization of a dilated bile duct system may be feasible. In addition, the diagnostic accuracy of the ultrasound is limited in patients with a history of a former occlusive jaundice, since a dilated bile duct system may persist for years. Thus, the hepatobiliary scintigraphy is of

particular importance after a sphincterotomy or a biliodigestive anastomosis.

In patients with Caroli's syndrome dilated bile ducts can be delineated.

The suspicion of a congenital bile duct atresia is the principle indication in the differential diagnostic assessment of jaundice in pediatrics [33]. The complete bile duct occlusion is characterized by a tracer retention until 24 h p.i (Fig. 39.1a–c). Thus, the acquisition of delayed images is obligatory. The delineation of intrainestinal activity excludes an atresia of the bile ducts. In case of incomplete occlusion the appearance of intestinal activity is markedly reduced (> 1 h).

Biliary leakage, bile duct fistula and obstructions can be detected with high sensitivity using the hepatobiliary scintigraphy, as, for example, after an abdominal trauma and postoperatively. Therefore, hepatobiliary scintigraphy has regained clinical importance with the use of non-invasive surgical procedures, especially, after laparoscopic cholecystectomy [34]. The extrahepatic and extraintestinal detection limit of the labelled

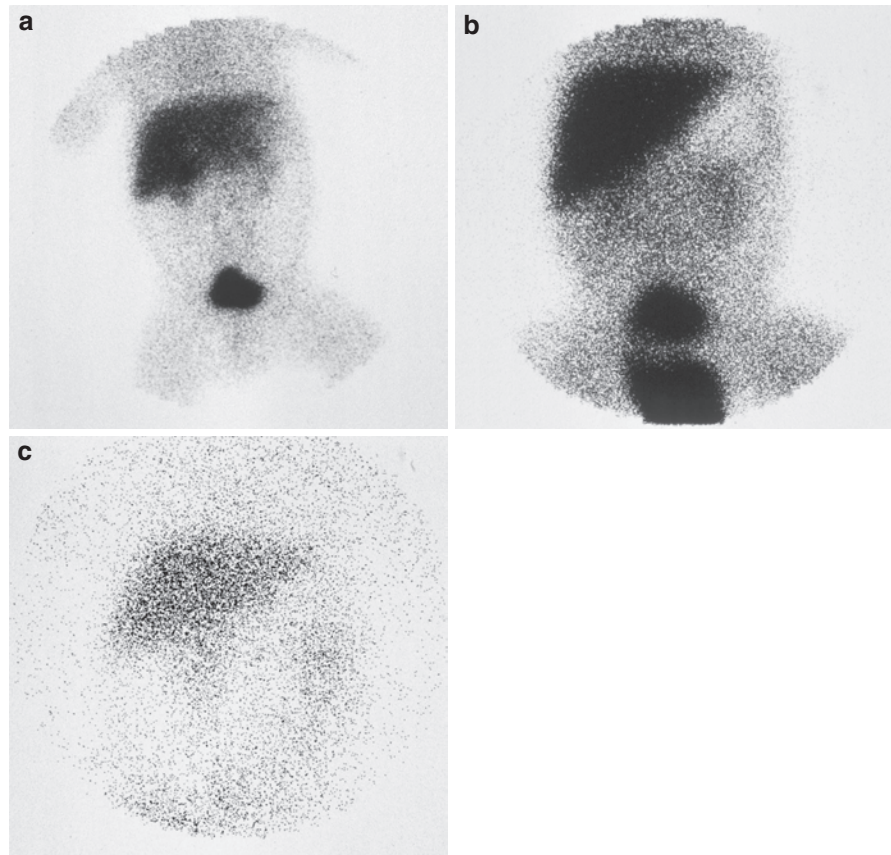


Fig. 39.1 Hepatobiliary scintigraphy (^{99m}Tc -HIDA; RAL). Bile duct atresia in a 9-day-old baby. (a) 52 min post-infusion (p.i.), (b) 6 h p.i., (c) 24 h p.i. Normal uptake in the liver parenchyma, the gallbladder is not visualized, renal elimination, no intestinal activity until 24 h p.i.

biliary acid in case of a leakage is 0.5 mL/min. Furthermore, the presence of bile duct obstructions or biliary leakage and anastomosis insufficiency, respectively, can be assessed.

A clearly delayed gallbladder visualization is found in chronic cholecystitis. The gallbladder cannot be delineated in patients suffering from acute cholecystitis and occlusion of the cystic duct [10]. In 20% of patients with acute cholecystitis a pericholecystic band with increased uptake can be found 30–60 min p.i. besides the missing intracystic tracer accumulation. This phenomenon is attributed to a stasis in inflammatory, edematously altered liver parenchyma in the gallbladder bed. Acute acalculous cholecystitis is predominantly seen in intensive-care patients, as for example after polytrauma or extensive burns, during sepsis and postoperatively. Due to an increased incidence of gallbladder gangrene and perforation it is clearly associated with a higher mortality rate than acute calculous cholecystitis. Therefore, an early diagnosis is mandatory. This can be achieved with hepatobiliary scintigraphy which is characterized by a high sensitivity of 91%.

Hepatobiliary scintigraphy is the only adequate non-invasive test for the detection of a biliary reflux. This procedure is almost exclusively performed in patients with (partial) gastric resection, because a biliary reflux can only be found in these patients (Fig. 39.2). The lower limit for the scintigraphic detection of a biliary reflux is 1% of the injected activity.

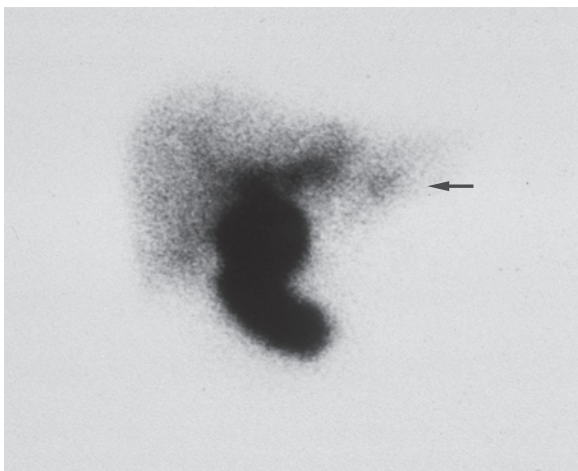


Fig. 39.2 Hepatobiliary scintigraphy (^{99m}Tc -HIDA; RAL). Biliary reflux after Billroth-II-gastrectomy with Braun-enteroanastomosis. Movement of the activity into the duodenal stump

However, the reproducibility amounts to only 75% due to the intermittent occurrence of the biliary reflux.

Focal Liver Lesions

Noninvasive imaging procedures play an elementary role in the diagnostics of focal liver lesions [13, 42]. Morphologic and functional nuclear medicine procedures yield complementary information for the differential diagnostics of hepatic lesions [17, 53]. The presumed diagnosis and the indication for the investigation, respectively, determine the selection and the sequence of the nuclear medicine techniques.

In addition to the three nuclear medicine procedures presented in detail there are further techniques available to visualize pathophysiological processes in the liver parenchyma or in hepatic tumors. Intrahepatic abscesses can be detected and differentiated from other space occupying lesions by monoclonal murine antibodies, which are directed against the surface antigen NCA-95 of neutrophil granulocytes [8]. Alternatively, focal infections of the liver can also be demonstrated using the more complex separation and extracorporeal labelling of autologous leucocytes with ^{111}In -Oxin or ^{99m}Tc -HMPAO.

Scintigraphy with ^{99m}Tc -labelled anti-alpha-fetoprotein-f (ab') antibody fragments with SPECT yields a high sensitivity of approximately 95% in the diagnostics of the HCC [14]. Somatostatin-positive hepatic metastases, which occur predominantly in neuroendocrine tumors including carcinoids, paragangliomas and islet cell tumors, can be visualized specifically using ^{111}In -labelled somatostatin analogs [35]. Therefore, ^{111}In -octreotide-scintigraphy is primarily used as a nuclear-medicine diagnostics in these tumors. In addition, $^{131/123}\text{I}$ -mlBG is a specific marker for tumors of chromaffin tissues.

The SPECT technique is an essential component of the scintigraphic assessment of hepatic lesions [43]. SPECT is superior to planar scintigraphy to visualize small, multiple or central lesions in the liver as well as lesions in the vicinity of the large blood vessels, the heart and the kidneys, respectively. High-resolution multi-headed SPECT systems permit the detection of lesions as small as 0.5 cm in case of a well-situated position of the lesion with regard to the neighbouring structures and a good tumor/background ratio [55].

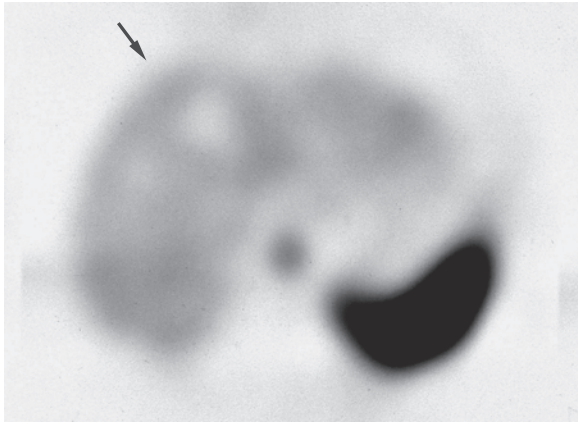


Fig. 39.3 Blood pool scintigraphy (^{99m}Tc -labelled autologous erythrocytes, in-vitro-technique). Liver tumor in a female patient with breast cancer and known bone metastasis. SPECT, transaxial view. A circular area of reduced uptake in projection of the right liver lobe (segment VIII) on tomography. The findings do not support the presence of a hemangioma

The SPECT technique clearly increases the sensitivity but not the specificity (Fig. 39.3).

Hemangioma

Cavernous hemangiomas are the most frequent benign liver tumors with incidences between one and 7% at autopsy. A major diagnostic challenge is the distinction from other liver tumors, in particular from hepatic metastases (Figs. 39.3 and 39.4). Compared to other noninvasive investigations the blood pool scintigraphy (“fill in”-phenomenon) is the procedure with the highest specificity (sensitivity 89%, specificity 95%). In a recent study with a high-resolution triple-headed SPECT camera the sensitivity reached 100% in hemangiomas > 1.4 cm [55]. A hemangioma can be excluded if a lesion shows a tracer uptake in the hepatobiliary scintigraphy (Table 39.1).

Focal Nodular Hyperplasia

Focal nodular hyperplasia (FNH) is the second most frequent benign tumor of the liver. Compared to normal liver parenchyma the density of the bile ducts is reduced. Accordingly, the FNH presents with hypervascularity and a reduced to normal tracer accumulation in the parenchymal phase of the hepatobiliary

scintigraphy because of its preserved hepatocytic function [42]. Furthermore, it shows a delayed excretion (“trapping”) due to its low density of bile ducts (Fig. 39.5). This typical scintigraphic constellation can be found in approximately 80% of the patients with FNH. In contrast, only about 2% of the patients with known hepatocellular carcinomas show this uptake pattern. In cases of doubt the diagnosis can only be proven histologically. The colloidal scintigraphy demonstrates a tracer accumulation in FNH because the phagocytic capacity of the RES is preserved [45]. “Cold” lesions are rather rare in this tumor entity. The preserved colloid uptake is characteristic and the occasionally increased tracer accumulation is pathognomonic for the FNH. This typical scintigraphic pattern facilitates the distinction from other hepatic tumors with a destroyed RES, like metastases, hemangiomas, adenomas and hepatocellular carcinomas (Table 39.1).

Hepatocellular Adenoma

Hepatocellular adenomas are the third-most frequent benign liver tumors. In the colloidal scintigraphy uptake defects are observed because bile ducts, portal fields and Kupffer cells are missing [44]. In addition, most of the adenomas with histologically proven Kupffer cells show focal “cold” defects. This finding is attributed to a decreased phagocytic activity or an altered blood flow due to an infarction or a thrombosis. In contrast, colloid-accumulating adenomas are very rare. Typically, hepatobiliary scintigraphy shows a normal perfusion and a reduced or missing tracer uptake in the parenchyma- and excretion-phase according to the histological structure of hepatocellular adenomas [45]. Thus, this tumor entity can be discriminated from FNH but not from HCC. HCC can only be diagnosed if tracer accumulating metastases are demonstrated. Otherwise, a histological verification is mandatory.

Liver Metastases

Metastases are the most frequent malignant liver tumors. Commonly, the static liver scintigraphy has been replaced by ultrasound, CT and MRI with regard to lesion detection [17]. This is due to the fact that colloidal scintigraphy is a nonspecific procedure with low sensitivity for small lesions due to its moderate spatial resolution.

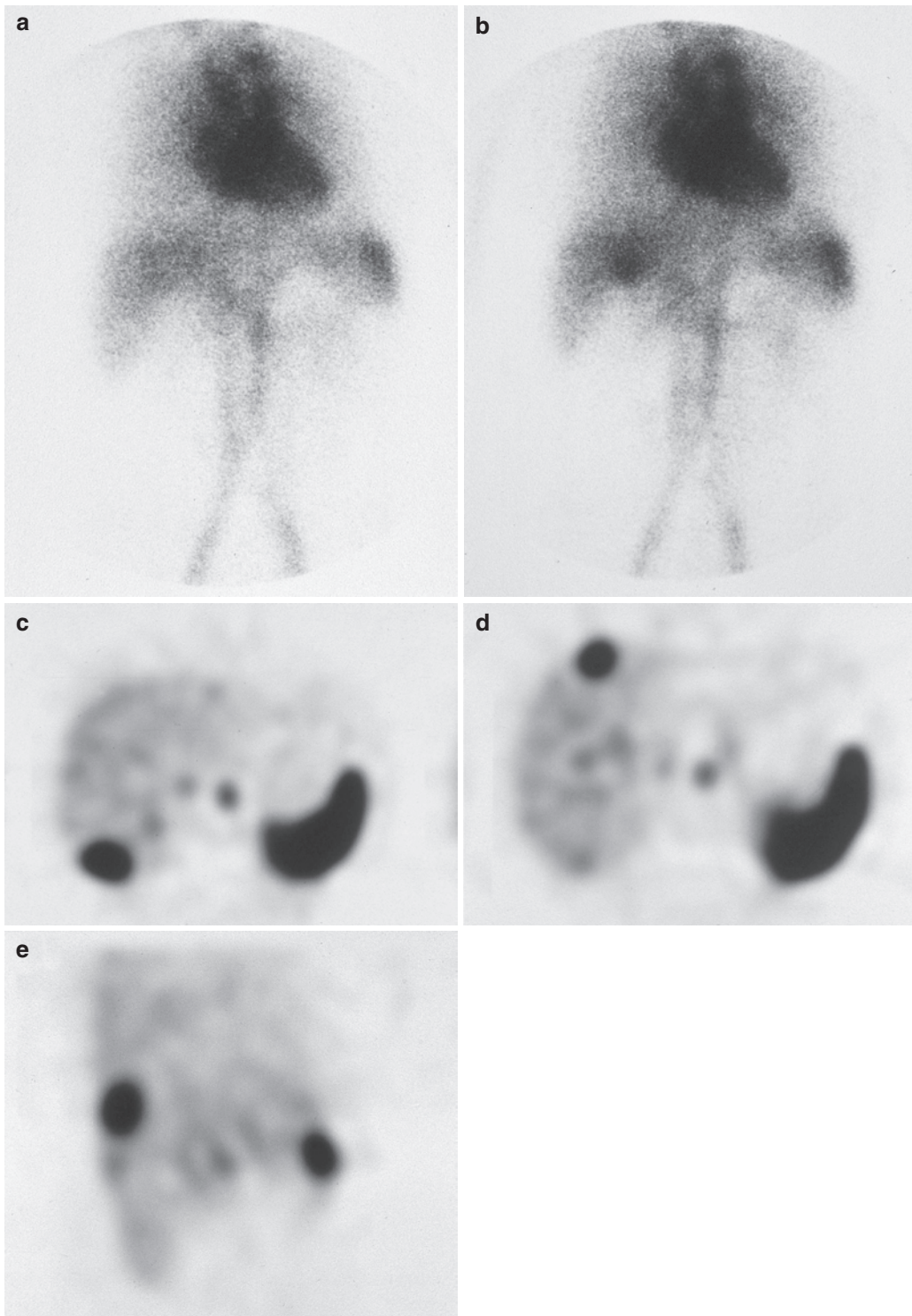


Fig. 39.4a–e Blood pool scintigraphy (^{99m}Tc -labelled autologous erythrocytes, in-vitro technique). Hemangiomas. (a, b) Sequential planar images (RAL). (c, d) SPECT, transaxial view.

(e) SPECT, sagittal view. Several intrahepatic areas of increased tracer accumulation with “fill in”-phenomenon

Fig. 39.5 Hepatobiliary scintigraphy (^{99m}Tc -HIDA; RAL). (a) Lesion in the area of the left liver lobe. Planar dynamic scintigraphy. (b) Gradual elimination of the radiopharmaceutical from the normal liver parenchyma into the gallbladder with “trapping” of activity in the area of the left liver lobe (segment II). The findings are compatible with a focal nodular hyperplasia

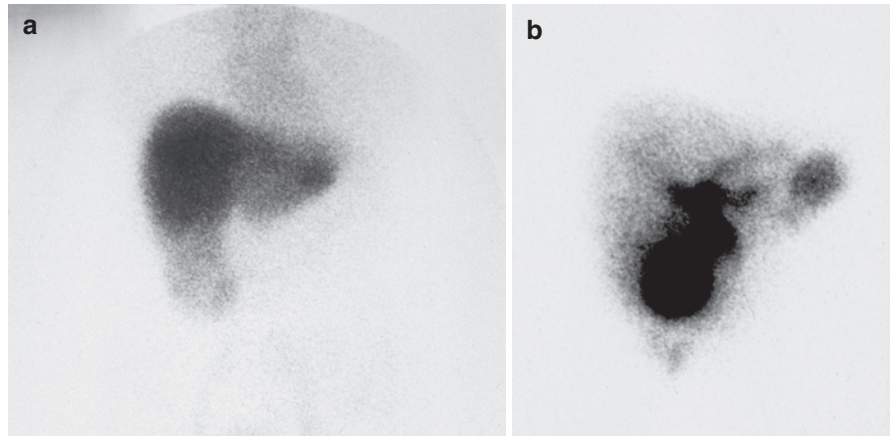


Table 39.1 Scintigraphic uptake patterns in hepatic tumors

	Hepatobiliary scintigraphy			Blood pool scintigraphy		Colloidal scintigraphy
	Perfusion	Parenchyma	Excretion/trapping	Perfusion	Blood pool	
Hemangioma	n, ↓	∅	∅	n, ↓	↑	∅
FNH	↑	n, ↑	↑	↑	n	↓, ↑
Adenoma/HCC	var	↓	↓, ↑	Var	var	↓, ∅
Metastasis	var	∅	∅	Var	n, ↑	↓, ∅

n normal, ↑ increased, ↓ reduced, ∅ no uptake, var variable

A differential diagnosis of uptake defects is not feasible. Diffuse hepatic parenchymal diseases like hepatitis, cirrhosis and storage diseases can per se reduce the colloid uptake preventing the detection of metastases with reduced tracer accumulation.

Typically, hepatic metastases cause uptake defects in the colloidal scan [16]. The sensitivity varies according to the primary tumor, the site and size of the metastases and the criteria of evaluation between 60–90%. The metastases can show a perfusion increase in the blood pool and hepatobiliary scintigraphy depending on their degree of vascularisation. A nonspecific defect is found in the parenchyma- and excretion-phases of the hepatobiliary scintigraphy [42]. Usually, a normal blood pool is observed in the blood pool scintigraphy. However, there may be variable findings which impede especially the distinction of metastases from hemangiomas but also from other tumors of hepatic origin (Table 39.1). More or less intensive uptake occurs in the ^{18}F -FDG-PET depending on the glucose metabolism (see below).

Hepatocellular Carcinoma

Hepatocellular carcinomas may present as unifocal, multifocal or diffuse infiltrating lesions. Accordingly,

uptake defects are found in colloidal scintigraphy [45]. Typically, an inhomogenously reduced or missing tracer accumulation is found in the parenchymal phase of the hepatobiliary scintigraphy. There is a correlation between the degree of differentiation and the uptake intensity. Multiple variations are possible ranging from the picture of a defect in the parenchyma- and excretion-phases to a normal uptake in the parenchymal phase and a “trapping” in the delayed phase. Therefore, no distinction from FNH and adenoma may be feasible in individual cases (Table 39.1). The findings are clear if metastases with increased tracer uptake are detected.

^{18}F -FDG-PET/ -CT

Positron emission tomography (PET) with the glucose analogue ^{18}F -Fluor-2-deoxy-D-glucose (^{18}F -FDG) has become the most important nuclear medicine procedure in the diagnostics of solid liver lesions within the last 10 years [5, 6, 9]. ^{18}F -FDG is taken up from the plasma into the cells by facilitated diffusion. Intracellularly, ^{18}F -FDG is phosphorylated by the hexokinase reaction to ^{18}F -FDG-6-phosphate which cannot leave the cell (“metabolic trapping”). ^{18}F -FDG-6-phosphate remains inside the cell,

since its dephosphorylation is a very slow enzymatic reaction. Time activity curves can be registered over different tissues and large arterial vessels during a dynamic ¹⁸F-FDG-PET [21]. Therefore, arterial blood samples are not necessary for the calculation of the metabolic rates.

PET reaches a sensitivity of 82% in the detection of histologically confirmed intrahepatic tumors, compared to 63% for ultrasound and 71% for CT [9, 23]. Though MRI yields a sensitivity of 96%, ¹⁸F-FDG-PET is superior in the diagnosis of extrahepatic metastases of intrahepatic tumors [53, 54].

Focal Liver Lesions

Three distinct tumor entities play a fundamental role in malignant liver tumors which show a different uptake pattern using ¹⁸F-FDG-PET,

- Hepatocellular carcinoma
- Cholangiocellular carcinoma
- Metastases of other solid tumors, especially colorectal carcinoma

Hepatocellular Carcinoma

The visualisation of hepatic tumors using ¹⁸F-FDG-PET is impaired because of the physiologically high metabolic activity of the hepatocytes. The diagnostics of HCC with PET is impeded by the variable uptake pattern of the individual tumors. According to metaanalyses, about 50% of all HCC show a positive contrast using ¹⁸F-FDG-PET. In particular, well differentiated and less aggressive HCC cannot be distinguished from

the background activity of the normal liver (Fig. 39.6). Some HCC show less tracer uptake than the surrounding healthy liver parenchyma [40]. Variable activities of the hexokinase and the glucose-6-phosphatase seem to be responsible for the different uptake patterns of the HCC [51]. In contrast to ¹⁸F-FDG-PET, CT reaches a sensitivity of 90% in the diagnostics of HCC [22]. Some authors demonstrated an improvement in the diagnostic assessment of HCC using delayed ¹⁸F-FDG-PET [40]. The combined ¹⁸F-FDG-PET-CT allows a more exact anatomical assignment of liver and, thereby, contributes to improved surgical management of patients with HCC. In addition, the application of ¹⁸F-FDG-PET can be useful in the detection of extrahepatic tumor manifestations in patients suffering from HCC [48]. In the literature, a sensitivity of 83% is reported for the detection of extrahepatic metastases of the HCC using ¹⁸F-FDG-PET.

Innovative PET tracers (e.g. [11]C-acetate) seem to have a higher sensitivity in the detection of HCC as compared to ¹⁸F-FDG. In first studies [11], C-acetate-PET was superior to ¹⁸F-FDG-PET in the detection of well differentiated tumors, whereas ¹⁸F-FDG-PET yielded better results in patients with poorly differentiated HCC [18]. The amino acid [11] C-methionine, which is successfully applied in patients with brain tumors, is accumulated in the normal liver to a larger degree than ¹⁸F-FDG. Thus, it seems to have little impact on the diagnostic evaluation of patients with HCC [12].

Because of the results mentioned above, the third German Interdisciplinary Consensus Conference (ONKO PET III) did not recommend ¹⁸F-FDG-PET for the diagnostic assessment of HCC [38]. Nevertheless, the application of ¹⁸F-FDG-PET-CT can be quite helpful in the diagnosis of unclear liver lesions.

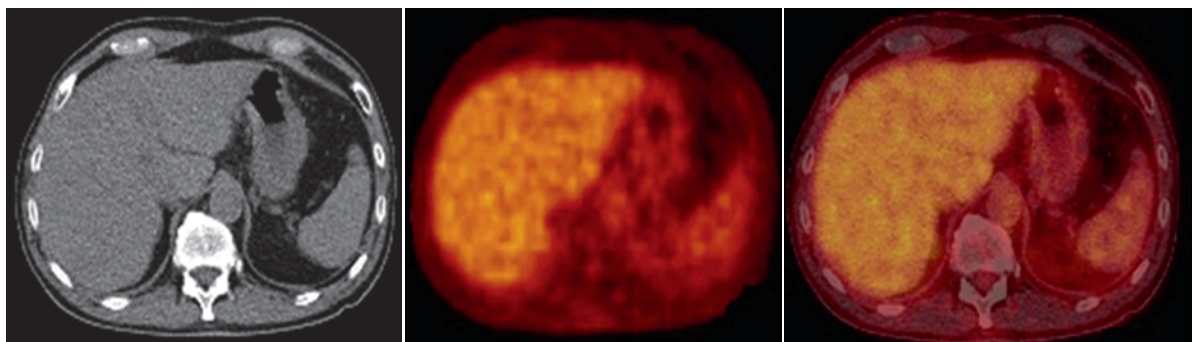


Fig. 39.6 Fifty-year-old patient with a hepatocellular carcinoma. The hypodense lesions on CT show no increased ¹⁸F-FDG-uptake on PET. Left CT, middle ¹⁸F-FDG-PET, right coregistered ¹⁸F-FDG-PET-CT

A positive ^{18}F -FDG uptake in a corresponding hepatic lesion on CT is highly suspicious for a malignant process.

Furthermore, sequential ^{18}F -FDG-PET-CT is feasible in PET positive primary tumors. It could be shown that ^{18}F -FDG-PET-CT is suitable for the evaluation of the therapeutic response to palliative local therapies such as thermal tumor ablation. ^{18}F -FDG-PET-CT is superior to ^{18}F -FDG-PET in the identification of residual tumor masses or recurrences after radiofrequency ablation.

Cholangiocellular Carcinoma

Cholangiocellular carcinoma (CCC) shows a higher ^{18}F -FDG uptake as compared to HCC [36, 37]. ^{18}F -FDG-PET is more sensitive in the detection of nodular neoplasms than infiltrating tumors [3]. In initial studies, high sensitivities of 92% and specificities of 93% were reported for the detection of primarily malignant lesions using ^{18}F -FDG-PET [24]. Distant metastases can be identified in up to 70% of cases. However, only approximately 13% of regional or hepatoduodenal lymph node metastases are visualized by ^{18}F -FDG-PET. High sensitivities of 83% are reported for the detection of CCC using ^{18}F -FDG-PET, however, its specificities are lower, particularly in mucous adenocarcinomas [15].

Liver Metastases

Hepatic metastases often complicate the progression of gastrointestinal malignancies. Most PET and PET-CT

investigations of liver metastases refer to colorectal carcinomas; therefore, these tumors will be presented in this section as an example. To date, only few data have been published on other malignancies with hepatic metastases.

Approximately 50% of patients with colorectal carcinomas develop liver metastases within the first 5 years after tumor diagnosis (Fig. 39.7) [1]. A surgical metastasectomy can improve the long-term survival of the patients. Despite combined application of primarily morphologic imaging techniques like ultrasound, CT and MRI some hepatic metastases prove to be inoperable during surgery. Therefore, an accurate pre-operative staging has to be performed in order to avoid unnecessary liver resections.

The benefit of ^{18}F -FDG-PET in the detection of hepatic metastases of colorectal carcinomas has been shown in numerous studies. According to metaanalyses, ^{18}F -FDG PET has a sensitivity of 97% in the identification of all metastases of colorectal cancers [20, 23, 49]. In comparison to ^{18}F -FDG-PET the corresponding sensitivities of ultrasound, CT and MRI amount only to 55%, 72% and 76%, respectively [9, 54]. An advantage of ^{18}F -FDG-PET is its possibility of whole body investigations in order to detect and/or exclude extrahepatic occult lesions, e.g. before a planned curative surgery. Unexpected extrahepatic metastases are discovered by ^{18}F -FDG-PET in more than 30% of patients considered for hepatic metastasectomy [28].

^{18}F -FDG-PET is able to detect intrahepatic tumor progression or recurrence after surgery of liver metastases several months before morphologic imaging (CT/MRI) does. This is often due to posttherapeutic morphological alterations which impede the image interpretation of CT/MRI [5, 46].

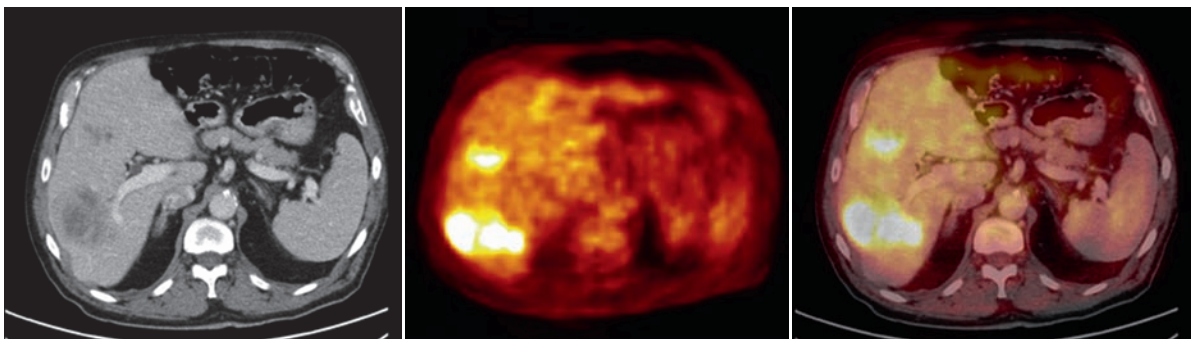


Fig. 39.7 Seventy-seven-year-old patient with a colon carcinoma and multiple liver metastases. Irregular hypodense liver lesions are delineated on CT which show corresponding foci

with increased metabolic activity on ^{18}F -FDG-PET. *Left:* CT, *middle:* ^{18}F -FDG-PET, *right:* coregistered ^{18}F -FDG-PET-CT

¹⁸F-FDG-PET allows the evaluation of the metabolic activity of tissues. Therefore, it is suitable to assess the early response to systemic or local therapies [50, 52]. A decrease of ¹⁸F-FDG uptake can be demonstrated, for example, in the lesions that show a good response to local chemoembolization. In addition, ¹⁸F-FDG-PET seems to be a promising test to evaluate the success of radiofrequency ablation [4, 7].

In addition, neuroendocrine tumors with hepatic metastases are a challenge for PET imaging. Somatostatin negative tumors are poorly differentiated and usually have a bad prognosis. Typically, they show a marked ¹⁸F-FDG accumulation and a diagnosis can be made with ¹⁸F-FDG-PET. However, ¹⁸F-FDG-PET often yields false negative results in well differentiated somatostatin receptor positive tumors [25].

Further PET radiopharmaceuticals are used in addition to ¹⁸F-FDG. ⁶⁸Ga-DOTATOC is used for the diagnostics of neuroendocrine tumors [19, 26]. It is also suited for the therapy planning with the beta emitter ⁹⁰Y-DOTATOC. Further PET tracers are currently under evaluation, however, they are not yet applied in clinical routine (e.g. [11] C-hydroxytryptamine, ¹⁸F-FP-TOCA and ⁶⁴Cu-TETA-octreotide) [2, 30].

The accurate anatomical and/or morphological assignment in the diagnostics of malignant liver processes may be impeded using PET, in particular, with regard to the topographic relationships to large vessels and bile ducts. Therefore, it is essential to correlate the PET findings with the results of the morphologic imaging procedures. In patients with colorectal carcinomas it could be shown that the combined ¹⁸F-FDG-PET-CT is superior to ¹⁸F-FDG-PET in the accurate localization of suspicious liver lesions [39]. According to the literature, the number of lesions with uncertain localization can be reduced by 55% with the help of ¹⁸F-FDG-PET-CT as compared to ¹⁸F-FDG-PET alone [11]. To date, no controlled studies have been published comparing ¹⁸F-FDG PET-CT with ¹⁸F-FDG-PET and CT alone [41].

References

- Abdel-Nabi H, Dörr RJ, Lamonica DM, et al (1998) Staging of primary colorectal carcinomas with fluorine-18 fluorodeoxyglucose whole-body PET: correlation with histopathologic and CT findings. *Radiology* 206: 755–60
- Anderson CJ, Dehdashti F, Cutler PD, et al (2001) ⁶⁴Cu-TETA-octreotide as a PET imaging agent for patients with neuroendocrine tumors. *J Nucl Med* 42: 213–21
- Anderson CD, Rice MH, Pinson CW, et al (2004) Fluorodeoxyglucose PET imaging in the evaluation of gallbladder carcinoma and cholangiocarcinoma. *J Gastrointest Surg* 8: 90–7
- Antoch G, Vogt FM, Veit P, et al (2005) Assessment of liver tissue after radiofrequency ablation: findings with different imaging procedures. *J Nucl Med* 46: 520–5
- Arulampalam TH, Francis DL, Visvikis D, et al (2004) FDG-PET for the pre-operative evaluation of colorectal liver metastases. *Eur J Surg Oncol* 30: 286–91
- Bares R, Lucignani G (1996) *Clinical PET*. Klüwer, Dordrecht/Boston/London
- Barker DW, Zagoria RJ, Morton KA, et al (2005) Evaluation of liver metastases after radiofrequency ablation: utility of ¹⁸F-FDG PET and PET/CT. *Am J Roentgenol* 184: 1096–1102
- Becker W (1992) Entzündungsdiagnostik mit autologen Leukozyten und murinen monoklonalen Antikörpern. *Nuklearmedizin* 4: 273–86
- Böhm B, Voth M, Geoghegan J, et al (2004) Impact of positron emission tomography on strategy in liver resection for primary and secondary liver tumors. *J Cancer Res Clin Oncol* 130: 266–72
- Chen CC (1996) The biliary System. In: Harbert JC, Eckelman WC, Neumann RD (eds) *Nuclear medicine: diagnosis and therapy*. Thieme, New York/Stuttgart, pp 685–705
- Cohade C, Osman M, Leal J, et al (2003) Direct comparison of ¹⁸F-FDG PET and PET/CT in patients with colorectal carcinoma. *J Nucl Med* 44: 1797–803
- Cook GJR, Maisey MN, Fogelman I (1999). Normal variants, artefacts and interpretative pitfalls in PET imaging with 18-fluoro-2-deoxyglucose and carbon-11 methionine. *Eur J Nucl Med* 26: 1363–78
- Delbeke D, Martin WH, Sandler MP, et al (1998) Evaluation of benign vs malignant hepatic lesions with positron emission tomography. *Arch Surg* 133: 510–6
- Dresel S, Kirsch CM, Tatsch K, et al (1997) Detection of hepatocellular Carcinoma with a new alpha-fetoprotein antibody imaging kit. *J Clin Oncol* 15: 2683–90
- Fritscher-Ravens A, Bohuslavizki KH, Bröring DC, et al (2001) FDG PET in the diagnosis of hilar cholangiocarcinoma. *Nucl Med Commun* 22: 1277–85
- Harbert JC (1996) The liver. In: Harbert JC, Eckelman WC, Neumann RD (eds) *Nuclear medicine: diagnosis and therapy*. Thieme, New York/Stuttgart, pp 651–83
- Helmberger T, Holzknicht H, Gregor M, et al (1998) Fokale Lebererkrankungen. *Radiologe* 38: 263–9
- Ho CL, Yu SC, Yeung DW (2003) ¹¹C-acetate PET imaging in hepatocellular carcinoma and other liver masses. *J Nucl Med* 44: 213–21
- Hofmann M, Mäcke H, Börner R, et al (2001) Biokinetics and imaging with the somatostatin receptor PET radioligand ⁶⁸Ga-DOTATOC: preliminary data. *Eur J Nucl Med* 28: 1751–7
- Hübner RH, Park KC, Shepherd JE, et al (2000) A meta-analysis of the literature for whole-body FDG PET detection of recurrent colorectal cancer. *J Nucl Med* 41: 1177–89
- Keiding S, Munk OL, Schiott KM, et al (2000) Dynamic 2-[¹⁸F]fluoro-2-deoxy-d-glucose positron emission tomography of liver tumours without blood sampling. *Eur J Nucl Med* 27: 407–12
- Khan MA, Combs CS, Brunt EM, et al (2000) Positron emission tomography scanning in the evaluation of hepatocellular carcinoma. *J Hepatol* 32: 792–7

23. Kinkel K, Lu Y, Both M, et al (2002) Detection of hepatic metastases from cancers of the gastrointestinal tract by using non-invasive imaging methods (US, CT, MR imaging, PET): a meta-analysis. *Radiology* 224: 748–56
24. Kluge R, Schmidt F, Caca K, et al (2001) Positron emission tomography with [¹⁸F]fluoro-2-deoxy-D-glucose for diagnosis and staging of bile duct cancer. *Hepatology* 33: 1029–35
25. Koukouraki S, Strauss LG, Georgoulas V, et al (2006) Comparison of the pharmacokinetics of ⁶⁸Ga-DOTATOC and [¹⁸F]FDG in patients with metastatic neuroendocrine tumours scheduled for ⁹⁰Y-DOTATOC therapy. *Eur J Nucl Med Mol Imaging* 33: 1115–22
26. Kowalski J, Henze M, Schuhmacher J, et al (2003) Evaluation of positron emission tomography imaging using [⁶⁸Ga]-DOTA-D Phe(1)-Tyr(3)-Octreotide in comparison to [¹¹¹In]-DTPAOC SPECT. First results in patients with neuroendocrine tumors. *Mol Imaging Biol* 5: 42–8
27. Krause T, Hauenstein K, Studier-Fischer B, et al (1993) Improved evaluation of technetium-99m-red blood cell SPECT in hemangioma of the liver. *J Nucl Med* 23: 375–80
28. Lai DT, Fulham M, Stephen MS, et al (1996) The role of whole-body positron emission tomography with [¹⁸F]fluoro-deoxyglucose in identifying operable colorectal cancer metastases to the liver. *Arch Surg* 131: 703–7
29. Lassmann M, Biassoni L, Monsieurs M, et al (2007) The new EANM paediatric dosage card. *Eur J Nucl Med Mol Imaging* 34: 796–8
30. Meisetschläger G, Poethko T, Stahl A, et al (2006) Gluc-Lys([¹⁸F]FP)-TOCA PET in patients with SSTR-positive tumors: biodistribution and diagnostic evaluation compared with [¹¹¹In]DTPA-octreotide. *J Nucl Med* 47: 566–73
31. Menzel J, Schober O, Reimer P, et al (1997) Scintigraphic evaluation of hepatic hemodynamics after intrahepatic porto-systemic shunt (TIPS). *Eur J Nucl Med* 24: 635–41
32. Middleton ML (1996) Scintigraphic evaluation of hepatic mass lesions: emphasis on hemangioma detection. *Semin Nucl Med* 26: 4–15
33. Nadel HR (1996) Hepatobiliary scintigraphy in children. *Semin Nucl Med* 26: 25–42
34. Negrin JA, Zanzi I, Margoueff D (1995) Hepatobiliary scintigraphy after biliary tract surgery. *Semin Nucl Med* 25: 28–35
35. Olsen JO, Pozderac RV, Hinkle G, et al (1995) Somatostatin receptor imaging of neuroendocrine tumors with Indium-111-pentetreotide (OctreoScan). *Semin Nucl Med* 25: 251–61
36. Petrowsky H, Wildbrett P, Husarik DB, et al (2006) Impact of integrated positron emission tomography and computed tomography on staging and management of gallbladder cancer and cholangiocarcinoma. *J Hepatol* 45: 43–50
37. Prytz H, Keiding S, Björnsson E, et al (2006) Dynamic FDG-PET is useful for detection of cholangiocarcinoma in patients with PSC listed for liver transplantation. *Hepatology* 44: 1572–80
38. Reske SN, Kotzerke J (2001) FDG-PET for clinical use. Results of the 3rd German Interdisciplinary Consensus Conference, “Onko-PET III”, 21 July and 19 September 2000. *Eur J Nucl Med* 28: 1707–23
39. Riemann B, Weßling J (2008) Tumoren der Leber und des unteren Verdauungstrakts. In: Schober O, Heindel W (Hrsg) PET-CT. Thieme, Stuttgart, pp. 234–40
40. Risse JH, Grünwald F, Kersjes W, et al (2000) Intraarterial HCC therapy with I-131-Lipiodol. *Cancer Biother Radiopharm* 15: 65–70
41. Rosenbaum SJ, Stergar H, Antoch G, et al (2006) Staging and follow-up of gastrointestinal tumors with PET/CT. *Abdom Imaging* 31: 25–35
42. Rubin RA, Lichtenstein GR (1993) Hepatic scintigraphy in the evaluation of solitary solid liver masses. *J Nucl Med* 34: 697–705
43. Schillaci O, Scopinaro F, Angeletti S, et al (1996) SPECT improves accuracy of somatostatin receptor scintigraphy in abdominal carcinoid tumors. *J Nucl Med* 37: 1452–6
44. Schober O (2001) Gastrointestinaltrakt. In: Büll U, Schicha H, Biersack HJ, Knapp WH, Reiners Chr, Schober O (eds) (Hrsg) Nuklearmedizin. Thieme, Stuttgart/New York, pp 365–89
45. Schober O, B. Riemann (2007) Leber – Milz. In: Schicha H, Schober O (eds) (Hrsg) Nuklearmedizin. Schattauer, Stuttgart/New York, pp 234–40
46. Selzner M, Hany TF, Wildbrett P, et al (2004) Does the novel PET/CT imaging modality impact on the treatment of patients with metastatic colorectal cancer of the liver? *Ann Surg* 240: 1027–34
47. Shah AN, Dodson F, Fung J (1995) Role of nuclear medicine in liver transplantation. *Semin Nucl Med* 25: 36–48
48. Sugiyama M, Sakahara H, Torizuka T, et al (2004) 18F-FDG PET in the detection of extrahepatic metastases from hepatocellular carcinoma. *J Gastroenterol* 39: 961–968
49. Topal B, Flamen P, Aerts R, et al (2001) Clinical value of whole-body emission tomography in potentially curable colorectal liver metastases. *Eur J Surg Oncol* 27: 175–9
50. Torizuka T, Tamaki N, Inokuma T, et al (1994) Value of fluorine-18-FDG-PET to monitor hepatocellular carcinoma after interventional therapy. *J Nucl Med* 35: 1965–9
51. Torizuka T, Tamaki N, Inokuma T, et al (1995) In vivo assessment of glucose metabolism in hepatocellular carcinoma with FDG-PET. *J Nucl Med* 36: 1811–7
52. Vitola JV, Delbeke D, Meranze SG, et al (1996) Positron emission tomography with F-18-fluorodeoxyglucose to evaluate the results of hepatic chemoembolization. *Cancer* 78: 2216–22
53. Wernecke K, Rummeny E, Bongartz G, et al (1991) Detection of hepatic masses in patients with carcinoma: comparative sensitivities of sonography, CT and MRI. *Am J Radiol* 157: 731–9
54. Yang M, Martin DR, Karabukut N, et al (2003) Comparison of MR and PET imaging for the evaluation of liver metastases. *J Magn Reson Imaging* 17: 343–9
55. Ziessmann HA, Silverman PM, Patterson J, et al (1991) Improved detection of small cavernous hemangiomas of the liver with high-resolution three-headed SPECT. *J Nucl Med* 32: 2086–91

Endoscopic Retrograde and Percutaneous Transhepatic Cholangiography

40

Frank Stenschke, Henryk Dancygier, and Jason N. Rogart

Chapter Outline

Indications	438
Contraindications	439
Technique	439
Patient Preparation	439
Equipment	439
Technique of Procedure	439
Diagnostic Findings	441
Normal Findings	441
Pathological Findings	441
Complications	446
Endoscopic Retrograde Cholangiography	446
Percutaneous Transhepatic Cholangiography	446
References	446

The direct visualisation of the bile duct with a retrograde (endoscopic) or antegrade (transhepatic) approach has become a successful means for investigating biliary tract disease for more than 30 years. Percutaneous transhepatic cholangiography (PTC) was first reported in the literature in 1937 but did not become popular until the 1950s after it gained attention in the English-speaking literature [6]. Endoscopic retrograde cholangiography (ERC) was first reported in 1968 and spread throughout Europe and Japan to the United States in the early–mid-1970s after improved instruments were developed and the feasibility of therapeutic applications made it more attractive (initially biliary sphincterotomy and biliary stenting) [9]. Today, both methods allow for a variety of diagnostic and therapeutic maneuvers, though ERC is preferred over PTC as a first-line procedure as it is less invasive and generally has a lower risk of complications [38]. Indeed, ERC has become an indispensable tool in the practice of modern gastroenterology.

Despite providing revolutionary methods for investigating disorders and diseases of the biliary system, PTC and ERC are becoming less commonly used for purely diagnostic purposes, as this role has been taken over by less invasive imaging modalities, such as magnetic resonance cholangiopancreatography (MRCP) and endoscopic ultrasound (EUS). Therefore, in the vast majority of cases, ERC is performed with the intention of performing a therapeutic intervention such as bile duct stone removal, biopsy/brushing of a stricture or mass, biliary stenting, and more.

This chapter is meant as a general overview of the use of cholangiography (mainly ERC) in the diagnosis and management of patients with hepatobiliary disorders. Pancreatography and exclusively pancreatic disorders will therefore not be discussed, and we refer the interested reader to specialized textbooks for this

purpose. As one reads this overview, it is important to recognize that, due to the relative paucity of high-quality prospective controlled studies in the field of ERC, much of its clinical practice has been based mainly on expert opinion and experience.

Indications

As mentioned above, ERC is almost always favored over PTC for the initial evaluation and therapy of biliary disorders. When ERC fails, or when patients are not candidates for ERC, then PTC is often pursued. Examples of these situations include patients with profound hemodynamic instability or altered surgical anatomy making endoscopic access difficult (e.g., Bilroth II gastrectomy, Roux-en-Y gastric bypass, esophageal stricture). In some of the latter cases, endoscopic techniques have been developed in the past few years that, when in expert hands, can overcome these anatomical challenges (e.g. double-balloon ERC, laparoscopic-assisted transgastric ERC, and EUS-guided biliary access) [15, 24, 34]. On

the whole, indications for therapeutic interventions are unequivocally more common than those seeking only diagnostic information (Table 40.1).

Though MRCP is taking over more and more of the diagnostic evaluation of hepatobiliary and pancreatic disorders, there are still potential problems with MRCP including image artifacts, the need for patient compliance, and the lower sensitivity for small stones (<4 mm), ampullary lesions, and subtle strictures.

One must always take into account the clinical history before pursuing ERC, as several of the above-listed indications do not always warrant immediate ERC. If patients with pancreatic cancer and obstructive jaundice but no signs of cholangitis, for example, are due to undergo surgery within a short period of time, ERC with biliary stenting is probably not necessary. As another example, many endoscopists prefer to obtain an MRCP in patients with PSC or perihilar cholangiocarcinoma before embarking on ERC, in order to learn beforehand the extent of the disease and how easy or difficult it will be to achieve drainage of contrast after the biliary ducts are opacified.

Indication	Common maneuvers
Evaluation of obstructive cholestasis or jaundice when all other tests (e.g. labs, MRCP, EUS) are unrevealing	Diagnostic
Acute cholangitis	Diagnostic Stenting
Bile duct stones	Sphincterotomy Stone extraction ± stenting
Benign bile duct stricture <ul style="list-style-type: none"> • Post-liver transplant • Post-cholecystectomy • PSC with dominant stricture • Chronic pancreatitis 	Biopsy Brushings for cytology Dilation Stenting
Malignant bile duct stricture <ul style="list-style-type: none"> • Cholangiocarcinoma • Pancreatic head cancer • Metastatic lesion 	Biopsy Brushings for cytology Dilation Stenting (plastic or metal)
Bile leak <ul style="list-style-type: none"> • Trauma • Post-cholecystectomy • Post liver surgery 	Stenting ± sphincterotomy
Hemobilia with biliary obstruction <ul style="list-style-type: none"> • Post-liver biopsy • Hepatic, bile duct, gallbladder tumors • Hemorrhagic cholecystitis 	Clot extraction Stenting
Suspected sphincter of Oddi dysfunction	Manometry ± sphincterotomy

Table 40.1 Common indications for endoscopic retrograde cholangiography in patients with suspected or known hepatobiliary disorders

Contraindications

Presence of a visceral perforation is an absolute contraindication. Patients with coagulation abnormalities should have them corrected prior to ERC or PTC with the administration, for example, of vitamin K, fresh frozen plasma, and/or pooled platelets. Severe contrast allergy is more of a contraindication for PTC than ERC, though many physicians advocate premedicating with steroids prior to ERC even though only minimal amounts of intraductal contrast are absorbed into the systemic circulation. Uncomplicated acute pancreatitis and recent myocardial infarction are both relative contraindications.

Chilaiditi syndrome (interposition of a loop of transverse colon between the diaphragm and the liver) is a contraindication to PTC via the right hepatic ducts. Ascites is also a relative contraindication for PTC, as it may result in leakage of fluid through a percutaneous tract.

Technique

Patient Preparation

First and foremost, the patient's record should be thoroughly reviewed, including all prior imaging studies, so that a clear indication for ERC or PTC is confirmed. The patient undergoing ERC or PTC is ordinarily kept fasting for at least 8 h before the procedure. It is imperative that informed consent is obtained from the patient prior to the procedure and that the risks, benefits, and alternatives are discussed in detail. In particular, risks including infection, bleeding, bowel or bile duct perforation, sedation side effects, and pancreatitis should be clearly explained (see below). As mentioned above, clotting parameters should be checked and corrected prior to the procedure. Patients with long-standing obstructive jaundice, for example, may have a prolonged prothrombin time and INR due to vitamin K deficiency resulting from malabsorption. Prophylactic antibiotics are recommended for patients with bile duct obstruction in whom incomplete drainage is anticipated (e.g., PSC, hilar strictures) and in patients who also have a known pancreatic pseudocyst that communicates with the main pancreatic duct [4].

Equipment

ERC is performed with a specialized "side-viewing" duodenoscope, whose light and optics are located on one side of its tip to facilitate visualization of and access to the duodenal papilla. The duodenoscope's accessory channel also exits in this same location, and the angle at which instruments such as cannulas or wires exit the scope can be manipulated through the use of an "elevator," controlled from the handle of the scope. The procedure is performed under fluoroscopy, and there are several different units available including high-resolution fixed machines, as well as portable "C-arms." After cannulation of the bile duct, either full-strength or dilute contrast medium is injected so that the intra- and extrahepatic bile ducts are opacified. Further diagnostic and therapeutic interventions can then be performed using a variety of instruments, most of which today are single-use items (e.g., cytology brushes, guidewires, sphincterotomes, stents and stent delivery devices, dilators, balloons). Multi-use items (e.g., biopsy forceps), like the endoscope itself, must be sterilized and/or high-level disinfected according to standard guidelines. Using "therapeutic" duodenoscopes with larger accessory channels (4.2 mm), cholangioscopy can be performed by passing a "daughter" or "baby" scope through the working channel of the "mother" scope so as to obtain direct endoscopic visualization of the bile ducts. With the advent of newer, easier to use, and smaller cholangioscopes (SpyGlass® Direct Visualization System, Boston Scientific, Natick, Massachusetts), endoscopically-guided intraductal interventions are likely to become more popular (e.g., targeted biopsies of biliary lesions, electrohydraulic lithotripsy of large bile duct stones). For more on cholangioscopy, please refer to Chapter 41.

In PTC, a peripheral bile duct is punctured with a 21-gauge needle (Chiba needle) by using ultrasound or fluoroscopic guidance, and position confirmed with injection of a small volume of contrast material. Needles, guidewires, dilatation catheters, and biliary drainage sets are available as single-use instruments.

Technique of Procedure

Careful clinical monitoring of the patient by the operator, nurses, and assistants is mandatory since ERC and

PTC are complex procedures. The type of sedation should be carefully considered. Options include conscious sedation with benzodiazepines and narcotics, deeper sedation with short-acting anesthetic agents such as propofol, or general anesthesia. Regional and national differences as well as the availability of individuals trained to administer deeper levels of sedation will dictate the type of sedation routinely used at an institution. Electronic monitoring devices are mandatory, including heart rate and blood pressure recording machines and continuous pulse oximetry.

In *ERC*, a standard catheter or sphincterotome with a guidewire placed through its lumen is passed through the accessory channel of the duodenoscope, and an appropriate angle for cannulation is facilitated with the use of the scope's elevator. The location and direction of the bile duct within the major papilla is usually in the 12 o'clock position and follows an upward and slightly posterior trajectory. In contrast, the pancreatic duct is often located between the 1 and 3 o'clock positions and follows a slightly forward trajectory. In cases of difficult bile duct cannulation, several techniques have been used including wire-guided cannulation, leaving a wire in the pancreatic duct, and pre-cut needle-knife sphincterotomy. Further discussion of these advanced techniques are beyond the scope of this chapter. It should be noted, however, that pre-cut sphincterotomy carries a higher risk of complications and should be performed by expert endoscopists.

After successful deep cannulation of the bile duct, further diagnostic and therapeutic maneuvers can be performed. A cholangiogram is obtained by injection of contrast medium that opacifies the ducts (Fig. 40.1). A sphincterotomy is often performed prior to extracting bile duct stones or placement of large (or multiple) stents. It is performed with a sphincterotome, which is a bowed catheter with a cutting wire; usually a pure cutting or "endocut" current is used. Most interventions are performed over a stiff guidewire, which maintains biliary ductal access. In this fashion, strictures can be dilated over a wire using a tapered plastic or balloon dilator of varying sizes. Similarly, plastic or self-expanding metal stents can be placed across CBD, hepatic, and/or intrahepatic strictures using the wire as a guide.

In skilled hands, access to the biliary system with *ERC* is successful in greater than 90–95% of cases. In patients with Billroth II anatomy, the success rate is

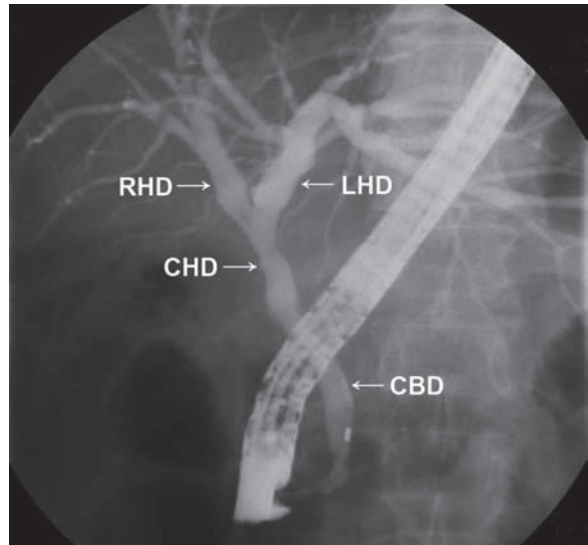


Fig. 40.1 A normal cholangiogram is obtained via endoscopic retrograde cholangiography (ERC). Contrast medium is injected using a cannula, and the relevant ducts are opacified. *CBD* common bile duct; *CHD* common hepatic duct; *RHD* right main hepatic duct; *LHD* left main hepatic duct

lower, reported to be between 60% and 80% depending on the experience of the endoscopist and the alternative means available for reaching the papilla (e.g. double-balloon enteroscope, laparoscopic-assisted transgastric approach) [15, 24, 34]. In cases where *ERC* is unsuccessful, *PTC* remains an excellent alternative.

Percutaneous cholangiography starts with opacifying the biliary system via a thin Chiba needle (22 gauge) using ultrasound or fluoroscope guidance to confirm access and positioning. Ultrasound guided procedures may have the advantage of a more precise technique even if its superiority has not yet been proven by randomized studies. After having visualized the biliary tree a convenient peripheral bile duct of the left or right system is chosen and a guidewire is passed through the Chiba needle and advanced into a central bile duct. A plastic cannula is then passed over the guidewire. Alternatively, a needle-catheter may be used, which can be passed through the needle and into a central duct. Indwelling guidewires, sheaths and dilators are used to create a percutaneous-biliary tract that will provide sufficient diameter (goal 12–16F) for further diagnostic and therapeutic maneuvers. The success rate of *PTC* is approximately 90–95% in patients with dilated bile ducts.

Diagnostic Findings

Normal Findings

The normal biliary tree in the periphery of the liver consists of fine tubular structures whose diameters progressively enlarge as they course toward the liver hilum. Here, the main left and right hepatic ducts converge to form the common hepatic duct, which becomes the common bile duct after having joined the cystic duct (Fig. 40.1). The normal diameter of the common bile duct is less than 6 mm, though an additional millimeter per decade is allowed for patients older than 70. Additionally, patients who have had their gallbladder removed often have a mildly enlarged common bile duct, up to 9–10 mm. The extrahepatic bile ducts may vary greatly in their course and distal configuration. The distal bile duct joins the pancreatic duct of Wirsung at the major papilla. In some cases, there is a long “common channel” that drains both these ducts. A further description of pancreatic ductal anatomy is beyond the scope of this chapter.

Pathological Findings

Bile Duct Stones

Bile duct stones can be visualized on cholangiography as round or oval filling defects, that can sometimes take bizarre forms especially in case of big stones (Fig. 40.2). In cases of multiple small stones, the cholangiogram may sometimes have the appearance of a column or tube stacked with marbles. During initial contrast injections, one must take special care to distinguish between small stones and air bubbles; the latter will rise when the patient’s body is tilted toward the feet, whereas stones will drop down toward the distal duct during this maneuver. Additionally, it is prudent to use dilute, “half-strength” contrast when stones are suspected, as full-strength solutions may cause overfilling of the duct and obscure small stones. The *Mirizzi syndrome* refers to common hepatic duct obstruction caused by extrinsic compression from an impacted stone in the cystic duct; sometimes, this entity may be difficult to distinguish from a stricture.

Standard therapy of bile duct stones consists of ERC with sphincterotomy, followed by stone extraction with a basket or balloon. The success rate is usually greater than

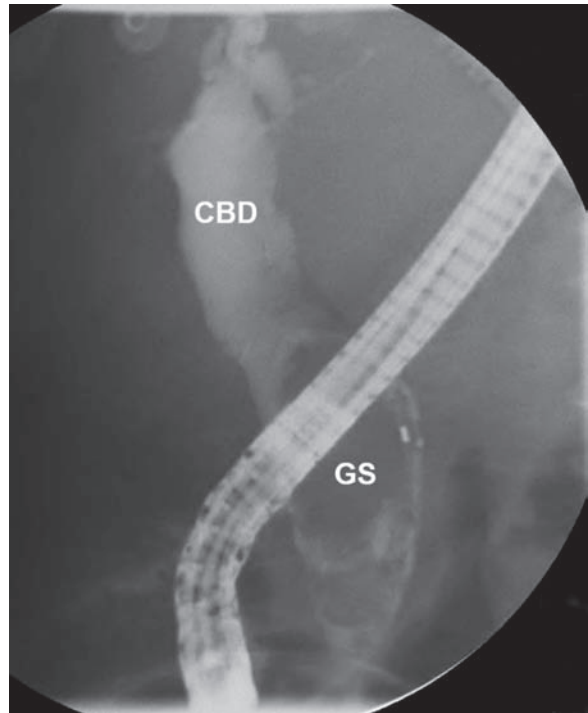


Fig. 40.2 Cholangiogram obtained via ERC showing a very large, >2 cm oval filling defect in the distal common bile duct (CBD), consistent with a gallstone (GS). The CBD is markedly dilated. The stone ultimately required cholangioscopy and intracorporeal electrohydraulic lithotripsy for fragmentation and complete clearance

80–90% for stones less than one centimeter in size. An alternative to sphincterotomy is papillary balloon dilation using larger sized balloons (>10 mm). This method is approximately equally as successful as endoscopic sphincterotomy, however it has been shown to carry a greater risk of pancreatitis [12]. Recent data has suggested that a small sphincterotomy followed by balloon dilation of the papilla may be a safer alternative [18]. At present time, however, papillary balloon dilation should probably be reserved for large bile duct stones, the presence of a periampullary diverticulum limiting an adequate sphincterotomy, and patients with coagulation disorders.

Most bile duct stones can be removed by the standard techniques described above, though 10–20% will present difficulties. These include stones impacted at the ampulla, large stones, recurrent stones or stones above a stricture. There are various techniques available for each of these circumstances. The easiest, and most commonly used instrument in most of these situations is a mechanical lithotripter (large crushing

basket), which has a success rate of >95% for large stones if they can be captured by the basket. In the United States, intracorporeal electrohydraulic lithotripsy (IEHL) is often the next choice when mechanical lithotripsy fails. This requires direct endoscopic visualization of the stone by cholangioscopy in order to avoid injuring the bile duct epithelium. Though cumbersome, IEHL has a very high success rate [3]. Other alternatives include intraductal laser lithotripsy using a variety of different lasers and extracorporeal shock-wave lithotripsy (not approved for use for bile duct stones in the United States) [19]. If these devices are unavailable or are unsuccessful, and the patient is not a candidate for surgical common bile duct exploration, then placement of plastic bile duct stents is an alternative strategy. Though these need to be changed approximately every 3 months (to prevent clogging), there is data that after 6 months of stenting, the stones may break up into smaller pieces in up to two thirds of patients and become amenable to standard extraction techniques [21].

In cases where access to the bile ducts is unsuccessful endoscopically, PTC can be performed to achieve biliary drainage. Subsequently, it is then possible to perform a “rendezvous” procedure, during which endoscopic biliary access is achieved by snaring and retrieving a guidewire placed through the percutaneous tract into the duodenum. Therapeutic maneuvers can then be performed over the guidewire from a retrograde approach, as would normally occur during routine ERC.

Patients with choledocholithiasis who are fit for surgery should also undergo cholecystectomy. The timing of ERC in relation to surgery is controversial, though in many centers ERC is performed pre-operatively. It is not recommended, however, that all patients undergoing cholecystectomy first have an ERC – only those with documented or a high-suspicion of bile duct stones. In cases where there is a low suspicion, an MRCP or EUS can be performed. When the risks of surgery are deemed to be too high, as is often the case for patients with decompensated cirrhosis, an alternative strategy is to perform endoscopic sphincterotomy without subsequent cholecystectomy, which may make it more likely for future bile duct stones to pass spontaneously into the duodenum without causing pancreatitis, cholangitis, or biliary obstruction [1]. There have also been a few reports suggesting that ERC with stenting of the gallbladder may be a feasible alternative in the treatment of symptomatic gallbladder disease in patients with end-stage liver disease [8, 33].

Benign Biliary Strictures

Etiologies of benign biliary strictures include primary sclerosing cholangitis (see below), chronic pancreatitis (up to 5–10%), autoimmune pancreatitis, trauma, post-surgical complications, or inflammation caused by cholangitis or gallstone passage. The latter often produces papillary strictures of unknown origin. Benign strictures are characterized as a clearly defined, usually long, smooth stenosis occurring in proximity to the causative lesion (e.g., clips from laparoscopic cholecystectomy or focal chronic pancreatitis in the head of the pancreas). Malignant strictures, however, will sometimes have a similar appearance, and many endoscopists will therefore perform biopsies and/or brush cytology of the stricture to exclude malignancy, as well as pursue additional imaging studies such as CT, MRI, and/or EUS.

The treatment of benign biliary strictures most commonly involves serial, incremental biliary dilatation via successive placement of increasing diameter and number of plastic stents that are electively exchanged every 2–3 months [7, 13]. Balloon dilation alone is unlikely to be successful long-term because its relatively transient effect is not enough to overcome the fibro-inflammatory response that is normally associated with biliary injuries. Sphincterotomy is often performed to facilitate exchange of stents over multiple sessions, and to allow the placement of multiple stents side-by-side. There is recent data that this process may be accelerated by temporary placement of a single “covered” (silicone membrane) self-expandable metal stent that has a larger diameter (10 mm) than any plastic stent [25]. There have not, however, been any randomized trials examining this alternative method, and safety data is not clear; therefore, at this time, it is still considered experimental. Time to successful stricture resolution varies depending on the etiology and degree of stricture, but can take up to 1 year or sometimes longer. Success after stent removal is defined as absence of symptoms, normalization of liver tests, and lack of need for further therapy. The success rate is approximately 50–75% for inflammatory, postoperative, and posttraumatic stenoses, however is lower in patients with chronic pancreatitis [13].

Malignant Biliary Strictures

Malignant biliary strictures are caused most commonly by cholangiocarcinoma (hilar = Klatskin tumor), pancreatic

head adenocarcinoma, ampullary carcinomas, or metastatic lesions. In general, malignant strictures are irregular in contour and of varying lengths. Often the downstream bile duct will appear normal. Definitive diagnosis at ERC can be made by intraductal tissue sampling via biopsy forceps or brush cytology, though the sensitivity of these techniques is only approximately 50%. In the future, DNA analysis of biopsy/brush specimens may increase the diagnostic yield [27]. Often times patients presenting for ERC will already have had a diagnosis made by EUS with fine needle aspiration of the tumor or an involved lymph node. Carcinoma of the papilla can almost always be identified endoscopically by an abnormal, enlarged, and sometimes ulcerated papillary mound. On ERC, there may be involvement of the distal bile duct, pancreatic duct, or both. Pancreatic head carcinoma mostly involves the pancreatic duct (seen as a stenosis, duct cut-off sign, or filling defect). Stenosis of both common bile duct and pancreatic duct, demonstrated by ERCP, is referred to as a “double-duct sign,” and is considered to be pathognomonic for pancreatic head cancer, although it can sometimes be seen in patients with chronic pancreatitis. Patients with chronic pancreatitis are at risk for developing pancreatic carcinoma, and differentiating between these two entities can at times be very difficult despite using alternative imaging methods such as MRI or EUS; occasionally, surgery is required to make the correct diagnosis.

Endoscopic therapy of malignant bile duct strictures is palliative and primarily involves placing a stent across the stricture to achieve biliary decompression and maintain bile flow. This intervention has been shown to decrease the risk of cholangitis, enable the administration of chemotherapeutic agents that are metabolized and excreted by the liver, and improve survival [20]. For patients without cholangitis or who will be immediately undergoing potentially curative surgery, biliary stenting is not necessary. For patients with an anticipated survival of 3 months or shorter, plastic stents are usually placed; generally, a larger diameter stent (e.g. 10F) is preferred, with a length that is long enough to traverse the stricture. In patients who are expected to survive longer than 6 months, self-expandable metal stents (SEMS) have been shown to have a longer patency and are more cost effective than plastic stents [2, 11, 22]. Unlike plastic stents that are usually electively exchanged every 3 months to prevent occlusion, SEMS are generally permanent. Most studies report a patency of 9–12 months for SEMS, however approximately 30% will ultimately occlude (mostly due to tumor ingrowth) and

require reintervention. In these cases, there is little data to guide the endoscopist on optimal therapy, though a recent report suggests that placement of another SEMS within the existing SEMS provides longer patency, results in fewer subsequent interventions, and is cost-effective compared with placement of a plastic stent through the SEMS [32]. SEMS with a silicone covering were developed to improve patency by preventing tumor ingrowth, however there is no conclusive data that they in fact improve outcome [37]. Furthermore, there is the additional risk of stent migration and cholecystitis (from obstructing the cystic duct), and they are not favored in cases of hilar tumors because of potential inadvertent obstruction of a major hepatic or intrahepatic duct.

Cholangiocarcinoma can occur anywhere along the biliary ductal system. Distal cholangiocarcinomas have the highest resectability rates. Perihilar cholangiocarcinomas are grouped by the Bismuth classification (see Chapter 116) and generally have the worst prognosis. If there is no invasion into adjacent organs or major vascular structures, and no evidence of distal or nodal metastases, MRI/MRCP or ERC may help evaluate features of local unresectability such as bilateral hepatic duct involvement extending to secondary biliary radicles. In order to inject enough contrast above the primary tumor to make this determination, it is often necessary to perform an occlusion cholangiogram by inflating a balloon at the hilum to prevent contrast from flowing backwards. Care must be taken, however, to drain any segments upstream to the stricture that are filled with contrast in order to prevent infection (prophylactic antibiotics are usually given). In patients who are not surgical candidates, palliation with either plastic or metal stents generally improves survival. For hilar tumors, bilateral (i.e., entering left and right hepatic systems) stents are often inserted; it is controversial whether plastic or smaller diameter (8mm) metal stents are superior in this situation. More recently, the addition of photodynamic therapy (PDT) to stenting has shown some benefit in patients with hilar tumors [14, 26, 30]. PDT, however, carries a risk of photosensitivity, is not widely available, requires additional expertise, and is expensive.

In cases where the bile duct cannot be accessed endoscopically, or the stricture can not be traversed with a guidewire at ERC, PTC remains an alternative therapy. Biliary drainage can be obtained percutaneously, and over the course of a few sessions, drainage can be completely internalized via percutaneous placement of

a metal stent. Given that only approximately 25% of the liver needs to be drained for adequate palliation, unilateral stenting of either the right or the left system as compared to bilateral stent placement appears to be sufficient in the absence of biliary tract sepsis.

Posttraumatic and Postoperative Lesions

ERC is a valuable tool in managing injuries to the bile ducts that result from trauma or as complications of surgical procedures. The two most common injuries are bile leaks and bile duct strictures. The principles of endoscopic treatment of bile leaks involve reducing the transpapillary pressure gradient and basal tone of the sphincter of Oddi, decreasing the pressure within the bile ducts, and establishing luminal patency areas of concomitant strictures – all of these will aid in increasing bile flow from the liver to the duodenum, thereby minimizing bile extravasation and bypassing injured sites. The principles of treating bile duct strictures are gradual stricture dilation and maintenance of luminal patency and therefore biliary drainage. The most commonly encountered scenarios are discussed here.

Laparoscopic cholecystectomy can result in injury to the biliary tree by either causing a bile leak, bile duct stricture, or both. *Bile leaks* are more common in laparoscopic than in open procedures, occurring in approximately 2% of cases. Strasberg et al. proposed a classification system for bile leaks that has been widely adopted [36]. The most common site of leakage is the cystic duct remnant, followed by branches of the right hepatic duct. Most bile leaks are amenable to endoscopic therapy with the exception of complete duct transections. We prefer the use of larger diameter (7–10F), short (5 cm) plastic stents to maximize bile flow across the ampulla. Except for severe cases, it is not necessary for the stent to traverse the site of the leak. Sphincterotomy alone is likely inferior to stenting in the treatment of bile leaks, and there is little evidence to suggest that performing sphincterotomy prior to stenting provides additional benefit [23]. If a biloma is also present on ultrasound or CT, then concomitant percutaneous drainage of the collection is also recommended.

Postoperative bile duct strictures (early or delayed) usually are a result of ischemia and are located just distal to the confluence of the right and left hepatic ducts. Treatment is similar to that of benign biliary strictures, discussed above.

Hepatic resection can be complicated by bile leaks in up to 10% of cases, though most of these are usually minor and resolve spontaneously. In cases requiring endoscopic therapy, the same principles of stenting for post-cholecystectomy leaks apply, though a longer stent may be chosen to better target a peripheral leak. Additionally, however, the use of tissue adhesives such as cyanoacrylate have been described for persistent leaks [28].

Orthotopic liver transplantation is complicated by biliary injuries in up to 20% of cases. The most common complications include bile duct strictures and bile leaks, though choledocholithiasis, sphincter of Oddi dysfunction, ampullary stenosis, and recurrent biliary disease (e.g. PSC) also occur. Prior to performing ERC in these patients, it is important to find out from the surgical team which kind of biliary anastomosis was performed – i.e., end-to-end choledocho-choledochostomy (most common) or Roux-en-Y with end-to-side choledocho-jejunostomy (e.g., in children, adults with PSC, or mismatches in bile duct size between donor and recipient). Bile leaks typically occur at the biliary anastomosis, but if they occur elsewhere ischemia as an etiology should be investigated by evaluating for hepatic artery thrombosis. Endoscopic therapy is the same as in other causes of bile leaks, as discussed above for laparoscopic cholecystectomy. *Bile duct strictures* can occur as an early (within 60 days) or late complication. In early cases, strictures may present with abnormal liver tests but *without* upstream biliary dilatation (Fig. 40.3); therefore, non-invasive imaging studies are less sensitive than ERC for detecting mild but clinically significant stenoses. Early strictures usually occur at the anastomosis and are a result of technical factors. They respond well to endoscopic balloon dilation and stenting, and may require only one session. Anastomotic strictures that develop later also respond to endoscopic therapy, but the later the onset, the more sessions and number of stents are needed, and the higher the relapse rate [31]. Nonanastomotic strictures that develop late, however, usually are ischemic in nature and more difficult to treat. They can occur at the anastomosis or proximal to it, and can be single or multiple. A significant proportion of patients with nonanastomotic strictures will require retransplantation despite endoscopic therapy.

Hemobilia is a rare cause of upper gastrointestinal (GI) bleeding, but should be considered in patients presenting with RUQ pain, jaundice, and acute GI

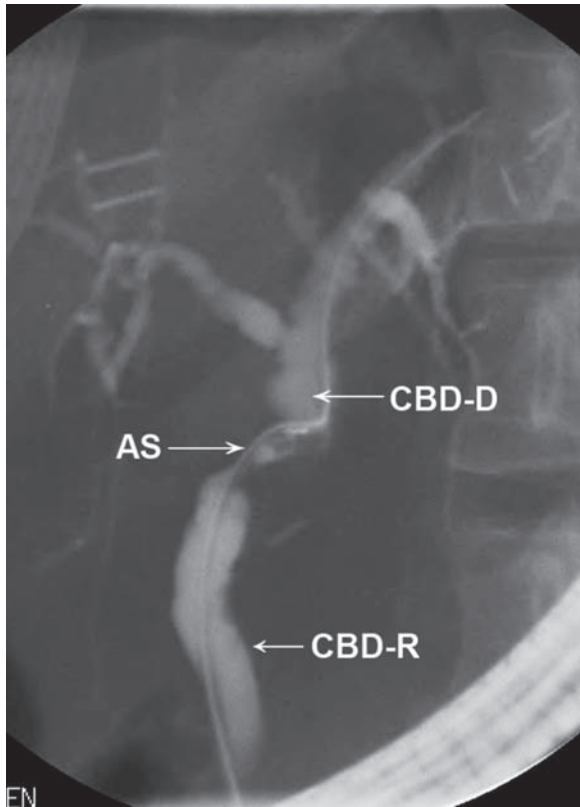


Fig. 40.3 A stricture at the surgical anastomosis (AS) is demonstrated by ERC in a patient who underwent orthotopic liver transplant 6 days earlier. *CBD-D* donor common bile duct; *CBD-R* recipient common bile duct

hemorrhage (Quinke's triad). The most common etiology of hemobilia in the Western world is iatrogenic liver injury, mainly due to percutaneous instrumentation such as liver biopsy, PTC, and transjugular intrahepatic portosystemic shunt procedures (TIPS). Other etiologies include liver, gallbladder or bile duct tumors, liver abscess, and hemorrhagic cholecystitis. ERC is useful for both diagnosis of hemobilia, as well as management of resultant biliary obstruction by extraction of clot and placement of a bile duct stent. In cases of severe, persistent bleeding, transcatheter arterial embolization has been shown to be a safe and effective life-saving treatment.

Cholangitis

Acute cholangitis, or inflammation of the bile ducts, most commonly results from bacterial infection in

association with biliary obstruction from either stones or tumor. Previous manipulation of the bile duct (e.g. ERC or PTC) is also a risk factor. Initial treatment is with antibiotics and ERC to achieve biliary drainage, as described in the above sections on bile duct stones and benign biliary strictures.

Recurrent pyogenic cholangitis, formerly known as *oriental cholangiopathy*, is a condition characterized by repeated episodes of acute cholangitis, particularly seen in patients from the Asian Pacific region. On cholangiography, multiple strictures and stones are seen in both the intrahepatic and extrahepatic ducts. In most cases, intrahepatic stones are confined to one lobe of the liver, with a predilection for the left one. It is thought that after colonization of the biliary tree with enteric flora or helminths, bacterial deconjugation of bilirubin leads to de novo intraductal stone formation. Endoscopic treatment via ERC is challenging and is aimed at dilating strictures and removing stones, which often involves passing small retrieval baskets into targeted intrahepatic segments. PTC, IEHL, and cholangioscopy may all be useful adjuncts. Because ERC is rarely curative, surgical resection of an affected hepatic segment can provide more definitive treatment.

Primary sclerosing cholangitis is perhaps the most commonly encountered etiology of *chronic cholangitis* and results from persistent biliary ductal inflammation of unknown cause. PSC almost always develops in the setting of inflammatory bowel disease. As technology has improved, MRC(P) is likely equivalent to ERC for diagnosis but in most centers ERC remains the current gold standard for imaging of the biliary tract in patients with PSC [29]. Cholangiography classically demonstrates multiple short or long strictures of the bile ducts with normal intervening areas, giving them a "beaded" appearance. It is important to avoid overfilling segments of the intrahepatic ducts with contrast if they cannot be subsequently drained. The risks of ERC in PSC, however, appear to be no greater than for other indications if prophylactic antibiotics are used, although a higher incidence of complications has been reported in patients undergoing ERC for acute episodes of cholangitis rather than for elective reasons [16]. ERC is increasingly being reserved for therapeutic purposes, primarily dilation and stenting of dominant strictures. When numerous strictures are present, however, it is unclear if biliary stenting alters the natural history of the disease and improves outcomes. One study, however, has suggested improved mortality with

maintenance of biliary patency, though there is a lack of prospective, controlled data [5]. Approximately 10–15% of patients with PSC will develop cholangiocarcinoma over the course of their life, and some authors have suggested additional monitoring with CEA and CA 19–9, as distinguishing malignant from benign biliary strictures at ERC in this population can be extremely challenging.

Complications

Endoscopic Retrograde Cholangiography

Acute pancreatitis is the most common complication of ERC with an overall incidence of approximately 2–5% [10, 17]. The majority of these cases will be mild, requiring only a few days of hospital admission. This risk increases in patients with suspected sphincter of Oddi dysfunction, younger patients, non-dilated bile ducts, difficult cannulation, and precut sphincterotomy. Attempts at prophylactic pharmacologic treatment (e.g. non-steroidal antiinflammatories, gabexate mesilate, somatostatin) to decrease the risk of pancreatitis have been largely disappointing. Placement of a small, soft pancreatic duct stent, however, has been shown to decrease post-ERCP pancreatitis in high-risk patients [35].

Significant *bleeding* occurs in fewer than 1% of cases and is likely more common when sphincterotomy is performed, or in patients with coagulopathy. Post-sphincterotomy bleeds that occur immediately can usually be successfully treated endoscopically with balloon tamponade, cautery, epinephrine injection, and/or hemoclips. Delayed bleeding days or weeks later can also occur when the clot falls off the sphincterotomy site, and can be treated endoscopically in the same fashion. In rare cases of severe bleeding that cannot be controlled endoscopically, angiographic embolization of the appropriate branch of the gastroduodenal artery is the preferred therapy.

Bowel or bile duct perforation is rare, occurring in fewer than 1% of cases. The risk is increased in patients undergoing sphincterotomy, stricture dilation, or intraductal electrohydraulic or laser lithotripsy. Most perforations are usually retroperitoneal and if minor can be managed conservatively, though early surgical consultation is mandatory. Because of the retroperitoneal

location, free air may not be seen on plain radiograph and CT scan should therefore be obtained if suspected (e.g. abdominal pain, fever, peritoneal signs on exam).

The risk of *infection* directly related to ERC is also uncommon when prophylactic antibiotics are used appropriately, as has been discussed elsewhere in this chapter. Infection can result from introduction of enteric bacteria into a normally sterile biliary system that is obstructed, from improperly disinfected equipment, and from cholecystitis if the cystic duct is compromised (e.g. after stenting). Patients who undergo biliary stenting with either plastic or metal endoprosthesis are also at risk of late infection related to stent occlusion.

Complications from *conscious sedation*, though rare, are a leading cause of death from ERC. They include hypoventilation and hypoxia, aspiration, hypotension, and cardiac arrhythmias. Collaboration with an anesthesiologist should be considered for high risk patients.

Percutaneous Transhepatic Cholangiography

The overall risks of PTC are higher than ERC, though differ slightly. For obvious reasons, pancreatitis is much less common after PTC, as is bowel perforation. The risks of PTC are increased in the absence of biliary ductal dilatation, as this makes initial access to the biliary system more difficult. Bile leaks can occur from inadvertently puncturing a large duct. Similarly, significant hemobilia can result from the puncture of a major vascular structure and if severe requires angiographic embolization. Bilovenous fistulas have also been reported but often close spontaneously. Infection is also a possible complication, both from enteric flora as well as skin flora.

References

1. Adler DG, Baron TH, Davila RE, et al (2005) ASGE guideline: the role of ERCP in diseases of the biliary tract and the pancreas. *Gastrointest Endosc* 62: 1–8
2. Arguedas MR, Heudebert GH, Stinnett AA, et al (2002) Biliary stents in malignant obstructive jaundice due to pancreatic carcinoma: a cost-effectiveness analysis. *Am J Gastroenterol* 97: 898–904
3. Arya N, Nelles SE, Haber GB, et al (2004) Electrohydraulic lithotripsy in 111 patients: a safe and effective therapy for difficult bile duct stones. *Am J Gastroenterol* 99: 2330–4

4. Banerjee S, Shen B, Baron TH, et al (2008) ASGE guideline: antibiotic prophylaxis for GI endoscopy. *Gastrointest Endosc* 67: 791–8
5. Baluyut AR, Sherman S, Lehman GA, et al (2001) Impact of endoscopic therapy on the survival of patients with primary sclerosing cholangitis. *Gastrointest Endosc* 53: 308–12
6. Carter RF, Saypol GM (1952) Transabdominal cholangiography. *JAMA* 148: 253–5
7. Catalano MF, Linder JD, George S, et al (2004) Treatment of symptomatic distal common bile duct stenosis secondary to chronic pancreatitis: comparison of single vs. multiple simultaneous stents. *Gastrointest Endosc* 60: 945–52
8. Conway J, Russo M, Shrestha R (2005) Endoscopic stent insertion into the gallbladder for symptomatic gallbladder disease in patients with end-stage liver disease. *Gastrointest Endosc* 61: 32–6
9. Cotton PB, Chapman M, Whiteside CG, et al (1976) Duodenoscopic papillotomy and gallstone removal. *Br J Surg* 63: 709–14
10. Cotton PB (2006) ERCP: risks, prevention, and management. In: Cotton PB, Leung J (eds) *Advanced digestive endoscopy: ERCP*. Blackwell, Malden, MA, 339–403
11. Davids PHP, Groen AK, Rauws EAJ, et al (1992) Randomized trial of self-expanding metal stents versus polyethylene stents for distal malignant biliary obstruction. *Lancet* 340: 1488–92
12. Disario JA, Freeman ML, Bjorkman DJ, et al (2004) Endoscopic balloon dilation compared with sphincterotomy for extraction of bile duct stones. *Gastroenterology* 127: 1291–99
13. Draganov P, Hoffman B, Marsh W, et al (2002) Long-term outcome in patients with benign biliary strictures treated endoscopically with multiple stents. *Gastrointest Endosc* 55: 680–6
14. Dumoulin FL, Gerhardt T, Fuchs S, et al (2003) Phase II study of photodynamic therapy and metal stent as palliative treatment for nonresectable hilar cholangiocarcinoma. *Gastrointest Endosc* 57: 860–7
15. Emmett DS, Mallat DB (2007) Double-balloon ERCP in patients who have undergone Roux-en-Y surgery: a case series. *Gastrointest Endosc* 66: 1038–41
16. Etzel JP, Eng SC, Ko CW, et al (2008) Complications after ERCP in patients with primary sclerosing cholangitis. *Gastrointest Endosc* 67: 643–8
17. Freeman ML, Nelson DB, Sherman S, et al (1996) Complications of endoscopic biliary sphincterotomy. *N Engl J Med* 335: 909–18
18. Heo JH, Kang DH, Jung HJ et al (2007) Endoscopic sphincterotomy plus large-balloon dilation versus endoscopic sphincterotomy for removal of bile-duct stones. *Gastrointest Endosc* 66: 720–6
19. Hochberger J, Tex S, Maiss J, Hahn EG (2003) Management of difficult common bile duct stones. *Gastrointest Endosc Clin N Am* 13: 623–34
20. Huibregtse K, Katon RM, Coene PP, et al (1986) Endoscopic palliative treatment in pancreatic cancer. *Gastrointest Endosc* 32: 334–8
21. Jain SK, Stein R, Bhuva M et al (2000) Pigtail stents: an alternative in the treatment of difficult bile duct stones *Gastrointest Endosc* 52: 490–3
22. Kaassis M, Boyer J, Dumas R, et al (2003) Plastic or metal stents for malignant stricture of the common bile duct? Results of a randomized prospective study. *Gastrointest Endosc* 57: 178–82
23. Kaffes AJ, Hourigan L, De Luca N, et al (2005) Impact of endoscopic intervention in 100 patients with suspected post-cholecystectomy bile leak. *Gastrointest Endosc* 61: 269–75
24. Kahaleh M, Hernandez AJ, Tokar J, et al (2006) Interventional EUS-guided cholangiography: evaluation of a technique in evolution. *Gastrointest Endosc* 64: 52–9
25. Kahaleh M, Behm B, Clarke BW, et al (2008) Temporary placement of covered self-expandable metal stents in benign biliary strictures: a new paradigm? *Gastrointest Endosc* 67: 446–54
26. Kahaleh M, Mishra R, Shami VM, et al (2008) Unresectable cholangiocarcinoma: comparison of survival in biliary stenting alone versus stenting with photodynamic therapy. *Clin Gastroenterol Hepatol* 6: 290–7
27. Khalid A, Pal R, Sasatomi E, et al (2004) Use of microsatellite marker loss of heterozygosity in accurate diagnosis of pancreaticobiliary malignancy from brush cytology samples. *Gut* 53: 1860–5
28. Kiltz U, Baier J, Adamek RJ (1999) Selective embolization of a bile leak after operative resection of an echinococcal cyst. *Dtsch Med Wochenschr* 24: 650–2
29. Moff SL, Kamel IR, Eustace J, et al (2006) Diagnosis of primary sclerosing cholangitis: a blinded comparative study using magnetic resonance cholangiography and endoscopic retrograde cholangiography. *Gastrointest Endosc* 64: 219–23
30. Ortner MEJ, Caca K, Berr F, et al (2003) Successful photodynamic therapy (PDT) for nonresectable cholangiocarcinoma: a randomized prospective study. *Gastroenterology* 125: 1355–63
31. Pasha SF, Harrison ME, Das A, et al (2007) Endoscopic treatment of anastomotic biliary strictures after deceased donor liver transplantation: outcomes after maximal stent therapy. *Gastrointest Endosc* 66: 44–51
32. Rogart JN, Boghos A, Rossi F, et al (2008) Analysis of endoscopic management of occluded metal biliary stents at a single tertiary care center. *Gastrointest Endosc* 68: 676–82
33. Schlenker C, Trotter JF, Shah RJ, et al (2006) Endoscopic gallbladder stent placement for treatment of symptomatic cholelithiasis in patients with end-stage liver disease. *Am J Gastroenterol* 101: 278–83
34. Siddiqui UD, Roberts KE, Duffy AJ, et al (2006) Laparoscopic assisted transgastric ERCP: the Yale experience. *Am J Gastroenterol* 101: AB905
35. Singh P, Das A, Isenberg G, et al (2004) Does prophylactic pancreatic stent placement reduce the risk of post-ERCP acute pancreatitis? A meta-analysis of controlled trials *Gastrointest Endosc* 60: 544–50
36. Strasberg SM, Hertl M, Soper NJ (1995) An analysis of the problem of biliary injury during laparoscopic cholecystectomy. *J Am Coll Surg* 180: 101–25
37. Telford JJ, Carr-Locke DL, Poneris JM, et al (2007) A randomized trial comparing the covered and uncovered Wallstent in the palliation of malignant distal biliary obstruction: interim analysis. *Gastrointest Endosc* 65: AB808
38. Teplick SK, Flick P, Brandon JC (1991) ranshepatic cholangiography in patients with suspected biliary disease and nondilated intrahepatic bile ducts. *Gastrointest Radiol* 16:193–7

Chapter Outline

Indications	449
Preparation of the Patient	450
Examination Technique	450
Peroral Cholangioscopy	450
Percutaneous-Transhepatic Cholangioscopy	451
Results	452
Complications	453
Outlook	453
References	453

Cholangioscopy utilizes miniaturized endoscopes to directly visualize the lumen of the bile ducts, which in certain circumstances can provide significant advantages over indirect fluoroscopic evaluation (as in endoscopic retrograde or percutaneous cholangiography). The first presentation of a choledochoscope, designed for intra-operative use, was in 1923 by Bakes at a surgical congress in Berlin [4]. More than 50 years later, cholangioscopy via a peroral route was first reported, followed shortly by reports via a percutaneous transhepatic route [20, 29, 30]. Though now currently well-established at specialized hepatobiliary centers, cholangioscopy remains to be a cumbersome procedure, utilizing expensive and fragile equipment, and typically requiring a highly skilled endoscopy team [12]. This chapter will provide a broad overview of cholangioscopy in the context of hepatobiliary disease. For a further, more detailed technical discussion we refer the interested reader to specialized textbooks on advanced endoscopy [21, 41].

Indications

Cholangioscopy permits the direct inspection of bile duct lumina, including the biliary epithelium and any abnormal contents such as tumors or stones. Cholangioscopy is typically employed after endoscopic retrograde cholangiography (ERC) when either further diagnostic information is needed (e.g., by visual inspection or targeted tissue sampling with biopsy forceps and/or brush cytology), or when conventional therapeutic maneuvers have been unsuccessful.

Table 41.1 Commercially-available cholangioscopes in the USA*

	Olympus CHF BP30	Pentax FCP-8P	Pentax FCP-9P	Boston Scientific SpyGlass®
Outer diameter	3.4 mm	2.8 mm	3.1 mm	0.77 mm (probe) 3.3 mm (catheter)
Channel diameter	1.2 mm	0.75 mm	1.2 mm	1.2 mm (catheter)
Tip angulation	160°/130° (up/down)	90°/90°	90°/90°	60°/60° up/down 60°/60° right/left
Field of view	90°	90°	90°	70°
Working length	1,870 mm	1,900 mm	1,900 mm	2,310 mm

*As of May 1, 2008.

The main indications for *diagnostic cholangioscopy* include the

- Differentiation of luminal filling defects whose cause remains undetermined despite other imaging modalities such as ERC, MRCP, EUS
- Evaluation of indeterminate bile duct strictures, to distinguish benign from malignant. Possibly providing prognostic information for cancers of the bile ducts [31]

As technology continues to improve and as our understanding of malignancies involving the bile duct increases, new frontiers in therapeutic cholangioscopy may be explored. For now, however, the most common indications for *therapeutic cholangioscopy* include the

- Dissolution and removal of complicated bile duct stones via electrohydraulic or laser lithotripsy
- Passage of guidewires under direct visualization through high-grade strictures, which can then be dilated and/or stented
- Removal of parasites
- Palliation of malignant lesions

Preparation of the Patient

The patient is prepared in the same manner as for ERC or PTC, which has been discussed in Chapter 40. In addition to choosing the appropriate means of sedation and ensuring proper monitoring of the patient's cardio-respiratory status, antibiotics are usually given peri-procedurally even though there are no major societal guidelines specifically addressing this issue.

Examination Technique

Modern cholangioscopes are essentially miniaturized versions of standard flexible forward-viewing endoscopes. To achieve their small size, however, certain

attributes are sacrificed such as the field of view, the ability for full tip deflection, and the size of the working channel. Additionally, the miniaturized optics are very fragile and often will need repair. In addition to the instrument itself, a separate processor, light source and monitor are required. Cholangioscopes that are commercially available in the United States are compared in Table 41.1. The newest of these is the SpyGlass® Direct Visualization System (Boston Scientific, Natick, MA), which consists of a 0.77 mm fiberoptic probe that can be used with a 10F delivery catheter that has four-way tip deflection, a 1.2 mm accessory channel, and two independent irrigation channels [11]. Because of its small size, this system can be easily used by a single operator which is currently its major advantage. The primary disadvantage is that in order to achieve its markedly reduced size, image quality is somewhat inferior to traditional cholangioscopes. There are many accessories available for use with cholangioscopes, including biopsy forceps and cytology brushes, stone baskets, and probes for electrohydraulic and laser lithotripsy.

Peroral Cholangioscopy

If the papilla can be reached with a therapeutic duodenoscope, the cholangioscope may be introduced through the working channel of the endoscope ("mother-baby" technique) into the bile duct either free-hand, or over a guidewire placed during ERC. A sphincterotomy is typically performed first, though with the thinner cholangioscopes this may not be necessary [44]. Fluoroscopy is used during cannulation to ensure proper orientation of the cholangioscope as it advances up the bile duct. After removing the guidewire (if used), the duct is continuously lavaged with normal saline to improve visibility. Irrigation can be performed through the cholangioscope

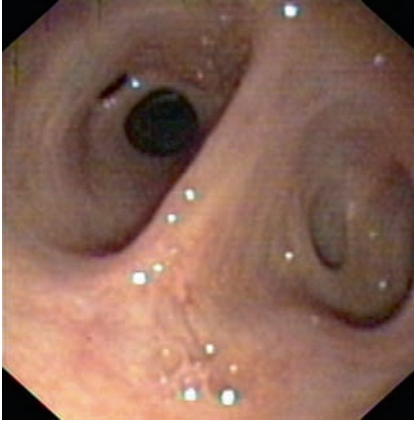


Fig. 41.1 Normal cholangioscopic aspect of right and left hepatic duct as seen from the common hepatic duct

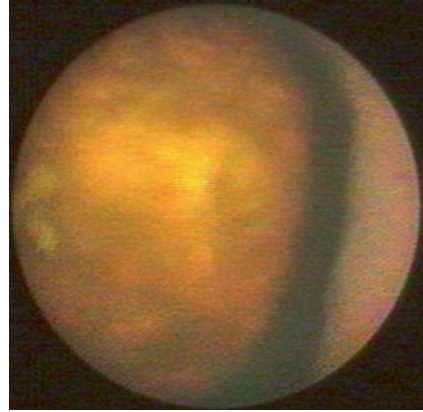


Fig. 41.2 Cholangioscopic appearance of common bile duct stone

or via placing an additional nasobiliary tube. During advancement of the cholangioscope further up the bile duct (see Fig. 41.1 for normal appearance), most of the steering is done by manipulation of the “mother” duodenoscope rather than by using the cholangioscope’s tip angulation wheel(s).

During diagnostic cholangioscopy the bile ducts are evaluated for abnormal epithelial areas, stones (Fig. 41.2), tumors, and other potential abnormalities. Adjunct techniques such as staining with methylene blue can be used for more detailed visual inspection of the epithelium [17]. Retrospective reports have suggested that areas of increased vascularity may be predictive of malignancy [22]. Abnormal areas, commonly strictures, are targeted with biopsy forceps and/or cytology brush so that tissue can be obtained for histology and cytology, respectively. If a bile duct stricture cannot be traversed, a guidewire can be advanced through the stricture under visual control and then dilated via standard ERC techniques, thereby allowing for subsequent passage of the cholangioscope [40].

In the case of *complicated bile duct stone(s)*, a thin fiber probe for either electrohydraulic or laser lithotripsy is advanced through the cholangioscope up to the stone. Under constant saline irrigation, the lithotripsy probe is activated and used to fragment the stone. The fragmented stones are then removed using standard ERC techniques. Both EHL and laser lithotripsy require continuous irrigation and visualization so as not to damage the surrounding bile duct epithelium. During EHL, 18,000V of electricity are discharged from a capacitor placed between two electrodes at the probe’s tip. This results in rapid plasma formation that expands at supersonic speed

and induces a shockwave. In the case of laser lithotripsy, there are a variety of lasers that can be used and the choice often depends on their local availability. Examples include the holmium:YAG laser, frequency-doubled double-pulse neodymium:YAG (FREDDY) laser, and the Rhodamine 6G dye laser. Some laser systems have the capacity to distinguish between stone and tissue and their safety using fluoroscopy only (i.e., without cholangioscopy) has been reported [16].

Cholangiocarcinoma and certain other intraductal tumors may be amenable to cholangioscopy-guided ablative therapy as a palliative measure. Photodynamic therapy (PDT), for example, has been receiving a lot of attention recently in the management of nonoperable cholangiocarcinoma, and cholangioscopic assessment of tumor extent in this setting may be helpful in targeting therapy [19]. Nd-YAG laser therapy and argon plasma coagulation have both been reported to be successful in debulking intraductal tumor [36, 43]. Ethanol injection into intraductal tumors has also been described [47].

Percutaneous-Transhepatic Cholangioscopy

If peroral (transpapillary) cholangioscopy is not possible because of failed bile duct cannulation or because the papilla cannot be reached for anatomic reasons (e.g. post-Roux-en-Y gastric bypass), then the percutaneous transhepatic approach should be considered, though in practice there are even fewer centers where this procedure is commonly performed [8, 25, 46].

Percutaneous-transhepatic cholangioscopy requires establishment of a stable, serially dilated cutaneous-biliary fistula that is at least 1–2 weeks old (see Chapter 40) [46]. The cholangioscope is then passed through this fistula to access the biliary ducts. Specialized percutaneous cholangioscopes are shorter and wider than their peroral counterparts, and therefore can be guided more precisely by both angulating the tip and applying torque to the shaft. Subsequent diagnostic and/or therapeutic interventions are then performed in a similar fashion to the peroral transpapillary approach discussed above. If percutaneous transhepatic drainage is not maintained after choalngioscopy, the bilio-cutaneous fistula usually closes spontaneously after approximately 1–2 days.

Results

Table 41.2 summarizes the efficacy of cholangioscopy for the most common indications. In 1999, Siddique et al. reported that peroral cholangioscopy resulted in a change in diagnosis in 30% of the 59 cases they reviewed [43]. Four patients suspected of having a complicated bile duct stone, for example, instead had a tumor. The body of literature on the diagnostic yield of peroral cholangioscopy in determining whether a *filling defect* or *stricture* is benign or malignant, however, is sparse and has not been adequately studied. Sensitivities range anywhere from 50% in older studies to 100% in more recent studies where cholangioscopically-guided biopsies were performed [14, 39, 42, 45]. In the most recent series utilizing the single-operator SpyGlass® system, presented in abstract form, the sensitivity for malignancy was 78% and specificity 100% [38]. The yield is also likely to be higher in patients at greater risk for malignancy, such as those with primary sclerosing cholangitis [3, 45]. In general, cholangioscopy by the percutaneous-transhepatic route

has resulted in consistently higher sensitivities, but has not been directly compared to the peroral route; furthermore, because of the heterogeneous populations studied, firm conclusions cannot be made with regard to superiority [26, 32]. Further, well-designed studies focussing on the yield of targeted biopsies under cholangioscopic guidance are needed.

Results of *therapeutic cholangioscopy*, however, consistently demonstrate a high success rate, particularly for disintegrating and clearing complicated bile duct stones. Clearance rates after EHL or laser lithotripsy range from 90–100% over an average of 1–2 sessions in experienced hands, but are a bit lower for isolated intrahepatic stones particularly when associated with severe strictures (e.g. recurrent pyogenic cholangitis) [1, 2, 5, 7, 9, 13, 15, 16, 24, 26, 34, 37, 48]. Cholangioscopy may also have the advantage of detecting stones missed by ERC [37]. Both the peroral and percutaneous-transhepatic approaches appear to be equally efficacious.

Cholangioscopy may be helpful in defining the local extent of nonoperable cholangiocarcinoma in order to apply ablative techniques such as photodynamic therapy via ERC. At least two studies, one randomized and the other retrospective, have demonstrated a significant mortality benefit for PDT compared with stenting alone – 16 months in both studies vs. 3 and 7 months [19, 35].

Complications

The complications of *peroral cholangioscopy* essentially reflect those of ERC, including the risk of pancreatitis. Transient bacteremia can be demonstrated in up to 15% of patients, perhaps from overdistension of the bile duct, however clinical cholangitis is less common [10]. If a large amount of irrigation fluid is used, this may also pool in the stomach and increase the risk for aspiration. The use of EHL or laser lithotripsy

Table 41.2 Success of cholangioscopy

	Peroral	Percutaneous - transhepatic
Indeterminate bile duct stricture (sensitivity for malignancy)	50–100% [11, 14, 38, 39, 42, 45]	82–88% [26, 32]
Extrahepatic stone clearance (EHL or laser lithotripsy)	90–100% [1, 2, 5, 13, 37]	92–96% ^a [7, 9, 15, 26]
Intrahepatic stone clearance (recurrence)	64% [22%] [34]	80% [30%] [7, 24, 48]
Guidewire insertion through stricture	80% [40]	n/a

^a Higher complication rate.

likely increases the risk of bile duct perforation and leaks, though significant bleeding is rare.

The complications of *percutaneous transhepatic cholangioscopy* are higher than that of the peroral route, mainly related to creation and dilation of the percutaneous tract. Up to one third of patients will experience pain and transient fever. The rates of sepsis and bleeding are each approximately 10% [41]. In one large series of 364 patients, the rate of severe complications (including severe hemobilia, hemoperitoneum, sinus tract rupture, ductal injury, bile peritonitis) was 4.7% [33].

Outlook

To most endoscopists, “seeing is believing,” and therefore cholangioscopy will remain an important tool in our armamentarium even though it can often be a cumbersome and expensive endeavour. As the choledochoscopes and instruments become more technically advanced and easier to use, it is likely that cholangioscopy will be practiced more frequently by a greater number of gastroenterologists and interventional radiologists, and for a wider range of indications.

As advanced imaging techniques become more commonly utilized in luminal gastroenterology, so too will they find a home in the biliary tract. Laser scanning confocal microscopy, for example, has already been performed in the bile duct via the use of a miniprobe (Cellvizio®, Mauna Kea Technologies, Paris) and can provide real-time, *in vivo* histology [27]. Narrow band imaging, already standard on the newest Olympus colonoscopes and gastroscopes, has been tested in prototype cholangioscopes and may be useful in macroscopically assessing the biliary epithelium for subtle changes (e.g. increased, irregular vascularity) that would allow for the rapid differentiation of benign vs. malignant tissue without having to interpret histology [18].

It is also possible that instead of future cholangioscopes getting smaller, cholangioscopy may be practiced with larger instruments already in existence: so-called “ultrathin upper endoscopes.” Several techniques have been described for *direct* peroral cholangioscopy using these scopes, which obviate the need for the “mother” duodenoscope, and provide better optics and a larger working channel [6, 23, 28, 36]. Regardless of which instrument we use to look in the bile duct, it is safe to say that the more we look inside, the more creative we will

become in stimulating ways to further our understanding, diagnosis, and therapy of biliary tract diseases.

References

1. Adamek HE, Maier M, Jakobs R, et al (1996) Management of retained bile duct stones: a prospective open trial comparing extracorporeal and intracorporeal lithotripsy. *Gastrointest Endosc* 44: 40–47
2. Arya N, Nelles SE, Haber GB, et al (2004) Electrohydraulic lithotripsy in 111 patients: a safe and effective therapy for difficult bile duct stones. *Am J Gastroenterol* 99: 2330–4
3. Awadallah NS, Chen YK, Piraka C, et al (2006) Is there a role for cholangioscopy in patients with primary sclerosing cholangitis? *Am J Gastroenterol* 101: 284–91
4. Bakes J (1923) Die Choledochopapilloskopie, nebst Bemerkungen über Hepaticusdrainage und Dilatation der Papille. *Arch klin Chir* 126: 473–83
5. Binmoeller KF, Bruckner M, Thonke F, Soehendra N (1993) Treatment of difficult bile duct stones using mechanical, electrohydraulic, and extracorporeal shock wave lithotripsy. *Endoscopy* 25: 201–6
6. Bohle W (2007) A simple and rapid technique of direct cholangioscopy. *Gastrointest Endosc* 65: 559
7. Bonnel DH, Liguory CE, Cornud FE, et al (1991) Common bile duct and intrahepatic stones: Results of transhepatic electrohydraulic lithotripsy in 50 patients. *Radiology* 180: 345–8
8. Brambs H-J, Leser H-G, Salm R, et al (1987) Perkutan-transhepatische Cholangioskopie. *Dtsch med Wschr* 112: 1943–6
9. Brambs HJ, Duda SH, Reiber A et al (1996) Treatment of bile duct stones: value of laser lithotripsy delivered via percutaneous endoscopy. *Eur Radiol* 6: 734–40
10. Chen MF, Jan YY (1996) Bacteremia following postoperative choledochofiberoscopy- a prospective study. *Hepatogastroenterology* 43: 586–9
11. Chen YK, Pleskow DK (2007) SpyGlass single-operator peroral cholangiopancreatography system for the diagnosis and therapy of bile-duct disorders: a clinical feasibility study. *Gastrointest Endosc* 65: 832–41
12. Devereaux CE, Binmoeller KF (2000) Endoscopic retrograde cholangiopancreatography in the next millennium. *Gastrointest Endosc* 10: 117–33
13. Farrell JJ, Bounds BC, Al-Shalabi S, et al (2005) Single-operator duodenoscope-assisted cholangioscopy is an effective alternative in the management of choledocholithiasis not removed by conventional methods, including mechanical lithotripsy. *Endoscopy* 37: 542–7
14. Fukuda Y, Tsuyuguchi T, Sakai Y, et al (2005) Diagnostic utility of peroral cholangioscopy for various bile-duct lesions. *Gastrointest Endosc* 62: 374–82
15. Harris VJ, Sherman S, Terotola SO, et al (1996) Complex biliary stones: treatment with a small choledochoscope and laser lithotripsy. *Radiology* 199: 71–7
16. Hochberger J, Tex S, Maiss J, et al (2003) Management of difficult common bile duct stones. *Gastrointest Endosc Clin N Am* 13: 623–34

17. Hoffman A, Kiesslich R, Moench C, et al (2007) Methylene blue-aided cholangioscopy unravels the endoscopic features of ischemic-type biliary lesions after liver transplantation. *Gastrointest Endosc* 66: 1052–8
18. Itoi T, Sofuni A, Itokawa F, et al (2007) Peroral cholangioscopic diagnosis of biliary-tract diseases by using narrow band imaging. *Gastrointest Endosc* 66: 730–6
19. Kahaleh M, Mishra R, Shami VM, et al (2008) Unresectable cholangiocarcinoma: comparison of survival in biliary stenting alone versus stenting with photodynamic therapy. *Clin Gastroenterol Hepatol* 6: 290–7
20. Kawai K, Nakajima M, Akasaka Y, et al (1976) A new endoscopic method: the per oral choledochopancreatography (translation). *Leber-Magen-Darm* 6: 121–4
21. Kelsey PB (2008) Cholangioscopy. In: Baron TH, Kozarek R, Carr-Locke DL (ed) *ERCP*, Philadelphia: Elsevier, pp 211–7
22. Kim HJ, Kim MH, Lee SK, et al (2000) Tumor vessel: a valuable cholangioscopic clue of malignant biliary stricture. *Gastrointest Endosc* 52: 630–4
23. Larghi A, Waxman I (2006) Endoscopic direct cholangioscopy by using an ultra-slim upper endoscope: a feasibility study. *Gastrointest Endosc* 63: 853–7
24. Lee SK, Seo DW, Myung SJ, et al (2001) Percutaneous transhepatic cholangioscopic treatment for hepatolithiasis: an evaluation of long-term results and risk factors for recurrence. *Gastrointest Endosc* 53: 318–23
25. Maier M, Kohler B, Benz C, et al (1995) Die perkutan transhepatische Cholangioskopie (PTCS)—Eine wichtige Ergänzung in der Diagnostik und Therapie von Gallenwegserkrankungen (Indikationen, Technik und Ergebnisse). *Z Gastroenterol* 33: 435–9
26. Martin WR, Riemann JF (1999) Perkutane transhepatische Cholangioskopie. In: Fruehmorgen P (ed) *Gastroenterologische Endoskopie*, Springer, Berlin, pp 159–64
27. Meining A, Frimberger E, Becker V, et al (2008) Detection of cholangiocarcinoma in-vivo using miniprobe-based confocal microscopy. *Gastroenterology* 134: A191
28. Moon JH, Ko BM, Choi HJ, et al (2008) Intraductal balloon guided direct peroral cholangioscopy using an ultra-slim upper endoscope. *Gastrointest Endosc* 67: AB103
29. Nakajima M, Akasaka Y, Yamaguchi K, et al (1978) Direct endoscopic visualization of the bile and pancreatic duct systems by peroral cholangiopancreatography (PCPS). *Gastrointest Endosc* 24: 141–5
30. Nimura Y, Hayagawa N, Toyoda S, et al (1981) Percutaneous transhepatic cholangioscopy (PTCS). *Stomach Intestine* 16: 681–9
31. Nimura Y (1993) Staging of biliary carcinoma: cholangiography and cholangioscopy. *Endoscopy* 25: 76–80
32. Nimura Y, Kamiya J (1998) Cholangioscopy. *Endoscopy* 30: 182–8
33. Oh HC, Lee SK, Lee TY, et al (2007) Analysis of percutaneous transhepatic cholangioscopy-related complications and the risk factors for those complications. *Endoscopy* 39: 731–6
34. Okugawa T, Tsuyuguchi T, K C S, et al (2002) Peroral cholangioscopic treatment of hepatolithiasis: Long-term results. *Gastrointest Endosc* 56: 366–71
35. Ortner MEJ, Caca K, Berr F, et al (2003) Successful photodynamic therapy (PDT) for nonresectable cholangiocarcinoma: a randomized prospective study. *Gastroenterology* 125: 1355–63
36. Park DH, Park BW, Lee HS, et al (2007) Peroral direct cholangioscopic argon plasma coagulation by using an ultraslim upper endoscope for recurrent hepatoma with intraductal nodular tumor growth. *Gastrointest Endosc* 66: 201–3
37. Parsi MA, Neuhaus H, Pleskow D, et al (2008) Peroral cholangioscopy guided stone therapy- report of an international multicenter registry. *Gastrointest Endosc* 67: AB102
38. Pleskow D, Parisi MA, Chen YK, et al (2008) Biopsy of indeterminate biliary strictures- does direct visualization help?—A multicenter experience. *Gastrointest Endosc* 67: AB103
39. Riemann JF (1999) Transpapilläre Endoskopie (Cholangioskopie, Pankreatikoskopie). In: Fruehmorgen P (ed) *Gastroenterologische Endoskopie*, Springer, Berlin, pp 151–8
40. Saisho H, Tsuyuguchi T, Yamaguchi T, et al (1995) A new therapeutic approach towards balloon dilatation of biliary strictures using a peroral cholangioscope. *Dig Endosc* 7: 50–5
41. Seo DW, Lee SK, Kim MH, Min YI (eds) (2002) *Cholangioscopy*. Koonja Publishing Inc., Seoul
42. Shah RJ, Langer DA, Antillon MR, et al (2006) Cholangioscopy and cholangioscopic forceps biopsy in patients with indeterminate pancreaticobiliary pathology. *Clin Gastroenterol Hepatol* 4: 219–25
43. Siddique I, Galati J, Ankoma-Sey V, et al (1999) The role of choledochoscopy in the diagnosis and management of biliary tract diseases. *Gastrointest Endosc* 50: 67–73
44. Soda K, Shitou K, Yoshida Y, et al (1996) Peroral cholangioscopy using a new fine-caliber flexible scope for detailed examination without papillotomy. *Gastrointest Endosc* 43: 233–8
45. Tischendorf JJ, Kruger M, Trautwein C, et al (2006) Cholangioscopic characterization of dominant bile duct stenoses in patients with primary sclerosing cholangitis. *Endoscopy* 38: 665–669
46. Yamakawa T, Hawes H (1996) Percutaneous choledochoscopy. *Gastrointest Endosc Clin N Am* 6: 217–34
47. Yamamoto H, Hayakawa N, Nagino M, et al (1999) Percutaneous transhepatic cholangioscopic ethanol injection for intrabiliary tumor thrombi due to hepatocellular carcinoma. *Endoscopy* 31: 204–6
48. Yeh YH, Huang MH, Yang JC, et al (1995) Percutaneous transhepatic cholangioscopy and lithotripsy in the treatment of intrahepatic stones: a study with 5 year follow-up. *Gastrointest Endosc* 42: 13–8

Chapter Outline

Indications and Limitations	455
Contraindications	456
Technique	456
Patient Preparation	456
Equipment	456
Examination	457
Complications	457
Results	457
Normal Anatomy	457
Pathological Findings	458
Clinical Significance	460
References	460

The aim of developing high-frequency (7.5–30MHz) intracorporeal ultrasound probes was to achieve close-range imaging and hence faithful reproduction of tissue structures that would allow for the detailed study of small or superficial lesions of the gastrointestinal tract. Higher ultrasound frequencies provide higher resolution but less penetration, while lower frequencies provide higher penetration at a lower resolution. Over the last several years endosonography (EUS) has evolved into a clinically valuable technique that provides high resolution images of the upper gastrointestinal tract and its surrounding tissues including the pancreas, gallbladder, and extrahepatic biliary system. It is used for local staging of esophageal, gastric and pancreatic tumors and in many specialized centers has widely replaced endoscopic retrograde cholangiopancreatography (ERCP) in the diagnosis of chronic pancreatitis. This chapter focuses on EUS of the extrahepatic bile ducts. Diseases of the gallbladder and liver are only briefly discussed, while diseases of the duodenum and pancreas are beyond the scope of this chapter. For further discussion of these topics, we refer the interested reader to textbooks on endoscopic ultrasound [9, 12].

Indications and Limitations

EUS allows for detailed visualization of the common bile duct (CBD) and its ampullary/papillary region. Its main indications in biliary diseases are

- Diagnostic work-up of extrahepatic obstructive jaundice, including fine needle aspiration of peri-ampullary or peri-ductal masses.
- Locoregional staging of tumors of the common bile duct and the papilla/ ampulla of Vater.
- Diagnosis of choledocholithiasis.

Furthermore, EUS allows for the observation of changes in vascular patterns such as portal venous thrombosis, collateral vessels in portal hypertension, or aneurysm.

Although the gallbladder may be visualized during EUS examination, EUS usually does not provide more clinical information than conventional transcutaneous ultrasound. Occasionally gallbladder polyps or neoplasms may be delimited precisely by EUS, or small amounts of sludge not identified on transcutaneous ultrasound can be visualized. Nevertheless diseases of the gallbladder do not represent a common indication for EUS.

Focal masses in the left liver lobe may occasionally be seen on EUS and even be punctured under EUS-guidance. A complete EUS examination of the left liver lobe, however, is not possible, and liver diseases are not traditional indications for EUS.

Contraindications

There are no absolute contraindications existing for performing EUS. In elderly patients with cardiorespiratory disorders the indication for EUS should be clearly identified and the benefits weighed against the risks of sedation, such as aspiration and respiratory arrest. Previously endoscopically placed biliary stents can be dislodged during EUS and therefore may necessitate repeating an ERCP with its own attendant risks. Large juxtapiapillary diverticula often make interpretation of EUS findings difficult. If a large juxtapiapillary diverticulum is known to exist and the region of interest is the distal common bile duct or its ampullary region, the use of EUS should be reassessed. Known stenosis of the upper gastrointestinal tract, particularly the esophagus, is a relative contraindication, because passing the echoendoscope through a stenosis is done relatively blindly due to the oblique angle of the endoscope's lens, and therefore even the smallest improperly directed forces may result in mucosal tears or even full-thickness perforations. In these circumstances, if EUS is necessary, dilating the stricture first with a balloon may decrease this risk.

Technique

Patient Preparation

There is no need for special preparation of the patient. The patient should be fasting for 8–10h prior to the

examination. Any dental prostheses should be removed. Transnasal oxygen insufflation with approximately 2–3L/min, started 2–3 min before the examination reduces the frequency of hypoxemia. Topical anesthesia of the throat is typically applied directly before beginning the procedure. Intravenous sedation with either propofol or midazolam and a narcotic (e.g., meperidine or fentanyl) is given.

Equipment

There are three main types of echoendoscopes:

- Longitudinal scan (“curvilinear array”)
- Radial scan (“sector” scan), and
- Intraluminal, through-the-scope EUS miniprobes

Longitudinal Scan

These devices, with a convex shaped transducer, generate an EUS image along the long axis of the instrument, which can be manipulated electronically. The echoendoscope allows an adequate endoscopic view at an oblique angle to the tip of the instrument. In addition, these instruments are equipped with a separate biopsy channel through which fine needle aspiration (FNA) or core biopsies of focal lesions may be performed under EUS-guidance (EUS-FNA).

Radial Scan

Radial echoendoscopes, either with a mechanical rotating or an electronic transducer, provide a circumferential ultrasound view which is perpendicular to the axis of the scope. The US frequency varies between 7.5, 12 and 20MHz. Some devices have a biopsy channel, but puncturing under direct EUS vision is not possible, since the tip of the needle cannot be placed in the radial US plane.

Intraluminal EUS-Miniprobes

Advancements in ultrasound technology have resulted in a continuous downsizing of ultrasound probes. Because of their small size, it is possible to insert these flexible miniprobes either through the biopsy channel

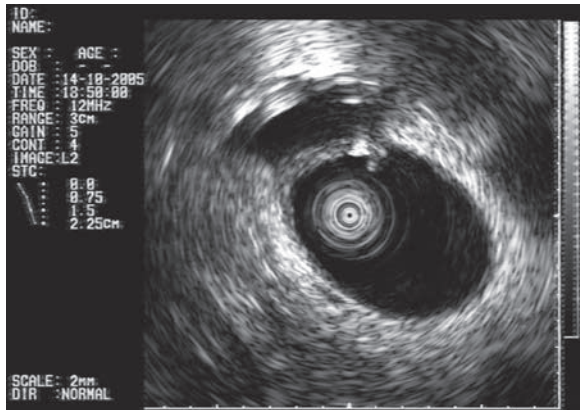


Fig. 42.1 Intraductal ultrasound (IDUS) of common bile duct

of a scope or through a percutaneous transhepatic catheter. Either approach enables insertion of the probe into the larger calibre bile ducts to perform intraductal ultrasound (IDUS) (Fig. 42.1) [15, 18]. Currently, most miniprobes work with electronic scanners.

Examination

Examination typically starts in the left lateral decubitus position, though if ERCP is planned for the same session, patients can also be positioned in the prone or supine position. The insertion of the scope is analogous to that of a duodenoscope. The transducer is then advanced to either the duodenal bulb or the level of Vater's papilla and all of the air inside the duodenum is extracted by suction. A water filled balloon at the tip of the scope is used to improve the transmission of ultrasound waves from the probe to the region of interest.

The common bile duct (CBD) is visualized best with the EUS transducer in the apex of the (distal) duodenal bulb. As soon as its tubular structure is identified, the CBD can be used as an anatomical landmark along which the instrument is moved toward the ampulla or the liver hilum.

EUS-FNA (usually 22 Gauge needle) of tumors or suspicious lesions of the peri-ampullary or peri-ductal region, or of enlarged lymph nodes may be performed. The material obtained is placed on a microscope slide and ideally should be examined by a cytopathologist immediately (i.e., at the bedside). Several passes with

the needle are made until adequate cells are obtained, and at least one is placed in specialized fluid to be sent to the cytology lab and centrifuged to create a cell block. EUS-puncture using a trucut needle (e.g. Quick-Core®, Cook Endoscopy, Winston Salem, NC) to obtain core tissue samples for histologic examination is also possible though technically more challenging [5].

Occasionally small amounts of ascites that is missed by other imaging techniques may be identified by EUS and aspirated for diagnostic purposes [11].

Complications

Diagnostic EUS of the upper GI tract has a very low risk for complications. A retrospective analysis of over 40,000 endosonographic procedures showed severe complications in only 0.05% of the cases, with a 30 day mortality rate being very low (0.003%) [23]. Therapeutic EUS (e.g., FNA) may carry slightly more risk, though the overall complication rate is less than 1%.

Perforations occur most frequently when the passage through strictures, usually in the esophagus, is forced. Perforations may also occur in the pharynx while introducing the rigid distal end of the scope. Bleeding is a rare event but can occur into the lumen of the GI tract, or if FNA is being performed, into the peritoneal cavity or into the lesion being aspirated.

The prevalence of EUS associated bacteremia is not greater than bacteremia occurring during esophago-gastroduodenoscopy. Antibiotic prophylaxis is not required prior to diagnostic EUS examination with the exception of patients at high risk for endocarditis. When FNA of a cystic lesion is performed, however, many endosonographers will administer prophylactic antibiotics (e.g., ciprofloxacin) due to the risk of contaminating the cyst.

Results

Normal Anatomy

The common bile duct (CBD) is typically imaged from the apex of the duodenal bulb as well as with the scope tip adjacent to the major ampulla. The normal CBD

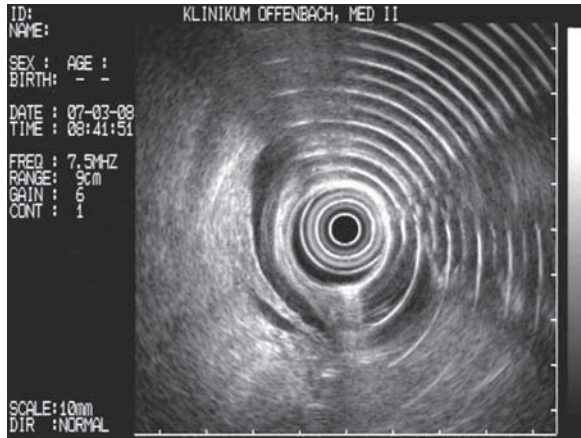


Fig. 42.2 EUS appearance of the CBD and the pancreatic duct merging into the ampulla of Vater

can be visualized by EUS in approximately 80–90% of cases, while the dilated CBD is detected in nearly 100%. It appears as a tubular structure with an echo-free lumen surrounded by a three layered wall. The central hypoechoic layer represents the tunica fibromuscularis. The inner echogenic layer reflects the entrance echo and the mucosa, while the outer echogenic layer represents the serosal structures. Distally, the CBD usually joins the main pancreatic duct at the ampulla of Vater (Fig. 42.2).

In two-thirds of patients, the CBD can be followed towards the hilum of the liver. In most cases, however, only the left hepatic duct can be visualized, while the right hepatic duct usually lies outside the sonographic field. Because of its contorted course, only sections of the cystic duct are usually seen. The gallbladder is best visualized from the duodenal bulb. It appears as an anechoic, oval cavity delimited by a two-layered wall structure. The outer, echogenic layer reflects the subserosal fat and serosa, while the inner hypoechoic layer represents the mucosa and muscularis propria.

The extent to which the liver is visualized depends in large part on the patient's anatomy, though usually views are limited to the left lobe. The liver can be imaged from the duodenal bulb, gastric antrum, and gastric fundus. The distinctive liver parenchyma with a homogenous echotexture and branching structures can be easily recognized. Branches of the portal venous system can be distinguished from intrahepatic bile ducts by their echogenic walls and the presence of a Doppler signal. As mentioned above, the liver cannot be imaged in its entirety with EUS.

Pathological Findings

Adenomas and Papillomas

Adenomas and papillomas of the biliary tract are rare and present as intraluminal polypoid structures with well defined borders. Despite its high resolution, EUS characteristics as a matter of principle do not allow for the differentiation between adenomas and frank carcinomas. Histological or cytological confirmation is necessary. EUS and IDUS, while valuable tools for local staging as well as differentiating bile duct adenomas and papillomas from stones, therefore do not obviate microscopical examination.

Common Bile Duct Strictures

In the case of a CBD stricture, EUS can exclude or demonstrate tumors especially if they infiltrate the surrounding tissue. However, as already mentioned, the EUS echopattern does not allow differentiating benign from malignant lesions. Thus the common and important clinical problem of determining the nature of a CBD stricture, for example in long-standing primary sclerosing cholangitis, cannot necessarily be resolved by EUS alone, and additional examinations, such as ERCP and cholangioscopy with brush cytology and biopsy are usually also required [6, 13]. EUS-FNA may be helpful in differentiating bile duct strictures following negative results or unsuccessful ERCP brush cytology, particularly when there is a definable mass or abnormal regional lymph node(s) [10].

Choledocholithiasis

Compared to transabdominal ultrasound, a major advantage of EUS is that it permits positioning of the ultrasound transducer in the immediate vicinity of the common bile duct, thereby allowing the visualization of the duct without interference from digestive gas. EUS has a high sensitivity (90–100%) for detecting bile duct stones, and is the most sensitive method for detecting small stones (≤ 3 mm) that are often overlooked at ERCP because of overfilling with contrast medium (Fig. 42.3) [1, 8, 17, 21, 28]. Because of its high sensitivity, EUS can be used to exclude bile duct

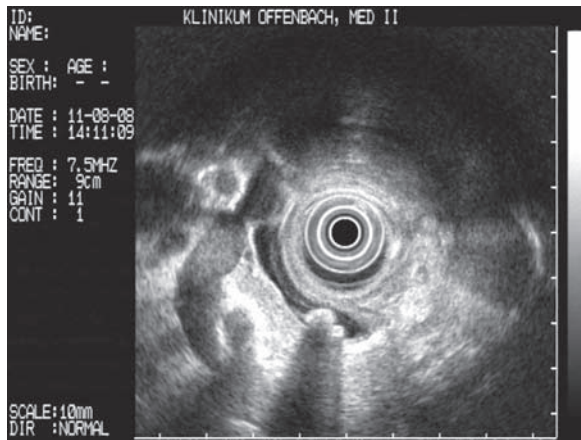


Fig. 42.3 EUS appearance of two small stones within the CBD

stones before cholecystectomy, without the risk of acute pancreatitis inherent in ERCP.

Carcinoma of the Common Bile Duct

The typical EUS image of an advanced cholangiocarcinoma is a hypoechoic mass that grows along the bile duct wall and also extends into its lumen, with infiltration of the surrounding tissue. EUS evaluation of vascular involvement or involvement of locoregional lymph nodes is of high clinical importance. Endobiliary stents are a handicap for tumor staging, because pneumobilia causes acoustical shadowing which hinders the exact assessment of the tumor [4]. For this reason EUS should be ideally performed before stent placement. Almost 100% of pT1 tumors and approximately 80% of pT2 and pT3 tumors are correctly staged preoperatively by EUS. The sensitivity in detecting lymph node metastasis (N1) is 80–90%, but the specificity is less than 30%. In our experience, the results of preoperative staging are better in distal than in proximal CBD tumors. Staging of Klatskin tumor by EUS is

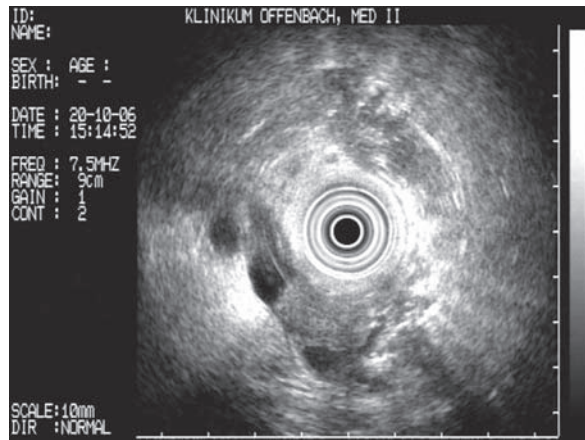


Fig. 42.4 EUS appearance of an ampullary carcinoma

extremely difficult and usually inaccurate. In [Table 42.1](#) the sensitivity of EUS, IDUS, US and CT in demonstrating tumors of the extrahepatic bile ducts is reviewed [7, 14, 25].

Ampullary Carcinomas

This often polypoid tumor that typically bulges into the duodenum shows a predominantly hypoechoic or mixed pattern and may infiltrate the duodenal wall, the common bile duct, the pancreas or the adjacent vessels ([Fig. 42.4](#)). Ampullary carcinomas can be visualized by EUS and IDUS in nearly 100% of cases, even if they are smaller than 2 cm in diameter. The T stage can be correctly defined preoperatively in 80–90% of cases, and the N stage in approximately 70% ([Table 42.2](#)) [19, 20, 22, 26, 27]. EUS/IDUS is the method of choice in local staging of small (≤ 2 cm) ampullary tumors, and is clearly superior in this regard to US, CT, and MRCP. As endoscopic techniques for resection of ampullary adenomas or intramucosal carcinomas (endosonographically, T1N0 lesions) have improved,

Table 42.1 Sensitivity of endoscopic ultrasonography (EUS), intraductal ultrasound (IDUS), conventional ultrasound (US) and computerized tomography (CT) in demonstrating tumors of the extrahepatic bile ducts

Author	Location of tumor	n	Tumor-size	EUS (%)	IDUS (%)	US (%)	CT (%)
Mukai et al., 1995	Bile duct	12	≤ 20 mm	100	ne	33	33
		9	> 20 mm	100	ne	56	67
Tamada et al., 1995	Liver hilum	11	na	71	100	73	18
	Central/distal CBD	14	na	100	100	57	28
Gilliams, Lees 1996	Liver hilum	8	na	75	100	75	75 ^a
	Central/distal CBD	18	na	94	94	61	78 ^a

^aSpiral CT, na not available, ne not examined.

Table 42.2 Accuracy of conventional endosonography (EUS) and intraductal ultrasonography (IDUS) in the preoperative staging of ampullary carcinoma

Author	Methods	n	T	N
Mitake et al., 1990	EUS	28	89%	69%
Rösch et al., 1992	EUS	12	83%	na
Mukai et al., 1995	EUS	32	75%	78%
Tio et al., 1996	EUS	32	84%	53%
Itoh et al., 1997	IDUS	32	91%	87%

T correct preoperative T-staging, N correct preoperative N-staging, na not available

EUS is being increasingly used to determine whether a patient is a candidate for endoscopic ampullectomy rather than for surgical resection.

Gallbladder Diseases

Gallbladder stones can be seen as round or square, mobile structures within the lumen of the gallbladder with acoustic shadowing. Sludge often appears as non-shadowing iso- or hypoechoic material either layering in the dependent portion of the gallbladder or floating in its lumen. Stones can be distinguished from gallbladder polyps, which appear fixed to the gallbladder wall and do not demonstrate acoustic shadowing. Polyps can be either benign (cholesterol, inflammatory, fibrous) or neoplastic (adenoma, carcinoma) and are more likely to be the latter if they are larger (>1 cm) and have a heterogenous echo pattern [24]. Gallbladder wall thickening can be seen in a number of disorders, including acute or chronic cholecystitis, xanthogranulomatous cholecystitis, cholangitis, portal hypertension, hypoalbuminemia, ascites, adenomyomatosis, or gallbladder carcinoma.

Liver Diseases

EUS is generally not performed specifically for diseases or abnormalities of the liver. Nonetheless, lesions in the left lobe may be accessible to EUS. Hepatic cysts, for example, are common and appear as anechoic round lesions with acoustic enhancement of the wall farthest from the transducer. Hepatic metastases have a variable appearance and may appear as hypoechoic or hyperechoic lesions without well-defined borders. Primary liver tumors (e.g., hepatocellular carcinoma) may also be visualized as either hypoechoic or hyperechoic

masses. A hyperechoic rim surrounding a liver lesion is highly predictive of malignancy. Depending on their location, liver masses may be accessible for EUS-FNA, and this method of obtaining diagnostic tissue can be considered when more traditional avenues fail or are not possible [2].

Clinical Significance

EUS of the common bile duct and the papillary region is a valuable clinical method in preoperative staging of distal CBD tumors. IDUS with miniprobe improves the assessment of small papillary tumors, but even high frequency probes do not allow for the discrimination between benign and malignant tumors, nor is it possible to determine the exact nature of a bile duct stricture. EUS guided FNA is increasingly being used to overcome these limitations of purely diagnostic EUS.

EUS has a very high sensitivity in demonstrating CBD stones. It should be used early in the work-up of patients with obstructive jaundice, particularly if MRI/MRCP is unavailable, since EUS findings have an impact on further therapeutic decisions (i.e., ERCP with stone extraction in the case of bile duct stones). If a tumor is demonstrated, local staging is completed and thereafter the decision is taken whether the patient is candidate for endoscopic or surgical resection, or neither.

At the present time, interventional *EUS-guided cholangiography* and *EUS-guided cholecystoduodenostomy* should be viewed as experimental techniques in patients in whom ERCP and the percutaneous approach to the biliary system is unsuccessful [2, 16].

References

1. Aslanian H (2006) EUS guided FNA of a liver mass. The DAVE Project (<http://daveproject.org/>)
2. Baron T, Topazian M (2007) Endoscopic transduodenal drainage of the gallbladder: implications for endoluminal treatment of gallbladder disease. *Gastrointest Endosc* 65: 735–37
3. Amouyal P, Amouyal G, Levy P, et al (1994) Diagnosis of choledocholithiasis by endoscopic ultrasonography. *Gastroenterology* 106: 1062–7
4. Cannon ME, Carpenter SL, Elta GH, et al (1999) EUS compared with CT, magnetic resonance imaging and angiography and the influence of biliary stenting on staging accuracy of ampullary neoplasms. *Gastrointest Endosc* 50: 27–33

5. Chang KJ (2006) State of the art lecture: Endoscopic ultrasound (EUS) and FNA in pancreatico-biliary tumors. *Endoscopy* 38: S56–60
6. Dancygier H, Classen M (1986) Endosonographic diagnosis of benign pancreatic and biliary lesions. *Scand J Gastroenterol* 21(Suppl 123): 119–22
7. Dancygier H, Rösch T, Lorenz R, et al (1988) Peroperative staging of a distal common bile duct tumor by endoscopic ultrasound. *Gastroenterology* 95: 219–22
8. Dancygier H, Nattermann C (1994) The role of endoscopic ultrasound in biliary tract disease: obstructive jaundice. *Endoscopy* 26: 800–2
9. Dancygier H, Lightdale CJ (1999) *Endosonography in gastroenterology. Principles, techniques, findings.* Thieme, Stuttgart/New York
10. DeWitt J, Misra VL, Leblanc JK, et al (2006) EUS-guided FNA of proximal biliary strictures after negative ERCP brush cytology results. *Gastrointest Endosc* 64: 325–33
11. DeWitt JM, LeBlanc J, McHenry L, et al (2007) Endoscopic ultrasound-guided fine-needle aspiration of ascites. *Clin Gastroenterol Hepatol* 5: 609–15
12. Dietrich CF (2006) *Endoscopic ultrasound. An introductory manual and atlas.* Thieme, Stuttgart/New York
13. Garrow D, Miller S, Sinha D, et al (2007) Endoscopic ultrasound: a meta-analysis of test performance in suspected biliary obstruction. *Clin Gastroenterol Hepatol* 5: 616–23
14. Gilliams AR, Lees WR (1996) Recent developments in biliary tract imaging. *Gastrointest Endosc Clin N Am* 6: 1–15
15. Itoh A., Goto H., Naito Y, et al (1997) Intraductal endosonography in diagnosing tumor extension of cancer of the papilla of Vater. *Gastrointest Endosc* 45: 251–60
16. Kahaleh M, Hernandez AJ, Tokar J, et al (2006) Interventional EUS-guided cholangiography: evaluation of a technique in evolution. *Gastrointest Endosc* 64: 52–9
17. Kondo S, Isayama H, Akahane M, et al (2005) Detection of common bile duct stones: comparison between endoscopic ultrasonography, magnetic resonance cholangiography, and helical-computed-tomographic cholangiography. *Eur J Radiol* 54: 271–5
18. Menzel J, Förster EC, Domschke W (1995) Adenoma of the papilla of Vater: a possible role for intraductal ultrasound. *Z Gastroenterol* 33: 539–42
19. Mitake M, Nakazawa S, Tsukamoto Y, et al (1990) Endoscopic ultrasound in the diagnosis of depth invasion and lymph node metastasis of carcinoma of the papilla of Vater. *J Ultrasound Med* 9: 645–50
20. Mukai H, Yasuda K, Nakajima M (1995) Tumors of the papilla and the distal common bile duct: diagnosis and staging by endoscopic ultrasonography. *Gastrointest Endosc Clin N Am* 5: 763–72
21. O’Toole D, Palazzo L (2006) Choledocholithiasis – a practical approach from the endosonographer. *Endoscopy* 38: S23–9
22. Rösch T, Braig C, Gain T, et al (1992) Staging of pancreatic and ampullary carcinoma by endoscopic ultrasonography. *Gastroenterology* 102: 188–99
23. Rösch TH, Dittler HJ, Fockens P, et al (1993) Major complications of endoscopic ultrasonography: results of a survey of 42105 cases. *Gastroenterology* 105: A558
24. Sadamoto Y, Oda S, Tanaka M (2002) A useful approach to the differential diagnosis of small polypoid lesions of the gallbladder, utilizing an endoscopic ultrasound scoring system. *Endoscopy* 34: 959–965
25. Tamada K, Ido K, Ueno N (1995) Peroperative staging of extrahepatic bile duct cancer with intraductal ultrasonography. *Am J Gastroenterol* 90: 239–46
26. Tio TL, Tytgat GNJ, Cikot RJML, et al (1990) Ampullopneumocyst carcinoma. Preoperative TNM-classification with endosonography. *Radiology* 175: 455–61
27. Tio TL, Sie H, Kallimanis G, et al. (1996) Staging of ampullary and pancreatic carcinoma: comparison between endosonography and surgery. *Gastrointest Endosc* 44: 706–13
28. Verma D, Kapadia A, Eisen GM, et al (2006) EUS vs MRCP for detection of choledocholithiasis. *Gastrointest Endosc* 64: 248–54

Chapter Outline

Definitions	464
How to Perform a Percutaneous Liver Biopsy	464
Technique and Risk Assessment	465
Laparoscopic Liver Biopsy	466
Technique and Risk Assessment	467
Ultrasound Guided Fine Needle Aspiration	469
Technique and Risk Assessment	469
The Candidate Patient for Liver Biopsy	469
Informed Consent	470
Compliance	470
Mechanical Biliary Obstruction	470
Cholangitis	470
Hemostasis	470
Ascites	470
References	470

A liver biopsy specimen for histological evaluation represents an important part of the clinical and laboratory work-up in any chronic liver disease and the monitoring of liver transplant grafts [56]. Although biochemical, serological and molecular biological tests, as well as non-invasive procedures such as elastography and laboratory scores have been continually improved, histology still remains the gold standard for many questions regarding liver diseases [9]. However, indications and the techniques employed have seen considerable changes since liver biopsy was first performed [50]. The first liver biopsy obtained by aspiration was performed by Paul Ehrlich in 1883 to assess hepatic glycogen content in a diabetic patient, and 12 years later by Lucatello to analyze a tropical abscess of the liver. Its first application for the diagnosis of liver cirrhosis in humans and rats was published in a series by Schüpfer in France in 1907, and the diagnostic potential was expanded by Bingel in Germany in 1923. Over the next 50 years the technique of obtaining liver biopsy samples was further developed in regard to approach, needle type and the combination with diagnostic imaging techniques such as ultrasound, computer tomography, angiography and laparoscopy. Since the publication of a “one second needle biopsy of the liver” by Menghini in 1958, the technique of liver needle biopsy has seen a broad introduction into clinical non-operative medicine and is performed by experienced fellows and hepatologists on a daily basis in hepatology centers [40, 50]. Although the etiology of most chronic liver diseases can be diagnosed by currently available biochemical, serological, immunological and molecular biological tests, histological evaluation remains firmly integrated into the management of chronic hepatic disease [57]. Not only are cases of undefined liver diseases subjected to histological analysis, but most importantly

the determination of inflammatory activity (grading) and degree of fibrosis/cirrhosis (staging) are relevant for the prognosis of the patient and for the indication for cost intensive as well as potentially side effect prone therapies (e.g. interferon alpha in chronic hepatitis C virus infection) [1]. The increasing number of liver transplant patients within the hepatological spectrum requires regular, safe and high quality biopsies as well as their appropriate assessment [17]. In addition, the management of infectious diseases allows for a fast and sensitive discovery of mycobacteria or viruses in hepatic tissues, i.e. in HIV-infected patients and in patients with granulomatous diseases. The determination of copper and iron content in hepatic tissue can be achieved in biopsies from patients with hereditary storage diseases such as hemochromatosis and Wilson's disease. Additionally, important clues to the etiology and for the further management of diseases such as alpha-1-antitrypsin deficiency, amyloidosis, unclear space occupying lesions, or suspected drug toxicity are reached [6, 24, 29, 33]. In view of these considerations liver biopsies are of considerable importance. In clinical practice, the hepatologist must not only determine the method by which to biopsy the liver, but also weigh the attendant risks with the probability of obtaining information that will answer clinical questions and lead to a modification or initiation of a therapeutic approach [53, 54].

Definitions

From a technical point of view liver tissue can be obtained either by cutting or by aspiration. Percutaneous liver biopsy can be performed via an intercostal or subcostal route. Additionally, ultrasound or computed tomography visual guidance and laparoscopically obtained biopsies are other options to consider under certain circumstances.

How to Perform a Percutaneous Liver Biopsy

Transcutaneous liver biopsy is performed in a supine patient with the right arm elevated behind the head. The span of the liver is examined by percussion. In our

center every transcutaneous liver biopsy is preceded by an abdominal ultrasound which not only confirms the presence of an accessible mass of liver tissue in the planned biopsy path, but also evaluates for the absence of complicating factors such as dilated bile ducts, venous collaterals, abnormal vascular findings such as hemangiomas, echinococcal cysts, Chilaiditi syndrome, very small cirrhotic livers, and an abnormally positioned gallbladder. Whether or not ultrasound reduces morbidity and mortality, however, continues to be debated in the literature [10, 12, 55, 61]. A recent study documents reduced complications and suggests that ultrasound guidance should be used as standard procedure [3]. Usually an intercostal puncture site in the mid axillary line pointed toward the xiphoid process is chosen. In very large livers biopsy can be performed subcostally. Complications appear to favor an intercostal (2.7%) over a subcostal route (4.1%), which is most often not possible in patients with small cirrhotic livers (Fig. 43.1) [45]. After local administration of anesthesia to the thoracic wall and the liver capsule (e.g. 1% lidocaine), a skin incision is made using a scalpel. Depending upon the

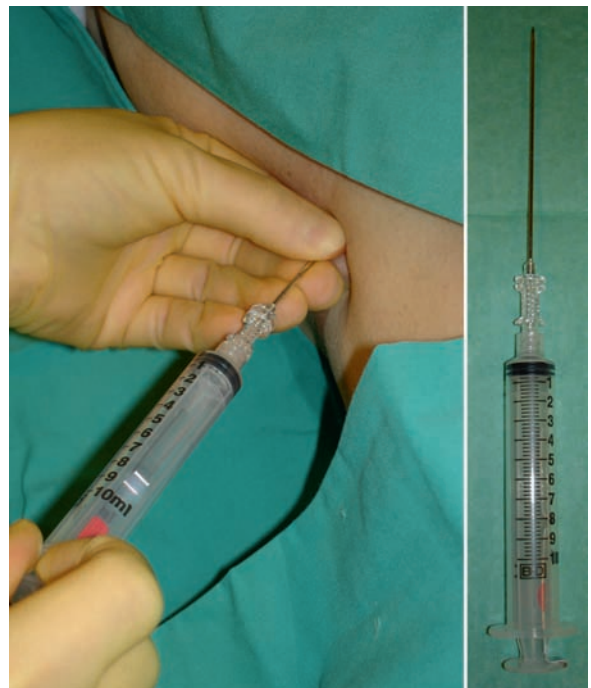


Fig. 43.1 Typical setting of a transthoracic liver biopsy using an aspiration needle device. Since the liver is frequently cirrhotic in candidates for liver biopsies and therefore small in size, an intercostal approach is most common

type of needle used, one of the two following procedures is then employed:

- Using a *Menghini (aspiration) device*, the needle, which is attached to a syringe optionally containing 10 mL sterile normal saline, is advanced to the liver surface and is flushed with 1–2 ml of saline. The patient is asked to exhale and upon end-expiration suction is applied by retracting the plunger and the needle is quickly advanced and withdrawn from the liver tissue. The specimen is visualized and deposited into the appropriate specimen container. A similar method is employed when using other suction needles (e.g. Klatksin, Jamshidi).
- Using a *Tru-Cut needle*, the tissue is obtained by cutting of a specimen lodged into a notch in the obturator needle by a second cylindrical needle sliding over it. To this end the needle is advanced into the liver and the sliding mechanism is triggered manually or automatically (“biopsy gun”). The needle is then withdrawn from the liver. The specimen is recovered from the obturator needle and placed in an appropriate specimen container.

Overall, the Tru-Cut needle remains in the liver for a longer time, increasing the possibility of patient movement and visceral injury, but it has been shown to produce superior tissue specimens. In a variation of the tru-cut needle technique, a plugged biopsy can be performed. In this case the needle is withdrawn from the cutting sheath which remains in the liver with the patient still holding his/her breath. It is replaced by a plastic cannula which is used to embolize the puncture canal with gelatin. This procedure can be considered as an alternative to transvenous liver biopsy in selected patients (see Chapter 44).

Technique and Risk Assessment

Number of Passes

When a small or fragmented tissue cylinder is obtained, the biopsy is repeated by a pass through the same incision [53]. The number of passes to obtain a representative biopsy has to be weighed against the increased risk of hemorrhage and other risks of biopsy. Irrespective of a subcostal or transthoracic approach, one study found an increased complication rate when more than

three passes were performed [39, 45]. However, the risk of hemorrhage in transcutaneous liver biopsy is also dependent on other factors which include age and the presence of malignant tumors as well as renal impairment [2, 22, 39]. Hemorrhage can occur long after the needle biopsy was performed [64]. Two passes during aspiration needle biopsy have been shown to increase diagnostic quality and minor complications in comparison to three passes [37].

Experience

As with every invasive measure complications are associated with the experience of the operator. The frequency of complications was 3.2% in physicians with a history of fewer than 20 biopsies compared to 1.1% when over 100 had been performed; no differences were seen between gastroenterologists and general practitioners [23]. It is important to realize that every needle biopsy leads to hemorrhage, which is usually minor and clinically irrelevant. This is best appreciated when laparoscopic biopsies are performed, as there is direct visualization of the puncture site. When computed tomography is performed directly after a transcutaneous liver biopsy, hepatic hemorrhage can be demonstrated which is otherwise clinically inapparent and unnoticed by determinations of blood counts (Fig. 43.2).

Tru-Cut Versus Aspiration Needle

In general, the accepted mortality rate from liver biopsy is between 0.01% and 0.10%. However, since most studies rely on retrospective data these numbers have been found to vary considerably [23, 39, 46]. Estimating this number is difficult for another reason. Patients subjected to liver biopsies usually suffer from advanced liver disease or malignancy with a high mortality rate which is not influenced by the actual liver biopsy. The overall mortality in one study was shown to be 19% within three months after liver biopsy [23]. But differences were also reported for the type of needle used. The overall complication rate in one series was 0.35% for Tru-Cut and 0.1% for Menghini needles [23]. This study identified a higher incidence of hemorrhage, pneumothorax, biliary leakage and peritonitis with Tru-Cut needles but puncture of other internal organs and sepsis occurred more often with Menghini needles. In contrast, a study comparing Jamshidi suction

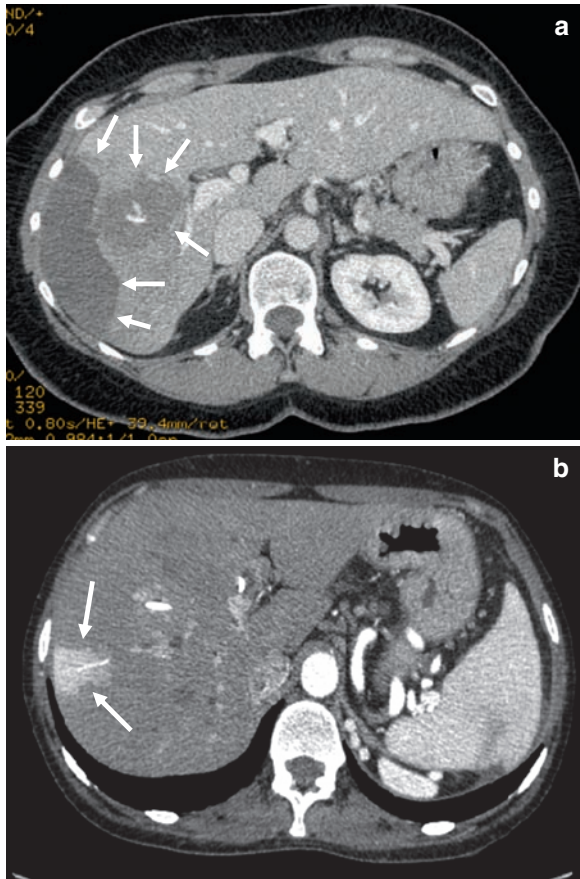


Fig. 43.2 Hemorrhage as a complication of transcutaneous liver biopsy. (a) The computed tomography scan shows a massive intrahepatic and subcapsular hemorrhage 24h after liver biopsy in a patient with normal coagulation studies biopsied for a treatment decision in chronic hepatitis C. This example shows that hemorrhage can occur late after transcutaneous liver biopsy in individuals without coagulopathy. (b) The computed tomography shows an arterial phase of a study performed incidentally after liver biopsy a few hours previously. The study demonstrates the extent of intrahepatic hemorrhage in a clinically inapparent patient with normal vital parameters and unchanged blood count following liver biopsy

needles with Tru-Cut Vim Silverman needles was unable to demonstrate such technique related differences [39, 45]. Whether the diameter of the needle is a factor predisposing to hemorrhage is controversial. While in humans no differences were observed between using a 1.6 or a 1.9mm Menghini needle, experiments on pigs under anesthesia showed more bleeding in 2.1 versus 1.6mm as well as 1.2 versus 1.6mm needles [19, 22]. When considering gauge as well as Menghini versus Tru-Cut needles, one should also keep in mind that smaller needles and smaller specimens may increase the number of passes or

necessitate repuncture, with an increase of bleeding risk, in order to obtain representative tissue [37].

Bacteremia

Bacteremia has been documented to result from biopsies of both normal and cirrhotic livers [31, 32, 38]. In patients with biliary-enteric anastomoses the occurrence of septic complications following liver biopsy has been controversial [4, 7, 14, 21]. At present, data is not sufficient to recommend routine antibiotic prophylaxis. Antibiotics should, however, be administered to patients suffering from valvular heart disease, a documented history of septic complications following liver biopsy, or in suspected cholangitis.

Laparoscopic Liver Biopsy

(For a detailed discussion see Chapter 45)

Laparoscopic liver biopsy is not a biopsy technique per se but an alternative route of obtaining a liver biopsy during visual assessment of the peritoneum and the abdominal organs [28]. Historically, minimally invasive abdominal procedures were developed by inter-nists for diagnostic reasons. In the 1960s laparoscopy was routinely performed for the assessment of liver disease [5, 44]. However, after the refinement of biochemical, serological and molecular biological tests in the diagnosis of liver diseases, laparoscopy was employed less frequently and the considerable body of experience of macroscopic assessment of liver diseases has seen a significant decline. In recent years laparoscopic liver biopsy has again begun to attract increasing attention in particular because of the development of the minimally invasive mini laparoscopy for routine clinical practice [63]. Mini laparoscopy is distinguished from standard or midi laparoscopy by the use of optical instruments with a diameter of < 2 mm and the use of a sheathed Veres-needle that allows for the application of a pneumoperitoneum and the abdominal introduction of the optical instrument through a single puncture (Fig. 43.3). The abdomen is punctured at the so-called Kalk position 2 cm left and cranially of the umbilicus, followed by introduction of approximately 3–4l of N₂O to produce a sufficient pneumoperitoneum. An instrumentation sheath is subsequently positioned under

direct visualization, typically in the lateral right upper quadrant within reach of the liver. After a macroscopic assessment of the cranial and inferior liver surface including the edges, the gall bladder, the hepatic ligament as well as the peritoneum, a liver biopsy can be performed either by the aspiration or trucut technique by advancing the respective biopsy device through the instrumentation sheath. This is preceded by macroscopically identifying a specific area of interest on the liver surface, thereby increasing the likelihood of a representative biopsy specimen relative to the original indication for the biopsy. The site of puncture can be monitored and in case of prolonged hemorrhage monopolar electric coagulation can be employed. In addition, the presence of ascites is not a limiting factor since ascitic fluid can be evacuated during laparoscopy prior to the liver biopsy procedure.

Technique and Risk Assessment

Mini laparoscopy is less invasive than standard laparoscopy but has the disadvantage of a 0° optical instrument of 1.9–2.0 mm diameter with decreased brightness and therefore a reduced overview of the abdominal organs (Fig. 43.3). For the representative diagnosis of liver cirrhosis a number of studies have

suggested laparoscopy to represent the gold standard [28, 43, 63]. The macroscopic diagnosis of nodular cirrhosis and increased tissue consistency by direct palpation is relatively simple and leads to an increased sensitivity in comparison to “blind” biopsy or ultrasound visualization and biopsy. A recent study using Menghini aspiration needles has found the sensitivity to detect cirrhosis to be 96.4% for standard and 91.9% for mini laparoscopy compared to 68% for histology without laparoscopy [63]. Compared to transcutaneous liver biopsies, the rate of complications appears to not be increased for mini laparoscopy [25]. An important issue is the feasibility of this approach in patients with coagulation disorders. Mini laparoscopy has been shown to be feasible in patients with prolonged international normalized ratios (INR) > 1.5 , thrombocytopenia $< 50/\text{nl}$, and even in cases of von Willebrand’s disease or hemophilia without significant hemorrhage [16]. The risk assessment includes risks of the laparoscopy itself, i.e. sedation, accidental vascular injection of N_2O , injury of the viscera, and hemorrhage of abdominal wall vessels. During 63,845 standard laparoscopies with 48,766 liver biopsies the reported rate of hemorrhage was 0.09%, overall complications 2.5% and the mortality rate 0.03% [5, 44].

An important issue surrounding liver biopsies is the attempt to obtain a representative sample of the liver. Many chronic liver diseases including primary sclerosing

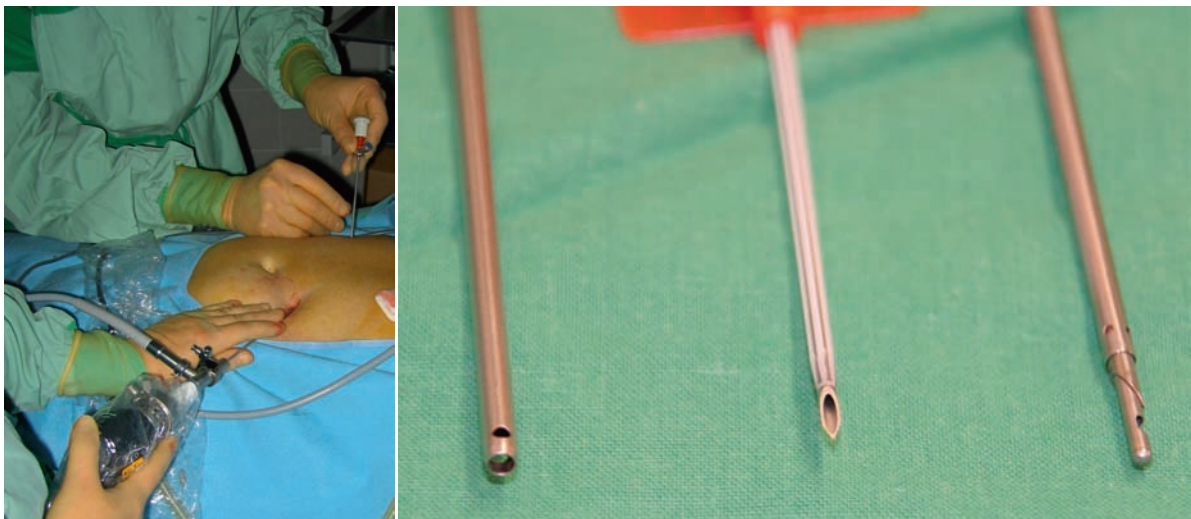
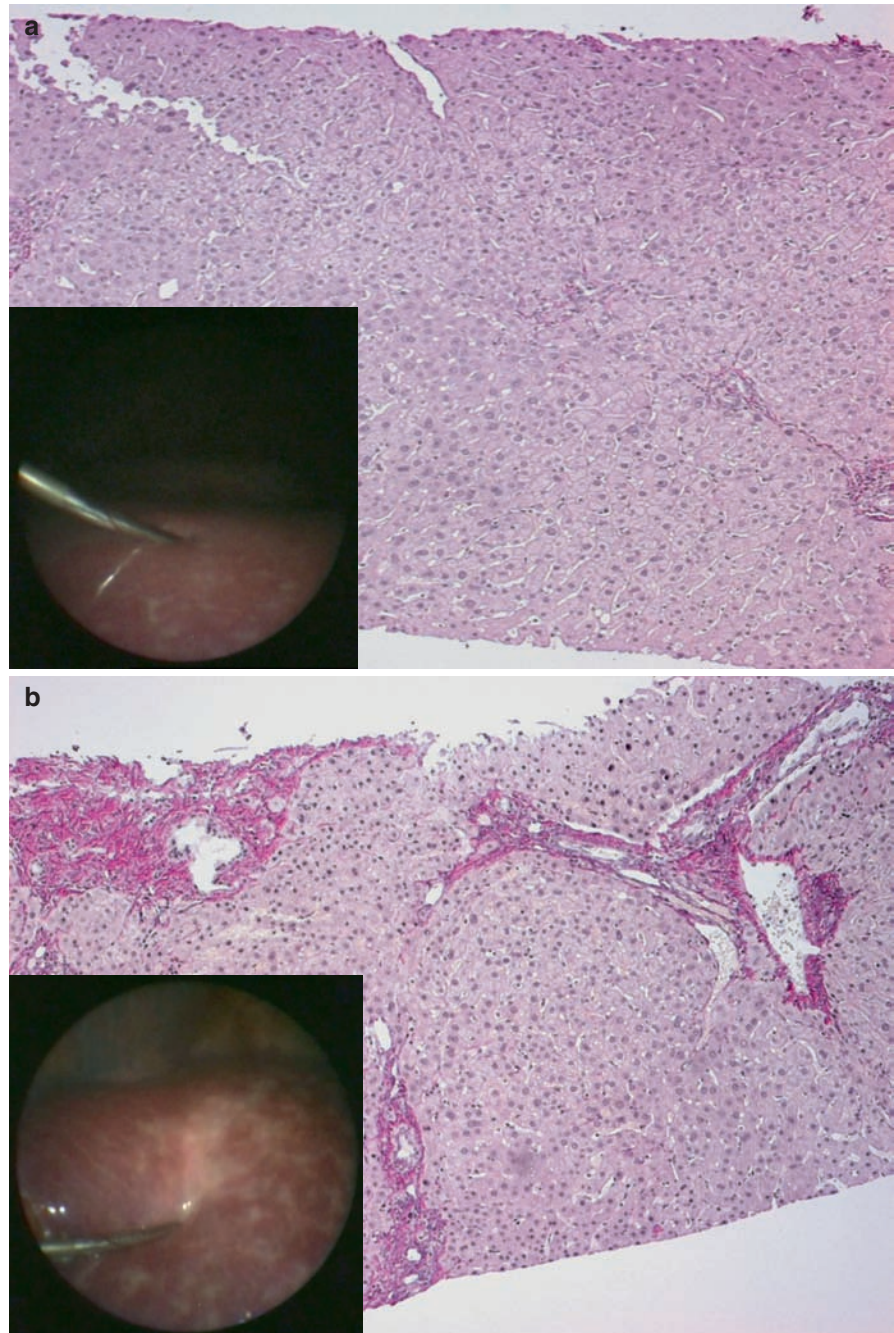


Fig. 43.3 Typical setting of mini laparoscopy with an inserted optical instrument prior to the insertion of the instrumentation cannula (left panel). Mini laparoscopy in this image uses equipment with a diameter of 2 mm which is approximately the size of

a 14 gauge venous cannula. The right panel shows the size comparison of the fiber optic instrument (*left*), a 14 gauge venous cannula (*middle*) and the Veres needle with the surrounding insertion sheath (*right*)

Fig. 43.4 Example of the variability of visually directed biopsy of the liver of a single patient with primary sclerosing cholangitis. Biopsy within an area with the appearance of mild fibrosis, histologically shows an image with almost no changes of microscopical architecture (**a**). Biopsy of an area within the same liver which appears more affected leads to the histological picture of advanced fibrosis (**b**). In these patients biopsies of the areas of interest lead to an accurate assessment of histological stage superior to a “blind” transcutaneous approach



cholangitis, viral hepatitis, and nodular regeneration affect the liver in a zonal fashion. A “blind” biopsy is unlikely to accurately reflect the extent and variation of hepatic disease in these cases. Mini laparoscopy offers the advantage of visual guidance of the biopsy needle to a region or multiple regions of interest which considerably increases the accurate subsequent histological

assessment (Fig. 43.4). In addition, unclear hepatic masses can be directly biopsied even in those cases when vascular structures limit a transcutaneous approach since laparoscopy includes the possibility of electrocautery hemostasis. Finally, in diseases such as primary sclerosing cholangitis, cholangiocellular carcinoma or hepatic metastases the peritoneum can be visualized and

evidence of peritoneal carcinomatosis documented and biopsied, which is important for the decision between operative and conservative treatment strategies.

Ultrasound Guided Fine Needle Aspiration

Ultrasound guided fine needle aspiration is extensively used to obtain histological or cytological information regarding the dignity of focal hepatic lesions. It is not routinely employed to determine the grade of liver inflammation or the stage of hepatic fibrosis [62]. The indication for fine needle aspiration cytology of diffuse hepatic diseases is controversial. The hepatic lesion is visualized by ultrasound and a path for the needle aspiration is plotted to avoid intersecting vessels. Usually, an ultrasound array with an integrated needle guidance slot is employed. A needle with a diameter of < 1 mm is advanced into the lesion while the patient holds her/his breath, suction is applied with a syringe connected to the needle, and after 3–5 passes the needle is withdrawn from the liver. The aspirated material is spread on a glass microscopy slide, dried and forwarded to the cytologist. Ultrasound guided biopsy can also be performed with cutting needles. In general, a cirrhotic liver in a patient with a higher likelihood of bleeding would be a candidate for fine needle aspiration versus cutting needle biopsy. In addition, biopsy of the liver can be performed under CT guidance.

A number of studies have documented that the specificity of fine needle aspiration cytology is accurate with sensitivities and specificities near 100% [18, 26, 27]. In one study comparing fine needle aspiration and cutting needle aspiration, the diagnostic accuracy was 78% for both, but rose to 88% when the techniques were combined [20]. Based on these studies fine needle aspiration cytology is a safe and sensitive diagnostic procedure.

Technique and Risk Assessment

Hemorrhage

Hemorrhage with fine needle aspiration using < 1 mm needles is rare. The mortality rate has been estimated to range between 0.006% and 0.1% [48]. The lowest complication rate has been reported in an analysis of 2,091 biopsies for the use of non-cutting needles [8].

Dissemination of Malignant Cells

One of the most controversial issues surrounding the biopsy of space occupying lesions is the potential seeding of cancer cells along the biopsy path following fine needle aspiration [35]. This is a problem because the diagnostic role of this technique is most often the assessment of suspect hepatic lesions. Seeding rates of biopsies obtained from all abdominal organs have been estimated to range between 0.0003% and 0.009% [13, 52]. However, in a retrospective study by Takamori the rate in hepatocellular carcinomas was 5.1%, therefore bringing into question the use of needle aspirations in patients with hepatocellular carcinoma [58]. When polymerase chain reaction for the detection of α -1-antitrypsin messenger RNA was employed, tumor cell dissemination after fine needle aspiration was suggested [36]. The evaluation of hepatic masses without fine needle biopsy in one study showed that standard imaging procedures led to a diagnostic accuracy of 99.6% and a sensitivity of 98.6% for hepatocellular carcinoma and was similar for liver metastases [59]. However, the issue of tumor cell seeding and its clinical relevance remains controversial and is different with respect to the lesion to be biopsied [11, 15, 42, 49, 60]. Based on these considerations the biopsy of hepatocellular carcinomas or other suspect malignant lesions of the liver should be cautiously weighed against the risk of dissemination, the therapeutic consequences of the biopsy, and the availability of other imaging tests with sufficient information. In a recent study no negative impact of HCC biopsies for the indication for liver transplantation was reported [17]. Fine needle aspiration should be considered in patients with unclear hepatic lesions in whom the side effects of therapy outweigh the consequences of seeding. For HCC, a lesion that is typically considered for fine needle aspiration is one that is < 2 cm, lacks typical features of HCC on other imaging tests, and is associated with a normal serum AFP.

The Candidate Patient for Liver Biopsy

The technical aspects of a successful and therapeutically or diagnostically relevant liver biopsy can only be viewed in light of a general risk assessment of the patient and the observation of contraindications.

Informed Consent

Informed written consent should always be obtained, prior to the planned biopsy. Care should be taken to provide information in the candidate's native language or through an interpreter.

Compliance

Most techniques (exception: laparoscopy) require a patient who is cooperative and is able to hold her/his breath for the required period of time. In a frightened patient medication with midazolam can be considered but should be weighed against the ability to cooperate.

Mechanical Biliary Obstruction

This is a relative contraindication. Biliary peritonitis, sepsis and pain are possible consequences. If the benefit of the biopsy outweighs these complications a biopsy can be performed, but a transvenous approach should be considered.

Cholangitis

Bacterial cholangitis is a relative contraindication and may actually provide useful bacteriological information in some patients. In view of the risk of disseminating pathogens during the biopsy, the procedure should only be performed under antibiotic treatment. However, patients with bacterial cholangitis will be treated with antibiotics anyway even if a liver biopsy is not performed.

Hemostasis

A normal INR is desired but frequently not present in patients requiring a liver biopsy. The fact that 90% of hemorrhages occur in patients with an INR < 1.3 reflects the fact that although abnormal INR values predispose to bleeding, a normal INR does not represent an absolute

reassurance that a hemorrhage will not occur (Fig. 43.2) [23]. This can also occur much later than anticipated [64]. Coagulation studies should be performed 24 h prior to the biopsy and should result in an INR < 1.4. If this is not the case, other strategies such as transvenous biopsy or mini laparoscopy should be considered, in addition to the administration of clotting factors (e.g. fresh frozen plasma) [16, 30, 51]. The platelet counts are also a matter of controversy. In some patients such as hemodialysis patients or individuals with renal impairment as well as those with hematological disorders or cholestasis, platelet function may be compromised despite normal numbers [47]. Evidence suggests that a liver biopsy can be safely performed when platelets are above 60,000/mm³ [39]. The use of aspirin and other non-steroidal anti-inflammatory drugs 1 week prior to biopsy is a controversial issue but currently lacks data confirming an increased risk in these patients.

Ascites

There are no randomized controlled studies to suggest that ascites is a strict contraindication for a liver biopsy although in many publications a potentially higher rate of post interventional bleeding is assumed. Experience with CT guided liver biopsies has not demonstrated an increase in complications in patients with ascites [30, 34, 41].

References

1. Actis GC, Olivero A, Lagget M, et al (2007) The practice of percutaneous liver biopsy in a gastrohepatology day hospital: a retrospective study on 835 biopsies. *Dig Dis Sci* 52: 2576–9
2. Ahmad A, Hasan F, Abdeen S, et al (2004) Transjugular liver biopsy in patients with end-stage renal disease. *J Vasc Interv Radiol* 15: 257–60
3. Al Knawy B, Shiffman M (2007) Percutaneous liver biopsy in clinical practice. *Liver Int* 27: 1166–73
4. Ben-Ari Z, Neville L, Rolles K, et al (1996) Liver biopsy in liver transplantation: no additional risk of infections in patients with choledochojejunostomy. *J Hepatol* 24: 324–7
5. Bruhl W (1966) Incidents and complications in laparoscopy and directed liver puncture. Result of a survey [in German]. *Dtsch Med Wochenschr* 91: 2297–9
6. Brunt EM (2004) Nonalcoholic steatohepatitis. *Semin Liver Dis* 24: 3–20
7. Bubak ME, Porayko MK, Krom RA, et al (1991) Complications of liver biopsy in liver transplant patients:

- increased sepsis associated with choledochojejunostomy. *Hepatology* 14: 1063–5
8. Buscarini L, Fornari F, Bolondi L, et al (1990) Ultrasound-guided fine-needle biopsy of focal liver lesions: techniques, diagnostic accuracy and complications. A retrospective study on 2091 biopsies. *J Hepatol* 11: 344–8
 9. Carvalho-Filho RJ, Schiavon LL, Narciso-Schiavon JL, et al (2008) Optimized cutoffs improve performance of the aspartate aminotransferase to platelet ratio index for predicting significant liver fibrosis in human immunodeficiency virus/hepatitis C virus co-infection. *Liver Int* 28: 486–93
 10. Caturelli E, Biasini E, Bartolucci F, et al (2002) Diagnosis of hepatocellular carcinoma complicating liver cirrhosis: utility of repeat ultrasound-guided biopsy after unsuccessful first sampling. *Cardiovasc Intervent Radiol* 25: 295–9
 11. Caturelli E, Ghittoni G, Roselli P, et al (2004) Fine needle biopsy of focal liver lesions: the hepatologist's point of view. *Liver Transpl* 10: S26–29
 12. Caturelli E, Giacobbe A, Facciorusso D, et al (1996) Percutaneous biopsy in diffuse liver disease: increasing diagnostic yield and decreasing complication rate by routine ultrasound assessment of puncture site. *Am J Gastroenterol* 91: 1318–21
 13. Cedrone A, Rapaccini GL, Pompili M, et al (1992) Neoplastic seeding complicating percutaneous ethanol injection for treatment of hepatocellular carcinoma. *Radiology* 183: 787–8
 14. De Diego Lorenzo A, Romero M, Duran F, et al (1997) Bacteremia following liver biopsy in transplant recipients with Roux-en-Y choledochojejunostomy. *Rev Esp Enferm Dig* 89: 289–95
 15. De Sio I, Castellano L, Calandra M, et al (2002) Subcutaneous needle-tract seeding after fine needle aspiration biopsy of pancreatic liver metastasis. *Eur J Ultrasound* 15: 65–8
 16. Denzer U, Helmreich-Becker I, Galle PR, et al (2003) Liver assessment and biopsy in patients with marked coagulopathy: value of mini-laparoscopy and control of bleeding. *Am J Gastroenterol* 98: 893–900
 17. Durand F, Belghiti J, Paradis V (2007) Liver transplantation for hepatocellular carcinoma: role of biopsy. *Liver Transpl* 13: S17–23
 18. Fornari F, Civardi G, Cavanna L, et al (1990) Ultrasonically guided fine-needle aspiration biopsy: a highly diagnostic procedure for hepatic tumors. *Am J Gastroenterol* 85: 1009–13
 19. Forssell PL, Bonkowsky HL, Anderson PB, et al (1981) Intrahepatic hematoma after aspiration liver biopsy. A prospective randomized trial using two different needles. *Dig Dis Sci* 26: 631–5
 20. Franca AV, Valerio HM, Trevisan M, et al (2003) Fine needle aspiration biopsy for improving the diagnostic accuracy of cut needle biopsy of focal liver lesions. *Acta Cytol* 47: 332–6
 21. Galati JS, Monsour HP, Donovan JP, et al (1994) The nature of complications following liver biopsy in transplant patients with Roux-en-Y choledochojejunostomy. *Hepatology* 20: 651–3
 22. Gazelle GS, Haaga JR, Rowland DY (1992) Effect of needle gauge, level of anticoagulation, and target organ on bleeding associated with aspiration biopsy. *Work in progress. Radiology* 183: 509–13
 23. Gilmore IT, Burroughs A, Murray-Lyon IM, et al (1995) Indications, methods, and outcomes of percutaneous liver biopsy in England and Wales: an audit by the British Society of Gastroenterology and the Royal College of Physicians of London. *Gut* 36: 437–41
 24. Guido M, Ruge M (2004) Liver biopsy sampling in chronic viral hepatitis. *Semin Liver Dis* 24: 89–97
 25. Helmreich-Becker I, Meyer zum Büschenfelde KH, Lohse AW (1998) Safety and feasibility of a new minimally invasive diagnostic laparoscopy technique. *Endoscopy* 30: 756–62
 26. Hertz G, Reddy VB, Green L, et al (2000) Fine-needle aspiration biopsy of the liver: a multicenter study of 602 radiologically guided FNA. *Diagn Cytopathol* 23: 326–8
 27. Jain D (2002) Diagnosis of hepatocellular carcinoma: fine needle aspiration cytology or needle core biopsy. *J Clin Gastroenterol* 35: S101–8
 28. Jalan R, Harrison DJ, Dillon JF, et al (1995) Laparoscopy and histology in the diagnosis of chronic liver disease. *QJM* 88: 559–64
 29. Jevon GP, Dimmick JE (1998) Histopathologic approach to metabolic liver disease: Part 1. *Pediatr Dev Pathol* 1: 179–99
 30. Kamphuisen PW, Wiersma TG, Mulder CJ, et al (2002) Plugged-percutaneous liver biopsy in patients with impaired coagulation and ascites. *Pathophysiol Haemost Thromb* 32: 190–3
 31. Larson AM, Chan GC, Wartelle CF, et al (1997) Infection complicating percutaneous liver biopsy in liver transplant recipients. *Hepatology* 26: 1406–9
 32. Le Frock JL, Ellis CA, Turchik JB, et al (1975) Transient bacteremia associated with percutaneous liver biopsy. *J Infect Dis* 131(Suppl): S104–7
 33. Li MK, Crawford JM (2004) The pathology of cholestasis. *Semin Liver Dis* 24: 21–42
 34. Little AF, Ferris JV, Dodd GD 3rd, et al (1996) Image-guided percutaneous hepatic biopsy: effect of ascites on the complication rate. *Radiology* 199: 79–83
 35. Liu YW, Chen CL, Chen YS, et al (2007) Needle tract implantation of hepatocellular carcinoma after fine needle biopsy. *Dig Dis Sci* 52: 228–31
 36. Louha M, Nicolet J, Zylberberg H, et al (1999) Liver resection and needle liver biopsy cause hematogenous dissemination of liver cells. *Hepatology* 29: 879–82
 37. Maharaj B, Bhoora IG (1992) Complications associated with percutaneous needle biopsy of the liver when one, two or three specimens are taken. *Postgrad Med J* 68: 964–7
 38. McCloskey RV, Gold M, Weser E (1973) Bacteremia after liver biopsy. *Arch Intern Med* 132: 213–5
 39. McGill DB, Rakela J, Zinsmeister AR, et al (1990) A 21-year experience with major hemorrhage after percutaneous liver biopsy. *Gastroenterology* 99: 1396–400
 40. Menghini G (1958) One-second needle biopsy of the liver. *Gastroenterology* 35: 190–9
 41. Murphy FB, Barefield KP, Steinberg HV, et al (1988) CT- or sonography-guided biopsy of the liver in the presence of ascites: frequency of complications. *Am J Roentgenol* 151: 485–6
 42. Ng KK, Poon RT, Lo CM, et al (2004) Impact of preoperative fine-needle aspiration cytologic examination on clinical outcome in patients with hepatocellular carcinoma in a tertiary referral center. *Arch Surg* 139: 193–200

43. Nord HJ (1982) Biopsy diagnosis of cirrhosis: blind percutaneous versus guided direct vision techniques—a review. *Gastrointest Endosc* 28: 102–4
44. Nord HJ (1992) Complications of laparoscopy. *Endoscopy* 24: 693–700
45. Perrault J, McGill DB, Ott BJ, et al (1978) Liver biopsy: complications in 1000 inpatients and outpatients. *Gastroenterology* 74: 103–6
46. Piccinino F, Sagnelli E, Pasquale G, et al (1986) Complications following percutaneous liver biopsy. A multicentre retrospective study on 68,276 biopsies. *J Hepatol* 2: 165–73
47. Pihusch R, Rank A, Gohring P, et al (2002) Platelet function rather than plasmatic coagulation explains hypercoagulable state in cholestatic liver disease. *J Hepatol* 37: 548–55
48. Pitman MB (1998) Fine needle aspiration biopsy of the liver. Principal diagnostic challenges. *Clin Lab Med* 18: 483–506
49. Shah JN, Fraker D, Guerry D, et al (2004) Melanoma seeding of an EUS-guided fine needle track. *Gastrointest Endosc* 59: 923–4
50. Sheela H, Seela S, Caldwell C, et al (2005) Liver biopsy: evolving role in the new millennium. *J Clin Gastroenterol* 39: 603–10
51. Shin JL, Teitel J, Swain MG, et al (2005) A Canadian multicenter retrospective study evaluating transjugular liver biopsy in patients with congenital bleeding disorders and hepatitis C: is it safe and useful? *Am J Hematol* 78: 85–93
52. Smith EH (1991) Complications of percutaneous abdominal fine-needle biopsy. Review. *Radiology* 178: 253–8
53. Sporea I, Sirlu R, Popescu A, et al (2007) The quality of the fragment obtained by liver biopsy for staging chronic hepatitis. *J Gastrointest Liver Dis* 16: 263–6
54. Storch IM, Sussman DA, Jorda M, et al (2007) Evaluation of fine needle aspiration vs. fine needle capillary sampling on specimen quality and diagnostic accuracy in endoscopic ultrasound-guided biopsy. *Acta Cytol* 51: 837–42
55. Stotland BR, Lichtenstein GR (1996) Liver biopsy complications and routine ultrasound. *Am J Gastroenterol* 91: 1295–6
56. Strassburg CP, Manns MP (2006) Approaches to liver biopsy techniques—revisited. *Semin Liver Dis* 26: 318–27
57. Strassburg CP, Manns MP (2000) Autoimmune tests in primary biliary cirrhosis. *Baillieres Best Pract Res Clin Gastroenterol* 14: 585–99
58. Takamori R, Wong LL, Dang C, et al (2000) Needle-tract implantation from hepatocellular cancer: is needle biopsy of the liver always necessary? *Liver Transpl* 6: 67–72
59. Torzilli G, Minagawa M, Takayama T, et al (1999) Accurate preoperative evaluation of liver mass lesions without fine-needle biopsy. *Hepatology* 30: 889–93
60. Torzilli G, Olivari N, Del Fabbro D, et al (2004) Indication and contraindication for hepatic resection for liver tumors without fine-needle biopsy: validation and extension of an Eastern approach in a Western community hospital. *Liver Transpl* 10: S30–3
61. Vautier G, Scott B, Jenkins D (1994) Liver biopsy: blind or guided? *Bmj* 309: 1455–6
62. Wee A (2005) Fine needle aspiration biopsy of the liver: Algorithmic approach and current issues in the diagnosis of hepatocellular carcinoma. *Cytojournal* 2: 7
63. Weickert U, Siegel E, Schilling D, et al (2005) The diagnosis of liver cirrhosis: a comparative evaluation of standard laparoscopy, mini-laparoscopy and histology[in German]. *Z Gastroenterol* 43: 17–21
64. Yeo WT, Tan LK, Dan YY, et al (2008) Delayed bleeding after liver biopsy: a dreaded complication. *Singapore Med J* 49: 76–80

Chapter Outline

Development of the Transjugular Liver Biopsy	474
Success Rate and Specimen Quality	474
Indications	474
Contraindications	475
Technical Considerations	476
Biopsy Technique	476
Correction of Coagulopathy	476
Vascular Access	476
Biopsy Needle – Cutting, Aspiration, and Spring-Loaded	477
Complications and Mortality	477
Vascular Access Complications	478
Bleeding Complications	478
Biliary Complications	478
Cardiac Complications	478
Risks of Fluoroscopy and Intravenous Contrast	478
Special Populations	478
Bleeding Diatheses	478
Fulminant Hepatic Failure	480
Pediatrics	480
End-Stage Renal Disease	481
Liver Transplant Recipients	481
Summary	482
References	482

Interpretation of liver biopsy findings serves as the foundation for the understanding and treatment of liver diseases. Despite rapidly improving molecular, biochemical, and serologic testing, liver biopsy remains the diagnostic gold standard. Histologic assessment provides critical prognostic information and is frequently pivotal in therapeutic decisions. For most individuals, liver biopsy is safely and efficiently performed by the standard percutaneous approach. However, in patients with advanced liver disease, for whom liver biopsy findings may be most critical, bleeding complications after invasive procedure such as a percutaneous liver biopsy can be associated with unacceptable risk. Alternatives for this group have included open or laparoscopic liver biopsy, transjugular liver biopsy (TJLB) or empiric treatment without histology. Of these TJLB provides the least invasive method to obtain reasonable diagnostic material.

TJLB has been safely and successfully performed for the past 40 years. Until recently, however, TJLB has been limited by relatively small size of the core liver sample, leading to frequently uninterpretable histologic results. However, greatly improved tissue sampling is now achieved with increased technical experience, incorporation of better radiologic imaging, and improvements in the biopsy needle. In this chapter we review the development of the transjugular liver biopsy, with particular emphasis on the safety and efficacy of this technology, and discuss its role in special patient populations such as children, fulminant hepatitis, and liver transplant recipients.

Development of the Transjugular Liver Biopsy

Although the first documented liver biopsy was performed by Paul Ehrlich in 1883 to determine the hepatic glycogen content in a diabetic patient, it was not until 1958 when Menghini published his seminal report of a “one-second needle biopsy of the liver” that percutaneous liver biopsy was perceived as a safe, non-operative procedure, fully integrated into the routine assessment of hepatic disorders [65]. With experienced operators and carefully selected patients, percutaneous liver biopsy is a safe procedure with complication rates of about 1% and mortality of 0.01–0.1% (see Chapter 43) [85].

The presence of coagulopathy, thrombocytopenia, and large ascites commonly encountered in patients with advanced liver disease poses an unacceptable increased risk of hemorrhagic complications with percutaneous liver biopsy. The transjugular liver biopsy was proposed to obtain tissue in this situation as the biopsy needle enters the hepatic parenchyma from within the hepatic veins. In this manner, bleeding occurs along the biopsy tract and returns to the systemic venous circulation.

The first transvenous liver biopsy was performed in 1964 in an experimental canine model [32]. In 1967, Hanafee and Weiner showed that this approach could be used to safely catheterize the hepatic vein in humans, and several years later these authors reported the first successful TJLB in patients with hepatobiliary disease [42, 91].

Success Rate and Specimen Quality

Tissue can be readily obtained in nearly all (~97%) patients undergoing TJLB [44]. Specimen adequacy after TJLB, particularly for patients with cirrhosis, has historically been a major concern. Early studies using aspiration needles often yielded small (<1 cm), thin, and highly fragmented specimens leading to the perception that tissues obtained via TJLB were suboptimal for histologic evaluation [12, 15, 18, 22, 34, 35, 48, 61, 80].

Due to recent improvements in technique, however, the TJLB is no longer clearly inferior in terms of specimen adequacy. Until recently, an adequate biopsy for

diagnosis required ≥ 15 mm length and at least 6–8 complete portal tracts. It has now been shown that specimens 20–25 mm long and/or containing ≥ 11 complete portal tracts further improve accuracy of grading and staging chronic liver disease [9, 24]. In contradistinction to percutaneous biopsy where multiple passes lead to increased bleeding complications, numerous cores can be safely obtained by the TJ route providing adequate tissue for diagnosis, grading, and staging [28, 29, 63, 73].

In a recent study aimed to dispel the assumption that TJLB yields “second-rate” specimens, the adequacy of transjugular and percutaneous liver biopsy was compared [18]. 326 TJLB and 40 percutaneous comparator controls were assessed for length, number of complete and partial portal tracts, fragmentation, and adequacy for histologic diagnosis. TJLB specimens were obtained with three passes of a 19-gauge Tru-Cut biopsy needle. No significant difference in median biopsy length or number of complete portal tracts was observed between TJLB (22 mm, 8 complete portal tracts) and percutaneous (17 mm, 7 complete portal tracts) liver biopsy specimens. Of the 326 transjugular biopsies, 290 (89%) were greater than 15 mm, 213 (63%) greater than 20 mm, and 116 (36%) greater than 25 mm in length; 76% of samples had at least 6 complete portal tracts while 26% of samples contained at least 11 complete portal tracts. Transjugular biopsy performed similarly, if not better, than standard percutaneous liver biopsy in achieving hepatic tissue sufficient for diagnosis; nearly 90% of specimens were either ≥ 15 mm in length or contained ≥ 6 complete portal tracts. This study is limited by the small number of percutaneous samples, leading to a possible selection bias, but did show that TJLB does provide adequate tissue in the vast majority of cases.

Indications

Transjugular liver biopsy is indicated when histologic examination is required but routine percutaneous liver biopsy is contraindicated and/or evaluation of hepatic vasculature or portal pressure is required or desirable (Table 44.1). The most common reason to proceed with TJLB is a heightened risk of bleeding due to coagulopathy, thrombocytopenia, ineffective platelet function, or ascites [2, 63, 86]. Consensus is lacking on what criteria

Table 44.1 Indications for transjugular liver biopsy

- Coagulopathy
- Thrombocytopenia
- Ineffective platelet function
- Recent use of NSAIDs, anti-platelet agent
- Large ascites
- Vascular tumor
- Hepatic peliosis
- Need for concomitant ancillary diagnostics, particularly measurement of hepatic vein wedged pressure

for INR or platelet count represents a contraindication to percutaneous biopsy, and a survey of transplant centers indicated that thresholds vary considerably. However, expert opinion suggests that transjugular liver biopsy be considered for patients with a platelet count of less than 50,000 to 70,000 and/or and INR of > 1.4 [38, 86, 87].

Although correction of a prolonged bleeding time could facilitate a safer percutaneous liver biopsy, the administration of standard amounts of fresh frozen plasma reverses coagulopathy in only 12.5% of patients with advanced liver disease and leads to volume overload in many patients. In addition, patients requiring systemic anticoagulation may be unable to tolerate the required interruption in warfarin or heparin therapy due to thrombotic risk. Therefore, in the presence of coagulopathy arising from hepatic synthetic dysfunction or systemic use of anticoagulants, TJLB is the preferred method of liver biopsy.

Quantitative and qualitative platelet disorders are also common in patients with liver disease. Thrombocytopenia due to marrow suppressive medications, marrow failure, or portal-hypertensive splenic sequestration, and impaired hepatic thrombopoietin production are commonly encountered. Viral hepatitis is prevalent in patients with end-stage renal disease in whom uremia-induced platelet dysfunction leads to impaired clot formation [2].

Perihepatic ascites prevents tamponade of the biopsy tract and theoretically increased the risk of bleeding after standard percutaneous liver biopsy. Although the safety of percutaneous biopsy in the presence of ascites has never been rigorously assessed in randomized trials, experience with CT-guided biopsy in the presence of ascites has not demonstrated increased risk [53, 70]. Nevertheless, most hepatologists regard the presence of significant ascites as an indication for TJLB.

Less common indications for percutaneous liver biopsy include the known or suspected presence of vascular tumors or hepatic peliosis [44]. In addition, in the absence of significant contraindications to percutaneous liver biopsy, TJLB is indicated when there is a need for ancillary diagnostic assessment. Using the same minimal venous access, liver biopsy can be performed simultaneously with measurement of hepatic hemodynamics to assess for portal hypertension and mapping of hepatic and portal venous systems with contrast venography and CO₂ portography, respectively.

Some have thought that patients would prefer TJLB due to the routine use of sedation and a belief that there would be less frequent periprocedural pain. In our practice, the vast majority of patients (predominantly post-transplant) who have had biopsies with both methods prefer the percutaneous route. Decreased procedure time and neck vein access are the most frequently cited reasons for dislike of the TJLB.

Contraindications

Contraindications to transjugular liver biopsy are listed in [Table 44.2](#). Uncooperative patients who cannot be safely sedated should not undergo liver biopsy with any approach other than laparoscopically with general anesthesia. Because transient bacteremia after hepatic biopsy is common, TJLB should be cautiously performed in patients with an infected biliary system due to the risk of precipitating a disseminated infection or septic shock [38, 55, 62]. Similarly, biopsy should be avoided in cases of known or suspected echinococcal hepatic cysts [12].

Table 44.2 Absolute and relative contraindications to transjugular liver biopsy

Absolute contraindications

- Uncooperative patient
- Hydatidiform disease
- Pregnancy

Relative contraindications

- Extreme coagulopathy
- Cholangitis
- Chronic renal insufficiency

Technical Considerations

Biopsy Technique

Despite significant modifications in the biopsy needle employed, little has changed in the technique of TJLB since Hanafee and Weiner's first report. It is usually performed in a dedicated procedure room with cardiac monitoring, fluoroscopy, and trained support staff. In the United States, TJLB is most commonly performed by interventional radiologists, whereas in Europe experienced hepatologists frequently perform the procedure.

After the administration of local anesthesia (with or without conscious sedation), the internal jugular vein is typically cannulated under ultrasound guidance to minimize carotid arterial puncture [25]. A guidewire is inserted into the inferior vena cava and an angled tip catheter is passed over the wire through the right atrium using the Seldinger technique into the inferior vena cava and then into the right or middle hepatic vein. The right and middle hepatic veins are the preferred biopsy sites because the volume of surrounding hepatic parenchyma is sufficient to promote adequate biopsy material while avoiding capsular rupture. After the guidewire is replaced with a transvenous biopsy needle and its position is verified with the injection of contrast material, the needle is advanced beyond the end of the catheter 1–2 cm into the hepatic parenchyma during suspended patient respiration. After removal of the biopsy needle, a contrast venogram is performed through the catheter to assess for hepatic capsule rupture that, if present, is occluded with embolization coils. On average, the entire procedure requires approximately 40 min to complete [44, 73].

Correction of Coagulopathy

As in percutaneous liver biopsy, there is no universally accepted threshold INR at which transjugular liver biopsy can be safely performed [87]. The use of fresh frozen plasma, platelets, and DDAVP varies amongst centers and no formal recommendations are available. However, correction of extreme coagulopathy should be attempted to minimize bleeding complications.

Vascular Access

The short, straight, and easily navigable course to the intrahepatic vasculature makes the right internal jugular the preferred access site for transvenous biopsy. However, occasionally the right internal jugular is unavailable or inaccessible due to thrombosis or the presence of non-removable central venous catheters. Additionally, the hepatic veins may be difficult to cannulate due to sharp angles off the intrahepatic vena cava and more negotiable from a different approach [45]. This is especially the case in chronic liver disease with significant atrophy and compensatory hypertrophy or following liver transplant or partial hepatectomy [16, 28]. In cases in which the right internal jugular route was either not available or unsuccessful, transvenous liver biopsy has been successfully performed via the left internal jugular, the external jugular, and the femoral veins [10, 46, 52, 68, 82, 83, 88, 93].

In a series of 223 biopsies performed over a 10-year period, 19 (6.5%) were via the left internal jugular due to the presence of partial or total right jugular vein thrombosis, tunneled catheter or mediport, or difficulty with hepatic vein catheterization from the right internal jugular route arising from distorted hepatic anatomy [93]. Although the procedure was technically challenging and more time consuming, sufficient tissue to make a histologic diagnosis was obtained in all cases. There were no major cardiac or hemorrhagic complications. However, two individuals developed self-limited chest pain as the stiff biopsy cannula was advanced obliquely across the mediastinum.

External jugular vein entry to avoid deep neck puncture in severely coagulopathic patients has been advocated. In a series of 24 patients, this approach was successful in 21 (88%) without complications [83]. With the prevailing use of ultrasound guidance to identify the internal jugular vein, however, few centers employ the smaller caliber external jugular vein as standard vascular access.

Finally, transfemoral liver biopsy using the Mansfield biopsy forceps is successful in 89–98% of cases yielding adequate tissue for diagnosis in 80–89% of procedures [10, 46, 52, 68, 82, 88]. Because the catheter does not pass through the cardiac chambers, the risk of arrhythmia in clinically unstable patients is decreased. However, the frequency of crush artifact of the biopsy is possibly greater [82].

Biopsy Needle – Cutting, Aspiration, and Spring-Loaded

The devices employed for TJLB can be broadly classified into two distinct needle systems, aspiration and cutting needles.

The *aspiration transjugular biopsy* is based on the Menghini technique for percutaneous biopsy (1958) that was modified by Colapinto (1983) to reduce catheter perforations and biopsy fragmentation [23, 66]. A hollow Cooks transjugular needle with a sharp cutting edge is inserted through the wall of the hepatic vein into the liver parenchyma. Using gentle suction to create negative pressure, the biopsy specimen is aspirated into the biopsy needle. Although wide cores can be obtained with the large aspiration needle (16 gauge), aspiration biopsy of cirrhotic livers is frequently complicated by fragmentation of the specimens, and cores are not reliably obtained with each pass since the small, firm cirrhotic livers may “bounce” away from the biopsy needle [48, 73]. Finally, the risk of inadvertent capsular puncture is increased since the depth of biopsy is difficult to control [73].

The second type of biopsy needle consists of a disposable, semi-automated side *cutting needle* (Quick-core) based on the Tru-Cut needle [15, 34]. It is capable of providing large, unfragmented specimens with only a minor risk of complications (0–15%) [8, 14, 20, 27, 36, 37, 45, 54, 73, 84]. The cutting system employs thin (18-, 19-, or 20-gauge) spring loaded Tru-Cut needles that are sharp enough to easily penetrate cirrhotic or densely fibrotic livers. Technical success is nearly universal (92–100%) and tissue adequate for histologic diagnosis is nearly always achieved (97–100%) [8, 14, 20, 27, 36, 37, 45, 54, 73, 84].

Although transjugular liver biopsy was developed using the aspiration technique, the use of the Tru-Cut needle now is dominant. Experience from several centers indicate that the Tru-Cut device is superior to the standard aspiration technique in terms of success in obtaining tissue and in obtaining tissue adequate for diagnosis with increased length and decreased fragmentation [21, 58, 79]. In the only randomized prospective trial comparing the two classes of biopsy needles, the Tru-Cut needle was associated with shorter procedure duration, decreased number of passes with the biopsy needle, and increased histologic diagnosis [8].

In a comprehensive and systemic review of TJLB over the past 20 years, Kalambokis (2007) concluded that biopsies obtained with the aspiration needle were more likely to be fragmented, while the Tru-Cut needle was associated with longer specimens more likely to be adequate for histologic diagnosis [44].

Complications and Mortality

Despite selection of high-risk patients, transjugular liver biopsy is an extremely safe procedure. Major complications (Table 44.3) are infrequent (1–3%) and procedure related mortality is estimated at only 0–0.5% in most series [2, 7, 11, 12, 25, 44, 45, 48, 65, 67, 73]. In a recent review of 64 published series representing 7,469 transjugular liver biopsies, the overall complication rate was 7.1% of which 487 (92%) were considered minor and 42 (8%) major as defined by the Society of Interventional Radiologists [43, 44]. The most common minor complications included abdominal pain, subclinical capsular perforation, pyrexia, and neck bleeding/hematoma.

Table 44.3 Complications of transjugular liver biopsy

Minor
<ul style="list-style-type: none"> • Pyrexia • Neck bleeding or hematoma • Neck pain • Carotid puncture • Horner’s syndrome • Dysphonia • Supraventricular arrhythmia • Self-limited hypotension • Abdominal pain • Subclinical capsular perforation • Small hepatic hematoma • Hepatic-portal vein fistula • Biliary fistula • Hemobilia
Major
<ul style="list-style-type: none"> • Large hepatic hematoma • Intraabdominal hemorrhage • Perforation of the inferior vena cava • Perforation of the renal vein • Pneumothorax • Respiratory arrest • Ventricular arrhythmia

Vascular Access Complications

Vascular access complications include hematoma, carotid artery puncture, and pneumothorax, the frequency of which can be reduced with the use of ultrasound guidance [25]. The incidence of these complications is significantly reduced in those series that employed ultrasound for internal jugular localization (33/173 (1.9%) vs. 80/2,808 (2.8%), $p = 0.04$) [44].

Bleeding Complications

Coagulopathy that predisposes the patient to post-procedure bleeding along the biopsy tract is rarely associated with hemodynamic significance since the blood returns to the venous circulation [12, 73]. By injecting contrast dye after each biopsy pass, capsular perforation and bleeding is readily identified at the time of the procedure and can be controlled with deployment of embolization coils [12, 86]. Unlike percutaneous biopsy where the risk of major bleeding increases with successive passes of the biopsy needle, multiple passes with the TJLB have not been associated with increased bleeding complications [44, 63].

Biliary Complications

Biliary complications after transvenous liver biopsy are exceedingly rare and are generally described in the literature in the form of isolated case reports [5, 47]. In the Kalambokis (2007) review of nearly 7,500 TJLB there were only three reports of hemobilia (0.04% of all biopsies) and one occurrence of post-biopsy biliary fistula (0.01%) [44].

Cardiac Complications

Since the biopsy catheter traverses the right atrium, supraventricular tachyarrhythmia (SVT) due to myocardial irritation is a well-described complication necessitating cardiac monitoring for the duration of the procedure. These events are usually mild, self-limited and

not associated with long-term sequelae. In the Kalambokis review SVT occurred in 0.3% of all biopsies [44].

Risks of Fluoroscopy and Intravenous Contrast

Unlike percutaneous biopsy, patients undergoing the transjugular procedure are exposed to both fluoroscopy and contrast dye. Pregnancy, therefore, is an additional contraindication to performing a transvenous biopsy. Administration of contrast dye can be complicated by allergic reaction and contrast induced nephrotoxicity, particularly in the presence of well-recognized risk factors that include diabetes, dehydration, chronic renal failure, and advanced age (>70). To limit this complication, patients should be well hydrated, nephrotoxic medications such as NSAIDs and diuretics should be held, and the volume of administered contrast dye minimized. The benefit of prophylactic agents such as N-acetylcysteine (Mucomyst®) has inconsistently been demonstrated in clinical trials and formal guidelines from the American College of Radiology neither endorse nor discourage its use. Alternatively, CO₂ contrast can be used to avoid contrast exposure but likely provides inferior imaging of the hepatic veins.

Special Populations

Bleeding Diatheses

Virus-inactivated clotting factors became widely available in 1987 [85], and routine screening of the blood supply for hepatitis C virus (HCV) entered standard practice in 1992 [30]. Prior to that time, many individuals with congenital bleeding disorders (CBD), such as hemophilia and von Willebrand disease, were exposed to and chronically infected with HCV [13, 60, 90]. At the present time, the prevalence of HCV in CBD patients is estimated at 86–98% [48, 94]. Since factors known to accelerate the progression of HCV infection (male gender, HIV coinfection, prolonged duration of infection) are commonly encountered, this patient population bears an enormous degree of morbidity from the complications of advanced liver disease.

Since serum liver function tests do not reliably predict the degree of underlying liver disease, histologic evaluation is an invaluable tool to guide treatment decisions. However, concern about severe bleeding complications initially discouraged the performance of liver biopsy in the CBD population as the early experience indicated an unacceptable post-biopsy bleeding complication rate of 12.5% with percutaneous liver biopsy [4]. Moreover, mortality in this patient population was estimated at 1%, a rate that was roughly 100-fold higher than the risk for non-hemophiliacs (<0.01%) undergoing the same procedure [63]. Although several small series have subsequently demonstrated that percutaneous liver biopsy can be safely performed in patients with CBD when appropriate factor replacement and medical monitoring is performed, the experience and safety record of TJLB in patients with acquired coagulopathy has made it the preferred approach for most centers in inherited bleeding diathesis as well [3, 51, 59, 64, 89].

In the first report of TJLB in severe hemophiliacs, six HIV positive, HCV negative patients with persistent liver function abnormalities were successfully biopsied without evidence for bleeding complications [39]. Since this initial paper, several studies have shown that inpatient TJLB is safe and clinically useful in patients with CBD and HCV infection [26, 29, 85]. In the first of these reports, DiMichelle published their experience with 13 HCV/CBD patients, six of whom were co-infected with HIV [29]. All patients received prophylactic factor replacement and/or DDAVP per protocol and were admitted up to 48 h after the biopsy. No periprocedural bleeding was observed and the mean decrease in hemoglobin was only 4% (range 0–9%). Although three patients developed late symptoms of abdominal pain 3–4 days after discharge, radiologic imaging did not show evidence of capsular hematoma and symptoms resolved spontaneously in all.

Similar results were observed in a European review of 88 TJLB performed in patients with hemophilia A (68%), B (24%), or other congenital bleeding disorder (8%) [85]. With prophylactic factor and/or DDAVP infusion and a brief inpatient hospital stay (2–4 days), the procedure proved both clinically useful (33% of patients with minimal histologic evidence of disease subsequently avoided antiviral therapy) and safe in this high-risk population. There were no major complications reported and mild adverse events occurred in seven cases (8%); these included neck hematoma in two, one case of transient right arm palsy due to possible brachial

plexus hematoma, three cases of transient abdominal pain without evidence of bleeding, and one hematoma at the site of a central line used for factor replacement. As operator confidence in the safety of TJLB increased, the amount and duration of factor replacement decreased over the course of this 10-year retrospective, substantially diminishing the cost of the procedure by more than 50% [85].

Abbreviated post-procedure monitoring has also been evaluated and shown to be both safe and associated with significant cost-savings [78, 81]. After a pre-biopsy infusion of factor 8 or 9, 11 patients with hemophilia A or B were successfully biopsied and discharged to home several hours after the procedure [78]. Although there were no immediate post-procedure complications, two patients developed clinically insignificant transient abdominal pain 7 days after the biopsy. This small, retrospective study was followed by a larger (n = 65) multicenter review from Canada that similarly demonstrated the safety of outpatient TJLB in patients with hemophilia, von Willebrand disease, or other bleeding diathesis [81]. After a brief four-hour post-biopsy observation period, patients were discharged to home and, when indicated, continued factor replacement was self-administered. Adequate biopsy specimen (mean length 10.4 mm) was obtained in 63/65 (97%) patients. Post-biopsy venogram was performed in all patients and four cases of minor subcapsular bleed were identified and promptly embolized with gelfoam pledgets. On post-biopsy day 3, one patient (1.4%) developed significant bleeding and abdominal pain requiring admission and PRBC transfusion.

With coordinated care between experience hepatologists, hematologists, and interventional radiologists, TJLB can be safely performed in patients with CBD and chronic liver disease. While brief post-procedure observation appears safe and cost-effective, late bleeding complications after invasive procedures are well described in patients with hemophilia or other CBD and these patients should be counseled on the recognition of symptoms associated with delayed bleeding [47]. Although direct comparison with the percutaneous method has not been undertaken, the safety experience to date dictates that sonographically guided TJLB is likely the procedure of choice. Since all the above-mentioned studies excluded patients with circulating inhibitors, the safety of TJLB in such patients is inconclusive [39, 78, 81, 85].

Fulminant Hepatic Failure

Although the King's College criteria, and more recently the MELD score (see Chapters 30 and 78) predict prognosis and guide critical transplant decisions for patients presenting with fulminant hepatic failure (FHF), liver biopsy may be a useful adjunct by clarifying/confirming the diagnosis and establishing the degree of hepatocellular necrosis. Since FHF is associated with a profound and multifactorial derangement in hemostasis explained by qualitative and quantitative platelet dysfunction, decreased circulating fibrinogen and coagulation factors, as well as enhanced fibrinolysis, liver biopsy in this critical situation presents significant bleeding risk. Moreover, since the INR (or prothrombin time) serves as a barometer for the severity of liver disease, the use of FFP to correct coagulopathy can confuse the clinical scenario and interfere with decisions to proceed with transplantation.

Transjugular liver biopsy appears to have an emerging role in the early and accurate diagnosis and prognosis of patients presenting with FHF. Donaldson retrospectively evaluated 61 patients with FHF who underwent TJLB [31]. Biopsy was technically successful in 60 of 61 attempts (98%) and complications were rare and minor requiring conservative treatment only. Since only 2 of the 19 patients who survived without transplant had more than 70% hepatocellular necrosis on biopsy specimens, the study suggested that early histologic assessment possesses and important discriminatory prognostic function in the early management of FHF patients.

Miraglia recently described 17 patients in acute liver failure with a mean INR of 2.7 ± 1.2 who underwent TJLB to guide selection and timing of liver transplantation [69]. Using a Quick-core needle, biopsy was technically successful and satisfactory for histologic interpretation in all patients with no reported procedure-related complications. In 14 patients (82%) the initial clinical diagnosis was confirmed, yet in 3 patients (18%) the presence of unexpected cirrhosis altered the clinical impression. Treatment was significantly influenced by the histologic data; 7 patients with less than 60% necrosis were treated conservatively and 6 patients with submassive necrosis (>85%) were transplanted. In this small cohort, severe necrosis and the presence of cirrhosis predicted increased mortality. Of the four patients that died, three were cirrhotic and

one had evidence of massive hepatocellular necrosis. The average time required for TJLB and rapid histologic evaluation of frozen section was only 80min, thereby providing "real-time" information for clinicians. However, since significant heterogeneity is known to exist in fulminant liver disease there is great risk for sampling error. Therefore, liver histology should not be considered a substitute for clinical assessment in determining which patients should be managed conservatively versus offered liver transplant. We use TJLB when the diagnosis is unclear, e.g., to decide on the use of steroids for possible fulminant autoimmune hepatitis, or when the need for transplant is equivocal. It is especially useful when patients appear to be following a subfulminant rather than a fulminant course.

Pediatrics

To date, there are only few data evaluating the safety and utility of TJLB in children. Collectively, they represent just over 150 biopsies and yet they appear to indicate that pediatric TJLB is an important, relatively safe tool for the rapid evaluation of acute and chronic liver disease in children.

The largest and most contemporary report is a retrospective evaluation of 74 TJLB in 64 children [40]. Biopsy success was nearly universal with 73/74 (98.6%) of samples sufficient for histologic diagnosis. Complications including neck hematoma, small subcapsular hematomas, and extravasation of contrast were reported in 8.1% of cases. There was one patient death (1.35%) after TJLB from a ventricular arrhythmia that, upon autopsy, was not felt to be procedure related. The last 37 patients in the series were biopsied with combined sonographic and fluoroscopic guidance that was felt to improve visualization of the biliary tree and facilitate safer biopsy of smaller patients and transplanted liver segments.

Although Habdank et al. did not observe an association between the rate of complications and patient weight or age, the recent review by Kalambokis identified young age as an independent risk factor for major and liver-puncture related complications [40, 44]. When these four series were compared in aggregate with the published adult experience, there were increased overall (6.7% vs. 17%, $p < 0.001$), major (0.5% vs. 1.9%, $p = 0.02$), and minor complications (6.5% vs. 20%,

$p < 0.001$). In addition, pediatric mortality (0.6%) was significantly greater than that observed in adult series (0.09%, $p = 0.04$). These data may, in part, reflect the limited published experience in children and the technical challenges of performing biopsies in smaller livers with horizontal hepatic veins leading to increased risk of capsular perforation.

End-Stage Renal Disease

Liver disease is common among end-stage renal disease (ESRD) patients on hemodialysis or awaiting renal transplantation, largely due to the heightened prevalence of HCV in dialysis units which ranges from 4% to more than 70% in different parts of the world. Characterization of liver disease is essential to guide treatment and to facilitate liver and kidney transplant evaluation. Since ESRD is associated with abnormal hemostasis from dysfunctional platelets, hemorrhagic complications are frequent with invasive procedures. Ahmad et al. demonstrated that TJLB was a safe and effective tool in 32 ESRD patients with abnormal liver function tests undergoing hemodialysis [2]. After three passes of the biopsy needle, tissue containing at least eight evaluable complete portal tracts was obtained in all patients with an average specimen length of 16 ± 4 mm. When compared to a control cohort of 32 ESRD patients who underwent percutaneous liver biopsy, TJLB was safer with decreased incidence of hemorrhagic complications (0% vs. 12%, $p < 0.05$) leading the authors to suggest that TJLB be the preferred mode of liver biopsy in ESRD individuals. This study has not been replicated and we among others believe that ESRD alone is not an indication for TJLB in the absence of other risk factors for bleeding.

Liver Transplant Recipients

End-stage liver disease (ESLD) frequently engenders contraindications to standard percutaneous liver biopsy, making the transvenous approach a vital adjunct to the evaluation of patient for liver transplantation [6, 56]. In the immediate post-operative period after transplant, inflammation and edema of the liver parenchyma can result in luminal narrowing of hepatic vessels and

distortion of the angles between the intrahepatic IVC and the hepatic veins as well as concerns about traversing a fresh vascular anastomosis [1]. Despite this increase in technical complexity, post-transplant transvenous catheterization and hepatic biopsy is well tolerated and highly successful in all reported series [1, 7, 11, 41, 61, 67].

Azoulay et al. evaluated the safety, technical feasibility, and impact on clinical management of TJLB performed in 105 liver transplant recipients in the immediate post-transplant period (< 30 days) [7]. On average, biopsies were performed 10 ± 4 days after surgery (range 4–27 days). Primary indications for transvenous biopsy included persistent thrombocytopenia, coagulopathy, or clinically significant ascites. Technical success was reported in 87% of cases and specimens adequate for histologic diagnosis were obtained in 86%. Technical failure was almost entirely due to an inability to cannulate the hepatic veins in patients with preservation of the native IVC. In nearly all cases, biopsy data significantly influenced clinical management including modification of immunosuppressive therapy, initiation of antiviral agents, and even listing for retransplantation. No complications were observed.

In a smaller contemporary study, 23 patients suspected of acute rejection after orthotopic liver transplant underwent 32 TJLB [1]. The leading indications for the transjugular approach were persistent thrombocytopenia and coagulopathy. All 32 biopsy attempts were successful; 30/32 (94%) attempts resulted in sufficient tissue to effect histologic diagnosis influencing clinical management. There were no reported complications.

Blasco et al. recently reported the only prospective study comparing transjugular and percutaneous liver biopsy in HCV infected patients after liver transplantation [11]. Twenty-four hours after a routine 3- or 12-month protocol biopsy, 80 patients volunteered to undergo TJLB with hepatic hemodynamic measurements. A total of 116 such paired biopsies were obtained (51 at 3 months post, 65 at 12 months post) and blindly assessed by expert histopathologists. On average, TJLB were smaller than percutaneous samples (10 mm vs. 15 mm, $p < 0.01$) and contained fewer complete portal tracts (7 vs. 9, $p < 0.01$). However, there was good concordance between the two biopsy methods for both inflammation and fibrosis ($\kappa > 0.6$). The most striking advantage of TJLB was the added prognostic information obtained by measuring HVP. Although the presence of advanced fibrosis on

liver biopsy one year after transplant has been shown to predict patients at greatest risk for graft loss, sampling error and fibrosis heterogeneity can significantly underestimate liver disease severity [72]. In this series, direct measurement of portal pressure proved to be a better predictor of clinical decompensation than histologic evidence of advanced fibrosis. Increased HVPG, regardless of biopsy findings, might therefore prompt earlier or more aggressive antiviral therapy in post-transplant patients with recurrent HCV [76].

An unanswered question that has not been adequately addressed in the literature is whether percutaneous or TJLB is safer for patients immediately after living related donor liver transplant. Although there is no rational reason to anticipate increased risk in this population, physician preference seems to predominate and prospective studies detailing the safety and efficacy are warranted. The complication rates of percutaneous liver biopsy even with moderate thrombocytopenia (50–80 K) post-OLT is low, but TJLB is a useful adjunct particularly if there is persistent ascites or ongoing coagulopathy. Thus the role of TJLB in the post-OLT patient remains uncertain in most clinical scenarios.

Summary

Liver biopsy and histologic assessment remain the gold standard for diagnosing and assessing patients with liver disease. For most individuals, a percutaneous liver biopsy is a safe, reliable, and cost effective way to obtain tissue for analysis and is preferable. In the absence of contraindications, percutaneous liver biopsy is the first-line approach to tissue sampling. The presence of extreme coagulopathy, thrombocytopenia, or large ascites is common in advanced liver disease and may increase the risk of bleeding complications after standard biopsy. With the transvenous biopsy, complications are minimized since post-procedure bleeding along the biopsy tract is returned to the systemic venous system. Moreover, the ability to simultaneously obtain hepatic hemodynamic measurements assists in the assessment of portal hypertension and may also predict graft durability after transplant. With more than forty years of experience, transjugular liver biopsy has emerged as an important adjunctive tool for the management of select patients with liver disease.

References

1. Abjudeh H, Huggins R, Patel A (2004) Emergency transjugular liver biopsies in post-liver-transplant patients: technical success and utility. *Emerg Radiol* 10: 268–9
2. Ahmad A, Hasan F, Abdeen S, et al (2004) Transjugular liver biopsy in patients with end-stage renal disease. *J Vasc Interv Radiol* 15: 257–60
3. Ahmed MM, Mutimer DJ, Eliase E, et al (1996) A combined management protocol for patients with coagulation disorders infected with hepatitis C virus. *Br J Haematol* 95: 383–8
4. Aledort LM, Levine PH, Hilgartner M, et al (1985) A study of liver biopsies and liver disease among hemophiliacs. *Blood* 66: 367–72
5. Alvarez-Padin P, Fernandez-Fernandez FJ, Martinez-Vasquez C, et al (2005) Hemobilia as a complication of transjugular liver biopsy. *An Med Interna* 22: 97–8
6. Amesur NB, Zajko AB (2006) Interventional radiology in liver transplantation. *Liver Transpl* 12: 330–51
7. Azoulay D, Raccula JS, Roche B, et al (1996) The value of early transjugular liver biopsy after liver transplantation. *Transplantation* 61: 406–9
8. Banares R, Alonso S, Catalina MV, et al (2001) Randomized controlled trial of aspiration needle versus automated biopsy device for transjugular liver biopsy. *J Vasc Interv Radiol* 12: 583–7
9. Bedossa P, Dargere D, Paradis V (2003) Sampling variability of liver fibrosis in chronic hepatitis C. *Hepatology* 38: 1449–57
10. Bilbao JI, Sola J, Iglesias A, et al (1994) Transvenous liver biopsy in patients with cirrhosis with use of the femoral venous approach and a flexible forceps. *J Vasc Interv Radiol* 5: 460–2
11. Blasco A, Forns X, Carrion JA, et al (2006) Hepatic venous pressure gradient identifies patients at risk of severe hepatitis C recurrence after liver transplantation. *Hepatology* 43: 492–9
12. Bravo AA, Sheth SG, Chopra S (2001) Liver Biopsy. *N Engl J Med* 344: 495–500
13. Brettler D, Alter HJ, Dienstag JL, et al (1990) Prevalence of hepatitis C virus antibody in a cohort of hemophilia patients. *Blood* 76: 254–6
14. Bruzzi JF, O'Connell MJ, Thakore H, et al (2002) Transjugular liver biopsy: assessment of safety and efficacy of the Quick-Core biopsy needle. *Abdom Imaging* 27: 711–5
15. Bull HJM, Gilmore IT, Bradley RD, et al (1983) Experience with transjugular liver biopsy. *Gut* 24: 1057–60
16. Chevallier P, Dausse F, Berthier F, et al (2007) Transjugular liver biopsy: prospective evaluation of the angle formed between the hepatic veins and the vena cava main axis and modification of a semi-automated biopsy device in cases of an unfavorable angle. *Eur Radiol* 17: 169–73
17. Cholongitas E, Quaglia A, Samonakis D, et al (2006) Transjugular liver biopsy: how good is it for accurate histologic interpretation. *Gut* 55: 1789–94
18. Cholongitas E, Senzolo M, Standish R, et al (2006) A systematic review of the quality of liver biopsy specimens. *Am J Clin Pathol* 125: 710–21

19. Cholongitas E, Quaglia A, Samonakis D, et al (2007) Transjugular liver biopsy in patients with diffuse liver disease: comparison of three cores with one or two cores for accurate histological interpretation. *Liver Int* 27: 646–53
20. Choh J, Dolmatch B, Safadi R, et al (1998) Transjugular core liver biopsy with a 19-gauge spring-loaded cutting needle. *Cardiovasc Intervent Radiol* 21: 88–90
21. Choo SW, Do YS, Park KB, et al (2000) Transjugular liver biopsy: modified Ross transseptal needle versus Quick-core biopsy needle. *Abdom Imaging* 25: 505–11
22. Choy OG, Shimkin PM, Link RJ, et al (1978) The transjugular route as an alternative to direct percutaneous needle biopsy of the liver. *Am J Gastroenterol* 70: 653–6
23. Colapinto RF, Blendis LM (1983) Liver biopsy through the transjugular approach. *Radiology* 148: 306
24. Colloredo G, Guido M, Sonzogni A, et al (2003) Impact of liver biopsy size on histological evaluation of chronic viral hepatitis: the smaller the sample, the milder the disease. *J Hepatol* 39: 239–44
25. Corr P, Benningfield SJ, Davey N (1992) Transjugular liver biopsy: a review of 200 biopsies. *Clin Radiol* 45: 238–9
26. Dawson MA, McCarthy PH, Walsh ME, et al (2005) Transjugular liver biopsy is a safe and effective intervention to guide management for patients with a congenital bleeding disorder infected with hepatitis C. *Internal Med J* 35: 556–9
27. De Hoyos A, Loreda ML, Martinez-Rios MA, et al (1999) Transjugular liver biopsy in 52 patients with an automated Trucut-type needle. *Dig Dis Sci* 44: 177–80
28. De Hoyos A, Loreda ML, Martinez MA, et al (2004) Use of a stiff guidewire in transjugular liver biopsy in patients with a pronounced angle of the suprahepatic veins. *Ann Hepatol* 3: 72–3
29. DiMichelle DM, Mirani G, Canchis PW, et al (2003) Transjugular liver biopsy is safe and diagnostic for patients with congenital bleeding disorders and hepatitis C infection. *Haemophilia* 9: 613–8
30. Donahue J, Munoz A, Ness PM, et al (1992) The declining risk of post-transfusion hepatitis C virus infection. *N Eng J Med*. 327: 369–73
31. Donaldson BW, Gopinath R, Wanless IR, et al (1993) The role of transjugular liver biopsy in fulminant liver failure: relation to other prognostic indicators. *Hepatology* 18: 1370–6
32. Dotter CT (1964) Catheter biopsy: Experimental techniques for transvenous liver biopsy. *Radiology* 82: 312–4
33. Fried MW, Peter J, Hoots K, et al (2002) Hepatitis C in adults and adolescents with hemophilia: a randomized, controlled trial of interferon alfa-2b and ribavirin. *Hepatology* 36: 967–72
34. Gamble P, Colapinto R, Stronell RD, et al (1985) Transjugular liver biopsy: A review of 461 biopsies. *Radiology* 157: 589–93
35. Goldman ML, Gonzalez AC, Galambos JT, et al (1978) The transjugular technique of hepatic venography and biopsy, cholangiography, and obliteration of esophageal varices. *Radiology* 128: 325–31
36. Gonzalez-Tutor A, Garcia-Valtuille R, Cerezal L, et al (1998) Transjugular biopsy of the liver with an automated device. *Acta Radiol* 39: 686–9
37. Gorritz E, Reyes R, Lobrano MB, et al. (1996) Transjugular liver biopsy: a review of 77 biopsies using a spring-propelled cutting needle (biopsy gun). *Cardiovasc Intervent Radiol* 19: 442–5
38. Grant A, Neuberger J (1999) Guidelines on the use of liver biopsy in clinical practice. *Gut* 45(S4): 1–11
39. Gupta R, Druy EM, Kessler CM (1997) Safety and potential usefulness of liver biopsy in HIV seropositive employing a transjugular venous approach. *Haemophilia*. 3: 201–4
40. Habdank K, Restrepo R, Ng V, et al (2003) Combined sonographic and fluoroscopic guidance during transjugular hepatic biopsy in children: a retrospective study of 74 biopsies. *AJR AM J Roentgenol* 180: 1398–8
41. Hadengue A, Lebrech D, Gaudin C, et al (1991) Transvenous biopsy of orthotopic liver grafts – feasible and effective. *Transplantation* 51: 915–17
42. Hanafee W, Weiner M (1967) Transjugular percutaneous cholangiography. *Radiology* 88: 35–9
43. Haskal ZJ, Martin L, Cardella JF, et al (2001) Quality improvement guidelines for transjugular intrahepatic portosystemic shunts. SCVIR standards of practice committee. *J Vasc Interv Radiol* 12: 131–6
44. Kalambokis G, Manousou P, Vibhakorn S, et al (2007) Transjugular liver biopsy – Indications, adequacy, quality of specimens and complications. – A systematic review. *J Hepatol* 47: 284–94
45. Kardache M, Soyer P, Boudiaf M, et al (1997) Transjugular liver biopsy with an automated device. *Radiology* 204: 369–72
46. Khosa F, McNulty JG, Hickey N, et al (2003) Transvenous liver biopsy via the femoral vein. *Clin Radiol* 58: 487–91
47. Kruse-Jarres R, Leissing CA (2005) Haemobilia after transjugular liver biopsy in patients with severe haemophilia. *Haemophilia* 11: 642–3
48. Lebrech D, Goldfarb G, Degott C, et al (1982) Transvenous liver biopsy: an experience based on 1000 hepatic tissue samplings with this procedure. *Gastroenterology* 83: 338–40
49. Lee C, Dusheiko G (2002) The natural history and antiviral treatment of hepatitis C in haemophilia. *Haemophilia* 8: 322–9
50. Lesesne HR, Morgan JE, Blatt PM, et al (1977) Liver biopsy in haemophilia A. *Ann Intern Med* 86: 703–7
51. Lethagen S, Widell A, Berntorp E, et al (2001) Clinical spectrum of hepatitis C-related liver disease and response to interferon and ribavirin in hemophilia or von Willebrand disease. *Br J Hematol* 113: 87–93
52. Lipchik EO, Cohen EB, Mewissen MW (1991) Transvenous liver biopsy in critically ill patients: adequacy of tissue samples. *Radiology* 181: 497–9
53. Little AF, Ferris JV, Dodd GD, et al (1996) Image-guided percutaneous hepatic biopsy: effect of ascites on the complication rate. *Radiology* 199: 79–83
54. Little AF, Zajko AB, Orons PD (1996) Transjugular liver biopsy: a prospective study in 43 patients with the Quick-Core biopsy needle. *J Vasc Interv Radiol* 7: 127–31
55. Lofudice T, Buhac I, Balint J (1977) Septicemia as a complication of percutaneous liver biopsy. *Gastroenterology* 72: 949–51

56. Macedo G, Maia JC, Gomes A, et al (1999) The role of transjugular liver biopsy in a liver transplant center. *J Clin Gastroenterol* 29: 155–7
57. Macedo G, Maia JC, Carneiro F, et al (2000) Contribution of transjugular liver biopsy in fulminant hepatic failure. *Transplant Proc* 32: 2643
58. Maciel AC, Marchiori E, de Barros SG, et al (2003) Transjugular liver biopsy: histological diagnosis success comparing the trucut to the modified Ross needle. *Arq Gastroenterol* 40: 80–4
59. Makris M, Preston FE, Triger DR, et al (1990) Hepatitis C antibody and chronic liver disease in haemophilia. *Lancet* 325: 1117
60. Makris M, Baglin T, Dusheiko G, et al (2001) Guidelines on the diagnosis, management, and prevention of hepatitis in haemophilia. *Haemophilia* 7: 339–45
61. McAfee JH, Keefe EB, Lee RG, et al (1992) Transjugular liver biopsy. *Hepatology* 15: 726–32
62. McCloskey RV, Gold M, Weser E (1973) Bacteremia after liver biopsy. *Arch Intern Med* 132: 213–5
63. McGill DB, Rakela J, Zinsmeister AR, et al (1990) A 21-year experience with major hemorrhage after percutaneous liver biopsy. *Gastroenterology* 99: 1396–40
64. McMahon C, Pilkington R, Shea EO, et al (2000) Liver biopsy in Irish hepatitis C-infected patients with inherited bleeding disorders. *Br J Haematol* 109: 354–9
65. Meng HC, Lin HC, Huang CC, et al (1994) Transjugular liver biopsy: comparison with percutaneous liver biopsy. *J Gastroenterol Hepatol* 9: 457–61
66. Menghini G (1958) One-second needle biopsy of the liver. *Gastroenterology* 35: 190–9
67. Mentha G, Widman JJ, Schneider PA, et al (1990) Hepatic venography, manometric studies and transjugular liver biopsy in the follow-up of liver transplant patients. *Transplant Proc* 22: 1519–20
68. Mewissen MW, Lipchik EO, Schreiber ER, et al (1988) Liver biopsy through the femoral vein. *169: 842–3*
69. Miraglia R, Luca A, Gruttadauria S, et al (2006) Contribution of transjugular liver biopsy in patients with the clinical presentation of acute liver failure. *Cardiovasc Intervent Radiol* 29: 1008–10
70. Murphy FB, Barefield KP, Steinberg HV, et al (1988) CT- or sonography-guided biopsy of the liver in the presence of ascites: frequency of complications. *Am J Roentgenol* 151: 485–6
71. National Institute of Health Consensus Development Conference Statement (2002) Management of Hepatitis C. *Hepatology* 36(Suppl 1): 726–32
72. Neumann UP, Berg T, Bahra M, et al (2004) Fibrosis progression after liver transplantation in patients with recurrent hepatitis C. *J Hepatol* 41: 830–6
73. Papatheodoridis GV, Patch D, Watkinson A, et al (1999) Transjugular liver biopsy in the 1990s: a 2 year audit. *Aliment Pharmacol Ther* 13: 603–8
74. Preston FE, Triger DR, Underwood JC, et al (1978) Percutaneous liver biopsy and chronic liver disease in haemophiliacs. *Lancet* 2(8090): 592–4
75. Psooy BJ, Clark TWI, Beecroft JR, et al (2001) Transjugular liver biopsy with use of the shark jaw needle: diagnostic yield, complications, and cost-effectiveness. *J Vasc Interv Radiol* 12: 61–5
76. Roberts S, Gordon A, McLean C, et al (2007) Effect of sustained viral response on hepatic venous pressure gradient in hepatitis C-related cirrhosis. *Clin Gastroenterol Hepatol* 5: 932–7
77. Rosch J, Lakin PC, Antonovic R, et al (1973) Transjugular approach to liver biopsy and transhepatic cholangiography. *N Eng J Med* 289: 227–31
78. Saab S, Cho D, Quon DVK, et al (2004) Same day outpatient transjugular liver biopsies in haemophilia. *Haemophilia* 10: 727–31
79. Sada PN, Ramakrishna B, Thomas CP, et al (1997) Transjugular liver biopsy: a comparison of aspiration and trucut techniques. *Liver* 17: 257–9
80. Sawyer AM, McCormick PA, Tennyson GS, et al (1993) A comparison of transjugular and plugged-percutaneous liver biopsy in patients with impaired coagulation. *J Hepatology* 17: 81–5
81. Shin JL, Teitel J, Swain MG, et al (2005) Canadian multi-center retrospective study evaluating transjugular liver biopsy in patients with congenital bleeding disorders and hepatitis C: is it safe and useful? *Am J Hematol* 78: 85–93
82. Shulman HM, Gooley T, Dudley MD, et al (1995) Utility of transvenous liver biopsies and wedged hepatic venous pressure measurements in sixty marrow transplant recipients. *Transplantation* 59: 1015–22
83. Siegel EL, Caresio J, Eckard DA (1992) Use of the external jugular vein approach for transvenous liver biopsy. *J Vasc Interv Radiol* 3: 371–4
84. Smith TP, Presson TL, Heneghan MA, et al (2003) Transjugular biopsy of the liver in pediatric and adult patients using an 18-gauge automated core biopsy needle: a retrospective review of 410 consecutive procedures. *Am J Roentgenol* 180: 167–72
85. Stieltjes N, Ounnoughene N, Sava E, et al (2004) Interest of transjugular liver biopsy in adult patients with haemophilia or other congenital bleeding disorder infected with hepatitis C virus. *Br J Haematol* 125: 769–76
86. Strassburg CP, Manns MP (2006) Approaches to liver biopsy techniques – revisited. *Semin Liv Disease* 26: 318–27
87. Sue M, Caldwell SH, Dickson RC, et al (1996) Variation between centers in technique and guidelines for liver biopsy. *Liver* 16: 267–70
88. Teare JP, Watkinson AF, Erb SR, et al (1994) Transfemoral liver biopsy by forceps: a review of 104 consecutive procedures. *17: 252–7*
89. Venkataramani A, Behling C, Rond R, et al (2000) Liver biopsies in adult hemophiliacs with hepatitis C: a United States center's experience. *Am J Gastroenterol* 95: 2374–6
90. Watson HG, Ludlam CA, Rebus S, et al (1992) Use of several second generation serologic assays to determine the true prevalence of hepatitis C virus infection in haemophiliacs treated with non-virus inactivated factor VIII and IX concentrates. *Br J Haematol* 80: 514–8
91. Weiner M, Hanafee WN (1970) A review of transjugular cholangiography. *Rad Clinics N Am* 8: 53–68
92. Wong VS, Baglin T, Beacham E, et al (1997) The role of liver biopsy in haemophiliacs infected with hepatitis C virus. *97: 343–7*
93. Yavuz K, Geyik S, Barton RE, et al (2007) Transjugular liver biopsy via the left internal jugular vein. *J Vasc Interv Radiol* 18: 237–41
94. Yee TT, Friffoen A, Sabin CA, et al (2000) The natural history of HCV in a cohort of haemophiliac patients infected between 1961 and 1985. *Gut* 47: 845–51

Chapter Outline

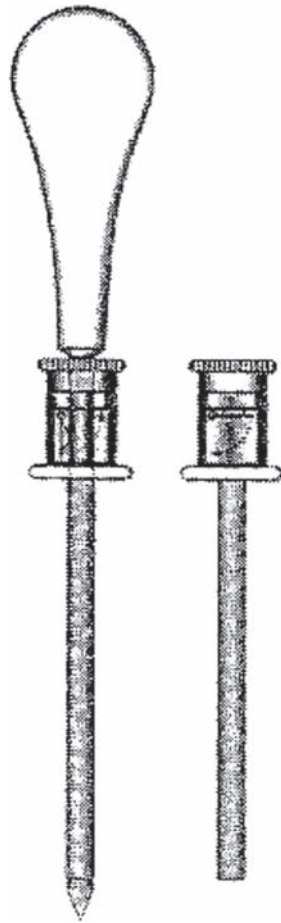
A Short History of Diagnostic Laparoscopy in Internal Medicine and Hepatology	485
Technique of Diagnostic Laparoscopy	487
Preparation and Sedation of the Patient	487
Equipment	487
Insertion of Veres-Needle, Pneumoperitoneum and the “Optimal” Gas	4920
Inspection of the Abdomen, Introduction of a Second Trocar and Organ Biopsy	492
Risk Profile of Diagnostic Laparoscopy	493
Local Anesthesia/Conscious Sedation	495
Insertion of Veres-Needle and Trocar	495
Pneumoperitoneum	495
Laparoscopic Inspection	495
Laparoscopic Biopsy of the Liver and other Intraabdominal Organs.....	496
Diagnostic Laparoscopy in Liver Diseases	496
Chronic Liver Disease.....	496
Laparoscopy and Laparoscopic Liver Biopsy in Acute and Subacute Liver Failure.....	499
Laparoscopy for the Staging of Primary and Secondary Liver Tumors	500
Primary Hepatobiliary Cancers.....	500
Secondary Liver Tumors	503
Conclusion	507
References	507

A Short History of Diagnostic Laparoscopy in Internal Medicine and Hepatology

The term “laparoscopy” was implemented in 1911 by Hans Christian Jacobaeus, a Swedish physician and scientist, who was the first to use this method in defined clinical indications and a larger number of patients [52–54]. However, the first description of minimal invasive penetration of the abdominal wall with a trocar for diagnostic purposes was done and published by the German gastroenterologist and surgeon Gerhard Kelling in 1902. Kelling examined methods to non-surgically treat gastrointestinal bleeding in the abdominal cavity, which was common at this time due to the high prevalence of abdominal tuberculosis, and was associated with a high mortality. The only available method to establish diagnosis and provide treatment was laparotomy. However, Kelling observed that opening the abdomen often worsened the patient’s condition. To decrease blood loss, he implemented high-pressure insufflation of air into the abdominal cavity, a technique he called “Lufttamponade” (air-tamponade) [67]. In order to observe the effects of the air-insufflation on the abdominal organs he introduced a rigid Nitze cystoscope through the unopened abdominal cavity [91]. He termed this procedure “coeloscopy”, but did not pursue the work on the method as a potential diagnostic tool in other diseases [68].

Unaware of Kelling’s work, this was done by Jacobaeus between 1910–1912. As was Kelling, Jacobaeus was seeking a treatment for the complications of abdominal tuberculosis and with respect to artificial pneumothorax, which was an emerging treatment for lung tuberculosis at this time, he developed the method of pneumoperitoneum via a short trocar with a trap-valve (Fig. 45.1).

Fig. 45.1 “Jacobaeus” trocar
1910



For visualization of the abdominal organs he utilized (as Kelling did) a cystoscope which was inserted through the trocar [52]. With this technology Jacobaeus was the first to examine a larger number of patients and to generate detailed descriptions of his observations. He noted for instance, that the liver is an organ easily accessible by laparoscopy, while stomach and other organs were more difficult to examine. It is remarkable that the majority of the 97 patients who were laparoscopically examined by Jacobaeus between 1910 and 1912 suffered from acute or chronic ascites, presumably mostly due to abdominal tuberculosis, which was removed prior to inspection of the abdomen [54]. However, after 1912 Jacobaeus focussed mainly on thoracoscopy and this fact, beside other reasons (one of which was a failing international acceptance of the method in particular in the Anglo-American countries) laparoscopy did not enter mainstream medical practice for another 20 years.

The international acceptance of laparoscopy as a powerful diagnostic tool was encompassed by the work of physicians in the 1930s, namely Heinz Kalk in Germany and John C. Ruddock together with Edward Benedict in the United States. While Ruddock and Benedict termed their procedure “peritoneoscopy” and focussed mainly on the peritoneal manifestations of gastric malignancies, Kalk adopted the term “laparoscopy” for his procedure and devoted his efforts mainly to the evaluation of liver diseases [4, 104]. Kalk developed many new technological details such as smaller trocars, a 135-degree optical system with an oblique-viewing optic and several instruments for the retrieval of tissue specimens. Furthermore, in 1929 he was the first to advocate the dual-puncture technique, which later opened the way for the development of operative laparoscopy [64]. A very important innovation regarding the safety of laparoscopy was introduced by the Hungarian physician J. Veres in 1938. He described a spring-loaded needle with a blunt inner stylet that automatically converted after penetration of the body wall the sharp cutting edge to a rounded end incorporating a side hole. Veres designed the needle originally to create a safe artificial pneumothorax but the device quickly became the standard method until today for creating a pneumoperitoneum (Fig. 45.2) [122, 123].

Why the surgeon Kalk was so committed to the laparoscopic evaluation of the liver and did not appreciate the potential of the method in the diagnosis and staging of gastrointestinal malignancies is not clear. However, the epidemic spread of hepatitis with which Kalk was confronted caused him to intensify his pioneering efforts on liver diseases. During this time he introduced and perfected the technique of laparoscopic liver biopsy, which did not show at this time the often fatal complications of “blind” liver biopsy [65]. After the second World War, Kalk’s work was accepted in other European countries, and since this time laparoscopy has become an important tool in the diagnosis of liver diseases and is increasingly used by gastroenterologists and hepatologists.

Simultaneously with the development of indirect imaging techniques, such as computed tomography (CT-scan) and ultrasound, the number of diagnostic laparoscopies performed by gastroenterologists constantly decreased in Europe over the past 2 decades [32]. This development was further supported by misconceptions about the reported overall safety and complication rate and increased popularity of radiologically guided biopsy techniques [6, 92]. The rapid development of laparoscopic surgery




Fig. 45.2 The principle of the Veres needle

since 1990 caused, however, a reinvention also of diagnostic laparoscopy, but since then is mostly being performed by surgeons.

An important further technical development in the recent decade represents mini-laparoscopy. Since its

first description in 1998, this less invasive variant of standard laparoscopy has been increasingly used also among gastroenterologists and hepatologists, since it is safe even in an outpatient setting [40].

The following chapter will describe the techniques of diagnostic standard- and mini-laparoscopy, and will discuss these methods with a main focus on their importance for the determination of etiology and status of liver diseases. In addition, the value of diagnostic laparoscopy in the context of staging the different gastrointestinal malignancies which may cause liver metastases and other, more miscellaneous indications will be delineated (Table 45.1).

Technique of Diagnostic Laparoscopy

Preparation and Sedation of the Patient

A great advantage of diagnostic laparoscopy and in particular mini-laparoscopy is that the examination can be performed at the endoscopy suite; neither an operation theater nor general anesthesia are necessary. However, from a hygienic point of view it is desirable that laparoscopy ideally is not performed in the same room as examinations of microbiologically colonized orifices, such as gastroscopy or colonoscopy. At a minimum, it should be done at the beginning of the daily routine in a freshly disinfected room. Patients are adequately informed about the procedure and give written consent. Absolute and relative contraindications have to be

Table 45.1 Indications for diagnostic laparoscopy

Chronic liver disease	<ul style="list-style-type: none"> • Staging of liver disease (in particular diagnosis of liver cirrhosis) • Increased safety of biopsy if coagulopathy is present • Additional information about stage and etiology of chronic liver disease of unknown origin by macroscopic evaluation
Acute and subacute liver failure	<ul style="list-style-type: none"> • Diagnosis of underlying chronic liver disease • Safe liver biopsy
Staging of gastrointestinal malignancies	<ul style="list-style-type: none"> • Exclusion of peritoneal metastases • Exclusion of disseminated liver metastases • Safe tumor biopsy of superficial nodules with minimized risk of seeding
(Hepato-) Splenomegaly of unknown origin	
Ascites of unclear etiology	
Acute and chronic abdominal pain of unknown etiology	
Abdominal lymphoma	

Table 45.2 Contraindications for diagnostic laparoscopy

Absolute
Uncooperative patient
Abdominal wall sepsis
Gross coagulopathy
Large ventral hernia
Relative
Previous abdominal surgery
Marked obesity
Poor cardiorespiratory performance
Biliary obstruction

excluded, with particular emphasis on prior abdominal surgery (Table 45.2). This instance is not always a reason to not perform diagnostic laparoscopy, but the presence of abdominal adhesions has to be considered. Adhesions may partly or completely impede the view within the abdomen and may cause an enhanced risk of lacerating abdominal organs (Fig. 45.3). Therefore, in the presumed existence of adhesions, the indication has to be valid enough and laparoscopy should be done by experienced examiners who are trained to modify the access to the abdominal cavity, if necessary.

Patients usually stay fasting from the evening before the examination. A specific pre-medication is not necessary. In male patients, the abdomen should be shaved. In all patients, intravenous access is established before the procedure. Once in the examination room, the abdominal wall of the patient is disinfected according to institutional surgical standards. The patient is covered with sterile sheets with exception of the abdomen. Diagnostic laparoscopy can be performed under conscious sedation. Deep sedation (or general anesthesia) is not necessary and even not desirable, since during insertion of the Veres-needle the patients help is preferable (see below). After insertion of the optical system and verification of a clear view into the abdominal cavity the patient can be sedated more deeply, for example with the addition of disoprivan. It has to be noted that although laparoscopy is considered as the more invasive examination, the patient undergoing this procedure needs much less medication than a patient undergoing flexible endoscopy of the upper- or lower GI-tract to reach the same level of sedation (see paragraph on anesthesia).

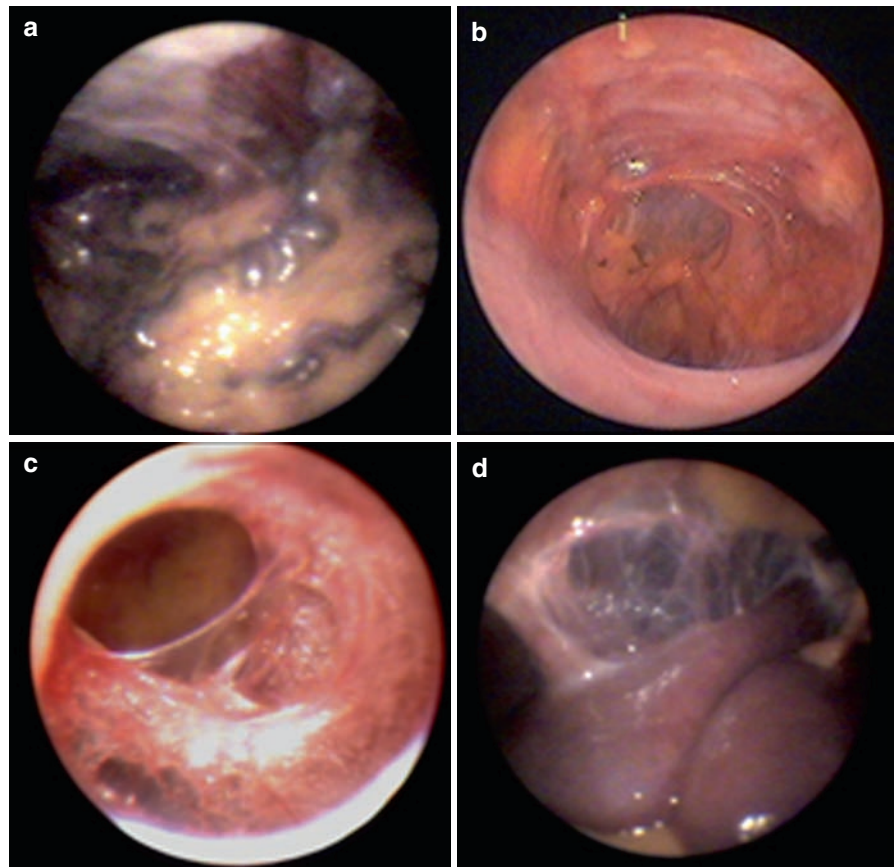


Fig. 45.3 Adhesions in diagnostic laparoscopy. (a–c) Major adhesions preventing further inspection of the abdominal cavity. (d) Minor adhesions after previous peritonitis

Equipment

The following description includes the techniques for standard- and mini-laparoscopy. The main technical difference between standard- and mini-laparoscopy is that mini-laparoscopy uses trocars and corresponding optical instruments with smaller diameters (2.8 mm) and is therefore considered less invasive (Fig. 45.4a). An additional difference is that in mini-laparoscopy, the trocar sheathes the Veres-needle and is inserted directly

with the needle through a single puncture (Fig. 45.4b). In contrast, for standard laparoscopy the trocar has to be inserted separately from the Veres-cannula. As soon as an adequate pneumoperitoneum is established, the cannula is removed and the trocar is introduced at the same position, which is usually the point of Kalk (2 cm cranio-lateral of the umbilicus). A differential insertion of Veres needle at the point of Monroe (lower left abdominal quadrant) and the trocar at the point of Kalk for diagnostic purposes is not necessary. For standard

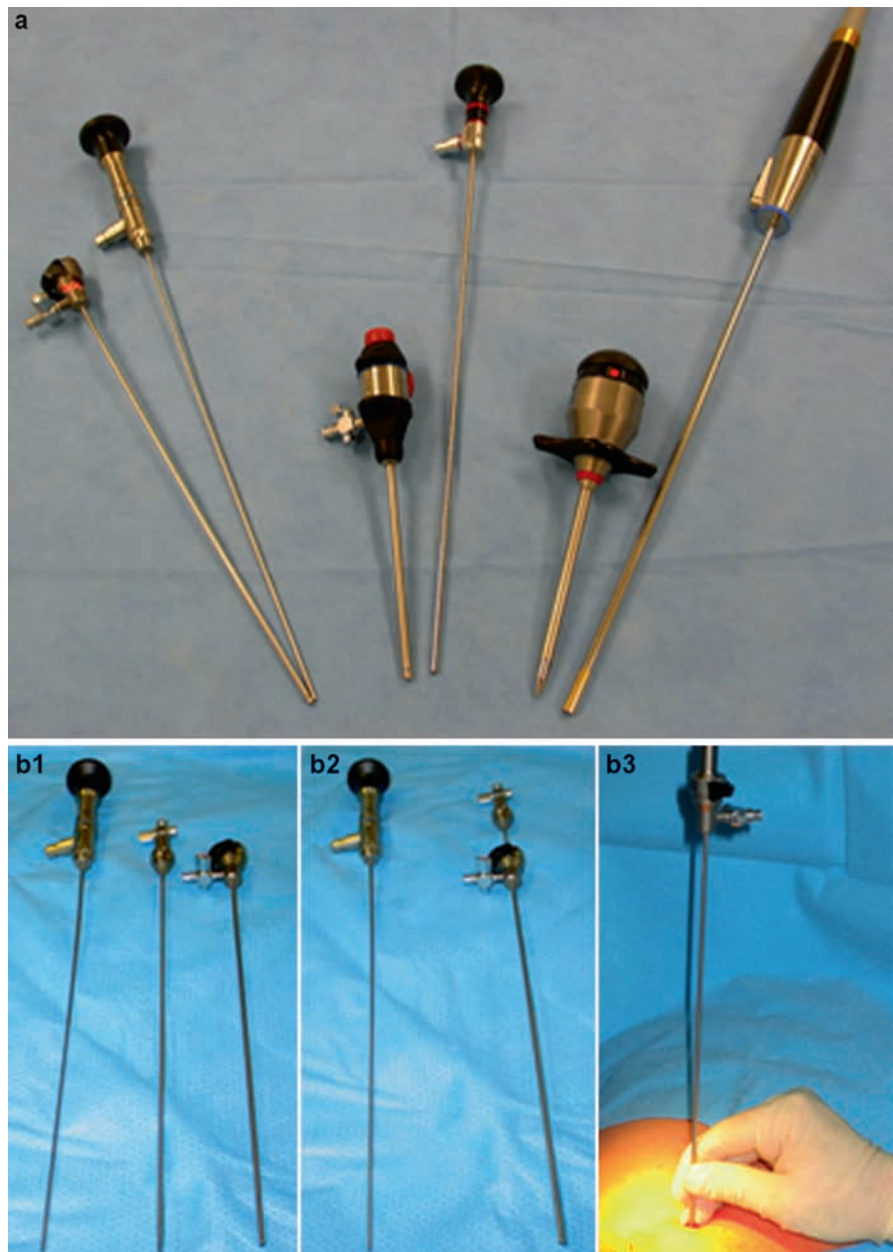

Fig. 45.4 Different instruments for diagnostic laparoscopy. (a) Instruments for mini-laparoscopy (left side – diameter of the trocar 2.8 mm) or “midi”-laparoscopy performed in standard technique (diameter of the trocar 3.9 and 5.5 mm). (b1–b3) Sheathing and simultaneous insertion of trocar and Veres needle in midi-laparoscopy

laparoscopy we use 3.9 or 5.5 mm trocars in combination with a 3 or 4.8 mm optical system, respectively. Although it has been shown that the complication rates of standard laparoscopy with 10 mm trocars are equivalent to those of mini-laparoscopy, we do not recommend the application of such high diameter trocars for diagnostic laparoscopy, since imaging quality and therefore the diagnostic yield between a 4.8 and 10 mm optical system, with a CCD-chip on the tip of the laparoscope, is equivalent [108]. Imaging angle and quality of the mini-laparoscopes, which are today still based on a fiberoptic technique, are a little lower, but for diagnostic purposes are completely sufficient.

The decision regarding which laparoscopy equipment to use is dependent on the indication and the constitution of the patient. The standard system, in particular for hepatological indications, is in our center the smallest mini-laparoscopy system with a 2.8 mm trocar. In obese patients we choose the 3.9 mm trocar, since the leverage effect on the abdominal wall while moving the laparoscope may cause damage to the smaller system. The 5.5 mm trocar with the CCD-chip on the tip of the laparoscope is used for the same reason in addition to specific situations, where the best possible imaging quality is desirable (e.g. staging laparoscopy).

Insertion of Veres-Needle, Pneumoperitoneum and the "Optimal" Gas

Prior to insertion of the Veres-needle, adequate local anesthesia is applied at the point of Kalk, and must include the parietal peritoneum since this is the most pain susceptible layer of the abdominal wall (in patients with prior abdominal surgery the location of the puncture site with the Veres-needle may vary due to suspected adhesions). During the insertion of the Veres-needle, the patient is asked to actively lift the abdominal wall forward as much as possible without exerting the front abdominal muscles too much. After entering the abdominal cavity, indicated by resilient egression of the blunt inner stylet of the Veres-needle (produces a typical "click"), we recommend the subsequent application of 20 ml of saline and then of room air to verify the intraabdominal position. If this manoeuvre induces pain, a position within the

abdominal wall is expected and the Veres-needle has to be further advanced. Alternatively the needle can be retracted, followed by a new puncture attempt.

Once the intraabdominal position of the needle tip is verified, the Veres needle is connected to the pressure controlled gas insufflator and 2,000 to 3,000 ml of gas are allowed to enter the abdomen to a maximum pressure of 8–12 mmHg (Fig. 45.5a and e). Exceeding this pressure limit may result in suppression of cardio-respiratory function regardless of the type of gas or the body position [63]. The two most widely used types of gas used for laparoscopy are carbon dioxide (CO₂) and nitrous oxide (N₂O). It is noteworthy, that although many other aspects of laparoscopy, such as smaller incisions, decreased postoperative pain, shortened hospital stay, better cosmetic outcome, and faster return to work have been well documented, one of the most important aspects of laparoscopy, namely the optimal insufflation gas, has not been determined in randomized studies.

In the early days of laparoscopy, pneumoperitoneum was created with room air or oxygen. But since oxygen may prompt an intra-abdominal explosion, and both of these gases have a potential for venous embolism because they are poorly soluble in blood, carbon dioxide became the dominant insufflation gas for the past few decades [120]. CO₂ is a colorless, odorless, non-flammable soluble gas that does not support combustion and shows excellent dissolving properties in blood, thereby minimizing the risk of venous embolism [83, 105, 132]. The solubility of CO₂ is, on the other hand, responsible for the adverse events of this gas due to hypercarbia and associated with respiratory, hemodynamic and metabolic problems [5, 77]. For the vast majority of patients, these changes are mild and have no clinical significance, but patients with pulmonary or cardiac diseases may have difficulty clearing the gas and are at risk of decompensation. In addition, CO₂ has been suggested to cause pain during or after laparoscopic procedures [89, 110]. The precise cause of postoperative pain unique to CO₂ has not yet been found. One plausible proposed possibility is irritation of the peritoneum by carbonic acid, which is produced when CO₂ dissolves. However, this abdominal pain and discomfort has limited the use of CO₂ during diagnostic procedures under conscious sedation and only local anesthesia, while it is the most widely used gas in operative laparoscopy under general anesthesia.

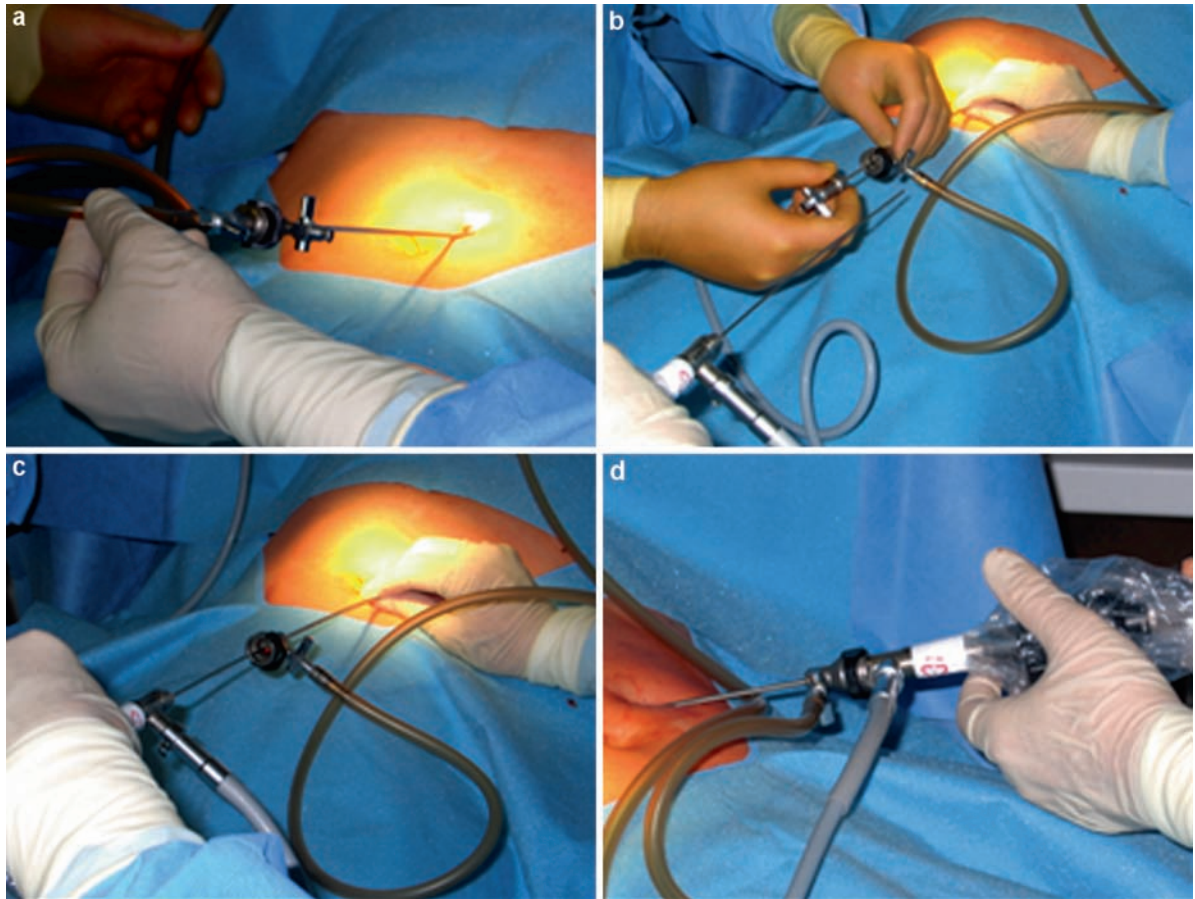


Fig. 45.5 Technical details of mini- and standard-laparoscopy. (a–d) Mini-laparoscopy. (e–h) Standard laparoscopy. (a) Gas insufflation via the Veres needle sheathed by the 2.9 mm trocar. (b) Retraction of Veres needle from the trocar after establishment of pneumoperitoneum. (c) Insertion of the 1.9 mm optical instrument via the empty trocar. (d) Inspection of the abdominal

cavity. (e) Gas insufflation via a separate Veres needle. (f) Veres needle has been retracted. Insertion of a 5.5 mm trocar through the same site after establishment of pneumoperitoneum. (g) Retraction of the sharp inner stylet. (h) Insertion of the 4.8 mm “chip on the tip” laparoscope and inspection of the abdominal cavity

In the 1970s and 1980s, nitrous oxide (N_2O) emerged as the preferred gas by gynecologists because of its low cost, high turnover, good water solubility and additional analgesic/anesthetic properties. Unfortunately, N_2O unlike CO_2 , does not completely suppress combustion *ex vivo*. Together with two case reports of intraoperative explosion associated with N_2O , this fact had (until recently) effectively banned the use of this gas in therapeutic laparoscopy [27, 36, 51]. In diagnostic laparoscopy, however, it is recommended by many examiners as the gas of choice because of the only minimal affection of acid–base status and cardiopulmonary function as well as the additional anesthetic and analgesic properties preventing the induction of peri- or

postinterventional abdominal discomfort. Whether even the main drawback of N_2O , its limited ability to suppress combustion as compared with CO_2 , represents a real risk for patients is recently increasingly questioned, since it has been shown that the concentrations of hydrogen and methane needed for combustion to occur in a nitrous oxide environment are not created in the peritoneum during laparoscopic gastrointestinal procedures [26, 51].

In conclusion, CO_2 maintains a dominant role as the primary insufflation gas in surgical laparoscopy. Many years of extensive use have proved it to be a good and safe choice. In diagnostic laparoscopy when general anesthesia is unwarranted or when acid–base changes

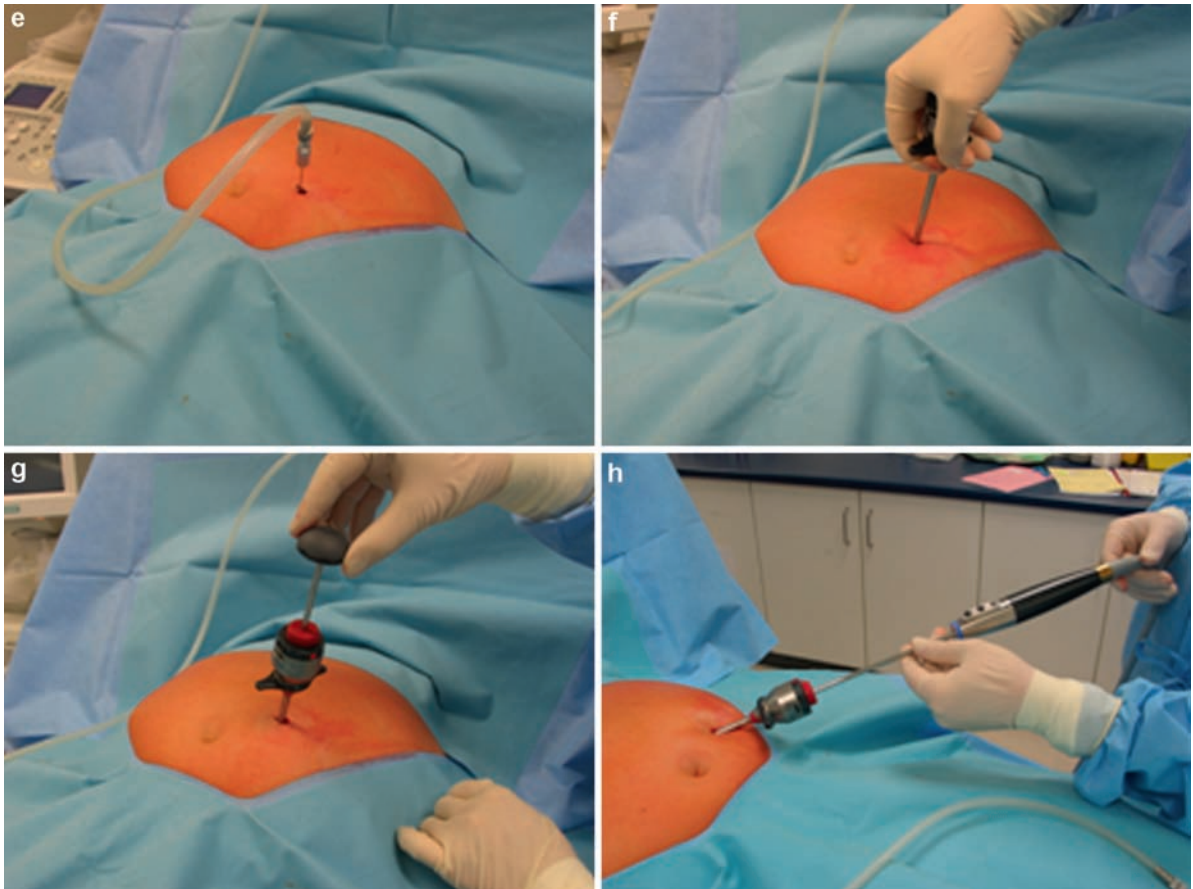


Fig. 45.5 (continued)

are a primary consideration, N_2O is the alternative of choice. In our own collective of > 1,200 examinations under N_2O we did not see a single adverse event associated with the insufflation gas. Other gases such as Argon, Helium, air, and N_2 should be only used in protocol studies mainly because of their potential for gas embolism.

When an adequate pneumoperitoneum is achieved, the gas supply is turned off. During mini-laparoscopy the Veres needle is now simply removed from the sheathing trocar and replaced by the optical instrument (Fig. 45.5b and c). In standard laparotomy the Veres needle is removed and the patient is once more requested to lift the abdomen forward. The trocar is carefully inserted through the same puncture site with sufficient pressure and under slight twisting agitation. After penetration into the abdominal cavity, the sharp conical (or pyramidal) inner stylet is removed and exchanged with the laparoscopy optical system (Fig. 45.5 f-h).

Inspection of the Abdomen, Introduction of a Second Trocar and Organ Biopsy

After the optical system is introduced, diagnostic inspection of the abdomen starts usually in the left upper quadrant of the abdomen. Potential changes on the visceral and parietal peritoneum are assessed. To visualize the spleen, it is often necessary to remove peritoneal fat from their surface by a blunt ended instrument inserted through a second trocar. Size, color, surface and structure of the parenchyma are noted. To visualize the left liver lobe, the tip of the laparoscope is moved a little to the left, taking into account the so called “fulcrum effect” [31]. This effect describes the visual paradox due to fixation of the instrument at the level of the abdominal wall: if the hand and instrument move to the right, the tip of the instrument inside the patient moves to the left. The liver is evaluated

according to size and color. The structure of its surface and edge is noted and the appearance and location of any focal changes within the parenchyma are described. In front or partly under the left liver lobe is the front side of the stomach with its greater curvature visible. Beside signs of malignancy, it is important to remark on the filling of the short gastric veins, which may be part of the collateral circulation in portal hypertension.

To view the right liver lobe, the laparoscope is withdrawn a little bit and the tip is moved caudal and right under the hepatic ligament, which is inspected for the presence of dilated vessels, to the right side of the abdomen. The right liver lobe is usually bigger than the left lobe and its margin is even in an undiseased organ not always sharp. The caudate lobe is usually not visible during laparoscopy in the absence of hepatomegaly or liver cirrhosis. The gallbladder is located under the right liver lobe.

Inspection of the abdominal cavity is continued by rotating the tip of the laparoscope further left and caudal in the direction of the pelvis under constant vision of the visceral and parietal peritoneum as well as the nooses of the small and large intestine. Without general anesthesia this maneuver has to be done carefully, and particular caution is directed to not touch the parietal peritoneum, since this may cause significant discomfort to the patient. The diagnostic examination of the abdomen is complemented by rotating the laparoscope tip back to the left upper and lower abdominal quadrant.

Focal lesions on the peritoneum, the peritoneal fat or the surface of the liver (or spleen) parenchyma are biopsied after completion of the visual inspection of the abdomen. To obtain tissue specimens during diagnostic laparoscopy with low diameter optical instruments, a second trocar is always necessary. The standard "biopsy" trocar we use has a diameter 2.8 mm and allows for the insertion of different biopsy instruments such as a needle and a forceps as well as a monopolar coagulation probe. In addition, it has a connection channel for further gas insufflation. The standard location for introduction of the second trocar (e.g. for biopsy of the liver) is the right upper abdominal quadrant, but it may vary according to the location of focal lesions that need to be reached. The puncture site for the trocar is locally anesthetized. Anaesthesia of the sensitive parietal peritoneum should be done under laparoscopic control. Then the second trocar is inserted under constant laparoscopic vision. As soon as the tip of the trocar has a

safe intraabdominal position, the inner stylet is withdrawn and the desired biopsy instrument is inserted (Fig. 45.6). For the biopsy of solid organs such as liver and spleen we recommend the "Tru Cut"-cutting needle system. It provides reproducible tissue cylinders and the loss of tissue during withdrawal of the needle is, in contrast to other biopsy systems such as the Menghini- or Silverman- needle, very rare. In relation to the surface of the organ, the biopsy of liver and spleen should be performed in a rather tangential angle, to prevent laceration of larger vessels or bile ducts and to allow effective coagulation. Peritoneal lesions can be biopsied with flexible or stiff laparoscopy biopsy forceps.

After puncturing the liver or spleen, we recommend routine coagulation of the biopsy site until complete hemostasis is achieved. Monopolar coagulation probes together with a high frequency electro-surgical unit are recommended. The first coagulation should be done as "soft" coagulation with the probe positioned just above of the biopsy site. During coagulation, the probe is vigorously pressed down into the tissue to effectively adapt and close the biopsy channel. Ongoing blood loss can be visualized by rinsing the biopsy site with sterile saline. If hemostasis is difficult to obtain (e.g. in some cases of portal hypertension or severe cholestasis), the additional application of fibrin glue under the liver capsule is feasible. Tumor biopsies on the visceral and parietal peritoneum usually do not require hemostatic measures.

After the desired biopsies have been taken, the examination is terminated. Therefore, the tip of the second trocar is withdrawn to the abdominal wall under laparoscopic vision. The optical system is positioned on the left side, and then removed from the trocar. Both trocars are now opened, so that the remaining gas can effectively exhaust. After pneumoperitoneum is reverted, both trocars are removed. Mini-laparoscopy does not require any suturing, the insertion site of a 5.5 mm trocar should be closed with one adaptive suture.

Risk Profile of Diagnostic Laparoscopy

The perception of high invasiveness and therefore a high risk profile of laparoscopy significantly contributed to the decline of diagnostic laparoscopies outside

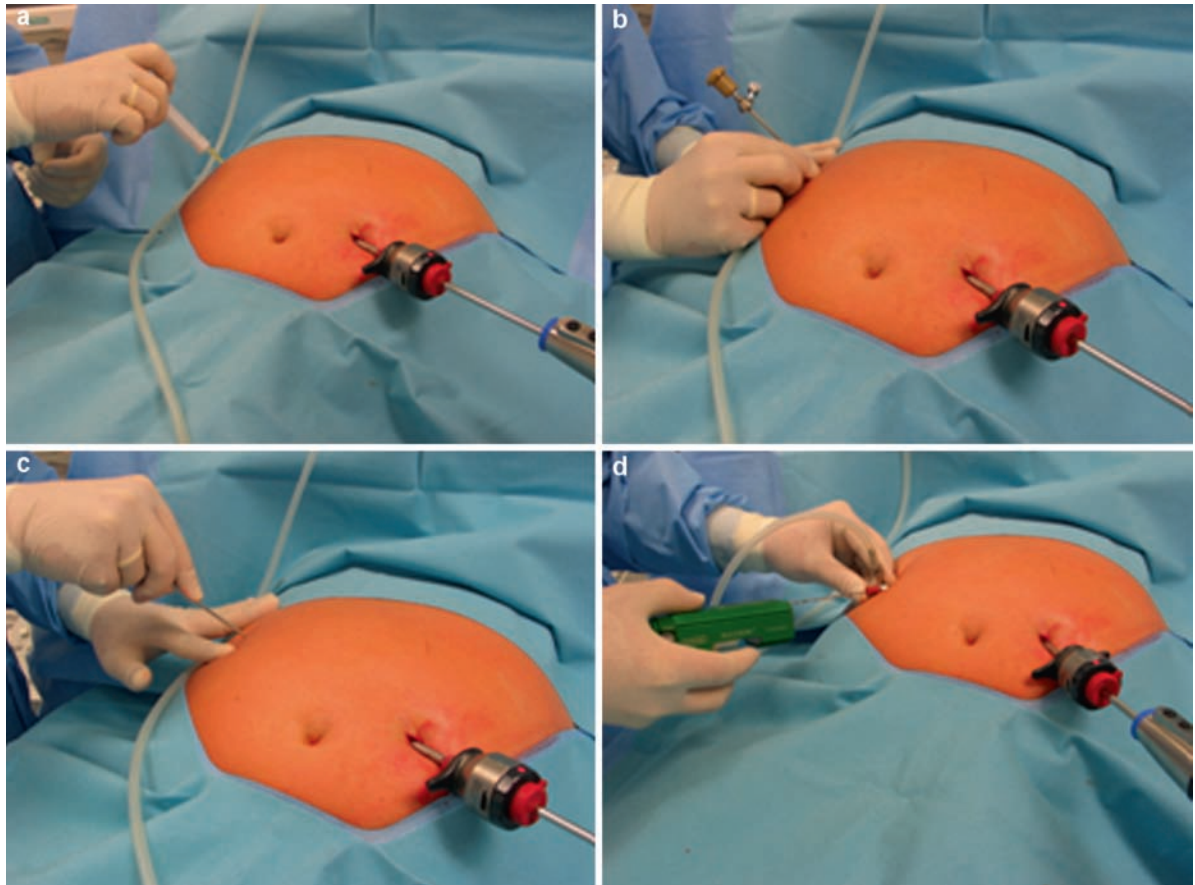


Fig. 45.6 Insertion of a second trocar during diagnostic laparoscopy for the retraction of tissue specimens. (a) Local anesthesia at a site in the right upper abdominal quadrant. (b, c)

Insertion of the second trocar under constant vision from the inside. (d) Retrieval of a liver biopsy

of an operation theater in the past decades. The data reported below will demonstrate that this perception is incorrect and that diagnostic laparoscopy, in particular after introduction of mini-laparoscopy, is a procedure with a risk profile equivalent, if not better, than other invasive biopsy techniques.

The reported complication rate from laparoscopy reported in the literature varies, depending on the definitions and the examined patient cohort. Major surveys have suggested a very favorable overall mortality rate of 0.03–0.06% [10, 44]. However, in these studies only serious complications were considered; it should be noted that a panel of minor complications do occur more frequently. **Figure 45.7** shows the spectrum of such minor complications in our own series of more than 1,200 (mini-) laparoscopies. These complications may occur at any point of the examination, but can usually be easily controlled during or after the intervention. The only serious

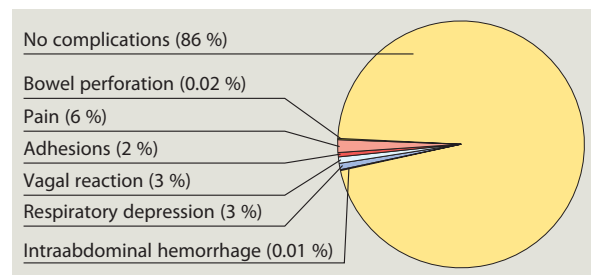


Fig. 45.7 Major and minor complications in a cohort of > 1,200 patients after mini- and standard-laparoscopy at the University Hospital Essen

complications that needed surgical intervention were injury of the small bowel in two patients and delayed intraabdominal hemorrhage in one patient. In the following sections, the steps during laparoscopy that are mainly responsible for these complications are discussed in detail.

Local Anesthesia/Conscious Sedation

As with other endoscopic examinations performed under conscious sedation, the synergistic interaction of analgesic and sedative drugs commonly affects the cardiopulmonary system. Most commonly, a slight respiratory depression is observed that usually can be easily treated and prevented by the nasal administration of 2–4 l/min of oxygen [7, 38]. Without therapy, sedation-induced respiratory depression may lead to subsequent problems such as cardiac arrhythmia and hypoxemia, hypercapnia and acidosis, a ventilation-perfusion mismatch or vaso-vagal phenomena [92, 112, 124].

The amount of sedative drugs used during laparoscopy, and in particular mini-laparoscopy, is usually significantly less than in patients undergoing other endoscopic examinations [25]. An explanation for this phenomenon may be provided by effects induced by the pneumoperitoneum (see below) and the slightly sedative effect of the nitrous oxide insufflation gas. Therefore, sedative medication during diagnostic laparoscopy should be administered carefully and fractionated under continuous monitoring of oxygen saturation, blood pressure and ECG. Under these conditions, hypoxemia and other cardiopulmonary problems during diagnostic laparoscopy are comparable if not lower than in other endoscopic procedures performed under conscious sedation. A judicious pre-procedure risk evaluation must include the identification of patients with existing cardiac and pulmonary disease.

Insertion of Veres Needle and Trocar

The most common complication induced by the Veres-needle is subcutaneous emphysema, due to incorrect placement of the needle tip outside of the abdominal cavity. Although this event rarely has serious complications, it may significantly impair adequate visualization of the viscera, and may necessitate termination of the procedure. In the mentioned historic laparoscopy series, a mortality rate of 0.014% has been attributed to bleeding from the trocar insertion site [10]. Significant bleeding is mostly caused by injury of the inferior or superior epigastric arteries or veins and may be recognized late following the return of the patient to the ward, because during the examination the trocar itself tamponades the torn vessel. In particular, bleeding from the epigastric veins

in patients with cirrhosis and portal hypertension has a poor prognosis and requires early surgical intervention [38, 92].

Perforation of the bowel is generally uncommon; however, the risk is increased in patients who have undergone previous abdominal surgery that may result in the fixation of bowels loops to the anterior abdominal wall. The same effect may occur after peritonitis of any etiology. In our laparoscopy series, two bowel perforations with the need of surgical intervention occurred (Fig. 45.7). In both cases, laparotomy revealed previous peritonitis with multiple adhesions.

Pneumoperitoneum

While the advantages and disadvantages of the two most commonly used insufflation gases, carbon dioxide and nitrous oxide, have been discussed earlier in this chapter, the generation of a pneumoperitoneum has some general adverse events due to the increased abdominal pressure. Distension of the abdominal wall and increase of the abdominal pressure may cause vaso-vagal phenomena. The hereby induced respiratory depression may be amplified by impediment of diaphragmatic mobility, causing a temporary restrictive ventilation disorder [110]. If pneumoperitoneum exceeds an intraabdominal pressure of 12 mmHg, further circulatory problems may occur. The pressure leads to a decrease of venous reflux to the heart, resulting in a reduction of cardiac preload and, consecutively cardiac output. As a compensatory mechanism, further supported by elevated concentrations of vasoconstrictive hormones, peripheral resistance increases and may result in a significant decrease of perfusion and thereby alteration of organ function [62, 94, 130]. However, mini-laparoscopy with low pressure pneumoperitoneum rarely shows these effects and even patients with pre-existing compensated cardiac or pulmonary disease can be examined safely [25, 40, 108].

Laparoscopic Inspection

Alteration of the parietal peritoneum, for instance following incorrect positioning of the trocar or inadequate analgesia, results in considerable discomfort and pain and should be corrected immediately. Special caution should be exercised in the presence of intra-abdominal

adhesions. While moving the laparoscope, they may be sheared, resulting in tension on the parietal peritoneum or other structures with sensitive innervation. If adhesions are torn, this may not only result in intraperitoneal bleeding, but also in the sudden onset of pain and nausea, accompanied by vaso-vagal reactions [43, 92]. The same adverse effects could be induced if the tip of the laparoscope incidentally streaks the parietal peritoneum while moving the instrument.

Laparoscopic Biopsy of the Liver and other Intraabdominal Organs

The main complication from liver biopsy is bleeding from the puncture site. Prolonged bleeding immediately after puncture is not rare. Whether this situation requires hemostasis by monopolar coagulation or a heater probe is questionable, since it has not been shown that omitting one of these measures results in increased intraabdominal hemorrhage. Most examiners, however, recommend the routine application of therapeutic hemostasis in this situation, particularly when impaired coagulation or thrombocytopenia are present. This may be the reason why recurrent hemorrhage with intraabdominal bleeding from a primarily coagulated and macroscopically “dry” biopsy site is very rare. In more than 1,200 mini-laparoscopies with liver biopsy we observed only one case (a patient with severe intrahepatic cholestasis due to hepatic graft-versus-host-disease) with recurrent intraabdominal bleeding and the subsequent need for surgical intervention. In the above-mentioned large historic series showed a rate of bleeding from the liver biopsy of 0.02–0.2% [10].

The favorable overall complication rate due to bleeding combined with the possibility of therapeutic hemostasis by different coagulation techniques (monopolar, bipolar, APC-heater probes) or application of fibrin glue, allows diagnostic laparoscopy to be done relatively independent of impaired coagulation parameters. With regard to the bleeding risk, laparoscopic liver biopsy can be considered as a safe examination even in high risk cases where percutaneous liver biopsy is already contraindicated such as acute and chronic liver failure of various etiologies, marked portal hypertension, or diffuse malignancies [24].

Diagnostic Laparoscopy in Liver Diseases

In liver diseases of known etiology, laparoscopy may help to exactly define the stage of the disease, since macroscopic assessment of the liver surface detects the signs of chronic liver disease, and in particular liver cirrhosis, with a very high sensitivity and specificity. Most chronic liver diseases show varying degrees of activity in different areas of the liver, producing the so called “sample error” in the standard percutaneous liver biopsy. While a “blind” liver biopsy has a limited probability to representatively reflect the extent of diffuse parenchymal diseases, laparoscopy offers the advantage of additional macroscopic visual information. This information contains an impression of the entire liver and therefore provides together with the histologic information a more comprehensive assessment of the stage of chronic liver diseases. If focal lesions or parenchymal differences are present, the biopsy needle may be precisely directed to these regions of interest, thereby improving the accuracy of the subsequent histologic examination. In these cases laparoscopy may even provide a great contribution to the clarification of the etiology in hepatic diseases of unknown origin.

Chronic Liver Disease

Histological examination of liver tissue in the evaluation of most chronic liver diseases is still indispensable. Therefore, diagnostic laparoscopy and laparoscopic liver biopsy compete in this situation with other methods of liver biopsy, namely percutaneous and transjugular liver biopsy. Since 1958, when Menghini introduced the aspiration needle technique for liver biopsy, the percutaneous access is today by most internists and hepatologists perceived to be the safer, easier, faster and cheaper method [87]. Therefore, performance of laparoscopy for obtaining a liver biopsy and for the diagnosis of chronic liver disease needs special consideration. The choice of which technique for liver biopsy is applied has to consider and appreciate the specific risks as well as the probability of obtaining information that will answer the substantial clinical questions and lead to initiation or modification of a therapeutic approach.

Diagnostic Accuracy of Laparoscopy Versus Percutaneous Liver Biopsy in the Diagnosis of Liver Cirrhosis

The etiology of most hepatic diseases can be discovered today by anamnestic information and non-invasive biochemical, serological and molecular biologic tests. However, to date they do not allow reliable determination of the inflammatory activity (grading), the degree of fibrosis (staging) and in particular the presence of cirrhosis, all of which have significant implications for prognosis and treatment. Patients with cirrhosis, for example, are at increased risk for the development of hepatocellular carcinoma and therefore should be enrolled in appropriate surveillance programs, and those with hepatitis C viral infection may show decreased responses to antiviral treatment with interferon-alpha than patients without cirrhosis [11, 50, 119].

In many cases, the diagnosis of liver cirrhosis is not difficult due to impaired liver function, explicit signs of cirrhosis on indirect imaging methods and/or the presence of portal hypertension. If diagnosis of cirrhosis is uncertain, the histologic examination of a biopsy specimen may lead to diagnosis. However, a typical liver biopsy represents approximately 1/50,000 of the entire liver volume [95]. Based on this information, many studies as well as our own data demonstrated that the histological examination of a single “blind” liver biopsy incorporates a significant risk of sample error, and even some clearly cirrhotic livers do not show the histologic features of cirrhosis [1, 9, 39, 45, 47, 92, 95, 113]. A well conducted study recently demonstrated the sample error phenomenon and re-established the superiority

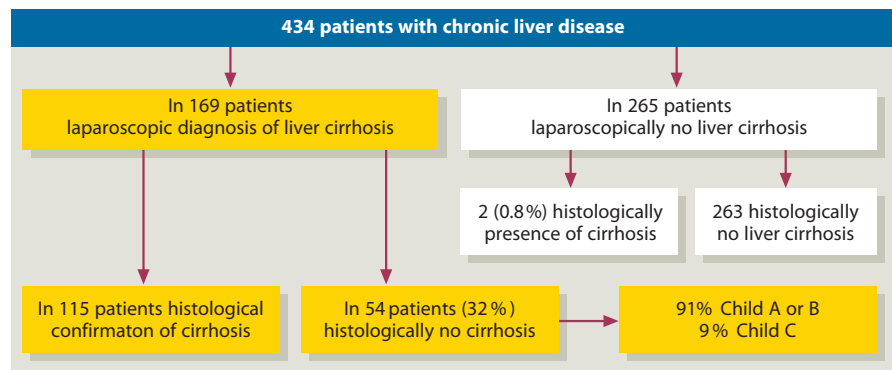
of macroscopic examination of the liver surface by laparoscopy for diagnosis of liver cirrhosis [99]. The authors demonstrated that from the 169 patients who had signs of liver cirrhosis at laparoscopy, histological examination of the corresponding liver biopsy, confirmed cirrhosis in only 67% of the cases. This corresponds to a sampling error of 32% (Fig. 45.8). In contrast, the situation that histology suggests cirrhosis without detection of cirrhotic nodules during laparoscopy is rare (0.8%).

As shown in subsequent studies, these results are reproducible for mini-laparoscopy, despite of the slightly inferior imaging quality. Another investigation found no difference in sensitivity or specificity of standard and mini-laparoscopy in the diagnosis of cirrhosis [108]. Independent of the laparoscopic method these investigators likewise reported a sampling error of 23%. In a further study of 204 patients with chronic liver disease and suspected Child A liver cirrhosis, macroscopic assessment of the liver by mini-laparoscopy led to the diagnosis of cirrhosis in 94 patients (46%). In contrast, only 68 of the biopsies that were taken from the right liver lobe of these 94 patients showed signs of liver cirrhosis in the histological examination [41]. Again, these results illustrate the sampling error risk during biopsy, which in this study was around 27%, and with regard to the diagnosis of cirrhosis can effectively be avoided by laparoscopic visualization of the liver.

A typical case with suspected Child A liver cirrhosis, in which only laparoscopic liver assessment established the diagnosis of cirrhosis, is depicted in Fig. 45.9.

The superiority of mini-laparoscopic assessment over percutaneous liver biopsy in the diagnosis of liver

Fig. 45.8 Results from Poiachik et al. (1996) documenting the sample error effect of liver biopsy in the diagnosis of liver cirrhosis



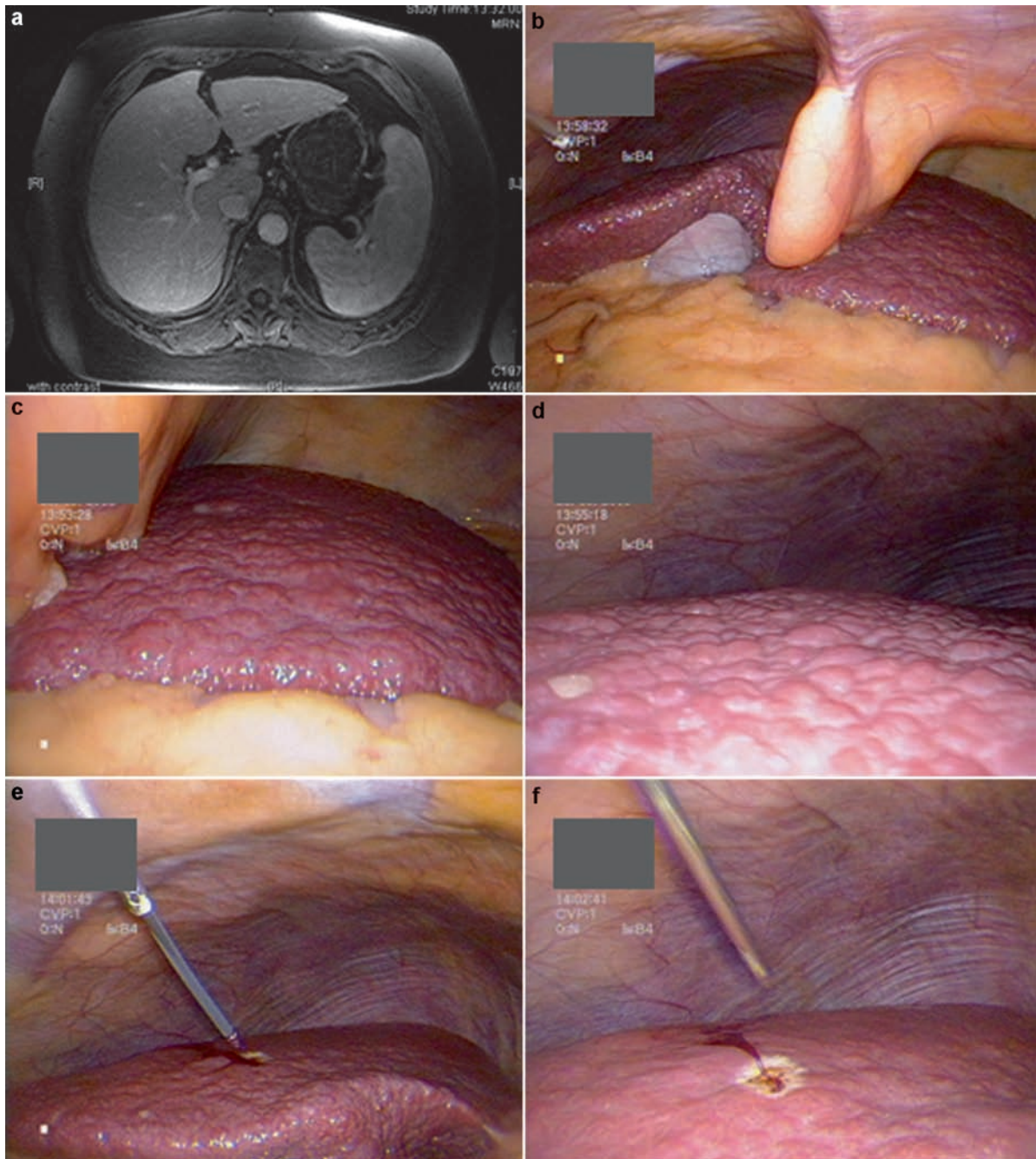


Fig. 45.9 Laparoscopic diagnosis of liver cirrhosis. (a) normal liver on CT scan. (b–d) Laparoscopic evaluation of the liver showing nodular surface. (e, f) Monopolar coagulation of the biopsy site during laparoscopy

cirrhosis was further demonstrated in a recent direct comparison between the two methods. Eight hundred and fifty seven patients were randomized either to mini-laparoscopic or percutaneous liver biopsy (Menghini aspiration needle method). In the latter group, cirrhosis was diagnosed by histology in 23% of

cases compared to the mini-laparoscopy group, where the additional visual information of the liver led to diagnosis of cirrhosis in 34% of patients [23]. Further analysis of this group demonstrated that macroscopic and microscopic liver assessment showed similar results in the detection of cirrhosis only in 74%, while

the diagnosis of cirrhosis was solely dependent on the macroscopic findings in 26%, which corresponds to the sampling error.

Complications of Laparoscopy Versus Percutaneous Liver Biopsy

The decision of which method of liver biopsy is applied in a particular patient has to consider not only the potential diagnostic yield but likewise has to appreciate the specific risk profile of the procedure and the patient. In general, both procedures are regarded as safe but contraindications have to be acknowledged (Table 45.2). The reported complications from percutaneous liver biopsy (PLB) have varied greatly in the literature, depending upon definitions used and the nature of the underlying liver disease. Most of the complications refer to peri- or post-interventional pain (in some studies occurrence in > 20% of cases) and other minor events [82]. In large series, the overall rate of serious complications associated with PLB is 0.12–0.63% [76, 84, 98, 111, 118]. Sixty percent of the encountered complications occur within 2h after the procedure and 96% within 24h [82, 84, 98]. The single most feared complication of PLB is hemorrhage, which in the case of hemoperitoneum may be lethal. Therefore, in this context we focus on this complication of PLB.

Hemorrhage after PLB occurs as intraabdominal, intrahepatic and (most commonly) subcapsular bleeding. Hemobilia as a result of bile duct laceration in combination with an arterio- (or veno-) biliary fistula is extremely rare. While intra- and subcapsular bleeding, which occurred in some series in up to 1.6% of cases, is mostly self limiting and clinically non-overt, intraabdominal bleeding is the main reason for the PLB-associated mortality of 0.01–0.12%. Several particular (patient associated) risk factors have been linked to the development of post PLB hemorrhage. Among others, acquired (or hereditary) coagulation disorders, thrombocytopenia, Child B and C liver cirrhosis, acute liver failure, renal insufficiency and AIDS are the most common of these risk factors [14, 76, 84, 98, 109, 117].

Laparoscopy as the alternative biopsy method has, as described in detail earlier in this chapter, no increased overall risk of major complications as compared to PLB. However, it offers the possibility of active control of post-biopsy bleeding by monopolar

coagulation, and thereby significantly decreases the risk of intraabdominal hemorrhage, in particular in patients with portal hypertension or coagulation disorders. In our own cohort of patients after mini-laparoscopy, only one of more than 1,200 cases (0.01%) needed surgical intervention because of intraabdominal hemorrhage, despite the fact that this cohort contained a high proportion of patients with liver cirrhosis and impairment of coagulation parameters.

In conclusion, (mini-)laparoscopy significantly improves the diagnosis of liver cirrhosis in particular in otherwise unclear cases with a functional class of Child A, and should be regarded as the diagnostic gold standard in this situation. Given the possibility of intraabdominal hemostasis during the examination, diagnostic laparoscopy should be considered, in patients with absolute or relative contraindications to standard percutaneous biopsy. Finally, laparoscopy is recommended for further evaluation of hepatic diseases of unknown origin, where the additional macroscopic information and guidance of the biopsy needle may significantly contribute to clarification of the etiology.

Laparoscopy and Laparoscopic Liver Biopsy in Acute and Subacute Liver Failure

Acute and subacute liver failure are not regarded as standard indications for diagnostic laparoscopy, and literature data about the value and risk in this situation is rare. However, in a variety of cases the macroscopic and microscopic evaluation may yield valuable information about etiology and prognosis of the underlying disease and even prevent liver transplantation. Therefore the use of laparoscopy and laparoscopic liver biopsy in this situation is based on a case by case decision, but some general circumstances should be distinguished.

It is unquestionable that neither laparoscopic nor percutaneous liver biopsy has a role in the case of fulminant acute liver failure with rapid deterioration of hepatic function. These patients must be treated with intensive care measures and liver transplantation as soon as possible. An exception may be given if an encephalopathic patient with liver failure on the basis of known alcohol abuse is admitted, to differentiate between a true acute or an acute-on-chronic liver failure.

Subacute liver failure, on the other hand, is characterized by a rapid initial decrease and then stabilization of hepatic function, providing a window for further etiologic and prognostic evaluation. As in chronic liver diseases, many causes of subacute liver failure can be determined today by serological and biochemical procedures. If the etiology is determined, the main indication to subject a patient to laparoscopic liver biopsy is the differentiation between a truly (sub)acute or an acute-on-chronic failure. Since the macroscopic evaluation detects in particular liver cirrhosis with a very high specificity, acute liver failure can, even without biopsy, be effectively distinguished from a situation with acute deterioration of chronic liver disease (acute-on-chronic liver failure). In addition, the histology may provide important information about the possibility of liver regeneration, in particular after immunohistochemical analysis of regeneration markers such as Ki-67. These data may support therapeutic decisions with regard to either continue conservative therapy or to rapidly pursue liver transplantation as the only therapeutic option.

Laparoscopy for the Staging of Primary and Secondary Liver Tumors

Effective multimodal therapeutic approaches, that are available today for most gastrointestinal (GI-) malignancies, are based on exact staging of the tumor disease. The decision whether a therapy is primarily palliative or whether there may be a curative surgical approach, potentially complemented by a neoadjuvant, perioperative or adjuvant (radio-) chemotherapy and/or additional application of locoregional tumor ablative therapies, depends on the appropriate diagnostic evaluation of the local extent of the primary tumor as well as on the presence of regional lymph node involvement and distant metastasis. On one hand, the individual choice of multimodal therapies should preserve a maximum quality of life and prevent unnecessary impositions for the patients. On the other hand, the maximal therapeutic benefit should be achieved. Although indirect imaging techniques such as abdominal and endoscopic ultrasound, computed tomography (CT), MRI and PET(-CT) have shown impressive advances in the recent decade, not all of the diagnostic requirements for a precise staging of the GI-tumors are met by these methods to date. The accuracy of detecting early peritoneal carcinomatosis, small liver metastasis, lymph node involvement and the

infiltration of adjacent structures is often not sufficient.

Therefore, direct visual examination of the abdominal cavity is still indispensable and provides the highest diagnostic accuracy with regard to the detection of peritoneal carcinomatosis and small liver metastasis. In particular, among surgeons it has been argued that open “diagnostic” laparotomy is the more precise and therefore superior method for staging. However, with regard to a lower complication rate, shorter hospitalization (and therefore favorable cost effectiveness) as well as faster recovery of the patient and initiation of (radio-) chemotherapy, laparoscopy has been shown to be the preferable staging method for all gastrointestinal malignancies [15, 18, 34, 69, 85, 115].

While in former times it was primarily performed by gastroenterologists, staging laparoscopy is currently, due to the rapid development and wide use of laparoscopic surgery, mainly in surgical hands. Surgeons sometimes augment diagnostic laparoscopy to a so called ‘expanded’ or ‘multiport’ staging laparoscopy, during which regions that are primarily not visible are dissected and, if required, complemented by laparoscopic ultrasound [28, 88]. This technique seems to have particular value for the malignancies of the posterior wall of the stomach and possibly the esophago-gastric junction, but to date no direct prospective comparison between the expanded and the standard version of diagnostic laparoscopy is available. In addition, retrospective comparisons do not imply a significant enhancement of sensitivity of the expanded method.

Therefore, this chapter will review the value of standard (non-surgical) staging laparoscopy, which, with respect to the implementation of mini-laparoscopy, found its way back into the endoscopy units of some countries during recent years. Outside of the United States, it is increasingly performed by gastroenterologists, hepatologists and GI-oncologists, to accomplish comprehensive staging of the different gastrointestinal tumor entities with the primary aim of avoiding non-therapeutic laparotomy for their patients.

Primary Hepatobiliary Cancers

Hepatocellular Carcinoma

Hepatocellular carcinoma (HCC) is the fifth most common neoplasm in the world and the third most common cause of cancer-related mortality. The incidence

of HCC has been increasing significantly in Western countries. The primary diagnosis is difficult, since patients are usually asymptomatic, and the tumor most often develops within preexisting liver cirrhosis. This is the main explanation for the fact that only approximately 30% of newly diagnosed patients with HCC qualify for surgical, and therefore potentially curative therapies, such as resection and transplantation. However, even if patients exceed the Milan criteria which determine eligibility for liver transplantation, they may still have a stage in which the tumor can be treated by locoregional therapies, such as radiofrequency ablation (RFA), transarterial chemoembolization (TACE) or selective internal radiotherapy (SIRT).

Depending on the individual tumor biology, local therapies may be very effective in local tumor control and some randomized studies even demonstrated a survival advantage in the palliative situation [78, 79]. As in surgery, precondition for a local ablative therapy is that no intrahepatic or peritoneal dissemination of the tumor is present, and that extrahepatic metastases have been excluded. This is even more important, since recently an effective systemic therapy for advanced HCC has been approved [80]. While the exclusion of extrahepatic metastases can be effectively done by cross sectional imaging, advanced intrahepatic tumors often present with small additional intrahepatic or peritoneal nodules not detected in CT or ultrasound. Although even very small superficial nodules within the liver or peritoneum are detected by laparoscopy with high sensitivity, the diagnostic potential of laparoscopy in HCC has been widely questioned because other important criteria determining the eligibility for resection or liver transplantation, such as vessel invasion and lymph node involvement, are difficult to evaluate laparoscopically [102].

Therefore laparoscopy is not included in the routine diagnostic workup of HCC, regardless of the fact that previous studies showed a considerable value for laparoscopic staging of HCC. In these studies, laparoscopy revealed additional bilobar disease or peritoneal dissemination in 16–39% and thereby prevented nontherapeutic laparotomy [20, 69, 81, 129].

In addition to the staging information, laparoscopy contributes to the management of HCC in the assessment of the underlying liver cirrhosis and the evaluation of the liver remnant prior to hepatic resection. As described earlier in this chapter, it allows for safe liver biopsy and the same is true for the biopsy of a

liver tumor. In HCC this is of particular importance, since the tumor is highly vascularised and portal hypertension as well as coagulopathy is often present. In addition, laparoscopic biopsy of a superficial tumor nodule effectively prevents seeding of tumor along the biopsy channel, which in percutaneous biopsy has been reported to occur in up to 1–3%. Although histology is not always a necessary element for the diagnosis of HCC if the primary nodule is > 2 cm, there is an emerging prognostic role for particular tissue determinants, such as tumor differentiation, genomic analysis and the loss microsatellite heterozygosity, all of which are reasons that in centers specialized in the treatment of this tumor, HCC is again increasingly biopsied [11].

Based on the facts reported above, at our center we routinely perform mini-laparoscopy including (if possible) laparoscopic biopsy in HCC patients with no extrahepatic disease in cross-sectional imaging that may be eligible for surgical or locoregional therapies.

Biliary Cancer

Biliary carcinomas are aggressive malignancies, for which radical surgical resection is the main therapy to improve life expectancy. Unfortunately, a large number of patients with biliary cancers have unresectable disease at laparotomy [3, 57, 70, 71]. Since the survival in patients who have incomplete tumor extirpation is identical to that in patients who do not undergo surgery and receive only palliative therapies, the importance of avoiding nontherapeutic laparotomy cannot be overemphasized [42, 57]. Because of the high incidence of occult unresectable disease, staging laparoscopy has been increasingly used during the last decade to complement preoperative imaging in patients with (mostly secondary) hepatic malignancies [20, 58, 100]. However, only a few of these studies focussed on biliary cancers [34, 128].

To evaluate the benefit of laparoscopic staging in biliary malignancies, these cancers should be classified as either predominantly intrahepatic cholangiocarcinoma, hilar cholangiocarcinoma, distal (extrahepatic) bile duct cancer, or gallbladder carcinoma (see Chapter 116). Typical positive laparoscopic findings in different biliary cancers are demonstrated in Fig. 45.10. The study of Goere et al. was one of the few to examine the specific value of laparoscopy in particular subsets

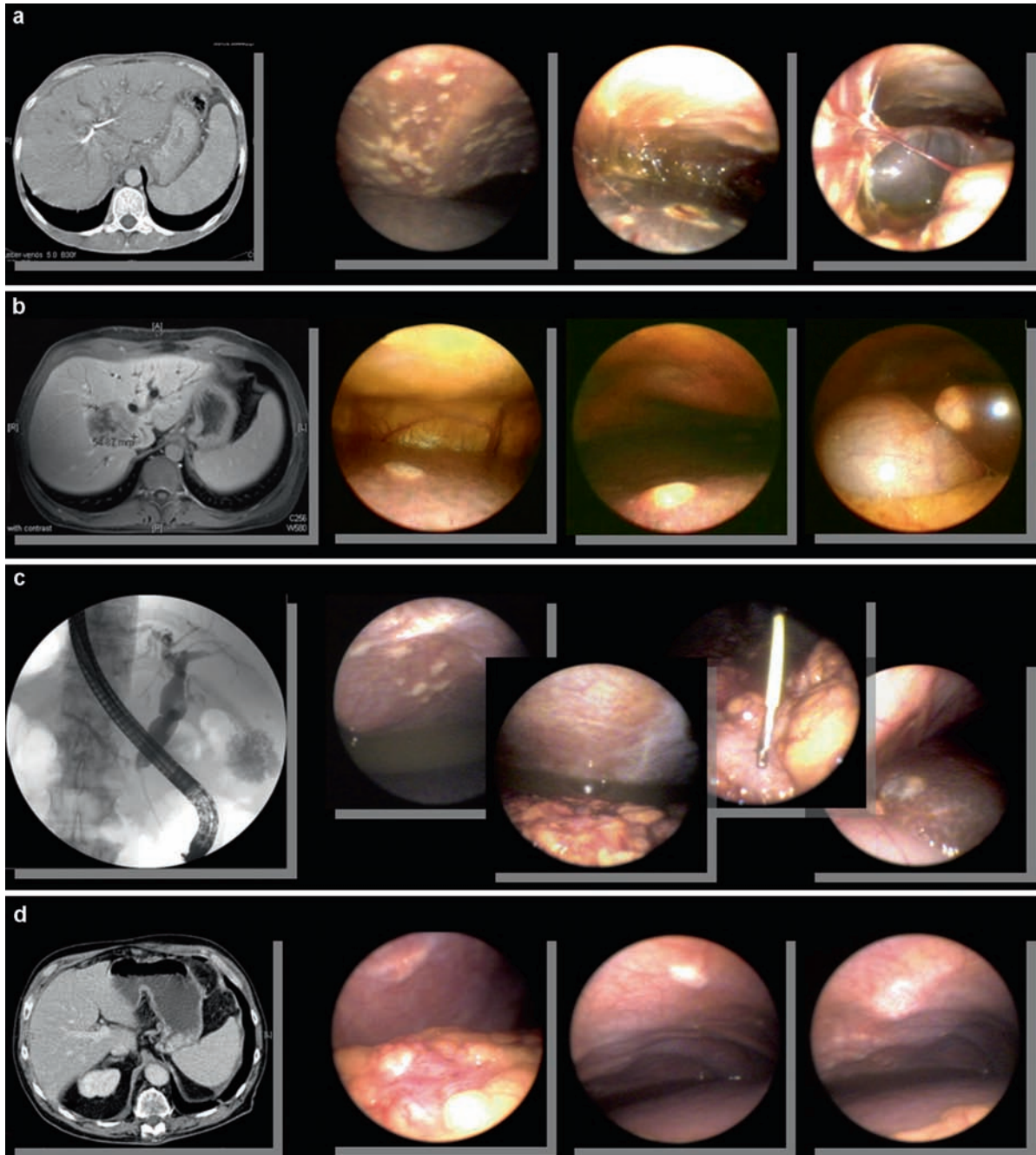


Fig. 45.10 Diagnosis of peritoneal or additional liver metastases in different biliary cancers by diagnostic mini-laparoscopy. (a) Patient with hilar cholangiocarcinoma with no visible mass in the liver and peritoneum on CT. (b) Patient with intrahepatic cholangiocarcinoma who was evaluated for resection. Laparoscopy

revealed multiple bilobar additional liver metastases not seen in MRI or CT. (c) Patient with cholangiocarcinoma of the distal common bile duct and peritoneal metastases not seen in preoperative CT. (d) Staging laparoscopy of a patient with gallbladder carcinoma

of cholangiocarcinoma in 39 patients [34]. The overall results, regardless of the tumor entity, are shown in Fig. 45.11. A total of 36% of patients were found to have

occult unresectable disease due to the presence of peritoneal or small liver metastases. However, of the 64% of patients that underwent laparotomy, only 38% were

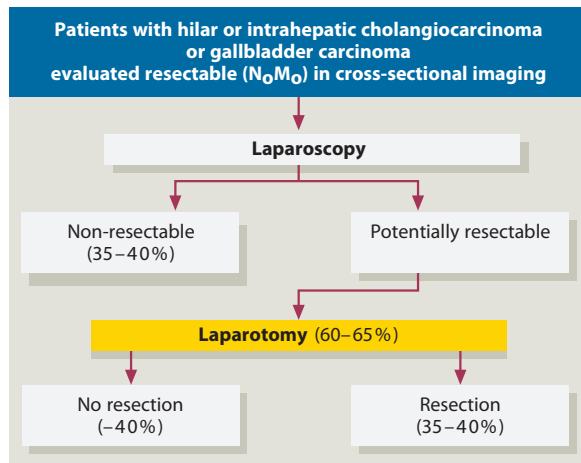


Fig. 45.11 Diagnostic yield of laparoscopy in different biliary cancers. (According to [5, 6])

finally resected, illustrating the limitations of laparoscopy in some subgroups of biliary cancers. In particular, in hilar cholangiocarcinoma distant abdominal spread is rather rare though the tumor is frequently unresectable due to vascular invasion, extended local spread, or occult lymph node involvement; these circumstances can neither be reliably detected with laparoscopy (even in combination of laparoscopic ultrasonography) nor with any other preoperative imaging technique [12, 15, 56, 74, 131]. Accordingly, the accuracy of laparoscopy in detecting unresectable disease in hilar cholangiocarcinoma was only 45%.

In contrast, in patients with gallbladder and intrahepatic cholangiocarcinoma laparoscopy had a much higher diagnostic yield (62% and 36%) because these subsets of biliary cancers have a much higher propensity to develop early peritoneal spread, which can be detected laparoscopically with high accuracy (83% and 67%). The work of Geore et al. confirms the results of an earlier study, with almost similar results [128]. It has to be noted that in both studies positive laparoscopic findings in hilar cholangiocarcinoma almost exclusively referred to advanced (>T2) tumors.

Taking the available data on biliary cancers together, it appears that laparoscopy produces the highest diagnostic yield in gallbladder carcinoma, followed by intrahepatic and distal extrahepatic cholangiocarcinoma [8]. Liver or peritoneal metastases of hilar cholangiocarcinoma seem, particularly in small tumors without a visible mass in CT or MRI, a rather infrequent

event, so that staging laparoscopy cannot be routinely advocated in this clinical setting.

Secondary Liver Tumors

Colon Cancer

Colon carcinoma is probably the most common tumor to metastasize to the liver. The routine use of laparoscopy for the staging of patients with hepatic metastasis from colorectal cancer has been widely questioned in an era of rapid advancements in imaging techniques and more aggressive surgical interventions. The overall diagnostic yield of staging laparoscopy in patients with hepatic metastases from colorectal origin has been shown in different studies to be approximately 10% [55, 56]. However, some patients may be at greater risk than others for harbouring radiographically occult, unresectable disease; therefore, the potential benefit of laparoscopy may be greater than in other patients. In the largest series addressing this issue, the authors applied a specific clinical risk score (lymph node–positive primary tumor, disease free interval fewer than 12 months, more than one hepatic tumor, largest diameter of hepatic tumor greater than 5 cm and a high carcinoembryonic antigen level) to identify patients at a larger risk for unrecognized extrahepatic disease [35]. They demonstrated that patients with a low risk score did not benefit, while in patients with a high risk score laparoscopy revealed peritoneal or disseminated intrahepatic or lymph node metastases in 24% of cases. This averted unnecessary laparotomy and shortened the hospital stay as well as the time interval to initiation of systemic chemotherapy.

Laparoscopy therefore cannot be routinely recommended in patients with liver metastases from colorectal cancer and should be restricted to high risk patients that are considered for surgery or an alternative locoregional treatment of the liver, such as intrahepatic chemotherapy, chemoembolization or selective internal radiotherapy. Since most of these patients will have had abdominal surgery for removal of their primary tumor, the expected adhesions will prevent (mini-)laparoscopy by gastroenterologists and should be performed by surgeons in an operating room. Only those patients who underwent prior laparoscopic surgery for removal of their primary tumor might be considered for standard staging laparoscopy in the situation of metachronous liver metastases.

Gastric Cancer

Gastric cancer is the fourth most common cancer and the second leading cause of cancer-related death worldwide [96]. In contrast to some Asian countries, where specific surveillance programs for this tumor exist, a majority of gastric cancers in the Western countries are diagnosed at an advanced stage [16, 103]. It is widely accepted that radical surgical resection including excision of the regional lymph nodes is the most significant factor determining long term survival. Whether surgery is beneficial for the individual patient depends on a careful selection, since the recurrence rate in patients with serosal infiltration (T3 and T4 stages) is high and may warrant neoadjuvant chemotherapy within clinical studies. In addition, occult metastatic disease within the peritoneum and/or liver is in this case often already present at the time of initial diagnosis.

For the preoperative evaluation of local cancer spread as well as nodal involvement, endoscopic ultrasound (EUS) has been established as the diagnostic modality of choice, although not all authors agree on the reported superiority of EUS over multislice CT-scanning or MRI [30, 61, 73]. However, there is less doubt that the indirect imaging methods can miss a considerable number of occult abdominal metastasis that can be detected only by laparoscopy. As shown in Table 45.3, different investigators have found that up to 40% of CT-occult metastatic disease may be identified by diagnostic laparoscopy. Thus, direct laparoscopic visualization of the peritoneal cavity spares approximately one third of patients with what was initially judged to be resectable gastric cancer from a nontherapeutic laparotomy. Based on these data, the US National Comprehensive Cancer Network (NCCN) recommends laparoscopy as part of the routine staging algorithm for patients with gastric cancer.

The discussion about the necessity of using laparoscopic ultrasonography in addition to conventional diagnostic laparoscopy is controversial. The major limitation of diagnostic laparoscopy is that inspection of the surface of the liver and peritoneal cavity is only two-dimensional and excludes the possibility of palpation. Therefore, the identification of small intraparenchymal hepatic metastases and perigastric lymph nodes is limited. Laparoscopic ultrasonography has been proposed to overcome some of these limitations and to further improve the diagnostic yield of the method [49]. However, the majority of studies utilizing laparoscopic

Table 45.3 Value of staging laparoscopy in adenocarcinoma of the esophagus or the esophago-gastric junction and gastric cancer [27–39]

	n	Upstaging by laparoscopy (%)	Use of laparoscopic ultrasound in selected cases
Adenocarcinoma of the Esophageal			
Dagnini et al., 1986	369	22	No
Haeth et al., 2000	59	17	No
Kaushik et al., 2007	47	17	Yes
Molloy et al., 1995	244	42	Yes
Stein et al., 1997	127	32	Yes
De Graaf et al., 2007	416	20	No
Gastric Cancer			
Blackshaw et al., 2003	100	21	No
Hünerbein et al., 1998	227	32	Yes
Conlon et al., 2001	103	37	No
Burke et al., 1997	110	37	No
Sotiropoulos, 2005	45	23	No
Zöpf et al., 2003	30	33	No
Onate-Ocara et al., 2003	151	40	No

ultrasound in the staging of gastric cancer are difficult to interpret because they employed different indirect imaging methods for pre-laparoscopy staging, and most results were reported without determining the specific added benefit of laparoscopic ultrasound over state-of-the-art CT plus laparoscopy alone. Given the limitations of the available data, the significant financial expenses associated with the laparoscopic ultrasound equipment, and the operator-dependent nature of the technique, laparoscopic ultrasound should be regarded as a technique that requires further investigation and should be performed primarily within the context of clinical studies.

Carcinoma of the Distal Esophagus, the Esophago-gastric Junction and the Gastric Cardia

A main reason for the problematic prognosis of distal (adeno-) carcinoma of the esophagus or the esophago-gastric junction, is the frequent presence of peritoneal carcinomatosis and small liver metastasis that are considered to be a strict contraindication for resectional procedures [93, 126]. Employing diagnostic laparoscopy within the staging of this cancer will therefore detect dissemination of this tumor more reliably. A

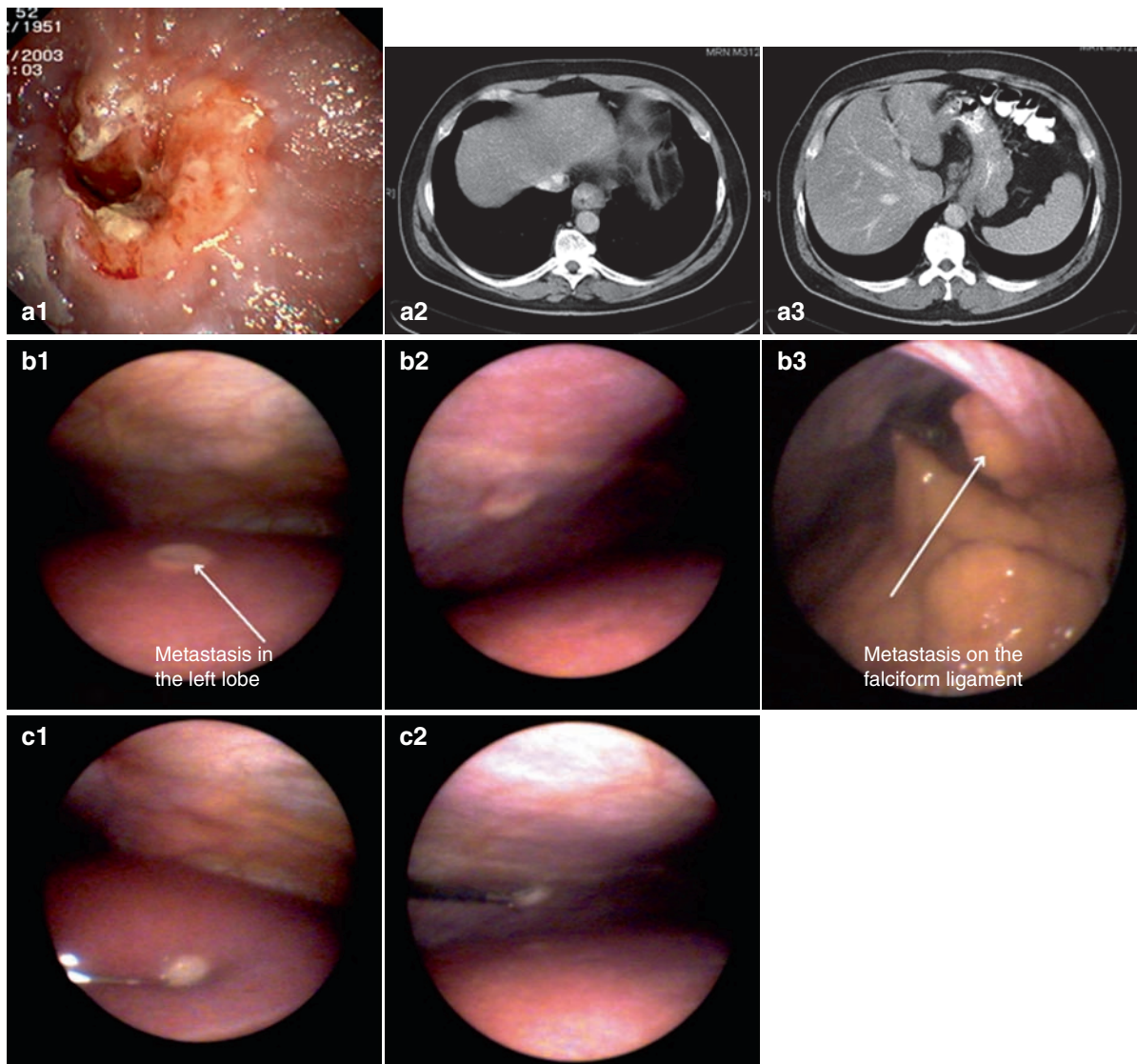


Fig. 45.12 Adenocarcinoma of the esophago-gastric junction with occult peritoneal and liver metastases. (a) Tumor of the esophago-gastric junction during gastroscopy (*left*) and normal

CT scans for staging (*right*). (b) Laparoscopy with detection of small liver and peritoneal metastases. (c) Biopsy of liver and peritoneal metastases

typical example is shown in Fig. 45.12, illustrating a case of a patient with dysphagia who was diagnosed with an adenocarcinoma of the esophago-gastric junction. High-resolution CT-scanning and endoscopic ultrasound for staging showed no signs of liver or peritoneal metastasis. Before the patient was referred to surgery, diagnostic mini-laparoscopy was performed. The visual inspection of the abdominal cavity clearly showed a couple of small nodules on the parietal peritoneum as well as on the liver surface that were verified as metastases by targeted biopsy and subsequent histological examination.

The determination of local spread and infiltration of adjacent structures, such as descending aorta, the prevertebral fascia, thoracic vertebrae, or the diaphragm are more effectively evaluated by indirect imaging techniques. In particular, EUS has been shown to accurately predict local resectability. With respect to lymph node involvement, EUS and surgical staging laparoscopy seem to be equivalent, in particular when EUS is combined with fine needle aspiration. In this case, EUS detects up to 90% of the nodes that can be detected by surgical laparoscopy, while the overall sensitivity detecting the correct (as

determined postoperative) N-stage for EUS is around 75% [66, 75, 134].

As shown in the case above, the major advantage of laparoscopic staging in adenocarcinoma of the distal esophagus or the esophago-gastric junction, respectively, is the detection of distant metastases. In a recent direct comparison with EUS, the overall staging accuracy of EUS compared with LS was 72%, and the major difference was attributed to the significantly higher sensitivity of laparoscopy in the detection of peritoneal dissemination and small liver metastasis (17%) [66]. These data correlate with older studies, which are summarized in [Table 45.3](#). They show that upon introduction of laparoscopy with or without laparoscopic ultrasound, previously undetected hepatic metastasis or peritoneal tumor dissemination can be detected in 20–30% of patients with potentially resectable adenocarcinoma. In addition to the detection of distant abdominal metastases, in these studies, laparoscopy detected in 2–5% of cases other important findings that potentially altered the curative surgical approach, such as previously unknown liver cirrhosis.

Therefore, the recommendation to regularly include laparoscopy in staging adenocarcinoma of the esophagus and/or esophago-gastric junction as well as the gastric cardia is reasonable. In contrast, squamous cell carcinoma of the esophagus, which usually shows a more proximal location, only rarely exhibits dissemination into the abdominal cavity [19, 21, 93, 116]. Consequently, the diagnostic gain of laparoscopy is much lower and the recommendation of regular inclusion in the diagnostic workup is not justified and has to be ideally performed within clinical studies and probably in combination with thoracoscopy [72].

Pancreatic Cancer

Due to its aggressive nature, a high recurrence rate after surgery and a significant lack of response to systemic therapy, pancreatic (ductal) adenocarcinoma is probably the most devastating abdominal tumor. It is presently the fourth leading cause of cancer-related death in the industrialized world with a five year survival rate below 5% and a median survival time of less than 6 months [37, 59]. Approximately 80% of patients with pancreatic cancer at the time of diagnosis are primarily not eligible for surgery, with respect to locally advanced or metastatic disease. Even after curative surgery with radical resection of pancreas and adjacent

structures, 5-year survival seldom exceeds 15–20% [46, 48]. Only a small subgroup of patients with small tumors, a favourable tumor biology, negative lymph nodes and no vessel invasion, may reach a 5 year survival rate of 40–50% [46].

These epidemiological facts illustrate why patients with ductal pancreatic carcinoma often undergo unnecessary laparotomy, although it has been shown that even exploratory or palliative laparotomy in patients with non-resectable pancreatic tumors is associated with a significant perioperative morbidity and mortality and reduced postoperative quality of life [22, 127]. Therefore, accurate staging of pancreatic cancer is of paramount importance prior to referring a patient to surgery.

Locoregional staging and evaluation of resectability today is primarily a domain of radiologic imaging with CT. The current high-resolution multidetector CTs have been shown to adequately assess the local tumor stage and resectability. Particularly if the tumor is locally unresectable, this is correctly predicted by CT in > 90% of cases. In contrast, the positive predictive value of surgical resectability has ranged from 40–70% in various studies due to an underestimation of vessel invasion, lymph node involvement or distant metastases [29, 97, 121]. Initiated by the work of Cuschieri et al., laparoscopy emerged as a reliable method for detecting distant metastases in patients with localized pancreatic cancer on radiologic imaging [17].

Although the favourable findings of this study have been verified in numerous subsequent studies, the value of laparoscopic staging in patients with pancreatic carcinoma is still controversially discussed and not fully established ([Table 45.4](#)). While some groups

Table 45.4 Value of staging laparoscopy in adenocarcinoma of the pancreas [15–22]

	n	Upstaging by laparoscopy (%)	Use of laparoscopic ultrasound in selected cases
Ahmed et al., 2006	59	24	No
Butturini et al., 2007	19	53	No
Reddy et al., 1999	109	31	No
Nieeven van Dijkum et al., 2003	297	13	Yes
Jimenez et al., 2000	125	38	No
Shoup et al., 2004	100	37	No
White et al., 2004	100	21	No
Andren-Sandberg et al., 1998	60	40	No

perform diagnostic or even surgical laparoscopy routinely prior to open surgery, other investigators recommend the use of laparoscopy only in very selected cases, such as locally advanced tumors, since some other studies only found additional abdominal metastases in 4–10% [60, 101, 106, 107, 133, 135].

The following recommendations for the utilization of laparoscopy in pancreatic cancer can be made with relative confidence: (1) Staging laparoscopy may be performed in advanced cancer of the pancreatic head or body according to the institutional diagnostic algorithms. (2) Laparoscopy is of little or no value in ampullary or duodenal cancer. (3) The use of laparoscopic ultrasound is not routinely advocated (see also section “Gastric Cancer”), although it may provide further information regarding vascular invasion and lymph node involvement, particularly with respect to the celiac trunk, the superior mesenteric artery and the portal vein [33, 86, 114, 125]. (4) Since tumors of the pancreatic tail have a high propensity to metastasize to the peritoneal cavity, staging laparoscopy should be performed in these cases regularly prior to surgery [2, 29]. (5) Laparoscopy may facilitate histopathological diagnosis of an unresectable mass in the head or the corpus of the pancreas whenever percutaneous or EUS guided biopsy or fine needle aspiration fail [13]. (6) Diagnostic laparoscopy is useful in cases with a high likelihood of a palliative surgical procedure, such as a gastric or biliary bypass [28, 90].

Conclusion

In conclusion, diagnostic laparoscopy, regardless whether performed as standard- or mini-laparoscopy, and laparoscopic liver biopsy are valuable tools for the physician working in the field of gastroenterology and hepatology. Diagnostic laparoscopy is recommended in the staging of chronic liver disease, and it should be regarded as an important part of the work-up in particular of liver diseases and ascites of unknown origin. For the diagnosis of early cirrhosis, laparoscopy has to be considered as the ‘gold standard’, since it is more effective in establishing the diagnosis of cirrhosis than histology. The procedure is indispensable in addition to radiological screening in the staging of primary or secondary liver cancer, since it avoids an unnecessary laparotomy, in particular when used to assess spread of liver tumours in patients with negative radiological

investigations. However, despite the advantages demonstrated in this chapter, laparoscopy seems to be underused and undervalued in most US and European centers. If the training of laparoscopists involves careful attention to the potential technical problems, adverse events and contraindications, the complication and mortality rates are similar or lower than those of percutaneous liver biopsy, in particular if coagulopathy or portal hypertension is present.

References

1. Abdi W, Millan JC, Mezey E (1979) Sampling variability on percutaneous liver biopsy. *Arch Intern Med* 139: 667–9
2. Ahmed SI, Bochkarev V, Oleynikov D, et al (2006) Patients with pancreatic adenocarcinoma benefit from staging laparoscopy. *J Laparoendosc Adv Surg Tech A* 16: 458–63
3. Bartlett DL, Fong Y, Fortner JG, et al (1996) Long-term results after resection for gallbladder cancer. Implications for staging and management. *Ann Surg* 224: 639–46
4. Benedict EB (1938) Peritoneoscopy. *New Engl J Med* 218: 713–9
5. Bongard FS, Pianim NA, Leighton TA, et al (1993) Helium insufflation for laparoscopic operation. *Surg Gynecol Obstet* 177: 140–6
6. Boyce HW, Henning H (1992) Diagnostic laparoscopy 1992: time for a new look. *Endoscopy* 24: 671–3
7. Brady CE, III, Harkleroad LE, Pierson WP (1989) Alterations in oxygen saturation and ventilation after intravenous sedation for peritoneoscopy. *Arch Intern Med* 149: 1029–32
8. Brooks AD, Mallis MJ, Brennan MF, et al (2002) The value of laparoscopy in the management of ampullary, duodenal, and distal bile duct tumors. *J Gastrointest Surg* 6: 139–145
9. Bruguera M, Bordas JM, Mas P, et al (1974) A comparison of the accuracy of peritoneoscopy and liver biopsy in the diagnosis of cirrhosis. *Gut* 15: 799–800
10. Bruhl W (1966) Incidents and complications in laparoscopy and directed liver puncture. Result of a survey. *Dtsch Med Wochenschr* 91: 2297–9
11. Bruix J, Sherman M (2005) Management of hepatocellular carcinoma. *Hepatology* 42: 1208–36
12. Burke EC, Jarnagin WR, Hochwald SN, et al (1998) Hilar Cholangiocarcinoma: patterns of spread, the importance of hepatic resection for curative operation, and a presurgical clinical staging system. *Ann Surg* 228: 385–94
13. Butturini G, Crippa S, Bassi C (2007) The role of laparoscopy in advanced pancreatic cancer diagnosis. *Dig Surg* 24: 33–7
14. Cadranet JF, Rufat P, Degos F (2000) Practices of liver biopsy in France: results of a prospective nationwide survey. For the Group of Epidemiology of the French Association for the Study of the Liver (AFEFL). *Hepatology* 32: 477–81
15. Corvera CU, Weber SM, Jarnagin WR (2002) Role of laparoscopy in the evaluation of biliary tract cancer. *Surg Oncol Clin N Am* 11: 877–91
16. Crew KD, Neugut AI (2006) Epidemiology of gastric cancer. *World J Gastroenterol* 21;12: 354–62

17. Cuschieri A, Hall AW, Clark J (1978) Value of laparoscopy in the diagnosis and management of pancreatic carcinoma. *Gut* 19: 672–7
18. D'Angelica M, Jarnagin W, Dematteo R, et al (2002) Staging laparoscopy for potentially resectable noncolorectal, non-neuroendocrine liver metastases. *Ann Surg Oncol* 9: 204–9
19. Dagnini G, Caldironi MW, Marin G, et al (1986) Laparoscopy in abdominal staging of esophageal carcinoma. Report of 369 cases. *Gastrointest Endosc* 32: 400–2
20. de Castro SM, Tilleman EH, Busch OR, et al (2004) Diagnostic laparoscopy for primary and secondary liver malignancies: impact of improved imaging and changed criteria for resection. *Ann Surg Oncol* 11: 522–9
21. de Graaf GW, Ayantunde AA, Parsons SL, et al (2007) The role of staging laparoscopy in oesophagogastric cancers. *Eur J Surg Oncol* 33: 988–92
22. de Rooij PD, Rogatko A, Brennan MF (1991) Evaluation of palliative surgical procedures in unresectable pancreatic cancer. *Br J Surg* 78: 1053–8
23. Denzer U, Arnoldy A, Kanzler S, et al (2007) Prospective randomized comparison of mini-laparoscopy and percutaneous liver biopsy: diagnosis of cirrhosis and complications. *J Clin Gastroenterol* 41: 103–10
24. Denzer U, Helmreich-Becker I, Galle PR, et al (2003) Liver assessment and biopsy in patients with marked coagulopathy: value of mini-laparoscopy and control of bleeding. *Am J Gastroenterol* 98: 893–900
25. Denzer U, Mollenhauer M, Kanzler S, et al (2005) Prospective comparison of cardiopulmonary events during mini-laparoscopy and colonoscopy under conscious sedation. *Endoscopy* 37: 460–5
26. Drummond GB, Scott DB (1976) Letter: Laparoscopy explosion hazards with nitrous oxide. *Br Med J* 1(6024): 1531
27. El-Kady AA, bd-El-Razek M (1976) Intraoperative explosion during female sterilization by laparoscopic electrocoagulation. A case report. *Int J Gynaecol Obstet* 14: 487–8
28. Feussner H, Hartl F (2006) Staging laparoscopy in oncology. *Chirurg* 77: 971–80
29. Freeny PC (2005) CT diagnosis and staging of pancreatic carcinoma. *Eur Radiol* 15(Suppl 4): D96–D99
30. Fusaroli P, Caletti G (2005) Endoscopic ultrasonography: current clinical role. *Eur J Gastroenterol Hepatol*; 17: 293–301
31. Gallagher AG, McClure N, McGuigan J, et al (1998) An ergonomic analysis of the fulcrum effect in the acquisition of endoscopic skills. *Endoscopy* 30: 617–20
32. Gandolfi L, Rossi A, Leo P, et al (1985) Indications for laparoscopy before and after the introduction of ultrasonography. *Gastrointest Endosc* 31: 1–3
33. Giger U, Schafer M, Krahenbuhl L (2002) Technique and value of staging laparoscopy. *Dig Surg* 19: 473–8
34. Goere D, Wagholikar GD, Pessaux P, et al (2006) Utility of staging laparoscopy in subsets of biliary cancers: laparoscopy is a powerful diagnostic tool in patients with intrahepatic and gallbladder carcinoma. *Surg Endosc* 20: 721–5
35. Grobmyer SR, Fong Y, D'Angelica M, et al (2004) Diagnostic laparoscopy prior to planned hepatic resection for colorectal metastases. *Arch Surg* 139: 1326–30
36. Gunatilake DE (1978) Case report: fatal intraoperative explosion during electrocoagulation via laparoscopy. *Int J Gynaecol Obstet* 15: 353–7
37. Hayat MJ, Howlader N, Reichman ME, et al (2007) Cancer statistics, trends, and multiple primary cancer analyses from the Surveillance, Epidemiology, and End Results (SEER) Program. *Oncologist* 12: 20–37
38. Haydon GH, Hayes PC (1997) Diagnostic laparoscopy by physicians: we should do it. *QJM* 90: 297–304
39. Heit HA, Johnson LF, Rabin L (1978) Liver surface characteristics as observed during laparoscopy correlated with biopsy findings. *Gastrointest Endosc* 24: 288–90
40. Helmreich-Becker I, Meyer zum Buschenfelde KH, Lohse AW (1998) Safety and feasibility of a new minimally invasive diagnostic laparoscopy technique. *Endoscopy* 30:756–62
41. Helmreich-Becker I, Schirmacher P, Denzer U, et al (2003) Mini-laparoscopy in the diagnosis of cirrhosis: superiority in patients with Child-Pugh A and macronodular disease. *Endoscopy* 35: 55–60
42. Hemming AW, Reed AI, Fujita S, et al (2005) Surgical management of hilar cholangiocarcinoma. *Ann Surg* 241: 693–9
43. Henning H (1994) Value of diagnostic laparoscopy in gastrointestinal diseases. The German Society of Digestive and Metabolic Diseases. *Z Gastroenterol* 32: 131–4
44. Henning H, Lightdale CJ, Look D (1994) Colour atlas of diagnostic laparoscopy, Thieme Publisher, Stuttgart, New York
45. Herrera JL, Brewer TG, Peura DA (1989) Diagnostic laparoscopy: a prospective review of 100 cases. *Am J Gastroenterol* 84: 1051–4
46. Hines OJ, Reber HA (2006) Pancreatic surgery. *Curr Opin Gastroenterol* 22: 520–6
47. Holund B, Poulsen H, Schlichting P (1980) Reproducibility of liver biopsy diagnosis in relation to the size of the specimen. *Scand J Gastroenterol* 15: 329–35
48. Howard TJ (1996) Pancreatic adenocarcinoma. *Curr Probl Cancer* 20: 281–328
49. Hunerbein M, Rau B, Hohenberger P, et al (1998) The role of staging laparoscopy for multimodal therapy of gastrointestinal cancer. *Surg Endosc* 12: 921–5
50. Hung CH, Lee CM, Lu SN, et al (2006 Jun) Long-term effect of interferon alpha-2b plus ribavirin therapy on incidence of hepatocellular carcinoma in patients with hepatitis C virus-related cirrhosis. *J Viral Hepat* 13: 409–14
51. Hunter JG, Staheli J, Oddsdottir M, et al (1995) Nitrous oxide pneumoperitoneum revisited. Is there a risk of combustion? *Surg Endosc* 9: 501–4
52. Jacobaeus HC (1910) Ueber die Möglichkeit die Zystoskopie bei Untersuchung seröser Höhlungen anzuwenden. *Münch Med Wochenschr* 57: 2090–2
53. Jacobaeus HC (1911) Kurze Übersicht über meine Erfahrungen mit der Laparoskopie. *Münch Med Wochenschr* 58: 2017
54. Jacobaeus HC (1912) Über Laparo- und Thorakoskopie. *Beitr Klein Tuberk* 25: 185–354
55. Jarnagin WR, Bodniewicz J, Dougherty E, et al (2000 Jan) A prospective analysis of staging laparoscopy in patients with primary and secondary hepatobiliary malignancies. *J Gastrointest Surg* 4: 34–43
56. Jarnagin WR, Conlon K, Bodniewicz J, et al (2001) A clinical scoring system predicts the yield of diagnostic laparoscopy in patients with potentially resectable hepatic colorectal metastases. *Cancer* 91: 1121–8
57. Jarnagin WR, Fong Y, DeMatteo RP, et al (2001) Staging, resectability, and outcome in 225 patients with hilar cholangiocarcinoma. *Ann Surg* 234: 507–17

58. Jarnagin WR, Zager JS, Klimstra D, et al (2003) Neoadjuvant treatment of hepatic malignancy: an oncolytic herpes simplex virus expressing IL-12 effectively treats the parent tumor and protects against recurrence-after resection. *Cancer Gene Ther* 10: 215–23
59. Jemal A, Siegel R, Ward E, et al (2007) Cancer statistics, 2007. *CA Cancer J Clin* 57: 43–66
60. Jimenez RE, Warshaw AL, Rattner DW, et al (2000) Impact of laparoscopic staging in the treatment of pancreatic cancer. *Arch Surg* 135: 409–14
61. Jones DB (2007) Role of endoscopic ultrasound in staging upper gastrointestinal cancers. *ANZ J Surg* 77: 166–72
62. Joris JL, Chiche JD, Canivet JL, et al (1998) Hemodynamic changes induced by laparoscopy and their endocrine correlates: effects of clonidine. *J Am Coll Cardiol* 32: 1389–96
63. Junghans T, Bohm B, Grundel K, et al (1997) Effects of pneumoperitoneum with carbon dioxide, argon, or helium on hemodynamic and respiratory function. *Arch Surg* 132: 272–8
64. Kalk H (1929) Erfahrungen mit der Laparoskopie. (Zugleich mit Beschreibung eines neuen Instrumentes). *Z Klin Med* 111: 303–48
65. Kalk H, Brühl W, Sieke W (1943) Die gezielte Leberpunktion. *Dtsch Med Wochenschr* 69: 693–5
66. Kaushik N, Khalid A, Brody D, (2007) Endoscopic ultrasound compared with laparoscopy for staging esophageal cancer. *Ann Thorac Surg* 83: 2000–02
67. Kelling G (1901) Die Tamponade der Bauchhöhle mit Luft zur Stillung lebensgefährlicher Intestinalblutungen. *Münch Med Wochenschr* 48: 1480–3
68. Kelling G (1902) Über Ösophagoskopie, Gastroskopie und Kötioskopie. *Münch Med Wochenschr*; 49: 21–4
69. Kim HJ, D'Angelica M, Hiotis SP, Shoup M, Weber SM (2007) Laparoscopic staging for liver, biliary, pancreas, and gastric cancer. *Curr Probl Surg* 44: 228–69
70. Klempnauer J, Ridder GJ, Werner M, et al (1997) What constitutes long-term survival after surgery for hilar cholangiocarcinoma? *Cancer* 79: 26–34
71. Kosuge T, Yamamoto J, Shimada K, et al (1999) Improved surgical results for hilar cholangiocarcinoma with procedures including major hepatic resection. *Ann Surg*; 230: 663–71
72. Krasna MJ, Jiao X, Mao YS, et al (2002) Thoracoscopy/laparoscopy in the staging of esophageal cancer: Maryland experience. *Surg Laparosc Endosc Percutan Tech* 12: 213–8
73. Kwee RM, Kwee TC (2007) Imaging in local staging of gastric cancer: a systematic review. *J Clin Oncol*; 25: 2107–16
74. Lang H, Sotiropoulos GC, Brokalaki EI, Radtke A, Frilling A, Molmenti EP, et al (2006) Left hepatic trisectionectomy for hepatobiliary malignancies. *J Am Coll Surg* 203: 311–21
75. Levy MJ, Topazian M, Keeney G, et al (2006) Preoperative diagnosis of extrapancreatic neural invasion in pancreatic cancer. *Clin Gastroenterol Hepatol* 4(12): 1479–82
76. Lindner H (1967) Grenzen und Gefahren der perkutanen Leberbiopsie mit der Menghini-nadel. Erfahrungen bei 80.000 Leberbiopsien. *Dtsch med Wochenschr* 92: 1751–7
77. Liu SY, Leighton T, Davis I, et al (1991) Prospective analysis of cardiopulmonary responses to laparoscopic cholecystectomy. *J Laparoendosc Surg* 1: 241–6
78. Llovet JM, Bruix J (2003) Systematic review of randomized trials for unresectable hepatocellular carcinoma: chemoembolization improves survival. *Hepatology* 37: 429–42
79. Llovet JM, Real MI, Montana X, et al (2002) Arterial embolisation or chemoembolisation versus symptomatic treatment in patients with unresectable hepatocellular carcinoma: a randomised controlled trial. *Lancet* 359(9319): 1734–9
80. Llovet JM, Mazzaferro V, et al (2008) Sorafenib in advanced hepatocellular carcinoma. *N Engl J Med* 359: 378–90
81. Lo CM, Lai EC, Liu CL, et al (1998) Laparoscopy and laparoscopic ultrasonography avoid exploratory laparotomy in patients with hepatocellular carcinoma. *Ann Surg*; 227: 527–32
82. Malnick S, Melzer E (2005) Routine ultrasound-guided liver biopsy: a time whose idea has come? *J Clin Gastroenterol*; 39: 900–03
83. Mann C, Boccaro G, Grevy V, et al (1997) Argon pneumoperitoneum is more dangerous than CO₂ pneumoperitoneum during venous gas embolism. *Anesth Analg* 85: 1367–71
84. McGill DB, Rakela J, Zinsmeister AR, et al (1990) A 21-year experience with major hemorrhage after percutaneous liver biopsy. *Gastroenterology* 99: 1396–400
85. McKinlay R, Sanfiel F, Roth JS (2005) The current role of laparoscopy in staging upper gastrointestinal malignancies. *Curr Surg* 62: 35–7
86. Menack MJ, Spitz JD, Arregui ME (2001) Staging of pancreatic and ampullary cancers for resectability using laparoscopy with laparoscopic ultrasound. *Surg Endosc*; 15: 1129–34
87. Menghini G (1958) One-second needle biopsy of the liver. *Gastroenterology*; 35: 190–9
88. Menon KV, Dehn TC (2003) Multiport staging laparoscopy in esophageal and cardiac carcinoma. *Dis Esophagus* 16: 295–300
89. Minoli G, Terruzzi V, Spinzi GC, et al (1982) The influence of carbon dioxide and nitrous oxide on pain during laparoscopy: a double-blind, controlled trial. *Gastrointest Endosc* 28: 173–5
90. Nieveen van Dijkum EJ, Romijn MG, Terwee CB, et al (2003) Laparoscopic staging and subsequent palliation in patients with peripancreatic carcinoma. *Ann Surg* 237: 66–73
91. Nitze M (1879) Beobachtung- und Untersuchungsmethode für Harnohre, Harnblase und Rectum. *Wien Med Wochenschr* 29: 649
92. Nord HJ (1992) Complications of laparoscopy. *Endoscopy* 24: 693–700
93. O'Brien MG, Fitzgerald EF, Lee G, et al (1995) A prospective comparison of laparoscopy and imaging in the staging of esophagogastric cancer before surgery. *Am J Gastroenterol* 90: 2191–4
94. O'Leary E, Hubbard K, Tormey W, et al (1996) Laparoscopic cholecystectomy: haemodynamic and neuroendocrine responses after pneumoperitoneum and changes in position. *Br J Anaesth* 76: 640–4
95. Pagliaro L, Rinaldi F, Craxi A, et al (1983) Percutaneous blind biopsy versus laparoscopy with guided biopsy in diagnosis of cirrhosis. A prospective, randomized trial. *Dig Dis Sci* 28: 39–43
96. Parkin DM (2004) International variation. *Oncogene*; 23: 6329–40
97. Phoa SS, Tilleman EH, van Delden OM, et al (2005) Value of CT criteria in predicting survival in patients with potentially resectable pancreatic head carcinoma. *J Surg Oncol*; 91: 33–40

98. Piccinino F, Sagnelli E, Pasquale G, et al (1986) Complications following percutaneous liver biopsy. A multicentre retrospective study on 68,276 biopsies. *J Hepatol*; 2: 165–73
99. Poniachik J, Bernstein DE, Reddy KR, et al (1996) The role of laparoscopy in the diagnosis of cirrhosis. *Gastrointest Endosc* 43: 568–71
100. Poon RT (2007) Current role of laparoscopic surgery for liver malignancies. *Surg Technol Int* 16: 73–81
101. Reddy KR, Levi J, Livingstone A, et al (1999) Experience with staging laparoscopy in pancreatic malignancy. *Gastrointest Endosc* 49: 498–503
102. Reddy MS, Smith L, Jaques BC, et al (2007) Do laparoscopy and intraoperative ultrasound have a role in the assessment of patients with end-stage liver disease and hepatocellular carcinoma for liver transplantation? *Transplant Proc* 39: 1474–6
103. Richards DA, Boehm KA, Anthony SP (2007) Systemic therapy for gastric cancer and adenocarcinoma of the gastroesophageal junction: present status and future directions. *Expert Opin Investig Drugs*; 16: 1059–68
104. Ruddock JC (1934) Peritoneoscopy and gynaecologic indications for laparoscopy. *West J Surg* 42: 392–405
105. Rudston-Brown B, Draper PN, Warriner B, et al (1997) Venous gas embolism – a comparison of carbon dioxide and helium in pigs. *Can J Anaesth* 44: 1102–7
106. Sarmiento JM, Sarr MG (2003) Staging strategies for pancreatic adenocarcinoma: what the surgeon really wants to know. *Curr Gastroenterol Rep*; 5: 117–24
107. Schachter PP, Avni Y, Shimonov M, et al (2000) The impact of laparoscopy and laparoscopic ultrasonography on the management of pancreatic cancer. *Arch Surg* 135(11): 1303–7
108. Schneider AR, Benz C, Adamek HE, et al (2001) Mini-laparoscopy versus conventional laparoscopy in the diagnosis of hepatic diseases. *Gastrointest Endosc* 53: 771–5
109. Sharma P, McDonald GB, Banaji M (1982) The risk of bleeding after percutaneous liver biopsy: relation to platelet count. *J Clin Gastroenterol* 4: 451–3
110. Sharp JR, Pierson WP, Brady CE, III (1982) Comparison of CO₂- and N₂O-induced discomfort during peritoneoscopy under local anesthesia. *Gastroenterology* 82: 453–6
111. Sherlock S, Dick R, Van Leeuwen DJ (1985) Liver biopsy today. The Royal Free Hospital experience. *J Hepatol* 1: 75–85
112. Silvis SE, Nebel O, Rogers G, et al (1976) Endoscopic complications. Results of the 1974 American Society for Gastrointestinal Endoscopy Survey. *JAMA* 235: 928–30
113. Soloway RD, Baggenstoss AH, Schoenfield LJ, (1971) Observer error and sampling variability tested in evaluation of hepatitis and cirrhosis by liver biopsy. *Am J Dig Dis* 16: 1082–6
114. Sperlongano P, Pisaniello D, Piatto A, et al (2006) The role of laparoscopy in pancreatic surgery. *Front Biosci* 11: 2203–5
115. Stefanidis D, Grove KD, Schwesinger WH, et al (2006) The current role of staging laparoscopy for adenocarcinoma of the pancreas: a review. *Ann Oncol* 17: 189–99
116. Stein HJ, Kraemer SJ, Feussner H, et al (1997) Clinical value of diagnostic laparoscopy with laparoscopic ultrasound in patients with cancer of the esophagus or cardia. *J Gastrointest Surg* 1: 167–72
117. Terjung B, Lemnitzer I, Dumoulin FL, et al (2003) Bleeding complications after percutaneous liver biopsy. An analysis of risk factors. *Digestion* 67: 138–45
118. Thaler H (1964) Über vorteil und risiko der leberbiopsie-methode nach Menghini. *Wien Kin Wochenschr* 76: 533–8
119. Trevisani F, Magini G, Santi V, et al (2007) Impact of etiology of cirrhosis on the survival of patients diagnosed with hepatocellular carcinoma during surveillance. *Am J Gastroenterol* 02:022–3
120. Uhlich GA (1982) Laparoscopy: the question of the proper gas. *Gastrointest Endosc* 28:212–3
121. Velanovich V, Wollner I, Ajlouni M (2000) Staging laparoscopy promotes increased utilization of postoperative therapy for unresectable intra-abdominal malignancies. *J Gastrointest Surg* 4: 542–6
122. Veres J (1938) Neues Instrument zur Ausführung von Brust-punktionen und Pneumothorax Behandlung. *Dtsch med Wochenschr* 64: 1480–9
123. Veres J (1961) A needle for the safe use of pneumoperitoneum. *Gastroenterologia* 96: 150–2
124. Vilardell F, Seres I, Marti-Vicente A (1968) Complications of peritoneoscopy. A survey of 1,455 examinations. *Gastrointest Endosc* 14: 178–80
125. Vollmer CM, Drebin JA, Middleton WD, et al (2002) Utility of staging laparoscopy in subsets of peripancreatic and biliary malignancies. *Ann Surg* 235: 1–7
126. Wakelin SJ, Deans C, Crofts TJ, et al (2002) A comparison of computerised tomography, laparoscopic ultrasound and endoscopic ultrasound in the preoperative staging of oesophago-gastric carcinoma. *Eur J Radiol* 41: 161–7
127. Watanapa P, Williamson RC (1992) Surgical palliation for pancreatic cancer: developments during the past two decades. *Br J Surg* 79: 8–20
128. Weber SM, DeMatteo RP, Fong Y, et al (2002) Staging laparoscopy in patients with extrahepatic biliary carcinoma. Analysis of 100 patients. *Ann Surg* 235: 392–9
129. Weitz J, Klimstra DS, Cymes K, et al (2007) Management of primary liver sarcomas. *Cancer* 109: 1391–6
130. Westerband A, Van De WJ, Amzallag M, Lebowitz PW, Nwasokwa ON, Chardavoyne R, et al (1992) Cardiovascular changes during laparoscopic cholecystectomy. *Surg Gynecol Obstet* 175: 535–8
131. White RR, Pappas TN (2004) Laparoscopic staging for hepatobiliary carcinoma. *J Gastrointest Surg* 8: 920–2
132. Yau P, Watson DI, Lafullarde T, et al (2000) Experimental study of effect of embolism of different laparoscopy insufflation gases. *J Laparoendosc Adv Surg Tech A* 10: 211–6
133. Yoshida T, Matsumoto T, Morii Y, et al (2002) Staging with helical computed tomography and laparoscopy in pancreatic head cancer. *Hepatogastroenterology* 49: 1428–31
134. Zhang X, Watson DI, Lally C, et al (2005) Endoscopic ultrasound for preoperative staging of esophageal carcinoma. *Surg Endosc* 19: 1618–21
135. Zhao ZW, He JY, Tan G, et al (2003) Laparoscopy and laparoscopic ultrasonography in judging the resectability of pancreatic head cancer. *Hepatobiliary Pancreat Dis Int* 2: 609–11

Chapter Outline

Indications	512
Contraindications	512
Technique	513
Results	513
Normal Values	514
Pathologic Values	514
Complications	515
Clinical Significance	516
References	517

Direct measurement of portal pressure by puncturing the portal vein is an inconvenient and invasive technique. It is associated with surgical and hemorrhagic risk, and severe complications such as portal vein thrombosis, capsular laceration with hemoperitoneum, subcapsular hematoma, hemobilia, and intrahepatic arteriovenous fistulae [4]. Therefore, *in clinical practice portal pressure is determined indirectly by measuring wedged hepatic venous pressure (WHVP)*, assuming that WHVP correlates closely with portal pressure. The measurement is based on the principle of communicating tubes. Introducing a catheter deeply into a branch of a hepatic vein, so that the tip of the catheter occludes the vein (wedge position), the pressure measured through the catheter corresponds to that of the nearest point of the free communication with the hepatic circulation. Thus WHVP is a measure of the pressure in the circulation “in front” of the catheter tip, i.e. in the sinusoidal and postsinusoidal circulatory system (Fig. 46.1).

The close correlation between the WHVP and the portal pressure was shown experimentally for the first time in 1951 by Myers and Taylor [19]. Later, measurements in man demonstrated that an elevated WHVP is present in sinusoidal and postsinusoidal portal hypertension, while this is not the case in neither prehepatic nor presinusoidal portal hypertension. In the normal liver, occlusion of blood flow in a hepatic vein with a catheter leads to the development of a static column of blood whose pressure propagates unto the first freely anastomosing vascular network, the hepatic sinusoids. The pressure of the static column of blood immediately equilibrates through the sinusoidal anastomoses. Therefore, *WHVP measures the hepatic sinusoidal pressure*, which is slightly lower (approximately 1 mmHg) than the actual portal pressure [4]. In the cirrhotic liver (i.e. in postsinusoidal portal hypertension),

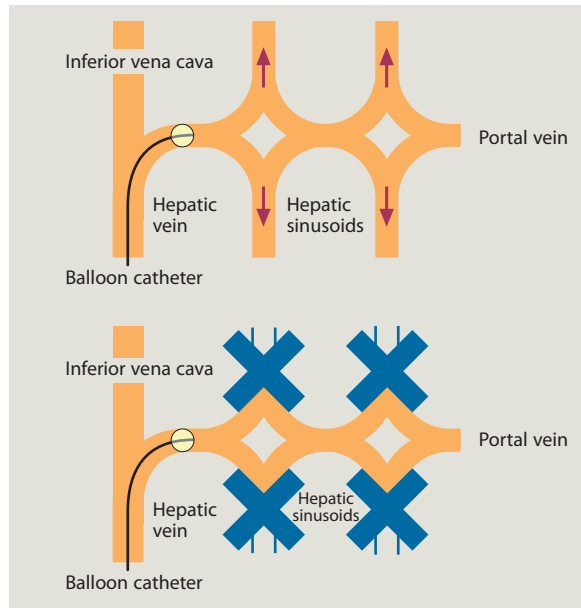


Fig. 46.1 Measurement of wedged hepatic venous pressure (WHVP). The blood flow in a hepatic vein is occluded with a balloon catheter. Through the interconnected sinusoids the pressure of the static column of blood equilibrates with sinusoidal pressure, which is slightly lower than portal pressure (~1mmHg) (Adapted from [4])

the pressure of the static column of blood cannot be decompressed at the sinusoidal level due to sinusoidal narrowing and disruption of the normal intersinusoidal architecture. Equilibration of WHVP with intrasinusoidal pressure is not possible; the static blood column in front of the catheter extends proximally and WHVP equilibrates with portal pressure. *In liver cirrhosis WHVP adequately reflects portal venous pressure.*

In prehepatic or presinusoidal portal hypertension, such as in portal vein thrombosis or schistosomiasis, respectively, equilibration of pressure through sinusoidal interconnections occurs when the balloon catheter is in the wedge position, since the lesions that obstruct blood flow are localized proximal to the intrasinusoidal segment. Therefore, in these clinical situations the WHVP is normal or slightly elevated at most.

Indications

The measurement of WHVP is the clinical gold standard for the determination of portal pressure. Because it is an invasive procedure it is not well-suited as a primary

Table 46.1 Indications for measurement of portal pressure

Indication	Significance
Portal hypertension	Definition and classification (prehepatic, intrahepatic [presinusoidal, postsinusoidal], posthepatic portal hypertension)
Liver cirrhosis	Prognostic evaluation
Esophageal varices	Assessment of prognosis and risk of bleeding (risk stratification); monitoring of drug therapy
Surgical or transjugular portal systemic shunts	Follow-up
Clinical studies	Evaluation of drug effects on portal hypertension

tool in the diagnosis of portal hypertension or for repeated follow-up measurements of portal pressure.

Measurement of WHVP may be helpful in the assessment of prognosis in patients with liver cirrhosis, assessment of disease progression and risk of variceal bleeding, evaluation of pharmacological therapy of portal hypertension, in the follow-up of patients with surgical or transjugular intrahepatic portal-systemic shunt (TIPS) procedures, and in the classification of portal hypertension (presinusoidal, sinusoidal, postsinusoidal).

In [Table 46.1](#) the indications for WHVP measurement are summarized.

Contraindications

Allergy to local anesthetics or to radiographic contrast medium constitutes the major contraindication to hepatic vein catheterization. Although coagulation disorders are usually seen in cirrhotic patients, measurements of WHVP will be possible in most of them. A bleeding tendency with platelet counts of <60,000/ μL , a prothrombin time prolonged by at least 3 s compared to controls, corresponding to an INR of >1.3, and a lengthened bleeding time (≥ 10 min) are only relative contraindications for WHVP measurements. Adequate replacement with Vitamin K (at least 6 h prior to puncture; in cholestatic patients Vitamin K should be administered parenterally), fresh frozen plasma, coagulation factors or pooled platelets (in severe thrombocytopenia [$< 20,000/\mu\text{L}$]) will enable measurements in most patients. However, given such a situation, in clinical

Table 46.2 Contraindications for measurement of portal pressure

Absolute contraindications	Allergy to contrast medium Unable to identify vessel to be punctured
Relative contraindications	Coagulation disorders <ul style="list-style-type: none"> • Thrombocytes < 60,000/μL • Prothrombin time prolonged \geq 3 s • INR > 1.3 • Prolonged bleeding time (\geq 10 min)

practice one would be very cautious and possibly refrain from the procedure. The contraindications for WHVP are summarized in [Table 46.2](#).

Technique

The procedure is performed after a fast of at least 6 h. Local anesthesia and conscious sedation are administered, with monitoring of vital signs and electrocardiogram. Due to the circadian rhythm of portal pressure, measurements of WHVP should be performed preferentially in the morning hours, and repeat follow-up measurements should always be done at the same time of the day [7].

The catheterization of a hepatic vein can be approached through the right jugular, antecubital or femoral vein. Compared to the jugular and antecubital venous approach, the femoral vein approach has the disadvantage of a longer recovery time, requiring the patient to rest in bed for 4–12 h after the procedure. The transjugular approach has the additional advantage of allowing for the combination of portal pressure measurements and transjugular liver biopsy in the same procedure (Chapter 44). The placement of TIPS (Chapter 80) or the determination of blood flow by indocyanine green (Chapter 35) can also be performed via transjugular access.

A venous introducer is placed under aseptic conditions using the Seldinger technique. Doppler ultrasound may be used to facilitate deep venous puncture. A 5–7-French balloon-tipped catheter filled with sterile saline solution is advanced under fluoroscopic control into a hepatic vein, preferentially the right one. WHVP is measured by occluding the hepatic vein, either by

advancing the catheter until it becomes “wedged” into a small branch of a hepatic vein or by inflating the balloon at the tip of the catheter. Free hepatic venous pressure (FHVP) is obtained by deflating the balloon and maintaining the tip of the catheter “free” in the hepatic vein, 4–5 cm from its opening into the inferior vena cava (IVC).

The *gradient between WHVP and FHVP defines the hepatic venous pressure gradient (HVPG)*. The HVPG corresponds to the pressure gradient between the portal vein and the IVC. The HVPG is the parameter most commonly used to report portal pressure in the medical literature. In the older literature, HVPG was frequently referred as “corrected” WHVP or “corrected” sinusoidal pressure.

Nowadays, the “balloon occlusion” technique is preferred to direct measurements of portal venous pressure because of the fact that it reflects the pressure of a greater area of the liver, and minimizes variability by allowing the tip of the catheter to be maintained in one position instead of being moved back and forth, thus facilitating repeat measurements. The transducer should be calibrated against known external pressures before starting measurements (e.g., 13.6 cm H₂O should read 10 mmHg, 27.2 cm H₂O should read 20 mmHg, and 40.8 cm H₂O should read 30 mmHg). The “wedged” or “occluded” position of the catheter should be checked by injection of 2–5 mL of contrast dye. The correct position is characterized by a lack of reflux of the contrast medium or washout through communications with other hepatic veins. The catheter should be rinsed with 5% dextrose and venous pressures should be allowed to stabilize over a period of at least 1 min for WHVP and 15 s for FHVP before starting pressure measurements. All measurements are performed at least in duplicate, and permanent tracings should be obtained using a multichannel recorder [4, 12, 17].

Results

In over 95% of patients investigated by the method described above, the procedure succeeds technically. This high technical success rate indicates that, despite its invasiveness, measurement of WHVP may be regarded as a relatively simple method of determining portal pressure.

Normal Values

Portal pressure is not a static parameter, but rather a dynamic variable that is influenced by many factors. It is, for example, subject to *circadian variations* [7]. Portal pressure increases slowly during nighttime and reaches a maximum in the morning hours around 9 a.m. Thereafter it continuously decreases until around 7 p.m. when it again begins to rise. Interestingly, the time of maximal portal pressure in the morning hours and the phase of rising pressure in the evening corresponds to the peak times when variceal bleeding is observed clinically (9 a.m. and 11 p.m.). Additionally, in patients with cirrhosis the HVPG increases postprandially and after physical exercise [8].

Excessive fluid replacement, e.g. in the context of variceal bleeding, may also increase portal pressure, to even higher values than before bleeding. This can result in perpetuating the bleeding, and increasing the risk of rebleeding. These variables should be kept in mind when measuring portal pressure.

The *normal WHVP* in a healthy person is 7–12 mmHg and corresponds to a normal portal pressure (Table 46.3). However, since portal flow is determined by the combination of hepatic resistance and the pressure gradient between portal vein and hepatic veins rather than by the absolute value of portal pressure, the WHVP should be interpreted in relation to the pressure values in hepatic veins, IVC and the right atrium. Thus, especially in conditions associated with increased intraabdominal pressure (e.g. in the presence of tense ascites), WHVP values are falsely elevated if right atrial pressure serves as the point of reference. Measurements of WHVP in the right and left hepatic vein may display a slight variability.

The *normal FHVP* fluctuates between 3–11 mmHg, and corresponds to the intraabdominal pressure. FHVP should not be more than 2 mmHg different from the IVC pressure, which should be measured at the level of the hepatic vein ostium. If the difference is greater, the possibility of hepatic outflow obstruction should be investigated (e.g. Budd-Chiari Syndrome).

The *normal HVPG*, i.e. the gradient between the portal pressure and the FHVP, is 1–4 mmHg.

Pathologic Values

An increased pressure gradient between WHVP and FHVP defines *portal hypertension*. Values between 5–8 mmHg are borderline, while a HVPG of ≥ 9 mmHg is clearly pathologic. In Table 46.4 changes of HVPG in various liver diseases associated with portal hypertension are shown.

HVPG is increased in *liver cirrhosis*, but it shows a marked variability (8–30 mmHg) between different patients and during repeat follow-up examinations of the same patient. In nearly 20% of untreated patients with cirrhosis and esophageal varices, an increased HVPG spontaneously falls to values <12 mmHg during 2-year follow-up, even in the absence of variceal bleeding. In patients with variceal bleeding, HVPG can occasionally increase to 40 mmHg [14, 22].

An HVPG of at least 8 mmHg is regarded as a prerequisite for the development of *ascites*.

The development of *esophageal varices* requires an HVPG of ≥ 10 mmHg. The risk of *variceal bleeding* increases with an HVPG of >12 mmHg, while it is

Table 46.3 Pressure parameters and their significance

Pressure	Normal value (mmHg)	Pathological value (mmHg)	Significance
Inferior vena cava (IVC)	-5 – + 5		
Free hepatic venous pressure (FHVP)	3–11		~ Intraabdominal pressure (“base line”)
Wedged hepatic venous pressure (WHVP)	7–12		~ Portal vein pressure
Hepatic venous pressure gradient (HVPG)	1–4	up to 8 >8 >10 >12 ≤ 12 $\geq 20\%$ ↓ from baseline	Borderline Formation of ascites Formation of varices Variceal bleeding No bleeding! Negative predictor for rebleeding

Table 46.4 Changes in hepatic venous pressure gradient in diseases associated with portal hypertension (Adapted from [14])

Disorder	Hepatic venous pressure gradient
Liver cirrhosis	Increased
Non-cirrhotic portal hypertension	
Pre- or extrahepatic	
• Portal vein thrombosis, compression or infiltration	Normal
Intrahepatic	
• Chronic liver diseases that often are associated with portal hypertension	
– Partial nodular transformation	Normal
– Focal nodular hyperplasia	Normal or slightly increased
– Congenital hepatic fibrosis	Normal or slightly increased
– Hepatoportal sclerosis or idiopathic portal hypertension	Normal or slightly increased
– Schistosomiasis	Normal or slightly increased
– Chronic active hepatitis	Slightly increased
– Alcoholic fibrosis	Slightly increased
– Primary (or secondary) biliary cirrhosis (in precirrhotic stage)	Increased
– Chronic venoocclusive disease	Increased
– Peliosis hepatis	Increased
• Chronic liver diseases that rarely are associated with portal hypertension	
– Rendu-Osler's disease	Increased
– Sarcoidosis, tuberculosis, amyloidosis, mastocytosis	Normal or slightly increased
– Multiple myeloma, Waldenström's disease	Normal or slightly increased
– Lymphoma, myeloproliferative diseases	Normal or slightly increased
– Metastasizing carcinoma	Normal or slightly increased
– Polycystic diseases	Normal or slightly increased
• Acute liver injury that may be associated with portal hypertension	
– Acute alcoholic hepatitis	Normal or slightly increased
– Acute or fulminant hepatitis	Slightly increased
– Acute fatty liver of pregnancy	Slightly increased
– Acute venoocclusive disease	Increased
Post- or suprahepatic	
– Budd-Chiari syndrome	Normal
– Obstruction of IVC	Normal
– Right heart failure	Normal

markedly reduced in patients with values <12 mmHg. Since a fall of HVPG to <12 mmHg is also associated with decreased mortality, the aim of medical treatment should be the reduction of portal pressure below this threshold or at least a 20% reduction from baseline HVPG [2, 3, 6, 9, 15, 21, 27, 29].

Complications

In experienced hands, measurement of portal pressure is a low risk and safe procedure. Complications are rare and mainly correspond to those that may occur during placement of a central venous line, during transjugular liver biopsy, or during TIPS procedure (Table 46.5). Injury of the vessel wall or bleeding with formation of a perivascular hematoma, especially due to inadvertent puncture of an artery (can be prevented by puncture under Doppler ultrasound guidance) is one potential complication. Occasionally local irritations or infections at the puncture site may occur, especially if the catheter is allowed to remain in place for a longer period of time. Cardiac arrhythmias during the passage of the guide wire or the catheter through the right atrium have also been reported. In rare cases pleural injury may lead to a pneumo- or hemothorax.

Table 46.5 Complications of measurement of portal pressure

Mild and transient complications
• Inadvertent puncture of carotid or femoral artery
• Hematoma at puncture site
• Arrhythmias, supraventricular tachycardia
• Vaso-vagal reaction
• Neck pain
• Bacteremia and fever
• Horner's syndrome
• Hoarseness
• Intolerance (not true allergy) to contrast medium
• (pruritus, burning eyes, cough, dyspnea, sneezing, nausea and vomiting)
Severe complications
• Venous thrombosis
• Pulmonary embolism
• Pneumothorax, hemothorax
• Ventricular extrasystoles/cardiac arrest
• Catheter break
• Catheter loop formation
• Death

A very rare event is the break of a catheter or the formation of a loop that necessitates operative removal. Complications leading to death are extremely rare. Allergy to contrast dye is a contraindication to portal pressure measurement, as severe allergic reactions can occur.

Clinical Significance

Today, measurement of HVPG is regarded as the gold standard for indirect assessment of portal pressure in patients with liver cirrhosis and sinusoidal and postsinusoidal intrahepatic portal hypertension. The procedure carries a low risk, is not technically demanding, and the results are reproducible. However, due to the time required (approximately 1 h) and the costs (both increase when associated procedures, such as repeat measurements after drug or test meal administration, determination of hepatic blood flow, measurement of cardiopulmonary pressures, or transjugular liver biopsy are performed) the technique is still limited to larger centers.

Measurements of portal pressure allow the physician to *diagnose* and *classify portal hypertension* as presinusoidal, sinusoidal, or postsinusoidal. In a patient with normal WHVP in face of a clinical syndrome of portal hypertension, a presinusoidal source of portal hypertension is likely. Portal vein thrombosis is an example of a prehepatic source, whereas examples of intrahepatic/presinusoidal sources include schistosomiasis, primary biliary cirrhosis, sarcoidosis, and “idiopathic” portal hypertension. In postsinusoidal portal hypertension due to Budd-Chiari syndrome, IVC obstruction, right heart failure, or constrictive pericarditis, both FHVP and WHVP are increased, although HVPG may remain normal.

HVPG allows the physician to *assess prognosis in liver cirrhosis*. It may predict clinical decompensation and mortality in patients with cirrhosis. Patients with an HVPG < 10 mmHg have a 90% probability of *not* developing clinical decompensation in a median follow-up of 4 years [23]. The 3–4-year mortality of patients with liver cirrhosis (irrespective of the cause) and an HVPG > 15 mmHg is significantly higher compared to patients with lower HVPG values. Patients in whom the HVPG during follow-up falls below the

threshold of 12 mmHg, either spontaneously or drug-induced, have significantly higher survival rates than patients in whom HVPG remains persistently elevated [10, 20, 26, 28, 30]. However, because HVPG increases with progression of liver disease, it is difficult to ascertain whether HVPG holds prognostic information independent from liver function, and measurements of HVPG are not performed routinely in clinical practice. Instead, prognosis of patients with cirrhosis is assessed with noninvasive clinical scores, such as the Child-Pugh-, the MELD-Score (see Chapter 30) or by the albumin concentration in serum.

HVPG is the most important independent *predictor of variceal bleeding*. Although HVPG does not correlate with variceal size, it can be used to assess the risk of first bleeding (risk stratification). In patients with acute variceal bleeding, early measurements of portal pressure may predict the outcome and the risk of rebleeding. An HVPG of ≥ 20 mmHg within 48 h after variceal bleeding is associated with a fivefold higher probability of continuing or recurrent bleeding [18]. An HVPG of ≥ 20 mmHg correlates with a significantly longer length-of-stay in the intensive care unit and in the hospital, an increased need for emergency shunt procedures, an increased need of transfusions, and a significantly increased 1-year mortality.

Current evidence supports the validity of HVPG end points to *monitor drug therapy* efficacy for variceal bleeding prophylaxis. A decrease in HVPG below 12 mmHg virtually eliminates the risk of bleeding. However, this goal is reached in only a minority of patients. Even with an HVPG of >12–16 (< 20) mmHg, the risk of rebleeding within 2 years significantly decreases, if after 3 months of drug treatment these HVPG values fall by at least 20% from their baseline value [1, 5, 11, 13, 16]. In patients treated with non-selective β -adrenergic blockers with or without nitrates, the 3-year incidence of first variceal bleeding was less than 10% in patients in whom HVPG decreased by more than 20% compared to a 20–40% incidence in nonresponders [25]. Thus, the *hemodynamic targets in the treatment of portal hypertension should be a stable HVPG ≤ 12 mmHg or a 15–20% decrease in HVPG from its baseline value, even without reaching the target value of 12 mmHg*. There are, however, authors who still view the current data as insufficient evidence to support the monitoring of a targeted reduction of HVPG as routine clinical practice [24].

References

1. Albillos A, Banares R, González M, et al (2007) Value of the hepatic venous pressure gradient to monitor drug therapy for portal hypertension: a meta-analysis. *Am J Gastroenterol* 102: 1116–26
2. Armonis A, Patch D, Burroughs A (1997) Hepatic venous pressure measurement: an old test as a new prognostic marker in cirrhosis? *Hepatology* 25: 245–8
3. Barrett G, Bosch J, Garcia-Tsao G, et al (1990) Hepatic venous pressure gradient as a predictor of survival in patients with cirrhosis. *Hepatology* 12: 850
4. Bosch J, Garcia-Pagán JC, Berzigotti A, et al (2006) Measurement of portal pressure and its role in the management of chronic liver disease. *Semin Liver Dis* 26: 348–62
5. Escorsell A, Ferayorni L, Bosch J, et al (1997) The portal pressure response to beta-blockade is greater in cirrhotic patients without varices than in those with varices. *Gastroenterology* 112: 2012–6
6. Feu F, Garcia-Pagan JC, Bosch J, et al (1995) Relation between portal pressure response to pharmacotherapy and risk of recurrent variceal haemorrhage in patients with cirrhosis. *Lancet* 346:1056–9
7. Garcia-Pagan JC, Feu F, Castells A et al (1994) Circadian variations of portal pressure and variceal hemorrhage in patients with cirrhosis. *Hepatology* 19: 595–601
8. Garcia-Pagan JC, Santos C, Barbera JA, et al (1996) Physical exercise increases portal pressure in patients with cirrhosis and portal hypertension. *Gastroenterology* 111: 1300–6
9. Garcia-Tsao G, Groszmann RJ, Fisher RL, et al (1985) Portal pressure, presence of gastroesophageal varices and variceal bleeding. *Hepatology* 5: 419–24
10. Glud C, Henriksen JH, Nielsen G (1988) Prognostic indicators in alcoholic cirrhotic men. *Hepatology* 8: 222–7
11. Groszmann RJ, Bosch J, Grace ND, et al (1990) Hemodynamic events in a prospective randomized trial of propranolol versus placebo in the prevention of a first variceal hemorrhage. *Gastroenterology* 99:1401–7
12. Groszmann RJ, Glickman M, Blei AT, et al (1979) Wedged and free hepatic venous pressure measured with a balloon catheter. *Gastroenterology* 76: 253–8
13. Iwao T, Toyonaga A, Ikegami M, et al (1994) Wedged hepatic venous pressure reflects portal venous pressure during vasoactive drug administration in nonalcoholic cirrhosis. *Dig Dis Sci* 39: 2439–44
14. Lebrec D, Sogni P, Vilgrain V (1997) Evaluation of patients with portal hypertension. *Baillieres Clin Gastroenterol* 11: 221–41
15. Merkel C, Bolognesi M, Bellon S, et al (1992) Prognostic usefulness of hepatic vein catheterization in patients with cirrhosis and esophageal varices. *Gastroenterology* 102: 973–9
16. Merkel C, Sacerdoti D, Bolognesi M, et al (1997) Hemodynamic evaluation of the addition of isosorbide-5-mononitrate to nadolol in cirrhotic patients with insufficient response to the beta-blocker alone. *Hepatology* 26: 34–9
17. Meßmann H, Holstege A, Schölmerich J (1994) Lebervenenverschlussdruckmessung. Indikation, Technik und Befunde. *Dtsch Med Wochenschr* 119: 1245–7
18. Moitinho E, Escorsell A, Bandi JC, et al (1999) Prognostic value of early measurements of portal pressure in acute variceal bleeding. *Gastroenterology* 117: 626–31
19. Myers JD, Taylor WJ (1951) An estimation of portal venous pressure by occlusive catheterization of an hepatic venule. *J Clin Invest* 30: 662–3
20. Patch D, Armonis A, Sabin C, et al (1999) Single portal pressure measurement predicts survival in cirrhotic patients with recent bleeding. *Gut* 44: 264–9
21. Ready JB, Robertson AD, Goff JS, et al (1991) Assessment of the risk of bleeding from esophageal varices by continuous monitoring of portal pressure. *Gastroenterology* 100: 1403–10
22. Reynolds TB, Ito S, Iwatsuki S (1970) Measurement of portal pressure and its clinical application. *Am J Med* 49: 649–57
23. Ripoll C, Groszmann R, Garcia-Tsao G, et al (2007) Hepatic venous pressure gradient predicts clinical decompensation in patients with compensated cirrhosis. *Gastroenterology* 133: 481–8
24. Thalheimer U, Mela M, Patch D, et al (2004) Targeting portal pressure measurements: a critical reappraisal. *Hepatology* 39: 286–90
25. Turnes J, Garcia-Pagan JC, Abraldes JG, et al (2006) Pharmacological reduction of portal pressure and long-term risk of first variceal bleeding in patients with cirrhosis. *Am J Gastroenterol* 101: 506–12
26. Urbain D, Muls V, Makhoul E, et al (1993) Prognostic significance of hepatic venous pressure gradient in medically treated alcoholic cirrhosis: comparison to aminopyrine breath test. *Am J Gastroenterol* 88: 856–9
27. Viallet A, Marleau D, Huet M, et al (1975) Hemodynamic evaluation of patients with intrahepatic portal hypertension. Relationship between bleeding varices and the portohepatic gradient. *Gastroenterology* 69:1297–300
28. Vinel JP, Cassigneul J, Levade M, et al (1986) Assessment of short-term prognosis after variceal bleeding in patients with alcoholic cirrhosis by early measurement of portohepatic gradient. *Hepatology* 6: 116–7
29. Vinel JP, Cassigneul J, Louis A, et al (1982) Clinical and prognostic significance of portohepatic gradient in patients with cirrhosis. *Surg Gynecol Obstet* 155: 347–52
30. Vorobioff J, Groszmann RJ, Picabea E, et al (1996) Prognostic value of hepatic venous pressure gradient measurements in alcoholic cirrhosis: a 10-year prospective study. *Gastroenterology* 111: 701–9

Chapter Outline

Indications	519
Contraindications	520
Technique	518
Patient Preparation	520
Equipment	520
Technique of Procedure	521
Diagnostic Findings	521
Normal Findings	521
Pathological Findings.....	522
Therapy	522
Complications	522
References	523

The sphincter of Oddi consists of three separate sphincter muscles surrounding the confluence of the common bile and pancreatic ducts as they enter the duodenal wall at the ampulla of Vater: the sphincter choledochus, sphincter pancreaticus, and the sphincter papillae. Endoscopic sphincter of Oddi manometry (SOM) is the standard method for investigation of motility and function of the Sphincter of Oddi [6, 10]. It has added to our basic understanding of physiology and pharmacology of the function of the papilla, however, its clinical value for management of patients is controversial. In experienced hands SOM offers an exact tool to determine papillary function in patients presenting with signs or symptoms suggestive of sphincter of Oddi dyskinesia/dysfunction (SOD)[9]. On the other hand, this relatively invasive method is associated with a significant risk of side effects and complications, in particular post-procedure pancreatitis [4]. Thus a clear risk benefit evaluation has to be carried out before embarking on this diagnostic strategy.

Indications

The indications for SOM are still controversial (see Chapter 111). The Rome III criteria (2006) for sphincter of Oddi disorders include the presence of epigastric and/or right upper quadrant pain and *all* of the following:

- Episodes lasting ≥ 30 min
- Recurrent symptoms occurring at varying intervals (not daily)
- Pain that crescendos and then plateaus at a constant level

- Pain that is bad enough to interrupt daily activities and/or result in visit(s) to the emergency room
- Pain that is not relieved with defecation or postural changes
- Pain that is not relieved by antacid medications
- Exclusion of structural disease

Supportive criteria include the following:

- Associated nausea and vomiting
- Radiation of pain to the back and/or underneath the right scapula
- Awakening from sleep due to pain

Criteria for functional *pancreatic* sphincter of Oddi disorders were also proposed and include all of the above, with the addition of abnormal serum amylase and lipase. These patients often present with idiopathic recurrent acute pancreatitis.

Contraindications

Sphincter of Oddi manometry should only be performed when the benefits of arriving at a diagnosis outweighs the risk, and when therapeutic maneuvers (i.e. sphincterotomy) can be carried out at the same time. SOM should not be performed during acute phases of pancreatitis, in severe inflammatory conditions (e.g. cholangitis) or in clinical conditions where sphincterotomy could not be performed due to an impairment of blood coagulation or thrombocytopenia.

Technique

Patient Preparation

The examination is performed in prone position like conventional ERCP. Conscious sedation with a benzodiazepene (diazepam, midazolam) or propofol with adequate surveillance is performed for patient comfort [13]. It has been shown that these particular medications do not exert any significant influence on sphincter of Oddi motility. For midazolam, a slight pressure-increasing effect was described in one study, however, no effect was observed in other examinations. All other medications

and substances which influence basal sphincter pressure or motility should be avoided. These include opiates (morphine), gastrointestinal hormones (glucagon, secretin), anticholinergics (atropine, butylscopolamine), and substances which relax the smooth muscle (e.g. nitro compounds, Ca²⁺-antagonists) [2].

Equipment

SOM is usually performed with a special perfused sterile manometry catheter. This catheter has an outer diameter of 1.7 mm (5 French) and contains three perfused channels with a diameter of 0.5 mm each.

The manometry catheter is continuously perfused by means of a pneumohydraulic perfusion pump with distilled and degassed water or with physiological saline solution. The perfusion system must be cleaned thoroughly, and perfusion channels must be rinsed with glutaraldehyde or an appropriate sterilizing solution corresponding to recommendations of the manufacturer.

A perfusion rate of 0.25 ml/min. is usually used and the perfusion pressure should be set so that a good pressure response steepness (>200 mmHg/s) and consequently good recording fidelities can be obtained. With a particular manometry catheter (Lehman-catheter), which contains a fourth channel ending at the very tip of the catheter, it is possible to withdraw the perfusion fluid from the duct systems at the time of recording. It has been demonstrated that using this aspirating catheter significantly lowers the rate of post-interventional pancreatitis [14]. As an alternative new measuring-tool, a small probe with one or two incorporated electronic pressure transducers was introduced recently and was tested in clinical application [19]. This electronic measuring-method offers the advantage of the relatively simple handling and avoids perfusion especially of the pancreatic duct systems, which could reduce possible complications.

For situations with difficult intubation of the papilla or suspected narrowing a special manometry catheter with a long introduction part and a tip guidewire can be used. Similarly, a guidewire can also be used with the electronic recording system. Especially in patients with SOD type I or II, the intubation with a guidewire-probe is recommended, to minimize the trauma and manipulation of the papilla.

Technique of Procedure

The manometry probe is passed through the working channel of the side viewing duodenoscope without application of a spasmolytic (butylscopolamine, glucagon). After establishing the baseline duodenal pressure level, the catheter is introduced into the papilla either by direct cannulation or after prior cannulation of the duct system with a diagnostic catheter and placement of a guidewire.

Some authors recommend an initial small injection of contrast media into the bile or pancreatic duct in order to get clear anatomical bearings. Others, however, recommend performing manometry before any injection of contrast media to avoid influencing the pressure-values through manipulation and injection. In this case, the presence of the catheter within a particular duct can be first confirmed by aspiration of the central lumen (yellow = bile duct, white = pancreatic duct). If using a guidewire system, the correct anatomical placement can be checked fluoroscopically with the guide wire without the need for injection of contrast media.

All pressure values of the sphincter of Oddi (both biliary and pancreatic sphincter pressures) are referenced to the initial baseline duodenal pressure (Fig. 47.1a). A separate intubation and measurement of the biliary and the pancreatic sphincter segment should always be attempted. After intubation of the bile or pancreatic duct is achieved, the catheter system is slowly and stepwise (1–2 mm) withdrawn until the sphincter segment (high pressure zone with phasic activity of 3/min) can be identified from the manometric curve (Fig. 47.1b). As soon as all pressure recording sites are located in the high pressure-zone of the sphincter of Oddi, a continuous recording of up to 2–6 min is executed in order to give a reliable statement about basal pressure and the contraction-frequency. In order to check the reproducibility of the measurement, this process is repeated 2–3 times. For evaluation, the mean values of the individual measurements from all three manometric channels are determined for the bile duct and pancreatic duct sphincter segment. If both sphincter segments have been studied, a pathological measurement in only one of the sphincters is found in 35–67% of the cases, while in the remaining cases an involvement of both sphincters can be seen [11, 15].

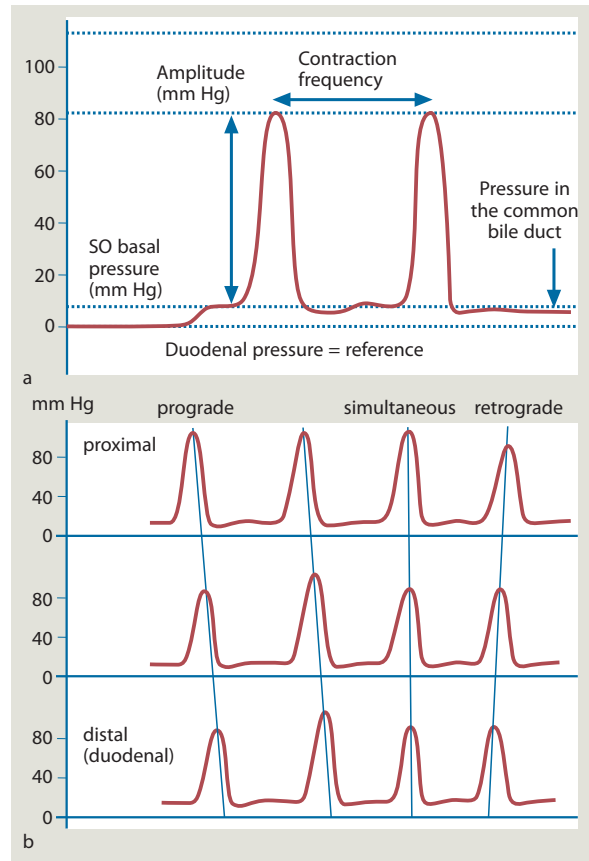


Fig. 47.1 Schematic representation of the pressure phenomena within the sphincter of Oddi. (a) Basal sphincter of Oddi pressure and pressure within the common bile or pancreatic duct are referenced to the duodenal pressure level. (b) Periodic phasic contractile activities are superimposed on the basal pressure of sphincter of Oddi

Diagnostic Findings

Normal Findings

Several studies have established normal values for sphincter of Oddi manometry [1, 3, 5–7, 10, 16]. The normal pressure in the common bile duct is 2–3 mmHg above the duodenal pressure and the basal sphincter pressure of the bile duct sphincter segment is 7–15 mmHg. Superimposed on this basal pressure are regular periodic peristaltic contractions with a pressure amplitude of up to 120 mmHg, a contraction duration of approximately 4–5 s, and a contraction frequency of 4–7/min.

Table 47.1 Normal values of sphincter of Oddi-manometry

Bile duct pressure (mmHg)	Basal SO pressure (biliary segment) (mmHg)	Contraction-amplitude (mmHg)	Frequency (min ⁻¹)	Subjects (n)	Author
11.4 ± 1.3	na	110 ± 11	7.5 ± 0.7	12	Csendes et al. (1979)
12.4 ± 1.5	16.4	101 ± 50	4.1 ± 0.9	26	Geenen et al. (1980)
3.0 ± 2.5	15.2 ± 8.2 ^a	53 ± 11	5.6 ± 2.4	25	Carr-Locke et al. (1981)
8.0 ± 0.6	17.0 ± 4	140 ± 13	4.0 ± 0.5	20	Toouli et al. (1982)
8.6 ± 1.0	14.9 ± 1.0	113 ± 9	6.9 ± 0.2	9	Meshkinpour et al. (1984)
9.1 ± 1.2	15.7 ± 3.4	98 ± 20	5.1 ± 1.8	23	Allescher et al. (1990)
7.7 ± 1.6	13.8 ± 3.0	106,3 ± 27,8	5.4 ± 1.2	17	
Na	18.6 ± 4.0	108 ± 25	5.1 ± 1.4	23	Wehrmann et al. (2000)

na not available.

The contractions are usually peristaltic from proximal to distal in the direction of the duodenal lumen. However, contractions can also occur simultaneously in up to 15–20%, and retrograde in up to 10%.

Table 47.1 shows the standard values of the SOM from different laboratories.

The values of these contraction phenomena for the diagnosis of sphincter of Oddi dyskinesia, however, has been controversial. Of these pathological findings, only an elevated basal pressure > 40 mmHg is generally accepted and is routinely used in clinical practice.

Pathological Findings

A series of abnormal manometric findings were described and several pathological cut off parameters for a pathological sphincter of Oddi manometry have been suggested (Table 47.2) [8, 10, 12, 16]. These include

- Sustained increased basal sphincter pressure (> 40 mmHg)
- Increased contraction frequency (tachyoddia) > 10/min
- Increased contraction amplitude (>180 mmHg)
- Prolonged contraction duration (>7 s)
- Increased occurrence of retrograde contractions (> 20%)
- Paradoxical reaction of the sphincter segment to intravenous infusion of cholecystokinin in octapeptide (CCK)

Table 47.2 Proposed cut off values for pathologic SO-manometry

Basal SO-pressure	> 35 mmHg
Bile duct pressure	> 13 mmHg
Phasic contractions	
Amplitude	> 220 mmHg
Duration	> 8 s
Frequency	> 10/min

Therapy

Treatment for the disorders of the sphincter of Oddi is reviewed in Chapter 111. While many medications have been tried to ameliorate symptoms, endoscopic sphincterotomy is currently accepted as the most effective, durable treatment by leading experts [17].

Complications

Due to the particular procedure requirements (no use of spasmolytics) and the patient characteristics, a complete SOM procedure can only be performed in 85–90% of patients even in experienced centers due to the inability to achieve cannulation of both common bile and pancreatic ducts. The most frequent complication of SOM is pancreatitis, the risk of which has been reported to be as high as 25% before the introduction of prophylactic pancreatic duct stenting. Special risk factors for the development of pancreatitis are an inexperienced endoscopist, high perfusion rate, long duration of manometry (>5 min), long manipulation of the papilla, and manometry of the pancreatic duct system. An appropriate detailed informed consent and post

interventional surveillance is therefore mandatory. It is the practice at some centers to routinely admit patients to the hospital for overnight observation following SOM.

In a study that included 207 patients with biliary SOD and 23 patients with pancreatic SOD, the pancreatitis rate ranged between 9% and 26% [18]. Patient characteristics that were identified to be risk factors for pancreatitis included elevated sphincter pressures during manometry and prior post-ERCP pancreatitis. A long duration of manometry (>5 min) and manometry of the pancreatic duct were found to be procedure-related risk factors. An endoscopic sphincterotomy following the manometry reduced the risk of pancreatitis. Therefore, if the manometry shows SOD with an indication for endoscopic sphincterotomy, the sphincterotomy should be performed during the same session. Other methods to reduce the risk of pancreatitis include the use of an aspiration manometric catheter, use of a non-perfused electronic manometric system, placement of a temporary small caliber (4 or 5 Fr) pancreatic stent, and possibly prior administration of a non-steroidal anti-inflammatory drug [14, 19].

Other complications such as cholangitis or cholecystitis are rare and occur mostly when stenosis is present or if biliary drainage is obstructed. In patients with suspected SOD the risk of complications of diagnostic ERCP and endoscopic sphincterotomy is also increased.

References

- Allescher HD (1993) How to sedate for sphincter of Oddi manometry. *Endoscopy* 25: 399–400
- Allescher, HD, Neuhaus H, Hagenmüller F, et al (1990) Effect of N-butylscopolamine on sphincter of Oddi motility in patients during routine ERCP manometric study. *Endoscopy* 22: 160–3
- Carr-Locke DL, Gregg JA (1981) Endoscopic manometry of pancreatic and biliary sphincter zones in man. Basal results in healthy volunteers. *Dig Dis Sci* 26: 7–15
- Chen YK, Foliente RL, Santoro MJ, et al (1994) Endoscopic sphincterotomy-induced pancreatitis: increased risk associated with nondilated bile ducts and sphincter of Oddi dysfunction. *Am J Gastroenterol* 89: 327–33
- Csendes, A, Kruse A, Funch-Jensen P, et al (1979) Pressure measurements in the biliary and pancreatic duct systems in controls and in patients with gallstones, previous cholecystectomy, or common bile duct stones. *Gastroenterology* 77: 1203–10
- Geenen JE, Hogan WJ, Dodds WJ, et al (1980) Intraluminal pressure recording from the human sphincter of Oddi. *Gastroenterology* 78: 317–24
- Guelrud M, Mendoza S, Rossiter G, et al (1990) Sphincter of Oddi manometry in healthy volunteers. *Dig Dis Sci* 35: 38–46
- Meshkinpour H, Mollot M, Eckerling GB, et al (1984) Bile duct dyskinesia. Clinical and manometric study. *Gastroenterology* 87: 759–62
- Meshkinpour H, Mollot M (1992) Sphincter of Oddi dysfunction and unexplained abdominal pain: clinical and manometric study. *Dig Dis Sci* 37: 257–67
- Nebel, OT (1975) Manometric evaluation of the papilla of Vater. *Gastrointest Endosc* 21: 126–8
- Rolny P, Ärleback A, Fuch-Jensen P, et al (1989) Clinical significance of manometric assessment of both pancreatic duct and bile duct sphincter in the same patient. *Scand J Gastroenterol* 24: 751–4
- Rolny P, Geenen JE, Hogan WJ, et al (1991) Clinical features, manometric findings and endoscopic therapy results in group I patients with sphincter Oddi dysfunction. *Gastrointest Endosc* 37: 84–5
- Schmitt T, Seifert H, Dietrich CF, et al (1999) Propofol-sedierung bei endoskopischer Manometrie des Sphincter Oddi. *Z Gastroenterol* 37: 219–27
- Sherman S, Hawes RH, Troiano FP, et al (1992) Pancreatitis following bile duct sphincter of Oddi manometry: utility of the aspirating catheter. *Gastrointest Endosc* 38: 347–50
- Silverman WB, Ruffolo TA, Sherman S, et al (1992) Correlation of basal sphincter pressures measured from the bile duct and the pancreatic duct in patients with suspected sphincter of Oddi dysfunction. *Gastrointest Endosc* 38: 440–3
- Toouli J, Geenen JE, Hogan WJ, et al (1982) Sphincter of Oddi motor activity: a comparison between patients with common bile duct stones and controls. *Gastroenterology* 82: 111–7
- Wehrmann T, Wiemer K, Lembcke B, et al (1996) Do patients with sphincter of Oddi dysfunction benefit from endoscopic sphincterotomy? A 5-year prospective trial. *Eur J Gastroenterol Hepatol* 8: 251–6
- Wehrmann T, Wendler OG, Jung M, et al (1997) Risikofaktoren der endoskopischen Manometrie bei Verdacht auf Sphinkter-Oddi-Dysfunktion. *Dtsch Med Wochenschr* 122: 808–14
- Wehrmann T, Schmitt T, Schonfeld A, et al (2000) Endoscopic sphincter of Oddi manometry with a portable electronic microtransducer system: comparison with the perfusion manometry method and routine clinical application. *Endoscopy* 32: 444–51

Approach to the Patient with Upper Abdominal Pain

48

Henryk Dancygier and Jason N. Rogart

Chapter Outline

Origin of Pain	527
Conduction of Pain	528
Types of Pain	529
Visceral Pain	529
Somatic Pain	529
Referred Pain.....	529
Clinical Evaluation.....	530
Biliary Pain	531
Hepatic Pain	532
References	532

Abdominal pain is one of the most common reasons for a patient's visit to the physician, and particularly for referral to a gastroenterologist. The evaluation of abdominal pain continues to be clinically challenging. It relies primarily on a thorough history of the pain, in addition to a comprehensive general medical history and physical examination. Unfortunately, it is not uncommon for technical diagnostic procedures to exclude etiologies rather than to lead to the correct diagnosis. The main focus of this chapter is the discussion of epigastric and notably right upper quadrant pain of hepatobiliary origin. We do not intend to provide a systematic analysis of all causes of abdominal pain.

Origin of Pain

Pain is a very individual and subjective experience and its sensation is influenced by behavioral, psychological and social factors. Intraabdominal pain results from irritation of specialized sensory nerve endings (nociceptors) located in the parietal and visceral peritoneum, the mesenteric attachment, certain structures of the gut wall and surrounding connective tissue, and the capsule of the liver and spleen. Chemical, mechanical and thermal stimuli of visceral pain receptors elicit painful sensations in the respective abdominal structures.

In 1760 the Swiss physiologist von Haller demonstrated that the visceral peritoneum is insensitive to mechanical stimuli, such as cutting and pinching, as well as to thermal stimuli such as heat and cold. He noted, however, that distension of hollow organs, stretching of the mesentery, and spasm of the intestinal muscles caused pain.

Intestinal ischemia per se does not necessarily produce pain though it may lower the pain threshold so

that stimuli which are usually non-noxious may generate pain. On the other hand ischemic, congestive, and inflammatory injury to the mucosa may lead to the local release of chemical transmitters (e.g. substance P) that stimulate nociceptive receptors in the intestinal wall and elicit pain.

Conduction of Pain

Sensory impulses from the abdominal cavity are conducted by fibers of the autonomic nervous system. Afferent visceral nerve fibers conduct “visceral pain” from the viscera and the peritoneum via the splanchnic nerves, the sympathetic ganglia, and the communicating branches to the spinal cord.

Segmentally arranged sensory somatic nerve fibers conduct nociceptive impulses from the abdominal wall, the parietal peritoneum, and the mesenteric attachment to the central nervous system (CNS) and mediate “somatic pain”.

The hepatic parenchyma does not have visceral afferent nerve fibers. However, free nerve endings and Vater-Pacini corpuscles are present in the walls of portal vein branches and the hepatic artery, and are sporadically scattered within the interlobular connective tissue. The corresponding afferent fibers run via the hepatic plexus and the sympathetic trunk to the CNS.

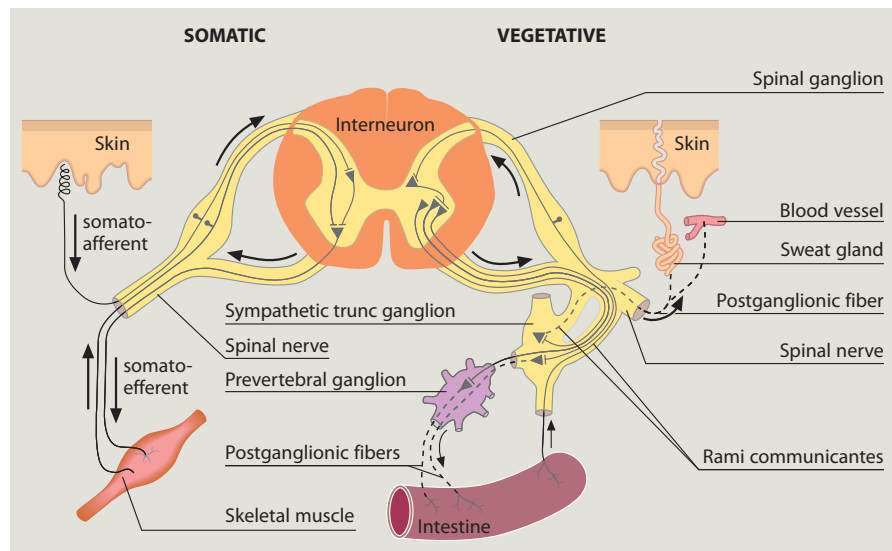
The liver capsule and the falciform ligament are endowed with sensory afferent fibers that run within the phrenic nerve.

Afferent pain fibers also arise from the gallbladder and the bile ducts, traverse the hepatic plexus and run to the pain centers in the CNS. In addition, afferent pain-conducting fibers originating in the extrahepatic biliary system accompany the phrenic nerve.

The afferent visceral neurons are mostly non-myelinated, slow conducting fibers. Impulses transported through these neurons produce a “slow,” dull pain that usually is poorly localized. In contrast, the afferent somatic neurons are made up of large, myelinated, rapidly conducting fibers. They elicit a “quick,” sharp and circumscribed pain [1, 2].

Afferent visceral and somatic neurons from the abdomen reach the spinal cord, where they cross to the opposite side and continue to the thalamus in the spinothalamic tract. In the thalamus the sensory abdominal impulses are conveyed to a third neuron whose axons are located in the postcentral gyrus of the cerebral cortex. Already at the level of the posterior horn of the spinal cord the sensory fibers from the abdomen come into contact with afferent impulses from the skin and from other regions of the body (e.g. the thorax) (Fig. 48.1). This means that within the CNS sensory impulses of visceral origin use the same pain-conducting pathways as sensory impulses originating in superficial and deep somatic structures. Along their common

Fig. 48.1 Schematic representation of the connections between the somatic and visceral nervous system at the sympathetic trunk (According to [4])



path within the CNS, visceral and somatic fibers communicate with each other (viscerosomatic convergence). This is the basis for understanding *referred pain*. Sir Henry Head (English neurologist) has systematically elaborated the peripheral distribution of referred hyperalgesic zones for each neural segment of the spinal cord (*Head's zones*).

Types of Pain

Three main types of abdominal pain are distinguished:

- Visceral pain
- Somatic pain
- Referred pain

Visceral Pain

Visceral pain is caused predominantly by obstruction, distension, or spasm of a hollow abdominal viscus, and by capsular tension. Visceral pain is dull, deep, aching, cramping, or colicky. It is often poorly localized and may be referred over a wide area and to remote cutaneous sites [2]. This is explained by the organization of nociceptive pain pathways within the CNS, with the absence of a separate visceral sensory tract and the relatively low number of afferent visceral fibers, compared to the large number of somatic fibers.

The localization of visceral pain roughly corresponds to the segmental allocation of the intraabdominal structure from where pain impulses originate. However, pain may also be referred to other areas. Visceral pain radiates into areas that belong to the same neural segment as the diseased organ. It may be accompanied by motor and autonomic reflexes, such as nausea, vomiting, perspiration and sweating. The patient with visceral pain often appears anxious or agitated. Despite wallowing and bending, he or she finds no position that provides relief. Examples of true visceral pain are the pain in the early phase of acute appendicitis that initially is felt in the mid abdomen, the pain in the initial phase of intestinal obstruction, or in acute cholecystitis. Although pain from cholecystitis has been referred

to as “biliary colic”, this pain is more commonly steady with a progressive increase in intensity.

Somatic Pain

Somatic pain arises from noxious stimulation (e.g. inflammatory mediators) of the parietal peritoneum or the mesentery. It is intense, sharp, stinging, and usually well localized to the area of injury, corresponding to the dermatomal distribution that innervates the affected portion of the peritoneum. Somatoparietal pain is aggravated by local pressure (palpation and percussion), movement, sneezing and coughing (change in peritoneal tension). Therefore, a patient with somatic pain tries to avoid any movement and assumes a relieving posture. An impressive example of somatic pain is acute peritonitis.

Referred Pain

Referred pain is characterized by a topographic dissociation between the diseased organ and the area where pain is felt. Visceral and afferent neurons from different anatomic regions converge at the same spinal cord segment at which pain is perceived, which can be areas remote from the organ of origin. Painful irritation of visceral or deep somatic structures may lead to pain in superficial body areas that are supplied by the same or immediately adjacent spinal segment, and use common tracts in the CNS. Referred pain may occur alone or together with visceral or deep somatic pain. Referred pain is characteristically sharp and relatively well circumscribed, and is often perceived on the lateral aspects of the abdomen or back. Examples are the diseased gallbladder causing right subscapular pain, and irritation of the right diaphragm causing pain in the right shoulder. The referred pain reaction may be lead to local changes in temperature, skin moisture, and muscular tone due to localized changes in blood flow, cutaneous glandular activity, and the contractile state of muscle fibers. Hyperalgesia and muscular guarding are most intense in somatic pain of acute generalized peritonitis [6].

Clinical Evaluation

Evaluating a patient with abdominal pain is one of the few occasions in clinical medicine when the dictum holds true that “listening and watching is more important than talking.” Pain is an unpleasant sensation and emotional experience. Each patient copes with it and reacts to it differently, and therefore it might be difficult to register the quality and intensity of pain, since both strongly depend on the experience and the personality of the individual patient.

Table 48.1 lists causes of epigastric and right upper quadrant pain. Frequent causes are cholecystitis, biliary colic, acute and chronic pancreatitis, pancreatic

cancer and a rapidly enlarging liver due to acute venous congestion or to acute inflammatory or infectious processes. The appearance of a patient with acute upper abdominal pain may provide important information. Does the patient assume a relieving posture and try to avoid any movement, or is she visibly anxious and agitated? The former is a clue to the somatic, the latter to the visceral nature of pain. The physician must assess already known diseases, evaluate the circumstances under which the pain developed, and further objectify pain characteristics with targeted questioning (see also Section VI). The following is of special interest:

- Onset and time course of pain
- Localization and radiation of pain

Table 48.1 Causes of epigastric and right upper quadrant pain

<p>Liver (acute distension of hepatic capsule)</p> <p>Acute hepatitis</p> <ul style="list-style-type: none"> – Viral – Alcoholic <p>Acute congestive hepatomegaly</p> <ul style="list-style-type: none"> – Right heart failure – Constrictive pericarditis – Venous outflow obstruction (e.g. Budd-Chiari syndrome) <p>Perihepatitis gonorrhoeica (Fitz-Hugh-Curtis syndrome)</p> <p>Liver abscess</p> <p>Subcapsular liver cysts (rapidly enlarging)</p> <p>Liver tumors (e.g. adenoma with bleeding or rupture)</p> <p>Gallbladder and Bile Ducts</p> <p>Obstruction of lumen (e.g. choledoch-, cholecystolithiasis, tumors)</p> <p>Inflammation (cholecystitis, cholangitis)</p> <p>Motility disturbances (dyskinesias, Sphincter of Oddi dysfunction)</p> <p>Choledochal cysts (rare)</p> <p>Stomach/Duodenum</p> <p>Gastritis</p> <p>Peptic ulcers</p> <p>Gastric carcinoma</p> <p>Gastric outlet obstruction</p> <p>Pancreas</p> <p>Acute and chronic pancreatitis</p> <p>Main pancreatic duct strictures or stones</p> <p>Vessels</p> <p>Rupture of aneurysm (e.g. hepatic artery)</p> <p>Intestinal ischemia (arterial embolism, venous thrombosis)</p> <p>Sickle cell anemia</p> <p>Henoch-Schönlein purpura</p> <p>Abdominal wall</p> <p>Infections</p> <p>Trauma</p> <p>Scar tissue</p>	<p>Diaphragm</p> <p>Pleuritis diaphragmatica</p> <p>Right Kidney</p> <p>Nephrolithiasis</p> <p>Pyelonephritis</p> <p>Perinephritic abscess</p> <p>Thorax</p> <p>Esophageal disease (e.g. esophagitis, spasm, rupture)</p> <p>Right lower lobe pneumonia</p> <p>Pulmonary infarction</p> <p>Pleurisy</p> <p>Myocardial infarction</p> <p>Pericarditis</p> <p>Chest wall</p> <p>Trauma</p> <p>Infection</p> <p>Neurogenic</p> <p>Degenerative lesions of thoracic spine</p> <p>Protrusion of intervertebral disc</p> <p>Herpes zoster</p> <p>Causalgia</p> <p>Metabolic/Genetic</p> <p>Diabetic ketoacidosis</p> <p>Uremia</p> <p>Porphyria</p> <p>Heavy metal intoxication (e.g. lead)</p> <p>C1-esterase deficiency</p> <p>Familial mediterranean fever</p> <p>Other</p> <p>Tense ascites</p> <p>Spontaneous bacterial peritonitis</p> <p>Retrocecal appendicitis</p> <p>Psychogenic</p>
---	--

- Quality of pain
- Pain intensity
- Exacerbating and mitigating factors and
- Circumstances under which pain arises

The onset may be insidious, slowly reaching a maximal pain plateau such as occurs in acute cholecystitis, or it may be acute such as in biliary colic. Acute mesenteric ischemia due, for example, to arterial embolism typically starts with severe pain out of proportion to the physical examination. The abdomen initially is soft, with little or no tenderness on palpation. As necrosis develops, signs of peritonitis appear, with abdominal (rebound) tenderness, guarding, rigidity, and the cessation of bowel sounds. However, compromised mesenteric blood flow does not necessarily always cause an abrupt onset of strong pain (“abdominal catastrophe”). It instead may be intermittent and cramping, slowly increasing in intensity (“intestinal angina”).

Depending on whether the pain is primarily visceral (deep seated, dull, and difficult to localize) or somatic (superficial, sharp and easy to localize), its quality varies (see above). Liver pain caused by capsular tension, for example, is dull and oppressive, and the patient realizes that he has a liver (“Organgefühl”).

The time course of pain may give clues to its etiology. The physician must first evaluate if the symptoms are occurring for the first time or if the pain is chronically relapsing. Intermittent, colicky pain, for example, is characteristic of biliary and renal colic. Chronic relapsing pain should turn one’s attention to chronic pancreatitis or cholecystitis.

Assessing severity of pain is subjective and not always easy. There is no neurophysiological or chemical test that can measure pain in individual patients. Pain due to biliary or renal colic and acute pancreatitis is perceived as extremely intense, while psychogenic pain is usually less severe and may be part of a multisomatoform disorder in patients with depression and anxiety disorders.

The appraisal of factors that initiate, exacerbate or reduce pain is also important in evaluating the causes of pain. Pain elicited by a fatty meal usually indicates a biliary or pancreatic origin. Pain caused by peritoneal irritation is typically aggravated by movement and changes of peritoneal tension, such as occurs during coughing and sneezing.

Finally, it is important to evaluate the circumstances under which pain arises. If right upper quadrant pain is

accompanied by an elevated temperature, for example, infectious causes such as ascending cholangitis or liver abscess should be considered. Whenever a patient with ascites, either chronic or new-onset, presents with even mild abdominal discomfort, spontaneous bacterial peritonitis must be considered. Additionally, in each patient with upper abdominal pain intrathoracic causes must be excluded, such as myocardial and pulmonary infarction, pneumonia, pleurisy, pericarditis, and esophageal diseases.

Neurogenic pain (e.g. in Herpes zoster), often is burning and can manifest before the appearance of the typical skin eruption. Furthermore, it is characterized by allodynia, where generally non-painful stimuli elicit pain in the respective area, and paresthesias and dysesthesias are present in between pain attacks.

Biliary Pain

Biliary pain arises from a rise in pressure in the bile ducts and the gallbladder that is registered by nociceptors. It is therefore perceived in the beginning as a rather vague and noncharacteristic pain in the epigastrium. If the pain impulses increase in such a manner as to activate neighbouring neurons in the dorsal spinal cord, or if the parietal nociceptors in the gallbladder wall are stimulated by inflammation and edema, the pain becomes sharper and more localized to the right upper quadrant. Typically biliary pain radiates into the right subscapular area.

The differential diagnosis of mild epigastric pain, therefore, should also include biliary disease. Occasionally the initial epigastric dysesthesias are so vague that the patient hardly realizes them, and he or she views the later-appearing, more intense right upper quadrant pain as the first symptom of his or her disease.

In the post-cholecystectomy patient, pain caused by stones in the common bile duct is felt in the mid-epigastrium rather than below the right costal arch. A similar type of pain may be experienced by this same population in the setting of sphincter of Oddi dysfunction. Not uncommonly, patients with choledocholithiasis are completely asymptomatic.

Extrahepatic bile duct obstruction, caused by a slowly growing tumor of the bile duct or pancreas, usually is painless in the early stages (i.e. “painless jaundice”). Pain may develop if cholangitis supervenes or if the tumor enlarges.

In acute cholecystitis, pain can be elicited by palpation below the right costal margin during deep inspiration (Murphy's sign). The pain radiates into the epigastrium, in a belt-like fashion into the back, and into the right scapula. The onset is abrupt and the pain is severe. An attack typically lasts for approximately 15–60 min before it abates, only to reoccur after a variable time interval. Although this pain is often described as “biliary colic,” it mostly lacks the characteristics of a true colicky pain because, though the fluctuating nature simulates a colicky character, painless intervals are generally not present. Biliary colic occurs more often with stones in the cystic duct than in the common bile duct [3, 5].

Hepatic Pain

The hepatic capsule contains pain receptors. Irritation of the liver capsule may be caused by extrahepatic lesions (e.g. in the context of peritonitis) or by intrahepatic processes that lead to an increase in liver volume. The rapidity with which hepatomegaly develops determines

the intensity of hepatic pain. Rapid distension of the liver capsule, as occurs for example in acute venous congestion, acute alcoholic or viral hepatitis, or blunt trauma, causes subcostal pain. If the parietal peritoneum is irritated pain radiates to the chest or back.

References

1. Aach RD (1974) Abdominal pain. In: MacBryde CM, Blacklow RS (eds) Signs and symptoms. Applied pathologic physiology and clinical interpretation, 5th edn. J.B. Lippincott, Philadelphia, Toronto, pp S. 181–92
2. Cervero F, Laird JMA (1999) Visceral pain. *Lancet* 353: 2145–48
3. Haubrich WS (1995) Abdominal pain. In: Haubrich WS, Schaffner F, Berk JE (eds) Bockus gastroenterology, 5th edn. WB Saunders, Philadelphia, PA, pp S. 11–29
4. Schiebler TH, Schmidt W, Zilles K (1999) Anatomie, 8th ed. Springer-Verlag, Berlin/Heidelberg/New York
5. Silen W (1987) Cope's early diagnosis of the acute abdomen, 17th edn. Oxford University Press, New York
6. Silen W (2001) Abdominal pain. In: Braunwald E, Fauci A, Kasper DL, Hauser SL, Longo DL, Jameson JL (Hrsg) Harrison's principles of internal medicine, 15th edn. McGraw Hill, New York, pp 67–70

Approach to the Patient with Abnormal Liver Enzymes

49

Henryk Dancygier and Jason N. Rogart

Chapter Outline

Abbreviations	533
General Considerations	534
Interpretation of Abnormal Liver Enzymes	535
Patterns of Injury	536
General Approach to the Patient with Elevated Liver Enzymes	544
References	546

Abbreviations

5'-NT	5'-nucleotidase
ACE	Angiotensin converting enzyme
α ATD	α_1 -antitrypsin deficiency
AH	Alcoholic hepatitis
AIH	Autoimmune hepatitis
ALT	Alanine aminotransferase
AMA	Antimitochondrial antibodies
ANA	Antinuclear antibodies
AP	Alkaline phosphatase
AST	Aspartate aminotransferase
BRIC	Benign recurrent intrahepatic cholestasis
CAH	Chronic active hepatitis
CBD	Common bile duct
CFTR	Cystic fibrosis transmembranous conductance regulator
ChE	Choline esterase
CMV	Cytomegalovirus
CPH	Chronic persistent hepatitis
CT	Computed tomography
EBV	Epstein Barr virus
EM	Electron microscopy
ERCP	Endoscopic retrograde cholangio-pancreatography
EUS	Endoscopic ultrasonography
γ -GT	γ -glutamyl transpeptidase (transferase)
GLDH	Glutamate dehydrogenase
HBV	Hepatitis B virus
HCV	Hepatitis C virus
HH	Hereditary hemochromatosis
HSV	Herpes simplex virus
IBD	Inflammatory bowel disease
IH	Ischemic hepatitis
LAP	Leucine aminopeptidase
LDH	Lactate dehydrogenase
LDL	Low density lipoproteins

LKM	Liver kidney microsomal antibodies
MRCP	Magnetic resonance cholangio-pancreatography
MRI	Magnetic resonance imaging
NAFLD	Nonalcoholic fatty liver disease
NASH	Nonalcoholic steatohepatitis
pANCA	Perinuclear anti cytoplasmic antibodies
PBC	Primary biliary cirrhosis
PFIC	Progressive familial intrahepatic cholestasis
PSC	Primary sclerosing cholangitis
SAA	Serum amyloid A
SD	Standard deviation
SLA/LP	Soluble liver antigen/liver-pancreas antibodies
SMA	Smooth muscle antibodies
TIBC	Total iron binding capacity
ULN	Upper limit of normal
US	Ultrasound
WD	Wilson's disease

See also Chapters 34–36, and 52.

General Considerations

There are currently many, simple and rapidly available laboratory tests at the physicians disposal to evaluate patients with liver disease. Within the context of a routine medical examination, most hepatologists will ask for AST, ALT, γ -GT, AP, bilirubin, iron, TIBC, ferritin, total serum protein, cholesterol, triglycerides, and blood glucose. Some may also be interested in GLDH levels. Viral serologies, immunologic investigations (e.g. serum autoantibodies), and genetic testing will complement these basic parameters in individual patients. The multitude of laboratory parameters available obliges the physician to make a rational choice in order to arrive at a diagnosis with a justifiable effort and with the least invasive means. The correct interpretation of altered laboratory parameters requires a thorough understanding of the structure and function of the liver and can only succeed if the laboratory results are interpreted within the context of the history and physical examination [12, 15, 17, 23].

The biochemical diagnosis of liver disease aims at various goals:

- Confirming or excluding hepatobiliary disease (“screening”)
- Classifying liver injury (e.g. necroinflammatory, cholestatic, metabolic, infiltrative)

- Distinguishing between a distinct hepatobiliary disease and a reactive hepatic lesion in disorders of other organs or systems
- Evaluating etiology
- Estimating severity and prognosis, and
- Following the course of disease

This chapter focuses on the enzymatic differential diagnosis of liver diseases. The diagnostic significance of various serum autoantibodies in hepatobiliary disease will be only briefly mentioned (see Section XIV). Disease-specific virologic, immunologic, genetic markers, parameters of the synthetic capacity of the liver, serum bilirubin, and quantitative tests of liver function will not be discussed; for these, the reader is referred to the respective chapters.

Liver enzyme activities in serum permit one to exclude or to confirm liver disease, and to classify liver injury according to patterns of injury that reflect the respective morphological hepatic changes. Serum enzymes are also helpful in following the course of liver disease, but changes in their activities are nonspecific and do not allow for distinguishing a distinct hepatobiliary disease from reactive hepatic lesions, nor for evaluating etiology or estimating prognosis.

Although liver enzymes in hepatology have been routinely used for more than half a century, the definition of “normal” with regard to aminotransferases is still under discussion and not universally accepted. Current standards for “normal” ALT levels were defined by using populations that included persons with subclinical liver disease. Consequently, in a study of 7,044 persons (6,835 healthy blood donors negative for anti-HCV; 209 anti-HCV positive persons with HCV viremia in 131 of them) an updated definition of healthy ranges for serum ALT was attempted [36]. Serum ALT activity was independently related to body mass index and to laboratory indicators of abnormal lipid or carbohydrate metabolism. Updated upper limits of normal (30U/L for men, and 19U/L for women) were lower than current limits (40U/L for men, and 30U/L for women). During 6-month follow-up, these updated normal values showed superior sensitivity in identifying anti-HCV positive persons with HCV viremia. The increased sensitivity targeted patients with minimal to mild histologic lesions. Thus, in patients with chronic HCV infection or nonalcoholic fatty liver disease, revision of normal limits for ALT level might be advisable.

In addition, there is a significant association between age and serum ALT activity, with the upper limit of

normal being lower in the aging population. This association resembles an inverted-U-like relation. Thus, when interpreting the laboratory results of a person suspected of having liver disease, age should probably also be taken into account [11].

The prevalence of elevated aminotransferases depends on geographical and ethnic factors. In one investigation of nearly 2,000 healthy, young military conscripts in the USA, only 99 (0.5%) cases of increased ALT were found. An etiology could be identified in 12 of them (chronic hepatitis C, autoimmune hepatitis, cholelithiasis), however no specific diagnosis could be made in the remaining 87 cases [27]. The current prevalence of elevated ALT activity in the United States in a representative population survey is 8.9% and is strongly associated with risk factors for nonalcoholic fatty liver disease [22]. In Iran and in rural southern Italy, a Mediterranean area where dietary habits are different from those in industrialized countries, approximately one eighth of the general population has abnormal ALT, AST and γ -GT, and here too nonalcoholic fatty liver disease appears to emerge as a prime cause [34, 35]. Central adiposity, hyperleptinemia, hyperinsulinemia, and insulin resistance are the major determinants of the association of being overweight with elevated serum ALT activity [14, 21, 38, 46]. In addition, it has been suggested in a large, population-based study that the risk of elevated ALT levels and liver injury is also associated with increased serum iron and decreased antioxidant levels [39]. Conversely, coffee and especially caffeine consumption seems to be associated with a reduced risk of elevated serum ALT activity in the United States [26, 40].

In addition to liver disease, new data are emerging that hint at a possible relationship between serum aminotransferase levels, mortality and coronary atherosclerosis. There is some evidence that elevated serum aminotransferases may predict mortality in the general population. In a large community study, for example, there was a significant increase in the standardized mortality ratio with increasing AST and ALT levels, whereas a normal AST or ALT level was associated with a risk of death lower than expected [25]. AST levels two times the upper limit of normal had a mortality ratio of 1.79 and ALT levels two times the upper limit of normal had a mortality ratio of 1.63. The relationship between AST and ALT values and subsequent risk of death in both genders was near-linear. The association between aminotransferase concentration and mortality from liver disease was positive even within normal range (35–40 IU/L) [25].

In another recent study, an elevated ALT:AST ratio in women predicted coronary atherosclerosis independently of the metabolic syndrome and serum CRP concentration [1]. If confirmed, these interesting new data emphasize the need to closely observe and perhaps perform further diagnostic testing in persons with even slightly increased aminotransferase activity.

Interpretation of Abnormal Liver Enzymes

Liver enzymes are located within different hepatocellular compartments and different acinar regions. Increased enzyme activities in serum, especially of aminotransferases, are a clue to liver damage which may range from a simple permeability disorder of the liver cell membrane to cell death [24].

Increased liver enzymes in serum are due to

- Increased release of cytosolic and mitochondrial enzymes from injured hepatocytes
- Increased enzyme synthesis with consequent release, or
- Diminished enzyme clearance

The lack of a sinusoidal basement membrane allows enzymes to be rapidly released into the circulation. With increasing liver fibrosis and “capillarization” of sinusoids, the transport of enzymes from hepatocytes into the circulation becomes increasingly difficult. The duration of enzymatic activity in serum, among other factors, depends on the duration of hepatobiliary damage and on the half life of individual enzymes (Table 49.1). Enzymes are degraded primarily in the liver (sinusoidal endothelia), kidneys and lungs. The most important factor for

Table 49.1 Mean serum half-lives of some liver enzymes in serum

Enzyme	Half-life
Alkaline phosphatase	1–7 days ^a
Alanine aminotransferase	50 h
Aspartate aminotransferase	17 h
Choline esterase	10 days
Glutamate dehydrogenase	18 h
γ -Glutamyl transpeptidase	3–4 days
Lactate dehydrogenase (isoenzyme 5)	7–12 h

^aThe half-life depends on the source of AP: placenta > liver > bone > intestine

enzymatic activity in serum, however, is the degree of their release into the circulation. Primarily cytosolic enzymes (ALT) are released in mild liver injury, whereas mitochondrial enzymes (AST, GLDH) are also released in more severe liver damage. Already the death of 1 g of liver tissue leads to a measurable increase in aminotransferase concentration in serum. However, *the absolute level of aminotransferase increase in serum does not strictly correlate with the extent of hepatocellular injury and is neither specific for the cause of liver disease nor predictive of outcome* [16]. Despite this shortcoming the ratio of individual enzymatic activities in serum permits the determination of various patterns of injury that may provide a clue to the cause of hepatic damage. Usually these patterns of injury must be differentiated further by immunologic, serologic, and imaging techniques, in order to arrive at a final diagnosis.

Patterns of Injury

Since the etiology of liver disease cannot be determined reliably based solely on the increase in enzyme concentration, the interpretation of abnormal liver chemistries is based on the recognition of enzymatic patterns of injury. In a simplistic way the following injury patterns may be distinguished:

- Hepatic (necroinflammatory)
- Cholestatic
- Mixed pattern

Some authors also describe an additional infiltrative pattern.

The differentiation between hepatocellular (hepatic) and cholestatic liver injury is easily accomplished performing only a few screening tests (Tables 49.2 and 49.3). Distinguishing intra- from extrahepatic cholestasis, based solely on biochemical laboratory parameters, however, is not possible, and generally requires imaging

Table 49.2 Enzymatic markers of hepatocellular injury and cholestasis

Cell injury, cell death	Cholestasis
AST	AP
ALT	γ -GT
GLDH	LAP
	5'-NT

methods. Space occupying lesions (e.g. primary and secondary neoplasms, abscesses, cysts), granulomas, steatotic changes, and amyloidosis are counted among the infiltrative lesions. There is no specific biochemical parameter to diagnose these entities.

Hepatic Pattern

Hepatic damage denotes liver injury in the context of a necroinflammatory process. Injury of liver cells can occur at different scales. Mild injury may manifest itself solely as a reversible disturbance in membrane permeability. The most severe form of cell damage is cell death, occurring as apoptosis or necrosis. Each type of liver cell injury may lead to elevations of certain liver enzymes.

The most important enzymatic indicators of cell injury and cell death are the aminotransferases (AST, ALT) and GLDH (Tables 49.2 and 49.3). The aminotransferases are sensitive indicators of hepatocellular injury within the context of a necroinflammatory process [24]. In chronic hepatitis, however, the correlation between the extent of necroinflammation and the aminotransferase concentration in serum is low. In liver damage with extensive parenchymal necrosis the enzyme pattern in serum corresponds to that of the parenchymal cell: LDH > AST > ALT > GLDH. In addition to enzymes, many other substances are also released into the circulation during liver injury, including ferritin, whose concentration in serum increases markedly in acute liver injury. The extent of the rise in ferritin depends on the degree of cell damage and the hepatic iron content.

Table 49.3 Constellation of aminotransferases, alkaline phosphatase (and γ -glutamyl transferase) in various patterns of liver injury

Enzyme	Hepatic	Cholestatic	Mixed
Aminotransferases	$\uparrow\uparrow$ to $\uparrow\uparrow\uparrow$	\leftrightarrow to \uparrow	$\uparrow\uparrow$ to $\uparrow\uparrow\uparrow$
Alkaline phosphatase (and γ -GT)	\leftrightarrow to \uparrow	$\uparrow\uparrow$ to $\uparrow\uparrow\uparrow$	\uparrow to $\uparrow\uparrow$
	ALT:AP = ≥ 5	ALT:AP = ≤ 2	ALT:AP = $> 2 - < 5^a$

\leftrightarrow unchanged, \uparrow mild increase, $\uparrow\uparrow$ moderate increase, $\uparrow\uparrow\uparrow$ high increase.

^a All enzyme levels expressed as multiples of ULN.

Table 49.4 Organ distribution of various enzymes

Enzyme	Organs
ALT	Largely liver specific
AST	Liver > heart muscle > skeletal muscle > kidneys > brain > pancreas > lungs > leucocytes > erythrocytes
GLDH	Liver > heart muscle > skeletal muscle > kidneys
AP	Liver, bone, intestine, placenta
γ -GT	Kidney, liver, pancreas, small intestine

Alanine aminotransferase. The ALT is a predominantly cytoplasmic enzyme that is expressed more strongly in periportal than in centrilobular hepatocytes. ALT is a more specific marker of liver injury than AST, since it occurs nearly exclusively in the liver (Table 49.4). ALT is also more sensitive than AST in indicating deranged hepatocellular integrity, and is released into the circulation prior to AST, already in milder forms of liver injury. *ALT activity is the most widely used laboratory test for the recognition of liver disease.* However, as already mentioned, the serum concentration of aminotransferases neither reliably indicates the severity of liver damage nor does it allow for predicting outcome. In acute liver injury, however, there is some correlation between the level of aminotransferase activity in serum and the extent of liver damage; with the continuing decrease in functioning liver cell mass, the concentration of aminotransferases in serum also declines. Thus the rapid “normalization” of highly elevated serum aminotransferases in fulminant liver failure does not indicate a swift recovery, but is rather an ominous sign that mirrors the massive loss of hepatic parenchyma. The low aminotransferase level in this case points to the relatively few hepatocytes remaining that are able at all to release enzymes. Therefore, in acute liver failure markedly increased aminotransferases that normalize within a few days portend a poor prognosis.

Aminotransferase concentrations near the lower limit of normal are not uncommon in advanced, “burnt out” cirrhosis. In addition, chronic liver injury leads to a reduced synthesis of ALT.

Aspartate aminotransferase. 80% of AST is located in the mitochondria and 20% in the cytoplasm. The AST is distributed uniformly throughout the liver lobule. AST is less organ specific than ALT and occurs in decreasing concentration in the liver, heart, skeletal muscle, kidneys, brain, pancreas, lungs, white and red

blood cells (Table 49.4). In contrast to ALT, the synthesis of AST is not restricted in chronic liver disease.

Selected hepatobiliary disorders that are associated with elevated aminotransferase levels and the approximate height of enzyme increase are listed in Tables 49.5 and 49.6. The highest increases in aminotransferase concentrations are seen in acute viral, toxin- or drug-induced, and in ischemic liver injury, conditions that are characterized by extensive loss of hepatic parenchyma.

De Ritis Quotient. The ratio of AST to ALT is known as the De Ritis quotient. It was originally used to distinguish aminotransferase elevations of the “inflammation type” (de Ritis < 0.7) from the “necrosis type” (De Ritis > 0.7) [9]. However, the determination of this ratio has lost its original relevance. Nowadays the De Ritis quotient is mostly of historical interest with perhaps the exception of alcoholic hepatitis, in which a quotient > 2 may aid in distinguishing this entity from other diagnoses. Nonetheless, the comparison between the relative increases in ALT and AST and that of aminotransferase concentration to the concentration of cholestasis-indicating enzymes (e.g. alkaline phosphatase) provides differential diagnostic clues, and therefore still today retains its value.

Glutamate Dehydrogenase. GLDH is located exclusively in the mitochondrial matrix of centrilobular hepatocytes. The enzyme is largely liver specific, though it also occurs in lower concentrations in heart and skeletal muscle, as well as in the kidneys. Due to its large molecular mass and its mitochondrial localization, GLDH is released only in relatively severe liver injury that also involves the mitochondria. The strict topographic localization of the enzyme in acinar zone 3 provides a clue to the causes of GLDH elevation in serum and confers a special differential diagnostic importance to GLDH. GLDH activities in serum rise in conditions associated with centrilobular liver damage, such as circulatory disturbances with acute venous congestion or severe hypotension in circulatory shock, sepsis, and toxin- and drug-induced liver damage (e.g. carbon tetrachloride, acetaminophen and alcohol). In addition, transient extrahepatic cholestasis, such as during the passage of a common bile duct stone through the papilla, is initially “felt” by centrilobular hepatocytes. Therefore, GLDH is a diagnostically helpful “early enzyme”. It rises acutely in the first hours of strain (circulatory, toxic, cholestatic) to centrilobular hepatocytes and returns to normal after approximately 3–4 days.

Table 49.5 Selected hepatobiliary diseases with increased aminotransferase activities in serum

Disease category/Disease	Complementary investigations (selection)
Infectious	
Acute and chronic viral hepatitis	Anti HAV-IgM, HBsAg, anti HBe-IgM, HBeAg, anti HBe, anti HDV, anti HEV, anti HCV, HBV-DNA, HCV-RNA
Liver abscess	US, amebic serology
Echinococcosis	US, echinococcal serology
Inflammatory reaction	EBV-, CMV-serology
Metabolic	
α_1 -Antitrypsin-Deficiency	Serum electrophoresis, α_1 -antitrypsin-phenotyping
Hereditary Hemochromatosis	Transferrin saturation, ferritin, HFE-gene mutation, (liver-iron-index)
Wilson's disease	Urinary Cu, ceruloplasmin in serum
Glycogenoses	Liver biopsy with EM-examination
Galactosemia	Enzymatic analysis: Galactose-1-P-Uridyl-Transferase in erythrocytes and leucocytes
Fructose intolerance	Genetic analysis of aldolase B
Cystic fibrosis	AP; sweat Cl^- test, genetic testing, CFTR Cl^- channels in airway epithelia
Acute and chronic porphyries	Heme precursors in urine
Nonalcoholic fatty liver	ALT > AST, US
Autoimmune	
Autoimmune hepatitis	ANA, AMA, SMA, LKM, SLA/LP
Primary-biliary cirrhosis	AMA with subtyping
Autoimmune cholangiopathy	ANA, liver biopsy
Primary sclerosing cholangitis	pANCA, MRCP, (ERCP)
Drug-induced/toxic	
Drugs	Acetaminophen level. Think of herbs!
Alcohol	Fall of elevated γ -GT levels during abstinence from alcohol
Vascular	
Right heart failure	INR, Bilirubin,
Constrictive pericarditis	GLDH, US, CT, MRI
Budd-Chiari syndrome	
Veno-occlusive-disease	
Ischemic "hepatitis" (shock liver)	
Biliary	
Cholangitis	AP and γ -GT; Bilirubin; US, ERC
Choledocholithiasis	US, EUS, MRC, ERCP
Acute biliary obstruction	Early and short-lived increase in aminotransferases and GLDH
Neoplastic	
Primary (benign, malignant)	AP, US, CT, MRI, liver biopsy
Secondary (metastases, lymphoma)	
Paraneoplastic	
Hodgkin's disease	Cholestatic pattern without infiltration of the liver by primary malignancy
Renal cell carcinoma	
Other causes	
Sarcoidosis	ACE, liver biopsy
Amyloidosis	SAA, liver biopsy
Langerhans cell histiocytosis	Liver biopsy (immunostaining: CD1 antigen on the cell surface and S-100 protein in the cytoplasm; EM: Birbeck granules)

Acute Viral Hepatitis A and B. Aminotransferase levels in serum in uncomplicated acute hepatitis A and B can reach values well above 1,000 U/L, with ALT concentration being higher than AST activity. The decline of

aminotransferase level typically is slow and gradual over several weeks. A rapid, precipitous fall within several days is prognostically unfavourable, indicating "exhaustion" of the liver with possible impending fulminant liver

Table 49.6 Aminotransferase concentrations in serum (expressed as multiple of ULN) in various liver diseases^a

Very high enzyme increases (> 15-fold the ULN)
Acute viral hepatitis
Toxin- or drug-induced liver damage
Ischemic/hypoxic liver damage (shock liver)
Fulminant Wilson's disease
Heat stroke
Malignant hyperthermia
Moderate enzyme increases (5- to 15-fold the ULN)
Acute viral hepatitis
Resolving acute viral hepatitis
Chronic hepatitis B (\pm D) and C
Hepatitis in EBV-, CMV-, and HSV-infection
Autoimmune hepatitis
Drug-induced hepatitis
Alcoholic hepatitis
Acute biliary obstruction ^b
Cocaine abuse
Hereditary hemochromatosis
Wilson's disease
Mild enzyme increases (\leq 5-fold the ULN)
Liver cirrhosis
Nonalcoholic steatosis and steatohepatitis
Cholestatic liver disease
Chronic hepatitis B (\pm D) and C
Hereditary hemochromatosis
Wilson's disease
α_1 -antitrypsin deficiency
Liver tumors
Celiac disease
Inflammatory bowel disease
Addison's disease
Hyper- and hypothyroidism

^a The reported multiples of ULN are approximate values. Overlapping is common.

^b Aminotransferase increase is short-lived (accompanied by a rise in GLDH) and precedes elevation of AP and γ -GT.

failure. In this situation monitoring parameters of hepatic synthetic capacity (e.g. prothrombin time) is suggested.

Chronic Viral Hepatitis B and C. When the inflammatory process of acute viral hepatitis B and C after 6 months merges into chronic hepatitis, aminotransferase levels generally are < 100 U/L. The ratio of ALT: AST is approximately 1, though the AST is usually slightly higher than ALT. An HBV infection is diagnosed by demonstrating HBsAg and anti-HBc. The presence of HBeAg in serum argues for continued viral replication and infectivity. Even if HBeAg is not present, however, occult HBV infection may be present in some cases. In these cases HBV-DNA or DNA-polymerase in serum should be determined. The detection of viral genome sequences in liver tissue is

still reserved for scientific research purposes and is not routinely available. Antibodies against HBsAg and HBcAg indicate immunity against HBV. If this antibody constellation is present, other causes for enzyme elevation should be investigated.

Currently, antibodies against HCV can be detected with a sensitivity of 92–97%. Prior to initiating therapy in anti-HCV positive patients, viral load (quantitative HCV-RNA) and genotype are determined, and in selected cases a liver biopsy is performed.

Autoimmune Hepatitis. The diagnosis of AIH initially requires the exclusion of all other causes of necroinflammation, and then demonstrating certain autoantibody profiles in serum (Chapters 36 and 72). Serum electrophoresis showing a polyclonal hypergammaglobulinemia in more than 80% of patients with AIH is suited as a simple screening test for AIH.

Cirrhosis. If the necroinflammatory process in a cirrhotic liver “burns out” and liver injury does not progress further, the aminotransferase levels are usually normal or may even be near the lower limit of normal.

Ischemic Hepatitis. Although referred to as ischemic “hepatitis” (IH), ischemic liver injury does not cause a true hepatitis. Patients with IH typically show a rapid and very high rise (several thousands U/L) of ALT, AST and LDH (often > 5,000 U/L) concentrations in serum which rapidly return to normal within a few days (Fig. 49.1). The determination of GLDH helps to localize liver injury

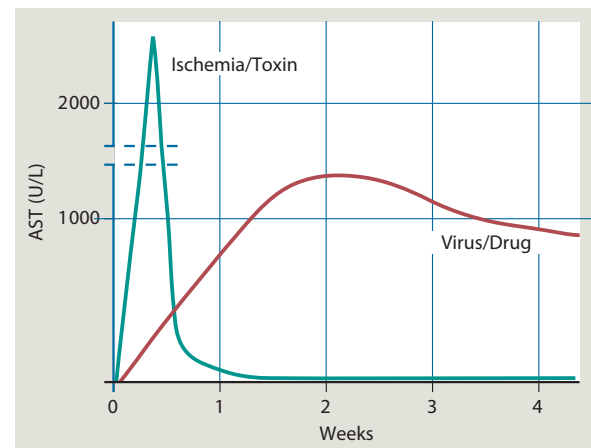


Fig. 49.1 Schematic representation of the time course of the rate of change of aminotransferase levels in ischemic or toxic liver injury compared to liver damage caused by drugs or in acute viral hepatitis. The ischemic and toxic damage begins abruptly and leads to a very high, but short-lived increase in aminotransferase levels. Drug-induced and viral liver disease usually develops over several days to weeks, and then slowly abates

to the center of the lobule. Despite the massive increase in aminotransferase concentrations, liver injury often runs a subclinical course in these severely ill patients (e.g., sepsis, extensive burns, decompensated heart failure, severe trauma, heat stroke), with the dysfunction of other organs being clinically more apparent than liver involvement. Prognosis depends on the underlying illness.

Alcoholic Hepatitis. In alcoholic hepatitis (AH), in contrast to acute viral hepatitis and nonalcoholic steatohepatitis, AST levels are typically higher than ALT concentrations (AST:ALT > 2) [6]. Generally the enzymes in AH are only moderately elevated. The AST seldom exceeds 8–10 × the ULN, and the ALT 5 × the ULN, whereas in severe acute alcoholic hepatitis the serum bilirubin can rise dramatically. The ALT levels may even be normal in alcoholic liver disease, and thus *a normal ALT concentration in serum does not exclude alcoholic liver damage*. This pattern is thought to be the result of two mechanisms. Chronic alcoholics often are deficient in pyridoxal 5'-phosphate (vitamin B₆) which is a necessary coenzyme for both ALT and AST synthesis, and deficiency of pyridoxal 5'-phosphate decreases ALT synthesis to a greater extent than AST synthesis [10]. In addition, alcohol itself induces the synthesis and release of mitochondrial AST, thereby increasing the AST:ALT ratio. The increase in mitochondrial AST is typical for alcoholic liver disease and may be demonstrated by measuring AST-isoenzymes, though this is not necessary in clinical practice.

Of practical importance in alcoholic liver disease is γ -GT. Increased γ -GT concentration is a sensitive but non-specific parameter of alcoholic liver disease. For practical purposes the *decline of elevated γ -GT activities during abstinence from alcohol* is more specific in this regard.

Although alcohol is a very frequent cause of liver disease, one should not forget to look also for other etiologies of liver damage in a patient with alcoholic liver injury, since often several morbid conditions coexist in the alcoholic, primarily chronic hepatitis B and C, obesity and diabetes mellitus. In a large, national, population-based study overweight and obesity increased the risk of alcohol-related abnormal aminotransferase activity [41].

Nonalcoholic Fatty Liver Disease. Bland steatosis of the liver is associated with only mild elevation of aminotransferase levels (usually < 70 U/L). In NASH aminotransferase concentrations are slightly higher but

still generally < 100 U/L. In contrast to AH, serum *ALT levels are typically higher than AST levels*. As liver fibrosis progresses, however, the AST level in patients with NASH increases, and once cirrhosis develops often is higher than the ALT level. Thus a reversal of the ALT:AST ratio in a patient with NAFLD with AST > ALT should be viewed as an expression of progressive fibrosis. This phenomenon likely results from increased mitochondrial damage with advancing liver disease and decreased hepatic clearance of AST [16].

Hereditary Hemochromatosis. The aminotransferase levels in HH are only mildly elevated. The diagnosis is based on parameters of iron metabolism (e.g. transferrin saturation > 45%) and on mutations of the HFE-gene. An iron-index in the liver biopsy > 1.9 hints towards HH as the cause of iron overload (Chapters 30 and 82).

Wilson's Disease and α_1 -Antitrypsin Deficiency. Aminotransferase levels are only mildly increased in WD and in α 1ATD. Diminished ceruloplasmin concentrations in serum (in 85% of patients with WD) and increased excretion of copper (> 100 μ g) in 24 h urine argue for WD. Determining copper concentration in a liver biopsy specimen (> 250 μ g/g dry weight) can confirm the diagnosis (Chapter 81).

α 1ATD should be considered whenever the α -globulin-band is missing on serum electrophoresis. The diagnosis can be confirmed by measuring directly α_1 -antitrypsin in serum. In interpreting α_1 -antitrypsin values one should consider that α_1 -antitrypsin is an acute phase reactant. It can be elevated even in patients with α_1 -antitrypsin deficiency in the context of an acute inflammatory reaction. Therefore α_1 -antitrypsin-phenotyping should be performed.

Drugs and Toxins. Nearly all drugs are able to cause an increase in liver enzymes (Chapter 92). A typical drug-induced pattern, however, does not exist, and hepatic, cholestatic and mixed drug reactions all occur. More important than laboratory parameters in drug-induced liver injury is a detailed history with a correlation between liver damage and the intake of foreign compounds. The resolution of abnormal liver enzymes after discontinuing the incriminated drug is of paramount diagnostic importance. One should, however, be aware that drug-induced liver injury may occur without an apparent reason after long-term use of a medication hitherto well tolerated, and in rare cases may also appear after a drug has been discontinued (e.g. amoxicillin-clavulanic acid). Frequent

causes of drug-induced liver injury are nonsteroidal anti-inflammatory compounds, antibiotics, anticonvulsive medication, and lipid lowering drugs (e.g. inhibitors of HMG-CoA-reductase). Liver damage by so called “natural” compounds, such as herbs that most persons even do not regard as drugs, is well documented. Anabolic steroids and toxins such as cocaine, ecstasy, toluene containing glues (“sniffer”), solvents with trichloroethylene, and chloroform are known hepatotoxins.

Nonhepatic Causes. Finally one must consider extrahepatic conditions as causes of elevated aminotransferase levels (Tables 49.7 and 49.8). *Macroenzymes* are generated by enzyme-immune-complex formation or by oligomerization. They increase the molecular weight and decrease clearance of circulating enzymes. *Type I macroenzymes* are generated by formation of antigen (enzyme)-antibody complexes. They have been described for ALT, AST, γ -GT and AP. *Type II macroenzymes* are formed by oligomerization, adsorption to membrane constituents or to other serum components. They have been described for AP, γ -GT, LAP and 5'-NT [47]. *Celiac disease* may be found in approximately 5–10% of patients with unexplained elevation of aminotransferase levels, even without gastrointestinal symptoms [2, 29, 50]. Histologically most patients with celiac disease and elevated aminotransferase levels show mild steatosis and minimal inflammatory changes, with no relation of aminotransferase levels to the degree of steatosis. The diagnosis is made by demonstrating antibodies against tissue transglutaminase. However, the efficacy of screening for celiac disease in this population by anti-tissue transglutaminase (anti-tTG) may be impaired by the high rate of positive anti-tTG found in chronic liver disease. Therefore, in cases of a positive anti-tTG these patients should be evaluated also by endoscopy and duodenal biopsy [29]. Especially in pediatric celiac disease patients hypertransaminasemia may be the sole manifestation of celiac disease [13]. Aminotransferases return to normal levels in many patients after 6–12 months on a gluten-free diet.

Mild abnormal hepatic biochemistries (aminotransferases and AP) may be found in up to one third of patients with *inflammatory bowel disease*, with surprisingly no association between IBD activity and abnormal liver enzymes. Trivial abnormalities in hepatic biochemistries in IBD patients should therefore not be attributed to IBD activity and may have a negative impact in the long-term prognosis of patients with IBD [31].

Table 49.7 Extrahepatic causes of elevated serum aminotransferase levels

Myocardial infarction
Persistent tachycardia
Pulmonary embolism
Muscle disease
• Hereditary (dystrophies, metabolic abnormalities)
• Acquired (myositis, traumatic rhabdomyolysis ^a , cramps)
Hyper- and hypothyroidism
Addison's disease
Hypothalamic-hypophyseal dysfunction
Celiac disease
Inflammatory bowel disease
Heat stroke
Malignant hyperthermia
Strenuous physical activity (e.g. long distance run)

^a In acute rhabdomyolysis, initially the AST:ALT ratio is greater than 3, but the ratio approaches 1 after a few days because of a shorter half-life and a faster decrease of AST levels. Patients with chronic muscle disease often have roughly equal serum AST and ALT concentrations.

Table 49.8 Causes for false positive increases of liver enzymes in serum [47]^a

– Delayed separation of erythrocytes from serum and hemolysis may lead to falsely elevated aminotransferase levels
– A too long (> 2 min) venous congestion (e.g. by tourniquet) prior to taking blood samples causes an increase of AP, ALT and γ -GT levels of 8–10%
– In blood samples taken after the patient has been sitting for 15 min, enzyme levels are approximately 5–10% higher than in the recumbent position
– Two hours after an opulent meal ALT may rise by 10%, AST by 20% and also AP levels may increase markedly
– Patients with blood group O and B may release intestinal AP into the circulation after a fatty meal
– Intensive sporting activity and strenuous physical work may lead to an increase in aminotransferase levels
– Both prolonged fasting and a high protein intake may lead to a rise in aminotransferase levels
– AP and AST levels increase with age, especially in women between 40 and 65 years
– In men ALT levels decrease in old age
– Macroenzymes

^a In uremia falsely low AST concentrations may be observed [5].

Mild elevations of aminotransferase levels have been described in *endocrine disease*, such as hypo- and hyperthyroidism, hypothalamic-hypophyseal dysfunction and in Addison's disease [18]. The significance of abnormal hepatic biochemistries in these patients is unknown.

Cholestatic Pattern

The primary disturbance in cholestatic liver injury is located at the level of the excretory apparatus of the hepatocyte and/or the downstream bile ducts. Cholestatic liver damage results in a reduction in bile flow. *AP and γ -GT are the most important enzymatic indicators of cholestasis, which is characterized by an elevation of AP and γ -GT levels out of proportion to AST and ALT (Table 49.3).* LAP and 5'-NT are not liver specific though their levels increase in intra- and extrahepatic cholestasis. During pregnancy the activities of LAP and AP rise, whereas 5'-NT levels remain constant. 5'-NT can therefore substitute for AP during pregnancy. In addition, abnormal lipoproteins have been described in cholestasis. Lipoprotein X, for example, is found in 99% of patients with histologic evidence of cholestasis, and may therefore be regarded as a sensitive and specific indicator of cholestasis [42]. Lipoprotein X belongs to the LDL, but does not contain apoprotein B. Like all other laboratory parameters of cholestasis it does not allow for differentiating intra- from extrahepatic bile duct occlusion. Nowadays lipoprotein X is only of historical interest.

The addition of LAP and 5'-NT to the measurement of the activities of AP and γ -GT does not add appreciably to the sensitivity and specificity of the latter two enzymes in cholestasis. Therefore, AP and γ -GT are practically the sole liver enzymes currently used in clinical practice to diagnose cholestasis, and their activities are interpreted in the context of elevated aminotransferase and GLDH values.

A mild to moderate, short-lived increase in aminotransferase levels (ALT > AST), accompanied by a rise in GLDH activities, may also be observed in acute cholestasis due to transient biliary obstruction by a stone. The aminotransferase increase precedes the rise of cholestatic parameters. Rare cases with marked elevation in serum aminotransferases (>1,000 U/L) have been described as an atypical presentation of choledocholithiasis [33].

Though serum bilirubin will not be specifically discussed in this chapter as it is not a liver enzyme, it is routinely used in conjunction with liver enzymes in the biochemical diagnosis of cholestatic liver injury (Chapter 52).

γ -Glutamyl Transpeptidase. The γ -GT is localized in the canalicular membrane of the hepatocyte and in biliary epithelial cells. In addition, the enzyme is found in the kidneys, pancreas and small intestine. An increased γ -GT serum concentration is a sensitive but non-specific indicator of hepatobiliary disease. On the other hand,

normal γ -GT activity has a very high negative predictive value for the presence of liver disease [51].

Increased levels of γ -GT are not necessarily due to cell damage, but may also be caused by increased synthesis due to enzyme induction with subsequent release from the cell membrane by the detergent action of bile acids. Isolated elevation of γ -GT concentration without any evidence of liver disease indicates induction of the microsomal enzyme system. The most frequent causes for enzyme induction are alcohol abuse, drugs (e.g., phenytoin, barbiturates), and metabolic diseases such

Table 49.9 Causes of elevated serum alkaline phosphatase

Hepatobiliary

- Extrahepatic cholestasis (e.g. CBD stones or strictures)
- Primary biliary cirrhosis
- Primary sclerosing cholangitis
- Autoimmune hepatitis
- Autoimmune cholangitis
- Sarcoidosis
- AIDS-cholangiopathy
- Biliary ductopenias
- Bile ductular hyperplasia
- Benign recurrent intrahepatic cholestasis
- Progressive familial intrahepatic cholestasis
- Cholestasis of pregnancy
- Langerhans cell histiocytosis
- Amyloidosis
- Space occupying lesions
- Medications (see Table 49.10)
- Venous congestion
- Sepsis
- Total parenteral nutrition

Osseous

- Physiologic increase during growth period
- Bone metastases with osteoblastic reaction^a
- Fracture healing
- Paget's disease

Intestinal

- Celiac disease
- Intestinal ischemia
- Patients with blood group O and B after a fatty meal

Endothelial

- Active generation of granulation tissue

Placental

- Last trimester of pregnancy
- Some parenteral albumin preparations

Others

- Hyperthyroidism
- Benign transient hyperphosphatemia
- Primary hyperparathyroidism

^a Note that in multiple myeloma serum AP is typically normal (no osteoblastic reaction).

Table 49.10 Medications that can cause elevations of serum alkaline phosphatase (Adapted from [17])

Anabolic steroids	Flucloxacillin
Allopurinol	Fluphenazine
Amoxicillin-clavulanic acid	Imipramine
Captopril	Indinavir
Carbamazepine	Nevirapine
Chlorpropamide	Methyltestosterone
Cyproheptadine	Quinidine
Diltiazem	Tolbutamide
Estrogens	Total parenteral hyperalimentation
Floxuridine	Trimethoprim-sulfamethoxazole

as obesity, type 2 diabetes mellitus and hyperlipidemia. However, *in up to one third of cases the etiology of an isolated elevation of γ -GT remains unexplained.* In 6% of the healthy male population serum γ -GT concentration is above the upper limit of normal. *A mild increase of γ -GT activity in serum (< 100 U/L) in an asymptomatic patient with otherwise normal liver chemistries should not prompt an extensive diagnostic work up.*

Very often in clinical practice γ -GT is wrongfully considered as a marker of alcohol consumption. Fewer than 50% of chronic alcoholics have pathologic γ -GT serum levels. As a matter of fact, in approximately one out of two patients with elevated γ -GT levels increased alcohol consumption is the culprit; this, however, also means that elevation of γ -GT concentration in approximately 50% of cases is not due to alcohol. With regard to alcoholic liver disease, the decline of initially increased γ -GT activity during abstention from alcohol is a more powerful indicator of the etiologic role of alcohol in elevation of γ -GT than the height of γ -GT level per se.

Long-lasting, mild increases of γ -GT and ALT in asymptomatic patients have been described both in isolated bile ductular hyperplasia and in idiopathic biliary ductopenia [32, 45]. These diagnoses can only be confirmed by histology.

Elevated serum levels of γ -GT in patients with chronic hepatitis C have been associated with progressive liver fibrosis.

Among nonhepatic causes for elevated γ -GT levels are pancreatic diseases, myocardial infarction, renal failure and chronic obstructive lung diseases.

Alkaline Phosphatase. The most important sources of AP are the liver, bones and intestine. Physiologic increases of AP levels in serum occur in children and adolescents during the growth phase (AP source: bone), and in the last trimester of pregnancy (AP source: placenta). Release of intestinal AP after a fatty

meal is increased in persons with blood groups O and B. Normal AP level is age-dependent; it increases, especially in women, between 40 and 65 years. Thus, the AP concentration in serum of a healthy 65 year old woman usually is approximately 50% higher compared to that of a healthy 30 year old woman [47].

The first question in an asymptomatic patient with elevated AP levels should address the source of AP. To answer this question an electrophoretic separation of AP isoenzymes will rarely be necessary in clinical practice. In an asymptomatic patient with only a mild elevation of AP (less than 50% above the upper limit of normal) and all other liver enzymes within normal limits, a further diagnostic work up initially is not necessary and the AP values should be repeated after approximately 3 months. If γ -GT or 5'-NT levels are concomitantly elevated with AP, for clinical purposes it may be assumed that AP originates from the liver. If liver AP levels remain elevated, imaging (e.g. US, CT, MRI, MRCP, ERCP) and immune-serologic investigations (e.g. AMA, ANA, SMA, pANCA, viral serologies) should be performed, in order to clarify whether a cholestatic and/or infiltrative disorder is present.

The sensitivity of AP for bile duct disease is approximately 80–90%. The increase of AP levels in cholestatic hepatobiliary disease is mostly due to an enhanced release of canalicular AP by the detergent action of bile acids.

If increased AP and γ -GT levels out of proportion to aminotransferase concentrations persist over a longer time period, a chronic cholestatic hepatobiliary disease may be assumed with a high probability. First and foremost PBC, PSC, and drug-induced liver injury should be ruled out. Similar enzyme patterns in serum may also be present in autoimmune cholangitis, cholestatic autoimmune hepatitis (overlap syndromes), AIDS-cholangiopathy, sarcoidosis of the liver and other granulomatous liver disorders, Langerhans cell histiocytosis (histiocytosis X) and ductopenias.

Isolated increases in AP concentration with normal γ -GT levels are observed in very rare hereditary cholestatic diseases, such as PFIC, BRIC and the hereditary disturbances in bile acid synthesis (Chapters 7, 52 and 85).

Various causes of AP elevations in serum are listed in [Tables 49.9 and 49.10](#).

Bile Acids. Bile acids in serum have an excellent sensitivity and specificity in demonstrating cholestasis though they cannot differentiate intra- from extrahepatic cholestasis [44]. Measurement of bile acids in clinical practice, however, is not routine, and this test has little role in evaluating a patient with suspected cholestasis.

Infiltrative Pattern

An infiltrative injury is present whenever liver tissue is “strained” by the deposition of foreign material, or is replaced or displaced by space occupying lesions. This pattern occurs predominantly with fat and iron overload, granulomas, and both primary and metastatic tumors. A characteristic enzymatic pattern of infiltrative liver lesions does not exist and diagnosis is based on noninvasive imaging and on liver biopsy. In the majority of cases only a mild elevation of AP and γ -GT levels is seen. Depending on whether the infiltrative lesion(s) will elicit an inflammatory reaction or will lead to a displacement of bile ducts a more hepatitic, cholestatic or mixed enzymatic pattern will prevail. In other words, in every patient

Table 49.11 Diagnostic sensitivity, specificity and predictive values of ALT, γ -GT and ChE in detecting hepatobiliary disease in a patient population with an a priori probability of liver disease of 8% [51]

	ALT	γ -GT	ChE
Diagnostic sensitivity (%)	83	95	75
Diagnostic specificity (%)			
• In relation to patients with a healthy liver	84	74	75
• In relation to healthy persons	98	96	-
Positive predictive value	31 ^a	25	21
Negative predictive value	98 ^a	99 ^a	97

^a Only one out of three patients with increased ALT levels has a discrete hepatobiliary disease. On the other hand, normal levels of ALT and γ -GT exclude liver disease with a high probability.

with abnormal liver chemistries infiltrative hepatic lesions must be excluded. However, liver enzymes may remain normal even with extensive infiltration of the liver by metastases.

General Approach to the Patient with Elevated Liver Enzymes

The diagnostic evaluation of a patient with elevated liver enzymes is a common clinical challenge. Although various algorithms are found in many texts, no one is all-encompassing and able to highlight all the diagnostic considerations required. *Diagnosis of liver disease along fixed algorithmic lines is not possible.* Therefore, rather than proceeding along rigid, prefabricated algorithmic pathways one should ask the right questions and interpret the data in the clinical context. One should aim to arrive at a diagnosis with simple and possibly noninvasive means, avoiding extensive (over) examinations in otherwise healthy people, despite elevated liver enzymes [15, 37].

Important questions to be asked with respect to the diagnostic interpretation of elevated liver enzymes are

- In which clinical context does elevation of liver enzymes occur?
- What is the gender, ethnic background, and occupation of the patient?
- Is the patient asymptomatic or symptomatic?

Table 49.12 Histologic findings in patients with unexplained elevations of aminotransferase levels

	Hulcrantz et al. (1986) n = 149	Hay et al. (1989) n = 47		Daniel et al. (1999) n = 81		Berasain et al. (2000) n = 109		Skelly et al. (2001) ^c n = 354	
Steatosis	64%	CAH	37%	Steatosis	50,5%	Nonspecific alterations	32,7% ^a	NASH	34%
CAH	10%	CAH + cirrhosis	35%	Steatohepatitis	32%	NASH	15,8% ^a	Steatosis	32%
CPH	10%	Steatohepatitis	21%	Steatosis + fibrosis	5%	Chronic hepatitis/cirrhosis	51,5% ^b	Other causes	
Cirrhosis	6%	Other causes	6%	Steatosis + cirrhosis	2,5%			Cryptogenic hepatitis	
α ATD	4%	PSC		Normal histology	10%			Drugs	
HH	3,5%	Septal fibrosis						PBC, PSC	
Other causes	3,5%	Biliary obstruction						Autoimmune hepatitis	
Schistosomiasis								Alcoholic liver disease	
Sarcoidosis								Hemochromatosis	
Collagen vascular disease								Amyloidosis	
No diagnosis								Glycogenosis	

^aHBV-DNA or HCV-RNA present in 14.3% of cases.

^bHBV-DNA or HCV-RNA present in 30.7% of patients with chronic hepatitis and in 61.5% of those with cirrhosis.

^cIn 18% of patients the histologic finding changed management strategy.

- Are elevated enzyme levels an incidental finding or do they occur in an ill patient?
- Do the laboratory abnormalities occur in an ambulatory or a hospitalized patient?
- Are enzyme elevations acute (<6 months) or chronic (>6 months)?
- Are there risk factors for infection with hepatitis viruses?
- Which enzymatic pattern of injury is present: hepatocellular/hepatitic, cholestatic or mixed?
- Do elevated liver enzymes reflect a distinct liver disease or a hepatic reaction to disorders of other organs? Are there signs of extrahepatic disease?
- Does the patient present signs of chronic liver disease?
- Does the patient have features of the metabolic syndrome (e.g. impaired glucose tolerance, diabetes mellitus, overweight/obesity, increased waist to hip ratio, hyperlipidemia, arterial hypertension)?
- Is the patient exposed to foreign compounds, especially medications (think of herbs!), drugs, and toxins, such as alcohol?
- What is the significance of the diagnosis with regard to prognosis and treatment?

The answers to these questions in most clinical situations will provide a sound framework for further diagnostic work-up and will prevent overdiagnosis and the use of unnecessary invasive procedures. Among the most important initial questions that will direct further action are (1) the presence of signs and symptoms of chronic liver disease, (2) risk factors for viral hepatitis (3) whether the patient is diabetic, obese, and (4) if he or she consumes alcohol or takes medications. The prevalence of elevated ALT is 3–4 times higher in patients with either type 1 or type 2 diabetes mellitus than in the general population [52]. In an asymptomatic patient with negative answers to these questions the probability of a significant liver disease is very low, even in the presence of elevated aminotransferases. Very often during follow-up ALT levels drop to normal in asymptomatic patients and no further examinations are necessary [48]. Furthermore it should be kept in mind that the statistical definition of the normal range (mean \pm SD) implies that 5% of the normal population will have a priori “pathological” liver enzymes, 2.5% below the lower limit of normal, and 2.5% above the upper limit of normal.

Permanently elevated aminotransferases in asymptomatic patients are not necessarily due to liver

disease. Therefore before initiating an extensive and elaborate diagnostic work-up, various causes of elevated liver enzymes that may mimic liver disease, such as the presence of macroenzymes, extrahepatic causes, and false positive increases of liver enzyme concentrations should be considered (Tables 49.7 and 49.8). Extrahepatic sources of AP should be considered, and the hepatic origin of an elevated AP should be confirmed with γ -GT. Usually there is no need to measure AP-isoenzymes.

Elevated liver enzymes occur in nearly one out of three to four hospitalized patients at one point or another during the hospital stay. However, the frequency of clinically significant and unexpected liver disease in these patients is less than 5%. The frequency of severe liver disease in patients with only slightly elevated liver enzymes depends, among other factors, on the prevalence of liver disorders in the respective patient population and on patient selection. It is obvious that patients with the same degree of aminotransferase elevation will have different underlying disorders depending on whether they are studied in a general practice, a community hospital, a referral center for liver disease, or a liver transplant center. Assuming a prevalence of liver disease of 1% and provided that normal AST and ALT values include 95% of the population with a healthy liver, fewer than 20% of asymptomatic persons with mild elevations of aminotransferase levels will have a discrete severe liver disease. If other liver enzymes also are elevated along with aminotransferases, these abnormalities will indeed reflect discrete liver disease. The combination of ALT, γ -GT and ChE allows for a very sensitive screening for liver disease (Table 49.11). *Only every third patient with an isolated ALT-elevation has a discrete liver disease.* Conversely, normal ALT and γ -GT values exclude liver disease with a high probability. In 95% of all patients with liver disease at least one of the three parameters is in the pathologic range. This excellent sensitivity, however, is opposed by a poor specificity [51].

Elevated aminotransferase levels in serum have a different connotation in different populations. They also depend on geographical and ethnic factors. In Asia and Africa one should consider hepatitis B, schistosomiasis and malaria, while in Europe and the United States chronic hepatitis C, alcoholic and nonalcoholic fatty liver disease as well as drug-induced liver injury prevail. In Wales 50% of selected hospitalized patients with AST concentrations in serum > 400 U/L showed ischemic/hypoxic liver lesions within the context of

sepsis, right heart failure, hypoxia or hypotension. The second most common etiology, comprising 25% of this same population, was biliopancreatic disease such as cholangitis, pancreatitis, choledocholithiasis, and pancreatic carcinoma. 8.5% of patients had drug-induced liver injury and only 3.5% suffered from acute viral hepatitis [53]. These figures mirror the clinical situation in most hospitals in industrialized western countries. In contrast, hospitalized patients in Africa with AST concentrations > 400 U/L will exhibit a markedly different group of diagnoses, with infectious causes assuming a predominant role.

Even after all noninvasive diagnostic methods have been exhausted, the etiology for aminotransferase elevations in approximately 5–10% of patients will remain unexplained. In this situation liver biopsy may further clarify the cause for abnormal aminotransferases [8, 49]. In [Table 49.12](#) histological findings in patients with aminotransferase elevations of unknown cause are listed. In the era prior to the discovery of hepatitis C virus, chronic active hepatitis with and without cirrhosis predominated in this group of patients, whereas nowadays in up to two thirds of patients various degrees of hepatic steatosis are found histologically, accompanied by inflammatory changes and fibrosis. Unexplained ALT elevation in the United States is strongly associated with adiposity and other features of the metabolic syndrome, and thus represents nonalcoholic fatty liver disease. Indeed nonalcoholic fatty liver disease is part of the spectrum of the metabolic syndrome [4, 28].

However, even in patients with negative viral serologies, modern virological techniques performed on liver tissue obtained by biopsy will detect cryptic HBV and HCV infection in some patients with asymptomatic rise in aminotransferase levels of unknown etiology and minor nonspecific histologic findings [30]. Thus the optimal use of virological techniques performed on liver biopsy (presently available in research laboratories) should ideally complement the stepwise diagnostic approach to a patient with elevated aminotrasferases of unknown cause.

References

1. Adibi P, Sadeghi M, Mahsa M, et al (2007) Prediction of coronary atherosclerotic disease with liver transaminase level. *Liver Int* 27: 895–900

2. Bardella MT, Vecchi M, Conte D, et al (1999) Chronic unexplained hypertransaminasemia may be caused by occult celiac disease. *Hepatology* 29: 654–57
3. Berasain C, Betés M, Panizo A, et al (2000) Pathological and virological findings in patients with persistent hypertransaminasaemia of unknown aetiology. *Gut* 47: 429–35
4. Clark JM, Brancati FL, Diehl AM (2003) The prevalence and etiology of elevated aminotransferase levels in the United States. *Am J Gastroenterol* 98: 960–7
5. Cohen JA, Goffinet JA, Donabedian RK, et al (1976) Observations on decreased serum glutamic oxalacetic transaminase activity in azotemic patients. *Ann Intern Med* 84: 275–80
6. Cohen JA, Kaplan MM (1979) The SGOT/SGPT ratio – an indicator of alcoholic liver disease. *Digest Dis* 24: 835–8
7. Daniel S, Ben-Menachem T, Vasudevan G, et al (1999) Prospective evaluation of unexplained chronic liver transaminase abnormalities in asymptomatic and symptomatic patients. *Am J Gastroenterol* 94: 3010–4
8. De Ledinghen V, Combes M, Trouette H, et al (2004) Should a liver biopsy be done in patients with subclinical chronically elevated transaminases? *Eur J Gastroenterol Hepatol* 16: 879–83
9. De Ritis F, Coltori M, Giusti G (1972) Serum transaminase activities in liver disease. *Lancet* 1: 685
10. Diehl AM, Potter J, Boitnott J, et al (1984) Relationship between pyridoxal 5'-phosphate deficiency and aminotransferase levels in alcoholic hepatitis. *Gastroenterology* 86: 632–6
11. Elinav E, Ben-Dov IZ, Ackerman E, et al (2005) Correlation between serum alanine aminotransferase activity and age: an inverted U curve pattern. *Am J Gastroenterol* 100: 2201–4
12. Ellis G, Goldberg DM, Spooner RJ, et al (1978) Serum enzyme tests in diseases of the liver and biliary tree. *Am J Clin Path* 70: 248–58
13. Farre C, Esteve M, Curcoy A, et al (2002) Hypertransaminasemia in pediatric patients celiac disease patients and its prevalence as a diagnostic clue. *Am J Gastroenterol* 97: 3176–81
14. Fraser A, Ebrahim S, Smith GD, et al (2007) A comparison of associations of alanine aminotransferase and gamma-glutamyltransferase with fasting glucose, fasting insulin, and glycated hemoglobin in women with and without diabetes. *Hepatology* 46: 158–65
15. Giannini EG, Testa R, Savarino V (2005) Liver enzyme alterations: a guide for clinicians. *CMAJ* 172: 367–79
16. Goessling W, Friedman LS (2005) Increased liver chemistry in an asymptomatic patient. *Clin Gastroenterol Hepatol* 3: 852–8
17. Green RM, Flamm S (2002) AGA technical review on the evaluation of liver chemistry tests. *Gastroenterology* 123: 1367–84
18. Gurakuqi GC, Stadlbauer V, Stepan V, et al (2006) Addison's disease as a rare cause of chronically elevated liver enzymes. *Z Gastroenterol* 44: 179–83
19. Hay JE, Czaja AJ, Rakela J, et al (1989) The nature of unexplained chronic aminotransferase elevations of a mild to moderate degree in asymptomatic patients. *Hepatology* 9: 193–7
20. Hulcrantz R, Glaumann H, Lindberg G, et al (1986) Liver investigation in 149 asymptomatic patients with moderately

- elevated activities of serum aminotransferases. *Scand J Gastroenterol* 21: 109–13
21. Ioannou GN, Weiss NS, Boyko EJ, et al (2005) Contribution of metabolic factors to alanine aminotransferase activity in persons with other causes of liver disease. *Gastroenterology* 128: 627–35
 22. Ioannou GN, Boyko EJ, Lee SP (2006) The prevalence and predictors of elevated serum aminotransferase activity in the United States in 1999–2002. *Am J Gastroenterol* 101: 76–82
 23. Kamath PS (1996) Clinical approach to the patient with abnormal liver test results. *Mayo Clin Proc* 71: 1089–96
 24. Kew MC (2000) Serum aminotransferase concentration as evidence of hepatocellular damage. *Lancet* 355: 591–2
 25. Kim HC, Nam CM, Jee SH, et al (2004) Normal serum aminotransferase concentration and risk of mortality from liver diseases: prospective cohort study. *BMJ* 328: 983
 26. Klatsky AL, Morton C, Udaltsova N, et al (2006) Coffee, cirrhosis, and transaminase enzymes. *Arch Intern Med* 166: 1190–5
 27. Kundrotas LW, Clement DJ (1993) Serum alanine aminotransferase (ALT) elevation in asymptomatic US Air Force basic trainee blood donors. *Dig Dis Sci* 38: 2145–50
 28. Liangpunsakul S, Chalasani N (2005) Unexplained elevations in alanine aminotransferase in individuals with the metabolic syndrome: results from the third National Health and Nutrition Survey (NHANES III). *Am J Med Sci* 329: 111–6
 29. Lo Iacono O, Petta S, Venezia G, et al (2005) Anti-tissue transglutaminase antibodies in patients with abnormal liver tests: is it always coeliac disease? *Am J Gastroenterol* 100: 2472–7
 30. Madan K, Batra Y, Panda SK, et al (2004) Role of polymerase chain reaction and liver biopsy in the evaluation of patients with asymptomatic transaminitis: implications in diagnostic approach. *J Gastroenterol Hepatol* 19: 1291–9
 31. Mendes FD, Levy C, Enders FB, et al (2007) Abnormal hepatic biochemistries in patients with inflammatory bowel disease. *Am J Gastroenterol* 102: 344–50
 32. Moreno A, Carreno V, Cano A, et al (1997) Idiopathic biliary ductopenia in adults without symptoms of liver disease. *N Engl J Med* 336: 835–8
 33. Nathwani RA, Kumar SR, Reynolds TB, et al (2005) Marked elevation in serum transaminases: an atypical presentation of choledocholithiasis. *Am J Gastroenterol* 100: 295–8
 34. Pendino GM, Mariano A, Surace P, et al (2005) Prevalence and etiology of altered liver tests: a population-based survey in a Mediterranean town. *Hepatology* 41: 1151–9
 35. Pourshams A, Malekzadeh R, Monavvari A, et al (2005) Prevalence and etiology of persistently elevated alanine aminotransferase levels in healthy Iranian blood donors. *J Gastroenterol Hepatol* 20: 229–33
 36. Prati D, Taioli E, Zanella A, et al (2002) Updated definitions of healthy ranges for serum alanine aminotransferase levels. *Ann Intern Med* 137: 1–10
 37. Pratt DS, Kaplan MM (2000) Primary care: evaluation of abnormal liver -enzyme results in asymptomatic patients. *N Engl J Med* 342: 1266–71
 38. Ruhl CE, Everhart JE (2003) Determinants of the association of overweight with elevated serum alanine aminotransferase activity in the United States. *Gastroenterology* 124: 71–9
 39. Ruhl CE, Everhart JE (2003) Relation of elevated serum alanine aminotransferase activity with iron and antioxidant levels in the United States. *Gastroenterology* 124: 1821–9
 40. Ruhl CE, Everhart JE (2005) Coffee and caffeine consumption reduce the risk of elevated serum alanine aminotransferase activity in the United States. *Gastroenterology* 128: 24–32
 41. Ruhl CE, Everhart JE (2005) Joint effects of body weight and alcohol on elevated serum alanine aminotransferase in the United States population. *Clin Gastroenterol Hepatol* 3: 1260–8
 42. Seidel D, Gretz H, Ruppert C (1973) Significances of LP-X test in differential diagnosis of jaundice. *Clin Chem* 19: 86–90
 43. Skelly MM, James PD, Ryder SD (2001) Findings on liver biopsy to investigate abnormal liver function tests in the absence of diagnostic serology. *J Hepatol* 35: 185–9
 44. Skrede S, Solberg HE, Blomhoff JP (1978) Bile acids measured in serum during fasting as a test for liver disease. *Clin Chem* 24: 1095–9
 45. Sonzogni A, Colloredo G, Fabris L, et al (2004) Isolated idiopathic bile ductular hyperplasia in patients with persistently abnormal liver function tests. *J Hepatol* 40: 592–8
 46. Stranges S, Dorn JM, Muti P, et al (2004) Body fat distribution, relative weight, and liver enzyme levels: a population-based study. *Hepatology* 39: 754–63
 47. Thomas L, Stein W (1998) Enzyme. In: Thomas L (ed), *Labor and Diagnose. Indikation und Bewertung von Laborefunden für die medizinische Diagnostik*, 5th. edn, TH-Books Verlagsgesellschaft, pp. 29–102, Frankfurt/Main
 48. Torezan-Filho MA, Alves VA, Neto CA, et al (2004) Clinical significance of elevated alanine aminotransferase in blood donors: a follow-up study. *Liver Int* 24: 575–81
 49. Van Ness MM, Diehl AM (1989) Is liver biopsy useful in the evaluation of patients with chronically elevated liver enzymes? *Ann Int Med* 111: 473–8
 50. Volta U, De Franceschi L, Lari F, et al (1998) Coeliac disease hidden by cryptogenic hypertransaminasaemia. *Lancet* 352: 26–9
 51. von Herbay A, Strohmeyer G (1994) Die erhöhte gamma-GT – Ursachen und Interpretationen. *Dtsch med Wschr* 119: 1041–4
 52. West J, Brouil J, Gazis A, et al (2006) Elevated serum alanine transaminase in patients with type 1 or type 2 diabetes mellitus. *QJM* 99: 871–6
 53. Whitehead MW, Hawkes ND, Hainsworth I, et al (1999) A prospective study of the causes of notably raised aspartate aminotransferase of liver origin. *Gut* 45: 129–33

Approach to the Patient with Hepatomegaly 50

Henryk Dancygier and Jason N. Rogart

Chapter Outline

Determination of Liver Size	549
Etiology and Pathogenesis	550
Clinical Approach	550

The volume of the normal liver is closely related to body weight. Hepatomegaly denotes a disproportionate increase in liver volume in relation to the normal body weight. Since liver volume is not measured in clinical practice, in practical terms hepatomegaly simply signifies an increase in liver size. In this chapter we will briefly discuss some aspects of hepatomegaly as they pertain to the clinical hepatologist. It is not our intention to present a detailed and in-depth scientific discussion of the topic; for this, the interested reader is referred to the scientific literature.

Determination of Liver Size

See also Chapter 33. Measuring liver size by percussing the upper hepatic border in the sixth intercostal space and by palpating the lower liver margin below the right costal arch does not yield precise measurements, but for clinical purposes is sufficient. A more exact measurement of liver size is possible by sonographically determining the longitudinal extension of the organ in the midclavicular line (normal liver span is up to 12 ± 3 cm). The interpretation of the results should take into account the body constitution. Thus in slender people, because of a shorter ventro-dorsal distance, the lower margin of the liver often can be palpated far below the right costal arch, and the longitudinal extension on ultrasound examination may be more than 15 cm without the liver being pathologically enlarged. Measurement of liver volume by computed tomography, magnetic resonance imaging or by ultrasound is possible, however, not meaningful for clinical purposes.

Etiology and Pathogenesis

The causes of hepatomegaly are listed in [Table 50.1](#). Pathophysiologically, hepatomegaly may result from different processes that may act singly or in concert, such as

- Intracellular/interstitial edema
- Hepatocellular hyperplasia
- Intracellular deposition and storage of substances
- Extracellular deposits
- Space occupying lesions

Cell edema, seen microscopically as ballooning of liver cells, is an expression of hepatocyte injury. It occurs in acute, infectious and toxic liver disorders and is usually accompanied by an inflammatory cell infiltrate. The increased bile duct pressure in obstructive cholestasis, for example, induces the escape of fluid and solvated bile constituents into the portal tracts with subsequent portal tract edema. Disturbance of venous outflow, for example in right heart failure, constrictive pericarditis or in Budd-Chiari syndrome causes venous congestion of blood within the liver, dilatation of sinusoids with extravasation of blood, and the development of interstitial edema.

Liver cell hyperplasia occurs within the context of processes that exert a strong regenerative stimulus. Among these conditions are predominantly inflammatory and infectious disorders as well as drug- and toxin-induced liver lesions.

Excessive *intracellular storage* of different substances produces an increase in hepatocyte volume with an attendant swelling of the entire organ. Clinically, by far the most prevalent are the various forms of fatty liver with intracellular accumulation of predominantly triglycerides which may be accompanied by an inflammatory reaction. Inborn errors of metabolism, such as glycogenoses, lipidoses or α_1 -antitrypsin deficiency also should be considered. Storage phenomena in liver macrophages may also lead to hepatomegaly.

In *extracellular deposition* of substances one must consider primarily the early stages of fibrogenesis, i.e. remodeling of the extracellular matrix, which may lead to an increase in liver size. This phase of connective tissue formation generally is also accompanied by inflammatory processes, while parenchymal cells are still largely intact. While the disease process continues, the tendency of mature connective tissue to shrink prevails and the liver becomes smaller. In hepatic

Table 50.1 Causes of hepatomegaly

Metabolic/Genetic	Steatosis ^a Alcoholic cirrhosis Hemochromatosis Wilson's disease α_1 -antitrypsin deficiency Glycogen storage disease Lipidosis Mucopolysaccharidosis Amyloidosis Congenital liver fibrosis
Inflammatory/infectious	Viral hepatitis Autoimmune hepatitis Granulomatous hepatitis Parasitic infections Mycobacterial (e.g. in AIDS)
Drug-induced/toxic	Many drugs and toxins
Cholestatic	Extrahepatic cholestasis Primary sclerosing cholangitis Primary biliary cirrhosis
Circulatory/vascular	Right heart failure Constrictive pericarditis Budd-Chiari syndrome Veno-occlusive disease Peliosis hepatis
Hematologic	Leukemia Myeloproliferative disorders Extramedullary hematopoiesis
Mass lesions	Primary, secondary, benign and malignant tumors Cysts Hematoma Abscess
Others	POEMS syndrome ^b

^aSteatosis of the liver may have alcoholic and nonalcoholic etiologies.

^bIn *POEMS syndrome* (peripheral neuropathy, organomegaly, endocrinopathy, monoclonal gammopathy, skin lesions) the liver is the organ most often (80% of cases) enlarged.

amyloidosis, the liver enlarges while the hepatocytes become smaller. Hepatomegaly is due to deposition of the fibrillar material in the space of Disse, while the hepatocytes undergo pressure atrophy by the amyloid.

The increase of liver size by *space occupying lesions*, such as benign or malignant neoplasms, cysts or abscesses is self-explanatory.

Clinical Approach

Hepatomegaly is the most prevalent liver change. Every enlarged liver is sick. The diagnostic work up is based on the history, physical examination, liver

chemistries and, most importantly, on imaging modalities such as ultrasound, computed tomography and magnetic resonance imaging. Despite all noninvasive diagnostic efforts, liver biopsy will nonetheless often be necessary to evaluate the cause of hepatomegaly. Nuclear imaging techniques have lost much of their original importance.

In assessing an enlarged liver one should first determine whether hepatomegaly is *homogenous* or *irregular*. A homogenous liver enlargement occurs in metabolic diseases, predominantly steatosis, and in diffusely infiltrating and inflammatory processes. In most of these cases the liver has a soft consistency. At the same occasion one should investigate whether hepatomegaly is *painful* or *painless*. Fatty liver, for example, develops insidiously and is not painful, while acute inflammation or acute venous outflow obstruction lead to rapid distension of the liver capsule with an unpleasant sensation of pressure in the right upper quadrant (“Organgefühl”) and tenderness on palpation. Acute biliary obstruction is also often associated with pain; changes in the color of urine (dark) and stool (light), as well as the ensuing jaundice are additional clues to the diagnosis. The sonographic appearance of the liver and the enzymatic injury pattern – necroinflammatory, cholestatic or mixed – will guide the use of further methods, such as MRCP, ERCP and endoscopic

ultrasound. The diagnosis of sclerosing cholangitis is confirmed by MRCP or ERCP, and is usually diagnosed in the patient with underlying inflammatory bowel disease. The experienced examiner may precisely visualize common bile duct stones and extrahepatic bile duct tumors by endoscopic ultrasound. MRCP has widely replaced diagnostic ERCP, however, the inconsistencies in the quality of MRCP images between different centers still are considerable.

An irregularly enlarged liver suggests the presence of mass lesions. Despite the progress made in noninvasive imaging of the liver, evaluation of the etiology of a circumscribed lesion still often requires biopsy, especially in differentiating benign from malignant tumors. Clinical findings, however, may give important diagnostic hints. Regressive changes (e.g. hemorrhage) in a hepatic adenoma, for example, often cause acute right upper quadrant pain that leads the patient to see a physician. Focal nodular hyperplasia, on the other hand, does not cause pain and in the majority of cases is an incidental sonographic finding. Painful intratumoral hemorrhages into metastases have been described, but are rare.

The concomitant measurement of spleen size may also give clues to the cause of hepatomegaly. Portal hypertension, hemato-oncologic diseases, and infections are frequent causes of hepatosplenomegaly.

Chapter Outline

Imaging Techniques	553
Liver Biopsy	554
Diagnostic Approach.....	554
Differential Diagnosis	555
References	557

The diagnostic evaluation of focal liver lesions represents an interdisciplinary challenge. In this chapter a rational approach to a patient with a liver mass is presented. We would like to emphasize, however, that there is no gold standard in approaching this problem, and different ways are practiced in different centers and countries depending on the availability of imaging technology, the local expertise, and on federal regulations (e.g. contrast enhanced ultrasound has not yet been approved for hepatobiliary imaging in the United States by the Food and Drug Administration). For this reason, a detailed but fixed algorithm is not presented. The morphologic characteristics of focal liver lesions and the diagnostic accuracy of noninvasive imaging modalities are discussed in Chapters 37–39 (transabdominal ultrasonography, computed tomography, magnetic resonance imaging and nuclear imaging, respectively). Individual disorders are discussed in detail in Chapters 57 (Cystic Liver Diseases), 65 and 66 (Bacterial and Amebic Liver Abscess), 101 and 102 (Benign and Malignant Tumors).

Imaging Techniques

Focal liver lesions are detected by ultrasound (US), computed tomography (CT) or magnetic resonance imaging (MRI). Whenever appropriate, a directed liver biopsy may be performed. Nuclear imaging techniques and invasive angiographic procedures have lost much of their former importance and are nowadays very rarely employed in the diagnostic workup of a patient with a liver mass.

Ultrasound is a widely available, safe, versatile, and relatively inexpensive method of first choice in the primary diagnosis of focal liver lesions [5, 8]. The advancement

of sonographic technology with the development of contrast enhanced ultrasound has greatly improved sonographic diagnosis of focal liver lesions. Provided that an experienced and dedicated examiner is present, modern state of the art sonographic equipment is available, and ultrasound visibility is good, an adequate US examination can replace CT and MRI in the vast majority of patients with focal hepatic lesions. In countries where contrast enhanced ultrasound is not available, and in the US where transabdominal ultrasound is not performed first-hand by trained gastroenterologists/hepatologists or even radiologists, *triphasic contrast CT* and *contrast enhanced MRI* (with, for example, gadolinium-based contrast agents or superparamagnetic iron oxide [SPIO] that is taken up by liver macrophages) are the most sensitive and specific imaging tests. Nuclear imaging techniques using Technetium-labeled compounds (HIDA or PPIDA) and blood pool scintigraphy with Technetium-labeled red blood cells are not very sensitive, particularly for small lesions, and are nowadays rarely if at all used.

Liver Biopsy

Despite the availability of sophisticated noninvasive imaging techniques, there remain individual patients in whom a liver biopsy is necessary to complete the diagnostic workup (see Chapters 43-45). The cytologic and histologic evaluation of focal liver lesions is low-risk, as the complication rate of percutaneous liver biopsy is <0.1% with a mortality rate of 0.001% [18]. Biopsy of the mass itself, as well as normal surrounding liver tissue, is strongly recommended, since comparison between hepatocytes within and outside the mass can aid the pathologist [1]. The sensitivity of fine needle aspiration cytology in differentiating benign from malignant tumors is approximately 60–90%, with a specificity approaching 100% [10]. Furthermore, currently used biopsy needles (e.g. Klatskin, Jamshidi, Tru-cut) provide intact tissue cylinders suitable for histological examination, in addition to material for cytological analysis. The sensitivity of liver histology in distinguishing benign from malignant lesions is 90–95%. However, false negative biopsies of small lesions (<1–2 cm) may result from missing the lesion. Furthermore, one should not underestimate the danger of tumor seeding, which may occur in approximately 5% but, according to some reports, may even reach as high as 16% (which, however, does not correspond to our experience) [13, 15].

Diagnostic Approach

The diagnostic approach to a patient with a liver mass crucially depends on the clinical scenario in which the lesion is identified, the clinical characteristics of the patient, and on the morphological features of the lesion on US, CT or MRI. Thus, while in some patients a “wait-and-see” strategy can be justified, in others a rapid diagnostic evaluation will be required, including the use of invasive, elaborate and costly techniques.

While in some centers transabdominal US is followed by dynamic triphasic CT and contrast enhanced MRI examinations, in other centers contrast enhanced US is the procedure of choice, followed, when necessary by a liver biopsy, without needing to resort to CT or MRI. This “European” approach, however, is not shared by many investigators in the United States, who tend to believe that CT and MRI are the definitive noninvasive methods in diagnosing focal liver lesions (Fig. 51.1).

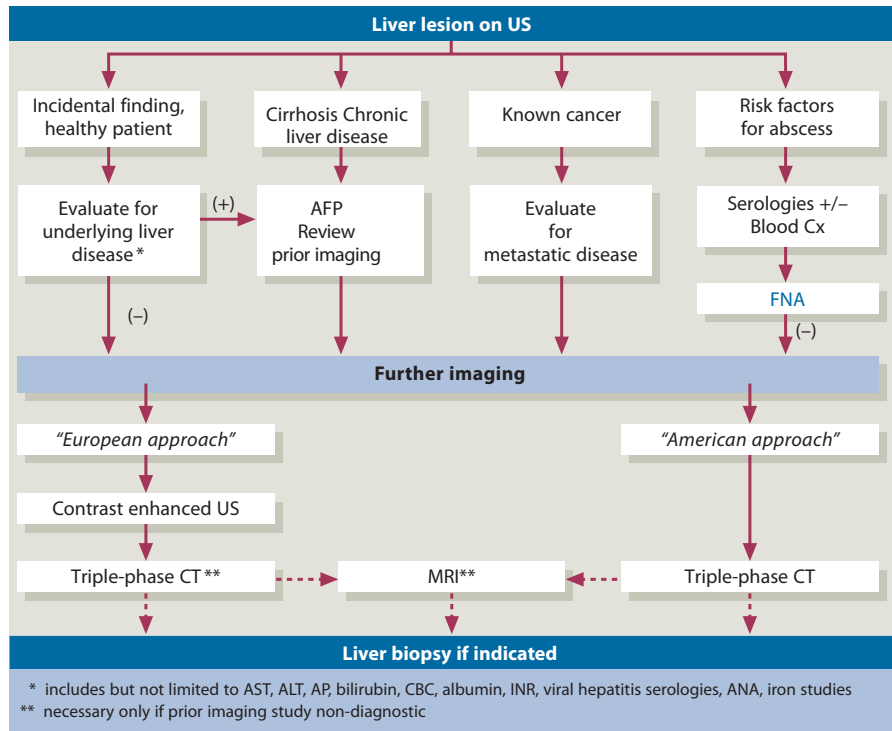
The diagnostic evaluation of a focal liver lesion is a stepwise process, integrating clinical data and morphological criteria of the lesion so as to arrive at a diagnosis with the least invasive and least costly means. Unfortunately in many centers US, CT and MRI are all applied to characterize one lesion with the hope of increasing diagnostic accuracy, when a more thorough analysis of the US image and of the clinical features would have yielded the diagnosis. In most western countries transabdominal US is the first procedure performed, followed by contrast enhanced US, when indicated, and by guided liver biopsy when necessary. Ultrasound followed by liver biopsy is a straight, cost-effective approach that often will make the use of contrast enhanced CT and MRI superfluous [12].

First and foremost, it must be determined whether the focal lesion is benign or malignant. In the next step, clarifying the etiology of the liver mass is attempted. Important initial questions in this regard are

- Is the lesion an incidental sonographic finding in an asymptomatic patient?
- Does the patient have cirrhosis or chronic liver disease?
- Does or did the patient suffer from malignant disease?
- Does the patient have risk factors for bacterial or amebic liver abscess?

These clinical data should be integrated with the US features of the liver mass, i.e. is the lesion predominantly hypo-/anechoic (i.e. liquid) or hyperechoic (i.e. solid)? [5, 8].

Fig. 51.1 Suggested general diagnostic approach to focal liver lesion



Differential Diagnosis

The most common benign focal liver lesions are developmental cysts. The prevalence of solitary solid lesions is reported in Table 51.1. Using a combination of imaging studies, laboratory parameters, and relevant clinical characteristics of the patient, the vast majority of cases can be correctly diagnosed without the need for liver biopsy [16].

Focal hepatic lesions in healthy asymptomatic patients often are incidental sonographic findings. These “*incidentalomas*”, particularly when smaller than 1 cm, are generally benign and clinically not significant. They should be followed for 3–6 months, and if no change is noted no further evaluation is needed. The greatest risk that these lesions pose is that they potentially may lead to unnecessary invasive procedures. It is important to avoid extensive and invasive evaluation of these lesions, because this may be associated with morbidity and even mortality (e.g. cumulative radiation and liver biopsy).

Simple *cysts* do not present a diagnostic challenge. They are round to oval, anechoic, well-defined, uni- or multiloculated lesions with a dorsal acoustic enhancement on US. They occur in 5–10% of patients older than 45 years and can be reliably diagnosed by US

without the need for CT or MRI. If the image of the cyst is complex with a thick wall, internal papillary infoldings, septations and irregularly scattered reflexes, then echinococcosis and liver abscess should be ruled out. Only 1–2% of all metastases are cystic and appear as completely anechoic lesions.

Pyogenic and *amebic liver abscesses* initially are not well-demarcated from the surrounding liver tissue, but becomes more hypoechoic and well-delineated with time. Their content never becomes completely anechoic. Typically, on contrast enhanced US they are surrounded by a hyperemic rim. Ninety percent of amebic liver abscesses are localized in the right liver lobe, predominantly in the subcapsular position. With gas forming pathogens, an abscess may contain

Table 51.1 Prevalence of the most common solitary solid lesions of the liver^a

Lesion	Prevalence (%)
Hemangioma	3–20
Focal nodular hyperplasia	3–8
Adenoma	<1
Metastatic lesion	<1
Hepatocellular carcinoma	<1

^aThe most common focal liver lesions are developmental (dysontogenetic) cysts
 Source: According to [2]

shadowing reflexes that correspond to gas inclusions. Often they are accompanied by a right-sided pleural effusion. Bacterial liver abscess often occurs in diabetic or immunocompromised patients.

The most common cause of a hyperechoic liver mass is a *hemangioma*. Hemangiomas are the most common benign liver tumors, and occur two to six times more frequently in women. Most hemangiomas are round or oval, uniformly echogenic and well delineated. However, a hemangioma in a steatotic liver is hypoechoic. Sixty to 70% of liver hemangiomas are smaller than 3 cm in diameter. On contrast enhanced US, approximately 80% of hemangiomas demonstrate a peripheral nodular contrast enhancement and a homogeneous centripetal filling (iris-diaphragm sign) [4]. Giant hemangiomas are defined as hemangiomas larger than 4 cm. These often acquire atypical sonographic features with internal heterogeneity. The size of most hemangiomas remains constant during follow-up. Most hemangiomas are found incidentally in asymptomatic patients. In these patients, a follow-up US examination in 3–6 months is sufficient. If the lesion remains unchanged, no further imaging studies and no liver biopsy is required. In rare cases of doubt, however, hemangiomas may be cautiously biopsied, provided they do not lie at the liver surface, but rather are surrounded by liver parenchyma [9, 17].

Focal nodular hyperplasia (FNH) and *liver cell adenoma* (LCA) are benign tumors that occur more often in women and require different management strategies. FNH is a hypervascularized lesion with a central fibrous core containing vessels. Biopsy of FNH might be misinterpreted as cirrhotic liver if the pathologist is not aware that a focal lesion has been biopsied. Finding hepatic arteries without accompanying bile ducts in fibrous septa, as well as thickened hyperplastic hepatic cords, are key diagnostic features [1]. LCA for the most part is build-up of hepatocytes arranged in cords that recapitulate the normal sinusoidal architecture. It lacks bile ducts, portal tracts, and hepatic veins. Excessive glycogen and lipid accumulation as well as arteries distinct from portal tracts is also characteristic [1]. Differentiating an adenoma from a well differentiated hepatocellular carcinoma may be very difficult. Biopsy from both lesional and non-lesional tissue is strongly recommended in LCA and FNH. Fine needle aspiration (cytology) is usually nondiagnostic when used to evaluate lesions such as LCA and FNH.

FNH is much more prevalent than LCA (Table 51.1) and generally is detected as an incidental finding in an

asymptomatic patient. On contrast enhanced US, FNH is a hypervascular lesion with a typical spoke-wheel appearance and a rapid venous outflow. However, these typical features may be difficult to recognize in small FNH. An adenoma may be asymptomatic, but usually comes to clinical attention because of regressive intratumoral changes, such as hemorrhage and necrosis, that cause acute right upper quadrant pain. Hemorrhage with subsequent intraperitoneal rupture is an uncommon event. Very rarely an adenoma may transform into a carcinoma, while malignant transformation of FNH does not occur. Therefore, in FNH a wait-and-see attitude is warranted, while adenomas usually should be resected. Although FNH and LCA present distinctive features on imaging, differentiation in small lesions may be especially difficult, and a liver biopsy will be required. Contrary to previous views, LCA do contain Kupffer cells. Therefore, they cannot be reliably differentiated from other space occupying lesions by scintigraphy with (99m -Tc) sulfur colloid (normally taken up by Kupffer cells) or by MRI using Kupffer cell specific contrast agents such as SPIO (see above). The “confirmation” of high quality US findings by CT or MRI, however, is neither warranted nor cost effective.

In several conditions focal changes of liver parenchyma on US may simulate a liver tumor. *Focal or irregular steatosis* appearing as a hypo- or hyperechoic zones, for example, may be misinterpreted by the inexperienced US examiner as tumorous lesions. The caudate liver lobe has its own venous outflow into the inferior vena cava; therefore, *hypertrophy of the caudate lobe* in Budd-Chiari syndrome may simulate a liver tumor. A *thrombosis of the inferior vena cava* within its hepatic segment may also wrongly give the impression of a tumor. *Cystically dilated bile ducts* in Caroli’s syndrome containing sludge, detritus, and pus may also give the impression of a bile duct tumor.

The most common malignant focal liver lesions are *metastases*. However, small (<1 cm) hepatic lesions in patients with cancer more frequently are benign rather than malignant. In one study these lesions represented metastases in only 11.6% of patients [14]. In contrast, incidentally found larger liver lesions in a patient with an underlying malignancy are metastases in approximately 20–40% of cases. A newly developed liver mass in a patient with known malignancy represents a metastasis in nearly 100% of patients.

Since liver metastases do not exhibit a pathognomonic US, CT or MRI pattern, *each focal hepatic*

lesion in a patient with a known malignancy, irrespective of its morphologic aspect, should be regarded as a metastasis, until proven otherwise. Intraoperative US is the most sensitive method to detect liver metastases, and should be performed in each patient undergoing an abdominal operation for malignancy [6, 7].

In patients with liver cirrhosis the yearly incidence of *hepatocellular carcinoma* (HCC) is 5–8%. In a healthy liver the incidence of HCC is low, albeit also rising. Therefore, patients with cirrhosis should undergo screening for HCC every 6 months with some imaging modality (e.g. US, CT, MRI). *In each case of a newly discovered focal lesion in a cirrhotic liver, first and foremost a HCC must be excluded.* Small lesions, measuring less than 1–2 cm in diameter, are very difficult to differentiate from benign regenerative and dysplastic nodules, even with liver biopsy. However, according to the guidelines of the American Association for the Study of Liver Diseases (AASLD), not every new nodule in a cirrhotic liver needs to be biopsied. (1) A mass found on surveillance ultrasound in a cirrhotic liver measuring <1 cm in diameter should be followed with a repeat US at 3–4 months intervals. If it remains stable over 18–24 months, return to standard surveillance protocol (6–12 monthly) is warranted. (2) Most small (1–2 cm) arterial phase-enhancing nodules seen on triphasic liver CT are not HCC [11]. If the lesion measures 1–2 cm in diameter, two dynamic imaging studies (US, CT or MRI, each with contrast enhancement to visualize the vascular pattern of the lesion) should be performed. If a typical vascular pattern is present on dynamic imaging with two methods the lesion should be treated as HCC without the need for liver biopsy. If a typical vascular pattern is seen with only one technique or an atypical vascular pattern with both techniques, a liver biopsy should be performed. (3) Mass lesions >2 cm in diameter with a typical vascular pattern on dynamic imaging with one technique (or AFP levels >200 ng/mL) should be treated as HCC without the need for biopsy. If the lesion shows an atypical vascular pattern, a biopsy is required to confirm or exclude the diagnosis of HCC [3]. According to the AASLD, contrast enhanced US, triphasic dynamic CT, and contrast enhanced MRI are equally effective.

References

- Anders RA, Kamel IR (2007) Biopsy considerations in the diagnosis of hepatic masses. *Clin Gastroenterol Hepatol* 5: 541–4
- Brown RS (2006) Asymptomatic liver mass. *Gastroenterology* 131: 619–23
- Bruix J, Sherman M (2005) Management of hepatocellular carcinoma. *Hepatology* 42: 1208–36
- Dietrich CF, Mertens JC, Braden B, et al (2007) Contrast-enhanced ultrasound of histologically proven liver hemangiomas. *Hepatology* 45: 1139–45
- Gebel M, Caselitz M, Manns MP (1997) Sonographische Diagnostik von Raumforderungen der Leber. *Internist* 38: 901–7
- Hartley JE, Kumar H, Drew PJ, et al (2000) Laparoscopic ultrasound for the detection of hepatic metastases during laparoscopic colorectal cancer surgery. *Dis Colon Rectum* 43: 320–4
- Herman K (1996) Intraoperative ultrasound in gastrointestinal cancer. An analysis of 272 operated patients. *Hepato-gastroenterology* 43: 565–70
- Lock G, Schölmerich J (1997) Vorgehen bei sonographisch nachgewiesener Raumforderung der Leber. *Internist* 38: 924–7
- Nakaizumi A, Iishi H, Yamamoto R, et al (1990) Diagnosis of cavernous hemangioma by fine needle aspiration biopsy under ultrasound guidance. *Gastrointest Radiol* 15: 39–42
- Neumann F, Wehle K, Schoppe WD (1995) Die Wertigkeit der Feinnadelaspirationszytologie in der ultraschallgesteuerten Punktionsdiagnostik abdominalen und thorakalen Raumforderungen. *Ultraschall* 16: 1
- O'Malley ME, Takayama Y, Sherman M (2005) Outcome of small (10–20 mm) arterial phase-enhancing nodules seen on triphasic liver CT in patients with cirrhosis or chronic liver disease. *Am J Gastroenterology* 100: 1523–8
- Pasha T, Gabriel S, Therneau T, et al (1998) Cost-effectiveness of ultrasound-guided liver biopsy. *Hepatology* 27: 1220–6
- Rodgers MS, Collinson R, Desai S, et al (2003) Risk of dissemination with biopsy of colorectal liver metastases. *Dis Colon Rectum* 46: 454–8
- Schwartz LH, Gandras EJ, Colangelo SM, et al (1999) Prevalence and importance of small hepatic lesions found at CT in patients with cancer. *Radiology* 210: 71–4
- Takamori R, Wong LL, Dang C, et al (2000) Needle-tract implantation from hepatocellular cancer: is needle biopsy of the liver always necessary? *Liver Transl* 6: 67–72
- Torzilli G, Minagawa M, Takayama T, et al (1999) Accurate preoperative evaluation of liver mass lesions without fine-needle biopsy. *Hepatology* 30: 899–93
- Tung GA, Cronan JJ (1993) Percutaneous needle biopsy of hepatic cavernous hemangioma. *J Clin Gastroenterol* 16: 117–22
- Weiss H, Düntsch U (1996) Complications of fine needle puncture. DEGUM survey II. *Ultraschall Med* 17: 118–30

Chapter Outline

Cholestasis	559
Definition	559
Etiology and Classification of Cholestasis.....	559
Pathogenesis.....	562
Histopathology	568
Diagnosis.....	569
Differential Diagnosis.....	573
Therapy	579
Jaundice	582
Definition	582
Etiology and Pathogenesis	582
Diagnosis and Differential Diagnosis	584
Therapy	590
References	590

Cholestasis

See also Chapters 20 and 26.

Definition

Cholestasis may be defined functionally, morphologically and clinically. *Functionally*, cholestasis denotes a condition in which too little bile per time unit reaches the duodenum. It is caused either by a decrease in bile formation or secretion, and/or by slowed or interrupted flow of bile or of some of its constituents. The cholestatic defect may be localized anywhere between the basolateral hepatocyte membrane, the entire biliary ductular tree and the papilla of Vater.

To the pathologist, hepatocellular cholestasis is the visible expression of impaired hepatocellular uptake, transcellular transport, canalicular secretion, or ductal flow of biliary constituents. The most striking histological feature of cholestasis, albeit not the only one, is the hepatic retention and deposition of bile constituents, notably bilirubin (bilirubinostasis), bile acids (feathery degeneration) and copper in chronic cholestasis.

Clinically, cholestasis is manifested by the retention of substances in the blood normally excreted in bile, by increased serum levels of cholestatic enzymes (see Chapter 49), by the consequences of diminished or absent bile in the duodenum, and by the impact of retained bile on the liver.

Etiology and Classification of Cholestasis

Impairment of bile secretion may be attributed to functional defects of bile formation at the level of the

hepatocyte or to interference with bile flow along the entire biliary tree starting at the canalicular hepatocyte membrane. Virtually all liver diseases may be associated with cholestasis. Chronic cholestasis is also a universal manifestation of cholangiopathies [45].

Cholestasis can be classified according to different criteria: time (onset, duration), anatomy, pathogenesis, and etiology. It can be

- Acute
- Chronic or
- Intermittent.

The primary pathogenetic defect can be located at the

- Hepato-canalicular
- Ductular or
- Ductal level.

In clinical practice a classification of cholestasis combining anatomical and etiopathogenetic criteria has proven useful. One cannot, however, always adhere strictly to anatomic criteria; on the one hand, primary lesions causing cholestasis may be localized at various anatomical levels, while on the other hand processes eliciting cholestasis may be responsible for secondary alterations of the bile ducts.

A simple and practical classification of cholestasis distinguishes mechanical-obstructive (intra- and/or extrahepatic) cholestasis from non-obstructive, intra-hepatic cholestasis.

The damage to the bile ducts may be localized anywhere along the entire biliary tree from the canalculus, via the canals of Hering, the interlobular, septal and segmental bile ducts to the papilla of Vater (Fig. 52.1). The injury may have a genetic, metabolic, immunologic, vascular, infectious, neoplastic, toxic, or drug-induced cause, or it may be idiopathic (Tables 52.1 and 52.2). Many diseases, however, cannot be ascribed unequivocally to only one etiopathogenetic category, as the pathogenetic process is usually multifactorial. Overlap between infectious, immunologic, metabolic-genetic and mechanical factors is the rule rather than the exception. It is also common during the course of a cholestatic disorder for several pathogenetic factors to act in concert and assume different levels of importance at various stages of the disease. Thus, for example, a primary immunologic bile duct injury may, with time, lead to anatomically fixed lesions which subsequently perpetuate cholestasis. Conversely, primary mechanical bile flow obstruction may lead to secondary functional changes of hepatocellular transporters involved in bile formation (Fig. 52.2).

Fig. 52.1 Schematic representation of the bile-draining system from the hepatocyte to the papilla of Vater. The primary anatomical levels of damage of selected cholestatic diseases are shown

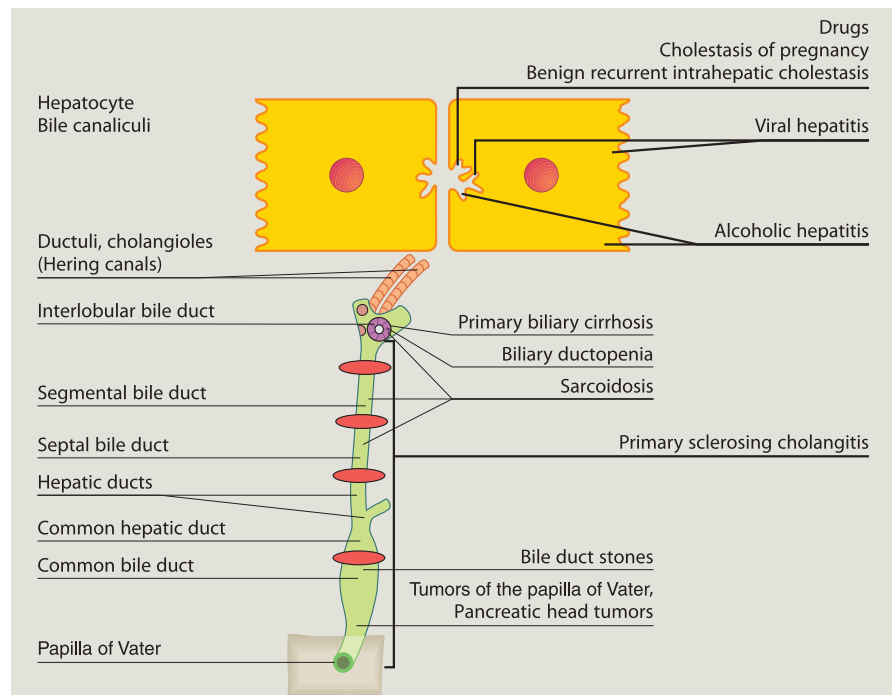


Table 52.1 Liver and bile duct diseases (cholangiopathies) that may be associated with cholestasis (there is a wide pathogenetic overlap between the various categories)**Genetic/metabolic**

- Alagille's syndrome
- α 1-Antitrypsin deficiency
- Cystic fibrosis
- Fibropolycystic diseases (e.g. Caroli's disease)
- Biliary atresia
- Progressive familial intrahepatic cholestasis (PFIC)
- Benign recurrent intrahepatic cholestasis (BRIC)
- Cholestasis of pregnancy
- Low phospholipid associated cholelithiasis (LPAC) syndrome^a
- Inborn errors of bile acid metabolism
- Amyloidosis
- Non-amyloidotic light chain disease
- Total parenteral nutrition
- Wilson's disease
- Hereditary hemochromatosis

Immune-mediated

- Primary biliary cirrhosis
- Primary sclerosing cholangitis
- Autoimmune cholangitis
- Autoimmune intrahepatic cholangiopathy associated with antiphospholipid antibody syndrome
- Autoimmune hepatitis
- Ductopenia syndrome (vanishing bile duct syndrome)
- Hepatic allograft rejection
- Graft vs. host disease involving the liver
- Eosinophilic cholangitis
- Immunoglobulin G4 associated cholangitis

Infectious

- Cholangitis
 - Bacterial cholangitis
 - Parasitic cholangitis (Ascaris, Clonorchis, Opisthorchis, Fasciola hepatica, G. lamblia, Echinococcus, cryptosporidia, microsporidia)
 - Viral cholangitis (cytomegalovirus)
 - AIDS cholangiopathy (Cytomegalovirus, cryptosporidia, microsporidia)
 - Fungal cholangitis
- Acute and chronic viral hepatitis
- Liver abscess
- Systemic infections
- Sepsis
- Toxic shock syndrome [35]

Drug-induced (see [Table 52.2](#))**Vascular/ischemic**

- Traumatic
- Postoperative
- Polyarteritis nodosa (vasculitis of hepatic artery)
- Sickle cell anemia
- Congestive hepatopathy
- Prolonged circulatory shock (ischemic "hepatitis")
- Post liver transplantation (e.g. hepatic artery stenosis)
- Ischemic cholangiopathy (sclerosing cholangitis in critically ill patients; "ICU-associated cholangiopathy" [5]; intra-arterial infusion of 5-fluorouridine or floxuridine)
- Hereditary hemorrhagic teleangiectasia (Osler's disease)
- Local irradiation to the liver

(continued)

Table 52.1 (continued)**Obstructive**

- Cholangiocarcinoma
- Pancreatic carcinoma
- Bile duct compression (e.g. lymphoma)
- Gallstones (e.g. bile duct stones and Mirizzi's syndrome)
- Strictures
- Foreign bodies
- Chronic pancreatitis
- Choledochal cysts

Neoplastic

- Hepatocellular carcinoma
- Liver metastases

Other conditions

- Liver cirrhosis
- Alcoholic hepatitis
- Postoperative cholestasis
- Isolated idiopathic bile ductular hyperplasia [74]
- Sarcoidosis
- Langerhans cell histiocytosis
- Macrophage activating syndrome^b
- Erdheim–Chester disease^c
- Mast cell-cholangiopathy (in systemic mastocytosis)
- Generalized pustular psoriasis^d
- Paraneoplastic (e.g. Hodgkin's lymphoma, Stauffer's syndrome in renal cell carcinoma)

^a*Low phospholipid associated cholelithiasis (LPAC) syndrome* (see Chapter 85) can arise in two different clinical settings. (1) Primary hepatolithiasis is highly prevalent in the far East and is characterized by the presence of intrahepatic cholesterol-rich brown pigment (calcium bilirubinate) stones (less frequent cholesterol stones). (2) Cholesterol stones and sludge, which typically recur following cholecystectomy. The common denominator for both clinical patterns is phosphatidylcholine deficient bile with subsequently impaired cholesterol solubility [85]. LPAC needs to be differentiated from “ordinary” cholesterol cholelithiasis, which, however, may also have a genetic basis.

^b*Macrophage activating syndrome (MAS)* is a rare hematological disorder associated with uncontrolled systemic T-cell activation. Persistent fever, fatigue and hepatosplenomegaly are frequent clinical manifestations, whereas hyperferritinemia, elevated serum lactate dehydrogenase levels and cytopenia are key criteria for the diagnosis of MAS. Destructive biliary lesions ranging from small bile duct injury to the vanishing bile duct syndrome and secondary biliary cirrhosis have been rarely described. The inflammatory changes and bile duct lesions are dominated by the presence of activated macrophages and T-cells, in particular CD8⁺ lymphocytes, and in part NK-cells. In MAS it is possible that various T-cell triggers such as infection, autoimmune disease and malignancy may result in the release of cytokines, which in turn activate macrophages to trigger a systemic acute phase response and local tissue damage [9].

^c*Erdheim-Chester disease* is a rare non-Langerhans form of histiocytosis, characterized by infiltration of foamy, lipid-laden histiocytes often affecting the lower extremities and resulting in symmetrical osteosclerosis. Internal organs involved primarily include the lung and the kidneys, reflecting progressive disseminated granulomatous infiltration. One patient with elevated serum levels of liver enzymes due to intra- and extrahepatic bile duct stenoses was reported [32].

^dA neutrophilic cholangitis with a PSC-like aspect on cholangiography has been described in patients with *pustular psoriasis* [88].

Pathogenesis

Bile is formed within hepatocytes (“*canalicular* or *hepatic bile*”) and is subsequently delivered into the bile ducts. The daily bile production in adult humans is approximately 600 mL. 450 mL are derived from hepatocytes, while 150 mL are generated by biliary epithelial cells. Bile formation and transport are complex processes that require many energy dependent synthetic and transport steps. The hepatocellular transport systems,

bile formation, secretion and bilirubin metabolism are discussed in detail in Chapters 5 and 7 (in order to facilitate reading, we allowed some redundancy to occur). The key features of these processes as they pertain to understanding cholestatic liver diseases in clinical practice are recapitulated briefly in this chapter. Special emphasis is placed on the active role of cholangiocytes in bile formation and modification (“*ductal bile*”).

Bile constituents are taken up from sinusoidal blood into the liver cells by transport systems localized in the

Table 52.2 Drugs that are known to cause cholestasis (Adapted from reference [47])

<p>Pure cholestasis (bland cholestasis)</p> <ul style="list-style-type: none"> • Anabolic steroids • Azathioprine • Cyclosporin A • Cytosine-arabinoside • Fosinopril • Infliximab • Sex steroids • Tamoxifen <p>Cholestatic hepatitis (hepatocanalicular hepatitis)^a</p> <ul style="list-style-type: none"> • Antibiotics (Amoxicillin/clavulanic acid, dapsone, erythromycin, trimethoprim/sulfamethoxazole, flucloxacillin, nitrofurantoin, azithromycin, roxithromycin, clarithromycin) • Azathioprine • Benzodiazepines • Carbamazepine (often granulomas) • Cetirizine • Chlorpromazine • Chlorpropamide • Cyclosporin A • Danazol • Gold • Herbal remedies (Chaparral leaf, casacara sagrada, greater celandine, glycyrrhizin, jin bu huan) • Loracarbef • Mesalamine • Methimazole • Nifedipine • NSAID's (Nimesulide, Sulindac, Diclofenac) • Pizotyline • Propoxyphene • Risperidone • Terbinafine • Tricyclic antidepressants • Troglitazone <p>Ductular cholestasis (cholangiolar cholestasis)</p> <ul style="list-style-type: none"> • Ajmaline • Arsenic • Allopurinol • Amoxicillin/clavulanic acid • Azathioprine • Barbiturates • Benoxaprofen • Captopril • Carbamazepine • Chlorpromazine • Chlorpropamide • Ciprofloxacin • Clindamycin • Enalapril • Flucloxacillin 	<ul style="list-style-type: none"> • Phenytoin • Trimethoprim-sulfamethoxazole • Terfenadine <p>Progressive ductopenia (vanishing bile duct syndrome)</p> <ul style="list-style-type: none"> • Aceprometazine • Ajmaline • Amineptine • Amoxicillin/clavulanic acid • Ampicillin • Azathioprine • Barbiturates • Carbamazepine • Carbutamide • Chlorothiazide • Chlorpromazine • Cimetidine • Clindamycin • Co-trimoxazole • Cyamemazine • Cyclohexylpropionate • Cyproheptadine • Erythromycin • Flucloxacillin • Glibenclamide • Glycyrrhizin • Haloperidol • Ibuprofen • Imipramine • Methyltestosterone • Norandrostenolone • Oestradiol • Phenytoin • Prochlorperazine • Tetracyclines • Thiabendazole • Tiopronin • Tolbutamide • Trimethoprim-sulfamethoxazole • Trioleandomycin • Xenalamin <p>Sclerosing cholangitis</p> <ul style="list-style-type: none"> • Floxuridine (following intra-arterial infusion) • 5-Fluorouracil (following intra-arterial infusion) • Scolicidal agents (injection into hydatid cysts) <p>Cholelithiasis</p> <ul style="list-style-type: none"> • Ceftriaxone • Clofibrate • Dipyridamole • Disulfone (or any other drug causing hemolysis: pigment gallstones) • Octreotide (intrahepatic lithiasis)
---	---

^aThis is the most common form of drug-induced cholestasis

basolateral membrane of the hepatocyte. They are transported, together with bile components synthesized within the cell, to the canalicular membrane at the apical pole of the hepatocyte. The directed, transcytotic vesicular transport of macromolecules and solutes to the canalicular membrane depends primarily on the integrity of the cytoskeleton (microtubuli, microfilaments, intermediary filaments). Gap junctions facilitate the communication between cells, while tight junctions seal off the canalicular lumen and inhibit the regurgitation of bile constituents into the plasma. Thus, *the structural integrity of hepatocytes combined with intact intercellular communication is a prerequisite for undisturbed bile formation and flow*. Bile salts, conjugated bilirubin, cholesterol, phospholipids, glutathione, proteins, electrolytes and water are secreted by specific transport systems localized in the canalicular (apical) membrane into the canalicular lumen (Fig. 52.3). An

actin-myosin-network localized in the hepatocellular ectoplasm surrounds the canalculus and, through coordinated contraction, aids in directing bile flow from the centrilobular region to the portal tract [59, 83].

The main determinant of bile flow is bile acid secretion (*bile acid dependent bile flow*), while *bile acid independent bile flow* is sustained primarily by the secretion of glutathione and bicarbonate. Hepatocellular transport systems are essential for the formation and secretion of bile. The basolateral (sinusoidal) membrane contains primarily two bile acid transport systems, both of which have already been cloned. The

- Sodium taurocholate cotransporting polypeptide (NTCP) and the solute carrier systems
- Organic anion transporting proteins (OATP), as well as the
- Organic cation transporters (OCT)

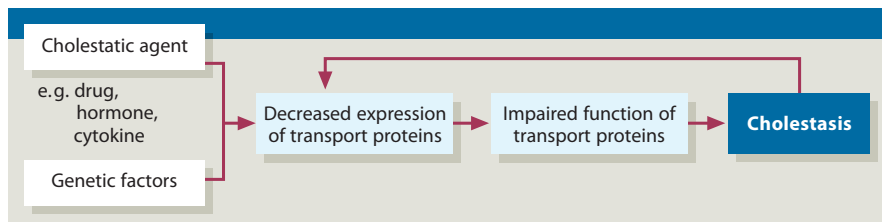


Fig. 52.2 Cholestasis is characterized by impaired transport. It may be caused by primary genetic defects or by mechanical obstruction to bile flow with secondary genetic repercussions, such as down-regulation of transporter expression

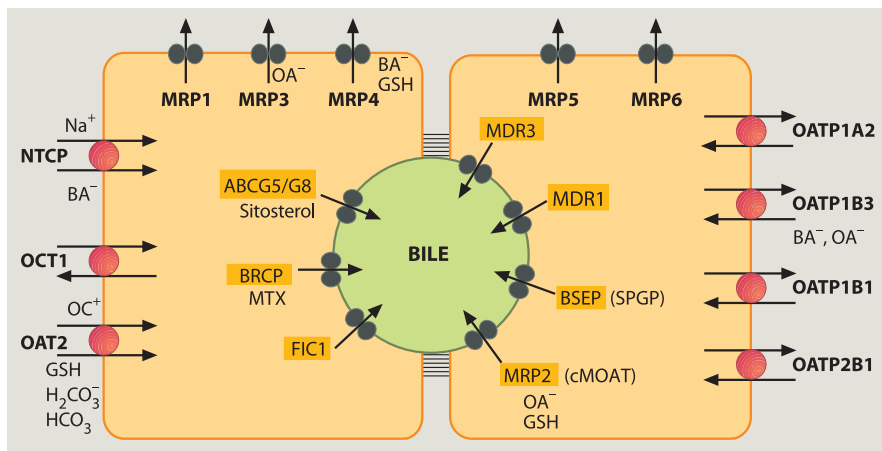


Fig. 52.3 Major hepatocellular transport systems. Efflux transporters (dark blue symbols). Uptake transporters (red symbols) (Adapted from [4, 64]). Abbreviations: *ABCG5/G8* cholesterol floppase, *BA⁻* bile acids, *BSEP* bile salt export pump, *FIC1* aminophospholipid flippase, *MDR* multidrug-resistance protein, *MRP* multidrug resistance-associated protein, *BCRP* breast cancer resis-

tance protein transporter, *NTCP* sodium taurocholate cotransporting polypeptide, *OATP* organic anion-transporting polypeptide, *OCT* organic cation transporter, *OAT* organic anion transporter, *OA⁻* organic anions, *OC⁺* organic cations, *GSH* reduced glutathione (see also Chapters 5 and 7)

NTCP mediates the Na^+ -dependent uptake of bile acids from the sinusoidal blood into the hepatocyte.

OATP is a multispecific carrier that mediates the Na^+ -independent uptake of bile acids and endogenous and exogenous anions and cations, such as hormones (estrogen conjugates), drugs (ajmalin) and bromosulphthalein. Furthermore, the efflux transporters multidrug resistance-associated proteins (MRP) 1, 3, 4, 5 and 6 are located in the basolateral membrane of human hepatocytes [4, 40, 41, 91].

The canalicular membrane contains

- ATP-dependent and
- ATP-independent transport systems (Table 52.3)

The transporter genes are transcriptionally regulated by nuclear receptors, such as constitutive androstane receptor (CAR), pregnane X receptor (PXR), and farnesoid X receptor (FXR). Thus, nuclear receptor-regulated target genes are intimately involved in bile formation. FXR is particularly integral to the hepatic response to cholestasis, mainly by orchestrating gene expression to unload the hepatocyte of bile acids (reducing import, increasing export) and also to reduce bile acid synthesis.

The “*canalicular bile*”, which accounts for 75% of daily bile production, is generated by osmotic filtration of water and electrolytes. The osmotic gradient required for flow of water and electrolytes is built up by active transport systems at the basolateral and canalicular membranes. Along its passage through the intra- and extrahepatic bile ducts into the duodenum, bile is modified by cholangiocytes. Although cholangiocytes account for only 3–5% of the entire cell population in

the liver, they play a significant role in bile formation, producing approximately 40% of total bile volume. Active biliary epithelial transport of electrolytes and solutes occurs mainly in large bile ducts and determines absorption and secretion across cholangiocytes, thus altering ductal bile composition and flow. Biliary epithelia express an array of transporters located on their luminal and basolateral plasma membrane domains. The periductular capillary plexus located under the basolateral cholangiocyte domain facilitates the communication of bile ducts with the systemic circulation (*cholehepatic shunt*) [45]. The ductal epithelium absorbs glucose, amino acids, and bile acids, and also secretes water, bicarbonate, chloride and hydrogen ions (“*ductal bile*”). Bicarbonate is a major constituent of ductal bile and the $\text{Cl}^-/\text{HCO}_3^-$ exchanger (AE2) on the apical membrane of cholangiocytes is responsible for bicarbonate secretion into the bile. Increased bile flow is associated with increased cholangiocyte secretion of bicarbonate into bile and a corresponding decrease of biliary chloride ion concentration (Fig. 52.4) [77, 78, 84].

Cholangiocytes also play an important role in the transport of bile salts. Uptake of bile salts from canalicular bile into cholangiocytes is mediated by the apical sodium dependent bile salt transporter ASBT. ASBT belongs to the superfamily of solute carriers and is identical with the gene product expressed in the terminal ileum of small intestine. Furthermore, the apical uptake of bile salts involves the organic anion transporting polypeptide 1A2, which belongs to the OATP superfamily of sodium independent solute transporters. After their uptake into cholangiocytes, bile salts are effluxed

Table 52.3 Transport systems of the canalicular liver cell membrane

ATP-dependent transport systems	
MDR 1	Multidrug export pump. Excretion of organic cations, e.g. drugs such as cytostatic agents, cyclosporin A, Ca^{2+} -antagonists
MDR 3	Phospholipid export pump. Phospholipid flippase
MRP 2 (cMOAT)	Conjugate export pump. Multispecific organic anion transporter. Transport of amphiphilic anionic conjugates, e.g. bilirubin diglucuronide
BSEP (SPGP)	Bile salt export pump Transport of conjugated monovalent bile acids
ATP-independent transport systems	
Glutathione-transporter	The molecular identity of this transporter has not yet been determined unequivocally. Possibly identical with MRP2
Anion exchanger	$\text{Cl}^-/\text{HCO}_3^-$. The anion exchanger is also present in the apical membrane of the cholangiocyte (see Fig. 52.4)
Chloride channel	The chloride channel of cholangiocytes is the cystic fibrosis transmembrane regulator (CFTR)

BSEP Bile salt export pump, *cMOAT* canalicular multispecific organic anion transporter (former name of MRP2), *MDR* multidrug resistance protein-1 (3-P-glycoprotein), *MRP* multidrug-resistance-related protein, *SPGP* sister gene of P-glycoprotein (former name of BSEP)

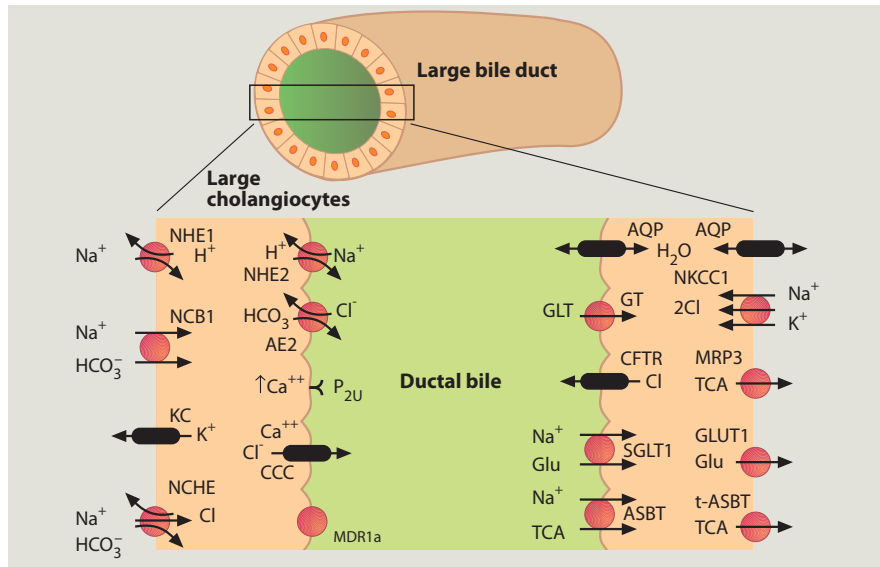


Fig. 52.4 Cholangiocyte transport systems. Mechanisms of fluid and electrolyte transport in cholangiocytes of large intrahepatic bile ducts. At the basolateral membrane acid secretion occurs through the Na⁺/H⁺-exchanger (NHE1), the Na⁺/HCO₃⁻-cotransporter (NCB1) or the Na⁺-dependent Cl⁻/HCO₃⁻-exchanger (NCHE). A second Na⁺-independent Cl⁻/HCO₃⁻-exchanger (AE2) is localized in the apical membrane of the cholangiocyte. The Na⁺/H⁺-exchanger in the apical membrane (NHE2) is associated with Na⁺-resorption from bile into the cholangiocyte. The cystic fibrosis transmembrane conductance regulator (CFTR) is localized in the apical membrane and is stimulated by secretin and cAMP. Aquaporin 1 (AQP), a water selective channel in the apical and basolateral membrane mediates the osmotic flow of water and is also regulated by secretin. In addition to CFTR, a Ca²⁺-activated Cl⁻-channel (CCC) is present on the apical domain of the cell and may be activated through purinergic receptors (P_{2U})

at the basolateral cholangiocyte membrane into the peribiliary plexus via an anion exchange mechanism. From here, bile salts reach the portal circulation and undergo the cholehepatic shunt pathway [63, 76].

The secretory and absorptive processes in cholangiocytes are regulated by gastrointestinal hormones, peptides, nerves and bile constituents. Expression of secretin receptors in the biliary tract is the molecular basis of the *secretin-induced bicarbonate-rich choleresis* in man. The action of secretin is mediated by cyclic AMP (cAMP), which stimulates the Cl⁻/HCO₃⁻-exchanger and opens the CFTR Cl⁻-channel. cAMP-induced ductal bicarbonate secretion depends on an autocrine signaling pathway that involves CFTR, and the apical release of ATP. Thus, the primary role of CFTR in bile duct secretion may be to regulate secretion of ATP rather than to secrete chloride and/or bicarbonate [55]. ATP may be demonstrated in micromolar concentration in the

by luminal purinergic nucleotides. A basolateral K⁺-channel (KC) and a Na⁺/K⁺-ATPase generate the membrane potential and the Na⁺-gradient. The uptake of chloride at the basolateral membrane occurs by the Na⁺/K⁺/2Cl⁻-cotransporter (NKCC1). The intrahepatic biliary epithelium may also resorb taurocholic acid (TCA) by an apical Na⁺-dependent bile acid cotransporter (ASBT). A truncated ASBT (t-ASBT) and multidrug resistance protein 3 (MRP3) may transport TCA out of the cholangiocyte across the basolateral membrane to the peribiliary capillary plexus. The uptake of glucose (Glu) from bile is coupled to Na⁺-uptake and occurs by the Na⁺-dependent glucose cotransporter-1 (SGLT1). Glucose leaves the cell at the basolateral surface by facilitated diffusion through the facilitated glucose transporter-1 (GLUT1). Glutathione (GLT) is taken up from bile by the glutamate transporter (GT) (Adapted from reference 45 and 78). *MDR1a* multidrug-resistance protein 1a

extracellular space and in bile where it functions as an autocrine and paracrine secretagogue. It is secreted by the hepatocyte across the canalicular membrane into the canaliculus and by biliary epithelial cells into the bile duct lumen. Intraluminal ATP activates purinergic receptors in the apical cholangiocyte membrane that strongly stimulate chloride secretion by a Ca²⁺-activated Cl⁻-channel (CCC). Increased levels of Cl⁻ in bile activate the apical Cl⁻/HCO₃⁻-exchanger (AE2) with subsequent alkalization of ductal bile (Fig. 52.4) [2, 45, 69].

Ion movements across the biliary epithelium are accompanied by flow of water into the ductal lumen through specialized channels (aquaporins). Secretin stimulates the movement of cytoplasmic vesicles associated with inactive aquaporins to the apical cholangiocyte membrane where they are transformed to active water channels. In Table 52.4 the effects of gastrointestinal hormones, peptides and neurotransmitters on ductal bile

secretion are summarized. In addition to flux molecules in their plasma membrane, cholangiocytes produce a number of peptides and mediators, such as interleukin-6, endothelin-1, monocyte chemoattractant protein-1 and nitric oxide, and may participate actively in immune mediated and inflammatory processes involving bile ducts.

In view of the important and complex contribution by cholangiocytes to the composition and flow of bile, it is evident that the biliary epithelium itself may play an important role in the pathogenesis of cholestasis. Understanding the fundamental transport processes involved in formation and flow of bile constitutes the basis for a pathophysiologic approach to cholestasis [43].

Cholestasis may result from

- Inherited mutations or acquired defects in gene expression of hepatocellular basolateral, canalicular and/or cholangiocyte transporters
- Derangement of intracellular transport mechanisms (vesicles, cytoskeleton)
- Damage to the pericanalicular actin-myosin-network
- Dysfunction of gap and tight junctions
- Structural alterations of cholangiocytes and/or bile ducts (e.g. inflammation, fibrotic strictures, stones, tumors) [39].

Structural and functional aspects always are intertwined in the pathogenesis of cholestasis. Thus, primary functional alterations of transport systems, if they persist long enough, will subsequently lead to secondary structural changes of the microtubular cytoskeleton, the canalicular membrane, and the gap and tight junctions. These secondary alterations will then perpetuate cholestasis. On the other hand, cholestasis due primarily to structural alterations of bile ducts will result in changes in gene expression of hepatocellular and biliary transporters with subsequent functional biliary disturbances [45]. Experimental models using endotoxin, animals treated with estrogen, and animals whose bile ducts are ligated (to simulate sepsis-induced cholestasis, cholestasis of pregnancy and mechanical cholestasis, respectively) have also contributed to a better understanding of cholestasis in humans [68]. In all these cases gene expression of NTCP, OATP, MRP2 and BSEP has been shown to be downregulated [66]. Inhibition of hepatobiliary transport systems occurs both at the transcriptional and post-transcriptional level leading to an impaired uptake and excretion of bile acids and organic anions. Interestingly, in these animal models the genes for MDR1 and MDR3 transport proteins were upregulated. It is possible that the enhanced expression of these transport systems represents a

Table 52.4 Effects of gastrointestinal hormones, peptides and neural transmitters on ductal bile secretion

Hormone/peptide	Second messenger	Effect on ductal bile secretion
Secretin	↑ cAMP	Induces bicarbonate rich choleresis ^a
Somatostatin	↓ cAMP	Inhibition of basal and secretin-induced choleresis ^a
Gastrin	IP ₃ , [Ca ²⁺], ↑ PKC	No effect on basal bile flow. Inhibits secretin-induced bicarbonate rich choleresis ^a
	Inhibits secretin-induced synthesis of cAMP	
Bombesin	Not yet identified	Increases bile flow by stimulating chloride/bicarbonate exchanger
VIP	cAMP?	Increases bile flow by stimulating chloride/bicarbonate exchanger
Insulin	Inhibits secretin-induced synthesis of cAMP	No effect on basal bile flow Inhibits secretin-induced bicarbonate rich choleresis
Endothelin	IP ₃ , [Ca ²⁺], inhibits secretin-induced synthesis of cAMP	No effect on basal bile flow. Inhibits secretin-induced bicarbonate rich choleresis
Acetylcholine	IP ₃ , [Ca ²⁺], enhances interaction between [Ca ²⁺] and cAMP. Increases secretin-induced synthesis of cAMP	Increases basal and secretin-induced bicarbonate secretion
Purinergic modulation	[Ca ²⁺]	Stimulation of chloride-secretion into bile and of the chloride/bicarbonate exchange with consequent alkalinization of bile

^aIn bile duct ligated rats

VIP Vasoactive intestinal polypeptide

Source: Adapted from [2]

compensatory mechanism by hepatocytes to limit the accumulation of hepatotoxic biliary substances. During cholestasis, multidrug resistance proteins MRP3 and MRP4 (two organic anion transporting systems) are expressed at the basolateral membrane. MRP3 mainly transports conjugates, such as bilirubin glucuronide; MRP4 transports bile acids together with glutathione [4].

Recently it was shown in humans that obstructive cholestasis also leads to a downregulation of Na⁺-dependent bile acid cotransporter (ASBT) mRNA expression in the distal part of the human duodenum [33].

Phalloidin (the toxic component of death cap [*Amanita phalloides*]), colchicine, cytochalasin B and androgens damage the pericanalicular actin-myosin network and thereby lead to cholestasis.

In *cystic fibrosis* (see below and Chapter 86) mutations of the CFTR-gene lead to impaired ductular chloride and bicarbonate secretion. The bile becomes viscous and bile casts obstruct the bile ducts, with ensuing inflammation, infection, focal fibrosis and, ultimately, secondary biliary cirrhosis.

Radiation-induced cholestasis most likely involves endothelial damage of the peribiliary arterial plexus with secondary alteration of bile ducts. However, primary radiation-induced damage of small bile ducts is also possible.

Histopathology

Over the last several decades the role of the pathologist in evaluating patients with cholestasis has changed. In the era prior to the development of ultrasound, CT, MRI, ERCP and MRCP the pathologist's chief goal in evaluating the cholestatic liver was to distinguish intrahepatic cholestasis (seen in conditions such as drug hepatotoxicity, viral hepatitis, sepsis, or genetic cholestatic syndromes) from large bile duct obstruction – i.e., to distinguish between “medical jaundice” and “surgical jaundice”, which necessitates different therapeutic approaches. After the advent of modern imaging techniques in clinical practice, mechanical obstructive cholestasis can be diagnosed accurately by clinical methods without the need for histopathological assessment of liver tissue. Today the diagnostic challenge for the histopathologist is in differentiating the many causes of intrahepatic cholestasis [46]. A close cooperation between clinician and histopathologist is necessary to

meet this challenge, since the histopathological lesions per se in many cases are not specific enough to allow for a definite diagnosis.

Many cholangiopathies associated with cholestasis are characterized by a progressive imbalance between cholangiocyte proliferation and their death. A comprehensive understanding of the mechanisms which regulate cholangiocyte proliferation is lacking. Acetylcholine, estrogens, interleukin-6, epidermal growth factor, 3-iodo-thyronine, selected bile acids, glucagon like peptide-1, nerve growth factor and hepatocyte growth factor have all been shown in experimental studies to promote cholangiocyte proliferation. Proliferating cholangiocytes secrete angiogenic factors (e.g., vascular endothelial growth factor [VEGF], angiopoietins 1 and 2) that, in addition to paracrine signaling to the endothelium (hepatic artery neovascularization), are capable of autocrine stimulation of cholangiocyte proliferation [28, 45, 51]. Recently the existence of an autocrine loop based on serotonin that limits the growth of the biliary tree in the course of chronic cholestasis was described [50].

Cholestasis-induced liver injury and cholestatic reactions are discussed in Chapters 20 and 26, respectively. The histopathology of distinct cholestatic liver diseases is covered in the clinical chapters dealing with the respective disorders. Therefore, in this chapter we present only a short summary of the time course of histopathologic liver alterations in large bile duct obstruction – exemplary for mechanical cholestasis (see Figs. 24.13 and 26.1–26.4). Mechanical obstruction of the large bile ducts results in three main characteristic portal tract changes: *connective tissue edema*, *bile ductular proliferation*, and *neutrophil infiltrates* [38, 46, 48, 58]. One should be aware that similar or identical portal changes may also occur near space-occupying hepatic masses in the absence of large bile duct obstruction.

First 3–4 Weeks After Bile Duct Obstruction

- Portal edema with inflammatory infiltration of portal tracts predominantly with neutrophilic granulocytes. Neutrophils surround and invade interlobular duct epithelium (*acute cholangitis*). In the very early stages of bile duct obstruction portal inflammatory changes may still be lacking.
- Proliferation and dilatation of interlobular bile ducts.
- Proliferation of cholangioles at the edge of portal tracts. Cholangioles often contain bile and are surrounded by neutrophils (“cholangiolitis”).

- Perivenular cholestasis with retention of bilirubin within hepatocytes; bilirubin and inspissated bile in dilated canaliculi (*bilirubinostasis*).
- Liver cell ballooning and hepatocellular necrosis (rarely) occurs in cholestatic areas. More often cell dropout with acidophilic bodies (apoptosis) is seen.
- Macrophages and Kupffer cells phagocytose bile constituents and PAS-positive material.
- Formation of liver cell rosettes, i.e. dilated bile canaliculi surrounded by more than two hepatocytes in a pseudoglandular arrangement.
- Periductal fibrosis is absent or minimal during the early stages.

Several Months After Bile Duct Obstruction

- Formation of bile extravasates (*bile lakes*) predominantly in the portal/periportal zones.
- Groups of necrotic hepatocytes (mostly periportal) become imbibed with fibrin and bile (*bile infarcts*). Bile infarcts are rarely seen, but their presence is virtually diagnostic of large bile duct obstruction.
- In the lobular parenchyma, single liver cells or groups of hepatocytes become swollen and pale with a finely reticular, foamy cytoplasm containing intracellular bile (*feathery degeneration, cholate stasis*).
- Accumulation of copper and copper-associated protein in periportal hepatocytes.
- Mallory-Denk bodies are found predominantly in periportal hepatocytes in approximately 2% of cases.
- Portal and periportal fibrosis develops.

Months to Years After Bile Duct Obstruction

- Portal and periportal fibrosis progresses with eventual portal–portal bridging and portal–terminal hepatic venular fibrosis.
- Development of secondary biliary cirrhosis. The regenerative nodules are small and irregular. The cirrhosis exhibits a jigsaw-type geographic pattern.

Diagnosis

The numerous causes of cholestasis require a systematic diagnostic approach that takes into consideration the conditions listed in [Tables 52.1 and 52.2](#). Despite the

etiologic diversity and the pathogenetic complexity of cholestasis, the clinician should initially answer a few relatively simple questions. Is cholestasis

- Intra- or extrahepatic?
- Mechanical-obstructive or nonobstructive?
- Icteric or anicteric?
- Acute or chronic?

History

A detailed history considering the clinical circumstances under which cholestasis occurred gives important clues to its etiology and may avoid long and costly examinations. A history of intravenous or intramuscular injections, blood transfusions, or dental treatments, accompanied by an insidious onset of fatigue, anorexia, mild nausea, and a feeling of pressure in the right upper quadrant hint towards a parenchymal, particularly a hepatic, disease.

A thorough evaluation of all xenobiotics ingested, including vitamins, homeopathic substances and herbal remedies, often provides important clues to the cause of cholestasis. If cholestasis is accompanied by fever, skin eruption and blood eosinophilia, a drug-induced cause should strongly be considered ([Table 52.2](#)). Generally patients with bland cholestasis (i.e. cholestasis not accompanied by inflammatory changes), in contrast to those with acute parenchymatous jaundice of hepatic disease, have only a slight impairment in their general condition. Most notable is the lack of fatigue which is instead seen so characteristically in parenchymatous liver disease.

An insidious course of many years with increasing pruritus in a middle-aged woman should arouse the suspicion of chronic, nonsuppurative, destructive cholangitis (PBC).

If cholestasis occurs in a patient with known chronic inflammatory bowel disease, especially ulcerative colitis, primary sclerosing cholangitis is the first disease which must be excluded. Cholestasis that develops within the context of sepsis, longstanding total parenteral nutrition, the postoperative state, or in the second or third trimester of pregnancy, is most likely due to the underlying condition itself and will often improve when the inciting condition is removed.

A thorough history should also include exposures to local irradiation of the liver, even if it occurred many years in the past, as radiation may lead to bile duct changes with cholestasis ([Chapter 22](#)).

Asking the patient about changes in the color of the stool and urine is obligatory. Light, clay-colored stools combined with dark, beer-brown urine are strong evidence for an intra- or extrahepatic obstruction to bile flow. The rapid development of fever $>38.5^{\circ}\text{C}$, increasing jaundice, epigastric and right upper quadrant pain, light stool and/or dark urine is most often the result of obstruction of the common bile duct by a gallstone. Compared with choledocholithiasis, bile duct obstruction by tumors (e.g. carcinoma of the pancreatic head, the papilla of Vater, bile ducts) usually develops at a slow rate, is painless, and is less often accompanied by high fevers. Significant weight loss in the weeks preceding the onset of cholestasis also hints toward a malignant process. In patients with a history of carcinoma or lymphoma, hepatic metastases or compression of the large extrahepatic bile ducts by metastases or lymphomas should also be considered.

Symptoms and Signs

The symptoms and signs of cholestasis may result from

- Too little bile in the gut, and
- Retention of biliary constituents in liver, blood and other tissues

A diminished quantity of bile in the gut leads to acholic stools, malabsorption with its sequelae (see below), and, if bile duct obstruction is complete, to a lack of urobilinogen in urine. Retention of biliary constituents damages the liver, causes a darkening of urine, jaundice, generalized pruritus, and results in hypercholesterolemia with the possible formation of xanthomas and xanthelasmas. When caring for patients with chronic cholestatic liver diseases, early recognition of its systemic manifestations and sequelae is imperative so that further complications are prevented and/or treated expeditiously.

Malabsorption

Lack of bilirubin in the gut results in a discoloration of stool. The deficiency of bile acids in the intestinal lumen causes an impairment of emulsification of fat with subsequent fat malabsorption and steatorrhea. The stool is soft, sallow, voluminous, and exudes a severely unpleasant odor. Malabsorption also involves the fat-soluble

vitamins A, D, E and K. If cholestasis persists long enough, signs of *vitamin deficiency* will develop. Deficiency of *vitamin K* appears relatively early and results in a prolonged prothrombin time and an increased bleeding tendency (bruises). *Vitamin A* deficiency becomes clinically apparent only in chronic cholestasis because the liver is able to store large amounts of vitamin A. It becomes noticeable as an increase in the difficulty of adapting one's vision to darkness, and may progress to night blindness. Pronounced *vitamin E* deficiency causes neuromuscular weakness and, in children, cerebellar and spinal ataxia, peripheral neuropathy, and retinal degeneration. A lack of *vitamin D* decreases intestinal Ca^{2+} -absorption and enhances the development of osteomalacia.

Metabolic Bone Disease

Hepatic osteodystrophy (which is essentially an osteoporosis; see also Chapter 80.9) may manifest locally as wrist and ankle pain, as diffuse skeletal pain, and as bone fractures (e.g., vertebral bodies or ribs) after minor trauma. Its pathogenesis is complex and involves vitamin D deficiency and deranged mineralization of osteoid. Chronic cholestasis leads to the accumulation of ill-defined substances which inhibit the activity of osteoblasts, with subsequent diminished formation of new bone and increased degradation of the osseous matrix. The long-term use of corticosteroids in patients with chronic cholestatic liver disease aggravates hepatic osteodystrophy.

Xanthelasmas and Xanthomas

Xanthelasmas are raised, flat, soft, yellowish cholesterol deposits in skin. They occur predominantly at the eyelids or periorbitally, but may also appear on the neck, chest, back or the creases of the palms. Xanthomas are more nodular cholesterol conglomerates (tuberous xanthomas) preferentially located on the extensor surfaces of the extremities, the fists, elbows, knees, ankle joints, buttocks, and in scars and tendons. Occasionally they may affect bones or peripheral nerves. Both may develop in patients with chronic cholestasis with serum cholesterol concentration $>450\text{mg/dL}$ for at least 3 months. They are usually reversible after cholestasis resolves.

Pruritus

The pruritus in chronic cholestasis is generalized and is frequently the most debilitating symptom of cholestatic liver disease. On initial examination of the patient, its extent can often be easily appreciated by observing varying degrees of excoriations. Itching can be extremely debilitating and limit the patient's daily activities as well as cause significant disruption of sleep. The severity of cholestasis, however, does not necessarily correlate with the severity of pruritus.

The pathophysiology of generalized pruritus in cholestasis is not well understood. The stimulus associated with the sensation of pruritus is transmitted by unmyelinated C-fibers, which also transmit pain. Bile acids accumulate in the tissues of patients with cholestasis, but a role of bile acids in the mediation of the pruritus of cholestasis has not been proven. Pruritogenic substances have not yet been identified unequivocally in blood. Mast cell products, such as histamine, tumor necrosis factor- α , tryptase, and prostaglandins may act as itch augmenting factors. Opioids may activate mast cells and potentiate histamine-induced pruritus. Over the last few years, there has been increased evidence for a central pathway of pruritus that involves increased opioidergic and serotonergic tone in the central nervous system, which explains why in some patients pruritus may be effectively relieved by opiate antagonists [7, 37]. In this context, increased plasma levels of met- and leukenkephalins, two of the endogenous opioid peptides, have been reported in patients with liver disease, including those with primary biliary cirrhosis [6, 82].

Fatigue

Approximately 50% of patients with a chronic cholestatic liver disease complain of pronounced fatigue which, together with pruritus, may become the most debilitating symptom [30, 54]. Fatigue is reported in up to 86% of patients with PBC and is regarded as the most disabling symptom by approximately one half of patients with PBC [31, 34]. Additionally, fatigue is associated with an unexpectedly high incidence of depression. Interestingly, fatigue is neither associated with the severity nor the duration of PBC. Fatigue associated with chronic cholestasis is poorly relieved by rest and is not related to exercise.

The pathogenesis of cholestasis-associated fatigue is multifactorial and of central origin [30]. Dysregulation of hypothalamic–hypophyseal–adrenal axis and serotonergic mechanisms seem to be involved. It is possible that centrally released cytokines, such as interleukin- β , may induce malaise and lethargy. Endogenous interferon may also contribute to fatigue [79].

Liver Failure

Cholestasis itself injures the liver and may contribute to the development of hepatic insufficiency. It is most likely, however, that the underlying chronic liver disease is the major factor responsible for liver failure, with cholestasis playing only a minor role. Although poorly understood, retained toxic bile acids and copper are believed to play a role in cholestasis-associated hepatic failure. Copper is excreted in bile and is deposited in liver parenchyma in all forms of cholestasis. Its tissue concentration in chronic cholestatic liver disease may reach and even exceed that in Wilson's disease. The decline in cytochrome P450 activity, with its subsequent impact on drug metabolism, is directly related to the severity and chronicity of cholestasis.

Other Organ Systems

Chronic cholestasis also affects the function of extra-hepatic organ systems. Cardiovascular regulation is impaired in hypotensive patients. The kidneys are more vulnerable to hypoxic and hypotensive injury. Immunologic dysfunction augments the risk of sepsis. Wound healing is impaired. The accumulation of cholesterol in red blood cell membranes leads to the formation of target cells.

Laboratory Findings

Alkaline phosphatase and γ -glutamyl transpeptidase are the most important cholestatic enzymes (see Chapters 34 and 49). Their concentrations are usually increased more than three times above the upper limit of normal. In icteric forms of cholestasis the concentration of conjugated bilirubin in serum rises. If the cause of cholestasis is not corrected, bilirubin values continue to rise for approximately 3 weeks, and then plateau

with mild fluctuations. After successful treatment of cholestasis, bilirubin levels are slow to decline because of the formation of bilirubin–albumin complexes. In primary cholestatic liver diseases (e.g., primary biliary cirrhosis, primary sclerosing cholangitis, ductopenic syndromes) the cholestatic enzymes are increased out of proportion to the comparatively mild rise in aminotransferase concentrations.

In primary biliary cirrhosis more than 95% of patients have antimitochondrial antibodies present in their serum. In primary sclerosing cholangitis pANCA may be present. Cholestatic autoimmune hepatitis may show various antibody profiles (e.g. ANA, AMA, SMA, LKM, SLA/LP) (see Chapters 36, and 72–77).

Serum levels of cholesterol are increased in chronic cholestatic liver disease, most likely due to an increased synthesis of cholesterol. The decreased activity of lecithin cholesterol acyl transferase (LCAT) in serum leads to an increase of low-density lipoproteins (LDL) and to a decrease of high density lipoproteins (HDL).

The demonstration of conjugated bilirubin and urobilinogen in urine depends on the amount of bile reaching the duodenum. In choledocholithiasis, the concentration of alkaline phosphatase and γ -glutamyl transpeptidase in serum typically rises. Choledocholithiasis, however, may also have an atypical presentation with marked elevation of serum aminotransferases to levels greater than 1,000 IU/L, which normalize rapidly once gallstone disease is appropriately managed [60].

Imaging Techniques

Imaging methods, such as US, CT, MRCP, EUS, ERCP, PTC and, to a lesser degree, liver biopsy are critically important in the diagnosis and differential diagnosis of cholestatic liver diseases (notably in diagnosing mechanical cholestasis). The individual methods are discussed separately in Chapters 37, 38, 40, 42–45. In this chapter their significance in the evaluation of a patient with cholestasis is only briefly mentioned.

Imaging the liver and bile ducts in a cholestatic/icteric patient focuses on the following questions:

- Are the intra- and/or extrahepatic bile ducts dilated?
- If so, at which anatomical level is bile duct obstruction present?

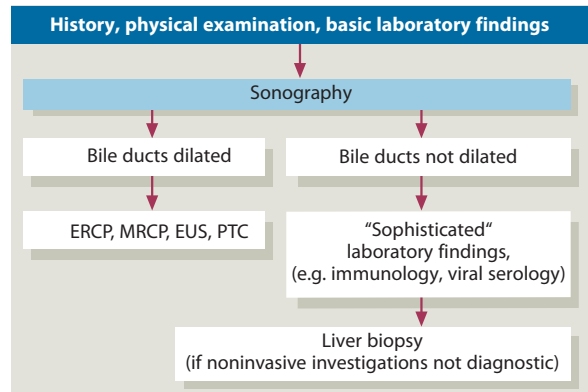


Fig. 52.5 Diagnostic approach to a patient with cholestasis. The ultrasound finding is pivotal for further work up

- Can the cause of bile duct obstruction (e.g. stone, tumor) be visualized?
- If bile ducts are not dilated, does the hepatic parenchyma display a homogeneous echopattern or are there focal liver lesions present?

Transabdominal ultrasound, due to its availability, non-invasiveness and diagnostic accuracy is the method of choice in differentiating obstructive from nonobstructive jaundice in cholestatic/icteric patients (Fig. 52.5). Experienced ultrasonographers can identify the anatomical level of bile duct obstruction in 92–95% of cases, and the cause in 71–88% of patients. Three different levels of obstruction are defined:

1. Liver hilum (obstructive jaundice is usually due to neoplasm, most often cholangiocarcinoma or lymph node metastases; rare causes include Mirizzi’s syndrome).
2. Between the hilum of the liver and the pancreas (frequent causes include primary neoplasms or lymph node metastases. Examples of less frequent causes are bile duct stones or inflammatory stenoses).
3. At the level of the pancreas (frequent causes include choledocholithiasis, neoplasms, inflammatory pancreatic lesions, and strictures).

The correct interpretation of sonographic images may be difficult, and sources of error exist even for the experienced and dedicated examiner. The infundibulum of the gallbladder, for example, may be misinterpreted for a dilated common bile duct. The demonstration of the respective regions in various section planes helps to avoid this error. A dilated or an accessory hepatic artery may also simulate a dilated common bile duct. With

color doppler ultrasound, a quick and correct assessment is possible. Hemobilia can result in echogenic material (blood) within the bile duct lumen, which may cause a dilated bile duct look normal. Older coagulated blood may appear as hypoechoic material in the bile duct or in the gallbladder and simulate a tumor.

Endoscopic ultrasound is a highly sensitive method, especially for detecting small (<5 mm) stones in the common bile duct, and for the local staging of tumors of the papilla of Vater and of the pancreatic head. In specialized centers the demonstration by transabdominal US of a dilated common bile duct is immediately followed by EUS and, if necessary, by therapeutic ERCP (stone extraction or stent placement) [15, 17]. CT or MRI can therefore be avoided in this clinical situation.

Diagnostic *ERCP* is being increasingly replaced by MRCP and EUS. The advantage of diagnostic ERCP is the possibility to obtain cytological brushings and biopsies. Currently, however, ERCP's main strength lies in its therapeutic options, such as sphincterotomy, stone extraction, stent placement, and biliary drainage.

Liver biopsy is still the gold standard in many cases of diffuse parenchymatous liver disease and in the etiologic evaluation of liver masses.

Differential Diagnosis

In evaluating patients with chronic cholestatic disease the conditions listed in [Tables 52.1 and 52.2](#) should be considered. [Table 52.7](#) summarizes the major findings in intrahepatic cholestasis. In this chapter, selected diseases and conditions that may elicit cholestasis are discussed briefly. Distinct cholestatic diseases listed in [Table 52.1](#) are discussed in separate chapters.

Inherited Syndromes of Intrahepatic Cholestasis

See Chapter 85.

Primary Biliary Cirrhosis, Primary Sclerosing Cholangitis, Autoimmune Cholangiopathy and Ductopenic Syndromes

See Chapters 73–77.

Total Parenteral Nutrition

Hepatobiliary dysfunction occurs in up to 90% of patients receiving long-term total parenteral nutrition (TPN; see Chapter 91) [3]. In adults mostly steatohepatic changes are found, while in children cholestatic alterations predominate and are accompanied by inflammatory reactions and various degrees of liver parenchymal injury.

The *pathogenesis* of TPN-associated cholestasis is not completely understood. Impairment of hepatocellular transport systems by components of TPN-solutions has been described. Chronic bacterial translocation and the induction of proinflammatory cytokines, along with increased formation of toxic bile acids (such as lithocholic acid) in the gut may be involved. Parenterally administered aminoacids appear to inhibit hepatocellular transporters in preterm infants. Immaturity of the bile secretory apparatus, including late ontogenic expression of MDR2/MDR3 (compared with other transporters), may contribute to the higher susceptibility to TPN-induced cholestasis in neonates [85]. High-dose oral erythromycin (12.5 mg/kg/dose every 6 h for 14 days) may decrease the incidence of parenteral nutrition-associated cholestasis in these newborns [62]. In addition to hepatic parenchymal injury, TPN may cause cholestasis by affecting gallbladder function and bile ducts. After TPN of 3 weeks duration sludge in the gallbladder is found in 50% of patients. After 4 months, sludge is present in practically every patient, with cholecystitis, cholecystolithiasis and hydrops of the gallbladder as possible consequences. After resuming oral nutrition the sludge disappears within a few days. The lack of enteral nutrition and TPN could be important contributing factors for bile duct injury described in long-term intensive care unit patients.

Clinically, most patients are asymptomatic with respect to cholestasis. Some complain of mild nausea and a slight sensation of pressure or discomfort in the right upper abdomen.

Laboratory examinations show a mild increase (usually less than five times the upper limit of normal) in aminotransferase levels, with more marked increases in AP and γ -GT and in serum bilirubin in icteric patients.

After discontinuing TPN the laboratory parameters usually normalize within 1–3 weeks. If for clinical reasons TPN cannot be discontinued completely, a TPN-free interval of at least 10 days should be attempted. An excessive supply of calories should be avoided.

This succeeds by limiting the supply of glucose to ≤ 6 g/kg body weight/day, and of lipids to ≤ 2 g/kg body weight/day.

Drug-Induced Cholestasis

Drug-induced liver injury is relatively rare, and fewer than 30% of cases with drug-induced liver injury are cholestatic. Both environmental and genetic factors (e.g., genetically determined variations of hepatobiliary transporter expression and function) may be important in determining an individual's susceptibility to drug-induced cholestasis [85]. A selection of drugs that are known to cause cholestasis is listed in Table 52.2. Fever, skin eruption, and/or eosinophilia in blood or in liver biopsy should direct one's attention to drugs as a potential cause of cholestasis. Considering the numerous medications that are usually consumed by patients, it is often difficult to identify the one drug that is responsible for cholestasis. Alternative-complementary drugs, such as herbal remedies and homeopathic medications, may also cause cholestasis in individual cases. In this regard, greater celandine (*Chelidonium majus*), which is taken quite often in Europe by patients with gallstones and dyspeptic symptoms, should be kept in mind.

The *pathogenesis* of drug-induced cholestasis may involve several mechanisms, including impairment of hepatocellular transporters, and damage to bile ducts by inflammatory or ischemic mechanisms [64, 76, 85]. Drugs and their metabolites (e.g. C17-alkylated steroids) can directly inhibit the function or the expression of hepatocellular transporters (e.g. MRP2, MDR3 and BSEP). Cholestasis due to impairment of hepatocellular transporters is usually "bland", i.e. not accompanied by hepatitic inflammatory changes. A "bland" cholestasis is most often caused by estrogens, oral contraceptives, 17 α -alkylated androgenic steroids, and by tamoxifen. Therapy with cyclosporin A, sirolimus, verapamil, or vinblastine (potential inhibitors of MDR3 expression and/or function), in individuals with genetic MDR3 variants and genetically determined low MDR3 expression or function, can impair biliary excretion and also cause cholestasis. Rifampicin, cyclosporin, bosentan, glibenclamide, or troglitazone competitively inhibit ATP-dependent taurocholate transport by BSEP, whereas estrogen and progesterone metabolites indirectly inhibit BSEP following their excretion into bile via MRP2 [85]. Women with a

personal or a family history of intrahepatic cholestasis of pregnancy are more prone to develop contraceptive-induced cholestasis. Usually the cholestatic alterations slowly subside after the causative drug is withdrawn. However, it is important to note that with some drugs (e.g. amoxicillin-clavulanic acid) cholestasis may become clinically manifest after the drug has been stopped. Cholestatic hepatitis caused by amoxicillin-clavulanic acid may even lead to the vanishing bile duct syndrome with secondary biliary cirrhosis. Ticlopidine also is increasingly implicated with a cholestatic hepatitis and an acquired loss of intrahepatic bile ducts.

Drugs (e.g., rifampicin or biliary contrast media) may selectively interfere with the sinusoidal uptake of substances that are destined for canalicular secretion. Thus, rifampicin, by impairing sinusoidal uptake of bile acids, leads to an increase in serum bile acid levels in approximately 70% of patients after only the first dose [24].

Drugs may induce an idiosyncratic inflammatory reaction associated with cholestasis (cholestatic hepatitis). A cholestatic hepatitis may occur especially after the intake of chlorpromazine, psychotropic drugs, erythromycin, clavulanic acid and nonsteroidal anti-inflammatory drugs. Carbamazepine can cause a granulomatous hepatitis accompanied by cholestasis.

Paraquat and 5-fluorouracil may damage the bile ducts by injuring the feeding arterial vessels.

Ischemic Cholangiopathy

Ischemia-induced bile duct lesions are commonly referred to as ischemic cholangitis although inflammation does not appear to be a primary factor. The integrity of the biliary epithelium depends on arterial blood flow, and is susceptible to injury when arterial blood flow is compromised. This compromise can occur at the level of the major branches of the hepatic artery or at the level of peribiliary capillary plexus, which stems from the major hepatic arteries. Ischemic bile duct injury results in segmental strictures and cholangiectasias with resulting mechanical impairment of bile flow, and, occasionally, secondary infection of the biliary system [5, 19].

Clinical features of ischemic cholangiopathy (IC) are usually latent during the initial period of the condition. Diagnostic evaluation commonly begins when serum levels of bilirubin or alkaline phosphatase and

γ -glutamyl transpeptidase rise, or if the patient develops cholangitic symptoms. Diagnosis is made by the typical cholangiographic findings (pauci- or multifocal strictures and dilatations) on ERCP or MRCP within the typical clinical context of a condition that is associated with impaired arterial blood flow to the liver (e.g., *sclerosing cholangitis in critically ill patients*) [26]. The middle third of the common bile duct is involved preferentially, followed by the confluence of the hepatic ducts. Pure intrahepatic involvement is the least common. At later stages of the disease, pruritis and jaundice appear, and hepatocellular failure may develop [19].

IC may be observed in various circumstances (see [Table 52.1](#)). Hepatic artery infusion with chemotherapeutic agents (e.g. 5-fluorouracil, floxuridine; cholangiopathy is particularly common when intra-arterial chemotherapy is combined with embolization), percutaneous ethanol injection, advanced AIDS (see below), liver transplantation (see below), injury during laparoscopic cholecystectomy, hereditary hemorrhagic telangiectasia, radiotherapy on the liver area, polyarteritis nodosa, and atherosclerosis.

Symptomatic cholangiopathy is observed in approximately 3% of patients with hereditary hemorrhagic telangiectasia (HHT) [25]. A possible explanation for IC in patients with HHT are telangiectasias with arteriovenous or arterioportal shunts that lead to blood “stealing” away from arterial peribiliary plexus.

Infectious Disease- and Sepsis-Associated Cholestasis

Acute and chronic *viral hepatitis* (especially acute hepatitis A) may have a cholestatic course. *Hepatic abscess* and an *echinococcal cyst* may mechanically obstruct bile flow and thereby lead to cholestasis.

AIDS-Related Cholangiopathy

AIDS-related cholangiopathy (ARC) is a sclerosing cholangitis of intra- and extrahepatic bile ducts. In 25% of these patients only papillary stenosis is present, while the extra- and intrahepatic bile ducts are dilated but otherwise regular. ARC is associated with bile duct infections caused by cytomegalovirus, cryptosporidia, microsporidia, or any combination of these

organisms. It affects patients at an advanced stage of AIDS with CD4 counts typically less than 100/mm³. Cholestatic enzymes (AP and γ -GT) are elevated, and the cholangiographic appearance on ERCP or MRCP is indistinguishable from primary sclerosing cholangitis [16]. Clinically, the cholangiopathy is initially asymptomatic. Later in the course of the disease, abdominal pain in the right upper quadrant and epigastrium may supervene, particularly if papillary stenosis is dominant. Jaundice is unusual. Therefore, the development of jaundice in a patient with advanced AIDS should prompt a workup of other causes, such as drugs, ethanol abuse, lymphoma, and Kaposi's sarcoma.

Systemic Infections

Cholestasis that develops in the setting of systemic infections may be due to direct invasion of liver parenchyma and/or bile ducts with infectious agent(s), or it may be related to the action of inflammatory mediators on hepatocellular transporters [18]. An intrahepatic cholestasis is often observed during the course of a variety of systemic infections, including, for example, *E. coli*, *Klebsiella pneumoniae*, *P. aeruginosa*, *H. influenzae*, *S. aureus*, *Proteus* species, *Bacteroides*, and aerobic and anaerobic streptococci. The pathogenesis of jaundice in systemic infection is multifactorial. Hemolysis with an increased bilirubin load, hepatocellular injury, and cholestasis related to sepsis or to various drugs used in the treatment of sepsis should be considered [13].

Sepsis

Sepsis and bacterial infection are responsible for up to 20% of cases of jaundice in patients in a community hospital setting [13]. Sepsis-associated cholestasis is predominantly linked to infections with gram-negative bacteria.

Endotoxin- and interleukin-1-induced stimulation of Kupffer cells to secrete a wide range of proinflammatory cytokines (TNF- α , interleukin-1 and interleukin-8) plays a critical role in the pathogenesis of sepsis-associated cholestasis (see Chapter 19). Endotoxin also increases the expression of adhesion molecules (ICAM-1) on sinusoidal endothelial cells and Kupffer cells, as well as expression of the neutrophil ligand Mac-1. Neutrophils

bind to ICAM-1 and release noxious substances (super-oxide radicals, hydrogen peroxide, enzymes) that sustain liver damage and cholestasis [49, 57]. Furthermore, endotoxins and cytokines modulate the expression of hepatocellular transporters [85]. The transport of organic anions across the sinusoidal and the canalicular membrane is impaired. The expression of NTCP mRNA, in particular, is decreased. Bile acid dependent and independent choleresis are decreased. The down-regulation of transporter genes is probably enhanced by retained bile constituents and the hepatocellular transport capacity is further impaired by increased cellular levels of nitric oxide. Infiltrating neutrophils release superoxide radicals and enzymes, such as elastase and proteases which damage hepatocytes and biliary epithelia and perpetuate cholestasis.

Histologically the most common change in patients with extrahepatic sepsis is a predominantly centrilobular *canalicular cholestasis*. It is generally accompanied by Kupffer cell activation, fatty change and portal inflammation. Hepatocellular necrosis is lacking or minimal. The second histological pattern is *ductular cholestasis and inflammation*. Bile ductular structures at the margins of portal tracts proliferate, dilate, and are filled with bile pigment and surrounded by neutrophils (see Chapter 26) [46, 72]. In toxemia associated with staphylococcal infection (toxic shock syndrome) a histological picture of cholangitis, similar to that of bacterial cholangitis may be seen.

Clinically, sepsis-associated cholestasis most often manifests as a reversible hepatocellular cholestasis with rising serum bilirubin values. In patients with a previously healthy liver bilirubin rises in approximately 6% of cases. If sepsis occurs in a patient with an already damaged liver, bilirubin levels rise in approximately 50% of cases. More than 60% of total bilirubin in blood is conjugated. *In sepsis-associated cholestasis, it is typical for the increase in serum bilirubin levels to be out of proportion to the concentration of alkaline phosphatase and aminotransferases.* Hyperbilirubinemia up to 20 mg/dL in patients with a predamaged liver is well documented [57]. Marked elevation of aminotransferase levels usually indicates additional ischemic injury to the liver. If septic shock is present, ischemic cholangiopathy with progressive sclerosing cholangitis of large bile ducts may develop.

The *prognosis* of sepsis-associated cholestasis is very poor, with mortality rates reaching 60–100%.

Postoperative Cholestasis

A postoperative cholestasis with jaundice is observed in fewer than 1% of elective abdominal operations, and in up to 15% of major heart operations, mostly within the first 3 postoperative weeks. The diagnostic evaluation of postoperative cholestasis and jaundice must consider the same differential diagnostic causes listed in [Tables 52.1 and 52.2](#). In addition to these, however, certain potential etiologies of jaundice and cholestasis need special attention in the postoperative situation. Infections, total parenteral nutrition, prolonged anesthesia times, intraoperative hypotension, drugs and blood transfusions may all contribute to postoperative cholestasis and jaundice ([Table 52.5](#)) [56].

Hemolysis

Postoperative hemolysis leads to an increased bilirubin load that cannot be adequately conjugated and excreted, especially by a previously injured liver. A hematoma of 1 L contains approximately 5 g of bilirubin, which corresponds to approximately 20 times the amount of normal daily bilirubin production. Roughly 10% of red blood cells are lysed within the first 24 h after

Table 52.5 Causes of postoperative cholestasis and postoperative jaundice

<p>Increased bilirubin load (jaundice usually appears > 3 weeks after the operation)</p> <ul style="list-style-type: none"> • Drug-induced hemolysis • Resorption of a large hematoma • Hemolysis due to intravasal mechanical devices (e.g. cardiac valves) • Multiple blood transfusions
<p>Parenchymal liver injury (jaundice usually appears ≤ 3 weeks after operation)</p> <ul style="list-style-type: none"> • Ischemia • Sepsis • Drugs (e.g. anesthetics) • Parenteral hyperalimentation • Viral hepatitis (jaundice usually appears > 3 weeks after operation) • Benign postoperative cholestasis
<p>Extrahepatic mechanical cholestasis</p> <ul style="list-style-type: none"> • Choledocholithiasis • Cholecystitis • Pancreatitis • Benign bile duct strictures (e.g. accidental arterial vessel ligation)

transfusion leading to a bilirubin load of 250 mg. Therefore, multiple transfusions favor the occurrence of postoperative jaundice.

Ischemia

Intra- and perioperative periods of hypotension, even if short-lived, may cause ischemic liver and bile duct damage resulting in postoperative jaundice. The differential diagnosis should consider circulatory shock, excessive blood loss, and inadvertent ligation of the hepatic artery.

Drugs

Drugs play an important role in the pathogenesis of postoperative cholestasis and jaundice. Jaundice is relatively often observed after the intake of sulfonamides and phenytoin, but only rarely after the administration of halogenated anesthetics, such as halothane, enflurane, methoxyflurane, isoflurane, sevoflurane or desflurane. Of these, Cholestasis due to halothane has been the most well-described. The reaction to anesthetics is characterized by the occurrence of fever and an acute hepatitis, usually within 3 weeks after exposure. A skin eruption and blood eosinophilia hint towards a potential idiosyncratic-allergic drug reaction. After several exposures, the interval to the appearance of a hepatic reaction shortens to less than a week. Halothane-induced fulminant liver failure is extremely rare (0.35–0.9 cases per 100,000 operations). Factors associated with an unfavorable prognosis in halothane-induced liver failure are age greater than 60 years, obesity, repeated exposures to halothane in short intervals, serum bilirubin levels > 10 mg/dL, and a prolongation of the prothrombin time > 20 s.

Acalculous Cholecystitis

Acalculous cholecystitis (AC) accounts for approximately 2–12% of all cases of acute cholecystitis. Although in a strict sense AC is not a postoperative cholestatic condition, we briefly mention this entity here because it most often is associated with surgical procedures, burns and severe trauma, and may cause cholestatic liver reactions. AC is two to three times more prevalent in men than in women. Anesthetics,

intestinal atony, total parenteral nutrition, hypovolemia, sepsis and shock all play a role in its development.

Viral Hepatitis

Since the discovery and characterization of hepatitis C virus in western countries, all blood donors and units of blood are screened so that in industrialized countries postoperative viral hepatitis does not play a notable role anymore. The significance of hepatitis G virus and of TT-virus cannot yet be assessed conclusively.

Benign Postoperative Cholestasis

Benign postoperative cholestasis generally occurs within the first postoperative week. The pathogenesis is not well understood. Despite a marked hyperbilirubinemia of up to 40 mg/dL, the prothrombin time is not prolonged and liver failure does not occur. The prognosis is favorable.

Cholestasis in Sarcoidosis

Sarcoidosis is a systemic granulomatous disease (see Chapter 95). The majority of patients with hepatic involvement present with portal granulomas and elevations of serum alkaline phosphatase concentrations. Rarely is cholestasis the primary clinical problem in sarcoidosis. Mechanical impairment of bile flow due to large portal granulomas occurs in only few patients with sarcoidosis. Cholestasis associated with hepatic granulomas may also be seen in carbamazepine-induced liver injury, and should be differentiated from hepatic sarcoidosis.

Cholestasis in Graft Versus Host Disease

Graft versus host disease (GVHD) is a severe complication of allogenic bone marrow transplant, in which donor T cells recognize antigens in the recipient with subsequent injury of the skin, gastrointestinal tract and the liver. The cholangiocytes of small bile ducts are the prime target of the immunologic attack in the liver. Compared to the manifold serious problems in these patients, however, cholestasis is only of minor clinical

importance. Acute GVHD usually begins in the third week, while chronic GVHD is seen approximately 6 months after transplantation.

Cholestasis Following Liver Transplantation

The causes of cholestasis following orthotopic liver transplantation (LTX) are manifold, and any of these causes can lead to graft loss if left untreated (see Chapter 103). Mechanical, ischemic, infectious (e.g., cytomegalovirus, fibrosing cholestatic hepatitis C), drug-induced factors, recurrence of the underlying disease in the transplanted liver (e.g., PSC, PBC, HCV), rejection reactions, and sepsis are among the factors to be considered. In acute cellular and chronic transplant rejection, immunologically mediated destruction of small bile ducts leads to cholestasis. Biliary complications are perhaps the most frequent causes of cholestasis after LTX. Mechanical causes such as bile leaks either immediately after surgery or later after T-tube removal (if used), as well as anastomotic bile duct strictures, can be treated with endoscopic CBD stenting. Ischemic cholangiopathy after LTX is becoming an important problem, with non-anastomotic biliary strictures and necrosis of bile ducts (with resultant bilomas or biliary casts) being well described complications of LTX. LTX-associated ischemic cholangiopathy likely is attributable to numerous factors, such as preservation and reperfusion injury, ABO incompatibility, rejection, cytomegalovirus infection, and stenosis or thrombosis of the hepatic artery. Hepatic artery thrombosis occurs in approximately 2–20% of patients who undergo LTX. Compared with late thrombosis which may lead to diffuse stricturing, bile lakes, or abscesses, early hepatic artery thrombosis induces a more severe cholangiopathy as well as an ischemic hepatitis, and more often requires re-transplantation [87]. In addition to the stenosis of bile ducts, ischemia/reperfusion has a negative impact on MDR3 expression and function. This effect might be exacerbated by the effects of immunosuppressive drugs (e.g. cyclosporin A and sirolimus) on hepatocellular transporter expression and function [85].

In post-LTX cholestasis, the changes in liver enzymes are non-specific, with an increase in alkaline phosphatase, γ -glutamyl transpeptidase and possibly bilirubin levels out of proportion to only mildly elevated aminotransferase levels. Ultrasonography, cholangiography (ERCP or MRCP) and histological assessment of liver biopsy are required in most cases

to arrive at the correct diagnosis. While some centers administer ursodeoxycholic acid (UDCA) to decrease post-LTX cholestasis, there is no good evidence to either support or refute this practice.

The following two disorders (intrahepatic cholestasis of pregnancy and cystic fibrosis) are genetic cholestatic syndromes and are discussed in detail in Chapters 86 and 98. Since they belong to the differential diagnostic spectrum in a patient presenting with cholestasis they are also briefly mentioned here.

Intrahepatic Cholestasis of Pregnancy (See Chapter 98)

Intrahepatic cholestasis of pregnancy (ICP) is the most common disease characteristic of pregnancy [53]. It shows a strong regional and ethnic clustering (rare in Central and Western Europe and North America with 0.2% of pregnancies; more prevalent in Scandinavia with 1–2% and Chile with 5–15% of pregnancies, as high as 28% within the Araucanian Indian subpopulation). Genetic factors (positive family history in 50%; possibly an increased susceptibility to estrogens and potentially also to progesterone) are important. Environmental factors probably also play a role, as a decreasing incidence has been observed since 1970.

MDR3 dysfunction is central to the pathogenesis of ICP. ICP is one of the best-characterized examples for a role of MDR3 mutations in adult cholestatic syndromes. ICP may be viewed as a classic example for decompensation of a heterozygous state of a transporter gene (MDR3) defect under hormonal challenge in a subset of patients who, under basal conditions, have sufficient MDR3 activity [85]. Other transporter genes such as BSEP (ABCB11), FIC1 (ATP8B1), and MRP2 (ABCC2) could also play a role in the pathogenesis of ICP with low (normal) γ -GT levels.

Clinically, ICP is characterized by intense, often excruciating pruritus which appears in the second half of pregnancy in 80% of affected women.

Occasionally it may be accompanied by mild nausea and right upper quadrant abdominal pain. The jaundice is mild with bilirubin levels of 5–6 mg% in approximately 20% of affected women. AP is always increased (approximately four-times the upper limit of normal), and is usually out of proportion to γ -GT, which is increased in only 30% of cases. The concentration of

bile acids in serum is also increased. AST and ALT can be elevated but are usually <500 IU/ml.

The *prognosis* of the disease is favorable. All liver changes normalize and symptoms abate within 2–4 weeks after delivery. However, cholestasis recurs in 60–70% of cases in a new pregnancy. In addition, cholestasis is often observed in these patients after the intake of estrogens (e.g. oral contraceptives). ICP is associated with an increased risk of postpartum bleeding, high miscarriage rates, and perinatal complications. The incidence of fetal mortality is 1–2%. Treatment with UDCA up to 15 mg/kg p.o. daily may improve pruritus and liver tests without adversely affecting the fetus.

Cholestasis in Cystic Fibrosis (See Chapter 86)

Cystic fibrosis is a hereditary multisystem disease that is characterized by mutations and deletions in the CFTR-gene, a cAMP-dependent chloride channel that is present in many epithelia. Like PFIC and BRIC it may be classified among the hereditary hepatobiliary transporter defects (see Chapter 85). CFTR is expressed in the apical membrane of cholangiocytes. Currently, approximately 750 different mutations in the CFTR-gene have been identified. Approximately 15% of patients with cystic fibrosis develop a cholestatic liver disease, typically prolonged neonatal cholestasis. inspissated bile plugs occlude the bile duct lumen, result in recurrent infections, secondary sclerosing cholangitis and ultimately cirrhosis. The majority of patients suffer from respiratory, gastrointestinal and pancreatic dysfunction.

Therapy

The goal of therapy in cholestatic liver disease is to eliminate its cause(s) and treat the consequences. In mechanical occlusion of large bile ducts, for example, this goal may be achieved by removing or bypassing the obstructing lesion endoscopically, percutaneously, or operatively. In drug-induced cholestasis, the challenge is to identify and remove the incriminating drug. Treatment of sepsis-induced cholestasis with antibiotics or antivirals is targeted at the underlying infectious organism.

In primary cholestatic liver diseases, however, treatment directed at the underlying cause, which is often unknown, is usually not available. Thus, the treatment of extrahepatic manifestations of cholestasis assumes prime importance.

Pruritus

The principles of management of pruritus are based on

- Increasing excretion of pruritogenic substances
- Hepatic enzyme induction
- Impairment of opioid neurotransmission, and on
- Other mechanisms

There are only few, small randomized controlled trials evaluating the efficiency of medications in the treatment of cholestasis-associated pruritus [80].

Increasing Excretion of Pruritogenic Substances

Cholestyramine and Colestipol. Cholestyramine and colestipol are nonabsorbable anion exchange resins that bind pruritogenic substances in the intestinal lumen, disrupt their enterohepatic circulation and thereby enhance their fecal excretion. Additionally, cholestyramine intake is associated with the release of cholecystokinin, a hormone with anti-opiate properties; therefore, the anti-pruritic effect of cholestyramine may also result from associated anti-opiate neurotransmission [7]. Despite a compensatory increase of bile acid synthesis by the liver, the total bile acid pool in the body diminishes during resin treatment.

The dose of cholestyramine is 4 g orally before and after breakfast, increased to 4 g at other meal times, not to exceed 16 g/day. The dose of colestipol is 5 g orally three times a day, taken with meals. There appears to be no advantage to dosing more frequently, and both substances are not well tolerated at higher doses. The anti-pruritogenic effect begins 2–4 days after treatment is initiated. The most common side effects are nausea, bloating, dyspeptic symptoms, constipation, and malabsorption of nutrients. Since both substances contain chloride, a hyperchloremic acidosis may ensue. Long-term use may aggravate steatorrhea and result in a deficiency of fat soluble vitamins. Both drugs may interfere with absorption of other medications when taken at the

same time, such as phenylbutazon, phenobarbital, propranolol, warfarin, digoxin, thyroxin. These drugs should therefore be administered 1 h prior or 4 h after the intake of cholestyramine or colestipol.

Hepatic Enzyme Induction

Phenobarbital. The exact mechanism of the anti-pruritic action of phenobarbital is unknown. It increases bile acid independent choleresis, induces the cytochrome P450 system and potentiates the hydroxylation of bile acids. It may also act on peripheral nerve endings or on the central nervous system to reduce the pruritic stimulus. Its oral dose is 3–5 mg/kg body weight/day divided in two doses, or 200–400 mg i.v./day.

Rifampicin (Rifampin). Rifampicin is a more potent enzyme inducer than phenobarbital. It competitively inhibits the hepatocellular uptake of bile acids, thereby reducing their concentration in liver and bile. Rifampicin may also diminish the hepatic release of as yet not well-defined pruritic substances. The dose is 150 mg orally three times a day, or 300 mg twice daily if serum bilirubin is <3 mg/dL. If serum bilirubin is >3 mg/dL the dose is reduced to 150 mg twice daily.

Untoward effects such as hepatitis, hemolytic anemia, renal insufficiency and thrombocytopenia should be kept in mind especially when rifampicin is administered long-term.

Changes in Opioidergic Neurotransmission

Naloxone. Naloxone is an opioid antagonist that may relieve pruritus when administered intravenously at a dose of 0.4 mg twice or three times daily. Due to a marked first pass extraction by the liver, its bioavailability is low. Alternatively it may be given as a continuous infusion 0.2 µg/kg body weight/minute preceded by 0.4 mg i.v. bolus.

Naltrexone. Naltrexone is a structural analog of naloxone. It may be considered as an alternative option to treat pruritus of cholestasis [81]. It is administered 25 mg orally twice a day on day 1, followed by 50 mg daily. Its main metabolite 6β-naltrexole has a low but long-lasting opioid-antagonistic effect. After a satisfactory clinical effect has been achieved the administration

interval of naltrexone may be prolonged to every third day. Doses >300 mg/day may induce a hepatitis.

In some patients with cholestasis opiate antagonists can provoke unpleasant symptoms and signs suggestive of an opiate withdrawal reaction. This reaction in cholestasis has been termed “opiate withdrawal-like syndrome” and is taken as evidence to suggest that central opioidergic tone is increased in some cholestatic patients [7].

5-HT₃ (Serotonin) Antagonists. These drugs inhibit the opiate-induced analgesia and affect neurotransmission modulated by 5-HT₃-receptors. In the hypothalamus serotonergic-enkephalinergic connections are present. *Ondansetron* 4–8 mg i.v. or p.o. three or four times a day may ameliorate cholestatic pruritus.

Other Substances and Treatment Modalities

Ursodeoxycholic Acid. Ursodeoxycholic acid (UDCA) is used in cholestatic liver disease, and in some patients it may relieve pruritus [67]. UDCA stimulates the expression of transporters for canalicular and basolateral bile acid export as well as the canalicular phospholipid flippase. It may act as a nuclear receptor ligand that stimulates transcription of key transporters and enzymes in hepatic bile acid and other organic solute uptake, synthesis, detoxification and secretion [10]. UDCA crosses the biliary epithelium by nonionic diffusion (“cholehepatic circulation”). Its choleric effect is mediated primarily by enhanced bicarbonate secretion. In addition UDCA may stimulate CFTR-dependent apical ATP release by cholangiocytes and thereby modulate purinergic signaling which might add to its choleric effect [22]. UDCA is administered at a dose of 10–15 mg/kg body weight p.o./day (up to 1,800 mg/day) in two to three divided doses.

Antihistamines. H₁ type antihistamines may relieve pruritus. Newer substances lacking significant central nervous system side effects are preferred. The use of antihistamines in patients with cirrhosis or drug-induced hepatitis (e.g., from terfenadine) is limited by their potential to elicit hepatic encephalopathy in these patients.

Androgenic Steroids. Despite their mild antipruritic effect these drugs may induce cholestasis and should therefore not be used.

Dexamethasone in high doses (12 mg p.o. or i.v. daily for 7 days) may ameliorate pruritus in intrahepatic cholestasis of pregnancy.

Dronabinol is the psychoactive compound extracted from marijuana. In a few patients with cholestasis, it has been shown to ameliorate intractable pruritus and improve sleep [61].

Antidepressants. The selective serotonin-reuptake-inhibitor *sertraline* was associated with an improvement in cholestatic pruritus in patients with primary biliary cirrhosis [11]. In a recent double-blind, placebo-controlled trial in 12 patients, sertraline at a dose of 75–100 mg p.o. qd improved itch scores on a visual analog scale [52].

Phototherapy with ultraviolet-light B may have a beneficial effect on cholestatic pruritus. The mechanism of action is poorly understood. Changes in skin sensitivity to pruritogenic compounds and chemical alterations of pruritogen(s) are being discussed.

Some effect of *S-adenosyl-methionine* on pruritus of intrahepatic cholestasis of pregnancy has been reported though data are controversial.

Gabapentin offers no therapeutic advantage over placebo in cholestatic pruritus [8].

In desperate cases, *hemoperfusion*, *plasmapheresis*, *extracorporeal albumin dialysis (MARS)*, *surgical bile diversion* and even *orthotopic liver transplantation* may be considered, although no controlled trials of these invasive procedures have been performed.

Malabsorption

Patients with a diminished concentration of bile acids in the gut benefit from a diet poor in neutral fats (<40 g/day), and enriched with medium chain triglycerides. Malabsorption in cholestasis also has implications for the absorption of lipophilic drugs, such as cyclosporin A, whose oral dose needs to be adjusted accordingly or be administered parenterally.

Vitamin A

Symptomatic vitamin A deficiency is treated with retinyl palmitate 100,000 IU (33,000 µg) intramuscularly once every 2 months. After three injections (6 months) substitution should continue with vitamin A 45,000–50,000 IU orally once a week.

Asymptomatic vitamin A deficiency is treated with vitamin A 15,000 IU p.o. daily or 45,000 IU p.o. weekly.

Vitamin E

Measurement of vitamin E concentration in serum is not always reliable. In cholestasis-associated hyperlipidemia, measurement may therefore yield normal serum levels of vitamin E despite the presence of vitamin E deficiency (main symptoms include hemolytic anemia and neurologic deficits) because vitamin E binds to lipoproteins that are increased in hyperlipidemia.

It takes 1–2 years in adults for vitamin E stores to be exhausted. Therefore, when malabsorption is short-lived substitution with vitamin E is not necessary. If malabsorption causes clinically evident deficiency, vitamin E 200 mg intramuscularly twice/month or 25–50 mg/kg body weight orally once a day should be given.

Vitamin K

Initially 2.5–5 mg of oral vitamin K should be given twice daily three times a week. If no improvement occurs, 10 mg should be given intravenously, intramuscularly, or subcutaneously. Maintenance therapy in chronic cholestasis is 10 mg intramuscularly once a month.

Vitamin D

400–800 IU (10–20 µg) of oral vitamin D is given daily; alternatively, 50×10^3 – 100×10^3 IU is given once a month intramuscularly. The dose should be adjusted to the serum levels of 25-OH-vitamin D (35–55 µg/mL).

Osteopenia

Physical Activity

In sun light.

Calcium

A dose of at least 1,000 mg/day is given, often with vitamin D.

Estrogens

0.6 mg/day in postmenopausal women are given.

Vitamin D

See above.

Bisphosphonates

They seem to have beneficial effects on bone density in chronic cholestatic diseases. *Etidronate* 400 mg orally once a day for 14 days every 3 months, or *alendronate* 70 mg orally once weekly. Calcium should be administered concomitantly with bisphosphonates.

The effects of *calcitonin* and *Na-fluoride* in chronic cholestatic liver disease are not documented.

Hyperlipidemia

Cholestasis-associated hyperlipidemia is not associated with an increased risk of atherothrombosis and does not predispose to coronary heart disease. The elevated serum cholesterol levels may be lowered by UDCA, cholestyramine and colestipol. Statins are not indicated in cholestasis-induced hyperlipidemia.

Fatigue

Currently no specific therapies for fatigue associated with chronic cholestasis are available. Successful treatment of the underlying disease may relieve fatigue. Stimulation of central serotonergic neurotransmission by activating 5 HT_{1A} receptors may represent a future pharmacological approach.

Jaundice

Definition

Jaundice is defined as a yellowish discoloration of tissues and body fluids due to an increased bilirubin level. When serum bilirubin levels are ≥ 2.5 mg/dL jaundice manifests initially as scleral and mucosal icterus; and, with serum bilirubin concentration >3 – 4 mg/dL the skin becomes icteric (see Chapter 33).

Etiology and Pathogenesis

The most frequent cause of hyperbilirubinemia is cholestatic jaundice. All conditions listed in Table 52.1 may be associated with jaundice. In Table 52.6 jaundice is classified according to the presence of predominantly unconjugated or conjugated hyperbilirubinemia.

The *metabolism of bilirubin* is discussed in detail in Chapter 7 and is therefore only briefly outlined in this Chapter. Bilirubin metabolism may be subdivided into various phases in different anatomical compartments.

- Synthesis of bilirubin
- Transport of bilirubin in plasma
- Uptake of bilirubin by hepatocytes
- Intracellular metabolism and transport of bilirubin
- Canalicular secretion of bilirubin
- Enterohepatic circulation of bilirubin

Bilirubin is the end product of the catabolism of heme, the prosthetic moiety of hemoglobin, myoglobin, cytochromes and other hemoproteins. The daily bilirubin production amounts to 250–350 mg. Seventy percent derives from the catabolism of ageing red blood cells in the reticuloendothelial system, 30% from the metabolism of other hemoproteins, particularly from hepatic cytochromes, and less than 1% from ineffective erythropoiesis in the bone marrow.

Bilirubin is a hydrophobic organic anion that circulates in plasma in three different forms

- Unconjugated
- Conjugated, and
- Bound to albumin

Bilirubin is transported to the liver, tightly but reversibly bound non-covalently to high affinity binding sites on albumin. If the molar ratio of bilirubin to albumin exceeds 1:1 (a bilirubin concentration of approximately 35 mg/dL), the additional bilirubin binds to lower affinity sites [42]. Various drugs may displace bilirubin from its binding to albumin, thereby causing a mild hyperbilirubinemia (Table 52.6). A small fraction of conjugated bilirubin is bound covalently and irreversibly to albumin. This fraction is denominated “delta-bilirubin”.

If highly sensitive measurement methods are used, approximately 95% of serum bilirubin in healthy people is unconjugated (“indirect bilirubin”) and most of it is tightly but reversibly bound to albumin. Only approximately 5% is conjugated (“direct bilirubin”),

Table 52.6 Classification of jaundice according to the predominant form of bilirubin in serum***Unconjugated hyperbilirubinemia*****Increased bilirubin production**

- Intra- and extravasal hemolysis^a
- Shunt hyperbilirubinemia^b; ineffective erythropoiesis
 - Megaloblastic anemia
 - Sideroachrestic anemia
 - Erythroleukemia
 - Erythropoietic porphyria
 - Lead intoxication^c
 - Hereditary defects of erythrocyte maturation
- Intestinal hypomotility^d
- **Displacement of bilirubin from its albumin binding/competitive inhibition at the hepatic uptake receptor**
- Drugs^e
 - Sulfonamides
 - Ampicillin
 - Indomethacin
 - Furosemide
 - Chinidin
 - Ajmalin
 - Rifampicin
 - Probenecid
 - Salicylates
 - Bile acids

Decreased hepatic uptake of bilirubin

- Right heart failure
- Portosystemic shunts

Impaired conjugation of bilirubin (glucuronidation)

- Ethinylestradiol
- Gentamicin
- Hyperthyroidism
- Neonatal jaundice
- Gilbert's disease^f
- Crigler–Najjar Syndrome Type I and II
- Acquired liver diseases^g, e.g. chronic hepatitis, advanced liver cirrhosis

Conjugated hyperbilirubinemia**Impaired canalicular bilirubin secretion^h and biliary obstruction**

- Dubin Johnson syndrome
- Rotor syndrome
- All conditions and drugs listed in [Tables 52.1 and 52.2](#)

^aSerum bilirubin usually ≤ 5 mg/dL, indirect bilirubin $>$ direct bilirubin, \uparrow LDH, \downarrow haptoglobin, \uparrow reticulocytes ($>20\%$), compensatory increase of erythrocytes in the bone marrow

^bPremature degradation of abnormal erythrocyte precursors in the bone marrow (ineffective erythropoiesis), haptoglobin normal, \downarrow reticulocytes, no compensatory increase in erythropoiesis, phagocytosis of erythrocytes in the bone marrow, \uparrow bone marrow sideroblasts

^cBasophil stippling of erythrocytes

^dResults in a prolonged intestinal contact time of bile pigments. Bacterial deconjugation leads to increased absorption of unconjugated bilirubin. This mechanism probably plays a role in the generation of unconjugated hyperbilirubinemia after prolonged fasting and in postoperative states

^eHyperbilirubinemia usually normalizes within 48–72 h after discontinuing the drug

^fGilbert's syndrome is the most common cause of a predominantly unconjugated hyperbilirubinemia in adults. Serum bilirubin is usually <5 mg/dL

^gGlucuronidation is a hepatocellular function characterized by a high reserve capacity that remains intact for long periods also in advanced liver disease

^hCanalicular secretion of bilirubin is the rate limiting step ("bottle neck") of bilirubin secretion. In all forms of intrahepatic cholestasis conjugated bilirubin refluxes into the plasma

also bound reversibly to albumin. "Delta-bilirubin" is also present in small amounts in healthy persons and in routine measurements of bilirubin is included in the conjugated bilirubin fraction. In patients with long-standing jaundice the "delta-fraction" increases and, due to a long half-life of albumin of approximately 17 days, decreases only slowly after successful treatment. This is clinically observed in successfully treated patients with cholestatic jaundice in whom cholestatic enzymes normalize quite rapidly but normalization of bilirubin values is slow and delayed.

Due to its poor water solubility and its tight binding to albumin, bilirubin is not excreted by the kidneys, but rather is cleared by the liver and excreted in bile. The albumin-bilirubin-complex crosses the fenestrated sinusoidal endothelia, traverses the space of Disse and reaches the sinusoidal (basolateral) hepatocyte membrane. After binding to the liver cell membrane bilirubin is transported by a specific carrier system for organic anions into the hepatocyte, while albumin returns to the plasma. The transport system for the hepatocellular uptake of bilirubin in healthy persons works far below its maximal capacity, and therefore the hepatocellular uptake of bilirubin is not the rate limiting step of bilirubin clearance. Normally bile acids do not interfere with bilirubin uptake, since they are taken up by a different carrier. In cholestasis with a marked increase of bile acids in serum, however, some of the bile acids may occupy the bilirubin transporter, displace bilirubin, and thus contribute to hyperbilirubinemia.

Following hepatocellular uptake, bilirubin partitions between the cytosol and the endoplasmic reticulum membranes. In the cytosol bilirubin is maintained in solution bound to a number of proteins of which the most abundant are the *ligandins*, members of the glutathione-S-transferase superfamily. Bilirubin bound to the membranes of the endoplasmic reticulum is conjugated with glucuronic acid, resulting in mono- and diglucuronide conjugates which are highly soluble in aqueous solutions. The enzyme responsible for bilirubin glucuronidation is the UDP-glucuronosyltransferase isoform UGT1A1.

Conjugated, water-soluble bilirubin is transported to the apical hepatocyte membrane and is secreted by a specific canalicular transporter into the canaliculus. The canalicular excretion is ATP-dependent and is mediated by the multidrug resistance-associated protein 2 (MRP2). Mutations of MRP2 result in conjugated

hyperbilirubinemia (Dubin-Johnson syndrome) (see below). The *bilirubin transport across the canalicular membrane is the rate limiting step ("bottle neck") of bilirubin clearance from plasma to bile*. In conditions with bile duct obstruction or in cholestatic hepatocellular diseases, canalicular secretion of bilirubin is affected more strongly than its uptake and conjugation within the hepatocyte. Reflux of conjugated bilirubin therefore causes a predominantly conjugated, direct hyperbilirubinemia in these conditions.

Conjugated bilirubin is excreted via the biliary tree into the proximal duodenum. Only very small amounts of conjugated bilirubin are absorbed by the intestine. For the most part bilirubin is deconjugated and converted by enteric bacterial β -glucuronidases to urobilinogens. Deconjugated bilirubin and urobilinogens are absorbed and undergo an *enterohepatic circulation*. 95% of enterically absorbed urobilinogens are extracted by the liver, and 5% are excreted renally. Thus, *the presence of urobilinogen in urine of jaundiced patients is evidence of bilirubin reaching the gut*, i.e. of incomplete bile duct obstruction.

It has been known for a long time that fasting for 48 hours or longer leads primarily to an increase of unconjugated serum bilirubin. Deranged uptake and conjugation of bilirubin were thought to be responsible for the rise in bilirubin levels in fasting persons although these mechanisms never have been substantiated in humans [23]. Recent investigations show that prolonged fasting is associated with decreased intestinal motility. The increase in bile pigments within the gut lumen coupled with a prolonged intestinal contact time leads to an increase in the absorption of deconjugated bilirubin. Thus, the enhanced enterohepatic circulation of bilirubin, and not its deranged hepatocellular transport, seems to be the basis of hyperbilirubinemia induced by fasting. Intestinal hypomotility is an important mechanism that may lead to a mild, unconjugated hyperbilirubinemia.

The intestinal microflora also greatly affects intraluminal metabolism of bilirubin, and prolonged use of certain antibiotics may lead to an increase in serum bilirubin levels [89].

Diagnosis and Differential Diagnosis

Hyperbilirubinemia results from an imbalance between bilirubin production and elimination. Jaundice is a simple

clinical diagnosis that is confirmed and quantified by measuring bilirubin concentration in serum. However, a yellowish discoloration of the skin may also be seen after eating large quantities of carrots or may be drug-induced, for example, by busulfan. In these cases bilirubin levels in serum are normal. The experienced clinician, through a detailed history and a thorough physical examination, will be able to ascribe jaundice to one of the following four categories in 80–85% of cases.

- Hematologic disease
- Hepatocellular disease

- Bile duct obstruction or
- Hereditary defect of bilirubin metabolism

Immunological, serological, biochemical and imaging modalities will clarify the etiology in the remaining 15–20%.

The differential diagnosis of jaundice should consider the conditions and diseases listed in [Tables 52.1, 52.2, 52.5, 52.6 and 52.8](#). In [Table 52.7](#), among other parameters, bilirubin values in various conditions with intrahepatic cholestasis are reported. In [Fig. 52.6](#) a simple diagnostic algorithm in patients with hyperbilirubinemia is shown.

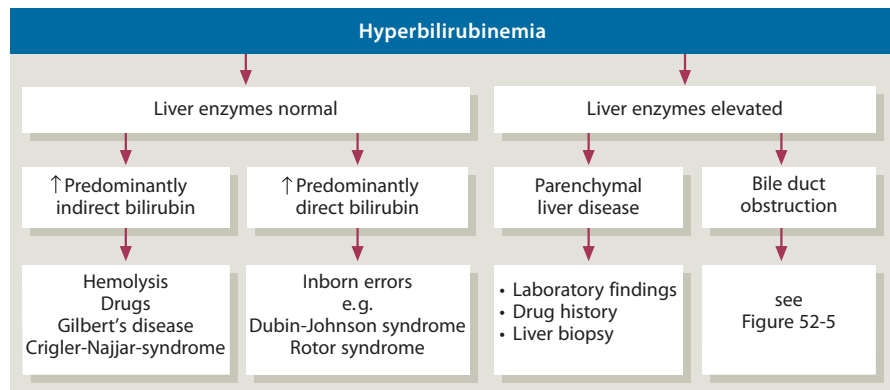


Fig. 52.6 Diagnostic approach to a patient with hyperbilirubinemia

Table 52.7 Constellation of findings in various forms of intrahepatic cholestasis

Disease	Bilirubin	γ-GT	AP	AST, ALT	Other
Gilbert's syndrome	↑(indirect)	0	0	0	Fasting test
BRIC	↑↑↑	0	↑↑	↑	
Sepsis	↑	↑	↑-(↑↑)	↑-(↑↑)	
Paraneoplastic	↑↑-↑↑↑	↑↑-↑↑↑	↑↑↑	↑↑	
Drug-induced	↑-↑↑	↑↑-↑↑↑	↑↑-↑↑↑	0-(↑)	Eosinophilia
Acute icteric viral hepatitis	↑↑-↑↑↑	↑	↑-(↑↑)	↑↑↑	HBsAg, antiHBc-IgM, HAV-IgM, HCV-RNA
Chronic hepatitis	↑	(↑)	0-(↑)	↑↑	HBsAg, HBV-DNA, HCV-RNA, HCV-Ab, ANA, SMA, LKM, IgG, IgM, IgA
Total parenteral nutrition	↑-↑↑	0	↑-↑↑	↑↑	Sludge in the gallbladder
Fatty liver of pregnancy	↑-↑↑	0-↑	(↑)-↑↑	↑↑-↑↑↑	Leucocytosis, ↑ INR, ↑ creatinine
Cholestasis of pregnancy	↑ (direct)	0-(↑)	↑↑-↑↑↑	↑-(↑↑)	
Toxemia of pregnancy	0-↑	0	↑	↑↑	Hemolysis, thrombocytopenia, fragmentocytes in HELLP-syndrome.
Primary biliary cirrhosis	0-↑-↑↑↑	↑↑	↑↑↑	↑	↑ IgM, AMA + (M2 and M9), antibodies against "nuclear dots", keratin, laminin
Primary sclerosing cholangitis	0-↑-↑↑	↑↑	↑↑↑	↑	pANCA, ERCP
Graft-versus-host reaction	↑-↑↑↑	↑↑-↑↑↑	↑-↑↑↑	↑↑-↑↑↑	
Sarcoidosis	0	0-(↑)	0-(↑)	0-(↑)	Angiotensin-converting enzyme

Bilirubin: ↑ ≤ 10 mg/dL, ↑↑ ≤ 20 mg/dL, ↑↑↑ > 20 mg/dL. **γ-GT:** ↑ < 100 U/l, ↑↑ < 500 U/L, ↑↑↑ > 500 U/L. **AP** ↑ 1- 3-times ULN, ↑↑ 3- 5-times ULN, ↑↑↑ > 5-times ULN. **AST, ALT:** ↑ < 100 U/L, ↑↑ < 500 U/L, ↑↑↑ > 500 U/L. 0 normal, BRIC benign recurrent intrahepatic cholestasis, ULN upper limit of normal.

Table 52.8 Differential diagnostic criteria of genetic defects of bilirubin conjugation and bilirubin secretion

	Crigler–Najjar Type I	Crigler–Najjar Type II	Gilbert syndrome	Dubin–Johnson syndrome	Rotor syndrome
Serum bilirubin	>20 mg/dL	6–20 mg/dL strongly fluctuating	<6 mg/dL strongly fluctuating	2–5 mg/dL	2–5 mg/dL
Primary defect	UGT deficiency	Activity of UGT < 10%	Activity of UGT 60–70%	Mutation/deletion of <i>MRP2</i> -gene on chromosome 10q23–24; impaired canalicular transport	Uptake and storage (?) of organic anions
Inheritance	Autosomal recessive	Autosomal dominant with varying penetrance	Autosomal dominant with varying penetrance	Autosomal recessive	Autosomal recessive
Age of manifestation	First postnatal days	From first year of life to second decade	After puberty; mostly men	Variable, mostly during second decade	Variable, mostly during childhood
Prognosis	Severe because of “Kernicterus”	Good	Very good	Good	Good
Important diagnostic findings	Phenobarbital has no effect on bilirubin concentration	Phenobarbital lowers bilirubin concentration	Fasting increases serum bilirubin concentration (nonspecific); liver histology normal	Deposits of brown-black pigment (lipomelanin) in the liver (“black liver jaundice”); total coproporphyrin in urine is normal. However, 80% is coproporphyrin I; BSP-test: biphasic elimination curve. Genetic defect may also be demonstrated in skin biopsy	No pigment deposition in the liver. Coproporphyrin elimination in urine increased six times normal

UGT UDP-glucuronosyltransferase, BSP bromosulfophthalein

Source: Adapted from [27]

Bile Duct Obstruction (See First Part of This Chapter)

As a potentially fatal but reversible condition, extrahepatic bile duct obstruction must always be considered early in the differential diagnosis of jaundice. The occlusion of one or more intrahepatic bile ducts, due to the large functional reserve capacity of the liver, does not lead to jaundice, although alkaline phosphatase and γ -glutamyl transpeptidase levels are elevated and bile ducts are dilated in the respective liver segments. In complete extrahepatic bile duct obstruction, however, bile formation not only ultimately ceases, but biliary stasis results in an increased risk of cholangitis. Hepatocellular transport systems become redistributed from the

canalicular to the basolateral membrane and conjugated bilirubin refluxes across the basolateral membrane or through damaged tight junctions into the sinusoidal blood, resulting in a primarily conjugated hyperbilirubinemia. *Therapy* for bile duct obstruction can be endoscopic (e.g. bile duct stenting, photodynamic therapy for cholangiocarcinoma), percutaneous, or surgical.

Hemolysis

Bilirubin concentration is only mildly elevated (≤ 5 mg/dL) in hemolytic states, and is composed mainly of unconjugated bilirubin. In the presence of normal hepatic bilirubin clearance, serum bilirubin levels may

in fact remain normal even when red blood cell survival is shortened to 50% of normal. If the amount of bilirubin produced exceeds the biliary elimination capacity, especially in acute severe hemolysis, the conjugated bilirubin may rise to values >15% of total bilirubin in plasma. Chronic hemolysis may cause the pigment to precipitate within the renal tubules and may lead to the formation of bilirubin gallstones [20].

Ineffective Erythropoiesis

The premature degradation of defective red blood cells within the bone marrow or spleen occurs as “primary shunt hyperbilirubinemia” (idiopathic dyserythropietic jaundice) or within the context of hematologic diseases, such as vitamin B₁₂ deficiency anemia. An increase of “early marked bilirubin” in serum is noted. Reticulocyte counts are normal or only slightly increased. Typically, urinary and fecal urobilinogen levels are increased, while the characteristic signs of hemolysis are lacking.

“*Primary shunt hyperbilirubinemia*” often shows familial clustering. The defect underlying the increased heme turnover is unknown. Jaundice manifests as fluctuating bilirubin values between 1.8 and 8 mg/dL in the second or third decade. Liver enzymes are normal. Fifty percent of patients have an enlarged spleen, while the liver is normal in size. A normoblastic erythroid hyperplasia is found in the bone marrow. Long-term prognosis is excellent.

Physiologic Jaundice of the Newborn

During the first week of life a transient increase in conjugated bilirubin up to 6–8 mg/dL may occur. The causes are multifactorial. Hemolysis, decrease in hepatocellular transport proteins (ligandins), impaired conjugation of bilirubin (immature UGT), an altered intestinal microflora and increased intestinal absorption of bilirubin are important pathogenetic factors. Bilirubin may not only be neurotoxic (see below), but also is a potent endogenous antioxidant preventing reactive oxygen species-induced damage [90]. Thus, the physiologic jaundice of the newborn might possibly be viewed as a protective mechanism of immature newborns.

Pregnanediol and long-chain fatty acids contained in breast milk may inhibit UGT-activity and lead to a mild indirect hyperbilirubinemia (“breast milk jaundice”).

Bilirubin Encephalopathy (“Kernicterus”)

Jaundice usually is primarily a cosmetic problem. However, high concentrations of unconjugated bilirubin may elicit an encephalopathy. With values of unconjugated bilirubin >20 mg/dL, bilirubin passively diffuses into the central nervous system where it may be neurotoxic and cause an irreversible damage of neurons in the basal ganglia and in the cerebellum.

The “Kernicterus” is observed primarily in immature newborns. It is elicited or exacerbated by a low UGT-activity, hemolysis, sepsis, respiratory insufficiency (acidosis) and malnutrition (free fatty acids).

Crigler–Najjar Syndrome Type I

Crigler–Najjar syndrome (CNS) type I is an autosomal recessively inherited disease caused by complete deficiency of UDP-glucuronosyltransferase which results in defective bilirubin conjugation [14]. Genetically, a homozygous mutation of an exon of the *ugt1* gene is present [36].

The disease is extremely rare with a prevalence of approximately five cases per 15 million inhabitants.

The jaundice begins 1–3 days after birth with rapidly associated neurologic symptoms of “Kernicterus”. Liver and spleen are normal in size.

Serum bilirubin concentrations fluctuate (higher values in winter and during intercurrent infections) between 25 and 45 mg/dL. The total bilirubin is unconjugated. Bilirubin clearance is reduced to 1–2% of normal and biliary bilirubin excretion is markedly reduced (<4 mg/100 mL). The relative proportion of unconjugated bilirubin IXa in bile is increased to 30–57%.

The liver enzymes and liver histology are normal. The bile is white and the stool has a normal color.

Bilirubin is absent from urine, or only traces of monoglucuronide or conjugates with glucose and xylose are present.

An effective *therapy* is not available. Phenobarbital is ineffective. Individual cases with induction of specific cytochrome P450 dependent isoenzymes by chlorpromazine with subsequent lowering of bilirubin concentration have been described. Exchange transfusions and plasmapheresis rapidly reduce increased bilirubin levels, but their effect is short-lived. Bilirubin concentration may be lowered to <10 mg/dL for a prolonged period of time by UV-phototherapy in some

children. The current practice is exchange transfusions immediately after birth followed by phototherapy for 10–12 h and by orthotopic liver transplantation.

Prognosis is extremely severe and most children die in the neonatal period. However, individual cases with survival into childhood are documented.

Crigler–Najjar Syndrome Type II (Arias Syndrome)

In CNS II a partial deficiency of UGT is present, caused by a mutation in an exon of the *ugt1* gene. The defect is autosomal dominant with variable penetrance.

The prevalence of CNS II (partial disease) is approximately twice as high as CNS I, but still very low.

The icterus may appear during the first year of life or manifest in young adulthood [1]. A “Kernicterus” is only occasionally observed. Most patients feel well, they do not have neurologic symptoms, and their intellectual development is normal.

The concentrations of unconjugated serum bilirubin fluctuate between 6 and 25 mg/dL. The hepatic bilirubin clearance is diminished. The predominant bile pigment is bilirubin-monoglucuronide.

Histologically, occasional canalicular bile casts may be seen. Otherwise no pathological alterations are found.

Phenobarbital (20–60 mg p.o. three times a day) or other enzyme inducers such as phenytoin lead to a marked reduction of bilirubin to <4 mg/dL within 2–3 weeks.

Gilbert’s Syndrome (See Chapter 92)

Gilbert’s syndrome (GS) (synonyms: intermittent juvenile jaundice, familial non-hemolytic jaundice, Meulengracht’s disease) is the most frequent cause of a predominantly unconjugated hyperbilirubinemia in adults [29]. Up to 5% of the population has GS [73]. Men are affected two to seven times more often than women. Familial clustering has been described. The syndrome is most likely inherited in an autosomal dominant fashion with variable penetrance. Various genetic variants may be present. Most often a dinucleotide-polymorphism in the TATA box promoter of the gene encoding UGT (*ugt-1a1*) and a heterozygous mutation of exon 1 of the *ugt-1a1* gene are seen. This results in diminished bilirubin UGT-protein expression and enzyme activity, with a resultant impaired ability to conjugate bilirubin.

The *pathogenesis* is not completely understood, and so far no one single defect has been described that may explain all the alterations observed. Hormonal effects on UGT are being discussed. The activity of UGT is reduced, and hepatic bilirubin clearance is 30% of normal. The relative proportion of bilirubin-monoglucuronide in bile is increased. In addition to impaired bilirubin conjugation, the quantity of ligandin and Z-proteins within the hepatocyte is diminished. Increases in the activity of hepatic heme oxygenase combined with an enhanced intestinal absorption of unconjugated bilirubin contribute in some patients to the increased formation of bilirubin. Sixty percent of patients have a mild, clinically completely compensated hemolysis.

The *diagnosis* is generally made in the second and third decade when a mild scleral icterus is incidentally discovered. Most patients are asymptomatic. Some complain of mild, generally nonspecific symptoms, such as fatigue and vague abdominal sensations, but it is not clear if these symptoms can be attributed to GS.

Laboratory parameters show a mild (usually 2–3 mg/dL, rarely >5 mg/dL) unconjugated hyperbilirubinemia with otherwise normal liver chemistries. Hyperbilirubinemia is intermittent with day-to-day- and seasonal variations of bilirubin levels. Bilirubin values rise during fasting states, a fat free diet, glucose and amino-acid infusions, systemic illnesses and infections.

A presumptive diagnosis of GS is made clinically by the generally incidental finding of slight hyperbilirubinemia in an asymptomatic person with normal liver enzymes. Neither the fasting test nor the intravenous nicotinic acid administration test is specific, and both tests do not allow for a reliable distinction between patients with GS and normal persons or patients with hepatobiliary disease. Therefore, these provocative tests should not be used anymore. A PCR-based analysis of the UGT1*1 TATA box is available to diagnose GS but is not required clinically.

Liver histology in GS is typically normal. Occasionally some lipofuscin is present in centrilobular hepatocytes.

The *differential diagnosis* should include hemolytic disorders, parenchymal liver disease, and medications that can cause hyperbilirubinemia. Indinavir (an antiretroviral drug) may inhibit UGT1A1 and thus cause a GS-like syndrome [42]. The protease inhibitor atazanavir is also an inhibitor of hepatic UGT activity and may lead to hyperbilirubinemia in individual patients [44].

Given the high prevalence and benign nature of GS, it may be considered a normal variant of the population rather than a disease state. There is *no need for treatment*. The patients should be informed about the absolutely benign nature and the excellent prognosis of the disorder.

Dubin–Johnson Syndrome

The Dubin–Johnson syndrome (DJS) is characterized by a conjugated hyperbilirubinemia and by an impaired canalicular secretion of anionic conjugates [21, 75].

The inheritance is autosomal recessive. The highest prevalence (1:1,500 to 3,000) is seen in sephardic Jews from Iraq and Iran who also often have an associated coagulation factor VII deficiency. Both genders are affected equally.

Pathogenetically, a marked impairment of biliary excretion of conjugated bilirubin is present. The molecular basis of DJS are mutations or deletions of *mutidrug resistance protein 2 (MRP2)*-gene on chromosome 10q23–24 with consequent dysfunction or absence of the ABC-transporter MRP2, an ATP-dependent conjugate export pump in the canalicular membrane [12, 65, 86]. MRP2 is a driving force of bile flow. It is involved in the transport of organic anions conjugated with glucuronate, glutathione or sulfate, such as bilirubin-glucuronate, glutathione-disulfide or cysteinyl-leukotriene. The reduced biliary excretion of bromosulphophthalein (BSP) may be used diagnostically (see below).

Clinically, DJS manifests with an intermittent jaundice in the first two decades of life in two thirds of the affected persons. Pregnancy or the intake of oral contraceptives may provoke manifestation of the disease. Except for the jaundice, most patients have no other complaints.

The *laboratory parameters* show a mild hyperbilirubinemia of approximately 5 mg/dL. However, individual cases with bilirubin levels up to 20 mg/dL are documented. Approximately 60% of bilirubin is conjugated (diconjugates > monoconjugates). Liver enzymes in serum are normal. Conjugated bilirubin and urobilinogen are present in the urine. The total coproporphyrin in urine is normal, but 85–90% of urinary coproporphyrin is coproporphyrin I, whereas in normal persons 75% of urinary coproporphyrin is coproporphyrin III.

The concentration of coagulation factor VII is diminished in 60% of patients with DJS, resulting in reduction in prothrombin activity. This change is encountered most often in sephardic Jews in the Middle East.[71]

The BSP-provocative test (see Chapter 35; the uptake of BSP into the hepatocyte is normal, its biliary excretion is markedly impaired) has a characteristic profile. Following intravenous injection, BSP is taken up at the basolateral membrane, is conjugated and accumulates within the hepatocyte, but cannot be secreted into bile and refluxes back into the circulation. Therefore, 60–90 min after intravenous infusion, a second BSP concentration peak in plasma is seen in more than 90% of patients with DJS.

In oral cholecystography (a procedure no longer performed) the gallbladder is not visualized even if the dose of the contrast agent is doubled. With ^{99m}Tc-HIDA, uptake in liver parenchyma is seen, but neither the bile ducts nor the gallbladder are visualized.

Histologically, intracellular deposits of a coarse, brown-black, lysosomal pigment (lipomelanin) are seen in centrilobular hepatocytes (see Fig. 24.12). The liver is darker than usual (“black liver jaundice”). The exact nature of DJS-pigment is not known. Lipofuscin and melanin components as well as polymers of epinephrine degradation products have been implicated. Lysosomal deposition of pigment is the consequence and not the cause of DJS. Regenerating hepatocytes in acute viral hepatitis lose the pigment transiently. It reaccumulates during the further course of disease.

Neither the BSP-test nor contrast studies are used anymore to diagnose DJS. Since MRP2 is also present in fibroblasts, the genetic defect may be demonstrated not only in the liver but also in skin, and the diagnosis of DJS can be made by skin biopsy.

The *prognosis* of DJS is favorable with a normal life expectancy. The jaundice may be aggravated by oral contraceptives or during pregnancy.

A *therapy* is neither available nor required.

Rotor Syndrome

Rotor syndrome (RS) is characterized by an autosomal recessive defect in the hepatic uptake and/or storage of organic anions. The impaired storage of conjugated bilirubin leads to its passage from the hepatocyte into the circulation.

The disease manifests before the 20th year of life with a mild, fluctuating jaundice. Occasionally the patients complain of mild abdominal discomfort and fever. Liver and spleen are not enlarged [70].

The *laboratory parameters* show a conjugated and unconjugated hyperbilirubinemia with bilirubin concentration ranging between 2 and 5 mg/dL, occasionally up

to 20 mg/dL. Liver enzymes are normal. Bilirubin clearance and BSP-elimination are reduced. In contrast to DJS, the elimination kinetics of BSP in RS are not biphasic, since BSP does not reflux into plasma.

The liver is macroscopically and microscopically normal. There is no deposition of pigment.

Urinary excretion of coproporphyrin I is six times normal. In contrast to DJS, however, no absolute increase in coproporphyrin III is present. Thus, the pattern of urinary coproporphyrin excretion allows for a differentiation between RS and DJS. A liver biopsy is not necessarily required.

A therapy is not necessary, and prognosis is good.

Table 52.8 summarizes the differentiating criteria of genetic defects of bilirubin conjugation and secretion.

Therapy

There is no generalized treatment for jaundice. Rather, the clinician's goal is to identify its cause and, if indicated, to direct treatment toward the particular underlying disorder. Please refer to each of the above sections for further discussion.

References

- Arias IM (1962) Chronic unconjugated hyperbilirubinemia without overt signs of hemolysis in adolescents and adults. *J Clin Invest* 41: 2233–45
- Baiocchi L, LeSage G, Glaser S, et al (1999) Regulation of cholangiocyte bile secretion. *J Hepatol* 31: 179–91
- Baker AL, Rosenberg JH (1987) Hepatic complications of total parenteral nutrition. *Am J Med* 82: 489–97
- Balistreri WF, Bezerra JA, Jansen P, et al (2005) Intrahepatic cholestasis: summary of an American Association for the Study of Liver Diseases single topic conference. *Hepatology* 42: 222–35
- Batts KP (1998) Ischemic cholangitis. *Mayo Clin Proc* 73: 380–5
- Bergasa NV (2002) Met-enkephalin immunoreactivity is enhanced in primary biliary cirrhosis. *Liver* 22: 107–13
- Bergasa NV (2005) The pruritus of cholestasis. *J Hepatol* 43: 1078–88
- Bergasa NV, McGee M, Ginsbur IH, et al (2006) Gabapentin in patients with the pruritus of cholestatics: a double-blind, randomized, placebo-controlled trial. *Hepatology* 44: 1317–23
- Bihl F, Emmenegger U, Reichen J, et al (2006) Macrophage activating syndrome is associated with lobular hepatitis and severe bile duct injury with cholestasis. *J Hepatol* 44: 1208–12
- Boyer JL (2007) New perspectives for the treatment of cholestasis: lessons from basic science applied clinically. *J Hepatol* 46: 365–71
- Browning J, Combes B, Mayo MJ (2003) Long-term efficacy of sertraline as a treatment for cholestatic pruritus in patients with primary biliary cirrhosis. *Am J Gastroenterol* 98: 2736–41
- Burchell B, Hume R (1999) Molecular genetic basis of Gilbert's syndrome. *J Gastroenterol Hepatol* 14: 960–6
- Chand N, Sanyal AJ (2007) Sepsis induced cholestasis. *Hepatology* 45: 230–41
- Crigler JF, Najjar VA (1952) Congenital familial nonhemolytic jaundice with kernicterus. *Pediatrics* 10: 169–80
- Dancygier H (1992) Endosonographic evaluation of biliary tract disease. *Gastrointest Endosc Clin N Am* 2: 687–713
- Dancygier H (1994) AIDS and gastrointestinal endoscopy. *Endoscopy* 26: 175–84
- Dancygier H, Nattermann C (1994) The role of endoscopic ultrasonography in biliary tract disease: obstructive jaundice. *Endoscopy* 26: 800–2
- Decker K (1990) Biologically active products of stimulated liver macrophages (Kupffer cells). *Eur J Biochem* 192: 245–61
- Deltenre P, Valla DC (2006) Ischemic cholangiopathy. *J Hepatol* 44: 806–17
- Dhumeaux D, Berthelot P (1975) Chronic hyperbilirubinemia associated with hepatic uptake and storage impairment. *Gastroenterology* 69: 988–93
- Dubin IN, Johnson FB (1954) Chronic idiopathic jaundice with unidentified pigment in liver cells. A new clinicopathologic entity with report of 12 cases. *Medicine* 33: 155–97
- Fiorotto R, Spirli C, Fabris L, et al (2007) Ursodeoxycholic acid stimulates cholangiocyte fluid secretion in mice via CFTR-dependent ATP secretion. *Gastroenterology* 133: 1603–13
- Gärtner U, Goeser T, Wolkoff AW (1997) Effect of fasting on the uptake of bilirubin and sulfobromophthalein by the isolated perfused rat liver. *Gastroenterology* 113: 1707–13
- Galeazzi R, Lorenzini I, Orlandi F (1980) Rifampicin-induced elevation of serum bile acids in man. *Dig Dis Sci* 25: 108–12
- Garcia-Tsao G, Korzenik JR, Young L, et al (2000) Liver disease in patients with hereditary hemorrhagic telangiectasia. *N Engl J Med* 343: 931–6
- Gelbmann CM, Rümmele P, Wimmer M, et al (2007) Ischemic-like cholangiopathy with secondary sclerosing cholangitis in critically ill patients. *Am J Gastroenterol* 102: 1221–9
- Gerok W (1995) Ikterus. In: Gerok W, Blum HE (Hrsg). *Hepatology*. 2nd edn. Urban & Schwarzenberg Verlag, S, Auflage, pp 230–45
- Gigliozzi A, Alpini G, Baroni GS et al (2004) Nerve growth factor modulates the proliferative capacity of the intrahepatic biliary epithelium in experimental cholestasis. *Gastroenterology* 127: 1198–1209
- Gilbert A, Lereboullet P, Herscher M (1907) Les trois cholémies congénitales. *Bulletins et Memoires de la Société Médicale des Hopitaux de Paris*. 24: 1203–10
- Glasova H, Beuers U (2002) Extrahepatic manifestations of cholestasis. *J Gastroenterol Hepatol* 17: 938–48
- Goldblatt J, Taylor PJ, Lipman T, et al (2002) The true impact of fatigue in primary biliary cirrhosis: a population study. *Gastroenterology* 122: 1235–41

32. Gundling F, Nerlich A, Heitland WU, et al (2007) Biliary manifestation of Erdheim-Chester disease mimicking Klatskin's carcinoma. *Am J Gastroenterol* 102: 452–4
33. Hruz P, Zimmermann C, Gutmann H, et al (2006) Adaptive regulation of the ileal apical sodium dependent bile acid transporter (ASBT) in patients with obstructive cholestasis. *Gut* 55: 395–402
34. Huet PM, Deslauriers J, Tran A, et al (2000) Impact of fatigue on the quality of life of patients. *Am J Gastroenterol* 95: 760–7
35. Ishak KG, Rogers WA (1981) Cryptogenic acute cholangitis-association with toxic shock syndrome. *Am J Clin Pathol* 76: 619–26
36. Jansen PLM (1996) Genetic diseases of bilirubin metabolism: the inherited unconjugated hyperbilirubinemias. *J Hepatol* 25: 398–404
37. Jones EA, Bergasa NV (1999) The pruritus of cholestasis. *Hepatology* 29: 1003–6
38. Kanel GC, Korula J (1992) Cholestasis and biliary tract disorders. In: Kanel GC, Korula J (eds) *Atlas of liver pathology*. W.B. Saunders, Philadelphia, PA, pp 35–51
39. Kawaguchi T, Sakisaka S, Mitsuyama K, et al (2000) Cholestasis with altered structure and function of hepatocyte tight junction and decreased expression of canalicular multi-specific organic anion transporter in a rat model of colitis. *Hepatology* 31: 1285–95
40. Keppeler D, König J (1997) Expression and localization of the conjugate export pump encoded by the MRP2 (cMRP/cMOAT) gene in liver. *FASEB J* 11: 509
41. König J, Rost D, Cui Y, et al (1999) Characterization of the human multidrug resistance protein isoform MRP3 localized to the basolateral hepatocyte membrane. *Hepatology* 29: 1156–63
42. Korenblatt KM, Berk PD (2005) Hyperbilirubinemia in the setting of antiviral therapy. *Clin Gastroenterol Hepatol* 3: 303–10
43. Kullak-Ubrich GA, Meier PJ (2000) Mechanisms of cholestasis. *Clin Liver Dis* 4: 357–85
44. Lankisch TO, Moebius U, Wehmeier M, et al (2006) Gilbert's disease and atazanavir: from phenotype to UDP-glucuronosyltransferase haplotype. *Hepatology* 44: 1324–32
45. Lazaridis KN, Strazzabosco M, Larusso NF (2004) The cholangiopathies: disorders of biliary epithelia. *Gastroenterology* 127: 1566–77
46. Lefkowitz JH (2004) Histological assessment of cholestasis. *Clin Liver Dis* 8: 27–40
47. Levy C, Lindor KD (2003) Drug-induced cholestasis. *Clin Liver Dis* 7: 311–30
48. Li MK, Crawford JM (2004) The pathology of cholestasis. *Semin Liver Dis* 24: 21–42
49. Luster MJ, Germolec DR, Yoshida T, et al (1994) Endotoxin-induced cytokine gene expression and excretion in the liver. *Hepatology* 19: 480–8
50. Marzioni M, Glaser S, Francis H, et al (2005) Autocrine/paracrine regulation of the growth of the biliary tree by the neuroendocrine hormone serotonin. *Gastroenterology* 128: 121–37
51. Marzioni M, Alpini G, Saccomanno S, et al (2007) Glucagon-like peptide-1 and its receptor agonist exendin-4 modulate cholangiocyte adaptive response to cholestasis. *Gastroenterology* 133: 244–55
52. Mayo MJ, Handem I, Saldana S, et al (2007) Sertraline as a first-line treatment for cholestatic pruritus. *Hepatology* 45: 666–74
53. McDonald JA (1999) Cholestasis of pregnancy. *J Gastroenterol Hepatol* 14: 515–18
54. Milkiewicz P, Heathcote EJ (2004) Fatigue in chronic cholestasis. *Gut* 53: 475–7
55. Minagawa N, Nagata J, Shibao K, et al (2007) Cyclic AMP regulates bicarbonate secretion in cholangiocytes through release of ATP into bile. *Gastroenterology* 133: 1592–602
56. Molina EG, Reddy KR (1999) Postoperative jaundice. *Clin Liver Dis* 3: 477–88
57. Moseley RH (1999) Sepsis and cholestasis. *Clin Liver Dis* 3: 465–75
58. Nakanuma Y, Ohta G (1986) Immunohistochemical study on bile ductular proliferation in various hepatobiliary diseases. *Lancet* 6: 205–11
59. Nathanson MH, Boyer JL (1991) Mechanism and regulation of bile secretion. *Hepatology* 14: 551–6
60. Nathwani RA, Kumar SR, Reynolds TB, et al (2005) Marked elevation in serum transaminases: an atypical presentation of choledocholithiasis. *Am J Gastroenterol* 100: 295–8
61. Neff GW, O'Brien CB, Reddy KR, et al (2002) Preliminary observation with dronabinol in patients with intractable pruritus secondary to cholestatic liver disease. *Am J Gastroenterol* 97: 2117–9
62. Ng PC, Lee CH, Wong SP (2007) High-dose oral erythromycin decreased the incidence of parenteral nutrition-associated cholestasis in preterm infants. *Gastroenterology* 132: 1726–39
63. Pauli-Magnus C, Stieger B, Meyer Y, et al (2005) Enterohepatic transport of bile salts and genetics of cholestasis. *J Hepatology* 43: 342–57
64. Pauli-Magnus C, Meier PJ (2006) Hepatobiliary transporters and drug-induced cholestasis. *Hepatology* 44: 778–87
65. Paulusma CC, Kool M, Bosma PJ, et al (1997) A mutation in the human canalicular multispecific organic anion transporter gene causes the Dubin-Johnson syndrome. *Hepatology* 25: 1539–42
66. Paulusma CC, Kothe MJC, Bakker CT, et al (2000) Zonal down-regulation and redistribution of the multidrug resistance protein 2 during bile duct ligation in rat liver. *Hepatology* 31: 684–93
67. Paumgartner G, Beuers U (2002) Ursodeoxycholic acid in cholestatic liver disease: mechanisms of action and therapeutic use revisited. *Hepatology* 36: 525–31
68. Roelofsen H, Schoemaker B, Bakker C, et al (1995) Impaired hepatocanalicular organic anion transport in endotoxemic rats. *Am J Physiol* 269: G427–34
69. Roman RM, Fitz JG (1999) Emerging roles of purinergic signaling in gastrointestinal epithelial secretion and hepatobiliary function. *Gastroenterology* 116: 964–79
70. Rotor AB, Manahan L, Florentin A (1948) Familial non-hemolytic jaundice with direct van den Bergh reaction. *Acta Medica Phillipina* 5: 37–48
71. Seligsohn U, Shani M, Ramot B, et al (1970) Dubin-Johnson syndrome in Israel. Association with factor-VII deficiency. *Quart J Med* 39: 569–72
72. Scheuer PJ, Lefkowitz JH (2006) *Liver biopsy interpretation*, 7th edn. Elsevier Saunders, Philadelphia, PA, pp 331–2

73. Sieg A, Arab L, Schlierf G, et al (1987) Die Prävalenz des Gilbert-Syndroms in Deutschland. *Dtsch med Wschr* 112: 1206–8
74. Sonzogni A, Colloredo G, Fabris L, et al (2004). Isolated idiopathic bile ductular hyperplasia in patients with persistently abnormal liver function tests. *J Hepatol* 40: 592–8
75. Sprinz H, Nelson RS (1954) Persistent nonhemolytic hyperbilirubinemia associated with lipochrome-like pigment in liver cells: report of 4 cases. *Ann Intern Med* 41: 952–62
76. Stieger B, Fattinger K, Madon J, et al (2000) Drug- and estrogen-induced cholestasis through inhibition of the hepatocellular bile salt export pump (Bsep) of rat liver. *Gastroenterology* 118: 422–30
77. Strazzabosco M (1997) New insights into cholangiocyte physiology. *J Hepatol* 27: 945–52
78. Strazzabosco M, Spirli C, Okolicsanyi L (2000) Pathophysiology of the intrahepatic biliary epithelium. *J Gastroenterol Hepatol* 15:244–53
79. Swain MG (2000) Fatigue in chronic disease. *Clin Sci* 99: 1–8
80. Tandon P, Rowe BH, Vandermeer B, et al (2007) The efficacy and safety of bile acid binding agents, opioid antagonists, or rifampin in the treatment of cholestasis-associated pruritus. *Am J Gastroenterol* 102: 1528–36
81. Terg R, Coronel E, Sorda J, et al (2002) Efficacy and safety of oral naltrexone treatment for pruritus of cholestasis, a crossover, double blind, placebo-controlled study. *J Hepatol* 37: 717–22
82. Thornton JR, Losowsky MS (1988) Opioid peptides and primary biliary cirrhosis. *Br Med J* 297: 1501–4
83. Trauner M, Meier PJ, Boyer JL (1998) Molecular pathogenesis of cholestasis. *N Engl J Med* 339: 1217–27
84. Trauner M, Meier PJ, Boyer JL (1999) Molecular regulation of hepatocellular transport systems in cholestasis. *J Hepatol* 31: 165–78
85. Trauner M, Fickert P, Wagner M (2007) MDR3 (ABCB4) defects: a paradigm for the genetics of adult cholestatic syndromes. *Semin Liver Dis* 27: 77–98
86. Tsujii H, König J, Rost D, et al (1999) Exon-intron organization of the human multidrug-resistance protein 2 (MRP2) genemutated in Dubin-Johnson syndrome. *Gastroenterology* 117: 653–60
87. Valente JF, Alonso MH, Weber FL, et al (1996) Late hepatic artery thrombosis in liver allograft recipients is associated with intrahepatic biliary necrosis. *Transplantation* 61: 61–5
88. Viguier M, Allez M, Zagdanski AM, et al (2004) High frequency of cholestasis in generalized pustular psoriasis: evidence for neutrophilic involvement of the biliary tract. *Hepatology* 40: 452–8
89. Vitek L, Zelenka J, Zadinova M, et al (2005) The impact of intestinal microflora on serum bilirubin levels. *J Hepatol* 42: 238–43
90. Vitek L, Kráslová I, Muchová L, et al (2007) Urinary excretion of oxidative metabolites of bilirubin in subjects with Gilbert syndrome. *J Gastroenterol Hepatol* 22: 841–5
91. Zollner G, Fickert P, Zenz R, et al (2001) Hepatobiliary transporter expression in percutaneous liver biopsies of patients with cholestatic liver diseases. *Hepatology* 33: 633–46

Chapter Outline

Definition.....	593
Epidemiology	593
Etiology	594
Pathogenesis.....	595
Increased Portal Vascular Resistance.....	595
Increased Splanchnic and Portal Blood Flow	596
Diagnosis	597
Signs and Symptoms.....	597
Technical Investigations.....	597
Differential Diagnosis	600
Complications.....	600
Course and Prognosis	600
Therapy	600
References.....	602

See also Chapters 4, 46 and 80

Definition

The normal pressure in the portal vein fluctuates between 3 and 6 mmHg. Portal hypertension is defined as a persistent elevation of portal vein pressure to ≥ 7 mmHg and/or a hepatic venous pressure gradient (HVPG) of >5 mmHg.

The HVPG is the gradient between wedged hepatic venous pressure and free hepatic venous pressure and corresponds to the pressure gradient between the portal vein and the inferior vena cava. *The HVPG (normal values 1–4 mmHg) is the parameter most commonly used in clinical practice to report portal pressure.* HVPG values between 5 and 8 mmHg are increased but still considered borderline, while an HVPG of ≥ 9 mmHg is clearly pathologic. The development of gastro-esophageal varices requires an HVPG of at least 10 mmHg, while variceal bleeding is typically not seen until the HPVG exceeds 12 mmHg.

Epidemiology

In Western Europe and in North America portal hypertension is due to alcoholic liver cirrhosis in 60–70% of cases. In Asia portal hypertension most often results from end stage liver disease due to chronic viral infection, notably hepatitis B and C, while in North Africa schistosomiasis is a frequent cause of portal hypertension. Approximately 50% of patients will develop clinical manifestations of portal hypertension (most commonly ascites) within 10 years of being diagnosed with compensated cirrhosis.

Etiology

The persistent elevation of portal venous pressure generally results from chronic liver disease with structural remodeling of the liver. *Cirrhotic* and *non-cirrhotic forms* of portal hypertension should be differentiated. In Europe and in North America alcoholic and viral cirrhosis are by far the leading causes of portal hypertension. In children prothrombotic disorders with portal vein thrombosis are a frequent cause of portal hypertension.

The term *non-cirrhotic portal hypertension (NCPH)* comprises diseases characterized by an increase in portal pressure in the absence of cirrhosis. The causes of NCPH are numerous (Table 53.1). Common to all forms of NCPH are obstructive vascular lesions, either in the portal vein, its branches or in the perisinusoidal area [35].

Non-cirrhotic portal fibrosis (NCPF; idiopathic portal hypertension; hepatoportal sclerosis; see Chapter 61) is a syndrome of obscure etiology leading to portal hypertension. It has been reported mainly in India and Japan but is also recognized in Western countries. The disease is characterized by massive splenomegaly with anemia, relatively well-tolerated episodes of variceal bleeding in young adults from low socioeconomic backgrounds, and preserved liver function.

On liver histology the lobular architecture is maintained. There is portal fibrosis of variable degrees, sclerosis and obliteration of small-sized portal vein radicals, and subcapsular scarring with collapse of the underlying parenchyma. NCPF develops insidiously and 85–95% of patients present with variceal bleeding as the first manifestation of a hitherto unrecognized liver disease.

NCPF is diagnosed by the presence of unequivocal evidence of portal hypertension in the definitive absence of liver cirrhosis and extrahepatic portal vein obstruction. Because the wedged hepatic pressure is near normal, measurement of intravariceal or intrasplenic pressure is needed to assess portal pressure in NCPH. These measurements, however, are rarely performed in clinical practice. Splenoportography shows massive dilatation of the portal and splenic veins, and the presence of collaterals. However, in industrialized countries this investigation is no longer performed and has been replaced by CT- or MRI angiography.

The prognosis of patients with NCPF is good and 5 year survival in patients in whom variceal bleeding can be controlled has been reported to be approximately 95–100% [10, 14, 30].

Table 53.1 Etiologic classification of non-cirrhotic portal hypertension

Prehepatic
<ul style="list-style-type: none"> • Portal vein thrombosis • Splenic vein thrombosis • Splenomegaly (e.g. lymphoma, storage diseases) • Arterio-venous shunts in the splanchnic area and/or the spleen [1]
Intrahepatic
<ul style="list-style-type: none"> • Alcoholic hepatitis (central hyaline sclerosis) • Acute hepatitis • Chronic hepatitis • Toxic <ul style="list-style-type: none"> – Vinyl chloride – Arsenic – Vitamin A – 6-Mercaptopurine – Methotrexate • Fulminant liver failure • Budd–Chiari syndrome • Venocclusive disease • Intrahepatic arterio-portal shunt • Peliosis hepatis • Primary or metastatic liver tumors • Myeloproliferative diseases, idiopathic myelofibrosis [3] • Mastocytosis • Nodular regenerative (micronodular) hyperplasia • Partial nodular (macronodular) transformation • Primary biliary cirrhosis (in pre-cirrhotic stage) • Sclerosing cholangitis • Sarcoidosis • Schistosomiasis • Secondary syphilis • HIV-1 infection^a • Wilson’s disease • Amyloidosis • Congenital liver fibrosis • Idiopathic <ul style="list-style-type: none"> – Non-cirrhotic portal fibrosis (hepatoportal sclerosis; obliterative portal venopathy)
Posthepatic (ca. 10%)
<ul style="list-style-type: none"> • Cardiac diseases <ul style="list-style-type: none"> – Constrictive pericarditis – Restrictive cardiomyopathy – Right heart failure • Obstruction of inferior V. cava

^aExposure to didanosine and/or a hypercoagulable tendency might predispose patients with HIV-1 to vascular changes (nodular regenerative hyperplasia, portal venulopathy) resulting in noncirrhotic portal hypertension [28]

Pathogenesis

According to Ohm's law portal pressure (P) is a function of blood flow (F) and vascular resistance (R) ($P = F \times R$). R primarily depends on the transhepatic vascular resistance and is inversely correlated to the vascular diameter. Blood flow correlates directly with vessel's radius to the fourth power (r^4). Thus, minor alterations in vessel diameter will result in marked changes of vascular resistance and blood flow. The intrahepatic vascular resistance of the normal liver adapts to the portal venous blood flow, so that the portal pressure remains constant across a wide range of portal venous inflow. Thus, under physiologic conditions (e.g. in the postprandial state) a rise in portal pressure is limited by sinusoidal dilatation even in the presence of increased blood flow.

Both, the increase in portal vascular resistance and the increase in splanchnic and portal blood flow contribute to the pathogenesis of the development and perpetuation of portal hypertension (Table 53.2) [16, 18].

Increased Portal Vascular Resistance

The very low intrahepatic resistance in the normal liver contributes only very little to the pressure in the portal vein. The main pathogenetic factor in the development of portal hypertension is increased vascular resistance. *Irreversible, structural changes* with mechanical impairment to blood flow as well as *reversible, functional disturbances* with elevation of intrinsic intrahepatic vascular tone may underly the increase in resistance. Depending

on the localization of the alterations responsible for an increase in resistance intrahepatic and extrahepatic forms of portal hypertension may be distinguished. The former may be further subdivided into presinusoidal (portal venules), sinusoidal (sinusoids), and postsinusoidal (terminal hepatic venules; central veins) forms.

One must not overlook, however, that such a sharp distinction actually does not reflect the actual situation, since in most diseases, especially when they are chronic, increased resistance is localized at various levels.

In extrahepatic portal hypertension pre- and posthepatic forms are differentiated.

Irreversible Structural Changes

Numerous structural changes may cause an increase in vascular resistance as is seen, for example, in portal and periportal fibrosis with formation of fibrous septa, capillarization of sinusoids (occlusion of endothelial fenestrae, deposition of collagen within the space of Disse, formation of a sinusoidal basement membrane), deposition of foreign material within the space of Disse (e.g. amyloid), swelling of hepatocytes, formation of tumor nodules or regenerative nodules, and thrombosis in various vascular provinces.

The explanation for a rise in pre- and posthepatic resistance in mechanical obstruction to blood flow in the portal or in the liver veins is self-evident.

Increased intrahepatic resistance is pathogenetically more complex, and the various causes cannot always be sharply delineated. Increased resistance may be localized at the level of portal venules (presinusoidal), sinusoids (sinusoidal), or the terminal hepatic venules (postsinusoidal). However, this simple anatomic classification does not give enough consideration to the dynamics of the processes involved in portal hypertension. First, changes leading to an increase in resistance are generally localized at several, rather than only one, anatomical level. Furthermore, during the course of chronic liver disease the pathological processes usually involve different vascular regions at different points in time. Most patients with non-cirrhotic portal hypertension have obliterative lesions of the small (diameter < 0.2mm) portal vein branches. This obliterative portal venopathy initially leads to focal atrophy followed by secondary nodular hyperplasia of liver parenchyma.

Table 53.2 Pathophysiologically important factors in the development of portal hypertension

<p>Factors that increase portal vascular resistance</p> <ul style="list-style-type: none"> • Fixed component <ul style="list-style-type: none"> – Fibrosis – Displacement of vessels by nodes • Variable component <ul style="list-style-type: none"> – Vasoconstricting factors, e.g. endothelins <p>Factors that increase portal blood flow</p> <ul style="list-style-type: none"> • Nitric oxide • Glucagon • Prostaglandins • Endotoxins • Tumor necrosis factor α
--

Reversible Functional Changes

Reversible changes in the intralobular vascular tone, in addition to fixed mechanical factors, are responsible for the dynamic modulation of intrahepatic vascular resistance. These dynamic changes require an interaction between vasoconstrictive (e.g. catecholamines, angiotensin, vasopressin, endothelin) and vasodilating (e.g. nitric oxide, prostacyclins, endotoxins, glucagon) mediators, and play a major role in the pathogenesis of portal hypertension. Intrahepatic vasoconstriction probably contributes more than 25% to the increased resistance in intrahepatic portal hypertension [19].

This dynamic component of portal hypertension requires active changes of sinusoidal resistance (diameter of sinusoidal lumen) which are based on elements that are able to react to vasoconstrictive and vasodilating factors. Hepatic stellate cells localized within the space of Disse possess these features. They contribute significantly to the regulation of the hepatic microcirculation. Contraction and relaxation of their cytoplasmic processes that are localized on the exterior surface of the sinusoids affect the sinusoidal tone and blood flow [24]. In the presence of hepatic injury they are activated, acquire contractile features, transform into myofibroblasts and function as liver specific pericytes (see Chapter 3).

Nitric oxide (NO) is a central mediator of vasoreactive and angiogenic abnormalities observed in portal hypertension. *Altered NO signaling plays a central role in the pathogenesis of portal hypertension.* Hepatic sinusoidal endothelia are an important local source of NO in the normal liver [31]. Not only is there diminished NO production by sinusoidal endothelial cells, but hepatic stellate cells also demonstrate resistance to NO mediated relaxation in intrahepatic portal hypertension. In contrast to diminished intrahepatic bioavailability of NO, there is a relative excess in splanchnic and systemic NO generation [17, 25, 32]. NO also is involved in promoting vascular remodeling in patients with portal hypertension and thereby contributes to decompression through collateral vessels.

Endothelins are proteins that react with surface receptors on hepatic stellate cell and stimulate their contraction, thereby increasing intrahepatic vascular resistance. However, recent data suggest that endothelin-1 contributes to maintenance of systemic and pulmonary hemodynamics without acutely affecting HVPG in patients with early cirrhosis [33].

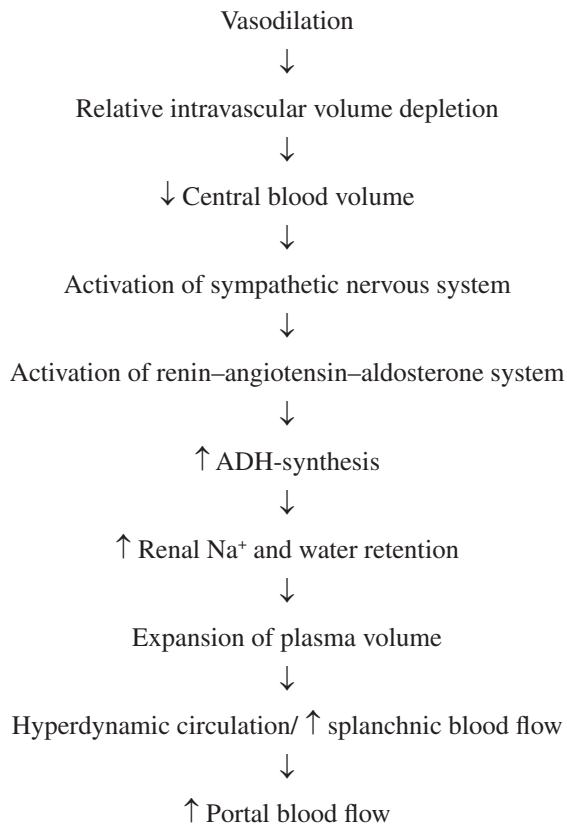
Additionally, *angiotensin II* induces the contraction of human stellate cells. By stimulating AT1-receptors, angiotensin II also acts as a mitogen and stimulates activated stellate cells to proliferate [4].

Increased Splanchnic and Portal Blood Flow

Portal circulation is actively regulated by changes in splanchnic blood flow. Increases in splanchnic and portal blood flow play an important role in the development of portal hypertension. *Hyperdynamic circulation*, often present in patients with liver cirrhosis, is characterized by chronically increased systemic and splanchnic blood flow, and is of major pathogenetic importance in portal hypertension. Peripheral vasodilation with a decrease in both systemic vascular resistance and peripheral arterial pressure most likely occurs at the onset of the development of hyperdynamic circulation. Activation of neurohumoral mechanisms leads to splanchnic vasodilation and to the expansion of plasma volume with a consequent increase in hepatportal blood flow. An elevated concentration of circulating vasodilatory factors, an increased endothelial production of locally acting vasodilators, and a diminished vascular reactivity to endogenous vasoconstrictors are responsible for peripheral vasodilation. Among the vasodilating substances whose serum concentration is increased in patients with portal hypertension are glucagon, prostacyclin, endotoxin and NO. These vasodilating compounds are generated in the splanchnic region and partly in the liver itself. Their synthesis is increased and their hepatic clearance is diminished. Recently, an increased production of NO in the aorta has been demonstrated in portal hypertension [22].

The vascular endothelium plays a major role in maintaining vascular tone. Two compounds produced by endothelial cells – NO and prostacyclin – cause peripheral and splanchnic vasodilation and an increase in splanchnic blood flow. Endotoxins and tumor necrosis factor α may enhance the synthesis of both substances. In addition to its vasodilating action, NO mediates a change in the vessel wall which makes it less reactive to vasoconstricting stimuli, such as norepinephrine, arginine-vasopressin and angiotensin II. The significance of glucagon, insulin and bile acids in the pathogenesis of hyperdynamic circulation is unclear. However, it seems rather unlikely that these substances play a major role in the development of splanchnic vasodilation.

The pathogenesis of hyperdynamic circulation overlaps with that of ascites (see Chapter 54), and most likely involves the following events:



Diagnosis

Signs and Symptoms

Early changes associated with portal hypertension cannot be detected by physical examination. Increased abdominal venous markings, ascites and splenomegaly are signs of advanced portal hypertension.

Technical Investigations

Abdominal sonography and esophago-gastro-duodenoscopy are the most important initial examinations in the workup of patients with portal hypertension. Both examinations allow for diagnosing portal hypertension

and its hemodynamic sequelae, and in many cases the cause of portal hypertension may also be assessed. In individual cases CT may complement and broaden the sonographic findings. Measurement of HVPG is the most exact method in determining intravascular pressures. However, despite its increasing clinical use, this invasive technique is applied clinically in a minority of patients with portal hypertension. It continues to be restricted mainly to clinical studies assessing the response to drugs which reduce portal pressure in liver cirrhosis.

Laboratory Examinations

Cytopenias – anemia, leukopenia, and/or thrombocytopenia – may be the expression of hypersplenism in portal hypertension. These changes, however, are non-specific and must be interpreted in conjunction with the patient's history, physical findings and the results of imaging techniques.

Abdominal Sonography

Transcutaneous B-mode abdominal ultrasound combined with duplex- and color Doppler sonography is the imaging method of choice in portal hypertensive patients. Its results rapidly yield information regarding the cause and severity of portal hypertension without burdening the patient [14, 20, 27]. On color Doppler ultrasound, hepato-fugal flow in the portal vein is found in approximately 10% of patients with liver cirrhosis (Fig. 53.1) [11]. The demonstration of porto-systemic venous collaterals can also be seen with color duplex sonography. In order to obtain reliable and reproducible data on duplex sonography exact guidelines must be observed (Fig. 53.2; Table 53.3). Despite the advantages of ultrasound, Doppler ultrasonography cannot estimate HVPG, and is not suitable for replacing HVPG as a means of assessing the severity of portal hypertension [7].

In addition to showing changes in blood flow, ultrasound allows for an accurate description of macronodular cirrhosis, space occupying hepatic lesions, splenomegaly, patency of the portal vein, and the presence of ascites.

Fig. 53.1 Complete reversal of blood flow in the portal vein (*blue*) and hepatic artery with wide lumen and with hepatopetal flow (*red*)

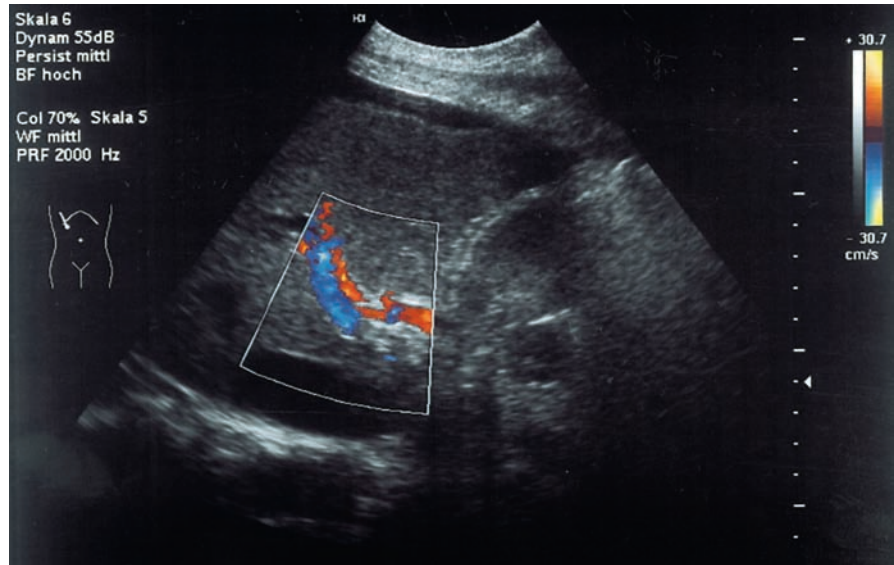
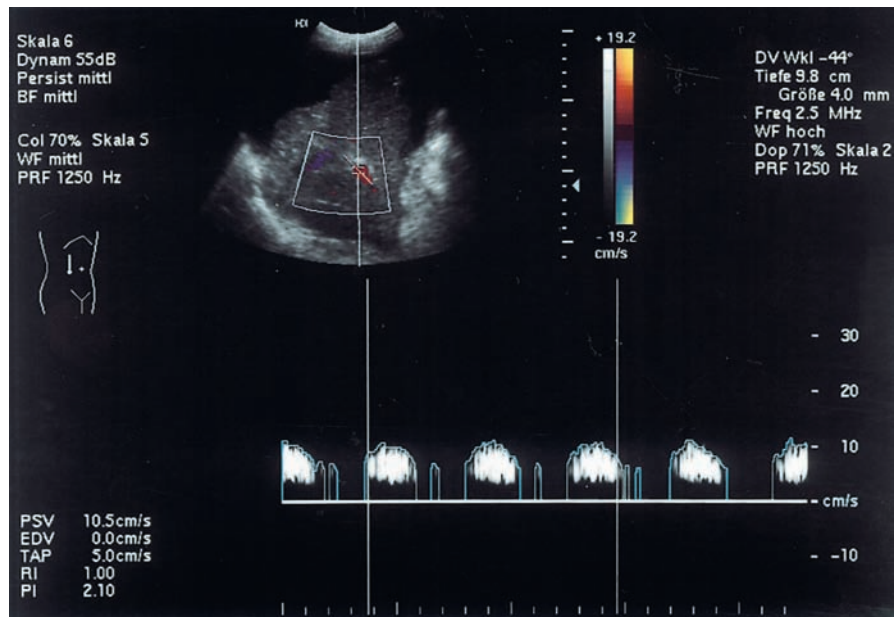


Fig. 53.2 Pulsatile flow in the portal vein with diastolic stop of perfusion and decrease in maximal flow velocity



Transient Elastography

Transient elastography (TE) is a novel noninvasive ultrasound-based technique that measures tissue elasticity. It attempts to quantify fibrosis by measuring liver stiffness and appears to accurately measure advanced fibrosis (see Chapter 28). Currently it does not discriminate between intermediate grades of fibrosis, and is not helpful in assessing early fibrosis [26].

A correlation between liver stiffness as determined by TE and the HVPG has been reported, so that in the future measuring liver stiffness by TE might serve as a noninvasive tool for identifying patients with portal hypertension [34]. The field of noninvasive assessment of liver fibrosis is in constant evolution, and is rapidly expanding. The definitive role of TE in the management of patients with portal hypertension cannot yet be determined.

Table 53.3 Guidelines for the sonographic determination of portal blood flow velocity

Measurements in mid-respiratory (suspended) position
Longitudinal scan of portal vein
Sample volume in center of the vessel, in the tract underneath hepatic artery, covering 50% of the vessel diameter
Doppler angle $\leq 55^\circ$
Pulse repetition frequency = 4 kHz; wall filter = 100 Hz
Simultaneous recording of Doppler and B-image tracings
Manual determination of average portal blood maximal velocity
Analysis across at least two complete cardiac cycles
Vessel diameter measured from the interior anterior to the inner posterior wall
Final results by calculating the mean of at least three reliable measurements

Source: According to [27]

Computed Tomography and Magnetic Resonance Imaging

CT and MRI may also visualize the solid organs and the intraabdominal vessels. These techniques, however, are costly and do not offer definite advantages over abdominal ultrasound in patients with portal hypertension, with the exception of obese or meteoristic patients in whom ultrasound imaging is often impaired. For MRI- and CT-angiography, see below.

Esophago-Gastro-Duodenoscopy

Esophago-Gastro-Duodenoscopy (EGD) is the method of choice in detecting, grading, and prognosticating intraluminal esophageal and gastric fundic varices as well as portal hypertensive gastropathy. Duodenal varices are rare and may “hide” beneath unusually prominent duodenal folds. Additionally, EGD offers prophylactic and therapeutic options in patients with varices.

Although portal hypertensive changes are more common in the upper gastrointestinal tract, they may be found throughout the entire gastrointestinal tract, from the esophagus to the anus (see Chapter 80) [23].

Endoscopic Ultrasound

Endoscopic ultrasound (EUS) is ideally suited for visualizing intra- and perimural varices (see Chapter 42) [8]. The diameter of the azygos vein may be easily

determined by EUS, and correlates with portal venous pressure [21]. Analogous to transcutaneous sonography, EUS duplex and Doppler examinations may be performed. The clinical relevance of the additional endosonographic information in patients with portal hypertension, however, remains to be determined.

Angiography

Radiographic angiography may visualize the entire portal system and its collaterals, but is rarely if ever performed nowadays in patients with portal hypertension. Magnetic resonance angiography is increasingly used for diagnosing arterial anomalies as well as thrombosis of splenic, mesenteric or portal vein, although the latter may also be demonstrated noninvasively by ultrasound. The advantage of MRI-angiography over radiographic angiography and spiral CT is that it does not require iodinated contrast and thus carries only a minor risk of nephropathy.

With the introduction of transjugular intrahepatic portosystemic shunt (TIPS), interventional angiography has obtained an important role in the treatment of portal hypertension.

Laparoscopy

The signs of portal hypertension in the abdominal cavity may easily be demonstrated by laparoscopy. Diagnostic laparoscopy, however, is an invasive technique and has been replaced by noninvasive methods in patients with portal hypertension. Nonetheless, in some situations laparoscopy still maintains its value in the diagnosis of liver cirrhosis and can be useful in targeting biopsies of circumscribed superficial liver lesions when less invasive methods have failed or are not possible (see Chapter 45).

Invasive Measurement of Portal Pressure

The measurement of HVPG is still not performed routinely in clinical practice, but is playing an increasingly important role in the management of patients

with portal hypertension [12]. The procedure is safe and relatively simple. The information obtained may be predictive of new or recurrent bleeding, and repeat measurements potentially may guide pharmacologic therapy (see Chapter 46) [5].

Differential Diagnosis

The differential diagnosis of portal hypertension encompasses primarily the numerous causes of liver cirrhosis (see Chapter 79), the noncirrhotic forms of portal hypertension (Table 53.1) as well as the various etiologies of ascites (see Chapter 54).

Complications

Portal hypertension, alone or in conjunction with the underlying disease may be the cause of life threatening complications. Since these complications represent distinct clinical entities, they are only briefly mentioned in this chapter, and are discussed in detail elsewhere (see Chapters 54 and 80).

The following are the most important complications of portal hypertension.

- Venous collaterals with variceal bleeding
- Ascites
- Splenomegaly with or without hypersplenism
- Spontaneous bacterial peritonitis

Portosystemic collaterals in the setting of portal hypertension may develop in various anatomical sites (esophagus, stomach, duodenum, small intestine, rectum, gallbladder). Initially vessels are probably passively reopened by the increased intravascular pressure. During the further course, angiogenesis becomes more and more important. Initially the collateral vessels contribute to decompression of the hypertensive portal system. Thus, patients with extensive collateralisation show less pronounced postprandial increases in HVPG [2]. Since their vascular resistance remains higher than the normal intrahepatic resistance, however, the collateral vessels are not able to normalize the portal pressure.

Clinically by far the most important collateral vessels are *gastro-esophageal varices*. They develop because of a collateral circulation through the gastric coronary vein, to the distal esophageal and proximal stomach veins, and via the azygos vein into the systemic circulation.

Although they serve to decompress the portal circulation, their most significant complication is *rupture* with subsequent *bleeding*, which occurs in 20–40% of untreated patients with cirrhosis. Every third patient with variceal hemorrhage dies. Without treatment the risk of rebleeding after a hemorrhage from esophageal varices is 70%. The risk of variceal bleeding correlates in a non-linear fashion with the pressure within the portal venous system. The risk is low with HVPG values <12 mmHg, and increases markedly when portal pressure rises to >12 mmHg. The risk of bleeding also correlates with variceal size. Superficial variceal changes, such as red spots and “red wale” markings are endoscopic stigmata of an increased bleeding risk. Further predictors of variceal hemorrhage are the intravascular variceal pressure and increasing severity of liver cirrhosis (according to the Child-Turcotte-Pugh score) [9].

Cruveilhier-von Baumgarten syndrome denotes the recanalization of the umbilical vein in portal hypertension. The recanalized vein connects the left portal vein branch with the systemic venous circulation (Fig. 53.3). A continuous flow murmur may be auscultated in the epigastrium below the xiphoid (“bruit de diable”).

Course and Prognosis

The natural history of portal hypertension is determined by the course of its complications. Prognosis primarily depends on the underlying disease, the level of portal pressure, and the therapeutic options.

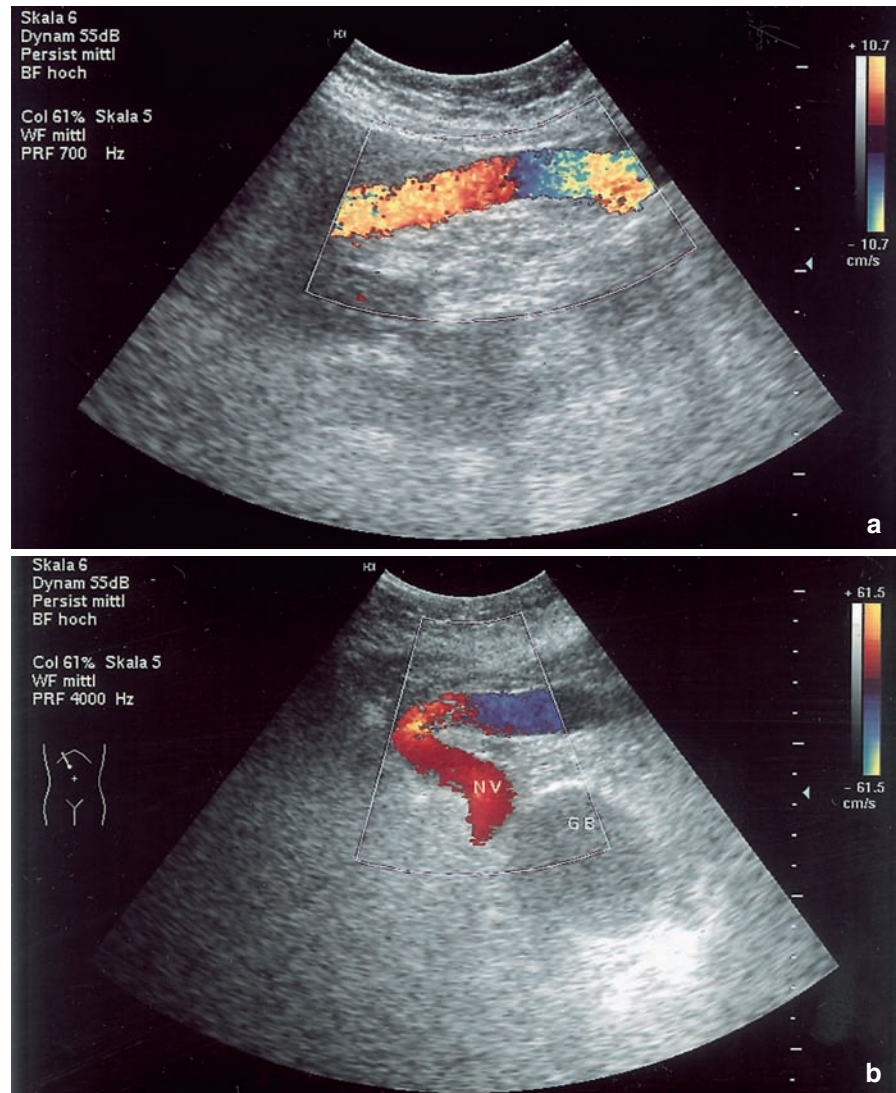
Thus, chronic progressive liver diseases that are difficult to treat will have a worse prognosis than, for example, a partial, well recanalized portal vein thrombosis. Since numerous diseases may be associated with portal hypertension their course and prognosis are discussed in separate chapters.

Therapy

The treatment of portal hypertension and its complications is based on pharmacological, endoscopic, radiological, and surgical principles.

Drug therapy and shunt procedures (TIPS; surgical shunts) are the sole treatments able to lower portal venous pressure. Endoscopic (band ligation, sclerotherapy) or surgical techniques may achieve an effective control of variceal bleeding and eradication of varices,

Fig. 53.3 Cruveilher-von Baumgarten syndrome. (a) Recanalized umbilical vein with hepatopetal flow (NV). (b) The curved vessel (NV) runs along the inner abdominal wall (“inner” caput medusae). GB gallbladder



but these procedures do not lower the pressure within the portal venous system.

The most widely used agents shown to lower portal pressures are non-selective beta-blockers, which reduce venous inflow through decreased cardiac output and increased splanchnic vascular tone. One recent study has demonstrated a decreased risk of developing esophageal varices in patients treated with timolol whose HVPG was reduced by more than 10% [13]. Spironolactone, a potassium-sparing diuretic, has also been shown to decrease HVPG in conjunction with a low-sodium diet.

Inhibition of endothelin synthesis or endothelin receptor blockade represents an interesting experimental

approach to portal hypertension [6]. Thus, candoxatri-
lat, an inhibitor of neutral endopeptidase (the enzyme
neutral endopeptidase generates endothelin-1 from
big-endothelin) has been shown in animal experiments
to have portal hypotensive actions based on effects
exerted on intrahepatic vascular resistance [29].
However, there is still a long way to go before these
experimental approaches can be implemented in clinical
practice. The various therapeutic modalities currently
used in patients with portal hypertension are discussed
in detail in Chapter 80. If all effective management
options have been exhausted liver transplantation
should be considered.

References

1. Aithal GP, Alabdi BJ, Rose JDG, et al (1999) Portal hypertension secondary to arterio-portal fistulae: two unusual cases. *Liver* 19: 343–7
2. Albillos A, Banares R, Gonzalez M, et al (2007) The extent of the collateral circulation influences the postprandial increase in portal pressure in patients with cirrhosis. *Gut* 56: 259–64
3. Alvarez-Larran A, Abraldes JG, Cervantes F, et al (2005) Portal hypertension secondary to myelofibrosis: a study of three cases. *Am J Gastroenterol* 100: 2355–8
4. Bataller R, Ginès P, Nicolás M, et al (2000) Angiotensin II induces contraction and proliferation of human hepatic stellate cells. *Gastroenterology* 118: 1149–56
5. Boyer TD (2004) Changing clinical practice with measurements of portal pressure. *Hepatology* 39: 283–5
6. Cho JJ, Hocher B, Herbst H, et al (2000) An oral endothelin-A receptor antagonist blocks collagen synthesis and deposition in advanced rat liver fibrosis. *Gastroenterology* 118: 1169–78
7. Choi YJ, Baik SK, Park DH, et al (2003) Comparison of Doppler ultrasonography and the hepatic venous pressure gradient in assessing portal hypertension in liver cirrhosis. *J Gastroenterol Hepatol* 18: 424–9
8. Dancygier H, Lightdale CJ (1999) Endosonography in gastroenterology. Principles, techniques, findings. Thieme, Stuttgart/New York, pp 48–53
9. De Franchis R (2005) Evolving consensus in portal hypertension. Report of the Baveno IV consensus workshop on methodology of diagnosis and therapy in portal hypertension. *J Hepatol* 43: 167–76
10. Dhiman RK, Chawla Y, Vasishta RK, et al (2002) Non-cirrhotic portal fibrosis (idiopathic portal hypertension): experience with 151 patients and a review of the literature. *J Gastroenterol Hepatol* 17: 6–16
11. Gaiani S, Bolondi L, Li BS, et al (1991) Prevalence of spontaneous hepatofugal portal flow in liver cirrhosis. Clinical and endoscopic correlation in 228 patients. *Gastroenterology* 100: 160–7
12. Groszmann RJ, Wongcharatrawee S (2004) The hepatic venous pressure gradient: anything worth doing should be done right. *Hepatology* 39: 280–2
13. Groszmann RJ, Garcia-Tsao G, Bosch J, et al (2005) Beta-blockers to prevent gastroesophageal varices in patients with cirrhosis. *New Engl J Med* 353: 2254–61
14. Haag K, Rössle M, Ochs A, et al (1999) Correlation of duplex sonography findings and portal pressure in 375 patients with portal hypertension. *AJR Am J Roentgenol* 172: 631–5
15. Hillaire S, Bonte E, Denninger MH, et al (2002) Idiopathic non-cirrhotic intrahepatic portal hypertension in the West: a re-evaluation in 28 patients. *Gut* 51: 275–80
16. LaBrecque DR (1997) (Guest ed.) Portal hypertension. *Clin Liv Dis* 1: 1–245
17. Langer DA, Shah VH (2006) Nitric oxide and portal hypertension: interface of vasoreactivity and angiogenesis. *J Hepatol* 44: 209–16
18. Lebrec D, Moreau R (2001) Pathogenesis of portal hypertension. *Eur J Gastroenterol Hepatol* 13: 309–11
19. Morales-Ruiz M, Cejudo-Martin P, Fernandez-Varo G, et al (2003) Transduction of the liver with activated Akt normalizes portal pressure in cirrhotic rats. *Gastroenterology* 125: 522–31
20. Moriyasu F, Ban N, Nishida O, et al (1988) Clinical application of an ultrasonic duplex system in the quantitative measurement of portal blood flow. *J Clin Ultrasound* 14: 579–88
21. Nattermann C, Dancygier H (1992) Endoskopische Sonographie bei portaler Hypertension. *Endosk. Heute* 5: 26–9
22. Pateron D, Tazi KA, Sogni P, et al (2000) Role of aortic nitric oxide synthase 3 (eNOS) in the systemic vasodilation of portal hypertension. *Gastroenterology* 119: 196–200
23. Rana SS, Bhasin DK, Jahagirdar S, et al (2006) Is there ileopathy in portal hypertension? *J Gastroenterol Hepatol* 21: 392–7
24. Rockey DC (1997) The cellular pathogenesis of portal hypertension: stellate cell contractility, endothelin and nitric oxide. *Hepatology* 25: 2–5
25. Rockey DC, Chung JJ (1998) Reduced nitric oxide production by endothelial cells in cirrhotic rat liver: endothelial dysfunction in portal hypertension. *Gastroenterology* 114: 344–51
26. Rockey DC (2008) Noninvasive assessment of liver fibrosis and portal hypertension with transient elastography. *Gastroenterology* 134: 8–14
27. Sabba C, Merkel C, Zoli M, et al (1995) Interobserver and interequipment variability of echo-Doppler examination of the portal vein: effect of a cooperative training program. *Hepatology* 21: 428–33
28. Saifee S, Joelson D, Braude J, et al (2008) Noncirrhotic portal hypertension in patients with human immunodeficiency virus-1 infection. *Clin Gastroenterol Hepatol* 6: 1167–9
29. Sansoe G, Aragno M, Mastrocola R, et al (2005) Neutral endopeptidase (EC 3.4.24.11) in cirrhotic liver: a new target to treat portal hypertension? *J Hepatol* 43: 791–8
30. Sarin SK, Kapoor D (2002) Non-cirrhotic portal fibrosis: current concepts and management. *J Gastroenterol Hepatol* 17: 526–34
31. Shah V, Haddad FG, García-Cardena G, et al (1997) Liver sinusoidal endothelial cells are responsible for nitric oxide modulation of resistance in the hepatic sinusoids. *J Clin Invest* 100: 2923–30
32. Shah V, García-Cardena G, Sessa WC (1998) The hepatic circulation in health and disease: report of a single-topic symposium. *Hepatology* 27: 279–88
33. Tripathi D, Therapondos G, Ferguson JW, et al (2006) Endothelin-1 contributes to maintenance of systemic but not portal haemodynamics in patients with early cirrhosis: a randomised controlled trial. *Gut* 55: 1290–5
34. Vizzutti F, Arena U, Romanelli RG, et al (2007) Liver stiffness measurement predicts severe portal hypertension in patients with HCV-related cirrhosis. *Hepatology* 45: 1290–7
35. Wanless JR (1997) Noncirrhotic portal hypertension: recent concepts. *Progr Liv Dis* 14: 265–78

Chapter Outline

Definition	603
Etiology	603
Pathogenesis	604
Regulation of Extracellular Fluid Volume	605
Theories of Ascites Formation	608
Diagnosis	609
Differential Diagnosis	611
Complications	612
Therapy	612
Prognosis	612
References	613

Ascites has been described by Hippocrates of Kos (ca. 460 to ca. 370 BC), and its treatment by large volume paracentesis has been already practiced by the ancient Greek physicians. See also Chapter 80 for the discussion of formation and treatment of cirrhotic ascites.

Definition

Ascites denotes the accumulation of fluid in the peritoneal cavity.

Etiology

Several main forms of ascites may be distinguished etiologically:

- Portal
- Cardiac
- Malignant
- Inflammatory/infectious, and
- Chylous

The features of portal and cardiac ascites are overlapping. Many different causes underlie these main forms of ascites.

The most common cause of ascites is liver cirrhosis in approximately 80% of cases, followed by malignant (12%) and cardiovascular diseases (5%). Malignant ascites is predominantly due to peritoneal carcinomatosis (e.g. in gastric or ovarian cancer) or to massive liver metastases. Congestive right heart failure and constrictive pericarditis are the leading cardiac causes of ascites. Disturbances of venous hepatic outflow such as Budd-Chiari syndrome or veno-occlusive disease

Table 54.1 Causes of ascites

Cause	Frequency (%)
Parenchymal Liver Disease	78
Cirrhosis	77
Fulminant Liver Failure	1
Malignancy	12
Cardiovascular Disease	5
• Congestive heart failure	
• Constrictive or restrictive cardiomyopathy	
• Thrombosis of inferior V. cava	
• Budd-Chiari syndrome	
• Veno-occlusive disease	
Infection	2
Tuberculosis	
Fitz-Hugh-Curtis syndrome (chlamydiae, gonococci)	
Coccidioidomycosis	
Whipple's Disease (Tropheryma whipplei)	
Renal	1.5
Nephrotic syndrome	
Uremia	
Hemodialysis	
Pancreatic	1
Bacterial Peritonitis	0.5
Marked Hypothyroidism	
Collagen Vascular Disease	
Familial Mediterranean Fever	
Amyloidosis	
Hereditary Angioneurotic Edema	
Menetrier's Disease and Protein-losing Enteropathy	
Starch Peritonitis	
Trauma	

Source: Adapted from [19]

are rare etiologies, as are infectious, renal and other causes. An isolated portal vein thrombosis, without concomitant parenchymal disease of the liver usually does not cause ascites. The numerous causes and various forms of ascites are reported in Tables 54.1–54.4.

Pathogenesis

The pathophysiology of ascites in peritonitis is self-evident. *Malignant* and *inflammatory/infectious ascites* is caused by the formation of an exudate due to peritoneal

Table 54.2 Different types of ascites and their etiologies

Form	Causes (selected examples)
Portal hypertensive ascites	<ul style="list-style-type: none"> • Liver cirrhosis • Acute viral hepatitis • Alcoholic steatohepatitis • Budd-Chiari syndrome • Veno-occlusive disease • Inferior vena cava thrombosis • Portal vein thrombosis^a
Cardiac ascites	<ul style="list-style-type: none"> • Right heart failure • Constrictive pericarditis
Malignant ascites	<ul style="list-style-type: none"> • Peritoneal carcinomatosis • Intraabdominal tumors • Massive liver metastases • Malignant lymphoma
Inflammatory ascites	<ul style="list-style-type: none"> • Tuberculosis • Bacterial peritonitis • Spontaneous bacterial peritonitis^b • Acute pancreatitis • Collagen vascular diseases • Familial mediterranean fever
Chylous ascites	<ul style="list-style-type: none"> • See Table 54.4

^aAn isolated portal vein thrombosis without accompanying parenchymal liver disease usually does not cause ascites

^bOccurs nearly always in the context of liver cirrhosis

Source: Adapted from [35]

Table 54.3 Macroscopic aspect of various forms of ascites

Serous	<ul style="list-style-type: none"> • Portal hypertensive • Infectious • Malignant • Pancreatic
Hemorrhagic	<ul style="list-style-type: none"> • Malignant • Pancreatic • Traumatic
Cloudy	<ul style="list-style-type: none"> • Infectious (bacterial) • Malignant • Pancreatic
Chylous	<ul style="list-style-type: none"> • Malignant • Portal hypertensive

irritation. The peritoneum, having a surface area of approximately 2 m² in the adult, behaves like a semipermeable membrane that enables the continuous exchange of water and solutes between the peritoneal cavity and the intraperitoneal blood and lymph vessels. Under physiologic conditions water and low molecular weight substances are absorbed by the hematogenous route, while high molecular weight substances are drained

Table 54.4 Causes of chylous ascites

Neoplastic (e.g. lymphoma, carcinoid tumors, Kaposi's sarcoma)
Cirrhotic (common in adults)
Infectious
• Tuberculosis
• Atypical mycobacteriosis (<i>Mycobacterium avium intracellulare</i>)
• Filariasis (<i>Wuchereria bancrofti</i>)
• Whipple's disease (<i>Tropheryma whipplei</i>)
Inflammatory
• Radiation
• Pancreatitis
• Constrictive pericarditis
• Retroperitoneal fibrosis
• Sarcoidosis
• Celiac sprue
• Retractable mesenteritis
Postoperative
• Abdominal aneurysm repair
• Retroperitoneal node dissection
• Catheter placement for peritoneal dialysis
• Inferior vena cava resection
Traumatic
• Blunt abdominal trauma
• Battered child syndrome
Congenital
• Primary lymphatic hypoplasia
• Yellow nail syndrome
• Klippel-Trenaunay syndrome
• Primary lymphatic hyperplasia
Bilateral hyperplasia
Intestinal lymphangiectasia
Other causes
• Right heart failure
• Dilated cardiomyopathy
• Nephrotic syndrome
• Lymphangiioleiomyomatosis (10% of cases show chylous ascites)

Source: Adapted from [8]

by the lymphatics, especially via the subdiaphragmatic lymph vessels. This process is facilitated by fenestrations in the peritoneal mesothelium and in the endothelium. The maximal transport capacity for fluids from the peritoneal cavity to plasma is approximately 720–840 mL/24 h. This flow cannot be further increased even by forced diuresis. In a healthy person the secretory activity of the peritoneal mesothelium is in equilibrium with its drainage systems, so that normally only a few millilitres of a transudate are present in the peritoneal

cavity to keep the peritoneal lining moist. Inflammatory peritoneal irritation regardless of its cause or conditions associated with impairment of lymphatic drainage compromise this balance and lead to an accumulation of fluid into the peritoneal cavity.

In contrast to peritonitis, the pathophysiologic mechanisms in the development of *cirrhotic ascites* are still not completely understood. However, decade long research has considerably improved our understanding of its pathogenesis. Patients with advanced cirrhosis regularly exhibit changes in the systemic circulation (such as an increased cardiac output, decreased peripheral vascular resistance, arterial hypotension, splanchnic vasodilation) and have an impaired renal excretion of Na⁺ and water. These alterations, to some extent are already present in the preascitic stage of cirrhosis. Whether they represent secondary adaptation processes to primary renal Na⁺ and water retention with consequent enlargement of extracellular and plasma volume, or whether they are the initiating factors in the wake of which renal dysfunction develops, is controversial. The present data favor the latter possibility. *Formation of ascites in liver cirrhosis is essentially regarded as a consequence of a primary peripheral and splanchnic vasodilation with reduction of the effective arterial blood volume, combined with an impairment of renal Na⁺ and water excretion.* The total body content of Na⁺ correlates directly with and is the most important determinant of extracellular fluid volume. In a healthy person a balance exists between the uptake of Na⁺ and its renal excretion, an increased uptake being followed by an increased excretion. Whatever might be the initiating mechanism, in patients with liver cirrhosis this *balance is disrupted; i.e., despite an elevated extracellular fluid volume, Na⁺ is inadequately retained* [33]. In addition, local factors must be operative which explain the preferred accumulation of fluid within the peritoneal cavity.

Regulation of Extracellular Fluid Volume

The volume of extracellular fluid in a healthy person is tightly controlled and regulated. This homeostatic process involves

- Afferent neural signals, and
- Efferent neuro-hormonal mechanisms.

Afferent Signals

The filling state of the arterial system is the primary afferent signal, which determines whether or not the kidneys will retain Na^+ and water. The most important determinants of arterial filling are cardiac output and peripheral vascular resistance. A decrease in cardiac output and arterial vasodilation signal a state of “arterial underfilling” and elicit mechanisms that lead to renal Na^+ and water retention [36, 37]. Sensors within the cardio-pulmonary circulation, the kidneys, and not yet precisely defined receptors in the peripheral circulation and central nervous system register the vascular filling state. *High pressure baroreceptors* are located in the left cardiac ventricle, carotid sinus, aortic arch, and in the renal juxtaglomerular apparatus. A decrease in pressure with diminished distension of these receptors leads to

- Activation of the sympathetic nervous system
- Activation of renin-angiotensin-aldosterone (RAA) system, and
- Non-osmotic release of arginine-vasopressin

All three mechanisms reduce renal water and Na^+ excretion. In addition, the release of norepinephrine from sympathetic nerve fibers directly activates the RAA system. Both stimulate the hypothalamic supraoptic and paraventricular nuclei to secrete arginine-vasopressin.

Sensitive *low pressure receptors*, which are stimulated by distension, are located in the cardiac atria, right heart chamber, and pulmonary arterial vessels. Distension of these receptors causes increased secretion of cardiac natriuretic peptides, and inhibition of vasopressin secretion, followed by enhanced diuresis. Compared to the volume sensitive sensors within the low-pressure system, arterial baroreceptors seem to play the major role in the pathogenesis of cirrhotic ascites, with renal Na^+ and water retention prevailing.

Efferent Mechanisms

The efferent neuro-hormonal factors that affect renal Na^+ and water handling are, among other things, *vasoconstricting* and *antinatriuretic substances*, such as

- Norepinephrine
- Angiotensin II

- Aldosterone
- Arginine-vasopressin, and
- Endothelins

as well as *vasodilating* and *natriuretic compounds*, especially

- Nitric oxide (NO)
- Vasodilating peptides
- Natriuretic peptides, and
- Prostaglandins

Patients with liver cirrhosis already exhibit arterial vasodilation in the precirrhotic stage. This “arterial underfilling” leads to a number of compensatory neuroendocrine responses that lead to vasoconstriction and to an increased renal Na^+ and water retention (see above). Initially these compensatory mechanisms are beneficial. By increasing intravascular volume they help to correct, at least partially, arterial underfilling, and thereby prevent the development of ascites. Once the increase in plasma volume is no longer able to normalize the homeostatic mechanisms, liver cirrhosis decompensates, and ascites develops.

Stimulation of the sympathetic nervous system causes peripheral and renal vasoconstriction. As a result of the preferential constriction of the efferent arterioles, vascular resistance initially increases, and renal blood flow diminishes. The filtration fraction is increased in the presence of normal or only slightly reduced glomerular filtration. The constriction of the efferent arterioles also alters the hemodynamic parameters in the peritubular capillaries with a decrease in hydrostatic and a rise in oncotic pressure, which leads to enhanced tubular Na^+ and water retention. Thus, increased sympathetic activity in patients with liver cirrhosis is pivotal for the maintenance of cardiovascular homeostasis. The sympathetic nervous system, by its action on renal vessels and tubules, may contribute to the expansion of extracellular fluid volume and to the development of ascites. By increasing the hepatic vascular resistance, the sympathetic system also contributes to the generation of portal hypertension (see Chapter 53) [5, 12].

Arterial underfilling and hyponatremia activate the *renin-angiotensin-aldosterone system*. Angiotensin II stimulates the secretion of aldosterone, which furthers renal tubular Na^+ resorption. In addition, angiotensin II itself may enhance Na^+ resorption in the proximal tubule and constricts the efferent arterioles with the above mentioned consequences. Recently it has been

suggested that the apparent mineralocorticoid effect is only partially explained by increased aldosterone concentrations, and that in addition to aldosterone, cortisol confers mineralocorticoid action. The underlying molecular pathology for this mineralocorticoid receptor activation by cortisol is a reduced activity of the 11β -hydroxysteroid dehydrogenase type 2, an enzyme protecting the mineralocorticoid receptor from promiscuous activation by cortisol in healthy individuals [13].

Arginine-vasopressin stimulates renal V_2 -receptors thereby enhancing water resorption in the collecting tubules. Inadequately elevated vasopressin levels in plasma are documented in patients with liver cirrhosis, ascites, peripheral edema and hyponatremia [32]. They correlate with the clinical and hemodynamic severity of the disease. In patients with cirrhosis, in contrast to normal persons, a water load does not reduce these increased hormone levels. This suggests that in cirrhotic patients elevated plasmatic vasopressin concentration is mediated by non-osmotic mechanisms [6].

Endothelins are potent vasoconstrictors and important regulators of liver blood flow (see Chapter 4). The intrahepatic endothelin-1 (ET-1) concentration is increased in patients with liver cirrhosis and it correlates with the severity of liver disease and the degree of ascites [1]. ET-1 may have a role in modulating intrahepatic resistance in cirrhotic portal hypertension. The endothelial cells in the splenic sinuses and potentially also B lymphocytes residing in the spleen, appear to be an important source of ET-1 in cirrhotic patients [27].

The counterpart of vasoconstrictory and antinatriuretic substances are atrial and brain natriuretic peptides (ANP and BNP), vasodilating peptides, NO, and the vasodilating prostaglandins. The precise significance of these substances in patients with liver cirrhosis is currently under intensive investigation.

The serum concentrations of *cardiac* and *brain natriuretic peptides* (ANP and BNP) in some patients with cirrhosis is increased [28]. These peptides are natriuretic by increasing the glomerular filtration rate, increasing the amount of sodium filtered, and by inhibiting sodium resorption in the collecting tubules. Furthermore, they inhibit the RAA-system and possibly also vasopressin and sympathetic activity, and they release vascular tension.

Their effects are attenuated in states of arterial underfilling. The causes of "ANP resistance" in liver cirrhosis are unclear. Downregulation of renal ANP and BNP receptors, secretion of biologically less active

natriuretic peptides, increased enzymatic degradation in the kidneys, and hyperaldosteronism are among the factors discussed [15, 31].

Nitric oxide is a short-lived intercellular messenger that is primarily synthesized by endothelial cells. Its actions are mediated by intracellular cyclic GMP. NO is a potent vasodilator and plays an important role in regulating vascular tone. In patients with liver cirrhosis an increased synthesis of NO and an increased plasmatic NO concentration already can be demonstrated in the preascitic, compensated stage [34]. NO concentration in portal venous blood is higher than in the peripheral venous circulation, which suggests increased NO synthesis in the splanchnic circulation [4]. Patients with liver cirrhosis and ascites show an increased endotoxin-induced release of NO as well as an increased activity of NO-synthase in polymorphonuclear granulocytes and monocytes [23]. From the data available it emerges that NO plays an important role in the pathogenesis of cirrhotic ascites, but a final assessment of its pathogenetic significance is not yet possible. NO could play a role in primary vasodilation (especially in the splanchnic area), in decreased vascular reactivity to vasoconstrictors such as angiotensin II, arginine-vasopressin and norepinephrine, and also be co-responsible for arterial hypotension in patients with advanced cirrhosis [26].

The plasma concentrations of *vasodilating peptides* such as glucagon, calcitonin gene-related peptide (CGRP), substance P and adrenomedullin are increased in patients with liver cirrhosis and ascites. These peptides could contribute to the hyperdynamic circulation of cirrhotic patients, either directly through their vessel relaxing effects or by inducing constitutive endothelial e-NO synthase [16]. *Adrenomedullin*, a potent endogenous vasodilating peptide of 52 amino acids, has been isolated from a human pheochromocytoma. Its circulating levels correlate with the hemodynamic and renal changes and with the activation of vasoconstrictor systems in patients with liver cirrhosis and ascites [10, 11, 18].

Prostaglandins normally do not regulate renal sodium handling. In patients with liver cirrhosis, however, vasodilating prostaglandins seem to assume an important role in sustaining renal blood flow and glomerular filtration. In decompensated liver cirrhosis prostaglandin synthesis is diminished with a consequent decrease in renal blood flow, glomerular filtration rate, sodium and free water excretion. Cyclooxygenase

inhibitors may cause an acute renal failure in patients with liver cirrhosis and ascites.

Theories of Ascites Formation

“Volume Deficiency” Hypothesis

According to this classic hypothesis, ascites is a result of increased hydrostatic pressure within the hepatic and splanchnic circulation, induced by portal hypertension. Impairment of the Starling-balance leads to the movement of fluid from the intravascular compartment to the interstitial space [22]. The accumulation of fluid is compensated initially by an increased lymphatic outflow via the thoracic duct into the systemic circulation. If, however, with increasing portal hypertension the lymphatic system is overburdened, fluid crosses into the peritoneal cavity, and the intravascular volume decreases [40, 41]. The decrease in intravascular volume results in hypovolemia (secondary underfilling) which activates neurohormonal regulatory mechanisms resulting in compensatory renal sodium retention. Since the retained fluid continuously flows into the peritoneal cavity a vicious circle develops with ongoing stimulation of Na^+ retaining mechanisms. However, this classic hypothesis is not able to explain the systemic hemodynamic changes observed in patients with liver cirrhosis, and nowadays is mainly of historical importance.

“Overflow” Hypothesis

This hypothesis assumes that the expansion of intravascular volume is the crucial event in the pathogenesis of ascites formation. Failure to escape from mineralocorticoid action in compensated cirrhosis is considered a major argument supporting the overflow theory of ascites. Portal hypertension combined with hypervolemia are then assumed to lead to an “overflow” of fluid into the peritoneal cavity.

Liver cirrhosis \rightarrow \uparrow renal Na^+ retention \rightarrow hypervolemia \rightarrow ascites

However, experimental and clinical data do not support this hypothesis. Failure to escape from mineralocorticoids

is uncommon in patients with compensated cirrhosis, is related to an inadequate expansion of effective plasma volume due to the accumulation of ascites, and occurs in patients with marked peripheral arteriolar vasodilation [25]. Thus, the arterial system is not “overfilled”, and increased renal sodium retention in the preascitic stage is due to vasodilation and does not lead to intravascular hypervolemia.

“Underfilling or Peripheral Arterial Vasodilation” Hypothesis

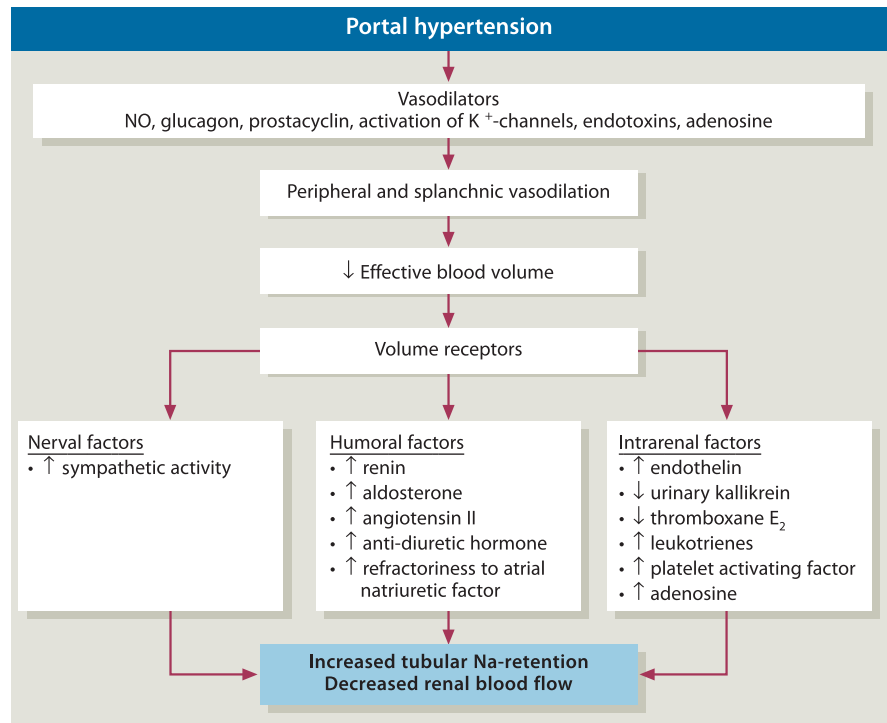
Primary arterial vasodilation with decreased effective arterial volume currently is considered to be the initiating and perpetuating event that results in increased renal sodium and water retention [38, 39]. The cause of peripheral and splanchnic vasodilation is not completely understood. Potential factors are an impaired clearance, porto-systemic shunts, or an increased synthesis of vasodilators such as NO, substance P, CGRP, glucagon, adrenomedullin and prostacyclin (see above). As a reaction to primary arterial vasodilation with decreased effective arterial volume, cardiovascular and renal receptors are activated that, via neurohormonal mechanisms, result in an increased retention of sodium and water. The compensatory increase (normalization) in plasma volume prevents the development of ascites. If these compensatory mechanisms succeed in normalizing effectively circulatory homeostasis, the activity of sodium retaining systems and renal sodium excretion normalize again—cirrhosis remains compensated. If, however, the compensatory systems are not sufficient to restore effective plasma volume, activation of sodium retaining systems persists and ongoing Na^+ retention results in ascites formation.

Liver cirrhosis \rightarrow peripheral arterial vasodilation \rightarrow \rightarrow ascites

The severity of liver disease is directly related directly to renal dysfunction, possibly induced by a biochemically or neurally mediated hepatorenal reflex [20, 24]. *The hepatorenal syndrome with systemic vasodilation and renal vasoconstriction is probably the most extreme manifestation of a disease state with reduced effective plasma volume* [14].

The theory of primary arterial vasodilation best unifies the numerous hemodynamic alterations observed

Fig. 54.1 Pathogenetic factors responsible for increased Na⁺ retention in liver cirrhosis



in patients with liver cirrhosis and ascites. The preferential accumulation of fluid within the abdominal cavity is explained by splanchnic vasodilation seen in portal hypertension. [Figure 54.1](#) summarizes our current pathophysiologic ideas of ascites formation according to the theory of peripheral arterial vasodilation.

Diagnosis

History will provide the first clues to the presence and possible etiology of liver disease. *Physical examination* is unreliable in diagnosing small amounts of ascites. Special attention should be paid to signs of chronic liver disease. Bulging flanks in the supine position, flank dullness to percussion, tympany at the top of the abdominal wall, shifting dullness when the patient turns to one side, and a fluid wave are sensitive (80%) but less specific (60%) signs of ascites. The most informative examination finding is dullness to percussion. However, dullness requires at least 1,000 mL of ascites (see Chapter 33).

Abdominal sonography is the imaging method of choice in demonstrating as little as 100 mL of ascites.

In addition, pleural and pericardial effusions may be demonstrated during the same examination. The sonographic evaluation of the liver, spleen and intraabdominal vessels will often provide an assessment of the cause of ascites as well as potential complications and the severity of portal hypertension. Ultrasound guided paracentesis allows for obtaining ascitic fluid for further laboratory examination [29]. Small amounts of ascites, especially in the retrogastric and periduodenal areas may also be visualized by *endosonography*, which, however, is rarely required in clinical practice. Since the presence of malignant ascites significantly alters patient management, especially in pancreaticobiliary malignancy, an active search for ascites and the use of *EUS-guided fine-needle aspiration* of ascites has been advocated to be included in the management of patients with known or suspected pancreaticobiliary malignancies [21].

Provided ultrasound images are technically satisfactory, cost-intensive techniques such as CT and MRI are usually not mandatory.

Paracentesis is the gold standard for the further evaluation of ascites by *biochemical*, *cytologic* and *bacteriologic* techniques. Ascites should be inspected macroscopically, be sent for a complete blood count with differential, albumin, total protein, and cholesterol

levels, and cultures (10–20 mL of ascitic fluid should be inoculated into two [aerobic and anaerobic] blood culture bottles at the bedside).

The macroscopic appearance of ascitic fluid often allows for a rough etiologic diagnosis (Table 54.3). A clear serous ascites usually has a portal hypertensive or cardiac etiology. In hemorrhagic ascites one should suspect malignancy. A cloudy fluid points towards infection.

Simple parameters such as the *serum-ascites-albumin gradient* (SAAG; serum albumin minus ascitic albumin concentration), the ascitic fluid to serum bilirubin concentration ratio, the protein and cholesterol levels and the number of leukocytes and differential are useful in determining the cause of ascites. They allow for classifying ascites into a transudate or an exudate and give hints to a possible malignant etiology or to a bacterial peritonitis (Tables 54.5–54.8) [9, 29, 30, 35].

Table 54.5 Causes of ascites based on serum-ascites albumin gradient

High gradient (≥ 1.1 g/dL)	Low gradient (< 1.1 g/dL)
<ul style="list-style-type: none"> • Cirrhosis • Alcoholic hepatitis • Cardiac failure • Massive liver metastases • Fulminant hepatic failure • Budd-Chiari syndrome • Venocclusive disease • Portal vein thrombosis • Fatty liver of pregnancy • Myxedema 	<ul style="list-style-type: none"> • Peritoneal carcinomatosis • Tuberculous peritonitis • Pancreatic ascites • Biliary ascites • Nephrotic syndrome • Serositis • Bowel infarction

Source: Adapted from [30]

A SAAG greater than 1.1 g/dL is 97% accurate in the diagnosis of portal hypertension (Table 54.5) [29]. Examining the total ascitic protein can help differentiate high-SAAG ascites as being more likely to be of cirrhotic (low protein) or cardiac (high protein) in origin. The *ascitic fluid to serum bilirubin concentration ratio* has been suggested to contribute to the differentiation between an exudate and a transudate, a ratio of > 0.6 being significantly associated with the presence of an exudate [9].

Increased ascitic amylase levels are found in pancreatic ascites with levels greater than 20,000 U/L suggesting a ruptured pancreatic duct or a leaking pseudocyst, while lower levels are seen in acute pancreatitis. Elevated levels of carcinoembryonic antigen favor a malignant cause.

Table 54.7 Diagnostic value of ascitic fluid parameters in differentiating benign from malignant ascites

Cut off	Total Protein 3 g/100 mL	Cholesterol 45 mg/100 mL	Cytology
Sensitivity	64%	83%	53% ^a
Specificity	77%	81%	100%
Positive Predictive Value	60%	70%	100%
Negative Predictive Value	77%	90%	73%

^aCytologic analysis is 96% sensitive for detecting peritoneal carcinomatosis if three samples are examined by an experienced examiner

Source: Adapted from [17]

Table 54.6 Biochemical findings in different forms of ascites

Ascitic Fluid	Portal Ascites	Malignant Ascites	Infectious Ascites
Protein (g%)	< 3 (Transudate)	> 3 (Exudate)	> 3 (Exudate)
Serum Albumin (g/dL)	> 1.1	< 1.1	< 1.1
Ascitic Albumin (g/dL)			
Leukocytes/mm ³	< 500	> 500	> 1,000 (> 250/500 Neutrophils)
Serum LDH:	< 1.4	> 1.4	> 1.4
Ascitic LDH			
pH	> 7.45	< 7.45	< 7.31
Lactate (mmol/L)		< 4.5	> 4.5
Cholesterol (mg/dL)		> 48	
Serum Glucose:		< 1	> 1
Ascites Glucose			
Tumor Markers	–	+	–
Bacterial Culture	–	–	+ ^a
Cytology	–	+	–

^aAscitic mycobacterial cultures are 50% sensitive.

Chylous ascites has a milky or creamy appearance due to lymph in the abdominal cavity. Its triglyceride concentration exceeds that of plasma. The underlying mechanisms for the formation of chylous ascites are related to disruption of the lymphatic system. Traumatic injury or obstruction by tumors, especially malignant lymphomas are the most frequent causes (Table 54.4) [8]. Chylous ascites is seen in 0.5–1% of patients with liver cirrhosis.

Three basic mechanisms for the formation of chylous ascites have been proposed [7]. (1) Leakage from the dilated subserosal lymphatics into the peritoneal cavity, (2) exudation of lymph through the walls of massively dilated retroperitoneal lymphatics, which leak fluid through a fistula into the peritoneal cavity (i.e. congenital lymphangiectasia), and (3) thoracic duct obstruction from trauma or tumor with resulting dilated retroperitoneal lymphatic vessels with consequent direct leakage of chyle through a lymphoperitoneal fistula.

In liver cirrhosis chylous ascites may develop as a result of increased hydrostatic pressure within the splanchnic lymphatics, with their consequent disruption.

Differential Diagnosis

Four initial questions are especially important in the differential diagnosis of ascites, since the answers will impact treatment and prognosis.

- What is the underlying cause?
- What is the SAAG (i.e., is it a transudate or an exudate) and the total ascitic protein content?
- Is ascites malignant?
- Is ascites infected?

The history and physical findings already yield important etiologic clues. Spider nevi, splenomegaly, dilated and prominent abdominal wall veins point toward liver cirrhosis. Congested neck veins, systolic pulsations of jugular veins or of the liver may be observed in congestive right heart failure. Pulsus paradoxus and a positive Kussmaul sign suggest a constrictive pericarditis. Visible veins on the patient's back suggest obstruction of the inferior vena cava, while palpable abdominal masses, an immobile mass at the umbilicus (Sister Mary Joseph nodule) or a coarse and nodular liver surface are highly suggestive of peritoneal carcinomatosis and metastatic liver disease.

In Western countries liver cirrhosis is the most frequent cause of ascites. (see Table 54.1). The differential diagnosis must consider the various etiologies of liver cirrhosis (see Chapter 79). Complications of long-standing cirrhosis such as hepatocellular carcinoma or portal vein thrombosis should be searched for specifically by ultrasound, CT or MRI.

The differentiation between a transudate and an exudate is important, since portal hypertensive ascites usually is a transudate, while malignant ascites is usually an exudate. Measuring total protein content in ascites is the most widely used initial biochemical method in differentiating between a transudate and an exudate (Table 54.6), as well as for further differentiating ascites with a SAAG greater than 1.1 g/dL. The ascitic fluid to serum bilirubin concentration may also help in this differentiation (see above) [9].

The cytologic examination of ascitic fluid is of prime importance in differentiating between a benign and malignant ascites. The sensitivity of cytology varies between 40% and 70%. The specificity and the positive predictive value reach nearly 100% by experienced examiners, if at least three specimens are examined (Table 54.7). In addition, elevated levels of lactic dehydrogenase, tumor markers such as carcinoembryonic antigen, fibronectin and cholesterol in ascites also suggest a malignant cause. Notably the latter two are of great differential diagnostic value, with cholesterol concentrations > 45–48 mg/dL strongly favoring a malignant cause of ascites [35]. Increased peritoneal permeability with increased diffusion of cholesterol from plasma to ascites in peritoneal carcinomatosis is thought to underlie this finding.

Ascites infection may occur either as spontaneous bacterial peritonitis (SBP) which may be acquired in or outside the hospital, or be due to secondary bacterial peritonitis, for example following paracentesis or intestinal perforation. SBP is ten times more frequent than secondary peritonitis and is seen in 10–20% of patients with liver cirrhosis (see Chapter 80). While SBP usually is monomicrobial, secondary bacterial peritonitis is nearly always polymicrobial, with Gram negative bacteria predominating in two thirds of cases. Because of the high mortality rate (up to 50% in SBP and 80% in the secondary forms), early diagnosis and treatment are of crucial importance. A high index of suspicion is necessary, since in approximately one third of patients with SBP fever, abdominal pain, guarding, or diminished bowel sounds are absent. The diagnosis is made by bacteriologic examination of

Table 54.8 Classification of infected ascites

Category	Analysis of Ascites
Spontaneous Bacterial Peritonitis	PMN \geq 250/mm ³ , one pathogen
Culture-negative Neutrocytic Ascites	PMN \geq 250/mm ³ , negative culture
Secondary Bacterial Peritonitis	PMN \geq 250/mm ³ , usually several pathogens
Monomicrobial Bacterascites	PMN $<$ 250/mm ³ , one pathogen
Polymicrobial Bacterascites	PMN $<$ 250/mm ³ , several pathogens

PMN polymorphonuclear granulocytes

Source: Adapted from [30]

ascites and by determining the number of granulocytes in ascites (Table 54.8). In order to ensure a high diagnostic accuracy (80–90%) freshly obtained ascitic fluid must be inoculated immediately at the bedside in appropriate aerobic and anaerobic culture bottles. An infected ascites nearly always contains $>$ 250/mm³ polymorphonuclear leukocytes (PMN), and usually more than 500/mm³ white blood cells. In the case of a “bloody tap,” 1 PMN should be subtracted for every 250 red blood cells.

Rare causes of an infected ascites are tuberculous peritonitis and peritoneal chlamydial infection. Tbc-peritonitis is found particularly in HIV infected patients with advanced immunodeficiency and in alcoholics with liver cirrhosis. Ascites cultures in peritoneal tuberculosis yield variable results and are positive in 20–80% of cases. In addition to ascitic mycobacterial culture, PCR should also be performed. Laparoscopy with biopsy is the best test to diagnose peritoneal tuberculosis. Chlamydial infection must be included in the differential diagnosis in sexually active, young women who present with fever and an infected ascites. Currently *Fitz-Hugh-Curtis syndrome* is caused more often by chlamydiae than by gonococci.

Complications

Complications of ascites are predominantly SBP, the hepatorenal syndrome, and hepatic hydrothorax (see Chapter 80). In longstanding cirrhosis the risk of hepatocellular carcinoma should be kept in mind. Disease exacerbation by a superimposed acute alcoholic hepatitis should be taken into account in patients with

alcoholic cirrhosis. The development of tense ascites that does not respond to sole diuretic therapy also indicates a complicated course.

Therapy

The management of ascites is discussed in detail in Chapter 80.

Prognosis

The diagnostic evaluation of a patient with liver cirrhosis and ascites includes the assessment of liver function, description of liver morphology, analysis of ascitic fluid, and the appraisal of hemodynamic parameters, endogenous vasoactive systems, and renal function. The prognosis of a patient with ascites depends on the results of these examinations, on the cause of ascites, and on the presence or absence of complications.

The development of ascites in a patient with liver cirrhosis is the expression of an advanced disease stage. Thus, *ascites itself is an adverse prognostic sign*. The one and five year survival probability after the first ascites episode is approximately 50% and 20%, respectively. A rise of serum creatinine concentration to $>$ 1.5 mg% in a patient with liver cirrhosis and ascites is associated with mortality rates of up to 80% within 6–12 months. Therefore, whenever the level of serum creatinine rises in a cirrhotic patient with ascites the need for a liver transplant should be discussed prior to the development of hepatorenal syndrome [2, 3].

The efficiency of diuretic therapy may be estimated in advance by determining urinary sodium excretion, glomerular filtration rate, serum creatinine, urea nitrogen and the degree of activation of the renin-angiotensin-aldosterone system. In order to avoid false results the patient should be placed on a Na⁺-poor diet (50–60 mEq/day) and should not take any drugs that may affect renal function (e.g. diuretics, nonsteroidal antiinflammatory drugs, β -adrenergic blocking agents, arterial vasodilators) before determining these parameters. Depending on the probability of whether the ascites will respond to sole diuretic therapy, it may be classified as *simple* or *problematic (tense)*. The features of simple and problematic ascites are summarized in Table 54.9.

Table 54.9 Differentiation between simple and problematic ascites

	Simple ascites ^a	Problematic ascites ^a
Magnitude	Moderate	Marked (tense ascites)
Encephalopathy	–	+
Na⁺ in 24-h urine	>20 mmol	<10 mmol
Na⁺ in serum	>130 mmol/L	<130 mmol/L
K⁺ in serum	3.6–4.9 mmol/L	<3.5 or >5 mmol/L
Creatinine in serum	<1.5 mg%	>1.5 mg%
Albumin in serum	>3.5 g/dL	<3.5 g/dL

^a*Simple ascites*: diuretic therapy will probably be successful. *Problematic ascites*: sole diuretic therapy will probably be not successful.

The term *refractory ascites* encompasses two conditions

- Ascites resistant to diuretics, and
- Ascites intractable with diuretics

An ascites is termed *diuretic resistant* if it cannot be mobilized despite dietetic sodium restriction (50 mEq/day) and intensive diuretic therapy (e.g. spironolactone 400 mg/day and furosemide 160 mg/day) for at least 1 week or if, despite intensive therapy, it recidivates early.

An ascites *intractable with diuretics* is present when complications associated with diuretic treatment such as diuretic-induced hepatic encephalopathy, renal insufficiency, hyponatremia, and hypo- or hyperkalemia preclude the administration of effective doses of diuretics.

A valid prognostication of the survival time in patients with cirrhotic ascites is extremely difficult. The usual laboratory parameters such as aminotransferases, coagulation parameters, serum albumin levels or quantitative tests of liver function are weak predictors of prognosis. Parameters that include kidney function such as the MELD score (see Chapter 30), and alterations in systemic hemodynamics are better suited for estimating prognosis.

Parameters of a poor prognosis in patients with still normal urea nitrogen and serum creatinine levels are

- Impaired ability of free water excretion (water diuresis after a water load)¹

¹5% glucose i.v. 20 mL/kg body weight within 45 min. Fifteen minutes after the end of infusion urine volume is determined over 90 min. Urine volume: > 8 mL/min = normal water diuresis, 3–8 mL/min = moderate restriction of water diuresis, <3 mL/min = marked restriction of water diuresis

- Dilutional hyponatremia
- Marked Na⁺ retention (diminished Na⁺ excretion)
- Decrease in glomerular filtration rate
- Increased plasma renin activity
- Increased plasma concentration of norepinephrine, and
- Arterial hypotension

References

1. Alam I, Bass NM, Bacchetti P, et al (2000) Hepatic tissue endothelin-1 levels in chronic liver disease correlate with disease severity and ascites. *Am J Gastroenterol* 95: 199–203
2. Arroyo V, Ginès P, Planas R, et al (1986) Management of patients with cirrhosis and ascites. *Semin Liv Dis* 6: 353–69
3. Arroyo V, Ginès P, Navasa M, et al (1993) Renal failure in cirrhosis and liver transplantation. *Transplantation Proc* 25: 1734–9
4. Battista S, Bar F, Mengozzi G, et al (1997) Hyperdynamic circulation in patients with cirrhosis: direct measurement of nitric oxide levels in hepatic and portal veins. *J Hepatol* 26: 75–80
5. Bichet DG, van Putten VJ, Schrier RW (1982) Potential role of increased sympathetic activity in impaired sodium and water excretion in cirrhosis. *N Engl J Med* 307: 1552–7
6. Bichet D, Szatalowicz VL, Chaimovitz C, et al (1982) Role of vasopressin in abnormal water excretion in cirrhotic patients. *Ann Int Med* 96: 413–7
7. Browse N, Wilson N, Russo F, et al (1992) Aetiology and treatment of chylous ascites. *Br J Surg* 79: 1145–50
8. Cárdenas A, Chopra S (2002) Chylous ascites. *Amer J Gastroenterol* 97: 1896–90
9. Elis A, Meisel S, Tishler T, et al (1998) Ascitic fluid to serum bilirubin concentration ratio for the classification of transudates or exudates. *Am J Gastroenterol* 93: 401–3
10. Fabrega E, Casafont F, Crespo J, et al (1997) Plasma adrenomedullin levels in patients with hepatic cirrhosis. *Am J Gastroenterol* 92: 1901–4
11. Fernandez-Rodriguez CM, Prada IR, Prieto J, et al (1998) Circulating adrenomedullin in cirrhosis: relationship to hyperdynamic circulation. *J Hepatol* 98: 250–6
12. Floras JS, Legault L, Morali GA, et al (1991) Increased sympathetic outflow in cirrhosis and ascites: direct evidence from intraneural recordings. *Ann Int Med* 114: 373–80
13. Frey FJ (2006) Impaired 11 β -hydroxysteroid dehydrogenase contributes to renal sodium avidity in cirrhosis: hypothesis or fact? *Hepatology* 44: 795–801
14. Ginès A, Escorsell A, Ginès P, et al (1993) Incidence, predictive factors, and prognosis of the hepatorenal syndrome in cirrhosis with ascites. *Gastroenterology* 105: 229–36
15. Ginès P, Jimenez W, Arroyo V, et al (1998) Atrial natriuretic factor in cirrhosis with ascites: plasma levels, cardiac release and splanchnic extraction. *Hepatology* 28: 636–42
16. Groszmann RJ (1994) Hyperdynamic circulation of liver disease 40 years later: pathophysiology and clinical consequences. *Hepatology* 20: 1359–63

17. Gülberg V, Gerbes AL (1998) Diagnostik und Therapie des Aszites bei Leberzirrhose. *Internist* 39: 254–62
18. Guevara M, Ginès P, Jimenez W, et al (1998) Increased adrenomedullin levels in cirrhosis: relationship with hemodynamic abnormalities and vasoconstrictor systems. *Gastroenterology* 114: 336–43
19. Jaffe DL, Chung RT, Friedman LS (1996) Management of portal hypertension and its complications. *Med Clin N Am* 80: 1021–34
20. Jalan R, Forrest EH, Redhead DN, et al (1997) Reduction in renal blood flow with acute increase in portal pressure gradient: evidence for the existence of hepatorenal reflex in man. *Gut* 40: 664–70
21. Kaushik N, Khalid A, Brody D, et al (2006) EUS-guided paracentesis for the diagnosis of malignant ascites. *Gastrointest Endosc* 64: 908–13
22. Korthuis RJ, Kinden DA, Brimer GE, et al (1988) Intestinal capillary filtration in acute and chronic portal hypertension. *Am J Physiol* 254: G339–45
23. Laffi G, Foschi M, Masini E, et al (1995) Increased production of nitric oxide by neutrophils and monocytes from cirrhotic patients with ascites and hyperdynamic circulation. *Hepatology* 22: 1666–73
24. Lang F, Tschernko E, Schulze E, et al (1991) Hepatorenal reflex regulating kidney function. *Hepatology* 14: 590–4
25. La Villa G, Salmeron JM, Arroyo V, et al (1992) Mineralocorticoid escape in patients with compensated cirrhosis and portal hypertension. *Gastroenterology* 102: 2114–9
26. Martin PY, Gines P, Schrier RW (1998) Nitric oxide as a mediator of hemodynamic abnormalities and sodium and water retention in cirrhosis. *N Engl J Med* 339: 533–41
27. Nagasue N, Dhar DK, Yamanoi A, et al (2000) Production and release of endothelin-1 from the gut and spleen in portal hypertension due to cirrhosis. *Hepatology* 31: 1107–14
28. Panos MZ, Anderson JV, Payne N, et al (1992) Plasma atrial natriuretic peptide and renin aldosterone in patients with cirrhosis and ascites: basal levels, changes during daily activity and nocturnal diuresis. *Hepatology* 16: 82–8
29. Runyon BA (1986) Paracentesis of ascitic fluid: a safe procedure. *Arch Intern Med* 146: 2259–61
30. Runyon BA (1999) Approach to the patient with ascites. In: Yamada T (ed) *Textbook of gastroenterology*, 3rd edon. Lippincott Williams & Wilkins, Philadelphia/New York/Baltimore, pp 966–91
31. Salerno F, Badalamenti S, Incerti P, et al (1988) Renal response to atrial natriuretic peptide in patients with advanced liver cirrhosis. *Hepatology* 8: 21–6
32. Salerno F, DelBo A, Maggi A, et al (1994) Vasopressin release and water metabolism in patients with cirrhosis. *J Hepatol* 21: 822–30
33. Sansoé G, Ferrari A, Baraldi E, et al (1999) Renal distal tubular handling of sodium in central fluid volume homeostasis in preascitic cirrhosis. *Gut* 45: 750–5
34. Sansoé G, Silvano S, Mengozzi G, et al (2002) Systemic nitric oxide production and renal function in nonazotemic human cirrhosis: a reappraisal. *Am J Gastroenterol* 97: 2383–90
35. Schölmerich J, Gerok W (1995) Aszites. In: Gerok W, Blum HE (eds) *Hepatologie*, Urban & Schwarzenberg, München-Wien-Baltimore, pp S. 288–302
36. Schrier RW (1988) Pathogenesis of sodium and water retention in high-output and low-output cardiac failure, nephrotic syndrome, cirrhosis, and pregnancy. *N Engl J Med* 319: 1065–72
37. Schrier RW (1988) Pathogenesis of sodium and water retention in high-output and low-output cardiac failure, nephrotic syndrome, cirrhosis, and pregnancy. *N Engl J Med* 319: 1127–34
38. Schrier RW, Arroyo V, Bernardi M, et al (1988) Peripheral arterial vasodilation hypothesis: a proposal for the initiation of renal sodium and water retention in cirrhosis. *Hepatology* 8: 1151–7
39. Schrier RW (1990) Body fluid volume regulation in health and disease: a unifying hypothesis. *Ann Intern Med* 113: 155–9
40. Witte MH, Witte CL, Dumont AE (1971) Progress in liver disease: physiological factors involved in the causation of cirrhotic ascites. *Gastroenterology* 61: 742–50
41. Witte CL, Witte MH, Dumont AE (1980) Lymph imbalance in the genesis and perpetuation of the ascites syndrome in hepatic cirrhosis. *Gastroenterology* 78: 1059–68

Index

A

- AA-amyloid, 1106–1107
- ABC transporters, 65
- Abdomen, auscultation, 312
- Abdominal pain, 531–536
- Abetalipoproteinemia, 1184
- Abscesses, 390–391
 - amebic, 418, 420
 - bacterial, 417–418
 - hepatic, 831
 - pylephlebitic, 832
- Absorption, 1190
- Absorptive phase, 81, 134
- Acalculous cholecystitis, 869
- Acanthocytosis, 1028
- Accelerated starvation, 1197
- Accessory liver lobe(s), 621
- Aceruloplasminemia, 93, 1046
- Acetaldehyde dehydrogenase
 - acetaldehyde, 1128
 - hepatic, 1119
- Acetaldehyde-protein adducts, 1129
- Acetaminophen, 932, 1228
- Acetaminophen intoxication, 934
- Acetic acid injection, 1363
- Acetylation, 128
- Acetyl-CoA carboxylase, 87
- Acidophilic necrosis, 210
- Acinus, complex, 18
- Acrodermatitis papulosa, 314, 747
- ACTH, 160
- Actin
 - filamentous, 32
 - filaments, 19
 - globular, 32
- Actinomycetaceae, 835
- Actinomycosis, 835
- Active septa, 258
- Activity index, histological, 729–730
- Acute alcoholic hepatitis, 1388
- Acute cholecystitis, 393
 - pathogenetic mechanisms, 1472
- Acute fatty liver of pregnancy
 - course, 1265
 - definition, 1263
 - diagnosis, 1264
 - differential diagnosis, 1264–1265
 - epidemiology, 1263
 - etiology, 1263–1264
 - pathogenesis, 1263–1264
 - pathology, 1264
 - prognosis, 1265
 - therapy, 1265
- Acute hepatic congestion, 641
- Acute hepatic porphyrias, 1088
- Acute hepatitis, 1387–1388
- Acute hepatitis C, therapy, 801
- Acute intermittent porphyria, 1078, 1080
- Acute leukemia, 1249
- Acute liver failure (ALF), 1388
 - acetaminophen intoxication, 934
 - acid-base balance, 942
 - acute fatty liver, 937
 - acute tubular necrosis, 941
 - APACHE-II-score, 933
 - autoimmune hepatitis, 937
 - Budd-Chiari syndrome, 937
 - cardiovascular system, 941
 - causes, 932
 - coagulation disorders, 942
 - definition, 931
 - drug-induced liver injury (DILI), 935
 - epidemiology, 931
 - etiology, 931–932
 - general considerations, 933
 - hemodynamics, 941
 - hepatocyte transplantation, 944
 - hepatorenal syndrome, 941
 - hyperdynamic circulation, 941
 - infections, 940–941
 - liver replacement, 943
 - liver transplantation, 943–944
 - metabolic disorders, 942
 - model for endstage liver disease (MELD) score, 933
 - multi-organ-failure (MOF), 941
 - mushroom poisoning, 934–935
 - N*-acetyl-cysteine, 934
 - nutrition, 942–943
 - pregnancy, 937
 - prognosis, 932–933
 - refractory shock, 941

- renal failure, 941–942
 - therapy, 937–944
 - viral hepatitis, 935–936
 - Wilson's disease, 936–937
- Acute phase proteins
- negative, 150
 - positive, 150
- Acute phase reaction, 150–151
- Acute porphyrias, 1079–1080, 1084–1087, 1089–1090
- differential diagnosis, 1087
 - therapy, 1089
- Acute rejection, 284
- BANFF grading, 285
- Acute variceal hemorrhage
- antibiotic prophylaxis, 983
 - balloon tamponade, 983–984
 - band ligation, 983
 - octreotide, 983
 - recombinant coagulation factor VIIa (rFVIIa), 983
 - sclerotherapy, 983
 - somatostatin, 983
 - terlipressin, 982
 - therapy, 982–984
 - vasopressin, 982
- Adaptation, cellular, 219–233
- Adaptins, 73
- Adefovir, 778
- Adefovir dipivoxil, 708–709, 770–772
- resistance, 779
 - results of treatment, 771–772
- Adenomas, 458
- ampullary, 1516
 - bile duct, 1288–1289
 - hepatocellular, 379, 382–384, 408–412, 430, 556, 1276–1279
 - telangiectatic, 1277
- Adenomatosis, 1508, 1511
- miliary hepatocellular, 1280
- Adenosine, 57, 58
- Adenoviruses, 827
- Adhesion molecules, 33
- Adiponectin, 1159–1160
- Adrenal cortical hormones, 160
- Adrenoleucodystrophy, neonatal, 1185
- Adrenomedullin, 607
- Advanced glycosylation end products (AGE), 154
- African iron overload, 1046
- Aggrecan, 45
- AIDS-cholangiopathy, 846
- Alagille's syndrome, 309, 629, 1093–1094
- AL-amyloid, 1106
- Alanine aminotransferase, 320, 541
- Alanine cycle, 81
- Albinterferon, 802
- Albumin, 226, 327–328
- Albumin dialysis, extracorporeal, 1015
- Alcohol, 1190
- absorption, 1114
 - annual consumption, 1113
 - associated diseases, 1113
 - drug metabolism, 1119
 - gastric first pass metabolism, 1114–1116
- Alcohol dehydrogenases, 1115–1117
- Alcoholic cirrhosis, 1120
- acetaldehyde, 1144
 - chicken wire fibrosis, 1144
 - clinical findings, 1144–1145
 - definition, 1142
 - differential diagnosis, 1145
 - epidemiology, 1142
 - histopathology, 1144
 - natural course, 1145
 - pathogenesis, 1142–1144
 - prognosis, 1145
 - survival rates, 1145
 - therapy, 1145–1146
 - transient elastography, 1145
- Alcoholic fatty liver, 1120
- alcohol oxidation, 1122
 - complications, 1125–1126
 - definition, 1121–1122
 - diagnosis, 1122
 - differential diagnosis, 1125
 - epidemiology, 1122
 - histopathology, 1123–1124
 - overweight, 1122
 - pathogenesis, 1122–1123
 - prognosis, 1126
 - sterol regulatory element binding protein, 1123
 - therapy, 1126
- Alcoholic foamy degeneration, 224
- Alcoholic hepatitis, 238, 544
- Alcoholic hepatitis index, 1137
- Alcoholic hepatocellular cancer, 1120
- Alcoholic liver disease, 1111–1148, 1358–1359
- epidemiology, 1120
 - guidelines, 1140
 - hepatocarcinogenesis, 1147
 - laboratory parameters, 1136
 - natural course, 1120
 - nutritional status, 1121
 - nutritional therapy, 1140
 - pathogenesis, 1130
 - retinoids, 1121
 - risk factors, 1120–1121
- Alcoholic steatohepatitis, 364, 1120
- abstinence, 1138–1139
 - antioxidants, 1140
 - clinical findings, 1135–1136
 - complications, 1137
 - CYP2E1, 1132
 - cytokines, 1131
 - definition, 1127
 - differential diagnosis, 1136–1137
 - drugs, 1140–1141
 - endotoxin, 1131
 - enteral nutrition, 1139
 - extracorporeal liver support, 1141
 - free fatty acids, 1132
 - giant mitochondria, 1135
 - glucocorticosteroids, 1140–1141
 - histomorphology, 1127
 - histopathology, 1134–1135
 - imaging, 1136

- laboratory findings, 1136
- liver transplantation, 1141–1142
- Mallory-Denk bodies, 1134
- malnutrition, 1139
- natural course, 1137–1138
- nutritional therapy, 1139–1140
- parenteral nutrition, 1139–1140
- pathophysiology, 1127–1134
- pentoxifylline, 1141
- perivenular sclerosis, 1135
- prognosis, 1137–1138
- proteasome inhibitors, 1134
- therapy, 1138–1142
- TNF α antibodies, 1141
- tumor necrosis factor α , 1131
- ubiquitin-proteasome pathway, 1134
- Alcohol metabolism, hepatic, 1116–1119
- ALD/NAFLD index, 1137
- Aldosterone, 606
- Alkaline phosphatase, 324–325, 540, 546, 547
- Alligator bile syndrome, 1185
- Allograft rejection
 - acute, 284
 - chronic, 284
- Alpers–Huttenlocher’s syndrome, 1186
- Amanita phalloides, 180, 934, 935
 - antidotes, 935
 - therapy, 935
- α -Amanitine, 1229
- Amantadine, 714, 802
- Amatoxins, 934
- Amebiasis
 - course, 845
 - definition, 843
 - diagnosis, 844
 - differential diagnosis, 845
 - epidemiology, 843–844
 - etiology, 844
 - pathogenesis, 844
 - pathology, 844
 - prognosis, 845
 - therapy, 845–846
- Amiloride, 971
- Amino acids, 82–83
 - glucogenic, 79, 83
 - imbalance, 1009–1010
 - ketogenic, 83
- Aminopyrine breath test
 - assessment, 342
 - confounding factors, 341
 - principle and technique, 341
 - side effects, 341–342
- Aminotransferase levels
 - extrahepatic causes of, 545
 - unexplained elevations, 548
- Aminotransferases, 320–322, 540, 542
 - normal values, 538
 - synopsis, 322
- Amiodarone, 225
- Ammonia, 84, 329
- Ammonia metabolism, 1008
- Ammonium, detoxification of, 134–135
- Amoxicillin-clavulanate, 932
- Ampulla of Vater
 - benign tumors, 1514–1517
 - malignant tumors, 1554–1556
- Ampullary adenomas, 1514
- Ampullary carcinomas, 459–460
 - TNM, 1528
 - UICC-classification, 1528
- Ampullectomy, 1516
- Amyloid, 654
 - globular, 226
- Amyloidoses, localized, 1106
- Amyloidosis, 1251
 - classification, 1106
 - definition, 1105–1106
 - familial, 1106
 - hepatic, 1107–1108
 - primary, 1106
 - secondary, 1106
- Amyloid P component, 1105
- Amylopectinosis, 225, 1182
- Anabolic androgenic steroids, 1249
- Anastomoses
 - arterio-portal, 21, 56
- Anatomy
 - descriptive, 11–13
 - functional, 13–14
 - microscopic, 15–47
- Andersen’s disease, 225, 1182
- Androgenic steroids, 580
- Anemia, 796
 - aplastic, 796, 1028
 - dilutional, 1028
 - hemolytic, 803, 1028
 - megaloblastic, 1028
 - sideroblastic, 1028
- Angina, intestinal, 535
- Angiogenesis, 160
- Angiokeratoma corporis diffusum, 1183
- Angiolipoma, 1298
- Angiomyolipoma
 - definition, 1298
 - diagnosis, 1300
 - epidemiology, 1298
 - pathology, 1298–1299
 - therapy, 1300
- Angiomyomyelolipoma, 1298
- Angiosarcomas, 204
 - anabolic steroids, 1340
 - arsenic, 1340
 - copper, 1340
 - course, 1341
 - definition, 1340
 - diagnosis, 1341
 - differential diagnosis, 1341
 - epidemiology, 1340
 - etiology, 1340
 - Fowler’s solution, 1340
 - hereditary hemochromatosis, 1340
 - pathogenesis, 1340
 - pathology, 1340–1341
 - polyvinyl chloride, 1340

- prognosis, 1341
- therapy, 1342
- thorium dioxide, 1340
- thorotrast, 1340
- vinyl chloride, 1340
- von Recklinghausen's disease, 1340
- Angiotensin converting enzyme, 1240
- Angiotensin II, 596, 606
- Antimitochondrial antibodies
 - immunofluorescence reactivities, 350
 - occurrence and significance, 350–351
 - target antigens, 350
- Anomalies, vascular, 637
- Anorectal varices, 976
- Anorexia, 306
- Anorexia nervosa, 1251
- Anthracotic pigment, 230
- Antibiotics, nonabsorbable, 1014
- Antibodies
 - antimitochondrial, 899
 - antinuclear, 900
- Antibodies, against asialoglycoprotein-receptor
 - detection systems, 353
 - occurrence and significance, 353
 - target antigens, 353
- Antibodies, against liver cytosol type 1
 - immunofluorescence reactivities, 352–353
 - occurrence and significance, 353
 - target antigens, 352
- Antibodies, against liver-kidney-microsomes
 - immunofluorescence reactivities, 351
 - occurrence and significance, 351–352
 - target antigens, 351
- Antibodies, against soluble liver antigen/liver-pancreas antigen
 - occurrence and significance, 352
 - target antigens, 352
- Antidepressants, 581, 1230
- Antigen presenting cells, 145
- Antihistamines, 580
- Antineutrophil cytoplasmic antibodies
 - immunofluorescence reactivities, 354
 - occurrence and significance, 354
 - target antigens, 353–354
- Antinuclear antibodies, 900
 - immunofluorescence reactivities, 347
 - occurrence and significance, 347–349
 - target antigens, 347
- Antioxidants, 178–180
- Antiphospholipid antibody syndrome, 1250
- Antiports, 64
- Antipyrine clearance
 - assessment, 341
 - confounding factors, 340
 - principle and technique, 340
 - side effects, 341
- Antisense-oligodeoxynucleotides, 716–717
- Antisense-oligonucleotides, 710–711, 1406
- α_1 -Antitrypsin, 226, 1071
 - structure, 1072
- α_1 -Antitrypsin deficiency, 544, 1071–1076
 - clinical manifestations, 1073–1075
 - course, 1075
 - definition, 1072
 - differential diagnosis, 1075
 - epidemiology, 1072
 - etiology, 1072–1073
 - immunohistochemical staining, 1073
 - intracytoplasmic inclusions, 1073
 - laboratory findings, 1075
 - neonatal cholestasis, 1074
 - pathogenesis, 1072–1073
 - pathology, 1073
 - prognosis, 1075
 - therapy, 1075–1076
- α_1 -Antitrypsin phenotypes, 1073
- Apical sodium bile acid transporter, 1425
- Aplastic anemia, 748, 796
- Apolipoproteins, 90
- Apoptosis, 209, 236
 - Fas-induced, 215
 - liver diseases, 217–218
 - molecular mechanisms, 214–217
 - morphology, 214
 - regulation, 217
- Apoptosome, 216
- Apoptotic bodies, 720, 728, 1163
- APRI index, 263
- Aquaporins, 70, 566
- Arachidonic acid, 85
- Arboviruses, 828
- Arenaviruses, 828–829
- Arginine-vasopressin, 606, 607
- Arias syndrome, 588
- Arsenic, 1340
- Arterial flow, 365
- Arterial underfilling, 606
- Arterial vascular malformations, 365
- Arteries
 - interlobar, 21
 - interlobular, 21
- Arteriohepatic dysplasia, 1093–1094
- Arterioles, terminal hepatic, 21
- Arteriopathy
 - plexogenic, 1021
 - rejection, 668
 - xanthomatous, 668
- Arterioportal fistula, 666
- Arterioportal shunts, 378
- Arteritis, 667–668
- Artery, hepatic. *See* Hepatic artery(ies)
- Ascites, 312, 470, 1395
 - abdominal sonography, 609
 - bed rest, 970
 - benign, 610
 - biochemical findings, 610
 - cardiac, 604
 - causes, 604
 - chylous, 604, 611
 - cirrhotic, 605
 - cloudy, 604
 - complications, 612, 969
 - definition, 603
 - diet, 970
 - different forms, 961

- differential diagnosis, 611–612
 - dilutional hyponatremia, 970
 - diuretic-intractable, 974
 - diuretic-resistant, 613, 974
 - diuretics, 970–971
 - errors in the treatment, 973
 - etiology, 603–604
 - fine-needle aspiration, 609
 - formation, 605
 - hemorrhagic, 604
 - history, 609
 - infected, 612
 - inflammatory, 604
 - large-volume paracentesis (LVP), 972–973
 - malignant, 604, 610
 - paracentesis, 609
 - pathogenesis, 604–605
 - portal hypertensive, 604
 - prognosis, 612–613
 - refractory, 613, 973–974
 - serous, 604
 - simple, 613
 - stepped care approach, 970
 - tense, 613
 - types, 969
 - uncomplicated, 969
- Ascites formation, theories, 608–609
- Ascitic fluid, cytologic examination, 611
- Asialoglycoprotein receptor, 82
- Aspartate aminotransferase, 320, 541
- Aspergillosis, 860
- Asterixis, 315–316, 1010
- Asteroid bodies, 1240
- Astrocyte
- function, 1007–1009
 - swelling, 1008
- Atazanavir, 1216
- Autoimmune regulator, 885
- Atresia, biliary, 628–630
- Atrial natriuretic peptides, 607
- Autoantibodies, 345–354, 883
- in liver diseases, 346
 - naturally occurring, 345–346
 - pathologic, 345–346
 - patterns, 349
- Autoimmune cholangitis, 909–910, 926
- Autoimmune hepatitis (AIH), 195, 237, 276–277, 364, 543, 925
- autoantibodies, 888
 - clinical presentation, 886–887
 - course and prognosis, 889
 - definition, 881
 - diagnosis, 883–884
 - differential diagnosis, 888–889
 - epidemiology, 881–882
 - etiology, 882
 - extrahepatic diseases, 887
 - genetic factors, 882–883
 - immunologic factors, 882
 - immunosuppressive therapy, 889
 - laboratory findings, 887–888
 - pathogenesis, 882
 - pathology, 883
 - relapses, 891
 - scoring system, 278, 885
 - standard treatment, 890
 - subtypes, 883, 886
 - therapy, 889–892
 - Type I, 884
 - Type II, 884–885
 - Type III, 886
 - treatment failure, 891
- Autoimmune overlap syndromes, 925–927
- Autoimmune pancreatitis, 1249
- Autoimmune polyglandular syndrome type I, 885
- Autoimmune reactions, 194–195
- Autoimmune thyroiditis, 748
- Autoregulation, 56–58
- Azathioprine, 1374
- ## B
- Babesiosis, 846
- Bacillary angiomatosis, 835
- Bacillary peliosis, 835
- Bacterial cholangitis
- antibiotics, 1498
 - prophylaxis, 1499
 - treatment, 1497
- Bacterial infections, 994–998
- Ballooning degeneration, 207
- Balloon occlusion technique, 517
- Balloon tamponade, 983–984
- BANFF grading, 285
- Banknote skin, 314
- Barcelona Clinic liver cancer staging classification, 1325
- Baroreceptors, high pressure, 606
- Bartonella (Rochalimaea) henselae, 650, 835
- Basiliximab, 1374
- Bassen–Kornzweig syndrome, 1184
- Bcl-2, 217
- Beau's lines, 315
- Benign bile duct tumors
- epithelial tumors, 1512
 - non-epithelial tumors, 1512
 - pathology, 1512
 - tumor-like Lesions, 1512
- Benign gallbladder tumors
- epithelial tumors, 1508
 - non-epithelial tumors, 1508
 - pathology, 1508–1509
 - tumor-like lesions, 1508
- Benign recurrent intrahepatic cholestasis, 1097–1098
- Benign tumors of ampulla, pathology, 1514–1515
- Betaglycan, 45
- Biglycan, 45
- Big spleen syndrome, 847
- Bile
- bacteria, 1495–1496
 - canalicular, 562, 565
 - composition, 103
 - ductal, 562, 565
 - formation, 104
 - functions, 104
 - hepatic, 562

- lithogenic, 119–122
- metabolism, 103
- secretion, 567
- Bile acids, 104, 107–108, 327, 547, 1258, 1423, 1476
 - enterohepatic circulation, 116–117
 - extraction, 135–136
 - genetic disturbances, 124
 - hypercholeretic, 114
 - monohydroxylated, 123
 - primary, 107
 - reabsorption, 118
 - secondary, 108–109
 - tertiary, 108–109
 - toxic, 123
 - transcellular transport, 118
 - transporter, 117
 - uptake, 66, 117–118
- Bile acid synthesis, 107–108
- Bile canaliculi, 19
- Bile duct adenoma
 - clinical manifestations, 1288
 - definition, 1288
 - differential diagnosis, 1288–1289
 - histology, 1288
 - therapy, 1289
- Bile duct lesions, ischemia-induced, 574
- Bile ducts
 - aberrant, 1433
 - accessory, 1433
 - anomalies, 625–630
 - carcinoma, 1487
 - cystically dilated, 556
 - cystic dilatations, 1434
 - cysts, 1434–1435
 - decompression, 1498
 - extrahepatic, 395–399, 1418–1421
 - hilar, 20
 - interlobular, 40
 - intrahepatic, 19
 - motility disorders, 1441–1454
 - obstruction, 586, 1496
 - segmental, 20
 - septal, 20, 40
 - strictures, 458, 1445
 - terminal, 9, 20
- Bile duct stones, 441, 1445
 - clinics, 1484
 - complications, 1485–1487
 - diagnosis, 1484–1485
 - endoscopically unextractable, 1489
 - endoscopic retrograde cholangio-pancreatography, 1484
 - endoscopic stone extraction, 1487–1488
 - endosonography, 1484
 - epidemiology, 1483–1484
 - magnetic resonance cholangio-pancreatography, 1484
 - percutaneous transhepatic cholangiography, 1485
 - primary, 1460
 - secondary, 1460
 - surgery, 1490
 - treatment, 1487–1491
 - ultrasound, 1484
- Bile ductules/ ductuli, 19, 40
- Bile flow
 - bile acid dependent, 564
 - bile acid independent, 564
- Bile formation, 137, 139
- Bile infarcts, 243, 569
- Bile lakes, 243, 569
- Bile leaks, 444
- Bile lipids, 105–106
- Bile salt export pump, 108
- Bile salts, 104, 107–108
- Bile secretion, 113
 - functional regulation, 115–116
- Biliary atresia
 - congenital, 1435–1436
 - embryonic-fetal type, 629
 - extrahepatic, 628
 - intrahepatic, 628
 - perinatal form, 629
- Biliary cancer, 503–505
 - chemotherapy, 1544
- Biliary carcinoma, intraluminal brachytherapy, 1549
- Biliary cirrhosis, 569
- Biliary colic, 1475
- Biliary cystadenoma
 - definition, 1289
 - diagnosis, 1289–1290
 - differential diagnosis, 1290
 - epidemiology, 1289
 - pathology, 1289
 - therapy, 1290
- Biliary ductopenia
 - causes, 922
 - course, 924
 - definition, 921
 - diagnosis, 924
 - differential diagnosis, 924
 - drugs, 923
 - epidemiology, 921
 - etiology, 921–923
 - pathogenesis, 921–923
 - pathology, 923–924
 - prognosis, 924
 - therapy, 924
- Biliary epithelial cells, 40, 146–147
 - intrahepatic, 136
- Biliary infections, 1495–1503
- Biliary microhamartomas, 1288
- Biliary obstruction, histopathology, 241–245
- Biliary pain, 535–536
- Biliary pancreatitis, 1474, 1486–1487
- Biliary papillomatosis
 - definition, 1291
 - diagnosis, 1291
 - differential diagnosis, 1291
 - epidemiology, 1291
 - etiology, 1291
 - pathogenesis, 1291
 - prognosis, 1291
 - therapy, 1291
- Biliary stenosis, 1435–1436

- Biliary strictures
 - benign, 442
 - malignant, 442–444
 - Biliary tract surgery, 1392, 1499
 - Biliopathy, portal hypertensive, 988
 - Bilirubin, 105–106, 330–331
 - delta fraction, 331
 - direct reacting, 330
 - encephalopathy, 587
 - excretion, 112
 - indirect reacting, 330
 - metabolism, 103–124
 - synthesis, 110
 - transport, 110
 - unconjugated, 110
 - uptake, 110
 - Bilirubinostasis, 242, 569
 - Bilitranslocase, 110, 113
 - Bilovenous fistulas, 446
 - Bilrubin, 230
 - Bioinactivation, 128
 - Biotransformation, 132, 1211
 - hepatic, 127–130
 - Bismuth-Corlette-classification, 1527
 - Bisphosphonates, 582, 1030
 - Black pigment stones, 1460, 1464–1465
 - Blastomycosis, 860–861
 - Bleeding signs, 314
 - Blood flow
 - hepatic, 55–56
 - portal, 596–597
 - portal venous, 366
 - retrograde portal venous, 367
 - splanchnic, 596–597
 - Blood pool scintigraphy
 - acquisition technology, 426–427
 - interpretation, 427
 - principle, 426
 - Blood vessels, intrahepatic, 21
 - Blue lunulae, 315
 - Boas sign, 1472
 - Bodies
 - multivesicular, 30, 31
 - residual, 30
 - Bone disease
 - metabolic, 570
 - posttransplant, 1030
 - Borreliae, 835–836
 - Botulinum toxin, 1450–1451
 - Boutonneuse fever, 839
 - Bouveret syndrome, 1474
 - Brain natriuretic peptides, 607
 - Branched chain amino acids, 1202
 - Branching enzyme, 80
 - Breakthrough
 - clinical, 777
 - virological, 777
 - Breast milk jaundice, 587
 - BRIC 1, 1095, 1097–1098
 - BRIC 2, 1098
 - Bridging necrosis, 721
 - Bromosulphthalein test
 - assessment, 335
 - confounding factors, 335
 - principle and technique, 335
 - side effects, 335
 - Bronchobiliary fistulas, 625
 - Brown pigment stones, 1460, 1465–1467
 - Brucellae, 836
 - Brunner's gland hyperplasia, 1514
 - Budd-Chiari syndrome, 370, 642–645
 - causes of, 643
 - Bumetanide, 972
 - Bunyaviruses, 828
 - Burkholderia pseudomallei, 836
 - Byler's disease, 124, 1095
 - Byler's syndrome, 1095
- C**
- Cachexia, 310
 - Cadherins, 25
 - Caffeine clearance
 - assessment, 340
 - confounding factors, 340
 - principle and technique, 339–340
 - side effects, 340
 - CAGE test, 1136
 - Calcineurin inhibitors, 1373
 - Calcitonin, 160, 1031
 - Calcium-bilirubinate stones, 1460
 - Caliciviruses, 674
 - C₁₇-alkylated steroids, 1276
 - Calpains, 177
 - Campylobacter* species, 836
 - Canalicular multispecific organic anion transporter, 112
 - Canals of Hering, 9, 19
 - Cancer
 - biliary, 503–505
 - gallbladder, 1521–1526
 - Cancer of the Liver Italian Program, 1324–1325
 - Candidiasis
 - biliary tract, 860
 - hepatic, 859
 - hepatosplenic, 859
 - Capillarization of sinusoids, 654
 - Capsule endoscopy, esophageal, 977
 - Capsule, hepatic, 8
 - Caput medusae, 310
 - Carbamazepine, 1276
 - Carbamoyl-phosphate synthetase, 85
 - Carbohydrate homeostasis, 80–82
 - Carbohydrate metabolism, 139–140
 - regulation, 80
 - Carbohydrate response element binding protein, 87
 - Carbohydrates, 76, 225–226
 - Carbon monoxide (CO), 55, 58
 - Carbon tetrachloride (CCl₄), 189, 190
 - Carcinoembryonic antigen (CEA), 19
 - Carcinoids, 1350
 - Carcinomas
 - ampullary, 459–460
 - cholangiocellular, 397–398, 434

- common bile duct, 459
- fibrolamellar, 1337–1338
- gallbladder, 1474
- hepatocellular, 412–413, 432, 433, 502–503, 1307–1329
- Cardiac natriuretic peptides, 607
- Cardiac surgery, 1393
- Cardiomyopathy, cirrhotic, 1025
- Carnitine shuttle, 87
- Caroli's disease, 627–628
- Caroli's syndrome, 627–628
- Carrier proteins, 63
- Carvedilol, 981
- Caspase, 216
- Caspase activity, 752
- Castleman's disease, 825
- Catalase, 179
- Catalase, hepatic, 1119
- Catecholamines, 160
- Caudate lobe. *See* Lobe, caudate
- Cavernous transformation, 368
- Celiac disease, 545, 1248
- Cell cycle, 163–164
- Cell death, 174, 209
 - programmed, 209
- Cell edema, 554
 - osmotic, 207
- Cell injury, 174
- Cell membrane, 25
- Cell proliferation, 157, 163–164
- Cell shrinkage, 138–140
- Cell swelling, hydropic, 207
- Cell types, 22–23
- Cellular adaptation, 219–233
- Cell volume, 137, 138, 140
- Central hyaline sclerosis, 258, 645
- Central vein, 16
- Cerebral edema, 938
- Cerebral hypertension, 938–940
 - drug therapy, 939–940
 - supportive therapy, 940
 - therapeutic measures, 939
- Cerebrotendinous xanthomatosis, 1184
- Ceroid pigment, 229–230
- Ceruloplasmin, 93, 1037
- Cestodes, 1502
- Chalk milk bile, 1473
- Channels, 63
- Chaperones, 177
- Chaperonins, 177
- Charcot-Gombault infarcts, 243
- Charcot's triad, 1486
- Chelators, 1057
- Chelidonium majus, 574
- Chenodeoxycholic acid, 107
- Cherry red spots, 979
- Chilaiditi's syndrome, 439, 622
- Child-Turcotte-Pugh score, 289–290
- Chlamydiae, 836
- Cholangiocarcinoma, 443, 1361
 - biliary papillomatosis, 1528
 - Bismuth-Corlette-classification, 1527
 - definition, 1526
 - epidemiology, 1526–1528
 - etiology, 1528–1529
 - extrahepatic, 1526–1554
 - fluoropyrimidines, 1546
 - gemcitabine, 1546
 - intrahepatic, 413–414
 - oncogenes, 1528
 - pathogenesis, 1528–1529
 - topoisomerase-inhibitors, 1546
- Cholangiocellular carcinomas, 434
 - color Doppler imaging, 397
 - contrast enhanced ultrasound, 398
 - conventional B-mode ultrasound., 397
- Cholangiocytes, 9
 - proliferation, 159
 - secretion, 1425
- Cholangiodysplasia, 626
- Cholangiography
 - endoscopic retrograde, 437–446
 - percutaneous transhepatic, 437–446
- Cholangiohepatitis, oriental, 627
- Cholangioles, periportal, 19
- Cholangiolitis, 568
- Cholangiopathies, 568
 - AIDS-related, 575
 - cavernoma-associated, 658
 - ischemic, 574–575, 665
 - oriental, 445
- Cholangioscopy, 449–453
 - percutaneous-transhepatic, 451–452
 - peroral, 450–451
- Cholangitis, 445–446, 470, 1486
 - acute, 445, 568
 - ascending, 244
 - autoimmune, 909–910
 - bacterial, 1495–1500
 - chronic non-suppurative destructive, 895
 - fungal, 1500
 - immunoglobulin G₄ associated, 916
 - parasitic, 1500–1501
 - primary sclerosing, 363, 911–917
 - recurrent pyogenic, 445, 627
 - secondary sclerosing, 397
 - small duct, 245
 - suppurative, 244
 - treatment, 1489
 - tuberculous, 838
- Cholangitis lenta, 245
- Cholate stasis, 209, 243, 569
- Cholecystectomy, 1477–1479
 - conventional, 1477
 - laparoscopic, 444, 1477
- Cholecystitis
 - acalculous, 393, 577, 869, 1472
 - acute, 393–394
 - acute bacterial, 1471–1473
 - chronic, 394, 1473
 - emphysematous, 393, 1473
- Cholecystolithiasis, 393
 - complications, 1471–1474
- Cholecystolithotomy, 1479
- Cholecystostomy, 1479

- Choledochal cysts, 395–396, 625
- Cholelithiasis, 396–397, 442, 458–459
 - endoscopic therapy, 1488
 - treatment, 1487–1491
- Cholehepatic shunt, 565
- Cholelithiasis
 - asymptomatic, 1470
 - symptomatic, 1470–1471
- Cholelitholysis, 1490–1491
- Choleresis, 114
 - secretin-induced, 566
- Cholestasis, 122
 - canalicular, 576
 - causes, 563
 - classification, 559–562
 - cystic fibrosis, 579
 - definition, 559
 - drug-induced, 574
 - drugs, 563
 - ductular, 576
 - endotoxin-induced, 197–198
 - etiology, 559–562
 - graft *versus* host disease, 577–578
 - histopathology, 568
 - imaging techniques, 572–573
 - intrahepatic, 585, 1093–1098
 - laboratory findings, 571–572
 - liver transplantation, 578
 - pathogenesis, 562–568
 - postoperative, 576–577
 - pregnancy, 578–579
 - progressive familial intrahepatic, 124
 - radiation-induced, 568
 - sarcoidosis, 577
 - sepsis-associated, 575–576
- Cholestasis of pregnancy, intrahepatic, 1096
- Cholestatic patterns, 320, 546–547
- Cholestatic reaction, 241–246
- Cholesterol, 89, 224–225
 - biosynthesis, 106
 - synthesis, 88
 - transport, 106
- Cholesterol-7 α -hydroxylase, 107
- Cholesterol concretions, 1460
- Cholesterol ester storage disease, 1184
- Cholesterolosis, 394, 1508
- Cholesterol polyps, 1509
- Cholesterol stones
 - diabetics, 1462
 - drugs, 1462
 - gallbladder motility, 1464
 - gallbladder mucus, 1463
 - genetic factors, 1462
 - hormonal aspects, 1462
 - hyperinsulinemia, 1462
 - hypomotility, 1462
 - lith genes, 1462
 - lithogenic bile, 1462
 - microliths, 1463
 - multilamellar vesicles, 1464
 - nucleation factors, 1463
 - obesity, 1462
- Cholesterol transport, reverse, 92
- Cholesteryl ester transfer proteins, 92
- Cholestyramine, 579, 1260
- Cholinesterase, 326–327
- Chondroitin sulfate, 45
- Chronic biliary disease, staging, 280
- Chronic granulomatous disease, 1251
- Chronic hepatic porphyria, 1088–1090
- Chronic hepatitis, 272–277
 - grading, 272–276, 729–731
 - semi-quantitative scoring, 729
 - staging, 272–276, 729–731
- Chronic hepatitis B
 - age, 754–755
 - coinfections, 756–757
 - HBeAg-negative, 751–752
 - HBeAg-positive, 750
 - HBV genotype, 755
 - HBV/HCV coinfection, 756
 - HBV/HDV coinfection, 756
 - HBV/HIV coinfection, 756
 - immunosuppression, 755
 - natural history, 754
 - viral load, 755–756
- Chronic hepatitis C, 712–717, 728
 - extrahepatic manifestations, 793–797
 - therapy, 801–805
- Chronic inflammatory bowel disease, 1248
- Chronic liver disease, 498–501
 - surgery, 1388–1390
- Chronic lobular hepatitis, 723
- Chronic lymphocytic leukemia, 1250
- Chronic myelocytic leukemia, 1249
- Chronic viral hepatitis, 1388–1389
- Chylomicrons, 90
- Chylous ascites, 611
- Circulation
 - enterohepatic, 584
 - hepatic, 55–58
 - hyperdynamic, 596
- Circulatory dysfunction, post-paracentesis, 973
- Cirrrose cardiaque, 649
- Cirrhosis, 543, 949–964
 - alcoholic, 955, 958, 1142–1146
 - biliary, 569
 - cryptogenic, 950
 - incomplete septal, 954
 - Indian childhood, 961
 - macronodular, 953–954
 - malnutrition, 1190
 - micronodular, 952–953
 - mixed forms, 954
 - monoacinar, 953
 - multiacinar, 953
 - primary biliary, 282, 362–363, 895
 - secondary biliary, 243
 - survival, 963
- Cirrhotic cardiomyopathy (CC), 1025
- Clathrin, 73
- Claudin, 690
- Clevudine, 774
- Clinical breakthrough, 777

- Clomiphene, 1276
 Clonorchis sinensis, 627, 1511
 Clostridium perfringens, 836–837
 Clotting factors, 328–329
 deficiency of, 1029
 CMV hepatitis, 825
 COACH syndrome, 626
 Coagulative necrosis, 210
 Coagulopathy, 1394–1395
 hepatic, 1029
 Coated pits, 72
 Coatomers, 72
 Coccidioidomycosis, 860–861
 Colestipol, 579
 Collagen, 39, 42
 biosynthesis, 43
 bundles, 42
 fibrils, 42
 degradation, 44
 structure, 42
 types, 43–44
 Collagenases, 44, 254
 Collapse fibrosis, 258
 Collaterals, portosystemic, 600
 Colloidal scintigraphy
 acquisition technology, 426
 interpretation, 426
 principle, 425–426
 Colon cancer, 505
 Colopathy, portal hypertensive, 988
 Color Doppler imaging (CDI), 365
 Combination therapy
 contraindications, 803–804
 side effects, 803–804
 Common bile duct
 carcinoma, 459
 duplication, 1433
 Compartment of uncoupling receptor and ligand
 (CURL), 71, 73
 Complex lipids, synthesis, 88
 Computed tomography, 405–421
 Confluent necrosis, 721
 Congenital erythropoietic porphyria, 1082, 1087, 1091
 Congestion
 acute hepatic, 641
 chronic hepatic, 641–642
 Congestive heart failure, 367–368
 Congo red staining, 1108
 Conjugation reactions, 128
 Connexins, 26
 Copper, 92–93, 201–202, 228, 1035
 excretion, urinary, 1038
 hepatic, 1040
 overload, 202
 transport, 1036
 Cori cycle, 81
 Coronaviruses, 829
 Corset liver, 622
 Cotransport, $\text{Na}^+/\text{HCO}_3^-$, 71
 Councilman bodies, 828
 Covalently closed circular, 746
 Cowdry A, 824
 Cowdry B, 824
Coxiella burnetii, 839
 Coxsackie virus, 827
 CpG-Oligo(deoxy)nucleotides, 712–713
 Crigler–Najjar syndrome type I/II, 587–588
 Crigler–Najjar type I/II, 586
 Cristae, 30
 Critical flicker frequency, 1011
 Cross talk
 hepatocyte-cholangiocyte, 1425
 viral, 194
 Cruveilhier-von-Baumgarten disease, 637
 Cruveilhier-von-Baumgarten syndrome, 600, 637
 Cryoglobulinemia, 793–794
 Cryoglobulins, 794
 Cryptococcosis, 860
 Cryptosporidiosis, 846
 Cyanoacrylate, 985
 Cyclin, 159
 Cyclin-dependent kinases, 165
 Cyclosporin A, 1217
 Cyclosporine, 1354, 1373
 Cystadenoma, biliary, 1289–1290
 Cystadenomas, 1511
 Cystic duct
 anomalies, 1429–1432
 long, 1445
 Cystic fibrosis, 364, 568, 579, 1096
 clinical manifestations, 1102
 course, 1102–1103
 definition, 1101
 epidemiology, 1101
 etiology, 1101–1102
 hepatobiliary manifestations, 1102
 pathogenesis, 1101–1102
 pathology, 1102
 prognosis, 1102–1103
 therapy, 1103
 Cystic fibrosis transmembrane regulator (CFTR), 1101
 Cystinosis, 1185, 1251
 Cysts, 555
 Cytochrome P452, 1118
 isoenzymes, 130
 mixed function, 128
 Cytochrome P450 system, 1213
 Cytokeratins 20, 1291
 Cytokeratins, 32
 Cytokines, 35, 142–149, 151, 253
 proinflammatory, 147
 Cytomegalovirus, 233, 825–826
 Cytomegalovirus infection, 869
 Cytoplasmic deposits, 208
 Cytoskeleton, 31–32, 66
 Cytosolic enzymes, 539
 Cytosolic function, 334
- D**
 Daclizumab, 1374
 Dcytb protein, 1048

- Death domain, Fas-associated, 215
Death inducing signaling complex, 215
Debranching enzyme, 80
Decorin, 45
Defects in fatty acid oxidation, 1186
Deferasirox, 1057, 1064
Deferoxamine, 1057, 1064
Deferoxamine testing, 1049
Degeneration
 alcoholic foamy, 224
 feathery, 209, 243, 569
 pseudoxanthomatous, 209
 vacuolar, 207
Delayed early genes, 165
Delta-bilirubin, 331, 584
Deltaviridae, 683
Dendritic cells (DC), 145, 149
Dengue virus, 828
Deposits
 extracellular, 554
 intracellular, 219–233, 554
 intracytoplasmic, 224–232
Depression, 804
De Ritis quotient, 321, 541
Dermatan sulfate, 45
Dermatologic disorders, 795–796
Desmet's score, 274, 275
Desmin, 37
Desmosomes, 25
Detoxification, 127
Development, embryonic, 7–10
Dexamethasone, 580, 1260
Diabetes mellitus, 1249
 gestational, 748
 hepatogenous, 1027
Diabetic hepatosclerosis, 654
Diabetic microangiopathy, 654
Diacytosis, 66
Dietary supplements, 1202
Diffusion
 facilitated, 63
 free, 63
Dilatation, sinusoidal, 649–650
Dioxygenases, 127
Direct hepatotoxins, 1223, 1224
Disarray, lobular, 720
Discoidin domain receptors (DDR), 255
Discriminant function, 291–292
Disse, space of, 17
Distal cholangiocarcinoma
 resection, 1535–1536
 survival, 1535
Diuretic therapy, practical approach, 972
Diverticulum, hepatic, 7, 8
DNA, 746
 ligase, 180
 polymerase, 180
 repair, enzymes of, 180
 vaccination, 710, 1407
 vaccines, 713
DNA-glycosylases, 180
Doppler indices, 365–366
Doppler ultrasound, 364–371
Doss-porphyrin, 1080–1081
Double target sign, 417
Doughnut granuloma, 249, 1237
Downhill-varices, 976
D-penicillamine, 1040
Dronabinol, 581
Drug-induced, 189–190
Drug-induced liver injury, 189–190, 875–876, 1223–1230
Drug metabolism
 age, 1212
 factors affecting, 1211–1220
 gender, 1212
 genetic factors, 1212–1217
 hepatic, 1211–1220
 pharmacogenetics, 1213
 phase I, 1213
 phase II, 1213
Drugs, 544–545, 577
 biliary excretion, 1217–1218
 high hepatic clearance, 1218
 low hepatic clearance, 1218
 toxicity, 1211–1220
Dubin–Johnson pigment, 228–229, 1277
Dubin–Johnson syndrome, 584, 586, 589, 1096
Ductal plate, 9
Ductal plate malformations, 625, 626
Ductopenia, biliary, 921–924
Ducts of Luschka, 392
Ductular hepatocytes, 158
Ductular proliferation, 1285
Ductular reaction, 41, 245–246, 721
Duct, venous, 13
Dupuytren's contracture, 316
Dynactin, 66
Dynein, 32, 66
Dysfunction
 granulocyte, 1028
 sexual, 307, 797, 1026
 sphincter of Oddi, 1445–1451
 thyroid, 1026–1027
Dyskinesia, sphincter of Oddi, 523, 1446, 1451–1454
Dysplasia
 large cell, 724, 1313–1314
 small cell, 724, 1314
Dysplastic foci, nodules, 1314
- E**
Ebola virus, 829
Echinococcal disease, 420–421
Echoviruses, 827
Eclampsia, 1267
Ectasia, gastric antral vascular, 987
Ectopy, 621–622
Edema, cerebral, 938
Ehrlichiae, 837
Ehrlichiosis, 837
Elastin, 42, 44–45
Elastosis perforans serpiginosa, 1040

- Electrohydraulic lithotripsy, 1489
- Eltrombopag, 796
- Embryonal sarcoma
 - course, 1346
 - definition, 1345
 - diagnosis, 1346
 - differential diagnosis, 1346
 - epidemiology, 1345
 - etiology, 1345
 - pathogenesis, 1345
 - pathology, 1345
 - prognosis, 1346
 - therapy, 1346
- Embryonic development. *See* Development, embryonic
- Emtricitabine, 774
 - resistance, 780
- Encephalopathy, 1395–1396
 - hepatic, 315, 938, 1005–1015
 - portosystemic, 306
- Endocrine cells, 1421
- Endocytosis, 66
 - receptor mediated, 72
- Endogenous pathway, 91
- Endonuclease, 180
- Endoplasmic reticulum, 27
- Endoplasmic reticulum stress, 173–180, 1158
 - defense mechanisms, 177
- Endoscopic retrograde cholangiopancreatography, 1499
- Endoscopic sphincterotomy
 - complications, 1488
 - results, 1488
- Endoscopic therapy, 443
- Endoscopic ultrasonography
 - gallbladder diseases, 460
 - liver diseases, 460
- Endoscopic retrograde cholangiography, complications, 446
- Endosomes, 30, 73
- Endothelial cells, sinusoidal, 17, 32–34, 57
- Endothelin-1 (ET-1), 254–255
- Endothelins, 57, 58, 596, 606, 607
- Endotoxins, 35, 197–198
- End-stage renal disease, 483
- Energy, 1196
- Energy metabolism, 1191
- Entactin, 47
- Entecavir, 709, 772–773, 779
 - resistance, 779
 - results of treatment, 772–773
- Enterohepatic circulation, 584
- Enteropathy, portal hypertensive, 988
- Enteroviruses, 827
- Enzymes, 319–327
 - branching, 80
 - clearance, 539
 - cytosolic, 539
 - debranching, 80
 - hepatitic patterns, 540
 - induction, 580
 - inhibitors, 714
 - mitochondrial, 539
 - organ distribution, 541
 - patterns of injury, 540–548
- Epidermal growth factor (EGF), 161
- Epithelial tumors, 1275
- Epithelioid granuloma, 248
- Epithelioid hemangioendothelioma
 - course, 1344
 - definition, 1343
 - diagnosis, 1344
 - differential diagnosis, 1344
 - epidemiology, 1343
 - etiology, 1343
 - pathogenesis, 1343
 - pathology, 1343–1344
 - prognosis, 1344
 - therapy, 1344–1345
- Epitope vaccine, 713–714
- Eplerenone, 971
- Epstein-Barr virus, 826–827
- Erdheim-Chester disease, 1251
- Erectile dysfunction, 1026
- Erythema infectiosum, 829
- Erythrophagocytosis, 231, 654
- Erythropoiesis, ineffective, 330, 587
- Erythropoietic and X-linked
 - protoporphyrin, 1082
- Erythropoietic protoporphyria, 1078, 1084, 1086–1088, 1090–1091
- Esophageal varices
 - acute bleeding, 980
 - anatomy, 976
 - β-blockers, 979, 980
 - bleeding, 978–979
 - carvedilol, 981
 - cherry red spots, 979
 - course, 978
 - definition, 976
 - diagnosis, 977–978
 - endoscopic grading, 977
 - endoscopic ultrasound, 977
 - epidemiology, 976
 - etiology, 976
 - multiband ligation, 981
 - nitrates, 981
 - octreotide, 981
 - pathophysiology, 976
 - preprimary prophylaxis, 979–980
 - primary prophylaxis, 980
 - prognosis, 978
 - prophylaxis, 979
 - red wale marks, 979
 - sclerotherapy, 981
 - secondary prophylaxis, 980
 - therapy, 979
 - white nipple sign, 979
- Essential thrombocytopenia, 1249
- Ethanol
 - bacterial metabolism, 1119
 - carcinogenesis, 1119
 - gastric first pass metabolism, 1114–1116

- metabolic diseases, 1117
- Euchromatin, 26
- EUS-miniprobe, 456–457
- Exchange pump, $\text{HCO}_3^-/\text{Cl}^-$, 71
- Exocytosis
 - non-triggered or constitutive, 65
 - triggered or nonconstitutive, 65
- Exogenous pathway, 90
- Extracellular matrix (ECM), 42, 159, 255
- Extracorporeal shock wave lithotripsy, 1489
- Extrahepatic bile ducts, 395–399
 - anatomy, 1415
 - anomalies, 1433–1436
 - benign strictures, 1437
 - benign tumors, 1511–1514
 - cell types, 1419
 - electron microscopy, 1419
 - embryonic development, 1415
 - form anomalies, 1434–1436
 - microscopy, 1419
 - physiology, 1424–1425
- Extrahepatic biliary tract, anomalies, 1429–1432
- Extrahepatic cholangiocarcinoma
 - adenocarcinomas, 1529
 - chemoradiation, 1545–1549
 - chemotherapy, 1543–1545
 - clinical manifestations, 1529
 - complications, 1553
 - diagnosis, 1529–1531
 - differential diagnosis, 1531–1532
 - endoprostheses, 1538
 - histologic types, 1529
 - mesenchymal tumors, 1529
 - molecular targeted therapy, 1551–1552
 - palliative management, 1538–1549
 - palliative radiotherapy, 1545
 - pathology, 1529
 - prognosis, 1532–1554
 - recurrent, 1553
 - stenting, 1538–1540
 - surgical palliation, 1543
 - survival rates, 1534
 - therapy, 1532–1554
 - TNM, 1527
 - UICC-classification, 1527
- Extrahepatic disease, hepatic involvement, 1247–1251

F

- Fabry's disease, 1183
- Facies alcoholica, 309
- False neurotransmitters, 1009–1010
- Familial amyloidosis, 1106
- Familial high density lipoprotein deficiency, 1184
- Family history, 301
- Farnesoid X receptor, 108
- Fas-dependent cell death, 193, 194
- Fas-ligand, 192
- Fas-receptor, 215
- Fatigue, 305, 571, 582
- Fat-soap-stones, 1466
- Fat storing cells, 36

- Fatty acid
 - degradation, 86–87
 - essential, 85
 - β -oxidation, 86
 - polyunsaturated, 176
 - synthesis, 87
 - transport protein, 86
- Fatty acid-binding proteins, 86, 119
- Fatty acid synthase, 87
- Fatty liver, 224, 277–280
 - pathophysiology, 1158
- Fatty liver disease, nonalcoholic, 544, 1153
- Fat vacuoles, 37
- FDG-PET/CT, 432–435
- Feathery degeneration, 209, 243, 569
- Felty's syndrome, 1250
- Fenestrae, 33
- Fenton-reaction, 175, 179
- Ferrokinetic measurements, 1049
- Ferroportin, 1061
- Ferroportin 1, 1048
- Ferroportin disease, 1061–1063
- Ferroportin mutants, 1062
- Fetor hepaticus, 310, 1010
- Fever, 307
 - hemorrhagic, 828
- Fibers, parasympathetic, 22
- Fibril
 - banded, 42
 - proteins, 1105
- Fibrinogen, 226
- Fibrinogen storage disease, 226
- Fibrin ring granulomas, 249, 1237
- Fibroblast growth factors (FGF), 9, 162
- Fibrogenesis, 252
 - biomarkers, 262–263
- Fibrogenic reaction, 251–266
- Fibro index, 263
- Fibrolamellar carcinoma
 - calcifications, 1337
 - collagen bundles, 1337
 - definition, 1337
 - diagnosis, 1337
 - differential diagnosis, 1337
 - epidemiology, 1337
 - immunocytochemical staining, 1337
 - mitochondrial hyperplasia, 1337
 - pathology, 1337
 - prognosis, 1338
 - survival rates, 1338
 - treatment, 1338
- Fibromodulin, 45
- Fibromyosarcoma, 1350
- Fibronectin, 46
- Fibropolycystic diseases, 626
- Fibropolycystic liver diseases, 625
- Fibrosing cholestatic hepatitis, 726, 729
- Fibrosis
 - biomarkers, 264
 - centrilobular, 258
 - indices, 263

- patterns, 260
 - pericellular, 257–258
 - periductal, 256
 - periportal, 256–257
 - perisinusoidal, 257–258
 - portal, 256–257
 - scores, 263
 - semiquantitative scoring system, 283–284
 - therapeutic approaches, 263–266
 - transmembrane conductance regulator, 65
 - Fibrotest, 263
 - Fibrous septa, 258
 - Fibrous tumors, 1301–1303
 - Filaments, intermediate, 32
 - Filoviruses, 829
 - Fine needle aspiration, ultrasound guided, 469
 - Fitz-Hugh-Curtis syndrome, 612, 836, 837
 - Flapping tremor, 1010
 - Flaviviridae, 686
 - Flaviviruses, 828
 - Floating gallbladder, 1430
 - Florid bile duct lesion, 897
 - Fluid volume, extracellular, 605–608
 - Fluorescence patterns, 347, 348
 - Fluoropyrimidines, 1546
 - Focal liver lesions, 371–391, 429–432, 553–557
 - Focal nodular hyperplasia, 379–382, 407, 430, 556
 - color Doppler imaging, 380
 - contrast-enhanced ultrasound, 380–381
 - CT-scanning, 1286
 - definition, 1284
 - diagnosis, 1285–1286
 - differential diagnosis, 1286–1287
 - epidemiology, 1284
 - etiology, 1284
 - hepatobiliary scanning, 1286
 - imaging, 1286
 - magnetic resonance imaging, 1286
 - natural history, 1287
 - pathogenesis, 1284
 - pathology, 1284–1285
 - prognosis, 1287
 - telangiectatic, 1277, 1285
 - therapy, 1287
 - ultrasonography, 1286
 - variant forms, 1285
 - Focal steatosis, 1298
 - ultrasound, 1298
 - Focus
 - dysplastic, 1314
 - iron-free, 1314
 - Forbe's/Cori's disease, 1182
 - Foreign bodies, 230–231
 - Foreign body granulomas, 247
 - Forms index, 263
 - Fowler's solution, 1340
 - Francisella tularensis, 837
 - Free radicals, 173–180
 - Free water excretion, 613
 - Fresh frozen plasma (FFP), 942
 - Fructose, 76
 - Fructose 1,6-biphosphatase, 79
 - Fructose intolerance, 1182
 - Fulminant hepatic failure, 482
 - Fulminant hepatitis, 721
 - Fungal infections, 859–861
 - Furosemide, 971
- G**
- Gabapentin, 581
 - Galactose, 76
 - Galactose-breath test, 338
 - Galactose elimination capacity
 - assessment, 338
 - confounding factors, 338
 - principle and technique, 337–338
 - side effects, 338
 - Gallbladder
 - adenomas, 1508
 - agenesis, 1429
 - anatomy, 1415
 - anomalies, 626, 1429–1432
 - benign tumors, 1507–1511
 - benign tumors, epidemiology, 1507–1508
 - bile, 105, 1423
 - bile excretion, 1423–1424
 - bile storage, 1423–1424
 - carcinoma, 395, 1474
 - duplication, 1430
 - embryonic development, 1415
 - empyema, 1473
 - examination, 311
 - hydrops, 1473
 - hypoplastic, 1102
 - left-sided, 1431
 - motility, 1424
 - numerical anomalies, 1429–1430
 - physiology, 1423
 - polyps, 395
 - positional anomalies, 1430–1431
 - sludge, 1467
 - stricture, 1431
 - tumors, classification, 1507
 - variations, 1430
 - varices, 988
 - Gallbladder cancer
 - adenocarcinoma, 1523
 - adjuvant treatment, 1525
 - chemotherapy, 1526
 - cholelithiasis, 1522
 - clinical manifestations, 1523
 - diagnosis, 1523–1524
 - differential diagnosis, 1524
 - epidemiology, 1521
 - etiology, 1522–1523
 - external-beam radiation therapy, 1525
 - gallbladder polyps, 1522
 - histologic types, 1523
 - K-RAS mutations, 1523
 - lymphadenectomy, 1525
 - palliative treatment, 1525–1526
 - pathogenesis, 1522–1523

- pathology, 1523
- prognosis, 1524–1526
- recurrent, 1526
- therapy, 1524–1526
- TNM-classification, 1522
- UICC-classification, 1522
- Gallbladder disease, 391–395
 - congenital anomalies, 392–393
- Gallbladder stones
 - cholecystography, 1468
 - computed tomography, 1469
 - endoscopic ultrasound, 1469
 - epidemiology, 1459–1461
 - etiology, 1461–1467
 - intravenous cholecystography, 1469
 - magnetic resonance cholangiography, 1469
 - natural course, 1469–1470
 - oral cholecystography, 1468
 - pathogenesis, 1461–1467
 - percutaneous transhepatic cholangiography, 1469
 - radiological techniques, 1467–1469
 - ultrasound, 1467
- Gallstone disease, ultrasound findings, 1467
- Gallstone(s)
 - prevalence, 1460
 - prophylaxis, 1474–1475
 - therapy, 1475–1479
- γ -Aminobutyric acid (GABA), 1009–1010
- Gamma-glutamyl transferase, 323–324
- Gangliocytic paraganglioma, 1514
- Gangliosidosis, 1183
- Gap junctions, 25–26
- Gas embolism, portal vein, 661
- Gastric antral vascular ectasia (GAVE), 987
- Gastric cancer, 506
- Gastric varices, 985–986
- Gastroesophageal varices, 600, 985
- Gastrointestinal symptoms, 306
- Gastropathy, portal hypertensive, 986–987
- Gaucher cells, 225
- Gaucher's disease, 225, 1183
- Gelatinases, 44
- Gemcitabine, 1546
- Generalized pustular psoriasis, 1251
- Genes
 - augmentation, 1407
 - delayed early, 165
 - expression, 1405
 - immediate early, 164, 165
 - repair, 1404
 - substitution, 1404
- Gene therapy, 1403–1409
 - antiangiogenic, 1408
 - suicide, 1407–1408
- Genetic classification, 1403
- Genetic hemochromatosis
 - mortality risk, 1053
 - survival of, 1051
- Genetic immunization, 710
- Genetic polymorphism, 1214
- Genetic vaccination, 710
- Genome, mitochondrial, 30
- Genotypic resistance, 777
- GERL-compartment, 30
- γ -Globulins, 328
- Ghrelin, 1160
- Gianotti-Crosti syndrome, 747
- Giant cells
 - arteritis, 1250
 - hepatitis, postinfantile, 722
 - multinucleated, 232
- Giardia lamblia, 846
- Giardiasis, 846
- Gilbert's disease, drug toxicity, 1214
- Gilbert's syndrome, 586, 588–589, 1214
 - phenotype, 1214
- Glands, peribiliary, 20
- Glasgow alcoholic hepatitis index, 1138
- Glazed tongue, 314
- Glisson's capsule*, 12
- Globular enhancement, 407
- Glomerulonephritis, 748, 776, 794
- Glucagon, 160
- Glucagon resistance, 1191
- Glucocerebrosides, 225
- Glucokinase, 76, 78
- Gluconeogenesis, 77–80
- Glucose, 76
 - activated, 80
 - metabolism, 133–134
 - requirement, 1201–1202
 - transporter, 76
 - transport proteins, 64
- Glucose homeostasis, alterations, 1027
- Glucose 6-phosphatase, 79
- Glucose 6-phosphate, 76
- Glucuronidation, 111–112, 128
- Glucuronidation enzymes, genetic organization, 1214–1215
- Glutamate, 84
- Glutamate dehydrogenase, 322, 541
- Glutamatergic transmission, 1008
- Glutamine, 84
- Glutamine cycle, intercellular, 135
- Glutamine synthesis, 1008
- γ -Glutamyl transferase, 540
- γ -Glutamyl transpeptidase, 546–547
- Glutathione, 114
- Glutathione peroxidase, 132
- Glutathione-S-transferase, 1121
- Glycogen, 25, 225–226, 232–233
 - inclusions, 24
- Glycogen metabolism, 79–80
- Glycogenesis type II, 225
- Glycogenesis type IV, 225
- Glycogen storage diseases, 383–384, 1182, 1276
- Glycolipids, 86
- Glycolysis, 76–77, 80
- Glycoproteins, adhesive, 42, 46
- Glycosaminoglycans, 42
- Glypican 3, 1317
- Golgi apparatus, functions, 29

- Gonococcal sepsis, 837
 Gonococci, 837
 Graft-vs.-host disease, 1251
 Granulocyte dysfunction, 1028
 Granulomas
 caseating, 1236
 doughnut, 249
 epithelioid, 248
 fibrin ring, 249, 725
 foreign body, 247
 hepatic, 1235–1238
 histiocytic, 826
 immune, 247
 lymphohistiocytic, 248
 mineral oil, 249
 non-caseating, 1237
 tuberculoid, 860
 Granulomatous hepatitis, 248
 Granulomatous phlebitis, 661
 Granulomatous reaction, 247–249
 Granuloma types, 247–248
 Granzymes, 193
 Greater celandine, 574
 Ground-glass hepatocytes, 219–222
 Ground-glass inclusions, 727
 Growth factors
 epidermal, 161
 fibroblast, 162
 hepatocyte, 159, 161
 insulin-like, 162
 transforming, 162
 vascular endothelial, 160
 Growth hormone, 161
 Günther's disease, 1087, 1084 (Guenther's on page 1084)
 Gynecomastia, 310
- H**
- Haber-Weiss-reaction, 175
 Hair growth, 315
 Hairpin ribozymes, 711
 Hairy cell leukemia, 1250
 Half and half nails, 315
 Halothane, 1230
 Hamartoma, mesenchymal, 1297
 Hammerhead ribozymes, 711
 Hantavirus, 828
 Harmonic imaging, 374
 Hashimoto's thyroiditis, 795
 HBsAg carrier, asymptomatic, 747
 HBsAg carrier state, inactive, 752
 HBV infection, silent, 756
 HBx-antigen, 679
 Heart failure, 1248
 congestive, 367–368
 Heat shock proteins (Hsp), 177
 Heat stroke, 1251
 Helicase inhibitors, 715
 HELLP syndrome, 1251, 1263, 1268–1269
 Hemangioendothelioma
 epithelioid, 1343–1345
 infantile, 1295–1296
 Hemangioma, 376–379, 407, 430–432, 556
 atypical, 377
 cavernous, 1292
 color Doppler imaging, 376
 contrast-enhanced ultrasound, 376–377
 conventional B-mode ultrasound, 376
 CT scan, 1293
 definition, 1292
 diagnosis, 1292–1294
 diagnostic criteria, 377
 differential diagnosis, 1294
 epidemiology, 1292
 fine needle biopsy, 1294
 giant, 556, 1292
 MRI, 1294
 natural history, 1294–1295
 pathology, 1292
 prognosis, 1294–1295
 sonography, 1293
 treatment, 1295
 Hemangiomas, diffuse systemic, 1292
 Hematoma, 391
 Hematopoiesis, extramedullary, 654
 Heme
 carrier, 95
 carrier protein 1, 94
 Hemobilia, 444
 Hemochromatosis, 96
 classification, 1046
 early diagnosis, 1051
 hereditary, 544, 1045–1065
 natural course, 1046
 neonatal, 1047
 secondary, 1046, 1047, 1063–1065
 survival, 1051
 Hemojuvelin, 1059
 Hemolysis, 576–577, 586–587
 Hemolytic anemia, 803
 Hemophagocytic syndrome, 865, 1250
 Hemorrhagic fevers, 828
 Hemosiderin, 227–228
 Hemostasis, 470
 Hemozoin, 847
 Henoch–Schönlein purpura, 1251
 Hepaciviridae, 686
 Hepadnaviruses, 675
 Heparan sulfate, 45
 Heparin, 45
 Hepar lobatum, 621
 Hepar succenturiatum, 621
 Hepatic acetaldehyde dehydrogenase, 1119
 Hepatic amyloidosis
 course, 1108
 diagnosis, 1107–1108
 differential diagnosis, 1108
 pathology, 1107
 prognosis, 1108
 Hepatic artery(ies), 21, 55, 366, 663–668
 accessory, 637
 aneurysms, 665–667
 congenital anomalies, 663
 occlusion, 663–664

- Hepatic blood flow. *See* Blood flow, hepatic
- Hepatic candidiasis, 859
- Hepatic catalase, 1119
- Hepatic choristoma, 621
- Hepatic circulation, 55–56. *See also* Circulation, hepatic
 autoregulation, 57
 neural factors, 57
 regulation, 56
 resistance elements, 57
- Hepatic clearance, 334
- Hepatic coagulopathy, 1029
- Hepatic copper, 1038
- Hepatic diverticulum. *See* Diverticulum, hepatic
- Hepatic drug metabolism, 1211–1220
- Hepatic encephalopathy, 315, 1197–1198
 ammonia-lowering, 1014–1015
 bacterial infections, 1006
 bispectral index, 1011
 branched chained amino acids (BCAA), 1013
 clinical grading, 1011
 clinical manifestations, 1010
 course, 1012
 definition, 1005
 diabetes mellitus, 1006
 diagnosis, 1010–1012
 dietary protein, 1006
 differential diagnosis, 1012
 drugs, 1007
 electrolyte disturbances, 1006–1007
 epidemiology, 1005
 etiology, 1005–1010
 fluid, 1006–1007
 gastrointestinal bleeding, 1006
 grades, 938
 lactitol, 1014
 lactulose, 1014
 liver transplantation, 1015
 malnutrition, 1006
 minimal, 1010
 neuroimaging, 1011
 nomenclature, 1006
 nutritional measures, 1013
 overt, 1010–1011
 pathogenesis, 1005–1010
 pathology, 1010
 precipitating factors, 1005
 prognosis, 1012
 psychometric tests, 1011
 therapy, 1012–1015
 toxins, 1007
- Hepatic failure, fulminant, 482
- Hepatic granulomas, 1235–1238
 causes, 1236
 diagnosis, 1237
 differential diagnosis, 1237–1238
 drugs, 1236
 pathogenesis, 1236–1237
 pathology, 1236–1237
- Hepatic growth, regulators, 160–163
- Hepatic hydrothorax
 clinical manifestations, 1022
 course, 1022
 definition, 1022
 diagnosis, 1022
 epidemiology, 1022
 pathogenesis, 1022
 prognosis, 1022
 therapy, 1022
- Hepatic iron index (HII), 292
- Hepatic lipase, 91
- Hepatic lymphangiomatosis, 1297
- Hepatic metabolism. *See* Metabolism, hepatic
- Hepatic microcirculation, 1211
- Hepatic nodule, 1321
- Hepatic osteodystrophy (HO)
 clinical manifestations, 1030
 definition, 1030
 diagnosis, 1030
 epidemiology, 1030
 pathogenesis, 1030
 therapy, 1030–1031
- Hepatic pain, 536
- Hepatic regeneration, 157–167
- Hepatic resection, 444, 1394
- Hepatic steatosis, drugs, 1126
- Hepatic stellate cells (HSC), 146, 252–253
- Hepatic stem cells, 159
- Hepatic veins, 641–646
 examination, 369–371
- Hepatic venous pressure gradient, 517
- Hepatitis patterns, 320, 540
- Hepatitis
 alcoholic, 238, 544
 autoimmune, 237, 276–277, 543, 881–892
 chronic lobular, 723
 chronic viral, 237
 clinical manifestations, 733–734
 cytomegalovirus, 825
 diagnostics, 690–707
 epidemiology, 733–734
 fibrosing cholestatic, 726, 729
 giant cell, 722, 824
 granulomatous, 248
 hypoxic, 664–665
 interface, 212, 722
 ischemic, 543
 molecular biology, 672
 necroinflammatory activity, 723
 prevention, 733–734
 steatoviral, 726
 therapy, 733–734
 viral, 542–543
- Hepatitis A virus, 724–725
 active immunization, 741–742
 acute liver failure, 739–740
 cholestasis, 726
 cholestatic hepatitis, 739
 clinical presentation, 736–737
 diagnosis, 737–738
 diagnostics, 690–691
 differential diagnosis, 738–739
 epidemiology, 734–736
 extrahepatic manifestations, 737
 fulminant hepatitis, 739–740

- genome organization, 673
- genotypes, 673
- immune globulin, 741
- incidence, 735
- incubation period, 735
- laboratory findings, 737, 738, 747
- molecular biology, 672
- natural course, 739
- passive immunization, 740
- pathogenesis, 735
- pathology, 724
- postexposure prophylaxis, 740–741
- preexposure prophylaxis, 740
- prevention, 740–742
- prognosis, 739
- relapsing hepatitis, 739
- risk and factors, 735, 742
- serotypes, 673
- therapy, 742
- transmission, 735
- vaccines, 742
- Hepatitis B virus, 1359–1360
 - active immunization, 760–761
 - acute, 747
 - asian patients, 776
 - capsid proteins, 677–678
 - children, 776
 - chronic, 747–748
 - cirrhosis, 758
 - clinical manifestations, 747–749
 - coinfection, 775–776
 - complete therapeutic response, 762
 - core particles, 233
 - definition, 743
 - diagnosis, 692, 749
 - differential diagnosis, 749–750
 - drug resistance, 777–780
 - drug resistant mutants, 778
 - envelope proteins, 676–677
 - epidemiology, 743–745
 - exacerbation, 757
 - extrahepatic manifestations, 748–749
 - fibrosing cholestatic hepatitis, 776
 - fibrosis, 725
 - fulminant, 754
 - genome organization, 675–676
 - genotypes, 679, 744
 - goals of therapy, 762–763
 - HBeAg seroconversion, 757
 - HBsAg seroconversion, 757
 - HBV/HCV coinfection, 775
 - HBV/HDV coinfection, 775
 - HBV/HIV coinfection, 775
 - hepatitis B immunology, 682
 - hepatitis flares, 757–758
 - hepatocellular carcinoma, 758–759
 - immune clearance phase, 746
 - immune globulin, 759
 - immune prophylaxis, 759
 - immune response, 682–683, 746
 - immune tolerant phase, 746
 - incubation period, 745
 - indications for therapy, 763
 - interferons, 764–768
 - laboratory findings, 738, 747
 - liver biopsy, 749
 - liver fibrosis, 758
 - liver transplantation, 776
 - major patterns, 750
 - molecular biology, 675
 - molecular diagnosis, 695–698
 - mutants, 750
 - natural course, 747, 753–759
 - non-replicative phase, 746, 747
 - nonresponders, 777–780
 - occult infection, 752–753
 - passive immunization, 759–760
 - pathogenesis, 745–746
 - pathology, 725
 - polymerase, 679
 - postexposure prophylaxis, 759
 - prevention, 759–761
 - prognosis, 753–759
 - progression, 758
 - reactivation, 747, 761
 - reactivation phase, 746
 - replication cycle, 679–682
 - seroconversion, 760
 - serological markers, 693
 - serotypes, 679
 - special therapeutic problems, 775–780
 - spontaneous resolution, 757
 - stages, 746–747
 - standard interferons, 764–765
 - surface antigen, 694
 - transmission, 744
 - treatment and guidelines, 761–774
 - vaccination, 760–761
 - vaccine escape mutants, 761
 - variants, 679, 750
- Hepatitis B virus infection
 - acute, 698
 - chronic, 698–699
- Hepatitis C virus, 1359
 - acute hepatitis C, 792
 - α_1 -antitrypsin deficiency, 800
 - biochemical breakthrough, 801
 - biochemical response, 801
 - children, 799, 807
 - chronic hepatitis C, 792–793
 - cirrhosis, 798
 - clinical manifestations, 791–797
 - coinfection, 799
 - diabetes mellitus, 800
 - diagnosis, 701–702, 791–797
 - end-of-treatment response, 801
 - end-stage renal disease, 807
 - epidemiology, 788–789
 - escape mutants, 791
 - ethnic groups, 808
 - fulminant hepatitis, 798
 - genome organization, 686–687
 - genotypes, 689
 - HBV/HCV coinfection, 799

- hepatocellular carcinoma, 798–799
- HIV/HCV coinfection, 800
- immune pathogenesis, 790
- individualizing treatment, 804–805
- intravenous drug users, 808
- iron overload, 791
- liver cirrhosis, 807
- malignant lymphoma, 1347
- molecular biology, 686
- molecular tests, 701
- natural course, 797–800
- needle stick injury, 800–801
- new approaches to treatment, 805
- nonresponders, 805–807
- non-structural proteins, 688–689
- normal aminotransferases, 799
- NS 5A gene, 688
- pathogenesis, 789–791
- persistently normal aminotransferase levels, 805
- porphyria cutanea tarda, 800
- postexposure prophylaxis, 801
- pregnancy, 799
- prevention, 800–801
- prognosis, 797–800
- quasispecies, 687–688
- recurrent disease, 807
- relapsers, 805–807
- replication cycle, 689–690
- results of treatment, 804
- serotypes, 689
- steatosis, 791
- stopping rules, 803
- structural proteins, 688
- sustained viral response, 801
- therapeutic problems, 805–808
- therapy, 801–808
- transmission, 789
- virologic breakthrough, 801
- virologic relapse, 801
- virologic response, 801
- Hepatitis-delta (D) virus, 683, 699–701, 729
 - antigen, 684–685
 - clinical manifestations, 817
 - coinfection with HBV, 817
 - diagnosis, 699, 817
 - epidemiology, 816
 - genetic heterogeneity, 816
 - genotypes, 684
 - immunology, 685–686
 - molecular biology, 683–684
 - molecular diagnosis, 700–701
 - natural course, 817–818
 - pathogenesis, 816
 - prevention, 818
 - prognosis, 817–818
 - quasispecies, 816
 - replication, 685
 - serology, 699–700
 - superinfection, 817
 - therapy, 818
- Hepatitis E virus, 729, 1265
 - cholestatic variant, 820
 - clinical presentation, 820
 - diagnosis, 691–692, 820
 - differential diagnosis, 820
 - epidemiology, 819
 - fulminant, 820
 - genome organization, 674
 - genotypes, 674–675
 - incubation period, 819
 - molecular biology, 674
 - morphology, 674
 - natural course, 820
 - pathogenesis, 820
 - prevention, 820–821
 - prognosis, 820
 - replication, 675
 - seroprevalence, 819
 - serotypes, 674–675
 - superinfection, 820
 - therapy, 821
- Hepatitis G virus, 733
- Hepatoallergens, 1224
- Hepatobiliary scintigraphy, 1449
 - acquisition technology, 427
 - interpretation, 428–429
 - principle, 427
- Hepatoblastoma
 - course, 1339
 - definition, 1338
 - diagnosis, 1339
 - epidemiology, 1338
 - pathology, 1338
 - prognosis, 1339
 - therapy, 1339
- Hepatoblasts, 7–9
- Hepatocavopathy, obliterative, 643
- Hepatocellular adenoma, 379, 382–384, 408–412, 430
 - color Doppler imaging, 382
 - contrast-enhanced ultrasound, 382
 - conventional B-mode ultrasound, 382
 - definition, 1276
 - diagnosis, 1277–1278
 - differential diagnosis, 382–383, 1278
 - dynamic CT, 1278
 - epidemiology, 1276
 - etiology, 1276
 - MRI imaging, 1278
 - pathogenesis, 1276
 - pathology, 1277
 - prognosis, 1279
 - therapy, 1279
 - ultrasonography, 1278
- Hepatocellular carcinoma, 412–413, 432, 433, 502–503, 557, 758–759, 1361–1364
 - ablative techniques, 1327–1328
 - acinar, 1315
 - advanced stage, 1325
 - afatoxin B₁, 1312–1313
 - alcoholic liver disease, 1308
 - anabolic androgenic steroids, 1309
 - angiotensinogen, 1317
 - Aspergillus flavus*, 1312

- Barcelona clinic liver cancer(BCLC) staging classification, 1325
- betel nut, 1312
- bile droplets, 1317
- Cancer of the Liver Italian Program, 1324–1325
- carcinosarcoma, 1316
- chemotherapy, 1329
- chronic HBV infection, 1308
- chronic hepatitis B virus infection, 1311
- chronic hepatitis C, 1308
- chronic hepatitis C virus infection, 1312
- chronic necroinflammation, 1310
- clear cell, 1316
- clinical findings, 1148
- clinical manifestations, 1317
- color Doppler imaging, 386
- contrast-enhanced ultrasound, 386–387
- conventional B-mode ultrasound, 386
- cryoablation, 1328
- cytokeratin immunostaining, 1317
- definition, 1307
- des- γ -carboxy-prothrombin, 1318
- diabetes mellitus, 1309
- diagnosis and therapy, 1148, 1317–1321
- diarrhea, 1317
- differential diagnosis, 1321
- diffuse type, 1315
- dysplastic foci, 1314
- dysplastic nodules, 1314
- early stage, 1325
- endoglin, 1318
- end-stage disease, 1325
- epidemiology, 1146–1147, 1307–1308
- epigenetic modification, 1310
- erythrocytosis, 1317
- ethnic factors, 1308
- etiology, 1308–1310
- α_1 -fetoprotein, 1317, 1318
- fibrolamellar, 1316
- gene expression profiles, 1314
- genetic susceptibility, 1310
- glutamine synthetase, 1318
- glycogen storage disease, 1309
- glypican 3, 1317, 1318
- grading, 1317
- gross anatomy, 1315
- ground glass inclusions, 1317
- growth factors, 1310
- growth patterns, 1315
- HCV core protein, 1312
- heat shock protein 72, 1318
- hepatic porphyrias, 1309
- hepatitis B carriers, 1326
- Hep Par 1, 1317
- hereditary hemochromatosis, 1309
- hereditary tyrosinemia, 1309
- high grade dysplastic nodules, 1314
- high incidence areas, 1307
- hormonal therapy, 1329
- hyaline inclusion bodies, 1316
- hypercalcemia, 1317
- hypertension, 1317
- hypoglycemia, 1317
- imaging, 1319
- incidence, 1307
- insulin resistance states, 1308
- intermediate stage, 1325
- intracellular inclusions, 1316–1317
- iron-free foci, 1314
- Japan integrated staging score, 1325
- laboratory findings, 1317–1318
- large cell dysplasia, 1313–1314
- liver cell dysplasia, 1313–1314
- liver cell-like, 1316
- liver cirrhosis, 1308, 1312
- liver transplantation, 1327
- low grade dysplastic nodules, 1314
- macroregenerative nodules, 1313
- Mallory–Denk bodies, 1317
- membranous obstruction of the inferior vena cava, 1309
- microcystine, 1312
- microscopic anatomy, 1315–1317
- Milan criteria, 1327
- molecular pathogenesis, 1310
- molecular prognostication, 1322
- mortality trend, 1322
- multinodular type, 1315
- nodule in nodule, 1313
- non-hepatitis B cirrhosis, 1326
- occult hepatitis C, 1312
- Okuda staging system, 1323–1324
- oncocytic, 1316
- oral contraceptives, 1309
- overall survival, 1322
- pale bodies, 1317
- paraneoplastic syndrome, 1317
- parathyroid hormone-related protein, 1317
- pathogenesis, 1147–1148, 1310–1313
- pathology, 1313–1317
- pedunculated HCC, 1315
- percutaneous ethanol injection, 1327, 1328
- pleomorphic, 1316
- precancerous lesions, 1313
- prevention, 1326
- prognosis, 1321–1325
- protein profiling, 1318
- pseudoglandular, 1315
- pseudosarcomatous, 1316
- radiation therapy, 1328
- radiofrequency ablation, 1327, 1328
- risk factors, 1309
- sarcomatoid, 1316
- scirrhous, 1316
- sclerosing hepatic carcinoma, 1316
- screening, 1326
- small cell dysplasia, 1314
- small HCC, 1315
- solid, 1316
- sorafenib, 1329
- spindle cell, 1316
- staging, 1321–1325
- staging systems, 1323

- stem cell, 1311
- surgical resection, 1326–1327
- surveillance, 1320, 1326
- survival, 1321
- survivin, 1317
- telomere hypothesis, 1310
- therapy, 1326–1329
- TNM system, 1323, 1324
- Tokyo score, 1325
- trabecular, 1315
- transarterial chemoembolization, 1327, 1328
- tumor stage, 1323
- uninodular, 1315
- vasoactive intestinal peptide, 1317
- Hepatocellular injury, 540
- Hepatocellular siderosis, grading, 283
- Hepatocellular transport. *See* Transport, hepatocellular
- Hepatocerebral syndrome, 1186
- Hepatocystin, 634
- Hepatocyte(s), 23–25
 - ballooned, 720
 - ductular, 158
 - ground glass, 219–222
 - induced, 221
 - oncocytic, 722
 - periportal, 134
 - perivenous, 134
 - prolapse, 646
 - proliferation, 1276
 - swelling, 138
 - transplantation, 1405
 - volumetric composition, 23
- Hepatocyte growth factor (HGF), 35, 159, 161
- Hepatoerythropoietic porphyria, 1086
- Hepatoolithiasis, therapy, 1490
- Hepatomegaly, 310–311
 - approach to the patient, 553–551
- Hepatopathies, mitochondrial, 1186
- Hepatoportal sclerosis, 252, 659–660, 865
- Hepatoptosis, 622
- Hepatopulmonary syndrome, 1369
 - clinical manifestations, 1018–1019
 - course, 1019
 - definition, 1017
 - diagnosis, 1018–1019
 - diagnostic criteria, 1019
 - differential diagnosis, 1019
 - epidemiology, 1017
 - etiology, 1017–1018
 - grading, 1019
 - pathogenesis, 1017–1018
 - pathology, 1018
 - prognosis, 1019
 - therapy, 1019–1020
- Hepatorenal reflex, 22
- Hepatorenal syndrome, 608
 - clinical manifestations, 1001–1002
 - course, 1002
 - definition, 999
 - diagnosis, 1001–1002
 - diagnostic criteria, 1001
 - differential diagnosis, 1002
 - epidemiology, 999
 - etiology, 999–1001
 - hemodialysis, 1003–1004
 - liver transplantation, 1004
 - midodrine, 1003
 - noradrenaline, 1003
 - octreotide, 1003
 - ornipressin, 1003
 - pathogenesis, 999–1001
 - predictive factors, 1000
 - prognosis, 1002
 - survival, 1002
 - terlipressin, 1003
 - therapy, 1003–1004
 - type 1, 1001
 - type 2, 1001–1002
 - vasopressin, 1003
- Hepatosplenic candidiasis, 859
- Hepato-splenic γ/δ T-cell lymphomas, 1347
- Hepatotoxicity, predictable, 1228
- Hepatotoxic pathway, 1223
- Hepatotoxins, 189, 1224
- Hepcidin, 96, 1048, 1059
- Hepeviridae, 674
- Hephaestin, 94
- Hep Par 1, 1317
- Heptaporphyrins, 1083
- Hereditary coproporphyrin, 1080
- Hereditary hemochromatosis, 544, 1045–1065
 - arrhythmias, 1055
 - arthropathy, 1055–1056
 - cardiomyopathy, 1055
 - chondrocalcinosis, 1055
 - diabetes mellitus, 1054–1055
 - differential diagnosis, 1052
 - early diagnosis, 1050–1052
 - endocrine abnormalities, 1056
 - gastric inhibitory peptide, 1054
 - genetic tests, 1050
 - heart disease, 1055
 - hyperinsulinemia, 1054
 - hypogonadism, 1056
 - insulin resistance, 1054
 - prognosis, 1058
 - screening, 1050–1052
 - sexual impotence, 1056
 - staging, 283
 - testicular failure, 1056
 - therapy, 1056–1058
- Hereditary hemorrhagic telangiectasia, 637, 1248, 1294
- Hering, canals, 41
- Herpes simplex hepatitis, 1265
- Herpes simplex virus, 233, 823–824
- Herpes viruses, 823–827
- Her's disease, 1182
- Heterochromatin, 26
- Heterogeneity
 - functional, 131
 - structural, 131
- Hexose monophosphate shunt, 77

- HFE gene, 1047
 HFE hemochromatosis
 diagnosis, 1048–1050
 epidemiology, 1047–1048
 etiology, 1048
 history, 1047
 laboratory tests, 1048–1049
 pathogenesis, 1048
 type 1, 1047–1052
 High clearance substances, 1218
 High density lipoproteins, 92
 Hilar cholangiocarcinoma
 adjuvant therapy, 1536
 liver transplantation, 1535
 photodynamic therapy, 1540–1543
 prognostic indicators, 1553–1554
 resection, 1533–1535
 survival, 1535
 Histiocytoma, fibrous, 1349
 Histological activity index, 729–730
 Histoplasmosis, 860, 869
 Histoplasmosis, 860, 869
 HIV cholangiopathy, 1501–1503
 HIV-infection, 865
 drug-induced liver injury, 875
 Hepatitis A, 866
 Hepatitis B, 866–867
 Hepatitis C, 867–868
 Hepatitis D, 867
 hepatocellular carcinoma, 873
 Kapsi's sarcoma, 873–874
 malignant lymphomas, 874
 opportunistic infections, 869
 viral hepatitis, 865–866
 HMG-CoA lyase, 89
 HMG-CoA reductase, 88
 HMG-CoA synthase, 89
 Hodgkin's lymphoma, 748, 1250
 Homocystinuria, 1185
 Hormone sensitive lipase, 91
 Hourglass gallbladder, 392
 Human herpesvirus 6, 824
 Human herpesvirus 7, 824
 Human herpesvirus 8, 825
 Hurler's disease, 1276
 Hyalin droplets, 221
 Hyaluronic acid, 45, 46
 4-Hydroxynonenal, 176
 Hydration, liver cell, 137–140
 Hydropic change, 207
 Hydrothorax, hepatic, 1022
 Hydroxyl-ethyl-radicals, 1128
 Hydroxyl radical, 174
 Hydroxyproline, 42, 44
 Hyperammonemia, 1009
 Hyperbilirubinemia, 584, 585
 Hypercholesterolemia, familial, 224
 Hyperdynamic circulation, 596
 clinical manifestations, 1024–1025
 differential diagnosis, 1024
 pathogenesis, 1024
 therapy, 1025
 Hyperferritinemia, 792
 Hyperferritinemia-cataract syndrome, 1063
 Hyperfibrinolysis, 1029
 Hyper- γ -globulinemia, 328, 883
 Hypericum perforatum, 1217
 Hyperlipidemia, 582
 Hyperpigmentation, 314
 Hyperplasia
 Brunner's glands, 1514
 focal nodular, 379, 407, 430, 556, 1284–1287
 liver cell, 554
 mitochondrial, 722
 nodular regenerative, 391, 1280–1283
 Hypersensitivity reactions, 189
 Hypertension
 cerebral, 938–940
 intracranial, 938–939
 portal, 366–367, 518
 portopulmonary, 1020–1022
 Hyperthyroidism, 1249
 Hypertrichosis, 315
 Hypocholeic areas, focal, 360
 Hypogonadism, 1026
 Hypopigmentation, 314
 Hypoplastic gallbladder, 1429
 Hypothermia, 940
 Hypothyroidism, 1249
 Hypoxemia, 1019
 Hypoxia, 181
 Hypoxic hepatitis, 664–665
 Hypoxic liver injury, 181–183
 Hypoxic vacuoles, 208
- I**
 Icterus, 312–313
 Idiosyncrasy, 189, 1224
 Idiosyncratic toxicity, 189
 Ileopathy, portal hypertensive, 988
 Immune granulomas, 247
 Immune mediated, liver injury, 191–195
 Immune phagocytosis, 142
 Immune reactions, antiviral, 192–194
 Immune responses, intrahepatic, 149–150
 Immune therapy, 1408
 Immune thrombocytopenic purpura, 796
 Immunglobulin G₄ associated cholangitis (IAC), 916
 Immunodeficiency, 1276
 Immunofluorescence microscopy, 346
 Immunoglobulin A nephropathy, 748
 Immunoglobulins, 226
 biliary, 147–148
 Immunologic tolerance, 148–149
 Immunomodulatory drugs, 709–710
 Incidentalomas, 555
 Inclusions
 Cowdry type A, 233
 Cowdry type B, 233
 ground-glass, 727
 intracellular, 219–233
 intracytoplasmic, 224–232

- nuclear, 27, 232
 - viral, 233
 - Indian childhood cirrhosis, 961
 - Indinavir, 1216
 - Indirect hepatotoxicity, 1223
 - Indirect hepatotoxins, 1224
 - Indocyanine green test
 - assessment, 336–337
 - confounding factors, 336
 - principle and technique, 336
 - side effects, 336
 - Induced hepatocytes, 221
 - Ineffective erythropoiesis, 587
 - Infantile hemangioendothelioma
 - definition, 1295
 - diagnosis, 1295–1296
 - epidemiology, 1295
 - pathology, 1295
 - therapy, 1296
 - Infections
 - bacteria, 831–841
 - biliary, 1495–1503
 - fungal, 859–861
 - protozoal, 843–848
 - Inferior vena cava, thrombosis, 556
 - Inflammation
 - endotoxin-induced, 197
 - portal vein, 660–661
 - Inflammatory bowel disease, 545
 - Inflammatory myofibroblastic tumor, 1301
 - Inflammatory pseudotumor, 391
 - definition, 1301
 - diagnosis, 1302–1303
 - differential diagnosis, 1303
 - epidemiology, 1301
 - etiology, 1301–1302
 - pathogenesis, 1301–1302
 - pathology, 1302
 - prognosis, 1303
 - therapy, 1303
 - Inflammatory reactions, 236–239
 - Injury
 - hepatocellular, 540
 - hypoxic, 664
 - infiltrative, 548
 - Innervation
 - peptidergic, 22
 - sympathetic, 22
 - Inosine monophosphate dehydrogenase, 712
 - Insulin, 160
 - Insulin-like growth factors (IGF), 162
 - Insulin resistance, 1027
 - Integrins, 47
 - Interface hepatitis, 212, 722, 883
 - Interfering peptides, 1406
 - Interferon(s), 771, 801–802
 - actions, 764
 - adverse reactions, 766
 - contraindications, 767
 - side effects, 803
 - Interleukin 6 (IL-6), 163
 - Interleukin 15 (IL-15), 163
 - Interleukin-11, recombinant, 796
 - Intermediale density lipoproteins, 91
 - Intestinal angina, 535
 - Intracellular deposits, 219–233
 - Intracellular inclusions, 219–233
 - Intracellular pH. *See* pH intracellular
 - Intracranial hypertension, 939–940
 - Intracranial pressure, 938–939
 - Intrahepatic cholestasis, inherited syndromes, 1093–1098
 - Intrahepatic cholestasis of pregnancy, 578
 - course, 1259–1260
 - definition, 1257
 - diagnosis, 1258–1259
 - differential diagnosis, 1259
 - epidemiology, 1257
 - etiology, 1258
 - fetal injury, 1260
 - imaging, 1259
 - pathogenesis, 1258
 - pathology, 1258
 - premature labor, 1260
 - prognosis, 1259–1260
 - therapy, 1260
 - Intrahepatic gallbladder, 1430
 - Intravascular coagulation, disseminated, 1029
 - Irinotecan
 - metabolism, 1215
 - toxicity, 1215
 - Irinotecan toxicity, 1215
 - Iron, 201–202, 227–228
 - absorption, 99
 - carrier, 1048
 - exporter ferroportin 1, 94
 - metabolism, 93
 - regulatory proteins, 94
 - removal, 1057
 - Iron-free focus, 1314
 - Iron index, hepatic, 292
 - Iron overload, 201, 1045–1065
 - complications, 1052–1056
 - diseases, definition, 1046–1047
 - hepatic, 282–283
 - therapy, 1057
 - Ischemia, 181–183, 577, 664
 - Ischemia-reperfusion injury, 185–186
 - Ischemic cholangiopathy, 574–575, 665
 - Ischemic hepatitis, 543
 - Ischemic liver injury, 181–183
 - Ishak score, 730
 - Isocitrate dehydrogenase, 327
 - Isoniazide, 1230
 - Itching, 571
 - Ito cells, 8, 36, 252–253
 - Ito cell tumor, 1304
 - Ivemark's syndrome, 626
- J**
- JAK2 tyrosine kinase, 642
 - Japan integrated staging score, 1325
 - Jaundice, 312–313

breast milk
 classification, 583
 definition, 582
 diagnosis, 584–586
 differential diagnosis, 584–586
 etiology, 582–584
 idiopathic dyserythropietic, 587
 pathogenesis, 582–584
 physiologic
 Jeune's syndrome, 626
 Junin virus, 829
 Juvenile hemochromatosis
 diagnosis, 1059
 natural history, 1059
 treatment, 1059–1060
 Juvenile hereditary hemochromatosis
 pathophysiology, 1058–1059
 prevalence, 1058

K

Kala-Azar, 846
 Kaposi's sarcoma, 1349–1350
 Kaposi's sarcoma, 825
 Kasabach–Merritt syndrome, 1293
 Kasai classification, 1435
 Kausch–Whipple resection, 1556
 Kayser–Fleischer rings, 316, 1037
 KDEL-receptors, 72
 Keratan sulfate, 45
 Kernicterus, 587
 Ketogenesis, 89
 Ketone bodies, 89
 Kinesin, 32, 66
 King's college criteria, 289, 292, 933
 Klatskin-mimicking lesions, 1532
 Klatskin tumor(s), 442, 1361, 1532
 Klinefelter's syndrome, 1276
 Knodell's score, 273
 K-sparing diuretics, 971
 Kupffer cells, 34–35, 136, 140, 142
 Kwashiorkor, 1188

L

Laboratory parameters, 319–331
 Labrea fever, 224
 Lactate dehydrogenase, 323
 Lactulose, 984
 Lafora bodies, 219, 222
 Laminin, 46–47
 Lamivudine, 708, 768–771
 duration of treatment, 768–769
 predictors of response, 769
 resistance, 777–779
 results of treatment, 769–770
 Langerhans cell histiocytosis, 1251
 Laparoscopy
 complications, 496
 contraindications, 490
 equipment, 491–492
 risk profile, 495–498
 technique, 489–490

Lassavirus, 828
 LDL receptor, 91
 LDL receptor related protein, 91
 Lead intoxication, 1085
 differential diagnosis, 1087
 Lecithin:cholesterol acyltransferase (LCAT), 92
Legionella pneumophila, 837
 Legionnaire's disease, 837
 Leiomyomas, 1304
 Leiomyosarcoma, 1350
 Leishmaniasis, 846
 Leptin, 39, 255, 1159
 Leptospira, 837–838
 Leptospirosis, 837
 Lesions, precancerous, 1313
 Leucin aminopeptidase, 326
 Leucocytoclastic vasculitis, 748
 Leukopenia, 1028
 Lichen planus, 314–315
 Ligament
 coronary, 12
 falciform, 12
 hepatorenal, 12
 triangular, 13
 venous, 13
 Ligandins, 110, 584
 Light chains, nonamyloidotic, 654
 Lille model, 289, 291–292
 Limit dextrinosis, 1182
 Lindsay nails, 315
 Linoleic acid, 85, 89
 Linolenic acid, 85
 Linton-Nachlas-tube, 984
 Lipase
 hepatic, 91
 hormone sensitive, 91
 Lipids, 85–86, 224–225
 homeostasis, 89
 peroxidation, 175–176, 1158
 Lipocytes, 36
 Lipodystrophy syndrome, 876
 Lipofuscin, 228
 Lipogranulomas, 249, 1237
 Lipoma, 1298
 Lipomatous tumors, 1298
 Lipomelanin, 1277
 Lipopolysaccharide, bacterial, 149
 Lipoprotein lipase, 90
 Lipoproteins, 89–92
 high density, 91
 low density, 91
 very low density, 91, 92
 Lipoprotein X, 546
 Liposarcoma, 1350
 Liposomes, 121
 Liquid crystals, 121
Listeria monocytogenes, 838
 Listeriosis, 994
 Lithocholic acid, 109
 Litholysis
 contact, 1476, 1477

- oral, 1475–1476
- Lithotripsy, 1489
 - extracorporeal shock wave, 1476–1477
 - intracorporeal electrohydraulic, 442
- Liver
 - agenesis, 622
 - aging, 153–155
 - atrophy, 622
 - cysts, 631–633
 - extraabdominal location, 622
 - hemodynamic parameters, 56
 - hypoplasia, 622
 - immune organ, 141–151
 - intraabdominal displacement, 622
 - malformations, 621–622
 - malpositions, 621–622
 - palpation, 310–311
 - percussion, 310–311
 - span, 310–311
 - transposition, 622
- Liver abscess, 555, 1486
 - amebic, 843–848
 - bacterial, 831–841
 - causes, 833
 - course, 834
 - definition, 832
 - diagnosis, 833–834
 - differential diagnosis, 834
 - epidemiology, 832
 - etiology, 832–833
 - pathogenesis, 832–833
 - prognosis, 834
 - therapy, 834–835
- Liver acinus, 15–16, 18
- Liver ageing, drug metabolism, 155
- Liver bile, 104
- Liver biopsy, 259–261, 554
 - biopsy technique, 478
 - complications and mortality, 479
 - contraindications, 477
 - indications, 476–477
 - percutaneous, 463–470
 - success rate, 476
 - transjugular, 476
 - transvenous, 475–484
- Liver bud, 7, 8
- Liver carcinoma, 1053
- Liver cell
 - adenoma, 556
 - adenomatosis, 1277
 - death, 209–218
 - degeneration, 207–209
 - dysplasia, 724, 1313–1314
 - hydration, 137–140
 - hyperplasia, 554
 - injury, 236
- Liver cell death, ischemic, 182
- Liver cell mass
 - functional, 334
- Liver cell rosettes, 212, 238, 242
 - regenerative, 722
- Liver cirrhosis, 360–361, 1052–1053
 - α_1 -antitrypsin deficiency, 955
 - APACHE III-score, 963
 - bacterial infections, 994–998
 - biliary cirrhosis, 955
 - capillarization of sinusoids, 951
 - cardiovascular, 1024–1025
 - causes, 950
 - cell death, 950–951
 - Child-Pugh stages, 958
 - chronic viral hepatitis B, 954
 - chronic viral hepatitis C, 955
 - circulatory disturbances, 951
 - clinical manifestations, 955–959
 - clonidine, 976
 - coagulopathy, 1028–1029
 - compensated, 962
 - complications, 967–988, 994–1015, 1017–1022, 1024–1031, 1245
 - course, 962–963
 - decompensated, 962
 - definition, 949
 - diagnosis, 955–961
 - differential diagnosis, 961–962
 - endocrine alterations, 1026–1027
 - endoscopic ultrasonography (EUS), 960
 - epidemiology, 949
 - etiology, 950–952
 - α_1 -fetoprotein, 962
 - hematologic alterations, 1028–1029
 - hemodynamic alterations, 951
 - hepatocellular carcinoma (HCC), 962
 - hepatocyte growth, 951–952
 - hepatocyte proliferation, 951
 - hereditary hemochromatosis, 955
 - histological findings, 954–955
 - hyperdynamic circulation, 958
 - imaging, 960–961
 - interface hepatitis, 954
 - intrahepatic vascular shunts, 951
 - laboratory findings, 959–960
 - laparoscopy, 960
 - liver biopsy, 960
 - liver cell failure, 956
 - liver transplantation, 975
 - magnetic resonance imaging, 960
 - malnutrition, 956
 - MELD score, 963
 - muscular complications, 1031
 - nodule, 1321
 - obesity, 962
 - operative risk stratification, 1390
 - operative mortality, 1386, 1392
 - outcome, 962
 - pathogenesis, 950–952
 - pathology, 952–955
 - physical findings, 958
 - portal hypertension, 956
 - prognosis, 520, 962–963
 - pseudolobuli, 951
 - pulmonary complications, 1017–1022

- scanning, 960
- screening, 962
- sexual dysfunction, 1026
- sonography, 960
- surgical risk, 1390
- terlipressin, 976
- therapy, 963–964
- thyroid dysfunction, 1026–1027
- transient elastography, 960
- vasoconstrictor drugs, 975
- vasopressin receptor antagonists, 975
- venous outflow obstruction, 955
- Wilson's disease, 955
- Liver cirrhotic, mass lesion, 1320
- Liver cyst(s), 376
 - acquired, 632
 - classification, 632
 - congenital, 632
- Liver damage
 - drug-induced, 277
 - oxidative, 176–177
 - toxic, 189
- Liver diseases(s)
 - alcoholic, 1111–1148, 1358–1359
 - autoimmune, 886, 888, 889
 - categories, 302
 - chronic, 498–501
 - fibropolycystic, 625
 - gene therapy, 1404
 - molecular prevention, 1408–1409
 - monogenic, 1404
 - nutrition, 1187–1203
 - nutritional therapy, 1196
 - operative risk, 1385–1394
 - polycystic, 633–635
 - surgery, 1383
- Liver enzymes
 - abnormal, 537–550
 - approach to the patient, 548–550
- Liver failure, 571
 - acute, 931–944
- Liver fibrosis
 - congenital, 625–627
 - resolution, 256
- Liver fibrosis, 251
- Liver flap, 1010
- Liver function, test, 333–342
- Liver heterotopia, 621
- Liver injury
 - cholestasis-induced, 199
 - cholestatic, 1225
 - drug-induced, 189–190, 1223–1230
 - endotoxin mediated, 197–198
 - enzyme patterns, 320
 - hepatocellular, 1225
 - hepatotoxic, 1224–1225
 - histological patterns, 1225–1227
 - hypoxic, 181–183, 664
 - idiosyncratic, 1224, 1225, 1230
 - ischemic, 181–183
 - laboratory parameters, 1225
 - metal-induced, 201–202
 - mixed, 1225
 - toxic, 1224
- Liver-iron-index, 1049
- Liver lesions
 - cystic, 555
 - diagnostic approach, 554–555
 - differential diagnosis, 555–557
 - focal, 371–391, 429–432, 553–557
 - solid, 555
- Liver lobule, 15–16
- Liver regeneration
 - alternate pathways, 167
 - molecular mechanisms, 164–166
 - morphology, 158–159
 - multi-step model, 166
 - pathologic, 158
 - physiologic, 158
 - reparative, 158
 - termination, 167
- Liver, segments, 13
- Liver size
 - determination, 553
 - etiology, 554
 - pathogenesis, 554
- Liver stiffness, 262
- Liver transplantation, 444, 1353–1379
 - acute cellular rejection, 1375
 - age, 1368–1369
 - alcoholic liver disease, 1358–1359
 - antibodies, 1374
 - α_1 -antitrypsin disease, 1364
 - arterial hypertension, 1375–1376
 - aspergillus* infection, 1378
 - azathioprine, 1374
 - bacteremia, 1378
 - bacterial infection, 1377
 - basiliximab, 1374
 - bile duct cast syndrome, 1376
 - bile duct obstruction, 1376
 - bile leaks, 1376
 - biliary complications, 1376
 - Budd–Chiari syndrome, 1364
 - candidiasis, 1378
 - cardiopulmonary contraindications, 1369
 - Child–Pugh classification, 1356
 - cholangiocarcinoma, 1361
 - cholestatic liver disease, 1360
 - contraindications, 1368–1370
 - corticosteroids, 1374
 - cyclosporine, 1373
 - cytomegalovirus infection, 1378
 - daclizumab, 1374
 - delisting criteria, 1371
 - delta MELD, 1356
 - diabetes mellitus, 1375
 - evaluation, 1355, 1366–1368
 - expected survival, 1357
 - fulminant hepatic failure, 1364–1365
 - fungal infection, 1378
 - hepatic malignancy in children, 1366

- hepatitis B, 1359–1360
 - hepatitis C, 1359
 - hepatitis in children, 1366
 - hepatocellular carcinoma, 1361–1364
 - hepatopulmonary syndrome, 1369
 - hereditary hemochromatosis, 1364
 - HIV infection, 1369–1370
 - hypercoagulable state, 1364
 - immunosuppression, 1373
 - indications, 1357–1366
 - infection, 1377–1378
 - infectious contraindications, 1369–1370
 - Klatskin tumor, 1361
 - listing, 1355, 1366–1368
 - living donor liver transplantation, 1363, 1371–1372
 - malignant diseases of the liver, 1360–1364
 - medical evaluations, 1355
 - metabolic liver disease, 1364
 - minimal listing criteria, 1357–1358
 - mycophenolate mofetil, 1374
 - opportunistic infection, 1377
 - organ allocation, 1355, 1356
 - pediatric cholestatic diseases, 1365–1366
 - pediatric end stage liver disease, 1356
 - pediatric metabolic liver diseases, 1366
 - perioperative period, 1372–1373
 - portal vein thrombosis, 1364
 - posttransplantation infection, 1377
 - posttransplant period, 1372–1378
 - pretransplant workup, 1367
 - primary biliary cirrhosis, 1360
 - primary sclerosing cholangitis, 1360
 - prioritization, 1356
 - psychosocial contraindications, 1369
 - psychosocial evaluations, 1355
 - rapamycin, 1374
 - recurrent disease, 1376–1377
 - rejection, 1375
 - retransplantation in children, 1366
 - scoring systems, 1356
 - tacrolimus, 1373
 - timing of transplantation, 1370–1371
 - vascular complication, 1376
 - vascular disease of the liver, 1364
 - veno-occlusive disease, 1364
 - viral hepatitis, 1359–1360
 - viral infection, 1378
 - waiting list, 1356, 1370–1371
 - Wilson's disease, 1364
 - Liver transplant, in child, 1365–1366
 - Liver transplant recipients, 483–484
 - Liver tumors, 372–374
 - secondary, 505–509
 - Liver weight, 157
 - Living donor liver transplantation, 1363, 1371–1372
 - LKM-1 autoantibodies, 793
 - Lobe, caudate, 13, 14, 645
 - hypertrophy, 556
 - Lobe, quadrate, 13
 - Longitudinal scan, 456
 - Loop diuretics, 971
 - L-ornithine-L-aspartate (LOLA), 1014
 - Low clearance substances, 1218
 - Low density lipoproteins, 91
 - Low-T₃ syndrome, 1026
 - LPAC syndrome, 1095
 - Lunulae, blue, 315
 - Lyme disease, 835
 - Lymphadenopathy, perihepatic, 361, 362
 - Lymphangioma, 1297
 - Lymphangiomatosis, hepatic, 1297
 - Lymphatics, 21–22
 - Lymph nodes, 21
 - Lymphocytes
 - $\alpha\beta$ -T cell receptor ($\alpha\beta$ -TCR), 143–144
 - $\gamma\delta$ -T cell receptor ($\gamma\delta$ -TCR), 144
 - intrahepatic, 142–145
 - large granulated, 40, 144
 - Lymphocytosis, intrasinusoidal, 826
 - Lymphohistiocytic granuloma, 248
 - Lymphoid aggregate, 638
 - Lymphoma
 - color Doppler imaging, 390
 - contrast enhanced ultrasound, 390
 - conventional B-mode ultrasound, 390
 - Lysosomes, 29–30
 - functions, 30
 - Lytic necrosis, 210
- M**
- Machupovirus, 829
 - Macrocytosis, 1028
 - Macroenzymes, 321, 545
 - Macronodular cirrhosis, 953–954
 - Macrophage activating syndrome, 1250
 - Macrophages, ceroid storing, 211
 - Macroregenerative nodules, 1313
 - Maddrey index, 289, 291–292
 - Maddrey score, 1137
 - Magnetic resonance imaging, 405–421
 - Malabsorption, 570, 581
 - Malacoplakia, 1508
 - Malaria, 847
 - Malarial pigment, 230
 - Malformations, arterial vascular, 365
 - Malignant cells, dissemination, 469
 - Malignant fibrous histiocytoma, 1349
 - Malignant lymphoma
 - B-cell, 1347
 - $\gamma\delta$ -lymphoma, 1347
 - primary hepatic, 1347–1348
 - T-cell, 1347
 - Malignant teratomas, 1350
 - Malignant tumors, 1305–1350
 - Mallory-Denk bodies, 226–227
 - Mall, space of, 21
 - Malnutrition, 1187–1203
 - cirrhosis, 1190
 - definition, 1188–1189
 - pathophysiology, 1190–1193

- patterns, 1189
 - prognosis, 1193–1194
- Malondialdehyde, 176, 1130
- Maltose cross structures, 1084
- Manganese superoxide dismutase, 1121
- Mannitol, 939
- Mannose/N-acetylglucosamine receptor, 33
- Manometry
 - complications, 526–527
 - contraindications, 524
 - equipment, 524
 - indications, 523–524
 - normal findings, 525–526
 - pathological findings, 526
 - sphincter of Oddi, 1447
 - technique, 524–525
- Marasmus, 1188
- Marburg virus, 829
- Massive necrosis, 721
- Matrix components, 42
- Matrix, extracellular, 159
- Matrix-metalloproteinases (MMPs), tissue
 - inhibitors of, 44, 255
- Mauriac syndrome, 226
- Mayo risk score, 289, 291
- McArdle's syndrome, 1182
- Measles virus, 827
- Mechanical lithotripsy, 1489
- Meckel–Gruber's syndrome, 626
- Medical history, 302–303
- Mediterranean spotted fever, 839
- Megamitochondria, 222–224, 1128
- Melanin, 230
- Melioidosis, 836
- Membrane
 - canalicular, 25
 - hepatocellular, 62
 - lateral, 25
 - sinusoidal, 25
- Membranoproliferative glomerulonephritis, 794
- Membranous glomerulonephritis, 748
- Menghini needle, 465
- Mercaptanes, 1009
- Mesenchymal hamartoma, 1297
- Metabolic diseases
 - amino acid metabolism, 1185
 - carbohydrate metabolism, 1182
 - lipid metabolism, 1183–1184
- Metabolic syndrome, 1154–1160
- Metabolism, hepatic, 75–99
- Metachromatic leucodystrophy, 1184
- Metallochaperons, 93
- Metalloproteinases, 159, 254
- Metalloproteinases, tissue inhibitors of, 44
- Metalloproteinases-1
 - tissue inhibitors of, 254
- Metallothioneins, 93
- Metals, 227–228
- Metal stents
 - self-expanding, 443, 1539
- Metal transporter 1, 94
- Metastases, 414–419, 430, 432, 434–435, 556
 - color Doppler imaging, 387
 - contrast enhanced ultrasound, 387–388
 - conventional B-mode ultrasound, 387
 - neuroendocrine, 388–390
- METAVIR score, 273
- Methotrexate toxicity, 278
- Methylation, 128
- Methyl-tertiary-butyl ether, 1477, 1490
- Meulengracht's disease, 588
- Micellar concentration, 119
- Michaelis Gutman, inclusion bodies, 1509
- Microabscesses, miliary, 838
- Microbodies, 30
- Microbubbles, 373
- Microcirculatory units, hepatic, 16
- Microfilaments, 32
- Microgallbladder, 392
- Microhamartomas, biliary, 1288
- Micronodular cirrhosis, 952–953
- Microsomal enzymes
 - induction, 1217
 - inhibition, 1217
- Microsomal ethanol oxidizing system, 1116–1119
- Microsomal function, 334
- Microsomal transfer protein, 90, 1157
- Microtubules, 32
- Microvesicular steatosis, 1265
- Milan criteria, 1327
- Milwaukee criteria, 1446
- Mineral oil granulomas, 249
- Mirizzi syndrome, 441, 1445, 1474
- Mitochondria, 30
 - matrix, 31
- Mitochondrial enzymes, 539
- Mitochondrial hepatopathies, 1186
- Mitochondrial hyperplasia, 722
- Mitochondriosis, 222
- Mixed function oxygenase, 1217
- Mixed micelle, 121
- Model for end-stage liver disease (MELD), 289–291, 1137, 1354
- Molecular adsorbents recirculation system (MARS), 943
- Monoacinar cirrhosis, 953
- Monoethylglycinexylidide test
 - assessment, 339
 - confounding factors, 339
 - principle and technique, 338
 - side effects, 339
- Mononeuritis multiplex, 797
- Monoxygenases
 - microsomal, 127
 - mixed reaction, 128
- Morula cells, 224
- Motor proteins, 32, 66
- Mucin carbohydrate antigens, 1291
- Mucin core proteins, 1291
- Mucormycosis, 860
- Muehrcke lines, 315
- Multiacinar cirrhosis, 953
- Multiband ligation, 981

- Multi drug resistance, 65
Multi-drug resistance-associated protein 2, 69, 108
Multidrug resistance protein, 112
Multilobular necrosis, 721
Multiple myeloma, 1250
Multiseptate gallbladder, 1431
Muralium duplex, 8
Muralium simplex, 8
Murphy's sign, 536, 1472
Muscle cramps, 307, 1031
Muscular complications, 1031
Mushroom poisoning, 934–935
Mutants, dominant-negative, 711–712
Mycobacteria, 838–839
Mycobacteriosis, atypical, 839
Mycobacterium avium intracellulare, 249, 838, 869
Mycobacterium leprae, 838
Mycobacterium tuberculosis, 249, 838
Mycophenolate mofetil, 1374
Mycoplasma pneumoniae, 839
Myofibroblastic tumor, inflammatory, 1301–1303
Myostatin, 1193
- N**
N-acetylcysteine (NAC), 934
N-acetyl-p-benzoquinone-imine (NAPQI), 934
Nadolol, 980, 981
NADPH oxidase, 186
Nail changes, 315
Naloxone, 580
Naltrexone, 580
Na-taurocholate cotransporter, 68
Natriuretic peptides, 606
Natural killer cells, 144–145, 194
Natural killer T cells, 144
Nausea, 306
Navajo neurohepatopathy, 1186
Necroinflammatory reaction, 235–239
Necrosis, 209
 acidophilic, 210
 bridging, 212
 coagulative, 210
 confluent, 211–212
 lytic, 210
 massive (panlobular), 211
 multilobular, 211
 patterns, 210
 piecemeal, 212
 porto-venous, 212
 single cell, 210–211
 submassive, 211
 surgical, 212–213
 veno-venous, 212
 zonal, 211
Nectins, 46
Nematode cholangitis, 1500–1501
Nematodes, 1502
Neonatal hemochromatosis, 1047
Nerves, 22
 parasympathetic, 22
 sympathetic, 22
Network, microtrabecular, 31
Neural factors, 57
Neurofibromatosis, 1251
Neurogenic pain, 535
Neurologic-psychiatric changes, 315–316
Neuropathy, 797
Neuropsychiatric symptoms, 306
Neurotoxins, 1007–1009
Neurotransmission, opioidergic, 580
Neurotransmitters, false, 1009–1010
Nidogen, 47
Niemann–Pick disease, 1183
Nieman-Pick type C disease, 224
Nitrates, 981
Nitric oxide (NO), 57, 58, 174, 596, 606, 607
Nitrogen, 1196
Nitrogen compounds, 83–85
Nocardiosis, 835
Nodular panniculitis, 315
Nodular regenerative hyperplasia, 391
 conditions associated, 1280
 definition, 1280
 diagnosis, 1282
 differential diagnosis, 1282
 epidemiology, 1280
 etiology, 1280–1281
 natural history, 1282–1283
 pathogenesis, 1281
 pathology, 1281–1282
 prognosis, 1282–1283
 therapy, 1283
Nodular transformation, partial, 1281
Nodules
 dysplastic, 557, 1314
 hepatic, 1321
 macroregenerative, 1313
 regenerative, 557
Nodule in nodule, 1313
Non-acute porphyrias, 1081–1082
Nonalcoholic fatty liver disease (NAFLD), 544,
 1153–1174, 1393
 bariatric surgery, 1174
 carbohydrate response element binding protein, 1156
 causes, 1155
 children, 1154
 chronic hepatitis C, 1154
 clinical manifestations, 1163–1164
 clinical scoring system, 1164
 definition, 1153
 diagnosis, 1163–1165
 differential diagnosis, 1165
 drugs, 1154
 epidemiology, 1153–1154
 ethnic differences in, 1154
 etiology, 1154–1155
 gastrointestinal surgical procedures, 1154
 glycogenated nuclei (Lochkerne), 1161
 HCV genotype 1, 1160
 HCV genotype 3, 1160
 imaging, 1164–1165

- insulin resistance, 1156
 - laboratory findings, 1164
 - lifestyle modifications, 1166
 - lipogenesis, 1157
 - lipolysis, 1156
 - macrovesicular steatosis, 1161
 - metabolic syndrome, 1154
 - metformin, 1173
 - microsomal transfer protein, 1157
 - microvesicular steatosis, 1161
 - natural course, 1165–1166
 - obesity, 1154
 - pathogenesis, 1155–1161
 - pathology, 1161–1163
 - peroxisomal proliferator activated receptors, 1166
 - pharmacological therapy, 1166–1173
 - polycystic ovary syndrome, 1154
 - prognosis, 1165–1166
 - steatosis, 1161
 - sterol regulatory element-binding protein-1c, 1156
 - therapy, 1166–1174
 - thiazolidinediones, 1166
 - type 2 diabetes mellitus, 1154
 - visceral adipose tissue, 1157
 - Nonalcoholic steatohepatitis, 239, 364, 1153
 - adipocyte hormones, 1159
 - adiponectin, 1159–1160
 - endotoxin, 1159
 - fibrosis, 1162
 - genetic influences, 1160
 - ghrelin, 1160
 - hepatocyte injury, 1162
 - histology, 1163
 - histomorphology, 1127
 - inflammation, 1163
 - iron overload, 1160
 - leptin, 1159
 - mitochondrial alterations, 1159
 - resistin, 1160
 - visceral fat, 1159
 - Nonamyloidotic light chains, 654
 - Non-A-Non-B hepatitis, 686
 - Nonepithelial tumors, 1275
 - Non-essential aminoacids, 1198
 - Nonhepatotropic viruses, 823–829
 - Non-Hodgkin's lymphoma, 796–797, 1250
 - Nonimmune phagocytosis, 142
 - Nonparenchymal cells, 136, 138, 140
 - Norepinephrine, 606
 - Nuclear changes, 232–233
 - Nuclear factor, hepatic, 9
 - Nuclear imaging, 425–435
 - Nuclear inclusions, 232
 - Nuclear swelling, 232
 - Nuclei, sanded, 233
 - Nucleos(t)ide analog, 708
 - Nucleosides, 768–774
 - 5'-Nucleotidase, 325–326
 - Nucleotides, 768–774
 - Nucleus, 26
 - Nutrient intake, 1190
 - Nutrition, 1396
 - cholestasis, 573
 - total parenteral, 573–574
 - Nutritional assessment, 1194–1195
 - Nutritional interventions, 1198
 - Nutritional management
 - alcoholic hepatitis, 1199
 - cirrhosis, 1199
 - fulminant hepatic failure, 1199–1200
 - guidelines, 1200
 - Nutritional requirement, 1196
 - Nutritional status, measurement, 1194
 - Nutritional supplements, 1202
 - Nutritional therapy, 1196
- O**
- Obesity, 1155–1160, 1189, 1203
 - Obliterative endarteritis, 667
 - Obliterative hepatocavopathy, 643
 - Obliterative portal venopathy, 1282
 - Obstructive sleep apnea, 1248
 - Occlusion, hepatic artery, 663–664
 - Octopamine, 1009
 - Octreotide, 981
 - Okuda staging system, 1323–1324
 - Oncocytic change, 222
 - Oncolytic viruses, 1408
 - ONKO PET, 433
 - Oral contraceptives, 1249, 1276
 - Organgefühl, 306, 535
 - Organic anion transporter
 - multispecific canalicular, 112
 - Organic anion transporting polypeptides, 68
 - Organic anion transporting proteins, 564
 - Organic cation transporters, 68, 564
 - Organization, structural, 15
 - Oriental cholangiohepatitis, 627
 - Oriental cholangiopathy, 445
 - Ornithine transcarbamylase, 327
 - Orrego index, 1137, 1138
 - Orthodeoxia, 1017, 1018
 - Osler–Weber–Rendu syndrome, 313, 371, 637, 1252
 - Osmosignaling, 138
 - Osteodystrophy, hepatic, 1030–1031
 - Osteomalacia, 1030
 - Osteomyelofibrosis, 1249
 - Osteopenia, 581–582
 - Osteoporosis, 1030
 - Outflow obstruction, hepatic venous, 370
 - Oval cells, 41, 167
 - Ovarian insufficiency, 1026
 - Ovarian tumors, 1276
 - Overflow hypothesis, 608
 - Overlap syndromes, autoimmune, 925–927
 - Oxidases, 127, 128
 - β-Oxidation, 86, 87
 - Oxidative stress, 174–180, 1158
 - defense mechanisms, 177
 - 2-Oxo-acid dehydrogenase enzymes, 350
 - Oxygen consumption, hepatic, 56

P

- Pain, 306
 biliary, 535–536
 causes, 534–536
 clinical evaluation, 534–536
 conduction, 532–533
 epigastric, 534, 535
 hepatic, 536
 neurogenic, 535
 origin, 531–532
 referred, 533
 right upper quadrant, 534, 535
 somatic, 532, 533
 types, 533
 visceral, 532, 533
- Palmar erythema, 313–314
- Pancreatic cancer, 508–509
- Pancreaticoduodenectomy, 1516
- Pancreatitis, biliary, 1474
- Panniculitis, nodular, 315
- Papillary adenomas, 1512
- Papillectomy, 1516
- Papillomas, 458
- Papillomatosis, 1511, 1512
 biliary, 1291
- Papulose acrodermatitis, 314
- Paraaminosalicylic acid, 1230
- Paracentesis
 large-volume, 972–973
 practical approach, 973
- Paracetamol, 1228
- Paracoccidiomycosis, 860–861
- Paramyxoviruses, 827
- Parathyroid hormone, 161, 1031
- Parenteral nutrition, 1202
- Paroxysmal nocturnal hemoglobinuria, 1250
- Partial nodular transformation, 1281
- Partial therapeutic, response, 762
- Partial thromboplastin time, 329
- Parvoviruses, 829
- Parvoviruses B19, 829
- Passive septa, 258
- Pattern recognition receptors (PRR), 149
- Patterns of injury
 cholestatic, 540
 hepatic, 540
 mixed, 540
- Pearson's syndrome, 1186
- Pegylated interferon, 765–768
- Peliosis hepatis, 650–651
- Peliosis hepatic, bacillary, 869
- Penicilliosis, 861
*Penicillium marneffei*¹, 861
- Pentose phosphate pathway, 77
- PEP carboxylase, 79
- Pepper-and-salt-stones, 1466
- Peptidergic transmitters. *See* Transmitters, peptidergic
- Peptides
 natriuretic, 606, 607
 vasodilating, 606, 607
- Percutaneous ethanol, 1363
- Percutaneous transhepatic cholangiography, 1499
 complications, 446
- Perforin, 193
- Performance status, 1323
- Perfusion scintigraphy
 acquisition technology, 426–427
 interpretation, 427
 principle, 426
- Peribiliary glands, hyperplasia, 1289
- Pericytes, 36, 57
- Pericytoma, spongiotic, 1304
- Periductal fibrosis, 256
- Perihepatitis gonorrhoea, 837
- Perioperative care, 1394–1395
- Perisinusoidal lesions, 654
- Peritoneovenous shunt, 974
- Peritonitis, spontaneous bacterial, 994–998
- Perivenous sclerosis, 258
- Perlecan, 45
- Peroxisomal disorders, 1185
- Peroxisome proliferator activated receptors (PPARs), 30
- Peroxisomes, 30
- PFIC. *See* Progressive familial intrahepatic cholestasis
- PFIC 1, 1095, 1097
- PFIC 2, 1095, 1098
- PFIC 3, 1098
- Phagocytosis
 immune, 142
 nonimmune, 142
- Phalloidin, 189, 568, 1229
- Phase II reactions, 127
- Phase I reactions, 127
- Phenobarbital, 580
- Phenoles, 1009
- Phenotypic resistance, 777
- Phenylethanolamine, 1009
- pH intracellular, 70–71
- Phlebitis, granulomatous, 661
- Phleboscrosis, 659
- Phlebotomy, 1056–1057
- Phosphofructokinase, 78
- Phospholipids, 86, 109–110, 225
- Photosensitivity, cutaneous, 1086
- Phototherapy, 581
- pH-regulation, systemic, 135
- Phrygian cap, 392, 1431
- Phycomycosis, 860
- Physical examination, 309–316
- Physiologic jaundice, 587
- Picornaviruses, 673
- Piecemeal necrosis, 212, 236
- Pigment, 228–230
 anthracotic, 230
 ceroid, 229–230
 Dubin-Johnson, 228–229
 malarial, 230
 schistosomal, 230
 wear and tear, 228
- Pinocytosis, 66
- Pit cells, 18, 39–40, 144
- Plasma cell granuloma, 1301

- Plasma cell hepatitis, 883
 Plasma membrane, 25
Plasmodium falciparum, 847
 Platelet-derived growth factor (PDGF), 254
 Platelets, 1028–1029
 Platypnea, 1018
 Plexogenic arteriopathy, 1021
Pneumococci, 839
Pneumocystis carinii (jiroveci), extrapulmonary, 869
 Pneumoperitoneum, 492–494
 POEMS syndrome, 554
 Pohl score, 263
 Polyarteritis nodosa, 667, 748, 794–795, 1250
 Polycystic kidney disease, autosomal recessive, 633
 Polycystic liver disease, autosomal dominant, 633
 Polycystic ovary syndrome, 1276
 Polycystin, 634
 Polycythemia vera, 1249
 Polyglandular syndrome, autoimmune, 885
 Polyglucosan bodies, 226
 Polymerase inhibitors, 715–716
 Polymorphism, genetic, 129, 1214
 Polyneuropathy, 748, 797
 Polyps, gallbladder, 395
 Pompe's disease, 1182
 Pontiac fever, 837
 Porcelain gallbladder, 394, 1473
 Pore complexes, nuclear, 26
 Porphyria cutanea tarda, 795, 1078, 1081–1084, 1086, 1088–1090
 iron overload, 1081
 Porphyrrias
 definition, 1077–1078
 enzyme defects, 1078
 epidemiology, 1078–1079
 gene mutations, 1079
 Porta hepatitis, 13
 Portal blood flow, sonographic determination, 599
 Portal fibrosis, non-cirrhotic, 594
 Portal flow, hepatofugal, 367
 Portal hypertension, 366–367, 518
 complications, 600
 course and prognosis, 600
 definition, 593
 diagnosis, 597–600
 differential diagnosis, 600
 epidemiology, 593
 etiology, 594
 idiopathic, 659
 non-cirrhotic, 594, 659, 961
 pathogenesis, 595
 therapy, 600–601
 Portal hypertensive colopathy, 988
 Portal hypertensive enteropathy, 988
 Portal hypertensive gastropathy
 clinical manifestations, 986–987
 course, 987
 definition, 986
 diagnosis, 986–987
 differential diagnosis, 987
 endoscopic changes, 987
 epidemiology, 986
 etiology, 986
 pathogenesis, 986
 pathology, 986
 prognosis, 987
 therapy, 988
 Portal hypertensive ileopathy, 988
 Portal pressure
 balloon occlusion technique, 517
 circadian variations, 518
 measurement, 515–520
 normal values, 518
 pathologic values, 518–519
 Portal tracts, 16
 Portal vein, 366, 657–663. *See also* Vein(s)
 cavernous transformation, 368, 637, 658
 examination techniques, 368–369
 fibrous obliteration, 637
 gas embolism, 661
 inflammation, 660–661
 Portal vein thrombosis, 365, 368–379, 657
 acute, 657–658
 chronic, 658–659
 etiology, 658
 Portopulmonary hypertension
 clinical manifestations, 1021
 course, 1021
 definition, 1020
 diagnosis, 1021
 differential diagnosis, 1021
 epidemiology, 1020
 etiology, 1020–1021
 pathogenesis, 1020–1021
 pathology, 1021
 prognosis, 1021
 therapy, 1021–1022
 Portosystemic collaterals, 600
 Portosystemic encephalopathy, 306
 Positron emission tomography (PET), 432
 Postabsorptive phase, 81, 134
 Postcholecystectomy syndrome, 1441–1445, 1478
 Postoperative lesions, 444–445
 Postoperative monitoring, 1396
 Posttraumatic lesions, 444–445
 Poulsen-Christoffersen lesion, 244
 Precancerous lesions, 1313
 Preeclampsia, 1267
 Pregnancy
 acute fatty liver, 1263–1265
 cholestasis, 1259
 pruritus, 1259
 Preoperative screening, 1394–1396
 Pre-procollagen, 43
 Pressure
 intracranial, 938–939
 sinusoidal, 515
 wedged hepatic, 515
 Pretransplant workup, 1367
 Primary amyloidosis, 1106
 Primary, bile, 104
 Primary biliary cirrhosis (PBC), 195, 362–363, 925
 AMA negative, 899, 910
 clinical presentation, 897–899

definition, 895
 diagnosis, 897
 differential diagnosis, 900
 drugs, 902
 environmental factors, 896
 epidemiology, 895
 etiology, 896
 extrahepatic diseases, 899
 genetic factors, 896
 grading and staging, 282
 immunologic factors, 896–897
 infectious organisms, 896
 laboratory findings, 899
 liver transplantation, 903
 Mayo-Risk-Score, 901
 mitochondrial antigens, 899
 natural course, 900
 pathogenesis, 896
 pathology, 897
 prognosis, 900
 serologic diagnosis, 899
 staging, 897
 therapy, 901
Primary hepatic malignant lymphoma
 course, 1348
 diagnosis, 1347–1348
 differential diagnosis, 1348
 epidemiology, 1347
 pathogenesis, 1347
 pathology, 1347
 prognosis, 1348
 therapy, 1348
Primary liver tumors, classification, 1275
Primary sclerosing cholangitis (PSC), 363, 925
 complications, 916
 course, 916–917
 definition, 911
 diagnosis, 913
 differential diagnosis, 915–916
 epidemiology, 911–912
 etiology and pathogenesis, 912
 extrahepatic diseases, 914
 genetic factors, 912
 imaging, 914–915
 immunological findings, 912
 laboratory findings, 914
 Mayo model, 916
 pathology, 912–913
 pericholangitis, 912
 prognosis, 916–917
 signs, 913
 small duct variant, 912
 staging, 913
 survival, 916
 symptoms, 913
 therapy, 917
Priming phase, 165
Procollagen, 43
Proelastin, 44
Progenitor cells, 159
Progressive familial intrahepatic cholestasis,
 1094–1098

Proinflammatory cytokines, 1158
Prolactin, 161
Proliferative phase, 165
Proline, 42
Prometheus-system, 943
Propranolol, 980, 981
Prostacyclin, 596
Prostaglandins, 606, 607
Protease inhibitors, 715
Proteinase inhibitor, jaundice, 1216
Protein, dietary allowance, 1191
Protein-energy malnutrition, 1189, 1193
Protein metabolism, 1190–1191
Protein restriction, 1198
Proteins, 82–83, 226–227
 acute phase, 150, 151
 multidrug resistance-associated, 69
 synthesis, 1192
 turnover, 1191
 vaccination, 709–710
 vaccines, 713
Proteoglycans, 42, 45–46
Prothrombin time, 329
Protoporphyrin crystals, 230
Protozoal diseases, 843–848
Pruritus, 307, 571, 579–581
Pseudocapillarization, 154
Pseudocysts, 631
Pseudo-Gaucher cells, 225, 226
Pseudo-Lafora bodies, 222
Pseudolipoma, 1298
Pseudolymphoma, 1348
Pseudomonas, 836
Pseudotumor, inflammatory, 391
Psychiatric disorders, 797
Pulmonary fibrosis, 797
Pulsatile liver, 311
Pulsatility, portal vein, 367
Pump, 64–65
 bile salt export, 69
 electrogenic, 65
Purpura, palpable, 314
Pylephlebitis, 660–661
 suppurative, 832
Pyrrrolizidine alkaloids, 651
Pyruvate carboxylase, 79
Pyruvate kinase, 78

Q

Q fever, 839
Quadrate lobe. *See* Lobe, quadrate
Quinke's triad, 445

R

Radial scan, 456
Radiation-induced liver damage, 203–204
Radiation therapy, 1549
Radiofrequency ablation, 1363
Raloxifene, 1030
Rapamycin, 1374
Reactive oxygen species (ROS), 173–180, 1128

- Receptors, low pressure, 606
 Receptosome, 73
 Recombinant activated factor VII (rFVIIa), 942
 Recombinant factor VIIa, 1394
 Recurrent pyogenic cholangitis, 627
 Red blood cells, 1028
 Red wale marks, 979
 Referred pain, 533
 Reflex, hepatorenal, 22
 Refractory ascites, 613
 Refsum's syndrome, infantile, 1185
 Regan-isoenzyme, 325
 Regeneration, hepatic, 157–167
 Regulator, autoimmune, 885
 Rejection arteriopathy, 668
 Relapsing fever, 836
 Remak's plates, 17
 Renal cell carcinoma, 1249
 Renal dysfunction, 1395
 Rendu–Weber–Osler disease, 1294
 Renin-angiotensin-aldosterone (RAA) system, activation, 606
 Reperfusion injury, 185–186
 Resection, partial hepatic, 164
 Residual bodies, 30, 1240
 Residual nodules, 236
 lipophagic, 249
 Resistance
 elements, intrahepatic, 57
 genotypic, 777
 phenotypic, 777
 Resistin, 1160
 Respiratory syndrome, severe acute, 829
 Restitution phase, 165
 Retinoate X receptor, 92
 Retinoic acid, 92
 Retinoic acid receptor, 92
 Retinoids, 92
 Retinol-binding protein, 92
 Retinol-binding protein 4, 792
 Retrocytosis, 66
 Reye's syndrome, 825
 Reynold's pentad, 1486
 Reynold's syndrome, 1486
 Rhabdomyosarcomas, 1350
 Rheumatoid arthritis, 1250
 Rhizomelic chondrodysplasia punctata, 1185
 Ribavirin, 712, 802
 contraindications, 803
 weight-based, 805
 Ribozymes, 711, 717, 1405–1406
 Rickettsiae, 839
 Riedel's lobe, 12, 621
 Rifampicin, 580, 1230
 Rifampin, 580
 Rimantadine, 714
 RNA interference, 1406–1407
 Rocky Mountain spotted fever, 839
 Rokitansky-Aschoff sinuses, 392–393
 Rosettes, liver cell, 212
 Rotor syndrome, 586, 589–590
 Rubella virus, 827
- S**
Saccharomyces cerevisiae, 716
 S-adenosyl-methionine, 581, 1117, 1264
 Salmonellae, 839–840
 Salt restriction, 1198
 Sanded nuclei, 233, 726
 Sandhoff's disease, 1183
 Sarcoid granulomas, 1238
 Sarcoidosis, 249, 795, 1251
 ascites, 1241
 Budd-Chiari syndrome, 1242
 cholestasis, 1241
 cholestatic alterations, 1240
 course, 1241–1242
 definition, 1239
 diagnosis, 1240–1241
 differential diagnosis, 1241
 epidemiology, 1239
 granulomatous phlebitis, 1240
 liver failure, 1242
 necroinflammatory changes, 1240
 pathogenesis, 1239–1240
 pathology, 1240
 portal hypertension, 1240
 prognosis, 1241–1242
 pseudotumors, 1240
 sarcomatoma, 1241
 therapy, 1242
 Sarcoma, embryonal, 1345–1346
 Scavenger cells, 135
 Scavenger receptor, 33
 Schaumann bodies, 1240
 Scheuer's score, 274
 Schistosomal pigment, 230
 Scintigraphy
 blood pool, 426–427
 perfusion, 426–427
 Sclerosing cholangitis
 primary, 445, 911–917
 secondary, 397
 Sclerosing hyaline necrosis, 645
 Sclerosis
 central hyaline, 258, 645
 hepatoportal, 252, 659–660, 865
 perivenous, 258
 Sclerotherapy, 982
 Scoring systems
 clinical, 289–292
 histopathological, 271–286
 Scratch effects, 313
 Scrotal edema, 309
 Secondary amyloidosis, 1106
 Secondary hemochromatosis, 1047
 diagnosis, 1064
 pathophysiology, 1063–1064
 therapy, 1064–1065
 Sengstaken-Blakemore-tube, 984
 SEN virus, 733
 Sepsis, 575–576
 gonococcal, 837
 Sepsis tuberculosa acutissima Landouzy, 838

- Septa, interlobular, 16
Septicemia, 1251
Septum transversum, 8, 9
Serine proteases, 177
Serotonin, 161, 1009
Serotonin antagonists, 580
Serpines, 1071
Serum amyloid P, 1105
Serum-ascites-albumin gradient, 610
Serum copper, 1038
Serum sickness, 316
Sex hormones, 1276
Sexual dysfunction, 307, 797, 1026
Shigellae, 840
Shock liver, 1248
Short-bowel syndrome, 1249
Shunts
 intrahepatic vascular, 951
 hyperbilirubinemia, 587
 peritoneovenous, 974
 transjugular intrahepatic, 371
 transjugular intrahepatic portosystemic, 974–975
Shuttle-vesicles, 72
Sicca syndrome, 748
Sickle cell anemia, 654
Sickle cell disease, 1250
Siderosis, 227
Silibinin, 935
Sinusoidal cells, 22
Sinusoidal contents, changes, 654
Sinusoidal dilatation, 649–650
Sinusoidal endothelial cells
Sinusoidal endothelial cells (SEC), 136, 140, 146
Sinusoidal obstruction syndrome, 203, 651–654
Sinusoidal pressure, 515
Sinusoids, 17, 649–654
 capillarization, 257, 654
Situs inversus, 622
Sjögren's syndrome, 795
Small hepatocellular carcinoma, 1315
Small interfering RNA, 1406
Small ubiquitin-related modifiers, 900
 α -Smooth muscle actin, 37
Smooth muscle antibodies
 immunofluorescence reactivities, 349
 occurrence and significance, 349–350
 target antigens, 349
Sodium benzoate, 1014–1015
Sodium taurocholate cotransporting polypeptide, 564
Solitary fibrous tumor, 1301
Somatic pain, 532, 533
Sorbitol clearance
 assessment, 337
 confounding factors, 337
 principle and technique, 337
 side effects, 337
Sorbitol dehydrogenase, 327
Space, perinuclear, 26
Spectrin, 66
SPECT technique, 429
Sphincter of Oddi
 anatomy, 1442
 dysfunction, 1445–1451
 manometry, 523–527, 1447
 physiology, 1425
 pressure phenomena, 525
Sphincter of Oddi dyskinesia, 1451–1454
 classification, 1446
 tests, 1446
Spider nevi, 313
Spider telangiectasia, 313
Spironolactone, 971
Spleen, examination, 311–312
Spongiotic pericytoma, 1304
Spontaneous bacterial peritonitis, 611
 bacterial translocation, 995
 clinical manifestations, 995
 course, 996
 definition, 994
 diagnosis, 995–996
 differential diagnosis, 996
 epidemiology, 994
 etiology, 994–995
 laboratory findings, 995
 microorganisms, 994
 pathogenesis, 994–995
 primary prophylaxis, 996–997
 prognosis, 996
 prophylaxis, 996–998
 secondary prophylaxis, 998
 therapy, 996–998
Spotty necrosis, 720
Squamous cell carcinomas, 1350
Staphylococcus aureus, 840
Starvation, 134
Stauffer's syndrome, 1249
Steatohepatitis, 224, 277–280, 1158–1160
 alcoholic, 1127–1142
 nonalcoholic, 239, 1153
 staging, 280
Steatosis, 360, 1156–1158
 focal, 384–386, 556, 1298
 hepatic, 1126
 irregular, 556
 macrovesicular, 224
 microvesicular, 224, 1265
Steatoviral hepatitis, 726
Stellate cells, 8, 18, 36–39, 42, 57, 58
 activation, 38
 apoptosis, 39
 extracellular matrix, 38
 hepatic, 140
 membrane receptors, 38
 secretory products, 38
Stem cell factor (SCF), 163
Stem cells, hepatic, 40–41, 159
Sterol regulatory element-binding protein, 87, 92
St. John's wort, 1217
Stone ileus, 1474
Stone perforation, 1474
Stones
 bile duct, 1483–1491

- black pigment, 1460
 - brown pigment, 1460
 - calcium-bilirubinate, 1460
 - chemical dissolution, 1490
 - cholesterol, 1460
 - gallbladder, 1459–1479
 - primary, 1460
 - secondary, 1460
 - Strawberry gallbladder, 1509
 - Strictures
 - benign biliary, 442
 - bile duct, 444
 - malignant biliary, 442–444
 - Stromelysins, 44
 - Submassive necrosis, 721
 - Sulfation, 128
 - Summerskill–Tygstrup–Walsh syndrome, 1095, 1097–1098
 - Superoxide anion, 175
 - Superoxide dismutase, 179
 - Surgery
 - bibiliary tract, 1392–1393
 - cardiac, 1393
 - cardiopulmonary complications, 1384
 - contraindication, 1387–1388
 - effects on the liver, 1383
 - hemodynamic effects, 1384
 - hepatic, 1393–1394
 - hepatopulmonary syndrome, 1384
 - hypoxemia, 1384
 - portopulmonary hypertension, 1384
 - Surgical necrosis, 212–213
 - Survival genes, 177
 - Survivin, 1317
 - Swelling, nuclear, 232
 - Sympathetic nervous system, activation, 606
 - Symports, 64
 - Syndecan, 45
 - Synovitis, 748
 - Syphilis, 840
 - Systemic lupus erythematosus, 1250
 - Systemic mastocytosis, 1251
- T**
- Tachyoddia, 526
 - Tacrolimus, 1373
 - Tangier disease, 224, 225, 1184
 - Target cell, 1028
 - Tarui's disease, 1182
 - Taste, distribution of, 306
 - Tay–Sachs disease, 1183
 - T cells
 - alternative, 143
 - conventional, 143
 - unconventional, 143
 - Telbivudine, 709, 773
 - resistance, 779
 - results of treatment, 773
 - Telomerase, 153
 - Telomeres, 153
 - Tenascin, 46
 - Tenofovir, 709, 773–774, 778
 - Terlipressin, 942
 - Terry nails, 315
 - Testicular atrophy, 316
 - Tetracyclines, 1228
 - Tetrathiomolybdate, 1041
 - Thalassemia, 1063, 1276
 - Thalassemia major, 1250
 - Therapy, gallstone, 1475–1479
 - Thorium dioxide, 203, 204, 1340
 - Thorotrast, 203, 204
 - Thrombocytopenia, 804, 1028
 - Thrombomodulin, 45
 - Thrombosis, portal vein, 365, 368–369, 657
 - Thyroid disorders, 795
 - Thyroid dysfunction, 1026–1027
 - Thyroid hormones, 160
 - Tight junctions, 25
 - Tissue inhibitors of metalloproteinases, 44
 - T lymphocytes, 142
 - cytotoxic, 193–194
 - TNF-related apoptosis-inducing-ligand (TRAIL), 216–217
 - TNM staging system, 1323, 1324
 - α -Tocopherol, 178
 - Tocopherol-radical, 178
 - Togaviruses, 827–828
 - Tokyo score, 1325
 - Tolerance
 - immunologic, 148–149
 - oral, 149
 - Toll-like receptors (TLR), 149
 - Topoisomerase-inhibitors, 1546
 - Torres bodies, 233, 828
 - Torse mide, 972
 - Total parenteral nutrition, 573–574
 - Toxemia of pregnancy
 - clinical manifestations, 1268
 - complications, 1268
 - definition, 1267
 - diagnosis, 1268
 - epidemiology, 1267
 - etiology, 1267
 - HELLP syndrome, 1268–1269
 - imaging, 1268
 - laboratory findings, 1268
 - liver disease, 1267–1269
 - pathogenesis, 1267
 - pathology, 1268
 - prognosis, 1269
 - therapy, 1269
 - Toxicity, idiosyncratic, 189
 - Toxic liver injury, 189–190
 - Toxic shock syndrome, 840
 - Toxins, 544–545
 - Toxoplasmosis, 847–848
 - Transaminases. *See* Aminotransferases
 - Transarterial chemoembolization, 1363
 - Transcription factors, 165
 - Transcytosis, 33, 66
 - Transfer protein, microsomal, 90
 - Transferrin receptor 1, 1060

- Transferrin receptor 2, 96
Transferrin saturation, 1049
Transforming growth factor- α (TGF- α), 162, 254
Transforming growth factor- β 1 (TGF- β 1), 253–254
Transforming growth factor beta (TGF- β), 162
Transient elastography, 262, 598
Transjugular intrahepatic portosystemic shunt (TIPS), 371, 974–975
Transmitters, peptidergic, 22
Transplant, pathology, 284–285
Transport
 active, 64
 hepatocellular, 61–74
 passive, 63
 vesicle, 65–66, 71–72
Transporters
 apical (canalicular), 69–70
 apical sodium bile acid, 1425
 basolateral (sinusoidal), 66–69
 canalicular, 114
 defects, genetic, 1095
 hepatocellular, 66, 114
Transport processes, cellular, 62
Transport proteins, 63–64
Transport systems, 113
 ATP-dependent, 565
 ATP-independent, 565
 cholangiocyte, 566
 hepatocellular, 564
Traube's space, 311
Trematode cholangitis, 1501
Trematodes, 1502
Treponema pallidum, 840
Triamterene, 971
Trientine, 1040, 1041
Triglycerides, 86, 224
Tropheryma whipplei, 841
Tropical splenomegaly syndrome, 847
Tropoelastin, 44
Tru-Cut needle, 465
TT virus, 733
Tuberculosis, extrapulmonary, 869
Tubulin, 32
Tuft cell, 1420
Tularemia, 837
Tumor-like lesions, 1275
Tumor necrosis factor alpha (TNF- α), 162
Tumor necrosis factor-related apoptosis-inducing ligand (TRAIL), 192, 194
Tumors
 epithelial, 1275
 extrahepatic bile duct, 398–399
 nonepithelial, 1275
 primary, 1275
Turner's syndrome, 1251
Type 3 hemochromatosis
 diagnosis, 1061
 natural history, 1060–1061
 pathophysiology, 1060
 prevalence, 1060
 therapy, 1061
Type 4 hemochromatosis
 diagnosis, 1063
 natural history, 1062–1063
 pathophysiology, 1061–1062
 prevalence, 1061–1062
 therapy, 1063
Typhoid nodules, 840
Tyrosinemia, 1185
- U**
Ubiquitin, 83, 178
Ubiquitination, 178
Ubiquitin proteasome pathway, 1134
UDP-glucuronosyl transferase, 1214
UGT1A gene locus, genetic variation, 1215
Ulcerative colitis, 748
Ultrasonography, 261–262, 359–399
 diffuse liver disease, 360
Ultrasound
 contrast-enhanced, 374
 transabdominal, 360
Ultrasound contrast agents, 373–374
Umbilical hernia, 310
Uncoupling protein-2, 178
Underfilling, arterial, 606
Underfilling hypothesis, 608–609
Undulin, 46
Unfolded protein response, 176–178
Uniports, 64
United Network for organ sharing, 1355
Urea, 84
 cycle, 85
 cycle disorders, 1185
Uremia, 1249
Urobilinogen, 112, 330
Uroporphyrin crystals, 230
Uroporphyrins, 1083
Ursodeoxycholic acid, 109, 580, 1260
Urticaria, 748
- V**
Variceal band ligation, 981
Variceal bleeding
 predictors, 520, 978–979
Variceal hemorrhage
 primary prophylaxis, 980–982
 recurrent, 984–985
 secondary prophylaxis, 984
Variceal pressure, 976
Varicella-Zoster virus, 233, 825
Varices
 anorectal, 976
 downhill, 976
 esophageal, 976–985
 gallbladder, 988
 gastric, 985–986
 gastro-esophageal, 600
Variegated porphyria, 1080
Vascular anomalies, 637
Vascular endothelial growth factor (VEGF), 160

- Vascular resistance, portal, 595
 Vasoactive substances, 57–58
 Vasoconstriction, intrahepatic, 596
 Vasodilating peptides, 606, 607
 Vasopressin, 161
 Vein(s)
 centrilobular, 21
 collecting, 21
 perilobular, 21
 portal, 21, 55
 sublobular, 21
 Venae spigellii, 645
 Veno-occlusive disease, 370, 651
 Venopathy, obliterative portal, 1282
 Venous outflow, 365
 Venules
 terminal hepatic, 18
 terminal portal, 21
 Veres needle, 489–494, 497
 Versican, 45
 Very low density lipoproteins, 91
 Vesica fellea divisa, 1430
 Vesica fellea duplex, 1430
 Vesicles
 clathrin coated, 73
 multilamellar, 121
 unilamellar, 121
 Vesicle transport. *See* Transport
 Vibrio vulnificus, 994
 Vimentin, 37
 Vim Silverman needles, 466
 Vinyl chloride, 1340
 Viral breakthrough, 770
 Viral cross talk, 194
 Viral hepatitis, 542–543, 577, 1359–1360
 acute, 361, 542–543
 chronic, 543
 pathology, 720
 treatment approaches, 707–717
 Viral hepatitis C, chronic, 362
 Viral inclusions, 233
 intranuclear, 824
 Viral infections, 671–821
 Viral kinetic analysis, 805
 Viramidine, 803
 Virchow's cells, 838
 Viruses
 inactivation, intracellular, 194
 nonhepatotropic, 823–829
 Visceral pain, 532, 533
 Vitamin A, 36, 38, 92, 570, 581
 Vitamin D, 570, 581
 Vitamin deficiency, 570
 Vitamin E, 178, 570, 581
 Vitamin K, 570, 581
 Vitamins, 1197
 Volume deficiency hypothesis, 608
 Volumetric composition, 22
 von Gierke's disease, 1182
 von Meyenburg complexes, 628, 1288
 von Recklinghausen's disease, 1251
 VX-499, 712
- W**
 Watermelon stomach, 987
 Wedged hepatic venous pressure, 515
 Weight loss diet, 1203
 Weil's disease, 837
 Whipple procedure, 1516
 Whipple's disease, 841, 1251
 White nipple sign, 979
 Wilson protein, 1036
 Wilson's disease, 544, 936–937
 clinical presentation, 1036–1037
 definition, 1035
 diagnosis, 1036–1037
 diagnostic findings, 1037–1039
 differential diagnosis, 1039
 epidemiology, 1035
 etiology, 1035
 family screening, 1039
 fulminant hepatic failure, 1037, 1039
 gene, 1035
 Kayser-Fleischer rings, 1037
 liver transplantation, 1042
 molecular studies, 1038
 neurological symptoms, 1037
 pathogenesis, 1035
 prognosis, 1039–1040
 psychiatric abnormalities, 1037
 survival rates, 1042
 treatment, 1040–1042
 Wilson's disease protein, 93
 Wolman's disease, 224, 225, 1184
- X**
 Xanthelasma, 314, 570
 Xanthine oxidase, 186
 Xanthoma cells, 244
 Xanthomas, 570
 Xanthomas, eruptive, 314
 Xanthomatous arteriopathy, 668
- Y**
 Y-binding-protein, 119
 Yellow fever, 233
 Yellow fever virus, 828
 Yersinia, 841
 Y-protein, 110
- Z**
 Zahn's grooves, 622
 Zellweger's syndrome, 1185
 Zieve's syndrome, 1028, 1126
 Zinc salts, 1040, 1041
 Zonation, metabolic, 131, 132
 Zonulae occludentes, 25
 Z-protein, 110
 Zygomycosis, 860