


Color Atlas

Antonella Tosti
Pearl E. Grimes
Maria P. De Padova
Editors

of Chemical Peels



 Springer

Antonella Tosti · Pearl E. Grimes · Maria Pia De Padova (Eds.)

Color Atlas of Chemical Peels

Antonella Tosti
Pearl E. Grimes
Maria Pia De Padova
(Eds.)

Color Atlas of Chemical Peels

With 175 Figures, in 286 separate Illustrations,
Mostly in Color, and 24 Tables

 Springer

Antonella Tosti, MD

Department of Dermatology,
University of Bologna, Via Massarenti 1,
40138 Bologna, Italy

Pearl E. Grimes, MD

Vitiligo and Pigmentation Institute
of Southern California and Division
of Dermatology, Department of Medicine,
David Geffen School of Medicine,
University of California, Los Angeles,
California, 5670 Wilshire Blvd., Suite 650,
Los Angeles, CA 90036, USA

Maria Pia De Padova, MD

Department of Dermatology,
University of Bologna, Via Massarenti 1,
40138 Bologna, Italy

Library of Congress Control Number: 2005926891

ISBN 10 3-540-21279-5 Springer Berlin Heidelberg New York
ISBN 13 978-3-540-21279-9 Springer Berlin Heidelberg New York

This work is subject to copyright. All rights are reserved, whether the whole or part of the material is concerned, specifically the rights of translation, reprinting, reuse of illustrations, recitation, broadcasting, reproduction on microfilm or in any other way, and storage in data banks. Duplication of this publication or parts thereof is permitted only under the provisions of the German Copyright Law of September 9, 1965, in its current version, and permission for use must always be obtained from Springer. Violations are liable to prosecution under the German Copyright Law.

Springer is a part of Springer Science+Business Media

springeronline.com

© Springer-Verlag Berlin Heidelberg 2006

Printed in Germany

The use of general descriptive names, registered names, trademarks, etc. in this publication does not imply, even in the absence of a specific statement, that such names are exempt from the relevant protective laws and regulations and therefore free for general use.

Product liability: the publishers cannot guarantee the accuracy of any information about dosage and application contained in this book. In every individual case the user must check such information by consulting the relevant literature.

Editor: Marion Philipp, 69121 Heidelberg, Germany
Desk Editor: Ellen Blasig, 69121 Heidelberg, Germany
Production: ProEdit GmbH, 69126 Heidelberg, Germany
Cover: Frido Steinen-Broo, EStudio Calamar, Spain
Typesetting: K. Detzner, 67346 Speyer, Germany

Printed on acid-free paper 24/3151/ML 5 4 3 2 1 0

Preface

This Atlas is an easy-to-understand book that gives the reader fact-based information about when and how to perform chemical peels.

Authors' experiences in cosmetic dermatology give rise to a guide for anyone interested in learning more about cosmetology.

The book provides information about each single chemical peel, fully explained in terms of its properties, formulations, indications, performing technique, advantages and disadvantages.

It also reviews different dermatological disorders showing step-by-step the procedure for the best peeling with which to treat them.

This is an up-to-date book which will help the clinician improve his skill in this field.

Antonella Tosti

Pearl E. Grimes

Maria Pia De Padova

Contents

Part I Types of Chemical Peels: Advantages/Disadvantages – an Illustrated Algorithm

1	Types of Chemical Peels	3
	Antonella Tosti, Maria Pia De Padova, Matilde Iorizzo	
1.1	Advantages/Disadvantages	4
1.1.1	Glycolic Acid	4
1.1.1.1	Advantages	4
1.1.1.2	Disadvantages	4
1.1.2	Jessner's Solution	4
1.1.2.1	Advantages	4
1.1.2.2	Disadvantages	4
1.1.3	Pyruvic Acid	5
1.1.3.1	Advantages	5
1.1.3.2	Disadvantages	5
1.1.4	Resorcinol	5
1.1.4.1	Advantages	5
1.1.4.2	Disadvantages	5
1.1.5	Salicylic Acid	5
1.1.5.1	Advantages	5
1.1.5.2	Disadvantages	5
1.1.6	Trichloroacetic Acid	5
1.1.6.1	Advantages	5
1.1.6.2	Disadvantages	6
1.1.7	Deep Chemical Peels	6
1.1.7.1	Advantages	6
1.1.7.2	Disadvantages	6
1.1.8	Combination Peels: Salicylic Acid + TCA	6
1.1.8.1	Advantages	6
1.1.8.2	Disadvantages	6
1.2	How to Choose the Best Peeling for the Patient	6
1.2.1	Acne	6
1.2.2	Actinic Keratosis	7

1.2.3	Dark Skin	8
1.2.4	Melasma	8
1.2.5	Photoaging	9
1.2.6	Post-inflammatory Hyperpigmentation	9
1.2.7	Rosacea	9
1.2.8	Solar Lentigo	10

Part II Modalities of Application

2	Glycolic Acid	13
	Gabriella Fabbrocini, Maria Pia De Padova, Antonella Tosti	
2.1	History	13
2.2	Chemical Background	13
2.3	Properties	13
2.4	Formulations	13
2.5	Indications	14
2.6	Contraindications	14
2.7	Peeling Preparation	14
2.8	Peeling Technique	16
2.9	Post-peeling Care and Complications	19
2.10	Disadvantages	19
2.11	Side Effects	19
2.12	Results	20
2.13	Informed Consent	20
	References	21

3	Jessner's Solution	23	5	Resorcinol	41
	Pearl E. Grimes			Ilaria Ghersetich, Benedetta Brazzini, Torello Lotti, Maria Pia De Padova, Antonella Tosti	
3.1	History	23	5.1	History	41
3.2	Chemical Background	23	5.2	Chemical Background and Properties	41
3.3	Formulations	24	5.3	Formulations	41
3.4	Indications	25	5.4	Indications	42
3.5	Contraindications	25	5.5	Contraindications	42
3.6	Skin Preparation	26	5.6	Peeling Preparation	44
3.7	Peeling Technique	27	5.7	Peeling Technique	44
3.8	Post-peel Care	27	5.8	After Peel Care	45
3.9	Advantages of Jessner's Peeling	27	5.9	Side Effects	45
3.10	Disadvantages of Jessner's Peeling	27	5.10	Advantages	46
3.11	Side Effects	28	5.11	Disadvantages	46
3.12	Patient's Informed Consent . .	28	5.12	Patient's Informed Consent . .	46
	References	29		References	47
4	Pyruvic Acid	31	6	Salicylic Acid	
	Ilaria Ghersetich, Benedetta Brazzini, Torello Lotti, Maria Pia De Padova, Antonella Tosti			Pearl E. Grimes	
4.1	History	31	6.1	History	49
4.2	Properties	31	6.2	Chemical Background/Properties	49
4.3	Indications	31	6.3	Formulations	50
4.4	Formulations	32	6.4	Indications	50
4.5	Contraindications	32	6.5	Contraindications	50
4.6	Peeling Preparation (Home Treatment)	32	6.6	Patient Preparation	51
4.7	Peeling Technique	32	6.7	Peeling Technique	51
4.8	Post-peeling Care	35	6.8	Post-peeling Care and Complications	55
4.9	Side Effects	35	6.9	Advantages	55
4.10	Advantages	35	6.10	Disadvantages	56
4.11	Disadvantages	35	6.11	Side Effects	56
4.12	Results	35	6.12	Patient's Informed Consent . .	56
4.13	Patient's Informed Consent . .	38		References	57
	References	39			

7	Trichloroacetic Acid	59	8.12.3	Scarring	86
	Christopher B. Harmon, Michael Hadley, Payam Tristani		8.12.4	Infection	86
7.1	History	59	8.12.5	Milia	86
7.2	Chemical Background	59	8.12.6	Acneiform Dermatitis	86
7.3	Chemical Formulations	59	8.12.7	Skin atrophy	87
7.4	Classification of Peel Depths	60	8.13	Advantages	87
7.5	Indications	61	8.14	Disadvantages	87
7.6	Facial Versus Non-facial Skin	63	8.15	Patient's Informed Consent	87
7.7	Peeling Preparation	63		References	88
7.8	Peeling Technique	64	9	Deep Chemical Peels for Post-acne Scarring	91
7.9	Post-peeling Care	65		Marina Landau	
7.10	Complications	66	9.1	History and Classification	91
7.11	Advantages/Disadvantages of TCA Peels	66	9.2	Indications	93
7.12	Conclusion	66	9.3	Contraindications	93
	References	67	9.4	Pre-peeling Preparation	93
8	Deep Chemical Peels for Photoaging	69	9.5	Peeling Technique	94
	Marina Landau		9.6	Aftercare	96
8.1	History	69	9.7	Advantages	96
8.2	Chemical Background	70	9.8	Disadvantages	96
8.3	Formulations	70		References	100
8.4	Histology	71	10	Combination Salicylic Acid/ TCA Chemical Peeling	103
8.5	Indications and Patient Selection	72		Pearl E. Grimes	
8.6	Contraindications	72	10.1	History	103
8.7	Pre-peeling Preparation	73	10.2	Chemical Background/Properties	103
8.8	Preparation of the Skin	73	10.3	Formulations	104
8.9	Peeling Preparation	74	10.4	Indications	104
8.10	Peeling Technique	75	10.5	Contraindications	105
8.11	Aftercare	79	10.6	Peeling Preparations	107
8.12	Complications	85	10.7	Peeling Technique	108
8.12.1	Cardiac Arrhythmias	85	10.8	Post-peeling Care and Complications	109
8.12.2	Pigmentary Changes	85	10.9	Advantages	109
			10.10	Disadvantages	109
			10.11	Side Effects	109
			10.12	Patient's Informed Consent	109
				References	110

Part III			
How to Choose the Best Peeling for the Patient			
11	Acne	113	
	Vincenzo Bettoli, Alessandro Borghi, Maria Pia De Padova, Antonella Tosti		
11.1	Definition	113	
11.2	Epidemiology	113	
11.3	Pathophysiology	113	
11.4	Clinical Patterns	114	
11.5	Clinical Types	119	
11.6	Differential Diagnosis	121	
11.7	Therapy	122	
	References	131	
12	Actinic Keratosis	133	
	Ilaria Ghersetich, Benedetta Brazzini, Maria Pia De Padova, Antonella Tosti		
12.1	Definition	133	
12.2	Etiology	135	
12.3	Clinical Types	135	
12.4	Histopathology	136	
12.5	Diagnostic Criteria	136	
12.6	Differential Diagnosis	136	
12.7	Therapy	136	
12.8	Management of the Patient	138	
	References	138	
13	Chemical Peels in Dark Skin	139	
	Pearl E. Grimes		
13.1	Definition	139	
13.2	Epidemiology	139	
13.3	Morphologic and Physiologic Skin Differences in Dark Skin	139	
13.4	Peeling Indications in Dark Skin	140	
13.5	Peel Selection	140	
13.6	Peeling Preparation	141	
13.7	Peeling Techniques	143	
13.8	Superficial Peeling Agents	143	
13.8.1	Glycolic Acid	143	
13.8.2	Salicylic Acid	144	
13.8.3	Jessner's Solution	144	
13.8.4	Tretinoin Peeling	144	
13.8.5	Trichloroacetic Acid	146	
13.8.6	Medium and Deep Peels	147	
13.9	Summary	147	
	References	148	
14	Melasma	149	
	Matilde Iorizzo, Antonella Tosti, Maria Pia De Padova		
14.1	Definition	149	
14.2	Epidemiology	149	
14.3	Etiology	150	
14.4	Clinical Features	150	
14.5	Diagnostic Criteria	151	
14.6	Therapy	152	
14.6.1	Sunscreens	152	
14.6.2	Hydroquinone	152	
14.6.3	Azelaic Acid	153	
14.6.4	Kojic Acid	153	
14.6.5	Retinoic Acid (Tretinoin)	153	
14.6.6	Chemical Peels	153	
14.7	Why Is a Combined Chemical Peel Useful for Treating Melasma?	158	
14.7.1	Laser	158	
14.7.2	Cryotherapy	158	
	References	159	
15	Photoaging	161	
	Pearl E. Grimes		
15.1	Definition	161	
15.2	Etiology	161	

15.3	Epidemiology	162	17	Rosacea	185
15.4	Clinical Types	164		Maria Pia De Padova, Matilde Iorizzo, Antonella Tosti	
15.5	Therapeutic Intervention	164	17.1	Definition	185
15.5.1	Photoprotection	164	17.2	Epidemiology	185
15.5.2	Retinoids	165	17.3	Pathology	185
15.5.3	Tretinoin	166	17.4	Clinical Types (Clinical Stages)	185
15.5.4	Tazarotene	167	17.5	Diagnostic Criteria	191
15.5.5	Retinol	167	17.6	Differential Diagnosis	191
15.5.6	Vitamin C	167	17.7	Therapy	191
15.5.7	Alpha Hydroxy Acids	168	17.8	Erythrosis	191
15.5.8	Polyhydroxy Acids	168	17.9	Papulo-Pustular Rosacea	192
15.6	Bleaching Agents	168	17.10	Rhinophyma	192
15.6.1	Hydroquinone	168	17.11	How to Perform the Best Peeling for the Treatment of Rosacea . . .	193
15.6.2	Azelaic Acid	169	17.12	Peeling Technique	196
15.6.3	Kojic Acid	169		References	198
15.6.4	Miscellaneous	169			
15.7	Chemical Peels for Photoaging .	169	18	Solar Lentigo	199
15.8	Superficial Peeling Agents	169		Ilaria Ghersetich, Benedetta Brazzini, Maria Pia De Padova, Antonella Tosti	
15.9	Medium-Depth Peeling	170	18.1	Definition	199
15.10	Summary	173	18.2	Epidemiology	199
	References	173	18.3	Etiology	199
16	Post-inflammatory Hyperpigmentation	177	18.4	Clinical Features	199
	Teresa Soriano, Pearl E. Grimes		18.5	Pathology	200
16.1	Definition	177	18.6	Diagnostic Criteria	200
16.2	Epidemiology	177	18.7	Therapy	200
16.3	Etiology	177		References	205
16.4	Clinical Types	178			
16.5	Diagnostic Criteria	178			
16.6	Differential Diagnosis	178			
16.7	Therapy	178			
16.8	Topical Agents	178			
16.9	Chemical Peels	180			
16.10	Summary	182			
	References	182			

Part IV
Management of the Patient

19	Management of the Patient . . .	209
	Maria Pia De Padova, Antonella Tosti	
19.1	Patient Selection	209
19.2	Patient Evaluation	209
19.3	Instructions	209
19.3.1	Pre-operative Phase	209
19.3.2	Post-operative Phase	210
19.4	Photographs	210
	Subject Index	213

List of Contributors

Vincenzo Bettoli, MD

(e-mail: vbettoli@ospfe.it)
Department of Dermatology,
University of Ferrara, Corso Giovecca 203,
44100 Ferrara, Italy

Alessandro Borghi, MD

Department of Dermatology,
University of Ferrara, Corso Giovecca 203,
44100 Ferrara, Italy

Benedetta Brazzini, MD

Department of Dermatology,
University of Florence, Via della Pergola 58,
Florence, Italy

Maria Pia De Padova, MD

(e-mail: depadova.mariapia@libero.it)
Department of Dermatology,
University of Bologna, Via Massarenti 1,
40138 Bologna, Italy

Gabriella Fabbrocini, MD

(e-mail: gafabbro@unina.it)
Department of Dermatology,
University of Naples, Via Pansini 5,
Building 10, Naples, Italy

Ilaria Ghersetich, MD

(e-mail: i.ghersetich@dermatology.it)
Department of Dermatology,
University of Florence, Via della Pergola 58,
Florence, Italy

Pearl E. Grimes, MD

(e-mail: pegrimesmd@earthlink.net)
Vitiligo and Pigmentation Institute
of Southern California and Division
of Dermatology, Department of Medicine,
David Geffen School of Medicine,
University of California, Los Angeles,
California, 5670 Wilshire Blvd., Suite 650,
Los Angeles, CA 90036, USA

Michael Hadley, MD

University of Utah
Department of Dermatology
4B454 School of Medicine
30N 1900E Salt Lake City
UT 84132, USA

Christopher B. Harmon

(e-mail: charmon887@pol.net)
Department of Dermatology
University of Alabama at Birmingham
Birmingham, AL, USA

Matilde Iorizzo, MD

Department of Dermatology,
University of Bologna, Via Massarenti 1,
40138 Bologna, Italy

Marina Landau, MD

(e-mail: mlandau@zahav.net.il)
Wolfson Medical Center,
Sackelr School of Medicine,
Tel Aviv University, 56 Joshua Ben Nun Street,
Herzlia Pituach 46763, Israel

Torello Lotti, MD

Department of Dermatology,
University of Florence, Via della Pergola 58,
Florence, Italy

Teresa Soriano, MD

(e-mail: tsoriano@mednet.ucla.edu)
Vitiligo and Pigmentation Institute
of Southern California and Division
of Dermatology, Department of Medicine,
David Geffen School of Medicine,
University of California, Los Angeles,
California

Antonella Tosti, MD

(e-mail: tosti@med.unibo.it)
Department of Dermatology,
University of Bologna, Via Massarenti 1,
40138 Bologna, Italy

Part I

Types of Chemical Peels: Advantages/Disadvantages – an Illustrated Algorithm



Types of Chemical Peels

Antonella Tosti, Maria Pia De Padova, Matilde Iorizzo

The author has no financial interest in any of the products or equipment mentioned in this chapter.

Contents

1.1	Advantages/Disadvantages	4
1.1.1	Glycolic Acid	4
1.1.1.1	Advantages	4
1.1.1.2	Disadvantages	4
1.1.2	Jessner's Solution	4
1.1.2.1	Advantages	4
1.1.2.2	Disadvantages	4
1.1.3	Pyruvic Acid	5
1.1.3.1	Advantages	5
1.1.3.2	Disadvantages	5
1.1.4	Resorcinol	5
1.1.4.1	Advantages	5
1.1.4.2	Disadvantages	5
1.1.5	Salicylic Acid	5
1.1.5.1	Advantages	5
1.1.5.2	Disadvantages	5
1.1.6	Trichloroacetic Acid	5
1.1.6.1	Advantages	5
1.1.6.2	Disadvantages	6
1.1.7	Deep Chemical Peels	6
1.1.7.1	Advantages	6
1.1.7.2	Disadvantages	6
1.1.8	Combination Peels: Salicylic Acid + TCA	6
1.1.8.1	Advantages	6
1.1.8.2	Disadvantages	6
1.2	How to Choose the Best Peeling for the Patient	6
1.2.1	Acne	6
1.2.2	Actinic Keratosis	7
1.2.3	Dark Skin	8
1.2.4	Melasma	8
1.2.5	Photoaging	9
1.2.6	Post-inflammatory Hyperpigmentation	9
1.2.7	Rosacea	9
1.2.8	Solar Lentigo	10

1.1 Advantages/Disadvantages

Summary

- Glycolic acid
- Jessner's solution
- Pyruvic acid
- Resorcinol
- Salicylic acid
- Trichloroacetic acid
- Deep chemical peels
- Combinations peels: salicylic acid + trichloroacetic acid

1.1.1 Glycolic Acid

1.1.1.1 Advantages

- Very mild erythema
- Mild desquamation
- Short post-operative period
- Useful in photodamage

1.1.1.2 Disadvantages

- Burning sensation and erythema during application
- No uniformity of application
- Neutralization is mandatory
- Necrotic ulcerations if time of application is too long and/or skin pH is reduced
- Cautious application in patients with active acne

1.1.2 Jessner's Solution

1.1.2.1 Advantages

- Excellent safety profile
- Can be used in all skin types
- Substantial efficacy with minimal "down time"
- Enhances the penetration of TCA

1.1.2.2 Disadvantages

- Concerns regarding resorcinol toxicity, including thyroid dysfunction
- Manufacturing variations
- Instability with exposure to light and air
- Increased exfoliation in some patients

1.1.3 Pyruvic Acid

1.1.3.1 Advantages

- Very mild erythema
- Mild desquamation
- Short post-operative period
- Can be used in skin types III and IV

1.1.3.2 Disadvantages

- Intense stinging and burning sensation during the application
- Neutralization is mandatory
- Pungent and irritating vapors for the upper respiratory mucosa

1.1.4 Resorcinol

1.1.4.1 Advantages

- Easy to perform
- Uniformity of application and penetration
- Useful in acne, post-inflammatory hyperpigmentation and melasma
- Not painful (the burning sensation during the peeling is usually mild)

1.1.4.2 Disadvantages

- Desquamative effect aesthetically unacceptable
- Unsafe in Fitzpatrick skin type higher than V
- Cannot be used in summer
- Resorcinol may be a sensitizing and toxic agent

1.1.5 Salicylic Acid

1.1.5.1 Advantages

- An established safety profile in patients with skin types I–VI
- Excellent in patients with acne
- Given the appearance of the white precipitate, uniformity of application is easily achieved
- After several minutes the peel can induce an anesthetic effect whereby increasing patient tolerance

1.1.5.2 Disadvantages

- Limited depth of peeling
- Minimal efficacy in patients with significant photodamage

1.1.6 Trichloroacetic Acid

1.1.6.1 Advantages

- Low-cost procedure
- Uniformity of application and penetration
- Depending on frost, it is easily modulable with different concentrations

1.1.6.2 Disadvantages

- Stinging and burning sensation during the application
- High concentrations are not recommended in skin types V and VI
- Hypo/hyperpigmentation can occur

1

1.1.7 Deep Chemical Peels

1.1.7.1 Advantages

- Useful in patients with photodamage
- Useful in patients with perioral wrinkles
- Useful in patients with atrophic acne scars
- Useful for facial skin rejuvenation

1.1.7.2 Disadvantages

- Cardiotoxicity
- Hyperpigmentation

1.1.8 Combination Peels: Salicylic Acid + TCA

1.1.8.1 Advantages

- Efficacy in all skin types
- Well tolerated in darker racial/ethnic groups
- Most beneficial in treating recalcitrant melasma and post-inflammatory hyperpigmentation

1.1.8.2 Disadvantages

- Increased depth of superficial peeling
- Increased desquamation in some patients lasting up to 7–10 days
- Post-inflammatory hyperpigmentation more common than with salicylic acid peeling alone

1.2 How to Choose the Best Peeling for the Patient

Summary

- Acne
- Actinic keratoses
- Dark skin
- Melasma
- Photoaging
- Post-inflammatory Hyperpigmentation
- Rosacea
- Solar lentigos

1.2.1 Acne

Acute phase (Fig. 1.1)

Comedonal acne
Salicylic acid 25%
Pyruvic acid 40–70%
Jessner's solution
Unna Paste
Glycolic acid 70%

Mild/moderate inflammatory acne
Salicylic acid 25–30%
Pyruvic acid 40–70%
Jessner's solution
Unna Paste
Glycolic acid 70%

Severe nodulo-cystic acne
Pyruvic acid 40–60%

Superficial post-acneic scars (Fig. 1.2)
Pyruvic acid 40–70%
Trichloroacetic acid 25–50% lotion
Salicylic acid 25% + trichloroacetic acid 25–30% gel

Medium-deep post-acneic scars
Phenol 45–80%
Trichloroacetic acid >40% lotion
Excision, elevation, subcision

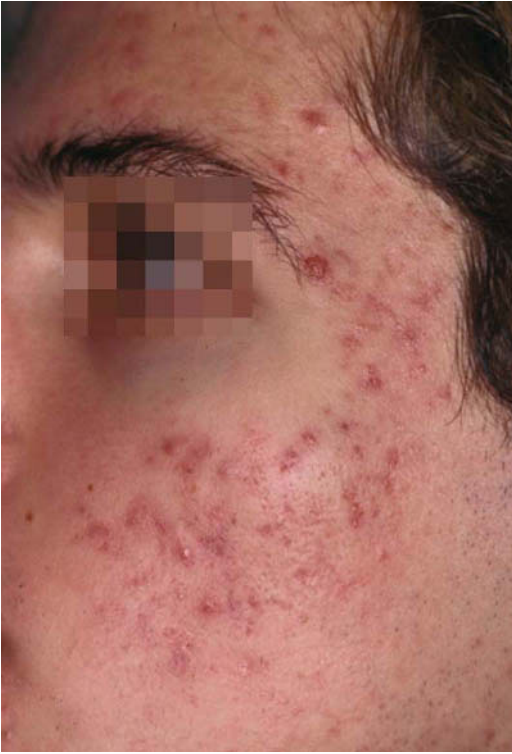

Fig. 1.1. Acne. Acute phase

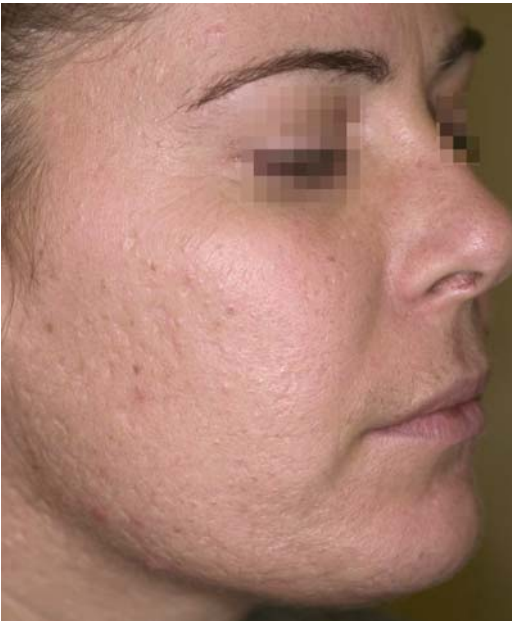

Fig. 1.2. Superficial post-acneic scars

1.2.2 Actinic Keratosis (Fig. 1.3)

- Trichloroacetic acid >30%
- Pyruvic acid 50–60%
- Salicylic acid 25% + trichloroacetic acid 25–30% gel

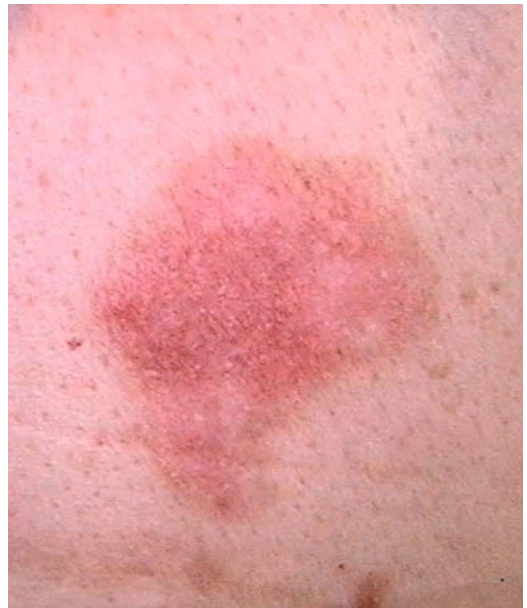

Fig. 1.3. Actinic keratosis

1

1.2.3 Dark Skin (Fig. 1.4)

- Salicylic acid 20–30%
- Jessner's solution
- Glycolic acid 20, 35, 50, 70%
- Trichloroacetic acid 10–30%

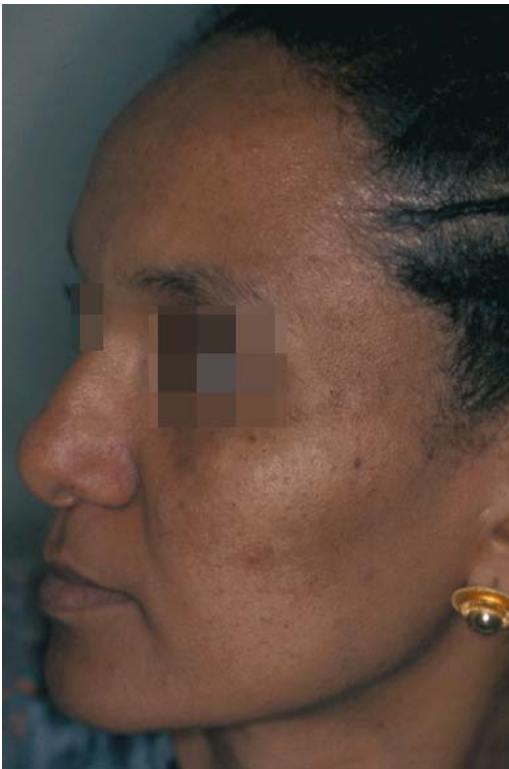

Fig. 1.4. Dark skin

1.2.4 Melasma (Fig. 1.5)

- Salicylic acid 25%
- Salicylic acid 25% + trichloroacetic acid 10% gel
- Pyruvic acid 40–50%
- Glycolic acid 50–70%
- Trichloroacetic acid 15–20%
- Resorcinol

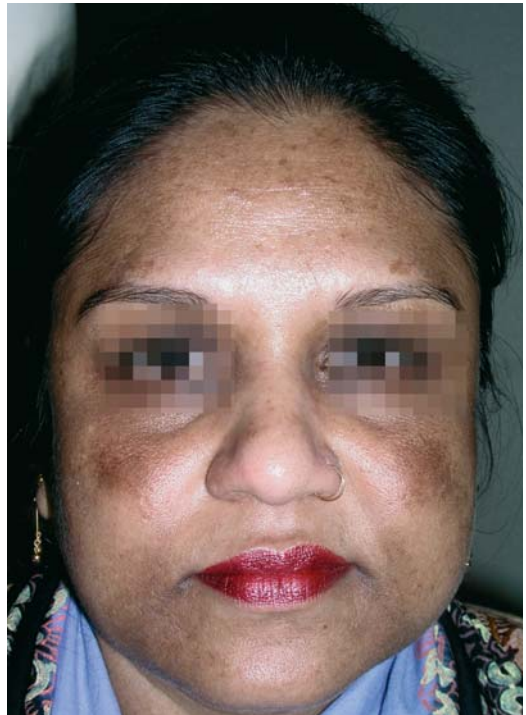

Fig. 1.5. Melasma

1.2.5 Photoaging (Fig. 1.6)

Mild to moderate	Glycolic acid 50–70% Trichloroacetic acid 50% Salicylic acid 20–30% Salicylic acid 25% + trichloroacetic acid >25% gel
Extensive	Glycolic acid 70% + trichloroacetic acid 35% Jessner's solution + trichloroacetic acid 35% Pyruvic acid 60–70% Phenol 45–80%

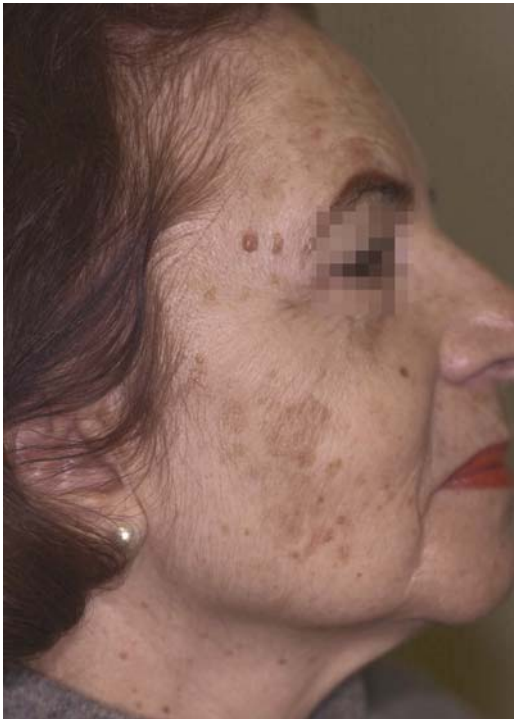

Fig. 1.6. Moderate photoaging

1.2.6 Post-inflammatory Hyperpigmentation (Fig. 1.7)

- Salicylic acid 20–30%
- Glycolic acid 70%
- Jessner's solution
- Pyruvic acid 40%

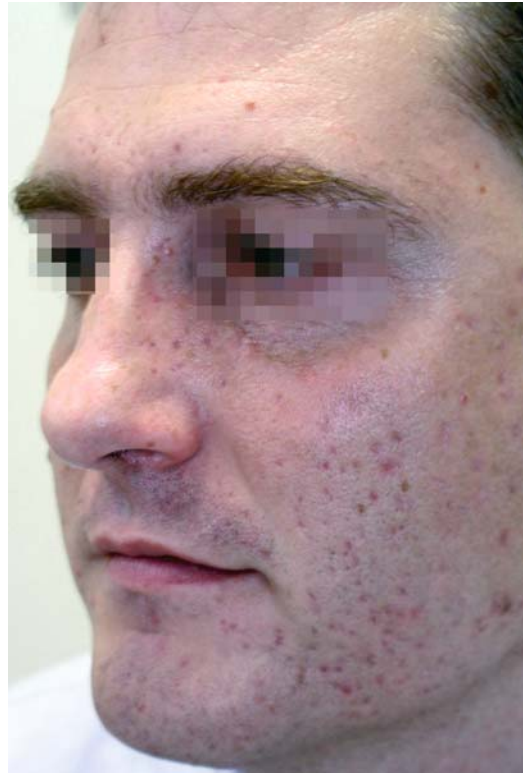

Fig. 1.7. Post-inflammatory hyperpigmentation

1.2.7 Rosacea

- Erythrosis (Fig. 1.8): salicylic acid 15–25–30%
- Papulo-pustular rosacea (Fig. 1.9): salicylic acid 25–30%

1

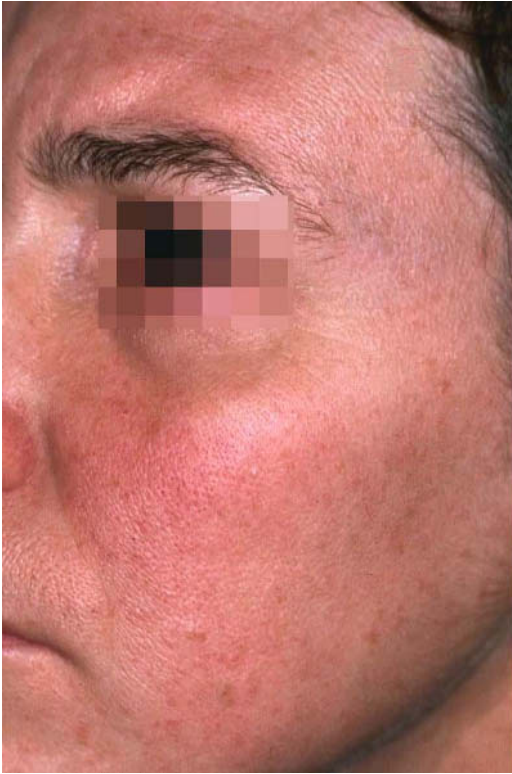

Fig. 1.8. Erythrosis

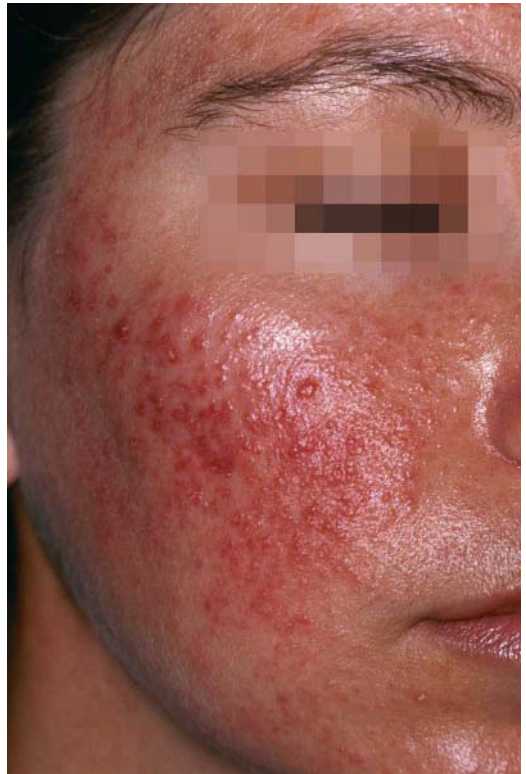

Fig. 1.9. Papulo-pustular rosacea

1.2.8 Solar Lentigos (Fig. 1.10)

- Trichloroacetic acid >25%
- Salicylic acid 25% + trichloroacetic acid 25–30% gel
- Pyruvic acid 50–70%
- Phenol 45–80%

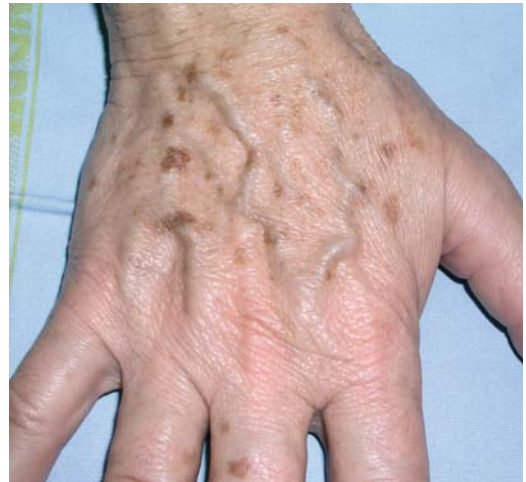

Fig. 1.10. Solar lentigos

Part II

Modalities of Application



Glycolic Acid

Gabriella Fabbrocini, Maria Pia De Padova, Antonella Tosti

The author has no financial interest in any of the products or equipment mentioned in this chapter.

Contents

2.1	History	13
2.2	Chemical Background	13
2.3	Properties	13
2.4	Formulations	13
2.5	Indications	14
2.6	Contraindications	14
2.7	Peeling Preparation	14
2.8	Peeling Technique	16
2.9	Post-peeling Care and Complications	19
2.10	Disadvantages	19
2.11	Side Effects	19
2.12	Results	20
2.13	Informed Consent	20
	References	21

2.1 History

In a study of more than 60 substances chosen for their possible antikeratinogenic properties, Van Scott and Yu [1] found that the most effective drug belongs to the group of alpha-hydroxy acids. A three times a day application of citric, glycolic, lactic, malic, pyruvic and glucuronic acid, for instance, gave excellent results in all forms of ichthyosis except epidermolytic hyperkeratosis. The substances were applied at 5% strength in a hydrophilic ointment, though the base was a matter of the patient's preference. Sustained remission was obtained as long as the treatment continued. The use of these

agents has been extended to other hyperkeratotic conditions. Glycolic acid became available in the late 1980s as a peeling agent.

2.2 Chemical Background

Glycolic acid is an alpha-hydroxy acid, soluble in alcohol, derived from fruit and milk sugars. It can be produced with ethylene glycol-oxidizing microorganisms such as *Pichia naganishii* AKU 4267 and *Rhodotorula* sp. 3 Pr-126. Under optimized conditions, they form 105 and 110 g/l of glycolic acid (corrected molar conversion yields 88.0 and 92.2%) during a 120-h reaction, respectively [2].

2.3 Properties

It has been shown that glycolic acid has a keratolytic, germinative layer and a fibroblast stimulating action.

Reported studies have shown its anti-inflammatory effects and anti-oxidant action. It acts by thinning the stratum corneum, promoting epidermolysis, dispersing basal layer melanin and epidermal and dermal hyaluronic acid and collagen gene expression that increases through an elevated secretion of IL-6 [3].

2.4 Formulations

The absorption of glycolic acid in human skin is pH-, strength- and time-dependent. Seventy percent glycolic acid solutions are commonly

used as superficial chemical peeling agents, the pH of these solutions ranges from 0.08 to 2.75. Peeling solutions with a pH below 2 have demonstrated the potential to induce crusting and necrosis, which has not been seen with the partially neutralized solutions with a pH above 2 [4]. The higher concentration acid (70%) created more tissue damage than the lower concentration (50%) compared to solutions with free acid. An increase of transmembrane permeability coefficient is observed with a decrease in pH, providing a possible explanation for the effectiveness of glycolic acid in skin treatment.

2.5 Indications

Glycolic acid has been recognized as an important adjunctive therapy in a variety of conditions including photodamage, acne, rosacea, striae albae pseudofolliculitis barbae, hyperpigmentation disorders, actinic keratoses, fine wrinkles, lentigines, melasma and seborrheic keratoses [5]. Moreover, it can reduce UV-induced skin tumor development and it has been proposed as a therapeutic modality against skin exfoliative conditions such as ichthyosis, xeroderma and psoriasis. In post-menopausal women a cream containing 0.01% estradiol and 15% glycolic acid, applied to one side of the face for 6 months, induces a significant improvement in reversing markers (rete peg pattern, epidermal thickness) of skin aging [6].

Glycolic acid chemical peels are an effective treatment for all types of acne, inducing rapid improvement and restoration of normal-looking skin. In these patients glycolic acid is more widely used than Jessner's solution, considering the equal treatment effect but a reduced exfoliation in glycolic acid [7]. Although the treatment of atrophic acne scars is difficult and generally unsatisfactory, many clinical studies have been performed to investigate the efficacy of glycolic acid in the treatment of acne vulgaris.

It is now widely used to treat many defects of the epidermis and papillary dermis in a variety of strengths, ranging from 20 to 70%, depending on the condition being treated [8].

2.6 Contraindications

Glycolic acid peels are contraindicated in contact dermatitis, pregnancy and in patients with glycolate hypersensitivity. Moreover, they can increase skin sensitivity to ultraviolet light.

2.7 Peeling Preparation

Patients with photodamage can apply a lotion containing 25% glycolic acid for 6 months. In such cases an increase in total skin thickness of approximately 25% was reported, accompanied by an increased thickness of viable epidermis and dermis, an increased content of acid mucopolysaccharides, a greater collagen density and an improved quality of the elastic fibers. This could be defined as self-treatment.

However, a better efficiency in peeling can be achieved with a concentration of 50–70% of glycolic acid and, for maximum benefit, glycolic acid peels are combined with retinoids and other antioxidants. Some studies have evaluated the efficacy of a cream containing 4% hydroquinone and 2% glycolic acid used alone or with salicylic acid in reversing actinic damage on the neck and upper chest for 12 weeks; salicylic acid peelings are performed every 3 weeks. This treatment induces a 33–71% improvement in cases of photodamage (Figs. 2.1a, b and 2.2a, b), hyperpigmentation, texture problems, fine lines, dryness, tone and clarity [9].

Other studies have demonstrated that the application of 50% glycolic acid peels mildly improves photoaging of the skin. Generally, for a light peeling, glycolic acid (50%) was applied topically for 5 min to one side of the face, forearms, and hands, once weekly for 4 weeks. The improvement observed was significant and included decrease in rough texture and fine wrinkling, fewer solar keratoses and a slight lightening of solar lentigines. Histology showed thinning of the stratum corneum, granular layer enhancement, and epidermal thickening. Longer treatment intervals may result in collagen deposition as suggested by the measured increase in mRNA.

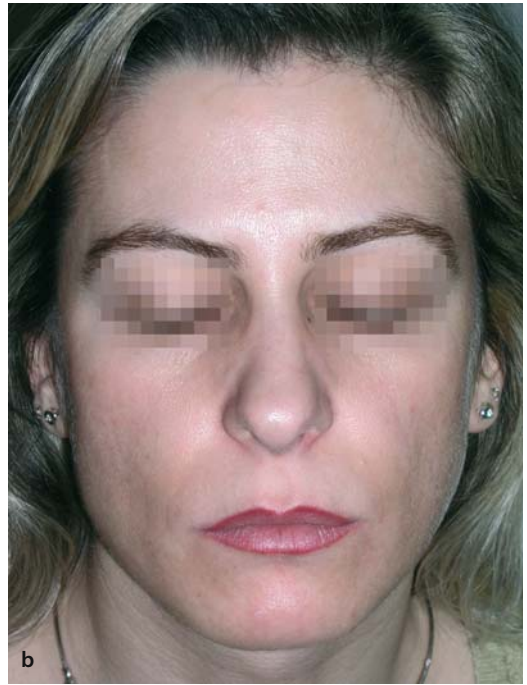
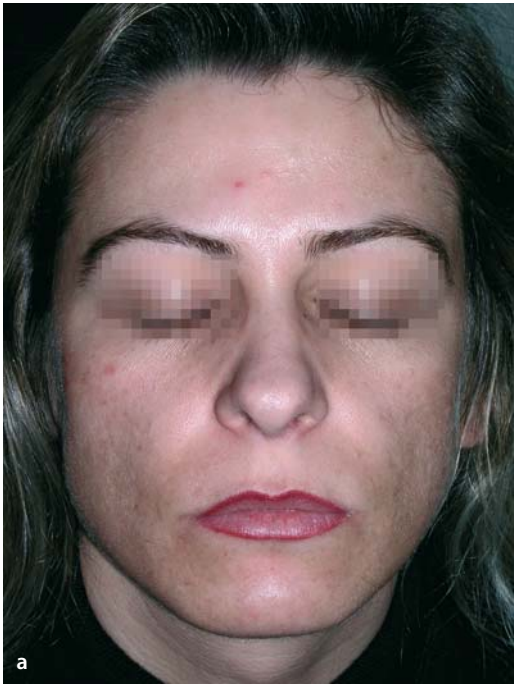
Fig. 2.1a, b. Improvement of photodamage after chemical peeling

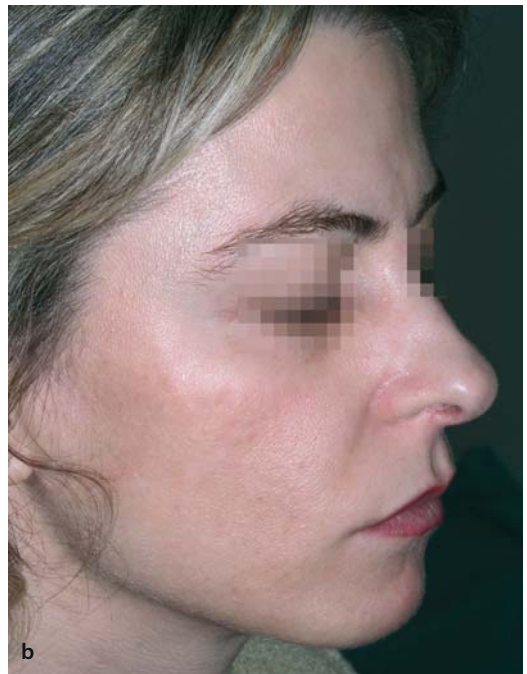
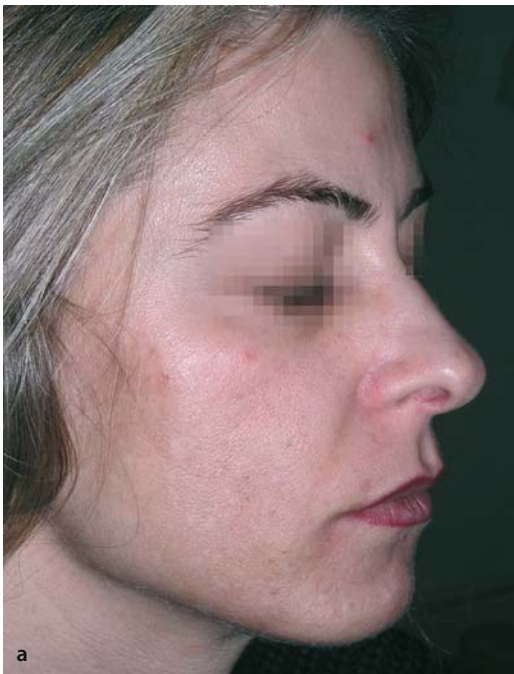
Fig. 2.2a, b. Lateral view of the same patient before and after peeling

2.8 Peeling Technique

2

Before applying glycolic acid the skin is cleaned with alcohol to reduce the acid neutralized by oily skin. Glycolic acid is applied in any cosmetic unit order, rapidly covering the entire face within about 20 s with a large cotton applicator. A starting application time for weekly or monthly applications with 50 or 70% unbuffered glycolic acid is generally in the range of 3 min, and the time is increased with subsequent peels. Neutralizers with sodium bicarbonate marketed to the physician have no advantage over water rinsing as long as all acid is removed thoroughly from all rhytidis and cosmetic units.

Glycolic acid applied simultaneously with TCA represents another technique for a medium-depth peel. Several weeks prior to a peel the skin may be prepared with topical tretinoin or glycolic acid, and immediately prior to the peel the skin may be degreased with a variety of agents. Some studies demonstrated that glycolic acid-trichloroacetic acid peels, called combination medium-depth peeling, are usually performed as a single procedure to remove actinic keratoses, mild rhytidis, or pigmentary dyschromias or to flatten depressed scars. These peelings can be repeated approximately every 6 or 12 months based on the amount of actinic damage still remaining or recurring after the peel or for continued scar effacement. The classic peel for this depth category was the 50% TCA peel.

Since TCA in higher concentrations tends to produce increased scarring and hypopigmentation, 70% glycolic acid solution was applied to the entire face of patients and diluted with water after 2 min. This was followed by the sequential application of EMLA cream (lidocaine 2.5% and prilocaine 2.5%) or ELA-Max cream (lidocaine 4%) to selected areas on the face for 30 min without occlusion. These agents were then removed and 35% TCA was applied to the entire face [10].

Patients with melasma (Fig. 2.3) applied topical sunscreens (sun protection factor 15) and 10% glycolic acid lotion at night for 2 weeks. They were then treated with 50% glycolic acid facial peels once a month for 3 consecutive months. At regular intervals and at the end of the follow-up period (3 months) after the last peel, the degree of improvement in pigmentation was assessed by measuring MASI (Melasma Area and Severity Index) [11].

In patients with acne (Fig. 2.4), the chemical peels were performed with a 70% glycolic acid solution, for 2 to 8 min. The number and frequency of the applications depended on the intensity of the clinical response. The most rapid improvement was observed in comedonic acne, in the papulo-pustular forms. An average of six applications were necessary (Fig. 2.5a, b).

Although nodular-cystic forms required eight to ten applications, a significant improvement of the coexisting post-acne superficial scarring was noted. The procedure was well tolerated and patient compliance was excellent [12]. In the treatment of atrophic acne scars (Fig. 2.6),

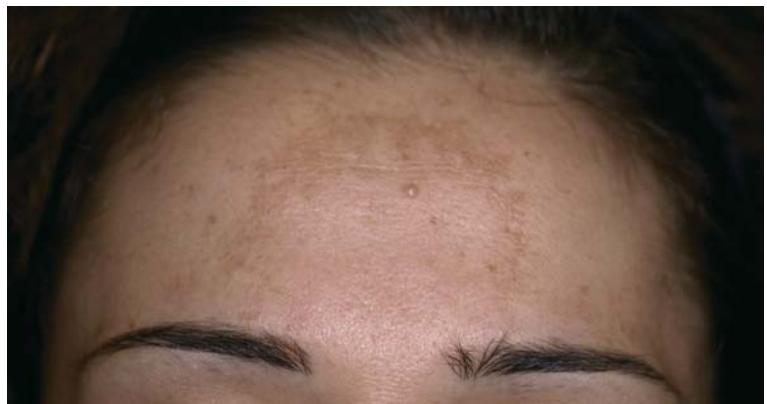

Fig. 2.3.
Melasma of the forehead

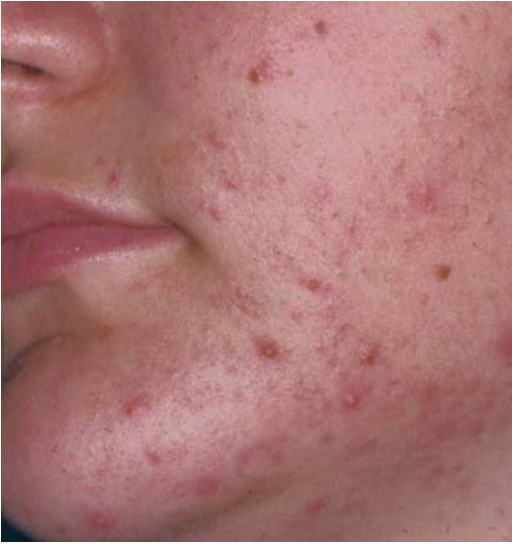

Fig. 2.4. Papulo-pustular acne

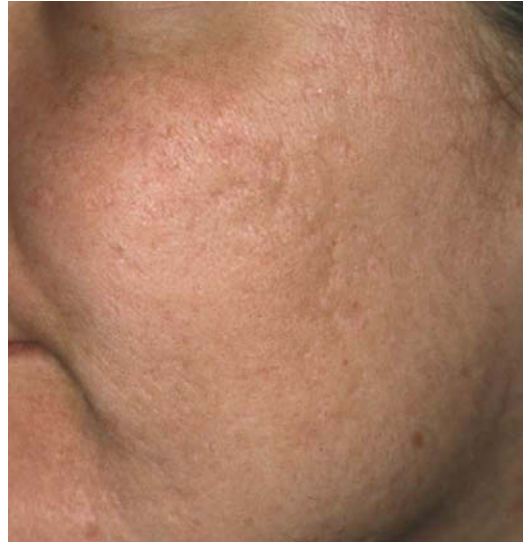

Fig. 2.6. Atrophic acne scars

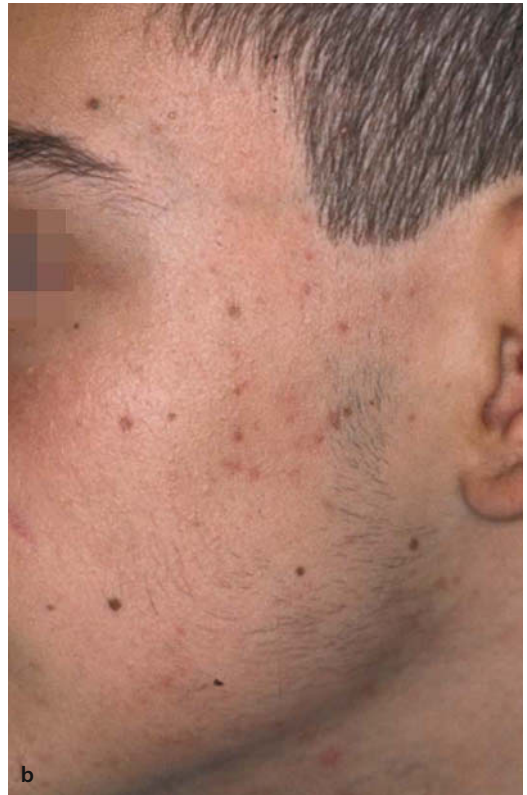
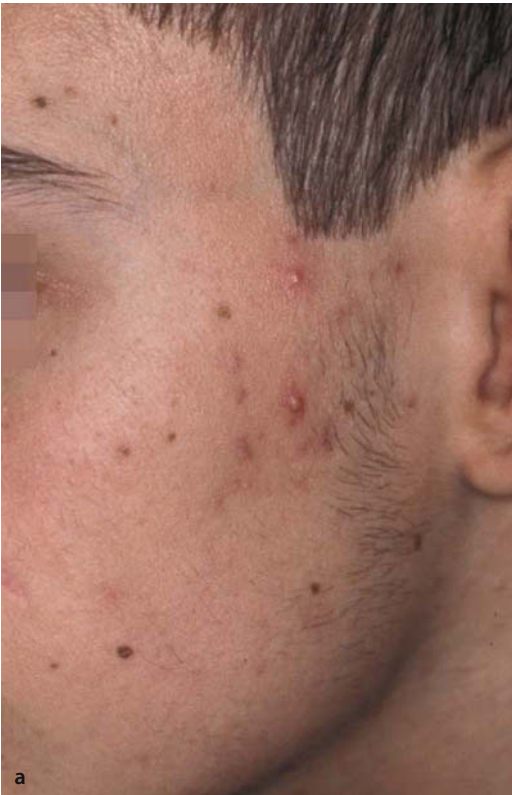
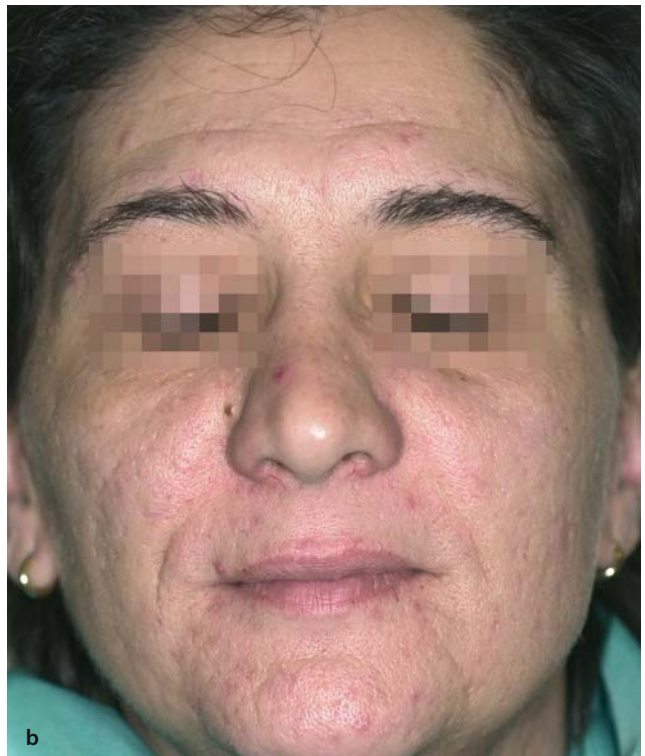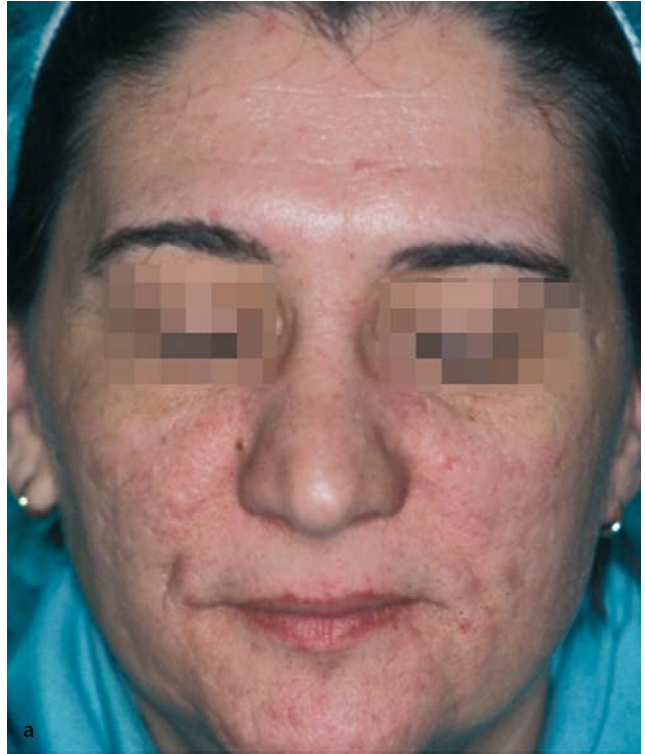Fig. 2.5a, b. Papulo-pustular acne before and after peeling

Fig. 2.7a, b. Acne scars before and after 70% glycolic acid peeling

2



repetitive glycolic acid peels (at least six times) at 70% concentration are necessary to obtain evident improvement. Long-term daily use of low-strength products may also have some useful effects on scars and may be recommended for patients who cannot tolerate the peeling procedure [13] (Fig. 2.7a, b).

Patients of varying skin types (I–V) having striae distensae alba on the abdomen or thighs can apply topical 20% glycolic acid daily to the entire treatment area. In addition, these patients apply 10% L-ascorbic acid, 2% zinc sulfate, and 0.5% tyrosine to half of the treatment area and 0.05% tretinoin emollient cream to the other half of the treatment area. The creams are applied on a daily basis for 12 weeks. Improvement is evaluated at 4 and 12 weeks with increased elastin content within the reticular and papillary dermis [14].

Pseudofolliculitis barbae is a foreign-body inflammatory reaction surrounding ingrown facial hair, which results from shaving. Topical application of glycolic acid lotion is an effective therapy and allows the patient to resume a daily shaving regimen [15].

In patients with scalp psoriasis a combination of a 10% glycolic acid scalp lotion is used as well as a 0.1% betamethasone scalp application, applied twice daily without any bandage for a period of 8 weeks [16].

2.9 Post-peeling Care and Complications

Following the peel the skin is carefully observed for any complications such as hyperpigmentation and infection. Results are maintained with serial peels and by using at-home tretinoin or glycolic acid, as well as by sun avoidance.

2.10 Disadvantages

Through the patient's history and physical examination, the physicians will identify any specific factor such as medications, prior procedures and medical conditions that can affect

the outcome of the peel [17]. Complications of glycolic acid peel like hyperpigmentation and infection are rare. Chemical peel with glycolic acid may cause sensible irritation symptoms, characterized by stinging, burning and itching. A substance capable of counteracting sensory irritation is strontium nitrate at 20 % concentration, which applied topically with 70% glycolic acid, potently suppresses the sensation of chemically induced irritation [18].

Moreover, some studies have demonstrated that glycolic acid could cause an increase in the level of skin damage in a dose- and time-dependent manner. Lower doses (1 and 3 mg/cm²) of glycolic acid caused erythema and eschar at most, whereas higher doses (5 and 7 mg/cm²) of glycolic acid caused redness, edema and necrotic ulceration.

Glycolic acid also increased the thickness of the epidermal layer, reduced the organization of the stratum corneum and eventually destroyed some parts of the epidermal layer at 7 mg/cm². UVB caused redness and edema and also reduced the integrity of the stratum corneum. Glycolic acid enhances UVB-induced skin damage without accompanying PGE (2) production or COX-2 protein expression. Therefore, caution should be exercised by those using glycolic acid chronically or in excessive amounts. Moreover, people with photosensitive skins and those particularly exposed to the sun should be particularly careful. However, this photosensitivity could be reversed within a week after terminating treatments [19].

Laboratory investigations have rarely shown a complex I deficiency in the mitochondrial oxidative phosphorylation of patients who had recurrent episodes characterized by nausea, vomiting, and signs of dehydration necessitating admission to the hospital. In these patients glycolic acid was detected in blood and they were diagnosed as having ethylene glycol intoxication [3].

2.11 Side Effects

Side effects, such as temporary hyperpigmentation or irritation, are not very significant.

2.12 Results

2

Finally, glycolic acid is a member of the alpha-hydroxy acid family, which provides an important adjunctive therapy in a variety of skin disorders. It is widely used in chemical peels in a variety of concentrations, ranging from 20 to 70%. People of almost any skin type and color are candidates and almost any area of the body can be peeled.

Glycolic acid can be applied simultaneously with TCA, which represents another technique for a medium-depth peel. Glycolic acid is also used in creams for self-treatment. Since complications such as hyperpigmentation, infection, irritation, and photosensitivity are very rare, it is well tolerated.

2.13 Informed Consent

Glycolic acid peeling is a medical procedure that requires the informed consent of the patient. The medical doctor must obtain from the patient a well-standardized formal consent that shows that all information about the medical procedure performed was explained to the patient. We include below the formal consent form submitted to the patient before the glycolic acid peeling procedure.

I, _____, after carefully reading the information regarding the glycolic acid peeling procedure, give my informed consent to undergo glycolic acid peeling treatment.

I have been well informed about side effects that the procedure could cause.

I have been well informed of temporary effects of the therapy.

I confirm that I have informed the medical doctor about all actual pathologies or pathologies that I have had.

I confirm that I have informed the medical doctor about pharmacological therapies that I am currently receiving or have received in the past.

I confirm that I want to perform the treatment of my own free will without any physical or moral conditioning and I confirm that I have the right to interrupt the therapy such as I want without the necessity of justifying my decision.

Surname and name

Date of birth

Place of birth

Address

Town

Tel

Signature of the patient

Date

I, medical doctor, _____, confirm that I have explained with accuracy the type, aim and possible risks of the medical procedure to be performed on the patient indicated, who has given consent to begin the treatment.

Surname and name of the medical doctor

Signature of the medical doctor

Date

References

1. Van Scott EJ, Yu RJ (1974) Control of keratinization with alpha-hydroxy acids and related compounds. I. Topical treatment of ichthyotic disorders. *Arch Dermatol* 110:586–590
2. Kataoka M, Sasaki M, Hidalgo AR, Nakano M, Shimizu S (2001) Glycolic acid production using ethylene glycol-oxidizing microorganism. *Biosci Biotechnol Biochem* 65(10):2265–2270
3. Bernstein EF, Lee J, Brown DB, Yu R, Van Scott E (2001) Glycolic acid treatment increases type I collagen mRNA and hyaluronic acid content of human skin. *Dermatol Surg* 27(5):429–433
4. Becker FF, Langford FP, Rubin MG, Speelman P (1996) A histological comparison of 50% and 70% glycolic acid peels using solutions with various pHs. *Dermatol Surg* 22(5):463–465
5. Moy LS, Murad H, Moy RL (1993) Glycolic acid peels for the treatment of wrinkles and photoaging. *J Dermatol Surg Oncol* 19(3):243–246
6. Fuchs KO, Solis O, Tapawan R, Paranjpe J (2003) The effects of an estrogen and glycolic acid cream on the facial skin of postmenopausal women: a randomized histologic study. *Cutis* 71(6):481–488
7. Kim SW, Moon SE, Kim JA, Eun HC (1999) Glycolic acid versus Jessner's solution: which is better for facial acne patients? A randomised prospective clinical trial of split-face model therapy. *Dermatol Surg* 25(4):270–273
8. Murad H, Shamban AT, Premo PS (1995) The use of glycolic acid as a peeling agent. *Dermatol Clin* 13(2):285–307
9. Gladstone HB, Nguyen SL, Williams R, Ottomeyer T, Wortzman M, Jeffers M, Moy RL (2000) Efficacy of hydroquinone cream (USP 4%) used alone or in combination with salicylic acid peels in improving photodamage on the neck and upper chest. *Dermatol Surg* 26(4):333–337
10. Koppel RA, Coleman KM, Coleman WP (2000) The efficacy of ELMA versus ELA-Max for pain relief in medium-depth chemical peeling: a clinical and histopathologic evaluation. *Dermatol Surg* 26(1):61–64
11. Javaheri SM, Handa S, Kaur I, Kumar B (2001) Safety and efficacy of glycolic acid facial peel in Indian women with melasma. *Int J Dermatol* 40(5):354–357
12. Atzori L, Brundu MA, Orru A, Biggio P (1999) Glycolic acid peeling in the treatment of acne. *J Eur Acad Dermatol Venereo* 12(2):119–122
13. Erbagci Z, Akcali C (2000) Biweekly serial glycolic acid peels vs. long-term daily use of topical low-strength glycolic acid in the treatment of atrophic acne scars. *Int J Dermatol* 39(10):789–794
14. Ash K, Lord J, Zukowski M, McDaniel DH (1998) Comparison of topical therapy for striae alba (20% glycolic acid/ 0,05% tretinoin versus 20% glycolic acid/ 10% L-ascorbic acid). *Dermatol Surg* 24(8):849–856
15. Perricone NV (1993) Treatment of pseudofolliculitis barbae with topical glycolic acid: a report of two studies. *Cutis* 52(4):232–235
16. Kostarelou K, Teknetzis A, Lefaki I, Ioannides D, Minas A (2000) Double-blind clinical study reveals synergistic action between alpha-hydroxy acid and betamethasone lotions towards topical treatment of scalp psoriasis. *J Eur Acad Dermatol Venereo* 14(1):5–9
17. Tung RC, Bergfeld WF, Vidimos AT, Remzi BK (2000) Alpha-hydroxy acid-based cosmetic procedures. Guidelines for patient management. *Am J Clin Dermatol* 1(2):81–88
18. Zhai H, Hannon W, Hahn GS, Pelosi A, Harper RA, Maibach HI (2000) Strontium nitrate suppresses chemically induced sensory irritation in humans. *Contact Dermatitis* 42(2):98–100
19. Parks KS, Kim HJ, Kim EJ, Nam KT, Oh JH, Song CW, Jung HK, Kim DJ, Yun YW, Kim HS, Chung SY, Cho DH, Kim BY, Hong JT (2002) Effects of glycolic acid on UVB-induced skin damage and inflammation in guinea pigs. *Skin Pharmacol Appl Skin Physiol* 15(4):236–245

Jessner's Solution

Pearl E. Grimes

The author has no financial interest in any of the products or equipment mentioned in this chapter.

Contents

3.1	History	23
3.2	Chemical Background	23
3.3	Formulations	24
3.4	Indications	25
3.5	Contraindications	25
3.6	Skin Preparation	26
3.7	Peeling Technique	27
3.8	Post-peel Care	27
3.9	Advantages of Jessner's Peeling	27
3.10	Disadvantages of Jessner's Peeling	27
3.11	Side Effects	28
3.12	Patient's Informed Consent	28
	References	29

3.1 History

Jessner's Solution has been used for over 100 years as a therapeutic agent to treat hyperkeratotic epidermal lesions [1]. This superficial peeling agent constitutes a mixture of salicylic acid, resorcinol, and lactic acid in 95% ethanol. Jessner's solution causes loss of corneocyte cohesion and induces intercellular and intracellular edema. Jessner's typically induces wounding to the level of the papillary dermis. Historically, resorcinol (a key component of Jessner's peels) was used in concentrations of 10–50% in the early twentieth century. High concentrations of resorcinol were associated with side effects such as allergic contact dermatitis, irritant contact

dermatitis, and skin discoloration. Subsequently, Jessner's solution was formulated by Dr. Max Jessner to lower the concentrations of any one agent contained in the mixture and to enhance its overall effects as a keratolytic agent.

3.2 Chemical Background

Each component of Jessner's solution has specific effects (Fig. 3.1). Salicylic acid (ortho hydroxy benzoic acid) is a beta hydroxy acid agent

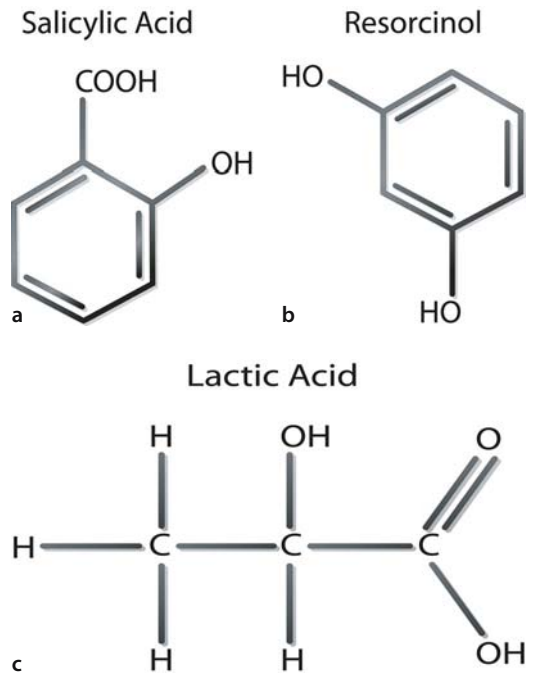


Fig. 3.1a–c. Chemical structures of Jessner's Peel components (a Salicylic acid, b Resorcinol, and c Lactic acid)

[2]. It is a lipophilic compound which removes intercellular lipids that are covalently linked to the cornified envelope surrounding epithelial cells [3]. It also enhances penetration of other agents. Resorcinol (m-dihydroxy benzene) is structurally and chemically similar to phenol. It disrupts the weak hydrogen bonds of keratin [4]. Lactic acid is an alpha hydroxy acid which causes corneocyte detachment and subsequent desquamation of the stratum corneum [5].

3.3 Formulations

The standard formulation of Jessner's solution is listed in Table 3.1. Modified Jessner's solutions that do not contain resorcinol are also available (Delasco, Council Bluffs, IA) (Table 3.2).

Table 3.1. Preparation of Jessner's Solution with resorcinol

Resorcinol 14 g
Salicylic acid 14 g
Lactic acid (85%) 14 g
Ethanol (sufficient quantity to make 100 mL)

Table 3.2. Modified Jessner's Solution

17% lactic acid
17% salicylic acid
8% citric acid
Ethanol (sufficient quantity to make 100 mL)

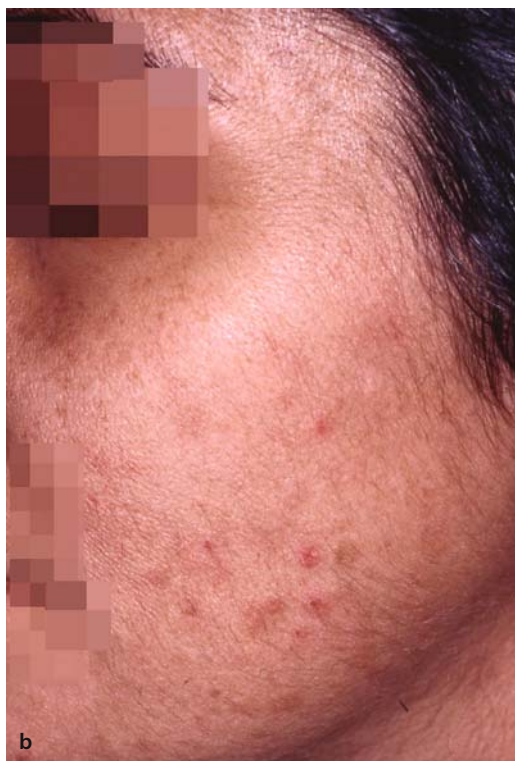
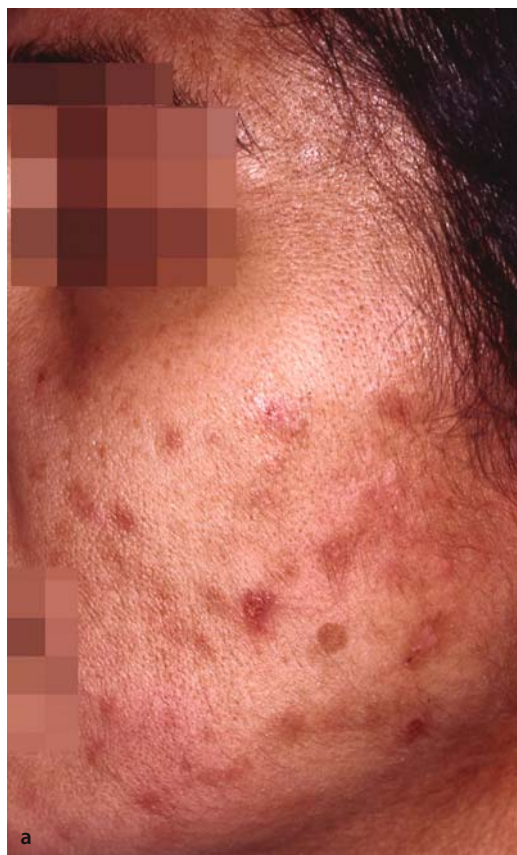
Fig. 3.2. a Patient with acne with excoriation. b Patient after treatment with three Jessner's peels

3.4 Indications

Jessner's peels have been used to treat acne, melasma, post-inflammatory hyperpigmentation, lentigines, freckles, and photodamage (Figs. 3.2a, b, 3.3a, b and 3.4a, b).

3.5 Contraindications

As with other superficial peeling agents, Jessner's peels are well tolerated with few contraindications. However, there is scant pub-

lished information on the use of Jessner's peels in Fitzpatrick's skin types V and VI. In the author's experience, Jessner's peels are also well tolerated in these groups. General contraindications include active inflammation, dermatitis, or infection of the area to be treated; isotretinoin therapy within 6 months of peeling; and delayed or abnormal wound healing. Jessner's peels are also contraindicated during pregnancy. Allergies to resorcinol, salicylic acid, or lactic acid are absolute contraindications. Patients should not have unrealistic expectations regarding peel outcomes.

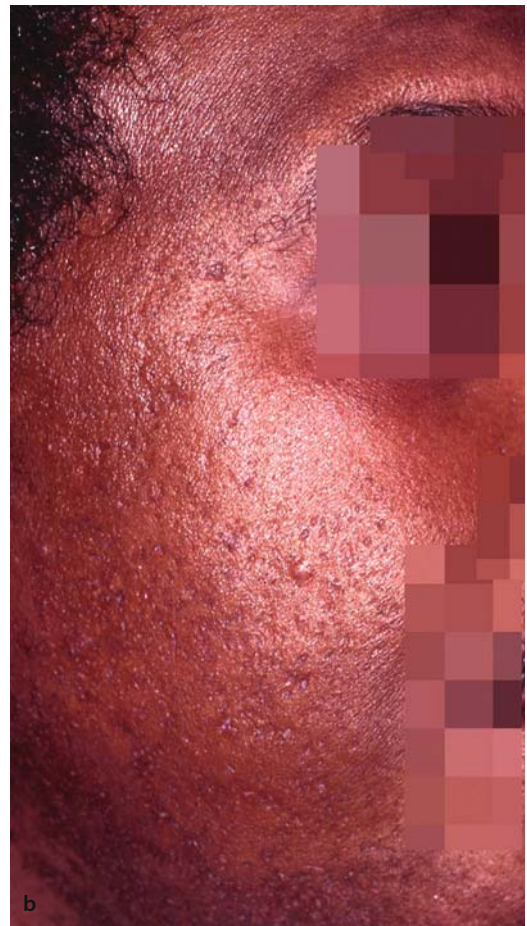
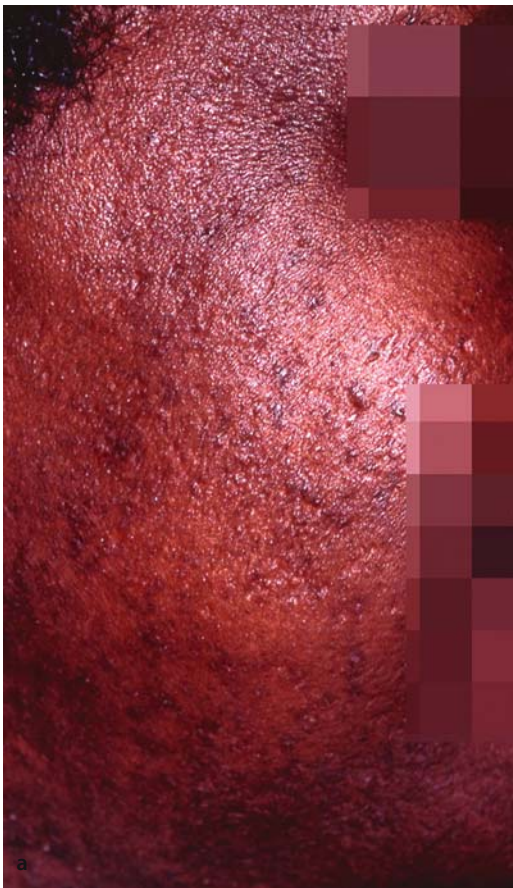
Fig. 3.3. a Patient with post-inflammatory hyperpigmentation. b Patient after treatment with a series of two Jessner's peels

3

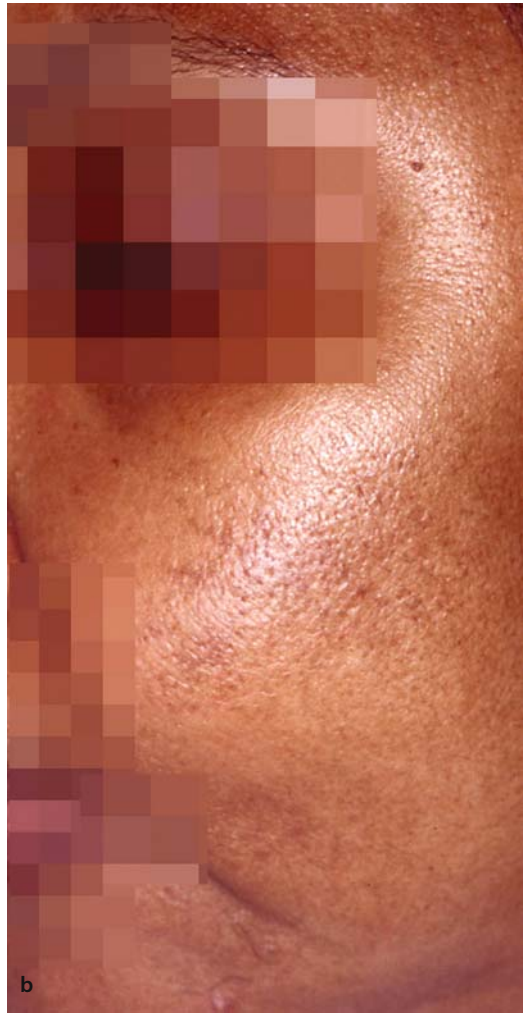
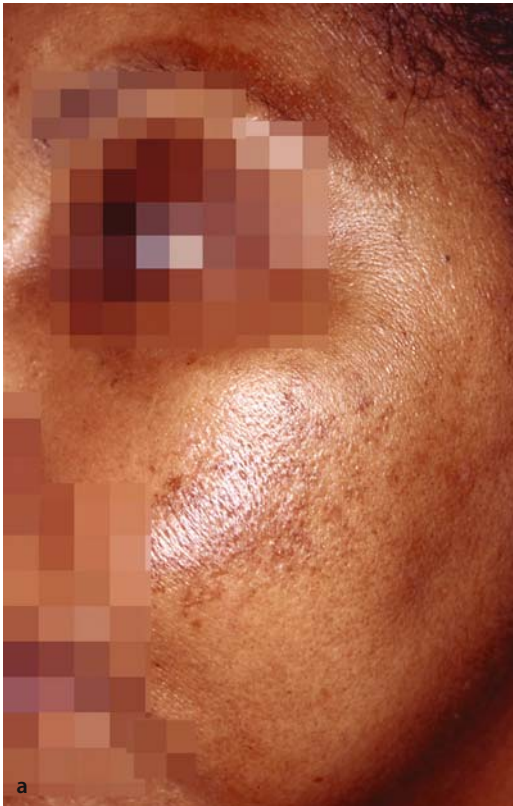
Fig. 3.4. a Patient with melasma. b Patient after treatment with Jessner's peeling

3.6 Skin Preparation

The general goals of preparing the skin for peeling are to maximize peel outcomes while minimizing the potential to develop post-peel complications. A detailed history and cutaneous examination should be performed prior to chemical peeling. Baseline full-face frontal and lateral photos are recommended. Skin preparation for Jessner's peeling includes the use of bleaching agents, topical retinoids, alpha hy-

droxy acids, and/or other topical exfoliating agents. However, as with other superficial peeling agents, the patient's diagnosis influences how the skin should be prepared for the peeling procedure. Skin preparation can impact penetration of the peeling agent and the overall efficacy of the peel. In addition, peel preparation can increase or decrease the potential to develop post-peel complications.

Use of topical retinoids (tretinoin, tazarotene, retinol formulations) for 2–6 weeks prior

to peeling thins the stratum corneum and enhances epidermal turnover [6]. Such agents also reduce the content of epidermal melanin and expedite epidermal healing. Retinoids also enhance the penetration of the peeling agent. They should be discontinued several days prior to the peeling procedure. Retinoids can be resumed post-operatively after all evidence of peeling and irritation subsides. When treating conditions such as melasma, acne, and post-inflammatory hyperpigmentation, as well as darker skin types, retinoids should be discontinued 1 or 2 weeks before peeling or even eliminated from the prep to avoid post-peel complications such as excessive erythema, desquamation, and post-inflammatory hyperpigmentation. Topical alpha hydroxy acid or polyhydroxy acid formulations can also be used to prep the skin. In general, they are less aggressive agents in impacting peel outcomes. The skin is usually prepped for 2–4 weeks with a formulation of hydroquinone 4% or higher compounded formulations (5–10%) to reduce epidermal melanin. This is extremely important when treating the aforementioned dyschromias. Although less effective, other topical bleaching agents include azelaic acid, kojic acid, arbutin, and licorice (see photoaging section). Patients can also resume use of topical bleaching agents post-operatively after peeling and irritation subsides [7, 8]. Broad-spectrum sunscreens (UVA and UVB) should be worn daily (see Photodamage, Sunscreen section).

3.7 Peeling Technique

The skin is usually degreased with alcohol followed by a mild acetone scrub. After cleaning, Jessner's solution is applied to the face with a sable brush, cotton tipped applicators, cotton balls, or 2 × 2 gauze sponges. The author prefers the use of cotton tipped applicators. Typically, the cheeks are treated first, working from medial to lateral areas followed by application to the chin and forehead area. For superficial peeling, two coats are usually applied. Additional coats increase the depth of peeling.

Neutralization or dilution with Jessner's solution is not indicated. After application of product, some visible precipitate may appear on the skin surface. This should be distinguished from true frosting which correlates with the depth of peeling. Extent of erythema and desquamation following a Jessner's peel correlates with extent of and type of pre-peel prepping, number of coats of product applied, and level or degree of frosting during the procedure [7].

3.8 Post-peel Care

Use of bland cleansers and moisturizers is essential. Recommended moisturizing agents include Cetaphil, SBR-Lipocream, or Aquaphor. Peeling related to Jessner's usually resolves in 2–7 days. Patients can resume the use of general skin care products after peeling subsides. Makeup can be worn to camouflage peeling. Excessive peeling, erythema, or irritation post-peel can be treated with low or mid- to high-potency steroids for 5–7 days. Use of such agents should be based on the extent of irritation and inflammation.

3.9 Advantages of Jessner's Peeling

- Excellent safety profile
- Can be used in all skin types
- Substantial efficacy with minimal "down time"
- Enhances the penetration of TCA

3.10 Disadvantages of Jessner's Peeling

- Concerns regarding resorcinol toxicity, including thyroid dysfunction
- Manufacturing variations
- Instability with exposure to light and air
- Increased exfoliation in some patients

3.11 Side Effects

3

Despite concerns regarding resorcinol and salicylate toxicity, Jessner’s solution has been extremely well tolerated with minimal side effects. Allergic reactions to resorcinol are reported to be rare [9, 10]. Although the potential to induce thyroid disease has been reported, a recent toxicological review on the risk of resorcinol in inducing thyroid abnormalities did not support an association [9]. However, resorcinol administered at high doses to rodents can disrupt thyroid hormone synthesis and can produce goitrogenic effects. Clinical case reports from patients undergoing resorcinol therapy for dermatological indications reveal thyroid side effects in instances where copious amounts of resorcinol-containing ointments are applied to integrity-compromised skin for months to years. However, a risk assessment comparing potential worst-case exposures to resorcinol through its use in dermatological preparations supports the conclusion that under real-life conditions, human exposures to resorcinol are not expected to cause adverse effects on thyroid function [9]. In addition, we are aware of no case reports of salicylism from Jessner’s formulation. Resorcinol has also been implicated in the induction of exogenous ochronosis in Africa. However, resorcinol has not been implicated in the rare cases of ochronosis in the United States [11].

3.12 Patient’s Informed Consent

I, _____, hereby consent to having my _____ (site) treated with CHEMICAL PEELING USING JESSNER’S SOLUTION. Jessner’s peeling is often used to treat photodamage (sun-damaged skin), hyperpigmentation (dark spots), texturally rough skin, acne, and scarring. It is a peeling agent which causes shedding of the outermost layer of the skin, the stratum corneum”.

The procedure involves first having the peel site prepped with alcohol, acetone or other

pre-peel cleansing agents. The peel is then applied. In general, Jessner’s peels are extremely well tolerated. However, the procedure can cause redness, flaking, dryness, or irritation in the area to be treated. The effects could last for 1–2 weeks.

I understand that there is a small risk of developing permanent darkening or undesirable pigment loss at the treated site. There is a rare chance that a scar could develop. There is also a small risk that a bacterial infection could develop or there could be a flare of a pre-existing Herpes infection at the treated site, or the condition being treated could worsen after the peeling procedure. The benefits and side effects of the procedure have been explained to me in detail. All of my questions have been answered.

- I am in stable health.
- I have not used Isotretinoin in the past 6 - months.
- I have no allergies to resorcinol, salicylic acid, or lactic acid.
- I am not pregnant.

Outcomes are not guaranteed.

Signature of Patient

Date

Patient Name (Please Print)

Witness

Date

References

1. Monheit GD (1989) Jessner's + TCA peel: a medium depth chemical peel. *J Dermatol Surg Oncol* 15: 945–950
2. Huber C, Christophers E (1977) Keratolytic effect of salicylic acid. *Arch Dermatol Res* 257: 293–297
3. Lazo ND, Meine JG, Downing DT (1995) Lipids are covalently attached to rigid corneocyte protein envelope existing predominantly as beta-sheets: a solid state nuclear magnetic resonance study. *J Invest Dermatol* 105: 296–300
4. Rook A, Wilkinson DS, Ebling FJG (1972) *Textbook of dermatology*. Blackwell Scientific, Oxford, England, pp 2072–2075
5. Van Scott EJ, Yu RJ (1984) Hyperkeratinization, corneocyte cohesion, and alpha hydroxy acids. *J Am Acad Dermatol* 11: 867–879
6. Matarasso SL, Glogau RG (1991) Chemical face peels. *Dermatol Clin* 9: 131–150
7. Rubin MG (1995) *Manual of chemical peels: superficial and medium depth*. J.B. Lippincott Company, Philadelphia, pp79–88
8. Brody HJ (1997) *Chemical peeling and resurfacing*, 2nd ed. Mosby, St. Louis, pp 82–86
9. Lynch BS, Delzell ES, Bechtel DH (2002) Toxicology review and risk assessment of resorcinol: thyroid effects. *Regul Toxicol Pharmacol* 36: 198–210
10. Barbaud A, Modiano P, Cocciale M, et al (1996) The topical application of resorcinol can provoke a systemic allergic reaction. *Br J Dermatol* 135: 1014–1015
11. Thomas AE, Gisburn MA (1961) Exogenous ochronosis and myxedema from resorcinol. *Br J Dermatol* 73: 378–381

Pyruvic Acid

Ilaria Ghersetich, Benedetta Brazzini, Torello Lotti, Maria Pia De Padova, Antonella Tosti

The author has no financial interest in any of the products or equipment mentioned in this chapter.

Contents

4.1	History	31
4.2	Properties	31
4.3	Indications	31
4.4	Formulations	31
4.5	Contraindications	32
4.6	Peeling Preparation (Home Treatment)	32
4.7	Peeling Technique (Figs. 4.2, 4.3, 4.4, 4.5, 4.6, 4.7 and 4.8)	32
4.8	Post-peeling Care	35
4.9	Side Effects	35
4.10	Advantages	35
4.11	Disadvantages	35
4.12	Results	35
4.13	Patient's Informed Consent	38
	References	39

4.1 History

Pyruvic acid is an alpha-ketoacid, a chemical group that has properties of both acids and ketones [1, 2, 3]. Griffin first showed 60% pyruvic acid in ethanol to be effective as a peeling agent [4]. According to personal communication with Griffin, the acid induces more even penetration when 5 cc is combined with eight drops of an emulsifying agent such as polyethylene laurel ether and one drop of crotonoil as an epidermolytic inflammatory agent in a solution similar to Baker's phenol formula [5].

4.2 Properties

- α -keto-acid ($\text{CH}_3\text{-CO-COOH}$)
- Converts physiologically into lactic acid
- Soluble in water and alcohol
- Keratolytic action
- Desmoplastic property
- Increases collagen, elastic fibers and glycoproteins production
- Anti-microbial activity
- Activity related to its concentration, solvent used, time and number of applications

4.3 Indications

- Inflammatory acne, especially microcystic acne (Fig. 4.1)
- Greasy skin
- Moderate acne scars
- Warts [6]
- Actinic keratosis
- Moderate photoaging (fine wrinkles, textural alterations, diffuse dyschromias, yellowing and mottling)

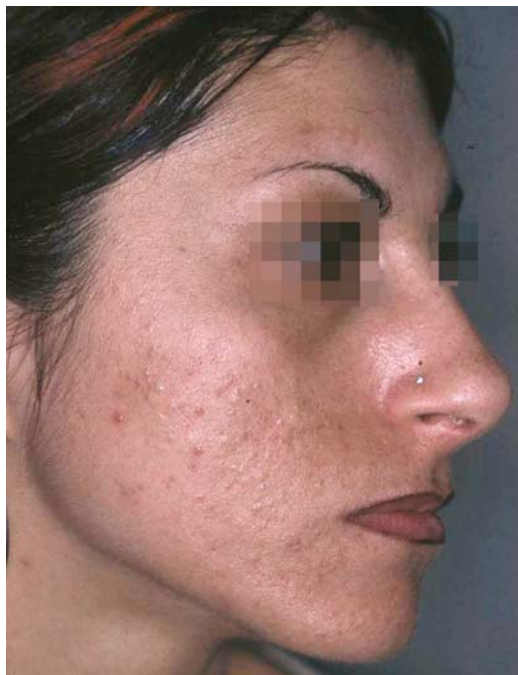

Fig. 4.1. Microcystic acne

4.4 Formulations

- 40% pyruvic acid solution
- 50% pyruvic acid solution
- 60% pyruvic acid solution

5 Contraindications

- History of recurrent herpes simplex virus infection
- LED
- Pregnancy
- Daily sun exposure

4.6 Peeling Preparation (Home Treatment)

- Acne, greasy skin and photoaging: 8% pyruvic acid cream once a day or 8–15% glycolic acid cream (remembering that this priming reduces the thickness of the stratum corneum and helps a more uniform and deeper penetration of the peeling agent)
- Photoaging: also add topical tretinoin (0.025%) and topical bleaching agents (4% hydroquinone, 20% azelaic acid) for at least 2 weeks once a day (in the evening) to decrease the risk of post-inflammatory hyperpigmentation and promote wound healing

4.7 Peeling Technique (Figs. 4.2, 4.3, 4.4, 4.5, 4.6, 4.7 and 4.8)

- Degrease the skin with alcohol
- Solution application:
 - Apply the solution with a brush (for a light and uniform peel) in two to three layers and keep the acid on the skin until erythema appears
 - Apply the solution with gauze, scrub gently and continuously for 1–3 min to obtain a deeper penetration
- Apply the solution to small areas (forehead, one cheek at a time, chin, nose and upper lip) and neutralize each area with sodium bicarbonate before progressing to the next area
- A small fan should be used during the application of pyruvic acid to avoid inhaling the vapors
- Moisturizing creams and sunscreens must be applied after the peel
- Three to five peeling sessions are needed at 4-week intervals (Figs. 4.9a, b, 4.10a, b and 4.11a, b)

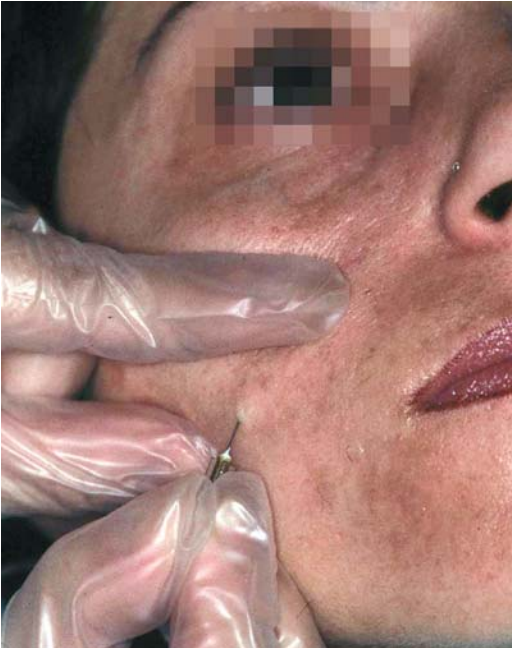

Fig. 4.2. Peeling procedure in a patient with microcystic acne: the microcysts are broken with a 30¹/₂ gauge needle

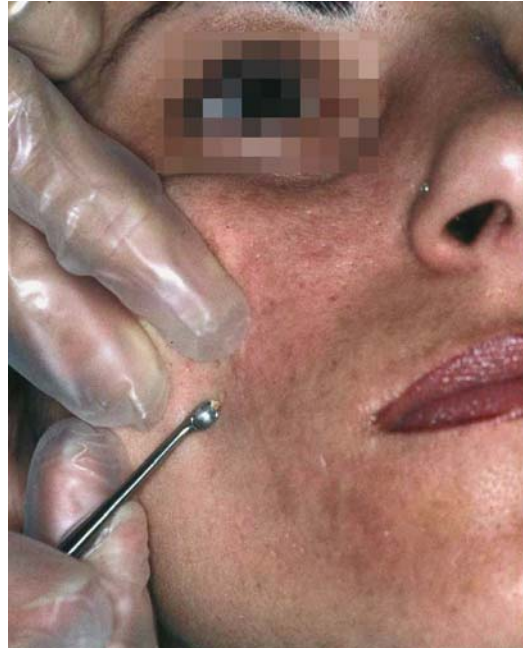

Fig. 4.3. Peeling procedure in a patient with microcystic acne: Toilette with a surgical spoon

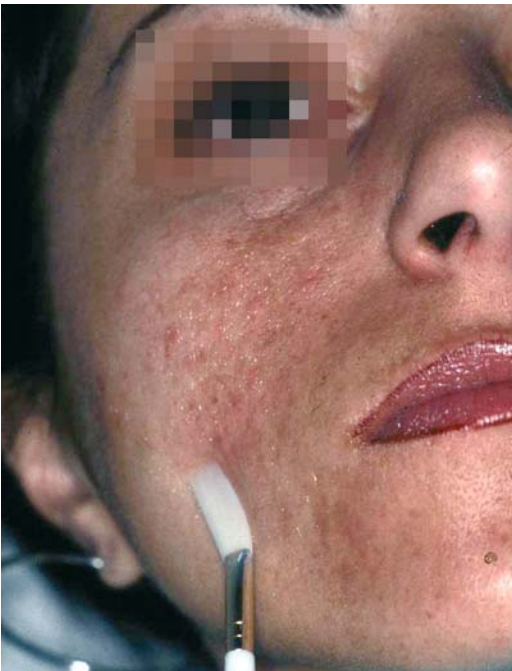

Fig. 4.4. Peeling procedure in a patient with microcystic acne: application of the formulation

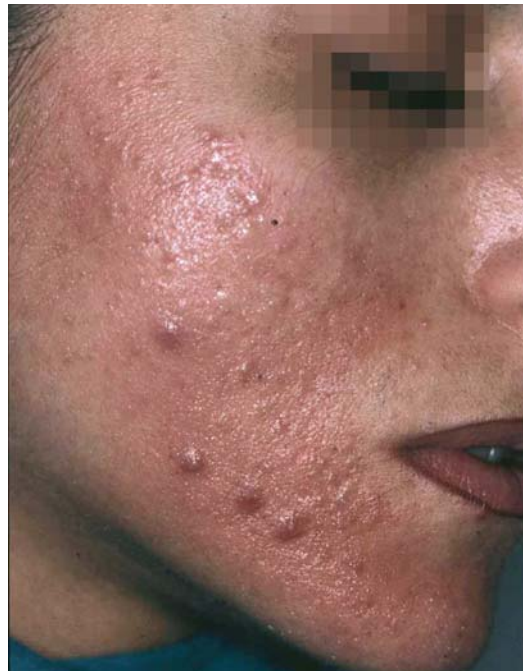
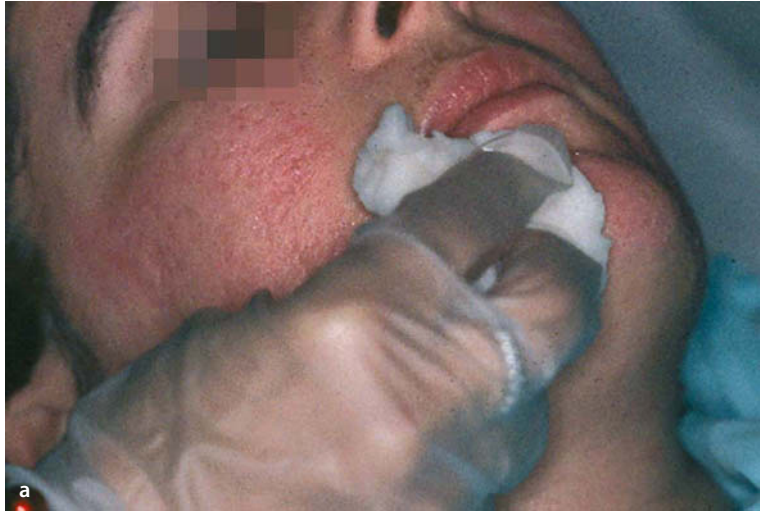
Fig. 4.5. Peeling procedure in a patient with microcystic acne

Fig. 4.6a. Neutralization
with sodium bicarbonate



4

Fig. 4.6b. Uniformity of ery-
thema after neutralization

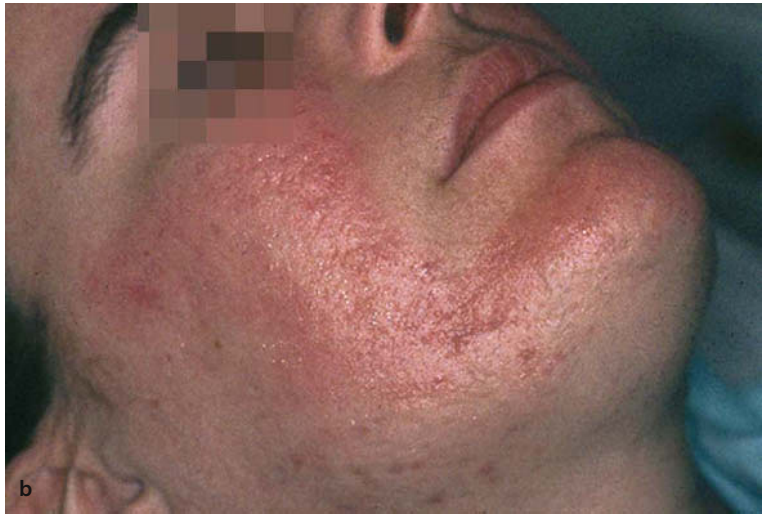



Fig. 4.7. The fan used during the procedure

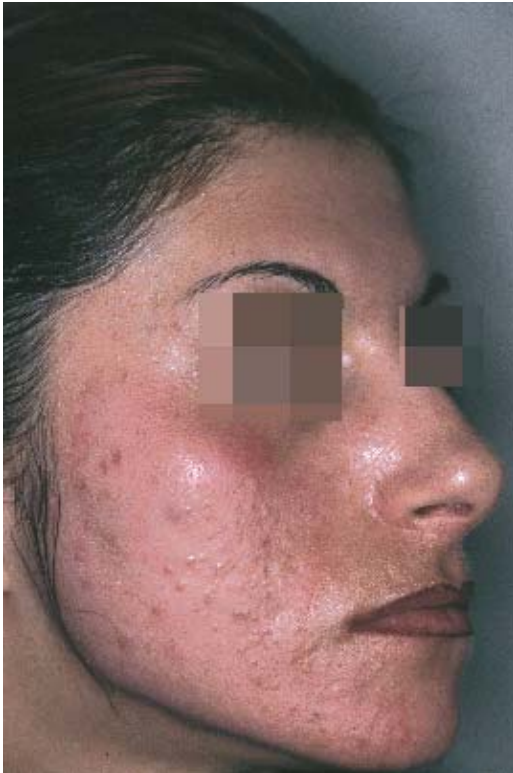

Fig. 4.8. The patient after peeling

4.8 Post-peeling Care

- Daily use of moisturizing facial cream and sunscreens
- Cease the use of retinoid creams, a-hydroxy acid and pyruvic acid creams for a week after the peel

Side Effects

- Desquamation
- Crusting in areas of thinner skin

4.10 Advantages

- Very mild erythema
- Mild desquamation
- Short post-operative period
- Can be used in Fitzpatrick skin type III and IV

4.11 Disadvantages

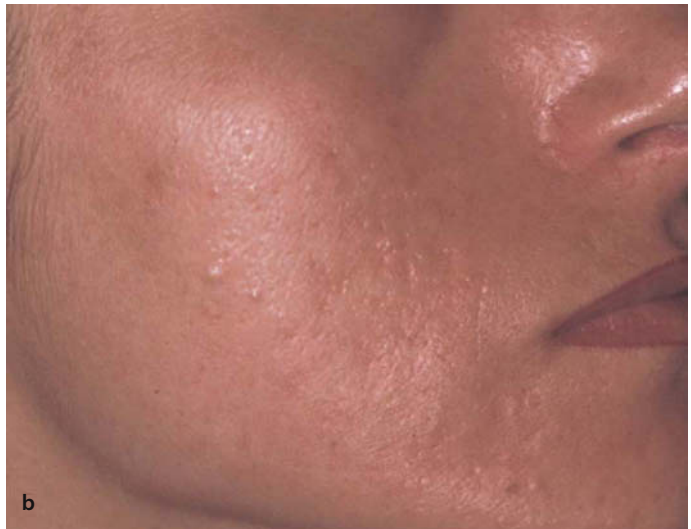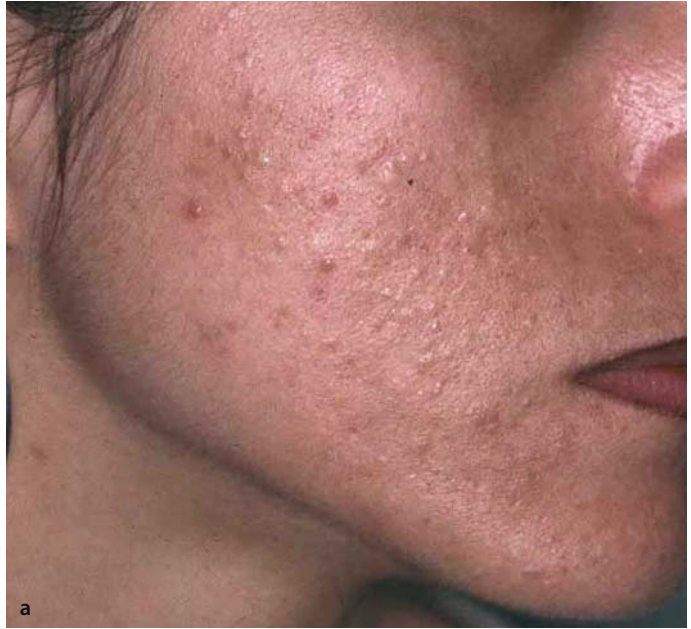- Intense stinging and burning sensation during the application
- Pungent and irritating vapors for the upper respiratory mucosa

4.12 Results

- Patients with photoaging showed a smoother texture, less evident fine wrinkles and an important lightening of hyperpigmentations (freckles and lentigines) [7, 8]
- Acne and greasy skin: improvement of acne lesions and important decrease of seborrhea

Fig. 4.9a, b. Before and after chemical peeling with 50% pyruvic acid

4



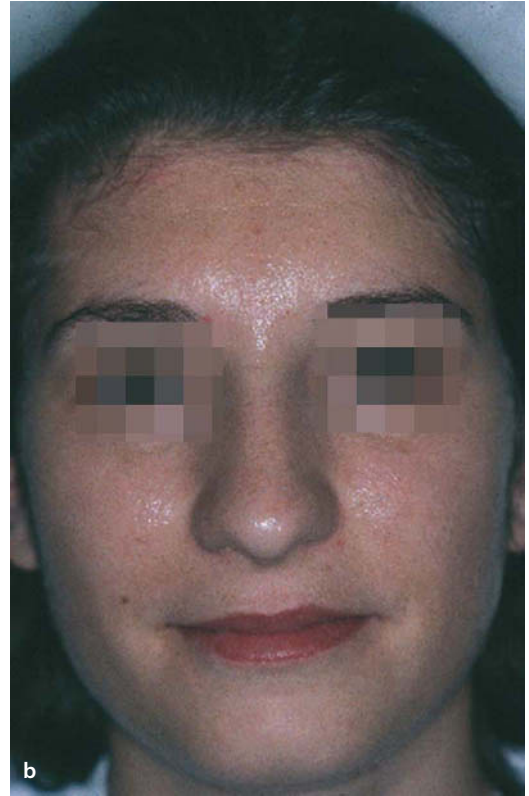
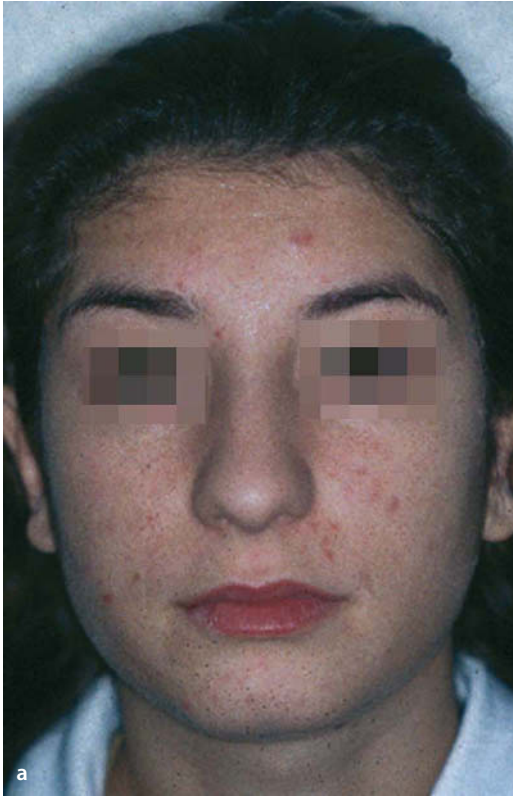
Fig. 4.10a, b. Before and after chemical peeling with 50% pyruvic acid

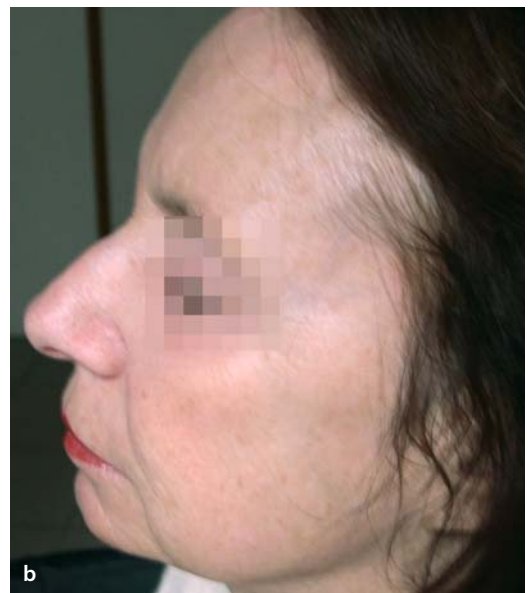
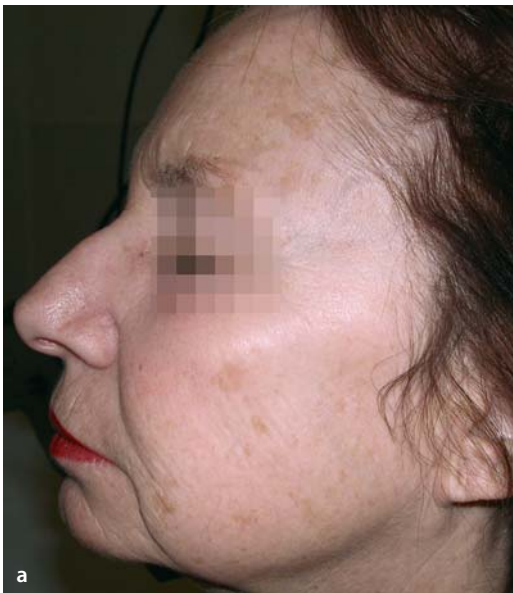
Fig. 4.11a, b. Photodamage with wrinkles and solar lentigo before and after peeling

4.13 Patient's Informed Consent

1. I hereby request and authorize Dr. _____, M.D., to treat me for the purpose of attempting to improve my appearance.
2. The effect and nature of the treatment to be given, as well as possible alternative methods of treatment, have been fully explained to me.
3. It has been explained that well-qualified and trained personnel will assist with certain portions of the treatment under his/her supervision.
4. I hereby authorize Dr. _____, OR, to administer such treatment to me, and agree to hold him/her free and harmless for any claims or suits for damages or injury or complications whatsoever resulting from conditions beyond the doctor's control.
5. I know that the practice of medicine and surgery is not an exact science and that, therefore, reputable practitioners cannot properly guarantee results.
6. I acknowledge that no guarantee or assurance has been made to me by anyone regarding the treatment which I have herein requested and authorized.
7. I am advised that though good results are expected, they cannot be and are not guaranteed, nor can there be any guarantee against untoward results.
8. I acknowledge that no guarantee has been given me as to the number of years I may appear younger following treatment.
9. I acknowledge that no guarantee has been given me as to the condition of the complexion or size of the skin pores following treatment, complete healing of acne lesions or fading of hyperpigmentations.
10. I acknowledge that during the procedure pyruvic acid in an alcoholic solution will be applied for 1–5 min on my face.
11. I acknowledge that no guarantee has been given me as to the painlessness of the procedure. Some individuals, because of emotional makeup or low pain threshold, may experience pain. This procedure will cause a modification in the treated area of my face (body), which may be unpleasant. My face will become red and subsequently dry and in some cases areas of dry hyperpigmented skin may occur. Crusts may occur in some areas and must be medicated with topical antibiotics. Exfoliation will then start and last about 5–10 days. An erythema may persist for 15–20 days.
12. I have been advised that the following conditions may arise after treatment. These conditions are uncommon and usually not serious, but may appear at any time because of circumstances beyond the doctor's control:
 - a. A darkening (hyperpigmentation) of the skin or blotchiness may occur at any time up to 3 months following treatment. This is usually due to excess sun or heat exposure. Special medication may be prescribed for this and will usually clear the condition completely. Occasionally, further treatment may be required, consisting of a second procedure. Persons with dark complexions undergoing treatment are advised that a blotchy complexion may arise, which will usually even out over a period of 3–6 months.
 - b. The skin may be red for 10–20 days.
13. I have been advised that exposure to sun must be avoided at all costs for a period of 6 months. No sunbathing is permitted for 6 months. To do so would encourage blotchy skin pigmentation requiring further treatment.
14. I give my permission that my before and after pictures will be used for:
 - Educational purposes only
 - Patient demonstration
 - Medical congresses and medical articles

The operation has been explained to me and I fully understand the nature of the procedure and the risks involved. I acknowledge and understand that no expressed or implied warranty has been given to me.

Date _____ Signature _____

References

1. Cotellessa C, Manunta T, Ghersetich I, Brazzini B, Lotti T, Peris K (2005) The use of pyruvic acid in the treatment of acne. *J Eur Acad Dermatol Venereol* (in press)
2. Ghersetich I, Brazzini B, Peris K, Cotellessa C, Manunta T, Lotti T (2005) Pyruvic acid peels for the treatment of photoaging. *Derm Surg* (in press)
3. Ghersetich I, Brazzini B, Lotti T (2003) Chemical peeling. In: Lotti TM, Katsambas AD (eds) *European handbook of dermatological treatments*, 2nd ed. Springer, Berlin, Heidelberg, New York
4. Griffin TD, Van Scott EJ, Maddin S (1989) The use of pyruvic acid as a chemical peeling agent. *J Dermatol Surg Oncol* 15:1316
5. Griffin TD, Van Scott EJ (1991) Use of pyruvic acid in the treatment of actinic keratoses: a clinical and histopathologic study. *Cutis* 47:325–329
6. Halasz CL (1998) Treatment of warts with topical pyruvic acid: with and without added 5-fluorouracil. *Cutis* 62(6):283–285
7. Moy LS, Peace S, Moy RL (1996) Comparison of the effect of various chemical peeling agents in a mini pig model. *Dermatol Surg* 22:429–432
8. Seitz JC, Whitmore CG (1988) Measurement of erythema and tanning response in human skin using a Tri-Stimulus colorimeter. *Dermatologica* 177:70–75

Resorcinol

Ilaria Ghersetich, Benedetta Brazzini, Torello Lotti,
Maria Pia De Padova, Antonella Tosti

The author has no financial interest in any of the products or equipment mentioned in this chapter.

Contents

5.1	History	41
5.2	Chemical Background and Properties	41
5.3	Formulations	41
5.4	Indications [4, 5]	42
5.5	Contraindications	42
5.6	Peeling Preparation	44
5.7	Peeling Technique	44
5.8	After Peel Care	45
5.9	Side Effects	45
5.10	Advantages	46
5.11	Disadvantages	46
5.12	Patient's Informed Consent	46
	References	47

- Soluble in water, ether and alcohol
- Bactericidal agent
- Reducing agent
- Keratolytic properties

5.3 Formulations

Modified Unna Paste (Fig. 5.1)

Resorcinol	40 g
Zinc Oxide	10 g
Ceyssatite	20 g
Benzoinated axungia	28 g

5.1 History

In 1882 Unna described the use of resorcinol in chemical peels in concentrations of 10, 20 and 30% [1]. The formula was later modified to obtain a 50% concentration [2, 3].

5.2 Chemical Background and Properties

- m-dihydroxybenzene is isomeric with cathecol and hydroquinone
- Related to phenol both structurally and chemically



Fig. 5.1. Modified Unna paste

5.4 Indications [4, 5]

- Acne in active phase (papulo-pustular lesions) (Fig. 5.2a, b)
- Post-acneic disorders (post-inflammatory hyperpigmentation, erythema and shallow scars) (Fig. 5.3a, b)
- Epidermal melasma (Fig. 5.4a, b)
- Photoaging mild
- Freckles

5.5 Contraindications

- Skin type more than V
- Allergic reaction to resorcinol
- Pregnancy
- Herpes simplex in active phase

5

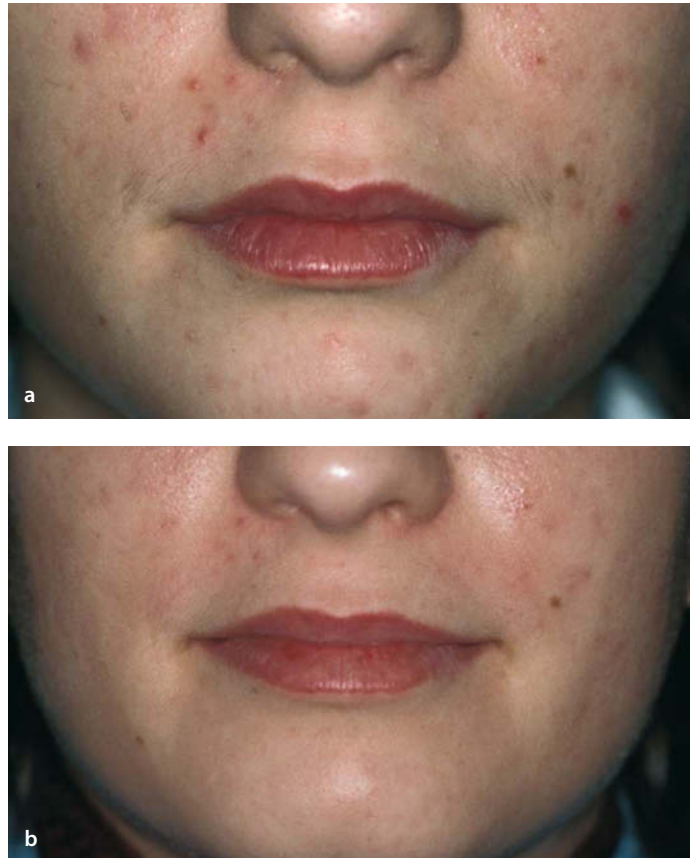

Fig. 5.2a, b.
Patient with papulo-pustular acne
before and after treatment

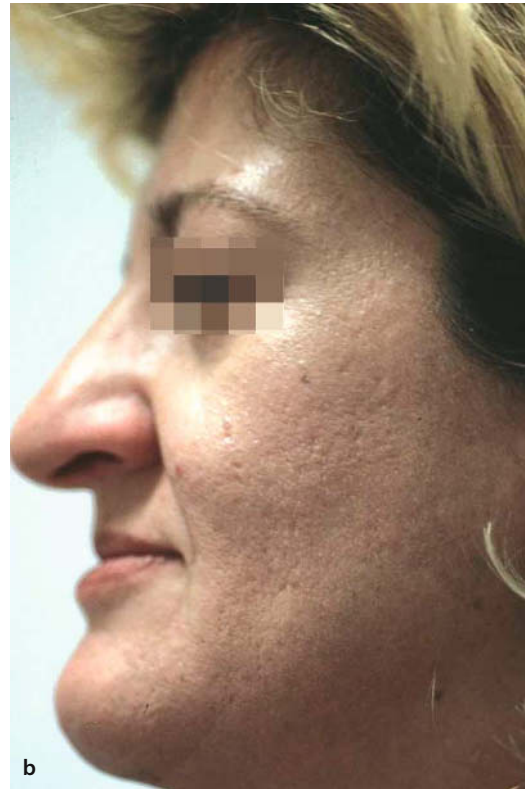
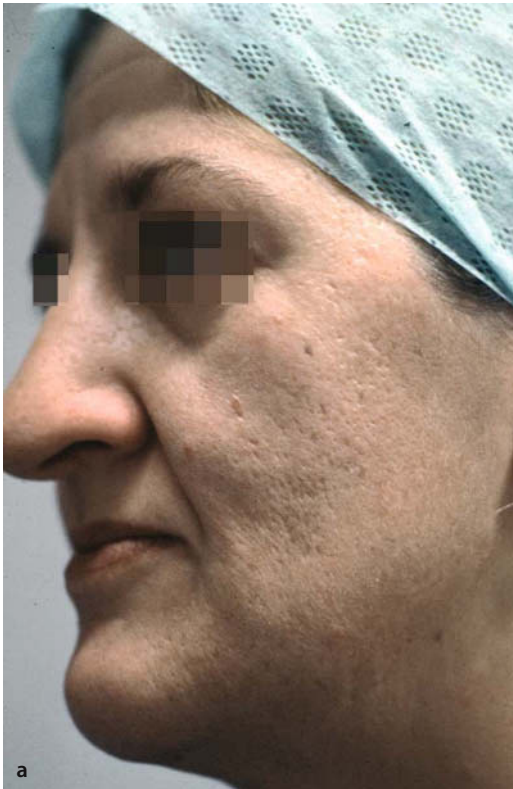
Fig. 5.3a, b. Patient with cicatricial acne before and after treatment (courtesy of Dr. P. Teofoli)

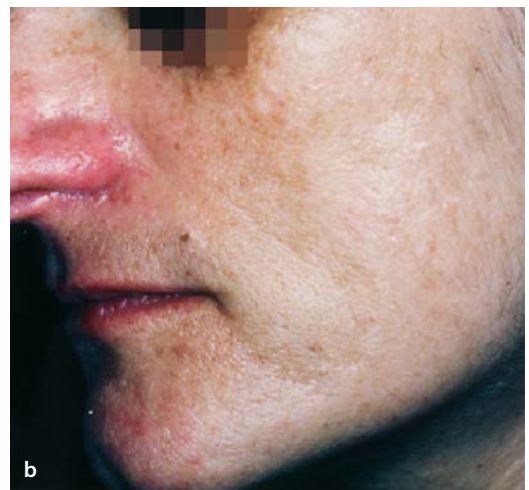
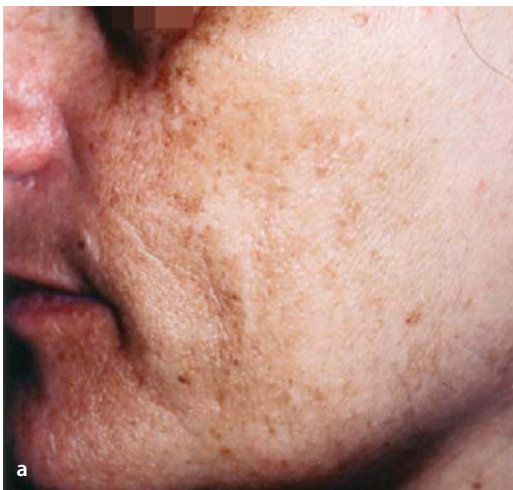
Fig. 5.4a. Patient with melasma before treatment

Fig. 5.4b. Patient with melasma after treatment

5.6 Peeling Preparation

- 0.05% tretinoin cream for 2 weeks before the peeling

5.7 Peeling Technique

- The skin is scrubbed with alcohol or acetone
- The paste is spread over the face with a tongue depressor (Fig. 5.5)
 1. Start on forehead
 2. Continue on the cheeks
 3. Then the nose and the chin up to 1 cm below the mandibular margin

- The patient is instructed to keep the eyes and the mouth closed to prevent accident spillage
- The paste is kept from 1 to 2 h
- The paste is removed with water or water in oil emulsion
- The patient complains a burning sensation or paresthesia during the peeling
- After the removal of the paste the skin is white but turns to pink within 2 to 3 h
- At the end of the peel some patients feel dizzy for a few minutes, probably due to the flushing that occurs secondary to resorcinol application

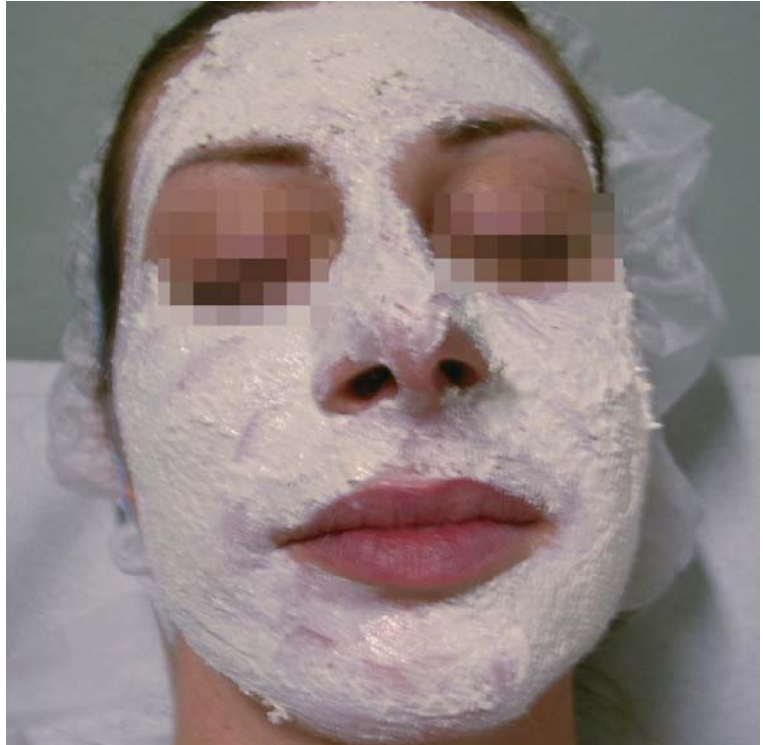

Fig. 5-5.
Patient during application
of resorcinol paste

5.8 After Peel Care

- The skin becomes brownish and tight the second day; crust separation starts the third day (Fig. 5.6a, b)
- Patients are instructed to minimize the expressions of the face and not to pull off the partly detached crusts
- Micronized water four times daily
- Moisturizing creams
- Photoprotection
- Per os corticosteroids if the patient is swollen

5.9 Side Effects

- Post-inflammatory hyperpigmentation (very rarely)
- Allergic reaction to resorcinol
- Herpes simplex reactivation to be promptly treated with topical or general acyclovir

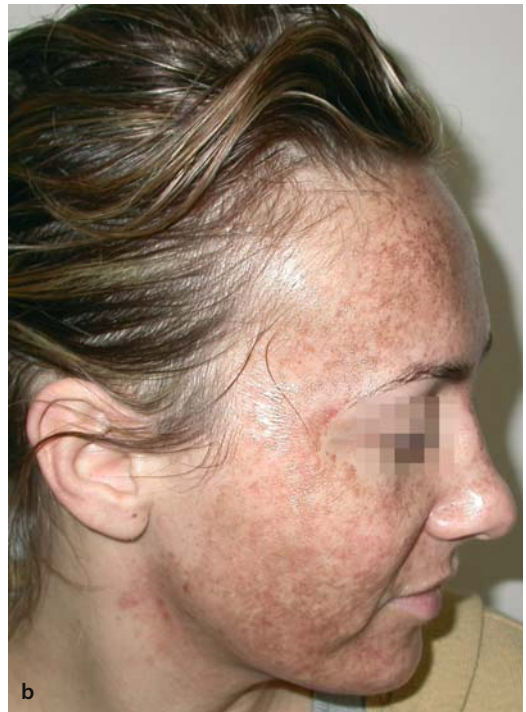
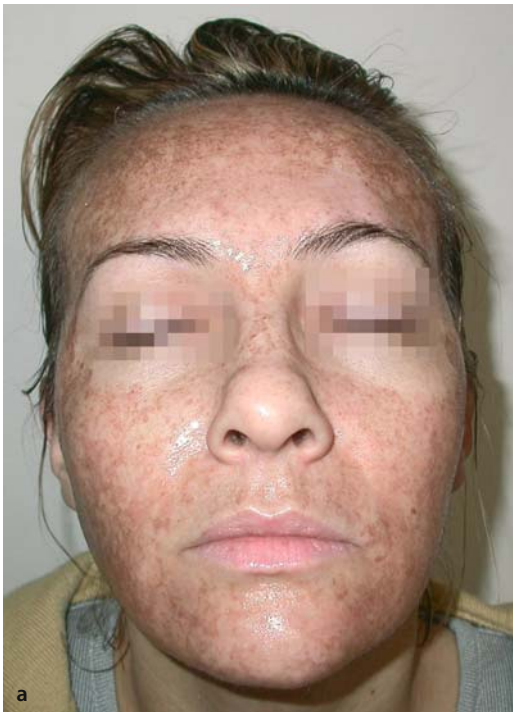
Fig. 5.6a, b. The skin become brownish and tight the second day after treatment

5.10 Advantages

- Easy to perform
- Uniformity of application and penetration
- Effective especially in acne, post-inflammatory hyperpigmentation and melasma
- Safe until Fitzpatrick skin type V
- Not painful (the burning sensation during the peeling is usually mild)

5.11 Disadvantages

- Desquamative effect aesthetically unacceptable
- Unsafe in Fitzpatrick skin type more than V
- Cannot be used in summer
- Resorcinol may be a sensitizing agent
- Additional histological studies are necessary to understand the mechanism of action in facial rejuvenation

5.12 Patient's Informed Consent

1. I hereby request and authorize Dr. _____, M.D., to treat me for the purpose of attempting to improve my appearance.
2. The effect and nature of the treatment to be given, as well as possible alternative methods of treatment, have been fully explained to me.
3. It has been explained that well-qualified and trained personnel will assist with certain portions of the treatment under his/her supervision.
4. I hereby authorize Dr. _____, M.D., to administer such treatment to me, and agree to hold him/her free and harmless for any claims or suits for damages or injury or complications whatsoever resulting from conditions beyond the doctor's control.
5. I know that the practice of medicine and surgery is not an exact science and that, therefore, reputable practitioners cannot properly guarantee results.
6. I acknowledge that no guarantee or assurance has been made to me by anyone regarding the treatment which I have herein requested and authorized.
7. I am advised that though good results are expected, they cannot be and are not guaranteed, nor can there be any guarantee against untoward results.
8. I acknowledge that no guarantee has been given me as to the number of years I may appear younger following treatment or that the scars will heal completely.
9. I acknowledge that no guarantee has been given me as to the condition of the complexion or size of the skin pores following treatment.
10. I acknowledge that during the procedure my face will be covered by masks for 1 to 2 hours.
11. I acknowledge that no guarantee has been given me as to the painlessness of the procedure. Some individuals, because of emotional makeup or low pain thresh-

old, may experience discomfort. This procedure will cause a modification in the treated area of my face (body), which may be unpleasant. My face will become red and subsequently dry and hyperpigmented. Exfoliation will then start and last about 5–10 days. An erythema may persist for 15–20 days.

12. I have been advised that the following conditions may arise after treatment. These conditions are uncommon and usually not serious, but may appear at any time because of circumstances beyond the doctor's control:
 - a. A darkening of the skin or blotchiness may occur at any time up to 3 months following treatment. This is usually due to excess sun or heat exposure. Special medication may be prescribed for this and will usually clear the condition completely. Occasionally, further treatment may be required, consisting of a second procedure. Persons with dark complexions undergoing treatment are advised that a blotchy complexion may arise, which will usually even out over a period of 3–6 months.
 - b. The skin may be red for a 6- to 8-week period or possibly redness is due to increased blood supply to the new skin. This usually disappears over a 3- to 6-month period and the final complexion is somewhat lighter than the original complexion.
 - c. On occasion, small areas of the neck and chin may show thickening for a variable period of time following treatment. These areas are buildups of underlying collagen and scar tissue and are usually easily controlled by periodic injections of medication.
 - d. Every facial procedure is accompanied by swelling of the tissue of the face and neck. This is usually only temporary and disappears within a short period of time. On occasion the swelling may be persistent and will require further medication.

13. I have been advised that exposure to sun must be avoided at all costs for a period of 6 months. No sunbathing is permitted for 6 months. To do so would encourage blotchy skin pigmentation requiring further treatment.
14. I give my permission that my before and after pictures will be used for:
 - Educational purposes only
 - Patient demonstration
 - Medical congresses and medical articles

The operation has been explained to me and I fully understand the nature of the procedure and the risks involved. I acknowledge and understand that no expressed or implied warranty has been given to me.

Date _____ Signature _____

References

1. Unna PG (1882) *Therapeutiques generales des maladies de la peau*
2. Letessier S (1989) Chemical peel with resorcin. In: Roenigk RK, Roenigk HH (eds) *Dermatologic surgery: principles and practice*. Marcel Dekker, New York, p 1017
3. Karam PG (1993) 50% resorcinol peel. *Int J Dermatol* 32:569
4. Ghersetich I, Teofoli P, Gantcheva M, Ribuffo M, Puddu P (1997) Chemical peeling: how, when, why? *J Eur Acad Dermatol Venereol* 8:1
5. Ghersetich I, Brazzini B, Lotti T (2003) Chemical peeling. In: Lotti TM, Katsambas AD (eds) *European handbook of dermatological treatments*, 2nd ed. Springer, Berlin, Heidelberg, New York

Salicylic Acid

Pearl E. Grimes

The author has no financial interest in any of the products or equipment mentioned in this chapter.

Contents

6.1	History	49
6.2	Chemical Background/Properties . . .	49
6.3	Formulations	50
6.4	Indications	50
6.5	Contraindications	50
6.6	Patient Preparation	51
6.7	Peeling Technique	51
6.8	Post-peeling Care and Complications .	55
6.9	Advantages	55
6.10	Disadvantages	56
6.11	Side Effects	56
6.12	Patient's Informed Consent	56
	References	57

6.1 History

P.G. Unna, a German dermatologist, was the first to describe the properties and use of salicylic acid. It has since been used for many decades as a keratolytic agent in concentrations of 3 to 6%. Salicylic acid is frequently utilized in topical acne preparations because of its comedolytic effects. In addition, it facilitates the penetration of other topical agents.

6.2 Chemical Background/Properties

Salicylic acid (ortho-hydroxybenzoic acid) is a beta hydroxy acid agent (Fig. 6.1). It is a lipophilic compound which removes intercellular lipids that are covalently linked to the cornified envelope surrounding cornified epithelioid cells [1]. Due to its antihyperplastic effects on the epidermis, multiple investigators have used salicylic acid as a peeling agent [2, 3, 4]. Recently, histologic assessments using salicylic acid peels in hairless mice reported loss of cornified cells followed by activation of epidermal basal cells and underlying fibroblasts. These findings suggest that salicylic acid peeling can alter the underlying dermal tissue without directly wounding the tissue or causing inflammation [5]. Salicylic acid has also been shown to have anti-inflammatory and antimicrobial properties. When used in combination with benzoic acid in Whitfield's ointment, it has fungicidal properties.

Salicylic Acid

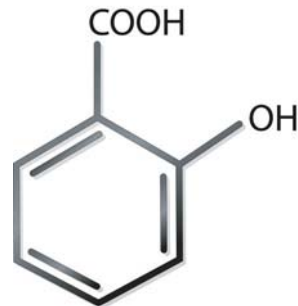


Fig. 6.1. Chemical structure

6.3 Formulations

A variety of formulations of salicylic acid have been used as peeling agents. These include 50% ointment formulations (Table 6.1) [2, 3], as well as 10, 20 and 30% ethanol formulations (Table 6.2) [4, 6]. More recently, commercial formulations of salicylic acid have become available (BioGlan Pharmaceuticals Company, Malvern, PA; Bionet Esthetics, Little Rock, AR).

6.4 Indications

The efficacy of salicylic acid peeling has been assessed in several studies. Fifty percent salicylic acid ointment peeling was first used by Aronsohn to treat 81 patients who had freckles, pigmentation, and aging changes of the hands [3]. He reported excellent results. Subsequently, Swinehart [7] successfully used a methyl-salicylate buffered, croton oil-containing, 50% salicylic acid ointment paste for treatment of lentigines, pigmented keratoses and actinically

Table 6.1 Formulations of salicylic acid: salicylic acid ointment

Salicylic acid powder USP	50%
Methyl salicylate	16 drops
Aquaphor	112 g

From Swinehart [7]

Table 6.2 Formulations of salicylic acid: salicylic acid solutions

Salicylic acid peel %	Weight of salicylic acid powder (g)	Amount of ethyl alcohol 95% (cc)
10	10	100
20	20	100
30	30	100
40	40	100
50	50	100

From Draelos [6]

damaged skin of the dorsal hands and forearms. After pretreatment with topical tretinoin and localized TCA 20%, the 50% salicylic acid paste was applied to the affected area and occluded for 48 h. Following dressing removal, peeling and desquamation occurred and was relatively complete by the tenth day. Overall results were described as excellent. Despite these results, salicylic acid peeling did not move into the arena of popular peeling techniques until the mid 1990s. Kligman and Kligman [4] ushered salicylic acid into the current arena of superficial peeling agents. They treated 50 women with mild to moderate photodamage, reporting improvement in pigmented lesions, surface roughness and reduction in fine lines.

Grimes et al. [8] reported substantial efficacy and minimal side effects in 25 patients treated with 20 and 30% salicylic acid peels in darker racial-ethnic groups. Conditions treated included acne vulgaris, melasma and post-inflammatory hyperpigmentation.

Thirty-five Korean patients with facial acne were treated biweekly for 12 weeks with 30% salicylic acid peels [9]. Both inflammatory and non-inflammatory lesions were significantly improved. In general, the peel was well tolerated with few side effects.

Given these findings, indications for salicylic acid peels include acne vulgaris (inflammatory and non-inflammatory lesions), acne rosacea, melasma, post-inflammatory hyperpigmentation, freckles, lentigines, mild to moderate photodamage, and texturally rough skin.

6.5 Contraindications

In general, there are few contraindications to salicylic acid chemical peeling. Salicylic acid peels are well tolerated in all skin types (Fitzpatrick's I–VI) and all racial/ethnic groups. General contraindications include salicylate hypersensitivity/allergy; unrealistic patient expectations; active inflammation/dermatitis or infection at the salicylic acid peeling site; acute viral infection; pregnancy; and isotretinoin therapy within 3–6 months of the peeling procedure. The author has performed more than 1,000 salicylic acid peels without observing any

evidence of salicylate allergy/hypersensitivity following a salicylic acid peel.

6.6 Patient Preparation

Peel preparation varies with the condition being treated. Regimens differ for photodamage, hyperpigmentation (melasma and post-inflammatory hyperpigmentation) and acne vulgaris [10]. In addition there are special issues to be considered when treating darker racial-ethnic groups (see darker skin section). A detailed history and cutaneous examination is performed in all patients prior to chemical peeling. Standardized photographs are taken of the areas to be peeled including full-face frontal and lateral views.

Use of topical retinoids (tretinoin, tazarotene, retinol formulations) for 2–6 weeks prior to peeling thin the stratum corneum and enhance epidermal turnover. Such agents also reduce the content of epidermal melanin and expedite epidermal healing. Retinoids also enhance the penetration of the peeling agent. They should be discontinued several days prior to the peeling procedure. Retinoids can be resumed post-operatively after all evidence of peeling and irritation subsides. In contrast to photodamage, when treating conditions such as melasma, post-inflammatory hyperpigmentation, and acne as well as darker skin types, retinoids should be discontinued 1 or 2 weeks before peeling or even eliminated from the prep to avoid post-peel complications such as excessive erythema, desquamation, and post-inflammatory hyperpigmentation.

Topical alpha hydroxy acid or polyhydroxy acid formulations can also be used to prep the skin. In general, they are less aggressive agents in impacting peel outcomes. The skin is usually prepped for 2–4 weeks with a formulation of hydroquinone 4% or higher compounded formulations (5–10%) to reduce epidermal melanin. This is extremely important when treating hyperpigmentation. Although less effective, other topical bleaching agents include azelaic acid, kojic acid, arbutin, and licorice (see photodamage section). Patients can also resume use of topical bleaching agents post-operatively after peeling and irritation subsides.

When treating acne vulgaris, topical and systemic therapies (if indicated) are initiated 2 to 4 weeks prior to peeling. Topical antibiotics and benzoyl peroxide based products can be used daily and discontinued 1 or 2 days prior to peeling. However, unless a deeper peel is desired, retinoids should be discontinued 7–10 days prior to salicylic acid peeling. Broad-spectrum sunscreens (UVA and UVB) should be worn daily (see Photodamage, Sunscreen section).

6.7 Peeling Technique

Despite some general predictable outcomes, even superficial chemical peeling procedures can cause hyperpigmentation and undesired results. Popular standard salicylic acid peeling

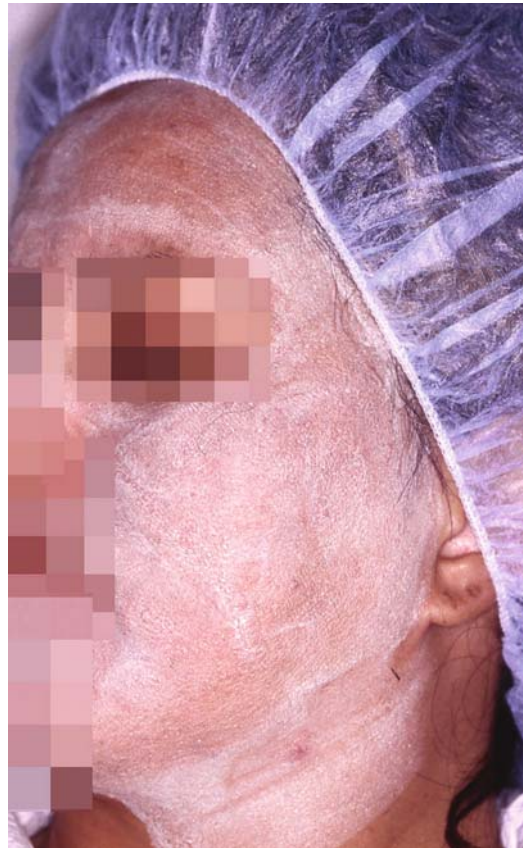

Fig. 6.2. Salicylic acid precipitate

techniques involve the use of 20 and 30% salicylic acid in an ethanol formulation. Salicylic acid peels are performed at 2- to 4-week intervals. Maximal results are achieved with a series of three to six peels.

The author always performs the initial peel with a 20% concentration to assess the patients' sensitivity and reactivity. Before treatment, the face is thoroughly cleansed with alcohol and/or acetone to remove oils. The peel is then applied

6

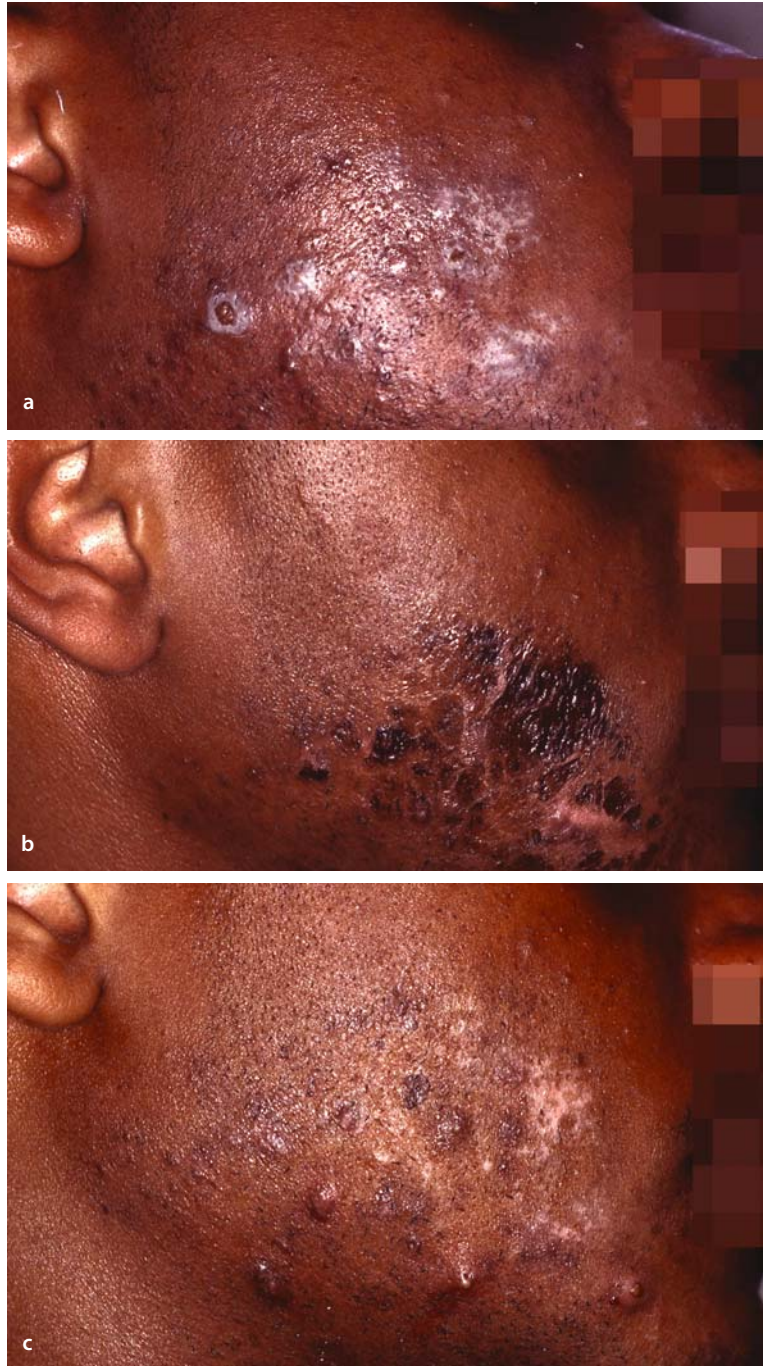
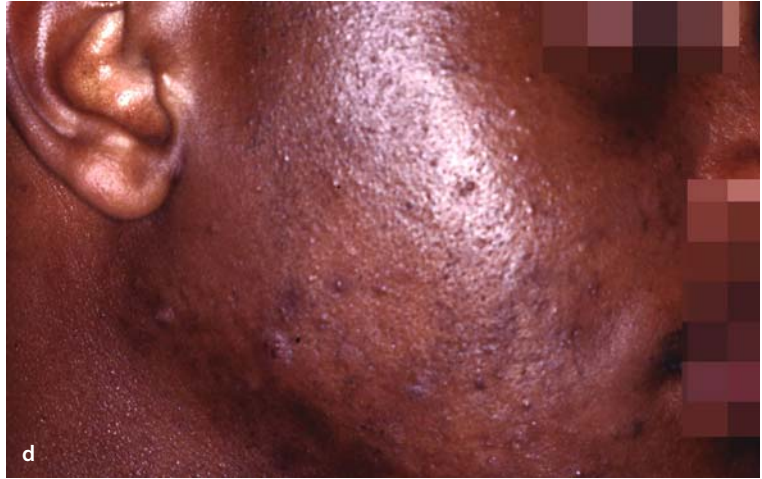
Fig. 6.3.
a Frosting after salicylic acid.
b Crusting 48 h later.
c Resolution of crusting
in 3 to 4 days

Fig. 6.3.
d Complete clearing
of hypopigmentation
by days 7–10. Note im-
provement in acne



with 2 × 2 wedge sponges, 2 × 2 gauze sponges, or cotton-tipped applicators. Cotton-tipped swabs can also be used to apply the peeling agent to periorbital areas. A total of two to three coats of salicylic acid is usually applied. The acid is first applied to the medial cheeks working laterally, followed by application to the perioral area, chin, and forehead. The peel is left on for 3–5 min. Most patients experience some mild burning and stinging during the procedure. After 1–3 min, some patients experience mild peel-related anesthesia of the face. Portable handheld fans substantially mitigate the sensation of burning and stinging.

A white precipitate, representing crystallization of the salicylic acid, begins to form at 30 s to 1 min following peel application (Fig. 6.2). This should not be confused with frosting or whitening of the skin, which represents protein agglutination. Frosting usually indicates that the patient will observe some crusting and peeling following the procedure (Fig. 6.3a–d). This may be appropriate when treating photo-damage. However, the author prefers to have minimal to no frosting when treating other conditions. After 3–5 min the face is thoroughly rinsed with tap water, and a bland cleanser such as Cetaphil is used to remove any residual salicylic acid precipitate. A bland moisturizer is applied after rinsing. My favorites are Cetaphil, Purpose, Theraplex, and SBR Lipocream (Figs. 6.4a, b, 6.5a, b and 6.6a, b).

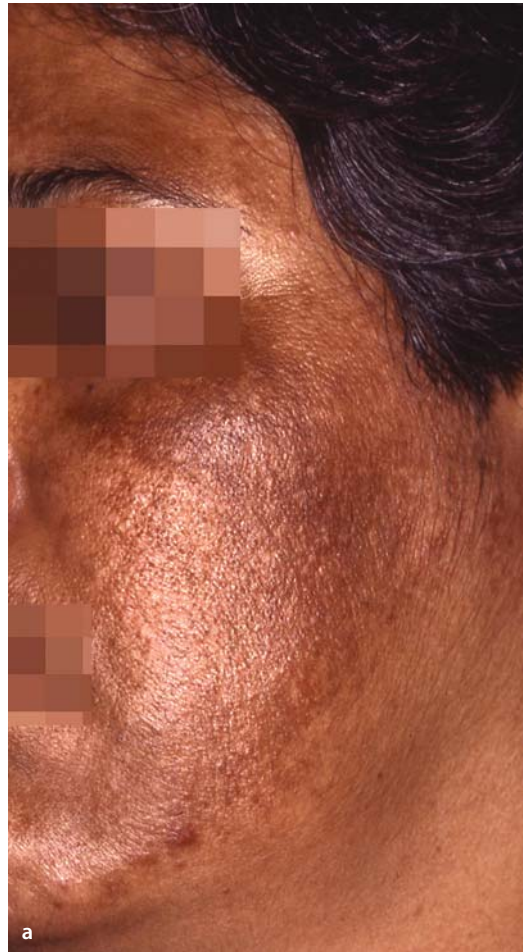

Fig. 6.4a. Melasma before and after a series of five salicylic acid peels and 4% hydroquinone

6

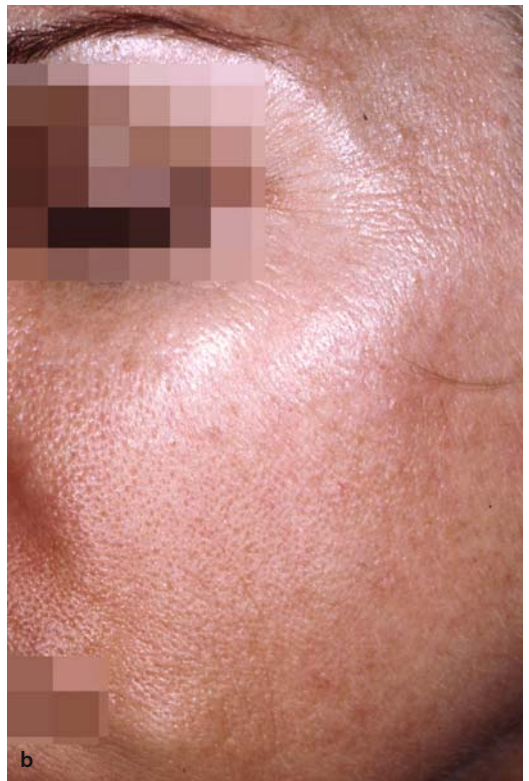
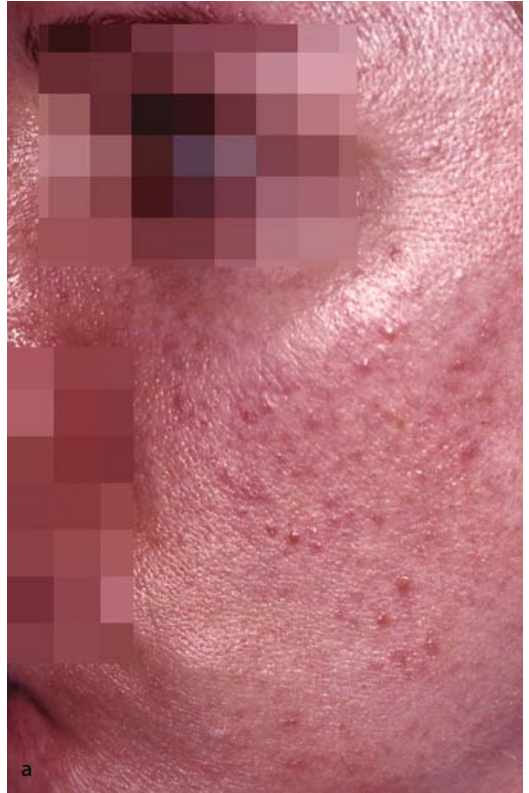
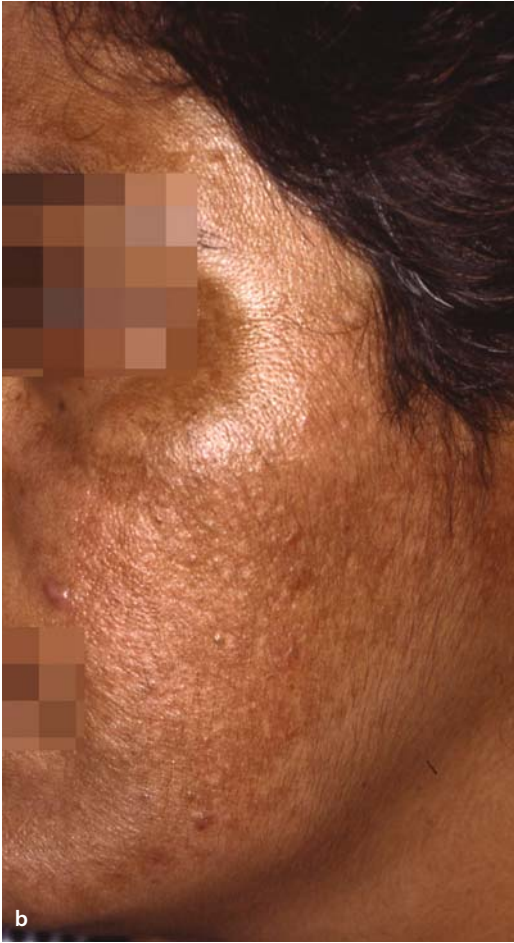Fig. 6.4b. Melasma before and after a series of five salicylic acid peels and 4% hydroquinone

Fig. 6.5a, b. Acne vulgaris before and after four salicylic acid peels

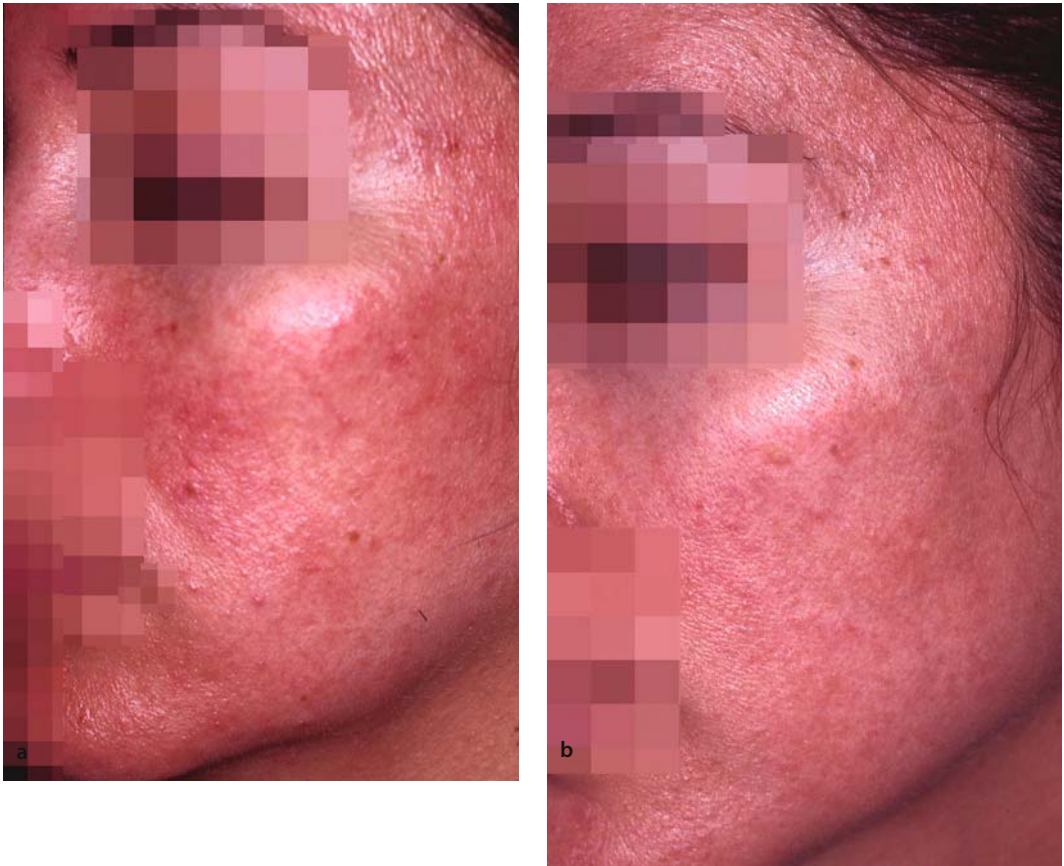

Fig. 6.6a, b. Acne rosacea before and after three salicylic acid peels, moderate improvement

6.8 Post-peeling Care and Complications

Bland cleansers and moisturizers are continued for 48 h or until all post-peel irritation subsides. Patients are then able to resume the use of their topical skin care regimen including topical bleaching agents, acne medications, and/or retinoids. Post-peel adverse reactions such as excessive desquamation and irritation are treated with low to high potency topical steroids. Topical steroids are extremely effective in resolving post-peel inflammation and mitigating the complication of post-inflammatory hyperpigmentation. In the author's experience, any residual post-inflammatory hyperpigmentation resolves with use of topical hydroquinone formulations following salicylic acid peeling.

6.9 Advantages

The key benefits of salicylic acid peeling include:

- An established safety profile in patients with skin types I–VI
- An excellent peeling agent in patients with acne vulgaris
- Given the appearance of the white precipitate, uniformity of application is easily achieved
- After several minutes the peel can induce an anesthetic effect whereby increasing patient tolerance

6.10 Disadvantages

- Limited depth of peeling
- Minimal efficacy in patients with significant photodamage

6.11 Side Effects

Side effects of salicylic acid peeling are mild and transient. In a series of 35 Korean patients, 8.8% had prolonged erythema that lasted more than 2 days [9]. Dryness occurred in 32.3%, responding to frequent applications of moisturizers. Intense exfoliation occurred in 17.6%, clearing in 7–10 days. Crusting was noted in 11.7%. There were no cases of persistent post-inflammatory hyperpigmentation or scarring. In a series of 25 patients comprising 20 African Americans and five Hispanics, 16% experienced mild side effects [8]. One patient experienced temporary crusting and hypopigmentation that cleared in 7 days. Three patients had transient dryness and hyperpigmentation that resolved in 7–14 days.

Salicylism, or salicylic acid toxicity, is characterized by rapid breathing, tinnitus, hearing loss, dizziness, abdominal cramps, and central nervous system reactions. It has been reported with 20% salicylic acid applied to 50% of the body surface, and it has also been reported with use of 40 and 50% salicylic acid paste preparations [7]. The author has peeled more than 1,000 patients with the current 20 and 30% marketed ethanol formulations and has observed no cases of salicylism.

6.12 Patient's Informed Consent

I, _____, hereby consent to having my _____ (site) treated with SALICYLIC ACID CHEMICAL PEELING. The peel will be performed to improve the overall appearance of the skin at the site of treatment. Salicylic ac-

id peels are used to improve acne vulgaris, hyperpigmentation (dark spots), rough texture, oily skin, and photodamage (sun damage).

The procedure involves first having the peel site prepped with alcohol, acetone or other pre-peel cleansing agents. The peeling agent is applied for 3–5 min followed by cleaning with tap water and a bland cleanser.

In general, salicylic acid peels are extremely well tolerated. However, the procedure can cause swelling, redness, crusting, dryness and obvious peeling of the face which could last for up to 7–10 days.

I understand that there is a small risk of developing permanent darkening after the procedure. There is a rare chance that the peel could cause undesirable pigment loss at the treated site, the condition being treated could worsen after the peeling procedure, or a scar could develop. In addition, there is a small chance that a bacterial infection could develop, or the peel could also trigger a flare of a pre-existing Herpes infection at the treated site. In addition, there have been uncommon cases of allergic reactions to salicylates (the active peel ingredient). The benefits and side effects of the procedure have been explained to me in detail. All of my questions have been answered.

- I am in stable health.
- I have not used Isotretinoin in the past 6 months.
- I have no allergies to salicylic acid.
- I am not pregnant.

Outcomes are not guaranteed.

Signature of Patient

Date

Patient Name (Please Print)

Witness

Date

References

1. Lazo ND, Meine JG, Downing DT (1995) Lipids are covalently attached to rigid corneocyte protein envelope existing predominantly as beta-sheets: a solid state nuclear magnetic resonance study. *J Invest Dermatol* 105:296–300
2. Swinehart JM (1992) Salicylic acid ointment peeling of the hands and forearms. *J Dermatol Surg Oncol* 18:495–498
3. Aronsohn RB (1984) Hand chemosurgery. *Am J Cosmet Surg* 24–28
4. Kligman D, Kligman AM (1998) Salicylic acid peels for the treatment of photoaging. *Dermatol Surg* 24:325–328
5. Imayama S, Ueda S, Isoda M (2000) Histologic changes in the skin of hairless mice following peeling with salicylic acid. *Arch Dermatol* 136:1390–1395
6. Draelos ZD (2000) *Atlas of cosmetic dermatology*. Churchill Livingstone, New York, pp 94–97
7. Swinehart JM (1992) Salicylic acid ointment peeling of the hands and forearms. Effective nonsurgical removal of pigmented lesions and actinic damage. *J Dermatol Surg Oncol* 18:495–498
8. Grimes PE (1999) The safety and efficacy of salicylic acid chemical peels in darker racial-ethnic groups. *Dermatol Surg* 18–22
9. Lee HS, Kim IH (2003) Salicylic acid peels for the treatment of acne vulgaris in Asian patients. *Dermatol Surg* 29:1196–1199
10. Brody HJ (1997) *Chemical peeling*, 2nd ed. Mosby, St Louis

Trichloroacetic Acid

Christopher B. Harmon, Michael Hadley, Payam Tristani

The author has no financial interest in any of the products or equipment mentioned in this chapter.

Contents

7.1	History	59
7.2	Chemical Background	59
7.3	Chemical Formulations	59
7.4	Classification of Peel Depths	60
7.5	Indications	61
7.6	Facial Versus Non-facial Skin	64
7.7	Peeling Preparation	64
7.8	Peeling Technique	64
7.9	Post-peeling Care	65
7.10	Complications	66
7.11	Advantages/Disadvantages of TCA Peels	66
7.12	Conclusion	66
	References	67

7.1 History

The use of trichloroacetic acid (TCA) as a peeling agent was first described by German dermatologist P.G. Unna in 1882. Over the past 40 years a number of innovations and applications of the TCA peel have been discovered. These discoveries include a more precise understanding of the exact depth of penetration of these agents and the ensuing histologic changes that occur. Other important advancements have been the use of TCA with a variety of other agents to achieve a deeper peel; these include the use of solid CO_2 , Jessner's solution, glycolic acid and manual dermasanding. More recently there has been promising reports of using higher strength TCA for treatment of deeper acne scarring.

7.2 Chemical Background

TCA occurs naturally as a colorless crystal and is easily formulated by mixture with distilled water. TCA is stable under normal conditions with a melting point of 54 deg Celsius. It is not light sensitive; however, it is hygroscopic so the crystals should be stored in a closed container to limit its absorption of water. Once mixed, TCA has a shelf life of at least 2 years.

7.3 Chemical Formulations

TCA concentrations are correctly formulated using a weight-in-volume (W/V) method. Simply stated a 30% TCA solution is made by adding 30 g of TCA with enough water to make 100 ml solution. This should not be mistaken by adding 30 g to 100 ml of water thus yielding a weaker concentration. Other methods including a weight in weight formulation, used in topical ointments and creams, is not accurate. Also, dilution of existing TCA with water should not be employed as the resulting concentration is higher than one would expect. TCA is readily obtained in a number of concentrations from suppliers such as Delasco who specialize in its production.

Recently there have been a variety of suppliers with chemical peel kits claiming ease of use and increased efficacy. These proprietary kits vary from the vehicle used in delivering the TCA to having color indicators to inform the physician of a peel's completion. Caution should be used when using such kits as many times the physician loses the ability to easily assess the degree of frosting and in turn the depth and safety of the chemical peel.

7.4 Classification of Peel Depths

TCA is a chemical cauterant the application of which to the skin causes protein denaturation, so called keratocoagulation, resulting in a readily observed white frost. The degree of tissue penetration and ensuing injury by a TCA solution is dependent on several factors, including strength of TCA used, skin preparation and anatomic site.

Selection of appropriate strength TCA is critical when performing a peel. TCA in strengths of 10–20% results in a very light superficial peel not penetrating below the stratum granulosum; a strength of 25–35% results in a light superficial peel with penetration encompassing the full thickness of the epidermis; 40–50% results in a medium-depth peel injury to the papillary dermis; and finally, greater than 50% results in injury extending to the reticular dermis. Unfortunately the use of TCA concentrations above 35% TCA can produce unpredictable results

including scarring. Therefore, the medium-depth chemical peel should only be obtained with the combination of 35% TCA and another agent such as Jessner's solution, solid CO₂ or glycolic acid. The use of TCA in strengths greater than 35%, should be discouraged with the exception of deliberate destruction of isolated lesions or where intentional controlled scarring is desired such as the treatment of ice-pick scars (Fig. 7.1).

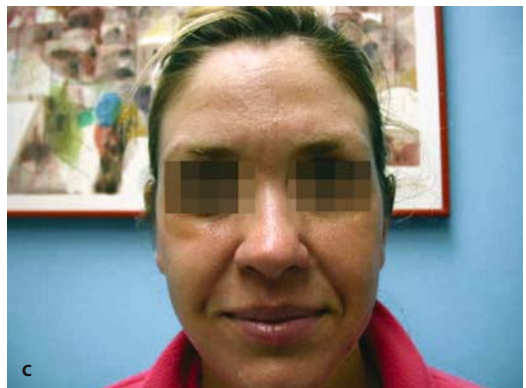
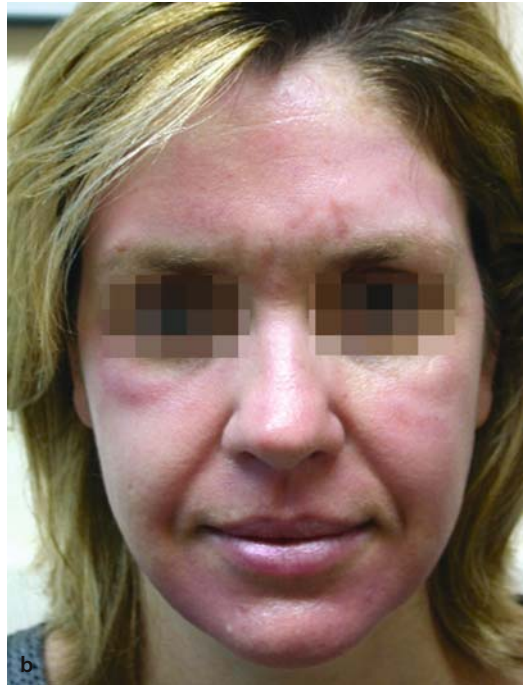
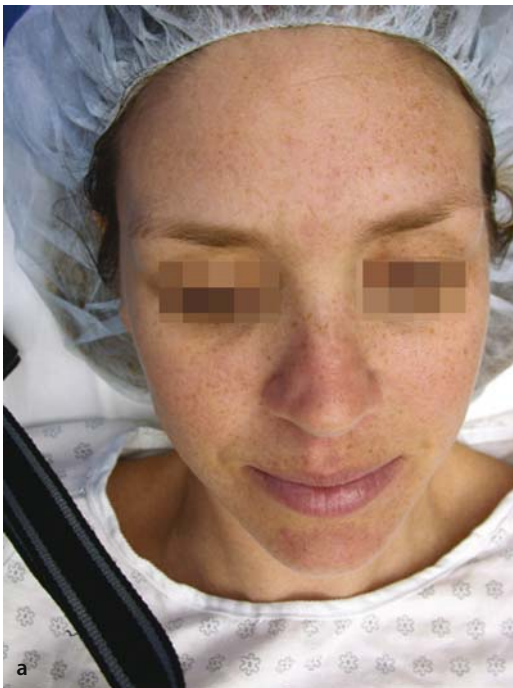Fig. 7.1a–c. Medium depth chemical peel for widespread lentigines in type II skin. (a) Pre-operative, (b) 10 days status post medium depth chemical peel, (c) One month status post medium depth chemical peel

7.5 Indications

The use of TCA as a peeling agent has a wide variety of applications depending on the concentration used (Fig. 7.2). The most important principal in determining response to a peeling agent is accurately assessing the depth of the condition for which treatment is intended. This principal applies to the depth of skin growths, pigmentation and degree of wrinkling. Superficial conditions such as epidermal melasma and actinic keratoses are readily treated with chem-

Table 1. Indications

Epidermal growths including actinic keratoses and thin seborrheic keratoses
Mild to moderate photoaging
Pigmentary dyschromias including melasma and post-inflammatory hyperpigmentation
Pigmented lesions including lentigines and ephelides
Acne
Acne scarring

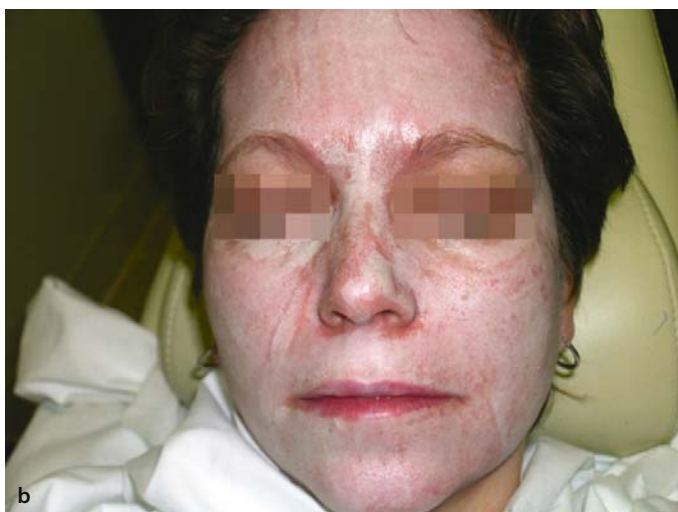
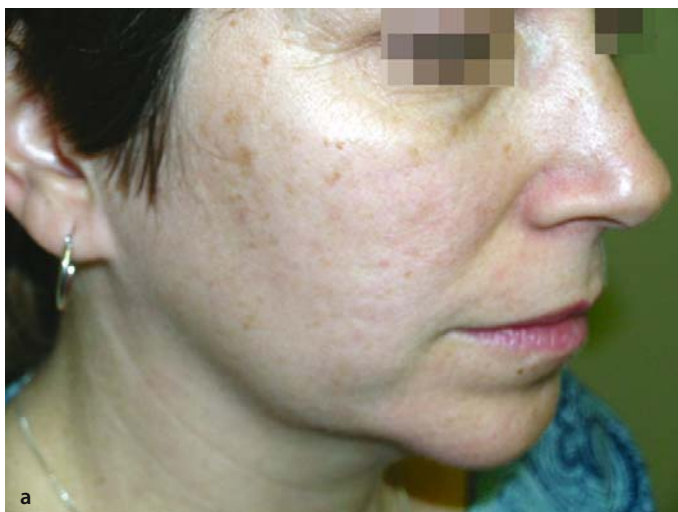
Fig. 7.2a, b. Medium depth chemical peel for melasma. (a) Pre-operative, (b) intraoperative - Level III frosting

ical peeling and may only require a superficial peeling agent, whereas deeper conditions such as dermal melasma and severe wrinkling may prove difficult if not impossible to treat despite using a deeper peeling agent (Fig. 7.3). As a general rule a higher concentration TCA results in deeper penetration yielding a more thorough and longer-lasting treatment; this of course must be balanced with the lengthened downtime associated with a deeper peel. Multiple superficial chemical peels generally do not equal the efficacy of a single medium-depth peel. Still, not all conditions need to be treated with a deeper chemical peel as consideration must be given to what type of condition is being treated and most importantly what the patient's goals and tolerance are for the prescribed peel.

Epidermal growths such as actinic keratosis, lentiginos or thin seborrheic keratoses can all be treated effectively with 25–35% TCA peels. Thicker epidermal growths or growths involving the dermis will be more resistant to treatment such as hypertrophic actinic keratoses and thicker seborrheic keratoses and may even be resistant to a medium-depth peel. Resistant lesions many times are best treated with a combination of a medium-depth chemical peel and other modalities such as manual dermasanding or CO₂ laser.

Table 2. Efficacy of Treatment

Excellent to Good Response
Actinic keratoses
Superficial melasma
Superficial hyperpigmentation
Ephelides
Lentiginos
Depressed scars (CROSS technique)
Variable Response
Seborrheic keratoses
Hypertrophic keratoses
Mixed melasma
Mixed hyperpigmentation
Poor Response
Thick seborrheic keratoses
Deep melasma
Deep hyperpigmentation

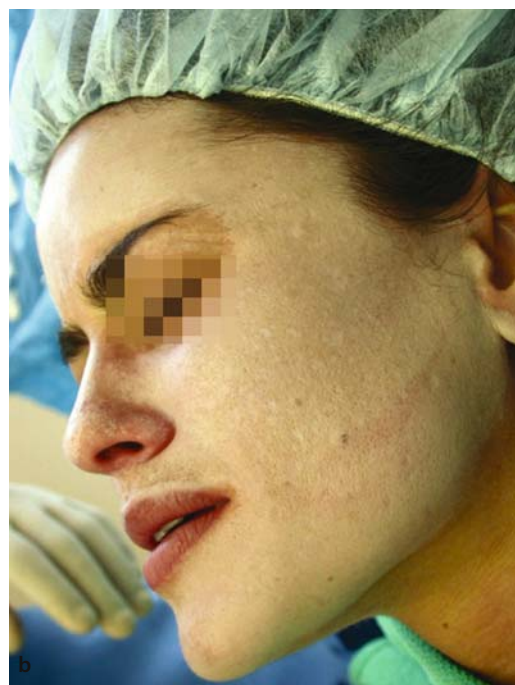
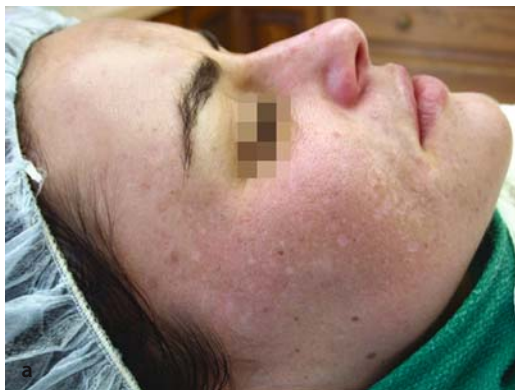
Fig. 7.3a, b. Medium depth chemical peel for melasma. (a) Pre-operative, (b) Intraoperative – Level III frosting

Mild to moderate photoaging can be effectively treated with TCA peels. Mild photoaging as defined by the Glogau classification as type 1 include mild pigmentary alterations and minimal wrinkles. Often a superficial TCA peel 10–25% will be all that is necessary to make improvements with mild photoaging; this is especially true if multiple superficial peels are employed at regular intervals of 3–6 weeks. Moderate photoaging defined by Glogau as type II

improves minimally with a superficial chemical peel, but can be improved with a deeper peel such as a medium-depth peel. This is truer for the pigmentary changes versus the wrinkles. While some pigmentary improvements can be made with a medium-depth peel in the advanced aging seen in Glogau types III and IV, often these individuals require a deeper peel (phenol), laser resurfacing or a face lift to deal with the profound wrinkling encountered.

Pigmentary dyschromias can be effectively treated with chemical peeling. This can include ephelides, epidermal melasma, lentigines and epidermal hyperpigmentation. Many times repetitive superficial peels are sufficient to deal with these conditions; however, single medium-depth peels are an important tool to utilize, particularly if there is a deeper pigmentary component. Often times a Wood's lamp can prove invaluable in assessing pigmentary levels as epidermal pigmentation is accentuated. The deeper pigment extends into the dermis effectiveness of chemical peeling diminishes. Other treatment modalities including Q switched Nd:YAG or Alexandrite lasers might prove more useful in conditions where pigment is below the papillary dermis.

One caveat in treating post-inflammatory hyperpigmentation is taking care in not being too aggressive with a peeling regimen. A medium-depth peel may produce more inflammation and a resultant worsening of hyperpigmentation in susceptible individuals. This is especially true in patients with Fitzpatrick skin types 3–6. It is better to start out with multiple superficial chemical peels in combination with bleaching agents before proceeding too soon to a medium-depth chemical peel.

The use of high-strength TCA (65–100%) for acne scarring has proven to be an exciting new application of TCA. In this technique chemical reconstruction of skin scars (CROSS technique) showed significant improvement. Specifically high-concentration TCA is focally applied to depressed or ice-pick scars and pressed hard with the wooden end of a cotton tip applicator. This induces a localized scar to occur, which over time effaces the depressed scar. Typically this requires five or six courses of treatment spread out over intervals of weeks to months.

7.6 Facial Versus Non-facial Skin

Another critical consideration when performing a peel is realizing the difference of peeling facial versus non-facial skin. As a rule non-facial skin takes much longer to heal and is at much greater risk of scarring than when using a similar concentration on the face. This is due to the higher concentration of pilosebaceous units on the face compared with non-facial sites. These units play a critical role in reepithelialization. As a result if a peel is performed on non-facial skin such as the arms, upper chest and lower neck, one should proceed cautiously and not attempt concentrations greater than 25% TCA. Beyond the poor wound healing and higher risk of scarring, another major limitation of chemical peeling off of the face is lack of efficacy in comparison with facial peels. The remainder of this chapter is limited to peeling facial skin.

7.7 Peeling Preparation

Proper skin preparation prior to TCA peels is not only a critical component of the peeling process, but is also important in avoiding post-peel complications such as post-inflammatory hyperpigmentation. The following adjunctive agents should ideally be started 6 weeks prior to peeling. It is important for patients to fully understand the role of these agents for priming of the skin:

- Broad spectrum UVA and UVB sunscreens
- Tretinoin 0.05–0.1% which is the most critical component of this regimen as it results in decreased stratum corneum thickness, increases the kinetics of epidermal turnover, and decreases corneocyte adhesion
- Exfoliants such as glycolic acid or lactic acid result in decreased corneocyte adhesion and stimulate epidermal growth by disrupting the stratum corneum
- Bleaching products such as hydroquinone 4–8% are particularly useful in patients with dyschromias and in patients with Fitzpatrick skin types III–VI

7.8 Peeling Technique

As with any other chemical peeling procedure, the art and science of TCA chemical peels is dependent on the proper peeling technique. TCA is a versatile peeling agent and depending on its concentration, can be used for superficial, medium, or deep chemical peels. However, the cleaning and peeling technique is essentially the same for each depth. In general for the superficial peels patients do not require any sedation; however, for medium-depth peels, a mild sedative such as diazepam 5–10 mg p.o. or ativan 0.25–0.5 mg p.o. may be used. The patient should be comfortably positioned with the head at a 30- to 45-deg angle. A topical anesthetic such as 4% lidocaine may be used prior to application of the TCA to reduce patient discomfort with burning and stinging.

Prior to the application of TCA, a thorough cleaning is of vital importance for defatting the skin to allow for even penetration of the peeling solution. The skin is first cleaned with either Hibiclens or Septisol. Subsequently either acetone or alcohol is used to remove the residual oils and scale until the skin feels dry.

After thorough cleaning, TCA is applied, using either 2–4 cotton-tipped applicators or folded 2 × 2 gauze in a pre-determined sequential manner, starting from the forehead, to temples, cheeks, lips and finally to the eyelids. It is imperative that following application to each area, the physician observes not only the degree of frosting, but also the duration to this reaction before proceeding to the next area. If the desired level of frosting is not reached within 2 to 3 min, an additional application of the agent should be performed. Care must be taken not to overcoat TCA as each application will result in greater depth of penetration. Patients experience a burning sensation, particularly with the higher concentrations of TCA.

If a Jessner's-35% TCA peel (Monheit) is performed, Jessner's solution is applied first prior to the TCA in an even sequential fashion from the forehead to the rest of the face, waiting 2 to 3 min to allow for penetration and assessment of frost. Typically this will produce a level 1 frost, erythema with faint reticulate whitening

(see below). An additional one or two coats of Jessner's may be applied if a level 1 frost is not obtained. Patience must be practiced before proceeding to the application of TCA, as the physician might perform a more aggressive peel than intended if they had waited the proper time to evaluate the degree of frosting produced by the application of the chemical. Always be mindful of this lag effect.

As noted previously, TCA results in kerato-coagulation or protein denaturation which is manifested by frosting of the skin. As the extent of frosting appears to correlate with the depth of penetration of TCA, the following classification can be used as a general guideline for TCA peels. It is imperative to keep in mind, however, that the results are dependent on multiple factors including type/thickness of skin, priming of skin, and technique of application of the TCA:

- Level 1: Erythema with blotchy or wispy areas of white frosting. This indicates a superficial epidermal peel as can be achieved with TCA concentrations <30%. This peel will result in light flaking lasting 2–4 days.
- Level 2: White frosting with areas of erythema showing through. This level of peel is indicative of a full-thickness epidermal peel to the papillary dermis and can be achieved with TCA concentration of >30%. This peel will result in full exfoliation of the epidermis (Fig. 4).
- Level 3: Solid white frosting with no erythema. This is indicative of penetration of TCA through the papillary dermis and can also be achieved with TCA concentrations >30%, depending on the number of applications (Fig. 5).

TCA in concentration of 10–25% can be used safely for superficial depth peels and in concentrations >30% can be used for medium-depth peels. However, multiple coats of even the lower concentrations of TCA can result in a deeper penetration of this agent, thus essentially resulting in a medium-depth peel. In general, use of TCA in concentrations >40% is not recom-

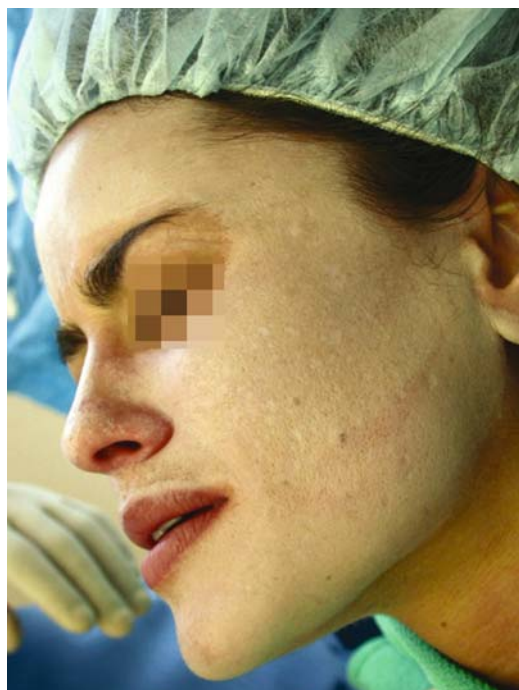

Fig. 7.4. Level II Frosting

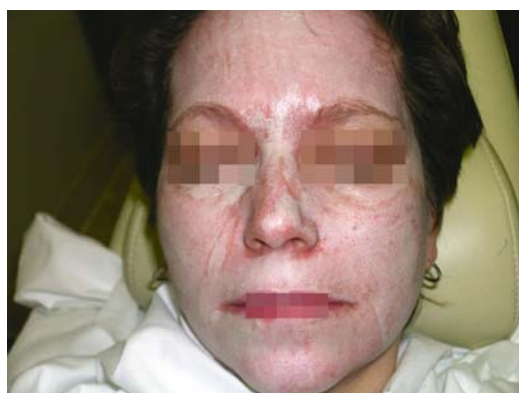

Fig. 7.5. Level III Frosting

mended as it results in uneven depth of penetration and a greater risk of scarring and pigmentary dyschromias.

Several areas of the face require particular consideration. Care must be taken in the peri-orbital area to prevent any excess TCA solution from rolling into the eye, and as such TCA

should not be applied to the upper eyelid. If tearing occurs, this can be gently wicked using a cotton-tipped applicator. With areas of deeper rhytides such as in the perioral area, the wrinkled skin should be stretched and the TCA applied over the folds. In addition, TCA should be applied evenly over the lip skin to the vermilion.

Once the desired frost is achieved, the skin can be rinsed off with water, or cooled down with cool wet compresses which are applied to the skin. The wet compresses can provide a welcome relief to the burning induced by the peel. Unlike glycolic peels the water does not neutralize the peel, as the frosting indicates the end-point of the reaction; rather, it dilutes any excess TCA. The compresses can be repeated several times until the burning sensation has subsided. Subsequently, a layer of ointment such as plain petrolatum or Aquaphor is applied and post-peel instructions and what to expect are reviewed with the patient prior to discharge to home.

7.9 Post-peeling Care

Patients should be counseled with the typical phases of wound healing post peeling. With superficial TCA peels, there may be mild to moderate erythema with fine flaking of the skin, lasting up to 4 days. Some patients may experience mild edema as well. With medium-depth TCA peels, patients should be advised that the peeled skin will feel and look tight. Pre-existing pigmented lesions will darken considerably, and appear grayish to brown. There is also a varying degree of erythema and edema. Edema may last several days (peaks at 48 h) and patients should elevate their head while sleeping. Frank desquamation typically begins by the third day and is accompanied by serous exudation. Reepithelialization is usually complete by the 7th to 10th day, at which time the skin appears pink.

Following the chemical peel, patients are advised to wash their skin gently twice daily with a mild nondetergent cleanser. Acetic acid soaks (0.25%, 1 tablespoon of white vinegar in 1 pint of warm water) are performed up to four times

per day, and have antiseptic as well as debriding properties. In addition, a bland emollient such as plain petrolatum is applied to prevent dryness of skin and formation of crust. The patient must be advised not to vigorously rub their skin or pick at the desquamating skin, as this can lead to scarring. If patients complain of pruritus and are at risk for scratching, a mild topical steroid such as 1% hydrocortisone can be recommended. Once reepithelialization is complete, patients can use a moisturizing cream instead of the occlusive emollient. Long-term care following TCA peels is essentially the same as pre-peel priming regimen and includes use of broad-spectrum sunscreens, bleaching creams, tretinoin or vitamin C, in combination with an exfoliating agent such as alpha-hydroxy acid. Patients should be advised that the post-peel regimen is necessary to maintain the benefits gained from the peel. Although superficial TCA peels can be repeated every 4–6 weeks, medium-depth chemical peels should not be repeated for a period of 6 months, until the phases of healing are completed.

7.10 Complications

It is of paramount importance that the dermatologic surgeon be familiar with the complications of TCA peels. These include infections (bacterial, viral, fungal), pigmentary changes, prolonged erythema, milia, acne, textural changes, and scarring. Bacterial infections include *Pseudomonas*, *Staphylococcus* or *Streptococcus*. In general, prophylaxis with antibiotics is not indicated and strict adherence to wound care instructions will prevent this untoward complication. In patients with a history of herpes labialis, even if remote, prophylaxis with antiviral agent is necessary. Scarring is a rare, yet feared complication of medium-depth chemical peels. Although the etiology of scarring is unknown, factors which are contributory include poor wound care, infections, uneven peeling depth, mechanical injury and previous history of ablative procedures. Localized areas of prolonged erythema, particularly on the angle of the jaw can be indicative of incipient scarring. Proper attention to risk factor, use of

mild topical steroids for localized areas of erythema and proper wound care and infection prophylaxis can minimize the risk of scarring. If scarring is imminent, use of higher-strength steroids (class I to II), silicone gel and/or sheaths, and pulsed-dye lasers may be beneficial. Prolonged erythema may be secondary to underlying rosacea, eczema, or use of tretinoin. Use of a mild topical steroid such as 2.5% hydrocortisone lotion is likely beneficial. Milia formation is most likely due to over occlusion and can be minimized with the use of less occlusive emollients after reepithelialization. As noted previously, use of sunscreens, bleaching agents, and tretinoin can minimize pigmentary changes which can develop post peeling.

7.11 Advantages/Disadvantages of TCA Peels

TCA peels confer several advantages for both the patient and physician. TCA is an inexpensive solution that can be easily prepared, is stable, and has a long shelf life. TCA, as opposed to peels such as Baker's phenol, does not have any systemic toxicity. In addition, as noted previously, it is a versatile agent that can be used for superficial, medium and deep chemical peeling. The frosting reaction can be a utilized as a reliable indicator for the depth of the chemical peel, making this a safe agent in the hands of the experienced dermatologist. However, TCA in concentrations >40% has an unreliable penetration depth and can result in scarring.

7.12 Conclusion

TCA is the most versatile of all the peeling agents and can be effectively used to perform superficial to medium-depth chemical peels in the treatment of a variety conditions ranging from pigmentary dyschromias to moderate photoaging. A proper understanding of the correct techniques, indications, limitations and complications is paramount before using TCA. When performed properly, peeling with TCA can be one of the most rewarding procedures we can do for our patients.

References

- Rubin MG (1995) Manual of chemical peel: superficial and medium depth. Lippincott, Philadelphia
- Monheit GD (2001) Medium-depth chemical peels. *Dermatol Clin* 3: 413–525
- Monheit GD (1996) Skin preparation: an essential step before chemical peeling or laser resurfacing. *Cosmet Dermatol* 9: 9–14
- Koppel RA, Coleman KM, Coleman WP (2000) The efficacy of EMLA versus ELA-Max for pain relief in medium-depth chemical peeling: a clinical and histopathologic evaluation. *Dermatol Surg* 26: 61–64
- Brody HJ (2001) Complications of chemical resurfacing. *Dermatol Clin* 3: 427–437

Deep Chemical Peels for Photoaging

Marina Landau

The author has no financial interest in any of the products or equipment mentioned in this chapter.

Contents

8.1	History	69
8.2	Chemical Background	70
8.3	Formulations	70
8.4	Histology	71
8.5	Indications and Patient Selection	72
8.6	Contraindications	72
8.7	Pre-peeling Preparation	73
8.8	Preparation of the Skin	73
8.9	Peeling Preparation	74
8.10	Peeling Technique	75
8.11	Aftercare	79
8.12	Complications	85
8.12.1	Cardiac Arrhythmias	85
8.12.2	Pigmentary Changes	85
8.12.3	Scarring	86
8.12.4	Infection	86
8.12.5	Milia	86
8.12.6	Acneiform Dermatitis	86
8.12.7	Skin atrophy	87
8.13	Advantages	87
8.14	Disadvantages	87
8.15	Patient's Informed Consent	87
	References	88

8.1 History

Since deep chemical peels are based on phenol-containing solutions, it seems that the history of this procedure starts at the moment of car-

bolic acid discovery in 1834 by German chemist Friedlieb Ferdinand Runge. The name phenol was coined in 1841 by Charles Frederick Gerhardt. Nowadays phenol is prepared synthetically in a process that utilizes chlorobenzene as a starting point.

One hundred years ago New York dermatologist George Miller MacKee, a chairman of the New York Dermatology and Syphilology Center, began using phenol peeling at this prestigious institution. Together with his colleague, dermatologist Florentine L. Karp, they published their experience with 540 treatments over a 10-year period with phenol peels for post-acne scarring [1]. Among other contributors to the development of phenol-based peels at that time were Bames [2], Urkov [3], Combes and Sperber [4], Brown [5], and Litton [6].

Most of the credit of phenol-based peels during the late 1940s and early 1950s is attributed to lay operators. Their illegal work was probably one of the reasons for rejection and skepticism related to the procedure by medical profession in those years.

The main role in the final revival of deep chemical peeling was played by two American plastic surgeons, Thomas J. Baker and Howard L. Gordon, who during the 1960s medically legitimated this procedure by discussing it in national meetings and demonstrating their impressive results [7, 8].

Since then numerous other authors such as Stone [9], Spira [10], Hetter [11], and Fintsi [12] have contributed to the procedure and helped it emerge from semi-obscurity to its respectable and valued place in the field of aesthetic surgery.

8.2 Chemical Background

Following the fundamental work by Gregory Hetter [11], it is now commonly accepted that at the “heart” of solutions for deep peeling is a combination of croton oil and phenol.

Phenol (C_5H_5OH) or carbolic acid is an aromatic hydrocarbon derived originally from coal tar, but prepared synthetically in a process that utilizes monochlorobenzene as a starting point. Ninety-eight percent phenol appears as transparent crystals, while liquefied phenol consists of 88% USP solution of phenol in water.

Other chemicals such as hydroquinone and resorcinol, widely used in cosmetic dermatology, share a similar chemical structure with phenol (Fig. 8.1).

Croton oil is an extract of the seed of the plant *Croton tiglium* and has been commercially prepared as Croton resin since 1932. Its activity on the skin is related to free hydroxyl groups, which cause skin vesiculation even in low doses.

Other chemicals in use in deep chemical peel formulas include sepiisol, water, and vegetable oils (glycerin, olive, sesame).

8.3 Formulations

All the modern phenol formulas are based on and modified from a few lay peelers' formulations. Names such as Grade, Coopersmith, Kelsen, and Maschek are the origins of Baker-Gordon's, Brown's, Hetter's, Stone's, Litton's, Ex-

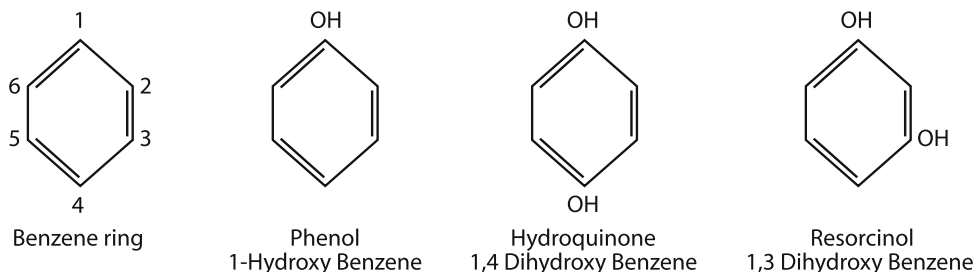


Fig. 8.1. Formulas of common benzene ring components

Table 8.1 Various phenol-containing formulas

Baker-Gordon's Formula		Brown's Formula	
Phenol, USP, 88%	3 ml	Phenol	60–95%
Tap or distilled water	2 ml	Saponated cresol	0.3%
Septisol liquid soap	8 drops	Olive or sesame oil	0.25%
Croton oil	3 drops	Distilled water	ad 100%
Venner-Kellson's Formula		Litton's Formula	
Concentrated Lysol	1.0 oz	Phenol crystals	1 lb
Olive oil	0.5 oz	Distilled water	8 cc
Distilled water	1.5 oz	Glycerine	8 cc
Croton oil	10 drops	Liquefied phenol	4 oz
Melted losses phenol crystals	8 oz	Croton oil	1 cc
		Distilled water	4 oz

Fig. 8.2.
Phenol content in various peeling solutions. VK Venner-Kellson

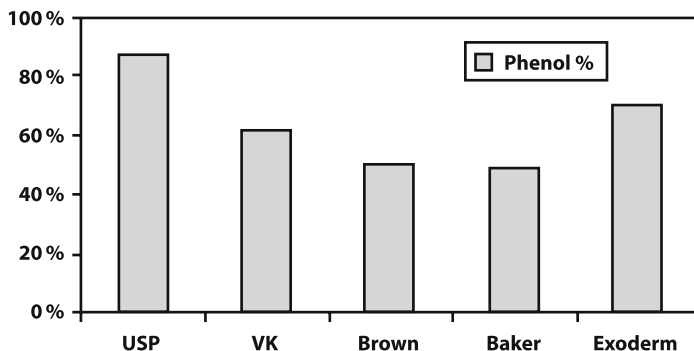
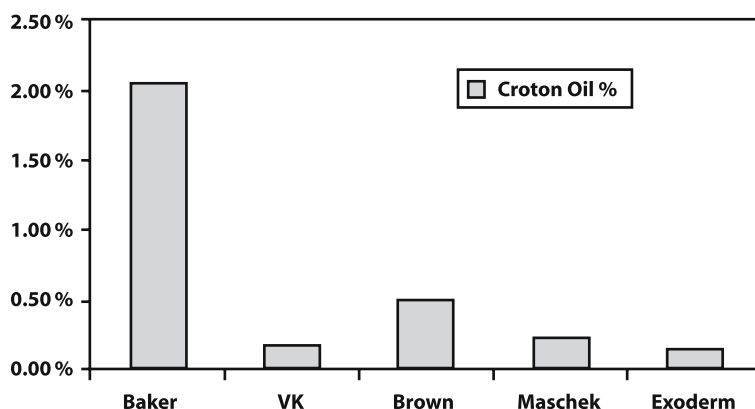


Fig. 8.3.
Croton oil content in various peeling solutions. VK Venner-Kellson



oderm, and other formulas. All of them are based on the aforementioned chemical components in different concentrations (Table 8.1). Concentration of phenol ranges from 45 to 80% (Fig. 8.2), while croton oil ranges from 0.16 to 2.05% (Fig. 8.3). It is generally accepted that the role of liquid soap is to reduce the skin surface tension and to improve solution penetration. In spite of this, sepiisol is not included in all of the formulas. Some of the formulas contain oils, and the role of the oils in the formula has not been clarified yet. Our personal experience shows that oily phenol solution penetrates the skin in a slower and more controllable fashion.

So far no controlled study has been conducted to compare clinically and histologically between the various peeling formulations. However, a few ideas regarding phenol-based

peeling solutions have been challenged recently. The concept of the “all-or-none” effect of phenol on the skin was confronted by Gregory Hetter [11], who showed that a minute amount of croton oil deepens the penetration, prolongs the healing period, and improves the clinical outcome of the peeling.

8.4 Histology

Biopsies obtained 48 h after phenol peeling demonstrate necrosis of the epidermis, extending through the papillary dermis, surrounded by a marked inflammatory reaction [6]. Epidermal regeneration is completed within 7 days, while dermal healing usually lags behind. Histological changes in human skin induced by

deep chemical peeling include newly formed bands of dermis found directly beneath the epidermis consisting of horizontal compact bundles of collagen and dense network of fine elastic fibers, as well as even and uniform shaped keratinocytes in epidermis. Although peeled skin tends to be hypopigmented, melanocytes are present [13]. These changes are evident even as long as 20 years after the peel [14].

and hair (Fig. 8.4a–d) [15]. As long as a patient is aware and cooperative in using bleaching preparation and potent sunscreens during the post-peel period, the procedure is equally effective and safe on dark skin.

Thick male skin is usually less responsive to deep peel, but men with severe actinic damage or acne scarring benefit significantly from the procedure.

8.5 Indications and Patient Selection

The main indications for deep chemical peel include: dyschromia, wrinkles, premalignant skin tumors, and acne scars.

Originally, the ideal patient for deep chemical peel was a blond, blue-eyed woman of fair complexion. Our experience shows that phenol-based peels can be safely performed on olive- and dark-skinned patients with dark eyes

8.6 Contraindications

There are few absolute contraindications for deep peeling, with the exception of physical or mental instability. During pregnancy and lactation any cosmetic intervention is considered to be undesirable. We have safely peeled patients with hypertension, diabetes mellitus, thrombocytopenia, thyroid malfunction, etc., as long as their disease is well controlled and stable. All pa-

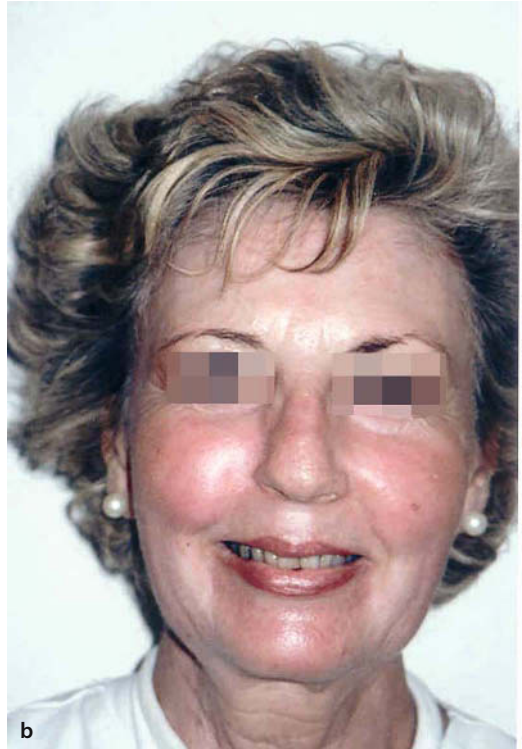
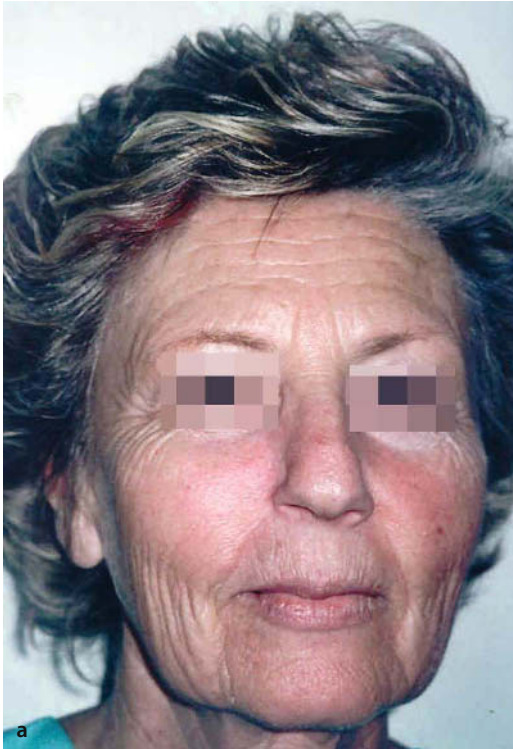
Fig. 8.4 a, b. “Ideal” candidate for deep chemical peeling: middle-aged fair-skinned woman with blue eyes and blond hair and photodamage-induced wrinkling before (a) and after (b) deep chemical peel

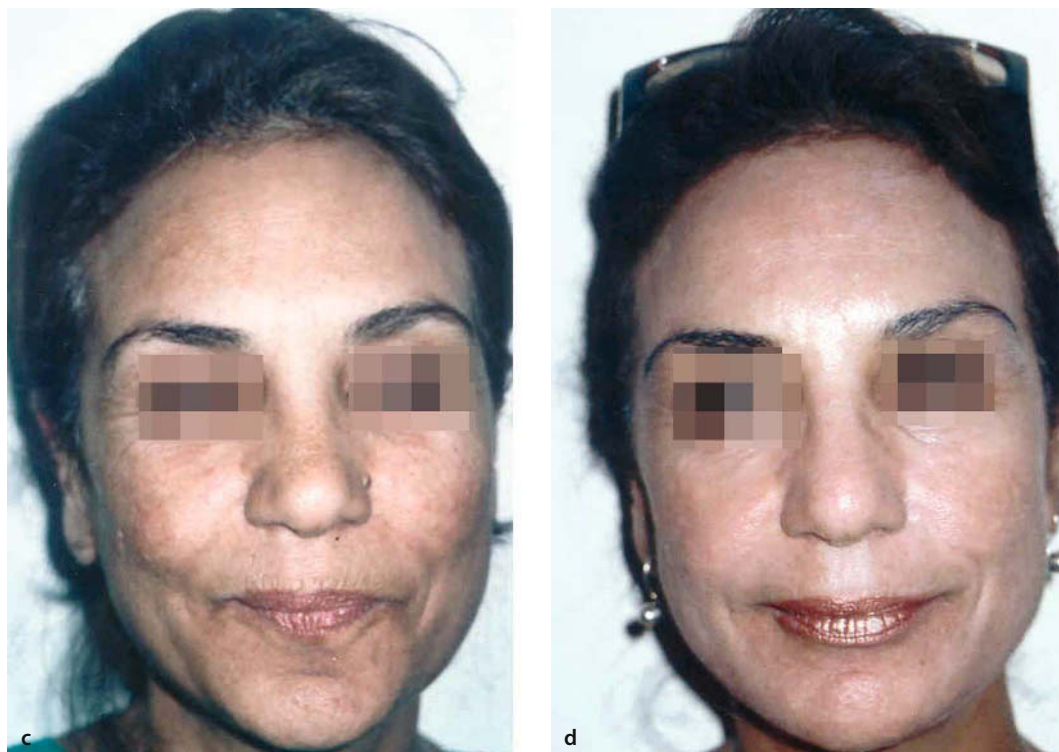

Fig. 8.4c, d Dark-skinned women are also possible candidates for deep chemical peels. Note the accentuation of intradermal nevus next to the left ala nasi following the peel (d)

tients are required to perform electrocardiogram and complete blood count tests prior to the procedure. Any heart disease requires special precautions and it is always recommended to work in cooperation with a patient's cardiologist.

8.7 Pre-peeling Preparation

Prophylactic acyclovir, valacyclovir or famvir is given to patients with a history of recurrent herpes simplex, starting a day before the procedure and continuing for 10 days until full re-epithelialization is achieved.

We do not discontinue use of any of the patient's medications including anticoagulants, aspirin or nonsteroidal anti-inflammatory drugs. Systemic isotretinoin (Acutane) is considered to be a contraindication to any external treatment of the skin. We feel that the minimal

interval to peeling after stopping this medication should be 6 months in thick sebaceous skin and 1 year for patients with thin skin.

According to our experience smoking does not have any adverse effect on post-peel healing or on the extent of the results.

8.8 Preparation of the Skin

It is still debatable whether preparation of the skin is required for deep chemical peeling. We feel that topical retin A preparations used daily for 3–6 weeks prior to the procedure may create better and more even penetration of the peeling solution in sebaceous and hyperkeratotic skins. We did not find any benefit of this regimen in thin-skinned patients.

Standard photography and a consent form are always obtained before the procedure.

8.9 Peeling Preparation

Phenol-based peel can be performed as a full-face or partial procedure. If only one cosmetic unit is peeled with phenol-based solution, it is strongly recommended to perform medium depth peel on the rest of the facial skin. Full-face peels should be carried out under full cardiopulmonary monitoring with intravenous

hydration throughout the procedure (Fig. 8.5). Intravenous sedation or regional blocks make the procedure pain-free. One day prior to the procedure a patient is required to avoid using any cosmetics or creams. Before the peeling, meticulous degreasing of the skin is performed using oil free acetone-soaked gauze sponges. This step is imperative to obtain even penetration of the solution into the skin.

8

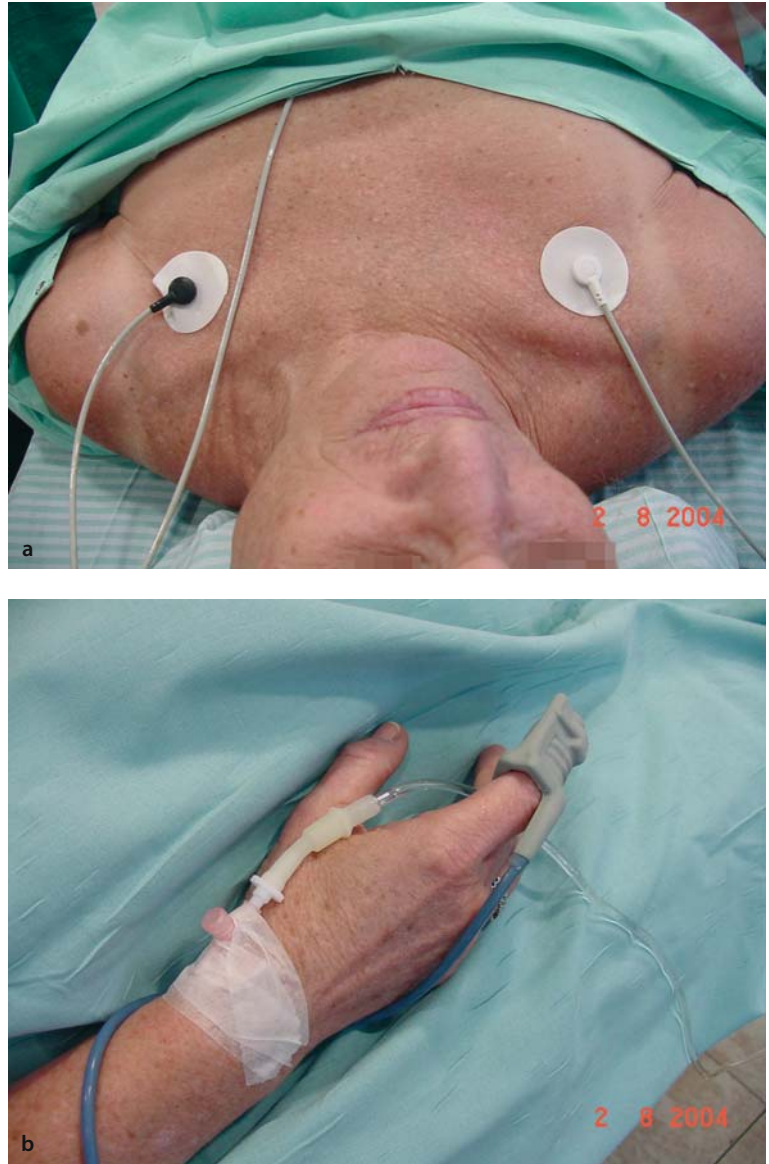
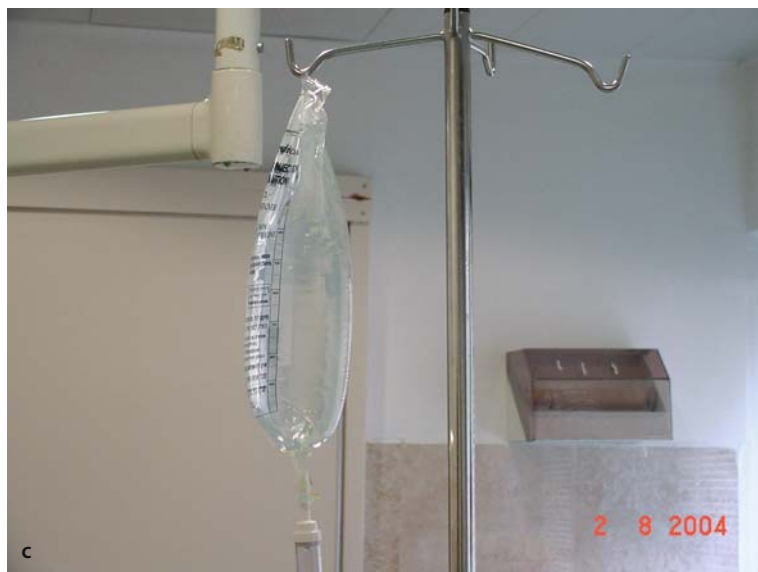

Fig. 8.5a-c. Full-face phenol-based peels are performed under cardiopulmonary monitoring with intravenous hydration

Fig. 8.5c.
Full-face phenol-based peels are performed under cardiopulmonary monitoring with intravenous hydration



In addition to good central ventilation, an electric fan to vent the phenol fumes is important for the comfort of the staff.

8.10 Peeling Technique

To conceal a potential demarcation line, before the administration of intravenous sedation a

line inferior to the mandible is placed while the patient is in sitting position (Fig. 8.6). For application of the peeling solution, cotton-tipped applicators are employed. The ready-to-use applicators come in different sizes, but usually a cotton tip is very condensed and has only limited absorption ability. Therefore, we suggest adding regular cotton to soften the tip (Fig 8.7). The application of phenol solution is accom-

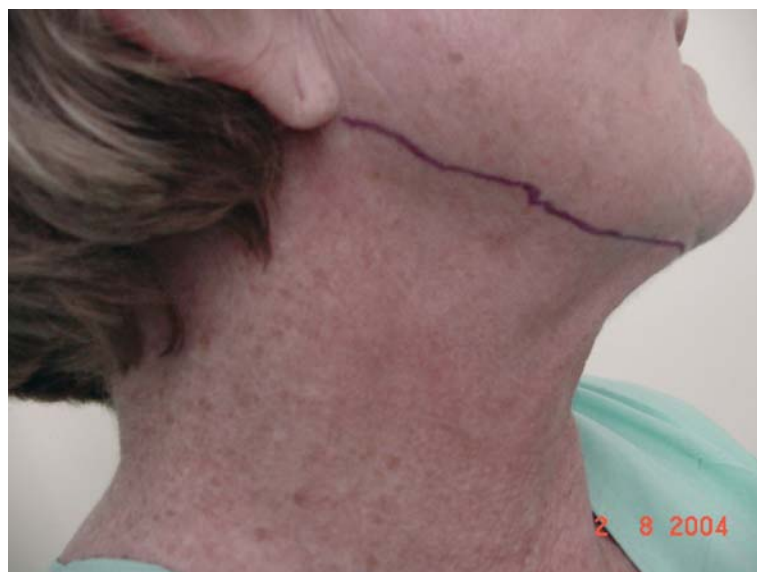

Fig. 8.6.
Marking of the lower margin of the treatment area with the patient in sitting position is important in order to avoid demarcation lines

Fig. 8.7.
Cotton tips are used
to apply peeling solution



8

plished with a semi-dry applicator. The usual end point is ivory-white to gray-white color of skin. The procedure starts on the forehead, and the solution is feathered into all hair-bearing areas, including scalp and eyebrows. Phenol does not affect hair growth. All the cosmetic units are gradually covered, including the earlobes and a “hidden” triangle above the ears. In

the most sensitive areas such as periorbital skin or periauricular area in post-surgical face-lift patients we use an almost dry applicator and only a single layer of the solution. In all other facial areas, after the frosting fades, additional application of peeling solution is advisable (Fig. 8.8).

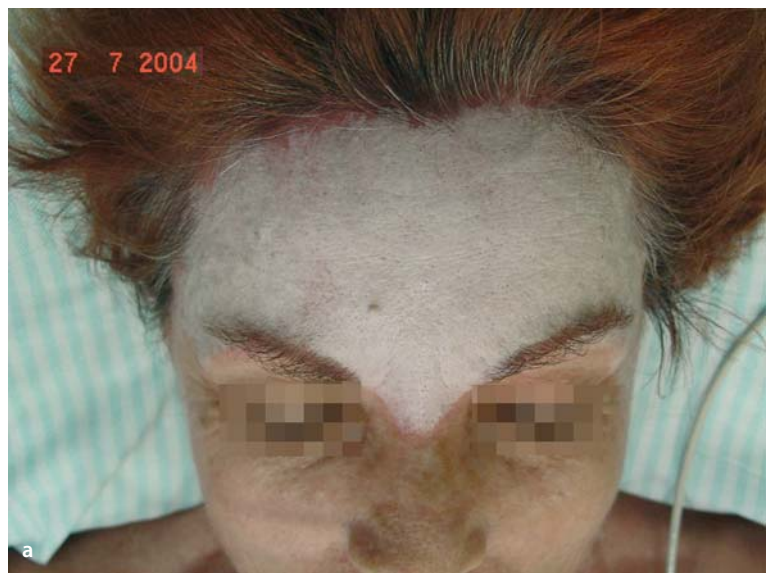
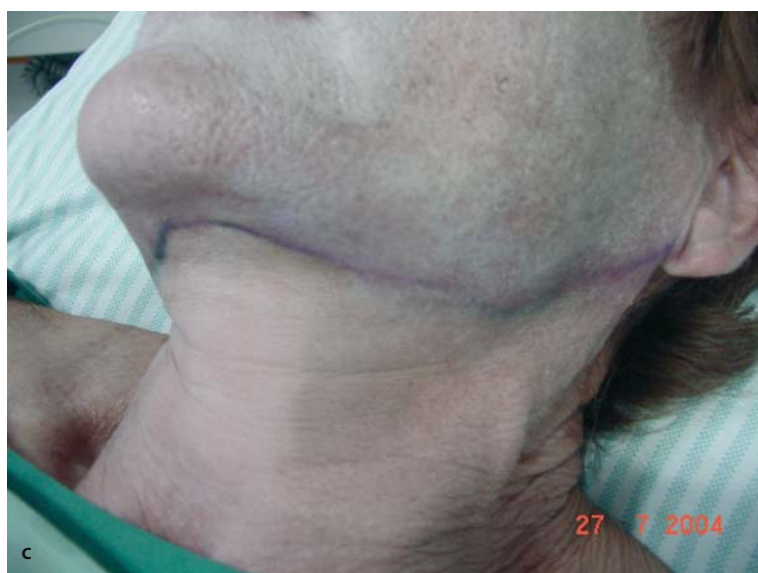
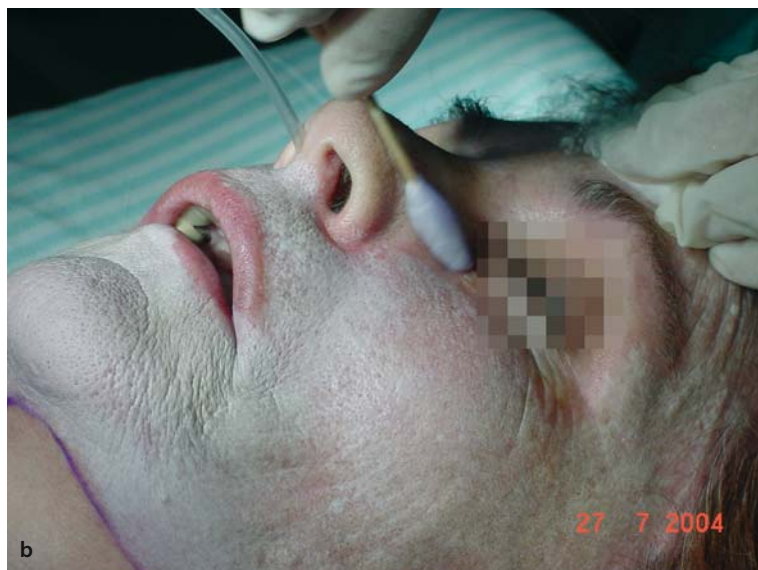Fig. 8.8a-c.
Application of the peeling
solution. Ivory-white
color of the skin is the end point
of the application

Fig. 8.8b, c.

Application of the peeling solution. Ivory-white color of the skin is the end point of the application



Trichloroacetic acid 25% can be applied on the neck at this stage. The entire peeling procedure should take about 60 min.

Immediately after the face is covered with the solution, waterproof zinc oxide non-permeable tape is applied to the skin, anchoring it to the hair line. Taping is made using short strips of 3.0 cm in the overlapping fashion. Over-

lapping allows slight motion and flexibility between the strips; therefore, swelling of the face does not cause separation of the tape from the skin surface. All the face is covered except for the upper eyelids and neck. At the end of the procedure we cover the face with elastic orthopedic grip, which keeps the mask adhered tightly to the face (Fig. 8.9).

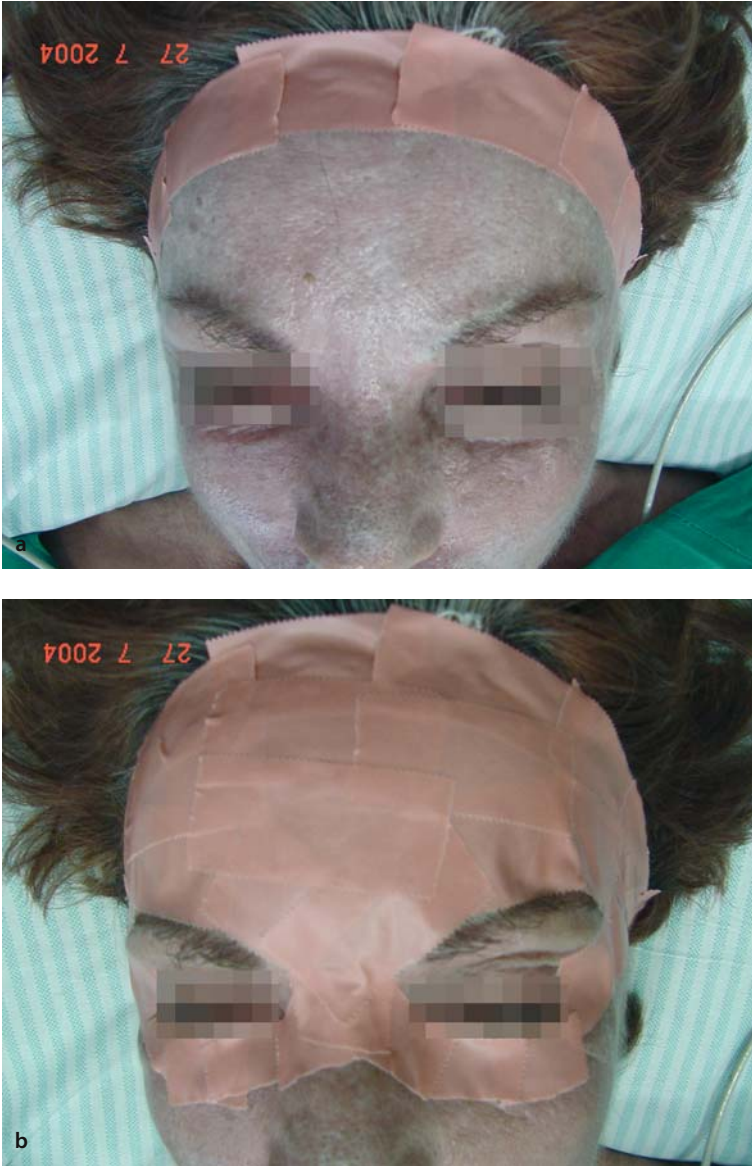

Fig. 8.9 a, b. Waterproof zinc oxide non-permeable tape is applied to the skin in short strips in overlapping fashion. d Elastic orthopedic grip keeps the tape mask adhered to the face while skin liquefaction occurs

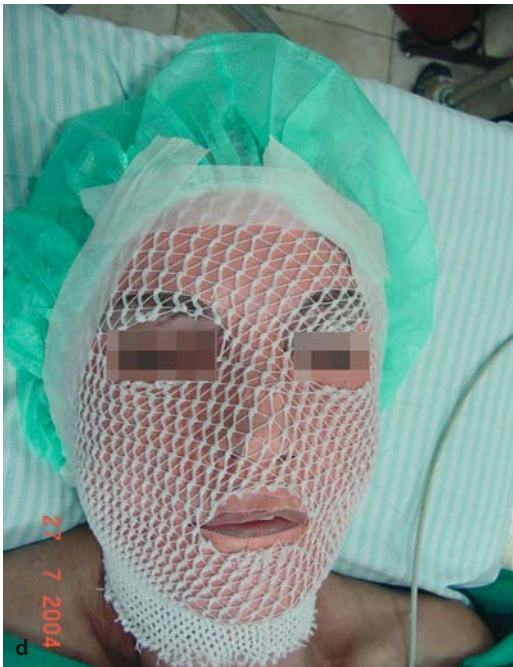
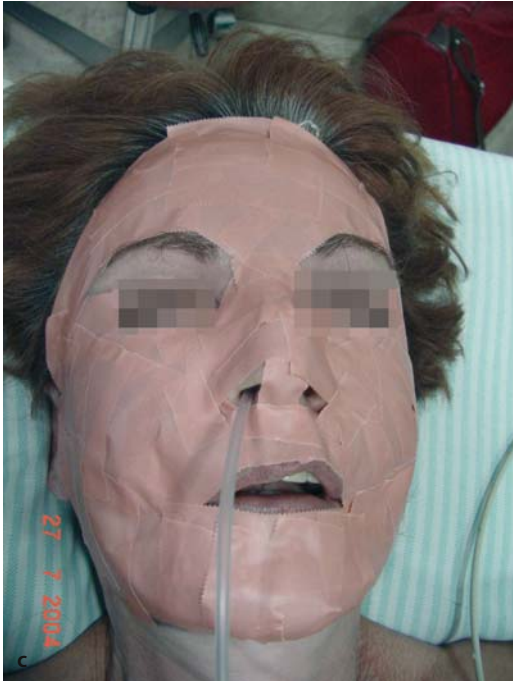
Fig. 8.9 c, d. Waterproof zinc oxide non-permeable tape is applied to the skin in short strips in overlapping fashion. **d** Elastic orthopedic grip keeps the tape mask adhered to the face while skin liquefaction occurs

8.11 Aftercare

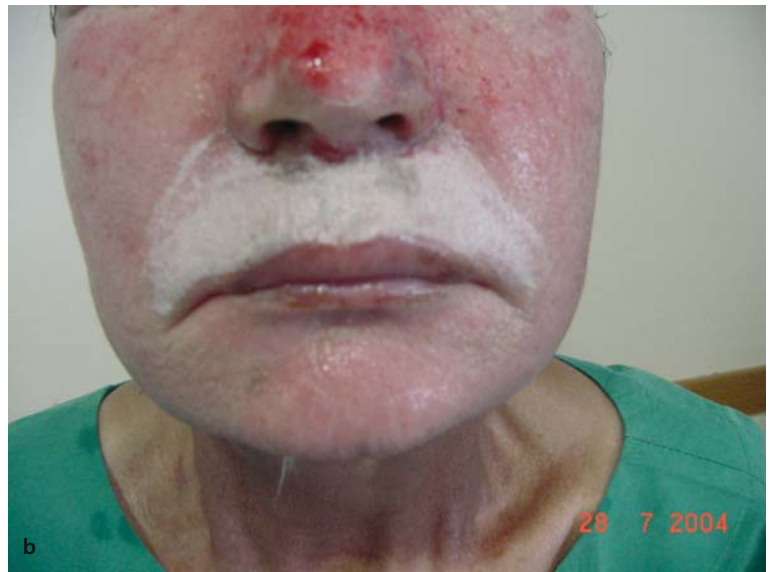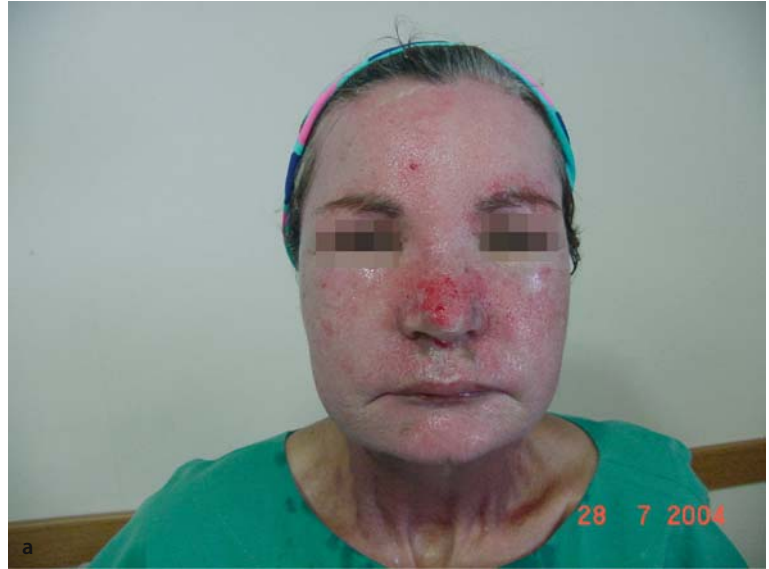After 24 h the grid is removed. Following removal of the grid, the mask comes off the face almost with no effort, since the skin exudate lifts the tape. Analgesia is not required, since the procedure is almost painless. Occasionally some physicians remove the mask at 48 h, but we find it unnecessary and more troublesome for the patients, since while the tape mask is on, the eyelids are frequently swollen shut. We feel that this inconvenient period must be minimized.

After the tape mask removal the exudate is cleaned by sterile saline. Spot peeling and re-taping may be done if the skin looks under-peeled, particularly in areas with severe wrinkling. It is usually accompanied by a short-duration burning sensation. The tape is left for an additional 4–6 h and then removed by the patient. We cover the face with bismuth subgalate antiseptic powder for 7 days (Fig. 8.10). Other options include occlusive moisturizers, antibiotic ointments, and biosynthetic occlusive dressings such as Meshed Omiderm.

At this stage we recommend using regular pain killers every 4 h for the first 2 days. Some physicians administer systemic corticoids to reduce the swelling and inflammation after the peel. Neck swelling is expected after deep peel. It disappears within 4–6 days.

Bismuth subgalate powder acts as a regenerative mask and absorbs skin exudate and gradually creates a firm and rigid mask. It may crack in some areas, usually around the mouth and eyes. Some patients experience itching and can be helped by oral antihistamines. On the eighth day wet soaking with tap water while standing in the shower is used to soften the powder mask. Repeated applications of Vaseline enhance the detachment of the “second mask” from a newly formed skin (Fig. 8.11).

After the procedure, the patient is advised to use water-based creams and potent sunscreens. The erythema is extremely intense in the first 2 weeks, and gradually resolves over a period of about 2 months. During this time, the use of makeup with a green foundation is encouraged to assist the patient in resuming daily activities.

Fig. 8.10.**a** Tape mask removal after 24 h.**b** Spot re-peeling and re-taping is performed if needed

In cases of patients with olive skin (Fitzpatrick skin type 3 or 4), the application of Kligman preparation is recommended to prevent reactive hyperpigmentation.

Results of phenol-based peels for various indications are shown in Figs. 8.11, 8.12, 8.13, 8.14 and 8.15.

Fig. 8.10.
c Face is covered by bismuth subgalate antiseptic powder

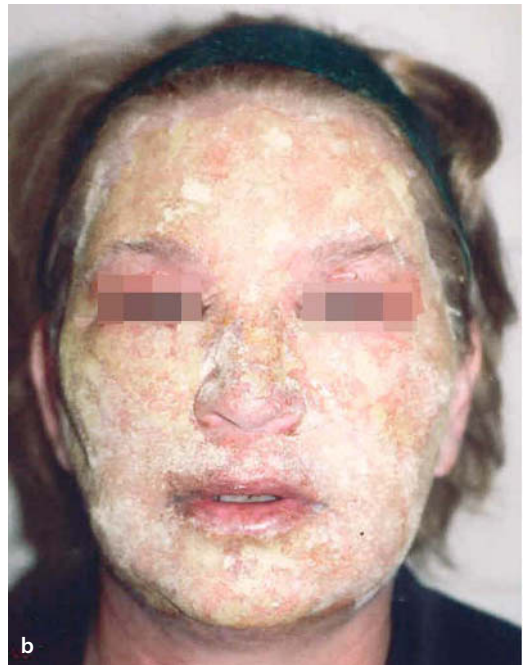
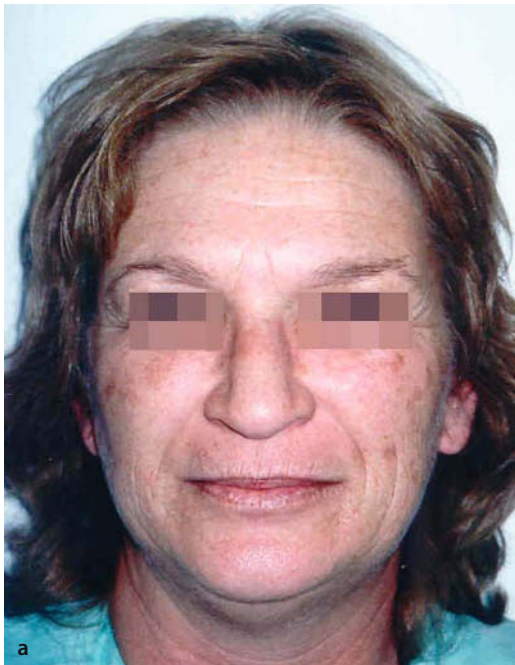
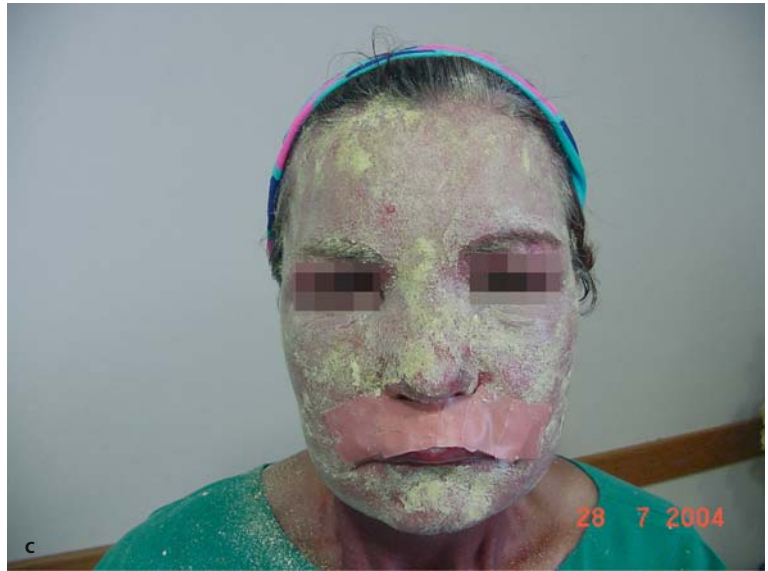Fig. 8.11. a Fifty-two-year-old patient with wrinkles and solar lentigines before the peel. b First day after the peel. The face is covered by bismuth subgalate powder

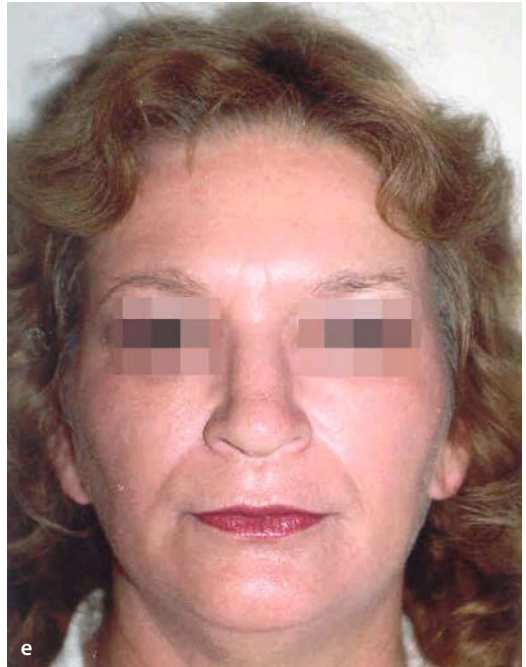
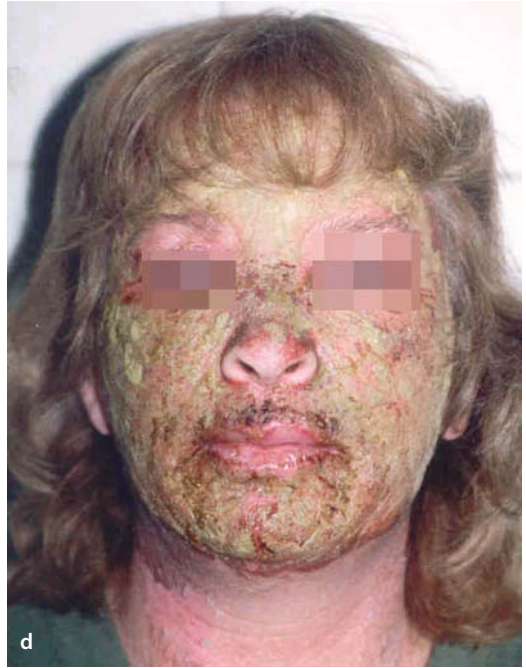
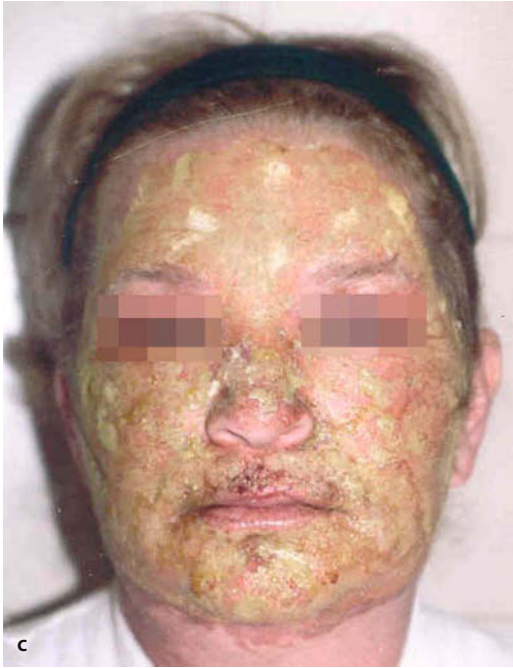Fig. 8.11. c–e Days 3–8. The powder hardens on the face, creating a rigid crust which cracks in the mimetic areas. e One week after the procedure. Patient is shown with make up to conceal erythema

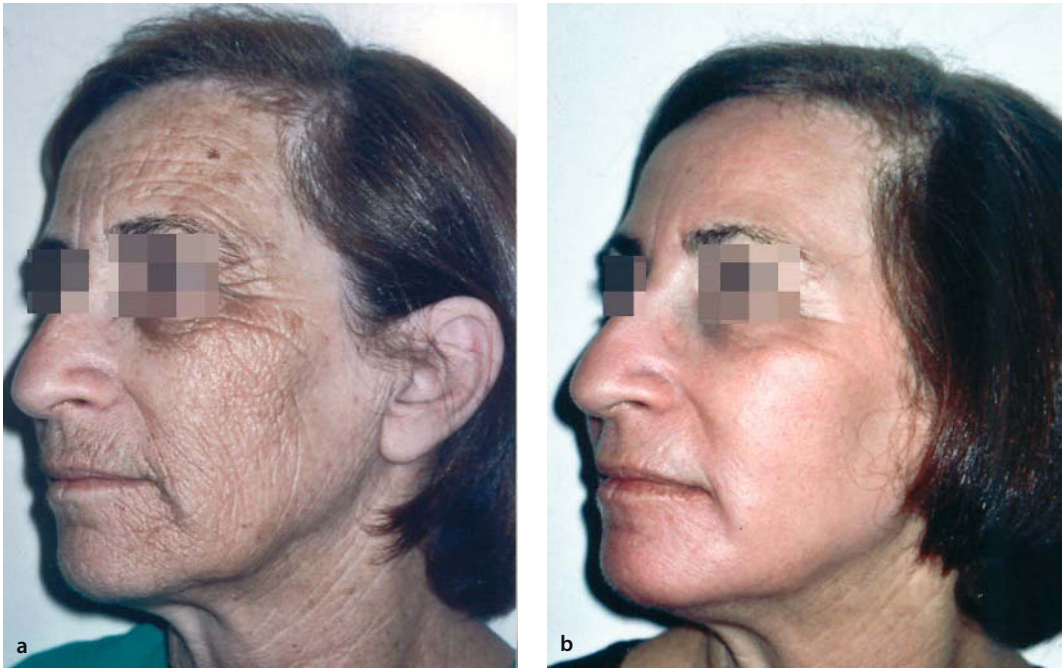

Fig. 8.12. Fifty-eight-year-old woman with premature skin aging before (a) and 2 weeks after (b) deep peeling

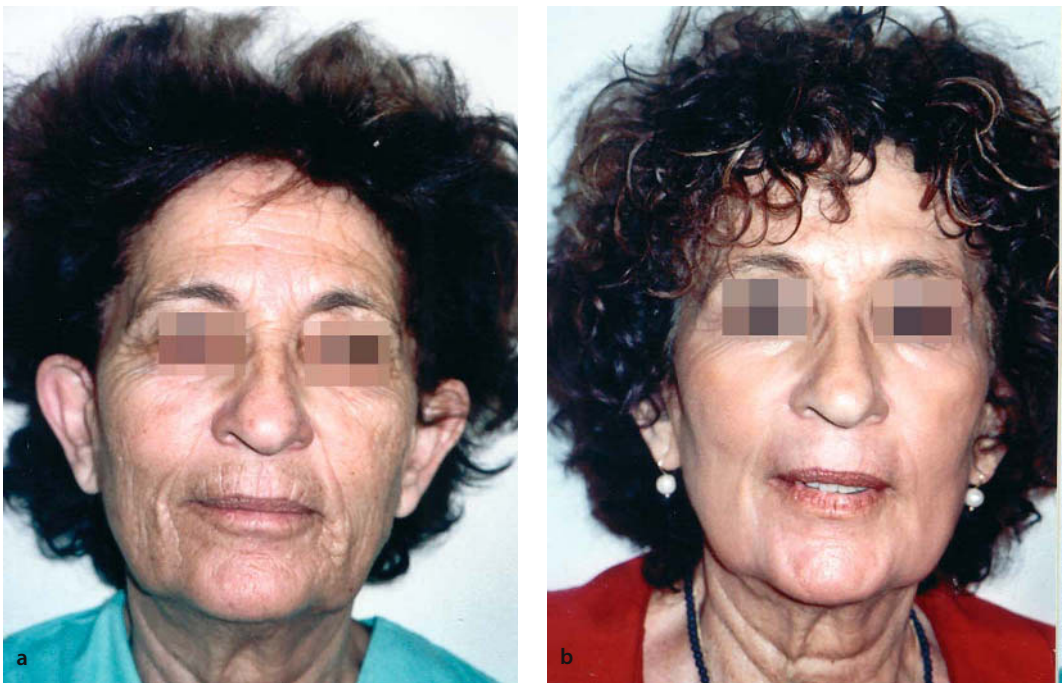

Fig. 8.13. Sixty-three-year-old dark-skinned woman before (a) and 2 months after (b) deep peeling. Note the effect on the upper eyelid retraction and dramatic improvement of upper lip wrinkles

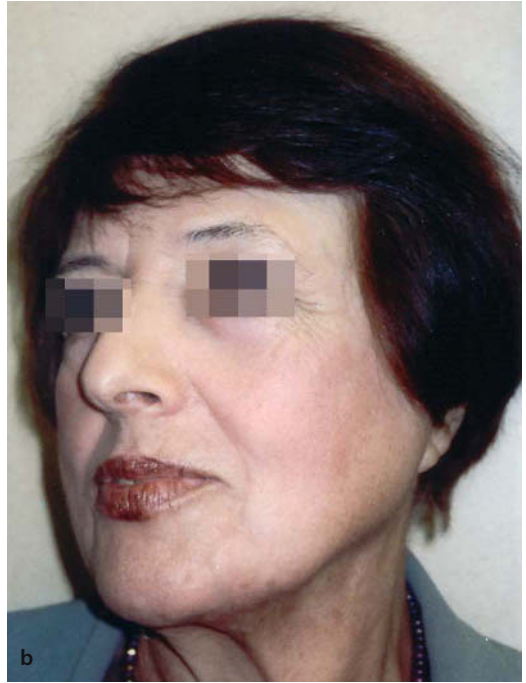
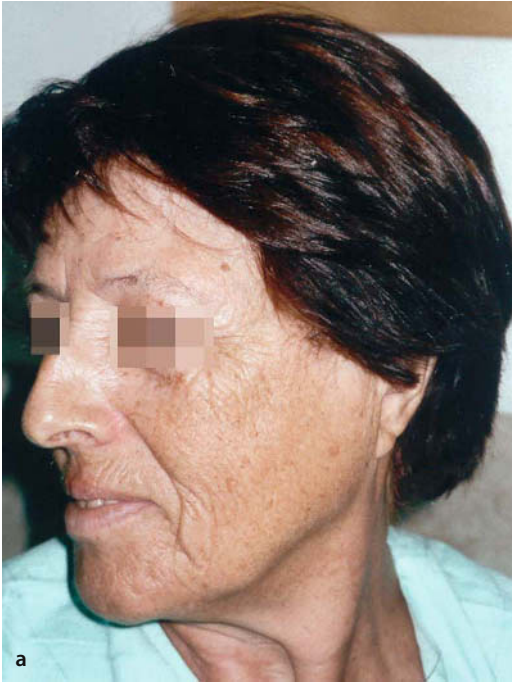
Fig. 8.14. a Sixty-eight-year-old woman with idiopathic thrombocytopenia that prevented any cosmetic surgical intervention. b One year after the performance of deep chemical peeling

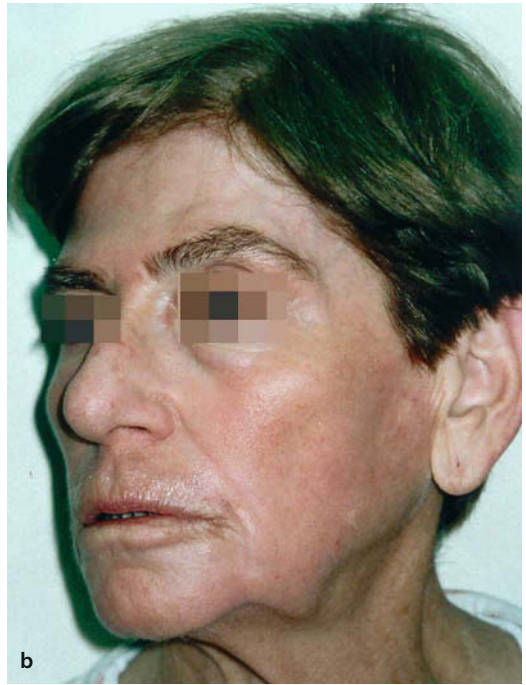
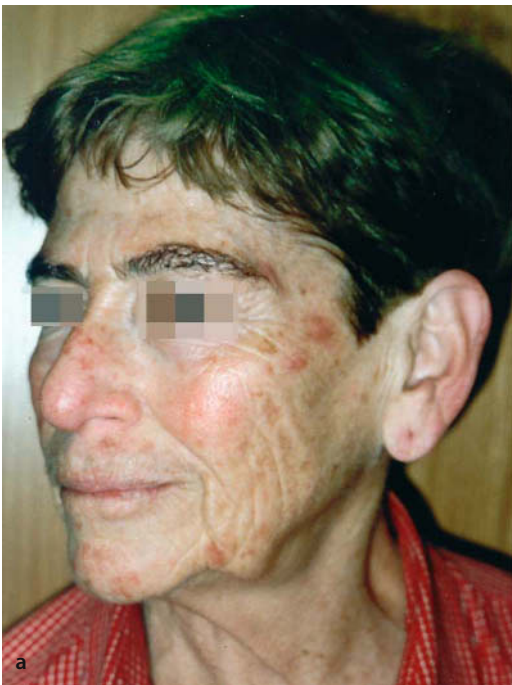
Fig. 8.15. a Seventy-two-year-old fair-skinned woman with farmer skin and multiple solar keratosis. b The results 3 - months after deep peeling

8.12 Complications

8.12.1 Cardiac Arrhythmias

The most important potential complication of phenol-based peels is cardiotoxicity. Phenol is directly toxic to myocardium. Studies in rats have shown a decrease in myocardial contraction and in electrical activity following systemic exposure to phenol [16]. Since fatal doses ranged widely in these studies, it seems that individual sensitivity of myocardium to this chemical exists. In humans neither sex/age nor previous cardiac history/blood phenol levels are accurate predictors for cardiac arrhythmia susceptibility [17].

After application of peeling solution, there is a quick absorption of phenol from the skin surface to the circulation [18]. Seventy-five percent of phenol is excreted directly through kidney or detoxified by liver. The other 25% is metabolized to CO₂ and water.

Phenol blood levels measured after application of 3 ml of 50% solution of phenol is 0.68 mg/dl, while in patients who survived accidental oral ingestion of phenol, a level of 23 mg/dl was found. Application of phenol to one cosmetic unit is equivalent to the application of phenol into a nail matrix for matrixectomy.

In humans cardiac arrhythmias have been recorded in 23% of patients when full-face peel was performed in less than 30 min. These arrhythmias included tachycardia, premature ventricular beats, bigeminy, atrial and ventricular tachycardia [19].

Therefore, full-face phenol-based peel should always be performed under full cardiopulmonary monitoring. The average lag time for the onset of the arrhythmias was 17.5 min from the beginning of the peel, and they are usually not delayed for more than 30 min after the peel. Cardiac arrhythmias are more common while applying the solution on the thin skin of eyelids. In this area skin absorption is maximal; therefore, application should be performed extremely cautiously. If arrhythmia occurs, the application of phenol should be stopped until

normal sinus rhythm returns. To reduce the incidence of arrhythmia, minimal amounts of phenol should be used during the peel. Hydration and diuresis promote metabolism and excretion of phenol, and thus, reduce arrhythmias. Proper pre-peel hydration (oral or intravenous) is imperative while working with phenol. Antiarrhythmia medications are needed if any arrhythmia occurs.

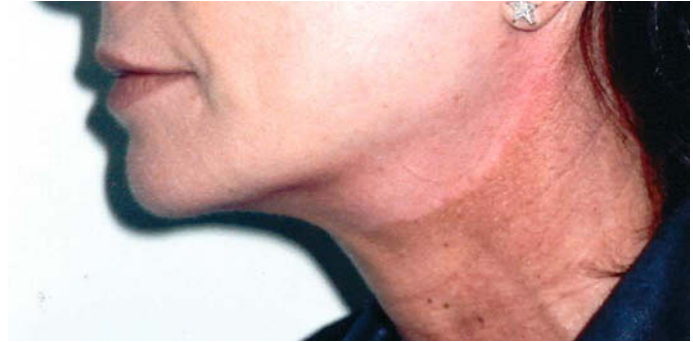Oral poisoning after accidental phenol ingestion has caused fulminant central nervous system depression, hepatorenal and cardiopulmonary failure [20]. No hepatorenal or central nervous system toxicities with properly performed chemical peels have been reported in the literature [21].

8.12.2 Pigmentary Changes

Delayed hypopigmentation is a reason why some doctors dislike the long-term results of deep peels. Hypopigmentation after phenol peels is proportional to the depth of the peel, amount of the solution used, inherent skin color, and post-peel sun-related behavior. Complete avoidance of any sun exposure years after the peel creates ivory skin color.

Reactive hyperpigmentation can occur after any depth of chemical peels. Usually lighter complexions have a lower risk for hyperpigmentation, but genetic factors play an important role, and sometimes light patients with “dark genes” will hyperpigment unexpectedly. Therefore, we recommend introducing bleaching preparation 2–3 weeks after the peel in all patients and continuing until erythema fades. Demarcation lines can be avoided if the boundaries of the peeling area are hidden under the mandibular line and feathered gradually to the normal skin (Fig. 8.16). Medium-depth neck peel is required in patients with blotchy pigmentation of the neck and in those with no clear mandibular line. Accentuation of the pigment in previously existing intradermal nevi is common and should be recognized when it occurs to avoid any unnecessary alarm of a “changing mole”.

Fig. 8.16.
Demarcation line due to wrong
positioning of the lower margin
of the treatment area



8.12.3 Scarring

Scarring is still the most dreadful complication of chemical peels. The contributing factors are not well defined yet. Incidence of scarring with traditional Baker' formula is less than 1% [22], while with less aggressive phenol peels, the incidence is lower. The most common location of the scars is in the lower part of the face, probably due to more aggressive treatment in this area or due to the greater tissue movement, because of eating and speaking, during the healing process. Previous surgical lift elevates the neck skin to the higher position, "imitating" normal facial skin appearance. Thus, special precautions should be taken while peeling lower lateral portions of the face in post-surgical face-lift patients, even years later. We do not recommend combining deep chemical peels with any other surgical facial procedure, since skin undermining severely compromises the post-peel healing process and increases the risk of scarring. Isotretinoin therapy interferes with normal tissue healing; therefore, deep peels should be postponed 6–12 months after completing acne therapy. Delayed healing and persistent redness are important alarming signs for forthcoming scarring. Topical antibiotics and potent steroid preparations should be introduced as soon as this diagnosis is made.

8.12.4 Infection

Bacterial and fungal complications in chemical peels are rare, since phenol is bacteriocidal and fungicidal. Patients with positive history of herpes simplex infection can be treated prophylactically with acyclovir or valacyclovir during the healing phase for 10 days.

8.12.5 Milia

Milia can appear in up to 20% of patients after deep peels 6–8 weeks after the procedure. Electrosurgery is a simple and effective method for treating this post-peel complication.

8.12.6 Acneiform Dermatitis

Acneiform eruption after deep chemical peel is a common phenomenon appearing immediately after reepithelialization. Its etiology is multifactorial and is related to either exacerbation of previously existing acne or is due to over-greasing of newly formed skin. Short-term systemic antibiotics together with discontinuation of any oily preparations will usually provide satisfactory solution.

8.12.7 Skin atrophy

Clinical loss of normal skin markings without scarring is reported after multiple sessions of traditional Baker's peels.

8.13 Advantages

The main advantage of deep chemical peel is in the treatment of photodamaged skin with wrinkles, dyschromia and precancerous lesions. Perioral wrinkling is a condition in which deep peel has an obvious advantage over other medical and surgical methods. Facial scars such as acne scars, especially if of atrophic character, may be significantly improved by deep chemical peel. In general, deep chemical peel is the most powerful and legitimate tool in the hands of a practicing dermatologist for facial skin rejuvenation.

8.14 Disadvantages

The main disadvantage of deep peel is the special set up needed for the procedure, due to the potential cardiotoxicity of phenol. In addition, special training is needed for the doctor and the office staff before the implementation of this technique in the daily practice.

8.15 Patient's Informed Consent

1. I hereby request and authorize Dr. _____, M.D., to treat me for the purpose of attempting to improve my appearance.
2. The effect and nature of the treatment to be given, as well as possible alternative methods of treatment, have been fully explained to me.
3. It has been explained that well-qualified and trained personnel will assist with certain portions of the treatment under his/her supervision.

4. I hereby authorize Dr. _____, M.D., to administer such treatment to me, and agree to hold him/her free and harmless for any claims or suits for damages or injury or complications whatsoever resulting from conditions beyond the doctor's control.
5. I know that the practice of medicine and surgery is not an exact science and that, therefore, reputable practitioners cannot properly guarantee results.
6. I acknowledge that no guarantee or assurance has been made to me by anyone regarding the treatment which I have herein requested and authorized.
7. I am advised that though good results are expected, they cannot be and are not guaranteed, nor can there be any guarantee against untoward results.
8. I acknowledge that no guarantee has been given me as to the number of years I may appear younger following treatment.
9. I acknowledge that no guarantee has been given me as to the condition of the complexion or size of the skin pores following treatment.
10. I acknowledge that during the procedure my face will be covered by masks for 8 days.
11. I acknowledge that no guarantee has been given me as to the painlessness of the procedure. Some individuals, because of emotional makeup or low pain threshold, may experience severe pain. Heavy premedication is given to make the procedure as comfortable for the patient as possible.
12. I have been advised that the following conditions may arise after treatment. These conditions are uncommon and usually not serious, but may appear at any time because of circumstances beyond the doctor's control:
 - a. A darkening of the skin or blotchiness may occur at any time up to 3 months following treatment. This is usually due to excess sun or heat exposure. Special medication may be prescribed for this

and will usually clear the condition completely. Occasionally, further treatment may be required, consisting of a second procedure. Persons with dark complexions undergoing treatment are advised that a blotchy complexion may arise, which will usually even out over a period of 3–6 months.

- b. The skin may be red for a 6- to 8-week period or possibly redness is due to increased blood supply to the new skin. This usually disappears over a 3- to 6-month period and the final complexion is somewhat lighter than the original complexion.
 - c. On occasion, small areas of the neck and chin may show thickening for a variable period of time following treatment. These areas are buildups of underlying collagen and scar tissue and are usually easily controlled by periodic injections of medication.
 - d. Every facial rejuvenation procedure is accompanied by swelling of the tissue of the face and neck. This is usually only temporary and disappears within a short period of time. On occasion the swelling may be persistent and will require further medication.
13. I have been advised that exposure to sun must be avoided at all costs for a period of 6 months. No sunbathing is permitted for 6 months. To do so would encourage blotchy skin pigmentation requiring further treatment.
14. I give my permission that my before and after pictures will be used for:
- Educational purposes only
 - Patient demonstration
 - Medical congresses and medical articles

The operation has been explained to me and I fully understand the nature of the procedure and the risks involved. I acknowledge and understand that no expressed or implied warranty has been given to me.

Date _____ Signature _____

References

1. Mackee GM, Karp FL (1952) The treatment of post acne scars with phenol. *Br J Dermatol* 64: 456–459
2. Bames HO (1927) Truth and fallacies of face peeling and face lifting. *Med J Record* 126: 86–87
3. Urkov JC (1946) Surface defects of the skin: treatment by controlled exfoliation. *Ill Med J* 89: 75
4. Combes FC, Sperber PA, Reisch M (1960) Dermal defects: treatment by a chemical agent. *NY Physician Am Med* 56: 36
5. Brown AM, Kaplan LM, Brown ME (1960) Phenol induced histological skin changes: hazards, techniques and users. *Br J Plast Surg* 13: 158
6. Litton C (1962) Chemical face lifting. *Plast Reconstr Surg* 29: 371
7. Baker TJ (1962) Chemical face peeling and rhytidectomy. *Plast Reconstr Surg* 29: 199
8. Baker TJ, Gordon HL (1961) The ablation of rhytids by chemical means: a preliminary report. *J Fla Med Assoc* 48: 541
9. Stone PA, Lefer LG (2001) Modified phenol chemical face peels: recognizing the role of application technique. *Clin Facial Plast Surg* 9: 351–376
10. Spira M, Dahl C, Freeman R, et al (1970) Chemosurgery: a histological study. *Plast Reconstr Surg* 45: 247
11. Hetter G (2000) An examination of the phenol-croton oil peel: Part I. Dissecting the formula. *Plast Reconstr Surg* 105: 239–248
12. Fintsi Y (1997) Exoderm—a novel phenol-based peeling method resulting in improved safety. *Am J Cosm Surgery* 14: 49–54
13. Baker TJ, Gordon HL, Seckinger DL (1966) A second look at chemical face peeling. *Plast Reconstr Surg* 37: 487
14. Baker TJ, Gordon HL, Mosienko P, et al (1974) Long-term histological study of skin after chemical face peeling. *Plast Reconstr Surg* 53: 522
15. Exoderm: phenol-based peeling in olive and dark skinned patients. *Int J Cosm Surgery Aesthet Dermatol* 2001;3: 173–178
16. Stagnone GJ, Orgel MB, Stagnone JJ (1987) Cardiovascular effects of topical 50% trichloroacetic acid and Baker's phenol solution. *J Dermatol Surg Oncol* 13: 999–1002
17. Litton C, Trinidad G (1981) Complications of chemical face peeling as evaluated by a questionnaire. *Plast Reconstr Surg* 67: 738–744
18. Wexler MR, Halon DA, Teitelbaum A, et al (1984) The prevention of cardiac arrhythmias produced in an animal model by topical application of a phenol preparation in common use for face peeling. *Plast Reconstr Surg* 73: 595–598
19. Truppman F, Ellenbery J (1979) The major electrocardiographic changes during chemical face peeling. *Plast Reconstr Surg* 63: 44

20. Gleason MD, Gosselin RF, Hodge HC, et al (1969) Clinical toxicology of commercial products. Williams & Williams, Baltimore, pp 189–192
21. Brody HJ (1997) Chemical peeling and resurfacing, 2nd ed. Mosby, pp 188–189
22. Brody HJ (1997) Chemical peeling and resurfacing, 2nd ed. Mosby, pp 168–178

Deep Chemical Peels for Post-acne Scarring

Marina Landau

The author has no financial interest in any of the products or equipment mentioned in this chapter.

Contents

9.1	History and Classification	91
9.2	Indications	93
9.3	Contraindications	93
9.4	Pre-peeling Preparation	93
9.5	Peeling Technique	94
9.6	Aftercare	96
9.7	Advantages	96
9.8	Disadvantages	96
	References	100

9.1 History and Classification

Acne is a common disease affecting almost 100% of youngsters [1, 2]. Acne settles in the vast majority by 20–25 years of age but 1% of males and 5% of females exhibit acne lesions at 40 years of age [3]. Scarring occurs early in the course of acne and may affect, to some degree, 95% of patients from both sexes [4]. Differences in the cell-mediated immune response are involved in the personal tendency to develop post-acne scarring [5].

Acne scars are debilitating and socially disabling for the individual. Treatment of acne scars presents a challenge for a treating physician. Usually they cannot be effectively corrected by a single treatment modality because of their widely varied depth, width and structure.

A few morphologic acne scar classifications have been proposed to assess the efficacy of different therapeutic options based on the scar

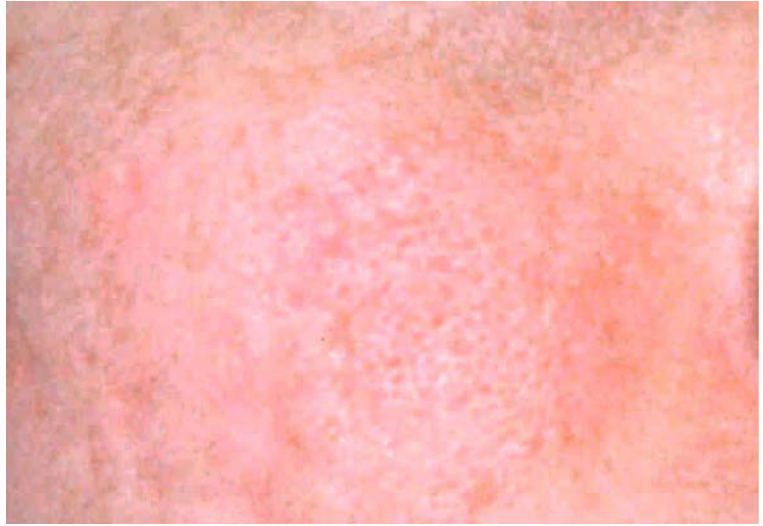types. Standard classification includes three basic types of scars: icepick scars, rolling scars, and boxcar scars [6]. Icepick scars are narrow (<2 mm), deep sharply marginated epithelial tracts that extend vertically to the deep dermis or subcutaneous tissue (Fig. 9.1). Rolling scars occur from dermal tethering of otherwise relatively normal-appearing skin and are usually wider (4–5 mm) (Fig. 9.2). The subdermal tether precludes treatment from the surface above, thus correction of subdermal component is essential. Boxcar scars are round to oval depressions with demarcated vertical edges, similar to varicella scars (Fig. 9.3). They may be shallow or deep. Other less common scars are sinus tracts, hypertrophic scars, and keloidal scars.

According to other classification acne scars are divided to elevated, dystrophic or depressed [7]. Elevated scars are subdivided to hypertrophic, keloidal, and papular, while depressed scars are subdivided to distensible and non-distensible (Fig. 9.4).

As far back as 1905, surgical methods have been used to improve skin that has been scarred by facial acne. One hundred years ago two New York dermatologists, George MacKee and Florentine Karp, began using phenol peels for post-acne scarring [8]. Thereafter, methods used to correct acne scars included dermatome dermaplaning [9, 10], dermabrasion [11, 12, 13], collagen implantation [14, 15, 16], demal overgrafting [17], punch excision, grafting and elevation [18, 19], dermal grafting [20, 21], subcision [6, 22], laser resurfacing [23, 24, 25, 26, 27, 28, 29] microdermabrasion [30], dermasanding [31] and their combinations [32, 33, 34].

But the mainstay of therapy for skin resurfacing continues to be chemical peels together

Fig. 9.1.
Icepick scars



9

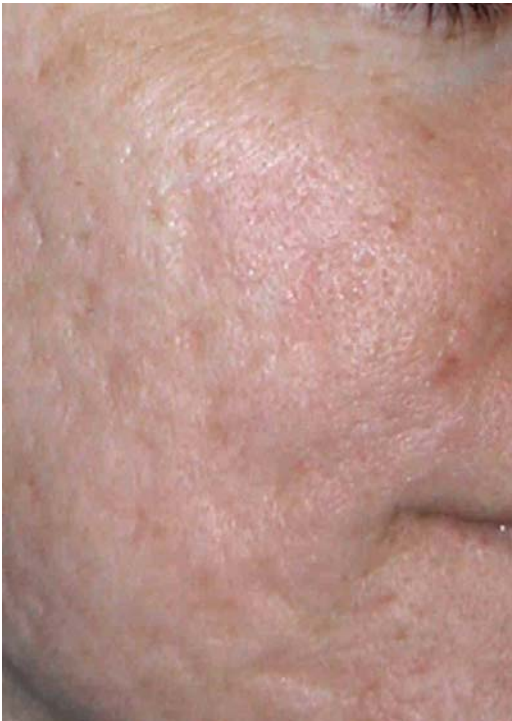

Fig. 9.2. Rolling scars

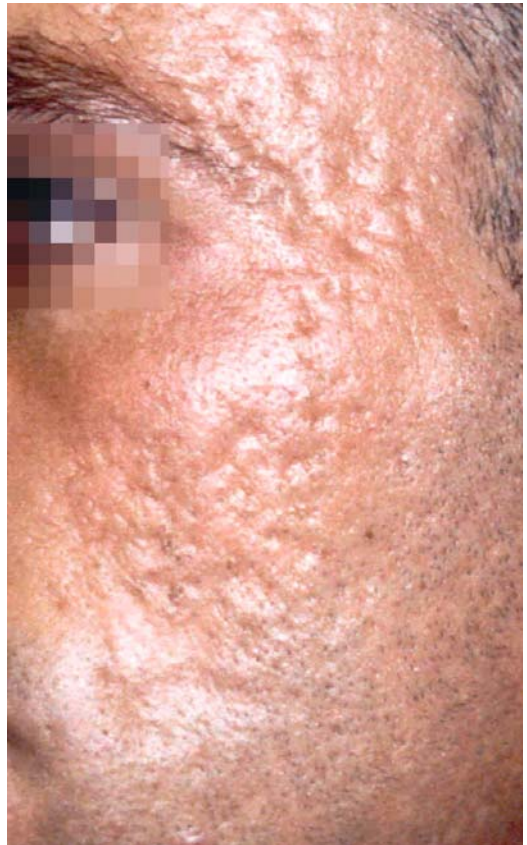

Fig. 9.3. Boxcar scars

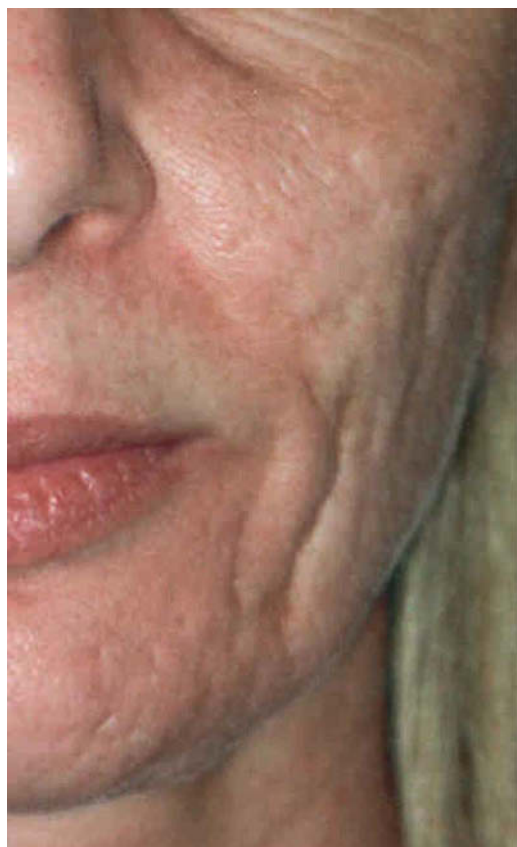


Fig. 9.4. Depressed distensible scars

with abrasion [35, 36, 37, 38, 39]. Chemical peels in use to improve facial scarring include alpha hydroxyl acid peels, trichloroacetic acid and deep phenol based methods [38, 39, 40, 41, 42, 43, 44]. In this chapter we discuss deep chemical peels for post-acne scar treatment.

9.2 Indications

Generally, best results are achieved in depressed and atrophic or rolling and boxcar scars. Icepick scars always need to be preceded by punch excision. Our experience shows that in older patients, when skin is less elastic, it is possible to achieve more significant improve-

ment of the scars. In male patients the improvement is usually less cosmetically significant.

In general it is important to manage patients' expectations, since usually no complete elimination of acne scars of any type is possible [6].

9.3 Contraindications

It is important to obtain details regarding isotretinoin (Accutane, Roacutane) treatment and history of keloid or hypertrophic scar formation. Isotretinoin use necessitates a delay period of 6–12 months (depending on the skin thickness and oiliness) until chemical peel is performed. Active acne is not a contraindication for chemical peel. In these cases the peel is combined with systemic antibiotics for 2–3 weeks. It is always advisable to consider isotretinoin treatment after the peel to avoid acne flare and scar reappearance.

There are a few absolute contraindications for deep peeling, mainly physical or mental instability. During pregnancy and lactation any cosmetic intervention is considered undesirable. All patients are required to perform electrocardiogram and complete blood count prior to the procedure. Any heart disease requires special precautions and it is always recommended to work in cooperation with the patient's cardiologist.

9.4 Pre-peeling Preparation

Treatment of acne scars must be individually tailored to address the specific findings. The patient has to understand that the scar revision process may require more than one surgical session. Punch excisions or elevations have to be performed 4–6 weeks before the peel, while subcision can be performed at the same session with the peel.

Before the peel prophylactic acyclovir, valacyclovir or famvir is given to patients with history of recurrent herpes simplex. Systemic antibiotics (minocycline) are important for patients with active acne.

9.5 Peeling Technique

The full description of the deep chemical peel procedure is found in Chapter 8. Before the peeling, the subcision (subcutaneous incision) technique is used to free the fibrous bands from the base of the scars. For this purpose we use an 18-gauge 1.5-inch NoKor Admix needle (Becton Dickinson and Co). This needle has a triangular tip similar to No. 11 blade (Fig. 9.5). It allows smooth separation of fibrous cords. The needle is inserted through a skin surface, and its sharp edges are maneuvered under the defect to make subcutaneous cuts or incisions. The depression

is lifted by the releasing action of the procedure, as well as from connective tissue that forms in the course of normal wound healing.

The Exoderm solution is applied evenly and gradually on the skin until full frosting is achieved (Fig. 9.6). At this stage we combine mechanical skin dermabrasion by using a Ti-polisher, which is sterile surgical equipment designed originally for cleaning cauthery tips during operations (Fig. 9.7). This simple disposable tool is available in any standard operating setting. Another option is to use sterilized gentle sandpaper. At this stage pint-point bleeding is observed. Reapplication of peeling solution coagulates most of the bleeding (Fig. 9.8).

9

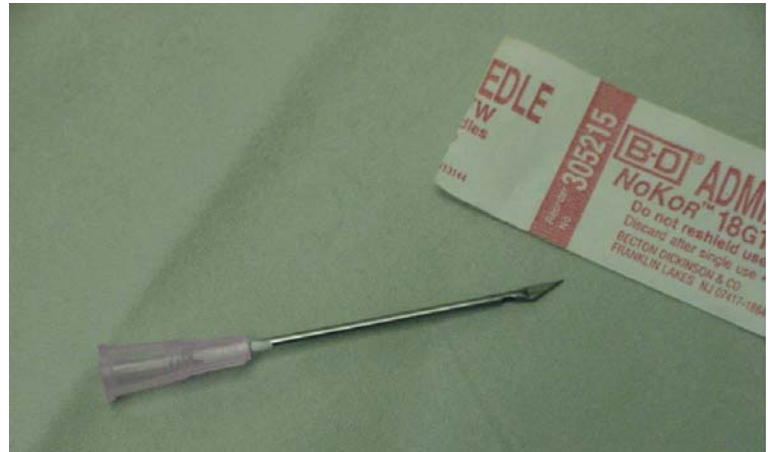


Fig. 9.5.
NoKor Admix subcision
needle

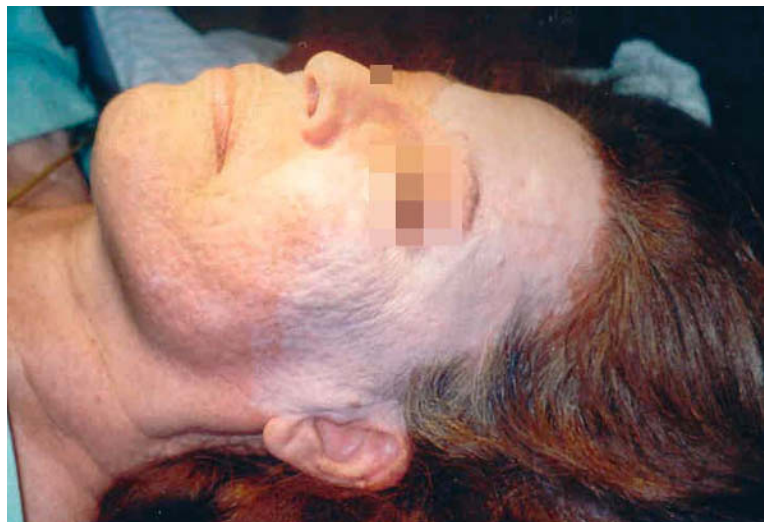

Fig. 9.6.
Frosting after application
of the peeling solution

Fig. 9.7.
Tipolisher

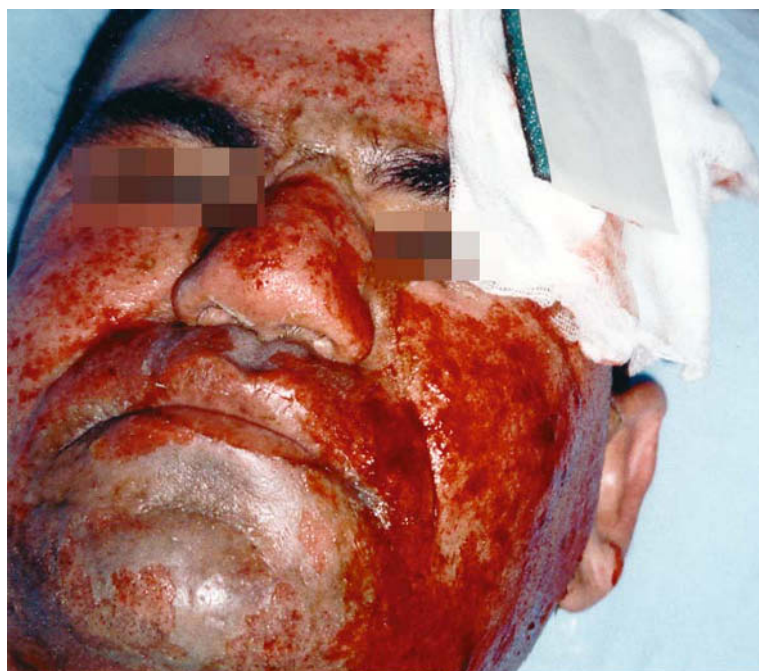


Fig. 9.8.
Skin dermabrasion
using Tipolisher

The face is covered with impermeable tape mask for 24 h. After 24 h the tape mask is removed and the exudate is cleansed with sterile saline. Regional re-application of peeling solution and re-taping of the scarred areas is performed and the tape is left for an additional 4–6 h and then removed by the patient. The face

is covered with bismuth subgalate antiseptic powder for 7 days. The third phase of the treatment is regional re-peeling, which is performed 6–8 weeks after the original treatment. This phase is optional for patients with residual scar areas.

9.6 Aftercare

After the procedure, the patient is advised to use water-based lotion creams and potent sunscreens. The erythema gradually resolves over about a 2-month period. During this time, makeup foundation is encouraged. In patients with dark skin (Fitzpatrick skin type 3 or 4), the application of Kligman preparation is recommended to prevent reactive hyperpigmentation. Systemic Isotretinoin is required in some patients and can be prescribed as soon as 2–3 weeks after the procedure, if no other surgical intervention is planned in the near future.

9.7 Advantages

Combination of deep chemical peel with other minor surgical procedures such as punch excision, elevation and subcision provides a possibility to tailor an effective treatment for each person.

9.8 Disadvantages

In spite of the fact that the final result is always significant, a complete elimination of all the scars is usually impossible. Patients need to be aware that use of multiple complimentary techniques and time-consuming treatments is needed to produce optimal results.

Results of a combination of phenol-based peel with abrasion and subcision are shown below (Figs. 9.9, 9.10, 9.11, 9.12, 9.13, 9.14 and 9.15).

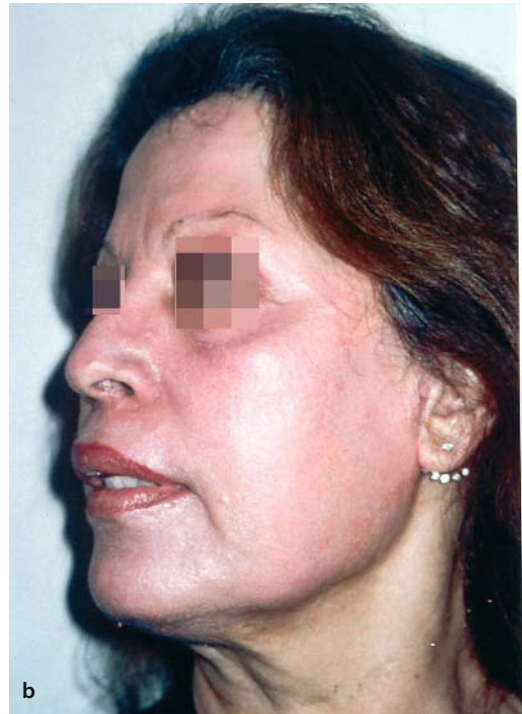
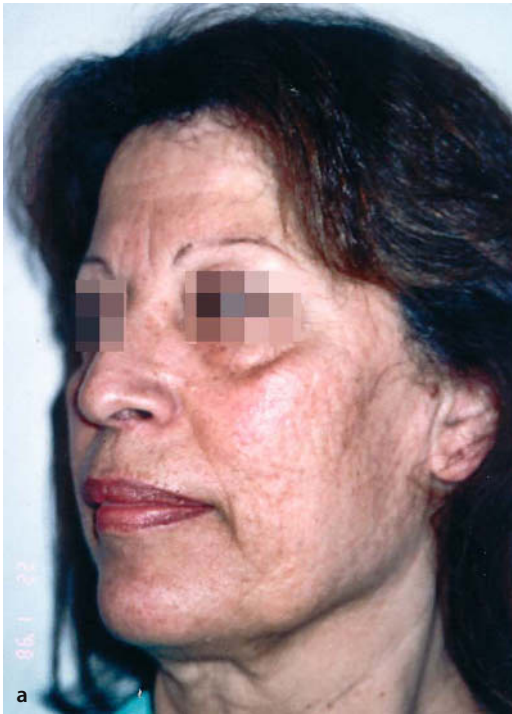
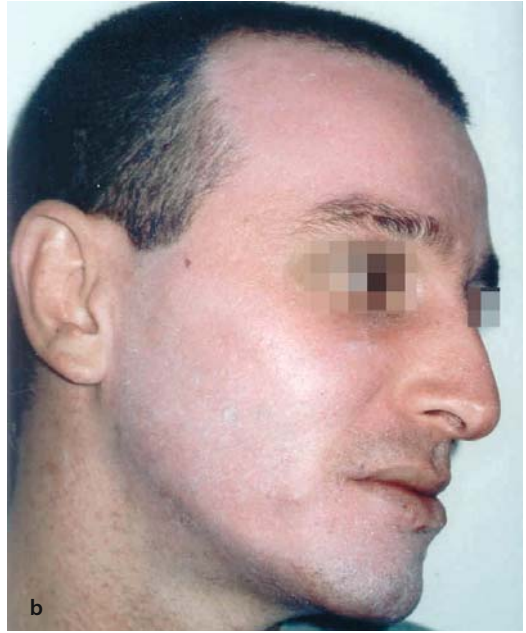
Fig. 9.9. A 52-year-old patient with boxcar acne scars before (a) and 1 month after (b) deep chemical peel and skin abrasion

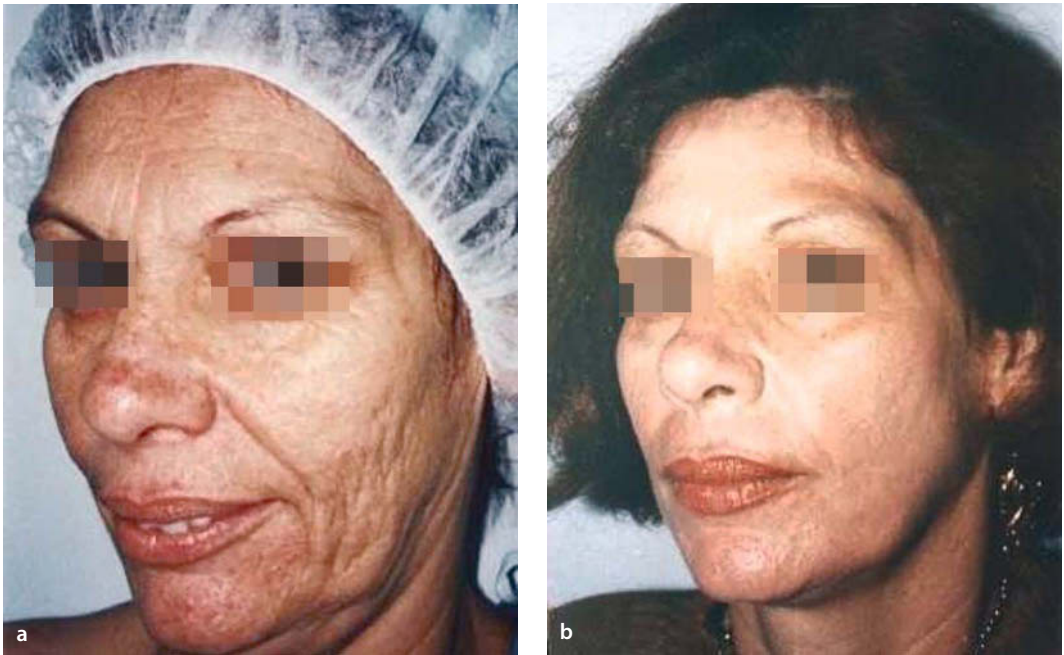

Fig. 9.10. A 48-year-old patient with acne scars and wrinkles before (a) and 6 months after (b) deep chemical peel with skin abrasion

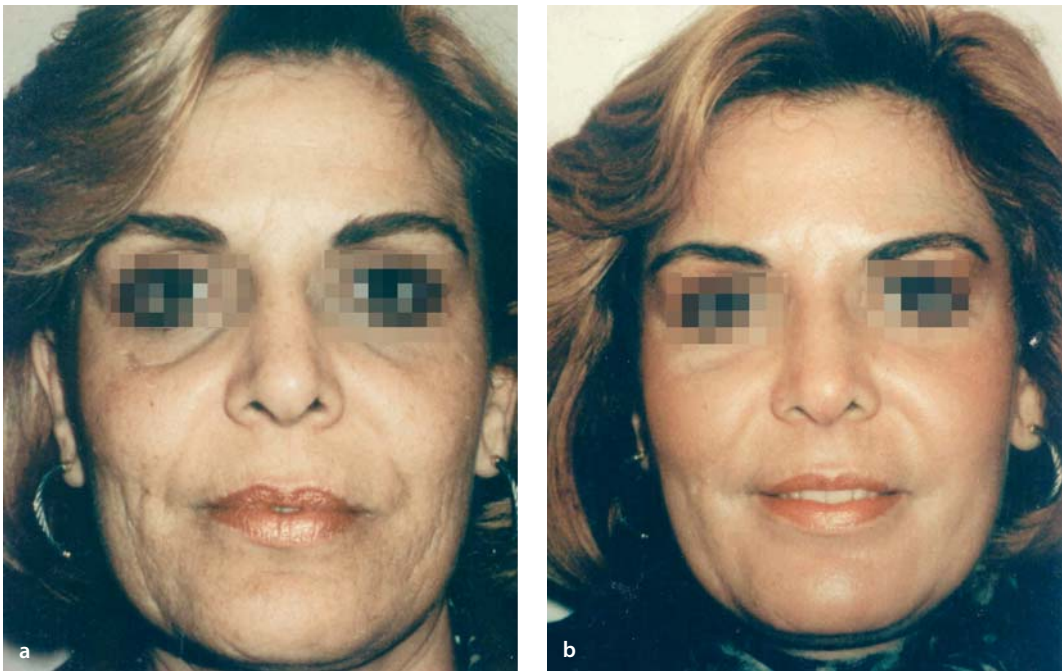

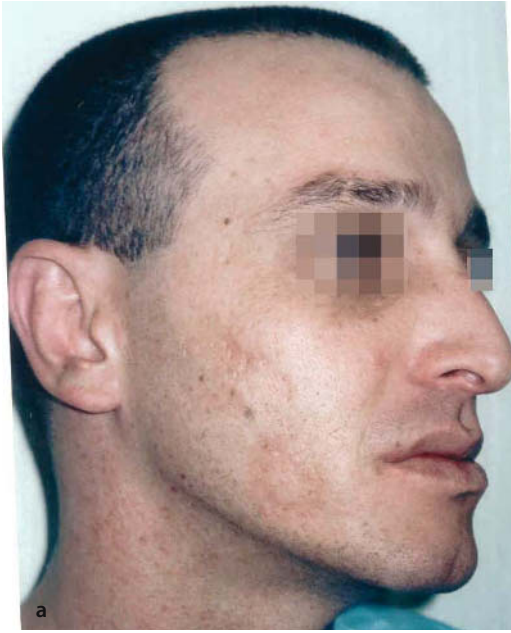Fig. 9.11. A 44-year-old patient with rolling acne scars before (a) and 3 months after (b) deep chemical peel combined with subcision and dermabrasion



9

Fig. 9.12. A 42-year-old male patient with boxcar acne scars before (a) and 2 weeks after (b) deep chemical peel and skin abrasion

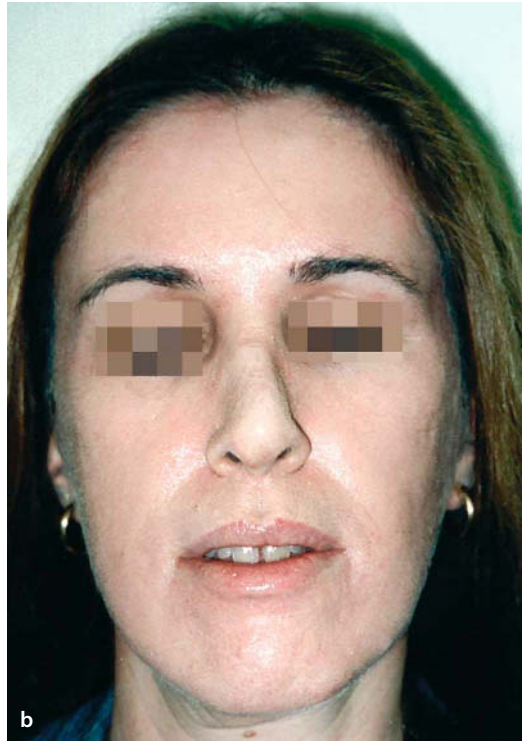
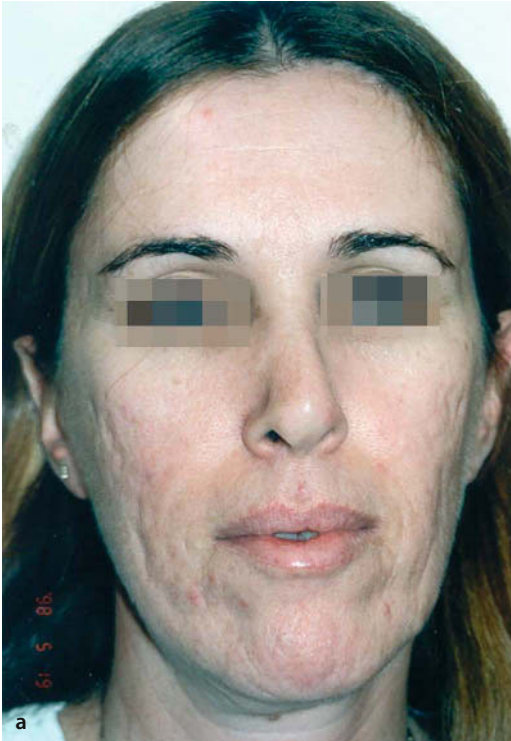
Fig. 9.13. A 38-year-old patient with rolling and depressed distensible scars before (a) and 1 month after (b) deep chemical peel combined with subcision and skin abrasion

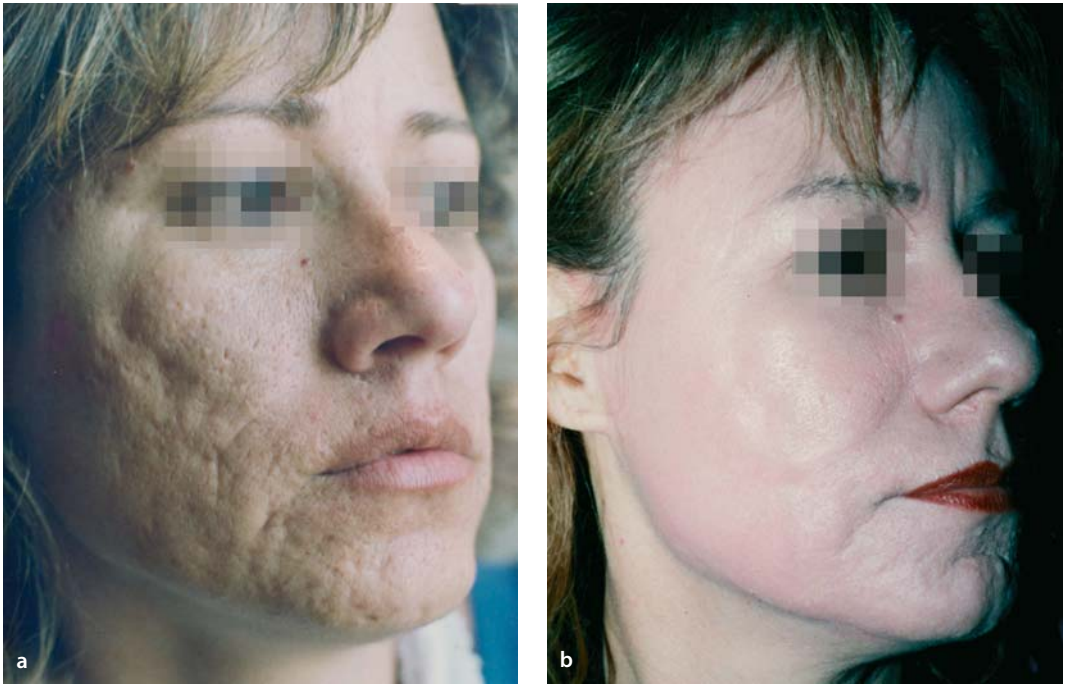

Fig. 9.14. A 51-year-old patient with severe facial scarring before (a) and 2 months after (b) deep chemical peel combined with subcision and skin abrasion

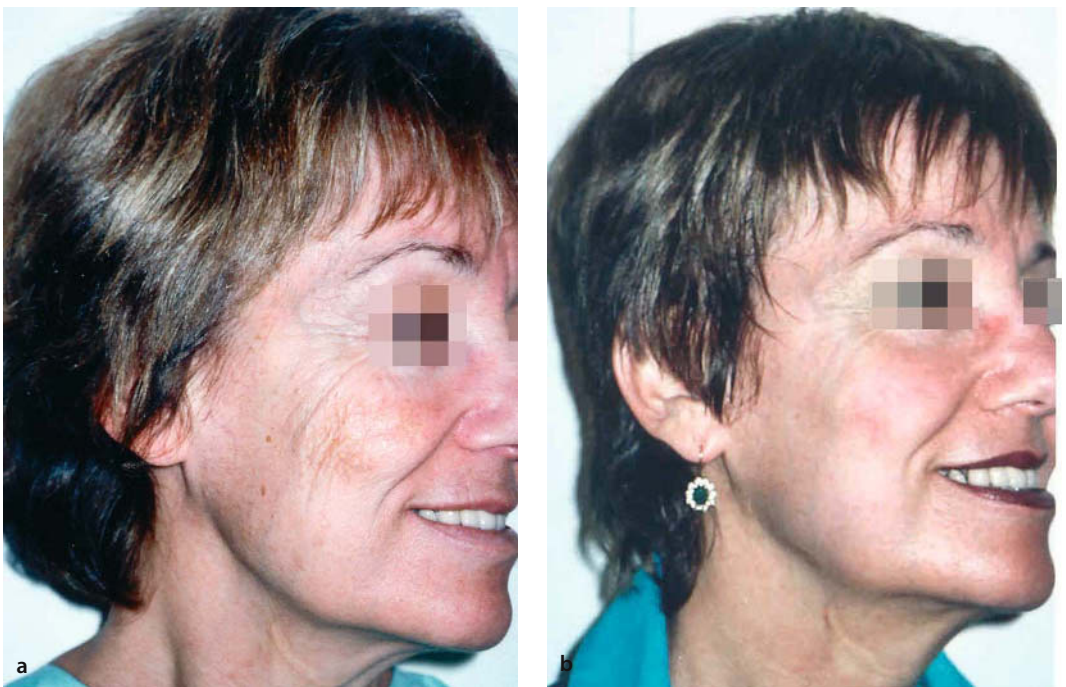

Fig. 9.15. A 56-year-old patient with wrinkles and atrophic scar due to old cutaneous leishmaniasis before (a) and 3 months after (b) deep chemical peel

References

1. Burton JL, Cunliffe WJ, Stafford I, Shuster S (1971) The prevalence of acne vulgaris in adolescence. *Br J Dermatol* 85: 119–126
2. Rademaker M, Garioch JJ, Simpson NB (1989) Acne in schoolchildren: no longer a concern for dermatologists. *BMJ* 298: 1217–1219
3. Cunliffe WJ, Gould DJ (1979) Prevalence of facial acne vulgaris in late adolescence and in adults. *BMJ* 1: 1109–1110
4. Layton AM, Henderson CA, Cunliffe WJ (1994) A clinical evaluation of acne scarring and its incidence. *Clin Exp Dermatol* 19: 303–308
5. Holland DB, Jeremy AHT, Roberts SG, Seukeran DC, Layton AM (2004) Inflammation in acne scarring: a comparison of the responses in lesions from patients prone and not prone to scar. *Br J Dermatol* 150: 72–81
6. Jacob CI, Dover JS, Kaminer MS (2001). Acne scarring: a classification system and review of treatment options. *J Am Acad Dermatol* 45: 109–117
7. Kadunc BV, Trindade de Almeida AR (2003) Surgical treatment of facial acne scars based on morphologic classification: a Brazilian experience. *Dermatol Surg* 29: 1200–1209
8. Mackee GM, Karp FL (1952) The treatment of post acne scars with phenol. *Br J Dermatol* 64: 456–459
9. Kurtin A (1953) Corrective surgical planing of skin: new technique for treatment of acne scars and other skin defects. *AMA Arch Derm Syphilol* 68: 389–397
10. Malherbe WD, Davies DS (1971) Surgical treatment of acne scarring, by a dermatome. *Plast Reconstr Surg* 47: 122–126
11. Orentreich N (1969) Dermabrasion. *J Am Med Womens Assoc* 24: 331–336
12. Kurtin A (1968) Dermabrasion. *Arch Dermatol* 98: 87
13. Rattner R, Rein CR (1955) Treatment of acne scars by dermabrasion; rotary brush method. *J Am Med Assoc* 159: 1299–1301
14. Knapp TR, Kaplan EN, Danieks JR (1977) Injectable collagen for soft tissue augmentation. *Plast Reconstr Surg* 60: 398–405
15. Stegman SJ, Tromovitch TA (1980) Implantation of collagen for depressed scars. *J Dermatol Surg Oncol* 6: 450–453
16. Varnavides CK, Forster RA, Cunliffe WJ (1987) The role of bovine collagen in the treatment of acne scars. *Br J Dermatol* 116: 199–206
17. Thrimbke JR (1983) Dermal overgrafting in dermatology. *J Dermatol Surg Oncol* 9: 987–993
18. Dzubow LM (1985) Scar revision by punch-graft transplants. *J Dermatol Surg Oncol* 11: 1200–1202
19. Besecker B, Hart CG (1999) A new treatment option for acne scars: allograft dermis. *Dermatol Nurs* 11: 111–114
20. Goodman G (1997) Laser-assisted dermal grafting for the correction of cutaneous contour defects. *Dermatol Surg* 23: 95–99
21. Mancuso A, Farber GA (1991) The abraded punch graft for pitted facial scars. *J Dermatol Surg Oncol* 17: 32–34
22. Sulamanidze MA, Salti G, Mascetti M, Sulamanidze GM (2000) Wire scalpel for surgical correction of soft tissue contour defects by subcutaneous dissection. *Dermatol Surg* 26: 146–150
23. Garrett AB, Dufresne RG Jr, Ratz JL, Berlin AJ (1990) Carbon dioxide laser treatment of pitted acne scarring. *J Dermatol Surg Oncol* 16: 737–740
24. Alster TS, West TB (1996) Resurfacing of atrophic facial acne scars with a high-energy, pulsed carbon dioxide laser. *Dermatol Surg* 22: 151–154
25. Alster TS, McMeekin TO (1996) Improvement of facial acne scars by the 585 nm flashlamp-pumped pulsed dye laser. *J Am Acad Dermatol* 35: 79–81
26. Kye YC (1997) Resurfacing of pitted facial scars with a pulsed Er: YAG laser. *Dermatol Surg* 23: 880–883
27. West TB (1997) Laser resurfacing of atrophic scars. *Dermatol Clin* 15: 449–457
28. Manusciatti W, Fitzpatrick RE, Goldman MP (2000) Treatment of facial skin using combinations of CO₂, Q-switched alexandrite, flashlamp-pumped pulsed dye, and Er: YAG lasers in the same treatment session. *Dermatol Surg* 26: 114–120
29. Jordan R, Cummins C, Burls A (2000) Laser resurfacing of the skin for the improvement of facial acne scarring: a systematic review of the evidence. *Br J Dermatol* 142: 413–423
30. Tsai RY, Wang CN, Chan HL (1995) Aluminum oxide crystal microdermabrasion. A new technique for treating facial scarring. *Dermatol Surg* 21: 539–542
31. Goodman GJ (2003) Post acne scarring: a review. *J Cosmet Laser Ther* 5: 77–95
32. Fulton JE Jr (1987) Modern dermabrasion techniques: a personal appraisal. *J Dermatol Surg Oncol* 13: 780–789
33. Solotoff SA (1986) Treatment for pitted acne scarring—postauricular punch grafts followed by dermabrasion. *J Dermatol Surg Oncol* 12: 1079–1084
34. Grevelink JM, White VR (1998) Concurrent use of laser skin resurfacing and punch excision in the treatment of facial acne scarring. *Dermatol Surg* 24: 527–530
35. Fulton JE Jr (1996) Dermabrasion, chemabrasion, and laserabrasion. Historical perspectives, modern dermabrasion techniques, and future trends. *Dermatol Surg* 22: 619–628
36. Ayhan S, Baran CN, Yavuzer R, Latifoglu O, Cenetoglu S, Baran NK (1998) Combined chemical peeling and dermabrasion for deep acne and posttraumatic scars as well as aging face. *Plast Reconstr Surg* 102(4): 1238–1246
37. Horton CE, Sadove RC (1987) Refinements in combined chemical peel and simultaneous abrasion of the face. *Ann Plast Surg* 19(6): 504–511

38. Fintsi Y, Kaplan H, Landau M (1999) Whether to peel or laser for acne scarring and hyperpigmentation. *Int J Cosm Surg* 7: 67-70
39. Fintsi Y (1998) Exoderm chemabrasion: original method for the treatment of facial acne scars. *Int J Cosm Surg* 6: 111-114
40. Atzori L, Brundu MA, Orru A, Biggio P (1999) Glycolic acid peeling in the treatment of acne. *J Eur Acad Dermatol Venereol* 12: 119-122
41. Jansen T (2000) Chemical peeling. Impressive results in acne scars and aging skin. *MMW Fortschr Med* 142: 39-41
42. Al-Waiz MM, Al- Sharqi AI (2002) Medium-depth chemical peels in the treatment of acne scars in dark-skinned individuals. *Dermatol Surg* 28: 383-387
43. Lee JB, Chung WG, Kwahck H, Lee KH (2002) Focal treatment of acne scars with trichloroacetic acid: chemical reconstruction of skin scars method. *Dermatol Surg* 28: 1017-1021
44. Wang KK, Lee M (1999) The principle of a three-staged operation in the surgery of acne scars. *J Am Acad Dermatol* 40: 95-97

Combination Salicylic Acid/ TCA Chemical Peeling

Pearl E. Grimes

The author has no financial interest in any of the products or equipment mentioned in this chapter.

Contents

10.1	History	103
10.2	Chemical Background/Properties . . .	103
10.3	Formulations	104
10.4	Indications	104
10.5	Contraindications	105
10.6	Peeling Preparations	107
10.7	Peeling Technique	108
10.8	Post-peeling Care and Complications .	109
10.9	Advantages	109
10.10	Disadvantages	109
10.11	Side Effects	109
10.12	Patient's Informed Consent	109
	References	110

10.1 History

In 2002, Grimes reported the efficacy of combination salicylic acid/TCA 10% peeling [1]. She treated patients with moderate to severe melasma with this combination regimen. In the series, nine patients were classified as Fitzpatrick skin type IV, eleven were skin type V, and seven were skin type VI. Many of the subjects included in the study had not responded to salicylic acid or glycolic acid peels. The concentration of salicylic acid was 20 and 30%, and the TCA concentration was 10%. A series of four peels was performed at 2-week intervals. Thirty percent of the patients experienced moderate improve-

ment, and 70% experienced significant improvement in hyperpigmentation. Sixteen percent had minimal to mild side effects, which cleared within 1 week. The results of the study suggested that the combination peel is safe and efficacious for treatment of moderate and severe melasma in darker racial ethnic groups. The peel has since been used successfully in all skin types. Swinehart pretreated a series of patients with lentigines, pigmented keratoses and actinic damage of the dorsal hands with TCA 20% prior to application of a 50% salicylic acid paste [2]. He reported excellent results.

10.2 Chemical Background/Properties

Salicylic acid (ortho hydroxybenzoic acid) is a beta hydroxy acid agent. It is a lipophilic compound which produces desquamation of the stratum corneum via removal of intercellular lipids [3] (see salicylic acid section). Given its keratolytic effects, it has become an increasingly popular superficial peeling agent. Salicylic acid peels induce injury via thinning or removal of the stratum corneum. In addition, salicylic acid potentially enhances the penetration of TCA.

Trichloroacetic Acid (TCA) causes precipitation of proteins and coagulative necrosis of epidermal cells [4]. The extent of damage is indeed concentration dependent. Concentrations range from 10 to 50%. Superficial TCA peeling is induced by concentrations of 10–30% whereas higher concentrations cause medium depth or deep peeling. The combination of salicylic acid followed by TCA 10–15% induces superficial wounding.

10.3 Formulations

Ethanol formulations of salicylic acid (20 and 30%) are used for combination peeling (see salicylic acid section). Trichloroacetic acid is prepared as an aqueous solution, since ethanol solutions do not penetrate the skin. It is prepared by mixing the appropriate concentration of crystals with up to 100 cc of distilled water. Ten and fifteen percent TCA is prepared by mixing 10 or 15 g of crystals in up to 100 cc of total volume, respectively. Aqueous solutions of TCA remain stable for up to 6 months unless contaminated. Other methods have been used to formulate TCA peeling solutions; however, the weight/volume methods appear to be the most reliable formulation [5]. Premixed TCA solutions are available from a variety of medical

suppliers (Delasco, Council Bluffs, IA; Moore Medical, New Britain, CT).

10.4 Indications

Despite the benefits of superficial peeling agents such as glycolic acid or salicylic acid, it is not uncommon to observe treatment failures. Some patients may require a more aggressive peeling regimen while minimizing the risk of side effects such as hyperpigmentation or hypopigmentation (Table 10.1). While TCA remains the gold standard of peeling agents, it is maximally efficacious in Fitzpatrick's skin types I–III [6]. In darker skin types, even TCA 15 or 20% can be fraught with post-peel complications. The combination of salicylic acid 20/30% and low-

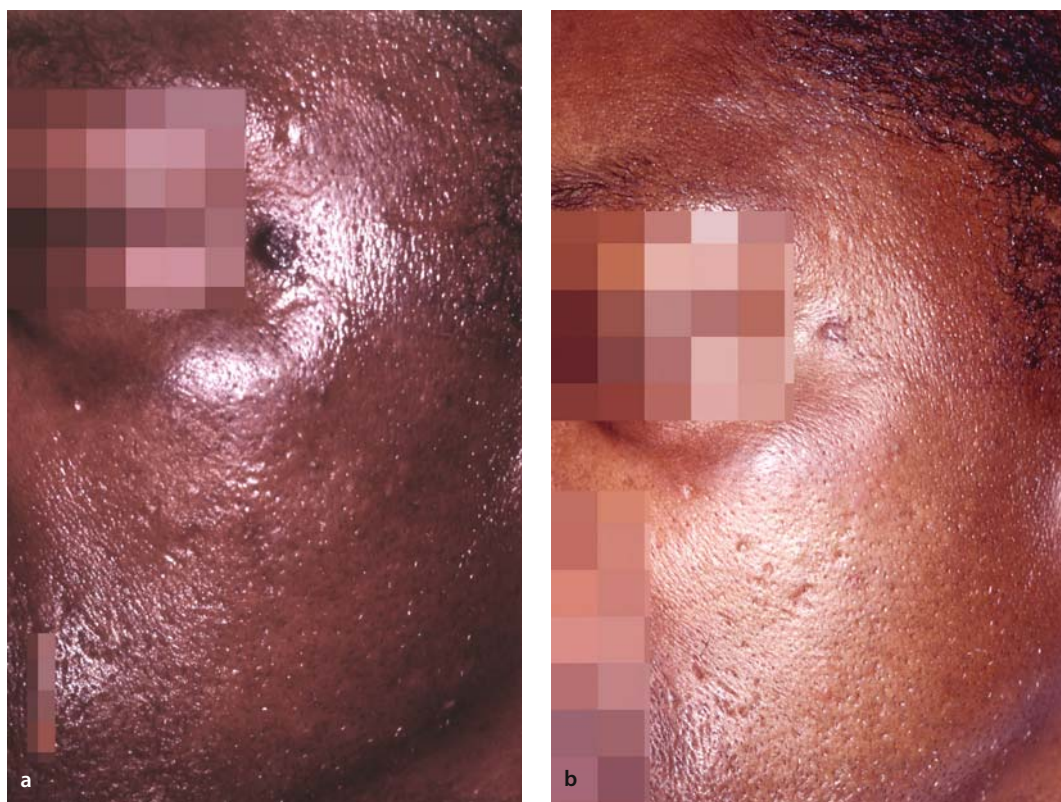

Fig. 10.1. a African American male with severe post-inflammatory hyperpigmentation. b Note significant improvement after combination salicylic acid/TCA peeling

Table 10.1 Indications for salicylic acid/TCA peeling

Hyperpigmentation
Melasma
Post-inflammatory hyperpigmentation
Solar lentigines
Photodamage
Acne
Texturally rough skin

strength TCA peeling produces additional efficacy compared with salicylic acid peels or TCA 10% peels, while minimizing complications reported with higher concentrations of TCA or glycolic acid, particularly in darker racial ethnic groups (Figs. 10.1a, b and 10.2a, b).

The combination of salicylic acid and TCA 15% is also an effective treatment for mild to moderate photodamage, acne and melasma in types I–III. Moderate to excellent improvement has been observed (Figs. 10.3a, b, 10.4a, b and 10.5a, b). Hence, the combination salicylic acid/TCA peeling protocol can be used in all skin types.

10.5 Contraindications

There are few contraindications to combination salicylic acid/TCA peeling. The combination regimen is tolerated in all skin types and all racial/ethnic groups. General contraindications include salicylate hypersensitivity; unrealistic patient expectations; active inflammation/der-

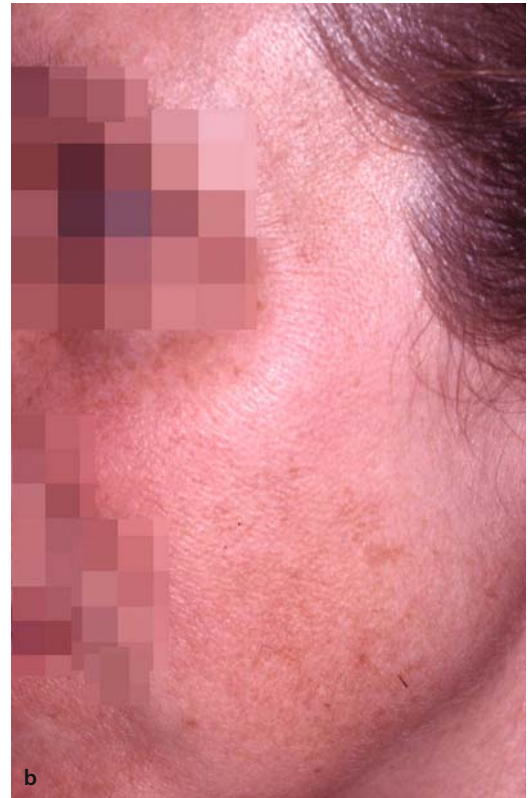
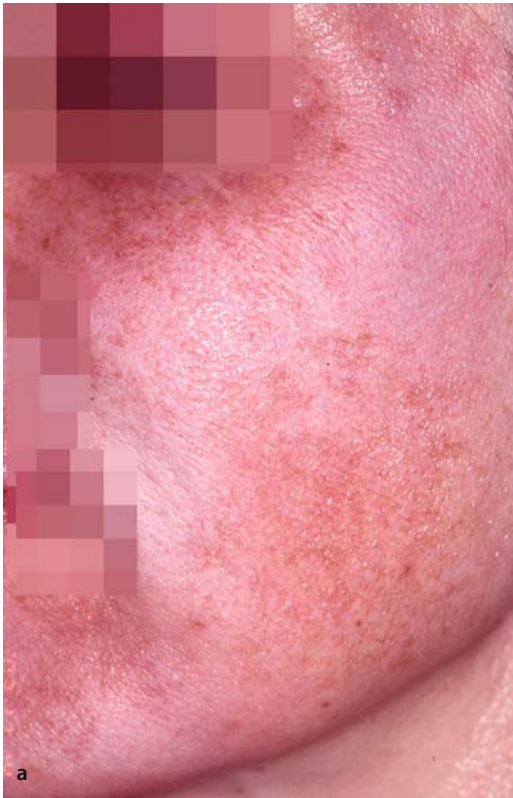
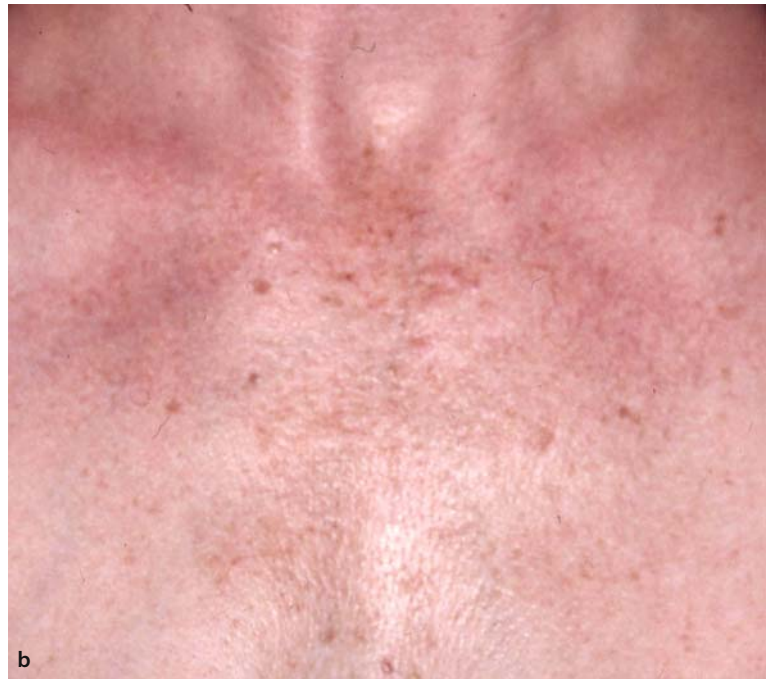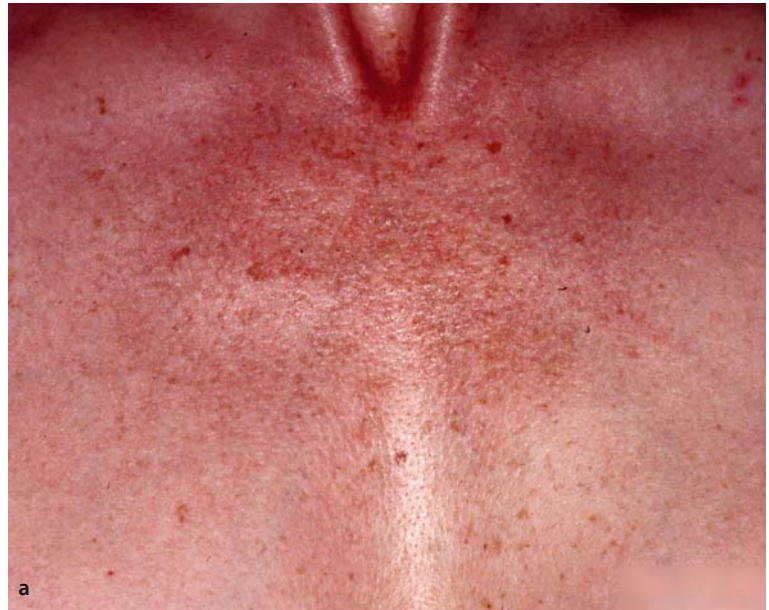Fig. 10.2. **a** Patient with recalcitrant melasma unresponsive to glycolic acid or salicylic acid peels. **b** Responded to combination salicylic acid/TCA peeling

Fig. 10.3. a Patient with photodamage of the chest. **b** Note significant improvement after combination salicylic acid/TCA peel



matitis of the site to be peeled; acute viral infection; pregnancy; isotretinoin therapy within 6 months of peeling; or history of poor or delayed wound healing. Having peeled more than 1,000

patients with salicylic acid, the author has observed no cases of salicylate hypersensitivity from topical peeling.

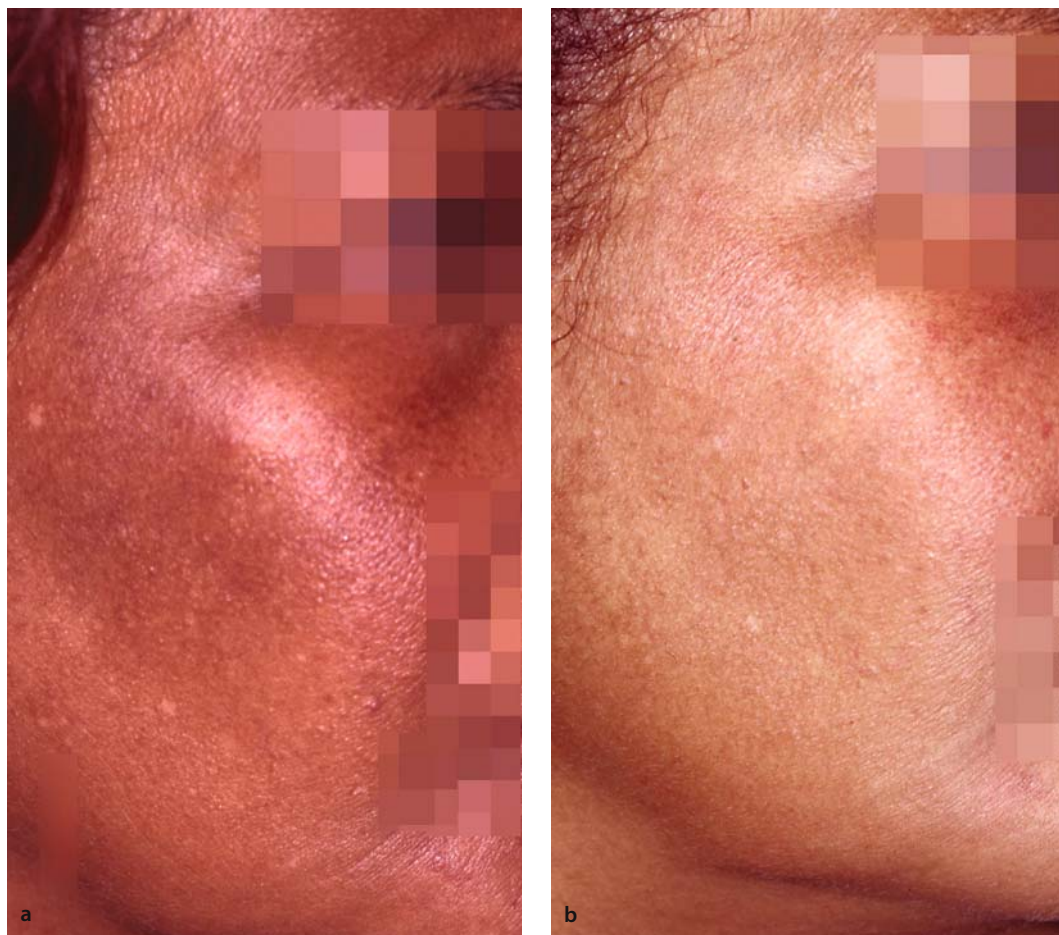

Fig. 10.4. a Facial melasma in skin type III. b Note significant improvement after combination salicylic acid/TCA peel

10.6 Peeling Preparations

A detailed history and cutaneous examination is performed in all patients prior to chemical peeling. The peeling procedure should be explained in depth to the patient including a discussion of the benefits, as well as the risks of the procedure. In addition, standardized photographs are taken of the areas to be peeled, including full frontal and lateral views.

The author has never observed a flare of Herpes following a superficial chemical peel. Hence, pretreatment with antiviral therapy is

usually not indicated. However, one can prophylactically treat with antiviral therapies including valacyclovir 500 mg bid, famciclovir 500 mg bid or Acyclovir 400 mg bid for 7–10 days beginning 1 or 2 days prior to the procedure.

Use of topical retinoids (tretinoin, tazarotene, retinol formulations) for 2 to 6 weeks prior to peeling thins the stratum corneum, reduces the content of epidermal melanin, and expedites epidermal healing. Retinoids also enhance the penetration of the peeling agent. They should be discontinued several days prior to the peeling procedure. Retinoids can be resumed post-operatively after all evidence of

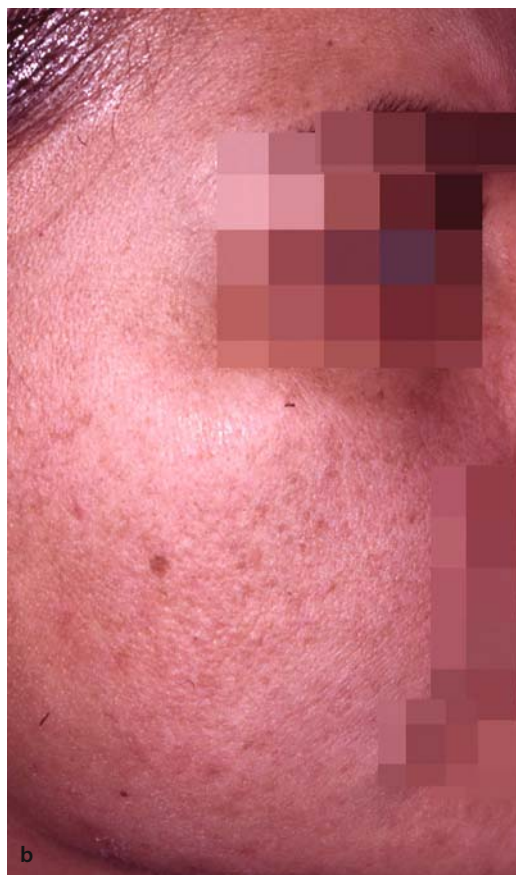
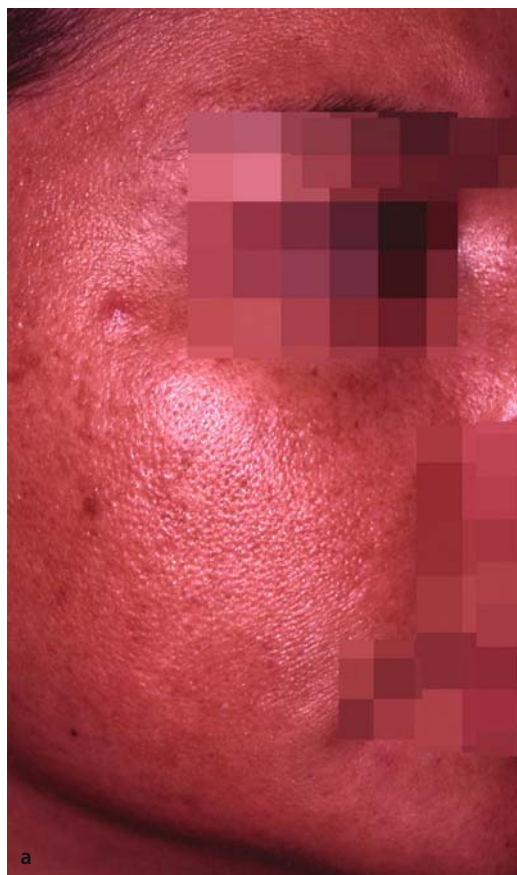
Fig. 10.5. a Patient with facial melasma. b Note improvement after combination salicylic acid/TCA peel

peeling and irritation subsides. When treating conditions such as melasma, post-inflammatory hyperpigmentation, and acne, as well as darker skin types, retinoids should be discontinued one or two weeks before peeling to avoid post-peel complications, such as excessive erythema, desquamation, and post inflammatory hyperpigmentation. The skin is usually prepped for two to four weeks with a formulation of hydroquinone 4% or higher compounded formulations (5–10%) to reduce epidermal melanin. Other topical bleaching agents include azelaic acid, kojic acid, arbutin, and licorice (see photoaging section). Patients can also resume use of topical bleaching agents post operatively after peeling and irritation subsides [7, 8].

10.7 Peeling Technique

After thorough cleansing of the face with alcohol and acetone, two or three coats of salicylic acid (20 or 30%) are applied to the entire face with a 2 × 2 wedge sponge, 2 × 2 gauze sponges, or cotton tipped applicators for 3–5 min. Typically, the cheeks are treated first, applying the peel from medial to lateral areas, followed by application to the chin and forehead. Most patients experience some mild burning and stinging during the procedure. Some patients experience a sensation of peel-related facial anesthesia. Portable hand-held fanning during the procedure substantially mitigates the sensation of burning and stinging.

A white precipitate which represents crystallization of the salicylic acid begins to form at 30 s to 1 min following peel application. This should not be confused with frosting or whitening of the skin, which represents protein agglutination. After 3–5 min the face is thoroughly rinsed with tap water to remove salicylic acid crystals. The face is gently blotted to remove excess water. When treating hyperpigmentation, TCA 10 or 15% is then applied to the areas of hyperpigmentation with a cotton-tipped swab for 2–3 min, producing minimal (Level 1) or no (Level 0) frosting. The face is again rinsed with tap water. If treating photodamage, acne, or texturally rough skin, TCA is applied to the entire face. This protocol usually involves a regimen of two or three combination peels performed at 2- to 4-week intervals.

10.8 Post-peeling Care and Complications

Bland, non-irritating moisturizers and cleansers are used after peeling until all desquamation and/or erythema subsides. Crusting, desquamation, or erythema can be treated with low to high potency steroids for 7–10 days. Given the depth of peeling, the author has observed no cases of scarring or persistent post-peel hyperpigmentation. Any residual post-inflammatory hyperpigmentation has responded to treatment with either hydroquinone 4% or higher strength formulations (5–10%)

10.9 Advantages

The advantages of combination salicylic acid/TCA peeling include:

- Efficacy in all skin types
- Well tolerated in darker racial/ethnic groups
- Most beneficial in treating recalcitrant melasma and post-inflammatory hyperpigmentation

10.10 Disadvantages

- Increased depth of superficial peeling
- Increased desquamation in some patients lasting up to 7–10 days
- Post-inflammatory hyperpigmentation more common than with salicylic acid peeling

10.11 Side Effects

As with salicylic acid peeling, the incidence of side effects is usually low. However, given the combination effects, erythema and desquamation can last longer than the usual changes observed with salicylic acid peels or TCA 10%. In a larger series of 50 patients treated by the author with combination peeling, six patients exhibited mild post-inflammatory hyperpigmentation which resolved within 1–2 weeks after the use of mid to high potency topical steroids.

10.12 Patient's Informed Consent

I, _____, hereby consent to having my _____ (site) treated with CHEMICAL PEELING USING A COMBINATION SALICYLIC ACID 20 AND 30% AND TRICHLOROACETIC ACID 10 OR 15%. The peeling procedure can improve dark spots (hyperpigmentation), photodamage (sun damage), textural roughness, acne, tone, and the overall appearance of the treated area. This combination peeling agent will cause shedding of the outermost layers of the skin. There may or may not be visible peeling. The procedure involves first having the peel site prepped with alcohol, acetone or other pre-peel cleansing agents. The salicylic acid peeling agent is applied first, followed by application of the trichloroacetic acid. The area is rinsed and blotted dry.

You may experience redness, crusting, and flaking of the skin. The effects could possibly

last for 1–2 weeks. In general, the combination salicylic acid/Trichloroacetic acid peel is extremely well tolerated.

I understand that there is a small risk of developing permanent darkening or undesirable pigment loss at the treated site. There is a rare chance that a scar could develop. There is a small risk that a bacterial infection could develop. There is a small chance the peel could also trigger a flare of a pre-existing Herpes infection at the treated site. There is a small chance that the condition being treated could worsen after the peeling procedure. The benefits and side effects of the procedure have been explained to me in detail. All of my questions have been answered.

- I am in stable health.
- I have not used Isotretinoin in the past 6 months.
- I have no allergies to salicylic acid, or trichloroacetic acid.
- I am not pregnant.

Outcomes are not guaranteed.

Signature of Patient

Date

Patient Name (Please Print)

Witness

Date

References

1. Grimes PE (2005) The use of a combination salicylic acid/ trichloroacetic acid 10% chemical peel for treatment of melasma in darker racial ethnic groups. *Dermatol Surg* (in press)
2. Swinehart JM (1992) Salicylic acid ointment peeling of the hands and forearms. Effective nonsurgical removal of pigmented lesions and actinic damage. *J Dermatol Surg Oncol* 18:495–498
3. Lazo ND, Meine JG, Downing DT (1995) Lipids are covalently attached to rigid corneocyte protein envelope existing predominantly as beta-sheets: a solid state nuclear magnetic resonance study. *J Invest Dermatol* 105:296–300
4. Matarasso SL, Glogau RG (1991) Chemical face peels. *Dermatol Clin* 9:131–150
5. Bridenstine JB, Dolezal JF (1994) Standardizing chemical peel solution formulations to avoid mishaps. Great fluctuations in actual concentrations of trichloroacetic acid. *J Dermatol Surg Oncol* 20:813–816
6. Nguyen TH, Rooney JA (2000) Trichloroacetic acid peels. *Dermatol Ther* 13:173–192
7. Rubin MG (1995) *Manual of chemical peels: Superficial and medium depth*. J.B. Lippincott Company, Philadelphia, pp 79–88
8. Brody HJ (1997) *Chemical peeling and resurfacing*, 2nd ed. Mosby, St. Louis, pp 39–71

Part III

How to Choose the Best Peeling for the Patient



Acne

Vincenzo Bettoli, Alessandro Borghi, Maria Pia De Padova, Antonella Tosti

The author has no financial interest in any of the products or equipment mentioned in this chapter.

Contents

11.1	Definition	113
11.2	Epidemiology	113
11.3	Pathophysiology	113
11.4	Clinical Patterns	114
11.5	Clinical Types	119
11.6	Differential Diagnosis	121
11.7	Therapy	122
	References	131

11.1 Definition

Acne is one of the most common skin diseases that physicians see in everyday clinical practice. It is a follicular eruption which begins with a horny impaction within the sebaceous follicle, the comedo. The rupture of the comedo leads to a foreign body inflammatory reaction which clinically presents as papules, pustules and nodules. The morphological expressions of acne are variable. Acne can affect persons of all ages, including neonates, infants and mature adults, being most prevalent and most severe during adolescence. Significant psychosocial disabilities can arise as a consequence of the disease. Patients may frequently experience poor self-image, anxiety, depression and social isolation; employment opportunities also seem to be influenced by the presence of acne. As a consequence, an effective management of acne can have a relevant impact on the acne patient's life.

11.2 Epidemiology

Acne vulgaris typically begins around puberty and early adolescence; it tends to present earlier in females, usually at about 12 or 13 years, than in males, 14 or 15 years, due to later onset of puberty in males. Acne has been estimated to affect 95–100% of 16- to 17-year-old boys and 83–85% of 16- to 17-year-old girls. Acne settles in the vast majority by 23–25 years of age, persisting for longer in some 7% of individuals; 1% of males and 5% of females exhibit acne lesions at 40 years of age. There is a small group of individuals who develop late-onset acne, beyond the age of 25 years.

Acne can present in the neonate, with an incidence that may be around 20%, considering the presence of only a few comedones. Infantile or juvenile acne (acne infantum) typically appears between the age of 3 and 18 months. Males are affected far more than females in a ratio of 4:1. The lesions usually occur on the face and in about 1 in 20 patients on the trunk. Acne infantum seems to be predictive of severer acne in the adolescent period.

11.3 Pathophysiology

The pilosebaceous follicles are the target sites for acne. The pathophysiology of acne centers on interplay of follicular hyperkeratinization, increased sebum production, action of *Propionibacterium acnes* (*P. acnes*) within the follicle, and production of inflammation (Table 11.1).

Table 11.1 Pathophysiology of acne

1. Sebaceous follicle ductal hypercornification
2. Hyperseborrhea
3. Increased number of *P. acnes*
4. Inflammation
(Genetic predisposition)

The earliest morphological change in the sebaceous follicle is an abnormal follicular epithelial differentiation, which results in ductal hypercornification. Cornified cells in the upper section of the follicular canal become abnormally adherent. Comedones represent the retention of hyperproliferating ductal keratinocytes in the duct. Several factors have been implicated in the induction of hyperproliferation: sebaceous lipid composition, androgens, local cytokine production (IL-1, EGF) and bacteria (*P. acnes*).

Sebum has a central role in the pathogenesis of acne; it provides a medium for the proliferation of *P. acnes*. Patients with acne also have seborrhea, a correlation existing between the amount of sebum produced and the severity of acne. In both sexes there is a gradual increase in sebum excretion from puberty, reaching a peak at about the age of 16–20 years. Sebaceous gland activity is under endocrine control and the main stimulus to the sebaceous glands is represented by androgens of both gonadal and adrenal origin. Testosterone and dihydrotestosterone are the two most potent androgens in stimulating sebum production.

P. acnes is an anaerobic diptheroid that populates the androgen-stimulated sebaceous follicles and is a normal constituent of the cutaneous microflora; even if acne is not infectious, the commensal *P. acnes* acts in acne pathogenesis. Three pieces of evidence support the role of *P. acnes* in acne: 1) higher counts of *P. acnes* in individuals with acne than in those without acne; 2) correlation between the reduction of *P. acnes* counts and the clinical improvement of the disease; and 3) correlation between development of acne and presence of antibiotic-resistant *P. acnes* organisms. *P. acnes* products mediate the formation of comedones and contribute to their rupture, leading to extrusion of

comedonal contents. In particular, *P. acnes* produces toxic substances such as free fatty acids, enzymes, including protease, lipase, lecithinase, hyaluronidase, phospholipase and RNase.

The leakage into the dermis of pro-inflammatory cytokines such as IL-1 and TNF-produced by the comedonal cells seems to be the first factor inducing inflammation in acne lesions. Release of pro-inflammatory mediators initiates the upregulation of adhesion molecules on periductal vascular endothelial cells, leading to an accumulation of neutrophils and mononuclear cells. On the other hand, *P. acnes*, producing a number of enzymes and being a potent chemoattractant for neutrophils and mononuclear cells, contributes to the inflammation process development. The initial antigen-independent cutaneous inflammation seems to promote a succeeding antigen-dependent amplification phase via antigen-dependent T-cell responses. *P. acnes* may represent the antigen inducing this cell-mediated response. Interestingly, cutaneous neurogenic factors such as Substance P also contribute to the onset and exacerbation of acne inflammation. Inflammatory infiltration of the pilosebaceous follicle wall causes comedonal disruption and consequent leakage of comedonal material (bacteria, ductal corneocytes and sebum) into the dermis.

Susceptibility to acne is also due to genetic factors. It does not follow Mendelian rules; however, if both parents had severe acne when adolescents, their children are likely to present with clinical acne in puberty. Genetic factors play an important role in determining the size and the activity of sebaceous glands, while exogenous factors such as colonization of *P. acnes* modulate the clinical expression of acne. Racial differences also exist. Caucasians are more prone to severe acne than black people.

11.4 Clinical Patterns

Acne is a polymorphic disease that occurs on the face (99%), back (60%) and chest (15%).

Acne vulgaris is the most common type of acne. The individual lesions of acne vulgaris are divisible into three types: non-inflamed lesions, inflamed lesions and scars (Table 11.2).

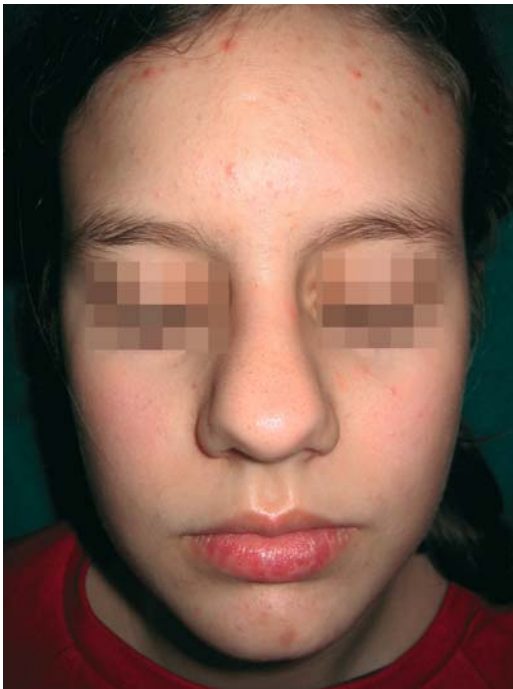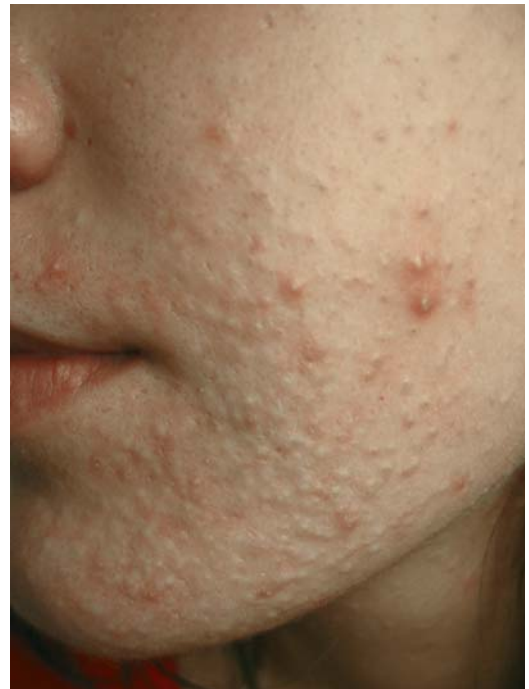Table 11.2 Acne lesions

- | |
|---|
| 1. Non-inflamed lesions |
| Microcomedones |
| Closed comedones (whiteheads) |
| Open comedones (blackheads) |
| 2. Inflamed lesions |
| Papules |
| Pustules |
| Nodules |
| Cysts |
| 3. Scars |
| Atrophic scars (icepick, rolling, boxcar) |
| Hypertrophic scars (keloids) |
| 4. Hyperpigmented macules |

Non-inflamed lesions are called comedones. Comedones may be microscopic (microcomedones) or evident to the eye as blackheads or whiteheads (Figs. 11.1, 11.2). The microcomedo

is an early distention of the follicle by corneocytes, detectable only in histological sections. The closed comedo, whitehead, is the first visible lesion, a firm whitish nodule resembling a milium, 1–2 mm in diameter. Open comedones (blackheads), 5 mm in diameter or even more, are secondary to the dilatation of the orifice by a protruding mass of darkly pigmented horny material. The pigment is mostly oxidated melanin. Closed comedones are more likely to become inflamed.

Most patients have a mixture of non-inflamed and inflamed lesions. Inflamed lesions can be superficial or deep, and arise from non-inflamed lesions. The superficial lesions are usually papules and pustules (5 mm or less in diameter), and the deep lesions are large pustules and nodules. Papules are small, raised, red spots, while pustules are predominantly yellow (Figs. 11.3, 11.4). Pustules frequently start as solid lesions, like papules, which soon liquefy. Usually, the roof of the pustule bursts, allowing the pus to escape. The pustule represents a par-

**Fig. 11.1.** Microcomedonic acne**Fig. 11.2.** White-head comedones

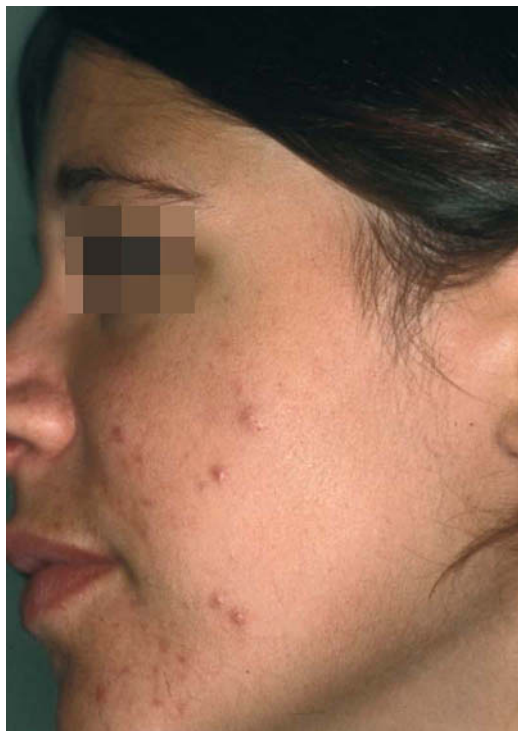

Fig. 11.3. Inflammatory acne: papules and pustules

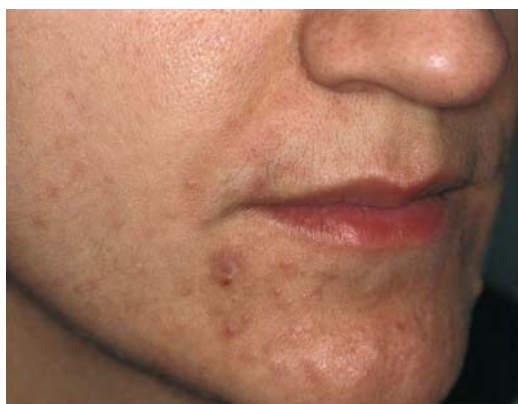

Fig. 11.4. Papulo-pustular acne localized on the chin

tial breakdown of the comedo. Nodules can be classified as small nodules if 5–10 mm and large nodules if greater than 1 cm. Nodules are initially firm, tender and very red. Then, they soften and the overlying skin breaks, producing a hemorrhagic crust. The nodule represents the

total disintegration of a comedo with far-reaching consequences. The dissolution of the adjacent pilosebaceous units propagate the inflammatory reaction and the abscess can reach the subcutaneous tissue (Fig. 11.5); sinus formation between nodules may also occur, with devastating cosmetic effects. The cysts are large, skin-colored, rubbery nodules, 5–20 mm in diameter, occurring mainly on the back and less frequently on the cheeks, especially in the case of acne conglobata (Figs. 11.6, 11.7 and 11.8). Histologically they are not true cysts as they are not lined by an epithelium. In fact, the cysts in acne are a result of repeated ruptures and re-encapsulations, and may be best defined as secondary comedones. Pressure releases a cheesy, crumbly material (corneocytes, hairs, bacteria and sebum).

Nodules are associated with scarring in any case, but even papular or pustular acne lesions can lead to scars. Scars have to be considered a hallmark of acne. Facial scarring affects both sexes equally and occurs to some degree in 95% of cases. Scars that result in a loss of tissue are

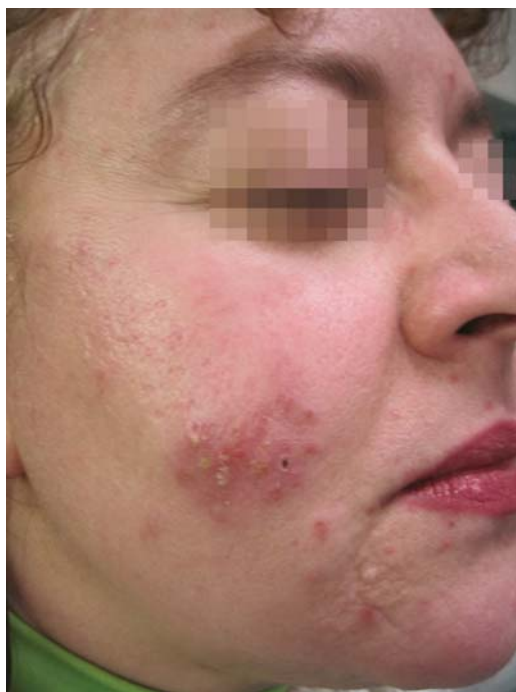

Fig. 11.5. Nodular acne

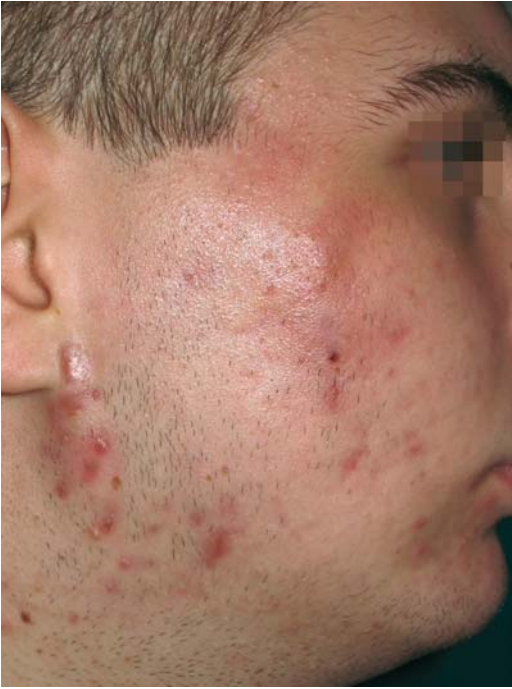

Fig. 11.6. Acne conglobata

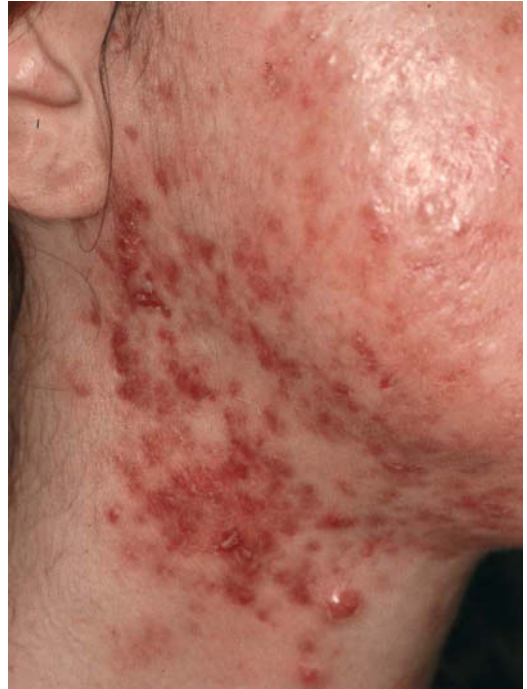

Fig. 11.7. Acne conglobata

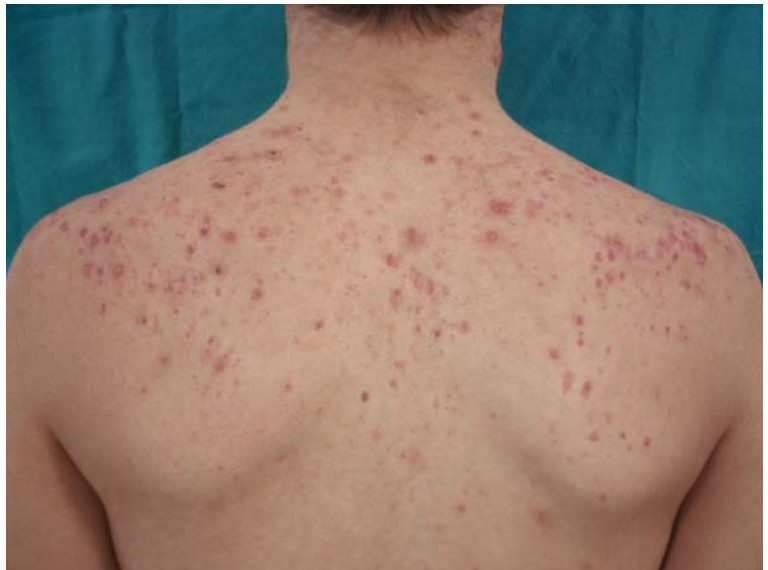

Fig. 11.8. Acne conglobata

the most common type. Atrophic acne scars can be divided into three basic types: icepick, rolling and boxcar.

- Icepick scars are narrow (<2 mm), deep, sharply marginated epithelial tracts that extend vertically to the deep dermis or subcutaneous tissue (Fig. 11.9).
- Boxcar scars are round to oval depressions with sharply demarcated vertical edges, similar to varicella scars (Fig. 11.10). They can be divided into shallow (0.1–0.5 mm) or deep (>0.5 mm).
- Rolling scars, usually wider than 4 to 5 mm, are the result of the abnormal fibrous anchoring of the dermis to the subcutis and give a rolling or undulating appearance to the overlying skin (Fig. 11.11).

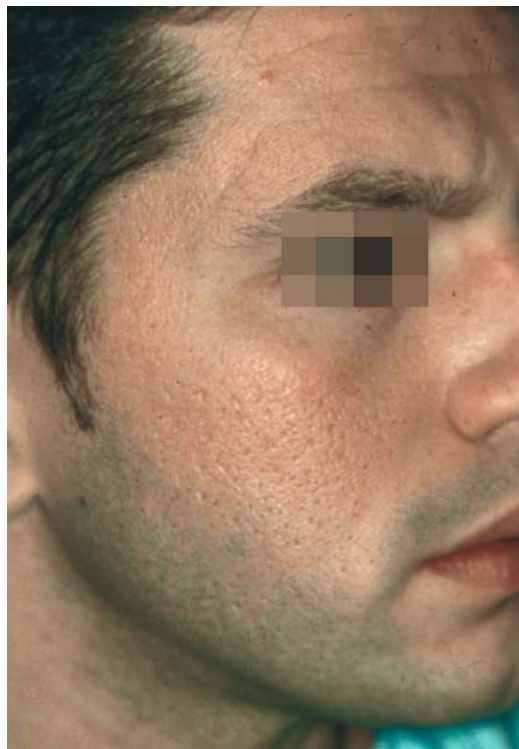

Fig. 11.9. Icepick scars

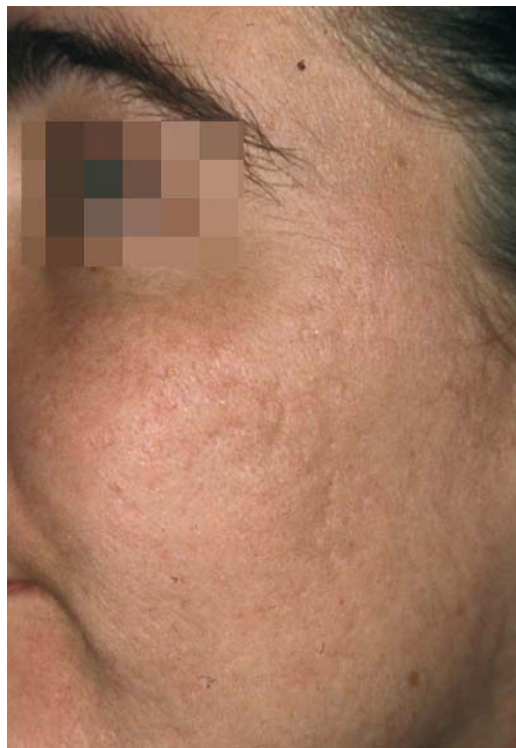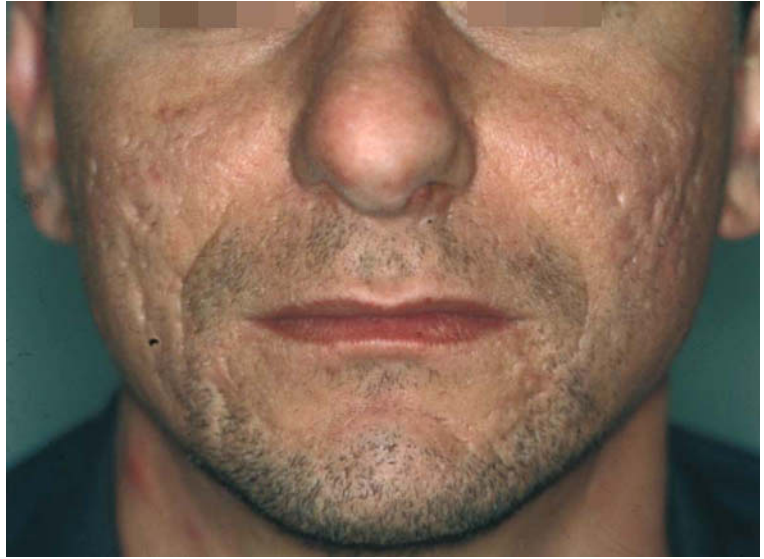


Fig. 11.10. Boxcar scars

Much less commonly, acne scarring may become thickened (hypertrophic or keloidal) rather than atrophic. Hypertrophic scars represent the presence of excessive fibrous tissue with marked vascularization. While hypertrophic scars tend to maintain the same size as the initial inflammatory lesion, keloids extend beyond the dimension of the original acne lesion.

In some patients, hyperpigmented macules may persist following resolution of inflammatory acne lesions. These dark areas have to be considered as healing lesions and not active acne. Post-inflammatory hyperpigmentation generally resolves, even if the resolution time may be very long.

Fig. 11.11. Rolling scars



11.5 Clinical Types

Even though acne vulgaris is the most common type of acne, other forms also exist (Table 11.3). 1) *Acne conglobata* is a chronic, severe form of inflammatory acne, characterized by grouped comedones, cysts, abscesses, draining sinus tracts and scars. 2) *Acne fulminans* is characterized by multiple intensely inflamed nodules, cysts and plaques (Fig. 11.12). Systemic signs and symptoms such as fever, arthralgias, osteo-

Table 11.3 Clinical variants of acne

Acne vulgaris
Acne conglobata
Acne fulminans
Acne excoriée
Acne mechanica
Occupational acne (chloracne)
Drug-induced acne
Acne neonatorum
Acne infantum
Acne in adults

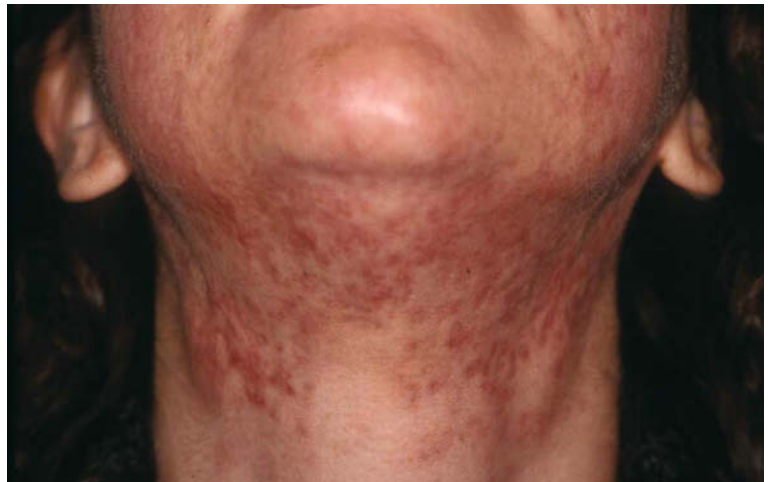

Fig. 11.12. Acne fulminans

lytic lesions of the clavicles or ribs can be present. Sudden onset, usual truncal involvement and failure to respond to antibacterial therapy represent other typical features of this form of acne. 3) *Acne excoriée*, also called “*acne excoriée des jeunes filles*”, is predominantly a disease of young, adult women and almost always involves the face. Picking and scratching lead to exacerbation of lesions, which appear as excoriated areas with inflammation and superficial crusting (Fig. 11.13). 4) *Acne mechanica* is exacerbated by repetitive rubbing or friction over a skin surface, and is most commonly observed with equipment (helmets, shoulder pads and chin straps), or among musicians, as violin and viola players. 5) In *occupational acne*, lesion development is consequent to industrial agents exposure (Fig. 11.14). *Chloracne* represents a well-known variety of occupational acne, almost always being the result of accidental industrial exposure to halogenated hydrocar-

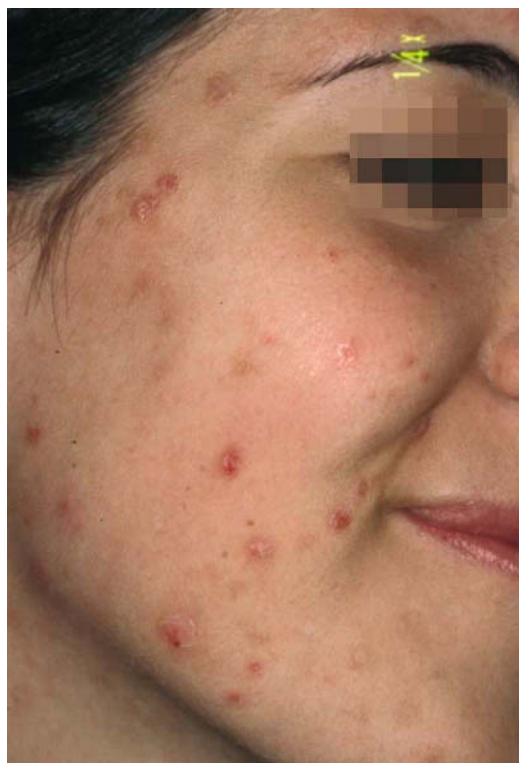

Fig. 11.13. *Acne excoriée*

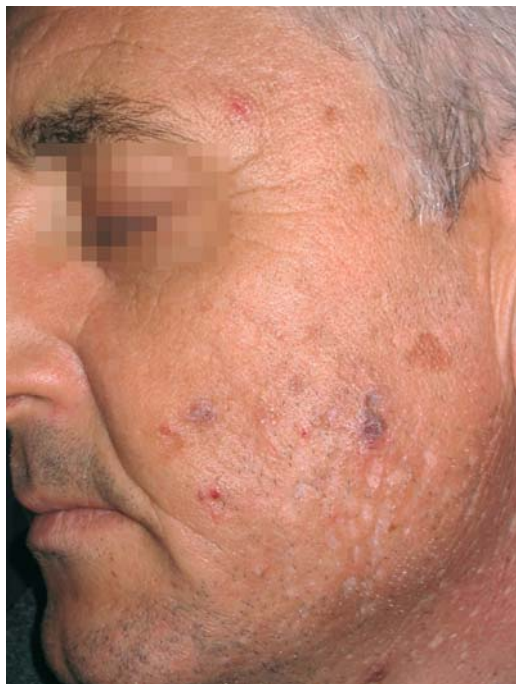

Fig. 11.14. Occupational acne

bons. 6) Acne also can be precipitated or aggravated by certain *drugs*. Androgenic hormones, anabolic steroids, oral and topical corticosteroids, lithium, halogens and radiation therapy are the most common causes of drug-induced acne. 7) *Neonatal acne* (*acne neonatorum*) is clinically characterized by the development of comedones and inflammatory papules and pustules usually affecting the cheeks. It is thought to result mostly from the fetal adrenal gland's androgen production. Neonatal acne generally resolves within the first 3 months of life, but it can persist longer in susceptible individuals. 8) *Infantile acne* (*acne infantum*), usually presenting between the age of 3 and 18 months, is clinically identical to adult acne, even if nodules and deep pustules are uncommon. However, severe forms will lead to scarring both of the hypertrophic and atrophic variety. Patients with infantile acne are otherwise in good health, but if acne presents beyond the age of 2 years or before the age of 7 years, the possibility of a significant endocrinopathy has to be considered. 9) *Adult acne*, particularly in

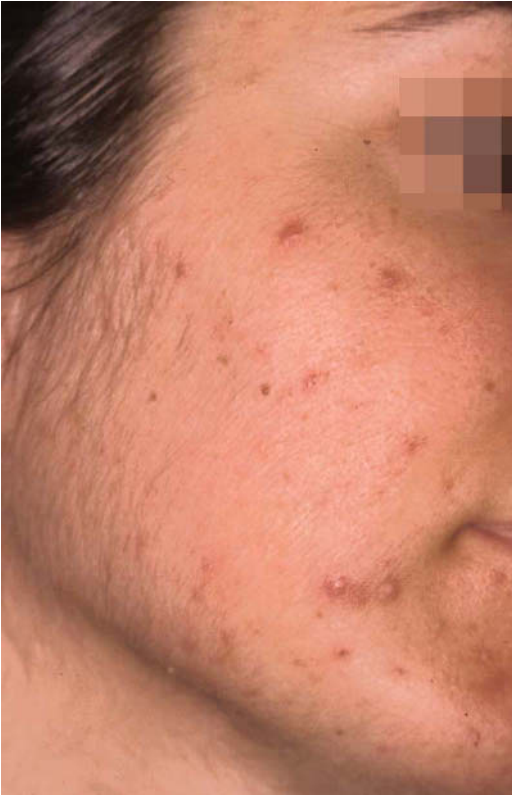

Fig. 11.15. Acne and hypertrichosis in a patient with hyperandrogenism

females, is of special note. Exact prevalence is not known, but it is estimated that one third of adult women seen in practice have a persistent low-grade acne. Originally, it was thought that post-adolescent acne was due to acnegenic substances in cosmetics and skin care products, but cosmetics do not account for most of the cases of this form of acne. The etiology remains not understood. A sudden onset of severe acne in an adult woman and acne accompanied by clinical signs of hyperandrogenism require some investigation to rule out an underlying endocrine abnormality (Fig. 11.15).

11.6 Differential Diagnosis

Acne is rarely misdiagnosed. Occasionally, however, there is ambiguity. The term *acnei-*

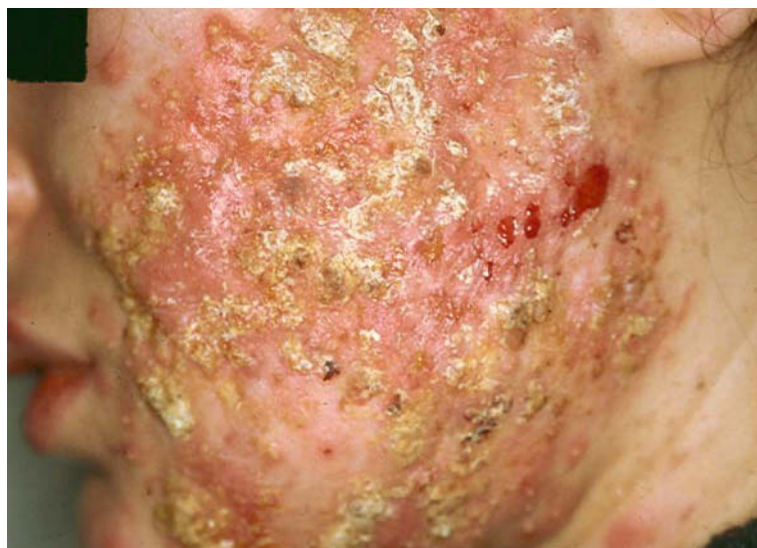form eruption denotes conditions resembling acne, which are almost always drug induced. Like acne, acneiform eruptions originate in sebaceous follicles, the initial lesions are inflammatory, typically papules and pustules, while comedones are always secondary lesions. These eruptions are independent of age, sudden in onset, monomorphous in their appearance and have typical localizations. Systemic signs of drug toxicity may occur. Acneiform eruptions clear with drug discontinuation. Corticosteroids, both systemic and topical, are potent acnegenes, but also aminopterin, phenytoin, lithium, PUVA, phenobarbitone, thiourea, thiouracil, iodides, bromides, and disulfiram can induce acneiform eruptions. In most cases, the pathogenesis is unknown. In general, drugs that cause acneiform eruptions can also exacerbate pre-existing acne.

Rosacea is a chronic disorder affecting the central parts of the face, characterized by flushing, persistent erythema and teleangiectasia. Inflammatory papules and pustules can develop within the areas of erythema. Rosacea typically occurs in adults with fair skin and light eye and hair color. In contrast to acne, rosacea is not typically follicular in nature and comedones and seborrhea are usually absent. Pyoderma faciale is deemed to be an explosive form of rosacea, often occurring in young women with a phenotype typical of rosacea patients, often in the context of stress (Fig. 11.16).

Perioral dermatitis is characterized by erythema, scaling and small papules and pustules symmetrically distributed around the mouth, sometimes extending to the nasolabial folds and the cheeks. This condition typically occurs in females 20–40 years of age. Topical corticosteroids can exacerbate the disease and should be avoided.

Gram-negative folliculitis is characterized by the sudden development of superficial pustules in patients suffering from long-standing acne, rosacea or folliculitis treated with oral or topical antibiotics. The long-term use of antibiotics creates an ecological imbalance of microbial flora, with suppression of the gram-positive resident organisms. A variety of gram-negative bacteria are involved, including *Pseudomonas* and Enterobacteriaceae.

Fig. 11.16. Pyoderma faciale



Folliculitis caused by colonization with *S. aureus* or *S. epidermidis* on the face can be sometimes misdiagnosed as acne. The prominent lesions are superficial follicular pustules that are often distributed on the lateral cheeks, the chin and the temporal sites of the forehead. The rare folliculitis due to *Candida* may also present as multiple pustular eruptions.

11.7 Therapy

Topical therapy may be useful 1) in the management of mild acne; 2) in combination with oral therapy in moderate to severe forms, with more inflammation and a tendency to scar; and 3) as maintenance treatment (Tables 11.4 and 11.5). Choice of topical agents depends upon acne variety. For comedonal acne, antimicrobogenic agents are indicated, whereas antibacterial agents are required in inflammatory acne. Retinoids, azelaic acid, salicylic acid, and benzoyl peroxide are effective for comedones. Benzoyl peroxide, azelaic acid and topical antibiotics such as erythromycin and clindamycin are most effective in reducing inflammatory lesions. Antibiotics act both as bacteriostatic/bactericidal on *P. acnes* and as direct anti-inflammatory agents. Inhibition of *P. acnes* growth indirectly reduces inflammation. Anti-

biotics currently used are tetracyclines, macrolides (erythromycin) and clindamycin. Topical antibiotics are indicated in the treatment of inflammatory acne, particularly milder forms and are available in a variety of vehicles such as creams, lotions, ointments, gels and solutions. Antibiotics have been formulated in combination with other anti-acne agents such as benzoyl peroxide and topical retinoids. The principal side-effect of topical antibiotics is the induction of bacterial resistance. Combination with benzoyl peroxide increases the bactericidal effect of the antibiotics, while reducing the risk of bacterial resistance development.

Topical retinoids acting on gene transcription regulate cell proliferation and differentia-

Table 11.4 Topical treatment

Topical drug	Main effects
Antibiotics (macrolides, clindamycin, tetracyclines)	<i>P. acnes</i> suppression Indirect anti-inflammatory
Retinoids	Comedolysis Direct anti-inflammatory
Benzoyl peroxide Azelaic acid	<i>P. acnes</i> suppression Antibacterial

Table 11.5 Topicals for acne

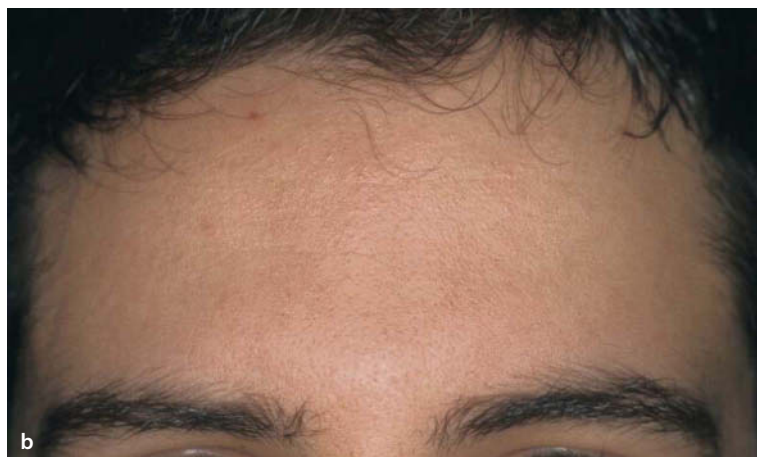
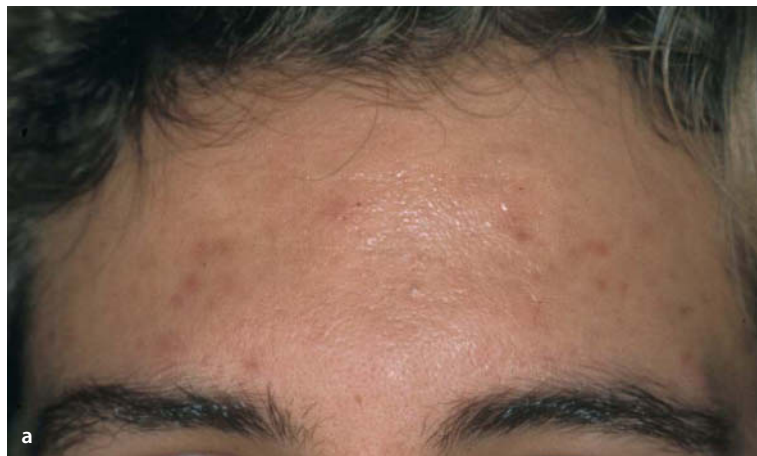
Comedonal acne			
Topical retinoids			
Retinoic acid	Cream, gel, liquid	0.01%, 0.02%, 0.025%, 0.04%, 0.05%, 0.1%	o.d.
Isotretinoin	Gel, cream	0.05%	o.d.
Adapalene	Cream, gel	0.1%	o.d.
Tazarotene	Cream, gel	0.05%, 0.1%	o.d.
Inflammatory acne			
Antibiotics			
Erythromycin	Cream, gel, solution	2%, 3%, 4%	o.d., b.i.d.
Clindamycin	Gel, lotion, solution	1%	o.d., b.i.d.
Benzoyl peroxide	Cream, gel	3%, 4%, 5%, 10%	o.d.
Azelaic acid	Cream, gel	15%, 20%	o.d., b.i.d.
Sodium sulfacetamide 10% (+ sulfur 5%)	Lotion, gel, pads	–	o.d., b.i.d.
Hydrogen peroxide	Cream	1%	o.d, b.i.d.
Combination of topicals			
Benzoyl peroxide 5% + erythromycin 3%	Gel	–	o.d., b.i.d.
Benzoyl peroxyde 5% + clindamycin 1%	Gel	–	o.d., b.i.d.
Isotretinoin 0.05% + erythromycin 2%	Gel	–	o.d., b.i.d.
Retinoic acid 0.025% + clindamycin 1%.	Gel	–	o.d, b.i.d
Retinaldehyde 0.1% + glycolic acid 6%	Cream	–	o.d, b.i.d.
Detergents			
Benzoyl peroxide	Creamy wash	4%, 5%, 8%, 10%	o.d., b.i.d.
Salicylic acid	Solution	2%	o.d., b.i.d.

o.d.: once & day; b.i.d.: twice a day (bi in die)

tion and to a lesser extent inflammation, they also prevent microcomedonal formation and resolve mature comedones leading to: a) reduced production of keratohyalin granules by follicular keratinocytes, and b) inhibition of corneocytes accumulation and cohesion, increasing in this way infundibular keratinocytes turnover. Retinoids, particularly adapalene, possess some anti-inflammatory activities, though they do not have a direct antibacterial effect. Tretinoin, the first topical retinoid used in acne, is available as a cream, gel or solution in a variety of concentrations. It has recently be-

come available in new formulations such as microsponges or propylpolymers in order to minimize irritation. Adapalene is a naphthoic acid derivative with retinoid-like activity. Adapalene has been demonstrated to be equally effective as tretinoin, but better tolerated than the latter (Fig. 11.17a, b). It is available as gel, cream and solution. Isotretinoin is an alternative preparation with similar properties to tretinoin. It is available as cream or gel, either alone or in combination with topical antibiotic (erythromycin, clindamycin). Tazarotene is a synthetic acetylenic retinoid authorized in psoriasis and

Fig. 11.17a, b.
Patient with mild acne
treated with topical
tretinoin



acne. Formulated into a topical gel, it is active on cell proliferation, cell differentiation and inflammation. Although epidemiological studies haven't demonstrated an increased risk of birth defects in infants whose mothers used topical retinoids during pregnancy, their use during pregnancy is not recommended due to their teratogenic potential.

Benzoyl peroxide exercises a potent antimicrobial activity through the release of free oxygen radicals. It suppresses *P. acnes* in sebaceous follicles much faster than antibiotics, leading to a rapid reduction of the inflammatory lesions number. *P. acnes* does not develop resistance to benzoyl peroxide, which maintains its efficacy after years of use. Benzoyl peroxide seems to have a mild comedolytic effect while it is not

sebosuppressive. It often induces skin irritation, but a true allergic contact dermatitis is very rare. Benzoyl peroxide is available in different formulations such as gels, creams, lotions, and soaps as well as in some combination products.

Azelaic acid is effective on *P. acnes* suppression, even if less than benzoyl peroxide. The anti-inflammatory effect of azelaic acid seems to be related to a decreased production of reactive oxygen species by neutrophils. Azelaic acid may also regulate the ductal cell keratinization, reducing the number of comedones. It is not sebosuppressive.

Chemical peels are usually considered as an adjunct to the basic treatment of acne vulgaris.

Table 11.6 shows types of peels used to treat acne and their indications. Unfortunately there are no conclusive clinical trials comparing chemical peels with standard acne therapy in terms of efficacy and tolerability.

In case of acne scarring, chemical peels are useful to treat superficial scars and to improve

medium-depth scars. In our experience the best option is the combined peel with 25% salicylic acid lotion and 25–30% TCA gel because the sequential use of two agents allows the application of low concentrations of TCA with maximum benefits and minimal side effects (Figs. 11.18a, b).

Table 11.6 Chemical peels for acne

Type	
Glycolic acid 70%	GA
Jessner's solution	JS
Salicylic acid 25%	SA
Pyruvic acid 40–70%	PA
Trichloroacetic acid 25–50% lotion	TCA-l
Trichloroacetic acid 25–30% gel	TACA-g
Unna paste (resorcin 40%)	U P-R
Phenol 45–80%	P
Indications	
Acute phase	
Comedonal acne	GA, JS, SA, PA, UP-R [1, 2, 3, 4, 5, 6, 7, 8, 9, 10, 11, 12, 13, 14, 15] UP-R [16]
Mild/moderate inflammatory acne	SA [1, 2, 3, 9, 14, 17] PA [1, 18] GA, JS [5, 6, 7, 8, 10, 17] UP-R [7, 8]
Severe nodulo-cystic acne	PA [1]
Superficial post-acneic scars	PA, TCA-l, SA+TCA-g [19]
Medium-deep post-acneic scars	P, TCA-l >40%
Frequency of application	
GA	3–6 times every 1–2 weeks [5, 11]
JS	3 times every 2 weeks [5]
SA	3–8 times every 2–4 weeks [1, 2, 3]
PA	3–8 times every 2–4 weeks [1, 15]
SA+TCA-g	5 to 6 times every 4–5 weeks
P	1 treatment
Advantages	
	SA: safety and efficacy in darker phototypes (Fitzpatrick V–VI) [4] Possible association with other substances such as TCA-g and PA to improve their absorption [1] Easier to manage than GA in terms of uniformity of application [1] SA and PA better than GA and JS in terms of risk of side effects and patient discomfort during treatment [1] GA better than JS: equal treatment effect but lesser degree of exfoliation in GA [5]

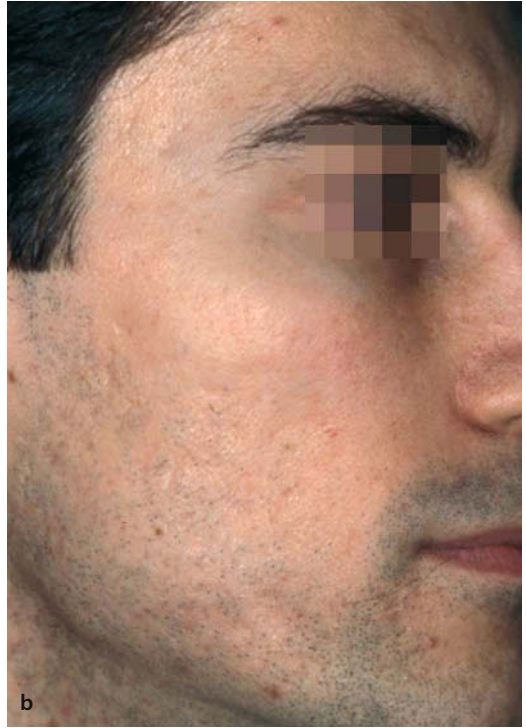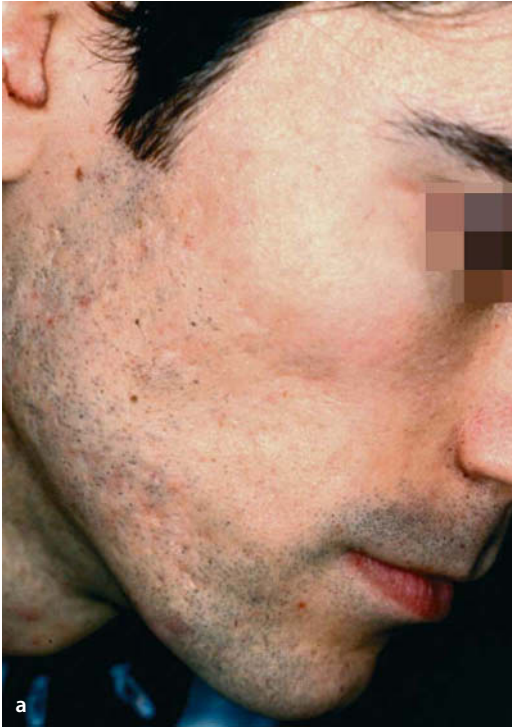


Fig. 11.18. Acne scarring treated with combined peel

11

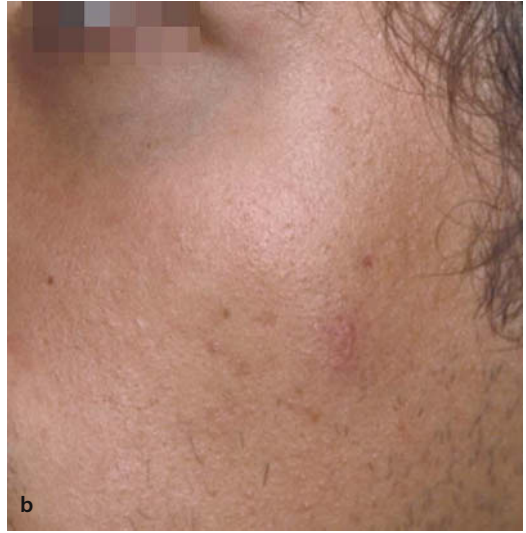
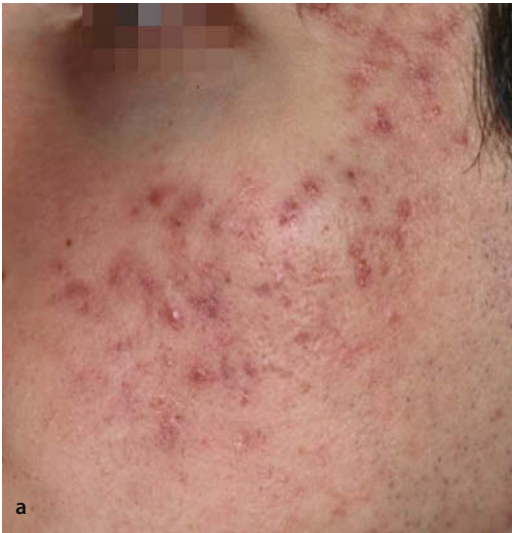
Fig. 11.19. Papulo-pustular acne and scarring treated with combined peel

For medium and deep scars other treatments are available (Table 11.7).

Systemic therapy for acne includes antibiotics, isotretinoin and hormones (Tables 11.8 and 11.9). Oral treatment is indicated in cases of: 1) moderate and severe acne; 2) acne with tendency to scars development; and 3) psychological distress related to acne.

Systemic antibiotics are indicated for moderate-severe inflammatory acne not responding to topical treatments. Systemic antibiotics act on: 1) suppression of *P. acnes* growth; 2) inhibition of bacterial lipases; 3) reduction of free fatty acids; and 4) reduction of inflammation. Oxytetracycline and its derivatives are the most commonly used oral antibiotics. Second-generation tetracyclines such as minocycline, doxycycline and lymecycline present longer half-lives, enhanced bacterial activity and lower

toxicity compared with the first generation ones. Minocycline (100–200 mg daily), doxycycline (100–200 mg daily) and lymecycline (150–300 mg daily) are equally effective, while lymecyclines seems to have a lower side-effect profile. Antibiotics have to be given for prolonged periods of time; however, if a good response is not obtained after 3 months of treatment, an alternative therapy has to be kept in consideration. Side effects of tetracyclines include gastrointestinal symptoms, vaginal candidiasis, dizziness, phototoxicity (doxycycline) and pseudotumor cerebri, autoimmune disorders and pigmentation (minocycline). In patients allergic to tetracyclines or in females contemplating pregnancy, erythromycin represents an acceptable alternative. The third-line treatment is oral trimethoprim. The increasing *P. acnes* resistance to antibiotics, mostly macro-

Table 11.7 Treatment options for medium-deep post-acneic scars

Before treating a patient with acne scars always obtain information regarding oral isotretinoin use in the last year, history of keloids or hypertrophic scars. This will avoid further scarring and side effects.	
Excision [20]	Useful with icepick and narrow-deep boxcar scars that are excised with a 1.5-mm punch biopsy and sutured with a 6.0 or smaller suture. Nonabsorbable sutures are preferred to avoid inflammation and must be removed within 5 days.
Elevation [20]	Useful with wide-shallow boxcar scars associated with laser resurfacing. It is made with different biopsy punch, according to the size of the scar. The scar is first excised and then the punched specimen is elevated higher than the surrounding skin and fixed with a suture.
Subcision [20]	Useful for rolling scars to free the fibrous bands that cause the scar. It is performed with a 18-gauge triangular tip needle that reaches the subcutaneous tissue and separates the fibrous cords. Once it is inserted through the dermal-subcutaneous junction plane, it is turned with the tip parallel to the skin surface. A piston-like motion is then used to release the fibers
Laser resurfacing [20]	Useful with shallow boxcar and rolling scars. CO ₂ and/or Er: YAG lasers are utilized for this technique. After the treatment, silicone sheeting, gauze and tube netting are placed over the treated area and maintained for 24 h (the silicone sheeting remains for another 48 h). The patient is instructed to soak the treated area every 2–4 h with cold water for 20 min and then apply an occlusive ointment. Re-epithelialization is completed in 10 days. A new treatment can be performed after 6–8 weeks.
Laser therapy [21]	Laser therapy deals only with superficial scars. Different lasers are reported in the literature to be effective (diode, Nd: YAG, pulsed Dye) even if they could have adverse effects such as hypo/hyperpigmentations.
Dermabrasion [22]	Gentian violet solution is used to delineate the areas to be treated. Refrigerant topical anesthesia is used to freeze the skin prior to the procedure. Holding the skin taut, the dermabrader treats one anatomic unit at a time. Post-operatively, patients may have an open or closed dressing system, use antiviral agents, antibacterials and corticosteroids. The re-epithelialization is complete in 5–7 days and residual erythema is common for up to 4 weeks.

Table 11.8 Systemic treatment

Systemic drug	Main effects
Antibiotics (Tetracyclines, Macrolides)	<i>P. acnes</i> suppression Anti-inflammatory
Isotretinoin	Sebum suppression Comedolysis Anti-inflammatory <i>P. acnes</i> suppression
Hormones	Sebum suppression

lides (erythromycin) and lincosamides (clindamycin) represents an important problem, to be suspected in cases of clinical response failure. Combining systemic antibiotics with topical retinoids provides more rapid efficacy, while the concurrent use of benzoyl peroxide reduces the risk of resistant *P. acnes* strains development.

Oral Isotretinoin (13-cis-retinoic acid) efficacy is based on its specific actions against all four factors implicated in acne pathogenesis. Isotretinoin targets are 1) sebum suppression;

2) comedolysis (normalization of follicular epithelial desquamation); 3) anti-inflammatory effect; and 4) *P. acnes* reduction ensuing to sebum suppression. Indications for systemic isotretinoin treatment are a) severe nodulo-cystic acne; b) acne unresponsive to conventional systemic antibiotic therapy; c) acne relapsing during or after conventional therapy; d) scarring acne; and e) severe psychological disability related to acne. The drug is usually administered at a daily dosage of 0.5 mg/Kg, until a total cumulative dose of 100–150 mg/Kg has been attained. A starting dosage lower than 0.5 mg/Kg/day with a gradual increase until the highest tolerable dosage reduces the risk of a severe flare of acne. Higher doses are associated with faster responses, but also with troublesome side effects. Isotretinoin treatment achieves a complete acne clearing in a large proportion of patients, while a further course is rarely required (Figs. 11.20a–d and 11.21a–d). Side effects of isotretinoin include first of all teratogenicity, mucocutaneous problems, ocular dryness, musculoskeletal symptoms, hyperostosis and DISH, headache, elevation in sebum tryglicerides and liver enzymes. Monitoring of liver function

Table 11.9 Systemic drugs for acne

	Daily dose	Duration
Mild/moderate acne		
Antibiotics: tetracyclines		
Tetracycline hydrochloride	1 g	3–4 months
Oxytetracycline	500 mg	3–4 months
Limecycline	150, 300 mg	3–4 months
Doxycycline	50, 100 mg	3–4 months
Minocycline	50, 75, 100 mg	3–4 months
Antibiotics: macrolides		
Erythromycin	1–2 g	3–4 months
Clarythromycin	250–500 mg	3–4 months
Azythromycin	500 mg	3–4 months
Hormonal therapy: contraceptive pill		
Cyproterone acetate	2–50 mg	6 months
Spironolactone	100 mg	6 months
Flutamide	125–250 mg	6 months
Severe nodulo-cystic acne		
Oral isotretinoin	0.5–1 mg/day	4–6 months

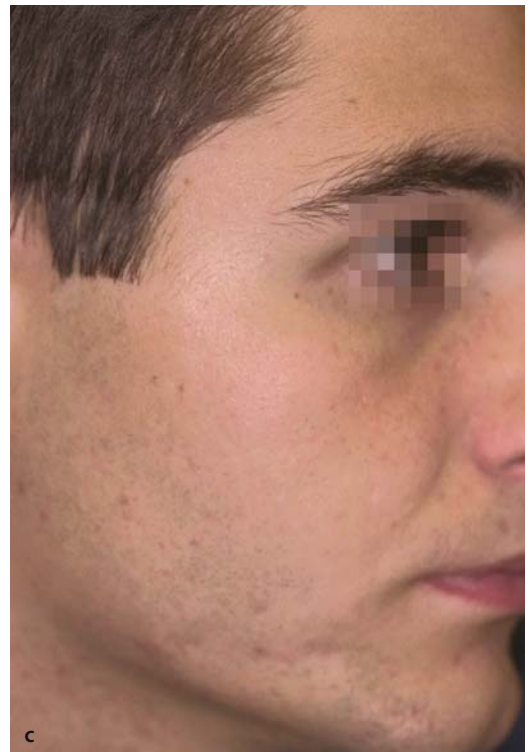
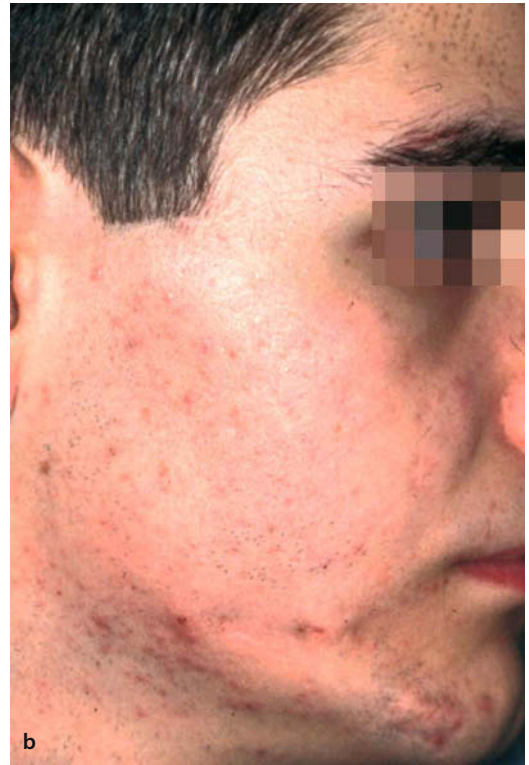
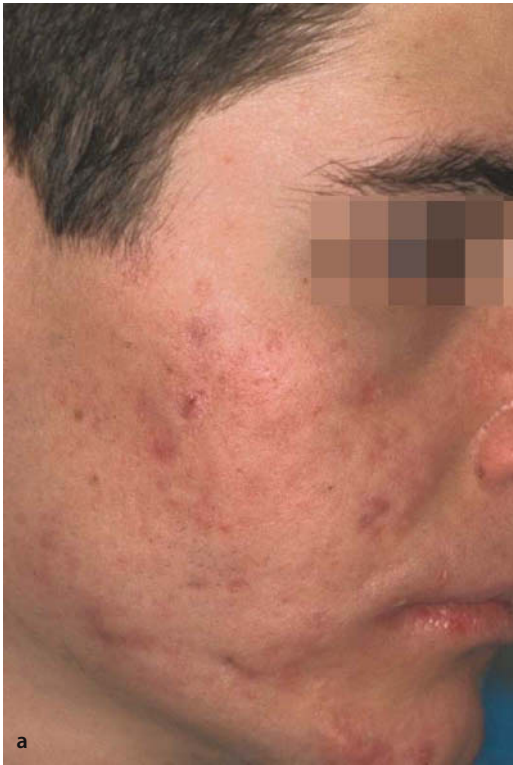

Fig. 11.20a-c. Improvement of papulo-pustular acne (a) after 3 sessions of 25% TCA peeling (b, c). This patient has been treated with oral isotretinoin 6 months before peeling procedure.

Fig. 11.20d. Cheilitis during isotretinoin treatment

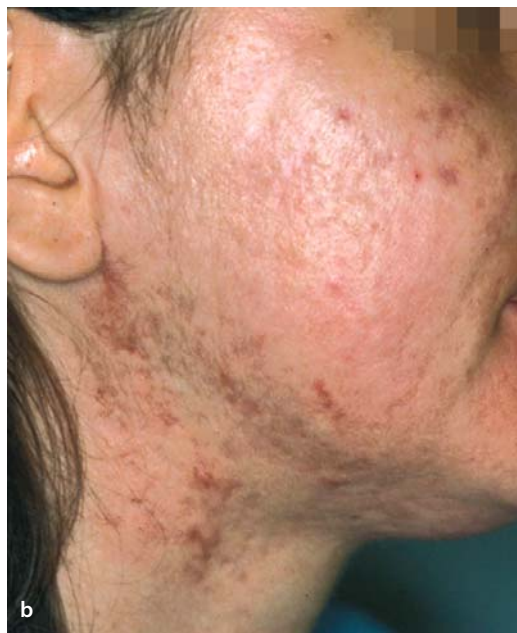
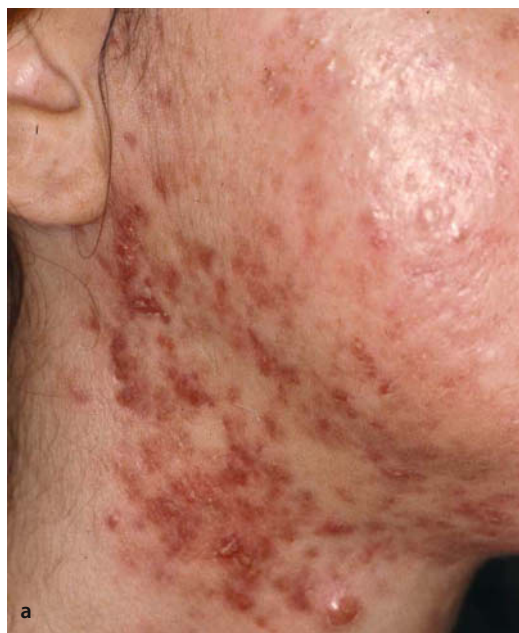
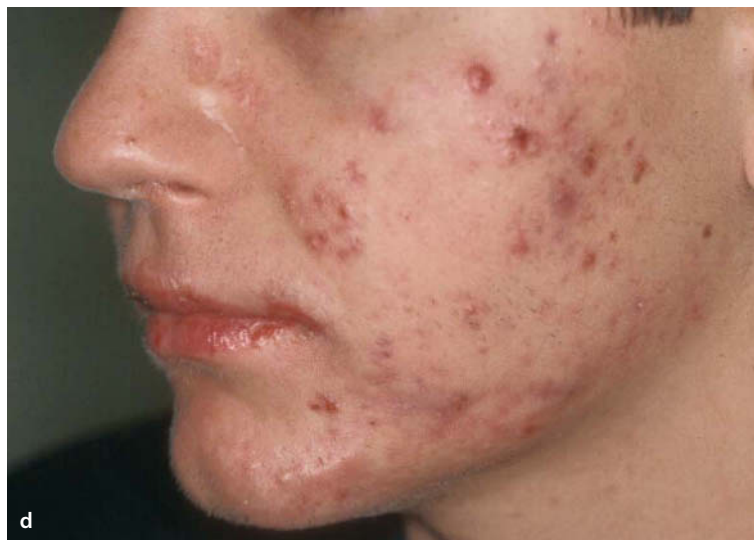Fig. 11.21a, b. Improvement of papulo-pustular acne (a) after 3 sessions of 25% TCA peeling (b). This patient has been treated with oral isotretinoin 6 months before peeling procedure.

tests and lipid profile is suggested before starting and during isotretinoin treatment.

Hormonal therapy can be an effective treatment in females affected by inflammatory acne. Different varieties of hormonal therapies are

available. Oral estrogens are used due to their anti-acne effect by decreasing the level of circulating androgens and increasing sex-hormone-binding protein. In contraceptive pills estrogens are administered as a combination with

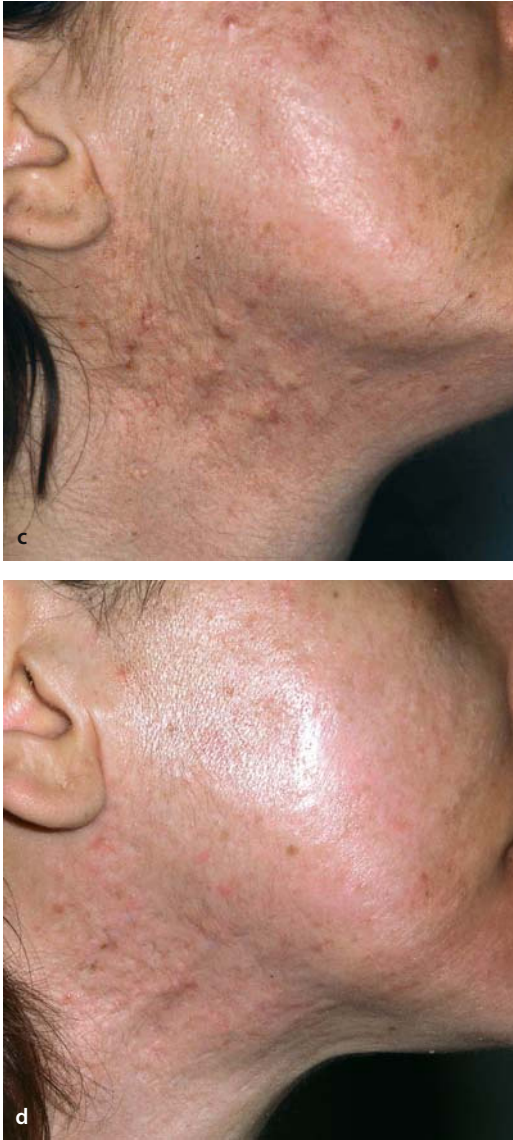

Fig. 11.21c, d. Improvement of papulo-pustular acne (c) after 3 sessions of 25% TCA peeling (d). This patient has been treated with oral isotretinoin 6 months before peeling procedure.

progestins. The most used estrogenic component is largely ethinyl estradiol. Second-generation progestins (ethynodiol diacetate, norethindrone, levonorgestrel) and third-generation progestins (desogestrel, norgestimate, gestodene) have a lower androgenic activity than

first-generation progestins. Inflammatory lesions, scarring and severe seborrhea can suggest the administration of the combination oral estrogen/progestin in women. The improvement is usually slow.

Cyproterone acetate (CPA) is a progestational antiandrogen that blocks the androgen receptors. It is combined with ethinyl estradiol in an oral contraceptive formulation, which is indicated in female acne patients with a high level of seborrhea, therapy resistant papulo-pustular acne or acne conglobata not responding to other treatments.

Spirolactone is an antiandrogen which blocks androgen-receptors, alters steroidogenesis by adrenals and gonads and inhibits 5- α reductase. In doses of 100–200 mg daily it reduces sebum production and improves inflammatory acne in women. During treatment, birth control measures are required due to the risk of male fetus feminization.

References

- Ghersetich I, et al (2002) Peeling per l'acne. In: Lotti TM (ed) *L'acne: nuovi concetti e nuove terapie*. UTET, pp 171–177
- De Padova MP, et al (2002) Peeling all'acido salicilico nel trattamento dell'acne: la nostra esperienza. *G Ital Dermatol Venereol* 137: 31–36
- Zerbinati N, et al (1999) Peeling all'acido salicilico. *Medicina estetica. Salus*, pp 443–451
- Grimes PE (1999) The safety and efficacy of salicylic acid chemical peels in darker racial-ethnic groups. *Dermatol Surg* 25: 18–22
- Seok WK, et al (1999) Glycolic acid versus Jessner's solution: which is better for facial acne patients? *Dermatol Surg* 25: 270–273
- Monti M (1998) Il peeling chimico. In: Cortina R (ed) *Manuale di Dermocosmetologia Medica*. pp 919–945
- Ghersetich I, et al (1997) Chemical peeling: how, when, why? *JEADV* 8: 1–11
- Ghersetich I, et al (1999) Chemical peeling. In: Katsambas AD, Lotti T (eds) *European handbook of dermatological treatments*. Springer, Berlin, Heidelberg, New York
- Kligman D (2001) Technologies for cutaneous exfoliation using salicylic acid. *Dermatologic Therapy* 14: 225–227
- Murad H, et al (1995) The use of glycolic acid as a peeling agent. *Dermatologic Clinics* 13: 285–307

11. Van Scott EJ, Yu RJ (1989) Alpha hydroxy acids: procedures for use in clinical practice. *Cutis* 43: 222–228
12. Stagnone JJ (1989) Superficial peeling. *J Derm Surg Oncol* 15: 924–930
13. Brody HJ (1992) *Chemical peeling*, 1st ed. Mosby
14. Kligman D, Kligman AM (1997) Salicylic acid as a peeling for the treatment of acne. *Cosmetic Dermatology* 10: 44–47
15. Brody HJ (1997) *Chemical peeling and resurfacing*, 2nd ed. Mosby
16. Cerullo F, Piazza P (1979) Il peeling chimico nella terapia dell'acne. *Cronica Dermatologica* 3: 439–444
17. Roberts WE (2004) Chemical peeling in ethnic/dark skin. *Dermatologic Therapy* 17: 196
18. Cotellessa C, et al (2004) The use of pyruvic acid in the treatment of acne. *JEADV* 18: 275
19. Al-Waiz MM, et al (2002) Medium-depth chemical peels in the treatment of acne scars in dark-skinned individuals. *Dermatol Surg* 28: 383–387
20. Jacob CI, et al (2001) Acne scarring: a classification system and review of treatment options. *J Am Acad Dermatol* 45: 109–117
21. Jemec GBE, et al (2004) Acne: treatment of scars. *Clin Dermatol* 22: 434–438
22. Gold MH (2003) Dermabrasion in dermatology. *Am J Clin Dermatol* 4: 467–471

Actinic Keratosis

Ilaria Ghersetich, Benedetta Brazzini, Maria Pia De Padova, Antonella Tosti

The author has no financial interest in any of the products or equipment mentioned in this chapter.

Contents

12.1	Definition	133
12.2	Etiology	135
12.3	Clinical Types	135
12.4	Histopathology	136
12.5	Diagnostic Criteria	136
12.6	Differential Diagnosis	136
12.7	Therapy	136
12.8	Management of the Patient	138
	References	138

12.1 Definition

Actinic keratoses are the most common epithelial precancerous lesions which occur primarily on sun-exposed skin of middle-aged and elderly people as multiple erythematous macules or papules with a dry adherent scale (Figs. 12.1, 12.2 and 12.3).

Actinic keratosis of the lip is known as *actinic cheilitis*; it usually affects the lower lip, which is more sun-exposed.

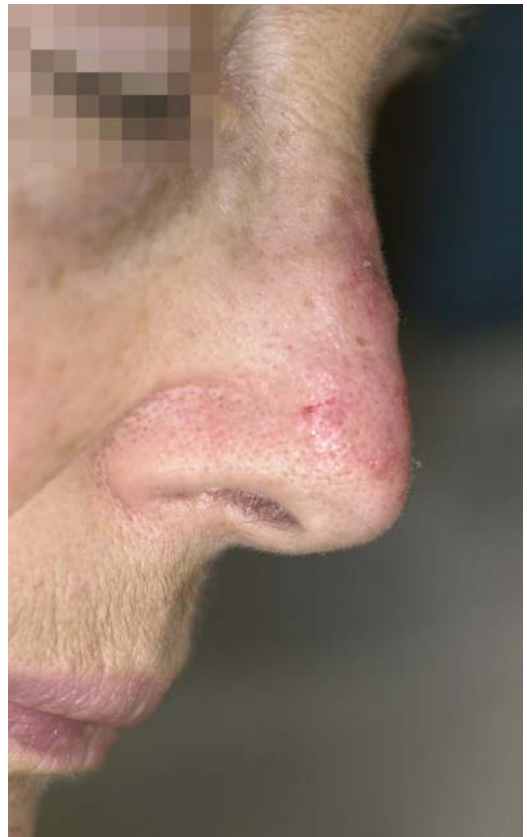
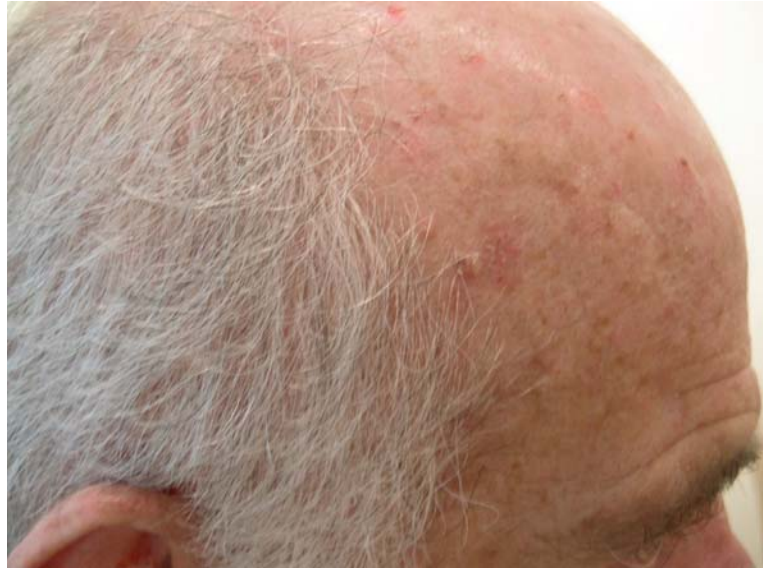
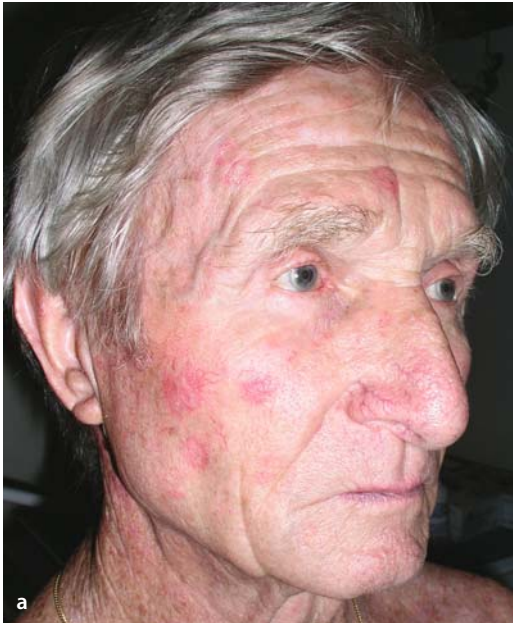Fig. 12.1. Erythematous maculo-papules localized on the dorsum of the nose

Fig. 12.2.
Erythematous macules
with a dry adherent scale
localized on the forehead

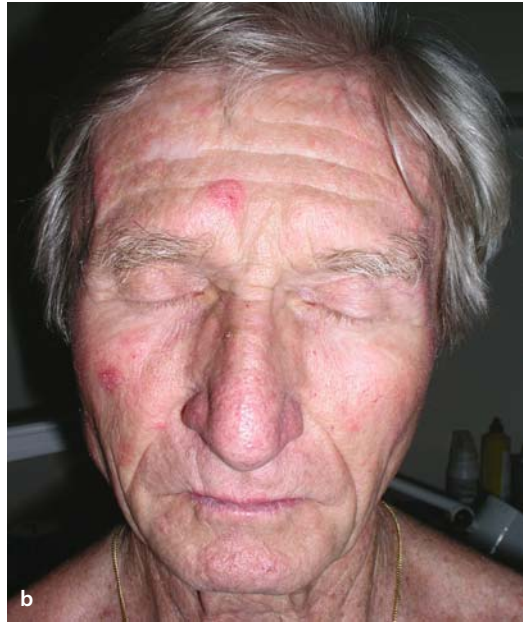

d

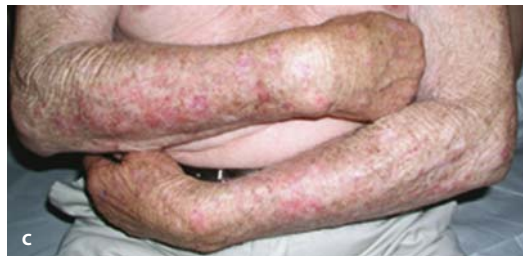12



a



b



c

Fig. 12.3. Actinic keratosis on the face (a, b) and upper arms (c)

12.2 Etiology

Causes of actinic keratosis include prolonged exposure to sun, ultraviolet light from artificial sources and x-radiations.

12.3 Clinical Types

Actinic keratoses are persistent, easily palpable, rough, usually erythematous patches that range in size between pinpoint to over 2 cm in diameter (Fig. 12.4a, b):

- **Asymptomatic:**
Developments such as tenderness, induration, erosions, and enlarging diameter may herald evolution into squamous cell carcinoma.
- **Hypertrophic AK:**
May appear clinically as a cutaneous horn due to the significant hyperkeratosis.
- **Spreading pigmented AK:**
Displays variation in pigmentation, with a smooth, verrucous or scaly surface, and centrifugal spreading, usually greater than 1 cm in diameter. When it expands to more than 3 cm in diameter with non-defined borders it is referred to as proliferative AK.
- **Lichenoid AK:**
Solitary or multiple violaceous or brown flat-topped papules resembling lesions of lichen planus.
- **Actinic cheilitis:**
Typical of the vermillion of the lower lip. Diffuse scaling, with a blotchy and atrophic appearance. When erosions appear, the occurrence of a squamous cell carcinoma must be considered.

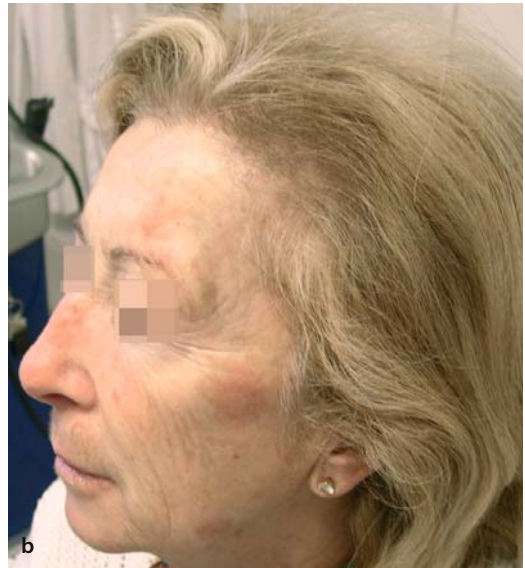
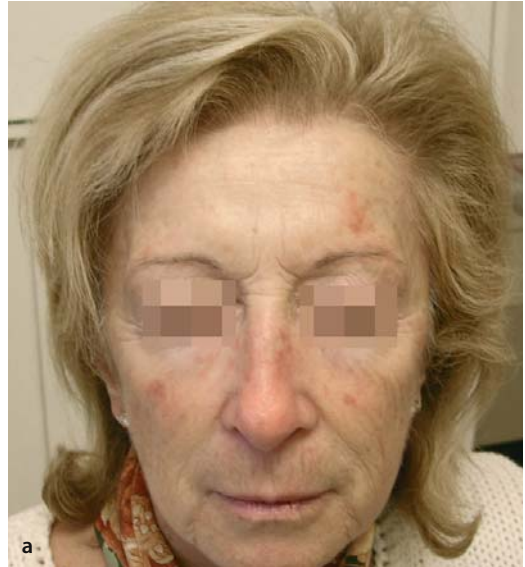
Fig. 12.4a, b. Erythematous patches that range in size

12.4 Histopathology

The histopathology of actinic keratosis is epidermal dysplasia with alterations in cell polarity and mild nuclear atypia. Alternating hyperkeratosis and parakeratosis, irregular acanthosis and thinning of the granular layer are commonly seen, with buds of atypical keratinocytes extending downward into the papillary dermis. Epithelium of the hair follicles is shielded from actinic damage and maintains normal structure, reaching the epidermis and extending over adjacent atypical cells to produce the characteristic umbrella sign. The dermis reveals solar elastosis and there is often a mild chronic inflammatory infiltrate.

12.5 Diagnostic Criteria

Diagnosis is based on clinical features. Biopsy and histologic examination may be useful when clinical appearance is not typical.

12.6 Differential Diagnosis

- Basal cell carcinoma: nodule with telangiectatic surface or ulcerated lesion with a pearly translucent border
- Discoid lupus erythematosus: discoid patches with adherent thick scales and follicular plugging, atrophic scarring
- Keratoacantoma: bud-shaped or dome-shaped nodule with a central horn-filled crater, skin colored or slightly reddish, rapid growth and possible spontaneous involution
- Seborrheic keratosis: uneven, verrucous surface, soft and friable consistency; present also on non-sun-exposed areas
- Solar lentigo: circumscribed pigmented macule, no surface scaling
- Verrucous naevi: present at birth or developed during childhood
- Warty diskeratoma: elevated papule with a keratotic umbilicated center, occasionally found on non-sun-exposed skin

12.7 Therapy

Treatment of AK is motivated by its potential for progression to invasive squamous cell carcinoma and its cosmetic liability and/or discomfort.

- Cryotherapy with liquid nitrogen: no anesthesia is necessary; there is mild to moderate discomfort; multiple sessions may be necessary; and scarring may occur (Fig. 12.5a, b) [1].
- Electrosurgery: electrodesiccation, electrocoagulation; local anesthesia is necessary; there is frequent scarring and moderate discomfort
- Dermabrasion: local anesthesia is necessary; frequent scarring and moderate discomfort occur
- CO₂ laser Erbium:YAG laser: no anesthesia is necessary [2]
- Chemotherapy with topical 5% 5-fluorouracil cream applied once or twice a day for 3–6 weeks: patients complain about great discomfort [3]
- Topical diclofenac gel applied once a day for at least 6 weeks: patients complain about discomfort [4]
- Topical tretinoin: only partially effective even after 1 year of daily application [5]
- Imiquimod 5% cream: an effective treatment for AK used three times per week for 16 weeks (Fig. 12.6) [6]
- Superficial medium chemical peel: 25–30% trichloroacetic acid (Fig. 12.7a, b)
- Medium depth chemical peels: 35% trichloroacetic acid, 50–70% pyruvic acid [7]
- Photodynamic therapy with 20% δ -aminolevulinic acid (ALA) or methyl aminolevulinate: expensive; has the best cosmetic results with no risk of scarring; early lesions not yet clinically perceptible are also treated [8, 9]
- Surgery: an option only when the AK is a firm horny papule with the possibility of invading the deeper layers

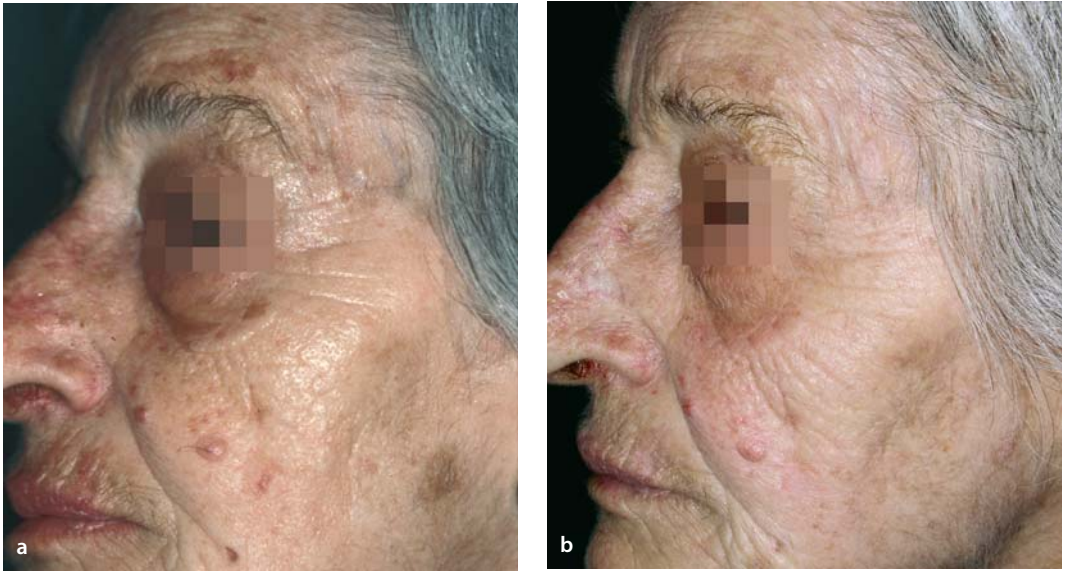

Fig. 12.5a, b. Actinic keratosis treated with cryotherapy and 25% TCA peeling

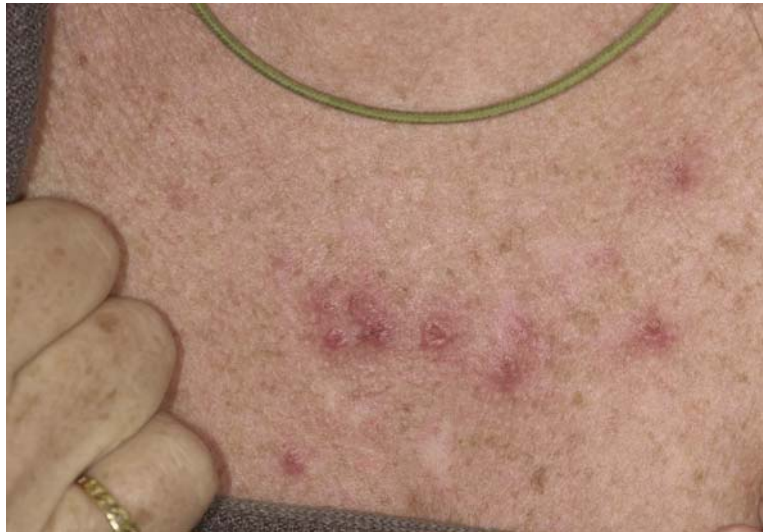

Fig. 12.6.
Actinic keratosis treated
with imiquimod 5% cream.
Clinical presentation after
15 days of treatment: vesicles
on an erythematous base

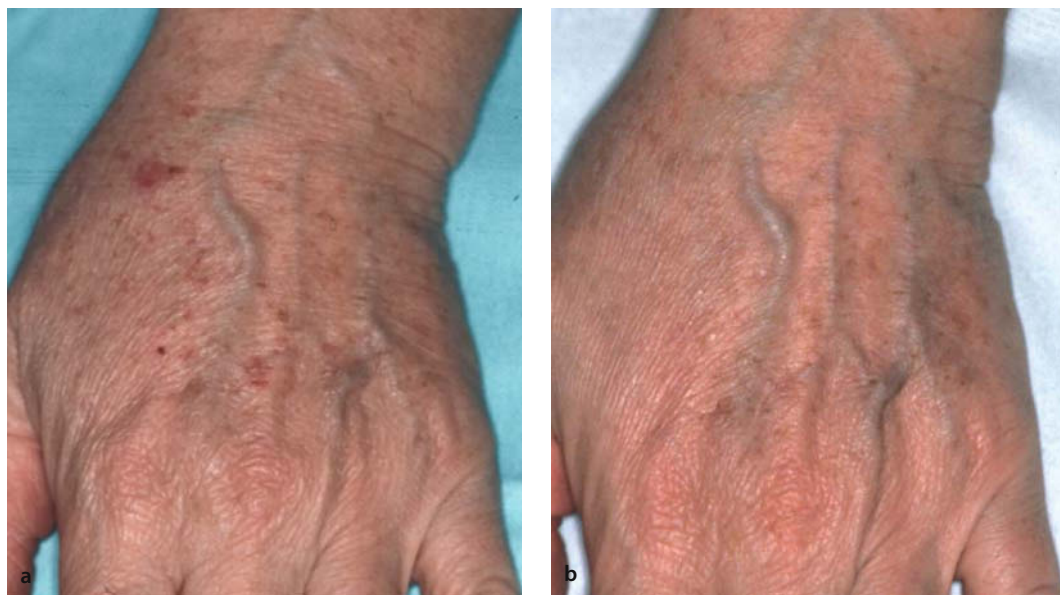

Fig. 12.7a, b. Actinic keratosis of the hands before and after six peelings with 25% TCA

12.8 Management of the Patient

After treatment, patients must avoid sun exposure and use sunscreens daily. A follow-up is necessary every 6 months to evaluate recurrences or development of new AK.

References

- Chiarello SE (2000) Cryopeeling (extensive cryosurgery) for treatment of actinic keratoses: an update and comparison. *Dermatol Surg* 26:728–732
- Iyer S, Friedli A, Bowes L, Kricorian G, Fitzpatrick RE (2004) Full face laser resurfacing: therapy and prophylaxis for actinic keratoses and non-melanoma skin cancer. *Lasers Surg Med* 34:114–119
- Labandeira J (2004) Efficacy and irritation in the treatment of actinic keratosis with topical 5-fluorouracil. *J Drugs Dermatol* 3:484
- Wolf JE Jr, Taylor JR, Tschien E, Kang S (2002) Topical 3.0% diclofenac in 2.5% hyaluronan gel in the treatment of actinic keratoses. *Int J Dermatol* 41:371–372
- Gilchrist BA (1992) Retinoids and photodamage. *Br J Dermatol* 127[Suppl 41]:14–20
- Griffin TD, Van Scott EJ (1991) Use of pyruvic acid in the treatment of actinic keratoses: a clinical and histopathologic study. *Cutis* 47:325–329
- Ghersetich I, Brazzini B, Lotti T (2003) Chemical peeling. In: Katsambas AD, Lotti TM (eds) *European handbook of dermatological treatments*, 2nd ed. Springer, Berlin, Heidelberg, New York, pp 599–612
- Szeimies RM, Gerritsen MJ, Gupta G, Ortonne JP, Serresi S, Bichel J, Lee JH, Fox TL, Alomar A (2004) Imiquimod 5% cream for the treatment of actinic keratosis: results from a phase III, randomized, double-blind, vehicle-controlled, clinical trial with histology. *J Am Acad Dermatol* 51:547–555
- Gold MH, Goldman MP (2004) 5-aminolevulinic acid photodynamic therapy: where we have been and where we are going. *Dermatol Surg* 30:1077–1083
- Pariser DM, Lowe NJ, Stewart DM, Jarratt MT, Lucky AW, Pariser RJ, Yamauchi PS (2003) Photodynamic therapy with topical methyl aminolevulinate for actinic keratosis: results of a prospective randomized multicenter trial. *J Am Acad Dermatol* 48:227–232

Chemical Peels in Dark Skin

13

Pearl E. Grimes

The author has no financial interest in any of the products or equipment mentioned in this chapter.

Contents

13.1	Definition	139
13.2	Epidemiology	139
13.3	Morphologic and Physiologic Skin Differences in Dark Skin	139
13.4	Peeling Indications in Dark Skin	140
13.5	Peel Selection	140
13.6	Peeling Preparation	141
13.7	Peeling Techniques	143
13.8	Superficial Peeling Agents	143
13.8.1	Glycolic Acid	143
13.8.2	Salicylic Acid	144
13.8.3	Jessner's Solution	144
13.8.4	Tretinoin Peeling	144
13.8.5	Trichloroacetic Acid	146
13.8.6	Medium and Deep Peels	147
13.9	Summary	147
	References	148

13.2 Epidemiology

In the year 2000, the US Census Bureau estimated that the total resident US population included 33 million Hispanic Americans (12%), 34 million African Americans (13%), 11 million Asians and Pacific Islanders (4%) and 2 million Native Americans, Eskimos, and Aleuts (1%). Statistical projections suggest continuing major growth of the non-white US population, with Hispanics having the most significant growth rate [1]. People of color comprise a substantial percentage of the global population. They include Africans, Hispanics, Pacific Islanders, Asians, East Indians, Aleuts, Eskimos, Middle Easterners, Caribbeans, Arabs, and Malaysians.

13.3 Morphologic and Physiologic Skin Differences in Dark Skin

A myriad of morphologic and physiologic features define pigmented skin. Although there are no quantitative differences in melanocytes amongst various racial/ethnic groups, the melanocytes of darker skin, in particular black skin, produce more epidermal melanin. Melanosomes are often large and singly dispersed within melanocytes and keratinocytes [2, 3, 4]. Melanosomes are distributed throughout the epidermis in black skin, whereas in whites, they are limited to the basal and lower malphigian layer of the epidermis. Melanosomes in whites and Asians are smaller and often aggregated and membrane bound, whereas in black skin, they are most often singly dispersed within

13.1 Definition

Dark skin is a commonly used phrase to describe people of color. Other terms used to describe darker skin types include ethnic skin, brown skin, and pigmented skin. The unifying feature represented is pigmented skin (i.e., shades of tan, olive, brown, and black). Such individuals are often classified as Fitzpatrick's skin types IV through VI. These individuals represent many of the faces of North America, South America, Africa, the Caribbean, Asia, Malaysia, and Australia.

melanocytes and keratinocytes. Dark skin (i.e., black skin) has more stage IV melanosomes. The transmission of ultraviolet radiation (UVA and UVB) through white and black skin has been assessed [5]. On average, five times as much ultraviolet light reaches the upper dermis of whites than in blacks. Differences in transmission between the stratum corneum of blacks and whites are less striking. The increased epidermal melanin content of black skin serves as a significant filter for blocking ultraviolet light transmission. In addition, other reported differences include increased stratum corneum cell layers, increased desquamation, increased lipid content, decreased ceramide content, and increased recovery time after tape stripping [6].

Dark skin demonstrates significantly greater intrinsic photoprotection because of the increased content of epidermal melanin. Clinical photodamage, actinic keratoses, rhytides, and skin malignancies are less common problems in deeply pigmented skin. However, darker skin types are frequently plagued with dyschromias because of the labile responses of cutaneous melanocytes [7]. In a survey of 2000 black patients seeking dermatologic care in a private practice in Washington, DC, the third most commonly cited skin disorders following acne and eczema was pigmentary problems other than vitiligo [8]. Of these patients, the majority had a diagnosis of post-inflammatory hyperpigmentation, followed in frequency by melasma. In a survey of 100 women of color assessing issues of cosmetic concerns for darker skin types, the most commonly cited problems were dark spots or blotchy skin, texturally rough skin, and increased sensitivity to topical products [9]. Patients surveyed also complained of oily skin. Wrinkles and photodamage were significantly less frequent issues of cosmetic concern when the data was compared with an age-matched Caucasian population of 141 women.

13.4 Peeling Indications in Dark Skin

Peel indications differ between light and dark skin. Key indications in Fitzpatrick's skin types I–III include photodamage, rhytides, acne,

scarring and the dyschromias characterized by hyperpigmentation. In contrast, survey data suggest that key indications in darker skin types include disorders of hyperpigmentation such as melasma and post-inflammatory hyperpigmentation, acne, pseudofolliculitis barbae, textural changes, oily skin, wrinkles, and photodamage.

Despite major concerns regarding peel complications such as post-inflammatory hyperpigmentation, hypopigmentation and scarring in darker racial-ethnic groups, recent studies suggest that peeling procedures, particularly superficial procedures, can be performed safely in darker racial-ethnic groups [10]. These peels induce epidermal and papillary dermal wounding (Fig. 13.1).

13.5 Peel Selection

Chemical peeling agents are classified as superficial, medium-depth, or deep peels [11]. Superficial peels target the stratum corneum to the papillary dermis (Fig. 13.1). They include glycolic acid, salicylic acid, Jessner's solution, tretinoin, and TCA in concentrations of 10–30%. Medium-depth peels penetrate to the upper reticular dermis and include TCA (35–50%) combination glycolic acid 70%/TCA 35%, Jessner's/TCA 35% and phenol 88%. Deep chemical peels utilize the Baker-Gordon formula and penetrate to the midreticular dermis. Analysis of morphologic, physiologic, and clinical data (see Introduction) suggests that the benefits of chemical peeling in dark skin can be maximally achieved utilizing superficial peels while simultaneously minimizing risks.

Grimes [12] compared the histologic alterations induced by a variety of chemical peels in 17 patients with skin types IV–VI, including glycolic acid 70%, salicylic acid 30%, Jessner's solution, and 25 and 30% trichloroacetic acid (TCA). Peels were applied to 4 × 4 cm areas of the back and 2 × 2 cm post auricular sites. Biopsies were performed at 24 h (Fig. 13.2a–d). Glycolic acid induced the most significant stratum corneum necrosis. Compared with the other tested peels, salicylic acid and Jessner's peels caused mild lymphohistiocytic dermal infil-

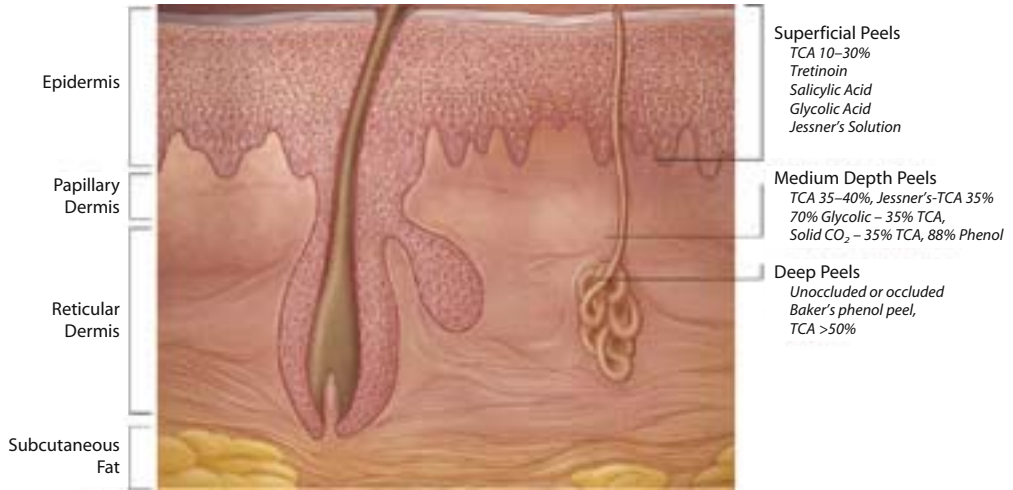

Fig. 13.1. Illustration of the depth of wounding caused by peeling agents

trates. The most severe damage was induced by 25 and 30% TCA, which caused deep epidermal necrosis and dense papillary dermal lymphohistiocytic infiltrates. TCA test sites developed post-inflammatory hyperpigmentation. These findings corroborate our clinical experience using these agents. In general, glycolic, salicylic acid, and Jessner's peels induce a lower frequency of post-peeling complications compared with 25 and 30% superficial TCA peels.

13.6 Peeling Preparation

Despite some general predictable outcomes, there is tremendous variability in the reactivity and responses to chemical peels. Even superficial chemical peeling can cause hyperpigmentation and scarring in susceptible individuals. Therefore, the author always performs the initial peel with the lowest concentration of the

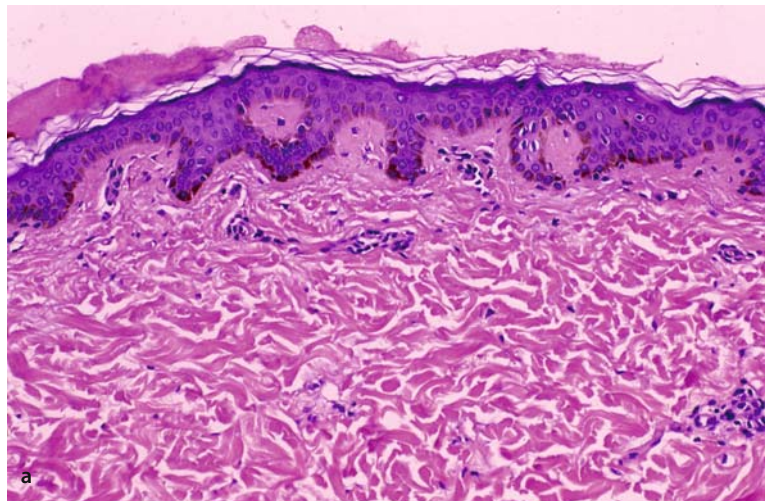


Fig. 13.2a-d. Hematoxylin/eosin stains of biopsies of back skin taken 24 h post-chemical peeling. **a** Glycolic acid peel 70%. Note stratum corneum necrosis

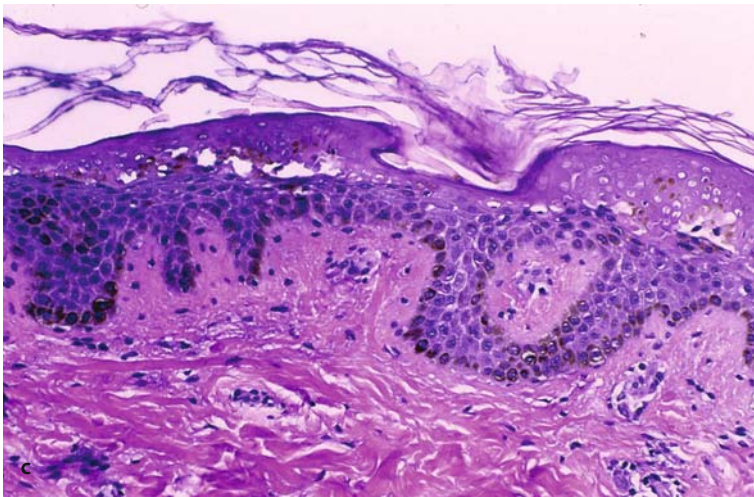
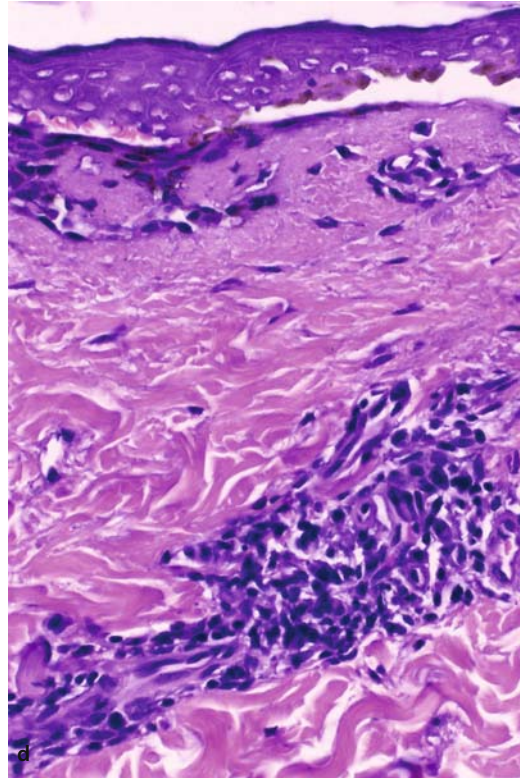
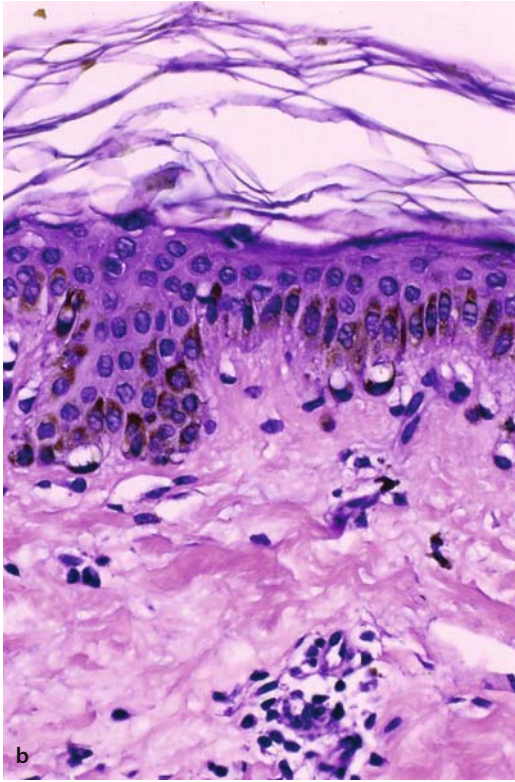


Fig. 13.2b-d. Hematoxylin/eosin stains of biopsies of back skin taken 24 h post-chemical peeling. **b** Salicylic acid 30%. Note mild lymphohistiocytic infiltrate.

c Twenty-five percent TCA induced mid-epidermal wounding/separation. **d** Thirty percent TCA peel caused deep epidermal separation

peeling agent to assess the patient's sensitivity and reactivity. The author's standard protocol involves initial pretreatment for 2–4 weeks with 4% hydroquinone formulations. Higher strength formulations (5–10%) can be compounded for recalcitrant hyperpigmentation. Azelaic acid or kojic acid formulations are used if patients are experiencing irritation or hypersensitivity to hydroquinone. Tretinoin, tazarotene and retinol are often used to treat acne, hyperpigmentation or photodamage in darker skin types. However, these agents should be discontinued 1–2 weeks prior to peeling to avoid post-peel complications in dark skin. Retinoids increase epidermal turnover and they increase the depth of the peeling agent. This may be a desired effect in skin types I–III; however, in dark skin increasing the depth of the peel may result in excessive erythema, crusting, desquamation, and post-inflammatory hyperpigmentation. Topical bleaching agents, which do not contain retinoids, lower strength alpha hydroxy acids, polyhydroxy acids, and beta-hydroxy acids can be continued up to 1 or 2 days prior to peeling. These are less aggressive agents compared with retinoids. Superficial peels are performed at 2- to 4-week intervals and a series of three to six are routinely performed.

13.7 Peeling Techniques

The author has observed cases of post-inflammatory hyperpigmentation even with low concentrations of superficial peeling agents. Hence, cautious titration is appropriate in darker skin types. Glycolic acid peels are titrated from 20–35%, 50%, and finally 70%. Similar titration methods are used for salicylic acid and TCA. Salicylic acid peels should be titrated from 20 to 30%. Despite the use of higher concentrations of TCA in some studies [12, 13], it is best to initiate TCA peeling in dark skin with low concentrations (i.e., 10–15%). Post-peel care includes the use of bland cleansers and emollients until irritation and peeling subsides. The patient then resumes the use of topical skin care products and bleaching agents. Post-peel reactions such as excessive erythema, desquamation, and irritation are treated with low-

high-potency topical steroids. Clearing usually occurs in 5–7 days.

13.8 Superficial Peeling Agents

13.8.1 Glycolic Acid

Glycolic acid, an alpha-hydroxy acid (AHA), has become the most widely used organic carboxylic acid for skin peeling. Glycolic acid formulations include buffered, partially neutralized, and esterified products. Concentrations for peeling range from 20 to 70%. Several published studies have assessed the efficacy of glycolic acid peels in darker-skinned racial-ethnic groups. A series of ten Asian women with melasma and fine wrinkles were treated with 2% hydroquinone and 10% glycolic acid applied to both sides of the face [13]. A series of 20–70% glycolic peels were performed on one side for comparison. Greater improvement with minimal side effects was noted on the side treated with the series of glycolic acid peels. Forty Asian patients with moderate to moderately severe acne were treated with a series of 35–70% glycolic acid peels [14]. The investigators noted significant improvement in skin texture and acne. Side effects were reported in 5.6% of patients.

Nineteen black patients with post-inflammatory hyperpigmentation were treated with glycolic acid peeling [15]. The control group was treated with 2% hydroquinone/10% glycolic acid twice a day and tretinoin 0.05% at bedtime, whereas the active peel group received the same topical regimen plus a series of six serial glycolic acid peels. Although not statistically significant, greater improvement was noted in the chemical peel group.

The safety and efficacy of a series of glycolic acid facial peels were investigated in 25 Indian women with melasma [16]. Patients were treated with 50% glycolic acid peels monthly for 3 months. Improvement was noted in 91% of patients with maximal clearing occurring in patients classified with epidermal melasma. Side effects were observed in one patient who developed brow hyperpigmentation.

In a separate study, the combination of glycolic acid peels with a topical regimen for the

treatment of melasma was assessed in a series of dark-skinned patients with melasma [17]. The authors compared the efficacy of serial glycolic acid peeling with a series of 3–30% glycolic peels and 3–40% peels in combination with a modified Kligman bleaching regimen (hydroquinone 5%, hydrocortisone acetate 1% and tretinoin 0.05%) to the use of the modified Kligman formulation alone. Forty women were included in each group. Both groups showed a statistically significant improvement in the Melasma Area Severity Index (MASI) score at 21 weeks. However, maximal improvement occurred in the group treated with the series of glycolic acid peels in combination with the topical bleaching regimen.

Glycolic acid peels are well tolerated in darker skinned racial-ethnic groups (Figs. 13.3a, b and 13.4a, b). Side effects are substantially minimized when concentrations are gradually titrated from the lower concentrations of 20–35% to the full-strength 70% peel. Glycolic acid peels are most advantageous when treating darker skin types with sensitive skin.

13.8.2 Salicylic Acid

Salicylic acid has been formulated in a hydroethanolic vehicle at concentrations of 20 and 30% for use as a superficial peeling agent [18]. It is a lipophilic agent that produces desquamation of the upper lipophilic layers of the stratum corneum. Grimes [19] treated 25 patients with skin types V and VI with salicylic acid peels. Conditions treated included acne vulgaris, post-inflammatory hyperpigmentation, oily skin, with textural changes, and melasma. Patients were pretreated for 2 weeks with hydroquinone 4%, followed by a series of two 20% and three 30% salicylic acid peels. Peels were performed biweekly. Moderate to significant improvement was observed in 88% of the patients treated. Minimal to mild side effects occurred in 16%. Three patients experienced hyperpigmentation that resolved in 7–14 days. Thirty-five Korean patients with facial acne were treated biweekly for 12 weeks with 30% salicylic acid peels [20]. Both inflammatory and non-inflammatory lesions were significantly

improved. In general, the peel was well tolerated with few side effects.

The author has observed enhanced improvement of oily skin, enlarged pores, and acne vulgaris with the use of salicylic acid peels compared with glycolic acid peels. Possible mechanisms for this observation include salicylic acid's effect on lipid solubility and microcomedone formation.

13.8.3 Jessner's Solution

Jessner's solution contains 14% resorcinol, 14% salicylic acid and 14% lactic acid. Jessner's solution has been used alone for superficial peeling, or in combination with TCA 35% to achieve a medium-depth peel. Increasing the number of coats applied to the treated area increases the depth and reaction induced by the Jessner's peel. These peels are well tolerated with minimal side effects in the author's practice. As with glycolic acid and salicylic acid peels, Jessner's peels are most commonly used as adjunctive therapy for moderate to severe facial dyschromias, acne, oily skin, texturally rough skin, fine wrinkles, and pseudofolliculitis barbae.

Lawrence et al. [21] compared the efficacy of Jessner's solution and 70% glycolic acid in a split-face study of 16 patients. Of the total group, five were skin type IV, three were skin type V, and one was skin type VI. There was no statistically significant difference in improvement between the two groups. The investigator did not report an increased frequency of side effects in patients of skin types IV–VI.

13.8.4 Tretinoin Peeling

Tretinoin 1% has also been used as a chemical peeling agent [22, 23]. The efficacy of tretinoin peels was compared with glycolic acid peels in the treatment of melasma in dark skinned patients [23]. In a split face study of ten Indian women, 1% tretinoin was applied to one half of the face, while 70% glycolic acid was applied to the opposite side. Peels were performed weekly. Significant improvement occurred on both sides as assessed by photographs and a Modi-

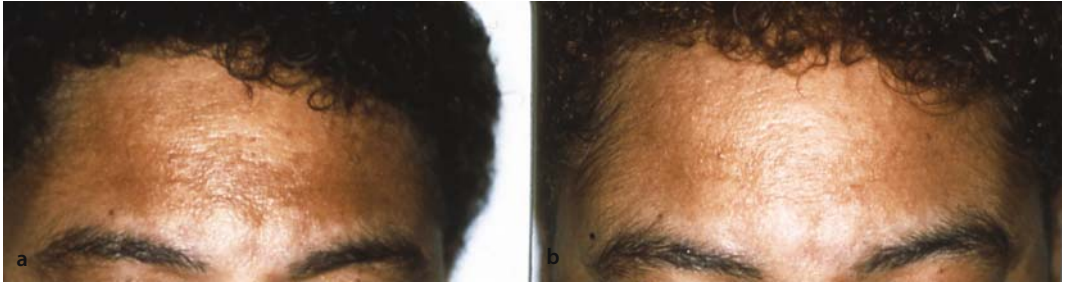

Fig. 13.3. a Forehead post-inflammatory hyperpigmentation. b Significant improvement in forehead hyperpigmentation following a series of glycolic acid 20–50% peels

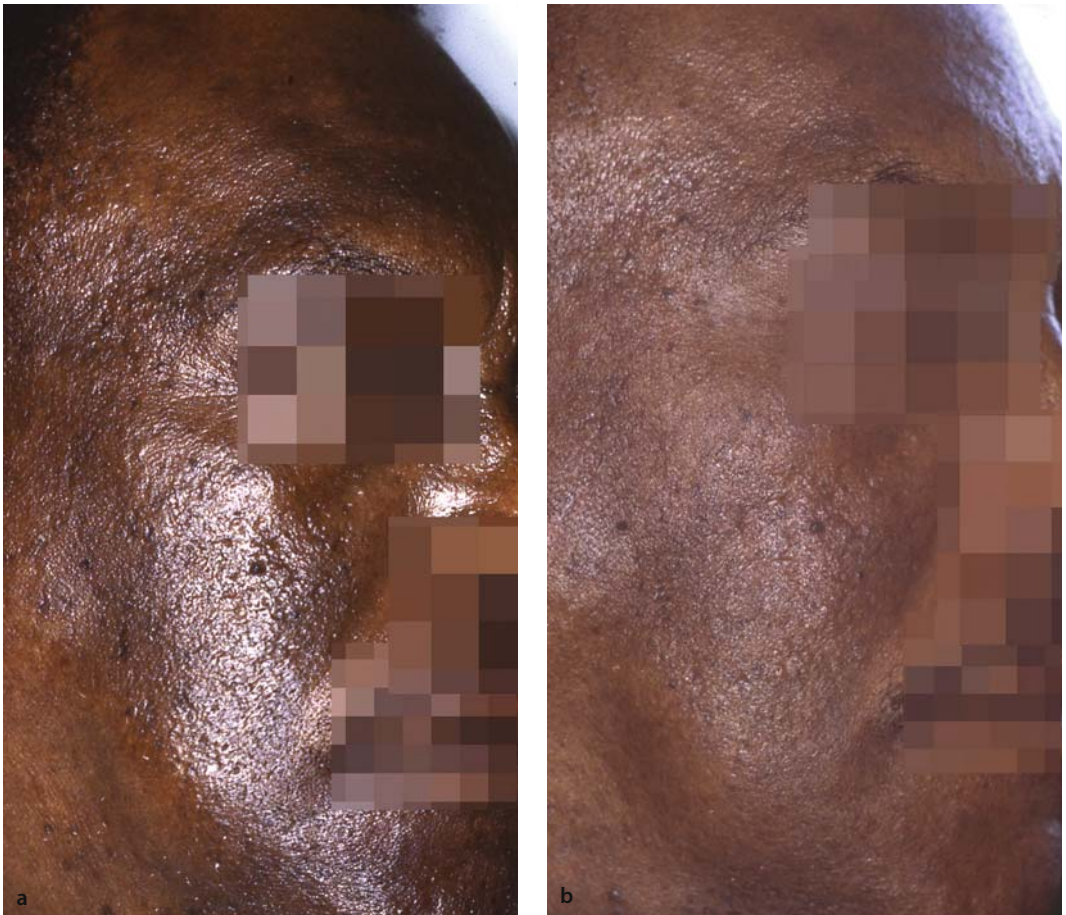

Fig. 13.4a, b. Significant improvement after a series of five glycolic acid 20–70% peels

fied Melasma Area and Severity Index Score. However, there were no significant differences between the tretinoin peeled side and the glycolic acid treated areas. Side effects despite the weekly frequency of peel applications were minimal throughout the 12-week study.

13.8.5 Trichloroacetic Acid

TCA peels were first described by Roberts in 1926. Many consider TCA the gold standard by which other peels are measured. Concentrations of 10–30% are used for superficial peeling. TCA precipitates epidermal proteins, causing sloughing and necrosis of the treated area. The extent of damage is concentration dependent. In contrast to glycolic acid, Jessner's solu-

tion, and salicylic acid, there is a substantially smaller window of safety when TCA peels are applied to skin types IV–VI. The frequency of post-peel hyperpigmentation is significantly more common in dark skin. Therefore, the author only uses TCA peels in patients recalcitrant to glycolic acid, salicylic acid, or Jessner's peels (Fig. 13.5a, b). TCA peels are cautiously used in darker-skinned patients. Indications include wrinkles, photodamage, stubborn pigmentation, and scarring.

In a histometric, immunohistochemical and ultrastructural study, TCA peeling in concentrations of 10, 20 and 30% were compared with dermabrasion in nine dark-skinned patients (Fitzpatrick's IV and V) with photodamage [24]. Both procedures induced increasing amounts of types I and III collagen. However,

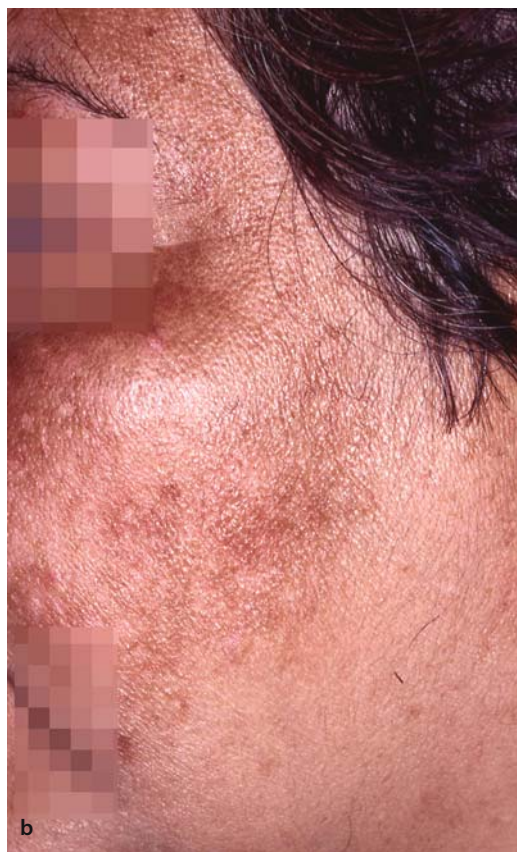
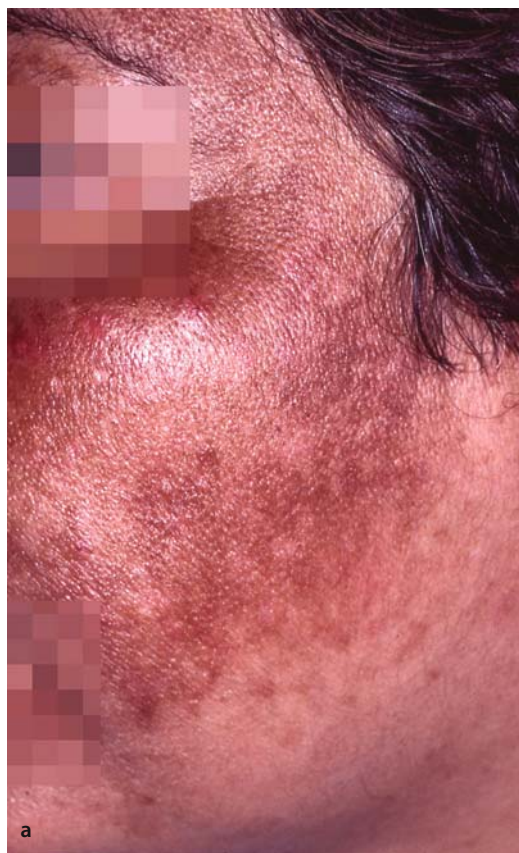
Fig. 13.5a, b. Moderate improvement in melasma after a series of two 15% TCA peels plus hydroquinone 6%

the most prominent changes were observed in the group treated with dermabrasion.

There is minimal published data on the use of combination peeling protocols in deeply pigmented skin (Fitzpatrick skin types IV–VI). The author has reported the efficacy of combination peeling with salicylic acid 20 and 30% in combination with 10% TCA for recalcitrant melasma patients. This peeling regimen was well tolerated with minimal side effects in darker racial ethnic groups (see Salicylic acid/TCA peel section).

13.8.6 Medium and Deep Peels

Medium and deep peels utilize TCA concentrations of 30–40% or greater or phenol combina-

tions. Medium-depth peels also utilize glycolic acid 70% or Jessner's solution in combination with 35% TCA. Combination medium-depth peels are often used to treat moderate to severe photodamage. Fifteen Middle Eastern patients with atrophic or pitted acne scars were treated with a combination of Jessner's solution and 35% TCA peeling [11]. All patients were of light brown to dark brown complexion. Six percent had excellent improvement, 53% had moderate improvement and mild improvement was noted in 27%. Nine patients (73.4%) developed transient post-inflammatory hyperpigmentation which resolved after 3 months. Patients with light brown complexions did not develop hyperpigmentation. In the author's experience, aggressive peels of this nature have a substantially greater likelihood of inducing persistent hyperpigmentation and hypopigmentation in darker skin types.

Clinicians should be acutely aware that deeper peels carry substantial risks of inducing scarring and hypopigmentation in darker-skinned racial-ethnic groups (Fig. 13.6).

13.9 Summary

In contrast to the previous decade, chemical peels are commonly performed in darker racial-ethnic groups, individuals comprising skin types IV–VI (Asians, Hispanics, Blacks, and Native Americans). Serial superficial glycolic acid, salicylic acid, Jessner's solution, and TCA peels (when appropriate) offer substantial benefits for post-inflammatory hyperpigmentation, melasma, acne, pseudofolliculitis barbae, oily skin, and texturally rough skin. When selecting a peeling agent, the benefits of the procedure should always substantially outweigh any associated risks or complications. Superficial peels with appropriate titration of concentrations are generally safe and efficacious for darker-skinned patients. However, given the labile nature of melanocytes of darker complexioned individuals, medium-depth and deep peels are more likely to induce substantial complications and side effects.

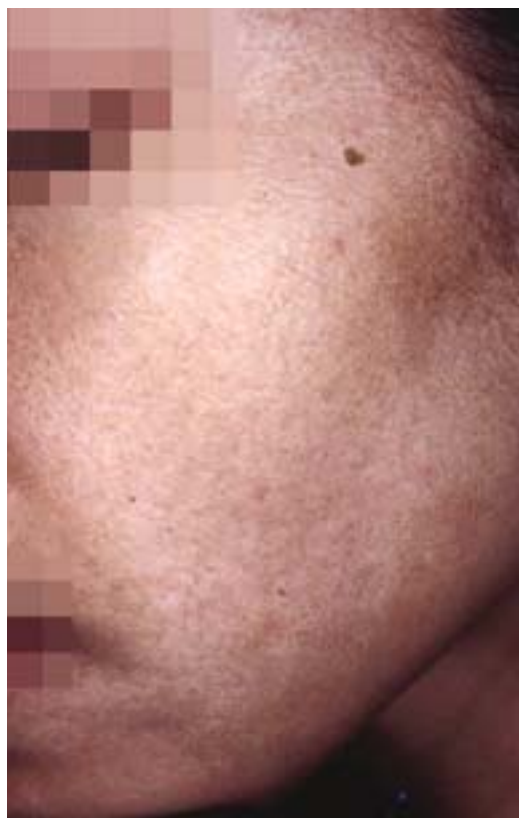

Fig. 13.6. Post-peel persistent hypopigmentation following a 35% TCA peel

References

1. US Census Bureau, Population Division, April 12, 2000
2. Montagna W, Prota G, Kenney JA (1993) Black skin structure and function. Academic Press, San Diego, pp 42-45
3. Szabo G, Gerald AB, Patnak MA, Fitzpatrick TB (1969) Racial differences in the fate of melanosomes in human epidermis. *Nature* 222:1081-1082
4. Olson RL, Gaynor J, Everett MA (1973) Skin color, melanin, and erythema. *Arch Dermatol* 108:541-544
5. Kaidbey KH, Agin PP, Sayre RM, Kligman A (1979) Photoprotection by melanin - a comparison of black and Caucasian skin. *J Am Acad Dermatol* 1:249-260
6. Berardesca E, Maibach H (1996) Racial differences in skin pathophysiology. *J Am Acad Dermatol* 34:667-672
7. Grimes PE, Davis LT (1991) Cosmetics in blacks. *Dermatol Clin* 9:53-63
8. Halder RM, Grimes PE, McLauren C, Kress MA, Kenney JA Jr (1983) Incidence of common dermatoses in a predominantly black dermatologic practice. *Cutis* 32:388-390
9. Grimes PE (2000) Skin and hair cosmetic issues in women of color. *Dermatol Clin* 15:659-665
10. Grimes PE, Hunt SG (1993) Considerations for cosmetic surgery in the black population. *Clin Plast Surg* 20:27-34
11. Al-Waiz MM, Al-Sharqi AI (2002) Medium-depth chemical peels in the treatment of acne scars in dark-skinned individuals. *Dermatol Surg* 28:383-387
12. Grimes PE (2000) Agents for ethnic skin peeling. *Dermatologic Ther* 13:159-164
13. Lim JT, Tham SN (1997) Glycolic acid peels in the treatment of melasma in Asian women. *Dermatol Surg* 20:27-34
14. Wang CM, Huang CL, Hu CT, Chan HL (1997) The effects of glycolic acid on the treatment of melasma among Asian skin. *Dermatol Surg* 23:23-29
15. Burns RI, Provost-Blank PC, Lawry MA, et al (1997) Glycolic acid peels for post inflammatory hyperpigmentation in black patients: a comparative study. *Dermatol Surg* 23:171-174
16. Javaheri SM, Handa S, Kaur I, et al (2001) Safety and efficacy of glycolic acid facial peel in Indian women with melasma. *Int J Dermatol* 40:354-357
17. Sarkar R, Kaur C, Bhalla M, et al (2002) The combination of glycolic acid peels with a topical regimen in the treatment of melasma in dark-skinned patients: a comparative study. *Dermatol Surg* 28:828-832
18. Kligman D, Kligman AM (1998) Salicylic acid peels for the treatment of photoaging. *Dermatol Surg* 24:325-328
19. Grimes PE (1999) The safety and efficacy of salicylic acid chemical peels in darker racial-ethnic groups. *Dermatol Surg* 25:18-22
20. Lee HS, Kim IH (2003) Salicylic acid peels for the treatment of acne vulgaris in Asian patients. *Dermatol Surg* 29:1196-1199
21. Lawrence NL, Cox SE, Brady HJ (1977) Treatment of melasma with Jessner's solution versus glycolic acid: a comparison of clinical efficacy and evaluation of the predictive ability of Wood's light examination. *J Am Acad Dermatol* 36:589-593
22. Cuce LC, Bertino MCM, Scattone L, Birkenhauer MC (2001) Tretinoin peeling. *Dermatol Surg* 25:12-14
23. Khunger N, Sarkar R, Jain RK (2004) Tretinoin peels versus glycolic acid peels in the treatment of melasma in dark-skinned patients. *Dermatol Surg* 25:270-273
24. El-Domyati MB, Attia SK, Saleh FY, Ahmad HM, Uitto JJ (2004) Trichloroacetic acid peeling versus dermabrasion: a histometric, immunohistochemical, and ultrastructural comparison. *Dermatol Surg* 30:197-188

Melasma

Matilde Iorizzo, Antonella Tosti, Maria Pia De Padova

The author has no financial interest in any of the products or equipment mentioned in this chapter.

Contents

14.1	Definition	149
14.2	Epidemiology	149
14.3	Etiology	150
14.4	Clinical Features	150
14.5	Diagnostic Criteria	151
14.6	Therapy	152
14.6.1	Sunscreens	152
14.6.2	Hydroquinone [4]	152
14.6.3	Azelaic Acid [6]	153
14.6.4	Kojic Acid [7]	153
14.6.5	Retinoic Acid (Tretinoin) [8]	153
14.6.6	Chemical Peels [9]	153
14.7	Why Is a Combined Chemical Peel Useful for Treating Melasma?	158
14.7.1	Laser	158
14.7.2	Cryotherapy	158
	References	159

14.1 Definition

Melasma is an acquired hyperpigmentation disorder characterized by “moth-eaten” tan or brownish macules and patches that occur on the sun-exposed areas of the skin (Fig. 14.1) [1]. Melasma is most commonly observed in women, but also in 10% of men. It affects all racial groups but is more prevalent in skin types IV–VI. When melasma is associated with pregnancy it is called *chloasma* or “mask of pregnancy”.

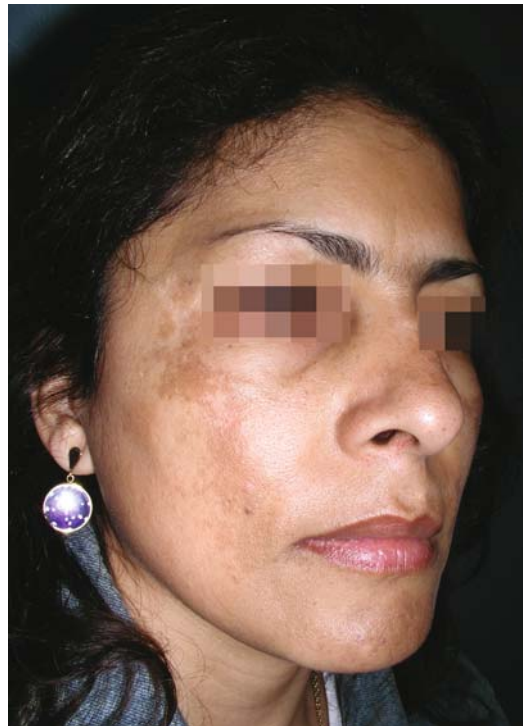

Fig. 14.1. Melasma: typical irregular brownish macules and patches localized on the face

14.2 Epidemiology

The true incidence of melasma is unknown.

14.3 Etiology

Although the etiology remains unknown, many factors have been implied as causative agents:

- Idiopathic
- Sun exposure
- Genetic predisposition
- Pregnancy
- Oral contraceptives
- Ovaric dysfunctions (elevated levels of LH, FSH and estradiol)
- Thyroid dysfunctions
- Antiseizure drugs (phenytoin)
- Cosmetics containing perfumes

Among these factors, sun exposure remains the most important, although all of them significantly increase the activity of tyrosinase in producing melanin.

14.4 Clinical Features

Clinical features of melasma usually evolve rapidly, especially after UV exposure. Lesions are uniformly light to dark brown, often symmetric, and three clinical patterns can be distinguished:

- Centrifacial (Fig. 14.2)
- Malar (Fig. 14.3)
- Mandibular (Fig. 14.4)

Two thirds of cases of melasma are localized on the face (cheeks, forehead, nose, superior lip and chin), while one third is localized on the dorsal forearms.

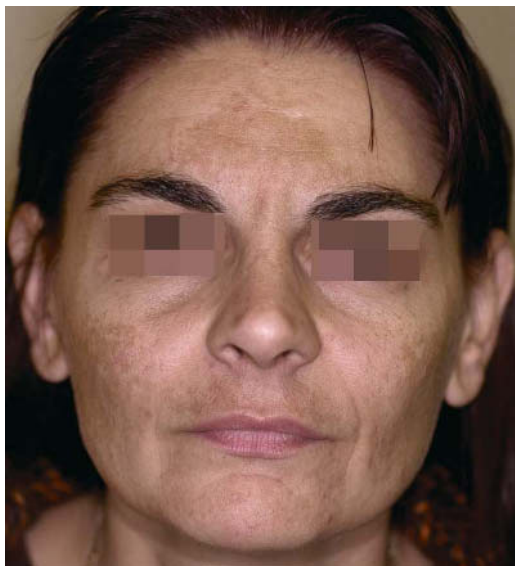

Fig. 14.2. Centrifacial localization of melasma

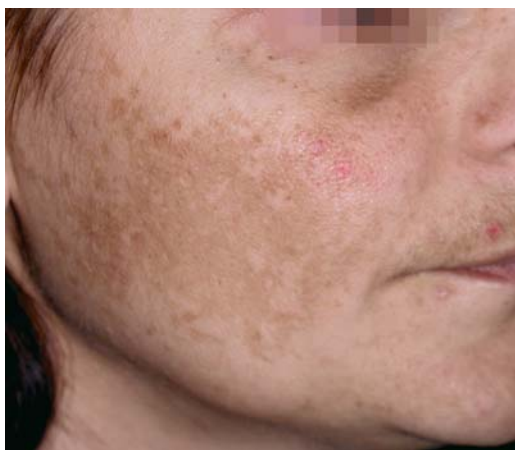

Fig. 14.3. Malar localization of melasma

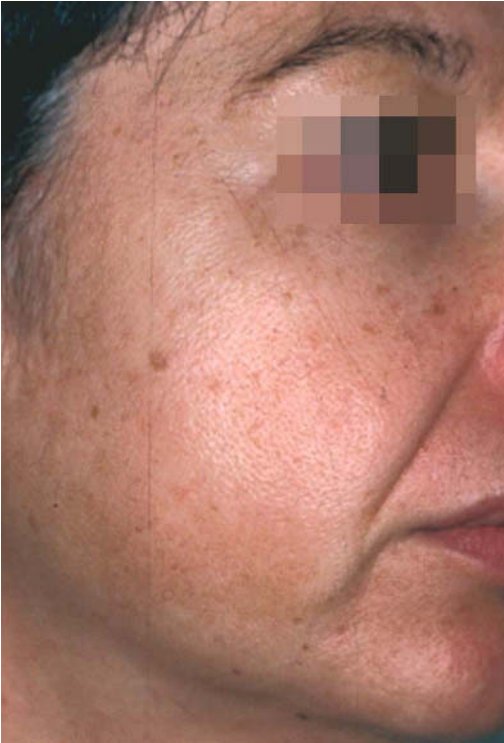

Fig. 14.4. Mandibular localization of melasma

14.5 Diagnostic Criteria

- **Wood's light:** this technique is useful to determine depth of pigmentation in order to predict a patient's treatment response. It is able to distinguish four types of melasma.
 - *Epidermal melasma:* increased melanin in the basal, suprabasal and stratum corneum layers. Clinically, melasma is light brown and its appearance is enhanced by Wood's light.
 - *Dermal melasma:* increased melanin in the superficial and deep dermis. Clinically, melasma is dark brown to gray and its appearance is not enhanced by Wood's light.
 - *Mixed melasma:* increased melanin in the epidermis and dermis. Clinically, melasma is dark brown and its appearance is not enhanced by Wood's light.
 - *Indeterminate melasma:* melasma in patients with skin type VI.
- **Histopathology:** this classifies melasma in epidermal, dermal and mixed.
- **MASI (Melasma Area and Severity Index):** according to this subjective classification, the face can be divided into four areas: F, forehead (30%); MR, right malar (30%); ML, left malar (30%); C, chin area (10%). In each of these areas, melasma is graded on:
 - A, percentage of total area involved (0: no involvement, to 6: 90–100% involvement)
 - D, darkness (0: absent, to 4: maximum)
 - H, homogeneity of hyperpigmentation (0: minimal, to 4: maximum)

MASI is then calculated by the following formula:

$$30\% (DF + HF) AF + 30\% (DMR + HMR) \\ AMR + 30\% (DML + HML) AML + 10\% \\ (DC + HC) AC$$

The maximum value of MASI is 48 and means severe hyperpigmentation [2].

14.6 Therapy

It is important to treat melasma because this condition has a severe impact on the quality of life and it is particularly disturbing to patients because of its location on the face.

Objectives of therapy are:

- To slow the proliferation and growth of melanocytes
- To inhibit the formation and promote the destruction of melanosomes

It is commonly accepted that epidermal melasma is more responsive to therapy due to its superficial distribution.

Treatment options are:

- Broad-spectrum sunscreens (SPF of 30 and above + UVA filters)
- Topical depigmenting agents
 - Tyrosinase inhibitors (hydroquinone, azelaic acid, kojic acid)
 - Antioxidants (magnesium, ascorbic acid, alpha-tocopherol)
 - Melanogenesis inhibitors (retinoic acid, benzoic acid)
 - Exfoliants (AHA: glycolic acid, BHA: salicylic acid)
- Chemical peels
 - Superficial (15–20% TCA, 50–70% glycolic acid, 25% salicylic acid)
 - Medium (resorcinol, 50% pyruvic acid)
 - Combined chemical peels (25% salicylic acid + 10% TCA gel)
- Laser [3]
- Cryotherapy

14.6.1 Sunscreens

Sunscreens are the gold standard for skin protection from UV light. Two types of sunscreens are recognized: organic and physical blocking agents. Organic agents absorb UVB radiation, UVA radiation, or both. These sunscreen ingredients include octyl-dimethyl-PABA (UVB), 2-ethylhexyl-p-methoxycinnamate (UVB), octocrylene (UVA/UVB), octyl salicylate (UVB), benzophenones (UVB/UVA), and methyl anthranilate (UVA). Avobenzone or Parsol 1789 and mexoryl, a benzylidene camphor, block UVA. Physical agents include zinc oxide and titanium dioxide. These reflect UVA and UVB. Sunscreens should be worn regularly to prevent worsening of melasma and to maintain results of treatment.

14.6.2 Hydroquinone [4]

The most commonly used bleaching agent, hydroquinone is a phenolic derivative available at concentrations that may vary from 2 to 5%. Sometimes, for short course therapy, it can be prescribed at concentration of 10%. It has to be applied once a day, usually nightly. It inhibits tyrosinase and consequently melanine synthesis. Side effects include irritant and allergic contact dermatitis, nail discoloration, post-inflammatory hyperpigmentation and ochronosis. Due to these side effects, 2% concentration is the only one available on the marketplace. Higher concentrations need to be prepared as galenic formulations.

Hydroquinone is usually more effective when utilized in combination with other agents such as topical retinoids alone or topical retinoids and topical steroids (see Table 14.1). The addition of a weak topical steroid reduces the irritant effect of hydroquinone, but the treat-

Table 14.1 Hydroquinone combination formulas [3]

0.1% tretinoin	5% hydroquinone	0.1% dexamethasone (Kligman cream) [5]
0.1% tretinoin	5% hydroquinone	1% hydrocortisone
0.05% tretinoin	4% hydroquinone	0.01% fluocinolonone acetonide

ment regimen has to be short in time due to the side effects of topical steroids (folliculitis, telangectasia, atrophy). Glycolic acid and salicylic acid are also frequently used in association with hydroquinone.

14.6.3 Azelaic Acid [6]

Azelaic acid is a non-phenolic derivative (1,7-heptanedicarboxylic acid) used at concentration of 10–20% twice a day to treat melasma with minimal side effects (allergic reactions). It acts to disturb the tyrosinase synthesis and can be used as a bleaching agent in patients sensitive to hydroquinone. Better results are obtained if a glycolic acid cream is applied sequentially to azelaic acid treatment.

14.6.4 Kojic Acid [7]

Kojic acid is a fungal metabolite (5-hydroxy-4-pyran 4-1-2 methyl) known to inhibit tyrosinase and used to treat melasma at concentration of 2–4% twice a day. The stability is one of its advantages if compared with hydroquinone. Unfortunately, it is considered to have a high sensitizing potential.

Other topical bleaching agents include arbutin, licorice, unsaturated fatty acids, soy extracts, serine protease inhibitors, ellagic acid and resveratrol.

14.6.5 Retinoic Acid (Tretinoin) [8]

Generally used at a concentration of 0.05–1% with minimal side effects (erythema and desquamation), retinoic acid has to be applied once a day, usually nightly. It does not suppress melanogenesis, but accelerates epidermal turnover.

14.6.6 Chemical Peels [9]

Chemical peels can be performed both in fair and dark skin types, but in the latter case a ten-

dency to develop pigmentary changes and scarring is more probable.

Different agents are reported to be effective, but in our experience, the best options are:

- Superficial peeling with 25% salicylic acid in alcoholic solution (Figs. 14.5a, b and 14.6a, b)
- Combined peeling with 25% salicylic acid and 10% TCA gel (Figs. 14.7, 14.8, 14.9, 14.10 and 14.11)
- Medium peeling with 50% pyruvic acid

Patients should undergo a superficial peeling every 2 weeks or a medium peeling every month. With a medium chemical peel, the application of the solution must be reduced in time in order to avoid overpeel.

It is important that, 3 weeks before starting peeling treatment and 10 days after each treatment, the patient does the following routine:

- *In the morning:*
 - Wash skin with an alpha-hydroxy acid containing cleanser
 - Apply a UVA/UVB sunscreen
 - Wear a hat and avoid sun exposure
- *In the evening*
 - Wash with an alpha-hydroxy acid containing cleanser
 - Apply a product with a combination of hydroquinone and kojic acid once every 2 days
 - Apply a topical retinoid once every 2 days

In case of burning and stinging, the patient should stop the application of bleaching creams for few days and then start again.

It is very difficult to treat melasma. Better results are obtained if between chemical peeling treatments, patients apply topical depigmenting agents. The synergic action of the two treatments bleaches the skin and reduces melanin formation.

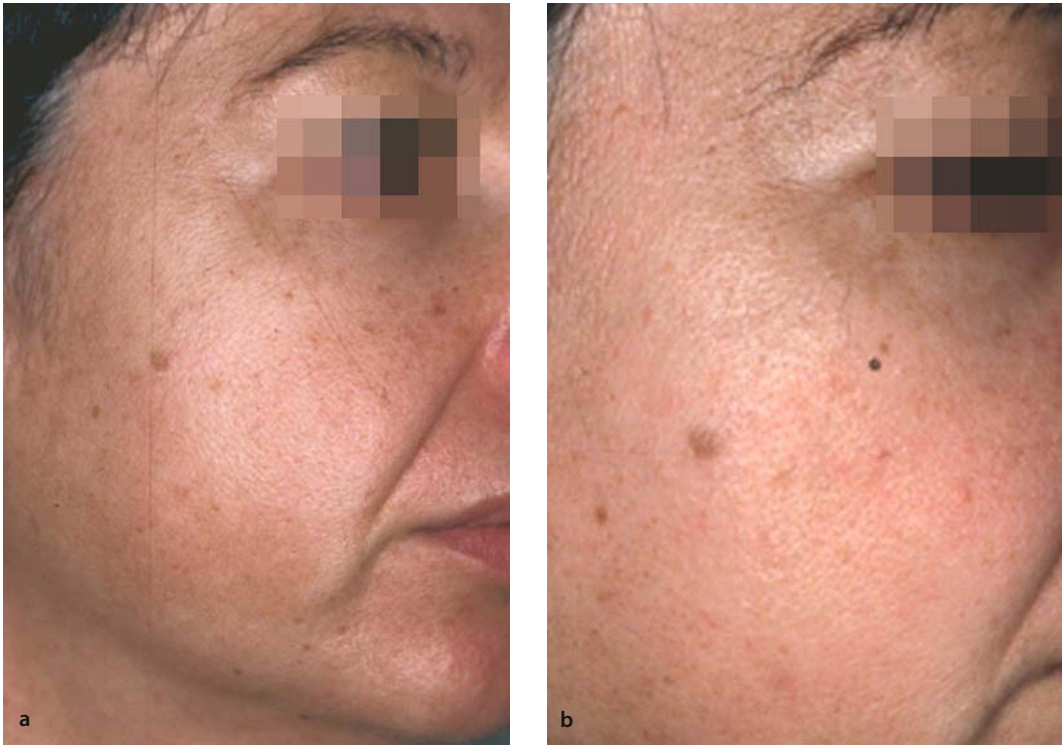

Fig. 14.5a, b. Mandibular melasma before and after superficial peeling with 25% salicylic acid

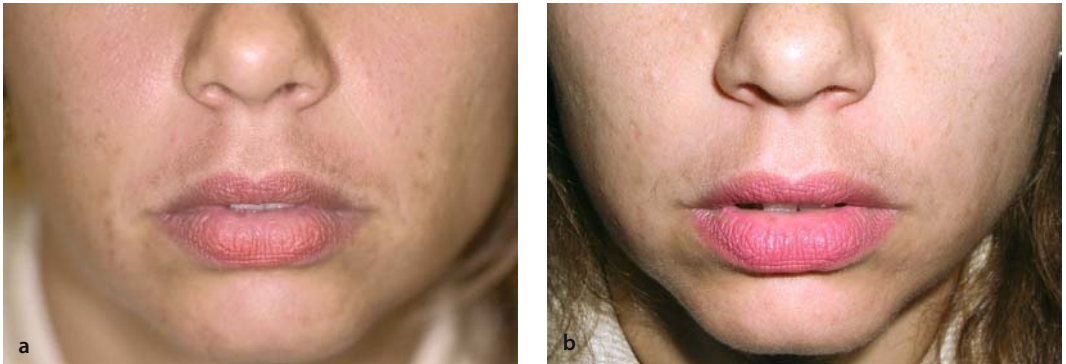

Fig. 14.6a, b. Melasma of the superior lip before and after superficial peeling with 25% salicylic acid

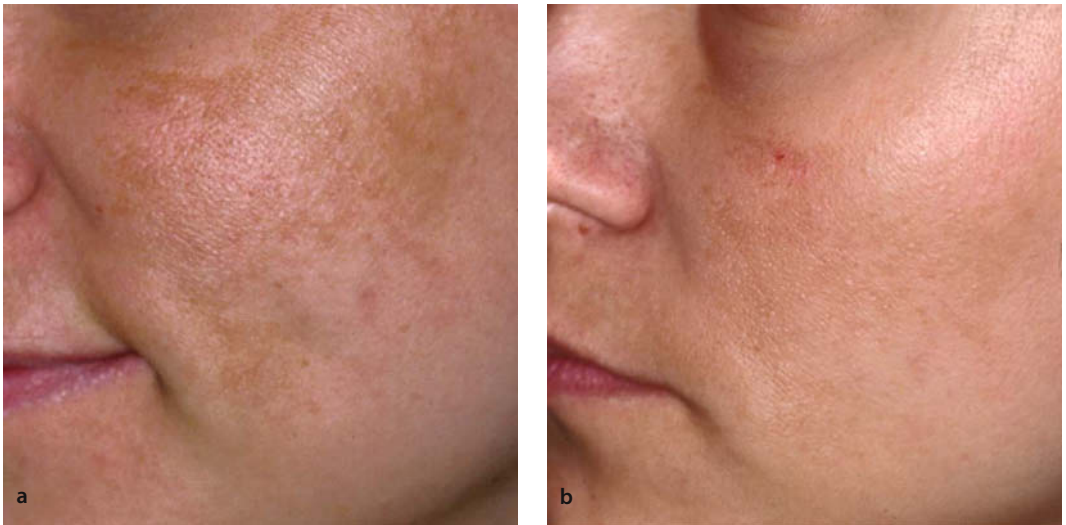

Fig. 14.7a, b. Malar melasma before and after combined peeling with 25% salicylic acid and 10% TCA gel

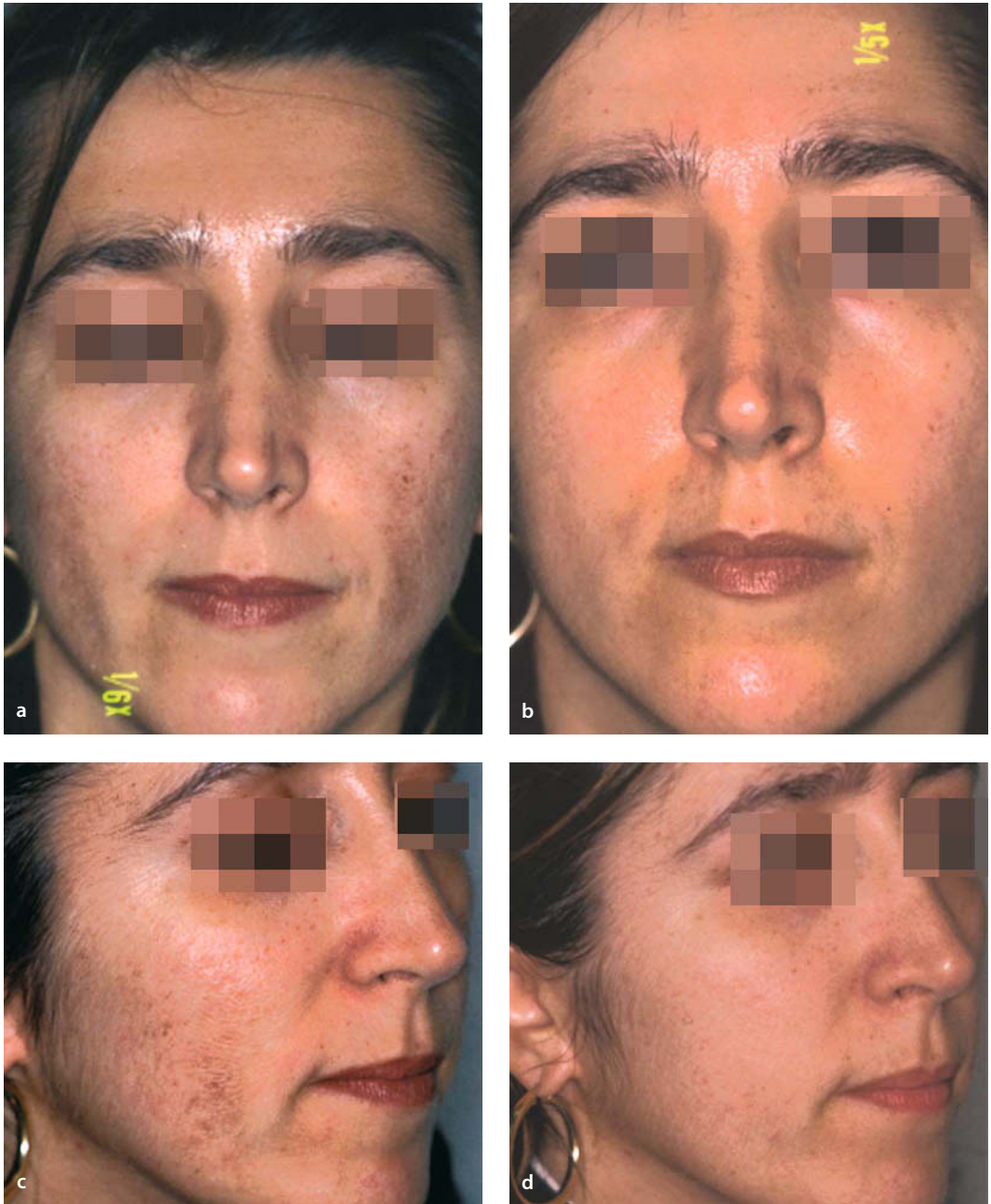

Fig. 14.8a–d. Melasma of the face before and after combined peeling with 25% salicylic acid and 10% TCA gel. Note in c skin xerosis 2 days after the first treatment

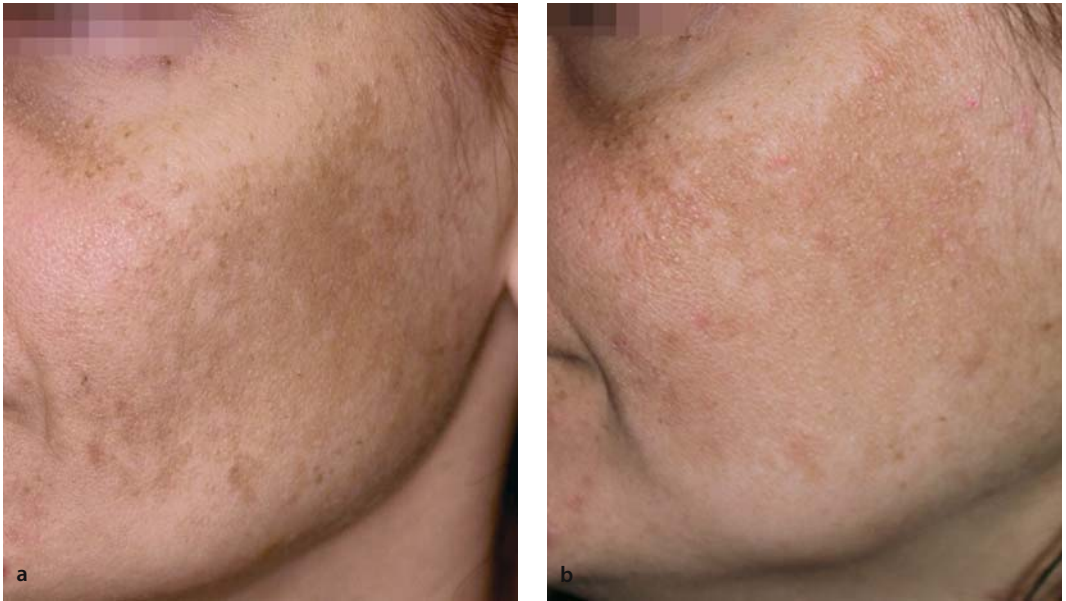

Fig. 14.9a, b. Malar melasma before and after combined peeling with 25% salicylic acid and 10% TCA gel. The improvement is mild

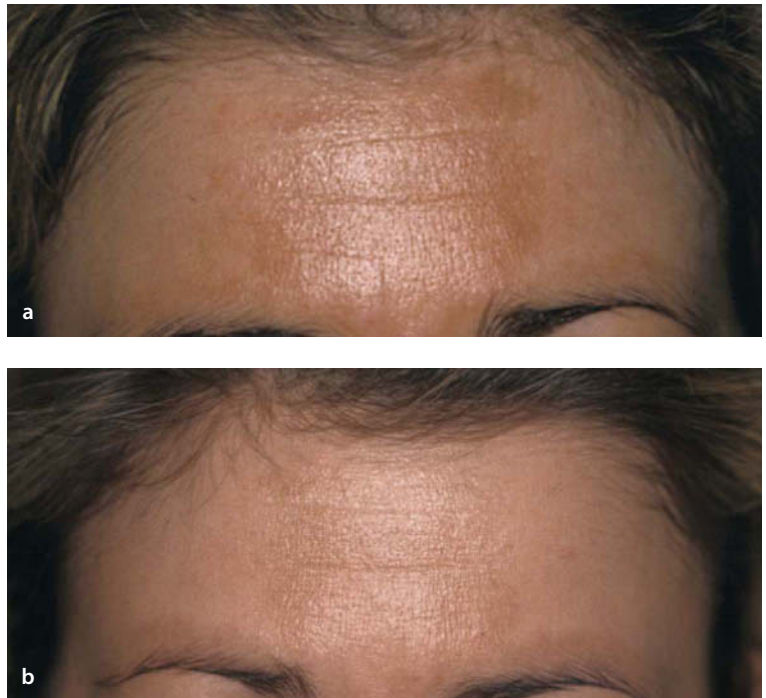

Fig. 14.10a, b. Melasma of the forehead before and after combined peeling with 25% salicylic acid and 10% TCA gel. The improvement is mild

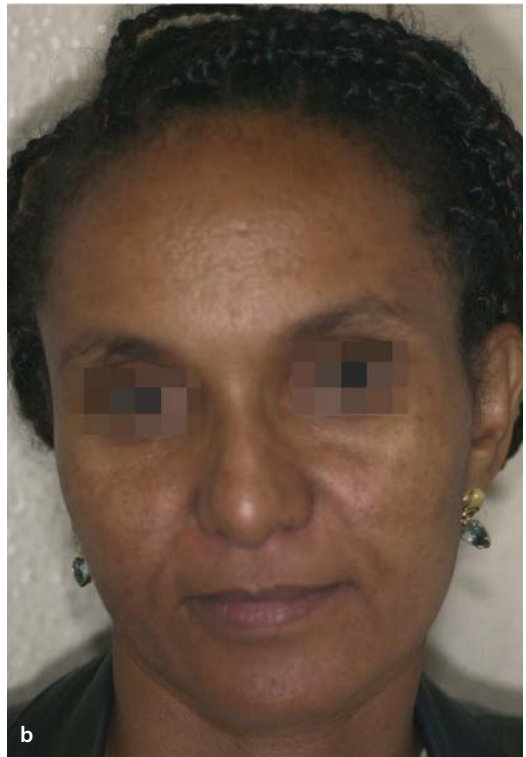
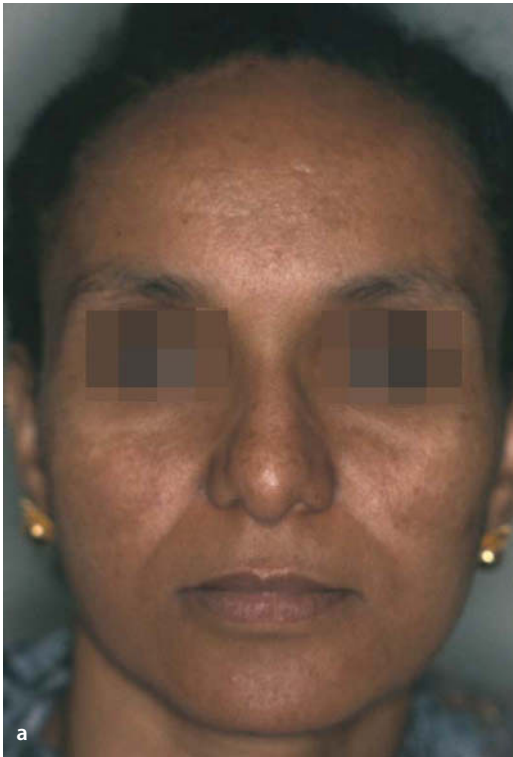
Fig. 14.11a, b. Melasma of the face in a patient with skin type VI before and after combined peeling with 25% salicylic acid and 10% TCA gel. The improvement is mild

14.7 Why Is a Combined Chemical Peel Useful for Treating Melasma?

14

Salicylic acid has a keratolytic effect, thus eliminating superficial pigmented keratinocytes and stimulating cells turnover. This superficial peeling allows TCA to act a low concentration to remove pigmented keratinocytes through papillary dermis (see Fig. 14.12).

In this way, moderate or no inflammation is produced and a lower number of peeling treatments is required to bleach the skin affected by melasma.

14.7.1 Laser

Despite the fact that several lasers have been used to try to depigment patients with melasma, none of them has been proven to be useful.

14.7.2 Cryotherapy

Cryotherapy with liquid nitrogen can be performed to treat melasma with different results. It produces lightening of the pigmented areas that are as much significantly striking as they are superficial.

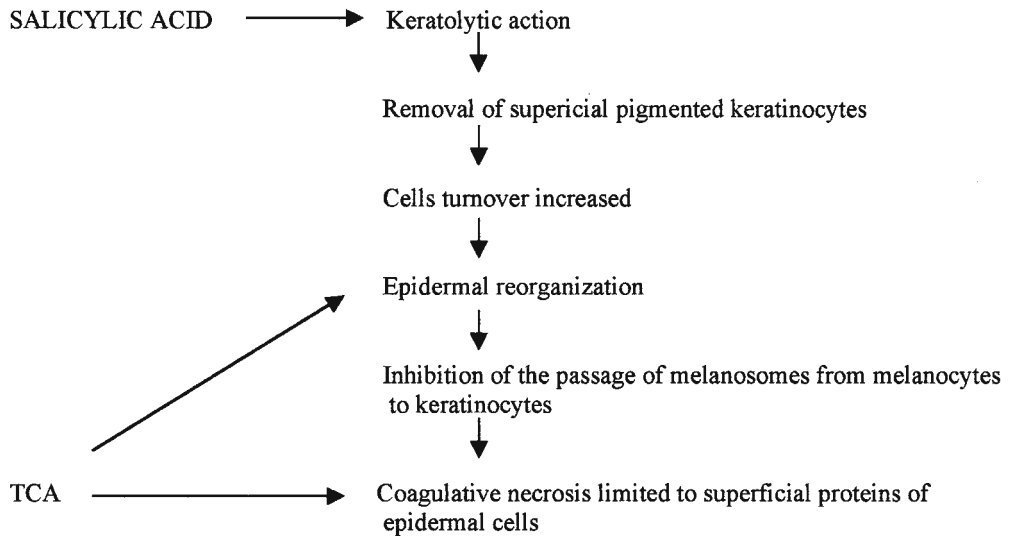


Fig. 14.12. Combined peel effects

References

1. Grimes PE (1995) Melasma. *Arch Dermatol* 131: 1453–1457
2. Kimbrough-Green CK, Griffiths CE, Finkel LJ, et al (1994) Topical retinoic acid (Tretinoin) for melasma in black patients—a vehicle controlled clinical trial. *Arch Dermatol* 130:727–733
3. Pezeshki S, Bell FE, Grummer S, McMichael AJ (2003) Therapeutic options for melasma. *Cosmetic Dermatology* 16:33–45
4. Haddad AL, Matos LF, Brunstein F, et al (2003) A clinical, prospective, randomized, double-blind trial comparing skin whitening complex with hydroquinone vs. placebo in the treatment of melasma. *Int J Dermatol* 42:153–156
5. Kligman AM, Willis I (1975) A new formula for depigmenting human skin. *Arch Dermatol* 111:40–48
6. Balina LM, Graupe K (1991) The treatment of melasma: 20% azelaic acid versus 4% hydroquinone cream. *Int J Dermatol* 30:893–895
7. Garcia A, Fulton JE Jr (1996) The combination of glycolic acid and hydroquinone or kojic acid for the treatment of melasma and related conditions. *Dermatol Surg* 22:443–447
8. Griffiths CE, Finkel LJ, Ditre CM, et al (1993) Topical tretinoin (retinoic acid) improves melasma: a vehicle-controlled, clinical trial. *Br J Dermatol* 129:415–421
9. Cotellessa C, Peris K, Onorati MT, et al (1999) The use of chemical peelings in the treatment of different cutaneous hyperpigmentation. *Dermatol Surg* 25:450–454

Photoaging

Pearl E. Grimes

The author has no financial interest in any of the products or equipment mentioned in this chapter.

Contents

15.1	Definition	161
15.2	Etiology	161
15.3	Epidemiology	162
15.4	Clinical Types [2, 3]	164
15.5	Therapeutic Intervention	164
15.5.1	Photoprotection	164
15.5.2	Retinoids	165
15.5.3	Tretinoin	166
15.5.4	Tazarotene	167
15.5.5	Retinol	167
15.5.6	Vitamin C	167
15.5.7	Alpha Hydroxy Acids	168
15.5.8	Polyhydroxy Acids	168
15.6	Bleaching Agents	168
15.6.1	Hydroquinone	168
15.6.2	Azelaic Acid	169
15.6.3	Kojic Acid	169
15.6.4	Miscellaneous	169
15.7	Chemical Peels for Photoaging	169
15.8	Superficial Peeling Agents	169
15.9	Medium-Depth Peeling	170
15.10	Summary	173
	References	173

15.1 Definition

Historically, photoaging has been defined as the superimposed effects of photodamage on intrinsically aging skin. It is a consequence of chronic ultraviolet light exposure. Photodam-

age is characterized by wrinkles, sallowness, laxity, mottled pigmentation, and texturally rough skin.

15.2 Etiology

All humans experience intrinsic aging. Typically, it is characterized by smooth, relatively atrophic, finely wrinkled or lax skin. Histologically, the stratum corneum is normal. However, the epidermis is atrophic and there is flattening of the dermo-epidermal junction. Dermal features include decreased thickness, loss of elastic fibers, and a decrease in the biosynthetic capacity of fibroblasts [1, 2] (Table 15.1).

In contrast, photoaging results from the long-term deleterious effects of sun exposure. Sunlight is divided into three components including ultraviolet, visible, and infrared light, with ultraviolet light representing the most important component. Ultraviolet light is divided into three groups based on the wavelength of light: 1) UVC (100–280 nm), which minimally affects the earth’s surface because it is blocked by the ozone layer; 2) UVB (290–320 nm), which causes erythema, sunburn, DNA damage, solar elastosis, hyperpigmentation, and skin cancer; and 3) UVA (320–400 nm), which requires a much higher dose to induce erythema. However, because UVA is more abundant and penetrates deeper, it is thought to play a more substantial role in the induction of photodamage [2].

Clinically, photodamaged skin is characterized by coarse and fine wrinkling, mottled pigmentary changes, sallowness, textural rough-

Table 15.1. Clinical and histological features of intrinsic (chronological) and extrinsic (photoaging) aging*

Clinical features	
Intrinsic	Smooth, atrophic, finely wrinkled, laxity, unblemished
Extrinsic	Fine and course wrinkles, sallowness, laxity, mottled, pigmentation, textural roughness, telangiectasias
Epidermis	
Intrinsic	Stratum corneum normal thickness (basket weave pattern), epidermis thinned, atrophic, flattened rete ridges
Extrinsic	Basket weave or compact stratum corneum, acanthosis and/or atrophy, keratinocyte atypia, flattened rete ridges
Dermis	
Intrinsic	Absent Grenz zone, loss of elastic fibers, elastogenesis, decreased thickness, microvasculature normal, no evidence of inflammation
Extrinsic	Grenz zone prominent, elastogenesis, elastosis, collagen degeneration, loss of anchoring fibrils
Microvasculature abnormal	Blood vessels dilated, twisted Later stages: sparse, perivenular lymphohistiocytic infiltrates

* Modified from Gilchrest [2] and Lavker [3].

ness, and telangiectasias. Histological features of photoaged skin include significant epidermal and dermal alterations [3]. The epidermal thickness may be increased or decreased corresponding to areas of hyperplasia or atrophy. There is loss of polarity of epidermal cells and keratinocyte atypia. Dermal features include elastosis, degeneration of collagen, and anchoring fibrils. Blood vessels become dilated and twisted. Ultraviolet light exposure activates matrix degrading metalloproteinase enzymes including collagenase. Cytokines are released from keratinocytes. The cumulative effect of these changes is chronic dermal inflammation [1, 2, 4].

15.3 Epidemiology

Photoaging affects all races and skin types. Signs of photoaging may begin at an early age, as evidenced by freckles following ultraviolet light exposure. However, the manifestations of photodamage may differ in lighter compared with darker skin types. In individuals with Fitzpatrick's skin types I–III, or lighter-com-

plexioned races, the clinical signs of photoaging (wrinkles, dyschromia, and sallowness) may also be accompanied by an increased occurrence of premalignant and malignant skin lesions including actinic keratoses, basal cell carcinoma, squamous cell carcinoma, and melanoma [5]. In contrast to lighter skin types, clinical observations document that people of color (skin types IV–VI) show less wrinkling with age than lighter-skinned individuals (Fig. 15.1a, b) [6]. The biological basis for these observations correlate with many of the well-documented morphological and physiological skin differences in dark as opposed to white skin (see section on dark skin). There appears to be a spectrum of photodamage in individuals with Fitzpatrick's skin types IV–VI with deeply pigmented skin showing minimal histological evidence of solar-induced changes (Fig. 15.2a, b). Clinical photodamage in black skin appears to be a subtle phenomenon, manifesting itself as diffuse or patchy hyperpigmentation and texturally rough skin. In addition, there is a significantly lower incidence of skin cancer in deeply pigmented people [7].

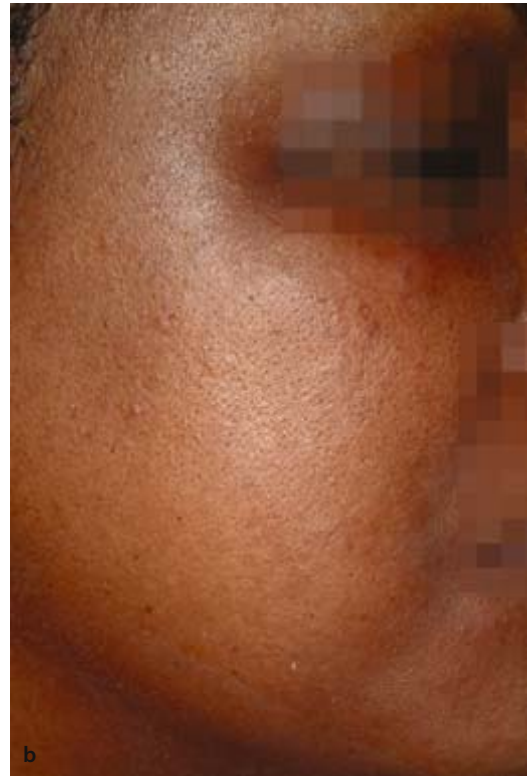
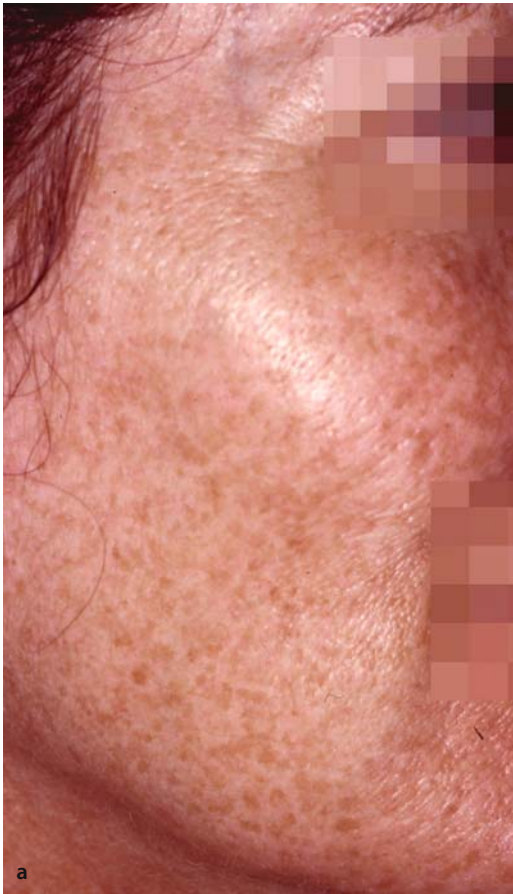
Fig. 15.1. a Fifty-seven-year-old Caucasian woman with fine wrinkling and significantly mottled hyperpigmentation. b Fifty-six-year-old African American woman with some textural irregularities, but no wrinkles

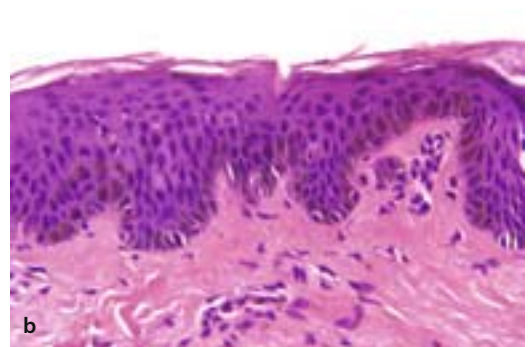
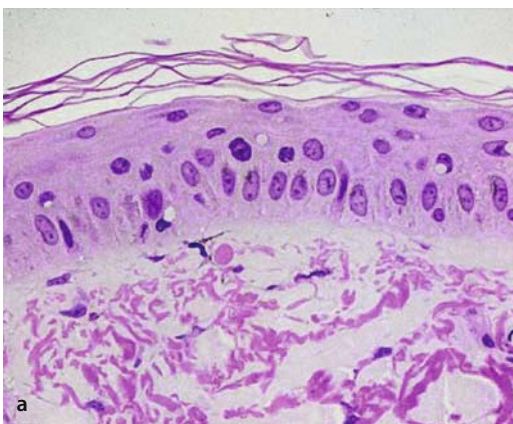


Fig. 15.2. a Biopsy of a 50-year-old Caucasian woman showing epidermal atrophy and collagen degeneration. b Biopsy of a 50-year-old African American woman showing minimal to no evidence of photodamage

15.4 Clinical Types [2, 3]

Glogau [8] classified the severity of photodamage based on the extent of epidermal and dermal degenerative changes (Table 15.2) (Fig. 15.3a–d). Severity of photodamage is categorized from I through IV, ranging from mild, moderate, advanced, to severely photodamaged skin. Patients with mild photodamage often respond to topical anti-aging regimens and superficial chemical peeling agents, whereas moderate to advanced photodamage often requires a medium-depth peel for substantial improvement (Table 15.3). Severe photodamage requires medium-depth or deep peeling procedures. Such patients may also require ablative resurfacing procedures in conjunction with lifting or rhytidectomies [9].

15.5 Therapeutic Intervention

15.5.1 Photoprotection

Prevention of photodamage requires a multifaceted approach. Photoprotection encompasses avoidance of sun exposure when possible, wearing protective clothing, and daily use of sunscreens (Table 15.3). Of the aforementioned strategies, sunscreens are the gold standard for skin protection from ultraviolet light. Sunscreens were initially developed to prevent UVB-induced sunburns. In the last 10–15 years, agents have been formulated which also absorb and/or block UVA radiation. Sunscreens are classified as organic or physical blocking agents. Organic sunscreens protect by absorbing UVB radiation, UVA radiation, or both.

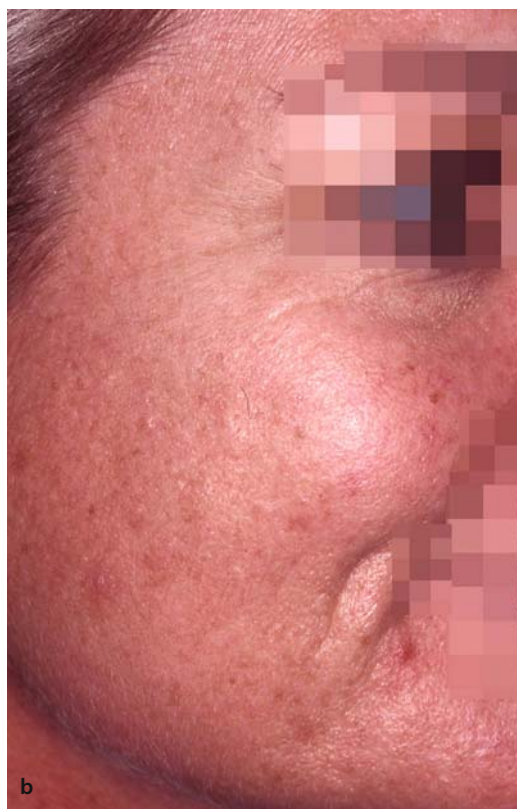
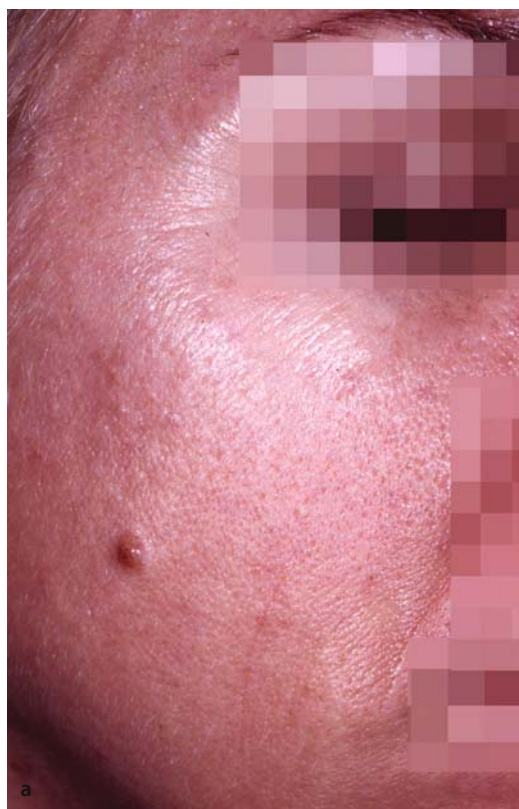
Fig. 15.3a, b. Series of patients showing Glogau's four photoaging groups. **a** Mild photodamage. **b** Moderate photodamage

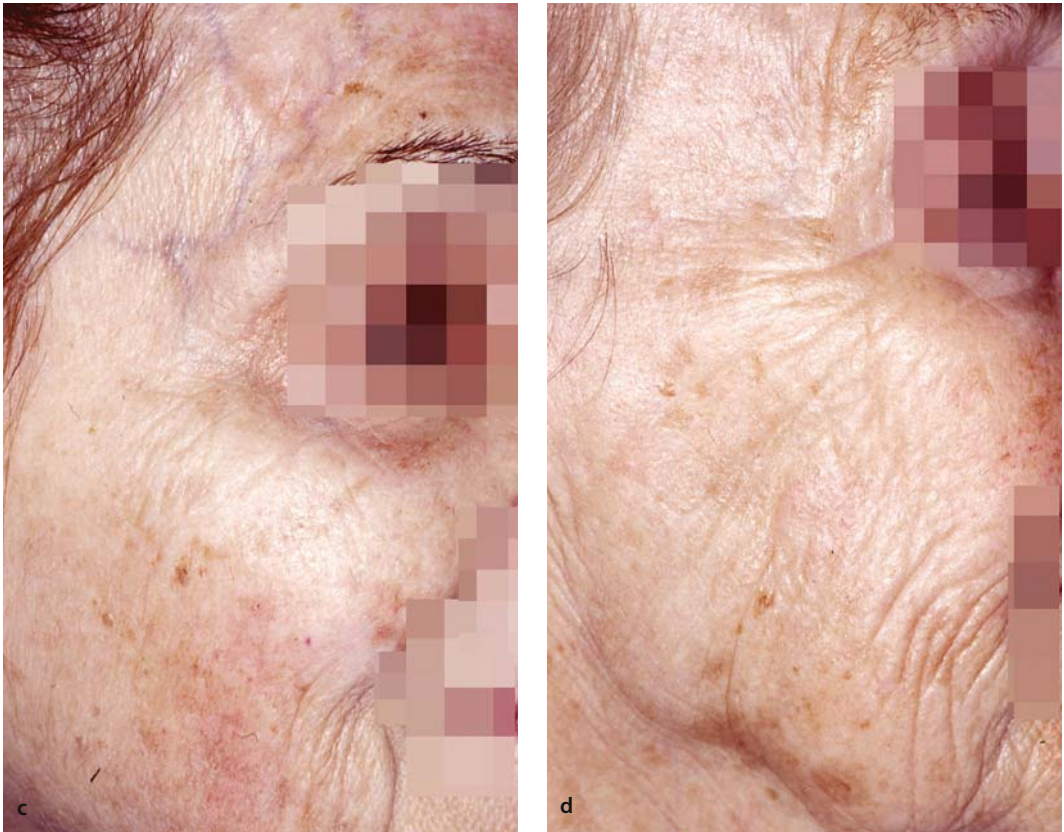


Fig. 15.3c, d. Series of patients showing Glogau's four photoaging groups. **c** Advanced photodamage. **d** Severe photodamage

These sunscreen ingredients include octyldimethyl-PABA (UVB), 2-ethylhexyl-p-methoxycinnamate (UVB), octocrylene (UVA/UVB), octyl salicylate (UVB), benzophenones (UVB/UVA), and methyl anthranilate (UVA). Avobenzone or Parsol 1789 and mexoryl, a benzylidene camphor, block UVA. Mexoryl is the most efficient of the UVA organic sunscreens [10]. Many sunscreen formulations combine ingredients to maximize photoprotection.

Physical agents include zinc oxide and titanium dioxide. These are the most effective sunscreens because they reflect UVA and UVB. When applied to the skin, they induce a white or ashen color, which many patients find cosmetically unacceptable. New micronized formulations of these agents are available which enhance cosmetic acceptability. Sunscreens

should be worn regularly prior to chemical peeling procedures.

15.5.2 Retinoids

Retinoids (i.e., tretinoin and tazarotene) mediate cellular responses primarily through activation of nuclear retinoid receptors [11]. There are two types of nuclear retinoic acid receptors: the retinoic acid receptors (RARs) and the retinoid X receptors. Each type of receptor contains three receptor subtypes: alpha, beta, and gamma [11, 12]. Among the commonly prescribed retinoids, tretinoin activates the RARs alpha, beta, and gamma directly, and the retinoid X receptors indirectly (through conversion of tretinoin to 9-cis-retinoic acid) [11, 13]. Conversely,

Table 15.2. Glogau's classification of photoaging*

Group	Clinical features
I (Mild)	Ages 20s–30s Early photoaging Mild dyschromia No keratoses Minimal wrinkling Minimal, no makeup Minimal, or no scarring
II (Moderate)	Late 30s–40s Early senile lentiginos Dyschromia Early actinic keratoses Parallel smile lines Early wrinkling Some foundation worn Mild acne scarring
III (Advanced)	Usually aged 50–65 Dyschromia, telangiectasias Visible keratoses Wrinkling at rest Always wears makeup Moderate acne scarring
IV (Severe)	Patient age 60–75 Actinic keratoses Prior skin cancers Wrinkling throughout Makeup cakes & cracks Severe acne scarring

* From Glogau [8]

tazarotenic acid, the metabolite of tazarotene, selectively binds to RARs beta and gamma and is unable to directly or indirectly activate retinoid X receptors [14]. This difference in receptor activity may explain the varying efficacy of the different retinoids in the treatment of dermatologic conditions. Retinoids show significant efficacy for treatment of photodamaged skin. Retinoids also increase the depth and penetration of peeling agents.

Table 15.3. Therapeutic approaches for photodamage

Topical agents	Broad spectrum sunscreens Retinoids Tretinoin Tazarotene Retinol Vitamin C formulations Alpha hydroxy acids Polyhydroxy acids Beta hydroxy acids Bleaching agents Kojic Acid Arbutin Licorice Azelaic Acid
Resurfacing procedures	Microdermabrasion Superficial chemical peeling Medium-depth peeling Deep peeling Ablative laser resurfacing Nonablative laser resurfacing Radio frequency therapy Facial lifting procedures

15.5.3 Tretinoin

Multiple open label and vehicle controlled studies have documented the efficacy and safety of tretinoin for treatment of photodamage [13, 15, 16, 17]. Griffiths et al. [15] assessed the efficacy of various concentrations of tretinoin in 100 subjects with photodamage. Subjects were randomized into three treatment groups treated with 0.1% tretinoin, 0.025% tretinoin or vehicle cream. Treatment with 0.1% tretinoin or 0.025% tretinoin induced statistically significant improvements in photoaging changes compared with vehicle. There were no clinically significant differences in the two tretinoin formulations. However, the degree of irritation was significantly greater with the 0.1% formulation.

In a double-blind study of photodamaged skin, it has been demonstrated that papillary dermal type I collagen formation was reduced by 56% in photodamaged skin compared with

sun-protected skin [18]. Skin treated with 0.1% tretinoin compared with vehicle resulted in an 80% increase in Type I collagen formation, whereas the vehicle-treated areas showed a decrease in collagen formation.

In an evaluation of the efficacy of tretinoin in the treatment of hyperpigmented lesions associated with photoaging in Asian (Chinese and Japanese) patients, 45 photoaged Asian patients were randomized to treatment with tretinoin 0.1% or vehicle for 40 weeks [16]. At the end of the treatment period, hyperpigmented lesions of the face and hands were lighter or much lighter in 90% of the tretinoin group, compared with 33% of the vehicle group. Moreover, colorimetry demonstrated significant lightening of the lesions after tretinoin treatment compared with vehicle.

15.5.4 Tazarotene

Tazarotene is a synthetic retinoid that mediates cell differentiation and proliferation [19]. Tazarotene, a pro-drug of tazarotenic acid, has recently been proven effective as a treatment for photodamaged skin [11].

In a 1-year evaluation of 563 patients with facial photodamage, 0.1% tazarotene cream was applied to one half of their faces and vehicle cream to the other half in a double-blinded study for 24 weeks [20]. Patients then continued treatment with tazarotene for an additional 28 weeks. At week 24, compared with the vehicle cream, tazarotene treatment was associated with a significantly greater occurrence of treatment success (defined as at least 50% global improvement), and at least a one-grade improvement in fine wrinkling, pore size, mottled hyperpigmentation, lentigines, elastosis, irregular depigmentation, roughness, and the overall assessment of photodamage. Moreover, Kang et al. also found that tazarotene improved mottled pigmentation and fine wrinkles and that these improvements were comparable to those seen with tretinoin cream [11].

In general, retinoids are also well tolerated in darker skin types; however, retinoid dermatitis may cause post-inflammatory hyperpigmentation. In addition, progressive hyperpigmenta-

tion can occur with retinoids without any clinical evidence of irritation.

15.5.5 Retinol

All trans-retinol, also known as vitamin A₁, is the predominant circulating retinoid in human tissue. Although retinol is believed to be a precursor of other retinoids, the metabolic pathways of the physiologic and pharmacologic effects are not well understood. They are used extensively in cosmeceutical formulations for photoaging. Retinols are generally recognized as safe ingredients in the United States and are widely used in cosmetics and toiletries, most often at a concentration of 0.1–1.0% [21, 22].

Kang et al. [23] compared the clinical, histologic, and molecular responses of normal human skin to topical retinol with that of retinoic acid. Application of retinol and retinoic acid produced epidermal thickening. However, retinol produced less erythema compared with retinoic acid. The authors suggest that these data are compatible with the idea that retinol may be a pro-hormone of retinoic acid.

15.5.6 Vitamin C

Ascorbic acid (Vitamin C) has been shown to protect against sunburn, delay the onset of skin tumors, and reduce ultraviolet-B radiation-induced skin wrinkling [24–27]. Ascorbic acid displays potent antioxidant properties and is the primary water soluble non-enzymatic biologic antioxidant in human tissues [28–31]. Vitamin C is necessary for the normal formation and maintenance of collagen and is a cofactor for several hydroxylating enzymes [32–34]. The topical application of vitamin C has been suggested in order to maximize its antioxidant properties and stimulate collagen production, as oral administration is believed incapable of generating adequate tissue ascorbic acid levels for these tissue effects [25]. The efficacy of various topical vitamin C preparations have been extensively evaluated and have been found to improve photodamage and stimulate new collagen formation [35]. Ascorbyl palmitate, a fat-

soluble synthetic ester of vitamin C has also been shown to reduce redness associated with sunburn 50% sooner than areas on the same patient that were left untreated [36]. Vitamin C formulations are typically non-irritating when applied topically and have also been shown to improve hyperpigmentation [37].

15.5.7 Alpha Hydroxy Acids

The alpha hydroxy acids (AHAs) are organic carboxylic acids having one hydroxyl group attached to the alpha position of the carboxylic carbon atom. Alpha hydroxy acids are naturally occurring products present in sugar cane juice, sour milk, tomato juice, grapes, and apples. Glycolic acid, a 2-carbon molecule, and the smallest of the AHA compounds, has gained widespread acceptance as a superficial exfoliant and peeling agent [38, 39].

AHAs induce changes in the epidermis and dermis. They cause exfoliation of the stratum corneum. Dermal effects have also been demonstrated. In a study by Ditre et al. [40], patients applied a lotion containing 25% glycolic, citric, or lactic acid to one forearm and a placebo lotion to the other for 6 months. Thickness of forearm skin was measured throughout the study. Treatment with AHAs caused an approximate 25% increase in skin thickness. The epidermis was thicker and papillary dermal changes included increased thickness, increased acid mucopolysaccharides, improved quality of elastic fibers, and increased density of collagen. No inflammation was evident. Treatment with AHAs produced significant reversal of epidermal and dermal markers of photoaging. Glycolic acid improves the tone and texture of the skin. It is used as a monotherapy, or in combination with retinoids and other bleaching agents for photodamage.

15.5.8 Polyhydroxy Acids

Polyhydroxy Acids (PHAs) provide similar effects as AHAs, but do not cause the sensory irritation responses that limit the use of AHAs. PHAs have also been found to have some addi-

tional benefits including humectant and moisturizing properties. They have been shown to improve photodamage when combined with retinyl acetate and retinoic acid [41]. Polyhydroxy acids are also well tolerated when treating photodamage in dark skin.

15.6 Bleaching Agents

15.6.1 Hydroquinone

Hydroquinone is a highly efficacious bleaching agent and is commonly used in the treatment of melasma and post-inflammatory hyperpigmentation, the dyschromia of photoaging, lentigines and freckles. It remains the gold standard for treating hyperpigmentation. Bleaching agents are often used in conjunction with retinoids and chemical peeling agents for photodamage (see peeling protocols). Hydroquinone acts by inhibiting tyrosinase and preventing the conversion of tyrosine to dopa [42, 43]. With repeated application, hydroquinone may cause destruction of melanosomes, melanocyte organelles, and melanocyte necrosis [42].

In the United States, concentrations range from 2% (over-the-counter) to 4% (by prescription). Higher concentrations can be compounded by pharmacists for stubborn cases of hyperpigmentation. Multiple studies have documented the efficacy of hydroquinone formulations [44].

A new combination formulation containing hydroquinone 4%, tretinoin .05% and fluocinolone .01% was approved in the United States for treatment of melasma. This combination has been approved for use in South America, Singapore, Korea, and Mexico. The formulation was based on the Kligman/Willis formula [44]. In addition, other new hydroquinone formulations contain 4% hydroquinone plus retinol in concentrations of 0.15 or 0.3%. These formulations also improve the dyschromia of photoaging.

Complications of hydroquinone therapy include acute and chronic reactions. Common acute reactions are irritant and allergic contact dermatitis, and post-inflammatory hyperpigmentation. Lesional and perilesional hypopigmentation may occur. This is usually a tempo-

rary complication. The major long-term concern regarding the use of hydroquinone is ochronosis. This condition is most often observed in African patients who have used products containing high concentrations of hydroquinone for prolonged periods [45, 46]. In contrast, cases in the United States are rare and are predominantly associated with the use of hydroquinone 2%. Clinically, ochronosis is characterized by reticulated, sooty hyperpigmentation of the face. Ochronosis is often considered permanent. The author has treated cases with topical retinoids and topical corticosteroids combined with a series of superficial salicylic acid chemical peels, achieving moderate to excellent improvement. Bellew and Alster [47] reported the efficacy of the 755-nm Q-Switched Alexandrite laser for exogenous ochronosis in two patients.

15.6.2 Azelaic Acid

Azelaic acid is a naturally occurring dicarboxylic acid (1,7-heptanedicarboxylic acid) that has demonstrated beneficial therapeutic effects in the treatment of acne and several disorders of hyperpigmentation [48]. There are minimal effects on normally pigmented human skin, freckles, senile lentiginos, and nevi. The cytotoxic and antiproliferative effects of azelaic acid may be mediated via inhibition of mitochondrial oxidoreductase activity and DNA synthesis. Disturbance of tyrosinase synthesis by azelaic acid may also influence its therapeutic effects. Azelaic acid can be used as a hypopigmenting agent in patients sensitive to hydroquinone.

15.6.3 Kojic Acid

Kojic acid (5-hydroxy-4 pyran 4-1-2 methyl) is a fungal derivative which inactivates tyrosinase via chelation of copper. Concentrations range from 2 to 4%. It can be used for monotherapy or in combination with retinoids or other cosmetic products such as glycolic acid. Compared with hydroquinone, these kojic acid formulations usually show less efficacy. However, they may be effective in patients who do not

tolerate hydroquinone. In addition, they can be used as maintenance therapies for treatment of hyperpigmentation following 4–6 months of hydroquinone treatment.

15.6.4 Miscellaneous

Other topical bleaching agents include arbutin, licorice, unsaturated fatty acids, soy extracts, serine protease inhibitors, ellagic acid, and resveratrol [49].

15.7 Chemical Peels for Photoaging

In 1982, Stegman reported the histologic effects of three peeling agents, including TCA, full strength phenol, Baker's phenol, and dermabrasion on normal and sun-damaged skin of the neck. This study demonstrated that 40–60% TCA caused epidermal necrosis, papillary dermal edema, and homogenization to the midreticular dermis 3 days after peeling. Findings were similar in sun-damaged compared with non sun-damaged skin. Ninety days after peeling, he observed an expanded papillary dermis, which he defined as the Grenz zone. The thickness of the Grenz zone increased as the depth of peeling increased. The investigative work of Stegman and others facilitated our understanding of the capacity of medium-depth and deep peeling agents to improve photodamage [50, 51, 52]. Superficial, medium-depth, and deep-peeling agents are currently utilized according to the degree of photodamage.

15.8 Superficial Peeling Agents

The benefits of superficial peeling agents have been reported for mild to moderate photodamage. Following the pioneering work of Van Scott and Yu on the effects of alpha hydroxy acids [53], these agents were popularized as peeling agents for photodamage [54, 55, 56]. Moy et al. [55], in a mini pig model showed that application of 50 and 70% glycolic acid was comparable to TCA 50% in stimulating collagen production.

Given the depth of injury induced by glycolic acid peeling, other investigators have reported no benefit when using a series of four 70% glycolic acid peels to treat moderate photodamage [57].

Several studies have reported the efficacy of salicylic acid peeling for treatment of photodamage. Kligman and Kligman [58] ushered salicylic acid into the modern arena of superficial peeling agents. They treated 50 women with mild to moderate photodamage, reporting improvement in pigmented lesions, surface roughness, and reduction in fine lines. Gladstone et al. [59] subsequently assessed the efficacy of hydroquinone cream 4% used alone or in combination with serial 20 and 30% salicylic acid peeling for treatment of moderate to advanced photodamage of the neck and chest.

Nineteen women were treated. Of that group, nine were treated with 4% hydroquinone and serial salicylic acid peeling. Both groups showed improvement in photodamage; however, there were no significant differences between the two treatments.

15.9 Medium-Depth Peeling

Trichloroacetic acid and phenol peels (see peel sections) have been used extensively to treat photodamage [60, 61]. However, TCA peels in concentrations above 35% are unpredictable. Albeit efficacious for severe photodamage, phenol peels are associated with myriad side effects [61]. Hence, combination medium-depth peeling agents have become increasingly popu-

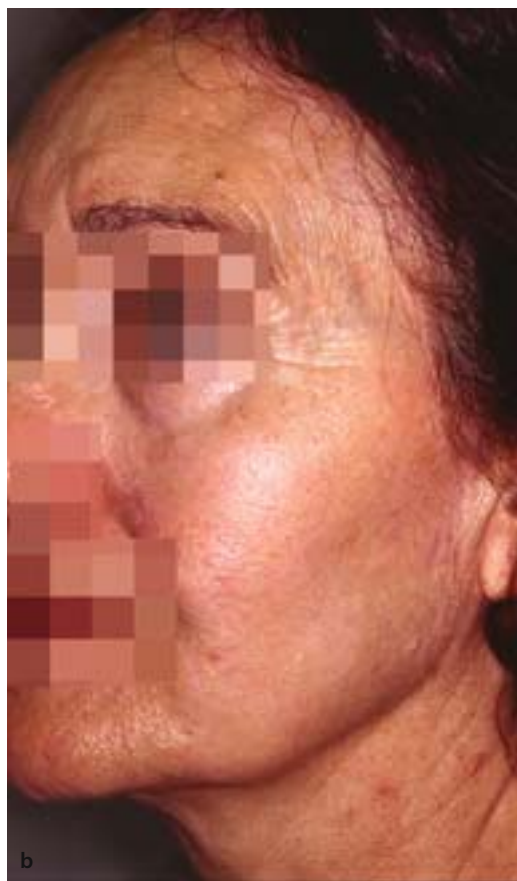
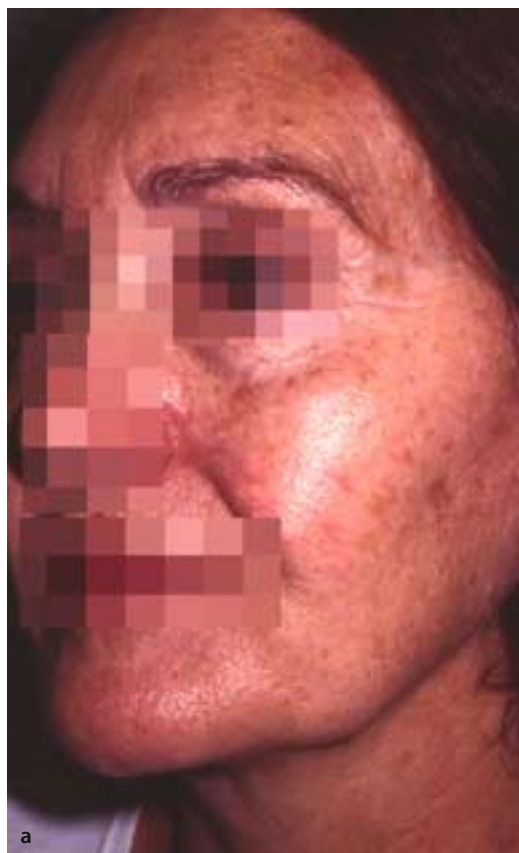
Fig. 15.4. a Moderate photodamage. b Significant improvement after a 35% TCA peel, (Dr. Mark Rubin)

lar for treatment of photodamage. Monheit and Coleman [62, 63] popularized the concept of combination peeling procedures using Jessner's solution or glycolic acid in combination with TCA 35%. The application of Jessner's solution prior to TCA peeling was effective in destroying the epidermal barrier allowing for deeper penetration and more even application of the TCA peel. Similar results are achieved with application of 70% glycolic acid prior to TCA peeling. Tse et al. [64] in a split face study of 13 patients with photodamage compared the efficacy of 70% glycolic acid and TCA 35% with Jessner's solution and TCA 35%. Clinical and histological assessments were performed at 7, 30, and 60 days after peeling. Clinically, the glycolic acid/TCA 35% peel was more effective for the

treatment of actinic keratoses. It induced a slightly thicker Grenz zone, greater papillary dermal fibrosis, and neovascularization compared with Jessner's solution/TCA 35% (Figs. 15.4, 15.5, 15.6 and 15.7).

Samaby et al. [65] performed medium-depth peeling using 70% glycolic acid and 35% TCA in five patients with facial photodamage. Biopsies were performed at baseline, prior to chemical peeling, and at 3 months following the peel. Histological and ultrastructural assessments showed markedly decreased epidermal intracytoplasmic vacuoles, decreased elastic fibers, increased activated fibroblasts, and organized arrays of collagen fibrils, suggesting that a combination medium-depth glycolic acid 70%/TCA 35% peel improves photodamage.

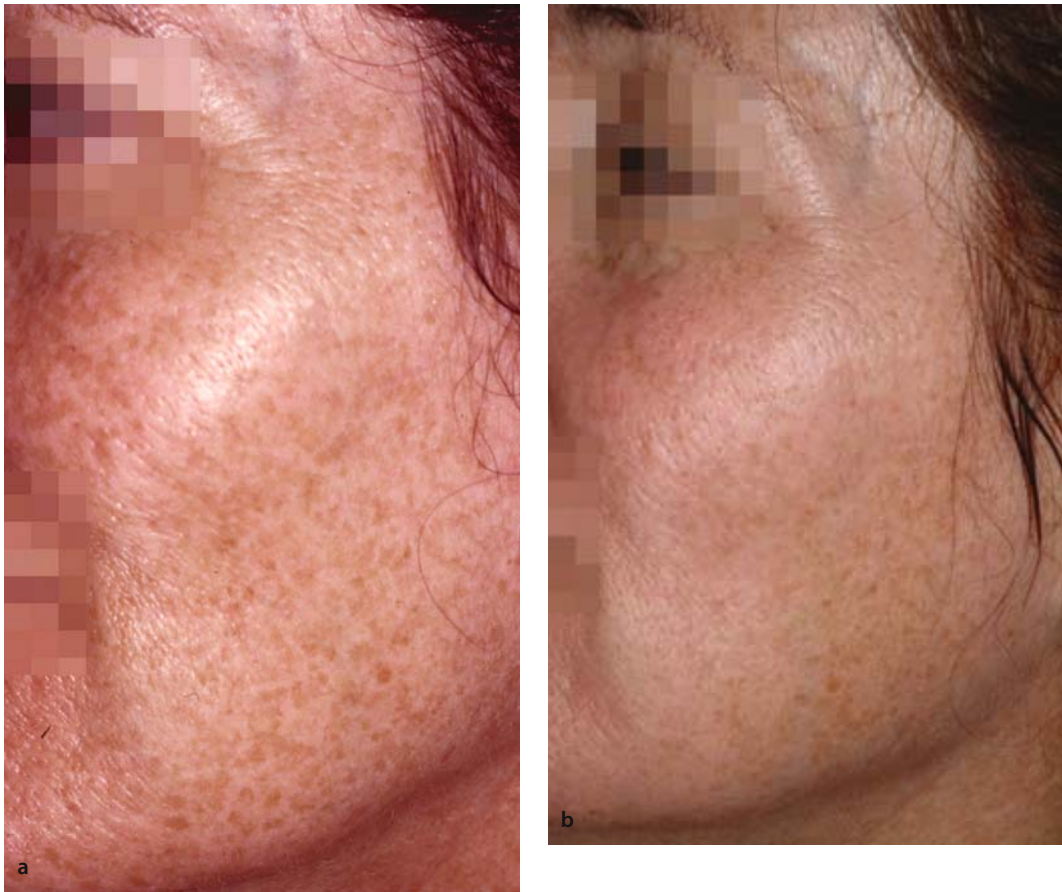

Fig. 15.5a, b. Fine wrinkles and mottled pigmentation before (a) and after (b) two 15% TCA peels

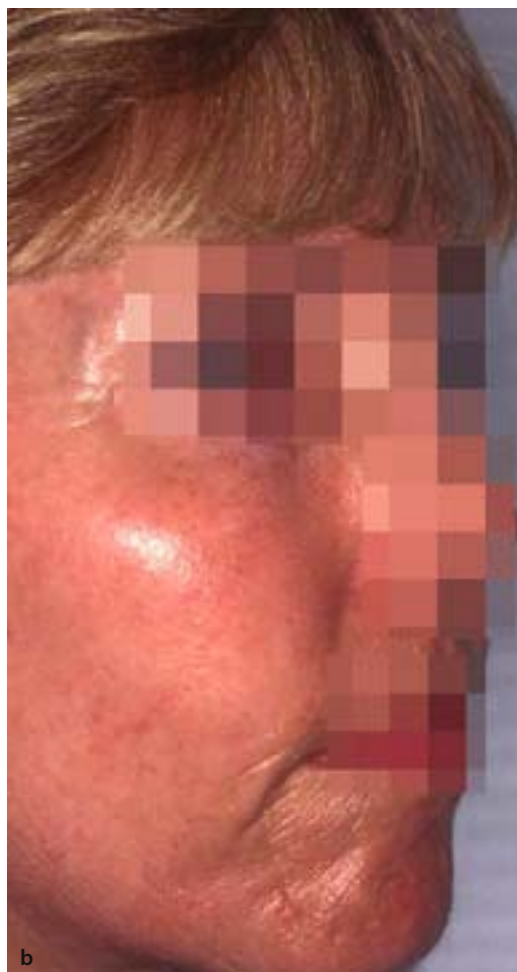
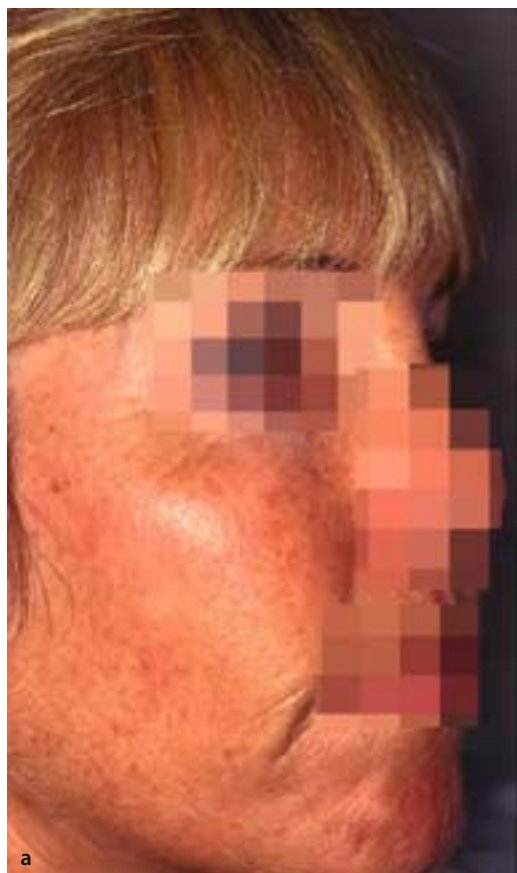
Fig. 15.6a, b. Before (a) and after (b) combination glycolic acid 70%/35% TCA peeling (Mark Rubin, MD)

15

Lawrence et al. [66] in a split face study, compared the efficacy and safety of Jessner's solution and 35% TCA with 5% fluorouracil in the treatment of widespread facial actinic keratoses. Fifteen patients were treated. Both treatments reduced the number of visible actinic keratoses by 75%. Similarly, both caused equivalent reductions in keratinocyte atypia, hyperkeratosis, and parakeratosis. Compared to fluorouracil, only one application of the peel was necessary.

Pyruvic acid peels have also been used for treatment of photodamage. Pyruvic acid is an α -keto acid which is converted physiologically to lactic acid. It is used in concentrations of 40–70% in water/ethanol solutions. Ghersetich et al. [67] treated 20 patients with Glogau's photoaging types I and II. A series of four peels were performed at 4-week intervals. After pyruvic acid peeling, subjects demonstrated a smoother texture, less evident fine wrinkles, and lightening of areas of hyperpigmentation. Side effects were minimal.

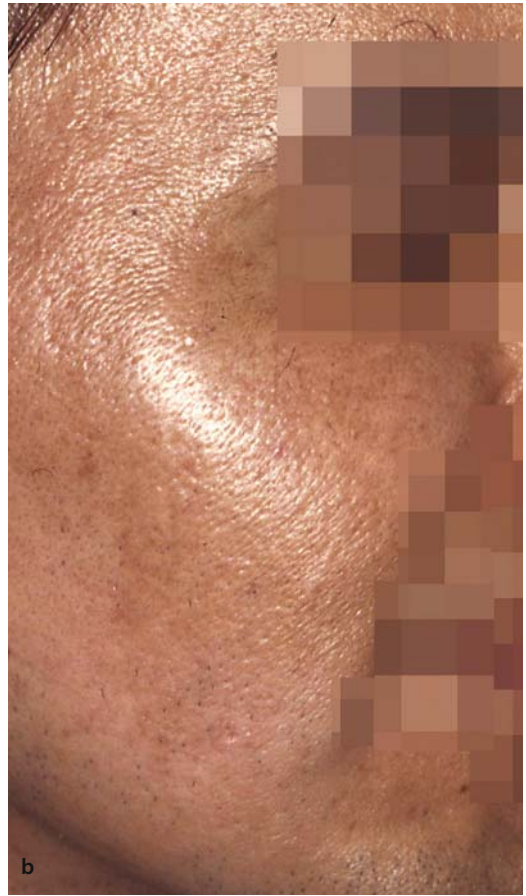
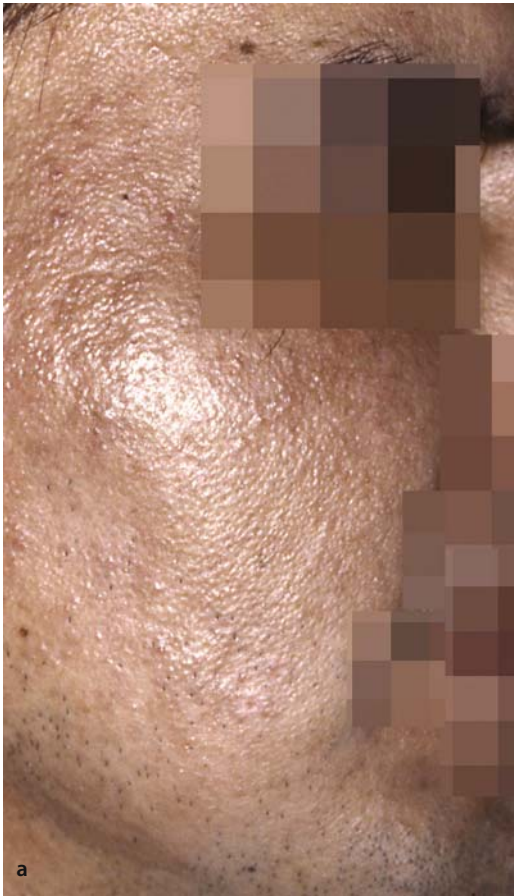
Fig. 15.7a, b. Texturally rough skin, a manifestation of photodamage, improved by a series of five salicylic acid 20%/30% peels

15.10 Summary

In summary, multiple studies have documented the efficacy of topical agents (retinoids, antioxidants, and topical bleaching agents) used in combination with superficial and/or medium-depth or deep peeling agents for photodamage. The treatment of photodamage requires a multifaceted approach incorporating sun protection, antioxidants, exfoliating agents, retinoids, and resurfacing procedures. Despite the evolution of new and advanced laser technologies, chemical peeling remains a viable, efficacious, and cost-effective treatment for photodamage.

References

1. Bhawan J, Andersen W, Lee J, Labadie R, Solares G (1995) Photoaging versus intrinsic aging: a morphologic assessment of facial skin. *J Cutan Pathol* 22:154–159
2. Gilchrist BA (1996) A review of skin aging and its medical therapy. *Br J Dermatol* 135:867–875
3. Lavker RM (1995) Cutaneous aging: chronologic versus photoaging. In: Gilchrist BA (ed) *Photodamage*. Blackwell Science, Cambridge, MA, pp 123–135
4. Vayalil PK, Mittal A, Hara Y, Elmets CA, Katiyar SK (2004) Green tea polyphenols prevent ultraviolet light-induced oxidative damage and matrix metalloproteinases expression in mouse skin. *J Invest Dermatol* 122:1480–1487

5. Spencer JM (2004) Premalignant manifestations of photoaging: actinic keratoses and atypical nevi. In: Goldberg DJ (ed) *Photodamaged skin*. Marcel Dekker, Inc., New York, pp 1–16
6. Grimes PE (2004) Benign manifestations of photo-damage: ethnic skin types. In: Goldberg DJ (ed) *Photodamaged skin*. Marcel Dekker, Inc., New York, pp 175–196
7. Washington CV, Grimes PE (2003) Incidence and prevention of skin cancer. *Cosmet Dermatol* 16(S3): 46–48
8. Glogau RG (1994) Chemical peeling and aging skin. *J Geriatr Dermatol* 2:30–35
9. Fulton JE, Porumb S (2004) Chemical peels: their place within the range of resurfacing techniques. *Am J Clin Dermatol* 5:179–187
10. Seite S, Colige A, Piquemal-Vivenot P, Montastier C, Fourtanier A, Lapiere C, Nusgens B (2000) A full-UV spectrum absorbing daily use cream protects human skin against biological changes occurring in photoaging. *Photodermatol Photoimmunol Photomed* 16:147–155
11. Kang S, Leyden JJ, Lowe NJ, et al (2001) Tazarotene cream for the treatment of facial photodamage. *Arch Dermatol* 137:1597–1604
12. Chandraratna RAS (1996) Tazarotene: first of a new generation of receptor-selective retinoids. *Br J Dermatol* 135:18–25
13. Weinstein GD, Nigra TP, Pochi PE et al (1991) Topical tretinoin for treatment of photodamaged skin: a multicenter study. *Arch Dermatol* 127: 659–665
14. Levin AA, Sturzenbecker LJ, Kazmer S, et al (1992) 9-cis Retinoic acid stereoisomer binds and activates the nuclear receptor RXR alpha. *Nature* 355: 359–361
15. Griffiths CE, Kang S, Ellis CN, Kim KJ, Finkel LJ, Ortiz-Ferrer LC, White GM, Hamilton TA, Voorhees JJ (1995) Two concentrations of topical tretinoin (retinoic acid) cause similar improvement of photoaging but different degrees of irritation. A double-blind, vehicle-controlled comparison of 0.1% and 0.025% tretinoin creams. *Arch Dermatol* 131: 1037–1044
16. Griffiths CEM, Goldfarb MT, Finkel LJ, et al (1994) Topical tretinoin (retinoic acid) treatment of hyperpigmented lesions associated with photoaging in Chinese and Japanese patients: a vehicle-controlled trial. *J Am Acad Dermatol* 30:76–84
17. Tadaki T, Watanabe M, Kumasaka K, Tanita Y, Kato T, Tagami H, Horii I, Yokoi T, Nakayama Y, Kligman AM (1993) The effect of topical tretinoin on the photodamaged skin of the Japanese. *Tohoku J Exp Med* 169:131–139
18. Griffiths CE, Russman AN, Majmudar G, Singer RS, Hamilton TA, Voorhees JJ (1993) Restoration of collagen formation in photodamaged human skin by tretinoin (retinoic acid) *N Engl J Med* 329: 530–535
19. Tzaneva S, Seeber A, Honigsmann H, Tanew A (2002) A comparison of psoralen plus ultraviolet A (PUVA) monotherapy, tacalcitol plus PUVA and tazarotene plus PUVA in patients with chronic plaque-type psoriasis. *Br J Dermatol* 147:748–753
20. Sefton J, Kligman AM, Kopper SC, Lue JC, Gibson JR (2004) Photodamage pilot study: a double-blind, vehicle-controlled study to assess the efficacy and safety of tazarotene 0.1% gel. *J Am Acad Dermatol* 43:656–663
21. *Cosmetic Ingredient Review* (1987) Final report on the safety assessment of retinyl palmitate and retinol. *J Am Coll Toxicol* 6:279–320
22. Suzuki S, Miyachi Y, Niwa Y, Isshiki N (1989) Significance of reactive oxygen species in distal flap necrosis and its salvage with liposomal SOD. *Br J Plast Surg* 42:559–564
23. Kang S, Duell EA, Fisher GJ, et al (1995) Application of retinol to human skin in vivo induces epidermal hyperplasia and cellular retinoid binding proteins characteristic of retinoic acid but without measurable retinoic acid levels or irritation. *J Invest Dermatol* 105:549–556
24. Bissett DL, Chatterjee R, Hannon DP (1990) Photoprotective effect of superoxide-scavenging antioxidants against ultraviolet radiation-induced chronic skin damage in the hairless mouse. *Photodermatol Photoimmunol Photomed* 7:56–62
25. Darr D, Combs S, Dunston S, Manning T, Pinnel S (1992) Topical vitamin C protects porcine skin from ultraviolet radiation-induced damage. *Br J Dermatol* 127:247–253
26. Black HS (1987) Potential involvement of free radical reactions in ultraviolet light mediated cutaneous damage. *Photochem Photobiol* 46:213–221
27. Eberlein-Konig B, Placzek M, Pryzbylla B (1998) Protective effect against sunburn of combined systemic ascorbic acid (vitamin C) and d-alpha-tocopherol (vitamin E). *J Am Acad Dermatol* 38: 45–48
28. Colvin RM, Pinnel SR (1996) Topical vitamin C in aging. *Clin Dermatol* 14:227–234
29. Bachowski GJ, Girotti AW (1988) Light-stimulated formation of hydrogen peroxide and hydroxyl radical in the presence of uroporphyrin and ascorbate. *Free Radic Biol Med* 5:3–6
30. Bacq ZM, Fischer P (1957) The action of various drugs on the suprarenal response of the rat to total-body x-irradiation. *Radiat Res* 7:365–372
31. Frei B, England L, Amos B (1989) Ascorbate is an outstanding anti-oxidant in human blood plasma. *Proc Natl Acad Sci USA* 86:6377–6381
32. Koch CJ, Biaglow JE (1978) Toxicity, radiation sensitivity modification, and metabolic effects of dehydroascorbate and ascorbate in mammalian cells. *J Cell Physiol* 94:299–306
33. Bartlett MK, Jones CM, Ryan AE (1942) Vitamin C and wound healing: II. Ascorbic acid content and tensile strength of healing wounds in human beings. *N Engl J Med* 226:474–481
34. Padh H (1990) Cellular functions of ascorbic acid. *Biochem Cell Biol* 68:1166–1173

35. Abt AF, von Schurching S (1961) Catabolism of L-ascorbic-1-C acid as a measure of its utilization in the intact and wounded guinea pig on scorbutic maintenance, and saturation diets. *Ann N Y Acad Sci* 92:148-158
36. Fitzpatrick RE, Rostan EF (2002) Double blind, half-face study comparing topical vitamin C and vehicle for rejuvenation of photodamage. *Dermatol Surg* 28:231-236
37. Perricone NV (1993) The photoprotective and anti-inflammatory effects of topical ascorbyl palmitate. *J Ger Dermatol* 1:5-10
38. Moy LS, Murad H, Moy RL (1993) Glycolic acid peels for the treatment of wrinkles and photoaging. *J Dermatol Surg Oncol* 19:243-246
39. Murad H, Shamban AT, Moy RL (1995) The use of glycolic acid as a peeling agent. *Dermatol Clin* 13:285-307
40. Ditre CM, Griffin TD, Murphy GF, Sueki H, Telegan B, Johnson WC, Yu RJ, Van Scott EJ (1996) Effects of alpha-hydroxy acids on photoaged skin: a pilot clinical, histologic, and ultrastructural study. *J Am Acad Dermatol* 34(2 Pt 1):187-195
41. Grimes PE, Green BA, Wildnauer RH, Edison BL (2004) The use of polyhydroxy acids (PHAs) in photoaged skin. *Cutis* 73[Suppl 2]:3-13
42. Jimbow K, Obata H, Pathak MA, et al (1974) Mechanism of depigmentation by hydroquinone. *J Inv Dermatol* 62:436-449
43. Amer M, Metwalli M (1998) Topical hydroquinone in the treatment of some hyperpigmentary disorders. *Int J Dermatol* 37:449-450
44. Grimes PE (1997) Melasma: dermatology: cutaneous medicine and surgery in primary care. Harcourt, Brace, and Co., pp 151-153
45. Findlay GH, Morrison JG, Simson IW (1975) Exogenous ochronosis and pigmented colloid milium from hydroquinone bleaching creams. *Br J Dermatol* 93:613-622
46. Mahe A, Ly F, Aymard G, Dangou JM (2003) Skin diseases associated with the cosmetic use of bleaching products in women from Dakar, Senegal. *Br J Dermatol* 148:493-500
47. Bellew SG, Alster TS (2004) Treatment of exogenous ochronosis with a Q-switched alexandrite (755 nm) laser. *Dermatol Surg* 30(4 Pt 1):555-558
48. Fitton A, Goa KL (1991) Azelaic acid. *Drugs* 41:780-798
49. Briganti S, Camera E, Picardo M (2003) Chemical and instrumental approaches to treat hyperpigmentation. *Pigment Cell Res* 16:101-110
50. Stegman SJ (1986) Medium-depth chemical peeling: digging beneath the surface. *J Dermatol Surg Oncol* 12:1245-1246
51. Baker TJ, Gordon HL, Mosienko P, et al (1974) Long-term histological study of skin after chemical face peeling. *Plast Reconstr Surg* 53:522
52. Behin F, Feuerstein SS, Marovitz WF (1977) Comparative histological study of minipig skin after chemical peel and dermabrasion. *Arch Otolaryngol* 103:271-277
53. Van Scott EJ, Yu RJ (1984) Hyperkeratinization, corneocyte cohesion, and alpha hydroxy acids. *J Am Acad Dermatol* 11(5 Pt 1):867-879
54. Moy LS, Howe K, Moy RL (1996) Glycolic acid modulation of collagen production in human skin fibroblast cultures in vitro. *Dermatol Surg* 22(5):439-441
55. Moy LS, Peace S, Moy RL (1996) Comparison of the effect of various chemical peeling agents in a minipig model. *Dermatol Surg* 22:429-432
56. Newman N, Newman A, Moy LS, Babapour R, Harris AG, Moy RL (1996) Clinical improvement of photoaged skin with 50% glycolic acid. A double-blind vehicle-controlled study. *Dermatol Surg* 22:455-460
57. Piacquadro D, Dobry M, Hunt S, Andree C, Grove G, Hollenbach KA (1996) Short contact 70% glycolic acid peels as a treatment for photodamaged skin. A pilot study. *Dermatol Surg* 22:449-452
58. Kligman D, Kligman AM (1998) Salicylic acid peels for the treatment of photoaging. *Dermatol Surg* 24:325-328
59. Gladstone HB, Nguyen SL, Williams R, Ottomeyer T, Wortzman M, Jeffers M, Moy RL (2000) Efficacy of hydroquinone cream (USP 4%) used alone or in combination with salicylic acid peels in improving photodamage on the neck and upper chest. *Dermatol Surg* 26:333-337
60. Dinner MI, Artz JS (1998) The art of the trichloroacetic acid chemical peel. *Clin Plast Surg* 25:53-62
61. Matarasso SL, Glogau RG (1991) Chemical face peels. *Dermatol Clin* 9:131-150
62. Monheit GD (1989) The Jessner's + TCA peel: a medium-depth chemical peel. *J Dermatol Surg Oncol* 15:945-950
63. Coleman WP 3rd, Futrell JM (1994) The glycolic acid trichloroacetic acid peel. *J Dermatol Surg Oncol* 20(1):76-80
64. Tse Y, Ostad A, Lee HS, Levine VJ, Koenig K, Kamino H, Ashinoff R (1996) A clinical and histologic evaluation of two medium-depth peels. Glycolic acid versus Jessner's trichloroacetic acid. *Dermatol Surg* 22:781-786
65. El Samahy MH, Ghaz MM, Ramzy N (1998) Morphological investigation of chemical peel on photodamaged facial skin *Int J Cos Sci* 20:269-282
66. Lawrence N, Cox SE, Cockerell CJ, Freeman RG, Cruz PD Jr (1995) A comparison of the efficacy and safety of Jessner's solution and 35% trichloroacetic acid vs. 5% fluorouracil in the treatment of widespread facial actinic keratoses. *Arch Dermatol* 131:176-181
67. Ghersetich I, Brazzini B, Peris K, Cotellessa C, Manunta T, Lotti T (2004) Pyruvic acid peels for the treatment of photoaging. *Dermatol Surg* 30:32-36

Post-inflammatory Hyperpigmentation

Teresa Soriano, Pearl E. Grimes

The author has no financial interest in any of the products or equipment mentioned in this chapter.

Contents

16.1	Definition	177
16.2	Epidemiology	177
16.3	Etiology	177
16.4	Clinical Types	178
16.5	Diagnostic Criteria	178
16.6	Differential Diagnosis	178
16.7	Therapy	178
16.8	Topical Agents	178
16.9	Chemical Peels	180
16.10	Summary	182
	References	182

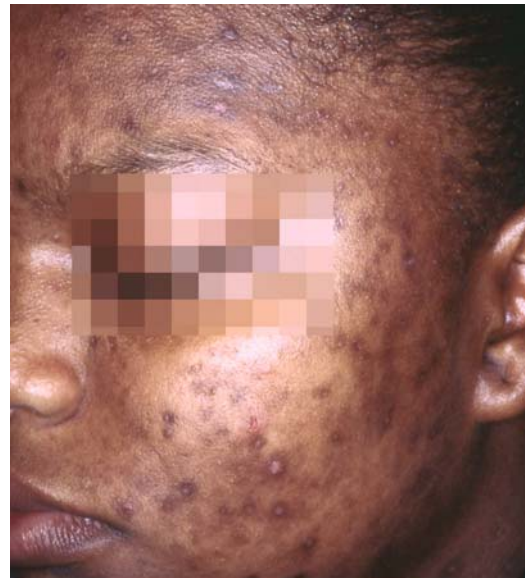

Fig. 16.1. Severe post-inflammatory hyperpigmentation caused by acne vulgaris

16.1 Definition

Post-inflammatory hyperpigmentation (PIH) is the acquired presence of darker macules and patches of skin occurring at sites of previous cutaneous inflammatory conditions. The processes preceding the altered skin color include mechanical injuries, allergic reactions, primary inflammatory skin disorders, and therapeutic interventions.

16.2 Epidemiology

PIH is one of the most common causes of altered skin color. Although it can manifest in various skin types, it is most frequently seen with greater intensity and persistence in darker

skin types (Fitzpatrick IV–VI) (Fig. 16.1) [1, 2]. Its incidence is equal in males and females.

16.3 Etiology

PIH can be observed after endogenous or exogenous inflammatory conditions. Essentially any disease with cutaneous inflammation can potentially result in PIH in individuals capable of producing melanin. Several skin disorders such as acne, atopic dermatitis, allergic contact dermatitis, incontinenti pigmenti, lichen planus, lupus erythematosus, and morphea have PIH as a predominant feature. Exogenous stimuli, both

physical and chemical, can cause injury to the skin followed by PIH. These include mechanical trauma, ionizing and nonionizing radiation, heat, contact dermatitis, phototoxic reactions, and laser therapies [2, 3, 4].

In PIH, there appears to be an increase in melanin production and/or an abnormal distribution of pigment. However, the exact pathophysiology linking cutaneous inflammation and altered pigmentation is not fully understood. Different stimuli may involve different mechanisms [5, 6].

Some have proposed that arachidonic-acid-derived chemical mediators may play a role in inducing PIH of the skin by stimulating increased melanin production and transfer to surrounding keratinocytes [6, 7, 8, 9]. Tomita et al. [8, 9] demonstrated that human epidermal melanocytes became more dendritic with an increase in tyrosinase when cultured with several arachidonic acid metabolites, including prostaglandin D₂, leukotriene (LT) B₄, LTC₄, LTD₄, LTE₄.

16.4 Clinical Types

In PIH, cutaneous pigmentary changes can be observed primarily in the epidermis, or in both the epidermis and dermis. In both instances, epidermal melanin is increased. In the epidermal/dermal type of PIH, pigment is seen within melanophages in the superficial dermis [2, 3]. Wood's light, by accentuating epidermal melanin, is a useful tool in defining the extent of pigment alteration. However, in deeply pigmented skin, it is frequently of no value. Clinically, heavy deposition of dermal pigment can be therapeutically challenging and it is often difficult to bleach or lighten the affected areas.

16.5 Diagnostic Criteria

The diagnosis of PIH is often made by history and clinical presentation. It is characterized by macules and patches of varying shades of hyperpigmentation limited to the sites of inflamed skin lesions. Lesions of the preceding inflammatory process may be present at vari-

ous stages of evolution and at other anatomic areas, and thus, helpful with the diagnosis.

Although the diagnosis is relatively straightforward when a patient provides a history of a preceding cutaneous eruption, it can be more challenging when no specific history of inflammation is noted. If the diagnosis is unclear, a skin biopsy should be performed. Histologically, PIH is characterized by increased epidermal melanin. In addition, a sparse superficial perivascular infiltrate with melanophages in the dermis can be seen [2, 3]. Basal cell vacuolation and band-like deposition of mucin have also been observed in some cases of PIH [10].

16.6 Differential Diagnosis

The differential diagnosis for PIH includes the following: fixed drug eruption, systemic drug-induced hyperpigmentation, macular amyloid, ashy dermatosis, melasma, and tinea versicolor. Medications such as tetracyclines, antimalarial drugs, arsenic, bleomycin, and doxorubicin can result in hyperpigmentation of the skin.

16.7 Therapy

The management of PIH involves prevention of further pigment deposition and diminishing altered discoloration. First and foremost, treatment or removal of the etiologic insult is essential to avert development of new lesions. Protecting the areas from sun exposure is also critical to prevent darkening of existing lesions. In some circumstances, the above measures along with a tincture of time result in the resolution of PIH. However, in cases of incomplete or slow resolution, other treatment modalities can aid in the management of PIH. Photoprotection is essential. Broad-spectrum sunscreens (UVA and UVB) should be worn daily (see Photodamage, sunscreen section).

16.8 Topical Agents

Monotherapy with topical retinoids has been shown to facilitate resolution of PIH. A random-

ized, double-blind, vehicle-controlled study using tretinoin 0.1% cream for 40 weeks to treat facial PIH in black patients demonstrated significant lightening with tretinoin 0.1% cream compared with vehicle [11]. The overall improvement was initially noted after 4 weeks of therapy. Fifty percent (12 of 24) of the tretinoin-treated patients experienced erythema and desquamation; however, none had any further hyperpigmentation or depigmentation as a side effect. In another double-blind, randomized, vehicle controlled study, Grimes and Callender [12] reported the efficacy of once-daily tazarotene 0.1% cream in the treatment of PIH from acne in patients with Fitzpatrick skin types IV–VI. Significant advantage over vehicle was noted at 10 weeks of therapy and only trace lev-

els of erythema, burning, and peeling were reported throughout the study. An open label study of darker-skinned patients with acne showed the utility of adapalene 0.1% gel to reduce in PIH [13].

The concomitant use of various bleaching agents has also been shown to improve PIH. In 1975, tretinoin in combination with hydroquinone and dexamethasone was reported as an effective treatment for PIH [14]. In a small study, the application of 2% hydroquinone and 10% glycolic acid gel twice daily and 0.05% tretinoin cream at night has been shown to provide benefit for darker-skinned patients with PIH [15]. Similarly, Yoshimura et al. [16] suggested efficacy of tretinoin combined with hydroquinone and lactic acid in reducing PIH. More re-

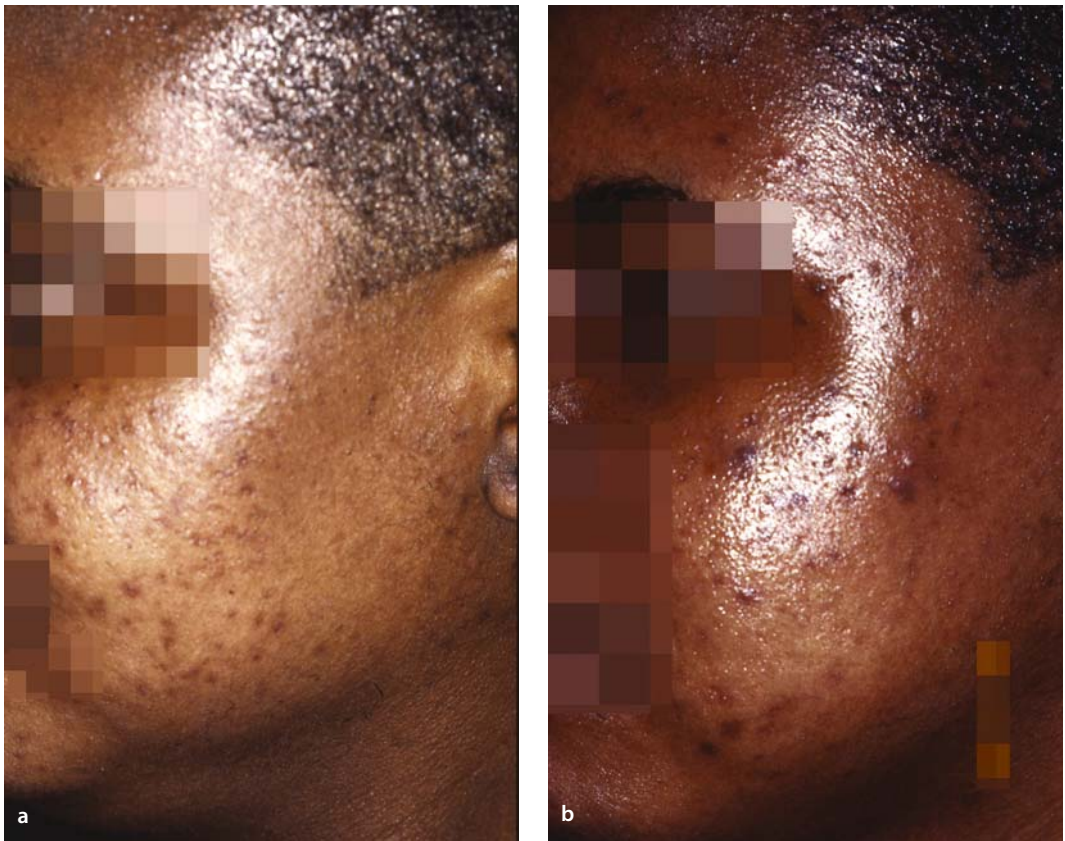

Fig. 16.2. **a** Post-inflammatory hyperpigmentation from acne vulgaris. **b** After a series of salicylic acid peels and hydroquinone 4%

cently, Cook-Bolden [17] reported significant improvement of PIH with the use of a combination bleaching cream (Glyquin) containing hydroquinone 4%, buffered glycolic acid 10%, vitamin C, vitamin E, and sunscreen. In this study, 35 patients with skin types IV–VI experienced clinical improvement after 12 weeks of twice daily treatment.

16.9 Chemical Peels

Chemical peeling can be a useful adjunct in treating cases of persistent PIH and those unresponsive to topical bleaching agents [18, 19]. As many cases of PIH occur in darker-skinned individuals, one must be aware of the inherent differences between light and darker skin types when considering the use of chemical peeling agents (see Darker Skin Peel Section). Although

no quantitative differences in melanocytes are seen in various ethnic groups, melanocytes of darker-skinned individuals produce greater quantities of melanin and demonstrate exaggerated responses to cutaneous injury. This translates clinically to an increased susceptibility to irritation and to a greater risk of further pigment alteration in darker-skinned individuals. To decrease the potential risk of exacerbation of hyperpigmentation, the authors' protocol in darker skin types include pre-treatment for 2–4 weeks with bleaching agents such as hydroquinone 4% cream. If indicated, higher concentrations of hydroquinone (5–10%) can be compounded. In addition, tretinoin is discontinued 1–2 weeks prior to the series of chemical peels performed at 2- to 4-week intervals [18]. In addition, retinoids can be eliminated from the topical skin care regimen used between peeling procedures.

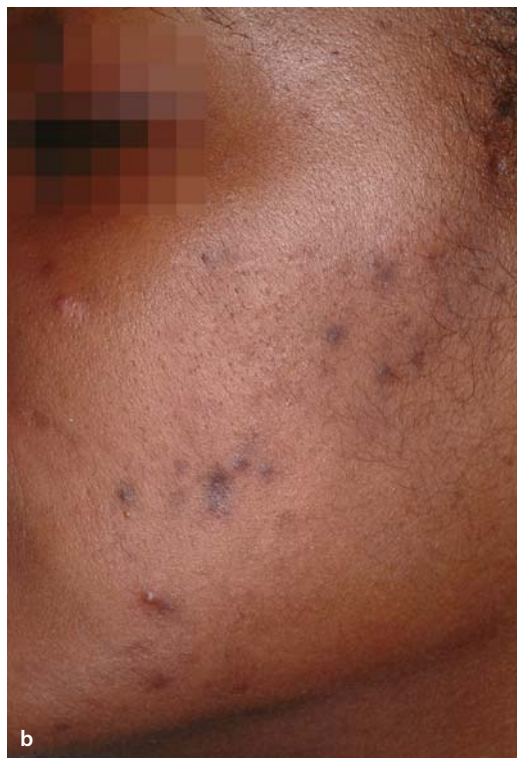
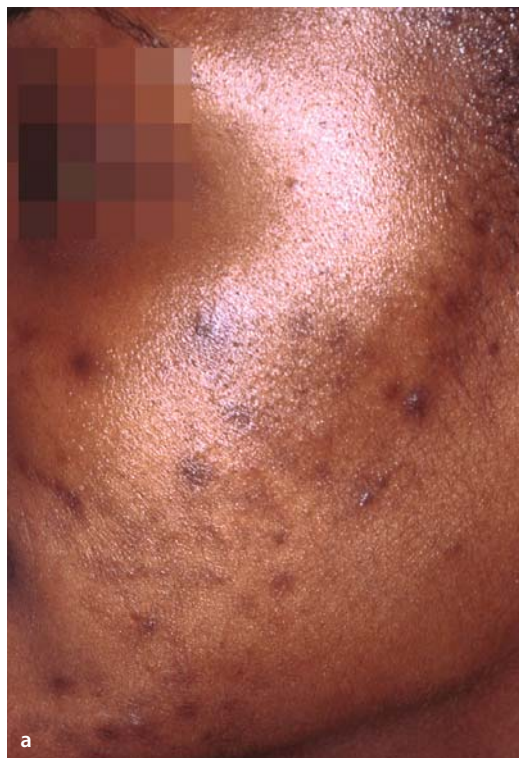
Fig. 16.3. **a** Severe recalcitrant post-inflammatory hyperpigmentation secondary to acne excorians. **b** After a series of four salicylic acid 20 and 30% peels and 10% hydroquinone cream

Superficial chemical peels, including salicylic and glycolic acids, and Jessner's peels target the stratum corneum to the papillary dermis. These agents can be safely used to facilitate the resolution of PIH (Figs. 16.2, 16.3, 16.4 and 16.5). To assess for variability in response and limit further PIH, when possible, chemical peels should be initiated at the lower concentrations and titrated to higher concentrations if necessary to increase efficacy while minimizing side effects (see Darker Skin Section).

Superficial salicylic acids have been shown to be safe and efficacious for treatment of PIH. In a study of five patients with Fitzpatrick's Skin Types V and VI with PIH, pretreatment for 2 weeks with hydroquinone 4% cream followed by a series of five 20–30% salicylic acid chemi-

cal peels (B-lift) at 2-week intervals resulted in 51–75% improvement in one patient and 75% improvement in four patients [20]. No adverse effect was noted.

Glycolic acid peels can also be used to facilitate resolution of PIH. Burns et al. [15] demonstrated greater and more rapid improvement with the addition of glycolic acid peels to a topical regimen of hydroquinone, glycolic acid gel, and tretinoin. In this study, patients with Fitzpatrick IV–VI who received six serial glycolic acid peels in addition to the topical regimen were found to have additional benefit with minimal adverse effects compared with the patients who were treated with the topical regimen alone.

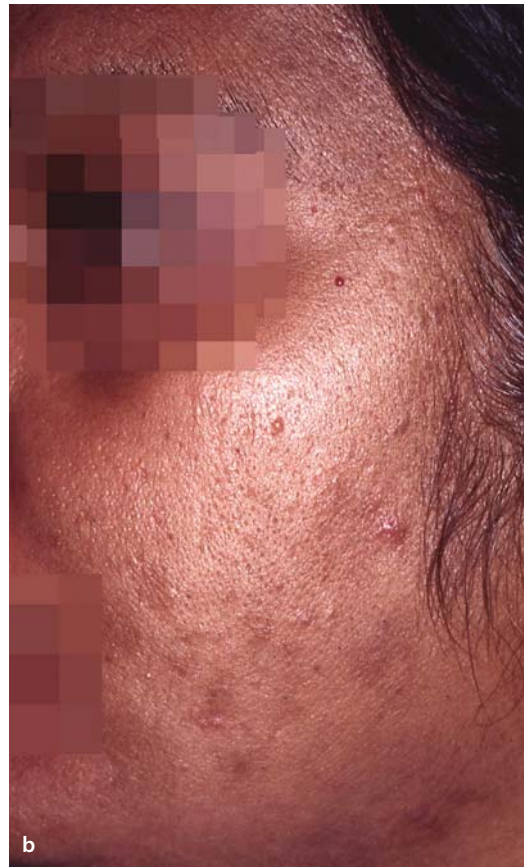
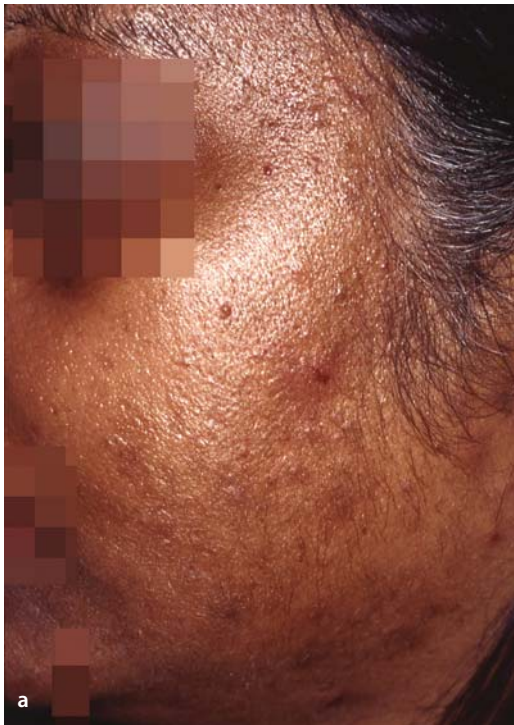
Fig. 16.4. **a** Post-inflammatory hyperpigmentation from unknown topical irritant. **b** Cleared after a series of two glycolic acid peels (20 and 35%)

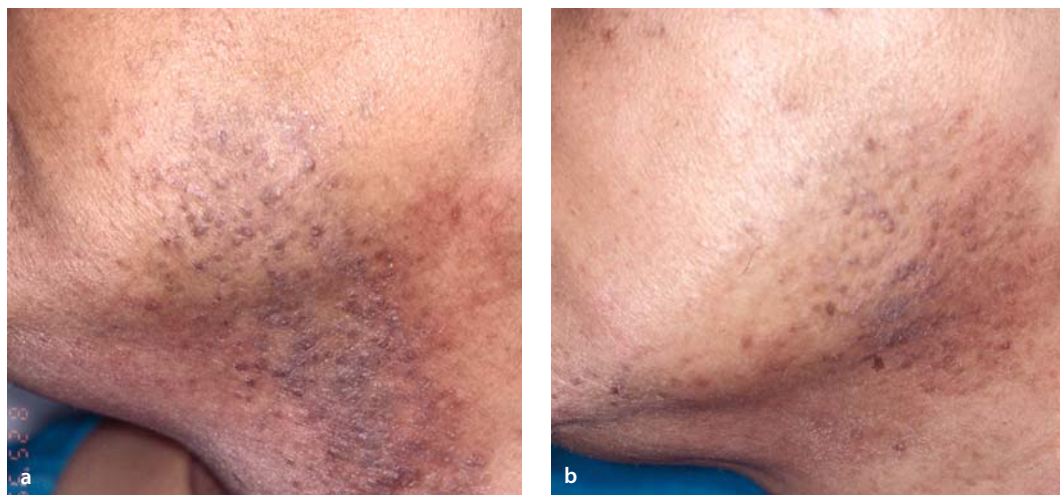


Fig. 16.5. a Pseudofolliculitis barbae and post-inflammatory hyperpigmentation. b After two Jessner's peels

16.10 Summary

Optimal treatment for PIH includes prevention of further pigment deposition and clearing of the deposited pigment. Chemical peels work best when used in combination with topical bleaching regimens. Given the propensity of darker skin types to develop post-inflammatory hyperpigmentation, superficial peels work best, while minimizing complications.

References

- Halder RM, Grimes PE, McLaurin CI, Kreiss MA, Kenney JA (1983) Incidence of common dermatoses in a predominantly black dermatologic practice. *Cutis* 32(4):388, 390
- Pandya AG, Guevara IL (2000) Disorders of hyperpigmentation. *Dermatol Clin* 18(1):91–98, ix. Review
- Epstein JH (1989) Postinflammatory hyperpigmentation. *Clin Dermatol* 7(2):55–65
- McBurney EI (2002) Side effects and complications of laser therapy. *Dermatol Clin* 20(1):165–176
- Nordlund JJ, Abdel-Malek ZA (1988) Mechanisms of post-inflammatory hyperpigmentation and hypopigmentations. *Prog Clin Biol Res* 256:219–236
- Johansson O, Ljungberg A, Han SW, Vaalasti A (1991) Evidence for gamma-melanocyte stimulating hormone containing nerves and neutrophilic granulocytes in the human skin by indirect immunofluorescence. *J Invest Dermatol* 96(6):852–856
- Morelli JG, Yohn JJ, Lyons MB, Murphy RC, Norris DA (1989) Leukotrienes C₄ and D₄ as potent mitogens for cultures human neonatal melanocytes. *Invest Dermatol* 93(6):719–722
- Tomita Y, Iwamoto M, Masuda T, Tagami H (1987) Stimulatory effect of prostaglandin E₂ on the configuration of normal human melanocytes in vitro. *J Invest Dermatol* 89(3):299–301
- Tomita Y, Maeda K, Tagami H (1992) Melanocyte-stimulation properties of arachidonic acid metabolites, possible role of post-inflammatory. *Cell Res* 5:357–361
- Noto G, Pravata G, Arico M (1998) Reticulate post-inflammatory hyperpigmentation with band-like mucin deposition. *Int J Dermatol* 37(11):829–832
- Bulengo-Ransby SM, Griffiths C, Kimbrough-Green CK, Finkel LJ, Hamilton TA, Ellis CN, Voorhees JJ (1993) Topical tretinoin (retinoic acid) therapy for hyperpigmented lesions caused by inflammation of the skin in black patients. *New Engl J of Med* 328:1438–1443
- Grimes PE, Callender VD (2003) Tazarotene cream 0.1% in the treatment of facial post-inflammatory hyperpigmentation associated with acne vulgaris: a two-center, double-blind, randomized, vehicle-controlled study. Poster presentation at the 61st Annual Meeting of the American Academy of Dermatology, San Francisco, CA, March 21–26, 2003
- Jacyk WK, Mpofu P (2001) Adapalene gel 0.1% for topical treatment of acne vulgaris in African patients. *Cutis* 68:48–54
- Kligman AM, Willis I (1975) A new formula for depigmenting human skin. *Arch Dermatol* 111:40–48

15. Burns R, Prevost-Blank PL, Lawry MA, Lawry TB, Faria DT, Fivenson DP (1999) Glycolic acid peels for postinflammatory hyperpigmentation in black patients. *Dermatol Surg* 25:18–22
16. Yoshimura K, Harii K, Aoyama T, Iga T (2000) Experience with a strong bleaching treatment for skin hyperpigmentation in Orientals. *Plast Reconstr Surg* 105:1097–1110
17. Cook-Bolden FE (2004) The efficacy and tolerability of a combination cream containing 4% hydroquinone in the treatment of postinflammatory hyperpigmentation in skin types IV–VI. *Cosmetic Dermatol* 17(3):149–155
18. Grimes PE (2000) Agents for ethnic skin peeling. *Dermatol Ther* 30:159–164
19. Callender VD (2004) Acne in ethnic skin: special considerations for therapy. *Dermatol Ther* 17:184–195
20. Grimes PE (1999) The safety and efficacy of salicylic acid chemical peels in darker racial-ethnic groups. *Dermatol Surg* 25:18–22

Maria Pia De Padova, Matilde Iorizzo, Antonella Tosti

The author has no financial interest in any of the products or equipment mentioned in this chapter.

Contents

17.1	Definition	185
17.2	Epidemiology	185
17.3	Pathology	185
17.4	Clinical Types (Clinical Stages)	185
17.5	Diagnostic Criteria	191
17.6	Differential Diagnosis	191
17.7	Therapy	191
17.8	Erythrosis	191
17.9	Papulo-Pustular Rosacea	192
17.10	Rhinophyma	192
17.11	How to Perform the Best Peeling for the Treatment of Rosacea	193
17.12	Peeling Technique (Figs. 17.18, 17.19, 17.20, 17.21, 17.22 and 17.23)	196
	References	198

17.1 Definition

Rosacea is a chronic inflammatory disorder that typically affects the central facial area.

17.2 Epidemiology

Rosacea is quite common, especially in middle-aged women. The disorder is frequently seen in the elderly and occasionally during childhood. It is most frequently observed in patients with fair skin, but it can also affect Asians and African Americans.

17.3 Pathology

The etiology and pathogenesis of rosacea are not well established and there are no histologic or serologic markers for the disease.

The pathogenesis of rosacea is multifactorial. Vascular hyperactivity is the primary phenomenon that is complicated by inflammatory changes. Endocrine, psychological, pharmacological, immunological, infectious, thermal and alimentary factors contribute to produce vascular instability and tissue damage (Fig. 17.1). The role of *Helicobacter pylori* is still being discussed.

The erythema of rosacea is caused by dilatation of the superficial vessels of the face. Visualization of the dermal capillaries is favored by skin atrophy due too photoaging. Edema can develop as a result of the increased blood flow in the superficial vessels. This edema might contribute to the late stage of fibroplasia and rhinophyma.

17.4 Clinical Types (Clinical Stages)

Clinically, rosacea presents with different degrees of severity, ranging from facial erythema to evident inflammatory lesions. Symptoms of rosacea include skin dryness and sensitivity, stinging and burning [1].

Fig. 17.1.
Etiopathogenesis of rosacea

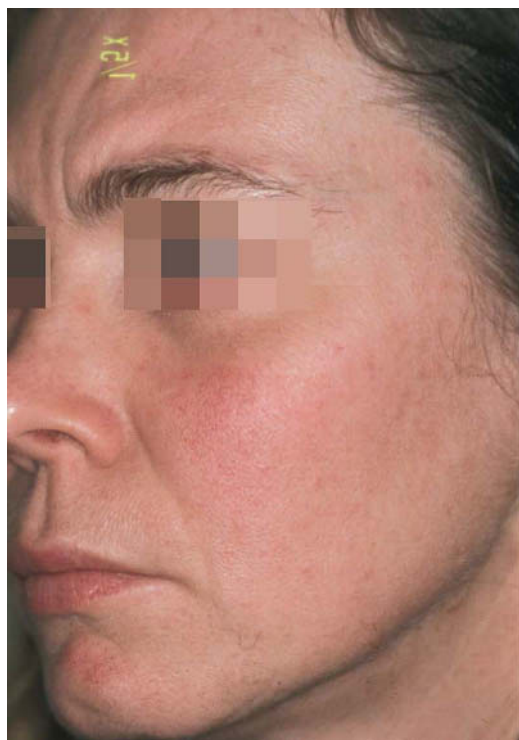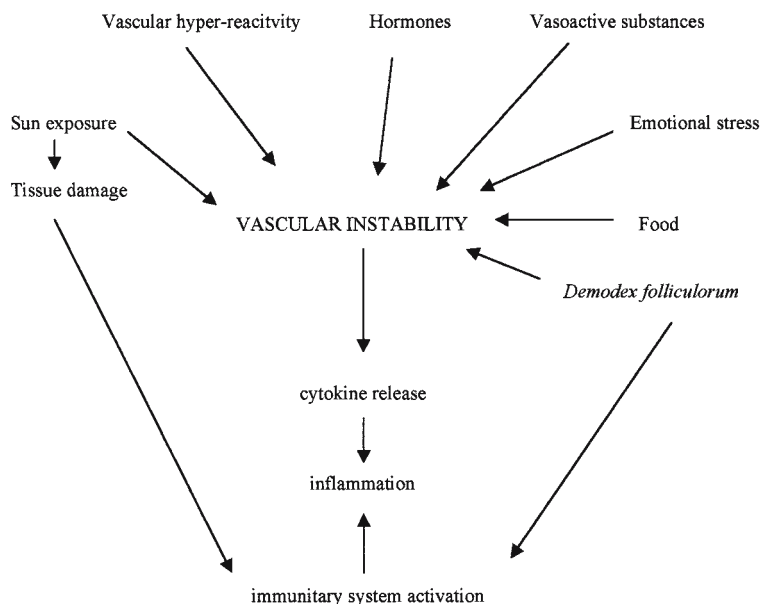


Fig. 17.2. Erythematoteleangiectatic rosacea

- **Erythematoteleangiectatic:** flushing and persistent centro-facial erythema usually associated with telangiectasia (Figs. 17.2, 17.3)
- **Papulopustular:** persistent centro-facial erythema associated with inflammatory papules and pustules (Figs. 17.4, 17.5 and 17.6)
- **Phymatous:** irregular skin thickening due to sebaceous hyperplasia (Fig. 17.7)
- **Ocular:** eye involvement is common and may precede skin lesions. Ocular symptoms include foreign body sensation, burning or stinging, dryness, itching, ocular photosensitivity, telangiectasia, periorbital edema, chalazia (Fig. 17.8)

The granulomatous variant of rosacea is characterized by papular and nodular lesions that affect the cheeks and periorificial areas (Figs. 17.9, 17.10, 17.11 and 17.12).

Rosacea may rarely affect the non-facial skin, especially the scalp, the neck and the shoulders.

Fig. 17.3.
Erythemato-teleangiectatic
rosacea

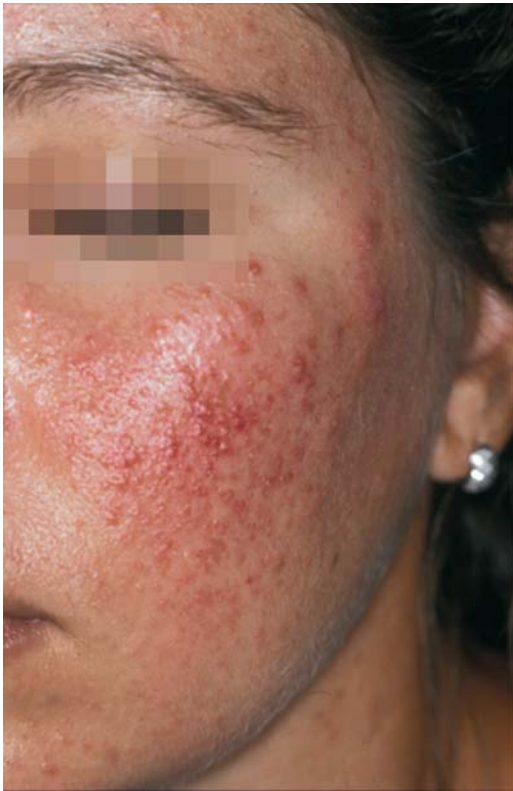
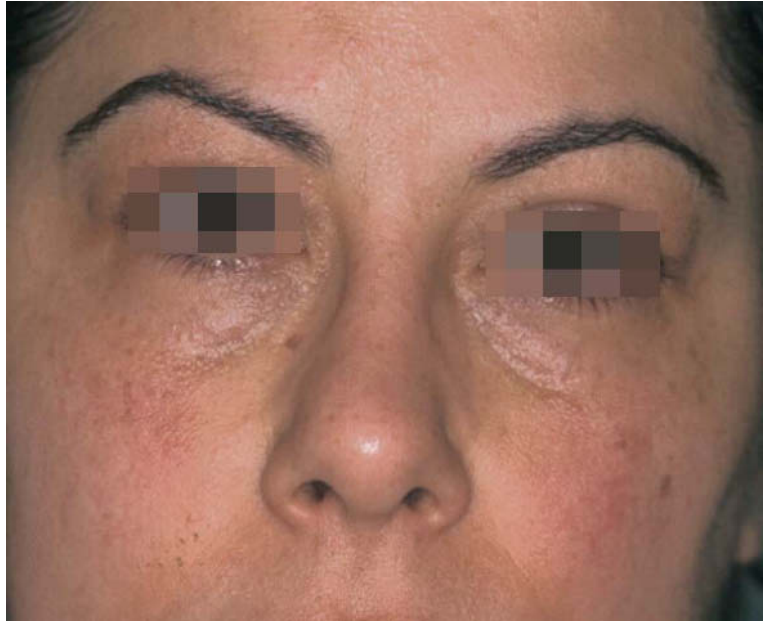
Fig. 17.4. Papulo-pustular

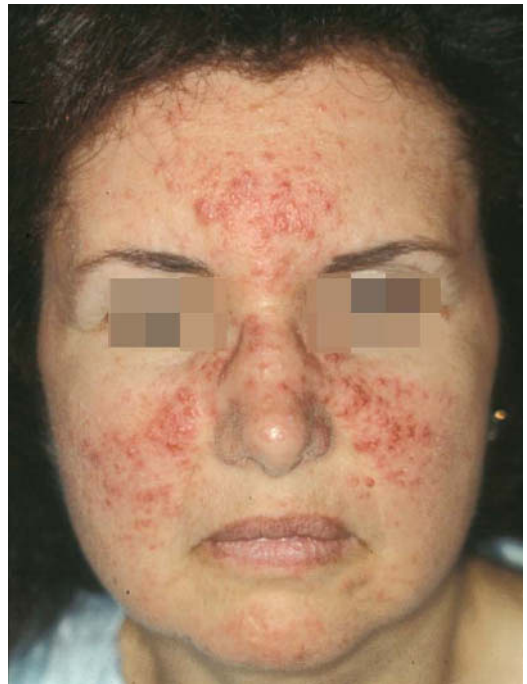

Fig. 17.5. Papulo-pustular

Fig. 17.6. Papulo-pustular

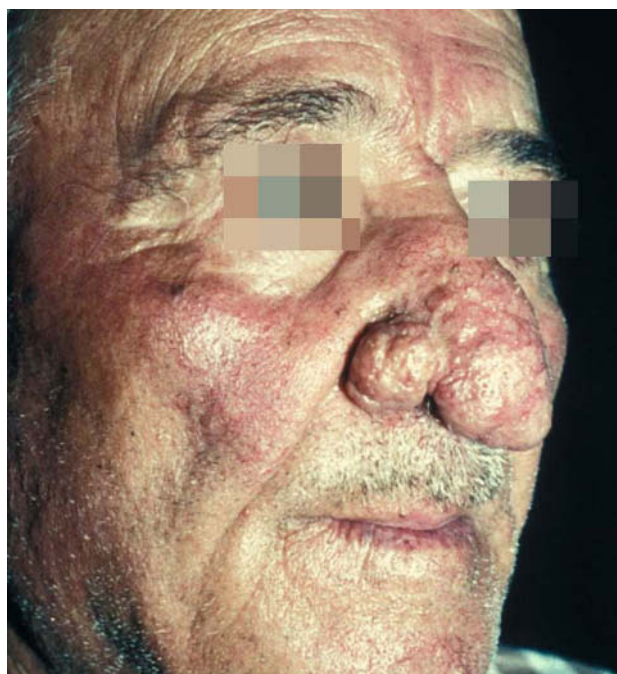
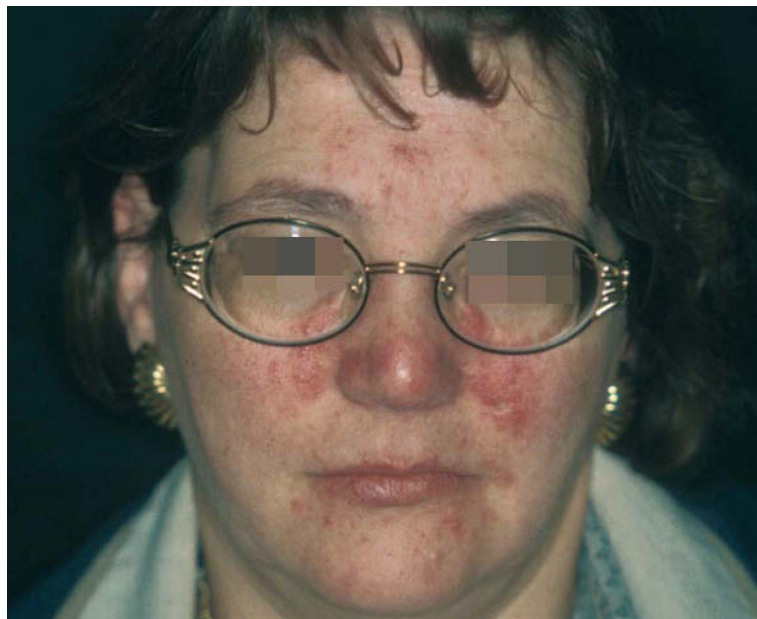
Fig. 17.7. Rhinophyma

Fig. 17.8. Ocular rosacea

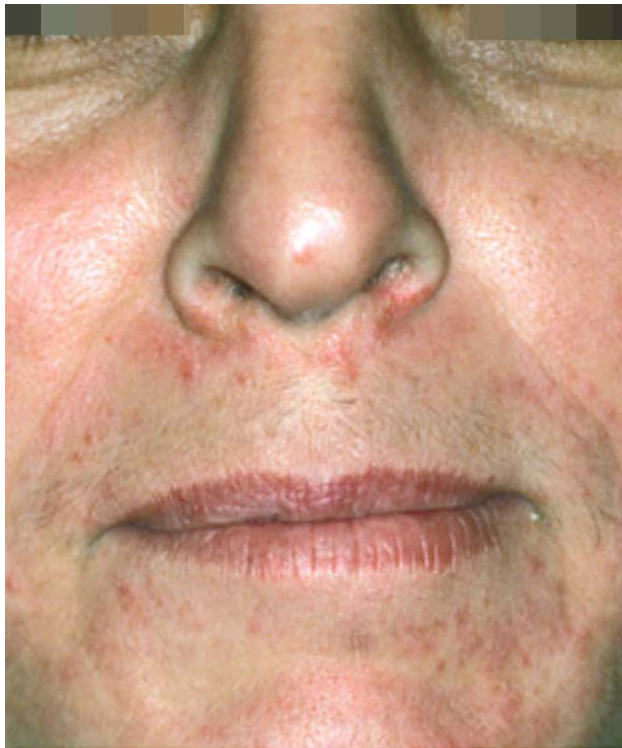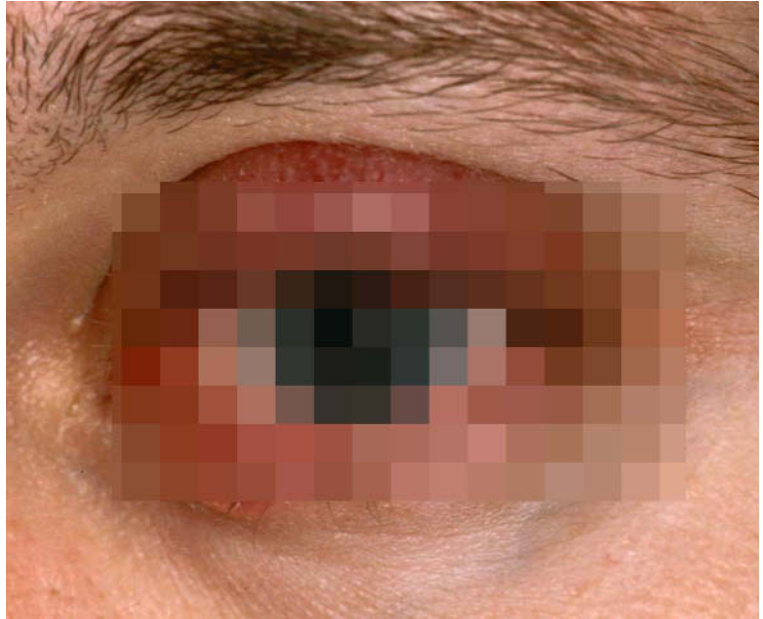


Fig. 17.9. Granulomatous rosacea: light degree

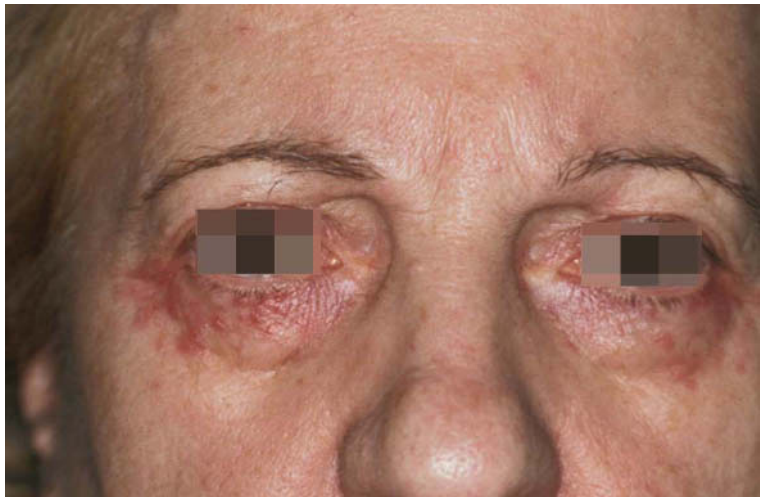
Fig. 17.10.
Granulomatous rosacea:
medium degree

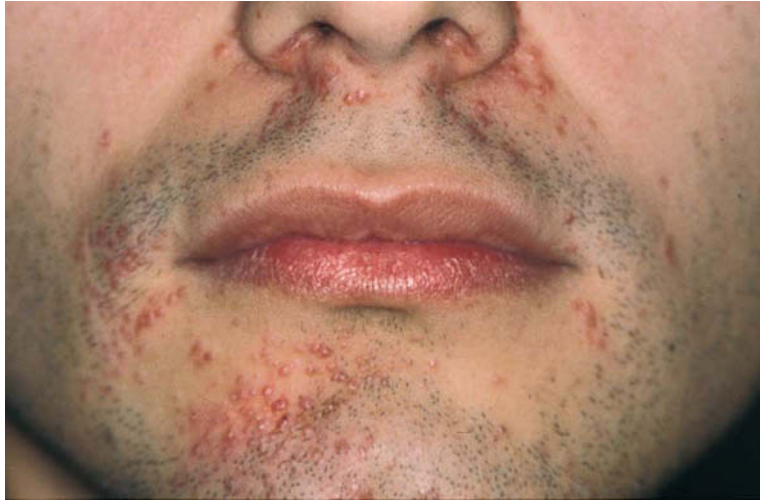

Fig. 17.11.
Granulomatous rosacea
in children: medium degree

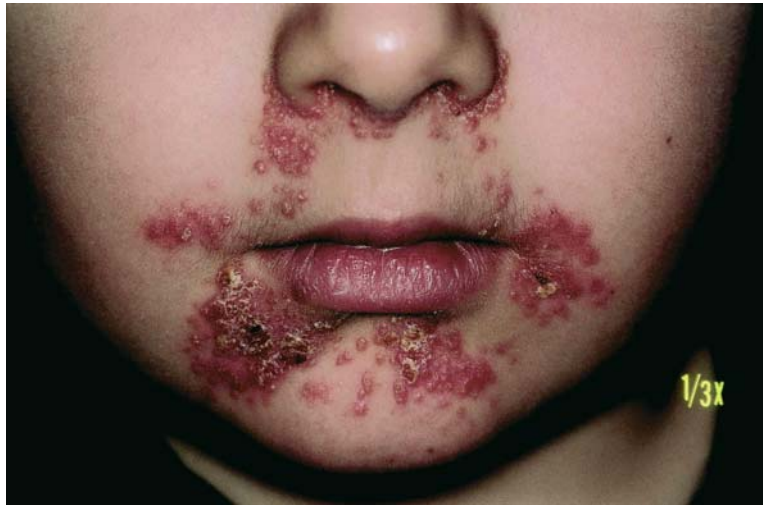

Fig. 17.12.
Granulomatous rosacea:
periocular localization



17.5 Diagnostic Criteria

- Clinico-morphological
- Detection and identification of *Helicobacter pylori* and *Demodex folliculorum* (Fig. 17.13).

17.6 Differential Diagnosis

Skin conditions share some clinical features with rosacea:

- Acne vulgaris
- Seborrheic dermatitis
- Systemic lupus erythematosus
- Lupus miliaris disseminatus faciei
- Sarcoidosis

17.7 Therapy

An important step in the treatment of rosacea is the avoidance of factors that could cause a flare-up of the flushing through vasodilation (Table 17.1). Topical steroids are absolutely contraindicated in rosacea.

17.8 Erythrosis

- Apply facial sun block when outdoors
- Azelaic acid 15% gel or 20% cream twice a day [2]
- Metronidazole 0.75–1% cream or gel (twice a day the 0.75% and once a day the 1%) [3, 4]
- Sulfacetamide 10%/sulfur 5% cream or lotion once a day (in certain patients might be less irritating than metronidazole) [5]
- Topical clindamycin 1% or erythromycin 2–3% [6]
- Topical retinoic acid has been shown to have a beneficial effect on the vascular component of rosacea (0.025–0.05% cream once a day) [7]
- Topical 0.05% retinaldehyde is generally well tolerated [7]
- Topical 5% vitamin C preparations have recently been evaluated in the erythematous stage of rosacea [8]
- Cryotherapy [9]
- Laser therapy [10, 11]
- Systemic treatment of erythroderma [9]

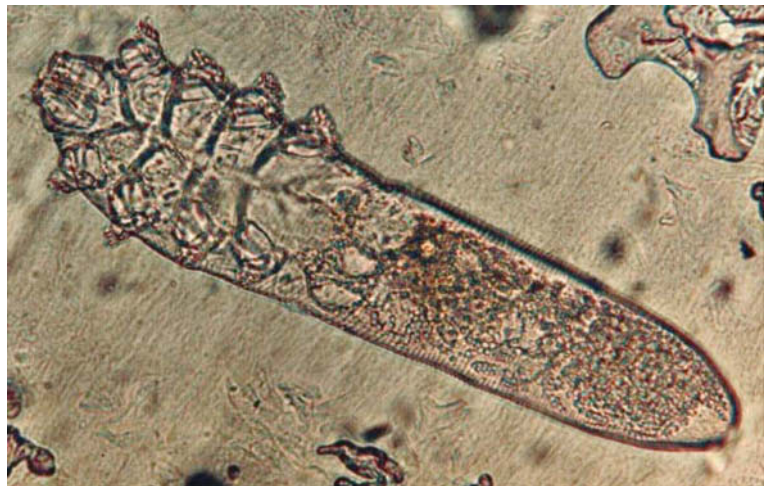

Fig. 17.13.
Demodex folliculorum

Table 17.1. Flushing triggers

Climatic triggers
Sun exposure
Extreme temperatures, hot or cold
Humidity
Windy weather
Sudden variation in the environmental temperature
Emotional triggers
Anger
Anxiety
Embarrassment
Stress
Triggers related to temperature
Sauna, hot bath
Working under high temperatures (kitchens, etc.)
Triggers related to physical exercise
Triggers related to beverages and foods
Alcoholic drinks (red wine, beer, etc.)
Hot beverages (coffee, chocolate, tea)
Spicy foods
Hot meals
Chocolate, vanilla
Vinegar
Vegetables (tomatoes, spinach, beans, etc.)
Fruits (banana, lemon, grapefruit, avocado, etc.)
Drugs
Antidepressants
ACE inhibitors, calcium antagonists
Statines
Vasodilators, nicotinic acid
Topical corticosteroids
Cosmetics
Skin and hair cosmetics containing alcohol, perfume and other ingredients that may irritate sensitive skin
Soaps

Systemic treatment of erythrosis finds its rationale in the association of rosacea with *H. Pylori* infection. The following scheme has been suggested: clarithromycin 250 mg twice daily + metronidazole 400 mg twice daily; clarithrom-

ycin 500 mg twice daily + amoxicillin 1,000 mg twice daily; or metronidazole 400 mg twice daily + amoxicillin 500 mg twice daily. In Europe, a 7-day course of therapy is considered adequate, in the USA 10–14 days of therapy are currently recommended.

17.9 Papulo-Pustular Rosacea

Combination therapy with oral and topical medications gives the best results.

- Azelaic acid 15% gel or 20% cream twice a day [12, 13, 14]
- Topical metronidazole 0.75–1% cream or gel (twice a day the 0.75% and once a day the 1%) [15]
- Oral metronidazole 400 mg once daily for 20–50 days [9]
- Oral tetracyclines that probably act as anti-inflammatory and marked immunodepressing agents. Dosages currently used are: 250 mg twice daily for oxytetracycline; 100 mg twice daily for minocycline; 100 mg once daily for doxycycline; and 400 mg for lymecycline. Therapy should be prolonged for 20 days [9]
- Systemic clarithromycin 250–500 mg twice daily [9]
- Systemic erythromycin 250–500 mg twice daily (especially suitable for children) [9]
- Oral isotretinoin is useful in severe and recalcitrant forms at 0.5–1 mg/kg/day for 6–28 weeks [9]

17.10 Rhinophyma

- Surgery
- Laser therapy (carbon dioxide; argon; Nd:YAG)
- Cryotherapy
- Shaw scalpel

17.11 How to Perform the Best Peeling for the Treatment of Rosacea

Salicylic acid peelings performed at 3- to 4-week intervals are a good choice for patients with rosacea. Salicylic acid peeling has antimicrobial activity, reduces erythrosis and prevents relapses.

In erythrosis 15% to 25% to 30% salicylic acid peeling should be performed at 3-week intervals for a total of three to four peelings (Fig. 17.14a, b). Suggested topical treatment between peeling includes: 0,75% metronidazole cream once a day or 1–2% salicylic acid cream once a day and sunblock creams

In papulo-pustular rosacea 25–30% salicylic acid peeling is utilized in association with systemic treatment with metronidazole or antibiotics and topical treatment as for erythrosis (Figs. 17.15, 17.16 and 17.17).

Salicylic acid penetrates more deeply in the areas of inflammation and produces rapid drying of papules and pustules 1 or 2 days after the peeling. These beneficial effects are determined by the antimicrobial activity of salicylic acid, which also stimulates fibroblasts, inducing an improvement of the vascular component of rosacea. Application of salicylic acid in inflammatory rosacea is equally as safe and effective in residual or initial lesions.

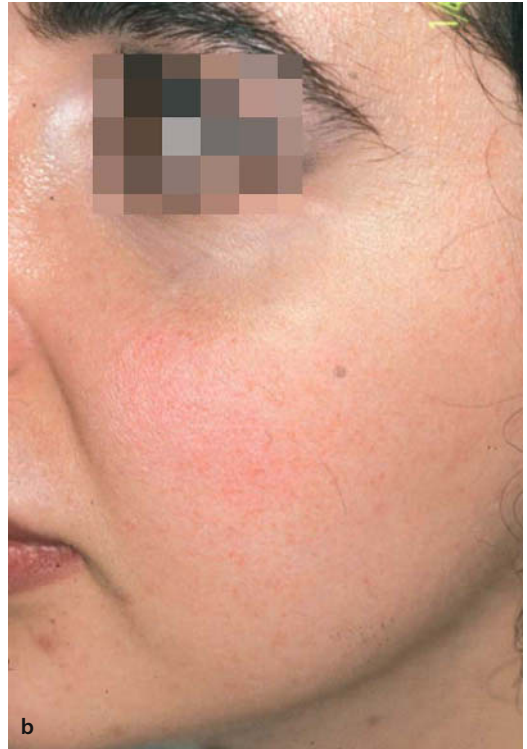
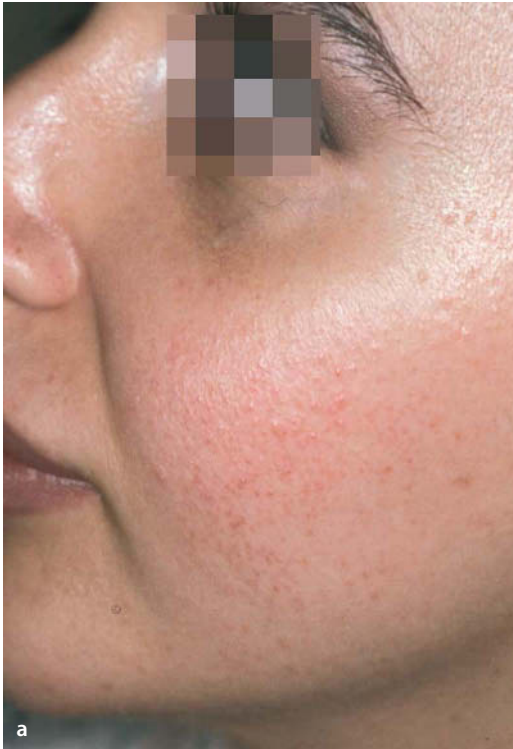
Fig. 17.14a, b. Erythrosis: before (a) and after (b) chemical peel

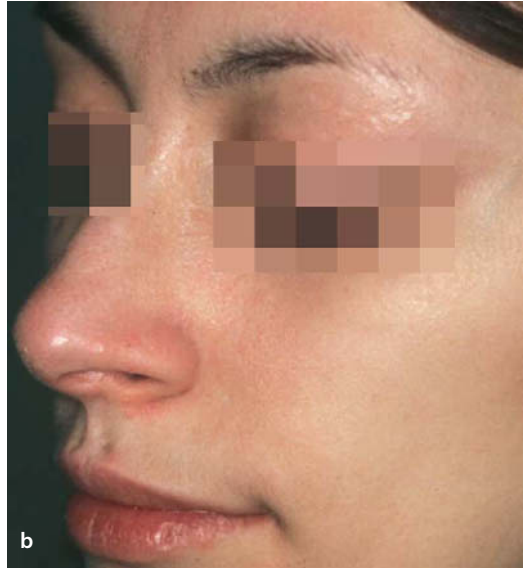
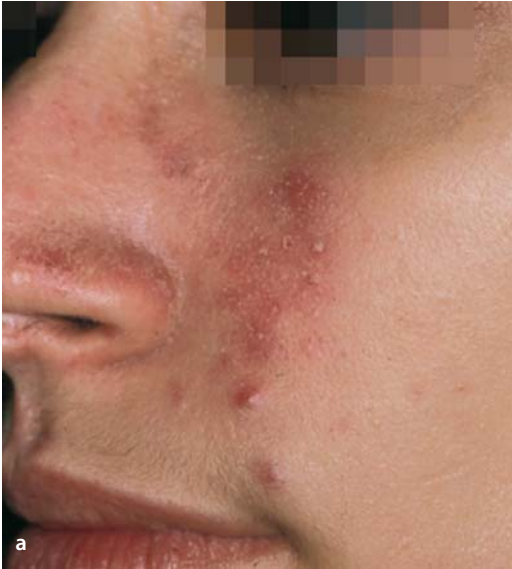
Fig. 17.15a, b. Papulo-pustular rosacea: before (a) and after (b) chemical peel

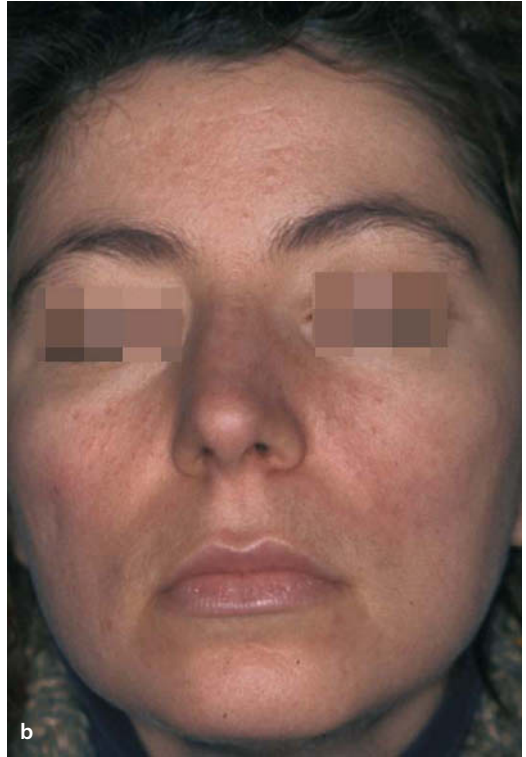
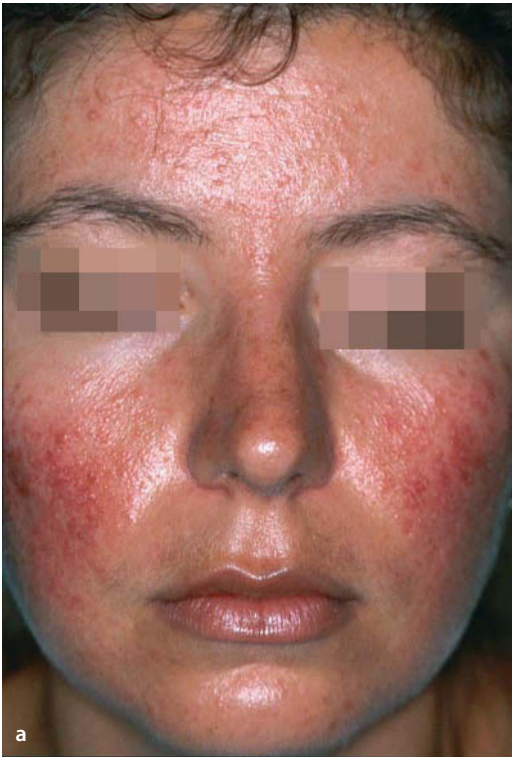
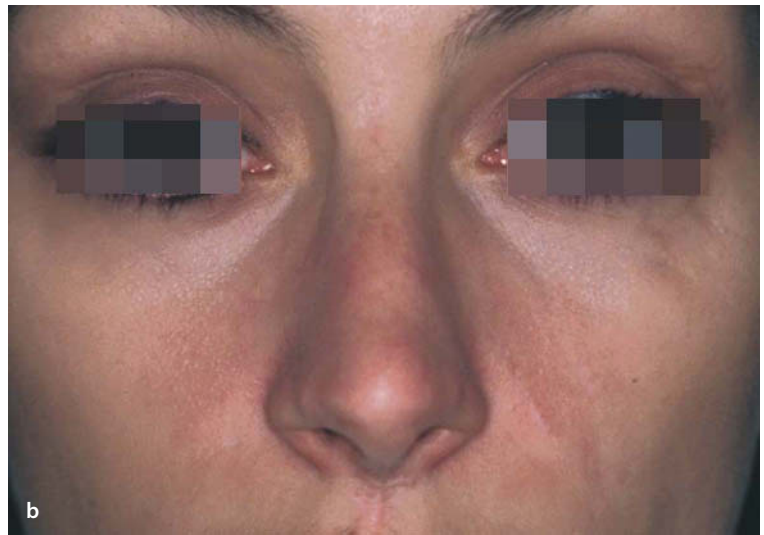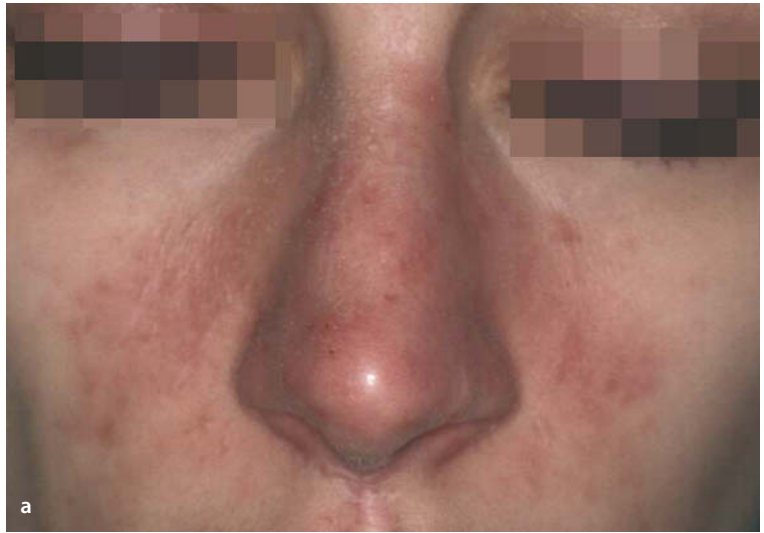Fig. 17.16a, b. Papulo-pustular rosacea: before (a) and after (b) chemical peel

Fig. 17.17a, b.
Papulo-pustular rosacea:
before (a) and after (b)
chemical peel



17.12 Peeling Technique

- Clean the skin with physiological solution (Fig. 17.18).
- Apply the formulation with a fan brush (proceed for single anatomic units: as a matter of habit, we treat the forehead first and then, in order, the cheeks, nose, chin and upper lips). The first session should be mild (one application) to check patients' reactivity. For following sessions we treat with one to two applications for erythrosis and two to three applications for papulo-pustular (Fig. 17.19). The formulation exists also in gel (Fig. 17.19b).
- Wait 2–3 min for alcohol evaporation (Fig. 17.20, 17.21).
- Moisturize the skin and apply sunscreen (Fig. 17.22).
- After-peel care (for 6 months after peeling):
 - Twice a day moisturizing creams and UVB-UVA sunscreen (with a sun protection factor [SPF] of at least 15)
 - Topical therapy with 0.75 metronidazole or 1–2% salicylic acid

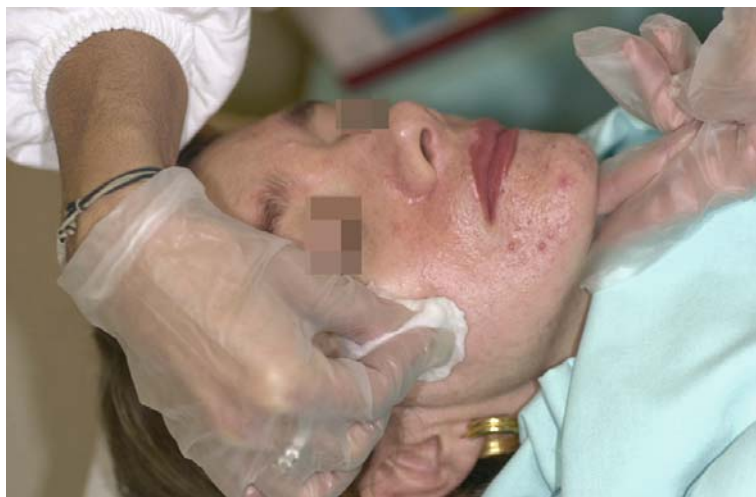

Fig. 17.18.
Peeling technique: cleansing

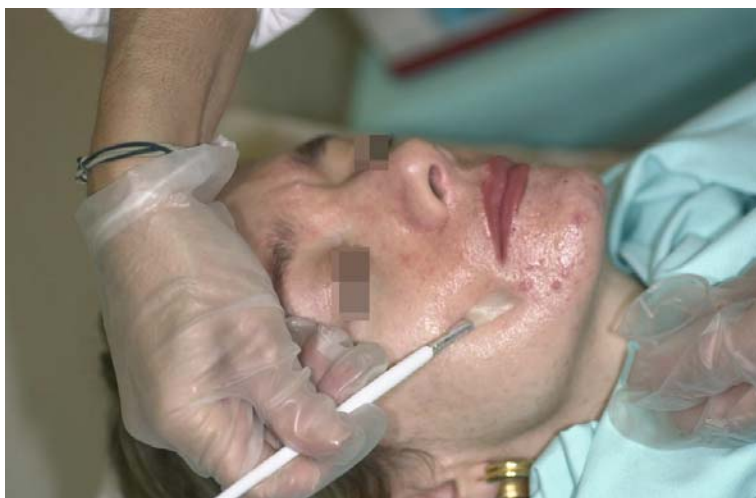

Fig. 17.19a.
Peeling technique: application of the formulation

Fig. 17.19b.
The 15% salicylic gel
formulation is easily
removed after 15–20 min

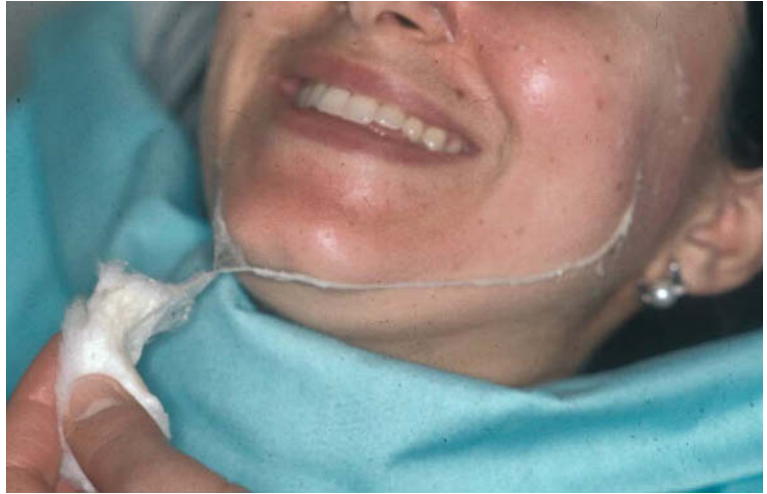

Fig. 17.20.
Peeling technique.
Note the uniform
precipitate representing
crystallization of the
salicylic acid

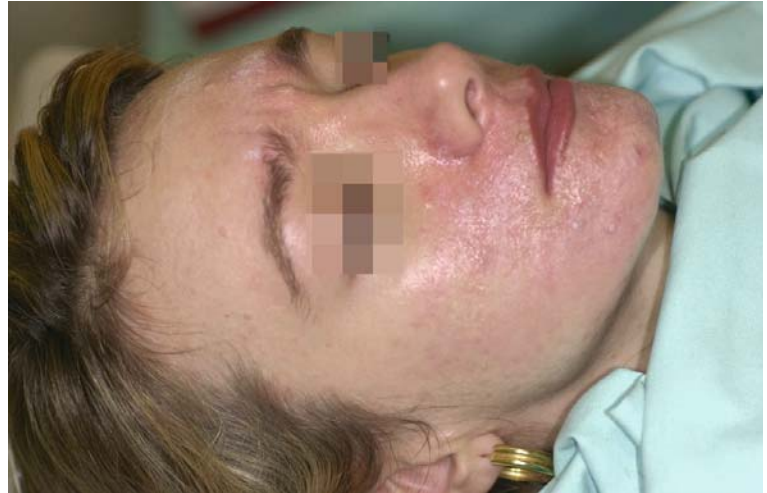
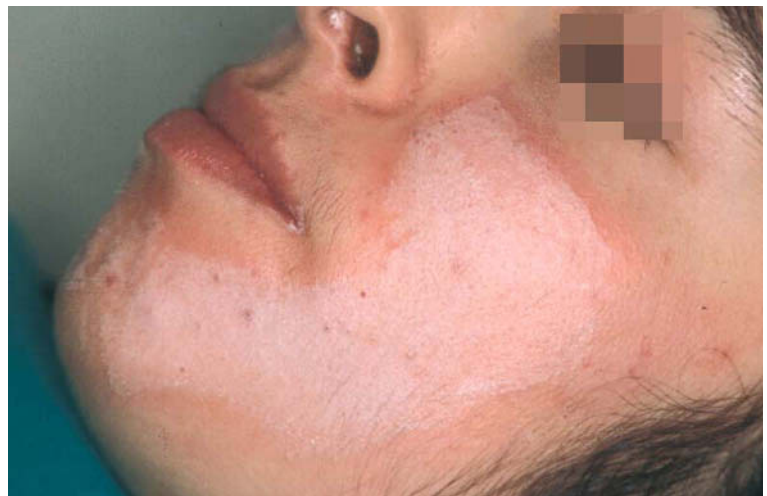
Fig. 17.21.
Peeling technique.
In this case the precipitate
is more uniform



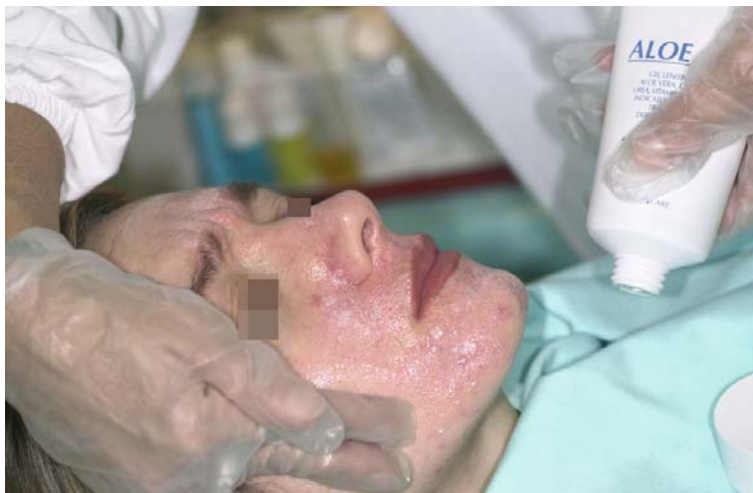

Fig. 17.22.
Peeling technique: moisturizing phase

References

- Odom R (2004) The nosology of rosacea. *Cutis* 74(S3):5–8
- Carmichael AJ, Marks R, Graupe KA, Zaumseil RP (1993) Topical azelaic acid in the treatment of rosacea. *J Dermatol Treat* 4(S1):19–22
- Thiboutot DM (2000) Acne and rosacea. New and emerging therapies. *Dermatol Clin* 18:63–67
- Breneman DL, Stewart D, Hevia O, Hino PD, Drake LA (1998) A double-blind, multicenter clinical trial comparing efficacy of once-daily metronidazole 1% cream to vehicle in patients with rosacea. *Cutis* 61:44–47
- Leyden JJ, Grove G, Zerweck C (2004) A double-blind, comparative facial tolerance study of a new 10% sodium sulfacetamide & 5% sulfur aqueous gel (in a 10% urea vehicle) vs a 10% sodium sulfacetamide & 5% sulfur topical suspension in rosacea & acne subjects with sensitive skin. In: Abstract of the 62nd Annual Meeting of the American Academy of Dermatology. Washington DC, February 6–11, 2004. Abstract P66
- Wilkin JK, DeWitt S (1993) Treatment of rosacea: topical clindamycin versus oral tetracycline. *Int J Dermatol* 32:65–67
- Vienne MP, Ochando N, Borrel MT, Gall Y, Lauze C, Dupuy P (1999) Retinaldehyde alleviates rosacea. *Dermatology* 199(S1):53–56
- Carlin RB, Carlin CS (2001) Topical vitamin C preparation reduces erythema of rosacea. *Cosmetic Dermatol* 2:35–38
- Rebora A (2002) The management of rosacea. *Am J Clin Dermatol* 3:489–496
- Taub AF (2003) Treatment of rosacea with intense pulsed light. *J Drugs Dermatol* 2:254–259
- Mark KA, Sparacio RM, Voigt A, et al (2003) Objective and quantitative improvement of rosacea-associated erythema after intense pulsed light treatment. *Dermatol Surg* 29:600–604
- Elewski B, Fleischer AB, Pariser DM (2003) A comparison of 15% topical azelaic acid gel and 0.75% metronidazole gel in the topical treatment of papulopustular facial rosacea: results of a randomized trial. *Arch Dermatol* 139:1444–1450
- Thiboutot D, Thieroff-Ekerdt R, Graupe K (2003) Efficacy and safety of azelaic acid (15%) gel as a new treatment for papulopustular rosacea: results from 2 vehicle-controlled, randomized, phase III studies. *J Am Acad Dermatol* 48:836–845
- Bjerke R, Fyrand O, Graupe K (1999) Double-blind comparison of azelaic acid 20% cream and its vehicle in treatment of papulopustular rosacea. *Arch Derm Venereol* 79:459–459
- Dahl MV, Jarratt M, Kaplan D, Tuley MR, Baker MD (2001) Once-daily topical metronidazole cream formulations in the treatment of the papules and pustules of rosacea. *J Am Acad Dermatol* 45:723–730

Solar Lentigo

Ilaria Ghersetich, Benedetta Brazzini, Maria Pia De Padova, Antonella Tosti

The author has no financial interest in any of the products or equipment mentioned in this chapter.

Contents

18.1	Definition	199
18.2	Epidemiology	199
18.3	Etiology	199
18.4	Clinical Features	199
18.5	Pathology	200
18.6	Diagnostic Criteria	200
18.7	Therapy	200
	References	205

used to describe early lentigo maligna, pigmented actinic keratoses and the flat type of seborrheic keratoses [1].

18.2 Epidemiology

Lentigo are so common that it is difficult to make an exact statement about their epidemiology.

18.3 Etiology

Photo-aging is the cause of solar lentigo.

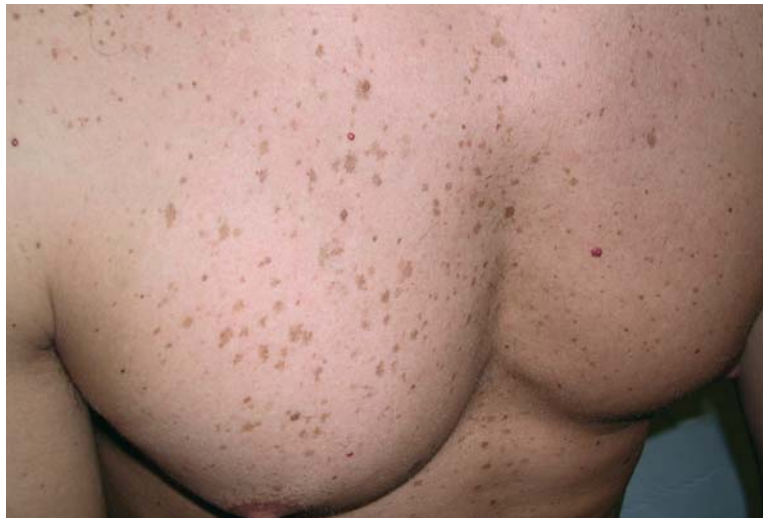18.4 Clinical Features

In younger patients solar lentigo are seen on sun-exposed areas (Fig. 18.1). There is usually a

18.1 Definition

Solar lentigo are a macular area of brown pigmentation appearing after either acute or chronic sun exposure. The term solar lentigo is preferred to senile lentigo, which is sometimes

Fig. 18.1.
In younger patients solar lentigo are seen on sun-exposed areas



history of acute sunburn followed by the sudden appearance of large numbers of these macular lesions.

In older patients these lesions are commonly seen on the face and back of the hands after chronic sun exposure (Figs. 18.2) [1].

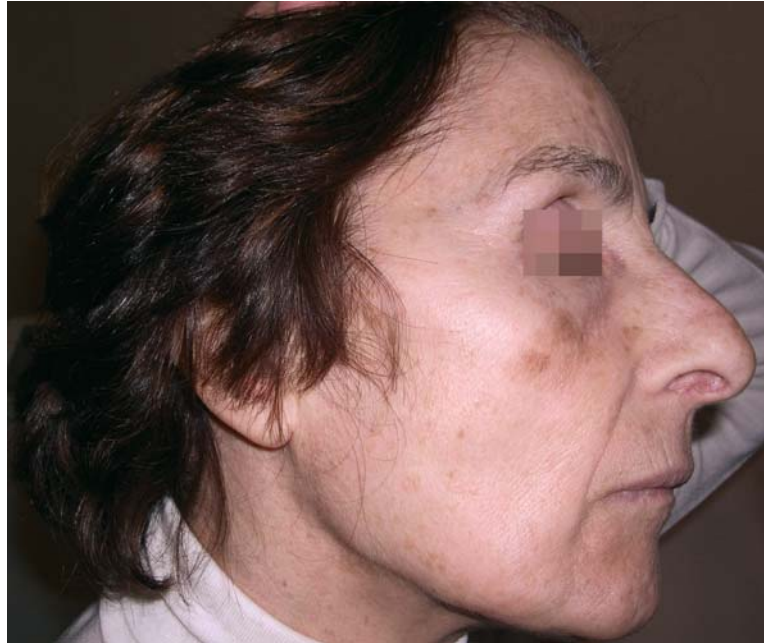

Fig. 18.2.
Solar lentigo after
chronic sun exposure

18.5 Pathology

- Linear increase of melanocytes at the dermoepidermal junction
- No cytological atypia
- Possible elongation of the papillae and interpapillary ridges [2]

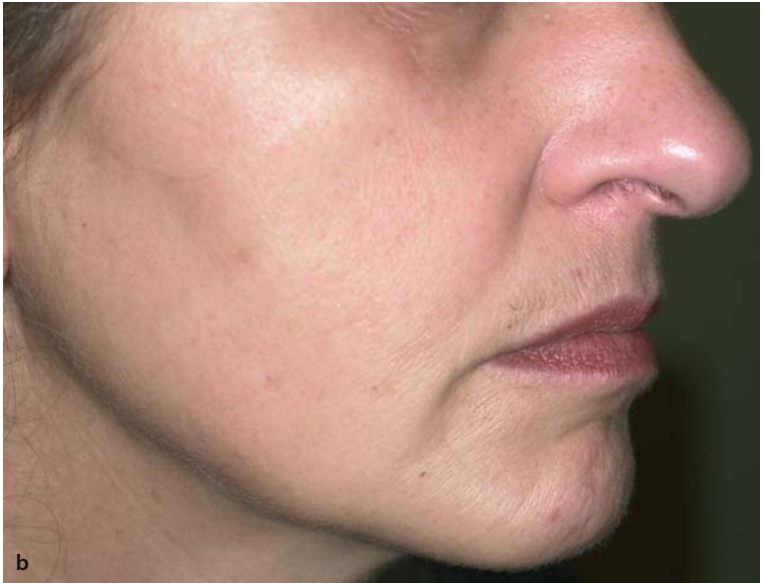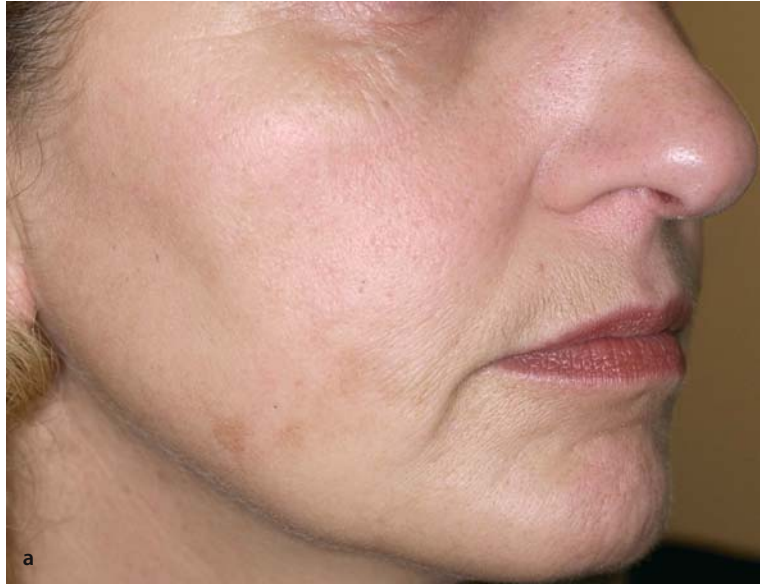18.6 Diagnostic Criteria

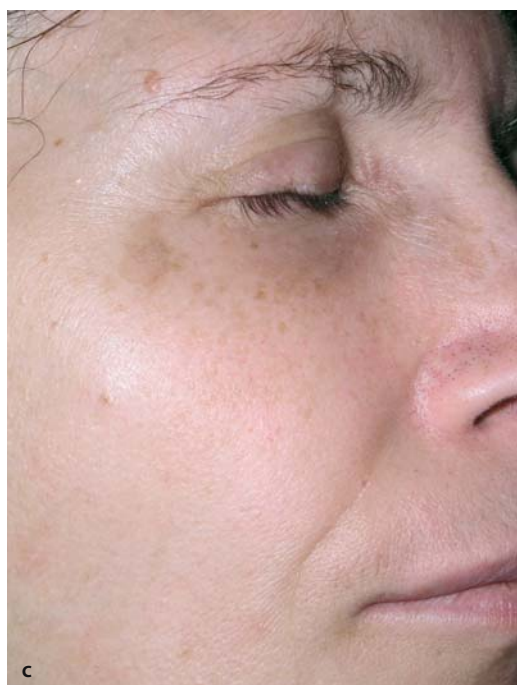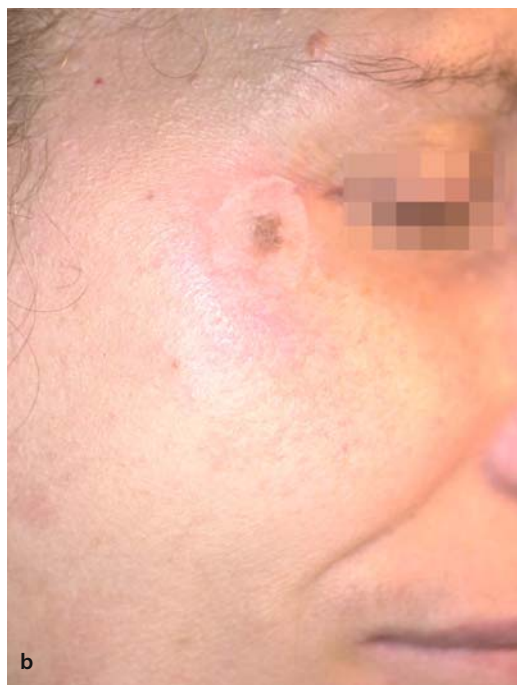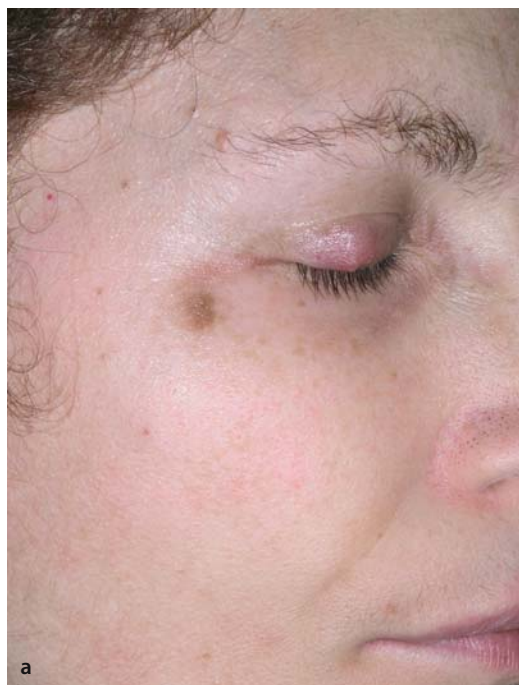- Histopathology
- Dermatoscopy

18.7 Therapy

- Sunscreens
- Topical depigmenting agents (tyrosinase inhibitors, antioxidants, peeling agents, melanogenesis inhibitors) [3]
- Chemical peelings (trichloroacetic acid) (Figs. 18.3, 18.4, 18.5 and 18.6) [4]
- Cryotherapy [5]
- Laser [6]

Fig. 18.3a, b.
Solar lentigo treated
with 25% TCA





18

Fig. 18.4a–c. Solar lentigo at baseline (a), during peeling with 25% TCA (b) and after 30 days (c). Note in c the presence of an inflammatory halo that could persist for 2–3 months

Fig. 18.5a, b.
Solar lentigo of the
forehead treated with
TCA 25%

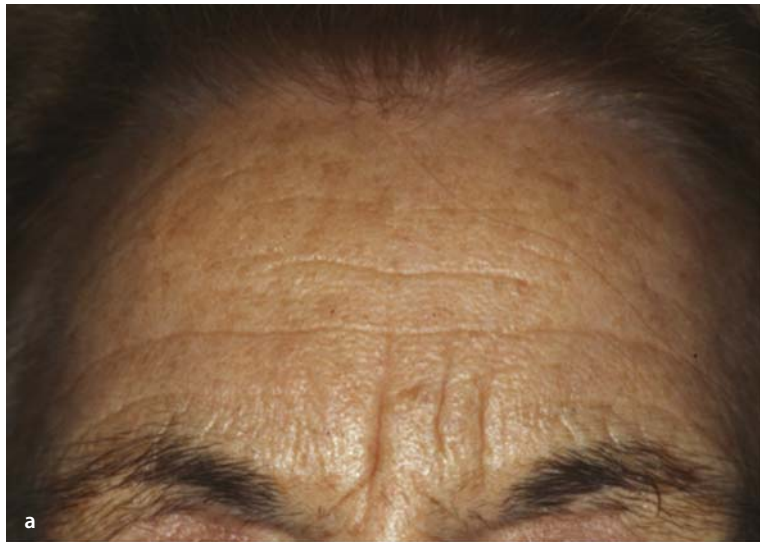
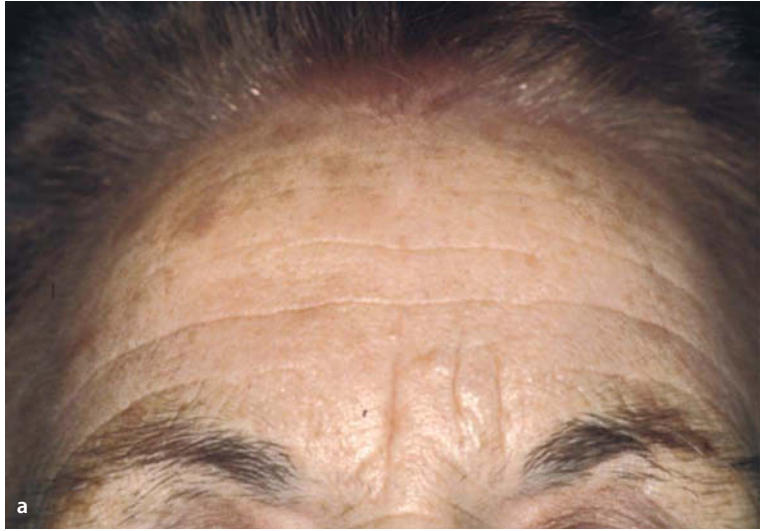
Fig. 18.6a, b.

Solar lentigo of the hands
treated with 25% TCA.

b Solar lentigo after 4 days of
peeling, dryness and hyper-
pigmentation

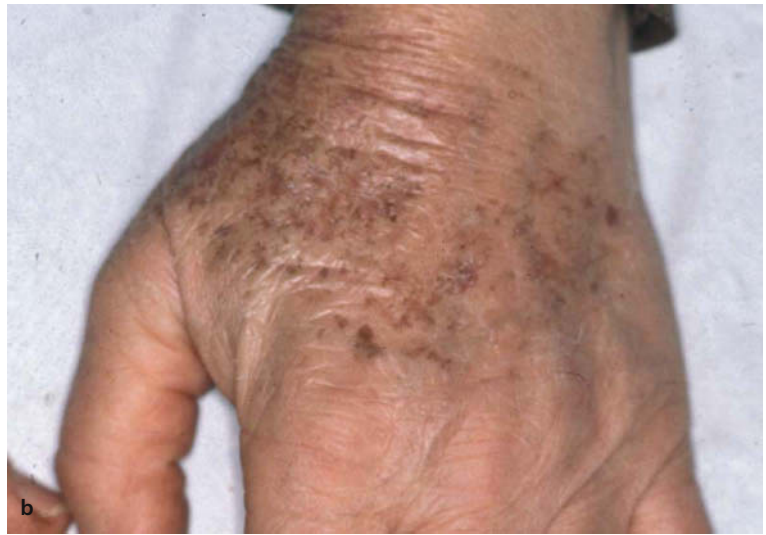
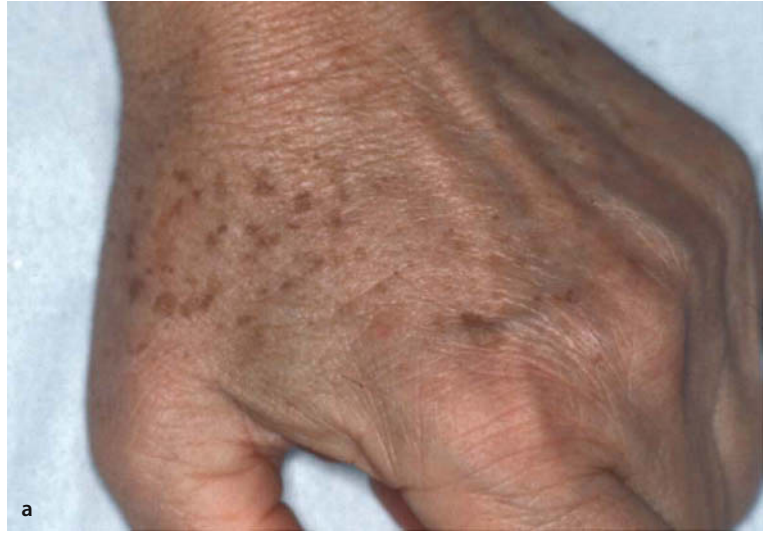
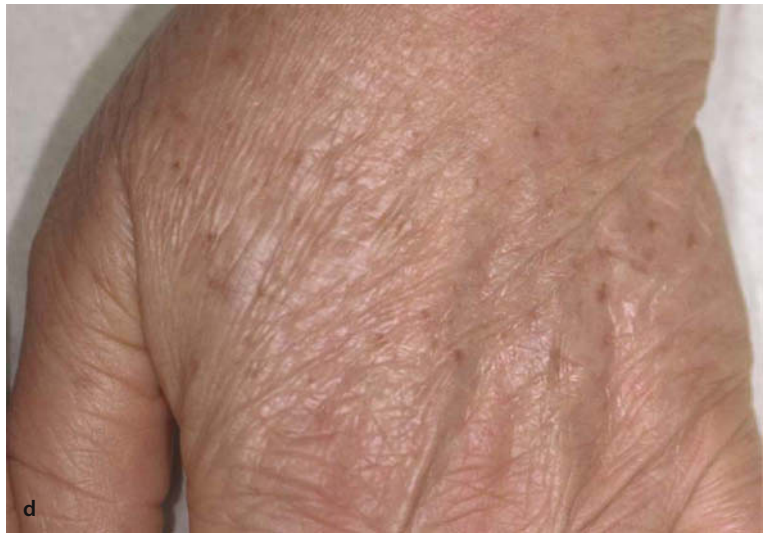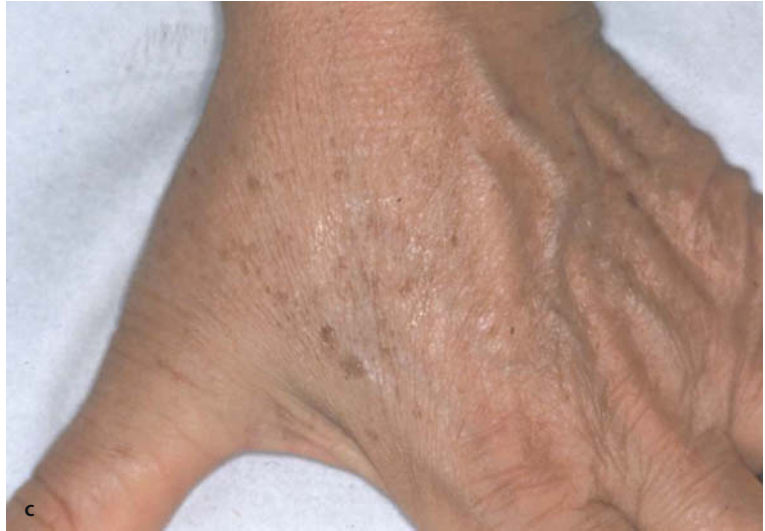Fig. 18.6c, d.
Solar lentigo 1 month
after 25% TCA peel



References

1. Kim NY, Pandya AG (1998) Pigmentary diseases. *Med Clin North Am* 82:1185-1207
2. Pierard GE, Pierard-Franchimont C, Laso Dosal F et al (1991) Pigmentary changes in skin senescence. *J Appl Cosmetol* 9:63-67
3. Dooley TP (1997) Topical skin depigmentation agents: current products and discovery of novel inhibitor of melanogenesis. *J Dermatol Treat* 8:275-279
4. Ghersetich I, Brazzini B, Lotti T (2003) Chemical peeling. In: Katsambas AD, Lotti TM (eds) *European handbook of dermatological treatments*, 2nd ed. Springer, Berlin, Heidelberg, New York, pp 599-612
5. Zouboulis CC, Rosenberger AD, Adler Y, Orfanos CE (1999) Treatment of solar lentigo with cryosurgery. *Acta Derm Venereol* 79(6):489-490
6. Chan HH, Kono T (2004) The use of lasers and intense pulsed light sources for the treatment of pigmentary lesions. *Skin Therapy Lett* 9(8):5-7

Part IV

Management of the Patient

IV

Management of the Patient

19

Maria Pia De Padova, Antonella Tosti

The author has no financial interest in any of the products or equipment mentioned in this chapter.

Contents

19.1	Patient Selection	209
19.2	Patient Evaluation	209
19.3	Instructions	209
19.3.1	Pre-operative Phase	209
19.3.2	Post-operative Phase	210
19.4	Photographs	210

19.1 Patient Selection

- Identify and exclude patients with body dysmorphic disorders.
- Obtain medical history and exclude patients with specific contraindications (Table 19.1).
- Discuss patient’s expectations and clarify.
- Discuss alternative procedures.
- Explain procedure and discuss pain during procedure and post-operative morbidity complications (Table 19.2). Don’t minimize the severity of the post-peeling phase, which may preclude social activities for several days.
- Obtain informed consent (see related chapters).

19.2 Patient Evaluation

- Assess phototype, degree of sebaceous activity, skin thickness, and pigmentary abnormalities (Wood’s light).
- Exclude viral or bacterial infections and inflammatory dermatosis including retinoid dermatitis and skin irritation (shaving, use of facial scrubs) in the area that should be treated.

Photographic documentation permits the evaluation of results and programming of future procedures.

19.3 Instructions

19.3.1 Pre-operative Phase

- Topical 0.025–0.1% retinoic acid:
 - Favors homogeneous penetration of the peelings
 - Accelerates post-peeling healing
- Topical 1–2% salicylic acid:
 - Favors homogeneous penetration of the peelings
 - Reduces risks of the post-peeling pigmentation

Table 19.1 Specific contraindications

Active labial <i>HSV</i> infection. Prescribe prophylaxis with oral antivirals in patients with relapsing <i>HSV</i> (2 days pre- and 5 days post-operatively)	
Phototype IV and VI except for salicylic acid and TCA <than 25%	
Recent plastic surgery procedures, wait at least 6 months	
Drugs:	
Aspirin allergy	Salicylic peeling
Isotretinoin, wait at least:	6/12 months for medium-deep peels
	3/6 months superficial peels
Anticoagulants	Medium-deep
History of local radiotherapy	
History of Keloid formation	Medium-deep
Pregnancy/breast-feeding	
Heavy smokers	Medium-deep
Occupations associated with heavy sun exposure	
Inflammatory dermatoses in the area of the peels:	
Eczema	
Urticaria	
Seborrheic dermatitis	
Psoriasis	

19.3.2 Post-operative Phase

- Absolute sun protection (SPF of 30 and above + UVA filters)
- Topical medication:
 - Topical moisturizer (three to four times daily)
 - Antibiotic ointment (medium/deep three to five times a day)
- Ice packs in case of burning
- Avoid excessive activity (medium/deep)
- Sleep with the head elevated (medium/deep)
- Topical tretinoin α -hydroxy acid when reepithelialization is complete

19.4 Photographs

Photographic documentation is important for:

- Medicological purposes. Polaroid photographs are recommended for this purpose.
- Evaluation of cosmetic benefits with the patient. Digital photographs are the best, permit easy comparison and are inexpensive. It is helpful to show the patient the necessity of photoprotection, to inform the patient about the procedure and to show the post-peeling course.
- Scientific documentation. Comparable high quality digital photographs are necessary.

Table 19.2 Complications

Local		Systemic
Transitory	Infections	Cardiac arrhythmias
	Pigmentary changes (Fig. 19.1, 19.2)	Laryngeal edema
	Ecchymoses	Toxic Shock Syndrome
	Subjective skin hyperreactivity (Fig. 19.3, 19.4)	Salicylism
	Contact allergy	Ochronosis
	Contact urticaria	Myxedema
	Acneiform eruption	Methaemoglobinaemia
Persistent	Pigmentary changes	Hypotension
	Scarring	Collapse
	Persistent erythema	
	Sensitive skin	
	Textural changes	
	Skin thinning	
	Milia	

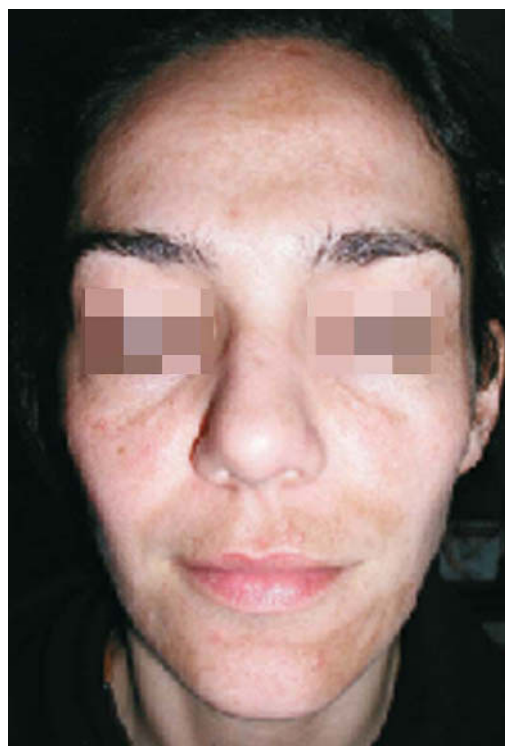

Fig. 19.1. Pigmentary changes after a contained peel

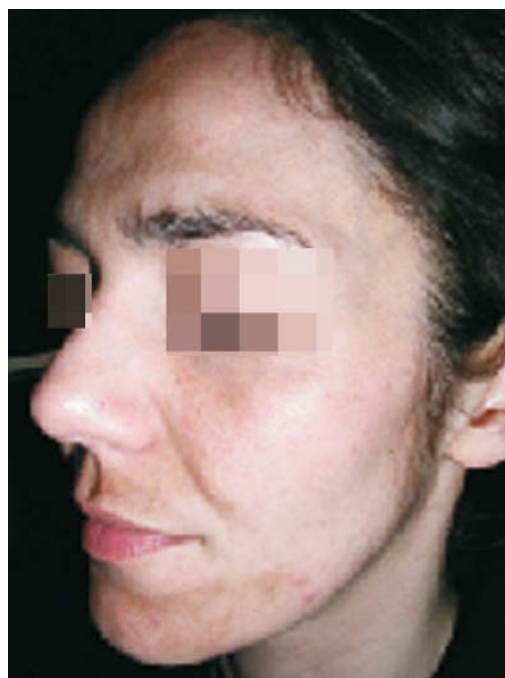

Fig. 19.2. Pigmentary changes after a contained peel

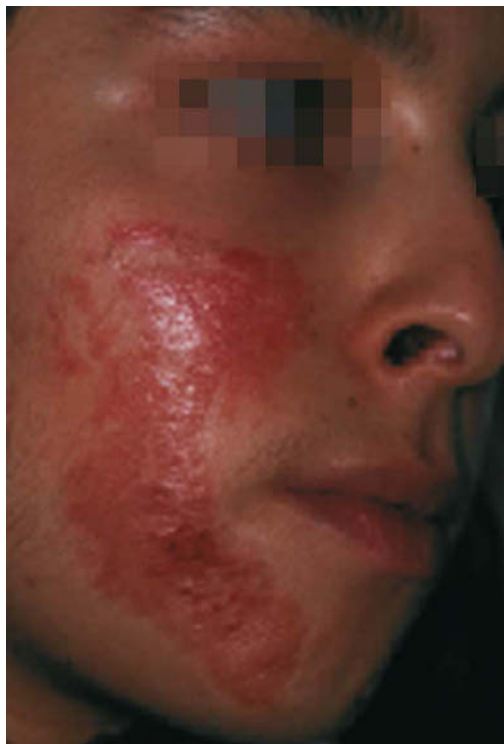

Fig. 19.3. Subjective skin hyperreactivity after salicylic acid peel

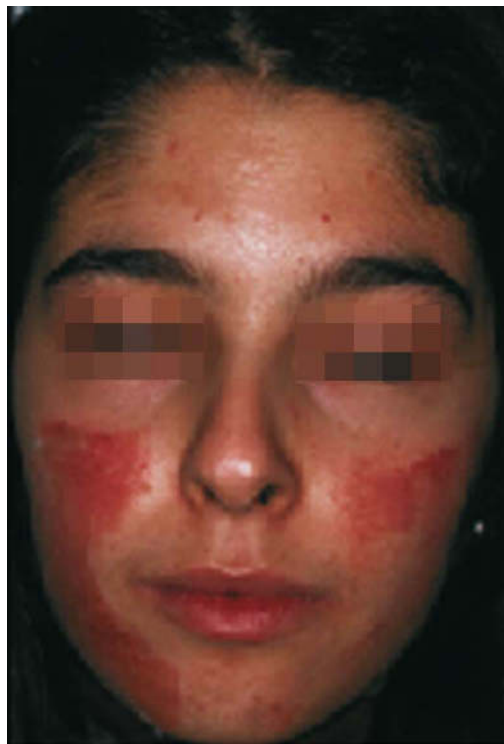

Fig. 19.4. Subjective skin hyperreactivity after salicylic acid peel

Subject Index

A

acid

- alpha-hydroxic 13, 51, 143, 168
- azelaic 122, 153, 169
- glycolic 4, 16, 104, 143, 181
- Kojic 153, 169
- lactic 24
- polyhydroxic 51, 168
- pyruvic 5, 36, 172
- retinoid 153
- salicylic 5, 23, 49–57, 143, 144, 179, 181, 197
- trichloroacetic 5, 16, 59–67, 143, 146, 170, 171

acne 6, 109, 113–132

- cicatricial 43
- comedonal 6
- conglobata 116, 117
- drug-induced 119
- excoりée des jeunes filles 120
- fulminans 119
- infantum 119
- inflammatory 6, 116
- mechanical 119
- microcomedonic 115
- microcystic 32
- neonatorum 119
- nodular 116
- nodulo-cystic 6
- occupational 120
- papulo-pustular 42, 116, 126, 129
- rosacea 55
- scarring 59, 91, 126
- vulgaris 54, 55, 113, 177, 179

acneiform

- dermatitis 86
- eruption 211

actinic

- cheilitis 133, 135
- keratosis 7, 62, 133–138
- - hypertrophic 135
- - lichenoid 135
- - spreading pigmented 135

ALA, see delta-aminolevulinic acid

alpha-hydroxic acid 13, 51, 143, 168

alpha-ketoacid 31

antibiotics 122

anticoagulants 210

ascorbic acid, see vitamin C

aspirin allergy 210

atrophic scar 99

atrophy, epidermal 163

azelaic acid 122, 153, 169

B

bacterial infection 66

benzoyl peroxide 122

bismuth subgallate powder 79, 81, 95

blackheads 115

bleaching agent 168, 180

body dysmorphic disorder 209

boxcar scar 92, 96, 98, 118

breast-feeding 210

C

cardiac arrhythmia 85, 211

cardiotoxicity 85

centrofacial melasma 150

cheilitis 130, 133

- actinic 133, 135

chloasma 149

chloracne 120

cicatricial acne 43

clarithromycin 192

clindamycin 122

collagen degeneration 163

collapse 211

combination peel 6

comedo 113

comedonal acne 6

contact

- allergy 211

- urticaria 211

contraceptive pill 128

CROSS technique 63

croton oil 70, 71

cryotherapy 137, 158

- with liquid nitrogen 136

cyproterone acetate 128

cysts 116

D

dark skin 8, 139
 deep chemical peel 6, 69, 91–101
 – ideal patient 72
 – patient's informed consent 87
 delta-aminolevulinic acid (ALA) 136
 demarcation line 75
Demodex folliculorum 191
 depigmenting agent 152
 – topical 200
 depressed distensible scar 93, 98
 dermabrasion 127, 136
 dermatitis, acneiform 86
 diclofenac 136
 dyschromia 162

E

ecchymoses 211
 eczema 210
 edema 65
 – laryngeal 211
 elderly people 133
 electrosurgery 136
 elevation 127
 eosin stain 141
 epidermal atrophy 163
 erythema 34, 65
 erythematoteleangiectatic rosacea 186
 – persistent 211
 erythromycin 192
 erythroslis 193
 estrogen 130
 ethylene glycol intoxication 19
 excision 127

F

facial
 – melasma 106, 107
 – scarring 99
 – skin 63
 farmer skin 84
 Fitzpatrick's skin types 25, 50, 104, 162
 5-fluorouracil 136
 flutamide 128
 follicular hyperkeratinization 113
 frosting 64, 65, 94

G

Glogau's four photoaging groups 165
 glycolic acid 4, 16, 104, 143, 181
 – patient's informed consent 20
 granulomatous rosacea 189, 190
 Grenz zone 169

H

Helicobacter pylori 185
 hematoxylin stain 141
 hormone 128
 Herpes Simplex Virus (HSV) 210
 hydroquinone 27, 53, 70, 107, 146, 152, 168
 hyperkeratotic epidermal lesion 23
 hyperpigmentation 63, 85, 109
 – mottled 163
 – post-inflammatory 9, 25, 104, 143, 145, 177, 179
 hypertrichosis 121
 hypopigmentation 56, 85
 hypotension 211

I

ice pack 210
 icepick scar 92, 118
 idiopathic thrombocytopenia 84
 imiquimod 136, 137
 infection 66, 86, 211
 – bacterial 66
 inflamed lesion 114
 inflammatory acne 116
 – mild/moderate 6
 informed consent, see also patient's informed consent
 20
 intradermal nevus 73
 isotretinoin 93, 128, 131, 210
 – oral 192
 – systemic 73
 itching 79

J

Jessner's solution 4, 23–29, 64, 144, 171
 – modified 24
 – patient's informed consent 28
 Jessner's peeling 26

K

keloid formation 210
 keratinocytes 140
 keratocoagulation 60
 keratosis
 – actinic 62, 133–138
 – – hypertrophic 135
 – – lichenoid 135
 – – spreading pigments 135
 – multiple solar 84
 – seborrheic 62
 Kojic acid 153, 169

L

- lactic acid 24
- laryngeal edema 211
- laser 158
 - resurfacing 127
 - therapy 127
- lentigines 60
- lesion
 - hyperkeratotic epidermal 23
 - inflamed 114
 - non-inflamed 114
- lidocaine 64

M

- macrolides 122
- malar melasma 150, 155, 157
- mandibular melasma 150
- MASI, see Melasma Area and Severity Index
- mask of pregnancy 149
- melanin 150, 178
- melanocytes 139, 200
- melanosomes 139
- melasma 8, 16, 26, 43, 53, 61, 149
 - centrofacial 150
 - dermal 151
 - epidermal 151
 - facial 106, 107
 - indeterminate 151
 - malar 150, 155, 157
 - mandibular 150, 154
 - mixed 151
 - of the forehead 157
 - of the superior lip 155
 - recalcitrant 105
- Melasma Area and Severity Index (MASI) 16, 151
- methaemoglobinaemia 211
- metronidazole 191
 - oral 192
- microcomedonic acne 115
- microcystic acne 32
- milia 86, 211
- mottled pigmentation 171
- myxedema 211

N

- neutralizer 16
- nevus, intradermal 73
- nodular acne 116
- nodules 115
- nodulo-cystic acne 6
- non-facial skin 63
- non-inflamed lesion 114

O

- occupational acne 120
- ochronosis 211
- ocular rosacea 186, 189

P

- papules 115
- papulo-pustular
 - acne 42, 116, 129
 - rosacea 194
- patient's informed consent
 - combination salicylic acid/TCA 109
 - deep chemical peel 87
 - glycolic acid 20
 - Jessner's solution 28
 - pyruvic acid 38
 - resorcinol 46
 - salicylic acid 56
- peeling
 - combination peel 109
 - deep chemical peel 72, 94
 - glycolic acid 16
 - Jessner's solution 27
 - medium 147
 - phenol-based 69, 74
 - pyruvic acid 32
 - resorcinol 44
 - salicylic acid 51
 - trichloroacetic acid 16
- phenol 63, 70, 71
- photoaging 9, 62, 161
 - Glogau's four groups 164
- photodamage 14, 56, 105, 109, 140
- photodynamic therapy 136
- photoprotection 140, 164
- photosensitivity 19
- phototype 209
- phymatous rosacea 186
- pigmentary
 - changes 211
 - dischromia 63
- pilosebaceous follicle 113
- polyhydroxy acid 51, 168
- post-acneic scar 6, 91
 - medium-deep 6
 - superficial 6
- post-inflammatory hyperpigmentation (PIH) 9, 25, 104, 143, 145, 177, 179
- pregnancy 210
- pro-inflammatory cytokines 114
- Propionibacterium acnes* 113
- pseudofolliculitis barbae 19, 182
- psoriasis 210
- pustules 115
- pyoderma faciale 122
- pyruvic acid 5, 36, 172
 - patient's informed consent 38

R

radiotherapy 210
 recalcitrant melasma 105
 resorcinol 5, 23, 24, 41–47, 70
 – paste 44
 – patient’s informed consent 46
 retinoid 26, 51, 106, 122, 153, 165
 – acid 153
 retinol 167
 rhinophyma 188
 rolling scar 92, 97, 98, 119
 rosacea 9, 185
 – erythematoteleangiectatic 186
 – granulomatous 189, 190
 – ocular 186, 189
 – papulopustular 194
 – phymatous 186

S

salicylic acid 5, 23, 49–57, 143, 144, 179, 181, 197
 – combination with TCA 103
 – patient’s informed consent 56
 salicylism 211
 sallowness 162
 scar 97, 114
 – atrophic 99
 – boxcar 92, 96, 98, 118
 – depressed distensible 93, 98
 – facial 99
 – icepick 92, 118
 – post-acneic 6, 91
 – rolling 92, 97, 98, 119
 scarring 66, 86, 116, 211
 seborrhea 114
 seborrheic
 – dermatitis 210
 – keratosis 62
 sebum 114
 sensitive skin 211
 skin
 – atrophy
 – dark 8, 139
 – dermabrasion 95
 – facial 63
 – hyperreactivity 211
 – non-facial 63
 – sensitive 211
 – thinning 211
 smoker 210
 sodium bicarbonate 34
 solar lentigos 10, 81, 199
 spironolactone 128

striae distensae 19
 strontium nitrate 19
 subcision 127
 subcutaneous incision 94
 sulfacetamide 191
 sun exposure 150, 161, 199
 systemic treatment 128

T

tape mask 79, 80, 95
 tazarotene 167
 TCA, see trichloroacetic acid
 teleangiectasia 186
 tetracyclines 122
 – oral 192
 textural changes 211
 thyroid disease 28
 titanium oxide 165
 tretinoin 50, 144, 153, 166, 179
 trichloroacetic acid (TCA) 5, 16, 59–67, 77, 143, 146, 170, 171
 – combination with salicylic acid 103
 – infections 66
 – peeling 130
 patient’s informed consent 28
 tyrosinase 150

U

ultraviolet light 135, 161
 Unna paste 41
 urticaria 210

V

vascular hyperactivity 185
 vitamin C 167

W

waterproof zinc oxide non-permeable tape 77
 weight-in-volume method 59
 whiteheads 115
 Wood’s light 151, 209
 wrinkles 81, 97, 99, 162, 171

Z

zinc oxide 77, 165