

# Small Animal ECGs

## **Dedication**

*To my family: my wife Mary  
and our three sons, David, Dennis and Sean*

# Small Animal ECGs

An introductory guide

Second Edition

Mike Martin

© 2000, 2007 Mike Martin

Blackwell Publishing editorial offices:

Blackwell Publishing Ltd, 9600 Garsington Road,  
Oxford OX4 2DQ, UK

Tel: +44 (0)1865 776868

Blackwell Publishing Professional, 2121 State Avenue,  
Ames, Iowa 50014-8300, USA

Tel: +1 515 292 0140

Blackwell Publishing Asia Pty Ltd, 550 Swanston Street,  
Carlton, Victoria 3053, Australia

Tel: +61 (0)3 8359 1011

The right of the Author to be identified as the Author of this Work has been asserted in accordance with the Copyright, Designs and Patents Act 1988.

All rights reserved. No part of this publication may be reproduced, stored in a retrieval system, or transmitted, in any form or by any means, electronic, mechanical, photocopying, recording or otherwise, except as permitted by the UK Copyright, Designs and Patents Act 1988, without the prior permission of the publisher.

Designations used by companies to distinguish their products are often claimed as trademarks. All brand names and product names used in this book are trade names, service marks, trademarks or registered trademarks of their respective owners. The Publisher is not associated with any product or vendor mentioned in this book.

This publication is designed to provide accurate and authoritative information in regard to the subject matter covered. It is sold on the understanding that the Publisher is not engaged in rendering professional services. If professional advice or other expert assistance is required, the services of a competent professional should be sought.

First Edition published 2000 by Blackwell Publishing Ltd  
Second Edition published 2007 by Blackwell Publishing Ltd

ISBN: 978-1-4051-4160-4

Library of Congress Cataloging-in-Publication Data

Martin, Mike W. S.

Small animal ECGs : an introductory guide / Mike Martin. – 2nd ed.  
p. ; cm.

Includes bibliographical references and index.

ISBN-13: 978-1-4051-4160-4 (pbk. : alk. paper)

ISBN-10: 1-4051-4160-3 (pbk. : alk. paper)

1. Veterinary electrocardiography. I. Title.

[DNLM: 1. Electrocardiography–veterinary. 2. Animals, Domestic.  
SF 811 M382s 2007]

A catalogue record for this title is available from the British Library

Set in 10/12pt Minion

by aptara Inc., New Delhi, India

Printed and bound in Singapore

by Fabulous Printers Pte Ltd.

The publisher's policy is to use permanent paper from mills that operate a sustainable forestry policy, and that has been manufactured from pulp processed using acid-free and elementary chlorine-free practices. Furthermore, the publisher ensures that the text paper and cover board used have met acceptable environmental accreditation standards.

For further information on Blackwell Publishing, visit our website:  
[www.blackwellpublishing.com](http://www.blackwellpublishing.com)

# Contents

	Preface to second edition	x
	Preface to first edition	xi
	About the author	xii
	Acknowledgements	xiii
<b>Part 1:</b>	<b>Understanding the electricity of the heart and how it produces an ECG complex</b>	<b>1</b>
1	What is an ECG?	3
2	<b>The electricity of the heart</b>	4
	Formation of the normal P–QRS–T complex	4
	Nomenclature of the QRS complex	8
3	<b>Rhythms of sinus origin</b>	<b>9</b>
	Sinus rhythm	9
	Sinus arrhythmia	9
	Sinus tachycardia	10
	Sinus bradycardia	11
<b>Part 2:</b>	<b>Abnormal electricity of the heart</b>	<b>13</b>
4	<b>Recognising and understanding ectopia</b>	<b>15</b>
	First identify the morphology of the normal QRS complex	15
	The morphology of an ectopic ventricular depolarisation	15
	The morphology of an ectopic supraventricular depolarisation	18

5	<b>Arrhythmias associated with ectopia</b>	<b>23</b>
	Ventricular premature complexes	23
	Supraventricular premature complexes	30
	Escape rhythms	31
	AV dissociation	34
	Fibrillation	34
6	<b>Abnormalities in the conduction system</b>	<b>40</b>
	Sinus arrest and block	40
	Sick sinus syndrome	40
	Atrial standstill	42
	Heart block	43
7	<b>Changes in the P–QRS–T morphology</b>	<b>48</b>
	Wandering pacemaker	48
	Changes associated with chamber enlargement	48
	Left atrial enlargement	49
	Right atrial enlargement	49
	Left ventricular enlargement	50
	Right ventricular enlargement	50
	Abnormal mean electrical axis (MEA)	50
	Low-voltage QRS complexes	51
	Electrical alternans	52
	Notching in the R wave	52
	Q–T interval abnormalities	53
	S–T segment abnormalities	53
	Abnormalities of the T wave	53
	Hyperkalaemia	55

<b>Part 3: More advanced electrocardiography</b>	<b>57</b>
8 <b>Understanding the ECG limb lead systems</b>	<b>59</b>
The six ECG limb leads	59
9 <b>Mean electrical axis explained</b>	<b>61</b>
How to calculate the mean electrical axis	62
10 <b>Intraventricular conduction defects</b>	<b>64</b>
Right bundle branch block	64
Left bundle branch block	65
Left anterior fascicular block	67
Intermittent ventricular aberrancy	69
11 <b>Some additional arrhythmias</b>	<b>70</b>
Ventricular pre-excitation	70
Atrial flutter	70
Accelerated idioventricular rhythm	71
<b>Part 4: Management and treatment of arrhythmias</b>	<b>73</b>
12 <b>Management of arrhythmias</b>	<b>75</b>
Does the arrhythmia suggest the presence of an underlying condition?	75
Is the arrhythmia of primary clinical significance?	76
13 <b>Treatment of arrhythmias</b>	<b>78</b>
Bradyarrhythmias	78
Tachyarrhythmias	81

14	<b>Pacemakers</b>	<b>88</b>
	Indications	88
	Contraindications	88
	Disadvantages	88
	Complications	88
	Prior diagnostics	89
	Equipment	89
	Types of permanent pacemakers	89
	Techniques of implantation	90
	Pacemaker follow-up	90
	Hazards	90
	<b>Part 5: Recording and interpreting ECGs</b>	<b>91</b>
15	<b>Approach to interpretation of the ECG recording</b>	<b>93</b>
	To calculate the heart rate (given as beats per minute)	93
	Determine the rhythm	93
	Measure the complex amplitudes and intervals	94
16	<b>Artifacts</b>	<b>96</b>
	Electrical interference	96
	Muscle tremor artifact	97
	Movement artifact	97
	Incorrectly placed electrodes	100
17	<b>Recording an ECG</b>	<b>102</b>
	The connectors (electrodes)	102
	Making the connection	102
	Where to place the electrodes	103
	Isolating the electrodes	104
	How to position the ECG cables	104
	Positioning the animal	104
	Setting up and preparing the ECG machine	109
	Recording an ECG – a suggested routine	111



<b>18</b>	<b>Choosing an ECG recorder</b>	<b>114</b>
	Quality	114
	Continuous recording	114
	Ease of use	114
	Automatic labelling	114
	Automatic vs. manual recording mode	114
	Interpretative software	115
	Multichannel vs. single channel	116
	Precordial chest leads	117
	Calibration settings	117
	Automatic centring vs. manual control	117
	Internal battery	117
	Jack plug lead fitting	117
	Monitor screen	118
	Thermal paper vs. ink paper	118
	New vs. second-hand	118
	Summary of features to look for in an ECG recorder	118
	<b>Further reading</b>	<b>119</b>
	<b>Index</b>	<b>120</b>

## Preface to second edition

This edition has been significantly changed and updated, I hope for the better. It is still aimed at the beginner, be they a veterinary student or graduate, veterinary nurse or technician. It is intended as an introduction, providing a fairly easy book to read and learn about electrocardiography, prior to embarking on the more established textbooks listed in the Further Reading list.

In continuing to lecture widely on ECGs, I found that the sequence in which I taught was different from that in my own book (the 1st edition). So in this 2nd edition, I have re-arranged the sequence to match my lecture course. I hope this works. I believe it should but, importantly, it should make reading and learning about ECGs much easier and more logical. Hopefully, it will help the reader to overcome any psychological fear and apprehension about understanding, interpreting and making good use of ECGs, and spread the use of ECGs more widely.

This edition contains more than fifty new ECG tracings, gradually gathered over the years. It is hoped that these will add greatly to the book, providing illustrations to match the text. There are new chapters on management and treatment of arrhythmias and on choosing an ECG recorder.

The positive feedback to the 1st edition was very gratifying and is always a pleasure to receive. I hope that this new edition has at least an equally good reception: hopefully even better. I wish you all an enjoyable beginning to electrocardiography and a life-long use that will continue to evolve with time and experience.

Mike Martin

## Preface to first edition

The aim of this guide is to provide an introduction to electrocardiography for anyone embarking on this subject. It has been written in such a way (I hope) that it is easy to understand. In part, it has been adapted and developed from frequent lecturing on this topic and feedback by audience interaction. This has resulted in a method of teaching electrocardiography that appears to have succeeded in providing the basis for understanding. Whether this transfers to a book remains to be seen, but I have deliberately used a number of diagrams to illustrate the points being made. Once this book has been read, the reader hopefully will be enthused and enlightened enough to proceed to more advanced ECG textbooks – a further reading list is given at the end. This book should not be used as a reference guide, but simply a stepping stone to such texts.

The book has been written in the expectation that the reader will read it from beginning to end, rather than try to pick out a chapter

to read. I think that anyone who is new to ECGs will find reading it from the beginning the easiest way to grasp the concepts of electrocardiography. In trying to keep this book as an introductory guide, I have (deliberately) not provided a comprehensive list of arrhythmias. In doing so I have had to decide which rhythm disturbances to leave out and which to keep in. This has been a difficult task! On balance I suspect even more rhythm disturbances and abnormalities should have been left out, such as intraventricular conduction disturbances. However, as these are occasionally seen in practice, I have therefore included them, although at the very end of the book!

Having said all that, I hope you, the reader, will find this an enjoyable and easy read, whilst also educational.

Mike Martin

## About the author

Mike Martin qualified from University College Dublin in 1986. He worked for two years in mixed practice and four years at the Royal (Dick) School of Veterinary Studies, University of Edinburgh, as a Housephysician and a Resident in Veterinary Cardiology, during which time he gained the Certificate and Diploma in Veterinary Cardiology and then RCVS Specialist status in Veterinary Cardiology in 1995, which has been renewed every five years since.

Mike runs his own private referral practice, the Veterinary Cardiorespiratory Centre, in Kenilworth, Warwickshire. He is an active

and well recognised cardiologist, having produced a number of publications and is a frequently invited speaker at meetings. He has been an examiner for the RCVS Certificate and Diploma, and he has been past Honorary Secretary and Chairman of the Veterinary Cardiovascular Society. He is a recipient of the BSAVA's Dunkin Award (1993) and Melton Award (2000). He is co-author of the book *Notes on Cardiorespiratory Diseases of the Dog and Cat* (2nd edition), also published by Blackwell Publishing.

# Acknowledgements

I would like to thank all those who have assisted in production of this book, from both those in the audience during lectures who provided feedback and my colleagues, peers and friends.

## **PART 1**

Understanding the electricity of the heart and how it produces an ECG complex

## 1 • What is an ECG?

An **electrocardiograph (ECG)**, in its simplest form, is a voltmeter (or galvanometer) that records the changing electrical activity in the heart by means of positive and negative electrodes (Fig. 1.1). **Electrocardiography** is the process of recording these changing potential differences.

While a positive (+ve) and negative (–ve) electrode can be placed almost anywhere on, or in, the body to record electrical changes, one of the most common and simplest methods is to place these electrodes on the limbs of the animal – referred to as a **body surface limb ECG recording**. In comparison, for example, electrodes can be placed on the chest (precordial chest ECG recording – commonly used in humans) or inside the cardiac chambers (used in electrophysiological studies). This book is confined to the limb ECG recording, which is the method most commonly used in veterinary medicine.

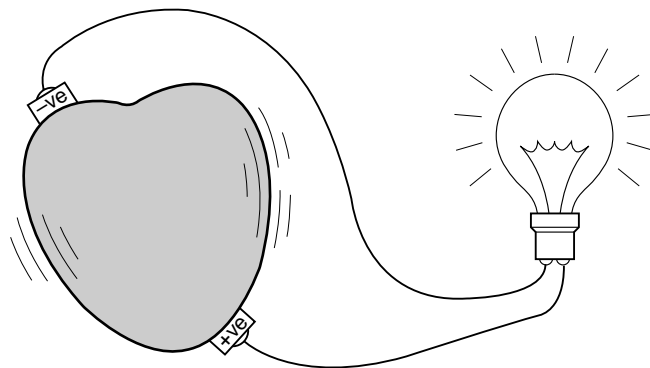


Figure 1.1 An ECG records the 'heart's electricity'.

## 2 • The electricity of the heart

For the heart to function efficiently as a ‘circulatory pump’ it must have a coordinated contraction, the two atria contracting and passing blood into the two ventricles, followed by contraction of the ventricles that push blood out of the heart and into the aorta and pulmonary artery, i.e. there must be a coordinated atrioventricular contraction. In order for the cardiac muscle cells to contract, they must first receive an electrical stimulus. It is this electrical activity that is detected by an ECG.

The electrical stimulus must first depolarise the two atria. Then, after an appropriate time interval, stimulate the two ventricles. The heart must then repolarise (and ‘refill’) in time for the next stimulus and contraction. Additionally, it must repeatedly do so, increasing in rate with an increase in demand and conversely, slowing at rest.

### Formation of the normal P–QRS–T complex

All cells within the heart have the potential to generate their own electrical activity, however the **sinoatrial (SA) node** is the fastest part of the electrical circuit to do so and is therefore the ‘rate controller’, termed the **pacemaker**. The rate of the SA node is influenced by the balance in autonomic tone, i.e. the sympathetic (increases rate) and parasympathetic (decreases rate) systems.

The electrical discharge for each cardiac cycle (Fig. 2.1) starts in the SA node. Depolarisation spreads through the atrial muscle cells. The depolarisation wave then spreads through the **atrioventricular (AV) node**, but it does so relatively slower, creating a delay. Conduction

passes through the AV ring (from the atria into the ventricles) through a narrow pathway called the **bundle of His**. This then divides in the ventricular septum into **left and right bundle branches** (going to the left and right ventricles). The left bundle branch divides further into **anterior and posterior fascicles**. The conduction tissue spreads into the myocardium as very fine branches called **Purkinje fibres**.

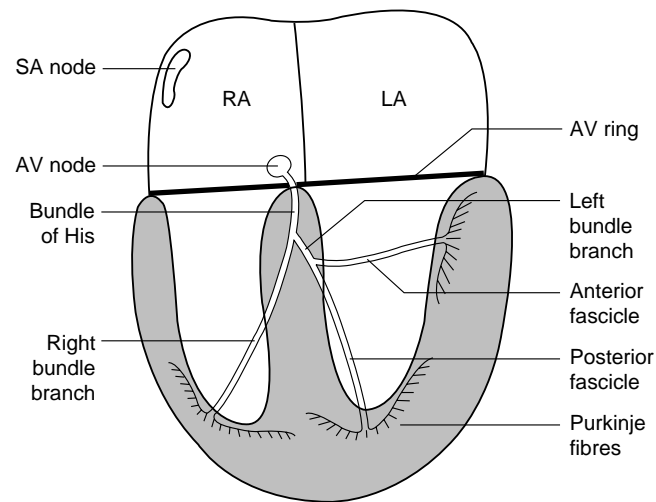


Figure 2.1 Illustration of the heart's electrical circuit. SA – sinoatrial; AV – atrioventricular; RA – right atrium; LA – left atrium.



### Formation of the P wave

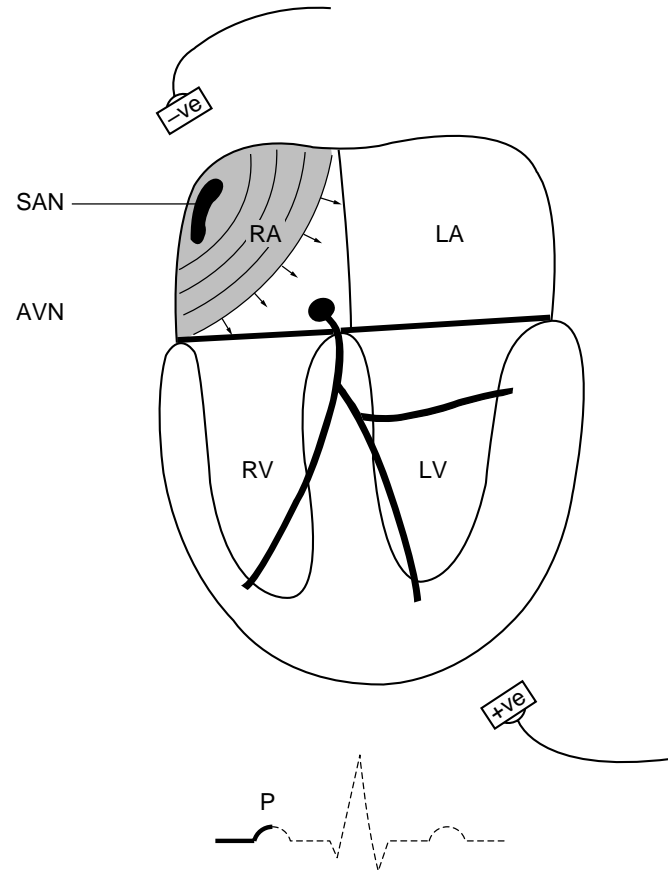
The SA node is therefore the start of the electrical depolarisation wave. This depolarisation wave spreads through the atria (somewhat like the ripples in water created by dropping a stone into it). As the parts of the atria nearest the SA node are depolarised (Fig. 2.2), this creates an electrical **potential difference** between depolarised atria and parts not yet depolarised (i.e. still in a resting state).

If negative (–ve) and positive (+ve) electrodes were placed approximately in line with those as shown on the diagram (Fig. 2.2), then this would result in the voltmeter (i.e. the ECG machine) detecting the depolarisation wave travelling from the SA node, across the atria, in the general direction of the +ve electrode. On the ECG recording, all positive deflections are displayed as an upward (i.e. positive) deflection on the ECG paper, and negative deflections are displayed downwards. The atrial depolarisation wave therefore creates an upward excursion of the stylus on the ECG paper.

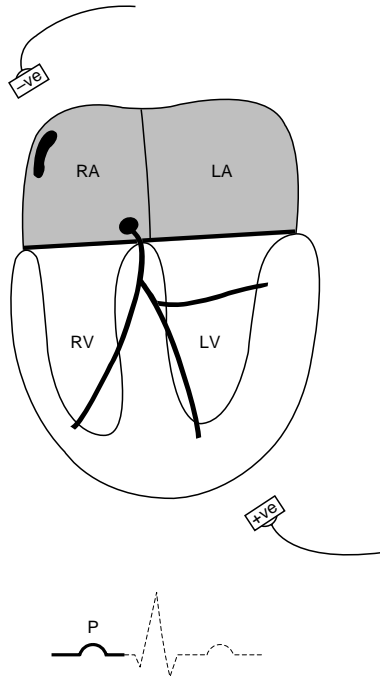
When the whole of the atria become depolarised then there is no longer an electrical potential difference and thus the stylus returns to its idle position – referred to as the **baseline**. The brief upward deflection of the stylus on the ECG paper creates the P wave, representing atrial electrical activity (Fig. 2.3). The muscle mass of the atria is fairly small and thus the electrical changes associated with depolarisation are also small.

### The P–R interval

During the course of atrial depolarisation, the depolarisation wave also depolarises the AV node. The speed with which the electrical depolarisation wave travels through the AV node is deliberately slow so that ventricular contraction will be correctly coordinated following atrial contraction. Once the depolarisation wave passes through the AV node, it travels very rapidly through the specialised conduction



**Figure 2.2** Illustration of partial depolarisation of the atria and formation of the P wave. The shaded area represents depolarised myocardial cells; the arrows represent the direction in which the depolarisation wave is travelling. RA – right atrium; LA – left atrium; RV – right ventricle; LV – left ventricle; SAN – sinoatrial node; AVN – atrioventricular node.



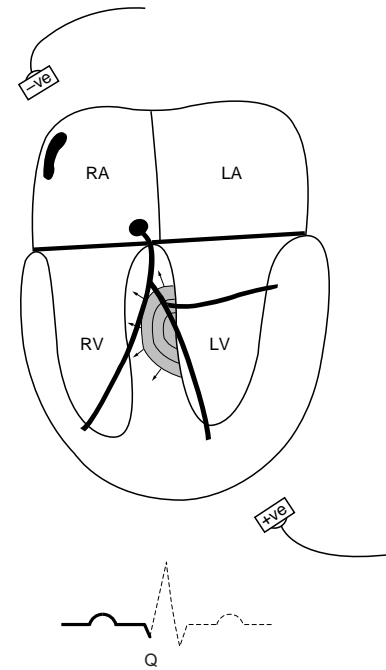
**Figure 2.3** Illustration of complete depolarisation of the atria and formation of the P wave. RA – right atrium; LA – left atrium; RV – right ventricle; LV – left ventricle.

tissues of the ventricles, i.e. the bundle of His, the left and right bundle branches and Purkinje fibres.

### *The formation of the QRS complex*

#### **The Q waves**

Initially the first part of the ventricles to depolarise is the ventricular septum, with a small depolarisation wave that travels in a direction

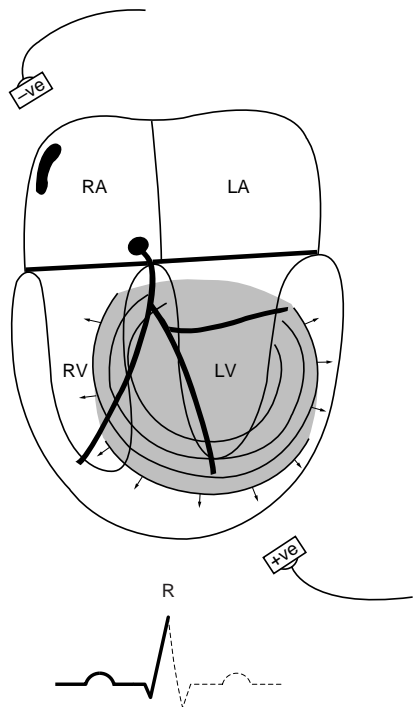


**Figure 2.4** Illustration of depolarisation of the ventricular septum and formation of the Q wave. RA – right atrium; LA – left atrium; RV – right ventricle; LV – left ventricle.

away from the +ve electrode (Fig. 2.4). This creates a small downward, or negative, deflection on the ECG paper – termed the Q wave.

#### **The R wave**

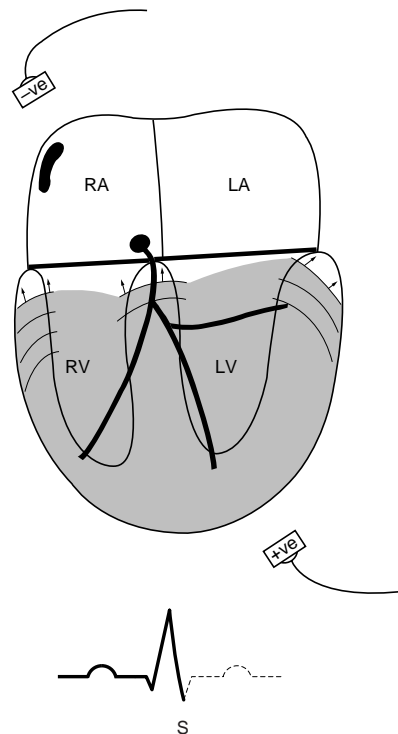
Then the bulk of the ventricular myocardium is depolarised. This creates a depolarisation wave that travels towards the +ve electrode (Fig. 2.5). As it is a large mass of muscle tissue, it usually creates a large deflection – this is termed the R wave.



**Figure 2.5** Illustration of depolarisation of the bulk of the ventricular myocardium and formation of the R wave. RA – right atrium; LA – left atrium; RV – right ventricle; LV – left ventricle.

### The S wave

Following depolarisation of the majority of the ventricles, the only remaining parts are basilar portions. This creates a depolarisation wave that travels away from the +ve electrode and is a small mass of tissue (Fig. 2.6). Thus, this creates a small negative deflection on the ECG paper – the S wave.



**Figure 2.6** Illustration of depolarisation of the basilar portions of the ventricles and formation of the S wave. RA – right atrium; LA – left atrium; RV – right ventricle; LV – left ventricle.

While the different parts of the QRS waveform can be identified, it is often easier to think of the whole ventricular depolarisation waveform as the QRS complex. This will avoid any confusion over the correct and proper naming of the different parts of the QRS complex.

## Nomenclature of the QRS complex

The different parts of the QRS complex are strictly and arbitrarily labelled as follows.

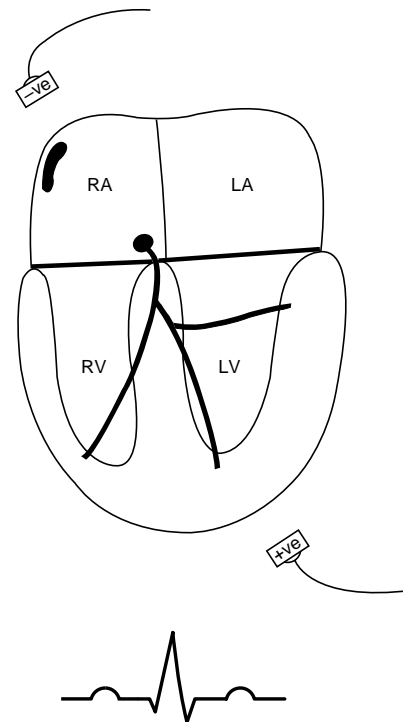
- The first downward deflection is called the Q wave; it always precedes the R wave.
- Any upward deflection is called the R wave; it may or may not be preceded by a Q wave.
- Any downward deflection after an R wave is called an S wave, regardless of whether there is a Q wave or not.

Having explained this, it is much easier to think of the ‘QRS complex’ as a whole, rather than to try to recognise its individual parts.

### The T wave

Following complete depolarisation (and contraction) of the ventricles they then repolarise in time for the next stimulus. This phase of repolarisation creates a potential difference across the ventricular myocardium, until it is completely repolarised. This results in a deflection from the baseline – termed the T wave (Fig. 2.7).

The T wave in dogs and cats is very variable, it can be negative or positive or even biphasic (i.e. a bit of both). This is because repolarisation of the myocardium in small animals is a little random, unlike in humans, for example, in which repolarisation is very organised and always results in a positive T wave. Thus, the diagnostic value obtainable from abnormalities in the T wave of small animals is very limited, unlike the very useful features of abnormal T waveforms seen in humans.



**Figure 2.7** Illustration of complete depolarisation and repolarisation of the ventricles and completion of the P–QRS–T complex. RA – right atrium; LA – left atrium; RV – right ventricle; LV – left ventricle.

The repolarisation wave of the atria ( $T_a$ ) is rarely recognised on a surface ECG, as it is very small and is usually hidden within the QRS complex.

## 3 • Rhythms of sinus origin

The formation of the normal ECG complex has been explained in the preceding chapter; this normal complex is termed a **sinus complex**. A sequence of beats originating from the SA node will form a sinus rhythm. Four common sinus rhythms are described below.

### Sinus rhythm

The stimulus originates regularly at a constant rate from the SA node (dominant pacemaker) depolarising the atria and ventricles normally producing a coordinated atrioventricular contraction. This is a normal rhythm.

#### *ECG characteristics*

There is a normal P wave followed by normal QRS–T waves. The rhythm is regular (constant) and the rate is within normal for age and breed (Fig. 3.1).

The size of the ECG complexes are typically small in cats (Fig. 3.2). Obtaining an artifact-free tracing is therefore important (in cats) in order to identify clearly the ECG complexes.

#### *Clinical findings*

There are regular heart sounds on auscultation (i.e. lubb dub) with a pulse for each heart beat and at a rate that is normal for age, breed and species.

### Sinus arrhythmia

The stimulus originates from the SA node, but the rate varies (increases and decreases) regularly. This is a normal and common rhythm in dogs. It is associated with an increase in parasympathetic activity (i.e. vagal tone) on the SA node. There is commonly a regular variation in rate often associated with respiration (i.e. it speeds up and slows down) and it is therefore often called **respiratory sinus arrhythmia**. Since sinus arrhythmia is an indicator of increased parasympathetic tone, conversely, it is also an indicator of reduced sympathetic tone. In dogs with heart failure one of the compensatory responses is an increase in sympathetic tone and therefore normal sinus arrhythmia is often lost and a sinus tachycardia develops. Sinus arrhythmia is uncommon in the cat and it might be seen in association with dyspnoea.

#### *ECG characteristics*

There is a normal P wave followed by normal QRS–T waves. The rhythm varies in rate; this is often associated with respiration (Fig. 3.3). The rhythm can sometimes be described as being regularly irregular, i.e. the variation in rate is fairly regular. The rate is within normal for age and breed.

#### *Clinical findings*

The heart rhythm varies with some regularity – increasing and decreasing in rate, and there is a pulse for every heart beat.

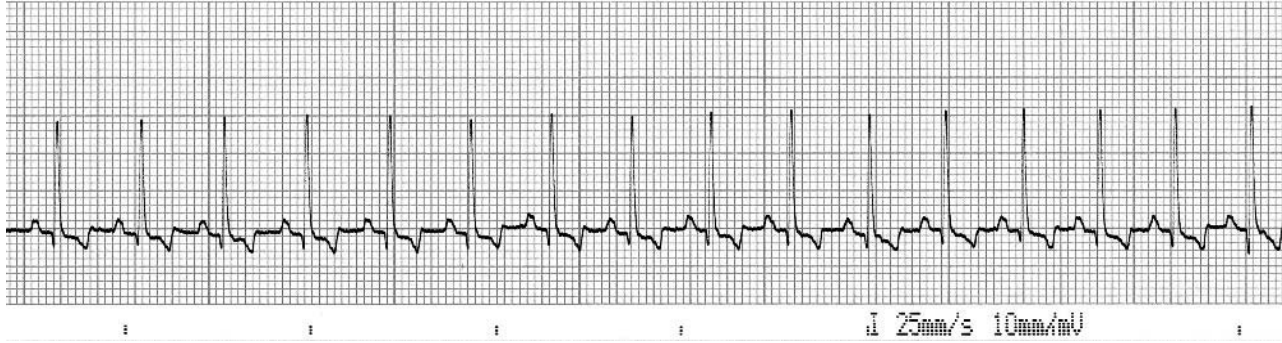

Figure 3.1 ECG from a dog showing a normal sinus rhythm at a rate of 140/min (25 mm/sec and 10 mm/mV).

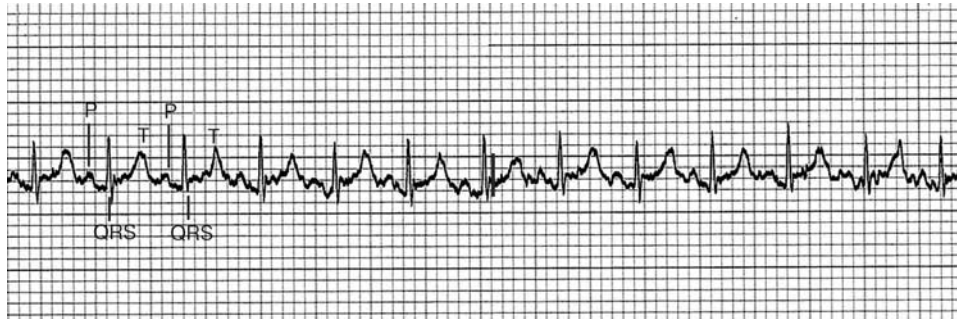

Figure 3.2 ECG from a cat showing a normal sinus rhythm at a rate of 220/min (25 mm/sec and 10 mm/mV).

### Sinus tachycardia

The SA node generates an impulse and depolarisation at a rate that is faster than normal.

### ECG characteristics

There is a normal sinus rhythm but at a faster rate than normal (Fig. 3.4).

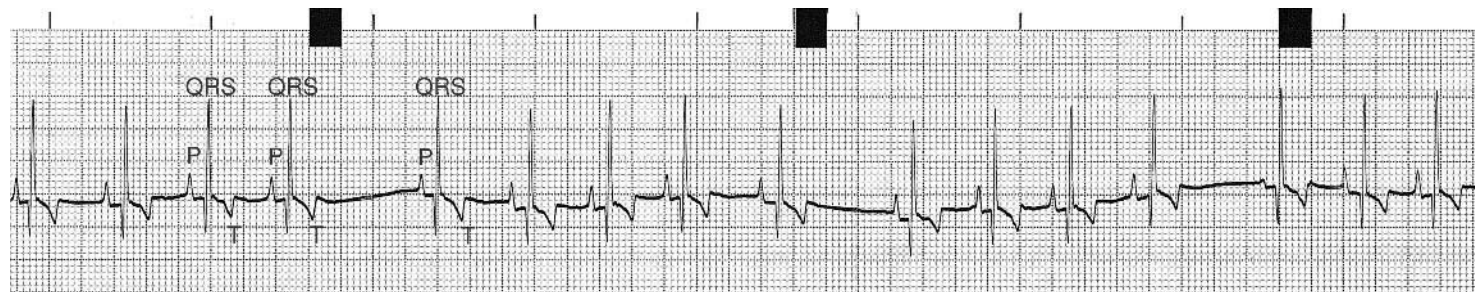


Figure 3.3 ECG from a dog showing a normal respiratory sinus arrhythmia at a rate of 110/min (25 mm/sec and 10 mm/mV).

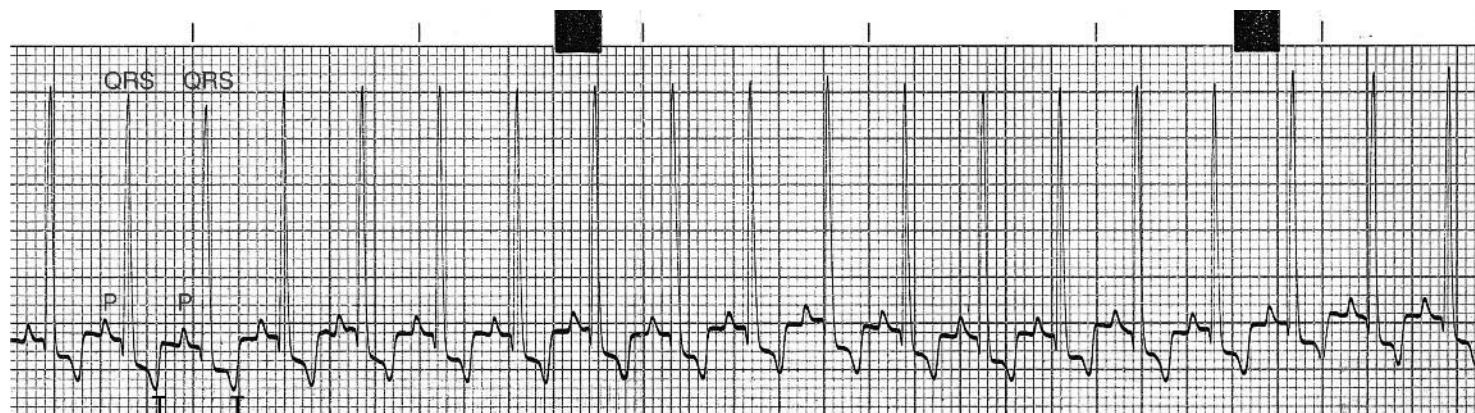


Figure 3.4 ECG from 13-year-old Cavalier King Charles spaniel dog in heart failure due to mitral valve disease. There is a sinus tachycardia at 180/min (25 mm/sec and 10 mm/mV).

### *Clinical findings*

The heart rate is faster than normal for age and breed with a pulse for every heart beat (although with very fast rates the pulse may become weaker).

### **Sinus bradycardia**

The SA node generates an impulse and depolarisation slower than normal. This can be a normal feature in some giant-breed dogs and in athletically fit dogs.

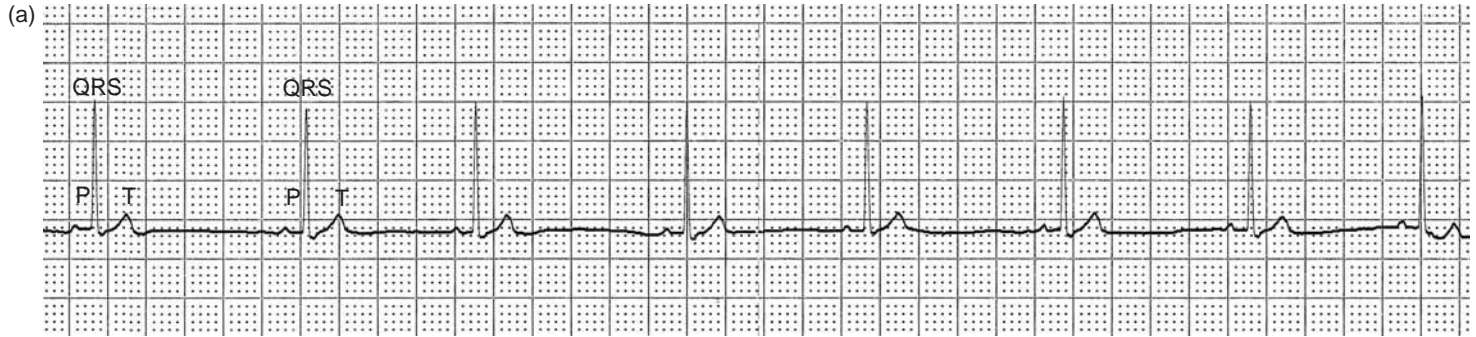


Figure 3.5 (a) ECG from a dog showing a sinus bradycardia at 65/min (25 mm/sec and 10 mm/mV).

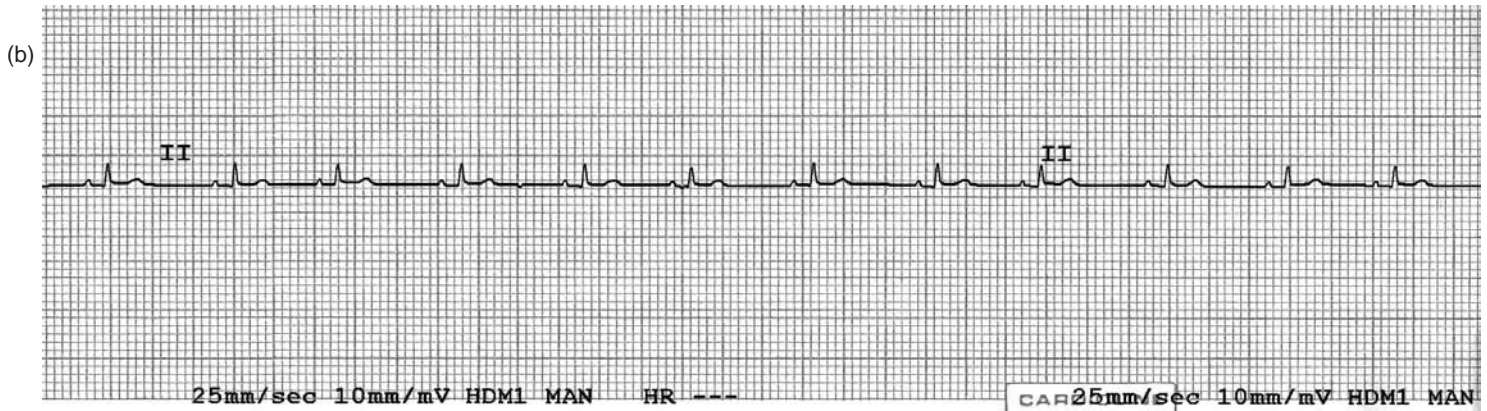


Figure 3.5 (b) ECG from a cat following sedation, showing a sinus bradycardia at 110/min (25 mm/sec and 10 mm/mV).

*ECG characteristics*

There is a normal sinus rhythm but at a slower rate than normal (Fig. 3.5).

*Clinical findings*

The heart rate is slower than normal for age and breed, with a pulse for every heart beat.



## **PART 2**

# Abnormal electricity of the heart

## 4 • Recognising and understanding ectopia

Arrhythmia and dysrhythmia are synonymous terms, meaning an abnormal rhythm. Arrhythmias include abnormalities in rate, abnormalities associated with ectopia and those associated with abnormalities in conduction. Arrhythmias that are essentially slow are referred to as **bradyarrhythmias**, and those that are fast as **tachyarrhythmias**.

### First identify the morphology of the normal QRS complex

Chapter 2 explained the formation of a normal sinus complex. It is important when examining an ECG tracing to identify (from the ECG recording) the normal sinus complex for that animal. Note the shape of the ventricular depolarisation and repolarisation waves, i.e. the QRS complex and T wave. To produce this shape of QRS and T, depolarisation of the ventricles has occurred by conduction from (or through) the AV node, i.e. ventricular depolarisation has been initiated from the AV node (see Chapter 2). It is of paramount importance in any tracing, especially if there are a variety of shapes of QRS complexes, to determine which shape represents conduction that has arisen (correctly) via the AV node.

### The morphology of an ectopic ventricular depolarisation

Any QRS–T complex, therefore, that is of a different shape (from the QRS–T of a normal sinus complex *for that animal*) represents an

abnormality. When the QRS–T complex is different from the normal sinus complex, depolarisation has (*almost certainly*) not arisen via the AV node (which would have produced a normal QRS shape) but from an ectopic location in the ventricles. Additionally these ventricular ectopic complexes are not associated with a preceding P wave (except by coincidence).

From Fig. 4.1a it can be seen that the direction of ventricular depolarisation is different from the direction that would have occurred from depolarisation arising from the AV node (cf. Figs 2.4–2.6). In this example the ventricular ectopic depolarisation wave is away from the +ve electrode and is therefore displayed on the ECG paper as below the baseline, i.e. the QRS complex is negative (Figs 4.1b, c). Secondly, because conduction has not travelled through the normal (therefore fast) electrical conduction tissue (it has depolarised the ventricular muscle mass from ‘cell to cell’) the time it takes to depolarise the ventricles is prolonged. Thus, not only is the QRS complex of the ventricular ectopic different in shape, but it is also prolonged (it takes a longer time). Quite often the T wave following the QRS complex of a ventricular ectopic is large and opposite in direction to the QRS.

Ventricular ectopic complexes can arise from any part of the ventricles and thus the direction in which they depolarise the ventricles is variable. To put it another way, since the direction in which the depolarisation wave travels in relation to the +ve electrode is variable, the shape and magnitude of the QRS complex of a ventricular complex will also be variable (Fig. 4.2a).

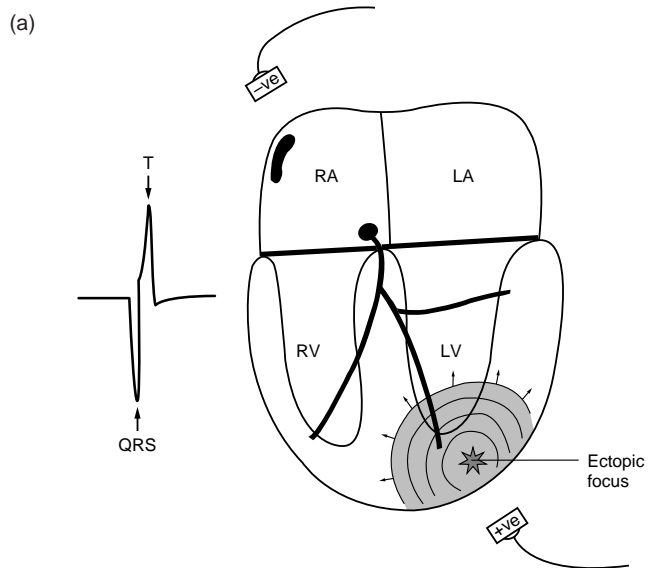


Figure 4.1 (a) Diagram illustrating an ectopic focus with the spreading out of the depolarisation wave (*left*), and the formation of a QRS-T complex (*right*) associated with the ventricular ectopic. RA – right atrium; LA – left atrium; RV – right ventricle; LV – left ventricle.

The important point is that the QRS of a ventricular ectopic complex is different from the QRS complex of one that has arisen from the AV node and travelled normally down the electrical conducting tissue to the ventricles (Fig. 4.2b, c).

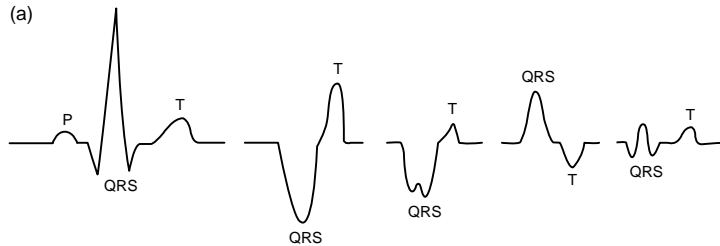
A ventricular ectopic complex can occur quickly (or early) and is therefore termed a **ventricular premature complex** (VPC). If a ventricular ectopic occurs after a pause (or with delay) then it is referred to as a **ventricular escape complex** (Fig. 4.3).

### Key points

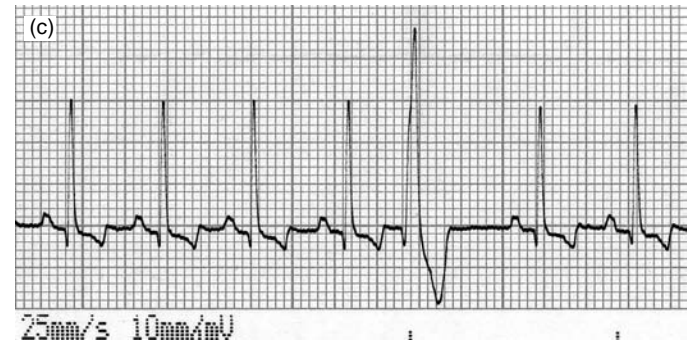
- First identify the morphology of the normal QRS complex for the animal.
- The QRS of a ventricular ectopic complex is different from the QRS complex of one that has arisen from the AV node.
- Ventricular ectopic complexes are not associated with a preceding P wave (except by coincidence).

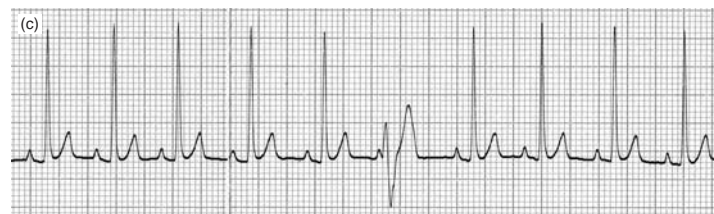
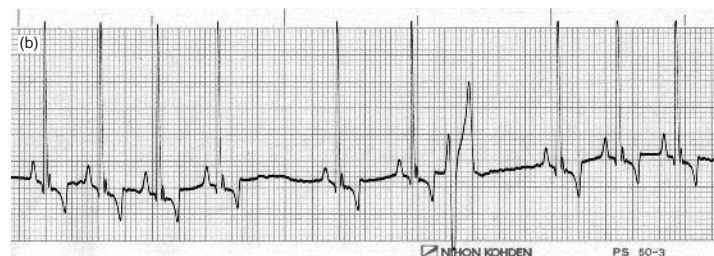
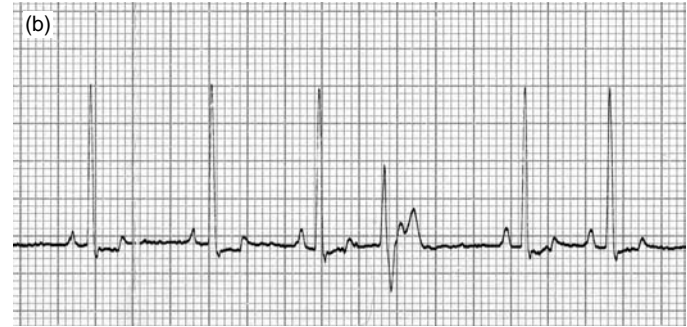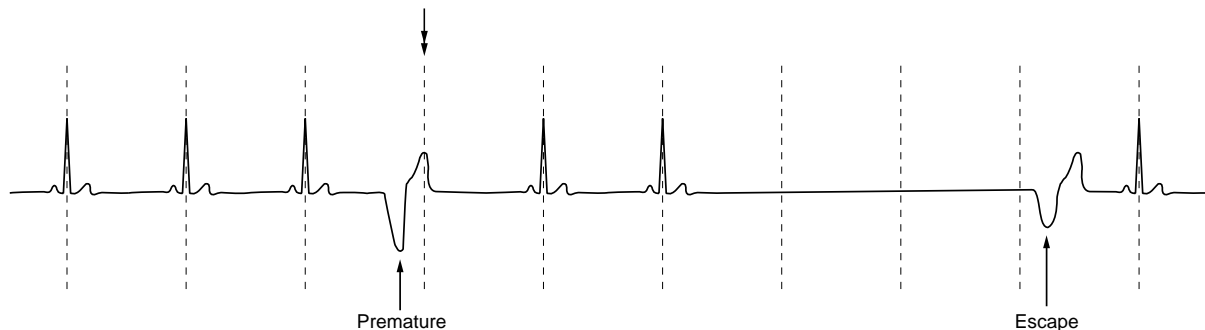
Figure 4.1 (b, c) ECGs from dogs each showing one VPC in which the QRS morphology has a negative morphology with an opposite and positive T wave morphology (25 mm/sec and 10 mm/mV).



**Figure 4.2** (a) Illustration of a normal complex (first complex), followed by four examples of QRS–T complexes with an abnormal morphology due to ventricular ectopic depolarisations. It is paramount to identify the morphology of the QRS complex associated with a sinus complex (first complex). Any QRS complexes of a different morphology (for that animal) must arise from an ectopic ventricular focus.



**Figure 4.2** (b, c) ECGs from dogs each showing one VPC in which the QRS morphology is not negative (cf. Fig. 4.1), but of differing morphologies. The fact that they are different from the morphology of the normal sinus QRS complexes is important in recognising that they are ventricular in origin, as well as being premature (25 mm/sec and 10 mm/mV).



**Figure 4.3** Illustration of (1) a ventricular premature complex (the double-headed arrow indicates the timing of when the next normal sinus complex would have occurred) and (2) a ventricular escape beat that occurred following a pause in the rhythm.

### The morphology of an ectopic supraventricular depolarisation

Any ectopic stimuli arising above the ventricles are referred to as supraventricular (Fig. 4.4). These can be divided into two categories: (1) those occurring in atrial muscle mass (atrial ectopics) and (2) those arising from within the AV node (junctional or nodal ectopics).

No matter where supraventricular ectopics arise, they must travel down the normal His–Purkinje tissue and depolarise the ventricles as normal. Thus, the morphology of the QRS complex associated with a supraventricular ectopic is normal,<sup>1</sup> i.e. the same as the QRS complex for a sinus complex. This means that the identification of a supraventricular ectopic can be difficult. In the vast majority of cases however, it occurs as a premature beat, and so it is primarily recognised by its premature timing (Fig. 4.5a, b).

Whether an ectopic arose from the atria (**atrial premature complex**) or the AV node (referred to as a **junctional or nodal premature complex**) is of little practical importance in small animals until studying advanced ECGs. Additionally, in small animals it does not often affect the management or treatment in the vast majority of cases. Therefore, distinguishing between atrial and junctional premature complexes will not be discussed in this book, but will be referred to by the broader term of **supraventricular premature complexes (SVPCs)**.

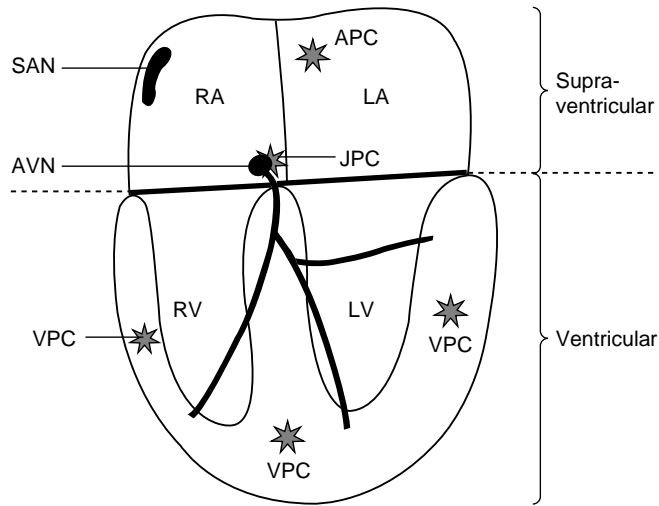
#### Key points

- The morphology of the QRS complex associated with a supraventricular ectopic is the same as a normal sinus complex.
- It is primarily recognised by its premature timing.

#### Terminology

The electrocardiographic interpretation of arrhythmias due to ectopia requires an understanding of the terminology used. If this is accomplished, interpretation becomes relatively easy.

<sup>1</sup> Except when there is aberrant conduction, see Chapter 10. However this is not common.



**Figure 4.4** Illustration of the origin of supra-ventricular and ventricular ectopic complexes. SAN – sinoatrial node; AVN – atrioventricular node; APC – atrial premature complex; JPC – junctional premature complex; VPC – ventricular premature complex; RA – right atrium; LA – left atrium; RV – right ventricle; LV – left ventricle.

The term ‘beat’ implies that there has been an actual contraction. In ‘ECG-speak’ it is better to use the term **complex** or **depolarisation** to describe waveforms on the electrocardiograph.

Ectopic complexes may be classified by the following:

- (1) *Site of origin* (Fig. 4.4). They are either ventricular or supra-ventricular. Supra-ventricular ectopics may be subclassified into ei-

ther: (a) atrial (originating in the atria) or (b) junctional or nodal (originating in the AV node or bundle of His).

- (2) *Timing*. Ectopic complexes that occur before the next normal complex would have been due are termed **premature**, and those that occur following a pause such as a period of sinus arrest or in complete heart block are termed **escape** complexes (Fig. 4.3).
- (3) *Morphology*. If all the ectopics in a tracing have a similar morphology to each other they are referred to as **uniform** and those in which there are different shapes are termed **multiform** (Fig. 4.6).
- (4) *Number of ectopics*. Premature ectopic complexes may occur singly, in pairs (Fig. 4.7), or in runs of three or more; the latter is referred to as a **tachycardia**. A tachycardia may be continuous, termed **persistent** or **sustained**, or intermittent, termed **paroxysmal**.
- (5) *Frequency*. The number of premature ectopic complexes in a tracing may vary from occasional to very frequent. When there is a set ratio such as one sinus complex to one ectopic complex it is termed **bigeminy** (Fig. 4.8) and one ectopic to two sinus complexes is termed **trigeminy**.

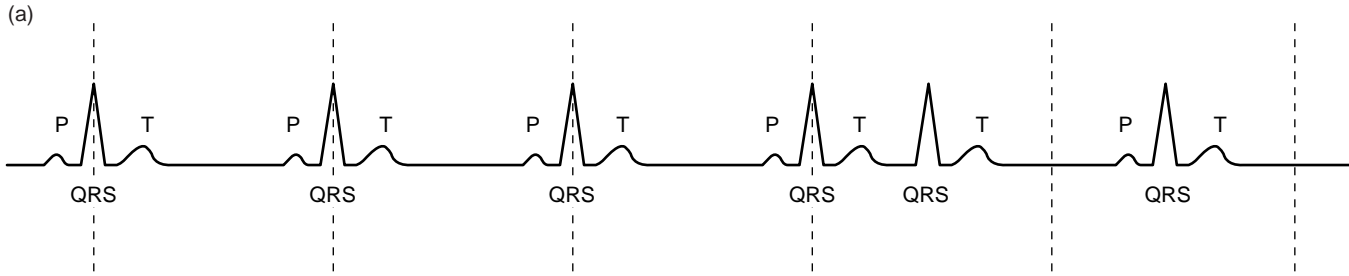


Figure 4.5 (a) Illustration of a supraventricular premature complex (fifth beat).

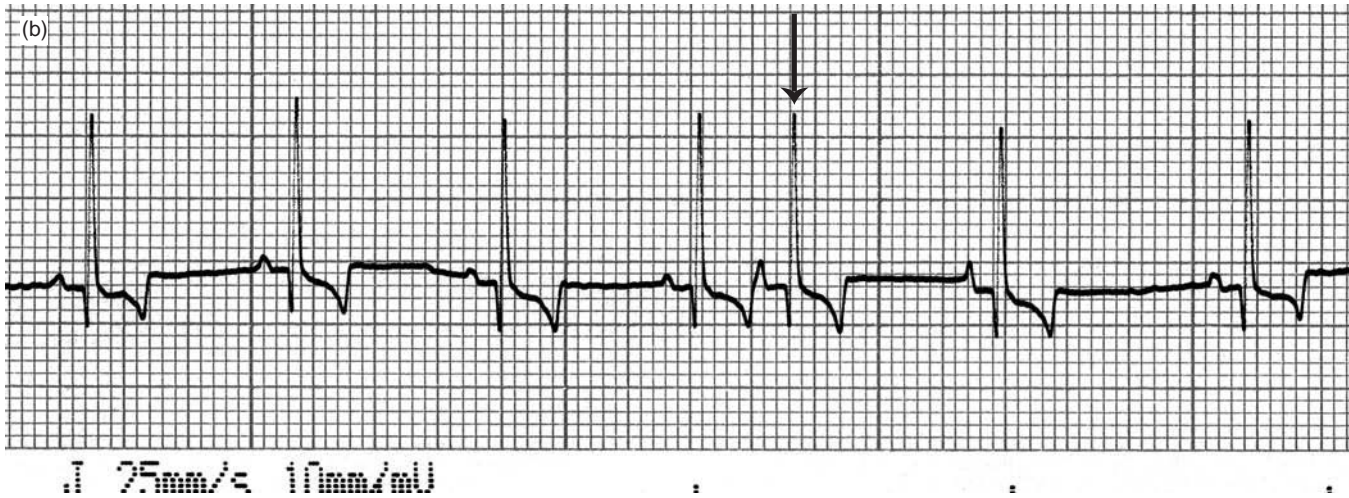
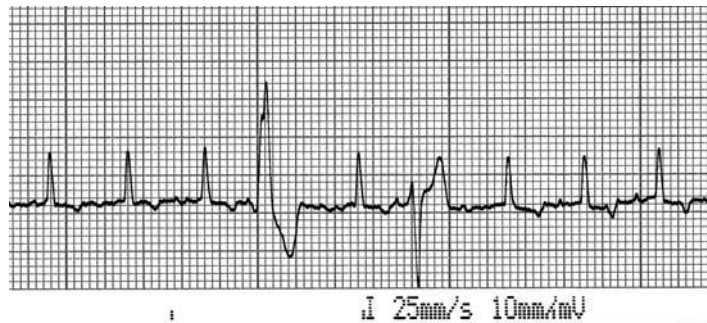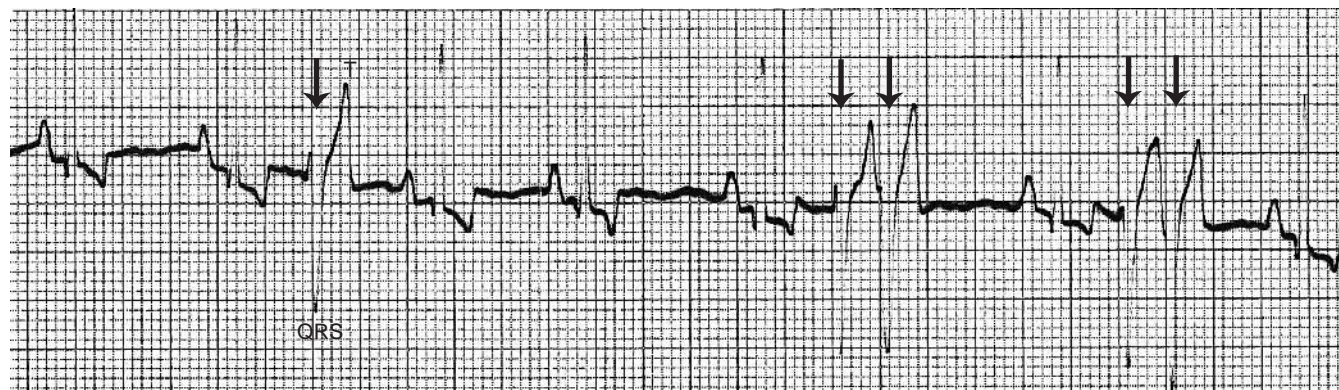


Figure 4.5 (b) ECG from a dog showing a supraventricular premature complex (arrowed). Note that the recognition is by its prematurity, as its QRS and T morphology is the same as a normal sinus complex (25 mm/sec and 10 mm/mV).



**Figure 4.6** ECG from a dog showing two VPCs of differing morphologies: the first with a positive QRS and the second with a negative QRS. These VPCs are very likely to have arisen from different foci in the ventricles. This ECG tracing is described as having multimorphic VPCs (25 mm/sec and 10 mm/mV).



**Figure 4.7** ECG with ventricular premature complexes (arrows), singly and in pairs. From a German Shepherd dog with a splenic mass (25 mm/sec and 10 mm/mV).



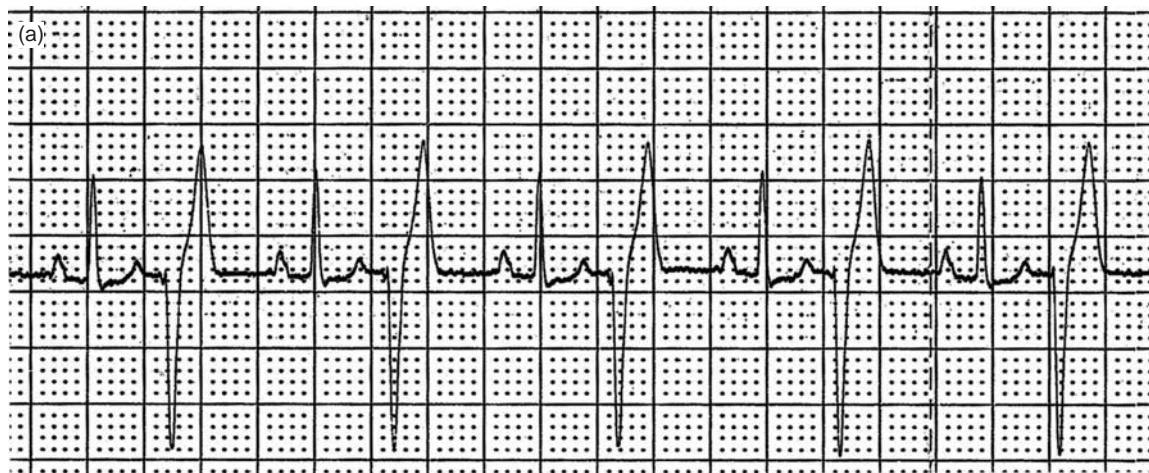


Figure 4.8 (a) ECG with ventricular premature complexes that alternate with normal sinus complexes; this is termed ventricular bigeminy. From a 13-year-old Standard Poodle with mitral valve disease (25 mm/sec and 5 mm/mV).

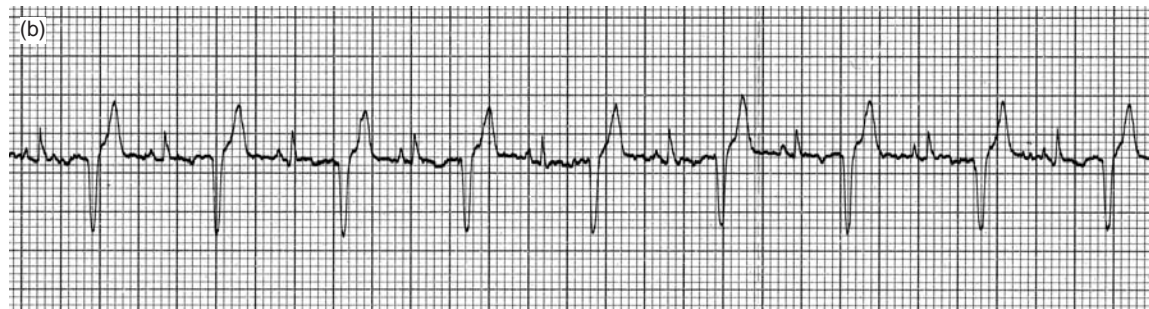

Figure 4.8 (b) ECG from a cat with hypertrophic cardiomyopathy showing a ventricular bigeminy (25 mm/sec and 10 mm/mV).

## 5 • Arrhythmias associated with ectopia

'Ectopia' literally means 'in an abnormal place'. In reference to the heart this means outside the SA node, the dominant pacemaker. Ectopic beats arise as a result of various mechanisms due to a number of causes (see Chapter 12).

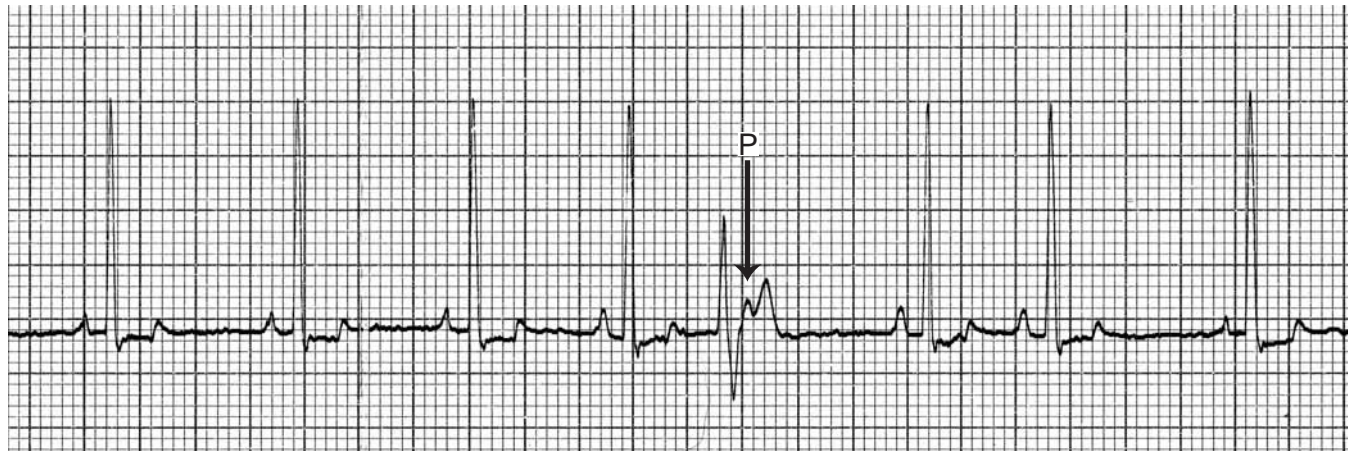
### Ventricular premature complexes

Ventricular premature complexes (VPCs) are a common finding in dogs and cats. VPCs arise from an ectopic focus or foci within the

ventricular myocardium. Depolarisation therefore occurs in an abnormal direction through the myocardium and the impulse conducts from cell to cell (not within the conduction tissue) as described in the preceding chapter.

### ECG characteristics

The QRS complex morphology is abnormal, i.e. unlike a QRS that would have arisen via the AV node. It is usually:



**Figure 5.1** ECG from a 10-year-old Springer spaniel showing a single VPC. Note the P wave within the ST segment (arrowed). However this normal sinus depolarisation arrived when the ventricles were still refractory (25 mm/sec and 10 mm/mV).

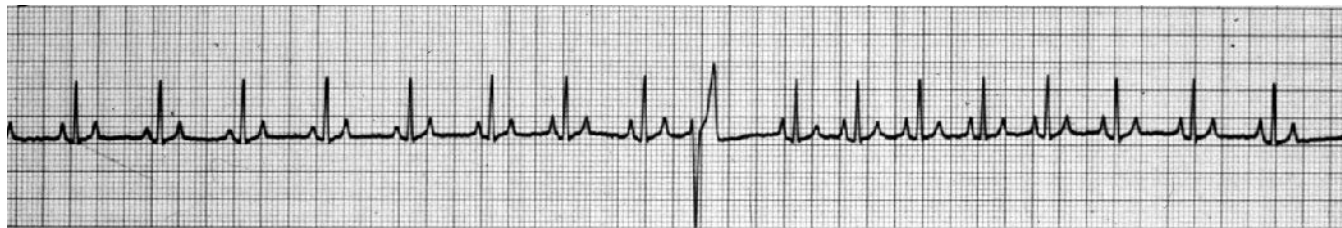


Figure 5.2 ECG from a 10-year-old Labrador dog with a single ventricular premature complex (25 mm/sec and 10 mm/mV).

- abnormal (bizarre) in shape;
- wide (prolonged), typically by ~50%;

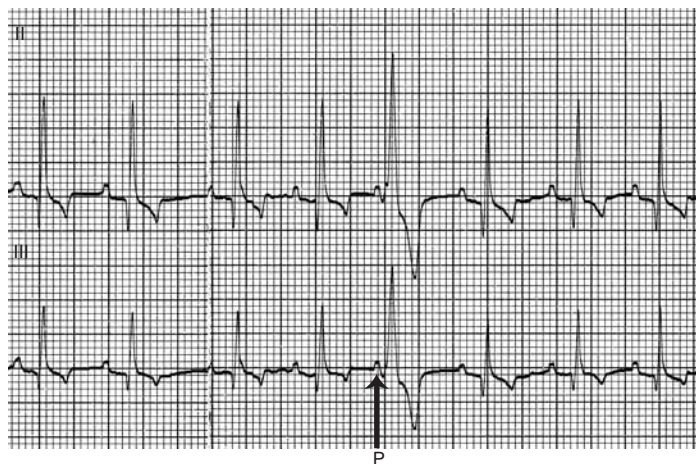


Figure 5.3 ECG from a Boxer with right ventricular arrhythmogenic cardiomyopathy showing a single VPC with a positive QRS morphology. (Note the P wave, arrowed, just preceding the QRS complex with a very short P–R interval. However the VPC occurred before the normal sinus depolarisation.) (Leads 2 and 3, 25 mm/sec and 10 mm/mV.)

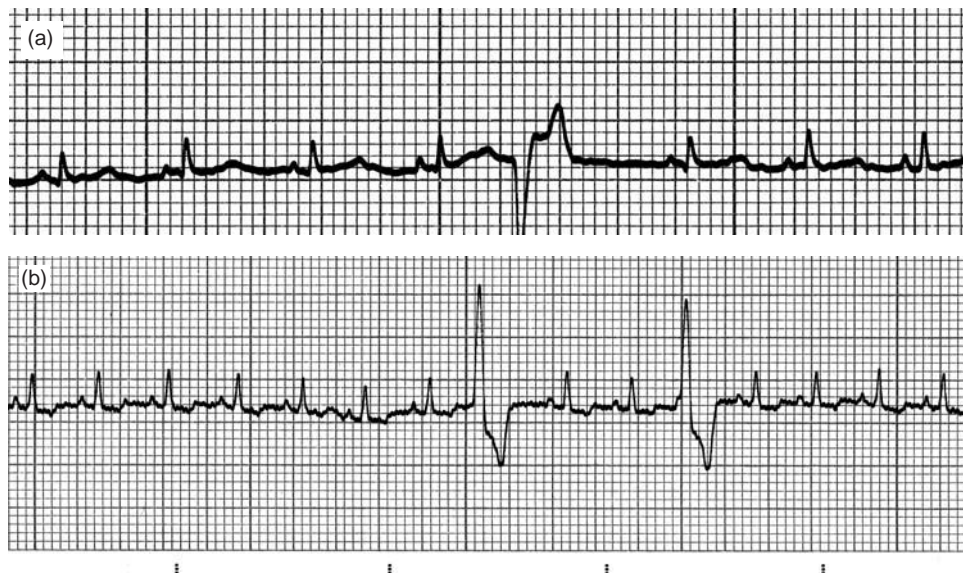- the T wave of a VPC is often large and opposite in direction to the QRS.

Figures 5.1–5.3 show examples of single VPCs in dogs and Fig. 5.4 shows an example in a cat. Additionally a VPC is not associated with a preceding P wave (except by coincidence). Since a VPC occurs prematurely, a normal atrial depolarisation (i.e. a P wave) arriving at the AV node will meet ventricles that are refractory (Figs 5.1 and 5.3), thus the P wave is usually hidden by the ventricular premature complex.

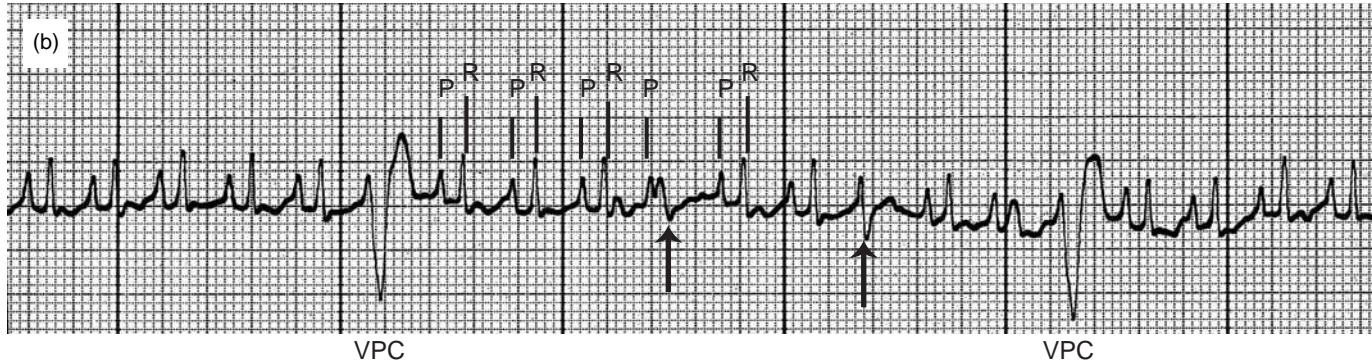
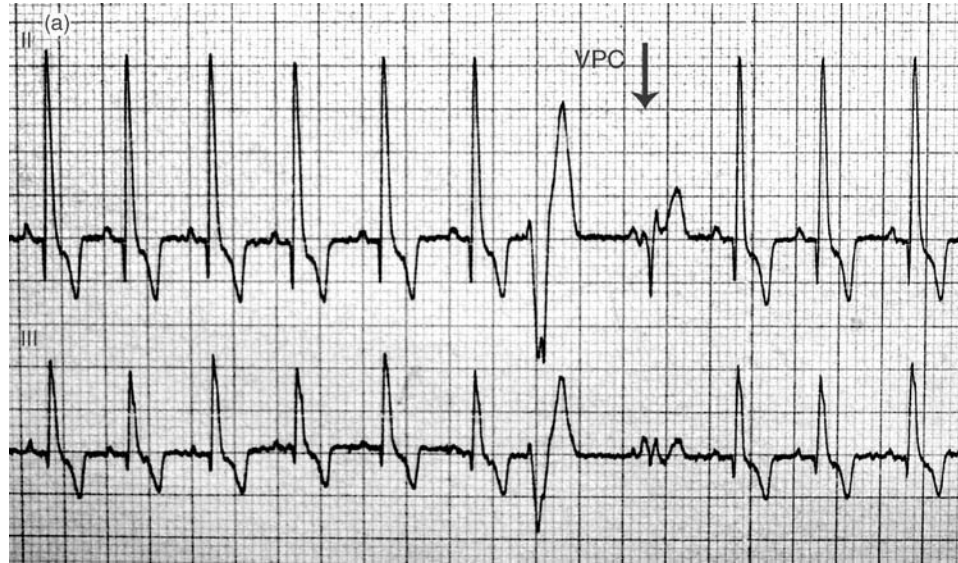
Occasionally a normal sinus complex QRS will occur at the same time as an ectopic VPC, resulting in fusion of the two wavefronts. This is seen on an ECG as a change in QRS & T morphology from the normal sinus QRS & T and the QRS & T of the VPC. Usually the combination tends to neutralise the deflections and the QRS is much smaller in comparison (Figs 5.5a, b).

When a VPC is so premature that it is superimposed on the T wave of the preceding complex (sinus or ectopic), i.e. the ventricles are depolarised before they have completely repolarised from the preceding contraction, this is termed **R-on-T** (Fig. 5.6).

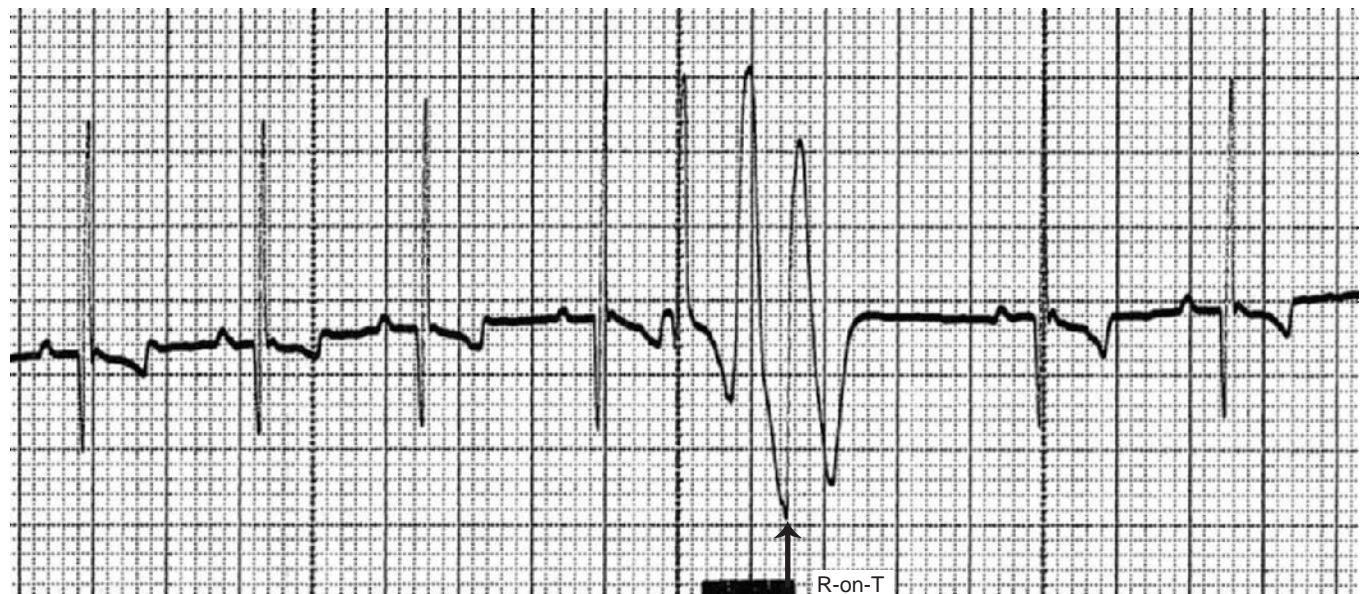
A run of three or more VPCs is termed a **ventricular tachycardia (VT)** (Figs 5.7a, b, c). In the vast majority of cases VT is fairly uniform and regular, however occasionally it can be multiform (Fig. 5.8).



**Figure 5.4** ECGs from two cats each showing a VPC, but of differing morphologies: (a) has a negative QRS morphology and (b) has two positive QRS morphology VPCs (25 mm/sec and 10 mm/mV).



**Figure 5.5** ECGs from a dog (a) and cat (b) showing fusion complexes (arrowed). Note the different morphology of the second VPC in each example; this may be a combination of a normal QRS complex and a VPC – this is termed a fusion complex. (a) is from a German Shepherd dog with a splenic mass (Leads 2 and 3, 25 mm/sec and 10 mm/mV) and (b) is from a 6-year-old domestic short-haired cat with hypertrophic cardiomyopathy (25 mm/sec and 20 mm/mV).



**Figure 5.6** ECG from a dog showing a two ventricular premature complex (VPC) occurring very quickly, such that the QRS complex of the second is virtually superimposed on the T wave of the previous VPC (arrowed) – this is termed R-on-T (25 mm/sec and 10 mm/mV).

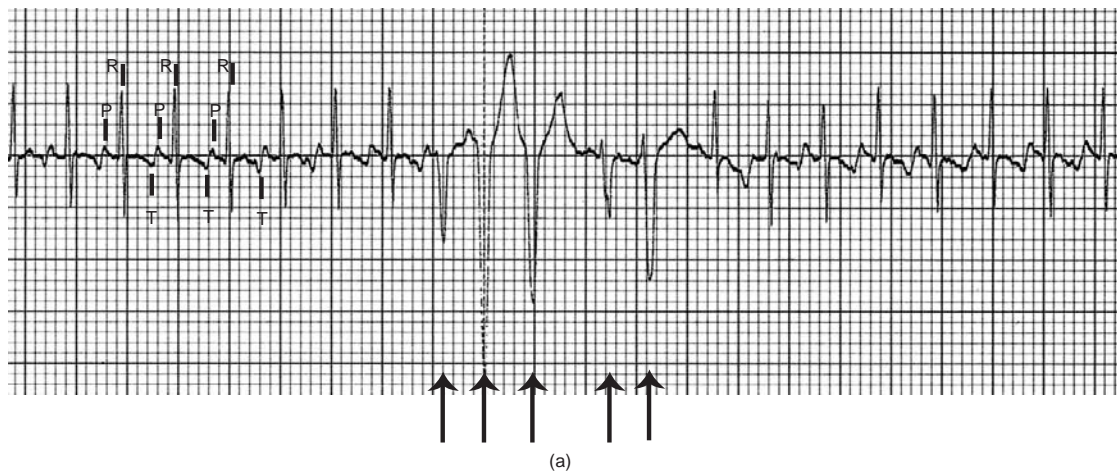


Figure 5.7 (a) ECG showing a paroxysmal ventricular tachycardia (arrows) (25 mm/sec and 10 mm/mV).

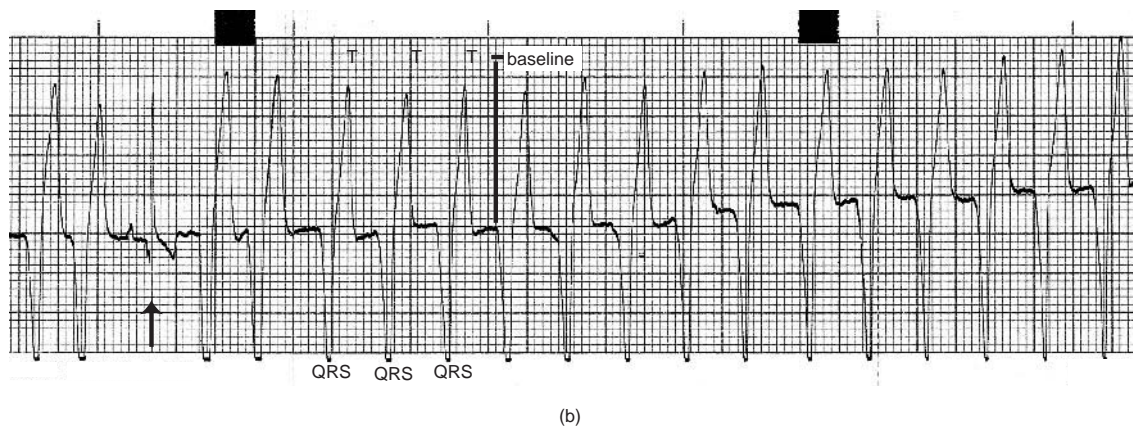


Figure 5.7 (b) ECG showing a ventricular tachycardia (VT) at 200/min with a negative QRS morphology. There is one normal sinus complex (arrowed). From a 10-year-old Labrador with liver neoplasia (25 mm/sec and 10 mm/mV).

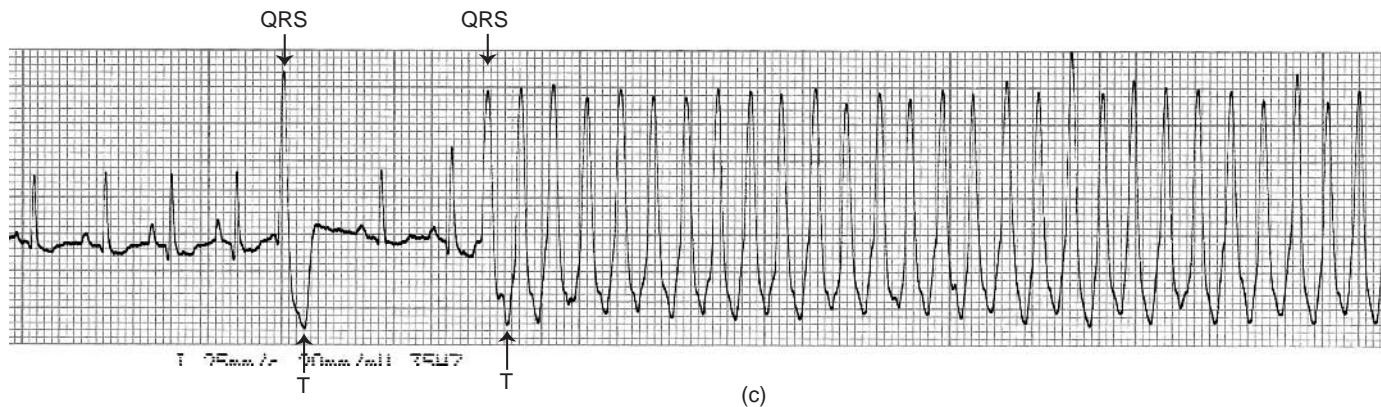


Figure 5.7 (c) ECG from a dog showing the start of a sustained VT, with a positive QRS morphology, preceded by a sinus rhythm and a single VPC (25 mm/sec and 20 mm/mV).

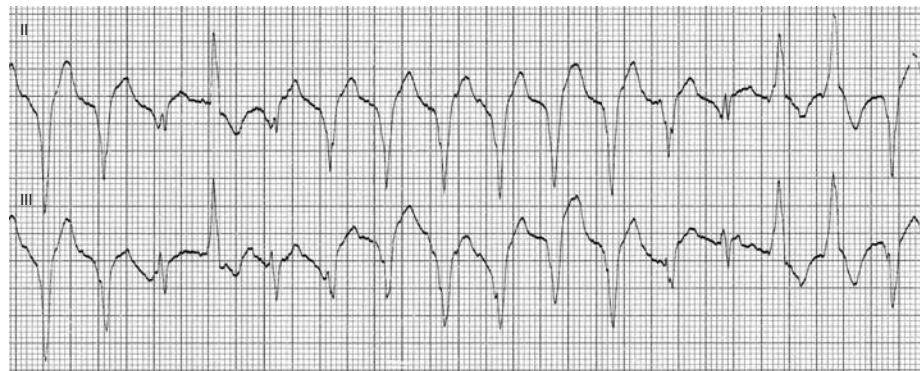


Figure 5.8 (a) ECG from a 14-year-old Jack Russell terrier showing a multimorphic VT (50 mm/sec and 10 mm/mV).



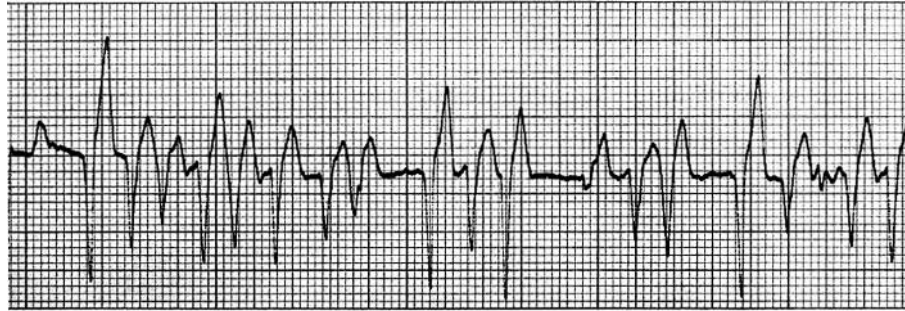


Figure 5.8 (b) ECG from a 10 year old Labrador showing a multimorphic VT (25 mm/sec and 10 mm/mV).

### Clinical findings

Occasional premature beats will sound like a ‘tripping in the rhythm’. Depending upon how early the beat occurs – the ‘extra’ premature beat may be heard or it might be ‘silent’ (and sound like a brief pause in the rhythm). There will be little or no pulse associated with the premature beat (i.e. a pulse deficit). If the premature beats are more frequent, the tripping in the rhythm will start to make the heart rhythm sound more irregular. With very frequent premature beats, the heart rhythm can sound quite chaotic, and with a pulse deficit for each premature beat, the pulse rate will be much slower than the heart rate. During a sustained ventricular tachycardia however, the heart rhythm will sound fairly regular – pulses will probably be palpable, but reduced in strength, becoming weaker with faster heart rates.

### Supraventricular premature complexes

Supraventricular premature complexes (SVPCs) arise from an ectopic focus or foci above the ventricles, i.e. in either the atria, the AV node or bundle of His. The ventricles are then depolarised,

normally producing a normal-shaped QRS complex with a normal duration.

### ECG characteristics

QRS–T complexes, which have a normal morphology, are seen to occur prematurely (Fig. 5.9). The ECG features are:

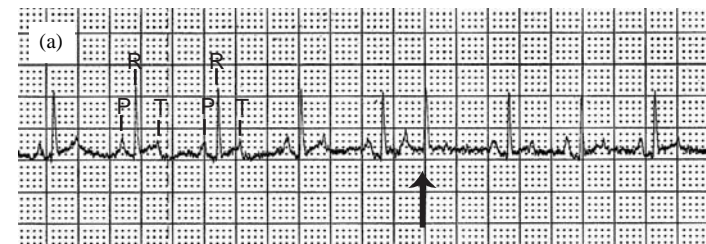


Figure 5.9 (a) ECG showing a single supraventricular premature complex (arrowed). Note the premature timing and absence of an obvious P wave. An incidental finding from a 9-year-old Newfoundland dog (25 mm/sec and 10 mm/mV).

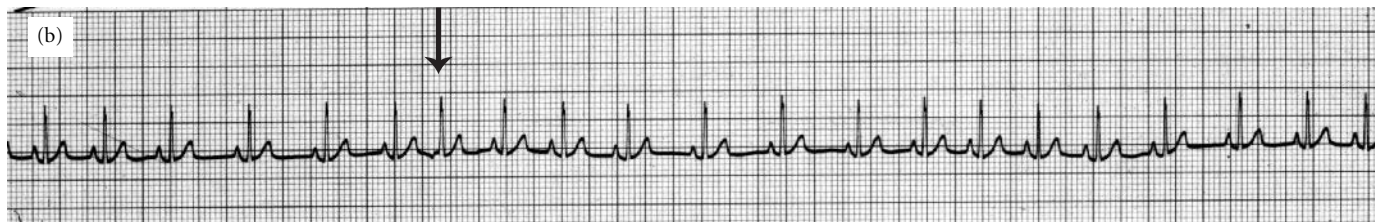


Figure 5.9 (b) ECG from a dog. Note the premature complex (arrowed) with a normal QRS–T morphology – this is a supraventricular premature complex (SVPC) (25 mm/sec and 10 mm/mV).

- normal QRS morphology;<sup>1</sup>
- QRS are seen to occur prematurely;
- P waves may or may not be identified; and
- if P waves are seen, they are usually of an abnormal morphology (i.e. non-sinus) and the P–R interval will differ from a normal sinus complex.

A run of three or more SVPCs is termed a **supraventricular tachycardia (SVT)**; it is usually at a rate in excess of 200/min (but can be as high as 400/min) and regular (Fig. 5.10). SVT needs to be distinguished from a sinus tachycardia.

### Clinical findings

On auscultation it is not possible to distinguish ventricular premature beats from supraventricular premature beats (see p. 18). Occasional premature beats will sound like a ‘tripping in the rhythm’, with little or no pulse associated with the premature beat. If the premature beats are more frequent, the tripping in the rhythm will start to make the heart rhythm sound more irregular. With very frequent premature beats, the heart rhythm can sound quite chaotic, and with a pulse deficit

for each premature beat, the pulse rate will be much slower than the heart rate. During a sustained supraventricular tachycardia however, the heart rhythm will sound fairly regular – pulses will probably be palpable, but reduced in strength, becoming weaker with faster heart rates.

### Escape rhythms

When the dominant pacemaker tissue (usually the SA node) fails to discharge for a long period, pacemaker tissue with a slower intrinsic rate (junctional or ventricular) may then discharge, i.e. they ‘escape’ the control of the SA node. This is commonly seen in

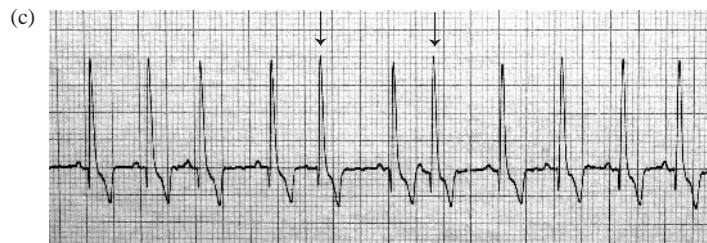


Figure 5.9 (c) ECG from a German Shepherd dog showing two SVPCs (arrowed).

<sup>1</sup> Except when there is aberrant conduction, see Chapter 10.

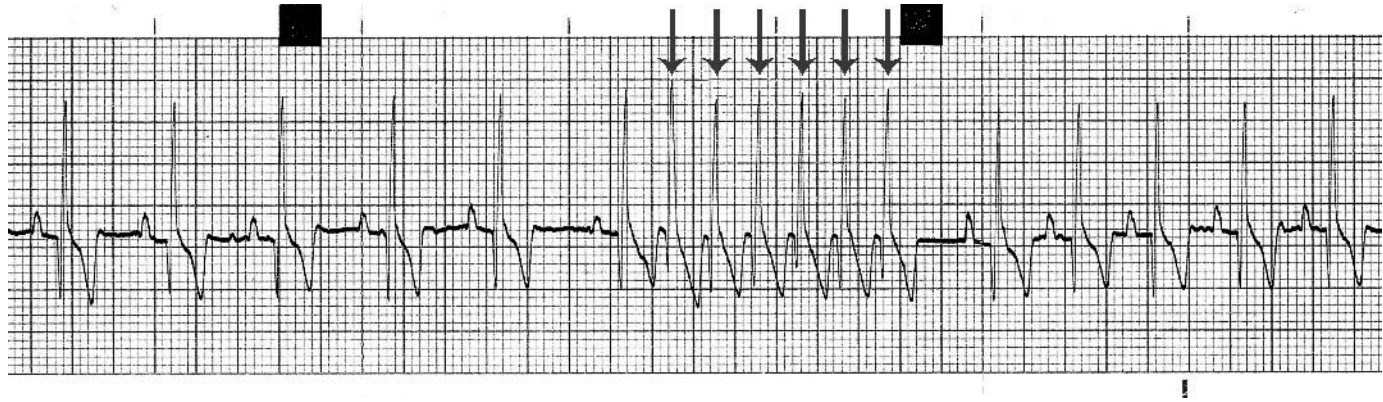


Figure 5.10 (a) ECG showing a paroxysmal supraventricular tachycardia (arrowed) (25 mm/sec and 10 mm/mV).

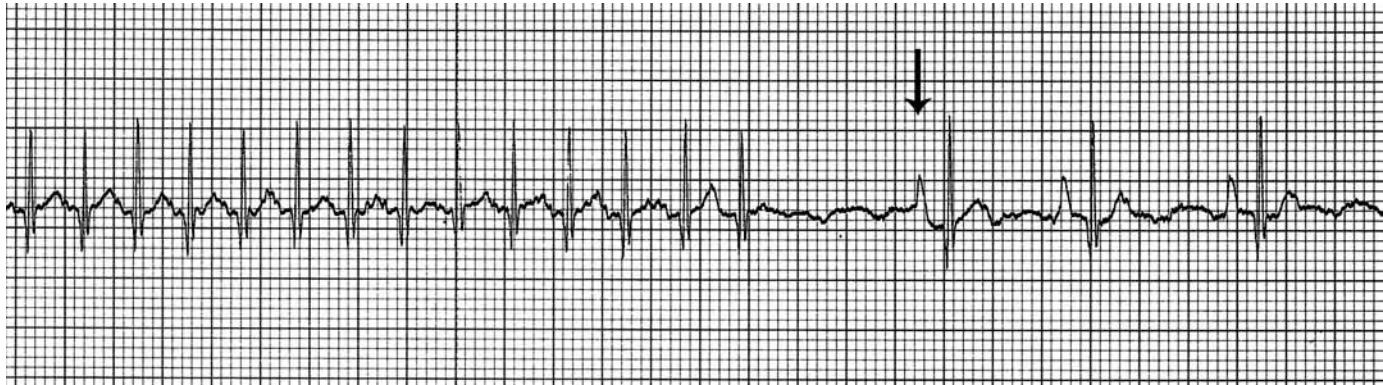


Figure 5.10 (b) ECG showing initially a supraventricular tachycardia at 280/min, which then breaks to a normal sinus rhythm at 90/min (the first sinus complex is arrowed). From a 6-year-old Irish Wolfhound with occult dilated cardiomyopathy (25 mm/sec and 10 mm/mV).

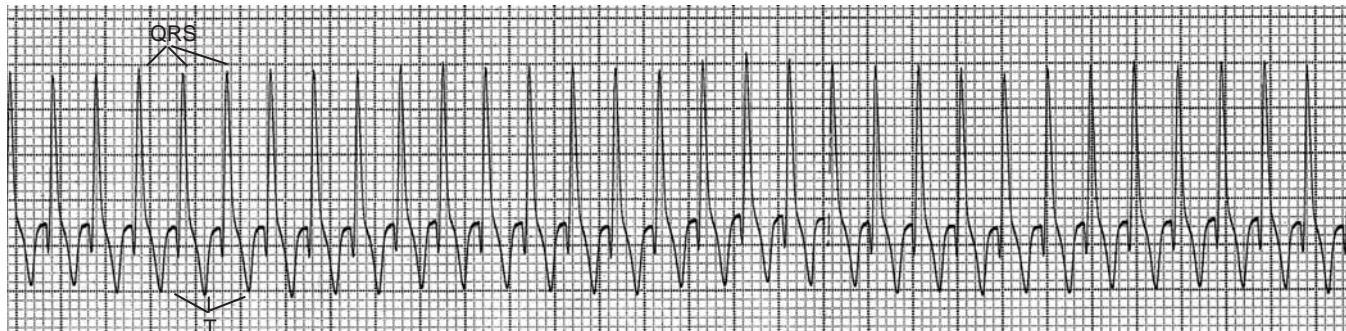


Figure 5.10 (c) ECG showing a sustained supraventricular tachycardia at 320/min. From a 9-year-old Weimaraner with myocarditis (25 mm/sec and 5 mm/mV).

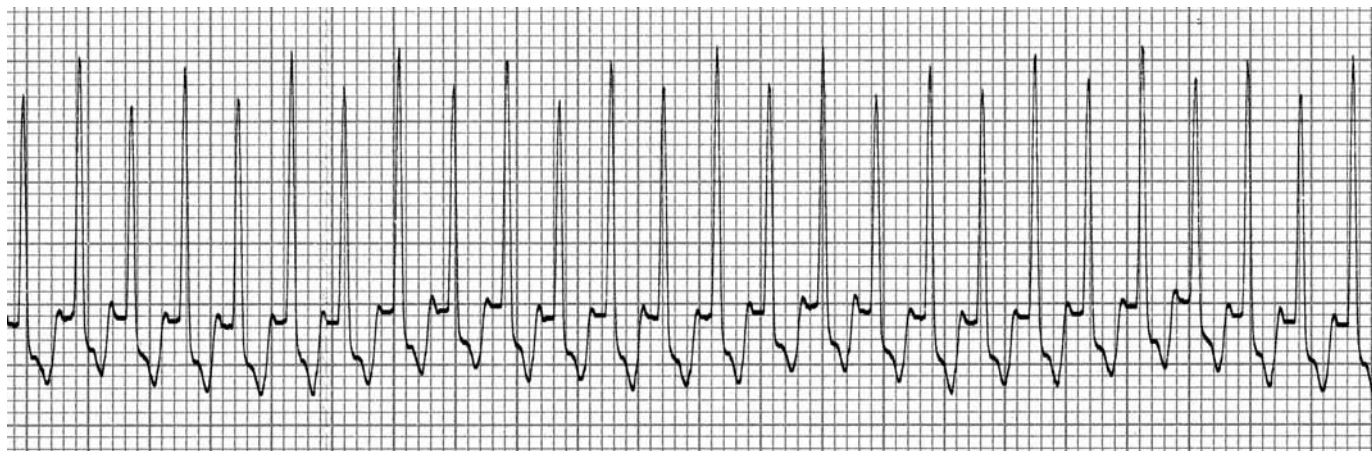


Figure 5.10 (d) ECG from a 7-month-old Labrador with a sustained SVT at 350/min (25 mm/sec and 10 mm/mV).

association with bradyarrhythmias (e.g. sinus bradycardia, sinus arrest, AV block). Escape complexes are sometimes referred to as rescue beats, because if they did not occur death would be imminent. Since they are rescue beats they should not be suppressed by any form of treatment. Treatment should be directed towards the underlying bradyarrhythmia.

If no escape rhythm has developed, i.e. there was no electrical activity of any kind, then this is termed **asystole**. It would not be dissimilar to sustained sinus arrest if no escape rhythm developed. This is a terminal event unless electrical activity returns. If there is a failure of an escape rhythm during complete heart block, i.e. there are P waves but no QRS complexes, then this is termed **ventricular standstill**. Again, if ventricular electrical activity does not return death is imminent.

Junctional escapes are fairly normal in shape (the same as a supraventricular ectopic), whereas ventricular escapes are abnormal and bizarre (the same as a ventricular ectopic): see Figs 5.11 and 6.2. A continuous junctional escape rhythm occurs at a rate of 60–70/min and a continuous ventricular escape rhythm occurs at a rate of less than 50/min. Either may be seen in complete AV block.

## AV dissociation

AV dissociation describes the situation when the atria and ventricles are depolarised by separate independent foci. This may occur due

to an accelerated junctional or ventricular rhythm, disturbed AV conduction or depressed SA nodal function.

## ECG characteristics

The ECG shows a ventricular rate that is usually very slightly faster than the atrial rate. The P waves may occur before, during or after the QRS complex. The P waves and QRS complexes are independent of each other with the QRS complexes appearing to ‘catch up’ on the P waves (Fig. 5.12). Complete AV block is one form of AV dissociation, but AV dissociation does not mean there is AV block.

## Clinical findings

The heart rhythm will sound fairly normal and the pulse should match the heart rate.

## Fibrillation

Fibrillation means rapid irregular small movements of fibres.

## Atrial fibrillation

This is probably one of the most common arrhythmias seen in small animals. In atrial fibrillation (AF) depolarisation waves occur randomly throughout the atria (Fig. 5.13). Since AF originates

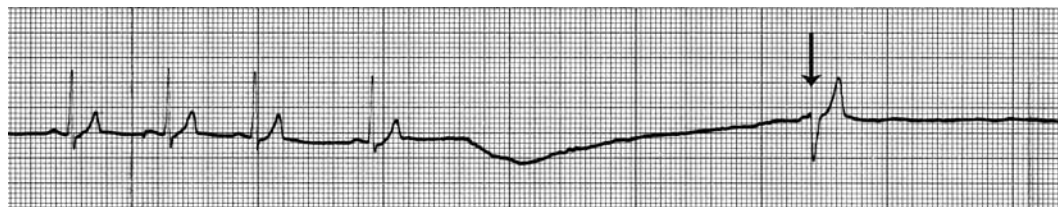
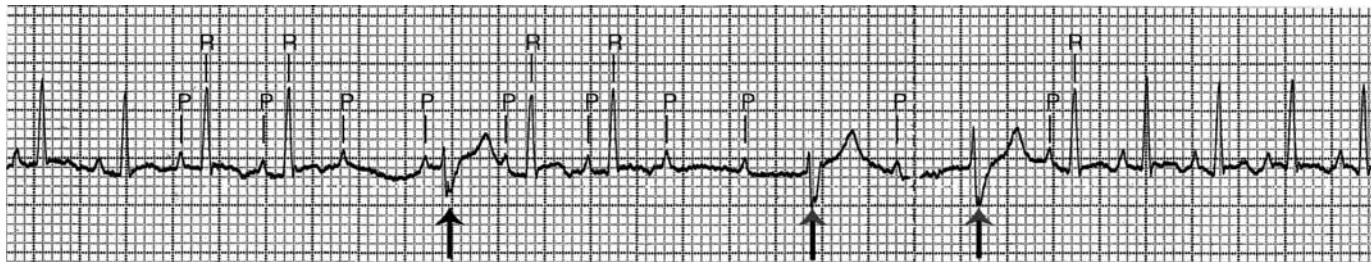
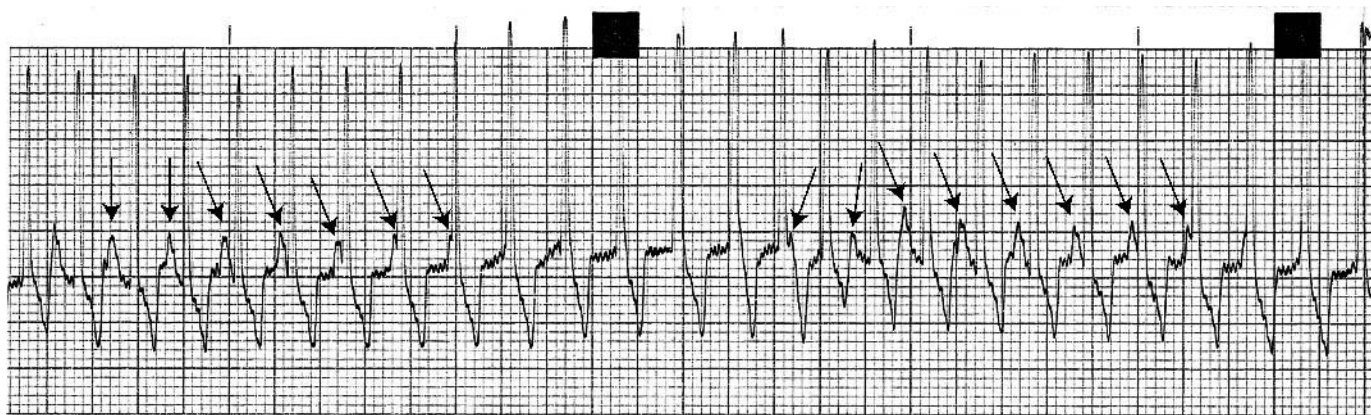


Figure 5.11 (a) ECG from a Springer spaniel with sinus arrest. Following the long flatline, there is a ventricular escape complex (arrowed) (25 mm/sec and 10 mm/mV).



**Figure 5.11 (b)** ECG from a 7-year-old cat with intermittent failure of AV nodal conduction through to the ventricles (non-conducted P waves), i.e. second degree heart block (see later). Following the consequential pauses in ventricular depolarisation, ventricular escape complexes occur (arrowed) (25 mm/sec and 20 mm/mV).



**Figure 5.12 (a)** ECG showing AV dissociation. Note how the P waves (arrows) appear to drift in and out of the QRS complexes (the P-R interval is variable). Incidental finding from a 13-year-old Samoyed dog (25 mm/sec and 10 mm/mV).

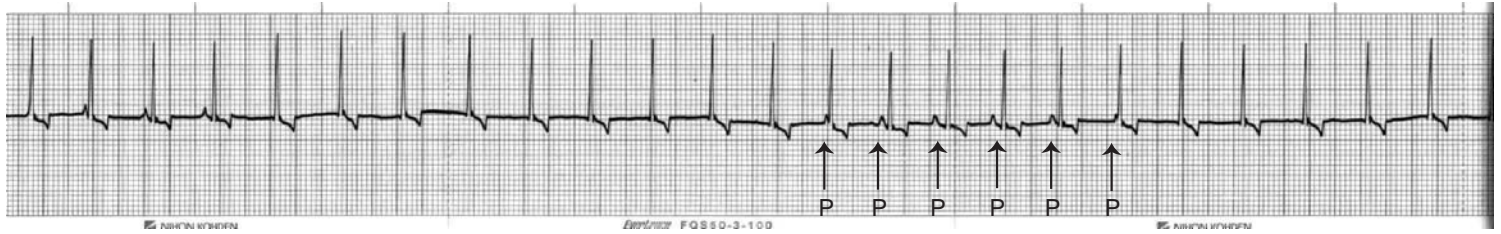


Figure 5.12 (b) ECG from a 6-year-old Labrador dog showing AV dissociation. This was an incidental finding. P waves are arrowed (25 mm/sec and 10 mm/mV).

above the ventricles, it could also be classified as a supraventricular arrhythmia.

### ECG characteristics

The QRS complexes have a normal morphology (similar to supraventricular premature complexes described previously) and occur at a normal to fast rate (Fig. 5.14). The ECG features are:

- normal QRS morphology;<sup>2</sup>
- the R–R interval is irregular and chaotic (this is easier to hear on auscultation);
- the QRS complexes often vary in amplitude;
- there are no recognisable P waves preceding the QRS complex; and

<sup>2</sup> Except when there is bundle branch block (see Chapter 10).

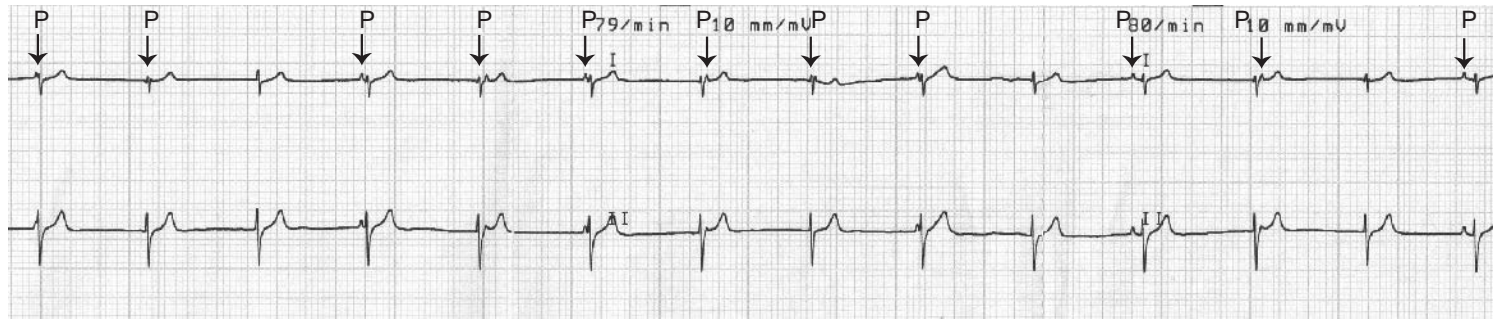
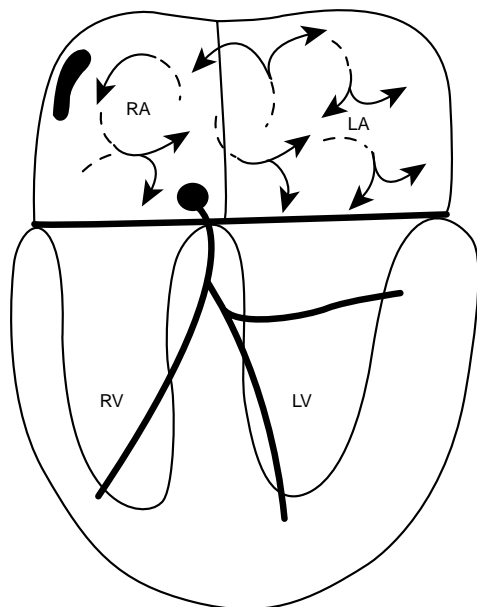


Figure 5.12 (c) ECG from a cat following sedation with medetomidine with a bradycardia (80/min) and AV dissociation. P waves are arrowed (Leads 1 and 2, 25 mm/sec and 10 mm/mV).

**Tip**

As a guideline<sup>3</sup>: Supraventricular QRS morphology + Irregular (chaotic) R–R intervals + Absence of P waves = Atrial fibrillation



**Figure 5.13** Diagram illustrating the wavelet theory for atrial fibrillation. Note the multiple small wavelets that randomly depolarise small portions of the atria. This is easiest to sustain when the atria are large such as in giant-breed dogs or animals in which there is atrial dilation.

- sometimes fine irregular movements of the baseline are seen as a result of the atrial fibrillation waves – referred to as ‘**f**’ waves, however these are frequently indistinguishable from baseline artifact (e.g. muscle tremor) in small animals.

**Clinical findings**

The heart rhythm sounds chaotic and the pulse rate is often half the heart rate, especially with fast atrial fibrillation. This is a very common arrhythmia in dogs, and can be strongly suspected on auscultation by its chaotic rhythm and 50% pulse deficit. However, very frequent premature beats (ventricular or supraventricular) can mimic it.

**Ventricular fibrillation (VF)**

This is nearly always a terminal event associated with cardiac arrest. The depolarisation waves occur randomly throughout the ventricles (Fig. 5.15). There is therefore no significant coordinated contraction to produce any cardiac output. If the heart is visualised or palpated, fine irregular movements of the ventricles are evident – likened to a ‘can of worms’. VF can often follow ventricular tachycardia.

**ECG characteristics**

The ECG shows **coarse** (larger) or **fine** (smaller) rapid, irregular and bizarre movement with no normal wave or complex (Fig. 5.16).

**Clinical findings**

No heart sounds are heard. No pulse is palpable.

<sup>3</sup>Except when there is bundle branch block, see Chapter 10.



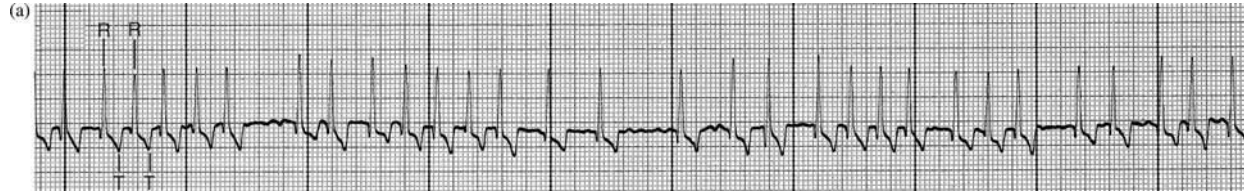


Figure 5.14 (a) ECG showing atrial fibrillation with an average ventricular response rate of 180/min. The QRS complexes are chaotic – this is usually easier to hear on auscultation of the heart. There are no P waves discernible, although the fine undulations of the baseline may be fibrillation waves in this instance (25 mm/sec and 10 mm/mV).

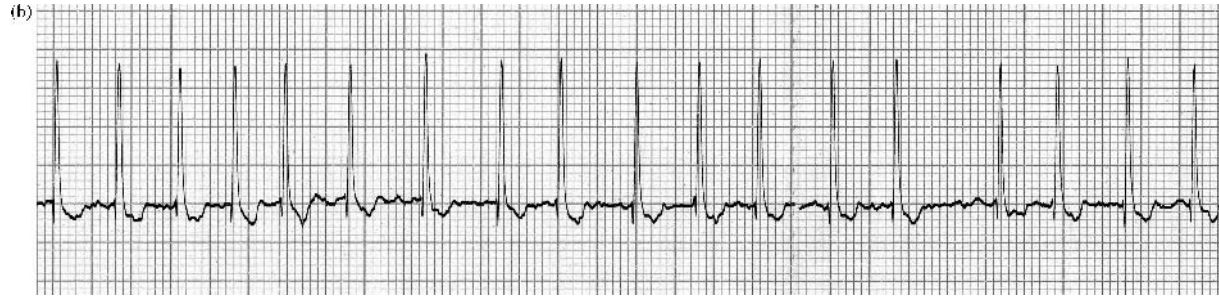


Figure 5.14 (b) ECG showing atrial fibrillation with an average ventricular response rate of 180/min. From a 10-year-old Whippet with mitral valve disease (25 mm/sec and 10 mm/mV).

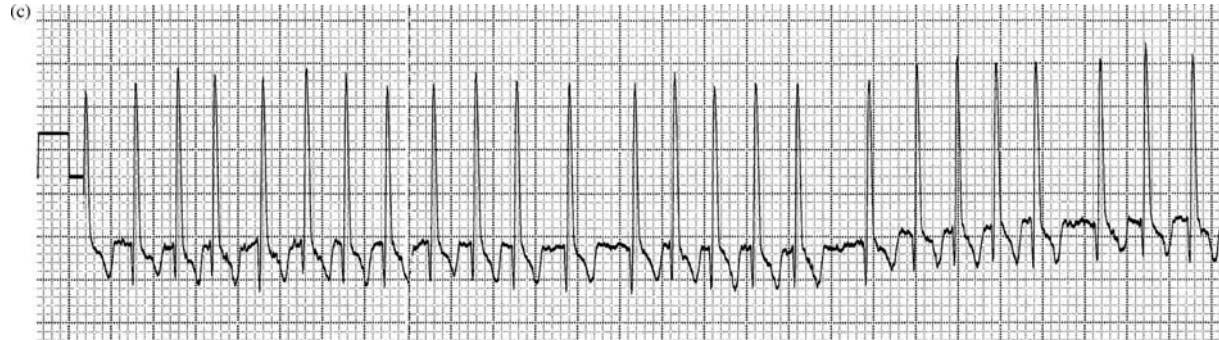
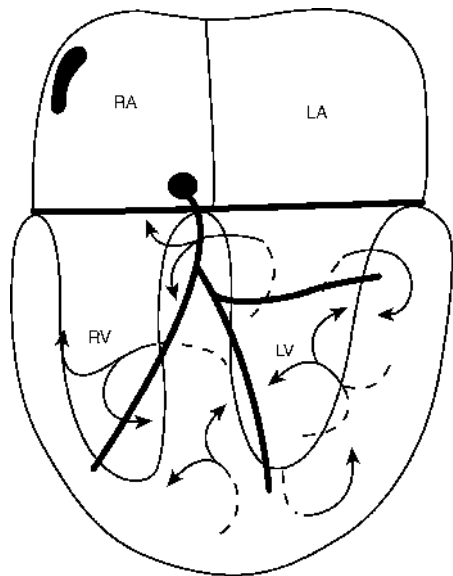
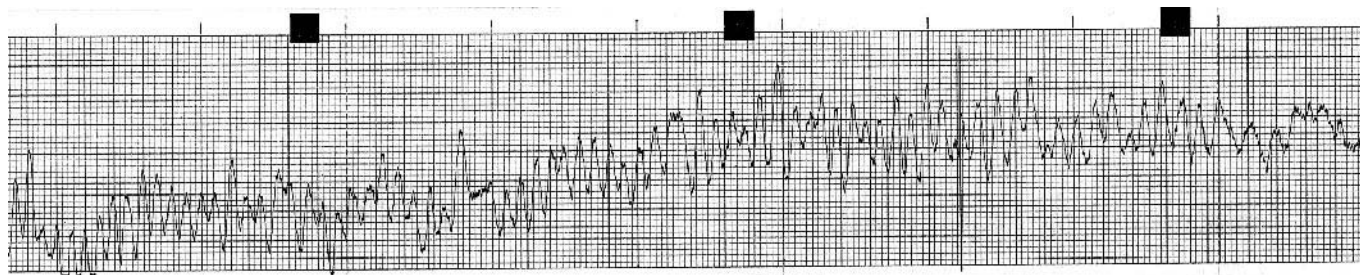


Figure 5.14 (c) ECG showing atrial fibrillation with an average ventricular response rate of 280/min. Such a fast ventricular rate is usually seen when the dog is in congestive heart failure. From a 7-year-old Dobermann with pulmonary oedema due to dilated cardiomyopathy (25 mm/sec and 5 mm/mV).



**Figure 5.15** Diagram illustrating the wavelet theory for ventricular fibrillation (VF). VF initially consists of large wavelets (coarse VF), that progress over a short period of time to a greater number of smaller wavelets (fine VF).



**Figure 5.16** ECG showing ventricular flutter/fibrillation. From an 11-year-old German Shepherd dog that died on arrival with advanced cardiac tamponade due to pericardial haemorrhage (25 mm/sec and 10 mm/mV).

## 6 • Abnormalities in the conduction system

Abnormalities in the conduction system are associated with faults in either the generation of the impulse from the SA node or abnormalities in conduction through the specialised conduction tissue, i.e. the AV node, bundle of His and Purkinje system.

### Sinus arrest and block

When there is a failure of the SA node to generate an impulse, i.e. the SA node has temporarily arrested – it is referred to as **sinus arrest**. **Sinus block** (also referred to as sinoatrial exit block) is when the electrical impulse from the SA node to the atria is blocked. These bradyarrhythmias can result in bradycardia and/or asystole.

### ECG characteristics

There is a pause in the rhythm with neither a P wave nor therefore a QRS–T complex, i.e. the baseline is flat (except for movement artifact if present). If the pause is only twice the R–R interval (or multiples of), it suggests sinus block. However, if the pause is greater than two R–R intervals (but not exact multiples of) it suggests sinus

arrest (Fig. 6.1). Long periods of arrest or block are often followed by ventricular ectopic escape complexes. Note: in comparison with atrial standstill (see p. 42), sinus arrest produces a ‘flatline’ that is intermittent, whereas atrial standstill results in a sustained absence of P waves.

### Clinical findings

A pause in the heart rhythm will be heard on auscultation (with no palpable pulse); it will effectively sound as if the heart has briefly stopped. With sinus block it will be a very short pause that can be difficult to discern from a normal pause such as in respiratory sinus arrhythmia. With sinus arrest the duration of the pause will depend upon the duration of the period of sinus arrest and if this is occurring episodically or not.

### Sick sinus syndrome

This is a term for an abnormally functioning SA node and is probably better termed **sinus node dysfunction**. This ‘umbrella’ term

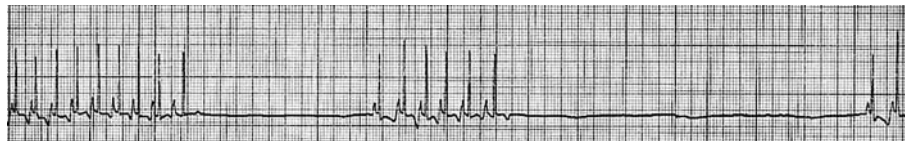

Figure 6.1 (a) ECG showing intermittent sinus arrest, from a 13-year-old West Highland White terrier with idiopathic pulmonary fibrosis (25 mm/sec and 10 mm/mV).

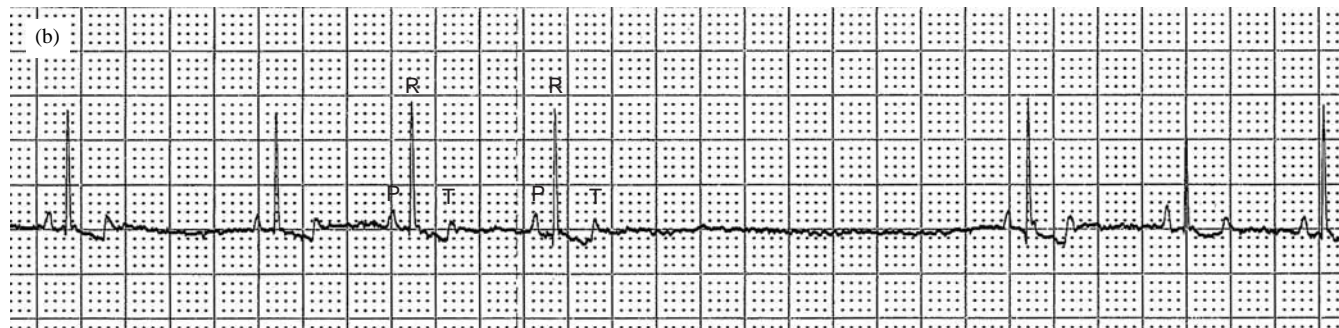


Figure 6.1 (b) ECG from a Lakeland terrier with sinus arrest – there is a 2-second pause (25 mm/sec and 10 mm/mV).

refers to any abnormality of sinus node function including severe sinus bradycardia and severe sinus arrest. In some situations the profound bradycardia alternates with a supraventricular tachycardia, this is termed the '**bradycardia–tachycardia syndrome**'. Sick sinus syndrome has been reported to occur most commonly in female miniature Schnauzers of at least 6 years of age and West Highland White and Cairn terriers. It has not been recorded in cats.

#### *ECG characteristics*

The electrocardiographic features are therefore quite variable and include persistent sinus bradycardia or episodes of sinus arrest without escape beats. One feature of sick sinus syndrome is that during long periods of sinus arrest there is often a failure of rescue escape beats. In the bradycardia–tachycardia syndrome there are periods of bradycardia such as sinus arrest, alternating with a supraventricular

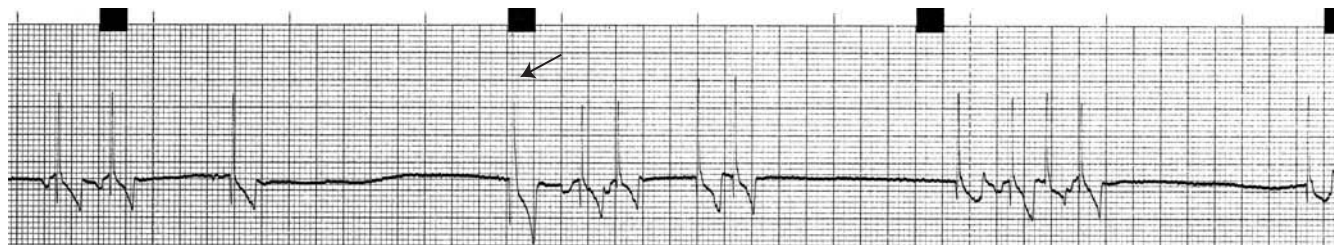

Figure 6.2 ECG from a 10-year-old miniature Schnauzer with sick sinus syndrome. This tracing shows periods of sinus arrest alternating with supraventricular premature complexes. There is one ventricular escape present (arrowed) (25 mm/sec and 10 mm/mV).

tachycardia (Fig. 6.2). The bradycardia may be unresponsive to an injection of atropine.

### *Clinical findings*

The findings on auscultation are very variable, from a markedly slow heart rate, to a variable rhythm, or with long pauses (associated with sinus arrest). The bradycardia–tachycardia syndrome sounds like periods of slow heart rate alternating with periods of very fast heart rate, and not necessarily with any regularity. There may be pulse deficits during the tachycardic episodes and no pulse produced during the periods of arrest.

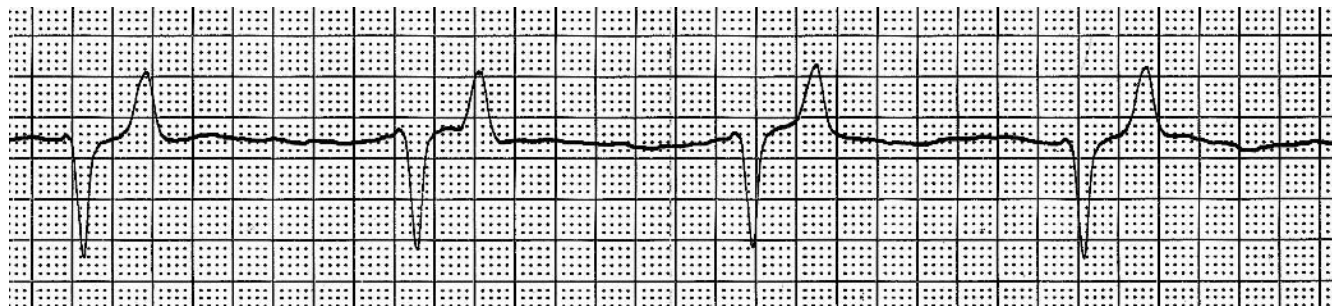
### **Atrial standstill**

In atrial standstill there is an absence of any atrial activity, which can be confirmed by fluoroscopy or echocardiography (there is no A wave on an M-mode of the mitral valve or no atrial contraction inflow on Doppler studies). This occurs due to a failure of atrial muscle depolarisation, i.e. the SA node may produce an impulse, but

the atria are not depolarised and remain inactive. If this occurs due to hyperkalaemia, the impulses are conducted from the SA node by internodal pathways to the AV node, thus there is a sinoventricular rhythm. If this occurs due to myocardial disease, the internodal pathways are also diseased and thus a nodal (or junctional) escape rhythm develops in these cases. Both of these rhythms look similar on ECG.

### *ECG characteristics*

The electrocardiographic feature is of the absence of P waves, usually with a slow (less than 60/min) escape rhythm (Fig. 6.3). The quality of the ECG has to be excellent (i.e. the baseline must be flat without any artifacts) to diagnose the absence of P waves confidently. The QRS complexes are often of a relatively normal shape (junctional escape), but sometimes with a slightly prolonged duration. In a few cases the escape rhythm can be ventricular. Note: in comparison with sinus arrest (see p. 40), atrial standstill results in a sustained absence of P waves, whereas sinus arrest produces an intermittent ‘flatline’.



**Figure 6.3** (a) ECG from a Cavalier King Charles spaniel with atrial standstill with a ventricular escape rhythm at 70/min. Note the absence of P waves. The absence of atrial activity can be confirmed by echocardiography (50 mm/sec and 10 mm/mV).

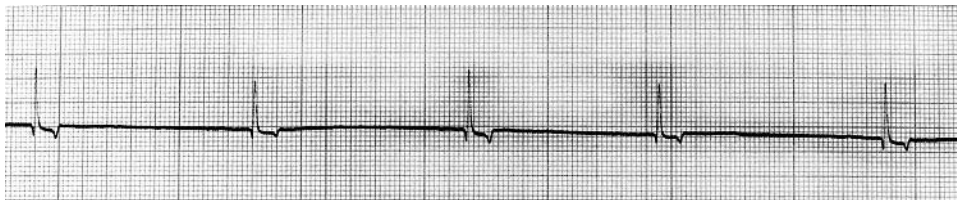

Figure 6.3 (b) ECG from a 7-year-old West Highland White terrier with atrial standstill (due to hyperkalaemia) with a junctional rhythm at 40/min (25 mm/sec and 10 mm/mV).

### *Clinical findings*

The normal heart sounds will be heard (and associated pulse felt) in association with ventricular depolarisation. The rate will vary in each case, although generally it is slower than normal (often less than 60/min). Note: in comparison with heart block (see below), no atrial contraction sounds are heard.

### **Heart block**

This is the failure of the depolarisation wave to conduct normally through the AV node; the correct term is therefore AV block. Heart block is often used as a synonymous term for AV block. AV block may be partial (first or second degree block) or complete (third degree block).

#### **First degree AV block**

First degree AV block occurs when there is a delay in conduction through the AV node and there is usually a sinus rhythm.

#### *ECG characteristics*

The P wave and QRS complexes are normal in configuration, but the PR interval is prolonged (Fig. 6.4).

### *Clinical findings*

No abnormality will be appreciated on auscultation or palpation of the pulse, and it cannot be distinguished from a normal sinus rhythm.

#### **Second degree AV block**

Second degree AV block occurs when conduction intermittently fails to pass through the AV node, i.e. there is atrial depolarisation that is not followed by ventricular depolarisation.

#### *ECG characteristics*

The P wave is normal, but there is either an occasional or frequent failure (depending on severity) of conduction through the AV node resulting in the absence of a QRS complex (Figs 5.9, p. 30, and 6.5).

Second degree AV block can be classified further. When the P–R interval increases prior to the block it is termed **Mobitz type I** (also known as **Wenckebach's phenomenon**). But when the P–R interval remains constant prior to the block, this is termed **Mobitz type II** and the frequency of the block is usually constant, i.e. 2:1, 3:1 and so on.

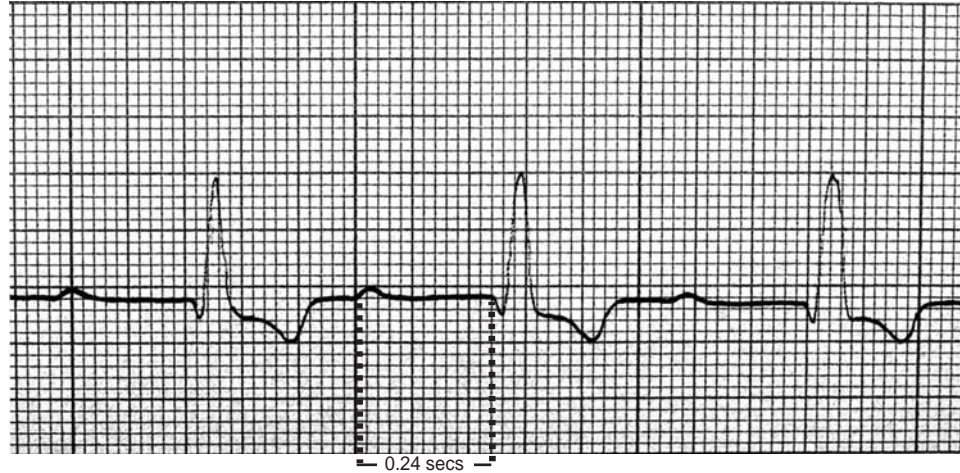

Figure 6.4 (a) ECG from a dog showing a prolonged P-R interval, i.e. 1st degree AV block (50 mm/sec and 10 mm/mV).

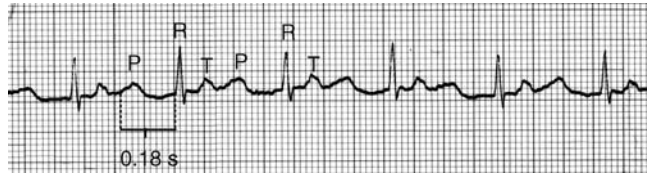


Figure 6.4 (b) ECG from a cat showing a prolonged P-R interval, i.e. first degree AV (heart) block (50 mm/sec and 10 mm/mV).

### Clinical findings

There will be occasional pauses in the rhythm associated with the absence of ventricular depolarisation. On very careful auscultation the atrial contraction sounds ('A' sound or S4) can often be appreciated as a faint noise in association with atrial depolarisation.

### Complete (third degree) AV block

Complete AV block occurs when there is a persistent failure of the depolarisation wave to be conducted through the AV node. A second pacemaker below the AV node (i.e. the block) discharges to control the ventricles. This second pacemaker may arise from:

- lower AV node or bundle branches producing a normal QRS (i.e. junctional escape complex) at approximately 60–70/min;
- Purkinje cells producing an abnormal QRS–T complex (i.e. ventricular escape complex) at approximately 30–40/min.

### ECG characteristics

On the ECG, P waves can be seen at a regular and fast rate but the QRS–T complexes are at a much slower rate, and usually fairly regular. The P waves and QRS complexes occur independently of each other

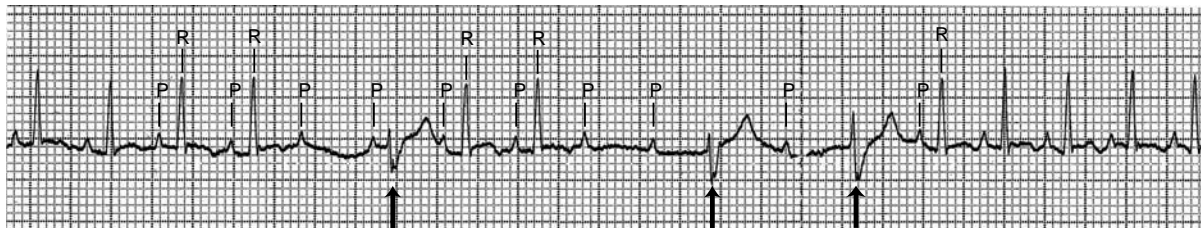


Figure 6.5 (a) ECG from a 7-year-old cat with intermittent failure of AV nodal conduction through the ventricles (non-conducted waves), i.e. second degree heart block. Following the consequential pauses in ventricular depolarisation, ventricular escape complexes occur (arrowed) (25 mm/sec and 20 mm/mV).

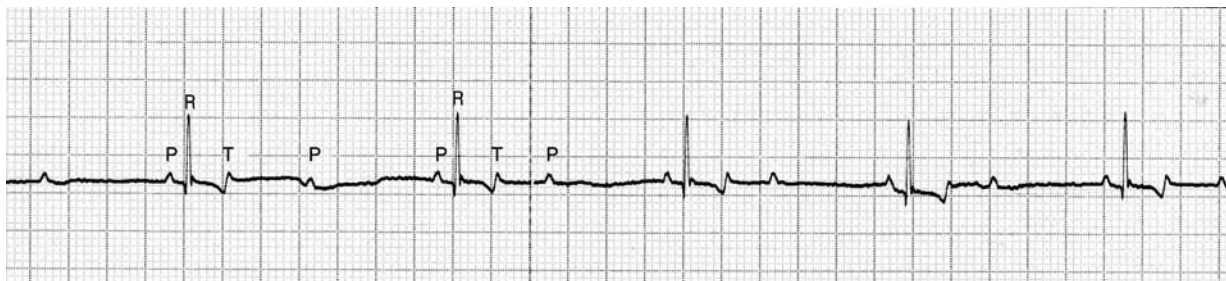


Figure 6.5 (b) ECG from a 9-year-old Labrador with second degree AV block (25 mm/sec and 5 mm/mV).

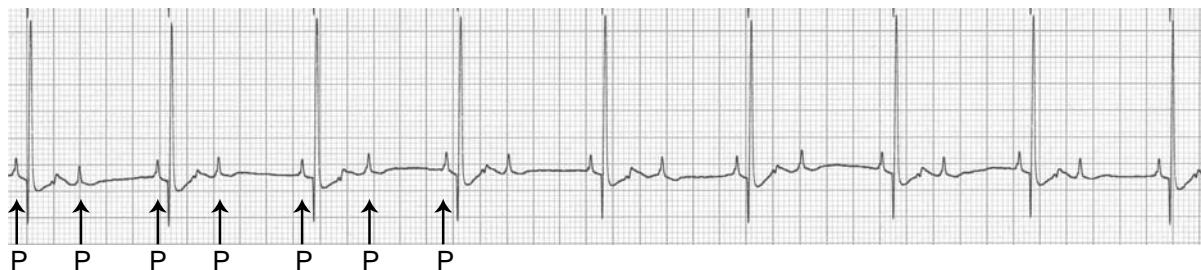


Figure 6.5 (c) ECG from an 11-year-old mixed breed dog with second degree AV block. The first few P waves are arrowed (25 mm/sec and 10 mm/mV).



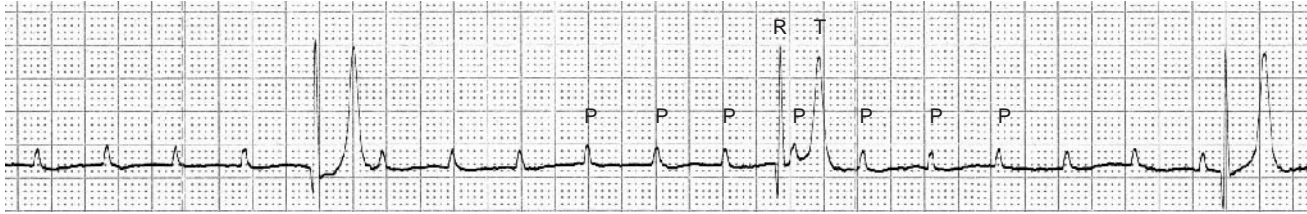


Figure 6.6 (a) ECG from an 8-year-old Labrador with third degree AV block (complete heart block) with a ventricular escape rhythm of 45/min (50 mm/sec and 10 mm/mV).

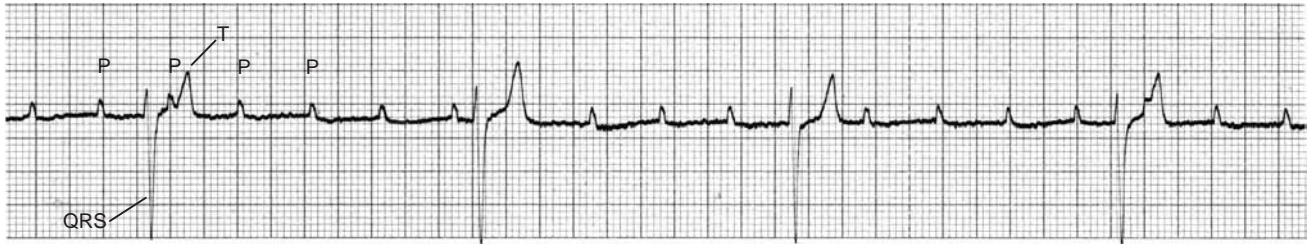

Figure 6.6 (b) ECG from a 10-year-old Collie dog with complete heart block with a slow ventricular escape rhythm at 30/min (25 mm/sec and 10 mm/mV).

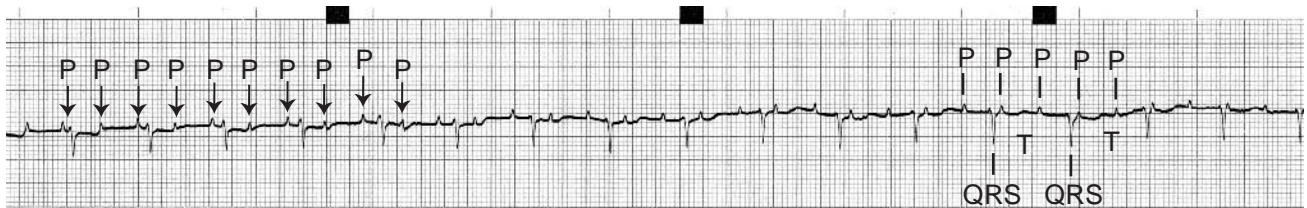


Figure 6.6 (c) ECG from a 14-year-old Siamese with complete AV block. The first few P waves are arrowed. Note that in the first half of the tracing, the T waves merge with some of the P waves, which makes this look like a sinus rhythm initially.

(Fig. 6.6). This is best demonstrated by plotting out each P wave and each QRS complex on a piece of paper (Fig. 15.1 on page 98).

### *Clinical findings*

In many cases the ventricular escape rhythm associated with complete heart block is very regular (metronomically so), although

slow. So a regular slow bradycardia is heard with normally a good palpable pulse (sometimes the escape rhythm is not regular). On very careful auscultation (sometimes using the bell of the stethoscope) the atrial contraction sounds (S4) can be faintly heard at a faster rate and not related to the normal lubb-dub of ventricular contraction.

## 7 • Changes in the P–QRS–T morphology

### Wandering pacemaker

This occurs as a result of the dominant pacemaker shifting from the SA node to other pacemaker cells with a high intrinsic rate within the atria. This is sometimes referred to as a wandering atrial pacemaker. This is a normal variant and not uncommon in dogs. It is thought to be associated with high vagal tone. Its significance is therefore similar to sinus arrhythmia (see page 9).

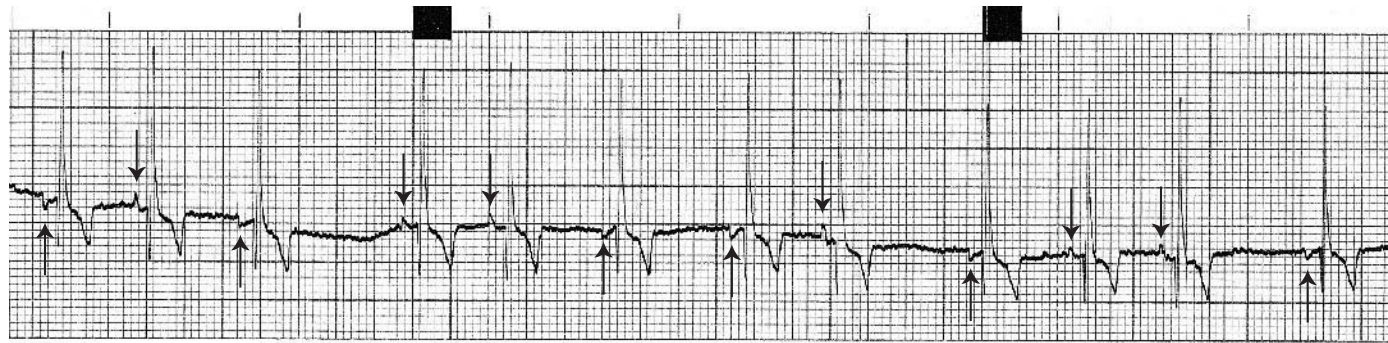
#### *ECG characteristics*

P waves can vary in morphology, i.e. there is a variation in amplitude, varying from positive, negative or biphasic, or they can even

be isoelectric (i.e. be so small that they are difficult to identify) (Fig. 7.1).

### Changes associated with chamber enlargement

The ECG should not be viewed as being a means to diagnose heart enlargement in small animals, but as an additional diagnostic test that might help to support such a clinical suspicion. Chest radiographs are often considered a better indicator of heart enlargement. Echocardiography is the best means to assess chamber size and morphology.



**Table 7.1.** Guidelines on normal values for cats and dogs (Tilley 1992).

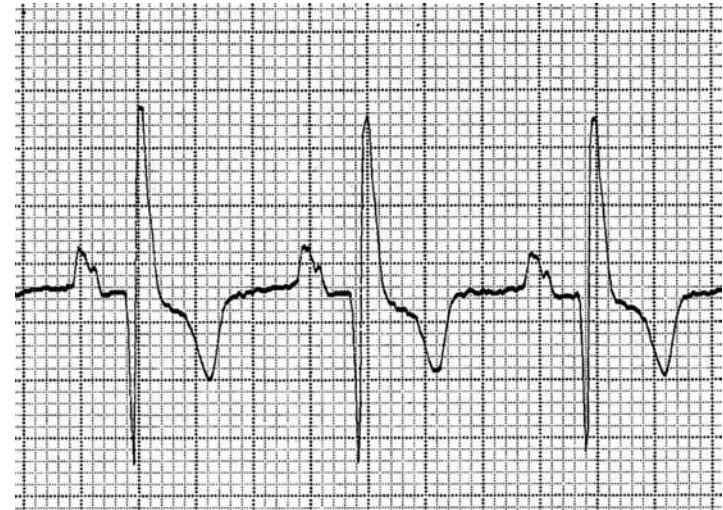
		Dog	Cat
Heart rate	Adult	70–160	120–240
	Puppy	70–220	
Measurements			
P wave duration		<0.04 sec	<0.04 sec
	Giant breeds	<0.05 sec	
P wave amplitude		<0.4 mV	<0.2 mV
P–R interval		0.06–0.13 sec	0.05–0.09 sec
QRS duration		<0.05 sec	<0.04 sec
	Giant breeds	<0.06 sec	
R wave amplitudes		<2.0 mV	<0.9 mV
	Giant breeds	<2.5 mV	
S–T segment	Depression	<0.2 mV	No depression
	Elevation	<0.15 mV	No elevation
T wave		<0.25 of normal R wave amplitude	<0.3 mV
Q–T interval		0.15–0.25 sec	0.12–0.18 sec
Mean electrical axis		+40° to +100°	0° to +160°

Note that in ‘ECG-speak’, ‘enlargement’ is commonly used to encompass either hypertrophy or dilation, as these can rarely be distinguished reliably on an ECG.

Table 7.1 lists normal values giving ECG complex durations and amplitudes. Measurements are usually measured in lead II at 50 mm/sec, unfiltered.

### Left atrial enlargement

When there is left atrial (LA) enlargement (or dilation) the P wave is often prolonged and sometimes also notched (Fig. 7.2). A prolonged and notched P wave is referred to as **P-mitrale** (as LA enlargement

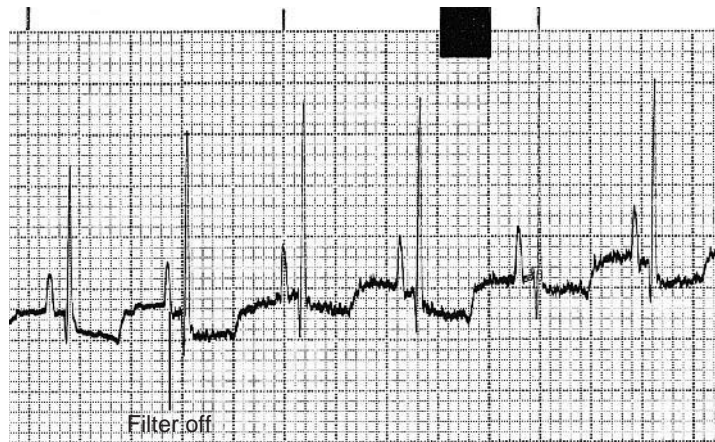

**Figure 7.2** ECG illustrating prolonged (0.06 sec) and notched P waves; this is termed P-mitrale. From an 8-year-old Dobermann with dilated cardiomyopathy (50 mm/sec and 10 mm/mV).

is often associated with mitral valve disease). The notching occurs as a result of asynchronous depolarisation of the atria, the dilated left atrium depolarising fractionally later than the right atrium. Note: giant breeds often normally have slightly prolonged P waves.

### Right atrial enlargement

When there is right atrial (RA) enlargement (or dilation) the P wave is increased in amplitude (Fig. 7.3). Such tall P waves are referred to as **P-pulmonale** (as RA enlargement may be associated with cor pulmonale). Note that P-pulmonale is commonly seen in breeds that are predisposed to chronic airway disease.



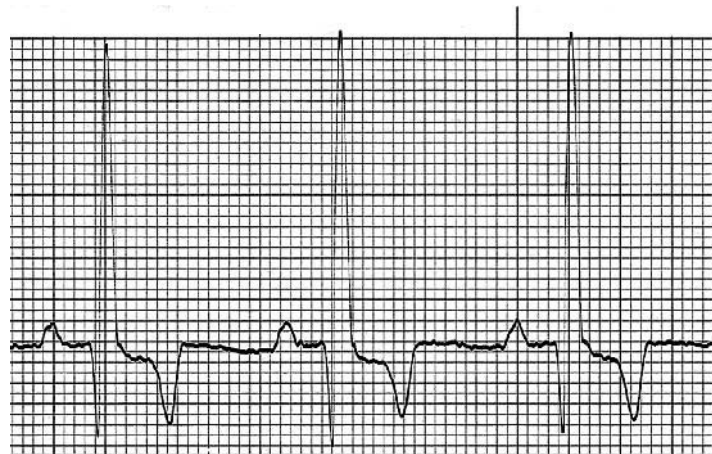**Figure 7.3** ECG illustrating tall P waves (0.5 mV); this is termed P-pulmonale. There is fine muscle tremor artifact affecting the baseline. From a 10-year-old Yorkshire terrier with long-standing tracheal collapse (25 mm/sec and 10 mm/mV).

### Left ventricular enlargement

Tall R waves are suggestive of left ventricular (LV) enlargement (Fig. 7.4). An R wave in lead I greater than leads II or aVF, may be associated with hypertrophy. An increase in R waves in leads I, II and III may be associated with dilation. Other ECG features that may be associated with LV enlargement are: prolongation of the QRS duration, S–T segment sagging/coving (see page 53) or a shift in the mean electrical axis (MEA) to the left.

### Right ventricular enlargement

Deep S waves are suggestive of right ventricular (RV) enlargement (Fig. 7.5). Other ECG features that may be associated with RV en-



**Figure 7.4** ECG illustrating tall R waves (6.0 mV) and prolonged QRS complex duration (0.06 sec), which is suggestive of left ventricular enlargement. From a 1-year-old German Shepherd dog with a patent ductus arteriosus (50 mm/sec and 5 mm/mV).

largement are: prolongation of the QRS duration or a shift in the MEA to the right.

### Abnormal mean electrical axis (MEA)

A **right axis** may suggest right ventricular enlargement (Fig. 7.5), but may be due to displacement of the heart within the chest to the right side or might even be a normal-variation. A conduction disturbance such as right bundle branch block (see Chapter 10) also produces a right axis deviation.

A **left axis** may be due to left ventricular enlargement, but may be due to displacement of the heart within the chest to the left or it may be a normal-variation. A conduction disturbance such as left anterior fascicular block (see Chapter 10) also produces a left axis deviation.

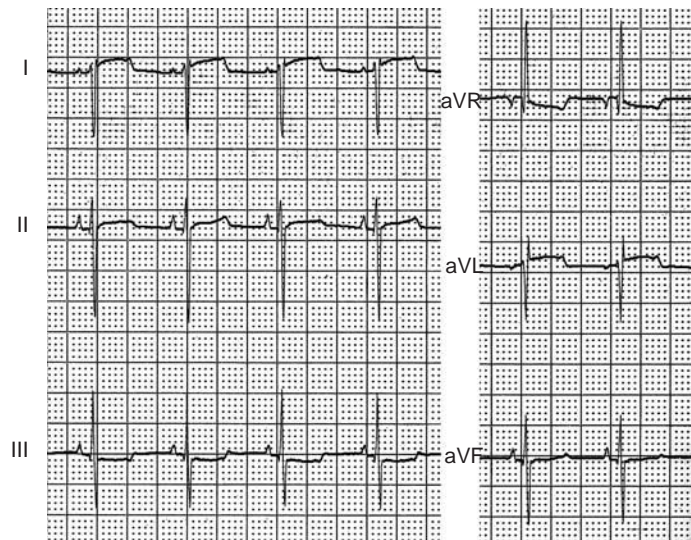


Figure 7.5 ECG illustrating deep S waves in Leads I and II and an axis shift towards aVR, i.e. to the right. From a 2-year-old West Highland White terrier with pulmonic stenosis (25 mm/sec and 5 mm/mV).

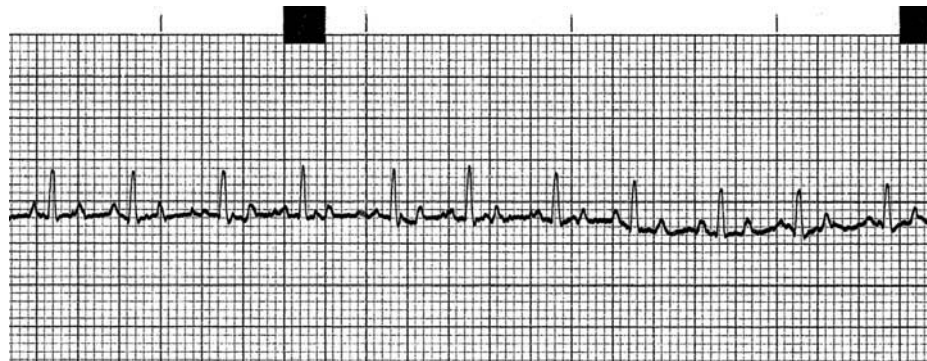


Figure 7.6 ECG illustrating small ECG complexes in a dog (25 mm/sec and 10 mm/mV).

## Low-voltage QRS complexes

QRS complexes will be smaller the further the electrodes are from the heart and depend on the resistance to electrical conduction between the heart and the electrodes. For example, the ECG complexes are larger in precordial chest leads, which are very close to the heart. However, complexes can be small in limb leads in obese animals. Heavy filtering on the ECG machine can also reduce the amplitude of the ECG complexes significantly.

Small complexes in dogs may be due to obesity, effusions (pericardial, pleural, ascites), hypothyroidism, hyperkalaemia, pneumothorax, some respiratory diseases, hypovolaemia or it may be a normal variation.

## ECG characteristics

An R wave amplitude less than 0.5 mV in the limb leads is considered small in dogs (Fig. 7.6). QRS complexes are usually small in normal cats.

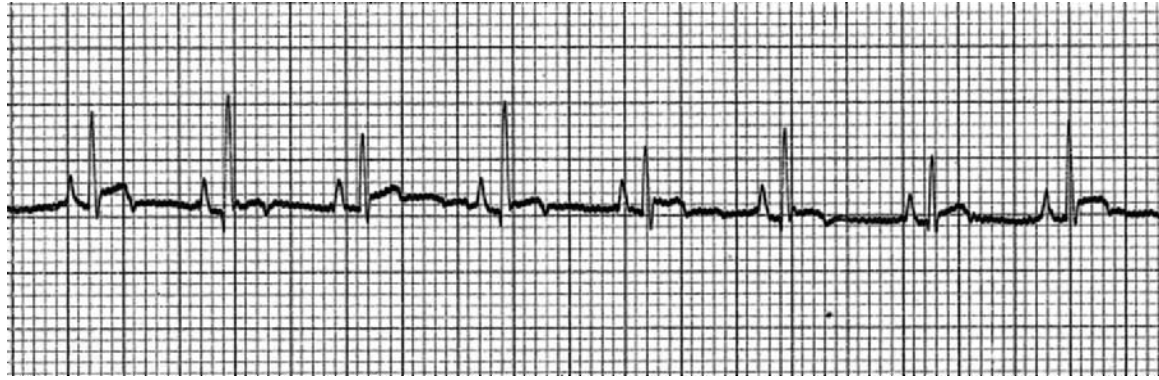


Figure 7.7 (a) ECG illustrating electrical alternans – note the alternating amplitude of the R waves. From a Golden Retriever with pericardial effusion due to idiopathic pericarditis (25 mm/sec and 10 mm/mV).

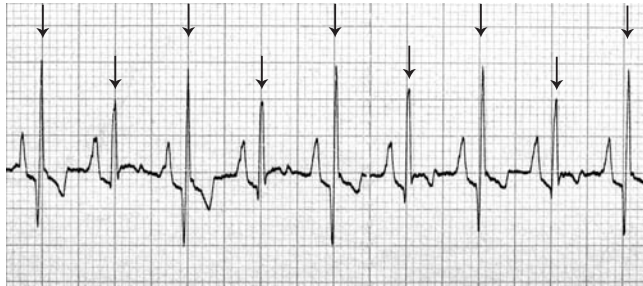


Figure 7.7 (b) ECG from a German Shepherd dog with pericardial effusion secondary to a right atrial haemangiosarcoma illustrating electrical alternans. The QRS complexes are arrowed. Note the alternating amplitudes of the R waves, S waves and T waves in this example (25 mm/sec and 10 mm/mV).

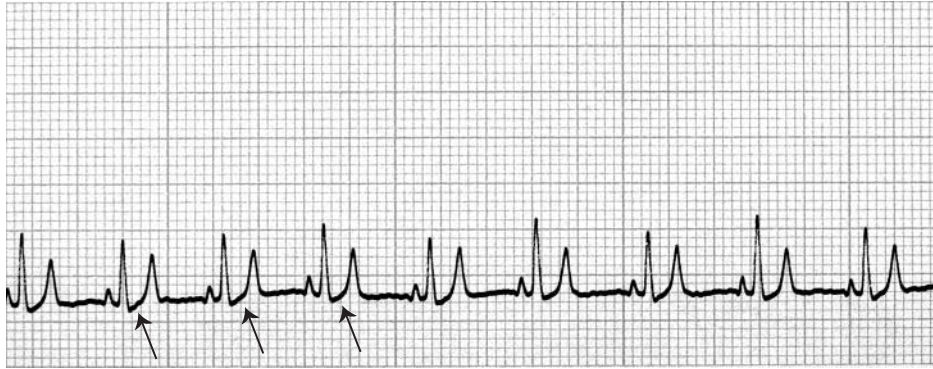
### Electrical alternans

This is an alternation in QRS amplitude that occurs nearly every other beat (Fig. 7.7).

Electrical alternans is associated with movement of the heart within pericardial effusion, which is evident on echocardiography where the heart can be seen to ‘bounce’ from side to side within pericardial fluid as it beats. This movement of the heart causes a slight alternating change in the cardiac axis and is seen on the ECG as an alternating variation in QRS amplitude. Note: this should not be confused with the more gradual variation in amplitude seen with respiration in some animals, nor the variation seen with a supraventricular tachycardia or atrial fibrillation.

### Notching in the R wave

Although these abnormalities can be seen commonly in heart disease in small animals, the significance of notches is debatable – it is the ‘heart disease’ that is of greater importance than trying to analyse every minutia. Notches in the QRS complex are reported to occur with microscopic intramural myocardial infarction or are associated with areas of myocardial fibrosis (Fig. 7.8). Notches in the



**Figure 7.7 (c)** ECG from a German Pointer with pericardial effusion. In addition to the electrical alternans, also note the rising S-T segment sometimes seen with pericardial disease (arrowed) (25 mm/sec and 10 mm/mV).

QRS complex are also seen with intraventricular conduction defects (see Chapter 10) and a slight notch is sometimes also seen with ventricular pre-excitation in the upstroke of the R wave (see Chapter 11). Notches can also be produced artifactually in tracings in which there is excessive muscle tremor or electrical interference.

### Q-T interval abnormalities

The Q-T interval varies a little, inversely with heart rate, so it is difficult to accurately define what is exactly abnormal.

Prolonged Q-T intervals may be seen in:

- hypocalcaemia
- hypokalaemia
- hypothermia
- quinidine
- ethylene glycol poisoning.

Shortened Q-T interval may be seen in:

- hyperkalaemia

- hypercalcaemia
- digitalis
- atropine
- beta-blockers and calcium channel antagonists.

### S-T segment abnormalities

S-T elevation is seen in:

- pericarditis (pericardial effusion) (Fig. 7.7c)
- severe ischaemia/infarction, e.g. full wall thickness.

S-T depression is seen in (Fig. 7.9):

- endomyocardial ischaemia (e.g. cardiomyopathy, trauma)
- potassium imbalance
- digitalis toxicity.

### Abnormalities of the T wave

The morphology of T waves in small animals is very variable and the diagnostic value of T wave changes is very limited compared



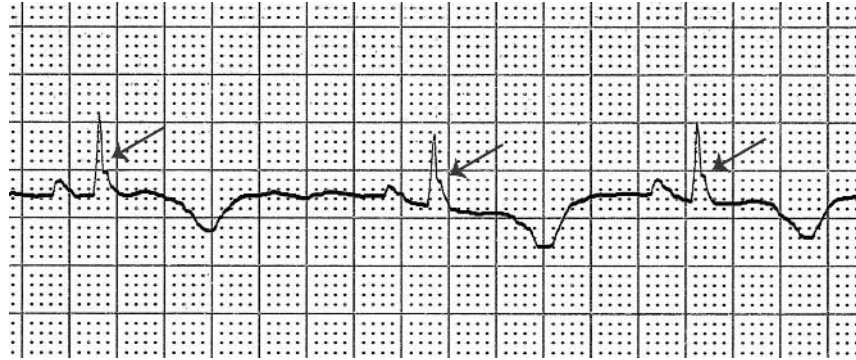

Figure 7.8 ECG illustrating notching in the QRS complex. From a cat with dilated cardiomyopathy (50 mm/sec and 20 m/mV).

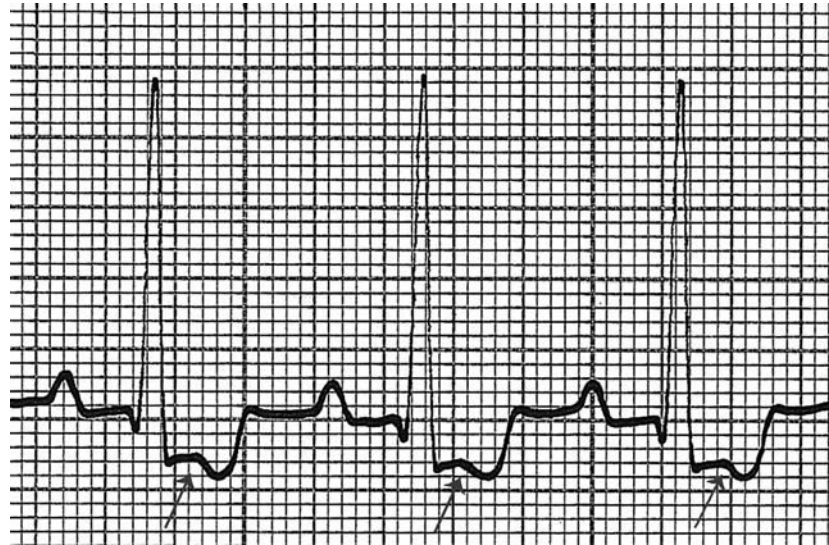
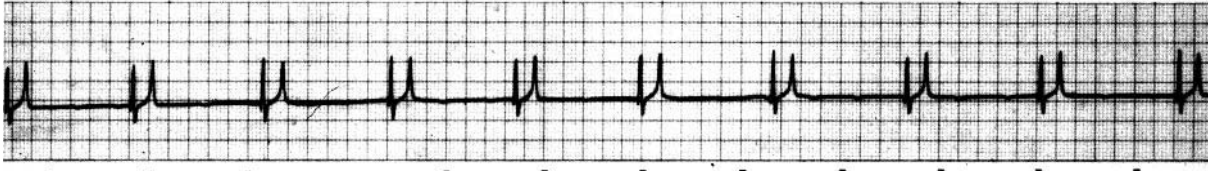


Figure 7.9 ECG illustrating depression of the S-T segment. From a 4-year-old Staffordshire Bull Terrier with mitral valve dysplasia (50 mm/sec and 10 mm/mV).



**Figure 7.10 (a)** ECG illustrating a bradycardia at 50/min, the absence of P waves (atrial standstill) and tall peaked T waves from a dog with hyperkalaemia (25 mm/sec and 10 mm/mV).

with that of humans. A higher value might be placed on T wave changes compared with a previous recording in the same animal. The most common abnormal change is the development of large T waves (Fig. 7.10). This can be associated with hyperkalaemia (see below) or myocardial hypoxia.

## Hyperkalaemia

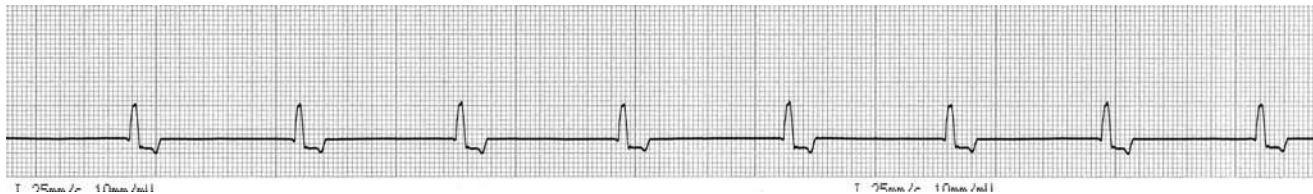Hyperkalaemia is a well known cause of ECG abnormalities (Fig. 7.10), but it must be remembered that a normal ECG would not exclude hyperkalaemia (e.g. Addison's disease) and serum electrolyte levels should always be measured (and an adrenocorticotrophic hormone test performed) if this is suspected.

Hyperkalaemia may be associated with Addison's disease, acute renal shutdown (e.g. feline urethral obstruction syndrome), diabetic ketoacidosis and severe skeletal muscle damage.

### ECG characteristics

The ECG changes vary with increasing severity of the hyperkalaemia as follows:

- there is a progressive bradycardia
- increased amplitude of the T wave, appearing narrow and spiked
- progressive decrease in amplitude of the R wave
- progressive reduction in amplitude of the P wave
- disappearance of the P wave, i.e. atrial standstill, with a slow junctional (nodal) rhythm
- finally, ventricular fibrillation or asystole.



**Figure 7.10 (b)** ECG from a young dog with Addison's disease and atrial standstill. Note that, unlike in Figure 7.10(a), the T waves are not tall and peaked. The absence of 'characteristic T wave morphology' on an ECG tracing does not exclude hyperkalaemia (25 mm/sec and 10 mm/mV).

## **PART 3**

### More advanced electrocardiography

## 8 • Understanding the ECG limb lead systems

An understanding of the ECG lead systems is necessary to understand both the cardiac electrical axis and intraventricular conduction defects, which follow this chapter.

### The six ECG limb leads

In Chapters 2 and 3, the +ve and -ve electrodes, in the diagrams, were placed so as to obtain a recording of the electricity of the heart. This *combination* of a +ve and -ve electrode is termed a **bipolar lead**, simply meaning between two poles, i.e. a +ve and a -ve pole (electrodes). For example, lead 2 is formed by the right fore electrode being the negative pole and the left hind electrode the positive pole. Leads 1, 2 and 3 are all bipolar leads (Figs 8.1 a, b, c). However, the term ‘lead’ can cause immense confusion, as an ECG cable or wire is often also called an ECG lead in common parlance. This potential confusion should be avoided.

While there are usually four ECG cables or wires (I’ll avoid the term ‘lead’ here!), one of these is an earth, each with an electrode clip (e.g. crocodile clip). The other three are the active cables to which the -ve and +ve electrodes are connected. All cables are labelled and/or colour coded for identification (Table 8.1), to ensure correct placement on each of the limbs (although the colour codings of Europe and America are not the same).

When the ECG clips are then attached to the animal, switching ‘channels’ on the ECG machine can provide different leads as shown below (Fig. 8.1). It can be seen how three ECG cables and electrodes

Table 8.1. ECG cable colour coding.

Limb	Standard	American	Labelling often on medical ECG machines
Right fore	Red	White	RA (right arm)
Left fore	Yellow	Black	LA (left arm)
Left hind	Green	Red	LL (left leg)
Right hind (earth)	Black	Green	RL (right leg)

can provide a total combination of six ECG leads.<sup>1</sup> Thus the six limb leads ‘look at’ the heart in six different directions.

Occasionally, I receive ECGs from students with only the first four leads recorded (i.e. I, II, III and aVR). On enquiring as to why the other two leads (aVL and aVF) were not recorded I am told: ‘because there are only four leads on the ECG machine’. That confusing term again! There are four cables, one is an earth and the other three are active, these three provide a combination of six ECG leads.

<sup>1</sup> A small portion of ‘poetic licence’ is used in this statement. Correctly, leads 1, 2 and 3 are bipolar leads, however leads aVR, aVL and aVF are augmented unipolar leads. Unipolar leads measure the electrical potential between a positive electrode and a central terminal created electronically within the circuitry of the ECG machine by combining the electric currents obtained from the two other electrodes. The deflections are smaller than the bipolar leads and thus they are also augmented (1.5 times).

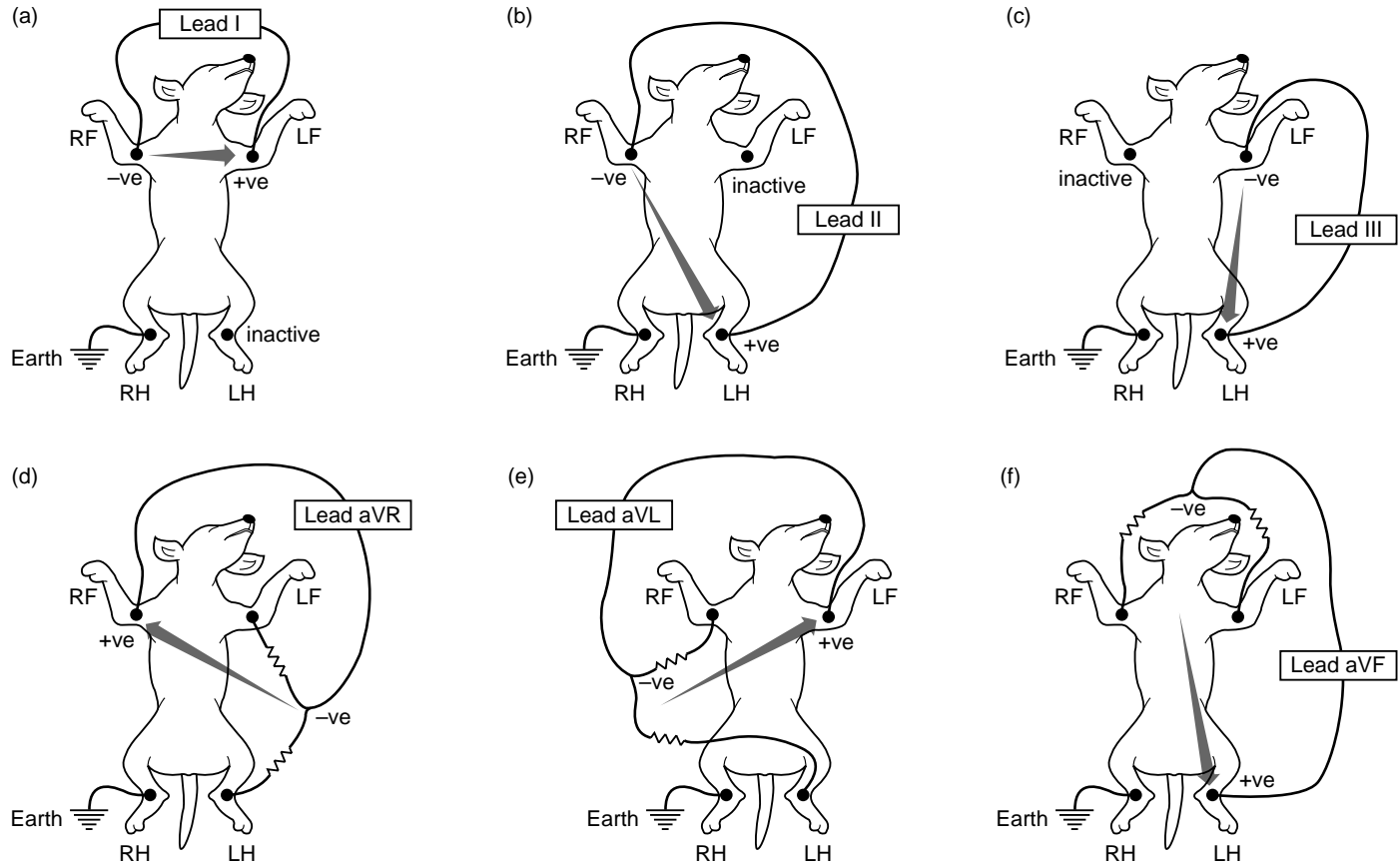


Figure 8.1 These diagrams illustrate how the six limb leads are generated by switching the electrode connections.

## 9 • Mean electrical axis (MEA) explained

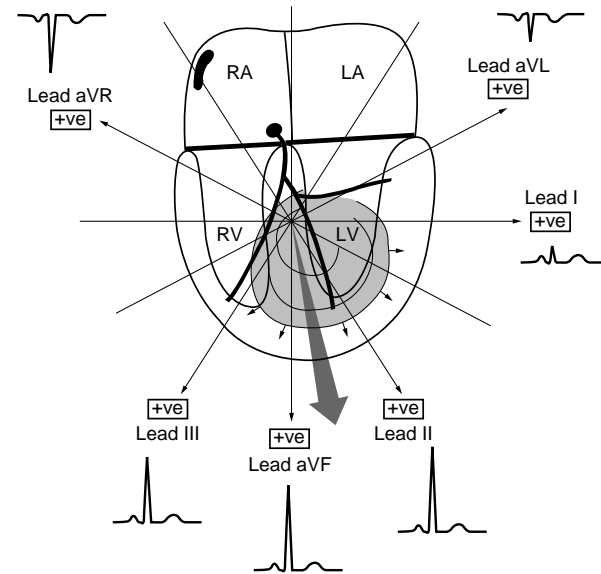
Although depolarisation waves spread through the heart in ‘all directions’, the average direction and magnitude is represented by the QRS complex. If the QRS is predominantly positive (upwards), the average direction of the depolarisation waves is towards the +ve electrode. Conversely, if it is predominantly negative (downwards) then the depolarisation wave is moving away from the +ve electrode. When the QRS complex is equally positive and negative (and usually also small) then the depolarisation wave is moving at right angles to the +ve electrode.

The limb leads ‘look at’ the heart from six different directions. The average direction and magnitude of the depolarisation wave through the ventricles is termed the mean electrical axis (MEA) or the cardiac axis. As can be seen from Fig. 9.1, in which there is a normal axis, leads I, II, III and aVF have positive deflections and aVR and aVL are negative.

### *Right axis deviation*

If the right ventricle becomes enlarged as illustrated (either with hypertrophy or dilation), then the MEA swings to the right, because the large increase in muscle mass on the right side creates a large electrical potential difference during depolarisation.

In Fig. 9.2, for example, leads III and aVR become large and positive. Leads I, II and aVL become negative. Lead aVF is isoelectric in this example. This is termed a right axis deviation.



**Figure 9.1** A normal mean electrical axis (large shaded arrow) and how this is ‘seen’ from the six limb leads. RA – right atrium; LA – left atrium; RV – right ventricle; LV – left ventricle.

### *Left axis deviation*

If the left ventricle becomes enlarged (either by hypertrophy or dilation), then the MEA swings to the left, because the large increase

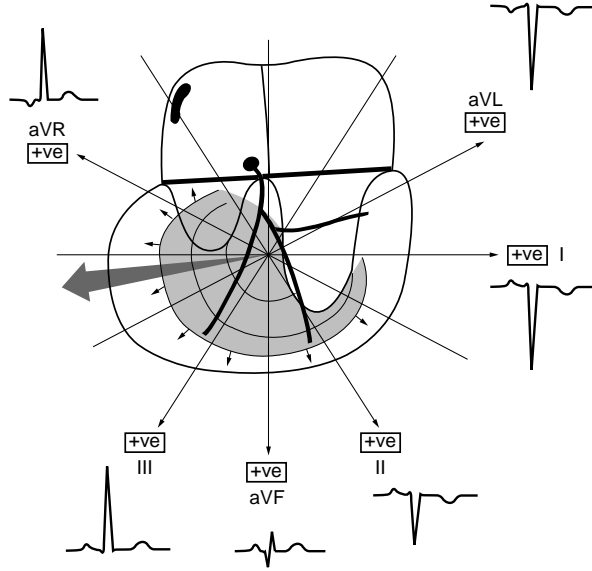


Figure 9.2 The mean electrical axis (large shaded arrow) in an animal with right ventricular enlargement (RVE) and how this is ‘seen’ from the six limb leads.

in muscle mass on the left side creates a large electrical potential difference during depolarisation.

In Fig. 9.3, for example, lead I becomes taller than lead II. Lead aVL is also positive. Leads III and aVR are negative and aVF is isoelectric. This is termed a left axis deviation.

### How to calculate the mean electrical axis

This is of limited value in small animals, in part because the vector in the frontal plane (which is the plane that is measured from limb leads) is less representative of the true direction of the vector in three dimensions, compared with humans. The MEA is used mainly

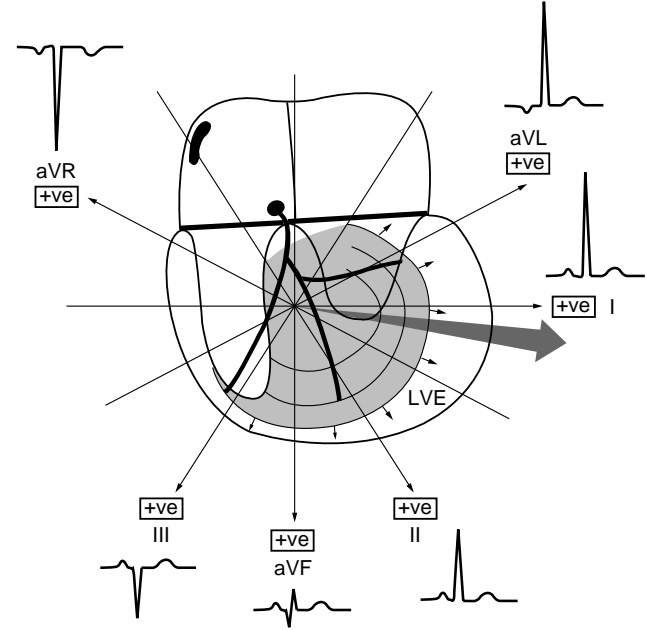


Figure 9.3 The mean electrical axis (large shaded arrow) in an animal with left ventricular enlargement (LVE) and how this is ‘seen’ from the six limb leads.

to assist in the assessment of ventricular enlargement and in the recognition of intraventricular conduction defects.

The value in exactly measuring the MEA in every case is questionable; a rough estimate of whether it is right or left is usually sufficient. However, the understanding of how it is measured and how it varies provides a better understanding of the ‘electricity of the heart’.

### How to estimate the MEA

There are a few methods of measuring the MEA; two are described here.

### (1) Eyeballing the MEA

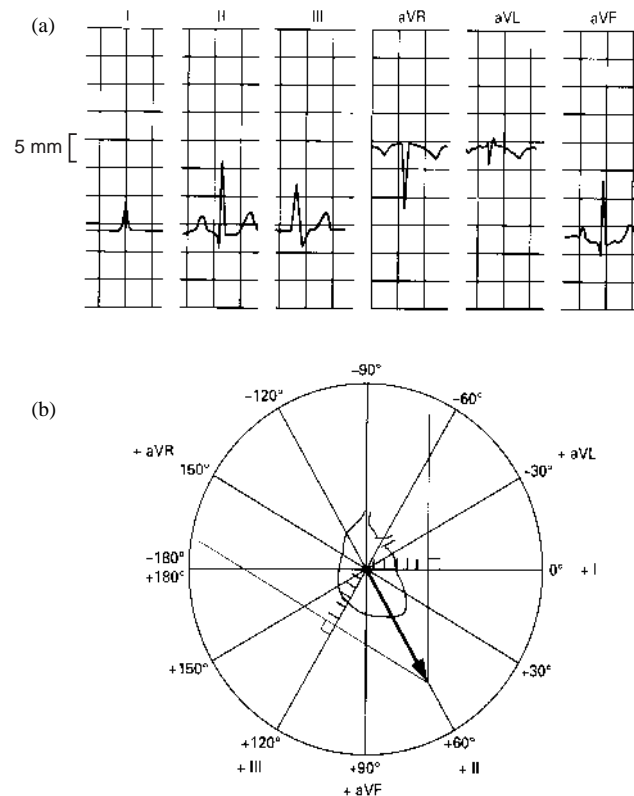
Using this method provides a quick system and, with practice, the MEA can often be ‘eyeballed’ to see whether it is normal or abnormal. Look again at the previous diagrams describing right and left axes, and how the amplitude of the QRS complex varies in leads I, II and III with these.

- (i) Using all six limb leads and the hexaxial lead system, find the lead in which the QRS complexes have the greatest (positive) net amplitude – the MEA is approximately in this direction.
- (ii) Similarly, find the most negative complexes, the MEA is opposite in direction to this.
- (iii) Alternatively, find the lead in which the QRS complex is equally positive and negative (and usually small) – this is called the isoelectric lead. The MEA will be perpendicular to this. Find which of the six limb leads is perpendicular to the isoelectric lead. If the perpendicular lead is positive, then the MEA is in that direction. If the perpendicular lead is negative, then the MEA is in the opposite direction to that lead.

### (2) Triangulation

Using two leads from a good-quality tracing, commonly leads I and III are used to measure the net amplitude of the QRS complex in each lead. In other words, measure the amplitude of the QRS complex that is positive and the amplitude that is negative. Subtract one (the smaller) from the other – this is the net amplitude. Plot this, to scale, on the hexaxial lead system shown below (Fig. 9.4). Draw perpendicular lines from each point. Where the two lines meet is the direction of the MEA from the centre point.

In fact, if the net amplitude in all six leads is calculated and plotted on the hexaxial lead system, the lines that are drawn perpendicular from each point *should* all meet at approximately the same point.



**Figure 9.4** Estimation of mean electrical axis. (a) *Method 1*. In this normal canine ECG, lead aVL is the most isoelectric lead. Perpendicular to this is lead II. Lead II is positive and therefore the MEA is towards the positive pole of this line, i.e.  $+60^\circ$ . (b) *Method 2*. In the same ECG. The net amplitude in lead I is  $+6$  ( $Q = 0$  and  $R = +6$ ). Plot 6 points along lead I in the hexaxial lead system diagram and draw a perpendicular. The net amplitude in lead III is  $+6$  ( $S = -2$  and  $R = +8$ ). Plot 6 points along lead III and draw a perpendicular. Draw an arrow from the centre to where the two perpendicular lines intersect. This is the direction of the MEA, i.e.  $+60^\circ$ .



## 10 • Intraventricular conduction defects

Having understood the ECG leads and mean electrical axis, we can now explain abnormalities due to intraventricular conduction defects (aka ventricular aberrancy).

The bundle of His divides into left and right bundle branches, supplying the left and right ventricles respectively (see Fig. 2.1 page 4). The left bundle branch further divides into anterior and posterior fascicles. As well as conduction block occurring in the AV node (i.e. heart block), a block can occur in conduction of the electrical impulse through one or more of these conduction pathways. The most commonly seen conduction defects seen are

in dogs:

- right bundle branch block (RBBB)
- left bundle branch block (LBBB)

and in cats:

- left anterior fascicular block (LAFB).

These result in abnormal depolarisation patterns as there will be a delay in depolarisation of the part of the ventricles supplied by the affected conduction tissue. This is also referred to as aberrant ventricular conduction or ventricular aberrancy.

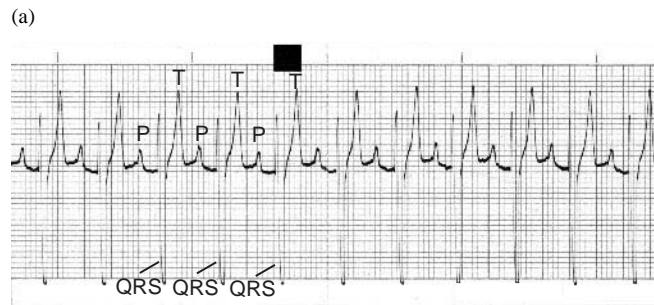
### Right bundle branch block

Right bundle branch block (RBBB) occurs due to failure/delay of impulse conduction through the RBB. Depolarisation of the left ven-

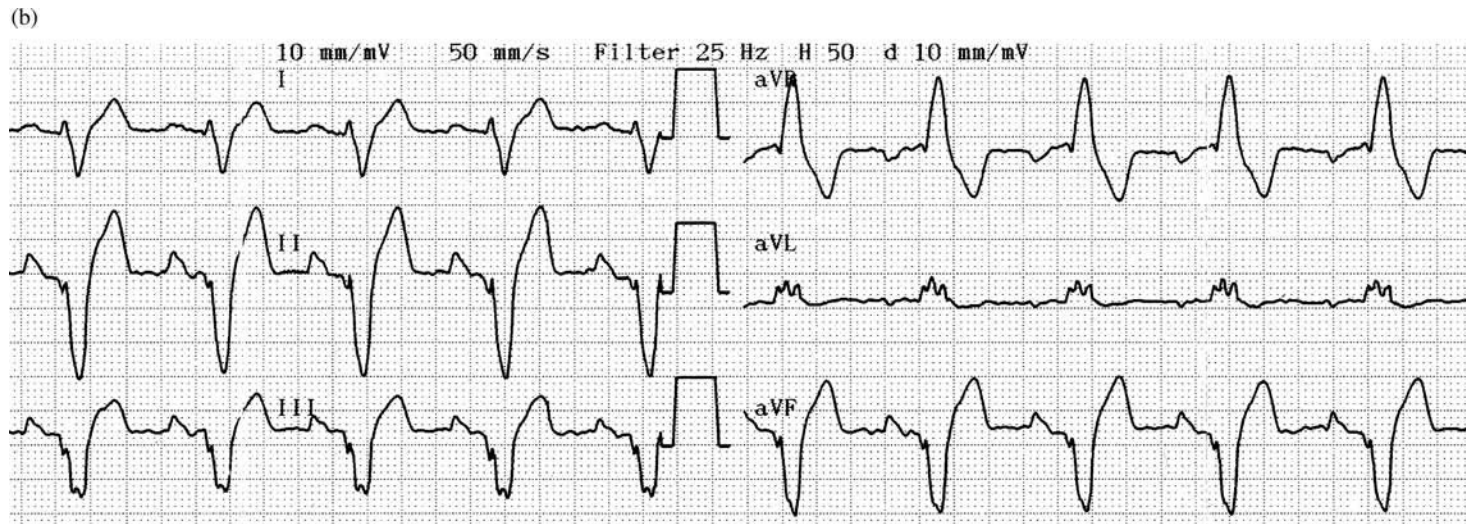
tricle occurs normally, but depolarisation of the right ventricular mass occurs through the myocardial cell tissue resulting in a very prolonged complex.

### ECG characteristics

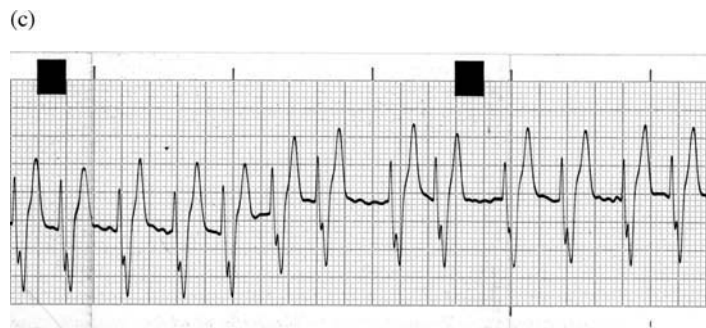
The QRS duration is prolonged ( $>0.07$  seconds). The QRS complex has deep and usually slurred S waves in leads I, II, III and aVF and is positive in aVR and aVL. The MEA is to the right (Fig. 10.1a and b). Note that RBBB needs to be differentiated from a right ventricular enlargement pattern.



**Figure 10.1** (a) ECG (lead II) from a 10-year-old mixed breed dog with a normal sinus rhythm at 140/min, but conducted with aberrancy through the ventricles due to right bundle branch block. This was an incidental finding. Note the abnormal morphology of the QRS complexes, with deep (negative) Q waves and prolonged QRS duration. There is a P for every QRS, indicating the sinus origin of the depolarisation (25 mm/sec and 10 mm/mV).



**Figure 10.1 (b)** ECG from a mixed breed dog with RBBB showing all six limb leads. The complexes are very prolonged and negative in leads 2, 3 and aVF and the most positive lead is aVR (50 mm/sec and 10 mm/mV).



**Figure 10.1 (c)** ECG (lead II) from dog with atrial fibrillation (note the irregular R-R intervals and the fibrillation waves) and right bundle branch block (deep S waves and prolonged QRS durations) (25 mm/sec and 10 mm/mV).

An animal with atrial fibrillation can concurrently have bundle branch block (Fig. 10.1c); this is often a more challenging ECG interpretation!

### *Clinical findings*

The heart sounds and rhythm will sound normal with associated palpable pulses. In some dogs, with very careful auscultation a split second heart sound (S2) may be heard, due to delayed closure of the pulmonic valve.

### **Left bundle branch block**

Left bundle branch block (LBBB) occurs due to failure of conduction through the LBB. Depolarisation of the right ventricle occurs

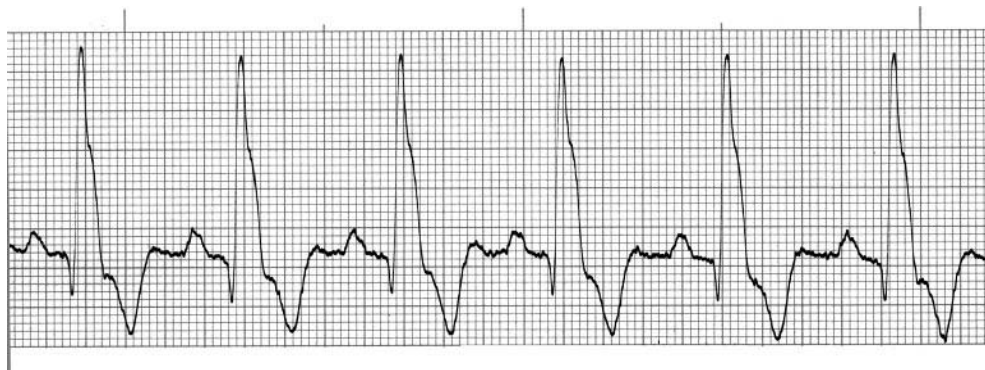

Figure 10.2 (a) ECG from a dog with a normal sinus rhythm conducted through the ventricles with aberrancy due to left bundle branch block. Note the abnormal morphology of the QRS complexes, yet related to the P waves, i.e. there is a P for every QRS, indicating the sinus origin of the depolarisations (50 mm/s and 10 mm/mV).

normally and depolarisation of the left ventricle is delayed and occurs through the myocardial cell tissue resulting in a very prolonged complex.

#### *ECG characteristics*

The QRS duration is very prolonged ( $>0.07$  seconds). There are positive complexes in leads I, II, III and aVF and negative in aVR and

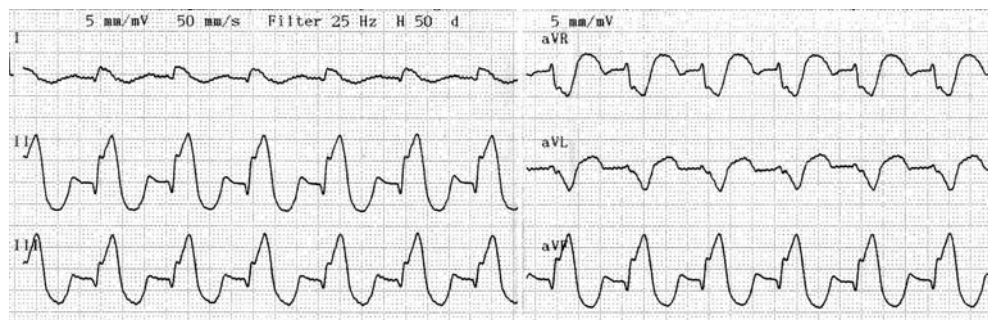
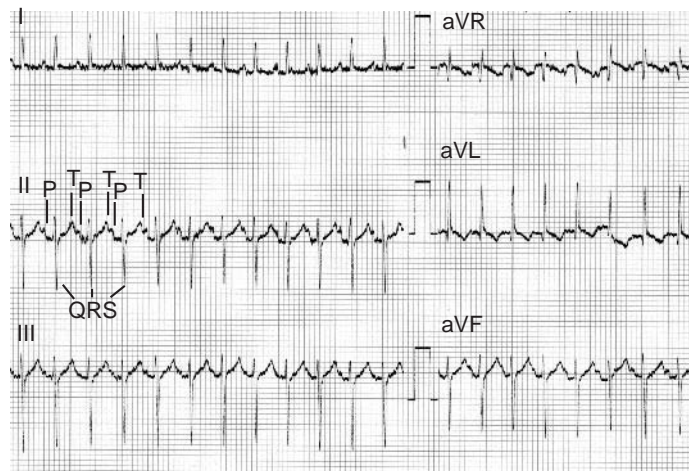


Figure 10.2 (b) ECG from an 8-year-old Boxer dog with LBBB showing all six limb leads. Note the very prolonged QRS complexes and leads I, 2, 3 and aVF are positive whereas aVR and aVL are negative (50 mm/sec and 5 mm/mV).



**Figure 10.3** (a) ECG from a cat with taurine-responsive dilated cardiomyopathy. There is a normal sinus rhythm but aberrant ventricular conduction due to anterior fascicular block (see text) (25 mm/sec and 10 mm/mV).

aVL (Fig. 10.2). LBBB needs to be differentiated from a left ventricular enlargement pattern.

### *Clinical findings*

The heart sounds and rhythm will sound normal with associated palpable pulses.

### **Left anterior fascicular block**

Left anterior fascicular block (LAFB) occurs due to failure of conduction through the anterior fascicle of the LBB. It is not an uncommon finding in cats but is rare in the dog.

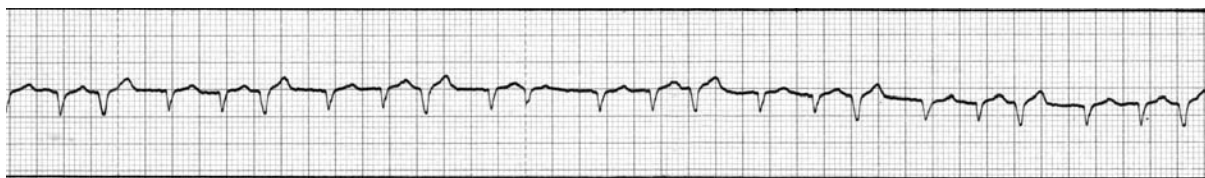### *ECG characteristics*

The QRS complex is normal in duration but there are tall R waves in leads I and aVL, deep S waves (>R wave) in leads II, III and aVF. The MEA is markedly to the left; approx.  $-60^\circ$  in the cat (Fig. 10.3a).

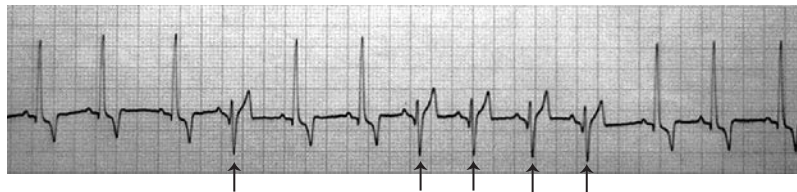A cat with atrial fibrillation can also concurrently have fascicular block (Fig. 10.3b).

### *Clinical findings*

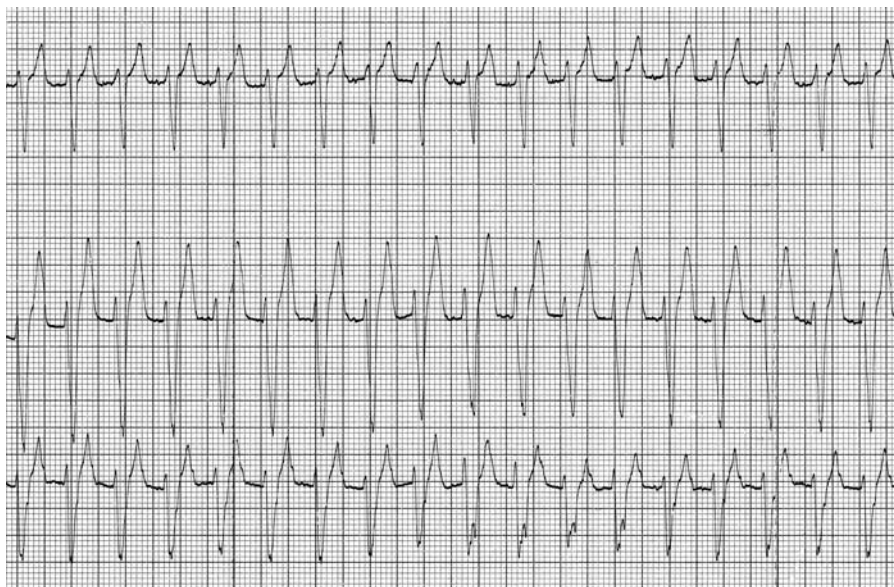
The heart sounds and rhythm will sound normal with associated palpable pulses.



**Figure 10.3** (b) ECG from a cat with atrial fibrillation and anterior fascicular block.



**Figure 10.4 (a)** ECG showing intermittent right bundle branch block. Note that there is a sinus rhythm throughout, with a P wave preceding every QRS complex, however there is a change in morphology with some (arrowed) (25 mm/sec and 10 mm/mV).



**Figure 10.4 (b)** ECG from 4-year-old Golden Retriever with a broad complex tachycardia, which could be either a ventricular tachycardia or an SVT with aberrancy. Following cardioversion an underlying right bundle branch block was evident, confirming this to be an SVT (50 mm/sec and 10 mm/mV).

**More terminology . . . . . VPC morphology**

In Chapters 4 and 5 the morphology of VPCs was described as having a –ve or +ve QRS complex. In ECG-speak however, the morphology of the QRS complex is described as being of LBBB or RBBB morphology. It is not until ventricular aberrancy has been explained, that this terminology can be used. So for example in Figs 4.1, 4.8b and 5.5a the VPCs would be described as having RBBB morphology and in Figs 4.2c, 5.3, 5.4b and 5.7c they would be described as having LBBB morphology.

In Boxer dogs with arrhythmogenic right ventricular cardiomyopathy, in which the VPCs arise from the right ventricular outflow tract, they are described as VPCs with LBBB morphology.

**Intermittent ventricular aberrancy**

This is sometimes seen when a supraventricular premature depolarisation reaches the bundle branches before one or other has fully repolarised (usually the right bundle branch), i.e. is still partially depolarised, which results in a functional block. Because the QRS complex is premature and bizarre in shape it mimics a VPC.

If a supraventricular tachycardia (SVT) is associated with aberrant ventricular conduction, this will mimic a ventricular tachycardia (VT). Thus the term a **broad complex tachycardia** is sometimes used to describe this ECG finding.

*ECG characteristics*

The QRS complex is bizarre and prolonged, often a right bundle branch block morphology and is premature. It can be very difficult to distinguish from a true VPC (Fig. 10.4a). If there is a preceding P wave visible (and not hidden by the previous T wave) then this might help to confirm it was a supraventricular complex.

An SVT with aberrancy will mimic a VT (Fig. 10.4b).

*Clinical findings*

It sounds like premature beat, and will have a pulse deficit. An SVT with aberrancy will simply produce a tachycardic sounding heart with weak pulses.

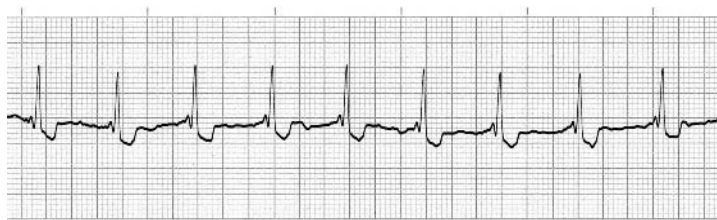## 11 • Some additional arrhythmias

### Ventricular pre-excitation

This occurs when the impulse from the SA node bypasses the AV node through an accessory conduction pathway to the ventricles and therefore depolarises the ventricles prematurely. The impulse conducted through the accessory pathway stimulates a portion of the ventricles with the rest of the ventricles being activated in the normal sequence through the AV node. There are believed to be three accessory pathways: bundles of Kent, James fibres and Mahaim fibres.

The **Wolff–Parkinson–White** (WPW) syndrome consists of ventricular pre-excitation with episodes of paroxysmal supraventricular tachycardia.

The heart rhythm (except with WPW syndrome) is unaffected and is usually regular.



**Figure 11.1** (a) ECG from a 3-year-old Labrador with pre-excitation. Note the abnormally short PR interval (25 mm/sec and 10 mm/mV).

### ECG characteristics

The electrocardiographic characteristics are within the P–QRS–T complex itself. There is a short PR interval, a slur or notch (delta wave) in the upstroke of the R wave and a slight prolongation of the QRS complex (Fig. 11.1). In WPW syndrome the supraventricular tachycardia is often in excess of 300/min.

### Clinical findings

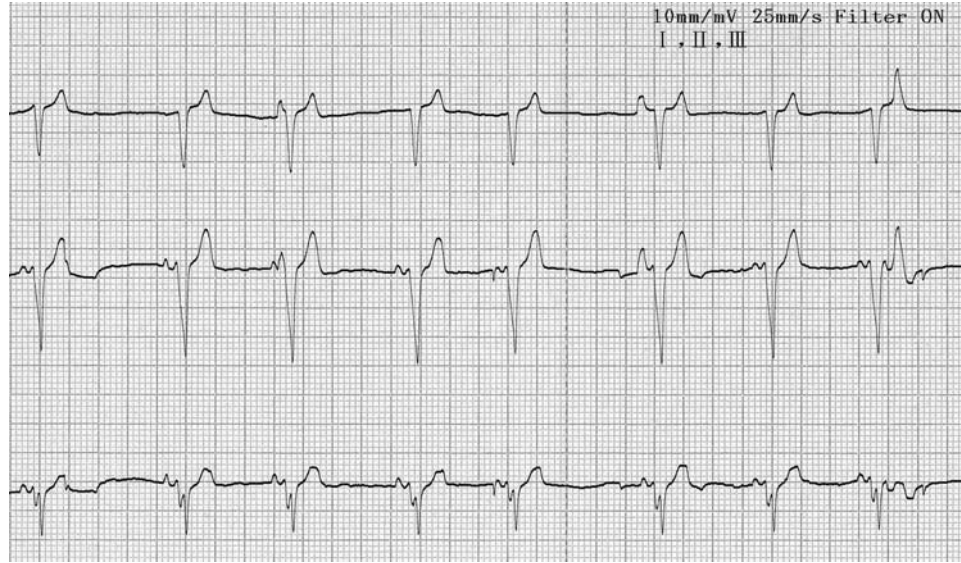
If examined during a period of tachycardia, this will be heard and weak femoral pulses appreciated. If there is not a tachycardia present, the pre-excitation will not produce an audible difference from that of a normal sinus complex.

### Atrial flutter

This is a rare arrhythmia in dogs and it has not been documented in cats.

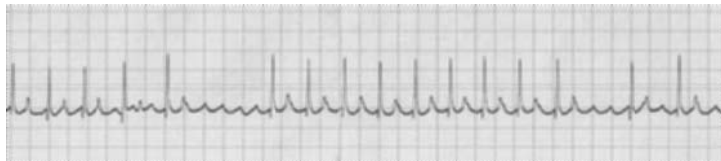
### ECG characteristics

The flutter waves (F waves) produce regular ‘saw-toothed’ deflections typically at a rate of 300–400/min, if seen. The ventricular response is typically to produce a supraventricular tachycardia (this



**Figure 11.1** (b) ECG from a 4-year-old Boxer with pre-excitation. Note the short PR interval and the aberrant ventricular conduction with a right bundle branch morphology (25 mm/sec and 10 mm/mV).

is thus another potential cause of SVT). At high rates there may be a functional AV block thus producing a 2:1 or 3:1 conduction ratio (Fig. 11.2). If the ventricular response rate is a regular rate the heart



**Figure 11.2** ECG from a 1-year-old Boxer dog with atrial flutter. Note the flutter waves and the variable capture rate, most of the time it is 2:1 (25 mm/sec and 10 mm/mV).

rate will be regular, however often the conduction can be variable, producing an irregular heart rate (similar to atrial fibrillation).

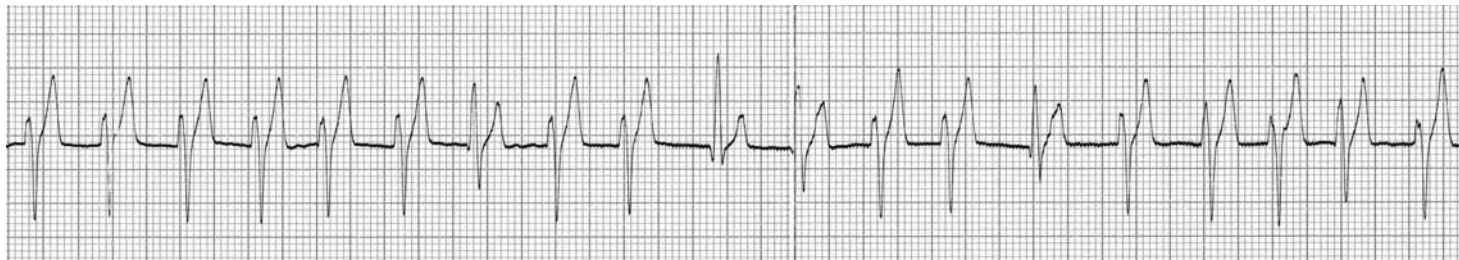### *Clinical findings*

The heart rate is typically very fast and can be regular or irregular.

### **Accelerated idioventricular rhythm**

This is an ectopic ventricular rhythm that is often not particularly fast (<180/min) and thus sometimes is described as a slow ventricular tachycardia (VT).





**Figure 11.3** ECG from an Old English Shepherd dog with pancreatitis and an idioventricular rhythm at 130/min (too slow to be considered a ventricular tachycardia, cf. Fig. 5.7, p. 28–29) (25 mm/sec and 10 mm/mV).

### *ECG characteristics*

It looks like a slow VT (Fig. 11.3).

### *Clinical findings*

The heart rate is typically regular to match to the rate, however the rhythm may be irregular if not constant and intermingled with the underlying sinus rhythm.

## **PART 4**

# Management and treatment of arrhythmias

## 12 • Management of arrhythmias

Arrhythmias are a frequent finding in cardiac disease but are also often secondary to systemic diseases.

Before using specific antiarrhythmic drugs, which have the potential to be proarrhythmic, two questions need to be answered.

- (1) Does the arrhythmia suggest the presence of an underlying condition?
- (2) Is the arrhythmia of primary clinical significance?

### **(1) Does the arrhythmia suggest the presence of an underlying condition?**

Possible underlying conditions can be broadly categorised into primary cardiac diseases and non-cardiac diseases.

#### *Primary cardiac diseases*

There is potential for any clinically significant cardiac disease to lead to myocardial stress, dilation or hypoxia that can be a stimulus for arrhythmias. Typically atrial dilation and stretch can lead to atrial arrhythmias such as supraventricular premature complexes and atrial fibrillation. Ventricular dilation or hypertrophy can lead to ventricular premature complexes. In general practice mitral valve disease would be the most common cause of atrial dilation in dogs leading to supraventricular arrhythmias and the cardiomyopathies would be a common cause of ventricular arrhythmias in both dogs and cats. In such cases it is important to manage and treat the heart failure

particularly if there are congestive failure signs prior to considering specific antiarrhythmic drugs.

A review of any concurrent antiarrhythmic drugs should also be considered as a possible iatrogenic cause of arrhythmias. For example, sotalol may lead to AV block, pimobendan may exacerbate re-entrant arrhythmias, digoxin may trigger ventricular arrhythmias and theophylline may result in supraventricular arrhythmias.

However there are some specific situations, i.e. Boxers and Dobermanns, with dilated cardiomyopathy; in addition to treatment for the heart failure, antiarrhythmic drugs are considered appropriate to reduce the likelihood of sudden death (see later).

#### *Non-cardiac diseases*

There is a very large list of medical conditions that can trigger effects on the heart leading to arrhythmias. These conditions may range from atrial standstill caused by hyperkalaemia to ventricular arrhythmias associated with splenic disease or gastric dilation, and from arrhythmias caused by hypoxia (e.g. due to respiratory disease) to bradyarrhythmia associated with intracranial disease. When presented with an animal in which diagnostics have not revealed the presence of a primary cardiac condition, then the search needs to be widened for a non-cardiac condition, by very thorough and comprehensive physical examination (and history) together with extensive blood profiles, urine analysis and radiography and/or ultrasonography to screen for non-thoracic diseases. In the vast majority of situations in which a non-cardiac disease has been found in association with an

arrhythmia, treatment directed towards the condition will lead to a resolution of the arrhythmia. Simple monitoring of the arrhythmia may be all that is required in many cases, unless the arrhythmia is of primary significance. Additionally monitoring of the arrhythmia can often be a good means to assess response to treatment of the medical condition, e.g. resolution of atrial standstill in dogs with Addison's disease.

It may be that arrhythmias develop as a consequence of medical drug therapy and a review of all concurrent medications should be performed.

## (2) Is the arrhythmia of primary clinical significance?

An arrhythmia may be of primary clinical significance if it results in signs of haemodynamic compromise, has the potential to lead to sudden death or could lead to heart failure, e.g. tachycardia-induced myocardial failure.

### *Arrhythmias causing haemodynamic compromise*

As a generalisation, animals with arrhythmias but no clinical signs should not be medicated with antiarrhythmic drugs. Haemodynamic compromise, and thus clinical signs, will occur when an arrhythmia results in a significant reduction in cardiac output. This can result due to either bradyarrhythmias or tachyarrhythmias.

$$\text{Cardiac output} = \text{Stroke volume} \times \text{Heart rate}$$

When the heart rate slows, there is a natural compensatory increase in stroke volume to sustain cardiac output (Starling's Law of the heart) and thus systemic blood pressure. However if a bradycardia were to be profound, it would reach a point at which there is an inability to compensate for the reduction in heart rate. Typically dogs with complete AV block with a heart rate of 30–40/min remain conscious

and are able to walk into the clinic, however heart rates lower than 25/min tend to start producing weakness or recumbency. Dogs with a sinus arrest pause of 20 seconds at rest (i.e. low metabolic demand) may not necessarily faint, however the same pause at exercise would result in syncope.

With tachyarrhythmias, as the heart rate increases there is less diastolic filling time, which consequently reduces the stroke volume and thus the cardiac output. The degree of reduction in stroke volume is greater with ventricular arrhythmias than with supraventricular arrhythmias. With a supraventricular arrhythmia, the depolarisation, and thus the contraction, of the left ventricle sustain a normal sequence, which is efficient. Whereas when there is a ventricular arrhythmia, depolarisation and contraction is inefficient and ejection of blood is not well coordinated, resulting in a greater reduction in stroke volume. Thus a supraventricular tachycardia may not result in signs of forward failure and weakness or collapse until it exceeds 300/min, whereas a ventricular tachycardia may produce haemodynamic compromise at rates as low as 200/min. The heart rate at which clinical signs of compromise occur will also be influenced by the presence of concurrent disease.

In contrast, it should be understood that occasional or even frequent arrhythmias are not likely to result in haemodynamic compromise. As a generalisation there needs to be a sustained reduction in cardiac output to produce signs, which will usually mean a sustained arrhythmia, or at least long periods of an arrhythmia.

The clinical signs of haemodynamic compromise are essentially those of forward failure, i.e. reduced mental status, weak/poor pulse strength and mucosal pallor. In more severe cases there may also be cold extremities. Blood pressure assessment is useful to check for hypotension, although it can often be difficult to obtain a blood pressure recording accurately in hypotensive animals. Animals may also present with a history of syncope or pre-syncope, recumbency or even sudden death. In animals with concurrent disease, whether

cardiac or non-cardiac, it can sometimes be difficult to ascertain if the signs are necessarily due to the arrhythmia or the disease. This requires clinical judgement and experience.

### *Life-threatening arrhythmias*

As a general rule a sustained and rapid ventricular tachycardia is considered the most likely to progress into ventricular fibrillation and result in death, and thus rapid i/v cardioversion is normally performed. Additionally very frequent and multimorphic ventricular arrhythmias are usually considered malignant and require drug suppression. Profound bradyarrhythmias, such as sinus arrest (or sick sinus syndrome) or AV block with an inconsistent and slow ventricular escape rhythm are considered life threatening and may require urgent pacemaker implantation.

### *Tachycardia-induced myocardial failure*

This occurs as a consequence of an incessant tachycardia sustained over a period of days or weeks. In dogs, this is most likely to be seen in association with a sustained supraventricular tachycardia. Myocardial failure develops, leading to signs of congestive heart failure. And whilst they may not seem urgent in the first few days, if cardioversion is not successful, the relentless progression into heart failure makes this a challenging case to manage, thus prompt cardioversion is preferable. The myocardial failure can be sustained for days or weeks following cardioversion to sinus rhythm and thus mimic dilated cardiomyopathy on echocardiographic examination.

### *Atrial fibrillation*

Atrial fibrillation is most commonly associated with dilation and stretch of one or both atria, resulting in the inability to sustain the normal depolarisation sequence. In such cases, animals present in heart failure with a sympathetic drive resulting in a rapid ventricular response rate and >50% pulse deficit. Control of the ventricular response rate is then desirable, minimising the pulse deficit. In dogs with myocardial disease, digoxin is considered the drug of choice, but other options include calcium channel antagonists and beta blockers. In contrast, in giant-breed dogs that present with lone AF, i.e. not in heart failure, it is debatable whether any treatment is required or not.

### *Treatment of arrhythmias*

Having made the decision that an arrhythmia is of primary significance, then antiarrhythmic drugs need to be chosen. However it is still important to remember that antiarrhythmic drugs may have proarrhythmic effects and can complicate the arrhythmia, thus continual monitoring and re-assessment is necessary. The aims of treatment also need to be considered in advance. It is often unlikely that animals with frequent ventricular arrhythmias will have a complete resolution of the arrhythmias following medication. Thus judgement of the response should not be based on ECG findings alone, but importantly by the clinical improvement in the animal with a reduction or resolution of the signs.

## 13 • Treatment of arrhythmias

### Bradyarrhythmias

#### Sinus bradycardia

##### *Clinical significance*

Sinus bradycardia could be due to hypothyroidism, hyperkalaemia, hypothermia, elevated intracranial pressure (e.g. following cranial trauma), systemic disease (e.g. renal failure) or drugs (tranquillisers or antiarrhythmic drugs) and, additionally in cats, feline dysautonomia. Cats sometimes present with a sinus bradycardia when in heart failure, which seems paradoxical, since one of the compensatory responses to heart failure is an increase in sympathetic tone (i.e. a tachycardia would be expected).

##### *Treatment*

This should be aimed at the primary cause. Vagolytic or beta agonist drugs can be used to increase the heart rate if symptomatic, but this is rarely necessary.

#### Sinus arrest/block

##### *Clinical significance*

Sinus arrest / block can be a normal finding in some brachycephalic dogs (i.e. exaggerated respiratory sinus arrhythmia).

A long period of sinus arrest may result in **syncope**, as no blood flows to the brain and fainting occurs. How long the period of

sinus arrest must be to result in syncope depends on the activity (or metabolic rate) of the animal, e.g. a 5-second pause may be sufficient when running, but it may require 15–25 seconds at rest. **Pre-syncope** occurs if the duration of the sinus arrest is not quite sufficient to result in collapse but does cause signs of weakness or stumbling.

There are several conditions that may be associated with sinus arrest that overlap with causes of sinus bradycardia (see Chapter 3):

- vagal stimulation associated with severe respiratory disease (it can be normal in dogs with brachycephalic upper airway syndrome, for example) or associated with a vasovagal response, e.g. with vomiting or tenesmus;
- atrial disease such as dilation, fibrosis, cardiomyopathy or neoplasia (e.g. haemangiosarcoma and heart base tumours);
- metabolic or endocrine diseases such as an electrolyte imbalance or hypothyroidism;
- drugs, either due to their effects or associated with toxicity, must also be considered;
- irritation of the vagus nerve by neoplasia in the cervical area (e.g. thyroid carcinoma) or in the thorax (e.g. aortic body tumour). Surgical manipulation within the thorax may also result in sinus arrest;
- profound and regular sinus arrest can be a feature of sick sinus syndrome.

### Treatment

Treatment is usually only required in symptomatic cases. Pacemaker implantation is a treatment option in some cases.

### Sick sinus syndrome (sinus node dysfunction)

#### Clinical significance

As for sinus arrest described previously, prolonged periods of no cardiac output will result in pre-syncope or syncope. A profound sinus bradycardia may present with lethargy and exercise intolerance due to an inability to increase cardiac output on demand. In the bradycardia–tachycardia syndrome either the bradycardia or the tachycardia may produce a significant drop in cardiac output and result in weakness or syncope. It is most commonly seen in West Highland White Terriers (with or without idiopathic pulmonary fibrosis); it has also been reported in older, female miniature Schnauzers. It has not been recorded in cats.

### Treatment

If atropine (see boxed text below) or exercise fail to increase the heart rate significantly, it would suggest that excessive vagal tone is not the cause of the bradycardia. The treatment of choice for symptomatic cases is pacemaker implantation and possibly also the addition of antiarrhythmic drugs. It is usually difficult to obtain satisfactory rate control with medical treatment alone.

#### Atropine response test

Inject 40 µg/kg s/c (dog and cat) and re-assess heart rate response (ECGs) in 30 to 40 minutes.

### Atrial standstill

#### Clinical significance

Atrial standstill can be classified into three types, based on the underlying condition.

- (1) One type has been reported in English Springer Spaniels, Old English Sheep Dogs and mixed breed dogs and the author has seen cases in Cavalier King Charles Spaniels. This type is referred to as **persistent** atrial standstill and is thought to be an atrial cardiomyopathy. The clinical signs are usually of weakness, lethargy and syncope associated with the reduction in cardiac output and inability to increase the heart rate during activity. Heart failure usually ensues insidiously.
- (2) Atrial standstill is described as **temporary** atrial standstill when it occurs as a consequence of a reversible condition. This may be due to hyperkalaemia, which can be secondary to Addison's disease, diabetic ketoacidosis and oliguric renal failure. Iatrogenic causes include excessive potassium infusion, transfusion of stored blood and potassium-sparing diuretics. Digitalis toxicity is also a possible cause that can be established from the history and measurement of serum levels. The clinical signs are similar to persistent atrial standstill, with the addition of the signs related to the primary condition.
- (3) Atrial standstill can occur in association with a 'dying' heart and is termed **terminal atrial standstill**.

Clinically signs include weakness, lethargy, syncope and congestive heart failure. The prognosis is often poor.

#### Treatment

Atropine usually does not increase the heart rate significantly. Treatment is directed towards congestive failure if present. Persistent atrial

standstill is poorly responsive to any medication, including atropine and also rarely responds to pacemaker implantation (in the author's experience).

## **AV (heart) block**

### **First degree AV block**

#### *Clinical significance*

First degree block does not, in itself, cause any clinical problems. It may occur normally in an animal with a slow heart rate or in ageing animals due to degenerative changes in the AV node. Other causes include digitalis toxicity or other drugs such as propranolol. It may occur when there is an abnormal potassium level. Treatment should be aimed at correcting the underlying cause.

### **Second degree AV block**

#### **Mobitz type II**

#### *Clinical significance*

Advanced cases of second degree AV block may present with weakness, lethargy or syncope; it depends on the severity of the heart block and the consequent reduction in cardiac output. Auscultation reveals an intermittent pause in the cardiac rhythm. Second degree AV block that is severe or advanced (meaning the block occurs frequently) is usually Mobitz type II. It is this type that may progress to complete AV block. It has been reported in older dogs with AV nodal fibrosis and hereditary stenosis of the bundle of His in the Pug, however many cases are idiopathic. It may also occur with digitalis toxicity or other drugs, e.g. xylazine, detomidine, atropine and quinidine, or with a potassium imbalance. The author is also aware of some anecdotal reports of heart block in hypothyroid dogs.

#### *Treatment*

See complete heart block below.

#### **Mobitz type I**

#### *Clinical significance*

Second degree AV block (Mobitz type I) is sometimes seen in normal dogs with sinus arrhythmia, particularly brachycephalic breeds.

### **Complete heart block**

#### *Clinical significance*

The clinical signs may include weakness, lethargy, syncope or sudden death, depending on how slow the ventricular rate is, and the subsequent reduction in cardiac output. A very slow ventricular escape rhythm is usually associated with more marked clinical signs, with the possibility of sudden death. It is common in chronic cases, with a slow ventricular response rate, to find a generalised cardiomegaly with or without evidence of congestive heart failure on thoracic radiography. On auscultation a characteristic finding is a very regular and steady, but slow heart beat together with the palpation of a hyperdynamic femoral pulse. In some cases the more rapid atrial contraction sounds may be faintly audible. Complete AV block can be associated with cardiomyopathy, cardiac neoplasia, digitalis toxicity, AV node fibrosis, endocarditis, electrolyte imbalance and Lyme disease.

#### *Treatment*

Treatment may be attempted with parasympatholytic drugs (atropine, probantheline) or sympathomimetic drugs (clenbuterol, terbutaline). Millophyline may be of some help in cats, or



theophylline in dogs. Pimobendan might also be tried, as this is a positive dromotrope.

In many cases however, pacemaker implantation is necessary to provide symptomatic relief and reduce the risk of sudden death.

### Drug doses

#### *Parasympatholytic drugs*

- Atropine: dog/cat: 20–60 µg/kg q6–8 hr *per os*
- Probantheline: dog: 0.5–2 mg/kg q8–12 hr; cat: 7.5 mg q8–12 hr *per os*

#### *Sympathomimetic drugs*

- Clenbuterol: dog: 1–5 µg/kg q8–12 hr; cat 1 µg/kg q12–24 hr
- Terbutaline: 1.25–5 mg per dog q8 hr; 1.25 mg per cat q8 hr

## Bundle branch block

### Right bundle branch block

#### *Clinical significance*

The right bundle branch (RBB) is long and slender, thus vulnerable to damage. RBBB is not uncommon in normal healthy dogs but can be associated with congenital or acquired heart disease, cardiac neoplasia and trauma. RBBB, in itself, does not cause any significant haemodynamic problems, however, if damage to the left bundle branch were also to occur it would lead to complete heart block.

### Left bundle branch block

#### *Clinical significance*

The left bundle branch is thick and therefore a larger lesion is required to produce conduction block. LBBB is therefore rare in normal healthy animals and when it does occur it is often associated with pathology: congenital (e.g. subaortic stenosis) or acquired heart disease (e.g. hypertrophic or dilated cardiomyopathy), myocardial ischaemia, cardiac neoplasia or trauma. In itself, it does not cause any significant haemodynamic problems.

### Left anterior fascicular block

#### *Clinical significance*

It is often considered a relatively specific indicator of left ventricular myocardial disease in the cat and can be seen with many heart diseases. It can be associated with hypertrophic or restrictive cardiomyopathy, and electrolyte imbalance such as hyperkalaemia.

## Tachyarrhythmias

### Sinus tachycardia

#### *Clinical significance*

Sinus tachycardia is a non-specific rhythm disturbance. Although it is often seen in heart failure, caused by a compensatory sympathetic drive, it is often due to a physiological response such as stress, excitement and fear. Thus, it is of paramount importance to evaluate the 'state' of the patient – which during an ECG recording may, of course, cause a degree of stress and fear! Comparing the heart rate obtained during physical examination, when the animal is relaxed, is therefore invaluable in assessing its significance. Sinus tachycardia

can also be as a result of a disease process such as pyrexia, pain, anaemia, shock, dehydration, haemorrhage, septicaemia, toxæmia or hyperthyroidism. Current medication, sedatives or anaesthetics should also be taken into consideration.

### *Treatment*

This should be aimed at the primary cause, usually negating the need to use antiarrhythmic drugs. Note: in animals in congestive heart failure, a sinus tachycardia is often a necessary compensatory response in an attempt to maintain cardiac output. Thus antiarrhythmic drugs are generally not used to slow the heart rate – treatment is directed towards the congestive failure following which the heart rate then slows as sympathetic drive reduces.

## **Ventricular arrhythmias**

### *Clinical significance*

Infrequent VPCs do not generally compromise the cardiac output and, therefore, often do not require treatment (treatment should be directed towards the underlying cause). However, with a rapid VT there is a marked reduction in cardiac output and animals may present with exercise intolerance, lethargy or collapse.

VPCs may:

- occur due to primary heart disease such as cardiac neoplasia, cardiomyopathy (particularly in Dobermanns and Boxers), myocarditis (e.g. traumatic myocarditis/contusion), endocarditis or
- be secondary to a systemic disorder (see also accelerated idioventricular rhythm) such as gastric dilation, pancreatitis, splenic masses, electrolyte imbalance, uraemia, pyometra and low blood oxygen saturation (e.g. hypoxia associated with congestive heart failure or respiratory diseases). Drugs such as digitalis, anaesthetics, atropine and isoprenaline may also produce VPCs.

VT, multiform VPCs and ventricular bigeminy are usually associated with severe underlying heart disease or a systemic disorder. R-on-T is believed to lead potentially to the development of ventricular fibrillation and sudden death. Therefore it is considered an important finding that would warrant management of the associated ectopia.

### *Treatment*

Treatment of the primary underlying cause (e.g. congestive heart failure) will often produce a significant reduction in VPCs, thus in many cases institution of antiarrhythmic drugs should be postponed to see if this occurs.

A ventricular arrhythmia is considered significant when it causes haemodynamic compromise and thus signs such as: pallor, exercise intolerance, systemic hypotension, weakness / recumbency, syncope.

True frequency of serious arrhythmias may only be detected by 24 hour Holter monitoring.

- <200 VPCs per 24 hours is considered a low frequency.
- >1000 VPCs per 24 hours is considered a high frequency.

In Dobermanns, a sustained ventricular tachycardia (VT) >30 seconds is considered a predictor of sudden death.

### **Indications for antiarrhythmic drug treatment of ventricular arrhythmias**

- Frequent multimorphic VPCs
- VPCs with a very short coupling interval, i.e. R-on-T
- VPCs frequently in pairs and triplets
- Rapid sustained VT (>200/min)
- Frequent VPCs or VT in Boxers and Dobermanns (with cardiomyopathy)
- VT with inherited ventricular arrhythmias of German Shepherd dogs (less than 18 months of age).

The aims of antiarrhythmic drug treatment are to reduce the risk of sudden death and/or improve clinical signs. However some studies have shown that antiarrhythmic drugs have the potential to cause sudden death (i.e. proarrhythmic), thus their use needs strong justification. In most circumstances institution of antiarrhythmics orally is satisfactory. If VPCs are life threatening i/v lidocaine is the drug of choice (see boxed text below).

### Lidocaine (lignocaine)

- Drug of choice for the cardioversion of acute life-threatening ventricular tachycardia.
- Its effects are nullified in the presence of hypokalaemia.
- Following i/v administration the half life is approximately 60–90 minutes but antiarrhythmic effects wane after 10 minutes.

### Dosage

- Dog: i/v dose at 2–3 mg/kg boluses, every three minutes, max. of 9 mg/kg in 20 minutes
- Cat: Slow i/v at 0.25–0.75 mg/kg, may give a repeat i/v injection after 20 minutes.

### Toxicity

Note: cats are very prone to toxicity (seizures and respiratory arrest).

- Signs of toxicity are neurological (twitching, nystagmus, seizures), these are usually self limiting and gastrointestinal (nausea, vomiting, salivation).
- Airway obstruction and/or respiratory arrest in cats following seizures.
- Control seizures with i/v diazepam – 0.1 mg/kg i/v, repeat every few minutes to effect (max. 0.3 mg/kg) + elevate head.

Following cardioversion of a ventricular arrhythmia with lidocaine, the options are as follows.

- Wait and see if the arrhythmia does return (in which case repeat cardioversion is required).
- Administer i/v lidocaine as a constant rate infusion.

Usual starting dose is 50 µg/kg/min.

Note: steady state levels take 3 to 6 hours to reach and thus small boluses of lidocaine may be required in the interim.

- Medicate with an oral antiarrhythmic such as mexiletine (which seems a pragmatic approach).
- If i/v lidocaine proves ineffective then alternative i/v options are esmolol and procainamide.

### Oral medications

Note: most antiarrhythmic drugs have a negative inotropic effect and should be used with caution in dogs with myocardial failure.

Response to treatment can be assessed from Holter monitoring pre and post treatment. A significant response to antiarrhythmic drug is considered to be a reduction in VPCs by 75% when the VPCs are frequent.

Mexiletine is one of the most common antiarrhythmics used in dogs. It is recommended for VT in the inherited ventricular arrhythmia of German Shepherd dogs (+/– atenolol or sotalol). It has similar properties to lidocaine, thus if lidocaine cardioverts an arrhythmia, mexiletine is often effective.

However there are other drug options – see text box below. Beta blockers are the drugs most commonly used to control ventricular arrhythmias in cats.

**Oral ventricular antiarrhythmic drugs**

- Mexiletine – dog: 5–8 mg/kg q8 hr *per os*
- Propranolol – dog: 0.2–2.0 mg/kg q8 hr; cat: 2.5 mg q8–12 hr
- Atenolol – dog: 0.5 mg/kg q12 hr; cat: 2 mg/kg q12–24 hr
- Sotalol – dog: 0.5–2.0 mg/kg q12 hr (often used in Boxers with VT)
- Amiodarone (dogs)
  - reported to have significant side effects, so tends to be used as a last resort
  - need to monitor liver and thyroid function regularly
  - loading dose: 10 mg/kg q12 hr for 1 week
  - maintenance dose: 5–10 mg/kg q24 hr
- Magnesium amino chelate (200 mg tablets) at 10 mg/kg daily with food

**Ventricular arrhythmias associated with GDV**

Approximately 40 to 50% of dogs with gastric dilation-volvulus (GDV) develop ventricular arrhythmias, 12 to 72 hours after the onset of GDV.

It is caused by:

- Myocardial ischaemia (decreased coronary perfusion)
- Reperfusion injury
- Hypokalaemia (can also make the arrhythmias resistant to anti-arrhythmic drugs)
- Acidosis
- Hypoxia
- Myocardial depressant factors

Treatment is therefore directed towards:

- the shock and maintenance of normal hydration status;
- correction of acid-base and electrolyte imbalances;
- monitoring Na and K regularly in such cases is very useful as hypokalaemia is a common problem (although measurement of serum K may not reflect total body K).

**Accelerated idioventricular rhythm***Clinical significance*

This is most commonly not associated with primary heart disease, but non-cardiac medical reasons, such as: splenic disease / neoplasia, gastric dilation or volvulus, pancreatitis, prostatitis, trauma or neurological disease. Treatment is directed towards to non-cardiac disease, and rarely if ever, are antiarrhythmics used to cardiovert the idioventricular rhythm.

**Supraventricular arrhythmias***Clinical significance*

Infrequent SVPCs do not generally compromise the cardiac output and therefore often do not require treatment (treatment should be directed towards the underlying cause). However, with a rapid SVT there is a significant reduction in cardiac output and animals may present with exercise intolerance, lethargy, episodic weakness or recumbency.

SVPCs can be due to:

- atrial disease, e.g. dilation/stretch secondary to AV valve regurgitation (associated with congenital and acquired AV valve disease,

cardiomyopathy, congenital cardiac shunts), right atrial haemangiosarcoma or

- be secondary to some systemic illness including hyperthyroidism in cats, or a side effect of some drugs, e.g. digitalis toxicity or 'stimulant'-type drugs.

Clinical signs can be caused by very frequent SVPCs or sustained SVT, and include: weakness, ataxia (presyncope), collapse and tachypnoea. Signs are more severe when there is underlying organic heart disease. When an SVT is maintained at a high rate (>250/min) for days or weeks it can result in tachycardia-induced myocardial failure and congestive heart failure (this mimics dilated cardiomyopathy).

### Treatment

Treatment should be directed to any underlying disease first, particularly when there is organic heart disease.

The aims of treatment are:

- SVT – cardiovert to a normal sinus rhythm and maintain rate control;
- SVPCs – reduce frequency, if very frequent and necessary.

Vagal manoeuvres such as carotid sinus massage (up and down moving pressure applied behind the angle of the jaw for 10 seconds):

- may terminate an SVT;
- may slow an SVT and help identify the type of arrhythmia;
- may be ineffectual when animals have a high sympathetic tone, such as when they are nervous or in heart failure;
- may work better after administration of beta blockers or calcium channel antagonists.

A precordial thump to the left apex beat may:

- produce a VPC and thus a break in the SVT, although it may sometimes be brief, it can help to determine the underlying rhythm.

In a dog with sustained SVT or collapse, i/v cardioversion is necessary – see boxed text below.

#### Intravenous supraventricular antiarrhythmic drugs

- Verapamil – calcium channel antagonist (often the conventional first drug of choice)
  - Dose in dog: 0.05 mg/kg i/v every five minutes to effect (max. 0.15 mg/kg in 10–15 minutes)
- Esmolol – short acting beta blocker with a half life of 9 minutes
  - Dose in dog: 0.25–0.5 mg/kg i/v over 1 minute
- Lidocaine – may have effects on some macroreentrant SVTs and worth trying if other drugs fail (this is often the author's first drug of choice for a re-entrant SVT and, if effective, mexiletine then administered orally).
  - 2–3mg/kg, repeated every 3 minutes to response, up to a max of 9 mg/kg
- Procainamide – 2 mg/kg i/v, repeated to response, up to a max of 15 mg/kg in 20 minutes

#### Oral supraventricular antiarrhythmic drugs

- Calcium antagonist
  - Diltiazem – dog and cat: 1–3 mg/kg q8 hr
  - Verapamil – dog: 1–3 mg/kg q8 hr
- Beta blockers
  - Atenolol – dog: 0.25–2 mg/kg q12 hr
  - Propranolol – dog: 0.2–2 mg/kg q8 hr

Note: when stopping beta blockers, they need to be weaned off slowly.

- Digoxin (drug of choice if there is ventricular myocardial failure)
  - Onset of action is too slow
  - Dose: see under Atrial fibrillation
- Sotalol
  - Dose in dog: 0.5–2 mg/kg q12 hr
- Amiodarone (dog)
  - Reported to have significant side effects, so tends to be used as a last resort
  - Need to monitor liver and thyroid function regularly
  - Loading dose: 10 mg/kg q12 hr for 7 days
  - Maintenance dose: 5–10 mg/kg q24 hr

## Ventricular pre-excitation

### *Clinical significance*

Ventricular pre-excitation itself is not haemodynamically significant, however WPW syndrome may cause weakness or syncope, as the very rapid tachycardia is associated with marked reduction in cardiac output. Pre-excitation may be present as a congenital lesion with or without organic heart disease.

## Fibrillation and flutter

### Ventricular fibrillation (VF)

#### *Clinical significance*

Death usually ensues unless rapid electrical defibrillation with cardiopulmonary resuscitation is initiated. However, the success of this

will depend on the extent of existing pathology. The causes are numerous, but not dissimilar to those of VPCs and VT.

## Atrial fibrillation

### *Clinical significance*

Atrial fibrillation usually occurs as a result of underlying organic pathology, i.e. dilation of one or both atria. Dilation and stretching of one or both atria is most commonly seen in medium- to large-breed dogs with dilated cardiomyopathy. However, it can occur in any breed of dog associated with atrial stretch secondary to AV valve incompetence, congenital cardiac shunts, heart base tumours and sometimes following rapid drainage of a pericardial effusion. It is uncommon in the cat, but is sometimes seen when there is severe left atrial dilation with hypertrophic or restrictive cardiomyopathy. Atrial fibrillation does not have major haemodynamic effects. The loss of the atrial contraction contribution to cardiac output is approximately 10–20%, which is compensated for primarily by an increase in rate.

Atrial fibrillation is sometimes seen in giant-breed dogs with no gross cardiac pathology – referred to as ‘**lone**’ AF. Lone AF usually has a fairly normal ventricular rate (<120 – 130/min), as there is no increase in sympathetic drive since the dogs are not in heart failure. However, many giant-breed dogs with lone AF progress to dilated cardiomyopathy and ultimately heart failure. Beta blockers may be useful to minimise tachycardia during periods of high sympathetic tones such as exercise or stress and may have long-term benefits (upregulation of beta receptors) in occult dilated cardiomyopathy.

### *Treatment*

Cardioversion of atrial fibrillation to sinus rhythm is generally not attempted because there is usually cardiac pathology. The drug of choice for rate control of AF is usually digoxin, because of its mild positive

Table 13.1. Digoxin starting dose in dogs.

Body weight	Tablet size	Tablet dose
1–5 kg	62.5 µg (PG)	$\frac{1}{2}$ q12 hr
6–13 kg	62.5 µg (PG)	1 q12 hr
14–23 kg	125 µg	1 q12 hr
24–36 kg	125 µg	$1\frac{1}{2}$ q12 hr
>37 kg	250 µg	1 q12 hr

Note: Doberman dose is 125 µg tablet 1 q12 hr.

inotropic properties. If there is good myocardial function, then calcium antagonists or beta blockers are alternative options – however these should be used with caution in dogs with myocardial failure.

#### Use of digoxin for rate control of AF

It is primarily used in dogs; indications for use in cats are rare.

- Dose in dog = 0.22 mg/m<sup>2</sup> every 12 hours, however Table 13.1 provides a simple guideline for a starting dose
- Dose in cat: <4 kg – 0.0625 mg tablet 1/2 q48 hr and >4 kg – 0.0625 mg tablet 1/2 q24 hr

Steady state levels are achieved in 5–7 days. Serum digoxin levels should be measured (approximately 6 hours post pill) to confirm the dose is correct, as it varies between individual patients. Therapeutic dose range is 0.8–2.5 ng/ml; 1–2 ng/ml is a good target. Therapeutic aims are to reduce the heart rate (at rest and non-stressed) to less than 150–160/min in dogs and less than 240/min in cats. Assessment of the heart rate in-clinic may result in falsely high heart rates, so clinical judgement needs to be made or Holter monitoring considered. Causes of a persistent high heart rate are listed in the boxed text below.

#### Causes of a persistently high heart rate in dogs with atrial fibrillation receiving digoxin

- Elevation of the heart rate in-clinic due to nervousness at the time of examination – may require 24 hour Holter to determine average heart rate at home
- Inadequate control of the congestive failure signs – sympathetic drive is still high
- Dehydration / Hypotension due to over diuresis / vasodilation
- Inadequate serum therapeutic levels of digoxin
- Concurrent medical disease, e.g. renal failure
- Advanced myocardial failure and end stage heart disease
- Heart rate poorly responsive to digoxin (check with 24 hour Holter) – may require additional antiarrhythmic drugs

Bioaccumulation may occur with: an azotaemia, low serum albumin, cachexia. Signs of overdose are: depression, anorexia, vomiting/diarrhoea, arrhythmias, in which case the drug should be stopped and re-introduced at a lower dose when signs have completely resolved.

#### Atrial flutter

##### *Clinical significance*

The consequence is the effects of a sustained SVT for which rate control is required. Cardioversion of atrial flutter can be difficult; i/v procainamide is considered a reasonable option in attempting to convert the atrial flutter. Atrial flutter can be associated with atrial disease, such as dilation, or may be a primary reentrant tachyarrhythmia. Treatment with flecainide or amiodarone can be tried.

## 14 • Pacemakers

Pacemakers have become recognised as an effective and worthwhile treatment of many bradyarrhythmias in symptomatic animals. Whilst the technique of implantation appears relatively simple, studies have shown a significantly reduced complication rate when performed by experienced personnel, primarily in specialist centres. However it is still important for practitioners to be aware of the indications and the pros and cons when discussing the possibility of a pacemaker with their client.

### Indications

Symptomatic bradyarrhythmias such as:

- complete AV block;
- 2nd degree Mobitz type II, persistent or intermittent;
- 2nd degree Mobitz type I, with symptoms;
- profound sinus bradycardia, with symptoms;
- sinus arrest;
- ‘tachy–brady’ sick sinus syndrome, when anti-tachyarrhythmia drugs produce symptoms;
- AF or flutter with a slow ventricular response (i.e. AV block) and symptoms (rare in dogs and cats);
- persistent atrial standstill.

### Contraindications

- Active infection
- Dilated cardiomyopathy
- Cardiac neoplasia

Note: bradyarrhythmia can occasionally be an early sign of cardiomyopathy and the long-term prognosis is poor due to the underlying heart disease.

### Disadvantages

The disadvantages are:

- cost;
- the owner needs to bring the dog for regular follow-up examinations and programming checks;
- there are potential risks (see below).

### Complications

Complications are significantly less with cardiologists experienced in implantation (>20 implants).

- Major complications are:
  - lead dislodgement;
  - pacemaker failure, e.g. premature battery death;
  - anaesthetic related death – reduced by preplacement of a temporary pacing lead, prior to induction of anaesthesia;
  - infection of pulse generator/pouch;
  - lead fracture;
  - venous thrombosis and chylothorax in cats.
- Minor complications are:
  - seroma formation;



- muscle twitch;
- induced arrhythmias;
- pacemaker movement (twiddler’s syndrome).

### Prior diagnostics

- Diagnostic ECG confirming cause of symptoms
- Comprehensive blood profile: haematology and biochemistry with electrolytes and thyroid screen
- Chest radiographs and echocardiography to screen for organic heart disease (e.g. neoplasia or DCM)
  - X-rays: check for congestive failure (pulmonary oedema), which may require treatment prior to anaesthesia
  - Echocardiography: check for persistent left cranial vena cava (if lead placement is via left jugular)

### Equipment

- Pacemaker
  - This contains electronic circuitry with lithium battery power source; last 5–10 years. The unit is hermetically sealed in titanium housing.
- Leads: unipolar or bipolar leads
  - Unipolar lead: the cathode (negative) is at the distal tip and the anode (positive) is the pacemaker.
  - Bipolar lead: the anode is 1 cm proximal to the cathode, in the form of a ring electrode. It is less sensitive to myopotential inhibition, and less prone to cause muscle twitch.
- Tined (passive) and screw-in (active) leads are available; there appears to be few advantages of one over the other.
- Pacemaker system programmer/analyser – these are different for every manufacturer; thus the assistance of a local hospital ECG technician is essential.

- The lead position is guided by fluoroscopic image intensification.
- External temporary pacemaker – this is used to assess the minimum amount of current required to stimulate the ventricle hence indicating good electrode to endocardial contact.
- Post-surgical protective bandages – these prevent the dog scratching out sutures and introducing potentially lethal infection.

### Types of permanent pacemakers

#### *Pacemaker modes and identification*

These have been classified by a universal lettering code. There are fourth and fifth letters (programmability and anti-tachyarrhythmic functions) that are not currently relevant to veterinary use.

Table 14.1. Universal lettering code for pacemakers.

First letter	Second letter	Third letter
Chamber paced	Chamber sensed	Pacing mode
V = ventricle	V	I = inhibited
A = atrium	A	T = triggered
D = dual	D	D = atrial triggered and ventricular inhibited
	O = none	O

#### *Requiring one ventricular lead*

- VVI, paces and senses only in ventricles; inhibited by intrinsic ventricular beats (demand pacemaker). This is the most commonly used type in animals.
- VVIR – additionally rate responsive (increased in rate) on detection of movement.

- VVI and VVIR are the common modes used in animals, as it requires only one lead.
- VDR – one lead, paces and senses the ventricle, but additionally there are sensors at atrial level, thus one can track P waves (in AV block) and pace ventricles following each P wave, thus providing atrioventricular synchrony and sinus node rate control. However available human leads are only suitable for very large breed dogs.
- VVT, paces and senses in ventricles, sensed event triggers stimulus.

### *Requiring dual chamber pacing*

- DDD = paces in either atrium or ventricle or both; senses in both; response can be inhibition of either chamber, or stimulation of atrium (demand pacemaker).

### *Rate responsive pacemakers*

- These are designed to increase in rate with the activity of the animal. Thus they are suitable for working dogs. The side effects are an undesirable increase in rate with vehicle movement.
- Other sensors under investigation include: oxygen saturation, pH, central body temperature, and respiratory rate (not suitable for dogs, due to the phenomenon of ‘panting’!).

### **Techniques of implantation**

- The transvenous (jugular) route is currently the preferred option. This involves the exposure of an external jugular vein, insertion of

the pacing lead with fluoroscopic guidance, and placing the pulse generator subcutaneously in the dorsal neck. The jugular vein is normally occluded.

- Epicardial lead placement requires direct exposure of the left ventricular apex, and thus surgical intervention (e.g. thoracotomy or laparotomy), but does not require fluoroscopy.

### **Pacemaker follow-up**

- 10–14 days, sutures out, check pacemaker sites for infection/seroma and correct function.
- 3–4 months following implantation, programming check and optimise settings to minimise battery use.
- Thereafter every 12 months, programming check to ensure function and detect evidence of reducing battery life by checking magnet rate.

### **Hazards**

- Pacemakers occasionally sense extrinsic electromagnetic interference (EMI), but with modern units this is minimised by pacemaker designs and shielding. However surgical cautery and MRI are problems.
- Disposal of a carcass: before this can be done, the pulse generator must be removed as cremation of the lithium battery results in explosion.

## **PART 5**

# Recording and interpreting ECGs

## 15 • Approach to interpretation of the ECG recording

It is important to develop, and use, a routine when reading ECGs. Always read an ECG from its beginning, i.e. from left to right. When the ECG is difficult to read, start from the easiest part of the tracing that is recognisable, then continue reading (left to right) from that point.

It is important to not over-read or be too dependent on ECG findings. Since the ECG records only the electrical activity of the heart, it should be remembered that this limits the information that can be gained from it. It is often poorly related to the mechanical function of the heart and does not provide information about aetiology or severity of organic heart disease. A normal ECG does not necessarily infer that the heart is normal and, likewise, an abnormal ECG is not necessarily indicative of heart disease. Additionally, if the ECG is abnormal, it is important to determine what the clinical significance is, and if treatment is indicated or not.

There are essentially four steps in ECG interpretation: rate, rhythm, complex measurement and mean electrical axis (see page 61).

### (1) To calculate the heart rate (given as beats per minute)

This should be fairly easy, as you have already examined the animal and determined the heart rate on auscultation. (!?)

The simplest method of calculating the rate from an ECG is to mark a 6-second strip of a representative part of the tracing. Count

the number of complexes and multiply by 10. If the P wave rate and QRS–T complex rates differ, then record these separately.

### *A method for the mathematician*

If there is not a 6-second strip or there is a short paroxysmal tachycardia, then the heart rate can be calculated from the P–P or R–R interval as follows. At a paper speed of 25 mm/sec there is 1500 mm per minute. Measure the distance, with a ruler, between two complexes (or count the number of small 1-mm boxes).

Heart rate (in beats per minute):

$$\text{HR (at 25 mm/sec)} = \frac{1500}{\text{R - R interval (mm)}}$$

At a paper speed of 50 mm/sec there is 3000 mm per minute, thus:

$$\text{HR (at 50 mm/sec)} = \frac{3000}{\text{R - R interval (mm)}}$$

### (2) Determine the rhythm

Check if the complexes are complete, i.e. that there is a P wave for every QRS–T complex, and a QRS–T complex for every P wave.

### *Identifying parts of the ECG complex*

In some instances it can be difficult to identify P waves, or it can be difficult to determine which are the P waves and which are the T waves (especially at fast heart rates).



- P wave amplitude and duration
- R wave amplitude and QRS duration
- P–R interval – from start of P to start of QRS (strictly therefore a P–Q interval)
- Q–T interval – from start of QRS to end of T wave

- Note T wave morphology
- Note S–T segment elevation or depression

Use the table of normal values (Table 7.1, page 49) to check if the measurements are within normal values or not.

## 16 • Artifacts

Artifacts are abnormal deflections reproduced on an ECG recording that are not associated with the electrical activity of the heart. They have the potential to either mask the ECG or mimic ECG activity: producing an artifact-free tracing is of paramount importance.

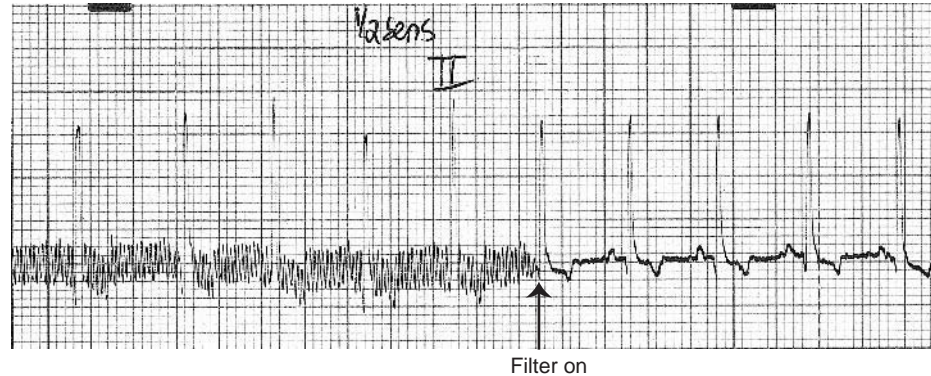
### Electrical interference

Electrical interference produces fine, rapid and regular movements on the baseline of the ECG recording (Fig. 16.1). They are often associated with interference due to electrical cables (electromagnetic

waves) within the room in which the recording is being made. They can be transmitted by the person restraining the animal who acts as an aerial or through the power-line of the ECG machine. The fine deflections usually occur at a rate of 50 per second (Hz) (60 per second in America).

To correct this problem:

- Ensure the clip-to-skin connections are good and are insulated (isolated), poor connections will permit electrical interference to manifest.



**Figure 16.1** (a) ECG showing 50-cycle alternating current interference artifact (which masks the P waves in this example) that has then been removed by filtering (arrow) (25 mm/sec and 5 mm/mV).

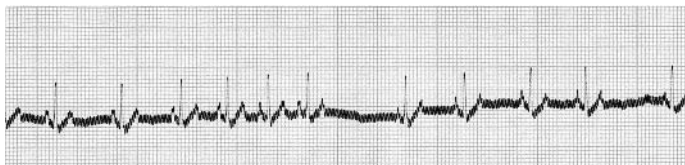


Figure 16.1 (b) ECG showing 50-cycle AC interference throughout the tracing (25 mm/sec and 10 mm/mV).

- Ensure the animal is insulated from the surface by placing a rug under it.
- Ensure the ECG machine is earthed (to the building), or try not to run on the mains supply but on battery.
- Try insulating the handler from the dog by having them wear gloves.

### Muscle tremor artifact

This can look a little similar to electrical interference, but the fine deflections in this instance are not regular but fairly random. It can

be produced by the animal trembling or shaking, or by trying to record the ECG in a standing animal (Fig. 16.2). Purring in a cat (Fig. 16.3) will also result in baseline ‘trembling’!

To correct this problem:

- Ensure the limbs are relaxed and supported.
- Find a position in which the animal will relax best, preferably not standing.
- Try holding the limbs to minimise the tremor.
- To stop a cat purring: dab a little spirit on the cat’s nose using cotton wool.

### Movement artifact

This is a more exaggerated form of tremor artifact, but in this case the deflections are not fine but variable and large. The stylus moves up and down the paper (Fig. 16.4a). It can be associated with respiratory movement (Fig. 16.4b) or if the animal is moving or struggling (Figs. 16.4c, d, e and 16.5).

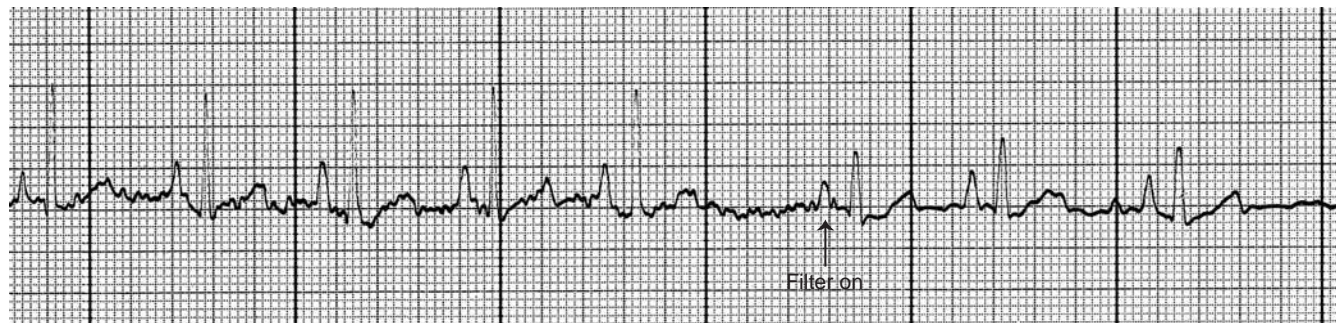


Figure 16.2 ECG showing muscle tremor artifact (see also Fig. 17.16, p. 112), which is then filtered out (arrow). Note the reduction in complex amplitudes when using the filter (50 mm/sec and 10 mm/mV).



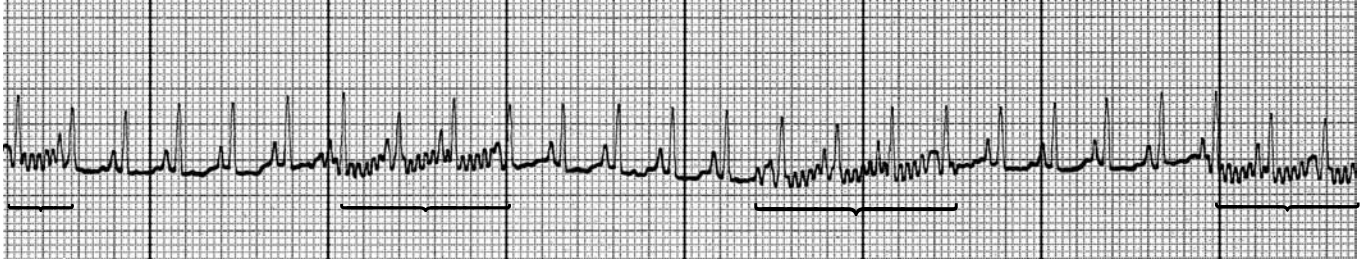


Figure 16.3 ECG from a cat with intermittent 'purring' artifact (brackets) (25 mm/sec and 10 mm/mV).

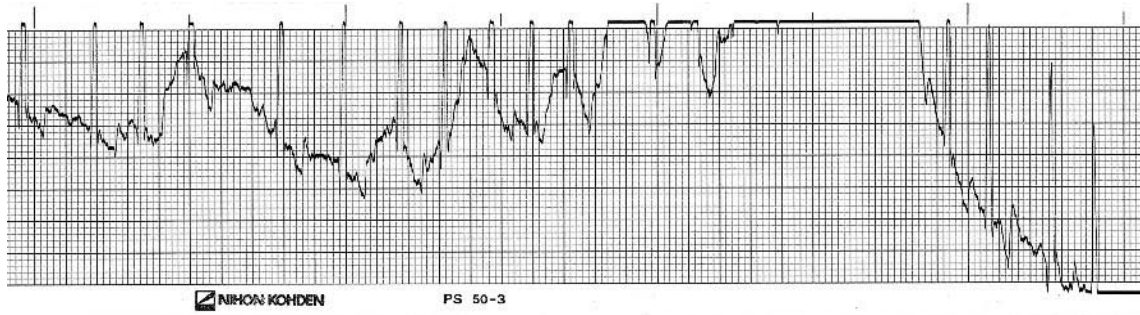


Figure 16.4 (a) ECG showing marked movement of the stylus due to movement or an unstable electrode (25 mm/sec and 10 mm/mV).

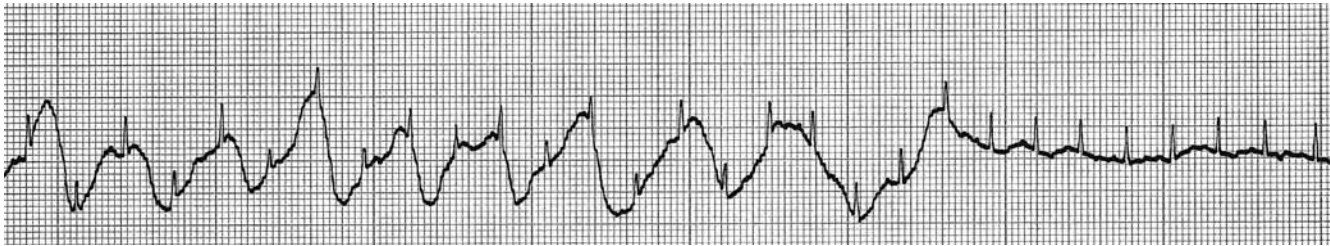

Figure 16.4 (b) ECG showing movement artifact synchronised with panting in a dog, which then stops panting towards the end of the recording (25 mm/sec and 10 mm/mV).

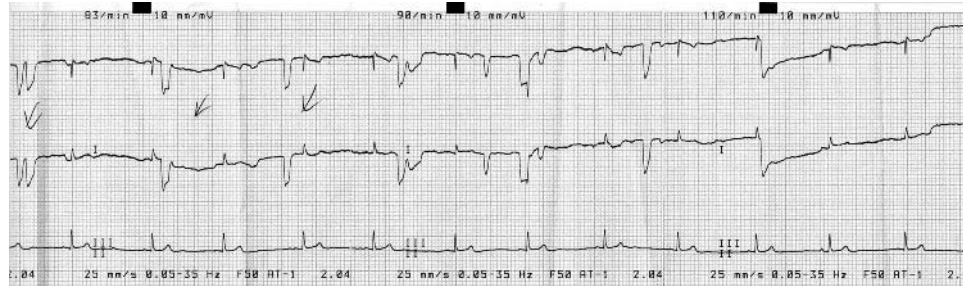

Figure 16.4 (c) ECG from a cat showing intermittent limb movement that mimics VPCs in leads 1 and 2, but, note, not lead 3 (25 mm/sec and 10 mm/mV).

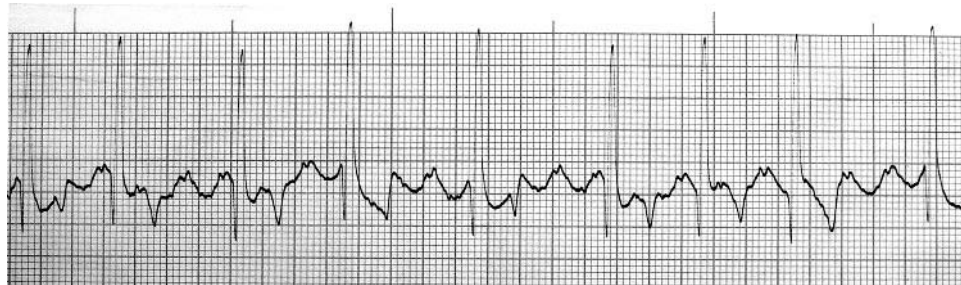

Figure 16.4 (d) ECG from a dog with leg movement and muscle tremor that mimics atrial flutter/fibrillation and makes identification of P waves very difficult (25 mm/sec and 10 mm/mV).

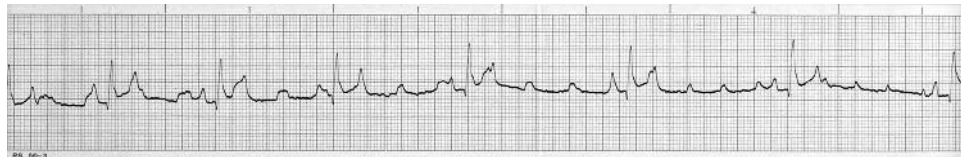
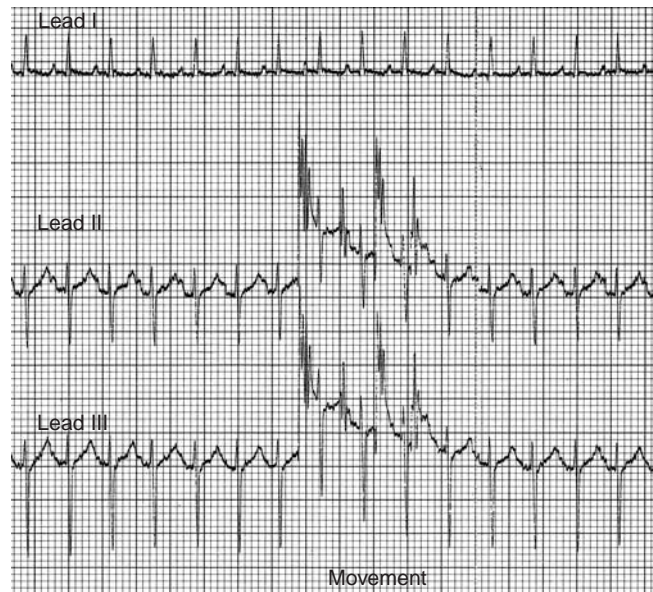
Figure 16.4 (e) ECG from a dog, in which the P-like movement artifacts create an effect that mimics heart block (50 mm/sec and 10 mm/mV).



**Figure 16.5** ECG from a three-channel recording in a cat (with left anterior fascicular block – see Chapter 10). Movement (bracketed) occurred in leads II and III, which can be deduced to be movement of the left hind leg or its electrode – this is the connection that is common to these two leads (25 mm/sec and 10 mm/mV).

To correct this problem:

- Correction of this is similar to tremor artifact.
- Try to get the animal to relax and remain still.
- Ensure the ECG cables are not moving with movement of the animal, e.g. respiratory movement (see Chapter 17), or because the clips are not stable and secure.

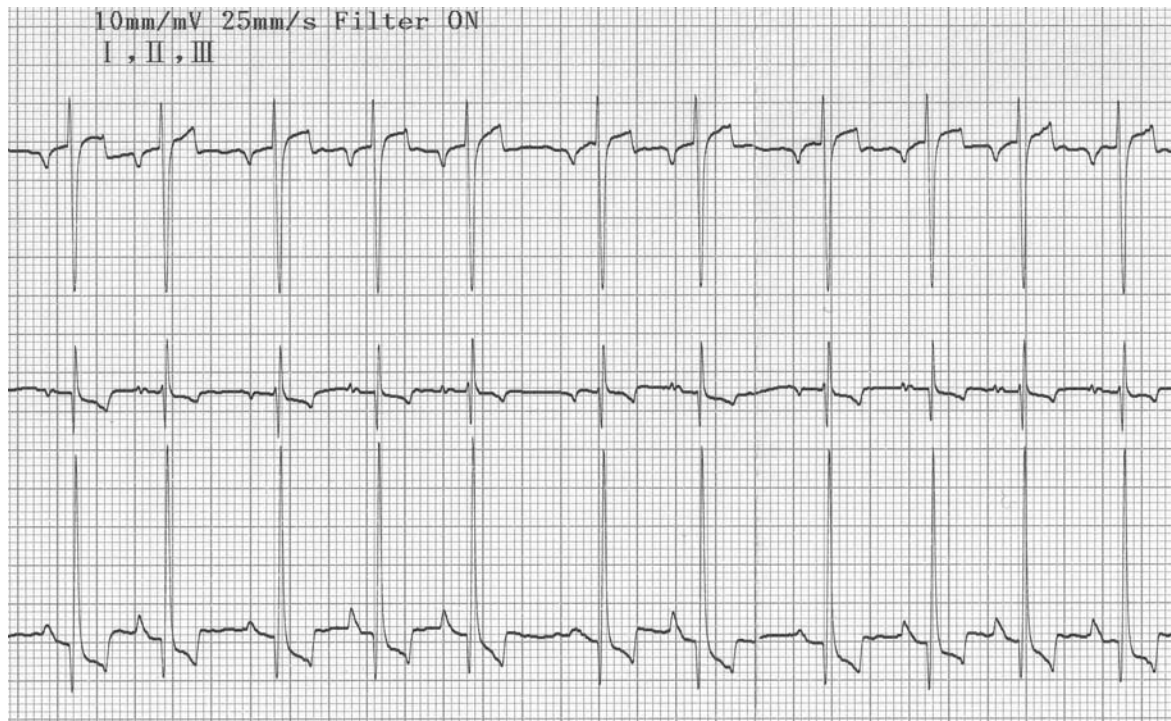
#### *Which leg moved?*

With the aid of Figs 8.1(a–c) one can determine which leg is moving or causing connection problems. For example, if interference is seen

in leads I and II, then the connection that is common to these leads is the right fore. Therefore, this connection needs to be checked and the connection improved or the leg held still. If interference is seen in leads I and III, then the left fore needs to be checked. And if interference is seen in leads II and III (Fig. 16.5), then the left hind needs to be checked.

#### **Incorrectly placed electrodes**

This may result in inverted complexes or a bizarre mean electrical axis (Fig. 16.6).



**Figure 16.6** ECG from a Border Collie in which lead 1 is inverted. Note the negative P waves (as well as the negative QRS complexes). This was because the red and yellow forelimb electrodes were placed back to front. This misplacement of the clip also swaps leads 2 and 3 in effect.

### Tip

P waves are nearly always positive in leads I, II and III. Double check the position of the ECG cables, use the colour code chart in Table 8.1 (page 59) if necessary.

## 17 • Recording an ECG

### The connectors (electrodes)

To connect the ECG cable to the animal's skin requires a connector – this is called an **electrode**. Since animals have a coat of hair, the commonly used human sticky adhesive electrodes (Fig. 17.1) are not convenient for everyday regular use. This is because a patch of hair would have to be shaved, the adhesive electrode applied and it still usually does not stick to animal skin! Therefore, it needs to be held in place by wrapping a bandage around the limb and electrode.

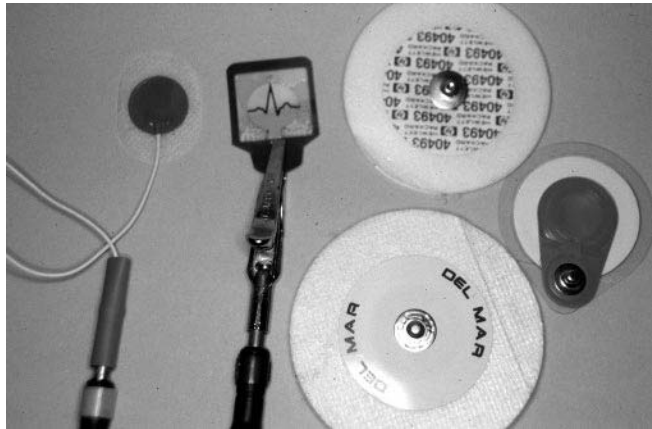


Figure 17.1 A selection of 'human' adhesive electrodes.

There are small metal plate electrodes – paediatric limb electrodes (Fig. 17.2a), that can be used instead of crocodile clips, but they need to be positioned on the limb by means of tape (Fig. 17.2b), bandage or Velcro tie.

The most commonly used electrode to connect the ECG cable to the animal's skin is a crocodile clip (Fig. 17.3). While these provide an excellent electrical connection, their bite can be painful to less stoical animals. To minimise the pain of crocodile clips the teeth can be filed down a little and the clips bent outwards (until they are atraumatic but still stay in place). Or a small conductive plate can be soldered into the tip of the teeth.

### Making the connection

This is the single most important part of ECG recording to obtain a good diagnostic quality tracing. Since crocodile clips are the most commonly used form of electrodes, the following discussion will be based on these. But if you have decided to use an alternative electrode, then adapt the description accordingly.

### Using spirit

It is often sufficient with crocodile clips to pick up a fold of skin between finger and thumb (rolling the skin to feel its edge through a hairy coat) and with the other hand open the crocodile clip maximally, part the hair and attach the clip to the skin (Fig. 17.4). To obtain good conduction between skin and crocodile clip requires the addition of

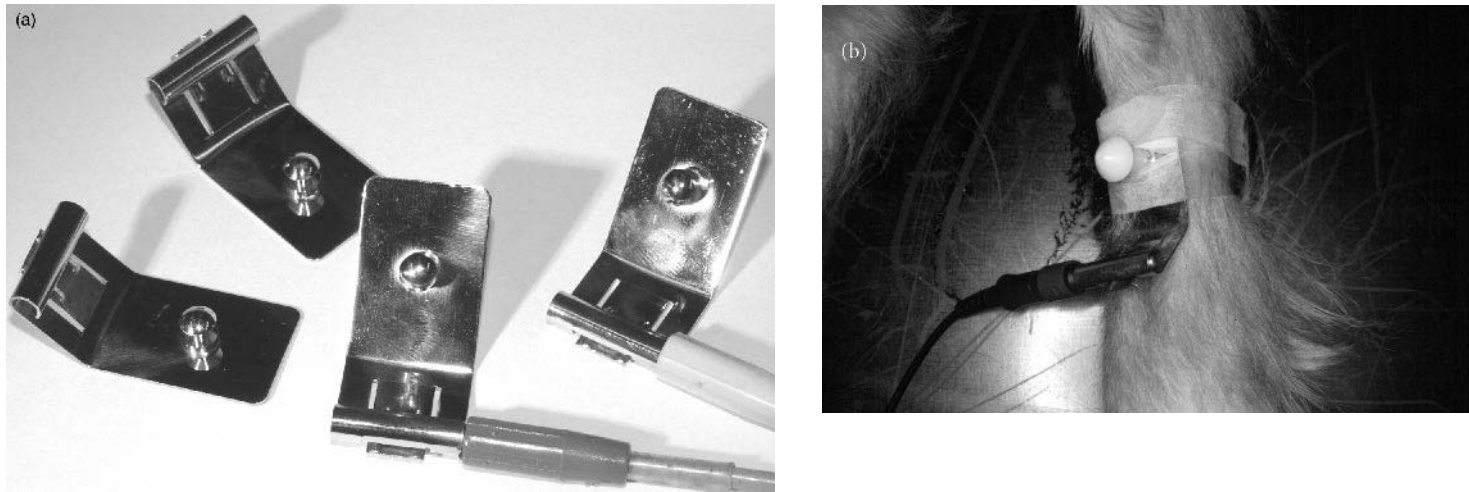


Figure 17.2 (a) ‘Human’ paediatric limb electrodes; (b) how an electrode can be attached with tape to the leg of an animal (the hair usually needs to be clipped to ensure good contact and gel used between the electrode and skin).

a conducting medium – spirit is often adequate. Spray with a little spirit (or alcohol), just sufficient to wet the crocodile clip and through the hair to the skin.

However, spirit evaporates after 5–10 min, so this method would not suffice if the ECG recording takes longer than this (such as during anaesthetic monitoring). Additionally, if spirit does not produce a good-quality, artifact-free recording, then an alternative method needs to be considered.

### *Using gel*

Shave the site where the crocodile clip is to be placed. Either: (1) rub a little gel (ECG gel is ideal, but ultrasound gel or K-Y jelly are

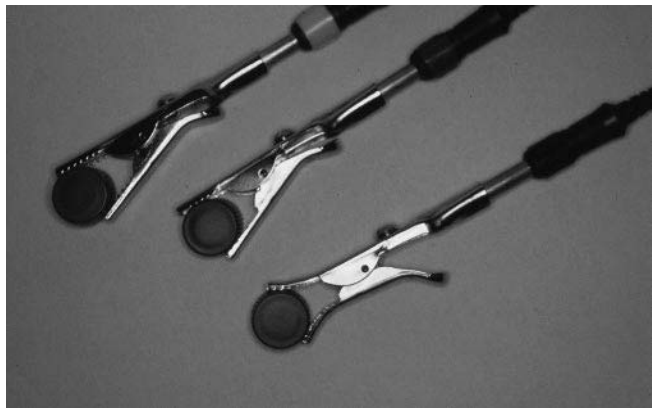cheap alternatives) on to the skin (Fig. 17.5) and then attach the crocodile clip as above; or (2) attach the crocodile clips then rub the gel on the clip and around it onto the skin (Fig. 17.6). This ‘way round’ is usually easier, as your fingers are not too slippery to open the crocodile clips thereafter!

### **Where to place the electrodes**

In each animal you need to pinch the skin at various sites on the limbs, preferably with little hair, to find the best site.

#### *Forelegs*

In the author’s experience, the flexor angle of the elbow is a useful site (Fig. 17.7).



**Figure 17.3** Crocodile clips commonly used in animals. The middle one has had its teeth filed down and the lower one also bent outwards – these are methods of softening the bite on this type of electrode.

An alternative site is caudal and just dorsal to the elbow. However, since this is close to the chest, respiratory movement can result in movement of the cable and clip, thus the ECG recording may be spoiled by movement artifact. Another site is halfway between the elbow and carpus, on the palmar aspect of the leg.

### *Hind legs*

In the author's experience, the flexor angle of the hock (or sometimes just above this) is a useful site (Fig. 17.8). Alternative sites are either above or below the knee, on the dorsal aspect of the limb.

### *When using adhesive electrodes*

Adhesive electrodes usually need to be held in place by a bandage, therefore shave sites on the forelegs above the carpus and on the hind legs above or below the hock (Fig. 17.9).

Adhesive electrodes can also be placed on the central pad (of the paw) in small animals (Fig. 17.10) – this provides a satisfactory site of contact, although instability of the electrode can result in some movement artifact. This can be a useful site in other domestic small and exotic animals seen by the veterinary practitioner.

### **Isolating the electrodes**

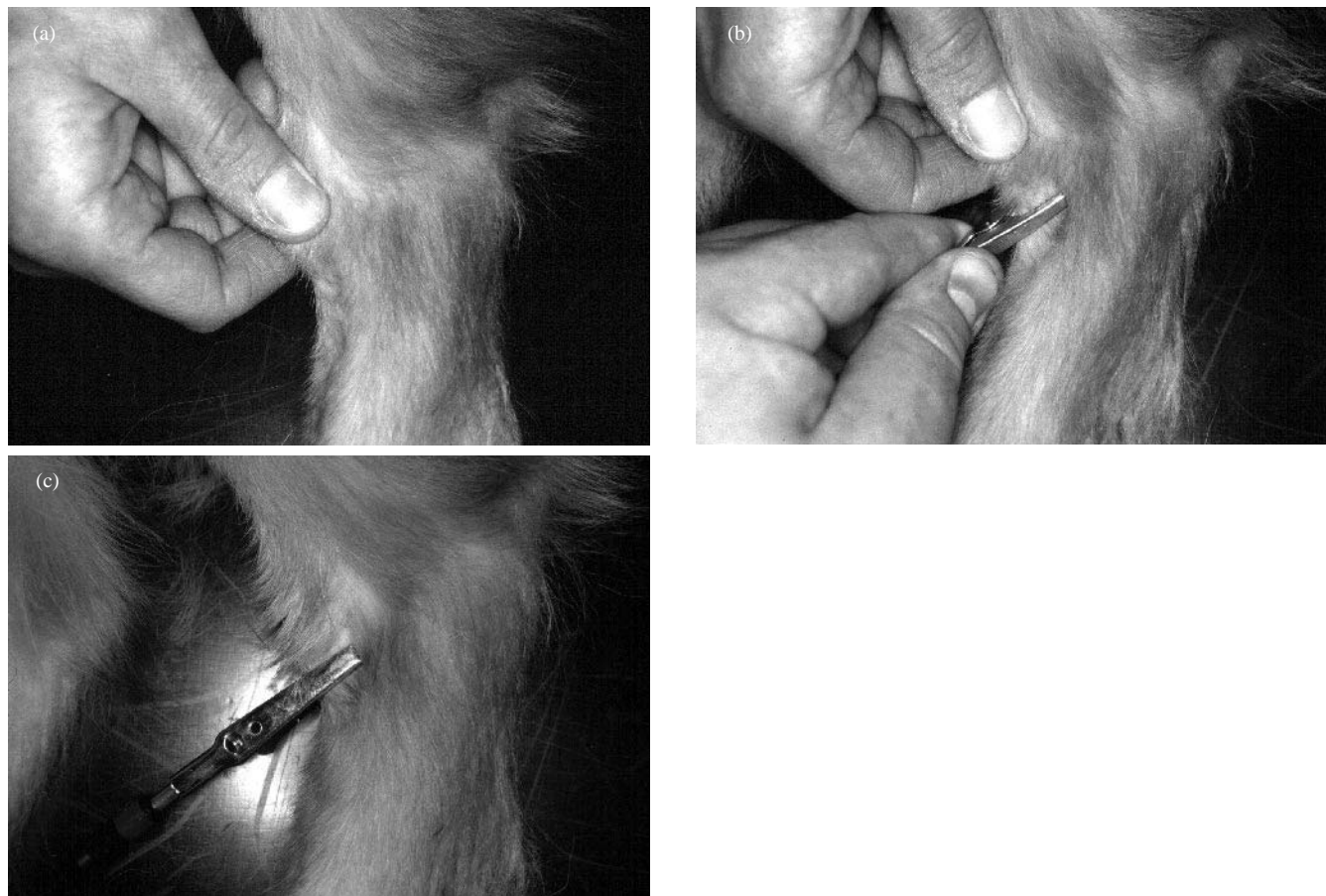
Once all the electrodes have been attached it is essential to ensure that each electrode, the skin to which it is attached and the conducting medium (e.g. the spirit or gel), are not touching any other part of the animal, the handler or the table. This has the potential to cause electrical shorting and introduce artifacts into the ECG recording.

### **How to position the ECG cables**

In addition to the above, it is prudent not to place the crocodile clips such that the ECG cable runs over the animal, which can lead to respiratory movement artifact (as mentioned above) or to then twist the cable and ultimately the clip and skin – even stoical animals may not tolerate this. When applying the crocodile clip have the ECG cable positioned away from the animal (Fig. 17.11) and resting on the table (or ground).

### **Positioning the animal**

To minimise the electrical activity of skeletal muscles the animal must be relaxed and resting. If the animal trembles, shakes, pants or purrs, then all this activity will be manifest on the ECG, resulting in baseline artifact. This may hide small ECG complexes such as P waves, especially in cats, or mimic ECG activity. Thus a good-quality



**Figure 17.4** Placing a crocodile clip to the skin of a dog (flexor angle of hock in this instance). Pinch a good piece of skin (a), position the crocodile clip with its jaws fully open and over the skin as far as possible (b), so that the clips maintains a good bite of skin (c) and therefore good clip–skin contact.



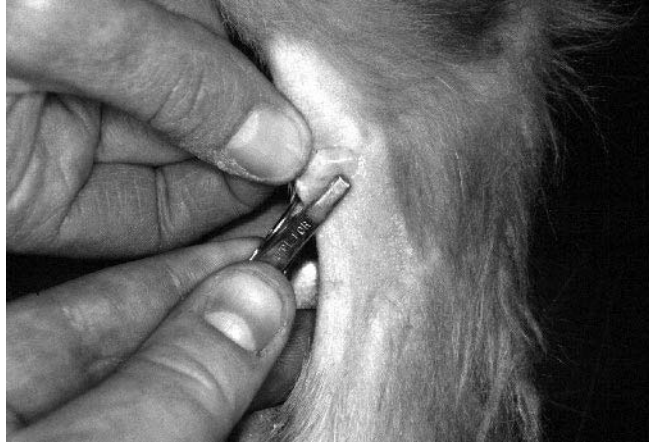

Figure 17.5 Gel can be applied to the skin before placement of the crocodile clip.

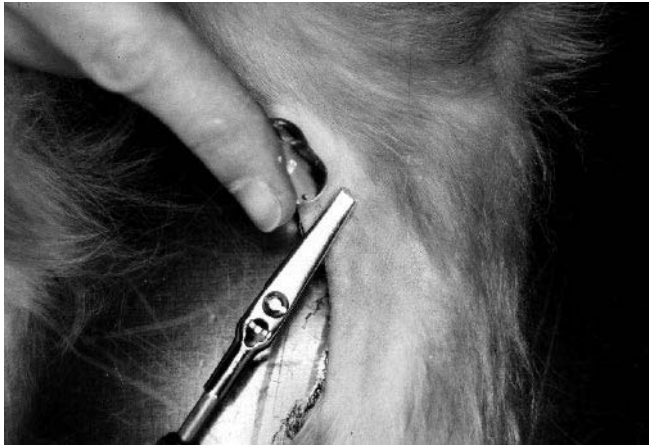

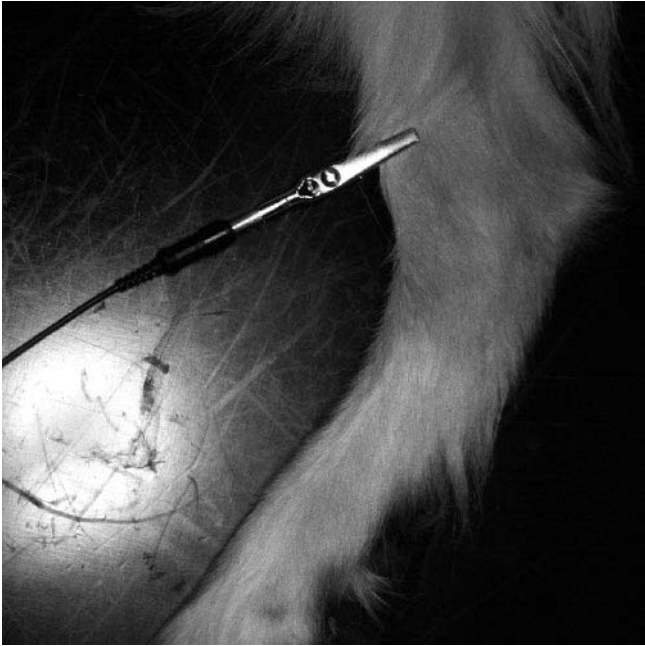
Figure 17.6 Alternatively gel can be applied after the crocodile has been attached, over the clip and adjacent skin.

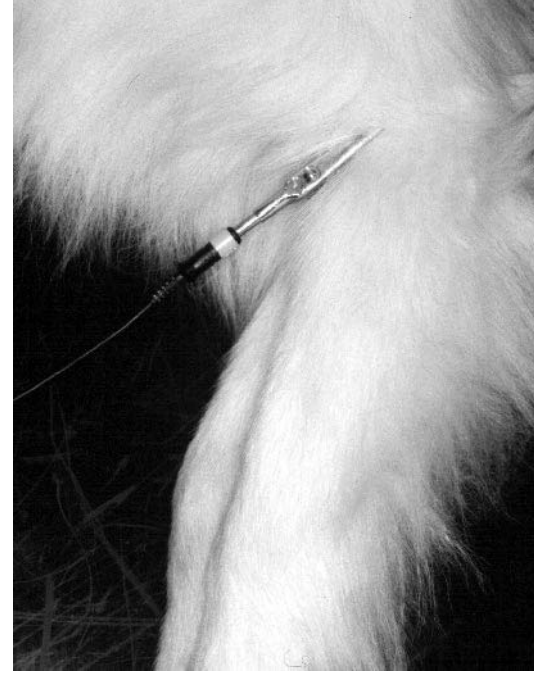

Figure 17.7 A useful site of attachment for the crocodile clips on the forelimbs is the skin at the flexor angle of the elbow.

ECG will have minimal movement and there should be a nice steady baseline in between each ECG complex.

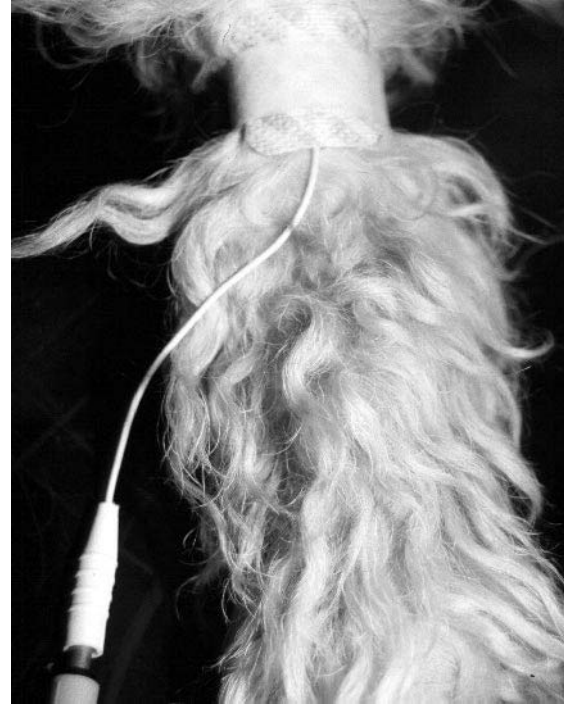If the animal would be put at risk (e.g. if it was in respiratory distress) by making it adopt a position (as follows) that it would not tolerate, then an ECG should be recorded in whatever position is achievable.



**Figure 17.8** A useful site of attachment for the crocodile clips on the hind legs is the skin at the flexor angle of the hock.

### *Dogs*

Dogs are preferably placed in right lateral recumbency (Fig. 17.12). In many dogs a recumbent position will reduce skeletal muscle electrical activity. And the normal values for the dog ECG have been determined based on this position. If measurement of amplitudes are not critical, such as when examining primarily an arrhythmia, then recording an ECG while the dog lies, sits or even stands is acceptable, provided a



**Figure 17.9** Placing an adhesive electrode on a dog's leg with the aid of tape to hold it in place.

good-quality tracing with minimal baseline movement artifact can be obtained.

### *Cats*

The normal values for cats have not been determined in a lateral recumbent position, thus recumbent positioning is less



Figure 17.10 An adhesive electrode on the central pad of a foot.

important. Many cats will often sit in a hunched position quite still (Fig. 17.13) – but each individual cat is different and the veterinary surgeon must determine how each cat prefers to keep still. In fractious cats (if the electrodes can be placed!) putting the cat back in a basket together with the electrodes attached and ECG cables until it settles is a useful method. When, or if, the cat settles,

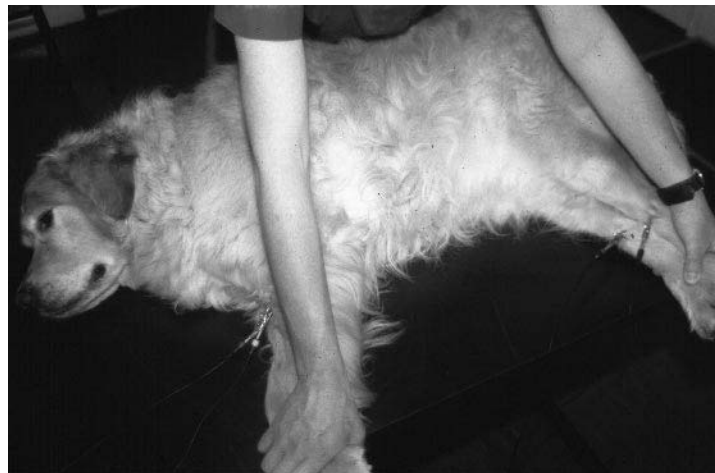

Figure 17.11 A dog having an ECG recording using crocodile clips.

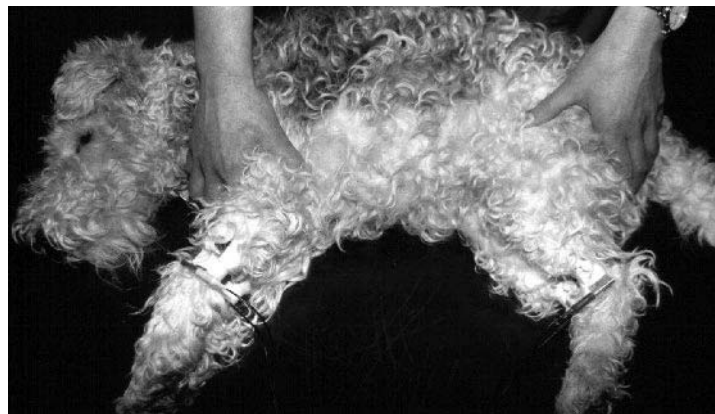

Figure 17.12 A dog having an ECG recording using paediatric limb electrodes.




Figure 17.13 A cat having an ECG recording using paediatric limb electrodes.

the ECG can be recorded while the cat sits in the basket. However, this method should, of course, be aborted if the cat starts to bite the ECG cables. Often cats do resent the crocodile clips, in which case, shaving a patch of hair and bandaging in place adhesive electrodes or metal plates, although more time consuming, is easier!

### *Chemical restraint*

All sedative and tranquilliser drugs have a variable effect on the heart and/or autonomic tone. Drugs can therefore change the rate and rhythm of the heart directly or through effects on the autonomic tone. So, if you are performing an ECG to determine what the arrhythmia is that you heard, then there is a possibility that this will change if a chemical restraint is used. Ideally, therefore, any form of chemical restraint should be avoided prior to recording an ECG. If chemical restraint cannot be avoided then, based on physical examination, determine the rate and rhythm before and after using the drugs, and any differences should be taken into account when interpreting the ECG recording.

### **Setting up and preparing the ECG machine**

This will vary a little between different ECG machines and adjustments to the following guidelines (which are based on a standard ECG machine) should be allowed.

#### *Paper speed*

Select the paper speed. Options are usually 25 or 50 mm/sec (Fig. 17.14), and sometimes 100 mm/sec. The paper speed selection is partly dependent on the animal's heart rate. As a guide: for normal heart rates in dogs set the speed at 25 mm/sec, but if

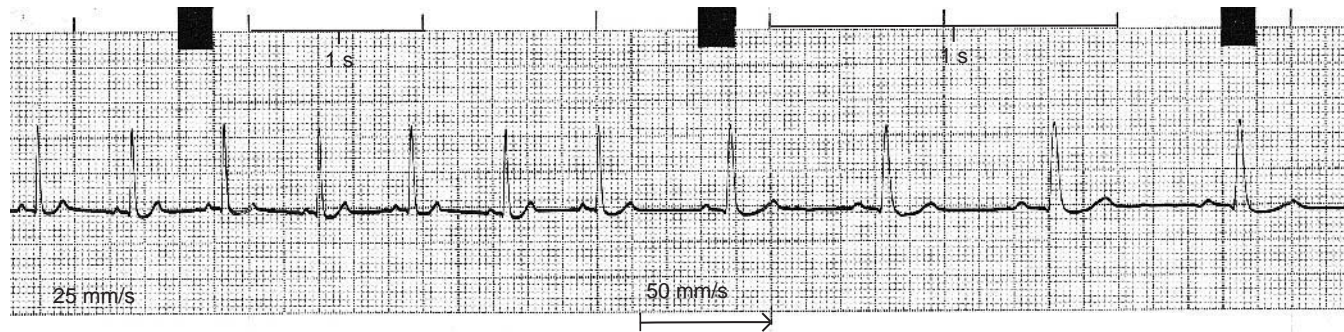


Figure 17.14 ECG showing the effect of paper speed.

there is a fast heart rate (and routinely for cats) set the paper speed at 50 mm/sec. In ECG machines with a computer-type print-out that produces a steppiness in the lines (i.e. pixel effect), measurement of ECG complex durations is best achieved at 100 mm/sec.

### Calibration

This is usually set at 1 cm/mV. However, if the complexes are very small this can be increased to 2 cm/mV and if the complexes are very large it can be reduced to 0.5 cm/mV. The calibration should be marked on the ECG paper by briefly running the ECG paper and pressing the 1 mV marker button (Fig. 17.15) – found on most standard ECG recorders.

### Filter setting

Ideally, if good connections have been made, this can usually be left off, i.e. no filter. Additionally amplitude measurement should always be performed in an unfiltered tracing, as the dampening effect of

the filter will reduce the amplitude of the complexes by a variable, although small, amount. If primarily examining for an arrhythmia and there is baseline artifact that cannot seem to be avoided, then filtering can reduce the baseline artifact and make reading of the ECG tracing easier (Figs 17.16 and 16.2, page 97).

### Positioning the stylus

During the recording the stylus should be positioned (if this is manually operated on the ECG machine) so that the whole of the ECG complex is within the ‘graph lines’ of the ECG paper. If the ECG produces particularly large complexes that run off the ‘graph paper’ (or outside the limits of the stylus or paper) this is referred to as **clipping** (Fig. 17.17). Remember then to move the stylus, up or down, so that the whole of the ECG tracing is within the graph paper (and not extending into the white margins) or alternatively reduce the calibration – whichever is more appropriate.

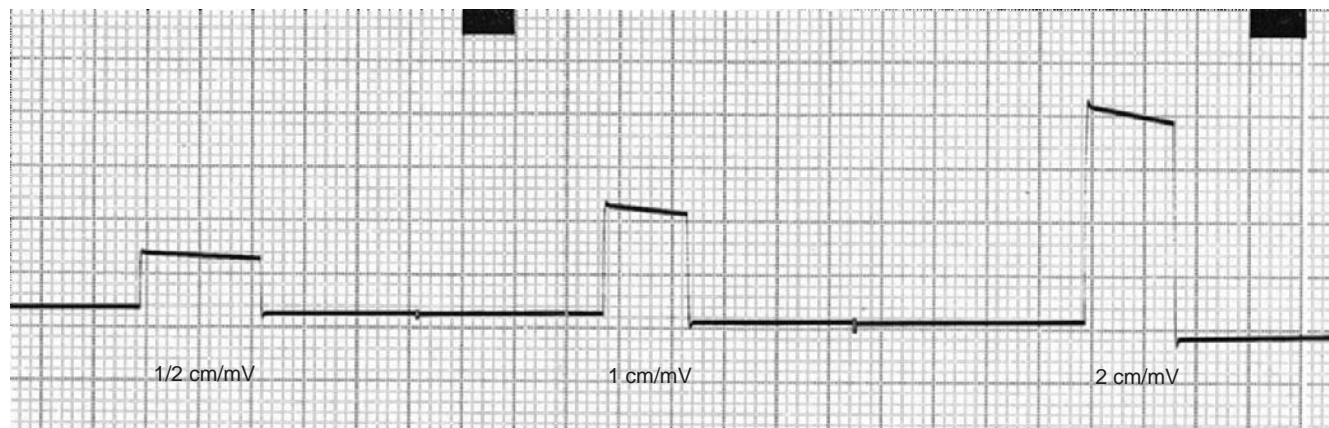


Figure 17.15 ECG showing three 1-mV calibration marks at different sensitivity settings: 0.5, 1 and 2 cm/mV.

## Recording an ECG – a suggested routine

### *Ten seconds of all six limb leads*

Run the ECG on each of the six bipolar leads, I, II, III, aVR, aVL and aVF, each for approximately 10 seconds. In order to ensure that each lead is well centred within the ‘graph lines’ of the ECG paper, briefly pause the ECG paper (with the stylus still moving) when switching the ECG machine from one lead to the next, until the stylus can be re-positioned as described above.

### *A rhythm strip*

Switch back to lead II and record a long rhythm strip, 30–60 seconds, depending on each individual case requirement. If you have auscul-

tated an occasional abnormal beat, then the ECG rhythm strip will need to be run until that abnormal beat is repeated. If lead II does not produce a good-quality tracing with satisfactorily large complexes, then run a rhythm strip on a lead that does. Or if you are searching for P waves (which can often be small and hard to see) then run the limb lead in which these are best shown.

### *A representative rhythm strip!*

If you auscultated what you thought was an arrhythmia, but it is not revealed on the ECG rhythm strip, then simultaneously auscultate the animal while continuing to run the ECG recording. It might be that the abnormality is only intermittently present, in which case you may have to continue to auscultate the animal until the arrhythmia is

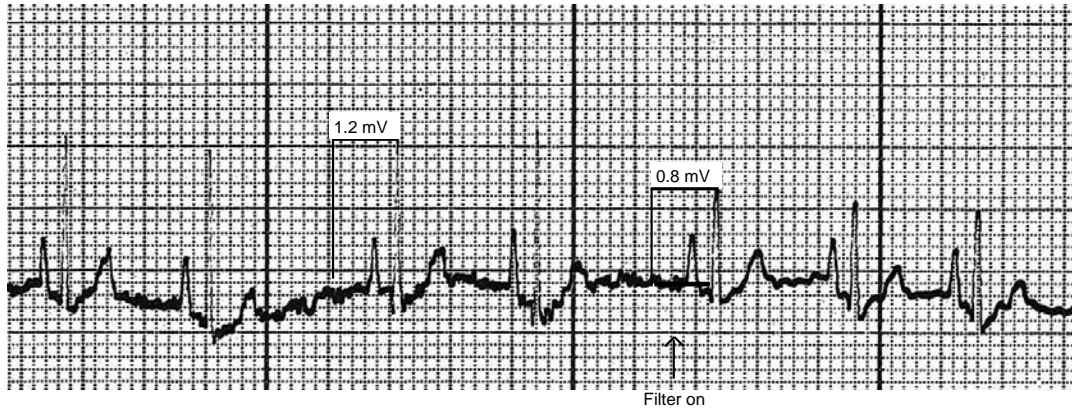


Figure 17.16 ECG showing the damping effect of the filter. Note the reduction in amplitude of the complexes (R waves from 1.2 to 0.8 mV) – measurements should be made from an unfiltered tracing to avoid potential underestimation of amplitudes. But also note the reduction in muscle tremor artifact (25 mm/sec and 10 mm/mV).

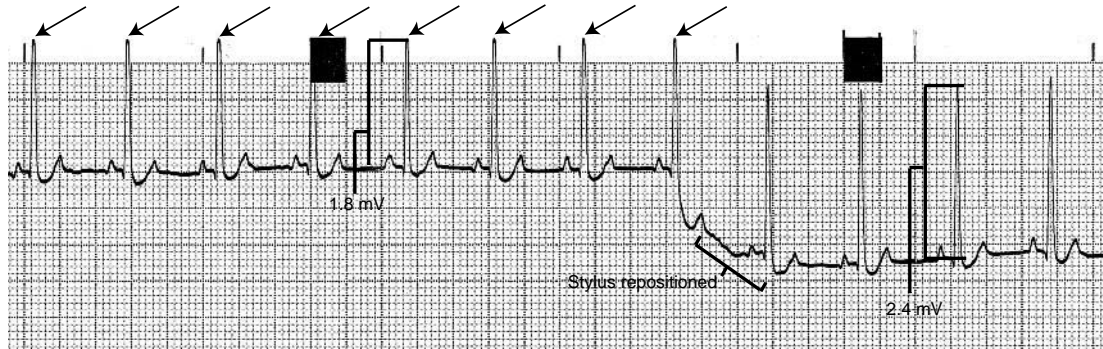


Figure 17.17 ECG showing the effect of clipping (arrows). If this went unnoticed, the R wave amplitude could mistakenly be measured as 1.8 mV when it should have measured 2.4 mV – potentially a considerable underestimation (25 mm/sec and 10 mm/mV).

heard and hopefully captured on ECG. Maybe the arrhythmia is still audible on auscultation but not recognised on the ECG – in this case the ECG tracing should be sent to a cardiologist for interpretation. Or, the abnormal heart sounds heard may not be an arrhythmia but, for example, could be a gallop sound. In summary, ensure that the ECG recording obtained is representative of what you found on physical examination.

### *Label the tracing*

Ensure the ECG recording is well labelled (unless the ECG machine does this automatically), either for future reference, or for other

colleagues within your practice to be able to examine the recording, or in case you need to submit the tracing to a cardiologist for interpretation.

#### **Checklist**

- State in which position the animal was restrained.
- State if any chemical restraint was used.
- Note paper speed and if, and where, it was changed.
- Note calibration and if, and where, it was changed.
- Label filter level, and when, and where, it was used.
- Label each lead at its beginning.



## 18 • Choosing an ECG recorder

In attempting to put down on paper some advice on choosing an ECG recorder – which is a question often asked of the author – I can only describe my own personal preferences and opinions. Other cardiologists may have differing opinions.

An ECG machine required for diagnostic purposes is preferably a recorder rather than a monitor. In other words using an ECG monitor (used in perianaesthetic or intensive care monitoring) is not the ideal for diagnostic ECG recordings. It is best to have ‘separates’ – a recorder for diagnostic electrocardiography and a monitor for anaesthesia.

### Quality

This is the most important factor for me. Recorders should produce a good-quality high-resolution tracing such that no pixelation (stepping) is evident. Older computerised recordings tended to produce a pixelated print-out (Figs 18.1a, b). Occasionally ECG recorders that print onto ECG tracing paper, yet the print-out is pixelated (Fig. 18.1c). Any pixelation in the tracing will affect the ability to recognise important small deflections, in particular when hunting for P waves.

### Continuous recording

The ability to record a continuous paper trace without interruption and in real time is preferred. This is not possible, for example, with machines and computers that print out onto sheets of A4 paper. This

will mean an ECG recorder with either paper in rolls or Z-fold paper. Sometimes Z-fold paper can fail to adequately allow scribing of a deflection on the fold itself (Fig. 18.2); however Z-fold paper is easy for storing, compared with paper rolls.

### Ease of use

The recorder is simple and intuitive to use, i.e. not so complex that a detailed users’ manual is required to understand it.

### Automatic labelling

It is very useful to purchase a machine that performs automatic labelling, on the paper trace, of the calibration, paper speed and filter level (Fig. 18.3). It is also best if any alteration to the settings are labelled immediately following a change rather than at fixed intervals.

### Automatic vs. manual recording mode

My preference is manual mode. Automatic mode means that the recorder runs through each of the leads, recording a set duration for each lead; however this is not a necessity. If automatic mode is used, it is useful to know how to stop the recording before attempting to print out unattached chest leads, or when the dog moves, or how to perform a continuous lead II rhythm strip.

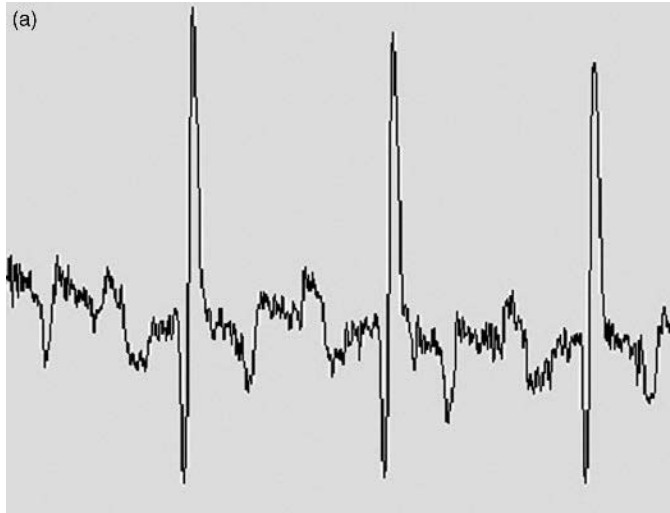


Figure 18.1 (a, b, c) Examples of the type of low-resolution pixelated tracings to avoid. These can make it difficult to identify the presence or absence of P waves (as in these examples) particularly when there is a complex arrhythmia and may be compounded by baseline artifact.

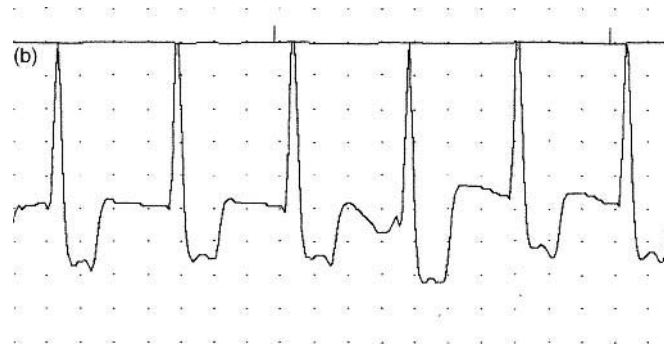

Figure 18.1

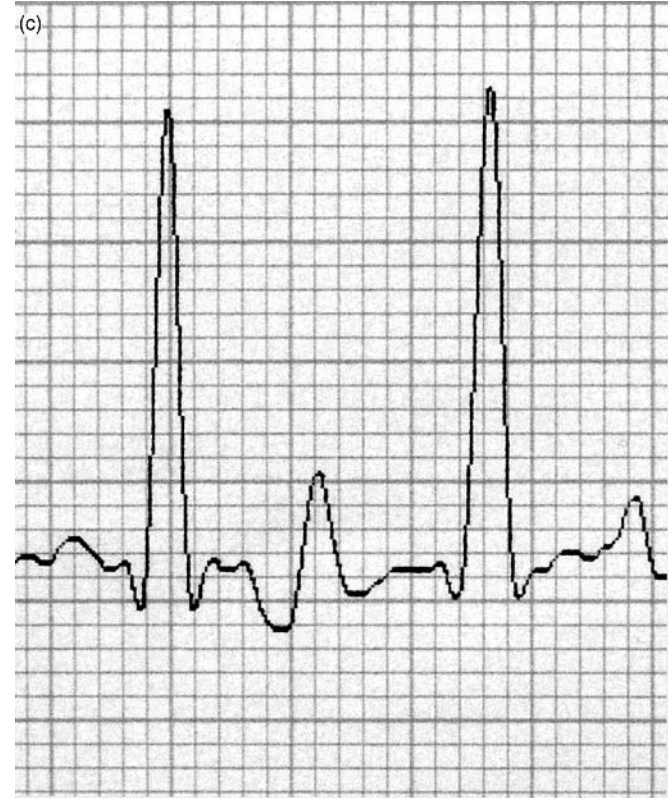
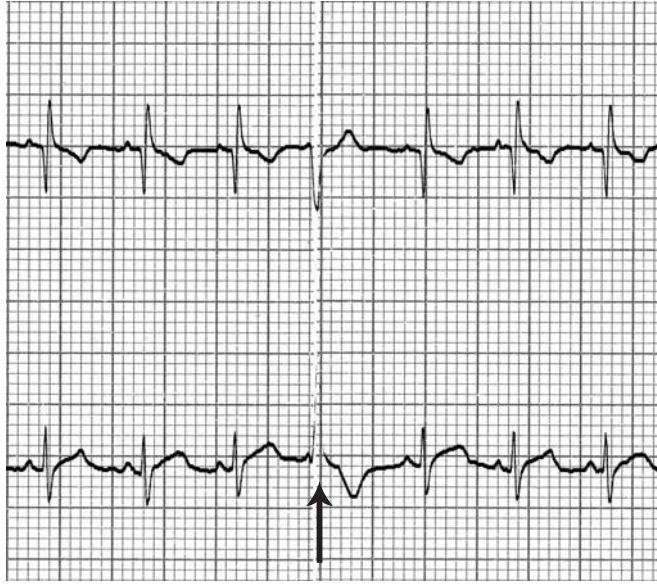


Figure 18.1

### Interpretative software

This does not appear to work reliably in animals: primarily due to attempts at interpreting baseline artifacts, particularly movement artifact. I have seen a number of owners referred on the basis of

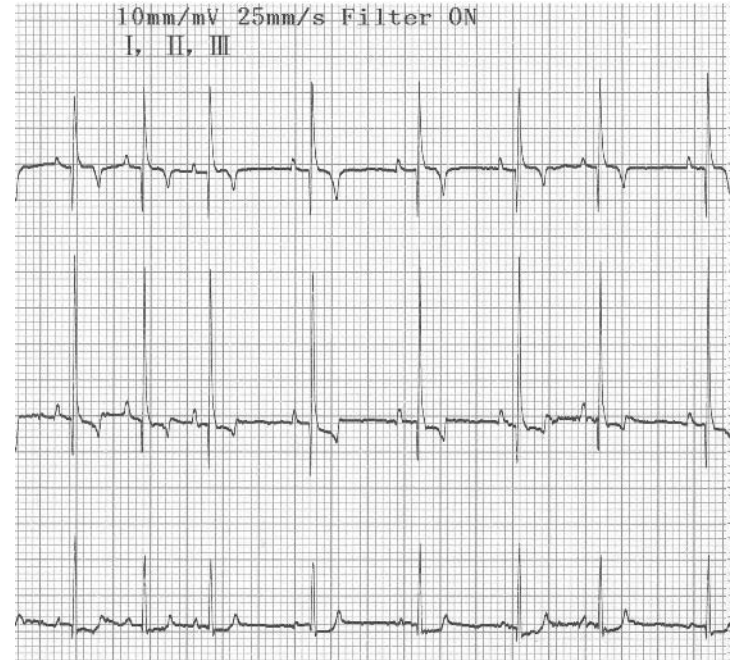


**Figure 18.2** Z-fold paper, whilst permitting a continuous recording, can also prevent proper scribing of the deflections on the Z-fold as in this example, which masks the VPC in this instance (arrowed).

misleading or wrong computer interpretation, such that I would be of the opinion that this should be avoided, except in the hands of someone experienced (in which case, interpretation is not required!).

### Multichannel vs. single channel

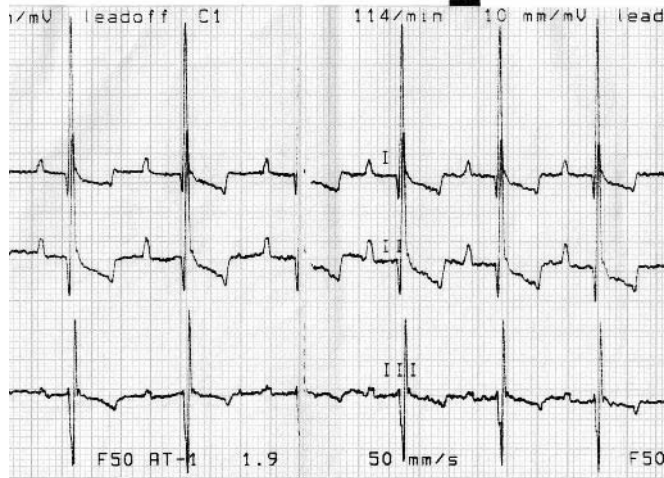
Multichannel recorders permit the simultaneous recording of more than one lead at a time, most commonly three leads, for example, leads I, II and III. If a leg moves during a recording, sometimes this



**Figure 18.3** Automatic labelling of the lead, paper speed and calibration is a useful feature.

can mimic an ectopic (Fig. 16.4c and 16.5), but in a three-channel recording, usually one lead will remain unaffected, and thus reveal the cardiac rhythm was normal.

Paper width is important when opting for a multichannel recorder. Some machines print out three (and sometimes four) leads on fairly miserly paper width resulting in the top and bottoms of QRS complexes overlapping (Fig. 18.4). This can make interpretation challenging. Halving the sensitivity is less than an ideal way to get round this



**Figure 18.4** A three-lead multichannel recorder on 8-cm wide paper, its just a bit of a miserly squeeze and can make rhythm analysis difficult, due to the overlap of the deflections.

problem on a regular basis. So if choosing a multichannel recorder chose one with respectably wide paper, which I would suggest should be >8 cm.

It is also preferable that the machine is set up so that there is not a repeat of the lead II rhythm strip, creating a fourth channel and compromising space.

### Precordial chest leads

These are generally not required for animal use. I occasionally use a single precordial lead in search of small deflections, such as P waves. But this is rarely required and the additional leads create an added storage problem.

### Calibration settings

The standard paper speed settings are 25 mm/sec and 50 mm/sec. Other speeds (5 mm/sec, 12.5 mm/sec or 100 mm/sec) are sometimes additionally available – these can occasionally be useful options, but are not essential.

The standard amplitude sensitivity is 10 mm/mV. A double sensitivity of 20 mm/mV is useful when the complexes are quite small, such as with cats. A half sensitivity of 5 mm/mV is required when the QRS complexes are very tall in some dogs that might have cardiomegaly.

A filter is often required in animals to reduce baseline artifact noise from electrical interference of muscle tremor. One filter level is usually sufficient, although some machines provide two filter levels.

### Automatic centring vs. manual control

Control of the stylus can either be performed manually (usually in older recorders) or automatically. Both options are fine, and the automatic centring in new machines usually works well, despite animal movement.

### Internal battery

This is a useful feature and in most machines comes as standard.

### Jack plug lead fitting

Crocodile clips and paediatric limb plates are the two most common types of electrodes used in animals; these both require jack plug type fitting. The press stud fittings are of limited use in animals; in humans they are used for attaching to circular adhesive electrodes.

**Monitor screen**

This is a useful optional extra on some machines. It means the ECG rhythm can be monitored for long periods without printing to paper (and thus wasting paper). Machines that have a memory function are useful in this setting, so that an arrhythmia seen on screen can then be printed out for the records or posting for an expert interpretation.

**Thermal paper vs. ink paper**

Thermal sensitive paper is more practical than ink, avoiding the need for replacement ink at difficult or busy times. Thermal paper that turns black (rather than blue) usually provides the better contrast for photography or scanning. However some papers do not have a long-term retention (> 1 year) of the image recorded, which gradually fades over time – something to watch for and try to avoid.

**New vs. second-hand**

Whilst a new ECG recorder is the ideal, the cost of this can prevent some practices from purchase of an ECG machine – which would be ‘the greater of two evils’! If cost is a limiting factor, then a second hand machine can be a good option. In these cases it is important to

have the machine serviced prior to use. If the machine comes without leads, there are companies that can make these up.

**Summary of features to look for in an ECG recorder**

- High-resolution tracing with no pixelation
- Continuous real time recording (not separate sheets of paper)
- Ease of use
- Automatic (and immediate) labelling of: lead, speed, calibration and filter
- Pre-set to manual mode
- Avoid interpretative software
- Multichannel recorder (3 leads) with paper width >8 cm (and no repeated lead II rhythm strip)
- Precordial chest leads are not necessary
- Calibration settings: pre-set to 25 mm/sec, 10 mm/mV and filter off
- Internal battery (can run off-mains)
- Jack plug fittings supplied with both crocodile clips and paediatric limb electrodes
- Monitoring screen – can be useful
- Records on thermal paper

## Further reading

### As a general reference guide the following text is recommended:

L. P. Tilley (1992) *Essentials of Canine and Feline Electrocardiography: Interpretation and Treatment*, 3rd edn, Lea & Febiger.

### For practising reading ECGs, which is strongly recommended:

L. P. Tilly and F. Smith (1993) *Canine and Feline Cardiac Arrhythmias: Self Assessment*, Lippincott, Williams & Wilkins.

### An audiotape or CD:

F. W. K. Smith, B. W. Keane and L. P. Tilley (2005) *Rapid Interpretation of Heart and Lung Sounds: A Guide to Cardiac and Respiratory Auscultation in Dogs and Cats*, Saunders.

C. Kvarn and J. Haggstrom (2002) *Cardiac Auscultation and Phonocardiography in Dogs, Horses and Cats*, Clarence Kvarn, Uppsala, Sweden.

### Books on veterinary cardiology:

P. Darke, J. D. Bonagura and D. F. Kelly (1996) *Color Atlas of Veterinary Cardiology*, Mosby-Wolfe.

P. R. Fox, D. Sisson and N. S. Moise (1999) *Textbook of Canine and Feline Cardiology*, WB Saunders.

M. D. Kittleson and R. D. Kienle (1998) *Small Animal Cardiovascular Medicine*, Mosby.

V. Luis-Fuentes and S. Swift (1998) *Manual of Small Animal Cardiorespiratory Medicine and Surgery*, BSAVA, Cheltenham.

M. W. S. Martin and B. Corcoran (2006) *Notes on Cardiorespiratory Disease of the Dog and Cat*, 2nd edn, Blackwell Publishing.

L. P. Tilly and J-K. Goodwin (2000) *Manual of Canine and Feline Cardiology*, Saunders.

O. L. Nelson (2001) *Small Animal Cardiology (The Practical Veterinarian)*, Butterworth-Heinemann Ltd.

T. Day (2005) *ECG Interpretation in the Critically Ill Dog and Cat*, Iowa State University Press.

B. W. Keane and R. Hamlin (1997) *Small Animal Cardiology*, Saunders.

W. Ware (2007) *A Colour Handbook of Small Animal Cardiology*, Mason Publishing.

# Index

- accelerated idioventricular rhythm, 71–2, 84
- Addison's disease, 55
- antiarrhythmic drugs, 82–4
- arrhythmias 23–39, 40–7
- defined, 15
  - management, 75–7
  - treatment, 78–87
- artefacts, 96–101
- asystole, 34
- atrial fibrillation, 34, 36–7, 38
- management, 77
  - treatment, 86–7
- atrial flutter, 70–1, 87
- atrial standstill, 42–3, 79–80
- atropine response test, 79
- AV (atrioventricular) node, 4
- AV block, 43–7
- first degree AV block, 43, 44
  - second degree AV block, 43–4, 45
  - third degree AV block, 44–7
  - treatment, 80–1
- AV dissociation, 34, 35, 36
- beta blockers, 85–6
- bradycardia,
- sinus origin, 10–11, 78
- bradycardia-tachycardia syndrome 41–2
- broad complex tachycardia, 69
- bundle branch block, 64–5, 65–7
- treatment, 81
- bundle of His, 4
- calcium antagonists, 85
- cardiac electrical activity, 4–8
- formation of normal P-QRS-T complex, 4–7
  - nomenclature of QRS complex, 7–8
- chamber enlargements, 48–51
- left atrial, 49–50
  - right ventricular, 50–1
- clipping techniques, 110
- conduction system abnormalities, 40–7
- atrial standstill, 42–3
  - heart block, 43–7
  - sick sinus syndrome, 40–2
  - sinus arrest and block, 40, 41
  - see also* intraventricular conduction defects
- digoxin, 87–8
- drug dosages, 81
- drug indications, 82–4
- dysrhythmia, *see* arrhythmias
- ectopia, 15–22
- assessment procedures, 15
  - classification and terminology, 18–19
  - morphology of supraventricular depolarisation, 18, 19–20
  - morphology of ventricular depolarisation, 15–18, 21–2
  - types of arrhythmias, 23–9, 70–2
- electrical activity, *see* cardiac electrical activity
- electrical alternans, 52–3
- electrical interference, 96–7
- electrocardiograph (ECG),
- definitions and types, 3
  - equipment choice considerations, 114–18
  - interpretation approaches, 93–5
  - interpretative software, 115–16
  - limb lead systems, 59–60
  - recording methods and procedures, 102–13
- electrode misplacements, 100–1
- electrode placements, 103–4
- escape rhythms, 18, 19, 31, 34–5
- 'f' waves, 37
- fibrillation, 34–9
- atrial, 34, 36–7, 86–8
  - ventricular, 37–9, 86
- gastric dilation-volvulus (GDV), 84
- heart block, *see* AV block
- heart enlargements, 48–51
- left atrial, 49–50
  - right ventricular, 50–1
- heart rate,
- normal values, 49
  - hyperkalaemia, 55
- intermittent ventricular aberrancy, 68, 69
- intraventricular conduction defects, 64–9
- intermittent ventricular aberrancy, 68, 69
  - left anterior fascicular block, 67

- left bundle branch block, 65–7, 81
- right bundle branch block, 64–5, 81
- left anterior fascicular block, 67
- left atrial enlargement, 49–50
- left bundle branch block, 65–7
  - treatment, 81
- left ventricular enlargement, 50
- lidocaine (lignocaine), 83
- limb lead systems, 59–60
- mean electrical axis (MEA), 61–3
  - abnormalities, 50–1
  - calculations, 62–3
  - normal values, 49
- mexiletine, 83
- Mobitz type I/II block, 43, 80
- movement artefacts, 97–100
- muscle tremor artefacts, 97, 98
- P wave formation, 5–6
  - normal values, 49
- P-mitrale, 49
- P-pulmonale, 49–50
- P-QRS-T complex, 4–8
  - morphological changes and associated conditions, 48–55
- P-R interval, 5–6
  - normal values, 49
- pacemakers, 88–90
- parasympathetic drugs, 81
- positioning animals, 104–9
- Purkinje fibres, 4
- Q wave formation, 6
- Q-T intervals,
  - abnormalities, 53
  - normal duration values, 49
- QRS complex,
  - electrical alternans, 52–3
  - formation, 6–7
  - general nomenclature, 8
  - low voltage complexes, 51–2
  - normal complexes, 15, 17
  - normal duration values, 49
  - ventricular ectopic abnormalities, 15–18
- R wave formation, 6–7
  - normal amplitude values, 49
  - notches, 52–3, 54
- R-on-T, 24, 27
- rescue beats, *see* escape rhythms
- respiratory sinus arrhythmia, 9, 11
- right bundle branch block, 64–5
  - treatment, 81
- right ventricular enlargement, 50–1
- S wave formation, 7
- S-T segment,
  - abnormalities, 53, 54
  - normal duration values, 49
- sick sinus syndrome, 40–2
  - treatments, 79
- sinoatrial (SA) node, 4
- sinus arrest, 40, 41
  - treatments, 78–9
- sinus arrhythmia, 9, 11
- sinus block, 40
  - treatments, 78–9
- sinus bradycardia, 11–12
  - treatments, 78
- sinus rhythm, 9, 10
- sinus tachycardia, 10, 11
  - treatments, 81–2
- sinus node dysfunction, *see* sick sinus syndrome
- supraventricular ectopic complexes, 18, 20, 30–3, 84–5
- supraventricular premature complexes (SVPCs), 18, 20, 30–3
  - treatments, 84–5
- sympathetic drugs, 81
- T wave formations, 8
  - abnormalities, 53, 55
  - normal amplitude values, 49
- tachyarrhythmias, 10, 11
  - treatment, 81–2
- ventricular ectopic complexes, 15–18, 21–2, 23–30, 69, 82–4
- ventricular fibrillation (VF), 37–9
  - treatment, 86
- ventricular pre-excitation, 70, 86
- ventricular premature complexes (VPCs), 23–30
  - morphology, 16–18, 21–2, 69
  - treatment, 82–3, 84
- ventricular standstill, 34
- ventricular tachycardia (VT), 24, 28–30
- VPCs, *see* ventricular premature complexes (VPCs)
- wandering atrial pacemaker, 48
- wavelet theory,
  - atrial fibrillation, 37
  - ventricular fibrillation, 39
- Wenckebach's phenomenon, 43
- Wolff-Parkinson-White syndrome, 70