

Parvin Ganjei-Azar  
Mehrdad Nadji

**Color Atlas**  
of Immunocytochemistry  
in Diagnostic Cytology

 Springer

Color Atlas of Immunocytochemistry  
in Diagnostic Cytology

# Color Atlas of Immunocytochemistry in Diagnostic Cytology

Parvin Ganjei-Azar, MD  
Mehrdad Nadji, MD

Department of Pathology, University of Miami Miller School  
of Medicine, Jackson Memorial Hospital, UM Sylvester  
Comprehensive Cancer Center, Miami, Florida

 Springer

Parvin Ganjei-Azar, MD  
Professor of Pathology  
Director of Cytopathology  
University of Miami  
Miller School of Medicine  
Jackson Memorial Hospital  
UM Sylvester Comprehensive  
Cancer Center  
Miami, FL 33136  
USA

Mehrdad Nadji, MD  
Professor of Pathology  
Director of Immunohistochemistry  
University of Miami  
Miller School of Medicine  
Jackson Memorial Hospital  
UM Sylvester Comprehensive  
Cancer Center  
Miami, FL 33136  
USA

Library of Congress Control Number: 2006923104

ISBN-10: 0-387-32121-7  
ISBN-13: 978-0387-32121-9

e-ISBN-10: 0-387-32122-5  
e-ISBN-13: 978-0387-32122-6

Printed on acid-free paper.

© 2007 Springer Science+Business Media, LLC

All rights reserved. This work may not be translated or copied in whole or in part without the written permission of the publisher (Springer Science+Business Media, LLC, 233 Spring Street, New York, NY 10013, USA), except for brief excerpts in connection with reviews or scholarly analysis. Use in connection with any form of information storage and retrieval, electronic adaptation, computer software, or by similar or dissimilar methodology now known or hereafter developed is forbidden.

The use in this publication of trade names, trademarks, service marks and similar terms, even if they are not identified as such, is not to be taken as an expression of opinion as to whether or not they are subject to proprietary rights.

While the advice and information in this book are believed to be true and accurate at the date of going to press, neither the authors nor the editors nor the publisher can accept any legal responsibility for any errors or omissions that may be made. The publisher makes no warranty, express or implied, with respect to the material contained herein.

Printed in Singapore. (BS/KYO)

9 8 7 6 5 4 3 2 1

springer.com



*To our families,  
for their love and support*

# Preface

In recent years, cytology has played an increasingly important role in the diagnosis of various disease processes, particularly those of neoplastic origin. In fact, it is not unusual for cytologic specimens to be the only diagnostic sample available from patients with cancer. Many ancillary tests traditionally performed on histologic material are now expected to be performed on cytologic specimens. One such technique, immunocytochemistry (ICC), has already proved to be important in diagnostic tumor pathology (1–4). The indication for the performance of ICC in cytology is not, however, as broad as it is in histopathology. This is partly because cytology is sometimes used to differentiate between a benign/reactive process and a neoplastic or preneoplastic condition. To that end, there are no markers at the present time that can distinguish a benign cell from a malignant one.

Because methods have been refined and high-quality reagents and automation are now available, technical problems no longer present a major concern in this field. We will therefore only briefly address the technical aspects of ICC by providing practical advice for the users. We will then concentrate on the analytical aspects of ICC, including the selection of appropriate markers for specific differential diagnoses and incorporation of results in the final cytologic interpretation. These include ICC of undifferentiated malignant neoplasms and, most importantly, its utilization in specific differential diagnoses that are based on cytomorphology and the patient's clinical history.

Cytology books and monographs abound, and some may address ICC as it may be applied to a specific disease process or organ system. There are also many excellent immunohistochemistry books and Web sites that define various antigens and discuss the frequency of their expression by different tumors. This atlas, in contrast, is an illustrated practical handbook that allows for quick reference in the selection and interpretation of markers in specific differential diagnoses in the daily practice of diagnostic cytology.

*Parvin Ganjei-Azar, MD  
Mehrdad Nadji, MD*

# Acknowledgments

This book represents the results of twenty-five years of undertaking and accomplishment by the team of pathologists and cytotechnologists in the Department of Pathology at the University of Miami, Jackson Memorial Hospital. We are indebted to all of them, but in particular to Drs. Merce Jorda, Carmen Gomez-Fernandez, Billie Pustai, CT (ASCP), and Alfredo Cordoves for their contributions toward our common goal of developing a practical immunocytochemical approach to the resolution of daily diagnostic problems in cytology.

We would be remiss if we did not specifically thank Dr. Weiyu Wu for his expertise in performing all immunocytochemical stains and Alicia Cabrera for her valuable efforts in preparing the text for publication.

This work would not have been possible without the continuous encouragement and support of Dr. Azorides Morales, Professor and Chairman of the Department of Pathology.

*Parvin Ganjei-Azar, MD  
Mehrdad Nadji, MD*

# Contents

Preface .....	vii
Acknowledgments .....	ix

## **Section I Immunocytochemistry**

1 Technical Considerations .....	3
Specimen .....	3
Fixation .....	4
Immunocytochemical Procedure .....	4
Controls .....	5
2 Selection of the Markers .....	6
3 Evaluation of Results .....	7
False-Positive Reactions .....	7
False-Negative Reactions .....	7
Background Staining .....	7

## **Section II Immunocytochemical Resolution of Diagnostic Problems: Case Examples**

4 Undifferentiated Neoplasms .....	11
5 Soft Tissue Tumors .....	27
6 Gastrointestinal Tract .....	53
7 Pancreas and Liver .....	67
8 Adrenal Gland .....	101
9 Head and Neck .....	117
10 Lung .....	143
11 Pleura and Mediastinum .....	169
12 Abdominal Cavity .....	195
13 Female Genital Tract and Breast .....	203

14 Urinary and Male Genital System .....	233
15 Lymphoreticular System .....	259
16 Nervous System .....	273
Suggested Readings .....	283
Index .....	289

# Section I

## Immunocytochemistry

# 1 Technical Considerations

## Specimen

Immunocytochemistry (ICC) can be performed on most cytology samples, including fine needle aspirations (FNA), serosal fluids, Pap smears, and wash and brush specimens (2–4). If the cell sample is adequate, one should prepare cell blocks, as these represent the ideal specimens for ICC. All too often, however, the cell sample is limited to few smears or cytocentrifuge preparations. In fact, the need to perform ICC usually arises only after reviewing the fixed and Papanicolaou-stained slides. In such cases, the coverslip is removed and the ICC can simply be performed on the previously stained slide without the need for destaining.

## *Tips*

- Filter preparations are not suitable for ICC because filters absorb the immunologic reagents and the chromogen. This causes unacceptable background staining. Filter preparations are also easily detached from the slide during wash steps.
- Cytocentrifugation of serosal fluids with high protein content may cause precipitation of a protein film over cellular material, thereby preventing adequate penetration of reagents. In such cases, a brief washing of the cells by isotonic saline solution before centrifugation will remove the excess protein.
- Fine needle aspirations and body cavity fluids with excess blood may interfere with ICC. These specimens can be preserved in Saccomonno's solution, which not only fixes the sample but also lyses the red cells.
- If the number of slides are limited, one could utilize a slide that was negative for a marker to be restained with a second antibody. No technical modification is needed.
- Although removal of glass coverslip from previously stained slides is relatively simple, some plastic and liquid-film coverslips are not easily removable and may interfere with performance of ICC.

## Fixation

Equally good ICC results could be achieved in cytologic samples fixed in 95% isopropyl alcohol, buffered formalin, formol-acetone, or a mixture of ethanol and formalin. A brief fixation in any of the above fixatives is adequate for most cytologic preparations (2).

### *Tips*

- Air-dried specimens are not optimal samples for ICC of most cytoplasmic and nuclear markers. Furthermore, most air-dried samples are stained with Diff Quick or similar Romonowski methods. These stains may also interfere with subsequent ICC procedures.
- Similar to histologic samples, prolonged fixation of cytology specimens in formalin (weeks or months) may result in gradual loss of their antigenicity. Prolonged fixation in alcohol-base fixatives, on the other hand, is not a major problem.

## Immunocytochemical Procedure

The immunostaining methods used for cytology specimens are identical to those used for histologic studies, including the antigen retrieval steps. There is no need for modification of the techniques, even for smears and cytocentrifuge preparations. The following is the stepwise immunocytochemical procedure as performed in the authors' laboratory.

1. Remove the cover glass by heating the slides on a heating block (2.0sec) and immediately immersing them in Xylene (2.0min).
2. Rehydrate slides in decreasing ethanol grades.
3. Block endogenous peroxidase activity by using a 6% solution of hydrogen peroxide in water (3.0min, room temperature).
4. Place slides in target retrieval solution (S1699, Dako, Carpinteria, CA) and heat at 90°C in a pressure cooker (10min).
5. Block endogenous biotin by the biotin-blocking reagent (X0590, Dako).
6. Incubate with the primary antibody (22min, room temperature).
7. Add the linking solution: biotinylated antimouse immunoglobulin, and incubate (22min) (K0690, Dako).
8. Add streptavidin-peroxidase conjugate and incubate (22min) (K0690, Dako).
9. Place slides in diaminobenzidine solution (10min) (K33468, Dako).
10. Counterstain with Harris hematoxyline (15sec).
11. For nuclear antigens replace step 10 with an application of 1% cupric sulfate (1.0min, room temperature) to intensify the signal; counterstain with 0.2% fast green (2.0sec).



12. Dehydrate in increasing grades of ethanol, clear in Xylene, and mount.

All washes and dilutions are made with tris-buffered saline (Dako, S1968). Steps 5 through 9 are carried out in an automated instrument (Autostainer Plus, Dako).

### ***Tips***

- Heat-induced antigen retrieval by microwave radiation may lead to inconsistent ICC results. Because vegetable steamers or pressure cookers induce uniform and gentle heat, they are currently used in most laboratories.
- If the retrieval of an antigen requires predigestion by a protease, one should reduce the digestion time for smears to one-fourth or one-fifth of what ordinarily is used for cell blocks.
- It is not unusual that in a cytologic sample the target cells for ICC are too few and too far between. To facilitate quick identification of cells, circle them with ink before ICC. Then use a diamond pen to etch the inked area from the back of the glass slide. After immunostaining, the target cells should be easy to identify in the etched circles.

## Controls

Because the sensitivity and specificity of cell marker identification is similar in histologic and cytologic preparations, it is not necessary to use separate positive and negative cytology controls with every run of ICC. Furthermore, preparation and storage of various cytologic samples to be used exclusively for ICC is not practical; it may even be impossible. It is therefore recommended that the same controls used in histology be used and evaluated for cytology cases.

### ***Tips***

The most valuable controls in immunochemistry are internal controls. But unlike histologic sections that are usually composed of several cellular components, cytology samples seldom contain more than two or three cell types. This reduces the possibility of having an internal control in cytology and, hence, negative ICC results in cytologic specimens are not as meaningful as positive reactions.

## 2

# Selection of Markers

A reasonable differential diagnosis usually is based on the cytomorphology of the tumor, clinical information, and the probability of certain disease processes occurring in the patient's age group and in the anatomic location of the tumor(2). Another important factor is the availability of markers for the entities within the differential diagnosis. Similarly, the experience of the observer is an essential factor in determining the clinical value of ICC. The latter has a major impact from the selection of the markers to the evaluation of results and rendering of a diagnosis. Because most diagnostic problems in cytology can be narrowed down to two or three possibilities, the choice of antibodies can also be restricted to two or three. This "tailor-made" approach requires the pathologist's input and necessitates her/his active participation in the formulation of a working diagnosis. The authors have used this nonalgorithmic, differential, diagnosis-driven, limited antibody approach in all cases discussed and illustrated in this book. This reflects our preoccupation with a practical approach to the ICC of cytologic specimens, particularly when the sample is insufficient for cell block preparation.

# 3

## Evaluation of Results

The hallmark of a true positive ICC reaction is heterogeneous distribution of crisp granular staining within single cells or among a group of cells. Depending on the antigen, the reaction may be seen on the cell membrane, occupy the entire cytoplasm, be limited to the perinuclear area, or appear intranuclear. With rare exceptions, diffuse monotonous pale brown staining of cells is in all likelihood nonspecific.

### False-Positive Reactions

Similar to findings in histopathology, a common source of false-positive reactions in ICC includes the nonspecific staining of crushed, degenerated, and necrotic cells. Histiocytes, macrophages, cells in mitosis, and tumor giant cells may also show false-positive reaction (2). Large, three-dimensional cellular clusters in FNA, brushing, or cytocentrifuge specimens may entrap immunologic reagents and lead to nonspecific positive results. In such cases, the evaluation of a positive reaction should be limited to single cells or two-dimensional groups.

### False-Negative Results

In the absence of internal controls, the true nature of a negative reaction in cytologic material is difficult to verify (5). Consequently, negative results in ICC are not as meaningful as positive reactions.

### Background Staining

Unlike in histological sections, nonspecific background staining is not a major problem in cytologic material. In fact, most of what appears to be a nonspecific reaction in the slide background in reality represents true

staining. For instance, a background reaction for thyroglobulin in an FNA of the thyroid or an immunoglobulin light chain reaction in a serosal fluid reflects the normal and expected presence of respective proteins in the sample. Similarly, when samples contain cells with delicate and fragile cell membranes, intracytoplasmic antigens may be released by the act of smearing. These may appear as nonspecific background staining. Examples include background staining for inhibin in adrenocortical neoplasms and the S100 protein reaction in FNA of granular cell tumors. On the other hand, cells in fluid cytology may show a nonspecific membrane staining for an antigen that is present in the fluid, but is not elaborated by those cells (i.e., nonspecific cytoplasmic membrane reaction of mesothelial cells in a body cavity effusion for immunoglobulins). Therefore, only nuclear or intracytoplasmic reactions are acceptable as truly positive because any cell that floats in such a background may show surface membrane staining regardless of whether it elaborates that antigen or not (2,6).

# Section II

## Immunocytochemical Resolution of Diagnostic Problems: Case Examples

### *Note to the Reader*

Before reading the chapters in this section, note the following:

1. This is not a comprehensive book on immunocytochemistry. It merely represents our attempt to provide the users with a simple and practical reference for the resolution of some of the most common (and occasionally uncommon) differential diagnostic problems in cytology (7).
2. In many cases, only one marker is used to confirm the favored cytomorphologic impression.
3. This book, for the most part, addresses the use of ICC on Papanicolaou-stained smears or centrifuged specimens. With few exceptions, ICC of cell blocks is not discussed or illustrated.
4. Most cases illustrated are FNAs of various organs and serosal fluid cytologies. There is no discussion on cervicovaginal Pap smears simply because there are not many diagnostic problems in these samples that could be resolved by ICC.
5. To facilitate a quick lookup, we have chosen to group the diagnostic problems by the organ systems (i.e., soft tissue, lung, female genital tract, and so on), as opposed to the type of specimen (i.e., effusion, brushing, FNA, and so on.)
6. Not all possible differential diagnoses are discussed in this book. This is simply because there are no reliable markers to separate every morphologically similar lesion from look-alikes.
7. The suggested markers are those that we have found most useful in our daily practice. A seasoned immunocytochemist may modify the selection according to her/his preference.
8. For the same reason, some of the most commonly used antibodies are absent from our list. Those are the ones that we find of no value even when used in a panel (i.e., vimentin, muscle actin, and so on).
9. It will be noticed that we have not addressed the comprehensive immunophenotyping of hematolymphoid neoplasms. The ICC of these groups of tumors is complex and beyond the scope of this publication. We only use a limited number of lymphoreticular markers when a malignant lymphoma is in the differential diagnosis.
10. Most illustrated examples in this book are from our daily cytology caseload. These actual cases are not handpicked to present typical examples.

In fact, most may show changes that we are all familiar with in our daily practice.

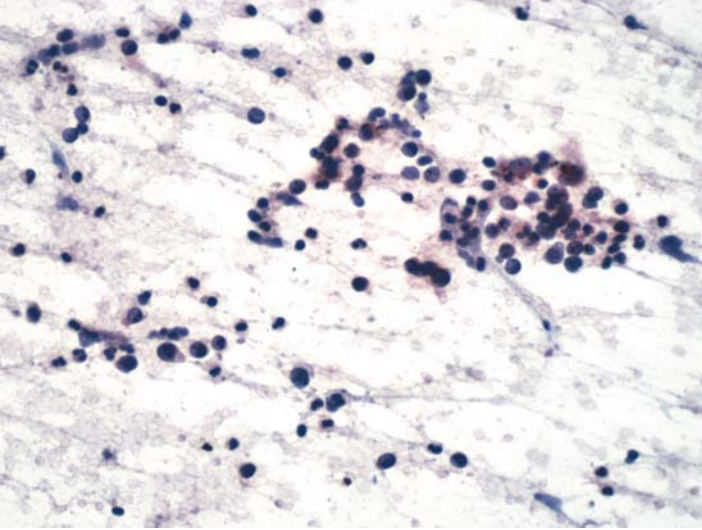
11. Finally, we recommend that users pursue the following guidelines to derive maximum benefit from this practical monograph:
  - First evaluate the cytomorphology of the lesion. Based on this primary observation, formulate either a favored diagnosis to be confirmed or a differential diagnosis to be resolved.
  - Next refer to the chapter of the book dealing with the lesions of that organ system. For example, if the differential diagnosis on cytology of the lung is a choice between a lung cancer and a metastatic breast carcinoma, refer to the chapter on the “Lung.”
  - In that chapter, we recommend differential diagnosis markers and the potential staining outcome. For example, lung adenocarcinomas are usually positive for TTF-1, whereas most breast cancers are expected to contain express estrogen receptors.
  - This is followed by “Tips,” in which we list important points about the markers and the potential technical and analytical problems that may be associated with their use.
12. Then we illustrate one or two examples, including the original Papanicolaou stain followed by positive and/or negative ICC results, and then the diagnostic conclusions. Whenever needed, a reference is suggested for further reading.

# 4

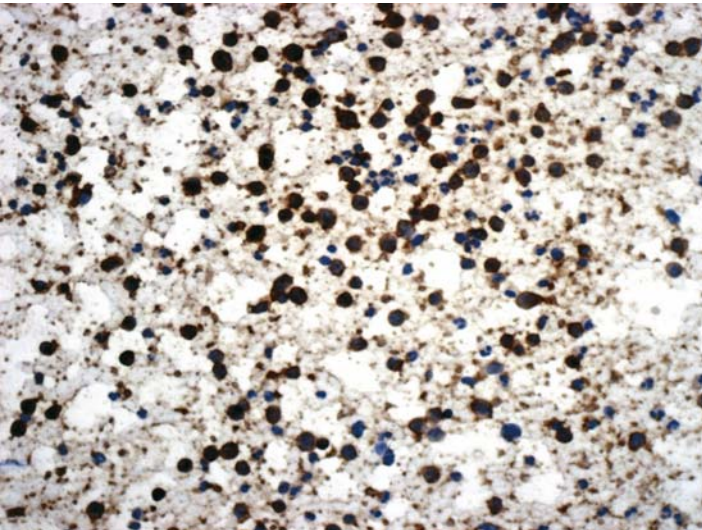
## Undifferentiated Neoplasms

## Case 1

---



**FIGURE 1A. Pap Stain:** FNA of a mediastinal lymph node in a 67-year-old male. There are isolated and loosely cohesive small cells. The differential diagnosis includes small cell carcinoma and malignant lymphoma.



**FIGURE 1B. Cytokeratin:** The majority of cells show positive cytoplasmic reaction for cytokeratin.



## ***Diagnosis***

Small Cell Carcinoma

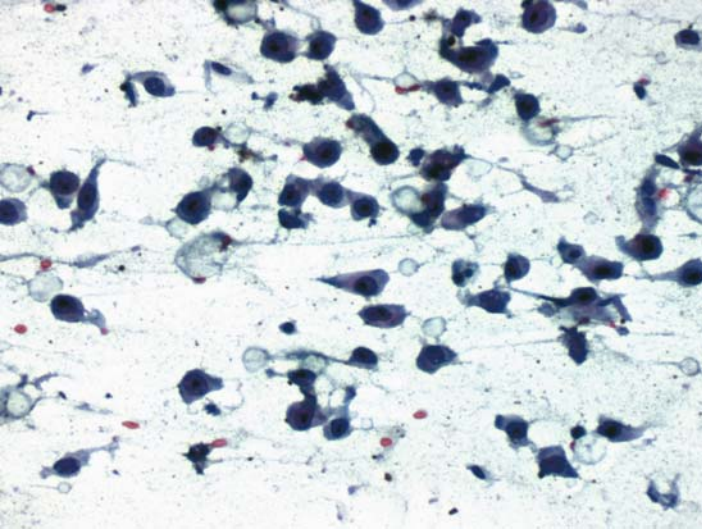
### ***Tips***

- The term “Cytokeratin” is used to denote a wide spectrum antibody that is also referred to as a “Cytokeratin Cocktail” or “Pancytokeratin.”
- Some of the antibodies marketed as “Pancytokeratin” may in fact have activity against only a few cytokeratin peptides and, hence, may lead to false-negative results in some epithelial tumors.
- Because there was only one slide available in this case, we chose to stain it for cytokeratin because morphology was more suggestive of a carcinoma. Had there been additional slides, we would have used CD45 as well, to exclude a malignant lymphoma.

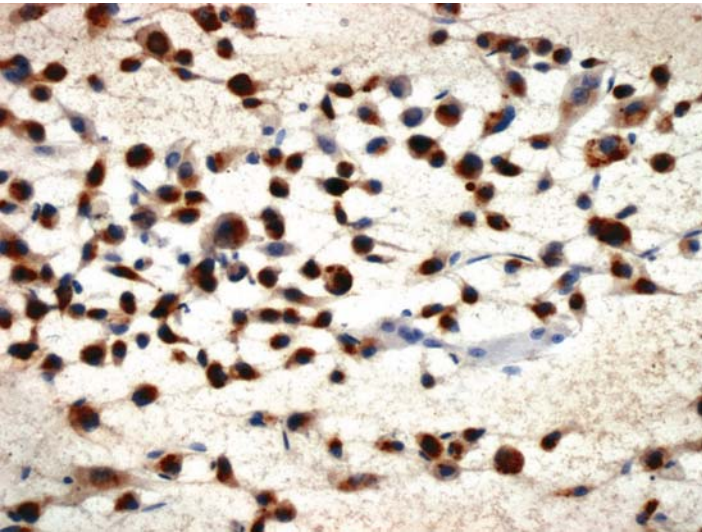
*Suggested Reading: 8*

## Case 2

---



**FIGURE 2A. Pap Stain:** FNA of a cervical lymph node in a 34-year-old male with a history of malignant melanoma. It shows large, mostly isolated, pleomorphic cells with an eccentric nuclei. It most likely represents a malignant melanoma but requires immunocytochemical confirmation.



**FIGURE 2B. S100 Protein:** Nuclear and cytoplasmic staining for S100 protein supports the impression of malignant melanoma.

## ***Diagnosis***

Malignant Melanoma

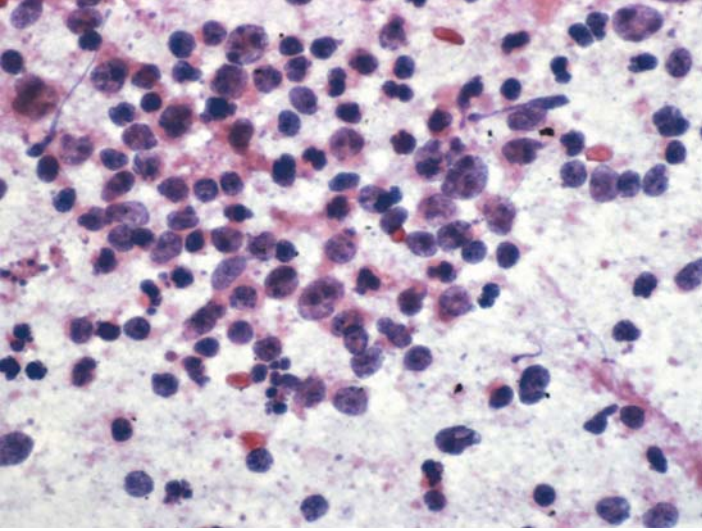
### ***Tips***

- True positive staining for S100 protein should be present in the cytoplasm and nucleus of the cell. In the absence of nuclear staining, one should question the specificity of S100 staining.
- S100 protein is the most sensitive marker for malignant melanomas. It is not as specific as HMB-45, but HMB-45 has a rather low sensitivity for malignant melanoma (approximately 50%). It is also usually negative in the spindle cell type of malignant melanoma.
- Alcohol fixatives in general are not the best for S100 staining. In cytology, however, the fixation time is usually short which has no practical effect on staining results.

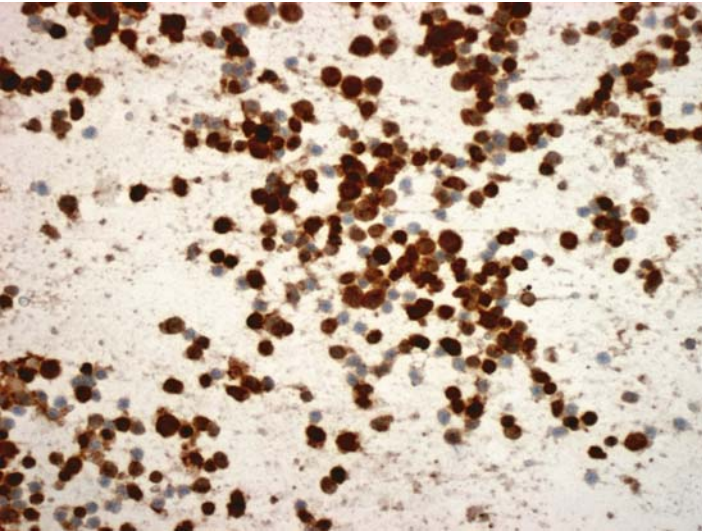
*Suggested Reading: 9, 10*

## Case 3

---



**FIGURE 3A. Pap Stain:** FNA of a retroperitoneal mass in a 65-year-old male with a history of lung cancer. There are isolated, large malignant cells with occasional apoptotic bodies that are highly suggestive of a large cell malignant lymphoma.



**FIGURE 3B. CD20:** The malignant cells are positive for CD20, confirming the diagnosis of a large B cell lymphoma.

## ***Diagnosis***

Large B Cell Lymphoma

### ***Tips***

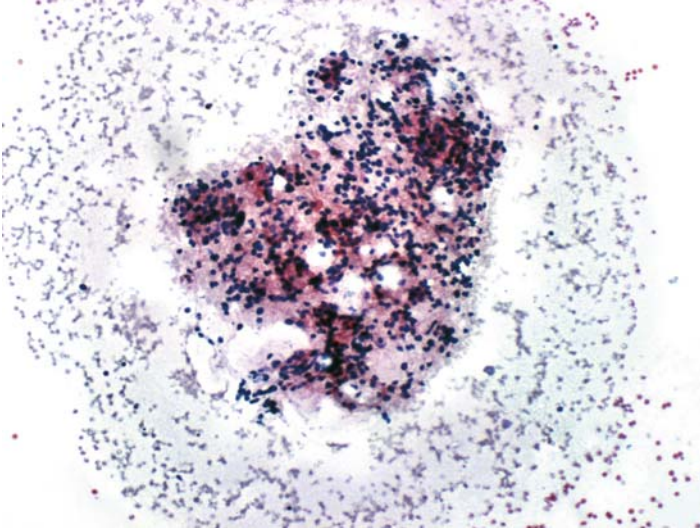
- CD45 is a general lymphoma marker, but because the majority of nodal and extranodal large cell lymphomas are of B cell phenotype, one could use CD20 as an alternative to CD45. CD79a is also a sensitive marker for B cell lymphomas, but it is not as specific as CD20.
- Both cytomorphology and immunocytochemistry are of limited value when the sample is composed of small lymphocytes. In such cases, we suggest flow cytometry or, if possible, PCR for gene rearrangement studies.

*Suggested Reading: 11–14*

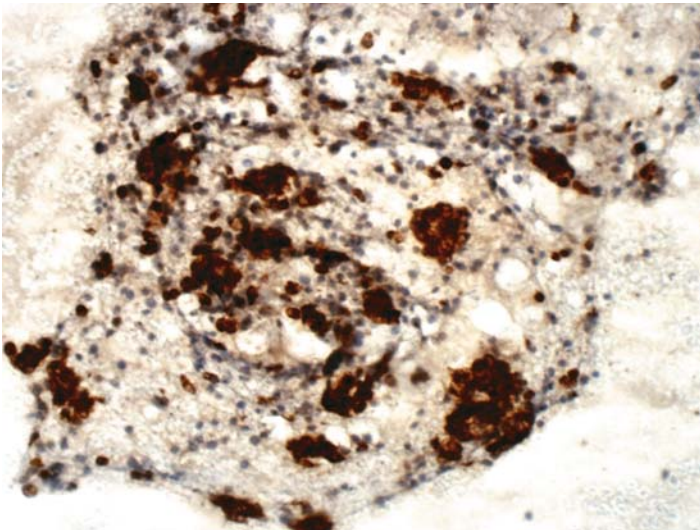


## Case 4

---



**FIGURE 4A. Pap Stain:** FNA of a mediastinal mass in a 74-year-old male with a history of smoking. The clinician suspected a lung primary. There are groups of predominantly isolated cells with ill-defined cytoplasm. The differential diagnosis includes malignant lymphoma and poorly differentiated carcinoma.



**FIGURE 4B. Cytokeratin:** Clusters of malignant epithelial cells that would otherwise have been overlooked are readily identifiable by their positive reaction for cytokeratin.

## ***Diagnosis***

Poorly Differentiated Carcinoma

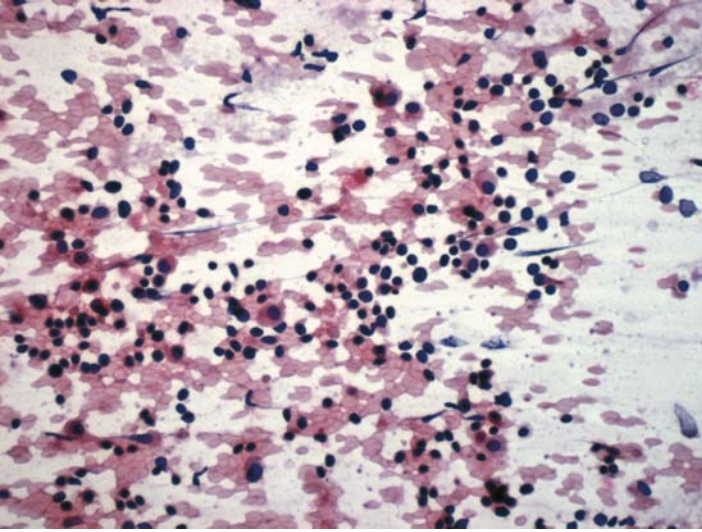
### ***Tips***

- Cytokeratin positivity highlights the epithelial cells that are otherwise difficult to distinguish from lymphocytes.
- The combination of epithelial cells and lymphocytes in an aspirate from mediastinum raises the possibility of a thymoma. The pattern of cytokeratin staining, that is, strong and intracytoplasmic, however, is not characteristic of thymoma (See Cases 80 and 81 for comparison).

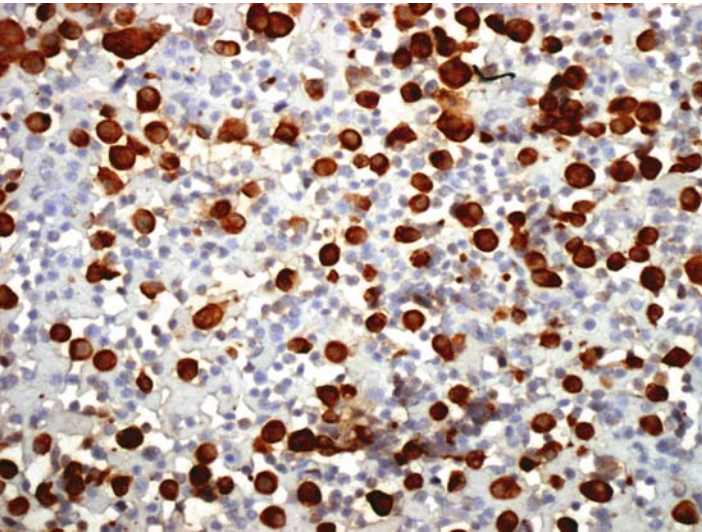
*Suggested Reading: 8, 11*

## Case 5

---



**FIGURE 5A. Pap Stain:** FNA of axillary lymph node in a female with a history of mammary carcinoma. The sample is composed predominantly of lymphocytes, with a few isolated larger cells containing eosinophilic cytoplasm.



**FIGURE 5B. Cytokeratin:** Metastatic tumor cells are positive, while lymphocytes remain negative. Tumor cells were also positive for estrogen receptor (not shown).



## ***Diagnosis***

Metastatic Mammary Carcinoma

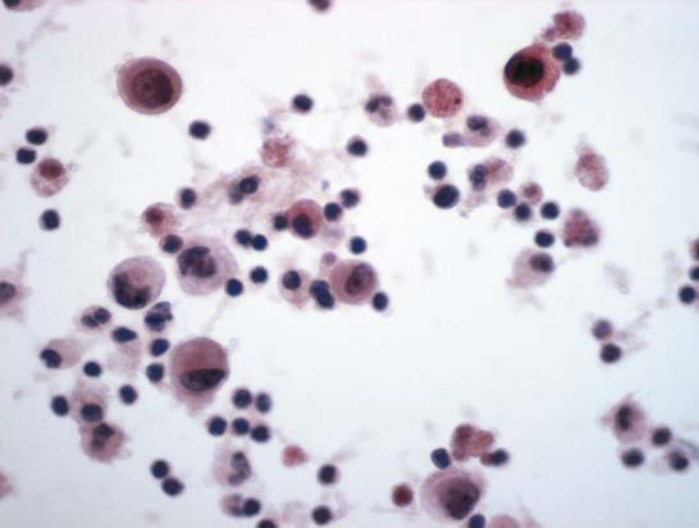
## ***Tips***

Cytokeratin staining reveals a large number of isolated epithelial cells. In a patient with a history of breast cancer, these cells are suggestive of a lobular carcinoma. Lobular carcinomas of the breast are almost always positive for estrogen receptor (See Case 100).

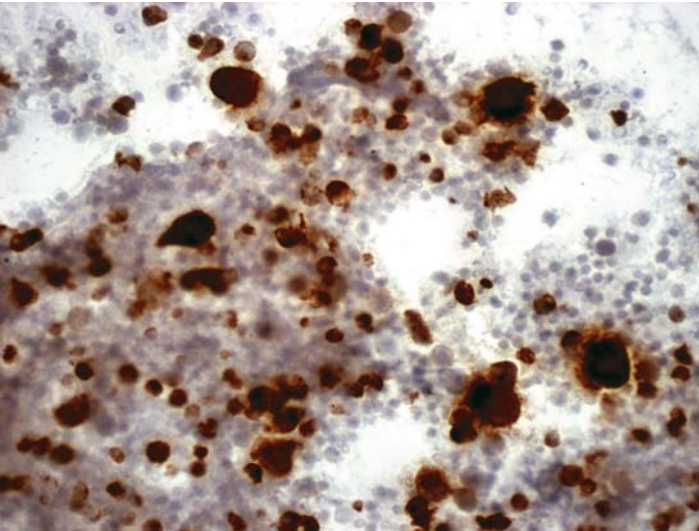
*Suggested Reading: 8, 49*

## Case 6

---



**FIGURE 6A. Pap Stain:** FNA of a neck mass in a 68-year-old male. There are isolated large pleomorphic cells on a background of small lymphocytes. The differential diagnosis includes carcinoma, melanoma, and lymphoma. Seminoma is less likely at this patient's age.



**FIGURE 6B. CD30:** The large cells are positive for CD30. The reaction for cytokeratin and S100 protein was negative.

## ***Diagnosis***

Anaplastic Large Cell Lymphoma

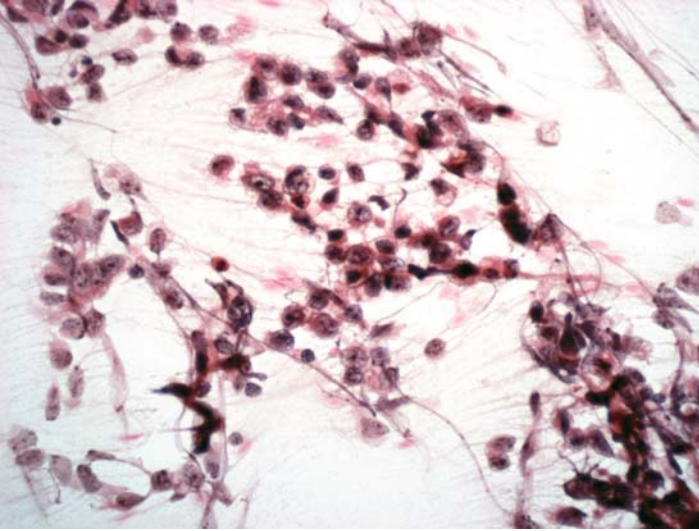
## ***Tips***

- In histology, anaplastic lymphomas show a characteristic cytoplasmic membrane staining for CD30, along with paranuclear dot-like antigen localization. This pattern, however, is not seen in most smears and cytocentrifuge specimens because the cells are not cut by microtome blade. Therefore, it becomes difficult to distinguish between a cell membrane and a cytoplasmic staining.
- Anaplastic large cell lymphomas may be negative for CD45.

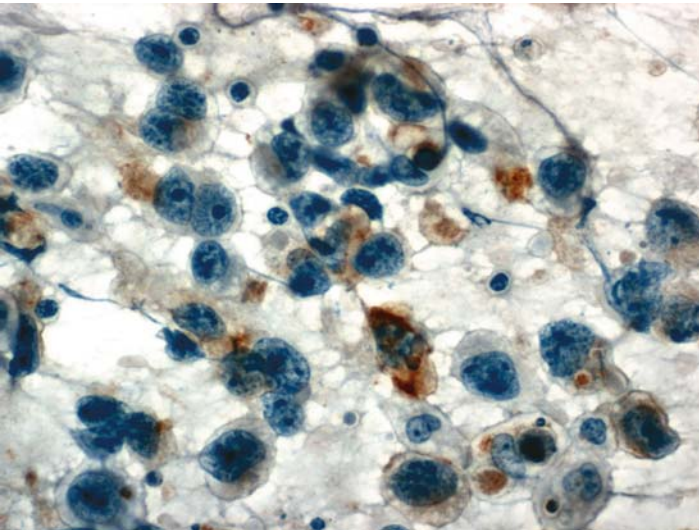
*Suggested Reading: 15*

## Case 7

---



**FIGURE 7A. Pap Stain:** Retroperitoneal FNA in a 26-year-old man. The loosely cohesive cells with crushing artifact contain large nuclei with open chromatin and nucleoli. The cytomorphology, along with the patient's age, raises the possibility of a metastatic seminoma.



**FIGURE 7B. Placental Alkaline Phosphatase (PLAP):** There is positive cytoplasmic staining for PLAP.

## ***Diagnosis***

Metastatic Seminoma

### ***Tips***

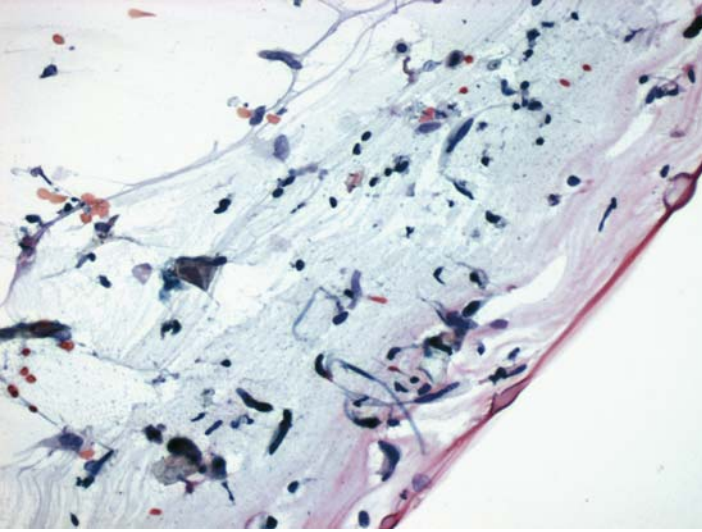
- Placental alkaline phosphatase is not specific for seminomas.
- Most seminomas are negative for cytokeratin.
- Seminomas may be a component of a mixed germ cell tumor. The nonseminomatous elements (usually embryonal carcinomas) are positive for cytokeratin.

*Suggested Reading: 16*

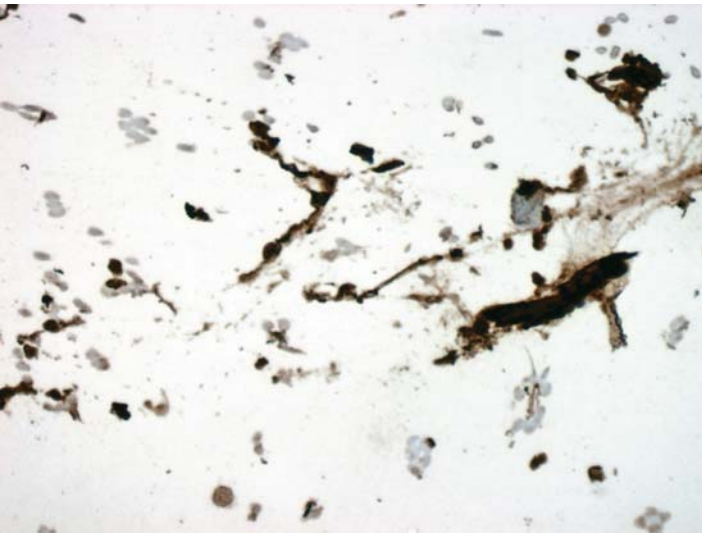
# 5 Soft Tissue Tumors

## Case 8

---



**FIGURE 8A. Pap Stain:** FNA smear from a subcutaneous mass of a patient with a history of neurofibromatosis. There are spindle-shaped nuclei on a myxoid background that are suggestive of neurofibroma. ICC for S100 protein was performed for confirmation.



**FIGURE 8B. S100 Protein:** There is positive nuclear staining for S100.

## ***Diagnosis***

Spindle Cell Neoplasm Consistent with Neurofibroma

## ***Tips***

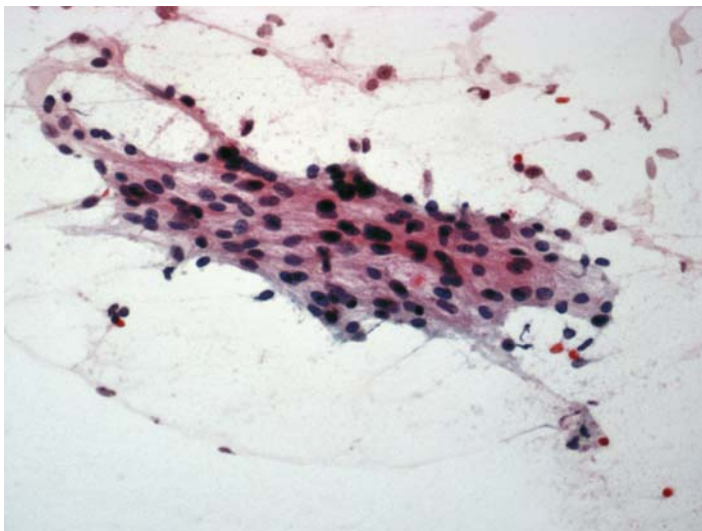
Aspiration cytology of neurofibromas yields very few cells, mostly in the form of naked nuclei. These cells, however, are usually positive for S100 protein.

*Suggested Reading: 17*

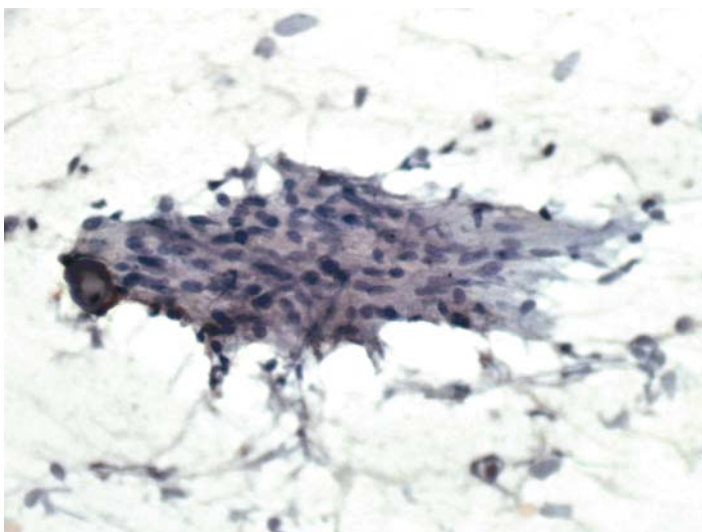

## Case 9

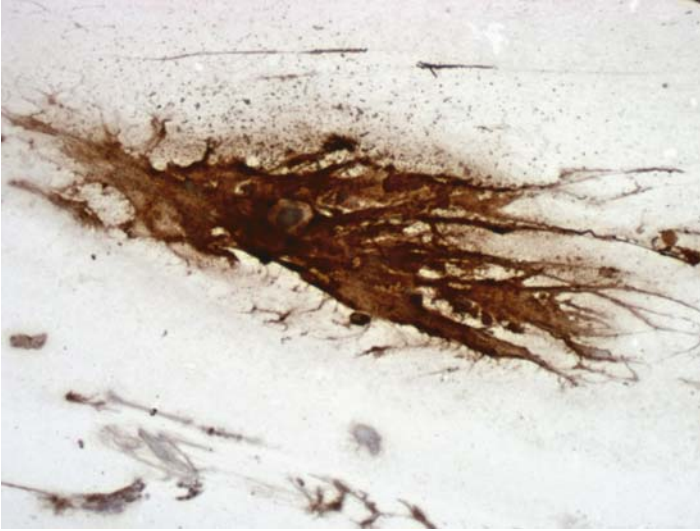
---



**FIGURE 9A. Pap Stain:** FNA of a thigh mass in a 45-year-old female. This is a spindle cell lesion with the differential diagnosis of a smooth muscle tumor and Schwannoma.



**FIGURE 9B. H-Caldesmon:** There is no reaction for this smooth muscle marker.



**FIGURE 9C. S100 Protein:** The reaction for S100 protein is strong and diffuse.

## ***Diagnosis***

Nerve Sheath Tumor, Consistent with Schwannoma

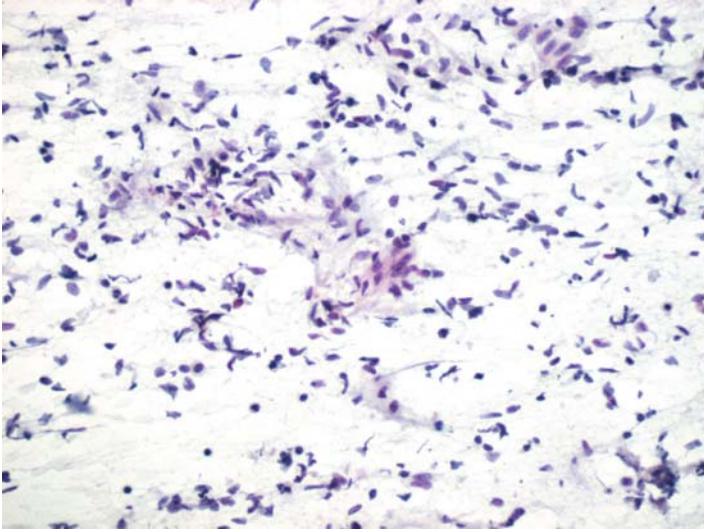
## ***Tips***

- H-Caldesmon is a sensitive and specific marker for smooth muscle tumors. It is superior to desmin because desmin may be negative in approximately one-half of nongynecologic smooth muscle neoplasms.
- The reaction for S100 protein is usually strong and different in benign nerve sheath tumors. Malignant nerve sheath tumors, on the other hand, may only show focal staining. In small samples, therefore, a negative reaction for S100 protein does not exclude the possibility of a malignant nerve sheath neoplasm.

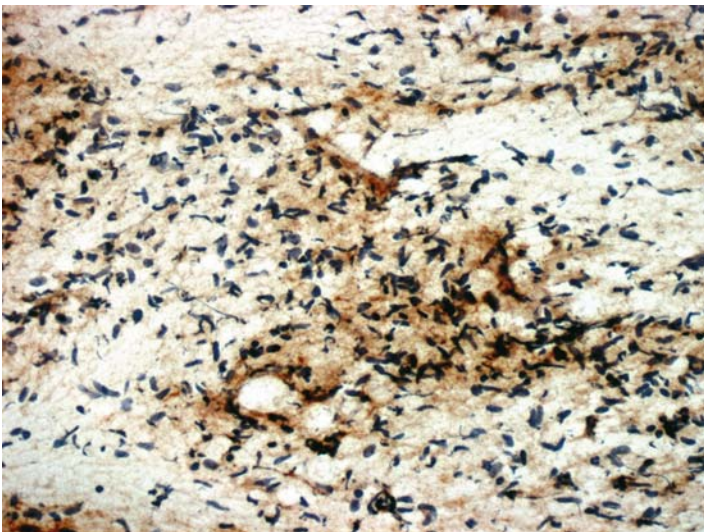
*Suggested Reading: 9, 18*

## Case 10

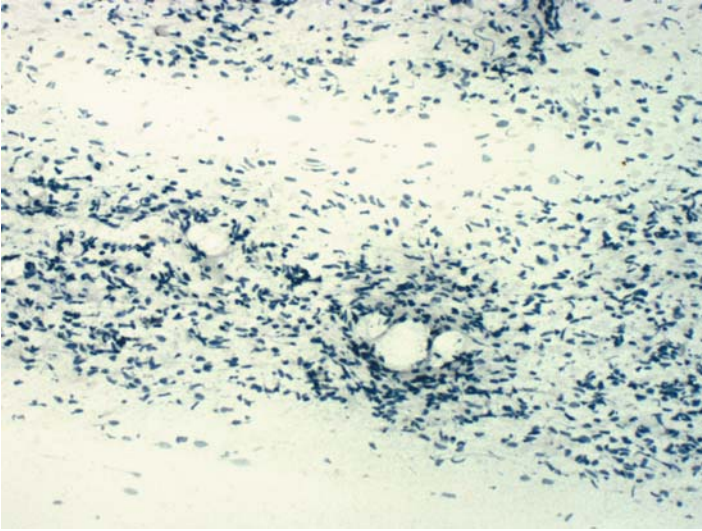
---



**FIGURE 10A. Pap Stain:** This rather cellular but bland-appearing spindle cell lesion is an imprint from an 0.8-cm asymptomatic cutaneous mass. Differential diagnosis includes a number of spindle cell lesions of the skin, including dermatofibroma, dermatofibrosarcoma, and neurofibroma.



**FIGURE 10B. CD34:** There is a positive reaction in some of the cells and in the background.



**FIGURE 10C. Factor XIIIa:** The negative reaction for this antigen excludes the possibility of a dermatofibroma. Cells were also negative for S100 protein.

## ***Diagnosis***

Spindle Cell Neoplasm Consistent with Dermatofibrosarcoma  
Protuberans

## ***Tips***

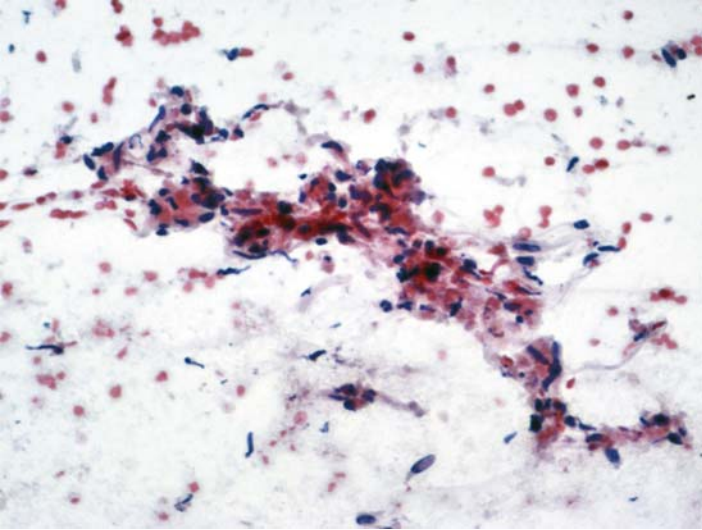
- CD34 staining in dermatofibrosarcomas is usually diffuse without a distinct pattern of cytoplasmic localization. This background type of staining is also seen in cytologic material.
- Dermatofibromas are usually small and, hence, are seldom aspirated.

*Suggested Reading: 19*

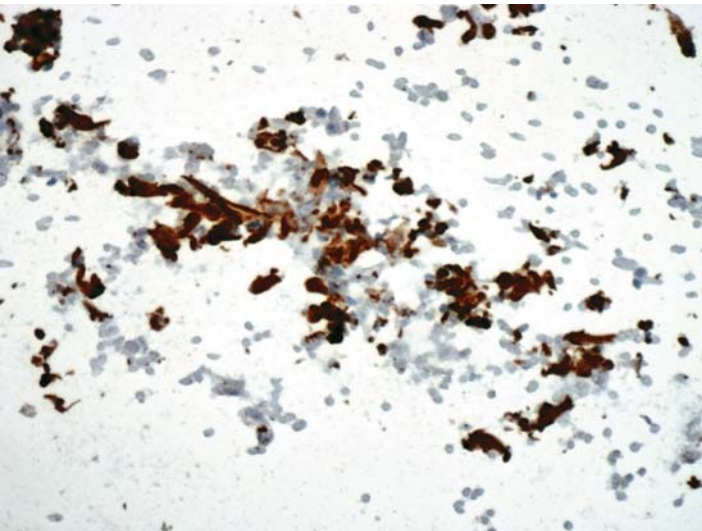


## Case 11

---



**FIGURE 11A. Pap Stain:** FNA of a retroperitoneal mass in a 57-year-old female. The relatively paucicellular specimen is composed of spindle cells with eosinophilic cytoplasm. A myogenic origin was suspected.



**FIGURE 11B. H-Caldesmon:** Strong positive reaction for H-Caldesmon supports the smooth muscle origin of this tumor.

## ***Diagnosis***

Smooth Muscle Neoplasm, Benign on Excision

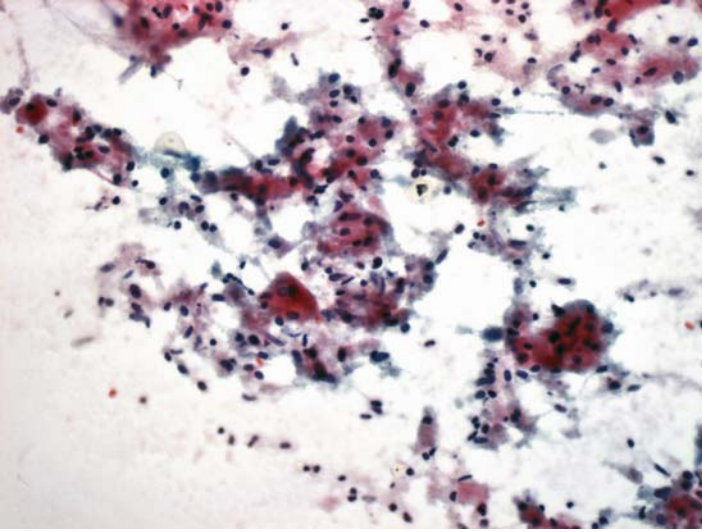
## ***Tips***

- While H-Caldesmon is specific for smooth muscle tumors, desmin may be expressed by both smooth and skeletal muscle neoplasms.
- Neither smooth muscle actin nor muscle specific actin are specific markers for smooth muscle neoplasms, as they are expressed by a wide variety of unrelated tumors.

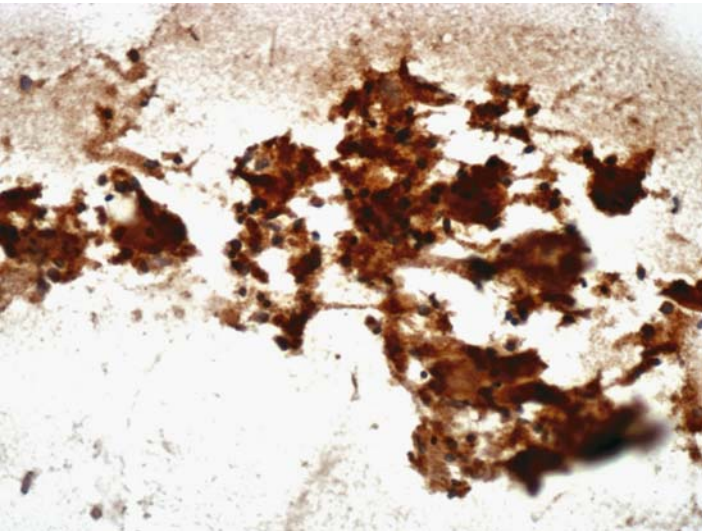
*Suggested Reading: 18, 20*

## Case 12

---



**FIGURE 12A. Pap Stain:** FNA of a soft tissue mass in the anterior chest of a 46-year-old female. There are large cells with abundant eosinophilic granular cytoplasm, small round nuclei, and ill-defined cytoplasmic borders. A granular cell tumor was suspected.



**FIGURE 12B. S100 Protein:** Strong positive reaction for S100 protein supports the cytologic impression.

## ***Diagnosis***

Granular Cell Tumor

## ***Tips***

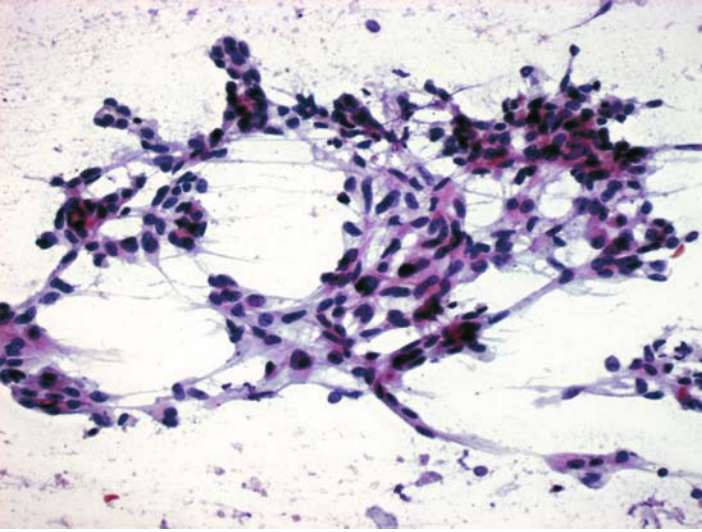
Granular cell tumors may be in the differential diagnosis of histiocytic reactions. One should not however use a histiocytic marker, such as CD68, in the panel, as they may also be expressed by granular cell tumors.

*Suggested Reading: 21*

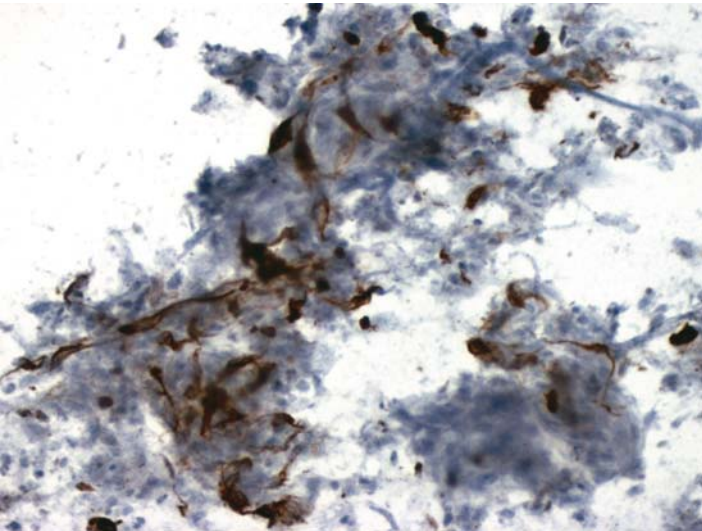


## Case 13

---



**FIGURE 13A. Pap Stain:** FNA of a 3.5-cm soft tissue mass in the ankle of a 34-year-old male. Large spindle and epithelioid cells, as well as the location of tumor and the age of patient, raise the possibility of a synovial sarcoma.



**FIGURE 13B. Cytokeratin:** The tumor is focally positive for cytokeratin.

## ***Diagnosis***

Synovial Sarcoma

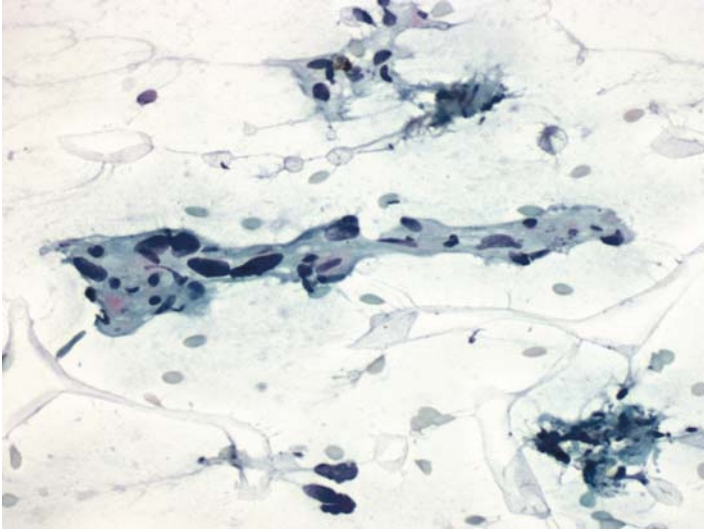
### ***Tips***

- In addition to cytokeratin, synovial sarcomas may focally express epithelial membrane antigen.
- Cytokeratin positivity does not differentiate synovial sarcomas from spindle-cell carcinomas. If additional slides are available, one may use CD99 and Bcl-2, both of which are usually expressed by synovial sarcomas, but rarely by spindle cell carcinomas.

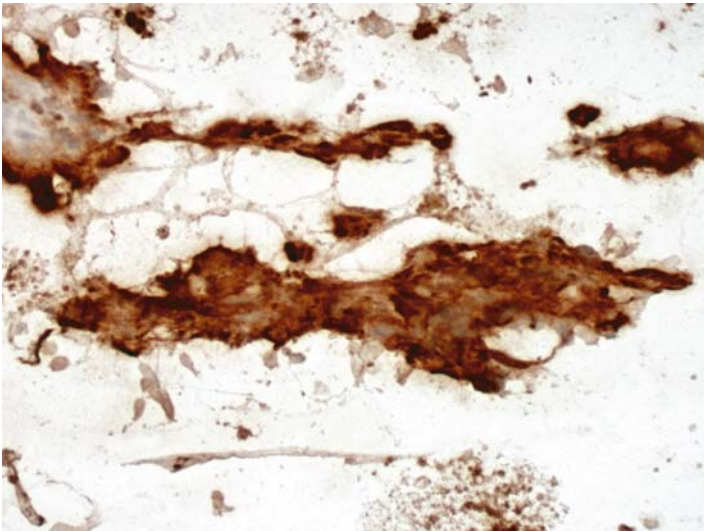
*Suggested Reading: 22*

## Case 14

---



**FIGURE 14A. Pap Stain:** FNA of a pelvic mass in a 53-year-old female with a history of hysterectomy for uterine sarcoma. Large spindle cells with pleomorphic nuclei raise the possibility of a sarcoma, probably leiomyosarcoma.



**FIGURE 14B. H-Caldesmon:** There is strong positive reaction for H-Caldesmon.

## ***Diagnosis***

Leiomyosarcoma

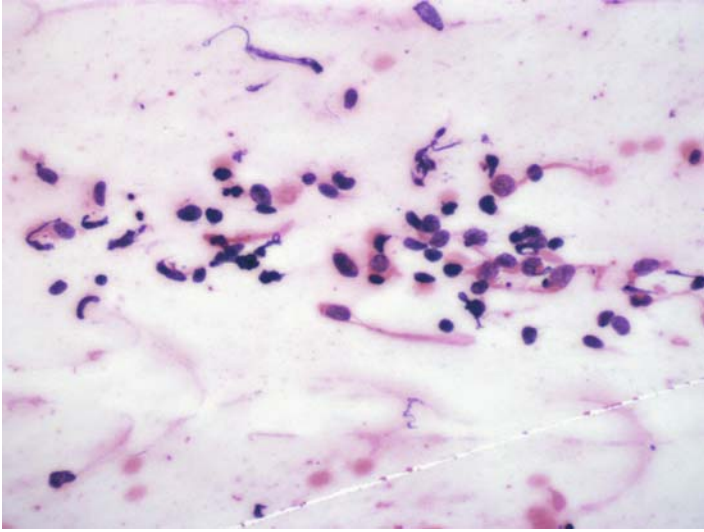
## ***Tips***

- In addition to H-Caldesmon, leiomyosarcomas of the female genital tract commonly express desmin.
- Uterine leiomyosarcomas may also be positive for estrogen and progesterone receptors. Positivity for these markers may provide the clinicians with additional treatment options.

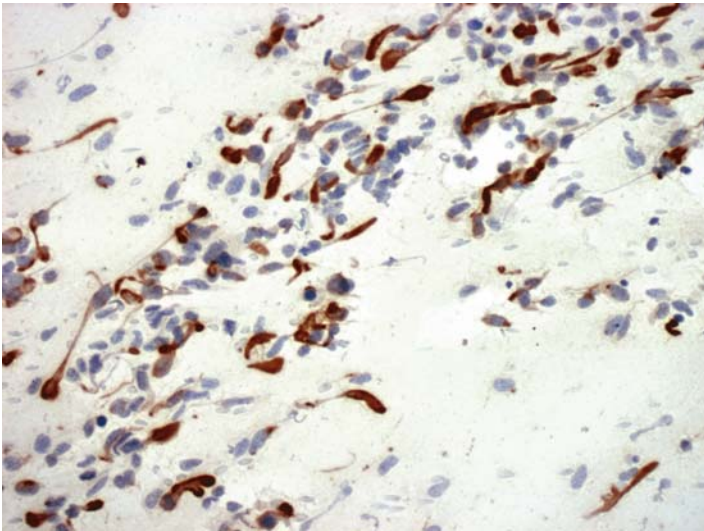
*Suggested Reading: 18, 20*

## Case 15

---



**FIGURE 15A. H&E Stain:** Imprint of a resected 1.5-cm neck mass in a 12-year-old male. Small cell malignant tumor; rule out a rhabdomyosarcoma.



**FIGURE 15B. Desmin:** Many tumor cells show positive cytoplasmic staining.

## ***Diagnosis***

Rhabdomyosarcoma

### ***Tips***

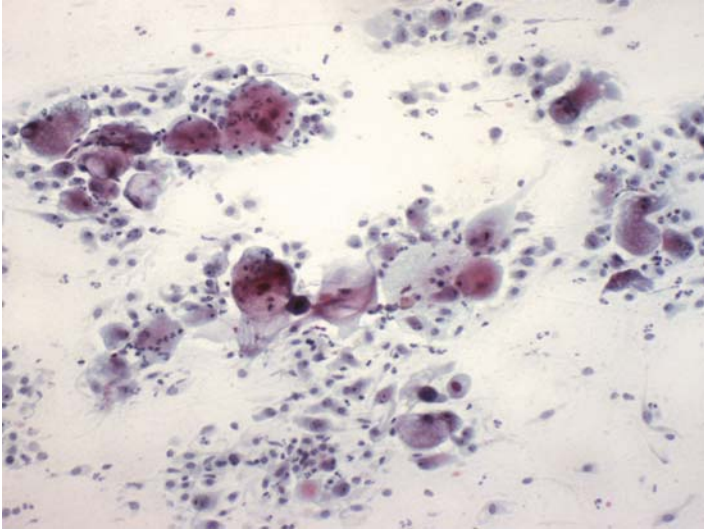
- Rhabdomyosarcomas are always positive for desmin. In embryonal type, the reaction may be punctate or perinuclear.
- Embryonal and alveolar rhabdomyosarcomas also express myogenin. Although this nuclear marker is specific for rhabdomyosarcomas, it may not be present in tumors that are better differentiated (i.e., show cross-striation).

*Suggested Reading: 23*

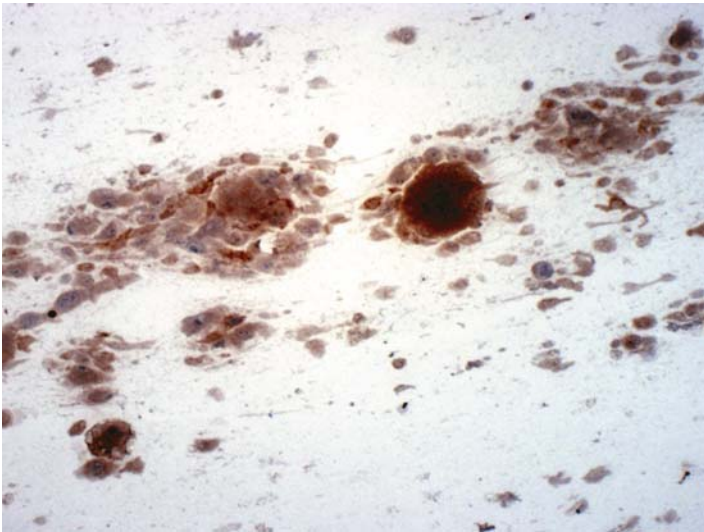


## Case 16

---



**FIGURE 16A. Pap Stain:** FNA from a large retroperitoneal mass in a 65-year-old male. There are many pleomorphic mononuclear and multinucleated cells, some with foamy cytoplasm.



**FIGURE 16B. CD68:** There is positive reaction for CD68 in some of the cells.

## ***Diagnosis***

Pleomorphic Sarcoma, Probably a Malignant Fibrous Histiocytoma

## ***Tips***

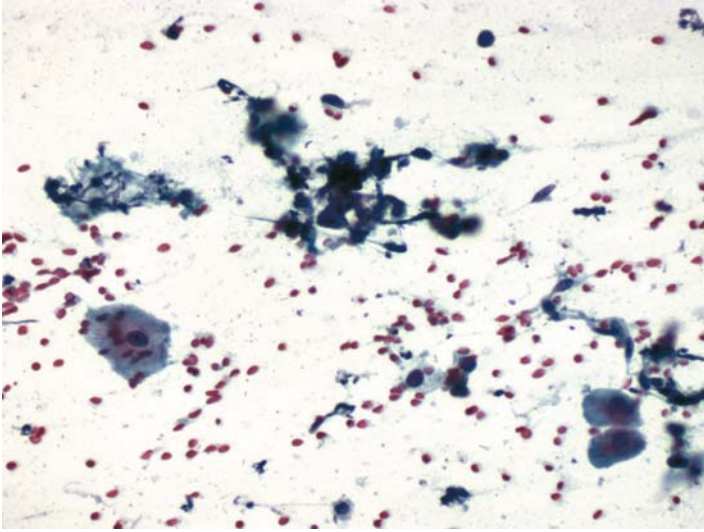
The differential diagnosis of pleomorphic sarcomas in general, and fibrous histiocytomas in particular, is difficult to resolve by immunocytochemistry. This is partly because CD68 positive tumor cells may be seen in a variety of other sarcomas and, therefore, are not diagnostic of malignant fibrous histiocytomas.

*Suggested Reading: 7*

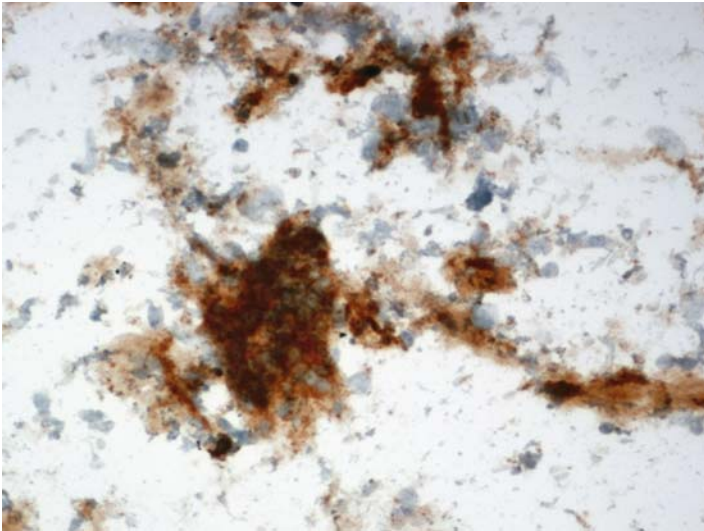


## Case 17

---



**FIGURE 17A. Pap Stain:** FNA of a hemorrhagic oral mucosal lesion in an immunosuppressed patient; Kaposi's sarcoma was suspected clinically. In addition to normal squamous cells, there are a few atypical spindle-shaped nuclei.



**FIGURE 17B. CD31:** The spindle cells are positive for CD31.

## ***Diagnosis***

Kaposi's Sarcoma

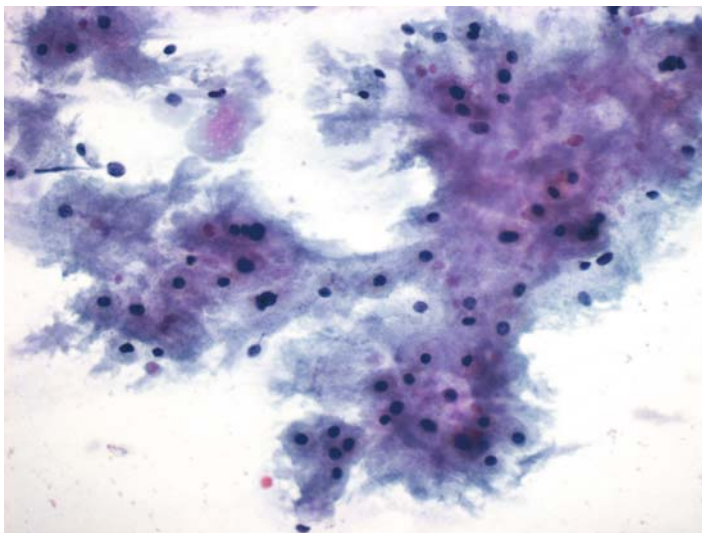
### ***Tips***

- FNA of Kaposi's sarcoma does not usually yield many cells. The few cells that may be present are always positive for CD31. The slide background is also positive because of the presence of platelets.
- Factor VIII-related antigen is less sensitive than CD31 for Kaposi's sarcoma.
- Kaposi's cells also react positively for D2-40, a marker for lymphatic endothelial cells.

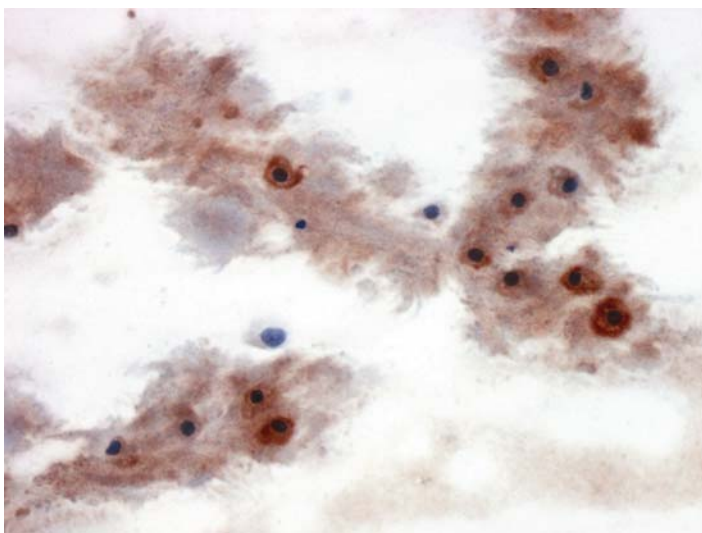
*Suggested Reading: 24–26*

## Case 18

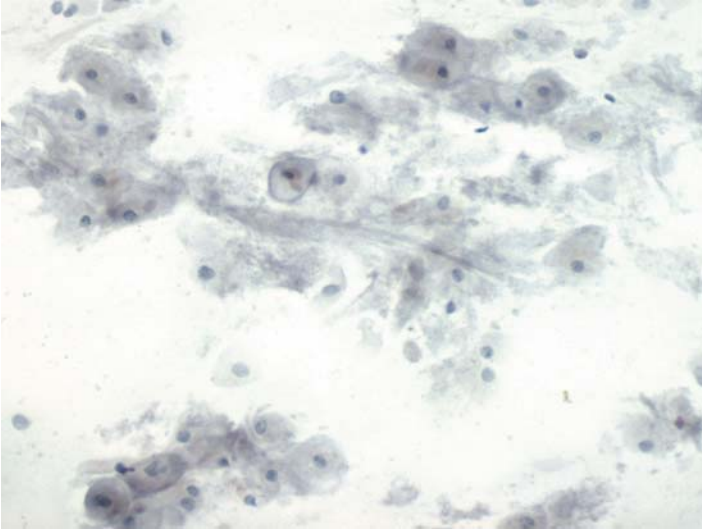
---



**FIGURE 18A. Pap Stain:** FNA of a sacroiliac lesion in a 66-year-old male. This is a chondroid lesion, but a chordoma should be excluded.



**FIGURE 18B. S100 Protein:** Tumor cells are positive for S100 protein.



**FIGURE 18C. Cytokeratin:** Cells are negative for cytokeratin, so a chordoma is excluded.

### ***Diagnosis***

Chondroid Neoplasm, Probably a Myxoid Chondrosarcoma

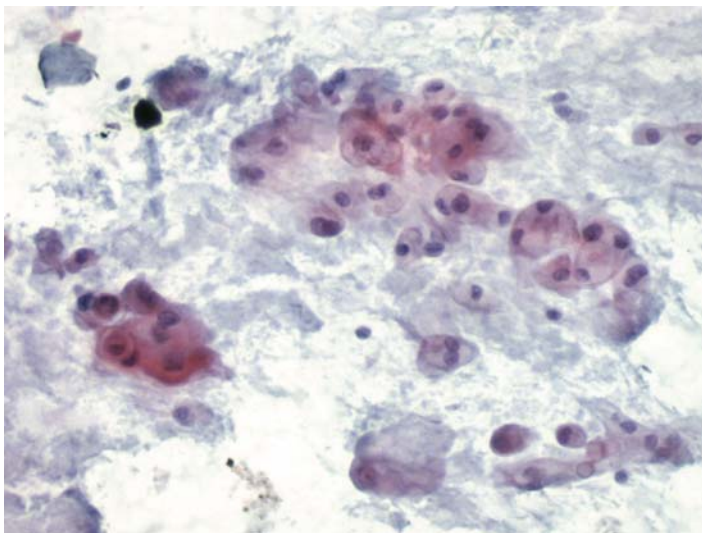
### ***Tips***

- S100 protein is expressed by both chordomas and chondrosarcomas. It, therefore, cannot be used to differentiate the two lesions.
- Chordomas are epithelial tumors and are always positive for cytokeratin, whereas chondroid neoplasms do not express cytokeratin (7).

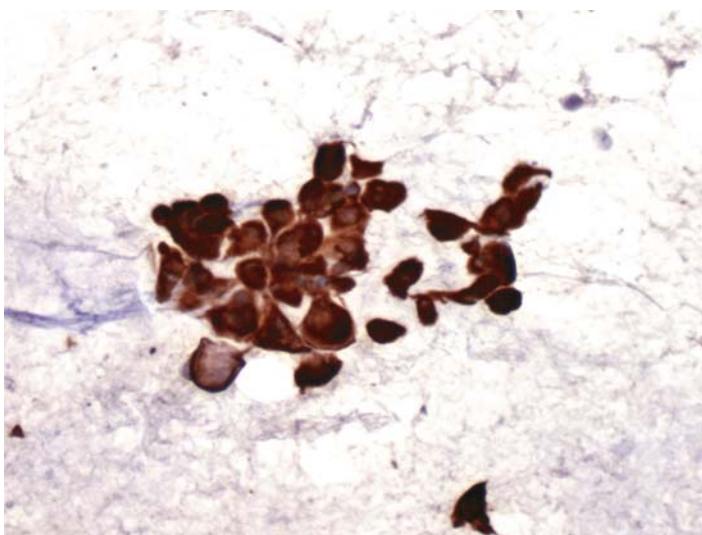
*Suggested Reading:* 7

## Case 19

---



**FIGURE 19A. Pap Stain:** FNA of a retropharyngeal mass in a 44-year-old male. The differential diagnosis includes chondrosarcoma and chordoma.



**FIGURE 19B. Cytokeratin:** The reaction is positive for cytokeratin confirming the impression of a chordoma.

## ***Diagnosis***

Chordoma

### ***Tips***

In addition to cytokeratin, chordomas are also positive for epithelial membrane antigen and CEA. None of these markers, however, are useful in differentiating chordomas from mucinous adenocarcinomas. For that purpose, one could use S100 protein; it is usually negative in mucinous adenocarcinomas.

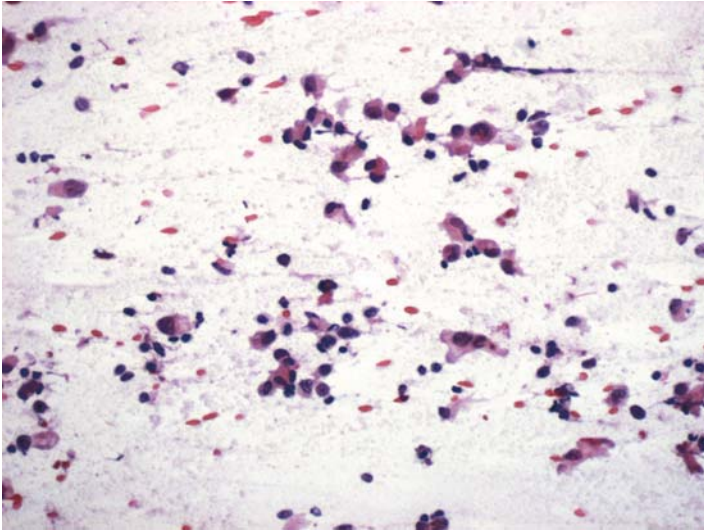
*Suggested Reading: 7*

# 6 Gastrointestinal Tract

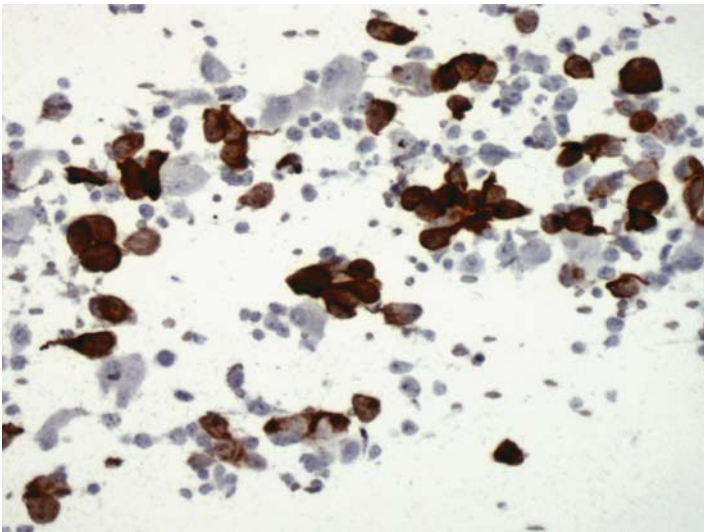


## Case 20

---



**FIGURE 20A. Pap Stain:** Endoscopic FNA of a large, ulcerated, gastric mass in a 76-year-old patient clinically suspected to have malignant lymphoma. There are isolated cells with eosinophilic cytoplasm more suggestive of a carcinoma.



**FIGURE 20B. Cytokeratin:** Positive reaction for cytokeratin supports the diagnosis of a carcinoma.



## ***Diagnosis***

Poorly Differentiated Carcinoma

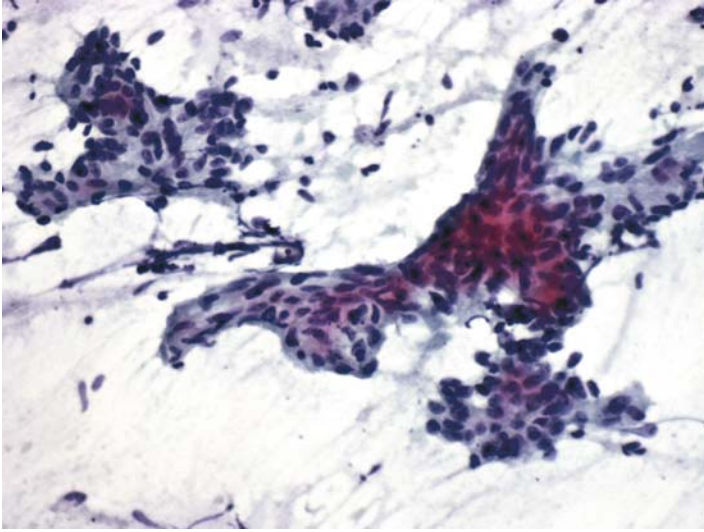
### ***Tips***

- Because the differential diagnosis is between an undifferentiated carcinoma and a malignant, large cell lymphoma, a combination of cytokeratin and CD45 should resolve the problem. We chose cytokeratin because there was only one extra slide and we suspected a carcinoma.
- The use of cytokeratin subtypes, such as CK7 and CK20, have no indication in this case.

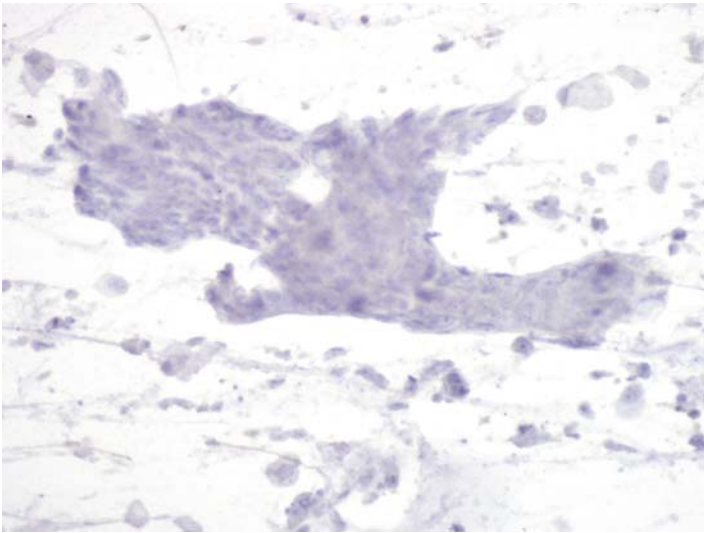
*Suggested Reading: 7*

## Case 21

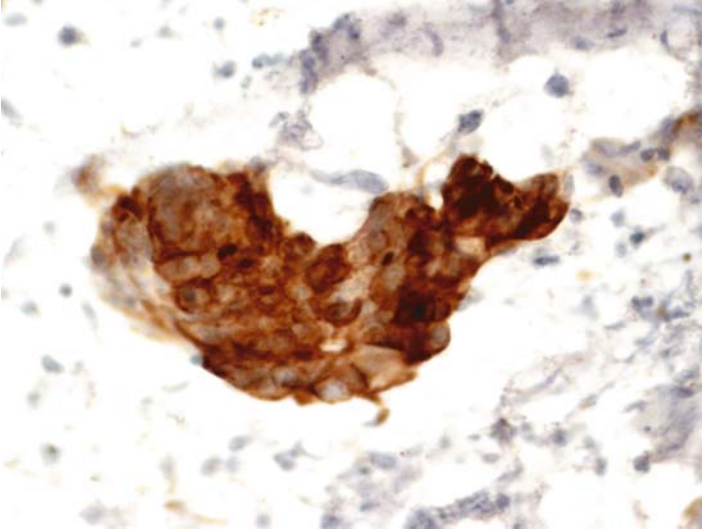
---



**FIGURE 21A. Pap Stain:** FNA of a periumbilical mass in a patient with a history of colonic adenocarcinoma. The slide shows a poorly differentiated adenocarcinoma.



**FIGURE 21B. Cytokeratin7:** Tumor cells are negative for CK7.



**FIGURE 21C. Cytokeratin20:** They are positive for CK20, supporting the diagnosis of recurrent colonic carcinoma.

## ***Diagnosis***

Colonic Adenocarcinoma

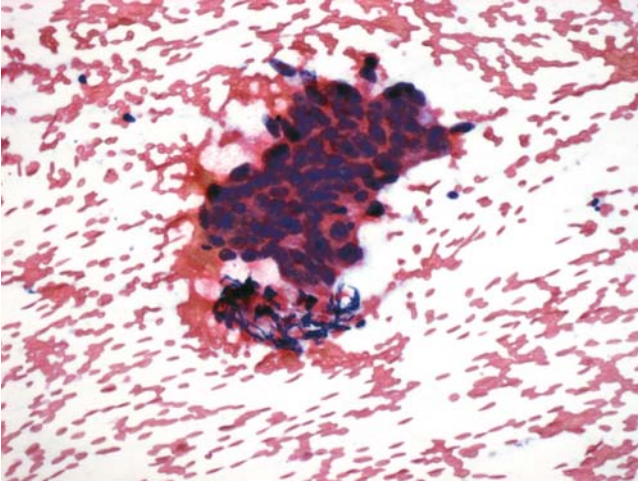
## ***Tips***

- Combination of positive cytokeratin 20 and negative cytokeratin 7 is highly suggestive of a colonic primary tumor.
- Other purported markers of colonic adenocarcinoma such as CDX-2 and villin are less specific.

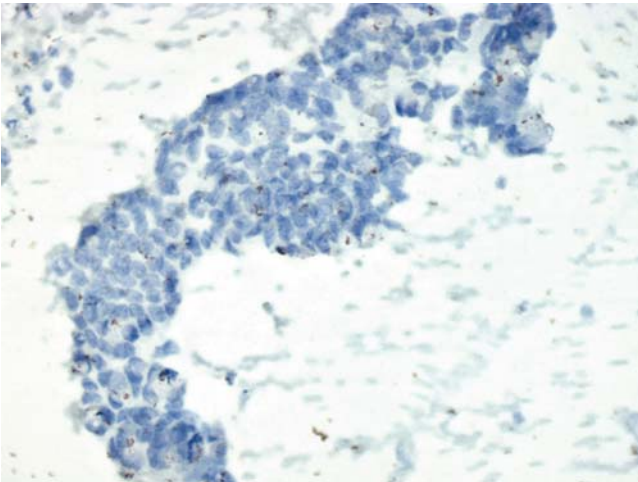
*Suggested Reading: 27, 28*

## Case 22

---



**FIGURE 22A. H&E Stain:** FNA of a periportal lymph node in a patient with history of colonic carcinoma. The cytology is consistent with adenocarcinoma of colon.



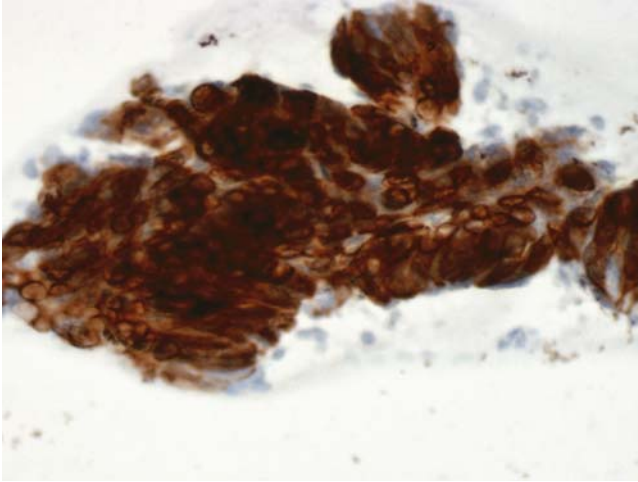
**FIGURE 22B. CK7:** Tumor cells are negative for CK7.

### *Diagnosis*

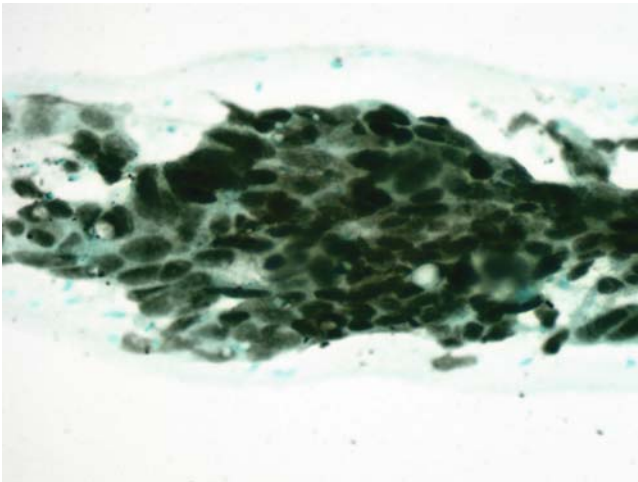
Metastatic Colonic Adenocarcinoma

### *Tips*

We added CDX-2 to the panel in this case to illustrate the nuclear localization of this antigen. Although most colonic adenocarcinomas are positive



**FIGURE 22C. CK20:** Tumor cells are strongly positive for CK20.



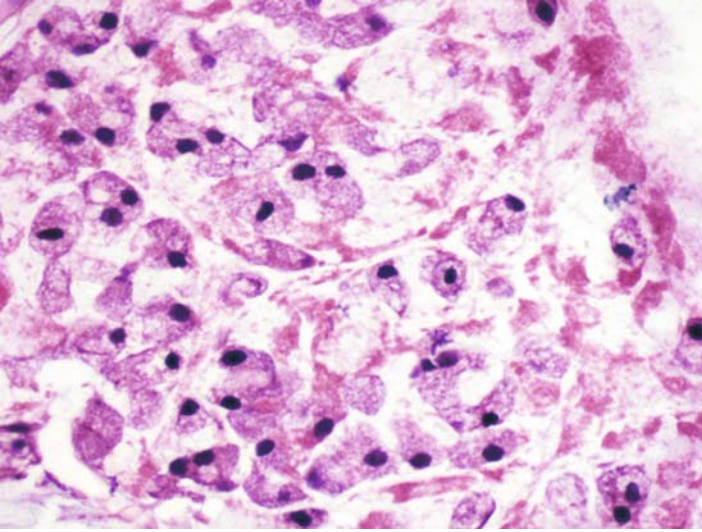
**FIGURE 22D. CDX-2:** There is also positive nuclear staining for CDX-2.

for CDX-2, adenocarcinomas of upper gastrointestinal tract and lung, as well as mucinous carcinomas of the ovary, may also express this marker.

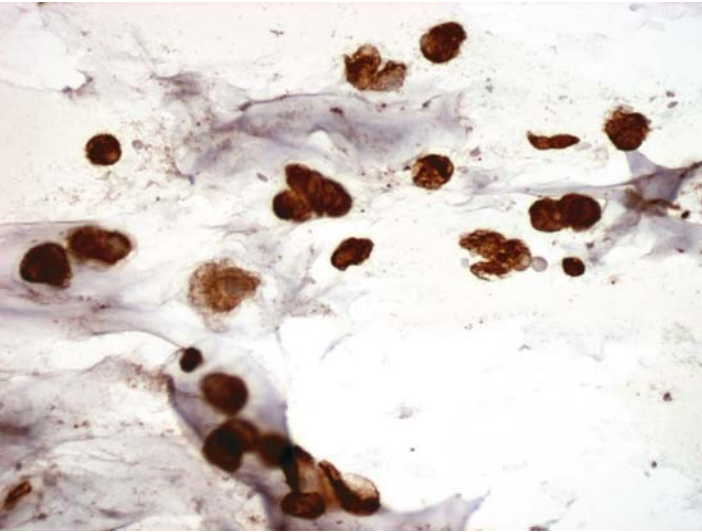
*Suggested Reading: 28*

## Case 23

---



**FIGURE 23A. H&E Stain:** Cell block preparation from laparoscopic FNA of a peritoneal nodule in a 44-year-old female. Morphologically, a signet ring cell carcinoma is suspected.



**FIGURE 23B. Cytokeratin:** Tumor cells are positive for cytokeratin.

## ***Diagnosis***

Signet Ring Cell Carcinoma (Appendiceal Primary)

## ***Tips***

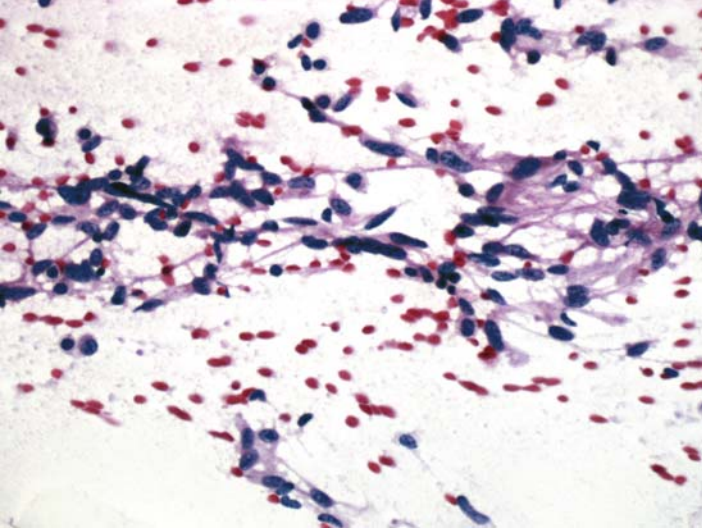
- The differential diagnosis in this case is between a signet ring cell carcinoma and a histiocytic reaction. Cytokeratin positivity confirms the diagnosis of carcinoma.
- Aspiration cytology of pseudomyxoma peritonei, whether of ovarian or appendiceal origin, may show only few epithelial cells and, hence, ICC for cytokeratin is useful in identifying them.

*Suggested Reading: 8*

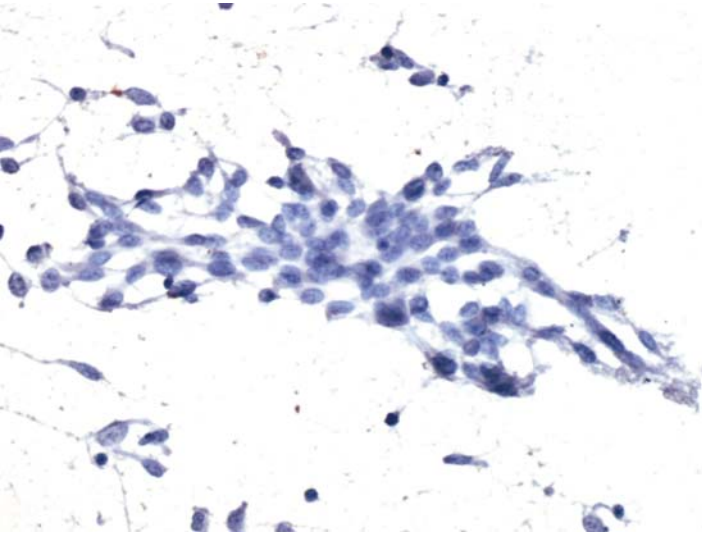


## Case 24

---

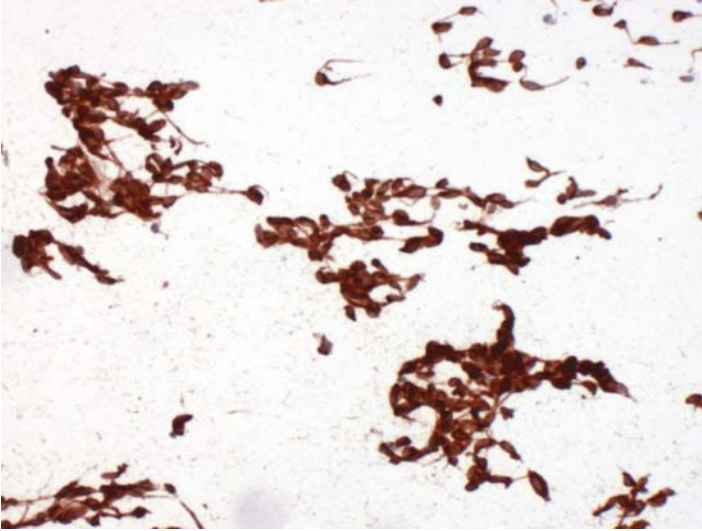


**FIGURE 24A. Pap Stain:** FNA of a gastric mass in a 68-year-old male. There is a spindle cell tumor: gastrointestinal stromal tumor versus a smooth muscle neoplasm.



**FIGURE 24B. Desmin:** Tumor cells are negative.





**FIGURE 24C. KIT (CD117):** There is strong and diffuse positive staining for KIT.

## ***Diagnosis***

Gastrointestinal Stromal Tumor (GIST)

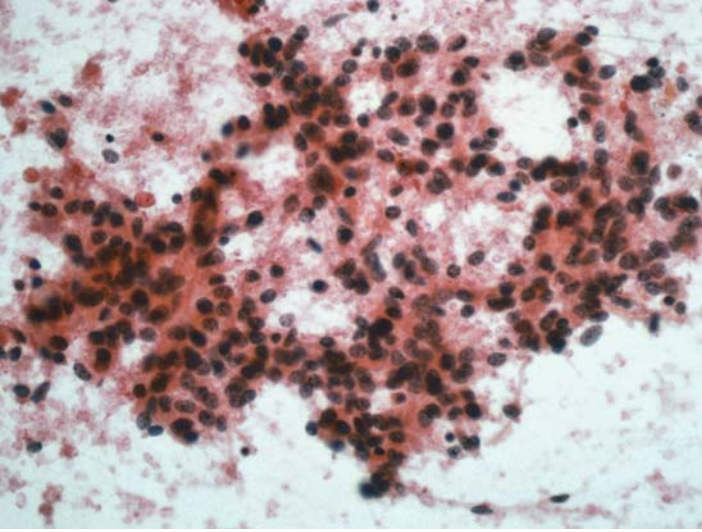
## ***Tips***

- Positive reaction for KIT in gastrointestinal tumors is usually strong and diffuse. Weak and focal reaction for KIT may be seen in a number of non-GIST tumors.
- Many GISTs may react positively for H-Caldesmon. Therefore, desmin is a better choice if a leiomyosarcoma is in the differential diagnosis.

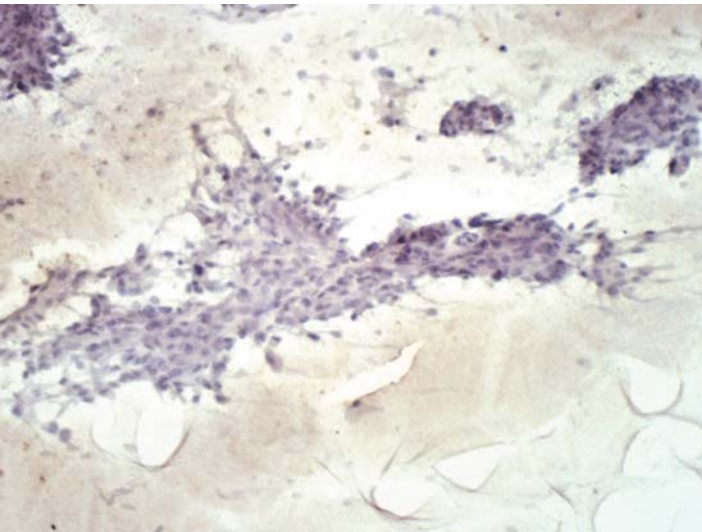
*Suggested Reading: 29*

## Case 25

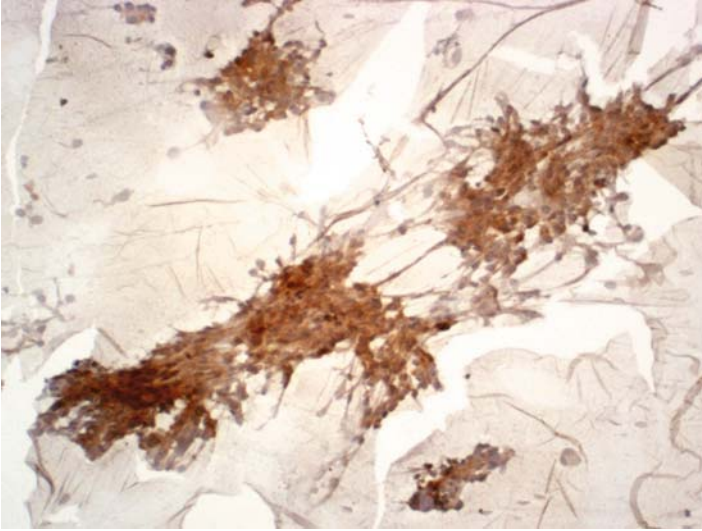
---



**FIGURE 25A. Pap Stain:** FNA of an abdominal mass in a 57-year-old male showing epithelioid cell with eosinophilic cytoplasm. The possibilities include a carcinoma and an epithelioid gastrointestinal stromal tumor.



**FIGURE 25B. Cytokeratin:** Negative reaction excludes the possibility of a carcinoma.



**FIGURE 25C. KIT (CD117):** There is a strong positive reaction.

## ***Diagnosis***

Epithelioid GIST

## ***Tips***

Epithelioid GISTs may be difficult to differentiate from carcinomas. Most epithelioid GISTs, however, have areas with spindle cell morphology. Also, ill-defined cytoplasmic borders, as in this case, are unusual for a carcinoma. Nevertheless, the final diagnosis rests on ICC confirmation.

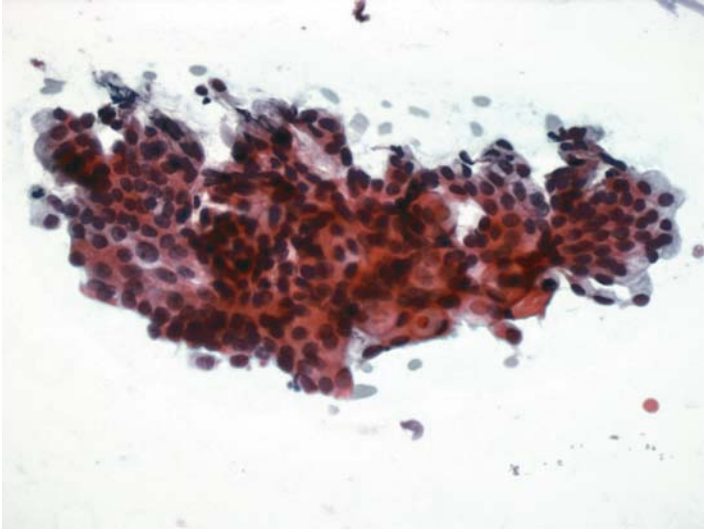
*Suggested Reading: 30*

# 7

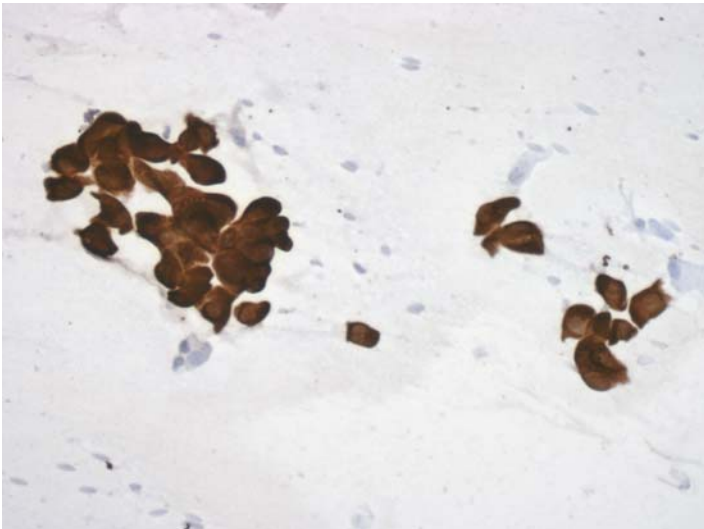
## Pancreas and Liver

## Case 26

---



**FIGURE 26A. Pap Stain:** FNA of pancreas of a 64-year-old male with a history of rectal carcinoma. This is an adenocarcinoma from the colon or the pancreas.



**FIGURE 26B. CK7:** Tumor cells are positive for CK7; a rectal metastasis is unlikely.

## ***Diagnosis***

Adenocarcinoma Consistent with a Pancreatic Primary

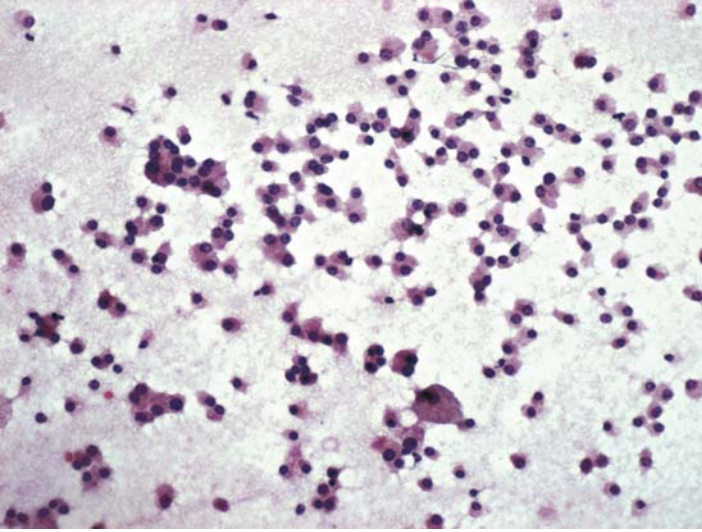
## ***Tips***

Most colorectal adenocarcinomas are negative for CK7, whereas pancreatic adenocarcinomas are always positive. When additional slides are available one should certainly include CK20 in the panel.

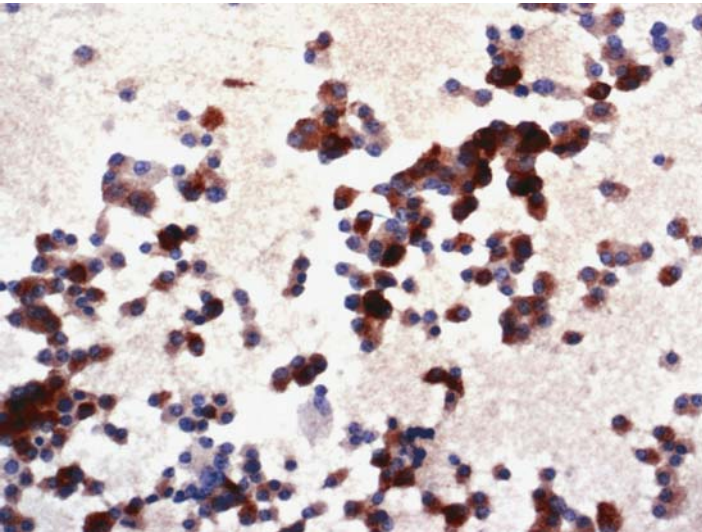
*Suggested Reading: 31*

## Case 27

---



**FIGURE 27A. Pap Stain:** Intraoperative FNA of pancreatic mass in a 46-year-old male. Loosely cohesive and isolated cells show eccentric nuclei. Rule out a neuroendocrine tumor.



**FIGURE 27B. Chromogranin:** The majority of tumor cells are positive for chromogranin.



## ***Diagnosis***

Pancreatic Islet Cell Tumor

### ***Tips***

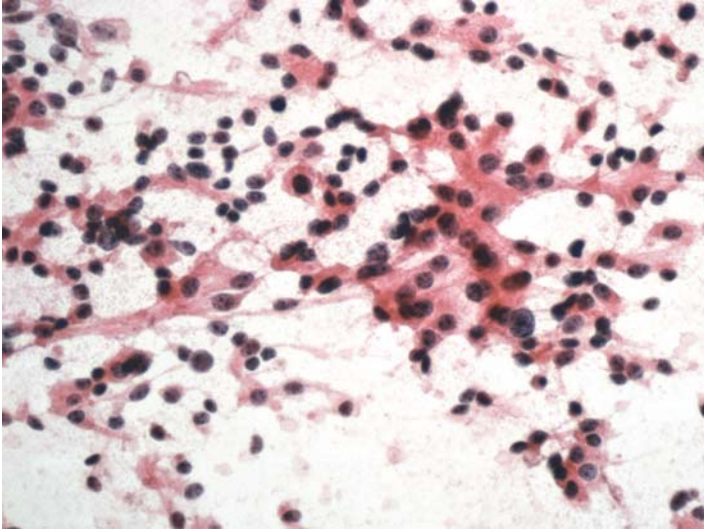
- Chromogranin is the most specific marker for neuroendocrine tumors. It is not however 100% sensitive as some islet cell tumors may be negative for this marker.
- Synaptophysin, on the other hand, is a more sensitive neuroendocrine marker, but it is less specific than chromogranin.

*Suggested Reading: 32, 33*

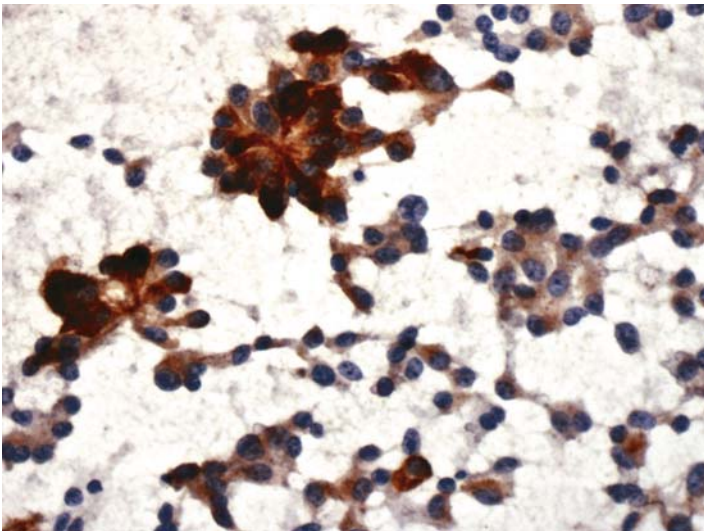


## Case 28

---



**FIGURE 28A. Pap Stain:** Pancreatic FNA in a 68-year-old patient. Differential diagnosis includes pancreatic ductal carcinoma and a neuroendocrine tumor.



**FIGURE 28B. Chromogranin:** Many tumor cells show positive cytoplasmic reaction for chromogranin.

## ***Diagnosis***

Pancreatic Islet Cell Tumor

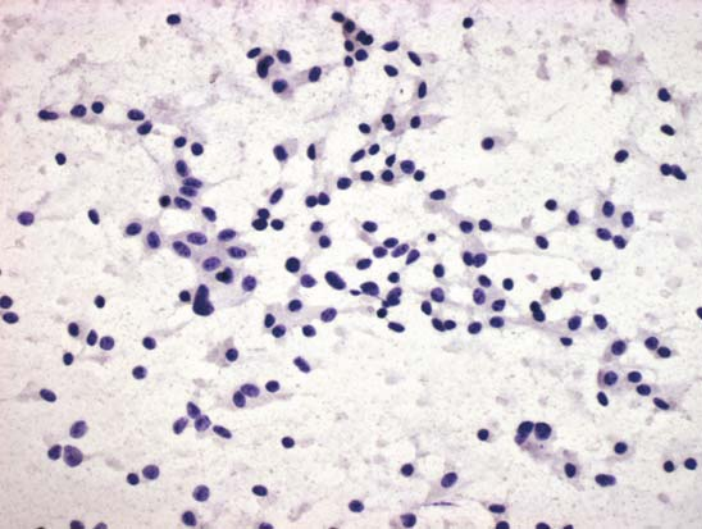
## ***Tips***

Neuroendocrine tumors of the pancreas can be in the differential diagnosis of acinic cell carcinomas and regular ductal carcinomas. When there is a choice of only one marker, we use chromogranin, particularly if cytology is more suggestive of an islet cell tumor.

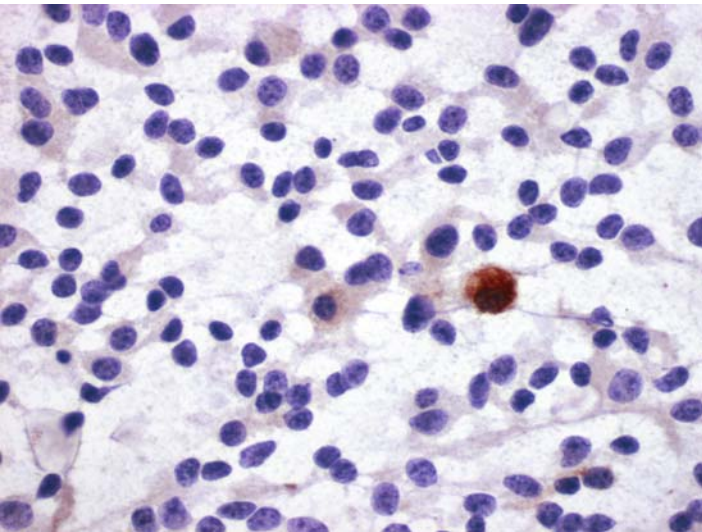
*Suggested Reading: 32, 33*

## Case 29

---



**FIGURE 29A. Pap Stain:** Pancreatic aspirate of a 28-year-old patient with a history of hypoglycemia. Isolated and loosely cohesive cells with eccentric nuclei suggest an islet cell tumor.



**FIGURE 29B. Insulin:** A few tumor cells are positive for insulin.

***Diagnosis***

Pancreatic Islet Cell Tumor (Insulinoma)

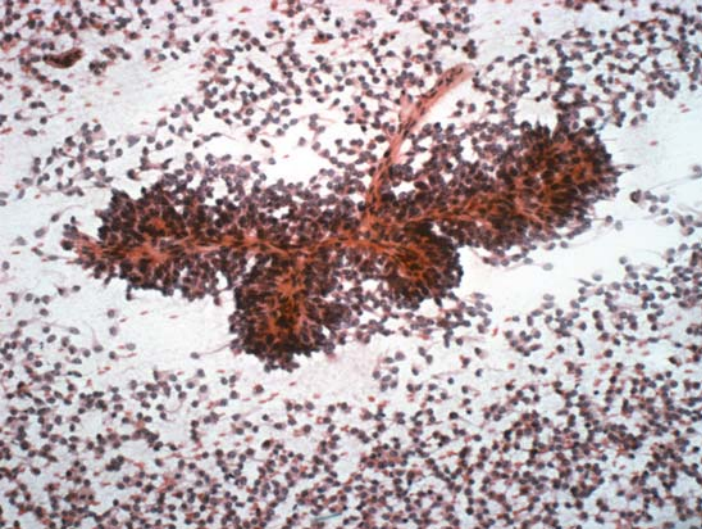***Tips***

The intensity of ICC reaction for a cellular protein does not necessarily correlate with its serum levels. Insulinomas, as in this case, are good examples; because many clinically hypersecreting tumors may only show focal reaction for insulin by ICC.

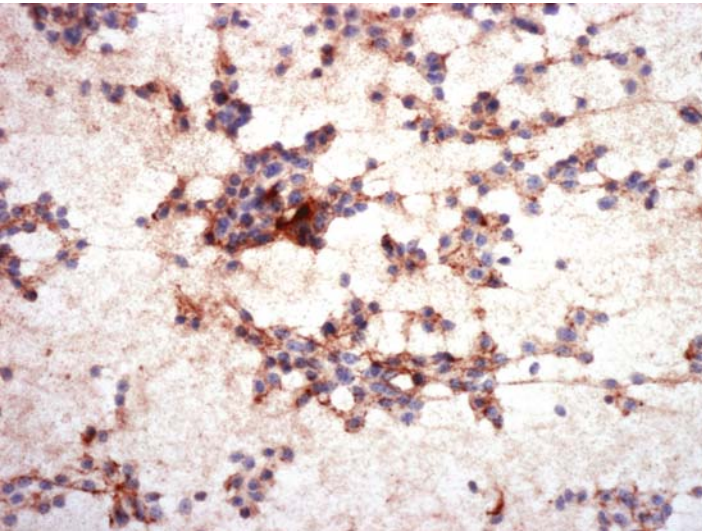
*Suggested Reading: 7*

## Case 30

---



**FIGURE 30A. Pap Stain:** This aspirate is from a 3.0-cm mass in the tail of pancreas of a 38-year-old female. Note the papillary pattern of the cells with fibrovascular stalk. The isolated cells have the morphology of an endocrine tumor. The reaction for chromogranin was negative. The same slide was used to stain for Neuronal Enolase (NSE).



**FIGURE 30B. NSE:** Tumor shows diffuse staining for NSE.

## ***Diagnosis***

Pancreatic Solid and Papillary Tumor

## ***Tips***

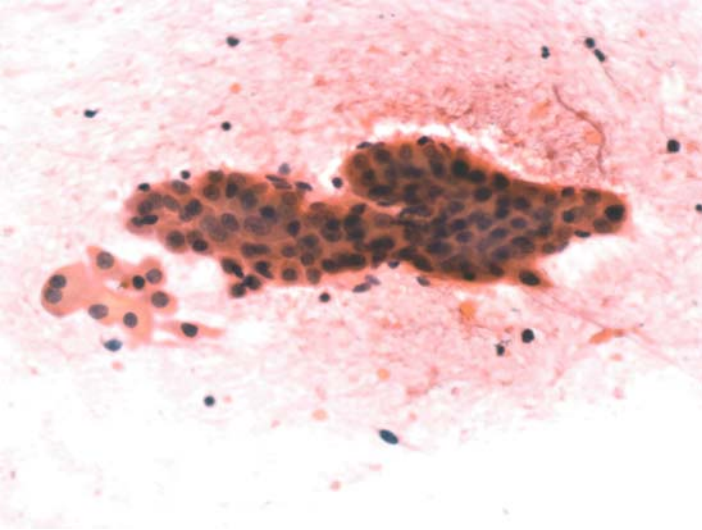
A pancreatic tumor with neuroendocrine morphology may represent a solid and papillary neoplasm. The combination of negative chromogranin and positive NSE strongly supports that diagnosis.

*Suggested Reading: 34*

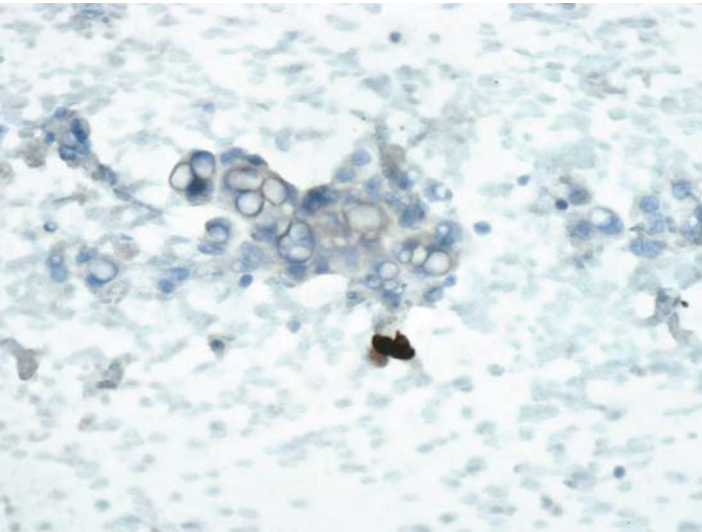


## Case 31

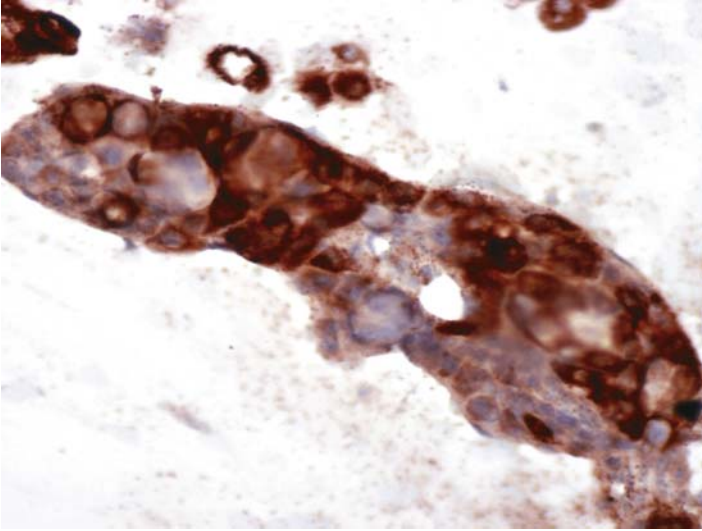
---



**FIGURE 31A. H&E Stain:** FNA of a liver mass in a patient with a history of hepatitis C and cirrhosis. The cytology is more suggestive of an adenocarcinoma. Few normal hepatocytes are also present.



**FIGURE 31B. CK7:** Tumor cells are negative for CK7 while a single ductal cell is strongly positive.



**FIGURE 31C. Hepatocellular Antigen (HCA, HepPar1):** There is positive granular cytoplasmic staining for HCA.

## ***Diagnosis***

Hepatocellular Carcinoma

## ***Tips***

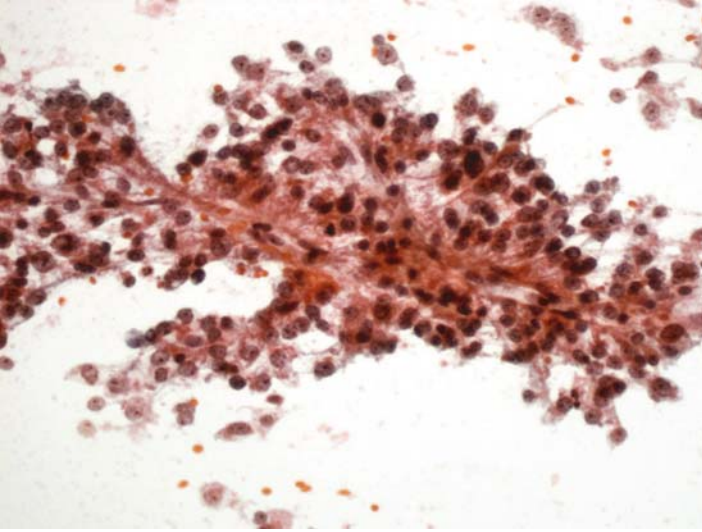
HepPar1, or HCA is a rather sensitive marker for hepatocellular carcinomas. On the other hand, most hepatocellular carcinomas do not express CK7, whereas cholangiocarcinomas and metastatic upper gastrointestinal tract and pancreatic carcinomas are always positive. The combination of HCA and CK7, therefore, usually resolves the differential diagnosis between a hepatocellular carcinoma (HCA-positive, CK7-negative) and a cholangiocarcinomas.

*Suggested Reading: 35, 36*

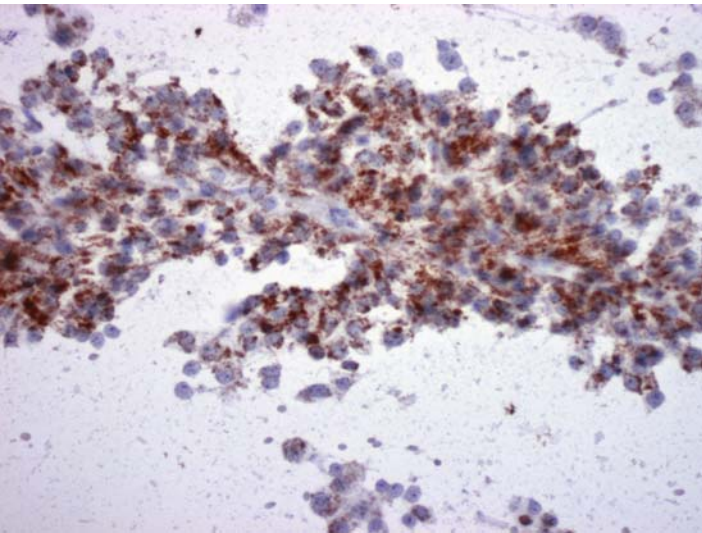


## Case 32

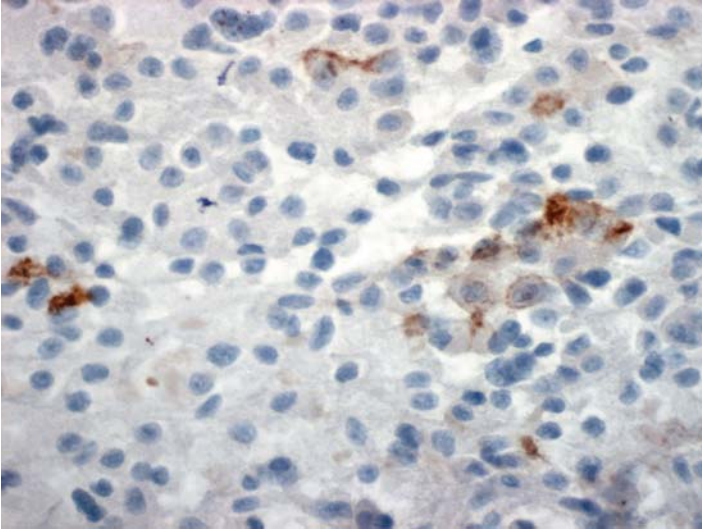
---



**FIGURE 32A. Pap Stain:** This liver aspirate is from a 69-year-old male with an elevated level of alpha-fetoprotein, but no predisposing factors for hepatocellular carcinoma. There is papillary arrangement of uniform cells with clear cytoplasm.



**FIGURE 32B. HCA:** There is positive granular cytoplasmic staining for HCA.



**FIGURE 32C. AFP:** Tumor cells are also positive for alpha-fetoprotein.

### ***Diagnosis***

Hepatocellular Carcinoma with Clear Cells

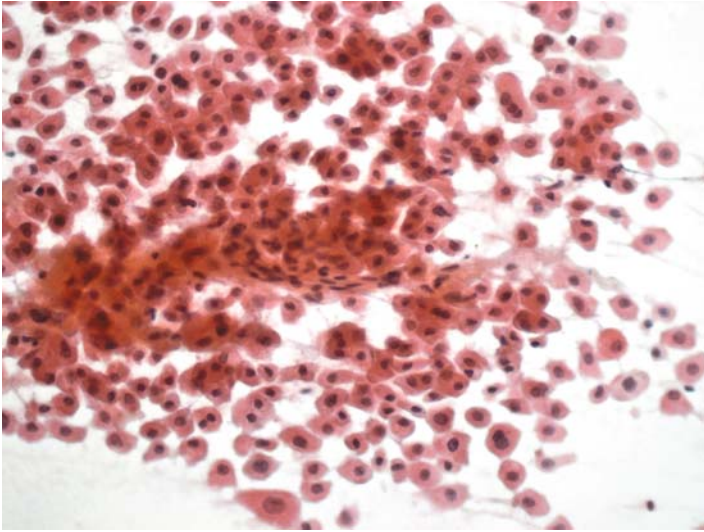
### ***Tips***

Alpha-fetoprotein is not a sensitive marker for hepatocellular carcinomas; less than 20% are positive in our experience. Also, in positive cases, the reaction is usually focal and limited to a few cells.

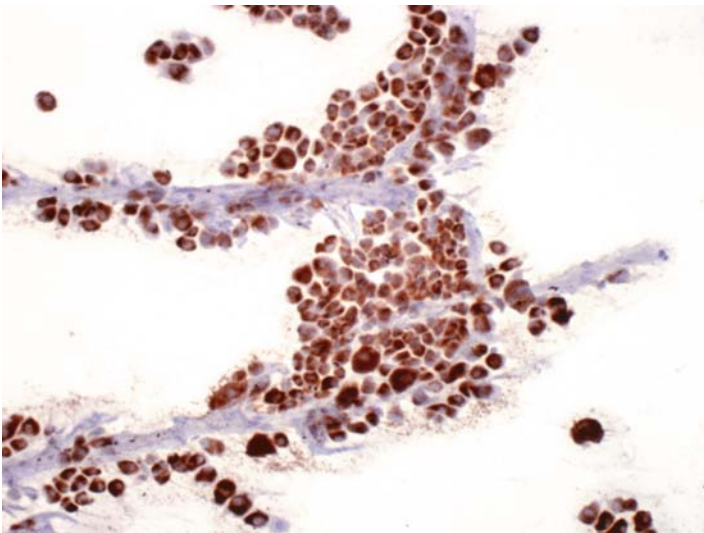
*Suggested Reading: 37*

## Case 33

---



**FIGURE 33A. Pap Stain:** FNA of a single liver nodule in a 39-year-old female without clinical evidence of cirrhosis. The radiologist is not sure whether it arises from the liver or is of renal/adrenal origin. Cells resemble normal hepatocytes and, in fact, the differential diagnosis is between a hepatocellular adenoma and a fibrolamellar hepatocellular carcinoma (ICC is not helpful for separating the latter two).



**FIGURE 33B. HCA:** Immunocytochemistry for hepatocellular antigen shows diffuse and strong positivity of tumor cells.

## ***Diagnosis***

Hepatocellular Neoplasm (Fibrolamellar Hepatocellular Carcinoma on Resection)

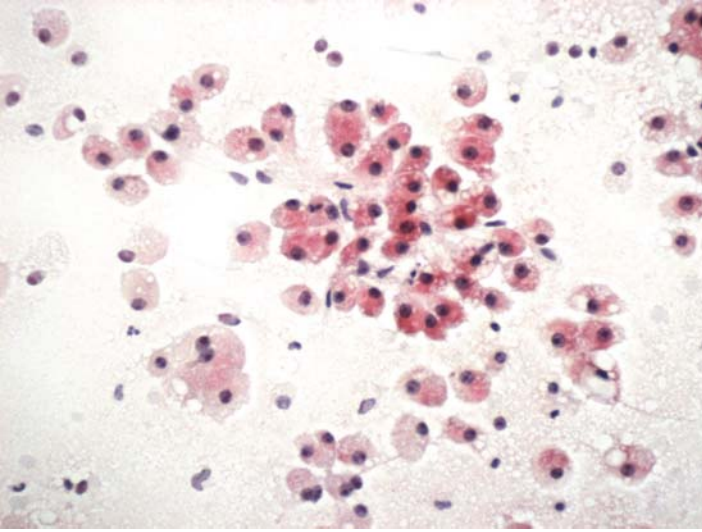
## ***Tips***

A positive HCA reaction cannot differentiate between hepatocellular adenoma, hepatocellular carcinoma, or the normal liver. It will, however, be helpful in segregating hepatocellular tumors from those of renal and adrenal origin.

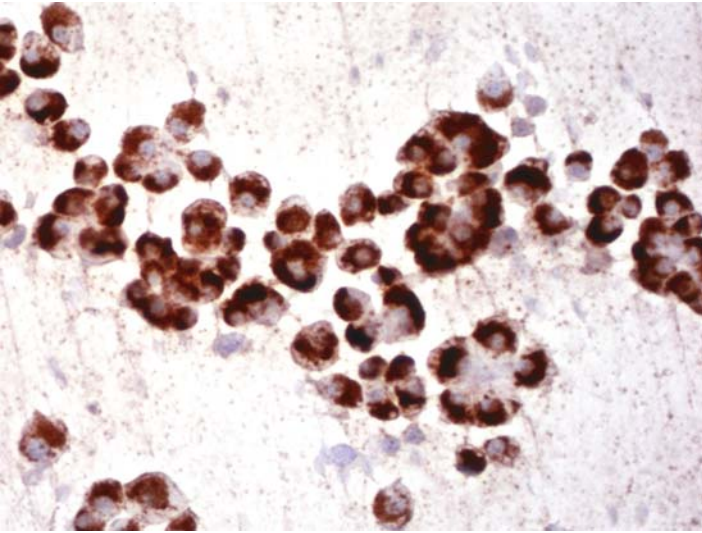
*Suggested Reading: 7*

## Case 34

---

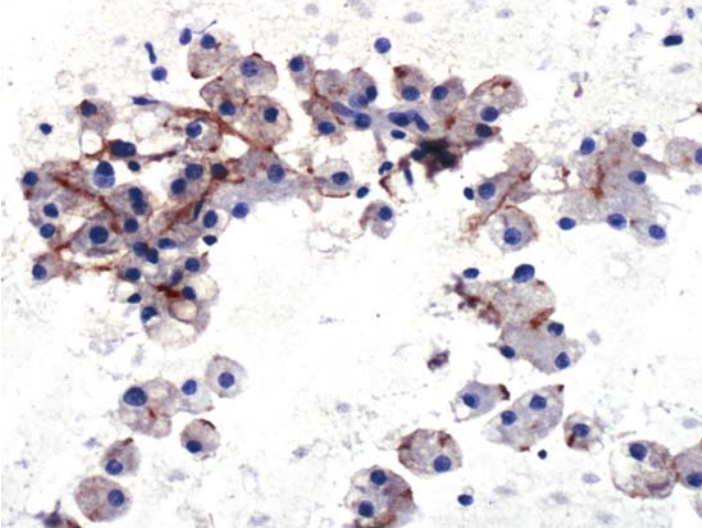


**FIGURE 34A. Pap Stain:** This aspirate is from a single liver nodule in a 72-year-old male. The differential diagnosis includes mucinous adenocarcinoma, a metastatic neuroendocrine tumor, and a hepatocellular neoplasm.



**FIGURE 34B. HCA:** Immunocytochemistry for hepatocellular antigen is strongly and diffusely positive.





**FIGURE 34C. Carcinoembryonic Antigen (Polyclonal Anti-CEA):** There is a characteristic cytoplasmic membrane (canalicular) staining in this hepatocellular neoplasm.

### *Diagnosis*

Hepatocellular Neoplasm with Fatty Changes (Hepatocellular Carcinoma on Resection)

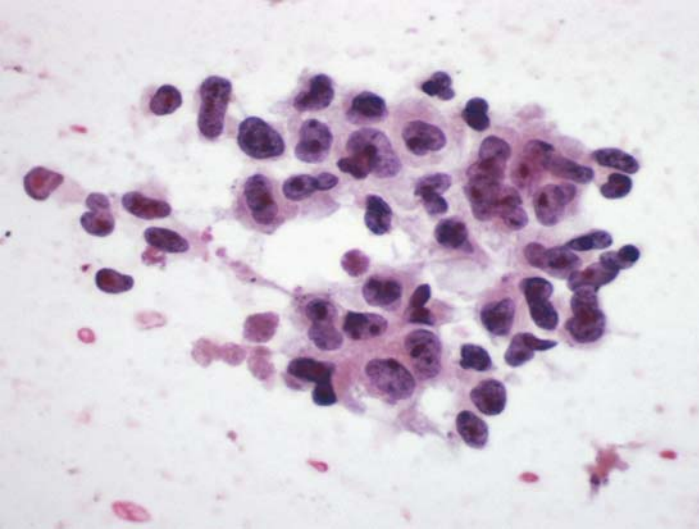
### *Tips*

- Liver neoplasms with fatty changes may occasionally be mistaken for mucin producing signet ring cell carcinomas.
- In addition to positivity for HCA, hepatocellular neoplasms show a characteristic “canalicular” reaction for CEA when a polyclonal anti-CEA antibody is used (because of the cross-reactivity with biliary glycoprotein).

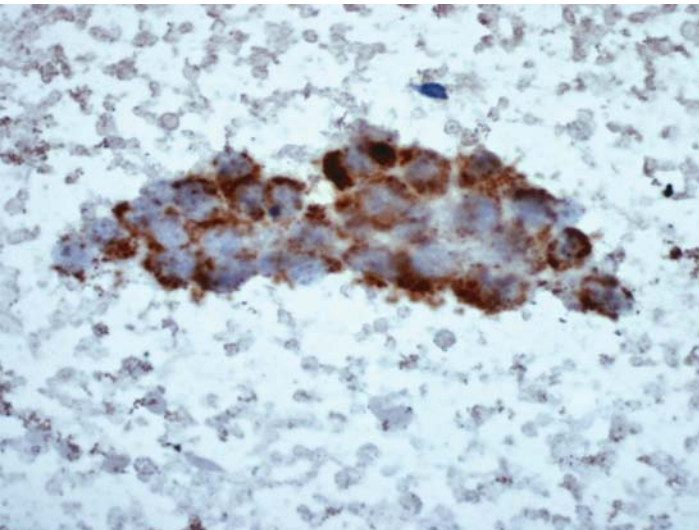
*Suggested Reading: 37*

## Case 35

---



**FIGURE 35A. Pap Stain:** FNA from a large hepatic mass in a 58-year-old male. This is a poorly differentiated carcinoma. The reaction for CK7 was negative so the same slide was used for HCA staining.



**FIGURE 35B. HCA:** Immunocytochemistry for hepatocellular antigen is positive.

***Diagnosis***

Hepatocellular Carcinoma, Poorly Differentiated

***Tips***

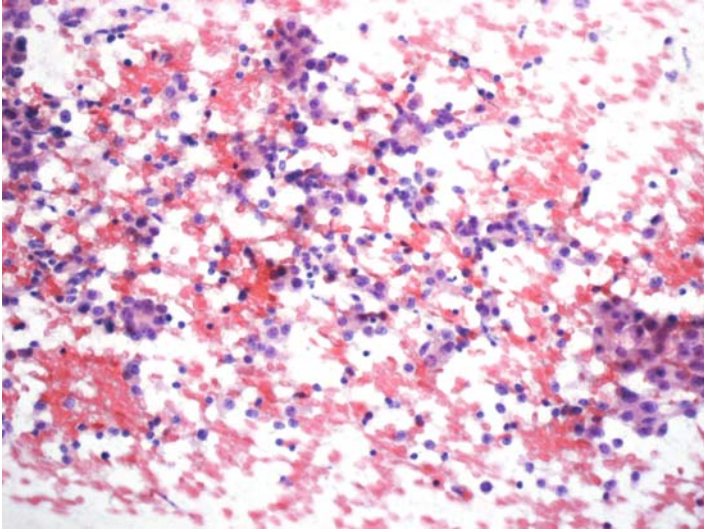
The cytologic separation of poorly differentiated hepatocellular carcinomas from metastatic carcinomas is difficult. While CKT is usually expressed by most metastatic carcinomas except those from the colon, it is seldom elaborated by hepatocellular carcinomas.

*Suggested Reading: 7*

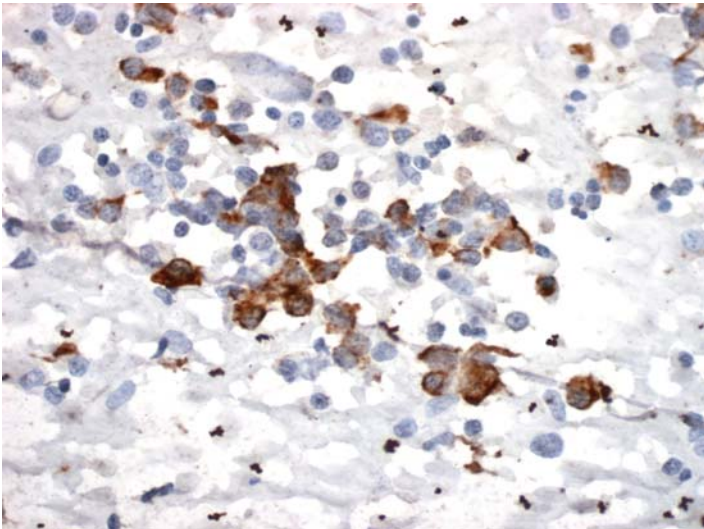


## Case 36

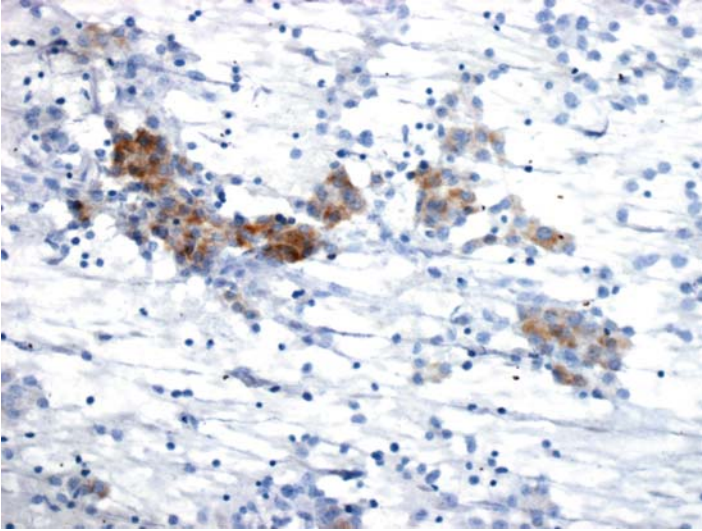
---



**FIGURE 36A. Pap Stain:** FNA of a resected hepatic mass. The differential diagnosis includes hepatocellular carcinoma and a metastatic neuroendocrine carcinoma.



**FIGURE 36B. HCA:** Tumor cells are focally positive for hepatocellular antigen.



**FIGURE 36C. AFP:** There is also a focal positive reaction for AFP.

### ***Diagnosis***

Hepatocellular Carcinoma

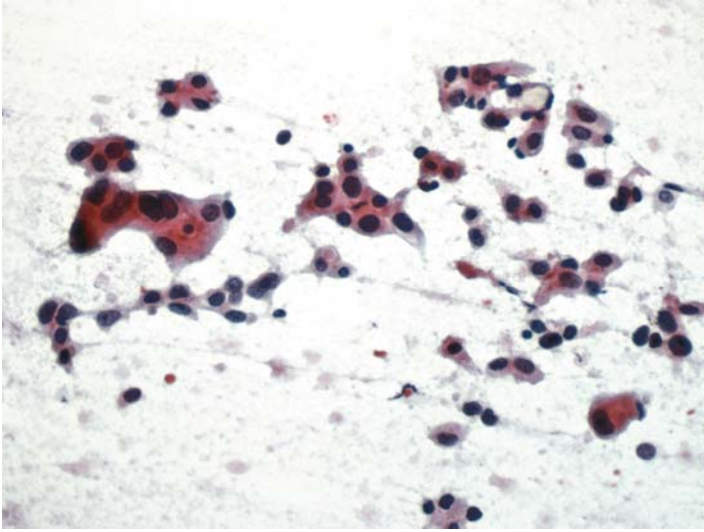
### ***Tips***

FNA from hepatocellular carcinomas may show many isolated needed and hence the possibility of a neuroendocrine carcinoma may be entertained. In those rare cases that are composed mainly of isolated cells, even a lymphoma may be considered in the differential diagnosis.

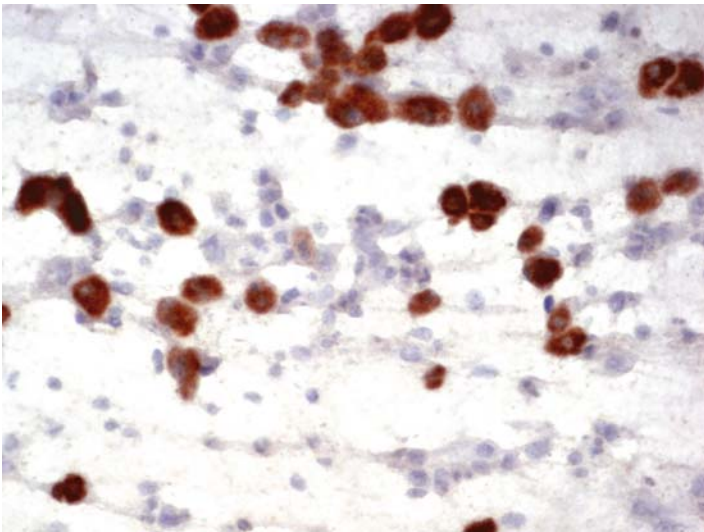
*Suggested Reading:* 36, 37

## Case 37

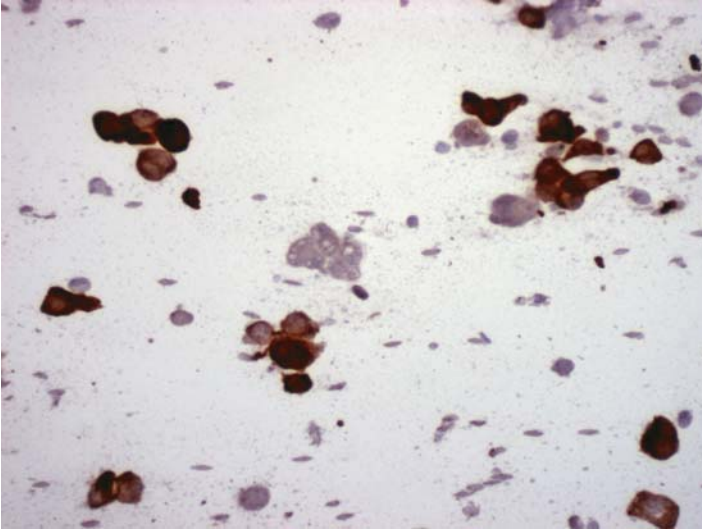
---



**FIGURE 37A. Pap Stain:** Aspirate of a single hepatic nodule in a 74-year-old female. Poorly differentiated carcinoma; the differential diagnosis includes a hepatocellular carcinoma and an adenocarcinoma.



**FIGURE 37B. HCA:** Immunocytochemistry for hepatocellular antigen is negative in tumor cells. Note positive hepatocytes in the background.



**FIGURE 37C. CK7:** Tumor cells are positive for CK7.

### ***Diagnosis***

Adenocarcinoma; Clinically a Cholangiocarcinoma

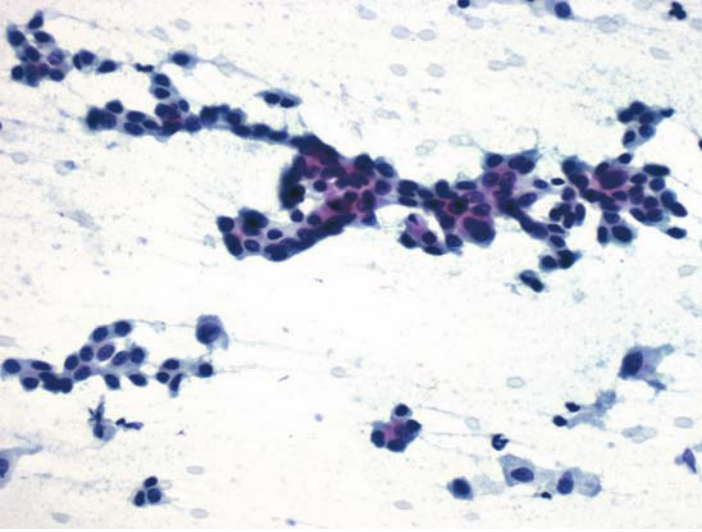
### ***Tips***

Cholangiocarcinomas cannot be separated immunocytochemically from upper gastrointestinal and pancreatic adenocarcinomas.

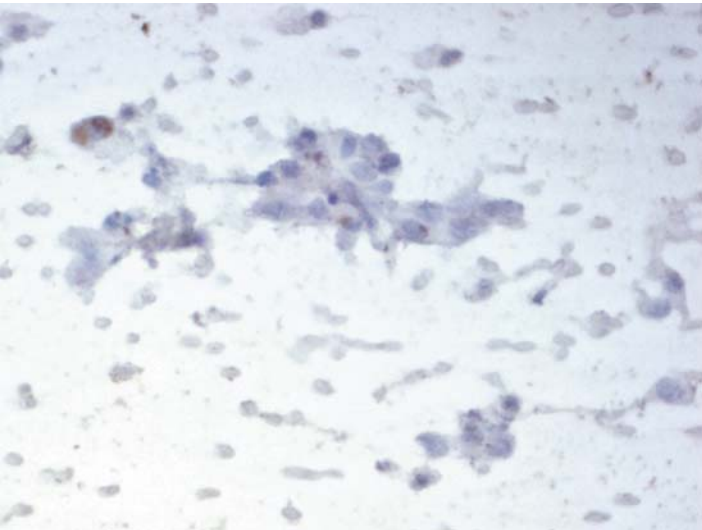
*Suggested Reading:* 7

## Case 38

---

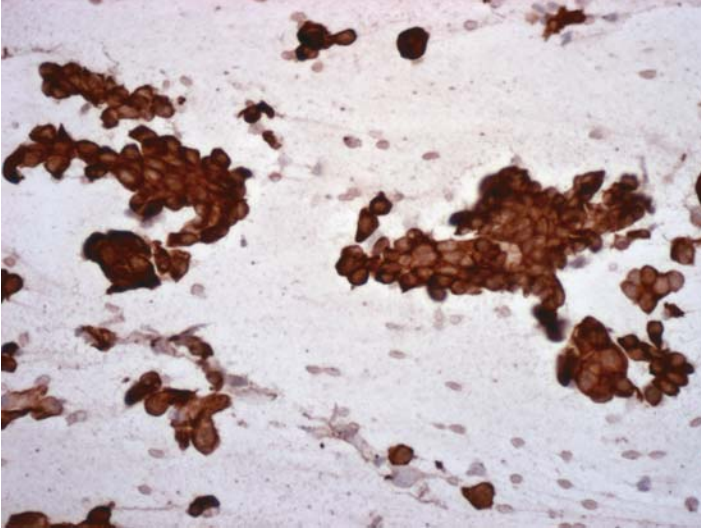


**FIGURE 38A. Pap Stain:** FNA of a hepatic mass in a 68-year-old female. Cytologically it is an adenocarcinoma; rule out a colonic primary.



**FIGURE 38B. CK20:** Immunocytochemistry is negative for CK20.





**FIGURE 38C. CK7:** Tumor cells are positive for CK7.

### ***Diagnosis***

Adenocarcinoma; Most Likely Noncolonic

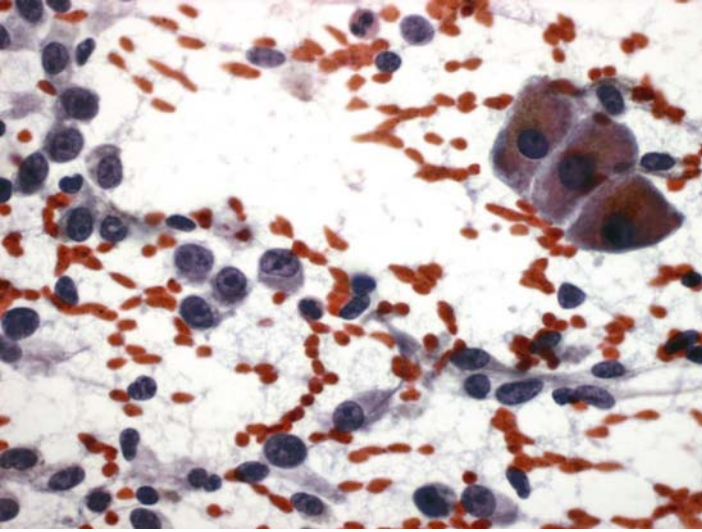
### ***Tips***

- A CK7-positive, CK20-negative metastatic adenocarcinoma is unlikely to be of colonic origin. This immunophenotype, however, is shared by a large number of adenocarcinomas, including those of upper gastrointestinal tract, pancreatobiliary system, lung, and breast.
- Additional markers may be needed to further characterize the tumor if slides are available (i.e., TTF-1 for lung and ER for breast and gynecologic cancers).

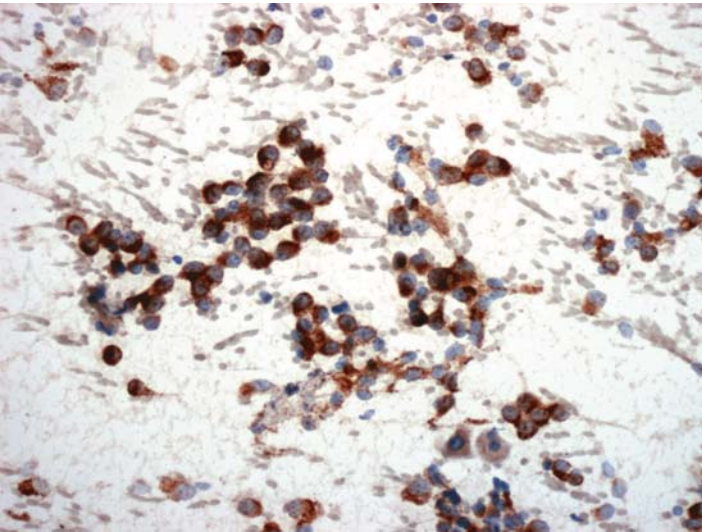
*Suggested Reading: 31*

## Case 39

---



**FIGURE 39A. Pap Stain:** This liver aspirate is from a 39-year-old male with a history of malignant melanoma. Isolated tumor cells and a few normal hepatocytes are seen.



**FIGURE 39B. HMB-45:** Immunocytochemistry is positive for HMB-45.

## ***Diagnosis***

Metastatic Malignant Melanoma

## ***Tips***

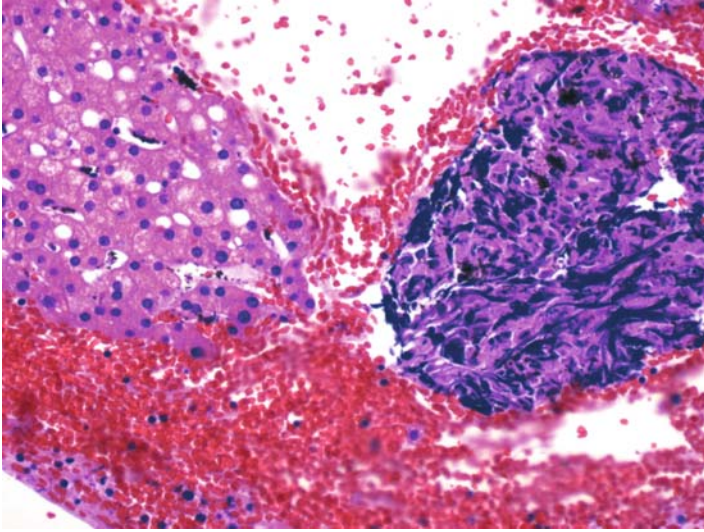
Although HMB-45 is not the most sensitive marker for malignant melanomas, it is by far the most specific. If the suspected malignant melanoma is not the spindle cell type—where usually it is negative—HMB-45 is a better choice than S100 protein.

*Suggested Reading: 10*

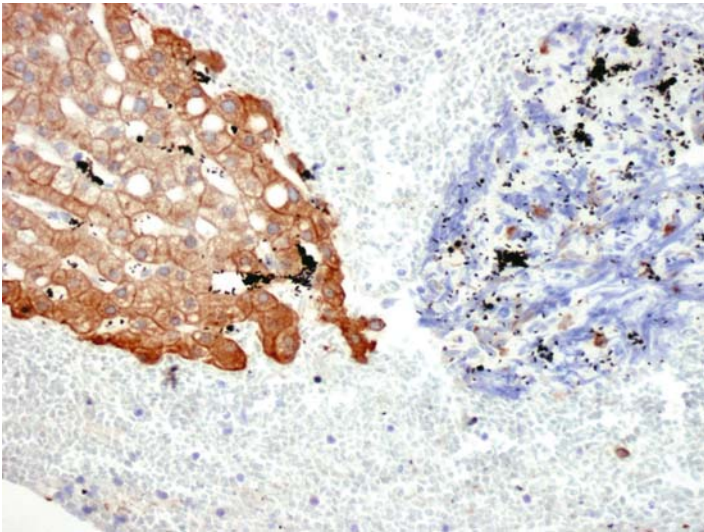


## Case 40

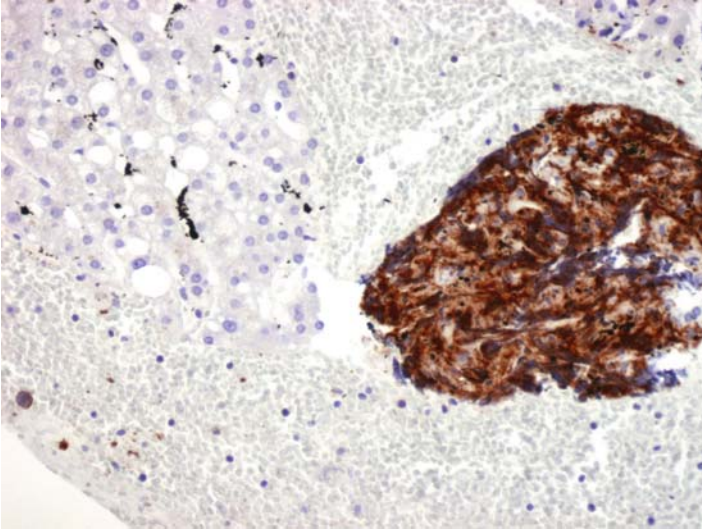
---



**FIGURE 40A. H&E Stain, Cell Block:** Liver aspirate from an immunosuppressed patient clinically suspected to have malignant lymphoma. There are crushed large abnormal cells suggestive of a malignant lymphoma.



**FIGURE 40B. HCA:** Immunocytochemistry for hepatocellular antigen is negative.



**FIGURE 40C. CD20:** The abnormal crushed cells are positive for CD20.

### ***Diagnosis***

Malignant B Cell Lymphoma

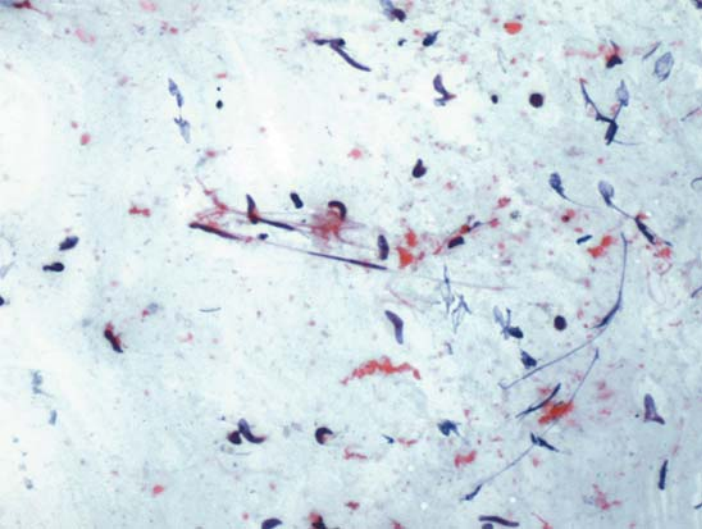
### ***Tips***

Several major ICC markers, such as cytokeratins, CD45, CD20 and S100 protein, can be used successfully if the target cells are crushed or necrotic. The specific staining of the cells is supported by negative reaction in the adjacent cells and tissue.

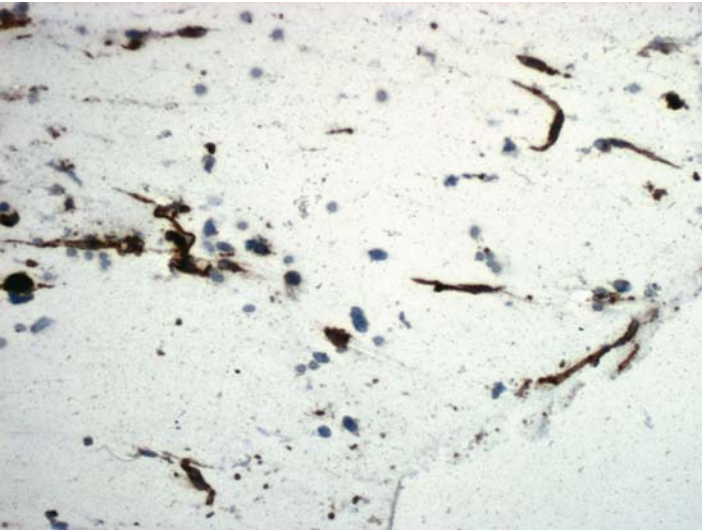
*Suggested Reading: 7*

## Case 41

---



**FIGURE 41A. Pap Stain:** FNA of a subcapsular cystic liver mass in a 55-year-old female with a history of breast cancer. Scattered spindle-shaped nuclei on a background of lysed blood suggests a hemangioma.



**FIGURE 41B. CD31:** The spindle cells are positive for CD31.

## ***Diagnosis***

Hemangioma

## ***Tips***

- Both Factor VIII-related antigen and CD31 are useful endothelial cell markers (CD34 is not!). Antibodies to CD31 react with all endothelial cells, whereas Factor VIII is seen primarily in endothelial cells lining blood vessels.
- Because CD31 also stains some lymphoreticular cells, it should not be used when there is a heavy inflammatory background.

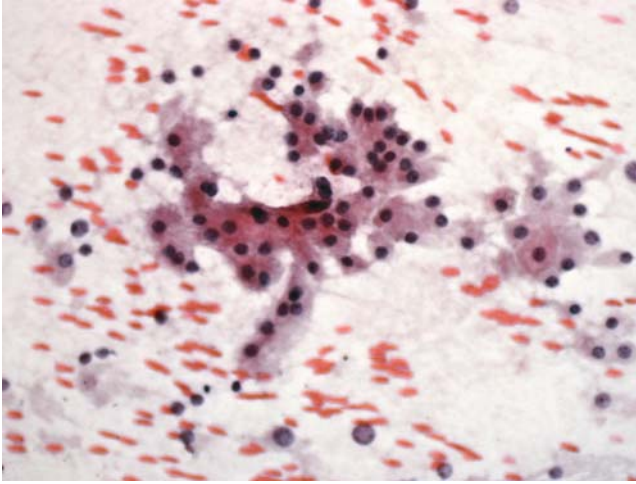
*Suggested Reading: 24, 25*

# 8

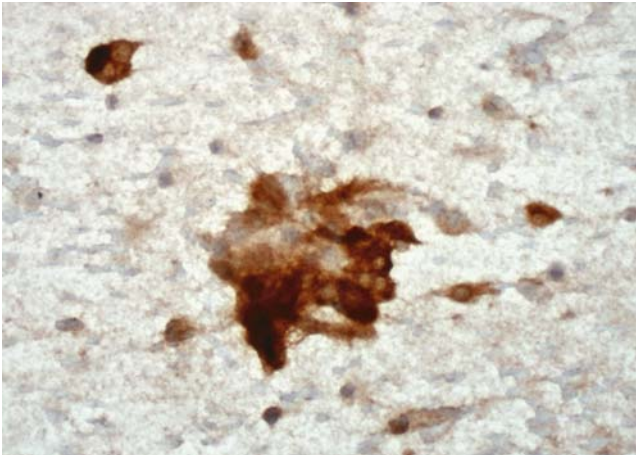
## Adrenal Gland

## Case 42

---



**FIGURE 42A. Pap Stain:** FNA of adrenal gland in a patient with lung cancer. Large cells with abundant eosinophilic cytoplasm and small nuclei are present, which is suggestive of adrenocortical hyperplasia or adenoma.



**FIGURE 42B. Calretinin:** Strong cytoplasmic and nuclear staining is observed.

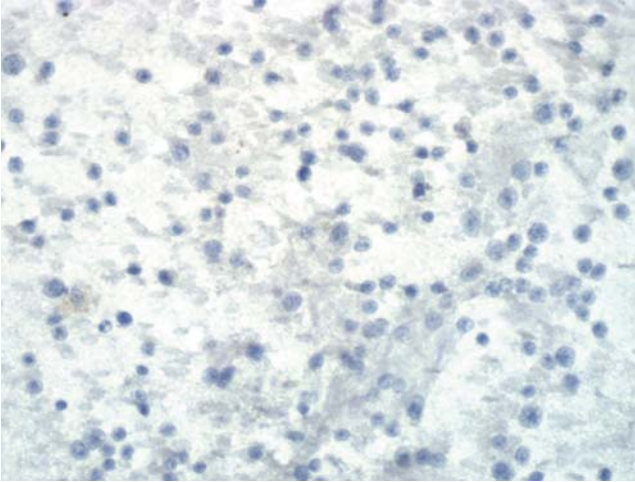
### *Diagnosis*

Adrenocortical Hyperplasia/adenoma

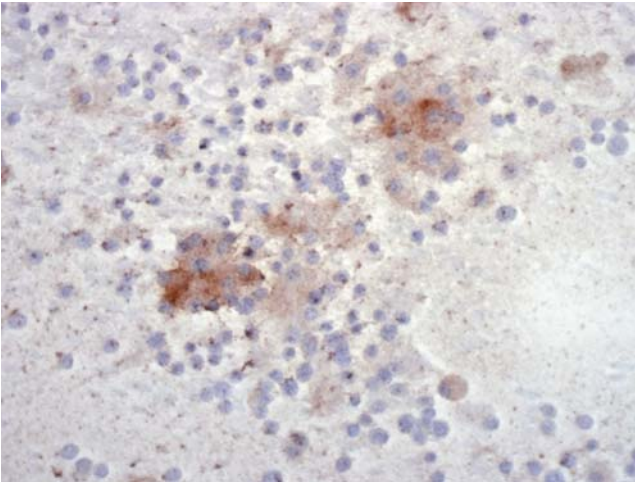
### *Tips*

- Both inhibin and calretinin stain normal adrenocortical cells and adrenocortical tumors. The reaction for these markers, however, is





**FIGURE 42C. Cytokeratin:** Immunocytochemistry for cytokeratin is negative; a metastatic lung cancer is unlikely.



**FIGURE 42D. Inhibin:** There is focal cytoplasmic reaction for inhibin.

usually focal. Melan A (Mart 1) also reacts with adrenocortical cells, but is far less useful because of its lack of specificity.

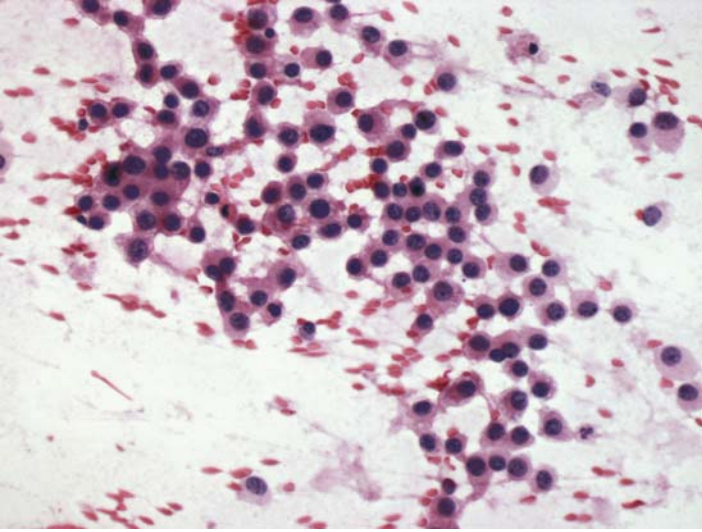
- Primary adrenal neoplasms, whether of cortical or medullary origin, are always negative for cytokeratin.

*Suggested Reading:* 38, 39

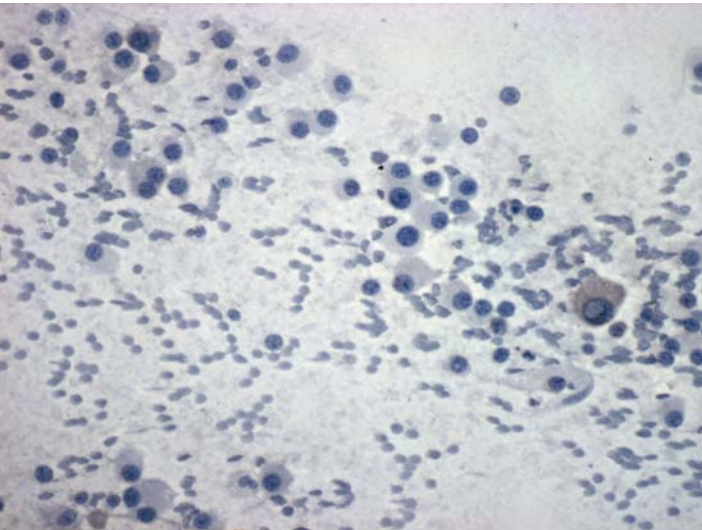


## Case 43

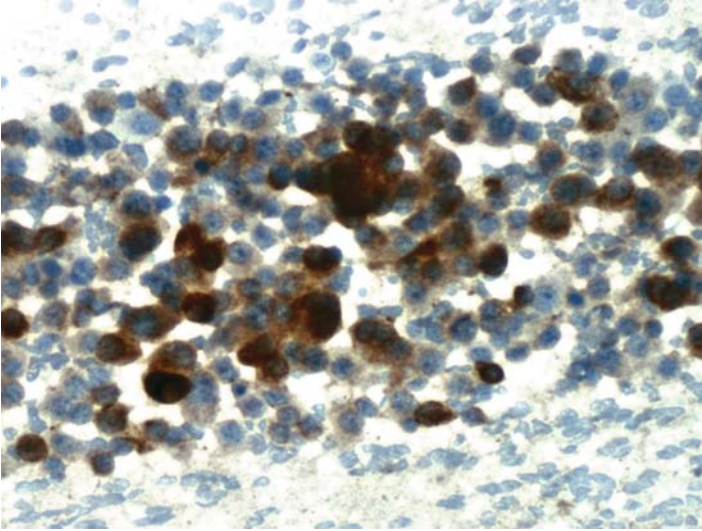
---



**FIGURE 43A. H&E Stain:** FNA of an excised lung mass in a 43-year-old male with a history of adrenocortical carcinoma.



**FIGURE 43B. Cytokeratin:** Tumor cells are negative.



**FIGURE 43C. Inhibin:** There is strong positive staining for inhibin.

### ***Diagnosis***

Metastatic Adrenocortical Carcinoma

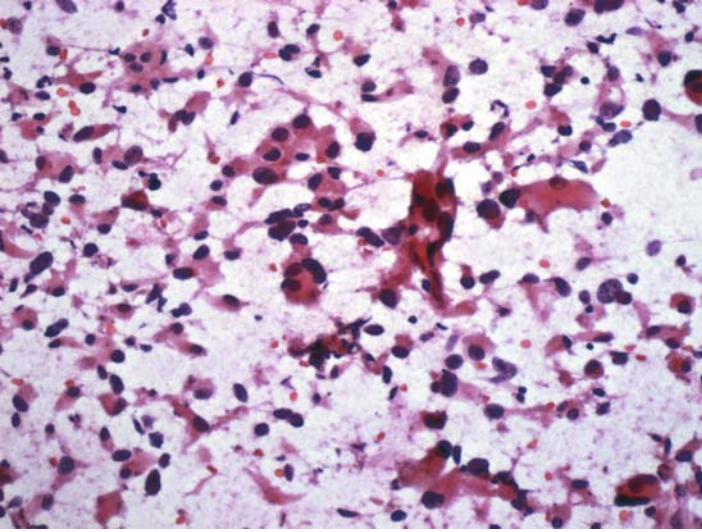
### ***Tips***

This diagnosis would have been very difficult to be made by cytology alone; the clinical history was essential.

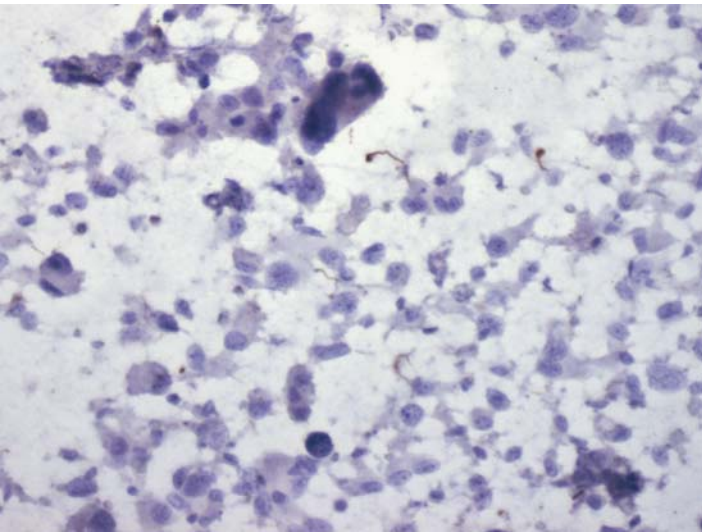
*Suggested Reading: 39*

## Case 44

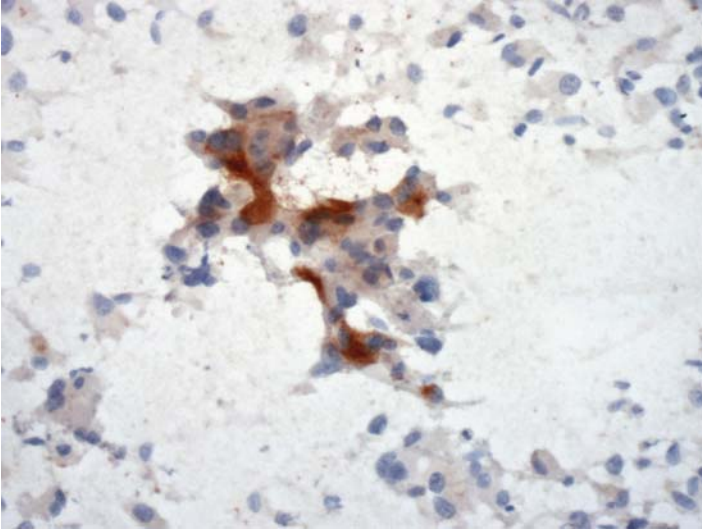
---



**FIGURE 44A. Pap Stain:** FNA of a resected adrenal mass in a patient with a clinical impression of pheochromocytoma. The cytomorphology is suggestive of a pheochromocytoma.



**FIGURE 44B. Inhibin:** Tumor cells are negative for inhibin.



**FIGURE 44C. Chromogranin:** Many tumor cells are positive for chromogranin.

## ***Diagnosis***

Pheochromocytoma

## ***Tips***

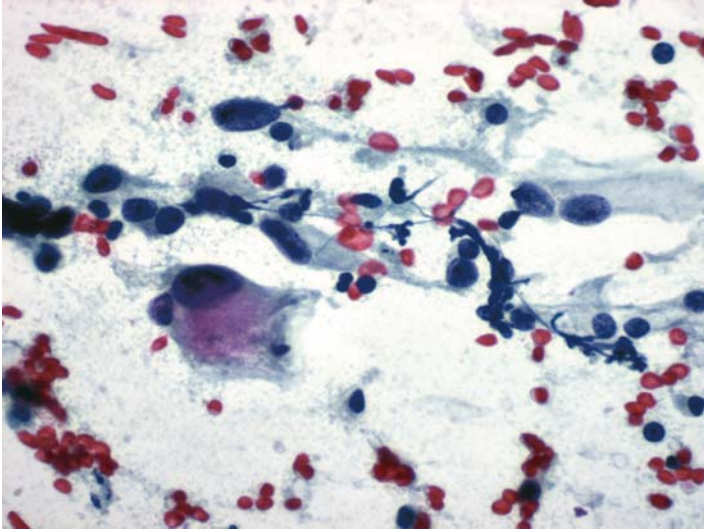
- Combination of chromogranin and inhibin resolves most differential diagnostic problems between pheochromocytomas and adrenocortical tumors. All pheochromocytomas are positive for chromogranin, but adrenocortical tumors are negative.
- Synaptophysin should not be used for this differential diagnosis because it is expressed by both tumors.

*Suggested Reading: 38*

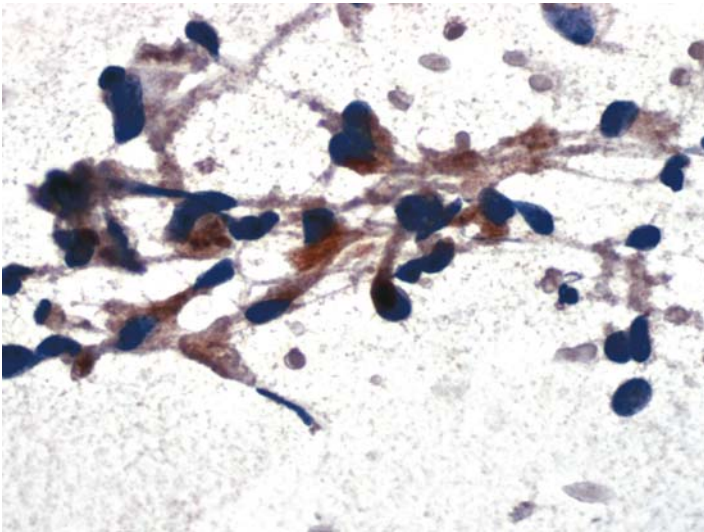


## Case 45

---



**FIGURE 45A. Pap Stain:** FNA of an asymptomatic adrenal mass. Large pleomorphic cells are present. The differential diagnosis includes a pheochromocytoma and metastatic carcinoma/melanoma.



**FIGURE 45B. Chromogranin:** Most tumor cells are positive for chromogranin.

## ***Diagnosis***

Pheochromocytoma

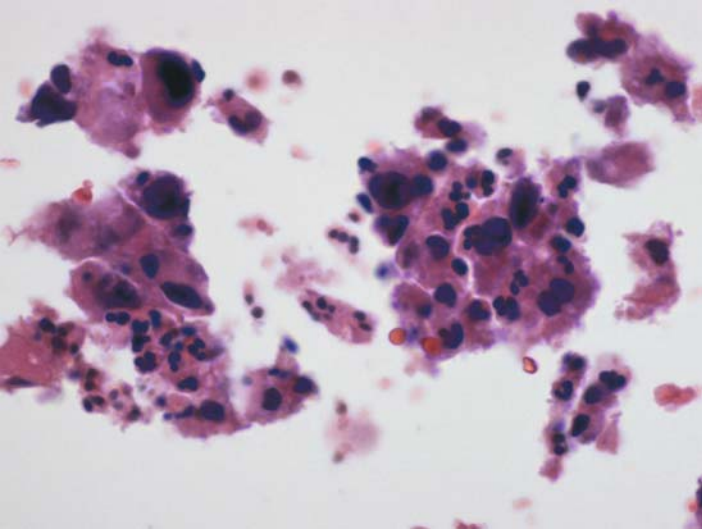
## ***Tips***

Extreme cytologic atypia is not uncommon in FNAs of pheochromocytomas. Undifferentiated carcinomas, melanomas, and sarcomas should, therefore, be excluded by ICC.

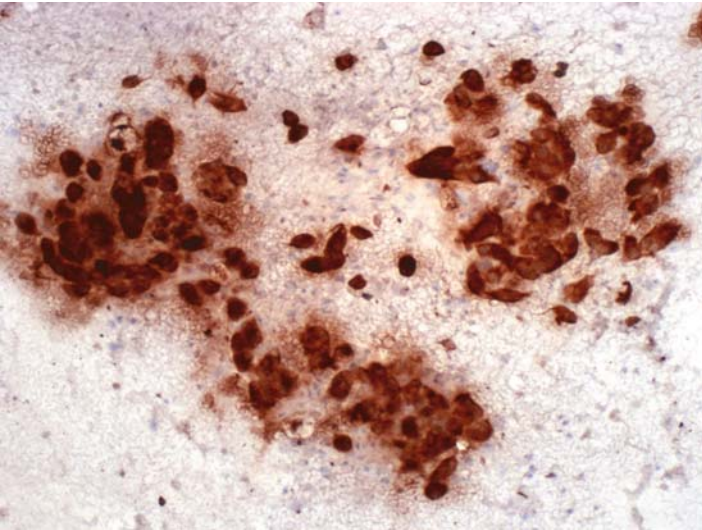
*Suggested Reading: 7*

## Case 46

---



**FIGURE 46A. H&E Stain, Cell Block:** FNA from adrenal in a 62-year-old patient. Differential diagnosis includes a metastatic carcinoma.



**FIGURE 46B. Cytokeratin:** Strong positive reaction for cytokeratin establishes the epithelial nature of tumor cells.



## ***Diagnosis***

Metastatic Carcinoma

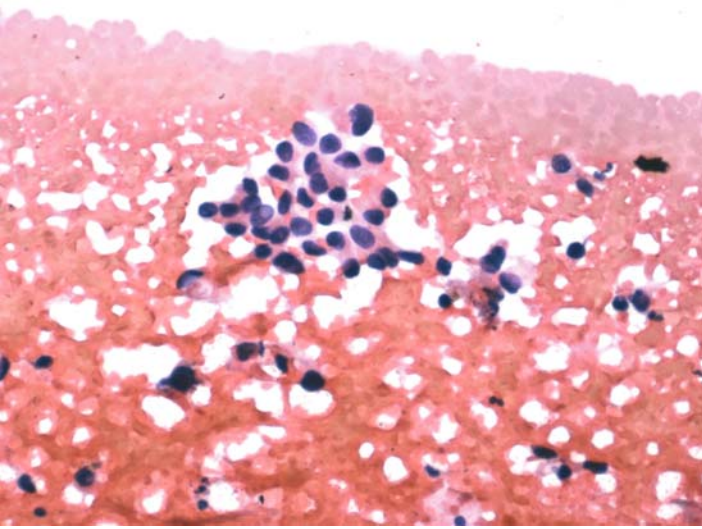
## ***Tips***

- Positive cytokeratin reaction in an adrenal tumor is usually indicative of a metastatic carcinoma.
- If carcinoma of the lung is suspected clinically, one could add TTF-1 to the panel, as is illustrated in the next case.

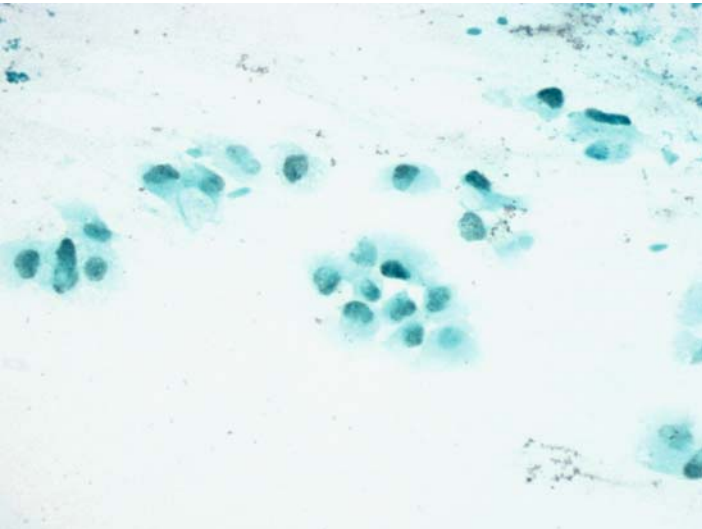
*Suggested Reading: 40*

## Case 47

---



**FIGURE 47A. Pap Stain:** FNA of adrenal in a patient with a history of lung cancer. Cohesive group of tumor cells is suggestive of an adenocarcinoma.



**FIGURE 47B. TTF-1:** Positive nuclear reaction confirms the lung origin of tumor cells.

## ***Diagnosis***

Metastatic Adenocarcinoma of the Lung

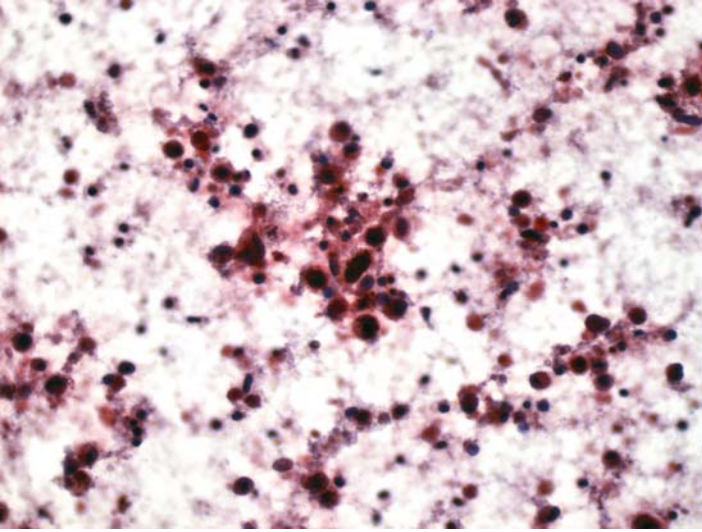
## ***Tips***

Most metastatic adenocarcinomas of the lung react positively for TTF-1. If a squamous cell carcinoma is suspected, one should utilize P63 instead.

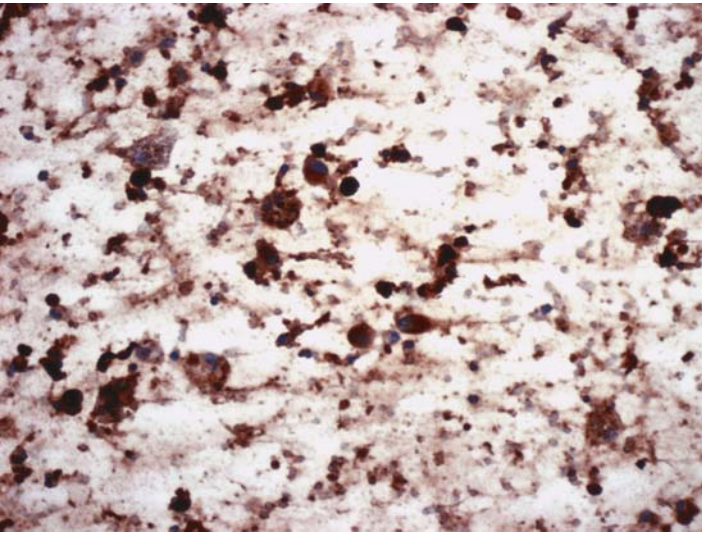
*Suggested Reading: 40*

## Case 48

---



**FIGURE 48A. Pap Stain:** FNA of adrenal tumor in a patient with metastatic disease in the brain. There are mostly necrotic tumor cells with questionable melanin pigment in the background.



**FIGURE 48B. S100 protein:** There is positive reaction in the cytoplasm and nuclei of cells as well as in the slide background.

## ***Diagnosis***

Metastatic Malignant Melanoma

## ***Tips***

A metastatic melanoma to the adrenal may be the initial presentation of this disease. Because pheochromocytomas may also be pigmented, the diagnosis of a metastatic melanoma should be confirmed by ICC.

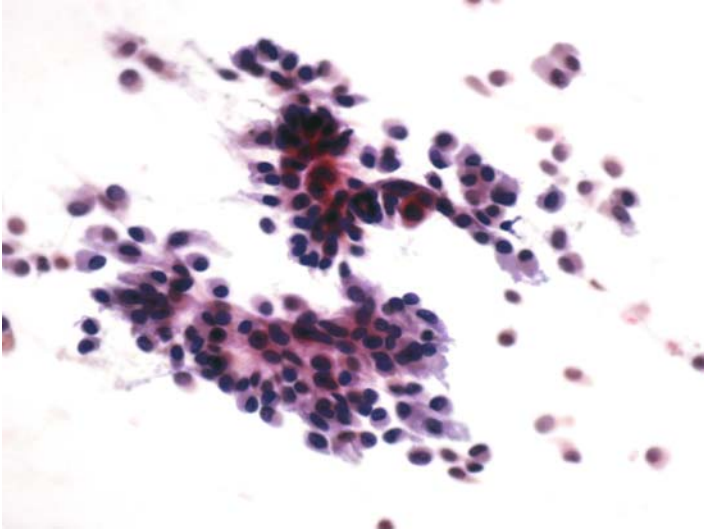
*Suggested Reading: 7, 9*

# 9

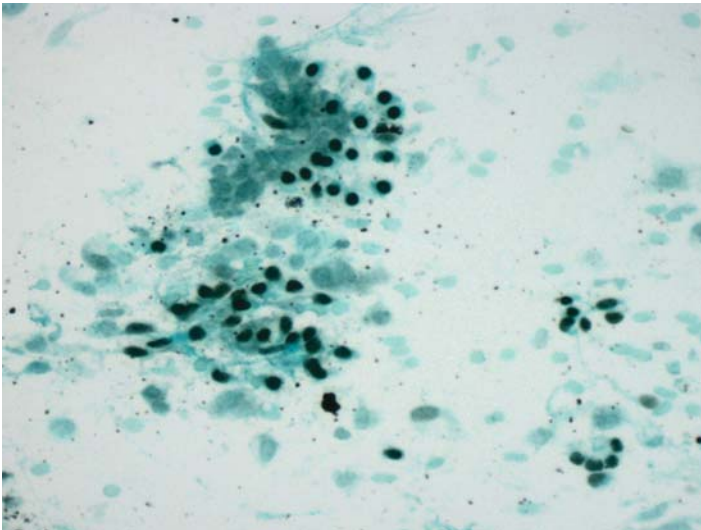
## Head and Neck

## Case 49

---



**FIGURE 49A. Pap Stain:** FNA of parotid gland in a 39-year-old male. Isolated and groups of cells show eccentric nuclei. The differential diagnosis includes adenocarcinoma and a myoepithelial tumor.



**FIGURE 49B. P63:** The majority of cells show positive nuclear staining for p63 supporting myoepithelial differentiation.



***Diagnosis***

Myoepithelial Neoplasm (Pleomorphic Adenoma on Excision)

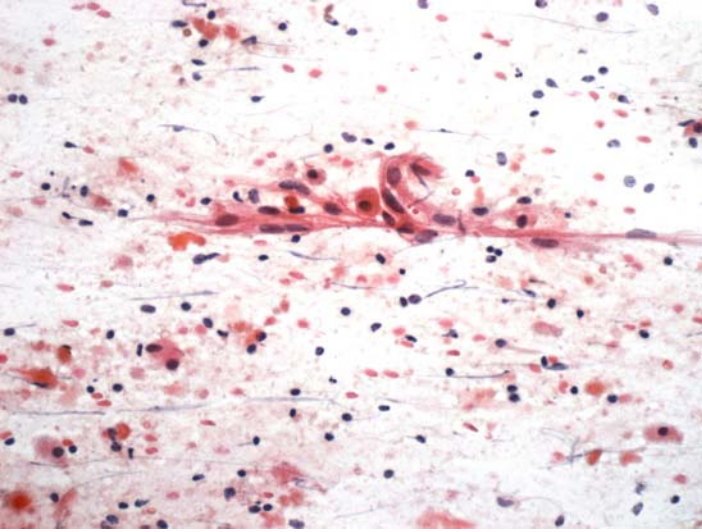
***Tips***

P63 marks myoepithelial cells, as well as basal cells of squamous and transitional epithelia. It is, therefore, useful for classifying myoepithelial tumors and squamous and transitional cell carcinomas.

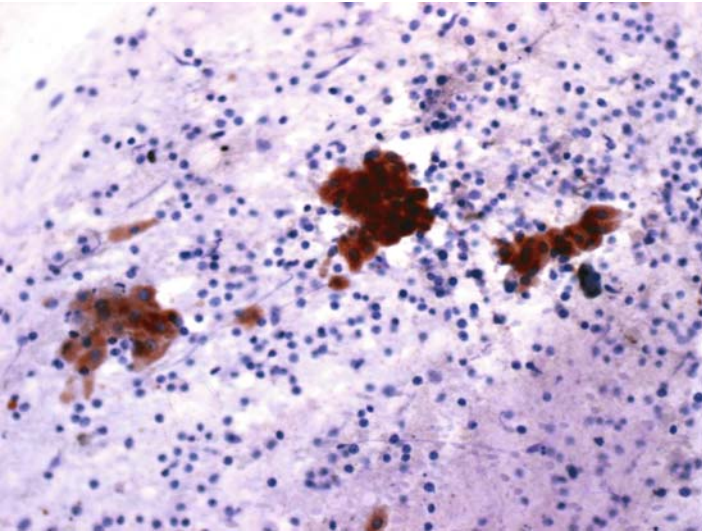
*Suggested Reading: 41*

## Case 50

---



**FIGURE 50A. Pap Stain:** FNA of a neck mass (? submaxillary gland). Large cells with granular eosinophilic cytoplasm on a lymphocytic background suggest a Warthin's tumor.



**FIGURE 50B. Cytokeratin:** The eosinophilic cells are positive for cytokeratin.

## ***Diagnosis***

Warthin's Tumor

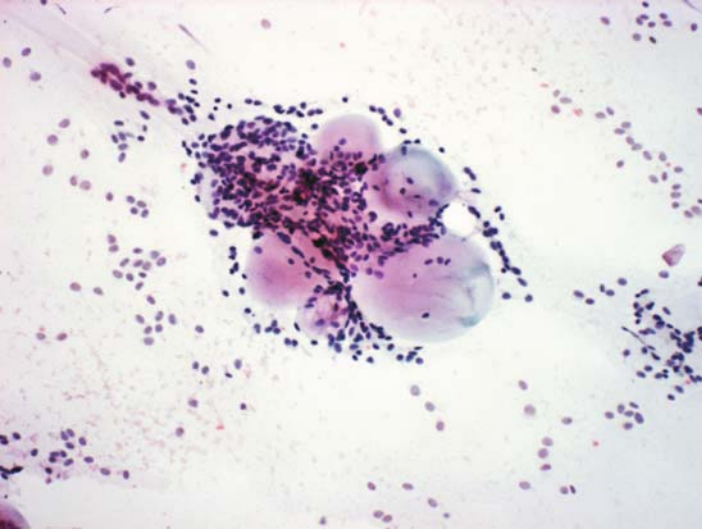
## ***Tips***

The differential diagnosis in this case also includes a granulomatous process with the eosinophilic cells representing histiocytes. Positive reaction for cytokeratin in these cells established the diagnosis of Warthin's tumor.

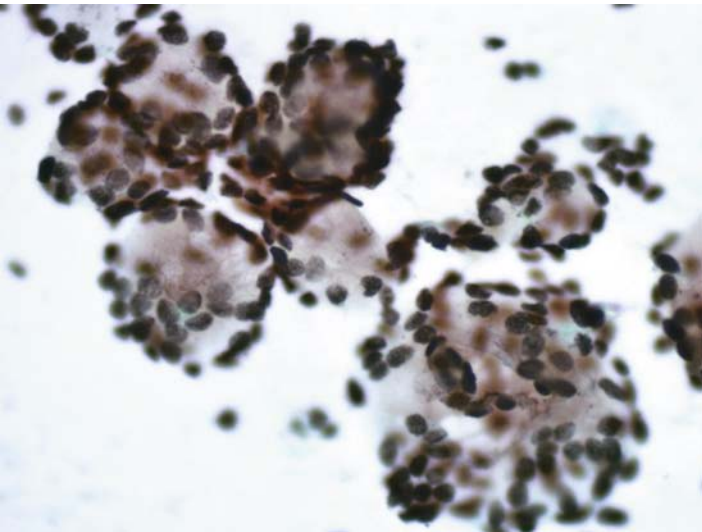
*Suggested Reading: 7*

## Case 51

---



**FIGURE 51A. Pap Stain:** FNA of a nodule in soft palate in a 52-year-old male. Small cells with ill-defined cytoplasmic borders surround round bodies. The cytomorphology is characteristic of an adenoid cystic carcinoma. Positivity for p63 will support this impression.



**FIGURE 51B. P63:** Nuclear staining for p63 is seen in all cells.

## ***Diagnosis***

Adenoid Cystic Carcinoma

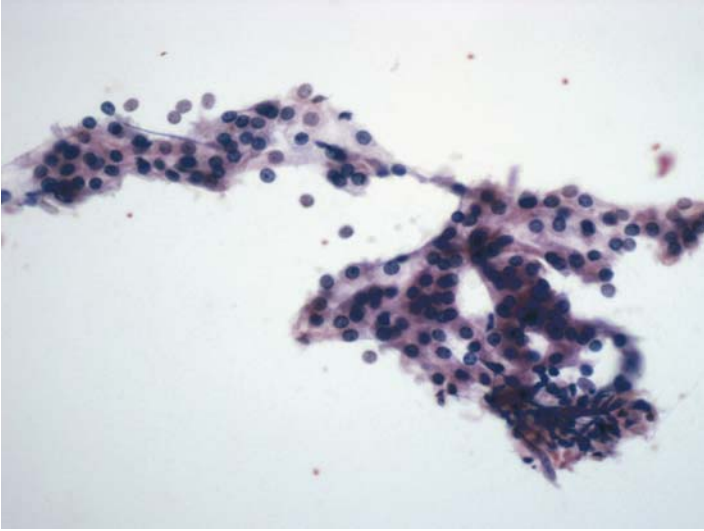
## ***Tips***

Adenoid cystic carcinomas are also of myoepithelial/basal cell origin and hence react positively for p63.

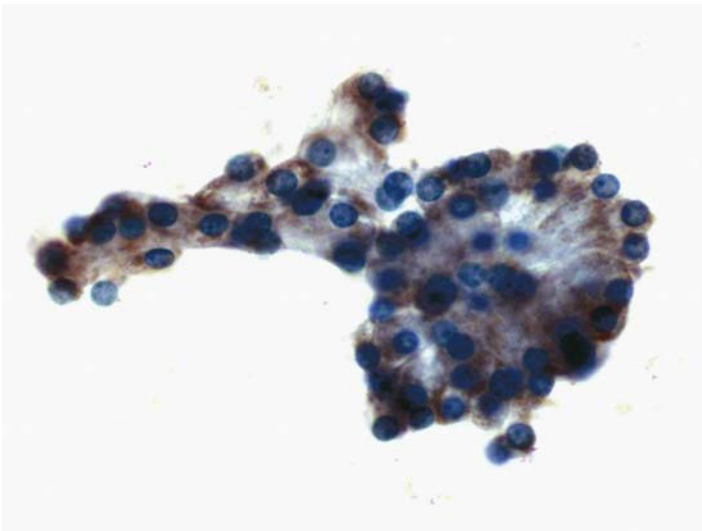
*Suggested Reading: 41*

## Case 52

---



**FIGURE 52A. Pap Stain:** FNA of a parotid mass showing epithelial cells with amphiphilic granular cytoplasm and uniform round nuclei. Rule out an acinic cell carcinoma.



**FIGURE 52B. Salivary Amylase:** Positive cytoplasmic stain is seen in most cells.

## ***Diagnosis***

Acinic Cell Carcinoma

## ***Tips***

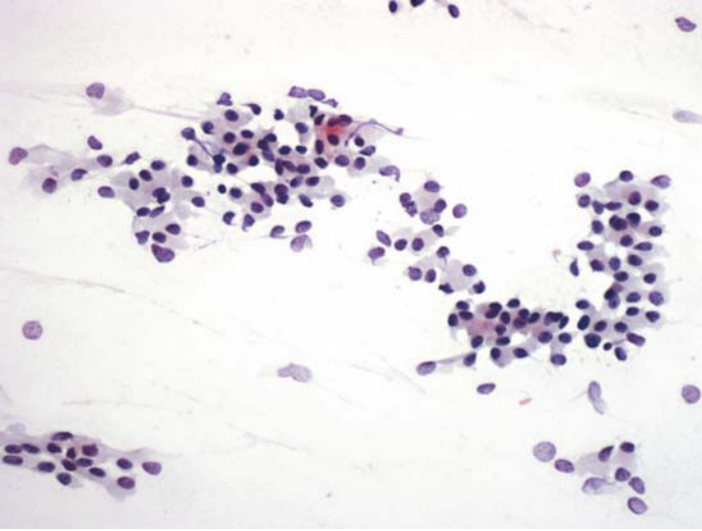
Most acinic cell carcinomas of the salivary gland express salivary amylase. One has to ensure that the anti-amylase antibody used in this situation is against the salivary and not the pancreatic amylase.

*Suggested Reading: 7*

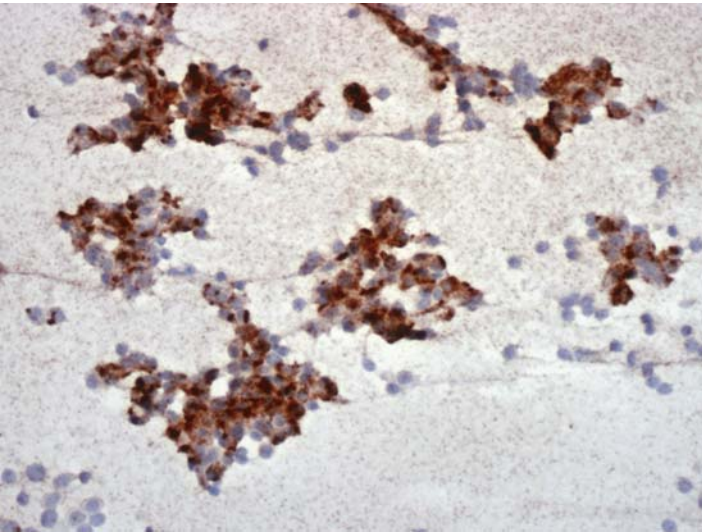


## Case 53

---



**FIGURE 53A. Pap Stain:** FNA of a thyroid nodule in a patient with hypercalcemia. Based on cytology alone the differential diagnosis includes a follicular or medullary thyroid neoplasm or a parathyroid lesion.



**FIGURE 53B. Parathyroid Hormone (PTH):** Positive cytoplasmic reaction for PTH supports the parathyroid origin of the cells.

***Diagnosis***

Parathyroid Hyperplasia/Adenoma (Intrathyroid Parathyroid Adenoma on Excision)

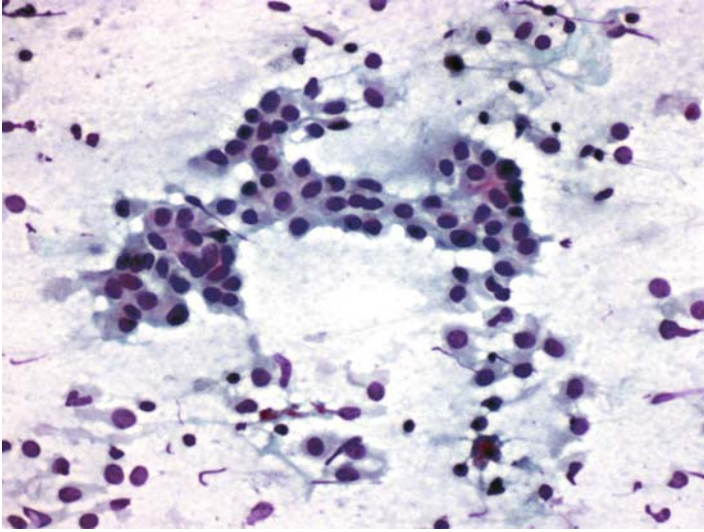
***Tips***

- Parathyroid hormone is only expressed by parathyroid neoplasms. Parathyroid hormone-like peptides, however, may be elaborated by other tumors, including some squamous cell carcinomas.
- The use of chromogranin alone in this case may have misclassified it as a medullary thyroid carcinoma.

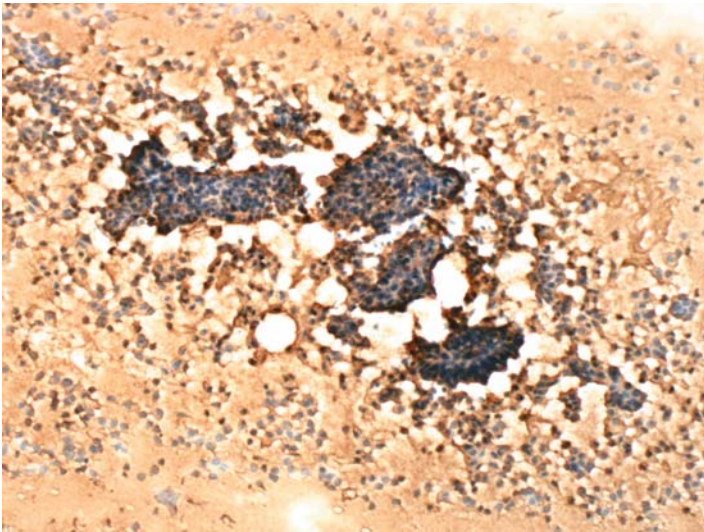
*Suggested Reading: 42*

## Case 54

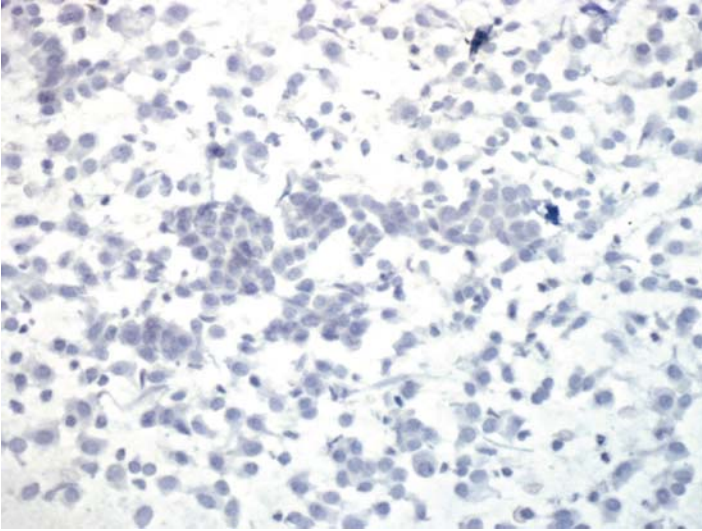
---



**FIGURE 54A. Pap Stain:** FNA of a thyroid nodule in a 68-year-old female patient with enlarged cervical lymph nodes. Cells are both in groups and isolated. The differential diagnosis includes a papillary carcinoma and a medullary carcinoma.



**FIGURE 54B. Thyroglobulin (TGB):** Strong positive reaction in tumor cells and in the slide background.



**FIGURE 54C. Calcitonin:** There is no staining for calcitonin.

### ***Diagnosis***

Papillary Thyroid Carcinoma

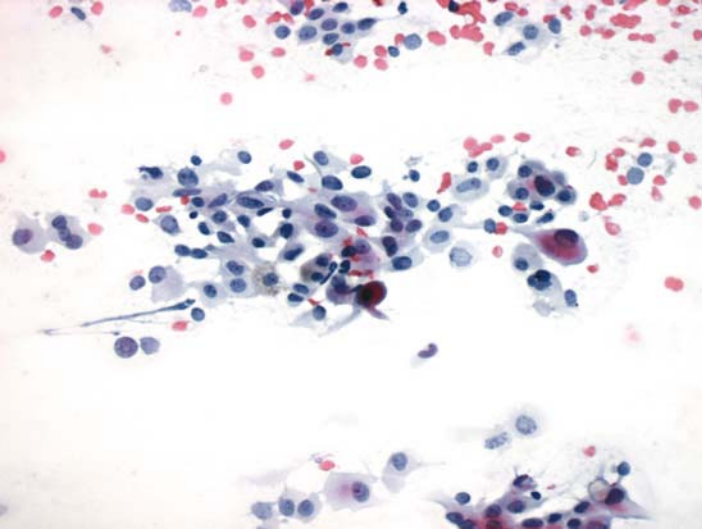
### ***Tips***

Thyroglobulin expression in aspirates from the follicular cell neoplasms of thyroid is seen in cells as well as in the slide background. It is the staining of the tumor cells that establishes the correct diagnosis because aspirates from medullary and metastatic carcinomas in the thyroid may also show thyroglobulin staining in the slide background.

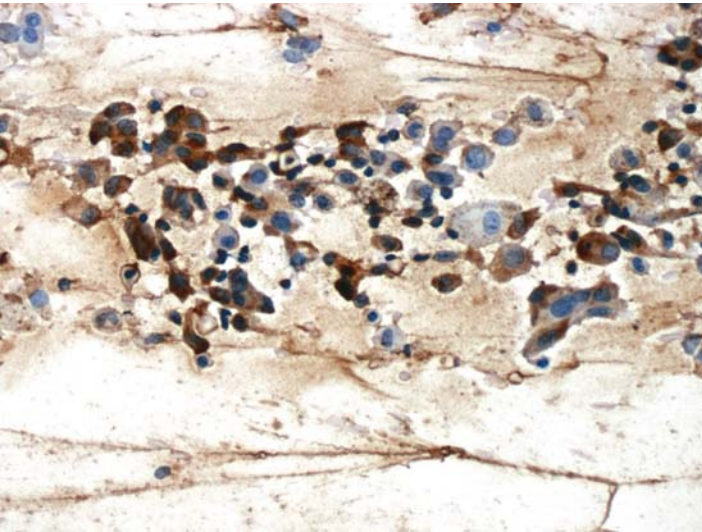
*Suggested Reading: 43*

## Case 55

---



**FIGURE 55A. Pap Stain:** FNA of a thyroid nodule. Pleomorphic epithelial tumor cells are present with the differential diagnosis of papillary, medullary, or metastatic carcinoma.



**FIGURE 55B. Thyroglobulin (TGB):** Positive cytoplasmic reaction for TGB in tumor cells and in slide background.

## ***Diagnosis***

Papillary Thyroid Carcinoma, Poorly Differentiated

## ***Tips***

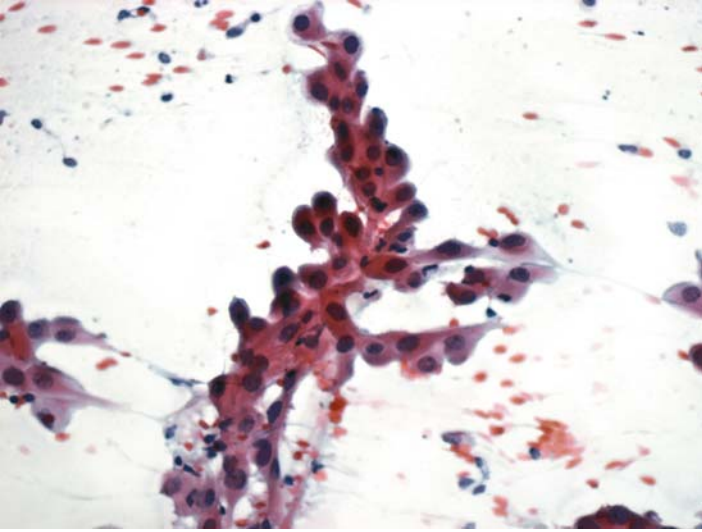
Positive reaction for thyroglobulin in a poorly differentiated carcinoma of thyroid excludes the diagnosis of an anaplastic thyroid carcinoma as these tumors are usually negative for thyroglobulin.

*Suggested Reading: 43*

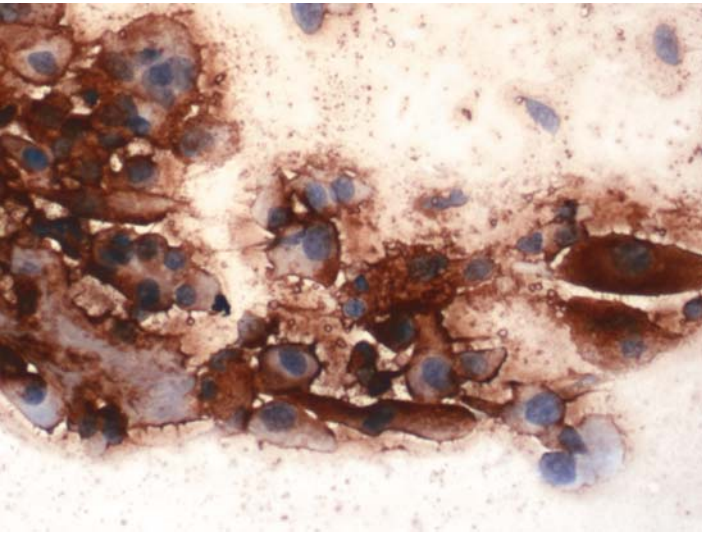


## Case 56

---



**FIGURE 56A. Pap Stain:** FNA of a cervical lymph node in a patient with a history of thyroid surgery. Large tumor cells with dense eosinophilic cytoplasm. The differential diagnosis includes a squamous cell carcinoma and a poorly differentiated papillary thyroid carcinoma.



**FIGURE 56B. Thyroglobulin (TGB):** Strong positive reaction for TGB in the cells and slide background.



## ***Diagnosis***

Metastatic Poorly Differentiated Papillary Carcinoma

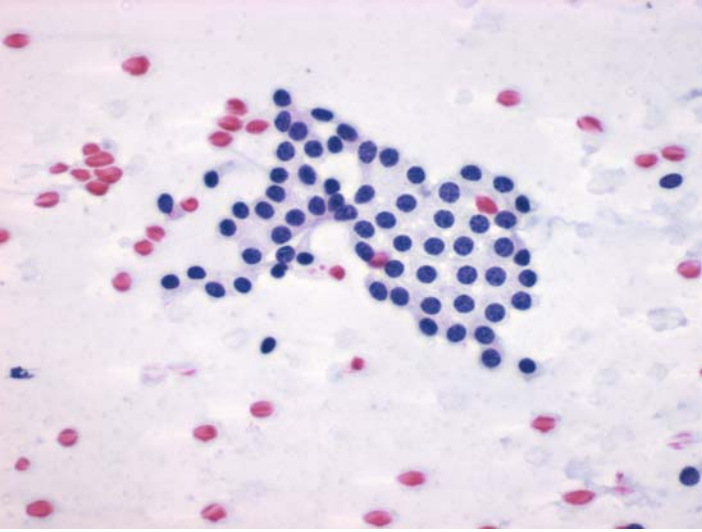
## ***Tips***

Since a squamous cell carcinoma was considered in the differential diagnosis, one could potentially include P63 in the ICC panel. It should be remembered, however, that papillary thyroid carcinomas may occasionally show squamous metaplasia and, hence, react positively for P63.

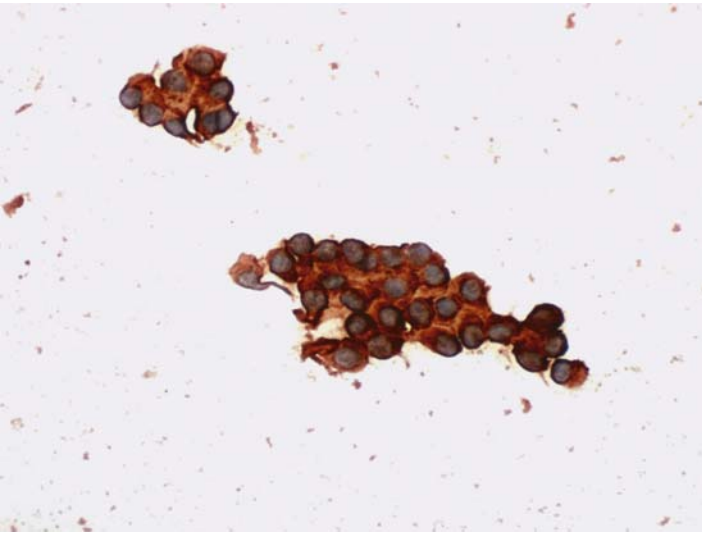
*Suggested Reading: 7*

## Case 57

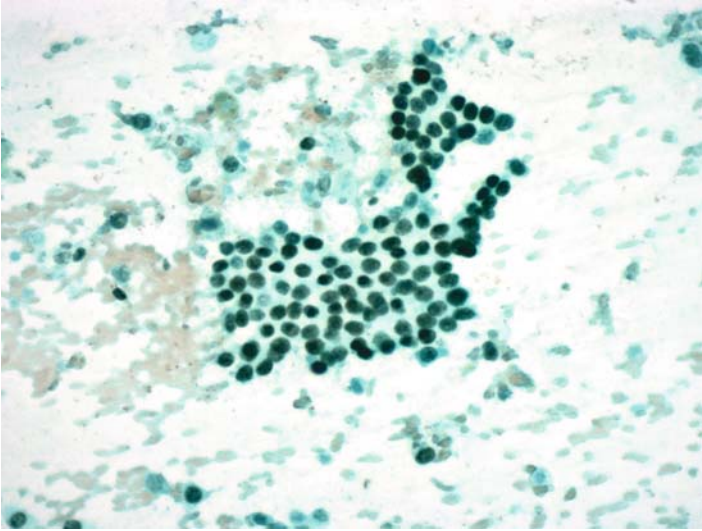
---



**FIGURE 57A. Pap Stain:** FNA of a cervical lymph node in a patient with no known primary cancer. Cytology is suggestive of a low grade adenocarcinoma; lung (broachiolqvlveolar type) or thyroid origin.



**FIGURE 57B. Thyroglobulin (TGB):** Strong cytoplasmic staining for TGB establishes the diagnosis.



**FIGURE 57C. TTF-1:** Tumor cells are also positive for TTF-1.

### ***Diagnosis***

Metastatic Papillary Thyroid Carcinoma

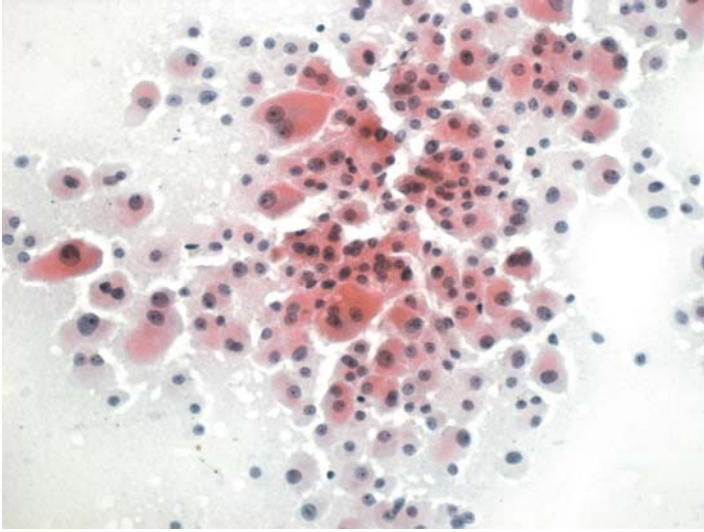
### ***Tips***

TTF-1 alone cannot differentiate between a lung and a thyroid primary because this nuclear antigen is expressed by most lung adenocarcinomas and by all follicular and C-cell tumors of the thyroid.

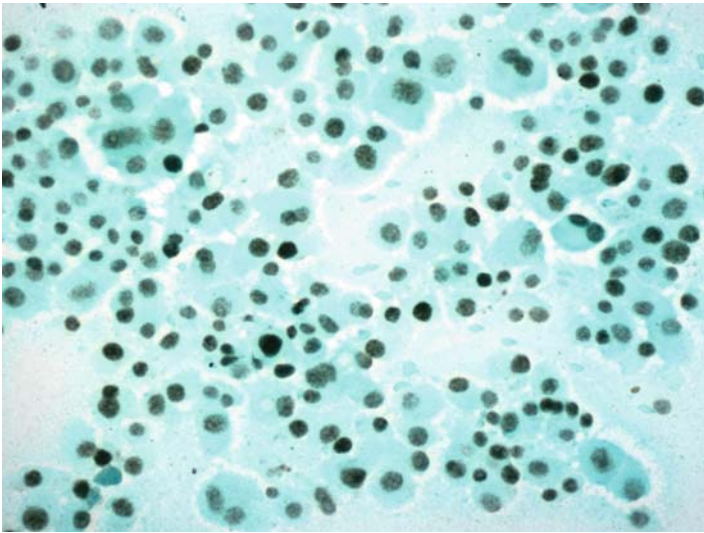
*Suggested Reading: 40, 43*

## Case 58

---



**FIGURE 58A. Pap Stain:** FNA of a cervical lymph node. The differential diagnosis includes a metastatic thyroid Hurthle cell carcinoma and a metastatic oncocytic salivary gland carcinoma.



**FIGURE 58B. TTF-1:** Positivity for TTF-1 is observed in the nuclei of most tumor cells.

## ***Diagnosis***

Metastatic Hurthle Cell Carcinoma of the Thyroid

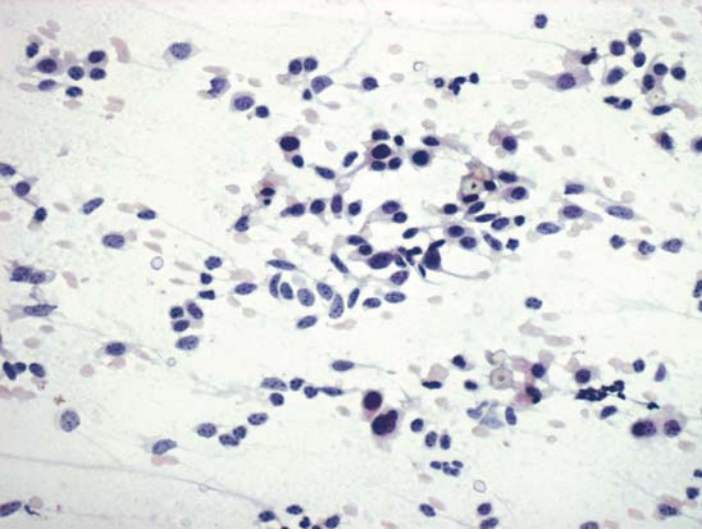
## ***Tips***

In a situation where the differential diagnosis is between a salivary gland tumor and a thyroid primary, TTF-1 positivity establishes the thyroid origin.

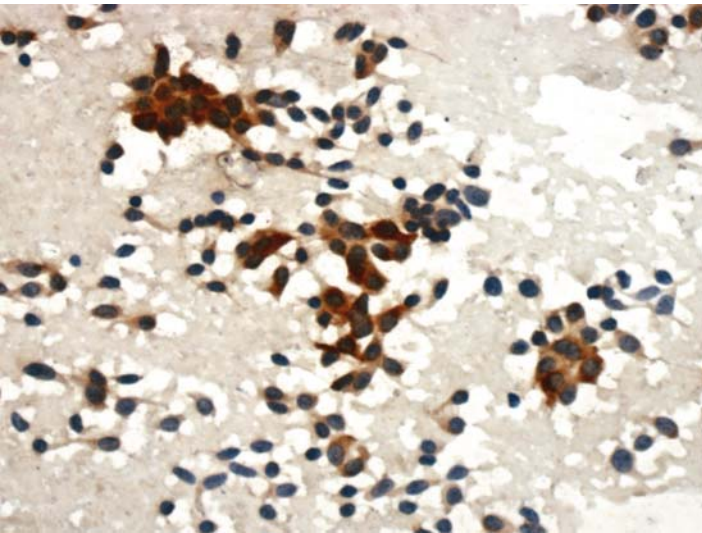
*Suggested Reading: 40*

## Case 59

---



**FIGURE 59A. Pap Stain:** FNA of the thyroid showing isolated and loosely cohesive cells highly suggestive of a medullary thyroid carcinoma.



**FIGURE 59B. Calcitonin:** Cells are positive for calcitonin.

## ***Diagnosis***

Medullary Thyroid Carcinoma

## ***Tips***

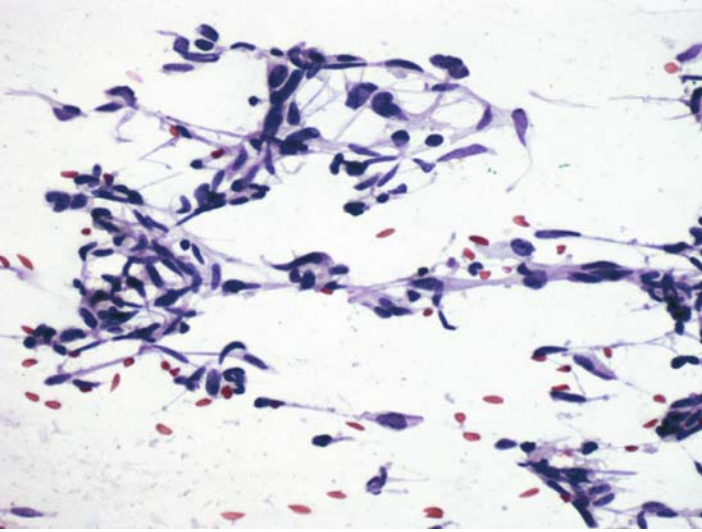
Medullary thyroid carcinomas are positive for calcitonin and CEA. The reaction for calcitonin may be focal but CEA expression is usually strong and diffuse.

*Suggested Reading: 44*

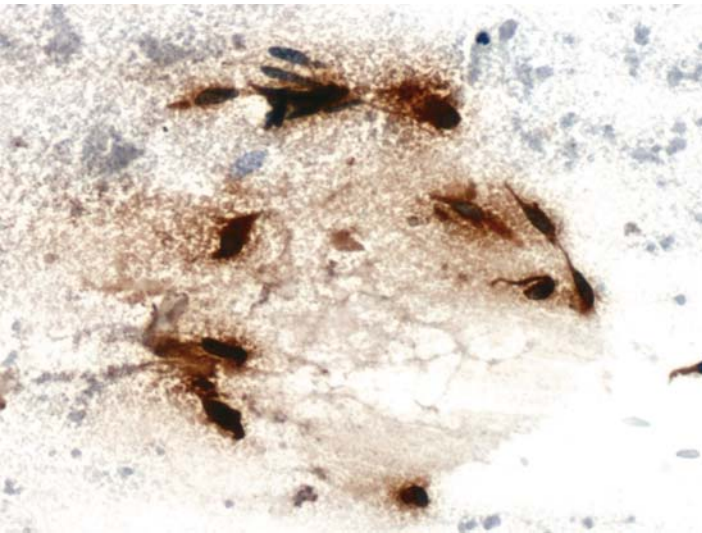


## Case 60

---



**FIGURE 60A. Pap Stain:** FNA of a cervical lymph node; patient also has a thyroid nodule. Pleomorphic spindle cells are present suggestive of a sarcoma or a metastatic medullary carcinoma.



**FIGURE 60B. Calcitonin:** Cells are positive for calcitonin.

***Diagnosis***

Metastatic Medullary Thyroid Carcinoma

***Tips***

Focal or diffuse spindle cell morphology may be seen in endocrine tumors, including medullary thyroid carcinomas.

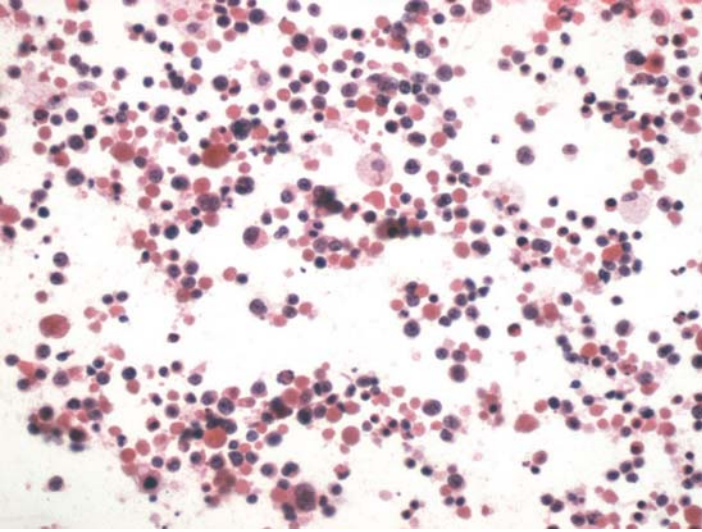
*Suggested Reading: 7, 44*

# 10

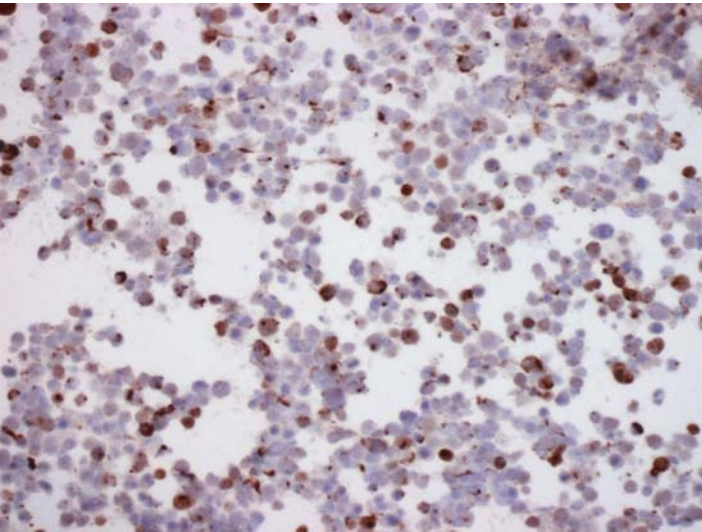
## Lung

## Case 61

---



**FIGURE 61A. Pap Stain:** Transbronchial FNA of a lung lesion showing mostly isolated small cells with pyknotic nuclei. Differential diagnosis includes small cell carcinoma and lymphoma.



**FIGURE 61B. Cytokeratin:** Many cells show paranuclear punctate staining for cytokeratin.

## ***Diagnosis***

Small Cell Carcinoma

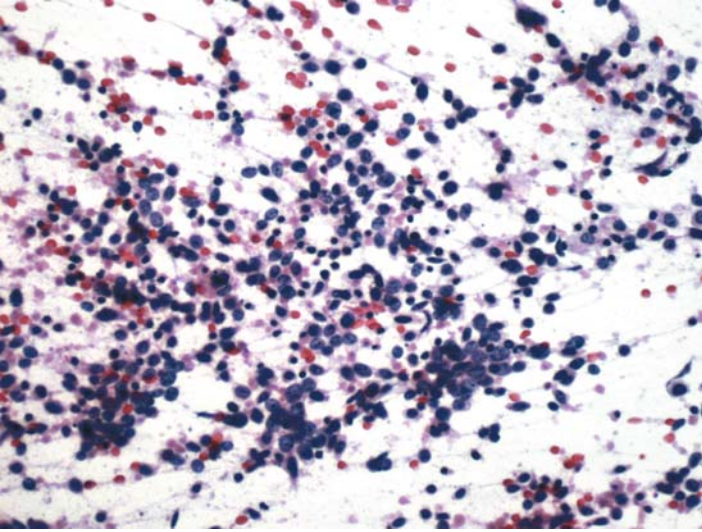
## ***Tips***

The diagnosis of a small cell carcinoma is usually confirmed by a positive cytokeratin staining; this excludes lymphomas. There is no need for including chromogranin and synaptophysin, because the former is expressed in less than 40% of small cell carcinomas and the latter may be expressed by nonsmall cell carcinomas.

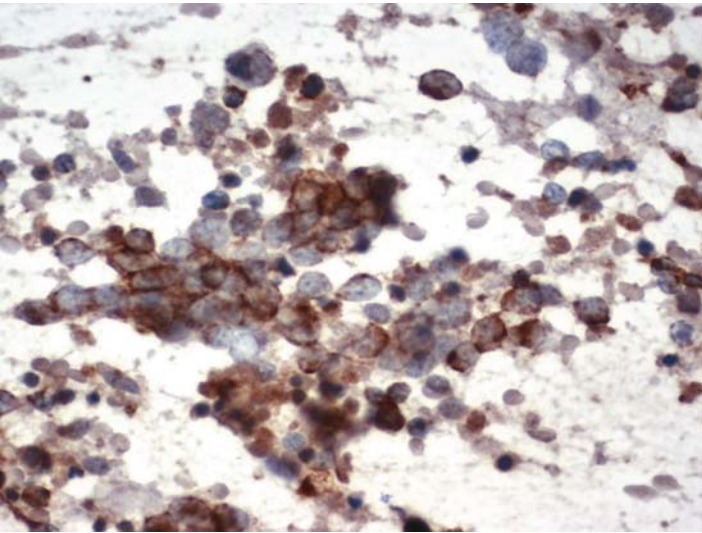
*Suggested Reading: 7*

## Case 62

---



**FIGURE 62A. Pap Stain:** Bronchial brushings from a 68-year-old male. Isolated small cells with hyperchromatic nuclei are seen; small cell carcinoma or malignant lymphoma.



**FIGURE 62B. Cytokeratin:** There is positive perinuclear reaction for cytokeratin.

## ***Diagnosis***

Small Cell Carcinoma

## ***Tips***

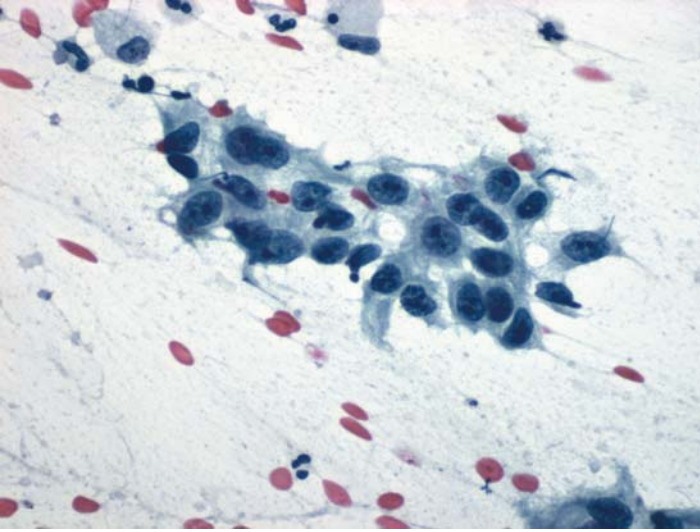
Cytokeratin reaction in small cell carcinomas is either in the form of punctate paranuclear or perinuclear staining pattern. This case shows the latter.

*Suggested Reading: 7*

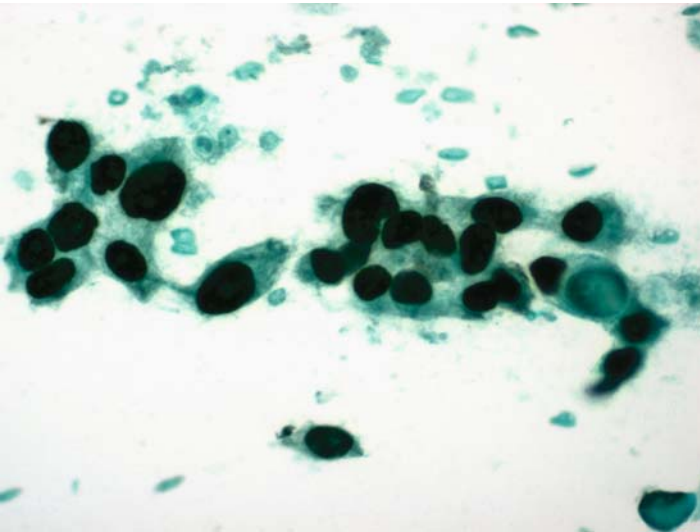


## Case 63

---



**FIGURE 63A. Pap Stain:** Poorly differentiated non-small cell carcinoma in bronchial brushings. One can further characterize this tumor by immunocytochemistry.



**FIGURE 63B. P63:** Positive nuclear staining of tumor cells for p63 favors the diagnosis of squamous cell carcinoma.

## ***Diagnosis***

Squamous Cell Carcinoma, Poorly Differentiated

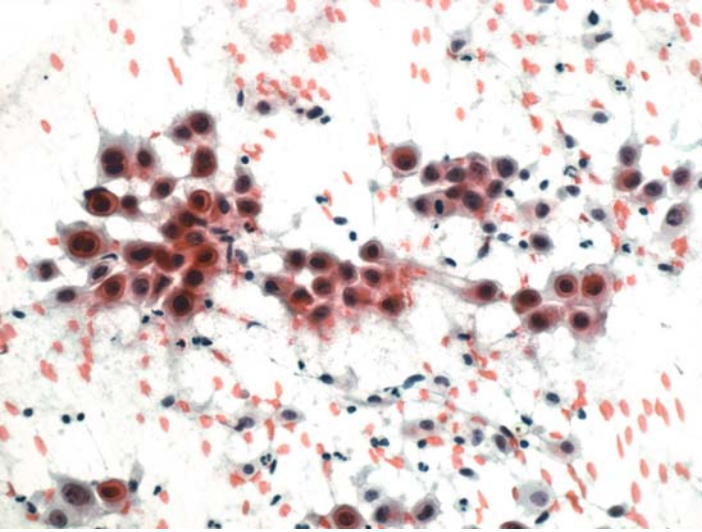
### ***Tips***

- A combination of TTF-1 and p63 should help to subclassify most nonsmall cell carcinomas of the lung. TTF-1 is expressed by most adenocarcinomas but not by squamous cell carcinomas, while p63 is seen only in squamous cell carcinomas.
- In adenosquamous carcinomas of lung there may be focal staining for TTF-1 and p63 in the same tumor.

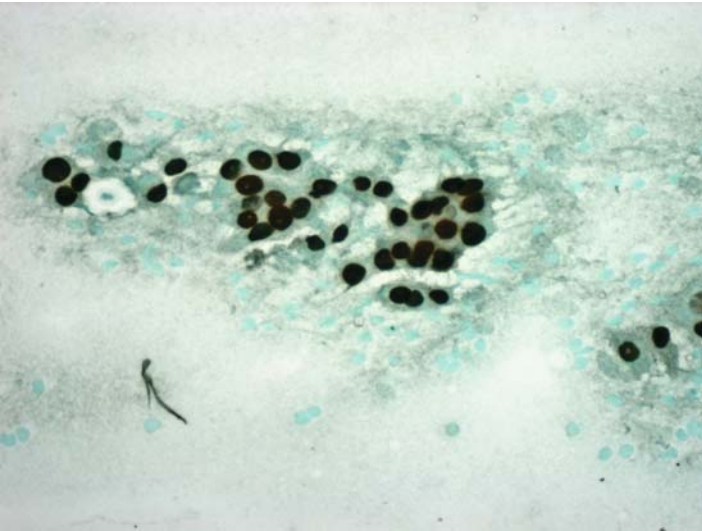
*Suggested Reading: 45*

## Case 64

---



**FIGURE 64A. Pap Stain:** FNA of a peripheral lung tumor in a 71-year-old female. The morphology is suggestive of squamous cell carcinoma.



**FIGURE 64B. TTF-1:** Tumor Cells show positive nuclear reaction for TTF-1. This favors the diagnosis of adenocarcinoma.

## ***Diagnosis***

Adenocarcinoma of the Lung

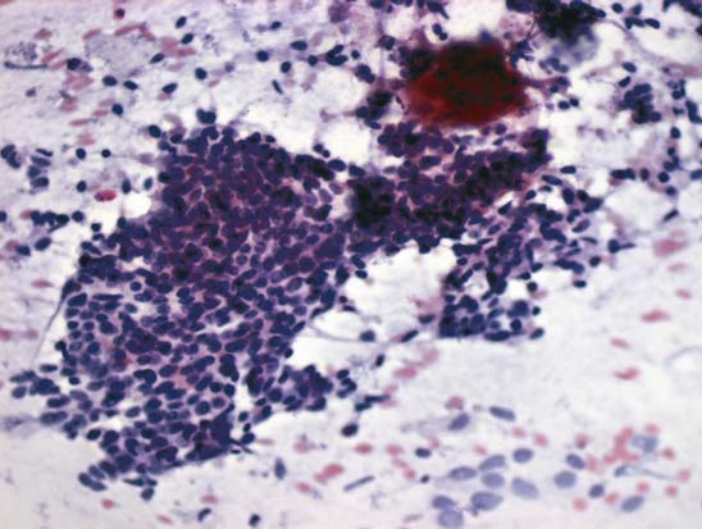
### ***Tips***

- A combination of TTF-1 and p63 should help to subclassify most nonsmall cell carcinomas of the lung. TTF-1 is expressed by most adenocarcinomas but not by squamous cell carcinomas, while p63 is seen only in squamous cell carcinomas.
- In adenosquamous carcinomas of lung there may be focal staining for TTF-1 and p63 in the same tumor.

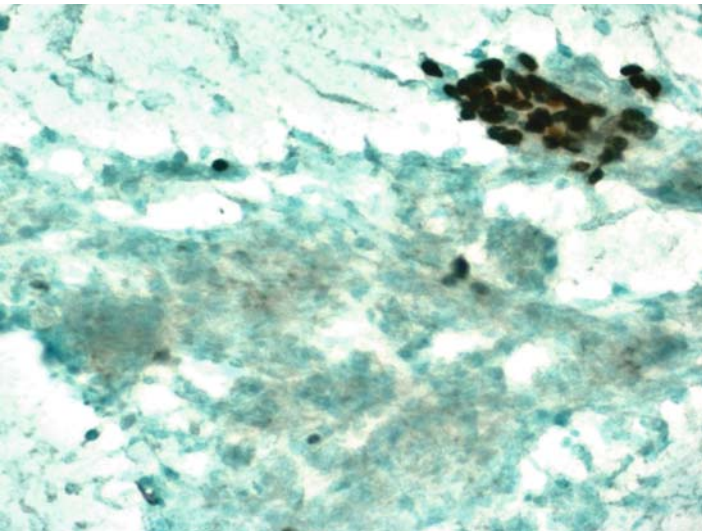
*Suggested Reading: 45, 47, 48*

## Case 65

---



**FIGURE 65A. Pap Stain:** FNA of lung in a 55-year-old male. There is a cluster of small cells with ill-defined cytoplasm and a small group of larger cells with eosinophilic cytoplasm (upper right).



**FIGURE 65B. P63:** Positive reaction for p63 in the cells with eosinophilic cytoplasm supports their squamous differentiation. The small cell component remains negative.

## ***Diagnosis***

Small Cell Carcinoma with Focal Squamous Differentiation

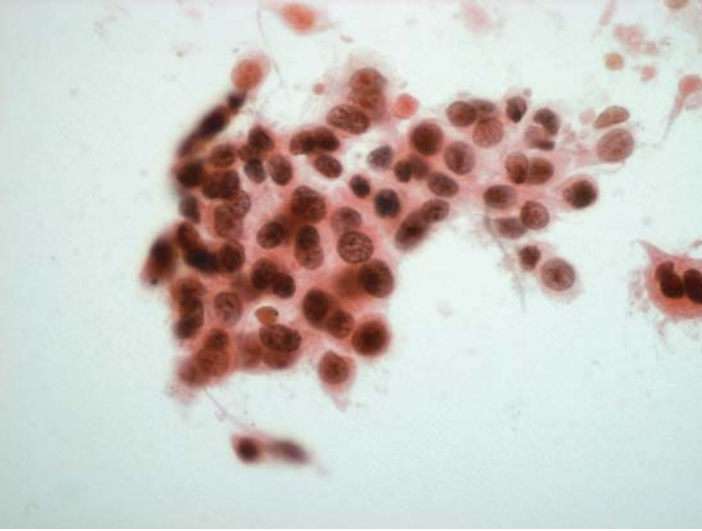
## ***Tips***

Small cell carcinomas of the lung do not stain for p63 unless they have focal squamous differentiation. Therefore, p63 is a good marker to separate positive basaloid squamous cell carcinomas from the negative small cell carcinomas.

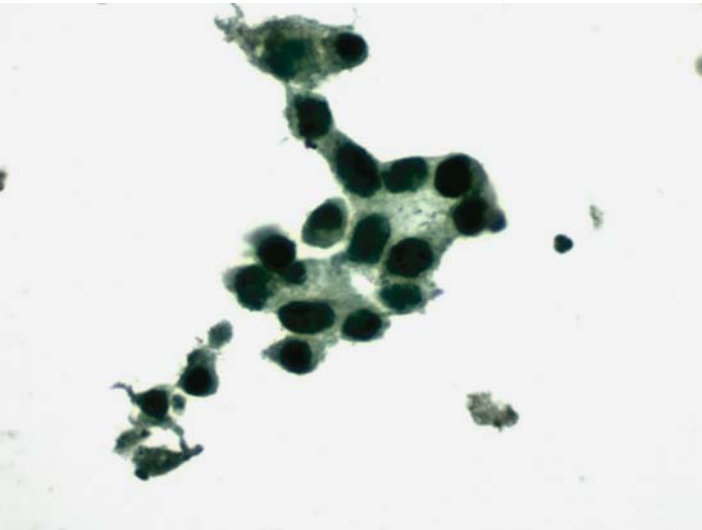
*Suggested Reading: 7*

## Case 66

---



**FIGURE 66A. Pap Stain:** FNA of lung in a 66-year-old female. Nonsmall cell carcinoma is favored, but a metastasis cannot be excluded.



**FIGURE 66B. TTF-1:** Tumor cells are positive for TTF-1, supporting their pulmonary origin.



## ***Diagnosis***

Adenocarcinoma of the Lung

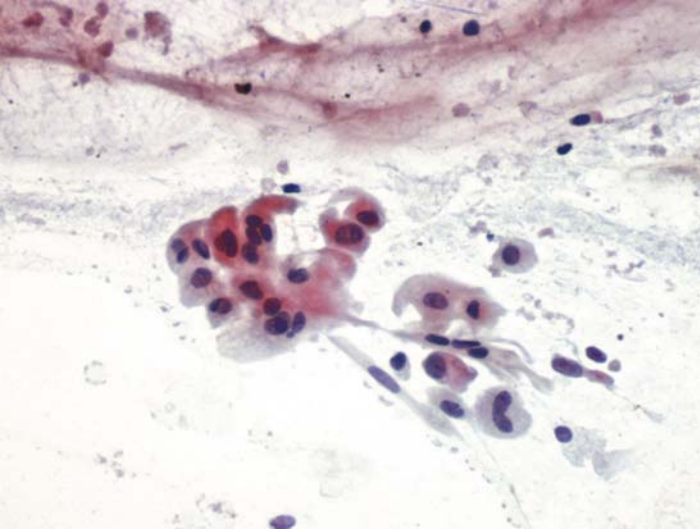
## ***Tips***

The only other possibility in this case is a TTF-1 positive metastatic thyroid carcinoma. Thyroglobulin should be used if that possibility is entertained.

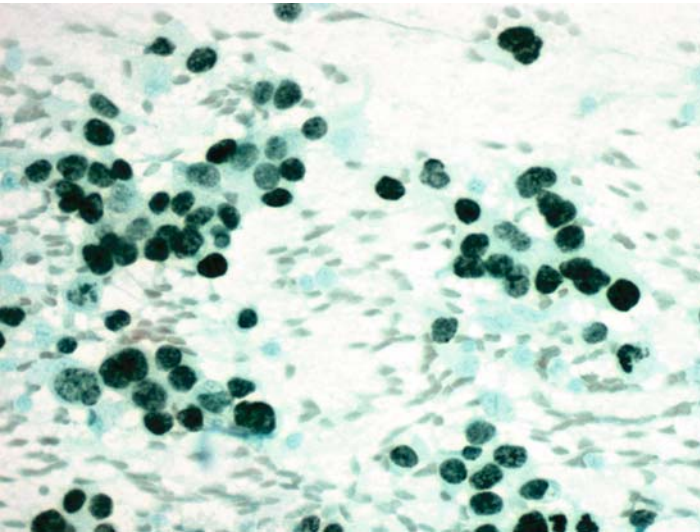
*Suggested Reading: 46*

## Case 67

---



**FIGURE 67A. Pap Stain:** FNA of lung in a patient with a history of bronchioloalveolar carcinoma of the contralateral lung. Is it an adenocarcinoma or a squamous cell carcinoma?



**FIGURE 67B. TTF-1:** Tumor cells are positive for TTF-1.

***Diagnosis***

Adenocarcinoma; Bronchioloalveolar by History

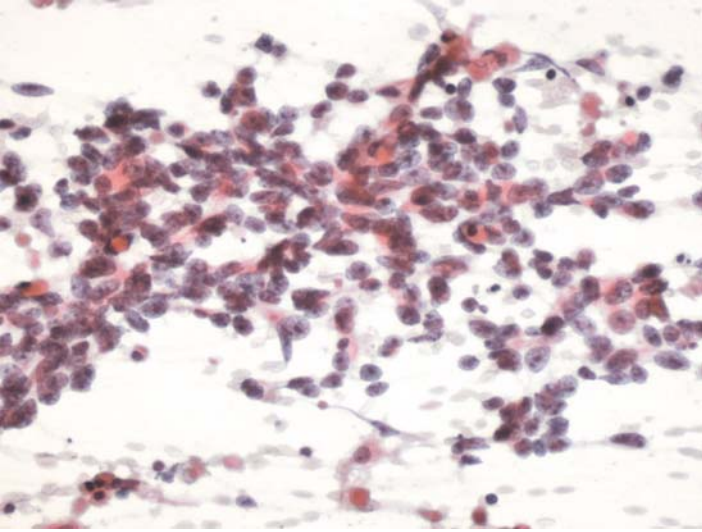
***Tips***

Most bronchioloalveolar carcinomas of the lung, with the exception of intestinal-type mucinous variants, are positive for TTF-1. Those tumors may also be positive for CK20 and CDX-2 and, hence, their differentiation from metastatic colonic carcinomas may be difficult.

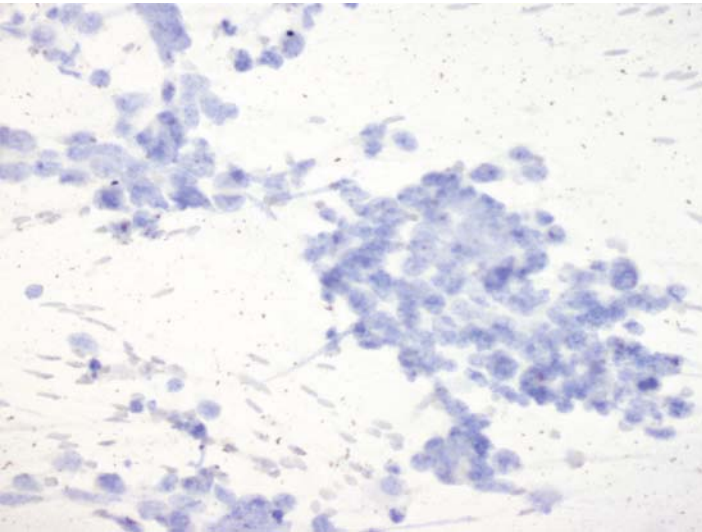
*Suggested Reading: 46, 47*

## Case 68

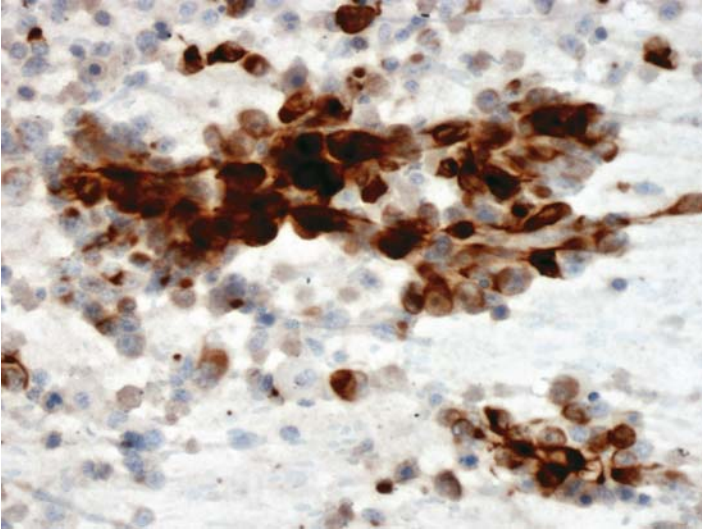
---



**FIGURE 68A. Pap Stain:** FNA of lung in a 76-year-old male with history of colonic carcinoma. The cytomorphology is suggestive of an adenocarcinoma.



**FIGURE 68B. CK20:** Tumor cells are negative for CK20.



**FIGURE 68C. CK7:** Positive reaction for CK7 is seen in most tumor cells.

## ***Diagnosis***

Adenocarcinoma of the Lung

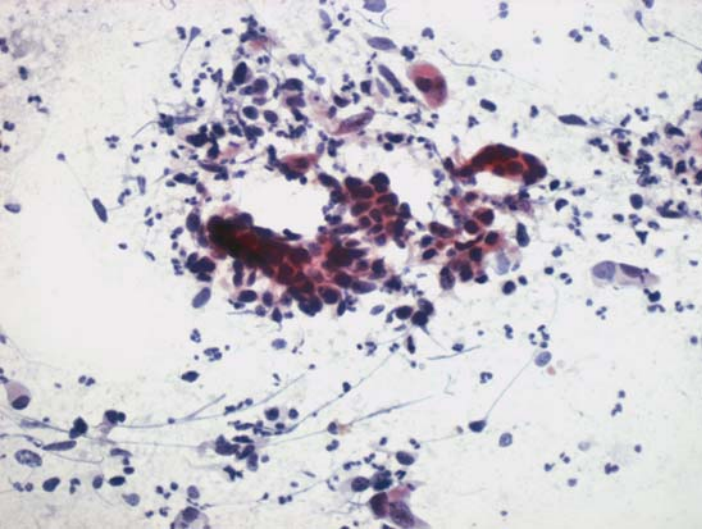
## ***Tips***

- When the differential diagnosis is between a primary lung adenocarcinoma and a metastatic colonic adenocarcinoma, a combination of CK20 and CK7 will be helpful as lung adenocarcinomas are usually positive for CK7 and negative for CK20.
- TTF-1 is also helpful (48).

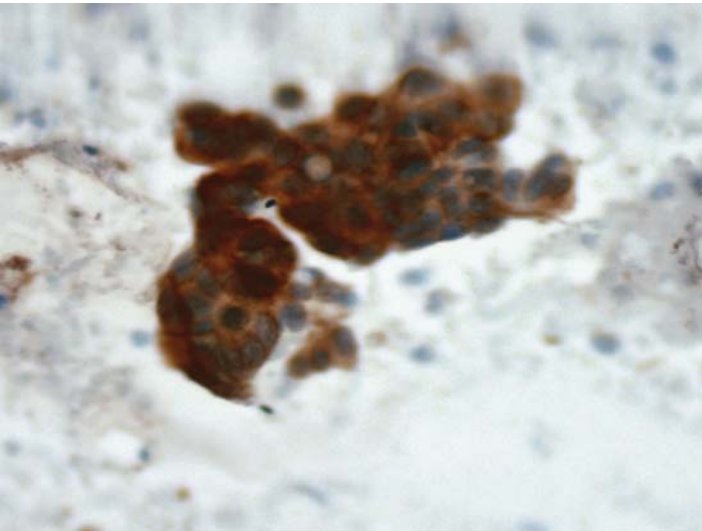
*Suggested Reading: 48*

## Case 69

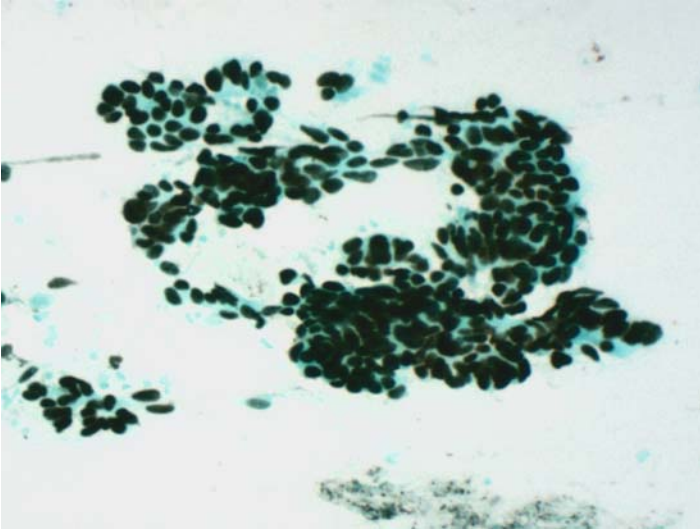
---



**FIGURE 69A. Pap Stain:** FNA of a solitary lung nodule in 63-year-old male with a history of colonic carcinoma.



**FIGURE 69B. CK20:** Tumor cells are positive for CK20.



**FIGURE 69C. CDX-2:** They are also positive for CDX-2.

### ***Diagnosis***

Metastatic Adenocarcinoma of the Colon

### ***Tips***

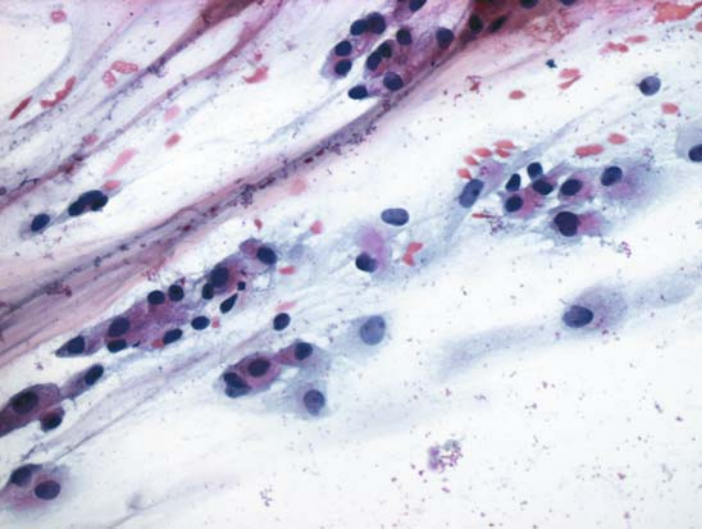
When adenocarcinoma of colon is suspected, CDX-2 can be used in addition to CK20 as a marker for the colon. CDX-2 positivity alone, however, is not specific for colonic carcinomas.

*Suggested Reading: 28*

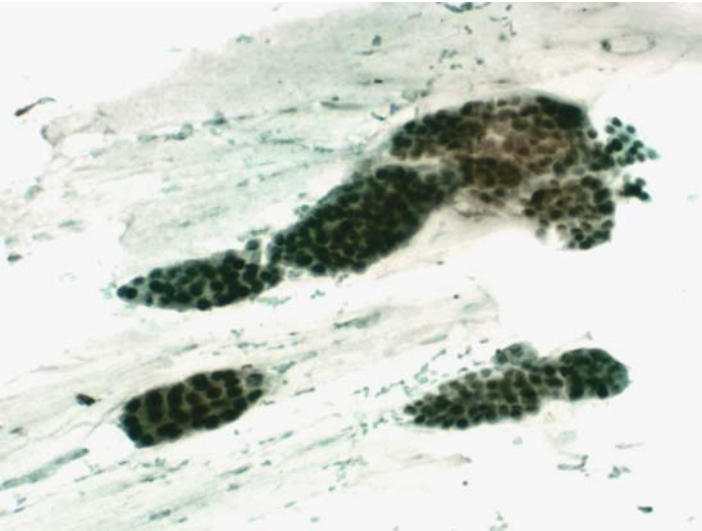


## Case 70

---



**FIGURE 70A. Pap Stain:** FNA of a lung in a female patient with a history of mammary carcinoma. Cytology is consistent with a mucinous adenocarcinoma.



**FIGURE 70B. Estrogen Receptor (ER):** Tumor cells are uniformly positive for ER.

## ***Diagnosis***

Metastatic Mammary Carcinoma

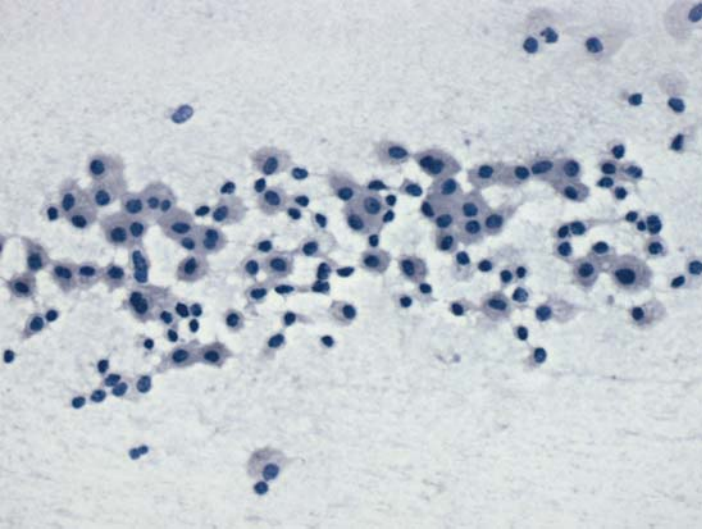
### ***Tips***

- When monoclonal antibody ER-ID5 is used, only mammary and gynecologic cancers stain positively. This is not the case when other ER antibodies, such as 6F11 are used. The latter frequently stains lung, thyroid, and other nonbreast, nongynecologic cancers. For that reason, we only use ER-ID5 antibody.
- The pattern of ER-ID5 staining in breast cancer is usually diffuse, whereas in gynecologic tumors it is expressed focally.

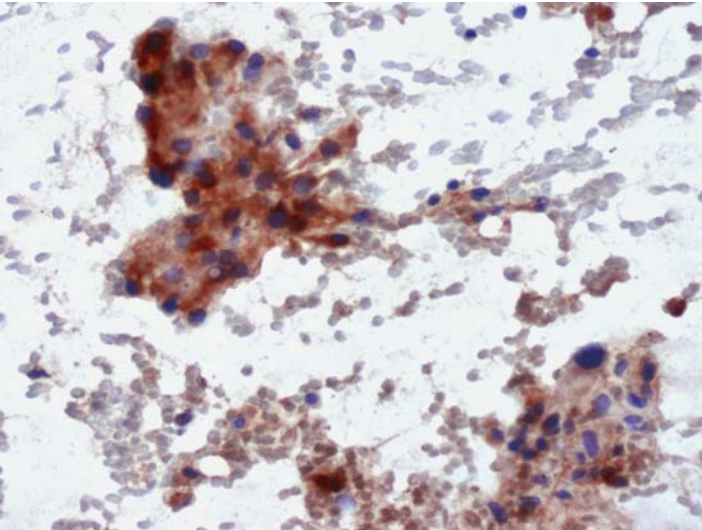
*Suggested Reading: 49*

## Case 71

---



**FIGURE 71A. Pap Stain:** FNA of a peripheral pulmonary nodule. The bland cytomorphology is suggestive of a carcinoid tumor.



**FIGURE 71B. Chromogranin:** All tumor cells are positive for chromogranin.

## ***Diagnosis***

Pulmonary Carcinoid

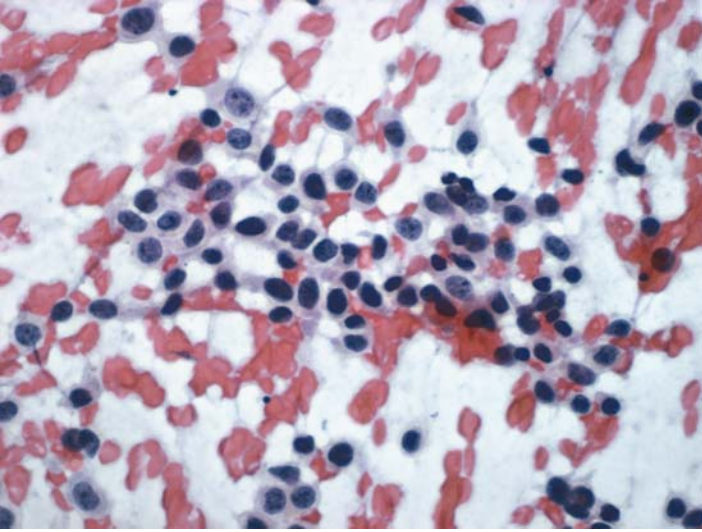
## ***Tips***

Most carcinoids of the lung express chromogranin. Staining for individual peptide hormones in these tumors however, is less rewarding. The differential diagnosis between a pulmonary carcinoid and a small cell carcinoma cannot be resolved by ICC. Cytologically, small cell carcinomas may show necrosis, chromatin streaking, and so on. The clinical information and X-ray findings may also be helpful.

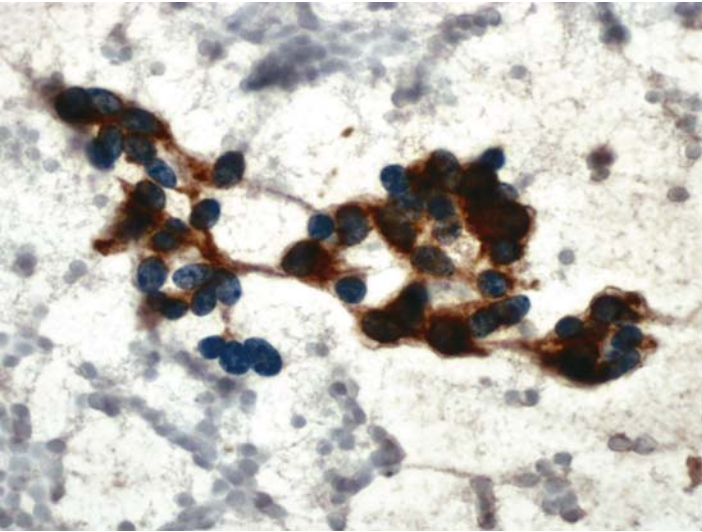
*Suggested Reading: 50*

## Case 72

---



**FIGURE 72A. Pap Stain:** FNA of peripheral lung lesion. There are loosely cohesive cells with pleomorphic nuclei. A neuroendocrine tumor is in the differential diagnosis.



**FIGURE 72B. Chromogranin:** Strong cytoplasmic staining for chromogranin supports the morphologic impression of a neuroendocrine neoplasm.

## ***Diagnosis***

Pulmonary Carcinoid

## ***Tips***

The differential diagnosis between a pulmonary carcinoid and a small cell carcinoma cannot be resolved by ICC. Cytologically, small cell carcinomas may show necrosis, chromatin streaking, and so on. The clinical information and X-ray findings may be helpful.

*Suggested Reading: 50*

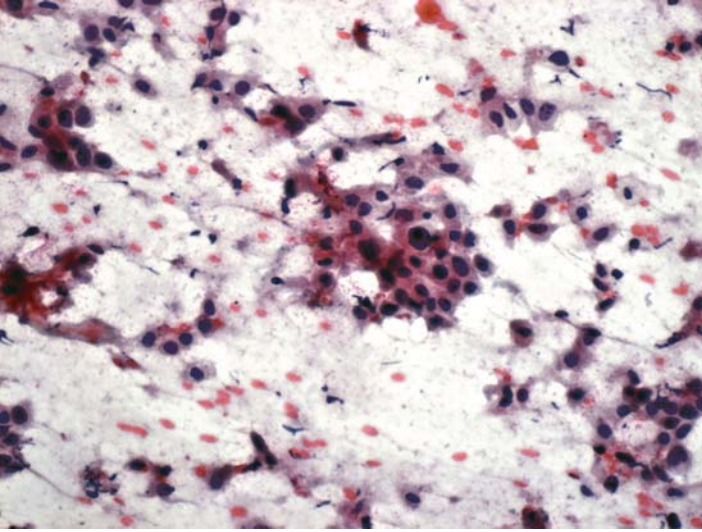
# 11

## Pleura and Mediastinum

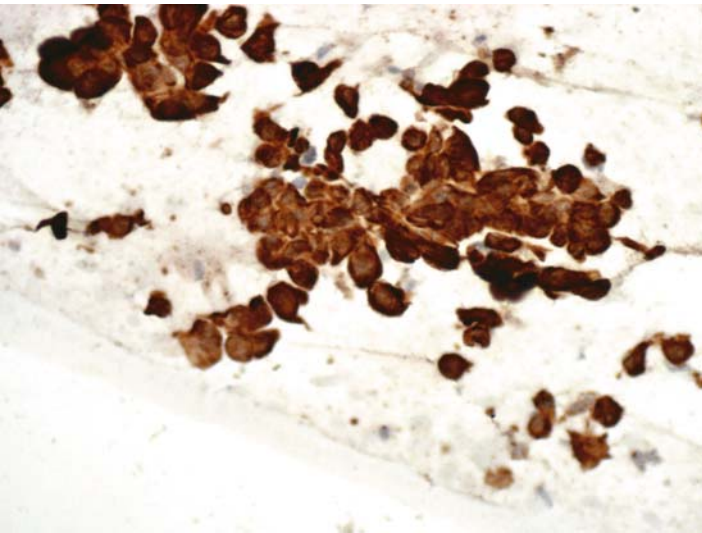


## Case 73

---



**FIGURE 73A. Pap Stain:** FNA of a pleural-based mass in a 62-year-old male. The differential diagnosis includes a mesothelioma and a poorly differentiated carcinoma.



**FIGURE 73B. Calretinin:** Strong positive nuclear and cytoplasmic staining for calretinin establishes the mesothelial nature of malignant cells.

## ***Diagnosis***

Malignant Mesothelioma

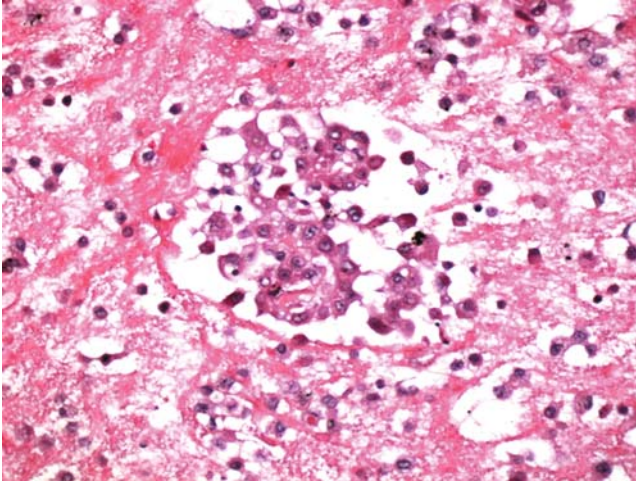
### ***Tips***

- Among more than two dozen purported mesothelial cell markers, we have found calretinin to be the most useful. Calretinin reaction in mesothelial cells is both cytoplasmic and nuclear; the latter is more important for the diagnosis.
- Desmoplastic and spindle cell (sarcomatoid) mesotheliomas are usually negative for calretinin (51,52).

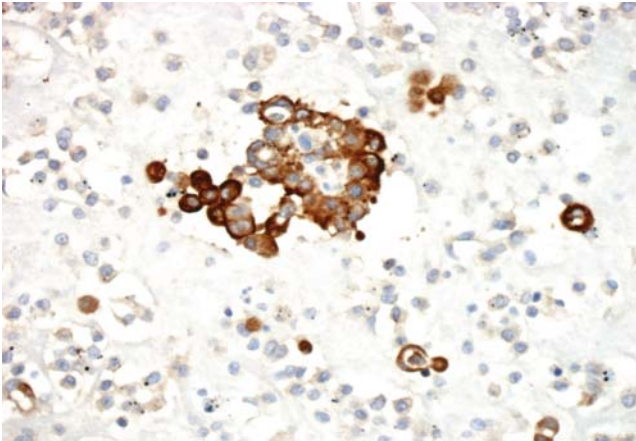
*Suggested Reading: 51, 52*

## Case 74

---



**FIGURE 74A. H&E Stain, Cell Block:** Pleural fluid in a 79-year-old male. The differential diagnosis includes reactive mesothelium, malignant mesothelioma, and adenocarcinoma of lung.



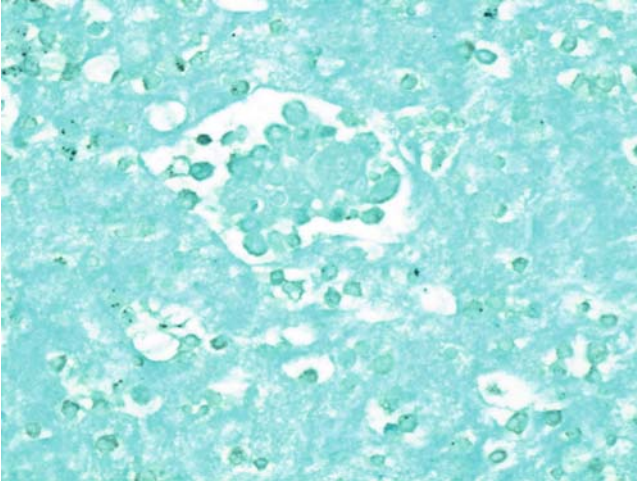
**FIGURE 74B. Epithelial Membrane Antigen (EMA):** Cells are strongly positive for EMA and hence, a reactive process is excluded.

### *Diagnosis*

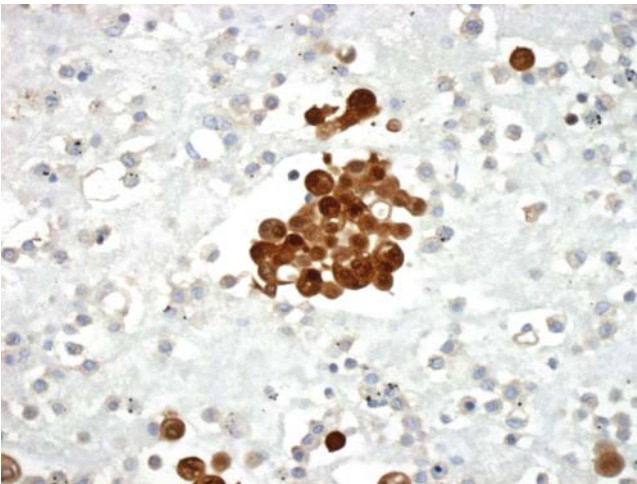
Malignant Mesothelioma

### *Tips*

- Strong cytoplasmic or membrane EMA staining of cells in a pleural fluid that is easily seen on low power magnification is highly indicative of their



**FIGURE 74C. TTF-1:** Tumor cells are negative for TTF-1. An adenocarcinoma of the lung is unlikely.



**FIGURE 74D. Calretinin:** Positive nuclear and cytoplasmic staining for calretinin establishes the diagnosis.

malignant nature. Reactive mesothelial cells usually do not express this antigen or show weak reaction that is difficult to identify on low power.

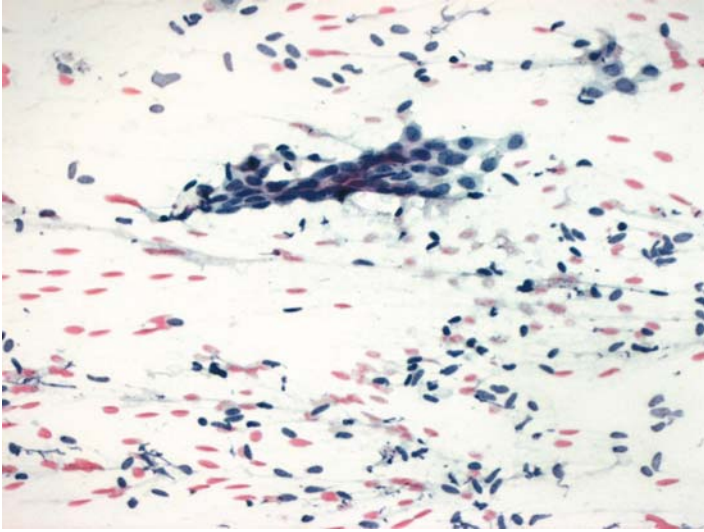
- When the diagnosis of malignancy is established, the differential between malignant mesothelioma and adenocarcinoma of the lung could, in most cases, be resolved by the use of calretinin and TTF-1.

*Suggested Reading: 45, 51, 52*

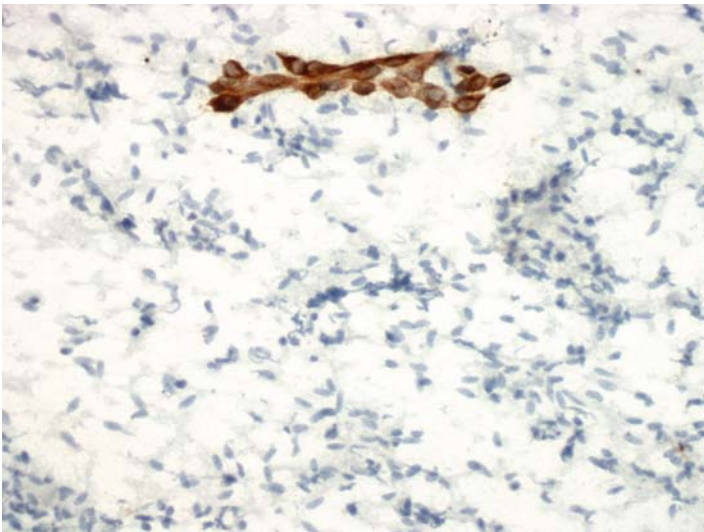


## Case 75

---



**FIGURE 75A. Pap Stain:** Imprint cytology of a fibrotic pleural nodule. Bland spindle-shaped nuclei and a cluster of epithelioid cells are seen. The differential diagnosis includes solitary fibrous tumor and sarcomatoid mesothelioma.



**FIGURE 75B. Cytokeratin:** Spindle cells are negative for cytokeratin, while the cluster of mesothelial cells is positive.

## ***Diagnosis***

Spindle Cell Neoplasm Consistent with Solitary Fibrous Tumor

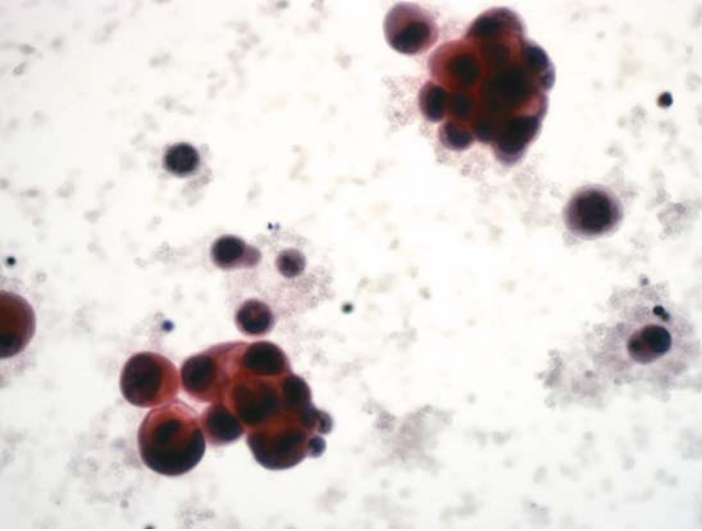
## ***Tips***

- Both desmoplastic and sarcomatoid mesotheliomas are positive for cytokeratin, while solitary fibrous tumors are not. As discussed in Case 73, calretinin is not useful in this situation.
- CD34 is usually expressed by solitary fibrous tumors.

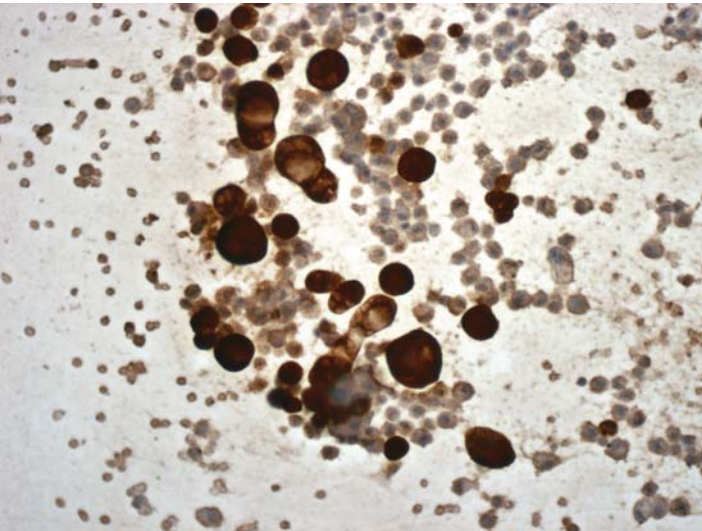
*Suggested Reading: 53*

## Case 76

---

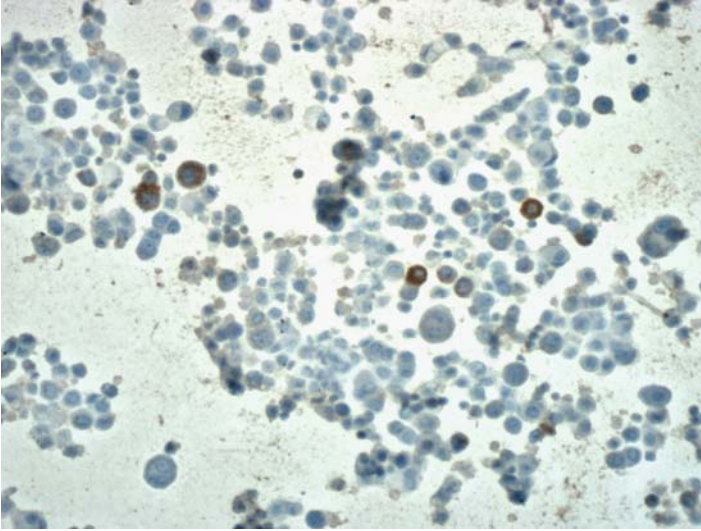


**FIGURE 76A. Pap Stain:** Cyto centrifuge preparation of a pleural fluid with clusters of cells suggestive of adenocarcinoma. This case shows the value of EMA staining in the differential diagnosis of adenocarcinomas from reactive mesothelial cells.



**FIGURE 76B. Epithelial Membrane Antigen (EMA):** The abnormal cells show strong positive cytoplasmic staining for EMA.





**FIGURE 76C. EMA:** In contrast, reactive mesothelial cells (from a different patient) are either negative or only show a focal weak reaction for EMA.

## *Diagnosis*

Adenocarcinoma (b), Reactive Mesothelial Cells (c)

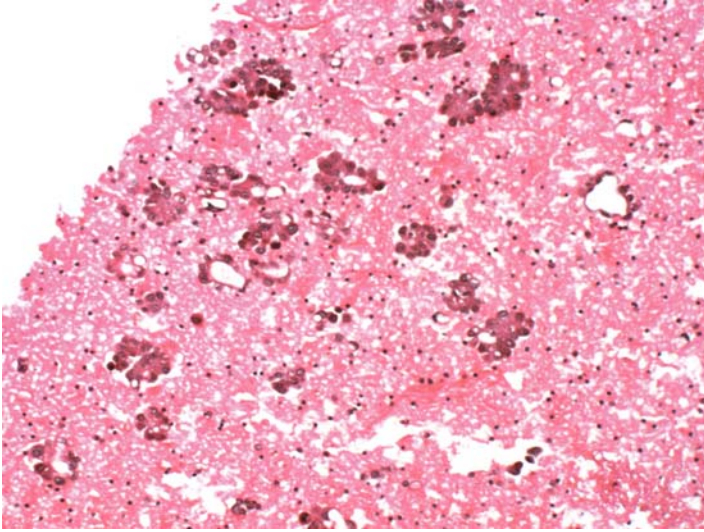
## *Tips*

The use of EMA for the differential diagnosis of reactive mesothelial cells from carcinomas and mesotheliomas is very much dependent on the sensitivity of the ICC. In a proper setting, EMA positivity of malignant cells is easily detected on low magnification. If one to use high magnification to evaluate a sample possible EMA positivity, it is in all likelihood a reactive process. Other important markers of reactive mesothelial cells include desmin and h-caldesmon.

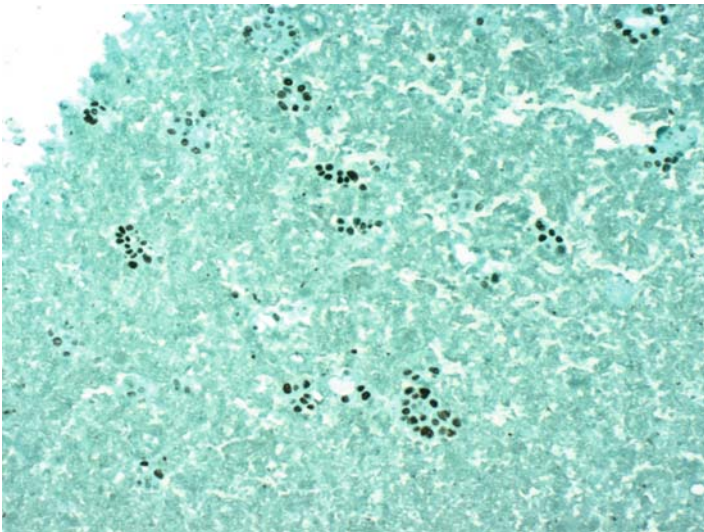
*Suggested Reading: 7*

## Case 77

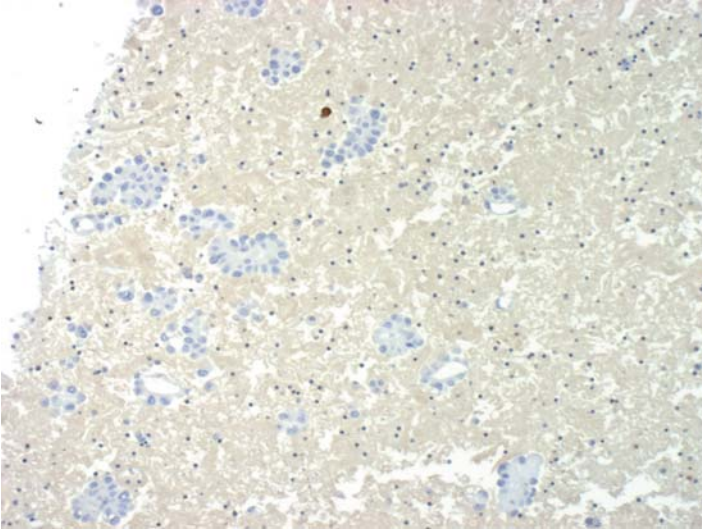
---



**FIGURE 77A. H&E Stain, Cell Block:** Pleural fluid cytology from a 64-year-old female with no prior history of malignancy. The differential diagnosis includes adenocarcinoma and mesothelioma.



**FIGURE 77B. TTF-1:** There is strong positive nuclear reaction for TTF-1.



**FIGURE 77C. Calretinin:** Tumor cells are negative for calretinin. A single mesothelial cell is positive (top).

## ***Diagnosis***

Pulmonary Adenocarcinoma

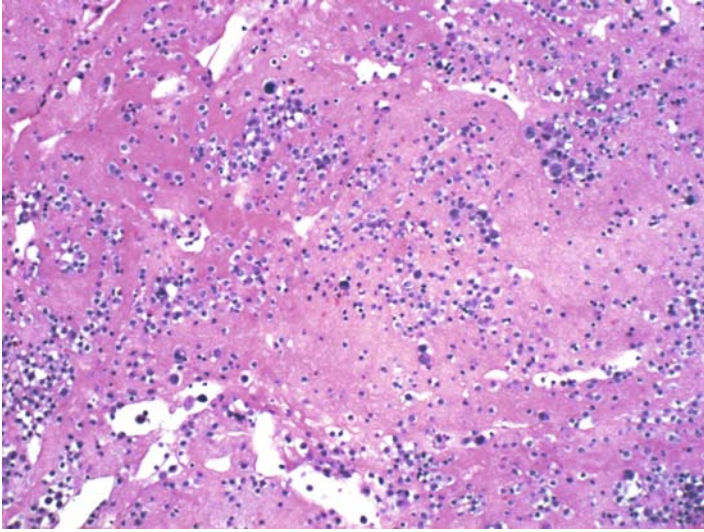
## ***Tips***

A negative reaction for calretinin in a serosal fluid does not necessarily exclude the possibility of cells being of mesothelial origin. In long-standing effusions, the degenerating mesothelial cells lose their reactivity for calretinin and cytokeratin and may show positivity for a histiocytic/macrophage marker, such as CD68.

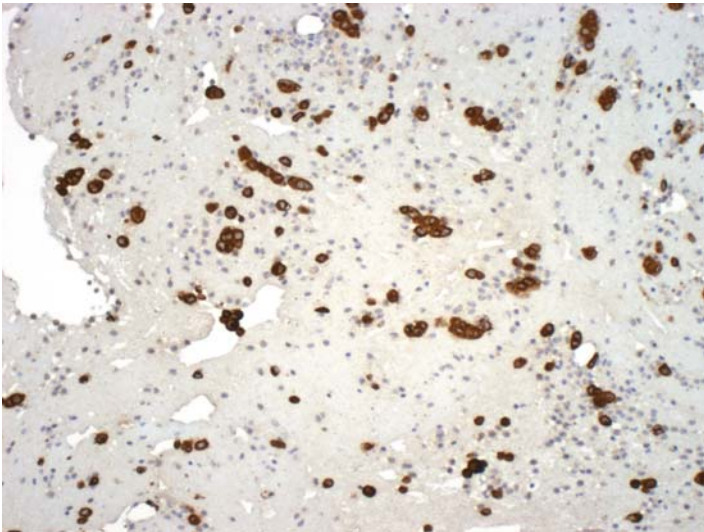
***Suggested Reading:*** 7

## Case 78

---

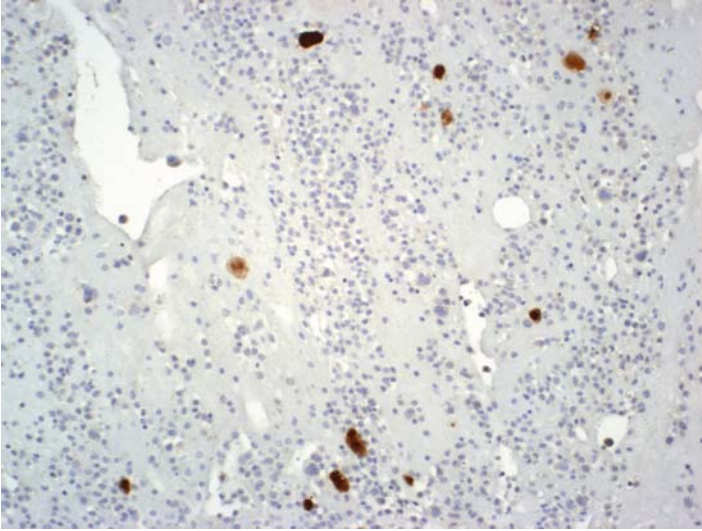


**FIGURE 78A. H&E Stain, Cell Block:** Pleural fluid of a 57-year-old female with a history of breast cancer. Specimen consists of mostly isolated cells, some of which show nuclear pleomorphism. The differential diagnosis includes carcinoma and reactive mesothelium.

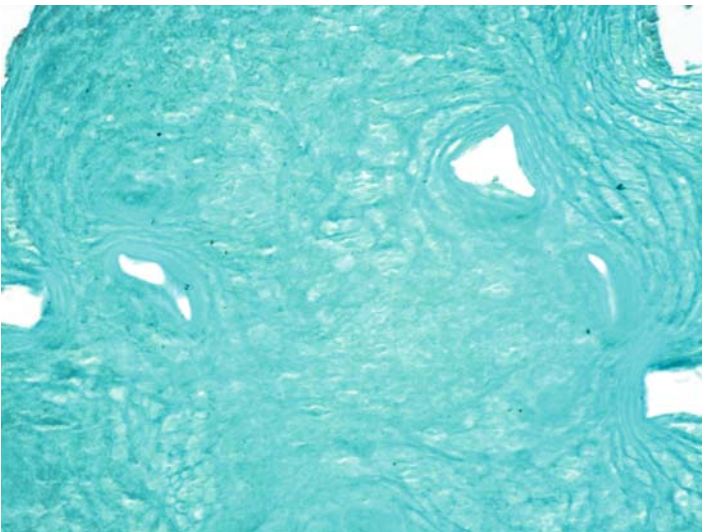


**FIGURE 78B. Epithelial Membrane Antigen (EMA):** Strong positive reaction for EMA supports the diagnosis of malignancy.

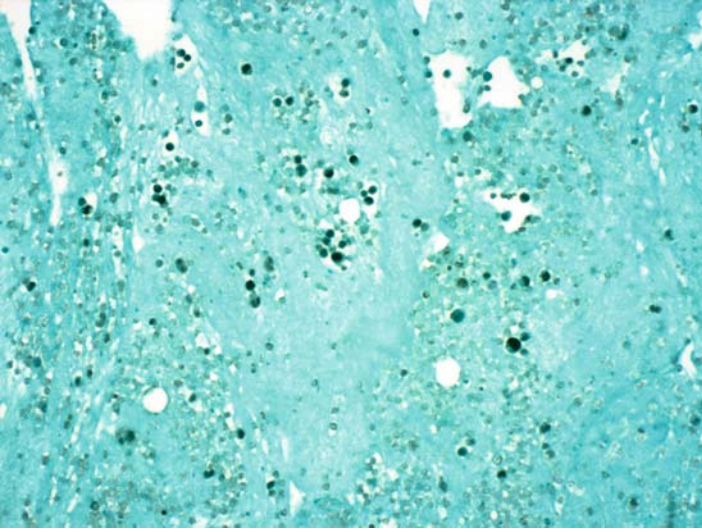




**FIGURE 78C. Calretinin:** Isolated reactive mesothelial cells are positive for calretinin.



**FIGURE 78D. TTF-1:** There is no reaction for TTF-1.



**FIGURE 78E. Estrogen Receptor (ER):** Many tumor cells are positive for ER.

## ***Diagnosis***

Metastatic Mammary Carcinoma

## ***Tips***

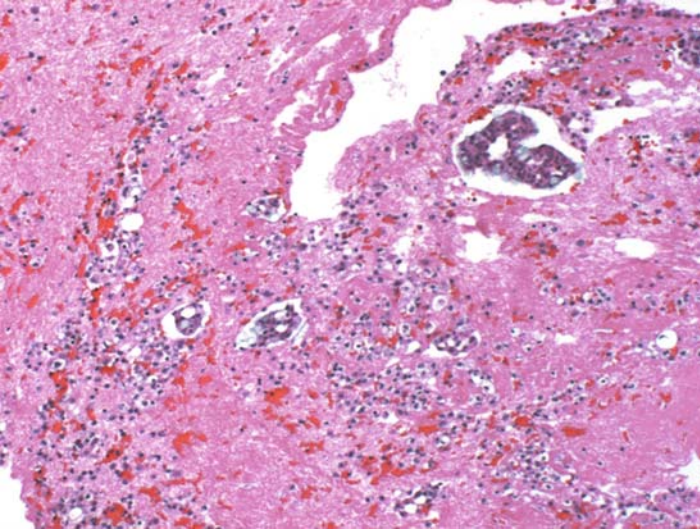
This case exemplifies the advantage of having a cell block preparation available as one could use several markers in an ICC panel and arrive to the specific diagnosis of metastatic breast cancer.

*Suggested Reading: 46–49*



## Case 79

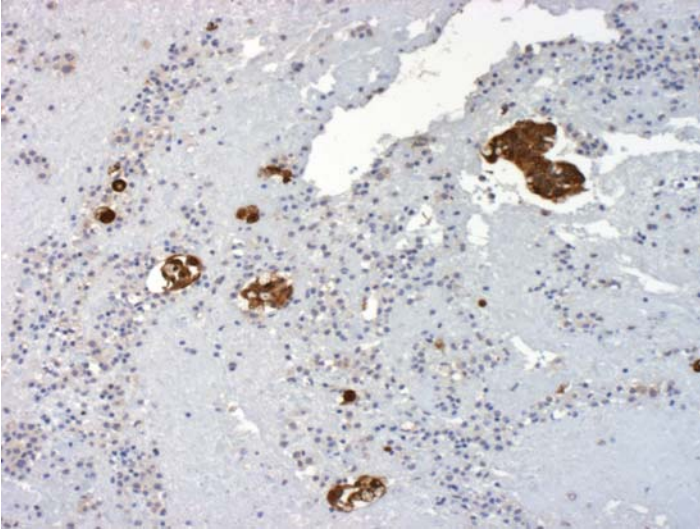
---



**FIGURE 79A. H&E Stain, Cell Block:** Pleural fluid from a 78-year-old patient with history of colonic adenocarcinoma. Cytologically it is an adenocarcinoma with focal mucin production; metastatic colonic adenocarcinoma versus primary lung carcinoma.



**FIGURE 79B. TTF-1:** The reaction for TTF-1 is negative.



**FIGURE 79C. CK20:** Tumor cells are positive for CK20.

### ***Diagnosis***

Metastatic Colonic Adenocarcinoma

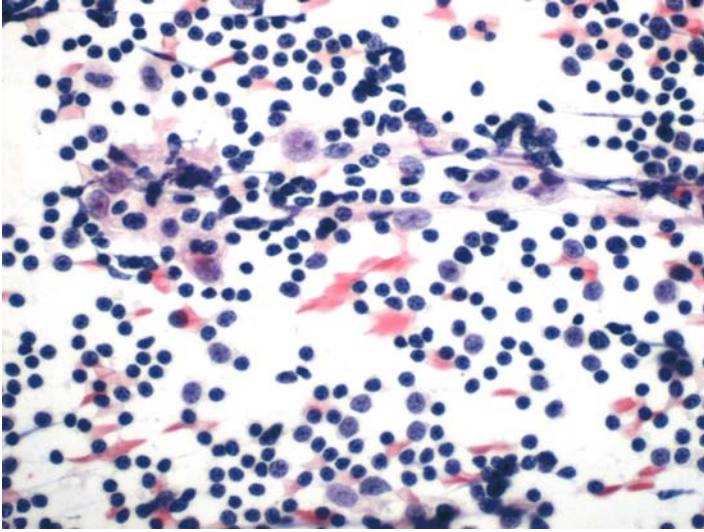
### ***Tips***

The TTF-1-negative, CK20-positive phenotype supports a colonic origin. As was discussed before, the intestinal type of mucinous bronchioalveolar carcinomas may also be negative for TTF-1 and positive for CK20. These tumors, however, usually express CK7.

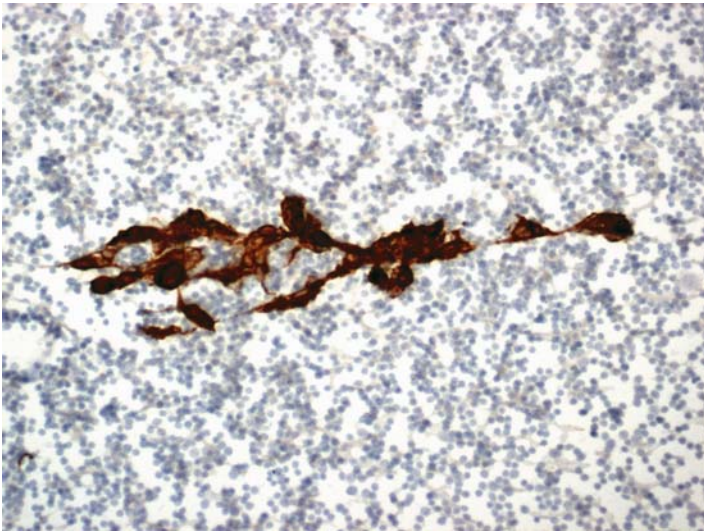
*Suggested Reading:* 7

## Case 80

---



**FIGURE 80A. Pap Stain:** FNA of a mediastinal mass in a 47-year-old male. The smear is mostly composed of lymphocytes. There are some larger nuclei with prominent nucleoli.



**FIGURE 80B. Cytokeratin:** The larger cells are positive for cytokeratin.

## ***Diagnosis***

Thymoma/Thymic Hyperplasia

## ***Tips***

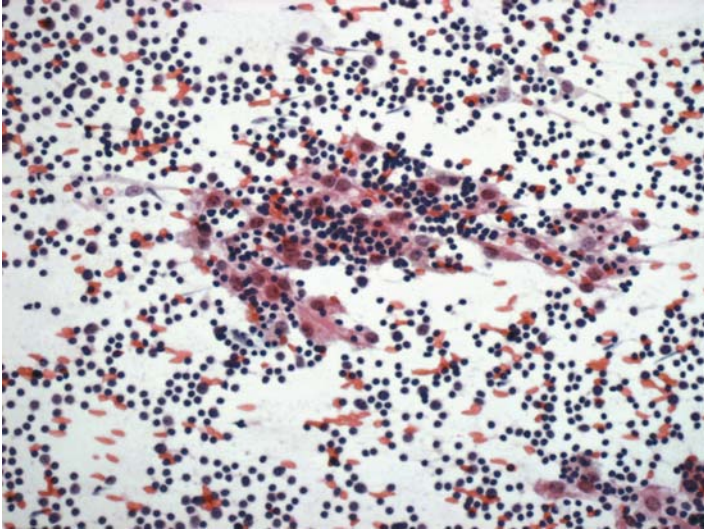
The combination of cytokeratin-positive epithelial cells on a background of lymphocytes in an aspirate from a mediastinal mass is consistent with either a thymoma or thymic hyperplasia. It will be difficult to segregate the above entities on the basis of cytology and ICC.

*Suggested Reading: 54*

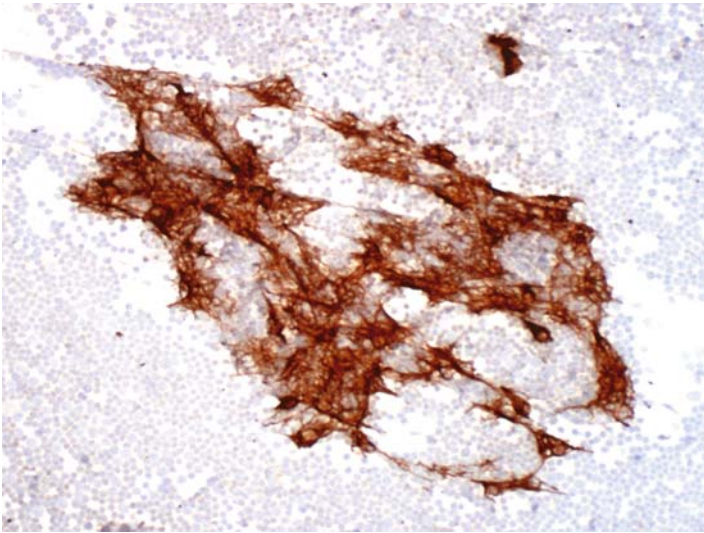


## Case 81

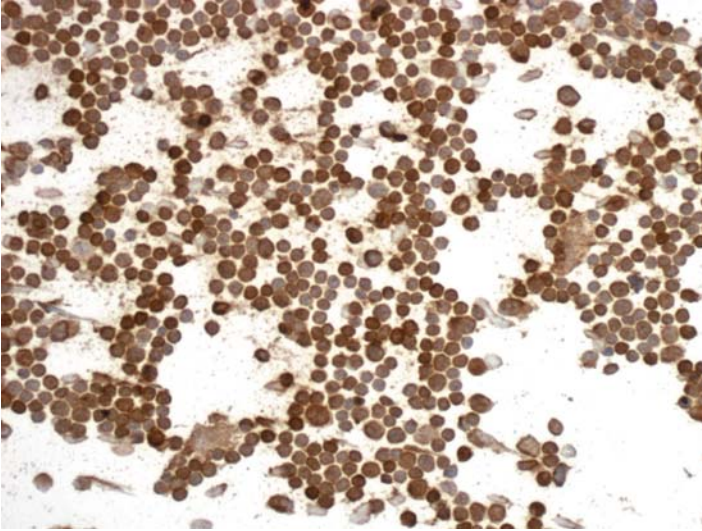
---



**FIGURE 81A. Pap Stain:** FNA of resected specimen from a 37-year-old female with a mediastinal mass and myasthenia gravis. Large cells with pale eosinophilic cytoplasm are seen on a background of lymphocytes.



**FIGURE 81B. Cytokeratin:** The epithelial cells show a reticular pattern of positivity for cytokeratin.



**FIGURE 81C.** CD3: Lymphocytes are positive for CD3.

## ***Diagnosis***

Thymoma

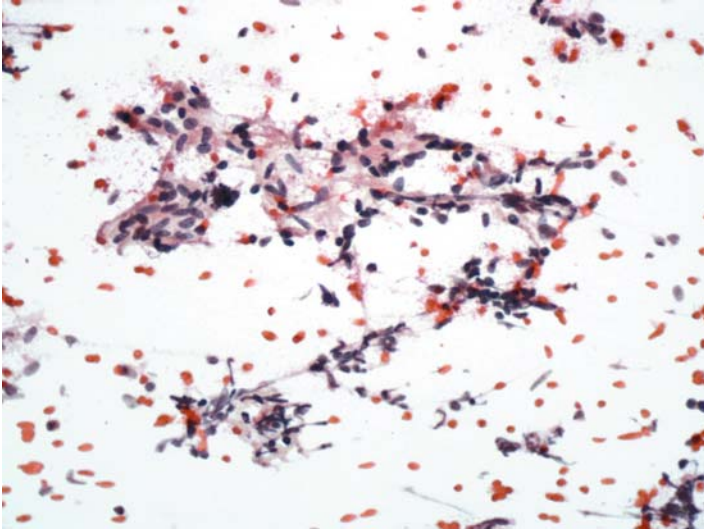
## ***Tips***

- The reticular pattern of cytokeratin staining of epithelial cells in thymomas is rather characteristic.
- The lymphocytes in thymomas are predominantly T cells, whereas in thymic hyperplasias a mixture of B and T cells is seen.

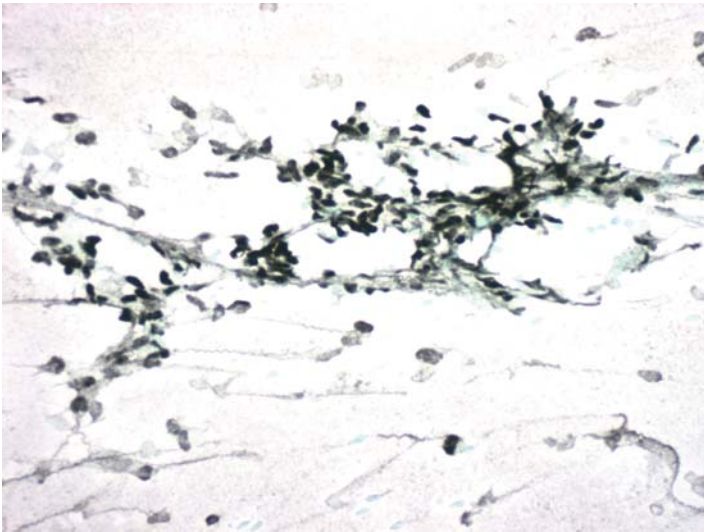
*Suggested Reading: 54*

## Case 82

---

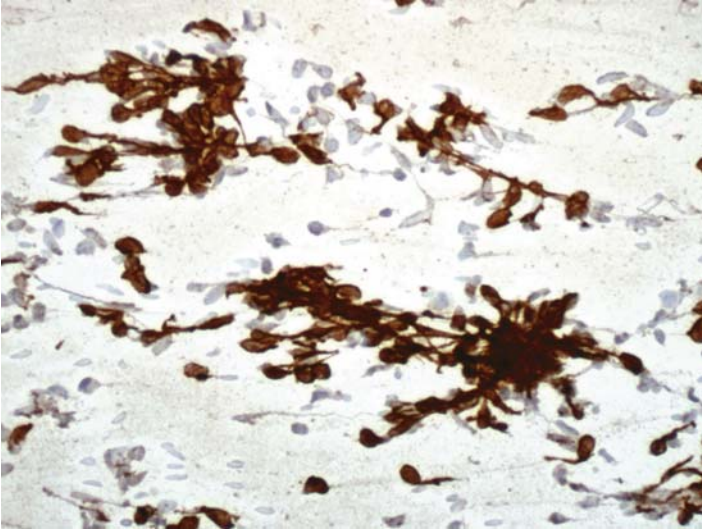


**FIGURE 82A. Pap Stain:** FNA of mediastinal mass showing a collection of spindle cells. The differential diagnosis includes spindle cell thymoma and a soft tissue tumor; Schwannoma?



**FIGURE 82B. P63:** Positive reaction for p63 is seen in the nuclei of tumor cells.





**FIGURE 82C. Cytokeratin:** Tumor cells are also positive for cytokeratin.

### ***Diagnosis***

Spindle Cell Thymoma

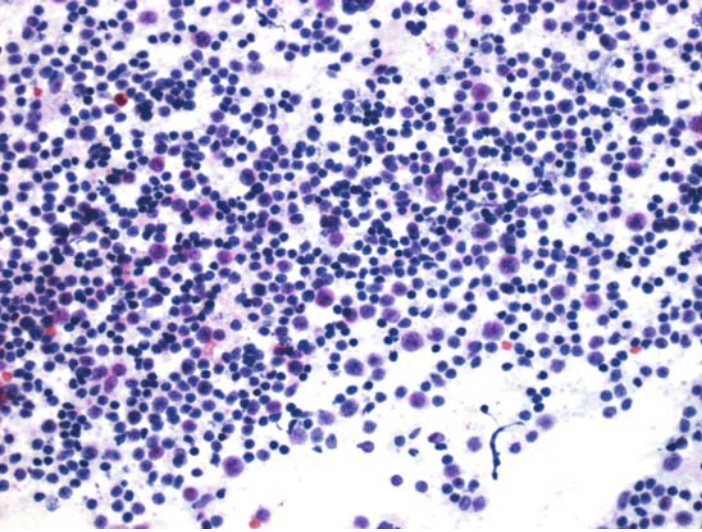
### ***Tips***

Thymic epithelium is a specialized type of squamous epithelium and, hence, both normal thymus and thymomas express p63. Demonstration of either cytokeratin or p63 in suspected spindle cell thymomas supports the diagnosis.

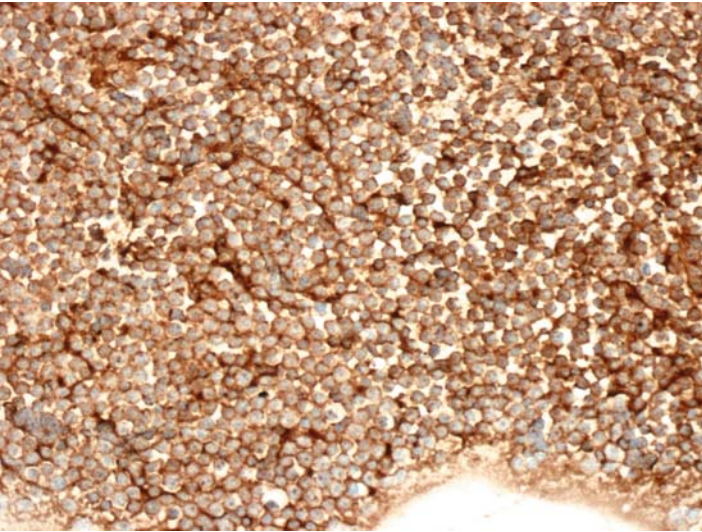
*Suggested Reading: 7*

## Case 83

---



**FIGURE 83A. Pap Stain:** FNA of a large mediastinal mass in a 39-year-old female with shortness of breath; lymphoma versus thymoma.



**FIGURE 83B. CD20:** Tumor cells are uniformly positive for CD20.

## ***Diagnosis***

Mediastinal Large B Cell Lymphoma

## ***Tips***

In most mediastinal lymphomas, the cells are of B lineage. In aspirates from these lesions, it is unlikely to find thymic epithelial cells.

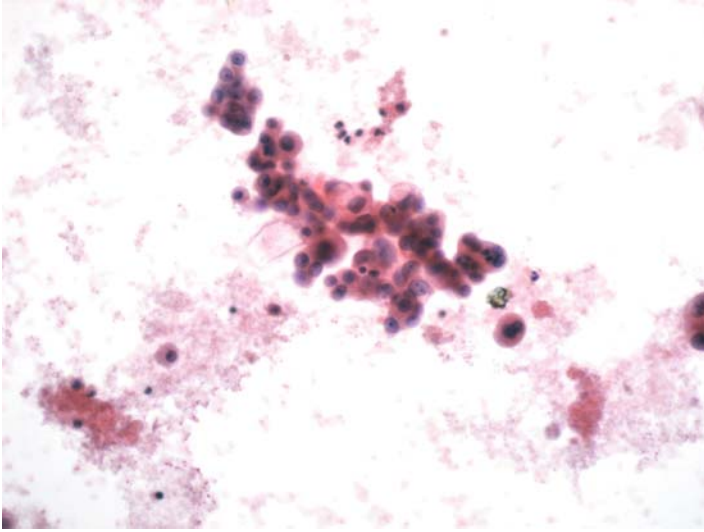
*Suggested Reading: 7*

# 12

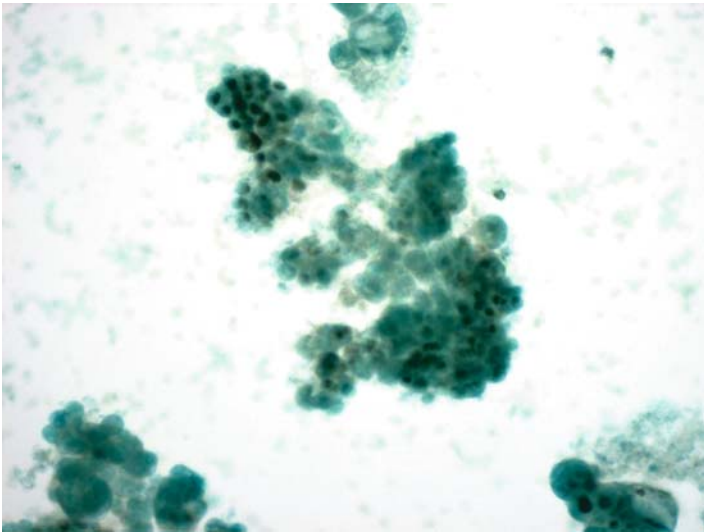
## Abdominal Cavity

## Case 84

---



**FIGURE 84A. Pap Stain:** Cytocentrifuge preparation of ascitic fluid from a 59-year-old female with a pelvic mass. This is an adenocarcinoma probably of ovarian origin.



**FIGURE 84B. Estrogen Receptor (ER):** There is focal nuclear staining for ER.

***Diagnosis***

Adenocarcinoma Consistent with a Gynecologic Origin

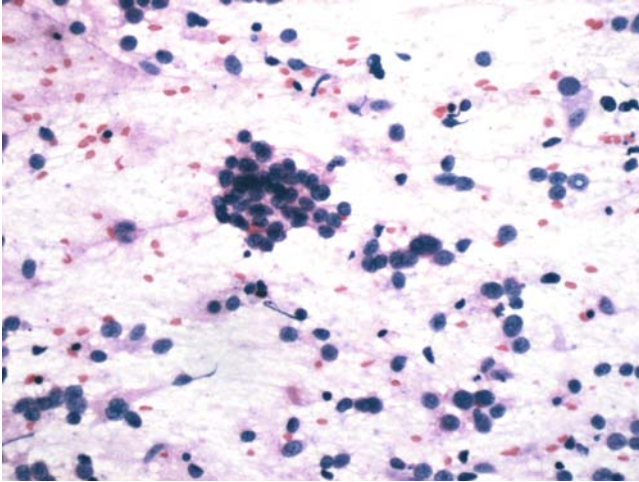
***Tips***

As was discussed in Case 70, with monoclonal antibody ER-ID5, only breast and gynecologic cancers stain for ER. Breast cancers are usually either diffusely positive for ER or completely negative. ER expression in gynecologic cancers, on the other hand, may only be focal, as is demonstrated in this case.

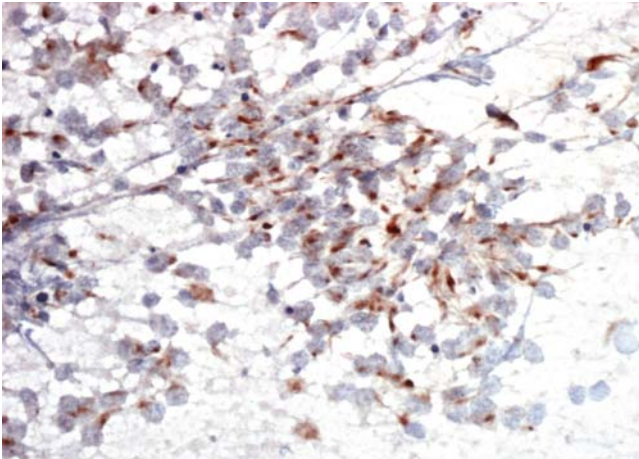
*Suggested Reading: 49*

## Case 85

---



**FIGURE 85A. Pap Stain:** FNA of an abdominal mass in a 14-year-old male. This is a small cell malignant neoplasm.



**FIGURE 85B. Desmin:** Tumor cells are positive for desmin.

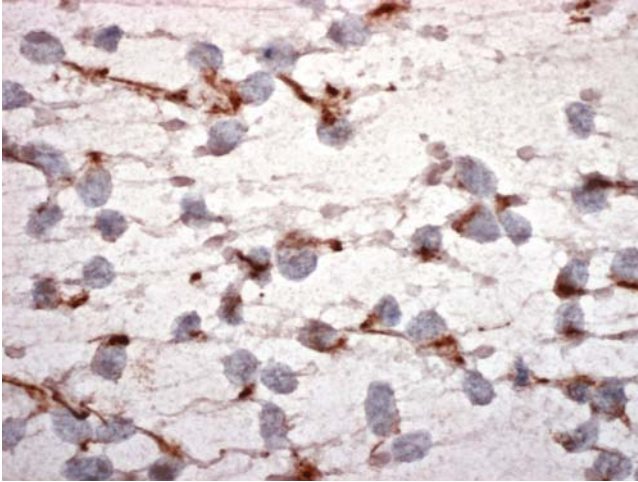
### *Diagnosis*

Desmoplastic Small Round Cell Tumor

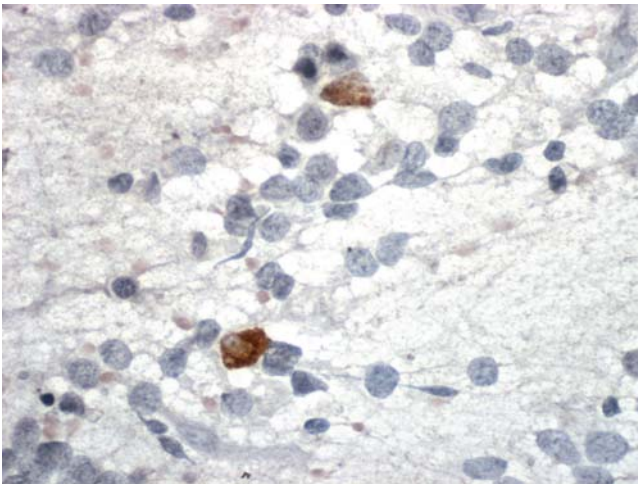
### *Tips*

Desmoplastic small, round cell tumors are the only small cell neoplasms that express a diverse group of antigens. These include cytokeratin, desmin,





**FIGURE 85C. Cytokeratin:** There is also positive cytokeratin staining.



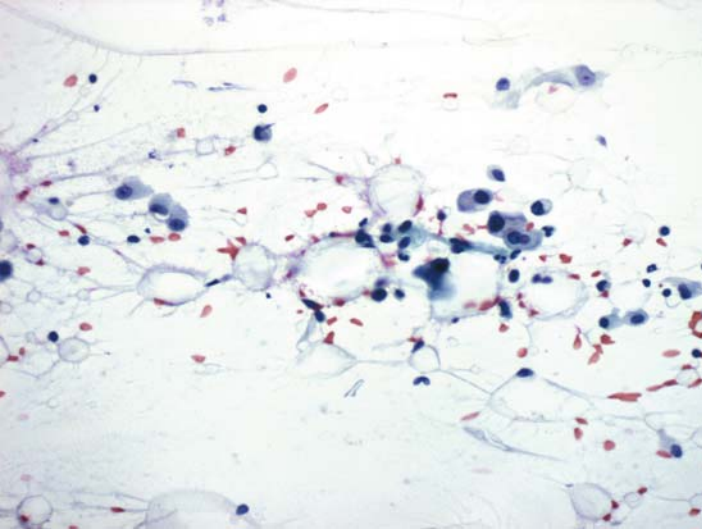
**FIGURE 85D. Chromogranin:** Few cells show chromogranin positivity.

EMA, chromogranin, and a few others. This immunophenotype separates desmoplastic small round cell tumors from other small cell neoplasms of children and young adults.

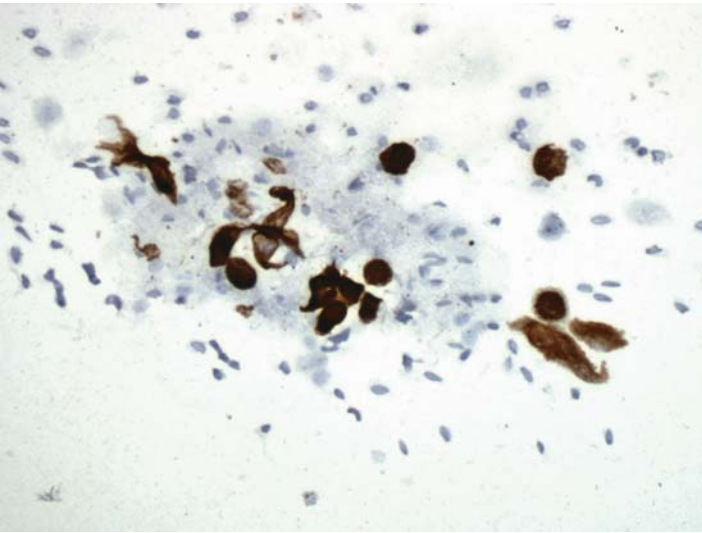
*Suggested Reading: 55*

## Case 86

---



**FIGURE 86A. Pap Stain:** FNA of an omental mass in a 58-year-old male. Scattered isolated atypical cells and adipocytes are present. The differential diagnosis includes metastatic carcinoma and fat necrosis.



**FIGURE 86B. Cytokeratin:** Positive reaction for cytokeratin establishes the epithelial nature of isolated cells.

## ***Diagnosis***

Metastatic Carcinoma (Cecal Primary by Surgery)

## ***Tips***

One can add CD68 for this differential diagnosis. The use of CD68 alone, however, may be misleading because cells from many epithelial tumors may coexpress CD68 and cytokeratin

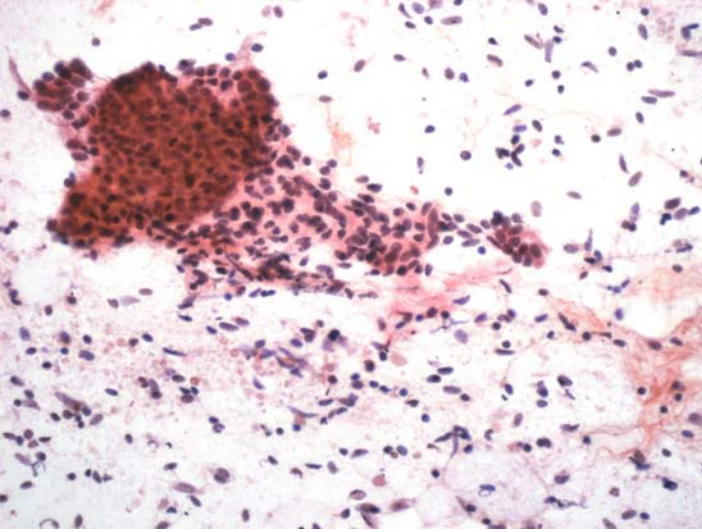
*Suggested Reading: 7*

# 13

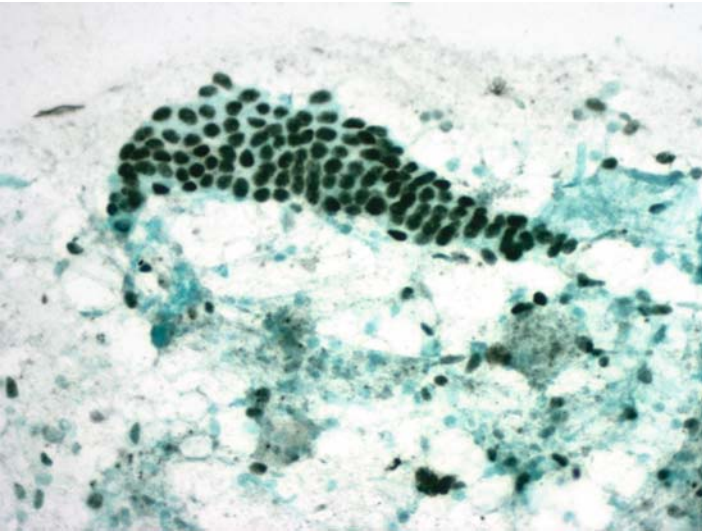
## Female Genital Tract and Breast

## Case 87

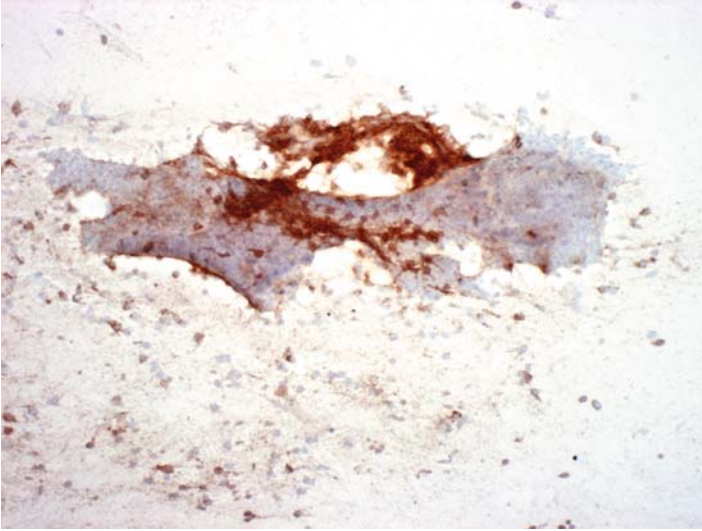
---



**FIGURE 87A. Pap Stain:** Laparoscopic FNA of pelvic adnexal nodules in a 27-year-old female. Epithelial cells and spindle nuclei are seen on a background of lysed red blood cells.



**FIGURE 87B. Estrogen Receptor (ER):** Both cellular elements are positive for ER.



**FIGURE 87C. CD10:** The spindle cells are positive for CD10.

### ***Diagnosis***

Endometriosis

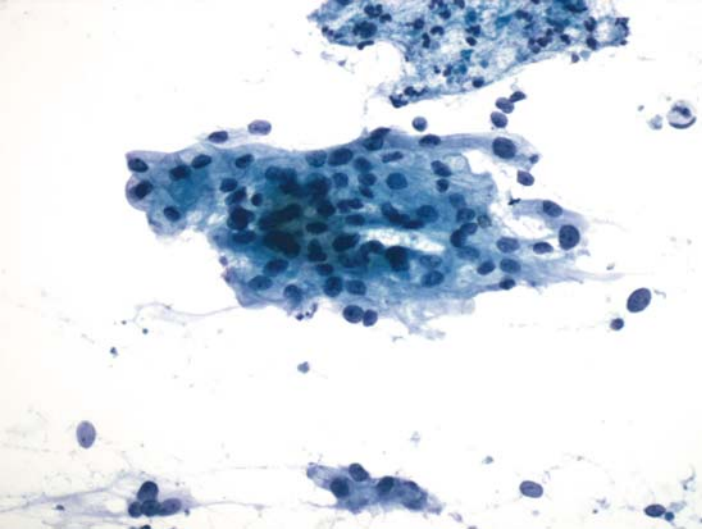
### ***Tips***

- The clinical history and cytomorphology is highly suggestive of endometriosis. Both epithelial and stromal cells of endometriosis are positive for ER.
- The endometrial stromal cells, but not the epithelium, are also positive for CD10.

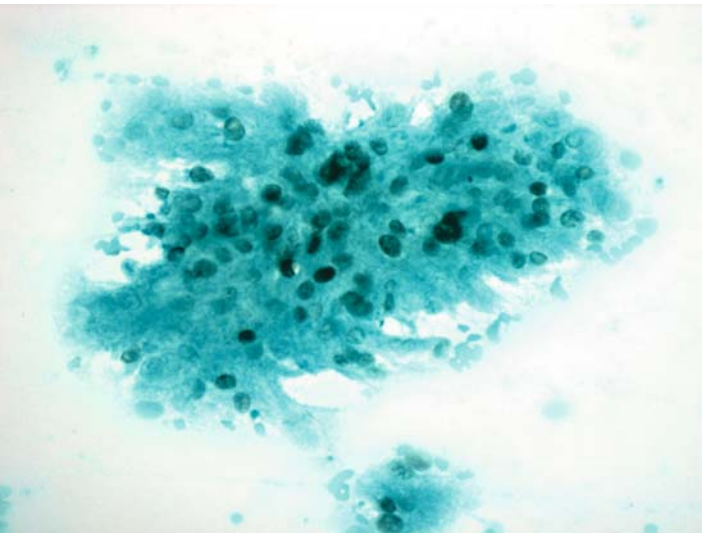
*Suggested Reading: 56*

## Case 88

---



**FIGURE 88A. Pap Stain:** FNA of a vaginal mass in a patient with history of endometrial cancer; the slide shows an adenocarcinoma.



**FIGURE 88B. Estrogen Receptor (ER):** Tumor cells are positive for ER.



## ***Diagnosis***

Recurrent Endometrial Adenocarcinoma

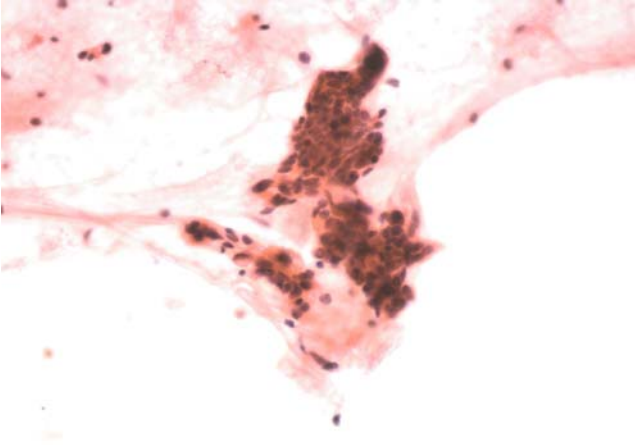
## ***Tips***

- Most endometrioid adenocarcinomas of the female genital tract are at least focally positive for ER.
- Endometrial and endocervical adenocarcinomas cannot be reliably distinguished from each other by ICC.

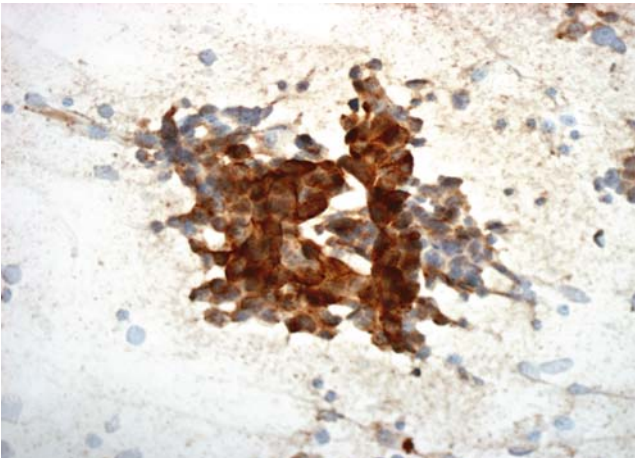
*Suggested Reading: 7*

## Case 89

---



**FIGURE 89A. Pap Stain:** Pelvic FNA of a female with history of ovarian cancer. Cytologically this is an adenocarcinoma, probably serous type.



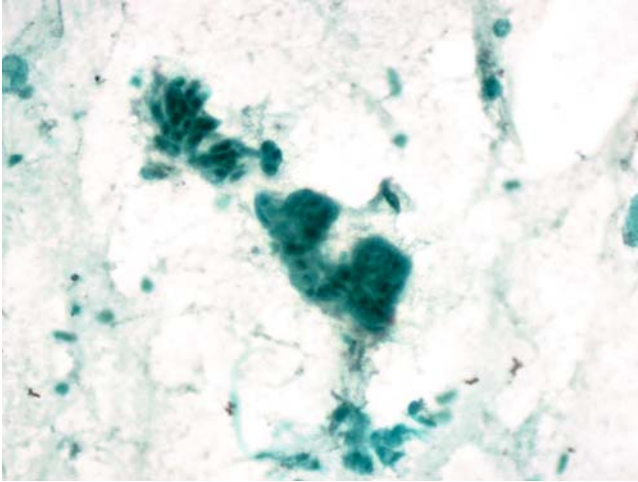
**FIGURE 89B. CA-125:** Tumor cells show positive cytoplasmic reaction for CA-125.

### *Diagnosis*

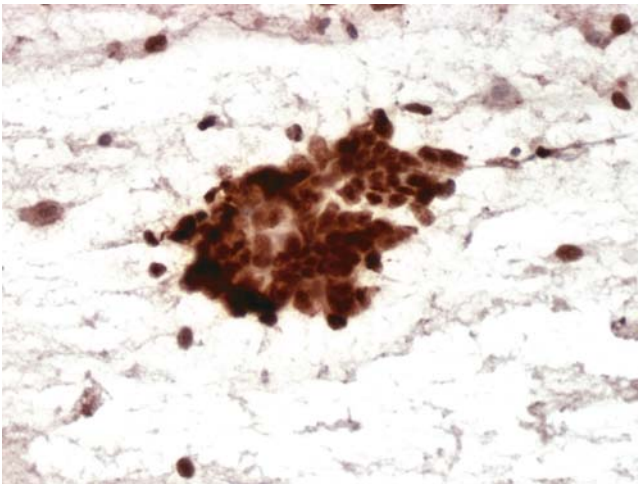
Recurrent Serous Carcinoma of the Ovary

### *Tips*

- Serous carcinomas of the ovary and endometrium usually express focal ER. They are also positive for WT-1 and CA-125, although neither is



**FIGURE 89C. Estrogen Receptor (ER):** There is also focal positive ER staining.



**FIGURE 89D. WT-1:** Strong nuclear and cytoplasmic staining is seen.

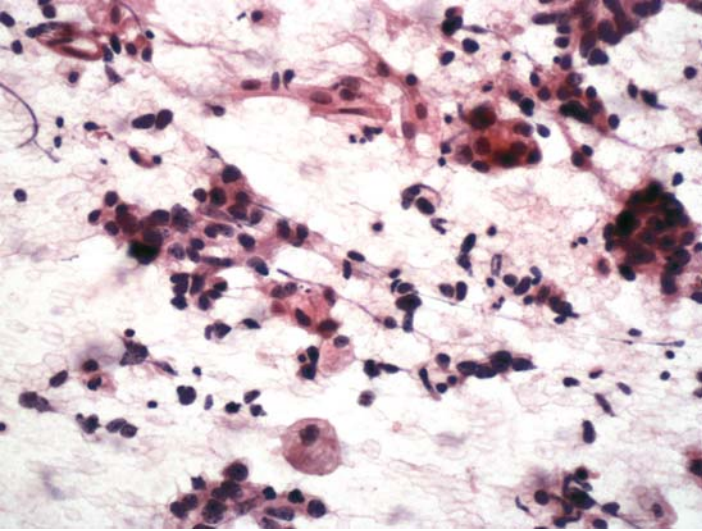
specific for serous carcinomas. CA-125, for example is always expressed by malignant mesotheliomas.

- A combination of calretinin and ER usually is sufficient to differentiate mesotheliomas (calretinin-positive, ER-negative) from ovarian carcinomas (ER-positive, calretinin-negative).

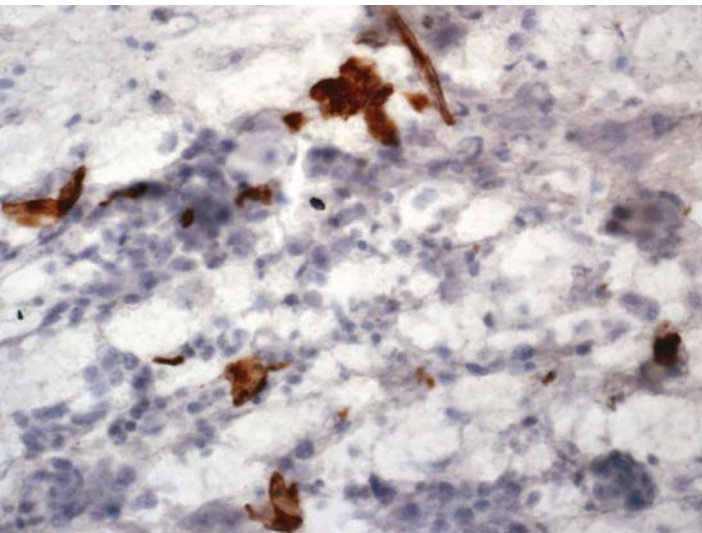
*Suggested Reading: 7, 57*

## Case 90

---



**FIGURE 90A. Pap Stain:** FNA of a pelvic mass in a 71-year-old patient with history of malignant mixed mesodermal tumor of the uterus. Clusters of carcinoma cells are seen with occasional large, isolated cells suggestive of a sarcoma component.



**FIGURE 90B. Desmin:** Some of the large cells react positively for desmin.

## ***Diagnosis***

Recurrent Malignant Mixed Mesodermal Tumor

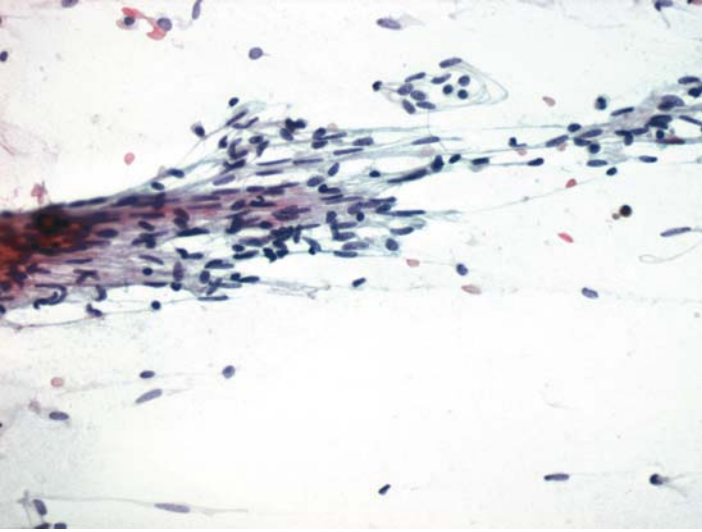
## ***Tips***

- Aspirates from malignant mixed mesodermal tumors of the female genital tract usually yield epithelial elements that are positive for cytokeratin.
- Because the most common sarcomatous cells in these tumors are rhabdomyoblasts, positive reaction for desmin will support the cytologic impression.

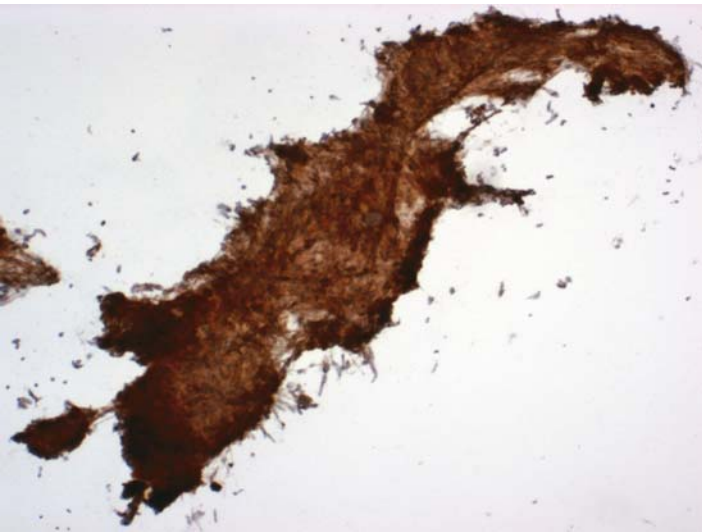
*Suggested Reading: 20*

## Case 91

---



**FIGURE 91A. Pap Stain:** FNA of a large abdominal mass in a 67-year-old female with a history of uterine leiomyosarcoma. Clusters of spindle cells are present, suggestive of recurrent leiomyosarcoma.



**FIGURE 91B. H-Caldesmon:** Tumor cells are strongly positive for caldesmon.

## ***Diagnosis***

Recurrent Leiomyosarcoma

## ***Tips***

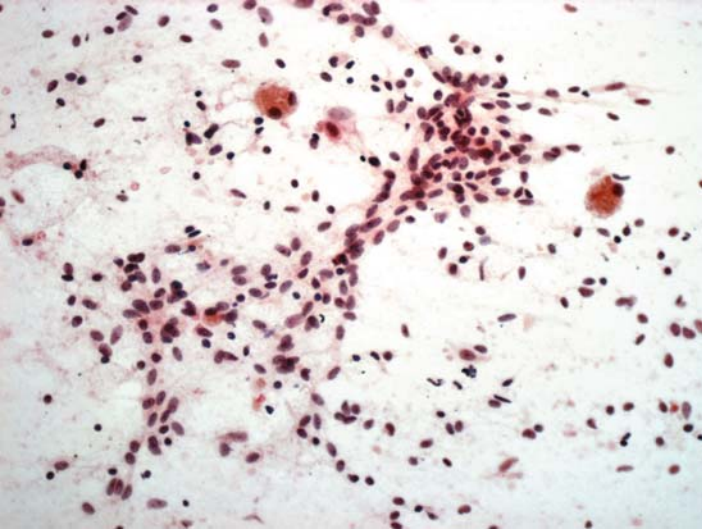
- H-Caldesmon is a more sensitive marker of smooth muscle tumors than desmin.
- Other purported smooth muscle markers, such as muscle specific actin and smooth muscle actin, are nonspecific, and we almost never use them for this purpose.

*Suggested Reading: 18, 20*

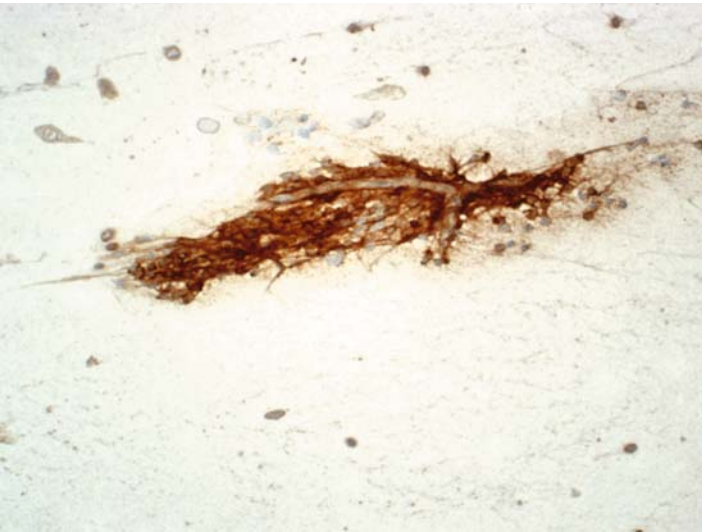

## Case 92

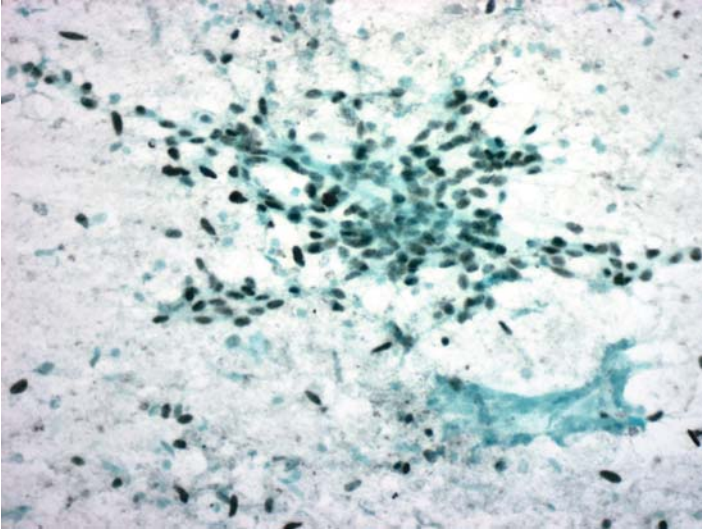
---



**FIGURE 92A. Pap Stain:** Pelvic FNA of a patient who had a hysterectomy for an unknown reason in the past. This is a spindle cell tumor suggestive of a sarcoma.



**FIGURE 92B. CD10:** Tumor cells are positive for CD10.



**FIGURE 92C. Estrogen Receptor (ER):** There is also positive ER staining of nuclei.

### ***Diagnosis***

Endometrial Stromal Sarcoma

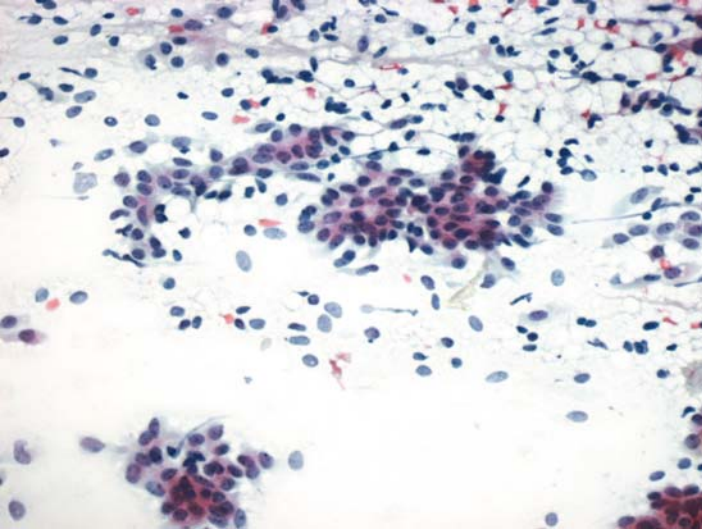
### ***Tips***

Endometrial stromal sarcomas express both ER and CD10 in a rather diffuse pattern. Rare cells in these tumors may also show smooth muscle differentiation.

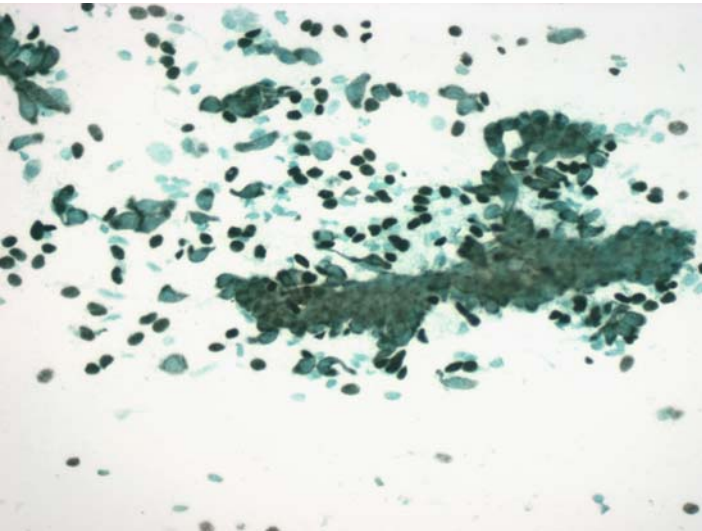
*Suggested Reading: 56*

## Case 93

---



**FIGURE 93A. Pap Stain:** FNA of a breast nodule in a 34-year-old female. Cluster of epithelial cells are seen, along with many isolated nuclei. The cytomorphology is suggestive of a fibroadenoma.



**FIGURE 93B. P63:** Positive reaction for p63 establishes the plasm/myoepithelial nature of isolated nuclei.

## ***Diagnosis***

Fibroadenoma

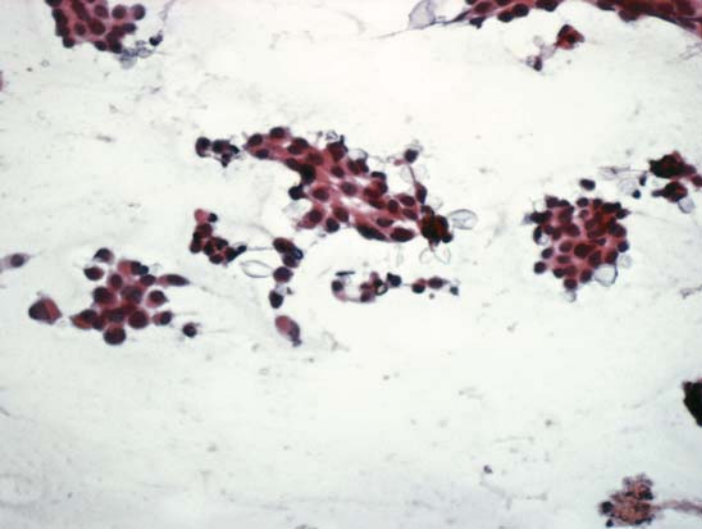
## ***Tips***

As a basal/myoepithelial cell marker, p63 is expressed by the myoepithelial cells in benign lesions of the breast, such as fibroadenomas and adenoses. This marker also shows that many of the isolated nuclei seen in aspirates from fibroadenomas are of myoepithelial origin.

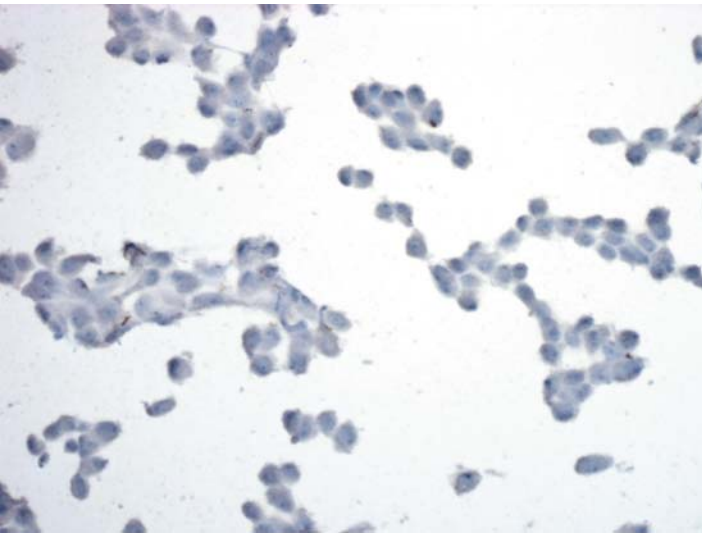
*Suggested Reading: 58*

## Case 94

---



**FIGURE 94A. Pap Stain:** FNA of a breast mass showing ductal carcinoma.



**FIGURE 94B. E-Cadherin:** There is no reaction for E-Cadherin.

## ***Diagnosis***

Ductal Carcinoma

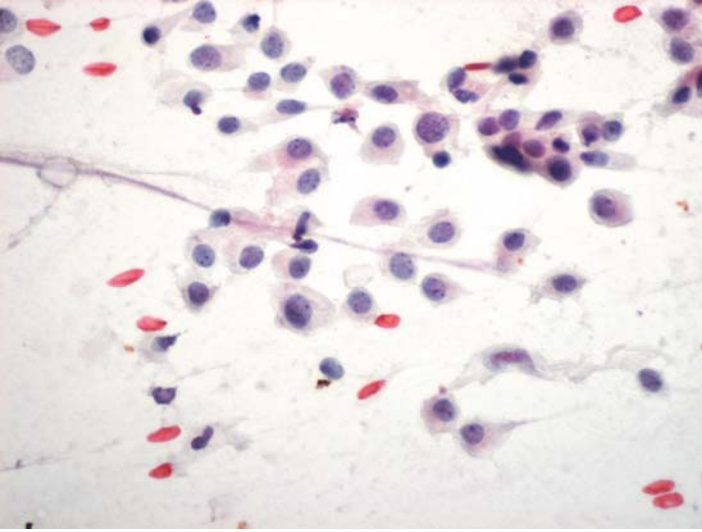
## ***Tips***

Cases 94 and 95 illustrate that E-Cadherin staining in breast cancer does not always separate negative lobular carcinomas from positive ductal cancers. Up to 10% of ductal carcinomas are negative for E-Cadherin, and conversely, lobular carcinomas may express this marker.

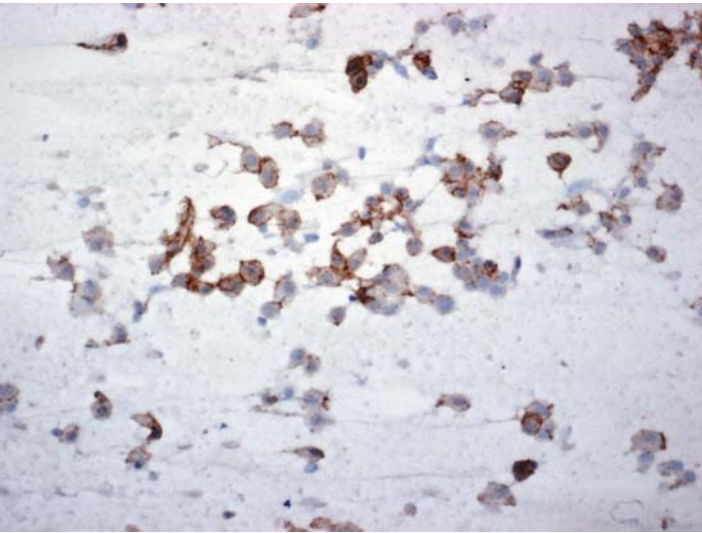
*Suggested Reading: 59*

## Case 95

---



**FIGURE 95A. Pap Stain:** FNA of breast in a 61-year-old female. The morphology is suggestive of a lobular carcinoma.



**FIGURE 95B. E-Cadherin:** Most tumor cells show cytoplasmic membrane staining for E-Cadherin.



***Diagnosis***

Lobular Carcinoma (Histologically Confirmed)

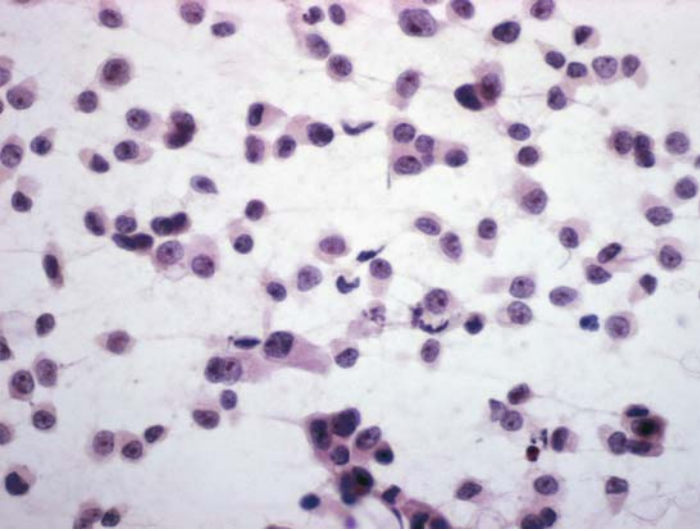
***Tips***

Cases 94 and 95 illustrate that E-Cadherin staining in breast cancer does not always separate negative lobular carcinomas from positive ductal cancers. Up to 10% of ductal carcinomas are negative for E-Cadherin, and conversely, lobular carcinomas may express this marker.

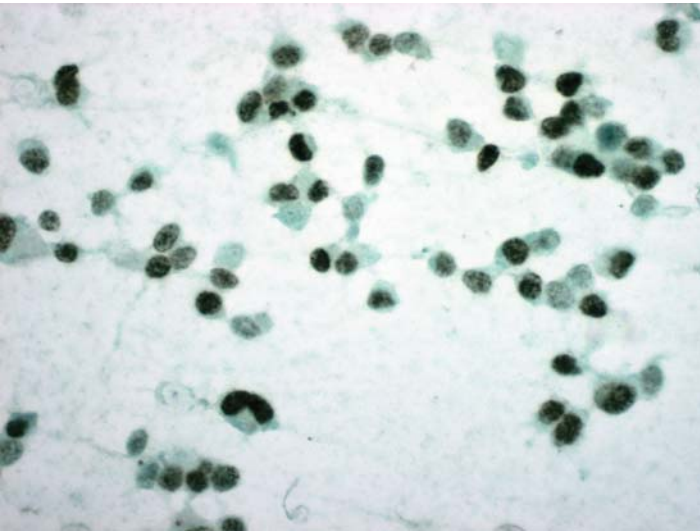
*Suggested Reading: 59*

## Case 96

---



**FIGURE 96A. Pap Stain:** FNA of a chest wall lesion in a patient with history of breast cancer. The cytology is suggestive of a lobular carcinoma.



**FIGURE 96B. Estrogen Receptor (ER):** Tumor cells are uniformly positive for ER.

## ***Diagnosis***

Lobular Carcinoma

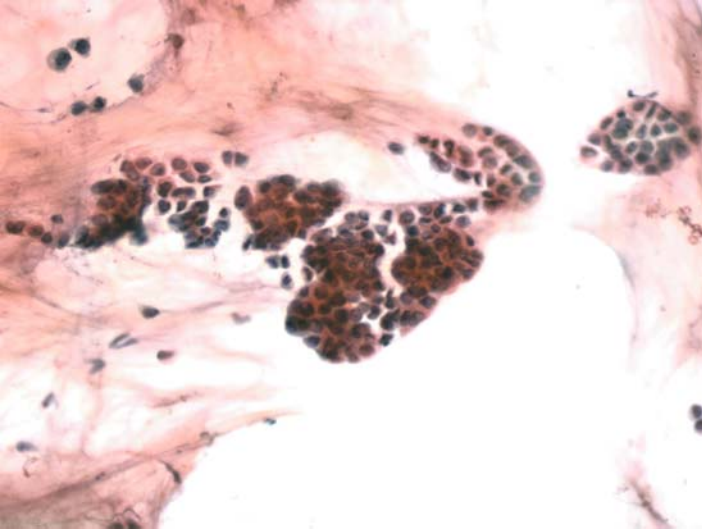
## ***Tips***

When ER-ID5 antibody is used, all lobular, tubular, and most colloid carcinomas of the breast are positive for ER, while true medullary and metaplastic carcinomas are negative.

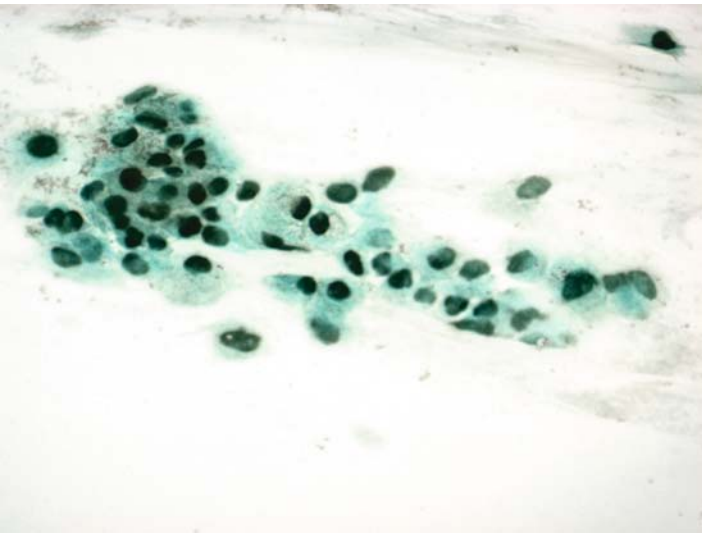
*Suggested Reading: 49*

## Case 97

---



**FIGURE 97A. Pap Stain:** FNA of a well-defined breast nodule; clusters of uniform epithelial cells are seen on a mucinous background, consistent with a mucinous adenocarcinoma.



**FIGURE 97B. Estrogen Receptor (ER):** Positive nuclear reaction for ER is present in all tumor cells.

## ***Diagnosis***

Mucinous (Colloid) Carcinoma of the Breast

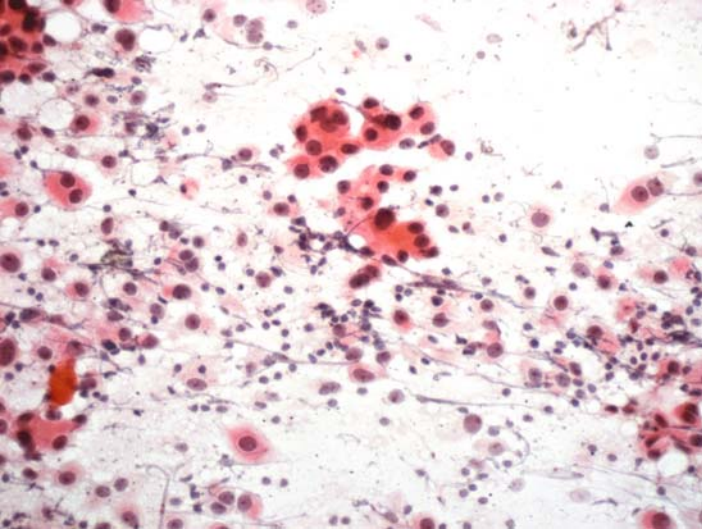
## ***Tips***

When ER-ID5 antibody is used, all lobular, tubular, and most colloid carcinomas of the breast are positive for ER, while true medullary and metaplastic carcinomas are negative.

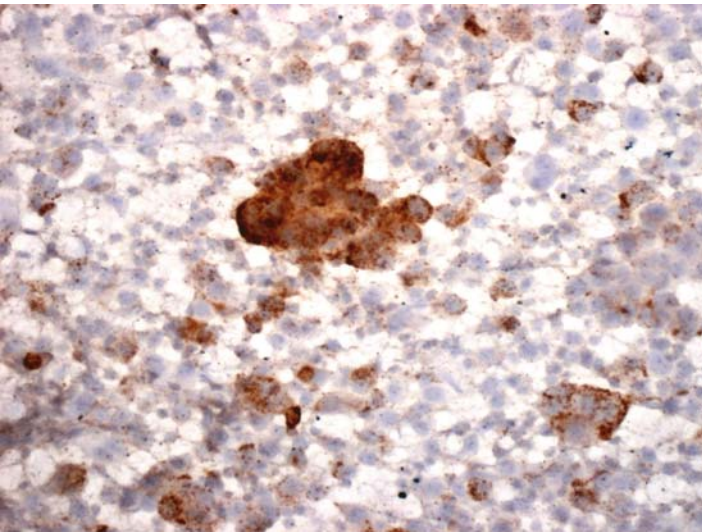
*Suggested Reading: 49*

## Case 98

---



**FIGURE 98A. Pap Stain:** FNA of a breast in a 45-year-old female. Poorly differentiated carcinoma cells and lymphocytes are seen; rule out medullary carcinoma.



**FIGURE 98B. HLA-DR:** Tumor cells are positive for HLA-DR.

## ***Diagnosis***

Medullary Carcinoma of the Breast

## ***Tips***

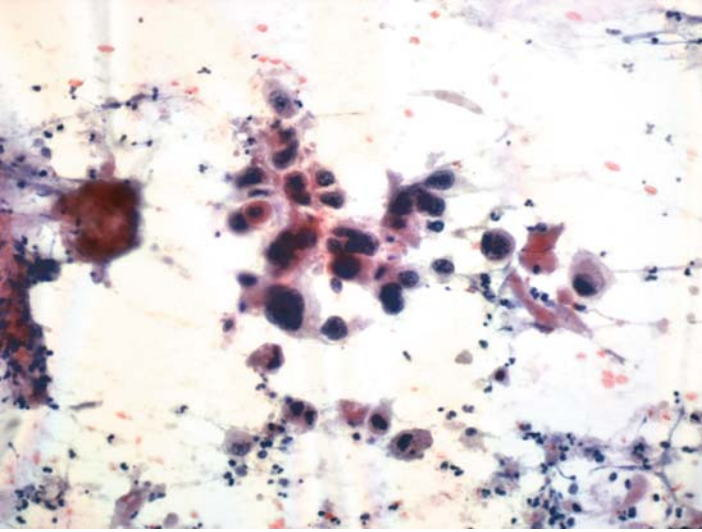
HLA-DR is expressed by true medullary carcinomas of the breast. Because all lymphoreticular cells also react for this antigen and they are abundant in medullary carcinomas, one should exercise caution in evaluating the ICC results in tumor cells that are mixed with lymphocytes.

*Suggested Reading: 60*

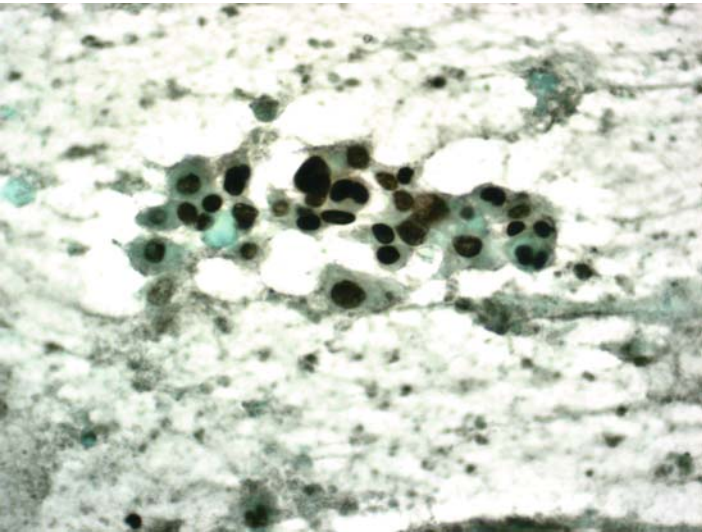


## Case 99

---



**FIGURE 99A. Pap Stain:** FNA of a large breast mass showing pleomorphic cells with dense eosinophilic cytoplasm and hyperchromatic nuclei.



**FIGURE 99B. P63:** Tumor cells show nuclear staining for p63.

***Diagnosis***

Metaplastic Carcinoma of the Breast

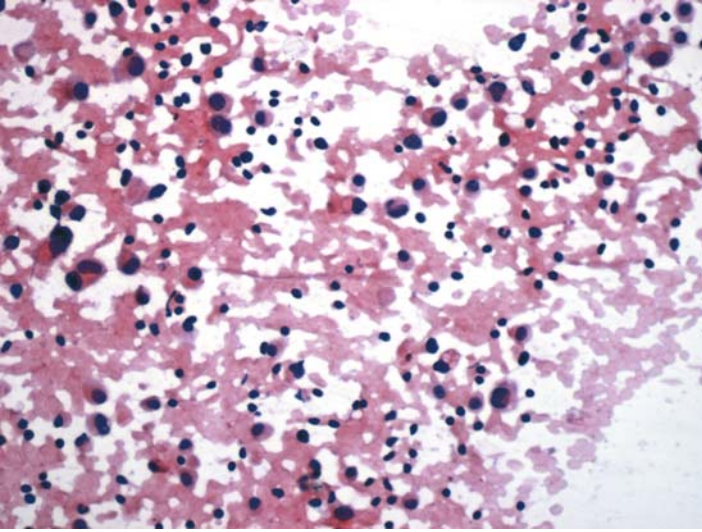
***Tips***

Metaplastic carcinomas of the breast show a wide morphologic spectrum of different morphologies, from squamous cell carcinomas to sarcomas. They all, however, share the “triple-negative” immunophenotype (ER/PR/HER2-negative) and positivity for p63.

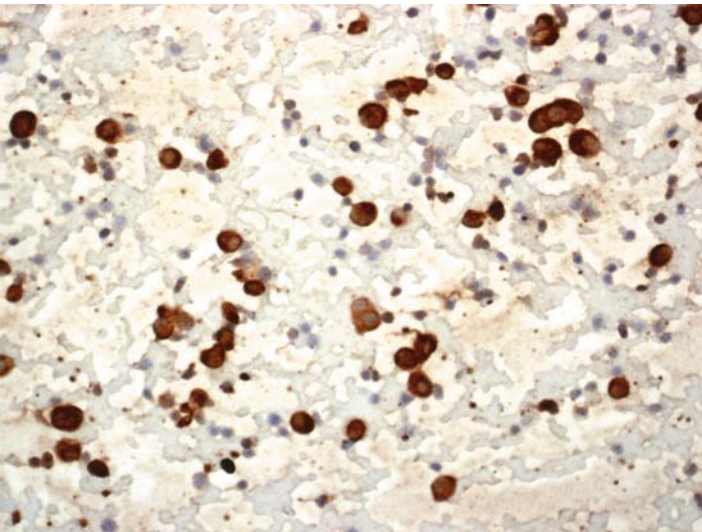
*Suggested Reading: 61*

## Case 100

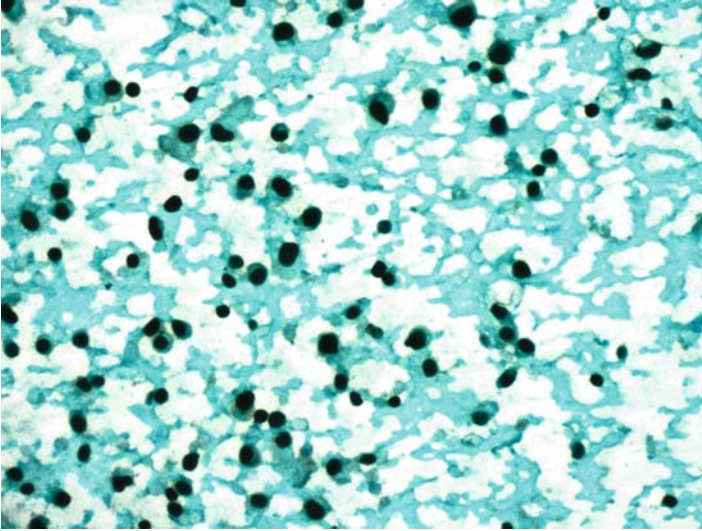
---



**FIGURE 100A. Pap Stain:** FNA of an axillary lymph node in a patient with a suspicious mammogram. Isolated large cells and lymphocytes are present.



**FIGURE 100B. Cytokeratin:** The large cells are positive for cytokeratin.



**FIGURE 100C. Estrogen Receptor (ER):** Tumor cells are also positive for ER.

## *Diagnosis*

Metastatic Mammary Carcinoma

## *Tips*

- Metastatic lobular carcinoma of the breast in lymph nodes may be difficult to be distinguished from lymphocytes. First, a cytokeratin stain establishes the epithelial nature of the cells and their positive reaction for ER confirms the breast origin of tumor cells.
- All lobular carcinomas of the breast are ER positive.

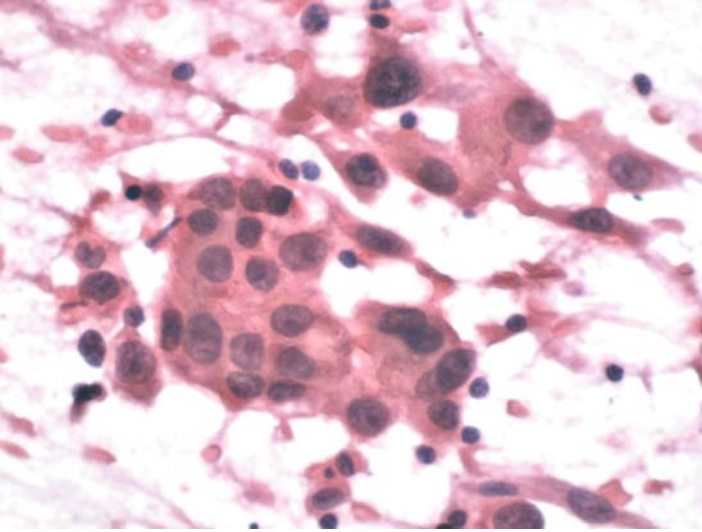
*Suggested Reading: 49*

# 14

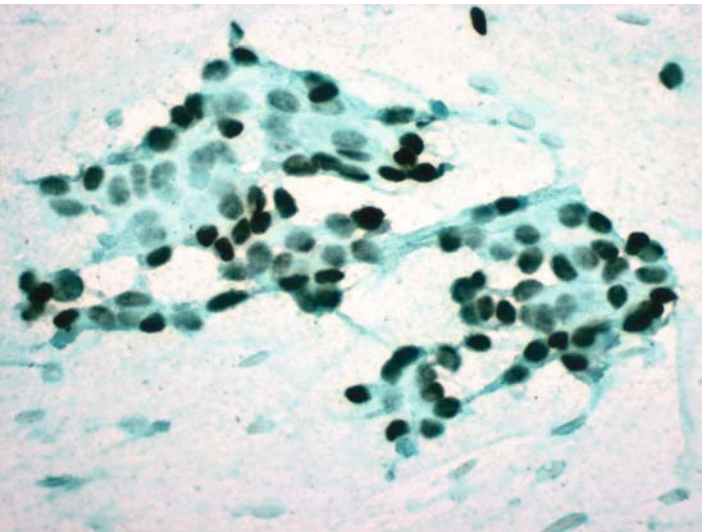
## Urinary and Male Genital System

## Case 101

---

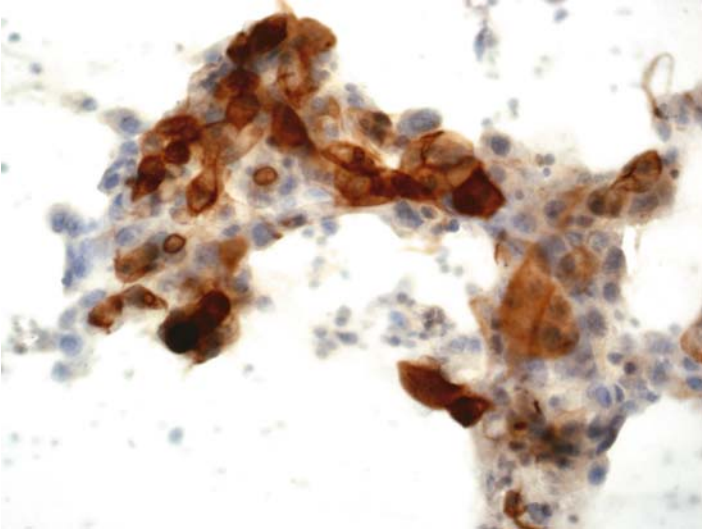


**FIGURE 101A. H&E Stain:** Imprint of a pelvic lymph node in a patient undergoing cystectomy for bladder cancer. Poorly differentiated carcinoma cells are present suggestive of metastatic transitional cell carcinoma.



**FIGURE 101B. P63:** There is nuclear staining for p63.





**FIGURE 101C. CK20:** Tumor cells also show focal positive reaction for CK20.

### ***Diagnosis***

Metastatic Urothelial Carcinoma

### ***Tips***

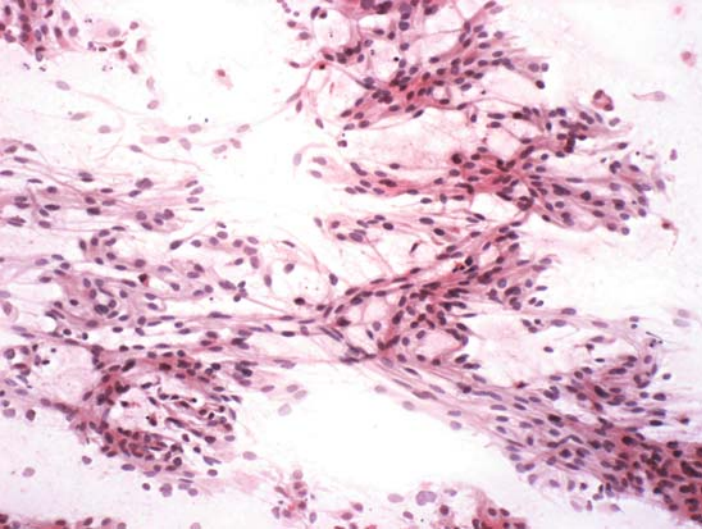
Transitional cell carcinomas of the urinary tract express p63. They may also be positive for CK20, although less frequently.

*Suggested Reading: 7*

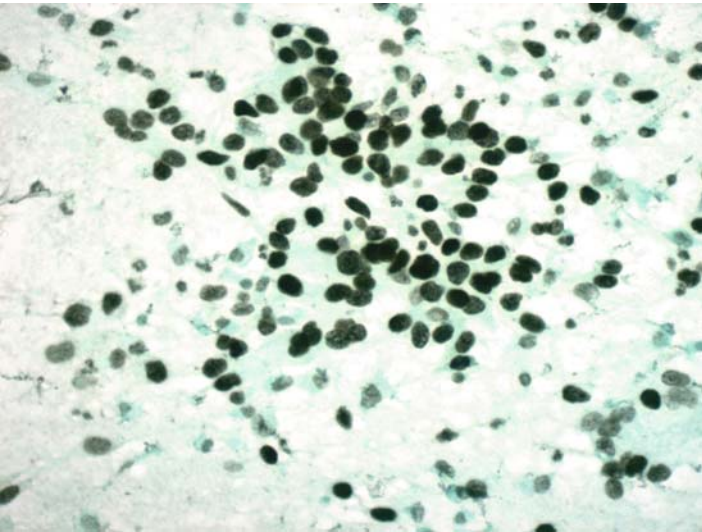


## Case 102

---



**FIGURE 102A. Pap Stain:** Imprint cytology of an exophytic urinary bladder tumor. The focally spindle shaped epithelial cells are suggestive of a low grade papillary urothelial carcinoma.



**FIGURE 102B. P63:** Positive nuclear staining for p63 supports the transitional epithelial nature of the cells.

## ***Diagnosis***

Papillary Urothelial Carcinoma

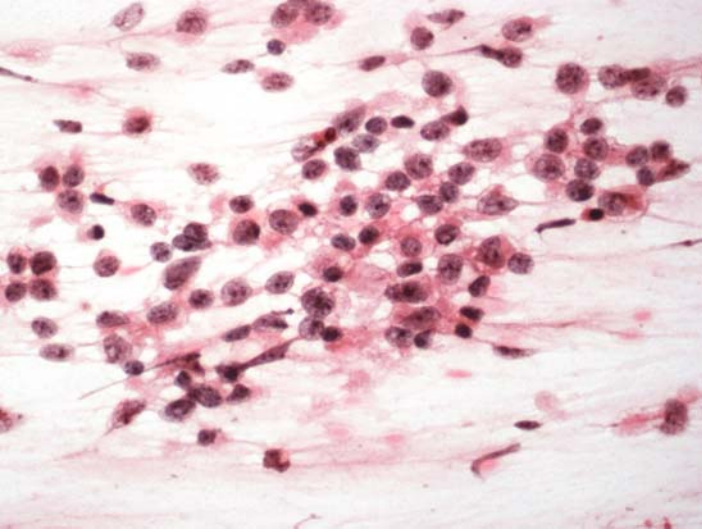
## ***Tips***

Low grade papillary transitional cell carcinomas may sometimes present with spindle cell morphology in imprint or aspiration cytology. Positivity for p63 separates them from morphologically similar tumors.

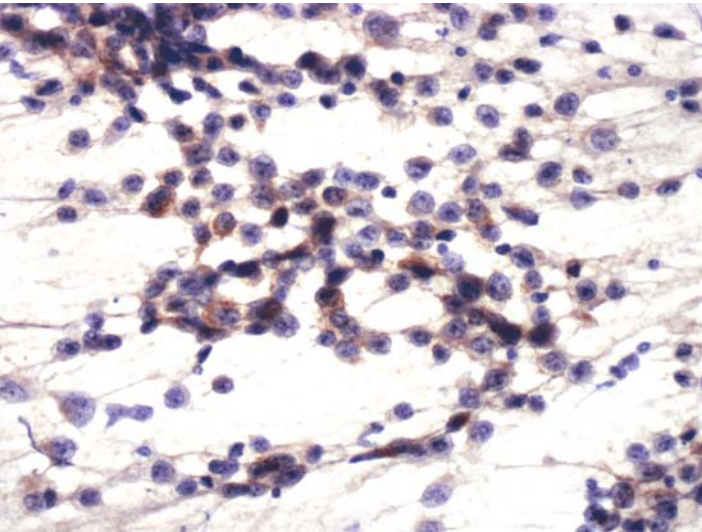
*Suggested Reading: 7*

## Case 103

---



**FIGURE 103A. Pap Stain:** FNA of retroperitoneum in a 26-year-old male with a history of orchiectomy for testicular cancer. Loosely cohesive cells with open chromatin and prominent nucleoli are suggestive of a seminoma.



**FIGURE 103B. Placental Alkaline Phosphatase (PLAP):** Tumor cells are focally positive for PLAP.

## ***Diagnosis***

Metastatic Seminoma

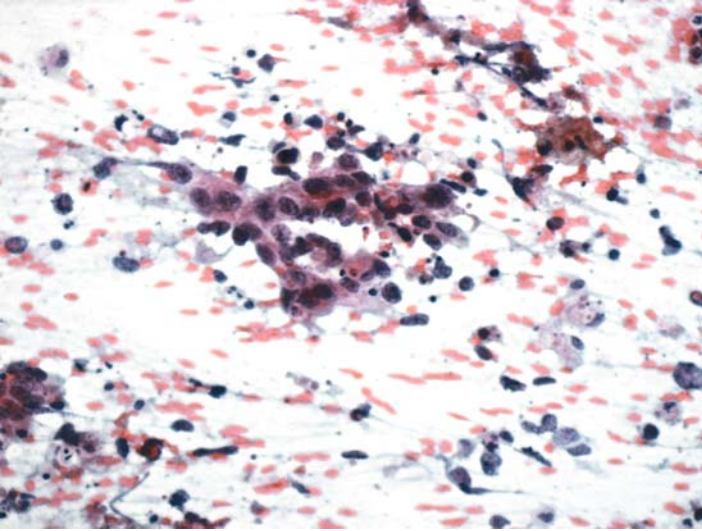
## ***Tips***

Seminomas express PLAP and KIT, but neither marker is specific for these tumors. It is the combination of clinical history, cytomorphology, and negative cytokeratin/positive PLAP that establishes the diagnosis of a seminoma.

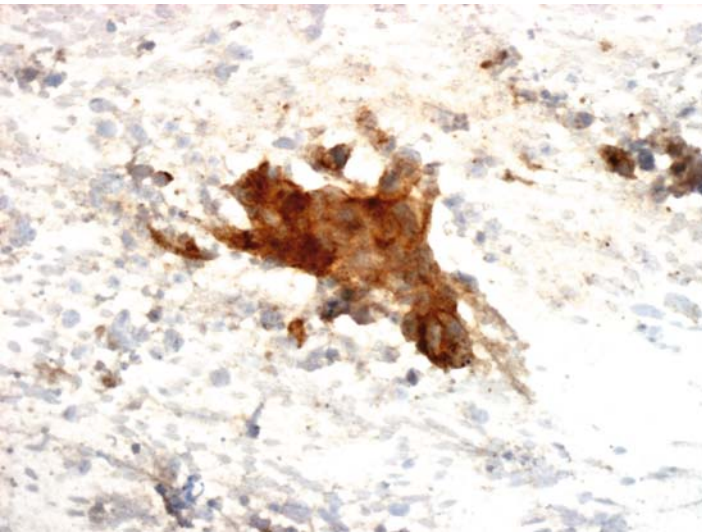
*Suggested Reading: 16*

## Case 104

---



**FIGURE 104A. Pap Stain:** Retroperitoneal FNA in patient with history of testicular embryonal carcinoma. This is a poorly differentiated carcinoma with many pyknotic nuclei.



**FIGURE 104B. CD30:** Tumor cells are positive for CD30.

## ***Diagnosis***

Metastatic Embryonal Carcinoma

## ***Tips***

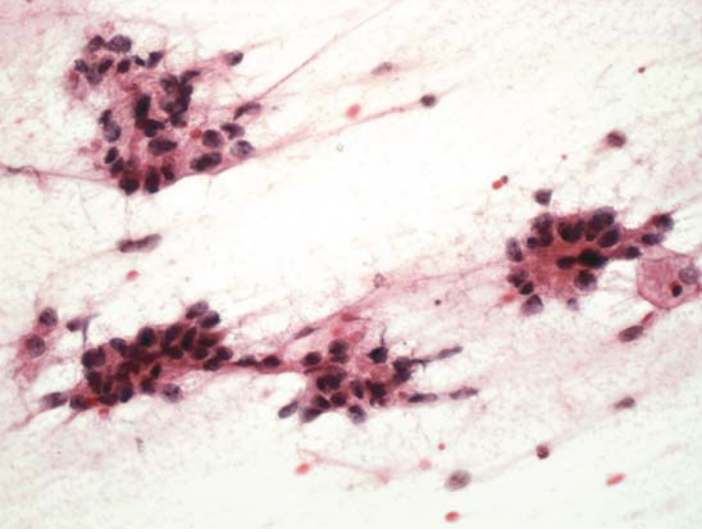
The cytomorphology of embryonal carcinomas is usually that of poorly differentiated adenocarcinoma. With proper clinical history, the diagnosis can be established by positivity of tumor cells for CD30.

*Suggested Reading: 62*

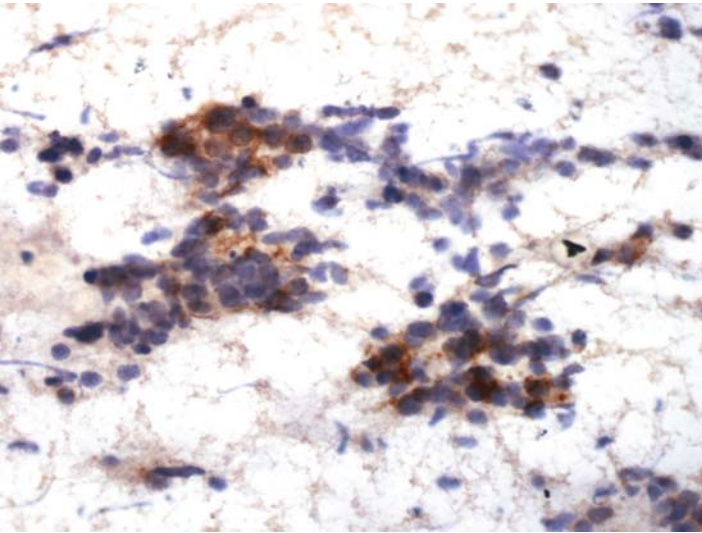


## Case 105

---



**FIGURE 105A. Pap Stain:** Fine needle aspiration of an enlarged inguinal lymph node in a two-year-old male. Cohesive groups of cells are seen with acinar arrangements. The differential diagnosis includes a metastatic germ cell tumor.



**FIGURE 105B. Alpha-Fetoprotein (AFP):** Tumor cells are positive for alpha-fetoprotein.



## ***Diagnosis***

Metastatic Endodermal Sinus Tumor (Yolk Sac Carcinoma)

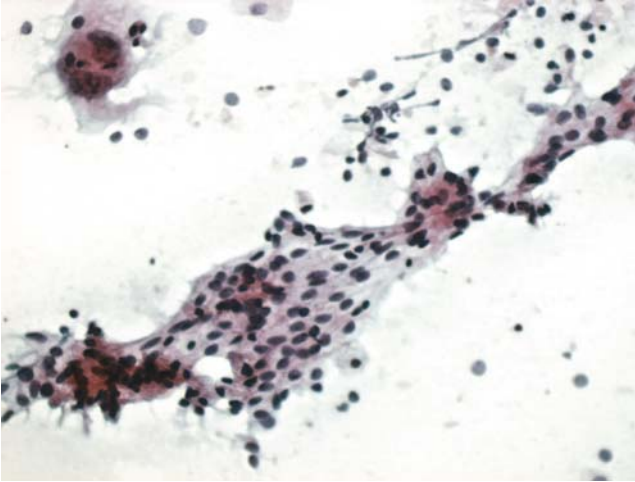
## ***Tips***

The most common testicular germ cell tumor in patients under five years of age is endodermal sinus tumor. This neoplasm is always, at least focally, positive for alpha-fetoprotein.

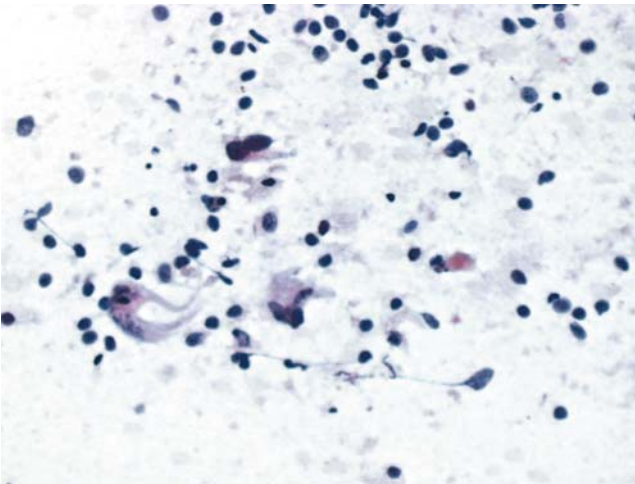
*Suggested Reading: 63*

## Case 106

---



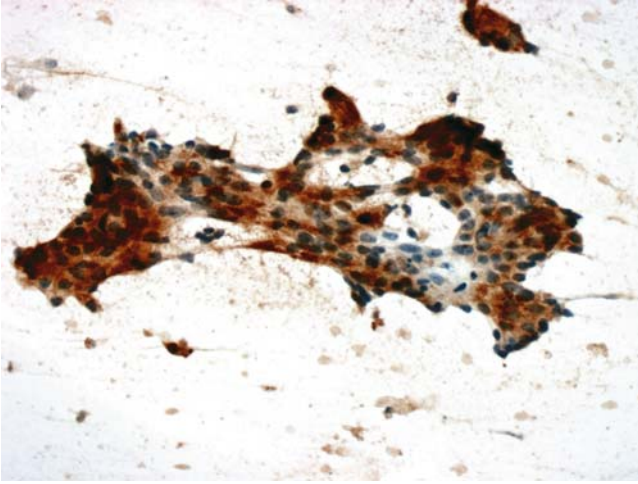
**FIGURE 106A. Pap Stain:** Imprint cytology of a prostatectomy specimen showing epithelial grouping and a single large cell with multiple abnormal nuclei (top left).



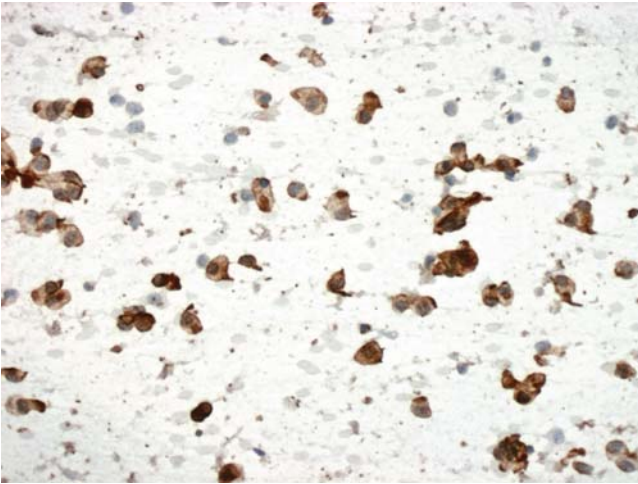
**FIGURE 106B. Pap Stain:** Another field of the same specimen showing predominantly isolated abnormal cells. The differential diagnosis includes poorly differentiated prostatic carcinoma and possibly a carcinosarcoma.

### *Diagnosis*

Carcinosarcoma of the Prostate Gland



**FIGURE 106C. Prostatic Specific Antigen (PSA):** The epithelial elements are positive for prostatic specific antigen.



**FIGURE 106D. Desmin:** Many of the isolated abnormal cells react positively for desmin.

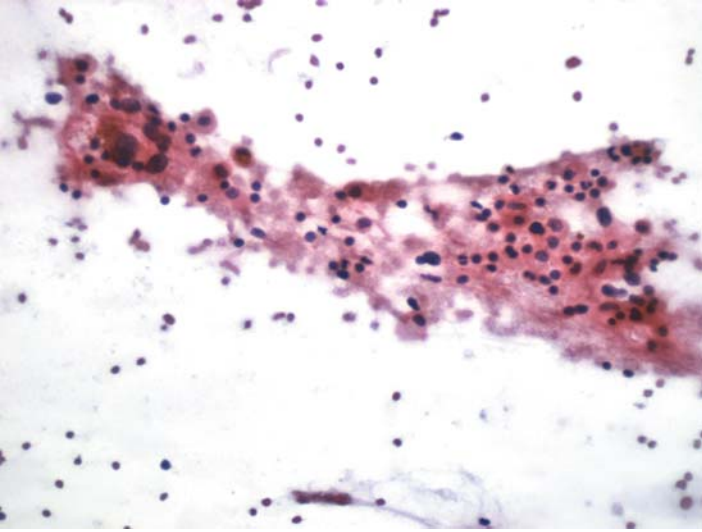
***Tips***

This rare case is included here to illustrate the value of ICC. The epithelial component of carcinosarcoma of prostate is positive for keratin and in this case for PSA. The sarcoma cells are positive for desmin supporting a myogenic differentiation.

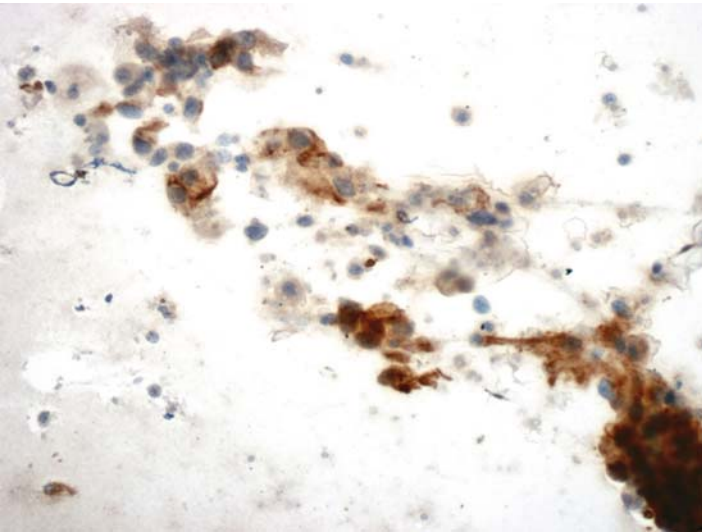
*Suggested Reading: 20, 23, 64*

## Case 107

---



**FIGURE 107A. Pap Stain:** FNA of a cystic renal mass showing cells with granular cytoplasm and indistinct cell membranes. The differential diagnosis includes renal cell carcinoma and histiocytes seen in a cyst fluid.



**FIGURE 107B. Epithelial Membrane Antigen (EMA):** Tumor cells show positive cytoplasmic staining for EMA.

## ***Diagnosis***

Renal Cell Carcinoma

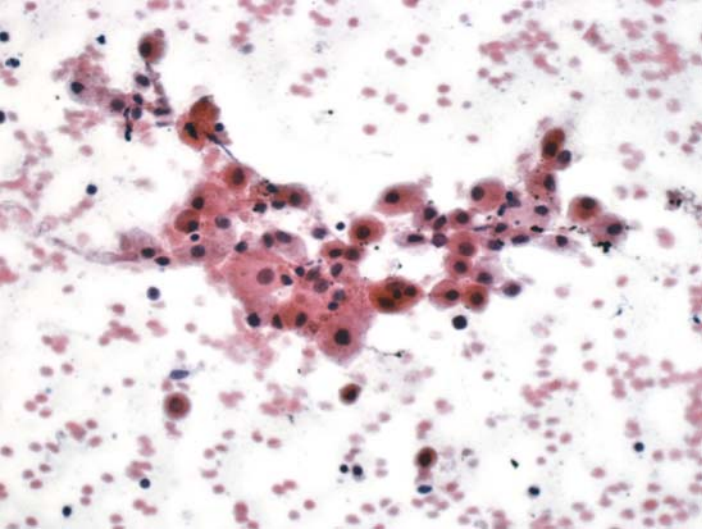
## ***Tips***

Aspirates of renal cell carcinomas, particularly when the lesion is cystic, may yield cells that are indistinguishable from histiocytes/macrophages. Demonstration of epithelial nature of cells by either cytokeratin or EMA helps to resolve the problem.

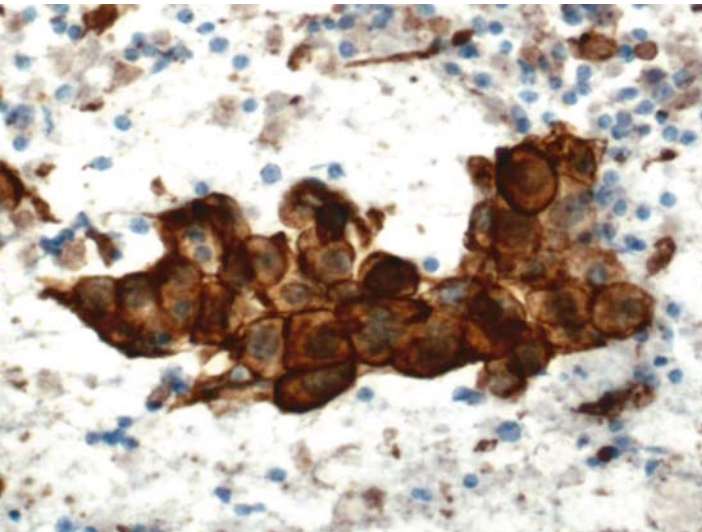
*Suggested Reading: 7*

## Case 108

---



**FIGURE 108A. Pap Stain:** FNA of lung in a patient with a history of renal cell carcinoma. Cohesive cells with abundant granular cytoplasm and mildly atypical nuclei; rule out a histiocytic reaction or a metastatic renal cell carcinoma.



**FIGURE 108B. Renal Cell Carcinoma Antigen (RCC):** Strong positive reaction for RCC is seen in all tumor cells.

***Diagnosis***

Metastatic Renal Cell Carcinoma

***Tips***

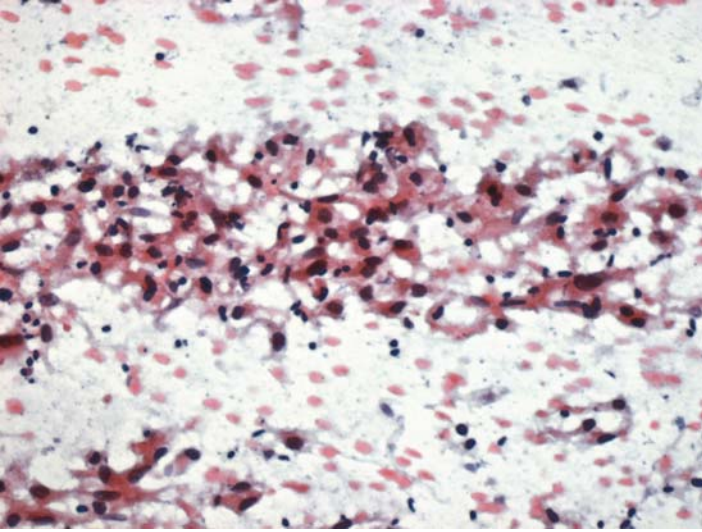
Renal cell carcinoma antigen is expressed by most clear cell renal cell carcinomas and by about 50% of nonclear cell types. Most other adenocarcinomas, including those of lung origin, are negative for the renal cell antigen.

*Suggested Reading: 65, 66*

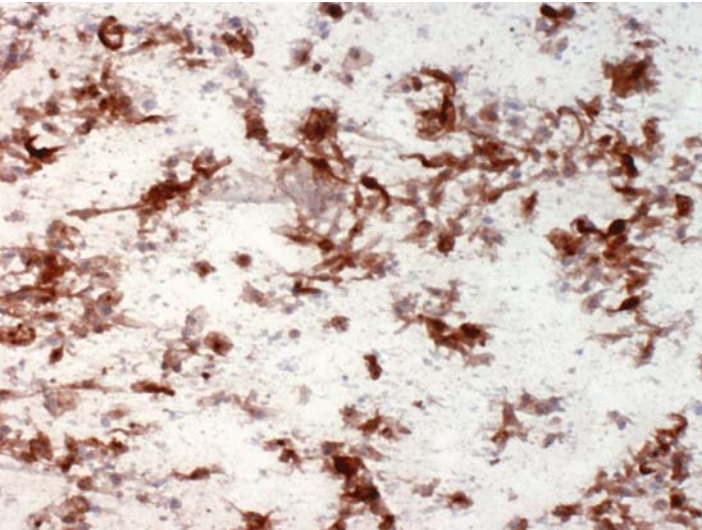


## Case 109

---



**FIGURE 109A. Pap Stain:** FNA of a renal mass showing loosely cohesive spindle cells with atypical nuclei. The differential diagnosis includes a sarcoma and a sarcomatoid renal cell carcinoma.



**FIGURE 109b. Cytokeratin:** Tumor cells are uniformly positive for cytokeratin.

## ***Diagnosis***

Renal Cell Carcinoma, Sarcomatoid Type

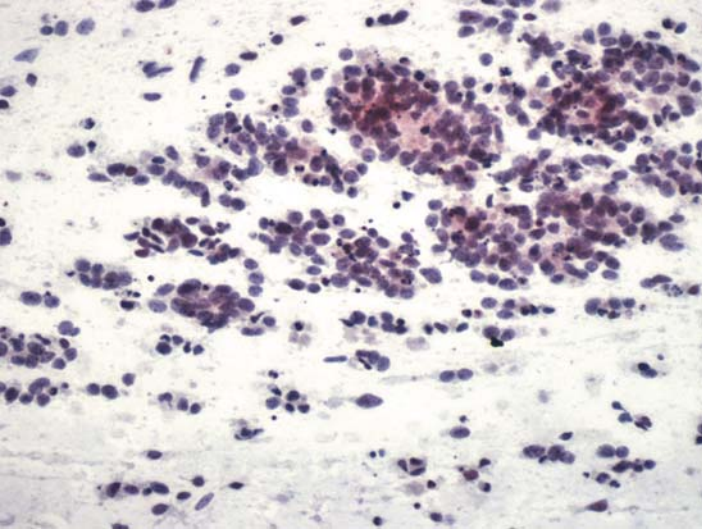
## ***Tips***

Most retroperitoneal sarcomas are negative for cytokeratin. The only exception is rare cases of synovial sarcomas.

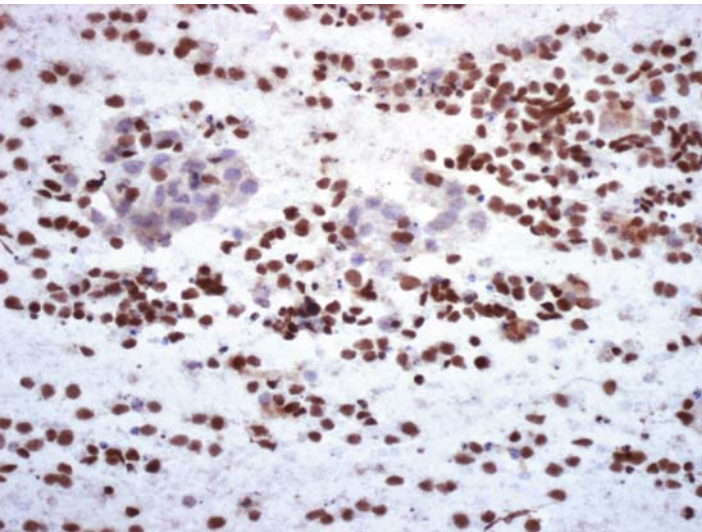
*Suggested Reading: 7*

## Case 110

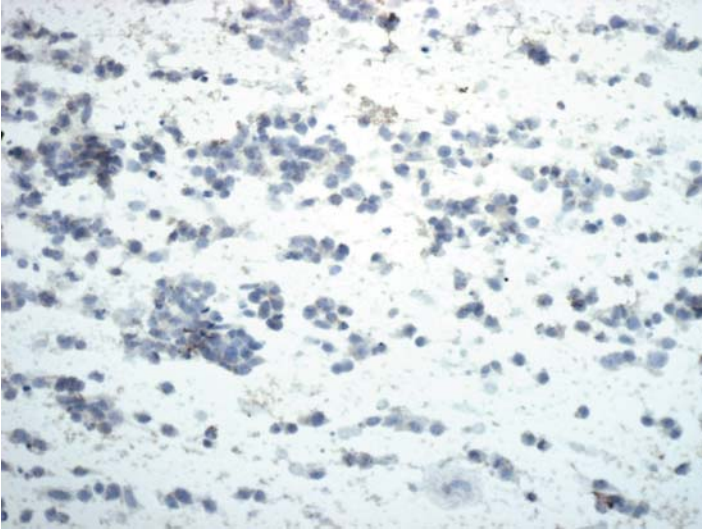
---



**FIGURE 110A. Pap Stain:** FNA of an abdominal tumor in a five-year-old male. This is a small cell malignant tumor with suggestion of rosette formation. The differential diagnosis includes neuroblastoma and Wilms tumor.



**FIGURE 110B. WT-1:** Most tumor cells show positive nuclear staining for WT-1.



**FIGURE 110C. Neuroblastoma Antigen (NB84):** There is no reaction for neuroblastoma antigen.

### ***Diagnosis***

Wilms Tumor

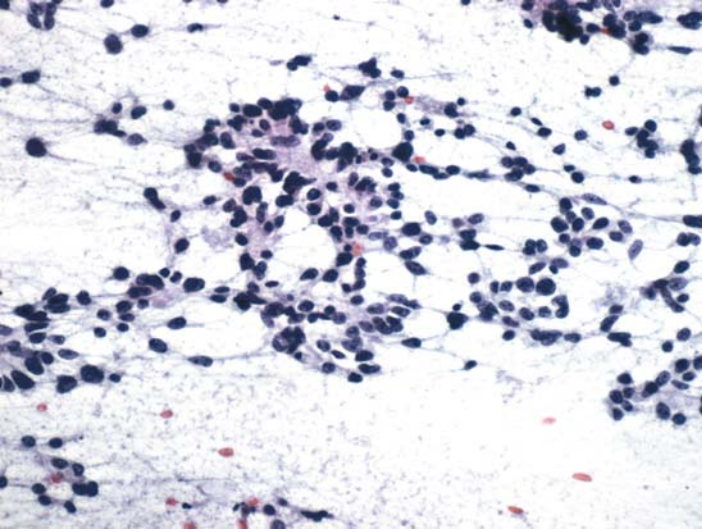
### ***Tips***

WT-1 is expressed by most Wilms tumor cells, but not by neuroblastomas. Conversely, neuroblastoma antigen is elaborated by most neuroblastomas and not by Wilms tumors.

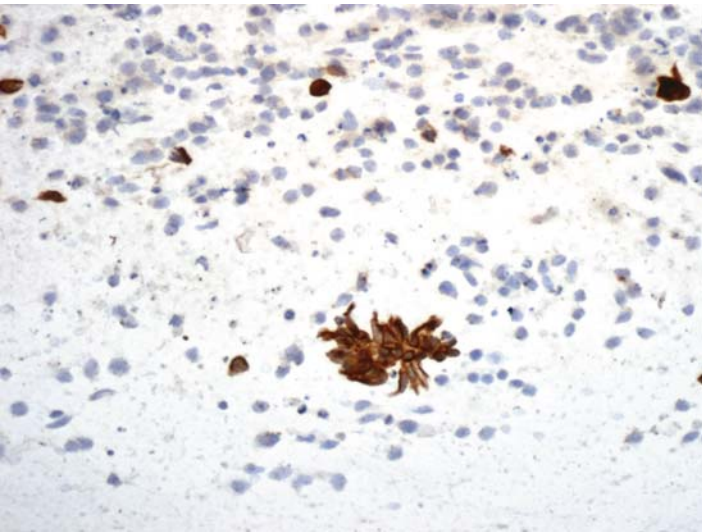
*Suggested Reading: 67, 68*

## Case 111

---

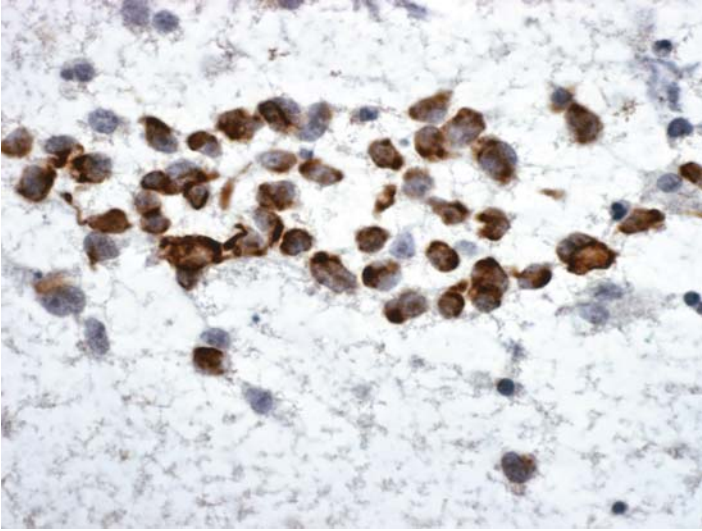


**FIGURE 111A. Pap Stain:** FNA of an abdominal mass in a child with history of nephrectomy for Wilms tumor. This small cell malignant tumor is morphologically consistent with recurrent Wilms tumor.



**FIGURE 111B. Cytokeratin:** Some tumor cells are positive for cytokeratin.





**FIGURE 111C. Desmin:** Some are also positive for desmin.

### ***Diagnosis***

Small Cell Malignant Neoplasm Consistent with Recurrent Wilms Tumor

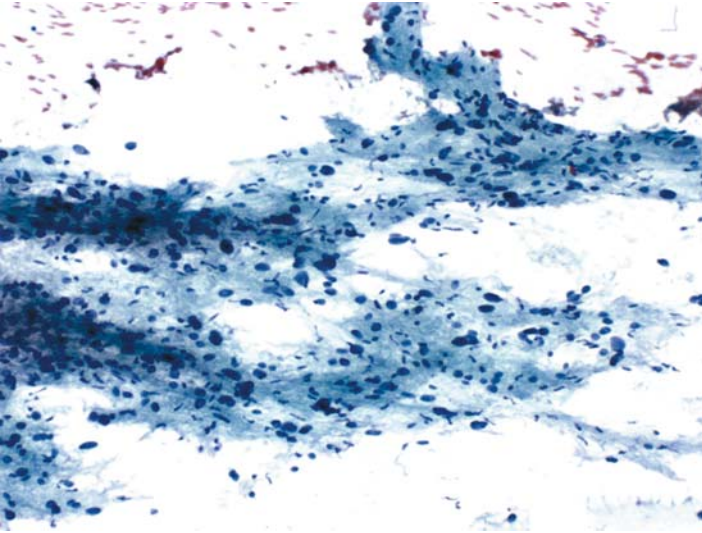
### ***Tips***

Wilms tumors may express both cytokeratin and desmin and, hence, could be mistaken for desmoplastic small round cell tumors (See Case 85).

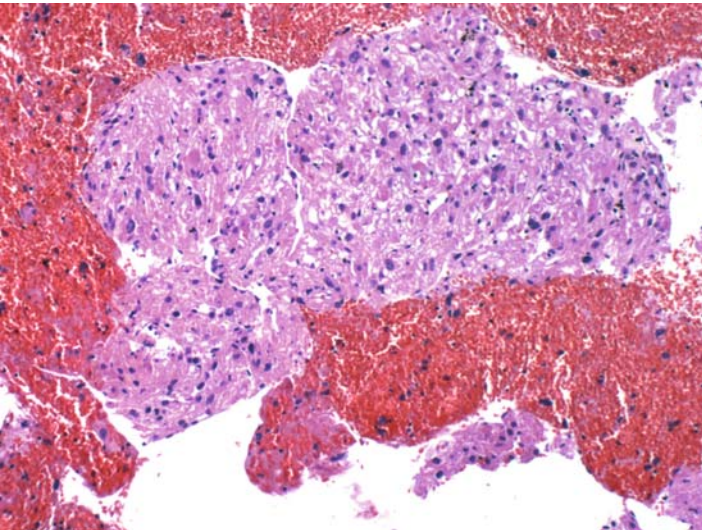
*Suggested Reading:* 7

## Case 112

---

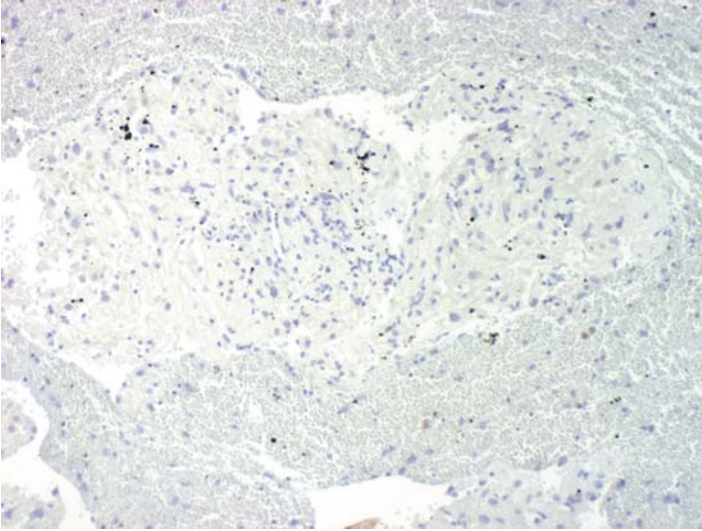


**FIGURE 112A. Pap Stain:** FNA of a liver mass in a 35-year-old female with a history of nephrectomy for a renal tumor. Highly pleomorphic cells with indistinct cytoplasmic borders suggestive of a sarcoma.

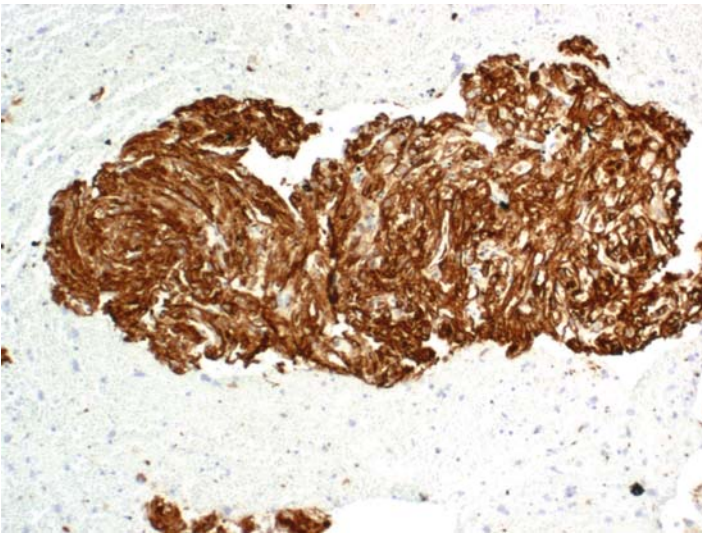


**FIGURE 112B. H&E Stain, Cell Block:** On this preparation the cells have abundant granular eosinophilic cytoplasm. The differential diagnosis includes sarcomatoid renal cell carcinoma, sarcoma, and metastatic malignant angiomyolipoma.

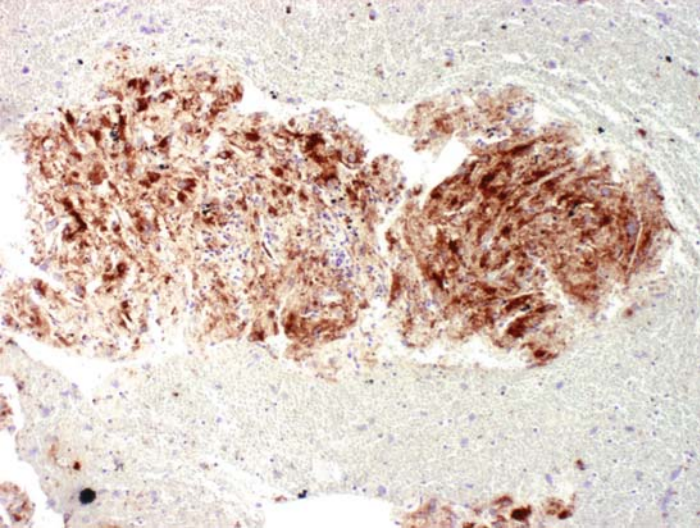




**FIGURE 112C. Cytokeratin:** Tumor is negative for cytokeratin; therefore, a renal cell carcinoma is unlikely.



**FIGURE 112D. H-Caldesmon:** Tumor cells are strongly positive for caldesmon.



**FIGURE 112E. HMB-45:** There is also positive reaction for HMB-45.

### ***Diagnosis***

Metastatic Malignant Angiomyolipoma, Epithelioid Type

### ***Tips***

This is a rather rare tumor that requires ICC for proper classification. Angiomyolipomas, whether benign or malignant, coexpress HMB-45 and smooth muscle markers. They are always negative for cytokeratin.

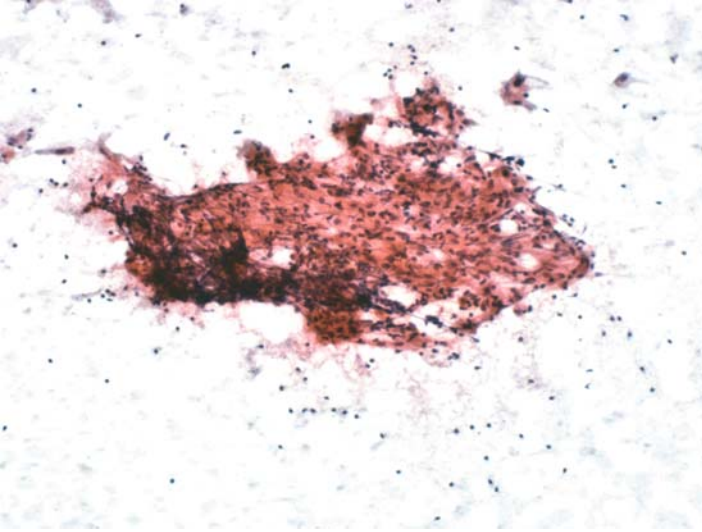
*Suggested Reading: 69*

# 15

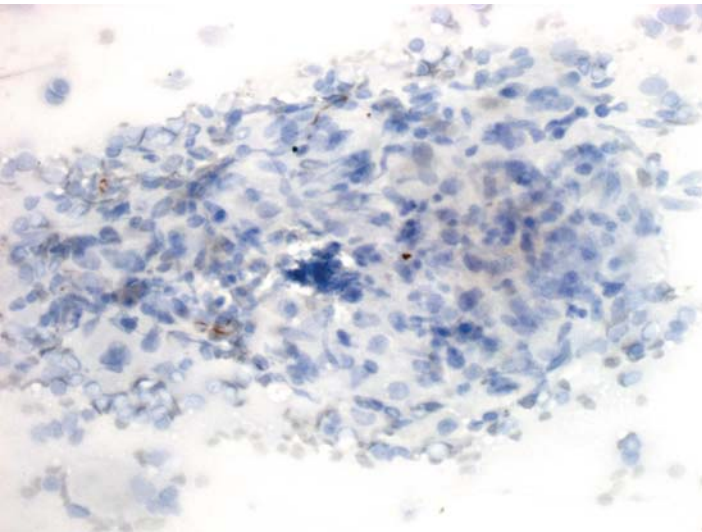
## Lymphoreticular System

## Case 113

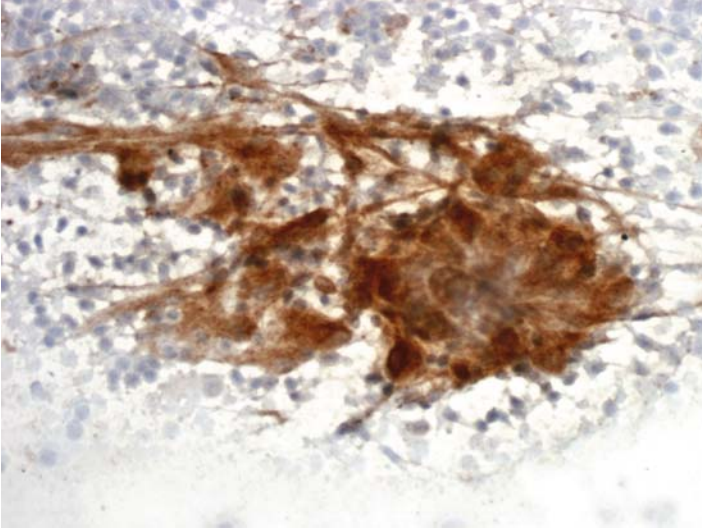
---



**FIGURE 113A. Pap Stain:** FNA of cervical lymph node in a 42-year-old female. A cluster of epithelioid cells with eosinophilic cytoplasm is present. The differential diagnosis includes metastatic carcinoma and granulomatous lymphadenitis.



**FIGURE 113B. Cytokeratin:** The epithelioid cells are negative for cytokeratin.



**FIGURE 113C. CD68:** Strong cytoplasmic reaction for CD68 is present in the epithelioid cells.

### ***Diagnosis***

Granulomatous Lymphadenitis (Sarcoid on Biopsy)

### ***Tips***

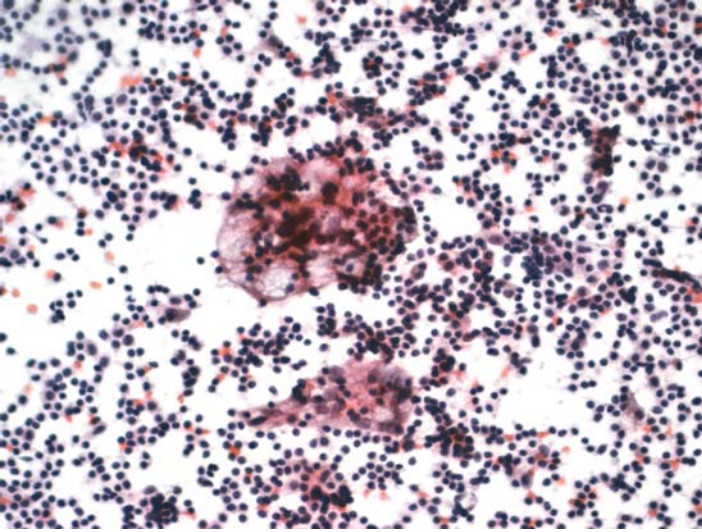
Although CD68 is a sensitive marker for histiocytes and macrophages, it is relatively nonspecific; a number of epithelial cells also express this antigen. It, therefore, should preferably be used in a panel that includes epithelial cell markers.

*Suggested Reading: 70*

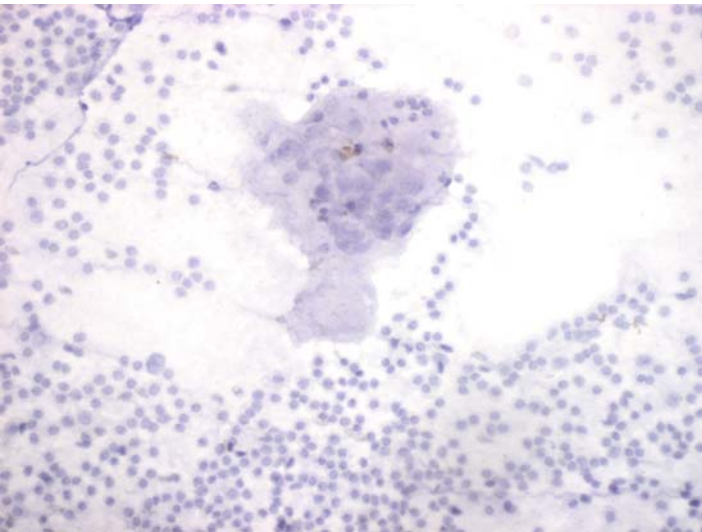


## Case 114

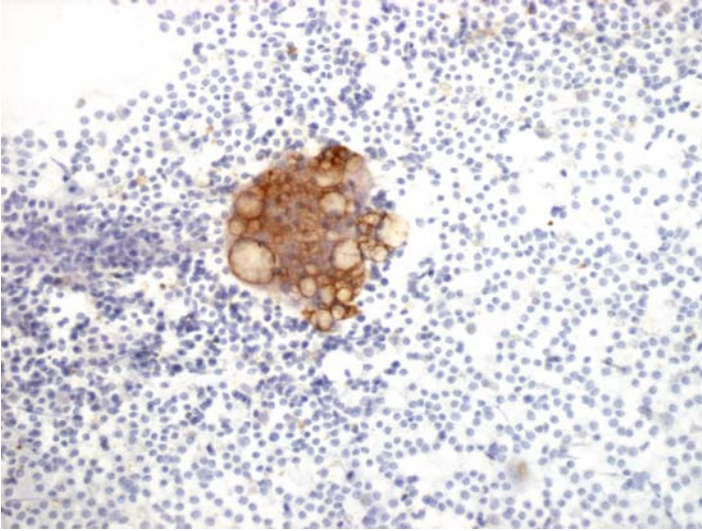
---



**FIGURE 114A. Pap Stain:** Imprint cytology of an enlarged periportal lymph node in a patient with pancreatic carcinoma; a metastatic mucinous carcinoma is in the differential diagnosis.



**FIGURE 114B. Cytokeratin:** The cells are negative for cytokeratin.



**FIGURE 114C. CD68:** There is positive reaction for CD68.

### ***Diagnosis***

Histiocytic Reaction Suggestive of Lipogranuloma

### ***Tips***

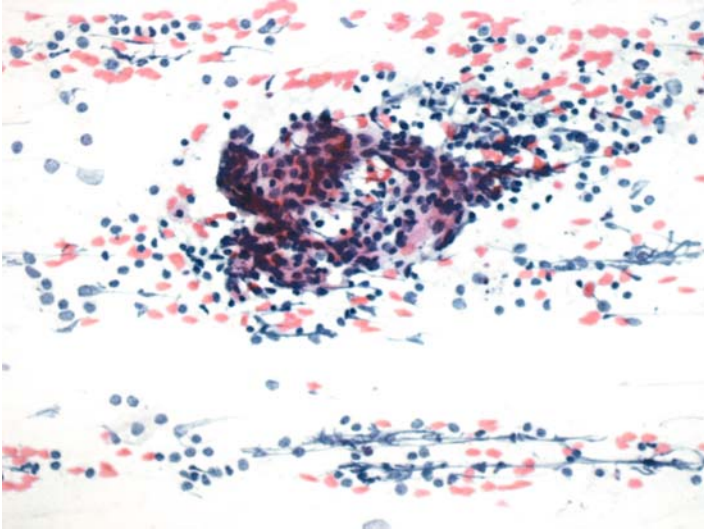
Although CD68 is a sensitive marker for histiocytes and macrophages, it is relatively nonspecific; a number of epithelial cells also express this antigen. It, therefore, should preferably be used in a panel that includes epithelial cell markers.

*Suggested Reading: 70*

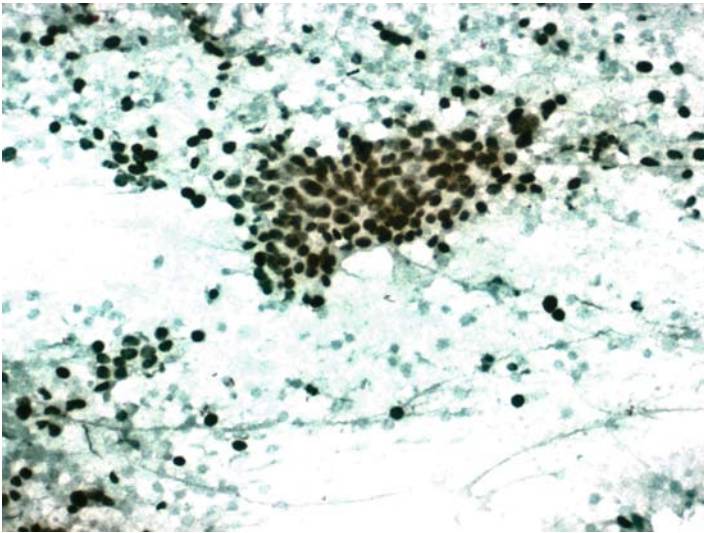


## Case 115

---



**FIGURE 115A. Pap Stain:** FNA of a cervical lymph node in a patient with a history of laryngeal squamous cell carcinoma; rule out a metastatic carcinoma or a reactive histiocytic process.



**FIGURE 115B. P63:** Cells are positive for p63 supporting their squamous nature.

## ***Diagnosis***

Metastatic Squamous Cell Carcinoma

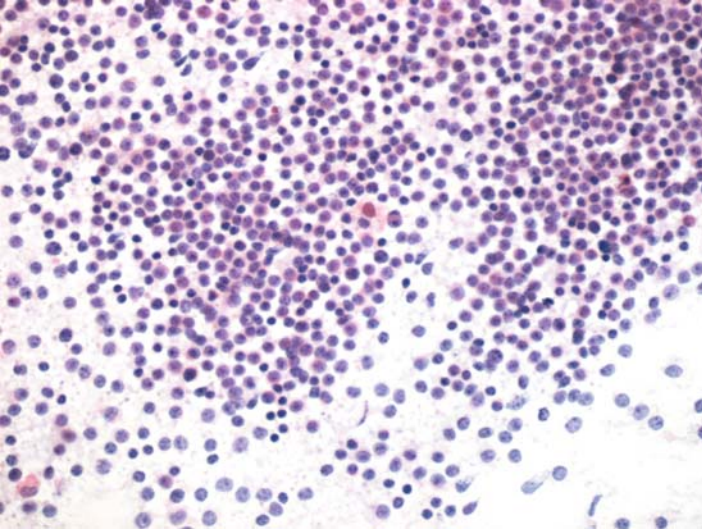
## ***Tips***

Other p63-positive tumors in the head and neck region include undifferentiated nasopharyngeal carcinomas and salivary gland neoplasms.

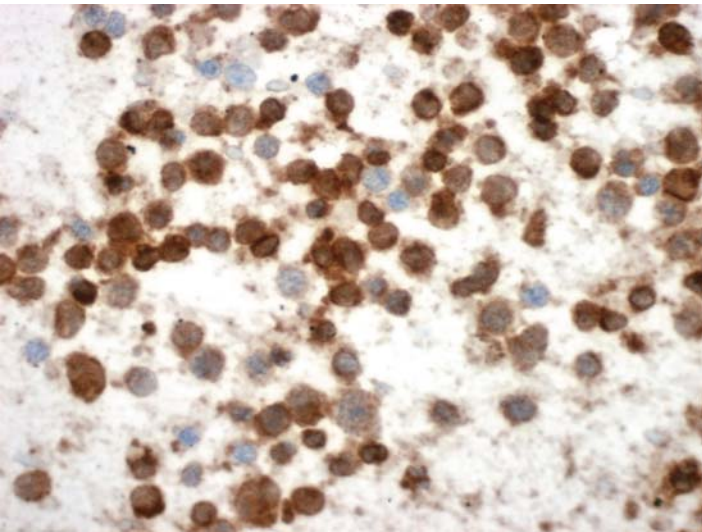
*Suggested Reading: 7*

## Case 116

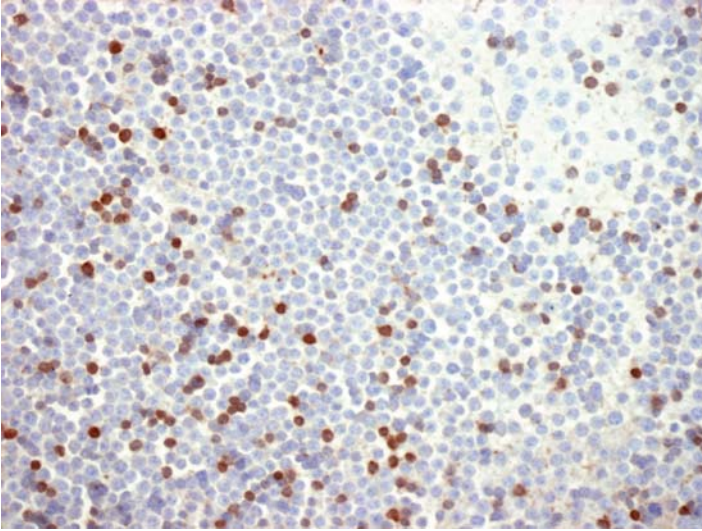
---



**FIGURE 116A. Pap Stain:** FNA of supraclavicular lymph node in an elderly male. The morphology is suggestive of lymphoma but metastatic carcinoma should be excluded.



**FIGURE 116B. CD20:** The larger cells are all positive for CD20.



**FIGURE 116C. CD3:** There are also scattered CD3 positive lymphocytes.

### ***Diagnosis***

Malignant Lymphoma, B Cell Type

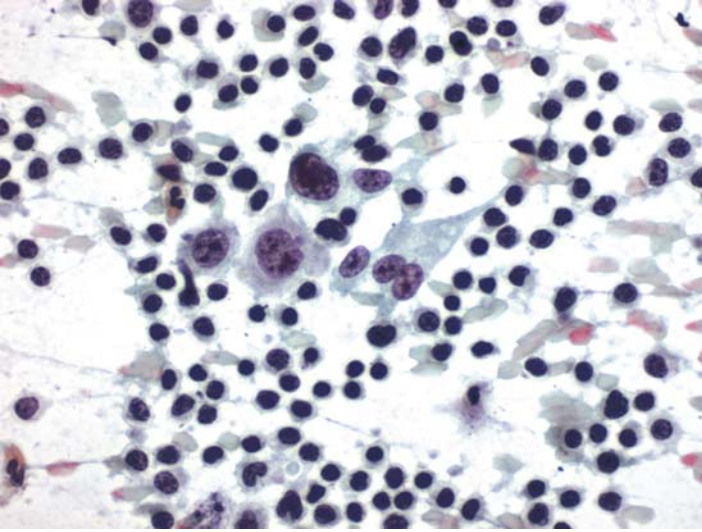
### ***Tips***

The majority of large cell malignant lymphomas are of B cell lineage and react positively for CD20. Lymphomas, akin to other cancers, may show a host reaction composed primarily of CD3-positive T lymphocytes. These cells, however, are usually small and are simple to identify as host cells.

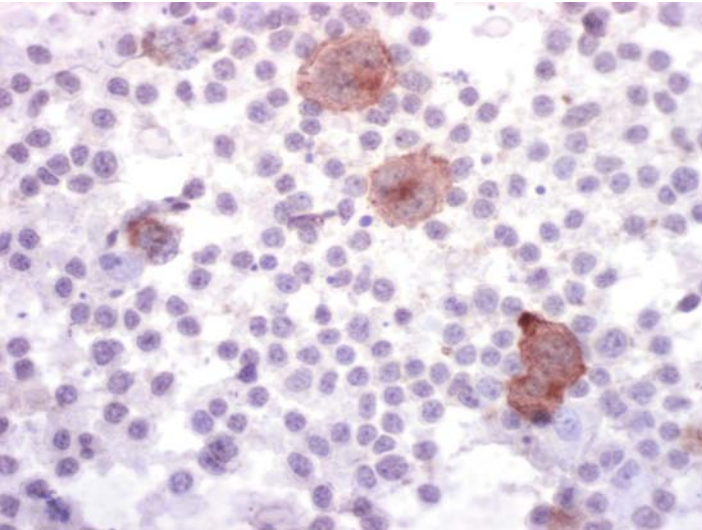
*Suggested Reading: 11–14*

## Case 117

---



**FIGURE 117A. Pap Stain:** FNA of mediastinum in a 21-year-old female. The cytomorphology is consistent with Hodgkin lymphoma.



**FIGURE 117B. CD30:** The large abnormal cells are positive for CD30.



## ***Diagnosis***

Hodgkin Lymphoma

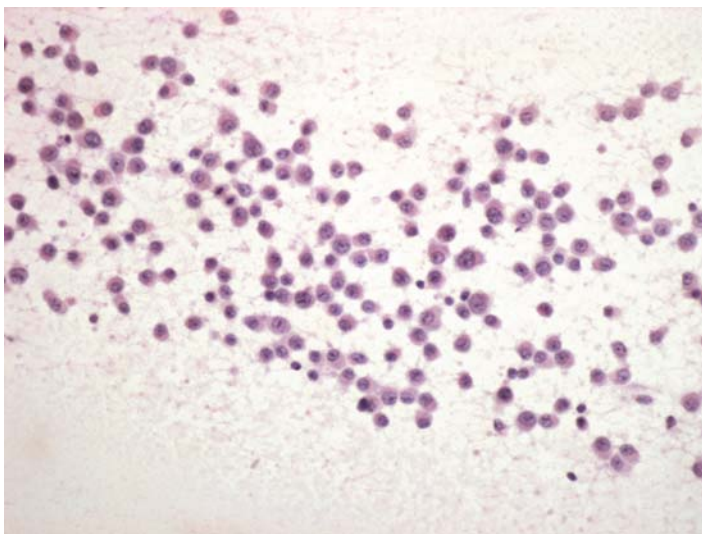
### ***Tips***

- The abnormal cells in Hodgkin lymphoma are positive for CD30 and CD15. These markers show a characteristic staining pattern that includes a large punctate area next to the nucleus and a cytoplasmic membrane reaction.
- CD30-positivity alone cannot distinguish Reed-Sternberg cells from anaplastic large cell lymphomas.
- There are a large number of purported Reed-Sternberg cell markers, in our hands however, CD30 and CD15 are the most useful.

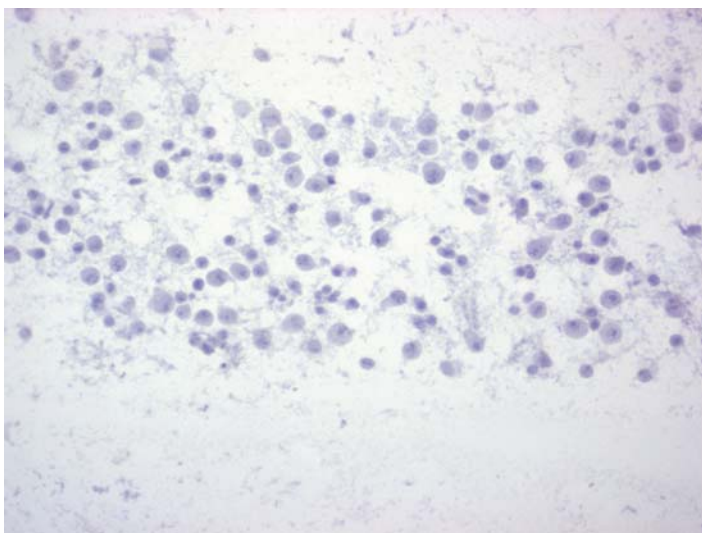
*Suggested Reading: 15*

## Case 118

---

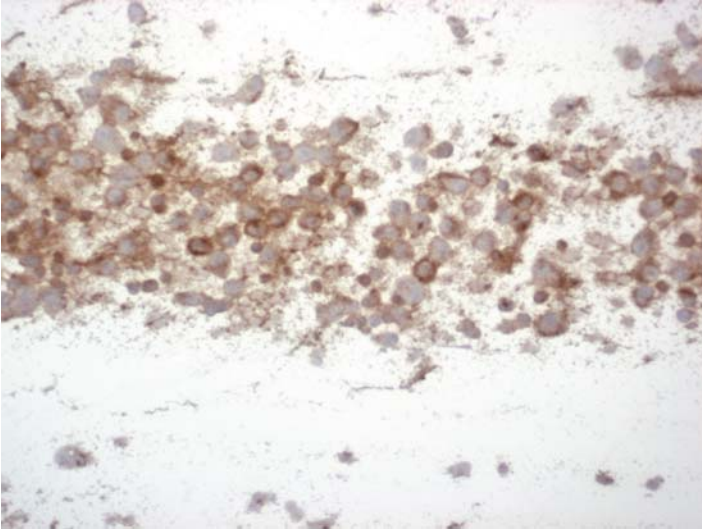


**FIGURE 118A. Pap Stain:** FNA of a paravertebral soft tissue mass in a 67-year-old male. The differential diagnosis includes plasmacytoma (myeloma) and reactive plasmacytosis.



**FIGURE 118B. Kappa Light Chain:** The cells are negative for kappa light chain.





**FIGURE 118C. Lambda Light Chain:** There is uniform positive cytoplasmic staining for lambda light chain.

### *Diagnosis*

Soft Tissue Plasmacytoma (Myeloma)

### *Tips*

- Demonstration of monoclonality in a plasma cell population is usually an indication of malignancy. Antibodies to two immunoglobulin light chains, kappa and lambda, usually are adequate for this purpose.
- In cytologic material, positive reaction for light chains immunoglobulins is always associated with some staining in the slide background as well.

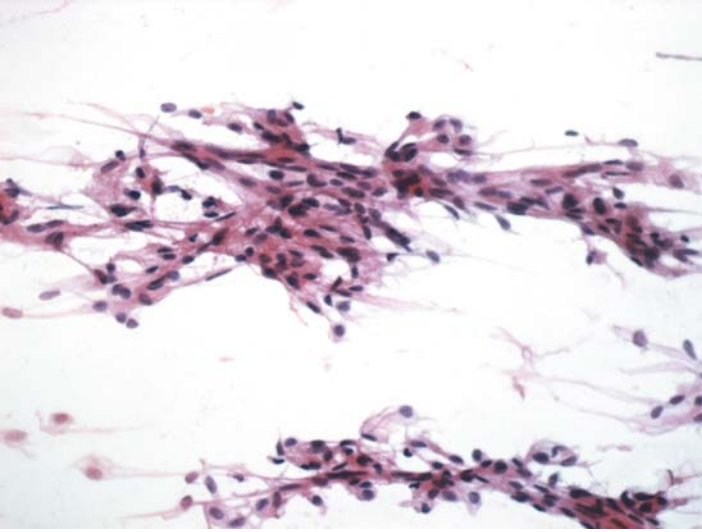
*Suggested Reading: 7*

# 16

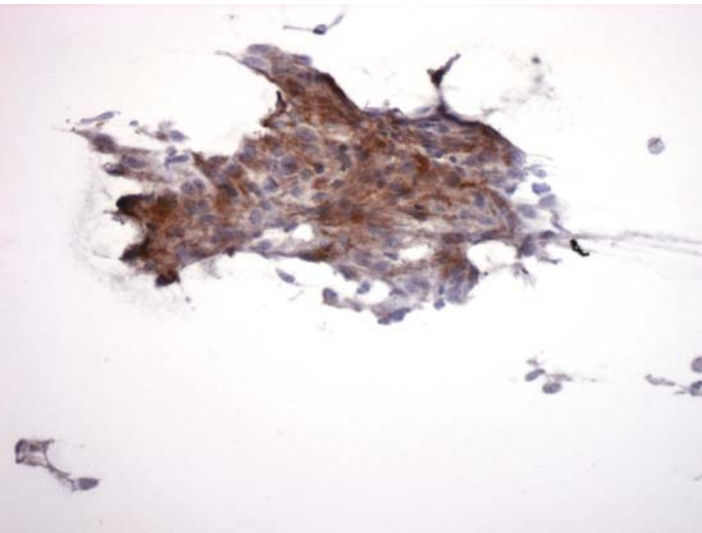
## Nervous System

## Case 119

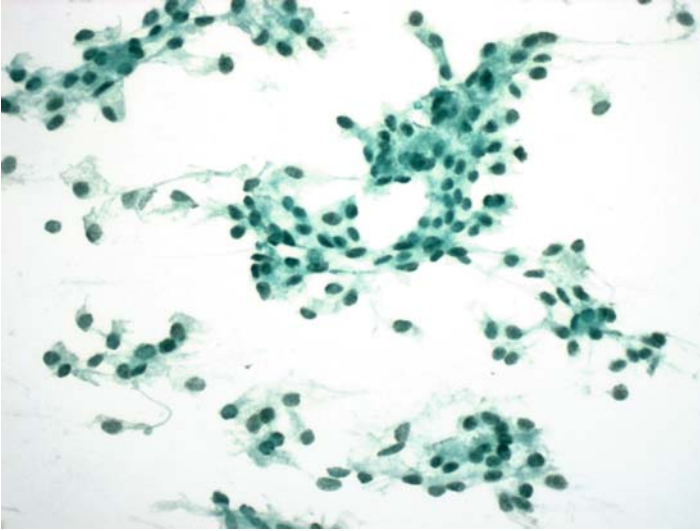
---



**FIGURE 119A. Pap Stain:** Imprint cytology of a brain tumor eroding into the skull bone. The differential diagnosis includes meningioma and schwannoma.



**FIGURE 119B. Epithelial Membrane Antigen (EMA):** Tumor cells show cytoplasmic staining for EMA.



**FIGURE 119C. Progesterone receptor (PR):** Most tumor cells are also positive for PR.

### ***Diagnosis***

Meningioma

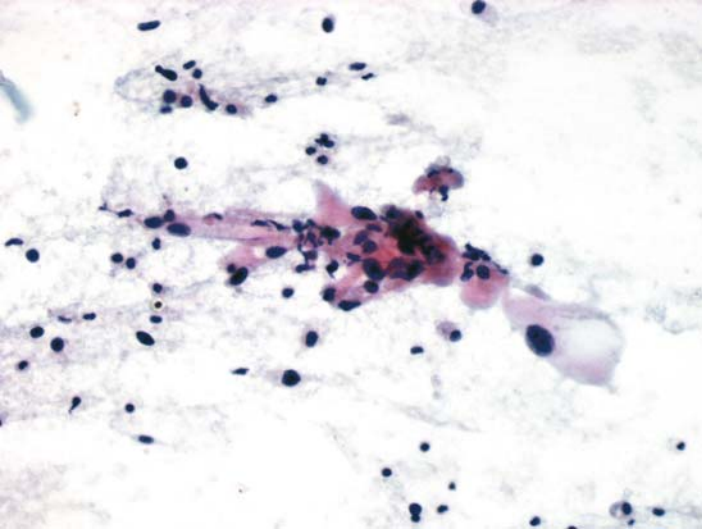
### ***Tips***

The best marker for meningiomas is progesterone receptor. Other antigens such as EMA and S100 are also expressed by these tumors.

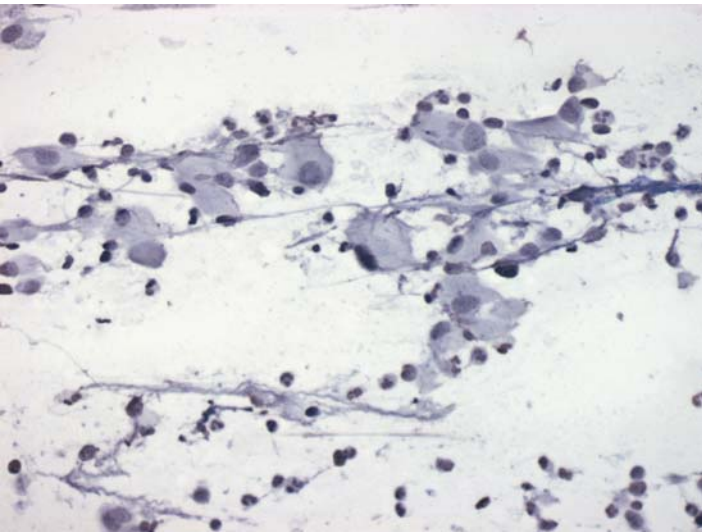
*Suggested Reading: 71*

## Case 120

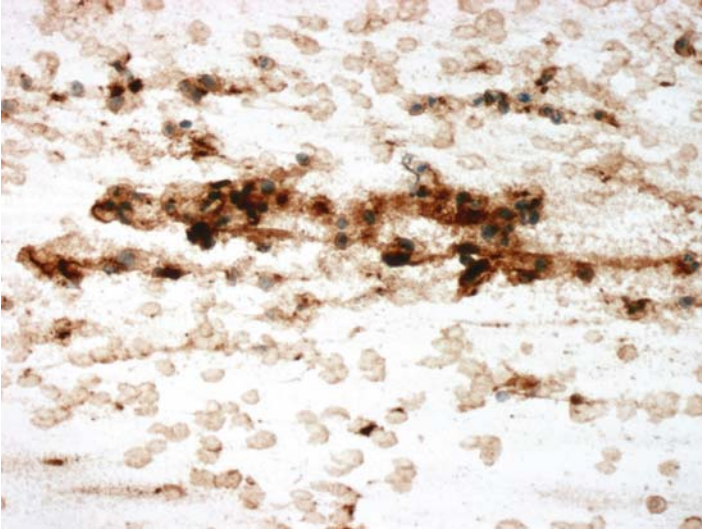
---



**FIGURE 120A. Pap Stain:** FNA of a subcutaneous nodule in the nasal bridge. The possibilities include a histiocytic lesion, a soft tissue tumor, an epithelial neoplasm, and so on.



**FIGURE 120B. Cytokeratin:** The cells are negative for cytokeratin.



**FIGURE 120C. Glial Fibrillary Acidic Protein (GFAP):** This stain was performed retrospectively following the excision of the nodule and histologic diagnosis. Positive reaction is seen in the cells and in the slide background.

### ***Diagnosis***

Nasal Glioma

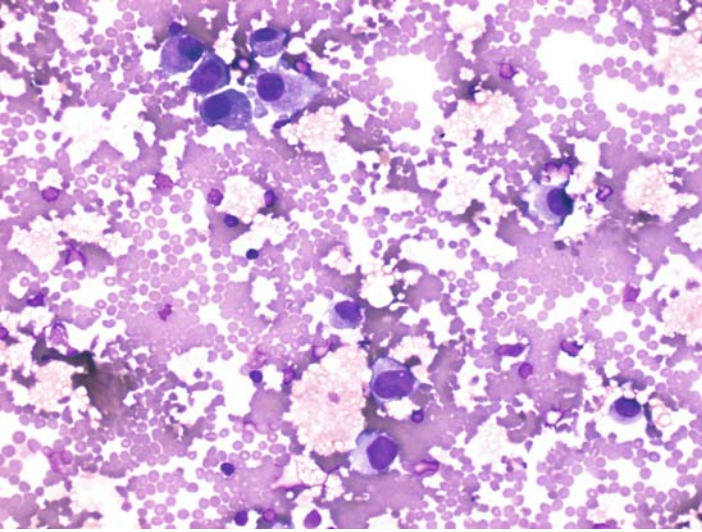
### ***Tips***

Gliomas are not normally seen in cytologic material; except in crush preparation of small brain biopsies. One could use GFAP as a specific marker to support the diagnosis of a glioma. In these preparations the slide background is also positive for GFAP.

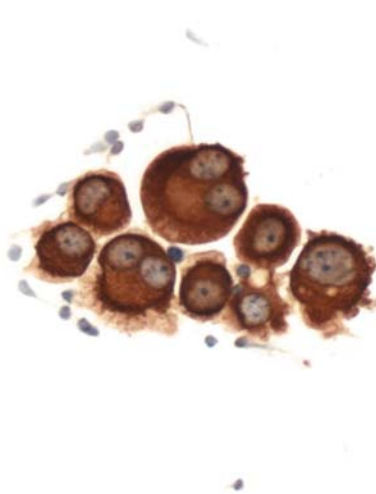
*Suggested Reading:* 72

## Case 121

---



**FIGURE 121A. Wright-Giemsa Stain:** Cytocentrifuge of CSF in a patient with gastric carcinoma and suspected carcinomatous meningitis. Isolated large cells are present, suggestive of metastatic carcinoma.



**FIGURE 121B. Epithelial Membrane Antigen (EMA):** Cells are strongly positive for EMA.



## ***Diagnosis***

Metastatic Carcinoma

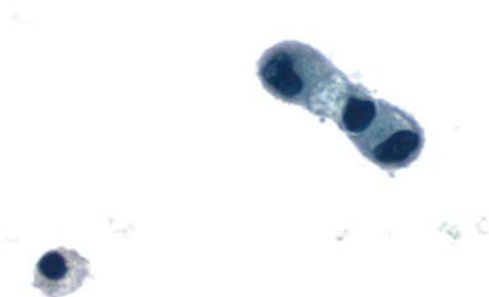### ***Tips***

- Malignant cells from the carcinomatous meningitis in CSF are usually very few and occur in isolated forms. As such, they may be mistaken for reactive pia-arachnoid mesothelial cells.
- Most carcinoma cells in CSF are positive for EMA, and this staining may even identify cells that are otherwise difficult to spot on Pap stain.
- Reactive pia arachnoid cells are negative for EMA (73).

*Suggested Reading: 73*

## Case 122

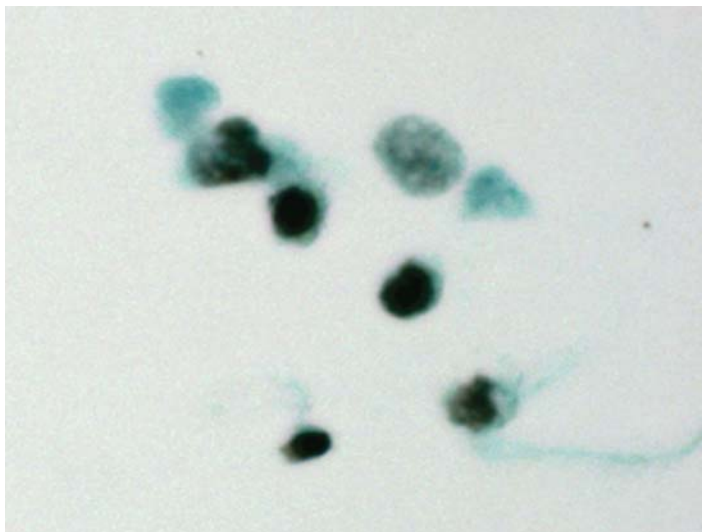
---



**FIGURE 122A. Pap Stain:** Cytocentrifuge preparation of CSF in a patient with a history of mammary carcinoma. Few highly abnormal cells are present.



**FIGURE 122B. Epithelial Membrane Antigen (EMA):** Strong positive reaction for EMA supports the diagnosis of carcinoma.



**FIGURE 122C. Estrogen Receptor (ER):** Tumor cells are also positive for ER.

### ***Diagnosis***

Metastatic Mammary Carcinoma

### ***Tips***

Cells from carcinomatous meningitis of breast origin are usually positive for EMA. If needed, ER could also be performed on additional slides.

*Suggested Reading: 73*

# Suggested Readings

1. Nadji M: The potential value of immunoperoxidase techniques in diagnostic cytology. *Acta Cytol* 24:442–447, 1980.
2. Nadji M, Ganjei P: Immunocytochemistry in diagnostic cytology. A 12-year perspective. *Am J Clin Pathol* 94:470–475, 1990.
3. Li CY, Lazcano-Villareal O, Pierre RU, Yam LT. Immunocytochemical identification of cells in serous effusions: technical considerations. *Am J Clin Pathol* 88:696–706, 1987.
4. Silverman JF, Nance K, Phillips B, Norris T. The use of immunoperoxidase panels for the cytologic diagnosis of malignancy in serous effusions. *Diag Cytopathol* 3:134–140, 1987.
5. Nadji M: The negative immunocytochemical result: What does it mean? *Diag Cytopathol* 2:81–82, 1986.
6. Nadji M, Ganjei P, Morales AR: Immunocytochemistry in contemporary cytology. The technique and its application. *Lab Med* 25:502–508, 1994.
7. Nadji M, Nassiri M, Morales AR. Efficient Tumor, Immunohistochemistry: A Differential Diagnosis-Driven Approach. *ASCP Press, Chicago*, 2005.
8. Miettinen M. Keratin immunohistochemistry: update of applications and pitfalls. *Pathol Ann* 28:113–143, 1993.
9. Cochran AJ, Lu HF, Li PX, Saxton R, Wen DR. S-100 protein remains a practical marker for melanocytic and other tumours. *Melanoma Res* 3:325–330, 1993.
10. Blessing K, Sanders D, Grant JJ. Comparison of immunohistochemical staining of the novel antibody Melan-A with S100 protein and HMB-45 in malignant melanoma and melanoma variants. *Histopathol* 32:139–146, 1998.
11. Poppema S, Lai R, Visser L, Yan XJ. CD45 (leucocyte common antigen) expression in T and B lymphocyte subsets. *Leuk Lymphoma* 20:217–222, 1996.
12. LinF, Staerckel G, Fanning TV. Cytodiagnosis of primary lymphoma of bone on fine-needle aspiration cytology specimens: review of 25 cases. *Diagn Cytopathol* 28:205–211, 2003.
13. Riley JK, Sliwkowski MX. CD20: a gene in search of a function. *Sem Oncol* 27:17–24, 2000.
14. Chu PG, Arber DA. CD79: A review. *Appl Immunohistochem Mol Morphol* 9:97–166, 2001.

15. Miettinen M. CD30 distribution. Immunohistochemical study on formaldehyde-fixed, paraffin-embedded Hodgkin's and non-Hodgkin's lymphomas. *Arch Pathol Lab Med* 116:1197-1201, 1992.
16. Koshida K, Wahren B. Placental-like alkaline phosphatase in seminoma. *Urol Res* 18:87-92, 1990.
17. McNutt NS. The S100 family of multipurpose calcium-binding proteins. *J Cut Pathol* 25:521-529, 1998.
18. Hisaoka M, Wei-Qi S, Jian W, Morio T, Hashimoto H. Specific but variable expression of h-caldesmon in leiomyosarcomas: an immunohistochemical reassessment of a novel myogenic marker. *Appl Immunohistochem Mol Morphol* 9:302-308, 2001.
19. Hsi ED, Nickoloff BJ. Dermatofibroma and dermatofibrosarcoma protuberans: an immunohistochemical study reveals distinctive antigenic profiles. *J Dermatol Sci* 11:1-9, 1996.
20. Truong LD, Rangaeng S, Cagle P, Ro JY, Hawkins H, Font RL. The diagnostic utility of desmin. A study of 584 cases and review of the literature. *Am J Clin Pathol* 93:305-314, 1990.
21. Ordonez NG, Mackay B. Granular cell tumor: a review of the pathology and histogenesis. *Ultrastruct Pathol* 23:207-222, 1999.
22. Miettinen M, Limon J, Niezabitowski A, Losata J. Patterns of keratin polypeptides in 110 biphasic, monophasic, and poorly differentiated synovial sarcomas. *Virchow's Arch* 437:275-283, 2000.
23. Cui S, Hano H, Harada T, Takei S, Masui F, Ushigome S. Evaluation of new monoclonal anti-MyoD1 and antimyogenin antibodies for the diagnosis of rhabdomyosarcoma. *Pathol Int* 49:62-68, 1999.
24. DeYoung BR, Swanson PE, Argenyi ZB, Ritter JH, Fitzgibbon JF, Stahl DJ, Hoover W, Wick MR. CD31 immunoreactivity in mesenchymal neoplasms of the skin and subcutis: report of 145 cases and review of putative immunohistologic markers of endothelial differentiation. *J Cutan Pathol* 22:215-222, 1995.
25. McComb RD, Jones TR, Pizzo SV, Bigner DD. Specificity and sensitivity of immunohistochemical detection of factor VIII/von Willebrand factor antigen in formalin-fixed paraffin-embedded tissue. *J Histochem Cytochem* 30:371-377, 1982.
26. Kahn HJ, Marks A. A new monoclonal antibody, D2-40 for detection of lymphatic invasion in primary tumors. *Lab Invest* 82:1255-1257, 2002.
27. Loy TS, Calaluce RD, Keeney GL. Cytokeratin immunostaining in differentiating primary ovarian carcinoma from metastatic colonic adenocarcinoma. *Mod Pathol* 9:1040-1044, 1996.
28. Li MK, Folpe AL. CDX-2, a new marker for adenocarcinoma of gastrointestinal origin. *Adv Anat Pathol* 11:101-105, 2004.
29. Miettinen M, Lasota J. Gastrointestinal stromal tumors: definition, clinical, histological, immunohistochemical, and molecular genetic features and differential diagnosis. *Virchows Arch* 438:1-12, 2001.
30. Dong Q, McKee G, Pitman M, Geisinger K, Tambouret R. Epithelioid variant of gastrointestinal stromal tumor: Diagnosis by fine-needle aspiration. *Diagn Cytopathol* 29:55-60, 2003.
31. Duval JV, Savas L, Banner BF. Expression of cytokeratins 7 and 20 in carcinomas of the extrahepatic biliary tract, pancreas, and gallbladder. *Arch Pathol Lab Med* 124:1196-1200, 2000.

32. Wick MR, Graeme-Cook FM. Pancreatic neuroendocrine neoplasms: a current summary of diagnostic, prognostic, and differential diagnostic information. *Am J Clin Pathol* 115:28–45, 2001.
33. Jimenez-Heffernan JA, Vicandi B, Lopez-Ferrer P, Gonzalez-Peramato P, Perez-Campos A, Viguier JM. Fine needle aspiration cytology of endocrine neoplasms of the pancreas. Morphologic and immunocytochemical findings in 20 cases. *Acta Cytol* 48:295–301, 2004.
34. Choi YL, Oh YL, Kim SH, Park CK, Ahn G. Comparative study of nonfunctional islet cell tumors and pancreatic solid and papillary neoplasms: biological behavior and immunohistochemistry. *Pathol Int* 52:358–366, 2002.
35. Lau SK, Prakash S, Geller SA, Alsabeh R. Comparative immunohistochemical profile of hepatocellular carcinoma, cholangiocarcinoma, and metastatic adenocarcinoma. *Hum Pathol* 33:1175–1181, 2002.
36. Siddiqui MT, Saboorian MH, Gokaslan ST, Ashfaq R. Diagnostic utility of the HepPar1 antibody to differentiate hepatocellular carcinoma from metastatic carcinoma in fine-needle aspiration samples. *Cancer* 96:49–52, 2002.
37. Ganjei P, Nadji M, Albores-Saavedra J, Morales AR. Histologic markers in primary and metastatic tumors of the liver. *Cancer* 62:1994–1998, 1988.
38. Jorda M, De Madeiros B, Nadji M. Calretinin and inhibin are useful in separating adrenocortical neoplasms from pheochromocytomas. *Appl Immunohistochem Mol Morphol* 10:67–70, 2002.
39. Fetsch PA, Powers CN, Zakowski MF, Abati A. Anti-alpha-inhibin: marker of choice for the consistent distinction between adrenocortical carcinoma and renal cell carcinoma in fine-needle aspiration. *Cancer* 87:168–172, 1999.
40. Lau SK, Luthringer DJ, Eisen RN. Thyroid transcription factor-1: a review. *Appl Immunohistochem Mol Morphol* 10:97–102, 2002.
41. Bilal H, Handra-Luca A, Bertrand JC, Fouret PJ. P63 is expressed in basal and myoepithelial cells of human normal and tumor salivary gland tissues. *J Histochem Cytochem* 51:133–139, 2003.
42. Sawady J, Mendelsohn G, Sirota RL, Taxy JB. The intrathyroidal hyperfunctioning parathyroid gland. *Mod Pathol* 2:652–657, 1989.
43. Albores-Saavedra J, Nadji M, Civantos F, Morales AR. Thyroglobulin in carcinoma of the thyroid: an immunohistochemical study. *Hum Pathol* 14:62–66, 1983.
44. Sikri KL, Varndell IM, Hamid QA, Wilson BS, Kameya T, Ponder BA, Lloyd RV, Bloom SR, Polak JM. Medullary carcinoma of the thyroid. An immunocytochemical and histochemical study of 25 cases using eight separate markers. *Cancer* 56:2481–2491, 1985.
45. Tan D, Li Q, Deeb G, Ramnath N, Slocum HK, Brooks J, Cheney R, Wiseman S, Anderson T, Loewen G. Thyroid transcription factor-1 expression prevalence and its clinical implications in nonsmall cell lung cancer: a high-throughput tissue microarray and immunohistochemistry study. *Hum Pathol* 34:597–604, 2003.
46. Chhieng DC, Cangiarella JF, Zakowski MF, Goswami S, Cohen JM, Yee HT. Use of thyroid transcription factor-1, PE-10, and cytokeratins 7 and 20 in discriminating between primary lung carcinomas and metastatic lesions in fine-needle aspiration biopsy specimens. *Cancer* 93:330–336, 2001.
47. Lau SK, Desrochers MJ, Luthringer DJ. Expression of thyroid transcription factor-1, cytokeratin 7, and cytokeratin 20 in bronchioloalveolar carcinomas:

- an immunohistochemical evaluation of 67 cases. *Mod Pathol* 15:538–542, 2002.
48. Moldvay J, Jackel M, Bogos K, Soltesz I, Agocs L, Kovacs G, Schaff Z. The role of TTF-1 in differentiating primary and metastatic lung adenocarcinomas. *Pathol Oncol Res* 10:85–88, 2004.
  49. Nadji M, Gomez-Fernandez C, Ganjei-Azar P, Morales AR. Immunohistochemistry of estrogen and progesterone receptors reconsidered: Experience with 5,993 breast cancers. *Am J Clin Pathol* 123:21–27, 2005.
  50. Wick MR. Immunohistology of neuroendocrine and neuroectodermal tumors. *Sem Diagn Pathol* 17:194–203, 2000.
  51. Comin CE, Novelli L, Boddi V, Paglierani M, Dini S. Calretinin, thrombomodulin, CEA and CD15: a useful combination of immunohistochemical markers for differentiating pleural epithelial mesothelioma from peripheral pulmonary adenocarcinoma. *Hum Pathol* 32:529–536, 2001.
  52. Yu GH, Soma L, Hahn S, Friedberg JS. Changing clinical course of patients with malignant mesothelioma: implications for FNA cytology and utility of immunocytochemical staining. *Diagn Cytopathol* 24:322–327, 2001.
  53. Van de Rijn M, Lombard CM, Rouse RV. Expression of CD34 by solitary fibrous tumors of the pleura, mediastinum, and lung. *Am J Surg Pathol* 18:814–820, 1994.
  54. Ring NP, Addis BJ. Thymoma: an integrated clinicopathological and immunohistochemical study. *J Pathol.* 149:327–337, 1986.
  55. Lae ME, Roche PC, Jin L, Lloyd RV, Nascimento AG. Desmoplastic small round cell tumor: a clinicopathologic, immunohistochemical, and molecular study of 32 tumors. *Am J Surg Pathol* 26:823–835, 2002.
  56. Toki T, Shimizu M, Takagi Y, Ashida T, Konishi I. CD10 is a marker for normal and neoplastic endometrial stromal cells. *Int J Gynecol Pathol* 21:41–47, 2002.
  57. Koelma IA, Nap M, Rodenburg CJ, Fleuren GJ. The value of tumour marker CA 125 in surgical pathology. *Histopathology* 11:287–294, 1987.
  58. Wang X, Mori I, Tang W, Nakamura M, Nakamura Y, Sato M, Sakurai T, Kakudo K. p63 expression in normal, hyperplastic and malignant breast tissues. *Breast Cancer* 9:216–219, 2002.
  59. Acs G, Lawton TJ, Rebbeck TR, LiVolsi VA, Zhang PJ. Differential expression of E-Cadherin in lobular and ductal neoplasms of the breast and its biologic and diagnostic implications. *Am J Clin Pathol* 115:85–98, 2001.
  60. Feinmesser M, Sulkes A, Morgenstern S, Sulkes J, Stern S, Okon E. HLA-DR and beta 2 macroglobulin expression in medullary and atypical medullary carcinoma of the breast: histopathologically similar but biologically distinct entities. *J Clin Pathol* 53:286–291, 2000.
  61. Reis-Filho JS, Milanezi F, Paredes J, Silva P, Pereira EM, Maeda SA, de Carvalho LV, Schmitt FC. Novel and classic myoepithelial/stem cell markers in metaplastic carcinomas of the breast. *Appl Immunohistochem Mol Morphol* 11:1–8, 2003.
  62. Pallesen G, Hamilton-Dutoit SJ. Ki-1 (CD30) antigen is regularly expressed by tumor cells of embryonal carcinoma. *Am J Pathol* 133:446–450, 1988.
  63. Niehans GA, Manivel JC, Copland GT, Scheithauer BW, Wick MR. Immunohistochemistry of germ cell and trophoblastic neoplasms. *Cancer* 62:1113–1123, 1988.



64. Nadji M, Tabei SZ, Castro A, Chu TM, Murphy GP, Wang MC, Morales AR. Prostatic-specific antigen: an immunohistologic marker for prostatic neoplasms. *Cancer* 48:1229–1232, 1981.
65. Yoshida SO, Imam A. Monoclonal antibody to a proximal nephrogenic renal antigen: Immunohistochemical analysis of formalin-fixed, paraffin-embedded human renal cell carcinomas. *Cancer Res* 49:1802–1809, 1989.
66. Gokden N, Mukunyadzi P, James JD, Gokden M. Diagnostic utility of renal cell carcinoma marker in cytopathology. *Appl Immunohistochem Mol Morphol* 11:116–119, 120, 2003.
67. Ghanem MA, Van der Kwast TH, Den Hollander JC, Sudaryo MK, Oomen MH, Noordzij Ma, Van den Heuvel MM, Nassef SM, Nijman RM, Van Steenbrugge GJ. Expression and prognostic value of Wilm's tumor 1 and early growth response 1 protein in nephroblastoma. *Clin Cancer Res* 6:4265–4271, 2000.
68. Thomas Jo, Nijjar J, Turley H, Micklem K, Gatter KC. NB 84: a new monoclonal antibody for the recognition of neuroblastoma in routinely processed material. *J Pathol* 163:69–75, 1991.
69. Sturtz CL, Dabbs DJ. Angiomyolipomas: the nature and expression of the HMB45 antigen. *Mod Pathol* 7:842–845, 1994.
70. Weiss LM, Arber DA, Chang KL. CD68: a review. *Appl Immunohistochem Mol Morphol* 2:2–8, 1994.
71. Khalid H. Immunohistochemical study of estrogen receptor-related antigen, progesterone and estrogen receptors in human intracranial meningiomas. *Cancer* 74:679–685, 1994.
72. De Armond SJ, Eng LF, Rubinstein LJ. The application of glial fibrillary acidic (GFA) protein immunohistochemistry in neurooncology. *Pathol Res Pract* 168:374–394, 1980.
73. Jorda M, Ganjei-Azar P, Nadji M. Cytologic characteristics of meningeal carcinomatosis; increased diagnostic accuracy using carcinoembryonic antigen and epithelial membrane antigen immunocytochemistry. *Arch Neurol* 55: 181–184, 1998.

# Index

## A

- Abdominal cavity pathology, 195–201
  - adenocarcinoma with gynecologic origin, 196–197
  - desmoplastic small round cell tumor, 198–199
  - metastatic carcinoma (cecal primary), 200–201
- Acinic cell carcinoma, 124–125
  - differentiated from pancreatic tumors, 73
- Actin, contraindication as recurrent leiomyosarcoma marker, 213
- Adenocarcinoma
  - CK7-positive, CK20-negative immunophenotype of, 93
  - colonic metastatic
    - differentiated from primary lung adenocarcinoma, 158–159
    - to the lung, 160–161, 184–185
  - colonic primary, 56–57
  - endocervical, 207
  - endometrial, recurrent, 206–207
  - hepatic, 92–93
  - mucinous, differentiated from chordoma, 51
  - of ovarian origin, 196–197
  - pancreatic, 68–69, 91
  - pulmonary, 58–59, 150–151, 154–155, 176–177
    - bronchoalveolar, 156–157
    - CDX-2 expression in, 58–59
    - differentiated from malignant mesothelioma, 172–173, 178–179
    - differentiated from metastatic colonic adenocarcinoma, 158–159
    - differentiated from primary thyroid carcinoma, 134–135
    - differentiated from reactive mesothelial cells, 176–177
    - differentiated from squamous cell carcinoma, 149, 150–151
    - metastatic to the adrenal gland, 112–113
    - upper gastrointestinal, cholangiocarcinoma and, 91
- Adenoid cystic carcinoma, 122–123
- Adenoma
  - adrenocortical, 102–103
  - hepatocellular, 82, 83
  - myoepithelial neoplasm, 118–119
  - parathyroid, 126–127
  - pleomorphic adenoma, 118–119
- Adrenal pathology, 101–115
  - adrenocortical hyperplasia/adenoma, 102–103
  - metastatic adenocarcinoma of the lung, 112–113
  - metastatic adrenocortical carcinoma, 104–105
  - metastatic carcinoma, 110–113
  - metastatic malignant melanoma, 114–115
  - pheochromocytoma, 106–109
- Adrenocortical carcinoma, metastatic, 104–105
- Adrenocortical hyperplasia, 102–103

Air-dried specimens, 4  
 Alcohol fixatives, contraindication in  
   S100 staining, 15  
 Alpha-fetoprotein  
   as endodermal sinus tumor marker,  
     242, 243  
   as hepatocellular carcinoma marker,  
     80, 81  
 Amylase, salivary, 124, 125  
 Angiomyolipoma, metastatic  
   malignant, epitheloid type,  
     256–258  
 Antiamylase antibody, 125  
 Antigen retrieval, heat-induced, 5  
 Antigens. *See also specific antigens*  
   as nonspecific background staining,  
     8  
 Apoptotic bodies, large-cell malignant  
   lymphoma-related, 16  
 Ascitic fluid, cytocentrifuge  
   preparation of, 196  
 Axillary lymph nodes, in metastatic  
   mammary carcinoma, 20

**B**

B cells, in thymic hyperplasia,  
   189  
 bcl-2, as synovial sarcoma marker,  
   39  
 Brain tumor. *See also Meningioma*  
   with skull erosion, 274–275  
 Breast carcinoma  
   ductal, 218–219  
   fibroadenoma, 216–217  
   lobular, 220–223  
     differentiated from ductal breast  
     carcinoma, 218–219  
     metastatic, 230–231  
   medullary, 226–227  
   metaplastic, 228–229  
     “triple-negative”  
     immunophenotype of, 229  
   metastatic, 20–21  
     as carcinomatous meningitis  
     cause, 280–281  
     lobular, 230–231  
     to the lung, 162–163, 180–183  
     mucinous (colloid), 224–225  
 Bronchoalveolar carcinoma, 156–157

**C**

(E)-Cadherin, as lobular breast  
   carcinoma marker, 219, 220, 221  
 Calcitonin, 129  
   as medullary thyroid carcinoma  
   marker, 138, 139  
 Calretinin  
   as adrenocortical cell/tumor marker,  
     102–103  
   as malignant mesothelioma marker,  
     170, 171, 173, 179  
   as metastases-related lung cancer  
   marker, 181  
 CA-125  
   as endometrial serous carcinoma  
   marker, 208–209  
   as ovarian serous carcinoma marker,  
     208–209  
 Carcinoembryonic antigen (CEA)  
   as chordoma marker, 51  
   as hepatocellular carcinoma marker,  
     85  
   as medullary thyroid carcinoma  
   marker, 139  
 Carcinoid, pulmonary, 164–167  
   differentiated from neuroendocrine  
   tumors, 166–167  
 CD3  
   as malignant B-cell lymphoma  
   marker, 267  
   as thymoma marker, 189  
 CD10  
   as endometrial stromal sarcoma  
   marker, 214, 215  
   as endometriosis marker, 205  
 CD15  
   as Hodgkin’s lymphoma marker, 269  
   as Reed-Sternberg cell marker, 269  
 CD20, as B-cell lymphoma marker, 16,  
   17  
   in hepatic B-cell lymphoma, 97  
   in malignant B-cell lymphoma, 266,  
     267  
 CD30  
   as anaplastic lymphoma marker, 22,  
     23  
   as Hodgkin’s lymphoma marker,  
     268, 269  
   as Reed-Sternberg cell marker, 269

- as testicular embryonal carcinoma marker, 240, 241
- CD31
  - as endothelial cell marker, 99
  - as hemangioma marker, 98, 99
  - as Kaposi's sarcoma marker, 46, 47
- CD34
  - as dermatofibrosarcoma protuberans marker, 32
  - as solitary fibrous tumor marker, 175
- CD45
  - as B-cell lymphoma marker, 17
  - as hepatic B-cell lymphoma marker, 97
  - as poorly-differentiated gastric carcinoma marker, 55
- CD68
  - contraindication as granular cell tumor marker, 37
  - as granulomatous lymphadenitis marker, 261
  - as lipogranuloma marker, 263
  - as malignant fibrous histiocytoma marker, 44, 45
  - as sarcoma marker, 45
- CD79a, as B-cell lymphoma marker, 17
- CD99, as synovial sarcoma marker, 39
- CD117, as gastrointestinal stromal tumor (GIST) marker, 63, 65
- CDX-2, s colonic adenocarcinoma marker, 58–59, 161
- Cecal carcinoma, metastatic, 200–201
- Cell block preparations, 3
  - of adrenal tumor, 110
  - of colonic carcinoma pulmonary metastases, 184
  - of malignant mesothelioma, 172
  - of metastases-related lung cancer, 180, 183
  - of pulmonary adenocarcinoma, 178
- Cerebrospinal fluid, carcinoma cells in, 278–281
- Cholangiocarcinoma, differentiated from hepatocellular carcinoma, 79
- Chondroid neoplasm, 48–49
- Chondrosarcoma, myxoid, 48–49
- Chordoma, 50–51
  - differentiated from chondrosarcoma, 48–49
- Chromogranin
  - as desmoplastic small, round cell tumor marker, 198–199
  - as neuroendocrine tumor marker, 71
  - as pancreatic islet cell marker, 70, 71, 72, 73
  - as pheochromocytoma marker, 107, 108
  - as pulmonary carcinoid marker, 164, 165, 166
- Clear cells, in hepatocellular carcinoma, 80–81
- Colon adenocarcinoma
  - metastatic, 58–59
    - differentiated from pulmonary adenocarcinoma, 158–159
    - to the lung, 160–161, 184–185
  - primary, 56–57
- Controls, in immunocytochemistry, 5
- Coverslips, 3
- Cytocentrifuge preparation, of
  - carcinomatous meningitis, 280
- Cytokeratin
  - as chordoma marker, 49, 50
  - as desmoplastic small, round cell tumor marker, 198–199
  - as embryonal carcinoma marker, 25
  - as epitheloid gastrointestinal stromal tumor (GIST) marker, 64
  - as metastatic breast carcinoma marker, 20, 21
  - as metastatic carcinoma marker, 110, 111
  - as metastatic lobular breast carcinoma marker, 230, 231
  - as poorly-differentiated carcinoma marker, 18
  - as poorly-differentiated gastric carcinoma marker, 54, 55
  - as renal cell carcinoma marker, 247, 250
  - as signet-ring carcinoma marker, 60
  - as small-cell lung carcinoma marker, 12, 13, 144, 145, 146, 147
  - as spindle-cell neoplasm marker, 174, 191

Cytokeratin (*cont.*)

- as spindle-cell thymoma marker, 191
- as synovial sarcoma marker, 38, 39
- as thymic hyperplasia marker, 186, 187
- as thymoma marker, 186, 187
- as Warthin's tumor marker, 120
- as Wilms' tumor marker, 254, 255

## Cytokeratin 7

- as cholangiocarcinoma marker, 91
- as colonic adenocarcinoma marker, 56, 57, 58
- as hepatic adenocarcinoma marker, 92
- as hepatocellular carcinoma marker, 78, 79
- as pancreatic adenocarcinoma marker, 68, 69
- as pancreatic cancer marker, 68, 69, 79
- as poorly-differentiated gastric carcinoma marker, 55
- as pulmonary adenocarcinoma marker, 159

## Cytokeratin 20

- as colonic adenocarcinoma marker, 57, 59, 160, 161
- as hepatic adenocarcinoma marker, 92
- as metastatic colonic carcinoma marker, 185, 185
- as pancreatic adenocarcinoma marker, 69
- as poorly-differentiated gastric carcinoma marker, 55
- as pulmonary adenocarcinoma marker, 158
- as urothelial carcinoma marker, 235

## Cytokeratin Cocktail, 13

**D**

- D2-40, as Kaposi's sarcoma marker, 47
- Dermatofibrosarcoma protuberans, 32-33
- Desmin
  - as desmoplastic small, round cell tumor marker, 198-199
  - as gastrointestinal stromal tumor (GIST) marker, 62, 63

- as leiomyosarcoma marker, 41
- as mixed mesodermal uterine cancer marker, 211, 212
- as prostate gland carcinosarcoma marker, 245
- as rhabdomyosarcoma marker, 42, 43
- as smooth muscle neoplasm marker, 35
- as Wilms' tumor marker, 255
- Desmoplastic small, round cell tumor, 198-199

**E**

- E-Cadherin, as lobular breast carcinoma marker, 219, 220, 221
- Embryonal carcinoma, 25
  - testicular metastatic, 240-241
- Endocervical adenocarcinoma, 207
- Endodermal sinus tumor, metastatic, 242-243
- Endometrial adenocarcinoma, recurrent, 206-207
- Endometrial stromal tumor, 214-215
- Endometriosis, 204-205
- Endothelial cells
  - CD31 expression in, 98, 99
  - Factor VIII-related antigen expression in, 99
  - lymphatic, D2-40 expression in, 47
- Epithelial cells
  - CD68 expression in, 261
  - isolated, in breast carcinoma, 20, 21
  - malignant, cytokeratin staining of, 18, 19
  - pleomorphic, 130
- Epithelial membrane antigen (EMA), 246, 247
  - as carcinoma cell marker, in cerebrospinal fluid, 278, 279
  - as carcinomatous meningitis marker, 280, 281
  - as chordoma marker, 51
  - as desmoplastic small, round cell tumor marker, 198-199
  - as malignant mesothelioma marker, 172-173
  - as meningioma marker, 274, 275

- as metastases-related lung cancer marker, 180
- as pulmonary adenocarcinoma marker, 176, 177
- Epithelium, thymic, 191
- ER-ID5 monoclonal antibody, 163, 197
- Estrogen receptor (ER)
  - as breast carcinoma marker, 20, 21
  - in lobular carcinoma, 222, 223, 231
  - in metastatic carcinoma, 183, 231
  - in mucinous (colloid) carcinoma, 224
- as carcinomatous meningitis marker, 281
- as endometrial serous carcinoma marker, 208–209
- as endometrial stromal sarcoma marker, 215
- as endometriosis marker, 204, 205
- as endometroid adenocarcinoma marker, 206, 207
- as leiomyosarcoma marker, 41
- as ovarian serous carcinoma marker, 208–209
- as pelvic adenocarcinoma marker, 196
- Ethanol-formalin mix, as fixative, 4
- F**
- Factor VIII-related antigen
  - as endothelial cell marker, 99
  - as Kaposi's sarcoma marker, 47
- Factor XIIIa, 32
- False-negative results, 7
- False-positive results, 7
- Female genital tract and breast pathology, 203–231
  - breast carcinoma/tumors
    - ductal, 218–219
    - fibroadenoma, 216–217
    - lobular, 218–219, 220–223
    - medullary, 226–227
    - metaplastic, 228–229
    - metastatic, 20–21, 162–163, 180–183, 228–231, 280–281
    - mucinous, 224–225
  - endometrial stromal sarcoma, 214–215
  - endometriosis, 204–205
  - recurrent endometrial adenocarcinoma, 206–207
  - recurrent leiomyosarcoma, 212–213
  - recurrent malignant mixed mesodermal tumor, 210–211
  - recurrent serous carcinoma of the ovary, 208–209
- $\alpha$ -Fetoprotein. *See* Alpha-fetoprotein
- Fibroadenoma, of the breast, 216–217
- Fibrous tumors, solitary pulmonary, 174–175
- Filter preparations, contraindication in immunocytochemistry, 3
- Fine-needle aspiration (FNA)
  - of adrenal tumors, 114
  - of adrenocortical hyperplasia/adenoma, 102
  - of anaplastic large cell lymphoma, 22
  - of benign smooth muscle neoplasm, 34
  - of breast carcinoma/tumors
    - of fibroadenoma of the breast, 216
    - of lobular breast carcinoma, 222
    - of lobular metastatic breast carcinoma, 230
    - of medullary breast carcinoma, 226
    - of metaplastic breast carcinoma, 228
    - of mucinous (colloid) breast carcinoma, 224
    - of bronchoalveolar carcinoma, 156
    - of desmoplastic small, round cell tumors, 198
    - of epitheloid gastrointestinal stromal tumor (GIST), 64
    - with excess blood, 3
    - of gastrointestinal stromal tumor (GIST), 62, 64
    - of granular cell tumor, 36
    - of hemorrhagic oral mucosal lesion, 46
    - of hepatocellular carcinoma, 88
    - of Kaposi's sarcoma, 46, 47
    - of large B-cell lymphoma, 16
    - of liver mass, 78, 86

- Fine-needle aspiration (FNA) (*cont.*)  
 of lung carcinoma, metastatic breast carcinoma-related, 162  
 of malignant mesothelioma, 170  
 of mediastinal B-cell lymphoma, 192  
 of mediastinal lymph node, 12  
 of medullary thyroid carcinoma, 138, 140  
 of metastatic adrenocortical carcinoma, 104  
 of metastatic Hurthle cell thyroid carcinoma, 138  
 of metastatic medullary thyroid carcinoma, 140  
 of metastatic seminoma, 24, 238  
 of nasal glioma, 276  
 of nerve sheath tumor, 30  
 of pancreatic islet cell tumor, 70, 72  
 of paravertebral soft mass, 270  
 of pelvic adnexal nodule, 204  
 of pheochromocytoma, 106, 108  
 of pulmonary adenocarcinoma, 154, 156, 158  
 of pulmonary carcinoid tumors, 166  
 of recurrent serous ovarian carcinoma, 208  
 of renal cell carcinoma, 248  
   sarcomatoid type, 250  
 of resected liver mass, 88  
 of retroperitoneal mass, 34, 44  
 of single liver nodule, 82, 90  
 of small-cell lung carcinoma, with focal squamous differentiation, 152  
 of soft-tissue plasmacytoma, 270  
 of thoracic soft-tissue mass, 36  
 of thymoma, 186, 188  
 of thymoma/thymic hyperplasia, 186  
 of yolk sac carcinoma, 242
- Fixation, of cytologic samples, 4  
 Formalin, buffered, as fixative, 4  
 Formol-acetone, as fixative, 4

**G**

- Gastric carcinoma, metastatic to cerebrospinal fluid, 278–279  
 Gastrointestinal stromal tumors (GIST), 62–63

- epitheloid, 64–65  
 Gastrointestinal tract pathology, 54–66  
   colonic adenocarcinoma, 56–57  
   metastatic, 58–59  
   gastrointestinal stromal tumor (GIST), 62–63  
   epitheloid, 64–65  
   poorly-differentiated gastric carcinoma, 54–55  
   signet-ring carcinoma, 60–61  
 Gene rearrangement studies, of B-cell lymphoma, 17  
 Genital system pathology  
   female. *See* Female genital tract and breast pathology  
   male. *See* Urinary and male genital system pathology  
 Germ cell tumors, testicular, 242–243  
 Glial fibrillary acidic protein (GFAP), as glioma marker, 277  
 Glioma, nasal, 276–277  
 Granular cell tumors, 8, 36–37  
 Granulomatous lymphadenitis, 260–261

**H**

- H-Caldesmon  
   as angiomyolipoma marker, 257  
   as gastrointestinal stromal tumor (GIST) marker, 63  
   as leiomyosarcoma marker, 40, 41  
   as nerve sheath tumor marker, 30, 31  
   as recurrent leiomyosarcoma marker, 212, 213  
   as smooth muscle neoplasm marker, 34, 35  
 Head and neck pathology, 117–141, 130–131  
   acinic cell carcinoma, 124–125  
   adenoid cystic carcinoma, 122–123  
   medullary thyroid carcinoma, 138–139  
   metastatic Hurthle cell carcinoma of the thyroid, 136–137  
   metastatic medullary thyroid carcinoma, 140–141



- myoepithelial neoplasm, 118–119
  - papillary thyroid carcinoma,
    - 128–129
    - metastatic, 134–135
    - poorly-differentiated, 130–131
    - poorly-differentiated, metastatic, 132–133
  - parathyroid hyperplasia, 126–127
  - Warthin's tumor, 120–121
  - Hemangioma, 98–99
  - Hepatocellular adenoma,
    - differentiated from
    - hepatocellular carcinoma, 82, 83
  - Hepatocellular antigen (HCA, HepParl), 90, 96
    - as hepatocellular carcinoma marker, 79, 80, 82, 84, 85
    - in poorly-differentiated carcinoma, 86
  - Hepatocellular carcinoma, 78–89, 82–83
    - with clear cells, 80–81
    - differentiated from
      - cholangiocarcinoma, 79, 90
      - hepatocellular adenoma, 82, 83
      - metastatic neuroendocrine carcinoma, 88–89
    - with fatty changes, 84–85
    - fibrolamellar, 82–83
    - hepatocellular antigen (HCA, HepParl) marker for, 79, 80, 82, 84, 85, 86
    - poorly-differentiated, 86–87
  - H&E stain preparations
    - of adrenal tumor, 110
    - of angiomyolipoma, 256
    - of colonic adenocarcinoma, 58
    - of colonic carcinoma pulmonary metastases, 184
    - of hepatocellular carcinoma, 78
    - of malignant B-cell hepatic lymphoma, 96
    - of malignant mesothelioma, 172
    - of metastases-related lung cancer, 180
    - of metastatic adrenocortical carcinoma, 104
    - of metastatic urothelial carcinoma, 234
    - of pulmonary adenocarcinoma, 178
    - of rhabdomyosarcoma, 42
    - of signet ring carcinoma, 60
  - Histiocytic reaction, differentiated
    - from signet-ring carcinoma, 61
  - Histiocytoma, malignant fibrous, 44–45
  - Histiolytic markers, contraindication
    - as granular cell tumor markers, 37
  - HLA-DR, as medullary breast carcinoma marker, 226, 227
  - HMB-45
    - as angiomyolipoma marker, 258
    - as malignant melanoma marker, 15, 94, 95
  - Hodgkin lymphoma, 268–269
  - Hurthle cell carcinoma, metastatic thyroid, 136–137
  - Hyperplasia
    - adrenocortical, 102–103
    - thymic, 186–187
- I**
- Immunocytochemistry (ICC)
    - evaluation of results in, 7–8
      - effect of background staining on, 7–8
      - false-negative results, 7
      - false-positive results, 7
    - procedures in, 4–5
    - technical considerations in, 3–5
  - Inhibin
    - as adrenocortical cell/tumor marker, 102–103
    - background staining for, 8
    - as metastatic adrenocortical carcinoma marker, 105
  - Insulin, as pancreatic islet cell tumor (insulinoma) marker, 74
  - Insulinoma, 74–75
  - Islet cell tumors, pancreatic, 70–71, 72–73, 74–75
  - Isopropyl alcohol, as fixative, 4
- K**
- Kaposi's sarcoma, 46–47
  - Kappa light chain, 270, 271
  - KIT, as seminoma marker, 239

**L**

- Lambda light chain, 270
- Leiomyosarcoma, 40–41  
 differentiated from gastrointestinal stromal tumors (GIST), 63  
 recurrent, 212–213
- Light chain immunoglobulins  
 kappa, 270, 271  
 lambda, 270
- Lipogranuloma, 262–263
- Liver cancer, 78–99  
 adenocarcinoma, 90–93  
 with fatty changes, misdiagnosis of, 85  
 hepatocellular carcinoma, 78–89  
 metastatic malignant B-cell lymphoma-related, 96–97  
 metastatic malignant melanoma-related, 94–95
- Lung cancer  
 adenocarcinoma, 58–59, 150–151, 154–155, 176–177  
 bronchioalveolar, 156–157  
 CDX-2 expression in, 58–59  
 differentiated from malignant mesothelioma, 172–173, 178–179  
 differentiated from metastatic colonic adenocarcinoma, 158–159  
 differentiated from primary thyroid carcinoma, 134–135  
 differentiated from reactive mesothelial cells, 176–177  
 differentiated from squamous cell carcinoma, 149, 150–151  
 metastatic to the adrenal glands, 112–113  
 carcinoid, 164–167  
 malignant mesothelioma, 170–173, 174–175, 209  
 metastatic, differentiated from  
 adrenal tumor, 111, 112–113  
 metastatic breast cancer-related, 180–183  
 metastatic colonic adenocarcinoma-related, 184–185  
 metastatic renal cell carcinoma-related, 248–249  
 reactive mesothelial cells, 176–177  
 small-cell, 144–147  
 differentiated from basaloid squamous cell carcinoma, 153  
 with focal squamous differentiation, 152–153  
 solitary fibrous tumor, 174–175  
 squamous cell, 148–149
- Lung pathology, 143–167. *See also*  
 Lung cancer
- Lymphadenitis, granulomatous, 260–261
- Lymphocytes, differentiated from epithelial cells, 19
- Lymphoma  
 anaplastic large-cell, 22–23  
 differentiated from Reed-Sternberg cells, 269
- B-cell  
 large, 16–17  
 large-cell malignant, 266–267  
 malignant hepatic, 96–97  
 mediastinal, 192–193  
 Hodgkin's, 268–269
- Lymphoreticular system pathology, 259–271  
 granulomatous lymphadenitis, 260–261  
 Hodgkin's lymphoma, 268–269  
 lipogranuloma, 262–263  
 malignant B-cell lymphoma, 266–267  
 metastatic squamous cell carcinoma, 264–265  
 soft-tissue plasmacytoma (myeloma), 270–271
- M**
- Markers. *See also specific markers*  
 selection of, 6
- Mediastinal pathology. *See* Pleural and mediastinal pathology
- Melan A (Mart 1), as adrenocortical cell/tumor marker, 103
- Melanoma, malignant, 14–15  
 HMB-45 protein expression in, 94, 95  
 metastatic to  
 the adrenal glands, 114–115  
 the liver, 94–95

- spindle cell varieties of, 15
  - S100 protein expression in, 95
  - Meningioma, 274–275
  - Meningitis, carcinomatous, 278–281
  - Mesothelial cells
    - positive for calretinin, 179
    - reactive, 176–177
  - Mesothelioma, malignant, 170–173, 209
    - desmoplastic, 171, 175
    - differentiated from pulmonary adenocarcinoma, 173
    - sarcomatoid, 175
      - differentiated from solitary fibrous tumors, 174–175
    - spindle-cell (sarcomatoid), 171
  - Mixed germ cell tumors, seminoma as component of, 25
  - Monoclonal antibody Er-Id5, 197
  - Monoclonality, in plasma cell populations, 271
  - Mucinous carcinoma, metastatic, 262
  - Muscle-specific actin, contraindication as recurrent leiomyosarcoma marker, 213
  - Myeloma, 270–271
  - Myoepithelial cells, p63 expression in, 216, 217
  - Myoepithelial neoplasm, 118–119
  - Myogenin, as rhabdomyosarcoma marker, 43
- N**
- Nerve sheath tumors, 30–31
  - Nervous system pathology, 273–281
    - carcinomatous meningitis, 278–281
    - meningioma, 274–275
    - nasal glioma, 276–277
  - Neuroblastoma, differentiated from Wilms' tumor, 252–253
  - Neuroblastoma antigen (NB84), 253
  - Neuroendocrine carcinoma/tumors
    - differentiated from pulmonary carcinoid tumors, 166–167
    - metastatic, differentiated from hepatocellular carcinoma, 88–89
  - Neurofibroma, 28–29
  - Neurofibromatosis, 28
- Neuronal enolase, as pancreatic solid and papillary tumor marker, 76, 77
  - Nodules
    - pleural fibrotic, 174–175
    - thyroid, 126, 128, 130
  - Nodules, single hepatic, 82, 84
  - Nose, glioma of, 276–277
- O**
- Omental mass, 200–201
  - Ovarian carcinoma
    - mucinous, 58–59
    - recurrent serous, 208–209
- P**
- Pancreatic cancer, 67–77
    - adenocarcinoma, 68–69, 91
    - CK7 expression in, 79
    - ductal, differentiated from islet cell tumors, 73
      - with enlarged periportal lymph node, 262
    - islet cell tumors, 70–71, 72–73
      - insulinoma, 74–75
    - solid and papillary tumors, 76–77
  - Pancreatic islet cell tumors, 70–71, 72–73
    - insulinoma, 74–75
  - Pancytokeratin, 13
  - Papanicolaou (Pap)-stained smears, 9
    - of acinic cell carcinoma, 124
    - of adenoid cystic carcinoma, 122
    - of adrenal tumors, 114
    - of adrenocortical hyperplasia/adenoma, 102
    - of anaplastic large cell lymphoma, 22
    - of breast ductal carcinoma, 218
    - of carcinomatous meningitis, 280
    - of cavernous hemangioma, 98
    - of cervical lymph node, 14
    - of cholangiocarcinoma, 90
    - of chondroid lesions, 48
    - of chordoma, 50
    - of colonic adenocarcinoma, 56
    - of dermatofibrosarcoma protuberans, 32

- Papanicolaou (Pap)-stained smears  
(*cont.*)
- of desmoplastic small, round cell tumors, 198
  - of endometriosis, 204
  - of epitheloid gastrointestinal stromal tumor (GIST), 64
  - of exophytic urinary bladder tumor, 236
  - of fibroadenoma, 216
  - of gastrointestinal stromal tumor (GIST), 62
  - of granular cell tumor, 36
  - of granulomatous lymphadenitis, 260
  - of hepatic mass, 92
  - of hepatocellular carcinoma, 84
    - adenocarcinoma, 92
    - with clear cells, 80
    - fibrolamellar, 82
    - poorly-differentiated, 86
  - of Hodgkin's lymphoma, 268
  - immunocytochemistry performance on, 3
  - of leiomyosarcoma, 40
  - of lipogranuloma, 262
  - of lung carcinoma, metastatic breast carcinoma-related, 162
  - of malignant fibrous histiocytoma, 44
  - of malignant mesothelioma, 170
  - of mediastinal B-cell lymphoma, 192
  - of medullary thyroid carcinoma, 138
  - of metastatic breast carcinoma, 20
  - of metastatic seminoma, 24, 238
  - of metastatic squamous cell carcinoma, 264
  - of nasal glioma, 276
  - of nerve sheath tumor, 30
  - of neurofibroma, 28
  - of pancreatic adenocarcinoma, 68
  - of pancreatic islet cell tumors, 70, 72
    - insulinomas, 74
  - of pancreatic solid and papillary tumors, 76
  - of papillary thyroid carcinoma, 128
  - of papillary urothelial carcinoma, 236
  - of parotid mass, 124
    - of pheochromocytoma, 106, 108
    - of poorly-differentiated carcinoma, 18
    - of poorly-differentiated gastric carcinoma, 54
    - of poorly-differentiated papillary thyroid carcinoma, 130, 132, 134
    - of prostate gland carcinosarcoma, 244
    - of pulmonary adenocarcinoma, 150, 176
    - of pulmonary carcinoid tumors, 166
    - of pulmonary squamous cell carcinoma, 148
    - of recurrent endometrial adenocarcinoma, 206
    - of recurrent leiomyosarcoma, 212
    - of renal cell carcinoma, 248
      - sarcomatoid type, 250
    - of retroperitoneal mass, 16
    - of sacroiliac lesion, 48
    - of small-cell lung carcinoma, 12, 144, 146
      - with focal squamous differentiation, 152
    - of spindle-cell neoplasm, 174
    - of subcapsular cystic liver mass, 98
    - of synovial sarcoma, 38
    - of testicular embryonal carcinoma, 240
    - of thymic hyperplasia, 186
    - of thymoma, 186, 188
    - of thyroid nodule, 126, 128, 130
    - of vaginal mass, 206
    - of Warthin's tumor, 120–121
    - of Wilms' tumor, 254
    - of yolk sac carcinoma, 242
  - Parathyroid adenoma, 126–127
  - Parathyroid hormone, as parathyroid neoplasm marker, 126, 127
  - Parathyroid hyperplasia, 126–127
  - Pheochromocytoma, 107–109
  - Pia-arachnoid mesothelial cells, 279
  - Placental alkaline phosphatase (PLAP), as seminoma marker, 24, 25, 238, 239
  - Plasma cell populations, monoclonality in, 271
  - Plasmacytoma, soft-tissue, 270–271

- Pleomorphic cells  
 isolated, 14  
 in metaplastic breast carcinoma, 228
- Pleomorphic sarcoma, 44–45
- Pleural and mediastinal pathology,  
 169–193. *See also* Lung cancer  
 adenocarcinoma, 176–179  
 metastatic breast cancer, 180–183  
 metastatic colonic adenocarcinoma,  
 184–185  
 solitary fibrous tumor, 174–175  
 thymoma, 188–189  
 mediastinal large B cell  
 lymphoma, 192–193  
 spindle-cell, 190–191  
 thymoma/thymic hyperplasia, 186–187
- Pleural fluid, cytocentrifuge  
 preparation of, 176
- Pleural nodules, fibrotic, 174–175
- Progesterone receptor (PR)  
 as leiomyosarcoma marker, 41  
 as meningioma marker, 275
- Prostate carcinosarcoma, 244–245
- Prostatectomy specimen, 244–245
- Prostatic-specific antigen (PSA), 245
- Pseudomyxoma peritonei, 61
- p63  
 as adenoid cystic carcinoma marker,  
 122, 123  
 expression in normal thymus, 191  
 as fibroadenoma marker, 216, 217  
 as metaplastic breast carcinoma  
 marker, 228, 229  
 as myoepithelial neoplasm marker,  
 118, 119  
 as pulmonary squamous cell  
 carcinoma marker, 148  
 as small-cell lung carcinoma, 152  
 as squamous cell carcinoma marker,  
 119, 264  
 as thymoma marker, 190, 191  
 as transitional cell carcinoma  
 marker, 119  
 as urothelial carcinoma marker, 234,  
 236, 237
- R**
- Reed-Sternberg cells, 269
- Renal cell carcinoma, 246–247  
 clear-cell, 249  
 metastatic, 249  
 sarcomatoid type, 250–251
- Renal cell carcinoma antigen, 248, 249
- Rhabdomyoblasts, 211
- Rhabdomyosarcoma, 42–43
- S**
- Saccomonno's solution, 3
- Salivary amylase, 124, 125
- Salivary gland carcinoma  
 acinic cell, 124–125  
 metastatic oncocytic, 136–137
- Sarcoma  
 endometrial stromal, 213–214  
 Kaposi's, 46–47  
 pleomorphic, 44–45  
 synovial, 38–39
- Schwannoma, 30–31  
 differentiated from meningioma,  
 274–275
- Seminoma, 22  
 metastatic, 24–25, 238–239  
 as mixed germ cell tumor  
 component, 25
- Serosal fluids, cytocentrifugation of, 3
- Signet-ring carcinoma, 60–61  
 mucin-producing, misdiagnosed, 85
- 6F11, 163
- Small-cell lung carcinoma  
 differentiated from basaloid  
 squamous cell carcinoma, 153  
 with focal squamous differentiation,  
 152–153
- Small round cell tumor, desmoplastic,  
 198–199
- Smooth muscle neoplasm, benign,  
 34–35
- Soft-palate nodules, 122–123
- Soft-tissue tumors, 27–51  
 benign smooth muscle neoplasm,  
 34–35  
 chondroid neoplasm, 48–49  
 chordoma, 50–51  
 dermatofibrosarcoma protuberans,  
 32–33  
 differentiated from spindle cell  
 thymoma, 190–191  
 granular cell tumor, 36–37

Soft-tissue tumors (*cont.*)

- Kaposi's sarcoma, 46–47
  - leiomyosarcoma, 40–41
  - malignant fibrous histiocyoma, 44–45
  - myxoid chondrosarcoma, 48–49
  - neurofibroma, 28–29
  - pleomorphic sarcoma, 44–45
  - rhabdomyosarcoma, 42–43
  - Schwannoma, 30–31
  - synovial sarcoma, 38–39
- S100 protein
- as chondroid neoplasm marker, 48, 49
  - as chordoma marker, 51
  - cytoplasmic staining for, 14
  - as granular cell tumor marker, 36
    - background reaction for, 8
  - as hepatic B-cell lymphoma marker, 97
  - as malignant melanoma marker, 14–15, 95, 114
  - as meningioma marker, 275
  - as metastatic malignant melanoma marker, 114
  - as neurofibroma marker, 28, 29
  - nuclear staining for, 14, 15
  - true positive staining for, 15
- Spindle cell(s)
- in endometrial stromal sarcoma, 214
  - in endometriosis, 204, 205
  - in Kaposi's sarcoma, 46
  - large, in leiomyosarcoma, 40
  - in papillary urothelial carcinoma, 236, 237
  - pleomorphic, 140
  - in recurrent leiomyosarcoma, 212
- Spindle-cell carcinoma/neoplasm, 32–33
- differentiated from synovial sarcoma, 39
  - melanoma, 15
  - pulmonary, with solitary fibrous tumor, 174–175
  - thymoma, 190–191
- Squamous cell carcinoma
- differentiated from poorly-differentiated papillary thyroid carcinoma, 132

- metastatic, 264–265
  - pulmonary
    - differentiated from
      - adenocarcinoma, 149, 150–151, 156–157
      - poorly-differentiated, 148–149
- Synaptophysin
- contraindication to, 107
  - as lung carcinoma marker, 145
  - as neuroendocrine tumor marker, 71
- Synovial sarcoma, 38–39

**T**

- Target cells, identification of, 5
- T cells
- in thymic hyperplasia, 189
  - in thymomas, 189
- Testicular carcinoma
- embryonal metastatic, 240–241
  - endodermal sinus tumor, 242–243
- Thymic hyperplasia, 186–187
- Thymoma, 186–189
- cytokeratin staining pattern of, 19
  - spindle-cell, 190–191
- Thymus, normal, p63 expression in, 191
- Thyroglobulin
- background reaction for, 8
  - as papillary thyroid carcinoma marker, 128, 129, 130, 131, 132, 134
- Thyroid carcinoma
- anaplastic, 131
  - C-tumors, TTF-1 expression in, 135
  - follicular, TTF-1 expression in, 135
  - medullary, 138–139
    - differentiated from parathyroid lesions, 126–127
    - metastatic, 140–141
    - misclassification of, 127
  - papillary, 128–129
    - poorly-differentiated, 130–133
    - poorly-differentiated metastatic, 132–133
- Transitional cell carcinoma
- p63 marker for, 119
  - of the urinary tract
    - metastatic, 234–235
    - p63 expression in, 234, 235

**TTF-1**

- as bronchoalveolar carcinoma marker, 156, 157
- as metastatic lung cancer marker, 110, 112
- as pulmonary adenocarcinoma marker, 149, 150, 154, 173, 178
- as thyroid carcinoma marker, 135, 136, 137

**U****Undifferentiated neoplasms, 11–25**

- anaplastic large cell lymphoma, 22–23
- large B-cell lymphoma, 16–17
- malignant melanoma, 14–15
- metastatic breast carcinoma, 20–21
- metastatic seminoma, 24–25
- poorly-differentiated carcinoma, 18–19
- small cell carcinoma, 12–13

**Upper gastrointestinal**

adenocarcinoma, 91

**Urinary and male genital system**

- pathology, 233–258
- metastatic embryonal carcinoma, 240–241
- metastatic seminoma, 238–239
- metastatic urothelial carcinoma, 234–235

papillary urothelial carcinoma, 236–237

prostate gland carcinoma, 244–245

renal cell carcinoma, 246–247

metastatic, 248–249

sarcomatoid type, 250–251

Wilms' tumor, 252–253

metastatic malignant

angiomyolipoma, 256–258

recurrent, 254–255

yolk sac carcinoma, 242–243

**Urothelial carcinoma**

metastatic, 234–235

papillary, 236–237

**Uterine cancer, recurrent malignant**

mixed mesodermal, 210–211

**W**

Warthin's tumor, 120–121

Wilms tumor, 252–253

recurrent, 254–255

**Wilms tumor protein (WT-1)**

as endometrial serous carcinoma marker, 208–209

as ovarian serous carcinoma marker, 208–209

as Wilm's tumor marker, 252, 253

Wright-Giemsa stain, 278

**Y**

Yolk sac carcinoma, 242–243