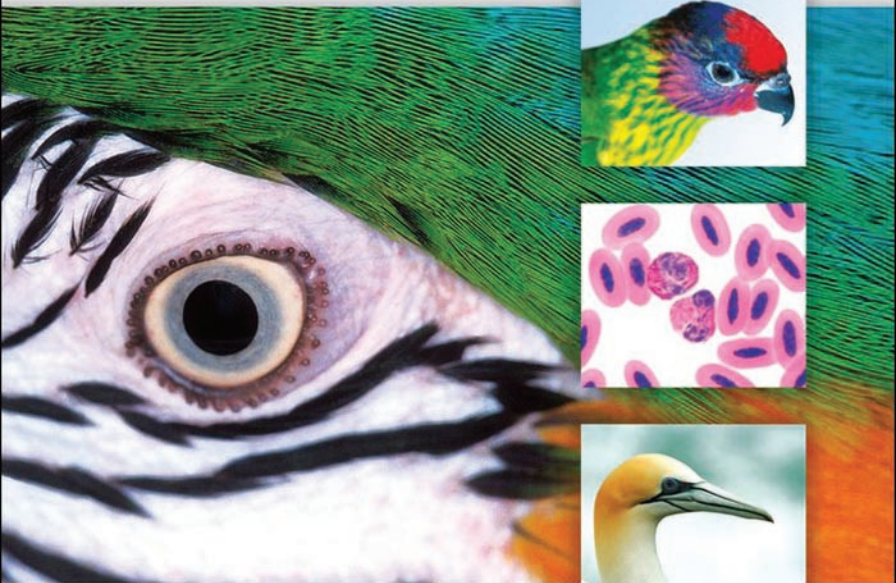

ATLAS OF CLINICAL AVIAN HEMATOLOGY

PHILLIP CLARK, WAYNE BOARDMAN AND SHANE RAIDAL



 WILEY-BLACKWELL

Atlas of Clinical Avian Hematology

Disclaimer

The information on this publication comprises general statements based on scientific research. The reader is advised and needs to be aware that such information may be incomplete or unable to be used in any specific situation. No reliance or actions should be made on information contained in this publication without seeking prior expert professional, scientific and technical advice. In addition, medical knowledge is constantly changing, particularly with regard to procedures, equipment and treatment. While all appropriate care has been

taken to verify the accuracy of the content at the time of publication, readers are advised to confirm that the information complies with the latest knowledge and best standards of practice and safety. To the extent permitted by law, the publishers and authors exclude all liability to any person for any consequences, including but not limited to damages, costs, expenses and any other compensation, arising directly or indirectly from using this publication (in part or whole) or any information or material contained in it.

Atlas of Clinical Avian Hematology

Phillip Clark
Wayne S. J. Boardman
Shane R. Raidal

This edition first published 2009
© 2009 by Phillip Clark, Wayne Boardman and Shane Raidal

Blackwell Publishing was acquired by John Wiley & Sons in February 2007. Blackwell's publishing programme has been merged with Wiley's global Scientific, Technical, and Medical business to form Wiley-Blackwell.

Registered office

John Wiley & Sons Ltd, The Atrium, Southern Gate, Chichester, West Sussex, PO19 8SQ, United Kingdom

Editorial offices

9600 Garsington Road, Oxford, OX4 2DQ, United Kingdom
2121 State Avenue, Ames, Iowa 50014-8300, USA

For details of our global editorial offices, for customer services and for information about how to apply for permission to reuse the copyright material in this book please see our website at www.wiley.com/wiley-blackwell.

The right of the author to be identified as the author of this work has been asserted in accordance with the Copyright, Designs and Patents Act 1988.

All rights reserved. No part of this publication may be reproduced, stored in a retrieval system, or transmitted, in any form or by any means, electronic, mechanical, photocopying, recording or otherwise, except as permitted by the UK Copyright, Designs and Patents Act 1988, without the prior permission of the publisher.

Wiley also publishes its books in a variety of electronic formats. Some content that appears in print may not be available in electronic books.

Designations used by companies to distinguish their products are often claimed as trademarks. All brand names and product names used in this book are trade names, service marks, trademarks or registered trademarks of their respective owners. The publisher is not associated with any product or vendor mentioned in this book. This publication is designed to provide accurate and authoritative information in regard to the subject matter covered. It is sold on the understanding that the publisher is not engaged in rendering professional services. If professional advice or other expert assistance is required, the services of a competent professional should be sought.

Library of Congress Cataloging-in-Publication Data

Clark, Phillip, 1966–

Atlas of clinical avian hematology / Phillip Clark, Wayne S.J. Boardman, Shane Raidal.
p. cm.

Includes bibliographical references and index.

ISBN 978-1-4051-9248-4 (hardback : alk. paper) 1. Birds–Diseases–Diagnosis. 2. Veterinary hematology–Atlases. I. Boardman, Wayne. II. Raidal, Shane. III. Title.

SF994.C53 2009
636.5089'615–dc22

2008047432

A catalogue record for this book is available from the British Library.

Set in 10.5/12.5 pt Sabon by SNP Best-set Typesetter Ltd., Hong Kong
Printed in Singapore

Contents

<i>Dedication</i>	vii	Leukocytes	40
<i>Authors</i>	viii	Thrombocytes	49
<i>Foreword</i>	ix	Hematopoiesis	51
<i>Preface</i>	xi		
<i>Acknowledgements</i>	xiii		
1 Collection and handling of blood samples	1	3 Particular hematological characteristics of birds	53
Introduction	1	Introduction	53
Taxonomy	2	Anseriformes (ducks, geese and swans)	54
Safety aspects	5	Apodiiformes (swifts and hummingbirds)	57
Effects of anesthesia on the hematological characteristics of birds	5	Caprimulgiformes (frogmouths, goatsuckers and owlet-nightjars)	57
Volume of blood	6	Charadriiformes (gulls and shorebirds)	58
General aspects of collection of blood from birds	6	Ciconiiformes (herons, ibis and storks)	60
Sites for vascular access in birds	7	Coliiformes (mousebirds)	61
Anticoagulants	15	Columbiformes (pigeons and doves)	62
Blood films	16	Coraciiformes (kingfishers, bee-eaters, hornbills, motmots, rollers and todies)	64
Post-collection artifacts	23	Cuculiformes (cuckoos, roadrunners and turacos)	66
Measurement of hematological cells	27	Falconiformes (falcons, hawks and eagles)	66
2 General hematological characteristics of birds	33	Galliformes (grouse, megapodes, curassows, pheasant, partridge, quail and turkey)	71
Introduction	33		
Erythrocytes	33		

Gaviiformes (divers and loons)	74	4 Physiological and pathological influences on the hematological characteristics of birds	97
Gruiformes (bustards, button quail, coots and cranes)	74	Introduction	97
Opisthocomiformes (hoatzin)	77	Physiological effects on the hematological characteristics of birds	97
Passeriformes (song birds)	77	Pathological effects on the hematological characteristics of birds	100
Pelecaniformes (cormorants, frigate birds, gannets, pelicans and tropicbirds)	81	5 Hemoparasites of birds	125
Phoenicopteriformes (flamingos)	82	Introduction	125
Piciformes (toucans and woodpeckers)	83	Detection of hemoparasites	127
Podicipediformes (grebes)	85	Morphology of hemoparasites	129
Procellariiformes (albatrosses, fulmars, petrels and shearwaters)	85	<i>References</i>	139
Psittaciformes (cockatoos, lorries, macaws and parrots)	86	<i>Species list: alphabetically by common name</i>	163
Sphenisciformes (penguins)	91	<i>Species list: by order</i>	168
Strigiformes (barn owls and “typical” owls)	92	<i>Glossary</i>	173
Struthioniformes (cassowaries, emus, kiwis, ostriches and rheas)	94	<i>Index</i>	177
Tinamiformes (tinamous)	96		
Trogoniformes (trogons and quetzals)	96		

Dedication

This book is dedicated to our children:

Michael, Lachlan, Cameron & Lauren Clark
Jamie Boardman
Lachlan & Jackson Raidal

Authors

Phillip Clark BVSc (Hons), PhD (*Melb*), DVSc (*Murd*), MACVSc, Diplomate ACVP, Diplomate ECVCP
P. O. Box 288, Daw Park, S. A. 5041, Australia.

Shane R. Raidal BVSc, PhD (*Syd*), FACVSc
Associate Professor in Veterinary Pathobiology, School of Agricultural and Veterinary Sciences, Charles Sturt University, Wagga Wagga, N.S.W. 2678, Australia.

Wayne S. J. Boardman BVetMed (*Lond*),
MRCVS, MACVSc
Head of Veterinary Conservation Programs,
Zoos South Australia, Adelaide, S.A. 5000,
Australia.

Foreword

This planet is home to a wide range of species of birds, many of which are wild, others captive, and a smaller number domesticated. Regardless of their habitat, there are occasions when, through illness or injury, they are seen by veterinarians. In such circumstances, the analysis of their blood can assume a matter of great significance. Until the availability of this book, the information on avian hematology was fragmented and not easily accessible, nor was it assembled in an orderly manner.

This volume, by three experts, provides such a logical compilation, which is both extensive and yet organised in such a manner that it takes the reader from the collection of a blood sample through a descriptive analysis of the hematological characteristics of avian species in general. It also assists the reader in attributing specific characteristics to some orders and explores the patho-physiological characteristics observed in response to disease, including a chapter on hemoparasites.

While the atlas is of great value in the pursuit of diagnostic information, it will also be of benefit to a wider readership, such as medical

scientists, zoologists, comparative hematologists, ornithologists and evolutionary biologists. Its excellent illustrations assist the reader in expanding their understanding of the complex processes involved in producing blood and maintaining its integrity and health. Given that species' differences can affect the morphological appearance of blood cells, which can also be perturbed by disease processes, the layout of the illustrations in this book is such that the reader is presented with the relevant information to guide them through these issues.

At a time when climatic changes are occurring, causing stress and altered migratory patterns, and shifts in the niches occupied by species are emerging, an atlas covering the global avian species will be of value.

The authors are to be congratulated on a fine volume that will be of value to many who have dealings with "our feathered friends". I commend the volume to you as a fine authoritative volume.

*Emeritus Professor David de Kretser
Governor of Victoria*

Preface

Many species of birds are maintained by aviculturalists, zoological institutions, Governments and other organizations for captive breeding programs, research and to educate and inspire those that have the opportunity to view them.

The task of maintaining the health of the many species of birds requires constant attention and great effort. Many birds do not exhibit clinical signs until late in a disease process. Consequently, diagnostic procedures, such as hematology, may provide valuable insight into the health status of an individual before clinical signs become apparent, and allow early intervention.

Interpretation of hematological results is most effective when the characteristics of a particular species, both in health and in response to disease are known. Unfortunately,

these basic facts are not known for the majority of avian species, necessitating extrapolation from knowledge of the characteristics of domestic species of birds and relatively few “milestone” studies undertaken on “important” or available species of birds.

This book aims to add to the available information by illustrating the general hematological characteristics of birds, the hematological characteristics of selected species of birds in health and the hematological response to disease by birds, using clinical cases from many different species with a range of clinical disorders.

In this way, further fragments of information are organized to increase our understanding of the hematological response to disease that may be encountered in these fascinating animals and further ensure their health.

Acknowledgements

We are grateful to the many people whom have assisted us in our endeavors that led to the production of this atlas. We would particularly like to thank the staff of the clinical pathology laboratories of Massey, Michigan State, Murdoch and Charles Sturt universities for their assistance in analysing blood samples from clinical cases. We are also extremely grateful to the staff of the Veterinary Department of the Zoological Society London for collecting many blood samples to assist this project and the faculty and staff of the clinical pathology laboratory of the Royal Veterinary College, University of London, for preparing many blood films.

We would like to thank the many individuals that have contributed material, knowledge, encouragement, or constructive criticism that have improved the quality of this book, including: Rachel Wicks, Pat Shearer, Nicolai Bonne, Tim Hyndman, Margaret Sharp, Ken Richardson, Peter Fallon, Trish Flemming, Todd McWhorter, Kathryn Napier, Sue Jaensch, David Schulz, Peter Holz, Padraig Duignan, Richard Norman, Matthew Johnston, Jonathon Cracknell and Claire Cunningham.

We are extremely grateful to Carmel Clark for proof reading the manuscript.

Collection and handling of blood samples

1

INTRODUCTION

The class Aves contains more than 9,000 extant species of birds in 199 families. They have evolved a wide range of morphological, physiological and functional adaptations that have allowed them to fill every ecological niche imaginable. **Hematology**, the study of blood, has provided insight into some of the physiological characteristics of birds and how they differ from mammals, the latter being the subject of the overwhelming majority of studies of “comparative” hematology. Interestingly, the total number of species of birds is approximately twice the number of species of mammals; consequently, many hematological differences within the class Aves should be expected (as well as differences in the hematological characteristics between birds and mammals and other classes of vertebrates).

However, the hematological characteristics, in health, have not been documented for the vast majority of bird species. Furthermore, in most instances, the impact that the interaction

of physiological factors (such as age, sex, reproduction, season, nutrition, habitat and migration) and pathological factors (such as infectious disease) may have upon the hematological characteristics of birds, has not been fully resolved. Hematology has an important role in the assessment of the health of birds. Many birds do not express clinical signs until late in a disease process and the signs that they do exhibit may be subtle and non-specific. Consequently, the use of hematological assays may aid in the early recognition of disease, thus facilitating the best opportunity for management and therapy to resolve the process. Furthermore hematology may, by characterizing the type of response, aid in the determination of the inciting etiology and allow institution of targeted therapy.

The hematological response to disease is complex and will depend on the inciting cause, magnitude and duration of the disease process, the bird’s intrinsic hematological characteristics and its ability to respond to a particular challenge.

The accurate interpretation of hematological data is facilitated by knowledge of

the hematological characteristics of healthy members of the species and how those characteristics change in response to a particular disease. Unfortunately, for most species of birds, neither their hematological characteristics in health nor their hematological response to disease have been documented. Consequently, the nuances in hematological characteristics exhibited in response to disease by a particular bird, may be difficult to recognize.

This atlas of clinical avian hematology provides examples of the hematological response to disease, with an emphasis on the morphology of hematological cells, in a wide range of non-domestic bird species. We consider the assessment of the morphology of hematological cells, both to ensure the accurate classification of those cells and to identify the presence of any morphological atypia, an extremely important component of the analysis of avian blood samples. The latter is particularly important because, as previously mentioned, of the uncertainty in the applicability of available reference intervals to any specific bird.

TAXONOMY

For the purposes of this book, we have undertaken to examine the hematological characteristics of birds within each order of the Aves. As differing authorities have conflicting classification systems, we have adopted the classification used in the “*Handbook of Birds of the World*” (del Hoyo et al. 1992). This is outlined in Table 1.1. Consequently, the ensuing sections that describe the collection of blood and the morphological characteristics of hematological cells are ordered so that, wherever possible, material from significant and representative species of each order has been included. Unfortunately, due to limitations in the material available it was not possible to describe the hematological characteristics of birds within all of the orders. Furthermore, we recognize that there may be distinct differences in the hematological characteristics of birds between species of birds placed within the same order, family or even the same genus. We hope that, in time, studies of individual species will document the nuances in the hematological characteristics of birds.

Table 1.1 Classifications of orders with the Aves. Adapted from “*Handbook of the Birds of the World*” (1992–2009).

Order	Family	Common names
Anseriformes	Anhimidae	Screamers
	Anatidae	Ducks, geese, swans
Apodiformes	Apodidae	Swifts
	Hemiprocnidae	Tree-swifts
	Trochilidae	Hummingbirds
Caprimulgiformes	Steatornithidae	Oilbird
	Podargidae	Frogmouths
	Nyctibiidae	Potoos
	Aegothelidae	Owlet-nightjars
	Caprimulgidae	Nightjars

(continued)

Table 1.1 (continued)

Order	Family	Common names
Charadriiformes	Jacaniidae	Jacanas
	Rostratulidae	Painted-snipe
	Dromadidae	Crab plover
	Haematopodidae	Oystercatcher
	Ibidorhynchidae	Ibisbill
	Recurvirostridae	Avocets, stilts
	Burhinidae	Thick-knees
	Glareolidae	Couriers, pratincoles
	Charadriidae	Plovers
	Scolopacidae	Sandpipers, snipe
	Thinocoridae	Seedsnipe
	Chionidae	Sheathbills
	Stercorariidae	Skuas
	Laridae	Gulls, terns
	Rynchopidae	Skimmers
	Alicidae	Auks
Ciconiiformes	Ardeidae	Hérons
	Scopidae	Hamerkop
	Ciconiidae	Storks
	Balaenicipitidae	Shoebills
	Threskiornithidae	Ibises, spoonbills
Coliiformes	Coliidae	Mousebirds
Columbiformes	Pteroclididae	Sandgrouse
	Columbidae	Pigeons, doves
Coraciiformes	Alcedinidae	Kingfishers
	Trogonidae	Todies
	Momotidae	Motmots
	Meropidae	Bee-eaters
	Coraciidae	Rollers
	Brachypteraciidae	Ground-rollers
	Leptosomatidae	Cuckoo-rollers
	Upupidae	Hoopoe
	Phoeniculidae	Woodhoopoes
	Bucerotidae	Hornbills
	Cuculiformes	Musophagidae
Cuculidae		Cuckoos
Falconiformes	Cathartidae	New world vultures
	Pandionidae	Osprey
	Accipitridae	Hawks, eagles
	Sagittariidae	Secretary bird
	Falconidae	Caracaras, falcons
Galliformes	Megapodiidae	Megapodes
	Meleagridae	Turkeys
	Odontophoridae	New world quail
	Cracidae	Guans, chachalacas, curassows
	Phasianidae	Pheasants, grouse
	Numidae	Guinea fowl

(continued)

Table 1.1 (continued)

Order	Family	Common names
Gaviiformes	Gaviidae	Divers
Gruiformes	Mesitornithidae	Mesites
	Turnicidae	Button quail
	Pedionomidae	Plains-wander
	Gruidae	Cranes
	Aramidae	Limpkin
	Psophiidae	Trumpeters
	Rallidae	Rails, coots
	Heliornithidae	Finfoots
	Rhynchotidae	Kagu
	Eurypigidae	Sunbittern
	Cariamidae	Seriemas
	Otididae	Bustards
Opisthocomiformes	Opisthocomidae	Hoatzin
Passeriformes	Six sub-orders (91 families)	Song birds
Pelecaniformes	Phaethontidae	Tropic birds
	Pelecanidae	Pelicans
	Sulidae	Gannets, boobies
	Phalacrocoracidae	Cormorants
	Anhingidae	Darters
	Fregatidae	Frigatebirds
Phoenicopteriformes	Phoenicopteridae	Flamingos
Piciformes	Galbulidae	Jacamars
	Bucconidae	Puffbirds
	Capitonidae	Barbets
	Indicatoridae	Honeyguides
	Rhamphastidae	Toucans
	Picidae	Woodpeckers
Podicipediformes	Podicipedidae	Grebes
Procellariiformes	Diomedeididae	Albatross
	Procellariidae	Petrels, shearwaters
	Hydrobatidae	Storm-petrels
	Pelecanoididae	Diving-petrels
Psittaciformes	Loriidae	Lories, lorikeets
	Cacatuidae	Cockatoos
	Psittacidae	Parrots
Sphenisciformes	Spheniscidae	Penguins
Strigiformes	Tytonidae	Barn owls
	Strigidae	Typical owls
Struthioniformes	Struthionidae	Ostrich
	Rheidae	Rheas
	Casuaridae	Cassowaries
	Dromaiidae	Emu
	Apterygidae	Kiwis
Tinamiformes	Tinamidae	Tinamous
Trogoniformes	Trogonidae	Trogons

SAFETY ASPECTS

Handlers of birds need to be aware of the defence mechanisms that an individual bird species may possess as well as the potential zoonotic diseases that birds may be excreting. Sharp beaks, talons and claws have the potential to inflict serious injury to anyone that approaches or attempts to capture and restrain birds for blood collection. Members of the Struthioniformes are large birds that can kick violently and cause significant injury with their claws. Psittaciformes have powerful beaks that can cause deep lacerations and crush injuries to fingers. Others with sharp straight beaks such as cranes, darters and bustards are renowned for selectively targeting the eyes of their captors to cause injury. Face shields or protective eyewear must be worn by all people in the close vicinity of such birds when they are being captured, handled and restrained. Protective gloves should be worn by handlers of birds that are potentially excreting zoonotic pathogens such *Chlamydophila psittaci*. This should also be done to protect subsequent birds if more than one is to be handled, with gloves changed between birds each time.

Restraint of birds to facilitate collection of blood samples

The amount of restraint that is required to safely collect a blood sample is dependent on the size of the bird, its capacity to inflict an injury, its familiarity with humans and the skills of the phlebotomist. For well-trained, humanized or human-imprinted birds it is often possible to collect a blood sample from the jugular vein with a minimal amount of restraint by using an approach that simulates allopreening of the head and neck region. Individual birds can be easily trained to not resist manipulation of the head and neck region in a way that readily presents the jugular vein for venipuncture. However, the vast majority of birds require physical restraint

that immobilizes their wings, legs and head in a way that presents the vein to be punctured.

A towel or cloth to wrap a bird can be useful for physical immobilization of the wings and legs and helps to prevent self-inflicted injuries such as wing fractures. The amount of trans-coelomic pressure must be just sufficient to hold and restrain the wings but not restrict respiratory movements.

In most circumstances blood can be collected from superficial veins that can be readily seen through the typically thin apterial avian skin. Only in the most obese of birds is there sufficient subcutaneous fat to obscure the view of most of the superficial vasculature. Some of these veins, such as the right jugular vein in long-necked birds, are relatively mobile owing to a relative lack of fascial attachments to adjacent anatomical structures and consequently the birds need to be held in a way that stretches the neck, thus stretching the vein and reducing its movement. In general, if a superficial vein cannot be visualized through the skin then venipuncture should not be attempted.

EFFECTS OF ANESTHESIA ON THE HEMATOLOGICAL CHARACTERISTICS OF BIRDS

The effects of anesthesia on the hematological characteristics of birds have not been comprehensively studied. A study of the hematological effects of 10 minutes of isoflurane anesthesia on American kestrels (*Falco sparverius*) showed a mild decrease in packed cell volume (PCV) (0.40–0.45 to 0.35–0.42 L/L), basophil concentration (0.1–0.4 to 0–0.2 × 10⁹/L) and plasma proteins (28–35 to 25–31 g/L) (Dressen et al. 1999). However, the hematocrits of red-tailed hawks (*Buteo jamaicensis*) administered ketamine hydrochloride intramuscularly, when assessed 10, 20 and 40 minutes after administration, showed no significant differences to the hematocrit values of conscious birds (Kollias and McLeish 1978).

VOLUME OF BLOOD

The blood volume of birds has been reported to be 67 ± 3 mL/kg for common pheasants (*Phasianus colchicus*), 62 ± 5 mL/kg for red-tailed hawks and 111 ± 3 mL/kg for redhead (*Aythya americana*) and canvasback (*Aythya valisineria*) ducks (Bond & Gilbert 1958), and 106 ± 3 mL/kg for galahs (*Eolophus roseicapillus*) (Jaensch & Raidal 1998). The spleen does not provide a reservoir of erythrocytes in birds (as it does in mammals) (Sturkie 1943). However, birds have been shown to rapidly recover from experimentally induced blood loss. After the removal of about 30% of the estimated blood volume of Japanese quail (*Coturnix japonica*), erythrocyte numbers recovered to baseline values within 72 hours (Gildersleeve et al. 1985, 1987a, Schindler et al. 1987a). Furthermore, birds have been shown to restore blood volume after an episode of hemorrhage far more rapidly than mammals (Djojosingito et al. 1968, Gildersleeve et al. 1985, Schindler et al. 1987a,b). For example, phlebotomized quail recovered their plasma volume by 1 hour after removal of blood (Schindler et al. 1987a). However, multiple blood samplings within a 24-hour period that resulted in the removal of an estimated 29% of total blood volume from ruffs (*Phalacrocorax pugnax*) and red knots (*Calidris canutus*) resulted in a decreased hematocrit that had resolved by the next sampling, 2 weeks later (Piersma et al. 2000). Similarly removal of about 10% of estimated blood volume, each day for 7 consecutive days, decreased the PCV (0.30 L/L on day 1 to 0.24 L/L on day 8) in chickens (Christie 1978). Over a longer period, removal of 0.9 mL of blood (about 10% of estimated total blood volume) from American kestrels weekly, for 20 weeks, did not alter the birds' PCV (Rehder et al. 1982a). Stangel (1986) removed up to 7% of estimated blood volume from small birds (about 25–100 g) without ill effect on the health of the birds.

It should be noted that all these studies were performed on clinically healthy birds. The amount of blood that can be safely harvested depends on the body size (and dependent blood volume) and the health status of a bird. Under most circumstances, the skilful removal of a single volume of blood less than 10% of the circulating blood volume (or approximately 1% or less of the bird's body weight) will not be detrimental to a healthy bird. When dealing with ill birds, only the minimum amount of blood necessary for analysis should be removed to minimize any physiological consequences.

GENERAL ASPECTS OF COLLECTION OF BLOOD FROM BIRDS

Collection of a high-quality sample of blood is the most important part of any hematological assessment. The integrity of the cellular and fluid components will deteriorate once removed from the circulating blood. Ultimately, skill, experience and care are required to consistently obtain good quality samples of blood.

Blood is usually collected from the venous component of the circulatory system. The most accessible vein for venipuncture depends on the size and anatomy of the species. Convenient sites for vascular access in birds of differing sizes and body shapes are described later in this chapter. However, some general concepts apply to all venipuncture.

Notably, adequate restraint of the bird is required to allow visualization of the vein and subsequent venipuncture and withdrawal of blood. In some cases physical restraint may be adequate. However, subtle "reactive" movements, especially in response to the needle entering the skin may thwart the harvest of blood.

To aid visualization of the vein, the feathers overlying the site may be dampened with an alcohol solution (such as 70% ethanol), or a

detergent then an alcohol solution. Contamination of the blood with excess alcohol should be avoided as this may cause hemolysis (Tietz 1994) and can exacerbate heat loss from the skin. In some species the overlying feathers may be plucked to aid in visualizing the vein but care must be taken when doing this because many species have thin and fragile skin that is easily torn.

In most species of bird, the veins do not need to be occluded to impede the flow of venous blood. Furthermore, such occlusion may result in perivascular egress of blood once the vein has been pierced and subsequent formation of a hematoma. Hematomas occur more frequently in birds (than in mammals) during venipuncture and may interfere with subsequent attempts at venipuncture, if a sample is not initially obtained. Practically, when a hematoma forms, the phlebotomist should collect blood from another vein.

In most cases a needle and syringe are employed to collect the sample of blood. The size and gauge of the needle and the size and volume of the syringe should be appropriate for the size of the vessel and the volume of blood to be collected. Both the needle and syringe should be sterile and needles should not be reused between animals to avoid both contamination of samples and the possible transmission of disease between birds.

The needle is placed on the syringe with bevel facing upwards, and the syringe aligned in the direction of the vein at an angle of approximately 15° to horizontal. The syringe is advanced in one fluid motion so that the needle pierces the skin, subcutaneous tissue and the vessel. Avoid lateral movement of the tip of the needle as laceration of the vein may result in subsequent hemorrhage and hematoma formation.

A small amount of negative pressure is applied to the plunger of the syringe as the vein is pierced and this is increased as the needle is aligned within the vein to facilitate harvest of blood. Vigorous suction must be

avoided as it may cause hemolysis and may cause the vein to “collapse”, which consequently hinders withdrawal of blood. Failure to apply any negative pressure typically results in leakage of blood around the needle.

Once blood has been collected into the syringe, negative pressure within the syringe is released, the needle is withdrawn and digital pressure applied to the vein for a period of at least 30 seconds to prevent blood flowing from the damaged vein. Due to the relatively loose connective tissue that surrounds them, avian veins are prone to develop hematomas and it is possible for small birds to suffer significant blood loss into the perivascular spaces or, in the case of the jugular vein, the clavicular air sacs.

The needle should be removed from the syringe before blood is gently expelled into an appropriate container containing an anticoagulant. Blood should not be squirted through a needle as it will cause hemolysis, particularly with the small-gauge needles often used for birds. Blood samples should then be mixed, thoroughly but not over-zealously (so as to avoid hemolysis), to permit adequate diffusion of the anticoagulant throughout the sample. Needles and syringes should be disposed of appropriately in “sharps biohazard” containers. Needles should not be recapped following use and care should be taken to avoid needle injuries.

SITES FOR VASCULAR ACCESS IN BIRDS

The most appropriate site for vascular access in birds will depend on the species of bird, the volume of blood required, the method of restraint and the skill of the operator.

Typically blood is collected from the venous system, although under some circumstances blood from capillary beds or arteries may be collected. The nomenclature of veins of birds is confusing with many publications employ-

ing alternative names for the same vein. This is particularly evident for the pectoral limb, with veins described as “basilic”, “brachial”, “cutaneous ulnar”, “median”, and “wing”. Usually there is no anatomical description of the site provided with the name and the reader is uncertain of the actual site used. Some sites that have been used to collect blood are reported in Table 1.2.

Description of the anatomical location of vessels that allow vascular access in birds

Pectoral limb

The **dorsal metacarpal vein** is the continuation of the **dorsal digital vein** of digit three. The former vein passes along the craniodorsal

border of the metacarpus and at the second digit runs across the dorsal aspect of the metacarpus to the caudal aspect of the carpus where it becomes the **ulnar vein**. The ulnar vein passes along the caudal aspect of the ulna, receiving several small tributaries. Approaching the elbow, it crosses to the medial surface of the forearm and, slightly proximal to the elbow, joins with the **radial vein** (the deepest of the forearm’s veins) to form the **basilic vein**. The basilic vein (also referred to as the median vein) is the largest vein of the brachium and passes along the medial surface of the triceps brachii muscle. The confluence of the basilic, **brachial** and **deep brachial** veins forms the **axillary vein** (Figure 1).

The ulnar vein provides convenient vascular access in a wide range of bird species. It can be visualized by wetting the area with alcohol. Using the appropriate size needle, blood

Table 1.2 Reported sites for the collection of blood from selected species of birds. Note that the terminology to describe the vein is as used in the original publication.

Species	Site (Vein)	Reference
Black duck	Brachial	Mulley 1979
Canvasback duck	Jugular	Kocan & Pitts 1976
Mallard	Jugular	Fairbrother et al. 1990
Snow goose	Brachial	Williams & Trainer 1971
Herring gull	Brachial	Grasman et al. 2000
Bald ibis	Brachial	Villegas et al. 2004
Puna ibis	Jugular	Coke et al. 2004
Rosy flamingo	Brachial	Hawkey et al. 1984b
White stork (immature)	Jugular	Montesinos et al. 1997
Victoria crowned pigeon	Brachial	Peinado et al. 1992
White winged dove	Medial metatarsal	Small et al. 2005
American kestrel	Jugular	Dressen et al. 1999
Bald eagle	Brachialis	Bowerman et al. 2000
Eurasian kestrel	Brachial	Kirkwood et al. 1979
Harris’s hawk	Basilic	Parga et al. 2001
Peregrine falcon	Ulnaris, jugular	Lanzarot et al. 2001
Red-tailed hawk	Brachial	Rehder et al. 1982b
Saker falcon	Right jugular	Samour et al. 1996
Sharp-shinned hawk	Median metatarsal	Phalen et al. 1995

(continued)

Table 1.2 (continued)

Species	Site (Vein)	Reference
Spanish imperial eagle	Cutaneous ulnar	Garcia-Montijano et al. 2002
Attwater's prairie chicken	Jugular	West & Haines 2002
Red-legged partridge	Jugular, heart	Lloyd & Gibson 2006
American coot	Metatarsal, basilic, right jugular	Newman et al. 2000
Rufous crested bustard	Ulnaris, jugular	Howlett et al. 2002
Sandhill crane	Brachial	Kennedy et al. 1977
Bar-tailed godwit	Brachial	Landys-Cianelli et al. 2002
Great tit	Brachial, tarsal	Ots et al. 1998
New Holland honey eater	Right jugular	Kleindorfer et al. 2006
Red knot	Brachial	Piersma et al. 2000
Swainson's thrush	Brachial	Owen & Moore 2006
Superb fairy wren	Alar	Breuer et al. 1995
Brown pelican	Medial metatarsal, cutaneous ulnar	Zais et al. 2000
Giant petrel	Jugular	Uhart et al. 2003
Great frigate bird	Cutaneous ulnar	Work & Rameyer 1996
Great skua	Tarsal	Bearhop et al. 1999
Manx shearwater	Brachial	Kirkwood et al. 1995
Northern fulmar	Medial metatarsal	Edwards et al. 2006
Waved albatross	Ulnar	Padilla et al. 2003
African grey parrot	Brachial	Hawkey et al. 1982
Amazon parrot	Cutaneous ulnar, jugular	Tell & Citino 1992
Budgerigar	Right jugular	Scope et al. 2005
Hyacinth macaw	Jugular, median metatarsal	Calle & Stewart 1987
Red lori	Right jugular	Scope et al. 2000
Black-footed penguin	Right jugular	Grim et al. 2003
Humboldt penguin	Brachial	Villouta et al. 1997
Rock-hopper penguin	Jugular	Karesh et al. 1999
Great horned owl	Brachiocephalic artery (arterial)	Hawkins et al. 2003
Snowy owl	Brachial	Evans & Otter 1998
Lesser rhea	Brachial	Reissig et al. 2002

can be collected by aspiration into a syringe or by allowing it to drip from the needle hub into a micro collection tube. Pressure is required after removal of the needle for longer periods as this site is prone to hematoma formation.

In larger species, the dorsal metacarpal vein may be pierced with a narrow gauge needle (25–27-gauge) and as the blood wells up in the hub of the needle it may be drawn away using capillary action of a glass tube.

Pelvic limb

The **medial metatarsal vein** is recognizable along the metatarsus in many species of birds. It is formed by the confluence of **plantar metatarsal vein** and **dorsal metatarsal vein 1** and subsequently forms the **caudal tibial vein**, after passing over the tarsus. The main **dorsal metatarsal vein** is formed from dorsal metatarsal veins 2 and 3. The **medial** and **lateral tarsal veins** are formed proximal to the tarsus

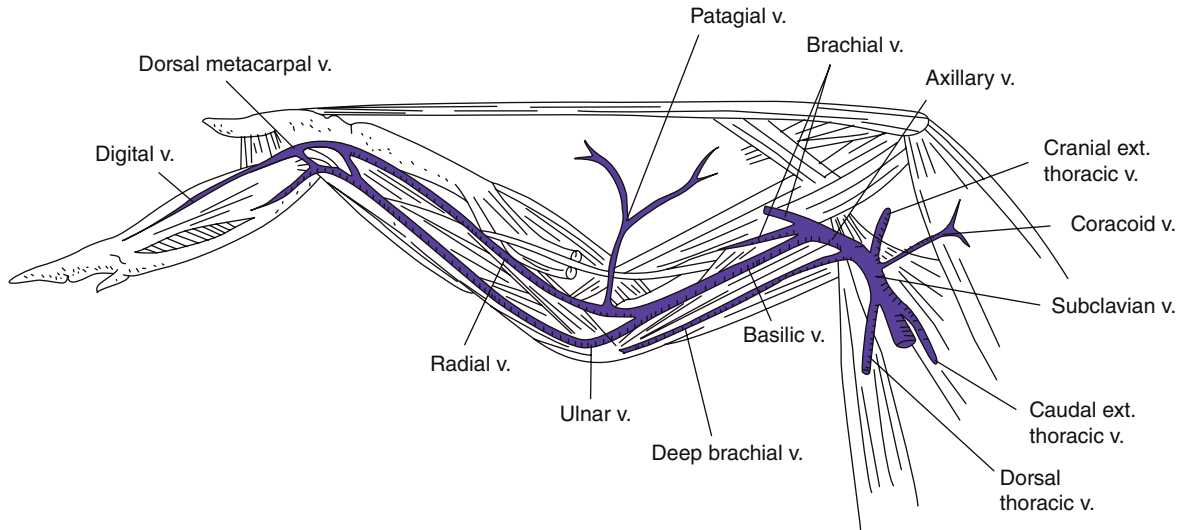


Figure 1 Veins of the pectoral limb, ventrolateral view. Modified from Fitzgerald, *The Coturnix Quail, Anatomy And Histology*. Copyright 1969, with permission of Blackwell Publishing.

by branching of the dorsal metatarsal vein and subsequently reform as the **cranial tibial vein**. The cranial tibial vein traverses the dorsal aspect of the tibia and combines with the caudal tibial vein to form the **popliteal vein**. The popliteal vein receives several smaller veins to form the **femoral vein** (Figure 2).

The medial metatarsal vein provides convenient vascular access in species that have legs of an adequate size and length (such as waterfowl) and also in species that have a dense plumage that covers alternate sites of vascular access (such as the jugular vein). In smaller species, the proximity of the metatarsal veins, tarsal veins and tibial veins may make it difficult to discern the individual vessels.

Head and neck

The **jugular vein** arises from the confluence of the **cranial** and **caudal cephalic veins**. The right jugular vein is typically larger and has a more ventral course (than the left jugular vein) through the cranial cervical region. Throughout its course, the jugular vein receives numerous tributaries including: **cutaneous veins**, **ingluvies veins**, **esophageal veins**, **tracheal**

veins, **dorsal vein** and **lateral occipital vein**. It terminates by joining the **subclavian vein** to form the **cranial vena cava**.

The jugular vein provides important vascular access in many species of birds. It is usually

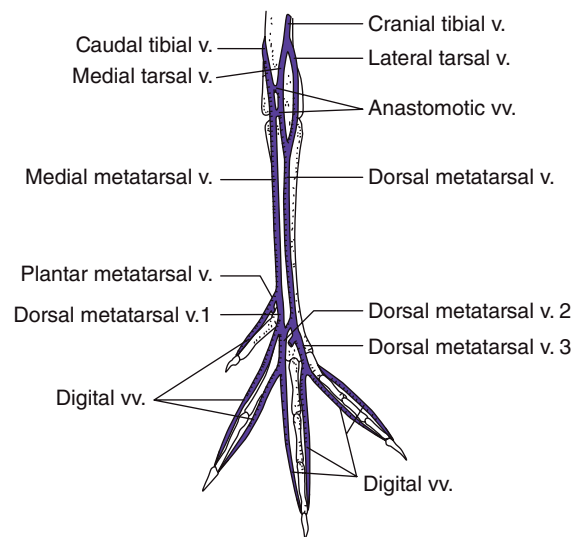


Figure 2 Veins of the pelvic limb, dorsal view. Modified from Fitzgerald, *The Coturnix Quail, Anatomy and Histology*. Copyright 1969, with permission of Blackwell Publishing.

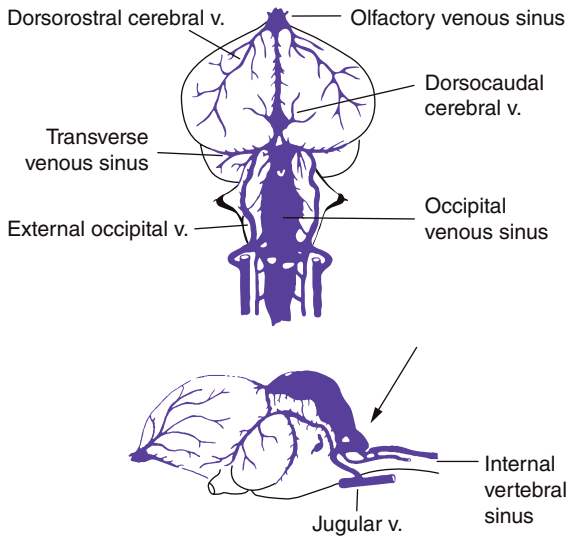


Figure 3 Access to the occipital venous sinus (modified from Kaku, *On the Vascular Supply in the Brain of the Domestic Fowl*. Copyright 1959, with permission of Fukuoka Acta Medica) can be achieved through the foramen magnum with the bird's head held in a flexed position. The needle is directed (arrow) perpendicular to the skin and just lateral to the midline. Whilst the technique has been tolerated well in ducks and geese there is a high risk of injury to the spinal cord and brain stem, particularly in small bird species whereby the technique should be learnt or performed only in anesthetized birds.

easily visualized by parting feathers over the ventral part of the neck. However, in some species, dense plumage may hinder visualization of the vein. Despite being able to readily visualize the jugular vein in most birds, the “mobility” of the vein may frustrate the phlebotomist's attempts to pierce the vein. Holding the skin of the bird's neck taut assists in restricting the lateral movement of the vein, and increases the likelihood of successful venipuncture. For most species of bird it is almost impossible to accidentally enter (or damage) the carotid artery while attempting jugular venipuncture because the artery is normally located deep within the epaxial muscles of the neck, below the ventral surfaces of the cervical vertebral bones.

Within the skull of birds, the **occipital sinus** is a vascular space containing venous blood, which lies within the dura mater and encircles the brain stem (Garrett et al. 1987). Collection of blood from the occipital sinus has been demonstrated to be an effective non-lethal method in ducks and geese (Vuillaume 1983, Garrett et al. 1987) and gallinaceous birds (Zimmermann & Dhillon 1985). When performed, the neck of the bird should be flexed and an appropriately sized needle (for the size of the bird) attached to a syringe is directed perpendicular to the skin and aimed lateral to the dorsal midline at the level of the foramen magnum (Figure 3). Penetration of this anatomical location presents a risk of trauma to the brain stem or spinal cord and hemorrhage into the cerebrospinal fluid. Consequently the occipital sinus should not be recommended as a site for routine blood collection. When the technique is used, the bird should be anesthetized and it should be considered only when blood collection is undertaken immediately prior to euthanasia.

Sites of vascular access for selected groups of birds

See Figures 4–11.

Apodiformes and small passeriformes

In small bird species, such as finches, honeyeaters and hummingbirds, the superficial veins may be too small to allow a hypodermic needle to be inserted into a vein and blood withdrawn. In these species it is still possible to collect small volumes of blood (50–150 μL) using a 28- or 30-gauge needle to puncture the skin overlying a vein. Blood can be collected directly from the hub of the needle or the skin into a capillary tube. Depending on the species, the medial metatarsal, basilar, and **external thoracic** (which runs caudally and dorsally from the axilla along the thorax) veins may provide suitable vascular access. Topical

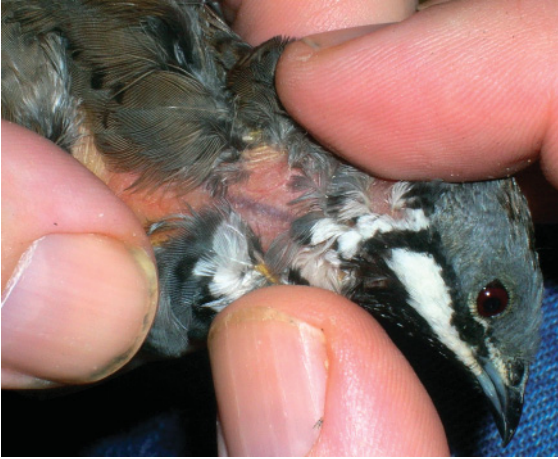

Figure 4 A blue-breasted quail (*Coturnix chinensis*), weight about 50 g, showing the right jugular vein. In small birds, the jugular vein provides the best site to obtain a sufficient volume of blood to allow quantitative analysis. Care must be taken not to apply too much negative pressure on the syringe, which acts to “collapse” the vein, prohibiting the flow of blood. Additionally, the typically slow flow of blood may result in the blood clotting in the syringe.

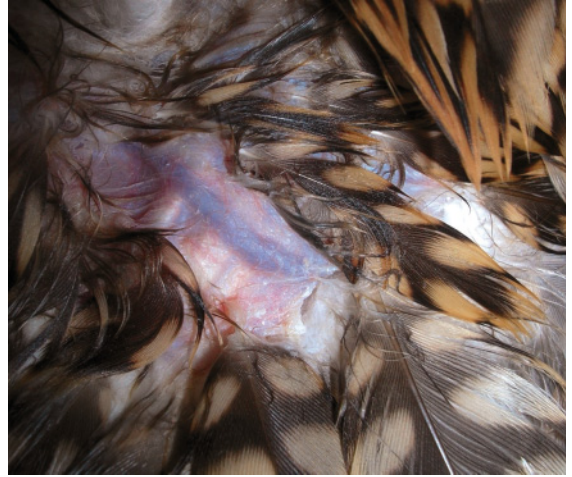

Figure 6 The left wing of a peregrine falcon (*Falco peregrinus*), weight about 700 g, showing the ulnar vein. The feathers have been dampened by the application of an alcohol solution which also disinfects the skin overlying the vein. Both the ulnar and basilic veins provide convenient vascular access in a bird of this size. Diligent manual pressure must be applied after venipuncture to effect hemostasis.

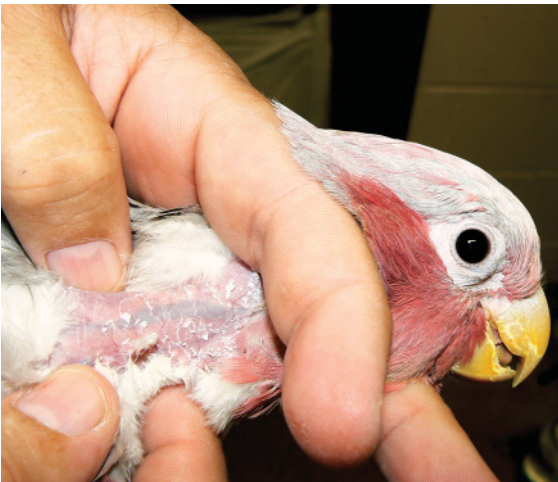

Figure 5 A galah (*Eolophus roseicapillus*), weight about 500 g, showing the right jugular vein. In larger birds, the jugular vein allows ready vascular access and sufficient blood volume to be collected for analysis.

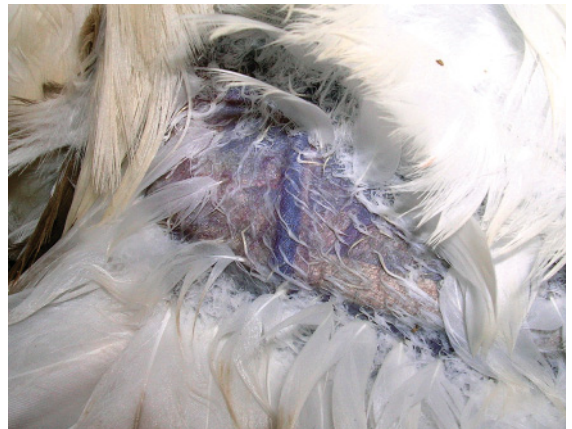

Figure 7 The left wing of an Australian gannet (*Morus serrator*), weight about 2.0 kg, showing its prominent basilic vein. The feathers have been dampened by the application of alcohol solution. Despite the large size of the bird, the jugular vein was not able to be used for vascular access due to the dense plumage which precluded visualization of the vein.

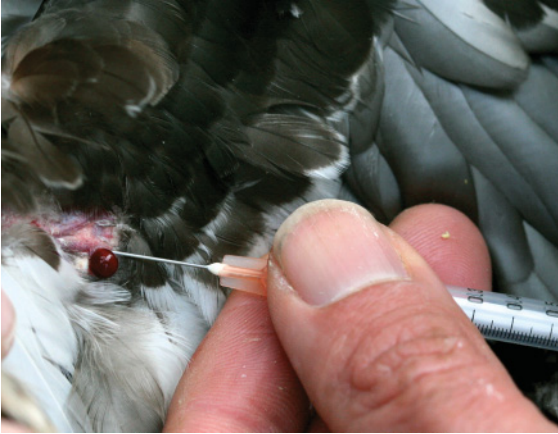

Figure 8 The wing of a grey teal (*Anas gracilis*) showing the leakage of blood from the ulnar vein, which occurs during venipuncture when the phlebotomist fails to apply slight negative pressure to the plunger of the syringe as the vein is pierced.

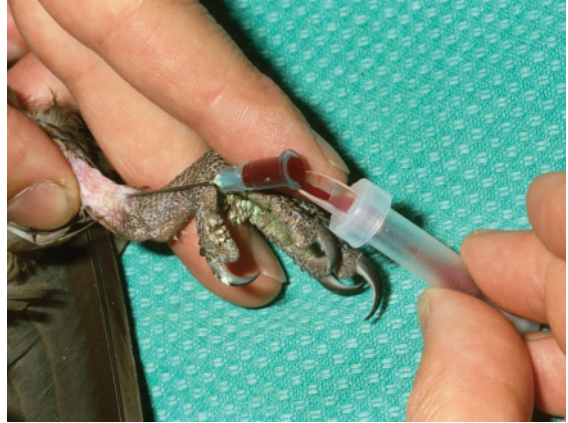

Figure 10 The leg of a galah (*Eolophus roseicapillus*) showing venipuncture of the cranial tibial vein with a 23-gauge needle. The blood is allowed to flow through the needle under hydrostatic pressure and is collected into a container containing anticoagulant.

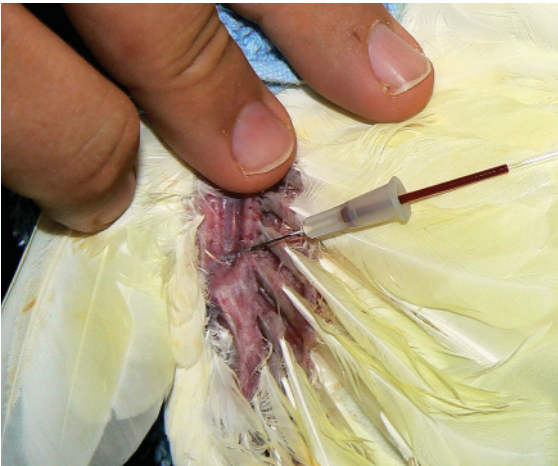


Figure 9 The wing of a little corella (*Cacatua sanguinea*), weight about 650 g, showing the dorsal metacarpal vein. The vein has been pierced with a 27-gauge needle and as the blood “wells up” in the hub of the needle it is drawn away by the capillary action of the tube.

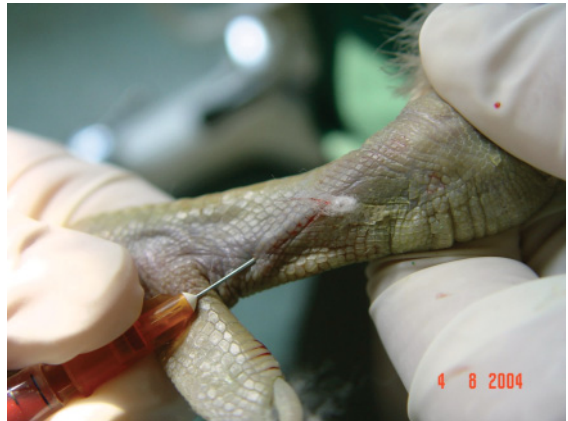

Figure 11 The leg of common eider (*Somateria mollissima*) illustrating venipuncture of the medial metatarsal vein and collection of blood into a syringe. (Courtesy of Claire Cunningham.)

application of potassium permanganate or ferric chloride solutions, using a cotton swab, can be used to achieve hemostasis.

Anseriformes

In larger species of ducks, geese and other birds that have webbed feet, it is possible to access the smaller superficial digital veins that course through the inter-digital skin (“webbing”). This can often be done with minimal restraint, with the bird in a standing position. Alternatively, the metatarsal, ulnar or basilic veins can be readily accessed in those species that have extensive cervical pterygiae (that obscure the jugular vein).

Columbiformes

Doves and pigeons have well developed cervical pterygiae that surround the neck and the cervical skin contains a well developed plexus of veins (**plexus venosus subcutaneous collaris**) that becomes engorged in both male and female adults that are reproductively active (Dalley et al. 1981). This plexus can make visualization of the jugular vein difficult and for this reason alone it is usually easier to collect blood from the ulnar or basilic vein.

Ciconiiformes

In the Ciconiiformes, the long legs possessed by most species make the medial metatarsal vein the most accessible site for collection of blood. The jugular and ulnar veins provide alternative sites (Waters 2003).

Falconiformes and strigiformes

Most species of raptors have long legs and in most species the medial metatarsal vein is readily visualized and accessed for blood collection. Care must be taken to properly restrain the legs to avoid being injured by the talons. Alternatively, blood can also be collected from the ulnar or basilic veins. Werney et al. (2004)

recommended the basilic vein for collection of blood from falcons, conscious and restrained manually in dorsal recumbency. These authors noted the importance of hemostasis following venipuncture at this site. In smaller species of Strigiformes, blood can be obtained from the right jugular vein (Aguilar 2003).

Galliformes

In most species of galliformes, blood can be collected from the right jugular vein or the ulnar or basilic veins. The jugular vein has been used successfully to obtain relatively large volumes of blood from relatively small birds, such as quail (Gildersleeve et al. 1985, 1987a,b, Schindler et al. 1987a,b).

Gruiformes

In cranes, blood can be collected from the right jugular vein or the medial metatarsal vein (Olsen & Carpenter 1997, Carpenter 2003). The birds should be held securely and the sample taken quickly. Blood is not often taken from the ulnar or basilic veins because of the difficulties encountered in restraining all but sedated birds.

Passerines

Blood can be collected from larger species of passerine birds by venipuncture of the right jugular vein. For example, a 30-gauge needle and a tuberculin syringe can be used to take blood from the right jugular vein in starling sized birds. Alternately, the ulnar vein can be used (Gentz 2003). Blood can be harvested from smaller species, as previously described, into a capillary tube after puncture of a superficial vein.

Pelecaniformes

Pelicans and cormorants normally have extensive subcutaneous emphysema that can extend to the tips of the wings and the feet. This can

interfere with visualization of the superficial veins of the wing and legs. Access to the jugular vein is also impeded by extensive cervical pterylae. Branches of the dorsal metatarsal vein or the ulnar vein are the best sites for collection of blood in these species.

Psittaciformes

Blood can be collected from the right jugular vein in all species of psittacine birds. Larger species, such as macaws, require restraint to extend the neck and prevent injury from their beak. Alternative sites are the veins of the wing, including the dorsal metacarpal vein. Most parrots and cockatoos have short tarso-metatarsi, which makes access to the medial metatarsal vein difficult, but it is best accessed as it crosses over the hock. In neonatal psittacine birds (and the neonates of other altricial species) that have sparse feathers, it can be difficult to restrain the chicks unless their feet and body are allowed to rest in a “neutral” sitting position. This then allows restraint of the head and neck, or extension of the wing, to facilitate venipuncture.

Sphenisciformes

Penguins have extensive pterylae and very thick plumage. Consequently, it is very difficult to visualize or access the jugular vein or the superficial veins of the flipper. Techniques have been described for blood collection from the brachial vein (Samour et al. 1983), but the digital, pedal or dorsal metatarsal veins are more readily visualized in most species as they run over the dorsal aspect of the feet between the second and third digits (Cheney 1993). However, there is considerable variation in the anatomical location of these veins even within members of the same species.

Dvorak et al. (2005) described techniques for training individual birds to stand while blood is collected. However, in most instances, the bird needs to be restrained in either dorsal

recumbency or held in a vertical position, to allow the leg to be held firmly and extended. An external heat source applied to the feet can help dilate the vein and facilitate the flow of blood.

Struthioniformes

Blood can be collected from the median metatarsal vein of large ratites, such as the ostrich and emu, with the bird in the standing position. Restraint of the bird by an assistant is effected by the person standing beside and leaning into the bird with moderate downward pressure to minimize movement of the legs of the bird. The median metatarsal vein on the leg selected for venipuncture is then best approached from the caudomedial aspect. Alternatively, the ulnar or brachial veins can also be used for blood collection but care must be taken when restraining the wing, as they are easily fractured.

ANTICOAGULANTS

In most species of birds, the use of ethylenediamine-tetra acetic acid (EDTA) as an anticoagulant provides the best preservation of cell morphology and samples of blood should be routinely mixed with EDTA to prevent the sample clotting (Jennings 1996, Wernery et al. 2004). Hattingh and Smith (1976) found, for blood from pigeons (*Columba livia*), that significant hemolysis was evident in samples mixed with heparin (30 hours) before it was evident in samples mixed with EDTA (70 hours). Interestingly, these authors found less hemolysis occurred in samples mixed with EDTA, maintained at 20°C than in samples maintained at 4°C. However, some birds may exhibit incomplete anticoagulation of the sample or hemolysis of the sample with EDTA (Campbell 2004).

Hemolysis may be evident when a sample of blood is centrifuged in a capillary tube, as

(red) discolored plasma and a decreased proportion of erythrocytes. Microscopically, hemolysed samples are characterized by a lack of intact, discernable erythrocytes and in their stead are nuclei with indistinct erythrocytic membranes and a distinctly eosinophilic background due to the presence of a large amount of “free” hemoglobin.

Hemolysis of blood samples mixed with EDTA has been reported in a number of species of birds including: ostriches (*Struthio camelus*) (Campbell 2004), black-crowned crane (*Balearica pavonina*), laughing kookaburra (*Dacelo novaeguineae*), many members of the Corvidae (Hawkey & Dennett 1989) and Megapodiidae (Vogelnest 1991). In species that exhibit EDTA-mediated hemolysis, heparin is the anticoagulant of choice. However, lithium heparin is not recommended as the routine anticoagulant for birds as it results in extensive clumping of all hematological cell types (Robertson & Maxwell 1990). Notably, clumping of leukocytes and thrombocytes may result in inaccurate counts for these cell types (Campbell 2004).

BLOOD FILMS

To examine the morphology of hematological cells using light microscopy, a blood film must be produced. These must leave cells intact and be thin enough to allow the transmission of light. Disruption of hematological cells is a significant impediment to the analysis of avian blood and is promoted by the small volumes of blood commonly available from birds. Lysed cells are commonly encountered in blood films and a spectrum of morphological effects may be encountered, from mild rupture of the cell's membrane to comprehensive destruction of the cell, rendering it unrecognizable. The latter have been termed “smudge cells”.

Making blood films

See Figures 12–21.

There are several methods that may be used to make blood films. Prior to making any blood film the sample must be thoroughly (but gently) mixed to avoid any sedimentation of cells.

Two slide “wedge” method

A commonly used technique for making blood films from a wide range of species is the “wedge” method, which is suitable for many situations. To produce a blood film using this method, place a slide on a flat surface (such as a bench top) then place a drop of blood (about a generous “pin-head” size) towards the end of the slide. Stabilize this slide with a digit (of the operator's non-preferred hand) then hold a second (“spreader”) slide, between thumb and forefinger of the preferred hand, at about 45 degrees to the (horizontal) first slide. To spread the drop of blood; touch the “spreader” slide to the first slide in front of the drop of blood, “reverse” the “spreader” slide into the drop of blood, pause momentarily while the blood spreads laterally towards the edges of the slide and then rapidly and smoothly propel the “spreader” slide forward. Blood films pro-

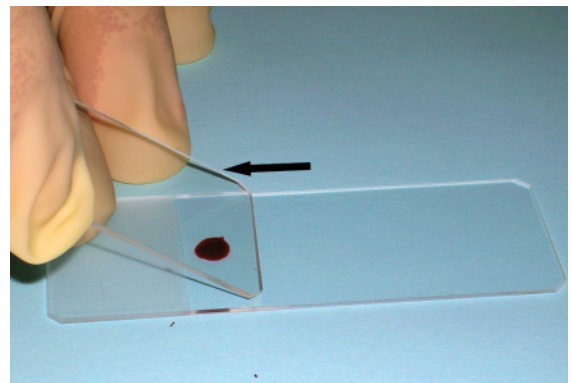


Figure 12 To make a blood film using the “wedge” method: a drop of blood is placed towards the end of a slide (on a flat surface) and the spreader slide is then “reversed” into the drop of blood.




Figure 13 To make a blood film using the “wedge” method: once the slide is in contact with the blood, movement of the slide is paused to allow the blood to spread laterally, then the spreader slide is propelled forward with a gentle, smooth motion to spread the blood along the slide.

duced by this method are typically thinnest at the leading edge of the blood film; however, the cells are often distorted at this margin. Optimal cell morphology is usually found in the region of the “body” of the film where the cells are present as a monolayer. The size of this region is dependent on the PCV of the




Figure 14 To make a blood film using the “cross” method: a drop of blood is placed on a slide (held by the operator), and then a second slide (held above and at right angles to the first slide to form a “cross”) is lowered to contact the drop of blood.

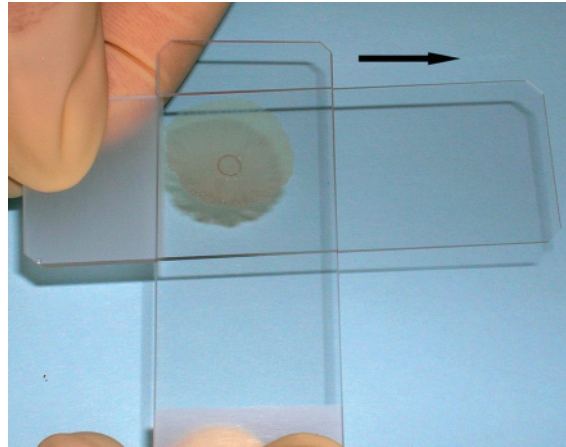


Figure 15 To make a blood film using the “cross” method: the blood is allowed to spread under the weight of the “upper” slide and then the upper slide is gently and smoothly advanced along the lower slide to further spread the blood.

blood and the operator’s technique in making the blood film.

Two slide “cross” method

This method is typically less disruptive to cells than the “wedge” method and is useful in the

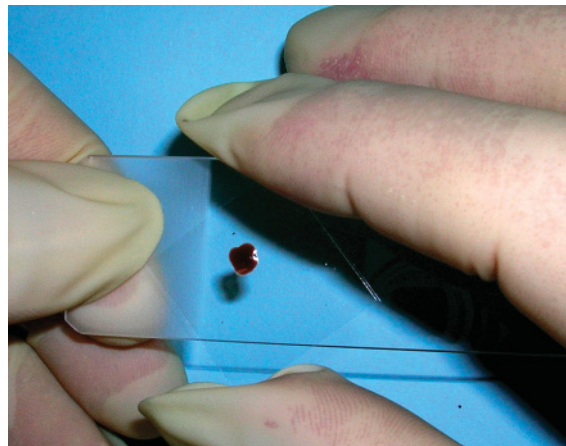


Figure 16 To make a blood film using the “slide and cover-slip” method: a drop of blood is placed on a slide and then a cover-slip is placed on the drop of blood.

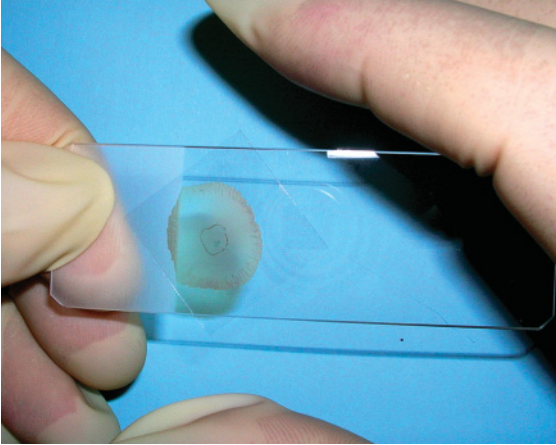


Figure 17 To make a blood film using the “slide and cover-slip” method: the blood is allowed to spread under the weight of the cover-slip.

“field” when no clean flat surface is available. A drop of blood is placed on a slide (held by the operator), and then a second (“spreader”) slide (held at right angles to the first slide to form a “cross”) is flatly touched to the drop of blood (with no downward pressure), the blood spreads under the weight of the slide and the slide is gently and smoothly advanced along the first slide. Blood films produced by this method typically have an ovoid shape that is thicker




Figure 18 To make a blood film using the “slide and cover-slip” method: the cover-slip is then drawn along the slide to further spread the blood.

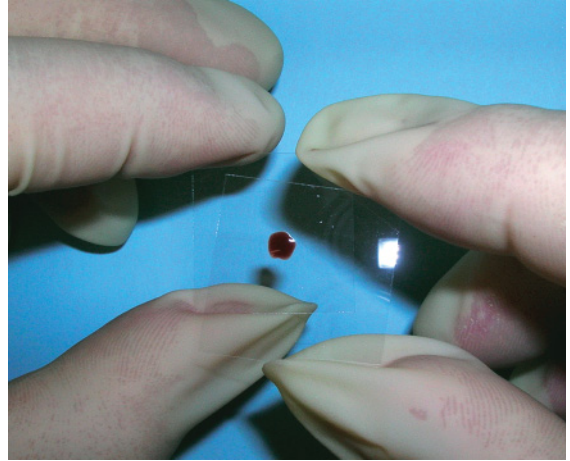


Figure 19 To make a blood film using the “two cover-slip” method: a drop of blood is placed on a cover-slip held between the thumb and forefinger of the operator’s non-preferred hand.

at the poles and less dense in the center and sides.

Cover-slip and slide method

Similar to the above method, a cover-slip may be used instead of the second slide. A drop of

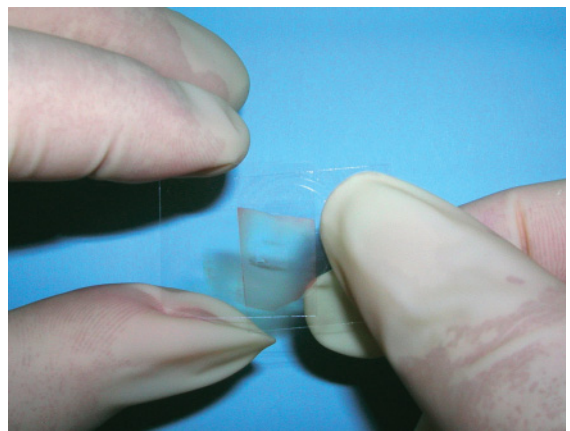


Figure 20 To make a blood film using the “two cover-slip” method: a second cover-slip is then gently placed on the drop of blood and blood is allowed to spread under its weight. The two cover slips are then gently drawn apart to further spread the blood.

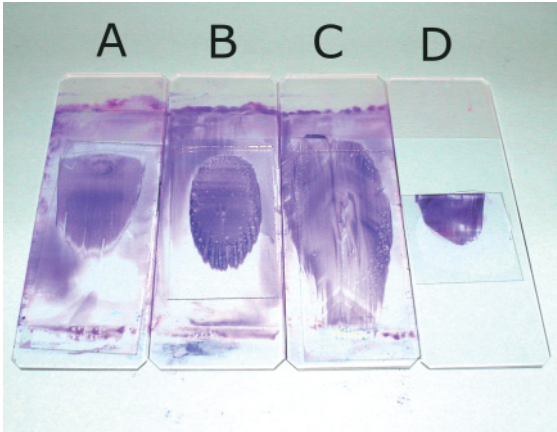


Figure 21 Blood films made from the blood of a lovebird (*Agapornis rosiecollis*) produced by the four methods described above. (a) “Wedge” method, (b) “cross” method, (c) “cover-slip and slide” method (all stained by an automated stainer Hematek, Bayer) and (d) “two cover-slip” method, manually stained with Diff Quik (and subsequently mounted on a slide).

blood is placed on a slide and then a cover-slip is placed on the drop of blood (with no digital pressure). The blood spreads under the weight of the cover-slip and the cover-slip is drawn along the long axis of the slide to further spread the blood. Any sized cover-slip may be used; however, greater dexterity is typically achieved with longer cover-slips. The operator must be careful not to apply too much pressure and fracture the cover-slip, as the resultant shards of glass may cause an injury.

Two cover-slip method

Finally, when very small volumes of blood are available the “two cover-slip” method is a useful way to produce films of blood. A drop of blood is placed on a cover-slip then a second cover-slip placed on top of the first. The blood spreads under the weight of the second cover-slip and when the two are drawn apart, two films are produced. This method is typically more time consuming than the other methods described, particularly as the films must be stained by manual methods. After staining, the

films are mounted on a slide, either in a permanent fashion using mounting medium or in a temporary fashion using immersion oil (with the side containing the blood film down).

All of the methods described may be used to produce blood films of sufficient quality to allow fruitful microscopic examination. The reader is encouraged to experiment with all of the methods to find which one produces the best quality results under their particular circumstances.

Staining blood films

See Figures 22–32.

The staining of slides allows cellular detail to be visualized and the tinctorial characteristics of standardized staining methods have been used to classify hematological cells (viz, “eosinophils” and “basophils”). Poor quality staining of a blood film will decrease the value of the film. Inadequately stained samples do not allow fine cellular detail to be visualized. Similarly, “over-stained” samples often do not allow fine cellular detail (particularly nuclear detail) or tinctorial nuance to be distinguished.

Avian blood films are commonly stained with Romanowsky stains, such as: Wright’s stain, May-Grünwald stain, Giemsa stain and Leishman’s stain, all of which contain varying proportions of methylene blue and eosin (Lynch et al. 1969), or “rapid stains” such as Diff Quik. All of these stains characteristically impart a basophilic color to nucleic acids and the cytoplasmic granules of basophils and impart an eosinophilic color to the hemoglobin-containing cytoplasm of erythrocytes and the cytoplasmic granules of heterophils and eosinophils. Prior to application of the stains, blood films must be thoroughly dry. The stains are generally applied by using either an automated stainer or by placing the slides in Coplin jars containing the stain for a period of time. Following application of the stain,

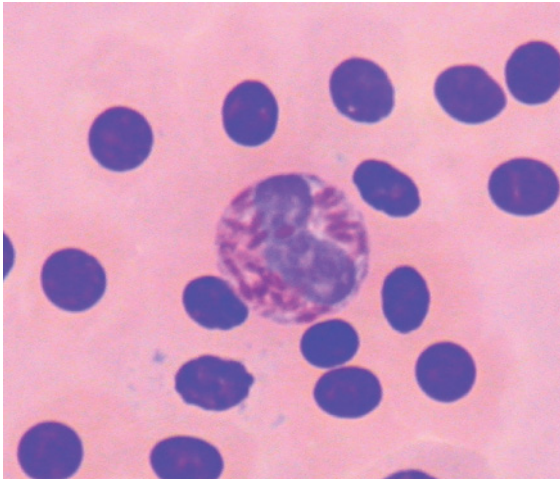


Figure 22 Blood from an Australian raven (*Corvus coronoides*) showing the lysis of all erythrocytes due to the effect of EDTA. The nuclei of erythrocytes are evident but no distinct cell membranes can be discerned. The “free” hemoglobin gives a uniform eosinophilic color to the background. Also present is a heterophil. (Modified Wright’s stain.)

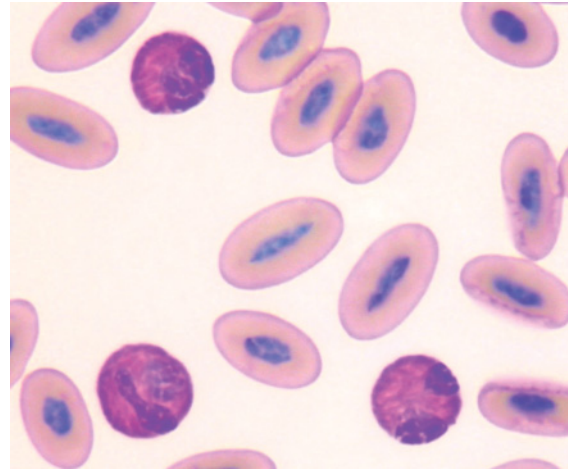


Figure 24 Blood from an ostrich (*Struthio camelus*) which has been mixed with heparin to act as an anti-coagulant (as EDTA causes hemolysis in this species). This slide has been stained with Diff Quik stain. Present are three heterophils that contain a high density of granules giving an overall brick-red color to the cytoplasm.

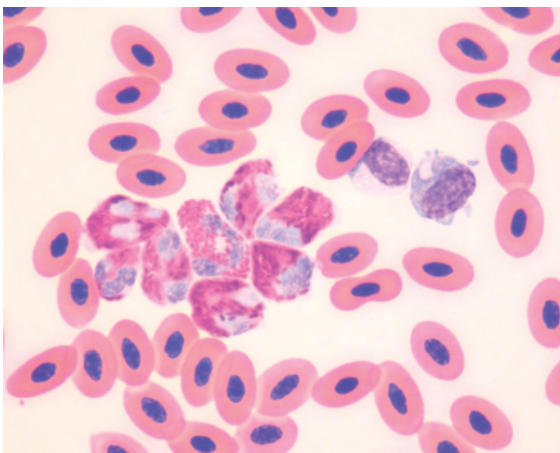


Figure 23 Blood from an Eurasian coot (*Fulica atra*) showing the aggregation of leukocytes that may occur with the use of heparin as an anticoagulant. The uneven distribution of leukocytes is likely to affect the accuracy of the determination of leukocyte concentration.

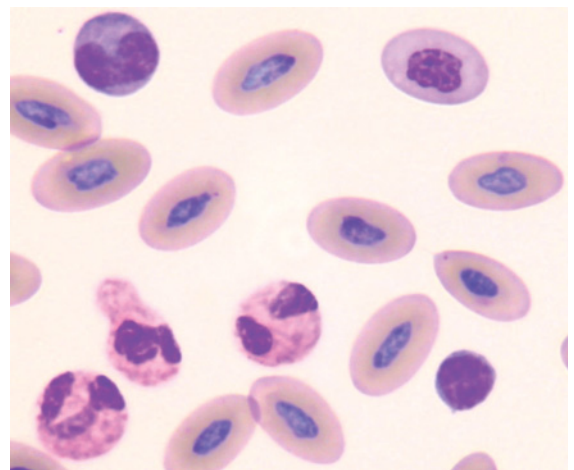


Figure 25 Blood from the same ostrich as in Figure 24. This slide has been stained with May-Grünwald and Giemsa stains. Present are three heterophils, a monocyte and a lymphocyte. Notably, the heterophils’ granules are not as distinct with this stain (as they were with Diff Quik), thus illustrating the effect the staining process may have on the morphological appearance of the cells. This appearance of the heterophils’ granules must not be misinterpreted as a “toxic change”.

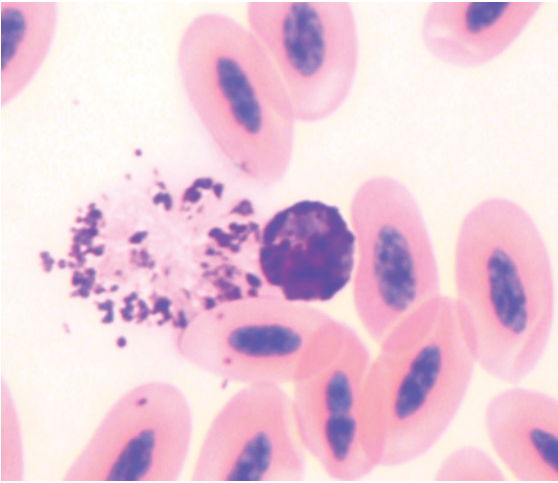


Figure 26 Blood from an Australian kestrel (*Falco cenchroides*). The blood film has been stained with modified Wright's stain. Present is a basophil showing typical darkly basophilic cytoplasmic granules that obscure much of the cell's nucleus and an adjacent, disrupted basophil with a lysed nucleus and dispersed basophilic granules.

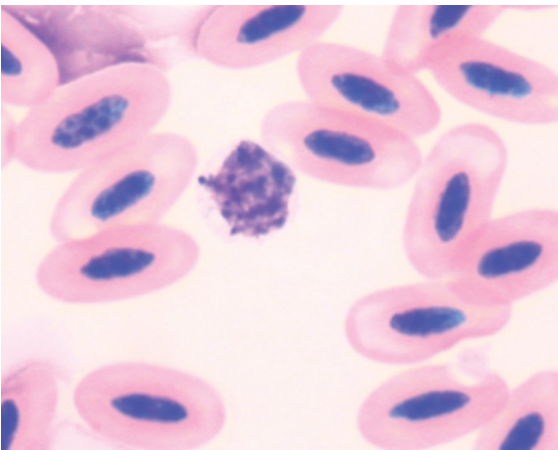


Figure 27 Blood from the same Australian kestrel as in Figure 26. The blood film has been stained with Diff Quik stain. Present is a basophil, in which most of the cytoplasmic granules have not stained. The cell is characterized by a round nucleus and pale cytoplasm with many cytoplasmic "vacuoles" and a few basophilic granules.

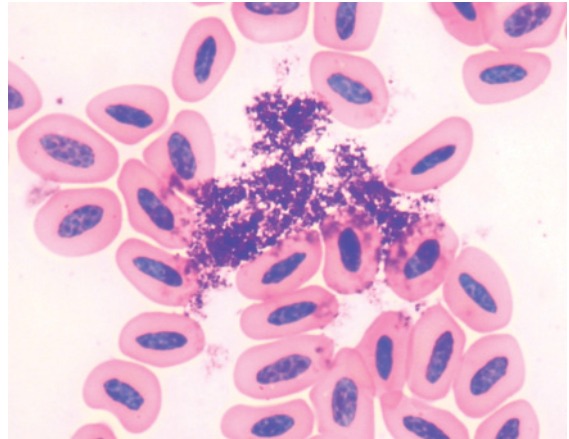


Figure 28 Blood from a Stanley crane (*Grus paradisea*) showing stain precipitate, characterized by large aggregates of purple to basophilic, flocculent material that overlies the erythrocytes and is present between cells. (Modified Wright's stain.)

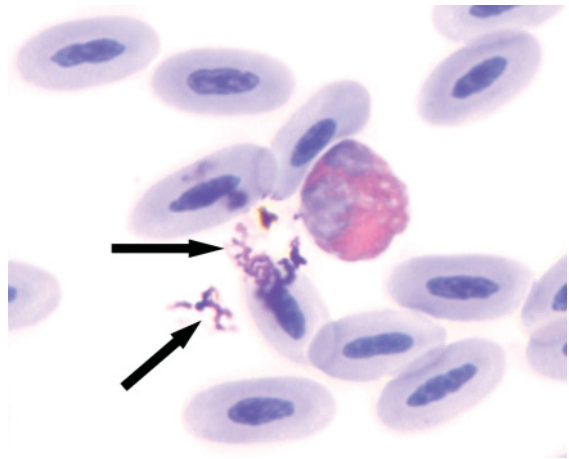


Figure 29 Blood from a saker falcon (*Falco cherrug*) showing small amounts of stain precipitate (arrows) overlying cells and in between the hematological cells (a heterophil and a number of erythrocytes are also present). (Modified Wright's stain.)

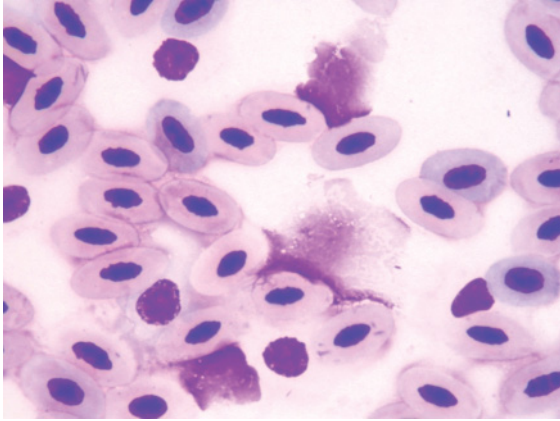


Figure 30 Blood from a masked lapwing (*Vanellus miles*) showing the remnant nuclear material of a number of markedly lysed cells amidst intact erythrocytes. The extensive damage to the cells precludes identification of the cell type. (Diff Quik stain.)

slides must be adequately washed (to remove excess stain) and dried. Slides should not be wiped dry as the sample is easily wiped from the slide. Contact with heated air or a heated

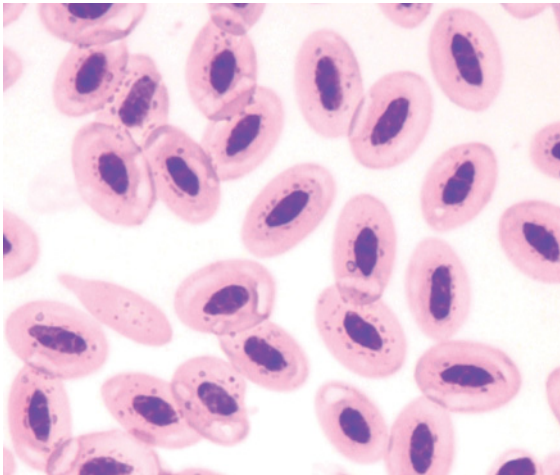


Figure 31 Blood from an orange-footed scrub fowl (*Megapodius reinwardt*) showing many erythrocytes with multiple, small, refractile "bodies" that occur as a result of incomplete drying of the blood film (and hence the presence of residual water) prior to being stained. This artifact is commonly encountered when atmospheric humidity is high. (Diff Quik stain.)

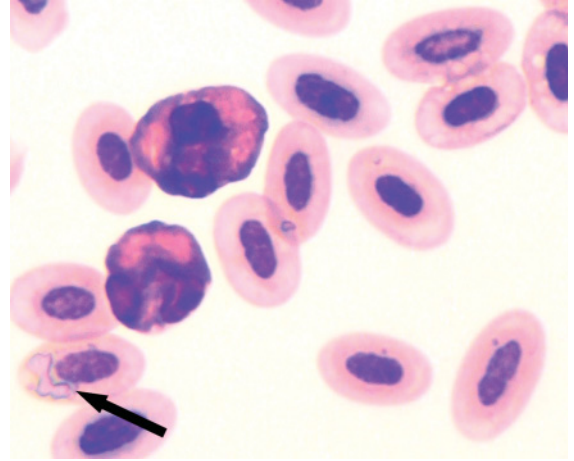


Figure 32 Blood from a green pygmy goose (*Nettion pulchellus*) showing mature erythrocytes that have a refractile appearance (arrow) or pale "moth-eaten" appearance due to incomplete drying of the blood film prior to being stained. Also present are two heterophils. (Diff Quik stain.)

surface expedites drying. Slides that will be archived should have a cover-slip applied using a suitable mounting medium and be stored away from direct sunlight to avoid fading of stain color. Alternative staining methods have been reported but have not been widely adopted (Rath et al. 1998, Kass et al. 2002).

The tinctorial characteristics of the hematological cells may be affected by many factors, including: the type of anticoagulant used to prevent the blood from clotting, the ratio of anticoagulant to blood, the type of stain, the use of the stain, fixation, and the time elapsed between the production of the blood film and staining the blood film.

Robertson and Maxwell (1990) found the quality of May-Grünwald and Giemsa staining of films of blood from domestic fowl was superior when EDTA, rather than lithium heparin, was used as an anticoagulant. These latter resulted in extensive clumping of all hematological cell types, heterophils showed marked vacuolation of the cytoplasm, cells had a blue color and small lymphocytes and thrombocytes were difficult to differentiate.

Similarly, Hawkey and Dennett (1989) reported blood films may stain with a “bluish” tinge with Romanowsky stains when heparin is used as an anticoagulant. However, addition of less than 40% of the “correct” amount of blood for the EDTA tube also compromised the quality of the staining of the blood film (Robertson & Maxwell 1993).

These authors also found unfixed blood films had superior quality staining than blood films fixed in methanol (for 6 minutes) when stained with May-Grünwald and Giemsa stain (Robertson & Maxwell 1990). However, Bennett (1970) noted that, “*Long delay in fixation results in deterioration of the smear and poor stain contrast with Giemsa’s stain. This is particularly noticeable in the cytoplasm of erythrocytes which stain progressively more blue as the time between making and fixing smear increases.*” This has also been the experience of the authors. Hawkey & Samour (1988) recommended that when the staining of a blood film was delayed for more than 48 hours, the film be fixed for 2 minutes in absolute methanol prior to storage.

Significant differences may be observed in the appearance of hematological cells (even for the same sample of blood) when rapid stains are compared to Romanowsky stains. Even within the Romanowsky stains, the colors of the cells and the fine cellular detail may be quite different with different stains. Similarly, different commercial preparations and even batches of the “same” preparation influence the appearance of cells. The greatest differences are typically apparent in the cytoplasmic granules of granulocytes. The hues of these granules vary with the type of stain and in some instances the cytoplasmic granules may not be evident. Instead of granules, colorless “vacuoles” are evident in the cytoplasm of the cell. In the authors’ experience, basophils are the granulocyte most commonly affected, particularly when rapid stains are employed. However, we have also observed that heterophil granules have had a greater intensity of color when a rapid stain was used than when

May-Grünwald and Giemsa stains were used. Recently, the effect of stain type on the appearance of eosinophils was demonstrated for the gyr falcon (*Falco rusticolus*) (Samour et al. 2005) with the “eosinophilic” granules most apparent with Wright’s and Giemsa stains and less apparent with May-Grünwald and Giemsa stains and a rapid stain.

The method used to apply the stain may also affect the tinctorial characteristics. Typically, blood films stained with automated stainers are more uniform in appearance than blood films stained by manual methods. However, manual methods are less costly and facilitate greater flexibility in staining and allow the user to tailor the tinctorial characteristics to the users’ preference.

As the blood films portrayed in this book were obtained from many sources and consequently were stained by different methods and types of stains, variation can be observed in the tinctorial characteristics of hematological cells between samples, sometimes even within individuals of the species. It is important to distinguish these variations in staining from pathological effects that result in morphological changes to hematological cells.

POST-COLLECTION ARTIFACTS

See Figures 33–40.

One of the most important decisions that a hematologist, clinician or researcher will make is whether the observed results are indicative of the hematological characteristics of the bird or whether they reflect changes in the sample that have occurred since the blood was collected. Failure to recognize the latter may result in incorrect interpretation of the data and consequently incorrect management of the case. Post-collection changes in the sample due to handling or processing may result in changes in cell morphology that may be visualized in blood films. Effects on cells may also result in changes in some of the hematological values

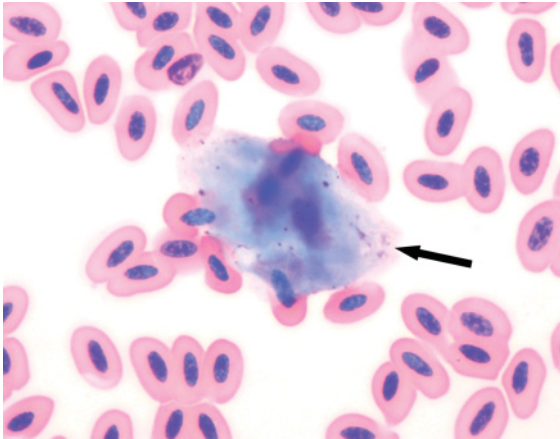


Figure 33 Blood from a lanner falcon (*Falco biarmicus*) showing large, polyhedral, pale basophilic anucleated squamous epithelial cells (arrow) amidst hematological cells. These are typically harvested from the skin overlying the vein during the performance of venipuncture. (Modified Wright's stain.)

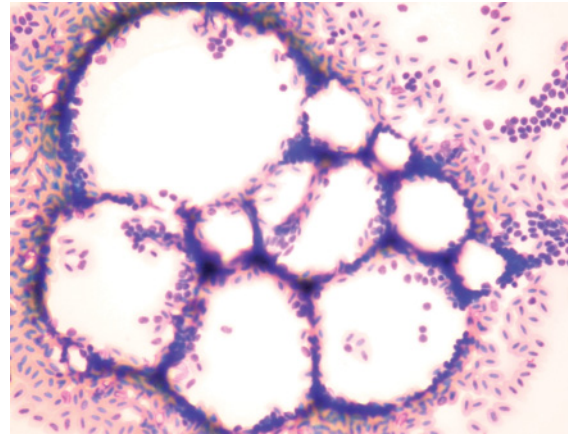


Figure 35 Blood from a cattle egret (*Bubulcus ibis*) showing adipocytes mixed with hematological cells. The adipocytes were most likely collected from perivascular adipose tissue during venipuncture. (Modified Wright's stain.)

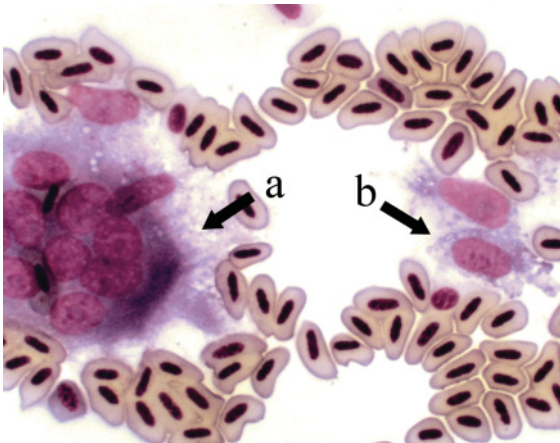


Figure 34 An osteoclast (a) and osteoblasts (b) in the blood of a rainbow lorikeet (*Trichoglossus haematoridus*) that had been collected by clipping a toenail (Clark & Tvedten 1999). The operator had clipped the nail too far proximal, resulting in an inadvertent biopsy of the bone. (Modified Wright's stain.)

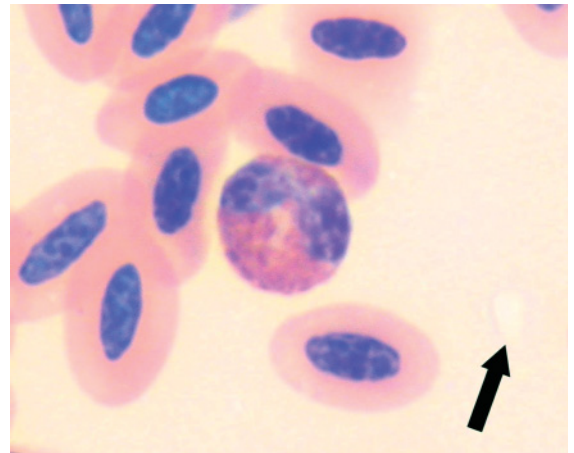


Figure 36 Blood from a peregrine falcon (*Falco peregrinus*). The sample of blood was grossly lipemic. Lipemia can be recognized on the blood film as an overall "milky" appearance (in contrast to clear areas in the background, see arrow). The lipemia also results in the cells present having a less distinct appearance. (Modified Wright's stain.)

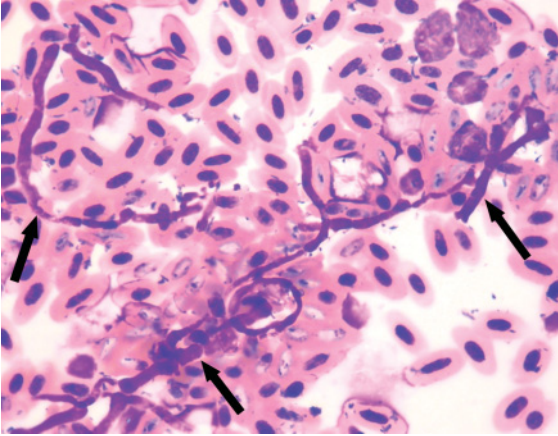


Figure 37 Blood from a whistling kite (*Haliastur sphenurus*). Several fungal hyphae (arrows) can be observed and bacteria were recognized on the blood film. These represent contamination of the blood film by extraneous organisms. The number and morphology of leukocytes was unremarkable, indicating no inflammatory response. In contrast, Figures 267 and 269 illustrate phagocytosis of etiological agents and morphological atypia of leukocytes in response to inflammatory challenge. (Diff Quik stain.)

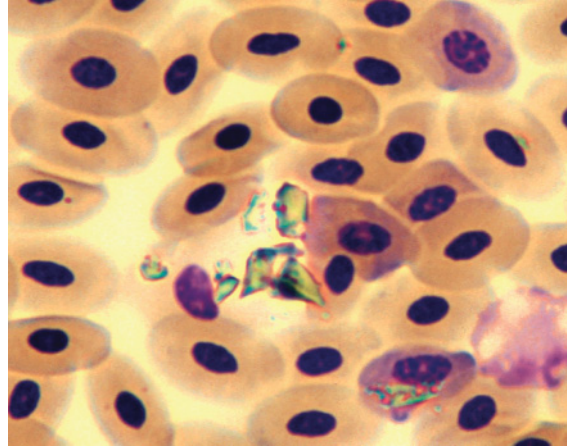


Figure 39 Blood from a yellow-eyed penguin (*Megadyptes antipodes*). Several refractile crystalline objects, consistent with particles of sand, are present amidst the erythrocytes. (Giemsa stain.)

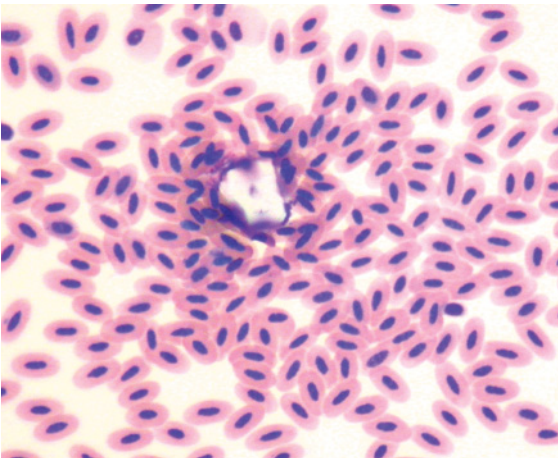


Figure 38 Blood from a rusty-barred owl (*Strix hylophila*) showing a crystalline, angular, pale particle of powder from the disposable gloves, worn by the phlebotomist. (Diff Quik stain.)

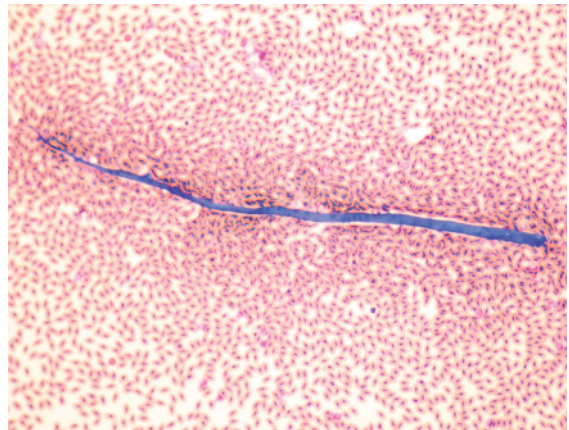


Figure 40 Blood from a brolga (*Grus rubicunda*) showing a large, linear, basophilic, clothing fiber amidst hematological cells. (Modified Wright's stain.)

measured or calculated by automated hematology analysers. For example, hemolysis will decrease the number of erythrocytes counted but the total amount of hemoglobin will be the same, resulting in a spuriously increased mean corpuscular hemoglobin concentration.

The artifacts that may be encountered in blood films may be broadly categorized as altered cell morphology, staining artifacts, non-hematological cells, extraneous material and contaminant etiological agents. Spurious hematological analytes may result from the disruption of cells, aggregation of cells or misclassification of cells.

A common problem leading to altered cell morphology is the disruption (lysis) of cells. Lysis of cells is promoted by delayed processing, exposure of the sample to temperature extremes (both heat and cold), “rough handling” of the blood sample (such as squirting blood through a narrow-bore needle into a container or over-exuberant mixing of blood samples), or as previously mentioned the effect of EDTA anticoagulant which effects almost total hemolysis in some species of birds. Marked hemolysis of avian blood is evident microscopically as nuclei suspended in a background of hemoglobin with no distinct cell membranes evident. Less pronounced hemolysis results the presence of “ghost cells”, that is erythrocytes with their cell membrane still evident but that contain decreased amounts of hemoglobin.

For leukocytes, the magnitude of damage to cells may vary and several forms may be recognized including: the “stripping” of cytoplasm from the cell to leave a “naked” nucleus; disruption of the cell membrane resulting in an “exploded” cell with dispersal of granules (if present) and less dense nucleus; almost complete disruption of the cell making identification unreliable; and the remnant nuclear material of disrupted cells, present as strands in the blood film. It is inappropriate to interpret lysed cells and consequently the differential leukocyte count may be biased if a significant number of cells are affected.

The morphology of cells is typically altered according to their location in the blood film. Towards the leading (“feathered”) edge of the film the cells may be distorted or lysed by the forces generated in the making of the blood film. In the thicker regions of the film, the cells may be “rounded up” because there is insufficient space for the cells to spread out, consequently less light is able to penetrate the cell and less cell detail is able to be visualized. The fine detail of the morphology of cells is best able to be discerned in the monolayer of the film. However, even in the monolayer, the shape of some cells may be distorted by adjacent cells. In addition, the use of heparin as an anticoagulant may result in clumping of leukocytes and thrombocytes (Hawkey & Dennett 1989, Robertson & Maxwell 1990, Campbell 2004).

A commonly encountered issue with the quality of blood films results from inadequately stained cells and consequently an inability to visualize fine cellular detail. This may be due to blood films that are too thick and stain penetration is decreased. Similarly, if the stain potency has decreased due to age or usage, the blood film may not be adequately stained. Additionally, exposure of the blood film to formalin vapors reduces the cells’ permeability to the stains.

If the stain used becomes partially insoluble, variably sized flocculent aggregates of small, round, basophilic granules will be evident throughout the slides (typically both on the surface of cells and in between cells). Large amounts of this precipitated stain may obscure cell detail. Small amounts, typically individual granules, may be misinterpreted as etiological agents (such as cocci bacteria or hematozoa) by inexperienced hematologists.

Characteristic morphological artifacts may result if the slide is incompletely dried prior to staining. When this occurs, the water on the surface of the cells may interfere with the penetration of the stain into the cell and results in inconsistent staining. Typically erythrocytes are most affected and exhibit either a “moth-

eaten” appearance, or small, irregularly shaped, refractile “structures”.

In some instances, non-hematological cells may be encountered in a blood film. Most commonly encountered are anucleated squamous epithelial cells from the skin of the bird, sampled during the venipuncture. Occasionally other cell types that are anatomically associated with the sampling site may be harvested. For example, cells from the bone may be observed in blood collected from a clipped nail (Clark & Tvedten 1999). Similarly adipocytes may be collected from subcutaneous adipose tissue adjacent to the vein selected for venipuncture.

Etiological agents, such as bacteria and fungi, that are not part of a disease process, may be observed in blood films. These may originate from contaminants in the sample which subsequently replicate in the sample (and therefore are most commonly encountered with samples that have a delay in processing) or from organisms that grow in the staining solution. To prevent the latter, a regular schedule of stain maintenance, either replacement or filtration, is recommended. In addition, airborne environmental contaminants may alight on slides that are drying or waiting to be stained. These are usually a single organism. In most cases there will be no phagocytosis of these organisms by leukocytes. However, in some cases of “delayed processing” leukocytes may phagocytose the proliferating contaminant bacteria.

Extraneous substances may be observed in blood films. Most commonly observed is glove powder, an irregularly round to polyhedral, pale colored structure of about 20 μm in diameter, often with a refractile center. Also commonly encountered are fibers from clothing. These are often present towards the leading edge of the film and are typically linear with a mildly basophilic color. A range of other substances may be encountered in specific circumstances, such as granules of sand in blood samples that are collected from birds in coastal environments.

“Numerical artifacts”, that is artifactual causes of a “change” in the concentration of cell(s), are only briefly reviewed here as the focus of this book is the morphological characteristics of haematological cells. Post-collection changes that disrupt cells or cause aggregation of cells will artifactually decrease the concentration of those cells. As previously mentioned, delayed processing, exposure to environmental extremes and rough handling of the sample may result in disruption of cells. Aggregation of thrombocytes occurs commonly in most species of birds and is promoted by tissue damage during the venipuncture or by stasis of blood during the collection (such as from small veins). As previously described, the type of anticoagulant used may affect the formation of the cells. Notably, the use of lithium heparin as an anticoagulant may cause “clumping” of leukocytes. Such clumping of leukocytes results in uneven distribution of cells throughout the sample and consequently affects the measurement of concentration of leukocytes.

MEASUREMENT OF HEMATOLOGICAL CELLS

See Figures 41–45.

As the measurement of hematological cell concentration is intertwined with the identification of cell type by morphological features using light microscopy (especially for leukocytes), the methods that may be used to provide a measurement of the erythrocytes, leukocytes and thrombocytes of a bird are briefly considered in the following text to allow the reader to interpret the data provided in the description of the cases.

The characteristics of the erythron may be assessed using the PCV, to give an overall estimate of erythrocyte “volume”, erythrocyte concentration and hemoglobin concentration. The concurrent interpretation of all of these values affords the best

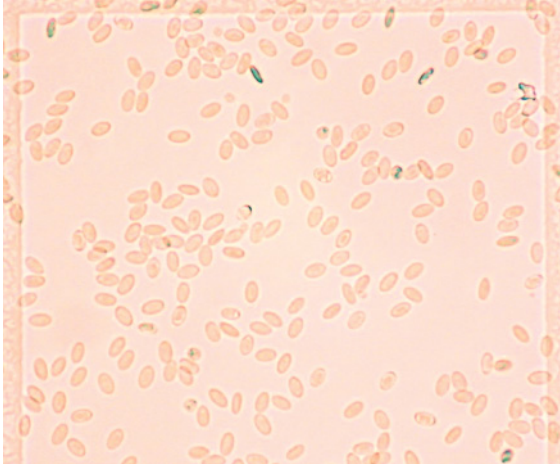


Figure 41 Blood from a Port Lincoln parrot (*Barnardius zonarius*) that has been diluted (1:200 with 0.85% saline) then applied to a disposable hemocytometer (KOVA® Glasstic® slide 10, Hycor Biomedical LTD, UK), showing hematological cells, predominantly erythrocytes.

interpretation of the status of the erythrocytes of the bird.

PCV is the proportion of the volume comprised of erythrocytes in the whole blood. It is typically measured after centrifugation of whole blood for 5 minutes at 10,000 G in a glass capillary tube. It is expressed as the fraction that the erythrocyte volume comprises of the whole blood volume, with the *Système International d'Unités* (SI units) of “litre of erythrocytes per litre of blood” (L/L). “PCV” is often used interchangeably with “hematocrit”; although in modern usage the latter usually refers to a value calculated from the number and volume of erythrocytes in a blood sample using an automated hematology analyzer. To complicate this interpretation, “hematocrit” has been used historically to refer to the fraction of erythrocytes determined by the sedimentation of a sample of blood.

Determination of the erythrocyte concentration of birds is typically not problematic and may be undertaken by counting an aliquot of blood in a hemocytometer or by an (appropri-




Figure 42 Blood from an Australian kestrel (*Falco cenchroides*) that has been quantitatively mixed with an acidophilic stain. Within the square of the hemocytometer central to the image, two acidophils can be recognized.

The whole blood was diluted 1:40 (50 μ L to 1.95 mL) with counting fluid, containing stain that is taken up by the cytoplasmic granules of acidophils, then added to a disposable hemocytometer (KOVA® Glasstic® slide 10, Hycor Biomedical LTD, UK) which has a volume of 0.9 μ L within the grid. The concentration of the acidophils (per microliter) is then calculated as: n (number of acidophils observed in the entire grid) \times 1.1 (to convert the volume of the grid to one microliter) \times 40 (dilution factor). In the current example, $n = 9$, consequently the acidophil count was $0.396 \times 10^3/\mu\text{L}$ ($9 \times 40 \times 1.1$) or $0.396 \times 10^9/\text{L}$. A differential leukocyte count from a Romanowsky stained blood film identified 26% heterophils, 66% lymphocytes, 2% monocytes, 1% eosinophils and 5% basophils. The absolute total leukocyte concentration = $0.396/(0.26 + 0.01) = 1.47 \times 10^9/\text{L}$ and consequently the component leukocyte concentrations were $0.38 \times 10^9/\text{L}$ heterophils, $0.97 \times 10^9/\text{L}$ lymphocytes, $0.03 \times 10^9/\text{L}$ monocytes, $0.01 \times 10^9/\text{L}$ eosinophils and $0.07 \times 10^9/\text{L}$ basophils.

Note that in both the current case and Figure 43 (Australian raven), the proportional values for the differential leukocyte count are the same, but as the total leukocyte concentration was different, the absolute concentration for each type of leukocyte was different. This illustrates the necessity to interpret absolute leukocyte values.




Figure 43 Blood from an Australian raven (*Corvus coronoides*) that has been quantitatively mixed with an acidophilic stain. Within the square of the hemacytometer central to the image, five acidophils can be recognized amidst numerous non-staining hematological cells (that can be distinguished because of the contrast achieved by a lowered condenser on the microscope).

In this example, the Australian raven had 70 acidophilic leukocytes in the grid; consequently, the acidophil count was $3.08 \times 10^3/\mu\text{L}$ ($70 \times 40 \times 1.1$) or $3.08 \times 10^9/\text{L}$. A differential leukocyte count from a Romanowsky stained blood film identified 26% heterophils, 66% lymphocytes, 2% monocytes, 1% eosinophils and 5% basophils. The absolute total leukocyte concentration = $3.08/(0.26 + 0.01) = 11.41 \times 10^9/\text{L}$ and consequently the component leukocyte concentrations were $2.97 \times 10^9/\text{L}$ heterophils, $7.53 \times 10^9/\text{L}$ lymphocytes, $0.23 \times 10^9/\text{L}$ monocytes, $0.11 \times 10^9/\text{L}$ eosinophils and $0.57 \times 10^9/\text{L}$ basophils. Note the effect of the proportion of acidophilic cells present can be illustrated by comparison with Figure 44 (an Australian black-shouldered kite) which has a similar acidophil concentration but a higher percentage of acidophils and consequently a lesser absolute total leukocyte concentration.

ately calibrated) automated hematology analyser (Campbell & Dein 1984, Hawkey & Samour 1988).

Colorimetric determination of hemoglobin concentration, by the cyanmethemoglobin method assessed at 540 nm, has been undertaken on avian blood following the lysis of erythrocytes and centrifugation to remove nuclei, which may contribute to turbidity of the samples and result in spuriously increased

results (Campbell & Dein 1984, Hawkey & Samour 1988). Recent reports have used a colorimetric method assessed at both 570 and 880 nm to compensate for turbidity of the sample (Samour et al. 2005).

Using the measured values, additional characteristics of erythrocytes can be calculated. The average volume of erythrocytes may be used to give an indication of erythrocyte “size”. **Mean corpuscular volume (MCV)** may be determined by direct measurement of erythrocytes using an automated hematology analyser or, if the packed cell volume and erythrocyte concentration are known, may be calculated according to the following formula:




Figure 44 Blood from an Australian black-shouldered kite (*Elanus axillaris*) that has been quantitatively mixed with an acidophilic stain. Within the square of the hemacytometer central to the image, four acidophils can be recognized.

In the current case, the Australian black-shouldered kite had 68 acidophilic leukocytes in the grid; consequently, the acidophil count was $2.99 \times 10^3/\mu\text{L}$ ($68 \times 40 \times 1.1$) or $2.99 \times 10^9/\text{L}$. A differential leukocyte count from a Romanowsky stained blood film identified 57% heterophils, 13% lymphocytes, 16% monocytes, 7% eosinophils and 7% basophils. The absolute total leukocyte concentration = $2.99/(0.57 + 0.07) = 4.67 \times 10^9/\text{L}$ and consequently the component leukocyte concentrations were $2.66 \times 10^9/\text{L}$ heterophils, $0.61 \times 10^9/\text{L}$ lymphocytes, $0.75 \times 10^9/\text{L}$ monocytes, $0.33 \times 10^9/\text{L}$ eosinophils and $0.33 \times 10^9/\text{L}$ basophils.




Figure 45 A hemacytometer containing blood from an Australian gannet (*Morus serrator*) that has been quantitatively mixed with an acidophilic stain. Eight acidophils are present within the central square of the hemacytometer. In the current case, the Australian gannet had 157 acidophilic leukocytes in the grid; consequently, the acidophil count was $6.91 \times 10^3/\mu\text{L}$ ($157 \times 40 \times 1.1$) or $6.91 \times 10^9/\text{L}$. The differential leukocyte count from a Romanowsky stained blood film identified 85% heterophils, 10% lymphocytes, 4% monocytes, 0% eosinophils and 1% basophils. The absolute total leukocyte concentration = $6.91/(0.85) = 8.13 \times 10^9/\text{L}$ and consequently the component leukocytes concentrations were $6.91 \times 10^9/\text{L}$ heterophils, $0.81 \times 10^9/\text{L}$ lymphocytes, $0.33 \times 10^9/\text{L}$ monocytes and $0.08 \times 10^9/\text{L}$ basophils.

$$\text{MCV (fL)} = \frac{\text{packed cell volume (L/L)}}{\text{erythrocyte concentration} (\times 10^{12}/\text{L})}$$

For example, an eclectus parrot (*Eclectus roratus*) with a packed cell volume of 0.48 L/L and an erythrocyte concentration of $2.9 \times 10^{12}/\text{L}$ had a MCV of $0.48/2.9 \times 10^{12} = 166 \times 10^{-15} \text{ L} = 166 \text{ fL}$.

The amount of hemoglobin per erythrocyte may be expressed by the calculated indices **mean corpuscular hemoglobin (MCH)** and **mean corpuscular hemoglobin concentration (MCHC)**. These may be used to determine the average amount of hemoglobin “per erythrocyte” which may aid the investigation of disorders of erythrocytes, particularly anemia.

The MCH may be calculated from the hemoglobin and erythrocyte concentrations according to the formula:

$$\text{MCH (pg)} = \frac{\text{Hemoglobin concentration (g/L)}}{\text{erythrocyte concentration} (\times 10^{12}/\text{L})}$$

For example, a blue-throated conure (*Pyrrhura cruentata*) with a hemoglobin concentration of 128 g/L and an erythrocyte concentration of $3.9 \times 10^{12}/\text{L}$ had a MCH of $128/3.9 = 32.8 \text{ pg}$

The MCHC may be calculated from hemoglobin concentration and packed cell volume according to the formula:

$$\text{MCHC (g/L)} = \frac{\text{Hemoglobin concentration (g/L)}}{\text{packed cell volume (L/L)}}$$

For example, a brown goshawk (*Accipiter fasciatus*) with a hemoglobin concentration of 146 g/L, and a packed cell volume of 0.42 L/L had a MCHC of $146/0.42 = 346 \text{ g/L}$.

Several methods have been used to determine the total leukocyte concentration of birds. These have included; automated counts by hematology analysers, phase contrast microscopy, quantitative staining of leukocytes, quantitative staining of acidophils in conjunction with a differential leukocyte count from a blood film, and flow cytometry.

The presence of nucleated erythrocytes and thrombocytes, as well as nucleated leukocytes, complicates the measurement of the leukocyte concentration in avian blood samples using automated hematology analysers. Post et al. (2003) used chicken blood mixed with EDTA to compare manual differential counts (100 cells) with automated differential counts (Cell Dyn 3500, Abbott Laboratories, IL, USA). These authors found similar values for heterophils and lymphocytes for both methods, but a significantly greater proportion of monocytes and a significantly lesser proportion of basophils with the automated method, compared to the manual method. A similar study

that assessed chicken blood mixed with lithium heparin, that compared manual differential counts (200 cells) with results from the Cell Dyn 3500, found the total granulocyte counts had a good correlation ($r = 0.80$ to 0.93) (Lilliehook et al. 2004). However, monocytes were less well correlated ($r = 0.70$) and there was poor correlation for lymphocyte counts.

Phase contrast microscopy has been used to distinguish the hematological cells in avian blood. Janzarik (1981) described the morphology of erythrocytes, leukocytes and thrombocytes of chickens. Dilution of blood with 1% ammonium oxalate solution (1:20) and examination by phase contrast microscopy has been used to identify leukocytes and thrombocytes from numerous species of non-domestic birds (Hawkey & Samour 1988, Samour et al. 1994, 1996, 2005).

Dein et al. (1994) reviewed “manual” methods, which used a hemocytometer and light microscopy, for the quantitative determination of the leukocyte concentration of avian blood. The use of various diluting fluids and stains has been employed to promote the identification of leukocytes. Nat and Herrick (1952) developed a solution containing methyl violet 2B that stains all types of leukocytes and thus allows the total leukocyte concentration to be determined from quantitative counting of cells in a hemocytometer. Typically, leukocytes have a dark blue color whereas erythrocytes have a palely basophilic nucleus and colorless cytoplasm. Dein et al. (1994) reported an overall coefficient of variation (CV) of 14.2% for this method.

Similarly stains, such as phloxine B, have been used to identify acidophilic granulocytes and when counted in a hemocytometer to allow a quantitative determination of their concentration to be made (Campbell & Dein 1984). The dilution of the sample and the volume of the particular hemocytometer employed will affect the calculation to determine the concentration of acidophils. Dein et al. (1994) reported an overall CV of 6.8% when using a prepackaged diluent system

(Unopette test 5877, Becton Dickinson, Rutherford, NJ).

When the acidophil concentration is determined in conjunction with a differential leukocyte count from a blood film, the total leukocyte concentration and subsequently differential leukocyte concentrations may be calculated. For example, an aliquot of the blood collected from a masked owl (*Tyto novaehollandiae*) was diluted in a solution that contained phloxine B. The stained cells (acidophils) were counted in a hemocytometer and their concentration determined to be $6.0 \times 10^9/L$. A differential leukocyte count from a Romanowsky stained blood film identified 62% heterophils, 25% lymphocytes, 5% monocytes, 2% eosinophils and 6% basophils. The absolute total leukocyte concentration = $6.0/(0.62 + 0.02) = 9.4 \times 10^9/L$ and consequently the component leukocytes concentrations were $5.8 \times 10^9/L$ heterophils, $2.4 \times 10^9/L$ lymphocytes, $0.5 \times 10^9/L$ monocytes, $0.2 \times 10^9/L$ eosinophils, and $0.6 \times 10^9/L$ basophils.

This method may also be influenced by measurement (counting) variations in the differential leukocyte count. Koepke (1980) presented 95% confidence limits for the percentage of leukocytes observed in differential leukocyte counts. For example, for an observed value of 30% (for any cell type), the value may be between 21 and 40% when 100 cells are counted and between 26 and 35% when 500 cells are counted. Furthermore, inaccurate identification of cells may affect the calculation of total leukocyte concentration. For example, if thrombocytes or rubricytes were misclassified as lymphocytes, the proportion of acidophils would be (erroneously) decreased and consequently the total leukocyte concentration (and subsequently the absolute concentration of each of the types of leukocytes) would be increased. Consequently, users of this method must be aware of the sources of error in the determination of leukocyte concentration.

Flow cytometry has been used for the measurement of avian leukocytes with populations

of erythrocytes, granulocytes, monocytes and lymphocytes able to be distinguished from the blood of Japanese quail, chickens and swan geese (*Anser cygnoides*) (Morimoto et al. 2002, Uchiyama et al. 2005). However, it is unlikely that this method will be routinely applied for the analysis of clinical samples in the foreseeable future.

In some instances, particularly with small birds, it is not possible to obtain a sufficient volume of blood to perform a “quantitative measurement” of the concentration of leukocytes. As an alternative, some authors have suggested that “estimation” of the leukocyte concentration from a blood film to provide an indication of the leukocyte concentration (Campbell and Dein 1984, Woepel & Rosskopf 1984). These methods have been employed by a number of researchers to estimate the leukocyte concentration of small birds (Tidemann et al. 1992, Ots & Horak 1998, Acquarone et al. 2002, Mazerolle & Hobson 2002, Ilmonen et al. 2003, Saks et al.

2003, Davis et al. 2004, Dunbar et al. 2005, Owen & Moore 2006). However, there is little scientific data available to objectively compare the results of such estimations with quantitative methods for the determination of leukocyte concentration.

A comparison of the leukocyte concentrations obtained by a quantitative hemocytometer method (Unopette eosinophil method) and estimated from a blood film, showed that for leukocyte concentrations greater than $14 \times 10^9/L$, there was a significant difference between the two methods with greater values recorded for the hemocytometer counts (Russo et al. 1986). These authors also found greater variability in the estimated counts (mean CV of 28%) than for quantitative counts (mean CV of 12.5%).

Consequently, in the authors’ opinion, “estimated counts” should be reserved for situations where there is no facility to perform quantitative measurement of leukocyte concentration.

General hematological characteristics of birds



INTRODUCTION

The blood of all birds contains erythrocytes, leukocytes and thrombocytes. In contrast to mammals, the mature cells of each of these lines retain their nucleus throughout the life of the cell. The vast majority of avian species require effective circulation of erythrocytes to provide adequate oxygen to the muscles of flight. Furthermore, given their adaptation to extremely disparate environments, from rainforest to desert and sea to mountain, it is no surprise to find physiological differences that may be reflected in the hematological characteristics of individual species. Table 2.1 illustrates some of the hematological characteristics reported for birds. However, the “species-specific” hematological characteristics have not yet been described for the majority of species of birds. Fewer studies still have assessed the hematological response to disease in birds. The hematological idiosyncrasies of any nominated species remain largely unknown and have the potential to embarrass the best extrapolation of available scientific knowledge.

This chapter describes the general morphological characteristics of the cells from the blood of healthy birds.

ERYTHROCYTES

See Figures 46–62.

The erythrocytes of birds, when examined in Romanowsky stained blood films by light microscopy, are ovoid with a centrally located ovoid nucleus and evenly colored eosinophilic cytoplasm. The “ovoid” shape varies between species with some species having noticeably rounded cells whereas other species have a narrower, elongated shape. The nucleus is ovoid and composed of darkly basophilic, coarsely clumped chromatin. When examined by scanning electron microscopy, mature erythrocytes are ovoid with a smooth, mostly flat surface that may be distended in the central region of the cell by the nucleus (Hawkey & Samour 1988). This “bulge” is distinct in the turkey (*Meleagris gallopavo*) (Hawkey & Dennett 1989) but was not distinct in the majority of cells from representatives of several

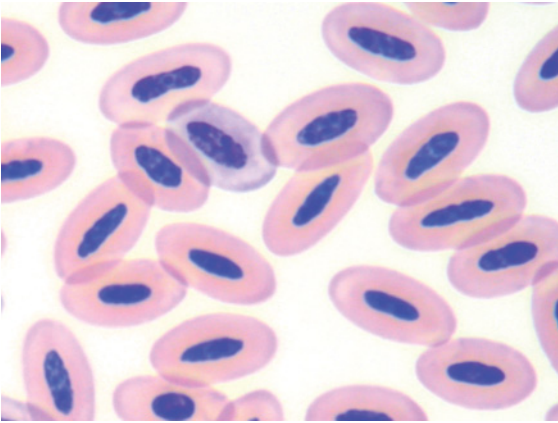


Figure 46 Typical avian erythrocytes in a thin blood film, stained with a Romanowsky stain, and viewed by light microscopy. The erythrocytes have an ovoid shape, eosinophilic cytoplasm due to their hemoglobin content and a central, ovoid nucleus composed of dense, coarsely clumped chromatin. Blood from a black swan (*Cygnus atratus*). (Modified Wright's stain.)

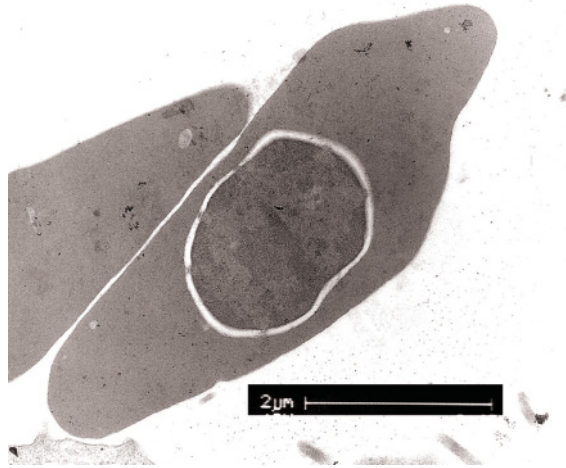


Figure 48 Blood from a clinically healthy Australian kestrel (*Falco cenchroides*). The transmission electron micrograph of an erythrocyte (lead citrate and uranyl acetate stains) shows a moderately dense cytoplasm, due to hemoglobin content, without notable organelles. The erythrocytes from this species have a narrower, more elongated, elliptical shape (compared with the rounded elliptical shape of the cell in the previous figure). Artifactual separation of the nucleus from the cytoplasm is evident. Figures 26 and 27 illustrate the light microscopic appearance of erythrocytes from this species.

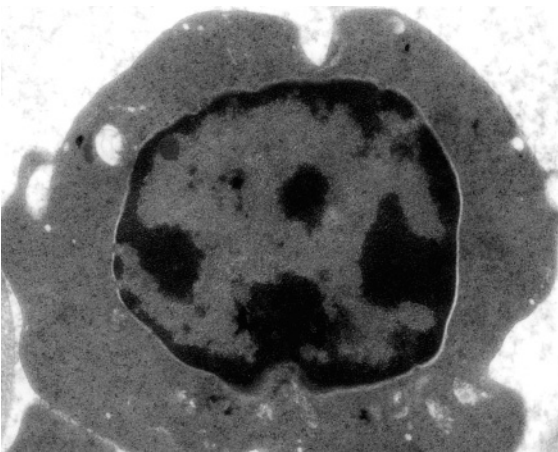


Figure 47 Blood from a clinically healthy takahe (*Porphyrio mantelli*). The transmission electron micrograph of an erythrocyte (lead citrate and uranyl acetate stains) shows a moderately dense cytoplasm, due to hemoglobin content, without notable organelles. The light microscopic appearance of erythrocytes from this species is depicted in Figure 56.

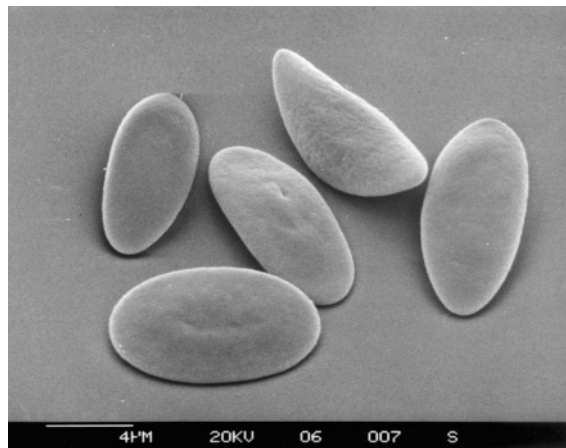


Figure 49 Erythrocytes from a grey-faced petrel (*Pterodroma macroptera gouldi*), examined by scanning electron microscopy. Illustrated is the ovoid shape and lack of a distinct central "bulge" and the relatively flat surface of erythrocytes in this species.




Figure 50 Erythrocytes from a red-tailed black cockatoo (*Calyptorhynchus banksii*) viewed by scanning electron microscopy. The erythrocytes are ovoid and lack a distinct distension of the central region of the cell. The light microscopic appearance of erythrocytes from this species is shown in Figures 68, 194 and 195.

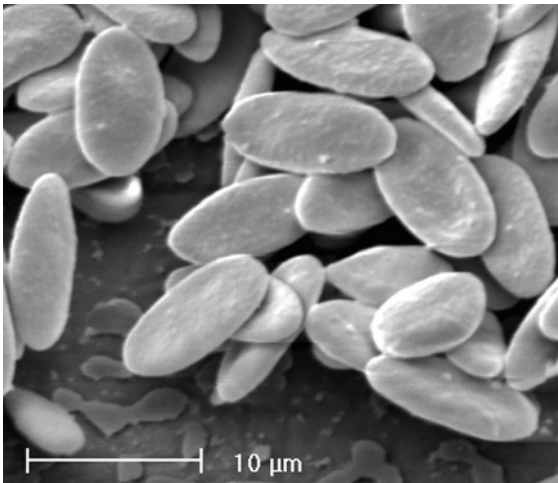


Figure 51 Erythrocytes from a barn owl (*Tyto alba*) viewed by scanning electron microscopy. The erythrocytes are ovoid and lack a distinct distension of the central region of the cell. Mild anisocytosis can be discerned. The light microscopic appearance of erythrocytes from this species is depicted in Figures 57, 73–78.

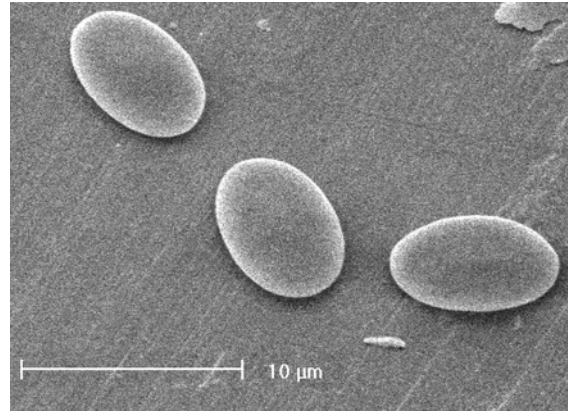


Figure 52 Scanning electron micrograph showing three erythrocytes from the blood of a blue-breasted quail (*Coturnix chinensis*). Note the rounded appearance of the erythrocyte, typical of Galliformes, and the lack of a distinct central bulge. The light microscopic appearance of erythrocytes from this species is illustrated in Figures 149, 150 and 244.

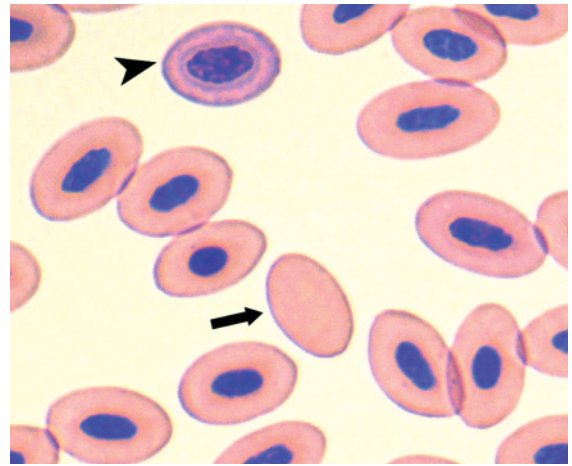


Figure 53 Blood from a New Zealand blue duck (*Hymenolaimus malacorhynchus*) illustrating several "types" of erythroid cells that may be distinguished by light microscopy including: mature erythrocytes, a polychromatophilic erythrocyte (arrow-head) and an anucleated erythrocyte or "erythroplastid" (arrow). (Diff Quik stain.)

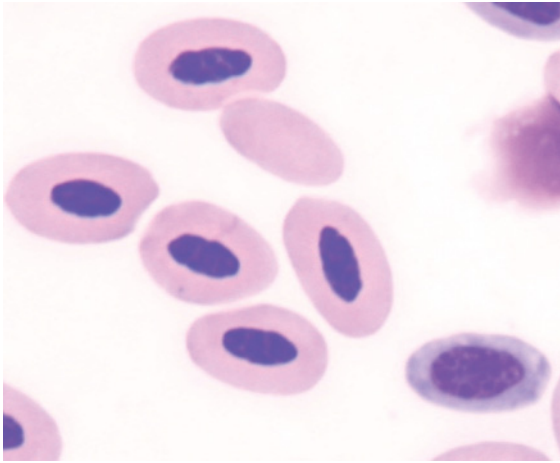


Figure 54 Blood from a Mindanao bleeding heart dove (*Gallicolumba criniger*) illustrating mature erythrocytes, a polychromatophilic erythrocyte and an erythroplastid. (Modified Wright's stain.)

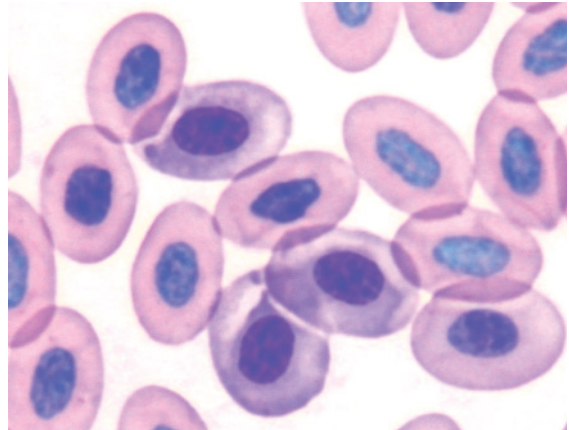


Figure 56 Blood from a takahe (*Porphyrio mantelli*) showing the rounded erythrocytes encountered this species including three polychromatophilic erythrocytes, identified by their more basophilic cytoplasm. (Diff Quik stain.)

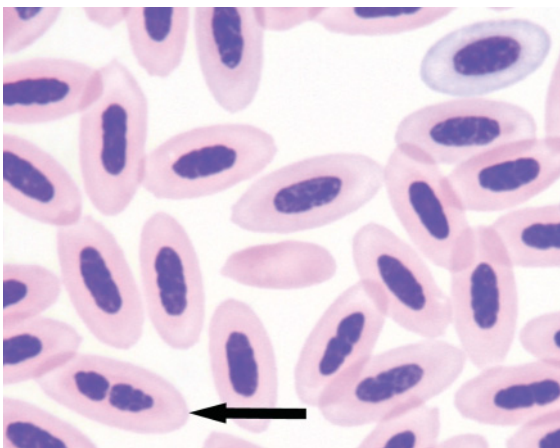


Figure 55 Blood from a helmeted honeyeater (*Lichenostomus melanops*) portraying mature erythrocytes, a polychromatophilic erythrocyte, an erythroplastid and an erythrocyte with a segmented nucleus (arrow). (Modified Wright's stain.)

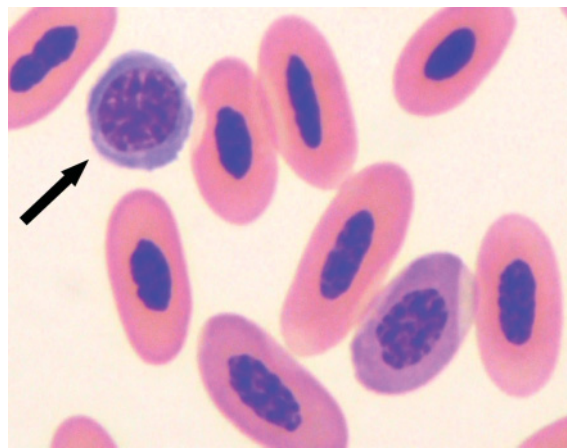


Figure 57 Blood from a barn owl (*Tyto alba*) illustrating a rubricyte (arrow) and a polychromatophilic erythrocyte amidst several mature erythrocytes. (Modified Wright's stain.) Rubricytes are rounded cells distinguished by their well delineated cell and nuclear membranes that contain, respectively, uniform agranulated basophilic cytoplasm and clumps of very dense chromatin interspersed with paler areas. A continuity of the nuclear structure from the rubricyte to polychromatophilic erythrocyte and mature erythrocytes can be seen. Lymphocytes from the same bird are illustrated in Figures 73–77.

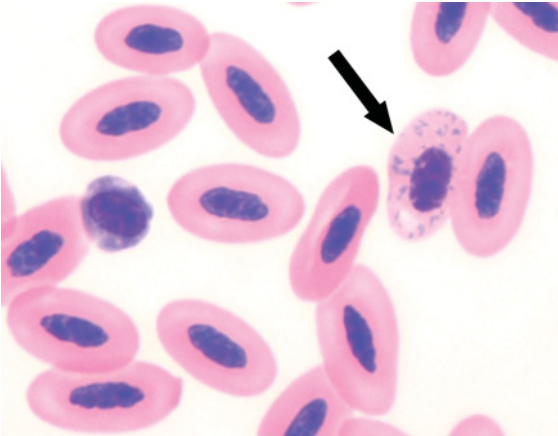


Figure 58 Blood from an anemic (PCV 0.20 L/L) Australian black-shouldered kite (*Elanus axillaris*) showing an erythrocyte with basophilic stippling (arrow) amidst erythrocytes. (Modified Wright's stain.) The basophilic stippling represents aggregates of rRNA in the cytoplasm of the erythrocytes.

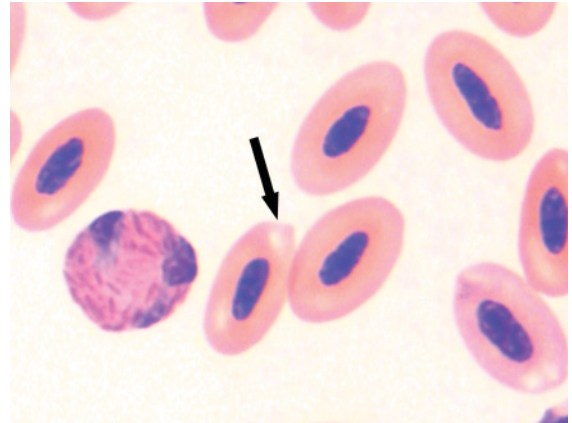


Figure 60 Blood from an Australian black-shouldered kite (*Elanus axillaris*) showing a Heinz body (arrow), evident as a rounded protrusion, at the pole of an erythrocyte. (Modified Wright's stain.) Heinz bodies represent aggregates of oxidized hemoglobin. Also present is a heterophil.

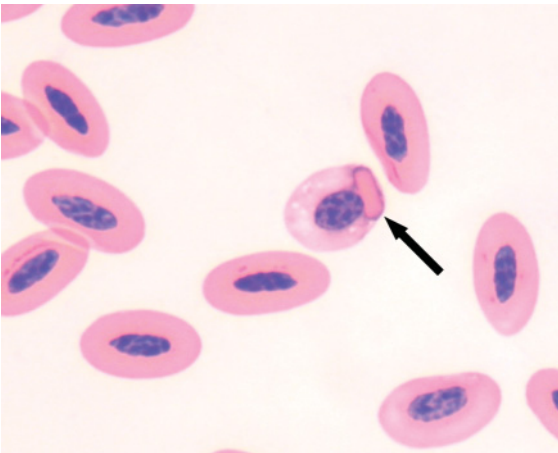


Figure 59 Blood from a black-necked aracari (*Pteroglossus aracari*) showing a hemoglobin crystal (arrow) within an erythrocyte and several mature erythrocytes. (Modified Wright's stain.) The bird exhibited only very small numbers of these crystals and consequently they were unlikely to be clinically significant.

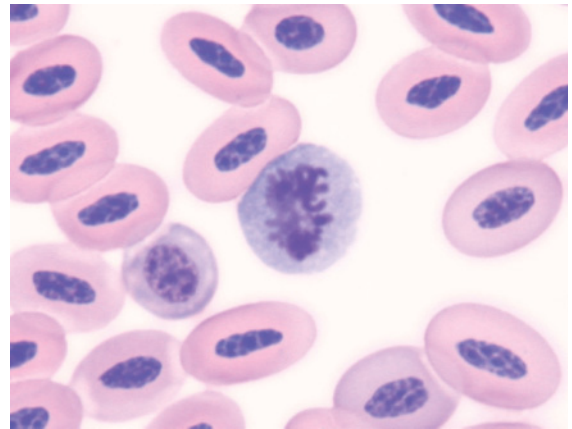


Figure 61 A mitotic figure from the blood of a clinically healthy emu (*Dromaius novaehollandiae*). (Modified Wright's stain.)

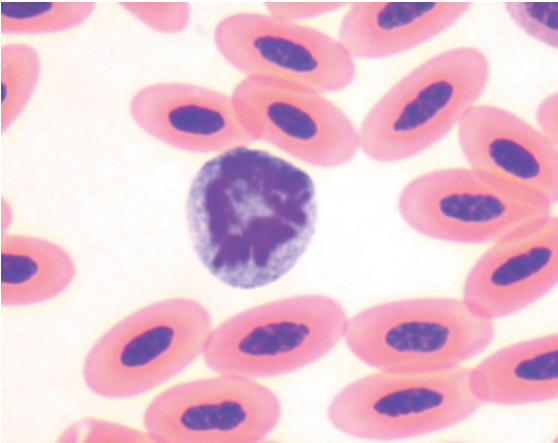


Figure 62 A mitotic figure from the blood of a barn owl (*Tyto alba*). (Modified Wright's stain.)

unrelated species including: barn owl (*Tyto alba*), red-tailed black cockatoo (*Calyptorhynchus banksii*), grey-faced petrel (*Pterodroma macroptera gouldi*) and blue-breasted quail (*Coturnix chinensis*). It is likely that some variation in the magnitude of distension occurs between species and consequently additional studies that encompass a wide range of species are needed to determine the “typical” three-dimensional form of avian erythrocytes.

Avian erythrocytes are larger than those encountered in mammals. Dimensions of erythrocytes from the marsh harrier (*Circus aeruginosus*) were $13.78 \pm 0.50 \mu\text{m}$ in length and $7.95 \pm 0.35 \mu\text{m}$ in width with nuclear dimensions of $6.46 \pm 0.15 \mu\text{m}$ in length and $2.42 \pm 0.16 \mu\text{m}$ in width (Lavin et al. 1992). The erythrocytes of another species of raptor, the gyr falcon (*Falco rusticolus*), were similar in size: $14.82 \pm 0.07 \mu\text{m}$ in length and $7.21 \pm 0.4 \mu\text{m}$ in width (Samour et al. 2005). Similarly, for the rock dove (*Columba livra*), the dimensions of erythrocytes were reported to be $12.20 \pm 0.35 \mu\text{m}$ in length and $6.60 \pm 0.00 \mu\text{m}$ in width with nuclear dimensions of $6.80 \pm 0.29 \mu\text{m}$ in length and $3.3 \pm 0.00 \mu\text{m}$ in width (Gayathri & Hedge 1994). These

dimensions correlate to a mean corpuscular volume of about 150 fL. Some variation occurs between species, with the mean MCV reported to be: demoiselle crane (*Grus virgo*) 154–162 fL (Hawkey et al. 1983); peregrine falcon (*Falco peregrinus*) 118–146 fL (Jennings 1996); Victoria crowned pigeon (*Goura victoria*) 135–178 fL (Peinado et al. 1992); and great skua (*Catharacta skua*) 135–222 fL (Bearhop et al. 1999).

In addition to typical “mature” erythrocytes that comprise the predominant type of cell in the blood of healthy birds, lesser numbers of cells representing the different stages of erythroid development may be encountered. Examination of the blood films of most birds reveals a small proportion of **polychromatophilic erythrocytes** amidst mature erythrocytes. Polychromatophilic erythrocytes are the penultimate stage of the development of erythrocytes. Compared to mature erythrocytes, polychromatophilic erythrocytes are characterized by cytoplasm which has a bluish coloration, due to increased amounts of ribosomal RNA. In addition, the nucleus typically has less dense chromatin than those of mature erythrocytes. Polychromatophilic erythrocytes typically comprise 1–5% of all erythrocytes in healthy birds (Campbell & Dein 1984, Campbell 1995). Increased numbers may be observed when increased erythropoiesis occurs in response to an anemia (a “regenerative response”).

Reticulocytes are erythrocytes that when stained, by the incubation of living cells with a “supravital” stain, such as new methylene blue, exhibit granular aggregations of RNA (“reticulum”). When stained in this manner, some residual cytoplasmic RNA will be evident in most avian erythrocytes. As a consequence, the term “reticulocyte” should be reserved for cells with aggregated “reticulum” that forms a distinct (but incomplete) ring around the nucleus. The number of these cells typically correlates well with the number of polychromatophilic erythrocytes in a Romanowsky stained blood film.

Less mature stages of erythroid development may be observed in the blood of birds. Most commonly encountered are **rubricytes**. Rubricytes are typically smaller and more rounded than mature erythrocytes. Their nucleus is typically round and is composed of coarsely clumped chromatin that is less dense than chromatin of mature erythrocytes. Rubricytes have a nuclear to cytoplasmic ratio that is greater than the nuclear to cytoplasmic ratio of mature erythrocytes, with a small to moderate rim of markedly basophilic cytoplasm. Erythroid cells undergoing division in the peripheral blood, observed as **mitotic figures**, may occasionally be encountered in blood films from clinically healthy birds.

A small number, typically less than 1%, of all erythrocytes in the blood of birds are anucleated. These are referred to as **erythroplastids**. There have been no reports of the number of these cells being specifically affected by a disease process.

Erythrocytes that exhibit a “variant” shape, that is not ovoid, are collectively known as **poikilocytes** and have been recognized in the blood of birds (Hawkey & Samour 1988, Campbell 1995, Fudge 2000, Campbell & Ellis 2007). These variant cells typically comprise a very small proportion of the total erythrocyte population in healthy birds. Example of variant shapes include: “drop-shaped” erythrocytes, fusiform erythrocytes and round erythrocytes. However, the association between increased proportions of these cells with variant shapes and a disease process is less well documented than it is for mammals.

The presence of hemoparasites such as *Haemoproteus* spp and *Plasmodium* spp may alter the morphology of erythrocytes. The presence of the organism(s) may distort the shape of the cell, enlarge the size of the cell, or displace the nucleus within the cell.

LEUKOCYTES

See Figures 63–80.

Five types of leukocytes are encountered in the blood of birds, namely: **heterophils**, **eosin-**

ophils, **basophils**, **lymphocytes** and **monocytes**. As heterophils, eosinophils and basophils all possess distinct cytoplasmic granules they may be collectively referred to as **granulocytes**. Furthermore, as the predominant cytoplasmic granules of heterophils and eosinophils both exhibit affinity for acidic stains (such as eosin) they may be referred to as **acidophils**. Lymphocytes and monocytes may be collectively referred to as **mononuclear cells**.

In many species of bird, **heterophils** are typically the most commonly encountered granulocyte and often the most commonly encountered leukocyte in the peripheral blood of birds. When examined in Romanowsky stained blood films by light microscopy, heterophils are typically irregularly round leukocytes with a lobed nucleus, basophilic nucleus and prominent acidophilic cytoplasmic granules. The nucleus commonly has two to three lobes, with the mean number of lobes reported to be 2.44 for chickens (Lucas & Jamroz

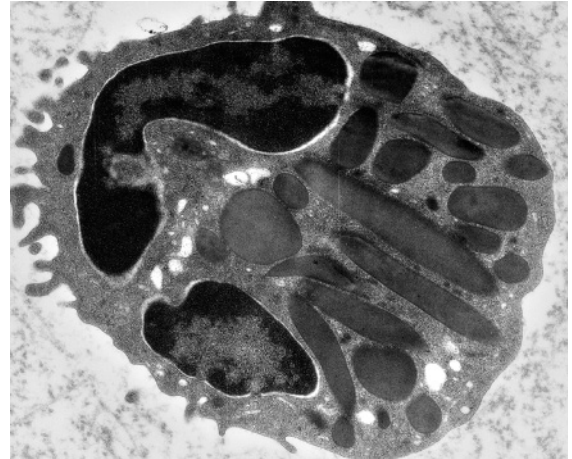

Figure 63 Blood from a clinically healthy takahe (*Porphyrio mantelli*). Transmission electron microscopy illustrates the ultrastructure of a heterophil (lead citrate and uranyl acetate stains). Notably, the structure of the large cytoplasmic granules can be seen to be fusiform in longitudinal section and “round” on cross section. Other organelles including smaller round granules, endoplasmic reticulum, mitochondria and vacuoles may be observed in heterophils. Small pseudopodia are commonly observed at the periphery of the cell. The light microscopic appearance of a heterophil from this species is portrayed in Figure 152.

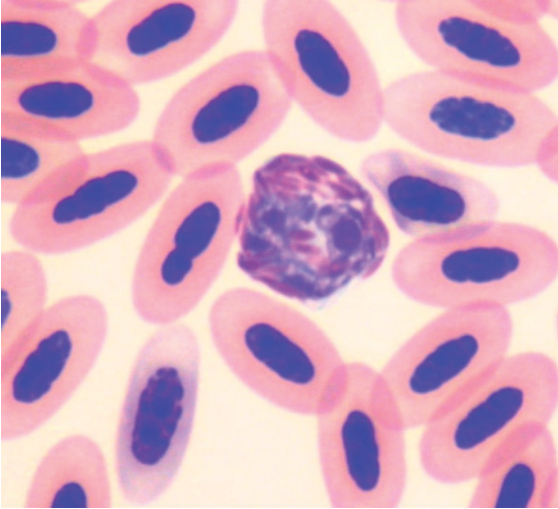


Figure 64 The light microscopic appearance of a typical avian heterophil is characterized by many brick-red, fusiform granules present at high density throughout the cytoplasm and a segmented nucleus composed of coarsely clumped chromatin that is partially obscured by the granules. Blood from a gang-gang cockatoo (*Callocephalon fimbriatum*). (Modified Wright's stain.)

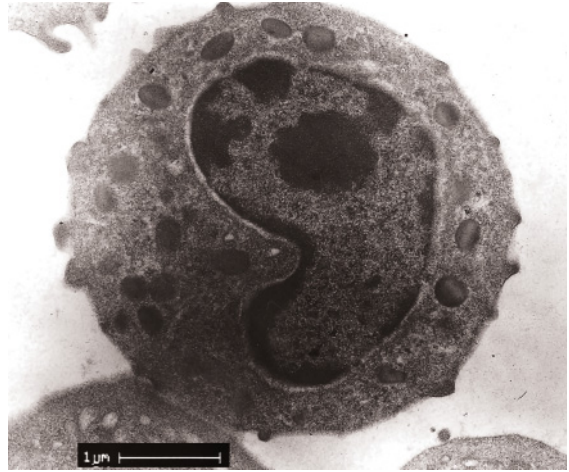


Figure 66 Blood from a clinically healthy Australian kestrel (*Falco cenchroides*). Transmission electron microscopy illustrates the ultrastructure of an eosinophil (lead citrate and uranyl acetate stains). Notably, ovoid granules with homogeneous density can be observed in the cytoplasm. Eosinophils may also contain other organelles such as endoplasmic reticulum, mitochondria and vacuoles. Figure 126 illustrates the light microscopic appearance of eosinophils from this species.

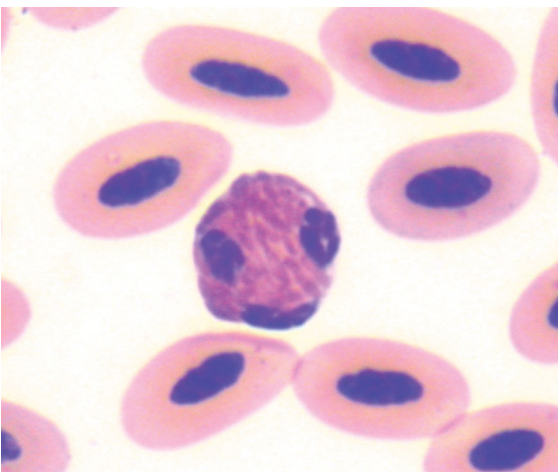


Figure 65 A heterophil from a red-billed toucan (*Ramphastos tucanus*). The typical brick-red, fusiform granules present at high density in the cytoplasm result in the nucleus being partially obscured with the result that the cell appears to have three separate nuclei. (Modified Wright's stain.)

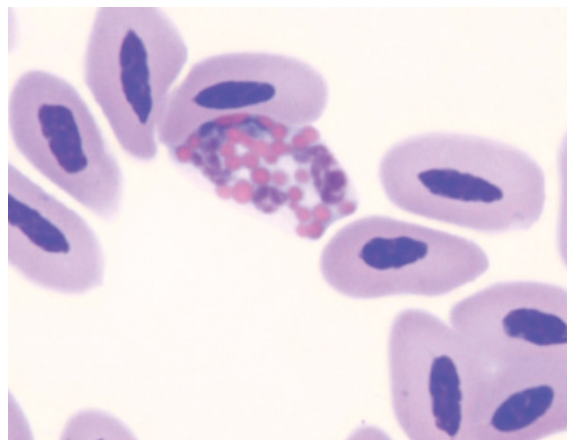


Figure 67 Blood from a greater flamingo (*Phoenicopterus ruber*) demonstrating the large round, brightly eosinophilic granules within pale basophilic cytoplasm, characteristic of eosinophils of this species. Also of note is the distinct segmentation of the nucleus in this cell. (Modified Wright's stain.)

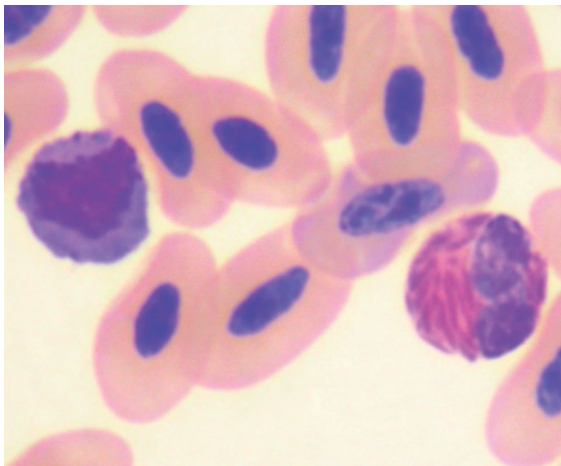


Figure 68 Blood from a red-tailed black cockatoo (*Calyptorhynchus banksii*) illustrating an eosinophil (left), with a high density of round, grey-mauve granules, and a heterophil, with fusiform brick-red granules, amidst mature erythrocytes. (Modified Wright's stain.) In a number of avian species the "eosinophil" is a misnomer as the granules do not stain distinctly eosinophilic. This is further illustrated in Chapter 3.

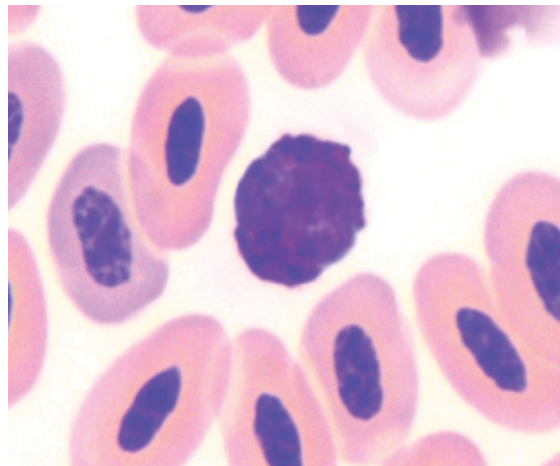


Figure 70 Blood from a sulphur-crested cockatoo (*Cacatua galerita*) showing a basophil with a high density of dark basophilic cytoplasmic granules that obscure the characteristics of the nucleus. (Modified Wright's stain.)

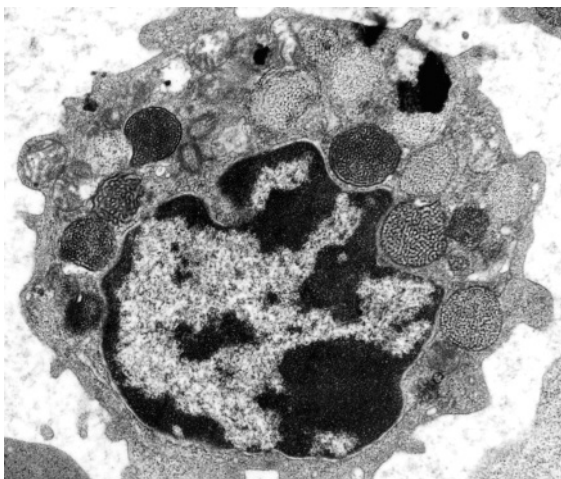


Figure 69 Blood from a clinically healthy takahe (*Porphyrho mantelli*). Transmission electron microscopy illustrates the ultrastructure of a basophil (lead citrate and uranyl acetate stains). Large, round granules with an internal "honey-comb" structure of variable density can be observed in the cytoplasm, along with mitochondria, regions of endoplasmic reticulum and vacuoles.

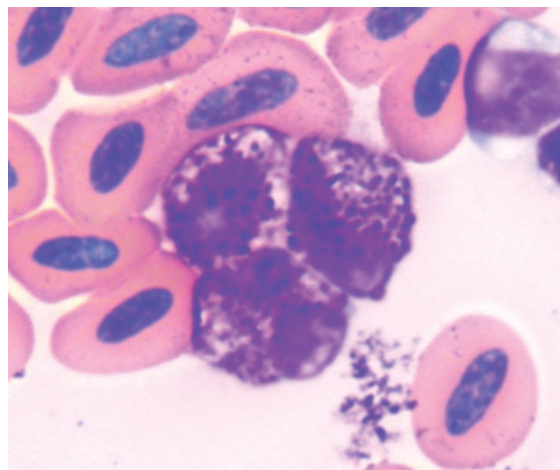


Figure 71 Three basophils from a Stanley crane (*Grus paradisea*) are illustrated. These have a low-moderate density of basophilic cytoplasmic granules that allow some nuclear and cytoplasmic characteristics to be assessed. (Modified Wright's stain.)

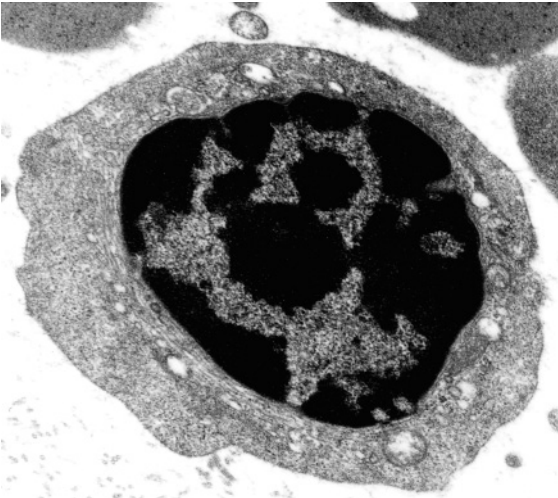


Figure 72 Blood from a clinically healthy takahe (*Porphyrio mantelli*). Transmission electron microscopy illustrates the ultrastructure of a lymphocyte (lead citrate and uranyl acetate stains). The cytoplasm typically exhibits relatively few organelles. In this cell only a small amount of endoplasmic reticulum and a few mitochondria are evident.

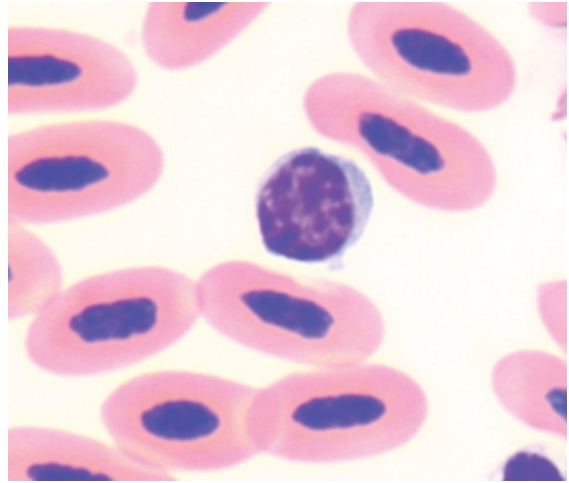
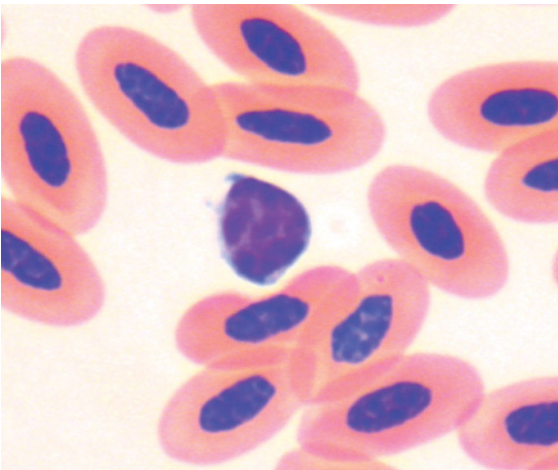


Figure 74 A medium sized lymphocyte, characterized by a rounded nucleus, less dense chromatin and a greater amount of basophilic agranulated cytoplasm compared to the small lymphocyte, is shown. (Modified Wright's stain.)



Figures 73–78 The mononuclear cells, comprising lymphocytes and monocytes, may have a pleomorphic appearance and certain identification of the cell's lineage may not be possible using solely light microscopic examination of Romanowsky stained thin blood films. The following six images all originated from the blood of a single bird (a barn owl, *Tyto alba*) and illustrate some of the morphologically identifiable categories of mononuclear cells.

Figure 73 A typical small lymphocyte characterized by a rounded nucleus composed of coarse dense chromatin and a small rim of basophilic cytoplasm is illustrated. (Modified Wright's stain.)

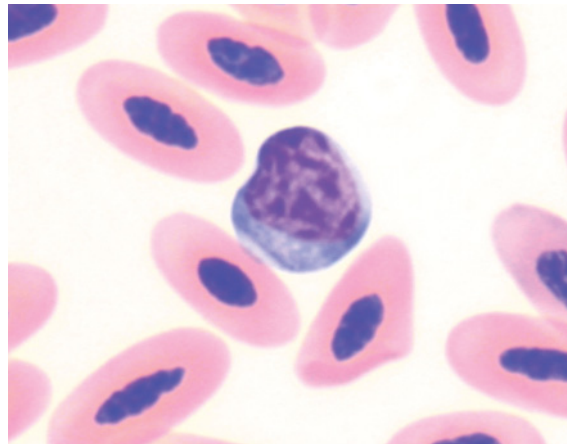


Figure 75 A large lymphocyte, with a large irregularly round nucleus with less dense chromatin and a greater amount of agranulated basophilic cytoplasm compared to the medium lymphocyte, is depicted. (Modified Wright's stain.)

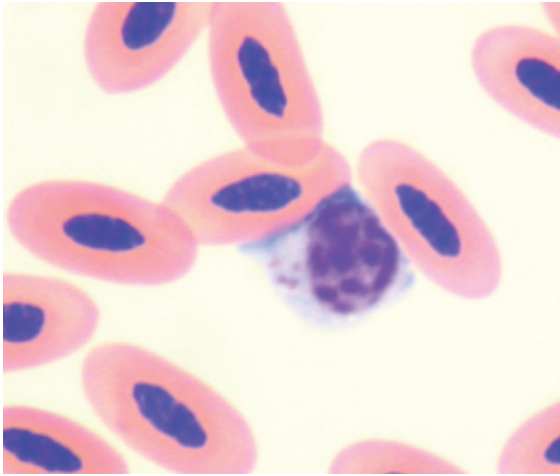


Figure 76 A “granular” lymphocyte, defined by the presence of small azurophilic granules in the cytoplasm of the cell, is illustrated. (Modified Wright’s stain.) These may be recognized in small numbers in the blood of clinically healthy birds of most species and have been commonly observed in the blood of Gruiformes.

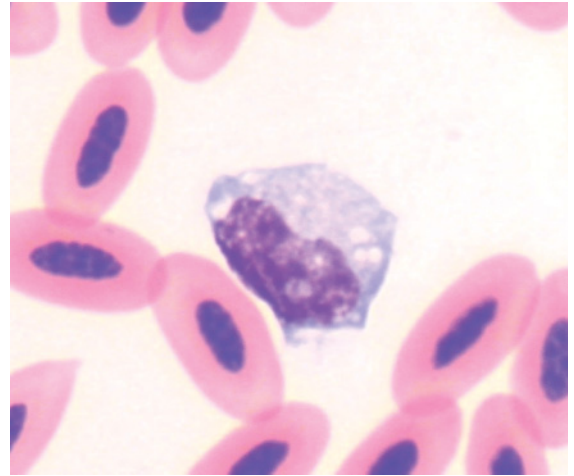


Figure 78 A monocyte, identified by its large size, an irregularly shaped nucleus composed of reticular chromatin and a moderate amount of basophilic cytoplasm with several, variably sized pale vacuoles is shown. (Modified Wright’s stain.)

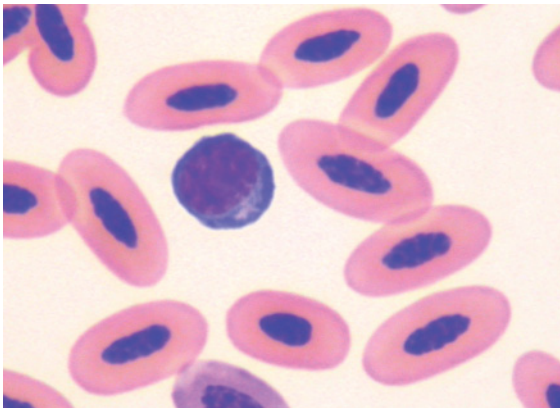


Figure 77 A stimulated (“reactive”) lymphocyte, identified by the increased basophilia of the cytoplasm (indicating increased amounts of RNA) and a pale perinuclear region (consistent with a Golgi zone) is portrayed. (Modified Wright’s stain.) The presence of these cells indicates a stimulated immune system.

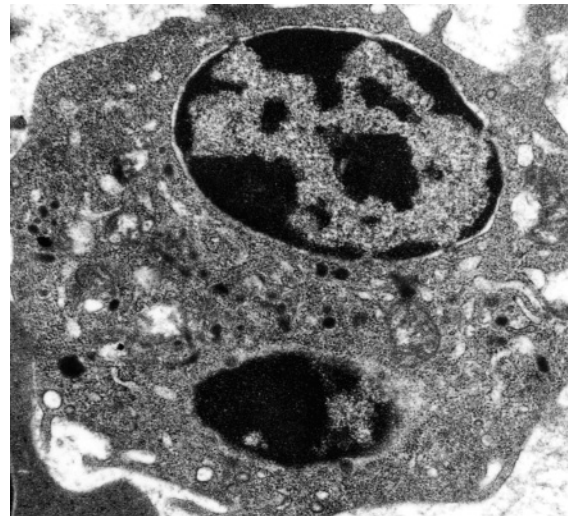


Figure 79 Blood from a clinically healthy takahe (*Porphyrio mantelli*). Transmission electron microscopy illustrates the ultrastructure of a monocyte (lead citrate and uranyl acetate stains). The cytoplasm typically exhibits a range of organelles, including endoplasmic reticulum, mitochondria, granules and glycogen particles.

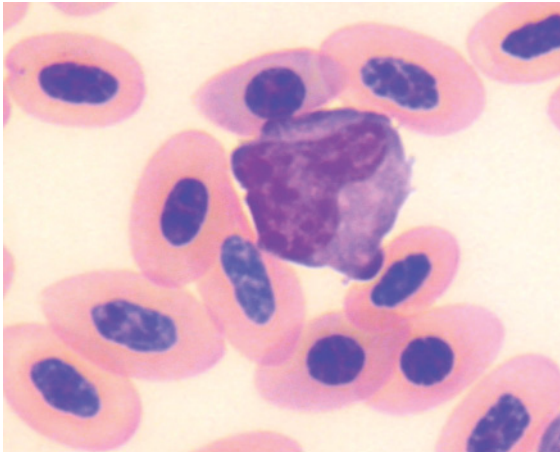


Figure 80 Blood from a little penguin (*Eudyptula minor*) that shows the light microscopic appearance of a monocyte. Monocytes are the most pleomorphic of the leukocytes and the appearance of monocytes within the same blood sample may be quite varied. (Modified Wright's stain.)

1961). In many cells, the lobes may not appear connected due to the presence of granules overlying the nucleus. The nucleus, although basophilic, is often dark at the periphery and fades to a pale aqua-blue color centrally.

Characteristically, the nucleus of heterophils is less basophilic than the nucleus of eosinophils (Maxwell & Robertson 1998). The cytoplasm contains robust granules that are characterized in shape as fusiform (that is elongated, tapering to a point at each end) in longitudinal section and round in cross section and are “brick-red” to brown in color. The relative length and width of the granules varies between species (Lucas & Jamroz 1961). The granules are typically evenly distributed at moderate to high density and often obscure most of the cytoplasm (which is palely basophilic when apparent) and some of the nucleus. In some heterophils, the granules may exhibit a “*central granular body*” (Maxwell & Robertson 1998). These are a round to ovoid, pale or refractile structure located in the mid-section of the granule. In some instances, the central granular body may be

more prominent than the surrounding matrix of the granule.

Few studies have assessed the ultrastructure of avian heterophils. Maxwell (1973) studied the ultrastructural characteristics of heterophils from six species of domestic birds and revealed variation between species in the size and length of granules and the morphology of the central granular body. Similarly a study of the roadside hawk (*Buteo magnirostris*) (Santos et al. 2003b), revealed a lobed nucleus with central euchromatin and peripheral heterochromatin, and cytoplasm that contained predominantly large, electron-dense granules with tapered extremities and lesser numbers of oval and “drop-shaped” granules. Also evident were lesser numbers of small elliptical, rod or dumbbell-shaped granules and rare, very small electron-dense granules. Golgi, rough endoplasmic reticulum (RER), mitochondria and small pinocytotic vesicles were also observed in the cytoplasm.

Eosinophils are the second type of acidophilic granulocytes that may be encountered in avian blood. They are typically less common than heterophils and in many species are defined by the expected brightly eosinophilic cytoplasmic granules when stained with Romanowsky stains. However, in some species “eosinophil” is a misnomer as the cytoplasmic granules are not “eosinophilic”, but may have a dull brown, aqua, grey or pale blue color.

Eosinophils are typically irregularly round cells with a lobed nucleus composed of dark basophilic chromatin. Most commonly the nucleus has two lobes, with a mean value of 1.97 reported for the eosinophils of chickens (Lucas & Jamroz 1961). Characteristically, the chromatin of eosinophils stains more darkly than that of heterophils in the same sample and, in contrast to heterophils, the intensity of the color is similar throughout the entire nucleus.

Typically, the cytoplasm is pale to moderately basophilic and contains “eosinophilic” granules. The number, shape, size, hue and

density of granules vary between species. For example, species of flamingos and cranes typically have prominent, round, brightly eosinophilic granules (Hawkey et al. 1983, 1984a,b, 1985) whereas, species within the Anatidae typically have many eosinophilic, rod-shaped granules. However, other species have less distinctive eosinophils. The appearance of “eosinophils” is very variable between groups of raptors (Lind et al. 1990). For example members of the genus *Falco* have eosinophils with a few, “bluish pink to light blue” granules in a pale blue cytoplasm (Lind et al. 1990) or few small eosinophilic granules (Wernery et al. 2004, Samour et al. 2005). Samour et al. (2005) noted the large effect the type of stain may have on the appearance of granules. In contrast to the falcons, birds within the genera *Buteo* and *Accipiter* typically have round, brightly eosinophilic granules (Lind et al. 1990, Santos et al. 2003b).

Inexperienced hematologists may have difficulty in distinguishing eosinophils from heterophils. When the color of the “eosinophil” granules is eosinophilic, it is usually a brighter “red–orange” color than the color of the granules of heterophils (typically a brown–red color). Additionally, the nucleus of eosinophils is typically less obscured by granules and usually stains a darker basophilic color than heterophils.

Few studies have assessed the ultrastructure of avian eosinophils. Maxwell and Siller (1972) initially reported the ultrastructural characteristics of eosinophils from six species of domestic birds, then noted variation in the internal structure of eosinophil granules, with non-crystalline (homogeneous) forms recognized in the European shag (*Phalacrocorax aristotelis*), crystalline in members of the Anseridae (Maxwell 1978), and “mixed” in the black-crowned crane (*Balearica pavonina*) (Maxwell 1979). A study of eosinophils from the roadside hawk (Santos et al. 2003b) revealed the cells had a lobed nucleus, with central euchromatin and peripheral heterochromatin and cytoplasm that contained large, spherical

electron-dense granules, RER, mitochondria and pinocytotic vesicles.

The **basophils** of birds are most readily identified by the darkly basophilic cytoplasmic granules they exhibit when stained with Romanowsky stains. Basophils are typically irregularly round cells that most commonly have a nucleus with a single lobe; with a mean of 1.01 lobes reported for the basophils of chickens (Lucas & Jamroz 1961). Classically, the cytoplasm contains darkly staining basophilic granules at such high density that the individual granules cannot be discerned. Commonly the nucleus appears pale (in comparison to the overall color of granules in the cytoplasm) and is partly obscured by the presence of the cytoplasmic granules, so that nuclear detail is often difficult to discern. Between species, there is some variation in the size, color, hue and density of granules. In some case, “all” or the majority of cytoplasmic granules may fail to stain. In these cases, “basophils” exhibit regular, round vacuoles in a pale cytoplasm with occasional basophilic granules. In such cases, the nucleus is apparent and is typically round to ovoid and composed of moderately dense chromatin. The authors have noted this most commonly when Diff Quik has been used to stain avian blood films.

Few studies have assessed the ultrastructure of avian basophils. Maxwell (1973) reported the ultrastructural characteristics of basophils from six species of domestic birds and a study of the roadside hawk (Santos et al. 2003b) revealed that basophils had a central non-lobed nucleus with a nucleolus and cytoplasm that contained granules with three distinct appearances, RER, mitochondria and small vacuoles.

Lymphocytes are the most commonly encountered mononuclear cell; in some species of birds, they are the most commonly encountered leukocyte in the peripheral blood. Morphologically, lymphocytes vary in appearance. When stained with Romanowsky stains and viewed by light microscopy, these may be

simply divided into small, medium and large lymphocytes.

Typical small lymphocytes are the smallest of the leukocytes and have a round nucleus composed of dense, coarsely clumped chromatin and a small, often incomplete “rim” of cytoplasm that is moderately to deeply basophilic. Medium-sized lymphocytes are larger than small lymphocytes, often similar in size to granulocytes, and have an irregularly round nucleus composed of moderately dense, irregularly clumped chromatin with a moderate amount of agranulated, moderately basophilic cytoplasm. Large lymphocytes are typically larger than granulocytes and may be of similar size to monocytes. Large lymphocytes typically have a round–ovoid nucleus composed of moderately dense, irregularly clumped chromatin with a moderate amount of agranulated, moderately basophilic cytoplasm.

Lymphocytes may exhibit several punctate, azurophilic to basophilic granules in their cytoplasm. They are found regularly in the blood of most birds and have been commonly noted in some birds, such as Gruiformes, where they are believed to be a “normal” feature (Hawkey et al. 1983).

Although there is often variation in the morphology of lymphocytes within the blood of an individual, there are no significant distinguishing differences in the morphology of lymphocytes between the different species of birds.

Few studies have assessed the ultrastructure of avian lymphocytes. Maxwell (1974) reported the ultrastructural characteristics of lymphocytes from six species of domestic birds, which he divided into small lymphocytes and medium-sized lymphocytes. Small lymphocytes were round with a large nuclear to cytoplasmic ratio and many pseudopodia. The nucleus showed considerable pleomorphism being round, ovoid, reniform or indented and was composed of equal amounts of heterochromatin and euchromatin, with one to two nucleoli. The cytoplasm typically con-

tained up to six mitochondria, a Golgi apparatus and centrioles, small amounts of RER and occasional pinocytotic vesicles, lipid droplets and small electron-dense membrane-bound granules. Medium-sized lymphocytes were round to ovoid with large nuclear to cytoplasmic ratio and small, thin pseudopodia. The nucleus was round or indented and was composed of peripheral heterochromatin and central euchromatin, with eccentric, variably sized nucleoli (some very large). The cytoplasm typically contained a paucity of organelles but mitochondria, endoplasmic reticulum, Golgi apparatus, centrioles, pinocytotic vesicles and membrane-bound granules with a whorl, stippled or homogeneous internal structure were observed in some cells.

Monocytes are large, pleomorphic leukocytes. When observed by light microscopy in Romanowsky stained blood films, monocytes have a nucleus that may be ovoid, indented (reniform), “horse-shoe” shaped or irregularly shaped and is composed of fine to reticular chromatin with a moderate to large amount of grey to basophilic cytoplasm. Granules are typically not evident in the cytoplasm; however, small eosinophilic granules may be observed in some cells. One to several small vacuoles may be evident in the cytoplasm of some monocytes.

Although the morphology of monocytes within the blood of an individual is often quite varied, there are no significant distinguishing differences in the morphology of monocytes between species. As monocytes and large lymphocytes have a similar size and morphological appearance when viewed in Romanowsky stained blood films, it may be difficult to distinguish between these cell types by this technique.

Few studies have assessed the ultrastructure of avian monocytes. Maxwell (1974) reported the ultrastructural characteristics of monocytes from six species of domestic birds. These were characterized by a reniform nucleus, composed of peripheral heterochromatin and central euchromatin with one to two nucleoli,

and extensive cytoplasm. The latter contained many organelles including a well defined Golgi apparatus and centrioles, microtubules, vesicles, mitochondria, RER, small dense membrane-bound granules, lipid droplets and pinocytotic vacuoles.

Atypical morphology of avian leukocytes

The morphology of “typical” leukocytes, as described earlier in this chapter, may be altered in response to inflammation. These changes may occur as a result of either the release of leukocytes from sites of hematopoiesis before they are mature, by the direct actions of toxins upon the cells in the peripheral blood, or by increased synthetic activity by the cell. Typically morphological atypia is most commonly encountered in heterophils and lymphocytes, less commonly encountered in monocytes and rarely recognized in eosinophils and basophils. The likelihood of morphological changes occurring in response to inflammation and the types and magnitude of the inflammation required to incite the changes, have not been established for most species of birds.

Atypical heterophil morphology may be observed in the nucleus, cytoplasm or both.

Usually, atypia of the nucleus is indicated by decreased segmentation, and consequently decreased number of nuclear lobes. This decreased complexity of the nucleus reflects decreased maturity of the heterophils and premature release from the bone in response to inflammatory demand. “Band” form heterophils, metamyelocytes and myelocytes may all be observed in response to significant inflammatory demand. Band heterophils have a non-segmented nucleus, metamyelocytes have a reniform-shaped nucleus and myelocytes have an ovoid (non-indented) nucleus. The chromatin is typically less clumped (more diffuse) in the less mature cells. Further indications of atypical myelopoiesis, such as an annular nucleus, may be observed in some cases of

severe inflammatory demand. The nuclear structure is often difficult to assess when the cell contains a typical number of cytoplasmic granules, as the granules commonly obscure part of the nucleus. Consequently, changes in the complexity of the nucleus are most easily assessed when there is a concomitant decrease in the density of cytoplasmic granules. Direct effects of toxins on the nucleus of leukocytes may result in karyolysis or karyorrhexis. These must be carefully distinguished from cells where the nucleus has been artifactually lysed during the production of the blood film or due to ageing of the blood sample. In the authors’ experience, artifactual causes of lysis are far more commonly encountered than true pathological effects on the cells in the peripheral blood.

As previously described, typical heterophils contain many elongated, fusiform granules that typically obscure the cytoplasm and partially obscure the nucleus. Atypical heterophils may exhibit morphological abnormalities that encompass changes in the cytoplasm and the granules it contains. The cytoplasmic granules of heterophils may change in shape, color and number (density) in response to inflammation. Typically, with mild inflammation, the granules are less pointed and maintain typical color. In more significant inflammation, the granules become round, larger and more basophilic than typical granules. The typical number of granules is usually maintained with mild inflammation. In cases of more significant inflammation, the number of granules within cells is decreased and agranulated heterophils or those that possess only one to several granules may be observed.

The decreased number of granules serves to make the cytoplasm more visible and provides greater opportunity to assess the characteristics of the cytoplasm. The cytoplasm may exhibit an increased basophilia, due to the presence of increased numbers of ribosomes. The cytoplasm may also exhibit a “foamy” or vacuolated appearance due to the direct action of toxins on the cells. However, these morpho-

logical changes must be differentiated from a similar appearance that may occur due to delayed processing of a sample of blood.

The morphological characteristics and the proportion of the cells that exhibit these characteristics vary with the severity of the inflammation. “Mild” changes typically include: mildly decreased numbers of granules, slightly rounded granules and increased basophilia of the cytoplasm. “Moderate” changes include: a greater decrease in the density of granules and rounded granules. Severe changes include: round granules, basophilic granules, large granules, “foamy”/vacuolated cytoplasm and karyolysis. The number of abnormal heterophils may be graded as “few” (5–10%), “moderate” (11–30%) and “marked” (greater than 30%) (Campbell 2004).

Lymphocytes may also exhibit variant morphology, affecting both cytoplasmic and nuclear characteristics; this reflects that they have responded to antigenic stimulation and have produced immunoglobulins. Typically, these are medium-sized cells with increased amounts of deeply basophilic cytoplasm, due to an increased concentration of ribosomes, and a prominent perinuclear halo that represents the Golgi apparatus. Additionally, lymphocytes that exhibit a prominent nucleolus may be observed. These “blast-transformed” cells usually represent a prelude to mitosis of stimulated lymphocytes. However, in large numbers these may indicate a neoplastic proliferation of lymphocytes.

The presence of hemoparasites, such as *Leukocytozoon* spp and *Hepatozoon* spp, may alter the morphology of their host cell, typically mononuclear leukocytes. The presence of the organism(s) may distort the shape of the cell, enlarge the size of the cell, or displace the nucleus within the cell.

Examples of leukocytes exhibiting atypical morphology, in response to disease, have been reported for a range of bird species. Morphological atypia, including areas of cytoplasm without granules, cytoplasmic vacuolation, increased cytoplasmic basophilia and baso-

philic granules, was recorded in three species from the genus *Buteo* with inflammatory disorders (Bienzle et al. 1997). A king shag (*Phalacrocorax albivenier*) with aspergillosis had heterophils that exhibited strongly basophilic spherical granules as well as oval eosinophilic granules (Hawkey et al. 1984c). Birds with mycobacteriosis, from several species of crane, that demonstrated a heterophilia and monocytosis, also had heterophils with a hypo-segmented nucleus, decreased concentration of granules and extra, round basophilic granules. The monocytes of these birds lacked nuclear indentation and exhibited cytoplasmic vacuolation (Hawkey et al. 1990). Houbara bustards (*Chlamydotis undulata*) with chronic inflammation exhibited heterophils with atypical morphology including: cytoplasmic basophilia, lack of granulation and decreased nuclear lobulation (D’Aloia et al. 1994). A lesser sulphur-crested cockatoo (*Cacatua sulphurea*) with a traumatic foot injury exhibited a heterophilia with atypical heterophil morphology including: decreased nuclear maturity (“left-shift”), decreased granulation, round basophilic granules and “rice-shaped” eosinophilic granules (Bienzle & Smith 1999).

Morphological atypia of leukocytes may not be present in all birds with inflammation, however. For example, in a study of two species of black cockatoos with inflammation or traumatic injury, only 3/21 (14%) of birds exhibited heterophils with morphological changes (Jaensch & Clark 2004).

THROMBOCYTES

See Figures 81–83.

Thrombocytes are the nucleated hemostatic cells of birds. Individual thrombocytes are typically smaller than all leukocytes and erythrocytes. They have a very dense, darkly staining, ovoid nucleus with a small to moderate amount of “colorless”, pale grey or pale basophilic cytoplasm. In some cases, fine

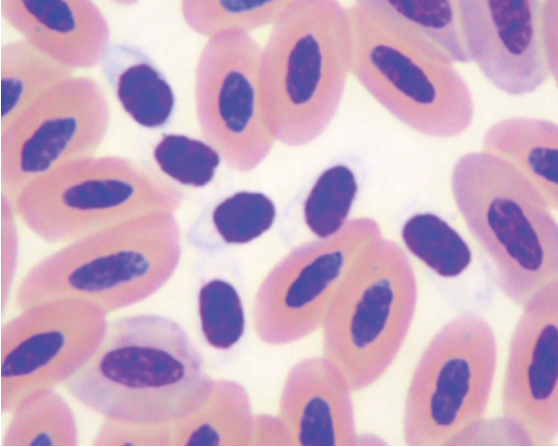


Figure 81 Blood from a royal spoonbill (*Platalea regia*) portraying an aggregation of six thrombocytes amidst mature erythrocytes. (Diff Quik stain.) Thrombocytes typically have an ovoid nucleus composed of uniformly dark, dense chromatin and a small amount of colorless to palely basophilic cytoplasm. Thrombocytes are smaller than erythrocytes and most leukocytes but may be similar in size to small lymphocytes.

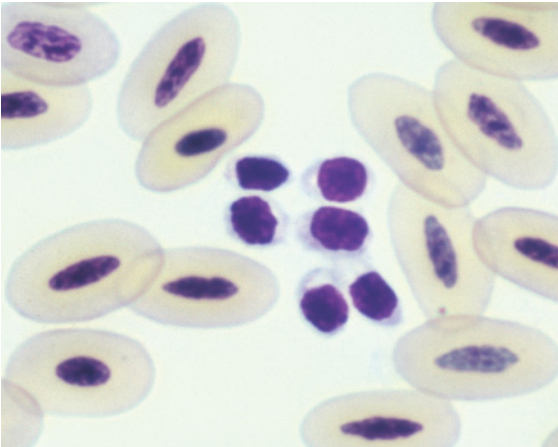


Figure 82 Blood from a bald eagle (*Haliaeetus leucocephalus*) showing aggregated thrombocytes amidst mature erythrocytes. (Modified Wright's stain.) Often thrombocytes are aggregated in blood films and this characteristic may be used to aid the identification of their cell type. However, if heparin is used as an anti-coagulant, leukocytes including lymphocytes may also occur in "clumps".

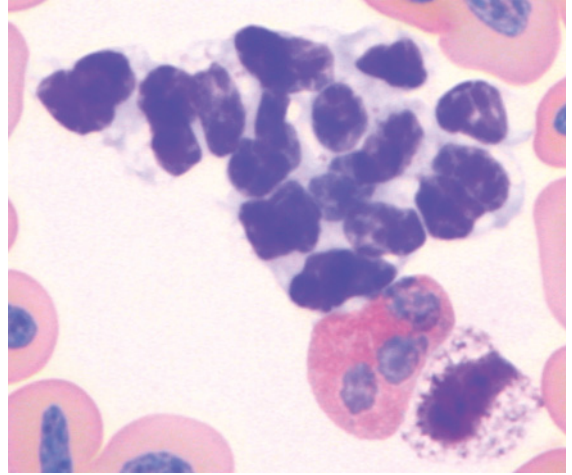


Figure 83 Blood from a wattled crane (*Grus carunculatus*) illustrating a larger aggregate of thrombocytes. (Modified Wright's stain.) In these thrombocytes the cytoplasm is a distinct grey-basophilic color. Also present are an eosinophil and a basophil (in which the majority of granules have not taken up the basophilic stain).

cytoplasmic projections ("pseudopodia") may be evident. Several small, punctate, eosinophilic or azurophilic granules may be observed in the cytoplasm of some thrombocytes.

In many cases, the thrombocytes will have aggregated into variably sized clumps throughout the blood film. In these aggregates, distinct, individual cell outlines may be difficult to discern. When trying to distinguish thrombocytes from small lymphocytes, it is often useful to assess the morphology of thrombocytes within aggregates to determine the morphological characteristics of thrombocytes for the particular bird (or species), then use those features to identify non-aggregated thrombocytes, and finally distinguish the lymphocytes in contrast to the thrombocytes.

A study of the ultrastructure of thrombocytes from roadside hawks revealed either a predominantly elliptical shape or spherical shape, with organelles that included Golgi, smooth endoplasmic reticulum, small mitochondria, dense osmiophilic granules, peripheral microtubules and canalicular system

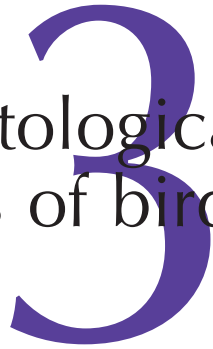opened to the cell's surface (Santos et al. 2003a).

HEMATOPOIESIS

Very few studies have assessed the hematological characteristics of bone marrow from birds, other than chickens. These include studies of the Japanese quail (*Coturnix coturnix japonica*) (Nazifi et al. 1999) and black-headed gull (*Larus ridibundus*) (Tadjalli et al. 2002). The former study assessed samples of blood and bone marrow (from the proximal tibiotarsus)

of 75 clinically healthy quails. They found the mean proportion of erythroid cells was 67.3%, the mean proportion of myeloid cells was 24.9% and the mean proportion of thrombocyte line cells was 3.3%. The age of the bird had a significant effect on the proportions of many of the cell types but no differences due to the sex of the bird were observed. In the latter study, samples of bone marrow were collected from the proximal tibiotarsus of 50 clinically healthy, adult gulls. The mean proportion of erythroid cells was 39.9%, the mean proportion of myeloid cells was 49.4% and the mean proportion of thrombocytic cells was 6.0%.

Particular hematological characteristics of birds



INTRODUCTION

The following chapter describes the hematological characteristics of birds, where known, within the orders of the Aves and highlights any known nuances in those characteristics. In the context of this book, a practical application of taxonomy has been used to structure the approach to the hematological characteristics of birds. Unfortunately, due to a dearth of published studies on species within some orders and difficulty in obtaining blood films and hematological data, it was not possible to include information about all the orders of the Aves. Further studies will no doubt elucidate further nuances in the hematological characteristics of particular species of birds. Until all species have been described, extrapolation from the closest species for which the hematological characteristics have been reported will remain necessary, albeit with the caveat that even species within the same genus may exhibit significant hematological differences.

There is considerable ongoing debate concerning the taxonomy of the class Aves and we have used arguably the most recent and reliable source of information to summarize the

information presented in this chapter. It should be noted that the vast majority of bird species belong within the Passeriformes, which encompasses six major sub-orders. To illustrate this point, the number of species contained within the 79 families of the Oscine sub-order, is greater than the combined number of species from all other orders. As previously described in Table 1.1, the orders within the Aves include:

- Order: Anseriformes
- Order: Apodiformes
- Order: Caprimulgiformes
- Order: Charadriiformes
- Order: Ciconiiformes
- Order: Coliiformes
- Order: Columbiformes
- Order: Coraciiformes
- Order: Cuculiformes
- Order: Falconiformes
- Order: Galliformes
- Order: Gaviiformes
- Order: Gruiformes
- Order: Opisthocomiformes
- Order: Passeriformes
- Order: Pelecaniformes
- Order: Phoenicopteriformes

Order: Piciformes
 Order: Podicipediformes
 Order: Procellariiformes
 Order: Psittaciformes
 Order: Sphenisciformes
 Order: Strigiformes
 Order: Struthioniformes
 Order: Tinamiformes
 Order: Trogoniformes

ANSERIFORMES (DUCKS, GEESE AND SWANS)

See Figures 84–95.

Several studies have described selected hematological characteristics of non-domestic Anseriformes, including: three species of geese (Williams & Trainer 1971), canvasback duck (*Aythya valisineria*) (Kocan 1972, Kocan & Pitts 1976), Pacific black duck (*Anas*

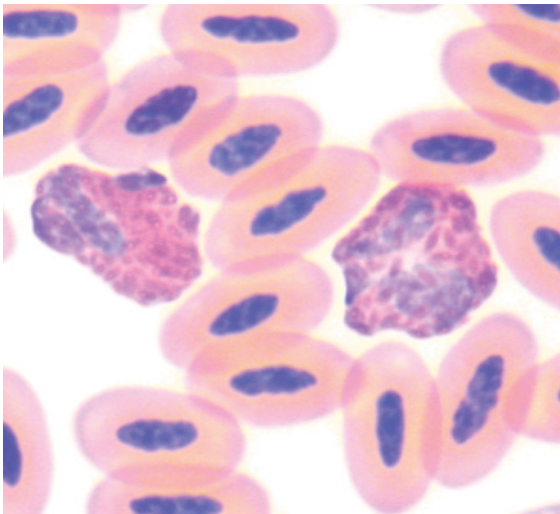


Figure 84 Blood from a black swan (*Cygnus atratus*) showing two heterophils amidst mature erythrocytes. The granules of the heterophils are fusiform and brick-red color. Some granules exhibit a central, round, refractile structure (“central granular body”). These are regularly observed in birds from this Order and should not be misinterpreted as a “toxic change”. (Modified Wright’s stain.)

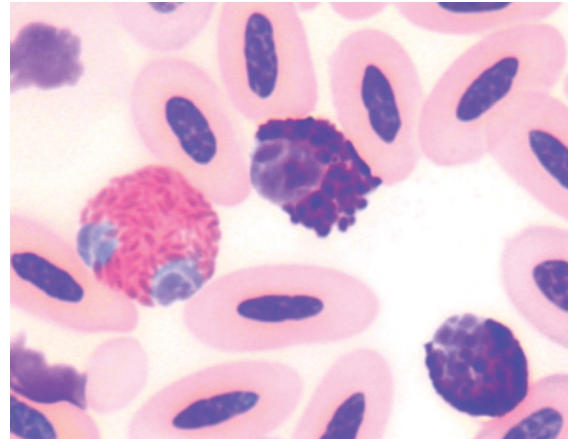


Figure 85 Blood from an Australian shelduck (*Tadorna tadornoides*) showing a heterophil with many uniform, fusiform brick-red granules and two basophils with variably sized round-ovoid basophilic granules. Note that the nucleus of the basophils is palely stained in comparison to the cytoplasmic granules. The nucleus of the heterophil is a light blue color, this is commonly observed and assists to distinguish heterophils from eosinophils (see Figure 86). (Modified Wright’s stain.)

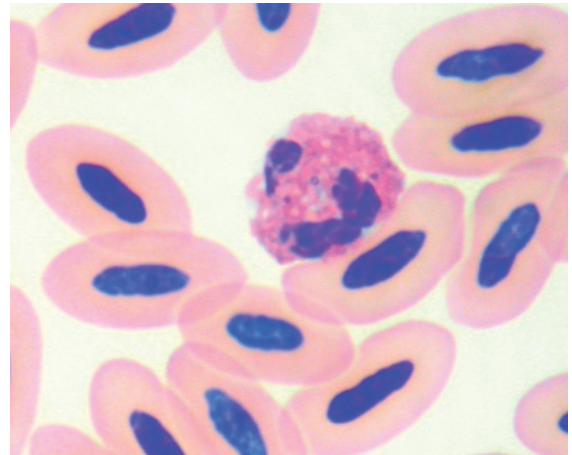


Figure 86 Blood from the same Australian shelduck as in Figure 85 showing an eosinophil characterized by a segmented nucleus composed of dark basophilic, coarse chromatin and many, brightly eosinophilic, rod-shaped granules. (Modified Wright’s stain.)

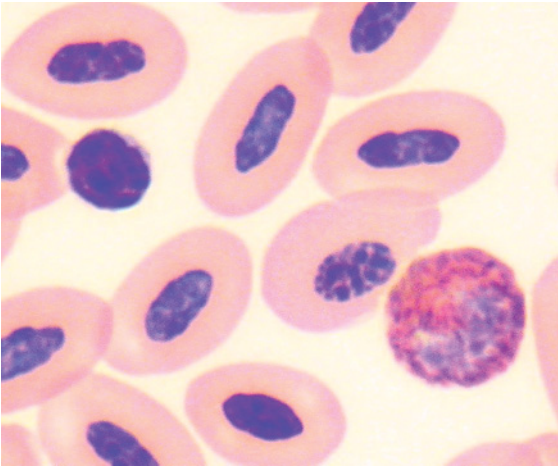


Figure 87 Blood from a Pacific black duck (*Anas superciliosa*), showing a typical small lymphocyte and heterophil amidst mature erythrocytes. (Modified Wright's stain.)

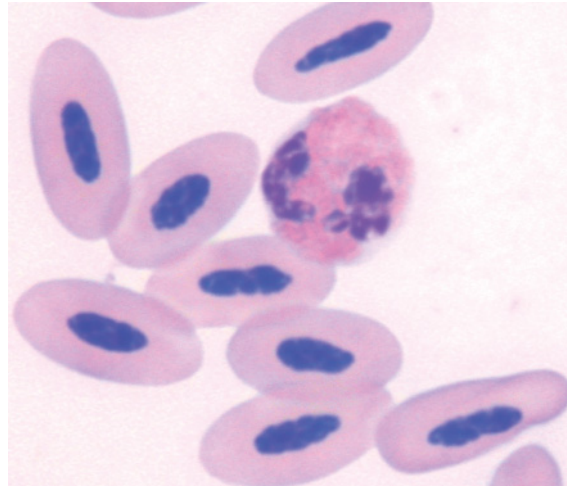


Figure 89 Blood from the same bird as in Figure 88 showing an eosinophil amidst mature erythrocytes. The cytoplasmic granules are typically rod-shaped and brightly eosinophilic. The nucleus can be seen to be a darker basophilic color than the nucleus of heterophils in Figure 88. (Modified Wright's stain.)

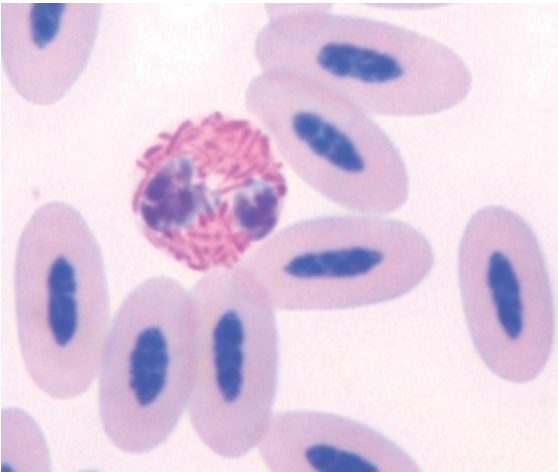


Figure 88 Blood from a Barrow's golden eye (*Bucephala islandica*) showing a heterophil, with distinct granules, amidst mature erythrocytes. (Modified Wright's stain.)

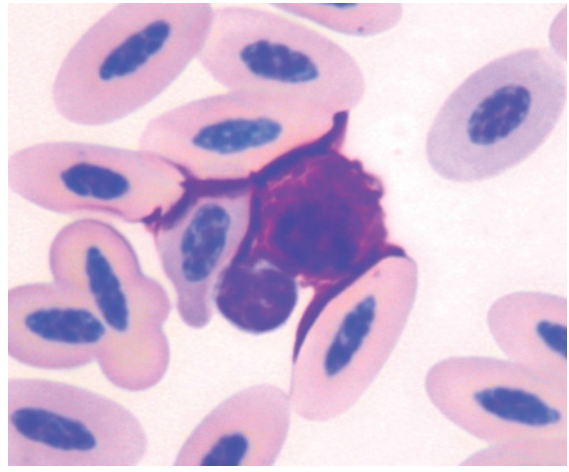


Figure 90 Blood from the same bird as in Figure 88 portraying a basophil and small lymphocyte amidst mature erythrocytes. The illustrated "bleeding" of basophilic color from the basophil to outline adjacent cells is regularly observed in avian blood films. (Modified Wright's stain.)

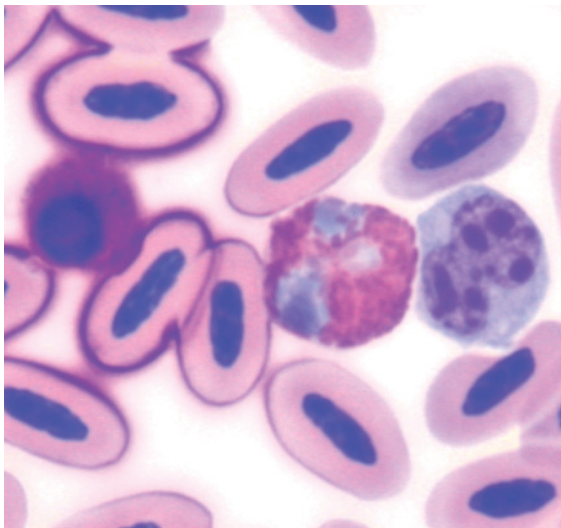


Figure 91 Blood from a goosander (*Mergus merganser*) showing a basophil (with some “bleeding” of the basophilic color to adjacent cells), heterophil (with palely staining nucleus) and monocyte amidst erythrocytes, including one polychromatophilic erythrocyte. (Modified Wright’s stain.)

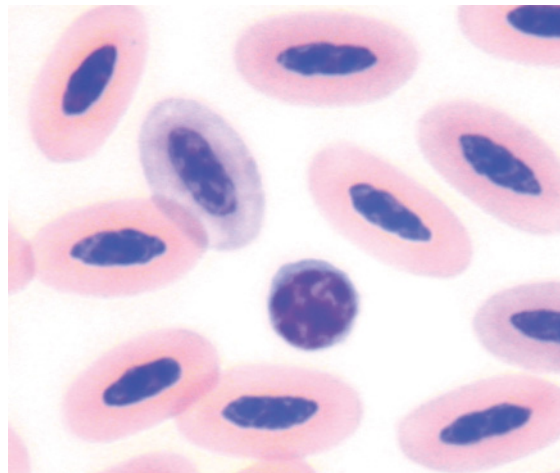


Figure 93 Blood from the same goosander as in Figure 91 showing a typical small lymphocyte amidst mature erythrocytes and a single polychromatophilic erythrocyte. (Modified Wright’s stain.)

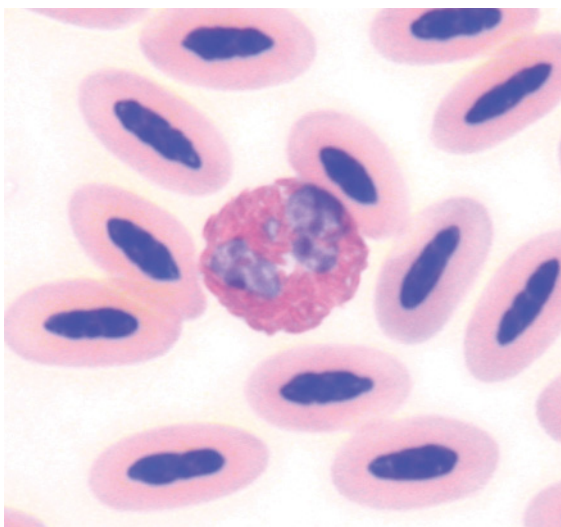


Figure 92 Blood from the same goosander as in Figure 91 showing a typical eosinophil; with a high density of brightly eosinophilic granules and segmented basophilic nucleus (darker than the nucleus of the heterophils), amidst mature erythrocytes. (Modified Wright’s stain.)

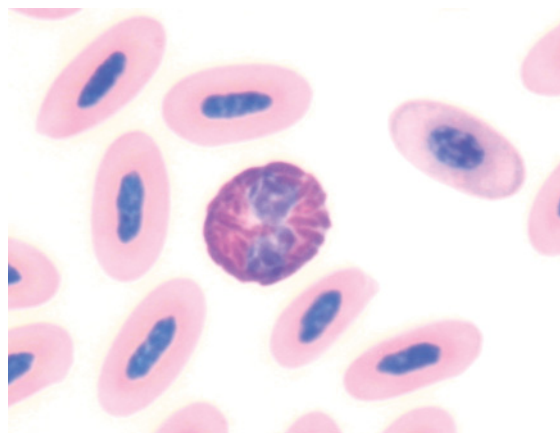


Figure 94 Blood from a Baer’s pochard (*Aythya baeri*) showing a heterophil amidst mature erythrocytes. (Modified Wright’s stain.)

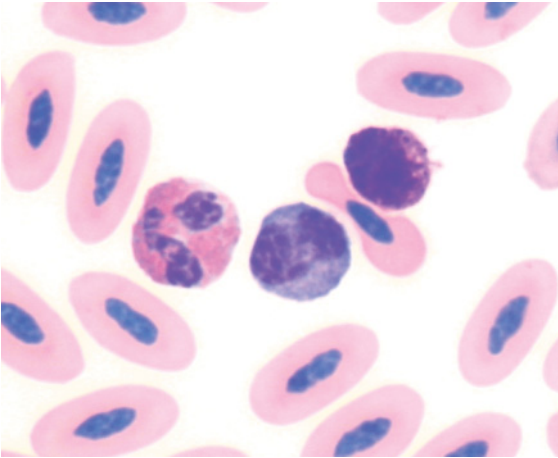


Figure 95 Blood from a Baer's pochard showing a basophil, monocyte and eosinophil amidst mature erythrocytes (Modified Wright's stain.)

superciliosa) (Mulley 1979), Australian wood duck (*Chenonetta jubata*) (Mulley 1980) and mallard (*Anas platyrhynchos*) (Driver 1981, Fairbrother et al. 1990, Fairbrother & O'Loughlin 1990, Levengood et al. 2000). Few of these have described the morphological characteristics of hematological cells.

Erythrocytes were ovoid cells with an ovoid nucleus composed of dense chromatin and homogeneous eosinophilic cytoplasm. Small numbers of polychromatophilic erythrocytes, exhibiting palely basophilic cytoplasm were evident. Heterophils had many fusiform, brick-red colored granules that were present at high density throughout the cytoplasm. Eosinophils had many small, rod-shaped, brightly eosinophilic granules present at high density throughout the cytoplasm. Basophils had many round, deeply basophilic granules that obscured both nucleus and cytoplasm. Lymphocytes and monocytes had morphology consistent with the general characteristics displayed by birds, as previously described.

APODIFORMES (SWIFTS AND HUMMINGBIRDS)

To the authors' knowledge few studies have described the hematological characteristics of species within the Apodiformes, and these did not describe the morphological characteristics of hematological cells.

CAPRIMULGIFORMES (FROGMOUTHS, GOATSUCKERS AND OWLET-NIGHTJARS)

See Figure 96.

Few studies have described the hematological characteristics of members of the Caprimulgiformes. McCracken (2003) reported selected hematological values for the tawny frogmouth (*Podargus strigoides*) and described eosinophils to have pale mauve granules.

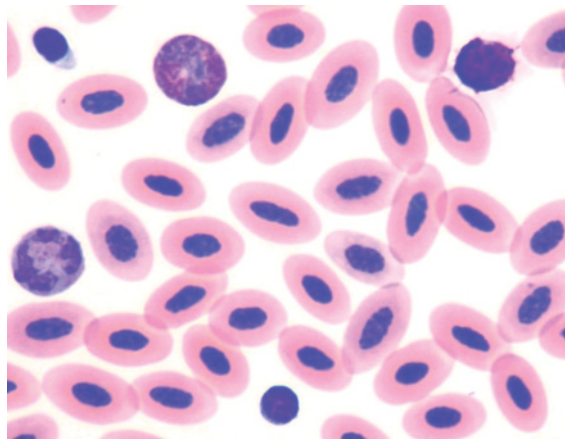


Figure 96 Blood from a tawny frogmouth (*Podargus strigoides*) showing: a heterophil, with brick-red granules and a basophilic nucleus (top middle); an eosinophil with a segmented basophilic nucleus and basophilic cytoplasm that contains sparse, pale eosinophilic granules (left); a basophil with many dark basophilic granules that preclude observation of the fine detail of the cell's structures (top right); a lymphocyte and a thrombocyte with a dark ovoid nucleus and pale basophilic cytoplasm (top left), amidst mature erythrocytes. (Modified Wright's stain.)

Erythrocytes from the tawny frogmouth were ovoid cells with an ovoid nucleus composed of dense chromatin and even eosinophilic cytoplasm. Heterophils were irregularly round cells with fine, fusiform, brick-red colored granules present at moderate–high density throughout the cytoplasm. Eosinophils had a palely basophilic cytoplasm with few, small pale blue–grey to eosinophilic granules (depending on the stain), consequently the nucleus is distinct and characterized by segmented coarse chromatin. Basophils had fine round, deeply basophilic granules present at high density that obscured both nucleus and cytoplasm. Lymphocytes and monocytes had morphology consistent with the general characteristics displayed by birds, as previously described.

CHARADRIIFORMES (GULLS AND SHOREBIRDS)

See Figures 97–104.

There have been few studies that have described the hematological characteristics of species within the Charadriiformes; these

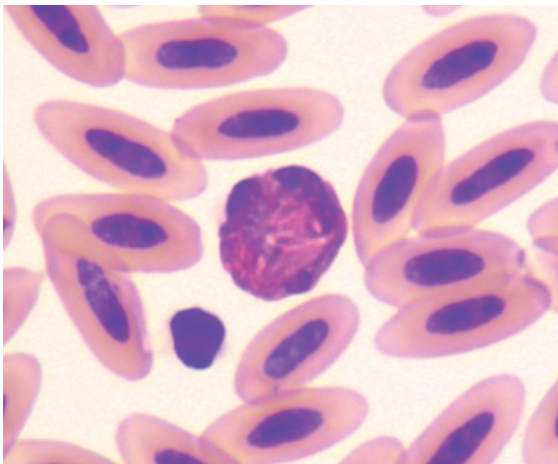


Figure 97 Blood from a great knot (*Calidris tenuirostris*). A heterophil and a thrombocyte are present amidst mature erythrocytes. (Diff Quik stain.)

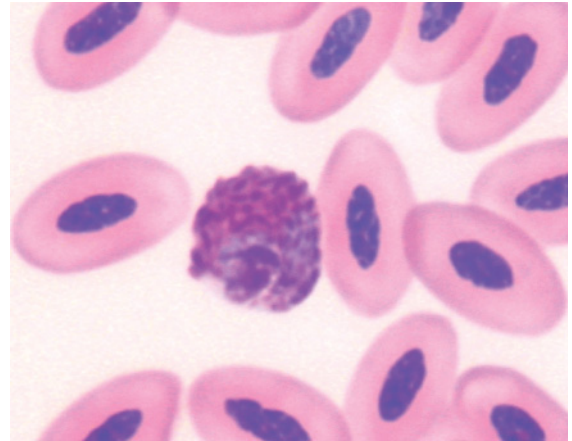


Figure 98 Blood from a fairy tern (*Sterna nereis*) showing a heterophil amidst mature erythrocytes. (Modified Wright's stain.)

include the pigeon guillemot (*Cepphus columba*) (Seiser et al. 2000), black-headed gull (*Larus ridibundus*) (Munoz & De la Fuente 2003, Mostaghni et al. 2005), the herring gull (*Larus argentatus*) (Threlfall 1966, Averbek 1992, Grasman et al. 2000), great black-backed gull (*Larus marinus*) and several species of wading birds (Ball 2003). The morphological characteristics of hematological cells were not described. Work (1996) described

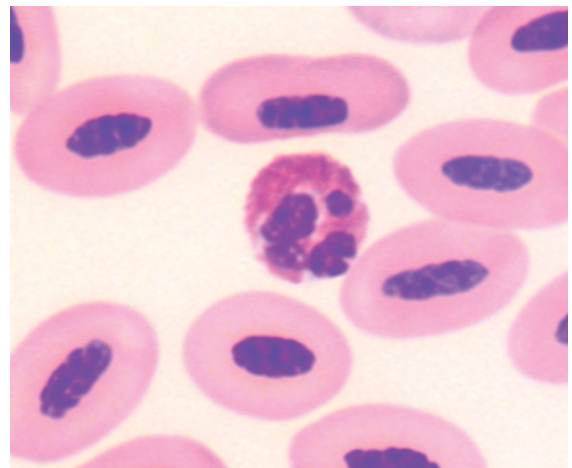


Figure 99 Blood from a fairy tern showing an eosinophil amidst mature erythrocytes. (Modified Wright's stain.)

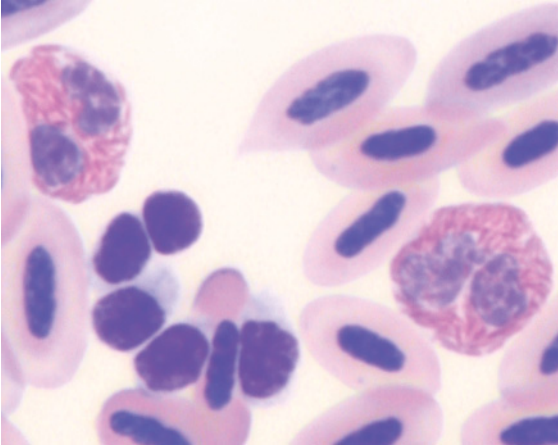


Figure 100 Blood from a stone curlew (*Burhinus oedicephalus*) showing two heterophils and an aggregation of thrombocytes amidst mature erythrocytes. Amongst the thrombocytes, several cells with a round nucleus and a cell with an elongated nucleus are evident. (Modified Wright's stain.)

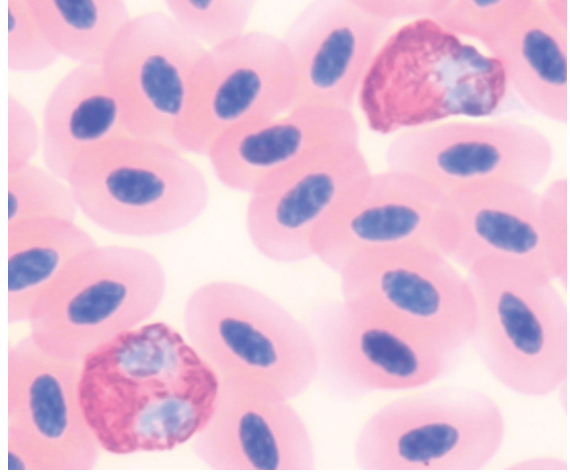


Figure 102 Blood from a silver gull (*Larus novaehollandiae*) showing two heterophils amidst mature erythrocytes. Note that the nucleus of each of the heterophils has not taken up an adequate amount of stain and appears as pale blue, rather than basophilic color. (Modified Wright's stain.)

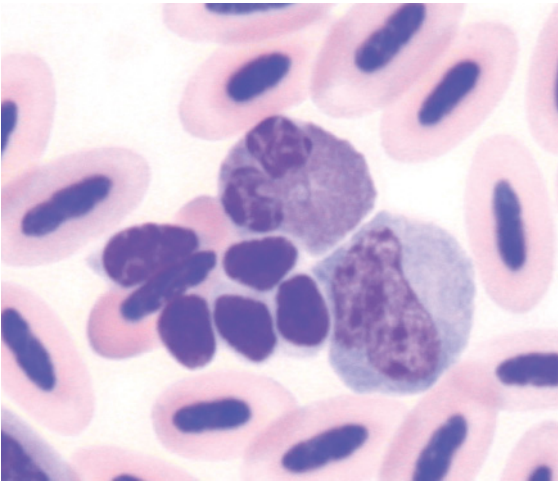


Figure 101 Blood from the same stone curlew as in Figure 100, showing an eosinophil, monocyte and aggregation of thrombocytes. The eosinophil contains many small round dull brown-eosinophilic granules within a basophilic cytoplasm. (Modified Wright's stain.)

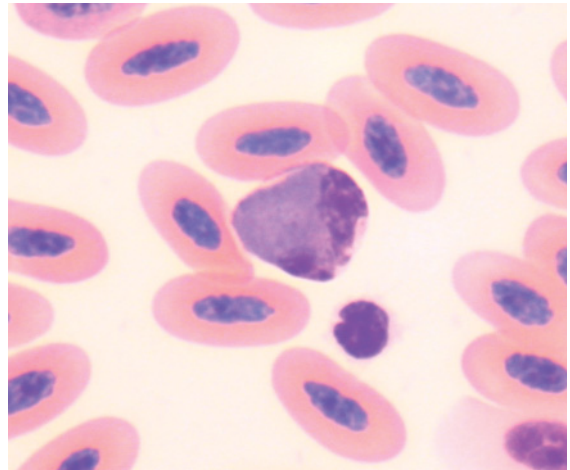


Figure 103 Blood from a silver gull showing an eosinophil with a high density of small brown-grey cytoplasmic granules. A thrombocyte and mature erythrocytes are also present. (Modified Wright's stain.)

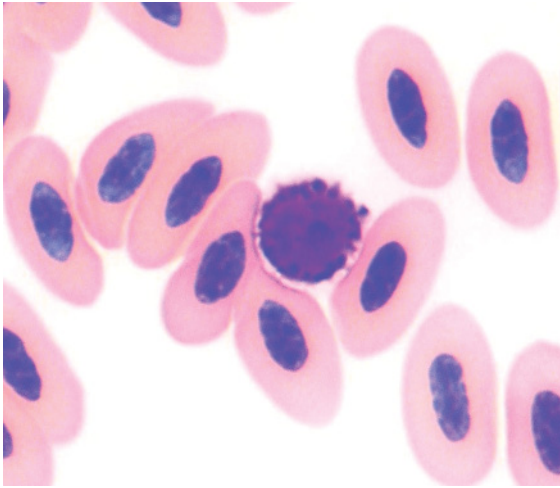


Figure 104 Blood from a silver gull showing a basophil amidst mature erythrocytes. (Modified Wright's stain.)

the morphology of hematological cells from the sooty tern (*Sterna fuscata*); heterophils, basophils, monocytes and lymphocytes had morphology similar to that previously described for birds. Eosinophils had “densely packed orange, round, plump granules”. The morphology of haematological cells of stone curlews (*Burhinus oedicanus*) has been described (Samour et al. 1998). These authors reported that eosinophils had a bi-lobed nucleus and pale blue cytoplasm that contained “very small round-oval shaped pink/red/orange” granules. The remaining leukocytes had an appearance similar to that previously described for birds.

In the species examined, heterophils were irregularly round cells with fine, fusiform, brick-red colored granules present at moderate–high density throughout the cytoplasm. Eosinophils of the silver gull (*Larus novaehollandiae*) had many small, grey–blue granules and, in contrast to a previously published report, the eosinophils of the stone curlew had small ovoid to rod-shaped, brown–eosinophilic granules. Consequently, variation in the morphology of eosinophils may be encoun-

tered within this order. Basophils had fine round, deeply basophilic granules present at high density that obscured both nucleus and cytoplasm. Lymphocytes and monocytes had morphology consistent with the general characteristics displayed by birds, as previously described.

CICONIIFORMES (HERONS, IBIS AND STORKS)

See Figures 105–107.

Reports of the hematological characteristics have been published for a number of species belonging to this order including: bald ibis (*Geronticus calvus*) (Dutton et al. 2002, Villegas et al. 2004), puna ibis (*Plegadis ridgwayi*) (Coke et al. 2004), white stork (*Ciconia ciconia*) (Alonso et al. 1991, Montesinos et al.

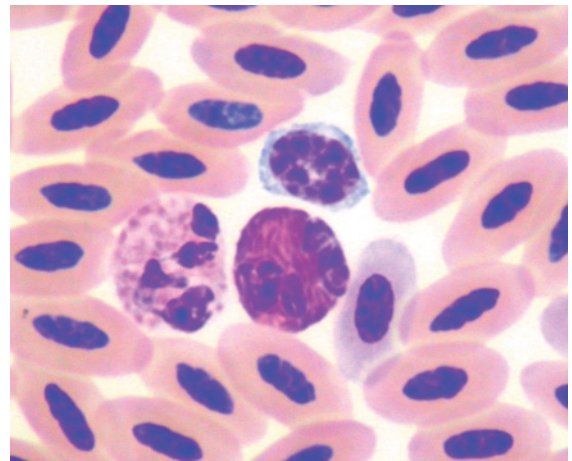


Figure 105 Blood from a royal spoonbill (*Platalea regia*) illustrating: an eosinophil (left) with four lobes to the nucleus evident and a moderate density of round, pale eosinophilic granules in the cytoplasm; a heterophil with a segmented nucleus and a high density of fusiform, brick-red granules; a lymphocyte with coarse clumped chromatin and basophilic cytoplasm, amidst mature erythrocytes and a single polychromatophilic erythrocyte. (Modified Wright's stain.)

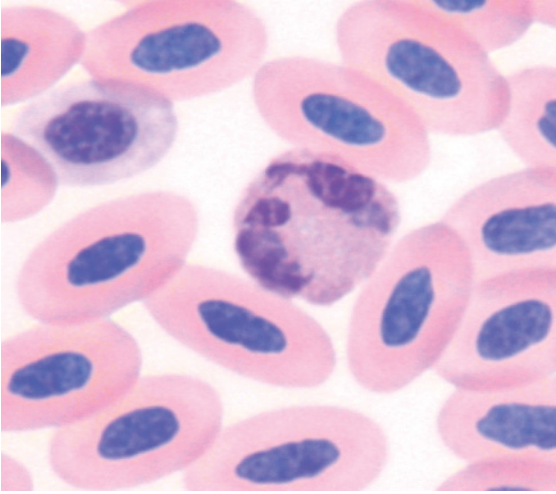


Figure 106 Blood from a cattle egret (*Bubulcus ibis*) showing an eosinophil with a segmented basophilic nucleus and a high density of small, indistinct eosinophilic granules in the cytoplasm. (Modified Wright's stain.)

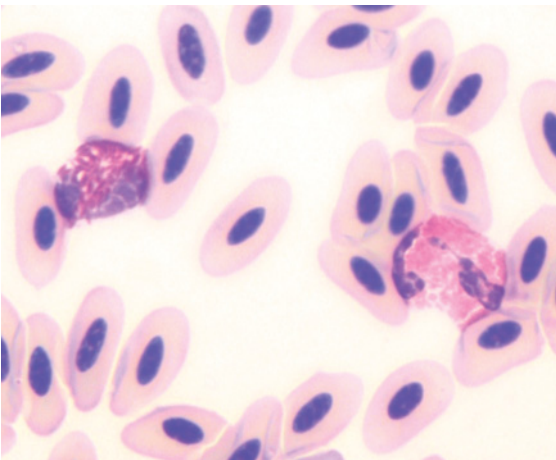


Figure 107 Blood from a black-faced ibis (*Theristicus melanopis*) showing a heterophil (left) with thin, fusiform brick-red cytoplasmic granules and an eosinophil with brightly eosinophilic round to rod-shaped cytoplasmic granules amidst erythrocytes. (Modified Wright's stain.)

1997), black stork (*Ciconia nigra*) (Puerta et al. 1989), night heron (*Nycticorax nycticorax*), cattle egret (*Bubulcus ibis*) and little egret (*Egretta garzetta*) (Celdran et al. 1994). However, these studies did not report the morphology of hematological cells.

Waters and Hart (2002) assessed the morphology of hematological cells from the scarlet ibis (*Eudocimus ruber*), American wood stork (*Mycteria americana*) and marabou stork (*Leptoptilos crumeniferus*) and described variation in the morphology of eosinophils, notably in the size and hue of the cytoplasmic granules.

Erythrocytes were ovoid cells with an ovoid nucleus composed of dense chromatin and eosinophilic cytoplasm. Heterophils were irregularly round cells with prominent fusiform, brick-red to dull brown colored granules that were present at high density and obscured the nucleus in many cells. Eosinophils typically had small round, brightly eosinophilic granules present at a moderate to high density in a palely basophilic cytoplasm. The size of the granules varied between species. Basophils were smaller, round cells with round, deeply basophilic granules present at high density that obscured both nucleus and cytoplasm. In some degranulated cells, the nucleus was round and the cytoplasm "colorless". Lymphocytes and monocytes had morphology consistent with the general characteristics displayed by birds, as previously described.

COLIIFORMES (MOUSEBIRDS)

To the authors' knowledge few studies have described the hematological characteristics of members of the Coliiformes. Pye (2003) presented selected hematological data for four species of mousebird but did not describe the morphological characteristics of hematological cells.

COLUMBIFORMES (PIGEONS AND DOVES)

See Figures 108–114.

The hematological characteristics were reported for five species of pigeons (Peinado et al. 1992), rock pigeons (*Columba livia*) (Gayathri & Hegde 1994) and three species of pigeons (Schulz 2003). These studies did not report the morphological characteristics of hematological cells.

Erythrocytes were ovoid cells with an ovoid nucleus composed of dense chromatin and even eosinophilic cytoplasm. Heterophils were irregularly round cells with prominent fusiform, brick-red to dull brown colored granules that were present at high density and filled most of the cytoplasm. Eosinophils had many small, round, eosinophilic granules. The color of the granules varied notably with the stain. Basophils had many, deeply basophilic granules that obscured both nucleus and cytoplasm. Lymphocytes and monocytes had morphology consistent with the general characteristics displayed by birds, as previously described.

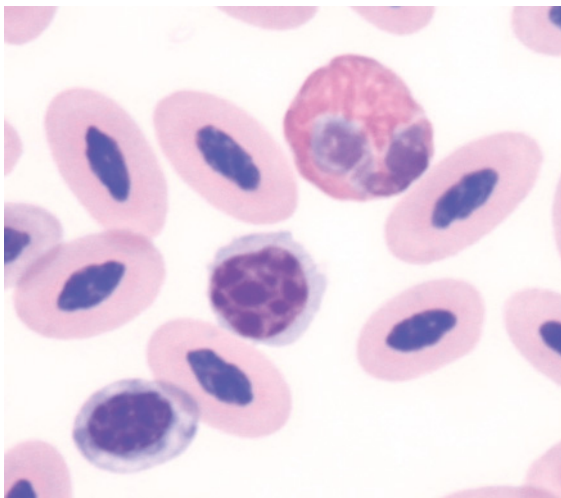


Figure 108 Blood from a Mindanao bleeding heart dove (*Gallicolumba criniger*) showing a heterophil and a lymphocyte amidst erythrocytes, including a single polychromatophilic erythrocyte. (Modified Wright's stain.)

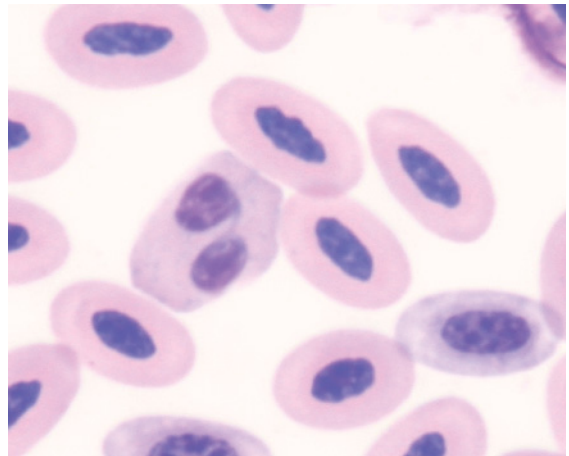


Figure 109 Blood from the same bird as in Figure 108 showing an eosinophil with a bi-lobed basophilic nucleus and many small round pale eosinophilic granules in a pale basophilic cytoplasm, amidst erythrocytes. (Modified Wright's stain.)

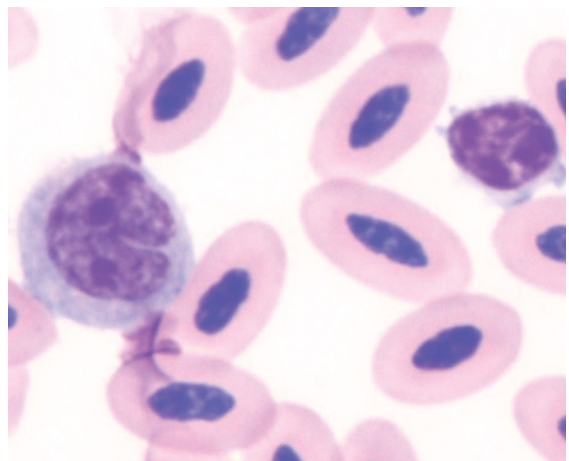


Figure 110 Blood from the same bird as in Figure 108 showing a classically shaped monocyte (left) with a "horse-shoe" shaped nucleus, reticular chromatin and a moderate amount of basophilic cytoplasm and a lymphocyte amidst mature erythrocytes. (Modified Wright's stain.)

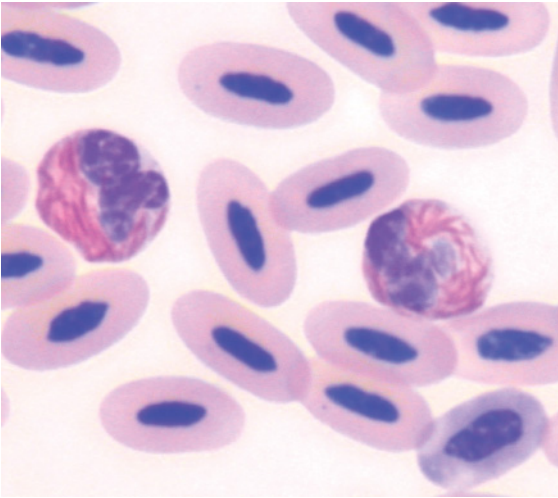


Figure 111 Blood from a chestnut-naped imperial pigeon (*Ducula aenea paulina*) illustrating two heterophils, each with many fusiform, brick-red granules. (Modified Wright's stain.)

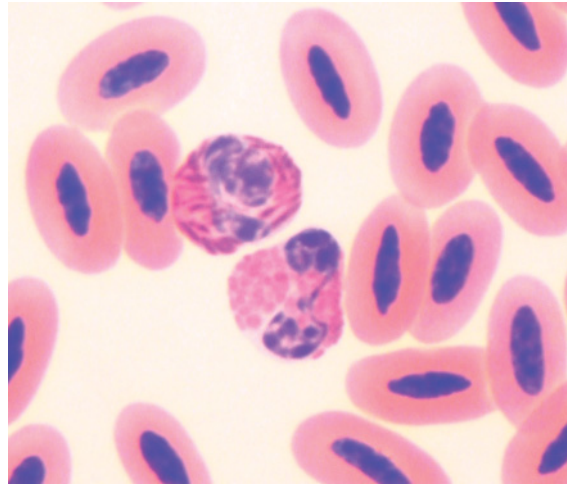


Figure 113 Blood from a spotted dove (*Streptopelia chinensis*) portraying a heterophil (top) with many fusiform, brick-red granules and an eosinophil with a bilobed basophilic nucleus and many small round brightly eosinophilic granules, amidst mature erythrocytes. (Modified Wright's stain.)

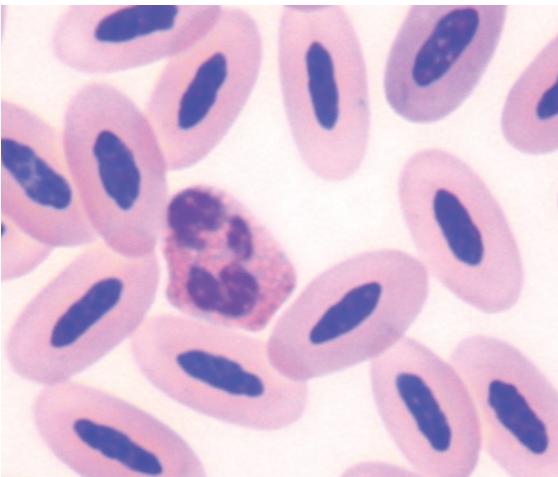


Figure 112 Blood from a chestnut-naped imperial pigeon showing an eosinophil with a lobulated basophilic nucleus and many small round pale eosinophilic granules in a pale basophilic cytoplasm, amidst erythrocytes. (Modified Wright's stain.)

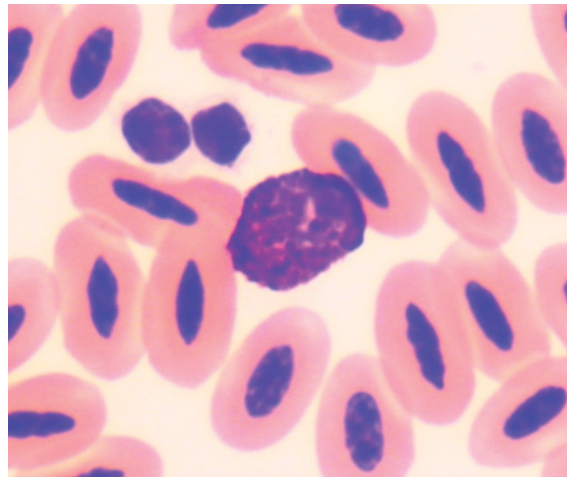


Figure 114 Blood from a spotted dove showing a basophil with many basophilic cytoplasmic granules that obscure the nucleus, and two thrombocytes amidst mature erythrocytes. (Modified Wright's stain.)

CORACIIFORMES (KINGFISHERS, BEE-EATERS, HORNBILLS, MOTMOTS, ROLLERS AND TODIES)

See Figures 115–124.

To the authors' knowledge few studies have described the hematological characteristics of members of the Coraciiformes. Selected hematological data was presented for eight species of Coraciiformes (Dutton 2003) but did not describe the morphological characteristics of hematological cells.

Several species of kingfishers, including the azure kingfisher (*Alcedo azurea*), sacred kingfisher (*Todirhamphus sanctus*) and laughing kookaburra, had erythrocytes that were ovoid cells with an ovoid nucleus composed of dense chromatin and even eosinophilic cytoplasm. Heterophils were irregularly round cells with many, prominent fusiform, brick-red to dull brown colored granules that partially obscured the nucleus in many cells. Eosinophils had many robust, round, brightly eosinophilic granules present at a moderate to high density in a palely basophilic cytoplasm. Basophils had many deeply basophilic granules present

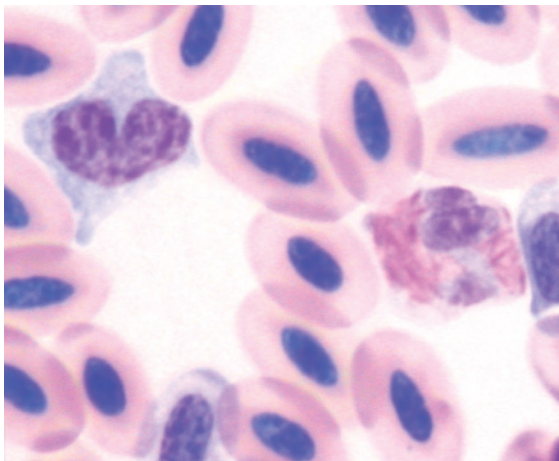


Figure 115 Blood from a laughing kookaburra (*Dacelo novaeguineae*) showing a heterophil with fine fusiform, brick-red granules in a pale basophilic cytoplasm and a monocyte amidst erythrocytes. (May-Grünwald and Giemsa stains.)

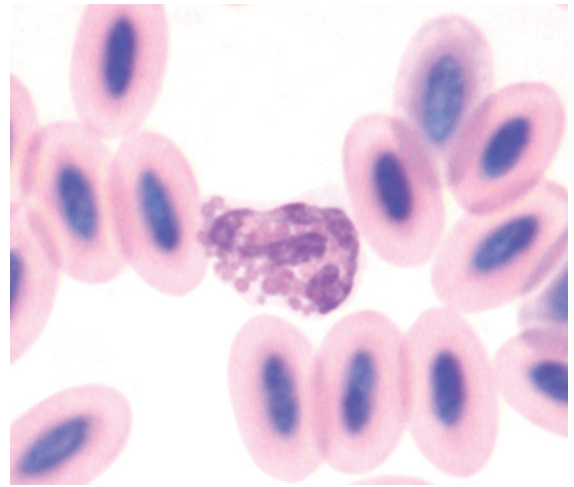


Figure 116 Blood from the same bird as in Figure 115 illustrating an eosinophil. Note the segmented nucleus and variably sized ovoid eosinophilic granules within a pale basophilic cytoplasm. (May-Grünwald and Giemsa stains.)

at high density that obscured both nucleus and cytoplasm. Lymphocytes and monocytes had morphology consistent with the general characteristics displayed by birds, as previously described.

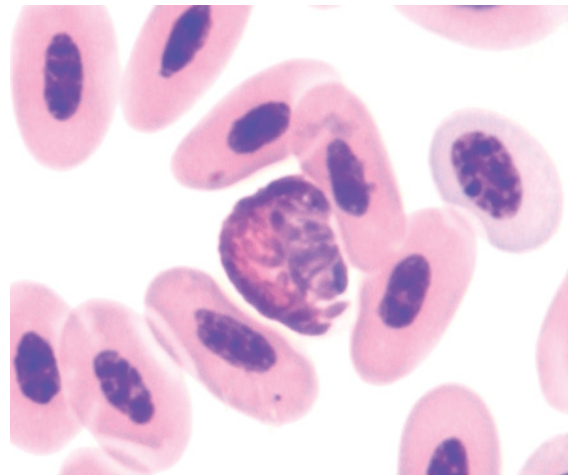


Figure 117 Blood from a blue-winged kookaburra (*Dacelo leachii*) showing a heterophil amidst erythrocytes. The density of cytoplasmic granules makes assessment of the fine detail of the cell difficult. (Diff Quik stain.)

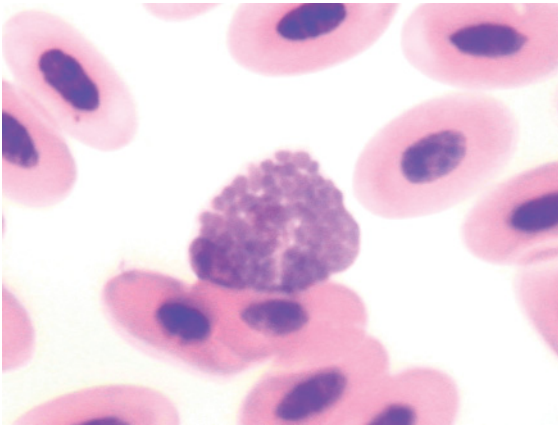


Figure 118 Blood from the same bird as in Figure 117 illustrating an eosinophil. In this sample the brownish color of the granules likely reflects the stain employed. (Diff Quik stain.)

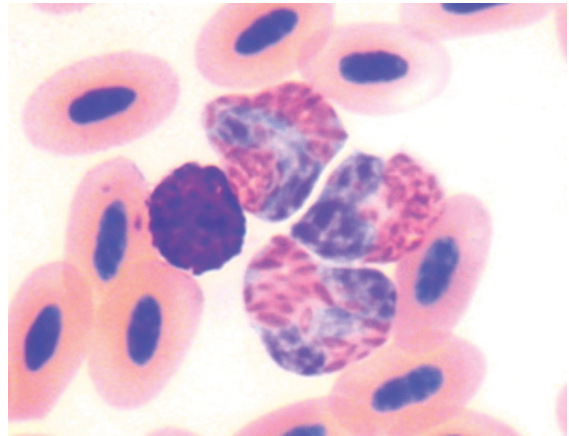


Figure 121 Blood from a sacred kingfisher (*Todirhamphus sanctus*) illustrating three heterophils and a basophil. A pale center can be distinguished in the some of the heterophils' granules. (Modified Wright's stain.)

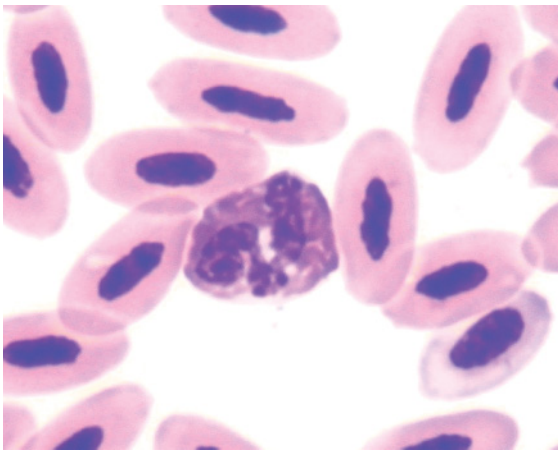


Figure 119 Blood from an azure kingfisher (*Alcedo azurea*) depicting a typical heterophil, amidst mature erythrocytes. (Diff Quik stain.)

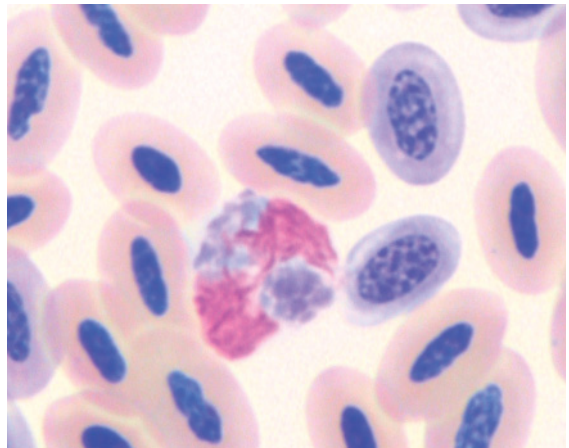


Figure 122 Blood from a Von der Decken's Hornbill (*Tockus deckeni*) showing a heterophil with "brick-red" cytoplasmic granules and palely-staining basophilic nucleus. Two polychromatophilic erythrocytes are also present amongst numerous mature erythrocytes. (Modified Wright's stain.)

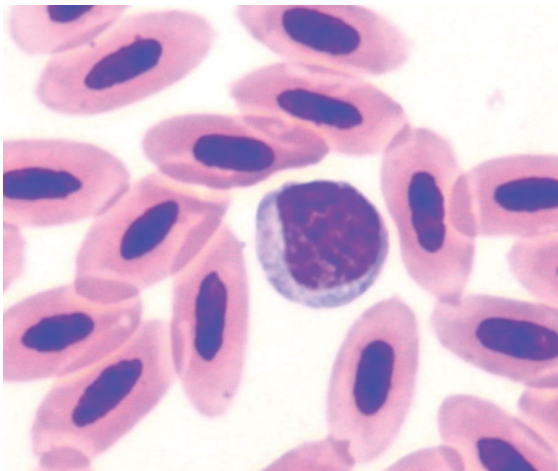


Figure 120 Blood from the same bird as in Figure 119 showing a lymphocyte. (Diff Quik stain.)

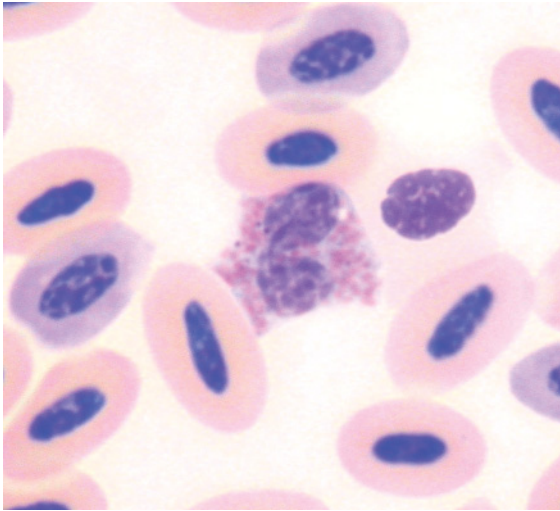


Figure 123 Blood from the same bird as in Figure 122 portraying an eosinophil identified by a bi-lobed basophilic nucleus and ovoid eosinophilic granules in a palely basophilic cytoplasm. (Modified Wright's stain.)

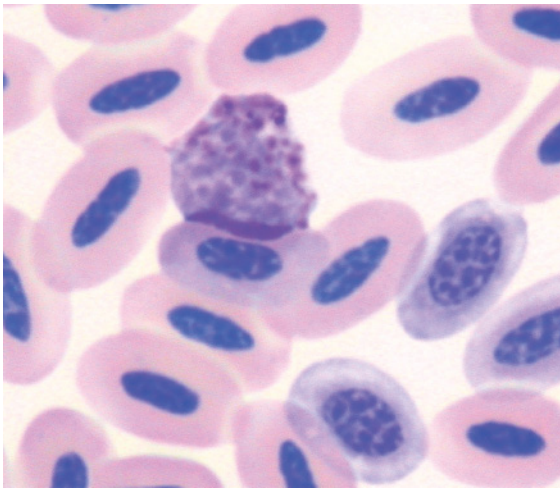


Figure 124 Blood from the same bird as in Figure 122 depicting a basophil with a relatively palely staining basophilic nucleus and ovoid, darkly basophilic cytoplasmic granules. (Modified Wright's stain.)

The hematocrit has been reported for birds from three genera of Bucerotidae (hornbills) (Villegas et al. 2006). For the Von der Decken's hornbill (*Tockus deckeni*), erythrocytes were ovoid cells with an ovoid nucleus composed of dense chromatin and even eosinophilic cytoplasm. Heterophils were irregularly round cells with many, prominent fusiform, brick-red to dull brown colored granules that partially obscured the nucleus in many cells. Eosinophils had many robust, round, brightly eosinophilic granules present at a moderate to high density in a palely basophilic cytoplasm. Basophils had many deeply basophilic granules present at high density that obscured both nucleus and cytoplasm. Lymphocytes and monocytes had morphology consistent with the general characteristics displayed by birds, as previously described.

CUCULIFORMES (CUCKOOS, ROADRUNNERS AND TURACOS)

To the authors' knowledge few studies have described the hematological characteristics of species within the Cuculiformes. Selected hematological values were presented from the Guira cuckoo (*Guira guira*) and greater roadrunner (*Geococcyx californianus*) (Abou-Madi 2003). These did not describe the morphological characteristics of hematological cells.

FALCONIFORMES (FALCONS, HAWKS AND EAGLES)

See Figures 125–140.

Numerous studies have reported selected hematological characteristics of the Falconiformes. The hematological characteristics of a number of species within the genus *Falco*, including the Eurasian kestrel (*Falco tinnunculus*) (Kirkwood et al. 1979), Mauritius kestrel (*Falco punctatus*) (Cooper et al. 1986), saker

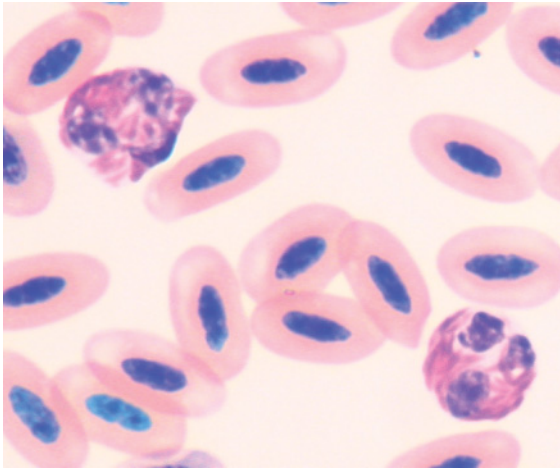


Figure 125 Blood from a clinically healthy Australian kestrel (*Falco cenchroides*) illustrating two heterophils, each with a segmented nucleus and fusiform, brick-red colored granules. (Diff Quik stain.)

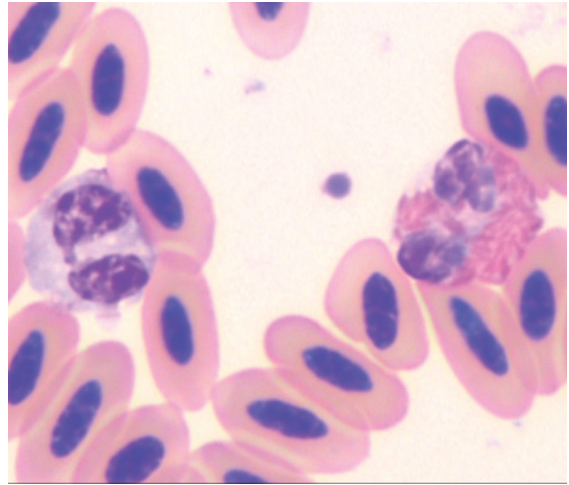


Figure 127 Blood from a Lanner falcon (*Falco biarmicus*) showing a heterophil (right), with a segmented nucleus and fusiform, brick-red cytoplasmic granules and an "eosinophil" with a bi-lobed nucleus and pale basophilic-grey cytoplasm with no distinct eosinophilic granules but small pale "vacuoles". (Modified Wright's stain.)

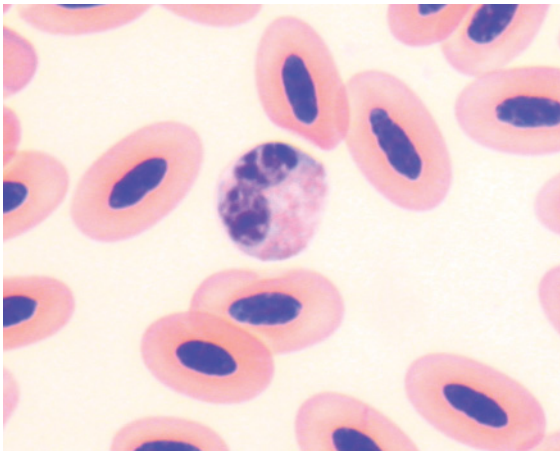


Figure 126 Blood from a clinically healthy Australian kestrel representing an eosinophil. The small eosinophilic granules evident within basophilic cytoplasm with modified Wright's stain were not apparent in a samples stained with Diff Quik stain. This staining characteristic of eosinophil granules has been observed in other species of falcons (Samour et al. 2005).

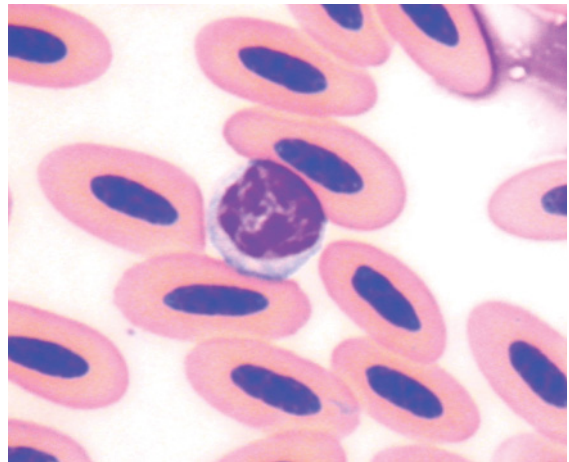


Figure 128 Blood from the same Lanner falcon as in Figure 127, showing a typical small lymphocyte. (Modified Wright's stain.)

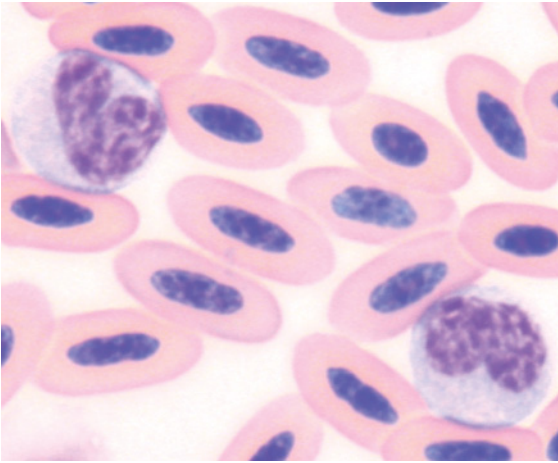


Figure 129 Blood from the same Lanner falcon as in Figure 127 showing two monocytes with reticular chromatin, reniform to horse-shoe shaped nucleus and moderate amounts of basophilic cytoplasm. (Modified Wright's stain.)

falcon (*Falco cherrug*) (Samour et al. 1996), peregrine falcon (Jennings 1996, Lanzarot et al. 2001) and gyrfalcon (Samour et al. 2005) have been published. Other species also studied include the marsh harrier (*Lavin* et al. 1992), sharp-shinned hawk (*Accipiter striatus*) and Cooper's hawk (*Accipiter cooperii*) (Phalen

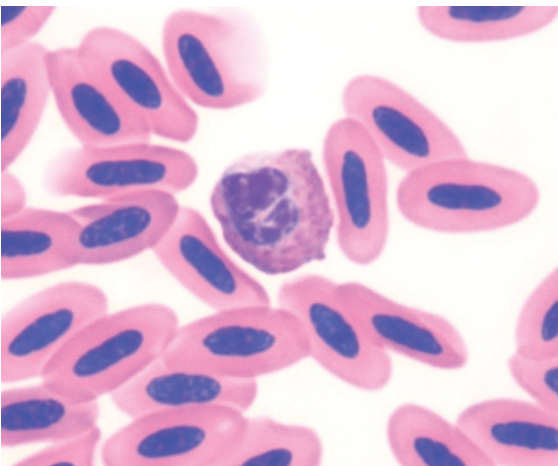


Figure 130 Blood from a peregrine falcon (*Falco peregrinus*) showing a heterophil with a high density of brick-red cytoplasmic granules, amidst erythrocytes. (Modified Wright's stain.)

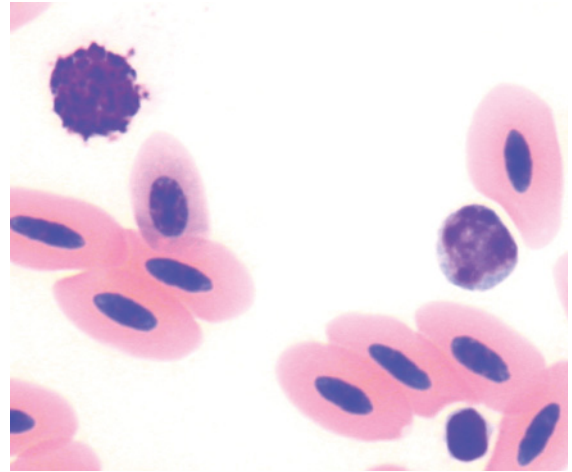


Figure 131 Blood from a peregrine falcon showing a basophil (top left), lymphocyte (mid right) and thrombocyte (bottom right) amidst erythrocytes. These "darkly staining cells" often need to be viewed at higher magnifications to be accurately distinguished. (Modified Wright's stain.)

et al. 1995), red-tailed hawk (Rehder et al. 1982b), white-backed vulture (*Gyps africanus*) (van Wyk et al. 1998), bald eagle (*Haliaeetus leucocephalus*) (Bowerman et al. 2000) and imperial eagle (*Aquila adalberti*) (Garcia-

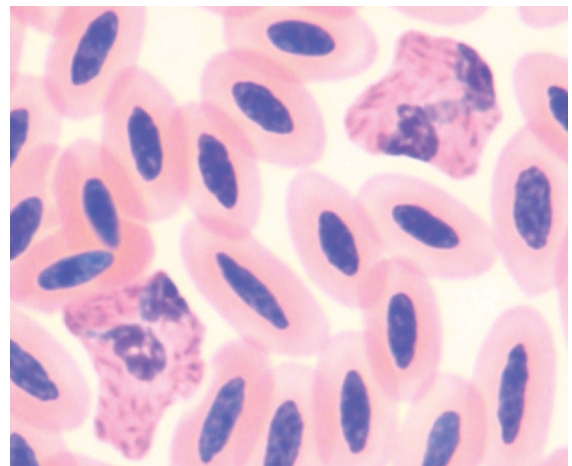


Figure 132 Blood from a brown goshawk (*Accipiter fasciatus*) showing two heterophils, each with a high density of brick-red fusiform granules, amidst erythrocytes. (Modified Wright's stain.)

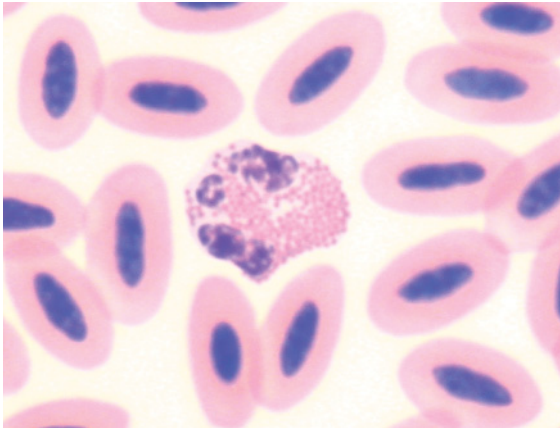


Figure 133 Blood from a brown goshawk showing an eosinophil amidst erythrocytes. Birds in this genus typically have round, brightly eosinophilic granules. (Modified Wright's stain.)

Montijano et al. 2002). However, few of these reported the morphology of the hematological cells.

Erythrocytes were ovoid cells with an ovoid nucleus composed of dense chromatin and even eosinophilic cytoplasm. Heterophils were irregularly round cells with fine fusiform to elongated, brick-red to dull brown colored

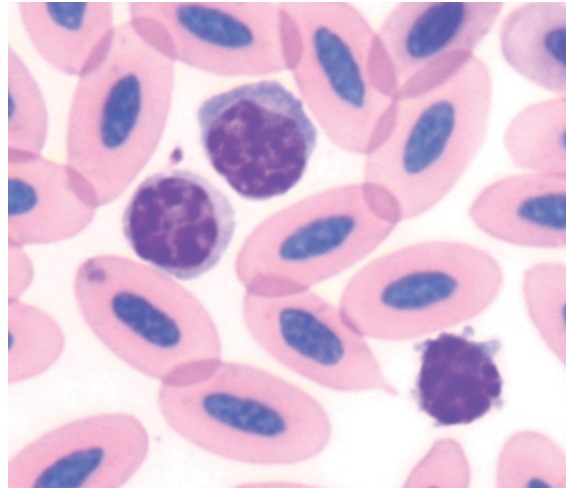


Figure 135 Blood from a red kite illustrating three lymphocytes. Mild anisocytosis is evident. These cells are typical of avian lymphocytes. (Modified Wright's stain.)

granules that were present at high density throughout the cytoplasm. Consequently the nucleus was (partially) obscured in many cells and the number of nuclear lobes could not be accurately determined. The appearance of "eosinophils" is very variable between groups

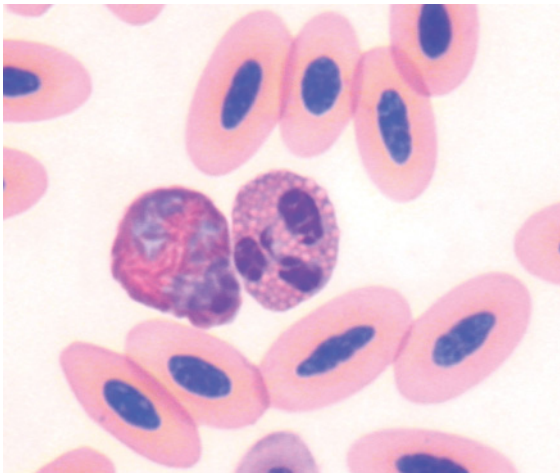


Figure 134 Blood from a red kite (*Milvus milvus*). A heterophil (left), with a pale blue nucleus and brick-red fusiform granules and an eosinophil, with basophilic segmented nucleus and many round, eosinophilic granules, are shown. (Modified Wright's stain.)

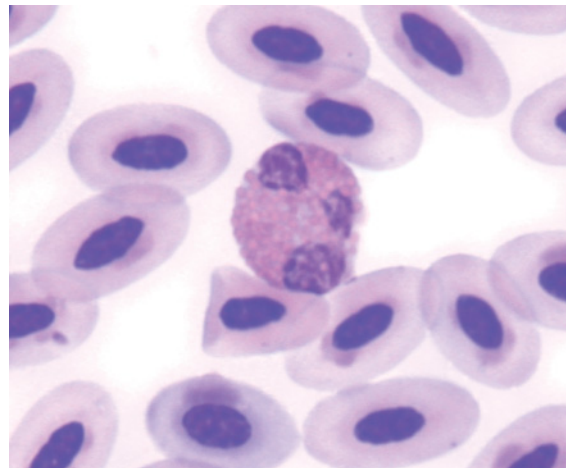


Figure 136 Blood from a black kite (*Milvus migrans*) illustrating an eosinophil with a segmented basophilic nucleus and many round brightly eosinophilic granules within basophilic cytoplasm. (Modified Wright's stain.)

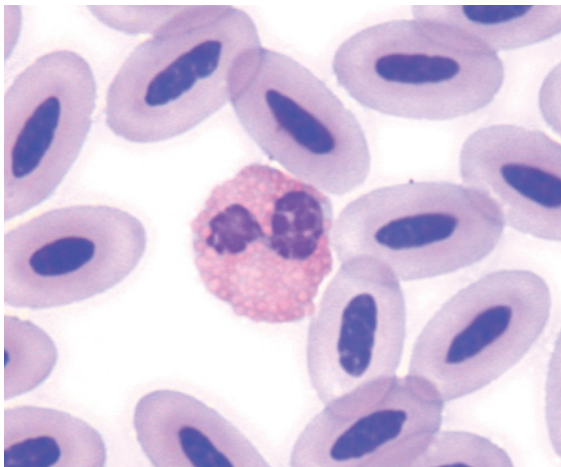


Figure 137 Blood from a tawny eagle (*Aquila rapax*) portraying an eosinophil with a bi-lobed basophilic nucleus and many round brightly eosinophilic granules in basophilic cytoplasm. Note the similarity between this cell and the eosinophil in Figure 136. (Modified Wright's stain.)

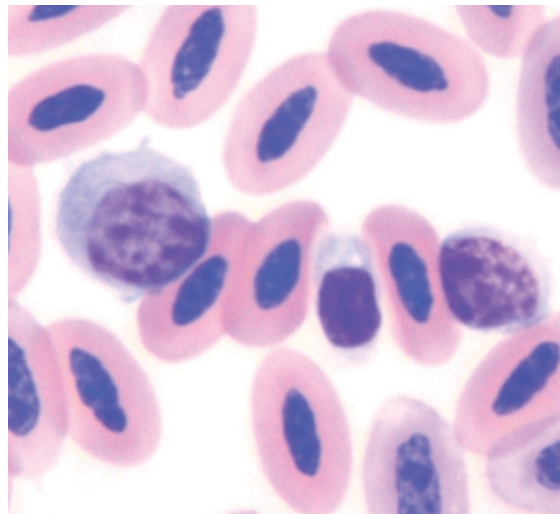


Figure 139 Blood from a black vulture illustrating a thrombocyte (center), a small lymphocyte and a large lymphocyte amidst erythrocytes. The thrombocyte is distinguished by its dense, dark-staining nucleus. The cytoplasm of all three cells has a similar appearance. (Modified Wright's stain.)

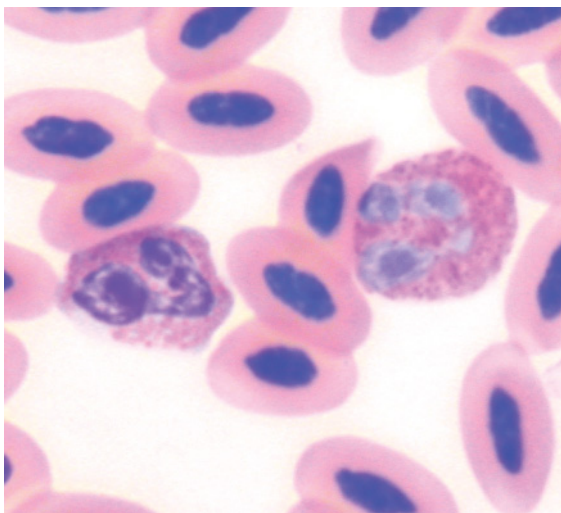


Figure 138 Blood from a black vulture (*Coragyps atratus*) showing an eosinophil (left) with a basophilic nucleus and rod-shaped eosinophilic granules within a basophilic cytoplasm and a heterophil with a pale blue nucleus and brick-red granules in which the central granular body is prominent and the granules are indistinct. (Modified Wright's stain.)

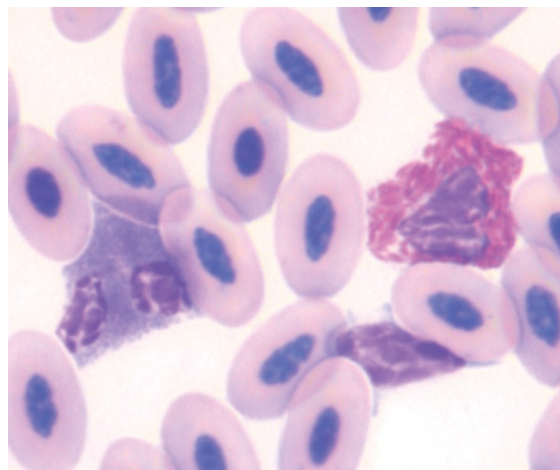


Figure 140 Blood from a king vulture (*Sarcorampus papa*) showing a heterophil (right), an eosinophil with cytoplasmic granules that are a dull brown–grey color and a lymphocyte (distorted by surrounding erythrocytes). (Modified Wright's stain.)

of raptors. Species within the genus *Falco* have eosinophils with a few, “bluish pink to light blue” granules in a pale blue cytoplasm (Lind et al. 1990) or few small eosinophilic granules (Wernery et al. 2004, Samour et al. 2005). Samour et al. (2001, 2005) noted the large effect the type of stain may have on the appearance of eosinophils’ granules, with granules most prominent when stained with modified Wright’s stain and least prominent when stained with Diff Quik stain. Birds within the genera *Accipiter*, *Aquila*, *Buteo* and *Haliaeetus* typically have prominent round, brightly eosinophilic granules (Lind et al. 1990, Santos et al. 2003b), and the northern harrier (*Circus cyaneus*) had round, lightly eosinophilic granules. Basophils were typically round cells with small round, intensely basophilic granules present at high density that obscured both nucleus and cytoplasm. Lymphocytes and monocytes had morphology consistent with the general characteristics displayed by birds, as previously described.

GALLIFORMES (GROUSE, MEGAPODES, CURASSOWS, PHEASANT, PARTRIDGE, QUAIL AND TURKEY)

See Figures 141–151.

Numerous studies have described the hematological characteristics of domestic fowl. The morphology of hematological cells from chickens was comprehensively described and beautifully illustrated by Lucas and Jamroz in their 1961 monograph, “*Atlas of Avian Hematology*”.

Species within the Galliformes for which hematological characteristics have been studied, include red grouse (*Lagopus lagopus scoticus*) (Wilson & Wilson 1978), turkey (Bounous et al. 2000), greater prairie-chicken (*Tympanuchus cupido*) (West & Haines 2002), sage grouse (*Centrocercus urophasianus*)

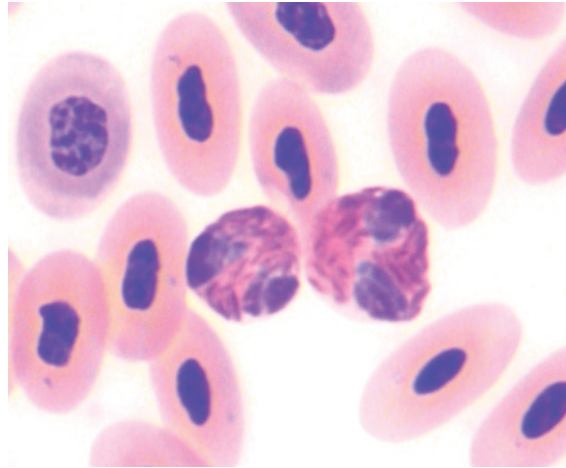


Figure 141 Blood from a Congo peafowl (*Afropavo congensis*) showing two typical heterophils amidst erythrocytes. (Modified Wright’s stain.)

(Dunbar et al. 2005) and common pheasant (Hauptmanova et al. 2006). These studies did not describe the morphology of hematological cells. The morphology of hematological cells from Japanese quail has been described (Tadjalli et al. 2003).

Erythrocytes were typically rounded ovoid cells with an ovoid nucleus composed of dense chromatin and even eosinophilic cytoplasm.

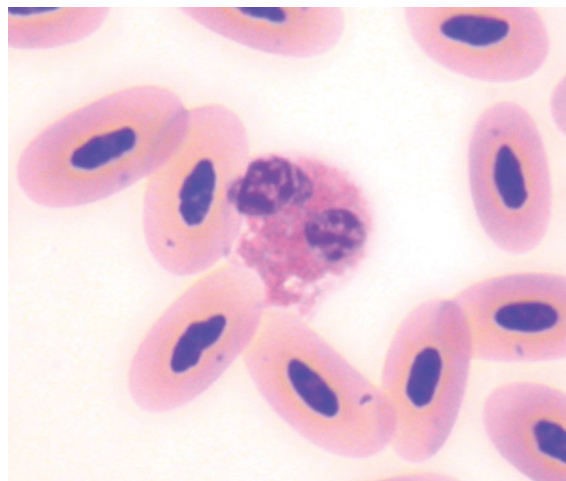


Figure 142 Blood from a Congo peafowl showing an eosinophil amidst erythrocytes. (Modified Wright’s stain.)

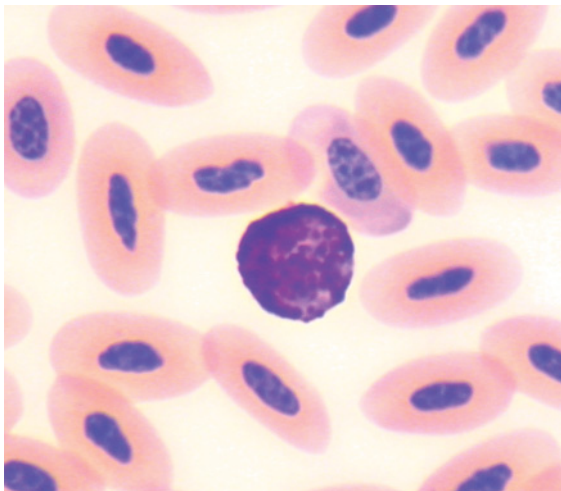


Figure 143 Blood from a Congo peafowl showing a basophil amidst erythrocytes. (Modified Wright's stain.)

Heterophils were irregularly round cells with prominent fusiform, brick-red to dull brown colored granules that were present at high density and consequently (partially) obscured the nucleus in many cells. Eosinophils had many discrete, round, brightly

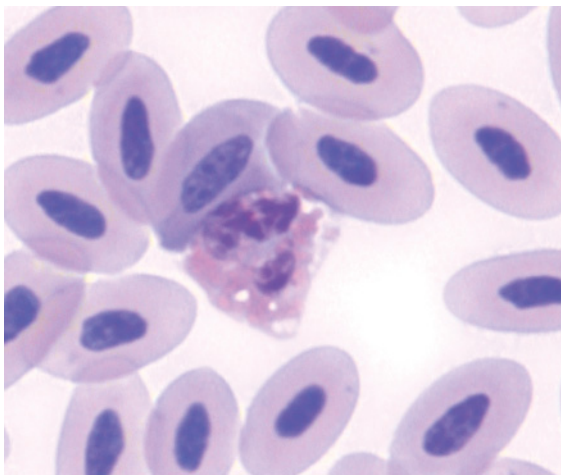


Figure 144 Blood from a green peafowl (*Pavo muticus*) showing an eosinophil with round eosinophilic granules and some colorless vacuoles in a pale basophilic cytoplasm, amidst erythrocytes. (Modified Wright's stain.)

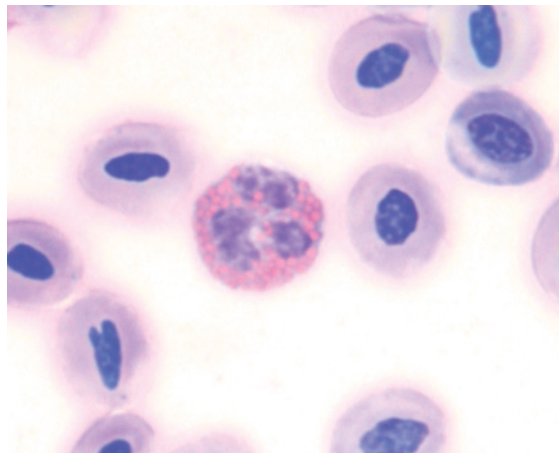


Figure 145 Blood from a crested wood partridge (*Rollulus roulroul*) showing an eosinophil amidst erythrocytes. Note the rounded shape of the erythrocytes. (Modified Wright's stain.)

eosinophilic granules present at moderate to high density in a palely basophilic cytoplasm. The size and number of the eosinophilic granules varied between species. Basophils were round cells with round, intensely basophilic granules present at moderate to high density that obscured both nucleus and cytoplasm. Lymphocytes and

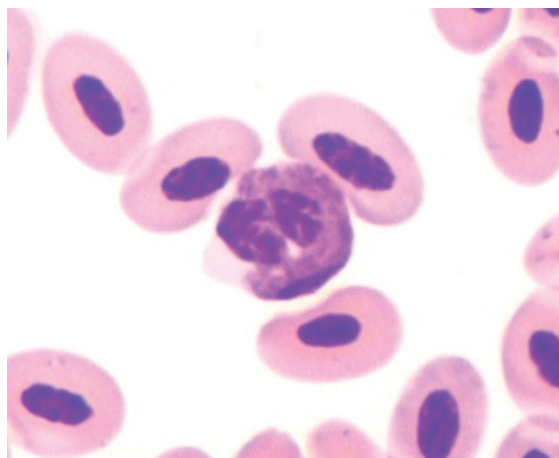


Figure 146 Blood from a brown quail (*Coturnix ypsilophora*) showing a heterophil amidst mature erythrocytes. (Diff Quik stain.)

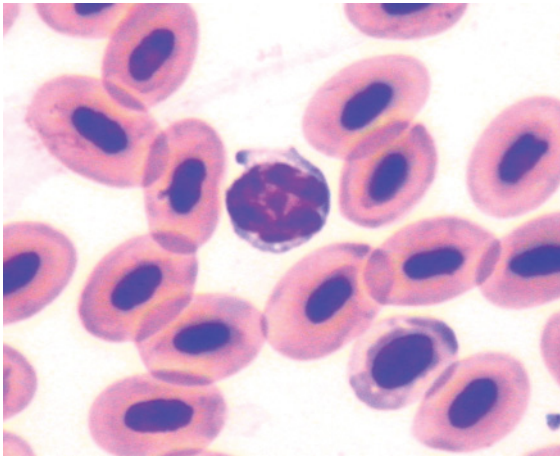


Figure 147 Blood from a brown quail showing a lymphocyte amidst erythrocytes, including a single polychromatophilic erythrocyte. (Diff Quik stain.)

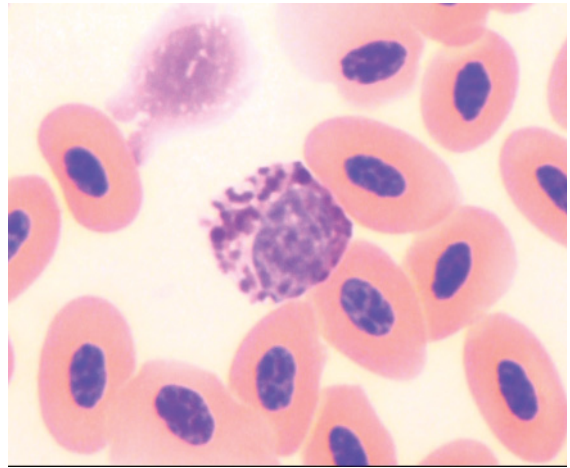


Figure 150 Blood from a blue-breasted quail showing a basophil with a moderate density of pleomorphic basophilic granules and several vacuoles within a pale basophilic cytoplasm, amidst erythrocytes. (Modified Wright's stain.)

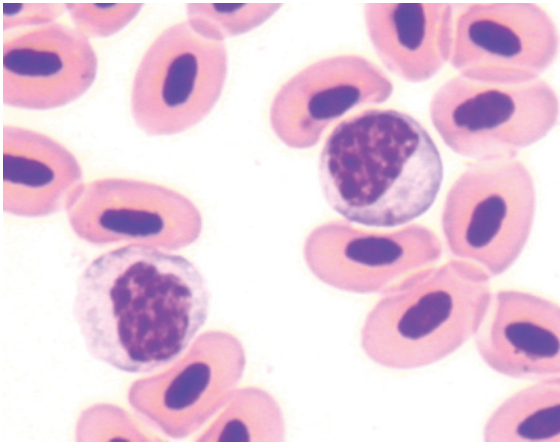


Figure 148 Blood from a brown quail showing two monocytes amidst mature erythrocytes. (Diff Quik stain.)

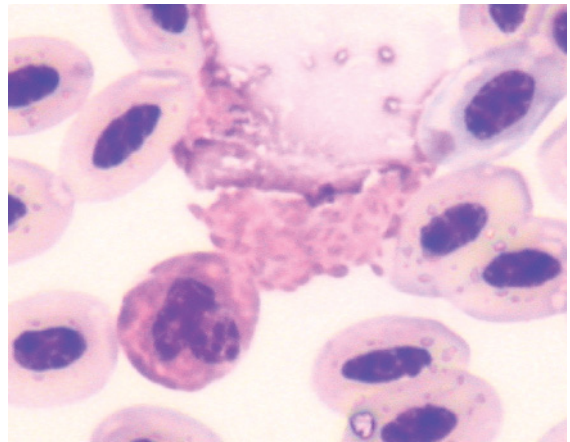


Figure 151 Blood from an orange-footed scrub fowl (*Megapodius reinwardt*) showing an intact heterophil and a lysed heterophil, the latter allowing individual fusiform granules to be visualized. (Diff Quik stain.)

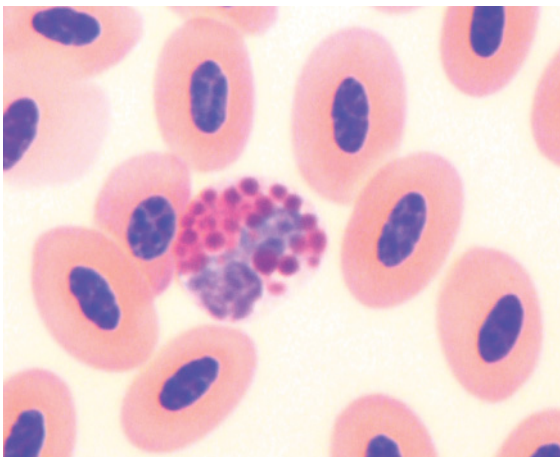


Figure 149 Blood from a blue-breasted quail (*Coturnix chinensis*) showing an eosinophil with large round-ovoid cytoplasmic granules, amidst erythrocytes. A heterophil from this species is shown in Figure 244. (Modified Wright's stain.)

monocytes had morphology consistent with the general characteristics displayed by birds, as previously described.

GAVIIFORMES (DIVERS AND LOONS)

Hematological data has been reported for common loons (*Gavia immer*) (Haefele et al. 2005). This study did not report the morphology of hematological cells.

GRUIFORMES (BUSTARDS, BUTTON QUAIL, COOTS AND CRANES)

See Figures 152–160.

Selected hematological values have been reported for a number of species of Gruiformes, including: demoiselle crane (*Grus virgo*) (Conetta et al. 1974), whooping crane (*Grus americana*), sandhill crane (*Grus canadensis*) (Gee et al. 1981), common crane

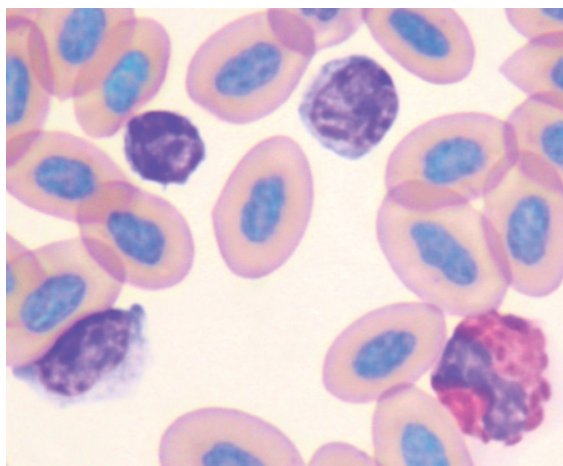


Figure 152 Blood from a clinically healthy takahe (*Porphyrio mantelli*) illustrating a heterophil, a small lymphocyte and two medium-sized lymphocytes amidst mature erythrocytes. Pleomorphism of lymphocytes is commonly observed in the blood of clinically healthy birds. (Diff Quik stain.)

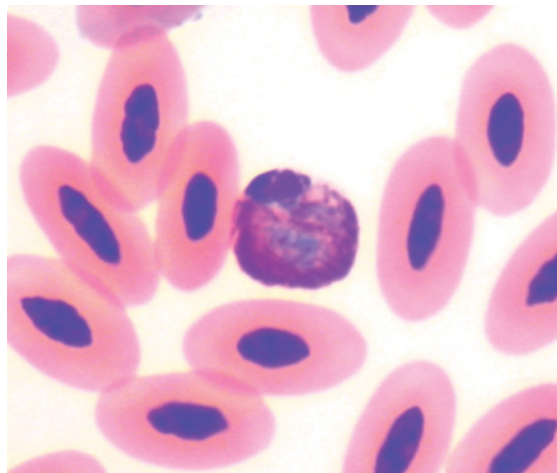


Figure 153 Blood from a broilga (*Grus rubicunda*) showing a typical heterophil amidst erythrocytes. (Modified Wright's stain.)

(*Grus grus*) (Abelenda et al. 1993) and several species of bustard (Samour et al. 1994, Flach 1995, D'Aloia et al. 1995, 1996, Howlett et al. 1995, 2002).

The morphology of hematological cells has been described for ten species of crane (Hawkey et al. 1983), the houbara bustard (Samour

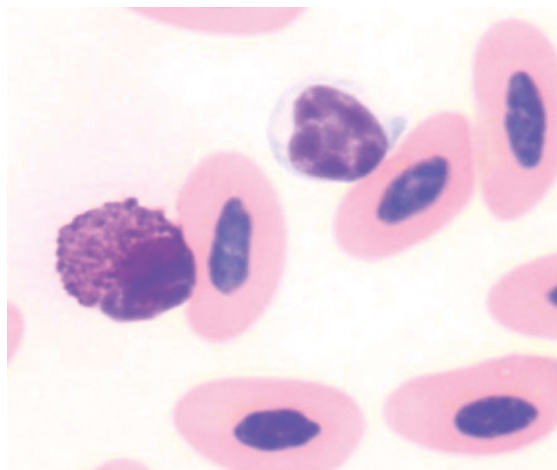


Figure 154 Blood from a broilga (*Grus rubicunda*) showing a basophil with a moderate density of cytoplasmic granules and a medium-sized lymphocyte, amidst erythrocytes. (Modified Wright's stain.)

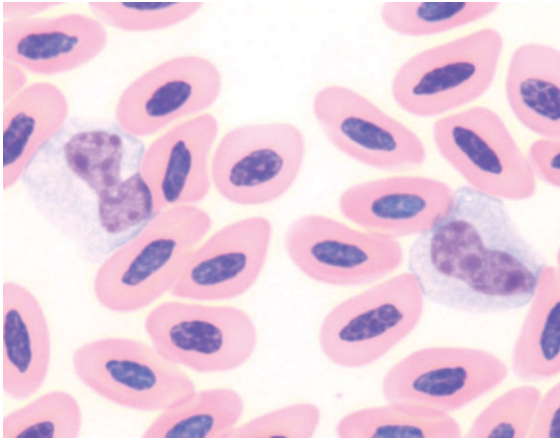


Figure 155 Blood from the same broilga as in Figure 154, showing two monocytes amidst erythrocytes. (Modified Wright's stain.)

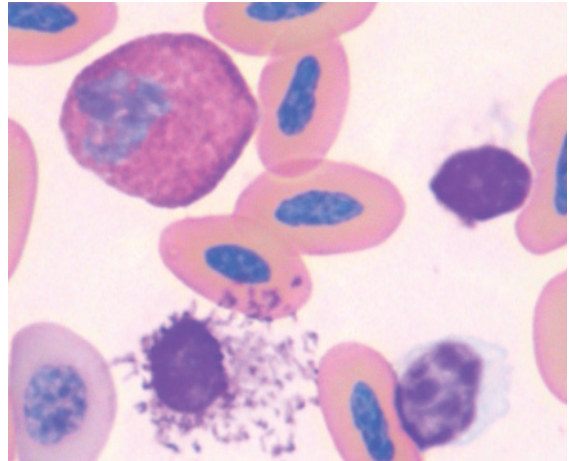


Figure 157 Blood from a wattled crane (*Grus carunculatus*) showing a heterophil, lymphocyte (bottom right) and a disrupted basophil, which allows the individual basophilic granules to be observed. (Modified Wright's stain.)

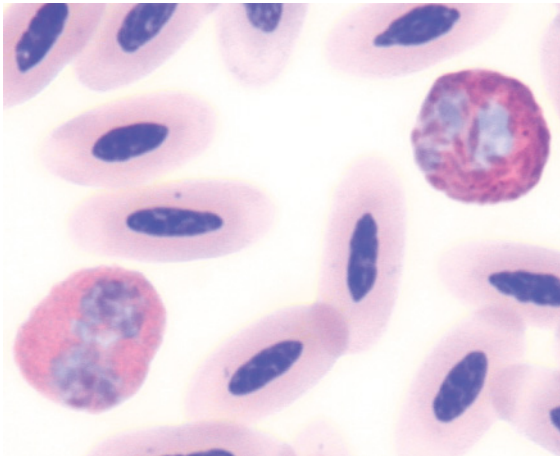


Figure 156 Blood from a Stanley crane (*Grus paradisea*) illustrating: a heterophil (top right) with pale blue nucleus and fusiform granules, some with a prominent central granular body; and an eosinophil with a basophilic nucleus and a high density of brightly eosinophilic granules that precludes recognition of individual granule shape, amongst mature erythrocytes. Basophils from this species are portrayed in Figure 71. (Modified Wright's stain.)

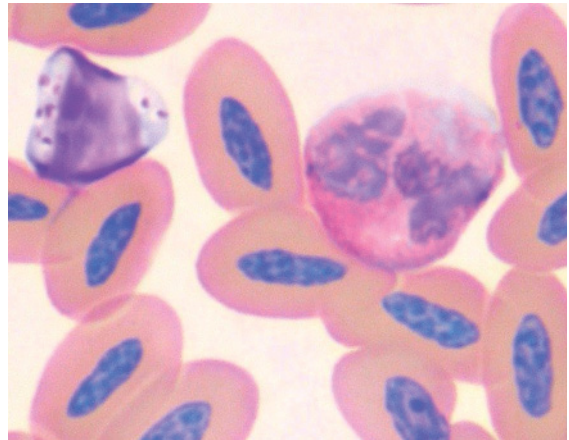


Figure 158 Blood from the same wattled crane as in Figure 157, portraying a granular lymphocyte and an eosinophil amidst erythrocytes. Hawkey et al. (1983) noted that lymphocytes from cranes commonly contained basophilic granules. (Modified Wright's stain.)

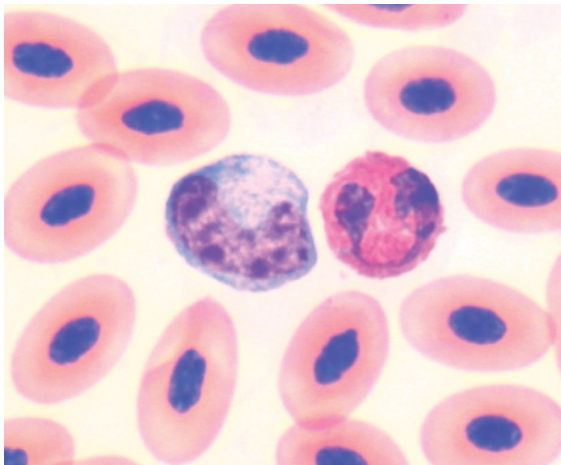


Figure 159 Blood from an Eurasian coot (*Fulica atra*) showing a monocyte and an eosinophil with brightly eosinophilic cytoplasmic granules, amidst mature erythrocytes. (Modified Wright's stain.)

et al. 1994) and kori bustard (*Ardeotis kori*) (Howlett et al. 1995).

Notably, the use of EDTA as an anticoagulant causes progressive hemolysis in crowned cranes (*Balearica* spp) (Hawkey et al. 1983) and should not be employed as an anticoagulant for that species. However, EDTA was

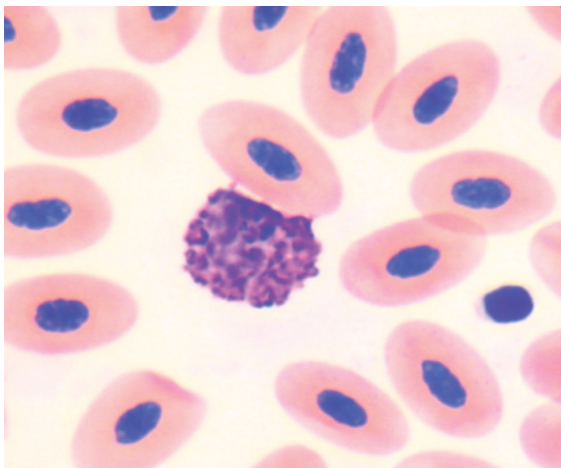


Figure 160 Blood from an Eurasian coot (*Fulica atra*) showing a basophil and thrombocyte amidst mature erythrocytes. (Modified Wright's stain.)

used as an anticoagulant in other species of cranes (Conetta et al. 1974, Hawkey et al. 1983) and bustards (Samour et al. 1994, Howlett et al. 1995) without untoward consequences.

Erythrocytes were ovoid cells with an ovoid nucleus composed of dense chromatin and even eosinophilic cytoplasm. Occasional polychromatophilic erythrocytes were evident. Heterophils were irregularly round cells with prominent fusiform, brick-red to dull brown colored granules that were present at high density throughout the cytoplasm. Hawkey et al. (1983) reported the nucleus of heterophils from cranes was typically bi-lobed. Eosinophils had many prominent, round, brightly eosinophilic granules present at moderate to high density in a palely basophilic cytoplasm. Samour et al. (1994) reported that eosinophils from the houbara bustard had a “bi-lobed nucleus with a slightly basophilic cytoplasm almost completely obscured by overlying large disc-like and slightly basophilic (blue-grey) granules”. Howlett et al. (1995) reported that for the kori bustard, “the eosinophil had a bi-lobed nucleus, enclosed by a slightly basophilic cytoplasm that contained distinct bright-red round granules”. Similarly, cranes were reported to have “brightly eosinophilic, round or oval granules” (Hawkey et al. 1983).

Basophils were typically round cells with round, intensely basophilic granules present at varied density. Some basophils contained only a few granules that allowed the fine detail of the cell to be discerned, whereas other basophils had a greater density of granules that obscured both nucleus and cytoplasm. Lymphocytes and monocytes had morphology consistent with the general characteristics displayed by birds, as previously described. Lymphocytes that contained one to several, azurophilic cytoplasmic granules were commonly observed in blood from cranes (Hawkey et al. 1983) and have been observed regularly, by the authors, in the blood from other species of Gruiformes.

OPISTHOCOMIFORMES (HOATZIN)

To the authors' knowledge no studies have described the hematological characteristics of the hoatzin (*Opisthocomus hoazin*) which is the sole extant representative of this order.

PASSERIFORMES (SONG BIRDS)

See Figures 161–175.

A substantial number of studies have employed hematological methods as a component of the study of effects of various physiological or pathological influences on species of Passeriformes. Notably, the use of EDTA as an anticoagulant causes hemolysis in samples from many species of Corvidae (Hawkey & Dennett 1989). Species for which some hematological data has been published include: house martin (*Delichon urbica*) (Kostelecka-Myrcha & Jaroszewicz 1993), superb blue wren (*Malurus cyaneus*) (Breuer et al. 1995), great tit (*Parus major*) (Ots & Horak 1998, Ots et al. 1998), rufous-collared sparrows (*Zonotrichia capensis*) (Ruiz et al. 2002), hooded crow (*Corvus corone*) (Acquorone et al. 2002), house finches (*Carpodacus mexicanus*) (Davis et al. 2004), welcome swallow (*Hirundo neoxena*), fairy martin (*Hirundo ariel*) (Simmons & Lill 2006) and three species of thrushes (Owen & Moore 2006). However, few of these have been primarily a study of the “hematological characteristics” of the species of bird and consequently very few have described the morphological characteristics of hematological cells. Furthermore, the small mass of many species of Passeriformes often precludes the collection of a sufficient volume of blood to allow a “complete” hematological assessment to be performed. However, the rigorous assessment of a blood film to estimate the concentration of hematological cells and particularly interpretation of the morphology

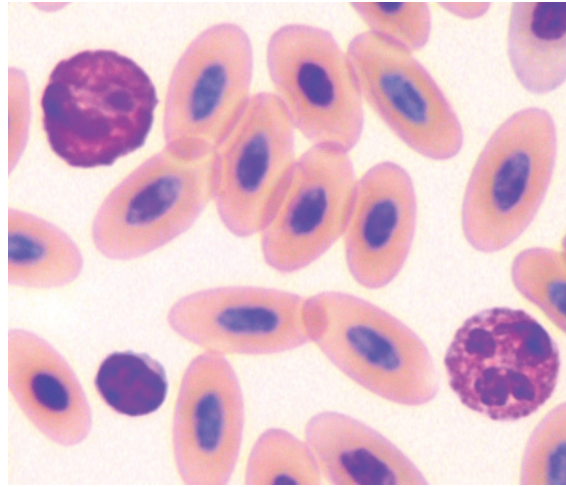


Figure 161 Blood from a superb lyrebird (*Menura novaehollandiae*) illustrating: a heterophil with a high density of brick-red fusiform granules that obscure part of the nucleus (top left); an eosinophil with a segmented basophilic nucleus and round to ovoid eosinophilic granules in basophilic cytoplasm (bottom right); and a typical small lymphocyte (bottom left), amidst mature erythrocytes. (Modified Wright's stain.)

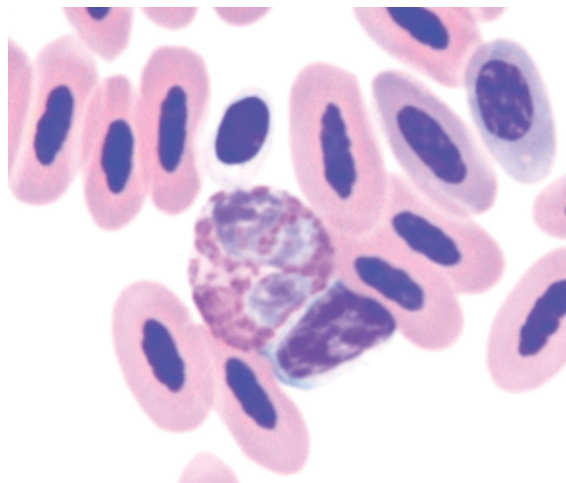


Figure 162 Blood from a New-Holland honeyeater (*Phylidonyris novaehollandiae*) showing a heterophil with a pale blue nucleus and brick-red fusiform granules, a lymphocyte and a thrombocyte (top) amidst erythrocytes. (Modified Wright's stain.)

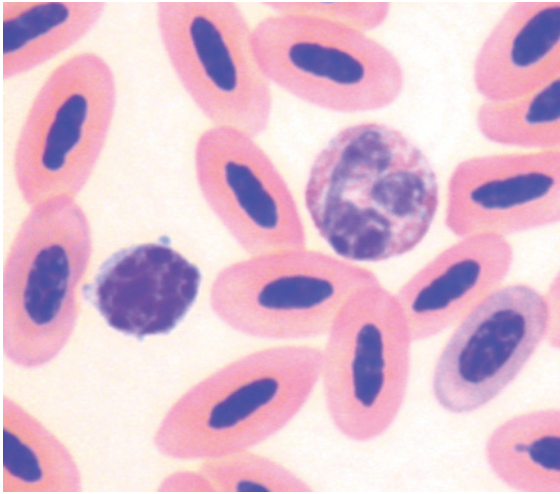


Figure 163 Blood from a New-Holland honeyeater showing an eosinophil and a lymphocyte amidst erythrocytes. (Modified Wright's stain.)

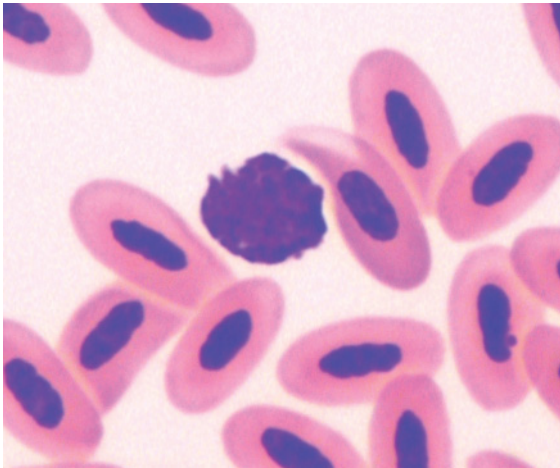


Figure 164 Blood from a New-Holland honeyeater depicting a basophil. The density of dark basophilic granules prevents visualization of the nucleus. (Modified Wright's stain.)

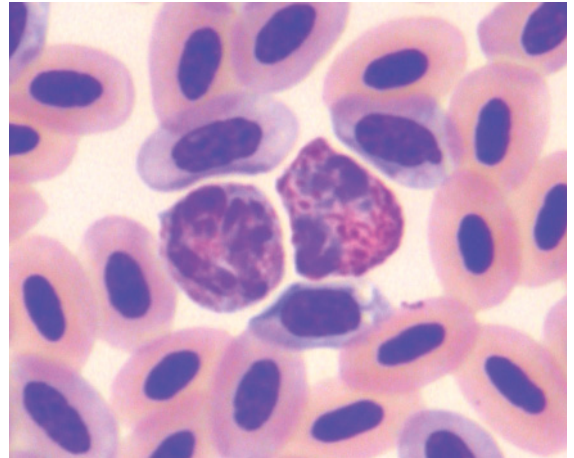
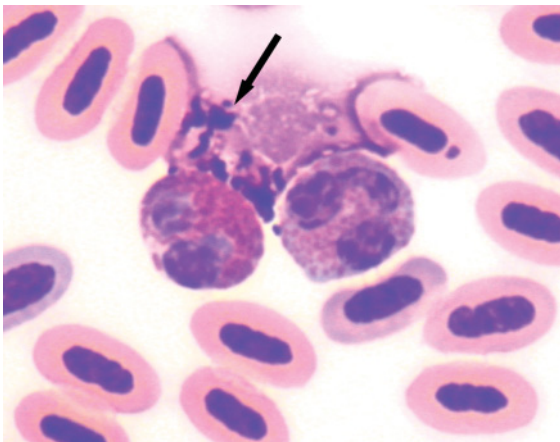


Figure 166 Blood from a red wattlebird (*Anthochaera carunculata*) showing a heterophil (right) and an eosinophil (left) amidst erythrocytes including several polychromatophilic erythrocytes. Note the similarity in the morphology of acidophils for the honeyeaters illustrated, representing three different genera. (Modified Wright's stain.)

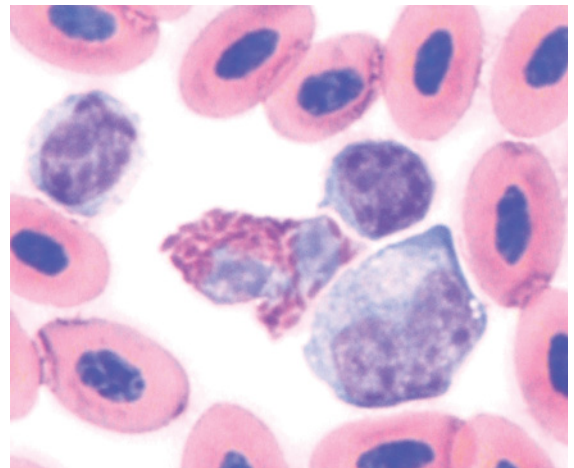


Figure 167 Blood from an Australian raven, with lithium heparin used as an anticoagulant, illustrating a heterophil, a monocyte and two lymphocytes. (Modified Wright's stain.) The use of heparin as an anticoagulant typically results in paler blue color of basophilic structures (than would occur with blood mixed with EDTA) and may result in clumping of leukocytes. However, heparin must be used in this species as EDTA will result in hemolysis (see Figure 22).

Figure 165 Blood from a singing honeyeater (*Lichenostomus virescens*) showing intact acidophils; a heterophil with a high density of brick-red fusiform granules (left) and an eosinophil with ovoid eosinophilic granules within a basophilic cytoplasm (right) as well as a disrupted basophil (arrow) amidst erythrocytes. (Modified Wright's stain.)

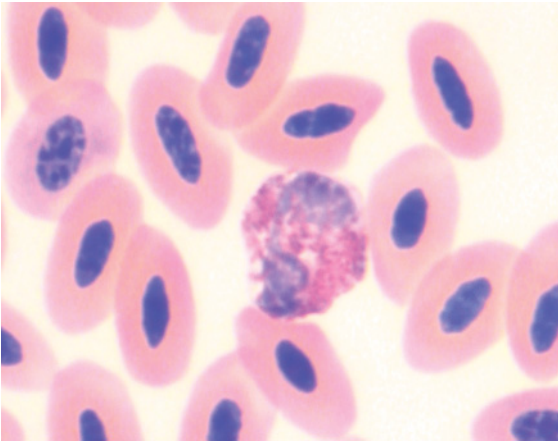


Figure 168 Blood from an Australian raven (*Corvus coronoides*) showing an eosinophil. (Modified Wright's stain.)

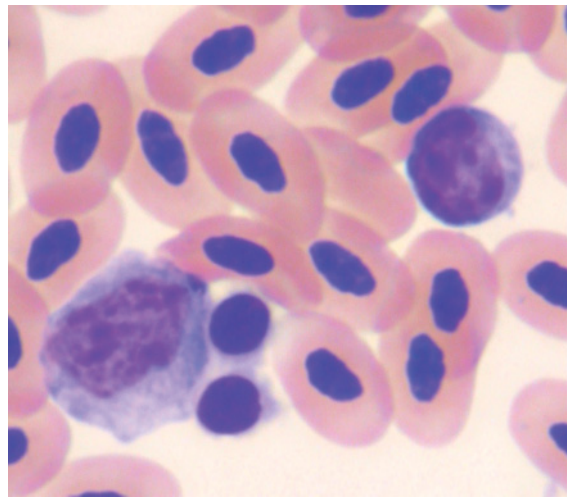


Figure 171 Blood from a hooded pitta exhibiting a monocyte (left), a lymphocyte and two thrombocytes (adjacent to the monocyte), amidst mature erythrocytes. The thrombocytes have a darker nucleus than the mononuclear leukocytes. (Modified Wright's stain.)

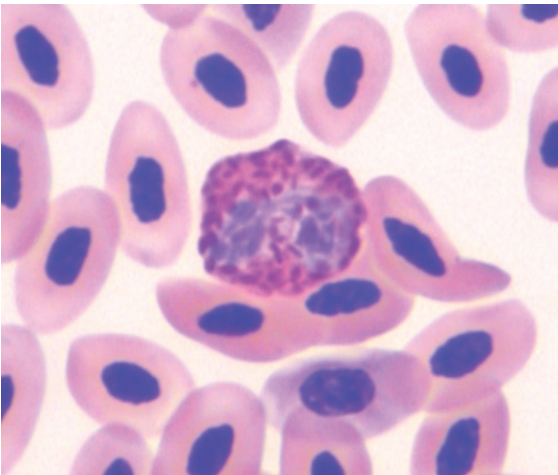


Figure 169 Blood from a hooded pitta (*Pitta sordida*) showing a typical avian heterophil amidst mature erythrocytes. (Modified Wright's stain.)

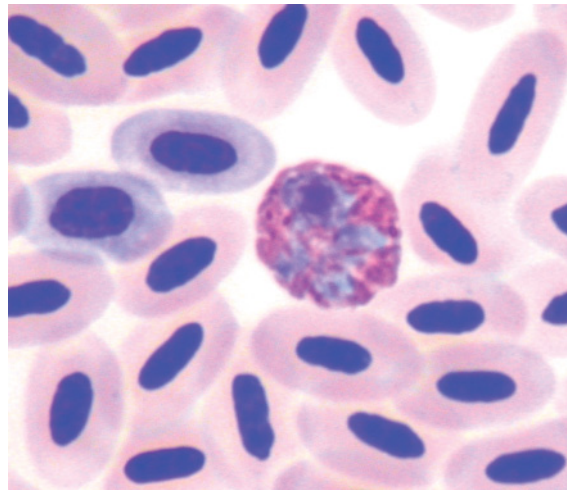


Figure 172 Blood from a superb starling (*Spreo superbus*) showing a heterophil amidst erythrocytes, including two polychromatophilic cells. (Modified Wright's stain.)

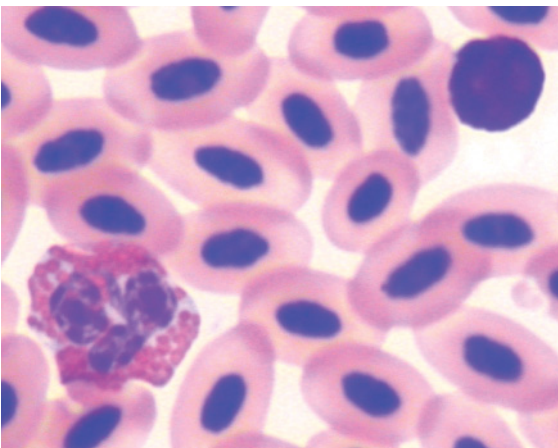


Figure 170 Blood from a hooded pitta portraying an eosinophil with a segmented basophilic nucleus and large, ovoid, brightly eosinophilic granules within a basophilic cytoplasm; and a basophil with such a density of basophilic granules that cellular detail cannot be discerned, amidst mature erythrocytes. (Modified Wright's stain.)

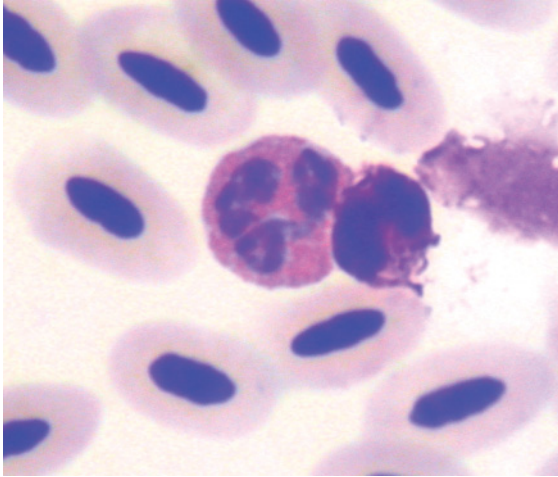


Figure 173 Blood from a superb starling showing an eosinophil (left) with a segmented basophilic nucleus and many eosinophilic granules within a basophilic cytoplasm and a basophil. The basophils of this bird exhibited variable numbers of granules. (Modified Wright's stain.)

of hematological cells can yield important information about the health of the bird.

The morphology of haematological cells of the hill mynah (*Gracula religiosa*) has been described (Archawaranon 2005). Heterophils

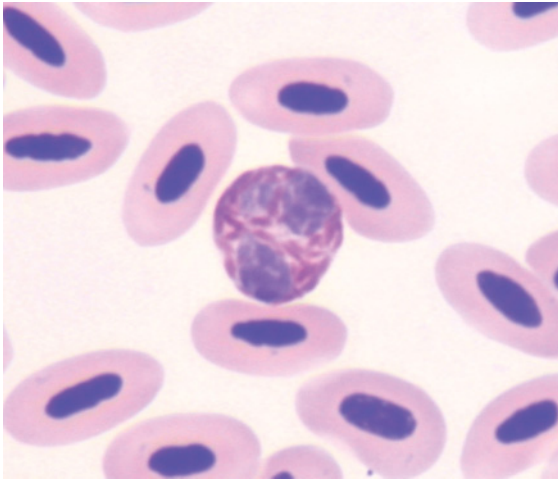


Figure 174 Blood from a violet-backed starling (*Cinnyricinclus leucogaster*) showing a heterophil with typical morphology amidst mature erythrocytes. (Modified Wright's stain.)

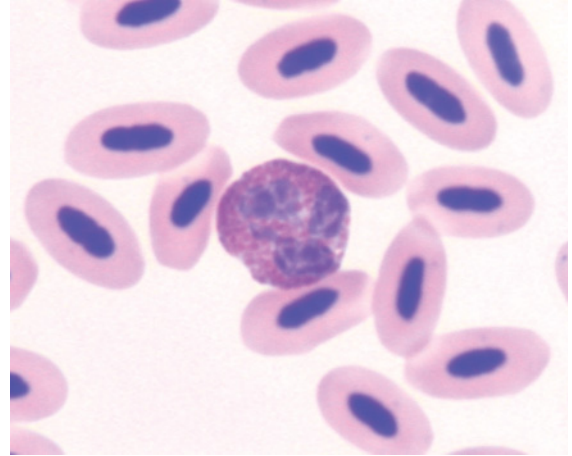


Figure 175 Blood from a violet-backed starling showing an eosinophil amidst mature erythrocytes. (Modified Wright's stain.)

had colorless cytoplasm with “eosinophilic rod-shaped granules” and a bi-lobed nucleus, whereas eosinophils had a darker nucleus, pale blue cytoplasm and round eosinophilic granules. Basophils had a central round nucleus often hidden by deeply basophilic granules.

For the species of passerine birds examined, erythrocytes were ovoid cells with an ovoid nucleus composed of dense chromatin and even eosinophilic cytoplasm. Variable numbers of polychromatophilic erythrocytes were evident.

Heterophils were irregularly round cells with prominent fusiform, brick-red to dull brown colored granules that were present at high density and filled most of the cytoplasm and consequently (partially) obscured the nucleus in many cells. Eosinophils had many small, irregularly round, dull eosinophilic granules present at moderate density in a pale basophilic cytoplasm. Basophils had many small round, deeply basophilic granules present at high density that often obscured both nucleus and cytoplasm. Lymphocytes and monocytes had morphology consistent with the general characteristics displayed by birds, previously described in this chapter.

PELECANIFORMES (CORMORANTS, FRIGATE BIRDS, GANNETS, PELICANS AND TROPICBIRDS)

See Figures 176–179.

The hematological characteristics of several species belonging to the Pelecaniformes have been reported, these include the white pelican (*Pelecanus onocrotalus*) (Puerta et al. 1991), brown pelican (*Pelecanus occidentalis*) (Weber 2003, Zais et al. 2000), pink-backed pelican (*Pelecanus rufescens*), guanay cormorant (*Phalacrocorax bougainvillii*) (Weber 2003), flightless cormorant (*Phalacrocorax harrisi*), black-faced cormorant (*Phalacrocorax fuscescens*) (Melrose & Nicol 1992), double-crested cormorants (*Phalacrocorax auritus*) (Kuiken & Danesik 1999) and brown boobies (*Sula leucogaster*) (Work 1999). These studies did not describe the morphological characteristics of hematological cells. Work (1996) described the morphology of hematological cells from three species of Pelecaniformes; red-footed boobies (*Sula sula*), red-tailed tropic birds (*Phaethon rubricauda*) and great frigate birds (*Fregata minor*). In these

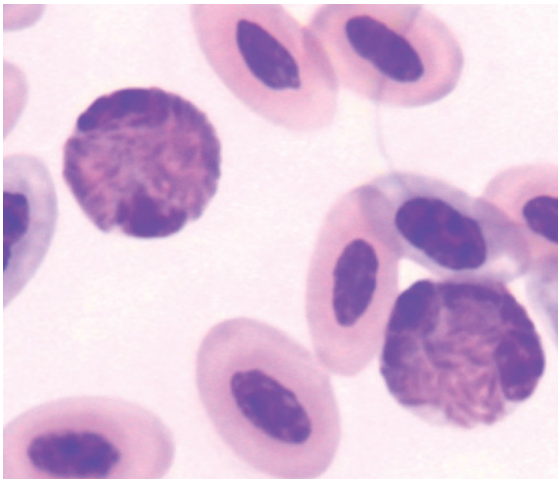


Figure 176 Blood from a brown booby (*Sula leucogaster*) portraying two heterophils each with a high density of brown-red fusiform cytoplasmic granules that partially obscure the nucleus of the cell, amidst erythrocytes including polychromatophilic erythrocytes. (Diff Quik stain.)

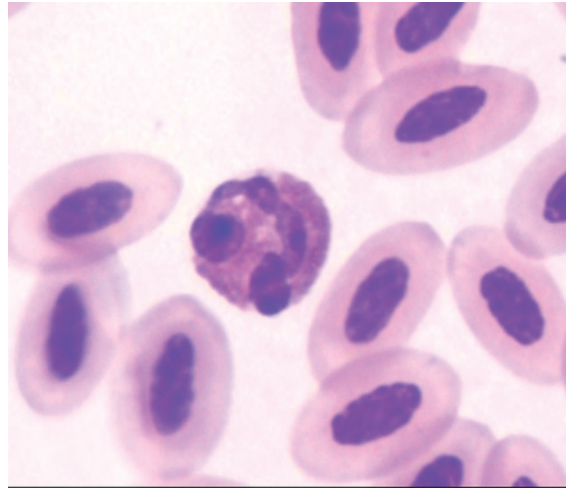


Figure 177 Blood from the same bird as in Figure 176 illustrating an eosinophil with a segmented basophilic nucleus and many round to ovoid eosinophilic granules within basophilic cytoplasm, amidst erythrocytes. (Diff Quik stain.)

species, heterophils, basophils, monocytes and lymphocytes had morphology similar to that previously described for birds. Eosinophils from the boobies had round large and brightly orange granules whereas the eosinophils from frigate

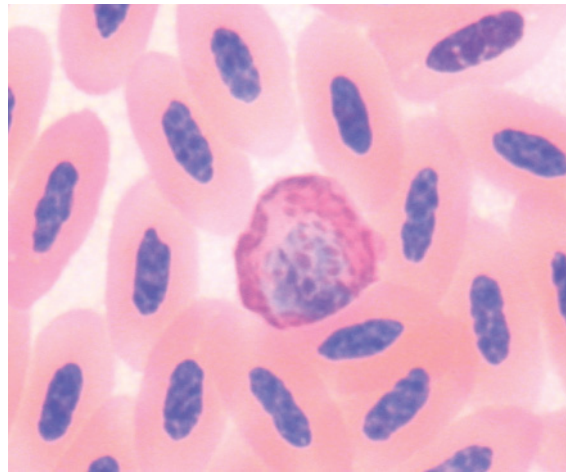


Figure 178 Blood from an Australian gannet (*Morus serrator*) depicting a heterophil with a high density of brick-red fusiform granules and a pale basophilic cytoplasm amidst mature erythrocytes. (Modified Wright's stain.)

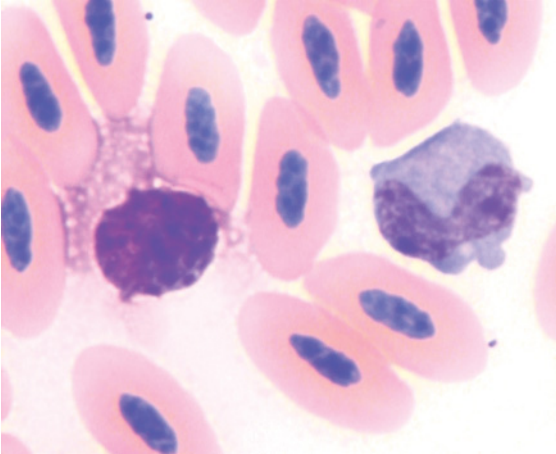


Figure 179 Blood from an Australian gannet showing a basophil and monocyte amidst mature erythrocytes. (Modified Wright's stain.)

birds had “loosely packed, plump, elliptical granules distributed among variably sized clear granules” and tropicbirds’ eosinophils had “sparse numbers of amorphous to round, large, dull-orange granules interspersed with numerous small, clear, well defined vacuoles”.

Erythrocytes were ovoid cells with an ovoid nucleus composed of dense chromatin and eosinophilic cytoplasm. Heterophils had prominent fusiform, brick-red to eosinophilic colored granules. Eosinophils observed in blood from the brown booby had small round eosinophilic granules that were present at moderate density in a palely basophilic cytoplasm. Basophils had many small round, deeply basophilic granules present at high density that often obscured both nucleus and cytoplasm. Lymphocytes and monocytes had morphology consistent with the general characteristics displayed by birds, as previously described.

PHOENICOPTERIFORMES (FLAMINGOS)

See Figure 180.

Hematological values have been reported for several species of flamingos including:

Chilean flamingos (*Phoenicopterus chilensis*) (Hawkey et al. 1984a), greater flamingos (*Phoenicopterus ruber*) (Hawkey et al. 1984b, 1985, Merritt et al. 1996, Mostaghni et al. 2005) and lesser flamingos (*Phoenicopterus minor*) (Hawkey et al. 1985). The morphological characteristics of hematological cells were described in a number of these studies (Hawkey et al. 1984a, b, 1985).

Erythrocytes were ovoid cells with an ovoid nucleus composed of dense chromatin and eosinophilic cytoplasm. Heterophils were irregularly round cells with prominent fusiform, brick-red to dull brown colored granules that were present at high density that obscured the nucleus in many cells. Eosinophils typically had robust round, brightly eosinophilic granules present at a moderate density in a pale basophilic cytoplasm. Basophils were smaller, round cells with round, deeply basophilic granules present at high density that obscured

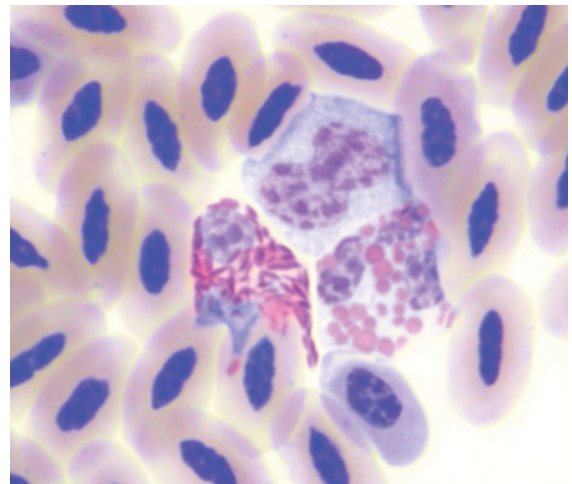


Figure 180 Blood from a greater flamingo (*Phoenicopterus ruber*), illustrating: a heterophil (left) with a pale basophilic nucleus and brick-red fusiform cytoplasmic granules; an eosinophil (right) with a segmented basophilic nucleus and variably sized, brightly eosinophilic, round to ovoid cytoplasmic granules; and a monocyte (top) with constricted nucleus composed of reticular chromatin and agranulated basophilic cytoplasm, amidst erythrocytes. Note that the shape of the cells has been distorted by the adjacent cells. (Modified Wright's stain.)

both nucleus and cytoplasm. Lymphocytes and monocytes had morphology consistent with the general characteristics displayed by birds, as previously described.

PICIFORMES (TOUCANS AND WOODPECKERS)

See Figures 181–188.

To the authors' knowledge, very few studies have described the hematological characteristics of Piciformes. Cubas (2003) provided selected hematological values for species of toucans, but did not describe the morphological characteristics of hematological cells.

Erythrocytes were ovoid cells with an ovoid nucleus composed of dense chromatin and eosinophilic cytoplasm. Heterophils had prominent fusiform, brick-red to eosinophilic colored granules. Eosinophils exhibited morphological variation in the cytoplasmic granules between species. These were typically round and present at high density (partially

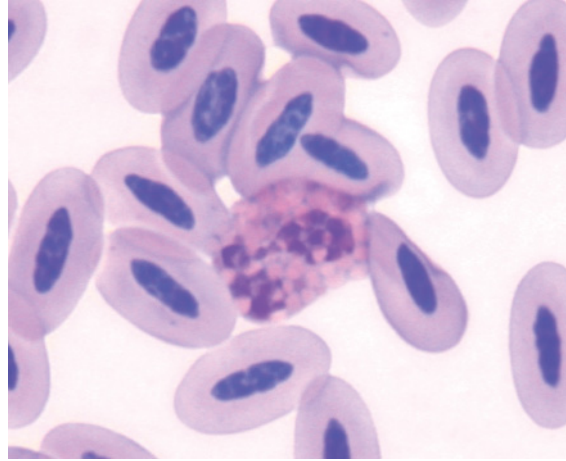


Figure 182 Blood from the same black-necked aracari as in Figure 181 showing an eosinophil, with a segmented basophilic nucleus and many prominent round faintly eosinophilic cytoplasmic granules that are outlined by the surrounding basophilic cytoplasm, amidst erythrocytes. (Modified Wright's stain.)

obscuring the nucleus) but varied in size and hue. For example, eosinophils from red-billed toucan (*Ramphastos tucanus*) had grey granules with a faint eosinophilic hue, whereas

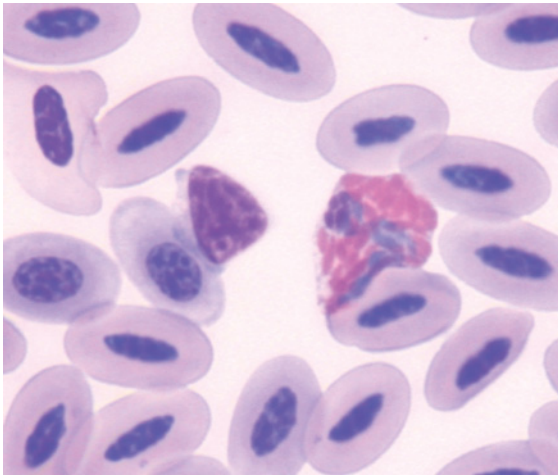


Figure 181 Blood from a black-necked aracari (*Pteroglossus aracari*) showing a heterophil with a basophilic nucleus and prominent robust fusiform brick-red cytoplasmic granules. Also present is a lymphocyte and erythrocytes. (Modified Wright's stain.)

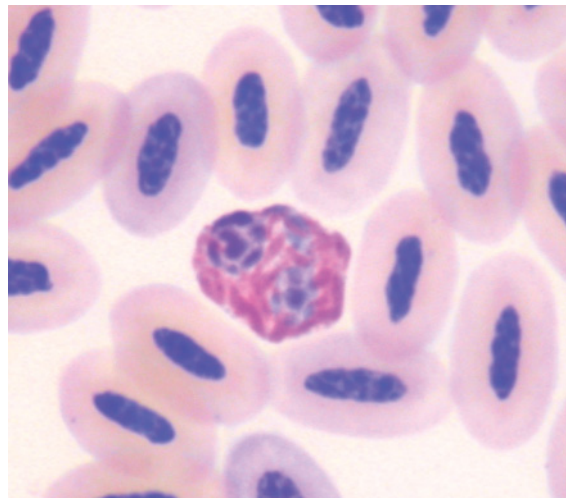


Figure 183 Blood from a toco toucan (*Ramphasto toco*) portraying a typical heterophil with a segmented basophilic nucleus and prominent robust fusiform brick-red cytoplasmic granules. (Modified Wright's stain.)

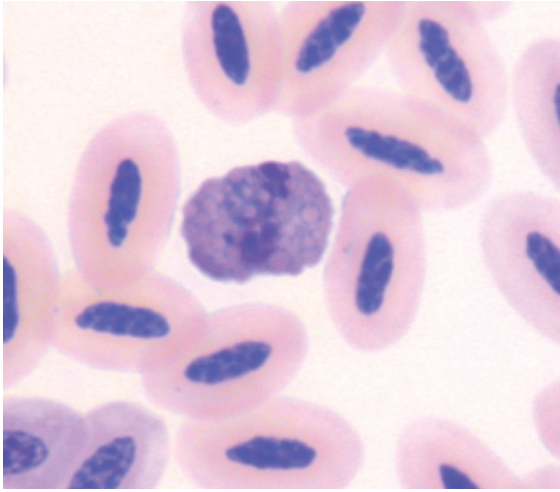


Figure 184 Blood from a toco toucan illustrating an “eosinophil” that has round granules that have a blue-grey color with a faint eosinophilic hue. Several individual granules can be discerned overlying the nucleus. (Modified Wright’s stain.)

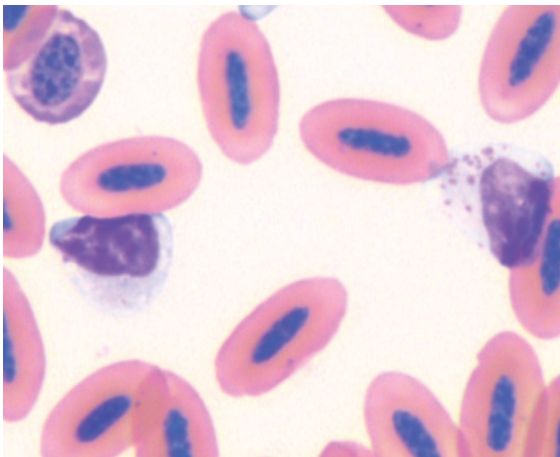


Figure 185 Blood from a toco toucan showing two lymphocytes; one (right) has about 20 small amphiphilic cytoplasmic granules whereas the other (left) exhibits only two small granules. (Modified Wright’s stain.)



Figure 188 Blood from the same bird as in Figure 187, showing a monocyte, characterized by its large size, reticular chromatin and agranulated basophilic cytoplasm. Also present is a thrombocyte exhibiting a single large cytoplasmic vacuole. (Modified Wright’s stain.)

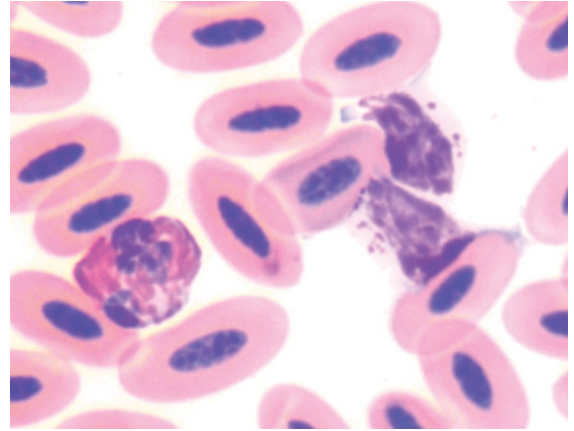


Figure 186 Blood from a red-billed toucan (*Ramphastos tucanus*) illustrating a typical heterophil and two lymphocytes, both of which contain several azurophilic granules. (Modified Wright’s stain.)

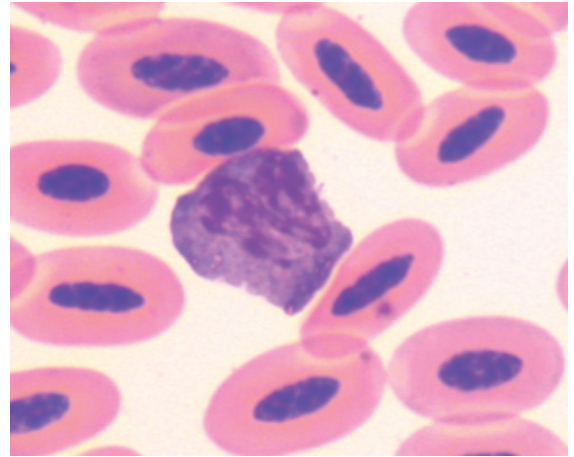
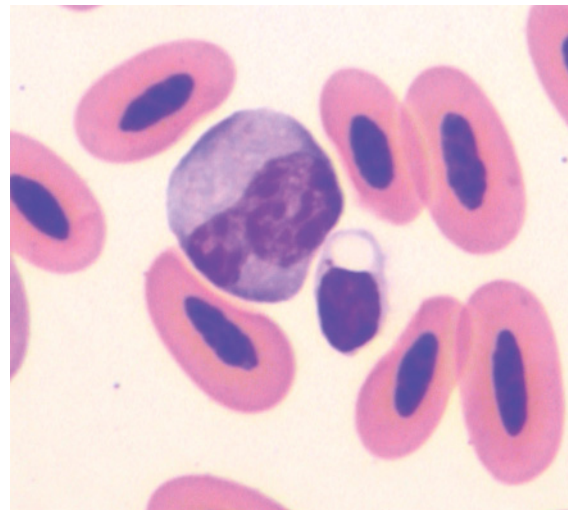


Figure 187 Blood from a red-billed toucan illustrating an “eosinophil”. The granules are mostly a blue-grey color with occasional eosinophilic granules observed. (Modified Wright’s stain.)



eosinophils from black-necked aracari (*Pteroglossus aracari*) had brightly eosinophilic granules. Basophils were not observed in the samples examined. Lymphocytes and monocytes had morphology consistent with the general characteristics displayed by birds, as previously described.

PODICIPEDIFORMES (GREBES)

See Figure 189.

To the authors' knowledge, no studies have described the hematological characteristics of the Podicipediformes.

Blood from an Australasian grebe (*Tachybaptus novaehollandiae*) contained erythrocytes that were ovoid cells with an ovoid nucleus composed of dense chromatin and eosinophilic cytoplasm. Heterophils had fine, fusiform, brick-red to eosinophilic colored granules. Eosinophils and basophils were not recognized. Lymphocytes and monocytes had morphology consistent with the general characteristics displayed by birds, previously described in this chapter.

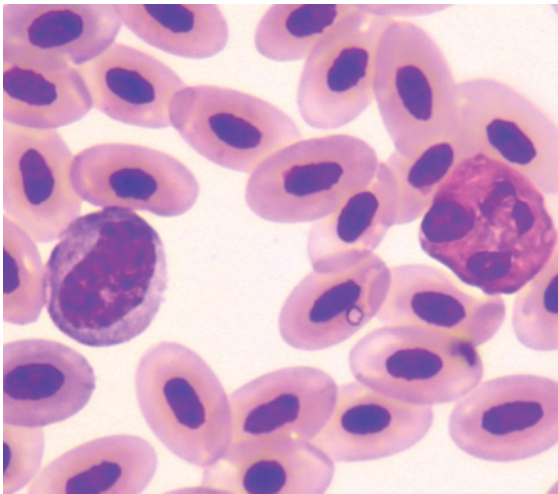


Figure 189 Blood from an Australasian grebe (*Tachybaptus novaehollandiae*). A heterophil and a large lymphocyte, amidst mature erythrocytes, are illustrated. (Diff Quik stain.)

PROCELLARIIFORMES (ALBATROSSES, FULMARS, PETRELS AND SHEARWATERS)

See Figures 190–191.

The hematological characteristics of several species belonging to the Procellariiformes have been reported, these include manx shearwaters (*Puffinus puffinus*) (Kirkwood et al. 1995), seven species of pelagic sea birds (Work 1996), great skua (Bearhop et al. 1999), waved albatross (*Diomedea irrorata*) (Padilla et al. 2003), southern giant petrels (*Macronectes giganteus*) (Uhart et al. 2003) and northern fulmar (*Fulmarus glacialis*) (Edwards et al. 2006). Most of these studies did not describe the morphological characteristics of hematological cells. Work (1996) described the morphology of hematological cells from three species of Procellariiformes, namely Hawaiian petrel (*Pterodroma phaeopygia*), wedge-tailed shearwater (*Puffinus pacificus*) and Laysan albatross (*Diomedea immutabilis*). The heterophils, basophils, monocytes and lymphocytes had morphology similar to that previously described for birds. Eosinophils from petrels

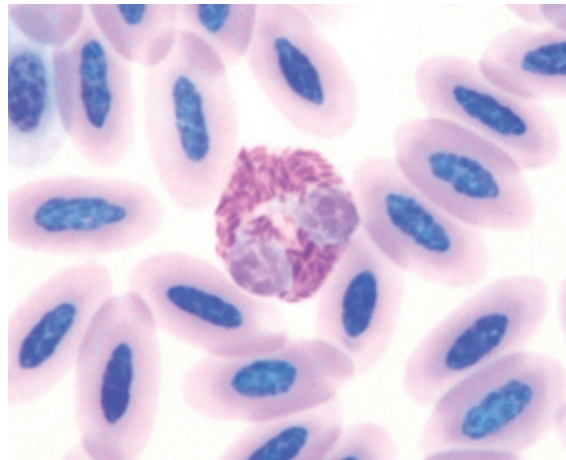


Figure 190 Blood from a fluttering shearwater (*Puffinus gavia*). Illustrated is a heterophil amidst mature erythrocytes. Overall, the basophilic stain is very pale, as can be determined by the pale color of the erythrocytes' nuclei. (May-Grünwald and Giemsa stains.)

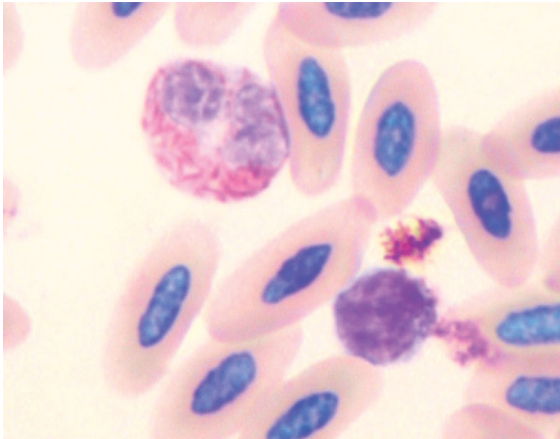


Figure 191 Blood from a short-tailed shearwater (*Puffinus tenuirostris*) showing a heterophil and a lymphocyte amidst mature erythrocytes. Some precipitated stain is also present around the lymphocyte. (May-Grünwald and Giemsa stains.)

and shearwaters had “densely packed orange, round, plump granules” whereas eosinophils from albatross had “loosely packed tiny round bright red-orange granules”.

Blood from fluttering shearwater (*Puffinus gavia*), short-tailed shearwater (*Puffinus tenuirostris*) and providence petrel (*Pterodroma solandri*) contained erythrocytes that were ovoid cells with an ovoid nucleus composed of dense chromatin and eosinophilic cytoplasm. Heterophils had fine, fusiform, brick-red to eosinophilic colored granules. Eosinophils from the shearwaters exhibited many, small rounded, eosinophilic granules that were present at high density. Lymphocytes and monocytes had morphology consistent with the general characteristics displayed by birds, as previously described.

PSITTACIFORMES (COCKATOOS, LORIES, MACAWS AND PARROTS)

See Figures 192–210.

The hematological characteristics of a number of species belonging to the Psittaci-

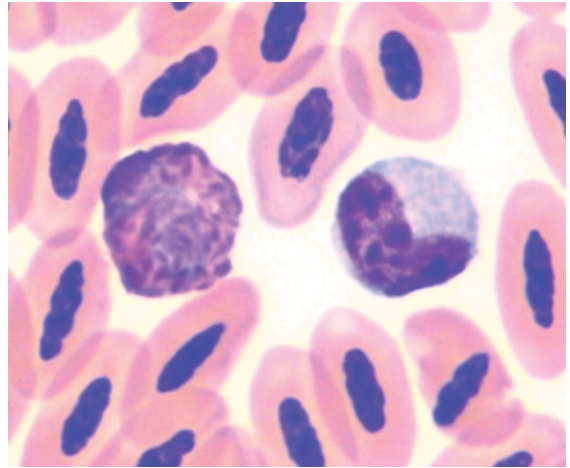


Figure 192 Blood from an eclectus parrot (*Eclectus roratus*) showing a typical heterophil (left) with a basophilic nucleus partially obscured by many fusiform brick-red cytoplasmic granules and a monocyte (right) with reticular chromatin and agranulated basophilic cytoplasm. (Modified Wright's stain.)

formes have been reported, including: 19 species of captive psittacine birds (Polo et al. 1998), hyacinth macaws (*Anodorhynchus hyacinthinus*) (Calle & Stewart 1987), red-fronted macaws (*Ara rubrogenys*) (Garcia del Campo et al. 1991), Cuban Amazon parrots (*Amazona leucocephala*) (Tell & Citino 1992),

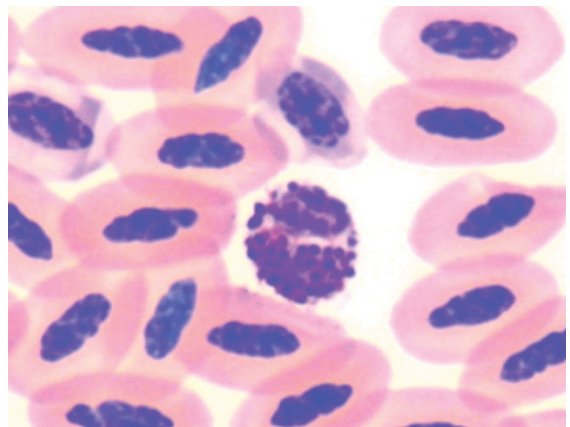


Figure 193 Blood from the same eclectus parrot as in Figure 192, showing a basophil with a moderate density of robust round to ovoid dark basophilic granules, amidst erythrocytes. (Modified Wright's stain.)

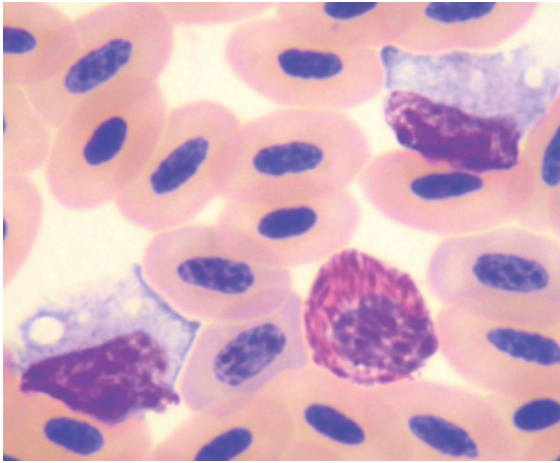


Figure 194 Blood from a red-tailed black cockatoo (*Calyptorhynchus banksii*) showing a heterophil and two monocytes each with vacuoles evident in their cytoplasm. The shape of the latter has been distorted by surrounding cells. (Modified Wright's stain.)

blue-fronted Amazon parrots (*Amazona aestiva*) (Deem et al. 2005), orange-bellied parrot (*Neophema chrysogaster*) (Melrose et al. 1995), budgerigars (*Melopsittacus undulatus*) (Harper & Lowe 1998, Fischer et al. 2006) and red lorries (*Eos* spp) (Scope et al. 2000). Most of these studies did not

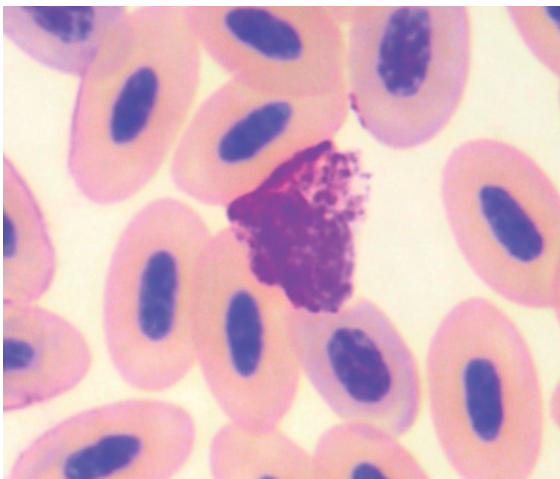


Figure 195 Blood from the same red-tailed black cockatoo as in Figure 194, showing a basophil with a moderate density of small basophilic granules. (Modified Wright's stain.)

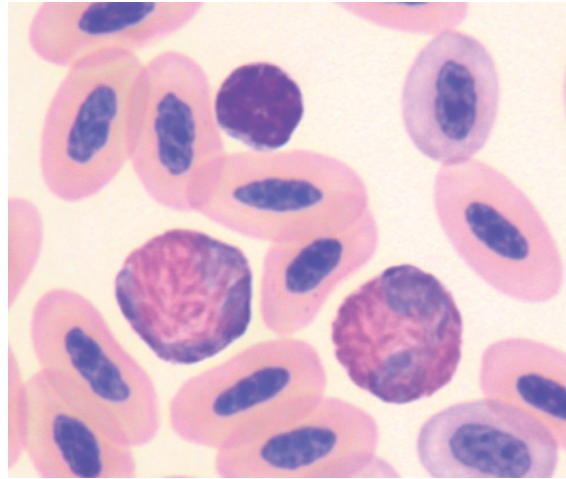


Figure 196 Blood from a white-tailed black cockatoo (*Calyptorhynchus baudinii*) portraying two typical heterophils and a small lymphocyte amidst erythrocytes. (Modified Wright's stain.)

describe the morphology of hematological cells. Hawkey et al. (1982) described the morphology of hematological cells from African grey parrots (*Psittacus erithacus*) but did not

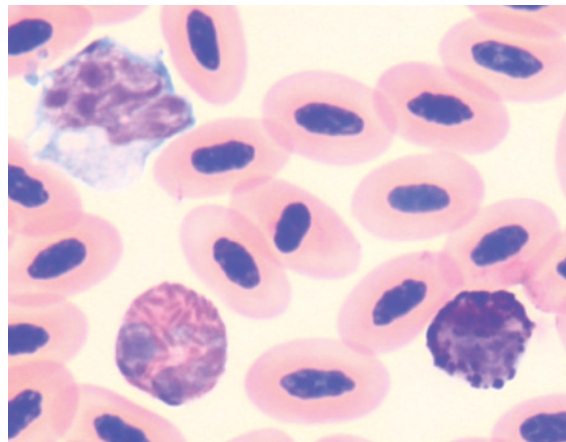


Figure 197 Blood from a Major Mitchell's cockatoo (*Cacatua leadbeateri*) depicting: a heterophil with a pale blue nucleus and many brick-red, fusiform cytoplasmic granules; a basophil with variably sized, unevenly distributed, dark basophilic cytoplasmic granules; and a monocyte with an irregularly shaped nucleus and basophilic cytoplasm containing several vacuoles, amidst erythrocytes. (Modified Wright's stain.)

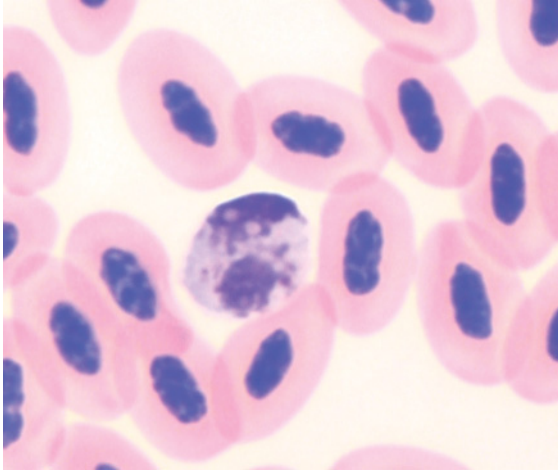


Figure 198 Blood from a Major Mitchell's cockatoo showing an "eosinophil" with a basophilic nucleus and ovoid, pale blue-grey with a faint eosinophilic hue, granules, amidst erythrocytes. (Modified Wright's stain.)

recognize eosinophils in clinically healthy birds. Campbell (2004) described the general morphological features of hematological cells from psittacine birds.

Erythrocytes were ovoid cells with an ovoid nucleus composed of dense chromatin and even eosinophilic cytoplasm. Heterophils were

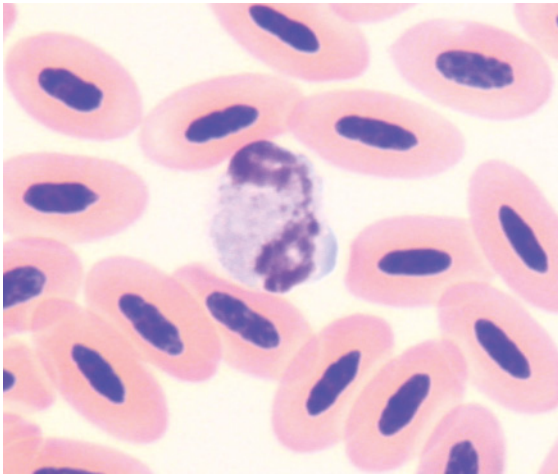


Figure 199 Blood from a galah (*Eolophus roseicapillus*) showing an "eosinophil" with a bi-lobed basophilic nucleus and many small ovoid, pale blue-grey, granules, amidst erythrocytes. (Modified Wright's stain.)

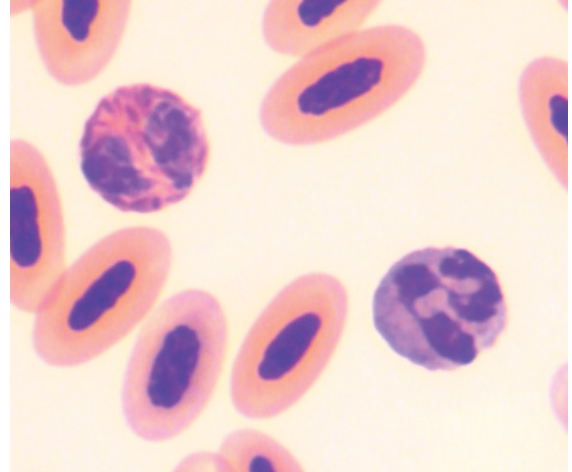


Figure 200 Blood from a Port Lincoln parrot (*Barnardius zonarius*) illustrating a heterophil (left) with a basophilic nucleus and many brick-red, fusiform cytoplasmic granules; and an "eosinophil", which in this species, has many blue-grey cytoplasmic granules. (Modified Wright's stain.)

irregularly round cells with prominent fusiform, brick-red to dull brown colored granules that were present at high density and consequently (partially) obscured the nucleus in many cells. The term "eosinophil" is a misno-

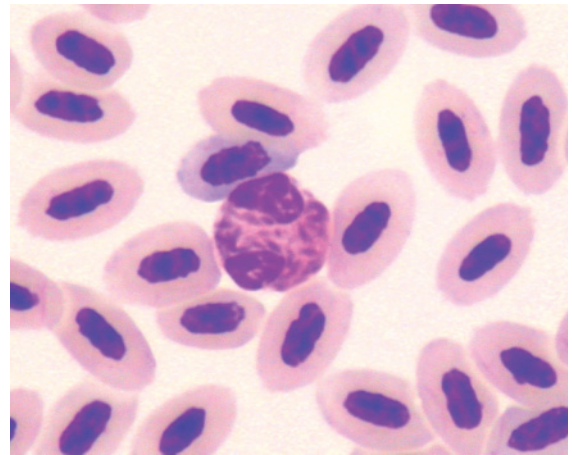


Figure 201 Blood from a northern rosella (*Platycercus venustus*) showing a heterophil, with a basophilic nucleus and many brick-red, fusiform cytoplasmic granules, amidst mature erythrocytes. (Diff Quik stain.)

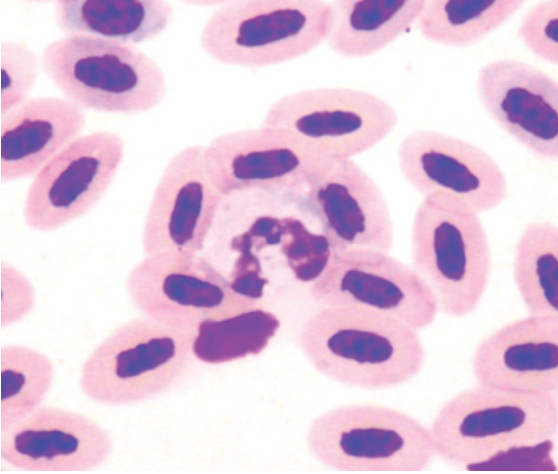


Figure 202 Blood from a northern rosella showing an “eosinophil” with a bi-lobed basophilic nucleus and many small ovoid, pale blue–grey granules, amidst erythrocytes. (Diff Quik stain.)

mer for many species of psittacine birds, for examples the cockatoos, as eosinophils lack classically eosinophilic cytoplasmic granules. Encompassing species and staining variation, the granules of “eosinophils” may be eosino-

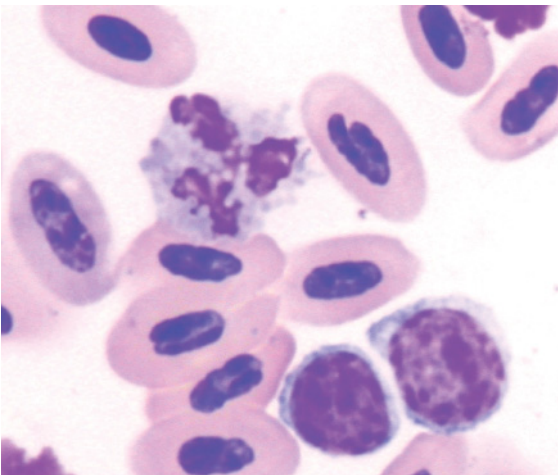


Figure 203 Blood from a princess parrot (*Polytelis alexandrae*) showing a disrupted “eosinophil” that allows the individual pale blue–grey cytoplasmic granules to be visualized. Also present are two lymphocytes amidst erythrocytes. (Modified Wright’s stain.)

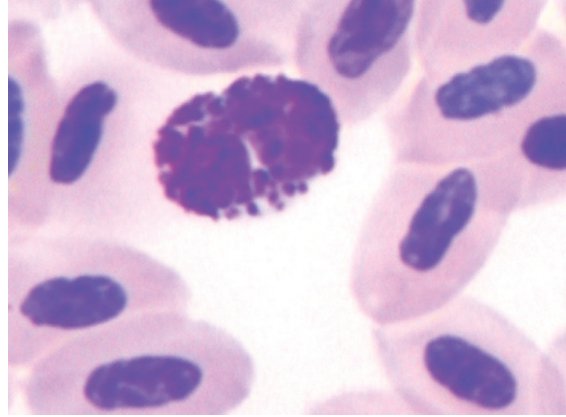


Figure 204 Blood from a princess parrot showing a basophil with a moderate density of round–ovoid basophilic cytoplasmic granules that permits some nuclear and cytoplasmic characteristics to be discerned. (Modified Wright’s stain.)

philic, aqua, pale blue or grey in color and are typically round to ovoid (with size varying between species) and present at high density. In some birds, the color of granules within the same cell may vary with palely eosinophilic granules, palely basophilic granules and colorless (degranulated) spaces all apparent.

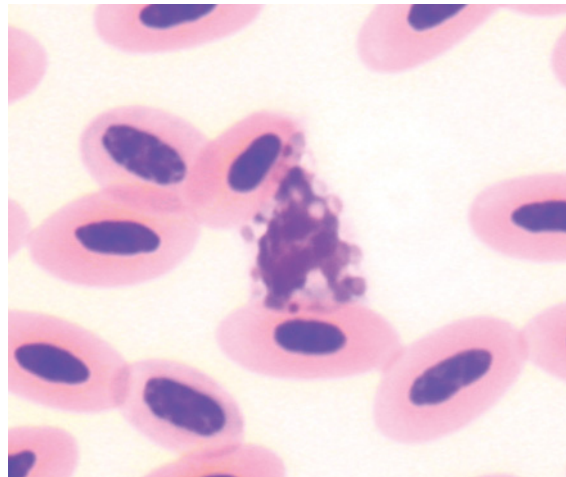


Figure 205 Blood from a sun conure (*Aratinga solstitialis*) showing an eosinophil with a basophilic nucleus and ovoid, variably sized, pale eosinophilic granules, amidst erythrocytes. (Modified Wright’s stain.)

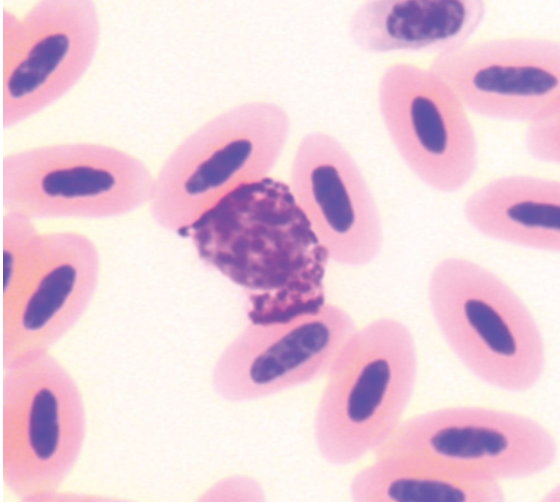


Figure 206 Blood from the same sun conure as in Figure 205 depicting a basophil with a moderate density of pleomorphic basophilic cytoplasmic granules that obscure nuclear and cytoplasmic characteristics. (Modified Wright's stain.)

Basophils were round cells with fine to robust round, deeply basophilic granules present at moderate high to density that often obscured both nucleus and cytoplasm.

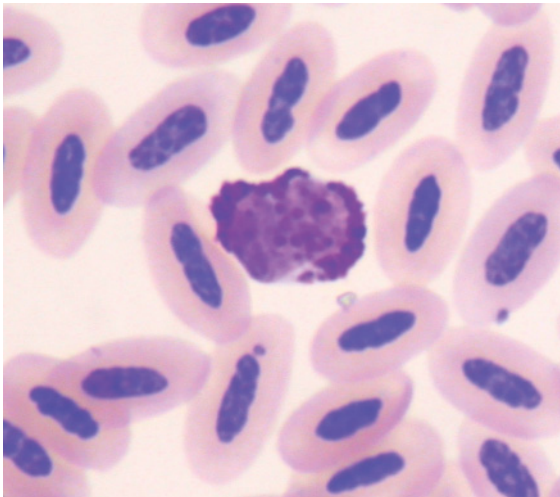


Figure 207 Blood from a blue-throated conure (*Pyrrhura cruentata*) showing a basophil with a moderate density of round-ovoid basophilic cytoplasmic granules, with a largely polar distribution, that permits some nuclear characteristics to be discerned. (Modified Wright's stain.)

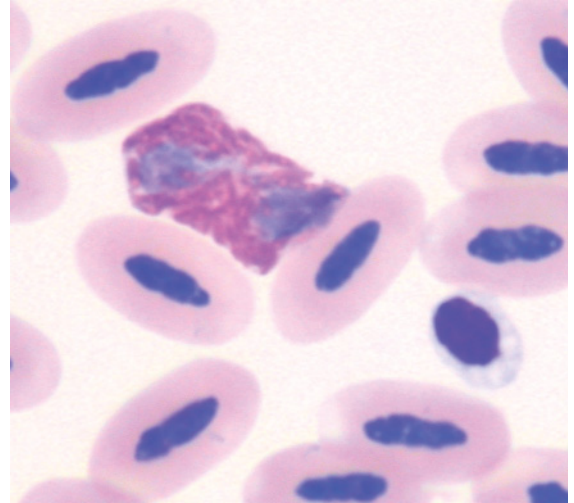


Figure 208 Blood from a military macaw (*Ara militaris*) illustrating a heterophil. The central granular body appears refractile and prominent in many of the cytoplasmic granules. Also present is a thrombocyte and several erythrocytes. (Modified Wright's stain.)

Lymphocytes and monocytes had morphology consistent with the general characteristics displayed by birds, as previously described.

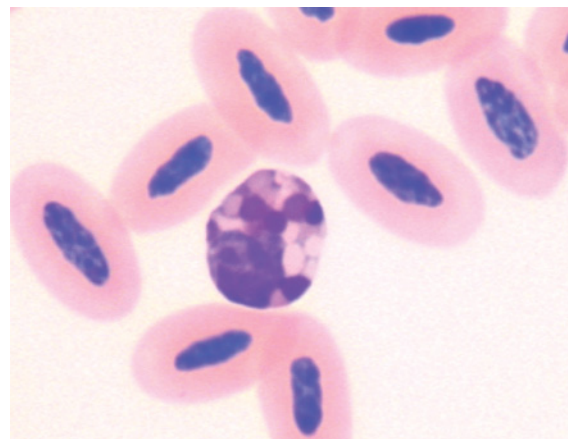


Figure 209 Blood from a military macaw showing an eosinophil with a basophilic nucleus and large, ovoid, variably colored (pale eosinophilic to amphophilic) cytoplasmic granules. (Modified Wright's stain.)

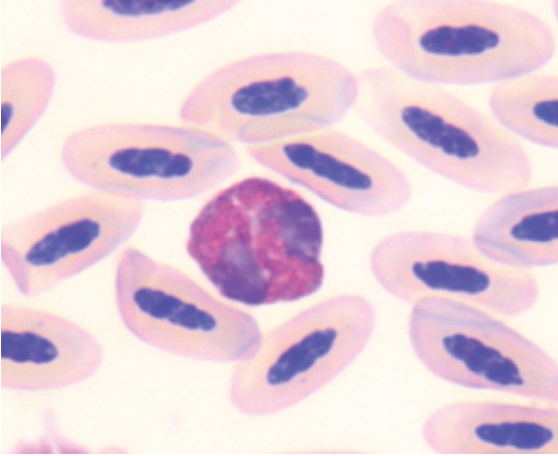


Figure 210 Blood from a green-winged macaw (*Ara chloropterus*) showing a heterophil amidst mature erythrocytes. The central granular body appears refractile in many of the cytoplasmic granules and its prominence makes overall structure of the granule difficult to discern. (Modified Wright's stain.)

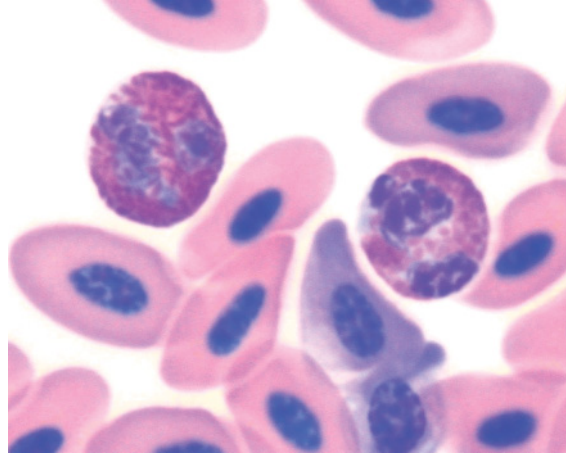


Figure 211 Blood from a little penguin (*Eudyptula minor*) depicting: a heterophil (left) with a pale basophilic nucleus and many brick-red fusiform cytoplasmic granules; and an eosinophil (right) with a segmented basophilic nucleus and many eosinophilic, round to ovoid granules within a basophilic cytoplasm, amidst erythrocytes. (Modified Wright's stain.)

SPHENISCIFORMES (PENGUINS)

See Figures 211–214.

Selected hematological characteristics have been reported for the little penguin (*Eudyptula minor*) (Nicol et al. 1988, Sargent et al. 2004), rock-hopper penguin (*Eudyptes chrysocomes*) (Hawkey et al. 1989, Karesh et al. 1999), gentoo penguin (*Pygoscelis papua*) and magellanic penguin (*Spheniscus magellanicus*) (Hawkey et al. 1989), Humboldt penguins (*Spheniscus humboldti*) (Wallace et al. 1995, Villouta et al. 1997, Cranfield 2003), king penguins (*Aptenodytes patagonicus*) (Cranfield 2003) and Galapagos penguin (*Spheniscus mendiculus*) (Travis et al. 2006). These studies did not describe the morphological characteristics of hematological cells.

Nicol et al. (1988) noted the relatively large size of erythrocytes (MCV 226 ± 26 fL, length 18.8 ± 1.6 and width 9.2 ± 0.8 μm) and low concentration of erythrocytes ($1.66 \pm 0.31 \times 10^{12}/\text{L}$) in the little penguin. Similar values were subsequently observed for other species of penguins (Hawkey et al. 1989).

Erythrocytes were “rounded ovoid” cells with an ovoid nucleus composed of dense chromatin and eosinophilic cytoplasm. Heterophils exhibited a high density of fusiform, brick-red to eosinophilic colored granules that partially obscured the nucleus in many cells.

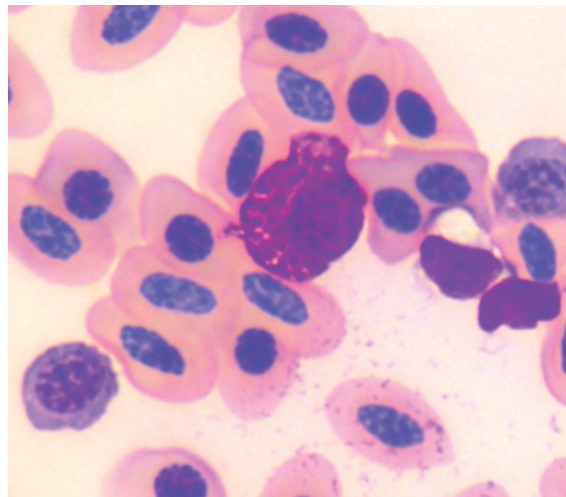


Figure 212 Blood from a little penguin exhibiting a basophil amidst erythrocytes. (Modified Wright's stain.)

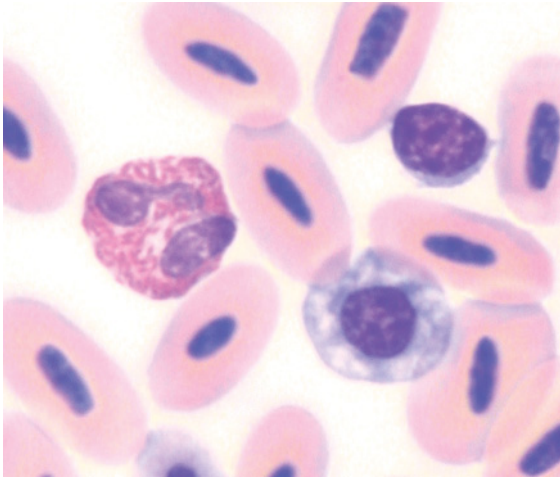


Figure 213 Blood from a black-footed penguin (*Spheniscus demersus*) portraying: a heterophil (left) with a segmented basophilic nucleus and many brick-red, short fusiform cytoplasmic granules; a small lymphocyte; a “round” polychromatophilic erythrocyte and several mature erythrocytes. (Modified Wright’s stain.)

Eosinophils typically had a segmented nucleus that was more basophilic and less obscured by granules than heterophils. The cytoplasm was moderately basophilic and contained many

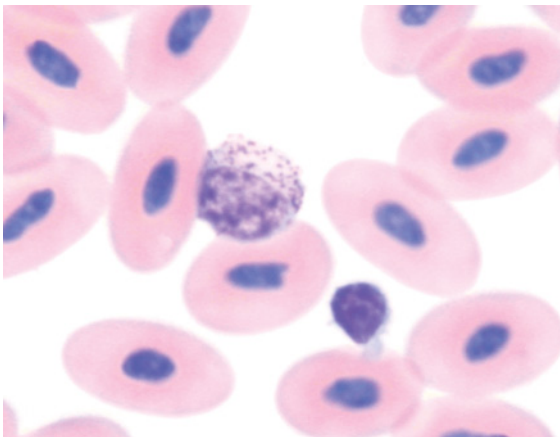


Figure 214 Blood from a black-footed penguin (*Spheniscus demersus*) showing a basophil with an ovoid (non-segmented) nucleus and sparse, fine basophilic cytoplasmic granules, and a small lymphocyte, amidst mature erythrocytes. (Modified Wright’s stain.)

ovoid eosinophilic granules. Basophils had many round, deeply basophilic granules present at high density that obscured both nucleus and cytoplasm. Lymphocytes and monocytes had morphology consistent with the general characteristics displayed by birds, as described in the previous chapter.

STRIGIFORMES (BARN OWLS AND “TYPICAL” OWLS)

See Figures 215–221.

Several studies have investigated the hematological characteristics of the Strigiformes and selected hematological characteristics have been reported for several species of owls (Cooper 1975, Elliot et al. 1974, Smith & Bush 1978, Hawkey & Samour 1988, Evans & Otter 1998). More recently, Aguilar (2003) presented hematological values for nine species of owl.

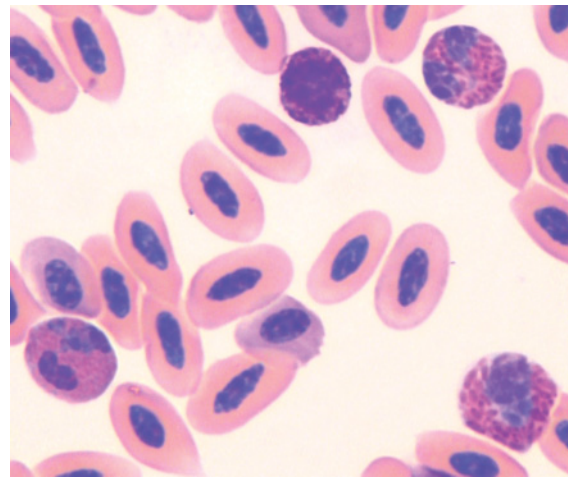


Figure 215 Blood from a southern boobook (*Ninox boobook*) exhibiting: two heterophils (right) with paler basophilic nucleus and many brick-red cytoplasmic granules; an eosinophil (left) with a segmented nucleus and many rod-shaped eosinophilic cytoplasmic granules; and a basophil with a number of prominent basophilic granules in an overall basophilic cytoplasm, amidst a number of erythrocytes including two polychromatophilic erythrocytes. (Modified Wright’s stain.)

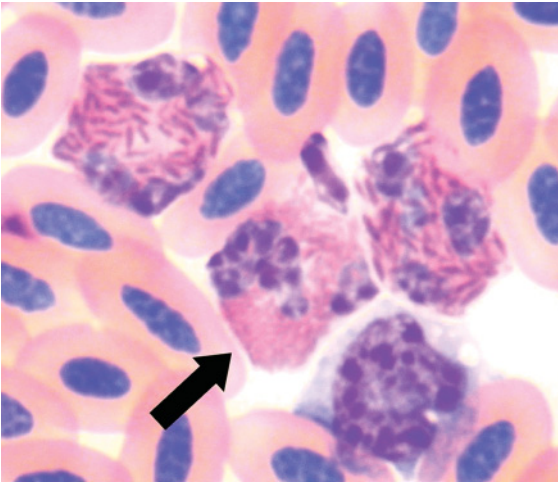


Figure 216 Blood from a masked owl (*Tyto novaehollandiae*) showing two heterophils, an eosinophil (arrow) and a monocyte. (Modified Wright's stain.) Note the subtle differences between the eosinophil, which has smaller rod-shaped more brightly eosinophilic granules, and the heterophils which have larger, more fusiform and brown-red colored granules. The shape of the leukocytes has been distorted by the surrounding cells.

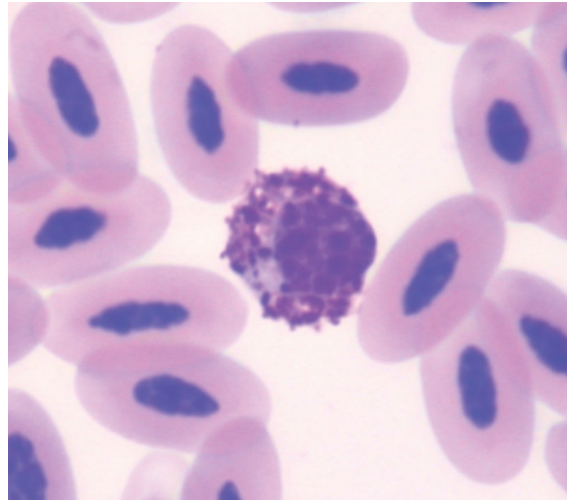


Figure 218 Blood from the same rusty-barred owl as in Figure 217 illustrating a basophil with a round-ovoid nucleus and moderate density of pleomorphic basophilic granules within a basophilic cytoplasm. (Modified Wright's stain.)

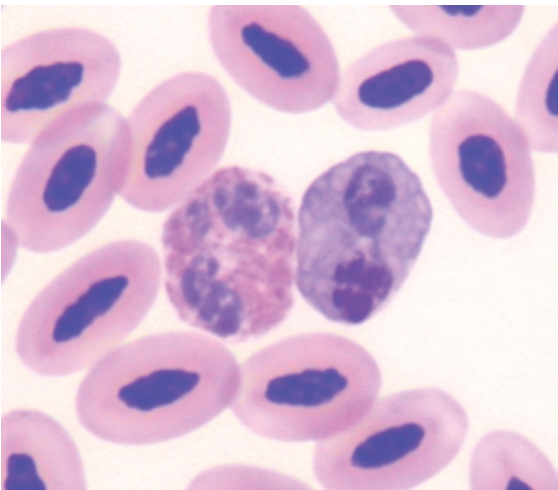


Figure 217 Blood from a rusty-barred owl (*Strix hylophila*) showing a heterophil (left) and an "eosinophil". The granules of the latter have a blue-grey color with a faint eosinophilic hue. (Modified Wright's stain.)

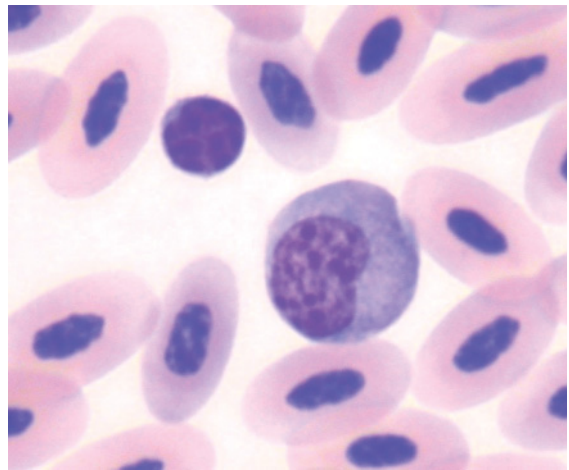


Figure 219 Blood from the same rusty-barred owl as in Figure 217 showing a lymphocyte (left) and a (larger) monocyte (right) amidst erythrocytes. (Modified Wright's stain.)

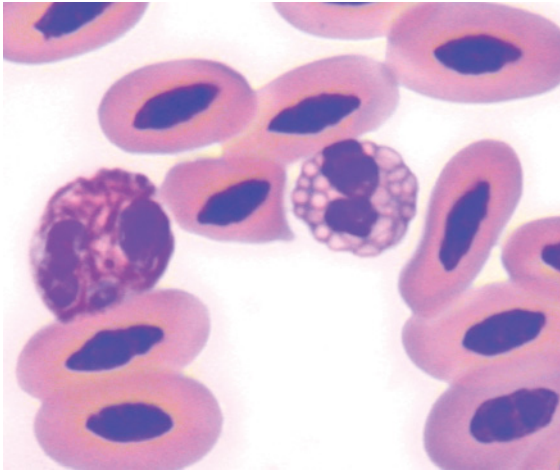


Figure 220 Blood from a spectacled owl (*Pulsatrix perspicillata*) portraying a heterophil (left) and an eosinophil. The latter has large round–ovoid brightly eosinophilic granules. (Modified Wright's stain.)

However, these studies did not report the morphological description of hematological cells.

Erythrocytes were ovoid cells with an ovoid nucleus composed of dense chromatin and eosinophilic cytoplasm. Heterophils had prominent fusiform, brick-red to eosinophilic

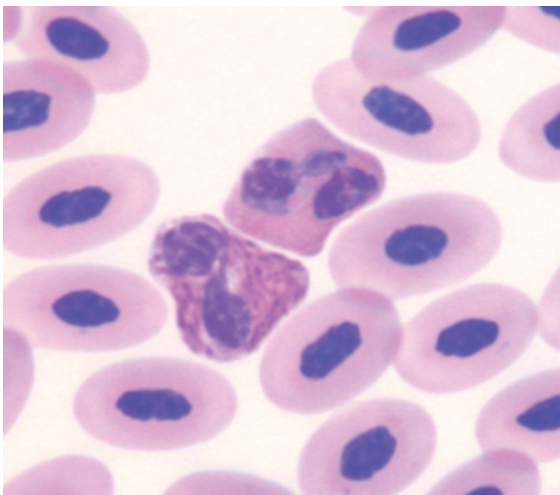


Figure 221 Blood from a white-faced scops owl (*Otus leucotis*) showing a heterophil (left) and an eosinophil, with small round eosinophilic granules within a basophilic cytoplasm. (Modified Wright's stain.)

colored granules. The morphology of eosinophils from Strigiformes has received careful description and marked variation between species has been noted (Lind et al. 1990). Species within the genus *Tyto* have long thin, rod-shaped eosinophilic granules, whereas species within the genus *Strix* have round, bluish to dull eosinophilic granules and species within the genera *Asio* and *Otus* have robust, round, brightly eosinophilic granules. Basophils had a high density of variably sized, round to ovoid, deeply basophilic granules that often obscured the nucleus. Lymphocytes and monocytes had morphology consistent with the general characteristics displayed by birds, as previously described.

STRUTHIONIFORMES (CASSOWARIES, EMUS, KIWIS, OSTRICHES AND RHEAS)

See Figures 222–228.

The hematological characteristics of ostrich (Palomeque et al. 1991, Fudge 2000), emu

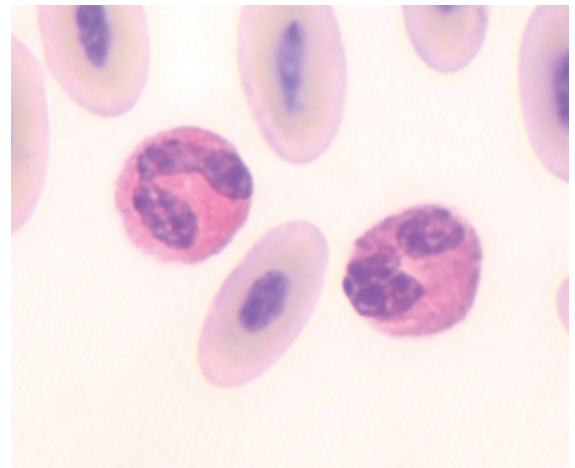


Figure 222 Heparinized blood from an ostrich (*Struthio camelus*) showing an eosinophil (left) with a segmented basophilic nucleus and many small round eosinophilic granules within a basophilic cytoplasm and a heterophil (right) with a segmented basophilic nucleus and indistinct brown–red fusiform cytoplasmic granules. (Diff Quik stain.)

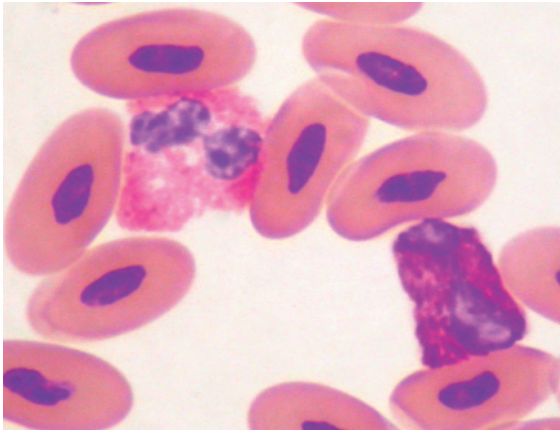


Figure 223 Blood from a southern cassowary (*Casuaris casuaris*) portraying an eosinophil (left) with a segmented basophilic nucleus and many small pleomorphic brightly eosinophilic granules within a basophilic cytoplasm and a heterophil (right) with a segmented basophilic nucleus and brick-red fusiform cytoplasmic granules, amidst mature erythrocytes. (Diff Quik stain.)

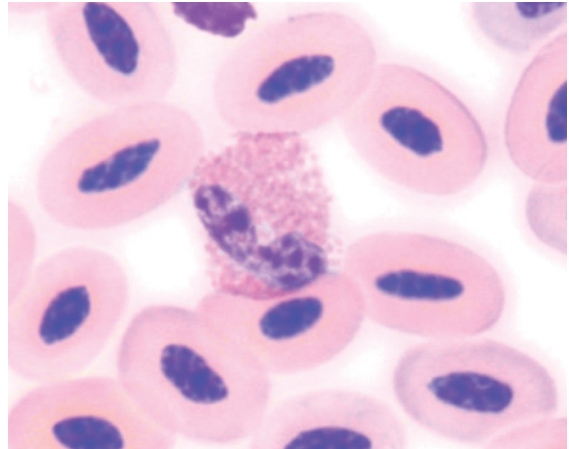


Figure 225 Blood from the same emu as Figure 224, portraying an eosinophil with a bi-lobed basophilic nucleus and many small round eosinophilic granules within a basophilic cytoplasm. (Modified Wright's stain.)

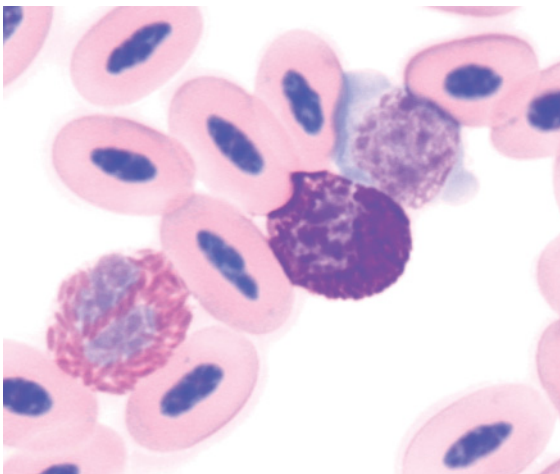


Figure 224 Blood from an emu (*Dromaius novaehollandiae*) exhibiting: a heterophil (left) with a segmented pale blue nucleus and brick-red fusiform cytoplasmic granules; a basophil many dark basophilic cytoplasmic granules that obscure the nucleus; and a monocyte with its nucleus folded, reticular chromatin and basophilic agranulated cytoplasm. (Modified Wright's stain.) Note the shape of some leukocytes has been distorted by adjacent cells.

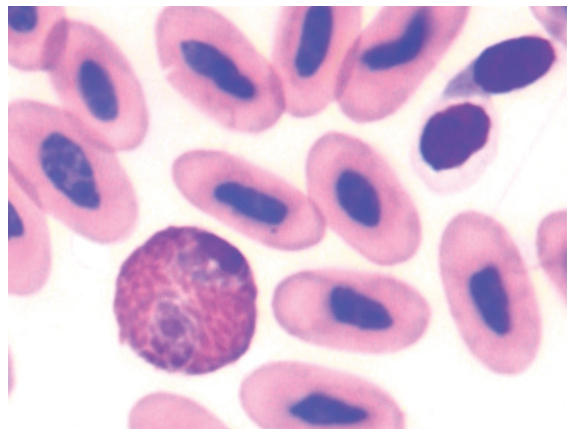


Figure 226 Blood from a brown kiwi (*Apteryx australis*) showing a heterophil with a basophilic nucleus that is largely obscured by the presence of many brick-red fusiform cytoplasmic granules. Also present are a number of erythrocytes and two thrombocytes (top right); one of which exhibits a "round" shape and the other a fusiform shape. (Modified Wright's stain.)

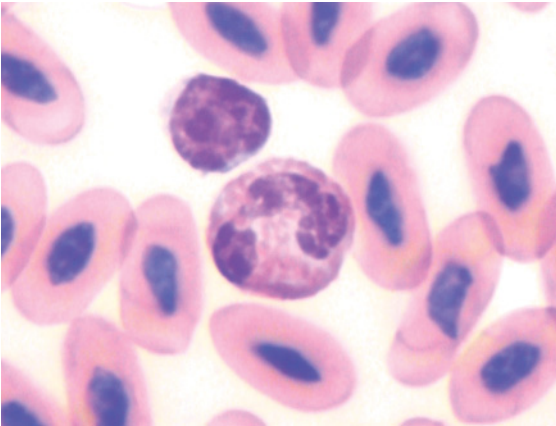


Figure 227 Blood from a brown kiwi illustrating: an eosinophil with a segmented basophilic nucleus and many small ovoid to rod-shaped eosinophilic granules within a basophilic cytoplasm; and a small lymphocyte, amidst erythrocytes. (Modified Wright's stain.)

(Fudge 2000), lesser rhea (*Rhea pennata*) (Reissig et al. 2002) and greater rhea (*Rhea americana*) (Uhart et al. 2006) have been reported. These studies did not describe the morphology of hematological cells.

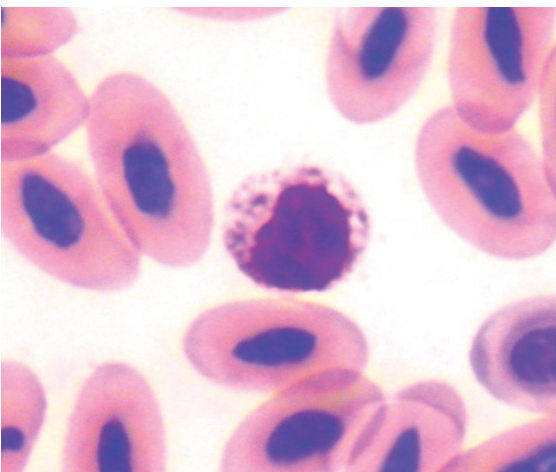


Figure 228 Blood from a brown kiwi showing a basophil in which many of the granules have not taken up the basophilic stain leaving negatively staining spaces in the cytoplasm. (Modified Wright's stain.)

EDTA has been reported to cause hemolysis of ostrich blood and consequently is not recommended as an anticoagulant (Hawkey & Dennett 1989).

Erythrocytes were ovoid cells with an ovoid nucleus composed of dense chromatin and even eosinophilic cytoplasm. Heterophils had prominent fusiform, brick-red to dull brown colored granules that were present at high density. Eosinophils typically had a basophilic nucleus and ovoid, dull to brightly eosinophilic granules present at high density throughout the cytoplasm. Basophils typically had ovoid, deeply basophilic granules present at high density that obscured both nucleus and cytoplasm. However, in some cells, the majority of granules did not stain. Lymphocytes and monocytes had morphology consistent with the general characteristics displayed by birds, as previously described.

TINAMIFORMES (TINAMOUS)

To the authors' knowledge, there have been few studies that have described the hematological characteristics of Tinamiformes. Smith (2003) presented selected hematological values for the red-winged tinamou (*Rhynchotus rufescens*); however, the morphological characteristics of hematological cells were not described.

TROGONIFORMES (TROGONS AND QUETZALS)

To the authors' knowledge, there have been few studies that have described the hematological characteristics of Trogoniformes. Neiffer (2003) reported selected hematological values for two species of trogon and two species of quetzal. The morphology of hematological cells was not reported.

Physiological and pathological influences on the hematological characteristics of birds



INTRODUCTION

The analysis of blood provides a minimally invasive way to gain an insight into the health status of an individual. To be able to recognize the hematological response to disease, the hematologist must be aware of the many factors, artifactual, physiological and pathological, that may affect the measured hematological values and morphology of hematological cells. In the following sections a number of physiological and pathological influences, that may affect hematological characteristics, are considered. In many cases, the physiological influences result in a change to the concentration of hematological cells but do not affect cell morphology and will only be briefly described here. Pathological influences may affect the concentration of hematological cells, the morphology of hematological cells or both the concentration and morphology of cells. As previously stated, our focus is the morphological appearance of cells and how changes in the morphology may be recognized and used to detect response to disease.

PHYSIOLOGICAL EFFECTS ON THE HEMATOLOGICAL CHARACTERISTICS OF BIRDS

A number of physiological influences, including age, sex and season, may affect the hematological characteristics of a bird and a number of studies have reported these effects. However, it is usually difficult to isolate the effect of a single physiological factor, as many such effects may be interrelated. For example, the age of a bird is often related to the season (such as fledged birds entering their first winter) which may affect the availability of food (and consequently the nutrition of the bird). These influences may affect the concentration of hematological analytes but usually do not affect the morphology of hematological cells. Consequently, physiological influences will be only briefly discussed.

Age

Age has been shown to affect the hematological characteristics of a number of species of

birds. A study of house martin nestlings showed a rapid increase in erythrocyte concentration and hematocrit, and a decrease in MCV with age (Kostelecka-Myrcha & Jaroszewicz 1993). A number of species have shown an increasing PCV, erythrocyte concentration and hemoglobin concentration with age (to maturity). That is, younger birds typically have lesser values than adults. This characteristic has been observed in a number of species including; Chilean flamingos (*Phoenicopterus chilensis*) (Hawkey et al. 1984a), houbara bustard (Jimenez et al. 1991, Samour et al. 1994), rufous-crested bustard (D'Aloia et al. 1995), ostrich (Palomeque et al. 1991), white storks (Montesinos et al. 1997) and common pheasant (Dos Santos Schmidt et al. 2007). A study of common loons revealed that chicks had lesser mean PCV than adults but adults had a wider range (Haefele et al. 2005).

In contrast, erythrocytic values did not differ between adult (greater than 1 year old) and young (less than 1 year old) common cranes (Abelenda et al. 1993).

Some of these studies also showed differences in the concentrations of leukocytes between juveniles and adults. Decreasing total leukocyte and lymphocyte concentrations were observed with increasing age in white storks (Montesinos et al. 1997); juvenile rufous-crested bustards had greater total leukocyte and lymphocyte concentrations, but a lesser basophil concentration, than adults (D'Aloia et al. 1995). The chicks of Chilean flamingos had greater and more variable concentrations of leukocytes than adults (Hawkey et al. 1984a).

Sex and reproductive status

The effect of the sex of the bird and its reproductive status has been investigated in a number of studies. They have been shown to affect the hematological characteristics of some species of birds but not in others.

No differences between sexes was observed in the measured hematological values of Eurasian kestrels (Kirkwood et al. 1979), Cooper's and sharp-shinned hawks (Gessaman et al. 1986), marsh harrier (Lavin et al. 1992), American kestrel (Rehder & Bird 1983, Dawson & Bortolotti 1997), great tits (Hauptmanova et al. 2002), houbara bustards (Samour et al. 1994) or common loons (Haefele et al. 2005).

Differences in the erythrocyte concentration and hemoglobin concentration were observed between males and females, during a non-breeding period, for a range of captive species of birds including cranes, geese, raptors, and quail (Gee et al. 1981). Mature male common pheasants had a greater PCV than mature females (Hauptmanova et al. 2006, Dos Santos Schmidt et al. 2007). Rehder et al. (1982a) noted that female American kestrels, while laying, had a lower PCV than males.

Hematological values may vary depending on the reproductive status of the bird. For example a higher PCV was observed in non-reproductive female pigeons (0.54 L/L) compared to those undertaking reproductive activities such courtship, mating, incubation and brooding (0.41–0.45 L/L) (Gayathri & Hegde 2006). Similarly, female great skuas that produced a greater number of eggs (six) had lesser erythrocytic values than females producing fewer eggs (two) (Kalmbach et al. 2004).

Season

Season has been reported to affect the hematological characteristics of some species of birds. Captive American kestrels exhibited maximum hematocrit in winter (mean 0.48 L/L for females) and minimum hematocrit in summer (0.29 L/L for females) (Rehder & Bird 1983). In contrast, no significant difference was observed in the PCV or erythrocyte concentration of captive red-tailed hawks between November and February (Rehder et al. 1982b).

A study of four passerine species of birds in south-eastern Australia revealed that an increased erythrocyte concentration and decreased MCV (but no significant change in hematocrit) occurred during winter (Breuer et al. 1995). A lesser hematocrit and erythrocyte concentration was seen in common cranes during early autumn than at other times of the year (Abelenda et al. 1993). Seasonal (and geographical) variation was observed in the hematological characteristics of several passerine birds (Booth & Elliot 2003). Hematocrit, erythrocyte concentration and hemoglobin concentration were greatest in winter and early spring and least in summer (erythrocyte concentration) and autumn (hematocrit and hemoglobin concentration) for snow geese (*Anser caerulescens*) and Canada geese (*Branta canadensis*) (Williams & Trainer 1971).

In contrast to the above reports for erythrocytes, no changes in the concentration of any leukocyte have been reported to be due to the season.

Time of day

Variation in the hematological values of birds with the time of day has been observed. Rose-ringed parakeets (*Psittacula krameri*) exhibited a circadian rhythm in the differential leukocyte count, with heterophil and eosinophil proportions greater at 0600 h than 2400 h and lymphocyte proportions less at 0600 h than 2400 h (Choudhury et al. 1982). Rehder et al. (1982b) noted the PCV and erythrocyte concentration of captive red-tailed hawks was greater in the morning and decreased throughout the day. A similar effect was noted for the PCV of American kestrels (Dawson & Bortolotti 1997). The mechanism underlying this observation was not elucidated. In contrast, the PCV of American kestrels was not significantly different between 0900 h and 1200 h (Rehder et al. 1982b).

Effect of migration

The effect of long-distance flight on the hematological characteristics of migratory birds has been studied. A decreased hematocrit, associated with decreased amounts of subcutaneous fat, has been observed during migration in goldcrests (*Regulus regulus*) and blue tits (Merila & Svensson 1995, Svensson & Merila 1996). Similarly, in bar-tailed godwits (*Limosa lapponica*) assessed during a stop-over in migration, the arriving birds had a lesser hematocrit and hemoglobin concentration than “refueling” birds, however no significant differences in reticulocytes were observed (Landys-Cianelli et al. 2002).

A study of the hematological characteristics of four species of passerine birds and red knots (*Calidris canutus*) undertaking endurance flight revealed that hematocrit was dependent on body mass (Jenni et al. 2006). For red knots, typically a small decrease in hematocrit (0.52 to 0.49 L/L) occurred within 1 hour after the commencement of the flight. Similarly, the hematocrit of pigeons after a 2–4-hour flight was, on average, 1.1% less than their pre-flight values (Adams et al. 1997).

In contrast, no significant differences were observed between pre-migration and post-migration hematocrit values of adult black headed gulls. However, juvenile females had lower values in the post-migratory period (Munoz & De la Fuente 2003).

Geographic location and population

Geographic location and population (that is the community of its species to which the bird belongs) may affect the hematological values of a bird. This is typically an overall indication of the complex interactions of many factors that include habitat, competition, nutrition, age, sex, social structure, “stress” and health status.

Reports of the effect of geographic location and population on hematological characteris-

tic have been published. For example, the hematological reference intervals of common loons differed with geographic location (Haefele et al. 2005), and Dutton et al. (2002) reported differences in the hematological value between two captive populations of bald ibis. The latter authors suggested the differences may be due to diet and state of hydration.

Beyond the described physiological influences, many additional factors have been studied to determine their effects on the hematological characteristics of birds. It is beyond the scope of this book to consider the many studies that have investigated the effects of physiological influences on the hematological characteristics of birds that include inactivity, molt, nutrition and territory. Furthermore, how the interaction of two or more of these factors may affect the hematological characteristics of the bird is complex and difficult to predict.

PATHOLOGICAL EFFECTS ON THE HEMATOLOGICAL CHARACTERISTICS OF BIRDS

In the following section, the hematological response(s) exhibited by birds in response to “disease” is considered. These may be evident as changes in the concentration of hematological cells or alterations in the morphology of hematological cells (or both). While dramatic changes in hematological values may be identified as a response to disease without reference to the hematological values of a particular type of bird in health, these represent a small minority of cases. In the vast majority of cases, the detection of a disease process is greatly assisted by the recognition of deviation from hematological values exhibited by comparable birds lacking the disease process.

Consequently, even without the influence of any disease process, the multitude of physiological factors that may affect the hematology

cal characteristics make it necessary to critically appraise the applicability of any reference intervals employed for comparative purposes. The greater the dissimilarity between the physiological state of the bird under study and that of the birds for which the reference intervals were established, the greater the uncertainty in the comparison and interpretation as to the cause of any recognized difference. As previously stated, physiological influences rarely manifest as morphological changes of hematological cells. Consequently, the presence of morphological atypia is strong evidence of response to a disease process.

Characteristics of the concentration and morphology of erythrocytes in response to disease

See Figures 229–243.

The clinical assessment of the erythrocytic characteristics of a bird is best achieved by considering the measurement of a bird’s PCV,

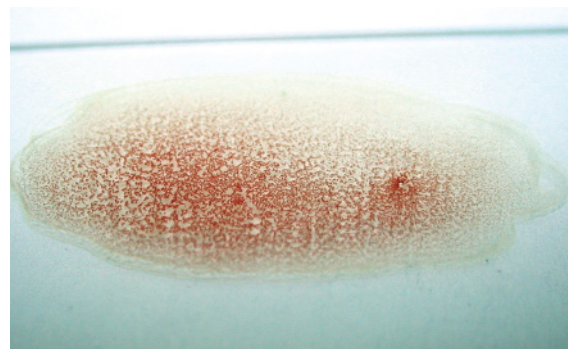


Figure 229 Gross agglutination of blood from an eclectus parrot (*Eclectus roratus*) with an agglutinating immune-mediated hemolytic anemia, resulting in a PCV of 0.17 L/L. The “particles” visible represent immune-mediated aggregates of erythrocytes. Reproduced from Johnston et al., Immune-mediated hemolytic anemia in an eclectus parrot, in *Journal of American Veterinary Medical Association*, copyright 2007 with permission of the American Veterinary Medical Association.

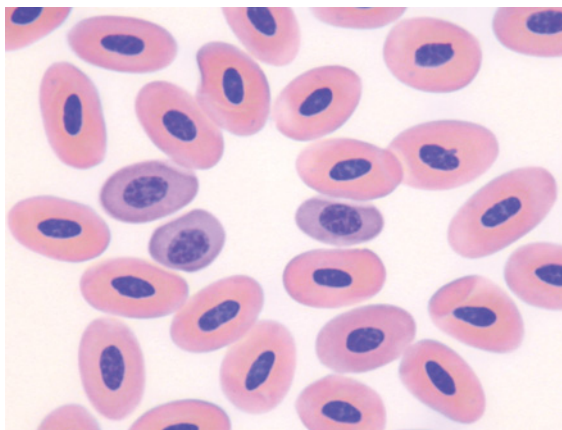


Figure 230 Blood from a black-footed penguin (*Spheniscus demersus*) with increased erythropoiesis, evidenced by 9% polychromatophilic erythrocytes in the peripheral blood. Three polychromatophilic erythrocytes are present near the center of the field. Figure 214 illustrates erythrocytes from this species, with typical morphology. (Modified Wright's stain.)

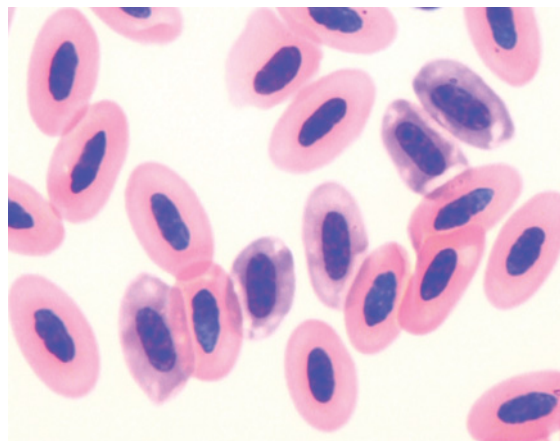


Figure 232 Blood from an Australian black-shouldered kite (*Elanus axillaris*) that had suffered trauma and blood loss after being hit by a motor vehicle. The bird had a PCV of 0.20 L/L and 19% polychromatophilic erythrocytes and 2% rubricytes indicated increased erythropoiesis in response to the anemia. Several polychromatophilic erythrocytes are shown. (Modified Wright's stain.)

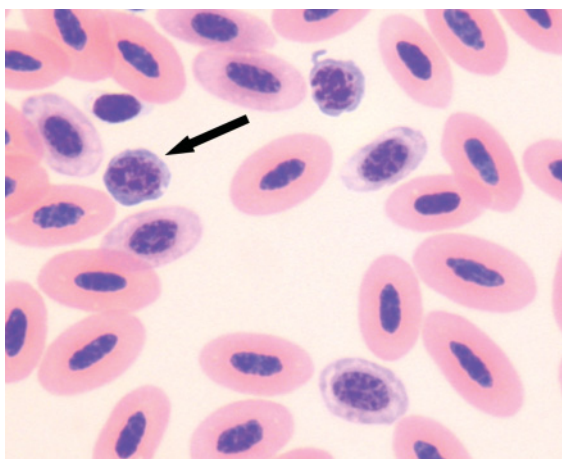


Figure 231 Blood from an injured and clinically dehydrated barn owl (*Tyto alba*) that had a PCV of 0.32 L/L. The hemoconcentration (relative polycythemia) due to dehydration may "mask" the magnitude of the anemia. Increased erythropoiesis was indicated by 10% polychromatophilic erythrocytes and 1% rubricytes. Illustrated are several polychromatophilic erythrocytes and two rubricytes (one identified by an arrow). (Modified Wright's stain.)

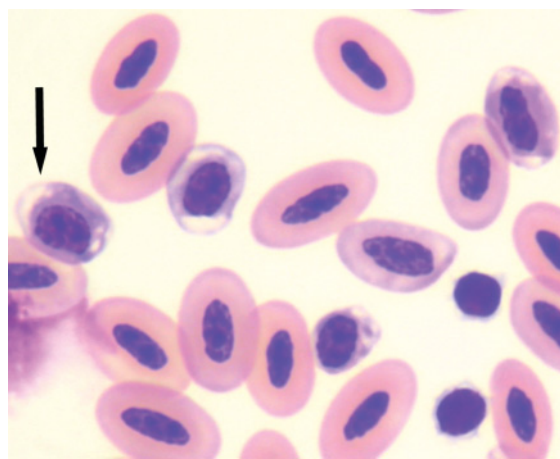


Figure 233 Blood from a white-tailed black cockatoo (*Calyptorhynchus baudinii*) with a PCV of 0.28 L/L. Polychromatophilic erythrocytes comprised 21% of erythrocytes which indicated increased erythropoiesis in response to the anemia. Illustrated are several polychromatophilic erythrocytes (one indicated by an arrow) amongst mature erythrocytes. (Modified Wright's stain.)

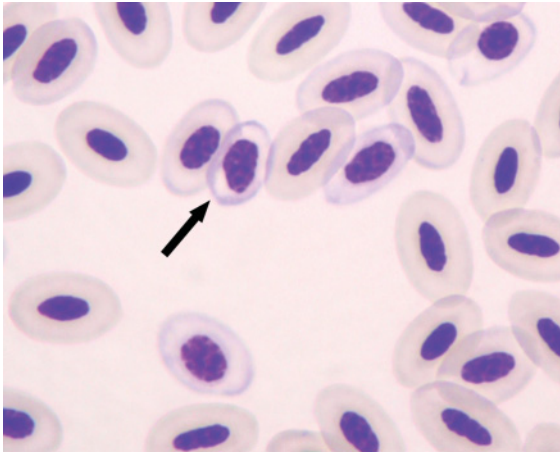


Figure 234 Blood from an eclectus parrot (*Eclectus roratus*) with a PCV of 0.30 L/L, erythrocyte concentration of $2.0 \times 10^{12}/L$, hemoglobin concentration of 59 g/L, MCV of 150 fL and MCHC of 197 g/L. A regenerative response was indicated by the presence of 12% polychromatophilic erythrocytes but the microcytosis and hypochromasia indicate decreased hemoglobin production. Illustrated are several polychromatophilic cells (one identified by an arrow). These are difficult to distinguish as most of the cells present are significantly hypochromatic. (Modified Wright's stain.)

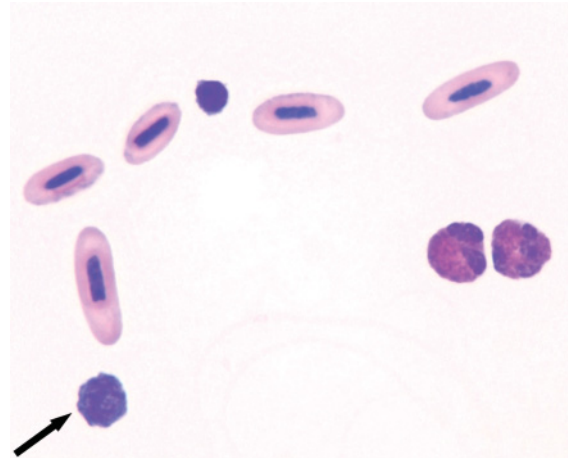


Figure 236 Blood from a severely anemic muscovy duck (*Cairina moschata*) (PCV = 0.09 L/L). The decreased density of erythroid cells may be observed at this magnification. A few mature erythrocytes and a rubricyte are present (arrow), as well as two heterophils and a lymphocyte. (Modified Wright's stain.)

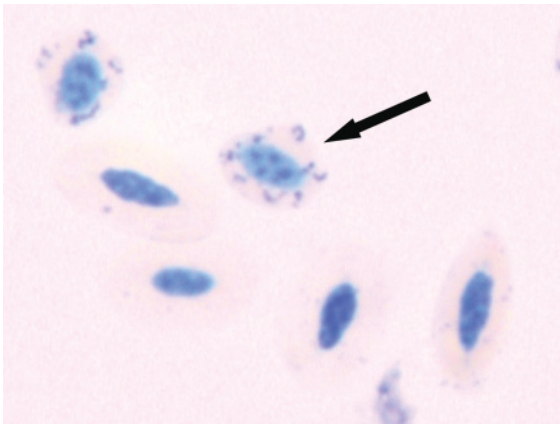


Figure 235 Blood from the same eclectus parrot as in Figure 234. The concentration of reticulocytes was $216 \times 10^9/L$ (10.8%, similar to the observed proportion of polychromatophilic cells). A reticulocyte is identified by the arrow. Note that most avian erythrocytes have some "reticulum" but are not classified as reticulocytes unless they contain multiple aggregates distributed around the nucleus. (New methylene blue stain.)

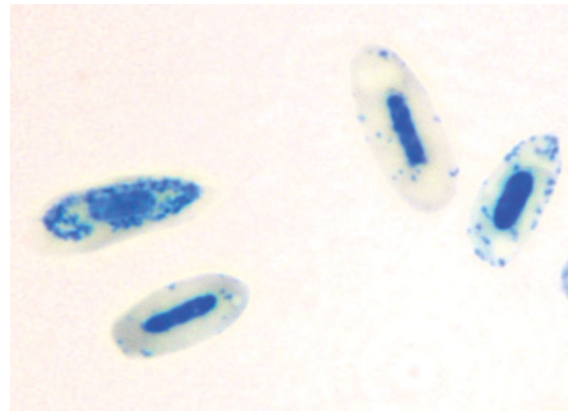


Figure 237 Blood from the same bird as in Figure 236 stained to illustrate reticulocytes. Reticulocytes comprised 37% of all erythrocytes, which correlated to a concentration of $185 \times 10^9/L$. (New methylene blue stain.) Note the importance of calculating the absolute values of reticulocytes, as the duck has a greater proportion but lesser absolute concentration of reticulocytes than the eclectus parrot in Figures 234 and 235.

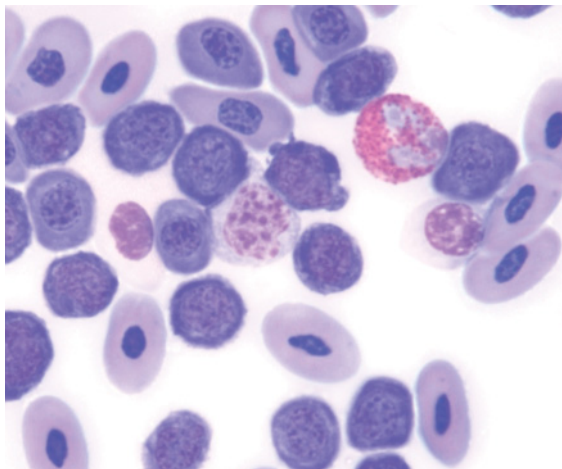


Figure 238 Blood from a black-footed penguin (*Spheniscus demersus*) with severe anemia and a marked regenerative response. A large number of immature erythroid cells are present, including polychromatophilic erythrocytes and rubricytes, with few mature erythrocytes. Also illustrated are a heterophil and a monocyte (center). In contrast, Figures 213 and 214 illustrate erythrocytes from this species with typical morphology, and Figure 230 shows an increased proportion of polychromatophilic erythrocytes. (Modified Wright's stain.)

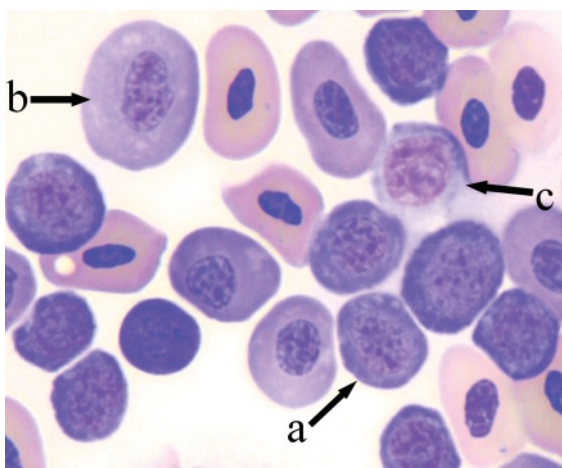


Figure 239 Blood from the same black-footed penguin as in Figure 238. Many rubricytes (a) and several polychromatophilic erythrocytes (b) are present amidst mature erythrocytes. Also present is a lymphocyte (c), identified by its finer chromatin. (Modified Wright's stain.)

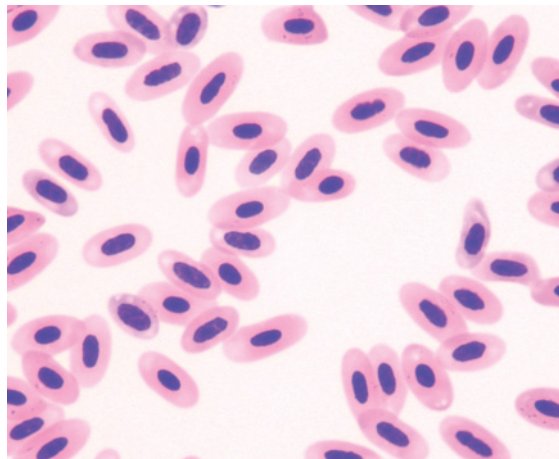


Figure 240 Blood from an anemic white-tailed black cockatoo (*Calyptorhynchus baudinii*) with a PCV of 0.24 L/L. No polychromatophilic erythrocytes are evident in the field, indicating the absence of a "regenerative response". (Modified Wright's stain.) This lack of response can be contrasted with the increased erythropoiesis in a different bird of the same species portrayed in Figure 233.

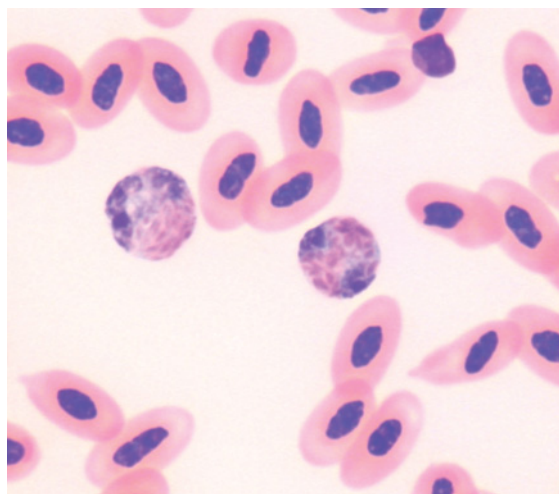


Figure 241 Blood from a depressed and lame Eurasian coot (*Fulica atra*) with a PCV of 0.32 L/L, which had less than 1% polychromatophilic erythrocytes, indicating a lack of response to the anemia. (Modified Wright's stain.) Two heterophils are also present, one of which (right) exhibits atypical cytoplasmic granules.

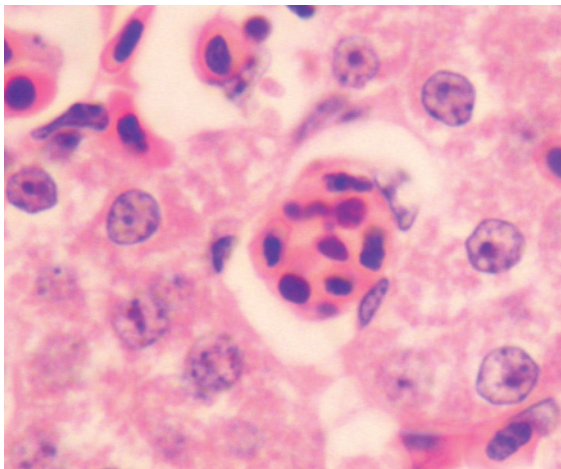


Figure 242 Tissue section of liver from a Port Lincoln parrot (*Barnardius zonarius*). (Hematoxylin and eosin stains.) A macrophage exhibiting erythrophagocytosis is illustrated; these were distributed throughout the liver but were not evident in other tissues. Peripheral blood was not available from this bird.

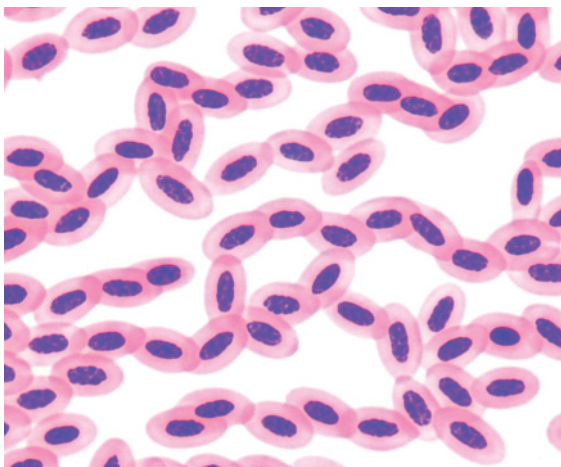


Figure 243 Blood from an Australian kestrel (*Falco cenchroides*) with heterophilic meningoencephalitis. Linear arrangement of erythrocytes, equivalent to rouleaux in mammals, is evident. Rouleaux are a viscosity mediated property, not usually encountered in the blood of birds. The addition of physiological saline to the sample typically will result in dissolution of the phenomenon. (Modified Wright's stain.)

hemoglobin concentration and erythrocyte concentration and the assessment of the morphology of the erythrocytes. The morphological characteristics that may be encountered are summarized in Table 4.1.

Polycythemia

The mechanisms resulting in **polycythemia**, the increase in the circulating mass of erythrocytes, and **erythrocytosis**, the increase in the circulating concentration of erythrocytes, are not as well described for birds as they are for mammals. These may occur due to **relative** changes in the blood that occur as consequence of the redistribution of the erythrocytic or fluid components; or due to an increased production of erythrocytes (erythropoiesis) that results in an **absolute** increase in the number (mass) of erythrocytes.

Birds do not store a reserve of erythrocytes in their spleen (Sturkie 1943). Consequently, relative polycythemia due to redistribution of erythrocytes (in response to exercise, excitement, fear or pain) is not encountered in birds as it is in mammals.

Relative polycythemia due to hemoconcentration of the blood as a result of water loss may occur in birds. The magnitude of such hemoconcentration is difficult to predict and may be complicated by variation in plasma volume between individuals and between species (Jaensch & Raidal 1998). Experimental deprivation of water from pigeons for 48 hours did not change the PCV but did result in significant changes in the total solids and serum osmolality (Martin & Kollias 1989). However, dehydration due to decreased water intake may incite differing hematological effects on different species of birds, even species within the same genus. For example, a comparison of blue-breasted quail, a wet grassland species, and stubble quail (*Coturnix pectoralis*), a dryland species, found notable differences in the measured hematological analytes following restriction of water intake (Roberts & Baudinette 1984). After 10 days

Table 4.1 Morphological characteristics of avian erythrocytes that may indicate a disease process.

Cell characteristic	Description	Significance
Altered erythrocyte content		
Ghost erythrocytes	Pale erythrocytes due to disrupted cell membrane that permits loss of hemoglobin	Indicative of hemolysis; may occur with contact with EDTA in some species; may also occur in aged samples.
Hypochromatic erythrocytes	Erythrocytes that have increased region of central pallor due to decreased hemoglobin content	Indicates decreased hemoglobin production, e.g. iron deficiency
Polychromatophilic erythrocytes	Contain ribosomes and resultant basophilic hue with Romanowsky stains due to rRNA content	Increased numbers indicate increased erythropoiesis, such as in young birds or response to anemia
Erythrocyte formation		
Agglutination	Clumping of erythrocytes usually mediated by antibodies "bridging" cells	Indicates immune-mediated hemolytic anemia
Anisocytosis	Variation in the size of cells, typically applied to erythrocytes	May be encountered with a range of disorders affecting production or destruction of erythrocytes
Decreased density of erythrocytes	Increased distance between cells, paucity of cells	May be indicative of anemia
Increased density of erythrocytes	Blood film may lack monolayer, crowding of cells	May be indicative of polycythemia
Rouleaux	Linear arrangement of erythrocytes mediated by plasma viscosity	Indicates increased protein concentration, such as acute phase proteins. Not commonly encountered in avian blood samples
Structures within erythrocytes		
Basophilic stippling	The presence of small, dark blue staining "granules" within erythrocytes, usually due to the presence of residual aggregations of RNA. (Also occasionally due to the presence of iron aggregations)	Indicative of increased erythropoiesis, occurs with a "regenerative response" to anemia
Heinz bodies	Rounded projections from the surface of erythrocytes that represent denatured hemoglobin that are eosinophilic with Romanowsky stains and blue when stained with new methylene blue stain	Indicative of oxidative injury
Intracellular hemoparasites	E.g. <i>Babesia</i> spp, <i>Haemoproteus</i> spp, <i>Hepatozoon</i> sp. Variable appearance depending on the type of hemoparasite. May increase the size, distort the shape or displace the nucleus of the erythrocyte	Variable depending on species of hemoparasite, host, immune function etc., insignificant to pathogenic

without water the weight of blue-breasted quail had decreased to 80.5% of their original weight but the PCV was not significantly increased (102% of the original value); however, plasma osmolarity had increased (119.9% of the original value). In comparison, after 20 days without water, the stubble quails' weight had decreased to 85.6% of their original with an increased PCV (115.4% of the original value) but unchanged osmolarity (101.2% of the original value).

Clinical disease causing dehydration has also been reported to increase the PCV of birds. Increased erythrocytic values were observed in common pheasants and red-legged partridges (*Alectus rufa*) with severe spironucleolysis due to relative polycythemia (hemoconcentration) as a result of diarrhea causing dehydration (Lloyd & Gibson 2006). Increased PCV in stranded wedge-tailed shearwater (*Puffinus pacificus*) chicks, compared to healthy chicks, was consistent with hemoconcentration (Work & Rameyer 1999). A study of American kestrels incubating eggs, revealed the hematocrit was increased with ambient temperature, likely reflecting hemoconcentration (Dawson & Bortolotti 1997).

Absolute polycythemia resulting in the increased production of erythrocytes may be due to autonomous production of erythrocytes (primary polycythemia), or be stimulated by an increased production of erythropoietin in response to hypoxia (secondary polycythemia). The latter may result from disease of the cardiovascular, pulmonary or renal systems or physiological response to high altitude.

Species of birds that have evolved to undertake high-altitude flight, such as the bar-headed goose (*Anser indicus*), Rueppell's griffon (*Gyps rueppellii*) and white-headed vulture (*Trigoniceps occipitalis*), possess hemoglobin with an increased affinity for oxygen, compared to species of birds that do not undertake such flight (Weber et al. 1988, Hiebl et al. 1989, Zhang et al. 1996). Consequently, these adapted species typically do not exhibit an increased erythrocyte concentration in response

to hypoxia, whereas other species may exhibit an erythrocytosis in response to the hypoxia of high altitude. For example, Pekin duck (*Anas platyrhynchos* forma domestica) developed erythrocytosis in response to acclimation to altitude (5640 m) but this did not occur in bar-headed geese (Black & Tenney 1980). A study of many species showed that highland birds had a mean hematocrit and mean erythrocyte concentration that were 7% and 23% greater than the values of the same species from lower altitudes (Carey & Morton 1976). Similarly, the embryos of American coots (*Fulica americana*) from montane regions had significantly greater hematocrit than embryos from lowland regions (Carey et al. 1993). The hematocrit of pigeons exposed to an experimental recreation of high altitude was increased (0.48 ± 0.02 L/L compared to 0.34 ± 0.6 L/L) when the birds were acclimated to high-altitude conditions but showed no significance difference when birds were acutely exposed (Weinstein et al. 1985). Japanese quail acclimated to a simulated altitude of 6100 m for 6 weeks had a 31% increase in mean hematocrit and 37% increase in mean hemoglobin concentration (Weathers & Snyder 1974).

Bond and Gilbert (1958) found that both "diving" and "dabbling" species of ducks had a greater blood volume than, but similar erythroid characteristics to, non-aquatic birds. More recent studies of the physiological characteristics of diving birds, including oxygen utilization, have not considered hematological values (Green et al. 2005, Halsey & Butler 2006). A study of burrowing owls (*Speotyto cunicularia*), which routinely become hypoxic below ground, had erythrocytic values similar to non-burrowing birds (Boggs et al. 1983). Maxwell et al. (1987) found that PCV, erythrocyte concentration and haemoglobin concentration were greater in young broiler chicks with experimentally induced hypoxia (compared to control chicks).

Most commonly, when the concentration of erythrocytes is increased, the erythrocytes typically have a "normal" morphological appear-

ance. However, if the polycythemia is due to increased erythropoiesis then an increased proportion of polychromatophilic erythrocytes (Romanowsky stains) or reticulocytes (new methylene blue stain) may be observed.

Anemia

Anemia, the decrease in the circulating mass of erythrocytes, may result from causes that may be broadly classed as “hemorrhagic” (loss of erythrocytes), “hemolytic” (destruction of erythrocytes) or “hypoproliferative” (decreased erythropoiesis). Erythrocytes with variant morphology may be evident, depending on the cause of the anemia and the hematological response. Anemia may be due to a lack of erythrocytes but those present exhibit typical size (normocytic) and hemoglobin content (normochromatic). Alternately, if erythropoiesis is increased in response to the anemia, an increased proportion of (morphologically distinct) immature erythroid cells may be evident in the peripheral blood.

A number of experimental and clinical examples of hemorrhagic anemia affecting birds have been reported. Experimental removal of 30% of estimated blood volume in Japanese quail induced peak reticulocytes at 48 hours and recovery of erythrocyte numbers by 72 hours after phlebotomy (Gildersleeve et al. 1985, Schindler et al. 1987a). Similarly, for pigeons with experimental blood loss (15–30% of estimated total blood volume), the birds recovered their PCV to about 90% of initial values within 168 hours (Finnegan et al. 1997).

Clinically evident hemorrhage, that resulted from brodifacoum toxicity, caused severe anemia in a captive white-winged wood duck (*Cairina scutulata*) (James et al. 1998). The duck had ongoing bleeding and was severely anemic (PCV of 0.16 L/L) 10 days after initial clinical signs. The PCV increased after treatment, including a blood transfusion, to 0.37 L/L at 16 days and 0.57 L/L at 45 days after initial clinical signs.

A number of experimental and clinical examples of hemolytic anemia affecting birds have been reported. Few cases of suspected primary immune-mediated hemolytic anemia have been reported. Presumed immune-mediated hemolytic anemia was reported in a blue-crowned conure (*Aratinga acuticaudata*) with a PCV of 0.28 L/L (Jones et al. 2002). Similarly, immune-mediated hemolytic anemia was reported in an eclectus parrot, that had gross agglutination of erythrocytes, a PCV of 0.17 L/L and 19.6% reticulocytes (indicating a marked increase in erythropoiesis) (Johnston et al. 2007).

A number of cases of hemolytic anemia incited by hemoparasites have been reported. Natural infection of snowy owls (*Nyctea scandiaca*) with *Haemoproteus noctuae* resulted in severe anemia (PCV of 0.13 L/L) with morphological evidence of regeneration (Evans & Otter 1998, Mutlow & Forbes 2000). Similarly, a sandhill crane (*Grus canadensis*) chick infected with *Haemoproteus balearicae* had a severe anemia (0.13 L/L) (Dusek et al. 2004). Natural infection with *Babesia shortii* resulted in anemia (PCV of 0.22 L/L) in a Eurasian kestrel (Munoz et al. 1999) and a saker falcon (PCV of 0.29 L/L) (Samour & Pierce 1996).

Extra-vascular hemolytic anemia due to oxidative damage to erythrocytes that results in the formation of Heinz bodies has been produced under experimental conditions and has been observed in naturally occurring disease. Heinz body anemia was experimentally induced in chickens by treatment with dimethyl disulphide. Birds maintained erythrocyte concentration with increased numbers of polychromatophilic erythrocytes and rubricytes (Maxwell 1981). Erythrocytes stained with methyl violet exhibited an average of six Heinz bodies 0.3–2.0 μm in diameter.

Experimental zinc toxicosis in mallards induced variable hematological effects (Christopher et al. 2004). Birds that died had severe anemia (0.19 ± 0.07 L/L) with many hypochromatic erythrocytes, fusiform erythrocytes

and erythrocytes with nuclear abnormalities. Birds that survived had PCV (0.48 ± 0.075 L/L) similar to the PCV of control birds (0.50 ± 0.04 L/L). Clinical cases of zinc intoxication have been reported for a number of species of birds, both captive and free-living, including a hyacinth macaw (Romagnano et al. 1995), a gray-headed chachalaca (*Ortalis cinereiceps*) (Droual et al. 1991) and a trumpeter swan (*Cygnus buccinator*) (Carpenter et al. 2004).

Heinz body formation and subsequent extra-vascular hemolytic anemia has been observed in herring gulls and Atlantic puffins (*Fratercula arctica*) administered crude oil (Leighton et al. 1983, Leighton 1985, 1986). Similarly, anemia with increased numbers of polychromatophilic erythrocytes was observed in wild white-winged scoters (*Melanitta fusca*) following contamination with fuel (Yamato et al. 1996). In contrast, rhinoceros auklets (*Cerorhinca monocerata*) experimentally administered crude oil did not develop Heinz bodies and had hematological values similar to control birds (Newman et al. 1999).

A number of experimental and clinical examples of hypoproliferative anemia affecting birds have been reported. A non-regenerative anemia was observed in wild herring gulls brought into captivity with the nadir in PCV occurring 12–20 days after capture (from 0.43 ± 0.04 L/L to 0.32 ± 0.05 L/L) (Hoffman & Leighton 1985). Similarly, the PCV of rhinoceros auklets maintained in captivity decreased (from 0.56 ± 0.02 L/L to 0.46 ± 0.01 L/L) within 3 weeks that persisted throughout the duration of the study (Newman et al. 1999).

A commonly encountered cause of hypoproliferative anemia is “anemia of inflammatory disease” that is typically mild, normocytic, normochromatic and non-regenerative (Means 2000, Waner & Harrus 2000). Anemia of inflammatory disease is mediated by increased secretion of cytokines during inflammation that results in decreased availability of iron (due to sequestration within macrophages), decreased erythrocyte lifespan, impaired production of erythropoietin and decreased eryth-

ropoiesis. A number of reports of birds with mild anemia associated with inflammatory disease have been published. Red grouse with an inflammatory response to *Trichostrongylus tenuis* also developed a mild anemia (Wilson and Wilson 1978). African grey parrots that had an inflammatory leukogram in response to a range of clinical disorders also exhibited anemia, microcytosis and hypochromasia (Hawkey et al. 1982). The majority of individuals (88%) from several species of cranes with naturally occurring mycobacteriosis exhibited an anemia (Hawkey et al. 1990). Mild anemia, consistent with anemia of inflammatory disease was reported in two species of black cockatoo with inflammatory disorders (Jaensch & Clark 2004).

Many other factors may also affect the production of erythroid cells. For example, thyroidectomy of redhead bunting (*Emberiza bruniceps*) reduced erythroid values (PCV, erythrocyte concentration and hemoglobin concentration) which was restored by administration of exogenous thyroxine, illustrating the necessity of thyroid hormones (Thapliyal et al. 1983). Similarly a deficiency of one or more nutrients may adversely impact on efficient production of hemoglobin and erythrocytes. However comprehensive discussion of these many factors is beyond the scope of this book.

Characteristics of the concentrations and morphology of leukocytes in response to disease

See Figures 244–286.

Interpretation of the avian leukogram is best served by consideration of the absolute differential concentration of each type of leukocyte and the morphology of the leukocytes, particularly the heterophils. The hematological indications of an inflammatory response exhibited by a particular bird is a complex interaction of many factors that include: the inherent hematological characteristics of the

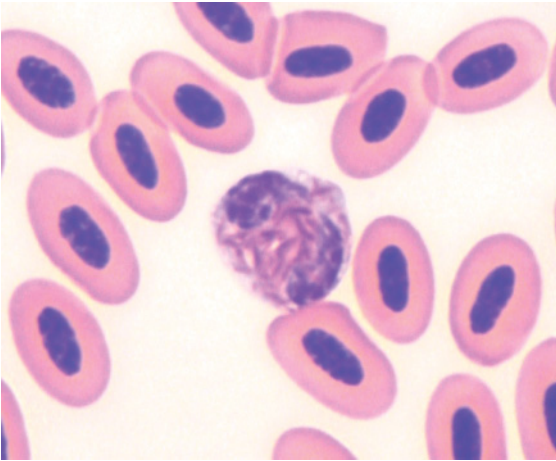


Figure 244 Blood from a blue-breasted quail (*Coturnix chinensis*) that had healing cutaneous wounds (inflicted by other quails). A band heterophil with notable cytoplasmic basophilia but typical granule morphology, representing a mild atypia, is shown. (Modified Wright's stain.)

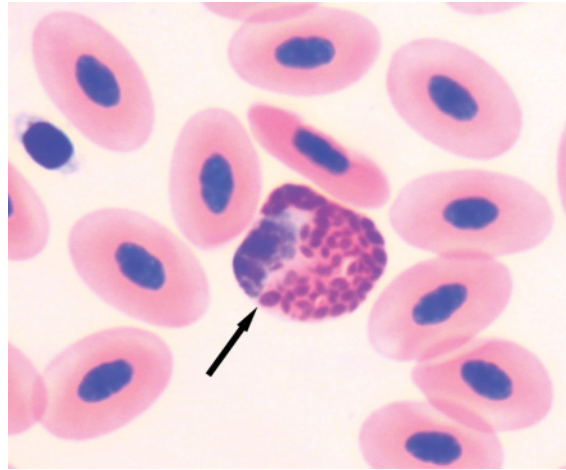


Figure 246 Blood from a wild Eurasian coot (*Fulica atra*) that presented with wounds inflicted by a predator. Illustrated is a heterophil showing mild morphological atypia, including rounded granules, large granules (arrow) and mild cytoplasmic basophilia. (Modified Wright's stain.)

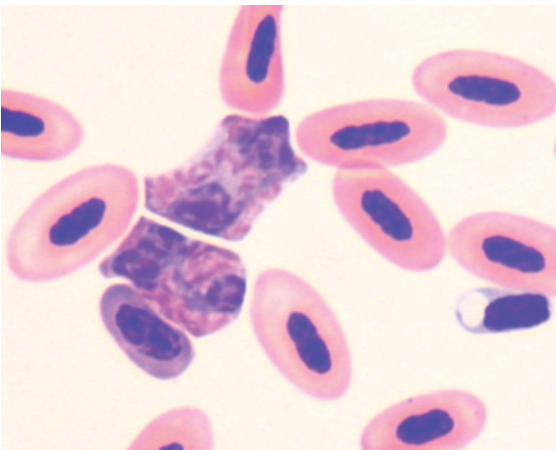


Figure 245 Blood from a wild galah (*Eolophus roseicapillus*) injured by a motor vehicle. Two heterophils are illustrated; one (upper) has distinctly basophilic cytoplasm and a decreased density of granules while the other (lower) heterophil has typical cytoplasmic granule morphology. (Modified Wright's stain.) Other heterophils (not shown) from this bird exhibited additional morphological atypia including: rounded granules, basophilic granules, hypossegmentation of the nucleus and decreased chromatin density.

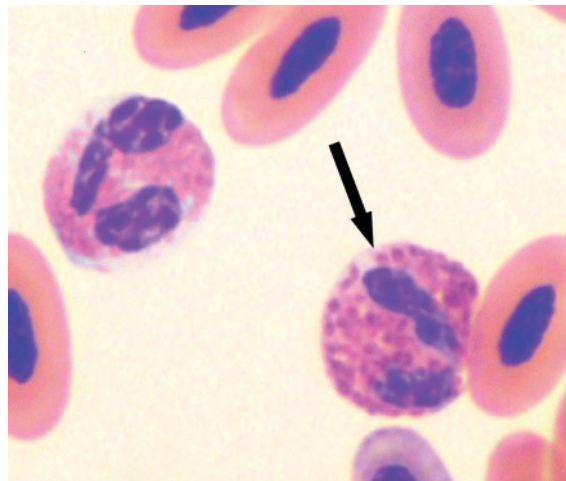


Figure 247 Blood from an injured barn owl (*Tyto alba*) that had a heterophil concentration of $6.1 \times 10^9/L$. Illustrated is a heterophil with rounded cytoplasmic granules and basophilic cytoplasm (arrow). Also present is an eosinophil, amidst erythrocytes. (Modified Wright's stain.) Many other heterophils from this bird also had a decrease in the overall number of cytoplasmic granules.

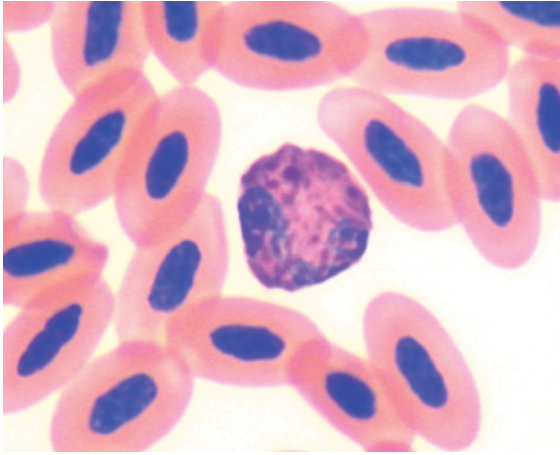


Figure 248 Blood from a wedge-tailed eagle (*Aquila audax*) that presented with blindness in both eyes. Hematological assessment revealed a heterophil concentration of $10.67 \times 10^9/L$, lymphocyte concentration of $0.58 \times 10^9/L$ and monocyte concentration of $1.30 \times 10^9/L$. Illustrated is a heterophil representative of the mild morphological atypia exhibited by most heterophils, which included rounded and basophilic granules amidst typical fusiform, brick-red granules.

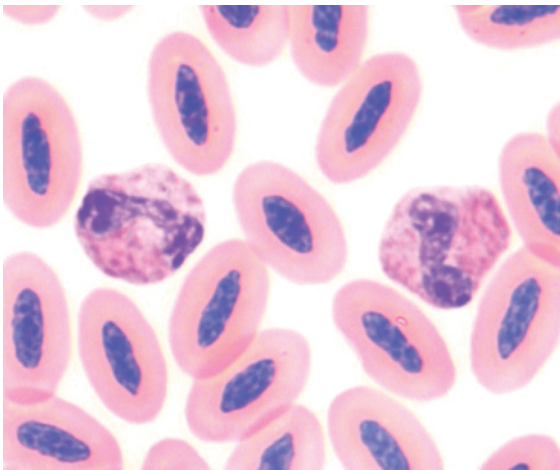


Figure 249 Blood from an Australian black-shouldered kite (*Elanus axillaris*) that was likely hit by a motor vehicle, that had a concentration of creatine kinase of 17,560 IU/L and a heterophil concentration of $2.67 \times 10^9/L$, lymphocyte concentration of $0.61 \times 10^9/L$, monocyte concentration of $0.75 \times 10^9/L$, eosinophil concentration of $0.33 \times 10^9/L$ and basophil concentration of $0.33 \times 10^9/L$. "All" of the heterophils exhibited some morphological atypia that included decreased segmentation of the cell's nucleus, an annular form nucleus, basophilic cytoplasm, decreased granulation, large granules and rounded granules. Illustrated are two heterophils, each with a "band" nucleus, decreased granulation and basophilic cytoplasm. (Modified Wright's stain.)

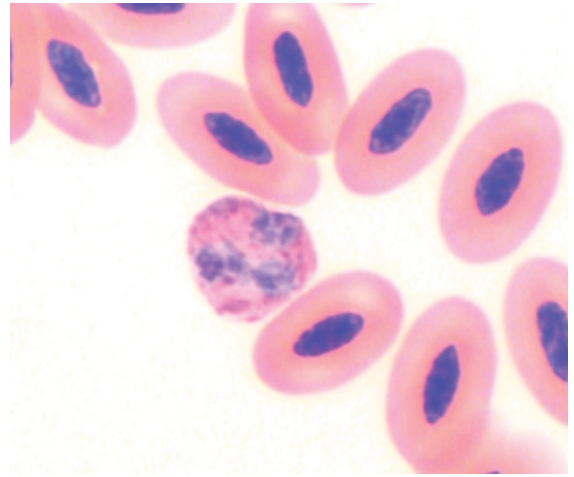


Figure 250 Blood from the same Australian black-shouldered kite as in Figure 249, 2 days later. It had a heterophil concentration of $9.10 \times 10^9/L$, lymphocyte concentration of $0.89 \times 10^9/L$ and a monocyte concentration of $1.11 \times 10^9/L$. Morphological atypia of heterophils that included basophilic cytoplasm, decreased granulation and rounded granules were observed. Fifty-two percent of heterophils exhibited some atypia. Illustrated is a heterophil with large and rounded granules, but a typical density of granules. (Modified Wright's stain.)

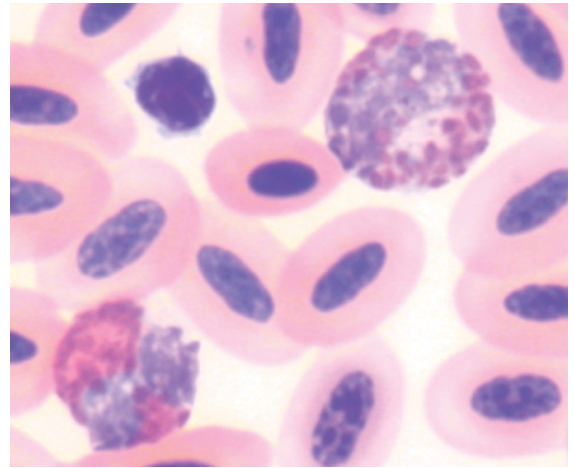


Figure 251 Blood from a brown falcon (*Falco berigora*) with a talon injury, which had a heterophil concentration of $5.94 \times 10^9/L$ and a lymphocyte concentration of $1.1 \times 10^9/L$. Many heterophils exhibited atypical morphology. A mature heterophil with fusiform granules (left) and an atypical heterophil with shorter more rounded granules, a decreased number of granules and basophilic cytoplasm are illustrated. (Modified Wright's stain.)

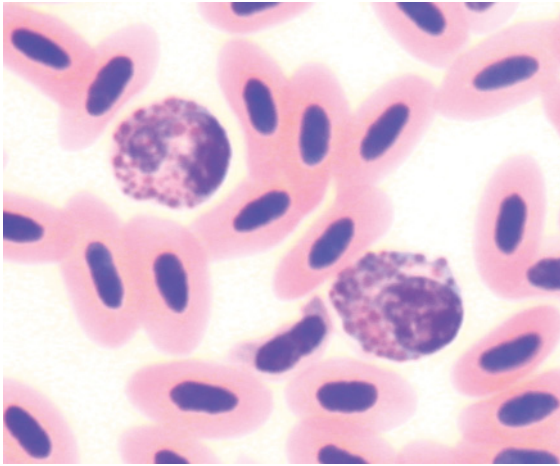


Figure 252 Blood from a red wattlebird (*Anthochaera carunculata*) with meningoencephalitis. Two heterophils with basophilic cytoplasm and rounded granules are shown, amidst erythrocytes. For comparison, Figure 166 illustrates typical heterophils from this species. (Modified Wright's stain.)

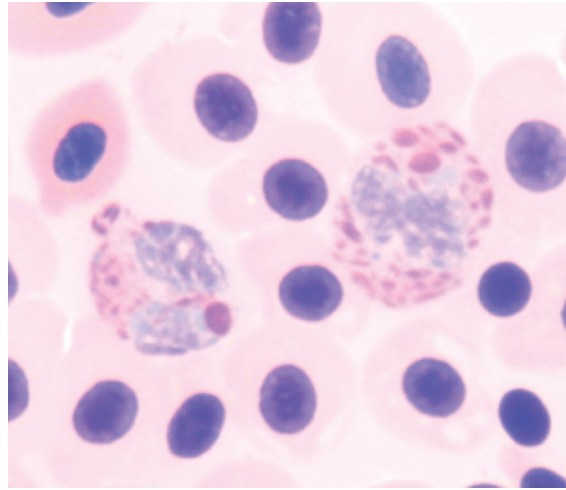


Figure 254 Blood from a clinically dehydrated Australian magpie (*Gymnorhina tibicen*) that had a PCV of 0.70 L/L (a marked polycythemia) and a heterophil concentration of $8.2 \times 10^9/L$ with atypical morphology, and a monocyte concentration of $2.0 \times 10^9/L$. The heterophils illustrated have large and rounded granules amidst more typical granules. This atypia indicated a response to inflammation by the bird. The erythrocytes have been partially lysed, as evidenced by the paler eosinophilic color of the cytoplasm and the distinctly eosinophilic background, most likely due to contact with the EDTA used as an anticoagulant.

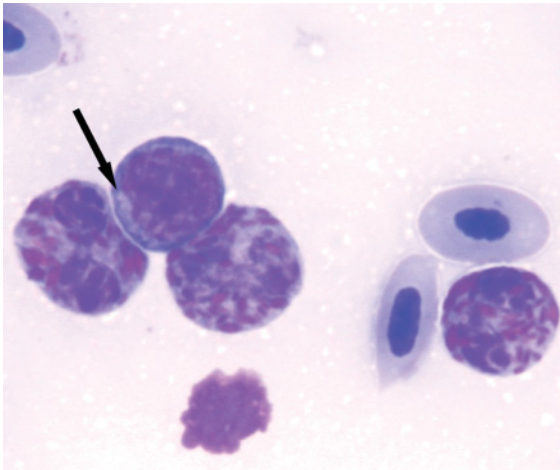


Figure 253 Blood from a yellow-throated laughing thrush (*Garrulax galbanus*). The bird's plasma is evident due its milky, opaque appearance that indicates lipemia. Three heterophils, that exhibit distinctly basophilic cytoplasm and a decreased density of granules with some rounded granules, are portrayed. The lymphocyte present has intensely basophilic cytoplasm and a small perinuclear pale zone (arrow). These morphological characteristics indicate an inflammatory response. (Modified Wright's stain.)

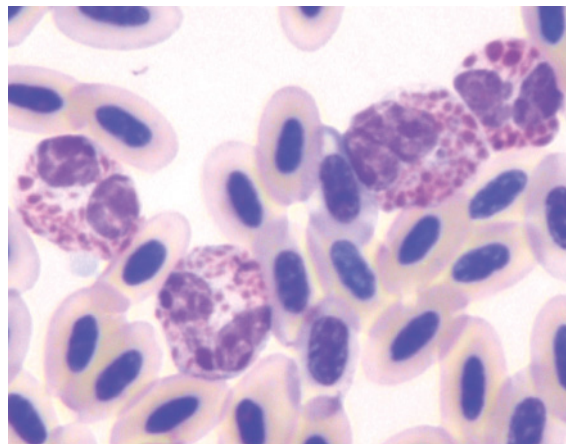


Figure 255 Blood from an Australian king parrot (*Alisterus scapularis*) that had a heterophil concentration of $34.0 \times 10^9/L$, a lymphocyte concentration of $4.8 \times 10^9/L$ and a monocyte concentration of $1.2 \times 10^9/L$. Illustrated are four heterophils that have rounded granules and a decreased density of granules as well as increased basophilic cytoplasm. Both the increased concentration of heterophils and heterophil morphology indicate significant inflammatory demand. (Modified Wright's stain.)

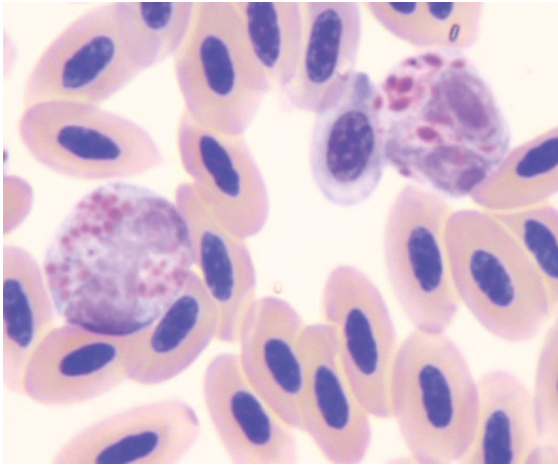


Figure 256 Blood from an Australian king parrot (*Alisterus scapularis*) with a notable heterophilia ($47.1 \times 10^9/L$) and atypical heterophil morphology. Lymphocyte concentration was $6.8 \times 10^9/L$ and monocyte concentration was $7.4 \times 10^9/L$. Two atypical heterophils are represented, one has small round granules (left); the other has larger granules that are slightly rounded. Both these cells have increased basophilic cytoplasm. (Modified Wright's stain.)

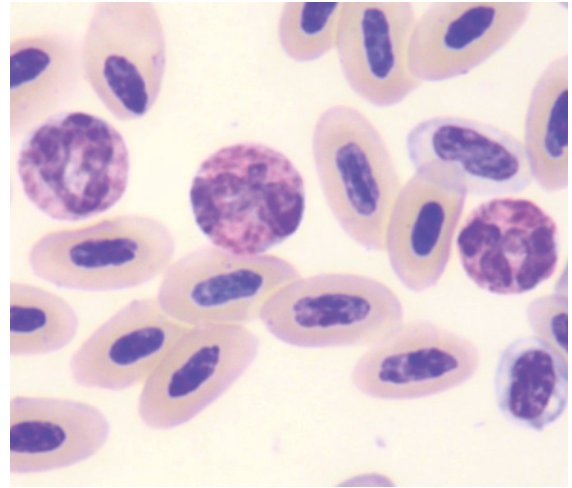


Figure 258 Blood from a princess parrot (*Polytelis alexandrae*) with a heterophil concentration of $19.2 \times 10^9/L$, lymphocyte concentration of $3.4 \times 10^9/L$ and monocyte concentration of $3.4 \times 10^9/L$, that indicated inflammation. Illustrated are three heterophils with decreased number of granules and rounded granules. (Modified Wright's stain.)

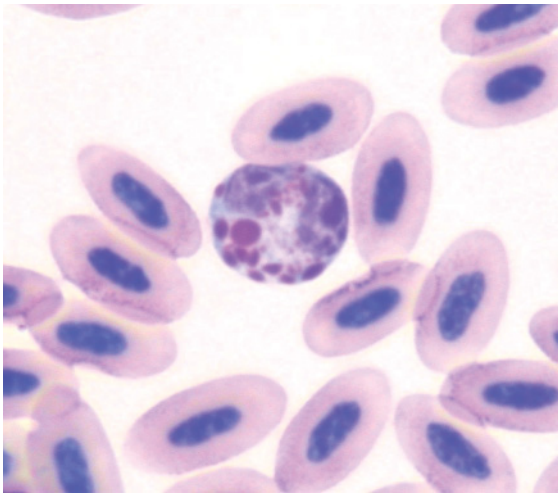


Figure 257 Blood from a Port Lincoln parrot (*Barnardius zonarius*) with a PCV of 0.36 L/L, heterophil concentration of $19.1 \times 10^9/L$, lymphocyte concentration of $6.2 \times 10^9/L$ and monocyte concentration of $1.6 \times 10^9/L$. Atypical heterophil morphology, including decreased granularity and rounded granules, was observed. Illustrated is a heterophil with decreased granule density, rounded granules (including one large, prominent, round granule) and increased basophilia of the cytoplasm. For comparison, Figure 200 illustrates typical heterophil morphology for this species. (Modified Wright's stain.)

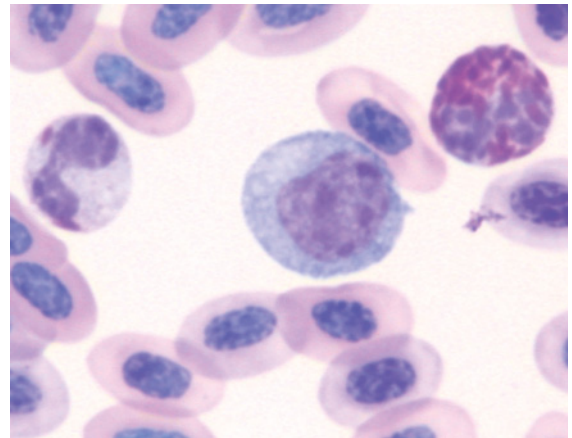


Figure 259 Blood from a sulphur-crested cockatoo (*Cacatua galerita*) with a PCV of 0.27 L/L, heterophil concentration of $58.8 \times 10^9/L$, lymphocyte concentration of $8.9 \times 10^9/L$ and monocyte concentration of $0.7 \times 10^9/L$. Illustrated are a granulated heterophil (right), a large mononuclear cell (center) and a heterophil that is markedly hypo-granulated, with only two needle-shaped granules evident (left). The heterophilia and atypical heterophil morphology indicate inflammation. In this case, concurrently increased amylase concentration indicated pancreatic disease. (Modified Wright's stain.)

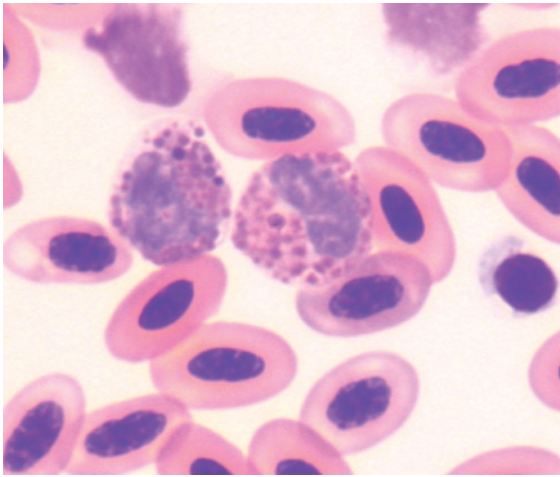


Figure 260 Blood from a Major Mitchell cockatoo (*Cacatua leadbeateri*) that had been injured by another bird, with a heterophil concentration of $24.1 \times 10^9/L$. Illustrated are two heterophils that exhibit atypical granule morphology, including rounded granules and basophilic granules, and decreased segmentation of the nucleus. For comparison, Figure 197 illustrates typical heterophil morphology for this species (Modified Wright's stain.)

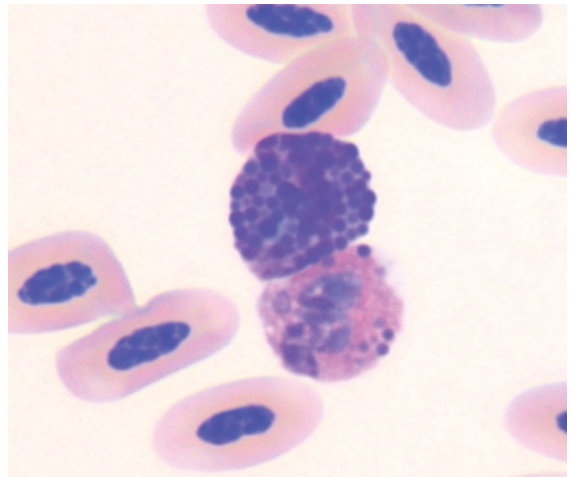


Figure 262 Blood from a rusty-barred owl (*Strix hylophila*) showing two heterophils with atypical appearance. One is characterized by indistinct, rounded eosinophilic granules and a few round strongly basophilic granules. The other bears little resemblance to a typical heterophil with a predominance of these strongly basophilic, round granules. These represent marked atypia in response to inflammatory demand. Comparison with the granulocytes from a healthy bird of the same species may be used to distinguish this as a "toxic change" (and not, for example a basophil). For comparison, Figures 217–219 illustrate the typical morphology of leukocytes from this species. (Modified Wright's stain.)

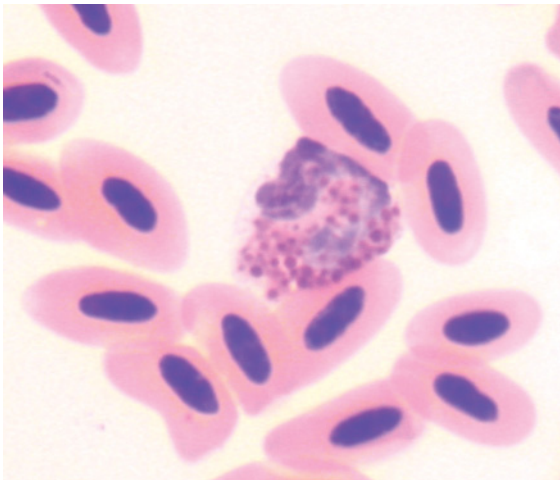


Figure 261 Blood from a sun conure (*Aratinga solstitialis*) that contained few heterophils ($0.89 \times 10^9/L$), "all" with atypical morphology, indicating a significant inflammatory demand. Represented is a heterophil with rounded cytoplasmic granules that have an increased basophilic color. (Modified Wright's stain.)

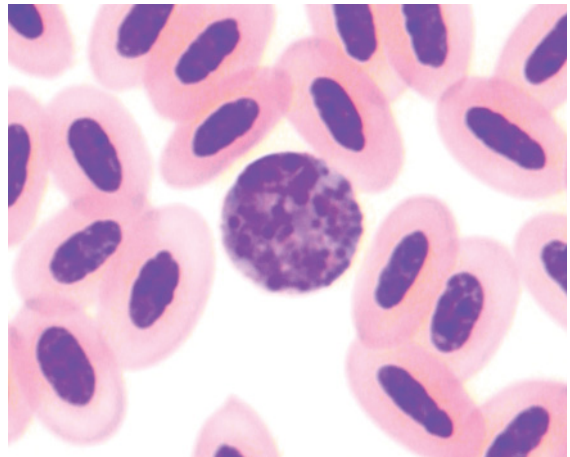


Figure 263 Blood from a blue bonnet (*Northiella haematogaster*) that presented in a weak state and with poor body condition. The bird had a PCV of 0.35 L/L, a heterophil concentration of $2.03 \times 10^9/L$, a lymphocyte concentration of $0.20 \times 10^9/L$ and a monocyte concentration of $0.86 \times 10^9/L$. The heterophils exhibited marked morphological atypia, notably rounded basophilic granules, which indicated significant inflammatory demand. (Modified Wright's stain.)

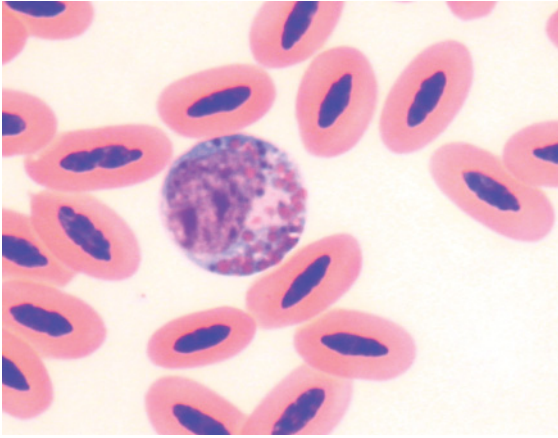


Figure 264 Blood from a wild spotted dove (*Streptopelia chinensis*) that had extensive cutaneous wounds that appeared to have been present for some time. "All" of the heterophilic lineage cells exhibited morphological atypia including: decreased granulation, rounded granules, basophilic granules, notable cytoplasmic basophilia, hyposegmentation of the nucleus, and decreased chromatin density. Illustrated is an example of such a heterophil. For comparison, Figure 113 illustrates typical heterophil morphology from this species. (Modified Wright's stain.)

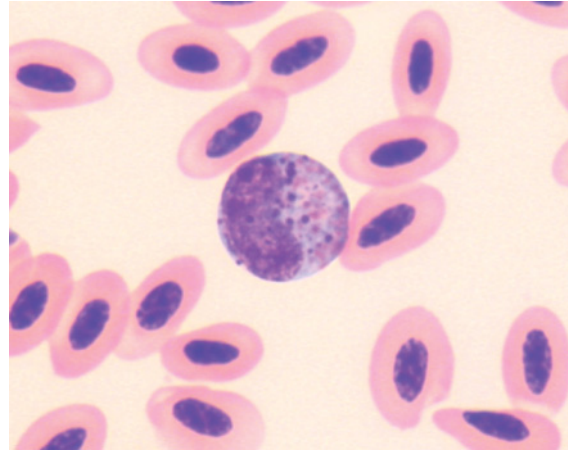


Figure 266 Blood from an Australian kestrel (*Falco cenchroides*) with heterophilic meningo-encephalitis and bacteremia. An immature heterophil exhibiting decreased granulation and basophilic granules and a hyposegmented nucleus is shown. For comparison, Figure 125 shows typical heterophil morphology from this species. (Modified Wright's stain.)

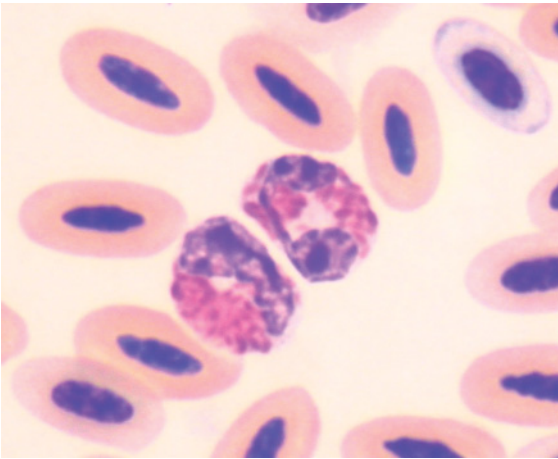


Figure 265 Blood from the same wild spotted dove as in Figure 264, 6 days after the initial blood sample was collected, during which time the wounds had been debrided and antimicrobial therapy administered. Two representative heterophils that exhibit mild morphological atypia, including decreased density of granules, mildly rounded granules and mildly cytoplasmic basophilia, are illustrated. (Modified Wright's stain.) The morphology of the bird's heterophils indicates it is now better able to produce heterophils in response to the inflammation. A subsequent blood sample from the same bird, 13 days after the initial sample, revealed heterophils with typical morphology.

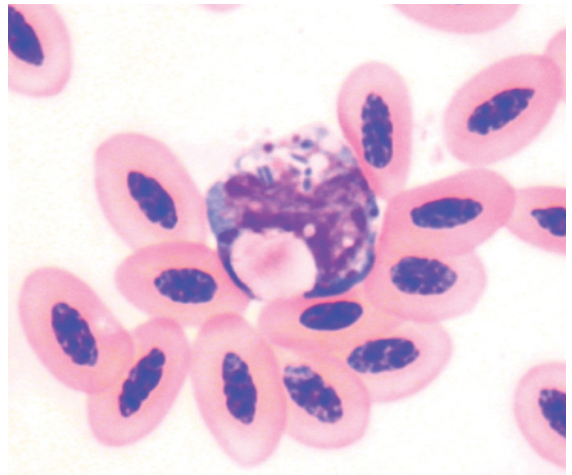


Figure 267 Blood from the same Australian kestrel as in Figure 266, with heterophilic meningoencephalitis and bacteremia. A macrophage that has phagocytosed several bacteria and some cellular material is shown. (Modified Wright's stain.)

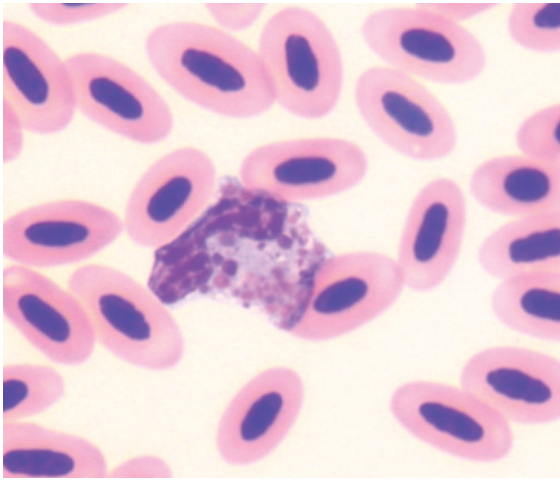


Figure 268 Blood from an Australian hobby (*Falco longipennis*) which had a heterophil concentration of $5.1 \times 10^9/L$, a lymphocyte concentration of $10.0 \times 10^9/L$ and a monocyte concentration of 1.15×10^9 . The heterophils exhibited marked morphological atypia. Illustrated is a heterophil with decreased numbers of cytoplasmic granules, which are rounded and have increased basophilia, in a cytoplasm that has increased basophilia. These indicate severe inflammation and marked demand for heterophils. Bacteria were evident in the sample (see Figure 269) and the bacteremia accounts for the severe inflammatory challenge indicated by heterophil morphology. (Modified Wright's stain.)

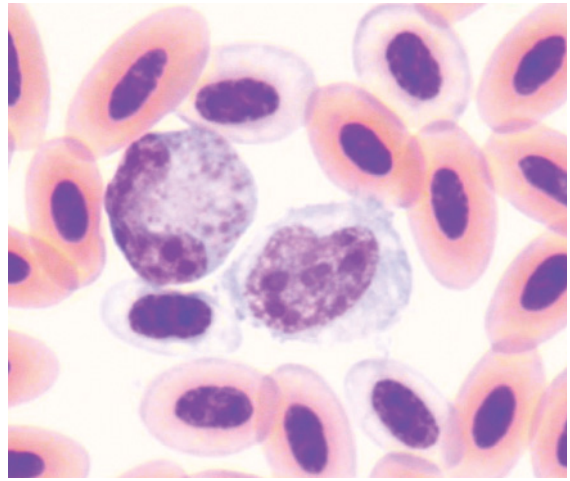


Figure 270 Blood from an injured southern boobook owl (*Ninox novaeseelandiae*). Present are a cell of heterophilic lineage that has decreased granules, which were round and basophilic, within basophilic cytoplasm. Also present is a mononuclear cell and several polychromatophilic erythrocytes. The latter indicate increased erythropoiesis, in this case, most likely in response to hemorrhage. For comparison, Figure 215 illustrates typical heterophil morphology for species. (Diff Quik stain.)

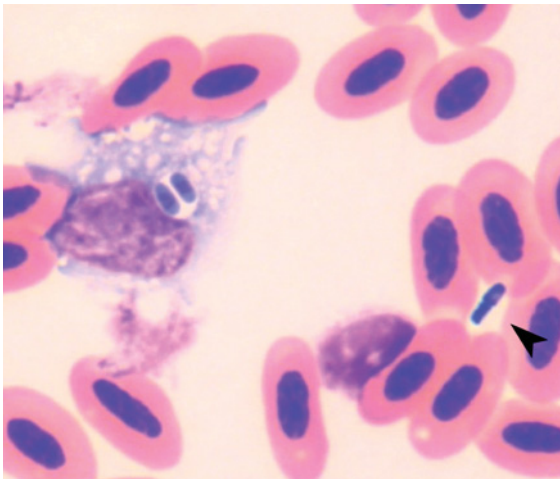


Figure 269 Blood from the same Australian hobby as in Figure 268. Two bacteria are evident within the monocyte. Bacteria were also evident throughout the film (arrowhead). (Modified Wright's stain.)

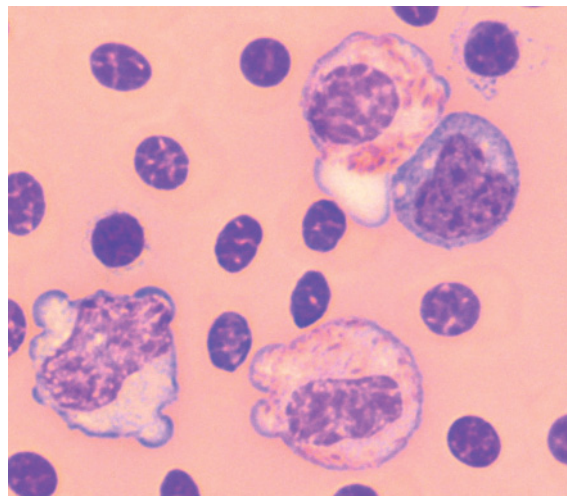


Figure 271 Blood from a Mallee fowl (*Leipoa ocellata*) with a fractured tibiotarsus, which had a heterophil concentration of $9.8 \times 10^9/L$ (all stages) and a monocyte concentration of $3.56 \times 10^9/L$. Numerous immature heterophils were observed, these exhibited a hypo-segmented nucleus and decreased cytoplasmic granularity. The erythrocytes had lysed due to contact with the EDTA anticoagulant. Illustrated are two immature heterophils, with no segmentation or indentation of the nucleus but some cytoplasmic granules evident, and two monocytes. (Modified Wright's stain.)

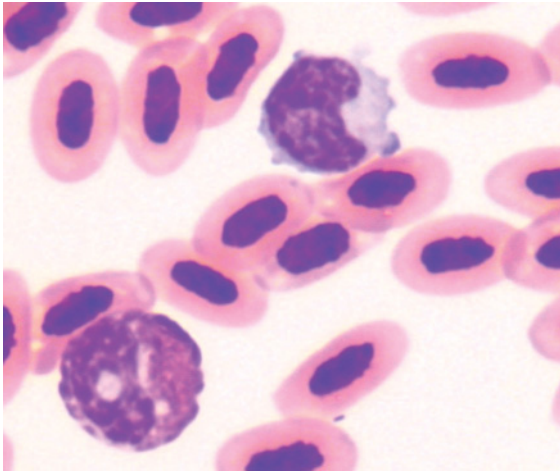


Figure 272 Blood from a pied butcher bird (*Cracticus nigrogularis*) showing a heterophil with an annular nucleus, which reflects atypical myelopoiesis. Also present is a monocyte. (Modified Wright's stain.)

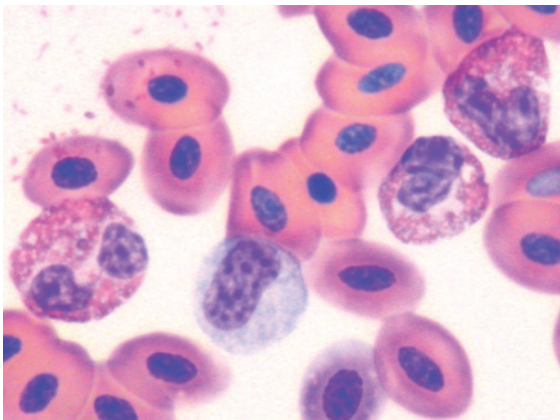


Figure 273 Blood from a little penguin (*Eudyptula minor*) with aspergillosis exhibiting a heterophilia and a monocytosis. Illustrated are three heterophils, two of which have a band form nucleus, and a mononuclear cell. Some amphiphilic, rounded cytoplasmic granules are evident in the segmented heterophil. However, the central granular bodies of the granules are also prominent, making the rounded granules more difficult to discern. Note also that some heterophil granules can also be discerned "free" in the background. For comparison, Figure 211 illustrates the typical heterophil morphology for this species. (Diff Quik stain.)

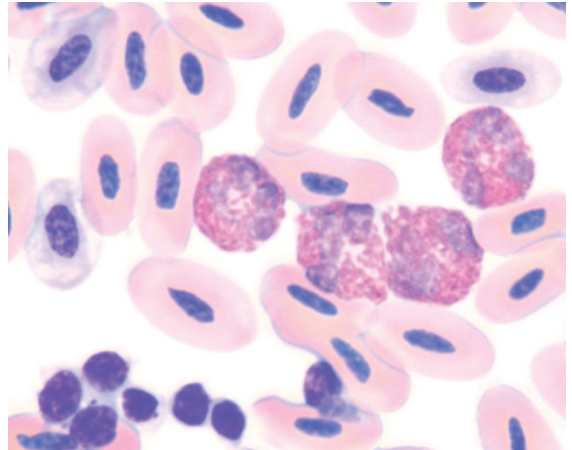


Figure 274 Blood from a black-footed penguin (*Spheniscus demersus*) with air sacculitis had a heterophilia ($32.0 \times 10^9/L$), lymphocytosis ($14.5 \times 10^9/L$) and monocytosis ($3.5 \times 10^9/L$). Illustrated are four heterophils, with typical morphology, amidst erythrocytes (including three polychromatophilic erythrocytes). The "mature" heterophilia indicates the bone marrow's production of heterophils is adequate for the inflammatory demand. Also present are aggregated thrombocytes (bottom left). (Modified Wright's stain.)

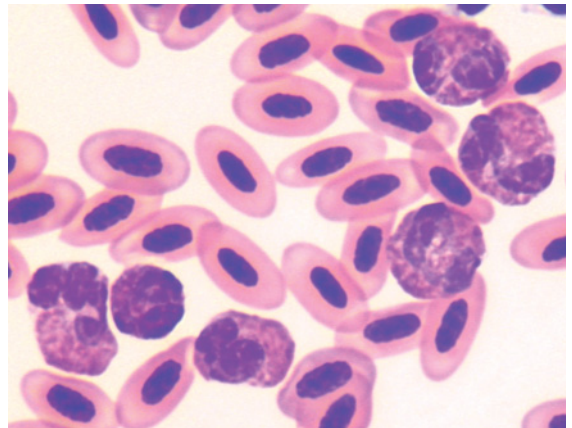


Figure 275 Blood from a white-tailed black cockatoo (*Calyptorhynchus baudinii*) with an ulnar fracture that had a PCV of 0.42 L/L, heterophil concentration of $34.6 \times 10^9/L$, lymphocyte concentration of $4.1 \times 10^9/L$ and monocyte concentration of $3.9 \times 10^9/L$, indicating an inflammatory response. Illustrated are six heterophils amidst mature erythrocytes. Most of the heterophils exhibit typical density of granules; however, rounded granules can be observed in some cells. (Modified Wright's stain.) For comparison, Figure 196 illustrates the typical heterophil morphology for this species.

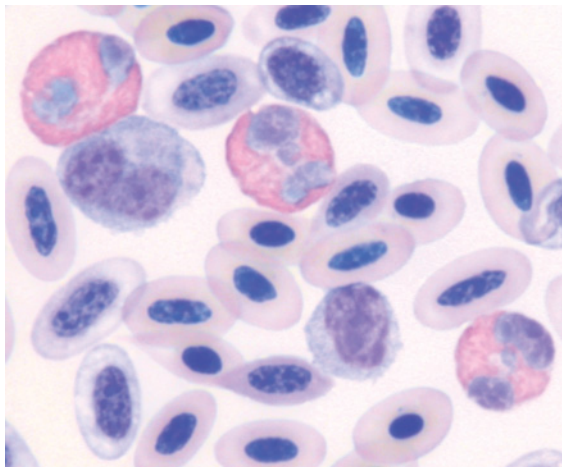


Figure 276 Blood from a woolly-necked stork (*Ciconia episcopus*) with bacterial pododermatitis that exhibited increased numbers of heterophils and monocytes. Illustrated are three heterophils, a monocyte and a lymphocyte amidst erythrocytes, including several polychromatophilic erythrocytes. The heterophils illustrated exhibited typical granule morphology whereas other heterophils had rounded granules. (Modified Wright's stain.)

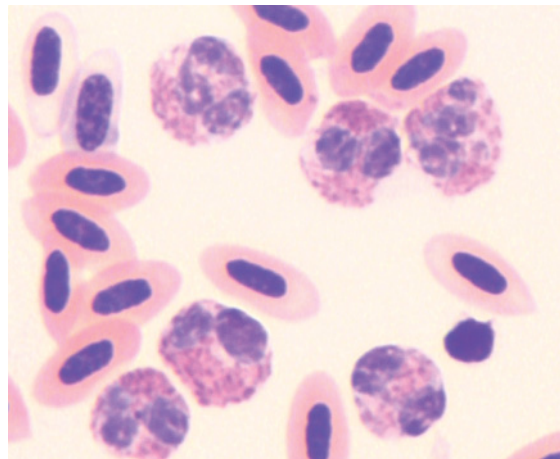


Figure 278 Blood from a red wattlebird (*Anthochaera carunculata*) with meningoencephalitis. A heterophilia was evident and six heterophils are illustrated. These show varied granule morphology within a basophilic cytoplasm. (Modified Wright's stain.)

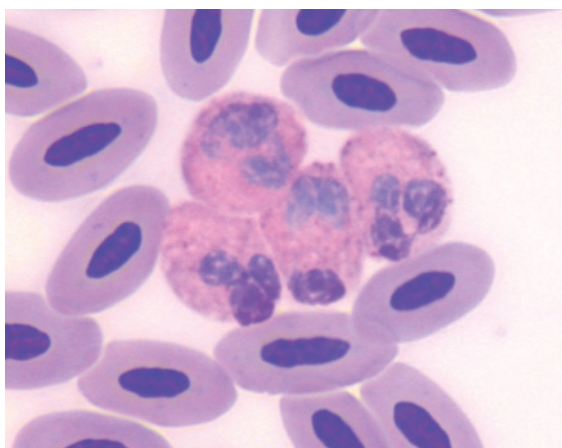


Figure 277 Blood from a Stanley crane (*Grus paradisea*) with aspergillosis; the four heterophils illustrated have mostly indistinct brick-red cytoplasmic granules with a few small, round basophilic granules. These cytoplasmic characteristics represent cytoplasmic immaturity and increased demand for cells in response to inflammation. For comparison, Figure 156 illustrates typical heterophils morphology for this species. (Modified Wright's stain.)

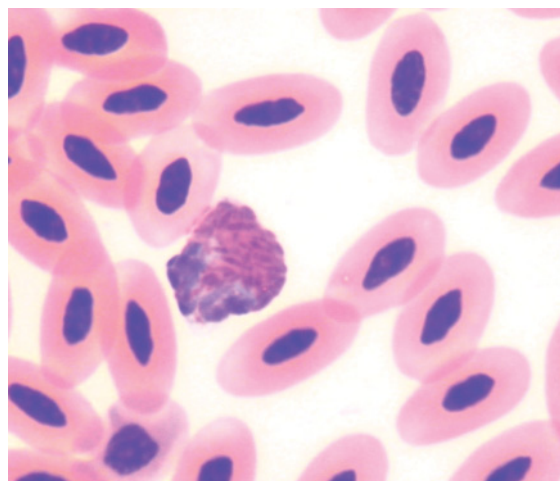


Figure 279 Blood from a male Brolga (*Grus rubicunda*) with diarrhea that had a heterophil concentration of $2.8 \times 10^9/L$, a lymphocyte concentration of $0.48 \times 10^9/L$, a monocyte concentration of $0.65 \times 10^9/L$ and a basophil concentration of $0.08 \times 10^9/L$. The heteropenia is consistent with inflammatory demand and the lymphopenia is consistent with concurrent "stress". The decreased concentration of heterophils with mostly typical morphology suggests a rapid consumption of circulating cells that have not yet been replaced from the bone marrow. Illustrated is a heterophil with mostly fusiform granules and a few rounded granules. (Modified Wright's stain.)

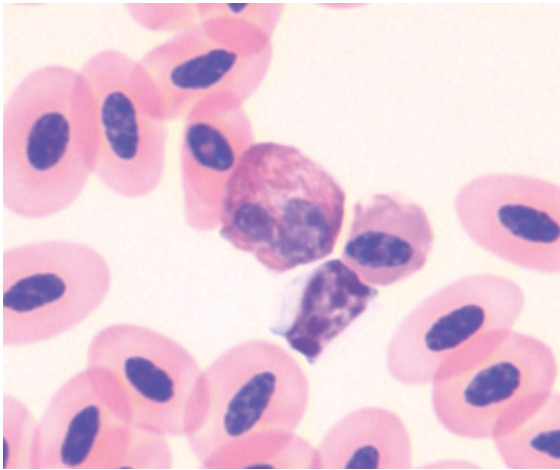


Figure 280 Blood from a tawny frogmouth (*Podargus strigoides*) with a fractured wing, which had a heterophil concentration of $1.1 \times 10^9/L$, lymphocyte concentration of $0.1 \times 10^9/L$ and monocyte concentration of $0.2 \times 10^9/L$. Despite the heteropenia, the heterophils exhibited mostly typical morphology, suggesting rapid, recent depletion of circulating heterophils. Illustrated is a heterophil with typical granule morphology with slight basophilia of the cytoplasm. For comparison, Figure 96 illustrates the typical heterophil morphology for this species. Also present are a lymphocyte and a number of erythrocytes. (Modified Wright's stain.)

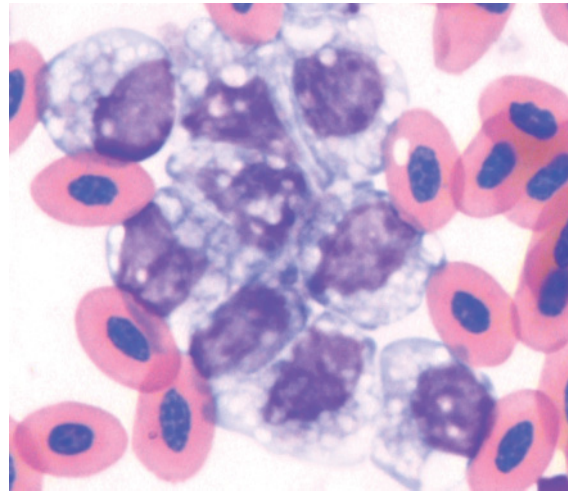


Figure 282 Blood from an Edwards' pheasant (*Lophura edwardsi*) with aspergillosis exhibiting a monocytosis. The clumping of cells and vacuolation of cells is an artifact due to the use of lithium heparin as an anticoagulant and delayed processing of the sample. (Modified Wright's stain.)

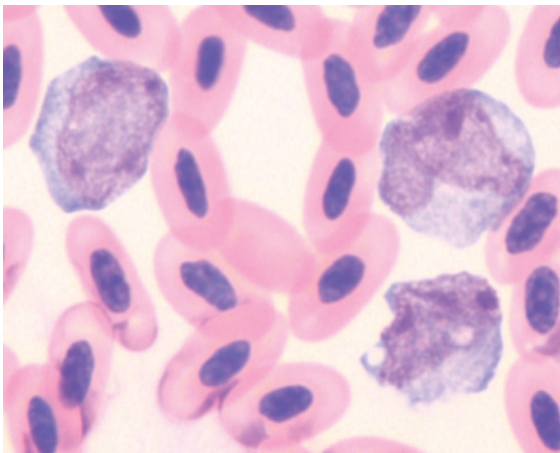


Figure 281 Blood from a white-tailed black cockatoo (*Calyptorhynchus baudinii*) with weight loss, vomiting and oral lesions, that had a PCV of 0.32 L/L, a heterophil concentration of $17.2 \times 10^9/L$, a lymphocyte concentration of $4.6 \times 10^9/L$, a monocyte concentration of $23.9 \times 10^9/L$ and a basophil concentration of $0.2 \times 10^9/L$. Illustrated are three monocytes amidst erythrocytes. (Also present is an erythroplastid). (Modified Wright's stain.) Monocytosis occurs more rapidly in birds than in mammals (Branton et al. 1997).

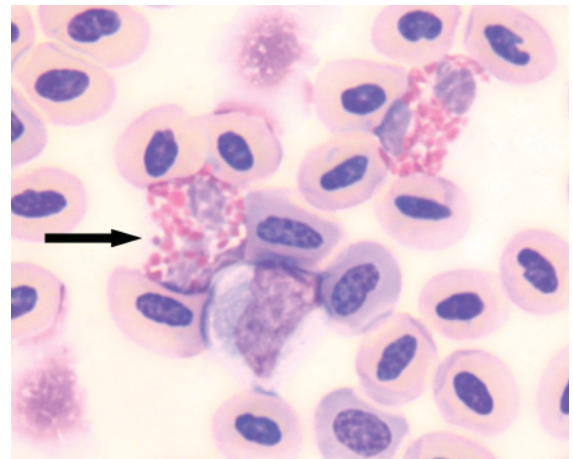


Figure 283 Blood from a crested wood-partridge (*Rollulus roulroul*) with dyspnea that exhibited a heterophilia ($25.8 \times 10^9/L$) and a monocytosis ($32.4 \times 10^9/L$). Depicted are a monocyte with typical morphology and two heterophils, one of which has atypical granulation (arrow). (Modified Wright's stain.)

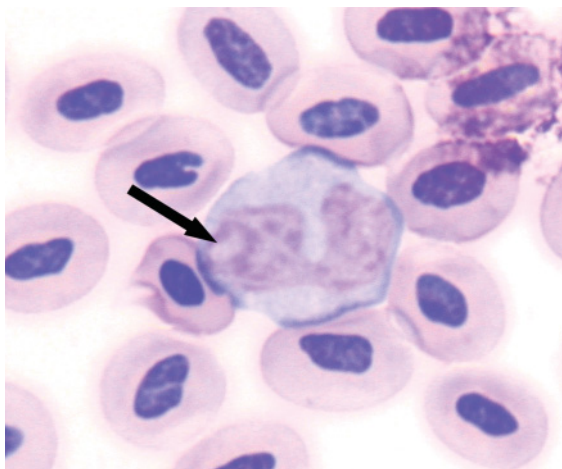


Figure 284 Blood from the same crested wood-partridge as in Figure 283. Illustrated is a monocyte with atypical morphology, namely a prominent nucleolus (arrow). (Modified Wright's stain.)

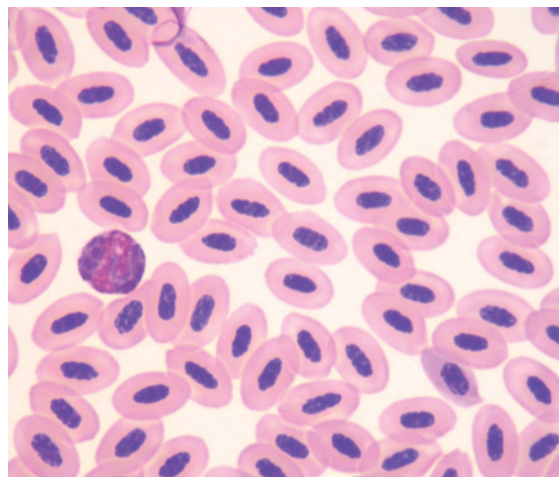


Figure 286 Blood from a varied lorikeet (*Psitteuteles versicolor*) with weight loss. The bird had a lymphopenia (lymphocyte concentration of $0.5 \times 10^9/L$). Illustrated is a field of erythrocytes with a single heterophil evident. Notably lymphocytes were absent from this and many of the fields observed. Those lymphocytes observed had a typical morphology. (Modified Wright's stain.)

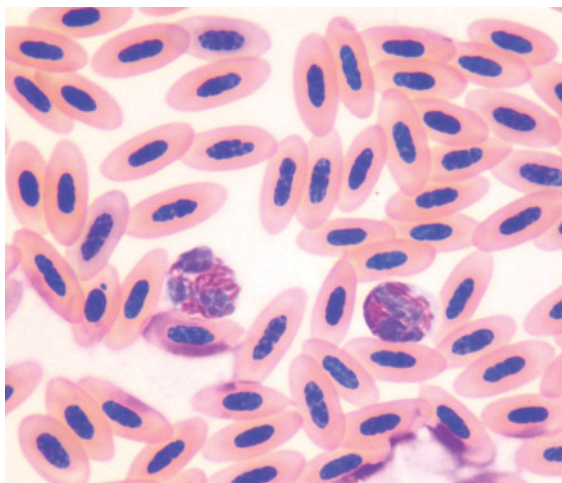


Figure 285 Blood from a cockatiel (*Nymphicus hollandicus*) with renal insufficiency, which had a lymphopenia ($0.14 \times 10^9/L$). Lymphocytes were absent from most of the fields examined. Hematological cells had typical morphology. Pictured are two heterophils amidst mature erythrocytes. (Modified Wright's stain.)

species; the characteristics of the individual bird; the etiological agent (or the cause of inflammation); the “magnitude” of inflammation; and the duration of the inflammation. The wide range of avian species and the dearth of information regarding specific response to defined etiological agents in a nominated species typically necessitate extrapolation from an unrelated species. In the following section selected studies are used to illustrate trends in the avian hematological response to disease. These characteristics are also summarized in Tables 4.2 and 4.3.

Amongst the Anseriformes, hematological response to an inflammatory challenge has been reported for individuals of several species (Bienzle et al. 1997). A captive teal (*Anas spp*) with a *Staphylococcus aureus* septicemia had a heteropenia ($0.6 \times 10^9/L$) with a left shift ($1.4 \times 10^9/L$) and “toxic changes”. The same authors reported a juvenile black-bellied whistling duck (*Dendrocygna autumnalis*)

Table 4.2 Disease processes indicated by changes in the leukocyte concentration of birds.

Leukocyte concentration	Description	Significance
Heterophilia	A concentration of heterophils that is greater than the upper limit of an appropriate reference interval. Increased numbers of heterophils may be evident on a blood film	Commonly indicative of inflammation
Heteropenia	A concentration of heterophils that is less than the lower limit of an appropriate reference interval. Decreased numbers of heterophils may be evident on a blood film	Indicative of marked inflammation resulting in depletion of bone marrow granulocyte reserve; may also occur with decreased granulopoiesis
Lymphocytosis	A concentration of lymphocytes that is greater than the upper limit of an appropriate reference interval. Increased numbers of lymphocytes may be evident on a blood film	Indicative of immune stimulation
Lymphopenia (lymphocytopenia)	A concentration of lymphocytes that is less than the lower limit of an appropriate reference interval. Decreased numbers of lymphocytes may be evident on a blood film	Commonly indicative of "stress"
Monocytosis	A concentration of monocytes that is greater than the upper limit of an appropriate reference interval. Increased numbers of monocytes may be evident on a blood film	Indicative of inflammation
Eosinophilia	A concentration of eosinophils that is greater than the upper limit of an appropriate reference interval. Increased numbers of eosinophils may be evident on a blood film	Indicative of inflammation, often of parasitic or allergic etiology

with osteoarthritis, and multifocal necrotizing tissue lesions caused by *S. aureus*, that had marked heterophilia with a left shift ($130.7 \times 10^9/L$ heterophils and $105.6 \times 10^9/L$ immature heterophils) and "toxic changes" evident as well as a lymphocytosis ($22.2 \times 10^9/L$), monocytosis ($11.1 \times 10^9/L$) and eosinophilia ($8.3 \times 10^9/L$). An Aleutian goose (*Branta canadensis leucopareia*) with multifocal, cutaneous inflammatory lesions that initially had $4.6 \times 10^9/L$ heterophils, $0.8 \times 10^9/L$ immature heterophils

and toxic changes evident had a maximum heterophil concentration of $12.2 \times 10^9/L$ with $0.7 \times 10^9/L$ immature heterophils, before the inflammation resolved with antimicrobial therapy.

Examples of changes in leukocyte concentration and morphology in response to naturally occurring disease have been documented for a number of species of Falconiformes. Bienzle et al. (1997) reported the hematological characteristics of representa-

Table 4.3 Morphological characteristics of avian leukocytes that may indicate a disease process.

Leukocyte morphology	Description	Significance
Heterophil		
<i>Nuclear immaturity</i> Band	The penultimate stage of granulocyte development that is characterized by a nucleus that has no constriction greater than half the width of the nucleus and less coarsely clumped chromatin and a smoother nuclear membrane than mature (segmented) granulocytes. Note granules may obscure nucleus and prevent classification as a band/segmented	Increased numbers are indicative of inflammation
Metamyelocyte/ myelocyte	Less mature stages of heterophil development with no constrictions of the nucleus. Typically not observed in the peripheral blood unless depletion of reserve of mature heterophils	Indicative of inflammation
<i>Cytoplasmic immaturity</i>		
Basophilia	Increased bluish coloration of the cytoplasm, due to increased number of ribosomes, when stained with a Romanowsky stain	Indicative of inflammation
Decreased density of granules	Fewer granules. Decreased granulation allows better visualization of the fine detail of the nucleus and cytoplasm	Indicative of inflammation
Changes in the morphology of granules	Larger granules, rounded granules, variably sized granules; indicative of atypical granulopoiesis	Indicative of inflammation
Changes in the color of granules	Granules are amphophilic or basophilic, instead of "brick-red" color. Often concurrent changes in the morphology of the granules. Indicative of atypical granulopoiesis	Indicative of inflammation
Lymphocytes		
Nucleolus	Complex of nuclear proteins and RNA where RNA transcripts are produced	Indicates cellular activity. May be encountered with both antigenic/mitogenic stimulation and neoplasia
Increased cytoplasmic basophilia	Represent increased amounts of cytoplasmic RNA	Indicates cellular activity
Perinuclear pale region	Represents the Golgi apparatus	Indicates cellular activity

tives from several birds of prey, namely red-tailed hawk, ferruginous hawk (*Buteo regalis*) and rough-legged hawk (*Buteo lagopus*) with naturally occurring bacterial and mycotic disease. A red-tailed hawk with aspergillosis

had heteropenia ($1.2 \times 10^9/L$) with a left shift ($3.1 \times 10^9/L$) and marked toxic changes. A second red-tailed hawk with aspergillosis and *Staphylococcus aureus* abscess, when initially assessed, had a heterophilia ($23.2 \times 10^9/L$)

with a left shift ($31.2 \times 10^9/L$) and mild toxic changes. The heterophil concentration had increased markedly by day 7 ($230.5 \times 10^9/L$) with a left shift ($7.8 \times 10^9/L$). Similarly, a captive ferruginous hawk with a mycotic infection had a heterophilia ($63.9 \times 10^9/L$) with a left shift ($20.7 \times 10^9/L$) and toxic changes. A rough-legged hawk with mycotic disease had heterophilia ($19.6 \times 10^9/L$) with a left shift ($3.5 \times 10^9/L$) and monocytosis ($6.3 \times 10^9/L$) at presentation and by day 28 had a greater heterophilia ($49.2 \times 10^9/L$) with a left shift ($5.8 \times 10^9/L$) and monocytosis ($13.0 \times 10^9/L$). All these birds died or were euthanased. Cellular morphology was a better predictor of outcome than the magnitude of the heterophilia.

Wernery et al. (2004) reported that falcons rarely exhibited leukocytosis of greater than $17.0 \times 10^9/L$ in response to inflammation and the interpretation of the leukogram was complicated by response to handling which could increase leukocyte concentration to $13 \times 10^9/L$. These authors also reported the hematological changes in falcons in response to various etiological agents, such as viral diseases (leukocytes $6.34 \pm 2.21 \times 10^9/L$), bacterial diseases (leukocytes $13.76 \pm 2.91 \times 10^9/L$) and aspergillosis (leukocytes $13.97 \pm 2.59 \times 10^9/L$).

Many studies have investigated and reported the leukocyte characteristics of commercial poultry and these studies provide an important reservoir of knowledge that may be extrapolated to non-domestic birds. It is beyond the scope of this book to comprehensively review the reservoir of studies of domestic poultry; however, selected, illustrative studies are presented. Acute inflammation, experimentally induced in chickens, caused a heterophilia that peaked at 12 hours ($18.3 \times 10^9/L$), with a "left shift" between 12 and 24 hours, and leukocytosis that persisted for 7 days (Latimer et al. 1988). Intravenous injection of lipopolysaccharide from *Salmonella typhimurium* into commercial broiler chickens resulted in decreased concentrations of total leukocytes (by about 66% of initial values), heterophils,

lymphocytes, monocytes and basophils, 1 hour post-injection (Wang et al. 2003). These values had returned to pre-injection values (in surviving birds) by 48 hours after injection. Similarly, injection of lipopolysaccharide into domestic turkeys incited a transient leukopenia due to lymphopenia (2–4 hours after injection) and then a leukocytosis due to heterophilia (8–24 hours after injection) (Carmichael in Harmon 1998). Japanese quail experimentally infected with *Aspergillus flavus* exhibited an increased total leukocyte concentration 3–7 days after infection that was characterized by an increased percentage of heterophils and a decreased percentage of lymphocytes (Pandita et al. 1991). Red grouse experimentally infected with cecal threadworm (*Trichostrongylus tenuis*) had increased concentrations of both heterophils and eosinophils (Wilson & Wilson 1978).

Leukocyte response to naturally occurring disease has been reported for several species of Gruiformes. Seventeen birds, representing several species of crane, naturally infected with *Mycobacterium avium*, all exhibited a leukocytosis due to a heterophilia and monocytosis and many (71%) had a concurrent lymphocytosis (Hawkey et al. 1990). Affected cranes exhibited heterophil concentrations up to $150 \times 10^9/L$ and morphological atypia of heterophils that included decreased segmentation of the nucleus, decreased concentration of granules, and atypical shape of granules, notably rounded granules were observed. Additionally, monocytes without indentation of the nucleus and with cytoplasmic vacuolation were observed.

Houbara bustards with chronic inflammatory disorders had leukocytosis, heterophilia, monocytosis and basophilia and morphologically atypical heterophils characterized by cytoplasmic basophilia, degranulation and decreased nuclear lobulation (D'Aloia et al. 1994). Reactive lymphocytes were also observed. Kori bustards infected with *Pseudomonas aeruginosa* had leukocytosis due to heterophilia and monocytosis (Bailey et al. 2000). Similarly, kori bustards with ventricular

foreign bodies exhibited a heterophilia (Bailey et al. 2001).

For Phoenicopteriformes, eight captive greater flamingos with a variety of disorders exhibited a heterophilia (Hawkey et al. 1984b). The concentration of heterophils was greater than $40 \times 10^9/L$ in two birds and one of these had heterophils with atypical morphology (round, strongly basophilic granules). One bird with biliary carcinoma and terminal peritonitis had a heteropenia ($0.6 \times 10^9/L$).

Hematological response to disease has been documented for some species of Procellariiformes. Monocytosis (maximum observed concentration of $2.38 \times 10^9/L$) was noted in some diseased manx shearwaters (Kirkwood et al. 1995) and 24% of stranded wedge-tailed shearwater chicks had heterophils with atypical morphology (Work & Rameyer 1999).

The hematological response to disease has been reported for a number of species of psittacine birds. An inflammatory leukogram with leukocytosis and heterophilia was encountered in 11 African grey parrots with a range of clinical disorders with the maximum heterophil concentration of $29.6 \times 10^9/L$ recorded for a bird with dyspnea (Hawkey et al. 1982). Heterophilia with a left shift was recorded for psittacine birds, namely, yellow-collared macaw (*Ara aricollis*), blue and gold macaw (*Ara ararauna*) and yellow-crowned Amazon (*Amazona ochrocephala*) (Tangredi 1981).

Heterophilia ($45.4 \times 10^9/L$) with a left shift ($6.1 \times 10^9/L$) and morphological atypia (rounded and basophilic granules) was documented in a lesser sulphur-crested cockatoo after surgery to debride a traumatic leg injury (Bienzle & Smith 1999). Heterophilia (maximum concentration of $25.28 \times 10^9/L$) and monocytosis (maximum concentration of $23.87 \times 10^9/L$) were observed in two species of black cockatoo with a range of disorders (Jaensch & Clark 2004). Morphological changes were infrequently encountered (3/28 cases).

Hematological response to inflammation has been reported for Sphenisciformes. The

majority of captive gentoo penguins with bumble foot (12/14) had a heterophilia ($8.9 \pm 3.4 \times 10^9/L$) compared to the heterophil concentrations of healthy birds (Hawkey et al. 1985) and black-footed penguins infected with eastern equine encephalitis virus exhibited a leukocytosis due to a heterophilia ($27.4 \pm 10.0 \times 10^9/L$) (Tuttle et al. 2005).

Overall, for a range of species and disorders, a hematological response to disease has been documented. Although these studies reveal a heterogeneous response, as would be expected for the broad range of species and the varied disorders, some general characteristics can be identified. Commonly a heterophilia is present, with variation in the magnitude (that is the concentration of heterophils obtained) observed. A "left shift" is regularly observed with significant inflammatory challenges, as are morphological atypia of heterophils. Monocytosis may be evident at levels greater than would be observed in mammals.

Effects of "stress" and excitement on hematological characteristics

The hematological effects of glucocorticoid mediated "stress" in birds due to increased concentrations of corticosterone have been reported both in experimental and clinical situations. Three-week-old chickens injected with ACTH initially showed a leukopenia, due to a lymphopenia, at 1 hour post-injection; then exhibited a leukocytosis, due to a heterophilia, at 4 and 12 hours post-injection (Davison & Flack 1981). There were no consistent changes in the basophils, eosinophils or monocytes. Similarly, administration of corticosterone to chickens via drinking water resulted in an increased heterophil concentration at 24 hours post-administration (Post et al. 2003). No significant effects were noted for other leukocytes.

Birds placed in "stressful" situations may be expected to exhibit similar hematological characteristics to the effects of increased corticosterone concentration determined experi-

mentally. Transported, untrained Harris' hawks (*Parabuteo unicinctus*) had a lymphopenia and eosinopenia (Parga et al. 2001). However, similarly handled peregrine falcons did not exhibit similar effects. In trained birds, a monocytosis was exhibited by the Harris' hawks but not the peregrine falcons. Wernery et al. (2004) stated that, in response to handling, the leukocyte concentration of falcons could increase to $13.0 \times 10^9/L$.

Humboldt's penguins captured from the wild and maintained in captivity exhibited mild changes in absolute heterophil concentration (increased from day 3 to week 3 then decreased between week 3 and 7) and lymphocyte concentration (decreased to week 7 then increased to a value similar to at capture by week 15) (Villouta et al. 1997). Racing pigeons showed an increased heterophil concentration and a decreased lymphocyte concentration, 3 hours after handling and transport (Scope et al. 2002). Transport of common pheasant

showed density dependent effects on the hematological characteristics (Voslarova et al. 2006). At the greatest density, total leukocyte and heterophil concentration was decreased and basophil concentration increased.

Overall, the wide variation in the hematological characteristics exhibited in clinically "stressful" situations likely reflects a complex interaction of the effect, magnitude and duration of the "stresses" on the intrinsic hematological characteristics of the individual and the typical responses of its species.

Decreased leukopoiesis

Leukopenia due to bone marrow hypoplasia in birds treated with either fenbendazole or albendazole has been reported (Howard et al. 2002). Similarly, painted storks (*Mycteria leucocephala*) treated with fenbendazole developed severe heteropenia (Weber et al. 2002).

Hemoparasites of birds

5

INTRODUCTION

There have been many hemoparasites described and reported that have been discovered in the blood of birds, and it is well beyond the scope of this atlas to comprehensively consider the great body of knowledge that has been accumulated. We aim to provide a “working” knowledge of the morphological characteristics that distinguish the various “types” of hemoparasites that may be encountered by a hematologist when examining avian blood films. Following recognition, investigation employing appropriate morphological and molecular biology methods may be undertaken to further classify the organism.

Hemoparasites that have been recognized in the blood of birds include: *Atoxoplasma* spp, *Babesia* spp, *Haemoproteus* spp, *Hepatozoon* spp, *Leukocytozoon* spp, *Trypanosoma* spp, *Plasmodium* spp, and the microfilaria(e) of filaroid nematodes. Selected examples of species reported from each of these groups of hemoparasites and their avian hosts are given in Table 5.1. Occasionally the motile intermediate or free-living stages of protozoal parasites from the alimentary tract such as

Trichomonads and Histomonads may develop sufficient parasitaemia to be detected in blood (Stabler 1954, McKeon et al. 1997) but such events are rare.

The significance of infection with a particular species of hemoparasite varies with the parasite, the magnitude of the parasitemia, the species of host, and the physiological state of the host. In many instances infection appears to have no significant detrimental effect on the health of the host. A review of 5640 articles published on avian hemoparasites concluded “*There are remarkably few reports of mortality caused by blood parasites in wild birds*” (Bennett et al. 1993). However, some hemoparasites may impact on the health or fitness of a particular host. Consequently, it is important for the hematologist to recognize hemoparasites during examination of blood films that are part of an investigation of avian health.

Some organisms are pathogenic and infection of a particular host results in clinical disease of that host. For example, natural infection of bobwhite quail (*Colinus virginianus*) with *Haemoproteus lophortyx* resulted in a cumulative mortality of 20% of birds within the affected flocks (Cardona et al. 2002).

Table 5.1 Selected reports of hemoparasites and their hosts. The references refer to the study in which the parasite was reported, not necessarily the original description of the organism.

Hemoparasite	Host	Reference
<i>Atoxoplasma</i> sp	Greenfinch	Ball et al. 1998
<i>Atoxoplasma</i> sp	Bullfinch	McNamee et al. 1995
<i>Atoxoplasma</i> sp	Tanagers	Adkesson et al. 2005
<i>Babesia bennetti</i>	Yellow-legged gull	Merino 1998
<i>Babesia poelea</i>	Brown booby	Work & Rameyer 1997
<i>Babesia shortii</i>	Saker falcon	Samour & Peirce 1996
<i>Babesia kiwiensis</i>	Brown kiwi	Peirce et al. 2003
<i>Haemoproteus balearicae</i>	Sandhill crane	Dusek et al. 2004
<i>Haemoproteus danilewskyi</i>	Blue jay	Garvin et al. 2003
<i>Haemoproteus iwa</i>	Great frigatebird	Work & Rameyer 1996
<i>Haemoproteus lophortyx</i>	Bobwhite quail	Cardona et al. 2002
<i>Haemoproteus nisi</i>	Eurasian sparrow hawk	Peirce et al. 1990
<i>Haemoproteus tinnunculi</i>	American kestrel	Apanius & Kirkpatrick 1988
<i>Hepatozoon kabeenin</i>	Sedge warbler	Kruszewicz & Dyrzcz 2000
<i>Hepatozoon kiwii</i>	Brown kiwi	Peirce et al. 2003
<i>Leucocytozoon atkinsoni</i>	Common jery	Savage et al. 2006
<i>Leucocytozoon ibisi</i>	White ibis	Adlard et al. 2002
<i>Leucocytozoon marchouxi</i>	Pink pigeon	Peirce et al. 1997
<i>Leucocytozoon toddi</i>	Eurasian sparrow hawk	Ashford et al. 1990
<i>Plasmodium forresteri</i>	Barred owl	Telford et al. 1997
<i>Plasmodium juxtannucleare</i>	Black-footed penguin	Grim et al. 2003
<i>Plasmodium relictum</i>	Lesser flamingo	Peirce 2005b
<i>Plasmodium rouxi</i>	Mountain thrush-babbler	Valkiunas et al. 2005b
<i>Plasmodium subpraecox</i>	Eastern screech owl	Tavernier et al. 2005
<i>Trypanosoma avium</i>	Common buzzard	Votypka et al. 2002
<i>Trypanosoma bennetti</i>	American kestrel	Kirkpatrick et al. 1986
<i>Trypanosoma everetti</i>	Common redstart	Rintamaki et al. 1999
Microfilariae	Red-billed blue magpies	Simpson et al. 1996
Microfilariae	Australian magpie	Reppas et al. 1995
Microfilariae	Willow ptarmigan	Holmstad et al. 2006
Microfilariae	Little owl	Bedin et al. 2007

Natural infection of a saker falcon and Eurasian kestrel with *Babesia shortii* resulted in significant anemia (Samour and Peirce 1996, Munoz et al. 1999). Deaths of black-footed penguins have been attributed to infection with *Plasmodium juxtannucleare*; both in wild birds admitted to a rehabilitation center (Grim et al. 2003) and captive birds, which may die

acutely before erythrocytic stages are evident in peripheral blood (Peirce 2005b). Similarly, extensive retinal and central nervous system lesions have been described associated with a fatal *Leucocytozoon* infection in Australian *Falco* species (Raidal & Jaensch 2000).

The pathogenic sequelae of infection may be greater in immature birds, which may be due

to a lack of immunity because of no previous exposure to the organism (Sol et al. 2003). An infection with both *Haemoproteus noctuae* and *Leucocytozoon ziemanni* was fatal in juvenile snowy owls (Evans & Otter 1998). Similarly, natural infection of pink pigeons (*Columba mayeri*) with *Leucocytozoon marchouxi* had the greatest pathological effect on squabs and juvenile birds (Peirce et al. 1997). However, infection of a young bird with a hemoparasite does not necessarily result in clinical disease; for example, a study of *Leucocytozoon toddi* in Eurasian sparrowhawks (*Accipiter nisus*) showed no significant evidence of initial mortality or decreased longevity (Ashford et al. 1991).

Under some circumstances, hemoparasites that typically do not incite clinical consequences to the host may assume greater significance when the host has decreased immunity. For example, stress and increased photoperiod were shown to induce recrudescence of latent, natural infections with *Haemoproteus belopolskyi* and *Trypanosoma* spp in blackcaps (*Sylvia atricapilla*) (Valkiunas & Iezhova 2004). Similarly, the greater burden of *Leucocytozoon dubreuilii* (compared to healthy birds) observed in an injured great tit was attributed to the debilitation of the host (Hautmanova et al. 2002). The increased numbers of *Leucocytozoon toddi* observed in the blood of Eurasian sparrow hawks during “spring relapse”, which coincides with nesting season, was believed to reflect the “stress” associated with reproduction (Ashford et al. 1990). Similarly, increased numbers of hemoparasites were observed during the breeding season in captive yellowhammer (*Emberiza citrinella*) (Allander & Sundberg 1997) and wild common redstarts (*Phoenicurus phoenicurus*) (Rintamaki et al. 1999).

There is an increasing body of knowledge that reveals that while infection with hemoparasites may not incite clinical disease in the host, it may have an effect on the complex, multi-factorial interactions that influence the fitness and reproductive success of the host.

Decreased defence of the nest was exhibited by Tengmalm’s owls (*Aegolius funereus*) infected with *Trypanosoma avium* (Hakkariinen et al. 1998). A study of great tits showed that urban birds infected with *Haemoproteus* spp had lower body weight than uninfected birds. However, rural birds did not exhibit a difference in body weight (Ots & Horak 1998). Female blue tits treated to reduce the level of infection with *Haemoproteus majoris* and *Leucocytozoon majoris* had better body condition and their offspring had a greater fledging success, than non-treated birds (Merino et al. 2000).

DETECTION OF HEMOPARASITES

As this text is intended primarily for hematologists, hemoparasites will typically be encountered during examination of a blood film to assess the hematological characteristics of the host. Commonly, this will be a thin blood film of adequate quality to permit reliable assessment of the host cells and typically stained with a Romanowsky stain and examined by light microscopy.

Initial examination of the blood film at lower power magnification ($\times 4$ or $\times 10$ objective lens) promotes the detection of larger organisms, such a microfilaria(e) and *Trypanosoma* spp, that may be present in low numbers (and may not be recognized if the microscopist omits this step). Distorted leukocytes containing *Leucocytozoon* spp and distorted erythrocytes containing *Haemoproteus* spp may also be recognized during the lower power examination of the film. Often, the larger organisms are found near the leading edge of the film and distributed throughout the thin (“monolayer”) region located behind the leading edge. After the initial examination of the blood, closer examination using $\times 20$, $\times 40$ and $\times 100$ objectives is employed to recognize smaller hemoparasites, such as *Plasmodium* spp and *Babesia* spp and to allow examination

of the fine detail of the structure of all organisms. Hemoparasites are more difficult to recognize in thick blood films and poorly stained blood films (particularly those that are insufficiently stained). The presence of large amounts of stain precipitate may complicate detection of small hemoparasites, such as *Babesia* spp.

Light microscopy, by an experienced and diligent operator, provides a simple and effective method to recognize hemoparasites in the blood of birds. The detection limit of light microscopic examination, specifically the ability to recognize the presence of small numbers of organisms, has been the subject of scientific discussion (Sehgal et al. 2001, Ribeiro et al. 2005). Typically, an infection of intra-erythrocytic organisms is considered “detectable” using light microscopic examination of thin blood films when the parasites are present in greater than 0.1% of erythrocytes (Gaunt 2000). Muñoz *et al.* (1999) detected parasitemias of 0.1% for *Leucocytozoon* spp. and *Haemoproteus* spp. in blood from a range of hosts.

Diagnosis of hemoparasite infections by light microscopy can also be complicated by the ability of some organisms to incite pathogenic consequences without appearing in the peripheral blood; for example, *Plasmodium* spp in penguins (Pierce 2005b, Pierce et al. 2005).

Increasingly, molecular biology methods, most notably the polymerase chain reaction (PCR), have been applied to the detection of avian hemoparasites (Sehgal et al. 2001, Votypka et al. 2002, Beadell et al. 2004, Hellgren et al. 2004, Ribeiro et al. 2005, Wiersch et al. 2007). PCR provides an effective way to detect hemoparasites when only small volumes of blood are available and few hemoparasites are present. Use of “multiplexed PCR” for the concurrent detection of different hemoparasites promotes convenient and expedient analysis of samples (Hellgren et al. 2004). However, Cosgrove et al. (2006) reported that primers designed to amplify DNA from *Plasmodium* spp and *Haemoproteus* spp also (unintentionally) amplified DNA from *Leucocytozoon* spp

and advised that additional methods, such as restriction fragment length polymorphism (RFLP) analysis or direct sequencing, were necessary to identify organisms. Similarly, the use of nested PCR for cytochrome b did not recognize mixed infections of haemosporidian parasites in naturally infected birds (Valkiūnas et al. 2006).

The relative ability of light microscopic examination of blood films and PCR to detect the presence of hemoparasites has been compared in a number of studies with varied outcome. Ribeiro et al. (2005) found that for *Plasmodium* spp, PCR detected organisms in 39.6% of samples tested whereas light microscopic examination detected organisms in 16.5% of samples. In contrast, in a study of *Plasmodium* and *Haemoproteus*, Beadell et al. (2004) found the same detection rate (35/40) for samples analyzed by both light microscopy and PCR and noted that the two primer sets had failed to detect infection in 17% and 30% of cases respectively. Similarly, a study of *Trypanosoma* spp initially detected organisms in 37/193 (19%) of samples by light microscopy and 53/193 (28%) of samples by PCR (Sehgal et al. 2001). Of the samples that had discordant results between the two methods, 6/193 (3%) samples were initially negative by PCR but had organisms observed by microscopy and when the PCR was repeated had a positive result. In the same study, 6/193 (3%) of blood films were initially classed as negative but, when re-examined after a positive PCR result, were found to contain organisms.

Concentration methods for the detection of hemoparasites may be applied to aid in the detection of certain avian hemoparasites when sufficient volume of blood is available. Bennett (1962) reported that the detection of hemoparasites could be increased by centrifugation of blood in a capillary tube and subsequent light microscopic examination of i) the serum immediately above “buffy coat” layer for *Trypanosoma* spp and microfilaria(e) and ii) a stained, thin film prepared from the “buffy coat” for hemoparasites such as *Haemoproteus* spp and *Leucocytozoon* sp. The author

noted these organisms' shape may be distorted by the process and consequently they may be difficult to speciate. Similarly concentration methods, such as Knott's test, may be employed to detect microfilaria(e) that may be present in circulation in small numbers (Zajac & Conboy 2006).

In the context of this book, the recognition of hemoparasites using morphological characteristics during examination of blood films by light microscopy is the most likely method used by the hematologist to initially detect hemoparasites. These characteristics are described in the following section. Additional methods may then be employed to further classify the organism, quantify infection or undertake hemoparasitological surveys of additional birds.

MORPHOLOGY OF HEMOPARASITES

The recognition of hemoparasites in avian blood films using light microscopy provides an important method for the detection of hemoparasites. The classification of hemoparasites has traditionally employed morphological characteristics (Peirce et al. 1990, 2003, Peirce 2000, Adlard et al. 2002) in conjunction with host specificity and life cycle information. Increasingly molecular methods are being utilized; however, Peirce et al. (2005a) stated "*The expanding use of molecular techniques in the study of avian hematozoa should eventually clarify the status of many species which have a similar morphology but occur in different host families or subfamilies. However, molecular studies should only be considered a useful adjunct in taxonomy; morphology and life cycle will remain the core attributes in defining a new species*". Similarly, Valkunias et al. (2005a) stated "*Certainly, molecular genetics provides inexhaustible opportunities for investigations into the phylogenetic relationships of haemosporidian parasites (1–4),*

but it is limited in what it can tell us about the basic life history strategies of these organisms."

From the hematologists' perspective, microscopy also provides important information on the parasites' effect on the health of its host; such as, if the bird is anemic, if there is increased erythropoiesis or if there is an inflammatory response. These effects are not currently able to be determined by molecular methods.

Plasmodium

See Figures 287–288.

Many species of *Plasmodium* have been reported from birds (Soulsby 1982, Laird 1988). Plasmodium infections are characterized by the concomitant presence of several stages of the life-cycle of the organism within the erythrocytes of the host. Notably, gametocytes and schizonts (containing merozoites) may be recognized (Soulsby 1982).

The morphology of the organism varies between species of *Plasmodium* and it is

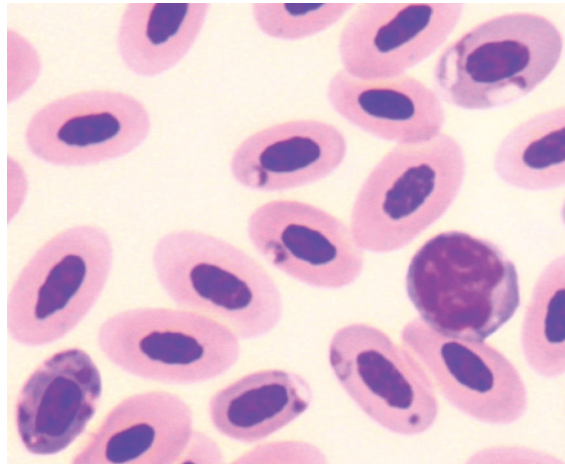


Figure 287 Blood from a pied currawong (*Strepera graculina*) with gametocytes of *Plasmodium* sp. evident within the cytoplasm of several mature erythrocytes and a schizont within one polychromatophilic erythrocyte (bottom left). Also present is a lymphocyte. (Modified Wright's stain.)

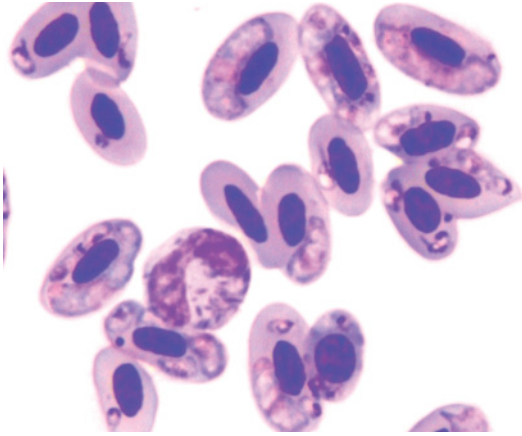


Figure 288 Blood from a sacred kingfisher (*Todirhamphus sanctus*) showing organisms consistent with gametocytes of *Plasmodium* sp. within the cytoplasm of erythrocytes. However, the morphological similarity of the large gametocytes to *Haemoproteus* sp demands that a dual infection with *Plasmodium* sp and *Haemoproteus* sp cannot be discounted solely by morphological assessment. Remarkably, the bird had 93% of its erythrocytes parasitized. (Diff Quik stain.)

beyond the scope of this book to detail the morphological characteristics of the many species. In general, the gametocytes of species of *Plasmodium* may be irregularly round, elongate, “U” or “V” shape, with a round amphophilic central nucleus, and moderately basophilic cytoplasm that contains several brown–black pigment granules. *Plasmodium juxtannucleare* has relative small round gametocytes and *P. relictum* has round to irregular gametocytes which, in both species, may displace the nucleus of the host erythrocyte (Soulsby 1982). In contrast, *Plasmodium forresteri* had elongate, slender gametocytes that rarely distorted the shape of the host erythrocyte but regularly displaced the nucleus (Telford et al. 1997) and *P. fallax* has large, elongate gametocytes that resemble *Haemoproteus* spp that tend to surround the nucleus of the host cell without displacing it (Soulsby, 1982).

Schizonts are round to ovoid structures within the cytoplasm of erythrocytes, lateral

or polar to the nucleus. Both mature erythrocytes and polychromatophilic erythrocytes may contain schizonts. Typically the shape of the host cell is not distorted by the presence of the schizont but the nucleus may be slightly displaced. Each schizont is composed of merozoites. The number of merozoites in a schizont varies between species of *Plasmodium* and within schizonts of the same species of *Plasmodium*. For example, *Plasmodium forresteri* had small schizonts with two to six merozoites (Telford et al. 1997).

Merozoites have a pleomorphic appearance and may be round, ovoid, elongate in shape with a small dark basophilic nucleus and basophilic cytoplasm. Merozoites within a schizont commonly exhibit a “fan” formation and may also exhibit a rosette, cruciform or “bow-tie” formation, depending on the number present in the schizont.

Babesia

See Figure 289.

The taxonomy of the organisms within the genus *Babesia*, that may be found within the blood of birds, has been reviewed and some

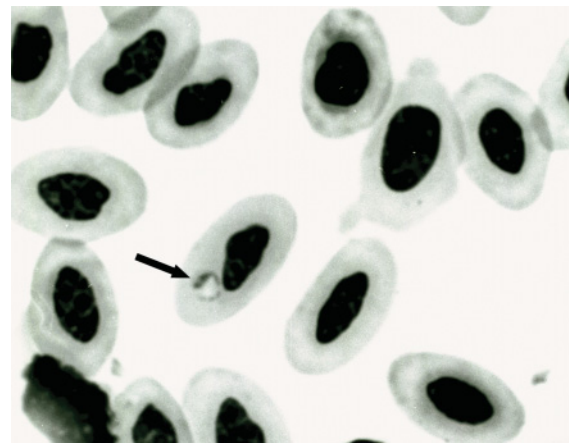


Figure 289 Blood from a brown kiwi (*Apteryx australis*) with a hemoparasite morphologically consistent with *Babesia* sp. (arrow) within the cytoplasm of an erythrocyte. (May Grünwald and Giemsa stains.)

13 valid species have been recognized (Peirce 2000). Typically, species of *Babesia* are small (1–3 µm in diameter), intra-erythrocytic organisms. Classically *Babesia* spp have a round “ring form” appearance with a single eccentric darkly basophilic, chromatin mass, and a fine limiting membrane that encloses pale basophilic cytoplasm (which often contrasts with the eosinophilic cytoplasm of the host erythrocyte). Other forms encountered include ovoid, elongate and pyriform. Schizonts are typically composed of several merozoites. For example, *B. shortii* is commonly observed to have four merozoites in a cruciform or fan-shaped configuration (Pierce 2000).

Haemoproteus

See Figures 290–293.

Organisms classified within the genus *Haemoproteus* have a cosmopolitan distribution with greater than 100 species identified from host birds representing many of the avian

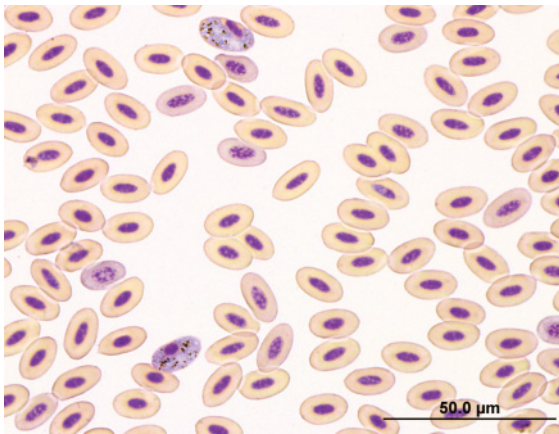


Figure 290 Blood from a grey teal (*Anas gracilis*) showing lower power magnification of many mature and several polychromatophilic erythrocytes. *Haemoproteus* sp. organisms can be identified in two of the erythrocytes. Observation at lower magnification allows detection of the organisms and an impression of the proportion of erythrocytes infected to be gained, but does not allow assessment of the fine morphological detail of the organism. (Modified Wright’s stain.)

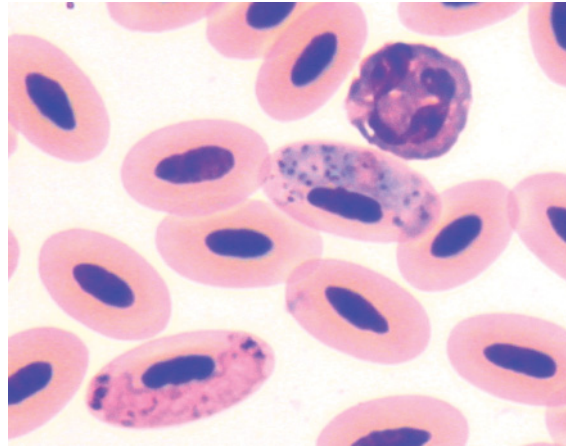


Figure 291 Blood from a blue-winged kookaburra (*Dacelo leachii*) showing intra-erythrocytic *Haemoproteus* sp. A basophilic macrogametocyte (within the erythrocyte adjacent to the heterophil) and a “pink” microgametocyte can be discerned. (Diff Quik stain.)

families (Bennett & Peirce 1988, 1990, Peirce et al. 1990, Peirce 2005a). Typically, gametogony of *Haemoproteus* spp occurs within erythrocytes, whereas schizogony occurs within endothelial cells. Consequently, only gametocytes are observed within erythrocytes (in con-

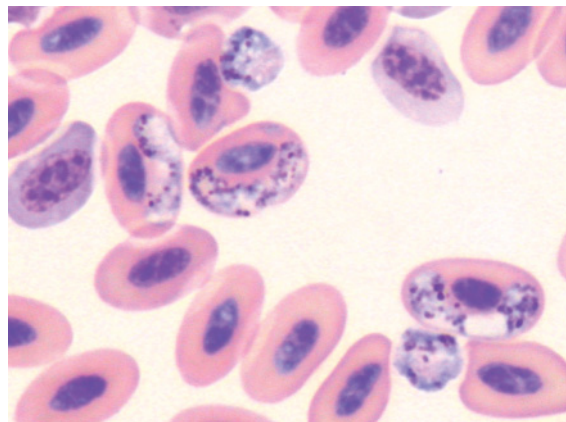


Figure 292 Blood from a southern boobook (*Ninox boobook*) with three gametocytes of *Haemoproteus* sp. evident within the cytoplasm of erythrocytes. In addition, two extracellular organisms are observed. The punctate, dark pigment often present in *Haemoproteus* spp is clearly visible in all the organisms. (May Grünwald and Giemsa stains.)

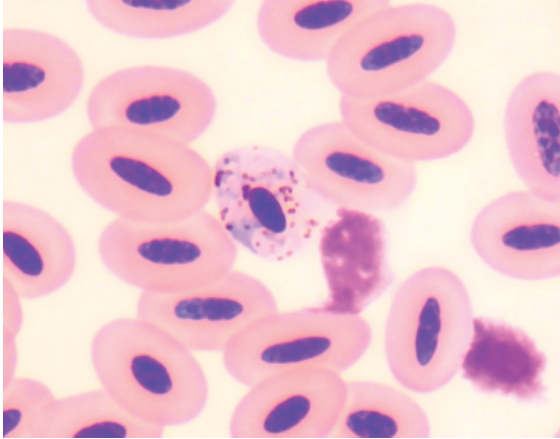


Figure 293 Blood from a brown falcon (*Falco berigora*) illustrating a “circumnuclear” form of a gametocyte of *Haemoproteus* sp. within the cytoplasm of an erythrocyte. (Modified Wright’s stain.)

trast to *Plasmodium* spp). Multiple gametocytes within a single erythrocyte are commonly observed with some species, such as *H. tinunculi* (Peirce et al. 1990). Occasional extracellular organisms may be observed.

Bennett & Peirce (1988) divided the macrogametocytes of *Haemoproteus* spp into five morphological categories according to body shape, namely: microhalteridial, halteridial, circumnuclear, rhabdosomal and discosomal. Classically, the gametocytes of *Haemoproteus* spp are halteridial; that is elongated and curved, often around the host erythrocyte’s nucleus. However, the predominant form of the gametocytes varies between species. For example, considering the haemoproteids of the order Falcoformidae, *H. tinunculi* is typically halteridial whereas *H. janovyi* is highly pleomorphic (Peirce et al. 1990). Similarly, *H. sacharovi* is typically a large and pleomorphic organism that may exhibit a leukocytozoid appearance (Bennett & Peirce 1990). The propensity of gametocytes to displace the nucleus of and cause distension of the host erythrocyte varies with the species of *Haemoproteus*.

In general, the gametocytes of *Haemoproteus* spp have a distinct peripheral outline, cytoplasm that contains variable amounts of a

yellow to black–brown granular pigment and punctate purple granules, and a centrally located nucleus. In some species, the morphological difference between macrogametocytes and microgametocytes may be identified. Macrogametocytes, in comparison with microgametocytes, typically have cytoplasm that stains a darker basophilic color with greater numbers of pigment granules distributed throughout the cytoplasm and a dense nucleus that stains an amphophilic to basophilic color. In contrast, microgametocytes typically have cytoplasm that stains a pale blue to “rose” color with fewer granules, that are often polar in distribution, and a nucleus that is more diffuse (less dense) and stains an amphophilic to red color.

Leukocytozoon

See Figures 294–300.

Numerous species of *Leucocytozoon* have been identified from many families of avian host (Bennett et al. 1991, Bennett & Peirce 1992, Adlard et al. 2002, Peirce et al. 2005,

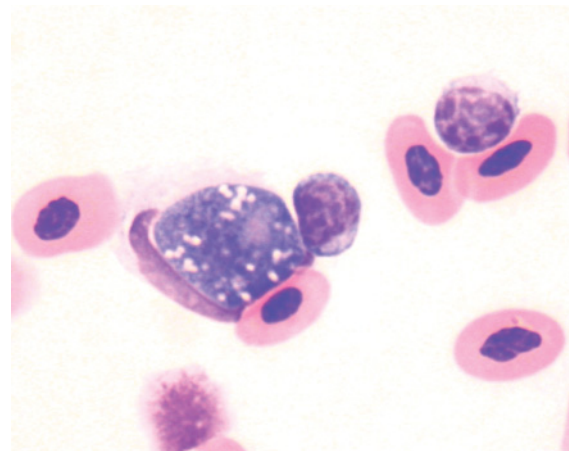


Figure 294 Blood from an Australian magpie (*Gymnorhina tibicen*) with the gametocyte of a *Leucocytozoon* sp. evident within a mononuclear leukocyte, which has been distorted by the organism. Also present are two lymphocytes and several erythrocytes. (Modified Wright’s stain.)

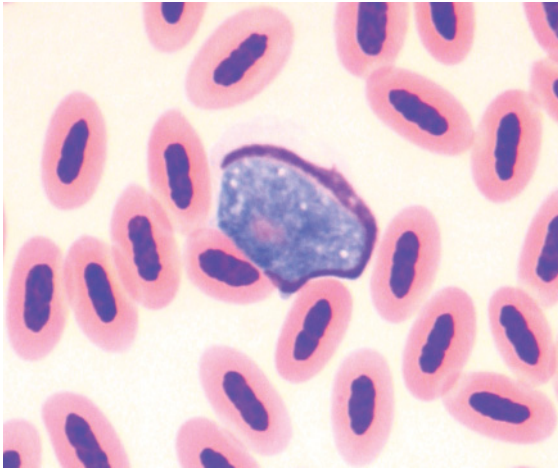


Figure 295 Blood from a singing honeyeater (*Lichenostomus virescens*) showing the gametocyte of a *Leucocytozoon* sp. within a leukocyte. (Modified Wright's stain.)

Peirce 2005b, Savage et al. 2006). The gametogony of species of *Leucocytozoon* occurs within hematological cells, whereas the schizogony occurs in various parenchymatous and endothelial cells.

The gametocytes of leucocytozoids are highly pleomorphic with some species exhibiting both fusiform and round forms whereas

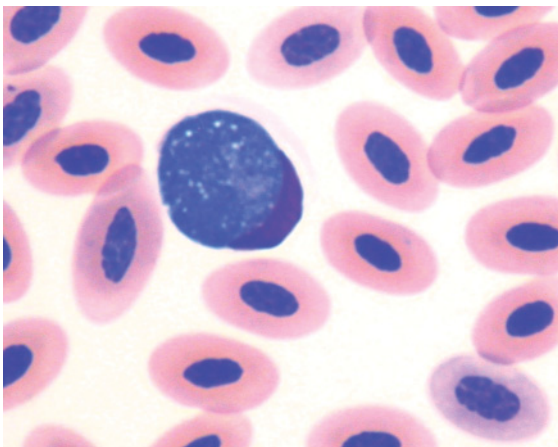


Figure 296 Blood from a tawny frogmouth (*Podargus strigoides*) showing the gametocyte of a *Leucocytozoon* sp. within a leukocyte. (Modified Wright's stain.)

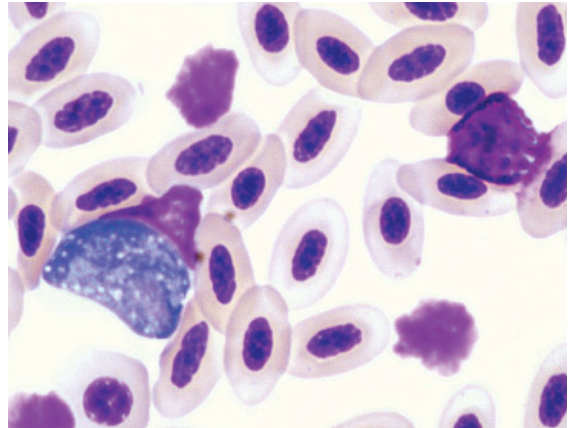


Figure 297 Blood from an Australian kestrel (*Falco cenchroides*) showing the gametocyte of a *Leucocytozoon* sp. within the cytoplasm of a mononuclear leukocyte. Also present are a basophil, two lysed cells and mature erythrocytes. (Modified Wright's stain.)

others exhibit only fusiform or only round forms. For example, both fusiform and round forms of *L. maclaeni* are recognized (Bennett et al. 1991). However, the leucocytozoids described from Passeriformes all exhibited round forms (Bennett & Peirce 1992), as did *L. podargii*, *L. ibisi* and *L. otidis* (Adlard et al. 2002).

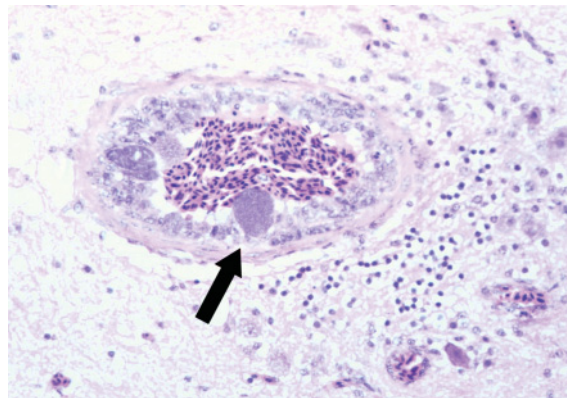


Figure 298 Tissue section of the brain from an Australian kestrel showing the schizont of a *Leucocytozoon* sp. within the wall of a vessel. (Haematoxylin and eosin stains.)

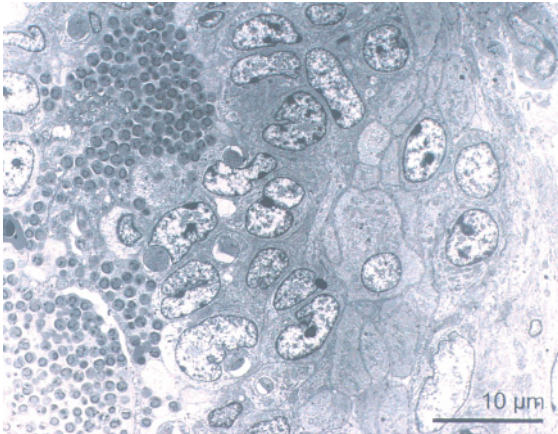


Figure 299 Transmission electron micrograph of a schizont from the brain of an Australian kestrel showing individual organisms. (Lead citrate and uranyl acetate stains.)

Typically, the round forms have a finely granular amphophilic to basophilic nucleus that may contain small vacuoles. The presence of the parasite may enlarge the host cell. The nucleus of the infected host cell is typically distorted to form a long dark homogeneous crescent along one edge of the parasite and displaced to the margin of the host cell. The

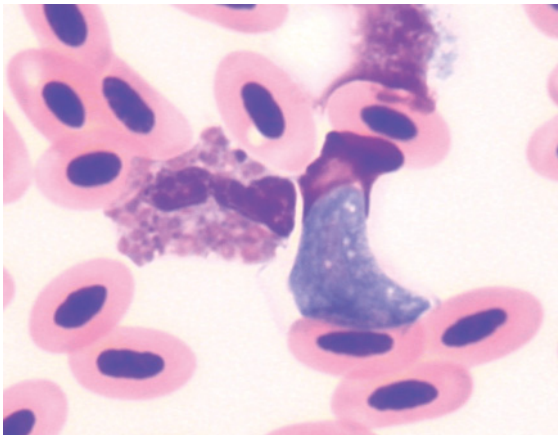


Figure 300 Blood from an Australian hobby (*Falco longipennis*) portraying the gametocyte of a *Leucocytozoon* sp. within the cytoplasm of a mononuclear leukocyte. Also present is a heterophil exhibiting morphological atypia due to an inflammatory challenge. (Modified Wright's stain.)

fusiform forms have an ovoid to elongated shape with the host cell's nucleus evident as a crescent along the long axis of the parasite and the host cell's cytoplasm tapering to a point at each pole of the long axis of the cell. Morphological differences between macrogametocytes and microgametocytes may be evident in some preparations for some species of *Leucocytozoon*. In general, macrogametocytes are larger and have a darker basophilic nucleus. In contrast microgametocytes are often more pleomorphic, slightly smaller (allowing more of the host cell to be visualized), and have a pale nucleus with less dense, amphophilic chromatin.

Atoxoplasma

See Figure 301.

Atoxoplasma spp (formerly *Lankesterella*) are coccidian parasites of birds. Reclassification of these organisms as *Isospora* spp has been considered (Upton et al. 2001). Gametogony typically occurs within intestinal enterocytes cells and merogony occurs within

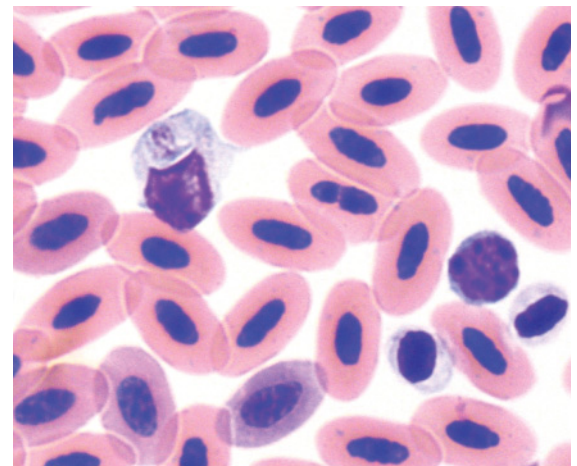


Figure 301 Blood from a Bali myna (*Leucopsar rothschildi*) exhibiting an organism morphologically consistent with *Atoxoplasma* sp. within a mononuclear cell. Also present are a small lymphocyte and two thrombocytes amidst erythrocytes. (Modified Wright's stain.) (Courtesy of Jonathon Cracknell.)

mononuclear leukocytes. Merozoites may be present at low concentration within leukocytes and detection of the organisms may be assisted by the concentration of leukocytes in a buffy coat preparation. Merozoites are difficult to definitively identify using solely light microscopy (Adkesson et al. 2005). The merozoites of *Atoplasma* spp are small round to ovoid structures with agranulated pale basophilic cytoplasm and a central to sub-central basophilic to amphophilic nucleus. Organisms are located within the cytoplasm of the host cell and may mildly displace the host cell's nucleus.

Hepatozoon

See Figure 302.

There have been some 15 species of *Hepatozoon* recorded from avian hosts (Bennett et al. 1992, Peirce et al. 2003). The gametocytes of *Hepatozoon* spp are usually encountered within the cytoplasm of mononuclear leukocytes, both monocytes and lymphocytes. The organisms are typically ovoid or elongate with rounded ends, with a round basophilic

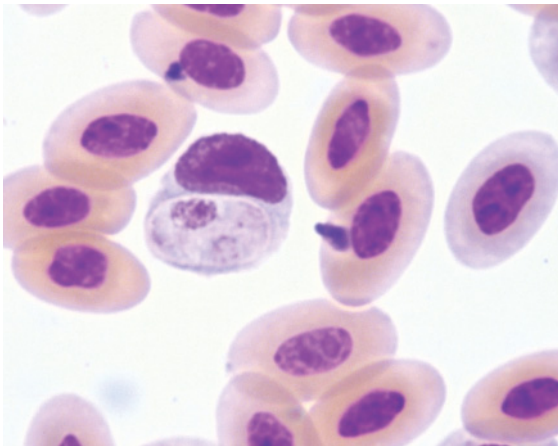


Figure 302 Blood from a brown kiwi (*Apteryx australis*) exhibiting a hemoparasite morphologically consistent with *Hepatozoon* sp. within the cytoplasm of a mononuclear leukocyte. (May Grünwald and Giemsa stains.)

nucleus, in a centric or eccentric sub-terminal location, and pale basophilic cytoplasm with occasional punctate azurophilic granules. A capsule, seen as a white halo around the parasite, is present in some species; for example, *H. kiwii* (Peirce et al. 2003).

The organism may displace the host's nucleus which becomes compressed at the periphery of the cell. The host cell may be distended as the parasite matures.

Macrogametocytes and microgametocytes cannot be distinguished morphologically.

Trypanosomes

See Figures 303–306.

Organisms classified within the genus *Trypanosoma* have life-cycle stages within the blood of a vertebrate host, which may be encountered by hematologists, as well as stages within an invertebrate host. Although about 100 species of avian trypanosomes have been described, the validity of many of these species has been questioned (Votypka et al. 2002). *Trypanosoma avium* has been reported in a wide range of birds and a number of “species”

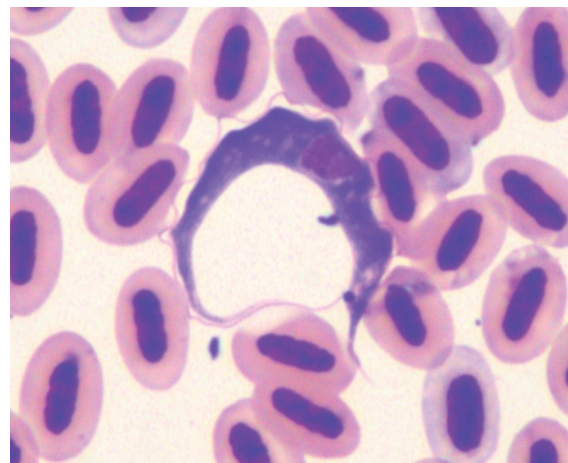


Figure 303 Blood from a red-collared lorikeet (*Trichoglossus haematodus rubritorquis*) depicting an extracellular *Trypanosoma* sp. amidst erythrocytes. (Diff Quik stain.)

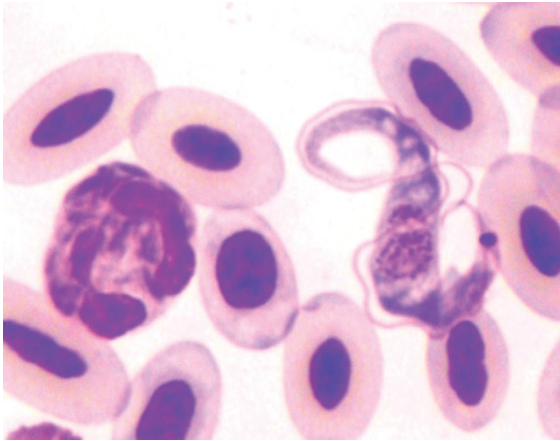


Figure 304 Blood from a whistling kite (*Haliastur sphenurus*) exhibiting a *Trypanosoma* sp. and a heterophil amidst erythrocytes. The morphological features of the organism, namely the kinetoplast, nucleus, undulating membrane and flagellum, can all be clearly discerned. (Diff Quik stain.)

of avian trypanosomes are considered to be part of the “*T. avium* complex”.

Typically, *Trypanosoma* spp have a low parasitemia. Consequently, blood smears need to be thoroughly examined at low magnification to facilitate the detection of parasites. Fortunately the size and distinctive morphology of the parasites assists their recognition

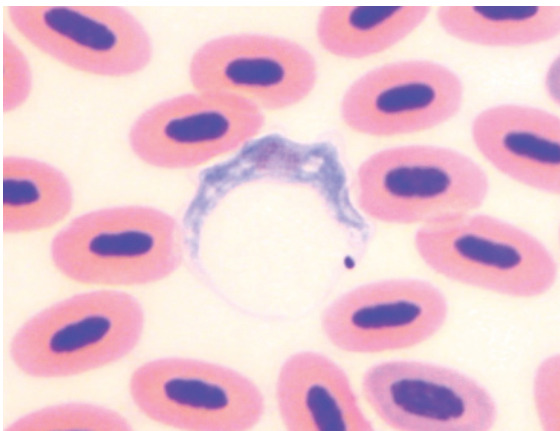


Figure 305 Blood from a brown honeyeater (*Lichmera indistincta*) illustrating a *Trypanosoma* sp. organism amidst erythrocytes. (Modified Wright’s stain.)

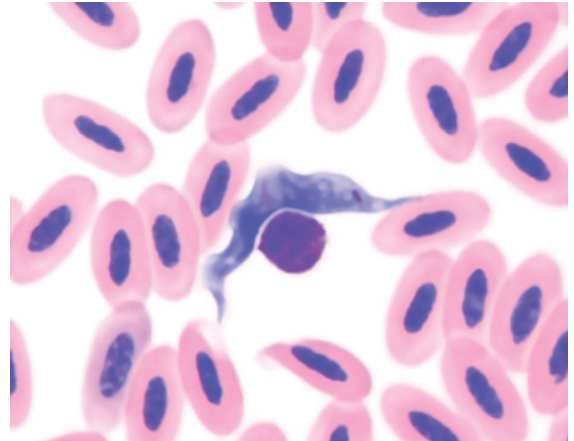


Figure 306 Blood from a New Holland honeyeater (*Phylidonyris novaehollandiae*) portraying a *Trypanosoma* sp. and a nucleus amidst erythrocytes. (Modified Wright’s stain.)

amidst the host’s hematological cells. Detection of organisms is further aided by centrifugation of a sample of blood in a capillary tube and examination of the buffy coat preparation (Bennett 1962).

The different life-cycle stages of *Trypanosoma* spp exhibit varied morphology. The most recognizable stage is the trypomastigote. In general, trypomastigotes have a “blade” like, elongated shape that tapers to a posterior flagellum and a pointed anterior. An undulating membrane extends along much of the organism’s length, a dark, basophilic focal kinetoplast is located in the anterior of the organism, and a round, basophilic to amphophilic nucleus is located around the mid-section of the organism. The cytoplasm is typically a pale basophilic color. The morphology and the relative dimension of the described structures vary with the species and the stage of development of the organism.

Microfilariae

See Figures 307–311.

The microfilaria(e) of filaroid nematodes are large (in comparison to all the host cells),

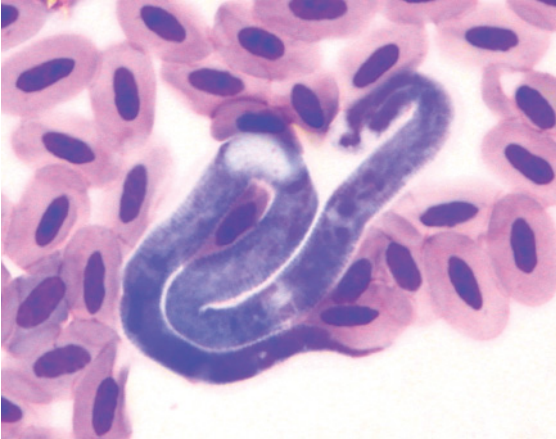

Figure 307 Blood from a brown falcon (*Falco berigora*) illustrating a serpentine microfilaria amidst mature erythrocytes. (Diff Quik stain.)

extracellular organisms that typically have a serpentine appearance and a basophilic color. Variation in the relative length and width occurs between species and results in a spectrum of shapes from relatively broad, short organisms to thin, elongated organisms.

Typically birds have a low microfilaremia and only a few organisms are present in the volume of blood used to make a blood film. Consequently, blood smears need to be thoroughly examined at low magnification to facilitate the detection of microfilaria(e).

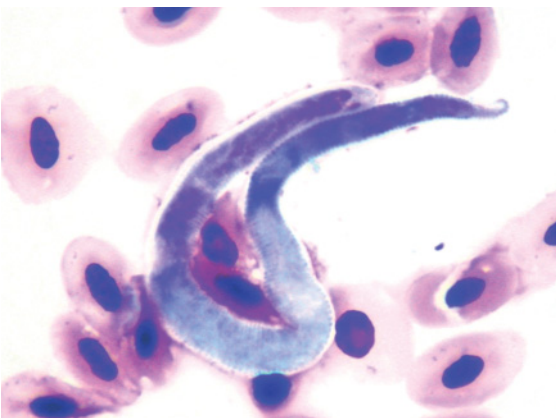


Figure 308 Blood from a tawny frogmouth (*Podargus strigoides*) showing a microfilaria amidst mature erythrocytes. (Diff Quik stain.)

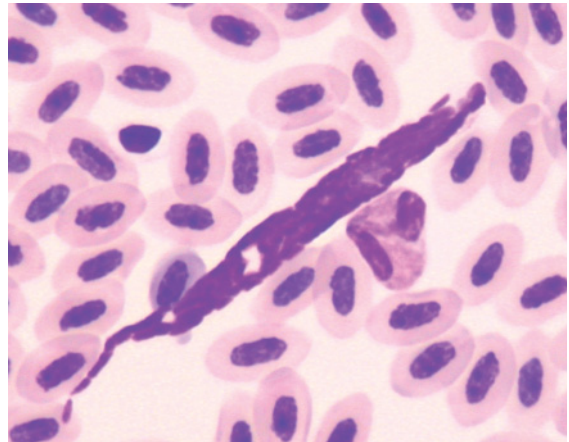


Figure 309 Blood from a northern rosella (*Platyercus venustus*) depicting a microfilaria amidst mature erythrocytes. Note the difference in shape between this organism and the microfilariae in Figures 307 and 308. (Diff Quik stain.)

Fortunately the large size and distinctive morphology of the parasites assists their recognition amidst the host's haematological cells. Detection of organisms is further aided by centrifugation of a sample of blood in a capillary tube and examination of the buffy

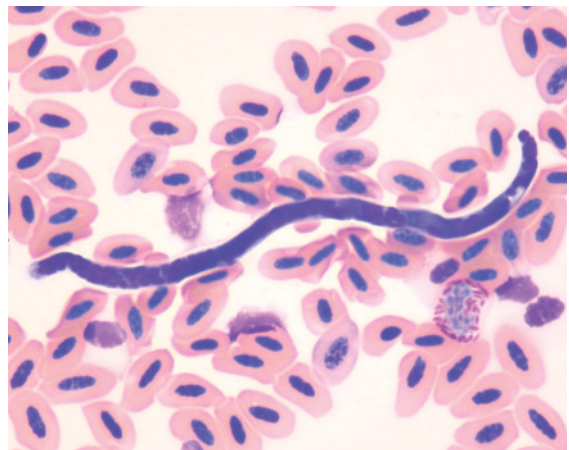


Figure 310 Blood from an Australian raven (*Corvus coronoides*) showing a microfilaria amidst mature erythrocytes, a single heterophil and several lysed cells. (Modified Wright's stain.) The lesser magnification needed to include the entire organism illustrates its greater size.

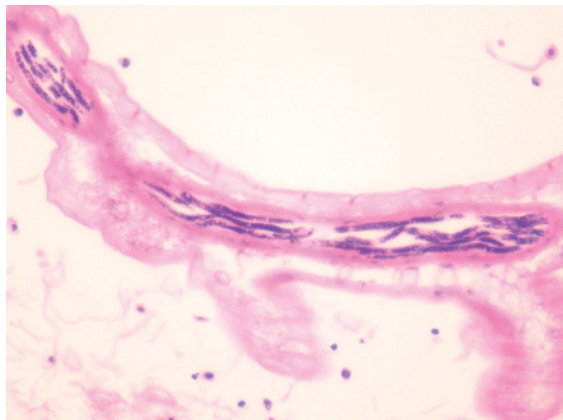


Figure 311 Histological section of subcutaneous tissue from an Australian magpie (*Gymnorhina tibicen*) showing many microfilariae within a subcutaneous vessel. (Hematoxylin and eosin stain.)

coat preparation (Bennett 1962) or concentration methods, such as a Knott's test (Zajac & Conboy 2006).

The adults of nematodes may be found in a range of anatomical locations, including air sacs, thoracic cavity, abdominal cavity and subcutaneous tissues (Mackerras 1962, Reppas et al. 1995).

References

- Abelenda, M., Nava, M.P., Fernandez, A., et al. (1993) Blood values of common cranes (*Grus grus*) by age and season. *Comparative Biochemistry and Physiology* **104A**, 575–578.
- Abou-Madi, N. (2003) Cuculiformes (cuckoos, roadrunners). In: *Zoo and Wild Animal Medicine*, (eds M.E. Fowler & R.E. Miller), 5th edn. pp. 211–213. Saunders, Missouri.
- Acquarone, C., Cucco, M., Cauli, S.L. & Malacarne, G. (2002) Effects of food abundance and predictability on body condition and health parameters: experimental tests with the hooded crow. *Ibis* **144**, E155–E163.
- Adams, N.J., Pinshow, B. & Gannes, L.Z. (1997) Water influx and efflux in free-flying pigeons. *Journal of Comparative Physiology B* **167**, 444–450.
- Adkesson, M.J., Zdziarski, J.M. & Little, S.E. (2005) Atoxoplasmosis in tanagers. *Journal of Zoo and Wildlife Medicine* **36**, 265–272.
- Adlard, R.D., Peirce, M.A. & Lederer, R. (2002) New species of *Leucocytozoon* from the avian families Otidae, Pogaridae and Threskiornithidae. *Journal of Natural History* **36**, 1261–1267.
- Aguilar, R.F. (2003) Strigiformes (owls). In: *Zoo and Wild Animal Medicine*, (eds M.E. Fowler & R.E. Miller), 5th edn. pp. 213–223. Saunders, Missouri.
- Allander, K. & Sundberg, J. (1997) Temporal variation and reliability of blood parasite levels in captive yellowhammer males *Emberiza citrinella*. *Journal of Avian Biology* **28**, 325–330.
- Alonso, J.C., Huecas, V., Alonso, J.A., Abelenda, M., Muñoz-Pulido, R. & Puerta, M.L. (1991) Hematology and blood chemistry of adult white storks (*Ciconia ciconia*). *Comparative Biochemistry and Physiology* **98A**, 395–397.
- Apanius, V. & Kirkpatrick, C.E. (1988) Preliminary report of *Haemoproteus tinnunculi* infection in a breeding population of American kestrels (*Falco sparverius*).

- Journal of Wildlife Diseases* **24**, 150–153.
- Archawaranon, M. (2005) Hematological investigations of captive hill mynah *Gracula religiosa* in Thailand. *International Journal of Poultry Science* **4**, 679–682.
- Ashford, R.W., Green, E.E., Holmes, P.R. & Lucas, A.J. (1991) *Leucocytozoon toddi* in British sparrowhawks *Accipiter nisus*: patterns of infection in nestlings. *Journal of Natural History* **25**, 269–277.
- Ashford, R.W., Wyllie, I. & Newton, I. (1990) *Leucocytozoon toddi* in British sparrowhawks *Accipiter nisus*: observations on the dynamics of infection. *Journal of Natural History* **24**, 1101–1107.
- Averbeck, C. (1992) Haematology and blood chemistry of healthy and clinically abnormal great black-backed gulls (*Larus marinus*) and herring gulls (*Larus argentatus*). *Avian Pathology* **21**, 215–223.
- Bailey, T.A., Kinne, J., Naldo, J., Silvanose, C.D. & Howlett, J.C. (2001) Two cases of ventricular foreign bodies in the kori bustard (*Ardeotis kori*). *Veterinary Record* **149**, 187–188.
- Bailey, T.A., Silvanose, C.D., Naldo, J.N. & Howlett, J.C. (2000) *Pseudomonas aeruginosa* infections in kori bustards (*Ardeotis kori*). *Avian Pathology* **29**, 41–44.
- Ball, R.L. (2003) Charadriiformes (gulls, shorebirds). In: *Zoo and Wild Animal Medicine*, (eds M.E. Fowler & R.E. Miller), 5th edn. pp. 136–141. Saunders, Missouri.
- Ball, S.J., Brown, M.A., Daszak, P. & Pittilo, R.M. (1998) *Atoxoplasma* (Apicomplexa: Eimeriorina: Atoxoplasmatidae) in the greenfinch (*Carduelis chloris*). *Journal of Parasitology* **84**, 813–817.
- Baumel, J.J. (1993) *Handbook of Avian Anatomy: Nomina anatomica avium*, (eds J.J. Baumel, A.S. King, J.E. Breazile, H.E. Evans & J.C. Vanden Berge), 2nd edn. Nuttall Ornithological Club, Cambridge.
- Beadell, J.S., Gering, E., Austin, J., et al. (2004) Prevalence and differential host-specificity of two avian blood parasite genera in the Australo-Papuan region. *Molecular Ecology* **13**, 3829–3844.
- Bearhop, S., Griffiths, R., Orr, K. & Furness, R.W. (1999) The normal haematology of great skuas (*Catharacta skua*) in the wild. *Comparative Haematology International* **9**, 107–109.
- Bedin, M., Petterino, C., Gallo, E., Selleri, P. & Morgante, M. (2007) Clinical pathological findings in an owl (*Athene noctua*) with microfilariemia in Italy. *Journal of Veterinary Medicine* **54**, 128–130.
- Bennett, G.F. (1962) The hematocrit centrifuge for laboratory diagnosis of hematozoa. *Canadian Journal of Zoology* **40**, 124–125.
- Bennett, G.F. (1970) Simple techniques for making avian blood smears. *Canadian Journal of Zoology* **48**, 585–586.
- Bennett, G.F., Earle, R.A., Peirce, M.A., Huchzermeyer, F.W. & Squires-Parsons, D. (1991) Avian Leucocytozidae: the leucocytozoids of the Phasianidae *sensu lato*. *Journal of Natural History* **25**, 1407–1428.
- Bennett, G.F., Earle, R.A. & Peirce, M.A. (1992) New species of avian *Hepatozoon* (Apicomplexa: Haemogregarinidae) and a redescription of *Hepatozoon neophrontis* (Todd and Wolbach, 1912) Wenyon 1926. *Systematic Parasitology* **23**, 183–193.

- Bennett, G.F. & Peirce, M.A. (1992) Leucocytoids of seven Old World passeriforme families. *Journal of Natural History* **26**, 693–707.
- Bennett, G.F. & Peirce, M.A. (1988) Morphological form in the avian Haemoproteidae and an annotated checklist of the genus *Haemoproteus* Kruse, 1890. *Journal of Natural History* **22**, 1683–1696.
- Bennett, G.F. & Peirce, M.A. (1990) The haemoproteid parasites of the pigeons and doves (family Columbidae). *Journal of Natural History* **24**, 311–325.
- Bennett, G.F., Peirce, M.A. & Ashford, R.W. (1993) Avian haematozoa: mortality and pathogenicity. *Journal of Natural History* **27**, 993–1001.
- Bienzle, D., Pare, J.A. & Smith, D.A. (1997) Leukocyte changes in diseased non-domestic birds. *Veterinary Clinical Pathology* **26**, 76–84.
- Bienzle, D. & Smith, D.A. (1999) Heterophilic leucocytosis and granulocytic hyperplasia associated with infection in a cockatoo. *Comparative Haematology International* **9**, 193–197.
- Black, C.P. & Tenney, S.M. (1980) Oxygen transport during progressive hypoxia in high-altitude and sea-level waterfowl. *Respiratory Physiology* **39**, 217–239.
- Boggs, D.F., Birchard, G.F. & Kilgore, D.L., Jr (1983) Blood characteristics, tracheal volume and heart mass of burrowing owls (*Athene cunicularia*) and bobwhite (*Colinus virginianus*). *Comparative Biochemistry and Physiology* **74A**, 693–696.
- Bond, C.F. & Gilbert, P.W. (1958) Comparative study of blood volume in representative aquatic and nonaquatic birds. *American Journal of Physiology* **194**, 519–521.
- Booth, C.E. & Elliott, P.F. (2003) Hematological responses to hematozoa in North American and neotropical songbirds. *Comparative Biochemistry and Physiology* **133A**, 451–467.
- Bounous, D.I., Wyatt, R.D., Gibbs, P.S., Kilburn, J.V. & Quist, C.F. (2000) Normal hematologic and serum biochemical reference intervals for juvenile wild turkeys. *Journal of Wildlife Diseases* **36**, 393–396.
- Bowerman, W.W., Stickle, J.E., Sikarskie, J.G. & Giesy, J.P. (2000) Hematology and serum chemistries of nestling bald eagles (*Haliaeetus leucocephalus*) in the lower peninsula of MI, USA. *Chemosphere* **41**, 1575–1579.
- Branton, S.L., May, J.D., Lott, B.D. & Maslin, W.R. (1997) Various blood parameters in commercial hens acutely and chronically infected with *Mycoplasma gallisepticum* and *Mycoplasma synoviae*. *Avian Diseases* **41**, 540–547.
- Breuer, K., Lill, A. & Baldwin, J. (1995) Haematological and body-mass changes of small passerines overwintering in south-eastern Australia. *Australian Journal of Zoology* **43**, 31–38.
- Calle, P.P. & Stewart, C.A. (1987) Hematologic and serum chemistry values of captive hyacinth macaws (*Anodorhynchus hyacinthinus*). *Journal of Zoo Animal Medicine* **18**, 98–99.
- Campbell, T.W. (1995) *Avian hematology and cytology*. Iowa State University Press, Ames.
- Campbell, T.W. (2004) Hematology of birds. In: *Veterinary Hematology and Clinical Chemistry*, (ed. M.A. Thrall),

- pp. 225–258. Lippincott, Williams & Wilkins, Philadelphia.
- Campbell, T.W. & Dein, F.J. (1984) Avian hematology. In: *Symposium on caged bird medicine*. (ed. G.J. Harrison), *Veterinary Clinics of North America: Small Animal Practice*, WB Saunders, Philadelphia. **14**, 223–248.
- Campbell, T.W. & Ellis, C.K. (2007) *Avian and Exotic Animal Hematology and Cytology*. Blackwell Publishing, Oxford.
- Cardona, C.J., Ihejirika, A. & McClellan, L. (2002) *Haemoproteus lophortyx* infection in bobwhite quail. *Avian Diseases* **46**, 249–255.
- Carey, C., Dunin-Borkowski, O., Leon-Velarde, F., Espinoza, D. & Monge, C. (1993) Blood gases, pH and hematology of montane and lowland coot embryos. *Respiration Physiology* **93**, 151–163.
- Carey, C. & Morton, M.L. (1976) Aspects of circulatory physiology of montane and lowland birds. *Comparative Biochemistry Physiology* **54A**, 61–74.
- Carpenter, J.W. (2003) Gruiformes (cranes, limpkins, rails, gallinules, coots, bustards). In: *Zoo and Wild Animal Medicine*, (eds M.E. Fowler & R.E. Miller), 5th edn pp. 171–179. Saunders, Missouri.
- Carpenter, J.W., Andrews, G.A. & Beyer, W.N. (2004) Zinc toxicosis in a free-flying trumpeter swan (*Cygnus buccinator*). *Journal of Wildlife Diseases* **40**, 769–774.
- Celdrán, J., Polo, F.J., Peinado, V.I., Viscor, G. & Palomeque, J. (1994) Haematology of captive herons, egrets, spoonbill, ibis and gallinule. *Comparative Biochemistry and Physiology* **107A**, 337–341.
- Cheney, C. (1993) A technique for restraining and drawing blood from Humboldt penguins. *Penguin Conservation* **5**, 1–4.
- Choudhury, S., Sahu, A. & Maiti, B.R. (1982) Diurnal rhythm in differential leucocyte population in adult male rose-ringed parakeet. *Mikroskopie* **39**, 28–31.
- Christie, G. (1978) Haematological and biochemical findings in an anaemia induced by the daily bleeding of ten-week-old cockerels. *British Veterinary Journal* **134**, 358–365.
- Christopher, M.M., Shooshtari, M.P. & Levensgood, J.M. (2004) Assessment of erythrocyte morphologic abnormalities in mallards with experimentally induced zinc toxicosis. *American Journal of Veterinary Research* **65**, 440–446.
- Clark, P. & Tvedten, H.W. (1999) What is your diagnosis? Peripheral blood from a young lorikeet (Diagnosis: osteoclasts). *Veterinary Clinical Pathology* **28**, 71, 74.
- Clubb, S.L., Schubot, R.M., Joyner, K., et al. (1991) Hematologic and serum biochemical reference intervals in juvenile macaws (*Ara* sp.). *Journal of the American Association of Veterinarians* **5**, 154–162.
- Coke, R.L., West, G.D. & Hoover, J.P. (2004) Hematology and plasma biochemistry of captive puna ibis (*Plegadis ridgwayi*). *Journal of Wildlife Diseases* **40**, 141–144.
- Conetta, J., Garner, E., Dolensek, E., Kobrin, H. & Strebel, R. (1974) Hematologic and biochemical profiles in normal demoiselle cranes (*Anthropoides virgo*). *Laboratory Animal Science* **24**, 105–110.
- Cooper, J.E. (1975) Haematological investigations in East African birds of prey. *Journal of Wildlife Diseases* **11**, 389–394.

- Cooper, J.E., Needham, J.R. & Fox, N.C. (1986) Bacteriological, haematological and clinical chemical studies on the Mauritius kestrel (*Falco punctatus*). *Avian Pathology* **15**, 349–356.
- Cosgrove, C.L., Day, K.P. & Sheldon, B.C. (2006) Coamplification of *Leucocytozoon* by PCR diagnostic tests for avian malaria: a cautionary note. *Journal of Parasitology* **92**, 1362–1365.
- Cranfield, M.R. (2003) Sphenisciformes (penguins). In: *Zoo and Wild Animal Medicine*, (eds M.E. Fowler & R.E. Miller), 5th edn. pp. 103–110. Saunders, Missouri.
- Cubas, Z.S. (2003) Piciformes (woodpeckers, barbets, puffbirds, jacamars, toucans). In: *Zoo and Wild Animal Medicine*, (eds M.E. Fowler & R.E. Miller), 5th edn. pp. 261–266. Saunders, Missouri.
- D'Aloia, M.-A., Howlett, J.C., Samour, J.H., Bailey, T.A. & Naldo, J. (1995) Normal haematology and age-related findings in the rufous-crested bustard (*Eupodotis ruficrista*). *Comparative Haematology International* **5**, 10–12.
- D'Aloia, M.-A., Samour, J.H., Bailey, T.A., Naldo, J. & Howlett, J.C. (1996) Normal haematology of the white-bellied (*Eupodotis senegalensis*), little black (*Eupodotis afra*) and Heuglin's (*Neotis heuglinii*) bustards. *Comparative Haematology International* **6**, 46–49.
- D'Aloia, M.-A., Samour, J.H., Howlett, J.C., Bailey, T.A. & Naldo, J. (1994) Haemopathological responses to chronic inflammation in the houbara bustard (*Chlamydotis undulata macqueenii*). *Comparative Haematology International* **4**, 203–206.
- Dalley, A.F., II., Baumel, J.J. & Quinn, T.H. (1981) The Plexus (venous) subcutaneous collaris of the pigeon (*Columba livia*). *Anatomic Record* **199**, 62A–63A.
- Davis, A.K., Cook, K.C. & Altizer, S. (2004) Leukocyte profiles in wild house finches with and without mycoplasmal conjunctivitis, a recently emerged bacterial disease. *EcoHealth* **1**, 362–373.
- Davison, T.F. & Flack, I.H. (1981) Changes in the peripheral blood leucocyte populations following an injection of corticotrophin in the immature chicken. *Research in Veterinary Science* **30**, 79–82.
- Dawson, R.D. & Bortolotti, G.R. (1997) Are avian hematocrits indicative of condition? American kestrels as a model. *Journal of Wildlife Management* **61**, 1297–1306.
- Deem, S.L., Noss, A.J., Cuéllar, R.L. & Karesh, W.B. (2005) Health evaluation of free-ranging and captive blue-fronted Amazon parrots (*Amazona aestiva*) in the Gran Chaco, Bolivia. *Journal of Zoo and Wildlife Medicine* **36**, 598–605.
- Dein, F.J., Wilson, A., Fischer, D. & Langenberg, P. (1994) Avian leucocyte counting using the hemocytometer. *Journal of Zoo and Wildlife Medicine* **25**, 432–437.
- del Hoyo, J., Elliot, A. & Sargatal, J. (1992) *Handbook of the Birds of the World*. Vol. 1. Lynx Edicions, Barcelona.
- Djojogugito, A.M., Folkow, B. & Kovach, A.G.B. (1968) The mechanism behind the rapid blood volume restoration after hemorrhage in birds. *Acta Physiologica Scandinavica* **74**, 112–114.
- Dos Santos Schmidt, E.M., Paulillo, A.C., Santin, E., Dittrich, R.L. & de Oliveira, E.G. (2007) Hematological and serum chemistry values for the ring-necked pheasant (*Phasianus colchicus*): variation with sex and age.

- International Journal of Poultry Science* **6**, 137–139.
- Dressen, P.J., Wimsatt, J. & Burkhard, M.J. (1999) The effects of isoflurane anesthesia on hematologic and plasma biochemical values of American kestrels (*Falco sparverius*). *Journal of Avian Medicine and Surgery* **13**, 173–179.
- Driver, E.A. (1981) Hematological and blood chemical values of mallard, *Anas p. platyrhynchos*, drakes before, during and after remige moult. *Journal of Wildlife Diseases* **17**, 413–421.
- Droual, R., Meteyer, C.U. & Galey, F.D. (1991) Zinc toxicosis due to ingestion of a penny in a gray-headed chachalaca (*Ortalis cinereiceps*). *Avian Disease* **35**, 1007–1011.
- Dunbar, M.R., Gregg, M.A., Crawford, J.A., Giordano, M.R. & Tornquist, S.J. (2005) Normal hematologic and biochemical values for prelaying greater sage grouse (*Centrocercus urophasianus*) and their influence on chick survival. *Journal of Zoo and Wildlife Medicine* **36**, 422–429.
- Dusek, R.J., Spalding, M.G., Forrester, D.J. & Greiner, E.C. (2004) *Haemoproteus balearicae* and other blood parasites of free-ranging Florida sandhill crane chicks. *Journal of Wildlife Diseases* **40**, 682–687.
- Dutton, C.J. (2003) Coraciiformes (kingfishers, motmots, bee-eaters, hoopoes, hornbills). In: *Zoo and Wild Animal Medicine*, (eds M.E. Fowler & R.E. Miller), 5th edn. pp. 254–260. Saunders, Missouri.
- Dutton, C.J., Allchurch, A.F. & Cooper, J.E. (2002) Comparison of hematologic and biochemical reference ranges between captive populations of northern bald ibises (*Geronticus eremita*). *Journal of Wildlife Diseases* **38**, 583–588.
- Dvorak, K., Ross, M.R. & McCormick, H.B. (2005) Operant conditioning of a king penguin (*Aptenodytes patagonica*) at Lincoln Park Zoo. *Association of Zoos and Aquariums, Regional Meeting Proceedings*. Kansas City. <http://www.aza.org/AZAPublications/2005ProceedingsReg/>
- Edwards, D.B., Mallory, M.L. & Forbes, M.R. (2006) Variation in baseline haematology of northern fulmars (*Fulmarus glacialis*) in the Canadian High Arctic. *Comparative Clinical Pathology* **14**, 206–209.
- Elliott, R.H., Smith, E. & Bush, M. (1974) Preliminary report on hematology of birds of prey. *Journal of Zoo and Wildlife Medicine* **5**, 11–16.
- Evans, M. & Otter, A. (1998) Fatal combined infection with *Haemoproteus noctuae* and *Leucocytozoon ziemanni* in juvenile snowy owls (*Nyctea scandiaca*). *Veterinary Record* **143**, 72–76.
- Fairbrother, A., Craig, M.A., Walker, K. & O'Loughlin, D. (1990) Changes in mallard (*Anas platyrhynchos*) serum chemistry due to age, sex, and reproductive condition. *Journal of Wildlife Diseases* **26**, 67–77.
- Fairbrother, A. & O'Loughlin, D. (1990) Differential white blood cell values of the mallard (*Anas platyrhynchos*) across different ages and reproductive states. *Journal of Wildlife Diseases* **26**, 78–82.
- Finnegan, M.V., Daniel, G.B. & Ramsay, E.C. (1997) Evaluation of whole blood transfusions in domestic pigeons (*Columba livia*). *Journal of Avian Medicine and Surgery* **11**, 7–14.

- Fischer, I., Christen, C., Lutz, H., Gerlach, H., Hässig, M. & Hatt, J.-M. (2006) Effects of two diets on the haematology, plasma chemistry and intestinal flora of budgerigars (*Melopsittacus undulatus*). *Veterinary Record* **159**, 480–484.
- Fitzgerald, T.C. (1969) *The Coturnix Quail*. Iowa State University Press, Ames.
- Flach, E.J. (1995) Seasonal changes in haematological parameters in the great bustard (*Otis tarda*). *Verth ber Erkrig Zootiere* **37**, 351–356.
- Fudge, A.M. (2000) *Laboratory Medicine of Avian and Exotic Pets*. Saunders, Philadelphia.
- García del Campo, A.L., Huecas, V., Fernández, A. & Puerta, M.L. (1991) Hematology and blood chemistry of macaws, *Ara rubrogenys*. *Comparative Biochemistry and Physiology* **100A**, 943–944.
- García-Montijano, M., García, A., Lemus, J.A., et al. (2002) Blood chemistry, protein electrophoresis, and hematologic values of captive Spanish imperial eagles (*Aquila adalberti*). *Journal of Zoo and Wildlife Medicine* **33**, 112–117.
- Garrett, P.D., Krista, L.M., Pedersoli, W.M., Spano, J.S. & Kemppainen, R.J. (1987) Techniques for venous blood sampling from the white Peking duck. *Avian Diseases* **31**, 358–364.
- Garvin, M.C., Homer, B.L. & Greiner, E.C. (2003) Pathogenicity of *Haemoproteus danilewskyi*, Kruse, 1890, in blue jays (*Cyanocitta cristata*). *Journal of Wildlife Diseases* **39**, 161–169.
- Gaunt, S.D. (2000) Hemolytic anemias caused by blood rickettsial agents and protozoa. In: *Schalm's Veterinary Hematology*, (eds B.F. Feldman, J.G. Zinkl & N.C. Jain), 5th edn. pp. 154–162. Lippincott, Williams & Wilkins, Philadelphia.
- Gayathri, K.L. & Hedge, S.N. (1994) Sexual differences in blood values of the pigeon, *Columba livia*. *Comparative Biochemistry and Physiology* **109B**, 219–224.
- Gayathri, K.L. & Hedge, S.N. (2006) Alteration in haematocrit values and plasma protein fractions during the breeding cycle of female pigeons, *Columba livia*. *Animal Reproduction Science* **91**, 133–141.
- Gee, F., Carpenter, W. & Hensler, L. (1981) Species differences in haematological values of captive cranes, geese, raptors, and quail. *Journal of Wildlife Management* **45**, 463–483.
- Gentz, E.J. (2003) Passeriformes (songbirds, perching birds). In: *Zoo and Wild Animal Medicine*, (eds M.E. Fowler & R.E. Miller), 5th edn. pp. 267–275. Saunders, Missouri.
- Gessaman, J.A., Johnson, J.A. & Hoffman, S.W. (1986) Hematocrits and erythrocyte numbers for Cooper's and sharp-shinned hawks. *The Condor* **88**, 95–96.
- Gildersleeve, R.P., Bryan, T.E., Keel, R.A., et al. (1987a) Reticulocyte numbers in Japanese quail chicks. *Comparative Biochemistry and Physiology* **86A**, 575–579.
- Gildersleeve, R.P., Galvin, M.J., Thaxton, J.P. & McRee, D.I. (1985) Hematological response of Japanese quail to acute hemorrhagic stress. *Comparative Biochemistry and Physiology* **81A**, 403–409.
- Gildersleeve, R.P., Satterlee, D.G., Scott, T.R., McRee, D.I., Parkhurst, C.R. & Cook, M.E. (1987b) Hematology of Japanese quail

- selected for high or low serum corticosteroid responses to complex stressors. *Comparative Biochemistry and Physiology* **86A**, 569–573.
- Grasman, K.A., Scanlon, P.F. & Fox, G.A. (2000) Geographic variation in hematological variables in adult and pre fledgling herring gulls (*Larus argentatus*) and possible associations with organochlorine exposure. *Archives of Environmental Contamination and Toxicology* **38**, 244–253.
- Green, J.A., Halsey, L.G. & Butler, P.J. (2005) To what extent is the foraging behaviour of aquatic birds constrained by their physiology? *Physiology Biochemistry Zoology* **78**, 766–781.
- Grim, K.C., Van der Merwe, E., Sullivan, M., Parsons, N., McCutchan, T.F. & Cranfield, M. (2003) *Plasmodium juxtannucleare* associated with mortality in black-footed penguins (*Spheniscus demersus*) admitted to a rehabilitation center. *Journal of Zoo and Wildlife Medicine* **34**, 250–255.
- Haeefe, H.J., Sidor, I., Evers, D.C., Hoyt, D.E. & Pokras, M.A. (2005) Hematologic and physiologic reference ranges for free-ranging adult and young common loons (*Gavia immer*). *Journal of Zoo and Wildlife Medicine* **36**, 385–390.
- Hakkarainen, H., Ilmonen, P., Koivunen, V. & Korpimäki, E. (1998) Blood parasites and nest defense behaviour of Tengmalm's owl. *Oecologia* **114**, 574–577.
- Halsey, L.G. & Butler, P.J. (2006) Optimal diving behaviour and respiratory gas exchange in birds. *Respiratory Physiology and Neurobiology* **154**, 268–283.
- Harmon, B.G. (1998) Avian heterophils in inflammation and disease resistance. *Poultry Sciences* **77**, 972–977.
- Harper, E.J. & Lowe, B. (1998) Hematology values in a colony of budgerigars (*Melopsittacus undulatus*) and changes associated with aging. *The Journal of Nutrition* **128**, 2639S–2640S.
- Hattingh, J. & Smith, E.M. (1976) Anticoagulants for avian and reptilian blood: heparin and EDTA. *Pflügers Archiv European Journal of Physiology* **363**, 267–268.
- Hauptmanová, K., Literák, I. & Bártová, E. (2002) Haematology and leucocytozoonosis of great tits (*Parus major* L.) during winter. *Acta Veterinaria Brno* **71**, 199–204.
- Hauptmanova, K., Maly, M. & Literak, I. (2006) Changes of haematological parameters in common pheasant throughout the year. *Veterinarni Medicina* **51**, 29–34.
- Hawkey, C.M. & Dennett, T.B. (1989) *A Colour Atlas of Comparative Veterinary Haematology*. Wolfe Publishing, Ipswich.
- Hawkey, C.M., Hart, M.G., Knight, J.A., Samour, J.H. & Jones, D.M. (1982) Haematological findings in healthy and sick African grey parrots (*Psittacus erithacus*). *Veterinary Record* **111**, 580–582.
- Hawkey, C., Hart, M.G. & Samour, H.J. (1984a) Age-related haematological changes and haemopathological responses in Chilean flamingos (*Phoenicopterus chiliensis*). *Avian Pathology* **13**, 223–229.
- Hawkey, C.M., Hart, M.G. & Samour, H.J. (1985) Normal and clinical haematology of greater and lesser flamingos (*Phoenicopterus roseus* and *Phoeniconaias minor*). *Avian Pathology* **14**, 537–541.
- Hawkey, C., Hart, M.G., Samour, H.J., Knight, J.A. & Hutton, R.E. (1984b) Haematological findings in healthy and sick

- captive rosy flamingos (*Phoenicopiterus ruber ruber*). *Avian Pathology* **13**, 163–172.
- Hawkey, C.M., Horsley, D.T. & Keymer, I.F. (1989) Haematology of wild penguins (Sphenisciformes) in the Falkland Islands. *Avian Pathology* **18**, 495–502.
- Hawkey, C., Kock, R.A., Henderson, G.M. & Cindery, R.N. (1990) Haematological changes in domestic fowl (*Gallus gallus*) and cranes (Gruiformes) with *Mycobacterium avium* infection. *Avian Pathology* **19**, 223–234.
- Hawkey, C.M., Pugsley, S.L. & Knight, J.A. (1984c) Abnormal heterophils in a king shag with aspergillosis. *Veterinary Record* **114**, 322–324.
- Hawkey, C., Samour, H.J., Henderson, G.M. & Hart, M.G. (1985) Haematological findings in captive gentoo penguins (*Pygoscelis papua*) with bumblefoot. *Avian Pathology* **14**, 251–256.
- Hawkey, C., Samour, J.H., Ashton, D.G., et al. (1983) Normal and clinical haematology of captive cranes (Gruiformes). *Avian Pathology* **12**, 73–84.
- Hawkey, C.M. & Samour, H.J. (1988) The value of clinical hematology in exotic birds. In: *Exotic Animals*. (eds E.R. Jacobson & G.V. Kollias), pp. 109–141. Churchill Livingstone, New York.
- Hawkins, M.G., Wright, B.D., Pascoe, P.J., Kass, P.H., Maxwell, L.K. & Tell, L.A. (2003) Pharmacokinetics and anesthetic and cardiopulmonary effects of propofol in red-tailed hawks (*Buteo jamaicensis*) and great horned owls (*Bubo virginianus*). *American Journal of Veterinary Research* **64**, 677–683.
- Hellgren, O., Waldenstrom, J. & Bensch, S. (2004) A new PCR assay for simultaneous studies of *Leucocytozoon*, *Plasmodium*, and *Haemoproteus* from avian blood. *Journal of Parasitology* **90**, 797–802.
- Hiebl, I., Kusters, J. & Braunitzer, G. (1987) High altitude respiration of birds. The primary structures of the major and minor hemoglobin component of adult goshawk (*Accipiter gentilis*, Accipitrinae). *Biological Chemistry Hoppe-Seyler* **368**, 333–342.
- Hiebl, I., Weber, R.E., Schneeganss, D. & Braunitzer, G. (1989) High altitude respiration of falconiformes. The primary structures and functional properties of the major and minor hemoglobin components of the adult white-headed vulture (*Trigonoceps occipitalis*, Aegypiinae). *Biological Chemistry Hoppe-Seyler* **370**, 699–706.
- Hoffman, D.J., Franson, J.C., Pattee, O.H., Bunck, C.M. & Murray, H.C. (1985) Biochemical and hematological effects of lead ingestion in nestling American kestrels (*Falco sparverius*). *Comparative Biochemistry and Physiology* **80C**, 431–439.
- Hoffman, A.M. & Leighton, F.A. (1985) Hemograms and microscopic lesions of herring gulls during captivity. *Journal of the American Veterinary Medical Association* **187**, 1125–1128.
- Holmstad, P.R., Jensen, K.H. & Skorping, A. (2006) Vector-borne parasites decrease host mobility: a field test of freeze or flee behaviour of willow ptarmigan. *International Journal of Parasitology* **36**, 735–740.
- Howard, L.L., Papendick, R., Stalis, I.H., et al. (2002) Fenbendazole and albendazole toxicity in pigeons and doves. *Journal of Avian Medicine and Surgery* **16**, 203–210.

- Howlett, J.C., Bailey, T.A., Samour, J.H., Naldo, J.L. & D'Aloia, M.-A. (2002) Age-related hematologic changes in captive-reared houbara, white-bellied, and rufous-crested bustards. *Journal of Wildlife Diseases* **38**, 804–816.
- Howlett, J.C., Samour, J.H., D'Aloia, M.-A., Bailey, T.A. & Naldo, J. (1995) Normal haematology of captive adult kori bustards (*Ardeotis kori*). *Comparative Haematology International* **5**, 102–105.
- Ilmonen, P., Hasselquist, D., Langefors, Å. & Wiehn, J. (2003) Stress, immunocompetence and leukocyte profiles of pied flycatchers in relation to brood size manipulation. *Oecologia* **136**, 148–154.
- Jaensch, S. & Clark, P. (2004) Haematological characteristics of response to inflammation or traumatic injury in two species of black cockatoos: *Calyptorhynchus magnificus* and *C. funereus*. *Comparative Clinical Pathology* **13**, 9–13.
- Jaensch, S.M. & Raidal, S.R. (1998) Blood volume determination in galahs (*Eolophus roseicapillus*) by indocyanine green clearance. *Journal of Avian Medicine and Surgery* **12**, 21–24.
- James, S.B., Raphael, B.L. & Cook, R.A. (1998) Brodifacoum toxicity and treatment in a white-winged wood duck (*Cairina scutulata*). *Journal of Zoo and Wildlife Medicine* **29**, 324–327.
- Janzarik, H. (1981) Nucleated thrombocytoid cells. *Cell and Tissue Research* **219**, 497–510.
- Jenni, L., Müller, S., Spina, F., Kvist, A. & Linström, Å. (2006) Effect of endurance flight on haematocrit in migrating birds. *Journal of Ornithology* **147**, 531–542.
- Jennings, I.B. (1996) Haematology. In: *Manual of Raptors, Pigeons and Waterfowl*. (eds P. H. Beynon, N.A. Forbes & N.H. Harcourt-Brown), pp. 68–78. British Small Animal Veterinary Association Limited, Gloucestershire.
- Jimenez, A., Barrera, R., Sanchez, J., et al. (1991) Clinical haematology of the great bustard (*Otis tarda*). *Avian Pathology* **20**, 675–680.
- Johnston, M.S., Son, T.T. & Rosenthal, K.L. (2007) Immune-mediated hemolytic anemia in an eclectus parrot. *Journal of the American Veterinary Medical Association* **230**, 1028–1031.
- Jones, J.S., Thomas, J.S., Bahr, A. & Phalen, D.N. (2002) Presumed immune-mediated hemolytic anemia in a blue-crowned conure (*Aratinga acuticaudata*). *Journal of Avian Medicine and Surgery* **16**, 223–229.
- Kaku, K. (1959) On the vascular supply in the brain of the domestic fowl. *Fukuoka Acta Medica* **50**, 4293–4306.
- Kalmbach, E., Griffiths, R., Crane, J.E. & Furness, R.W. (2004) Effects of experimentally increased egg production on female body condition and laying dates in the great skua *Stercorarius skua*. *Journal of Avian Biology* **35**, 501–514.
- Karesh, W.B., Uhart, M.M., Frere, E., et al. (1999) Health evaluation of free-ranging rockhopper penguins (*Eudyptes chrysolomes*) in Argentina. *Journal of Zoo and Wildlife Medicine* **30**, 25–31.
- Kass, L., Harrison, G.J. & Lindheimer, C. (2002) A new stain for identification of avian leukocytes. *Biotechnic and Histochemistry* **77**, 201–206.

- Kennedy, S., Crisler, J.P., Smith, E. & Bush, M. (1977) Lead poisoning in sandhill cranes. *Journal of the American Veterinary Medical Association* **171**, 955–959.
- Kirkpatrick, C.E. & Terway-Thomson, C.A. (1986) Biochemical characterization of some raptor trypanosomes. II. enzymes studies, with a description of *Trypanosoma bennetti* n. sp. *Canadian Journal of Zoology* **64**, 195–203.
- Kirkwood, J.K., Cooper, J.E. & Brown, G. (1979) Some haematological data for the European kestrel (*Falco tinnunculus*). *Research in Veterinary Science* **26**, 263–264.
- Kirkwood, J.K., Cunningham, A.A., Hawkey, C., Howlett, J. & Perrins, C.M. (1995) Hematology of fledging Manx shearwaters (*Puffinus puffinus*) with and without ‘puffinosis’. *Journal of Wildlife Diseases* **31**, 96–98.
- Kleindorfer, S., Lambert, S. & Paton, D.C. (2006) Ticks (*Ixodes* sp.) and blood parasites (*Haemoproteus* spp.) in New Holland honeyeaters (*Phylidonyris novaehollandiae*): evidence for site specificity and fitness costs. *Emu* **106**, 113–118.
- Kocan, R.M. (1972) Some physiologic blood values of wild diving ducks. *Journal of Wildlife Diseases* **8**, 115–118.
- Kocan, R.M. & Pitts, S.M. (1976) Blood values of the canvasback duck by age, sex and season. *Journal of Wildlife Diseases* **12**, 341–345.
- Koepke, J.A. (1980) Standardization of the manual differential leukocyte count. *Laboratory Medicine* **11**, 371–375.
- Kollias, G.V., Jr & McLeish, I. (1978) Effects of ketamine hydrochloride in red-tailed hawks (*Buteo jamaicensis*). II – Biochemical and hematological. *Comparative Biochemistry and Physiology* **60C**, 211–213.
- Kostelecka-Myrcha, A. & Jaroszewicz, M. (1993) The changes in the values of red blood indices during the nestling development of the house martin *Delichon urbica*. *Acta Ornithologica* **28**, 39–46.
- Kruszewicz, A.G. & Dyrz, A. (2000) *Hepatozoon kabeenin* sp. (Protozoa: Apicomplexa; Hemogregarina) from the sedge warbler, *Acrocephalus schoenobaenus* (Aves: Passeriformes). *Wiad Parazytol* **46**, 507–510.
- Kuiken, T. & Danesik, K.L. (1999) Hematology and serum chemistry of captive juvenile double-crested cormorants (*Phalacrocorax auritus*). *Canadian Veterinary Journal* **40**, 493–496.
- Laird, M. (1988) *Avian Malaria in the Asian Tropical Subregion*. Springer, Heidelberg.
- Landys-Cianelli, M.M., Jukema, J. & Piersma, T. (2002) Blood parameter changes during stopover in a long-distance migratory shorebird, the bar-tailed godwit *Limosa lapponica taymyrensis*. *Journal of Avian Biology* **33**, 451–455.
- Lanzarot, M.dP., Montesinos, A., San Andrés, M.I., Rodríguez, C. & Barahona, M.V. (2001) Hematological, protein electrophoresis and cholinesterase values of free-living nestling peregrine falcons in Spain. *Journal of Wildlife Diseases* **37**, 172–177.
- Latimer, K.S., Tang, K.-N., Goodwin, M.A., Steffens, W.L. & Brown, J. (1988) Leukocyte changes associated with acute inflammation in chickens. *Avian Diseases* **32**, 760–772.

- Lavin, S., Cuenca, R., Marco, I., Velarde, R. & Viñas, L. (1992) Hematology and blood chemistry of the marsh harrier (*Circus aeruginosus*). *Comparative Biochemistry and Physiology* **103A**, 493–495.
- Leighton, F.A. (1985) Morphological lesions in red blood cells from herring gulls and Atlantic puffins ingesting Prudhoe Bay crude oil. *Veterinary Pathology* **22**, 393–402.
- Leighton, F.A. (1986) Clinical, gross, and histological findings in herring gulls and Atlantic puffins that ingested Prudhoe Bay crude oil. *Veterinary Pathology* **23**, 254–263.
- Leighton, F.A., Peakall, D.B. & Butler, R.G. (1983) Heinz-body hemolytic anemia from the ingestion of crude oil: a primary toxic effect in marine birds. *Science* **220**, 871–873.
- Levengood, J.M., Sanderson, G.C., Anderson, W.L., Foley, G.L., Brown, P.W. & Seets, J. W. (2000) Influence of diet on the hematology and serum biochemistry of zinc-intoxicated mallards. *Journal of Wildlife Diseases* **36**, 111–123.
- Lilliehöök, I., Wall, H., Tauson, R. & Tvedten, H. (2004) Differential leukocyte counts determined in chicken blood using the Cell-Dyn 3500. *Veterinary Clinical Pathology* **33**, 133–138.
- Lind, P.J., Wolff, P.L., Petrini, K.R., Keyler, C.W., Olson, D.E. & Redig, P.T. (1990) Morphology of the eosinophil in raptors. *Journal of the American Association of Veterinarians* **4**, 33–39.
- Lloyd, S. & Gibson, J.S. (2006) Haematology and biochemistry in healthy young pheasants and red-legged partridges and effects of spironucleosis on these parameters. *Avian Pathology* **35**, 335–340.
- Lucas, A.M. & Jamroz, C. (1961) *Atlas of avian hematology*. Agriculture monograph 25. United States Department of Agriculture, Washington.
- Lynch, M.J., Raphael, S.S., Mellor, L.D., Spare, P.D. & Inwood, M.J. (1969) Preparation and staining of peripheral blood and bone marrow smears. In: *Medical Laboratory Technology and Clinical Pathology*, 2nd edn. pp. 640–646. Saunders, Philadelphia.
- Mackerras, M.J. (1962) Filarial parasites (Nematoda: Filarioidea) of Australian animals. *Australian Journal of Zoology* **10**, 400–457.
- Mandal, A., Chakraborty, S. & Lahiri, P. (1986) Hematological changes produced by lindane (gamma-HCH) in six species of birds. *Toxicology* **40**, 103–111.
- Martin, H.D. & Kollias, G.V. (1989) Evaluation of water deprivation and fluid therapy in pigeons. *Journal of Zoo and Wildlife Medicine* **20**, 173–177.
- Maxwell, M.H. (1973) Comparison of heterophil and basophil ultrastructure in six species of domestic birds. *Journal of Anatomy* **115**, 187–202.
- Maxwell, M.H. (1974) An ultrastructural comparison of the mononuclear leucocytes and thrombocytes in six species of domestic bird. *Journal of Anatomy* **117**, 69–80.
- Maxwell, M.H. (1978) The fine structure of granules in eosinophil leucocytes from aquatic and terrestrial birds. *Tissue and Cell* **10**, 303–317.
- Maxwell, M.H. (1979) The ultrastructure of eosinophil granules of the black-necked crowned crane. *Journal of Anatomy* **128**, 53–63.

- Maxwell, M.H. (1981) Production of a Heinz body anaemia in the domestic fowl after ingestion of dimethyl disulphide: a haematological and ultrastructural study. *Research in Veterinary Science* **30**, 233–238.
- Maxwell, M.H. & Robertson, G.W. (1998) The avian heterophil leucocyte: a review. *World's Poultry Science Journal* **54**, 155–178.
- Maxwell, M.H. & Siller, W.G. (1972) The ultrastructural characteristics of the eosinophil granules in six species of domestic bird. *Journal of Anatomy* **112**, 289–303.
- Maxwell, M.H., Tullett, S.G. & Burton, F.G. (1987) Haematology and morphological changes in young broiler chicks with experimentally induced hypoxia. *Research in Veterinary Science* **43**, 331–338.
- Mazerolle, D.F. & Hobson, K.A. (2002) Physiological ramifications of habitat selection in territorial male ovenbirds: consequences of landscape fragmentation. *Oecologia* **130**, 356–363.
- Means, R.T. (2000) The anaemia of infection. *Balliere's Clinical Haematology* **13**, 151–162.
- McCracken, H. (2003) Caprimulgiformes (goatsuckers). In: *Zoo and Wild Animal Medicine*, (eds M.E. Fowler & R.E. Miller), 5th edn. pp. 224–231. Saunders, Missouri.
- McKeon, T., Dunsmore, J. & Raidal, S.R. (1997) *Trichomonas gallinae* in budgerigars and columbid birds in Perth, Western Australia. *Australian Veterinary Journal* **75**, 652–655.
- McNamee, P., Pennycott, T. & McConnell, S. (1995) Clinical and pathological changes associated with toxoplasma in a captive bullfinch (*Pyrrhula pyrrhula*). *Veterinary Record* **136**, 221–222.
- Melrose, W.D., Brown, P.B., Holdsworth, M. C. & Bryant, S.L. (1995) Haematology and red cell enzymes of the Australian orange-bellied parrot, *Neophema chrysogaster*. *Comparative Haematology International* **5**, 7–9.
- Melrose, W.D. & Nicol, S.C. (1992) Haematology, red cell metabolism and blood chemistry of the black-faced cormorant *Leucocarbo fuscescens*. *Comparative Biochemistry and Physiology* **102A**, 67–70.
- Merila, J. & Svensson, E. (1995) Fat stores and health state in migrating Goldcrests *Regulus regulus*. *Functional Ecology* **9**, 842–848.
- Merino, S. (1998) *Babesia bennetti* n. sp. from the yellow-legged gull (*Larus cachinnans*, Aves, Laridae) on Benidorm Island, Mediterranean Sea. *Journal of Parasitology* **84**, 422–424.
- Merino, S., Moreno, J., Sanz, J.J. & Arriero, E. (2000) Are avian blood parasites pathogenic in the wild? A medication experiment in blue tits (*Parus caeruleus*). *Proceedings of the Royal Society of London B* **267**, 2507–2510.
- Merritt, E.L., Fritz, C.L. & Ramsay, E.C. (1996) Hematologic and serum biochemical values in captive American flamingos (*Phoenicopterus ruber ruber*). *Journal of Avian Medicine and Surgery* **10**, 163–167.
- Montesinos, A., Sainz, A., Pablos, M.V., Mazucchelli, F. & Tesouro, M.A. (1997) Hematological and plasma biochemical reference intervals in young white storks. *Journal of Wildlife Diseases* **33**, 405–412.

- Moritomo, T., Minami, A., Inoue, Y. & Nakanishi, T. (2002) A new method for counting quail leukocytes by flow cytometry. *Journal of Veterinary Medical Science* **64**, 1149–1151.
- Mostaghni, K., Badiei, K., Nili, H. & Fazeli, A. (2005) Haematological and biochemical parameters and the serum concentration of phosphorus, lead, cadmium and chromium in flamingo (*Phoenicopterus ruber*) and black-headed gull (*Larus ridibundus*) in Iran. *Comparative Clinical Pathology* **14**, 146–148.
- Mulley, R.C. (1979) Haematology and blood chemistry of the black duck *Anas superciliosa*. *Journal of Wildlife Diseases* **15**, 437–441.
- Mulley, R.C. (1980) Haematology of the wood duck, *Chenonetta jubata*. *Journal of Wildlife Diseases* **16**, 271–273.
- Muñoz, E., Ferrer, D., Molina, R. & Adlard, R.D. (1999) Prevalence of haematozoa in birds of prey in Catalonia, north-east Spain. *Veterinary Record* **144**, 632–636.
- Muñoz, F.J. & De la Fuente, M. (2003) Lymphoid distribution in the migratory gull *Larus ridibundus*. *Comparative Biochemistry and Physiology* **136A**, 749–756.
- Muñoz, E., Molina, R. & Ferrer, D. (1999) *Babesia shortti* infection in a common kestrel (*Falco tinnunculus*) in Catalonia (northeastern Spain). *Avian Pathology* **28**, 207–209.
- Mutlow, A. & Forbes, N. (2000) *Haemoproteus* in raptors: pathogenicity, treatment, and control. *Proceedings of the Association of Avian Veterinarians* 157–163.
- Nat, M.P. & Herrick, C.A. (1952) A new blood diluent for counting the erythrocytes and leucocytes of the chicken. *Poultry Science* **31**, 735–738.
- Nazifi, S., Tadjalli, M. & Mohaghheghzadeh, M. (1999) Normal haematopoiesis cellular components and M/E ratio in the bone marrow of Japanese quail (*Coturnix coturnix japonica*). *Comparative Haematology International* **9**, 188–192.
- Neiffer, D.L. (2003) Trogoniformes (trogons) In: *Zoo and Wild Animal Medicine*, (eds M.E. Fowler & R.E. Miller), 5th edn. pp. 245–253. Saunders, Missouri.
- Newman, S.H., Anderson, D.W., Ziccardi, M.H., et al. (2000) An experimental soft-release of oil-spill rehabilitated American coots (*Fulica Americana*): II. Effects on health and blood parameters. *Environmental Pollution* **107**, 295–304.
- Newman, S.H., Mazet, J.K., Ziccardi, M.H., et al. (1999) Haematological changes and anaemia associated with captivity and petroleum exposure in seabirds. *Comparative Haematology International* **9**, 60–67.
- Nicol, S.C., Melrose, W. & Stahel, C.D. (1988) Haematology and metabolism of the blood of the little penguin, *Eudyptula minor*. *Comparative Biochemistry and Physiology* **89A**, 383–386.
- Olsen, G.H. & Carpenter, J.W. (1997) Cranes. In: *Avian Medicine and Surgery*, (eds R.B. Altman, S.L. Chubb, G.M. Dorrestein & K. Quesenberry), pp. 973–991. Saunders, Philadelphia.
- Ots, I. & Hōrak, P. (1998) Health impact of blood parasites on breeding great tits. *Oecologia* **116**, 441–448.
- Ots, I., Murumägi, A. & Hōrak, P. (1998) Haematological health state indices of reproducing great tits: methodology and sources

- of natural variation. *Functional Ecology* **12**, 700–707.
- Owen, J.C. & Moore, F.R. (2006) Seasonal differences in immunological condition of three species of thrushes. *The Condor* **108**, 389–398.
- Padilla, L.R., Huyvaert, K.P., Merkel, J., Miller, R.E. & Parker, P.G. (2003) Hematology, plasma chemistry, serology, and *chlamydophila* status of the waved albatross (*Phoebastria irrorata*) on the Galapagos Islands. *Journal of Zoo and Wildlife Medicine* **34**, 278–283.
- Palomeque, J., Pinto, D. & Viscor, G. (1991) Hematologic and blood chemistry values of the Masai ostrich (*Struthio camelus*). *Journal of Wildlife Diseases* **27**, 34–40.
- Pandita, A., Sadana, J.R. & Asrani, R.K. (1991) Studies on clinical signs and haematological alterations in pneumonic aspergillosis due to *Aspergillus flavus* in Japanese quail. *Mycopathologia* **116**, 119–123.
- Parga, M.L., Pendl, H. & Forbes, N.A. (2001) The effect of transport on hematologic parameters in trained and untrained Harris's hawks (*Parabuteo unicinctus*) and peregrine falcons (*Falco peregrinus*). *Journal of Avian Medicine and Surgery* **15**, 162–169.
- Peinado, V.I., Polo, F.J., Celdrán, J.F., Viscor, G. & Palomeque, J. (1992) Hematology and plasma chemistry in endangered pigeons. *Journal of Zoo and Wildlife Medicine* **23**, 65–71.
- Peirce, M.A. (1974) Lankesterella from an East African crowned crane *Balearica pavonina gibbericeps*. *Veterinary Record* **95**, 441–442.
- Peirce, M.A. (1989) Blood parasites. In: *A Colour Atlas of Comparative Veterinary Haematology*, (eds C.M. Hawkey & T.B. Dennett), pp. 148–169. Wolfe Publishing, Ipswich.
- Peirce, M.A. (2005a) A checklist of valid avian species of *Babesia* (Apicomplexa: Piroplasmorida), *Haemoproteus*, *Leucocytozoon* (Apicomplexa: Haemosporida), and *Hepatozoon* (Apicomplexa: Haemogregarinidae). *Journal of Natural History* **39**, 3621–3632.
- Peirce, M.A. (2005b) Pathogenic subspecies of *Plasmodium relictum* found in African birds. *Veterinary Record* **156**, 328.
- Peirce, M.A. (2000) A taxonomic review of avian piroplasms of the genus *Babesia* Starcovici, 1893 (Apicomplexa: Piroplasmorida: Babesiidae). *Journal of Natural History* **34**, 317–332.
- Peirce, M.A., Bennett, G.F. & Bishop, M. (1990) The haemoproteids of the avian order Falconiformes. *Journal of Natural History* **24**, 1091–1100.
- Peirce, M.A., Greenwood, A.G. & Stidworthy, M.F. (2005) *Leucocytozoon* in captive penguins. *Veterinary Record* **157**, 819–820.
- Peirce, M.A., Greenwood, A.G. & Swinerton, K. (1997) Pathogenicity of *Leucocytozoon marchouxi* in the pink pigeon (*Columba mayeri*) in Mauritius. *Veterinary Record* **140**, 155–156.
- Peirce, M.A., Jakob-Hoff, R.M. & Twentyman, C. (2003) New species of haematozoa from Apterygidae in New Zealand. *Journal of Natural History* **37**, 1797–1804.
- Phalen, D.N., Taylor, C., Phalen, S.W. & Bennett, G.F. (1995) Hemograms and hematozoa of sharp-shinned (*Accipiter striatus*) and Cooper's hawks (*Accipiter cooperii*) captured during spring migration in north-

- ern New York. *Journal of Wildlife Diseases* **31**, 216–222.
- Piersma, T., Koolhaas, A., Dekinga, A. & Gwinner, E. (2000) Red blood cell and white blood cell counts in sandpipers (*Philomachus pugnax*, *Calidris canutus*): effects of captivity, season, nutritional status, and frequent bleedings. *Canadian Journal of Zoology* **78**, 1349–1355.
- Polo, F.J., Peinado, V.I., Viscor, G. & Palomeque, J. (1998) Hematologic and plasma chemistry values in captive psittacine birds. *Avian Diseases* **42**, 523–535.
- Post, J., Rebel, J.M.J. & ter Huurne, A.A.H.M. (2003) Automated blood cell count: a sensitive and reliable method to study corticosteroid-related stress in broilers. *Poultry Science* **82**, 591–595.
- Puerta, M.L., García del Campo, A.L., Huecas, V. & Abelenda, M. (1991) Hematology and blood chemistry of the white pelican (*Pelecanus onocrotalus*). *Comparative Biochemistry and Physiology* **98A**, 393–394.
- Puerta, M.L., Muñoz-Pulido, R., Huecas, V. & Abelenda, M. (1989) Hematology and blood chemistry of chicks of white and black storks (*Ciconia ciconia* and *Ciconia nigra*). *Comparative Biochemistry and Physiology* **94A**, 201–204.
- Pye, G.W. (2003) Apodiformes and Coliiformes (swifts, swiftlets, mousebirds). In: *Zoo and Wild Animal Medicine*, (eds M.E. Fowler & R.E. Miller), 5th edn. pp. 239–244. Saunders, Missouri.
- Raidal, S.R. & Jaensch, S.M. (2000) Central nervous disease and blindness in Nankeen kestrels (*Falco cenchroides*) due to a novel Leucocytozoon-like infection. *Avian Pathology* **29**, 51–56.
- Rath, N.C., Huff, G.R., Balog, J.M. & Huff, W.E. (1998) Fluorescein isothiocyanate staining and characterization of avian heterophils. *Veterinary Immunology and Immunopathology* **64**, 83–95.
- Rehder, N.B. & Bird, D.M. (1983) Annual profiles of blood packed cell volumes of captive American kestrels. *Canadian Journal of Zoology* **61**, 2550–2555.
- Rehder, N.B., Bird, D.M. & Laguë, P.C. (1982a) Variations in blood packed cell volume of captive American kestrels. *Comparative Biochemistry and Physiology* **72A**, 105–109.
- Rehder, N.B., Bird, D.M., Laguë, P.C. & Mackay, C. (1982b) Variation in selected hematological parameters of captive red-tailed hawks. *Journal of Wildlife Diseases* **18**, 105–109.
- Reissig, E.C., Robles, C.A. & Sager, R. (2002) Hematology and serum chemistry values of the lesser rhea (*Pterocnemia pennata*) raised in Patagonian farms (Argentina). *Journal of Zoo and Wildlife Medicine* **33**, 328–331.
- Reppas, G.P., Hartley, W.J. & Gill, P.A. (1995) Microfilaraemia in Australian native birds. *Australian Veterinary Journal* **72**, 356–357.
- Ribeiro, S.F., Sebaio, F., Branquinho, F.C.S., Marini, M.Â., Vago, A.R. & Braga, É.M. (2005) Avian malaria in Brazilian passerine birds: parasitism detected by nested PCR using DNA from stained blood films. *Parasitology* **130**, 261–267.
- Rintamäki, P.T., Huhta, E., Jokimäki, J. & Squires-Parsons, D. (1999) Leucocytozoonosis and trypanosomiasis in redstarts in Finland. *Journal of Wildlife Diseases* **35**, 603–607.

- Roberts, J.R. & Baudinette, R.V. (1984) The water economy of stubble quail, *Coturnix pectoralis*, and king quail, *Coturnix chinensis*. *Australian Journal of Zoology* **32**, 637–647.
- Robertson, G.W. & Maxwell, M.H. (1990) Modified staining techniques for avian blood cells. *British Poultry Science* **31**, 881–886.
- Robertson, G.W. & Maxwell, M.H. (1993) Importance of optimal mixtures of EDTA anticoagulant: blood for the preparation of well-stained avian blood smears. *British Poultry Science* **34**, 615–617.
- Romagnano, A., Grindem, C.V., Degernes, L. & Mautino, M. (1995) Treatment of a hyacinth macaw with zinc toxicity. *Journal of Avian Medicine and Surgery* **9**, 185–189.
- Ruiz, G., Rosenmann, M., Novoa, F.F. & Sabat, P. (2002) Hematological parameters and stress index in rufous-collared sparrows dwelling in urban environments. *The Condor* **104**, 162–166.
- Russo, E.A., McEntee, L., Applegate, L. & Baker, J.S. (1986) Comparison of two methods for determination of white blood cell counts in macaws. *Journal of the American Veterinary Medical Association* **189**, 1013–1016.
- Saks, L., Ots, I. & Hõrak, P. (2003) Carotenoid-based plumage coloration of male greenfinches reflects health and immunocompetence. *Oecologia* **134**, 301–307.
- Samour, J.H. (2000) *Pseudomonas aeruginosa* stomatitis as a sequel to trichomoniasis in captive saker falcons (*Falco cherrug*). *Journal of Avian Medicine and Surgery* **14**, 113–117.
- Samour, J.H., D'Aloia, M.-A. & Howlett, J.C. (1996) Normal haematology of captive saker falcons (*Falco cherrug*). *Comparative Haematology International* **6**, 50–52.
- Samour, J.H., Howlett, J.C., Hart, M.G., Bailey, T.A., Naldo, J. & D'Aloia, M.-A. (1994) Normal haematology of the houbara bustard (*Chlamydotis undulata macqueenii*). *Comparative Haematology International* **4**, 198–202.
- Samour, J.H., Howlett, J.C., Silvanose, C., Bailey, T.A. & Wernery, U. (1998) Normal haematology and blood chemistry of captive adult stone curlews (*Burhinus oedicnemus*). *Comparative Clinical Pathology* **8**, 219–224.
- Samour, J.H., Jones, D.M., Pugsley, S. & Fitzgerald, A.K. (1983) Blood sampling technique in penguins (Sphenisciformes). *Veterinary Record* **113**, 340.
- Samour, J.H., Naldo, J.L. & John, S.K. (2001) Staining characteristics of the eosinophil of the saker falcon. *Exotic DVM* **3**, 10.
- Samour, J.H., Naldo, J.L. & John, S.K. (2005) Normal haematological values of captive gyr falcons (*Falco rusticolus*). *Veterinary Record* **157**, 844–847.
- Samour, J.H. & Pierce, M.A. (1996) *Babesia shortti* infection in a saker falcon (*Falco cherrug*). *Veterinary Record* **139**, 167–168.
- Santos, A.A., Da Silva, A.M.J., De Carvalho, V.A.L. & Egami, M.I. (2003a) Morphocytochemical and ultrastructural characterization of peripheral thrombocytes of the roadside hawk *Buteo magnirostris* (Gmelin, 1788) (Avian, Falconiform). *International Journal of Morphology* **21**, 279–284.
- Santos, A.A., Da Silva, A.M.J., Silva, M.R.R., Segreto, H.R.C. & Egami, M.I. (2003b) Structural, cytochemical,

- immunocytochemical and ultrastructural characterization of blood granulocytes of the roadside hawk *Buteo magnirostris* (Gmelin, 1788) (Avian, Falconiform). *Journal of Submicroscopic Cytology and Pathology* **35**, 351–357.
- Savage, A.F., Ariey, F. & Greiner, E.C. (2006) *Leucocytozoon atkinsoni* n. sp. (Apicomplexa: Leucocytozoidae) from the avian family Timaliidae. *Systematic Parasitology* **64**, 105–109.
- Schindler, S.L., Gildersleeve, R.P., Thaxton, J.P. & McRee, D.I. (1987a) Blood volume recovery in hemorrhaged Japanese quail. *Comparative Biochemistry and Physiology* **88A**, 95–100.
- Schindler, S.L., Gildersleeve, R.P., Thaxton, J.P. & McRee, D.I. (1987b) Hematological response of hemorrhaged Japanese quail after blood volume replacement with saline. *Comparative Biochemistry and Physiology* **87A**, 933–945.
- Schulz, D.J. (2003) Columbiformes (pigeons, doves). In: *Zoo and Wild Animal Medicine*, (eds M.E. Fowler & R.E. Miller), 5th edn. pp. 180–186. Saunders, Missouri.
- Scope, A., Filip, T., Gabler, C. & Resch, F. (2002) The influence of stress from transport and handling on hematologic and clinical chemistry blood parameters of racing pigeons (*Columba livia domestica*). *Avian Diseases* **46**, 224–229.
- Scope, A., Schwendenwein, I., Enders, F., et al. (2000) Hematologic and clinical chemistry reference values in red lorries (*Eos* spp.). *Avian Diseases* **44**, 885–890.
- Scope, A., Schwendenwein, I. & Frommlet, F. (2005) Influence of outlying values and variations between sampling days on reference ranges for clinical chemistry in budgerigars (*Melopsittacus undulatus*). *Veterinary Record* **156**, 310–314.
- Sehgal, R.N.M., Jones, H.I. & Smith, T.B. (2001) Host specificity and incidence of *Trypanosoma* in some African rainforest birds: a molecular approach. *Molecular Ecology* **10**, 2319–2327.
- Seiser, P.E., Duffy, L.K., McGuire, A.D., Roby, D.D., Golete, G.H. & Litzowf, M.A. (2000) Comparison of pigeon guillemot, *Cephus columba*, blood parameters from oiled and unoiled areas of Alaska eight years after the Exxon Valdez oil spill. *Marine Pollution Bulletin* **40**, 152–164.
- Sergent, N., Rogers, T. & Cunningham, M. (2004) Influence of biological and ecological factors on hematological values in wild little penguins, *Eudyptula minor*. *Comparative Biochemistry and Physiology* **138A**, 333–339.
- Simmons, P. & Lill, A. (2006) Development of parameters influencing blood oxygen carrying capacity in the welcome swallow and fairy martin. *Comparative Biochemistry and Physiology* **143A**, 459–468.
- Simpson, V.R., MacKenzie, G. & Harris, E.A. (1996) Fatal microfilarial infection in red billed blue magpies (*Urocissa erythrorhynchus*). *Veterinary Record* **138**, 522–523.
- Small, M.F., Baccus, J.T., Mink, J.N. & Robertson, J.A. (2005) Hematologic responses in captive white-winged doves (*Zenaidura macroura*), induced by various radiotransmitter attachments. *Journal of Wildlife Diseases* **41**, 387–394.
- Smith, D.A. (2003) Ratites: Tinamiformes (tinamous) and Struthioniformes, Rheiformes, Cassuariformes (ostriches, emus, cassowaries and kiwis) In: *Zoo and Wild Animal Medicine*, (eds M.E. Fowler & R.E.

- Miller), 5th edn. pp. 94–102. Saunders, Missouri.
- Smith, E.E. & Bush, M. (1978) Haematologic parameters on various species of strigiformes and falconiformes. *Journal of Wildlife Diseases* **14**, 447–450.
- Sol, D., Jovani, R. & Torres, J. (2003) Parasite mediated mortality and host immune response explain age-related differences in blood parasitism in birds. *Oecologia* **135**, 542–547.
- Soulsby, E.J.L. (1982) *Helminths, Arthropods and Protozoa of Domesticated Animals*, 7th edn. Baillière Tindall, London.
- Stabler, R.M. (1954) *Trichomonas gallinae*, a review. *Experimental Parasitology* **3**, 368–402.
- Stangel, P.W. (1986) Lack of effects from sampling blood from small birds. *Condor* **88**, 244–245.
- Sturkie, P.D. (1943) The reputed reservoir of function of the spleen of the domestic fowl. *American Journal of Physiology* **138**, 599–602.
- Svensson, E. & Merila, J. (1996) Molt and migratory condition in blue tits: a serological study. *Condor* **98**, 825–831.
- Tadjalli, M., Nazifi, S. & Eemanparvar, A. (2003) Normal cellular morphology of the blood of Japanese quail (*Coturnix coturnix japonica*). *Comparative Clinical Pathology* **12**, 102–105.
- Tadjalli, M., Nazifi, S. & Hadipoor, M.M. (2002) Normal haematopoiesis, cellular components and M/E ratio in the bone marrow of the black-headed gull (*Larus ridibundus*). *Comparative Clinical Pathology* **11**, 217–222.
- Tangredi, B.P. (1981) Heterophilia and left shift associated with fatal diseases in four psittacine birds: yellow-collared macaw (*Ara auricollis*), yellow-naped Amazon (*Amazona ochrocephala auropalliata*), yellow-crowned Amazon (*Amazona ochrocephala ochrocephala*), blue and gold macaw (*Ara ararauna*). *Journal of Zoo Animal Medicine* **12**, 13–16.
- Tavernier, P., Sagesse, M., Van Wettere, A. & Redig, P. (2005) Malaria in an eastern screech owl (*Otus asio*). *Avian Diseases* **49**, 433–435.
- Telford, S.R., Nayar, J.K., Foster, G.W. & Knight, J.W. (1997) *Plasmodium forresteri* n. sp., from raptors in Florida and southern Georgia: its distinction from *Plasmodium elongatum* morphologically within and among host species and by vector susceptibility. *Journal of Parasitology* **83**, 932–937.
- Tell, L.A. & Citino, S.B. (1992) Hematologic and serum chemistry reference intervals for Cuban Amazon parrots (*Amazona leucocephala leucocephala*). *Journal of Zoo and Wildlife Medicine*: **23**, 62–64.
- Thapliyal, J.P., Lal, P., Pati, A.K. & Gupta, B.B.P.d (1983) Thyroid and gonad in the oxidative metabolism, erythropoiesis, and light response of the migratory redheaded bunting, *Emberiza bruniceps*. *General and Comparative Endocrinology* **51**, 444–453.
- Threlfall, W. (1966) Studies on the blood of herring gulls and domestic fowl with some observations on changes brought about by infection with *Cyathostoma lari* Blanchard, 1849 (Nematoda; Strongyloidea). *Bulletin of the Wildlife Disease Association* **2**, 41–51.
- Tidemann, S.C., Calley, M. & Burgoyne, C. (1992) An investigation of blood smears of

- northern Australian finches. *Emu* **92**, 114–117.
- Tietz, N.W. (1994) *Fundamentals of Clinical Chemistry*. Saunders, Philadelphia.
- Travis, E.K., Junge, R.E. & Terrell, S.P. (2007) Infection with *Mycobacterium simiae* complex in four captive Micronesian kingfishers. *Journal of the American Veterinary Medical Association* **230**, 1524–1529.
- Travis, E.K., Vargas, F.H., Merkel, J., Gottdenker, N., Miller, R.E. & Parker, P.G. (2006) Hematology, serum chemistry, and serology of Galápagos penguins (*Spheniscus mendiculus*) in the Galápagos Islands, Ecuador. *Journal of Wildlife Diseases* **42**, 625–632.
- Tuttle, A.D., Andreadis, T.G., Frasca, S., Jr & Dunn, J.L. (2005) Eastern equine encephalitis in a flock of African penguins maintained at an aquarium. *Journal of the American Veterinary Medical Association* **226**, 2059–2062.
- Uchiyama, R., Moritomo, T., Kai, O., Uwatoko, K., Inuoe, Y. & Nakanishi, T. (2005) Counting absolute number of lymphocytes in quail whole blood by flow cytometry. *Journal of Veterinary Medical Science* **67**, 441–444.
- Uhart, M., Aprile, G., Beldomenico, P., et al. (2006) Evaluation of the health of free-ranging greater rheas (*Rhea americana*) in Argentina. *Veterinary Record* **158**, 297–303.
- Uhart, M.M., Quintana, F., Karesh, W.B. & Braselton, W.E. (2003) Hematology, plasma biochemistry, and serosurvey for selected infectious agents in southern giant petrels from Patagonia, Argentina. *Journal of Wildlife Diseases* **39**, 359–365.
- Upton, S.J., Wilson, S.C., Norton, T.M. & Greiner, E.C. (2001) A new species of *Isospora* Schneider, 1881 (Apicomplexa: Eimeriidae) from the Bali (Rothschild's) mynah *Leucopsar rothschildi* (Passeriformes: Sturnidae), and comments concerning the genera *Atoxoplasma* Garnham, 1950 and *Isospora*. *Systematic Parasitology* **48**, 47–53.
- Valkiunas, G., Anwar, A.M., Atkinson, C.T., Greiner, E.C., Paperna, I. & Peirce, M.A. (2005a) What distinguishes malaria parasites from other pigmented haemosporidians? *Trends in Parasitology* **21**, 357–358.
- Valkiunas, G., Bensch, S., Iezhova, T.A., Krizanauskienė, A., Hellgren, O. & Bolshakov, C.V. (2006) Nested cytochrome b polymerase chain reaction diagnostics underestimate mixed infections of avian blood haemosporidian parasites: microscopy is still essential. *Journal of Parasitology* **92**, 418–422.
- Valkiunas, G. & Iezhova, T.A. (2004) The transmission of *Haemoproteus belopolskyi* (Haemosporida: Haemoproteidae) of black-cap by *Culicoides impunctatus* (Diptera: Ceratopogonidae). *Journal of Parasitology* **90**, 196–198.
- Valkiunas, G., Sehgal, R.N.M., Iezhova, T.A. & Smith, T.B. (2005b) Further observations on the blood parasites of birds in Uganda. *Journal of Wildlife Diseases* **41**, 580–587.
- Van Wyk, E., van der Bank, H. & Verdoorn, G.H. (1998) Dynamics of haematology and blood biochemistry in free-living African whitebacked vulture (*Pseudogyps africanus*) nestlings. *Comparative Biochemistry and Physiology* **120A**, 495–508.
- Villegas, A., Corbacho, C., Sánchez-Guzmán, J.M., Corbacho, P. & Morán, R. (2006) Hematocrit and blood chemistry values in

- three genera of captive hornbills. *Zoo Biology* **25**, 1–9.
- Villegas, A., Sánchez Guzmán, J.M., Corbacho, C., Corbacho, P. & Vargas, J.M. (2004) Blood values of bald ibis (*Geronticus eremita*) in captivity: comparative ranges and variability with age, sex and physical condition. *Journal of Ornithology* **145**, 98–104.
- Villouta, G., Hargreaves, R. & Riveros, V. (1997) Haematological and clinical biochemistry findings in captive Humboldt penguins (*Spheniscus humboldti*). *Avian Pathology* **26**, 851–858.
- Vogelnest, L. (1991) Avian clinical pathology. *Proceedings of the Sydney Post Graduate Foundation*, 243–316.
- Voslarova, E., Bedanova, I., Vecerek, V., Pistekova, V., Chloupek, P. & Suchy, P. (2006) Changes in haematological profile of common pheasant (*Phasianus colchicus*) induced by transit to pheasantry. *Deutsche Tierärztliche Wochenschrift* **113**, 375–378.
- Votýpka, J., Oborník, M., Volf, P., Svobodová, M. & Lukeš, J. (2002) *Trypanosoma avium* of raptors (Falconiformes): phylogeny and identification of vectors. *Parasitology* **125**, 253–263.
- Vuillaume, A. (1983) A new technique for taking blood samples from ducks and geese. *Avian Pathology* **12**, 389–391.
- Wallace, R.S., Teare, A., Diebold, E., Michaels, M. & Willis, M.J. (1995) Hematology and plasma chemistry values in free-ranging Humboldt penguins (*Spheniscus humboldti*) in Chile. *Zoo Biology* **14**, 311–316.
- Waner, T. & Harrus, S. (2000) Anemia of inflammatory disease. In: *Schalm's Veterinary Hematology*, (eds B.F. Feldman, J.G. Zinkl & N.C. Jain), 5th edn. pp. 205–209. Lippincott, Williams, Wilkins, Philadelphia.
- Wang, W., Wideman, R.F., Jr, Chapman, M.E., Bersi, T.K. & Erf, G.F. (2003) Effect of intravenous endotoxin on blood cell profiles of broilers housed in cages and floor litter environments. *Poultry Science* **82**, 1886–1897.
- Waters, M. (2003) Ciconiiformes (herons, ibises, spoonbills, storks). In: *Zoo and Wild Animal Medicine*, (eds M.E. Fowler & R.E. Miller), 5th edn, pp. 122–128. Saunders, Missouri.
- Waters, M. & Hart, M. (2002) A morphological comparison of blood cells of the scarlet ibis (*Eudocimus ruber*), the American wood stork (*Mycteria americana*) and the marabou stork (*Leptoptilos crumeniferus*). *Zoo Medicine* **2**, 36–38.
- Weathers, W.W. & Snyder, G.K. (1974) Functional acclimation of Japanese quail to simulated high-altitude. *Journal of Comparative Physiology B* **93**, 127–137.
- Weber, M. (2003) Pelecaniformes (cormorants, frigate birds, gannets, pelicans and tropicbirds). In: *Zoo and Wild Animal Medicine*, (eds M.E. Fowler & R.E. Miller), 5th edn. pp. 118–122. Saunders, Missouri.
- Weber, M.A., Terrell, S.P., Neiffer, D.L., Miller, M.A. & Mangold, B.J. (2002) Bone marrow hypoplasia and intestinal crypt cell necrosis associated with fenbendazole administration in five painted storks. *Journal of the American Veterinary Medical Association* **221**, 417–419.
- Weber, R.E. (2007) High-altitude adaptations in vertebrate hemoglobins. *Respiratory Physiology and Neurobiology* (online).

- Weber, R.E., Hiebl, I. & Braunitzer, G. (1988) High altitude and hemoglobin function in the vultures *Gyps rueppellii* and *Aegyptius monachus*. *Biological Chemistry Hoppe-Seyler* **369**, 233–240.
- Weinstein, Y., Bernstein, M.H., Bickler, P.E., Gonzales, D.V., Samaniego, F.C. & Escobedo, M.A. (1985) Blood respiratory properties in pigeons at high altitudes: effects of acclimation. *American Journal of Physiology – Regulatory, Integrative and Comparative Physiology* **249**, 765–775.
- Wernery, R., Wernery, U., Kinne, J. & Samour, J. (2004) *Colour Atlas of Falcon Medicine*. Schlütersche, Hannover.
- West, G.D. & Haines, V.L. (2002) Hematology and serum biochemistry values of captive Attwater's prairie chickens (*Tympanuchus cupido attwateri*). *Journal of Zoo and Wildlife Medicine* **33**, 122–124.
- Wiersch, S.C., Lubjuhn, T., Maier, W.A. & Kampen, H. (2007) Haemosporidian infection in passerine birds from Lower Saxony. *Journal of Ornithology* **148**, 17–24.
- Williams, J.I. & Trainer, D.O. (1971) A hematological study of snow, blue, and Canada geese. *Journal of Wildlife Diseases* **7**, 258–265.
- Wilson, G.R. & Wilson, L.P. (1978) Haematology, weight and condition of captive red grouse (*Lagopus lagopus scoticus*) infected with caecal threadworm (*Trichostrongylus tenuis*). *Research in Veterinary Science* **25**, 331–336.
- Woepel, R.W. & Rosskopf, W.J. (1984) Clinical experience with avian laboratory diagnostics. In: *Symposium on caged bird medicine. Veterinary Clinics of North America: Small Animal Practice*, (ed. G.J. Harrison), Vol. 14. pp. 249. Saunders, Philadelphia.
- Work, T.M. (1996) Weights, hematology, and serum chemistry of seven species of free-ranging tropical pelagic seabirds. *Journal of Wildlife Diseases* **32**, 643–657.
- Work, T.M. (1999) Weights, hematology, and serum chemistry of free-ranging brown boobies (*Sula leucogaster*) in Johnston Atoll, Central Pacific. *Journal of Zoo and Wildlife Medicine* **30**, 81–84.
- Work, T.M. & Rameyer, R.A. (1996) *Haemoproteus iwa* n. sp. in great frigatebirds (*Fregata minor* (Gmelin)) from Hawaii: parasite morphology and prevalence. *Journal of Parasitology* **82**, 489–491.
- Work, T.M. & Rameyer, R.A. (1997) Description and epizootiology of *Babesia poelea* n. sp. in brown boobies (*Sula leucogaster* (Boddaert)) on Sand Island, Johnston Atoll, Central Pacific. *Journal of Parasitology* **83**, 734–738.
- Work, T.M. & Rameyer, R.A. (1999) Mass stranding of wedge-tailed shearwater chicks in Hawaii. *Journal of Wildlife Diseases* **35**, 487–495.
- Yamato, O., Goto, I. & Maede, Y. (1996) Hemolytic anemia in wild seaducks caused by marine oil pollution. *Journal of Wildlife Diseases* **32**, 381–384.
- Zajac, A.M. & Conboy, G.A. (2006) *Veterinary Clinical Parasitology*, 7th edn. Blackwell Publishing, Oxford.
- Zais, J., Fox, W.P., Cray, C. & Altman, N.H. (2000) Hematologic, plasma proteins, and biomedical profiles of brown pelicans (*Pelecanus occidentalis*). *American Journal of Veterinary Research* **61**, 771–774.

- Zhang, J., Hua, Z., Tame, J.R., Lu, G., Zhang, R. & Gu, X. (1996) The crystal structure of a high oxygen affinity species of haemoglobin (bar-headed goose haemoglobin in the oxy form). *Journal of Molecular Biology* 255, 484–493.
- Zimmermann, N.G. & Dhillon, A.S. (1985) Blood sampling from the venous occipital sinus of birds. *Poultry Science* 64, 1859–1862.

Species list: alphabetically by common name

A

African grey parrot (*Psittacus erithacus*)
Aleutian goose (*Branta canadensis leucopareia*)
American coot (*Fulica americana*)
American kestrel (*Falco sparverius*)
American wood stork (*Mycteria americana*)
Atlantic puffin (*Fratercula arctica*)
Australasian grebe (*Tachybaptus novaehollandiae*)
Australian black-shouldered kite (*Elanus axillaris*)
Australian gannet (*Morus serrator*)
Australian hobby (*Falco longipennis*)
Australian king parrot (*Alisterus scapularis*)
Australian magpie (*Gymnorhina tibicen*)
Australian raven (*Corvus coronoides*)
Australian shelduck (*Tadorna tadornoides*)
Australian wood duck (*Chenonetta jubata*)
Azure kingfisher (*Alcedo azurea*)

B

Baer's pochard (*Aythya baeri*)
Bald eagle (*Haliaeetus leucocephalus*)
Bald ibis (*Geronticus calvus*)

Bali myna (*Leucopsar rothschildi*)
Bar-headed goose (*Anser indicus*)
Barn owl (*Tyto alba*)
Barrow's golden eye (*Bucephala islandica*)
Bar-tailed godwit (*Limosa lapponica*)
Black kite (*Milvus migrans*)
Black stork (*Ciconia nigra*)
Black swan (*Cygnus atratus*)
Black vulture (*Coragyps atratus*)
Black-bellied whistling duck (*Dendrocygna autumnalis*)
Blackcap (*Sylvia atricapilla*)
Black-crowned crane (*Balearica pavonina*)
Black-faced cormorant (*Phalacrocorax fuscescens*)
Black-faced ibis (*Theristicus melanopis*)
Black-footed penguin (*Spheniscus demersus*)
Black-headed gull (*Larus ridibundus*)
Black-necked aracari (*Pteroglossus aracari*)
Blue and gold macaw (*Ara ararauna*)
Blue bonnet (*Northiella haematogaster*)
Blue-breasted quail (*Coturnix chinensis*)
Blue-crowned conure (*Aratinga acuticaudata*)
Blue-fronted Amazon parrot (*Amazona aestiva*)
Blue-throated conure (*Pyrrhura cruentata*)
Blue-winged kookaburra (*Dacelo leachii*)
Bobwhite quail (*Colinus virginianus*)

Brolga (*Grus rubicunda*)
 Brown booby (*Sula leucogaster*)
 Brown falcon (*Falco berigora*)
 Brown goshawk (*Accipiter fasciatus*)
 Brown honey-eater (*Lichmera indistincta*)
 Brown kiwi (*Apteryx australis*)
 Brown pelican (*Pelecanus occidentalis*)
 Brown quail (*Coturnix ypsilophora*)
 Budgerigar (*Melopsittacus undulatus*)
 Burrowing owl (*Speotyto cunicularia*)

C

Canada geese (*Branta canadensis*)
 Canvasback (*Aythya valisineria*)
 Cattle egret (*Bubulcus ibis*)
 Chestnut-naped imperial pigeon (*Ducula aenea paulina*)
 Chilean flamingo (*Phoenicopterus chilensis*)
 Cockatiel (*Nymphicus hollandicus*)
 Common crane (*Grus grus*)
 Common eider (*Somateria mollissima*)
 Common loon (*Gavia immer*)
 Common pheasant (*Phasianus colchicus*)
 Common redstart (*Phoenicurus phoenicurus*)
 Congo peafowl (*Afropavo congensis*)
 Cooper's hawk (*Accipiter cooperii*)
 Crested wood partridge (*Rollulus roulroul*)
 Cuban Amazon parrot (*Amazona leucocephala*)

D

Demoiselle crane (*Grus virgo*)
 Double-crested cormorant (*Phalacrocorax auritus*)

E

Eclectus parrot (*Eclectus roratus*)
 Edwards' pheasant (*Lophura edwardsi*)
 Emu (*Dromaius novaehollandiae*)
 Eurasian coot (*Fulica atra*)

Eurasian kestrel (*Falco tinnunculus*)
 Eurasian sparrowhawk (*Accipiter nisus*)

F

Fairy martin (*Hirundo ariel*)
 Fairy tern (*Sterna nereis*)
 Ferruginous hawk (*Buteo regalis*)
 Flightless cormorant (*Phalacrocorax harrisi*)
 Fluttering shearwater (*Puffinus gavia*)

G

Galah (*Eolophus roseicapillus*)
 Galapagos penguin (*Spheniscus mendiculus*)
 Gang-gang cockatoo (*Callocephalon fimbriatum*)
 Gentoo penguin (*Pygoscelis papua*)
 Goldcrest (*Regulus regulus*)
 Goosander (*Mergus merganser*)
 Gray-headed chachalaca (*Ortalis cinereiceps*)
 Great black-backed gull (*Larus marinus*)
 Great frigate bird (*Fregata minor*)
 Great knot (*Calidris tenuirostris*)
 Great skua (*Catharacta skua*)
 Great tit (*Parus major*)
 Greater flamingo (*Phoenicopterus ruber*)
 Greater prairie-chicken (*Tympanuchus cupido*)
 Greater rhea (*Rhea americana*)
 Greater roadrunner (*Geococcyx californianus*)
 Green peafowl (*Pavo muticus*)
 Green-winged macaw (*Ara chloropterus*)
 Grey teal (*Anas gracilis*)
 Grey-faced petrel (*Pterodroma macroptera gouldi*)
 Guanay cormorant (*Phalacrocorax bougainvillii*)
 Guira cuckoo (*Guira guira*)
 Gyr falcon (*Falco rusticolus*)

H

Harris' hawk (*Parabuteo unicinctus*)
 Hawaiian petrel (*Pterodroma phaeopygia*)
 Helmeted honeyeater (*Lichenostomus melanops*)
 Herring gull (*Larus argentatus*)
 Hill mynah (*Gracula religiosa*)
 Hoatzin (*Opisthocomus hoazin*)
 Hooded crow (*Corvus corone*)
 Hooded pitta (*Pitta sordida*)
 Houbara bustard (*Chlamydotis undulata*)
 House finch (*Carpodacus mexicanus*)
 House martin (*Delichon urbica*)
 Humboldt penguin (*Spheniscus humboldti*)
 Hyacinth macaw (*Anodorhynchus hyacinthinus*)

I

Imperial eagle (*Aquila adalberti*)

J

Japanese quail (*Coturnix japonica*)

K

King penguin (*Aptenodytes patagonicus*)
 King shag (*Phalacrocorax albivenier*)
 King vulture (*Sarcoramphus papa*)
 Kori bustard (*Ardeotis kori*)

L

Lanner falcon (*Falco biarmicus*)
 Laughing kookaburra (*Dacelo novaeguineae*)
 Laysan albatross (*Diomedea immutabilis*)
 Lesser flamingo (*Phoenicopterus minor*)
 Lesser rhea (*Rhea pennata*)
 Lesser sulphur-crested cockatoo (*Cacatua sulphurea*)

Little corella (*Cacatua sanguinea*)
 Little egret (*Egretta garzetta*)
 Little penguin (*Eudyptula minor*)
 Lovebird (*Agapornis rosiecollis*)

M

Magellanic penguin (*Spheniscus magellanicus*)
 Major Mitchell's cockatoo (*Cacatua leadbeateri*)
 Mallard (*Anas platyrhynchos*)
 Mallee fowl (*Leipoa ocellata*)
 Manx shearwater (*Puffinus puffinus*)
 Marabou stork (*Leptoptilos crumeniferus*)
 Marsh harrier (*Circus aeruginosus*)
 Masked lapwing (*Vanellus miles*)
 Masked owl (*Tyto novaehollandiae*)
 Mauritius kestrel (*Falco punctatus*)
 Military macaw (*Ara militaris*)
 Mindanao bleeding heart dove (*Gallicolumba criniger*)
 Muscovy duck (*Cairina moschata*)

N

New Zealand blue duck (*Hymenolaimus malacorhynchus*)
 New-Holland honeyeater (*Phylidonyris novaehollandiae*)
 Night heron (*Nycticorax nycticorax*)
 Northern fulmar (*Fulmarus glacialis*)
 Northern harrier (*Circus cyaneus*)
 Northern rosella (*Platycercus venustus*)

O

Orange-bellied parrot (*Neophema chrysogaster*)
 Orange-footed scrub fowl (*Megapodius reinwardt*)
 Ostrich (*Struthio camelus*)

P

Pacific black duck (*Anas superciliosa*)
 Painted stork (*Mycteria leucocephala*)
 Pekin duck (*Anas platyrhynchos* forma
domestica)
 Peregrine falcon (*Falco peregrinus*)
 Pied butcher bird (*Cracticus nigrogularis*)
 Pied currawong (*Strepera graculina*)
 Pigeon guillemot (*Cepphus columba*)
 Pink pigeon (*Columba mayeri*)
 Pink-backed pelican (*Pelecanus rufescens*)
 Port Lincoln parrot (*Barnardius zonarius*)
 Princess parrot (*Polytelis alexandrae*)
 Providence petrel (*Pterodroma solandri*)
 Puna ibis (*Plegadis ridgwayi*)
 Pygmy-goose (*Nettapus pulchellus*)

R

Rainbow lorikeet (*Trichoglossus
 haematodus*)
 Red grouse (*Lagopus lagopus scoticus*)
 Red kite (*Milvus milvus*)
 Red knot (*Calidris canutus*)
 Red lory (*Eos bornea*)
 Red wattlebird (*Anthochaera carunculata*)
 Red-billed toucan (*Ramphastos tucanus*)
 Red-collared lorikeet (*Trichoglossus haema-
 todus rubritorquis*)
 Red-footed booby (*Sula sula*)
 Red-fronted macaw (*Ara rubrogenys*)
 Redhead (*Aythya americana*)
 Redhead bunting (*Emberiza bruniceps*)
 Red-legged partridge (*Alectus rufa*)
 Red-tailed black cockatoo (*Calyptorhynchus
 banksii*)
 Red-tailed hawk (*Buteo jamaicensis*)
 Red-tailed tropic bird (*Phaethon rubricauda*)
 Red-winged tinamou (*Rhynchotus rufescens*)
 Rhinoceros auklet (*Cerorhinca monocerata*)
 Roadside hawk (*Buteo magnirostris*)
 Rock dove (*Columba livia*)
 Rock-hopper penguin (*Eudyptes
 chrysocomes*)
 Rose-ringed parakeet (*Psittacula krameri*)

Rough-legged hawk (*Buteo lagopus*)
 Royal spoonbill (*Platalea regia*)
 Rueppell's griffon (*Gyps rueppellii*)
 Ruff (*Philomachus pugnax*)
 Rufous-collared sparrow (*Zonotrichia
 capensis*)
 Rufous-crested bustard (*Eupodotis ruficrista*)
 Rusty-barred owl (*Strix hylophila*)

S

Sacred kingfisher (*Todirhamphus sanctus*)
 Sage grouse (*Centrocercus urophasianus*)
 Saker falcon (*Falco cherrug*)
 Sandhill crane (*Grus canadensis*)
 Scarlet ibis (*Eudocimus ruber*)
 Sharp-shinned hawk (*Accipiter striatus*)
 Short-tailed shearwater (*Puffinus tenuirostris*)
 Silver gull (*Larus novaehollandiae*)
 Singing honeyeater (*Lichenostomus
 virescens*)
 Snow geese (*Anser caerulescens*)
 Snowy owl (*Nyctea scandiaca*)
 Southern boobook (*Ninox boobook*)
 Southern cassowary (*Casuarius casuarius*)
 Southern giant petrel (*Macronectes
 giganteus*)
 Spectacled owl (*Pulsatrix perspicillata*)
 Spotted dove (*Streptopelia chinensis*)
 Stanley crane (*Grus paradisea*)
 Stone curlew (*Burhinus oedicephalus*)
 Stubble quail (*Coturnix pectoralis*)
 Sulphur-crested cockatoo (*Cacatua galerita*)
 Sun conure (*Aratinga solstitialis*)
 Superb blue wren (*Malurus cyaneus*)
 Superb lyrebird (*Menura novaehollandiae*)
 Superb starling (*Spreo superbus*)
 Swan geese (*Anser cygnoides*)

T

Takahe (*Porphyrio mantelli*)
 Tawny eagle (*Aquila rapax*)
 Tawny frogmouth (*Podargus strigoides*)
 Tengmalm's owl (*Aegolius funereus*)

Toco toucan (*Ramphasto toco*)
 Trumpeter swan (*Cygnus buccinator*)
 Turkey (*Meleagris gallopavo*)

V

Varied lorikeet (*Psitteuteles versicolor*)
 Victoria crowned pigeon (*Goura victoria*)
 Violet-backed starling (*Cinnyricinclus leucogaster*)
 Von der Decken's Hornbill (*Tockus deckeni*)

W

Wattled crane (*Grus carunculatus*)
 Waved albatross (*Diomedea irrorata*)
 Wedge-tailed eagle (*Aquila audax*)
 Wedge-tailed shearwater (*Puffinus pacificus*)
 Welcome swallow (*Hirundo neoxena*)
 Whistling kite (*Haliastur sphenurus*)

White pelican (*Pelecanus onocrotalus*)
 White stork (*Ciconia ciconia*)
 White-backed vulture (*Gyps africanus*)
 White-faced scops owl (*Otus leucotis*)
 White-headed vulture (*Trigonoceps occipitalis*)
 White-tailed black cockatoo (*Calyptorhynchus baudinii*)
 White-winged scoter (*Melanitta fusca*)
 White-winged wood duck (*Cairina scutulata*)
 Whooping crane (*Grus americana*)
 Woolly-necked stork (*Ciconia episcopus*)

Y

Yellow collared macaw (*Ara aricollis*)
 Yellow crowned amazon (*Amazona ochrocephala*)
 Yellow-eyed penguin (*Megadyptes antipodes*)
 Yellowhammer (*Emberiza citronella*)
 Yellow-throated laughing thrush (*Garrulax galbanus*)

Species list: by order

Order: Anseriformes

Aleutian goose (*Branta canadensis leucopareia*)
Australian shelduck (*Tadorna tadornoides*)
Australian wood duck (*Chenonetta jubata*)
Baer's pochard (*Aythya baeri*)
Bar-headed goose (*Anser indicus*)
Barrow's golden eye (*Bucephala islandica*)
Black swan (*Cygnus atratus*)
Black-bellied whistling duck (*Dendrocygna autumnalis*)
Canada geese (*Branta canadensis*)
Canvasback (*Aythya valisineria*)
Common eider (*Somateria mollissima*)
Goosander (*Mergus merganser*)
Grey teal (*Anas gracilis*)
Mallard (*Anas platyrhynchos*)
Muscovy duck (*Cairina moschata*)
New Zealand blue duck (*Hymenolaimus malacorhynchus*)
Pacific black duck (*Anas superciliosa*)
Pekin duck (*Anas platyrhynchos* forma domestica)
Pygmy-goose (*Nettapus pulchellus*)
Redhead (*Aythya americana*)
Snow geese (*Anser caerulescens*)

Swan geese (*Anser cygnoides*)
Trumpeter swan (*Cygnus buccinator*)
White-winged scoter (*Melanitta fusca*)
White-winged wood duck (*Cairina scutulata*)

Order: Caprimulgiformes

Tawny frogmouth (*Podargus strigoides*)

Order: Charadriiformes

Atlantic puffin (*Fratercula arctica*)
Black-headed gull (*Larus ridibundus*)
Fairy tern (*Sterna nereis*)
Great black-backed gull (*Larus marinus*)
Great knot (*Calidris tenuirostris*)
Great skua (*Catharacta skua*)
Herring gull (*Larus argentatus*)
Masked lapwing (*Vanellus miles*)
Pigeon guillemot (*Cepphus columba*)
Red knot (*Calidris canutus*)
Rhinoceros auklet (*Cerorhinca monocerata*)
Ruff (*Philomachus pugnax*)
Silver gull (*Larus novaehollandiae*)
Stone curlew (*Burhinus oedicephalus*)

Order: Ciconiiformes

American wood stork (*Mycteria americana*)
 Bald ibis (*Geronticus calvus*)
 Black stork (*Ciconia nigra*)
 Black-faced ibis (*Theristicus melanopis*)
 Cattle egret (*Bubulcus ibis*)
 Little egret (*Egretta garzetta*)
 Marabou stork (*Leptoptilos crumeniferus*)
 Night heron (*Nycticorax nycticorax*)
 Painted stork (*Mycteria leucocephala*)
 Puna ibis (*Plegadis ridgwayi*)
 Royal spoonbill (*Platalea regia*)
 Scarlet ibis (*Eudocimus ruber*)
 White stork (*Ciconia ciconia*)
 Woolly-necked stork (*Ciconia episcopus*)

Order: Columbiformes

Chestnut-naped imperial pigeon (*Ducula aenea paulina*)
 Mindanao bleeding heart dove (*Gallicolumba criniger*)
 Pink pigeon (*Columba mayeri*)
 Rock dove (*Columba livia*)
 Spotted dove (*Streptopelia chinensis*)
 Victoria crowned pigeon (*Goura victoria*)

Order: Coraciiformes

Azure kingfisher (*Alcedo azurea*)
 Blue-winged kookaburra (*Dacelo leachii*)
 Laughing kookaburra (*Dacelo novaeguineae*)
 Sacred kingfisher (*Todirhamphus sanctus*)
 Von der Decken's hornbill (*Tockus deckeni*)

Order: Cuculiformes

Greater roadrunner (*Geococcyx californianus*)
 Guira cuckoo (*Guira guira*)

Order: Falconiformes

American kestrel (*Falco sparverius*)
 Australian black-shouldered kite (*Elanus axillaris*)
 Australian hobby (*Falco longipennis*)

Bald eagle (*Haliaeetus leucocephalus*)
 Black kite (*Milvus migrans*)
 Black vulture (*Coragyps atratus*)
 Brown falcon (*Falco berigora*)
 Brown goshawk (*Accipiter fasciatus*)
 Common kestrel (*Falco tinnunculus*)
 Cooper's hawk (*Accipiter cooperii*)
 Eurasian kestrel (*Falco tinnunculus*)
 Eurasian sparrowhawk (*Accipiter nisus*)
 Ferruginous hawk (*Buteo regalis*)
 Gray-headed chachalaca (*Ortalis cinereiceps*)
 Gyr falcon (*Falco rusticolus*)
 Harris' hawk (*Parabuteo unicinctus*)
 Imperial eagle (*Aquila adalberti*)
 King vulture (*Sarcoramphus papa*)
 Lanner falcon (*Falco biarmicus*)
 Marsh harrier (*Circus aeruginosus*)
 Mauritius kestrel (*Falco punctatus*)
 Northern harrier (*Circus cyaneus*)
 Peregrine falcon (*Falco peregrinus*)
 Red kite (*Milvus milvus*)
 Roadside hawk (*Buteo magnirostris*)
 Rough-legged hawk (*Buteo lagopus*)
 Rueppell's griffon (*Gyps rueppellii*)
 Saker falcon (*Falco cherrug*)
 Sharp-shinned hawk (*Accipiter striatus*)
 Tawny eagle (*Aquila rapax*)
 Wedge-tailed eagle (*Aquila audax*)
 Whistling kite (*Haliastur sphenurus*)
 White-backed vulture (*Gyps africanus*)
 White-headed vulture (*Trigonoceps occipitalis*)

Order: Galliformes

Blue-breasted quail (*Coturnix chinensis*)
 Bobwhite quail (*Colinus virginianus*)
 Brown quail (*Coturnix ypsilophora*)
 Common pheasant (*Phasianus colchicus*)
 Congo peafowl (*Afropavo congensis*)
 Crested wood partridge (*Rollulus roulroul*)
 Edwards' pheasant (*Lophura edwardsi*)
 Greater prairie-chicken (*Tympanuchus cupido*)
 Green peafowl (*Pavo muticus*)
 Japanese quail (*Coturnix japonica*)
 Mallee fowl (*Leipoa ocellata*)

Orange-footed scrub fowl (*Megapodius reinwardt*)
 Red grouse (*Lagopus lagopus scoticus*)
 Red-legged partridge (*Alectus rufa*)
 Sage grouse (*Centrocercus urophasianus*)
 Stubble quail (*Coturnix pectoralis*)
 Turkey (*Meleagris gallopavo*)

Order: Gaviiformes

Common loon (*Gavia immer*)
 Hoatzin (*Opisthocomus hoazin*)

Order: Gruiformes

American coot (*Fulica americana*)
 Black-crowned crane (*Balearica pavonina*)
 Brolga (*Grus rubicunda*)
 Common crane (*Grus grus*)
 Demoiselle crane (*Grus virgo*)
 Eurasian coot (*Fulica atra*)
 Houbara bustard (*Chlamydotis undulata*)
 Kori bustard (*Ardeotis kori*)
 Rufous-crested bustard (*Eupodotis ruficrista*)
 Sandhill crane (*Grus canadensis*)
 Stanley crane (*Grus paradisea*)
 Takahe (*Porphyrio mantelli*)
 Wattled crane (*Grus carunculatus*)
 Whooping crane (*Grus americana*)

Order: Passeriformes

Australian magpie (*Gymnorhina tibicen*)
 Australian raven (*Corvus coronoides*)
 Bali myna (*Leucopsar rothschildi*)
 Bar-tailed godwit (*Limosa lapponica*)
 Blackcap (*Sylvia atricapilla*)
 Brown honeyeater (*Lichmera indistincta*)
 Common redstart (*Phoenicurus phoenicurus*)
 Fairy martin (*Hirundo ariel*)
 Goldcrest (*Regulus regulus*)
 Great tit (*Parus major*)
 Helmeted honeyeater (*Lichenostomus melanops*)
 Hill mynah (*Gracula religiosa*)
 Hooded crow (*Corvus corone*)

Hooded pitta (*Pitta sordida*)
 House finch (*Carpodacus mexicanus*)
 House martin (*Delichon urbica*)
 New-Holland honeyeater (*Phylidonyris novaehollandiae*)
 Pied butcher bird (*Cracticus nigrogularis*)
 Pied currawong (*Strepera graculina*)
 Red wattlebird (*Anthochaera carunculata*)
 Redhead bunting (*Emberiza bruniceps*)
 Rufous-collared sparrow (*Zonotrichia capensis*)
 Singing honeyeater (*Lichenostomus virescens*)
 Superb blue wren (*Malurus cyaneus*)
 Superb lyrebird (*Menura novaehollandiae*)
 Superb starling (*Spreo superbus*)
 Violet-backed starling (*Cinnyricinclus leucogaster*)
 Welcome swallow (*Hirundo neoxena*)
 Yellowhammer (*Emberiza citronella*)
 Yellow-throated laughing thrush (*Garrulax galbanus*)

Order: Pelecaniformes

Australasian gannet (*Morus serrator*)
 Black-faced cormorant (*Phalacrocorax fuscescens*)
 Brown booby (*Sula leucogaster*)
 Brown pelican (*Pelecanus occidentalis*)
 Double-crested cormorant (*Phalacrocorax auritus*)
 Flightless cormorant (*Phalacrocorax harrisi*)
 Great frigate bird (*Fregata minor*)
 Guanay cormorant (*Phalacrocorax bougainvillii*)
 King shag (*Phalacrocorax albivenier*)
 Pink-backed pelican (*Pelecanus rufescens*)
 Red-footed booby (*Sula sula*)
 Red-tailed tropic bird (*Phaethon rubricauda*)
 White pelican (*Pelecanus onocrotalus*)

Order: Phoenicopteriformes

Chilean flamingo (*Phoenicopterus chilensis*)
 Greater flamingo (*Phoenicopterus ruber*)
 Lesser flamingo (*Phoenicopterus minor*)

Order: Piciformes

Black-necked aracari (*Pteroglossus aracari*)
 Red-billed toucan (*Ramphastos tucanus*)
 Toco toucan (*Ramphasto toco*)

Order: Podicipediformes

Australasian grebe (*Tachybaptus novaehollandiae*)

Order: Procellariiformes

Fluttering shearwater (*Puffinus gavia*)
 Grey-faced petrel (*Pterodroma macroptera gouldi*)
 Hawaiian petrel (*Pterodroma phaeopygia*)
 Laysan albatross (*Diomedea immutabilis*)
 Manx shearwater (*Puffinus puffinus*)
 Northern fulmar (*Fulmarus glacialis*)
 Providence petrel (*Pterodroma solandri*)
 Short-tailed shearwater (*Puffinus tenuirostris*)
 Southern giant petrel (*Macronectes giganteus*)
 Waved albatross (*Diomedea irrorata*)
 Wedge-tailed shearwater (*Puffinus pacificus*)

Order: Psittaciformes

African grey parrot (*Psittacus erithacus*)
 Australian king parrot (*Alisterus scapularis*)
 Blue and gold macaw (*Ara ararauna*)
 Blue bonnet (*Northiella haematogaster*)
 Blue-crowned conure (*Aratinga acuticaudata*)
 Blue-fronted Amazon parrot (*Amazona aestiva*)
 Blue-throated conure (*Pyrrhura cruentata*)
 Budgerigar (*Melopsittacus undulatus*)
 Cockatiel (*Nymphicus hollandicus*)
 Cuban Amazon parrot (*Amazona leucocephala*)
 Eclectus parrot (*Eclectus roratus*)
 Galah (*Eolophus roseicapillus*)
 Gang-gang cockatoo (*Callocephalon fimbriatum*)
 Green-winged macaw (*Ara chloropterus*)

Hyacinth macaw (*Anodorhynchus hyacinthinus*)
 Lesser sulphur-crested cockatoo (*Cacatua sulphurea*)
 Little corella (*Cacatua sanguinea*)
 Lovebird (*Agapornis* sp)
 Major Mitchell's cockatoo (*Cacatua leadbeateri*)
 Military macaw (*Ara militaris*)
 Northern rosella (*Platycercus venustus*)
 Orange-bellied parrot (*Neophema chrysogaster*)
 Port Lincoln parrot (*Barnardius zonarius*)
 Princess parrot (*Polytelis alexandrae*)
 Rainbow lorikeet (*Trichoglossus haematodus*)
 Red lory (*Eos bornea*)
 Red-collared lorikeet (*Trichoglossus haematodus rubritorquis*)
 Red-fronted macaw (*Ara rubrogenys*)
 Red-tailed black cockatoo (*Calyptorhynchus banksii*)
 Rose-ringed parakeet (*Psittacula krameri*)
 Sulphur-crested cockatoo (*Cacatua galerita*)
 Sun conure (*Aratinga solstitialis*)
 Varied lorikeet (*Psittenteles versicolor*)
 White-tailed black cockatoo (*Calyptorhynchus baudinii*)
 Yellow collared macaw (*Ara aricollis*)
 Yellow crowned amazon (*Amazona ochrocephala*)

Order: Sphenisciformes

Black-footed penguin (*Spheniscus demersus*)
 Galapagos penguin (*Spheniscus mendiculus*)
 Gentoo penguin (*Pygoscelis papua*)
 Humboldt penguin (*Spheniscus humboldti*)
 King penguin (*Aptenodytes patagonicus*)
 Little penguin (*Eudyptula minor*)
 Magellanic penguin (*Spheniscus magellanicus*)
 Rock-hopper penguin (*Eudyptes chrysocomes*)
 Yellow-eyed penguin (*Megadyptes antipodes*)

Order: Strigiformes

Barn owl (*Tyto alba*)
Burrowing owl (*Speotyto cunicularia*)
Masked owl (*Tyto novaehollandiae*)
Rusty-barred owl (*Strix hylophila*)
Snowy owl (*Nyctea scandiaca*)
Southern boobook (*Ninox boobook*)
Spectacled owl (*Pulsatrix
perspicillata*)
Tengmalm's owl (*Aegolius funereus*)
White-faced scops owl (*Otus leucotis*)

Order: Struthioniformes

Brown kiwi (*Apteryx australis*)
Emu (*Dromaius novaehollandiae*)
Greater rhea (*Rhea americana*)
Lesser rhea (*Rhea pennata*)
Ostrich (*Struthio camelus*)
Southern cassowary (*Casuarius casuarius*)

Order: Tinamiformes

Red-winged tinamou (*Rhynchotus rufescens*)

Glossary

Acidophil: a classification of granulocytes, that includes heterophils and eosinophils, based on the characteristic of cytoplasmic granules to imbibe acidophilic stains (such as eosin)

Adipocyte: a cell that has a specialized role to store fat

Agglutination: clumping of erythrocytes mediated by antibodies “bridging” between cells

Amphophilic: simultaneous staining with both basophilic and eosinophilic dyes

Anemia: a decreased mass of erythrocytes characterized by decreased hematocrit (packed cell volume), decreased erythrocyte concentration or decreased hemoglobin concentration

Anisocytosis: variation in the size of cells of the same type, commonly used to describe erythrocytes

Azurophilic granules: the granules that have an azure to basophilic color

Band: the penultimate stage of granulocyte development that is characterized by a nucleus

that has no constriction greater than half the width of the nucleus and less coarsely clumped chromatin and a smoother nuclear membrane than in mature (segmented) granulocytes

Basophil: a leukocyte (granulocyte) that contains basophilic cytoplasmic granules

Basophilia: 1. increased bluish color of the cytoplasm when stained with a Romanowsky stain. 2. a concentration of basophils that is greater than the upper limit of an appropriate reference range (basophilic leukocytosis)

Basophilic: staining readily with “basic” dyes that impart a blue–purple color

Basophilic stippling: the presence of small, dark blue staining foci within erythrocytes, usually due to the presence of residual aggregations of RNA but also occasionally may be due to the presence of aggregations of iron-containing substances

Bone marrow: the tissue typically found in the medullary cavity of bones that is the principle site of hematopoiesis in adult birds

Buffy coat: the layer of leukocytes and thrombocytes that collects immediately above the erythrocytes when whole blood is centrifuged

Chromatin: a complex of DNA and nuclear proteins

Cytoplasm: the portion of a cell that excludes the nucleus

Dacrocyte: a “drop-shaped” erythrocyte

Diff Quik: a commercially available rapid stain that is commonly used to stain blood films

EDTA: ethylene-diamine-tetra-acetic acid, a compound commonly used as an anticoagulant

Endothelial cell: the cell type that composes the inner lining of blood vessels

Eosinophil: a leukocyte (granulocyte) that typically contains eosinophilic cytoplasmic granules

Eosinophilia: a concentration of eosinophils that is greater than the upper limit of an appropriate reference range

Eosinophilic: characteristic of exhibiting an affinity for eosin that consequently imparts an orange to red color

Eosinopenia: a concentration of eosinophils that is less than the lower limit of an appropriate reference range

Erythrocyte: a red blood cell

Erythroplastid: an anucleated erythrocyte in the peripheral blood of a bird

Erythropoiesis: the production of erythrocytes

Ghost cell: erythrocyte that has lost hemoglobin content through a deficit in the cell membrane

Golgi apparatus (complex): an organelle composed of cisternae that are involved in the production of proteins that may be seen as a pale perinuclear region by light microscopy

Granulocyte: a leukocyte that contains prominent granules in the cytoplasm of the cell, e. g. heterophils, eosinophils and basophils

Granulopoiesis: the production of granulocytes

Hematocrit: the volume of erythrocytes relative to whole blood; typically calculated from the number and size of the erythrocytes measured by a hematology analyser but has also been determined by sedimentation of cells (see also packed cell volume)

Hematology: the study of blood

Hematopoiesis (hemopoiesis): the production of the cells present in the blood

Hemoglobin: the oxygen-carrying protein contained within erythrocytes

Hemolysis: lysis of erythrocytes

Hemolysate: the product of hemolysis

Hemosiderin: an insoluble form of iron that appears as a golden brown to black colored, granular cytoplasmic pigment with Romanowsky stain and has a blue color with Perl's Prussian blue stain

Heinz bodies: rounded projections from the surface of erythrocytes that represent denatured hemoglobin following oxidative damage; they typically appear eosinophilic with Romanowsky stains and blue when stained with new methylene blue stain

Heterophil: a leukocyte with a segmented nucleus and cytoplasm that contains typically many prominent, brick-red to eosinophilic, fusiform cytoplasmic granules (which often partially obscure the nucleus)

Heterophilia: a concentration of heterophils that is greater than the upper limit of an appropriate reference range

Heteropenia: a concentration of heterophils that is less than the lower limit of an appropriate reference range

Hypochromasia: erythrocytes that lack hemoglobin and consequently have a pale color

Karyolysis: the lysis of a cell's nucleus

Left shift: an increased concentration of immature heterophils, commonly band form cells, in the peripheral blood

Leukemia: a neoplastic proliferation of hematopoietic cells

Leukocyte: a white blood cell

Leukocytosis: a concentration of total leukocytes that is greater than the upper limit of an appropriate reference range

Leukopenia: a concentration of total leukocytes that is less than the lower limit of an appropriate reference range

Leukopoiesis: the production of leukocytes

Lymphocyte: a non-granulocytic white blood cell characterized (using Romanowsky stain) by a round nucleus composed of dense chromatin and a thin peripheral rim of basophilic cytoplasm

Lymphocytosis: a concentration of lymphocytes that is greater than the upper limit of an appropriate reference range

Lymphopenia: (lymphocytopenia) a concentration lymphocytes that is less than the lower limit of an appropriate reference range

Lymphopoiesis: the production of lymphocytes

Macrocyte: a large erythrocyte (increased volume)

Macrophage: a differentiated monocytic cell, present in tissues, that has roles in phagocytosis, antigen presentation and cytokine production

Microcyte: a small erythrocyte (decreased volume)

Monocyte: a large, pleomorphic, agranulated leukocyte characterized (using Romanowsky stain) by an irregularly shaped nucleus composed of reticular chromatin, and a blue to grey cytoplasm that frequently exhibits one to several small vacuoles

Monocytosis: a concentration of monocytes that is greater than the upper limit of an appropriate reference range

Monocytopenia: a concentration of monocytes that is less than the lower limit of an appropriate reference range

Monocytopenia: a concentration of monocytes that is less than the lower limit of an appropriate reference range

Monocytopenia: a concentration of monocytes that is less than the lower limit of an appropriate reference range

Monocytopenia: a concentration of monocytes that is less than the lower limit of an appropriate reference range

Monocytopenia: a concentration of monocytes that is less than the lower limit of an appropriate reference range

Myeloid: 1. pertaining to the bone marrow 2. pertaining to leukocyte precursor cells (e.g. myeloid:erythroid ratio)

New methylene blue stain: an aqueous stain used to identify reticulocytes and Heinz bodies

Non-regenerative anemia: an anemia that does not exhibit morphological features of increased erythropoiesis

Nuclei: more than one nucleus

Nucleus: the part of the cell that contains the nuclear material and typically stains basophilic with Romanowsky stains

Nucleolus: a typically round structure in the nucleus that is the site of RNA synthesis

Osteoblast: a cell that produces osteoid in bone

Osteoclast: a large multinucleated cell involved in the remodelling of bone

Packed cell volume (PCV): the proportion of erythrocytes relative to centrifuged whole blood (see also hematocrit)

Plasma: the non-cellular component of whole blood (in which coagulation has been prevented)

Plasma cell: a differentiated B-lymphocyte that has an eccentric nucleus with coarse chromatin and basophilic cytoplasm that may contain a pale, perinuclear Golgi zone or eosinophilic granules (Mott cell) or diffuse cytoplasmic eosinophilia (flame cell)

Poikilocyte: an abnormally shaped erythrocyte

Polychromasia: presence of increased numbers of polychromatophilic erythrocytes in a blood film

Polychromatophilic erythrocyte: the penultimate stage of erythrocyte production that has a bluish color with Romanowsky stain due to the presence of residual, diffuse RNA

Pyknotic cell: a cell with a shrunken nucleus comprised of condensed chromatin

Regenerative anemia: an anemia in which the bone marrow is attempting to correct by

releasing increased numbers of immature cells following increased erythropoiesis

Reticulocyte: the penultimate stage of erythrocyte development, that when stained with new methylene blue, shows aggregations of RNA; corresponds to the presence of polychromatophilic erythrocytes in Romanowsky stained blood films

Romanowsky stain: a class of stains that contain a combination of methylene blue and eosin, including: Wright's stain, Leishman's stain and Giemsa stain

Rouleau (pl. rouleaux): the viscosity mediated property of erythrocytes that results in overlapping linear or branching arrays of erythrocytes

Rubricyte: a stage of erythroid development immediately preceding polychromatophilic erythrocytes that can be identified in Romanowsky stained blood films as smaller cells with dense chromatin and more basophilic cytoplasm than mature erythrocytes

Serum: the fluid component of blood after clotting has occurred

Smudge cell: a cell that has been lysed and cannot reliably be identified

Thrombopoiesis: the production of thrombocytes

Toxic change: a number of morphological characteristics (such as: cytoplasmic basophilia, foamy/vacuolated cytoplasm, decreased density of granules, rounded granules, basophilic granules or karyolysis) that represents abnormal maturation of the heterophil in response to inflammatory demand or direct action of toxic substances upon the heterophil; also referred to as "morphological atypia"

Index

Note: page numbers in *italics* refer to figures, those in **bold** refer to tables

- acidophils 171
 - concentration measurement 31
- adipocytes 24, 27, 171
- age effects on hematological characteristics 97–8
- agglutination 171
 - erythrocytes **105**
- air sacculitis 116
- albendazole 124
- altitude, high 106
- anesthesia 5
- anemia 171
 - erythrocytes 38, 101, 102, 103, 107–8
 - erythropoiesis 101
 - Heinz bodies 107, 108
 - hemolytic 107
 - erythrocytes 100
 - extravascular 107, 108
 - hemoparasites 107
 - PCV effects 100
 - hemorrhagic 107
 - heterophils 103
 - hypoproliferative 107, 108
 - inflammatory disease 108
 - mycobacteriosis 108
 - PCV 101, 102
 - regenerative 174
 - regenerative response 103
 - reticulocytes 102
 - rubricytes 103
 - zinc toxicosis 107–8
- anisocytosis 36, 171
 - disease process **105**
 - Falconiformes 69
- Anseriformes 2, 167
 - hematological characteristics 54, 54–7, 57
 - vascular access sites 14
- anticoagulants 15–16, 22, 23
 - artifacts 27, 118
 - erythrocyte lysis 115
 - Gruiformes 76
 - Passeriformes 77, 78
 - Struthioniformes 96
 - see also* ethylenediaminetetraacetic acid (EDTA); heparin; lithium heparin
- Apodiformes 2, 57
 - vascular access sites 11, 14
- aspergillosis
 - heterophil changes 49, 116, 117, 120–2
 - monocytosis 118
- Atoxoplasma* 125, **126**, 134–5
- Aves 1, 2
- axillary vein 8, 10
- Babesia* 125, **126**, 130–1
- Babesia shortii* 107, 126

- bacteria
 blood film contamination 25, 27
 pododermatitis 117
 severe inflammation 115
- basilic vein 8, 10, 11, 12, 14
- basophils 19, 21, 24, 40, 42, 46, 171
 anesthesia effects 5
 Anseriformes 54, 55–6, 57
 artifacts 26
 Caprimulgiformes 57, 58
 Ciconiiformes 61
 Columbiformes 62, 63
 Coraciiformes 64, 66
 cytoplasmic granules 46
 disease-induced changes 118
 Falconiformes 68, 71
 Galliformes 72, 73
 Gruiformes 74, 75, 76
 Passeriformes 78, 79, 80
 Pelecaniformes 81, 82
 Phoenicopteriformes 82–3
 Podicipediformes 85
 Procellariiformes 85
 Psittaciformes 86, 87, 89, 90
 Sphenisciformes 91, 92
 stippling 105, 171
 stress response 124
 Strigiformes 93, 94
 Struthioniformes 95, 96
 ultrastructure 42, 46
- blindness, heterophil changes 110
- blood collection 6–7
 equipment 7
 restraint of birds 5
- blood films 16–19, 20–1, 22–3
 artifacts 23, 24–5, 26–7
 cover-slip and slide method for 18–19, 19
 cross method 17–18, 19
 fixed 23
 hemoparasites 127–8
 incomplete drying 22, 26–7
 non-hematological cells 24, 25, 27
 staining 19, 20–1, 22–3
 two cover-slip method for 18, 19
 unfixed 23
 wedge method for 16–17, 19
- blood volume 6
 diving birds 106
 Passeriformes 77
- bone marrow 51, 171
 hypoplasia 124
- brachial vein 8, 10, 15
 deep 8, 10
- brodifacoum toxicity 107
- buffy coat 172
 methods 128
- Caprimulgiformes 2, 167
 hematological characteristics 57–8
- carotid artery 11
 cell morphology in disease 105
 cephalic vein, caudal 10, 11
 Charadriiformes 3, 167
- hematological characteristics 58, 59, 60
- chromatin 48, 172
- Ciconiiformes 3, 167–8
 hematological characteristics 60–1
 monocytes 61
 vascular access sites 14
- circadian effects on hematological characteristics 99
- Coliiformes 3
 hematological characteristics 61
- Columbiformes 3, 168
 hematological characteristics 62, 62–3
 vascular access sites 14
- Coraciiformes 3, 168
 hematological characteristics 64, 64–6, 66
- cranial vein 10, 11
- Cuculiformes 3, 168
 hematological characteristics 66
- cutaneous vein 10, 11
- dehydration 104, 106, 111
- diarrhea
 dehydration 106
 heterophil concentration 117
- Diff Quick stain 19, 20, 21, 22, 172
- digital veins 14, 15
- diving birds, blood volume 106
- dorsal vein 10, 11
- dyspnea 118, 119
- EDTA *see* ethylenediaminetetraacetic acid (EDTA)
- eosinophils 19, 40, 41–2, 43, 45–6, 172
 Anseriformes 54, 55, 56, 57, 57
 Caprimulgiformes 57, 58
 Charadriiformes 58, 59, 60
 Ciconiiformes 60, 61
 Columbiformes 62, 63
 Coraciiformes 64, 65, 66
 cytoplasm 45–6
 cytoplasmic granules 55, 71
 Falconiformes 67, 69, 70, 71

- Galliformes 71, 72, 73
 granules 46
 Gruiformes 75, 76
 Passeriformes 77, 78, 79, 80
 Pelecaniformes 81–2
 Phoenicopteriformes 82
 Piciformes 83, 84, 85
 Podicipediformes 85
 Procellariiformes 85–6
 Psittaciformes 88–9, 90
 Sphenisciformes 91, 92
 Strigiformes 92, 93, 94
 Struthioniformes 94, 95, 96
 time of day effects 99
 ultrastructure 41, 46
 erythrocytes 22, 33, 35–9, 39–40, 172
 age effects 98
 agglutination 105
 aggregation 100
 anemia 38, 101, 102, 103, 107–8
 Anseriformes 55, 56, 57
 shape 57
 anucleated 36
 artifacts 26–7
 basophilic stippling 38
 Caprimulgiformes 58
 Ciconiiformes 60, 61
 Columbiformes 62, 63
 concentration 27, 28–9
 increase 106–7
 Coraciiformes 64, 65, 66
 cytoplasm 35, 37
 dehydration 111
 density 105
 development stages 39–40
 dimensions 39
 disease response 100, 100–4, 104, 105, 106–8,
 111
 Falconiformes 69
 Galliformes 71, 72, 73
 ghost 105
 Gruiformes 74, 75, 76
 Haemoproteus 131–2
 hemoglobin crystal 38
 hemolytic anemia 100
 hemoparasites 40
 heterophilic meningoencephalitis 104
 hypochromatic 105
 increased production 106
 lysis 115
 mature 36, 37, 38
 anemia 103
 Anseriformes 55, 56, 57
 Charadriiformes 58, 59
 Ciconiiformes 60, 61
 Columbiformes 62, 63
 Gruiformes 74, 75, 76
 Passeriformes 77, 79
 Pelecaniformes 81
 Sphenisciformes 92
 Struthioniformes 95
 trauma 116
 meningoencephalitis 104, 111
 nucleated 30
 nucleus 33, 37
 Anseriformes 57
 oxidative damage 107
 Passeriformes 77, 78, 79, 80
 Pelecaniformes 81, 82
 Phoenicopteriformes 82
 Piciformes 83
 Plasmodium schizonts 130
 Podicipediformes 85
 polychromatophilic 36, 37, 38, 39, 174
 anemia 101, 103
 Anseriformes 56
 bacterial infection 117
 Ciconiiformes 61
 Coraciiformes 65
 disease process 105
 erythropoiesis 101
 hemorrhage response 115
 Passeriformes 78, 79, 80
 Pelecaniformes 81
 Sphenisciformes 92
 Strigiformes 92
 trauma 101
 polycythemia 104, 106–7
 Procellariiformes 85, 86
 Psittaciformes 86, 87, 88, 89, 90
 reproductive status effects 98
 rouleaux 104, 105
 seasonal effects 99
 sex effects 98
 shape 33, 35, 36, 39
 variant 40
 size 39
 Sphenisciformes 91, 92
 staining 20
 Strigiformes 92, 93, 94
 Struthioniformes 95, 96
 time of day effects 99
 trauma 101
 volume 29–30

- erythrocytosis 104
 - hypoxia 106
- erythroid cells 51
 - anemia 103
 - disease effects on production 108
- erythrophagocytosis, macrophages 104
- erythroplastids 36, 37, 40, 172
- erythropoiesis 101, 172
 - anemia 101
 - hemorrhage 115
 - polycythemia 107
 - trauma 101
- esophageal vein 10, 11
- ethylenediaminetetraacetic acid (EDTA) 15, 20, 22, 172
 - erythrocyte lysis 115
 - Gruiformes 76
 - Passeriformes 77, 78
 - Struthioniformes 96
- Falconiformes 3, 168
 - hematological characteristics 66, 67, 68–9, 70, 71
 - vascular access sites 14
- femoral vein 10
- fenbendazole 124
- ferric chloride 14
- fitness of hemoparasite host 127
- flow cytometry 31–2
- fungal hyphae 24
 - blood film contamination 27
- Galliformes 3, 168
 - hematological characteristics 71–2, 73, 74
 - vascular access sites 14
- Gaviiformes 4, 168
 - hematological characteristics 74
- geographic location, effects on hematological characteristics 99–100
- ghost cells 26, 172
- Giemsa stain 19, 20, 22–3
- glove powder particles, blood film contamination 25, 27
- glucocorticoids, stress 123
- granulocytes 172
 - staining 31
- Gruiformes 4, 169
 - hematological characteristics 74, 75, 76
 - vascular access sites 14
- Haemoproteus* 40, 125, 126, 131–2
- handling of birds 5, 14, 15
- head and neck, vascular access 10–11
- Heinz body 38, 105, 107, 172
 - extra-vascular hemolytic anemia 107, 108
- hematocrit
 - age effects 98
 - dehydration 106
 - migration effects 99
 - seasonal effects 98, 99
- hematomas 7
- hematopoiesis 51, 172
- hemocytometer 31, 32
- hemoglobin 34, 172
 - age effects 98
 - colorimetric determination 29
 - decreased production 102
 - high-altitude flight birds 106
 - measurement 29–30
 - migration effects 99
 - seasonal effects 99
 - sex effects 98
- hemolysis 15–16, 20, 26, 172
 - Gruiformes 76
 - Passeriformes 77, 78
 - Struthioniformes 96
- hemoparasites 49, 125–38
 - blood films 127–8
 - clinical disease 125–7
 - concentration methods 128–9
 - detection 127–9
 - diagnosis 127–9
 - erythrocyte shape 40
 - fitness of host 127
 - hemolytic anemia 107
 - immature birds 126–7
 - immunity 127
 - intracellular 105
 - light microscopy 128
 - morphology 129–38
 - polymerase chain reaction 128
 - reproductive success of host 127
- hemorrhage 115
- hemostasis, blood collection 14
- heparin 16, 23
 - leukocyte clumping 50
 - Passeriformes 78
 - see also lithium heparin
- Hepatozoon* 49, 125, 126, 135
- heterophilia 112, 173
 - air sacculitis 116
 - aspergillosis 116
 - dyspnea 118

- lymphocytes 112
- meningoencephalitis 117
- pancreatic disease 112
- heterophils 20, 21, 34, 40, 41, 45, 173
 - anemia 103
 - Anseriformes 54, 55, 56, 57
 - aspergillosis 49, 116, 117, 120–2
 - atypical morphology 48, 112, 113, 114, 115
 - atypical myelopoiesis 116
 - band 48, 109
 - basophilic granules 49
 - Caprimulgiformes 57, 58
 - central granular body 45, 54
 - Charadriiformes 58, 59, 60
 - Columbiformes 62, 63
 - concentration with diarrhea 117
 - Coraciiformes 64, 65, 66
 - cytoplasmic granules 45, 48–9
 - dehydration 111
 - disease-induced changes 111, 112, 116, 117, 118
 - distinction from eosinophils 46
 - eosinophilic granules 49
 - Falconiformes 67, 68, 69, 70
 - Galliformes 73
 - Gruiformes 74, 75, 76
 - hemorrhage response 115
 - inflammation 48–9, 112, 113, 115, 120, 122–3
 - lipemia 111
 - meningoencephalitis 104, 111, 114, 117
 - mycobacteriosis 49
 - Passeriformes 77, 78, 79, 80
 - Pelecaniformes 81, 82
 - Phoenicopteriformes 82
 - Piciformes 83, 84
 - Podicipediformes 85
 - pododermatitis 117
 - Procellariiformes 85, 86
 - Psittaciformes 86, 87, 88, 90, 91
 - Sphenisciformes 91, 92
 - stress response 124
 - Strigiformes 92, 93, 94
 - Struthioniformes 94, 95, 96
 - time of day effects 99
 - trauma response 49, 109, 110, 113–16, 118
 - ultrastructure 38, 45
- hypochromasia 102, 173
- hypoxia, burrowing birds/high altitude 106
- immature birds, hemoparasites 126–7
- immunity, hemoparasites 127
- inflammation/inflammatory disease 108, 119–23
 - anemia 108
 - bacterial pododermatitis 117
 - heterophil response 48–9, 112, 113, 115, 120, 122–3
 - lipemia 111
 - lymphocytes 112, 115
 - monocytes 112, 115
 - toxic changes 119–20
- ingluvies vein 10, 11
- injury *see* trauma
- jugular vein 10–11, 12, 14, 15
- karyolysis 48, 173
- karyorrhesis 48
- Knott's test 129
- Leishman's stain 19
- Leucocytozoon* 126, 132–4
- leukocytes 20, 34, 40, 41–5, 45–9, 173
 - age effects 98
 - artifacts 26, 27
 - atypical morphology 48–9
 - basophilic granules 49
 - clumping 27
 - concentration measurement 30–2
 - estimation 32
 - count 28, 29
 - cytoplasmic changes with disease 49
 - differential counts 31
 - disease response 49, 108, 109–19, 119–24
 - concentration 120
 - morphological characteristics 121
 - hemoparasites 49
 - inflammation response 48, 108, 119–23
 - measurement 30–2
 - nucleated 30
 - nucleus atypia 48
 - nucleus toxin effects 48
 - staining 31
 - stress response 123–4
 - time of day effects 99
 - total concentration 31
 - see also* basophils; eosinophils; heterophils; lymphocytes; monocytes
- Leucocytozoon* 49, 125
- leukopenia 124, 173
- light microscopy, hemoparasite detection 128
- lipemia 24, 111
- lithium heparin 16, 22, 27, 118

- lymphocytes 20, 40, 43, 44, 46–7, 173
 - age effects 98
 - Anseriformes 55, 56, 57
 - atypical morphology 49
 - basophilic granules 47
 - blast-transformed cells 49
 - Caprimulgiformes 57, 58
 - Ciconiiformes 60, 61
 - Columbiformes 62, 63
 - Coraciiformes 64, 66
 - disease-induced changes 111, 117, 118, 119
 - Falconiformes 67, 69, 70, 71
 - Galliformes 72, 73, 74
 - Gruiformes 74, 75, 76
 - heterophilia 112
 - inflammation 112, 115
 - lipemia 111
 - nucleolus 49
 - Passeriformes 77, 78, 79, 80
 - Pelecaniformes 81, 82
 - Phoenicopteriformes 83
 - Piciformes 83, 84, 85
 - Podicipediiformes 85
 - Procellariiformes 85, 86
 - Psittaciformes 87, 89, 90
 - size 47
 - Sphenisciformes 92
 - stress response 124
 - Strigiformes 93, 94
 - Struthioniformes 96
 - time of day effects 99
 - trauma response 110, 116
 - ultrastructure 43, 47
- lymphocytosis 173
 - air sacculitis 116
- lymphopenia 119, 173
- lysis of cells 26
 - erythrocytes 115
 - see also hemolysis
- macrophages 173
 - erythrophagocytosis 104
 - heterophilic meningoencephalitis 114
- May–Grünwald stain 19, 20, 22–3
- mean corpuscular hemoglobin (MCH) 30
- mean corpuscular hemoglobin concentration (MCHC) 30
- mean corpuscular volume (MCV) 29–30, 34
 - age effects 98
- measurement of hematological cells 27–32
- meningoencephalitis
 - erythrocytes 111
 - heterophil changes 111, 117
 - heterophilic 104, 114, 117
- metacarpal vein, dorsal 9, 10, 13
- metamyelocytes 48
- metatarsal vein 14
 - dorsal 9, 10, 15
 - medial 9, 10, 11, 13, 14, 15
 - plantar 9, 10
- methyl violet 2B 31
- microcytosis 102
- microfilariae 126, 136–8
- microscopy
 - light
 - hemoparasite detection 128
 - leucocyte concentration determination 31
 - phase contrast 31
 - migration effects on hematological characteristics 99
- mitotic figure 39, 40
- monocytes 20, 40, 43, 44–5, 47–8, 173
 - Anseriformes 56, 57, 57
 - Caprimulgiformes 58
 - Charadriiformes 59, 60
 - Columbiformes 62
 - Coraciiformes 64, 66
 - disease-induced changes 112, 117, 118, 119
 - Falconiformes 68
 - Galliformes 73, 74
 - Gruiformes 75, 76
 - inflammation 112, 115
 - mycobacteriosis 49
 - Passeriformes 78, 79, 80
 - Pelecaniformes 81, 82
 - Phoenicopteriformes 83
 - Piciformes 84, 85
 - Podicipediiformes 85
 - Procellariiformes 85, 86
 - Psittaciformes 86, 87, 90
 - Sphenisciformes 92
 - Strigiformes 93, 94
 - Struthioniformes 96
 - trauma response 115, 116
 - ultrastructure 44, 47–8
- monocytosis 173
 - air sacculitis 116
 - aspergillosis 116, 118
 - disease-induced changes 118
 - dyspnea 118

- mononuclear cells 40, 43
 - hemoparasites 49
- mycobacteriosis
 - anemia 108
 - leukocyte changes 49
- myelocytes 48
- myeloid cells 51
- myelopoiesis, atypical 48, 116

- neck, vascular access 10–11
- nematodes
 - adults 138
 - microfilariae 126, 136–8
- nucleolus 174
 - lymphocyte 49

- occipital sinus, access 11
- occipital vein, lateral 10, 11
- Opisthocomiformes 4
 - hematological characteristics 77
- osteoblasts 24, 174
- osteoclasts 24, 174

- packed cell volume (PCV) 27–8, 34, 174
 - age effects 98
 - anesthesia effects 5
 - anemia 102
 - hypoproliferative 108
 - dehydration effects 106, 111
 - disease response 100, 100–4, 104
 - hemolytic anemia 100
 - reproductive status effects 98
 - sex effects 98
 - time of day effects 99
 - trauma 101
- pancreatic disease, heterophilia 112
- parasites *see* hemoparasites
- Passeriformes 4, 169
 - hematological characteristics 77, 77–80, 80
 - vascular access sites 11, 14
- pathological effects on hematological characteristics 100–24
- pectoral limb, vascular access 8–9, 10
- pedal veins 15
- Pelecaniformes 4, 169
 - hematological characteristics 81–2
 - vascular access sites 14–15
- pelvic limb, vascular access 9–10
- phase contrast microscopy 31
- phloxine B 31

- Phoenicopteriformes 4, 169
 - hematological characteristics 82–3
- physiological effects on hematological characteristics 97–100
- Piciformes 4, 169
 - hematological characteristics 83, 83–4, 85
- plasma proteins, anesthesia effects 5
- Plasmodium* 40, 125, 126, 129–30
- plexus venosus subcutaneous collaris 14
- Podicipediformes 4, 169
 - hematological characteristics 85
- poikilocytes 40, 174
- polycythemia
 - erythrocytes 104, 106–7
 - erythropoiesis 107
- polymerase chain reaction (PCR), hemoparasite detection 128
- popliteal vein 10
- population effects on hematological characteristics 99–100
- Procellariiformes 4, 169–70
 - hematological characteristics 85–6
- Psittaciformes 4, 5, 170
 - hematological characteristics 86–90, 91
 - vascular access sites 15

- radial vein 8, 10
- rapid stains 19, 23
 - see also* Diff Quick stain
- red blood cells (RBCs) 34
- renal insufficiency, lymphocytes 119
- reproductive status, effects on hematological characteristics 98
- reproductive success of hemoparasite host 127
- restraint of birds 5, 14, 15
- reticulocytes 39–40, 174
 - anemia 102
 - migration effects 99
- Romanowsky stains 19, 23, 31, 174
 - see also* Giemsa stain; Leishman's stain; May–Grünwald stain; Wright's stain
- rouleaux 104, 105, 174
- rubricytes 37, 40, 174
 - anemia 103
 - trauma 101

- sand particles, blood film contamination 25, 27
- seasonal effects on hematological characteristics 98–9
- sex effects on hematological characteristics 98

- species
 - common names 163–6
 - orders 167–70
- Sphenisciformes 4, 170
 - hematological characteristics 91–2
 - vascular access sites 15
- spironucleosis 106
- staining of blood films 19, 20–1, 22–3
 - artifacts 26
 - granulocytes 31
 - leukocytes 31
 - Romanowsky stains 19, 23, 31, 174
- stress, hematological effects 123–4
- Strigiformes 4, 170
 - hematological characteristics 92, 92–4, 94
 - vascular access sites 14
- Struthioniformes 4, 5, 170
 - hematological characteristics 94, 94–6, 96
 - vascular access sites 15
- subclavian vein 10, 11

- tarsal vein, lateral/medial 9–10
- taxonomy 2, 2–4, 53–4
 - see also* species
- thoracic vein, external 11
- thrombocytes 49–51
 - aggregation 27, 116
 - Caprimulgiformes 57
 - Charadriiformes 58, 59
 - clumping 50
 - Columbiformes 63
 - Falconiformes 68, 70
 - Passeriformes 77, 79
 - Piciformes 84
 - Psittaciformes 90
 - Struthioniformes 95
 - ultrastructure 50–1
- thrombocytic cells 51
- tibial vein
 - caudal 9, 10
 - cranial 10, 13
- time of day, effects on hematological characteristics 99
- Tinamiformes 4, 170
 - hematological characteristics 96
- toxic change 174
 - inflammation 119–20
- tracheal vein 10, 11
- trauma
 - erythrocyte changes 101
 - erythropoiesis 101
 - heterophil changes 49, 109, 110, 113–16, 118
 - lymphocyte changes 110, 116
 - monocytes 115, 116
 - PCV 101
- Trichostrongylus tenuis* 108
- Trogoniformes 4
 - hematological characteristics 96
- Trypanosoma* 125, 126, 135–6

- ulnar vein 8–9, 10, 12, 13, 14, 15

- vascular access sites 7–11, 12–13, 14–15
 - bird groups 11, 12–13, 14–15
- veins, access to 5, 6–7
- vena cava, cranial 10
- venipuncture 5, 6–7

- white blood cells *see* leukocytes
- Wright's stain 19, 20, 21, 23

- zinc toxicosis, anemia 107–8
- zoonotic diseases 5